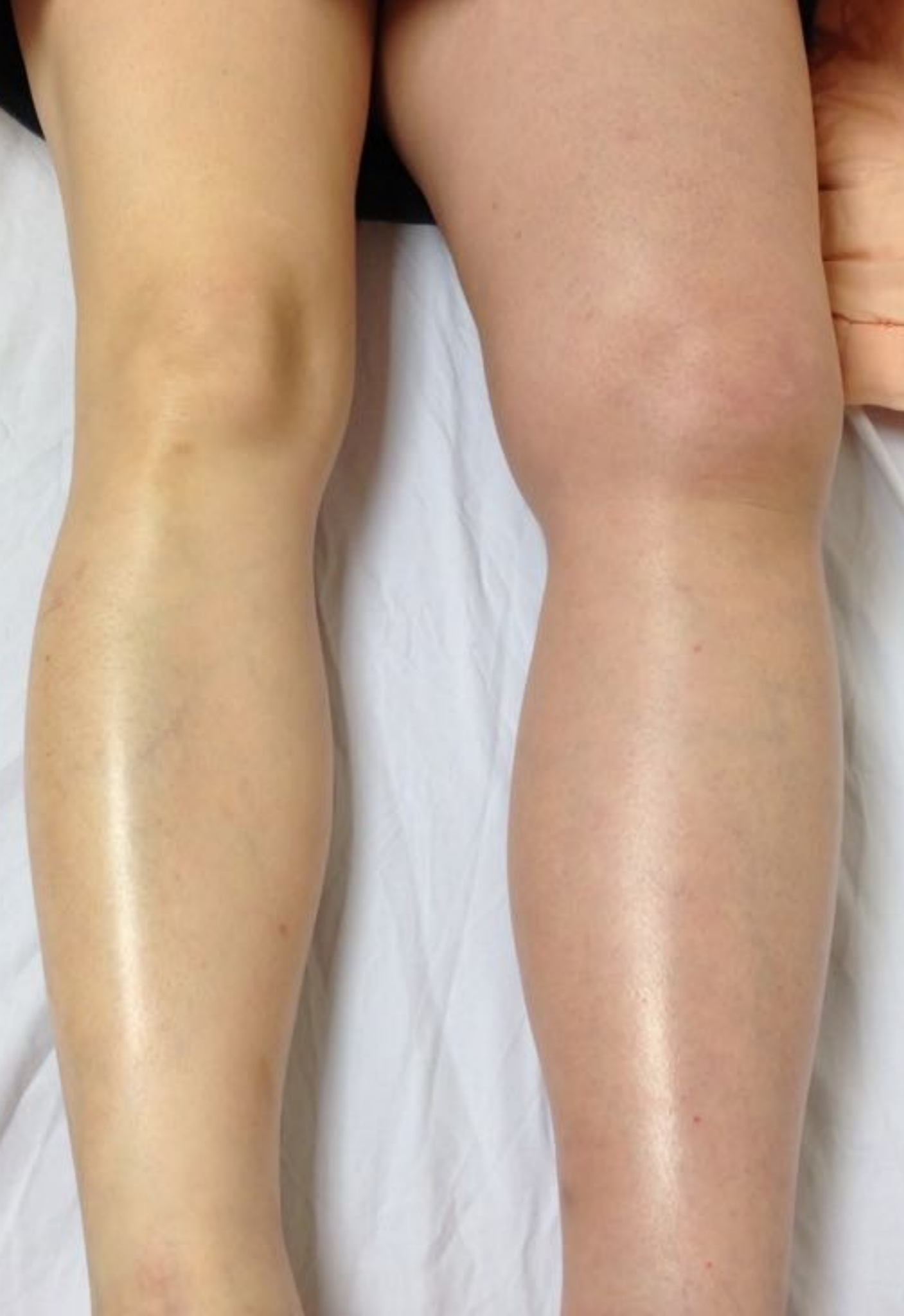



A swollen leg,  
what will you  
do ??



陳國智 醫師

西園醫院急重症



Cellulitis

Abscess

N.F.

DVT

Others ?



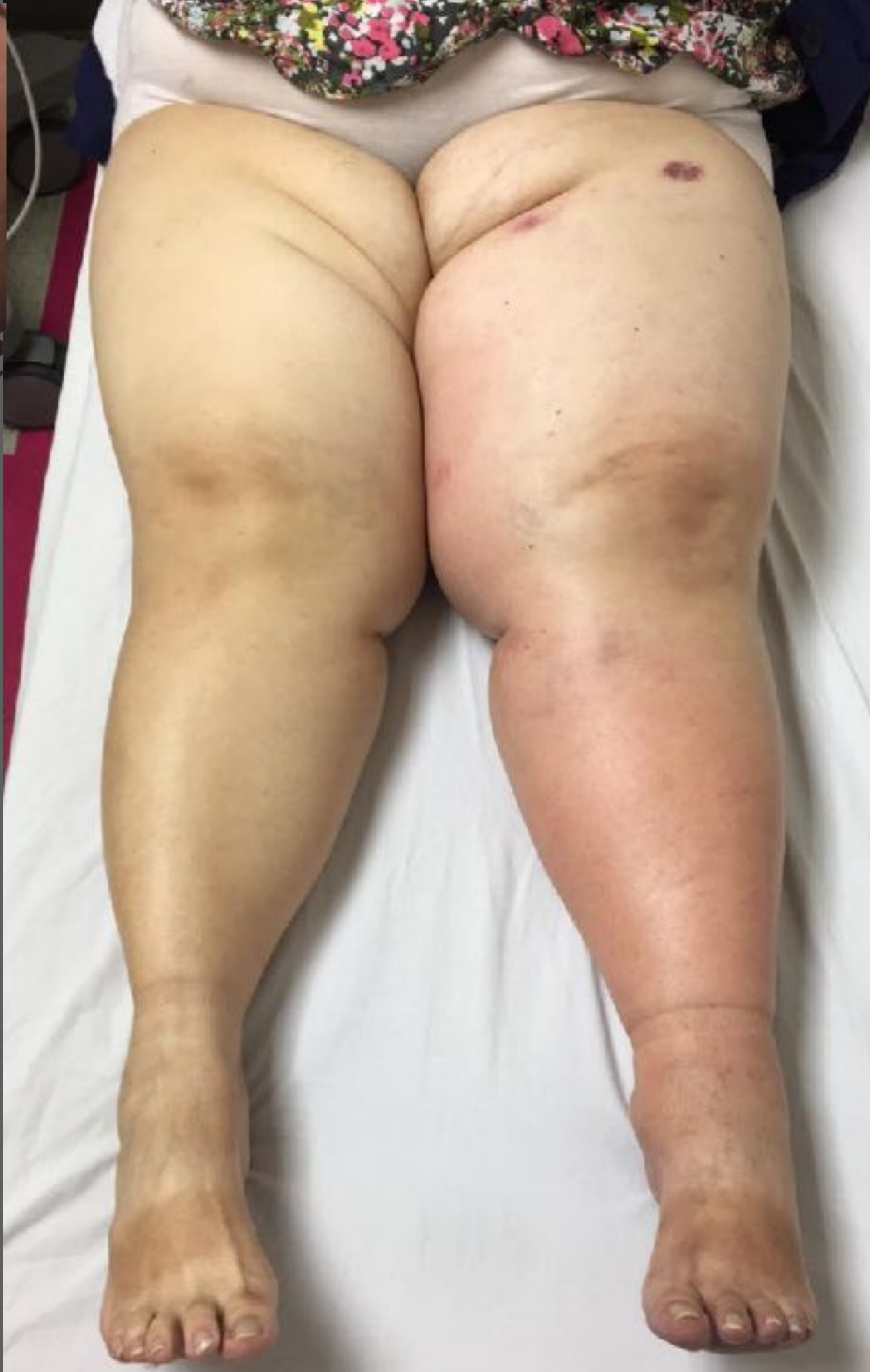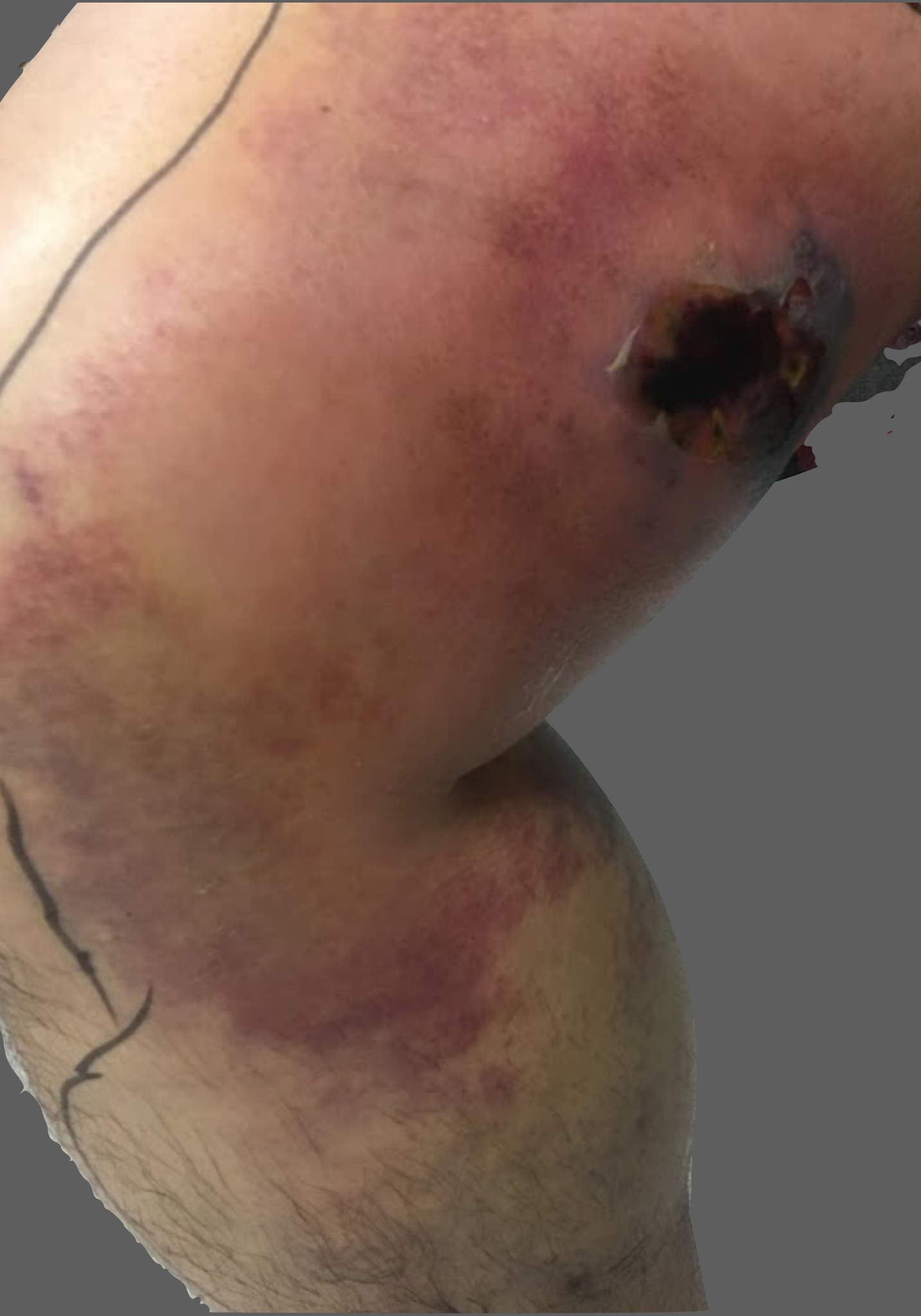Cellulitis

Abscess

N.F.

DVT

Others ?



Circulation

**CONSENSUS REPORT**

# **Ultrasound for Lower Extremity Deep Venous Thrombosis**

**Multidisciplinary Recommendations From the Society of Radiologists in Ultrasound Consensus Conference**

**Circulation 2018**

# Wells score for DVT assessment

Active cancer (patient receiving treatment for cancer within the previous 6 months or currently receiving palliative treatment)	1
Paralysis, paresis, or recent plaster immobilization of the lower extremities	1
Recently bedridden for $\geq 3$ days, or major surgery within the previous 12 weeks requiring general or regional anesthesia	1
Localized tenderness along the distribution of the deep venous system	1
Entire leg swollen	1
Calf swelling at least 3 cm larger than the asymptomatic side (measured 10 cm below the tibial tuberosity)	1
Pitting edema confined to the symptomatic leg	1
Collateral superficial veins (nonvaricose)	1
Previously documented deep venous thrombosis	1
Alternative diagnosis at least as likely as deep venous thrombosis	-2

$\geq 2$

Pretest <  
2

+

D-dimer  
-ve





**Likely**

**+ve D**

**US**



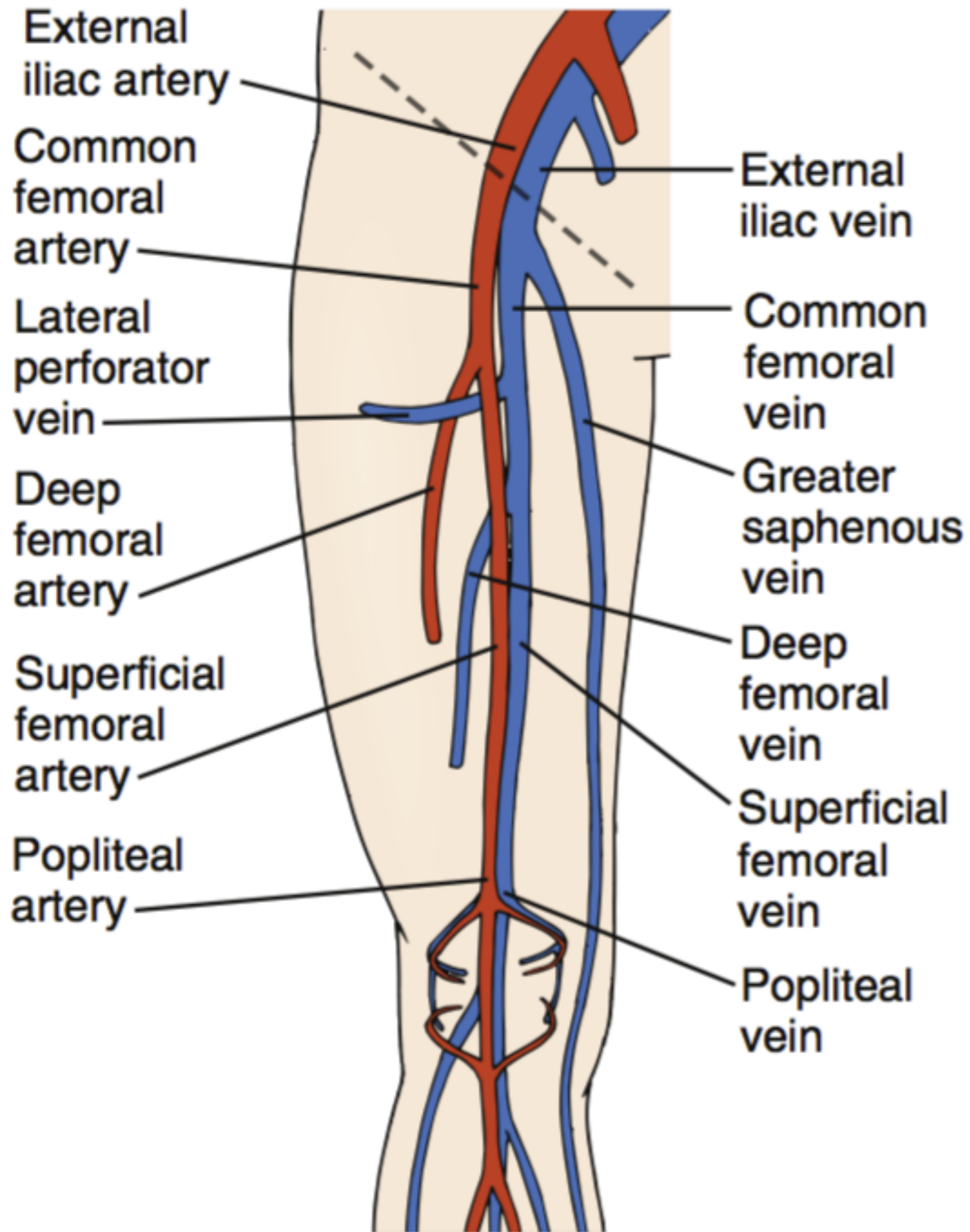
# Transducers

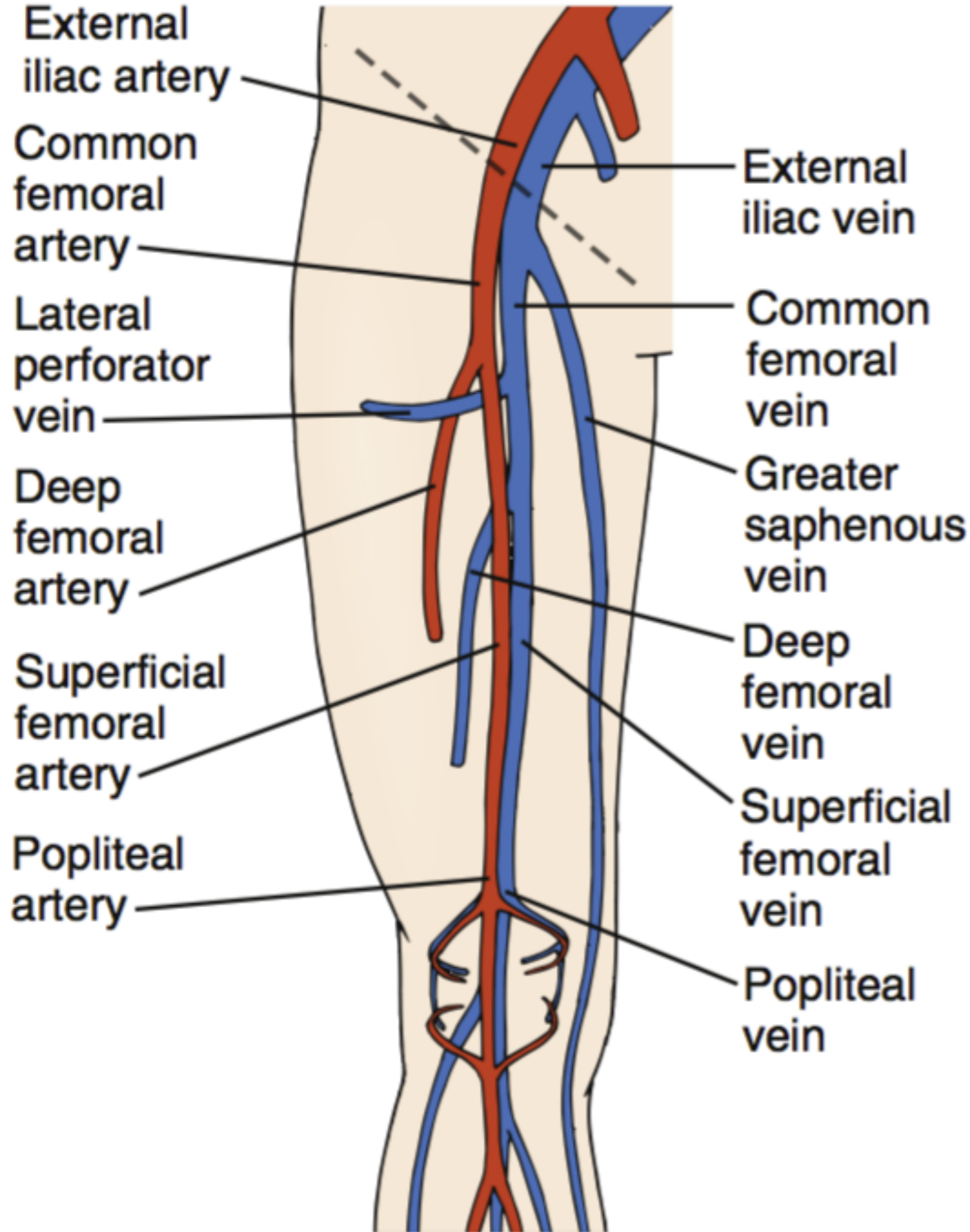


Transverse

Compression

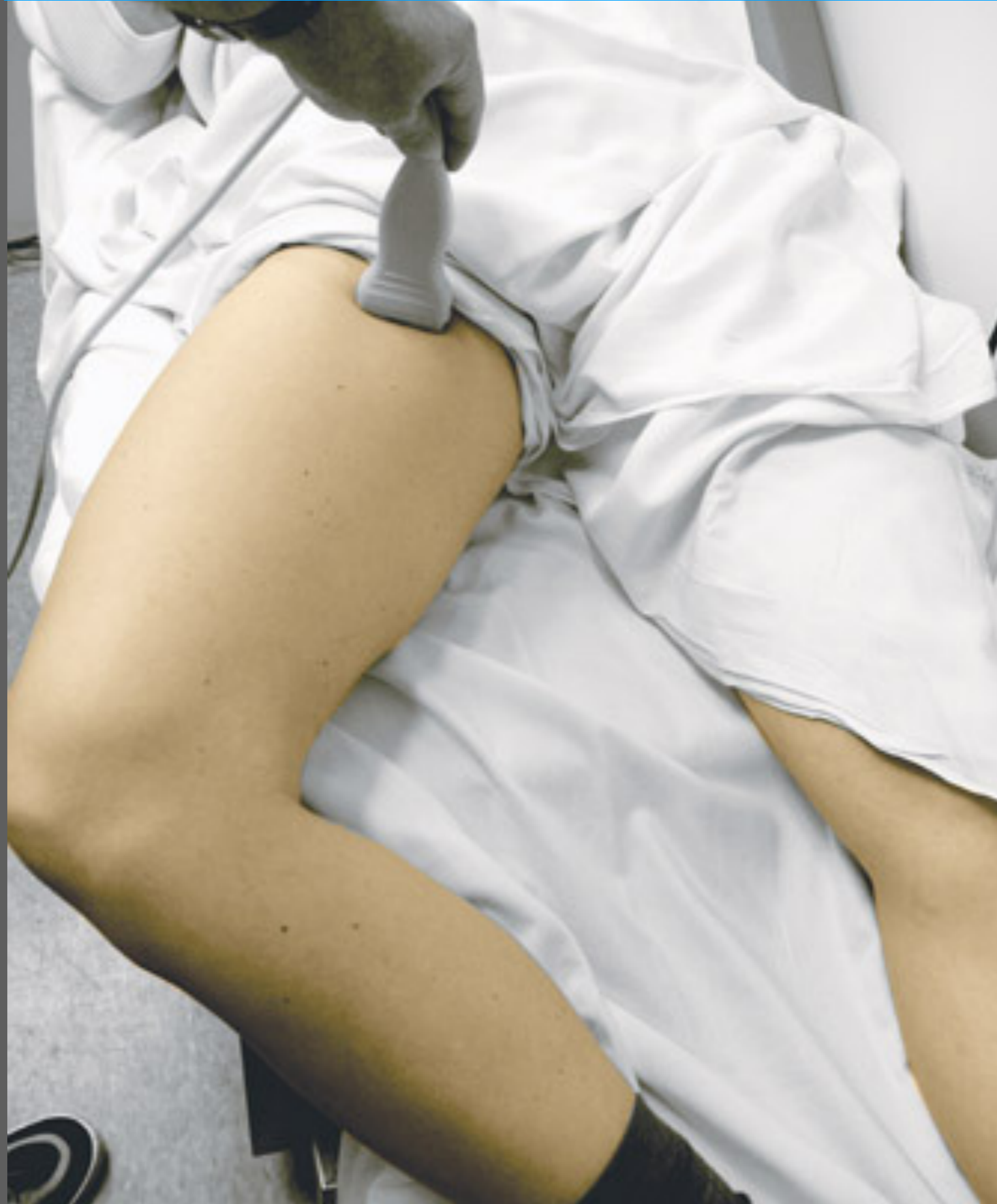3 regions

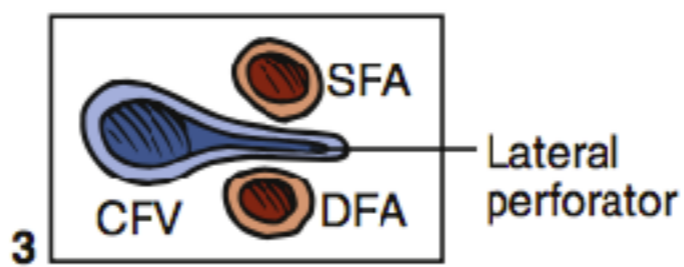
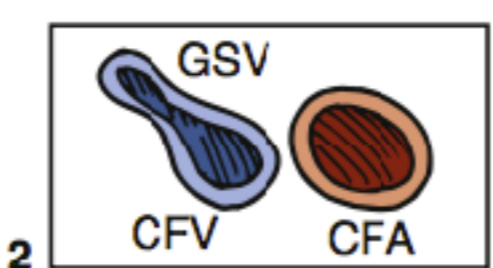
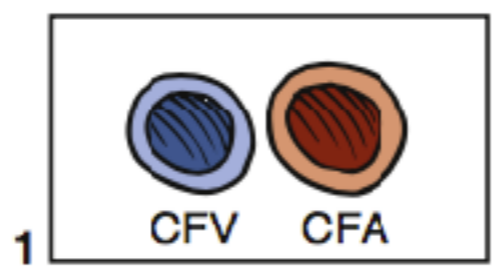
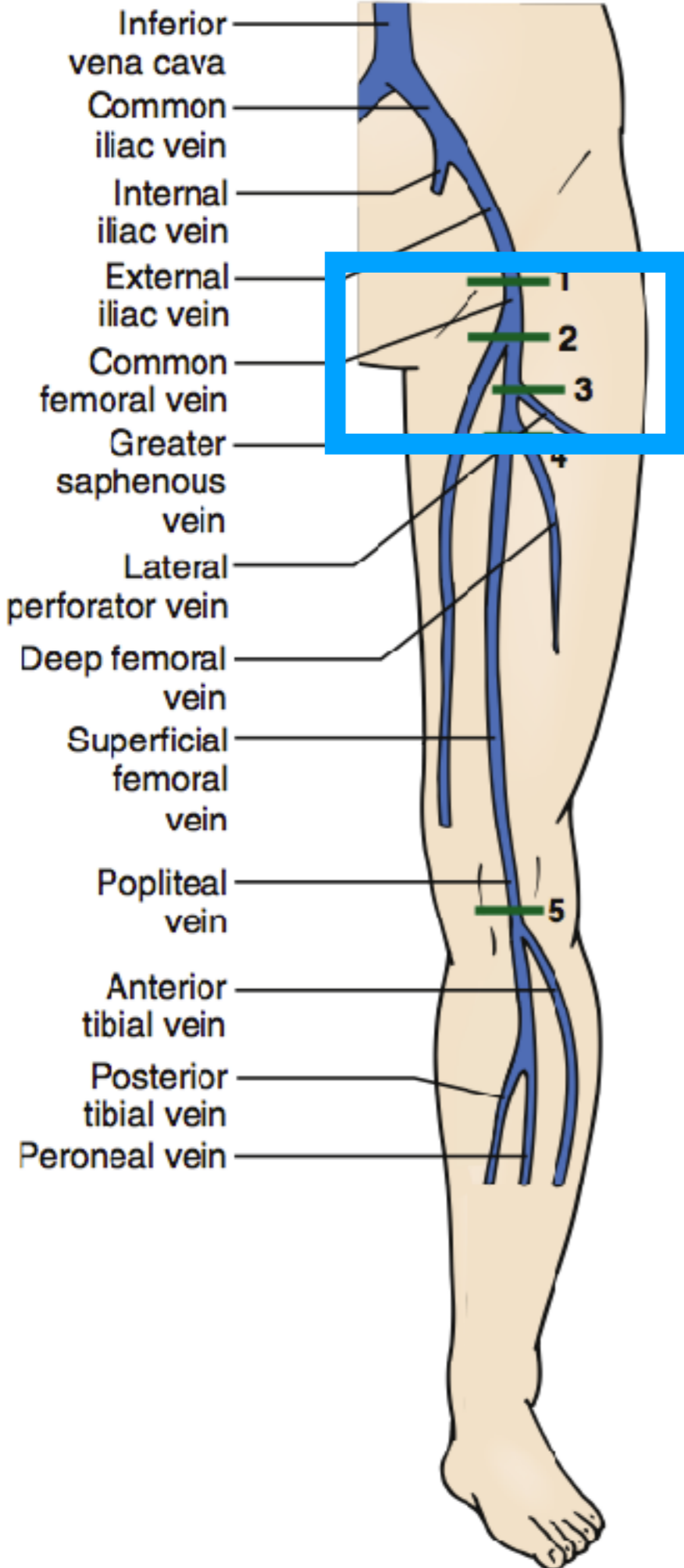




[Blank white box]

# Position



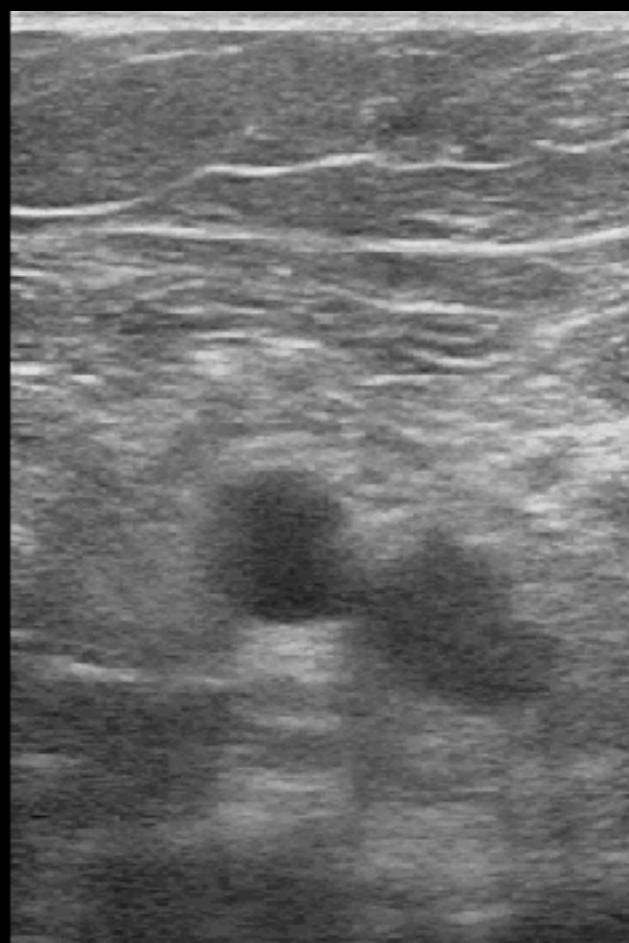


4

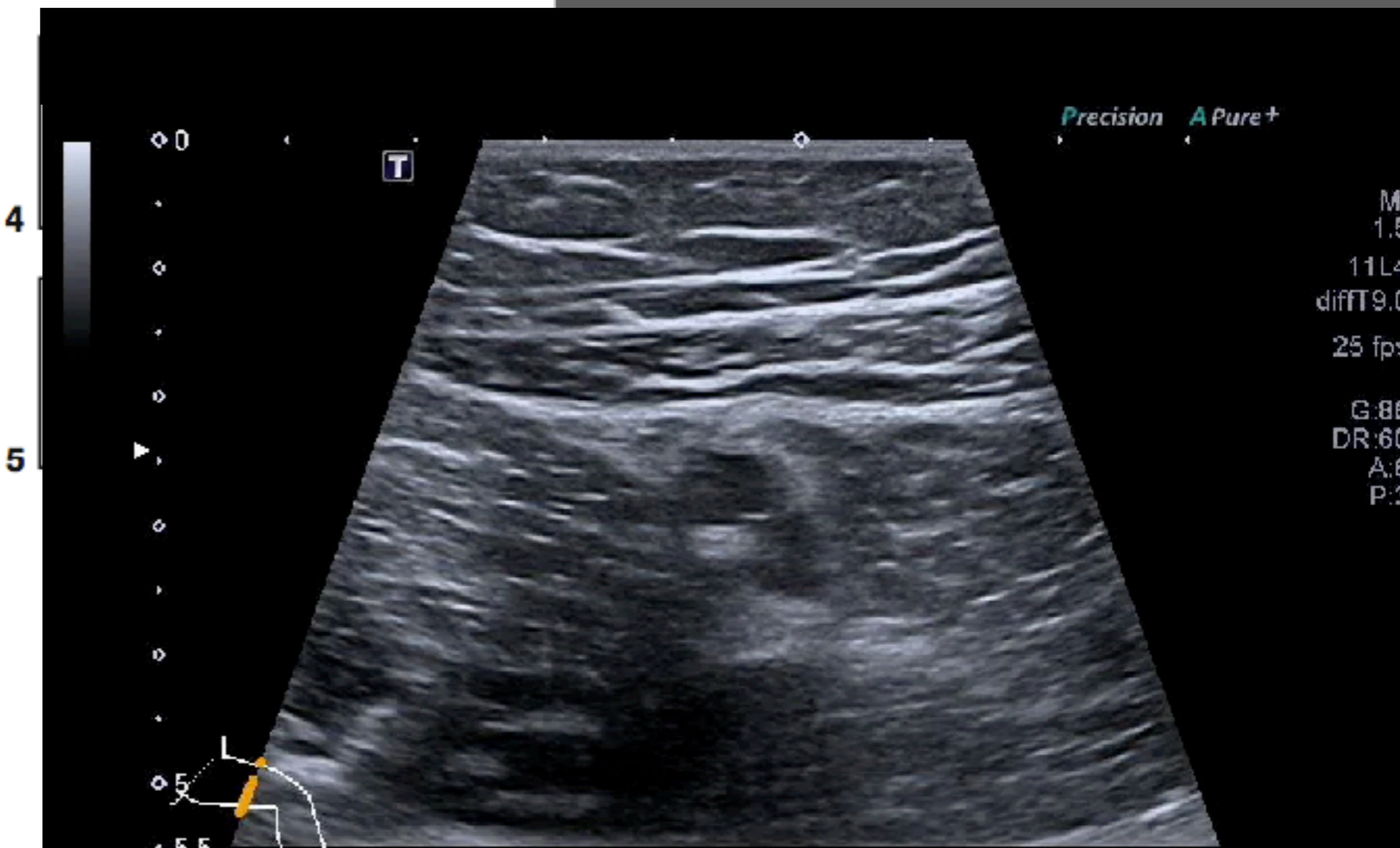
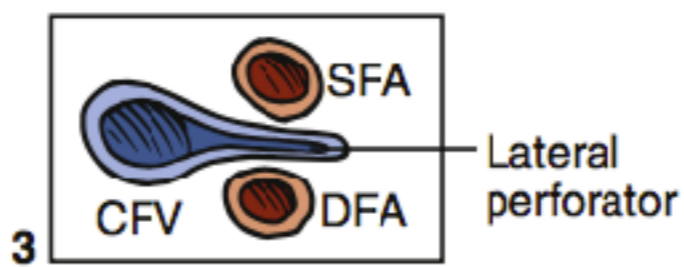
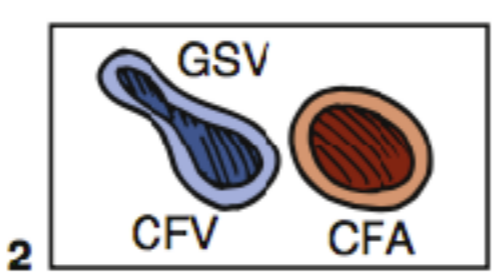
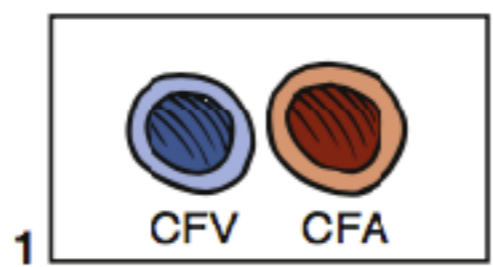
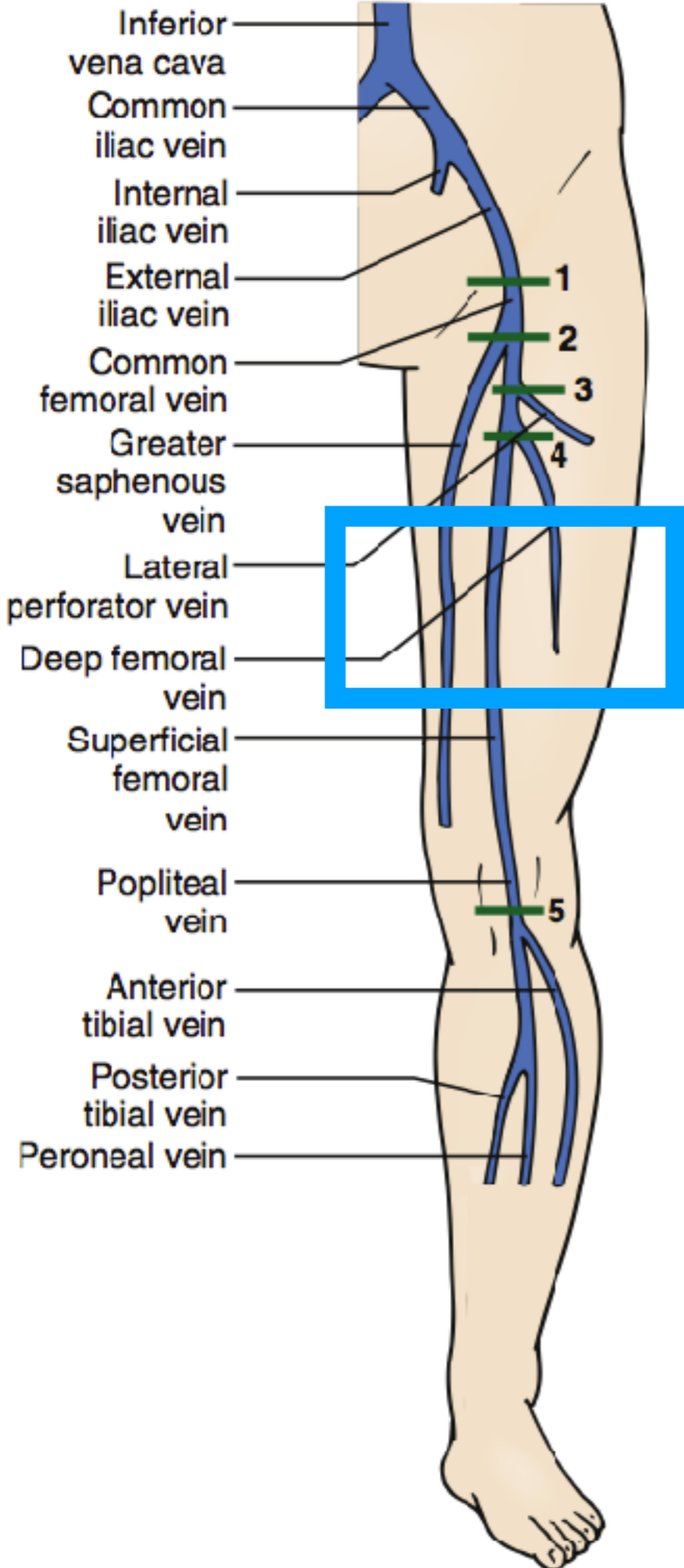
Venous  
L12-3  
31 Hz  
6.0cm

5D  
HGen  
(in 11)  
C 41  
3/3/2

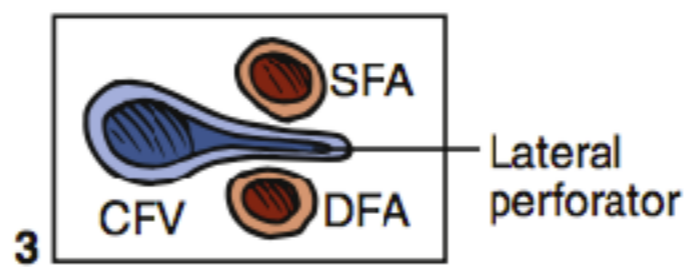
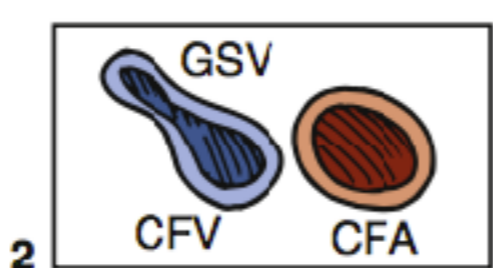
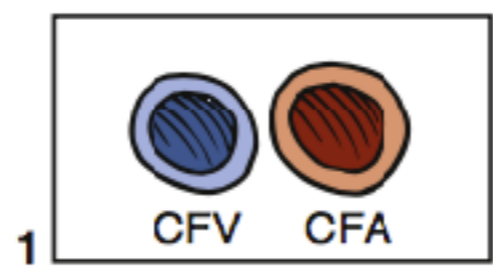
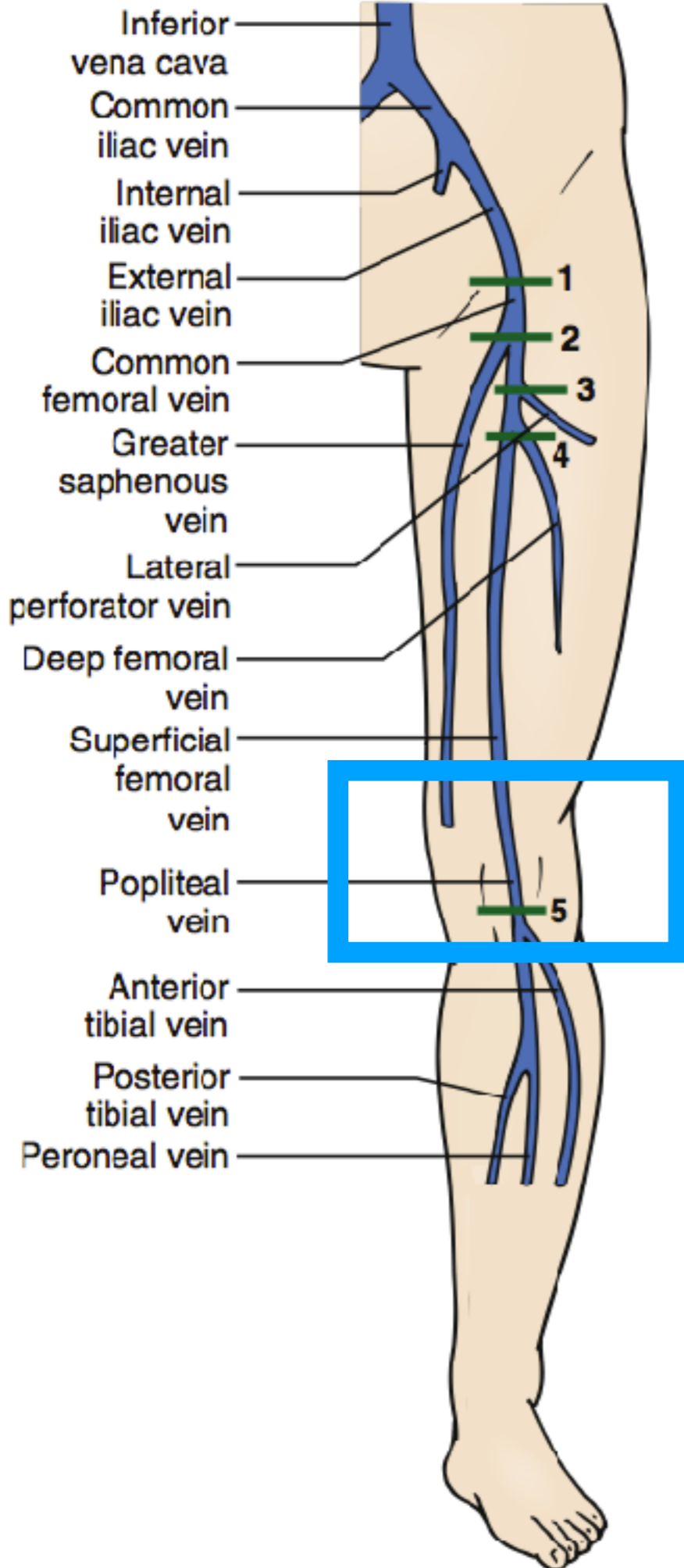
5



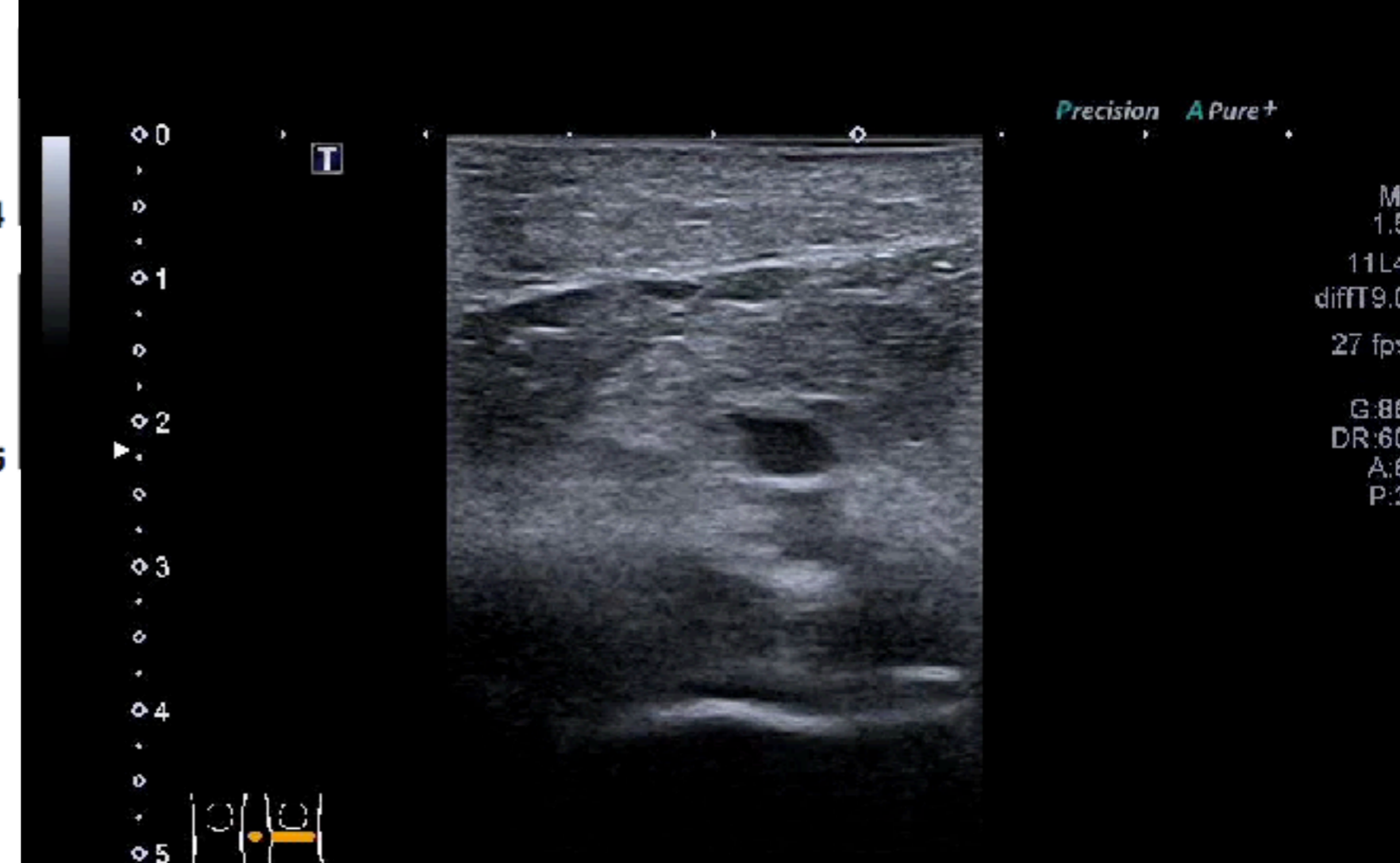
# 3



# 3

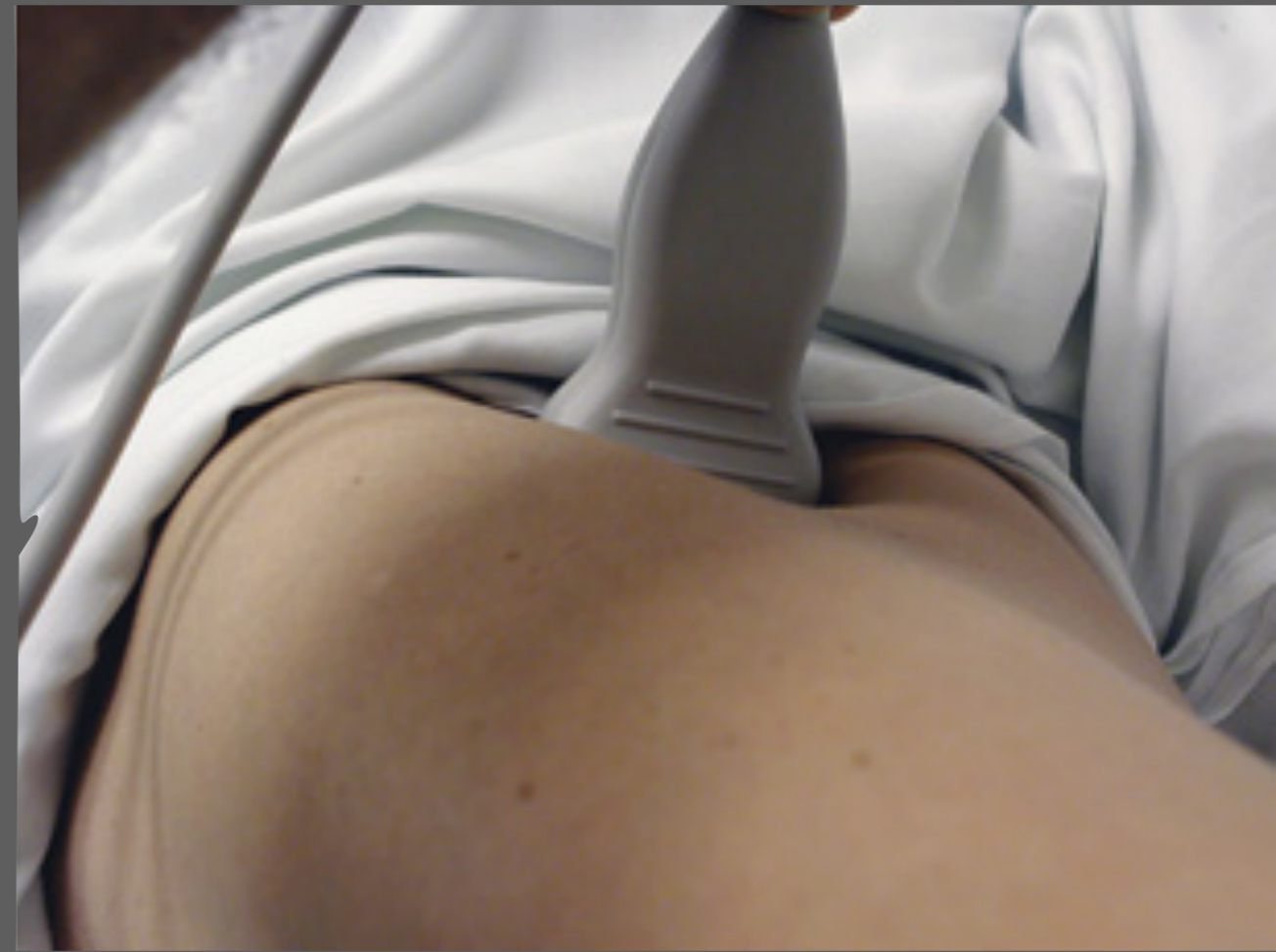
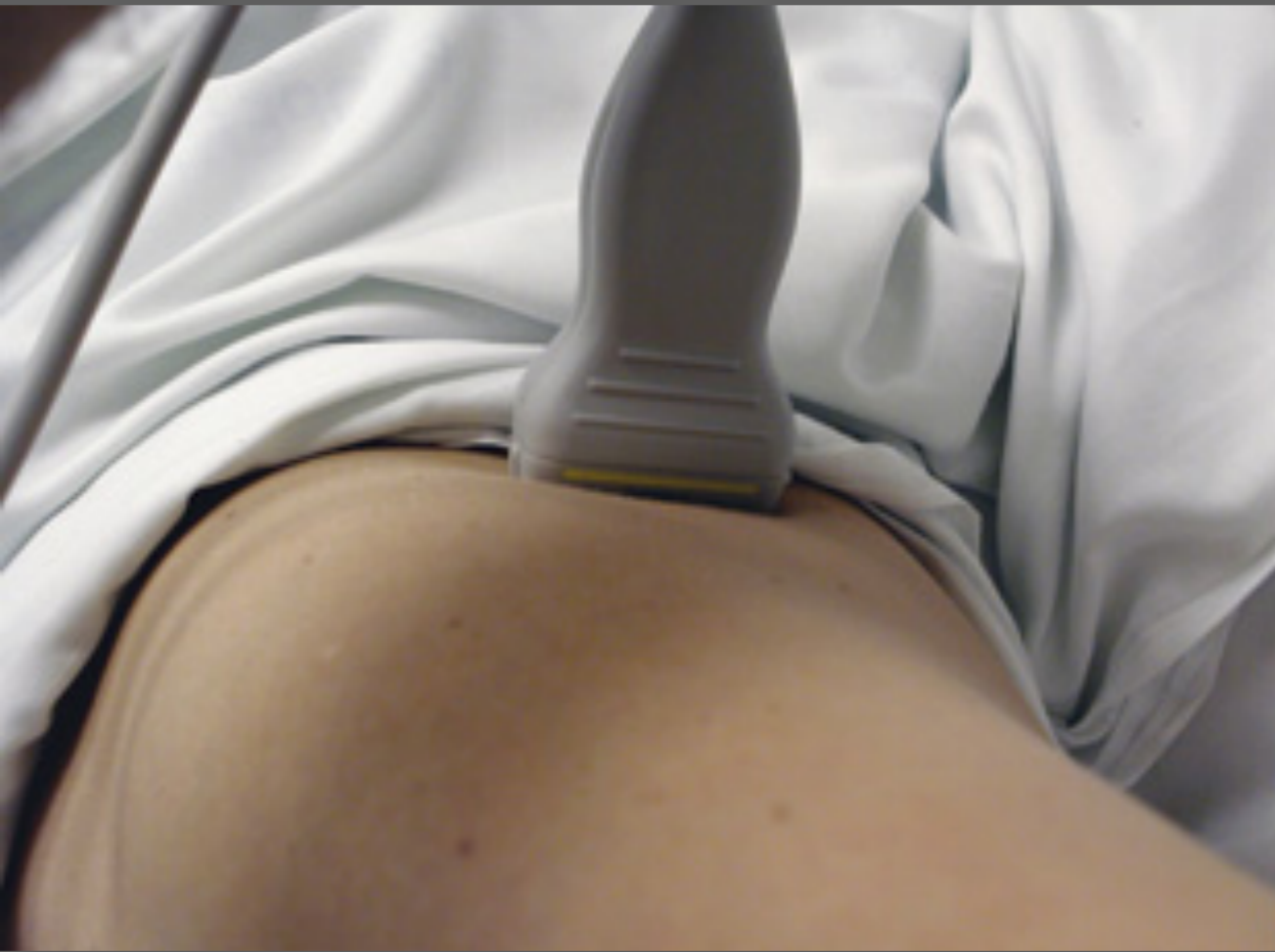
# 3

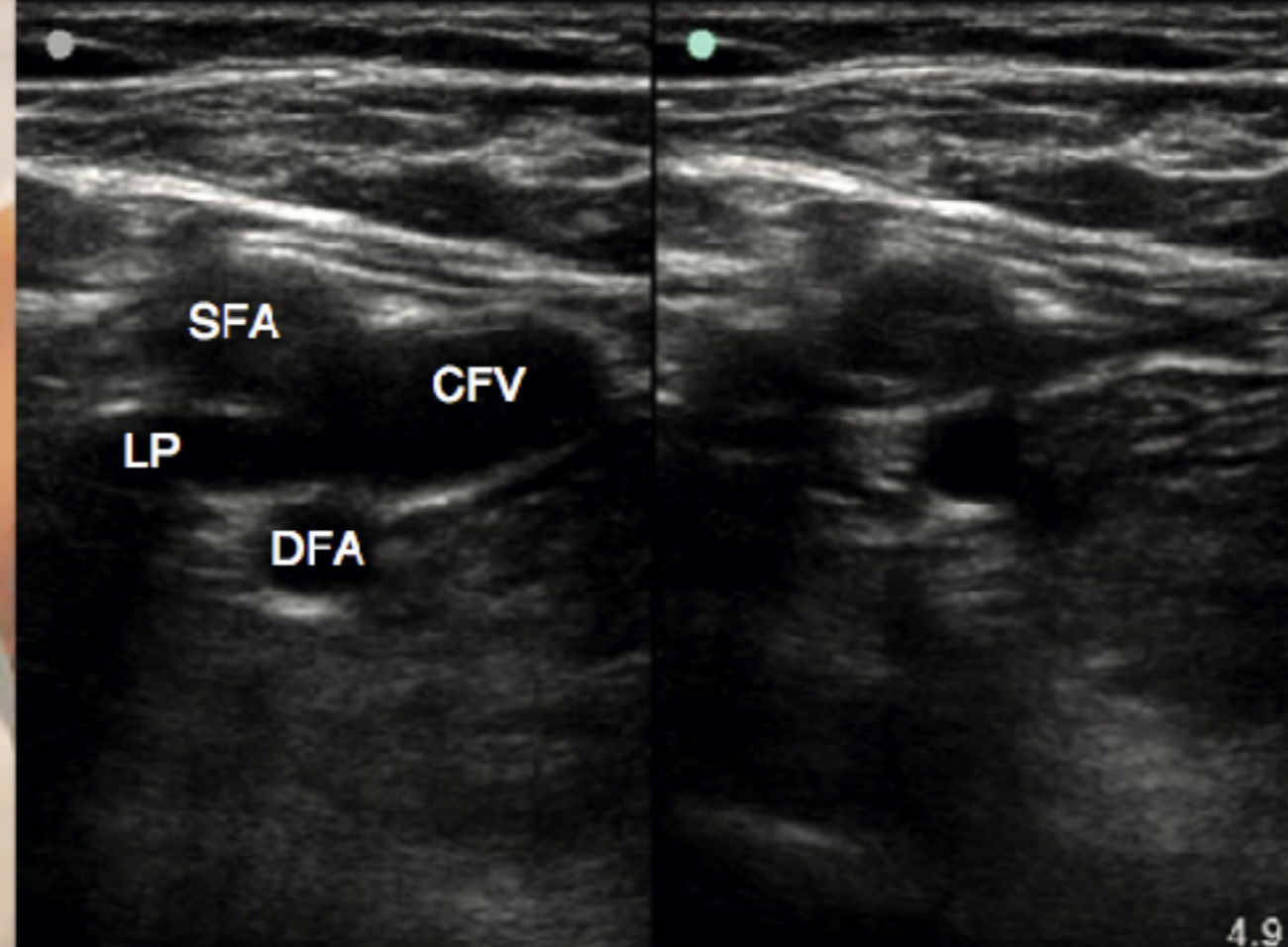
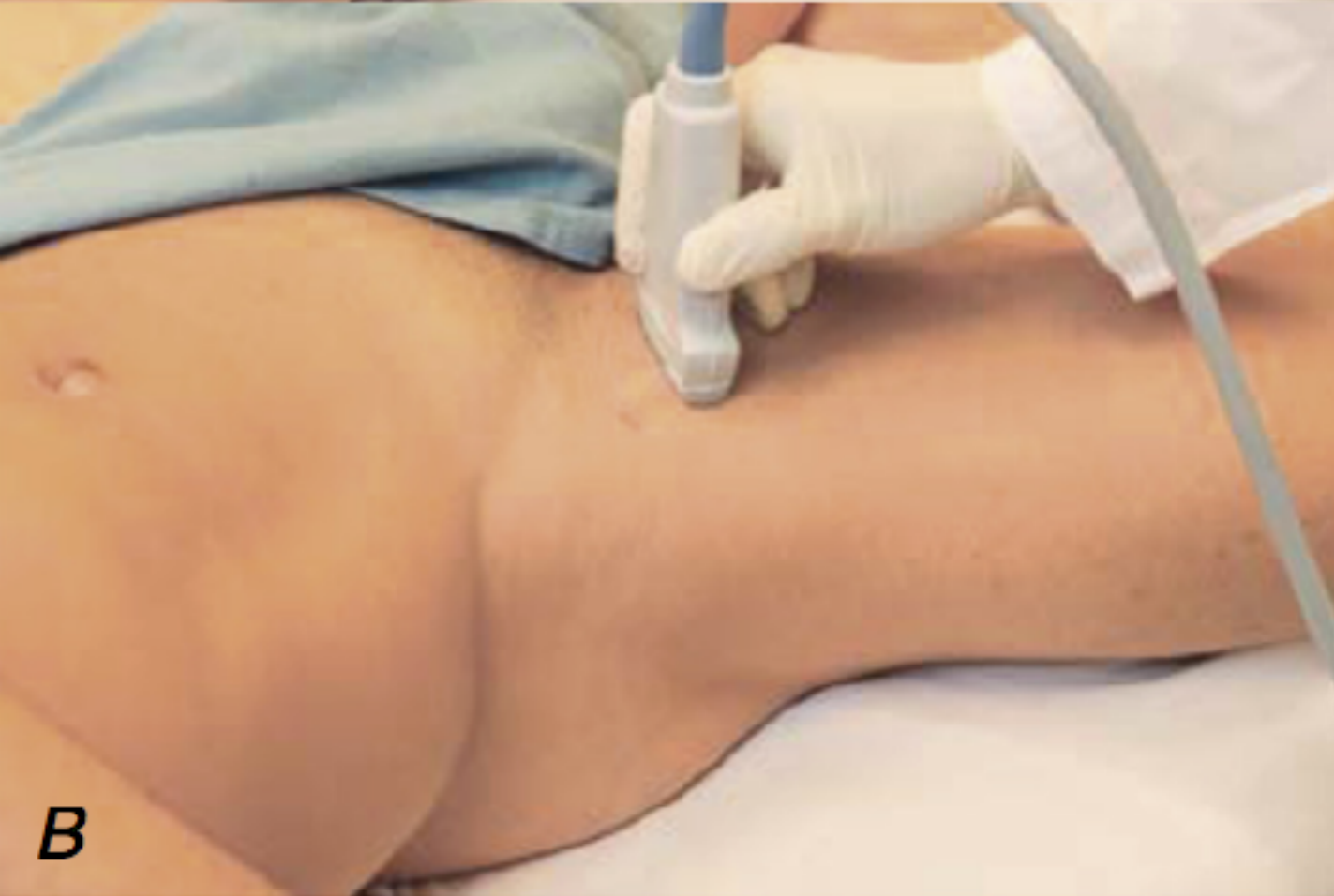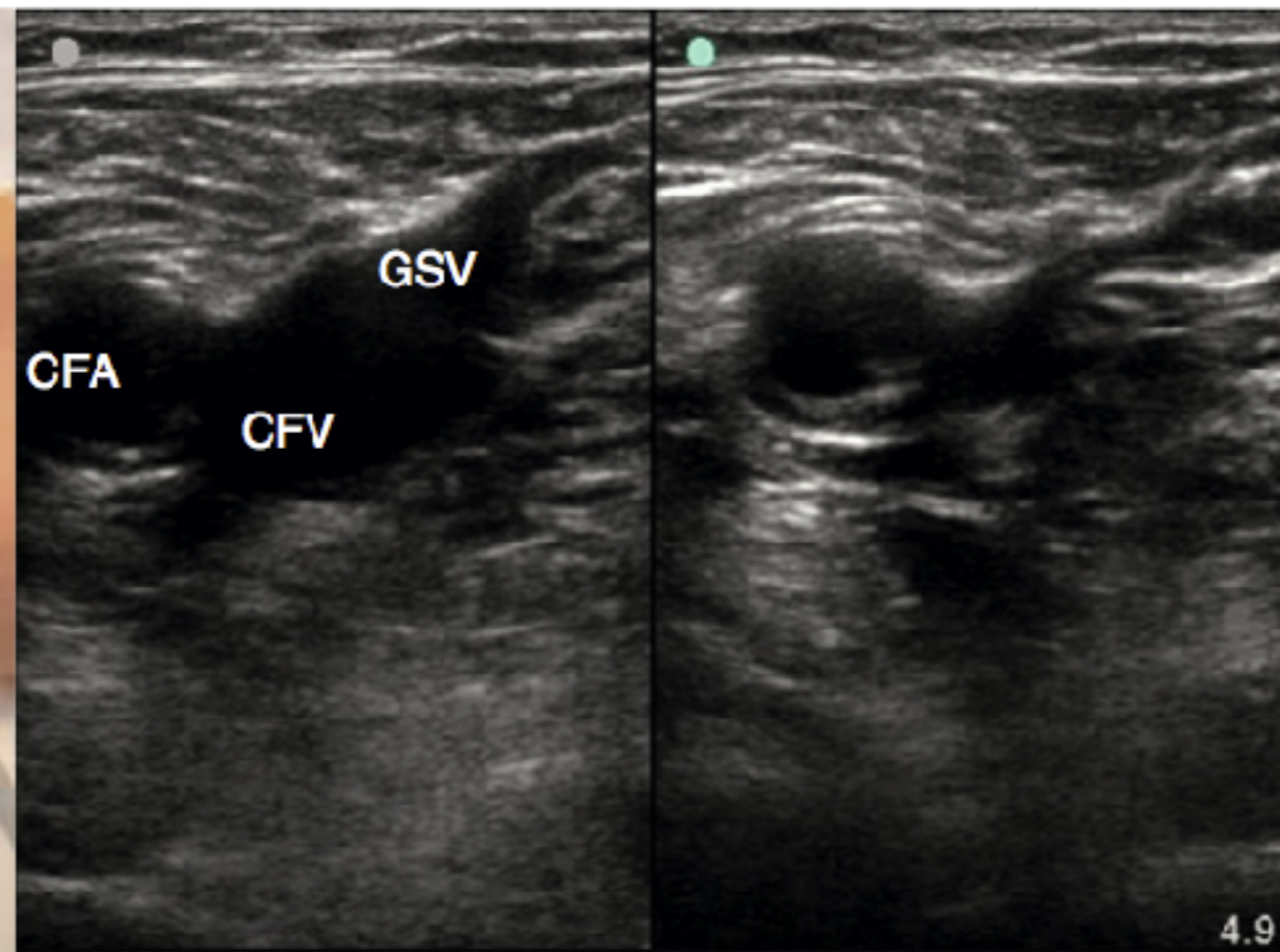

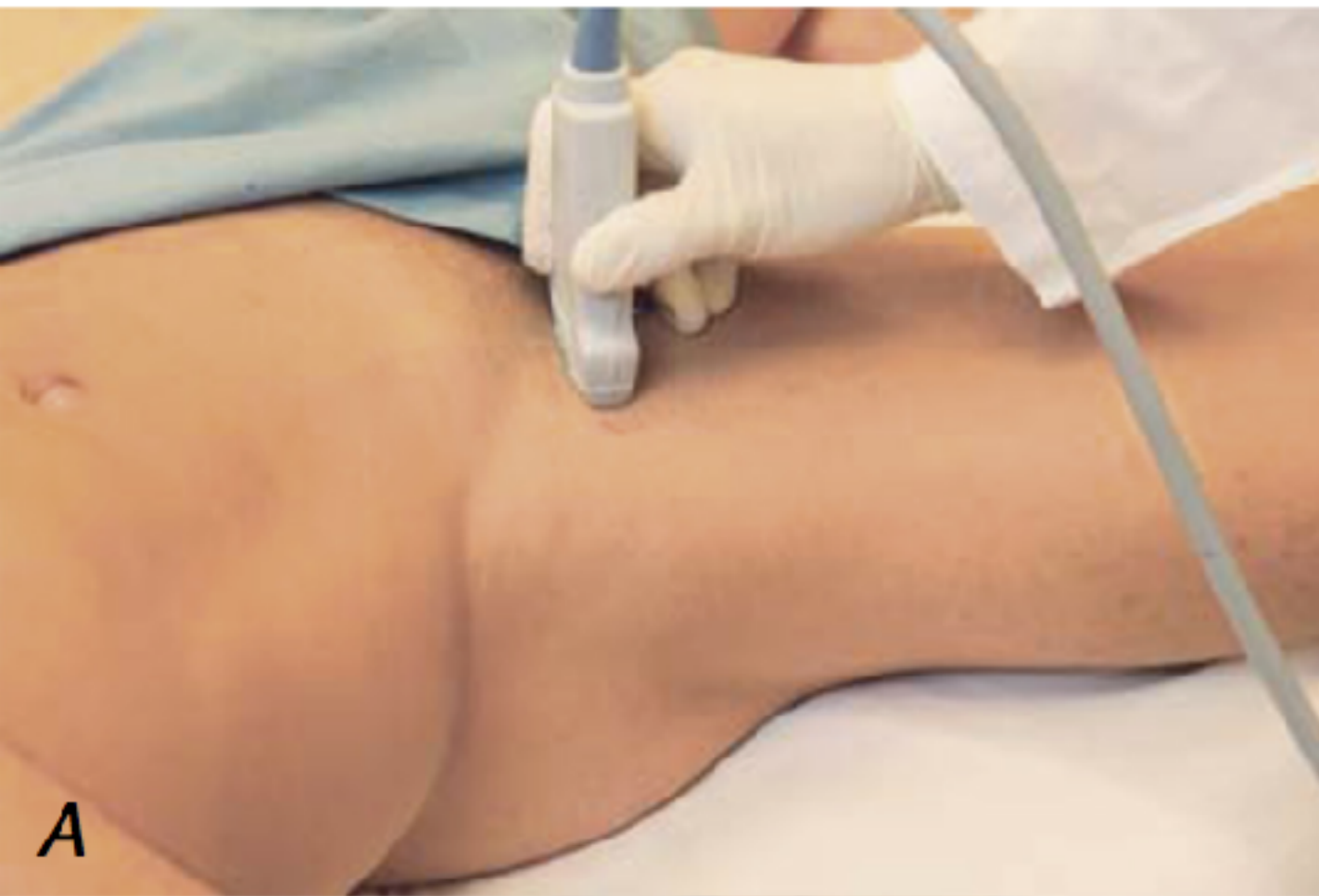
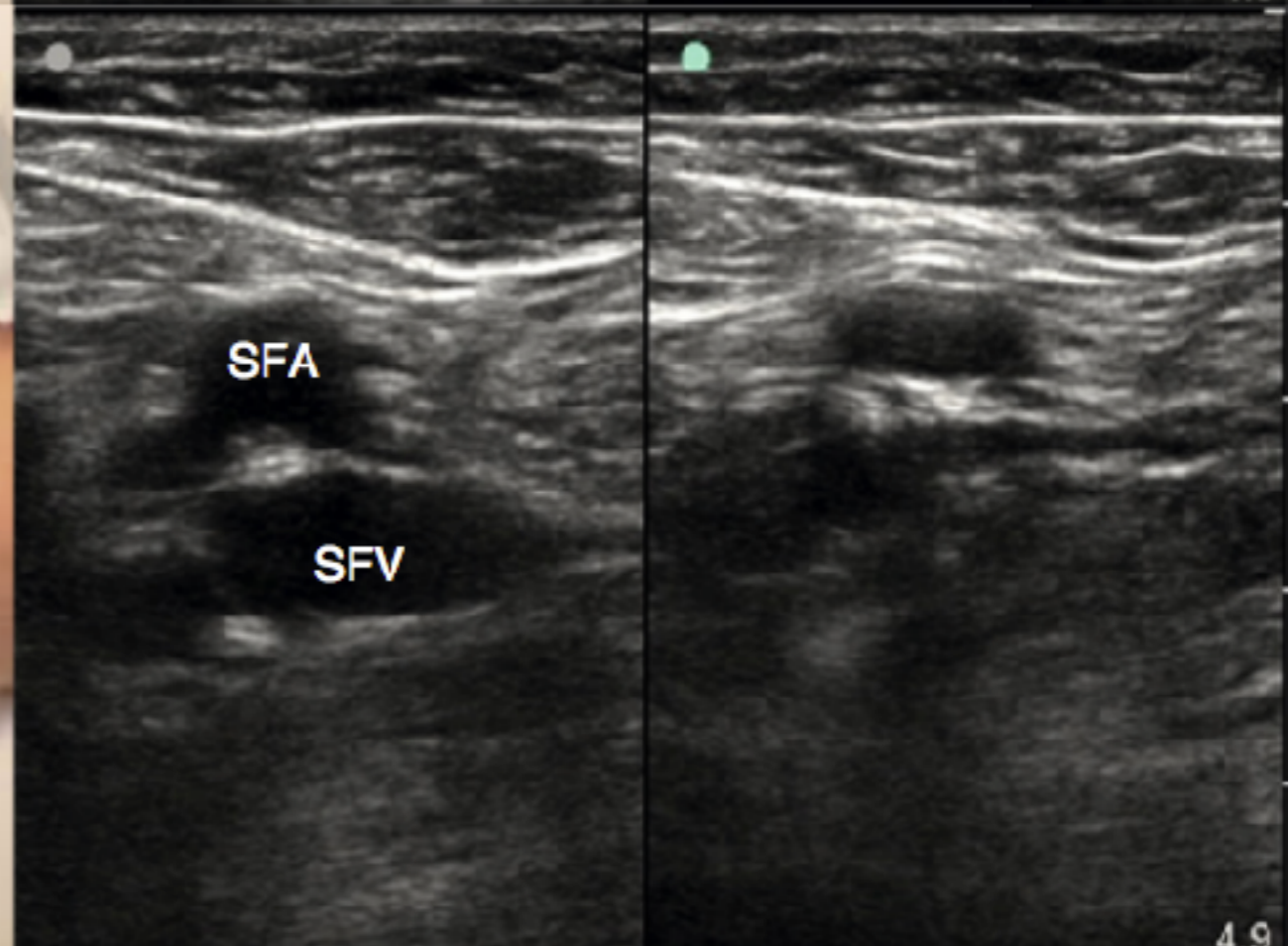
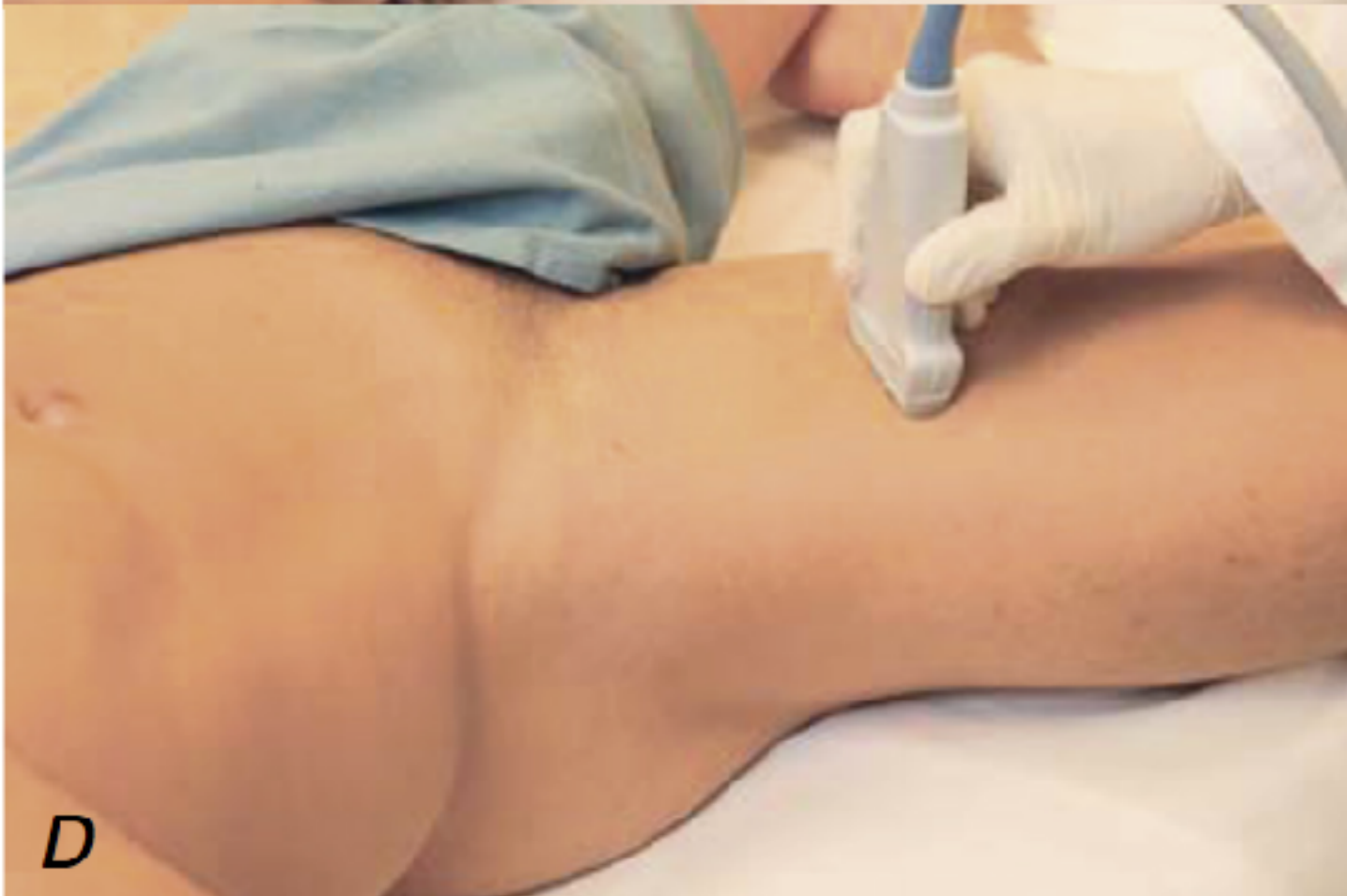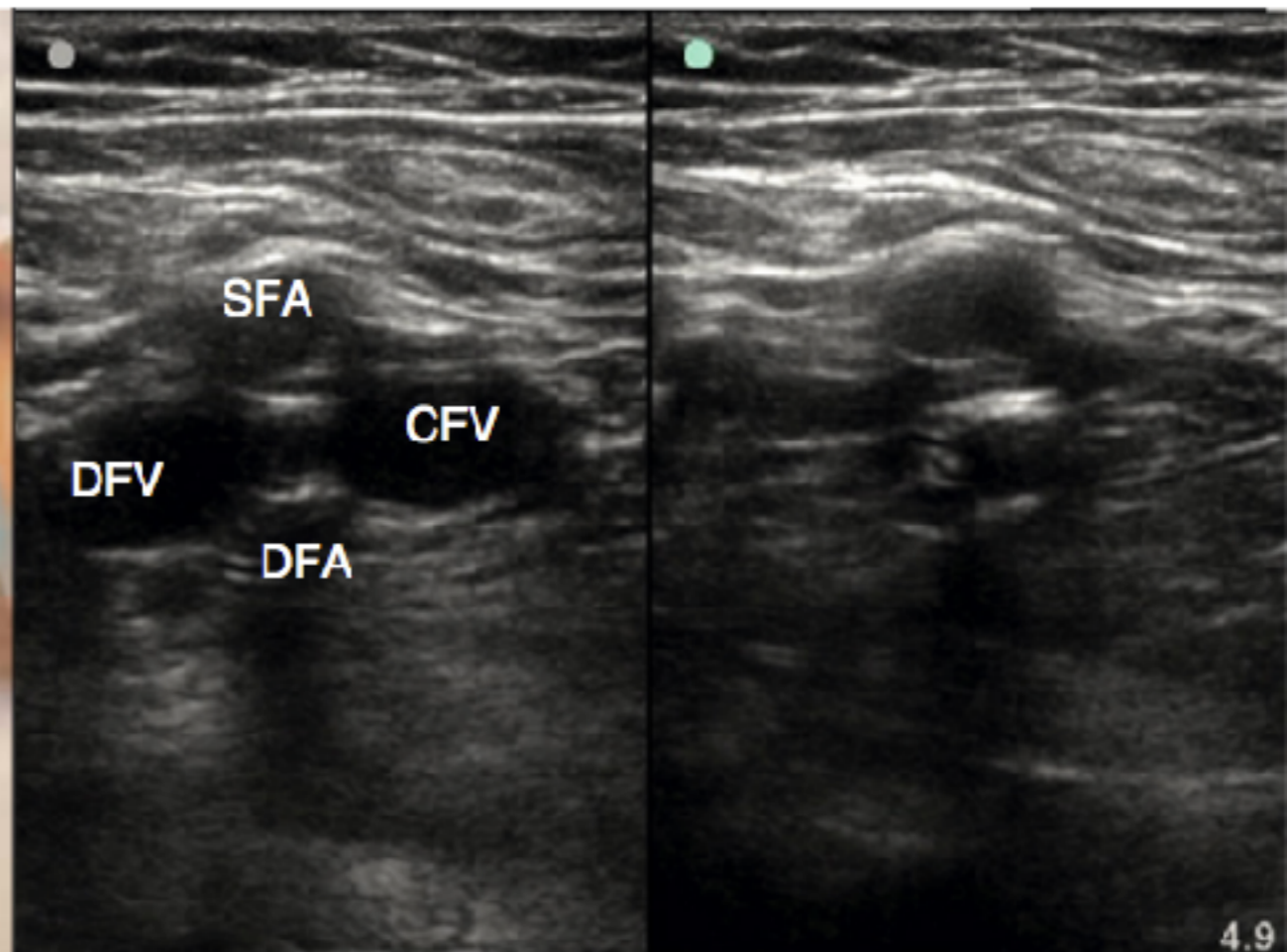
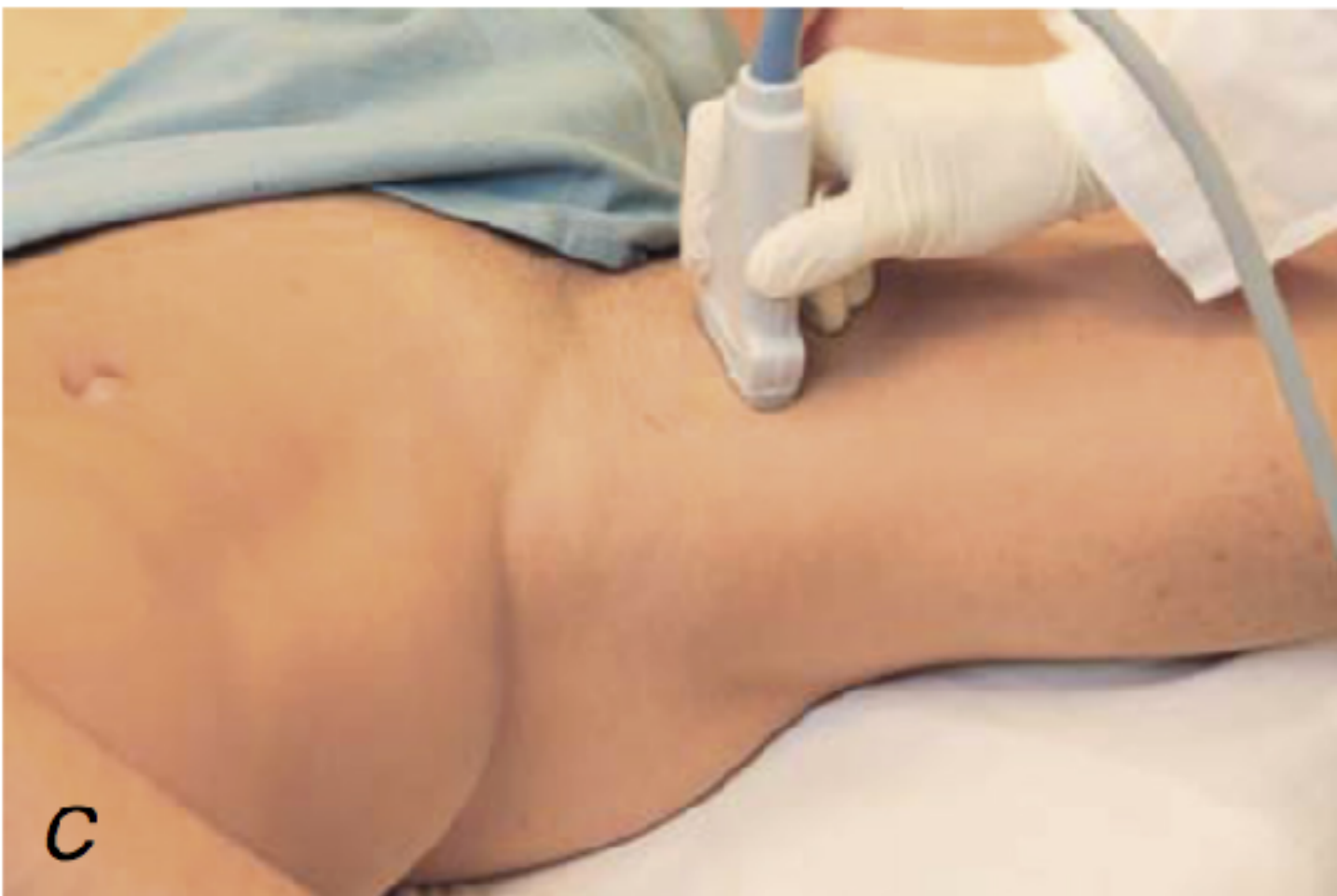# Compression

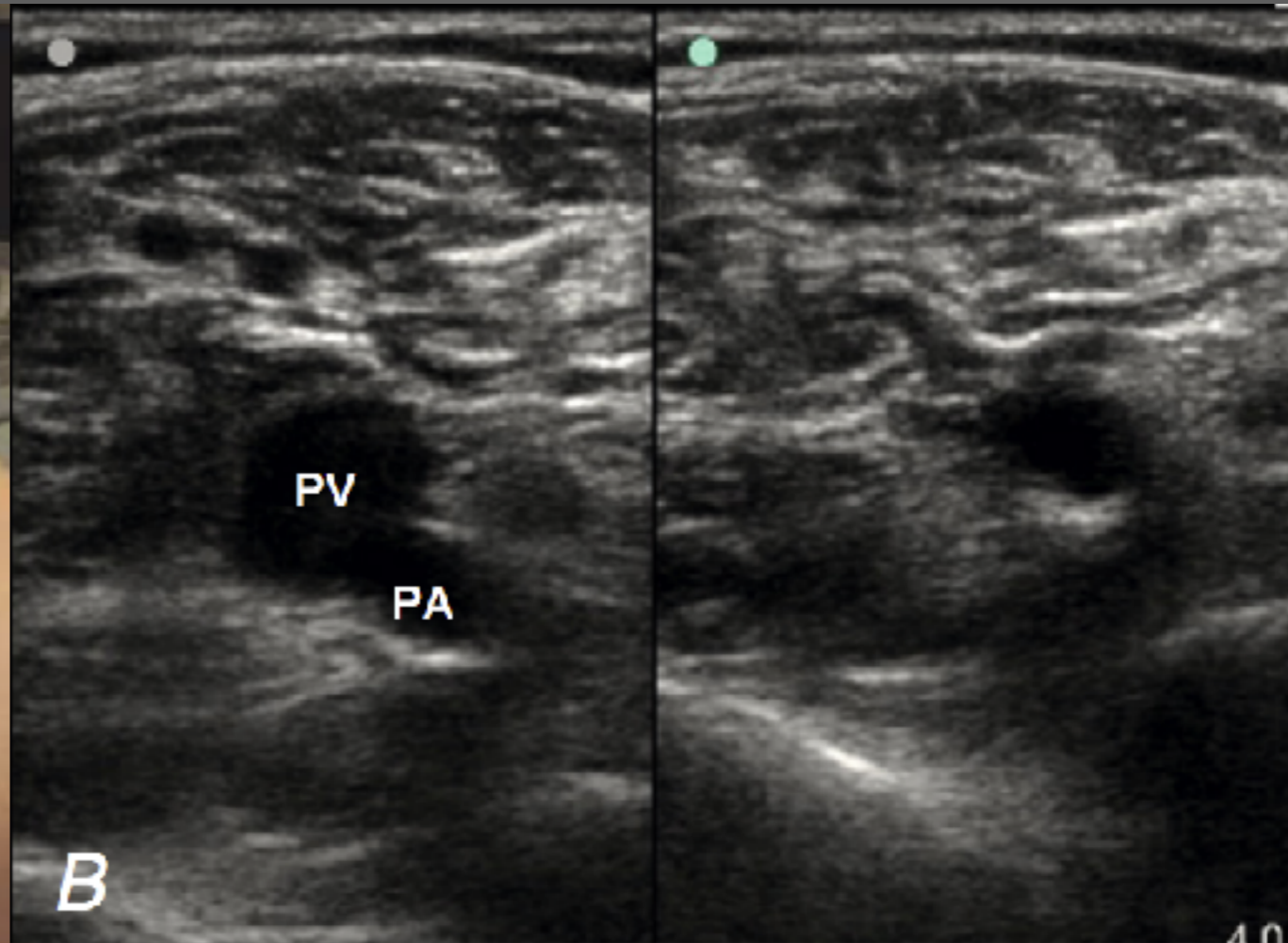
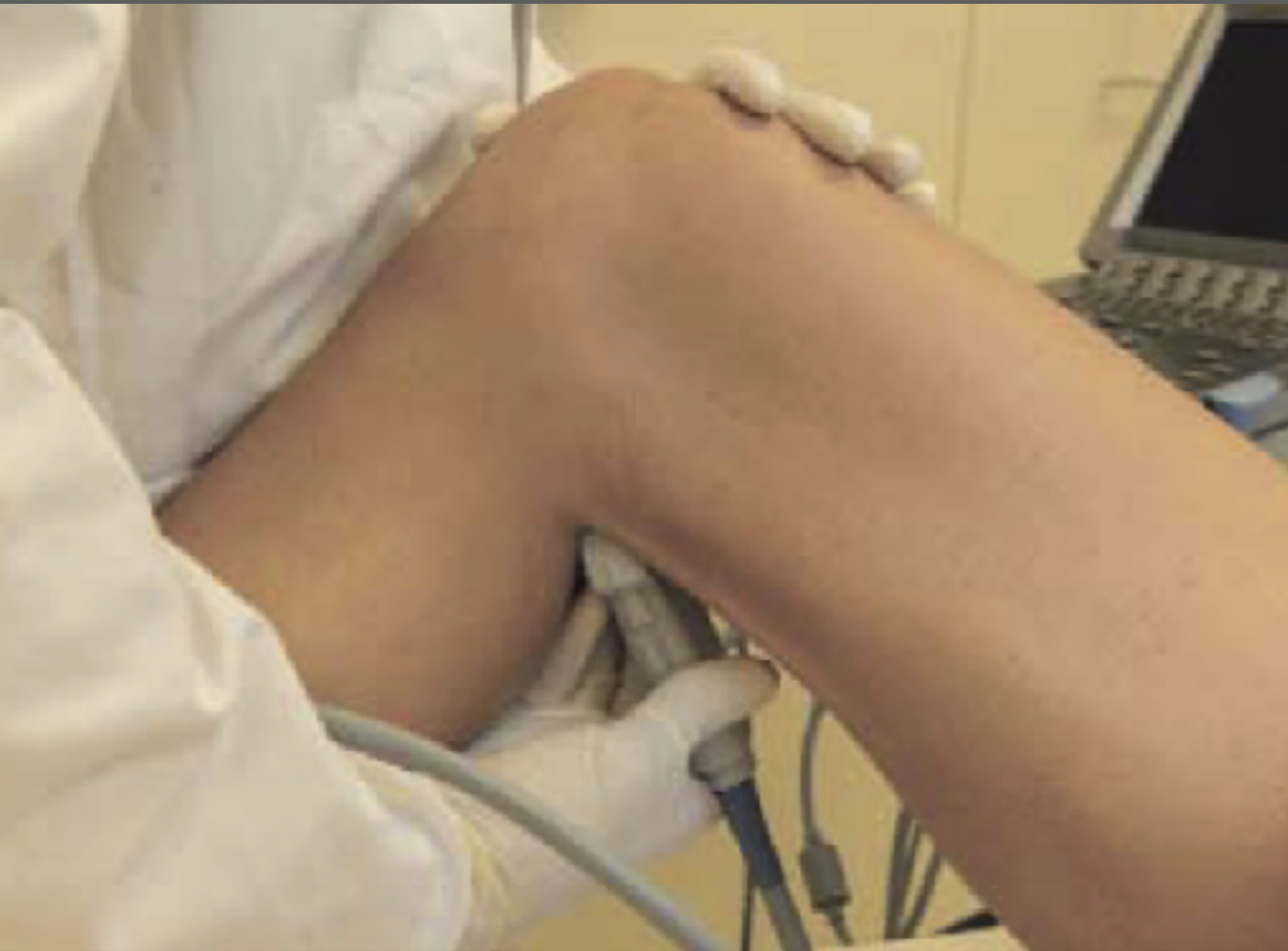Pressure ?  
No vessels ?











Inability to **completely compress** the venous lumen

**Presence of a clot**

Inadequate position or pressure

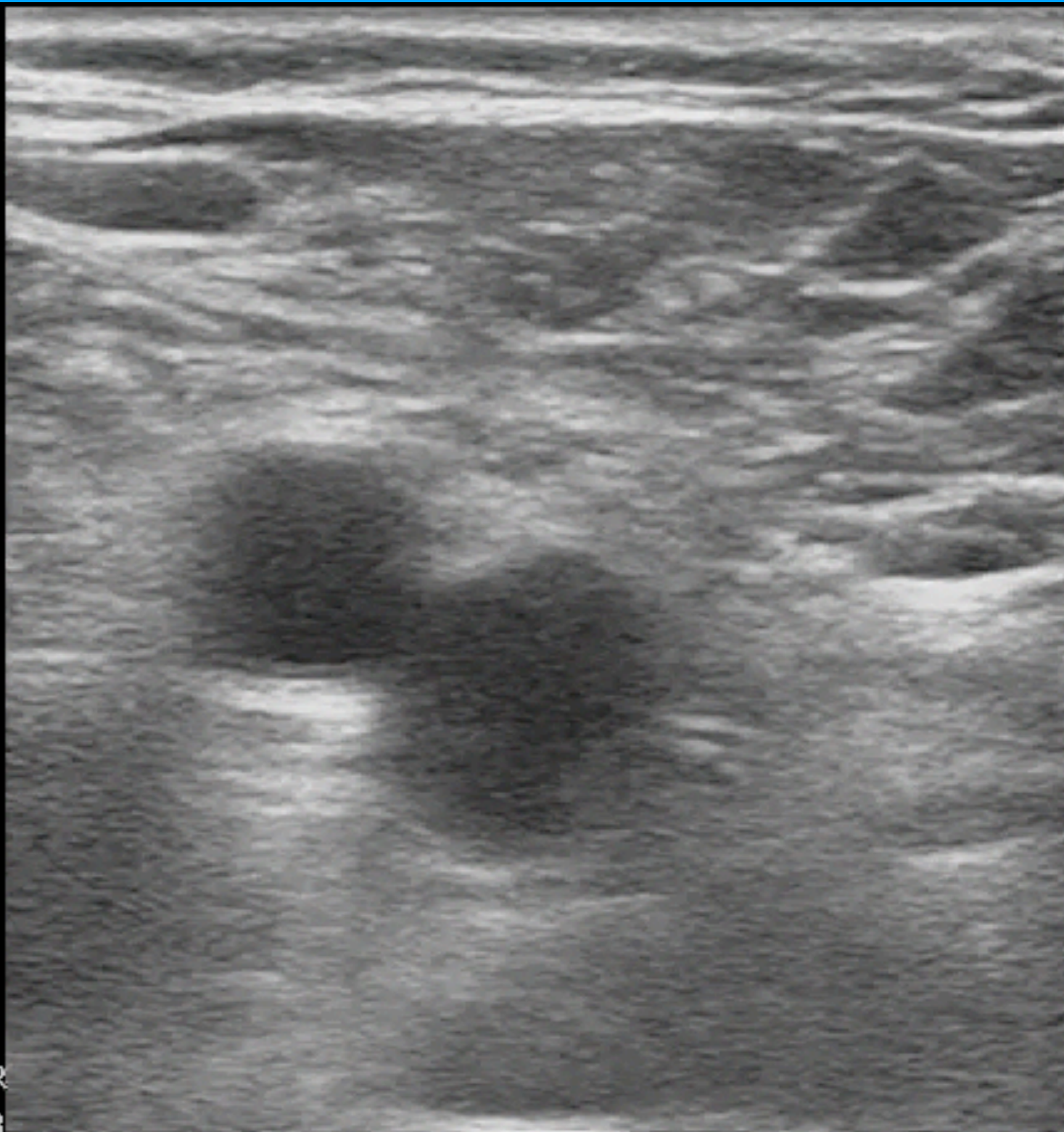
# CFV

Venous  
L12-3  
37 Hz  
4.0cm

2D

HGen  
Gn 96  
C 41  
3/3/2

P



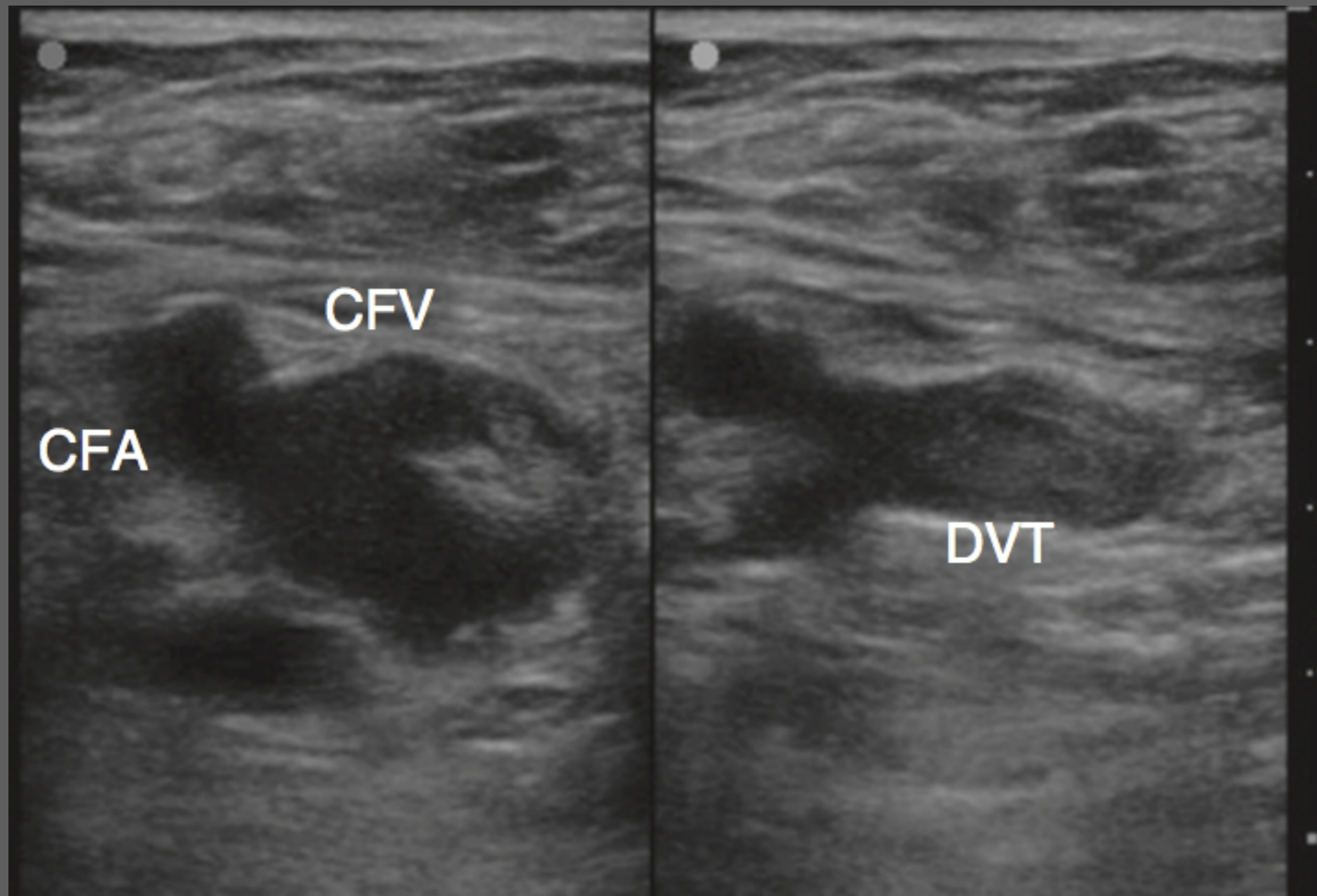
G  
P R  
4.4 8.8

2

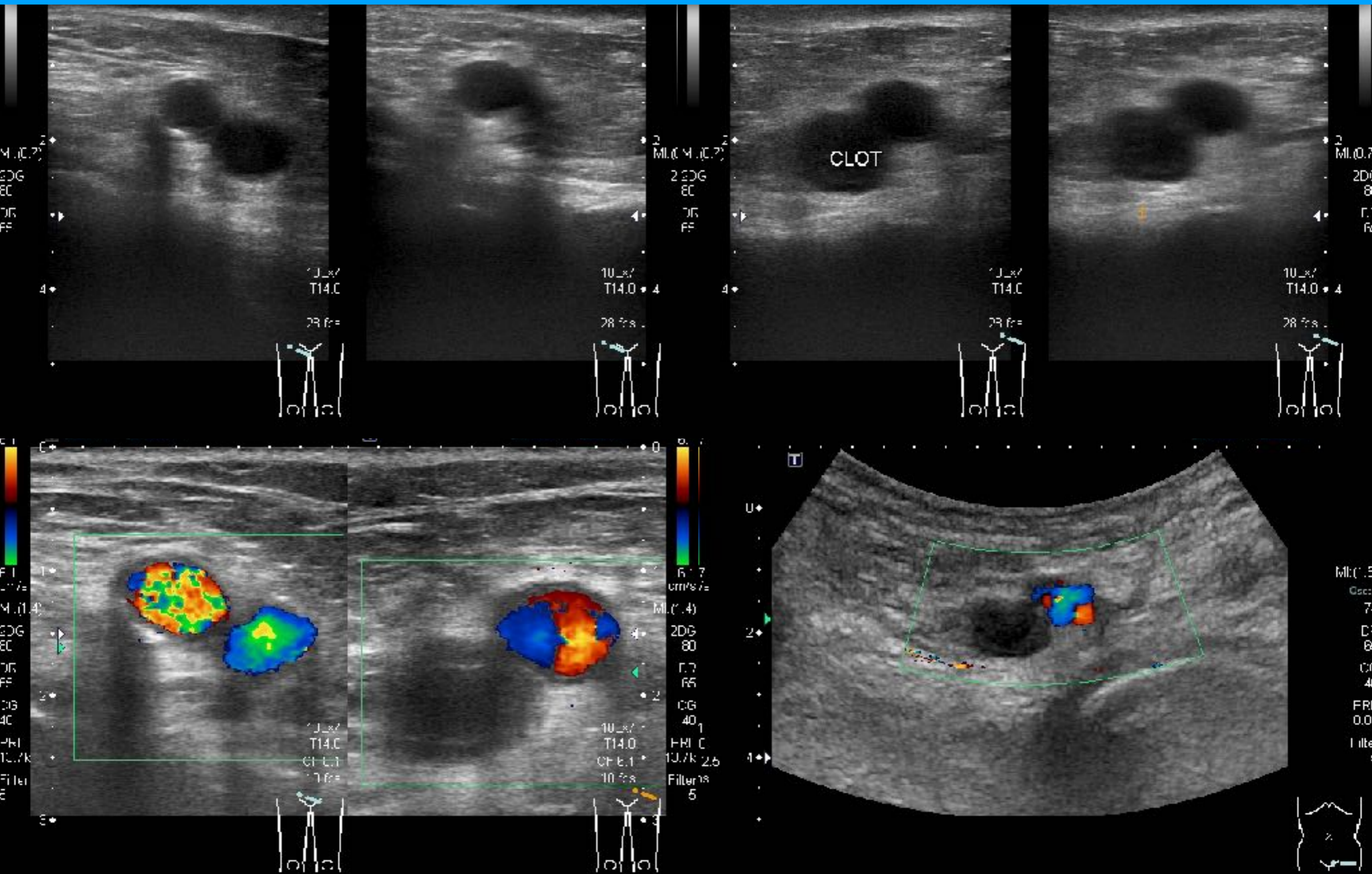
4.0cm

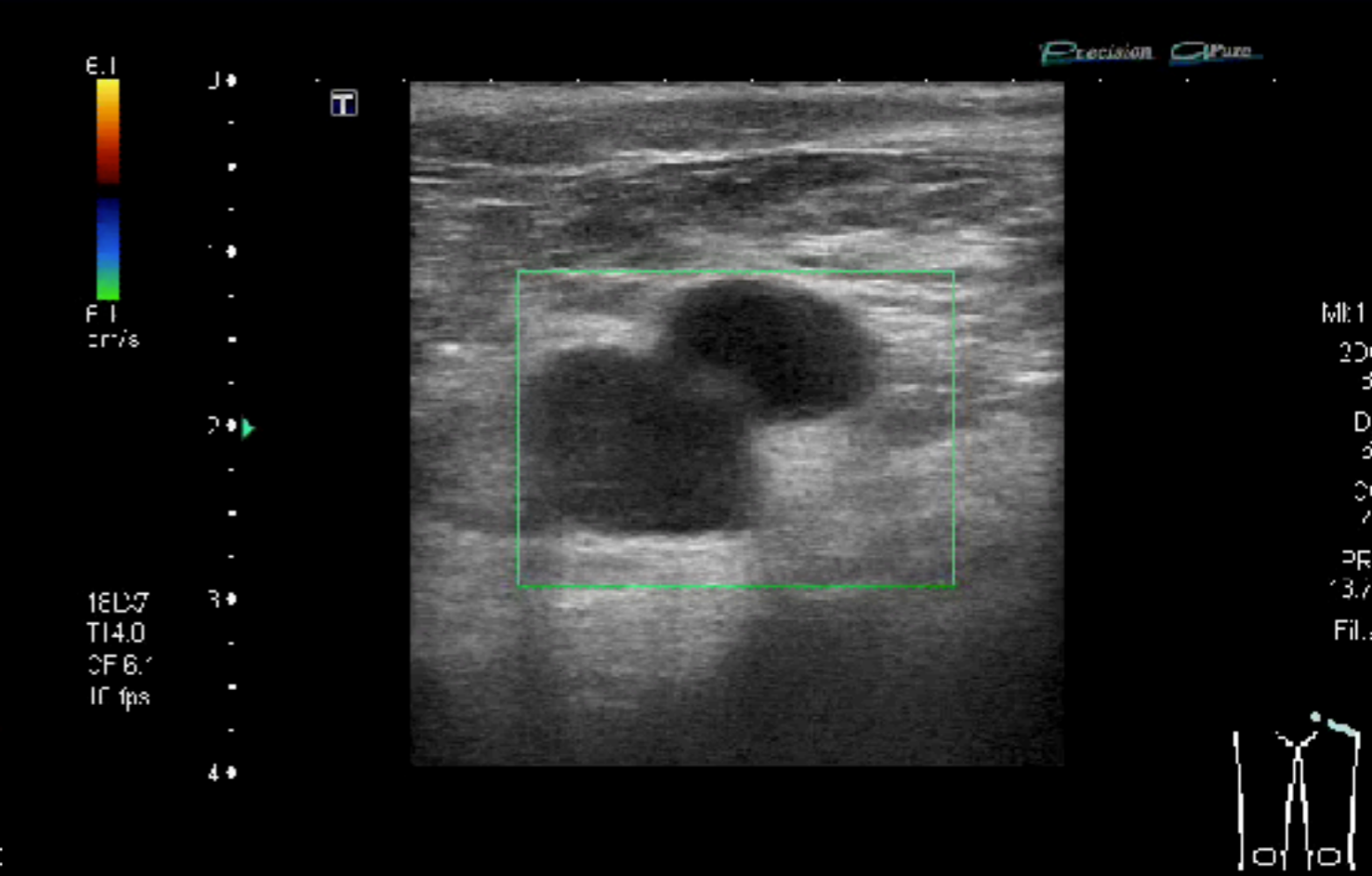
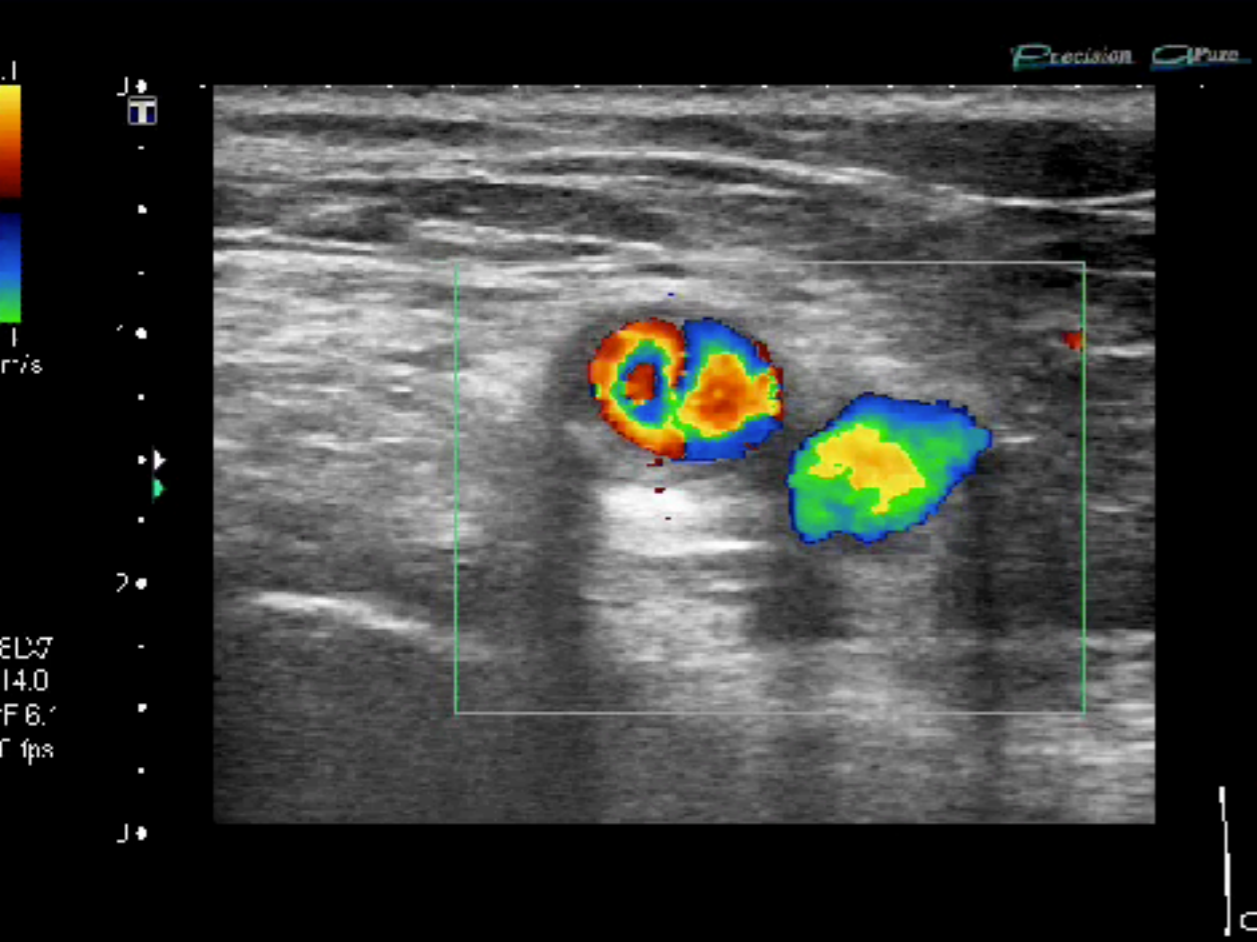
# Document

**Dual images:** w/ & w/o compression

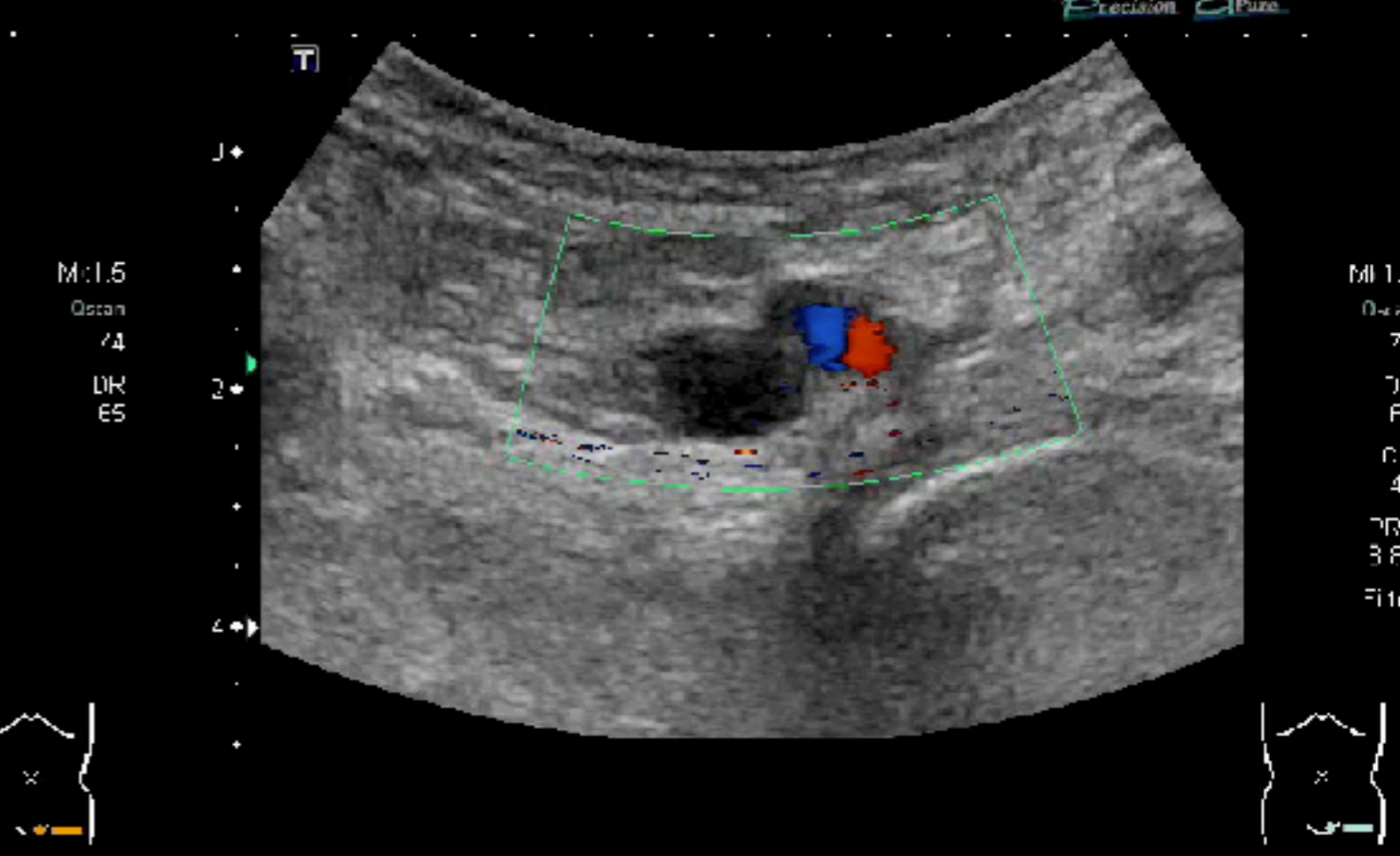
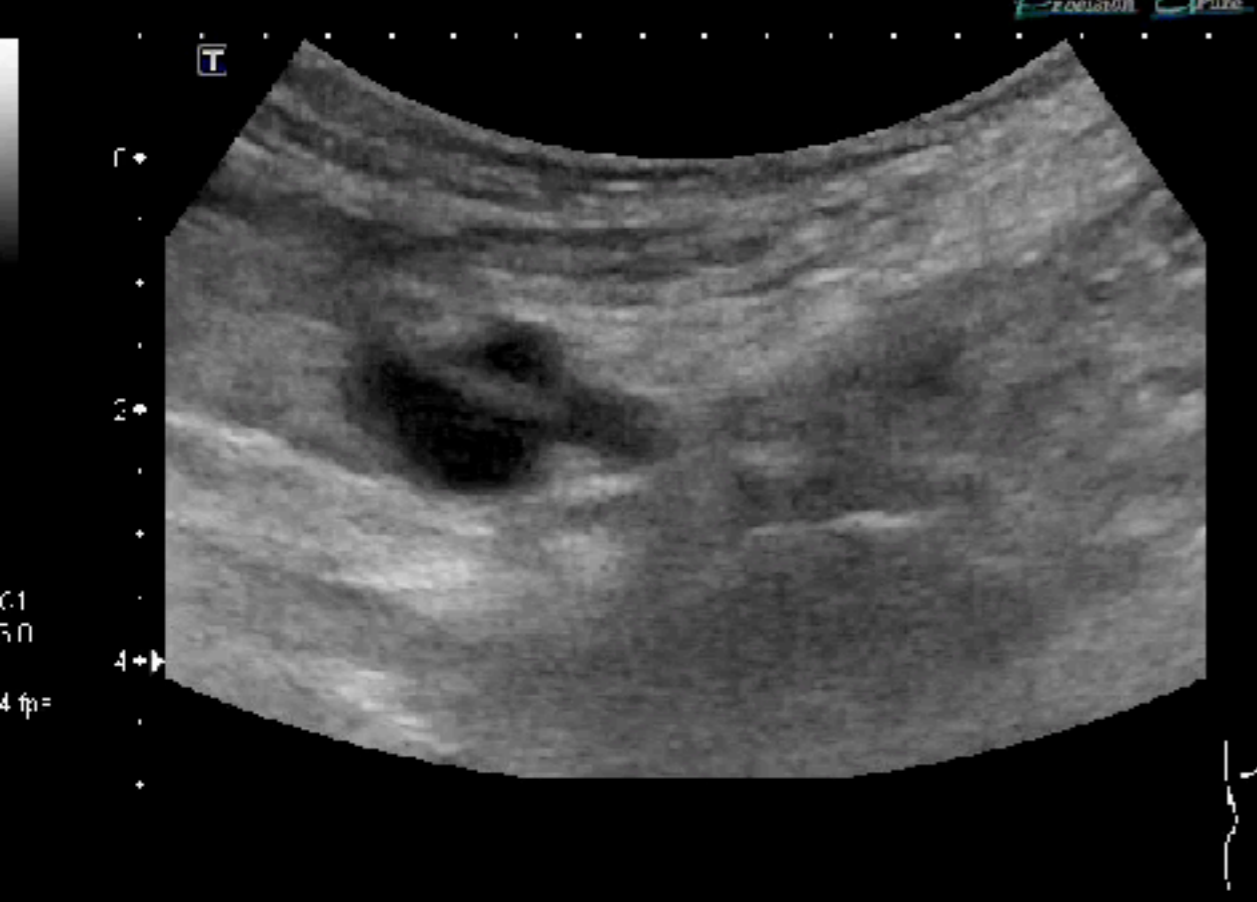


# Document



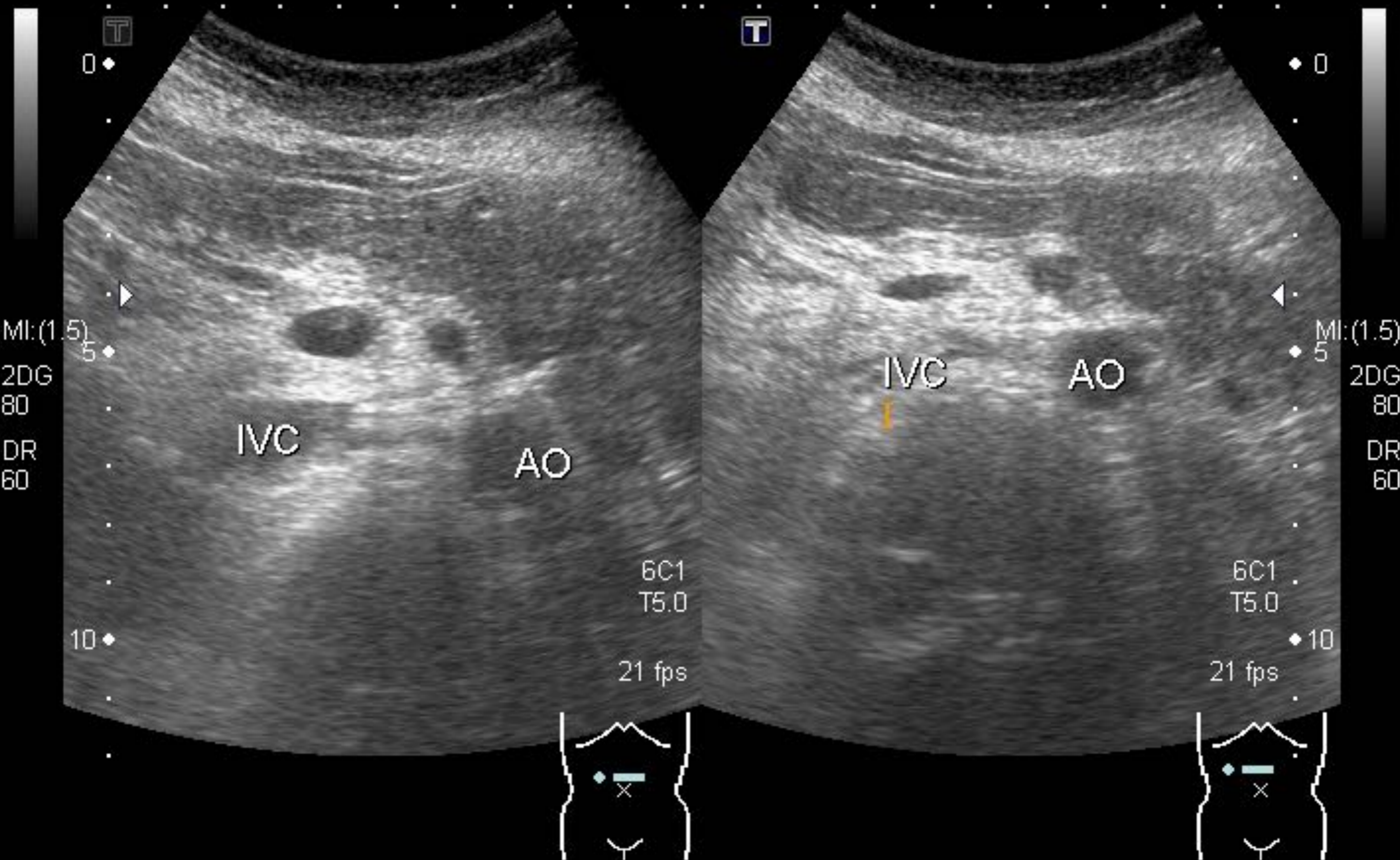


100% 74% CINE REVIEW 100% 74% SELECT

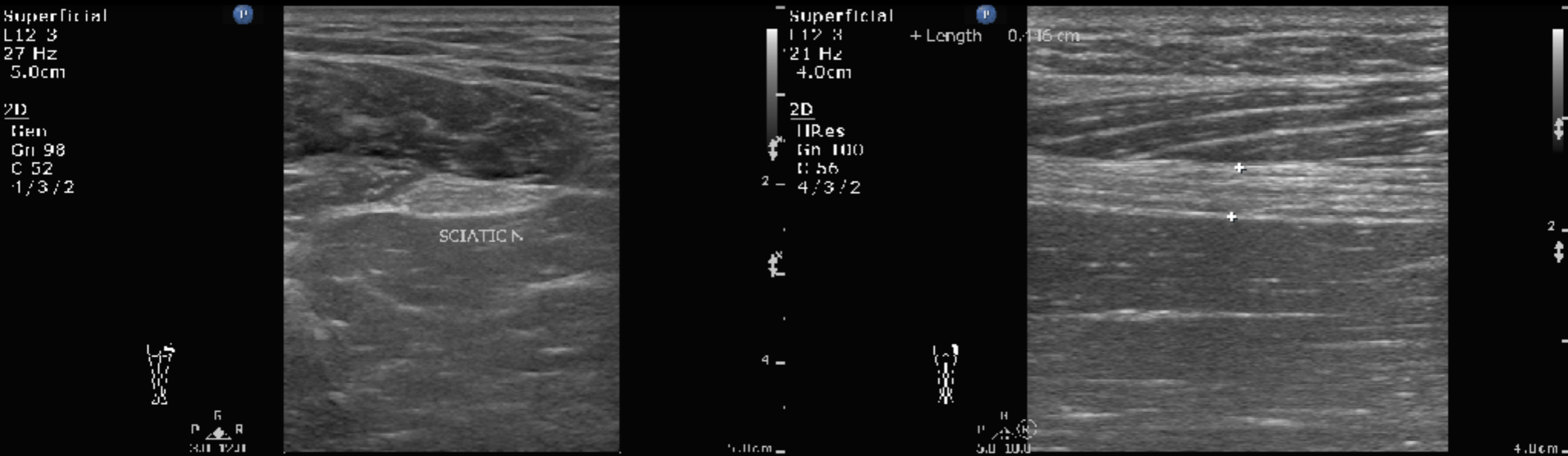




# Document



# 中年男性，右腳痛2-3週



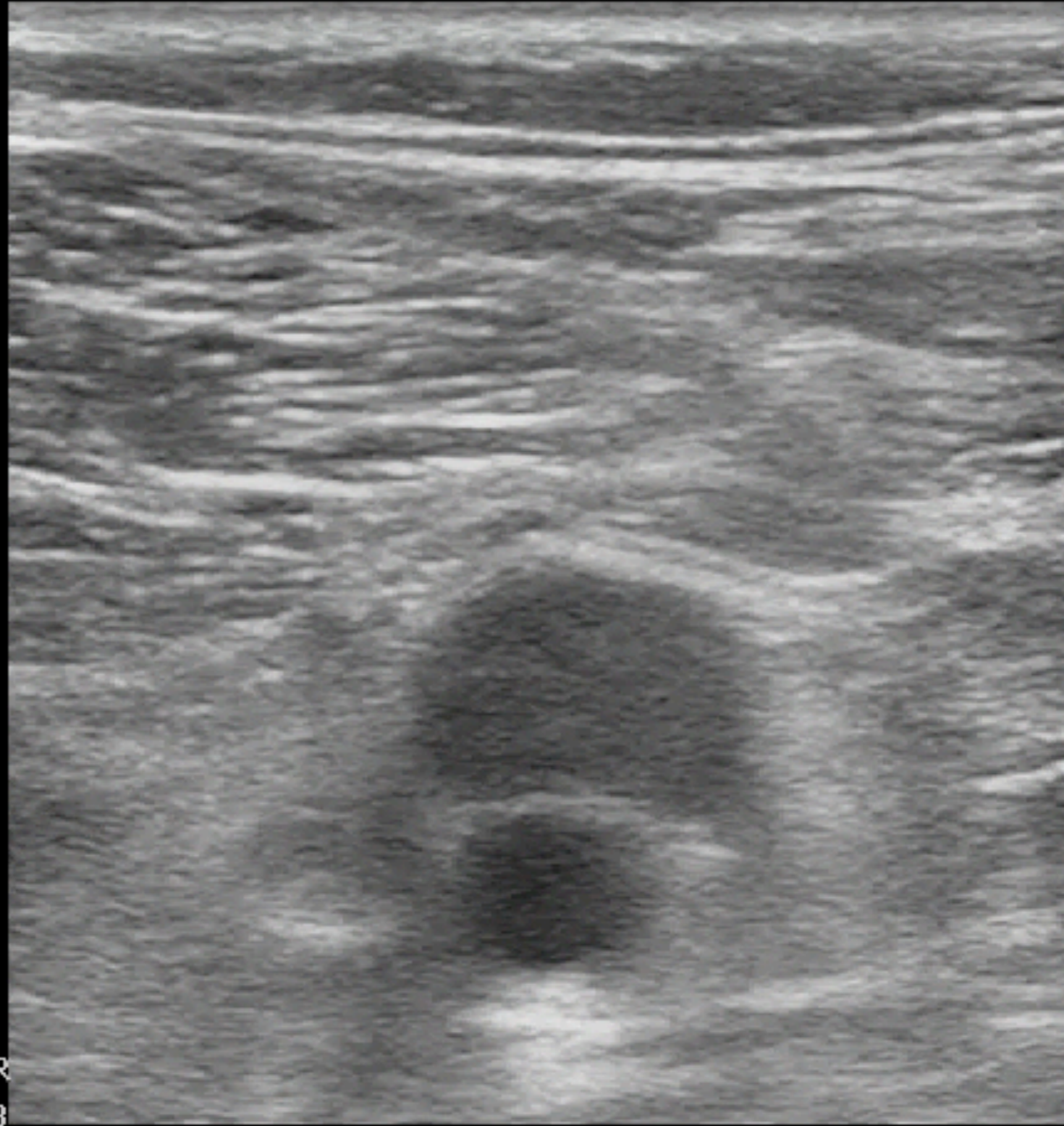
# Popliteal fossa

Venous  
L12-3  
37 Hz  
4.0cm

2D  
HGen  
Gn 96  
C 41  
3/3/2



P (P)  
G (G)  
P R  
4.4 8.8



4.0cm

# Inguinal area

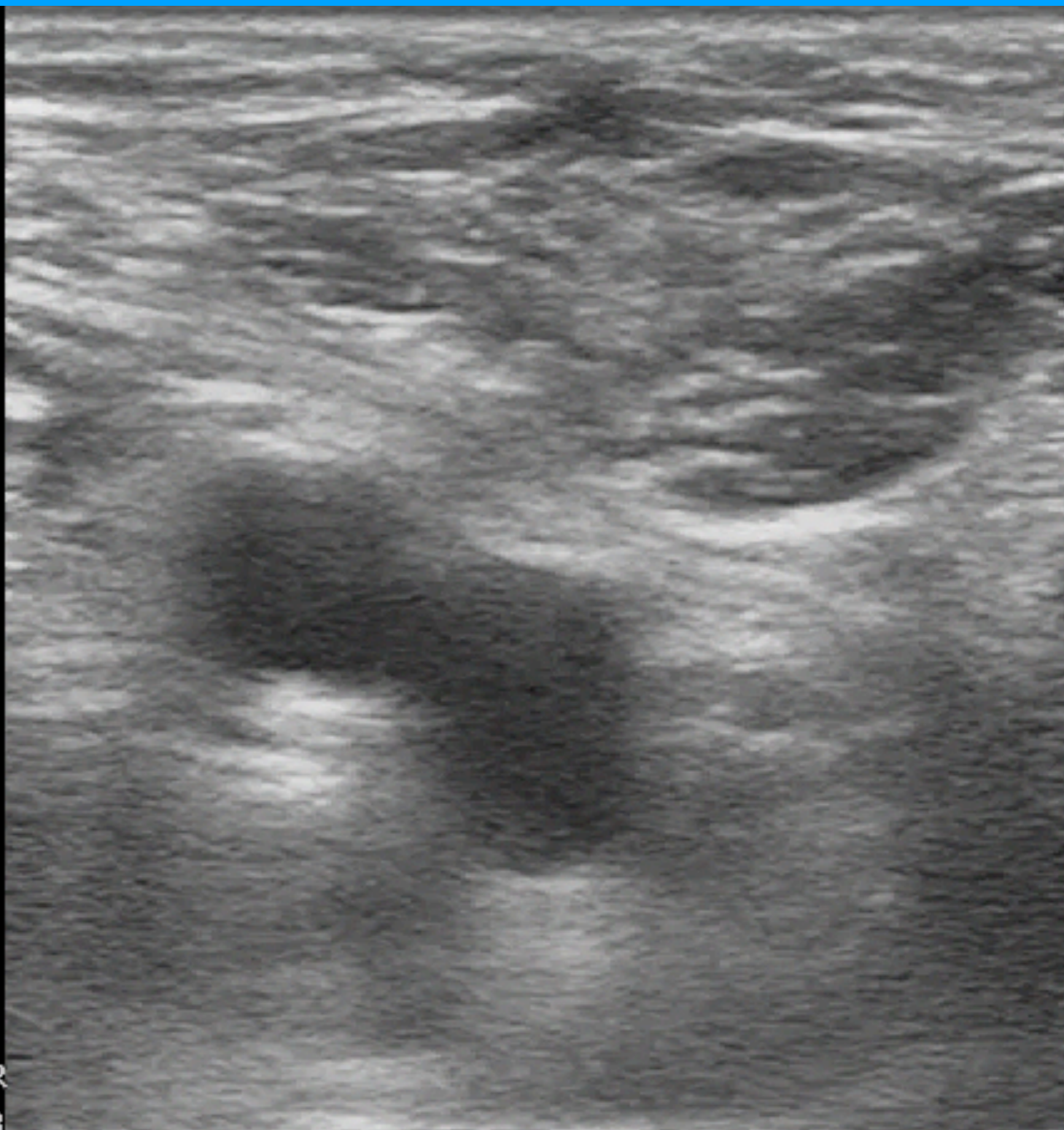
Venous  
L12-3  
37 Hz  
4.0cm

2D

HGen  
Gn 96  
C 41  
3 / 3 / 2

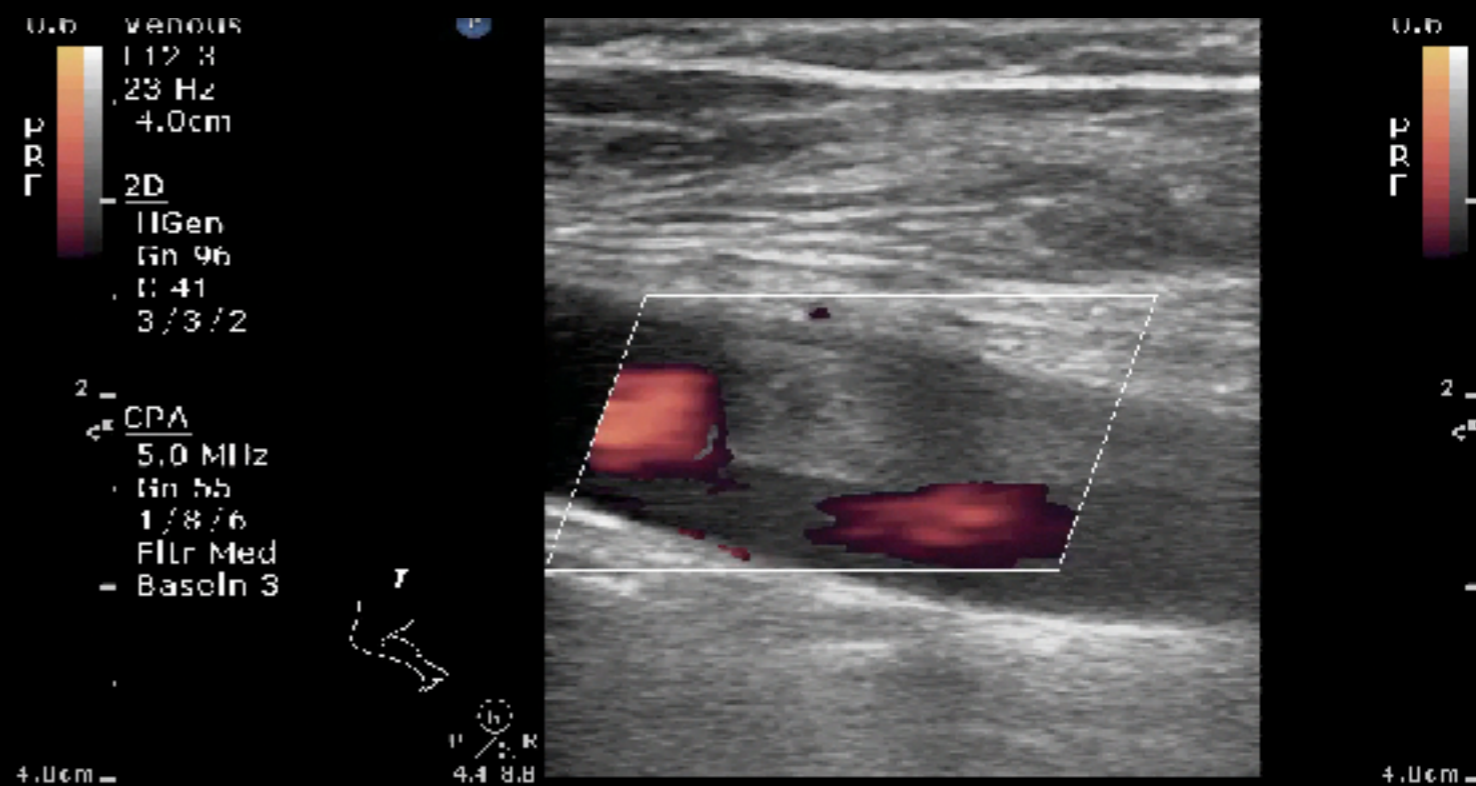
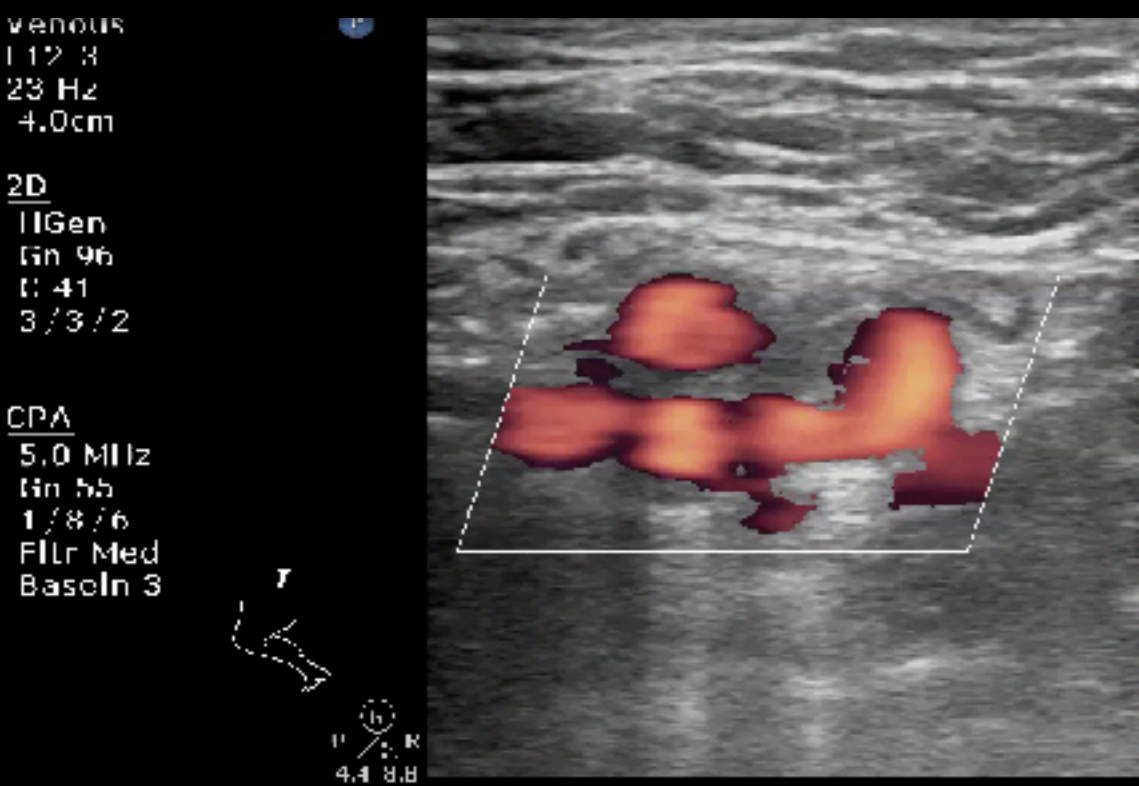


P (G) R  
4.4 8.8

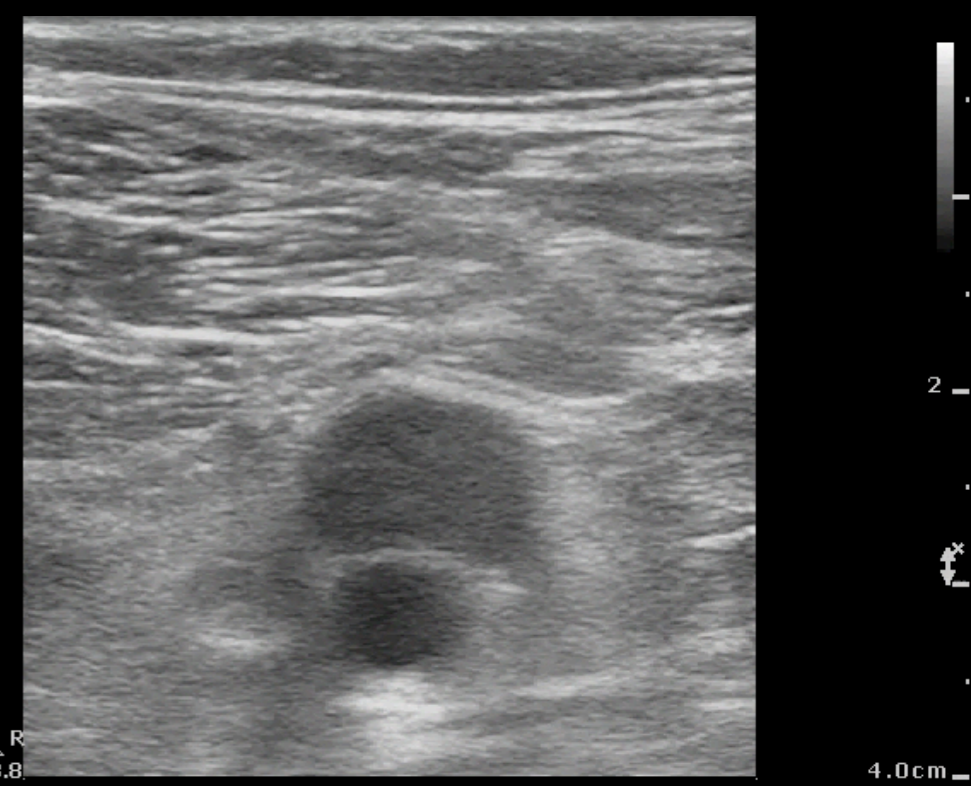
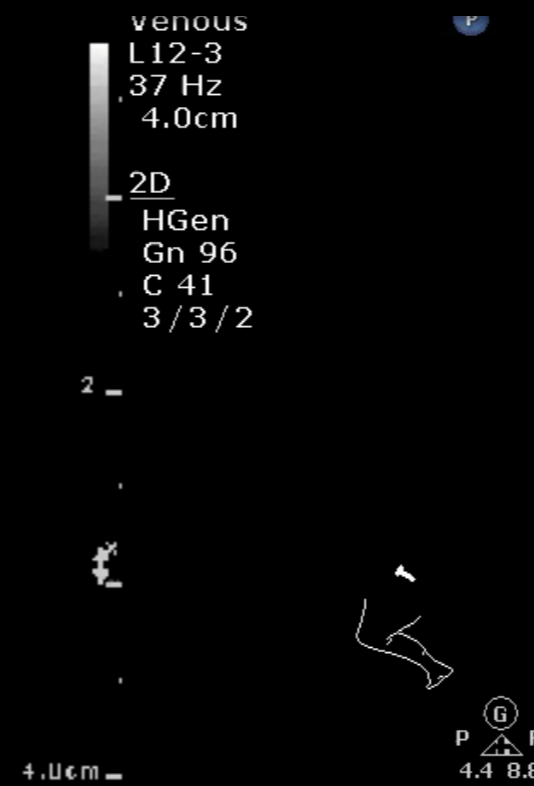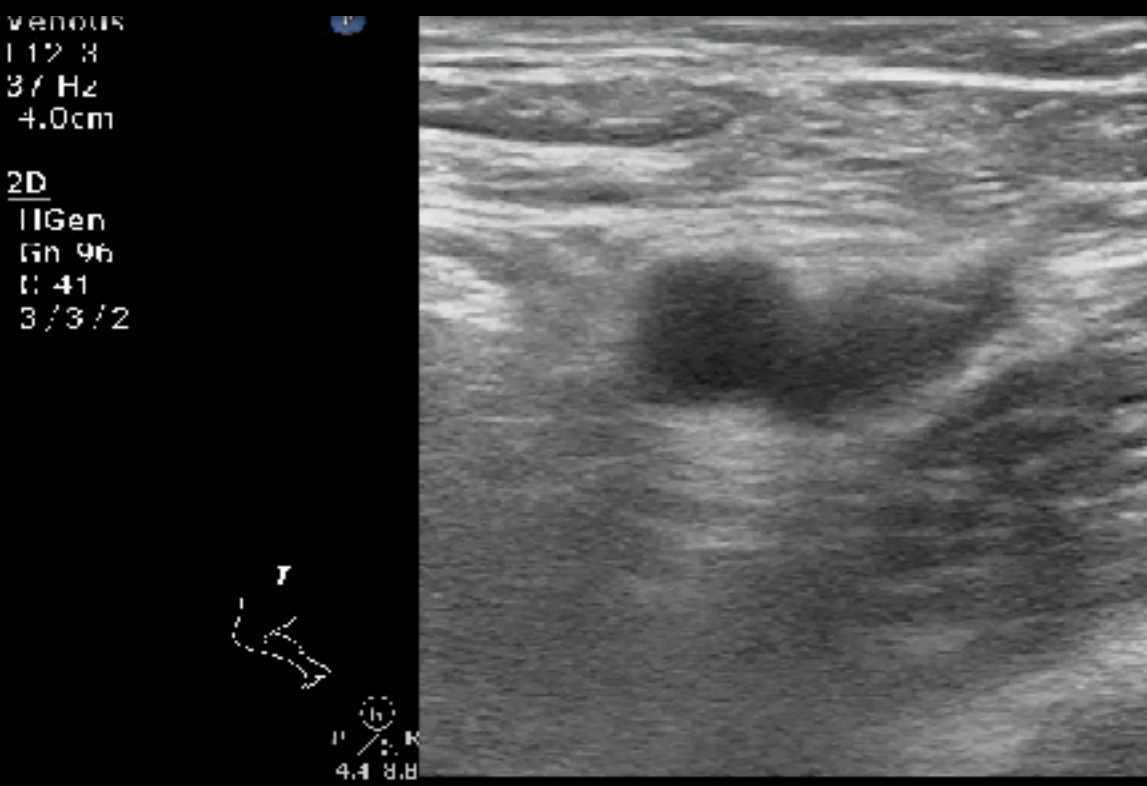


4.0cm

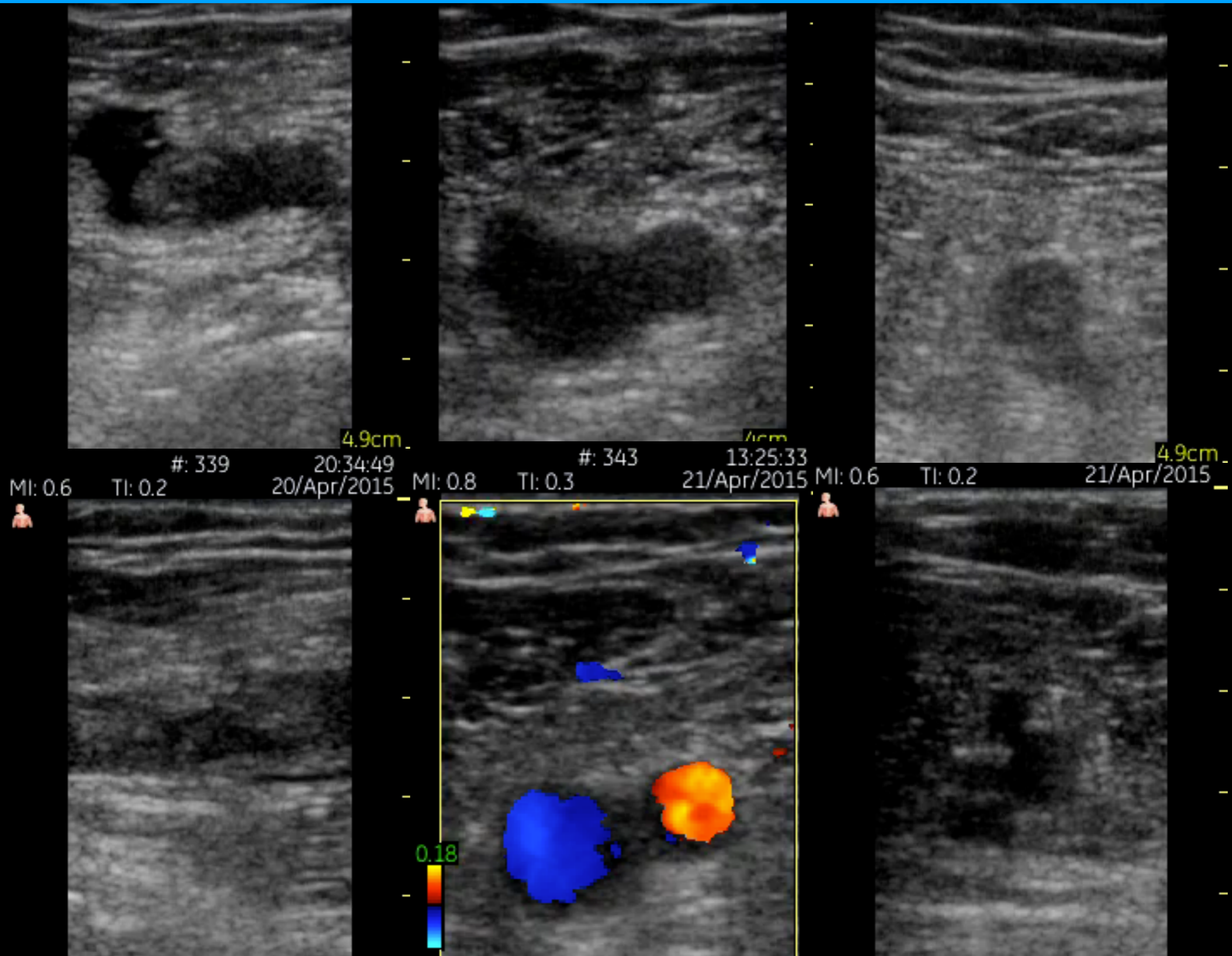
# Power Doppler



# DVT



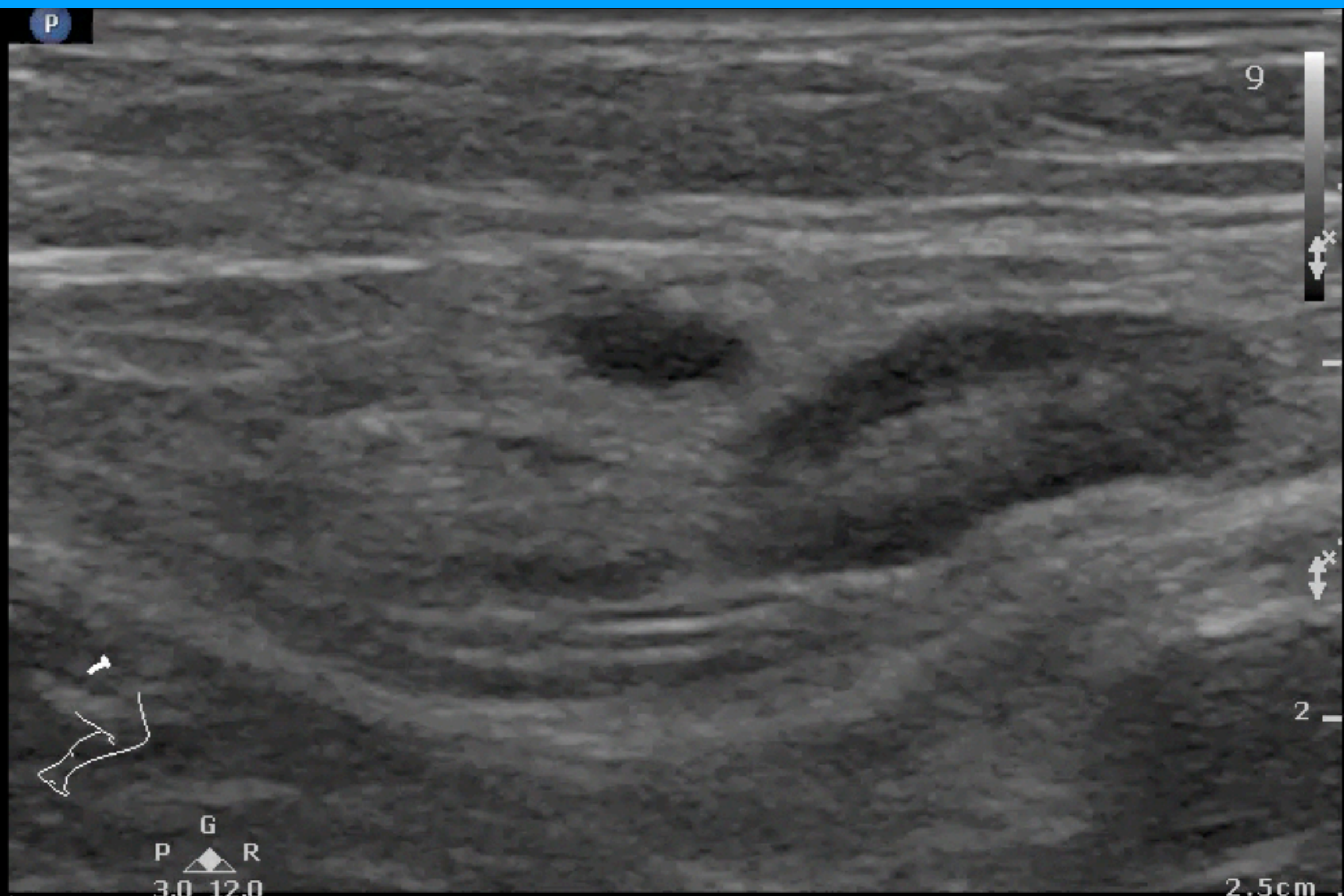# Diagnosis & Monitor



# DVT ?

Superficial  
L12-3  
34 Hz  
2.5cm

2D  
Gen  
Gn 60  
C 52  
4/3/2





# Lymphadenitis

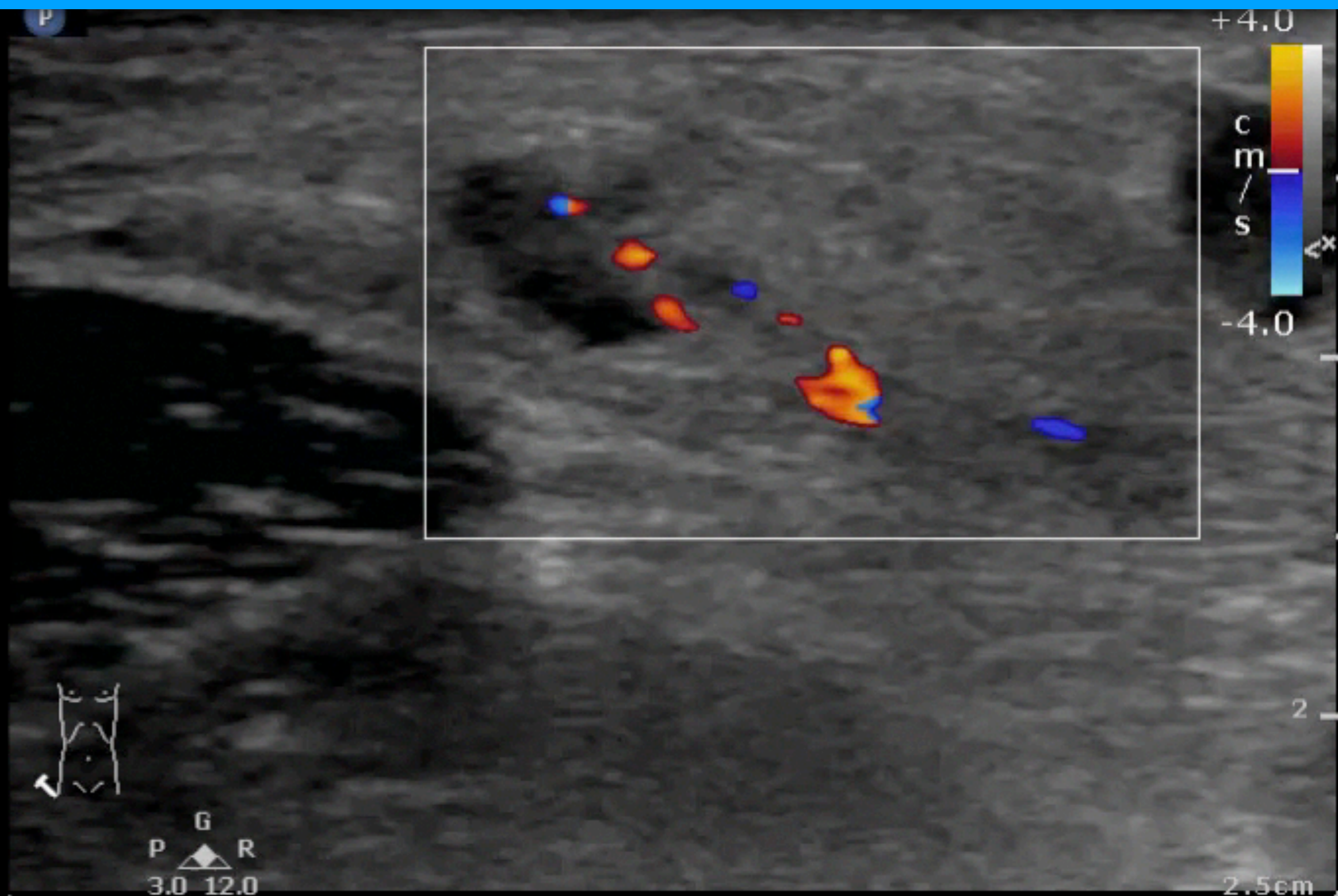
Superficial  
L12-3  
30 Hz  
2.5cm

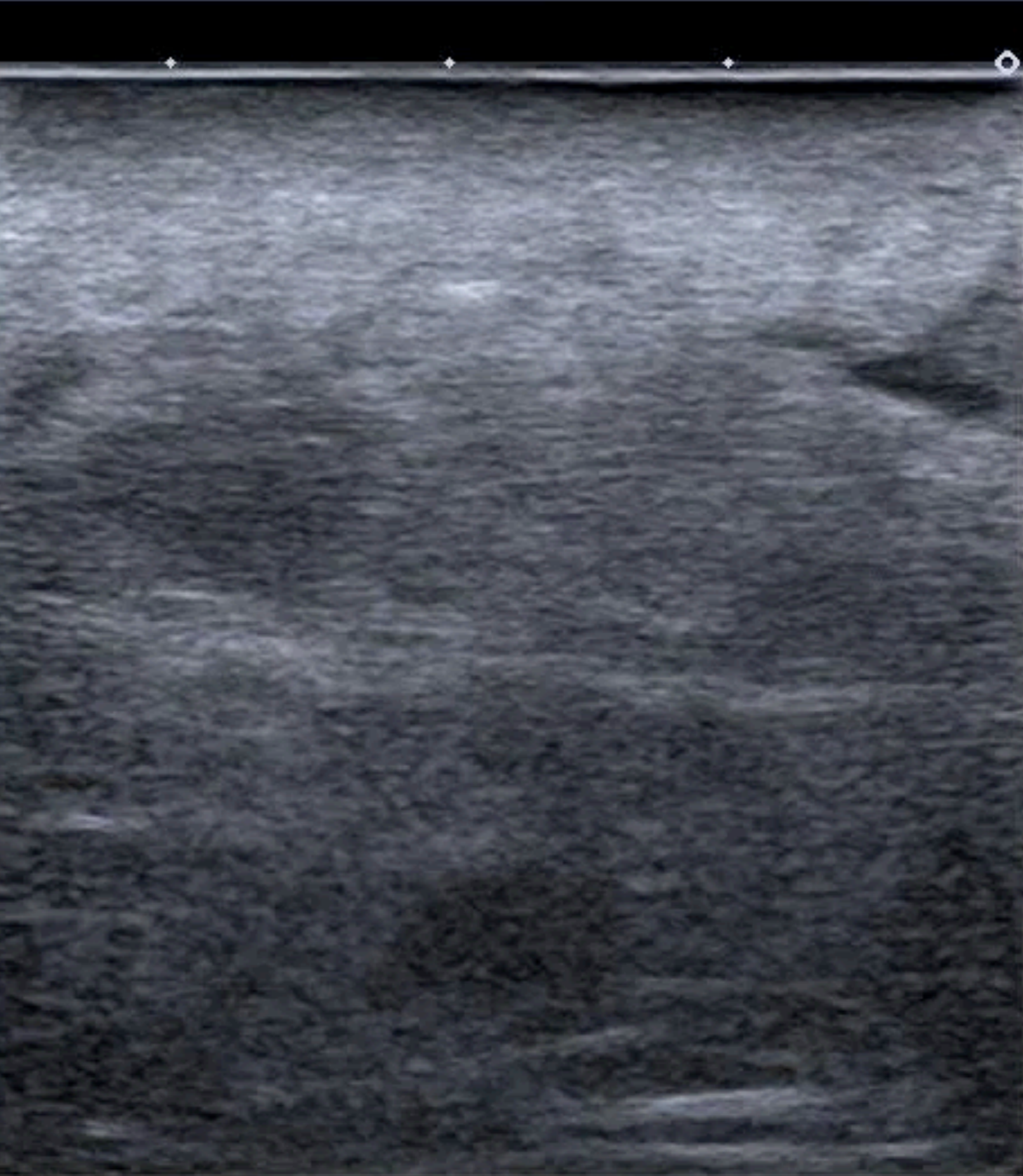
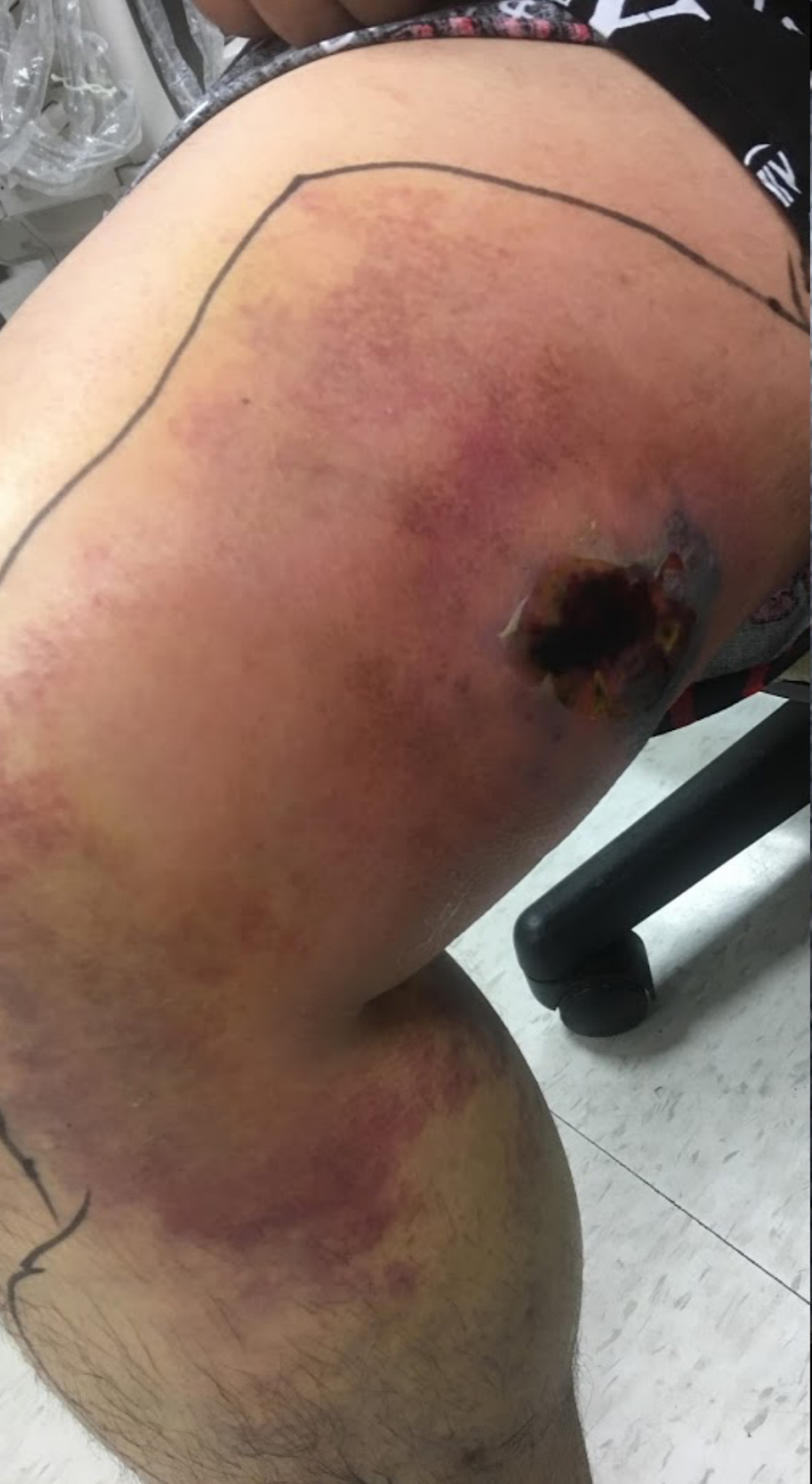2D

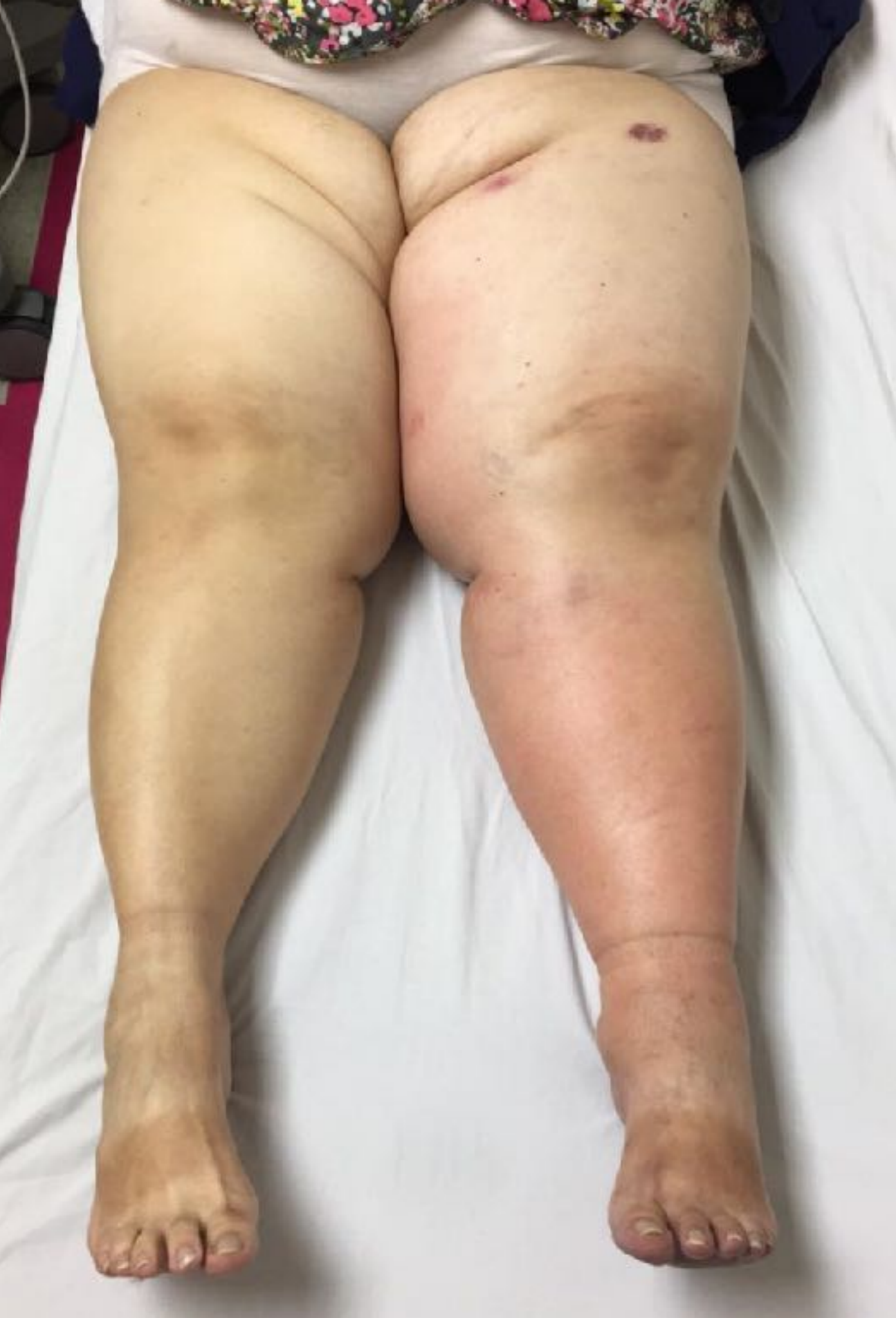Gen  
Gn 62  
C 55  
4/3/2

Color

6.7 MHz  
Gn 55  
6/4/2  
Filtr Med

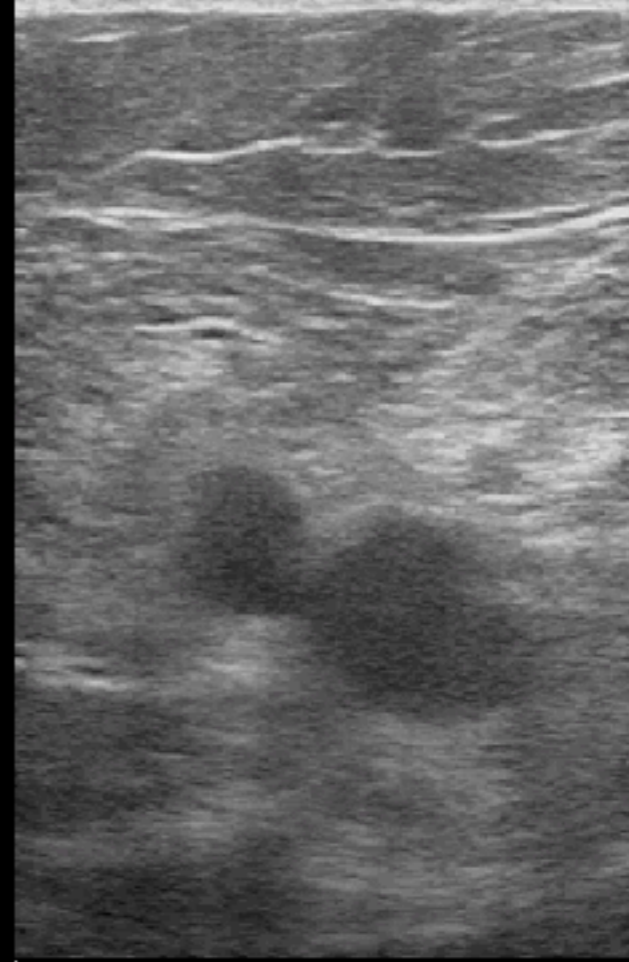




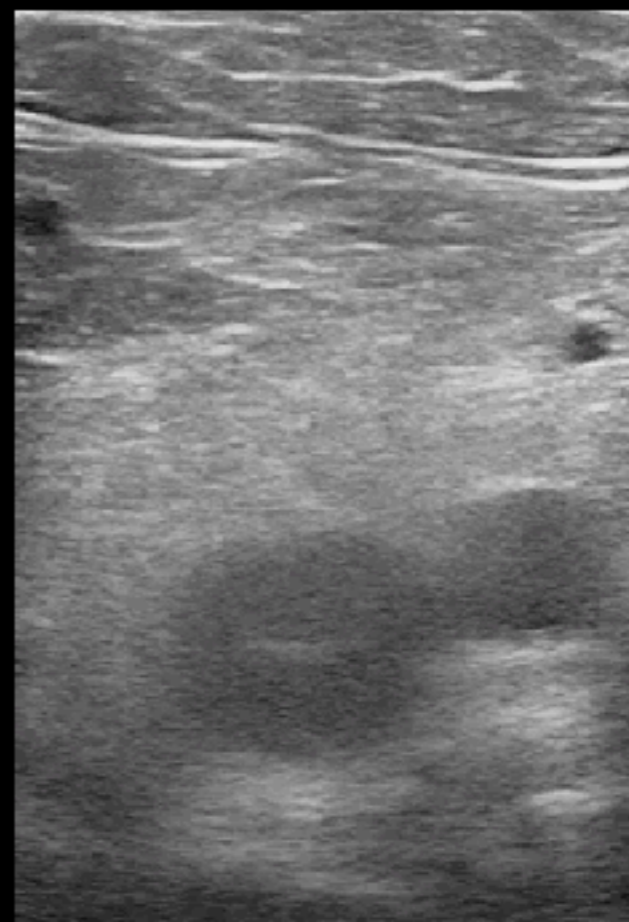


P  
R  
4.4 8.8

P  
R  
4.4 8.8



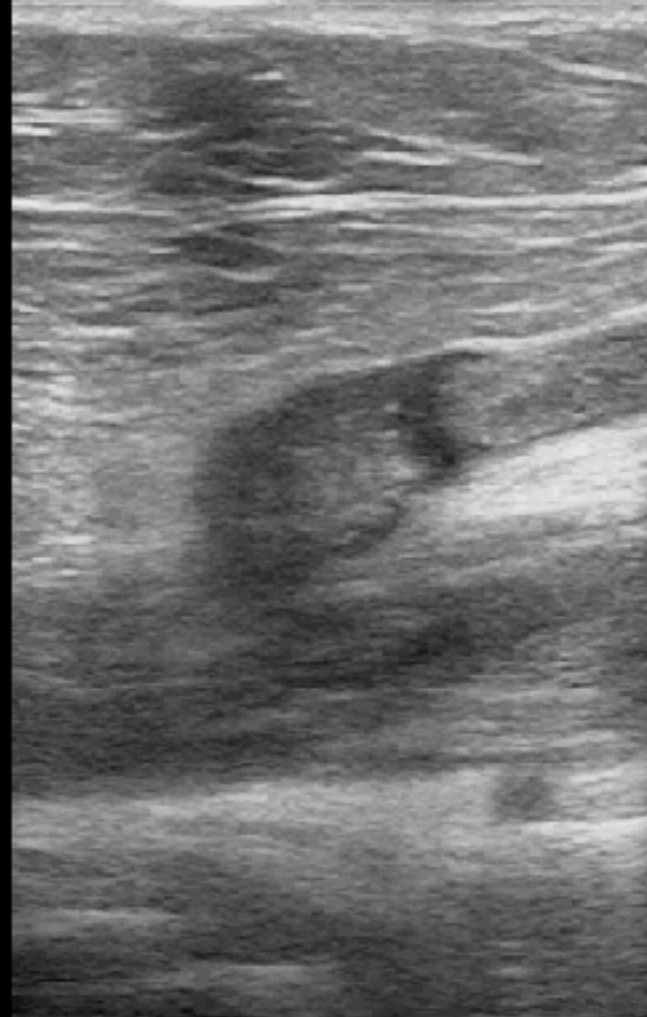
5.1  
6.0cm



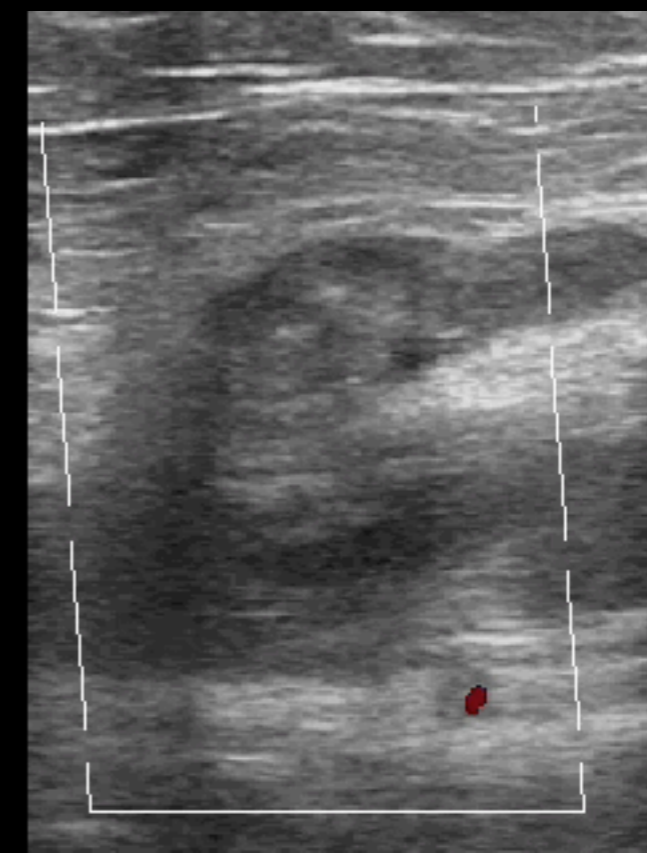5.1



©  
R  
+ 8.8



6.0cm

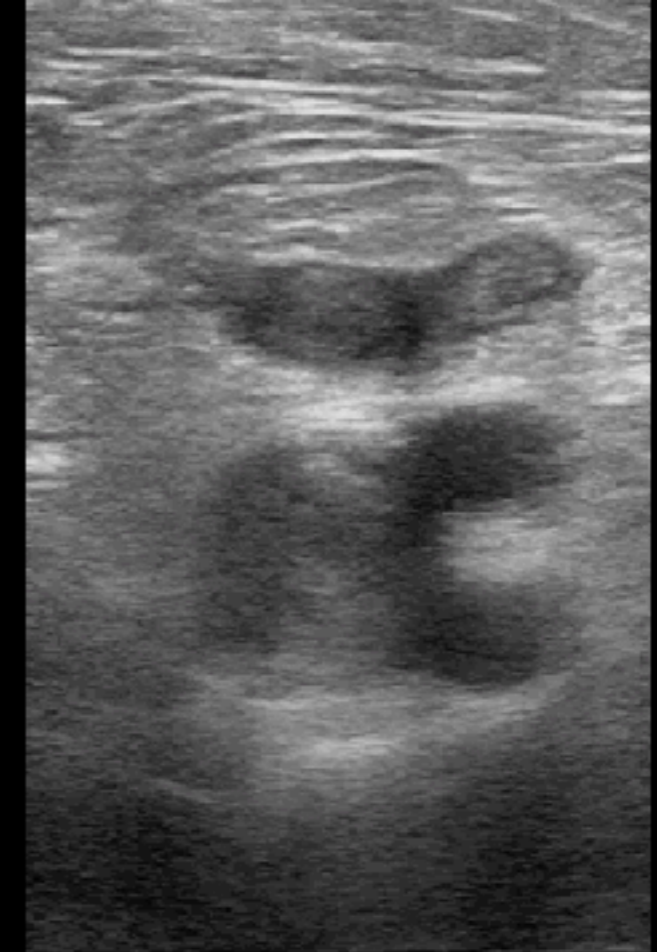

cm/s  
-7.0

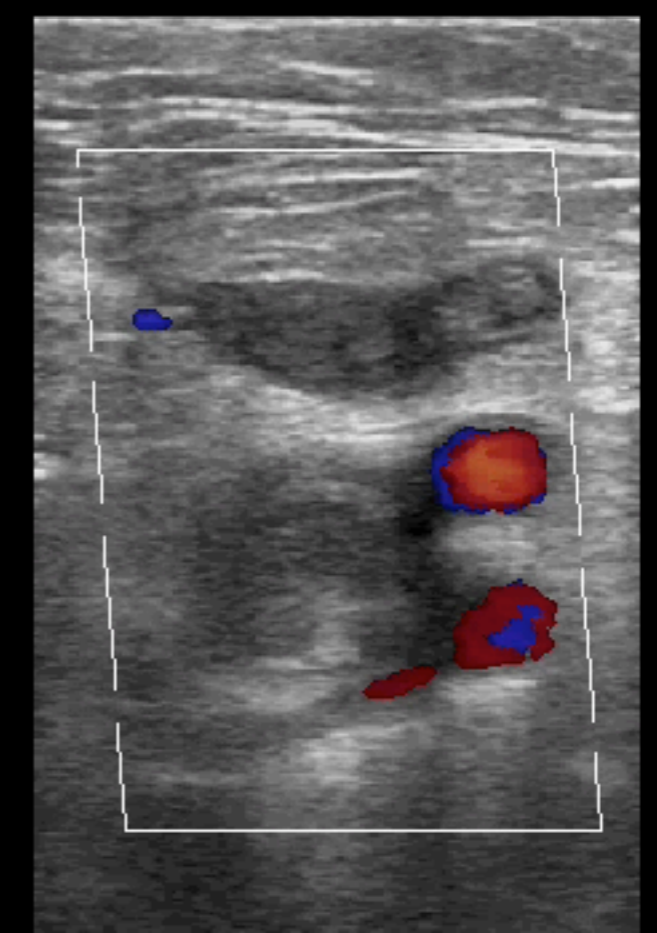
©  
P



Ⓞ  
P R  
4.4 8.8



6.0cm

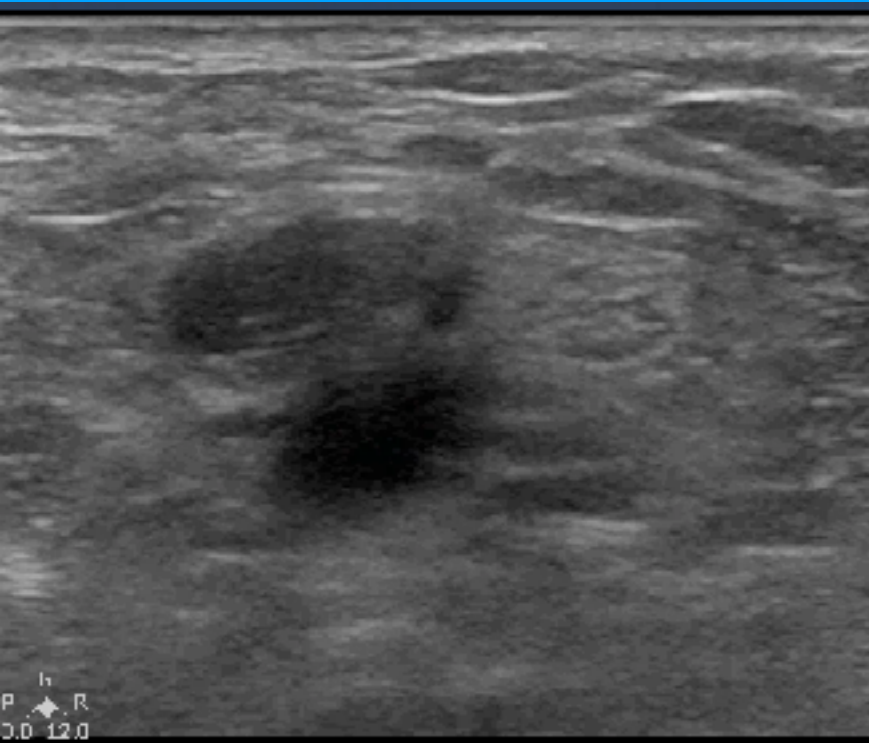

-7.0  
cm / s  
7.0

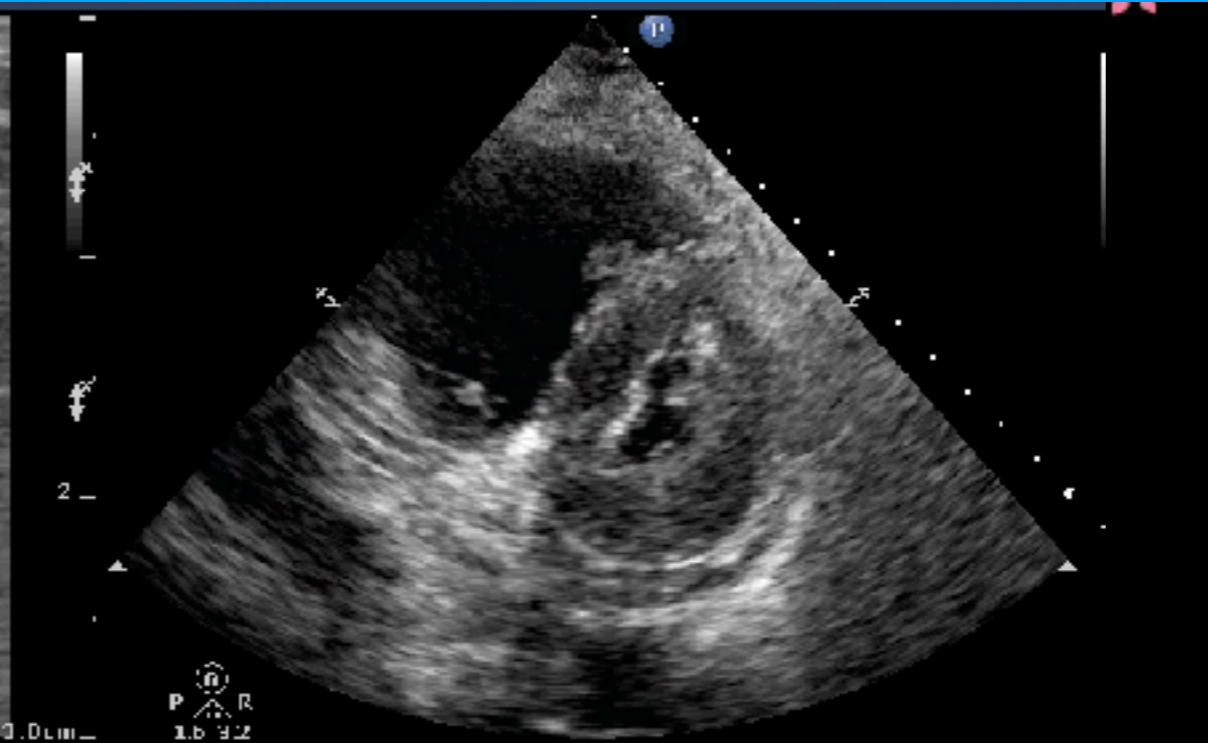
Ⓞ

# Pulmonary embolism ?

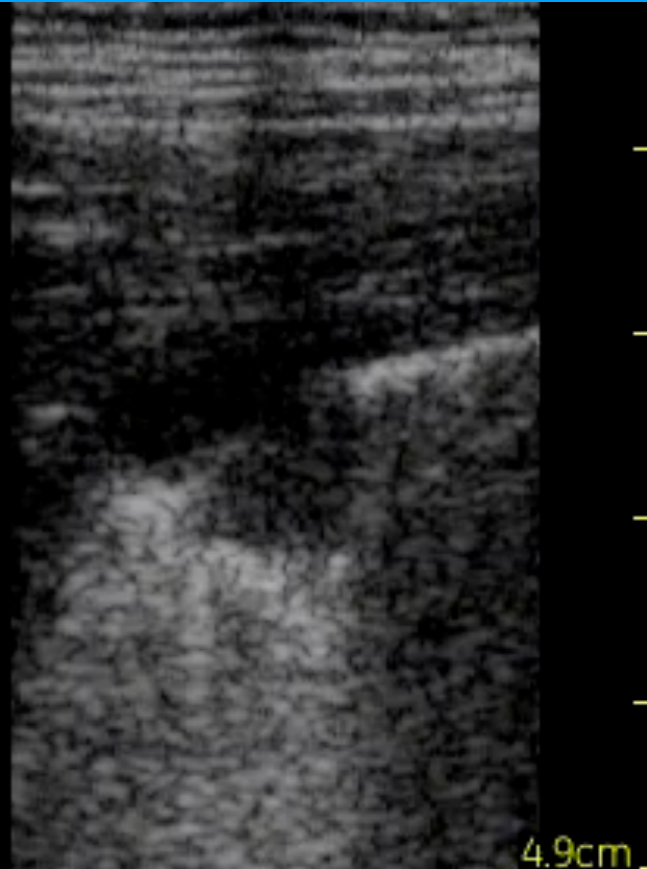
Vein



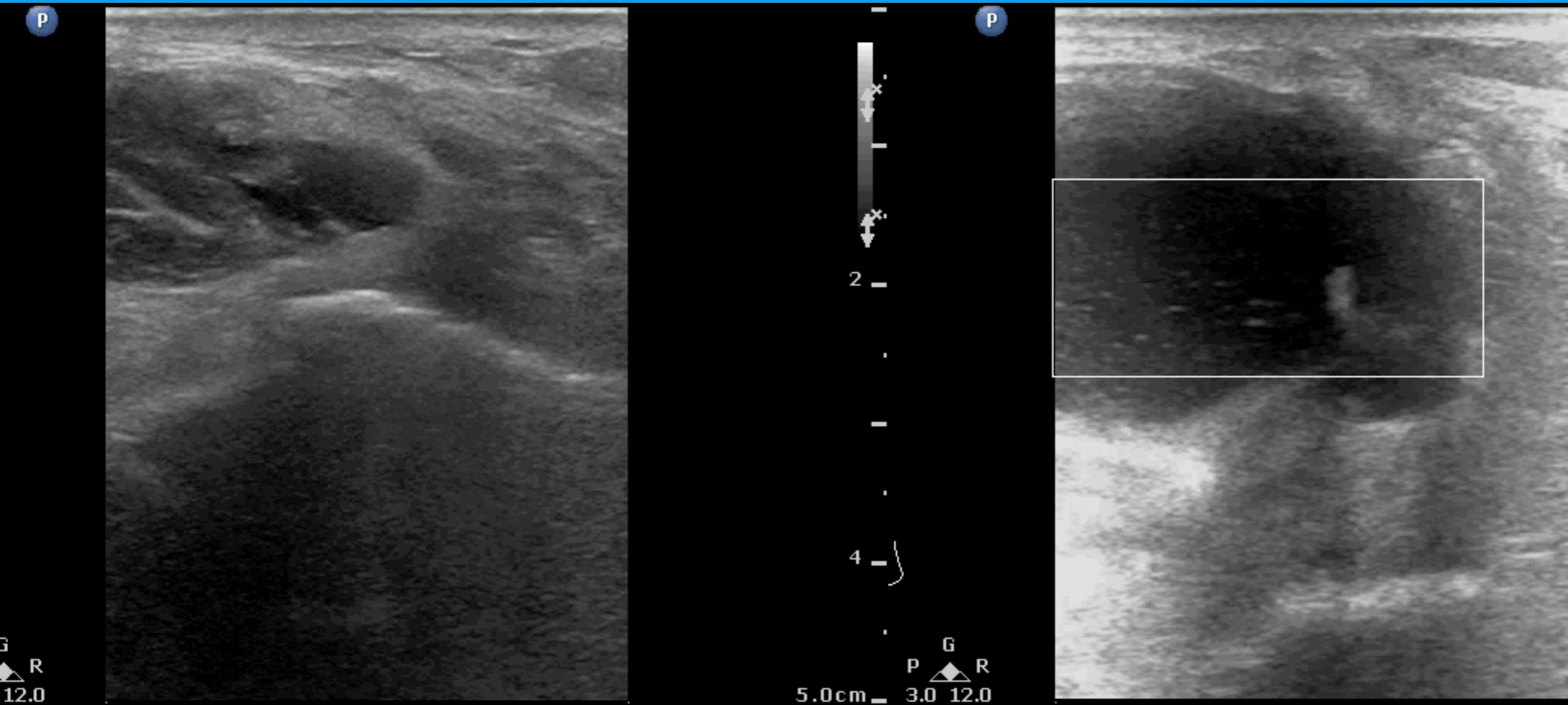
Heart



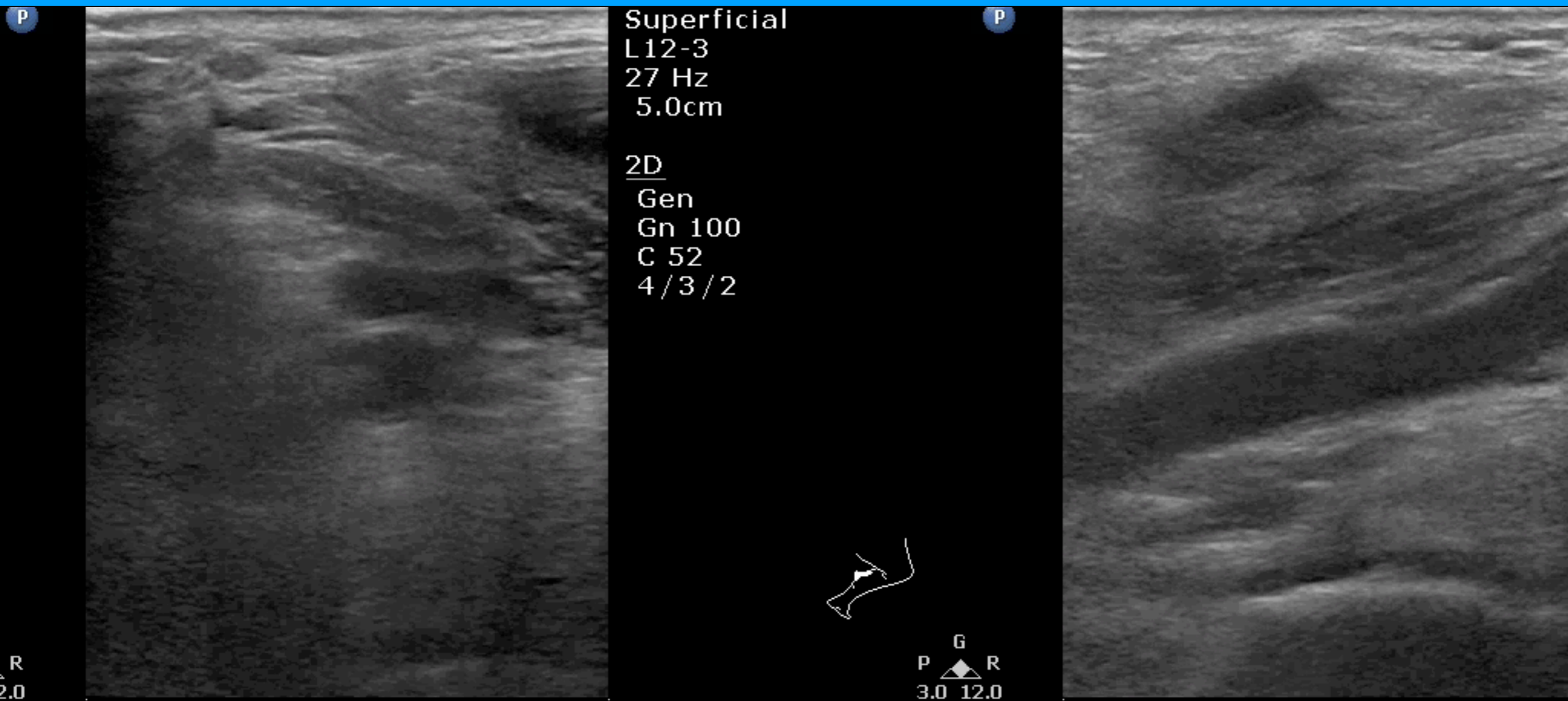
Lung



# Dyspnea, popliteal scan



# Dyspnea, popliteal scan





# Baker's cyst

Abd Gen2

25-1

47 Hz

9.0cm

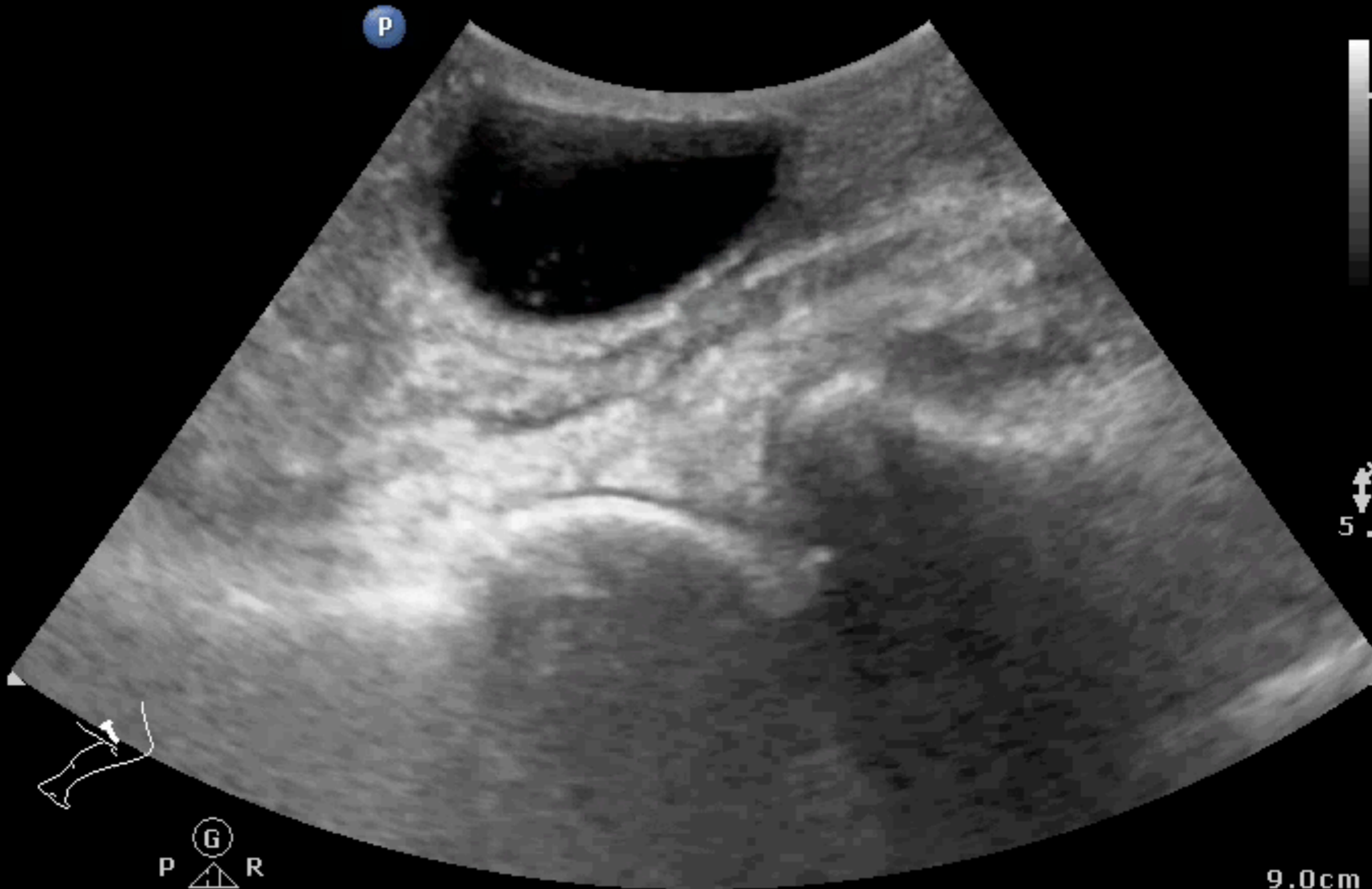2D

HGen

Gn 85

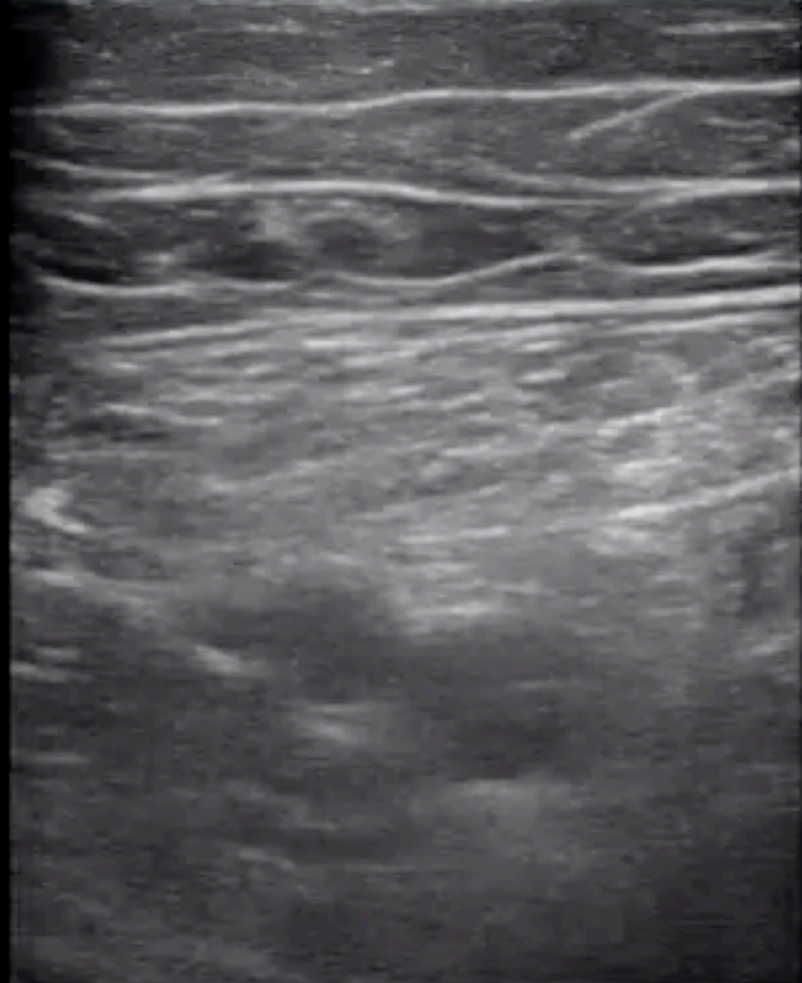
C 56

3/3/3

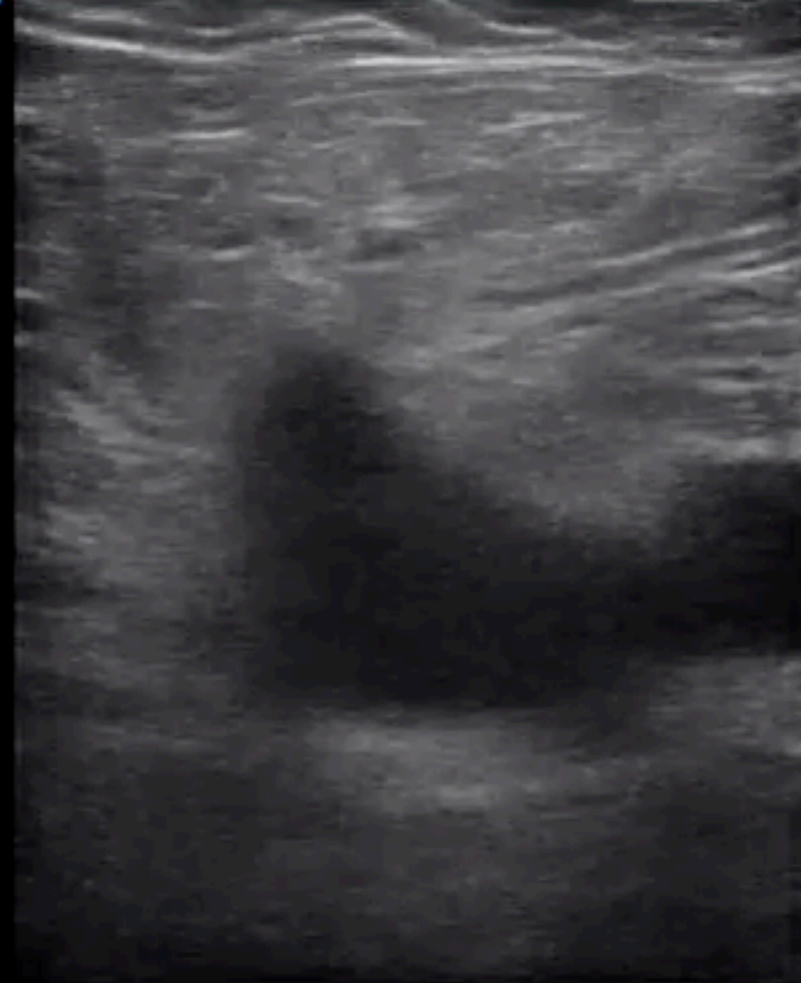

Ⓞ  
P     R  
1.8 3.6

9.0cm

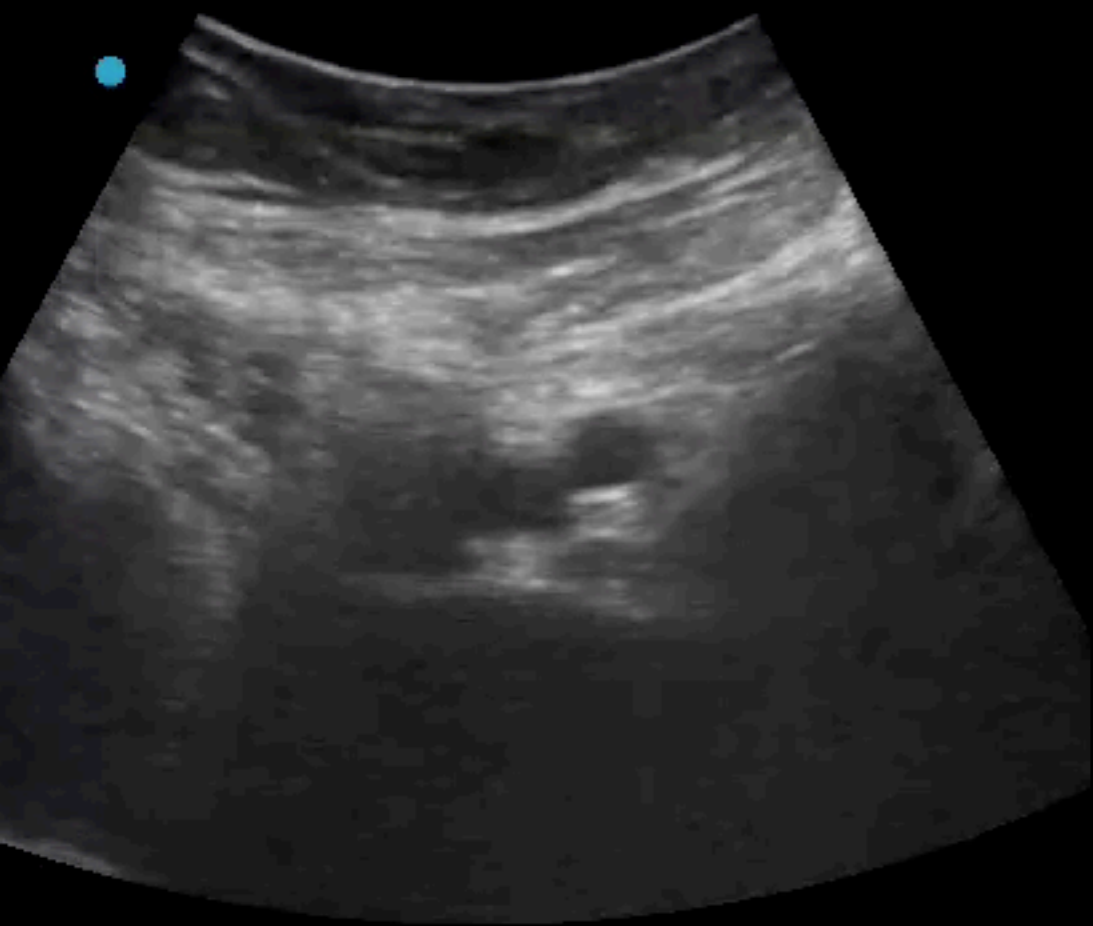


S MB

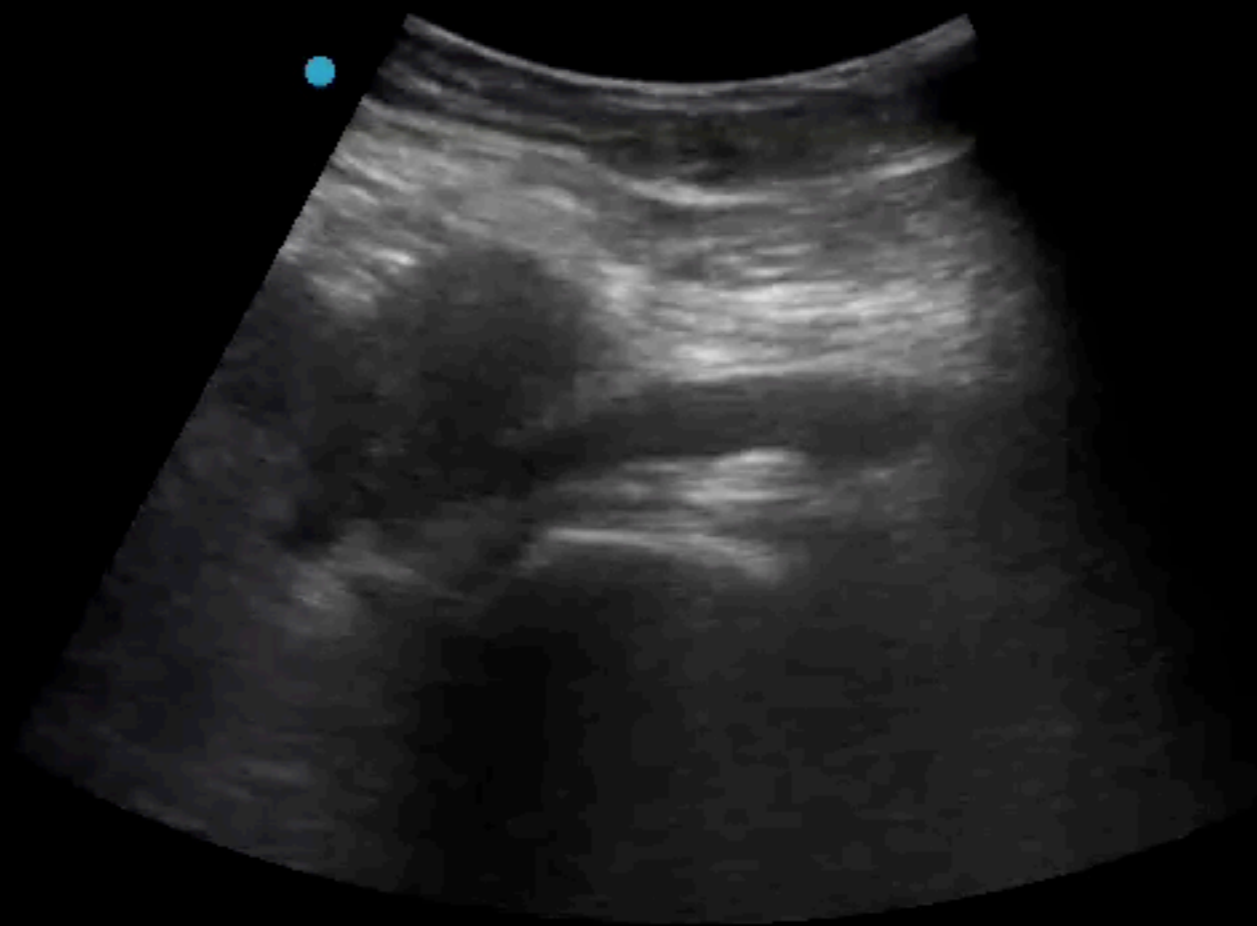


2018 Aug 1

Gen THI  
S MB



2018 Aug 10 16



4.9

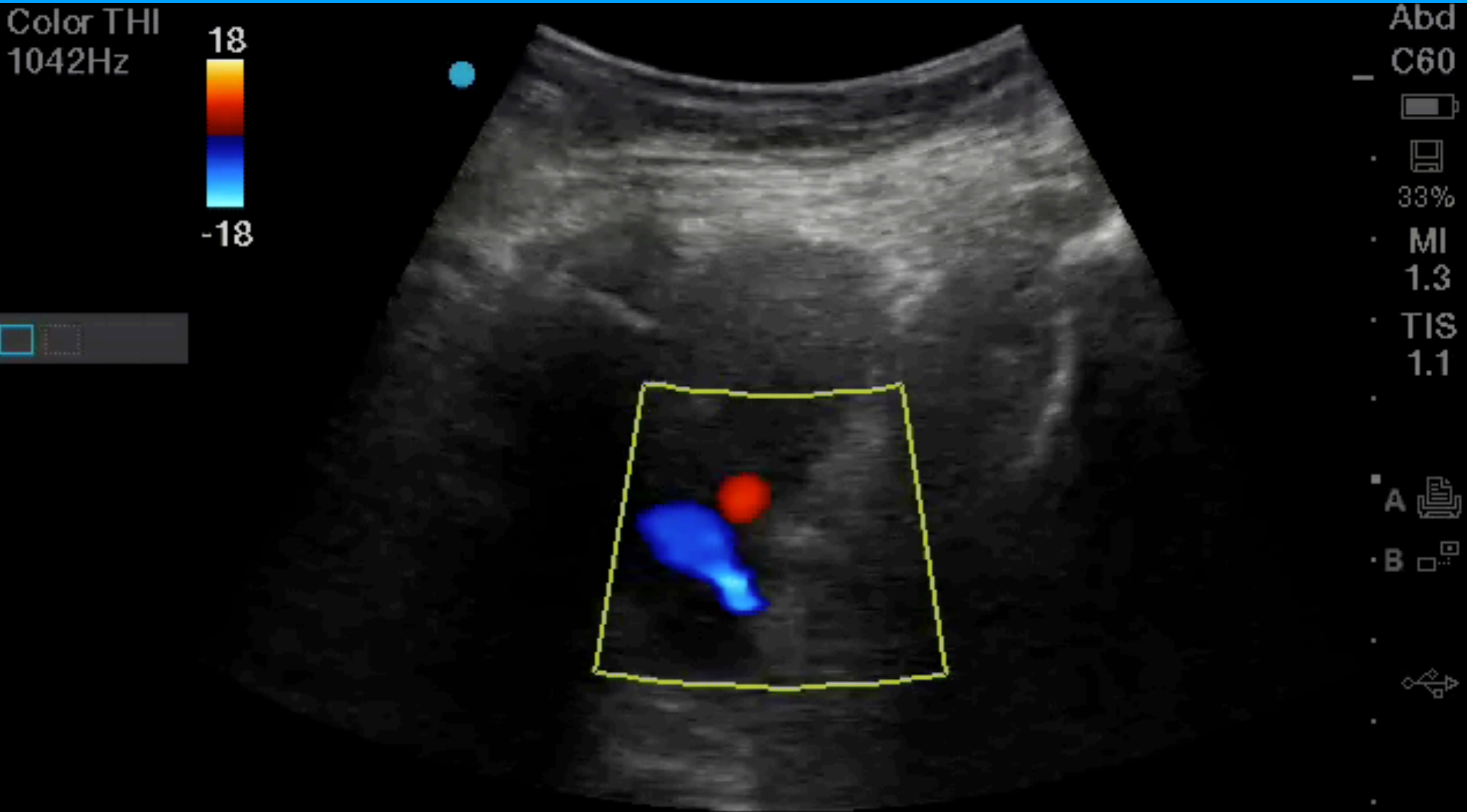
HF  
35  
M  
O  
T  
O  
A  
B  
A  
C  
3  
T  
C  
A  
B

# May-Thurner syndrome

## Iliac venous compression syndrome

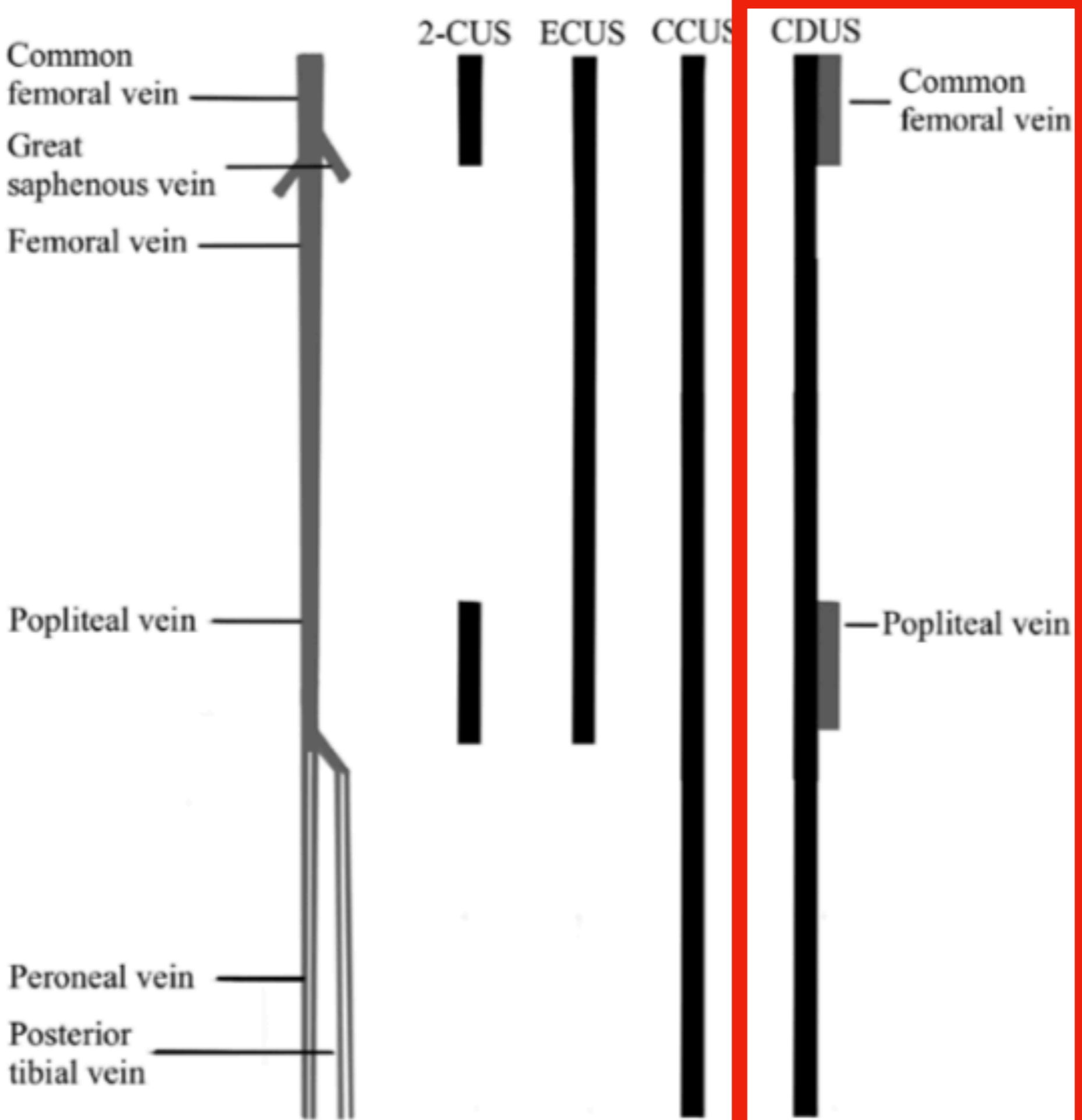
Color THI  
1042Hz

18  
-18



Abd  
C60  
33%  
MI  
1.3  
TIS  
1.1

A  
B



3 mo risk  
-ve CDUS

0.57%

CDUS for  
calf DVT

Sen 56.8%

# Complete Duplex Ultrasound (CDUS)

Whole

2<sub>cm</sub>

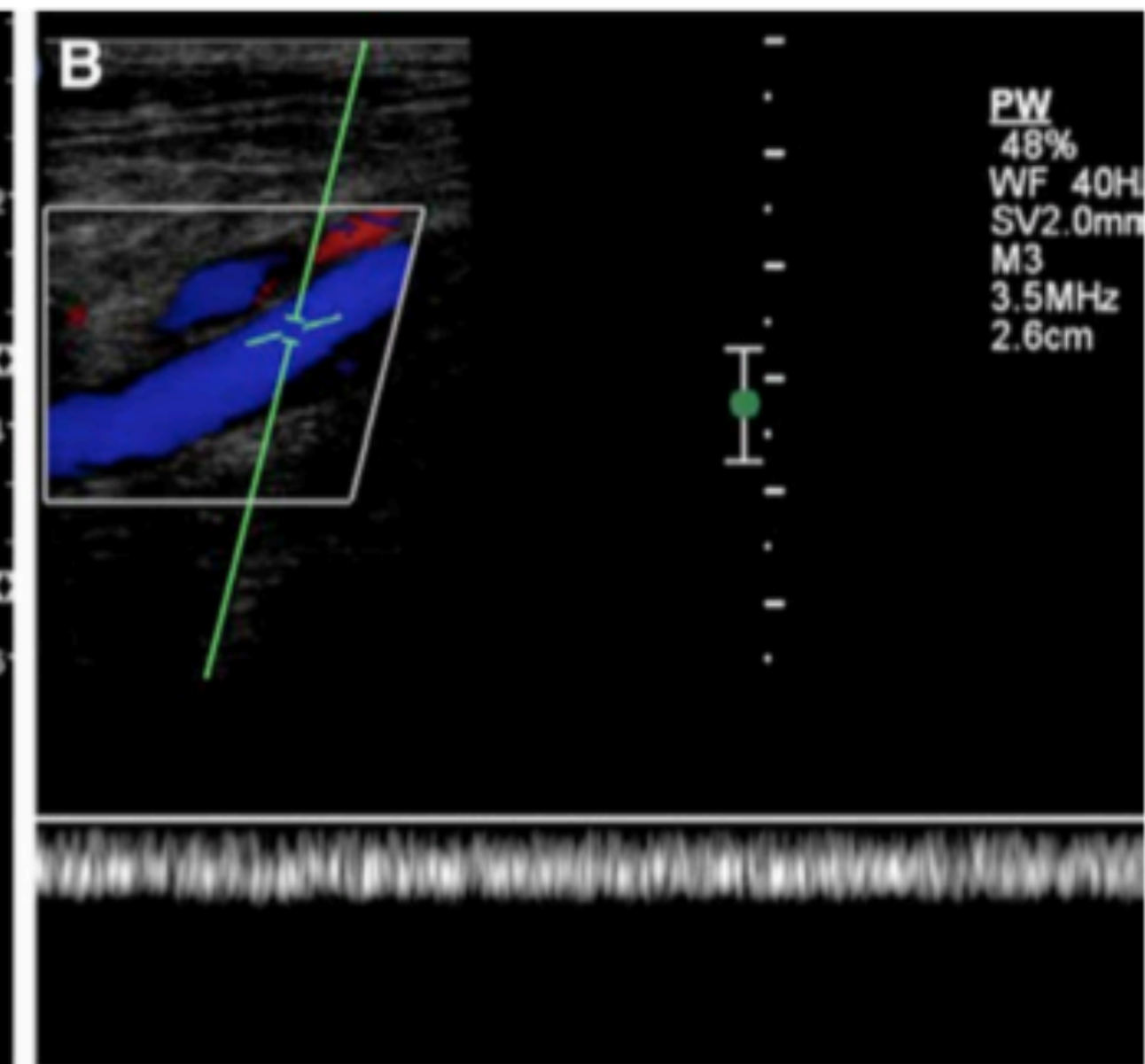
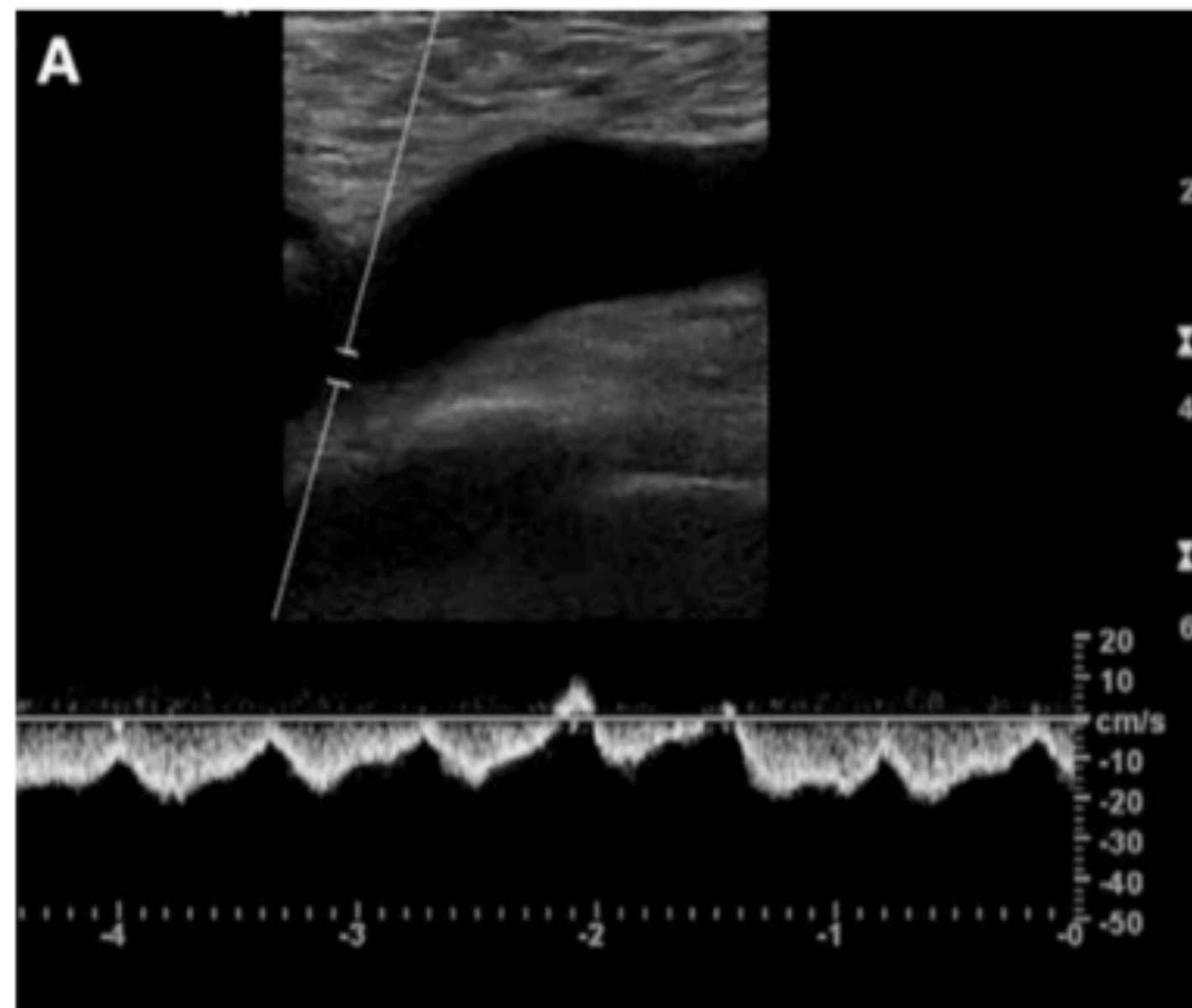
Both

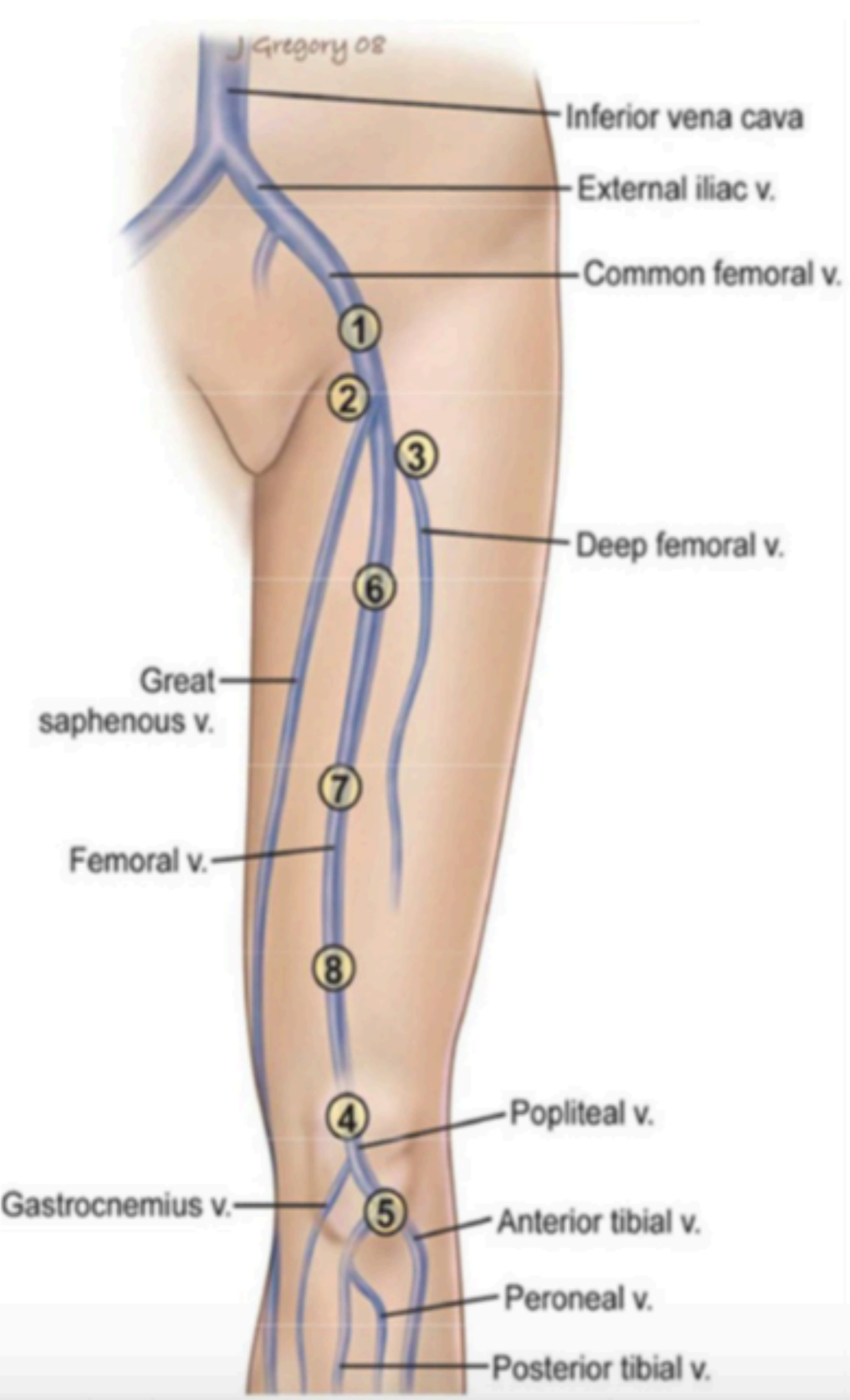
Compression

Spectral

Color

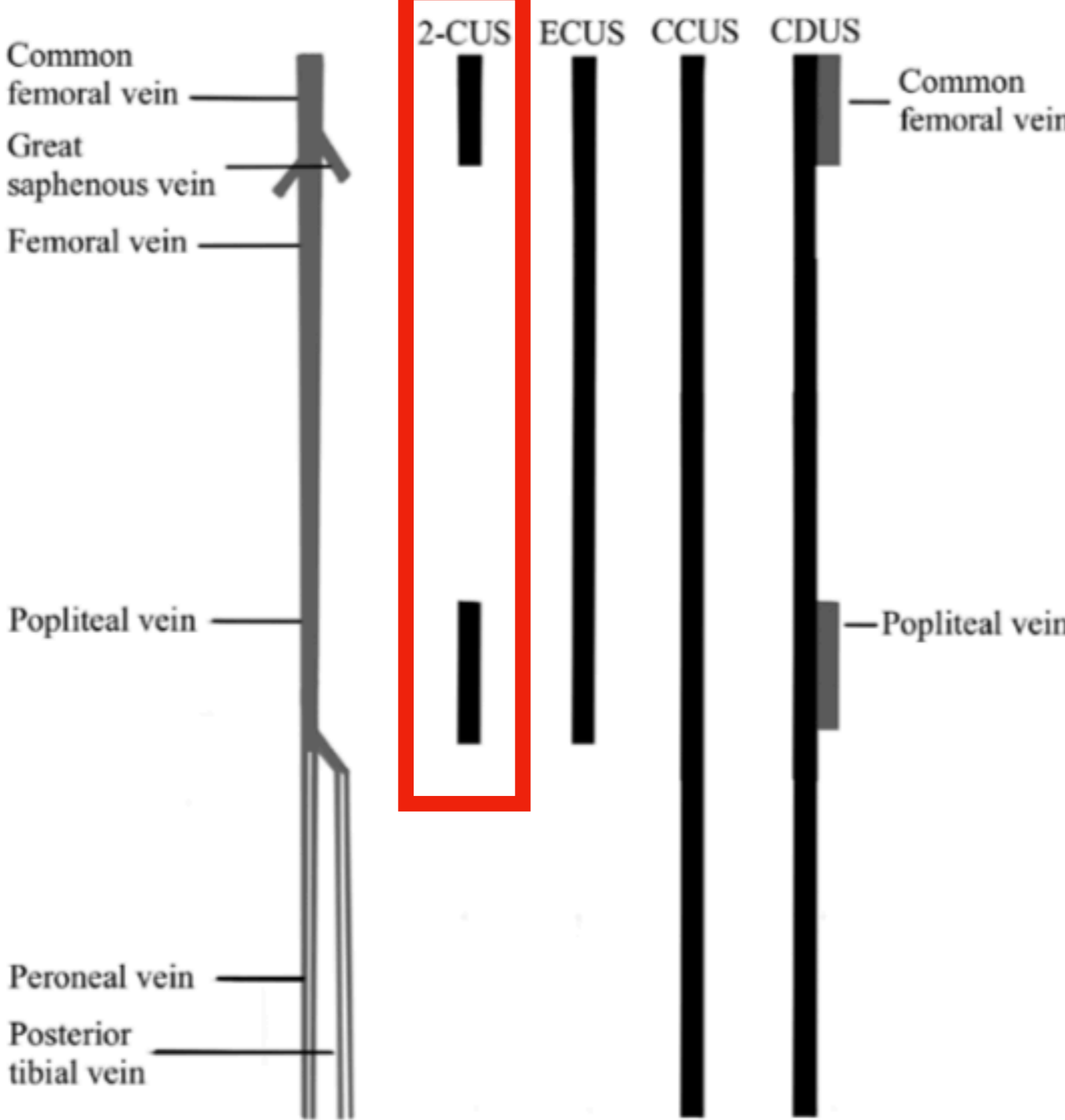
# Which one is abnormal ?





# Duplex US (AIUM)

	Proximal DVT	Distal DVT
Sen	100%	94%
Spe	98%	75%

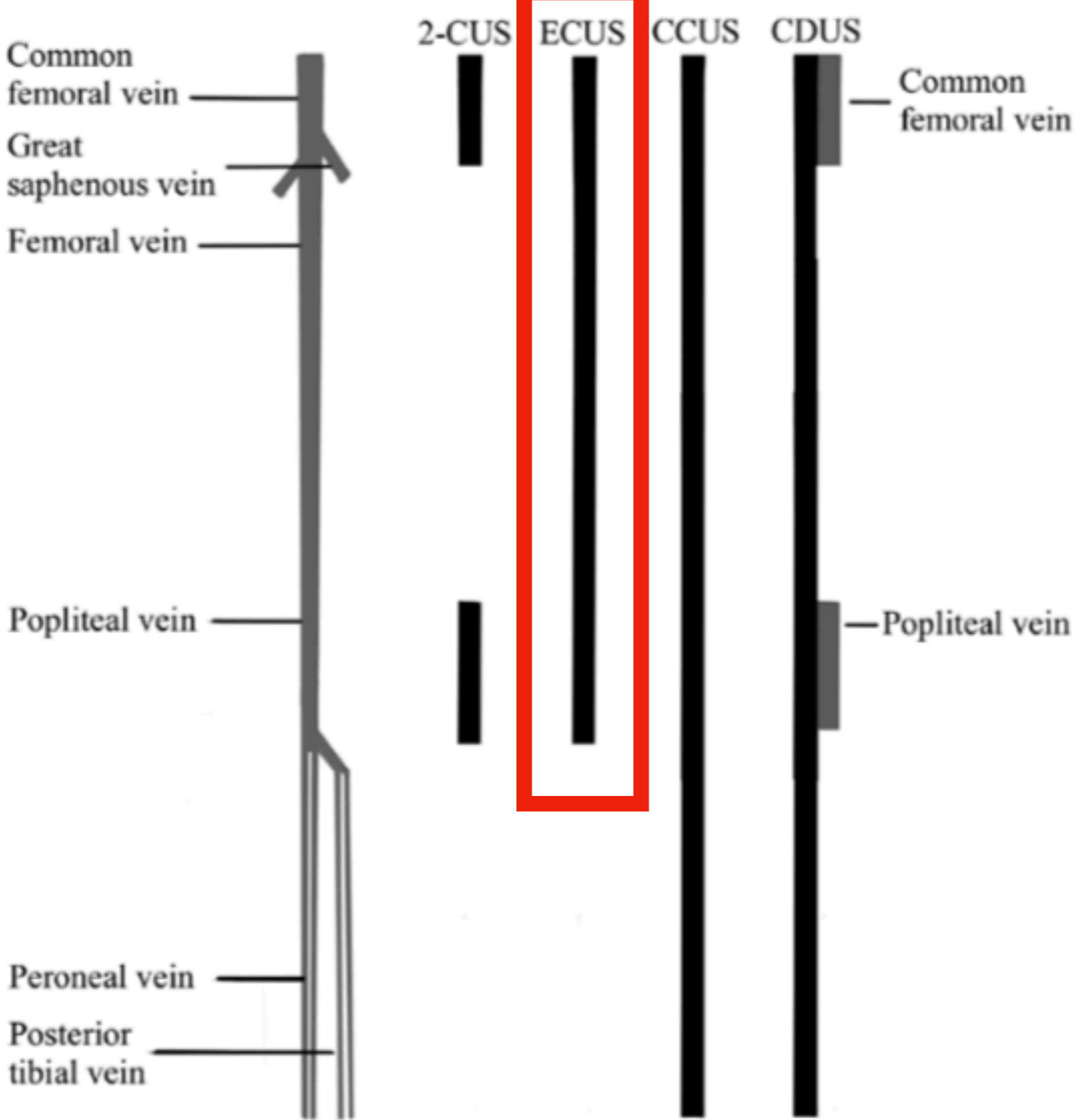


**POCUS  
(ACEP)  
2-regions**

**Isolated  
femoral DVT  
5-7%**

*Heather Hale, MD*

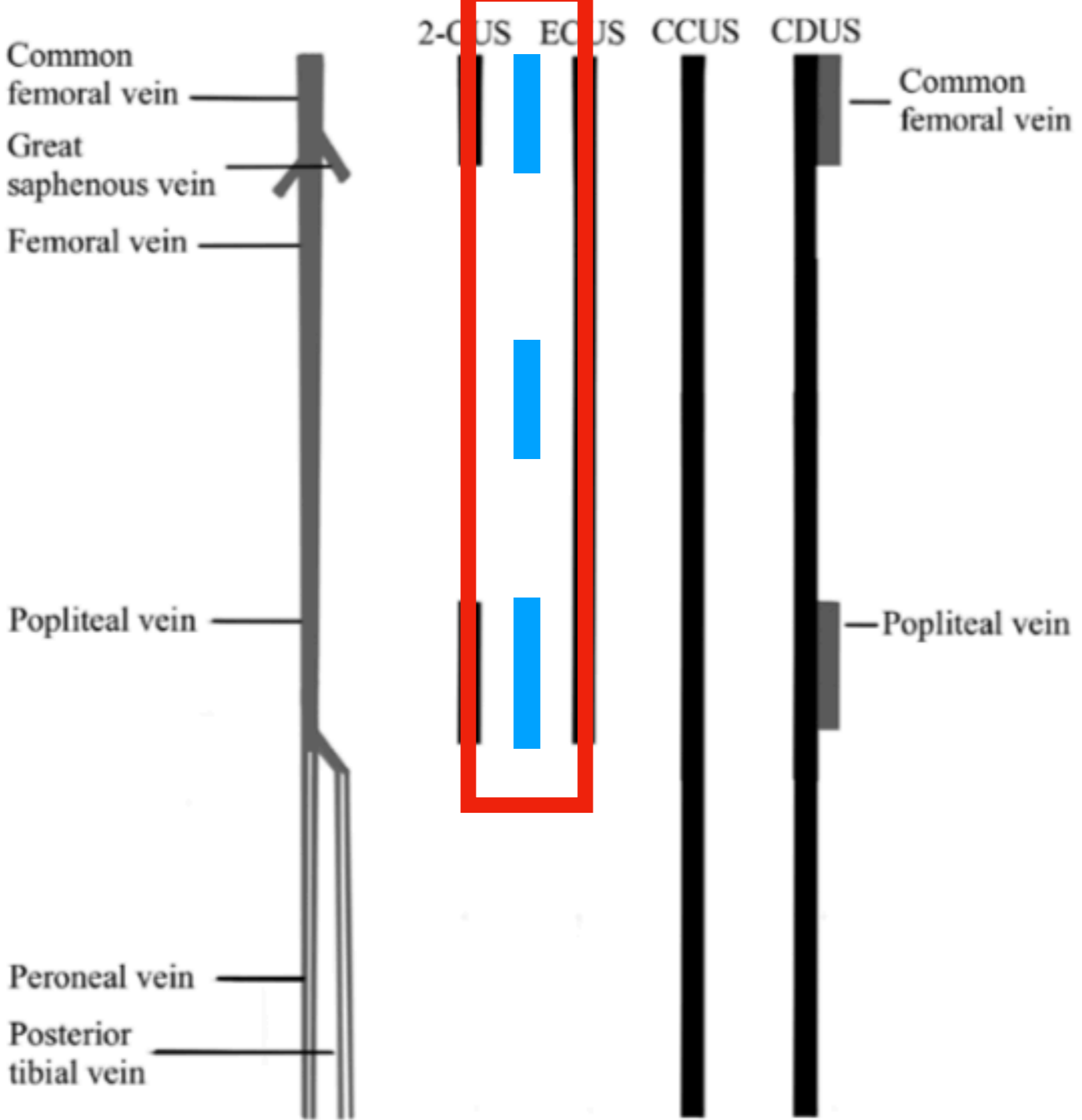




POCUS  
(Circulation)  
Inguinal-  
popliteal

-ve  
f/u in 5-7d

*Heather Hale, MD*



3 regions  
 Sen 90.57%  
 Spe 98.52%

2 regions  
 Sen 82.76%  
 Spe 98.52%

*Heather Hale, MD*



A swollen leg,  
what will you  
do ??





**DVT assessment**

**3 regions**

**Collapse 100%**

**Proximal only**

# POCUS Academy

## Let's transform EM practice



[juice119@gmail.com](mailto:juice119@gmail.com)

FB: Emergency Ultrasound Training Center

