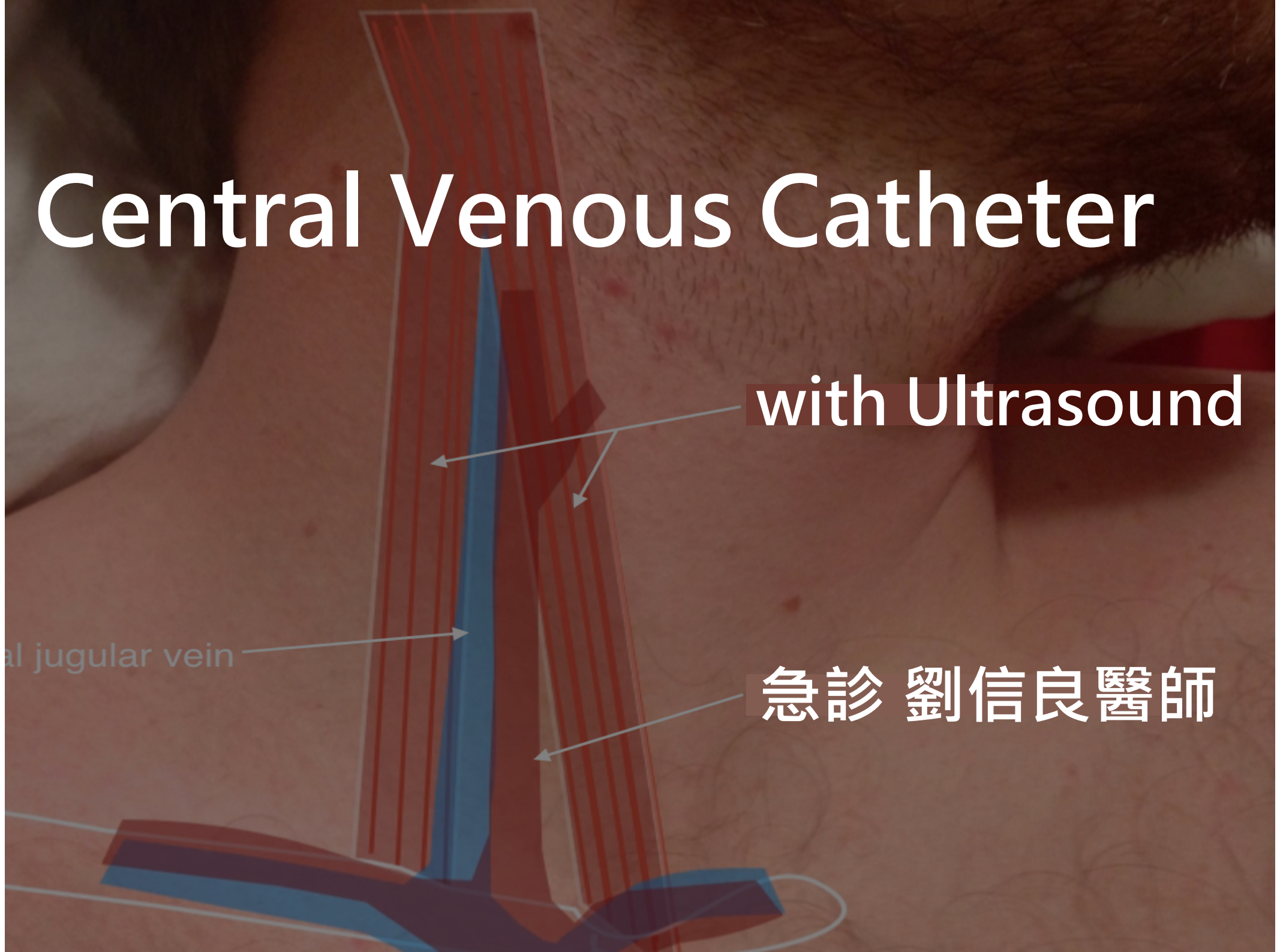

Central Venous Catheter

with Ultrasound

al jugular vein

急診 劉信良醫師



上完課就一定會

- 了解必要性
- 如何操作
- 第一次就上手

請問

在剛剛trauma的部分，你印象最深的是哪一部分？

有需要嗎？

請問

志玲學妹打CVC已經打了30分鐘，試過subclavian和neck，戳了好幾十次，淚眼汪汪地找你求助.....

**先照Chest X-ray！！
有氣胸不關我的事...**

請問

病人確診登革熱，血小板只剩一萬，PT又延長，合併休克，此時你要打CVC嗎？

如何操作

要選誰？

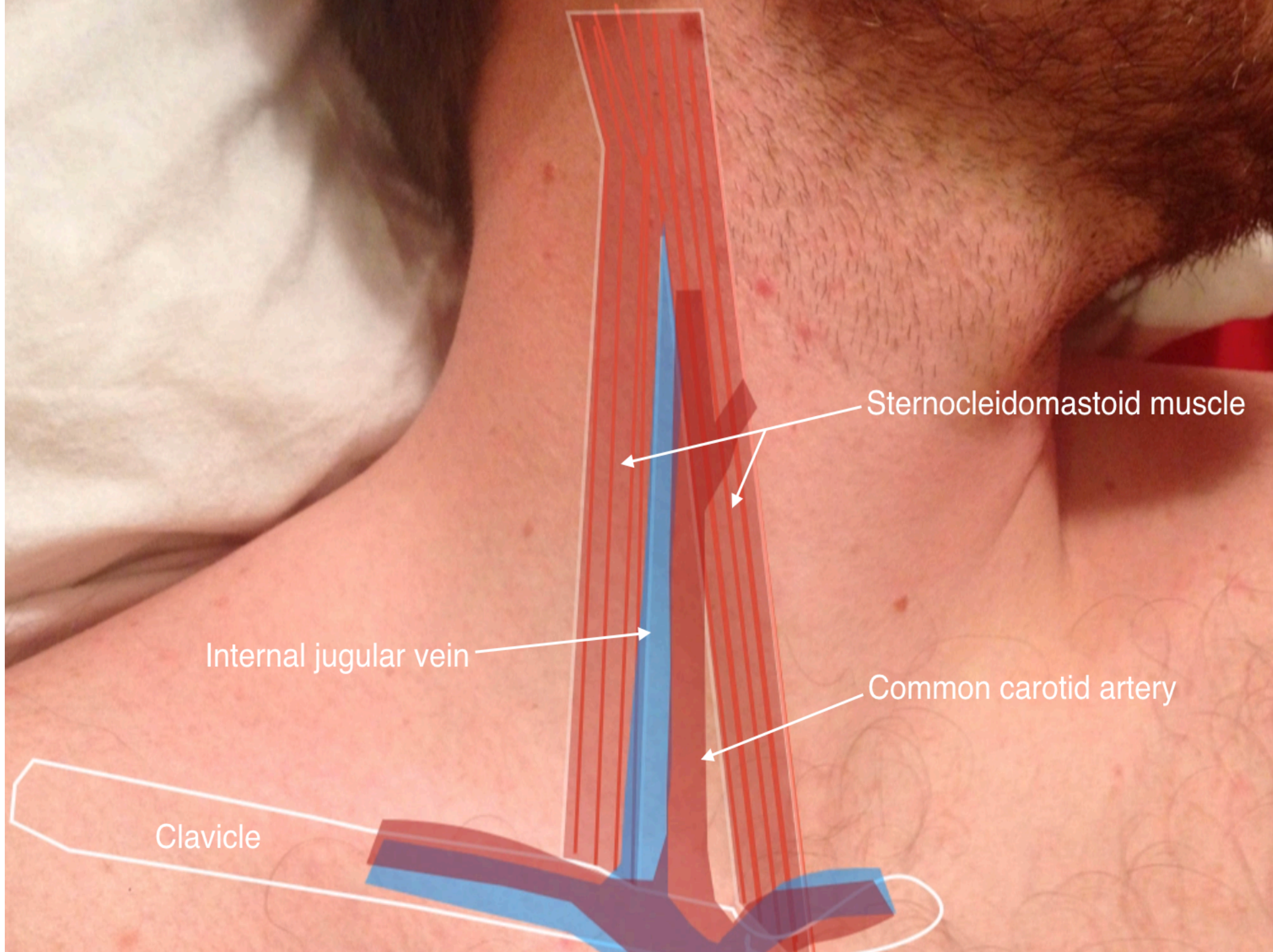
Subclavian

- 較少artery puncture
- 較多氣胸

Internal Jugular

- 較多artery puncture
- 較少氣胸



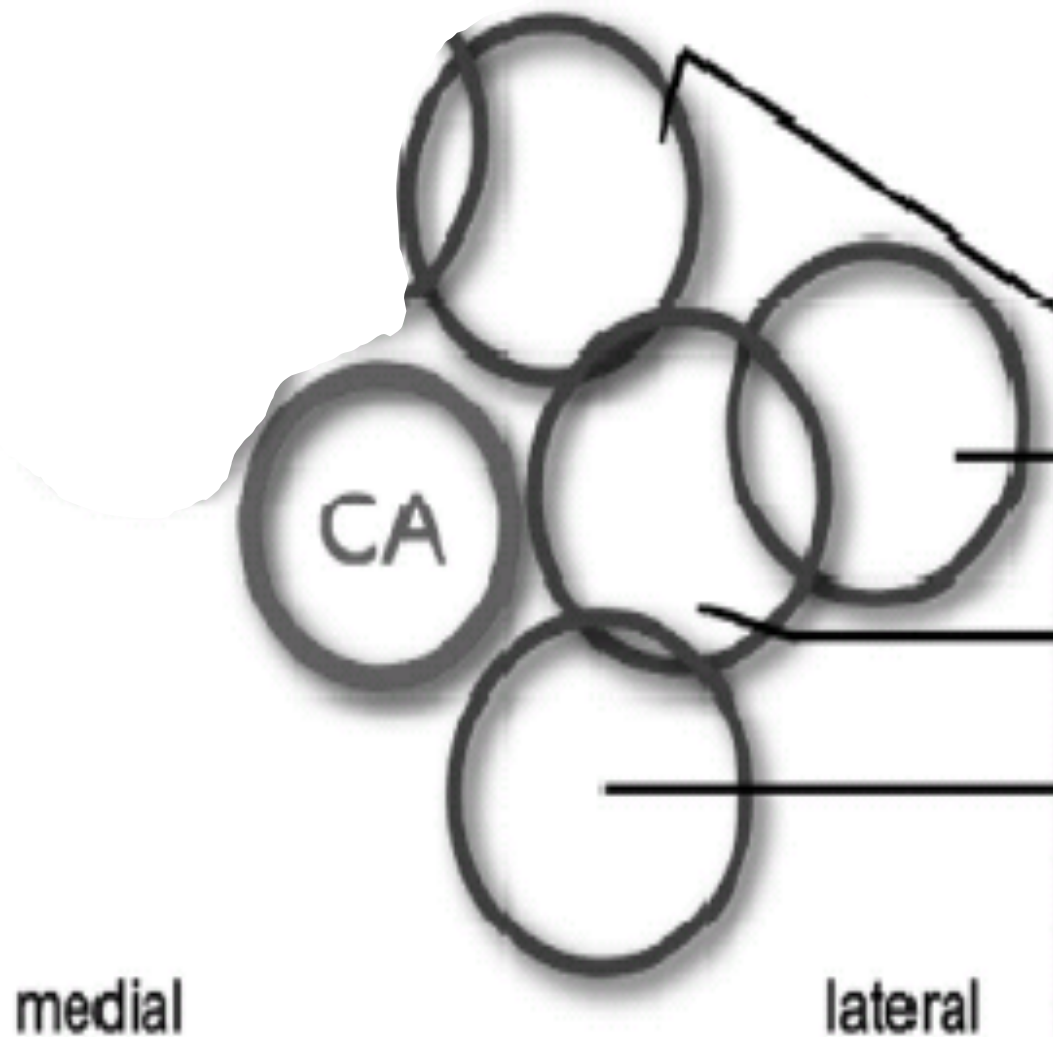


Sternocleidomastoid muscle

Internal jugular vein

Common carotid artery

Clavicle



antero-lateral	9 - 92
far lateral	0 - 4
lateral	0 - 84
posterior	0 - 9
not visible/ thrombosed	0 - 18

要選誰？



要選誰？

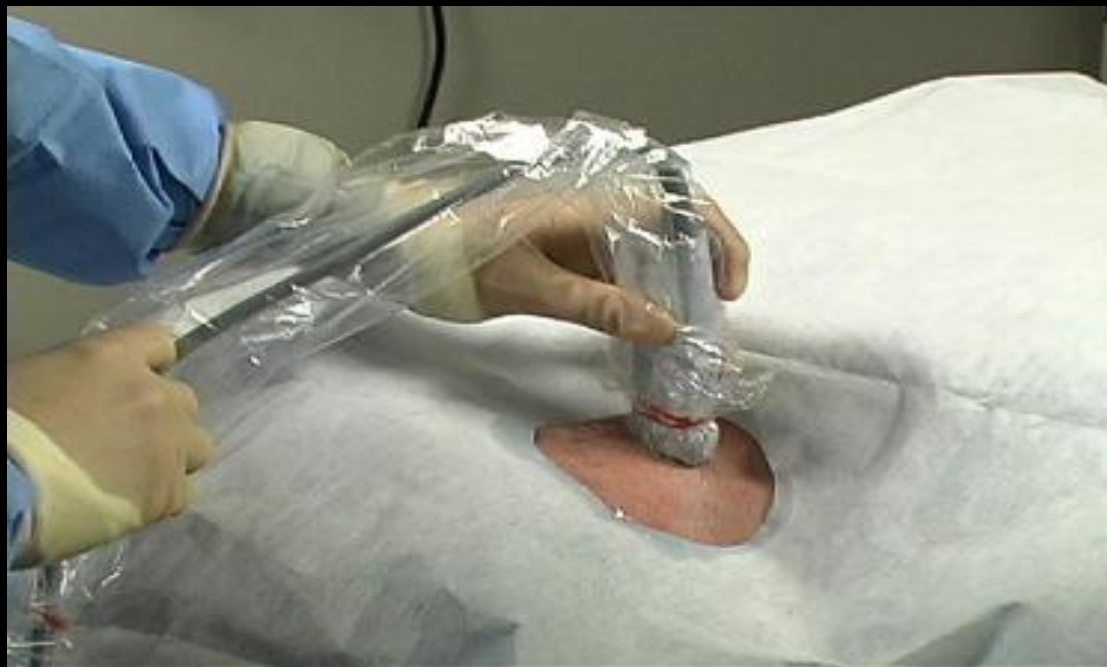定位

- 靜態
- 容易跑掉
- 不用無菌
- 好學

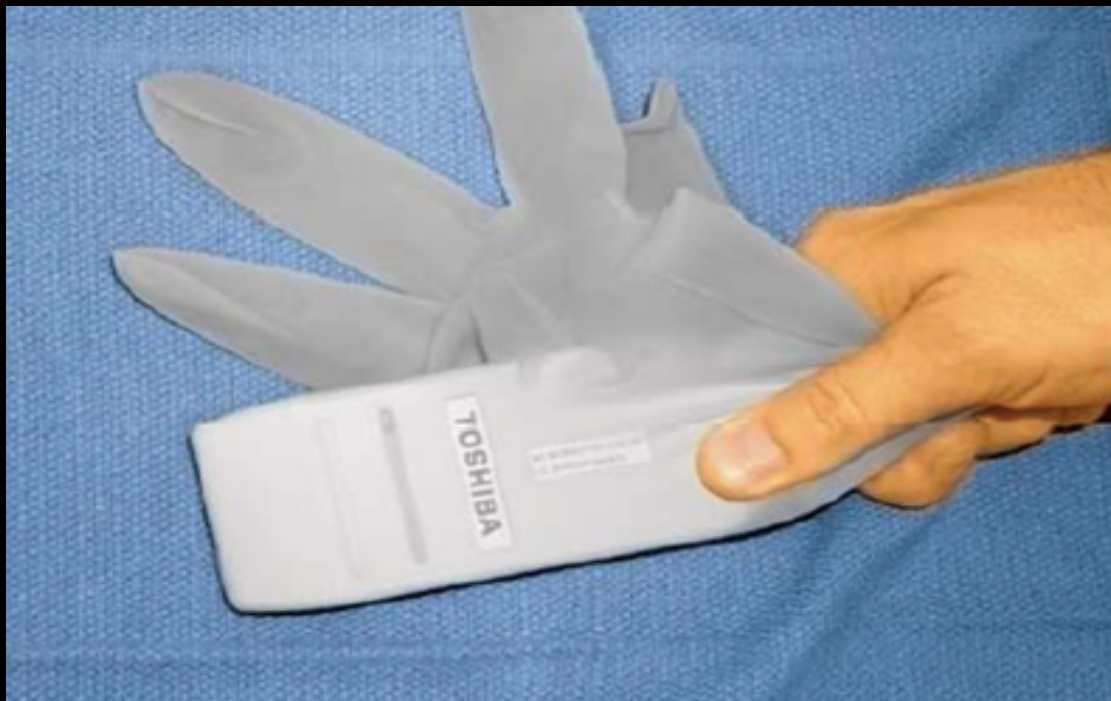即時導引

- 動態
- 不易跑掉
- 要無菌
- 要花時間

標準
做法

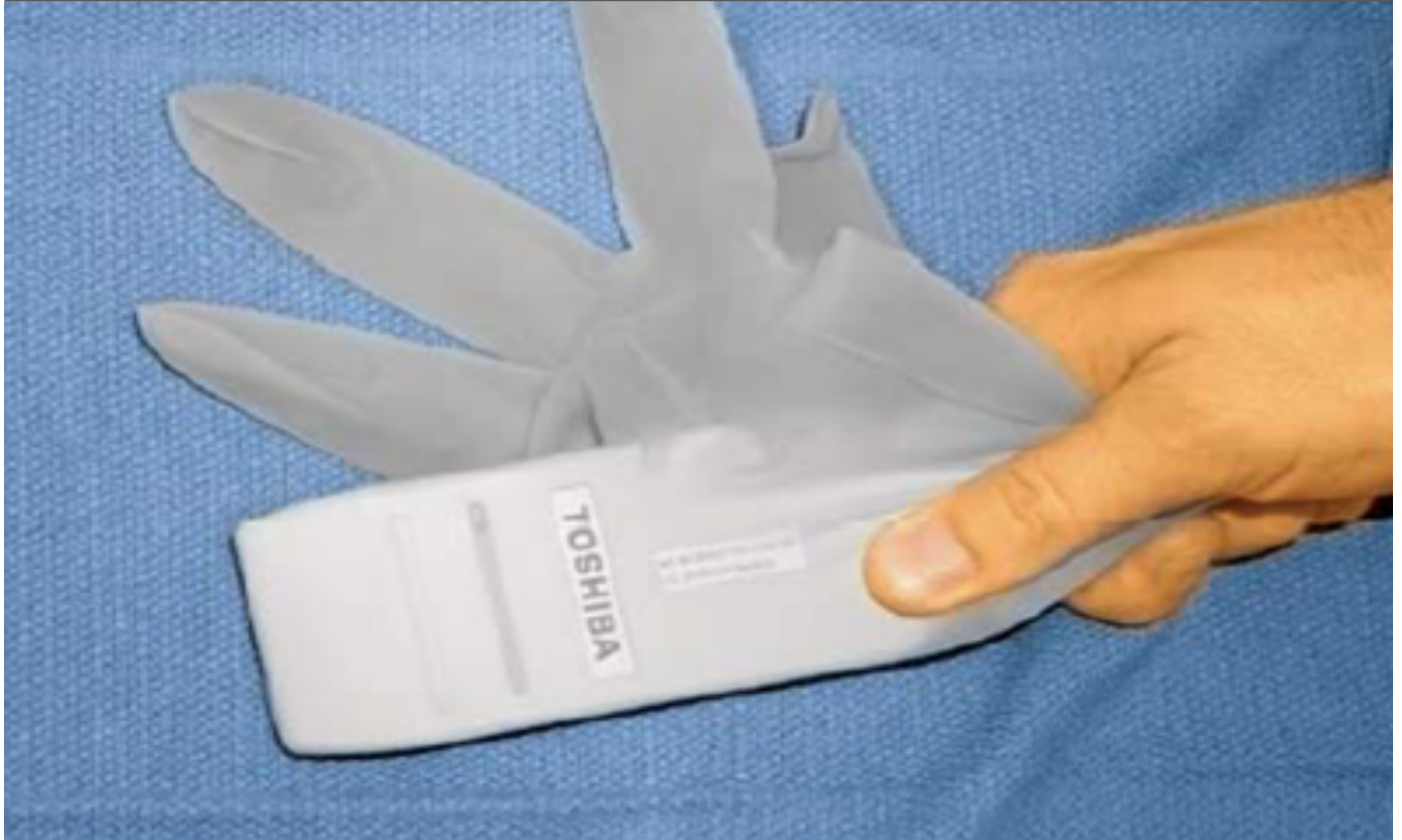

克難
做法





沒有無菌套怎麼辦？



2:54:50 pm

9L4 #52

17MHz 30mm

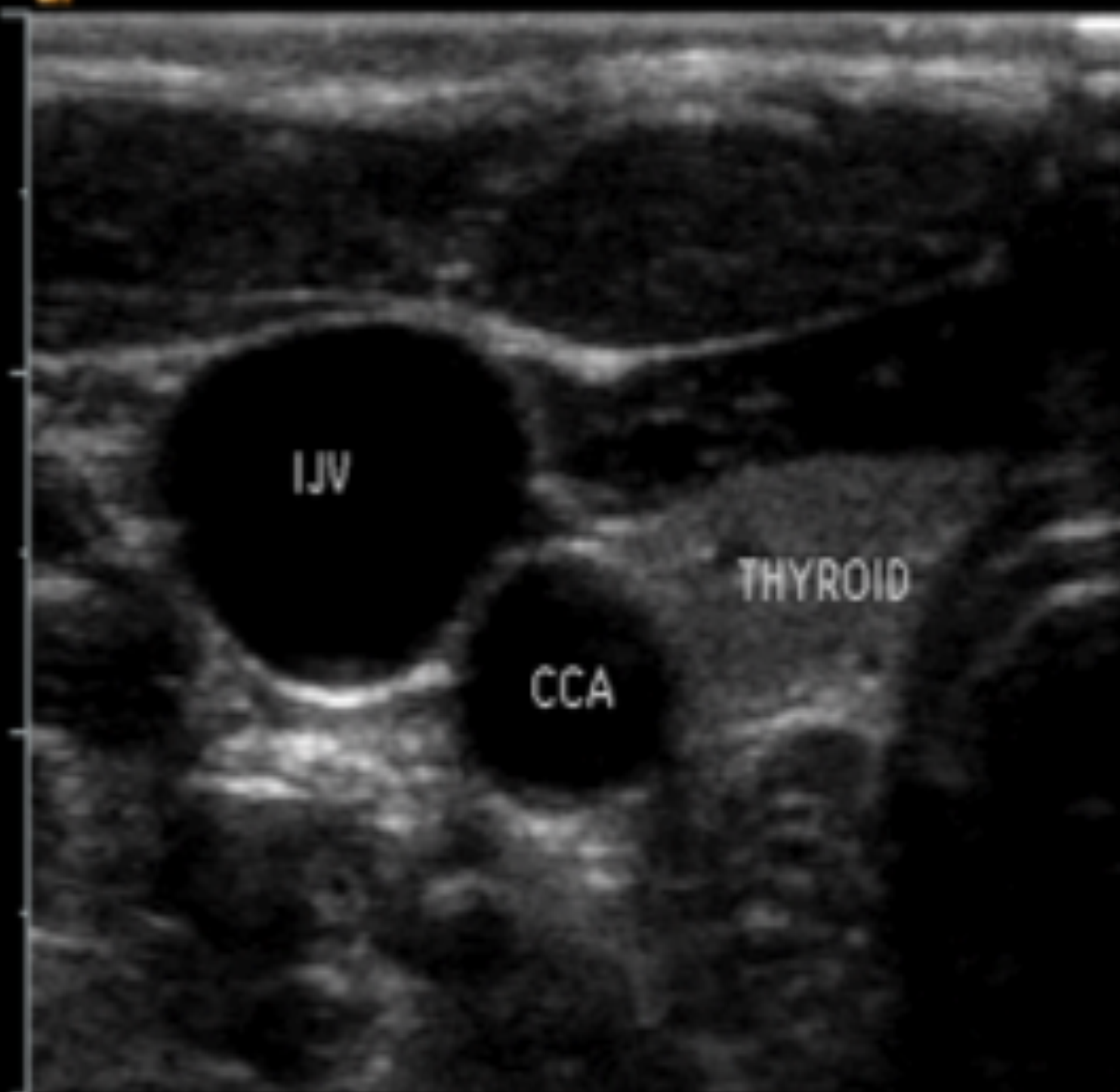
Venous=

Soft

67dB SC1/51/3/3

Gain= 14dB $\Delta=1$

Store in progress



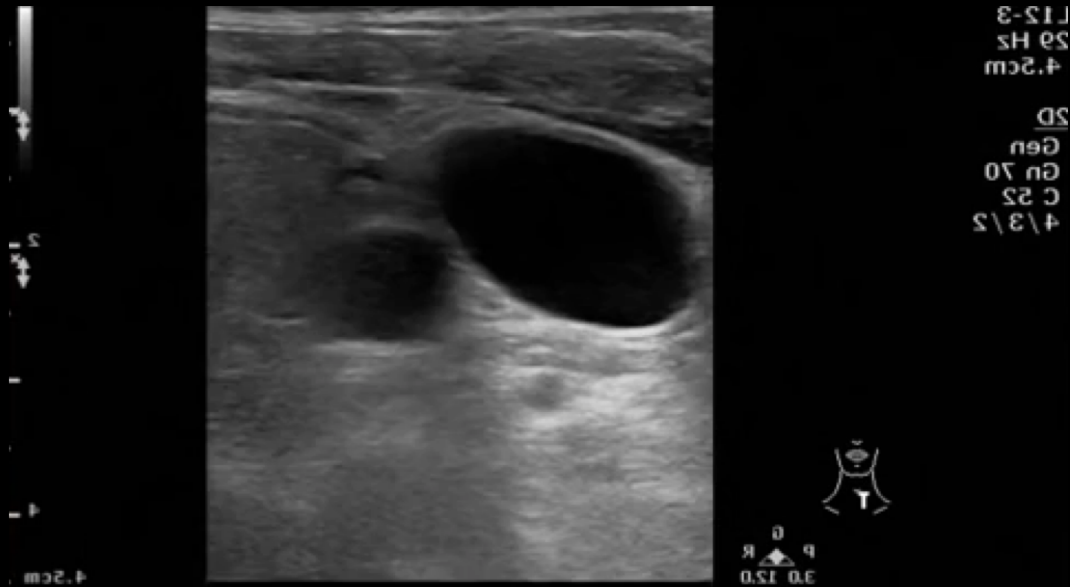
IJV

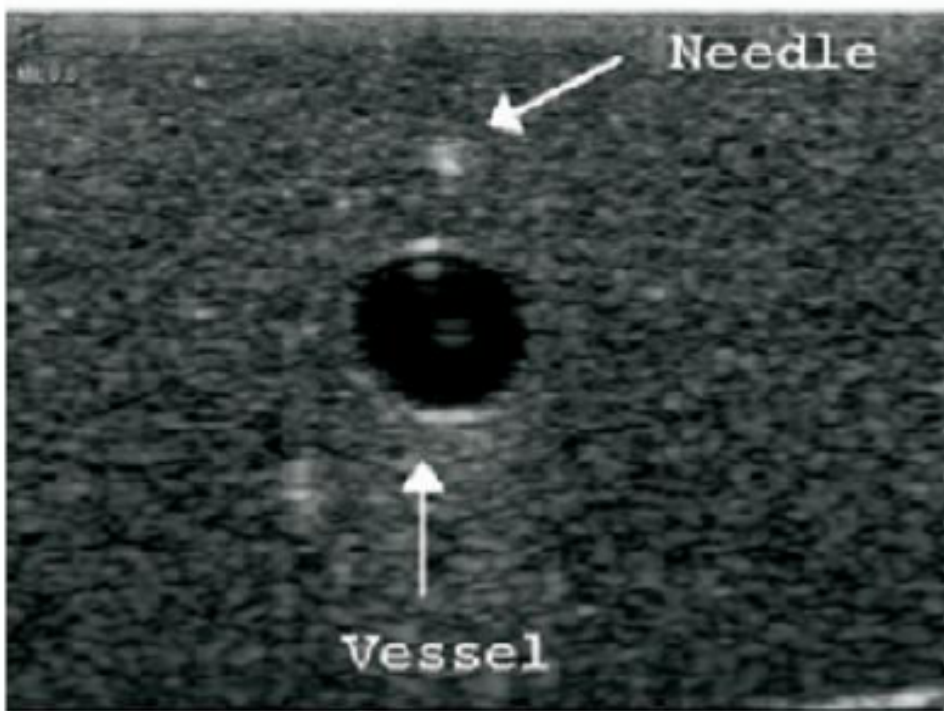
THYROID

CCA

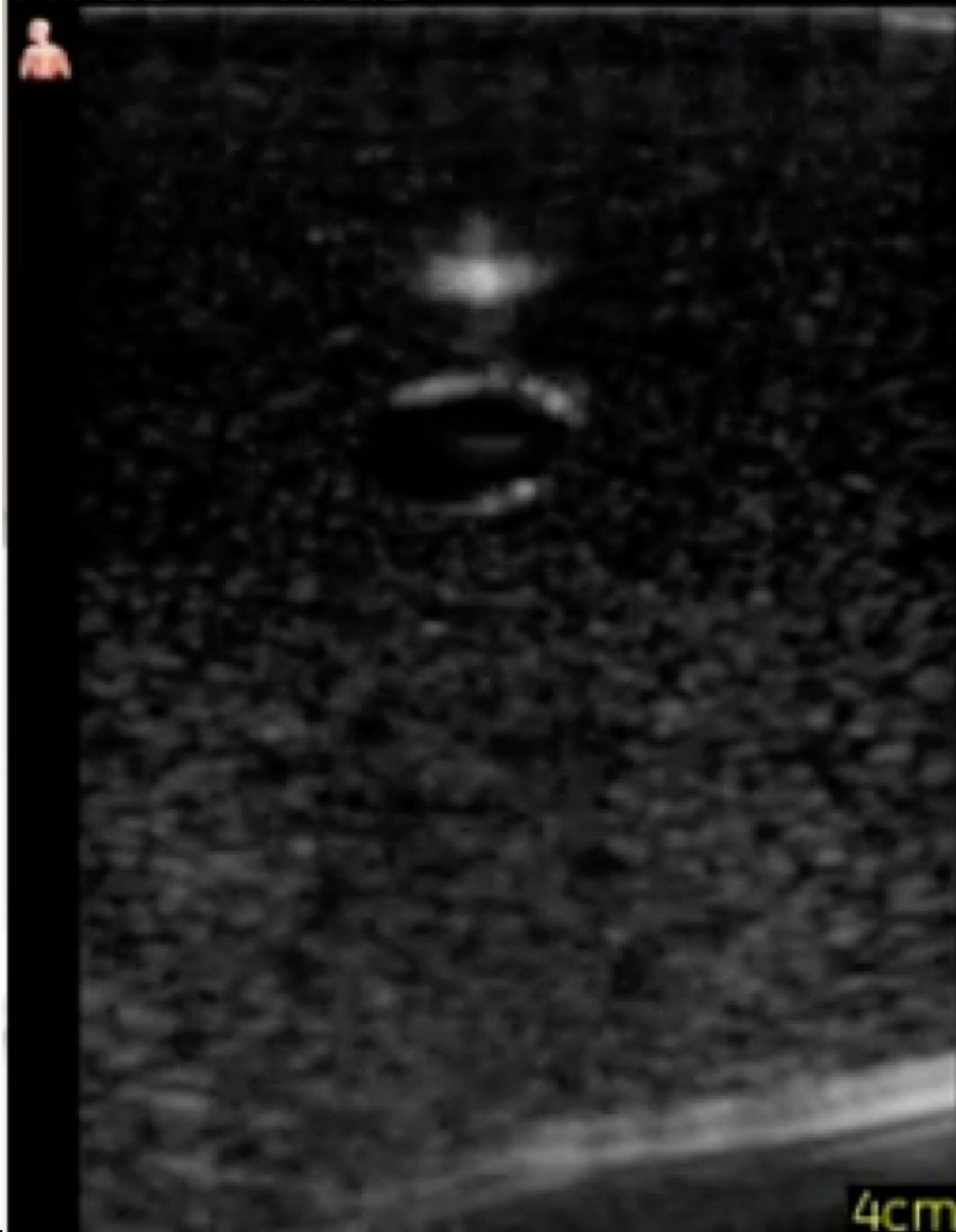Artery? Vein?

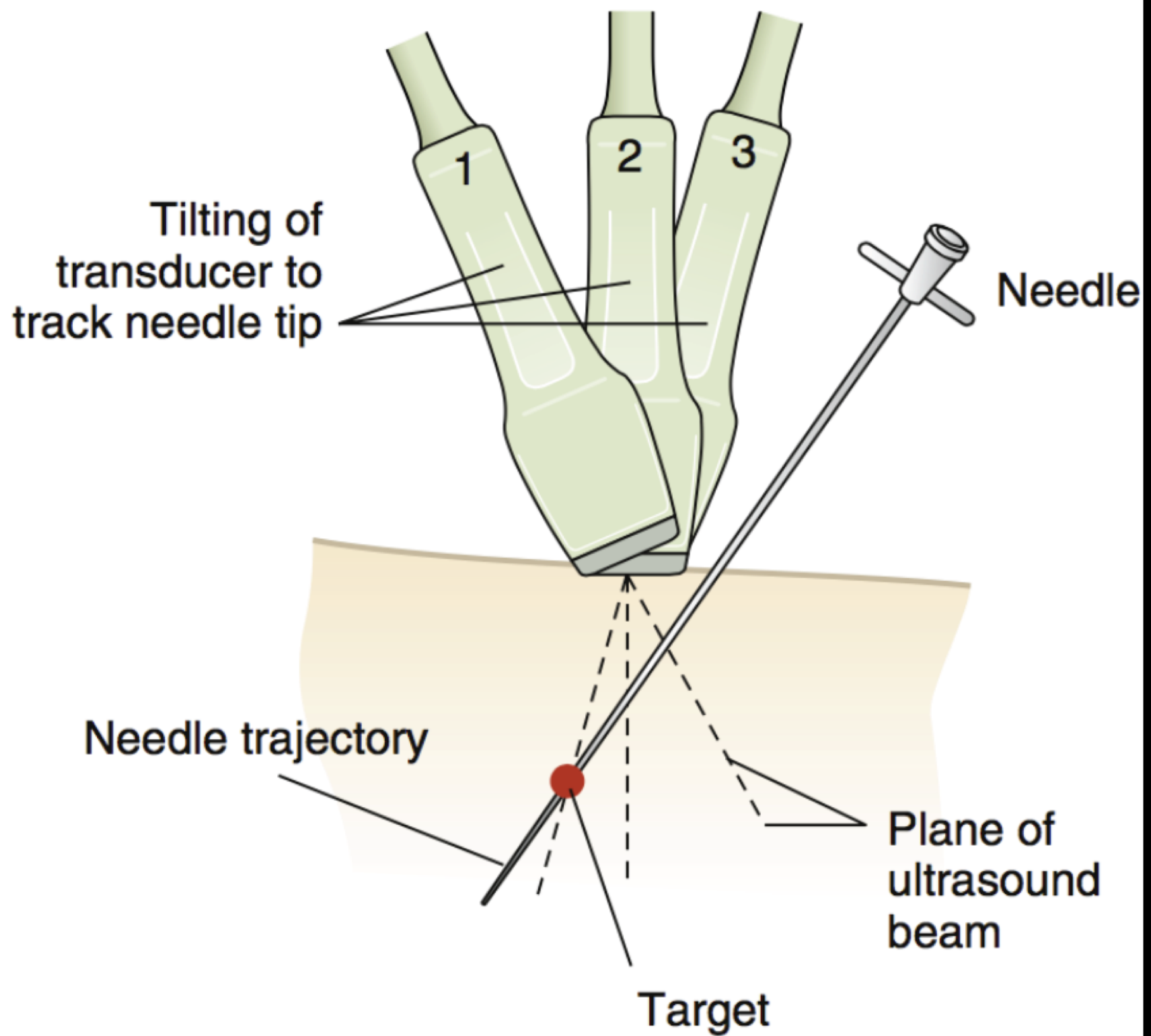
- 探頭的mark方向，相對位置
- 壓看看
- Doppler的 PW mode

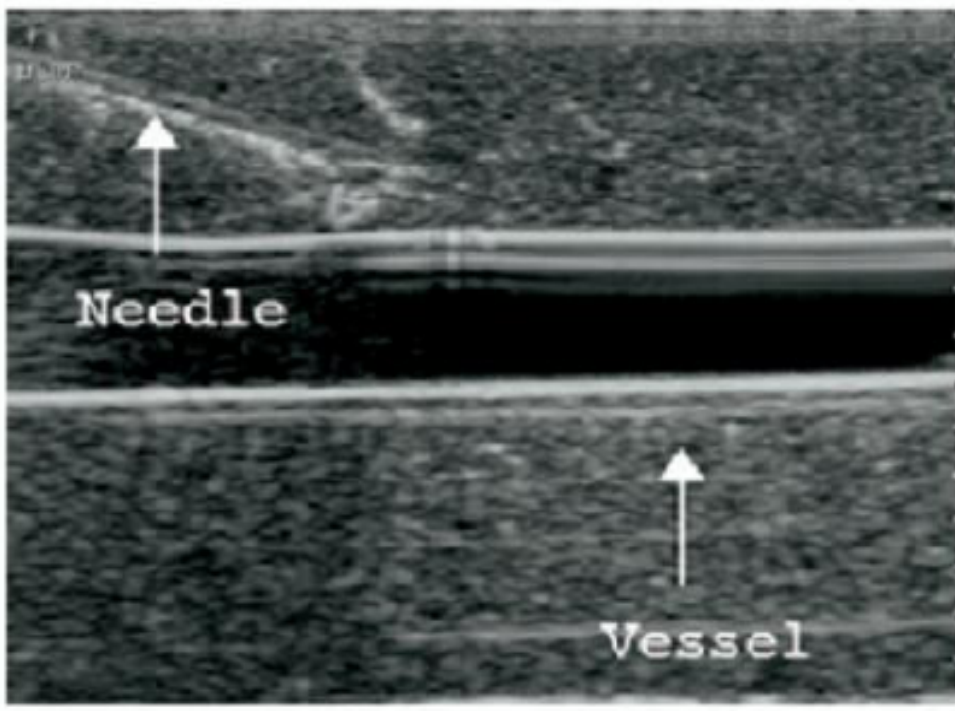




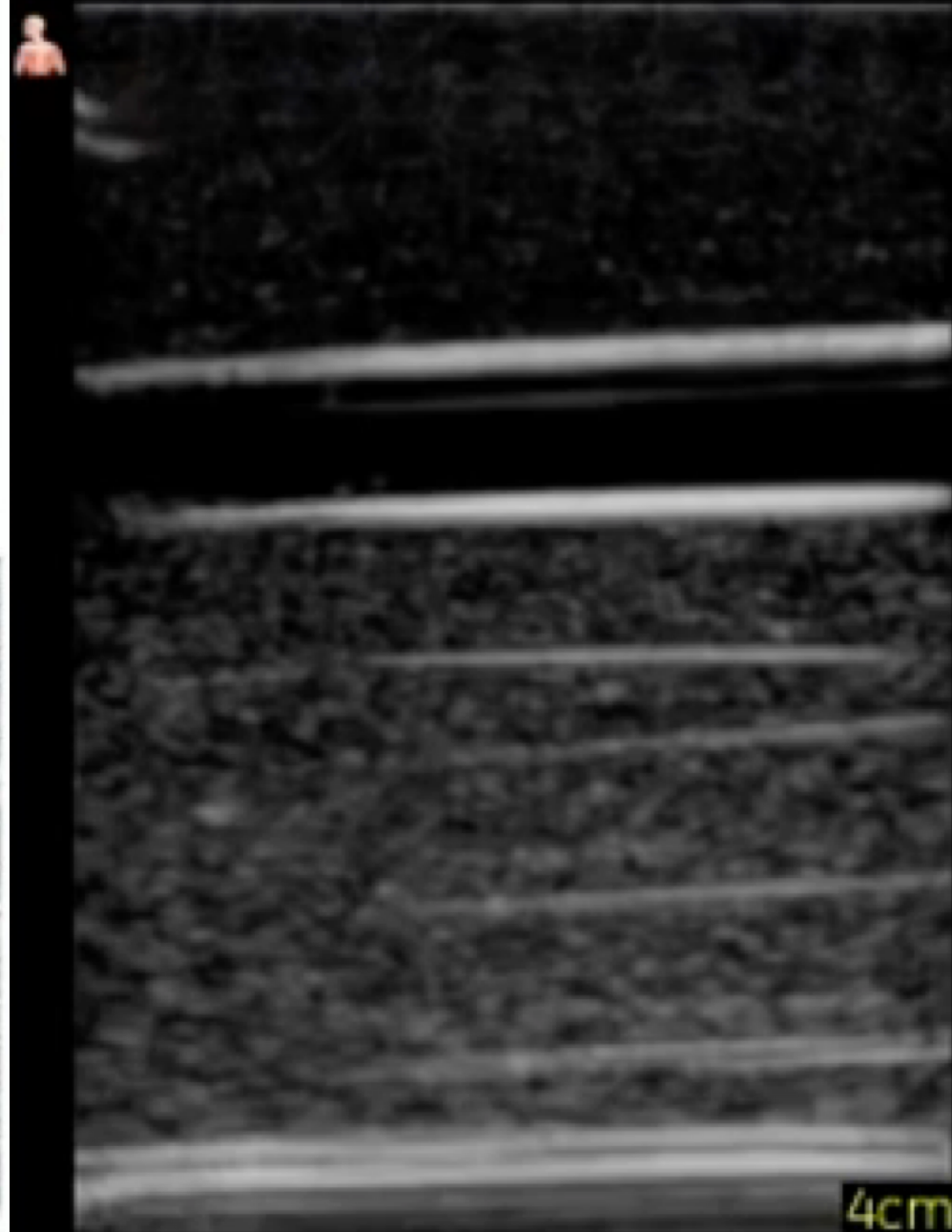
#: 34 1:52:06 PM
MI: 0.8 TI: 0.2 28/Mar/2015



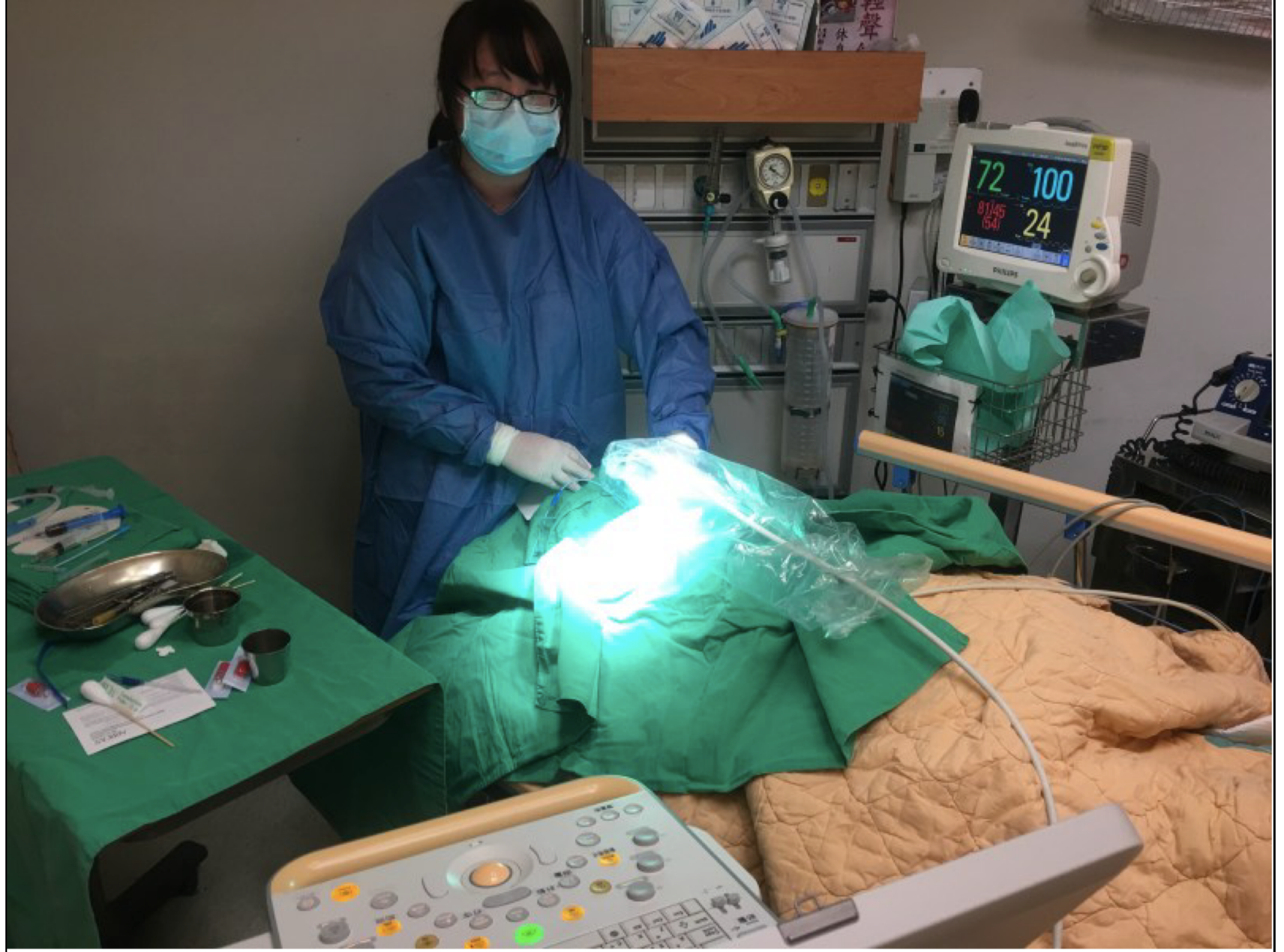



#: 34
MI: 0.8 TI: 0.2
1:51:27 PM
28/Mar/2015



上戰場吧！！



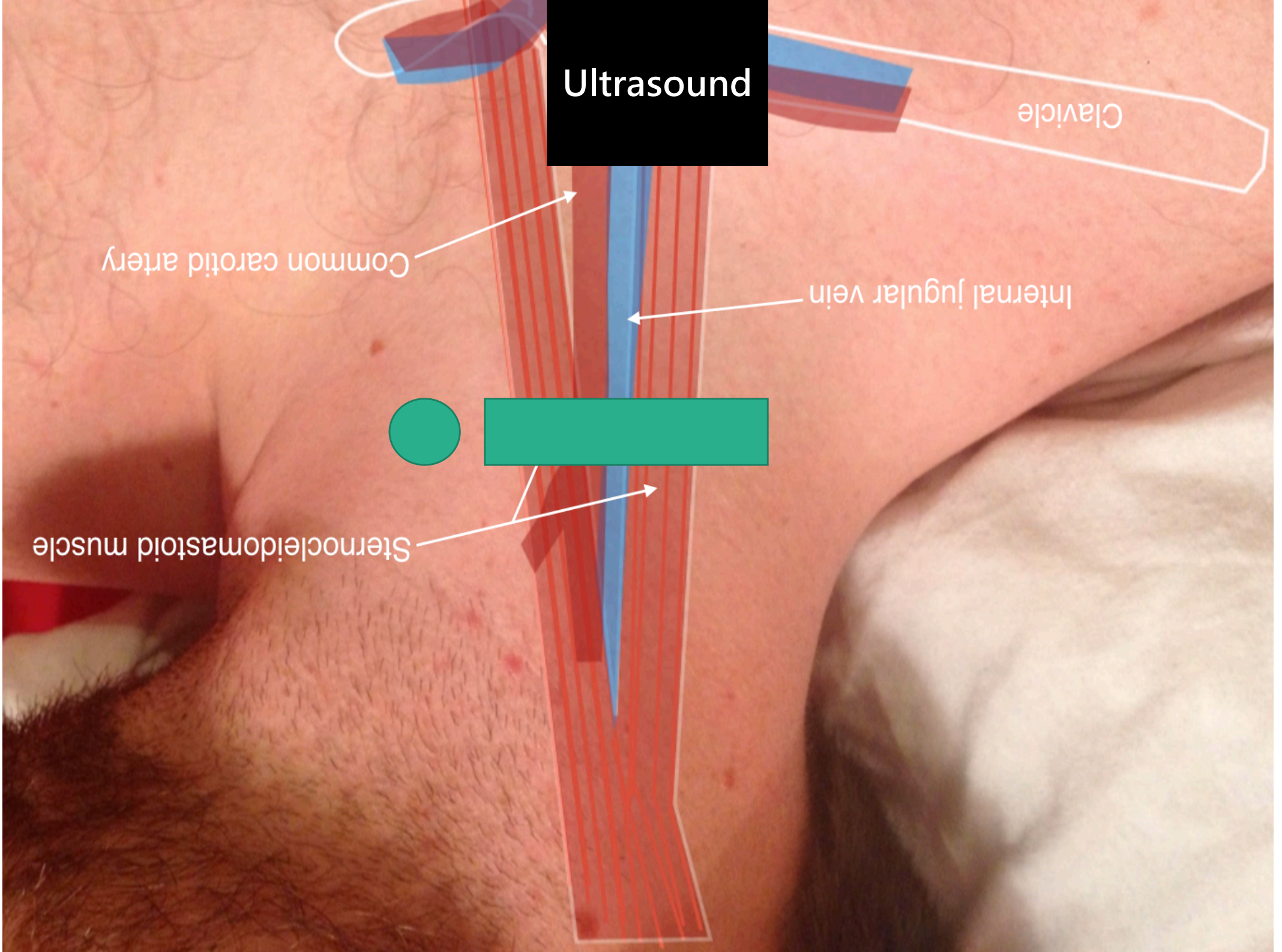
Ultrasound

Clavicle

Common carotid artery

Internal jugular vein

Sternocleidomastoid muscle

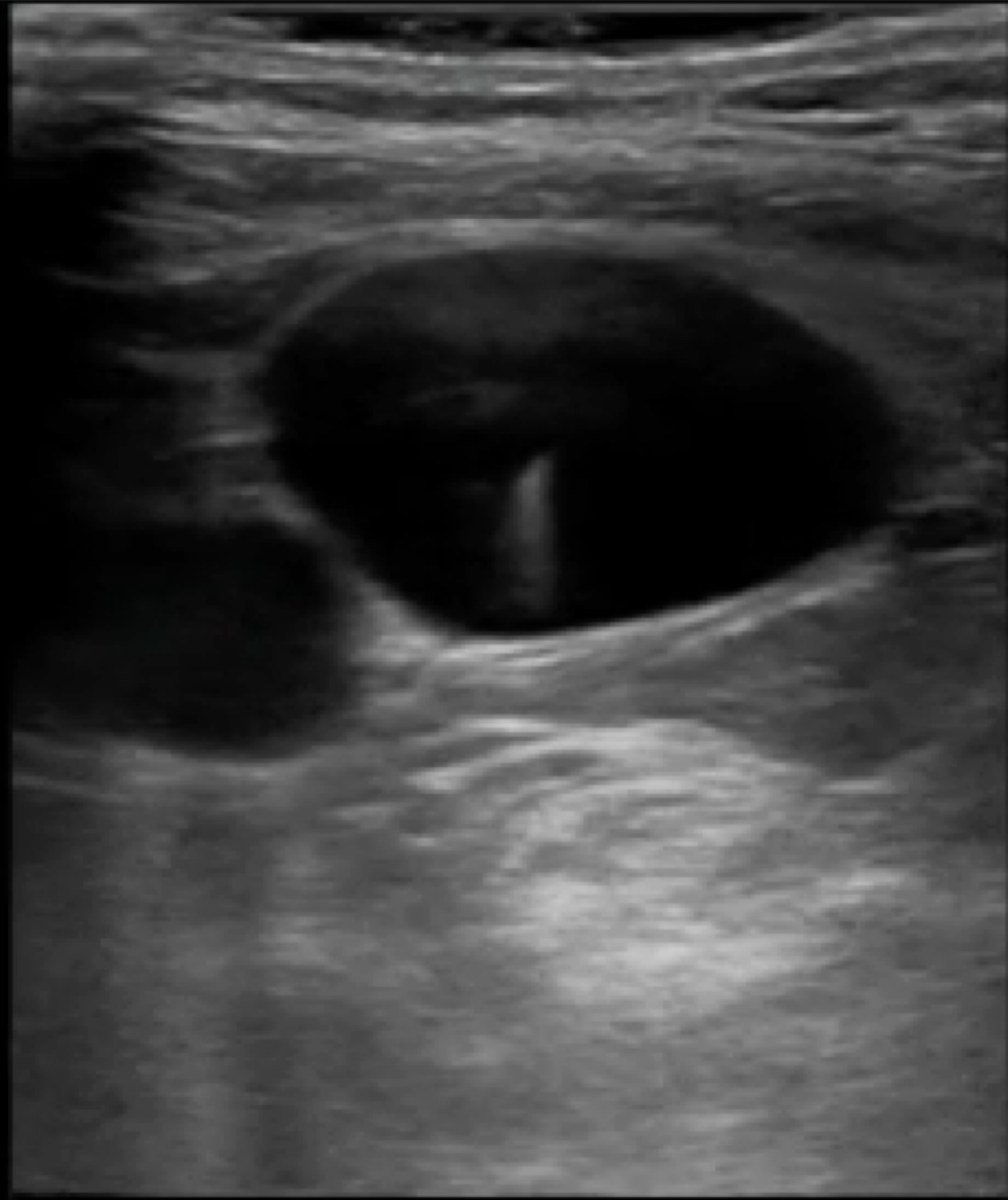



S
P

P

4.2cm



11

0.0 1.5 3.0
R B L

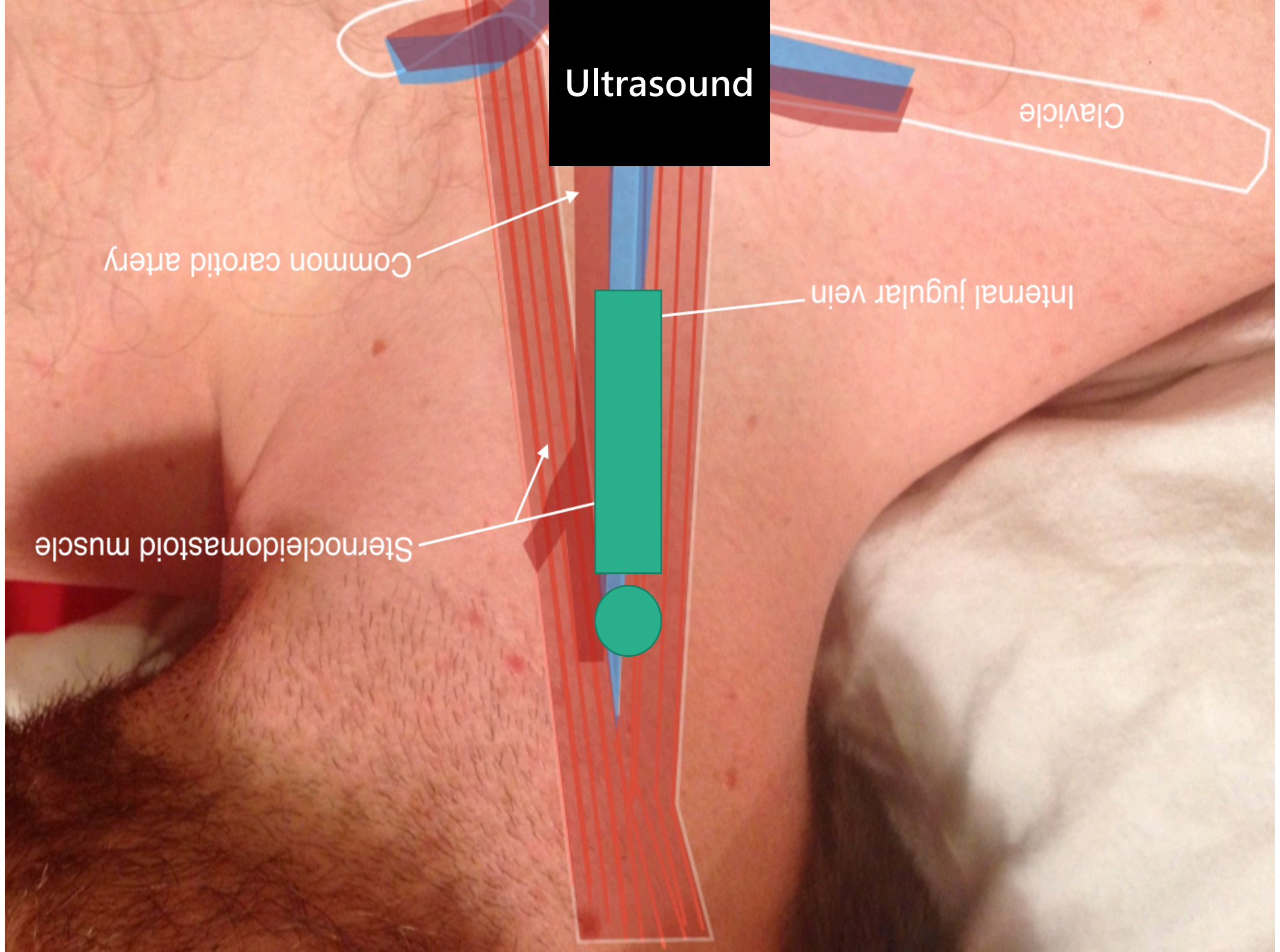
Ultrasound

Clavicle

Common carotid artery

Internal jugular vein

Sternocleidomastoid muscle


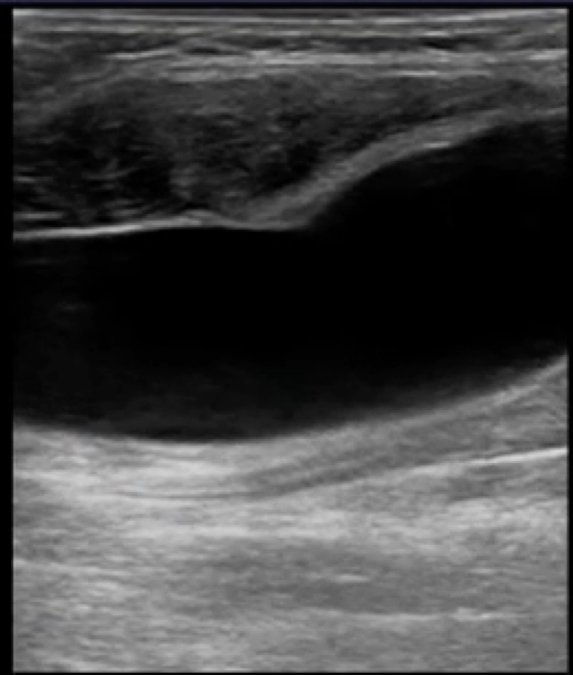


Superficial
L12-3
29 Hz
4.5cm

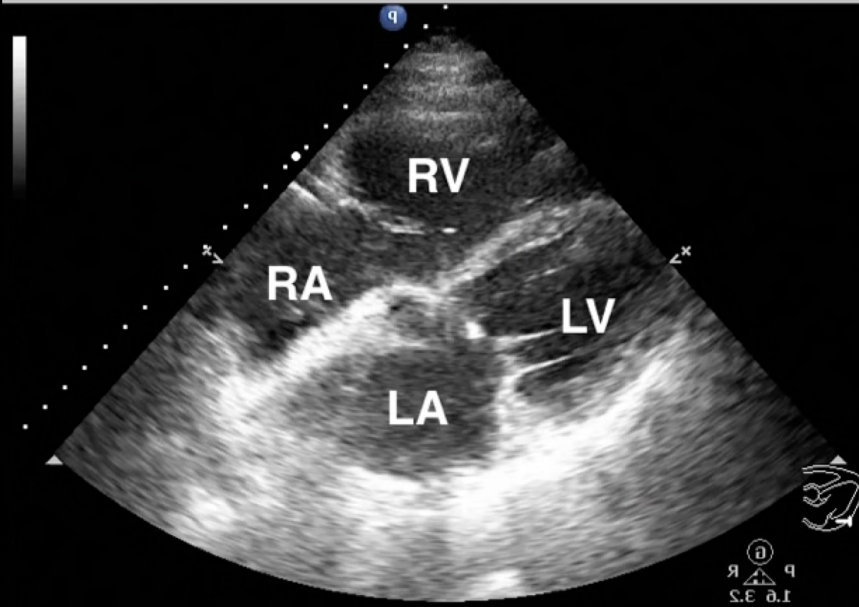
2D
Gen
Gn 70
C 52
4/3/2



G
P R
3.0 12.0



Bubble test /Subcostal 4



Adult Echo
1-22
26 Hz
21.0cm
SD
HGen
02 nD
C 20
3 \ 2 \ 0

Sonography for CVC

- 救援、解剖變異
- In / Out plane
- 擺位、擺位、擺位

急診 劉信良醫師

cutelpliu@gmail.com