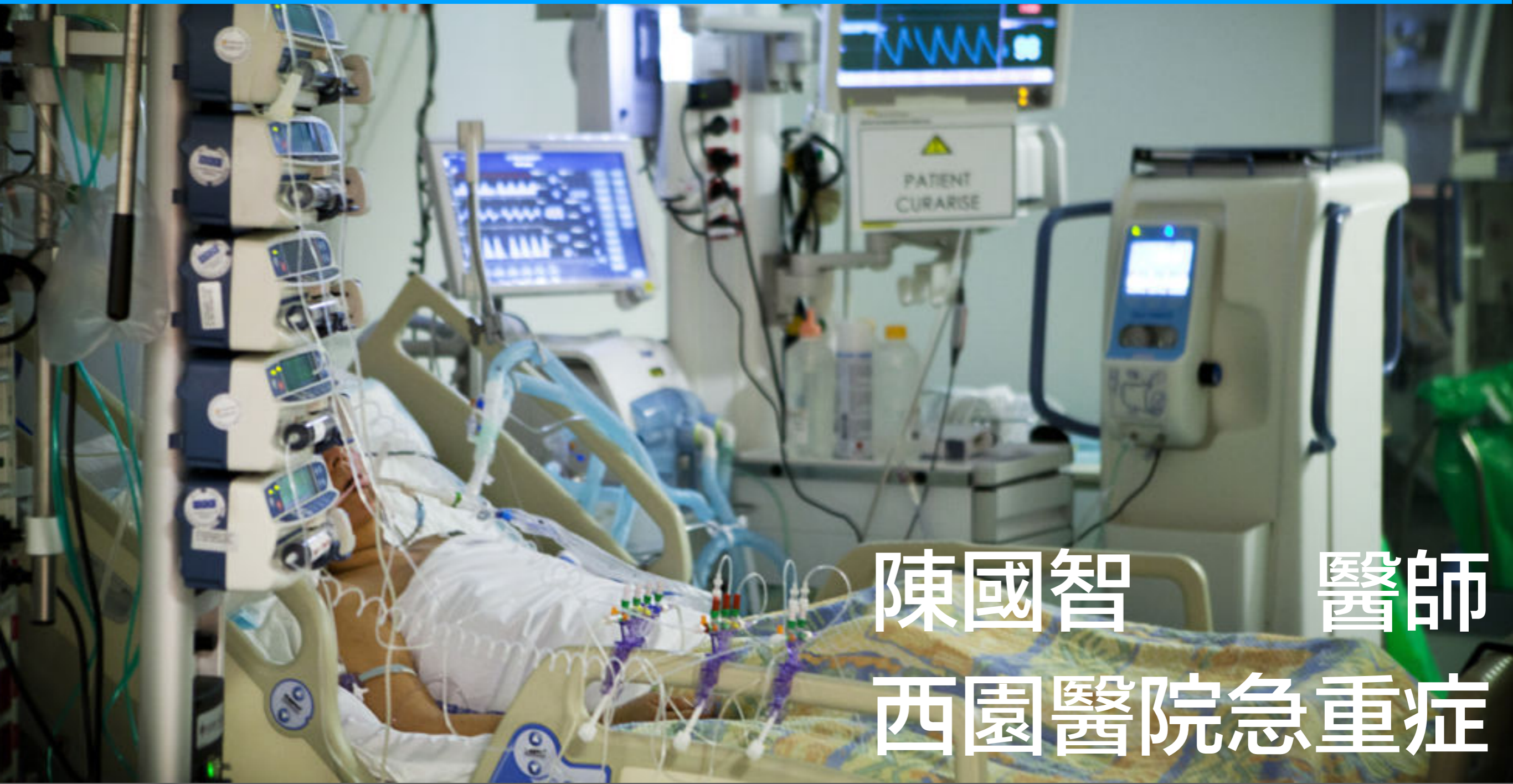

How to Start Critical Care UltraSound (CCUS) in my ICU




陳國智 醫師
西園醫院急重症

Conflict of Interest

None



NO. 0000 MONITOR UNIT 01
RESERVE 000000 000000 000000 000000



HR 131

RR

CVT (17)

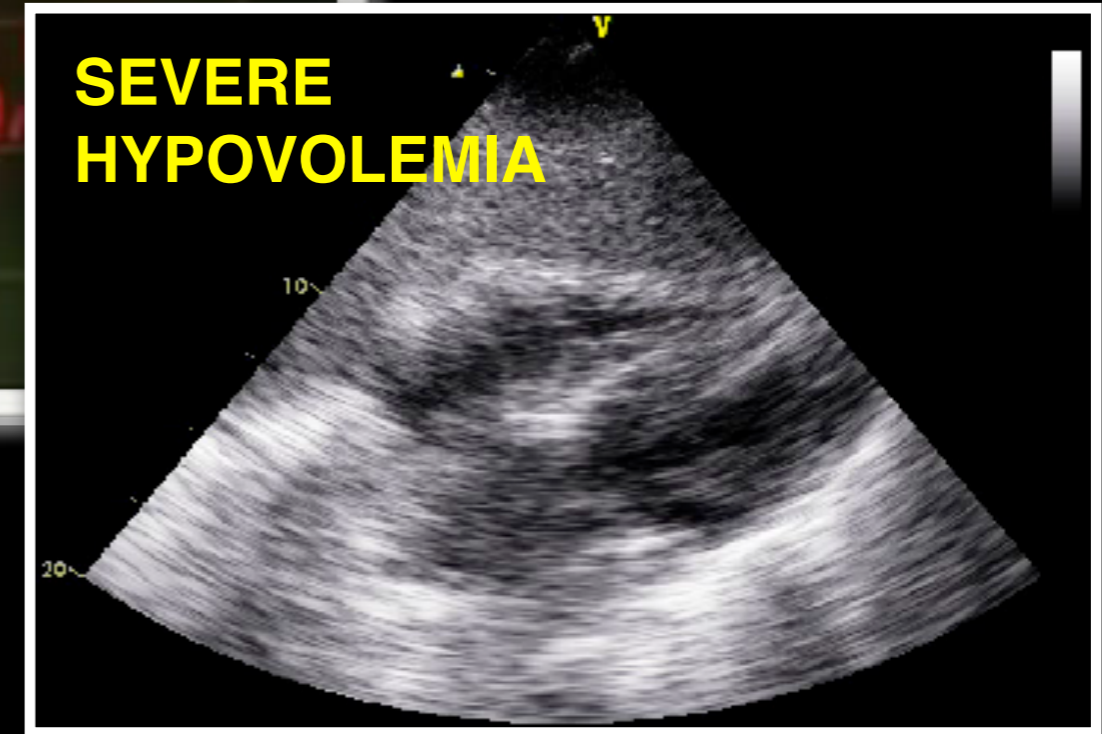
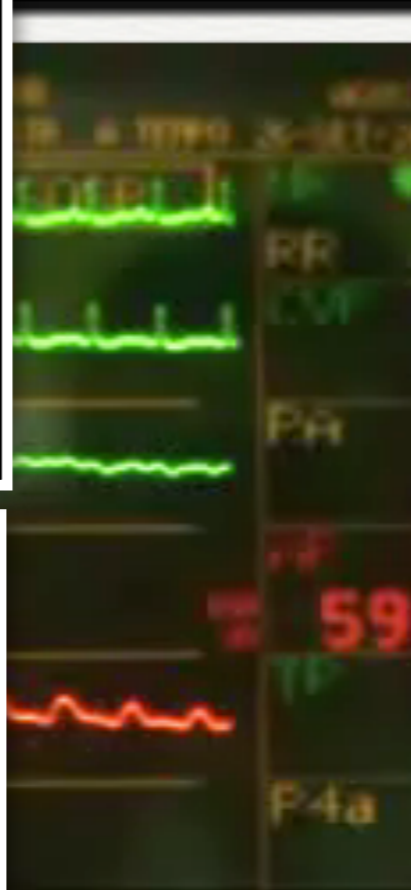
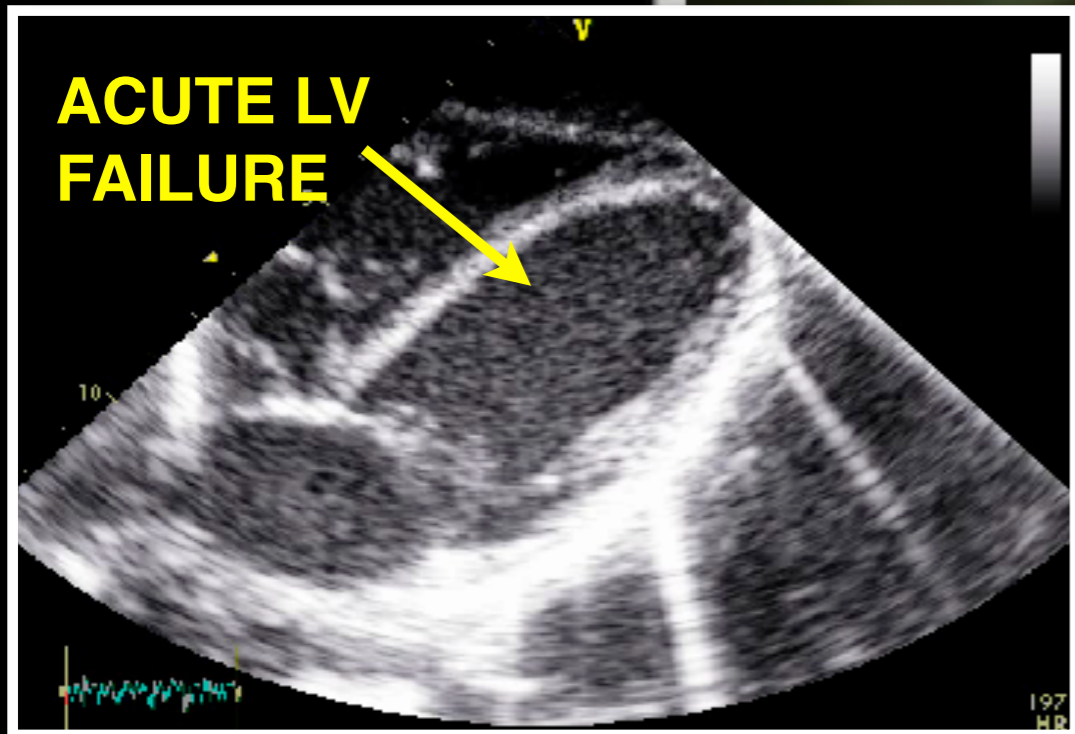
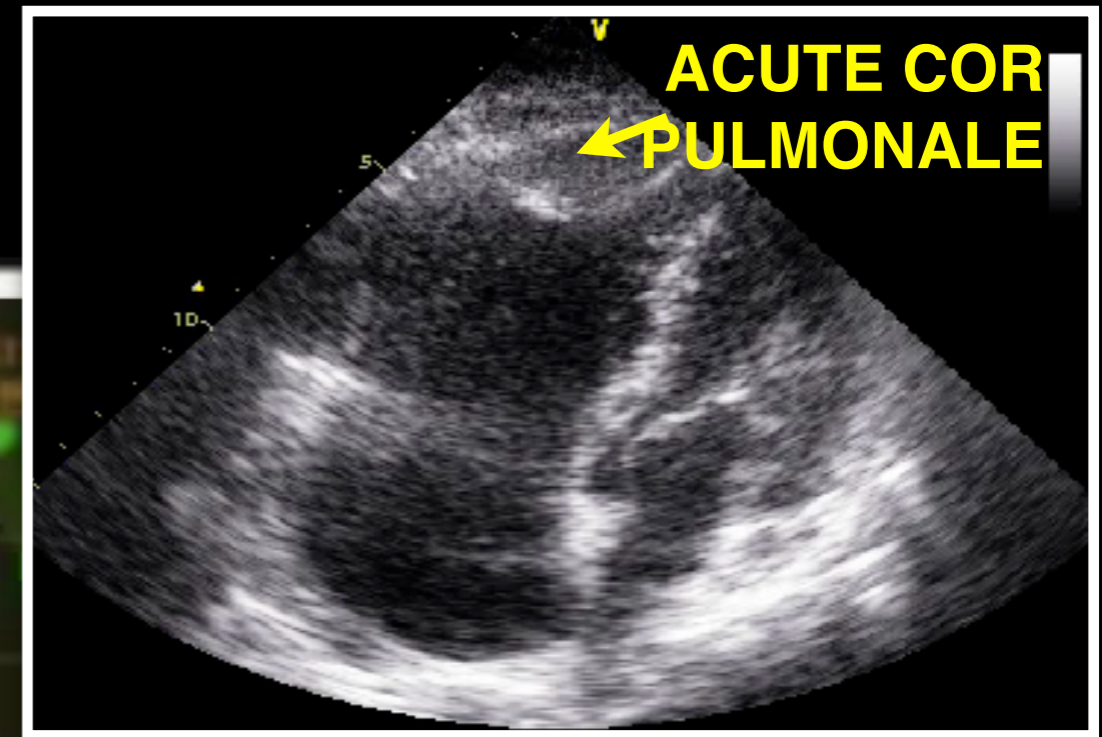
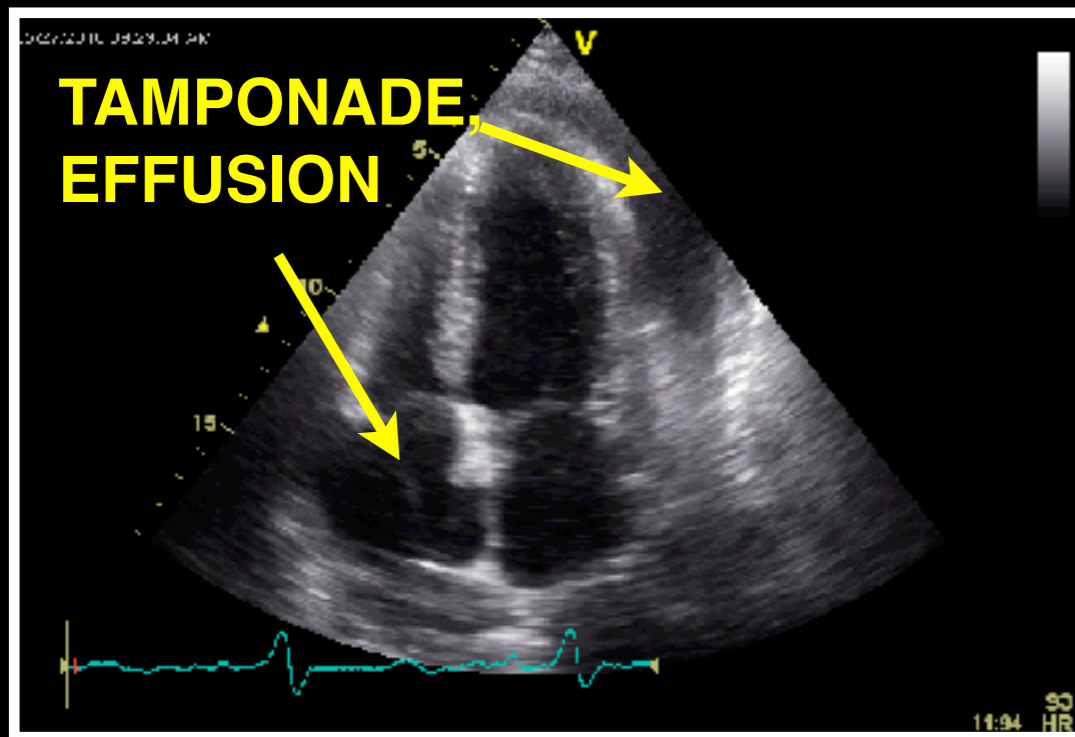
PR

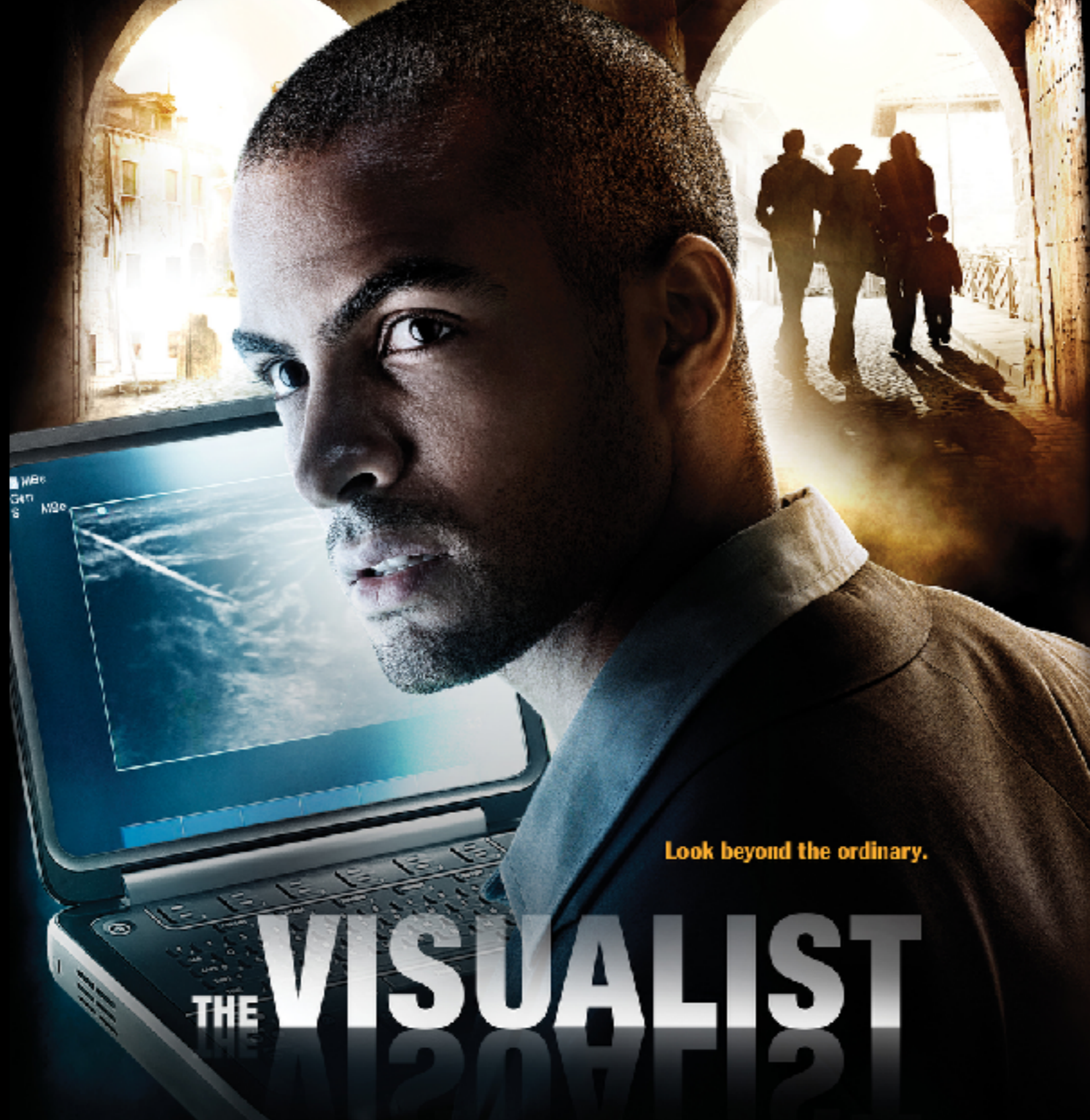
SP (49)

59/42

P-4a

Critically ill, shocked patient. **Then ??**

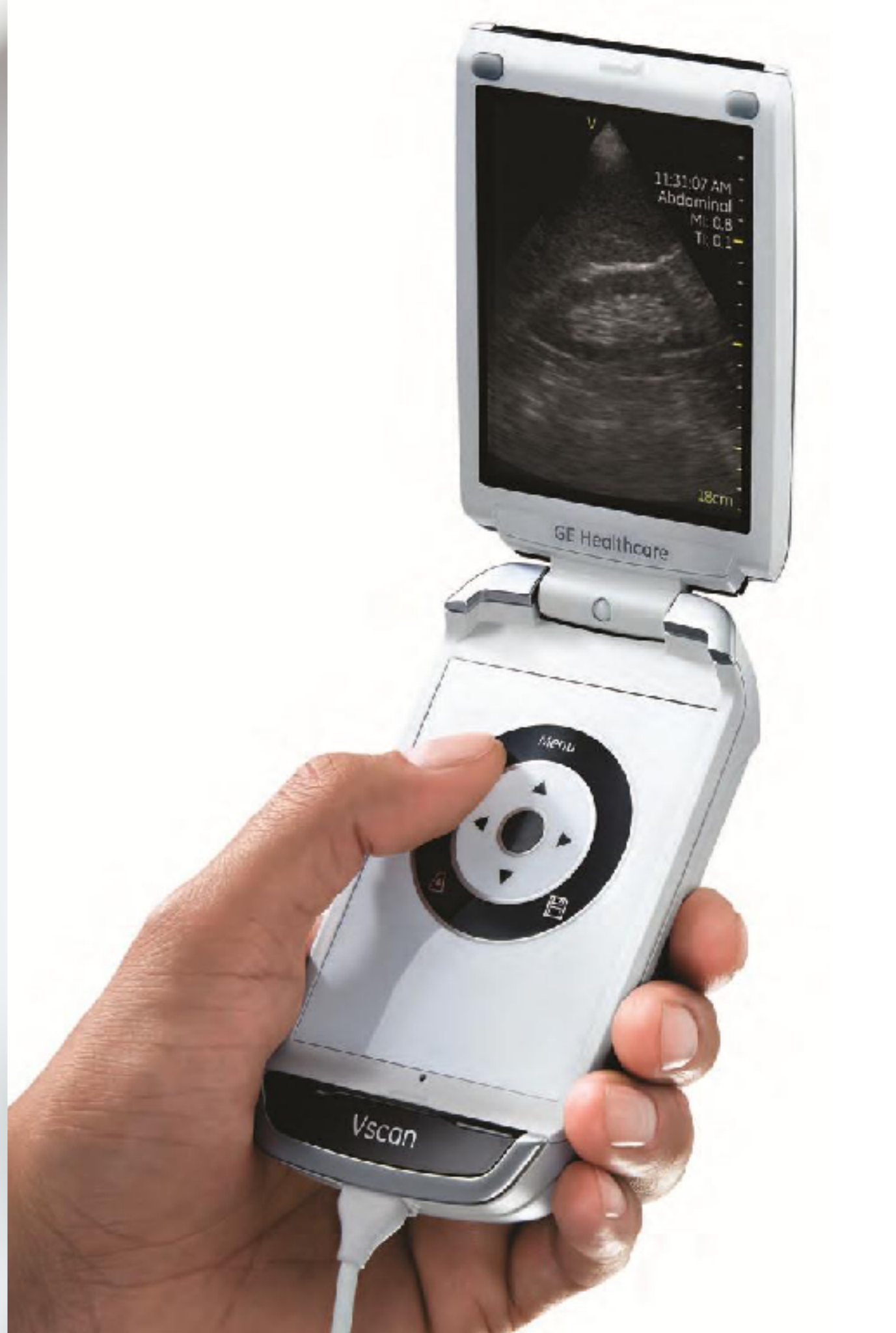



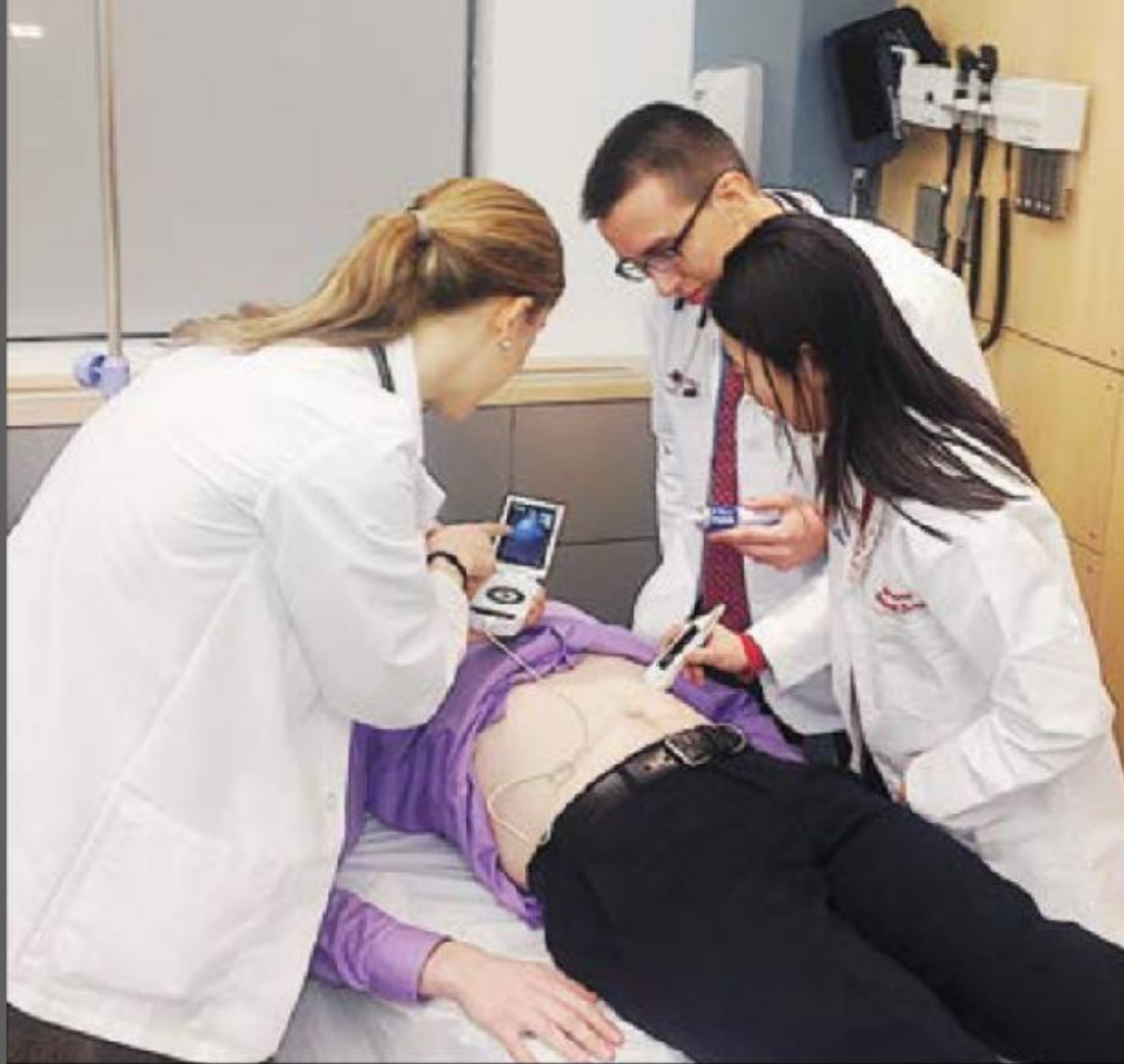Look beyond the ordinary.

THE VISUALIST

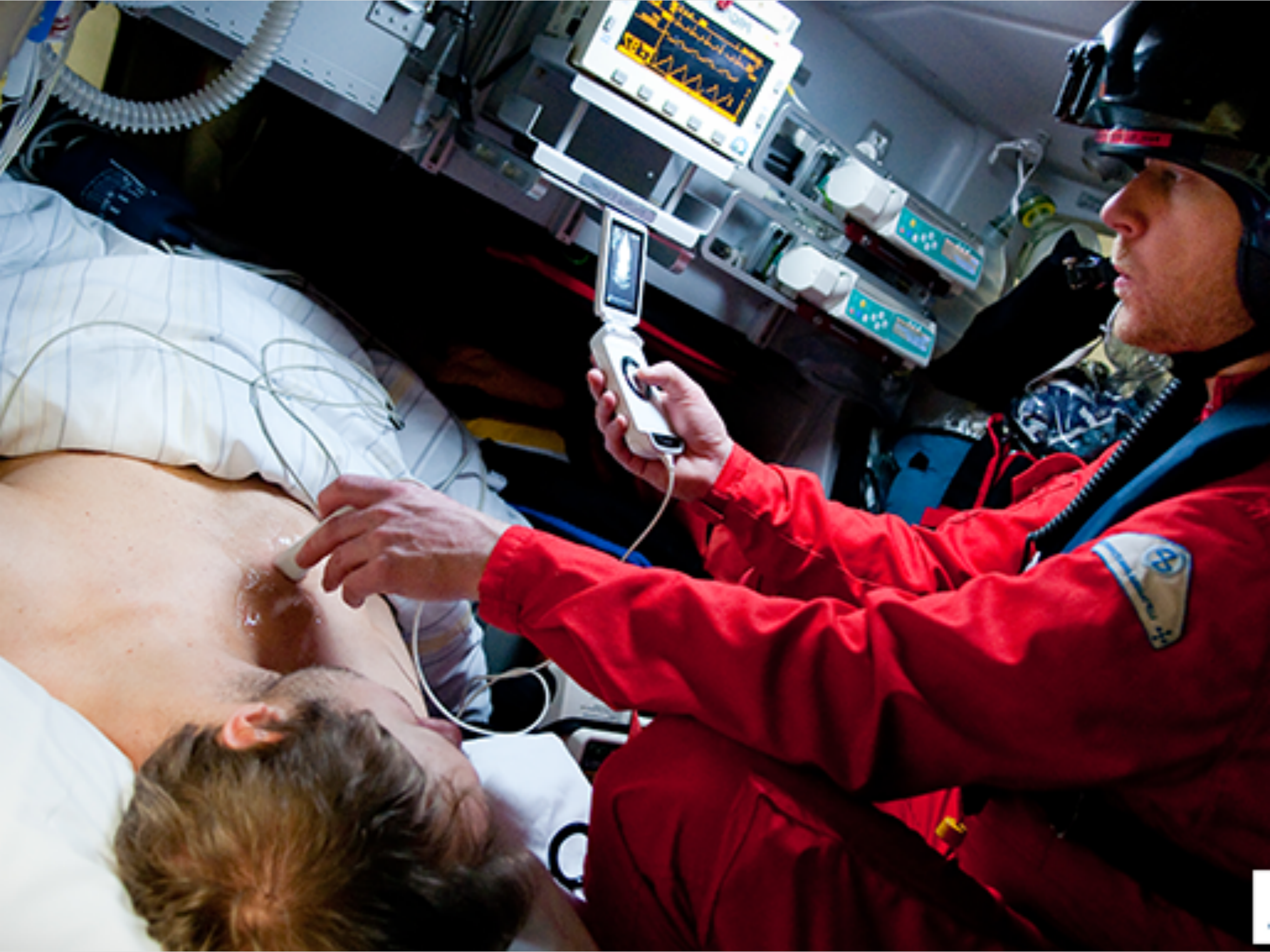21世紀醫師的視診器

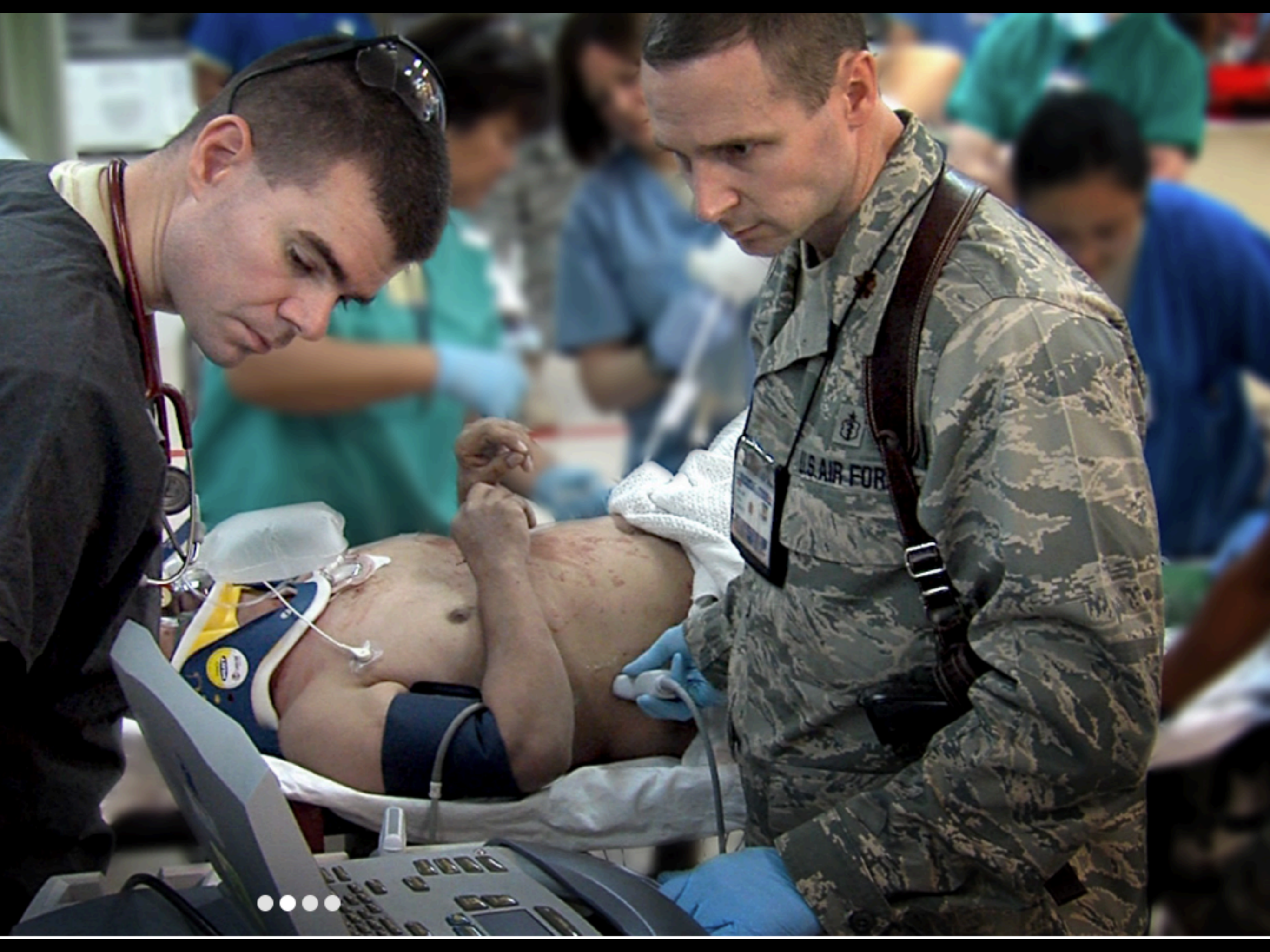

2014 NEJM

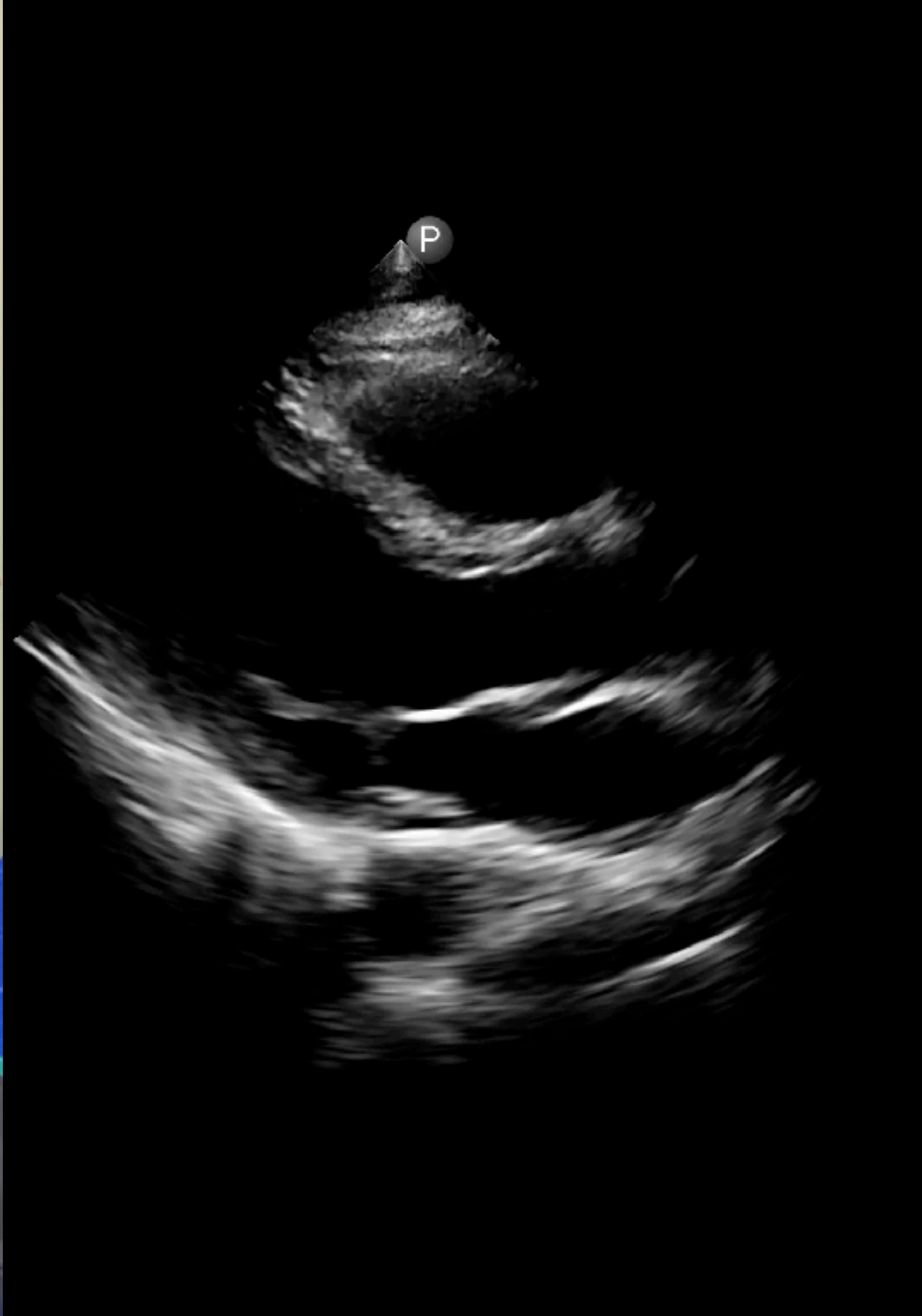

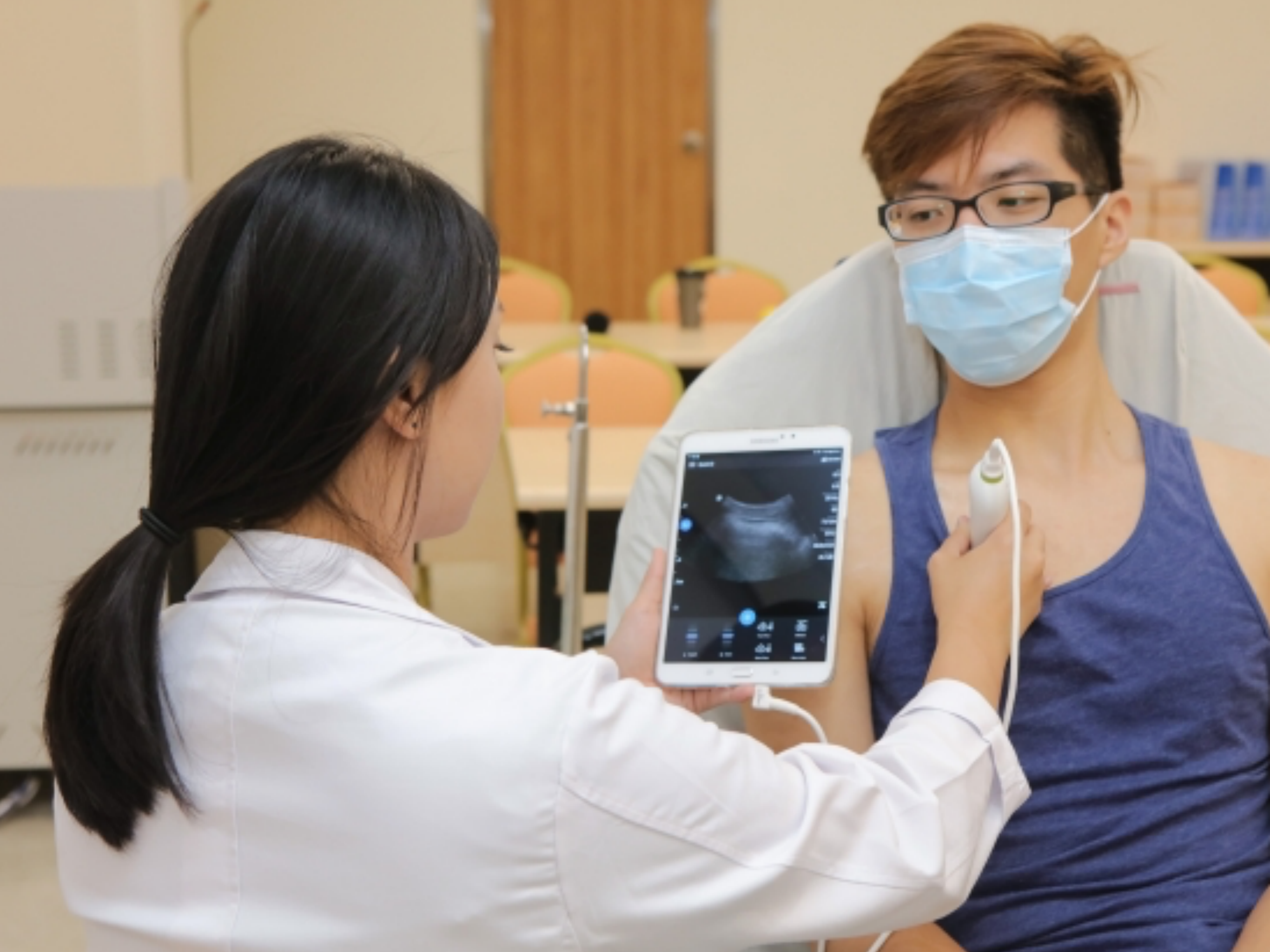Harvard Medical School Students Using a Handheld Ultrasound Machine in a Teaching Exercise.

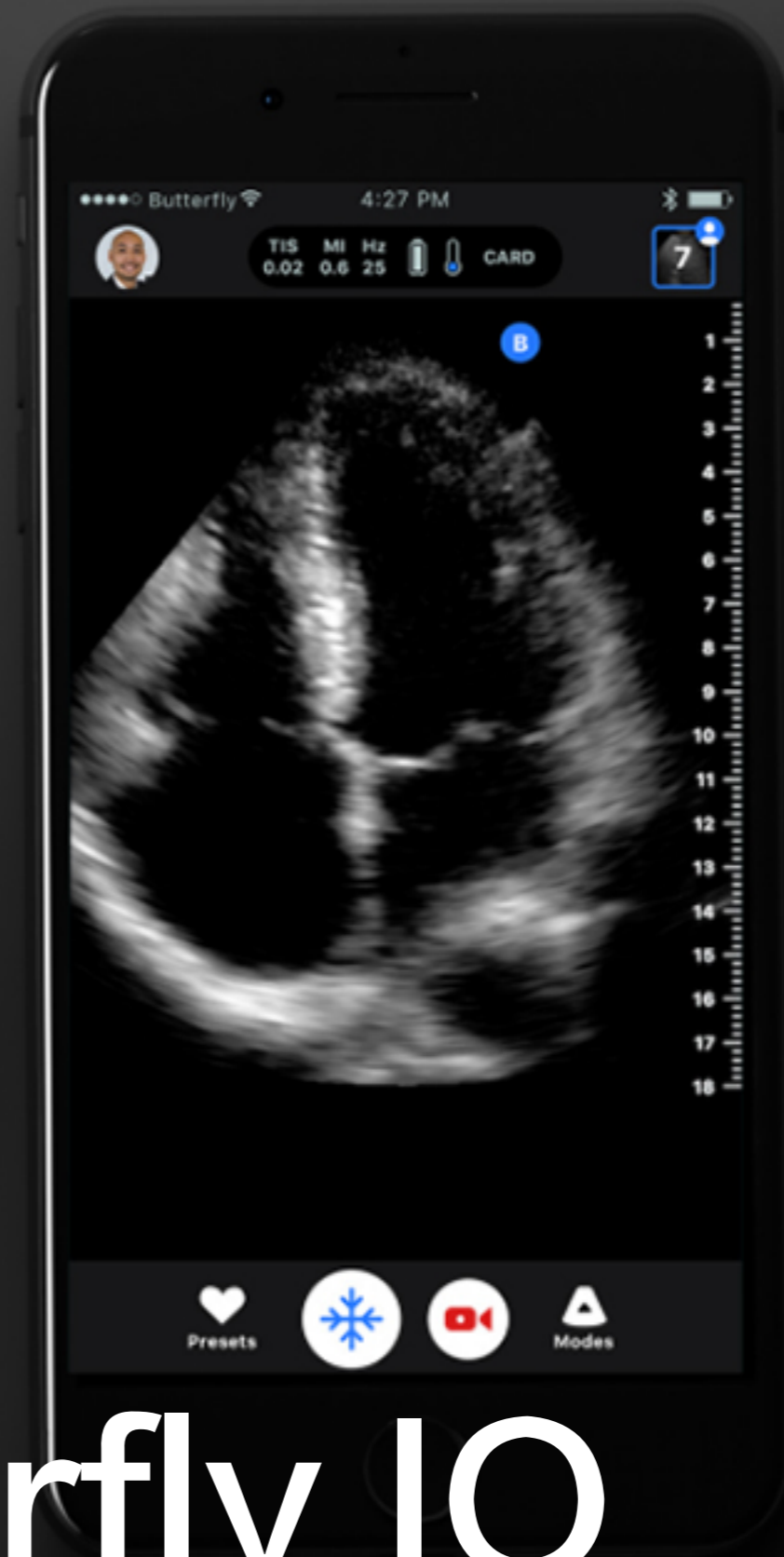











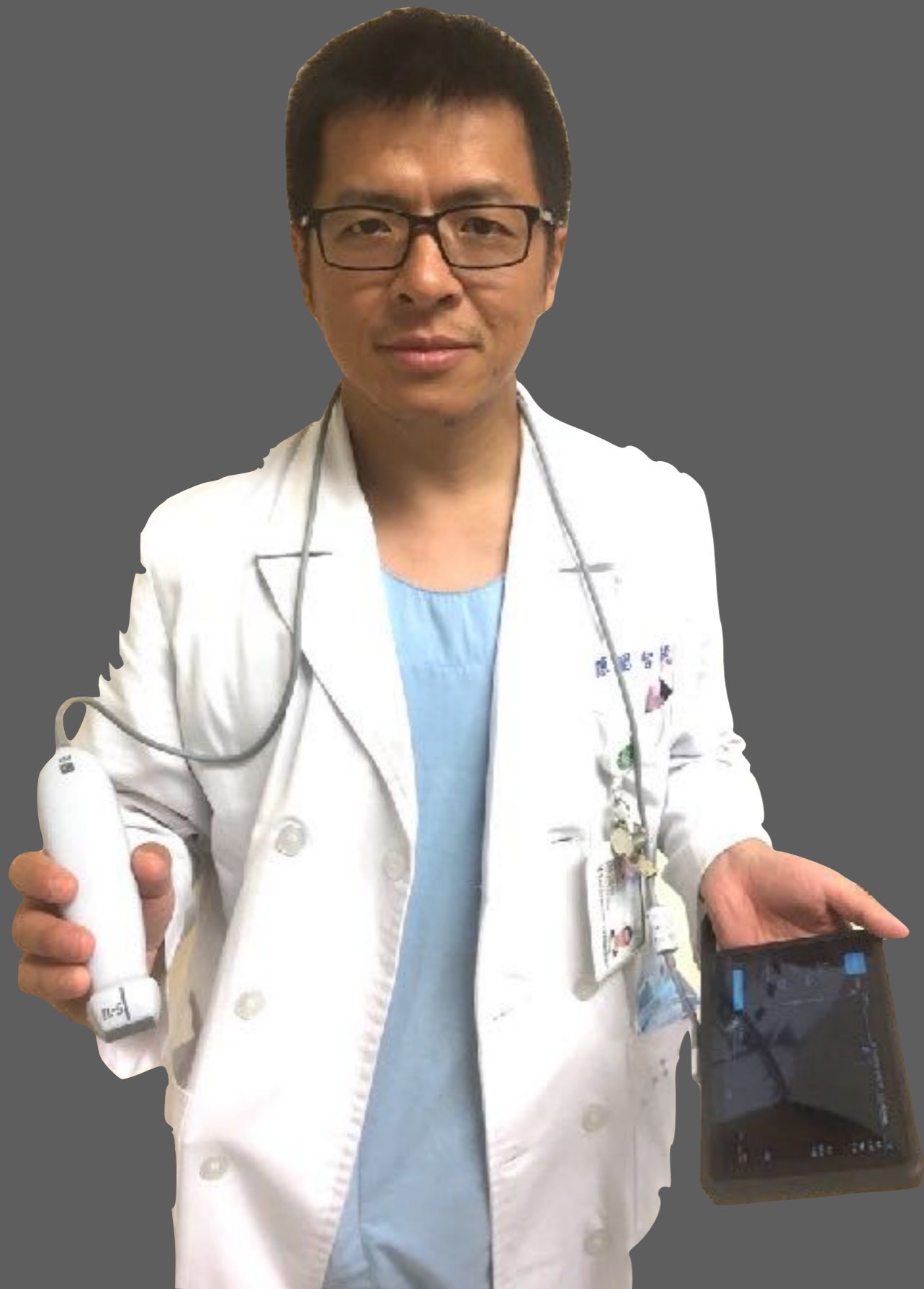Butterfly IQ
< 2,000 USD

Echoscropy

Single

Scope

Protocol



POCUS

Care
Time
You

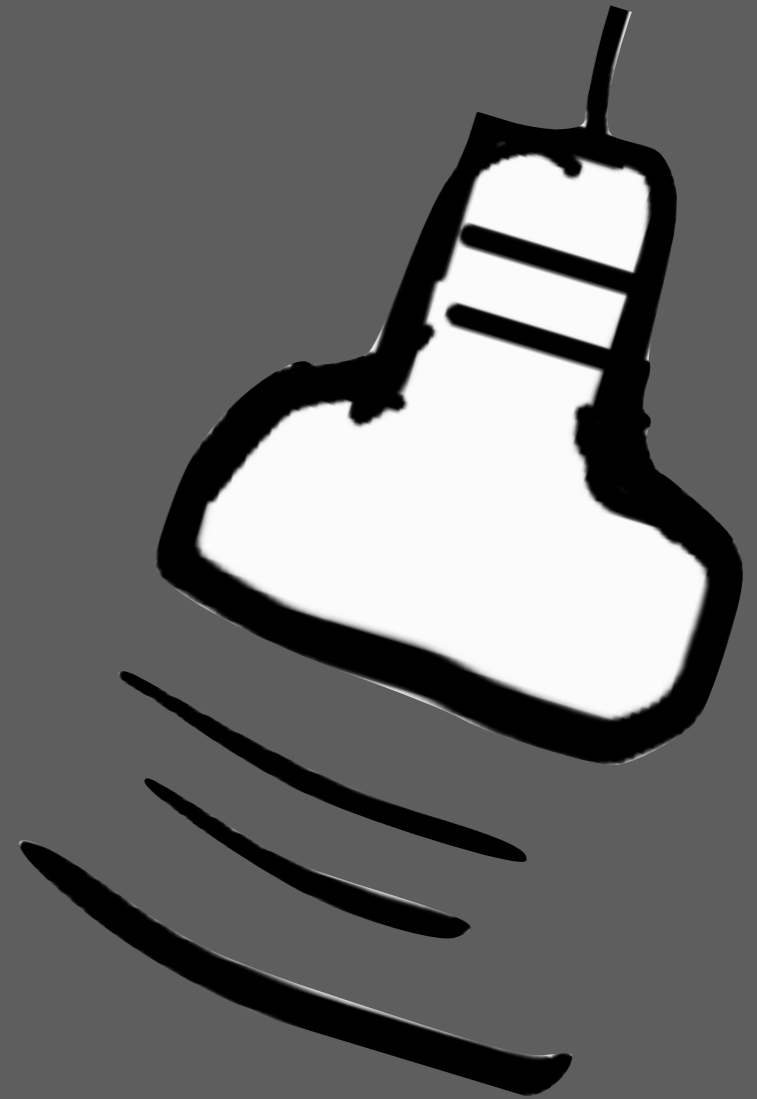
SCAN



READ



Decision Making



Diagnosis

Treatment

Procedure

ER



Diagnosis

Treatment

Procedure



ICU

Fluid

Sepsis

Shock

DVT

CVC

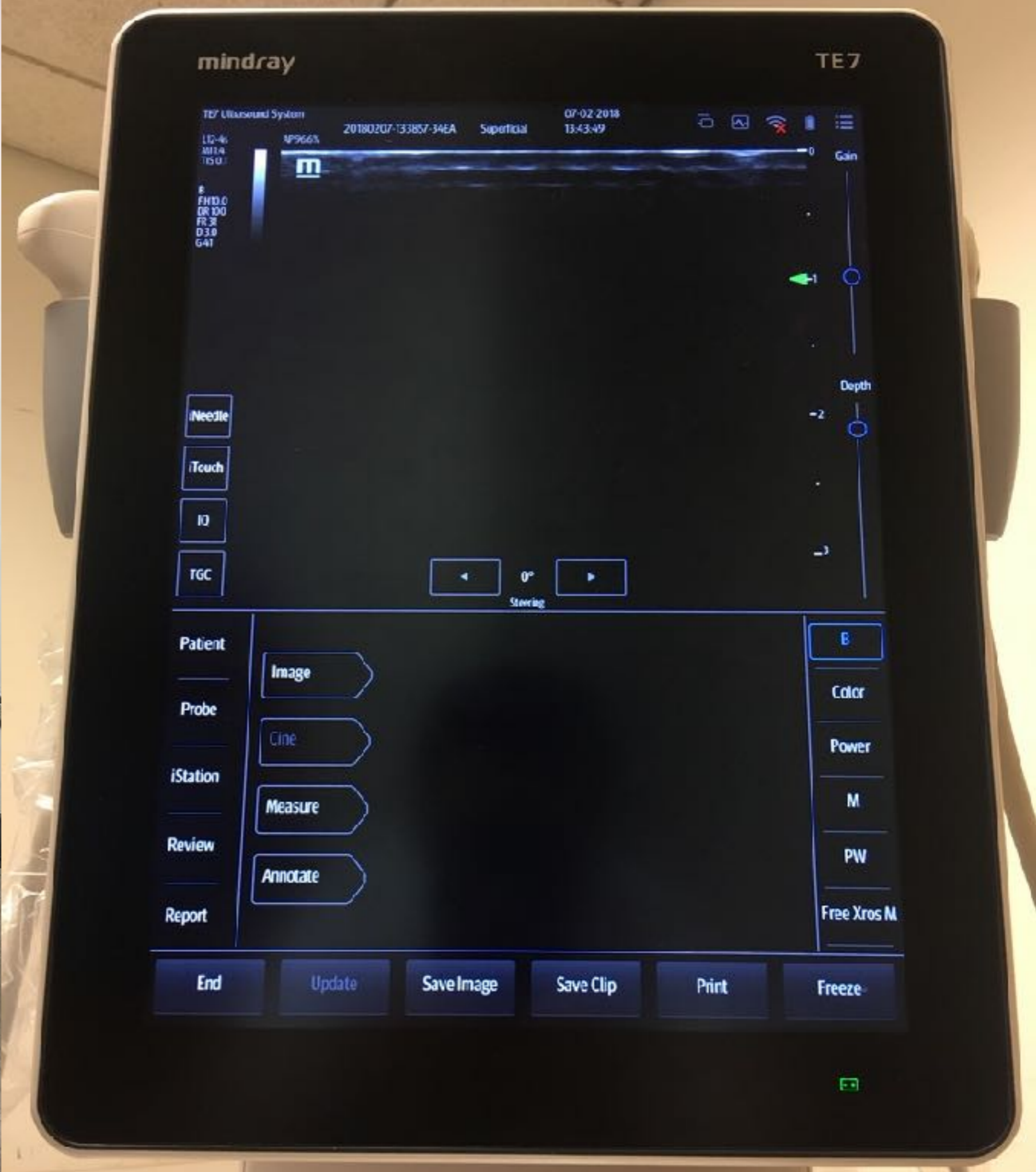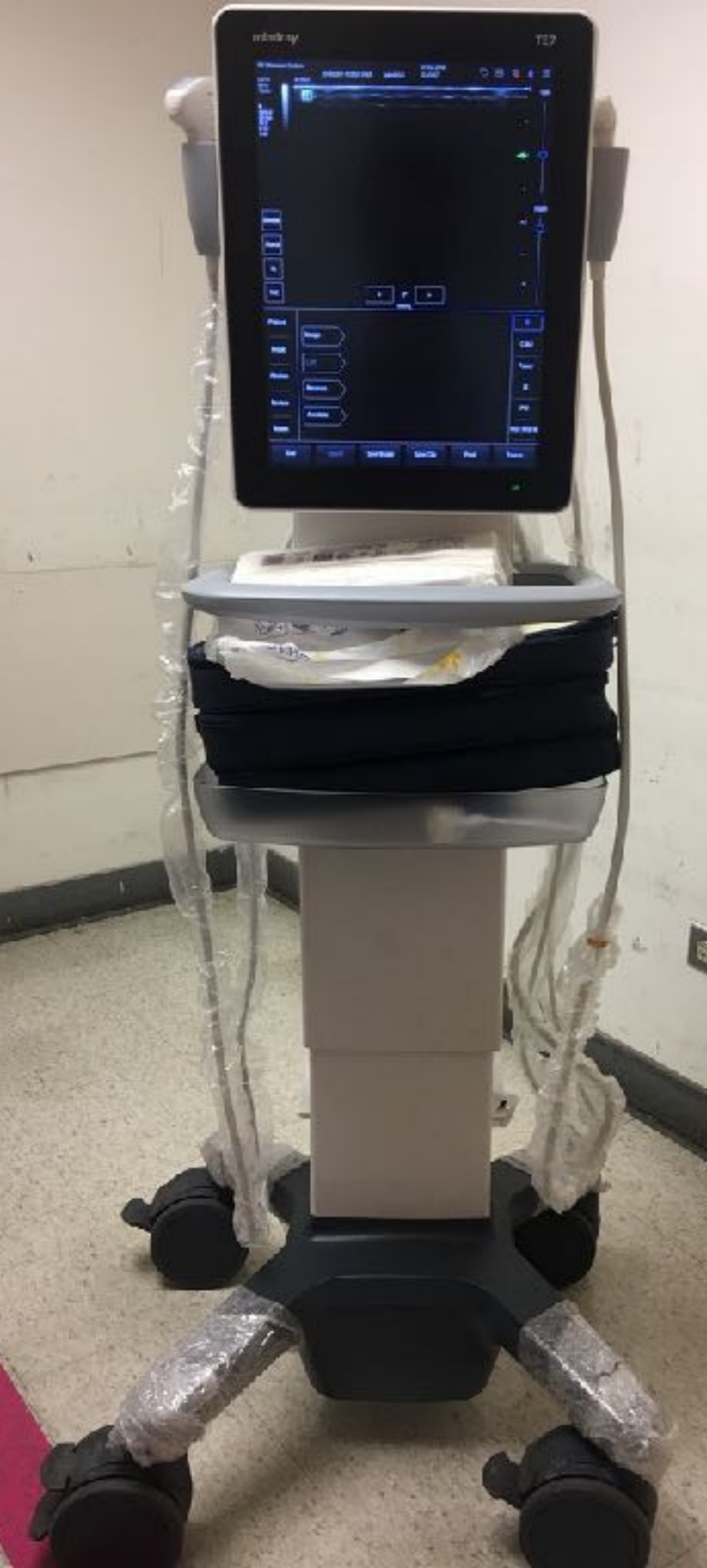Ileus

Dyspnea

Nutrition

Trauma







The Only Limitation Is Your **Imagination**

\$

\$

\$



Fluid

Shock

CVC

Dyspnea

Trauma


Fluid

Shock

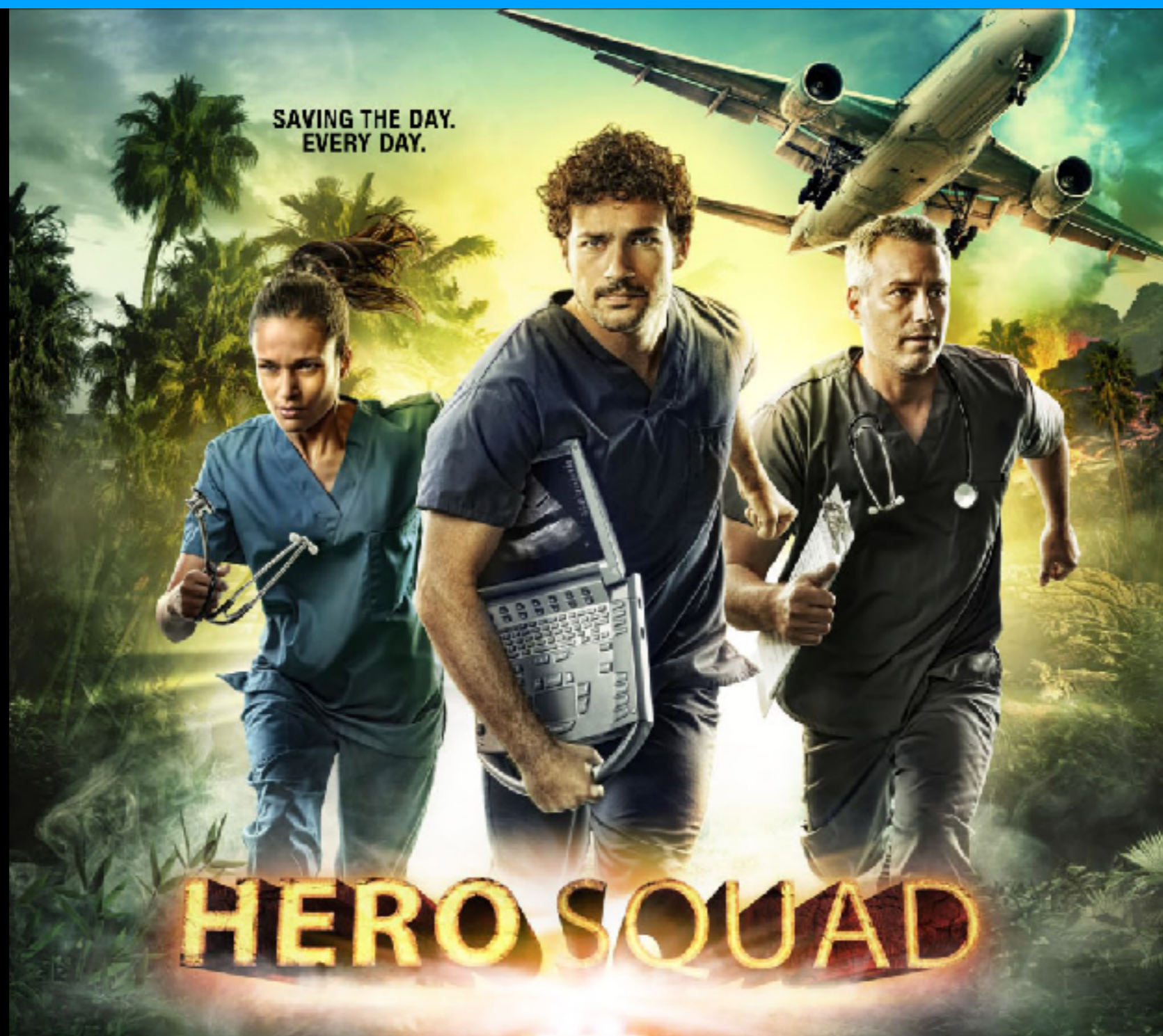CVC

Dyspnea

Trauma



Who



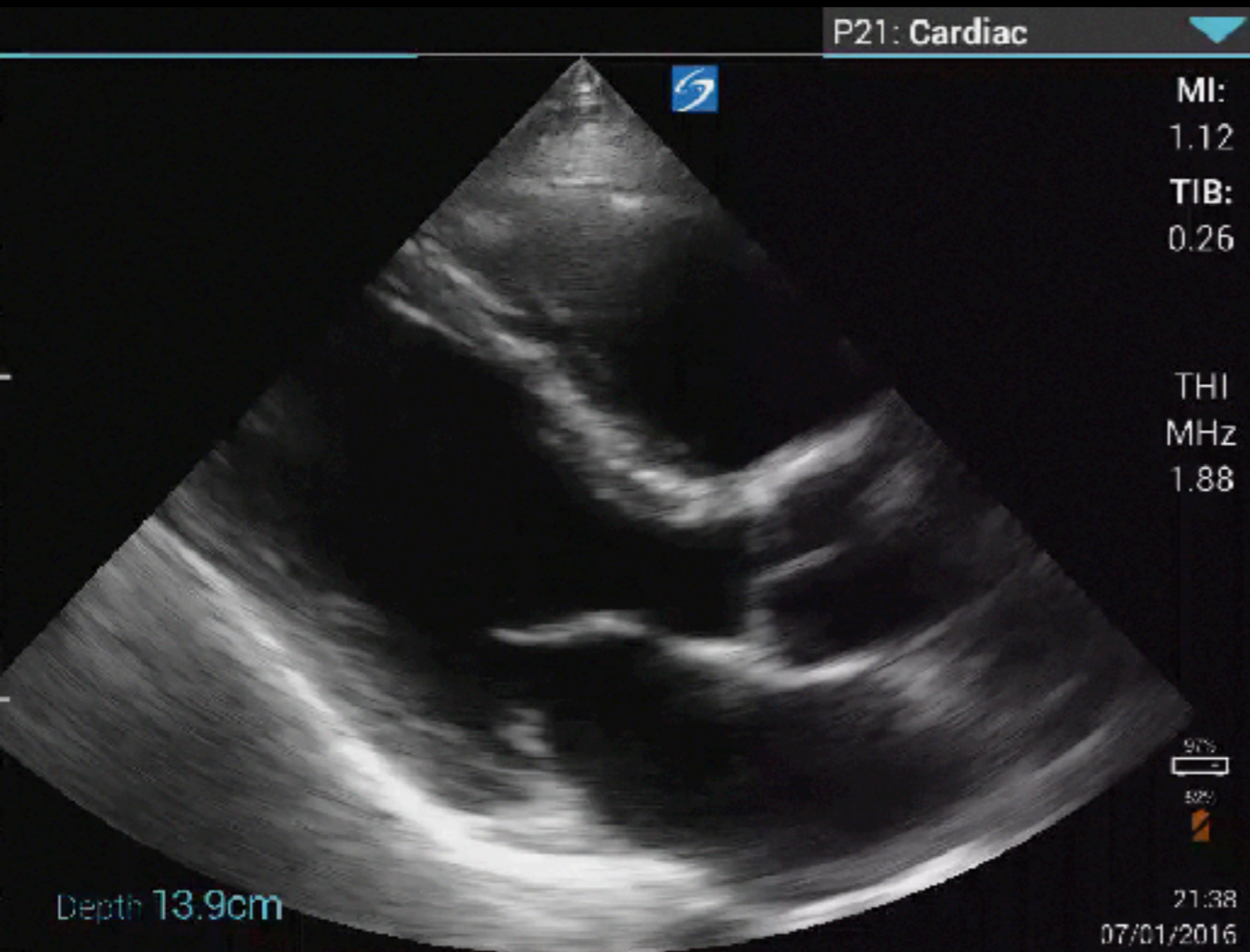
How



CCUS Workshop Faculty



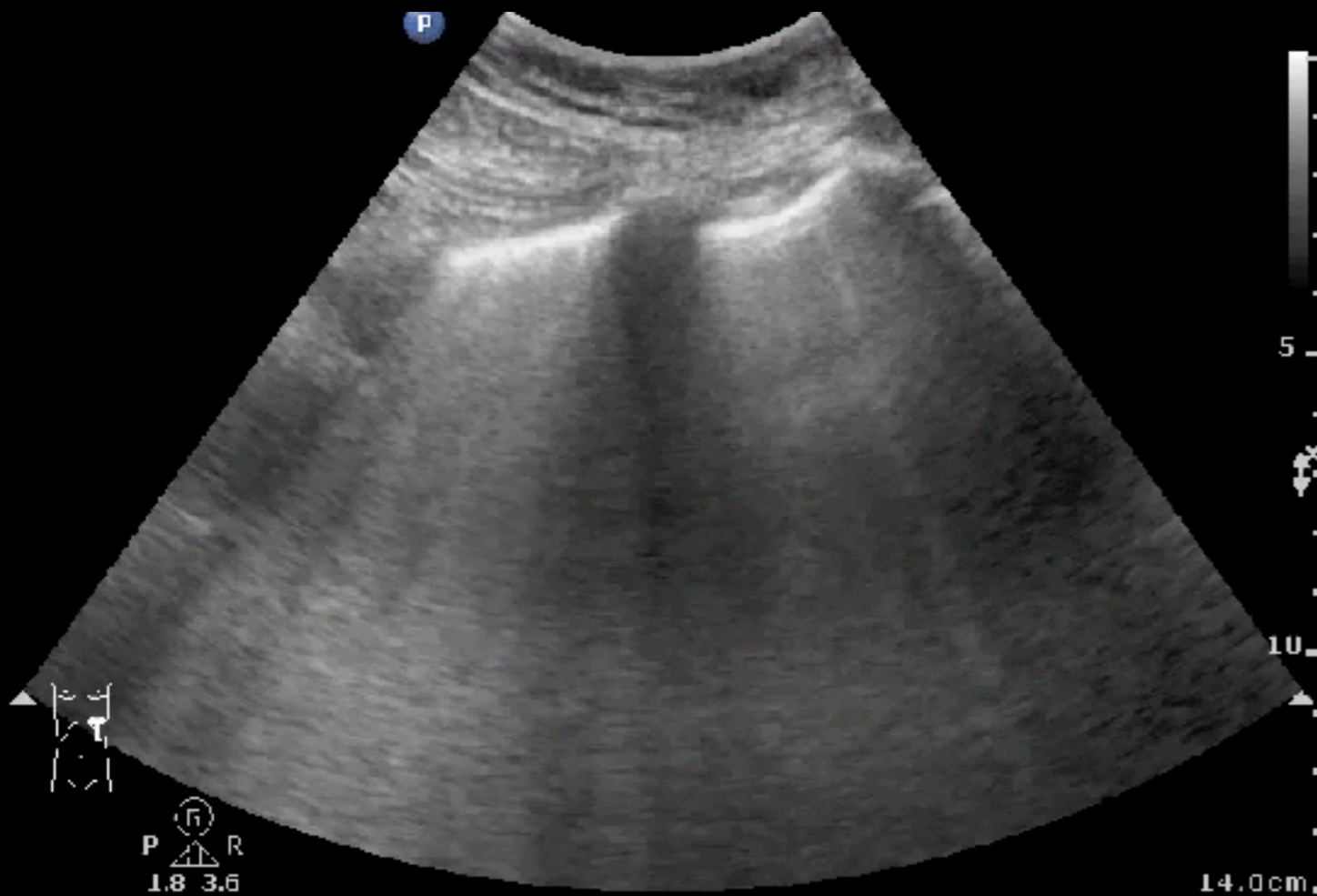
萬芳 黃文成醫師



亞東 孫仁堂醫師

Abd Gen
5-1
3 Hz
4.0cm

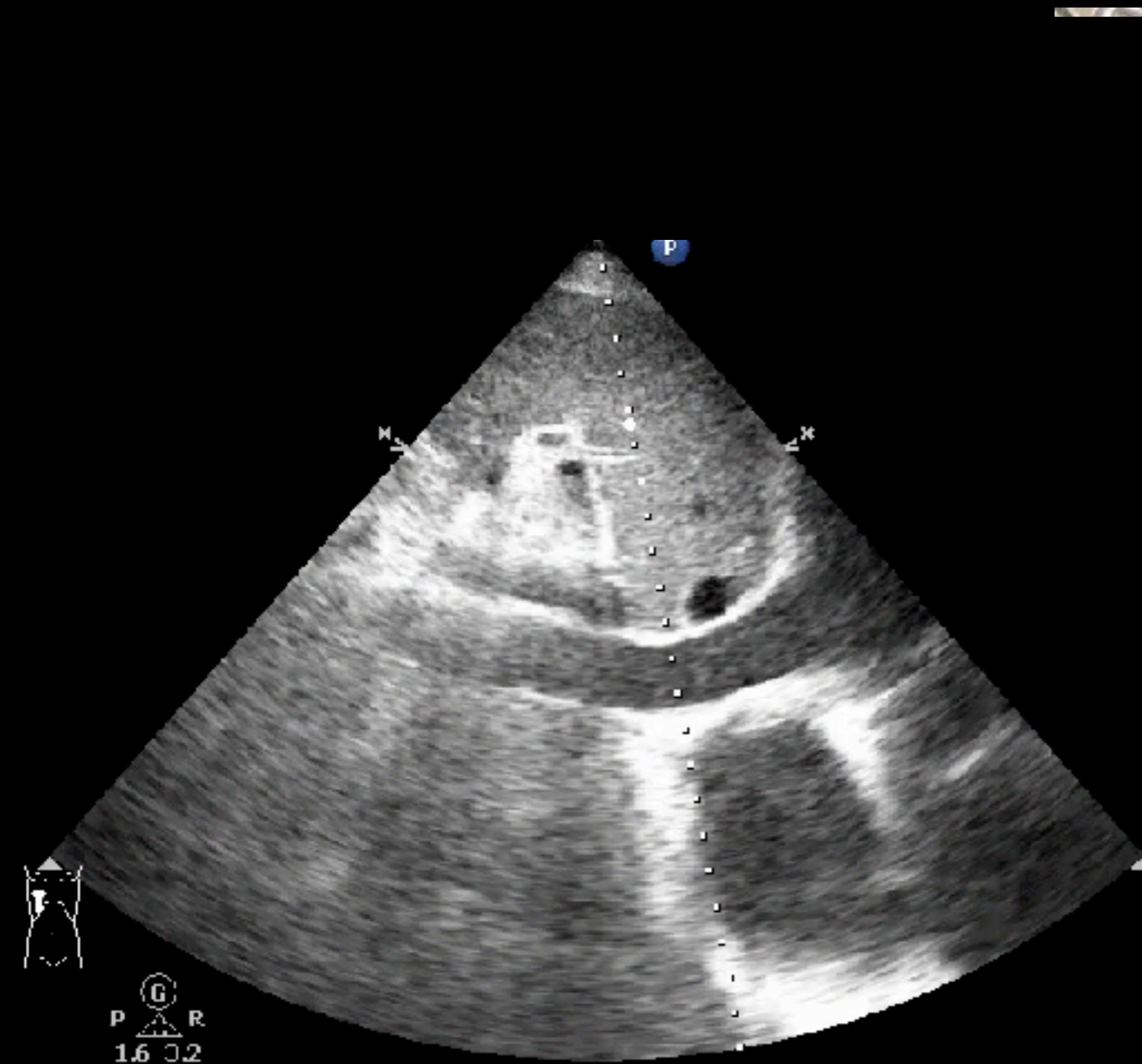
HGen
3n 100
56
3/3/3



P R
1.8 3.5



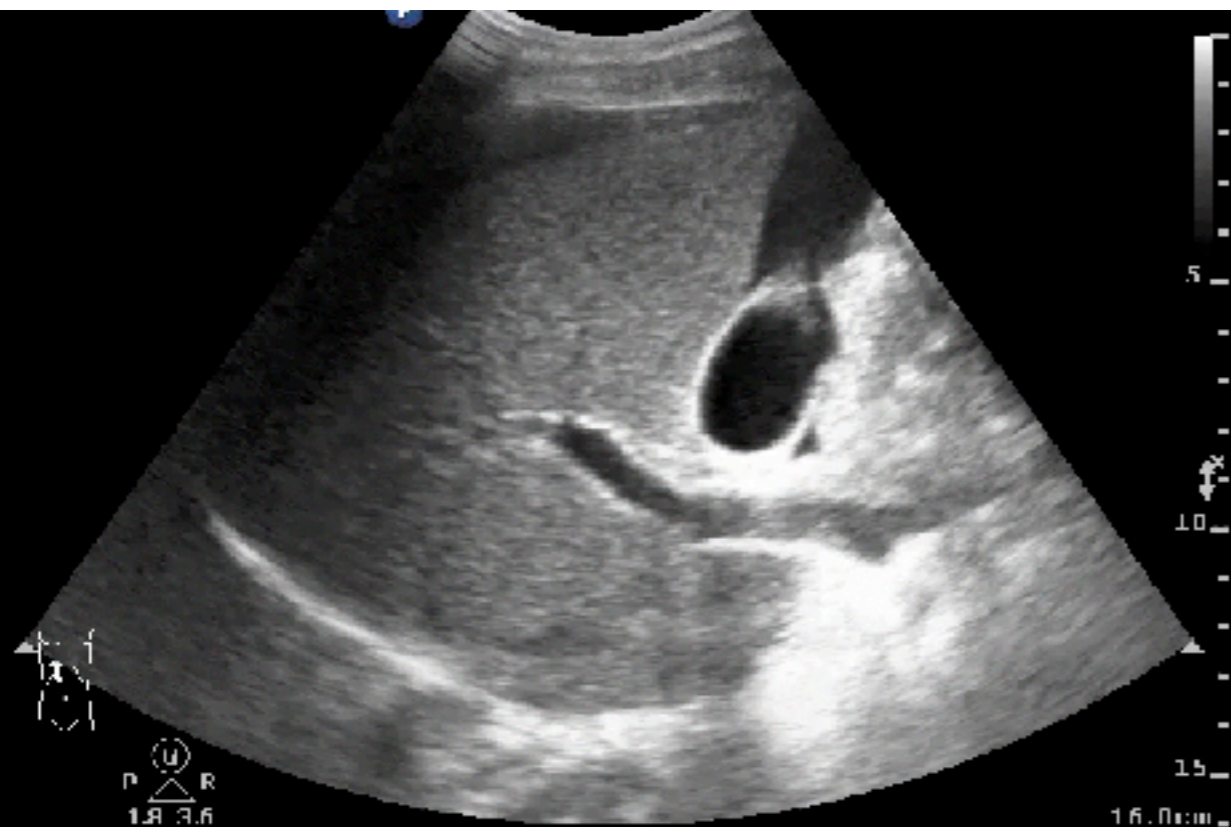
台大雲林 蔡揚名醫師



高醫 劉信良醫師

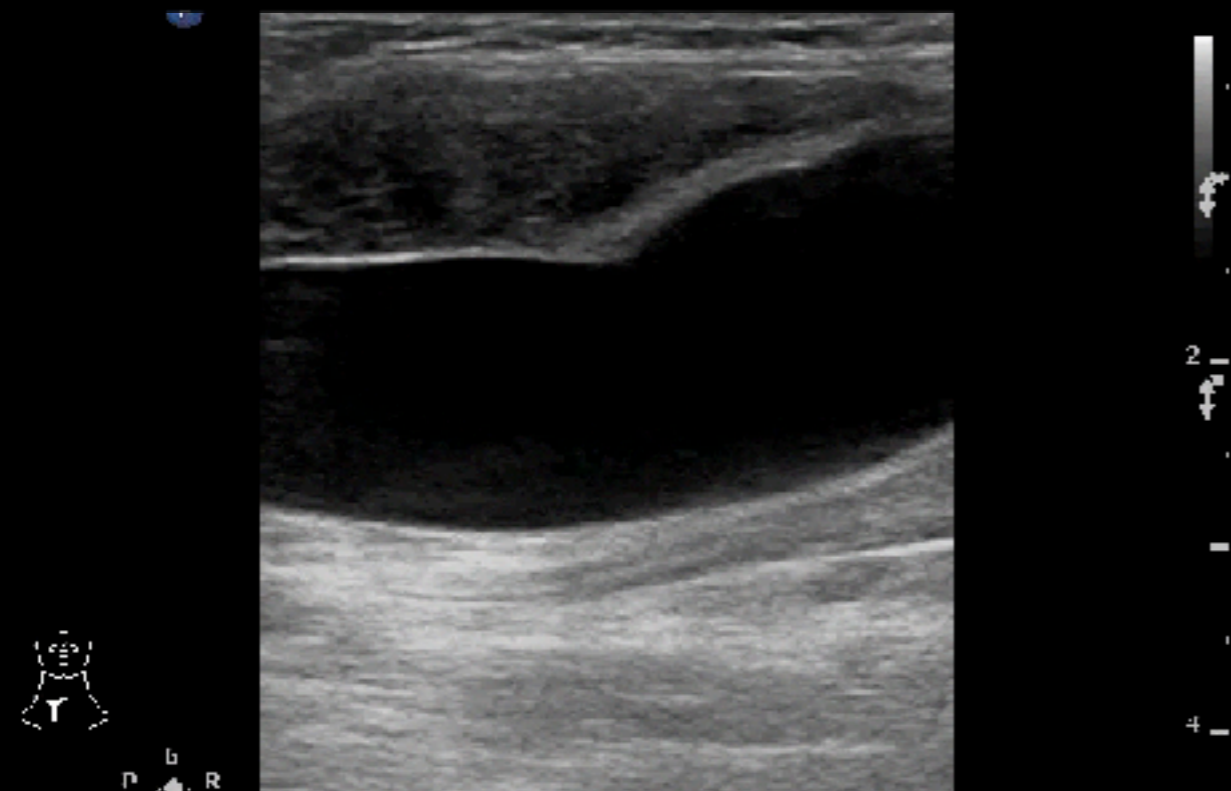
Abd Gen
C5-1
32 Hz
16.0cm

2D
HGen
Gn 90
C 56
3 / 3 / 3

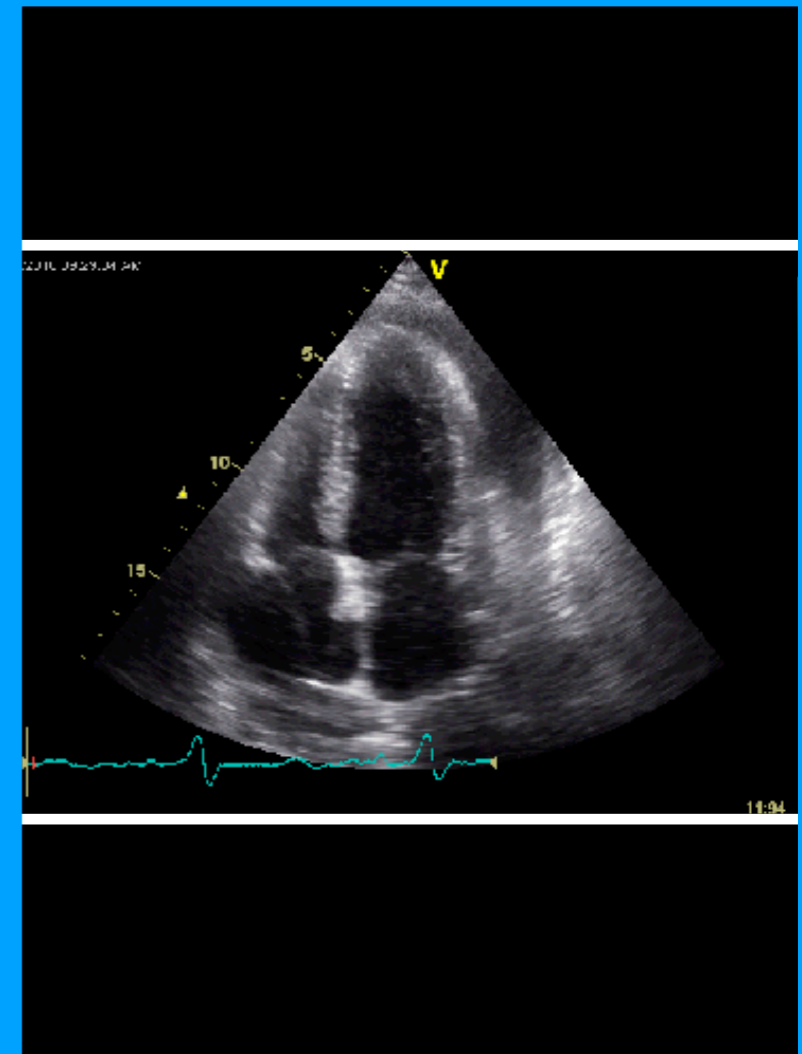

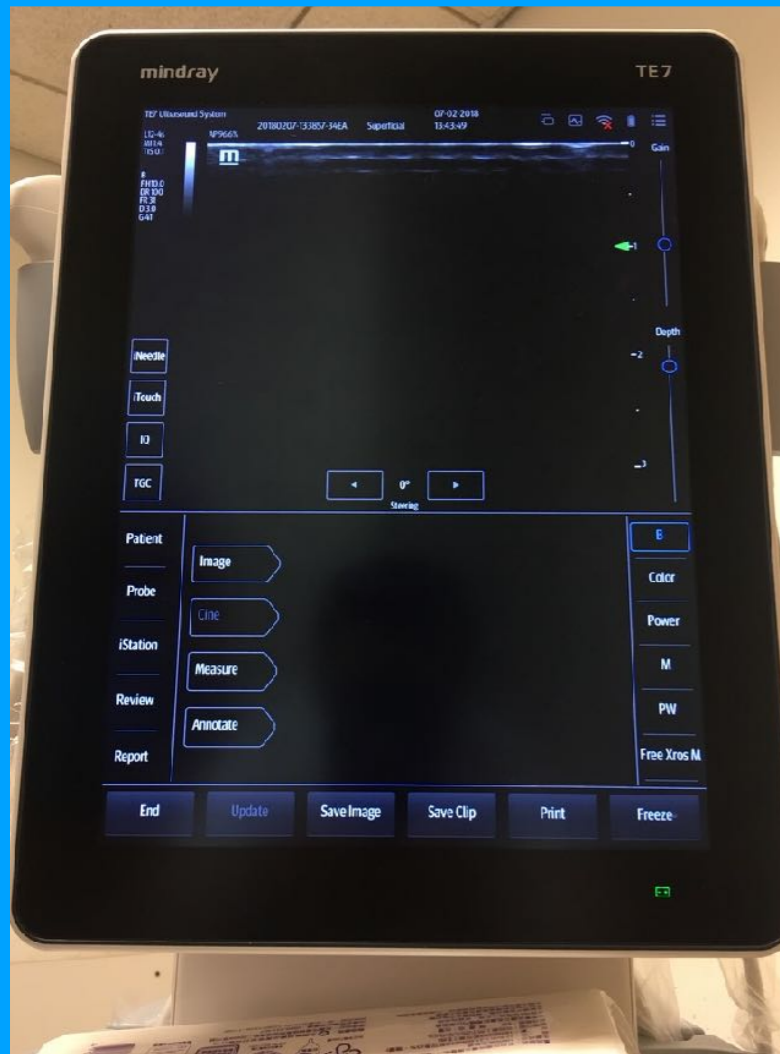


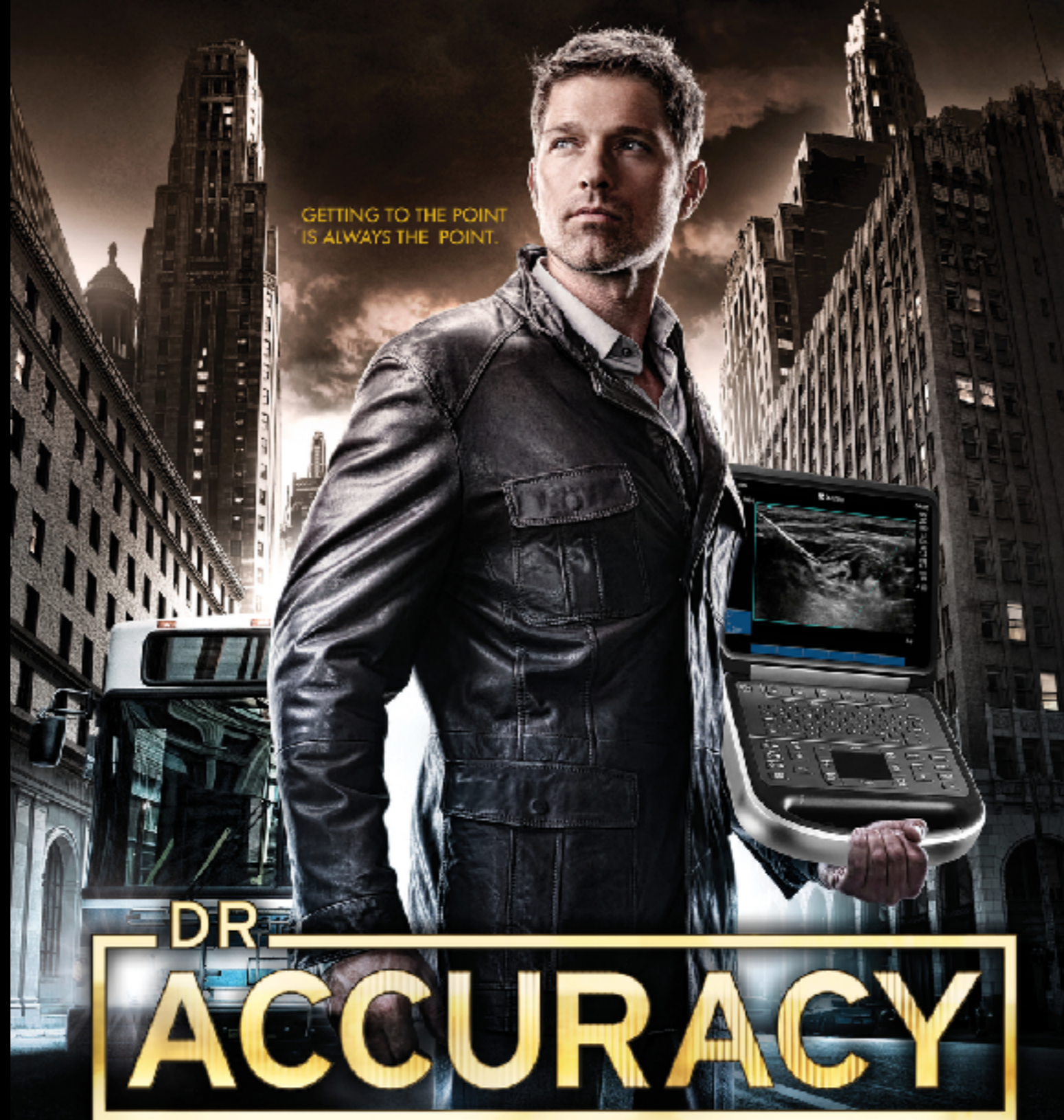
Superficial
L12-3
29 Hz
1.5cm

2D
Gen
Gn 70
C 52
4 / 3 / 2



How to Start Critical Care UltraSound (CCUS) in my ICU





改變病人看你的觀點

POCUS Academy

Point-of-care ultrasound is the visual stethoscope in the 21st century

[HOME](#) [LINKS](#)



juice119@gmail.com

FB: Emergency Ultrasound Training Center

