



Is "FAST"  
enough ?

Sonography for Trauma

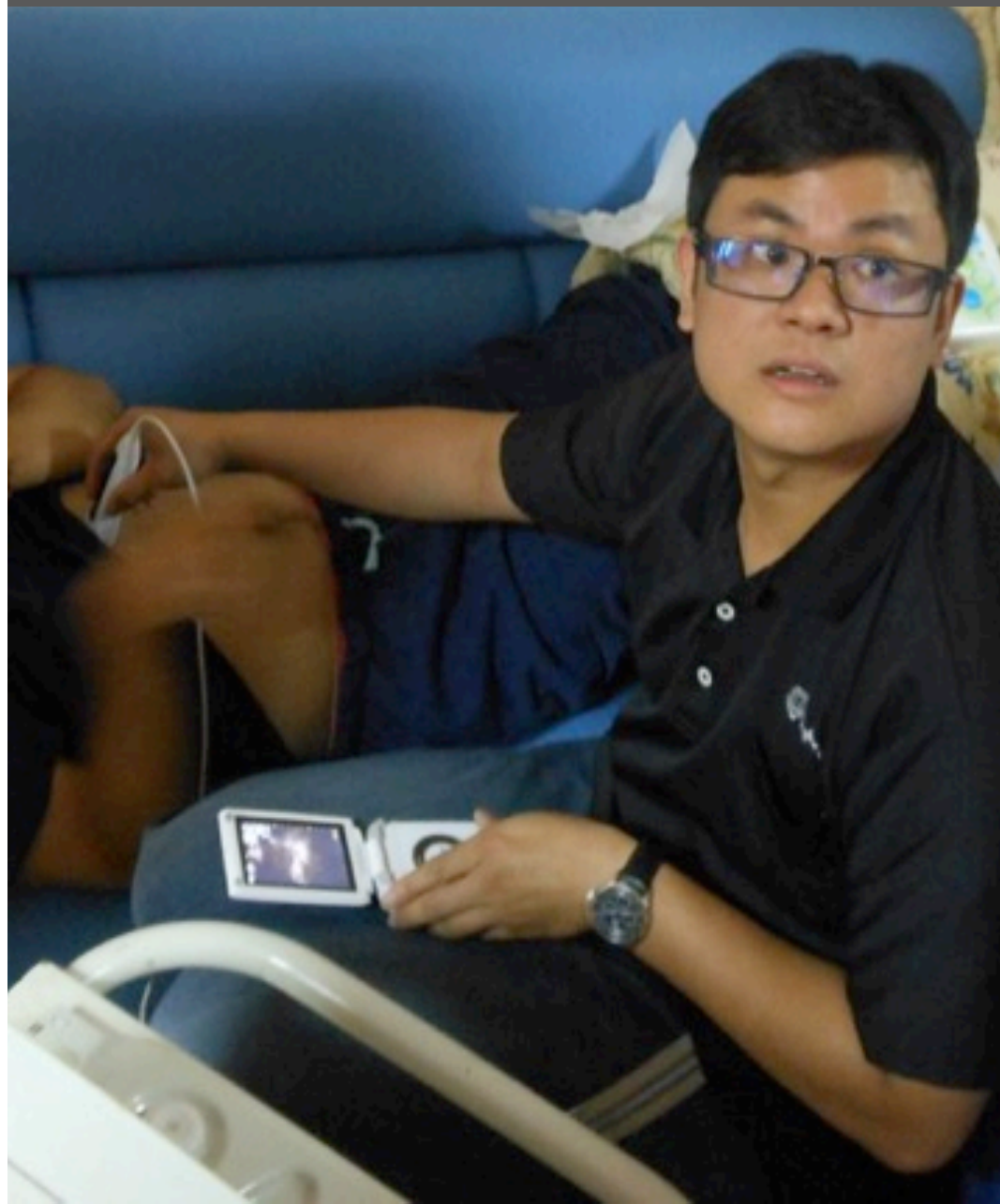
急診 劉信良醫師



天下武功，无坚不破，唯快不破



# 劉信良醫師



- 高醫急診主治醫師
- 急診超音波  
臨床評核醫師
- 高長、高醫、高榮、  
義大四院聯合急診  
超音波訓練講師

# 上完課就一定會

- More than “FAST”
- Cardiac arrest
- Linear

# 分組競賽



選隊長

FERRERO  
ROCHER

負責計分：

Push 舉手搶答



# 請問

劉信良是哪一科的醫師呢？

# 請問

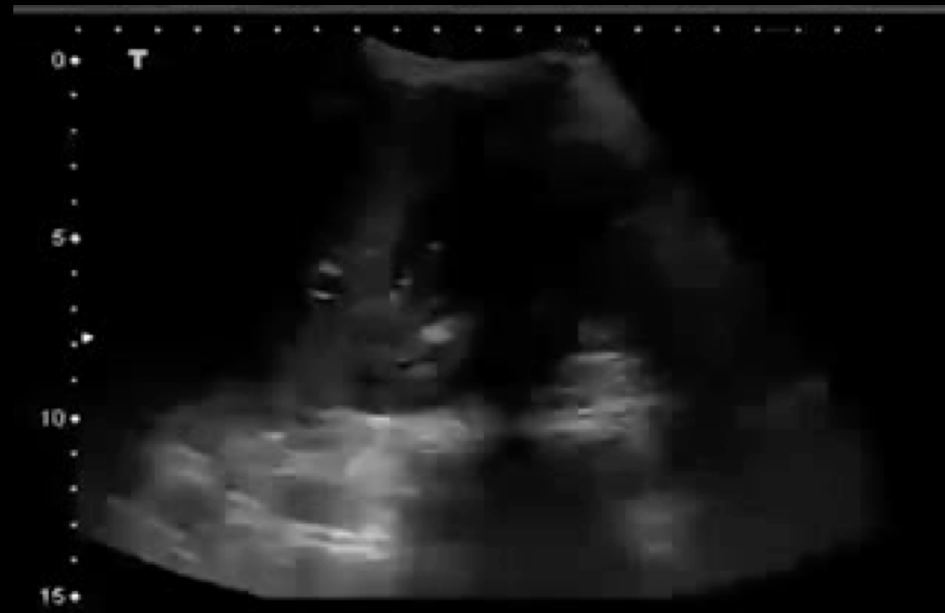在早上lung scan的分站，  
你看到什麼構造？

**More than EFAST**

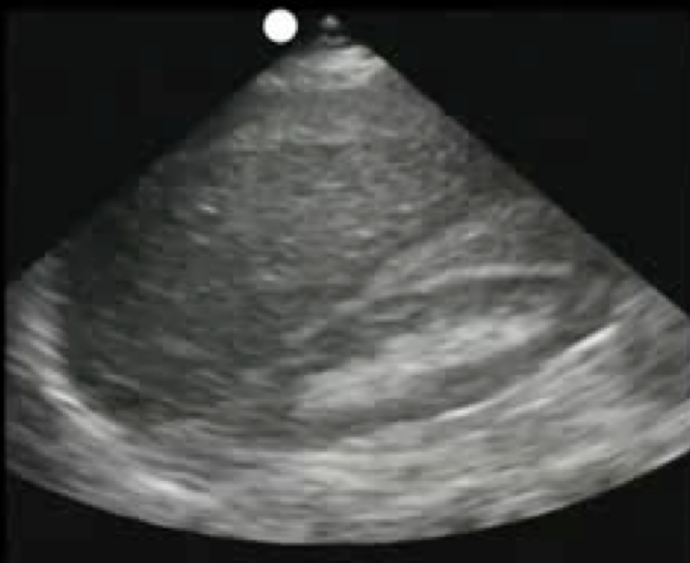


# 請問

出血在超音波下，看起來是什麼顏色??



hqmeded.com





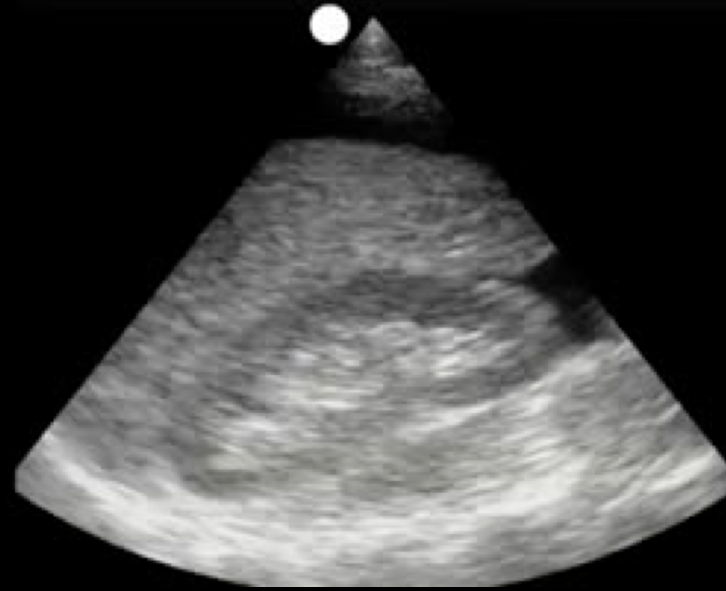
# Hemorrhage

- First : anechoic
- 0~4 hours : more echoic (clot)
- 12~24hours : turned anechoic (fibrinolysis)

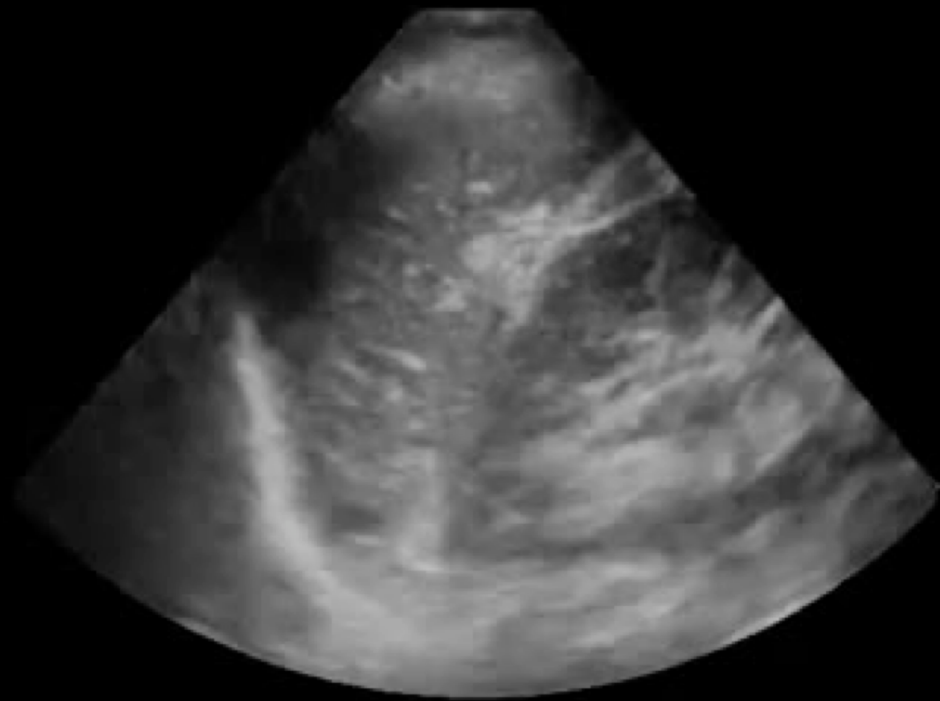
# 請問

出血在腹內哪些位置，FAST比較難掃到？

RUQ Abdominal-Hepatorenal View  
Fluid Prominent Around Caudal Tip of Liver



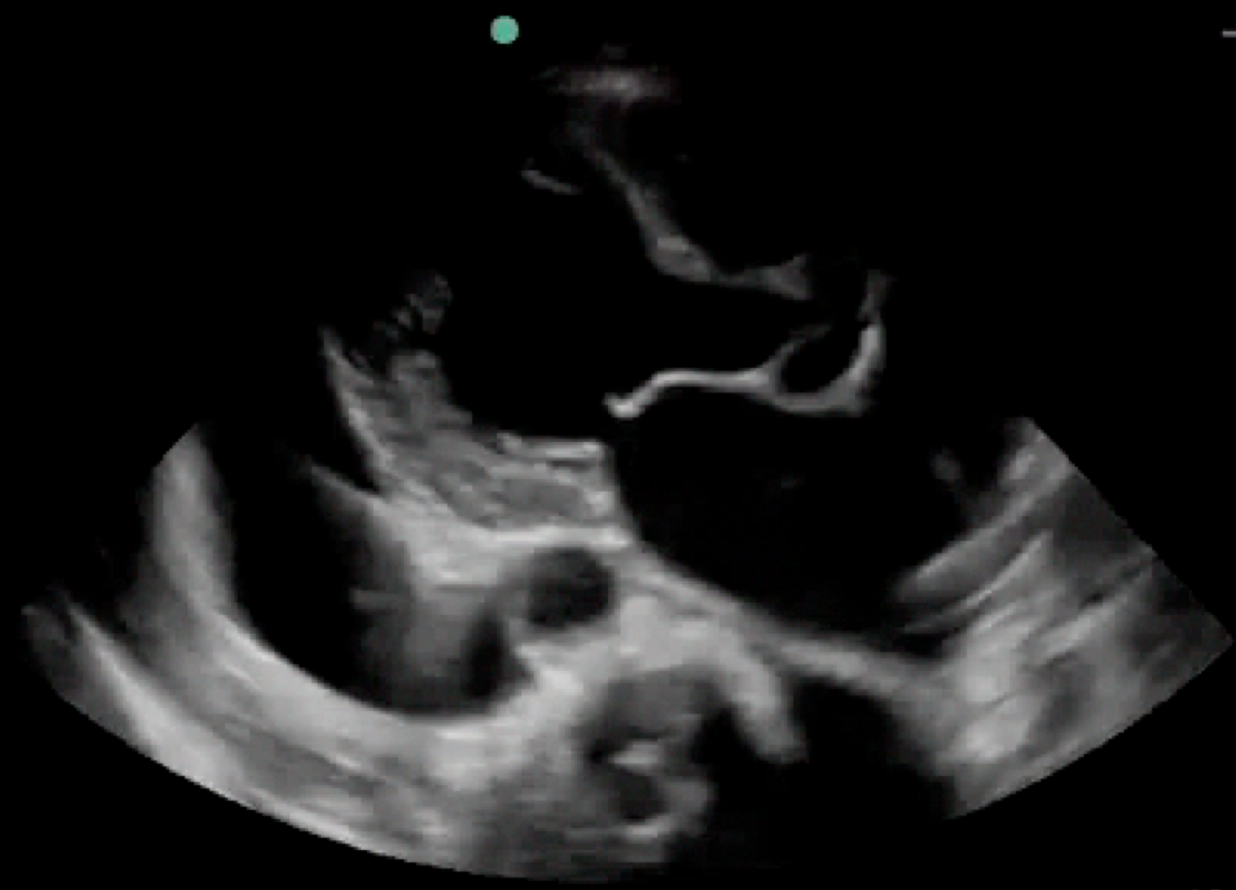



# 請問

Subxiphoid view 掃不到，怎麼辦？

Gen THI  
S MB



Abd  
P21



87%

MI

1.1

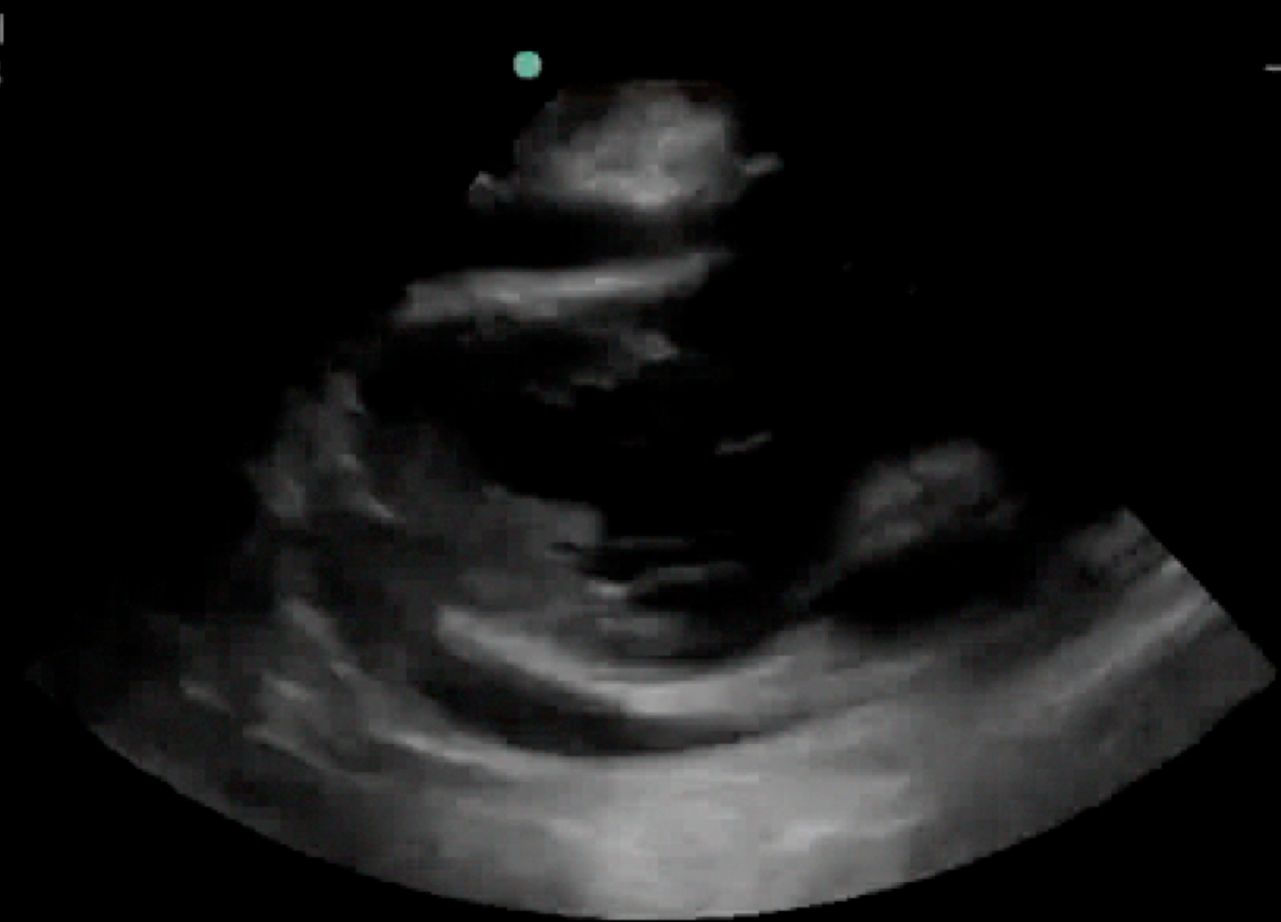A

B



16

Gen THI  
S MB



Abd  
- P21



87%

MI  
1.3



13

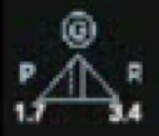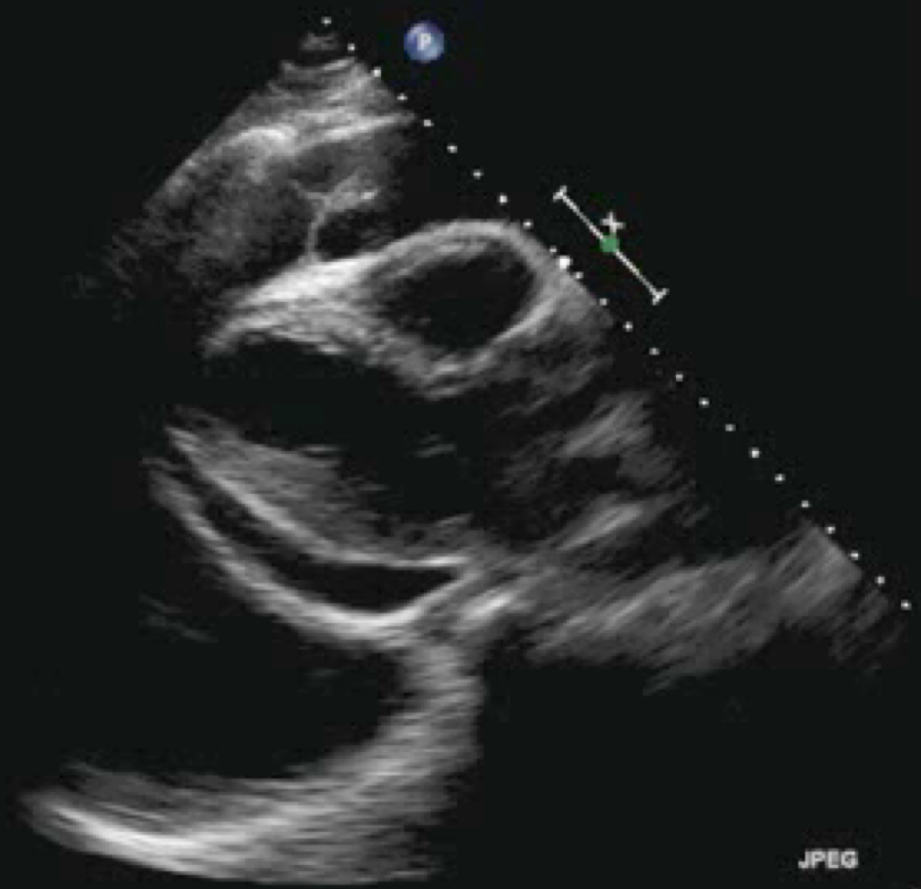0

1:1

FR 37Hz  
24cm

M3

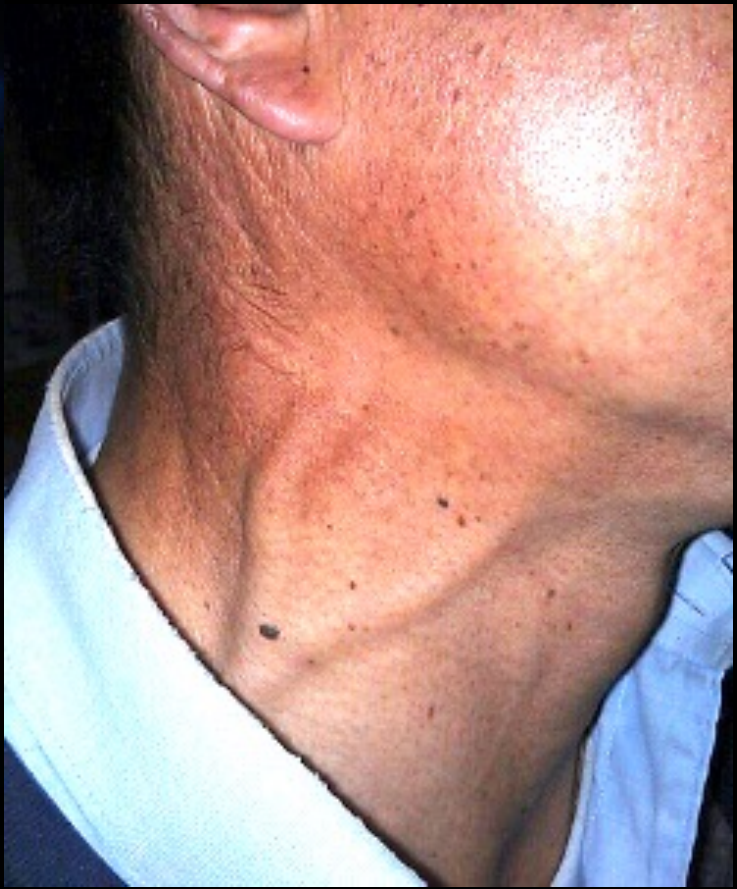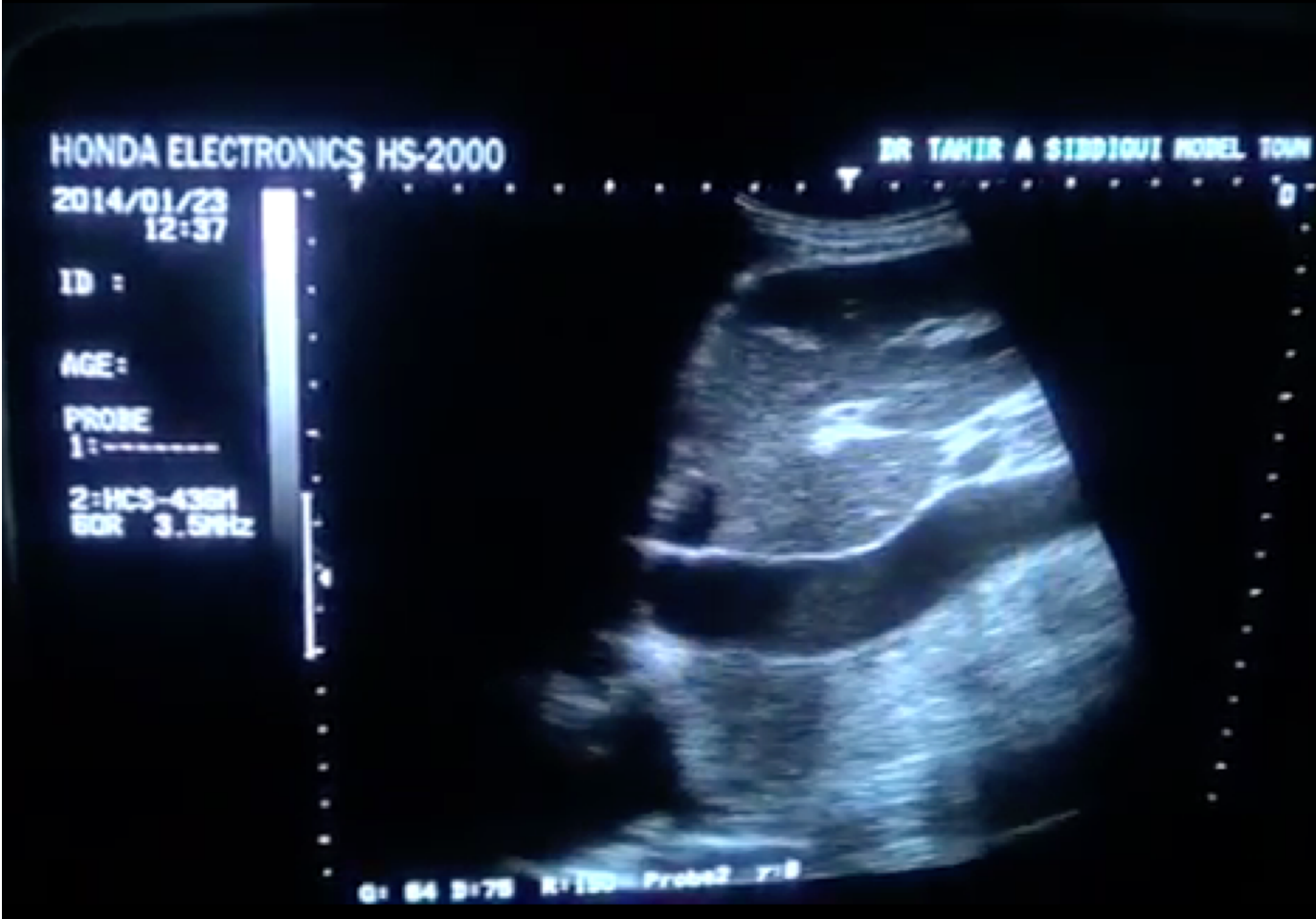2D  
59%  
C 50  
P Low  
HGen



JPEG

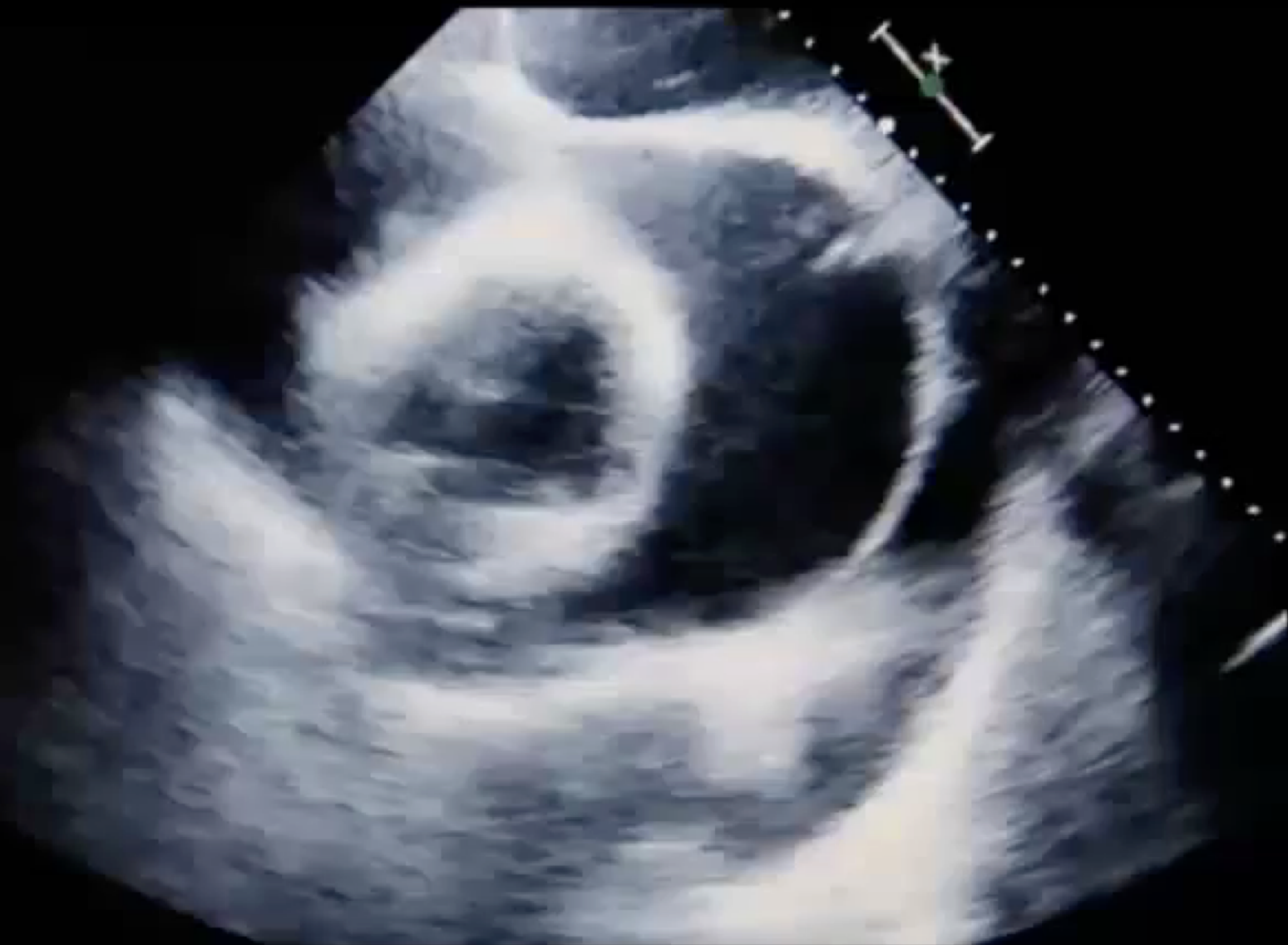
83 bpm

# 請問這個病人的volume status如何？





請問這個病人的volume status如何？

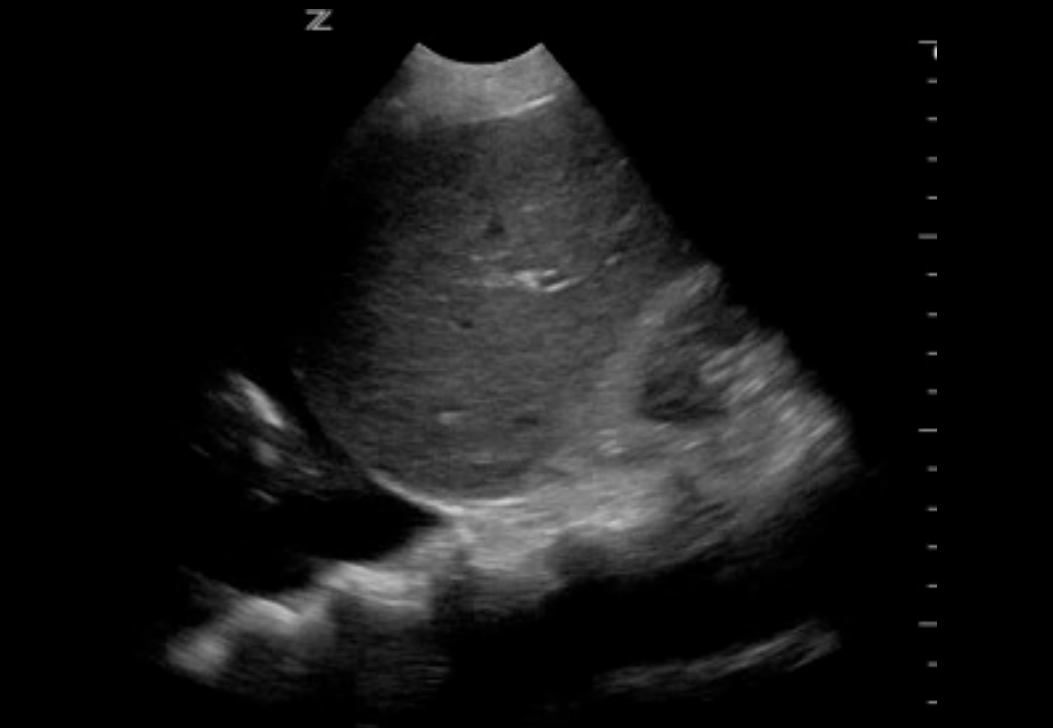
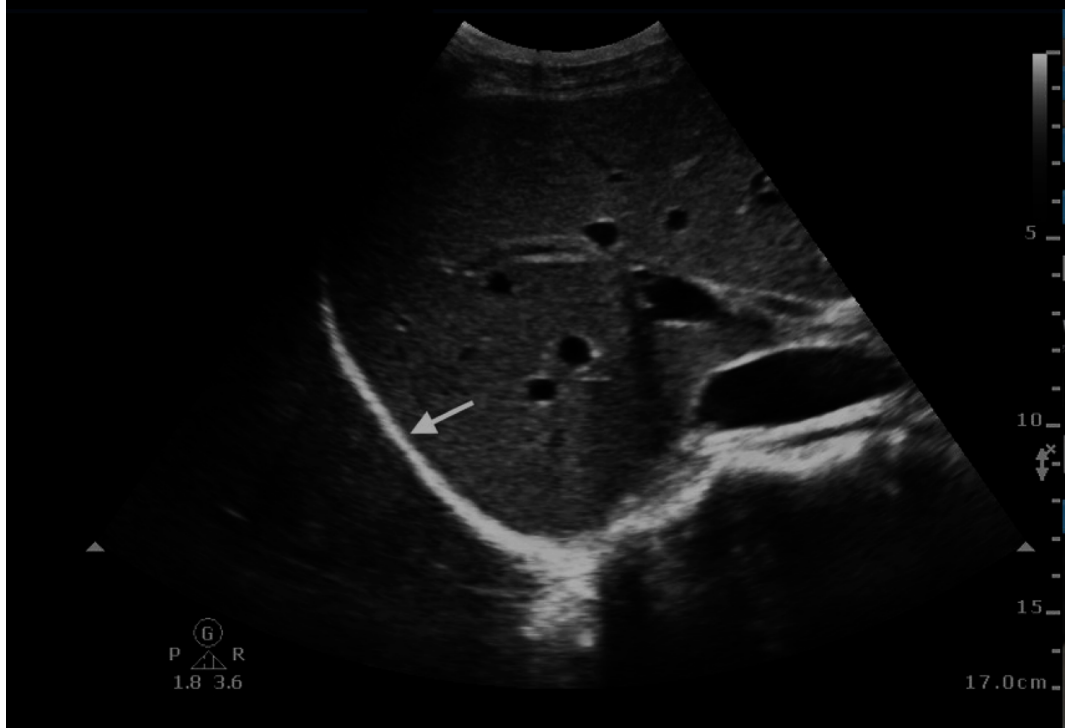
# 請問

Lung除了看氣胸，還能看什麼？



# Pleural effusion ?



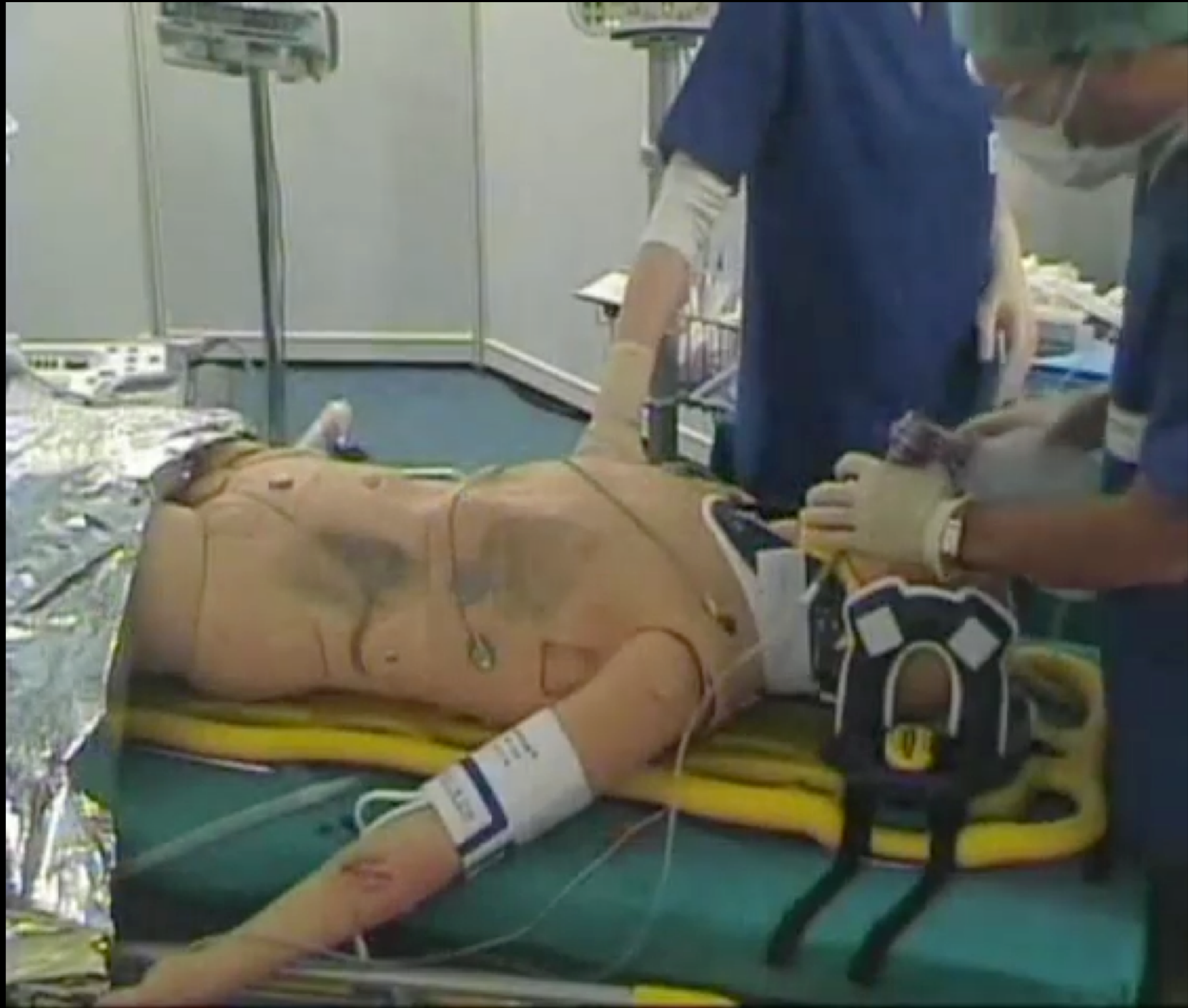# 請問

掃到fluid，一定是血嗎？還有可能是什麼？

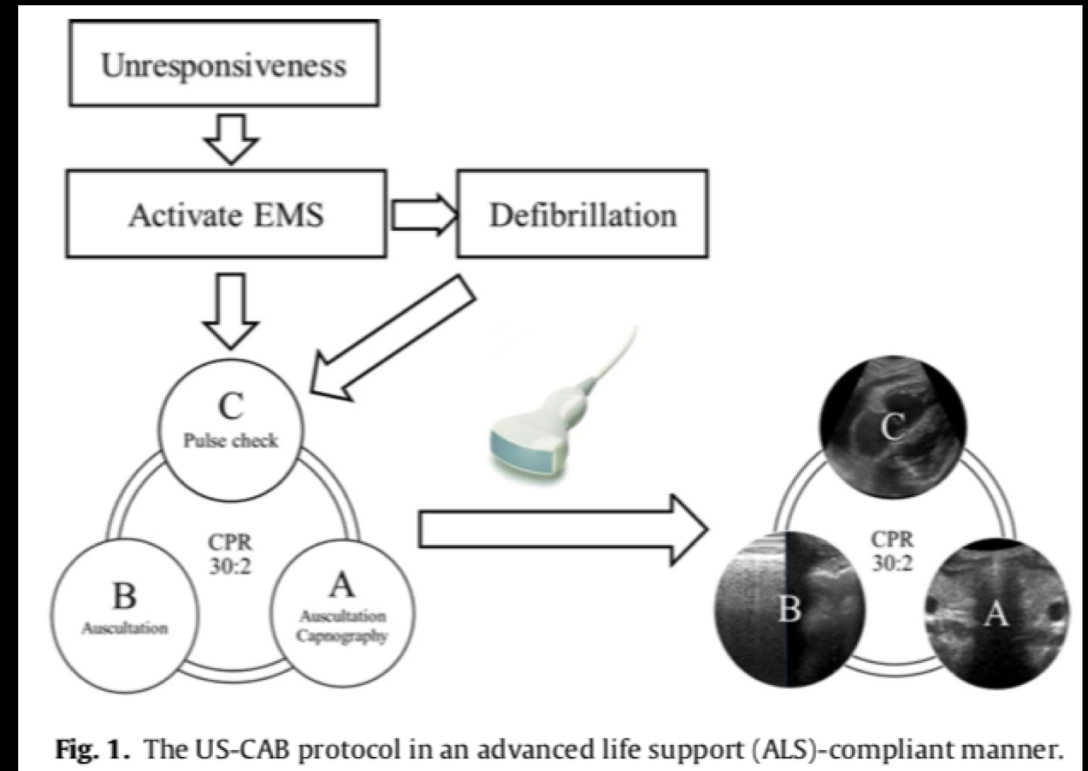
# Fluid

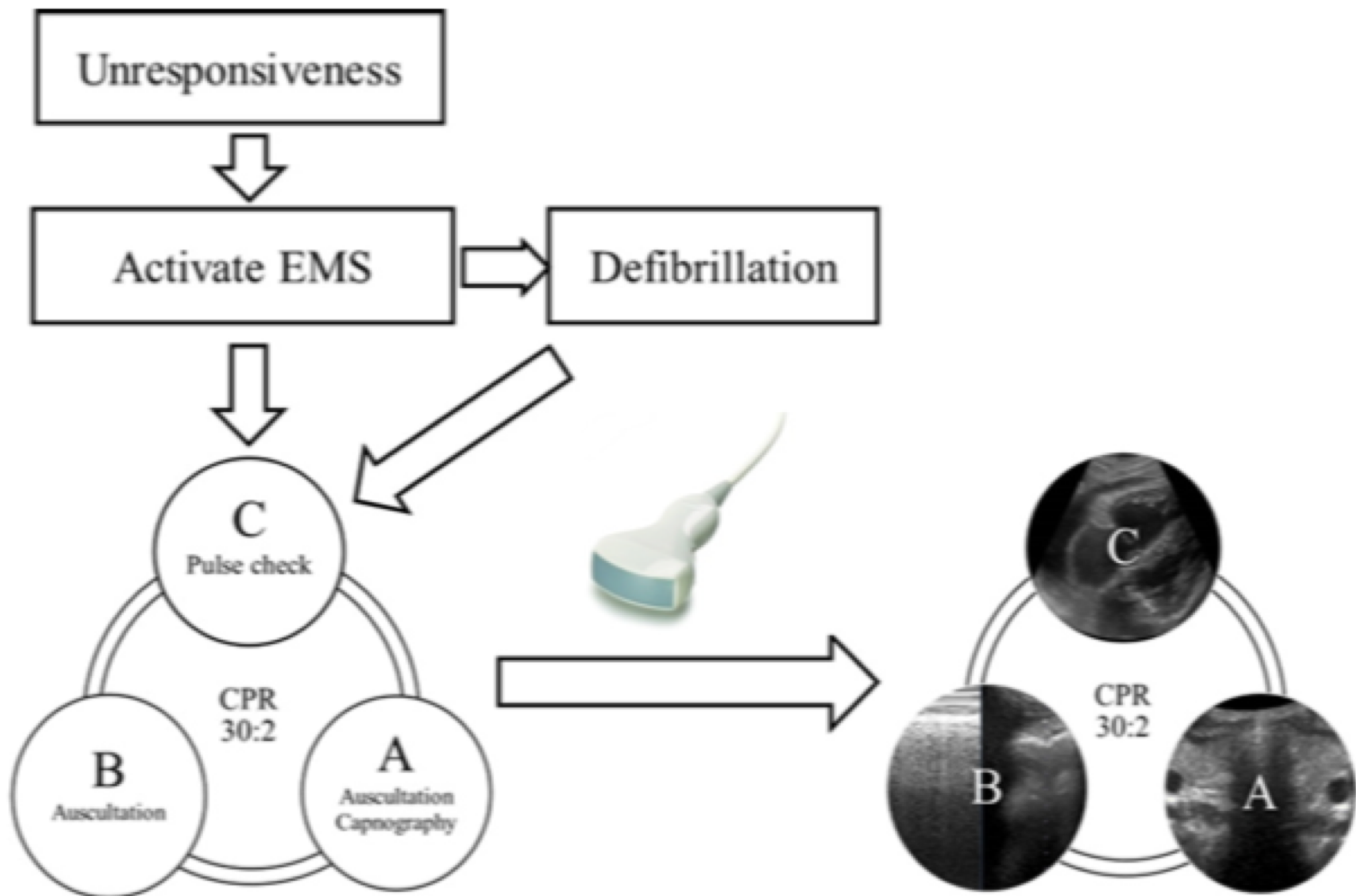
- Trauma
  - Blood
  - Urine
  - Bowel content
- Non-Trauma
  - Ascites
  - Fat
  - Seminal vesicles

# Cardiac Arrest



# US-CAB





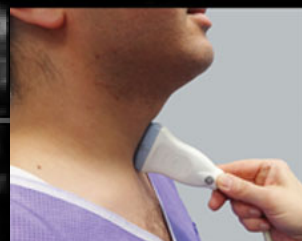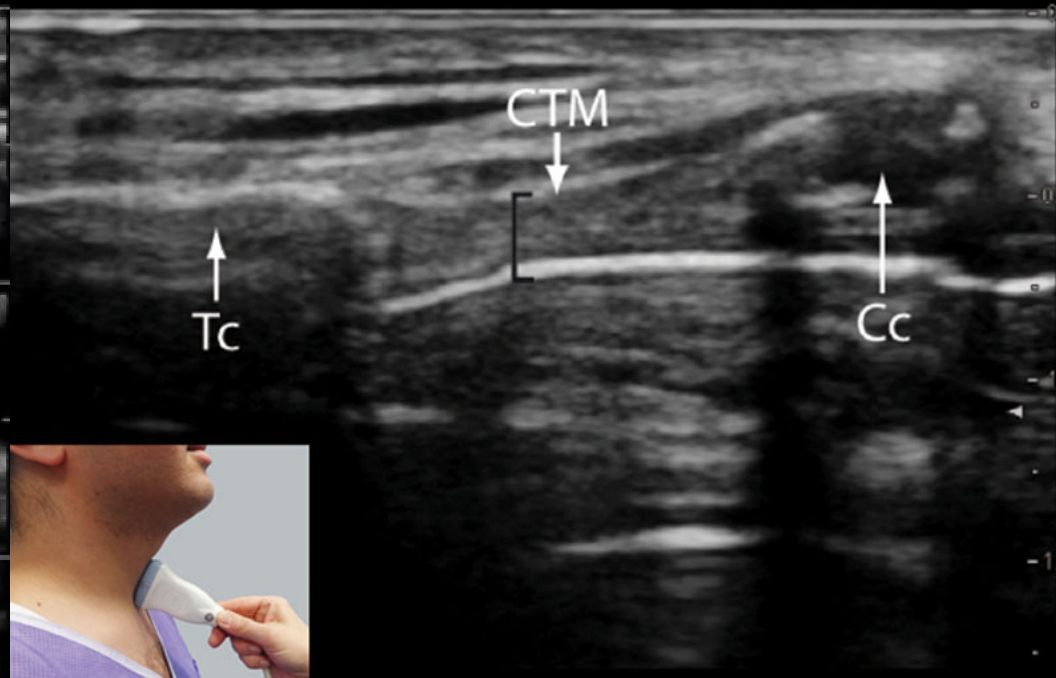
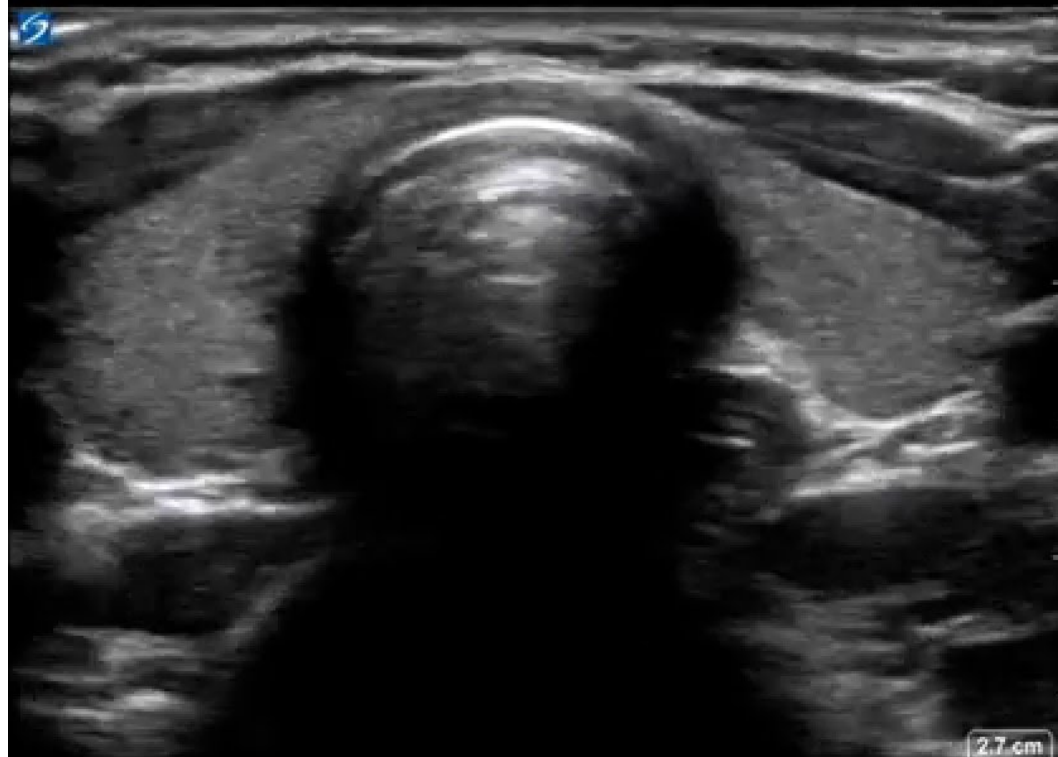**Fig. 1.** The US-CAB protocol in an advanced life support (ALS)-compliant manner.

# 請問

你敢做cricothyroidotomy嗎？



13 NOV 2015 / 17:42



SonoSite  
HFL38xp/13-6 Nerve

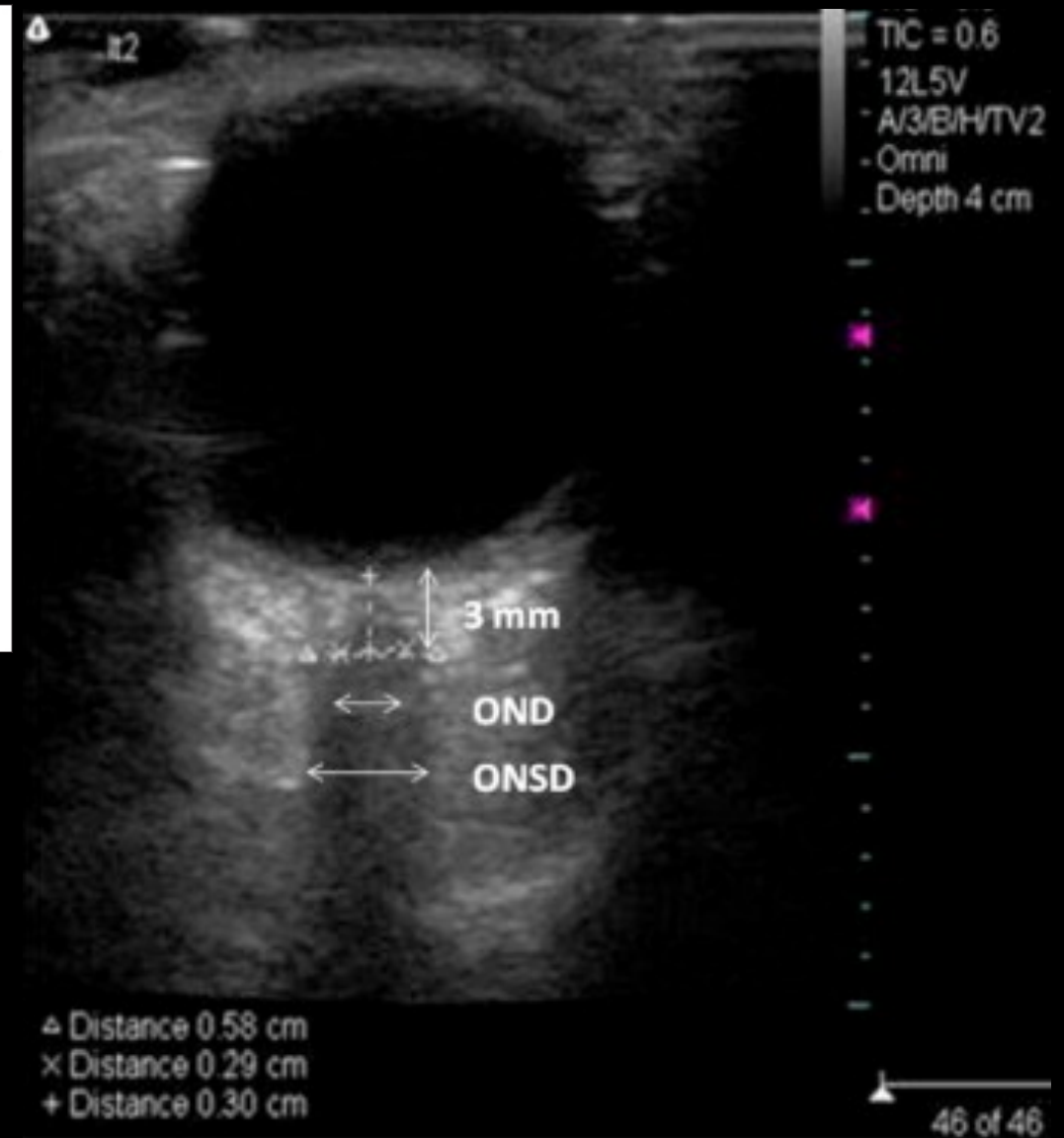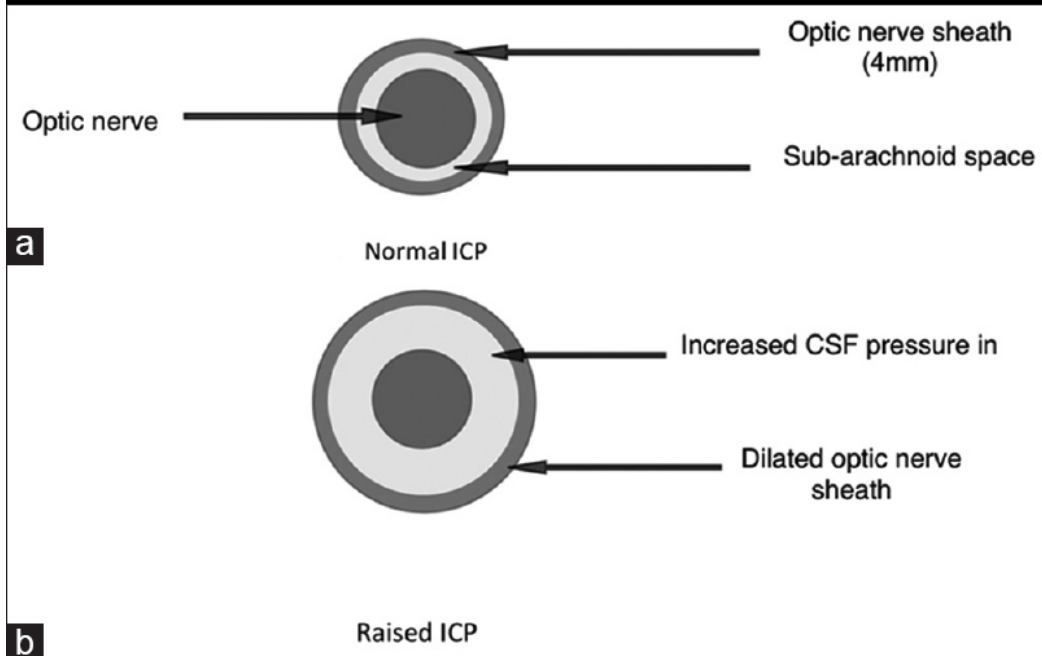
2.7 cm  
2D: G: 72  
DR: 0  
MB

**“Linear”**

# 請問

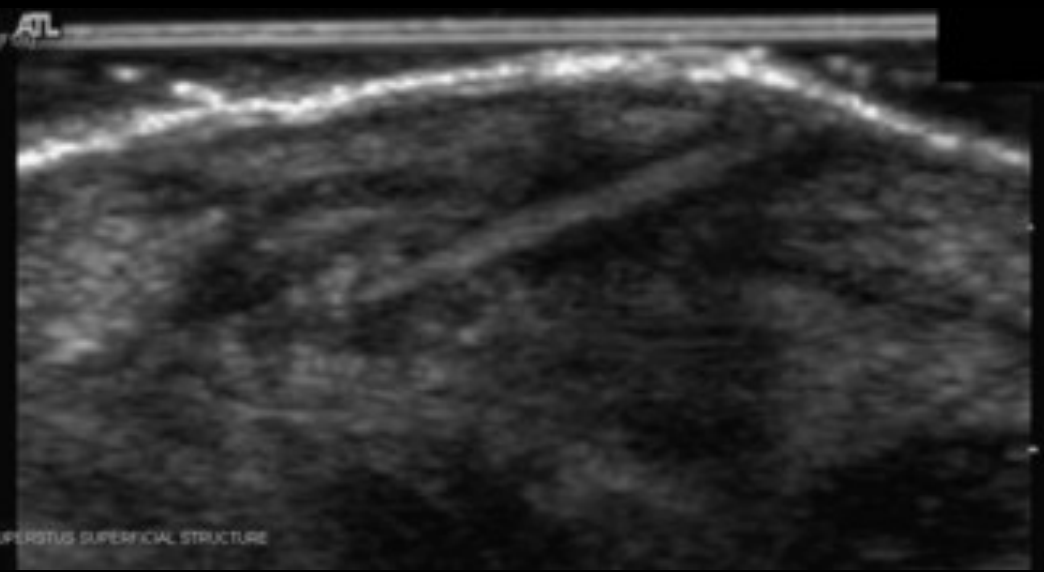
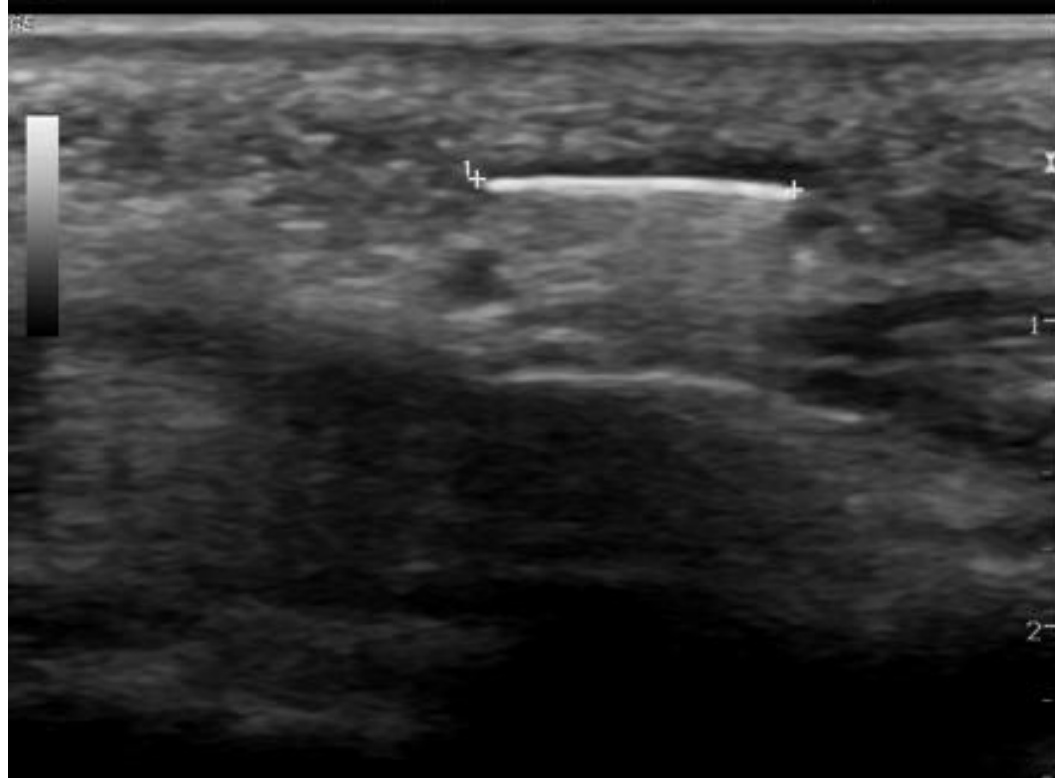
酒醉患者，頭部無明顯外傷，意識不清，你會做brain CT嗎？

# Optic Nerve Sheath Diameter



# 請問

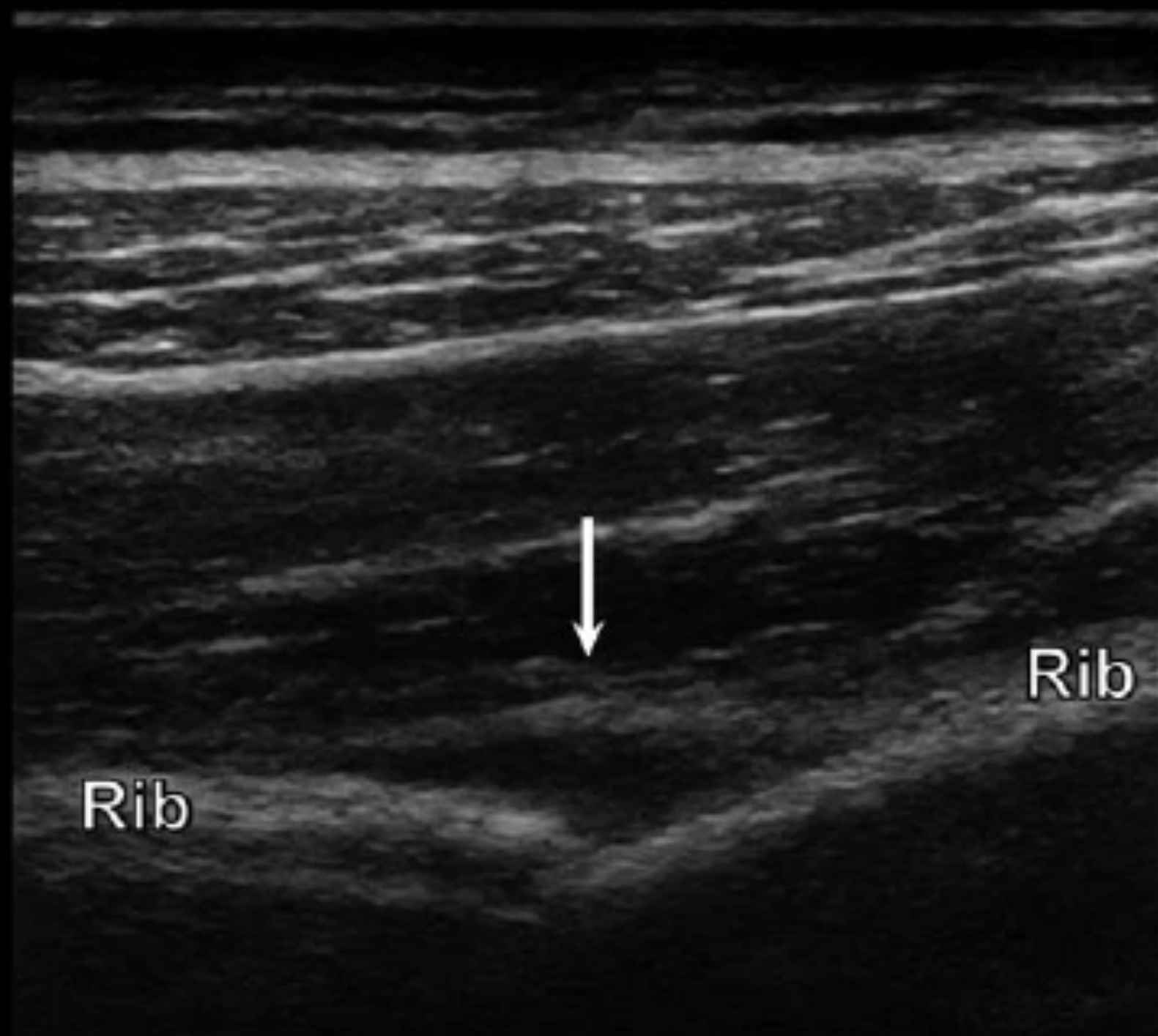
疑似木屑插進小腿，如何診斷？  
如何取出？



1 L 1.04 cm

# 請問

胸壁鈍挫傷，局部痛點，但X-ray  
看不到骨折，下一步是？



Rib

Rib

2

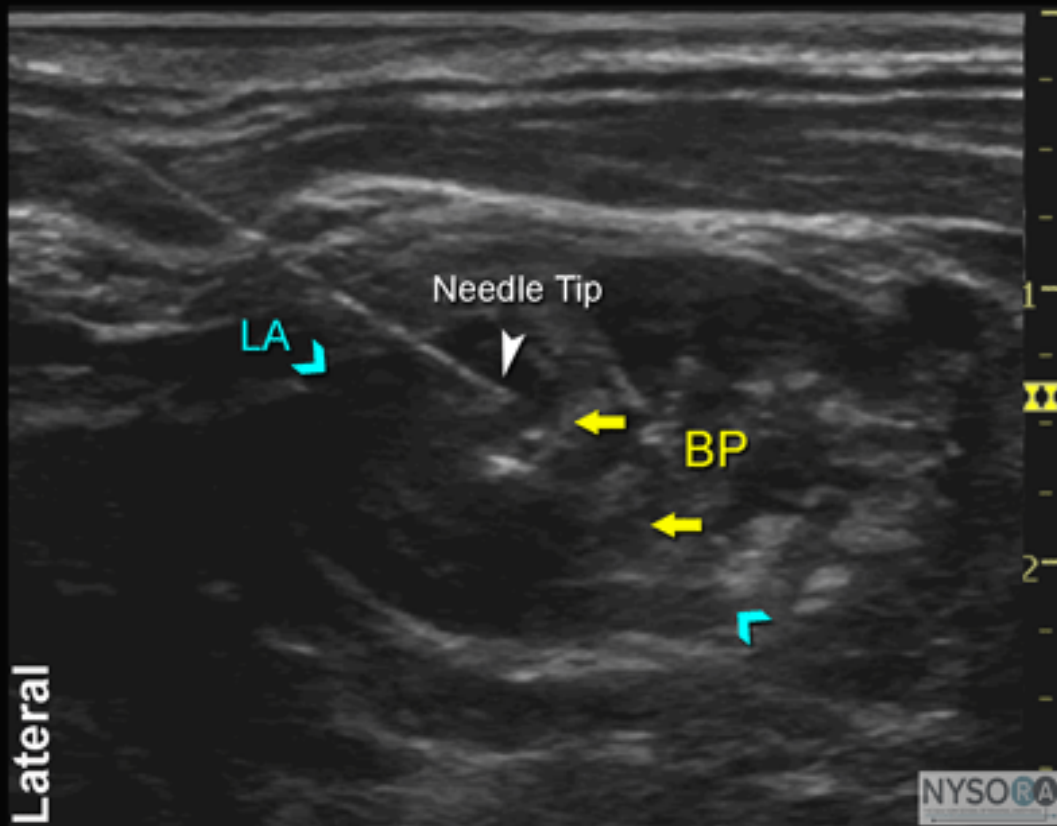
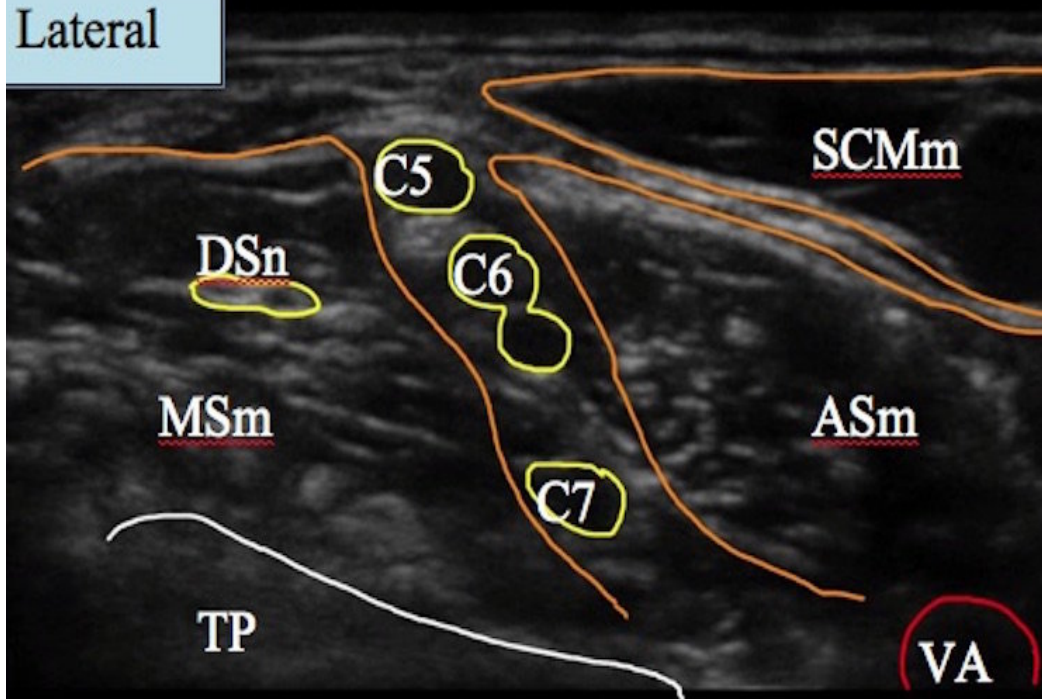
3



# 請問

100歲阿公，右肩脫臼，人有點喘喘的，血壓90/40mmHg，要打propofol嗎？

Lateral



Lateral

2.1

# 頒獎



# Sonography for Trauma

- More than “FAST”
- Cardiac arrest
- Linear

---

急診 劉信良醫師

cutelpliu@gmail.com