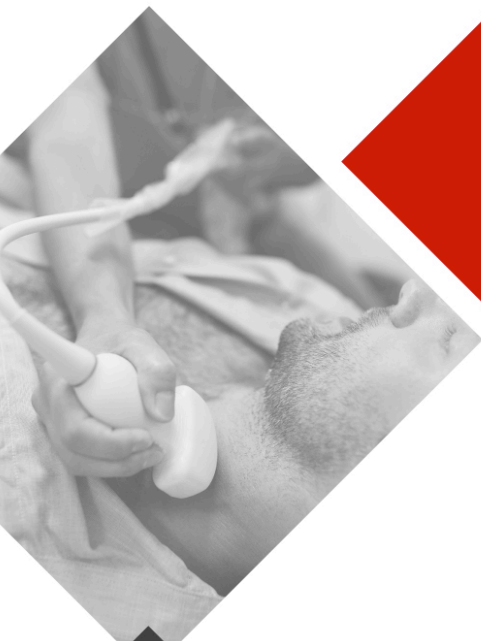


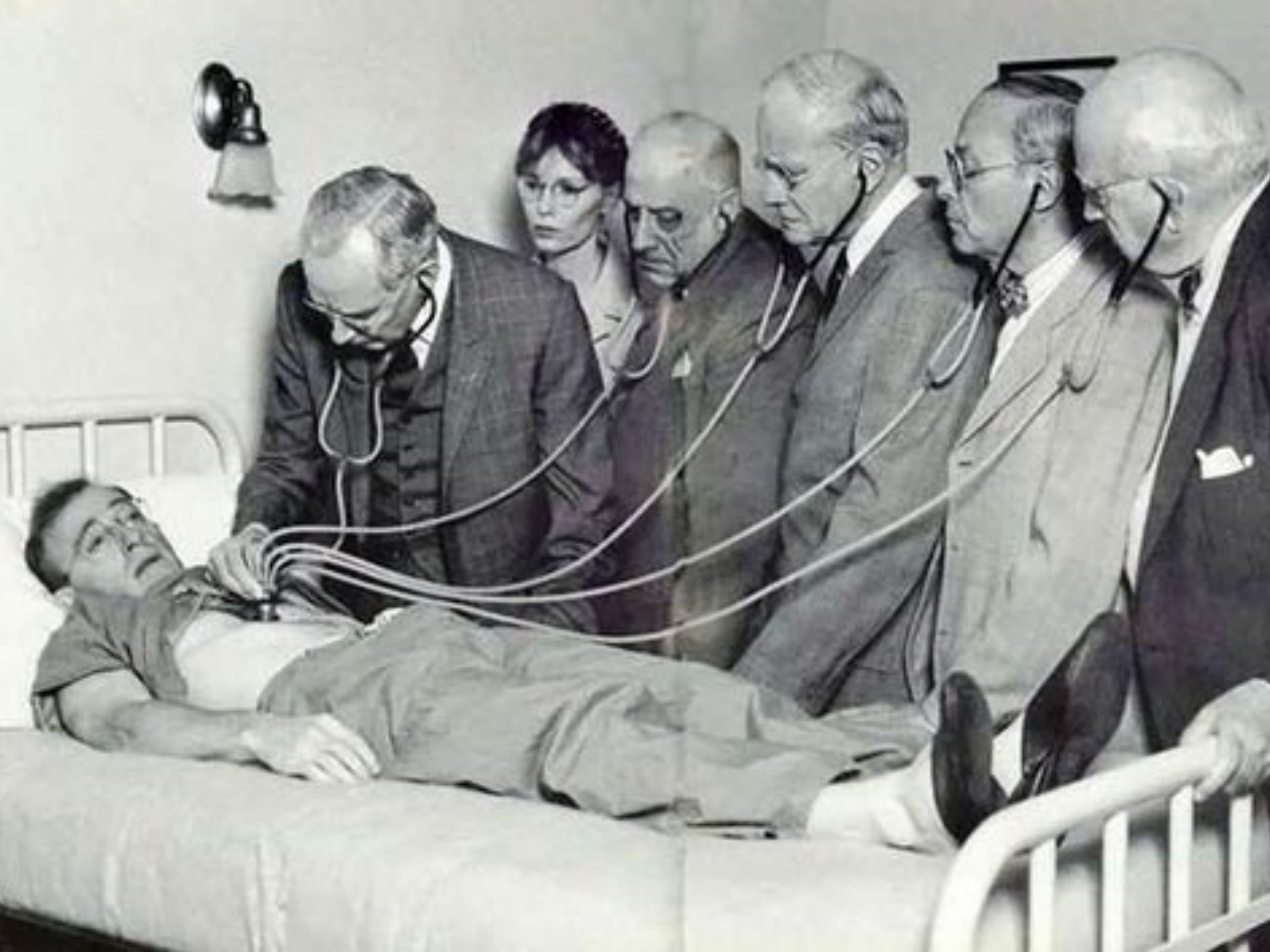
ULTRASOUND  
PROGRAM

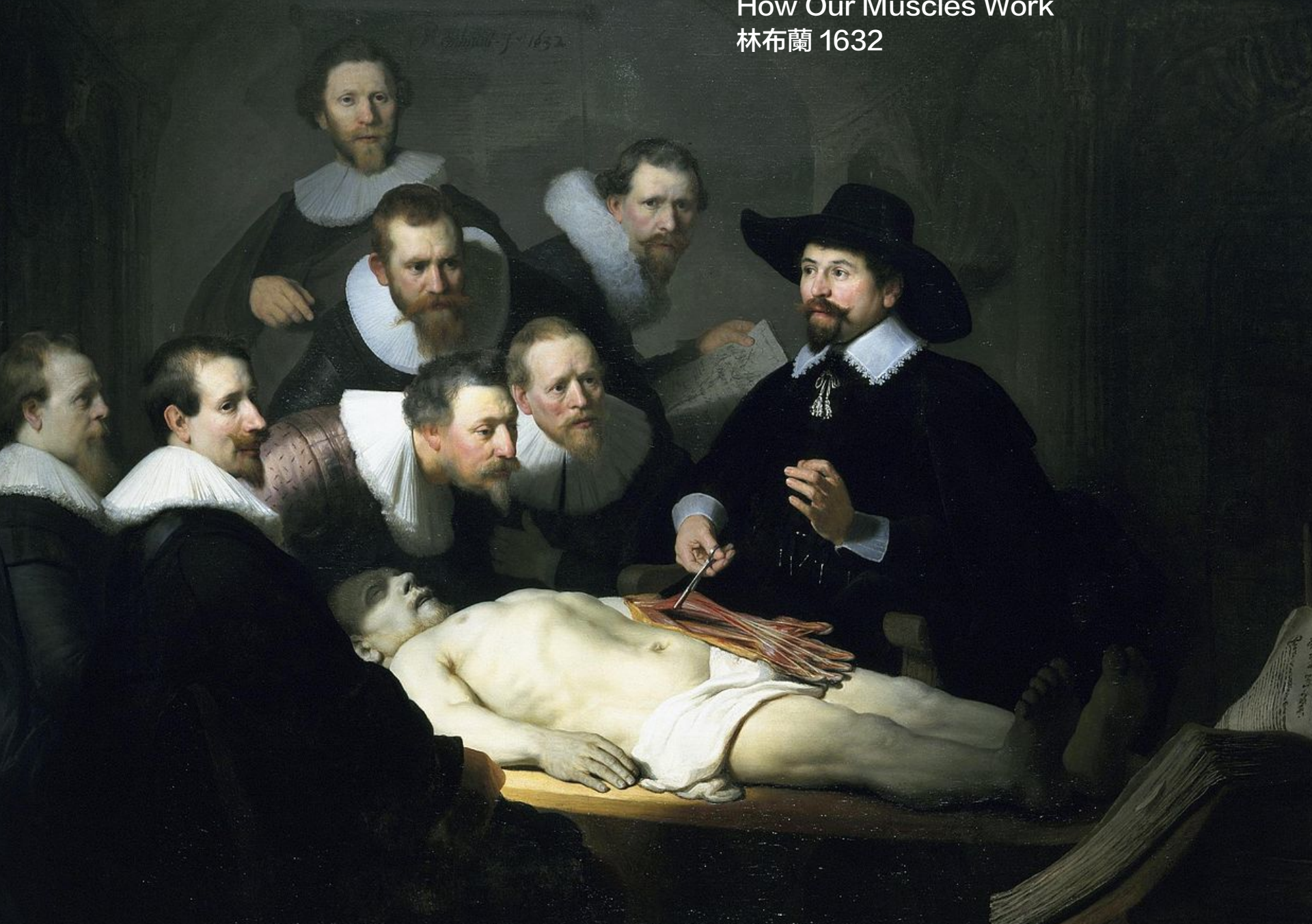

# 重點照護超音波 你該知道的大小事

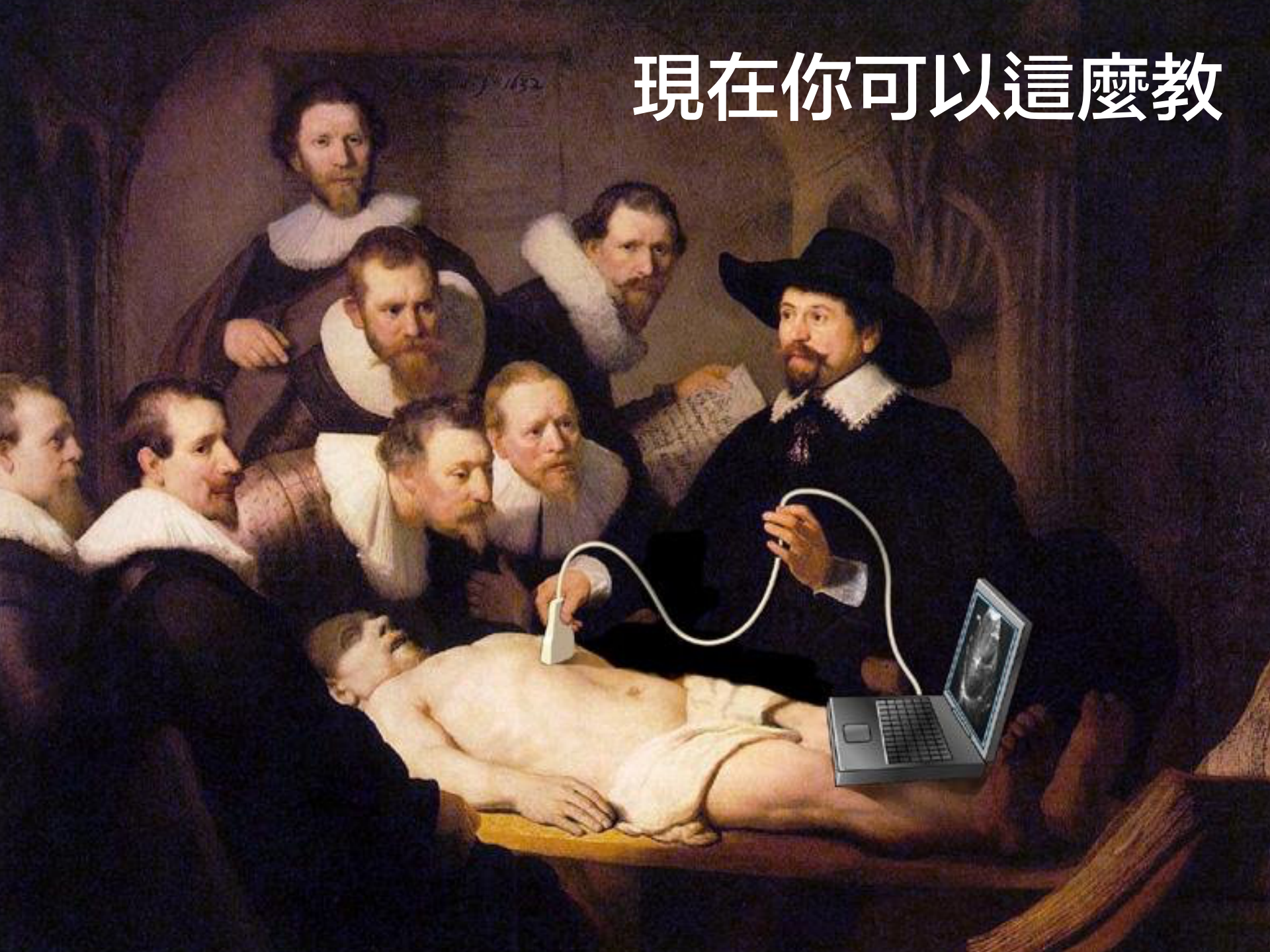
主講人：陳國智  
西園醫院急診科

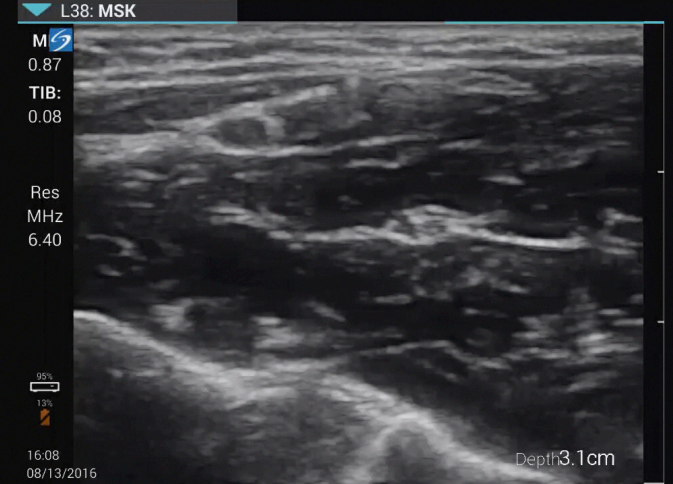
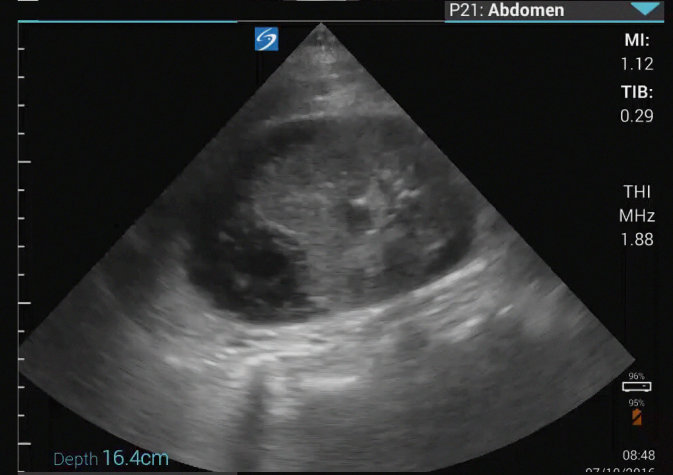
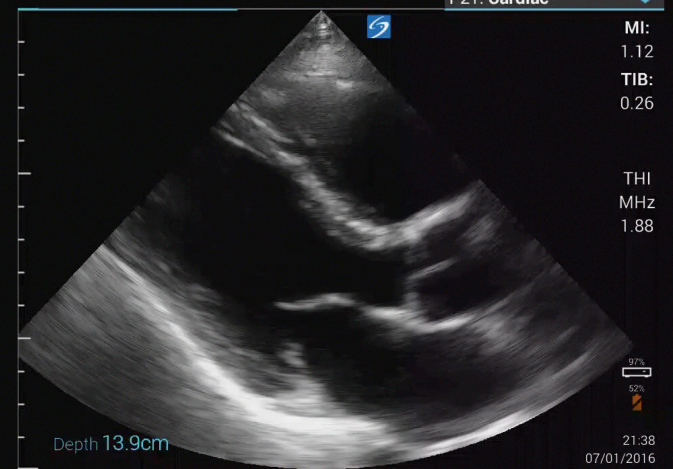
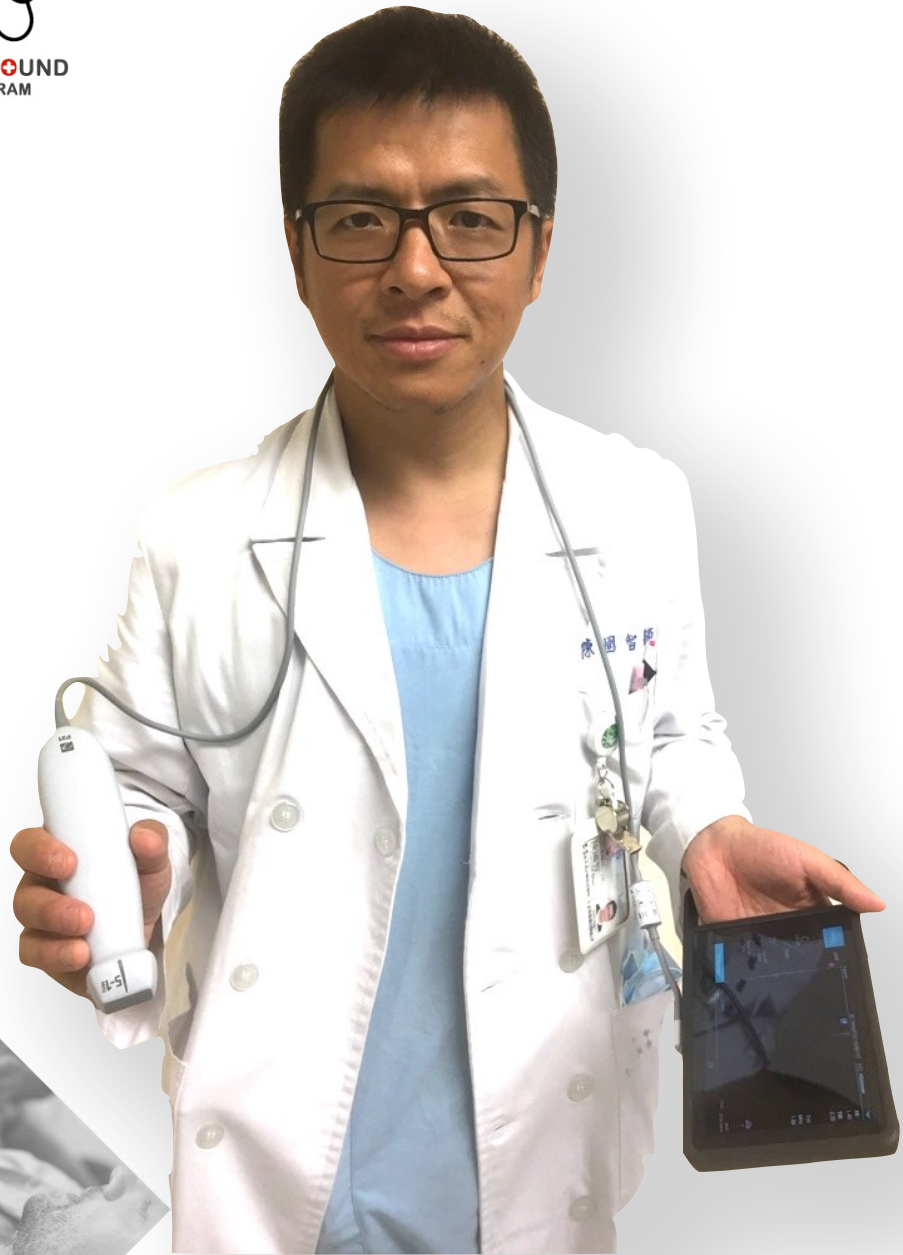

The Anatomy Lesson of Dr. Nicolaes Tulp  
How Our Muscles Work  
林布蘭 1632

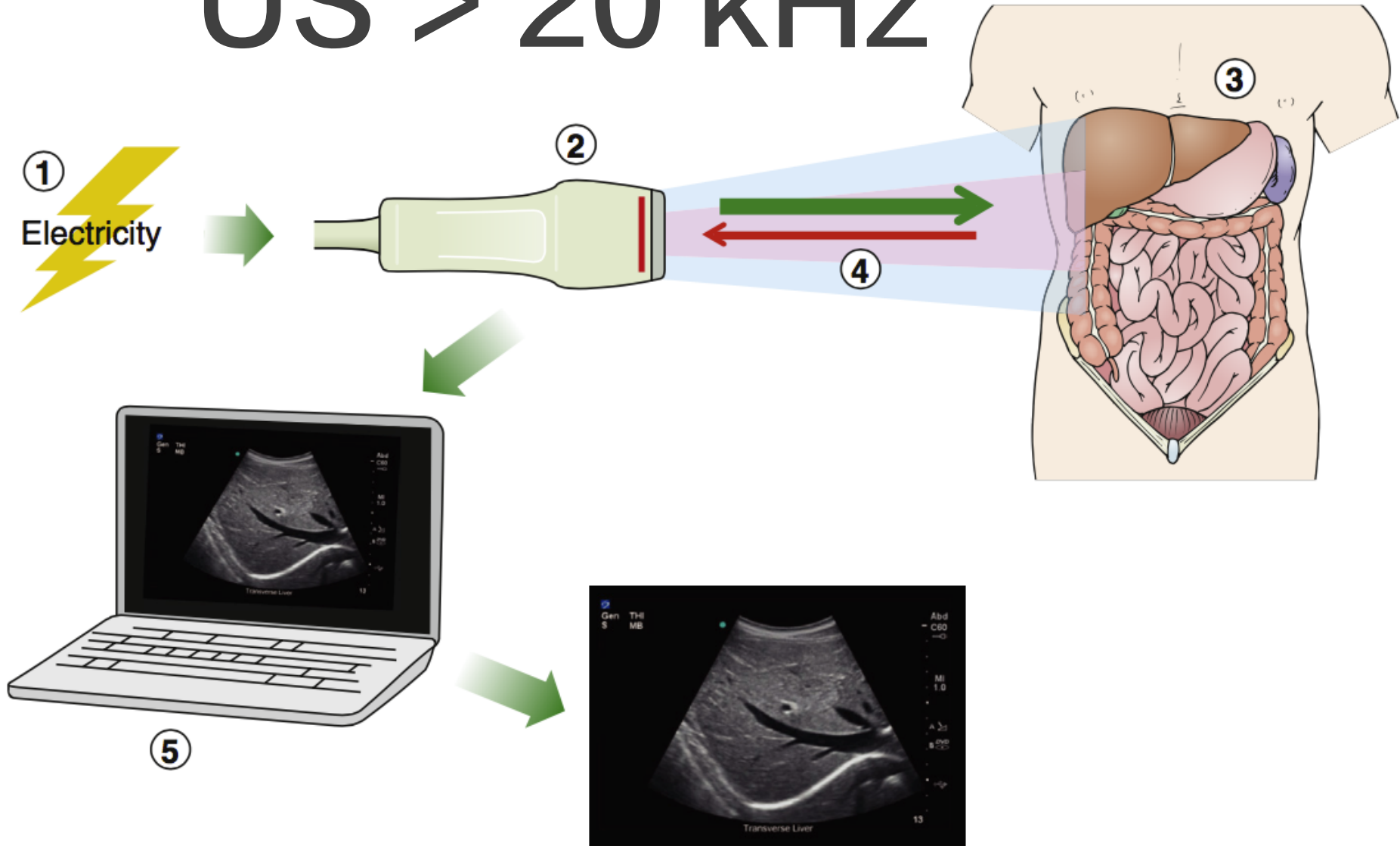


現在你可以這麼教

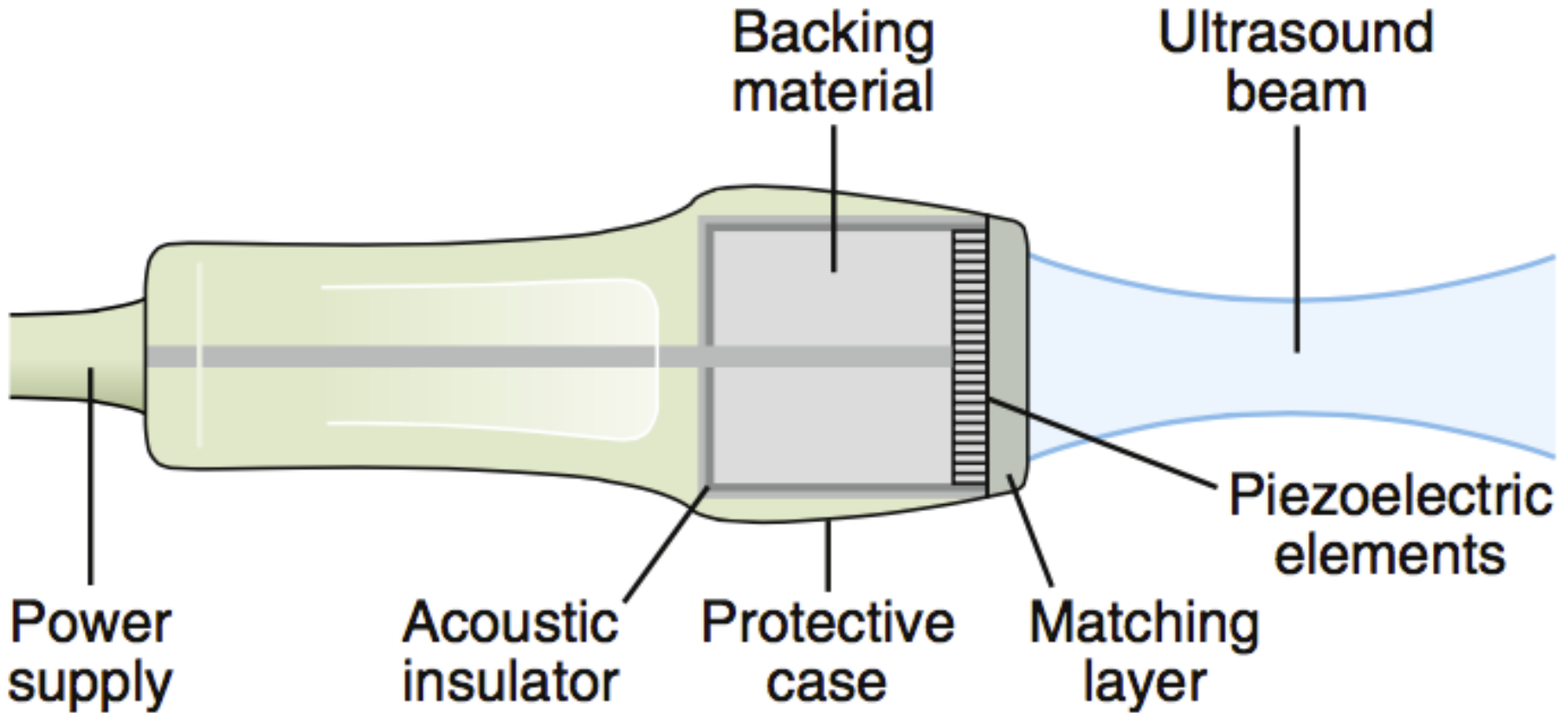




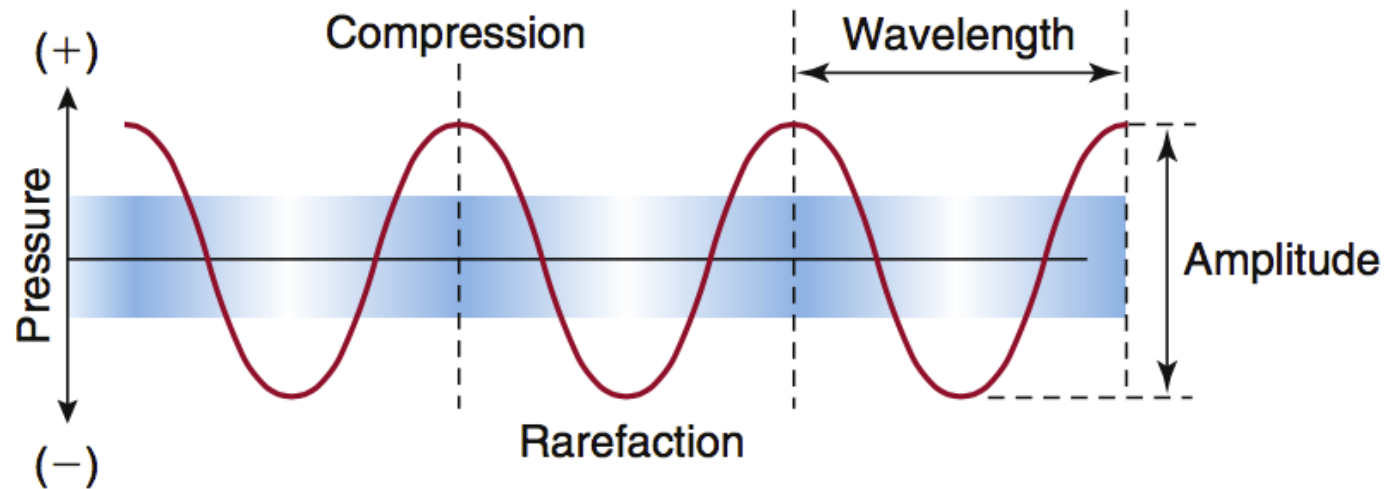

# US > 20 kHz



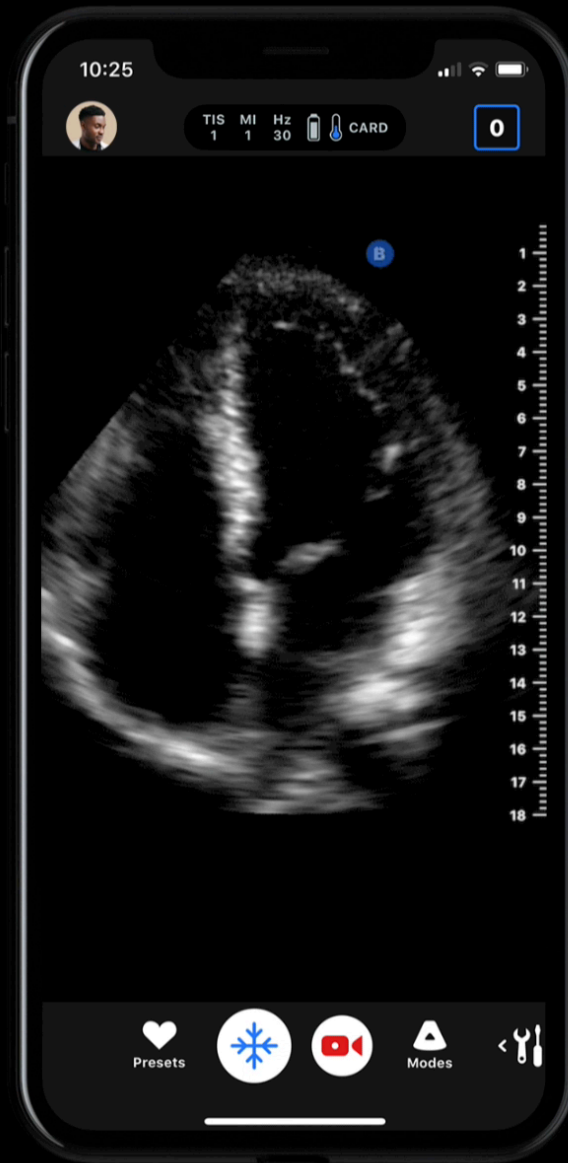# 探頭構造




# 發射 & 接收







Butterfly iQ  
\$ 2K





# Victor Hugo

“There is one thing stronger than all the armies in the world, and that is an idea whose time has come”

**POCUS' s time has come !!**

# POCUS

## Point-of-Care Ultrasound

“ultrasonography brought to  
the patient and performed by  
the provider in real time”

---

Moore, C. L., & Copel, J. A. NEJM 2011

# POCUS



ELSEVIER

Ultrasound in Med. & Biol., Vol. ■, No. ■, pp. 1–10, 2016  
Copyright © 2016 World Federation for Ultrasound in Medicine & Biology  
Printed in the USA. All rights reserved  
0301-5629/\$ - see front matter

<http://dx.doi.org/10.1016/j.ultrasmedbio.2016.06.021>

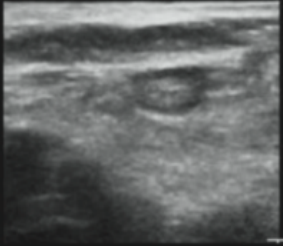
## POINT OF CARE ULTRASOUND: A WFUMB POSITION PAPER

CHRISTOPH F. DIETRICH,<sup>\*†</sup> ADRIAN GOUDIE,<sup>‡</sup> LILIANA CHIOREAN,<sup>§</sup> XIN WU CUI,<sup>\*†</sup> ODD HELGE GILJA,<sup>¶</sup>  
YI DONG,<sup>\*||</sup> JACQUES S. ABRAMOWICZ,<sup>#</sup> SUDHIR VINAYAK,<sup>\*\*</sup> SUSAN CAMPBELL WESTERWAY,<sup>††</sup>  
CHRISTIAN PÁLLSON NOLSØE,<sup>‡‡</sup> YI-HONG CHOU,<sup>§§</sup> and MICHAEL BLAIVAS<sup>¶¶</sup>

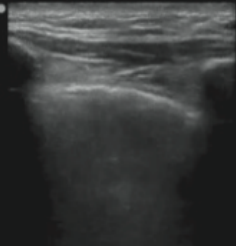


# 重點照護超音波

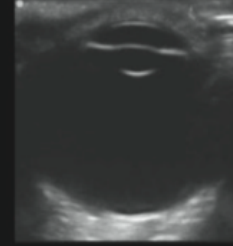
Lymph nodes



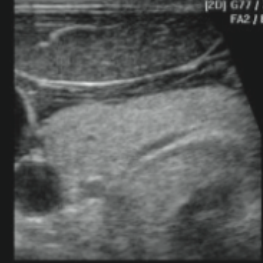
Lungs



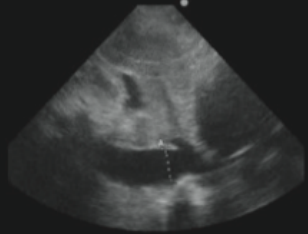Eyes



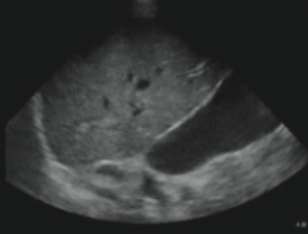
Thyroid



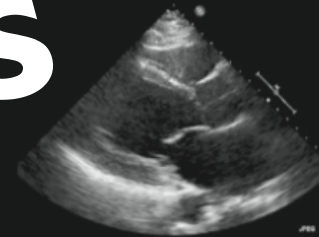
IVC



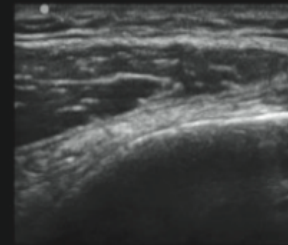
Gallbladder



Heart



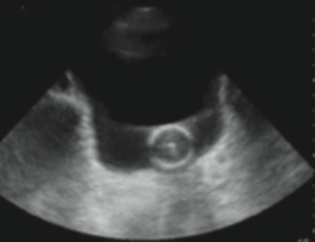
Musculoskeletal



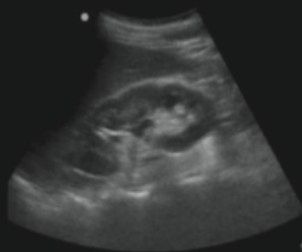
**POCUS**



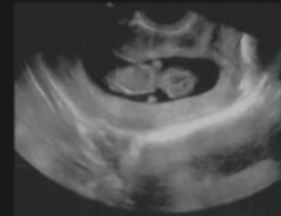
Bladder



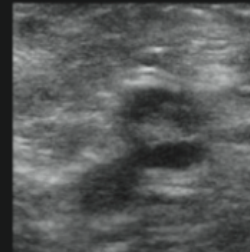
Kidneys



Male/female  
reprod



Vascular



# POCUS-急診緣由

症狀  
問題

線索  
時間

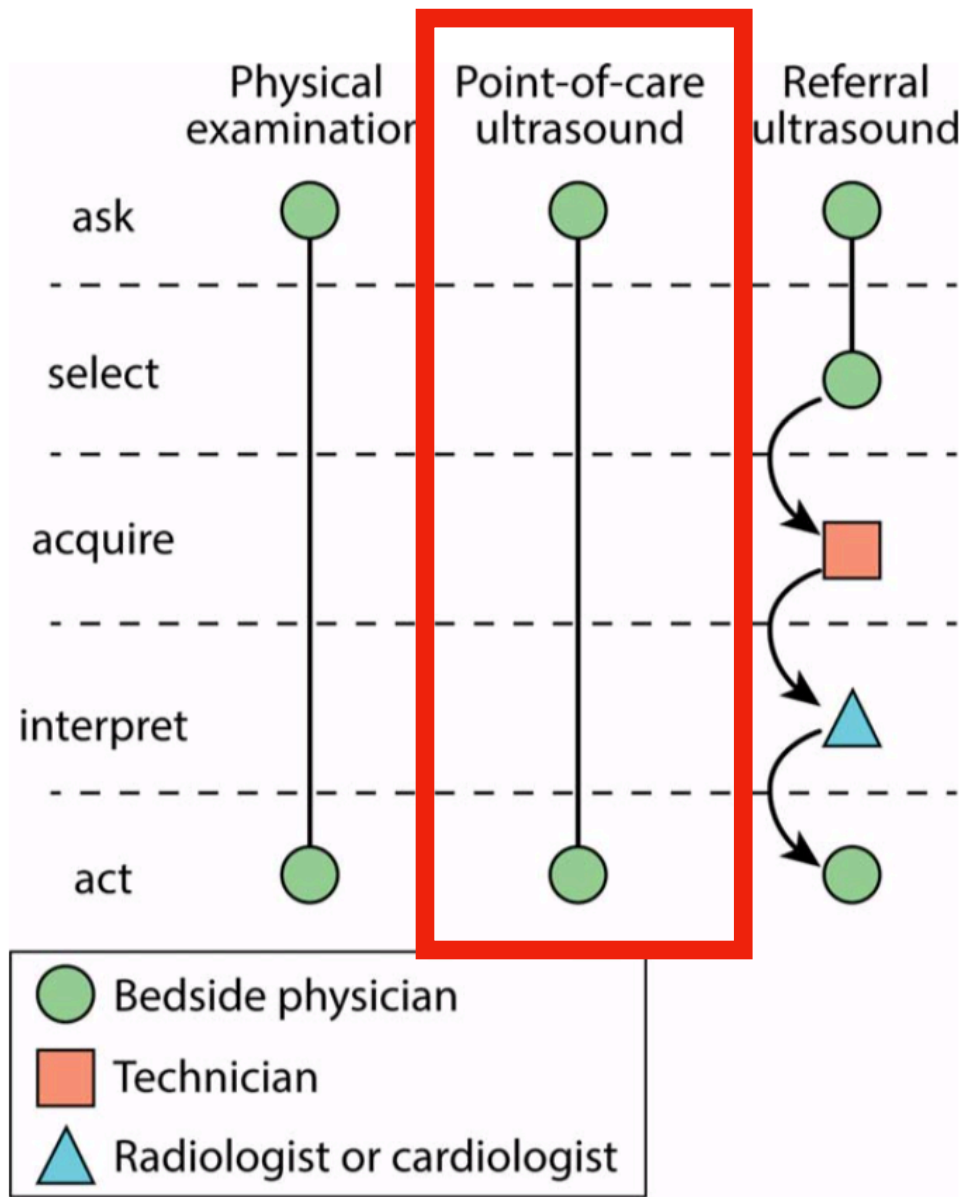
診斷  
治療

雜

少

快

# 簡 要 即 時



# 完 整 耗 時



急診

Time

重症

Care

POCUS

Site

病房

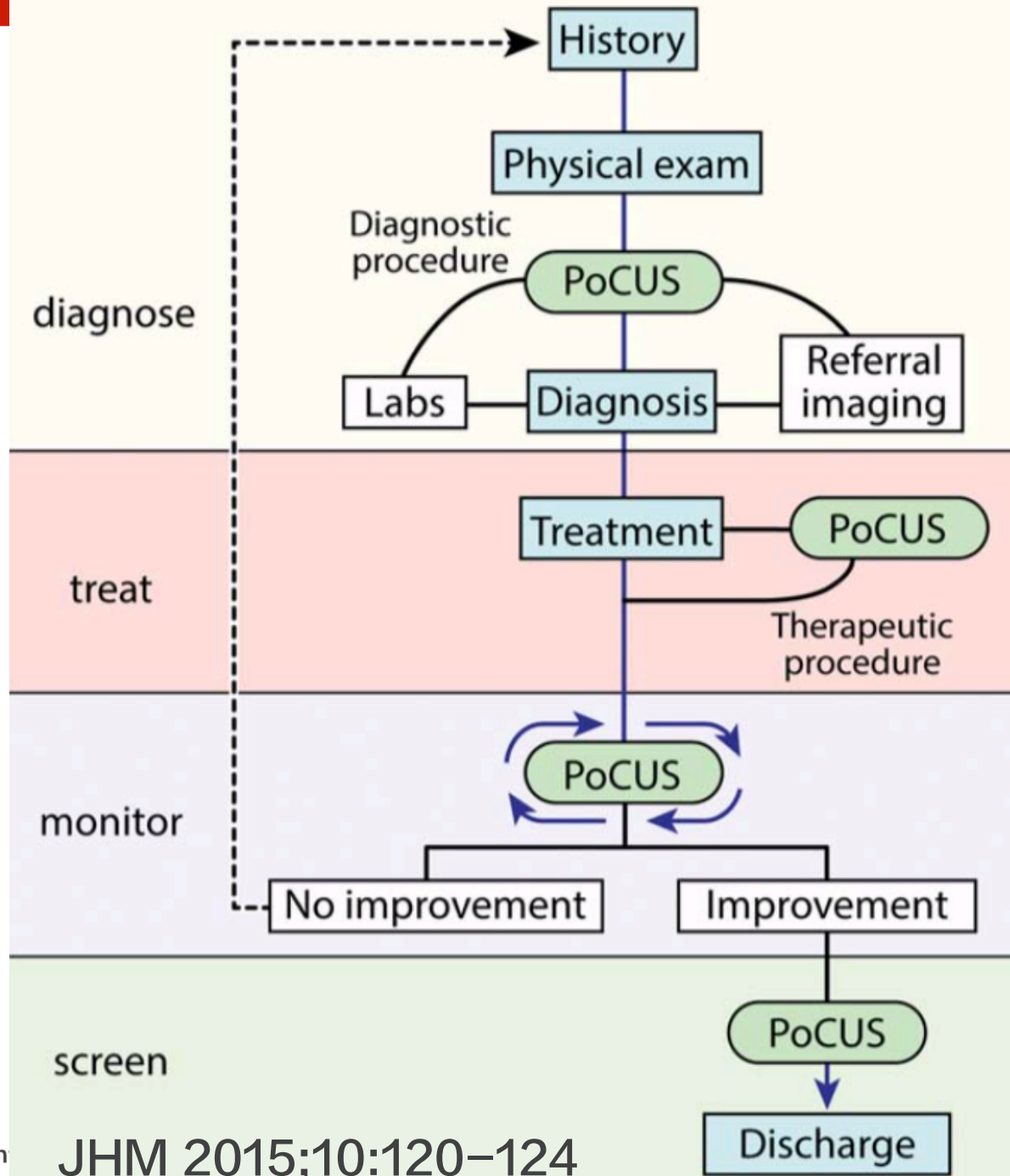
居家





# POCUS

## 住院病人



# I-AIM

## Indication



Acquisition

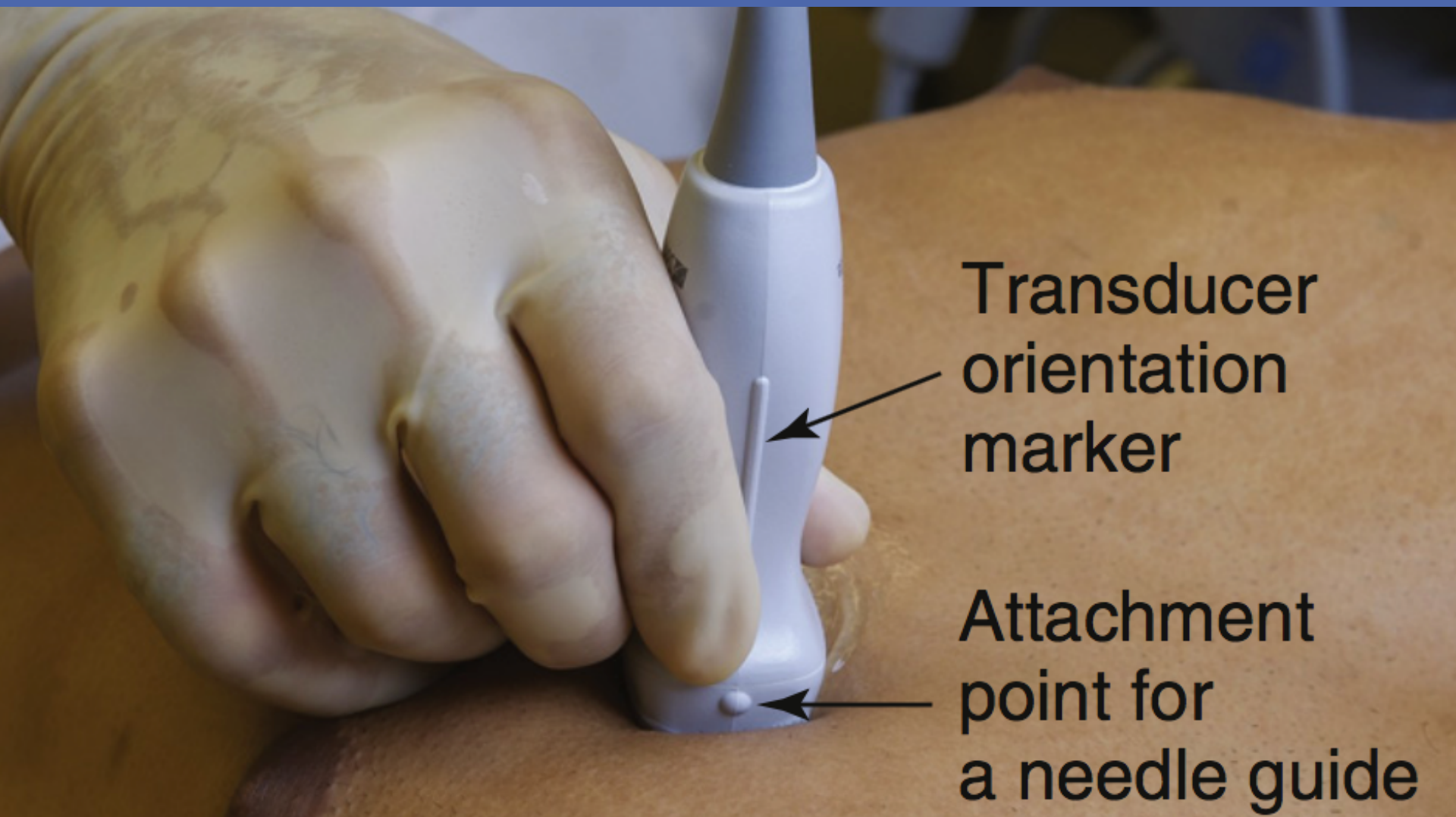

Interpretation



Making  
decision

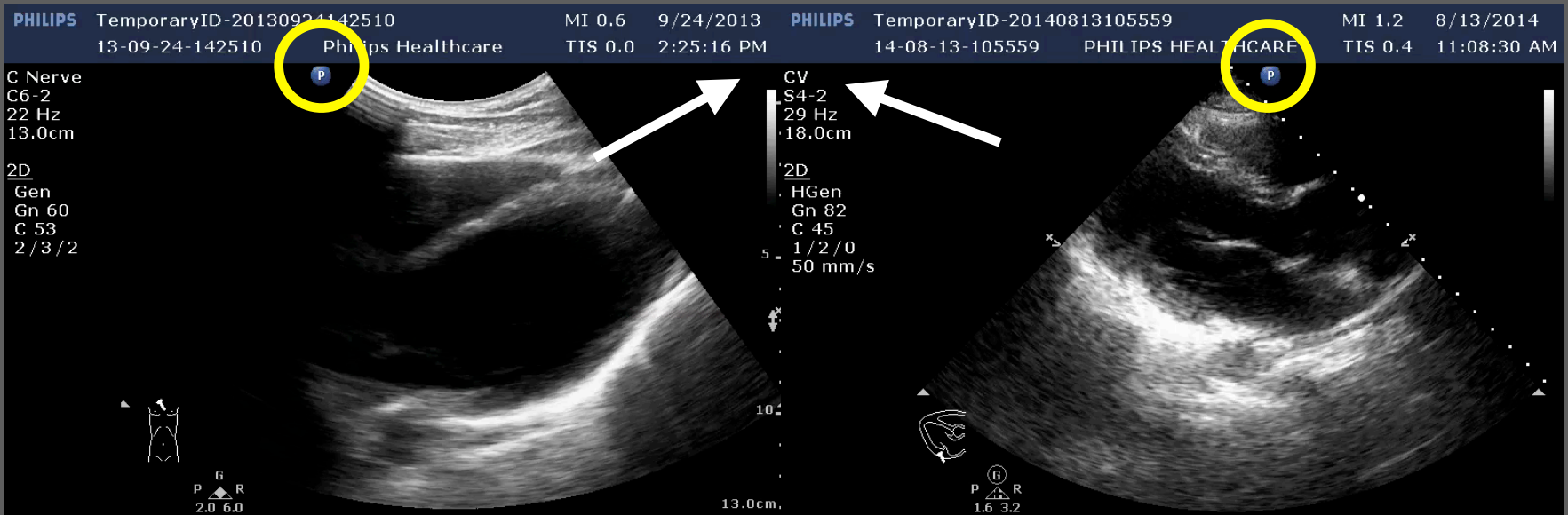
# 方向: 患者的右側和頭側



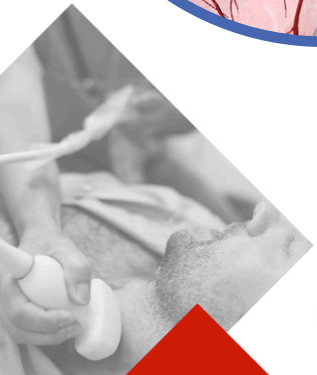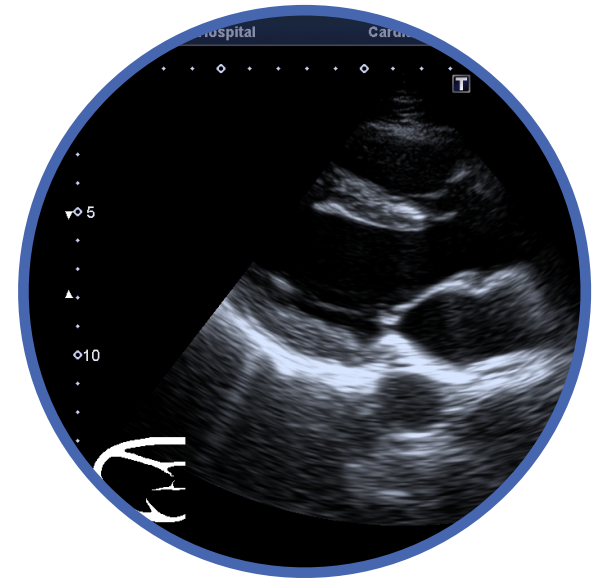
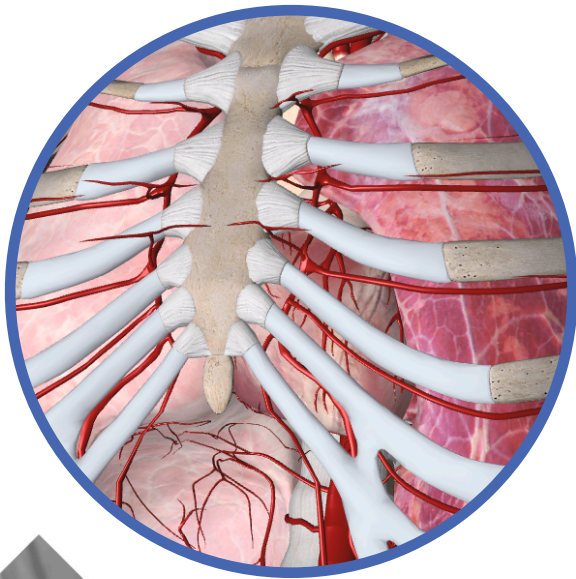
# 方向性要一致



Indicator  
Apex  
Setting



# 今天的目標



# 探頭操控 6 大技巧

X

Sweep

Fan

Y

Slide

Rock

Z

Rotate

Compress

# 探頭操控 6 大技巧

X

掃

傾

Y

滑

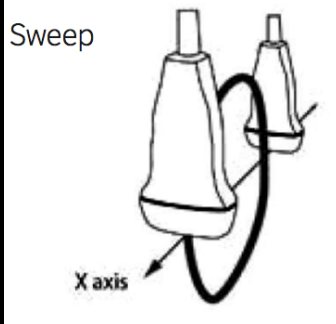
搖

Z

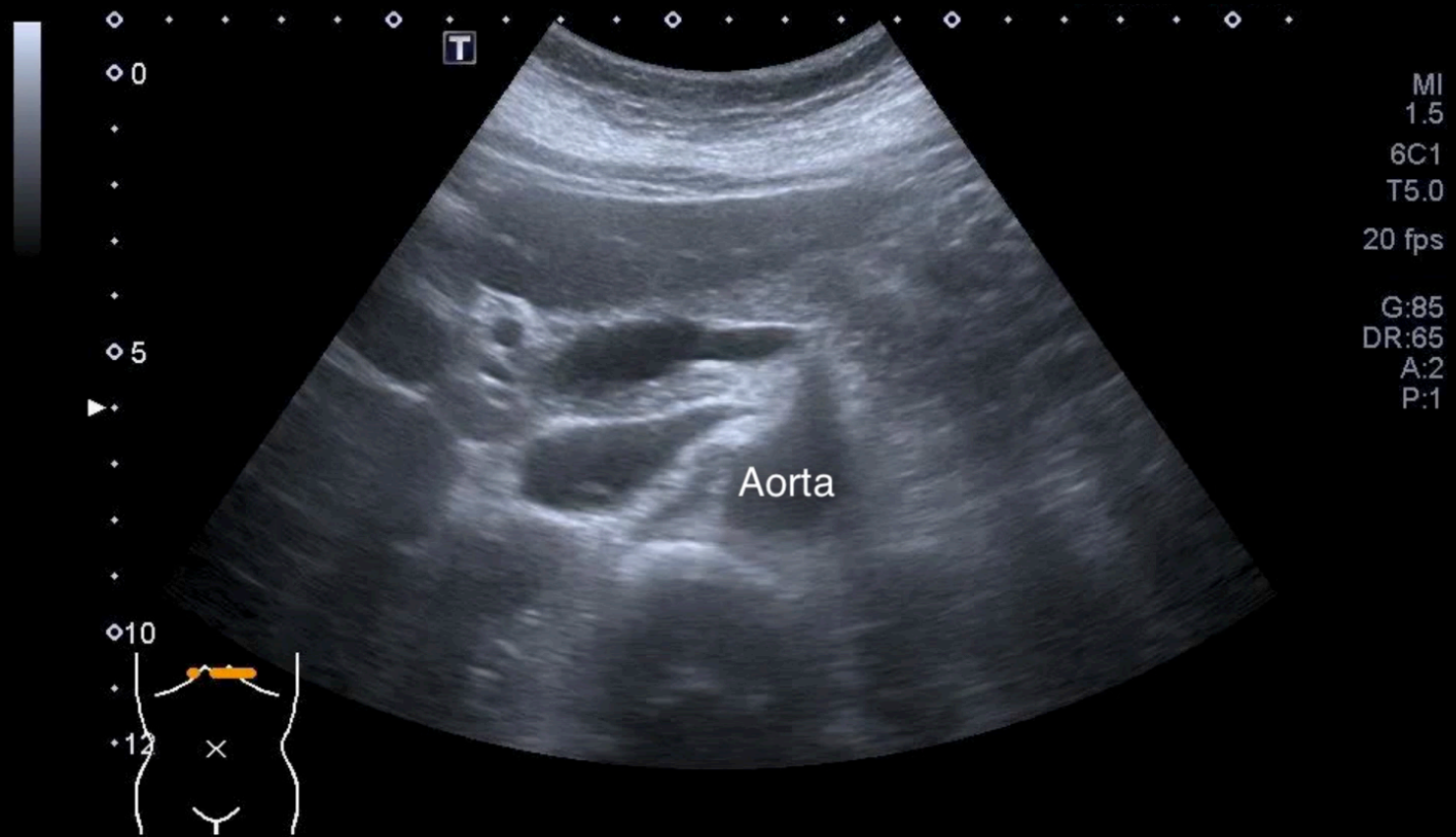轉

壓

掃

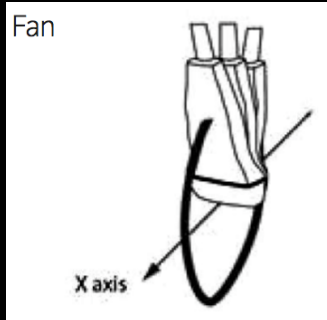


Sweep

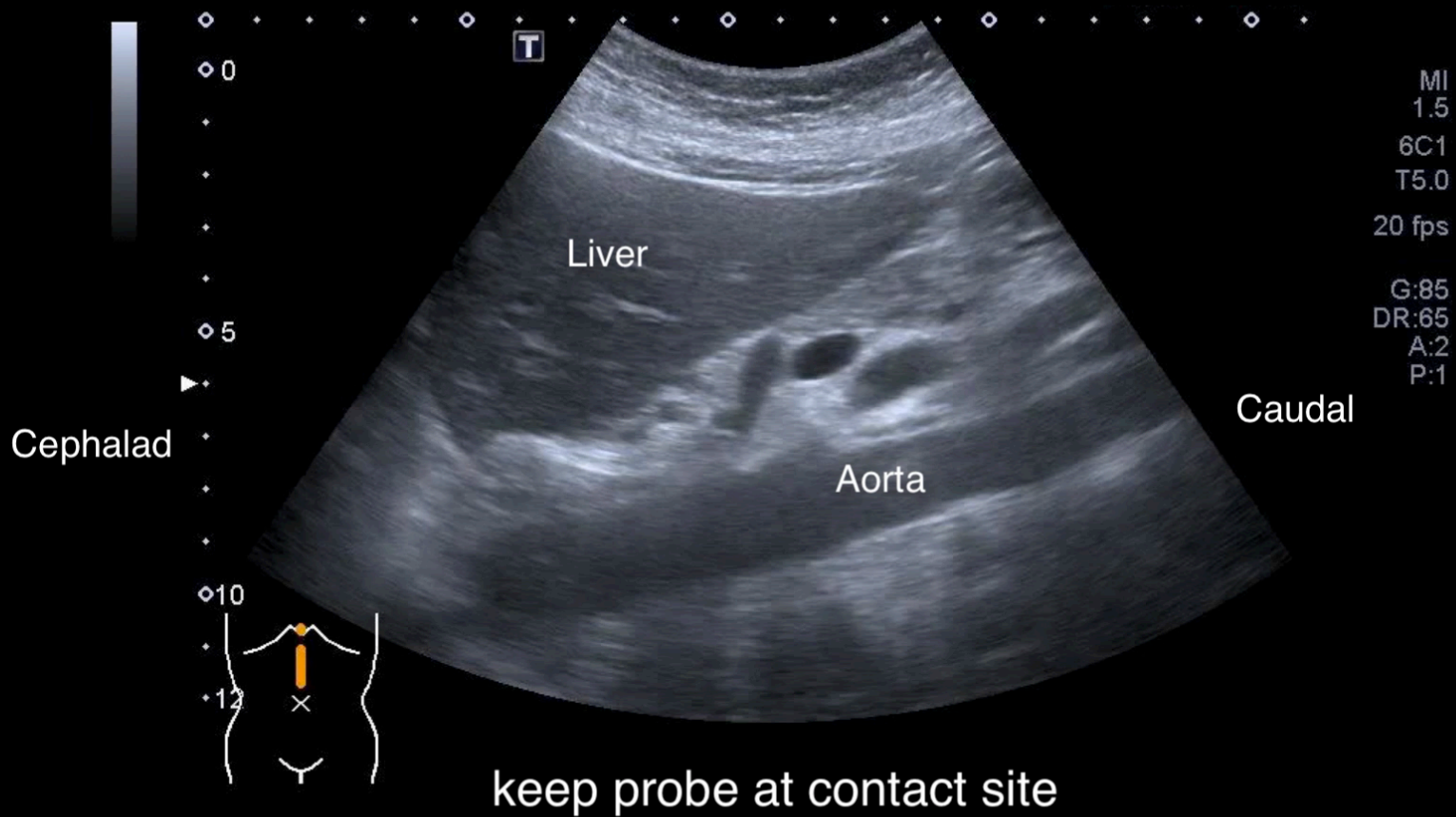



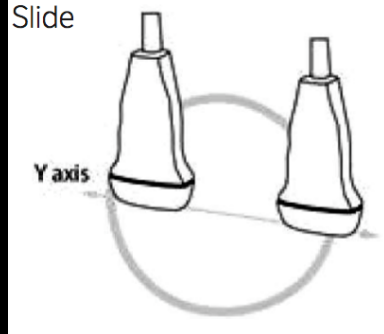
# 傾



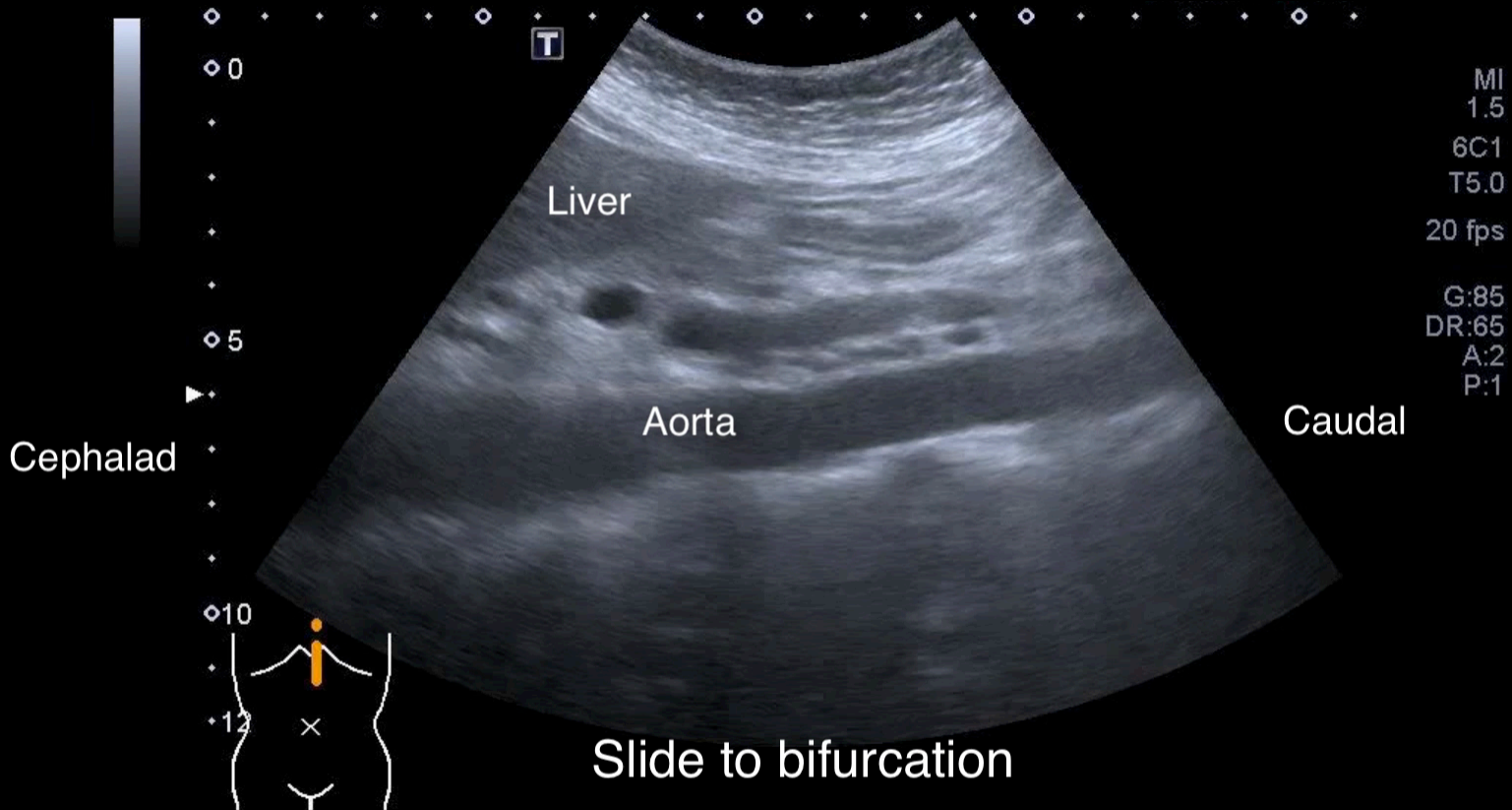
## Fan



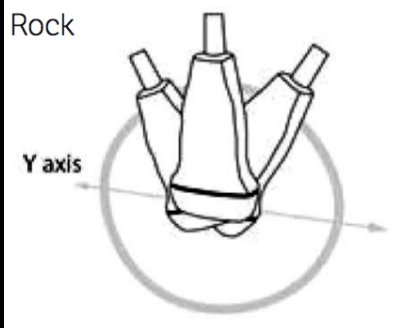
滑



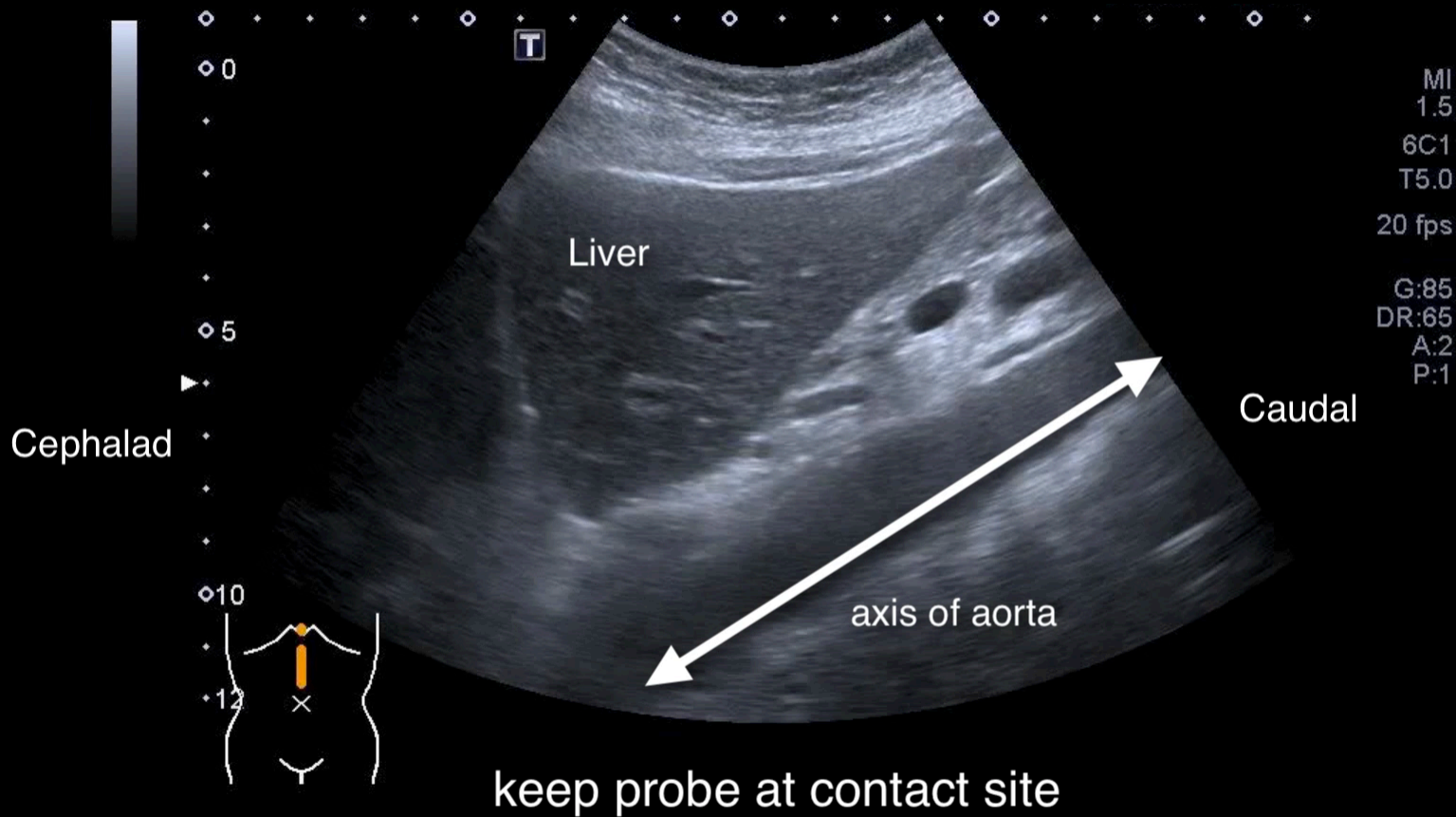
Slide



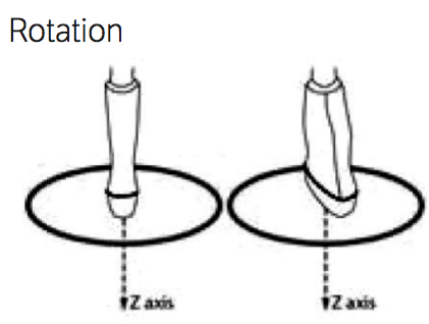
# 搖



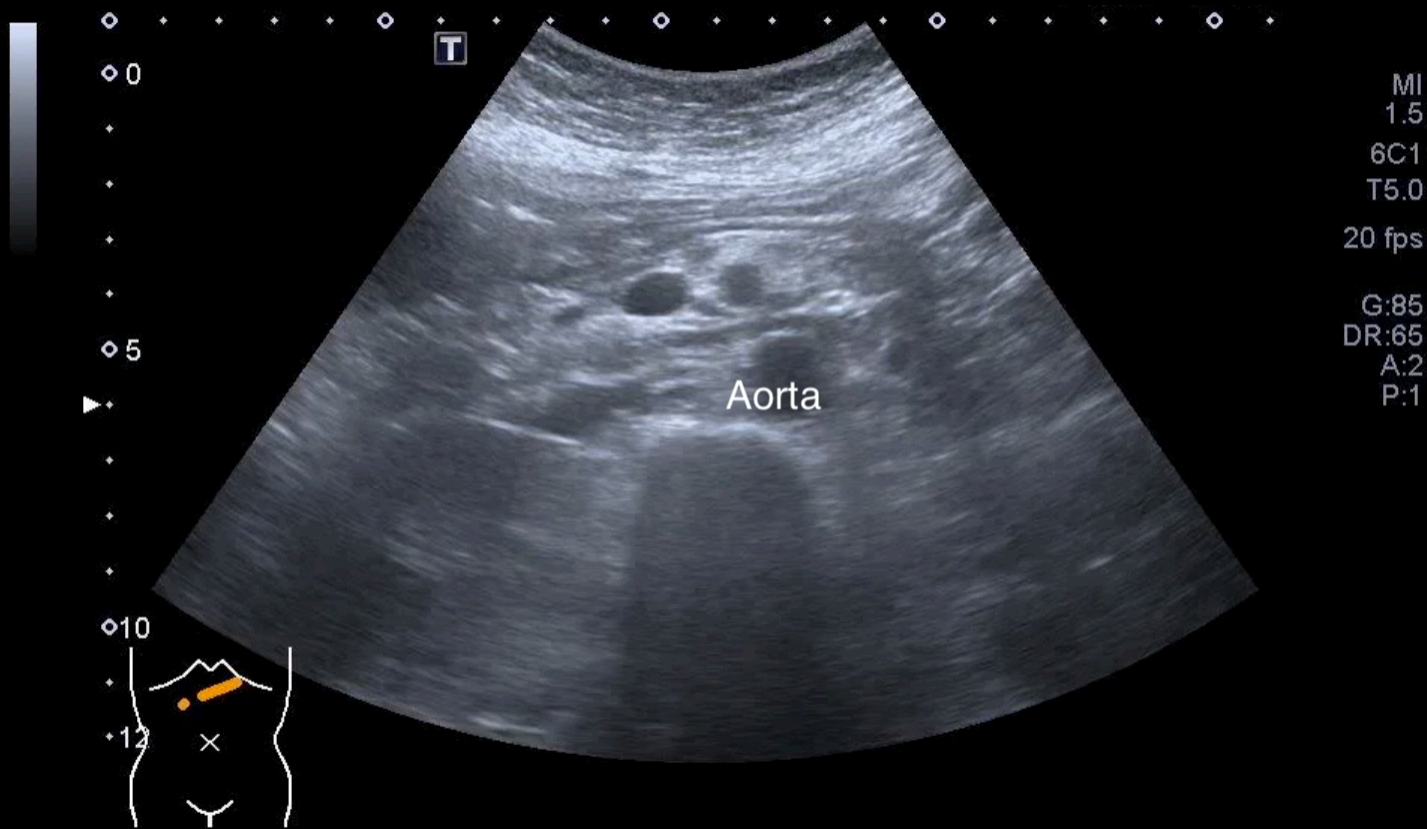
## Rock



轉

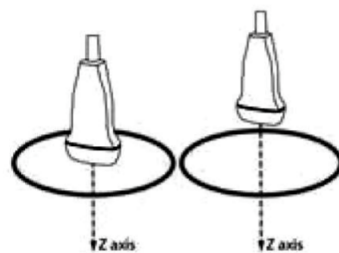


Rotation

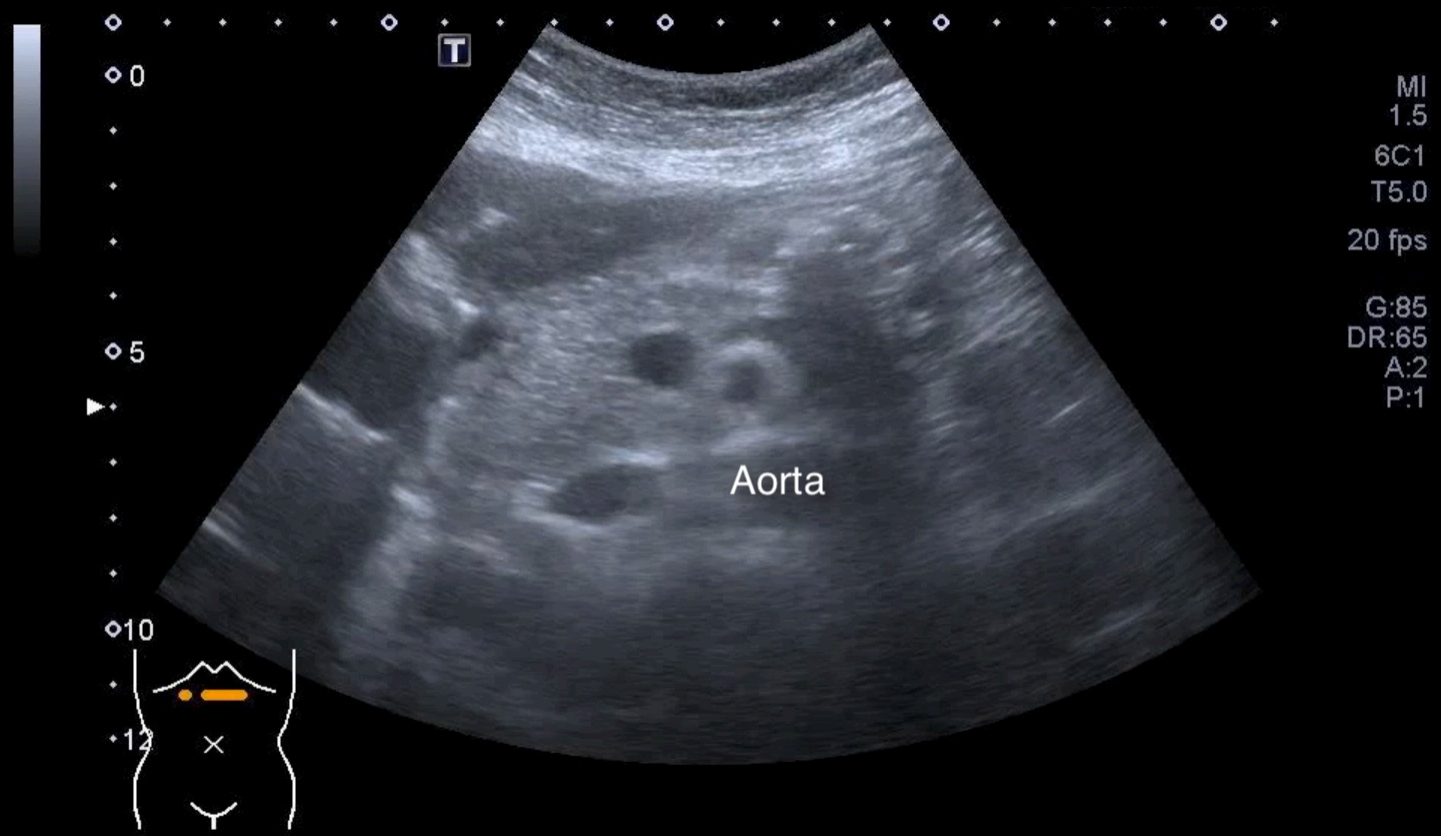

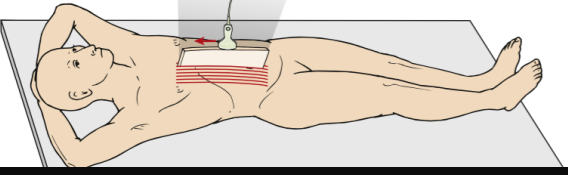
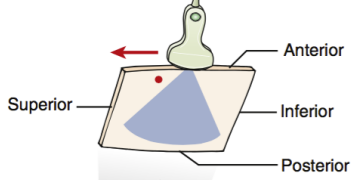
壓

Pressure/compression



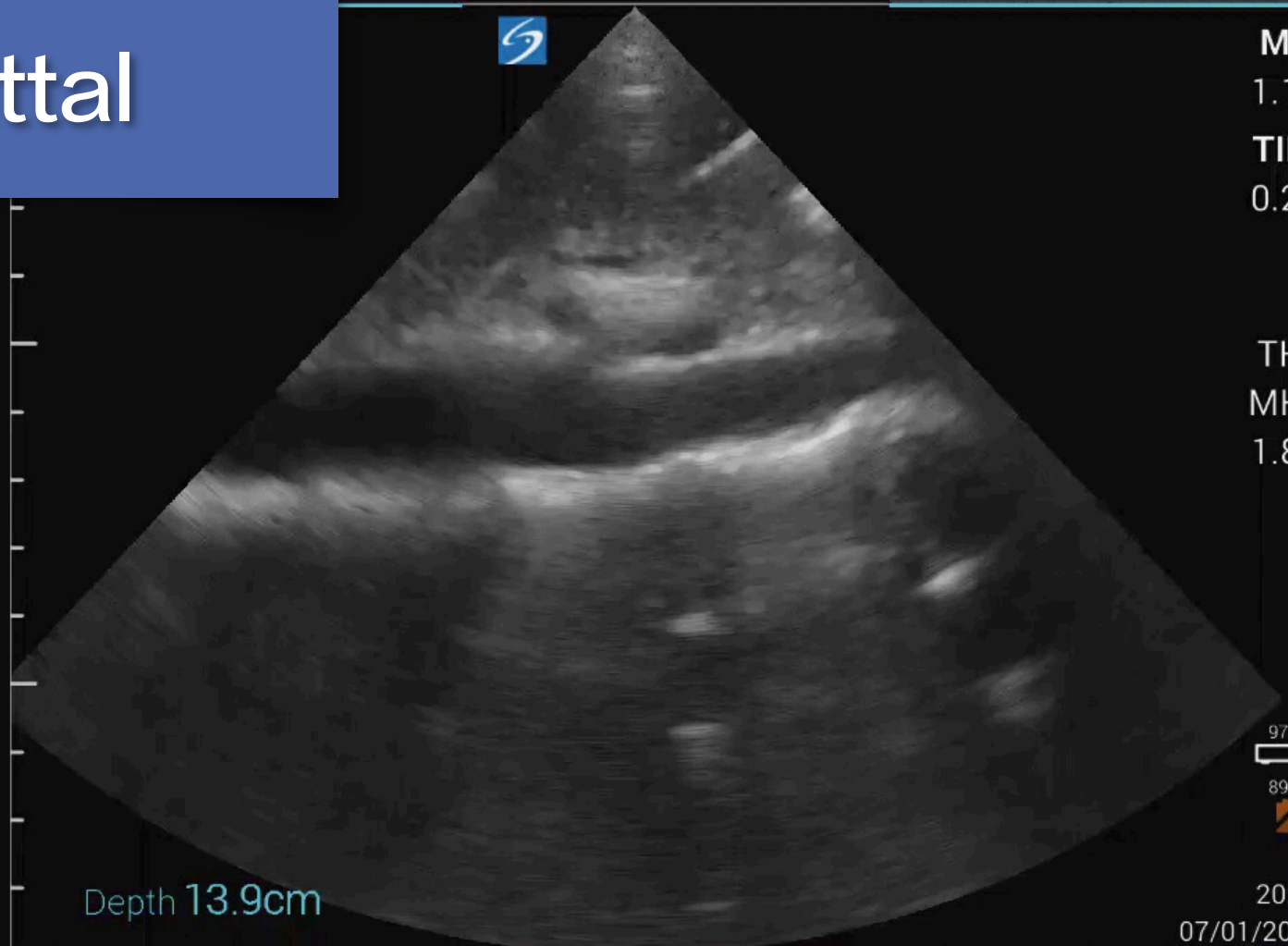
# Compression





# Sagittal

P21: Abdomen



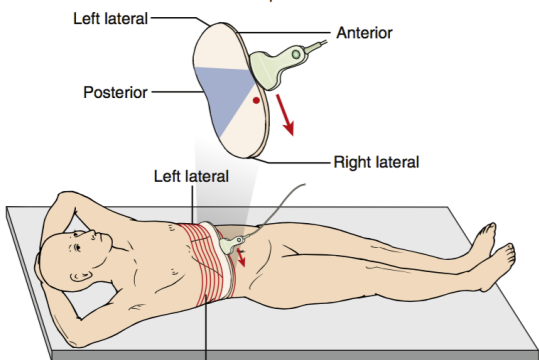
MI:  
1.12  
TIB:  
0.29

THI  
MHz  
1.88

97%  
89%

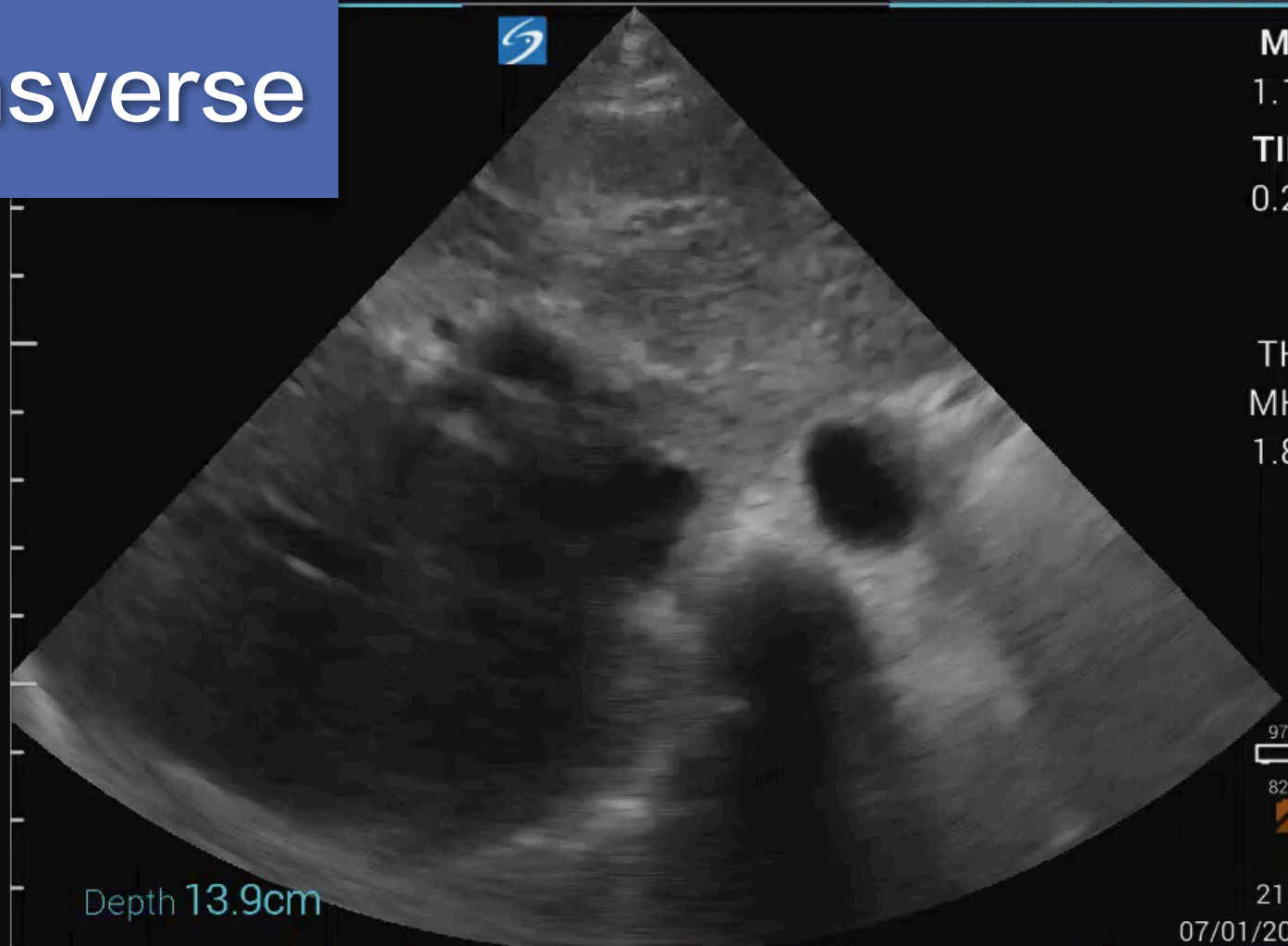
Depth 13.9cm

20:57  
07/01/2016



# Transverse

P21: Abdomen



MI:  
1.12

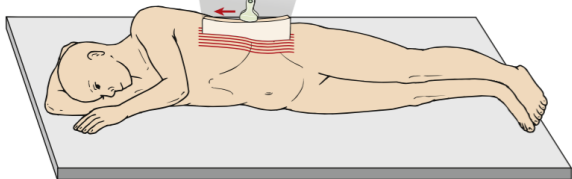
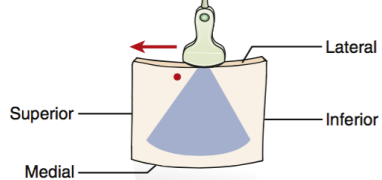
TIB:  
0.29

THI  
MHz  
1.88



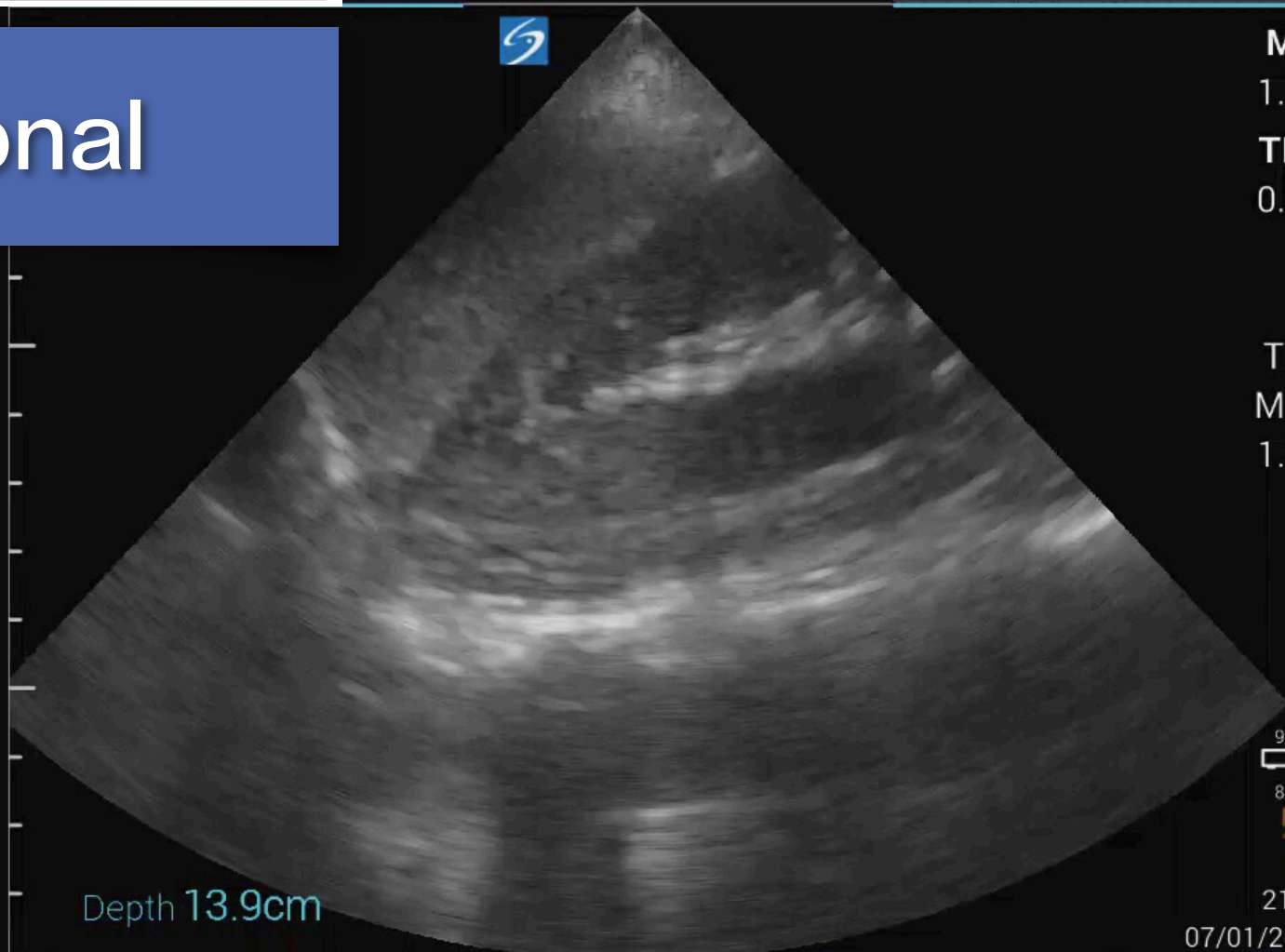
Depth 13.9cm

21:02  
07/01/2016



P21: Abdomen

# Coronal



MI:  
1.12  
TIB:  
0.29

THI  
MHz  
1.88



Depth 13.9cm

21:01

07/01/2016



# 常用的探頭

Linear

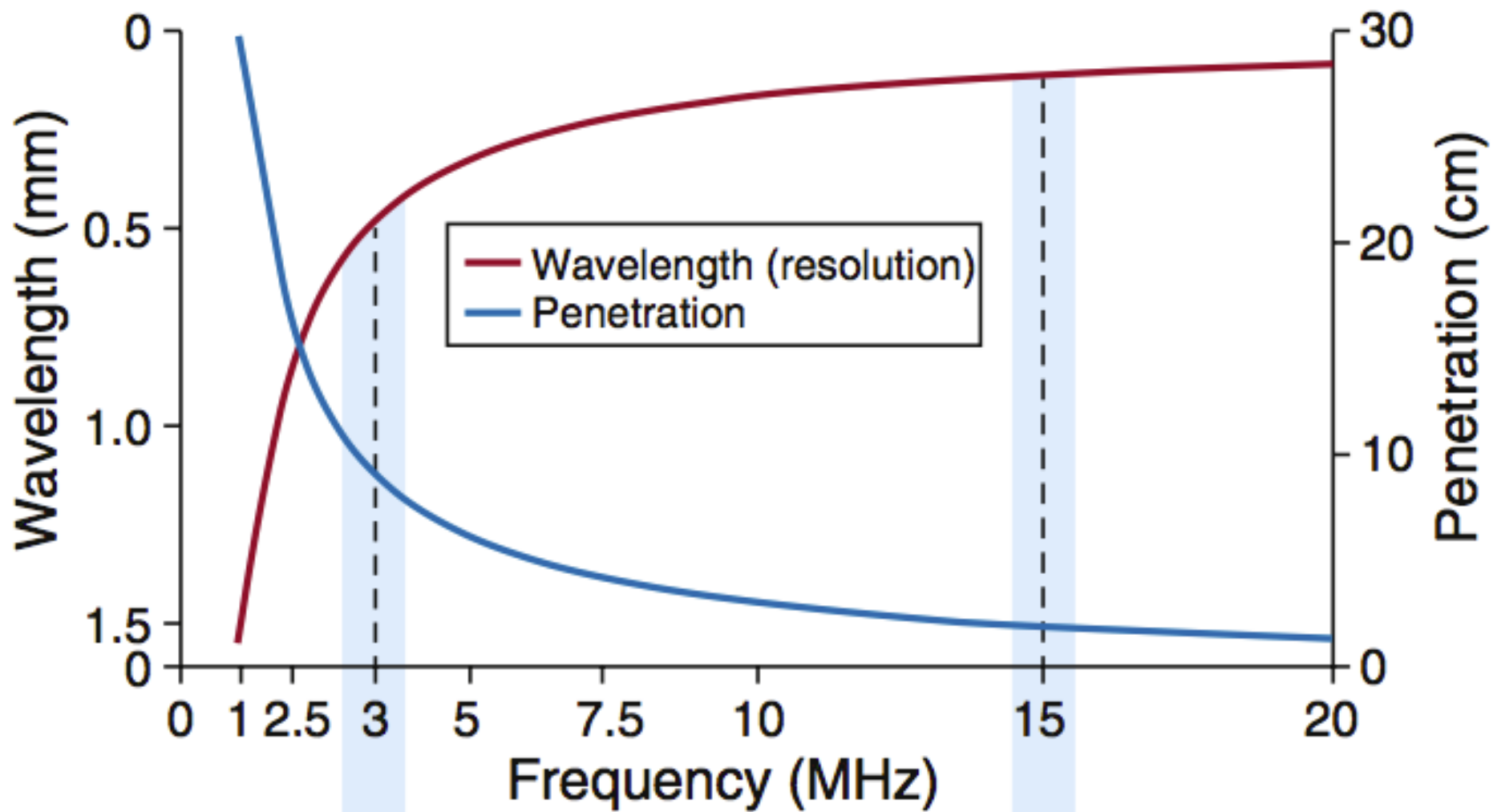


Curve

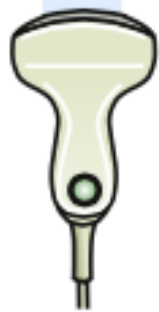

Sector





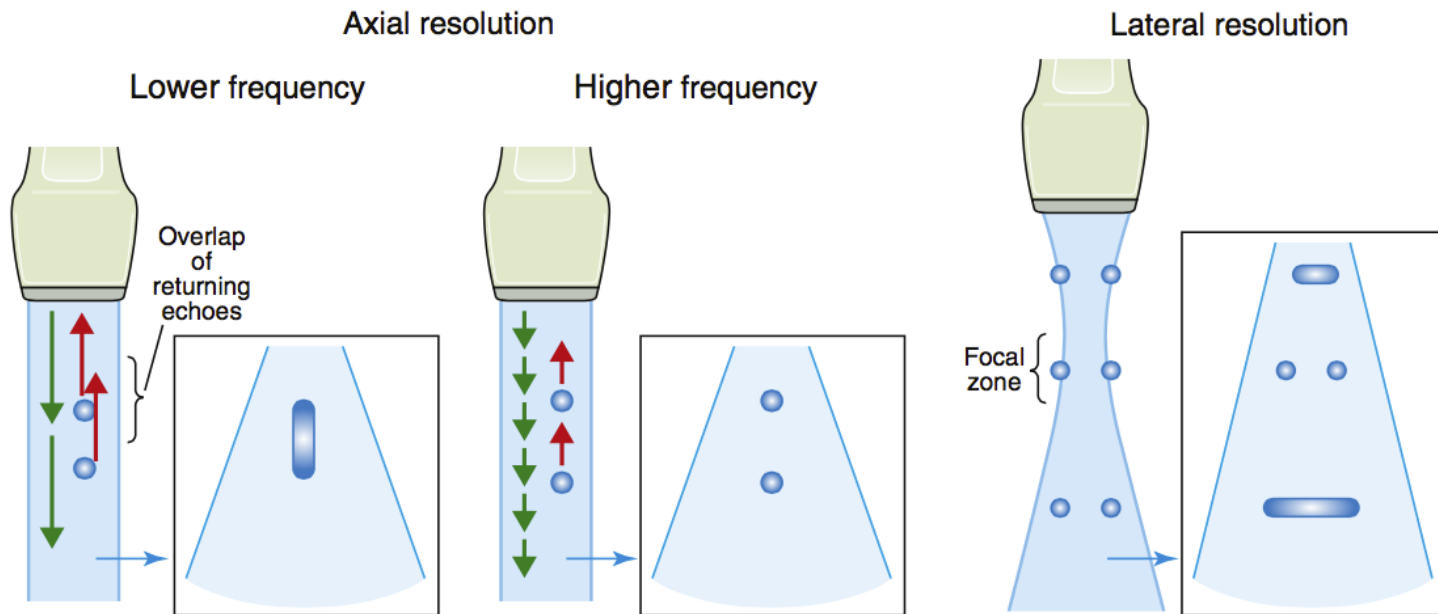
Low-frequency transducer



High-frequency transducer



# 漂亮影像的要素

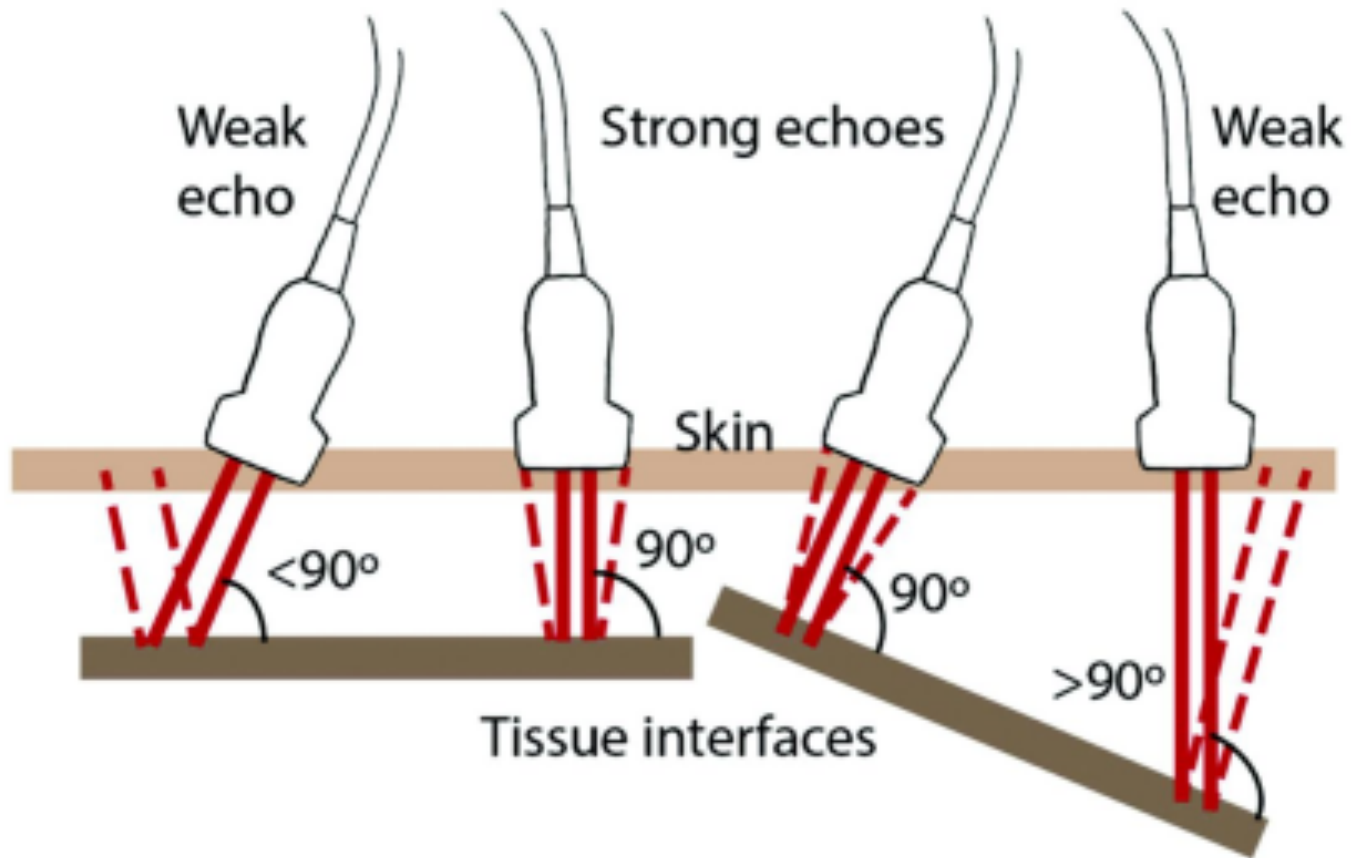


位置

探頭

焦點

# 垂直於掃描的目標



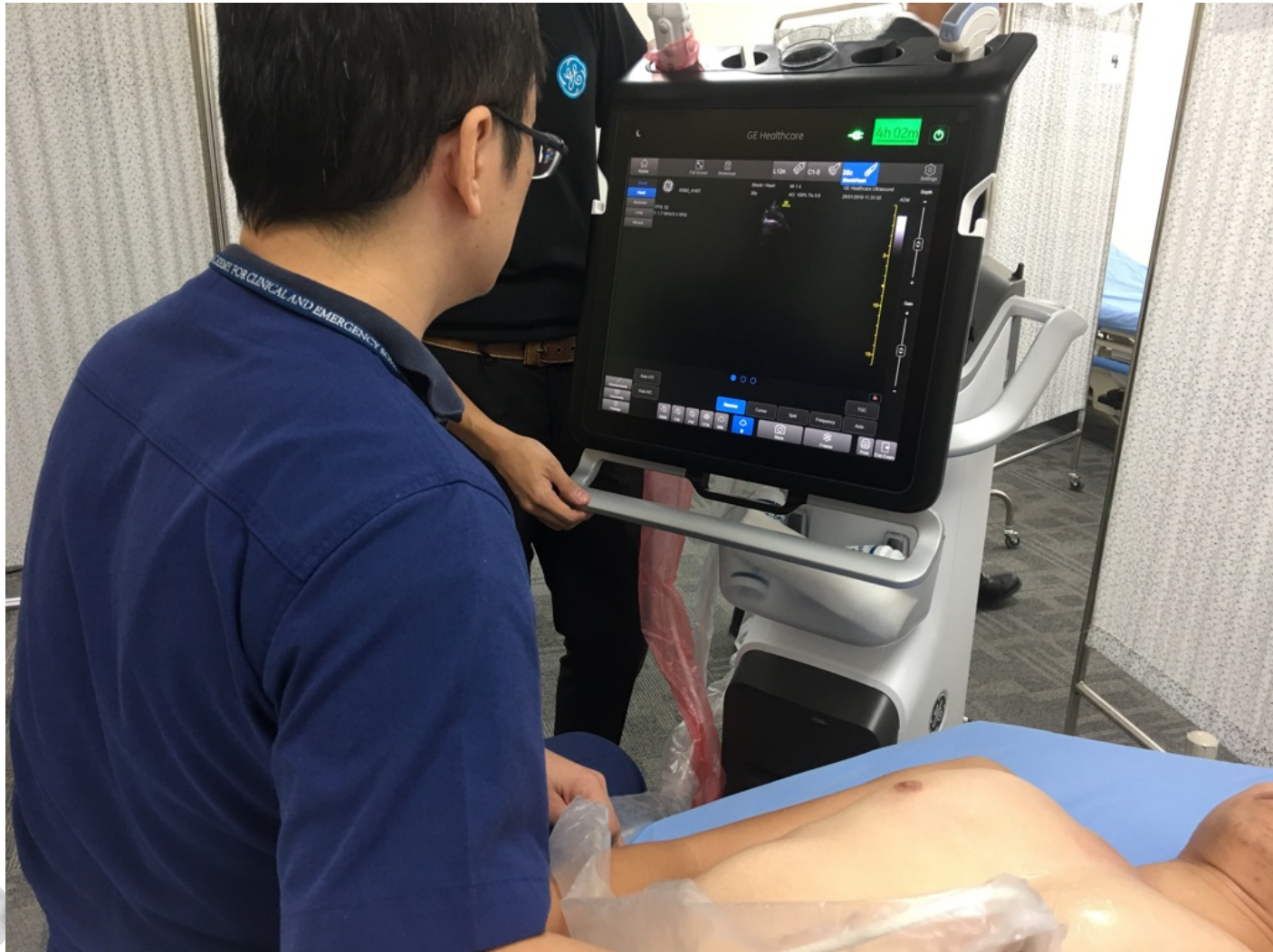

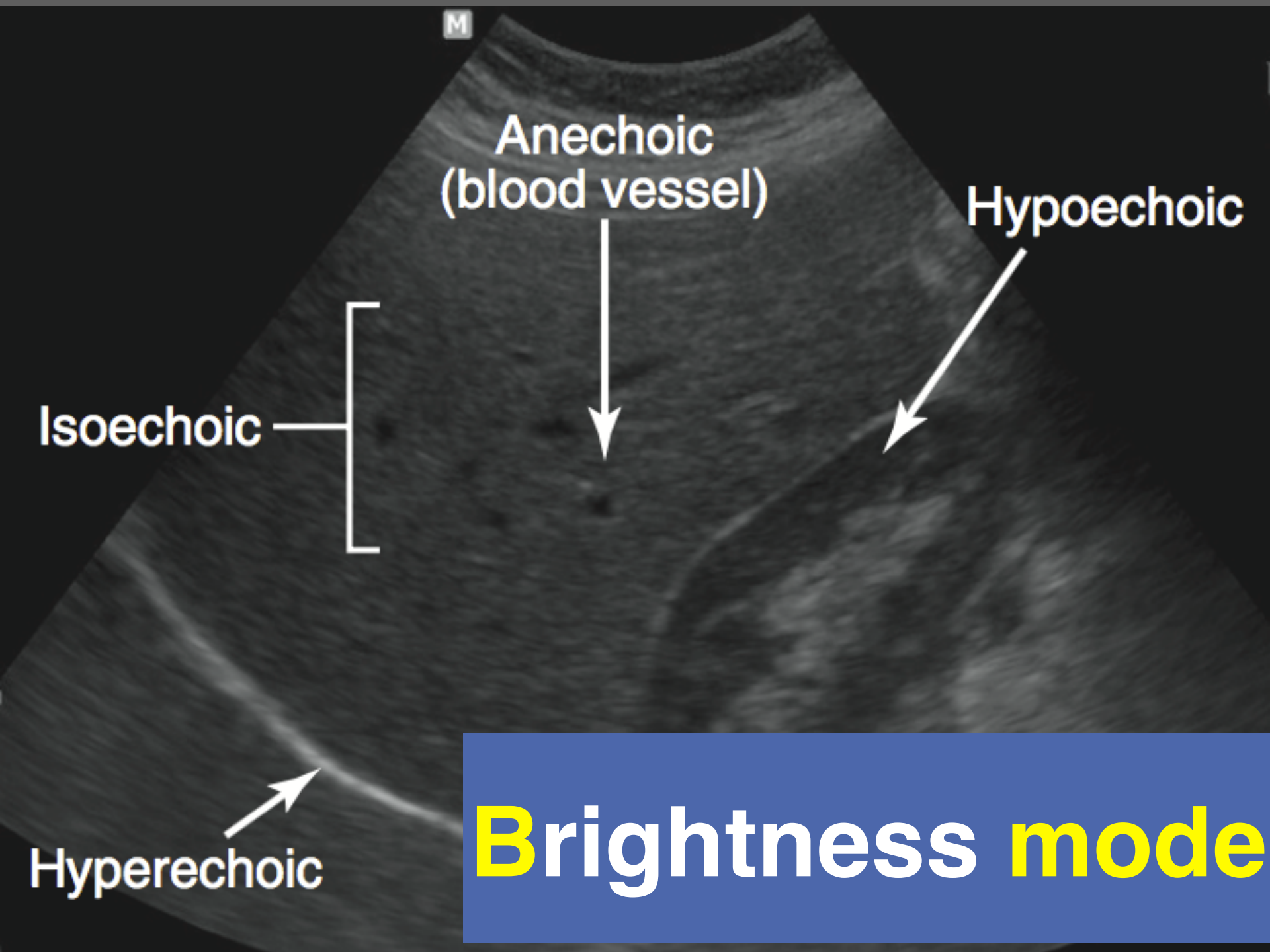
ULTRASOUND  
PROGRAM

# Knobology



# 按鈕呢？





Anechoic  
(blood vessel)

Hypoechoic

Isoechoic

Hyperechoic

**Brightness mode**



# 水是最好的視窗

<b>Tissue or Material</b>	<b>Attenuation (dB/cm/MHz)</b>
Water	0.0022
Blood	0.15
Soft tissues	0.75
Air	7.50
Bone	15.00

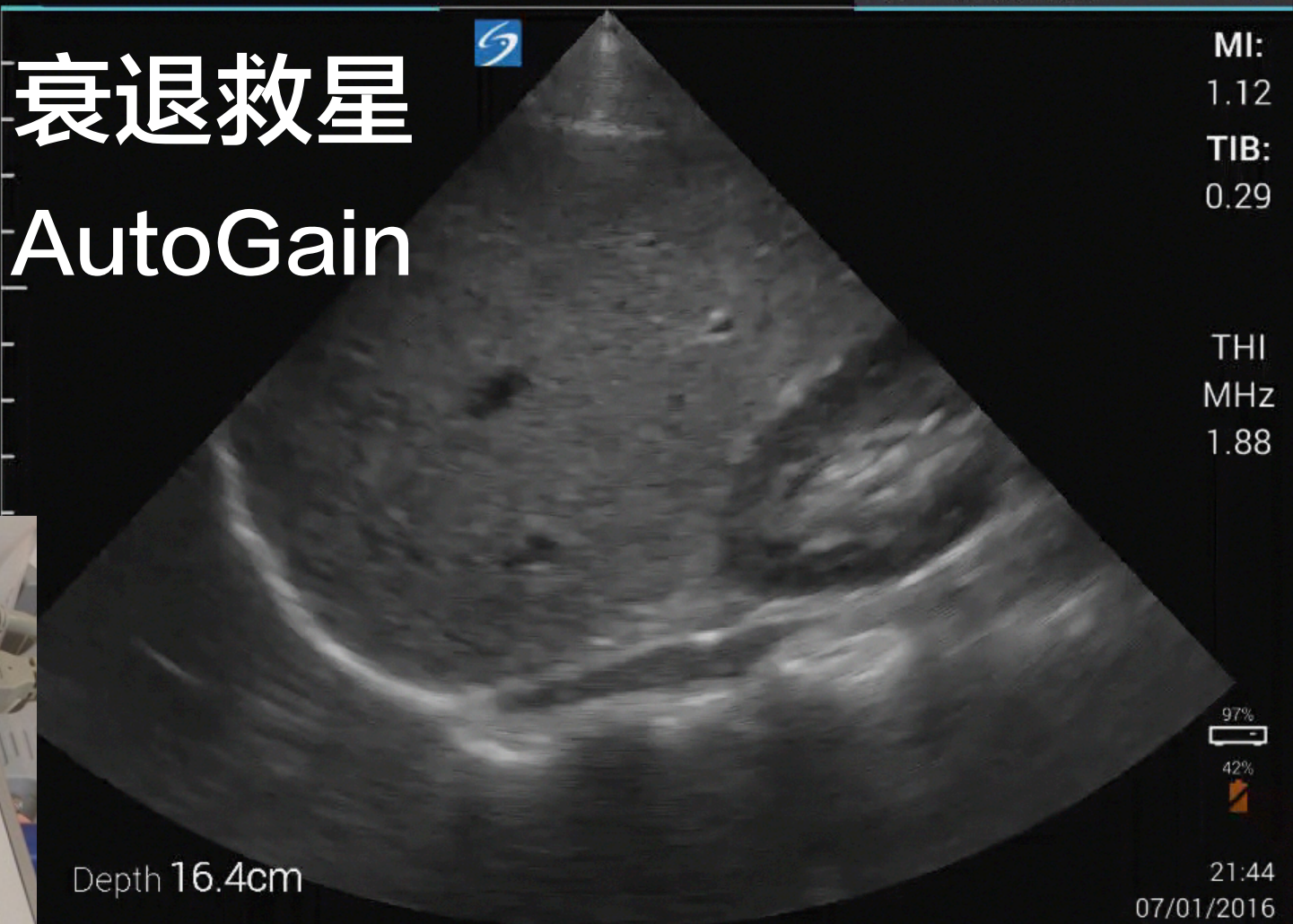




# Time Gain Compensation

衰退救星  
AutoGain

P21: Abdomen



Abd Gen  
C5-1  
39 Hz  
12.0cm

2D  
HGen  
Gn 63  
C 56  
3/3/3

阻抗差愈大  
交界面愈亮

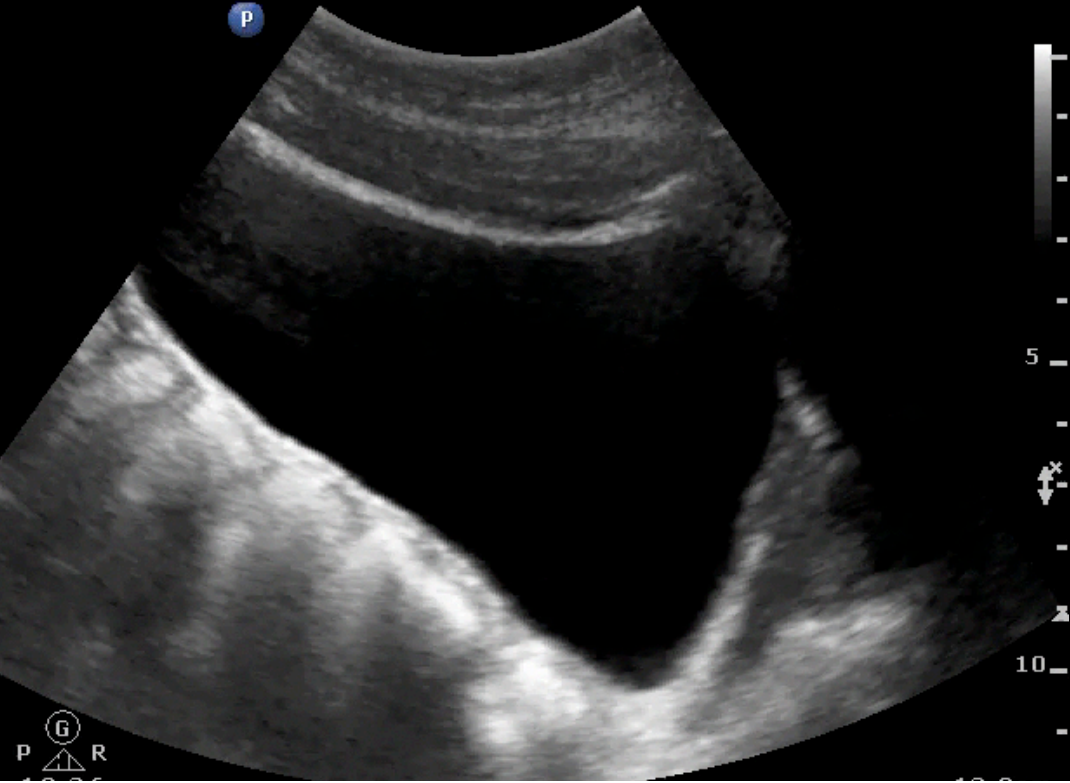
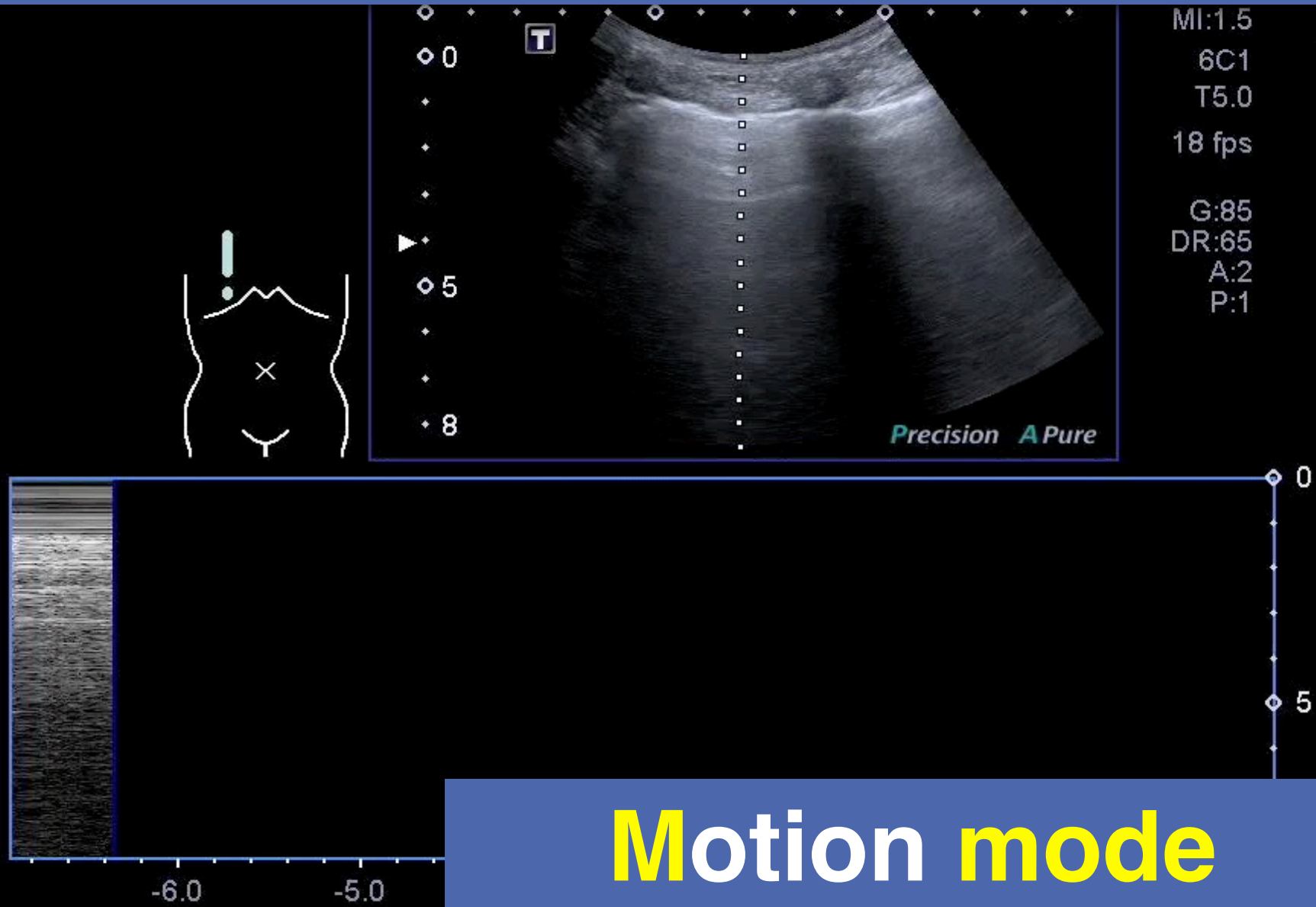


TABLE 2.1 ■ Acoustic Impedance of Different Tissues<sup>6-8</sup>

Tissue or Material	Density (g/cm <sup>3</sup> )	Speed of Sound (m/s)	Acoustic Impedance (kg/(s m <sup>2</sup> )) × 10 <sup>6</sup>
Air	0.001225	340	0.0004
Fat	0.95	1450	1.38
Blood	1.055	1575	1.66
Liver	1.06	1590	1.69
Bone	1.9	4080	7.75
Metal (e.g., titanium)	4.5	5090	22.9

# To record Motion

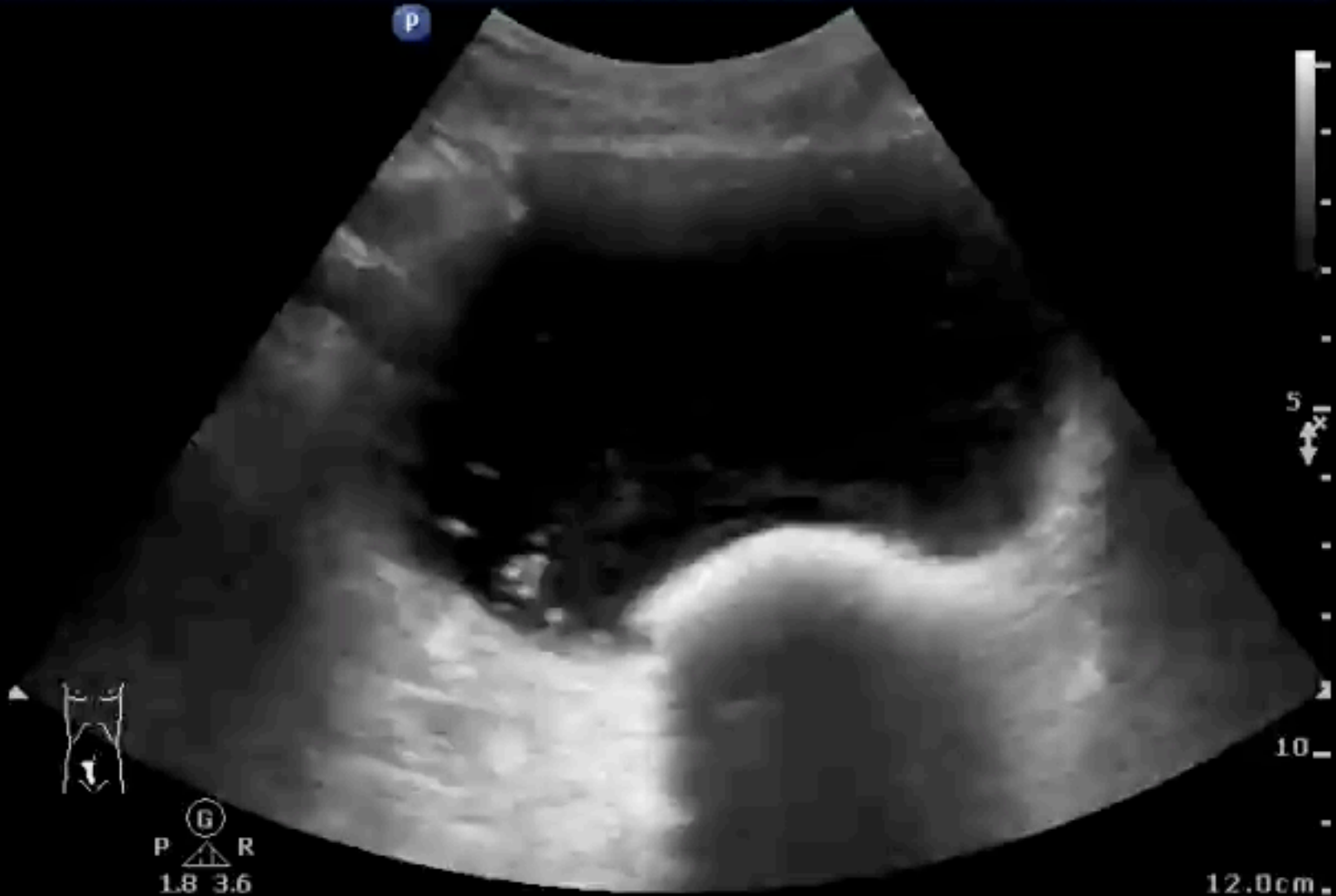

**Motion mode**

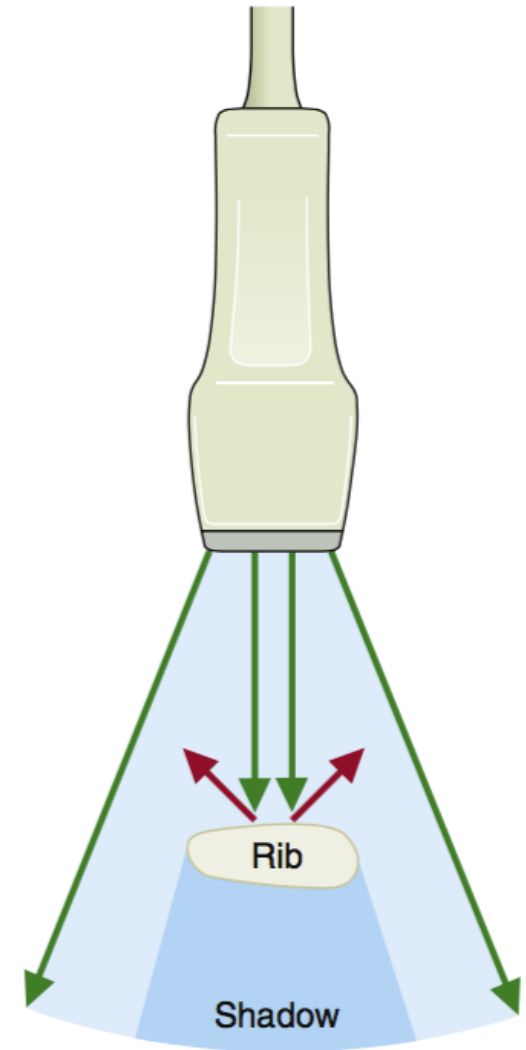
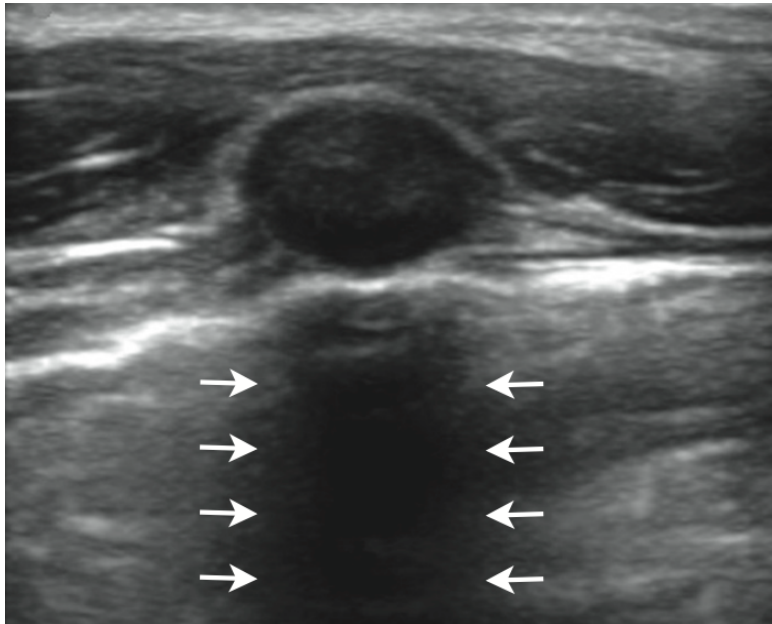
# 2 Artifacts ? Why ?

Abd Gen  
C5-1  
39 Hz  
12.0cm

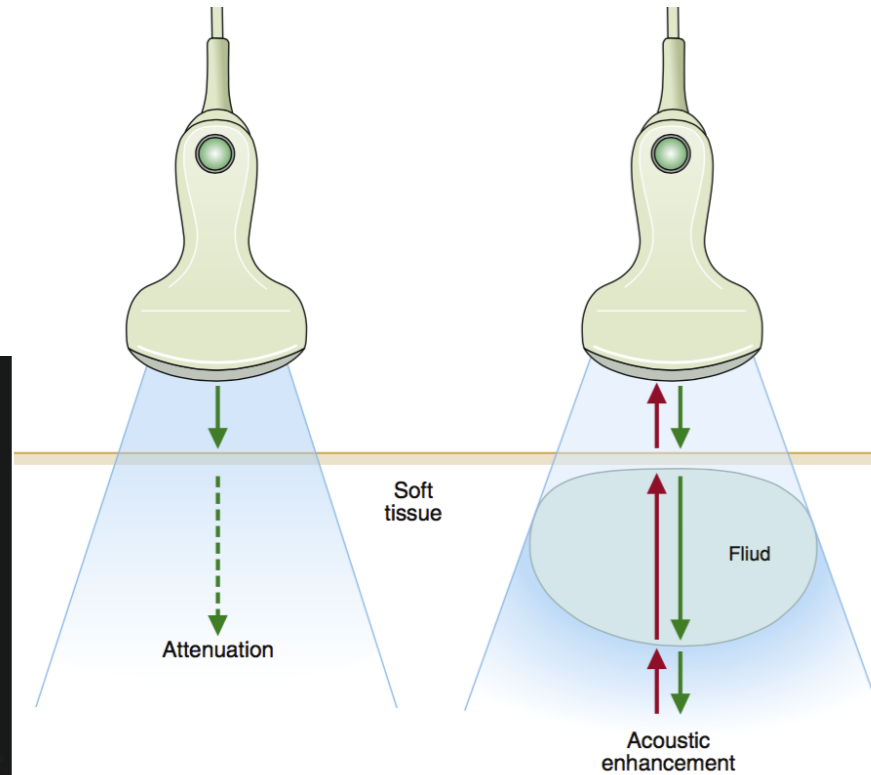
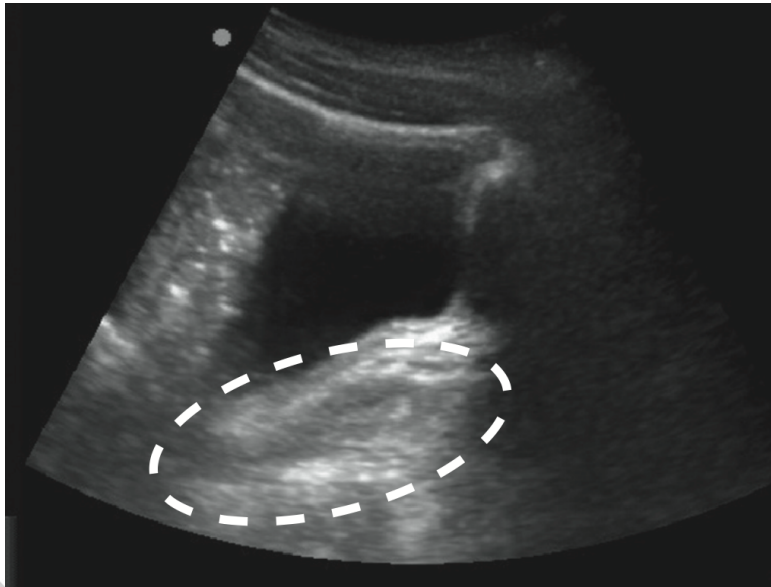
2D  
HGen  
Gn 72  
C 56  
3/3/3



# Acoustic Shadowing



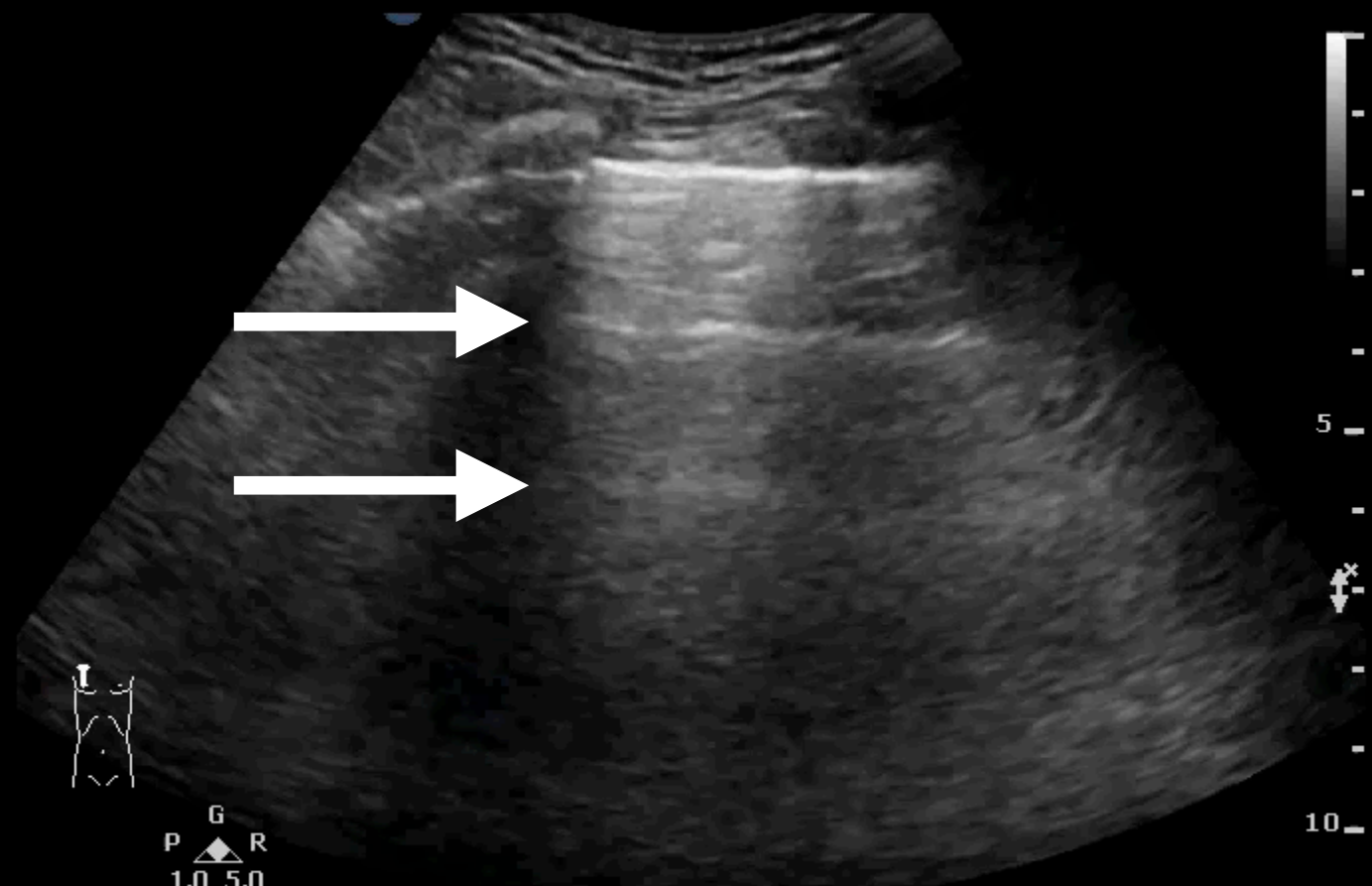
# Acoustic Enhancement



# Artifact ? Why ?

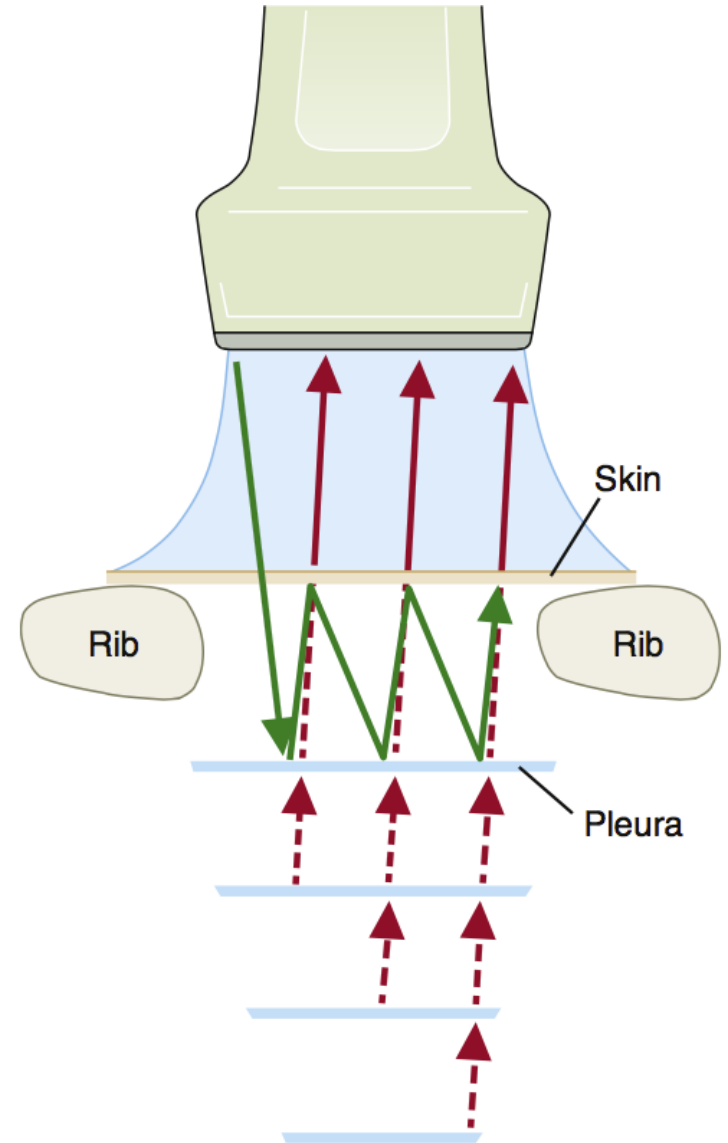
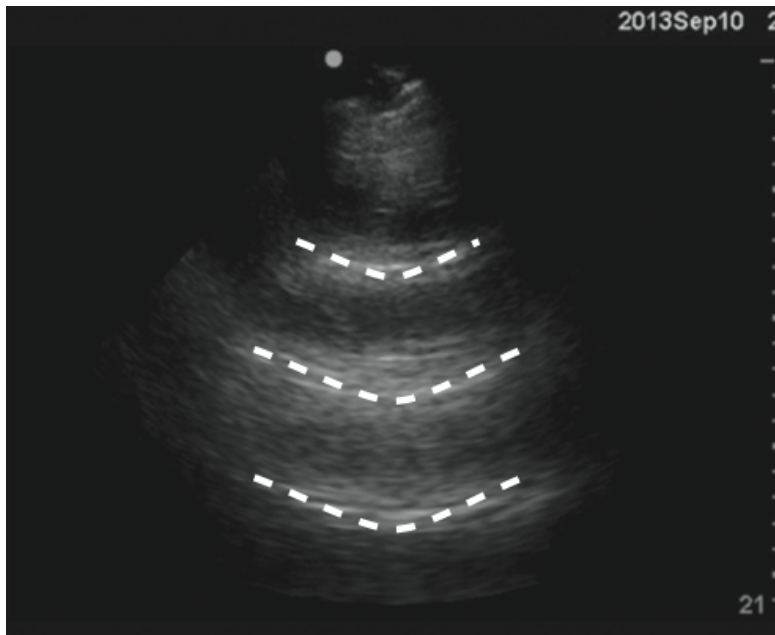
FAST  
C5-1  
42 Hz  
11.0cm

2D  
Gen  
Gn 60  
C 56  
1/3/3



P G R  
1.0 5.0

# Reverberation

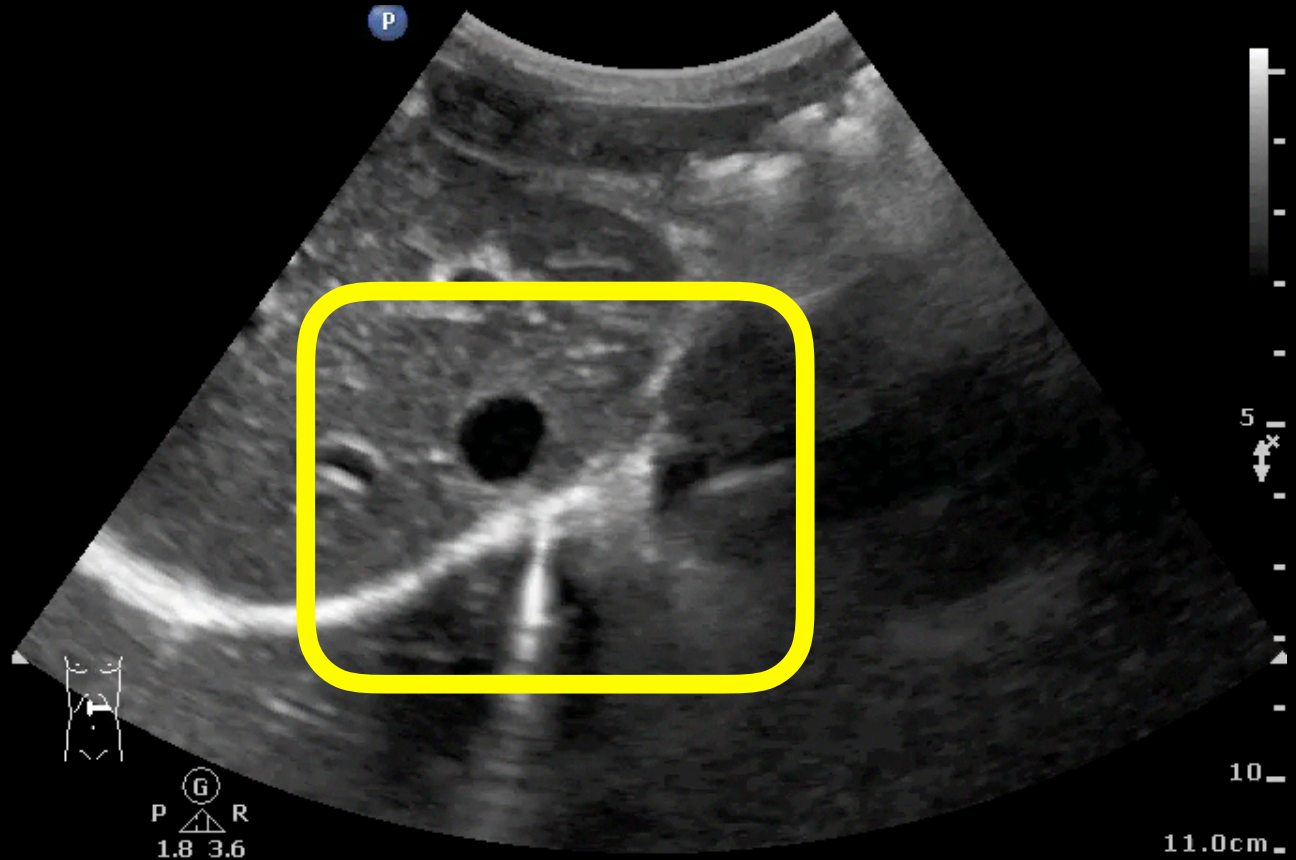




# Artifact ? Why ?

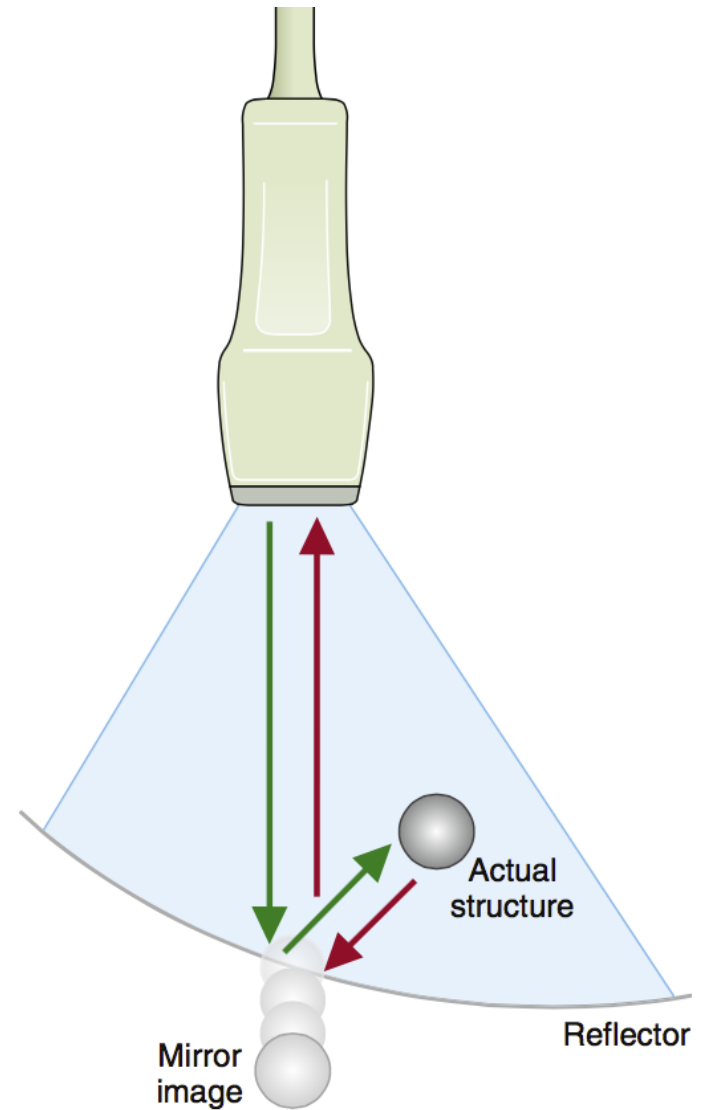
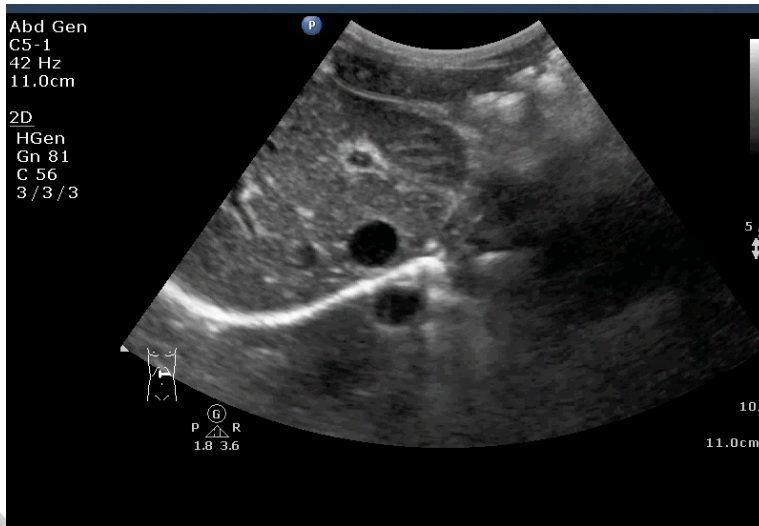
Abd Gen  
C5-1  
42 Hz  
11.0cm

2D  
HGen  
Gn 81  
C 56  
3/3/3

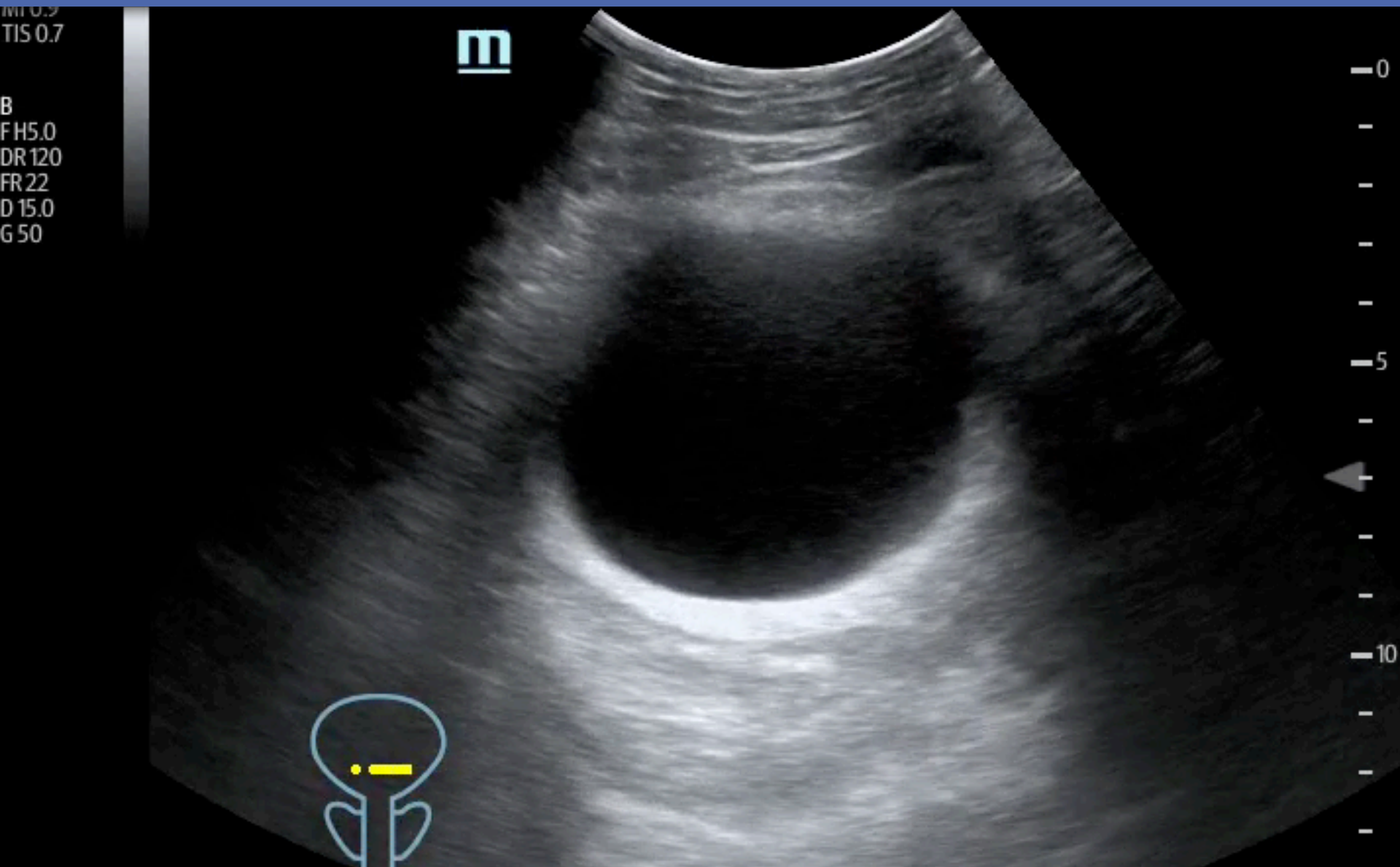




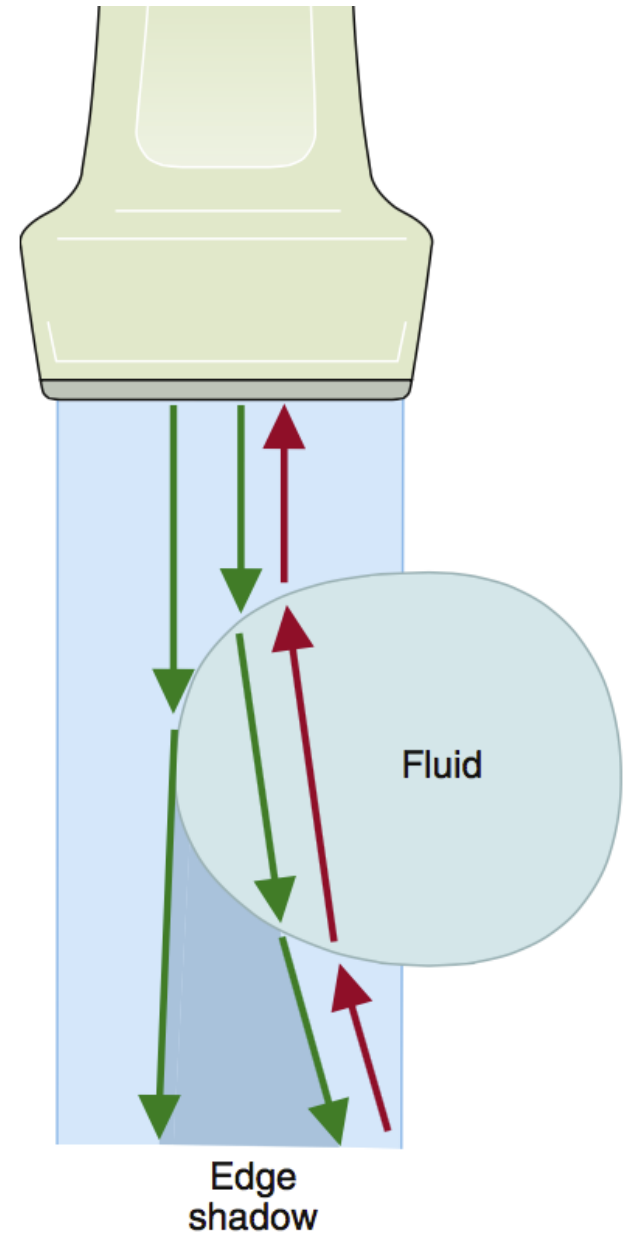
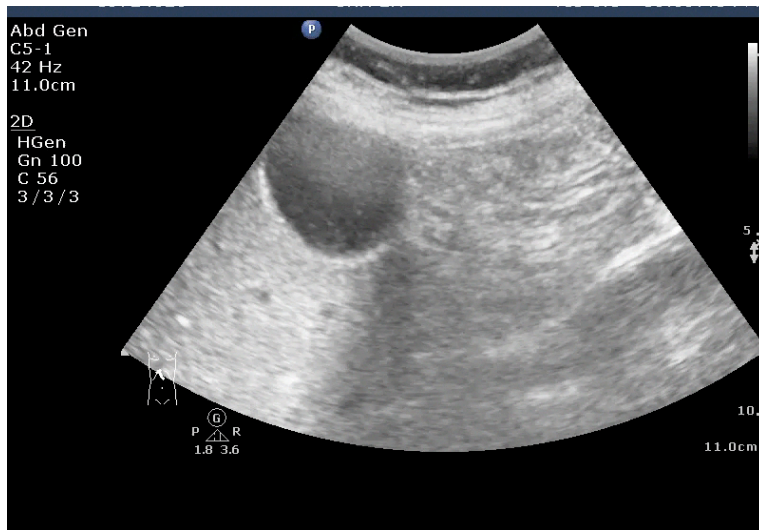
# Mirror Image



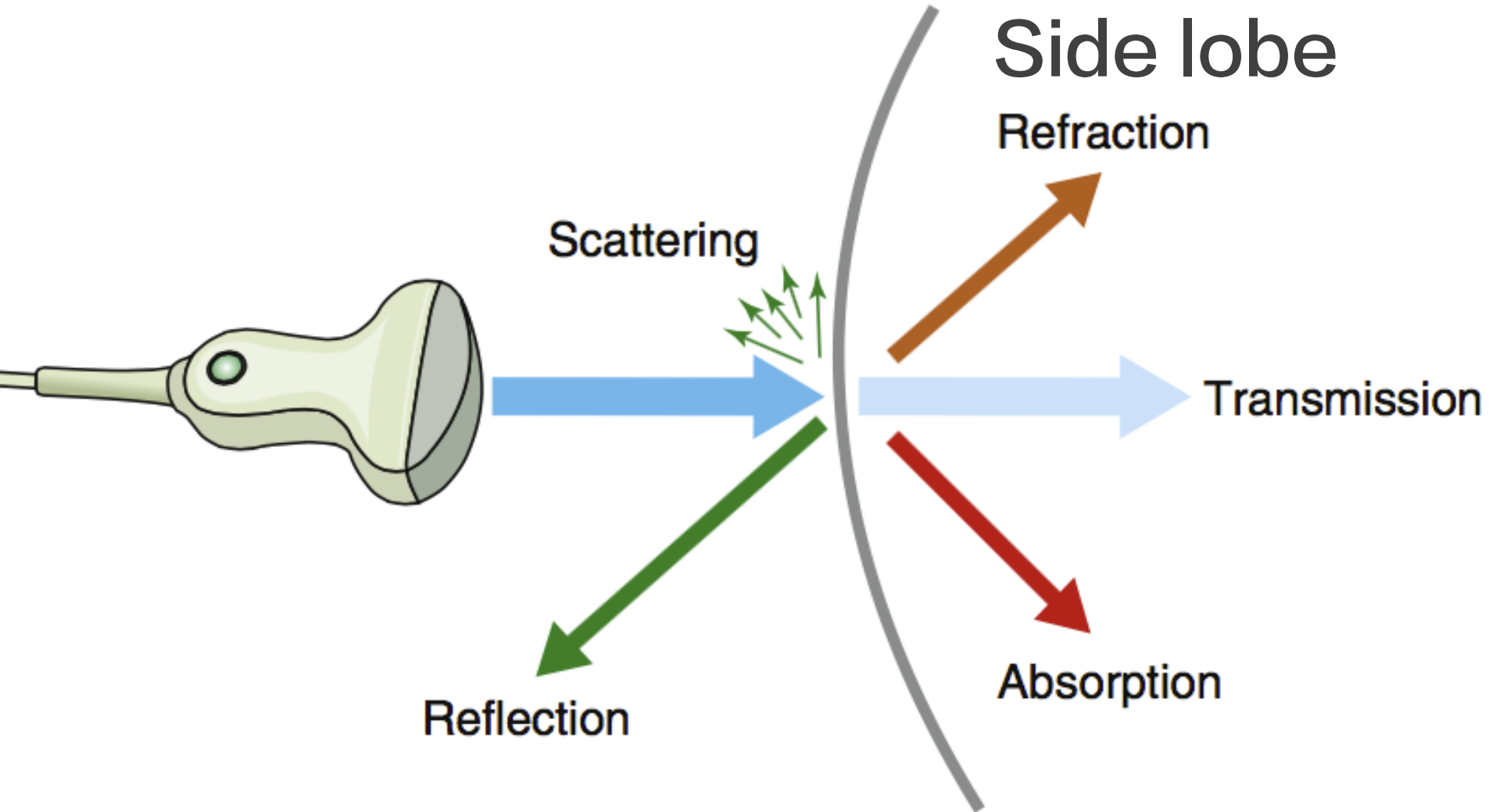
# 2 Artifacts ? Why ?

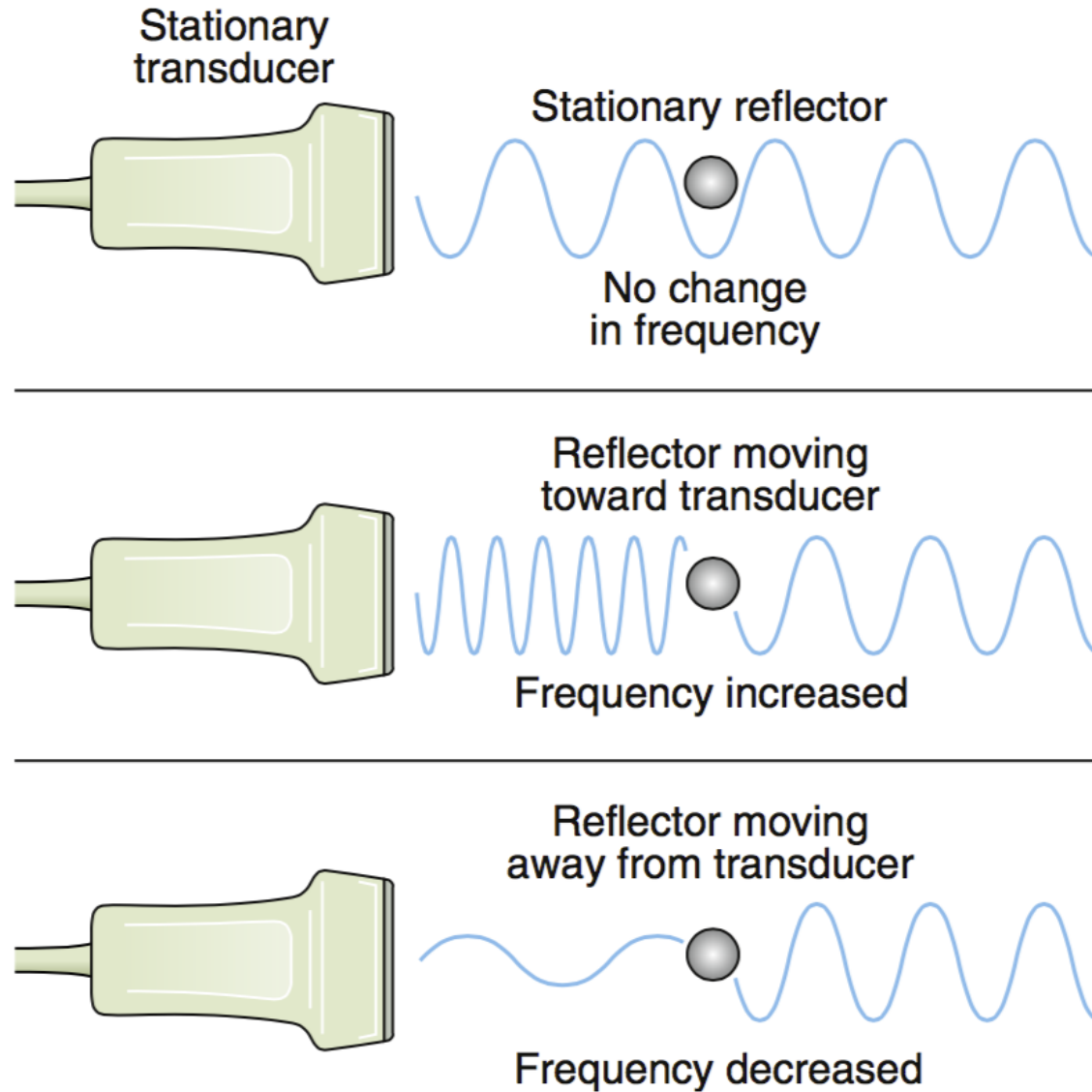


# Edge shadow Side lobe



Edge shadow  
Side lobe





# Power Doppler for Low Flow

Superficial

P

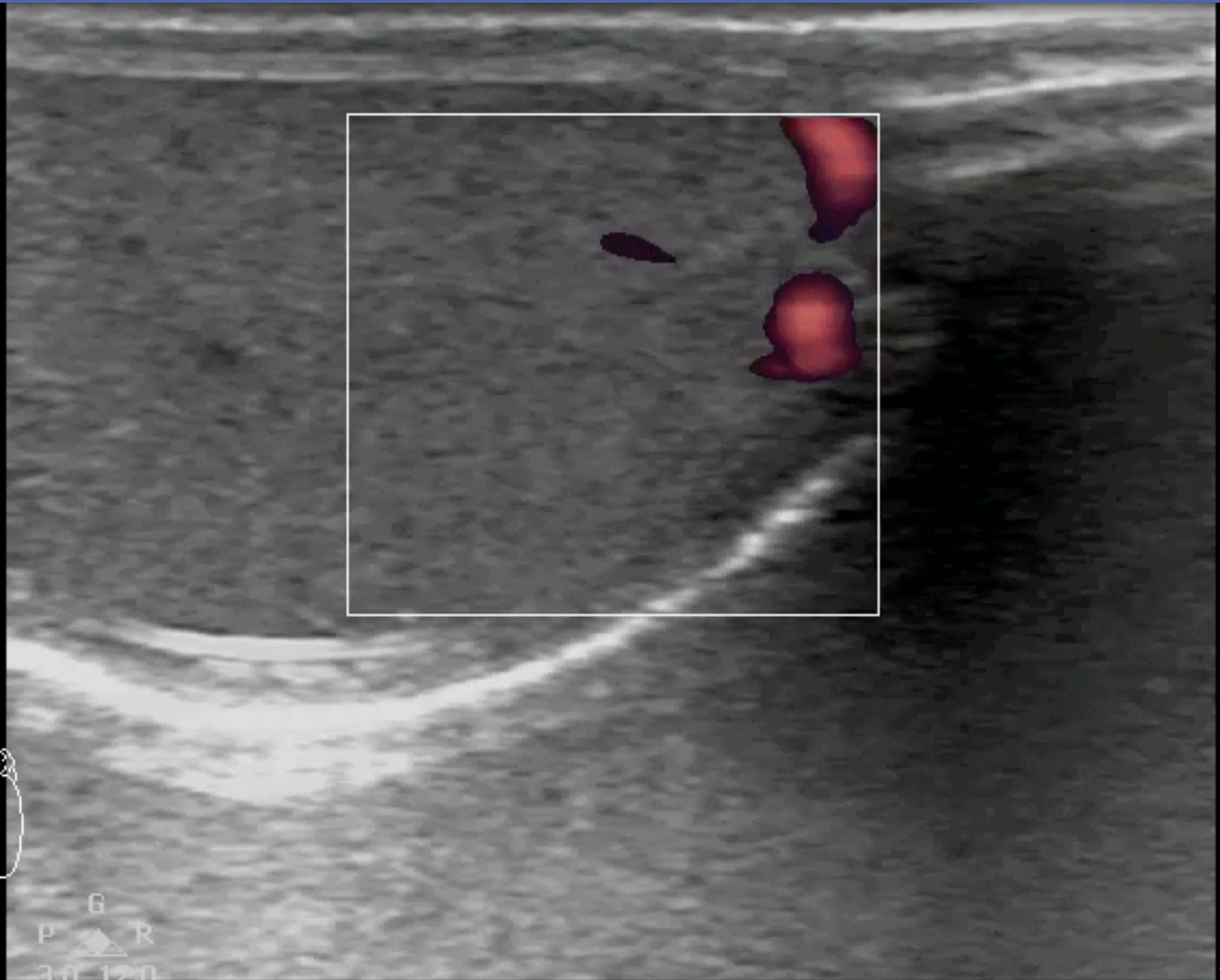
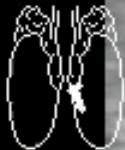L12-3  
42 Hz  
3.0cm

2D

Gen  
Gn 100  
C 52  
4/3/2

CPA

5.0 MHz  
Gn 57  
1/5/4  
Fltr Med  
BasIn 3



1.0

PRF

2

3.0cm

G  
P R  
3.0 12.0



# Color Doppler with Directions

Adult Echo

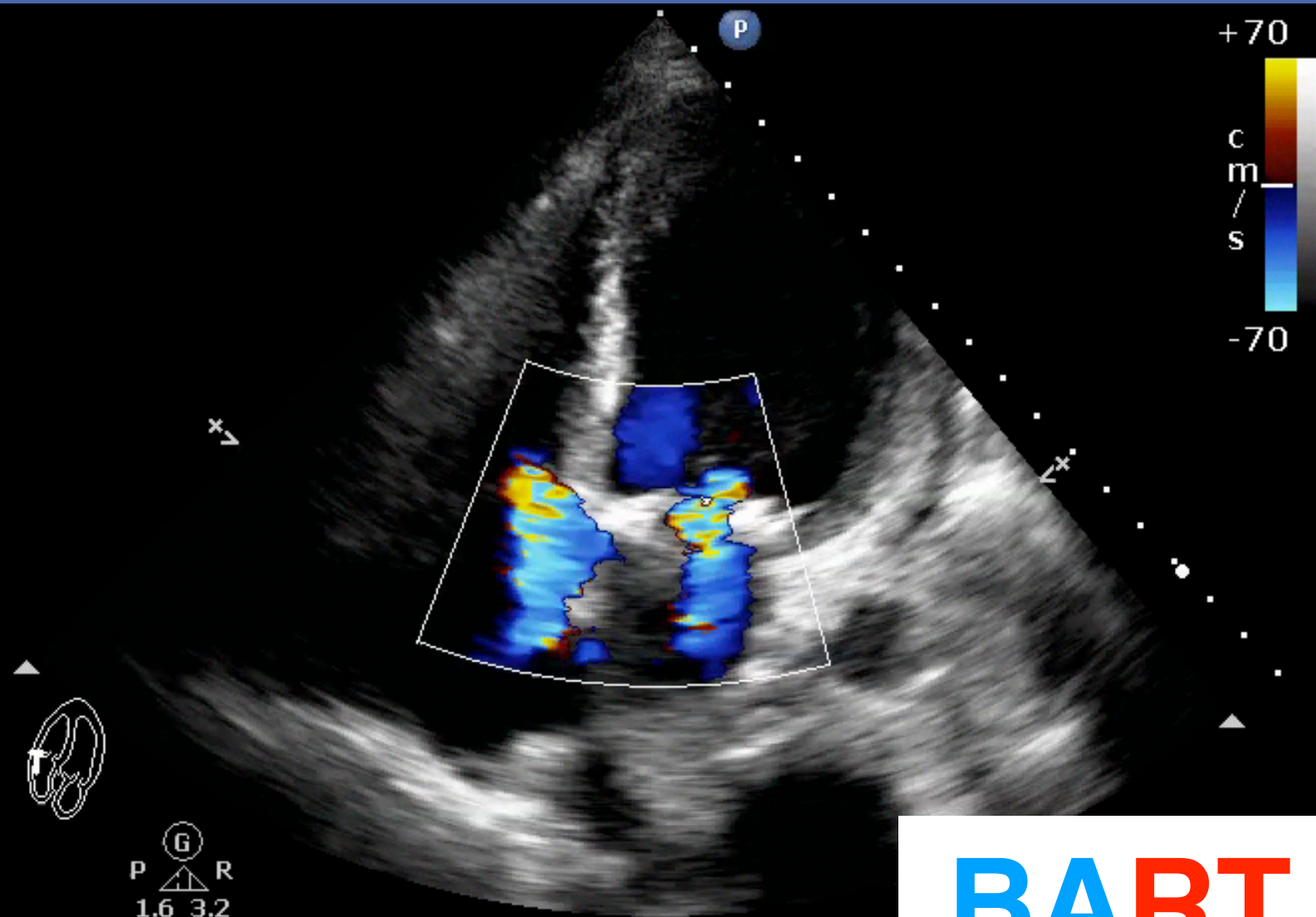
S5-1  
18 Hz  
18.0cm

2D

HGen  
Gn 34  
C 50  
3 / 2 / 0

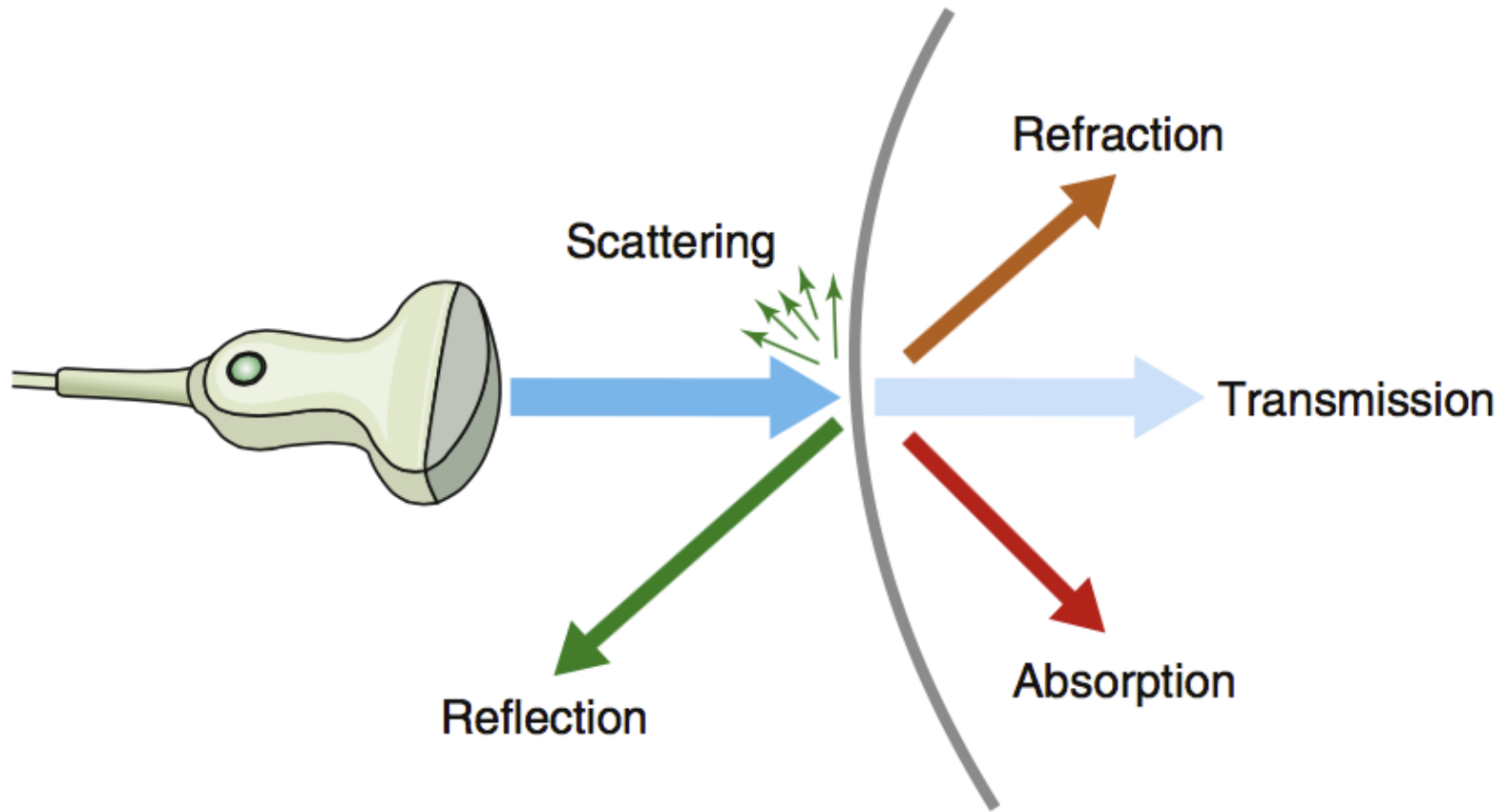
Color

2.5 MHz  
Gn 60  
4 / 5 / 0  
Fltr High



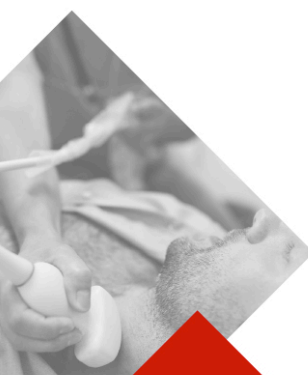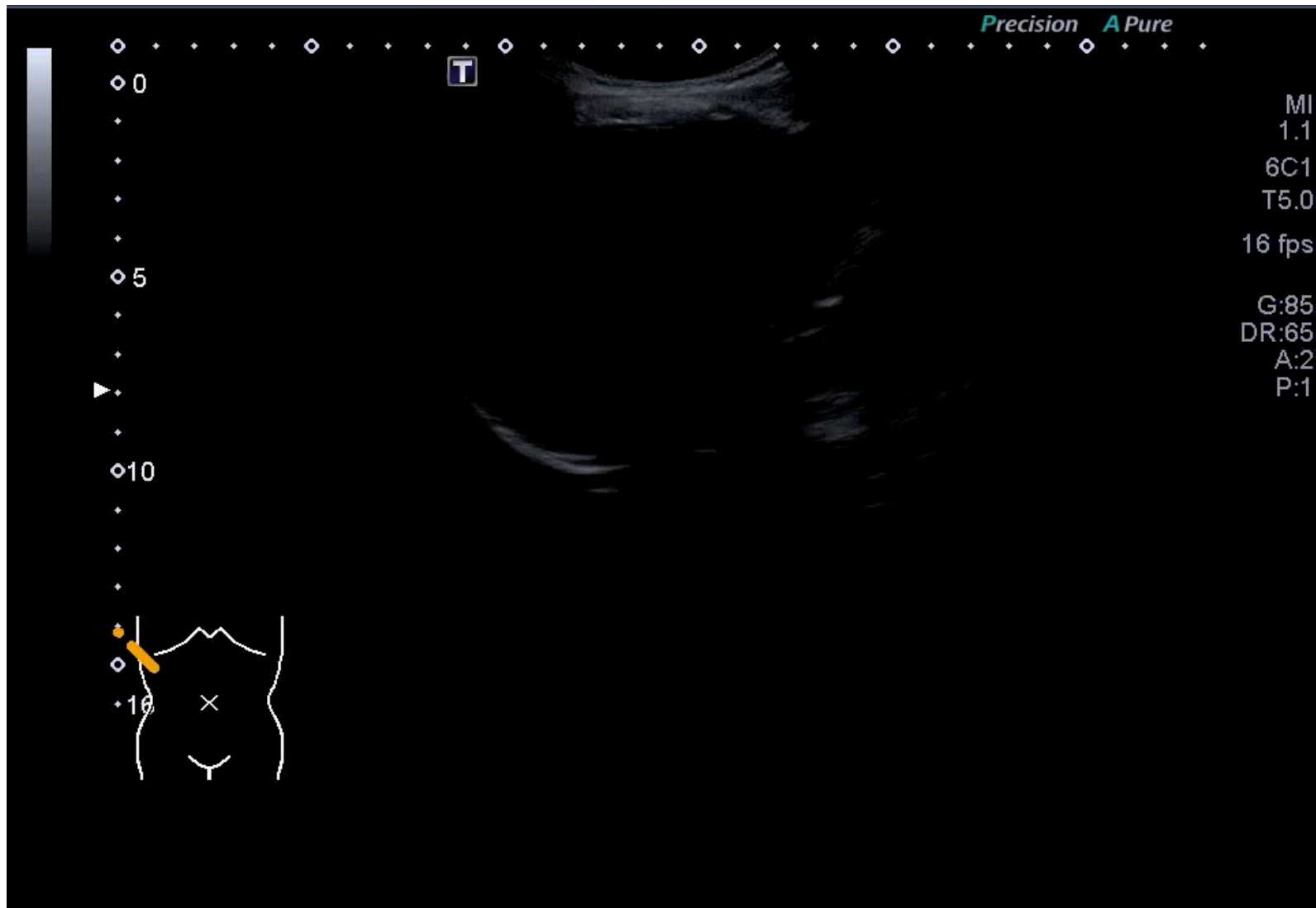
**BART**

# 如何對抗這些【敵人】？




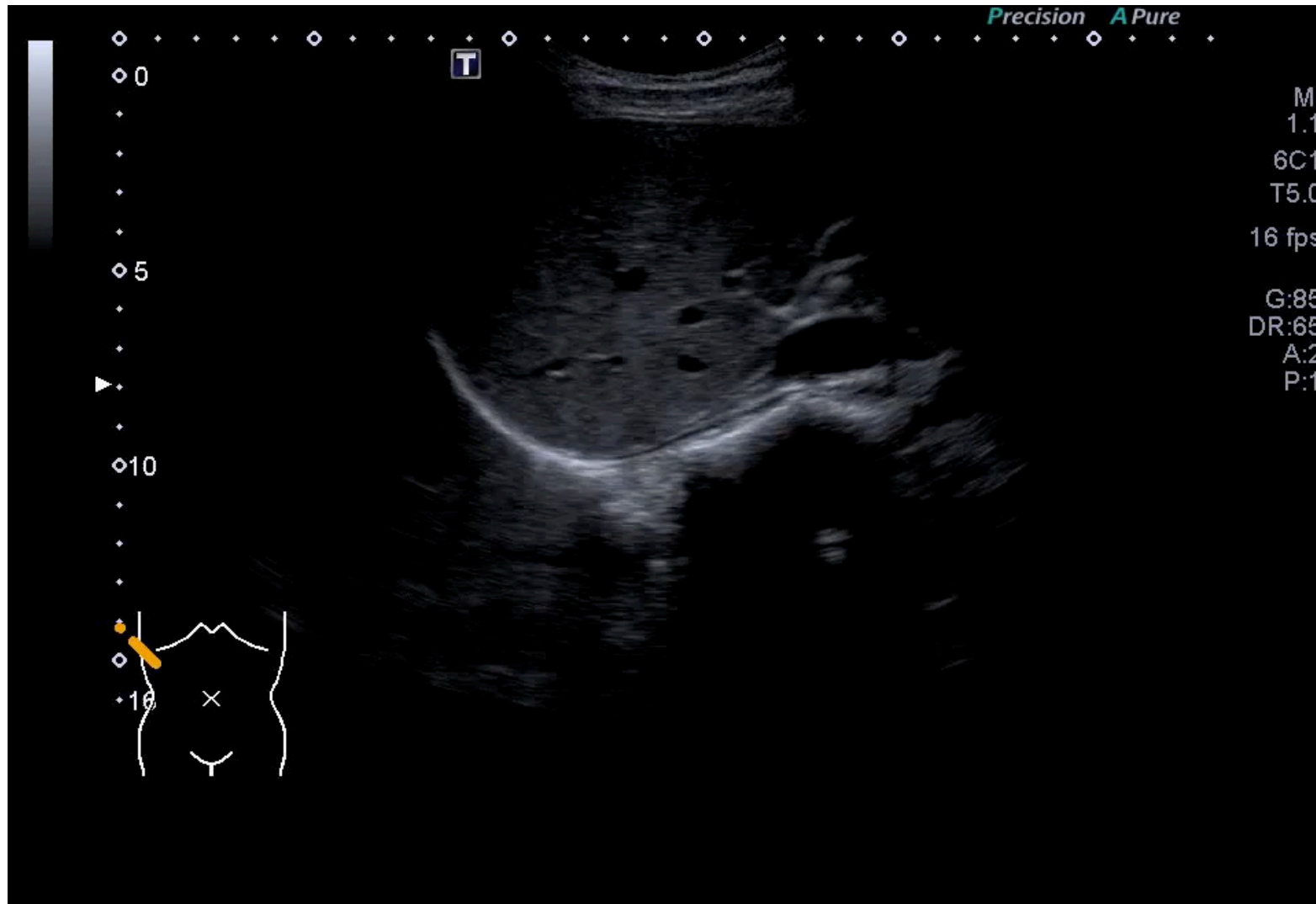
ULTRASOUND  
PROGRAM



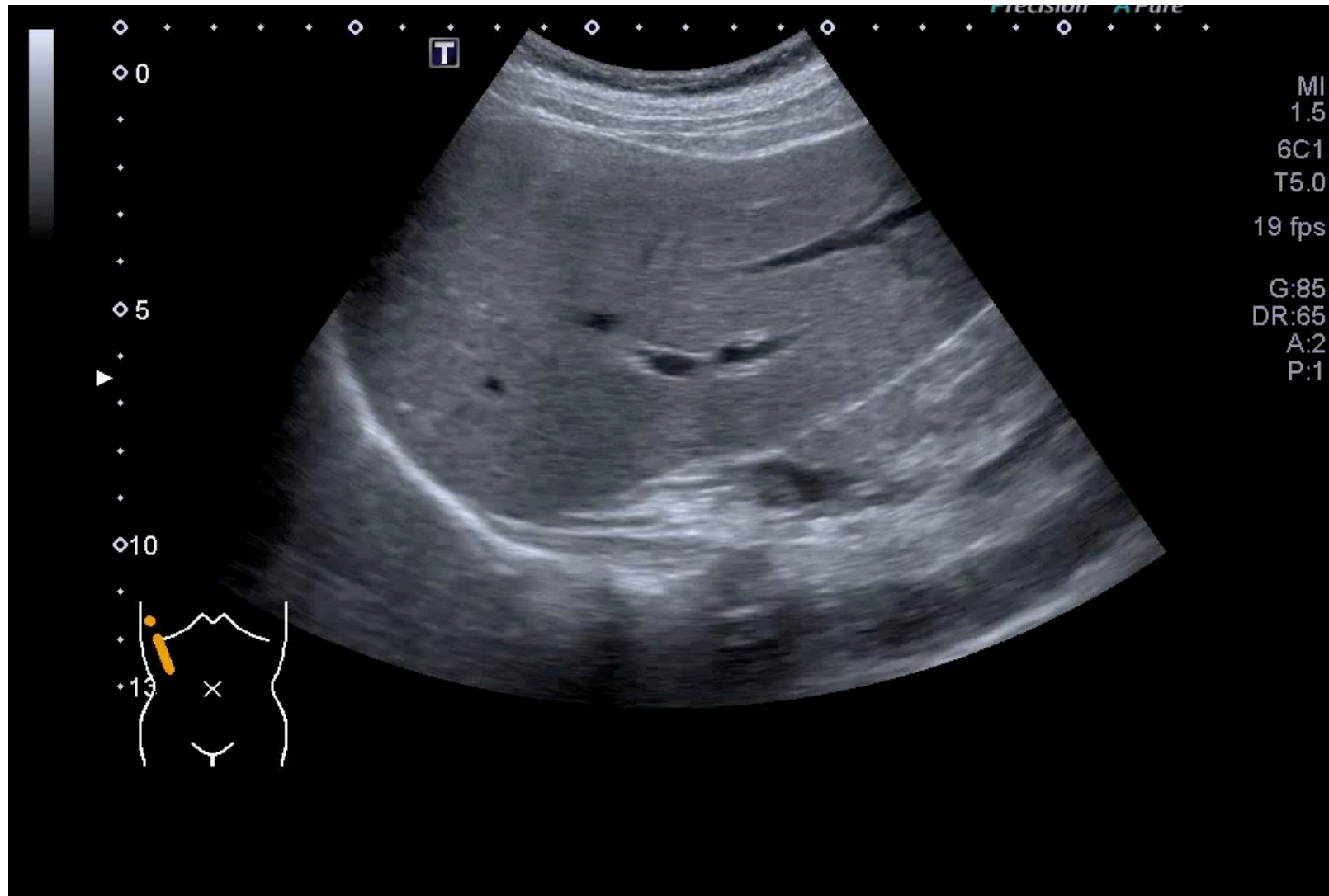


ULTRASOUND  
PROGRAM



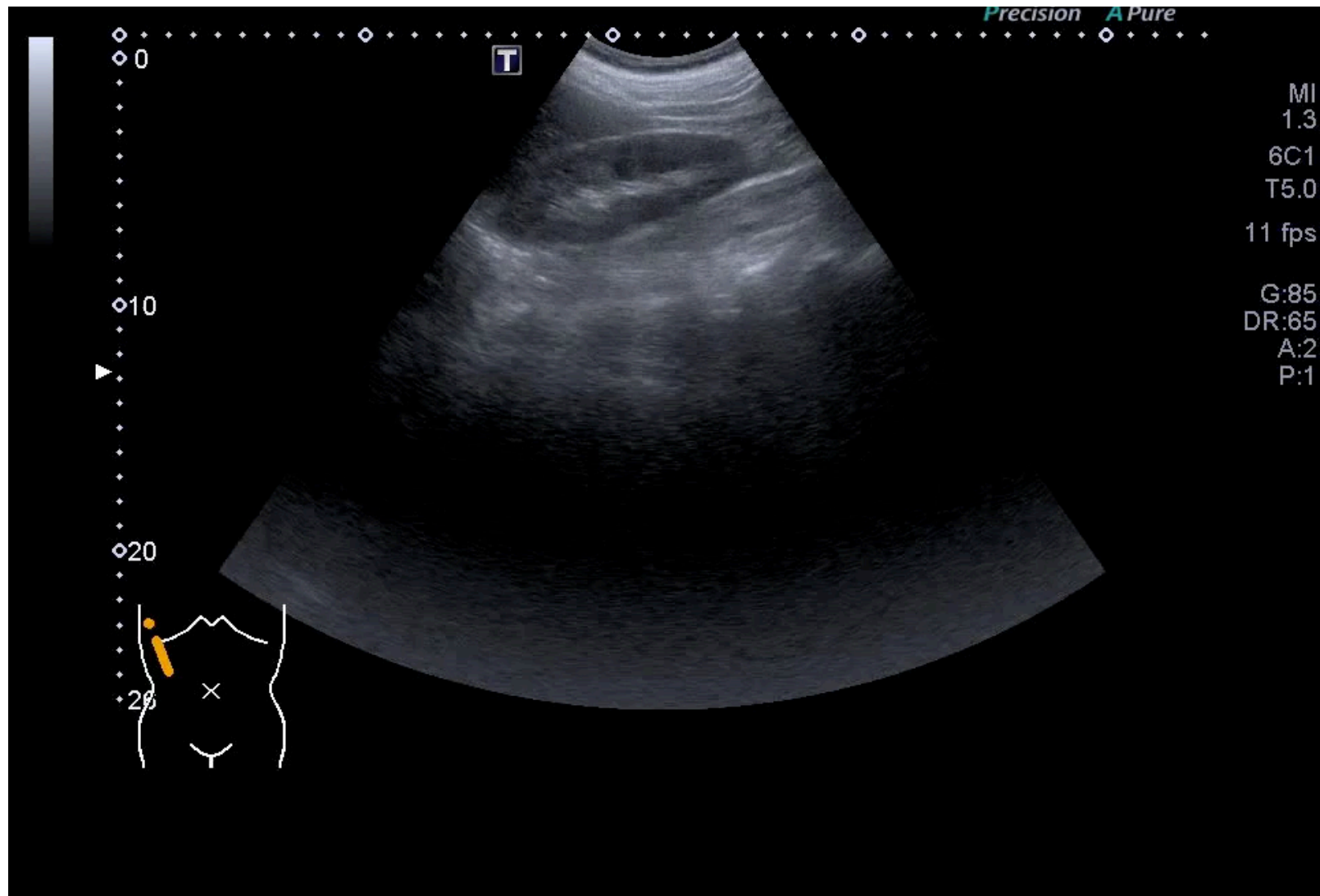


ULTRASOUND  
PROGRAM





ULTRASOUND  
PROGRAM



# POCUS幫你練就透視眼

