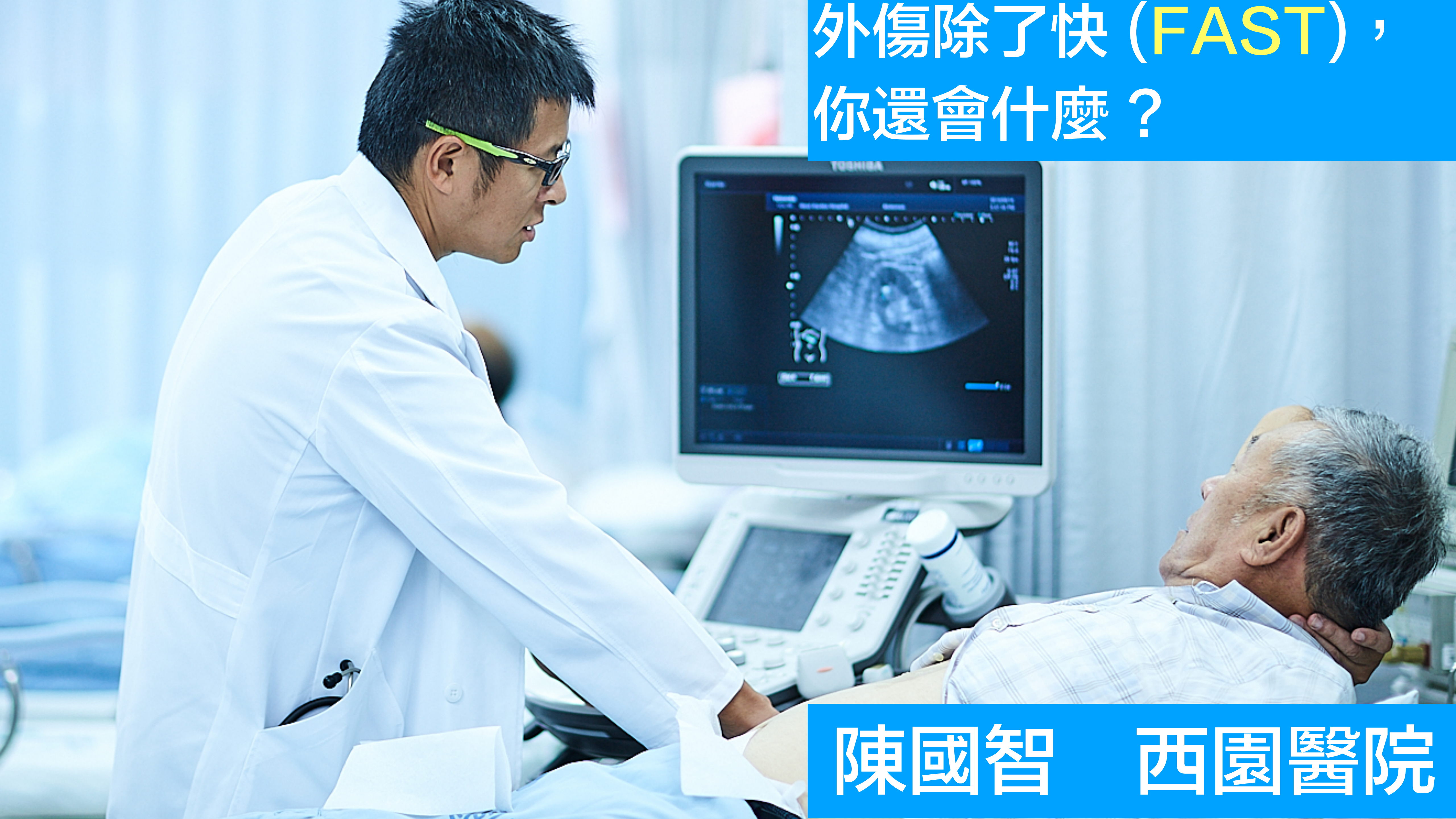
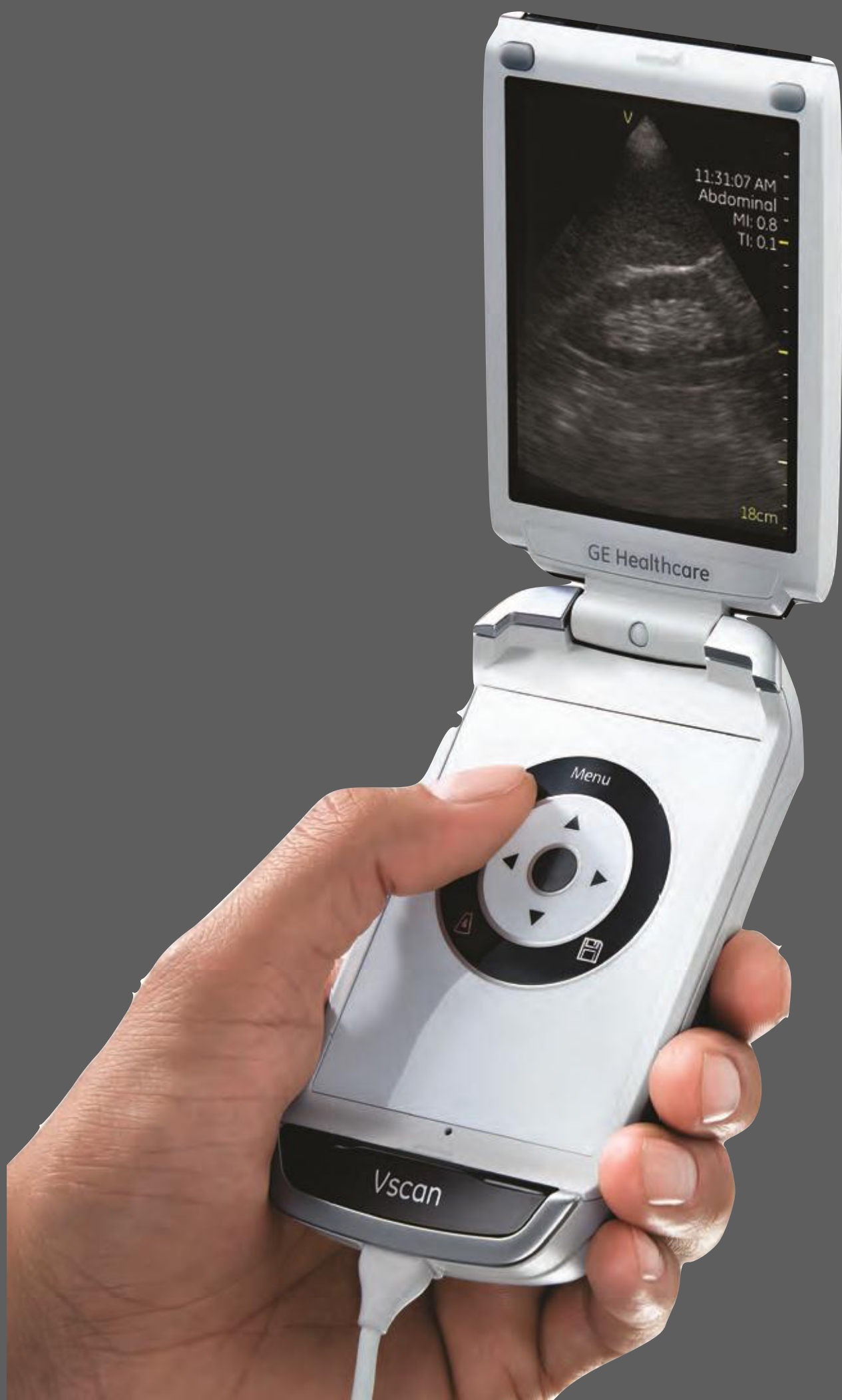
外傷除了快 (FAST)，
你還會什麼？



陳國智 西園醫院

Conflict of Interest



前急診超音波委員會主委

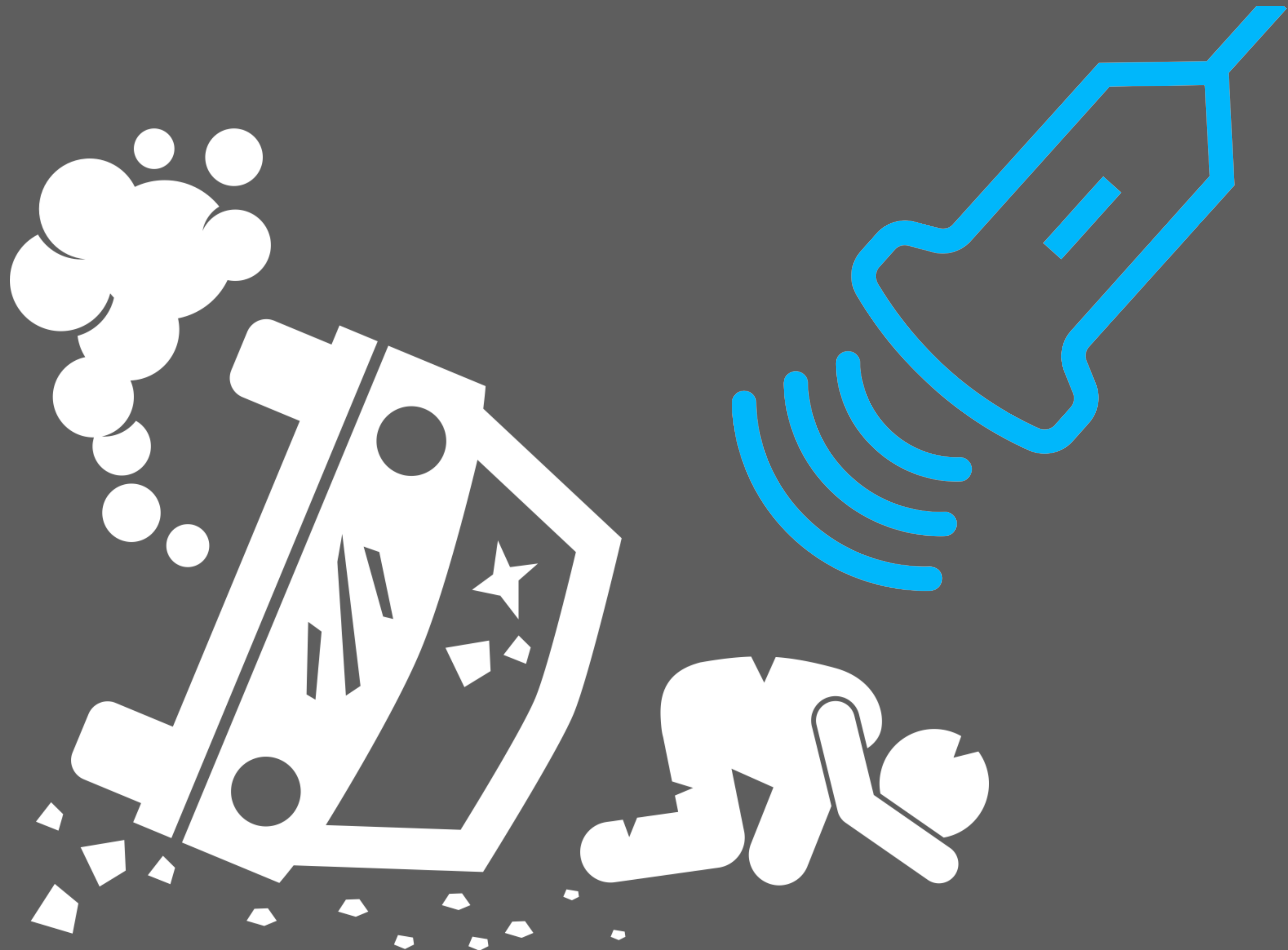
急救加護重症超音波工作坊負責人

WINFOCUS & PERCUSS 指導員


JUICE BAR 格主

POCUS Academy 小編

10/07 8th 226



FAST



EFAST



36M, Traffic accident
Tachycardia & Low BP
LUQ pain & bruise

Air

to exclude free air

EFAST

Fluid

to find free fluid



版權授權尚未談妥

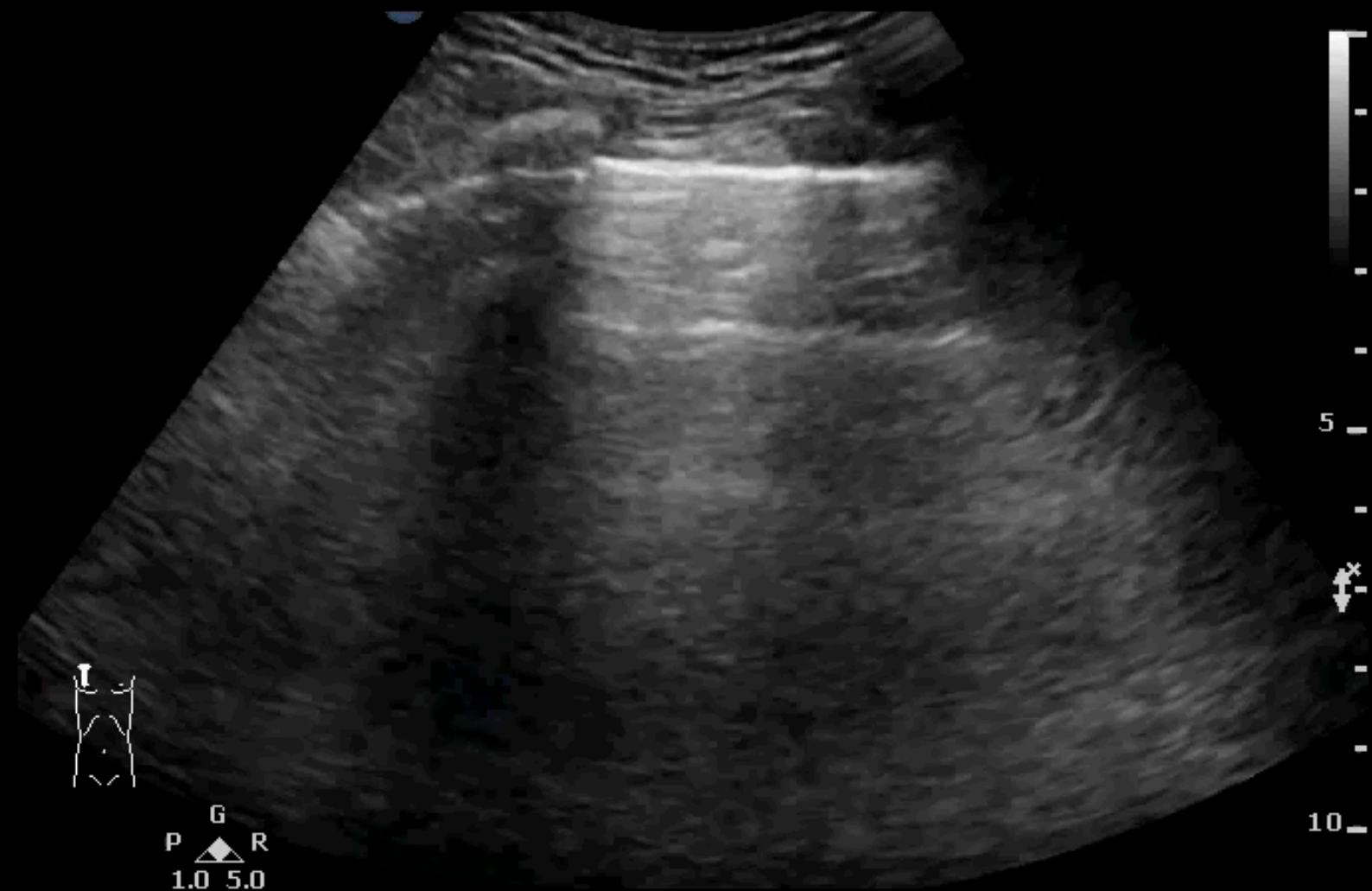

PHILIPS

SKH-EUTC@ChenKC

FAST
C5-1
42 Hz
11.0cm

2D
Gen
Gn 60
C 56
1/3/3

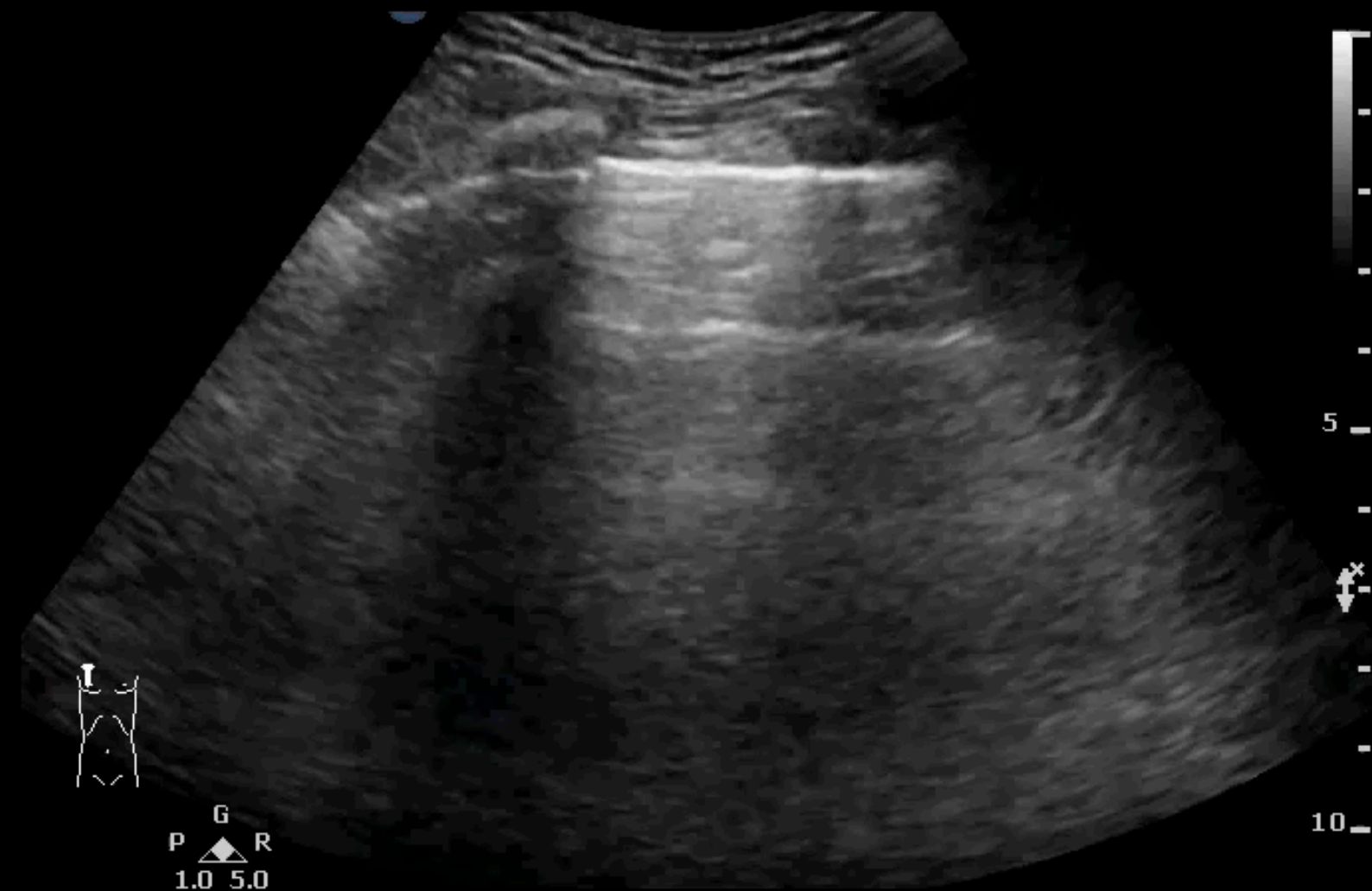

PHILIPS

SKH-EUTC@ChenKC

FAST
C5-1
42 Hz
11.0cm

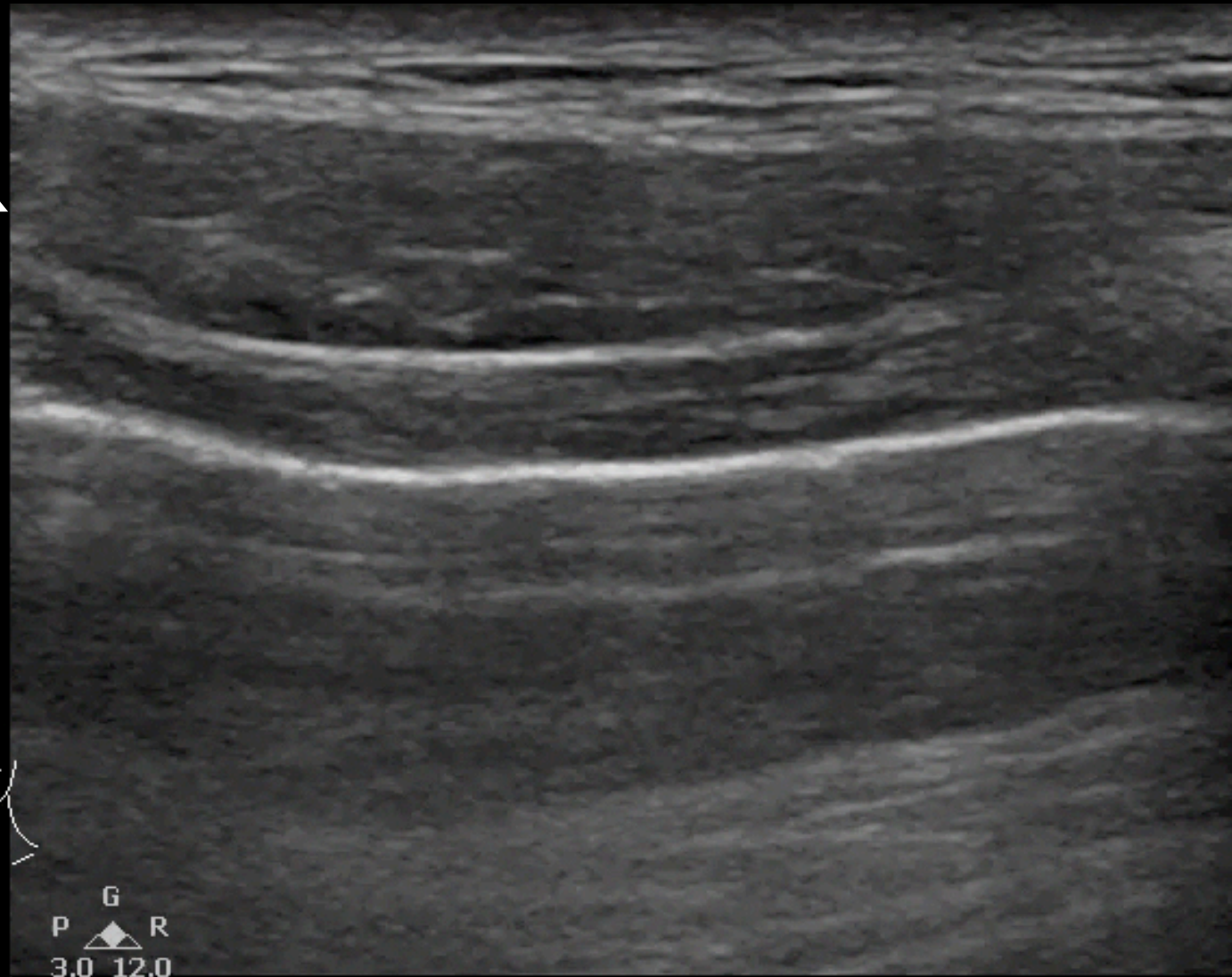
2D
Gen
Gn 60
C 56
1/3/3



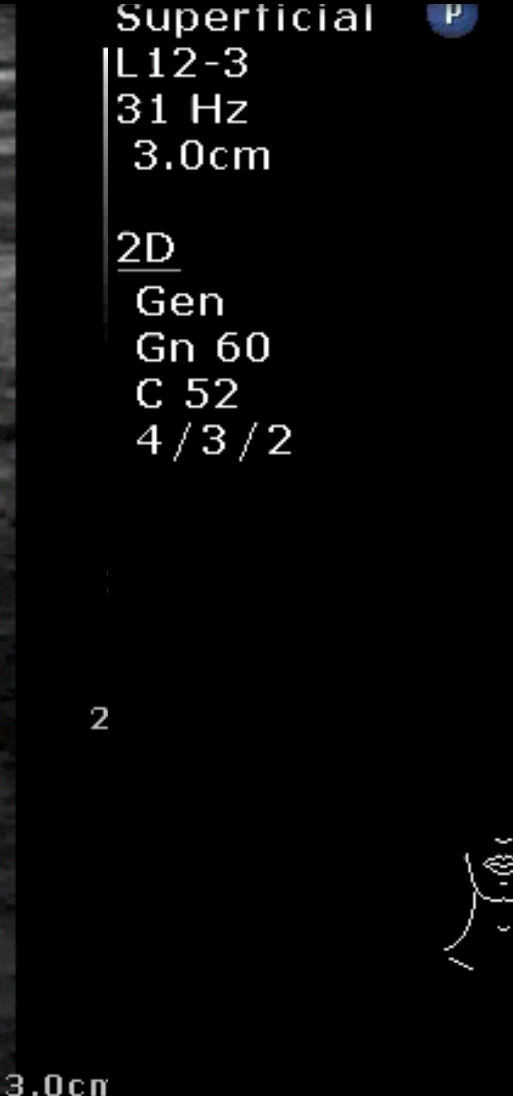


R

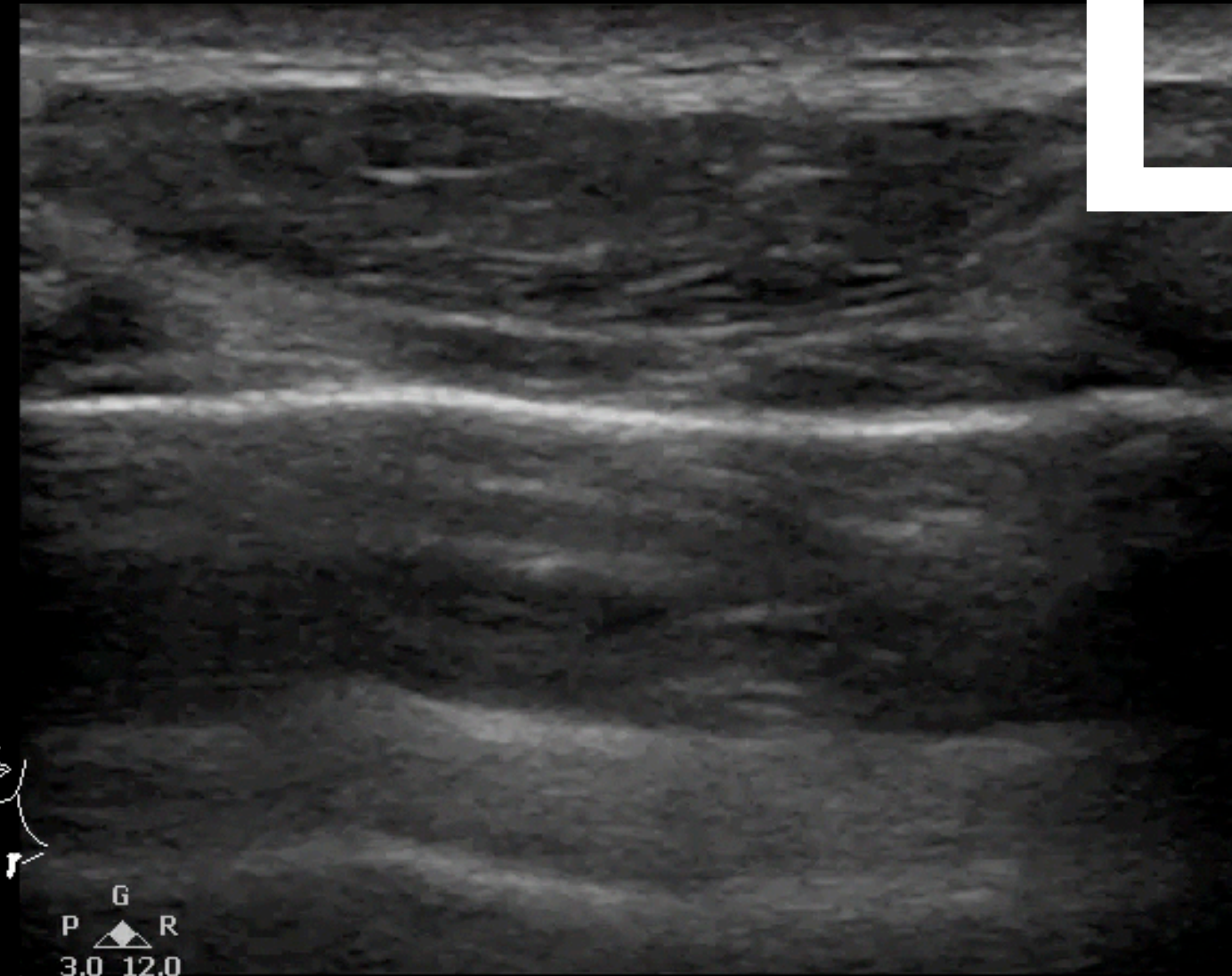
Superficial
L12-3
31 Hz
3.0cm
2D
Gen
Gn 60
C 52
4/3/2



Superficial P
L12-3
31 Hz
3.0cm
2D
Gen
Gn 60
C 52
4/3/2



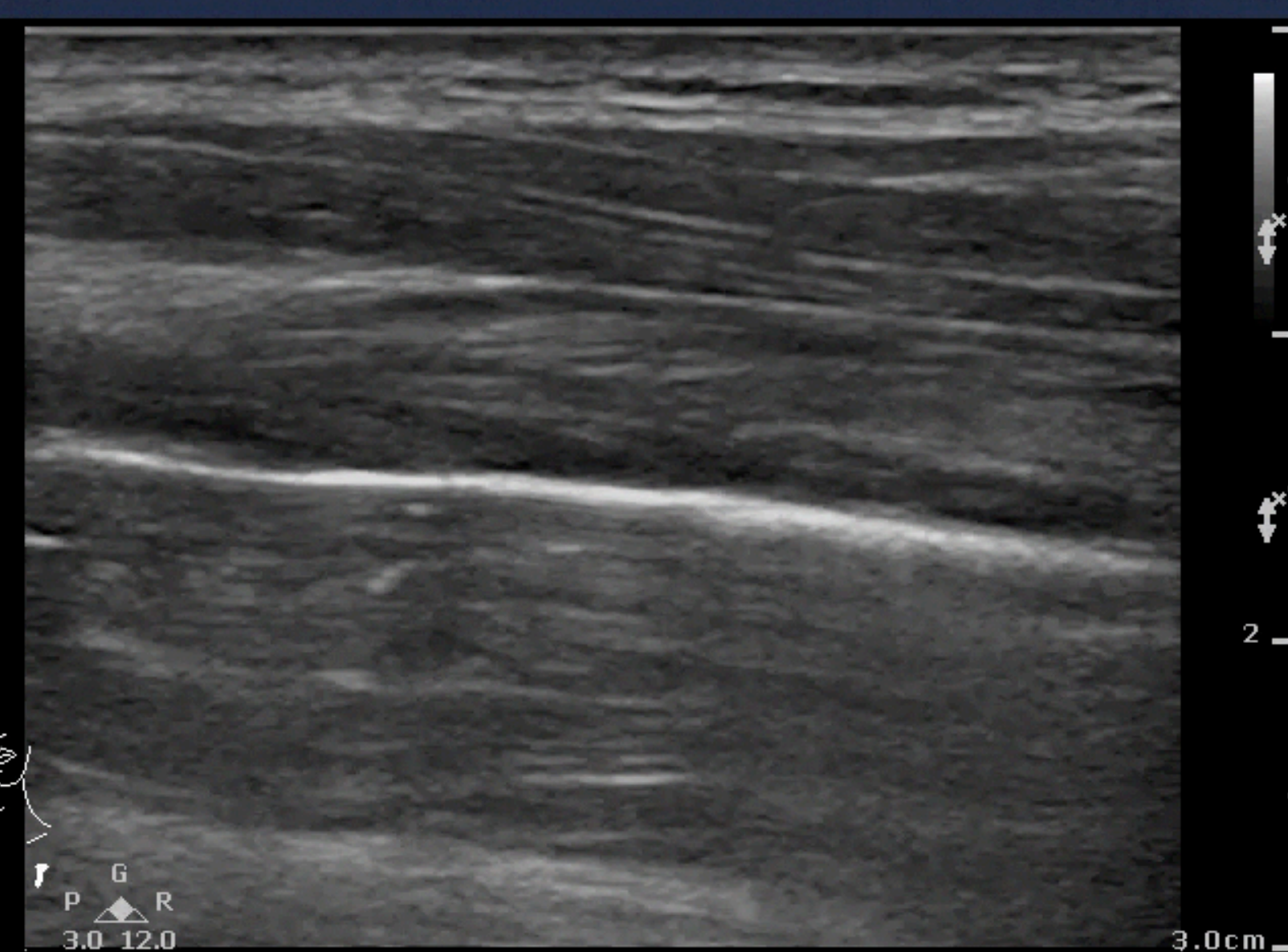
L



2
3.0cm

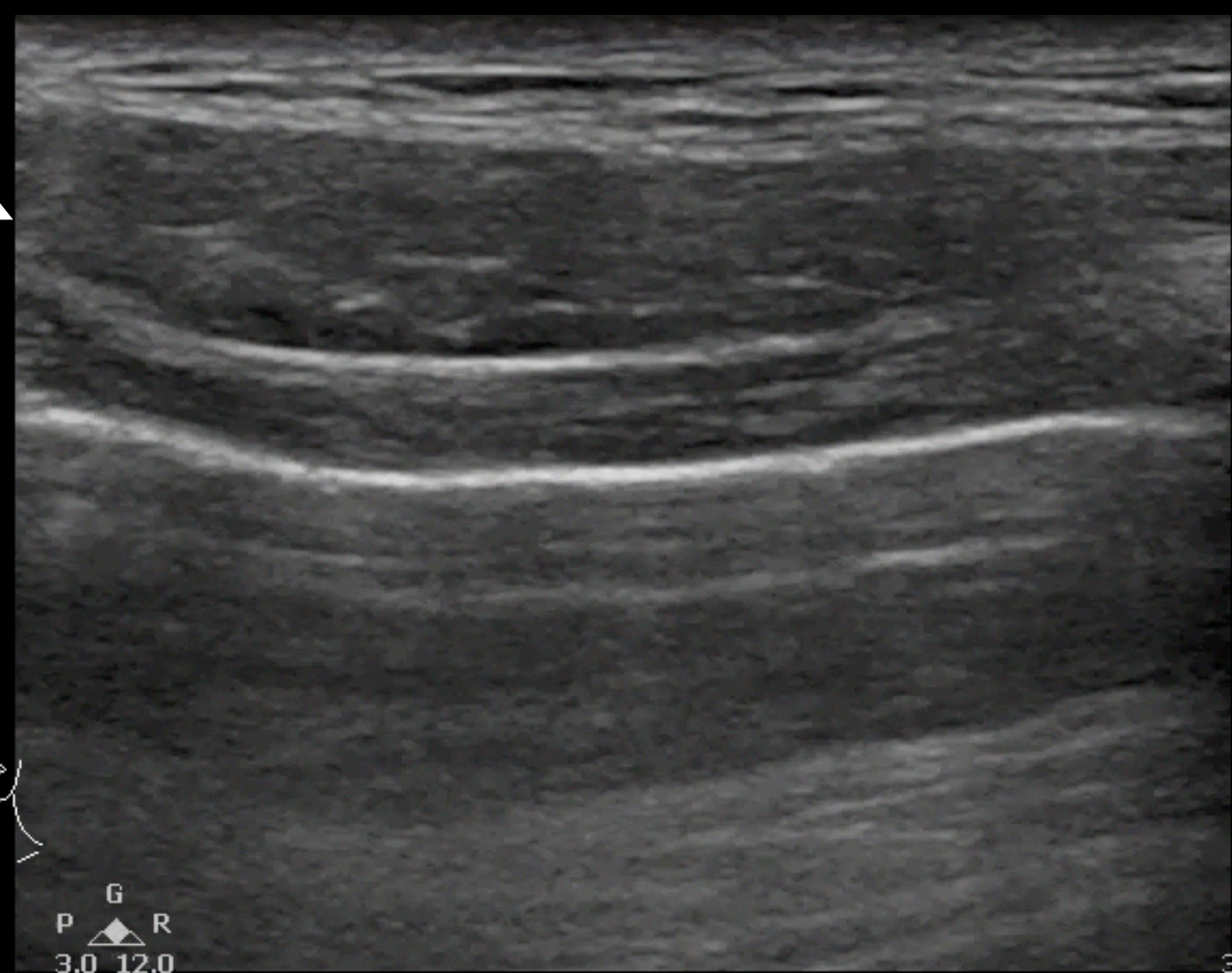
你有氣胸

Superficial P
L12-3
31 Hz
3.0cm
2D
Gen
Gn 60
C 52
4/3/2

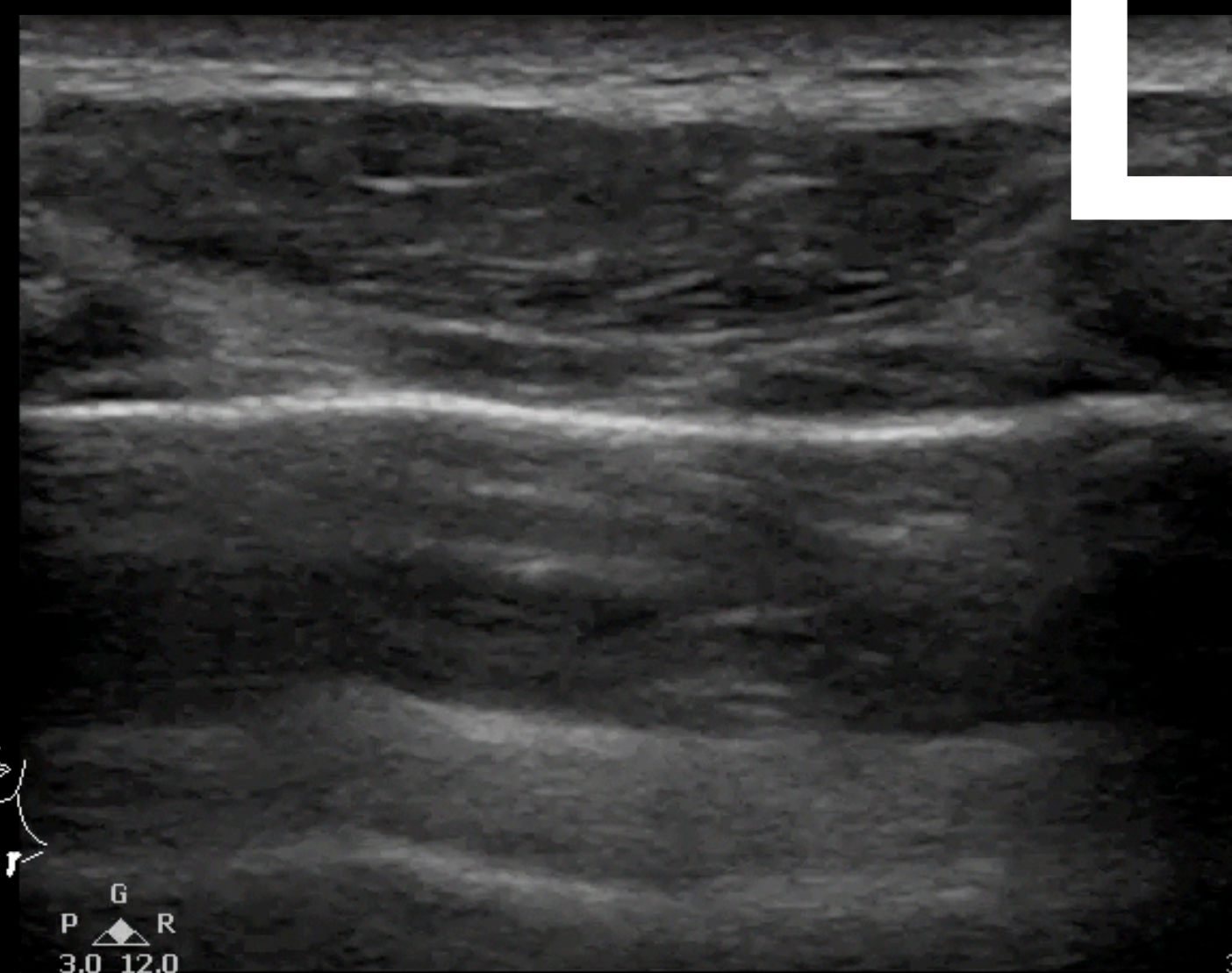


R

Superficial P
L12-3
31 Hz
3.0cm
2D
Gen
Gn 60
C 52
4/3/2



Superficial P
L12-3
31 Hz
3.0cm
2D
Gen
Gn 60
C 52
4/3/2



L

3.0 12.0

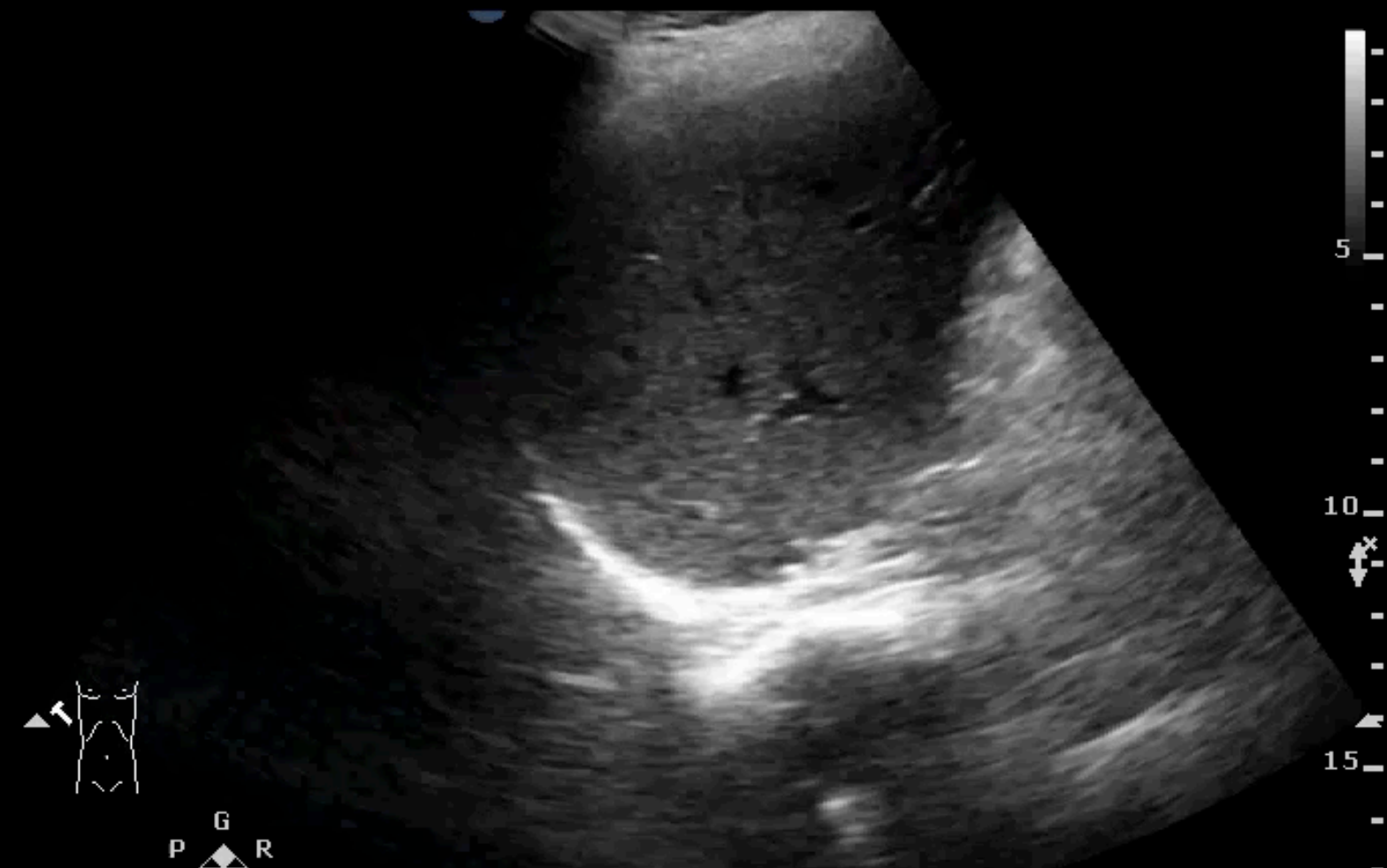3.0cm

PHILIPS

SKH-EUTC@ChenKC

FAST
C5-1
30 Hz
18.0cm

2D
Gen
Gn 82
C 56
1/3/3

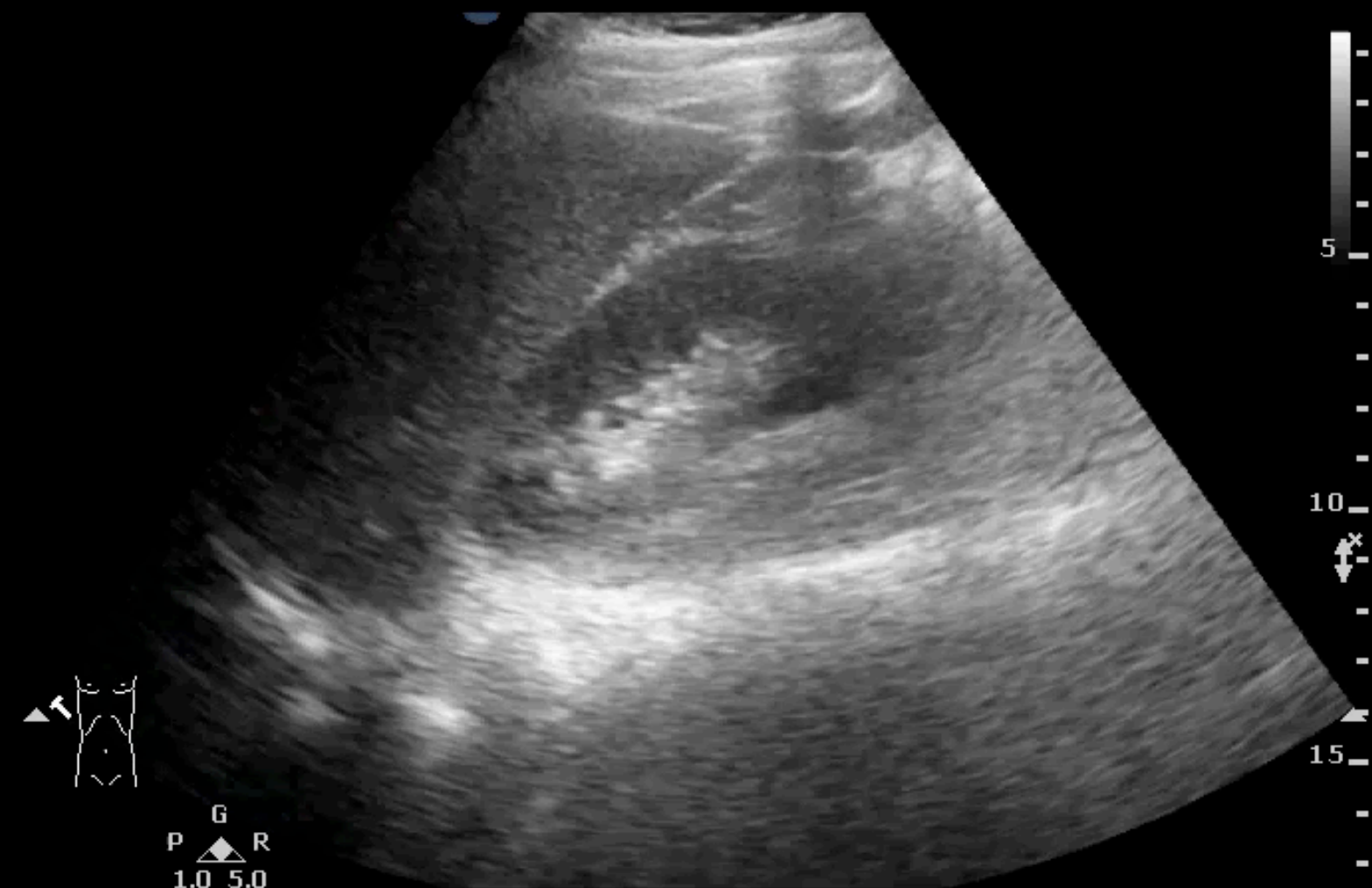


PHILIPS

SKH-EUTC@ChenKC

FAST
C5-1
30 Hz
18.0cm

2D
Gen
Gn 99
C 56
1/3/3



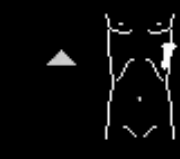

PHILIPS

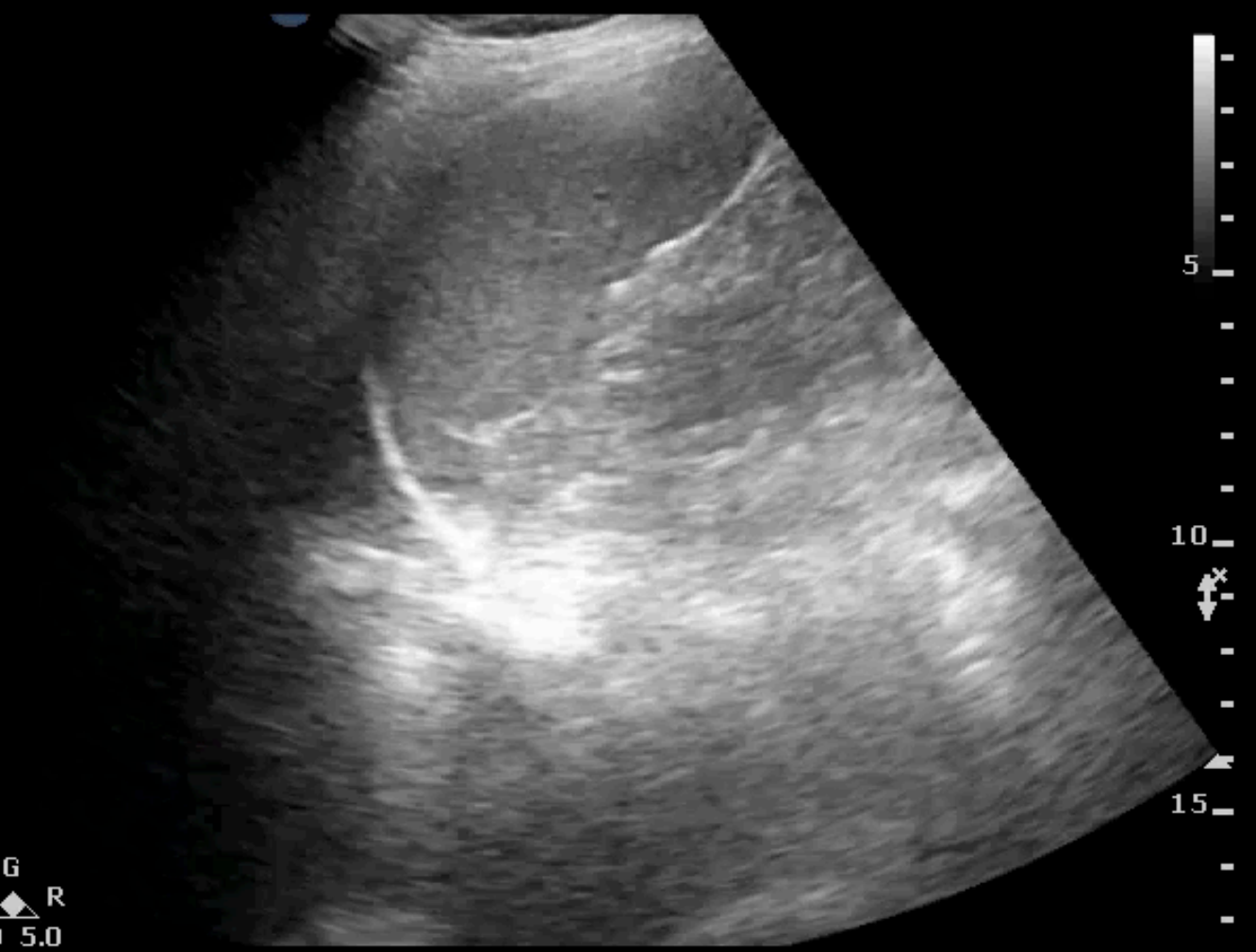
FAST
C5-1
30 Hz
18.0cm

2D
Gen
Gn 99
C 56
1 / 3 / 3

SKH-EUTC@ChenKC



G
P R
1.0 5.0

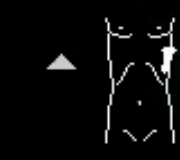

PHILIPS

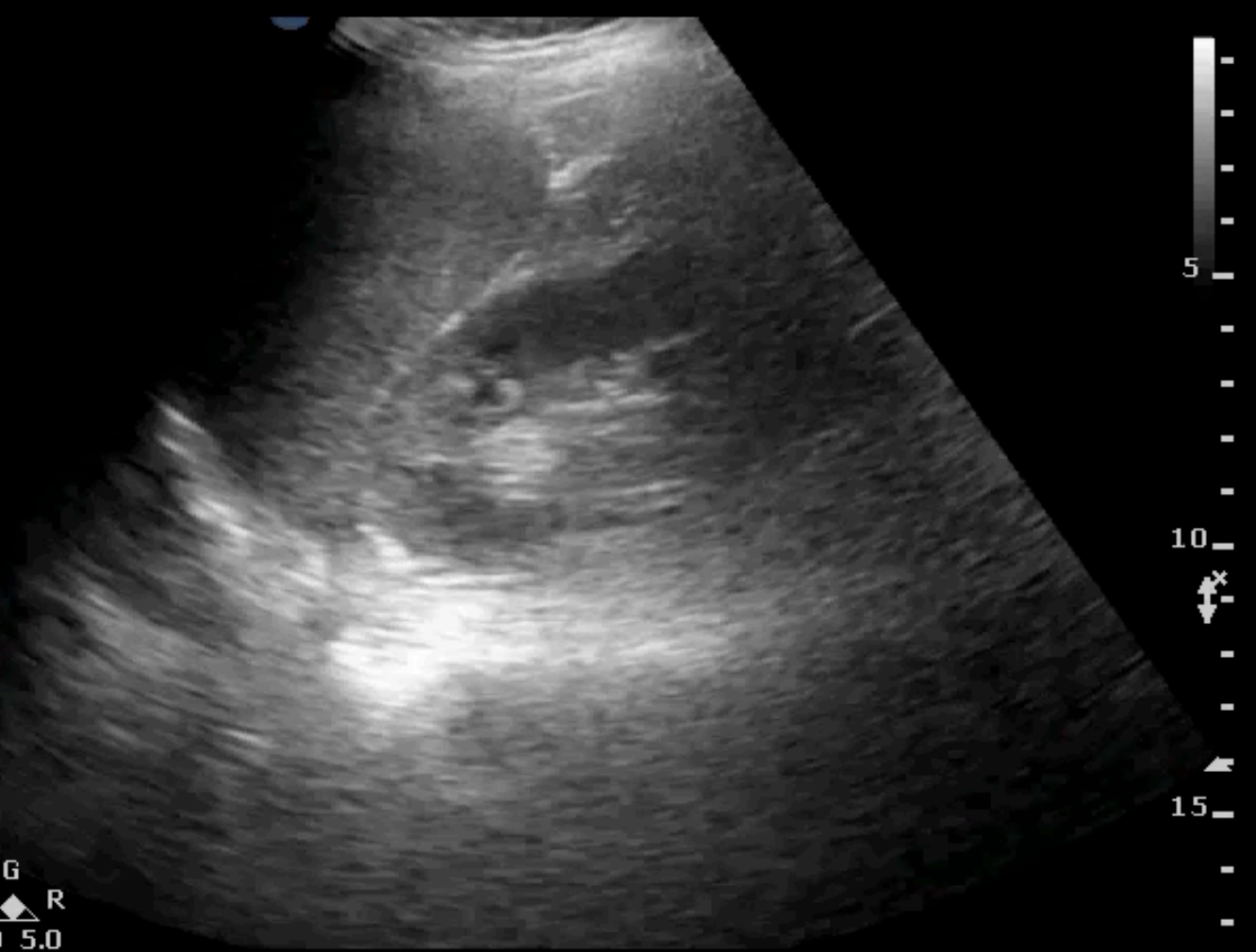
FAST
C5-1
30 Hz
18.0cm

2D
Gen
Gn 99
C 56
1 / 3 / 3

SKH-EUTC@ChenKC



G
P R
1.0 5.0



PHILIPS

SKH-EUTC@ChenKC

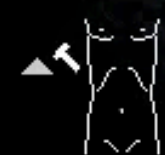FAST
C5-1
30 Hz
18.0cm

2D
Gen
Gn 82
C 56
1/3/3

你有血胸

Abd Gen
C5-1
31 Hz
17.0cm

2D
HGen
Gn 90
C 56
3/3/3



G
P R
1.0 5.0

15



G
P R
1.8 3.6

17.00





PHILIPS

SKH-EUTC@ChenKC

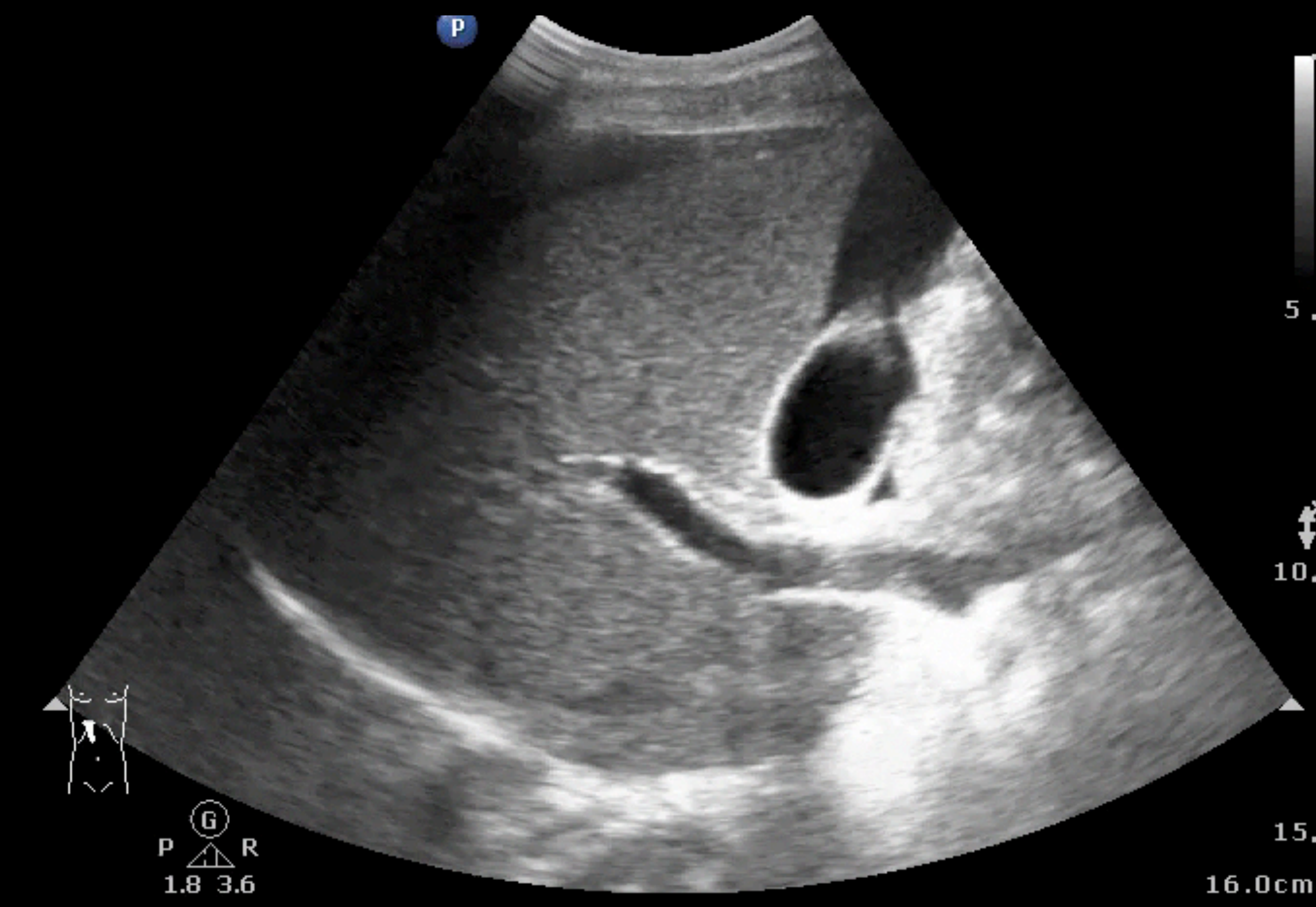
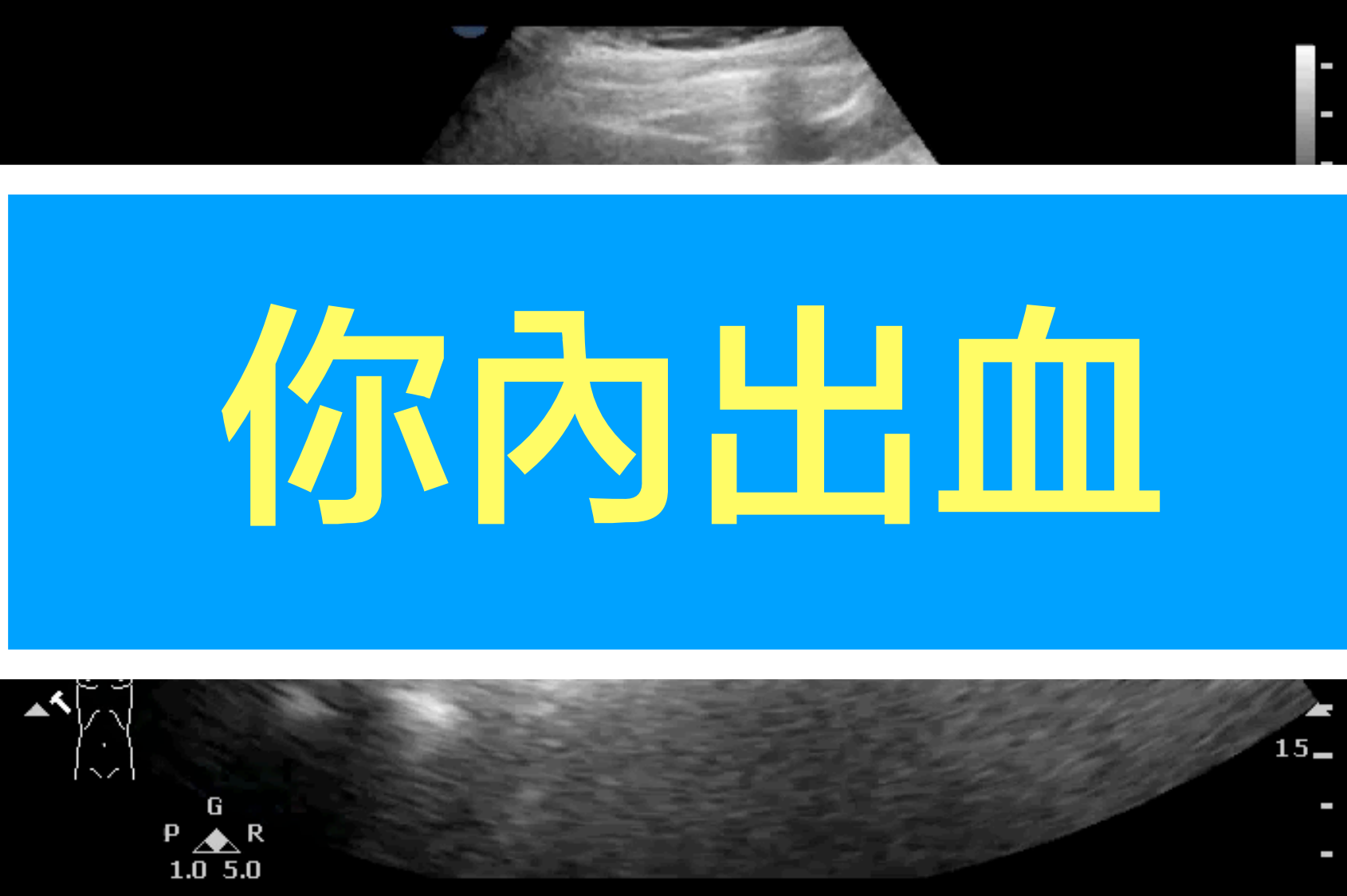FAST
C5-1
30 Hz
18.0cm

2D
Gen
Gn 99
C 56
1/3/3

你內出血

Abd Gen
C5-1
32 Hz
16.0cm

2D
HGen
Gn 90
C 56
3/3/3



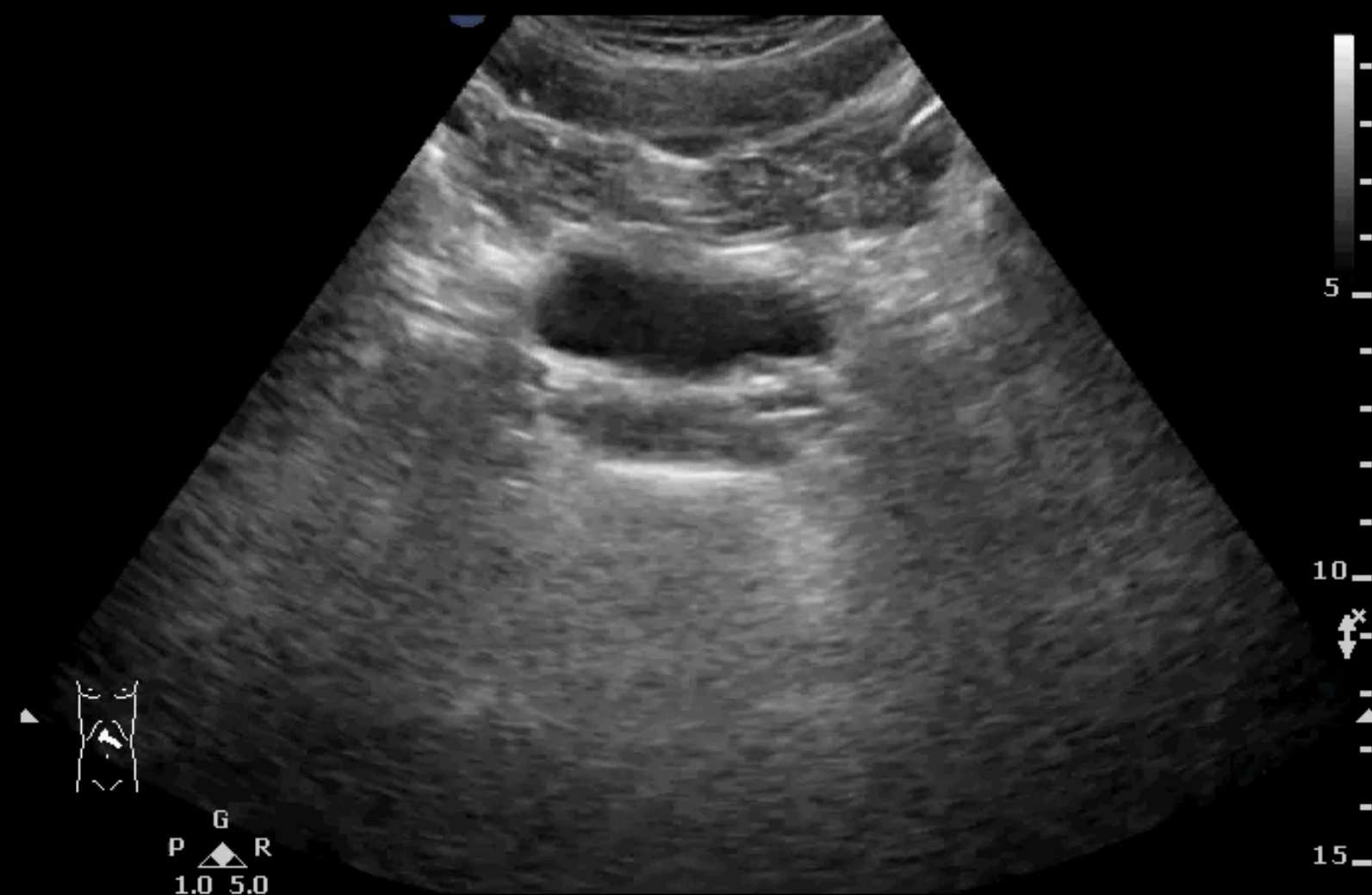

PHILIPS

SKH-EUTC@ChenKC

FAST
C5-1
33 Hz
16.0cm

2D
Gen
Gn 64
C 56
1/3/3

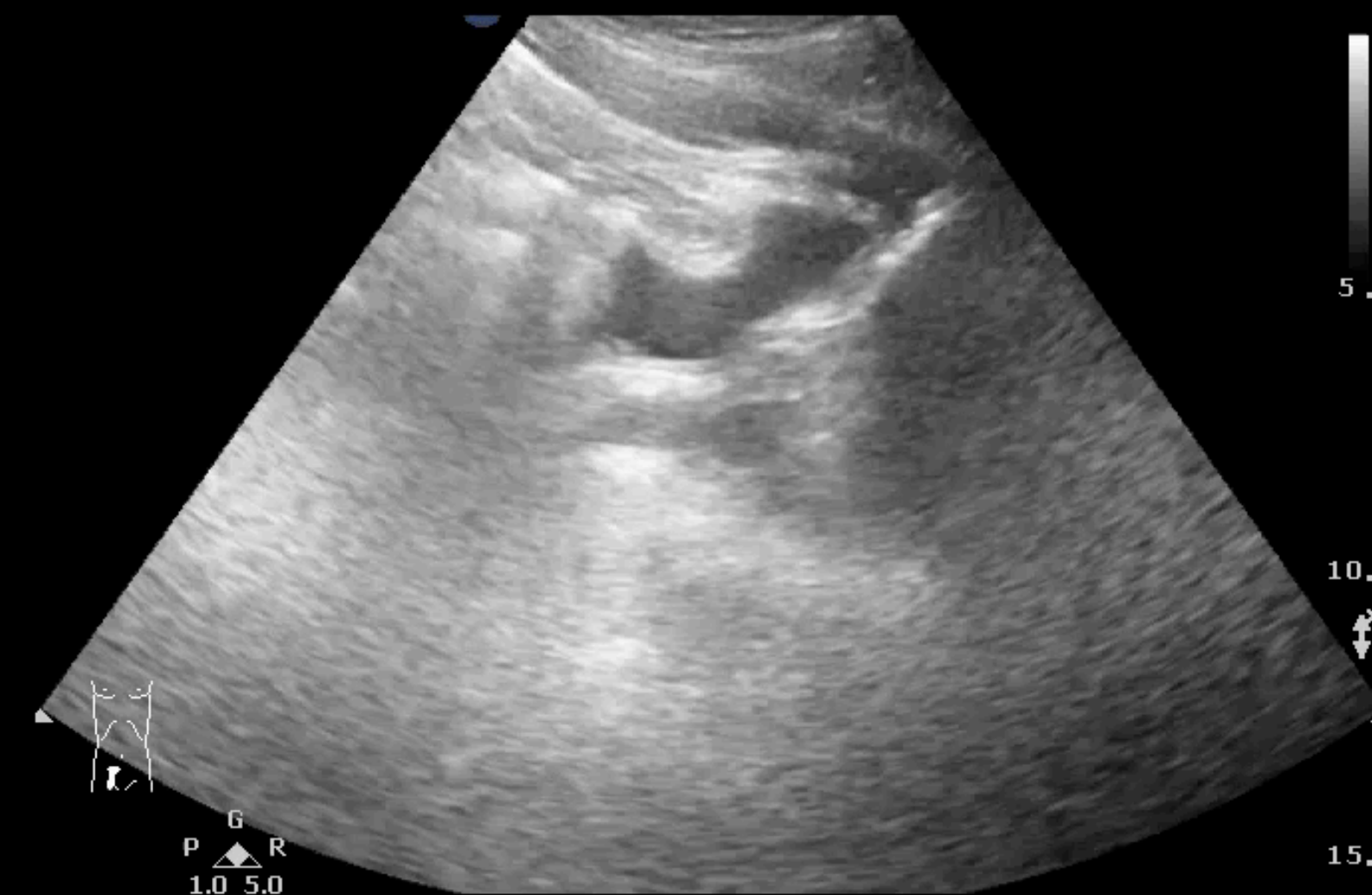

PHILIPS

SKH-EUTC@ChenKC

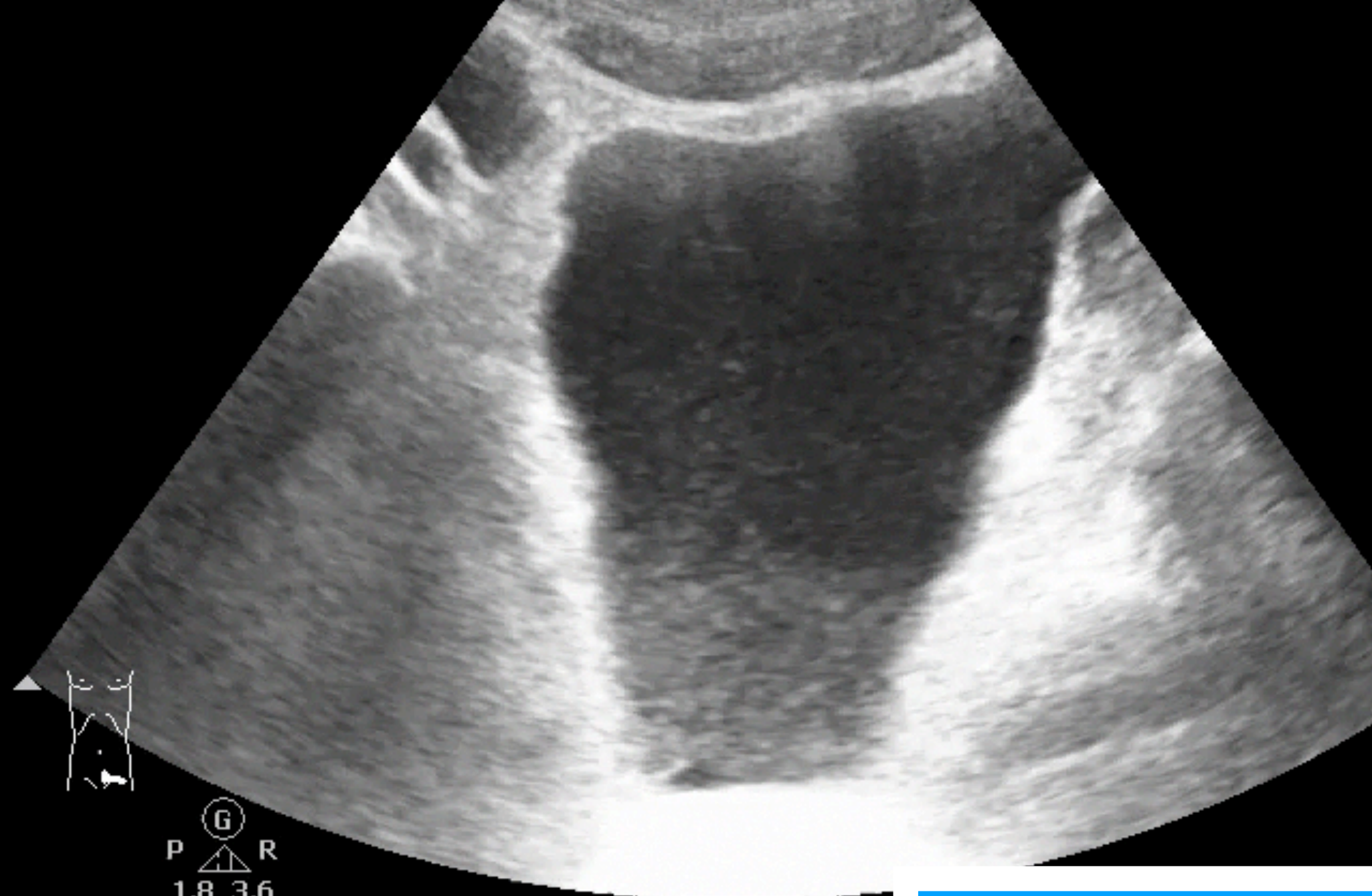
FAST
C5-1
33 Hz
16.0cm

2D
Gen
Gn 99
C 56
1/3/3

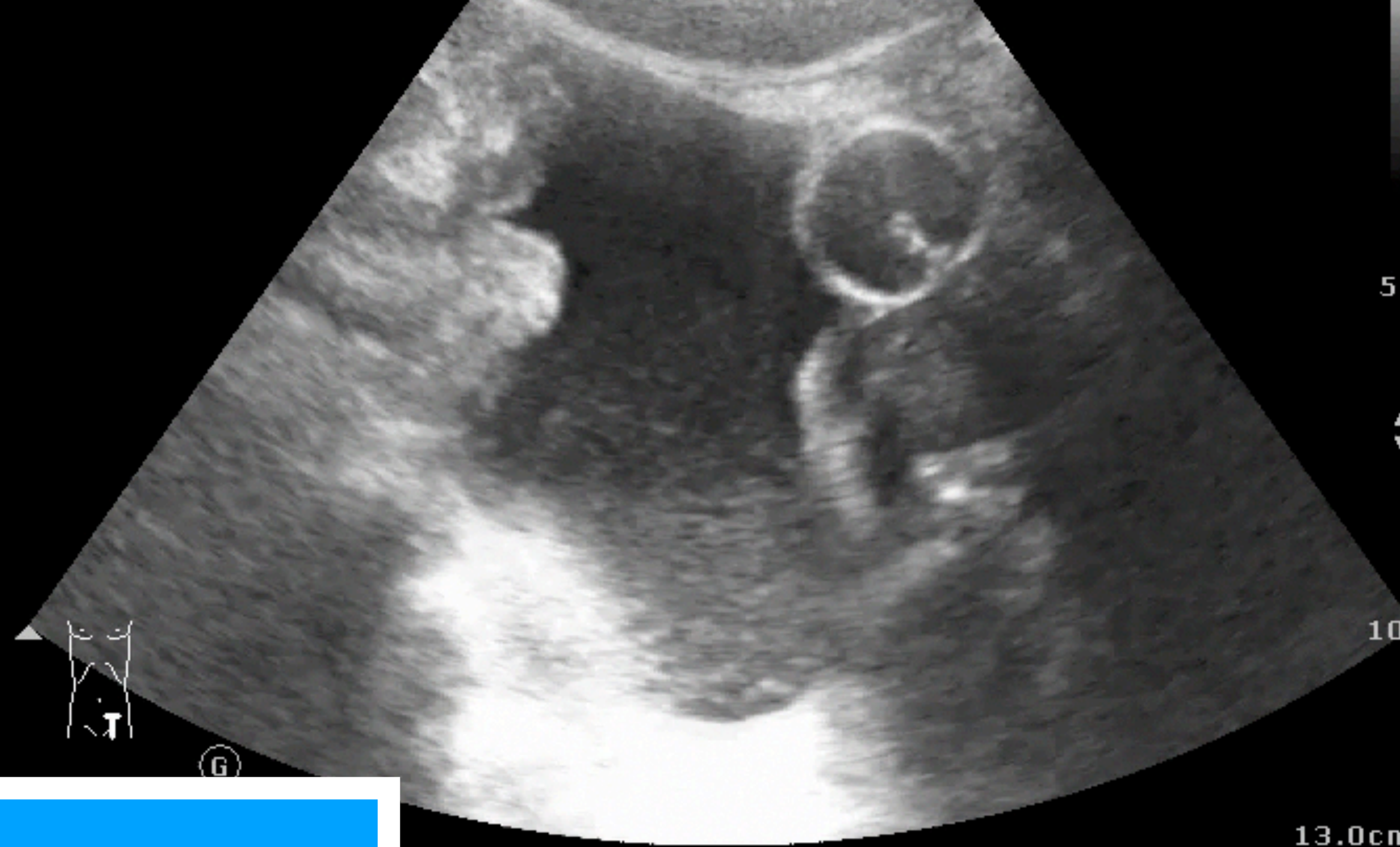

8 Hz
3.0cm

D
HGen
Gn 90
C 56
3/3/3



33 Hz
13.0cm
2D
HGen
Gn 90
C 56
3/3/3



G
P R
1.8 3.6



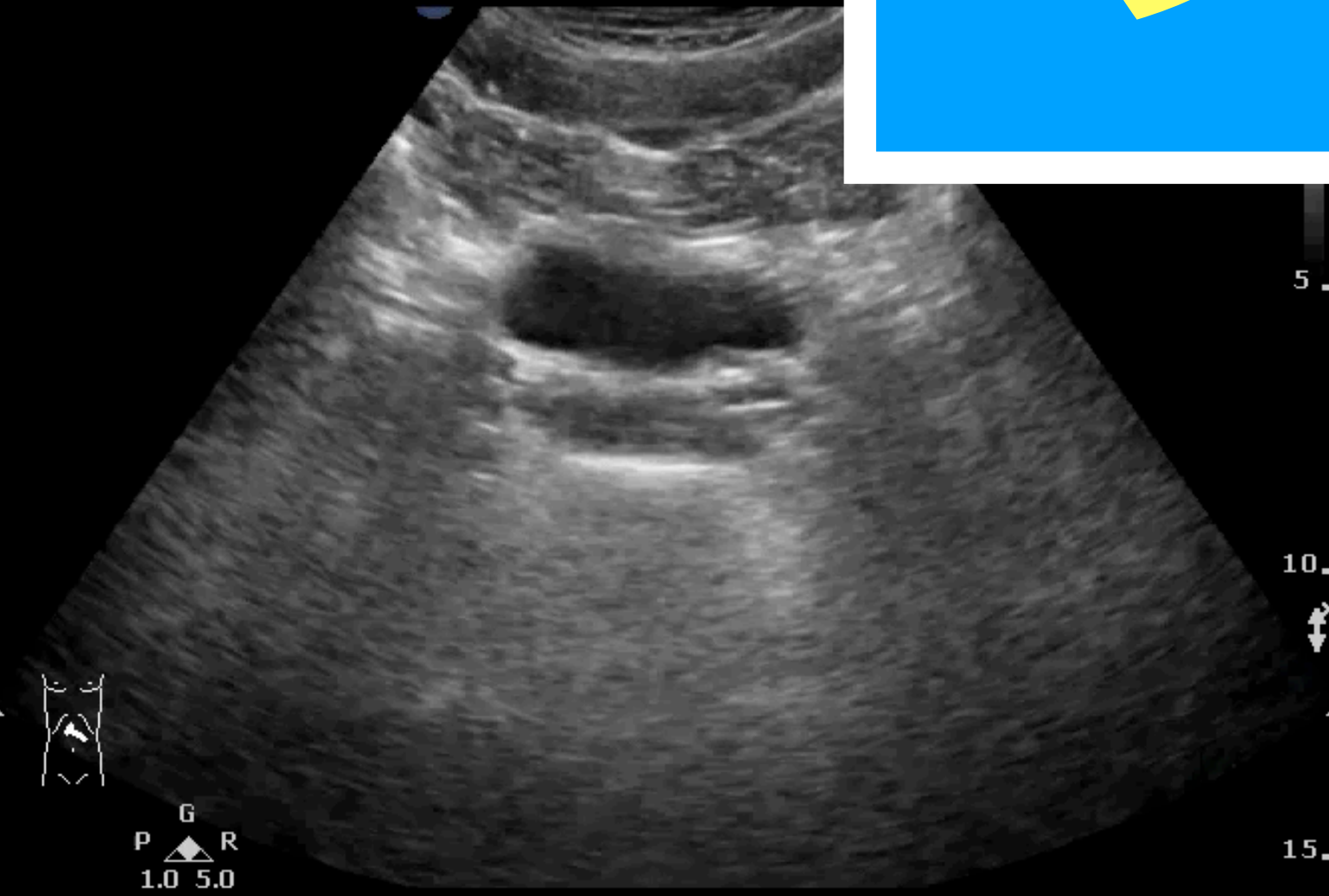
G

SKH-EUTC@C

歹誌不妙

FAST
C5-1
33 Hz
16.0cm

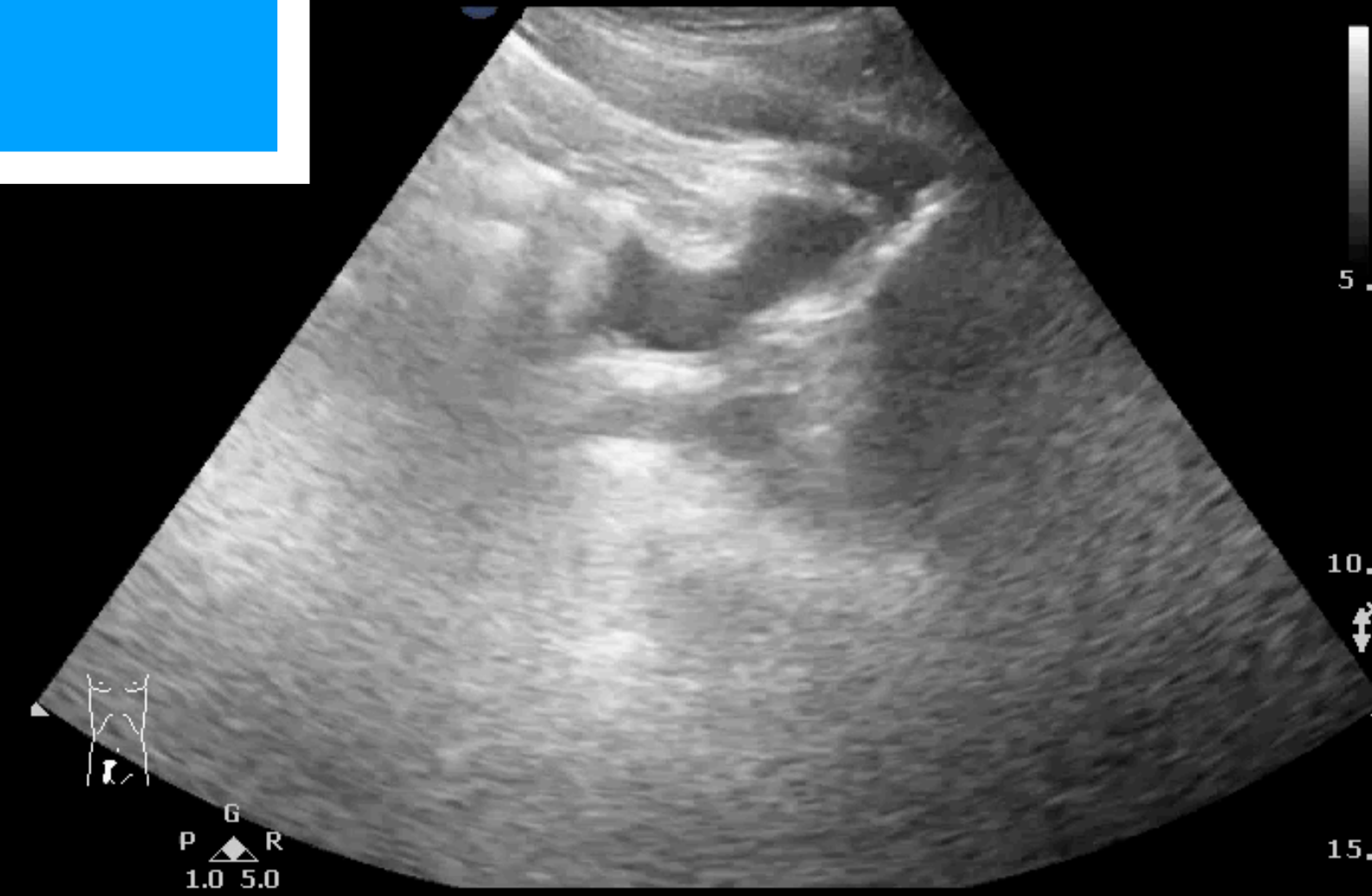2D
Gen
Gn 64
C 56
1/3/3



G
P R
1.0 5.0

5
10
15

2D
Gen
Gn 99
C 56
1/3/3



G
P R
1.0 5.0

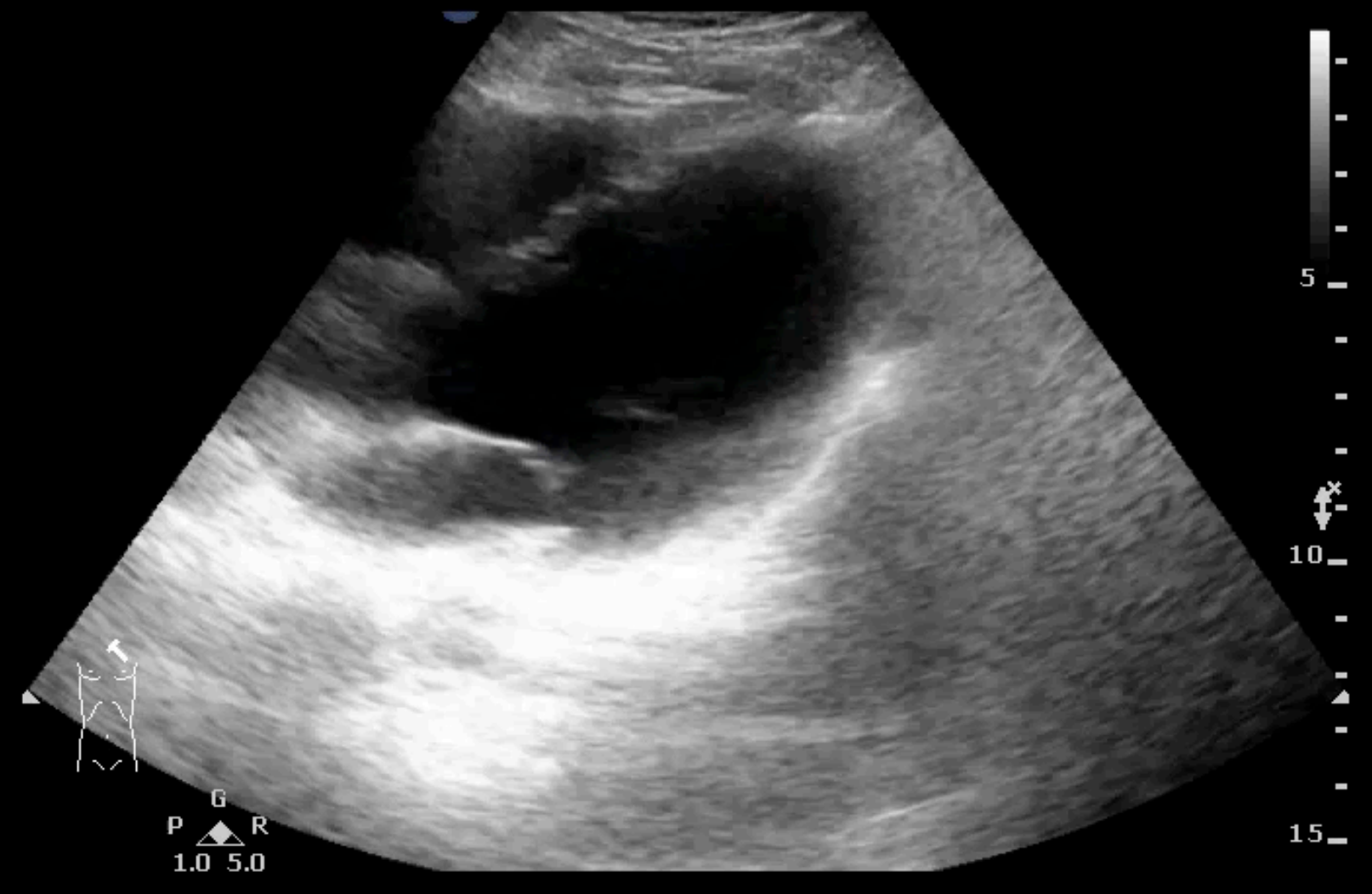
5
10
15

PHILIPS

SKH-EUTC@ChenKC

FAST
C5-1
33 Hz
16.0cm

2D
Gen
Gn 76
C 56
1/3/3

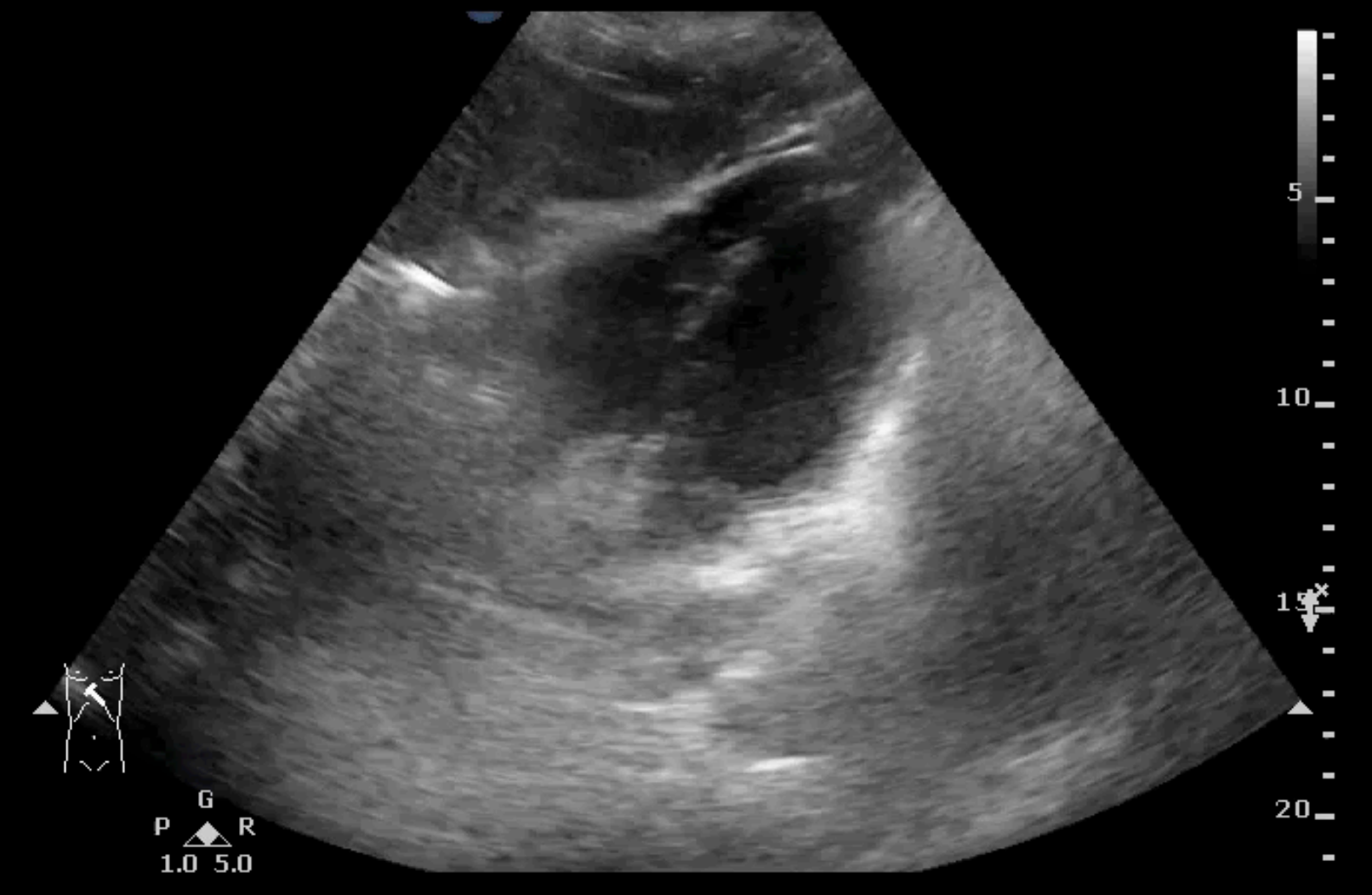

PHILIPS

SKH-EUTC@ChenKC

FAST
C5-1
26 Hz
22.0cm

2D
Gen
Gn 76
C 56
1/3/3

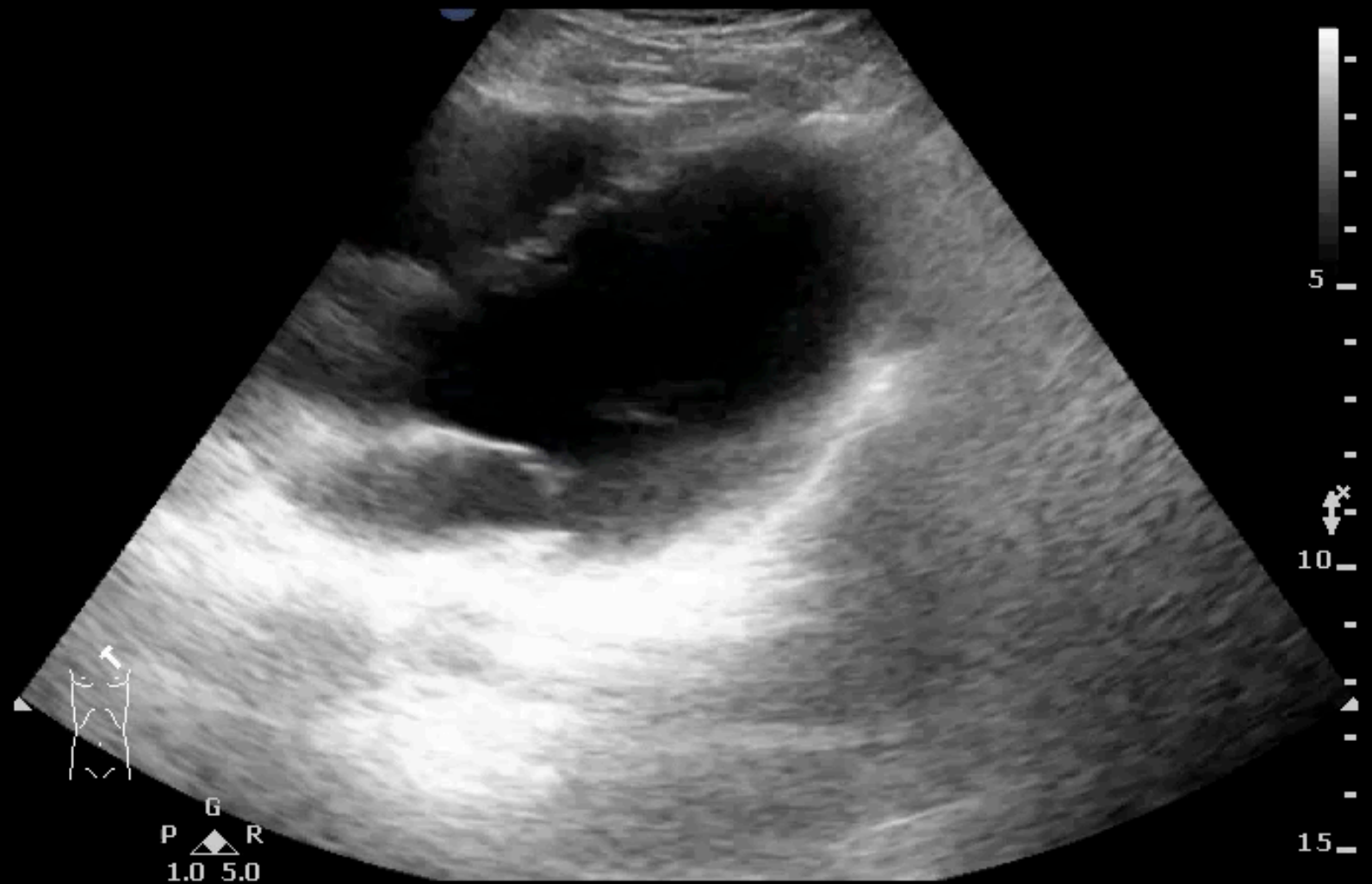


PHILIPS

SKH-EUTC@ChenKC

FAST
C5-1
33 Hz
16.0cm

2D
Gen
Gn 76
C 56
1/3/3

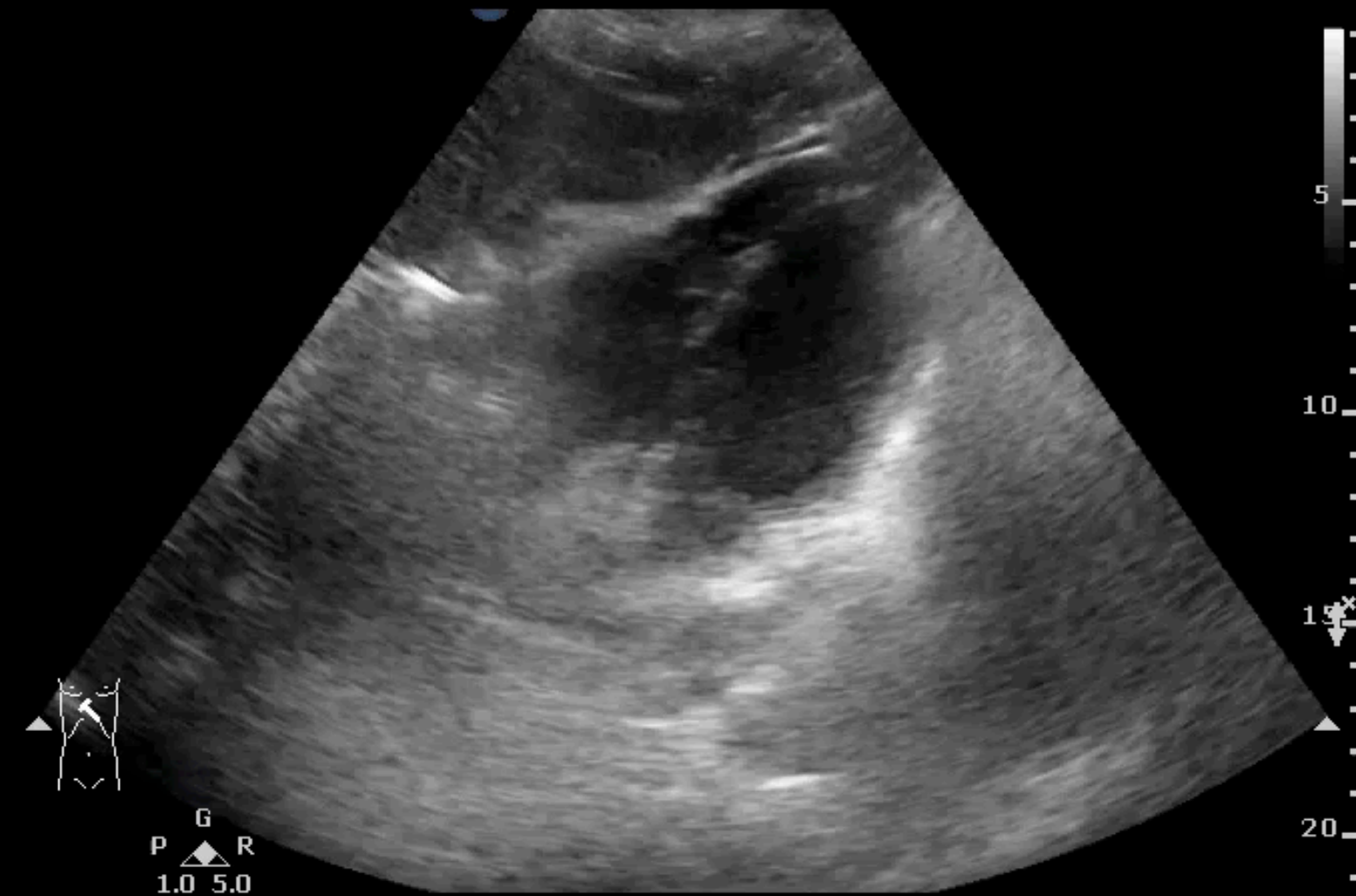


PHILIPS

SKH-EUTC@ChenKC

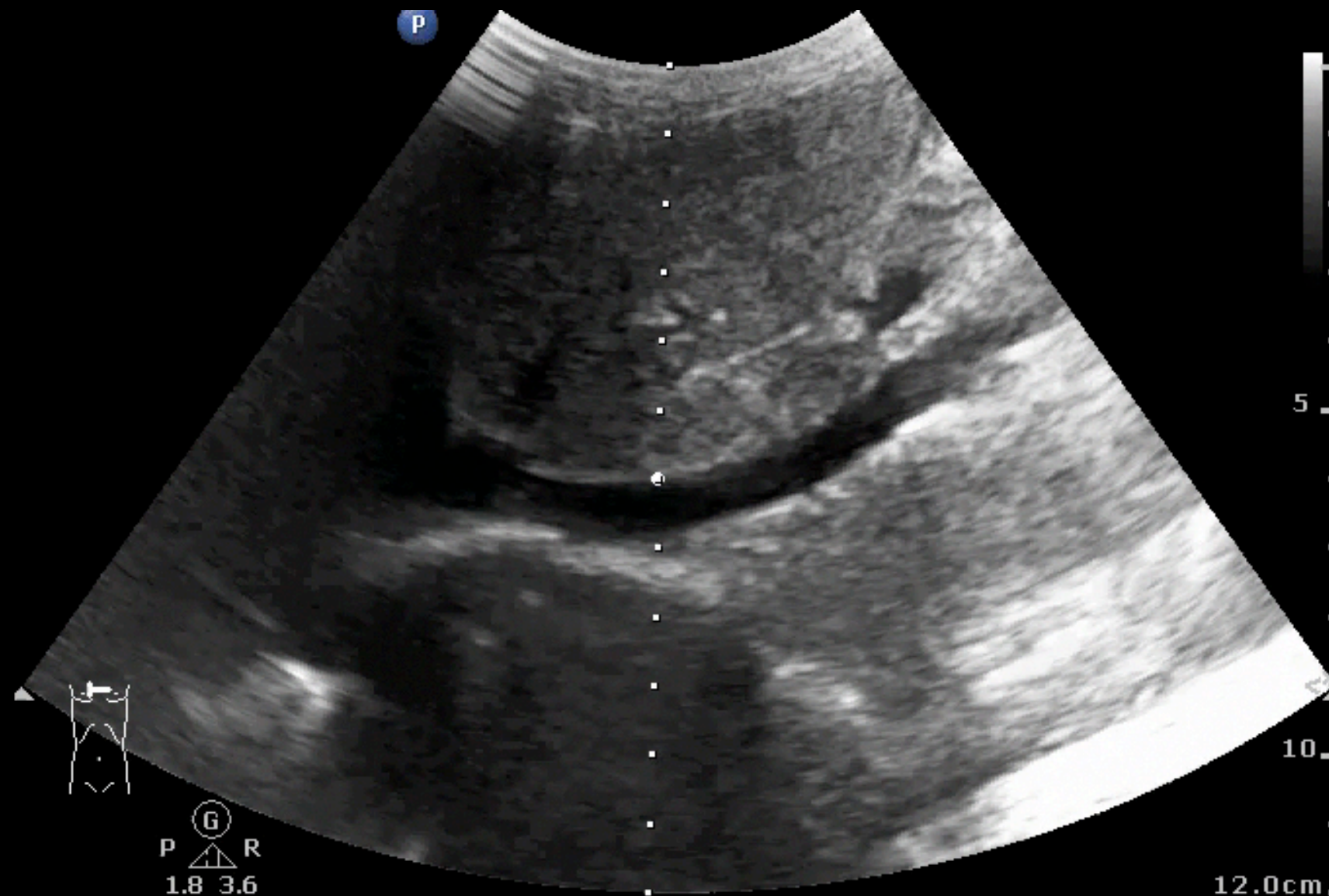
FAST
C5-1
26 Hz
22.0cm

2D
Gen
Gn 76
C 56
1/3/3



Abd Gen
C5-1
37 Hz
12.0cm

2D
HGen
Gn 87
C 52
3/3/3

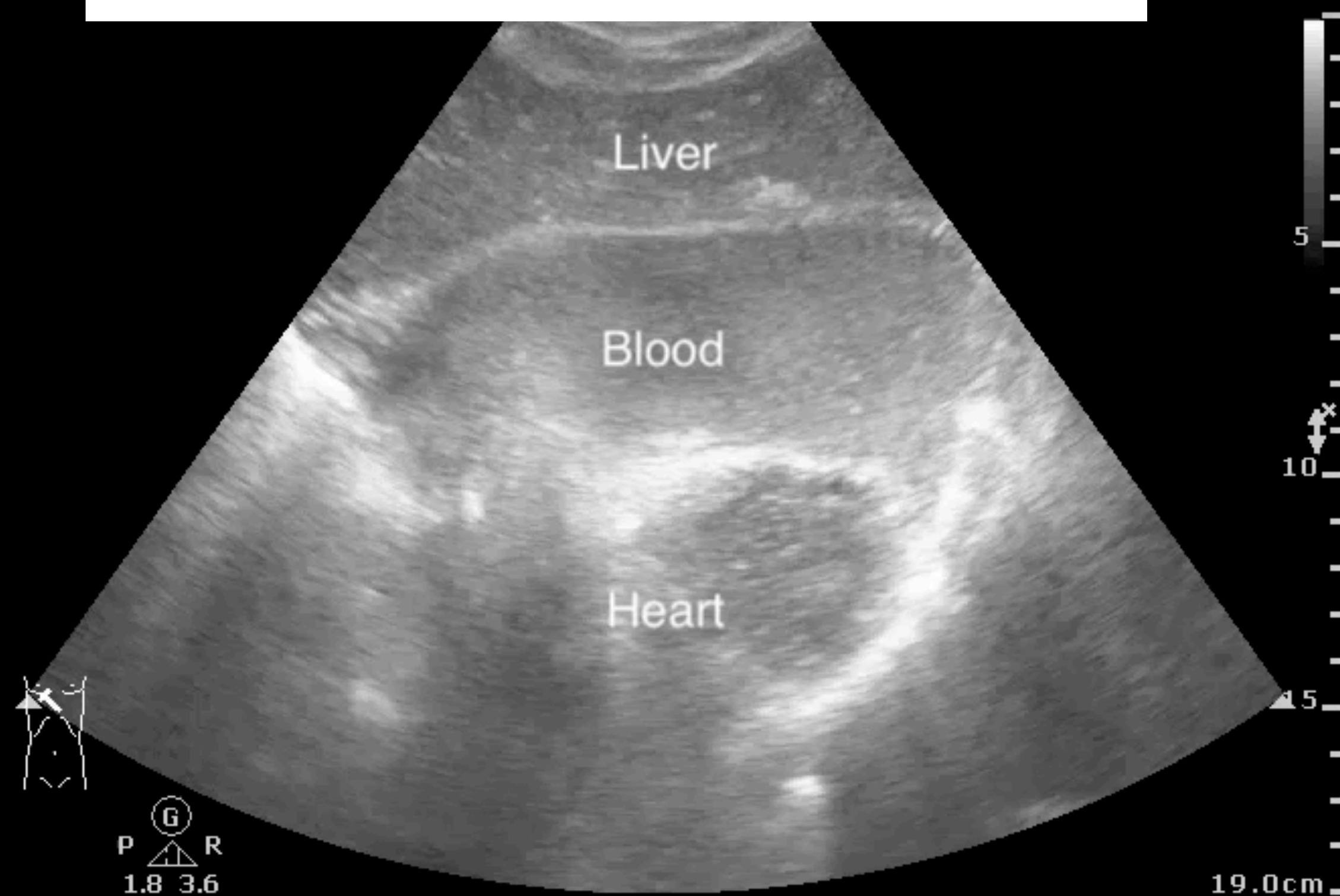


出大事了

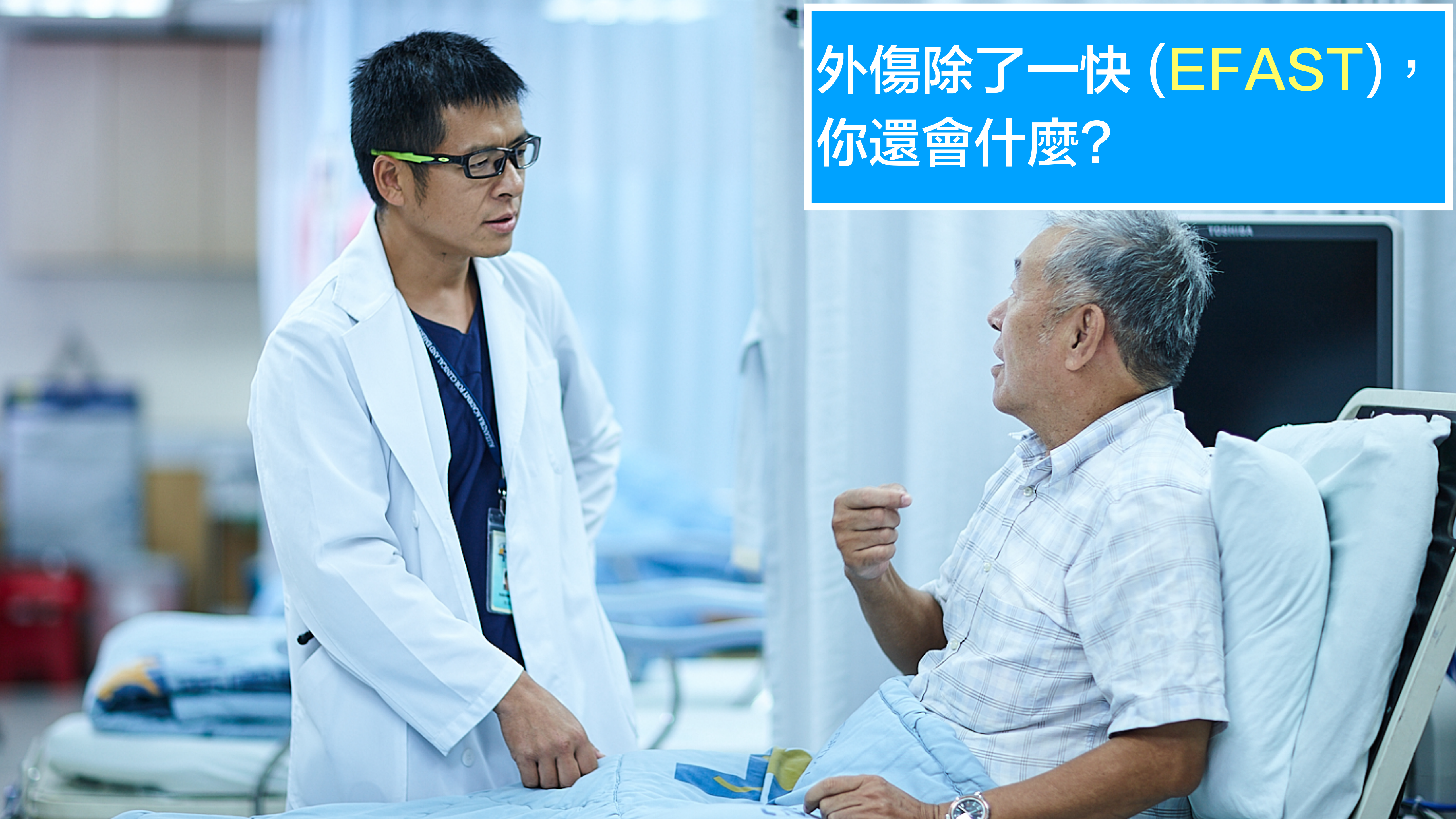PHILIPS

Abd Ger.
C5-1
29 Hz
19.0cm

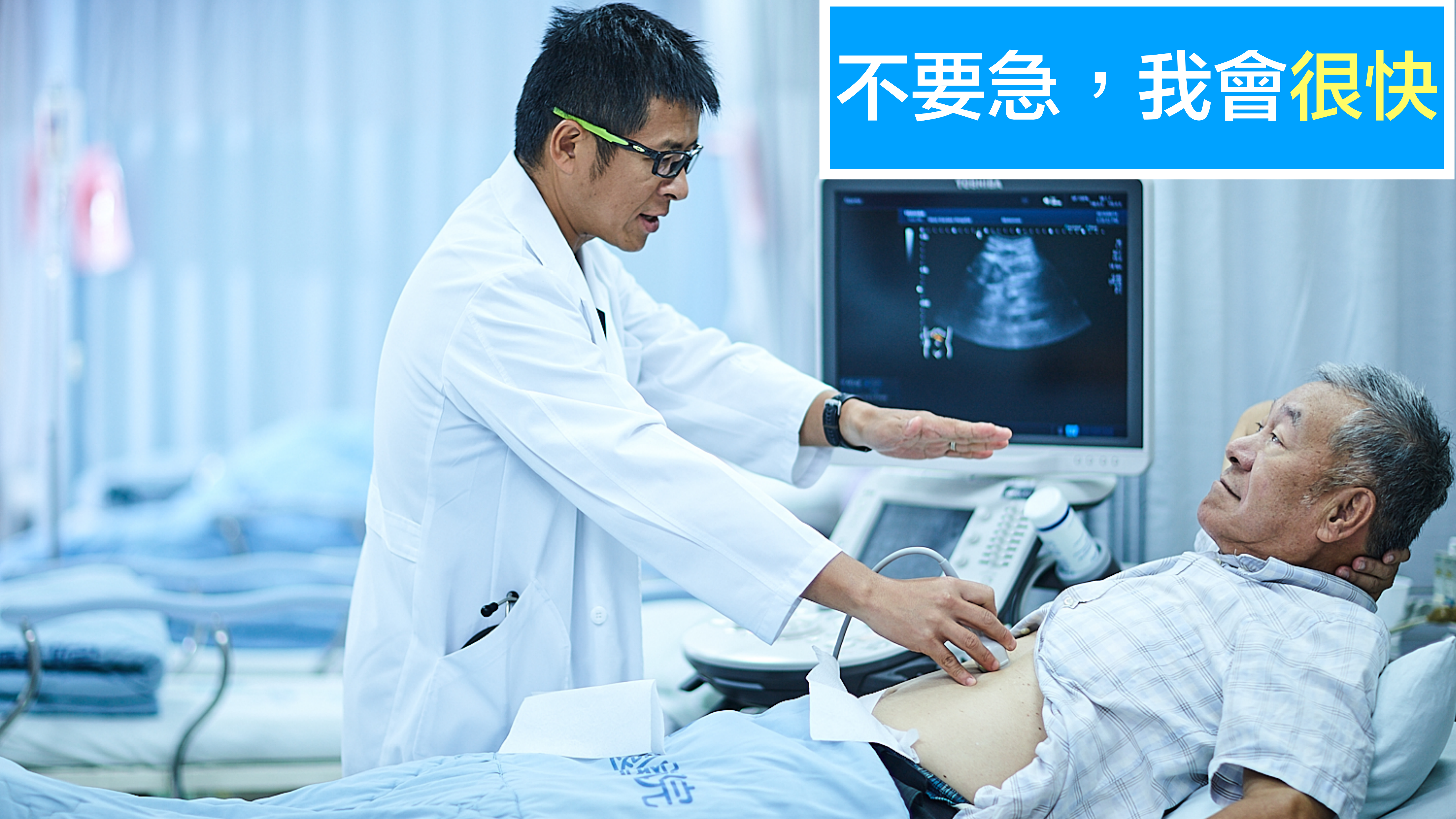2D
HGen
Gn 100
C 69
3 / 3 / 3



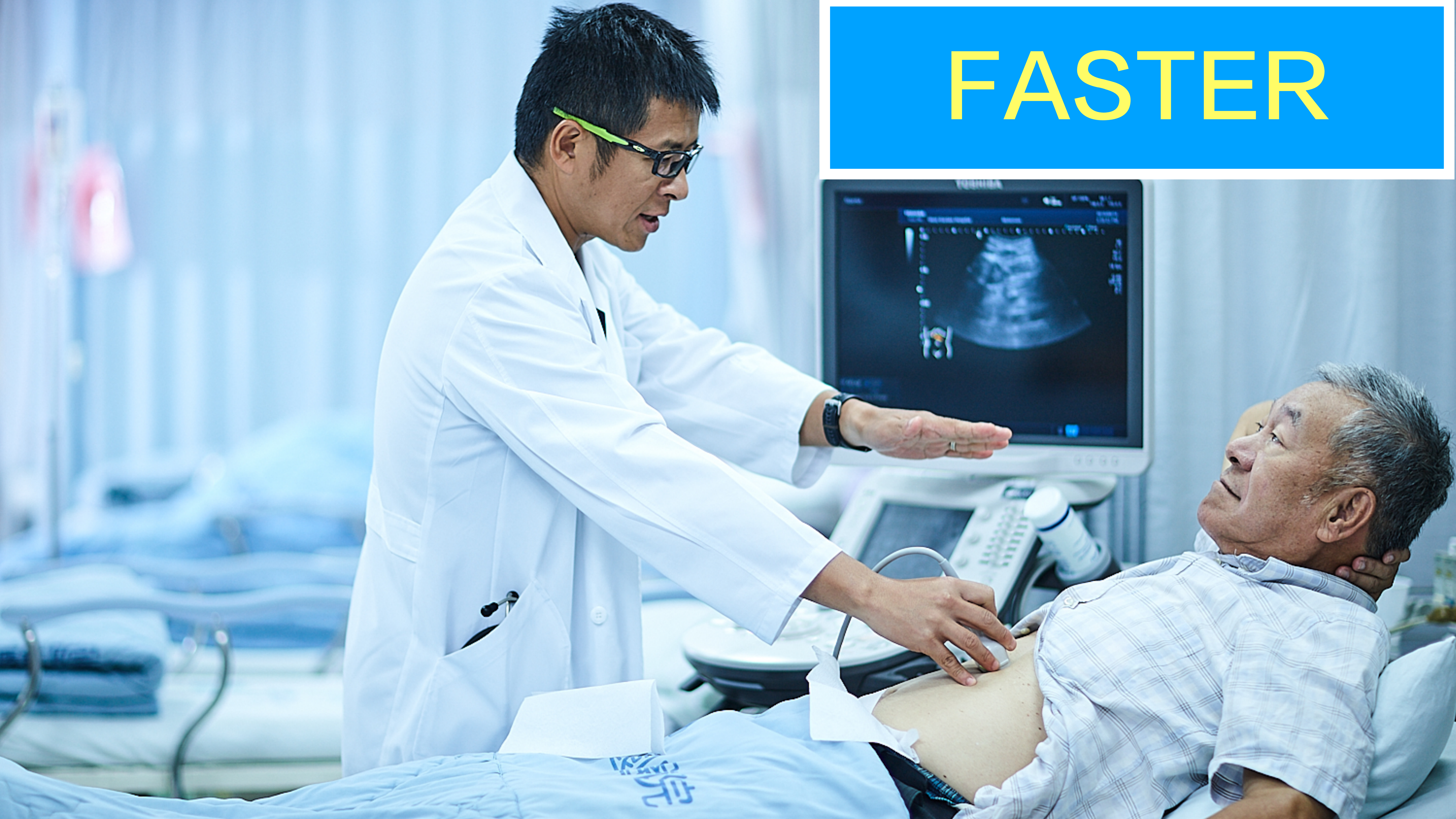外傷除了一快 (EFAST) ，
你還會什麼？



不要急，我會很快



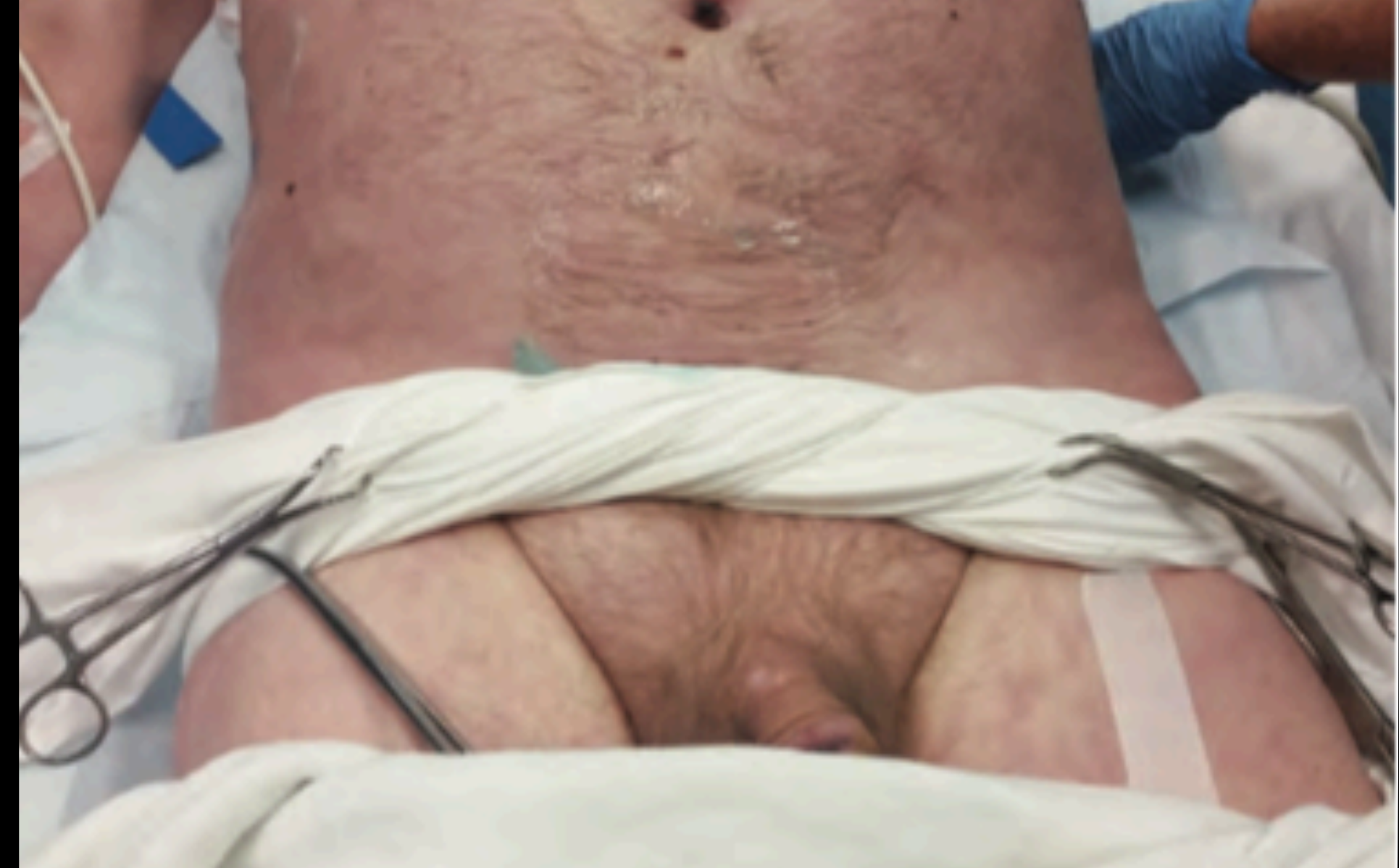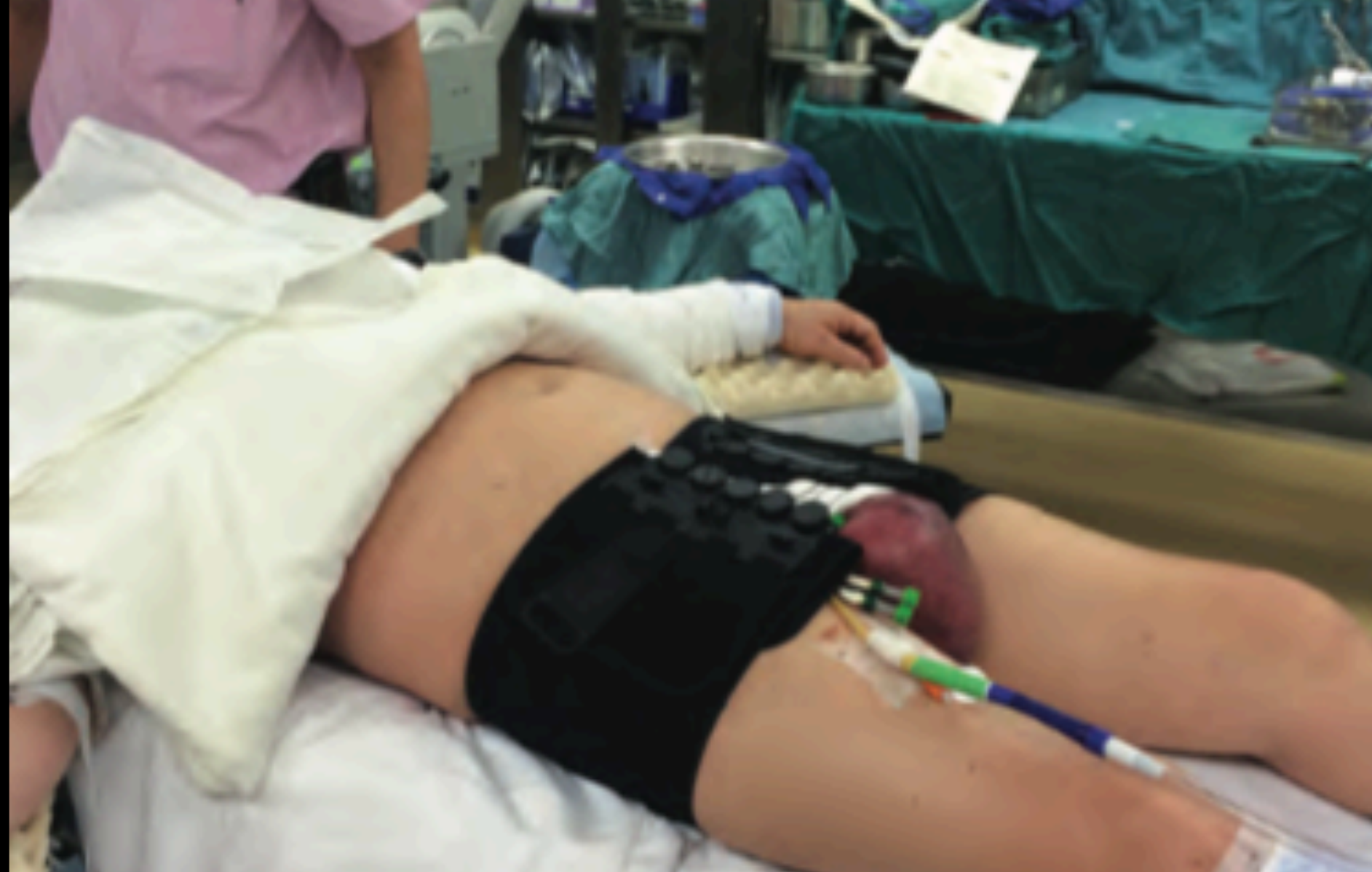FASTER



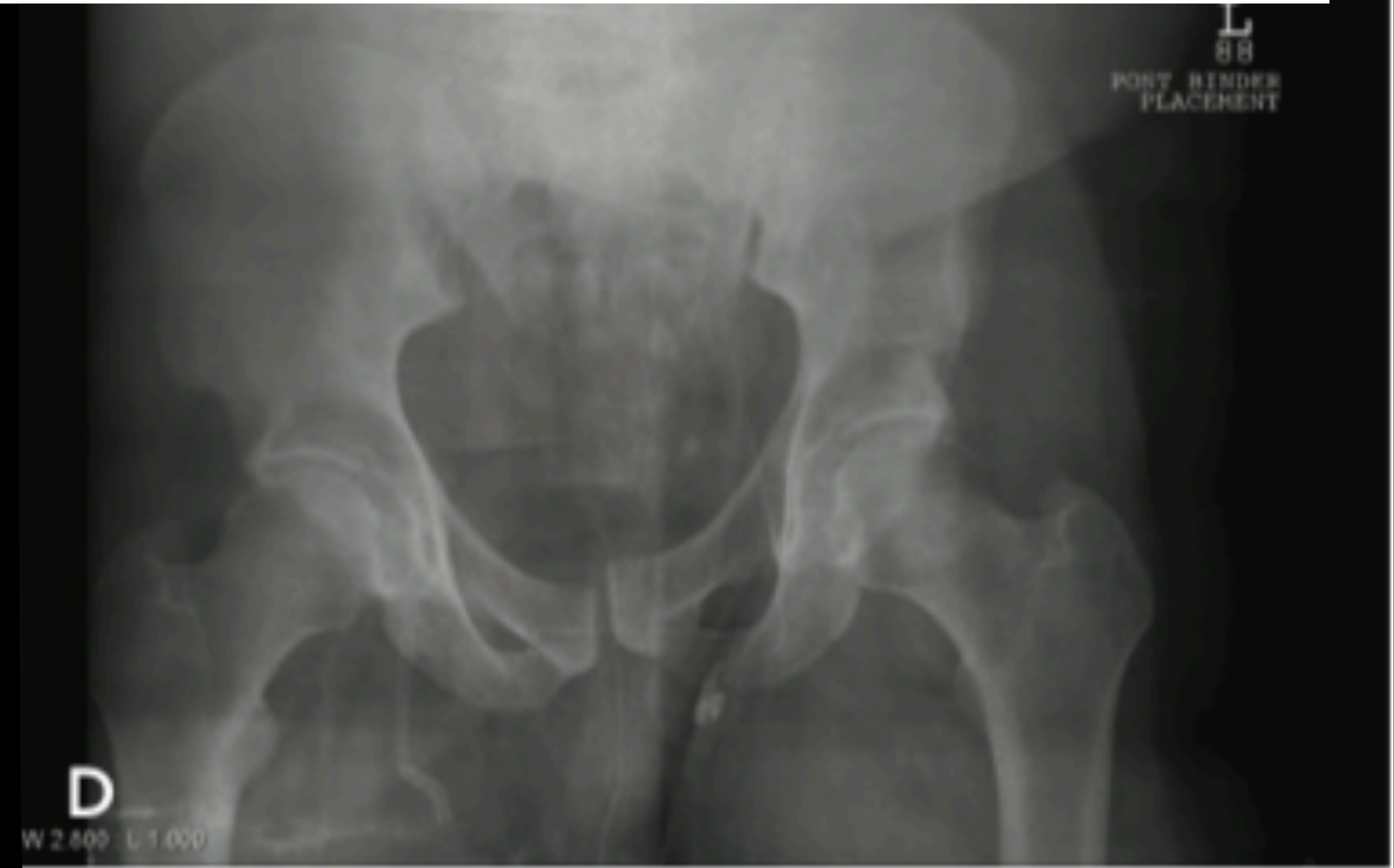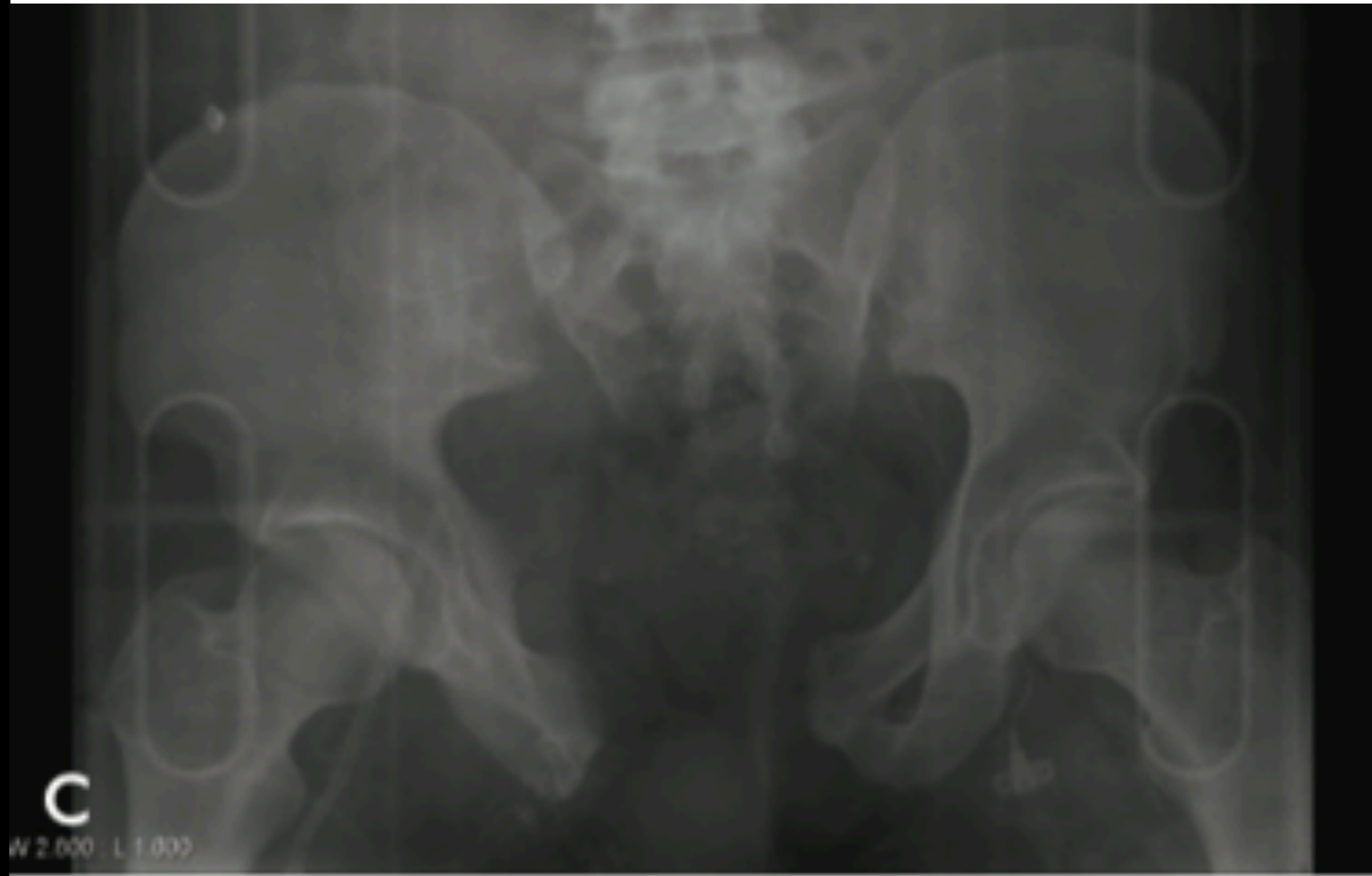FASTER

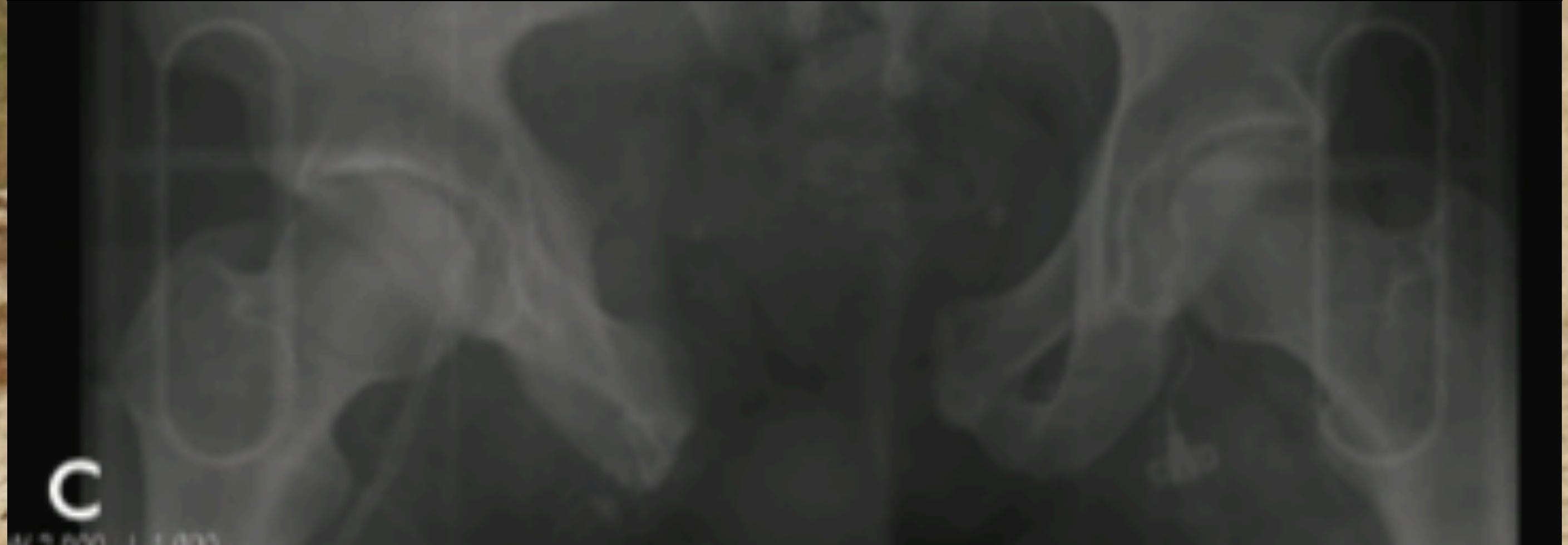
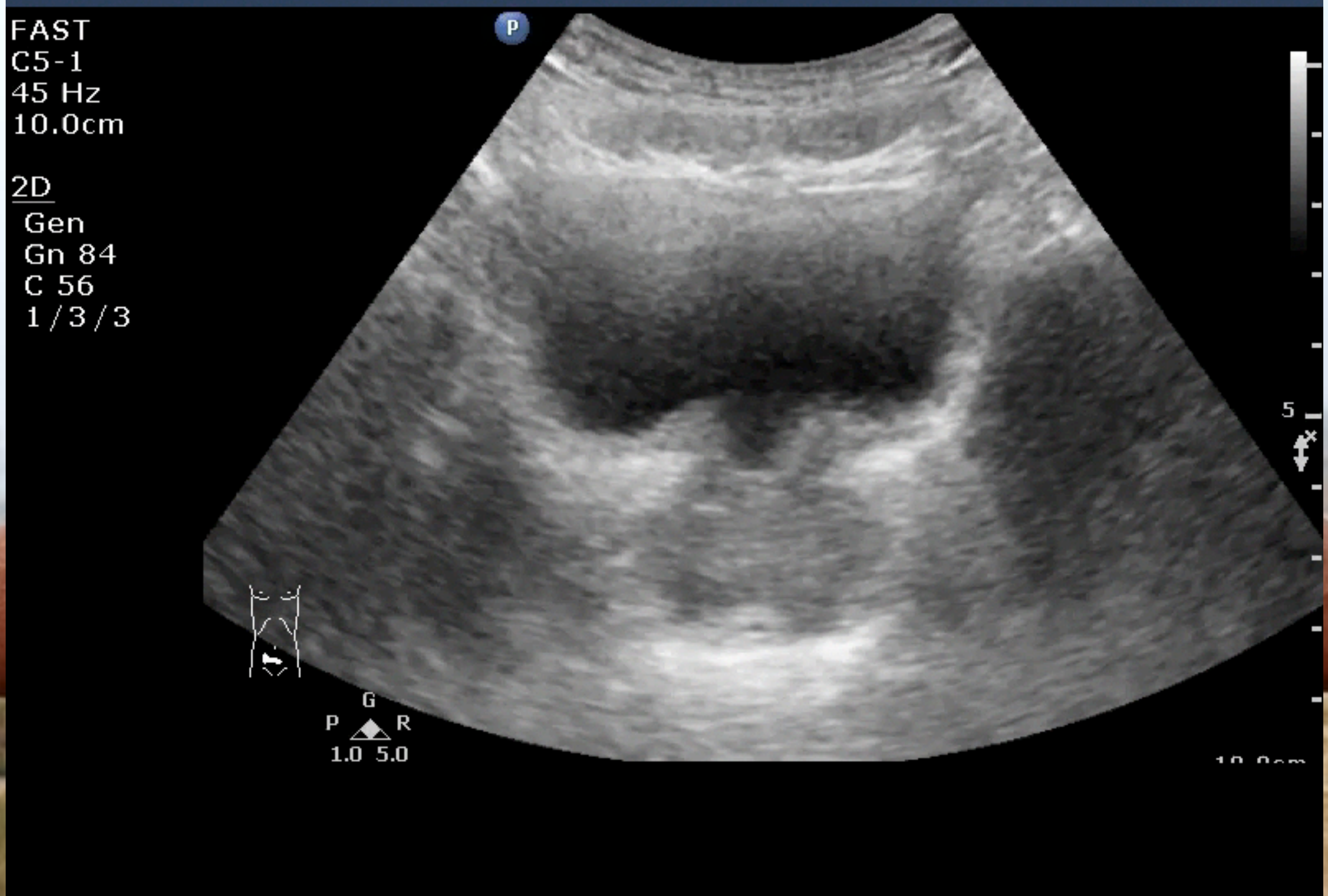


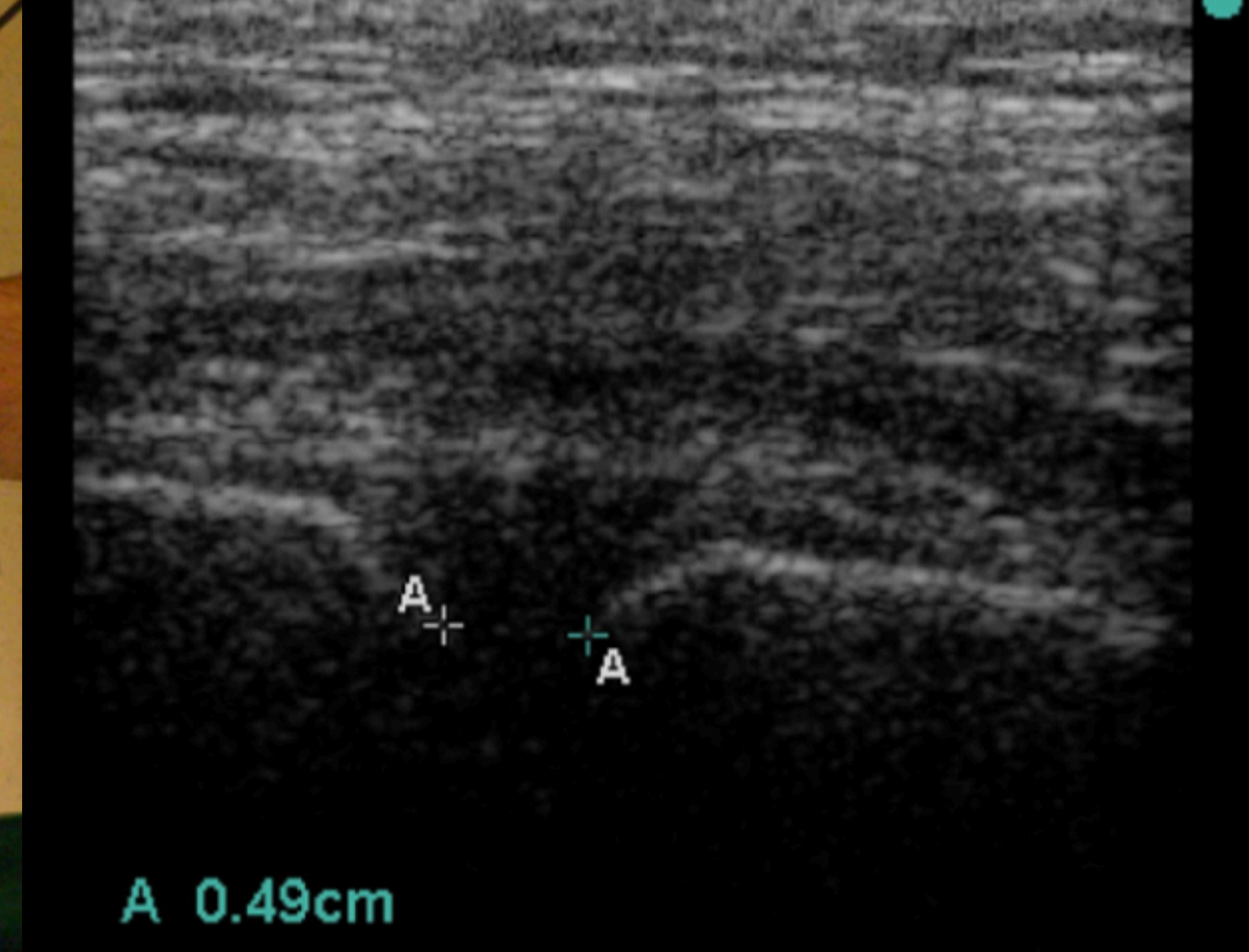
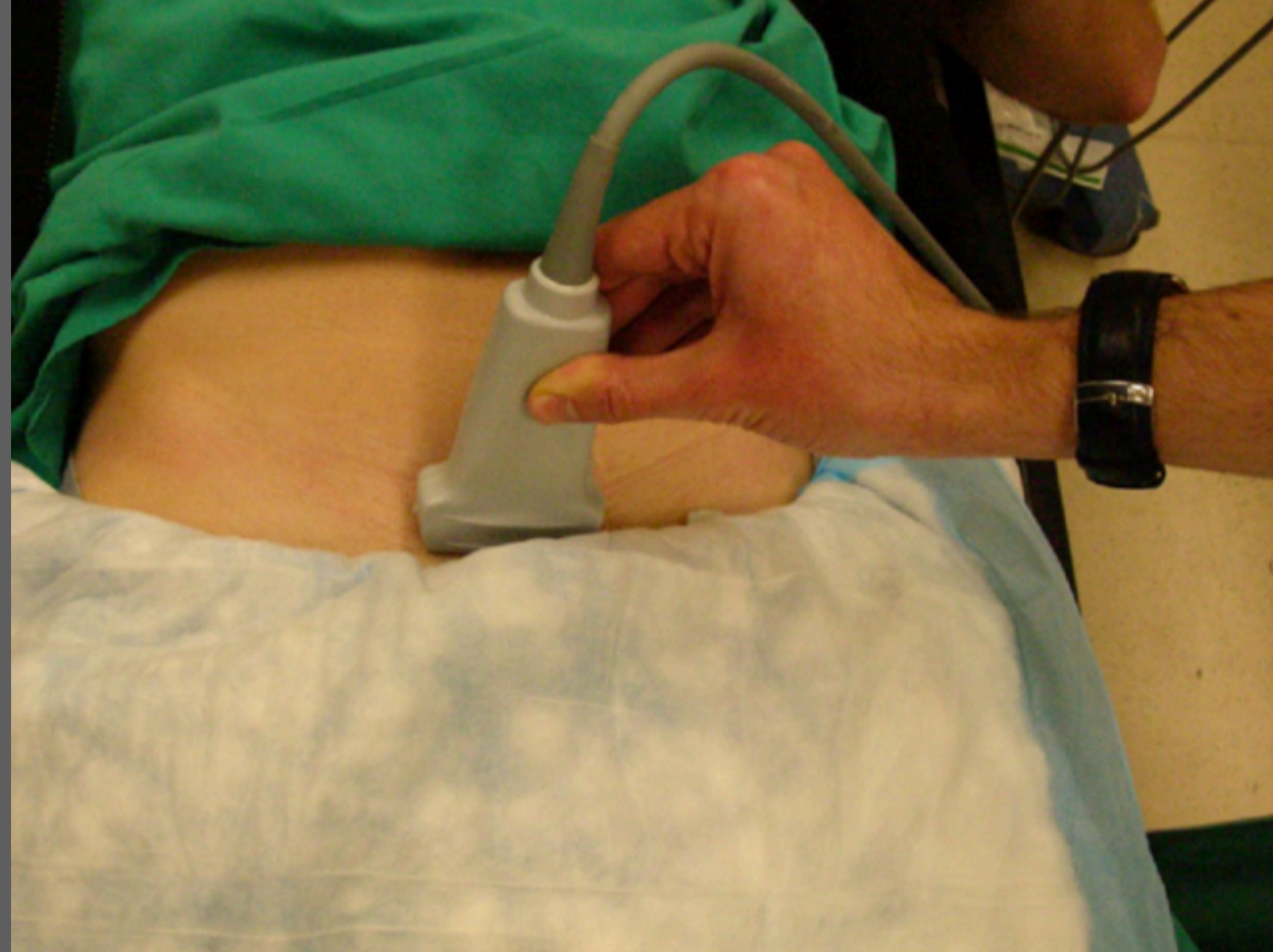一本書



Role of POCUS ?



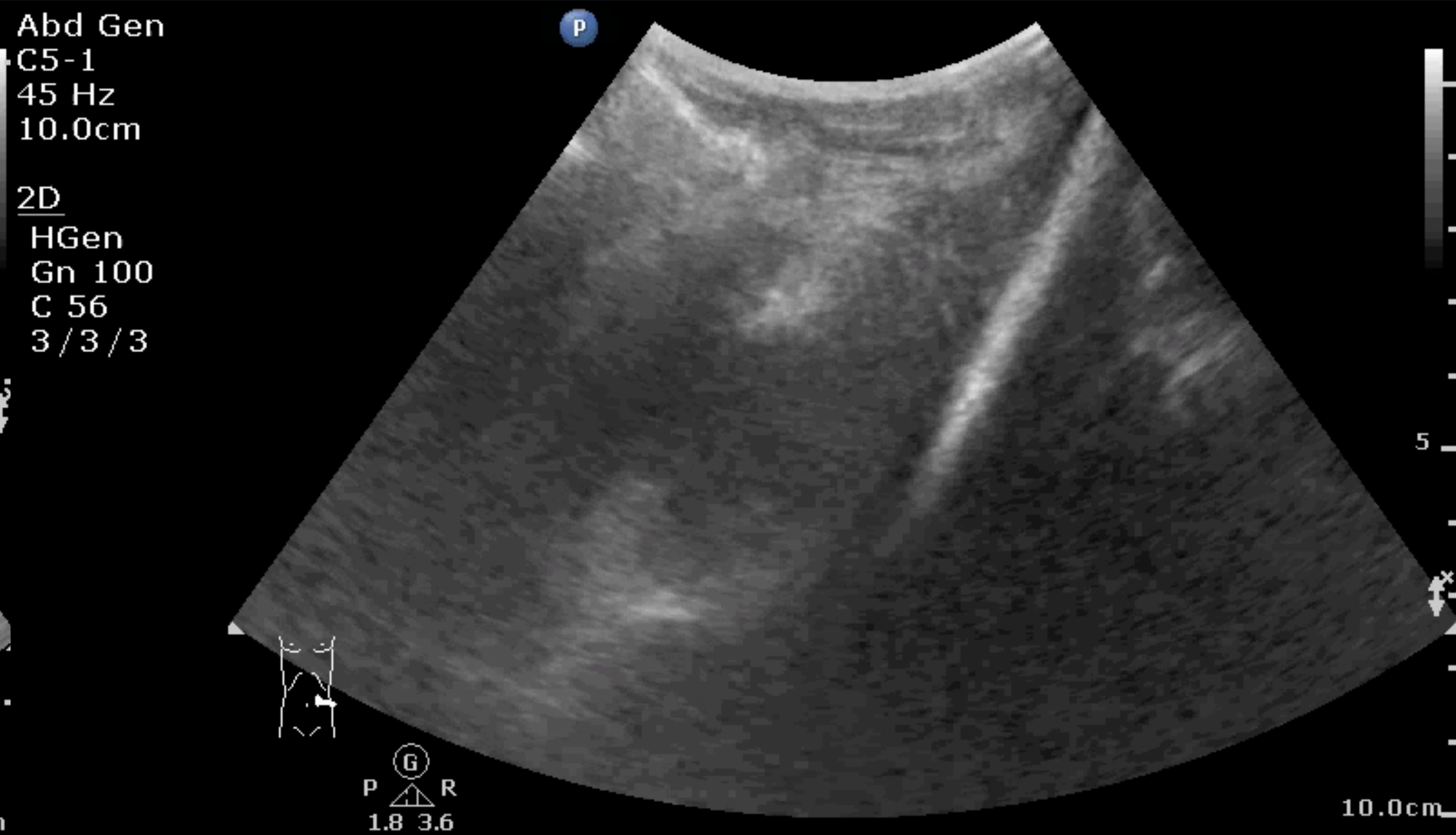
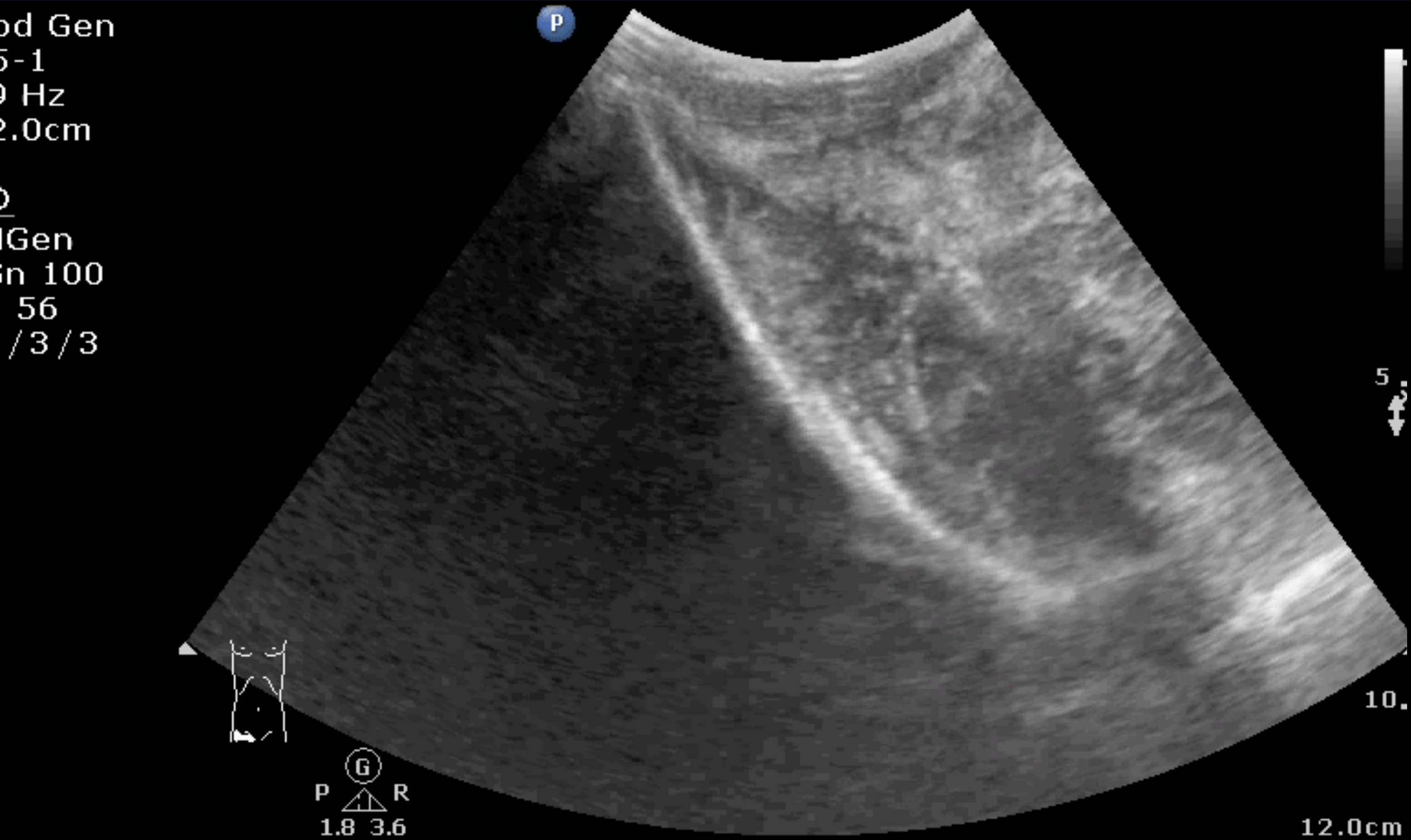
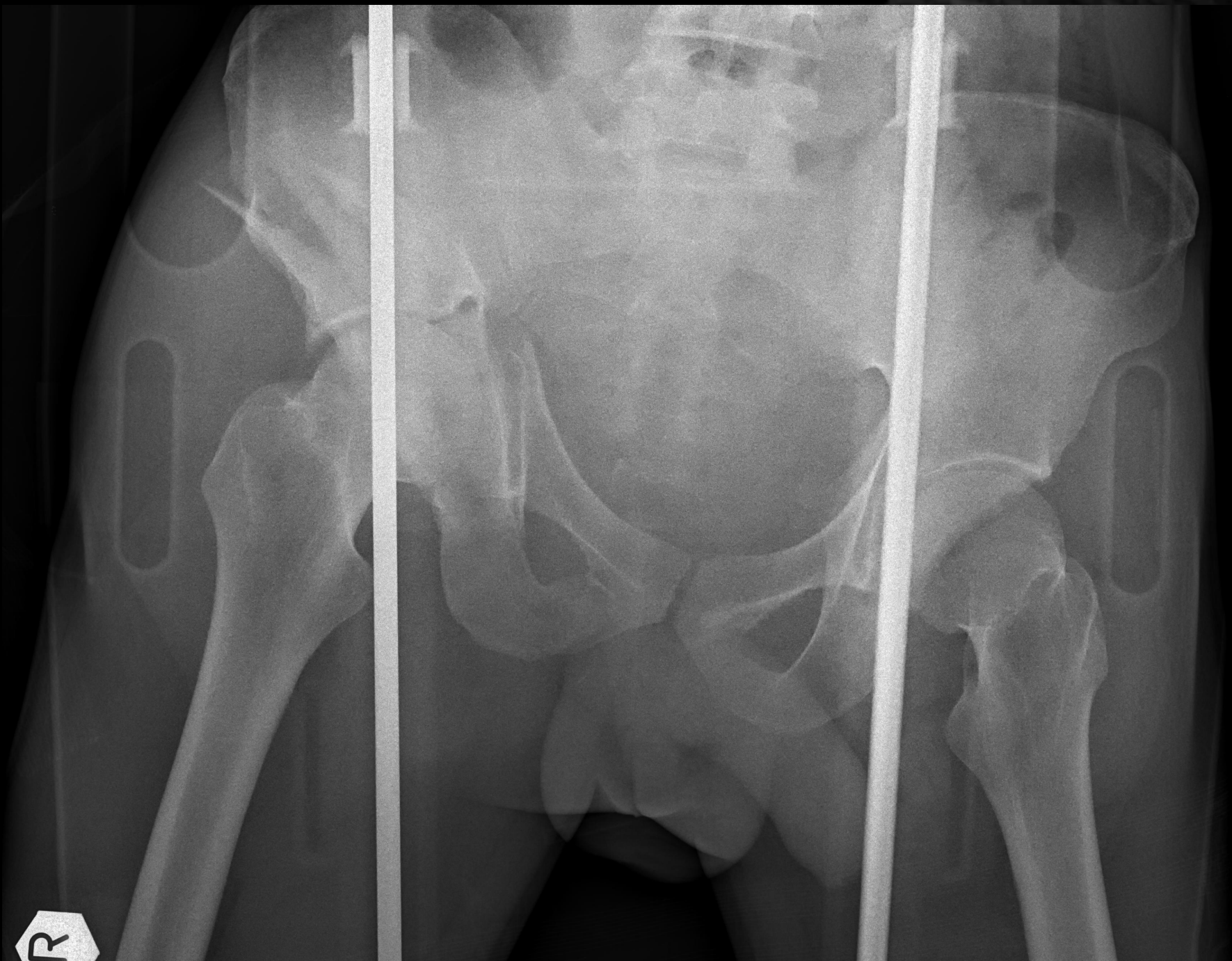
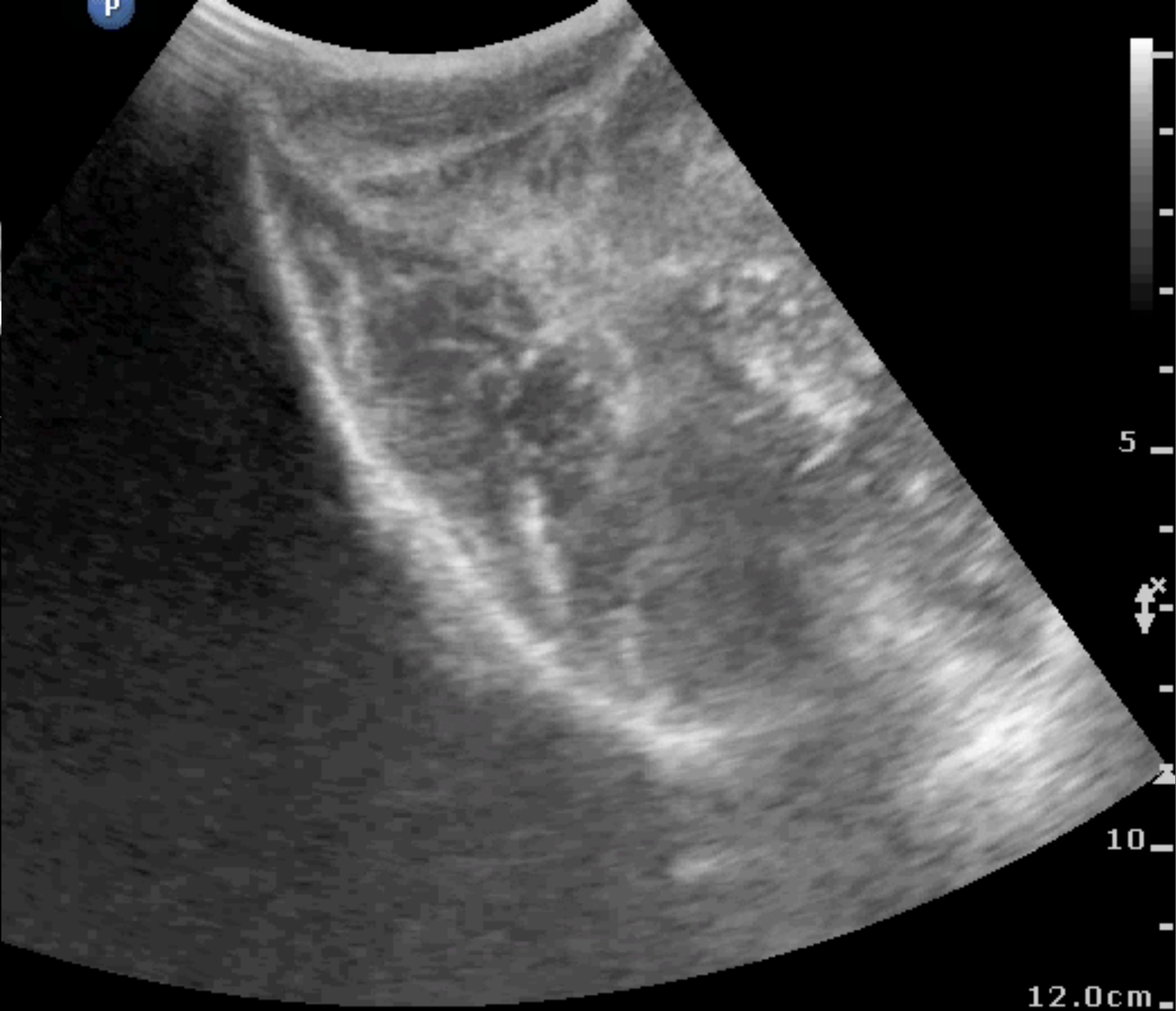
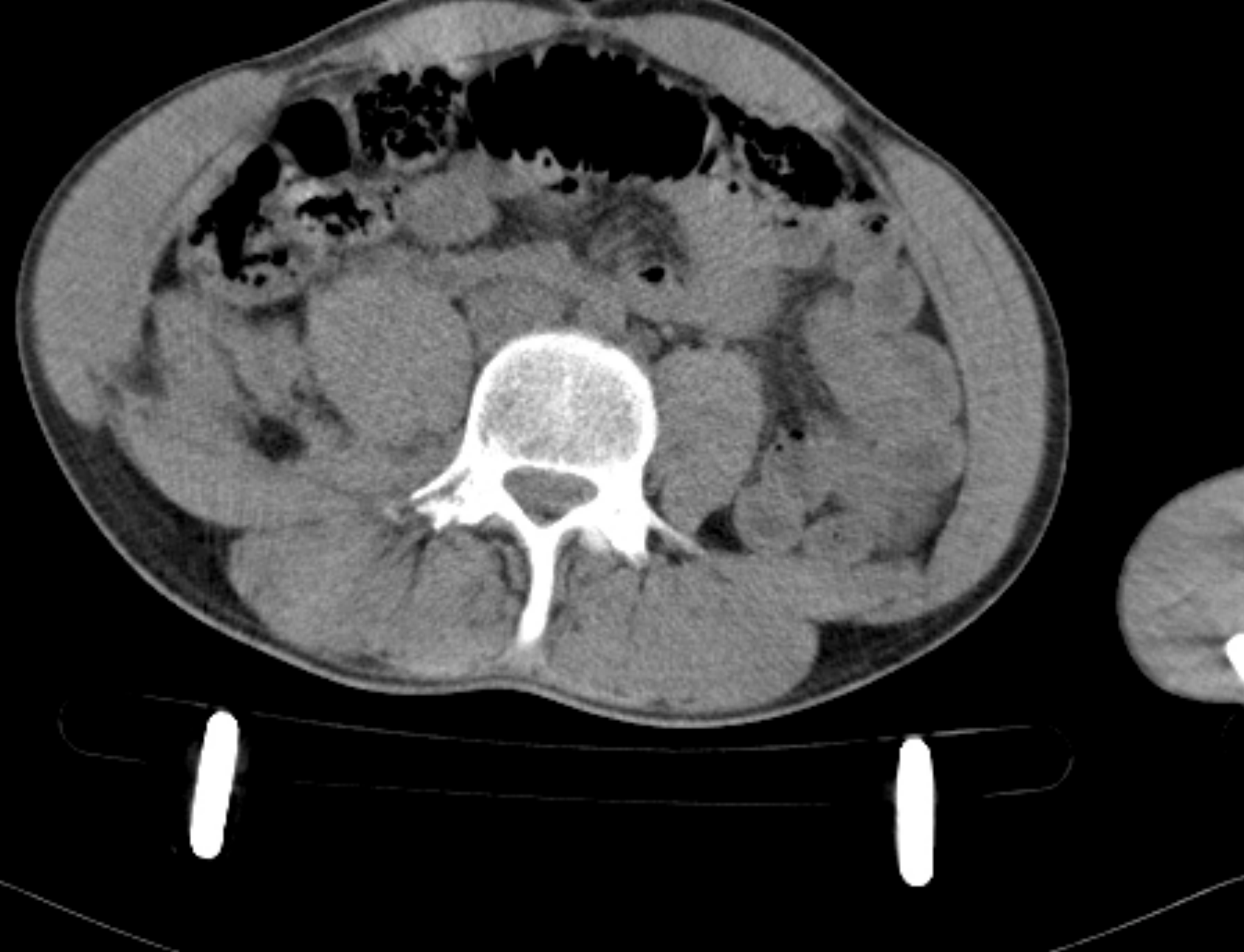


Cutoff : > 25mm

Sensitivity: 100% Specificity: 100%

RLQ & LLQ scan





FASTER



一本書

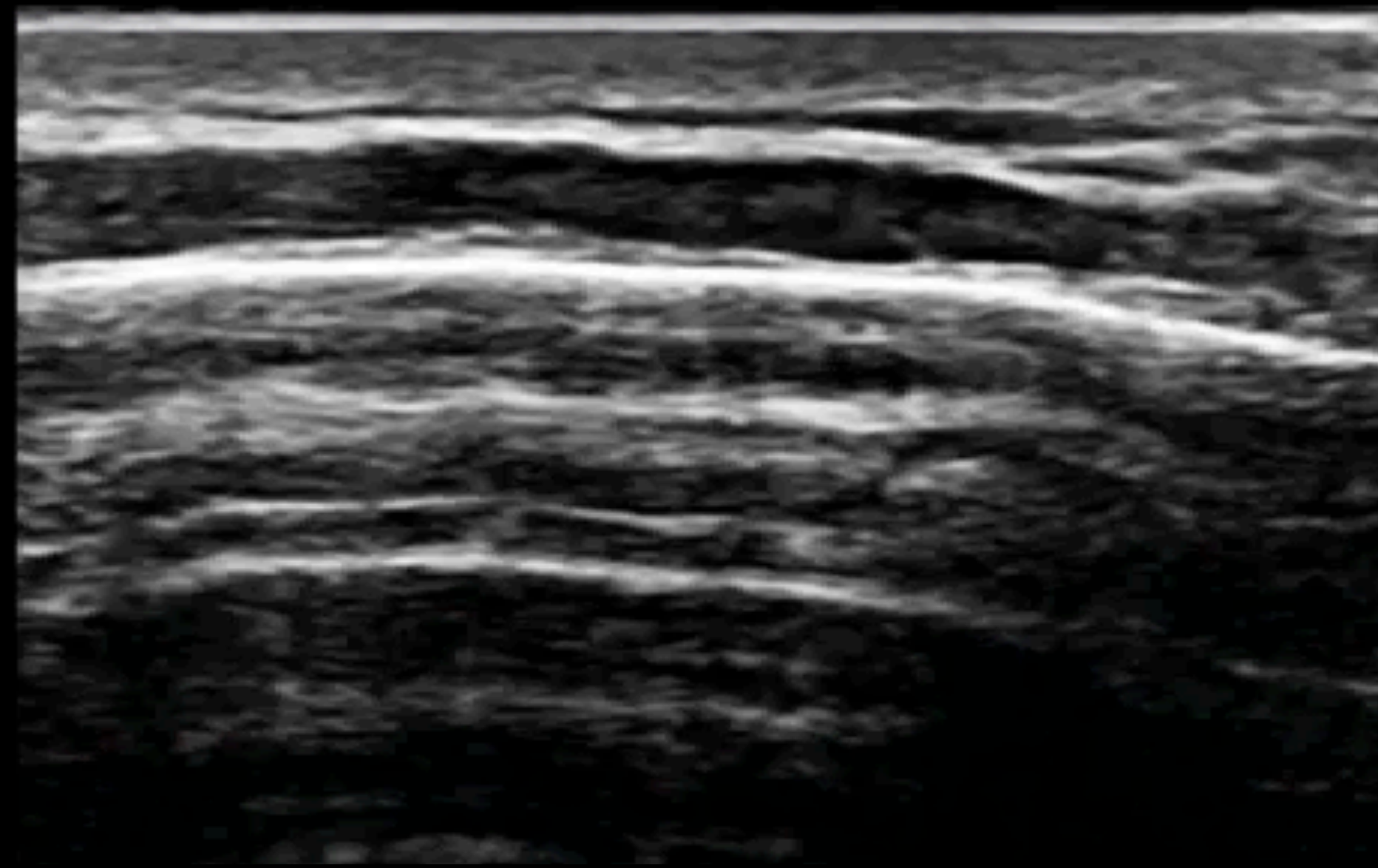


二根骨

SHIH-Linear
L12-4
27 Hz
3.5cm

2D
Gen
Gn 55
C 53
6 / 3 / 3

p

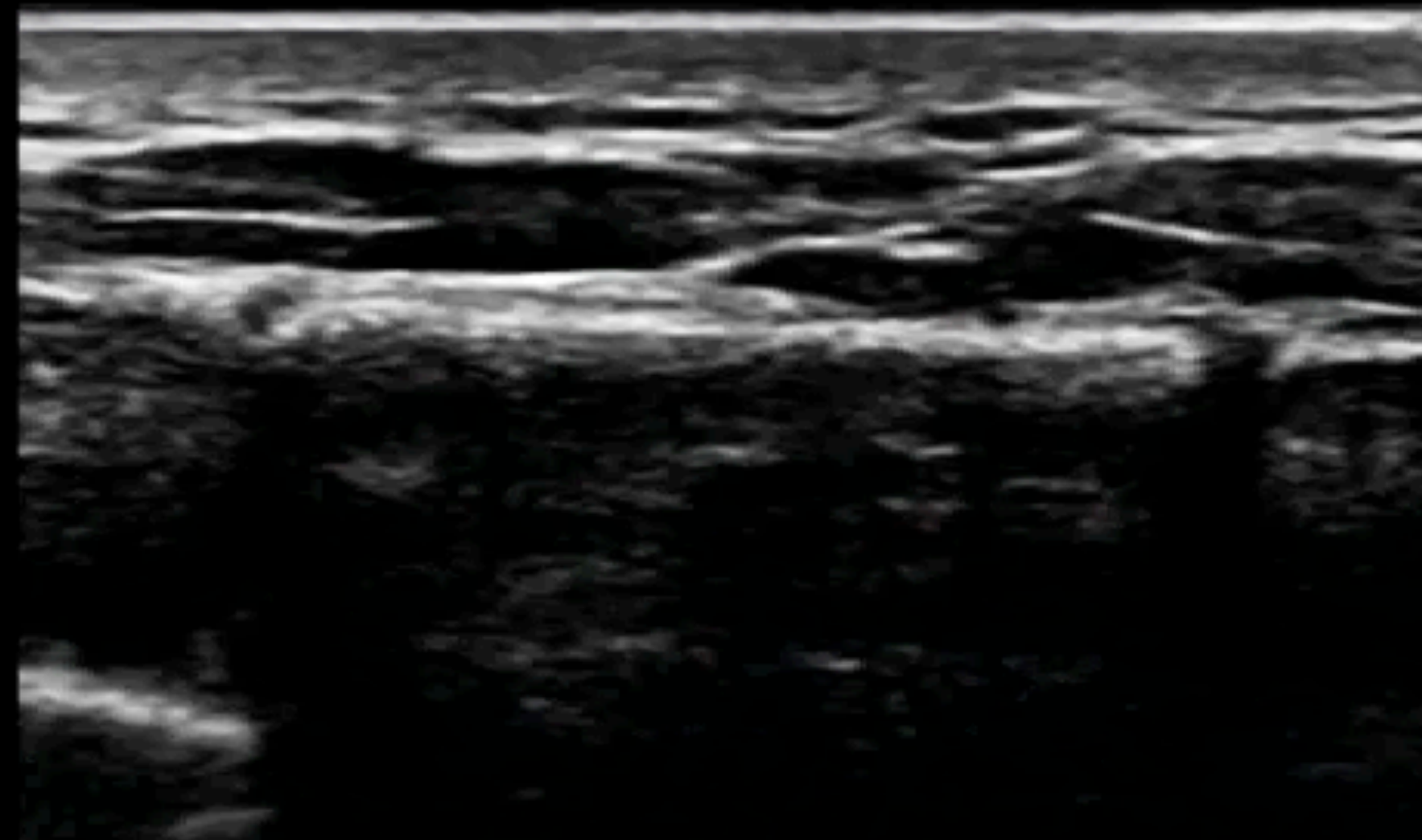


Smooth & hyperechoic cortical surface

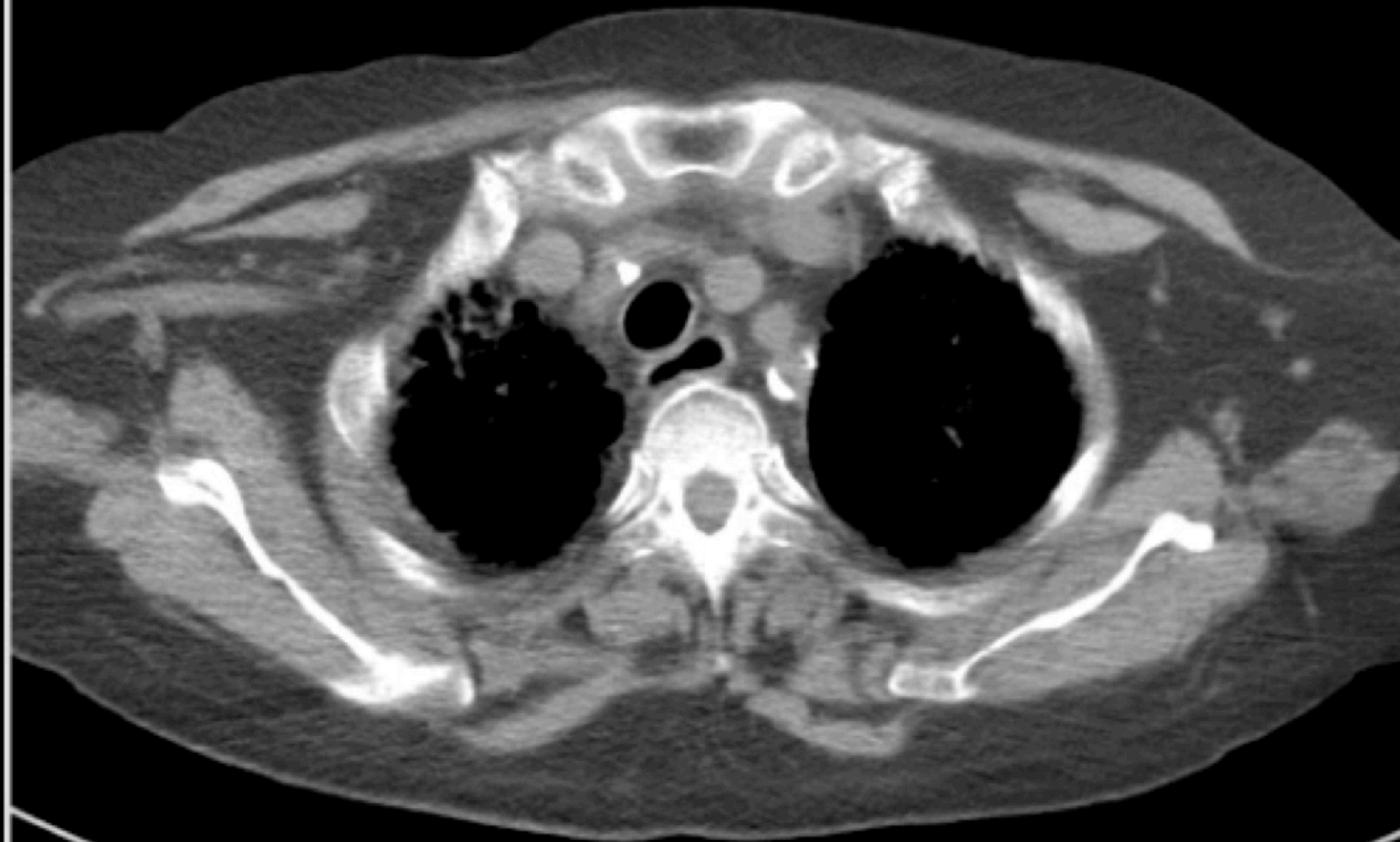SHIH-Linear
L12-4
27 Hz
3.5cm

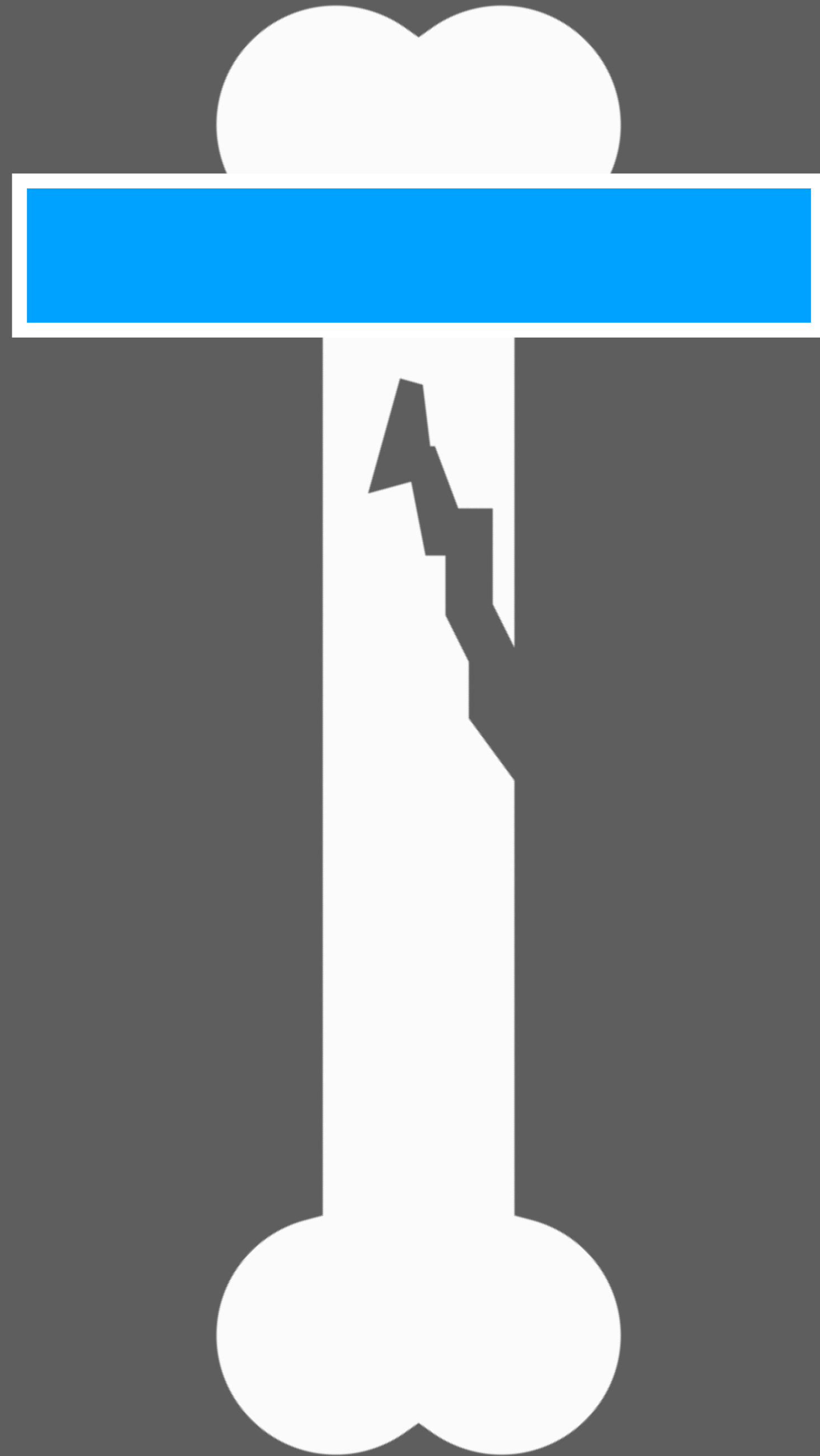
2D
Gen
Gn 55
C 53
6 / 3 / 3

p



你看到胸骨骨折了嗎？











G
P
3.0

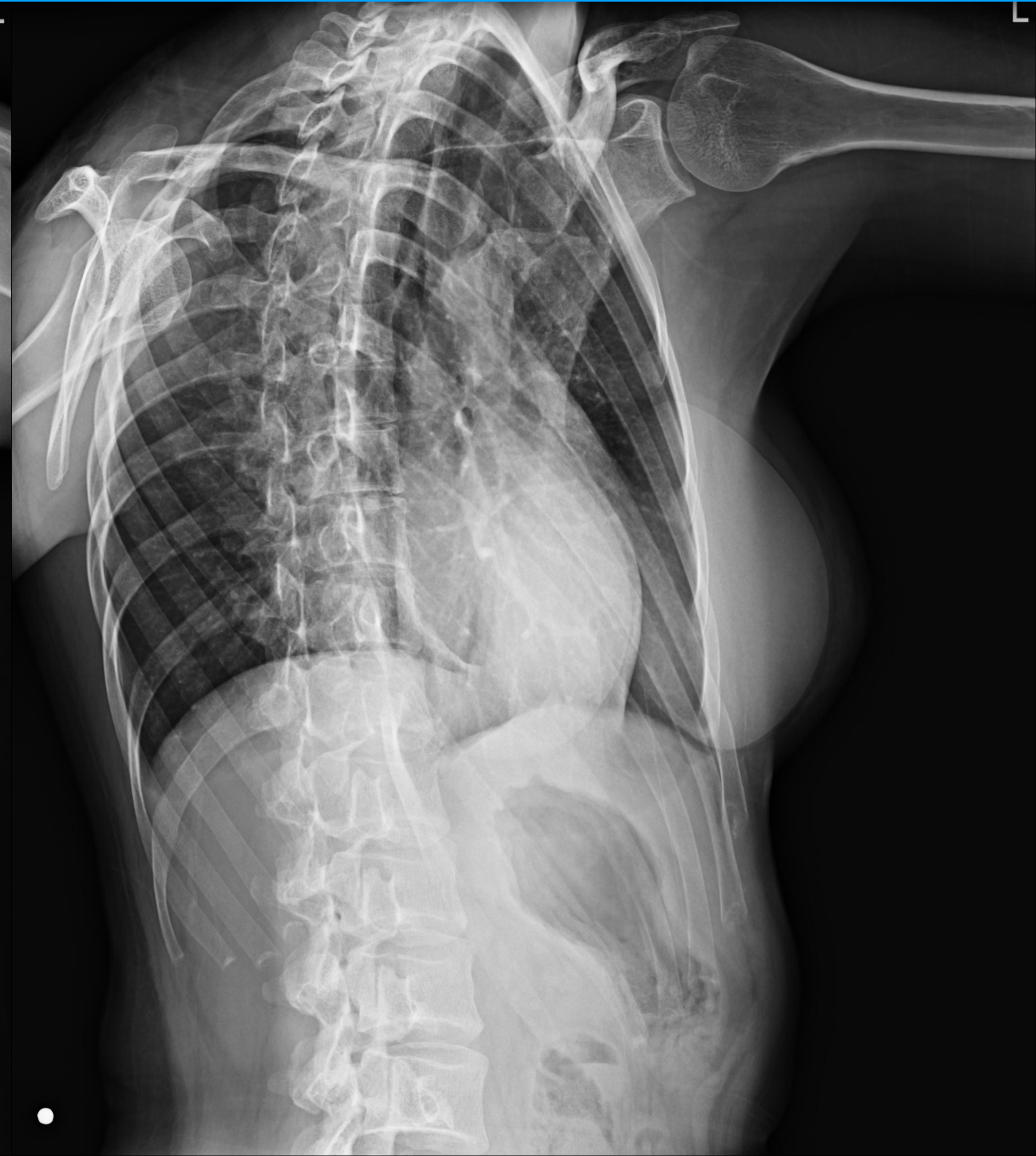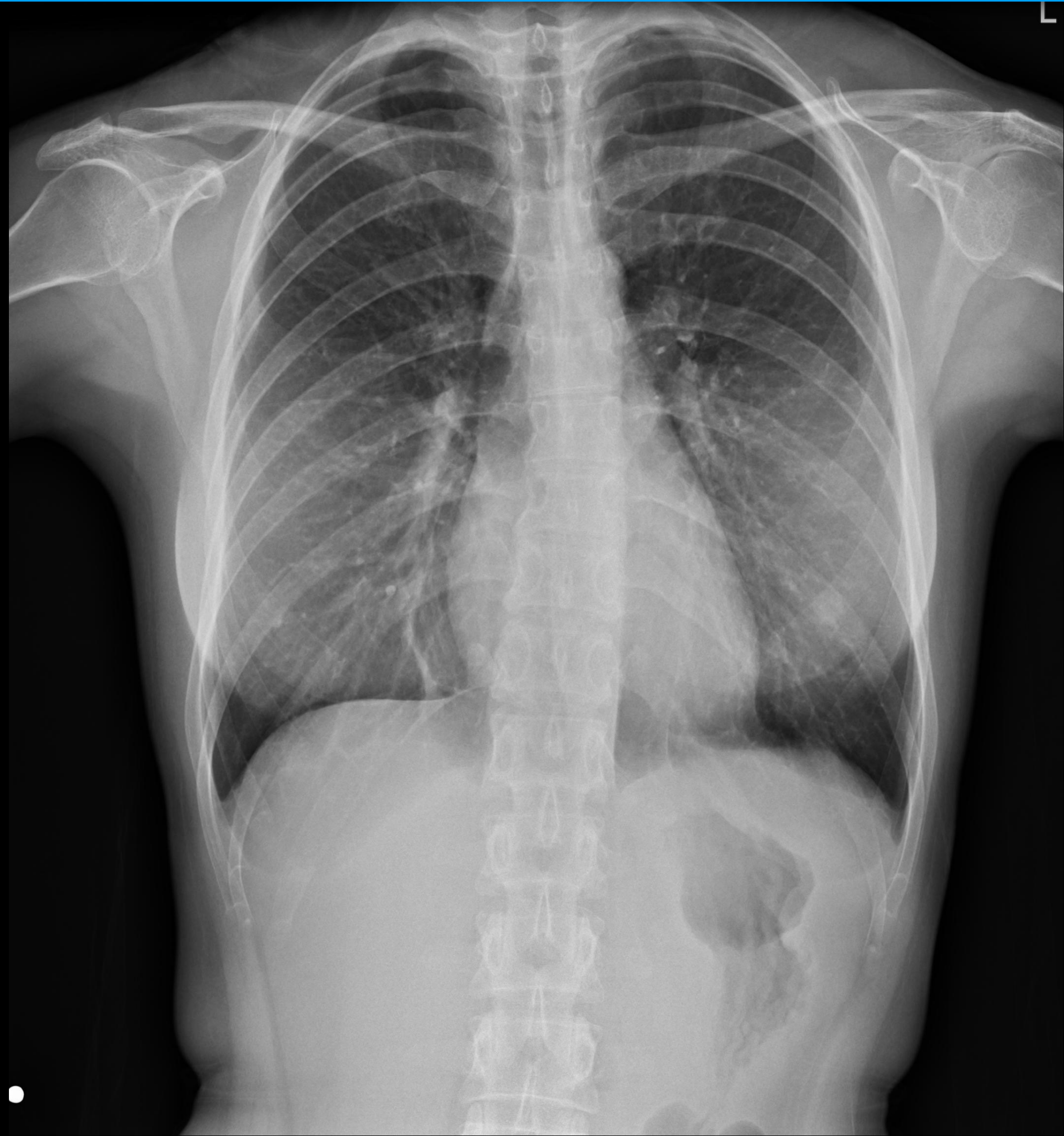
胸骨斷了

3.5cm

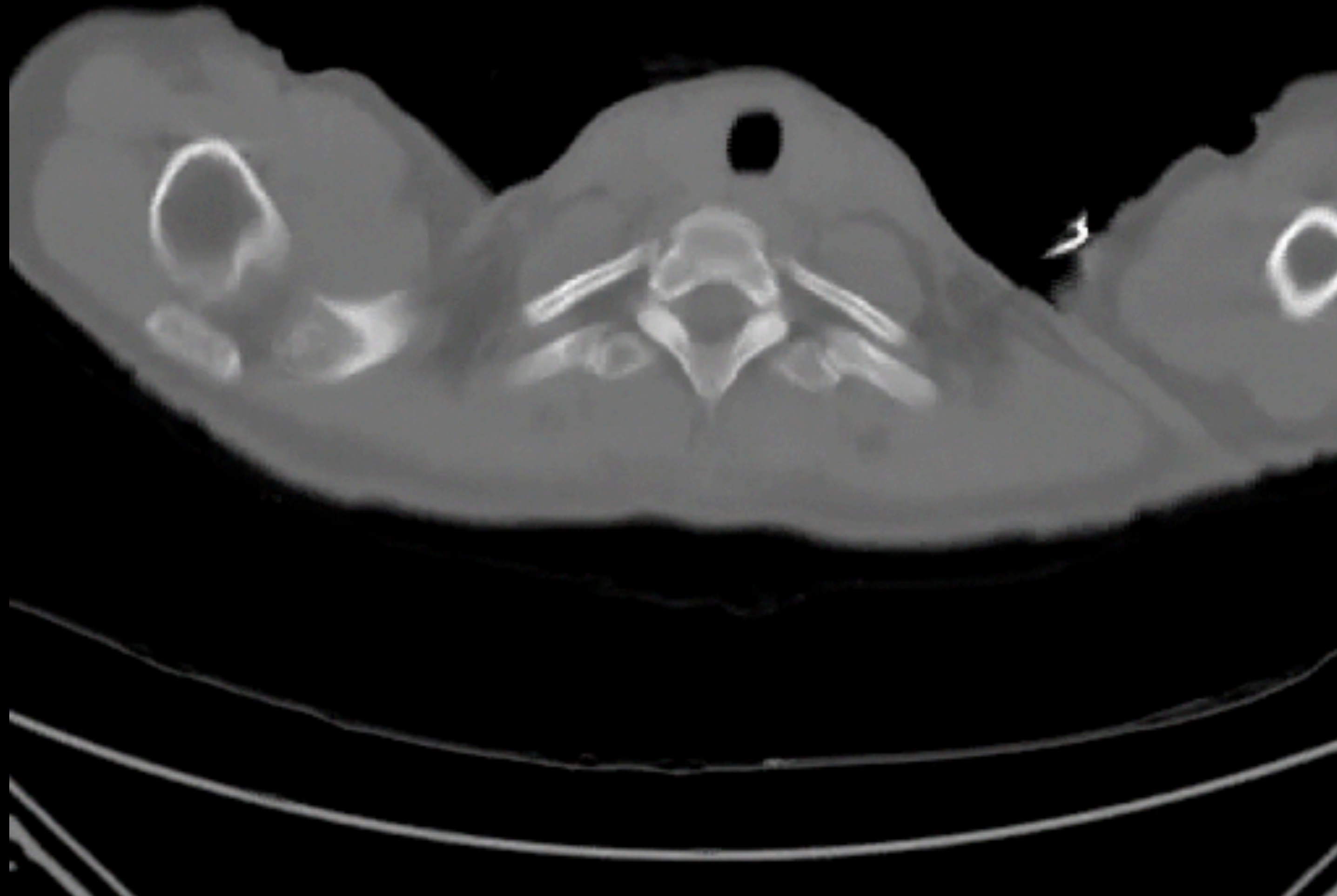
Spin: -90
Tilt: 0



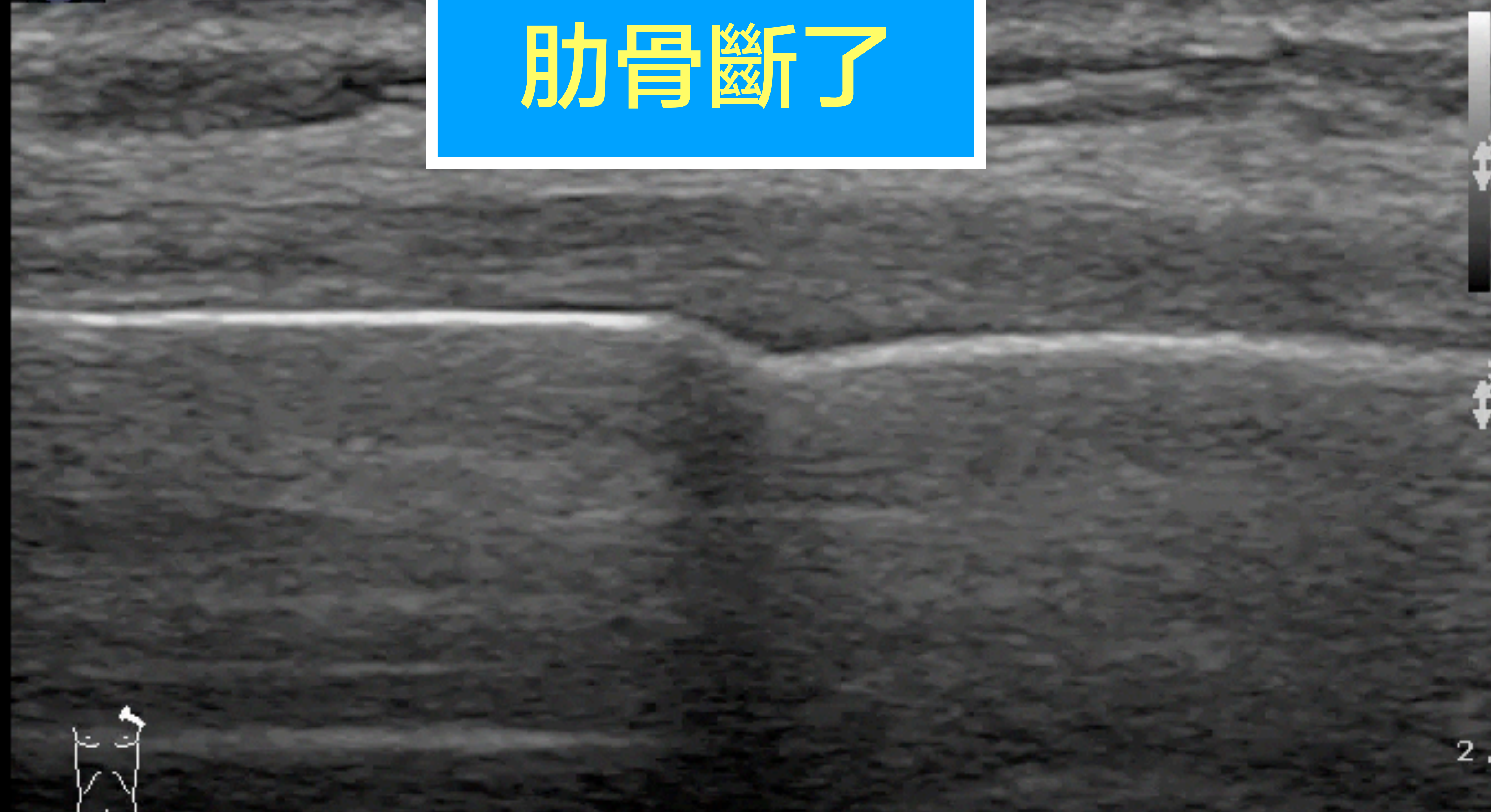
34F, motorcycle accident left chest pain

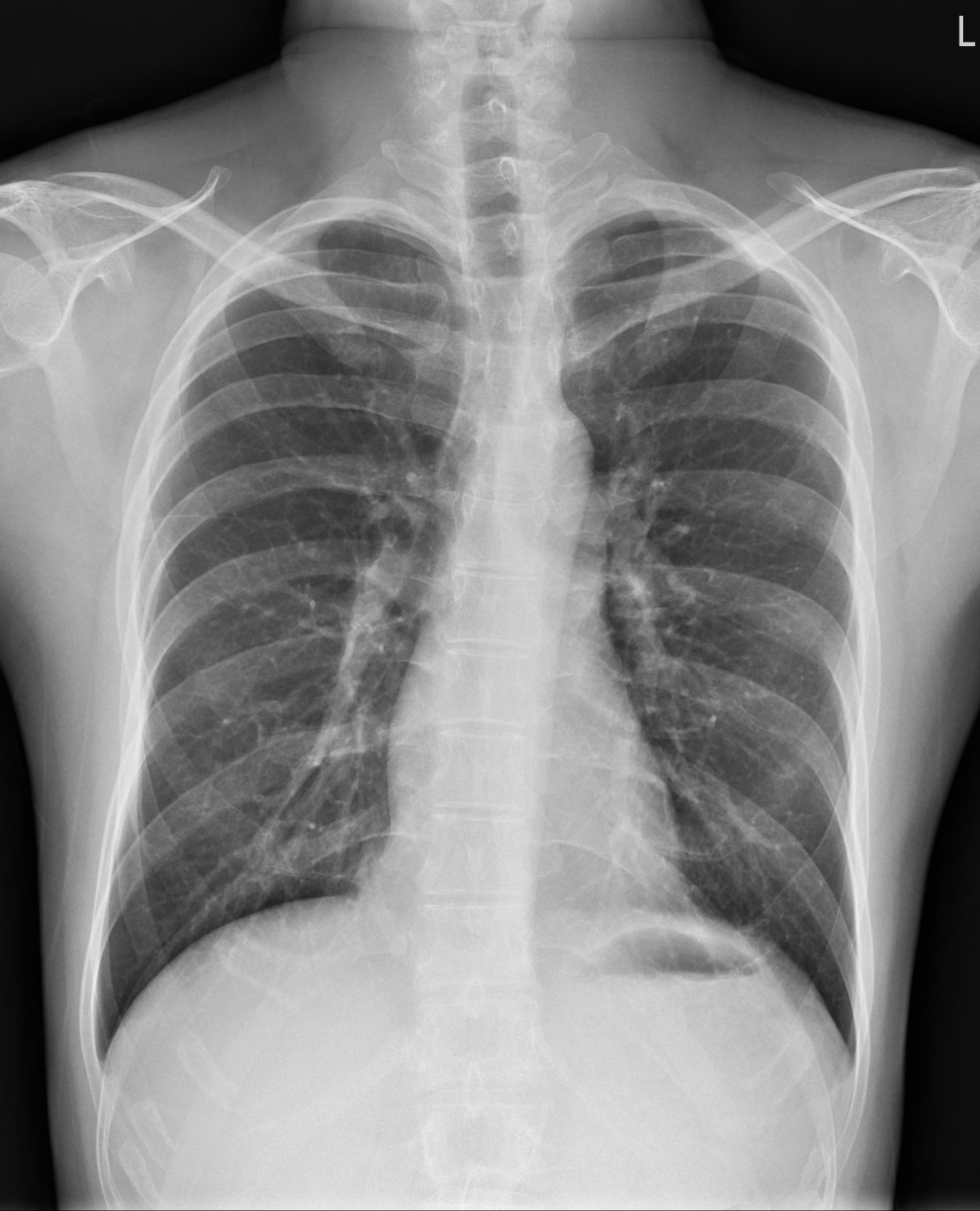

34F, motorcycle accident
left chest pain



肋骨斷了



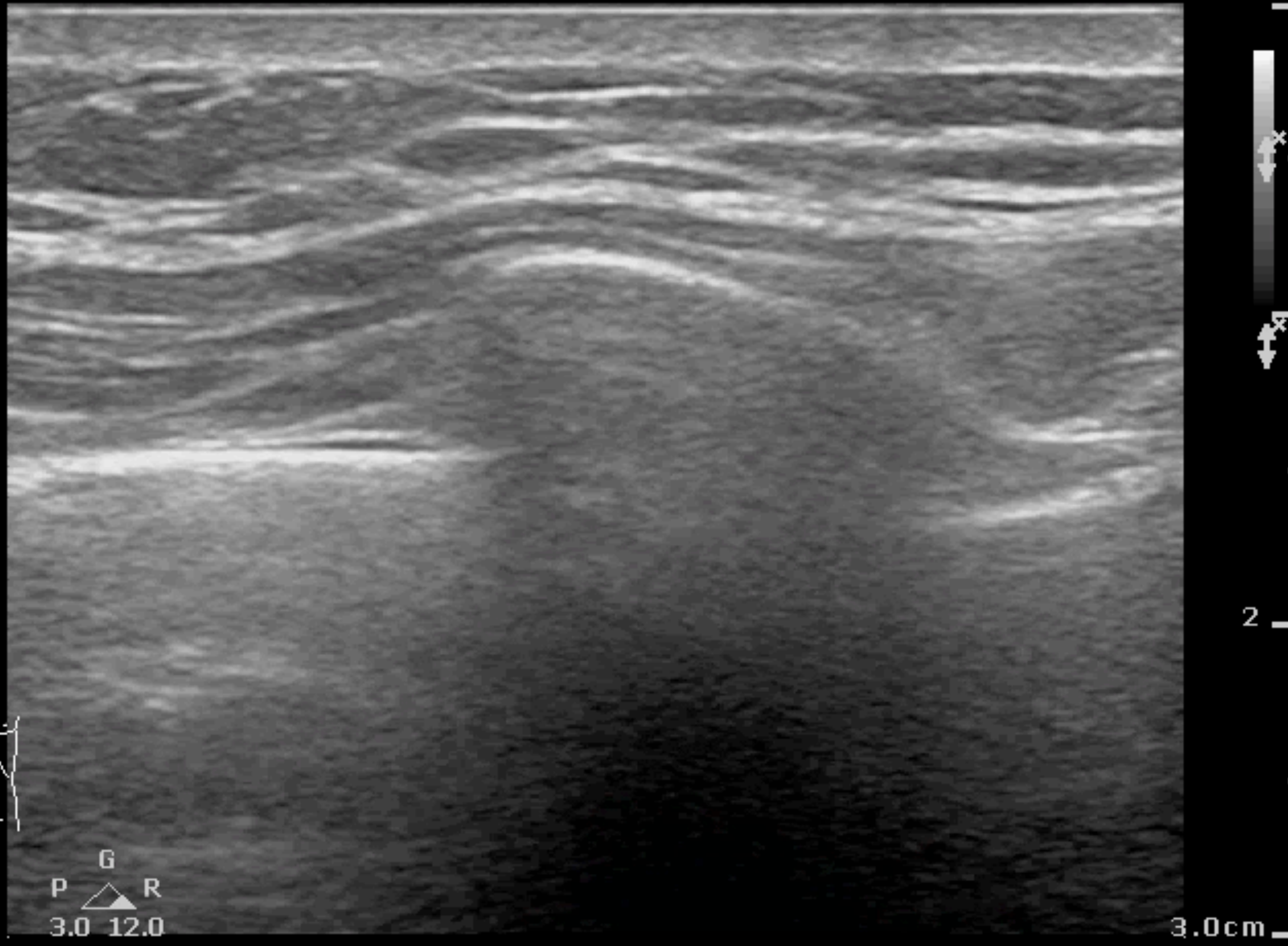


L Superficial
L12-3
46 Hz
3.0cm

2D
Res
Gn 96
C 56
3/2/1

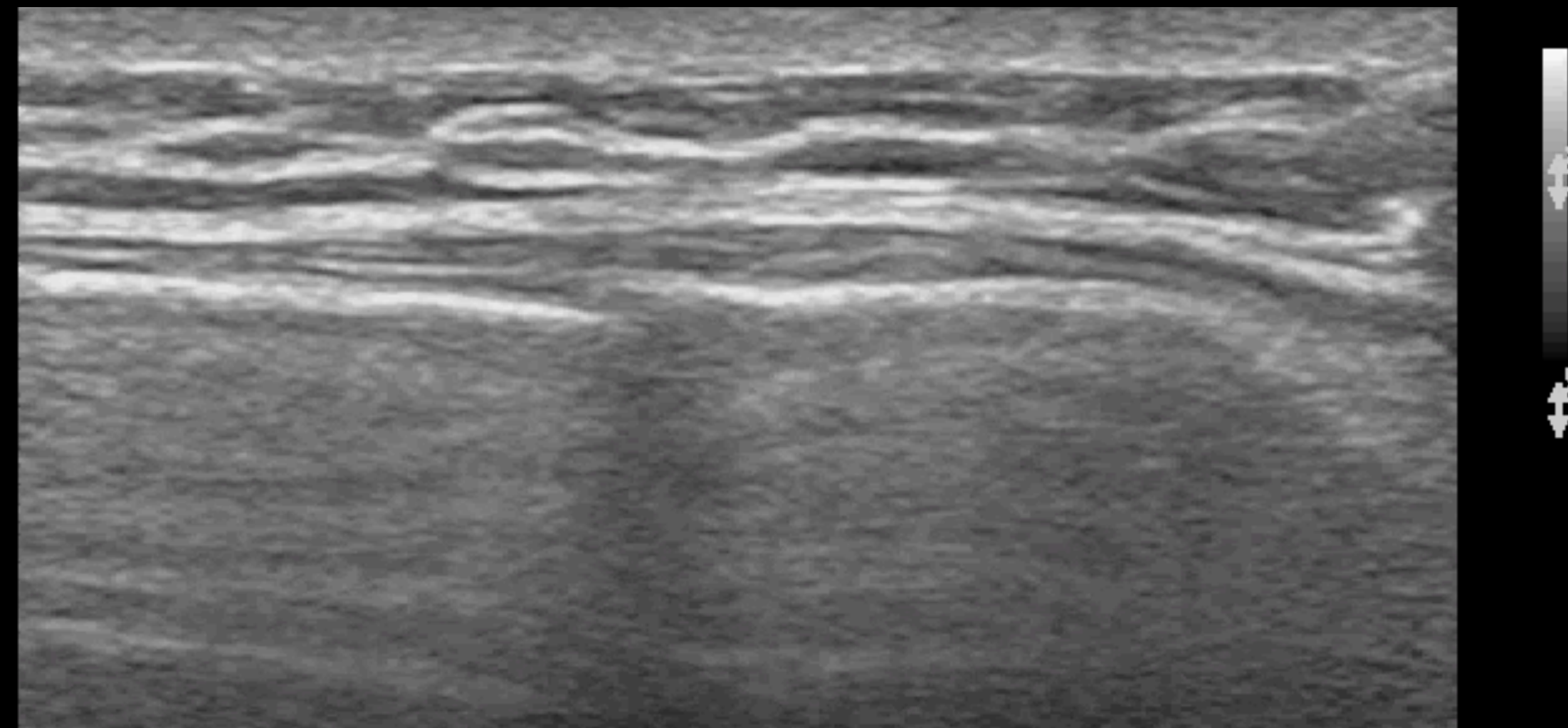


G
P R
3.0 12.0



superficial
.12-3
46 Hz
3.0cm

2D
Res
Gn 96
C 56
3/2/1



Sweep/ Rotate / Slide

TE7 Ultrasound System

L14-6Ns
MI 11
TIS 0.2

B
FH10
DR 110
FR 27
D 3.5
G 46

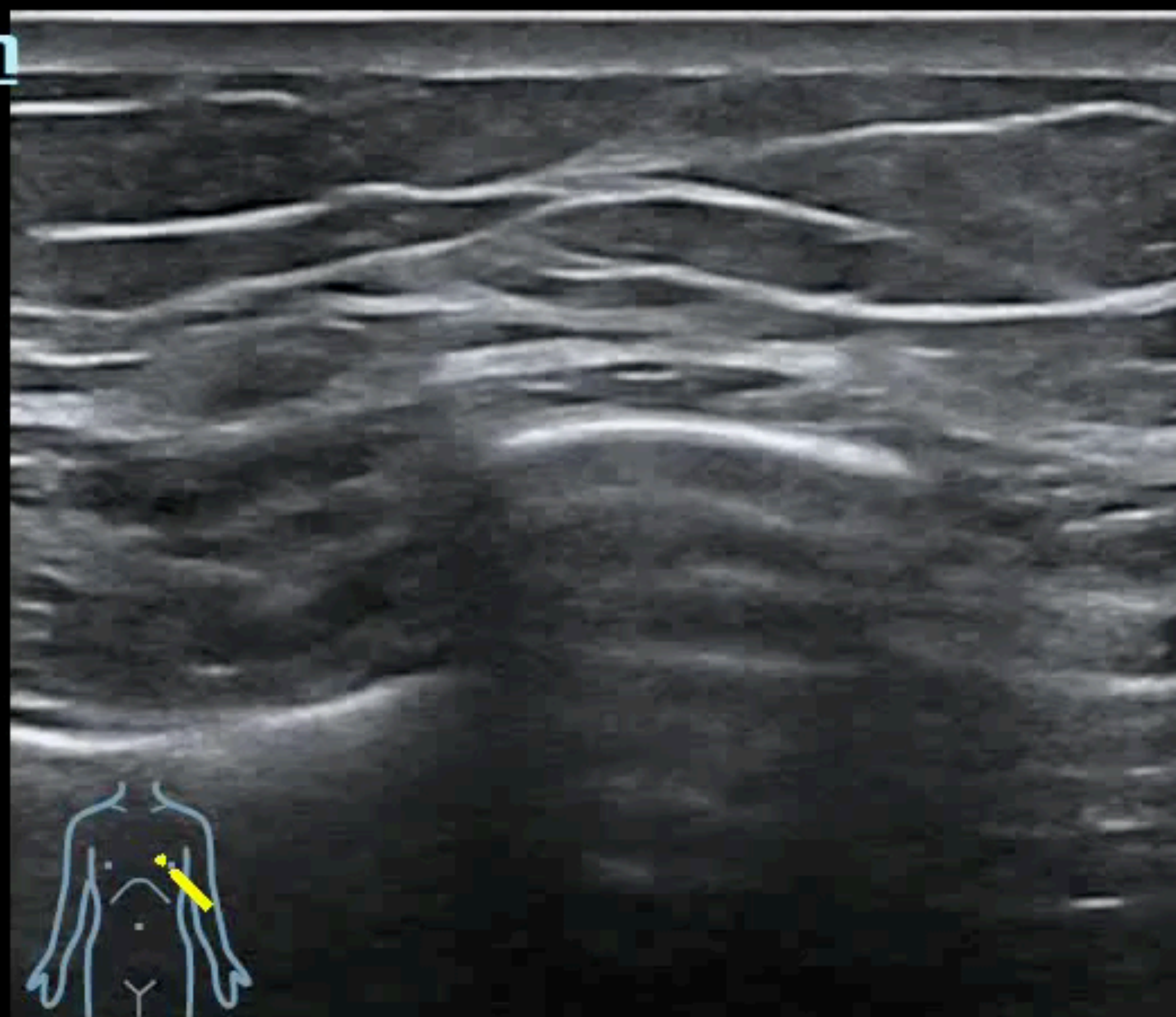
AP 96.6%

20180227-145917-34EA

MSK

27-02-2018

10:01:01



n

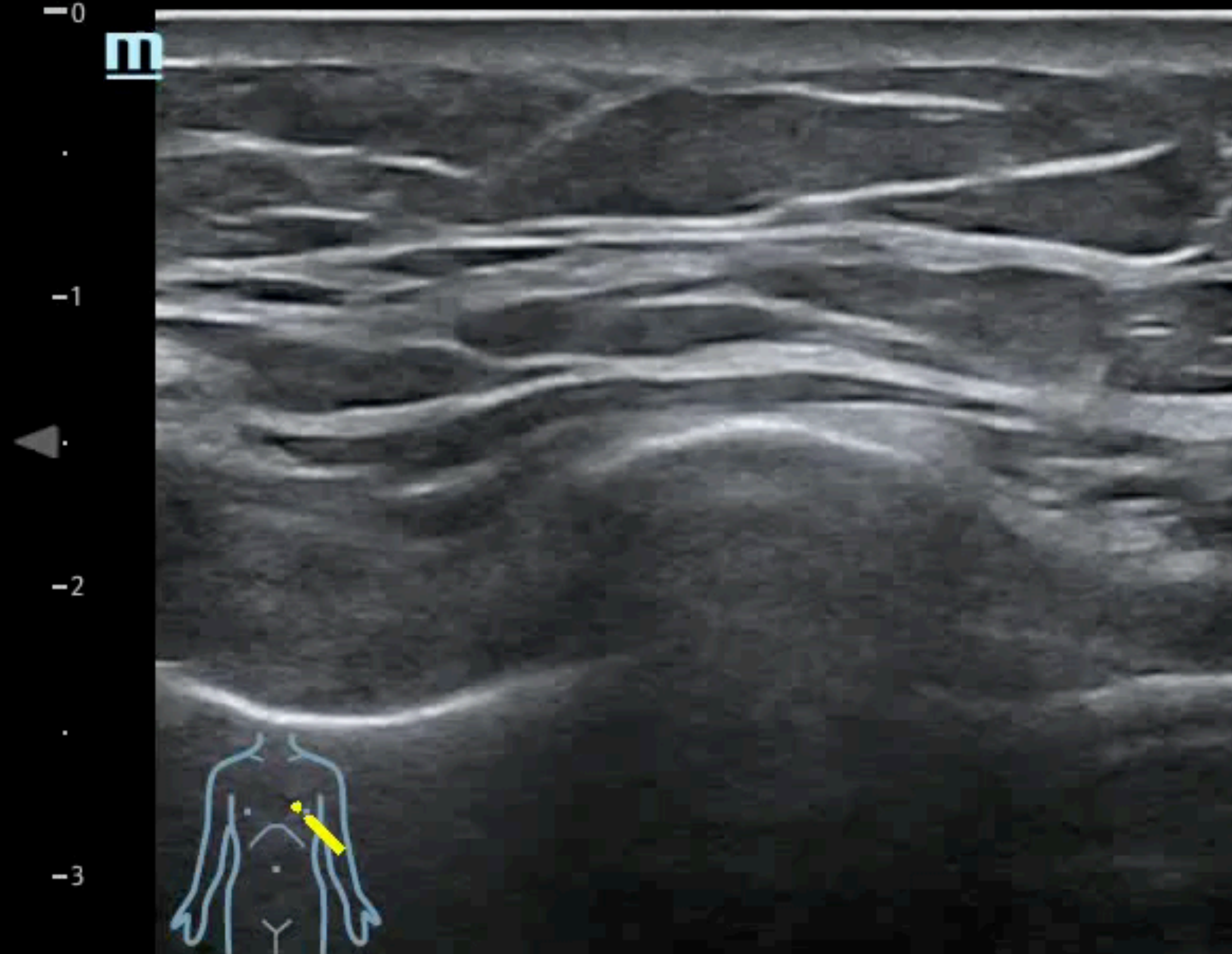
96.6%

20180227-145917-34EA

MSK

27-02-2018

10:01:18



五個你應該試試看的超音波小技巧

活用手中探頭的6個技巧

FASTER



一本書



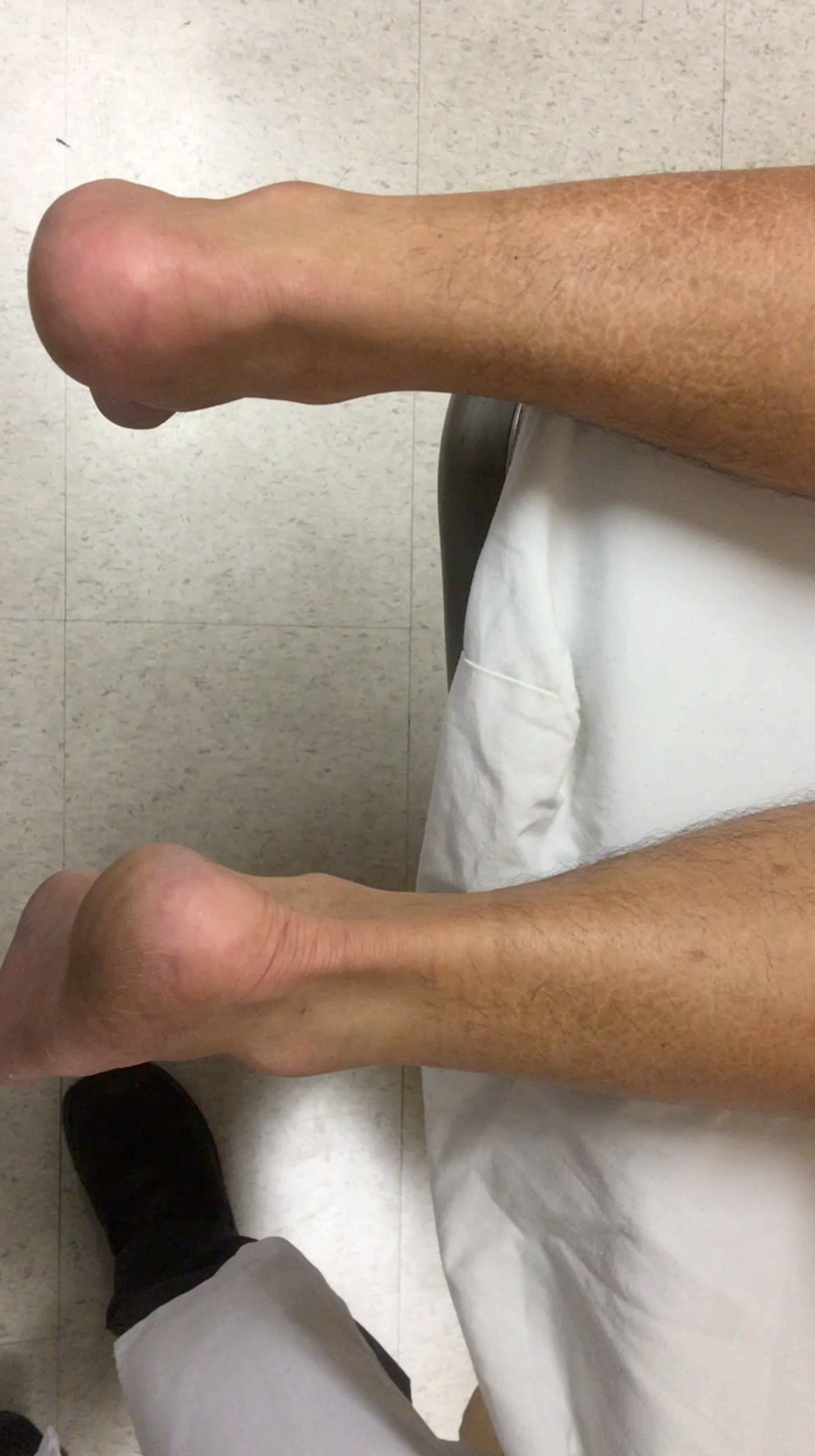二根骨



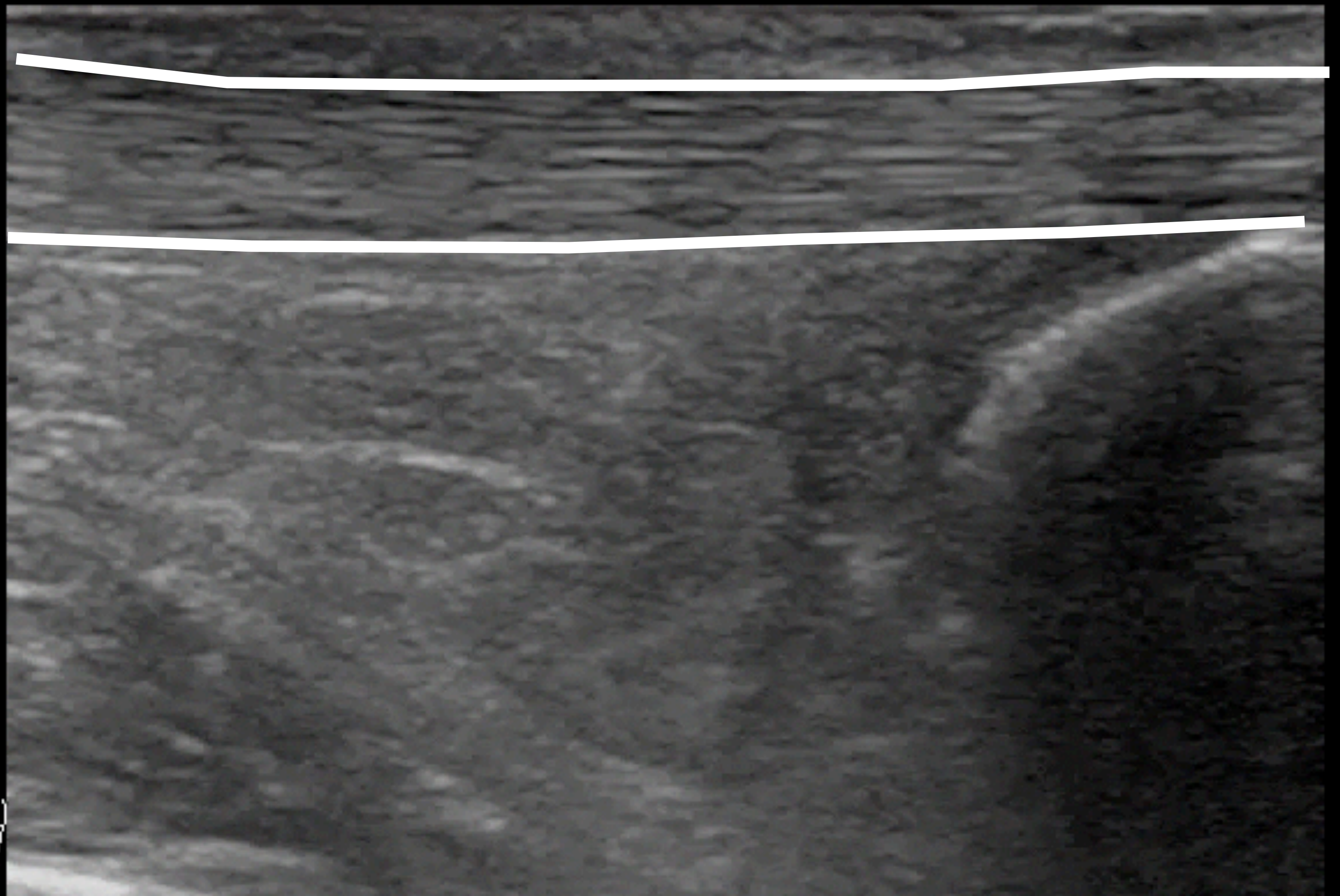
三條筋



Thompson test

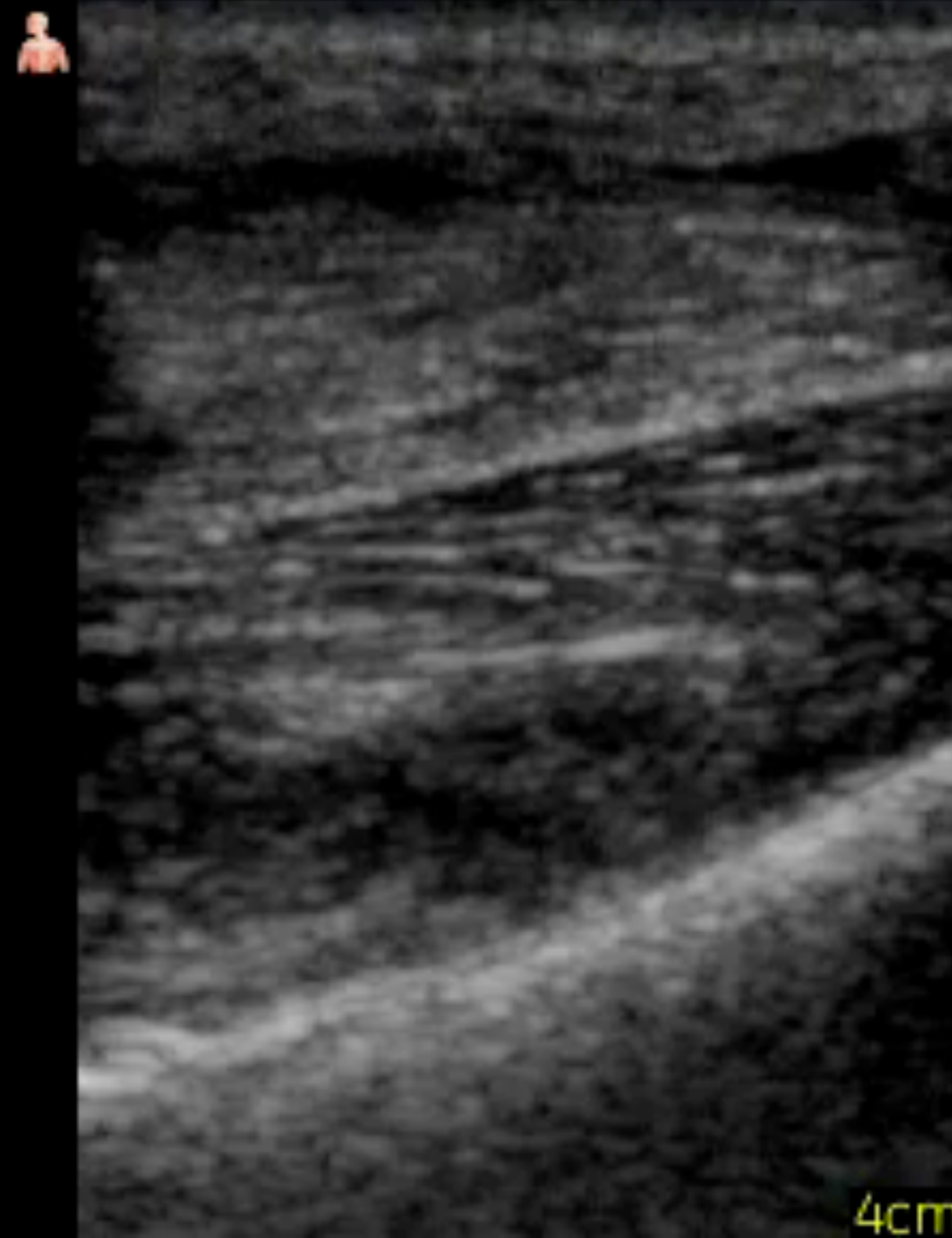


1 – Achilles tendon



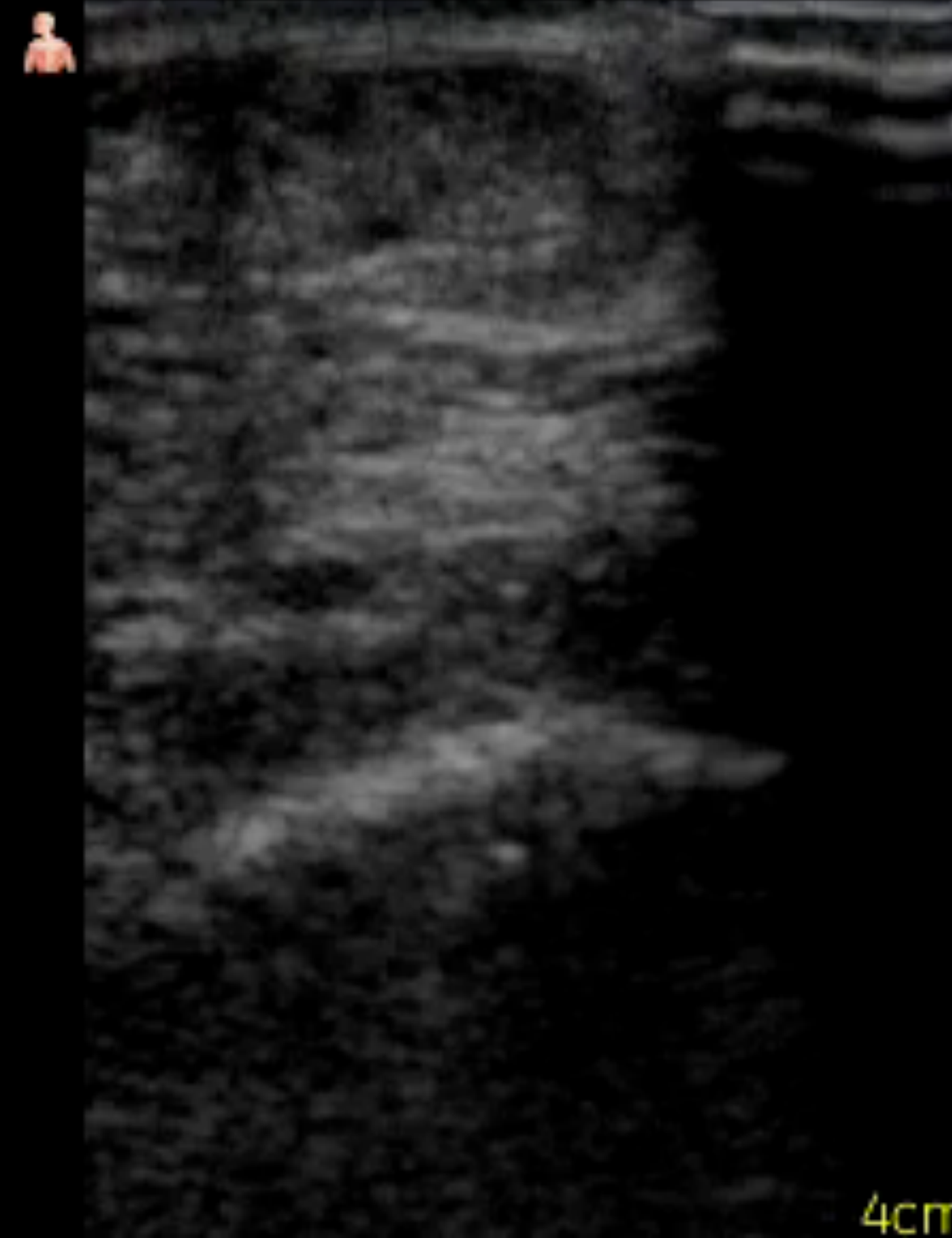
47M, left leg pain after jumping during badminton

MI: 0.8 TI: 0.2 #: 168 17:37:36
20/Mar/2015



4cm

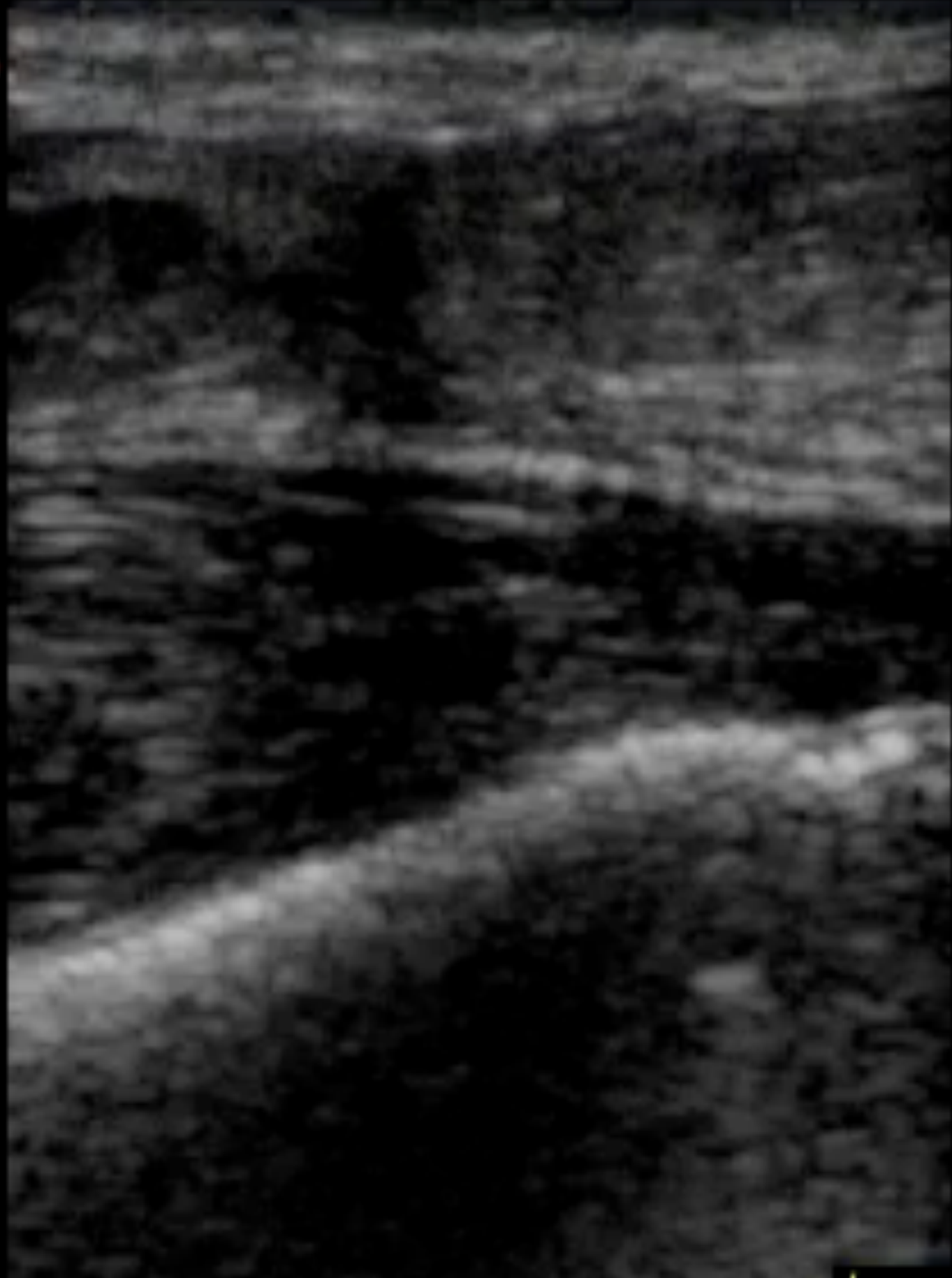
MI: 0.8 TI: 0.2 #: 168 17:39:13
20/Mar/2015



4cm

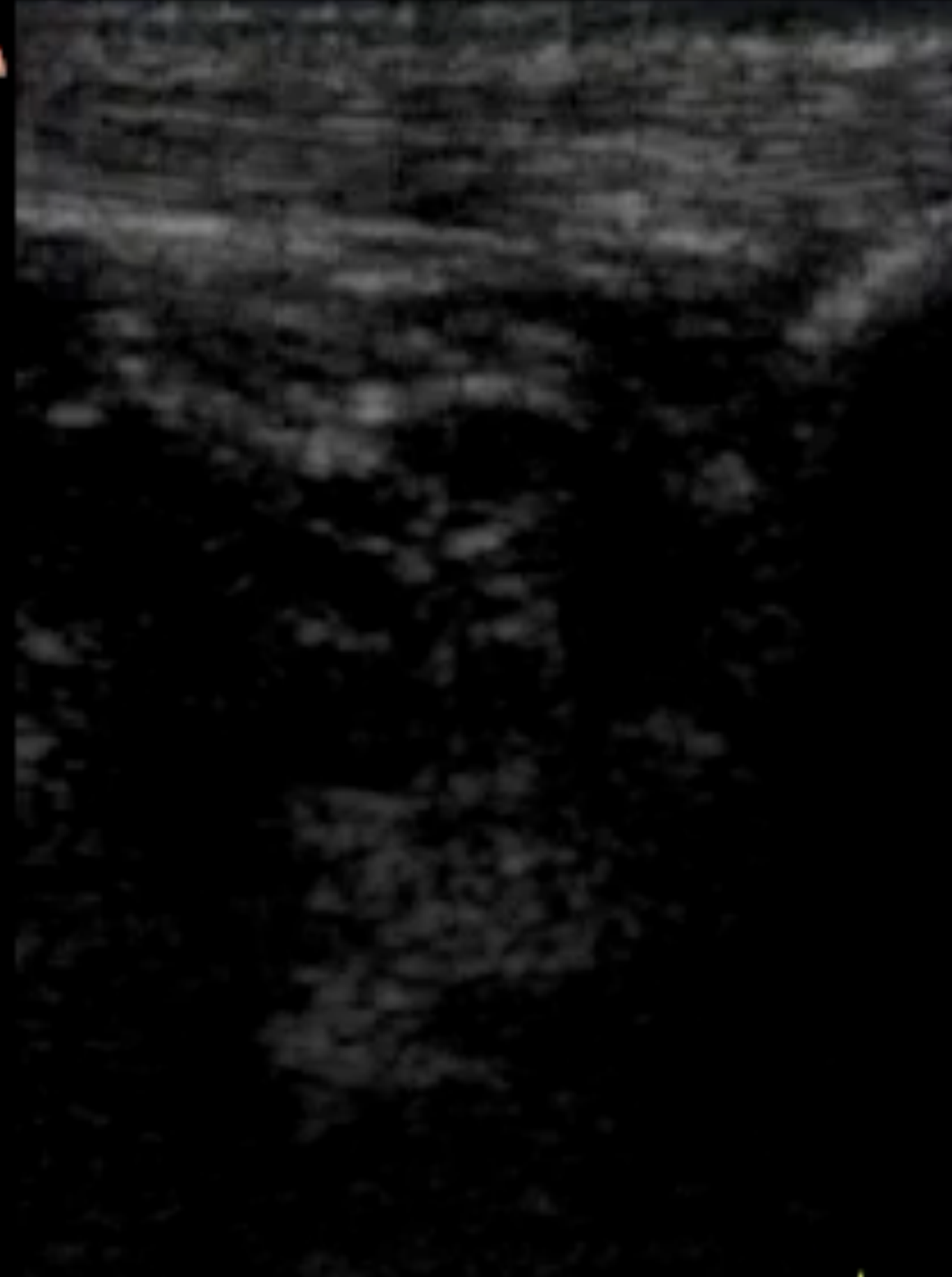
Dynamics & Comparison

MI: 0.8 TI: 0.2 #: 168 17:44:04
20/Mar/2015



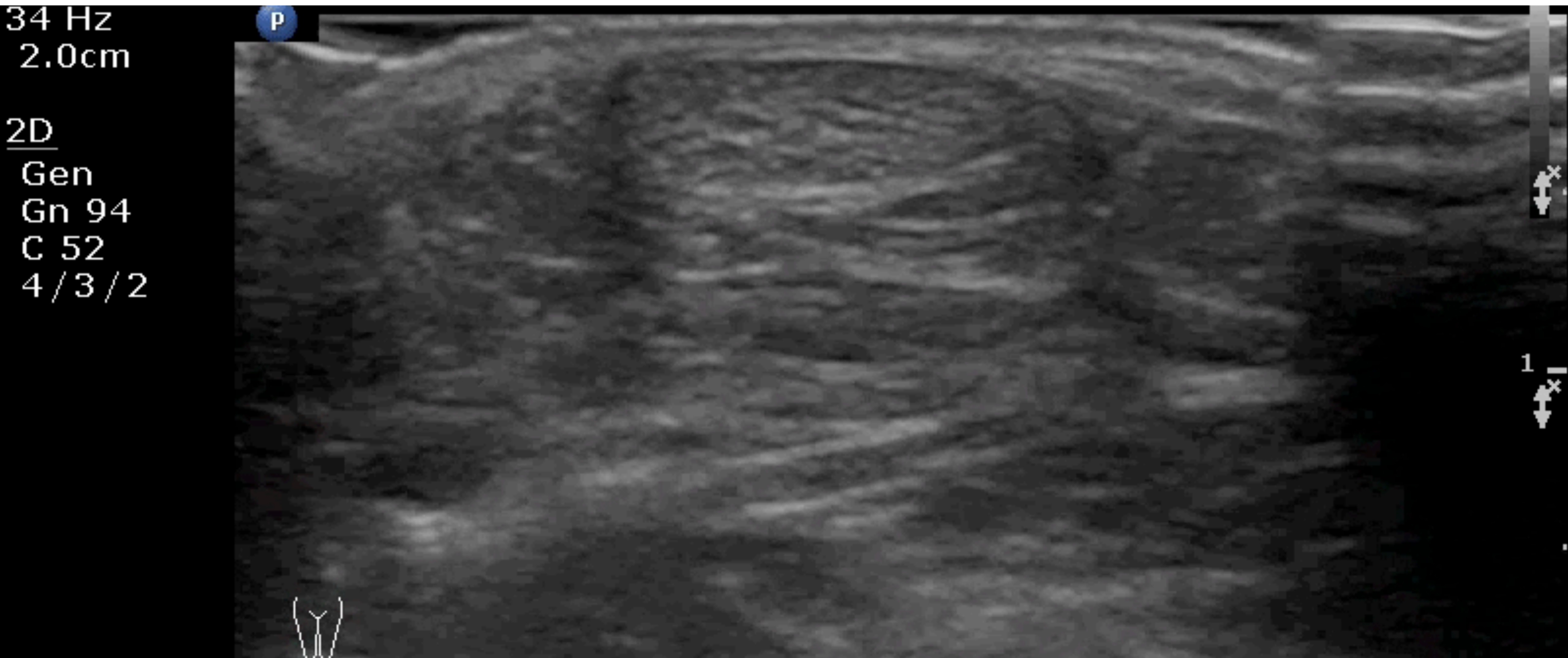
4cm

MI: 0.8 TI: 0.2 #: 168 17:40:12
20/Mar/2015



4cm

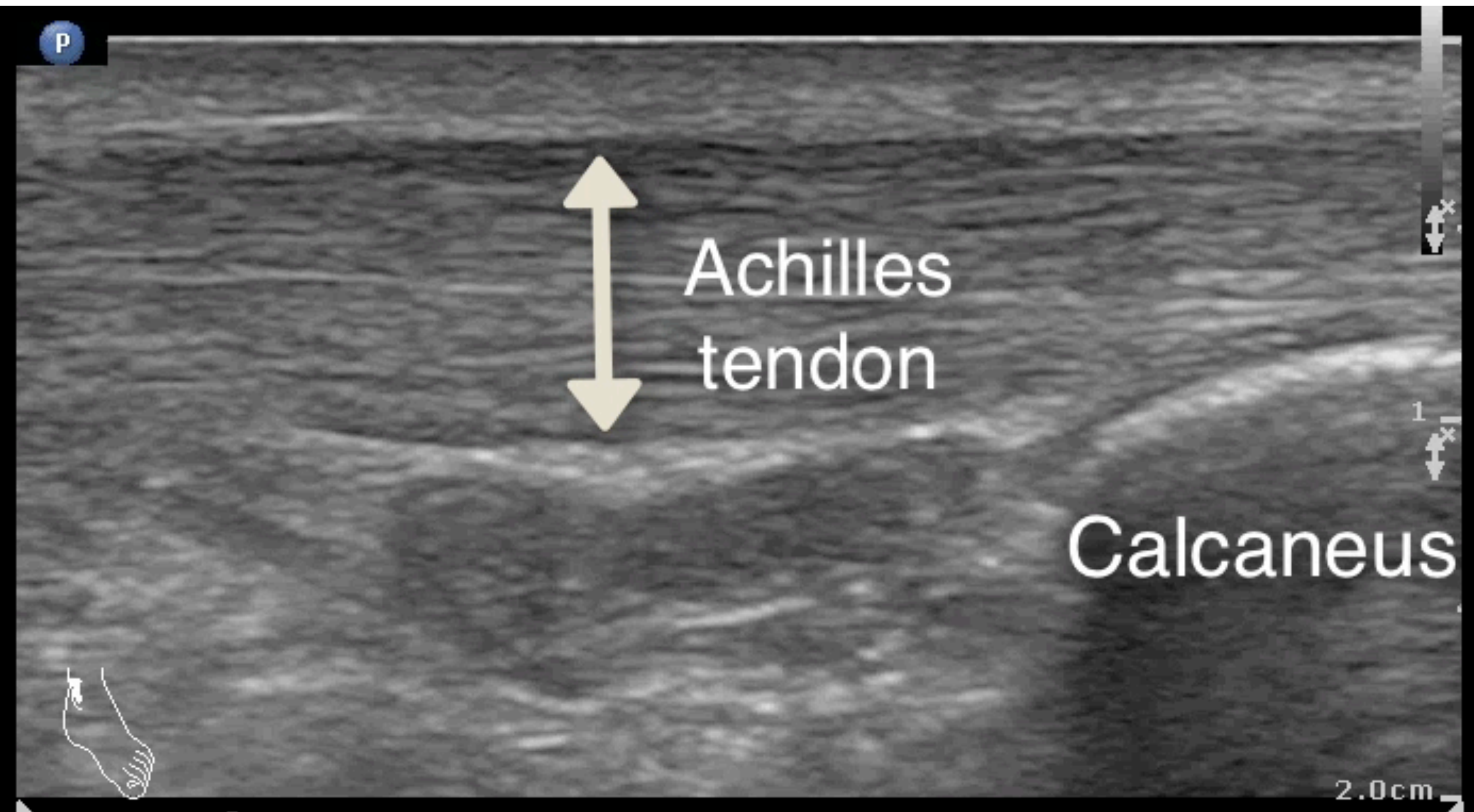
Achilles tendon rupture



Achilles tendon rupture

50 Hz
2.0cm

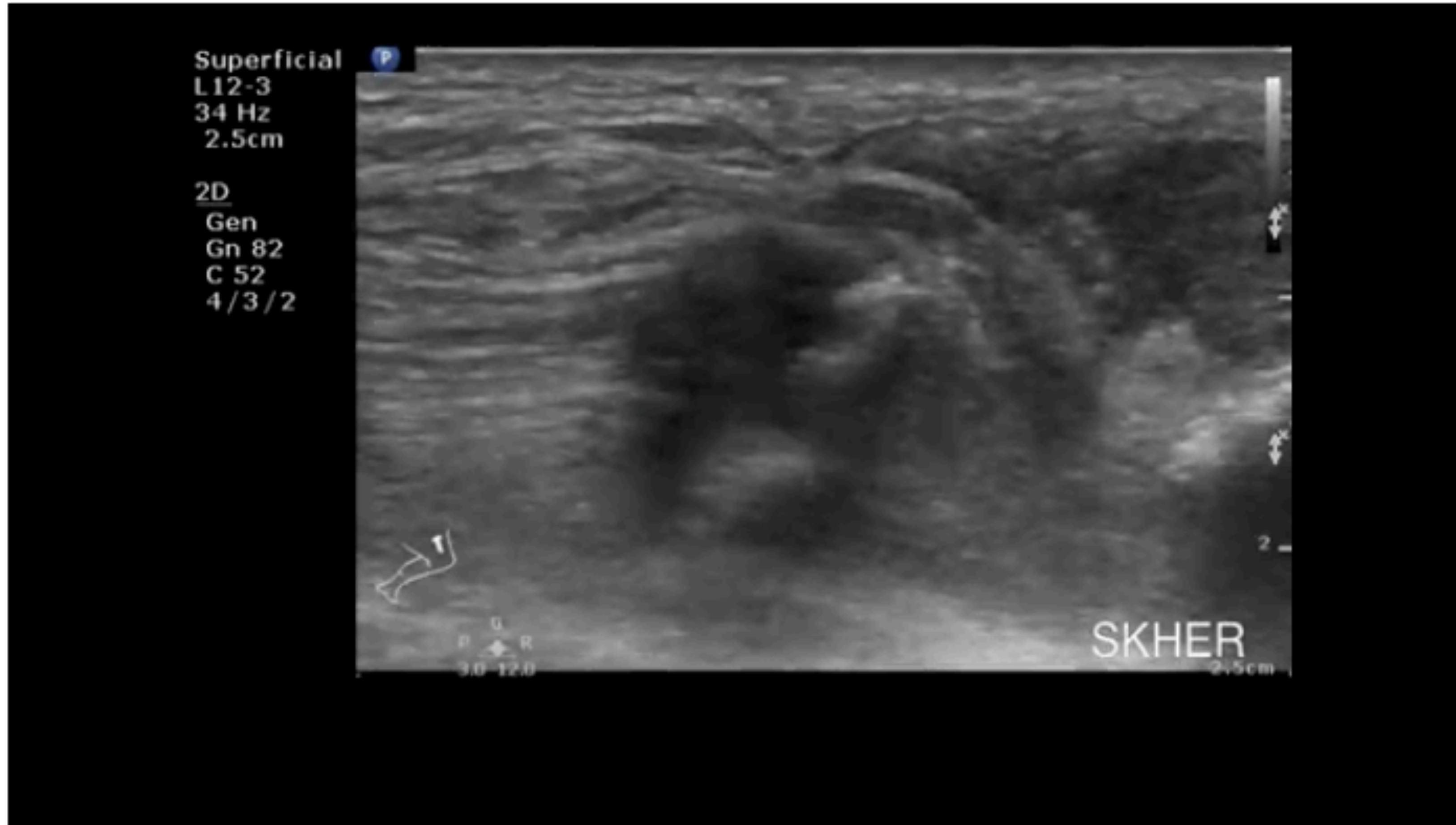
2D
Res
Gn 100
C 56
3/2/1



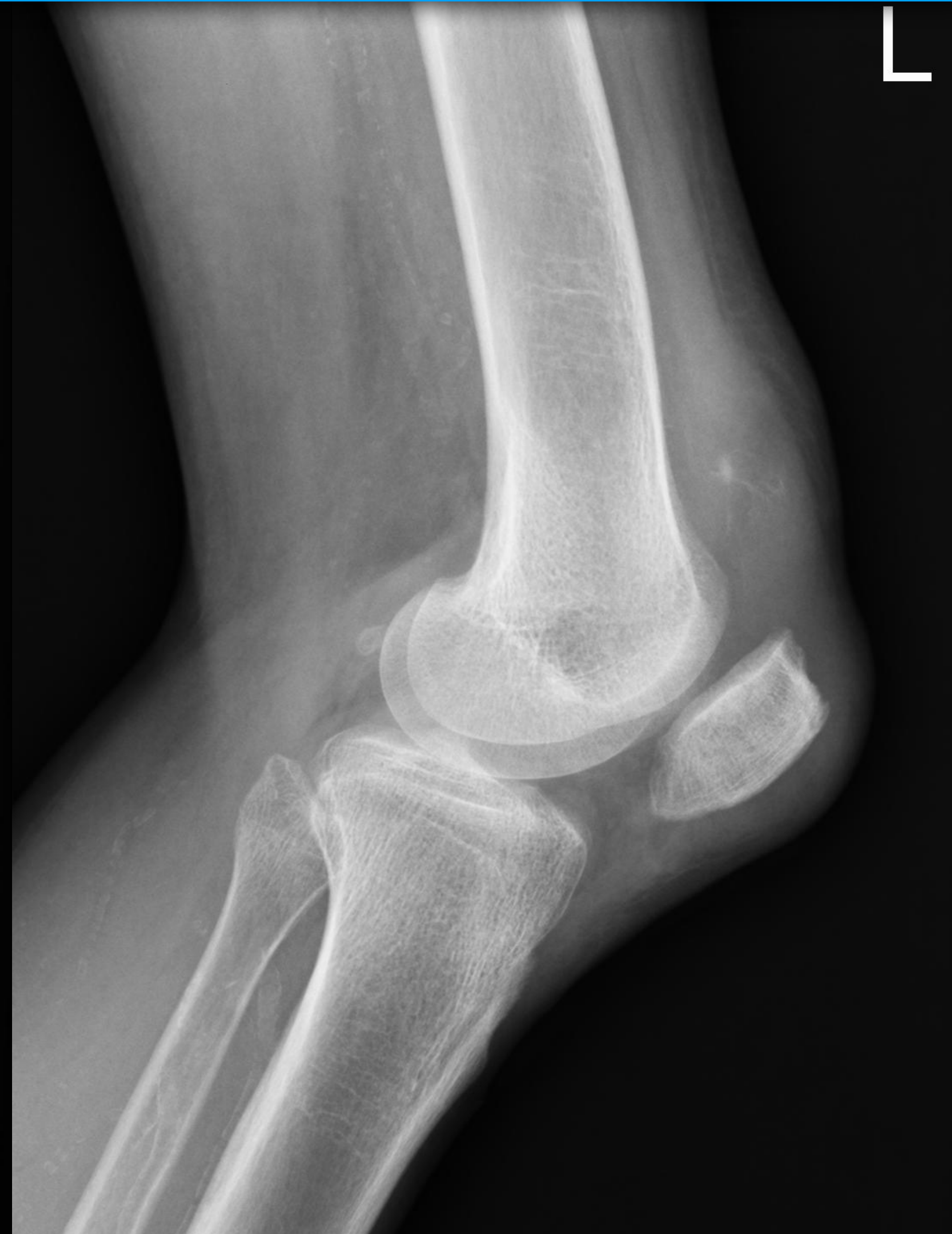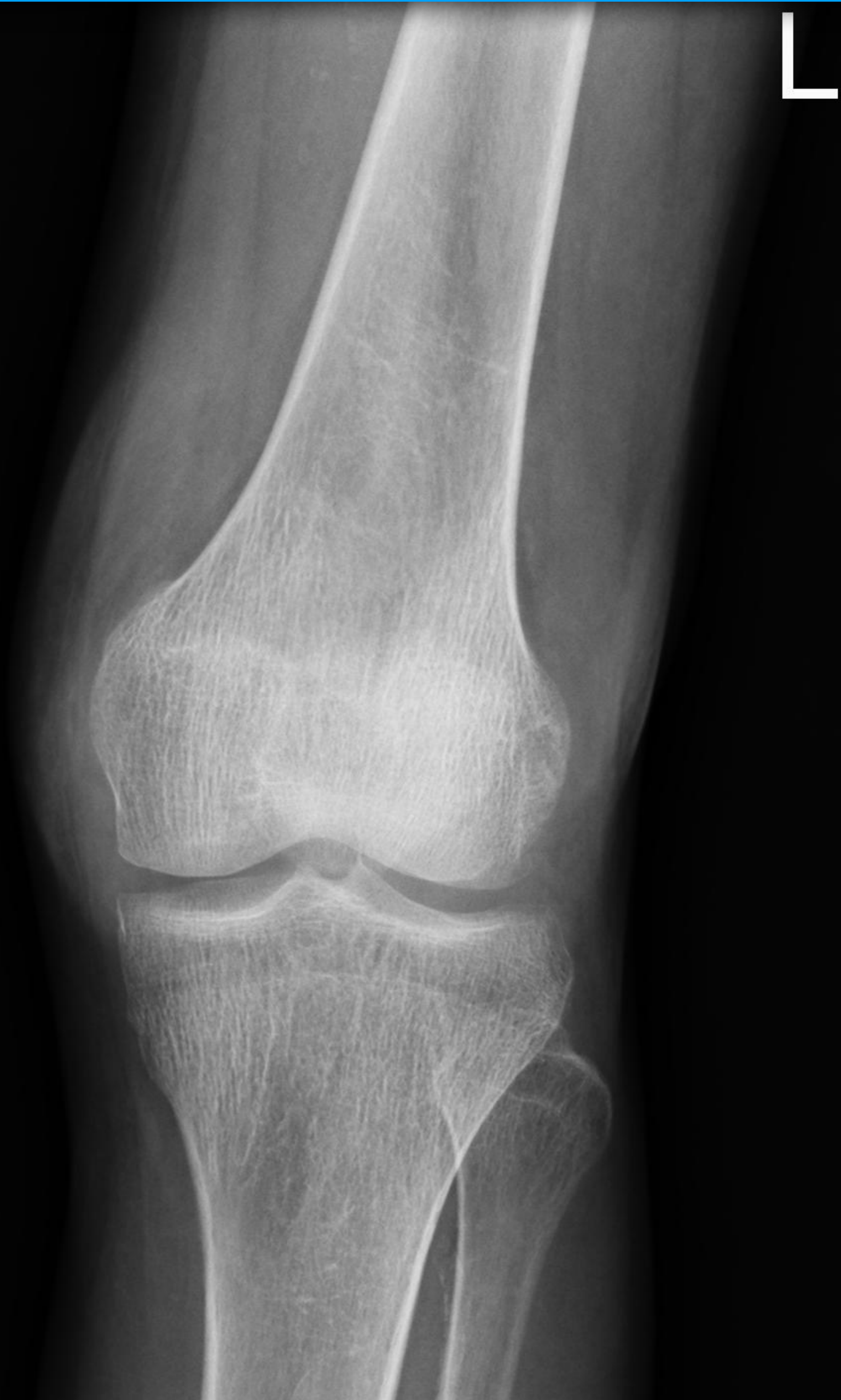2.0cm

60歲女性，走路滑倒，左膝腫痛

Posted on [2016-01-04](#) by [Chen KC](#) / [4 Comments](#)



60歲女性，走路滑倒，左膝腫痛



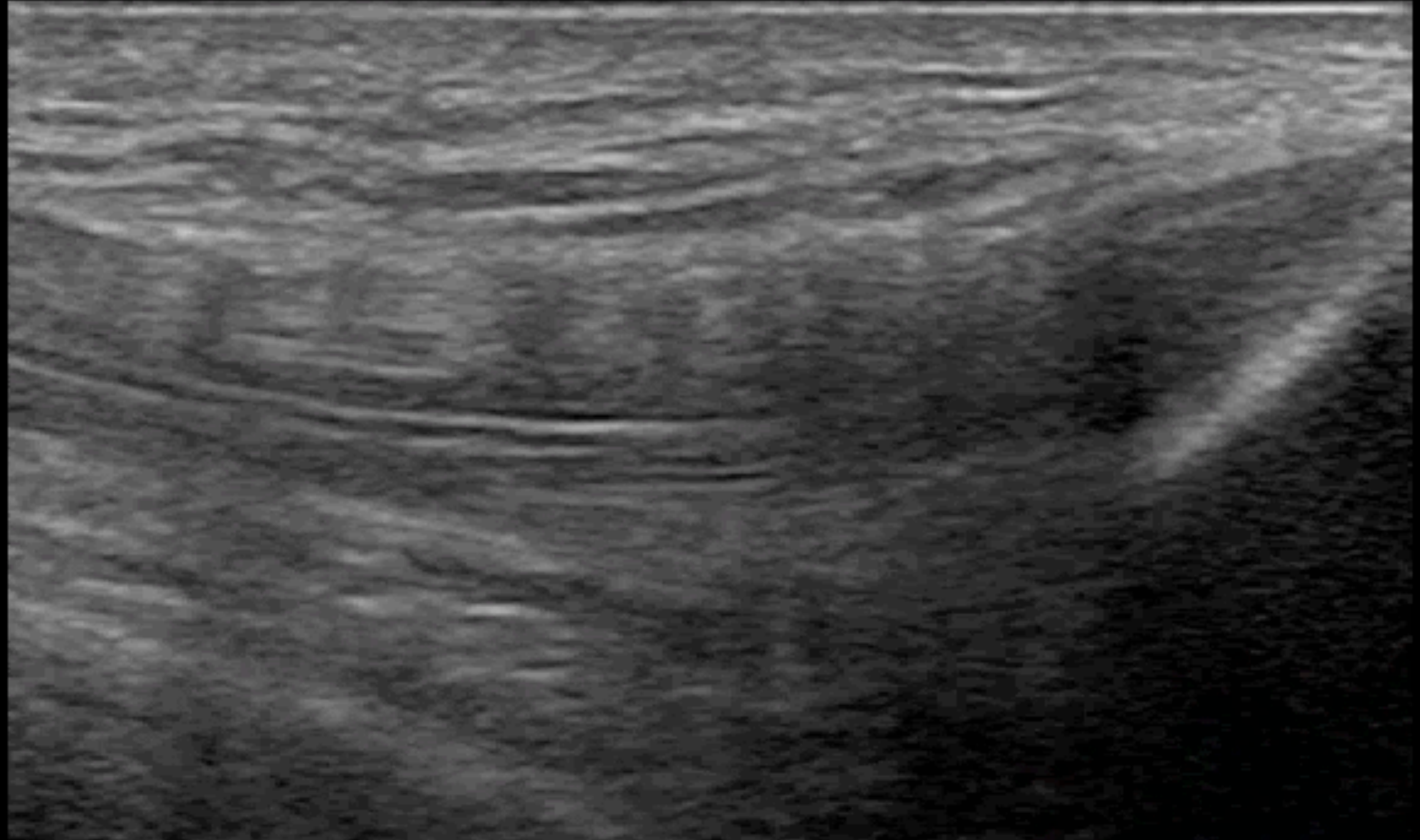
2 – Quadriceps tendon

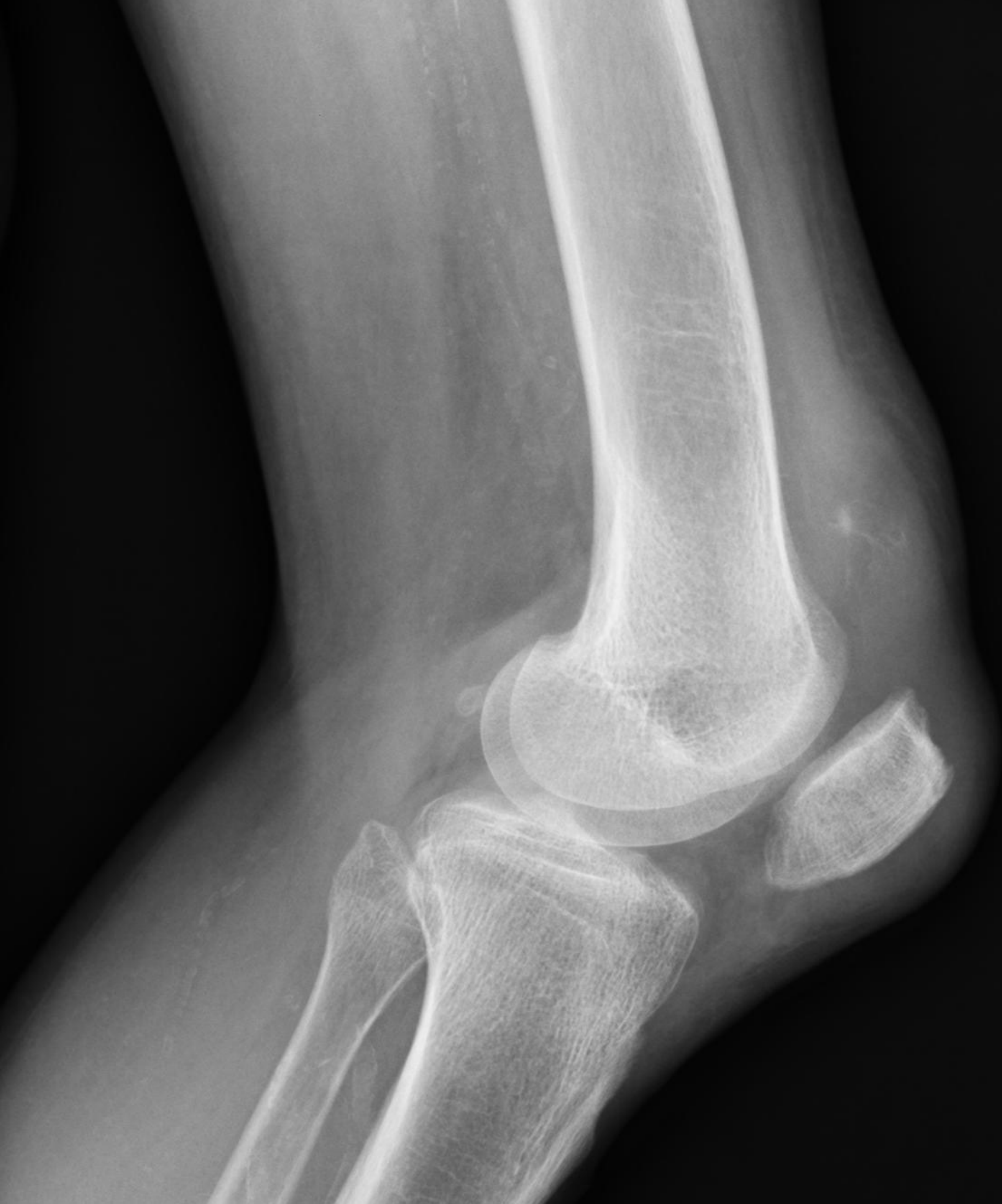Superficial
L12-3
46 Hz
3.0cm

P

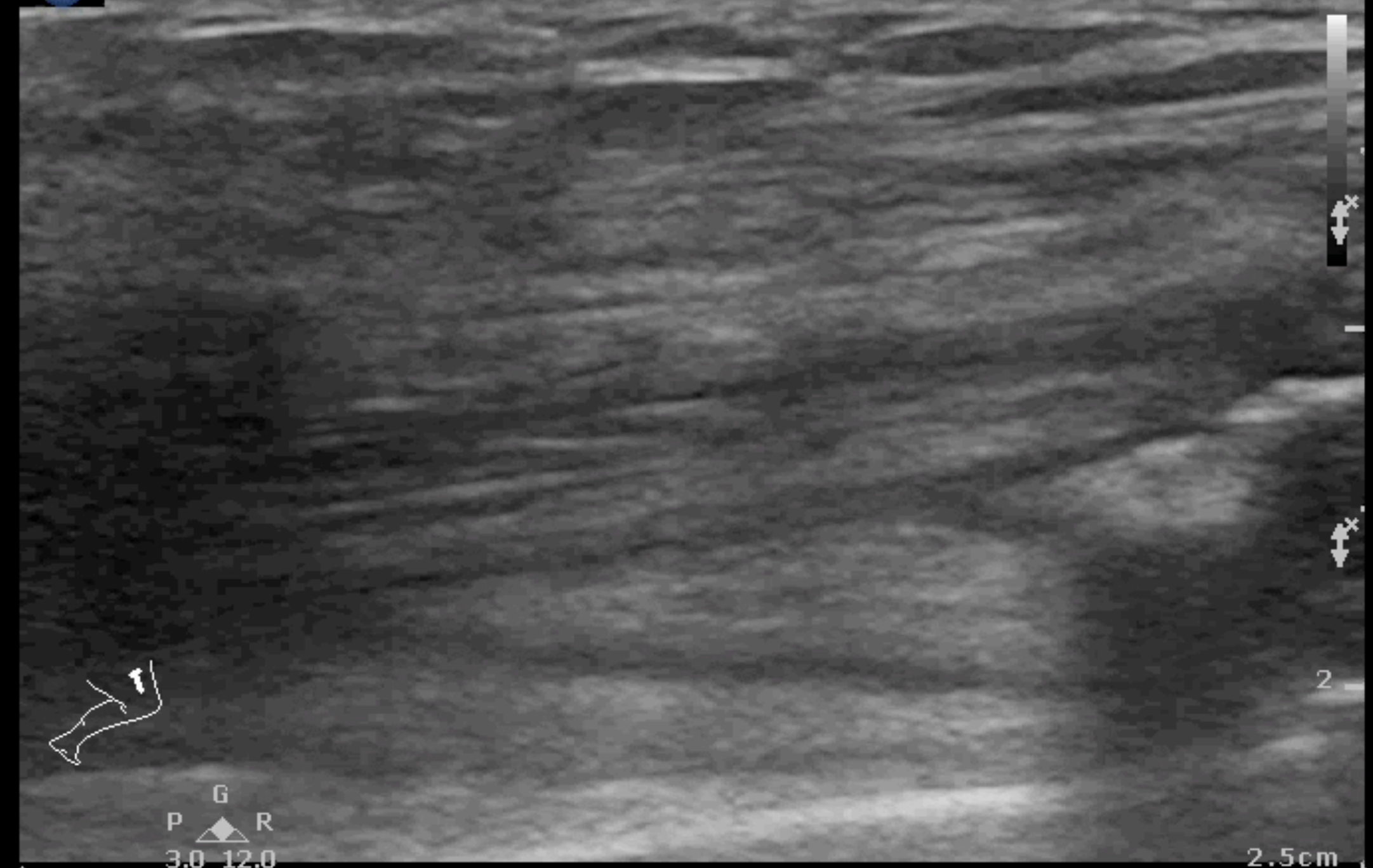
2D

Res
Gn 78
C 56
3 / 2 / 1

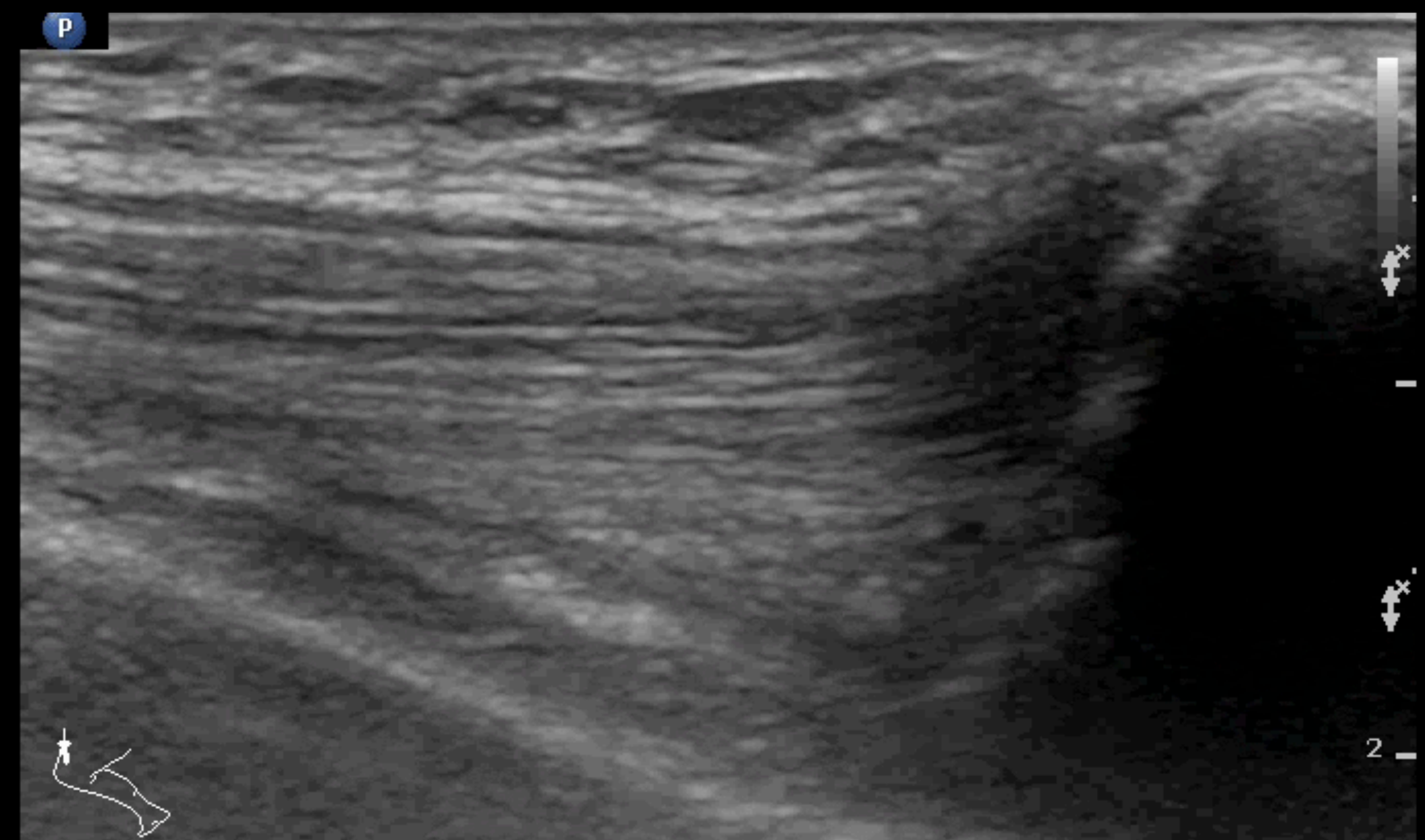




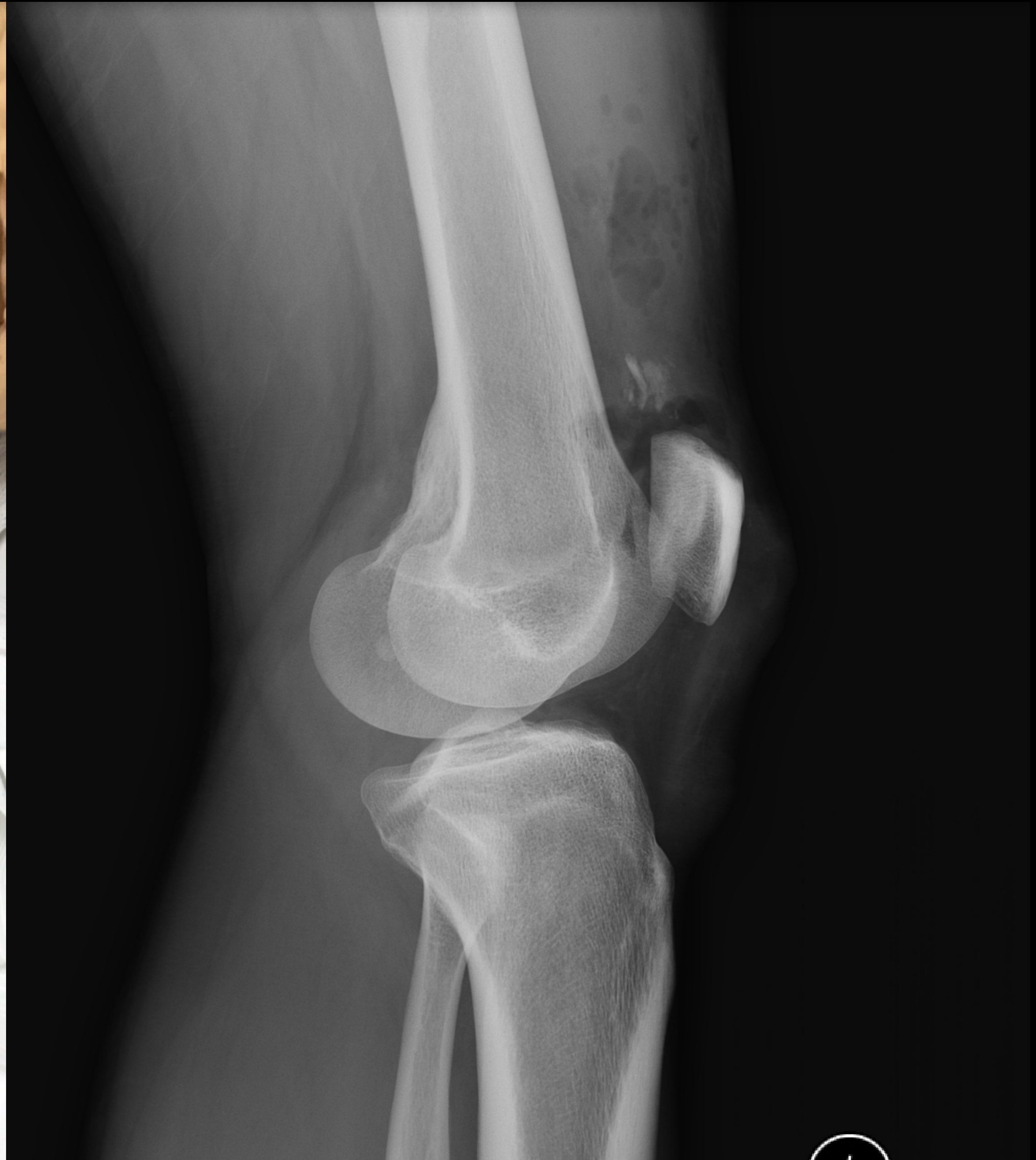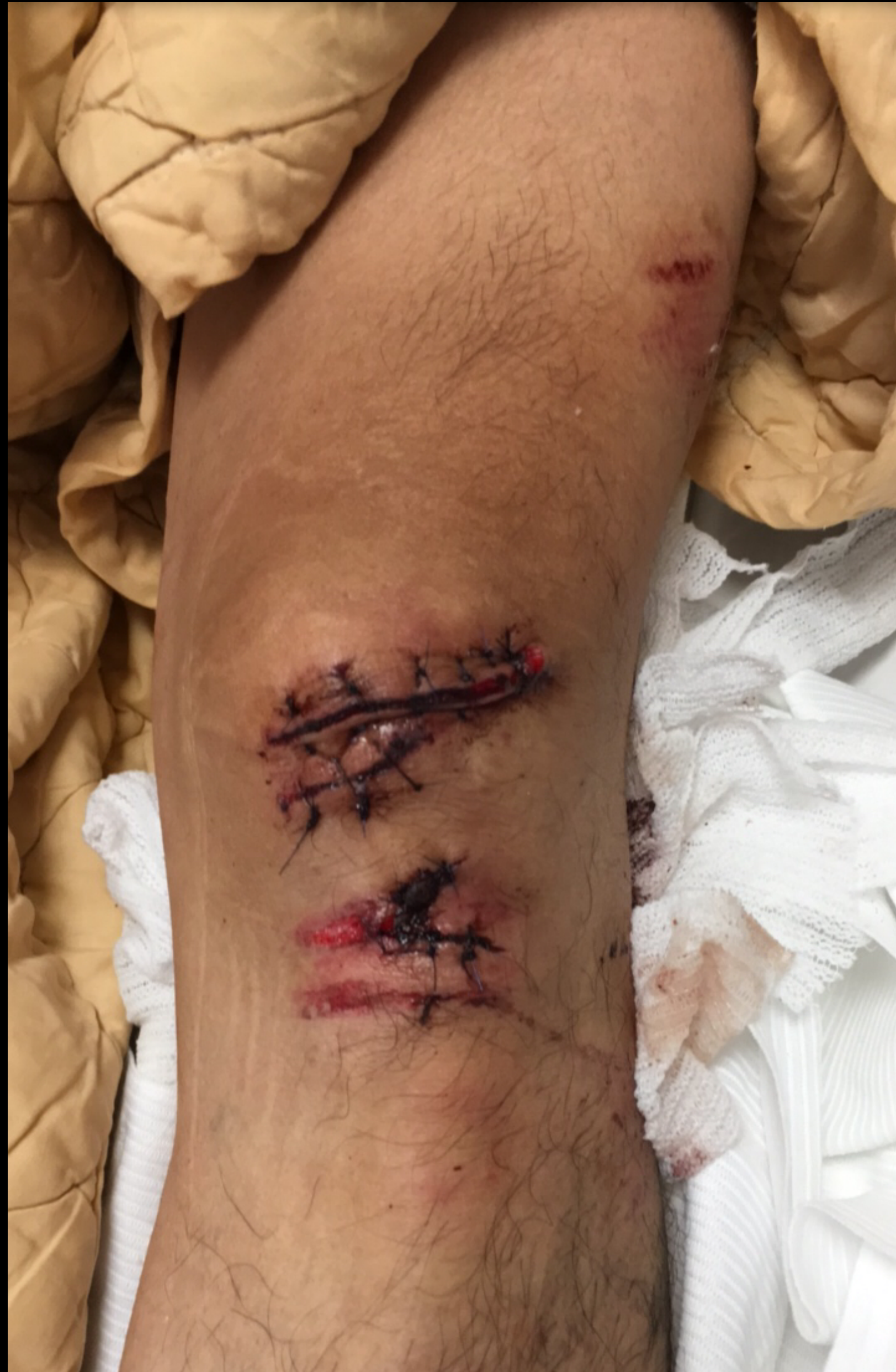12-3
34 Hz
2.5cm
2D
Gen
Gn 82
C 52
4/3/2



Superficial
12-3
34 Hz
2.5cm
2D
Gen
Gn 82
C 52
4/3/2



Trauma, for tendon repair

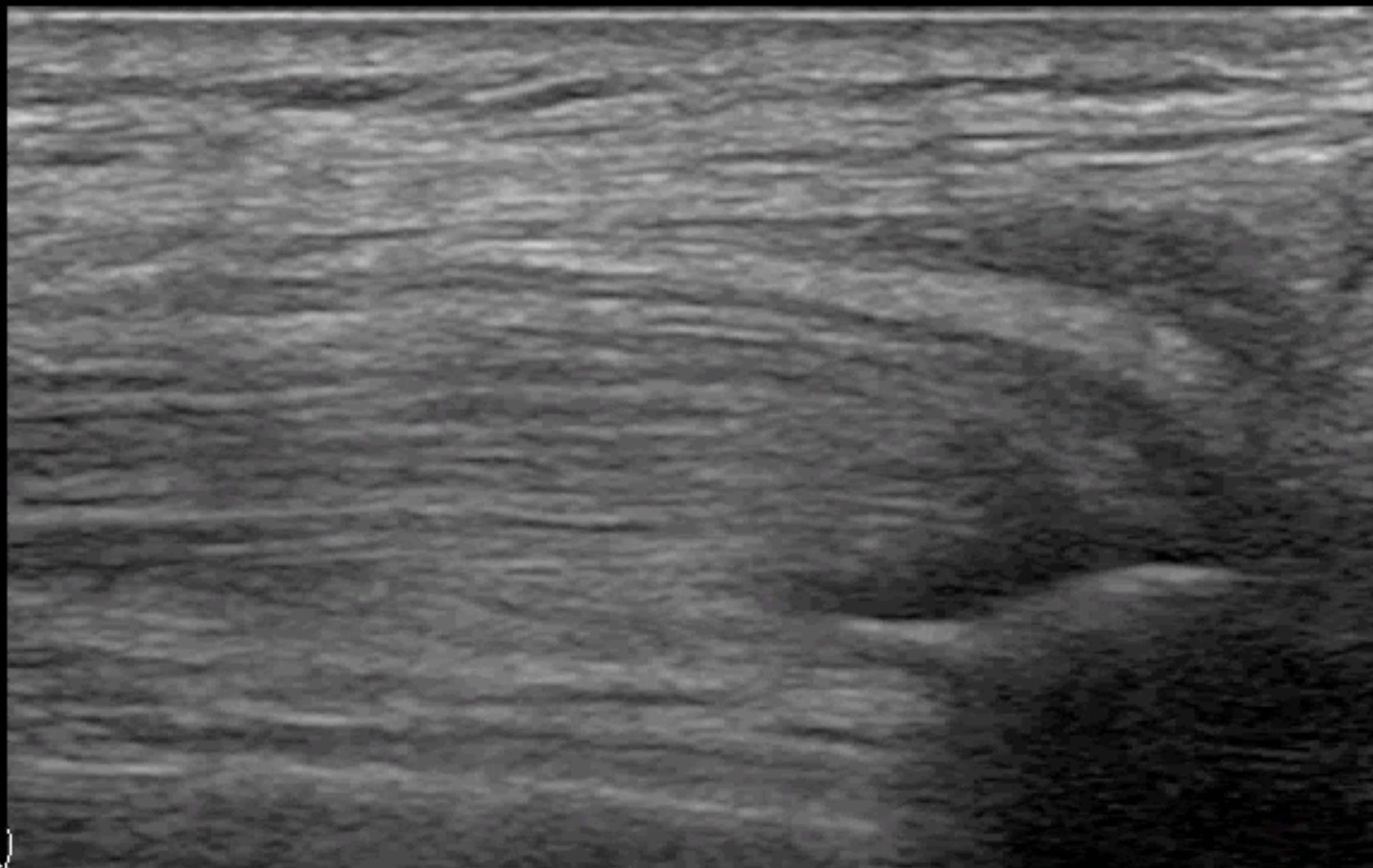


Supra-patellar scan

Superficial
12-3
6 Hz
3.0cm

P

D
Res
Gn 78
C 56
3 / 2 / 1



Jeremy Lin injury

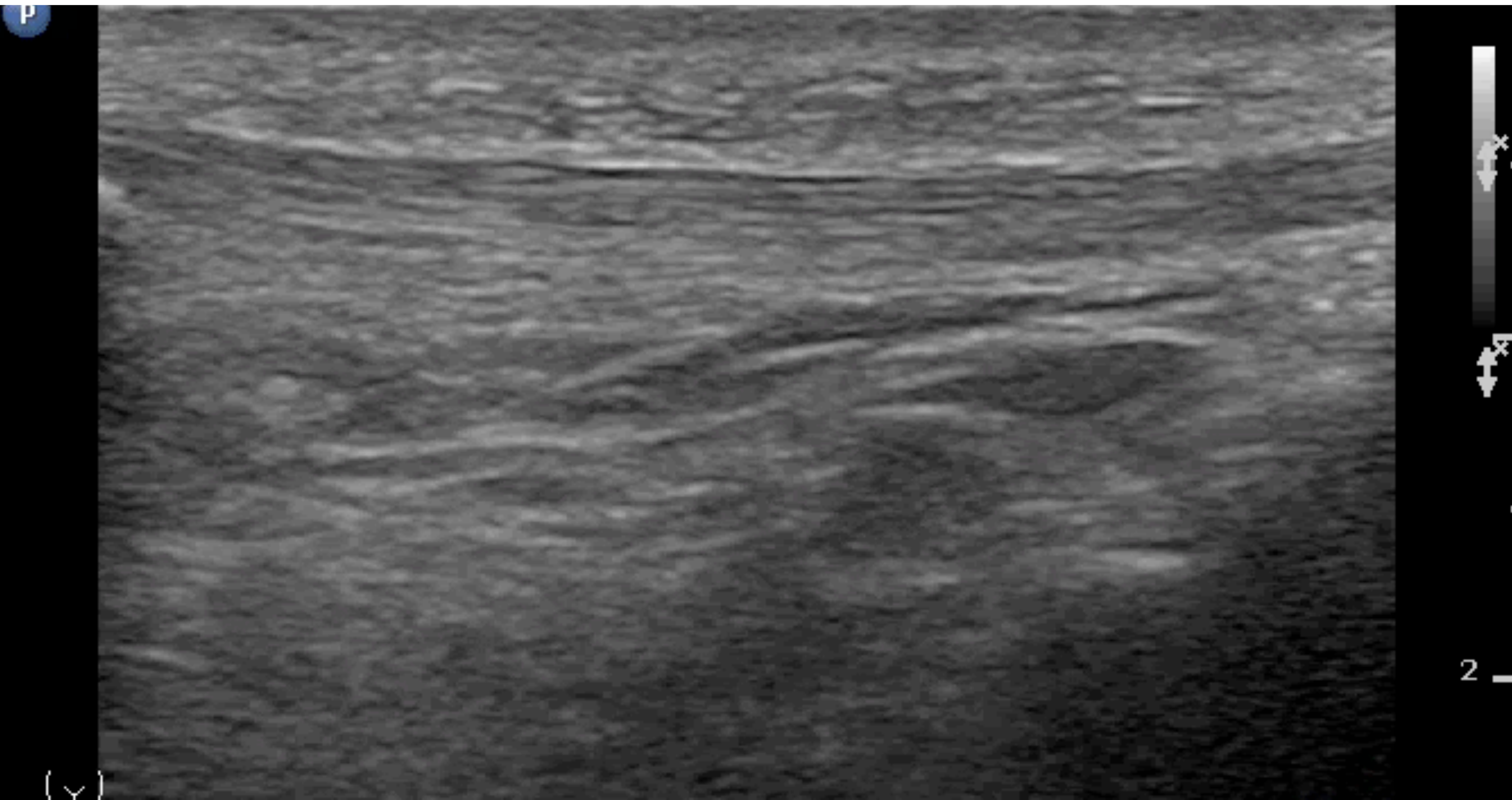


3 – Patellar tendon

Superficial
L12-3
46 Hz
3.0cm

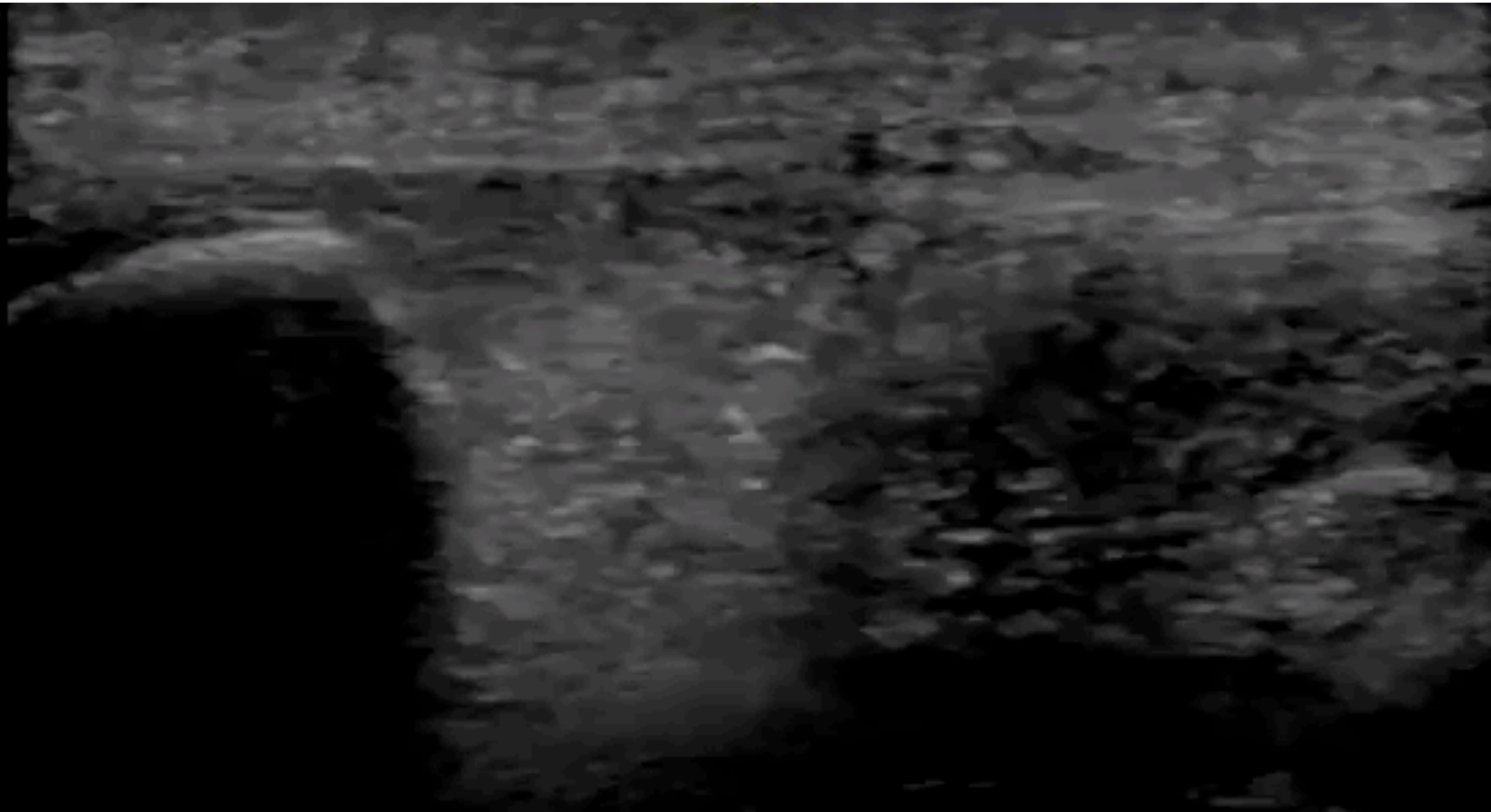2D

Res
Gn 78
C 56
3 / 2 / 1



Patellar tendon tear

Le



感謝安南符凌斌主任提供

不只快，還會更快



一本書



二根骨



三條筋

POCUS Academy

Point-of-care ultrasound is the visual stethoscope in the 21st century

The best way to earn respect is to consult for **definite treatment** !!



juice119@gmail.com

FB: Emergency Ultrasound Training Center

