

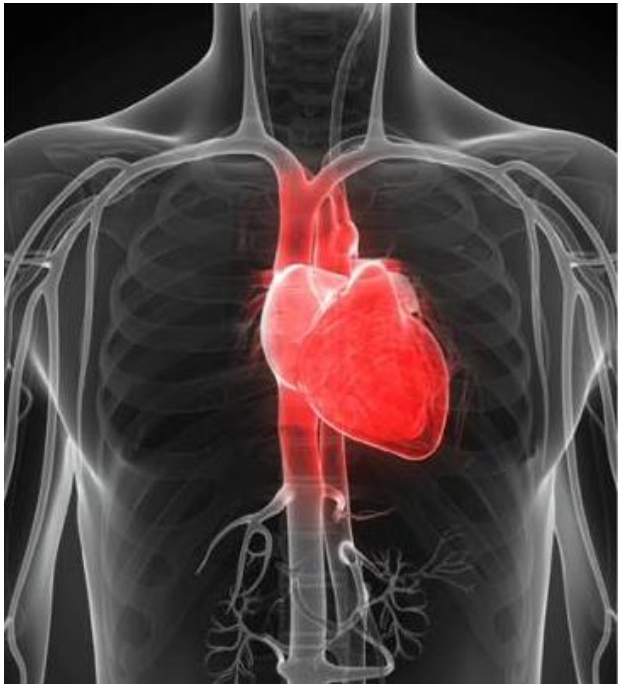To SPA

the

HEART



Essential Echocardiography Need To Know in ICU



雙和醫院 急診醫學科

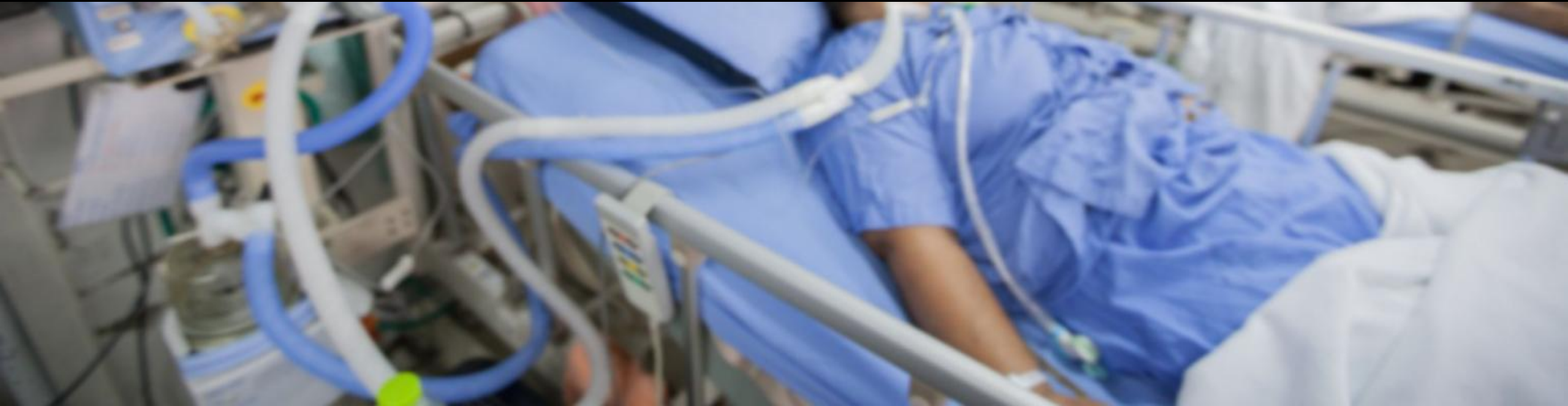翁健瑞 醫師



FoCUS

Focused Cardiac UltraSound

Vie et al. JASE 2014 IC; Level C





Phased Array Probe

I-AIM

Bahner DP, et al. J Ultrasound Med 2012



Indication

SPA

HEART

Acquire

Interpret

Make
Decisions

Indication

FoCUS

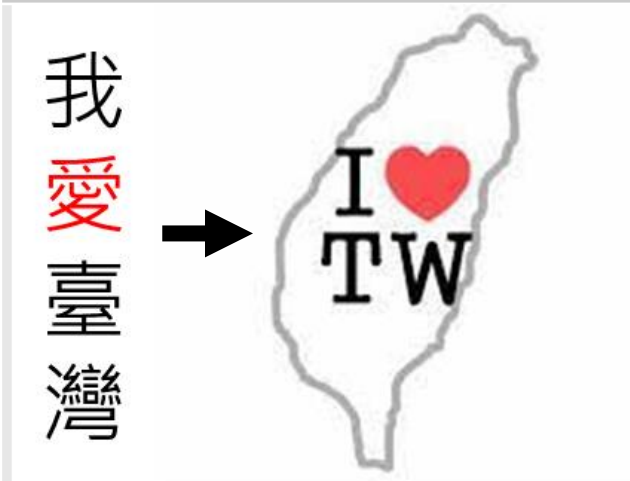
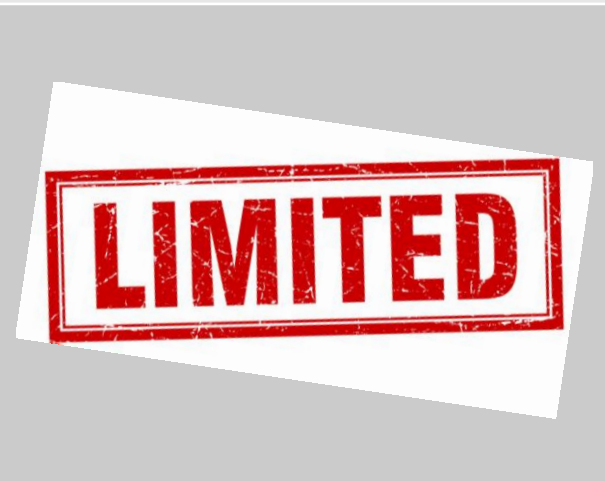
Focused Cardiac UltraSound

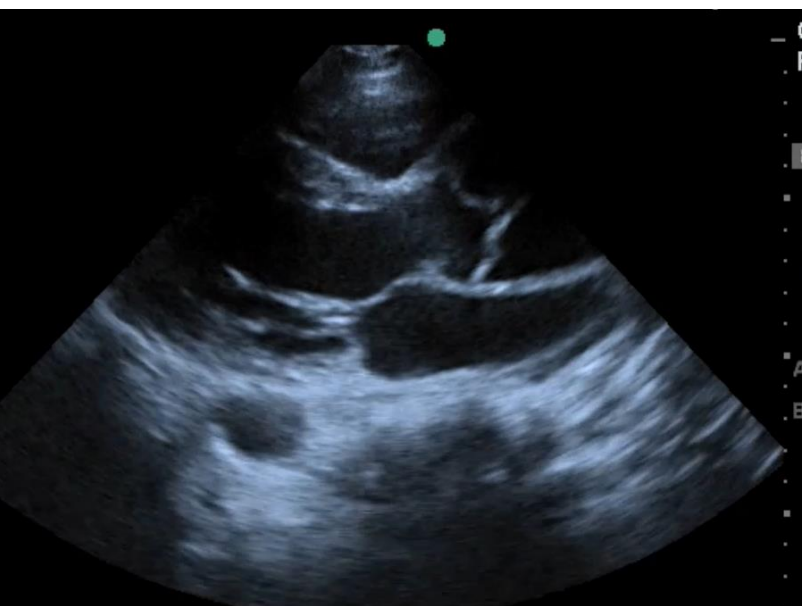
Goal-Directed

Problem Oriented

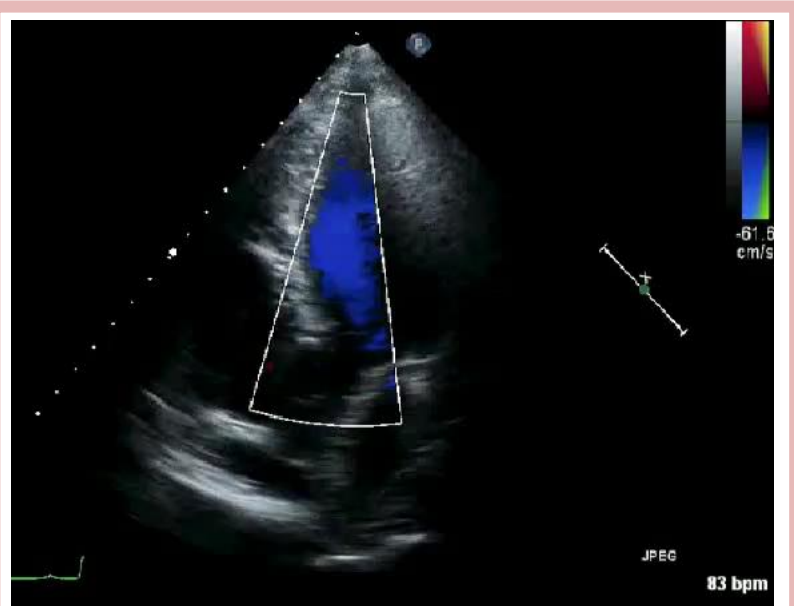Limited in Scope

Simplified

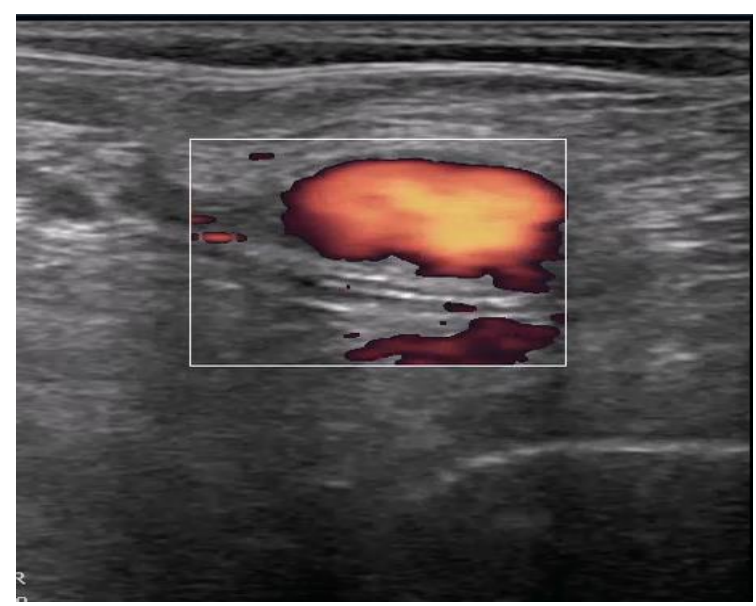




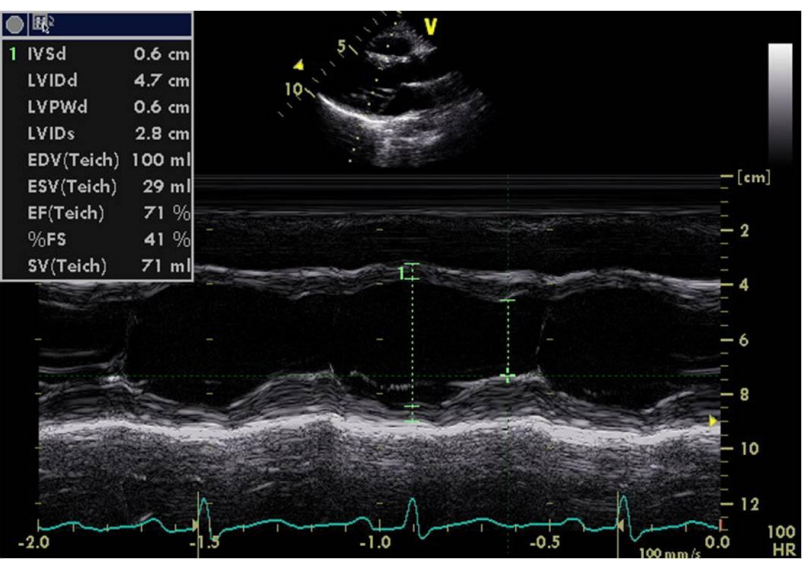
B-Mode



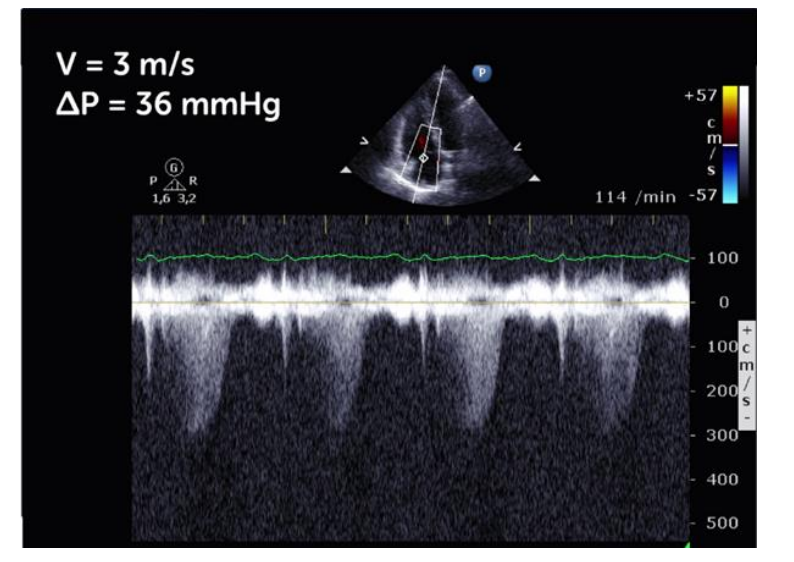
Color Doppler



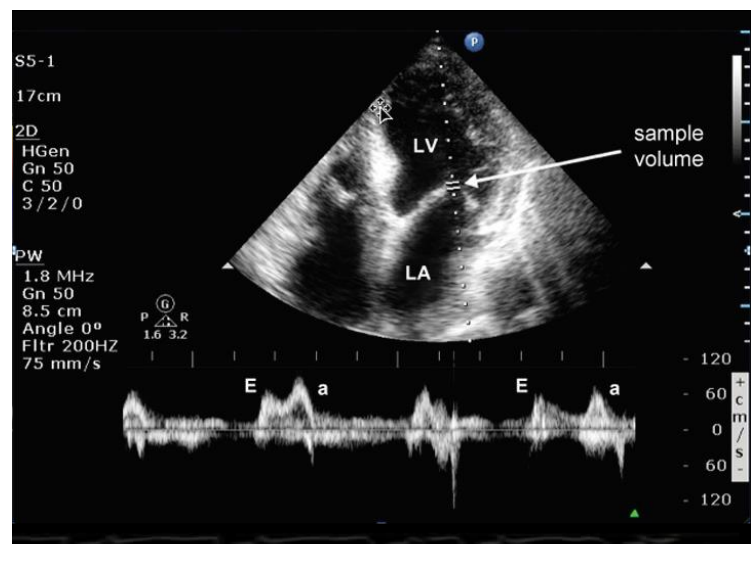
Power Doppler



M-Mode



Continuous Wave Doppler



Pulsed Wave Doppler

Table 5 Suggested targets of the FoCUS examination

LV dimension, systolic function

RV systolic function*

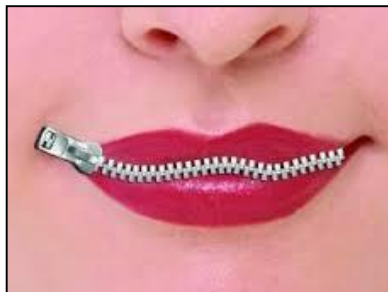Volume status

Pericardial effusion, tamponade physiology†

Gross signs of chronic heart disease‡

Gross valvular abnormalities§

Large intracardiac masses||

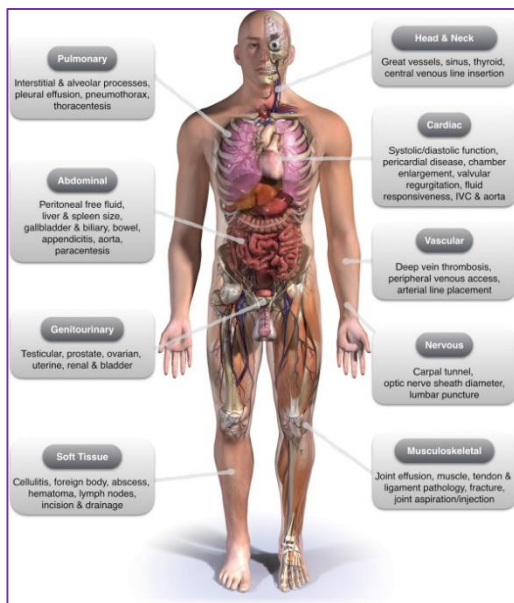


病史

理學檢查



床邊超音波



POCUS-assisted PE

Intern Emerg Med. 2017;12(3):371-378

Kimura BJ. Heart. 2017;103(13):987-994



Acquire

SPA 1

SPA 2



Scan

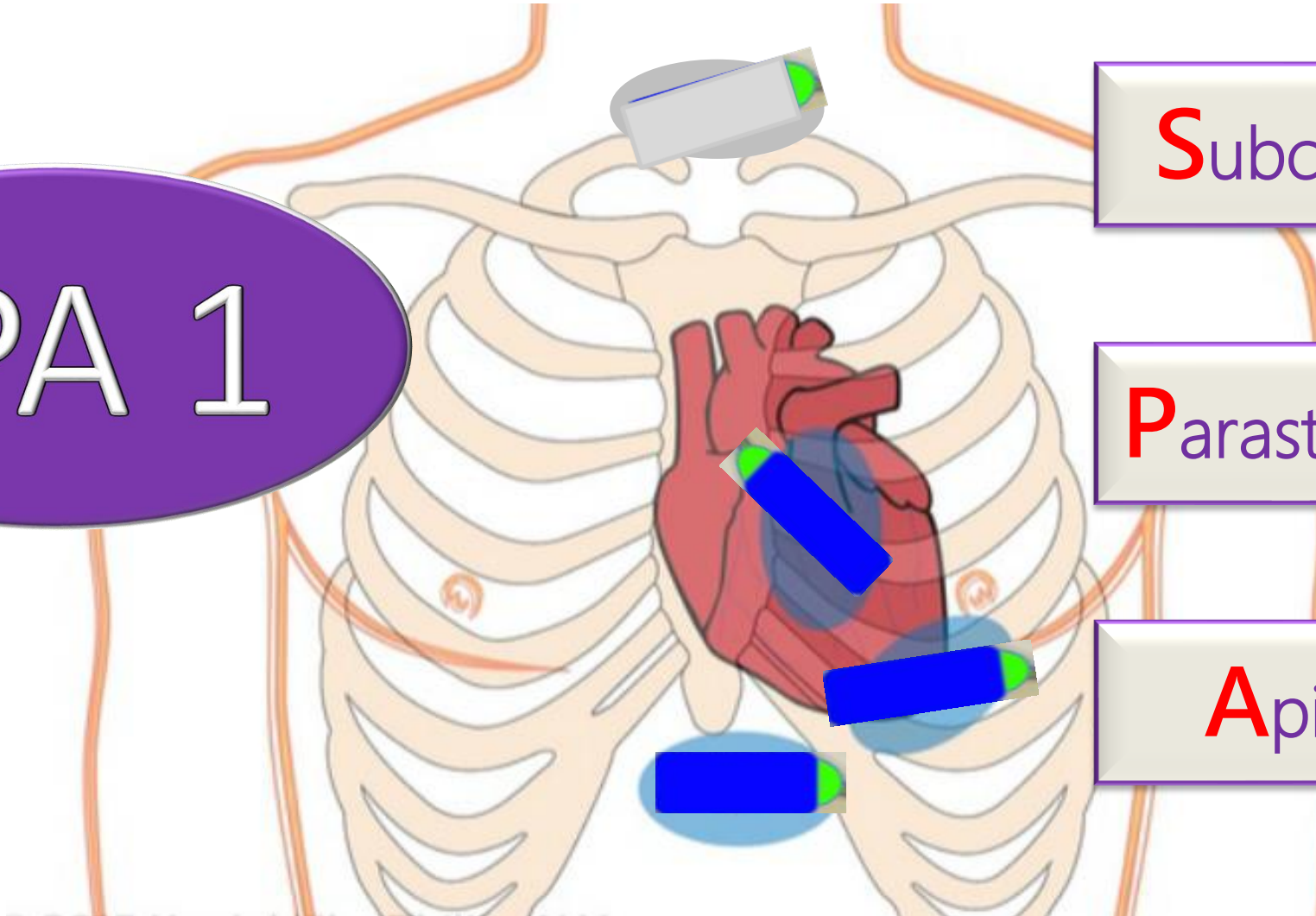
Suprasternal Notch View

Subcostal View

Parasternal View

Apical View

SPA 1



A close-up photograph of a person's face as they look through a pair of black binoculars. The person's hands are visible holding the binoculars. The background is a plain, light-colored wall. Several text overlays are present: a black oval with 'Read' in yellow at the top left; a black oval with 'S' in red and 'ono-anatomy' in yellow on the left lens; a black oval with 'P' in red and 'hysio-logical' in yellow on the right lens; a purple oval with 'SPA 2' in white on the bottom left; and a black oval with 'A' in red and 'ssess-ment' in yellow centered below the binoculars.

Read

S
ono
-anatomy

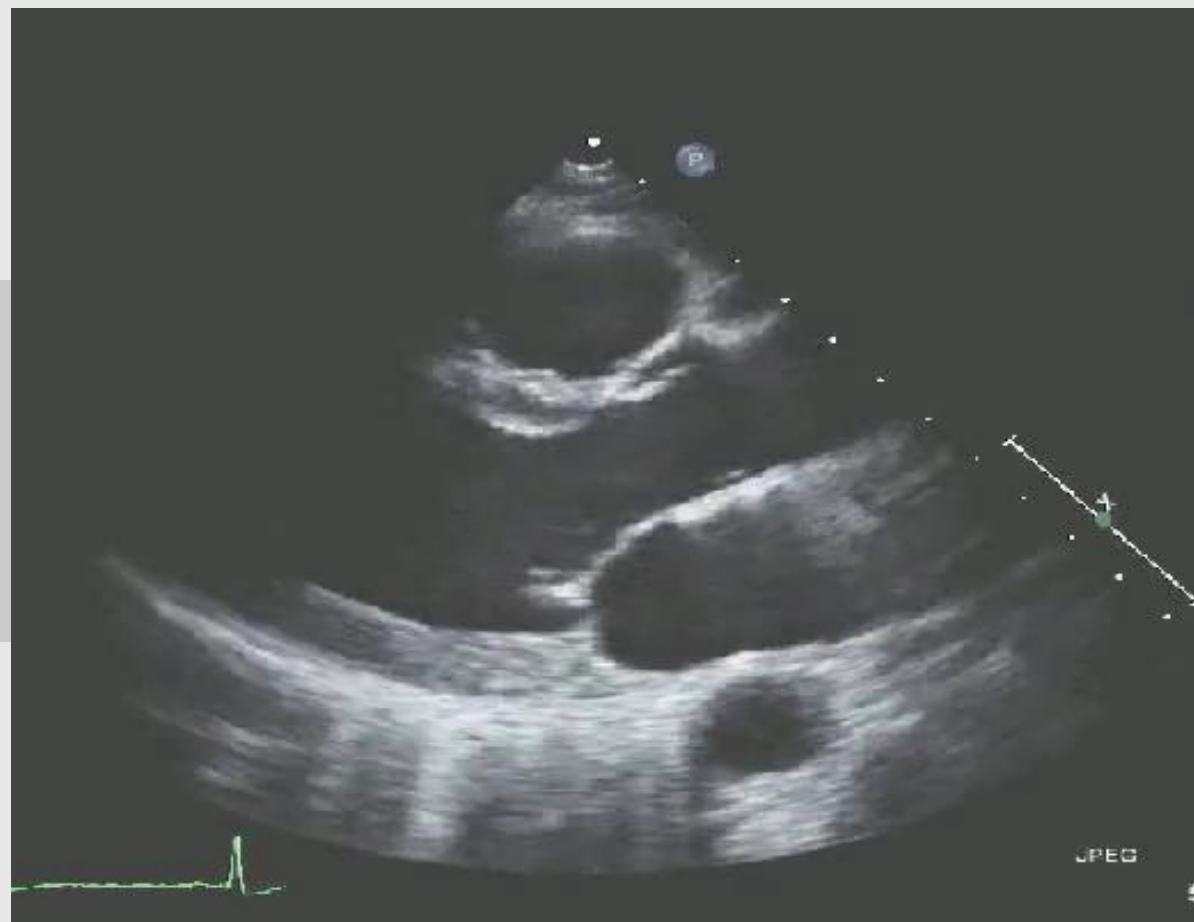
P
hysio
-logical

SPA 2

A
ssess
-ment

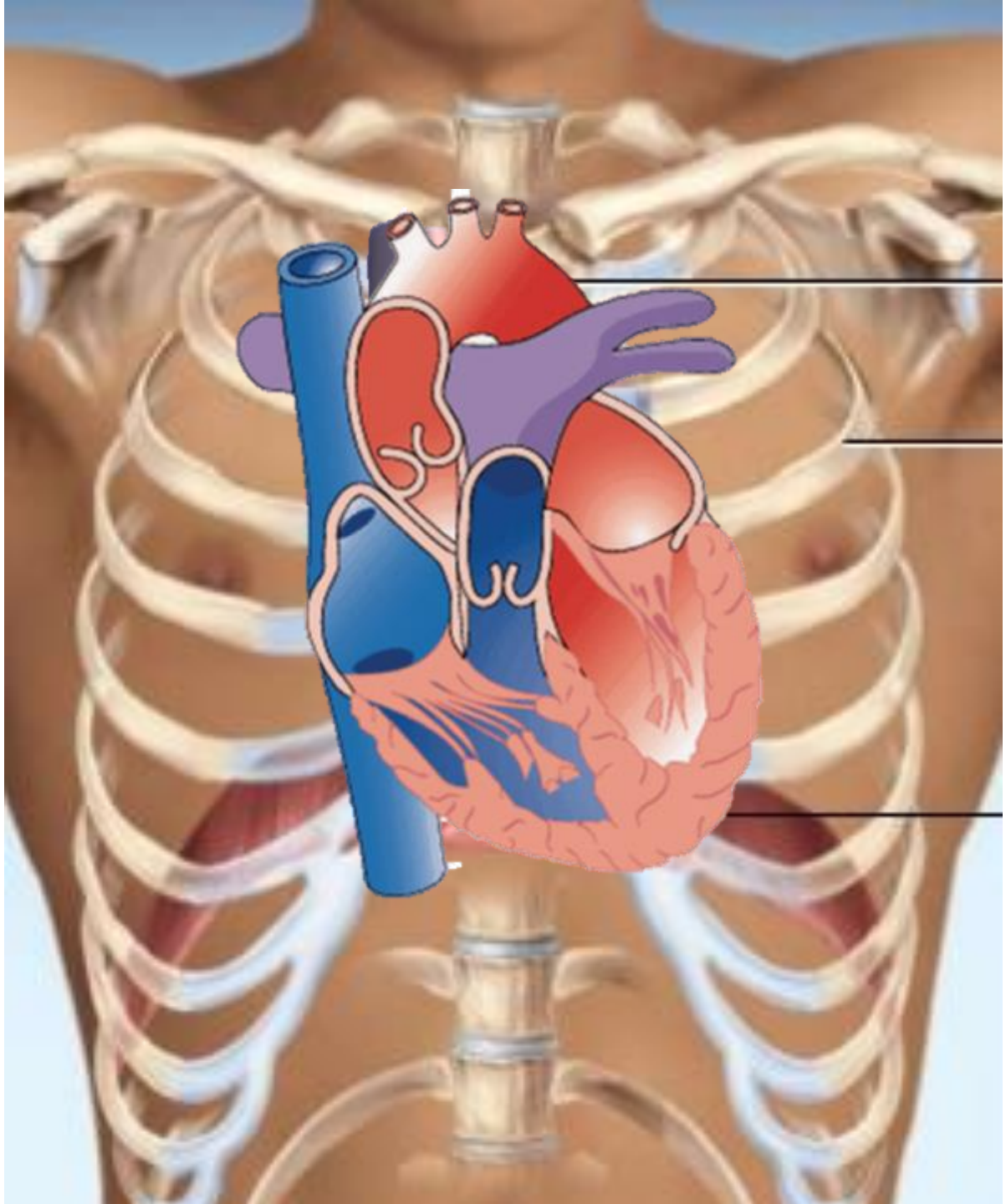
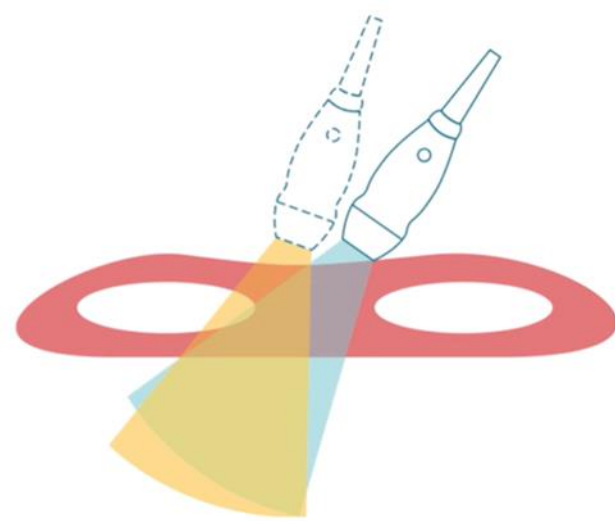
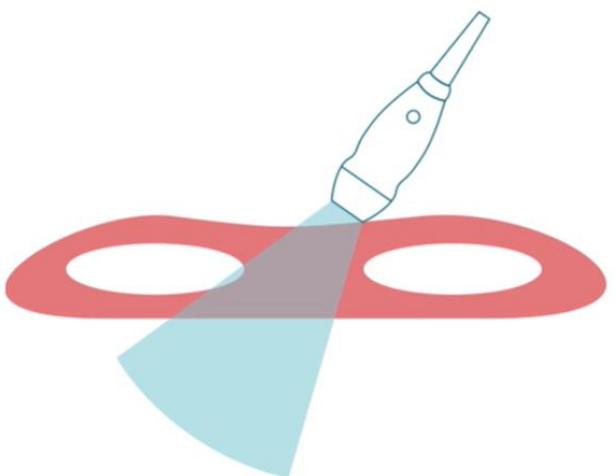
認構造

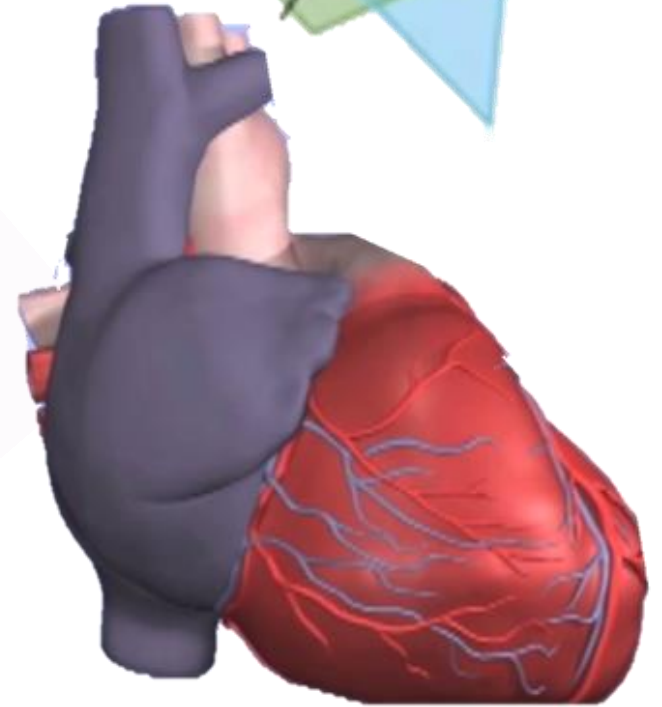
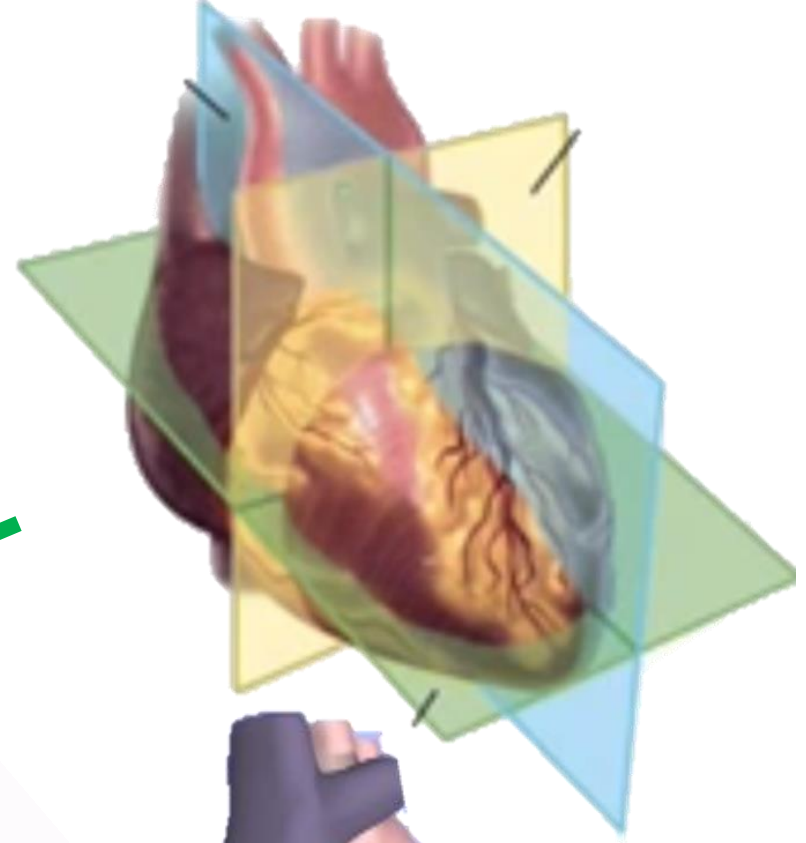
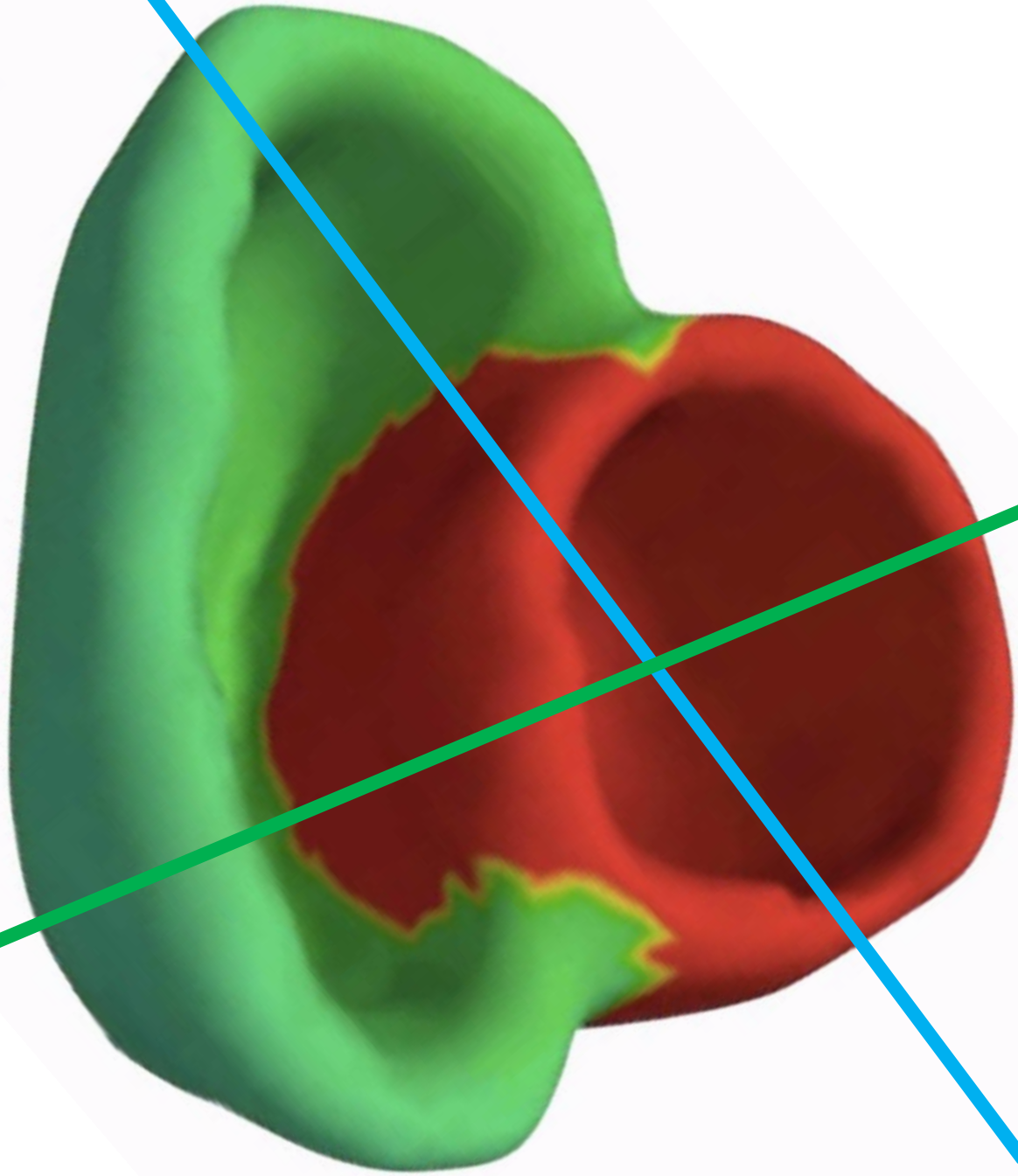
看功能





Cut Plane





Interpret

HEART

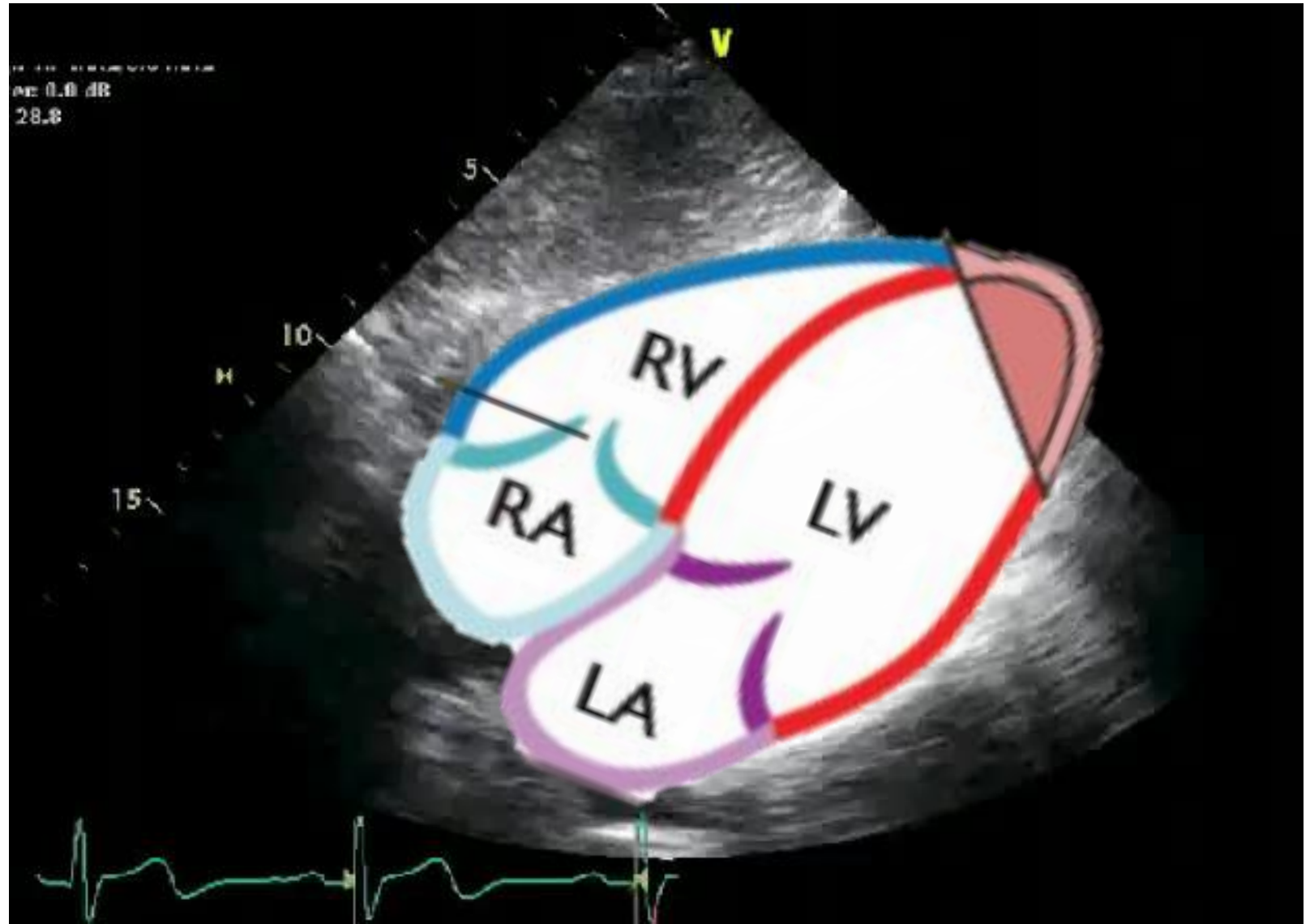
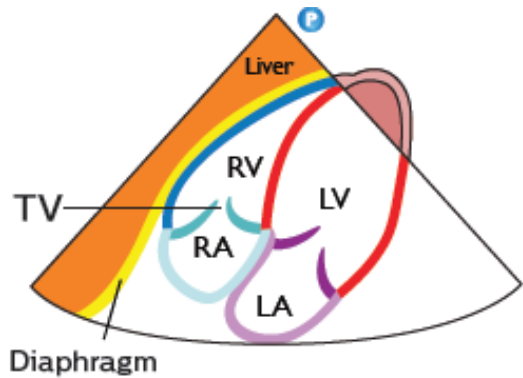
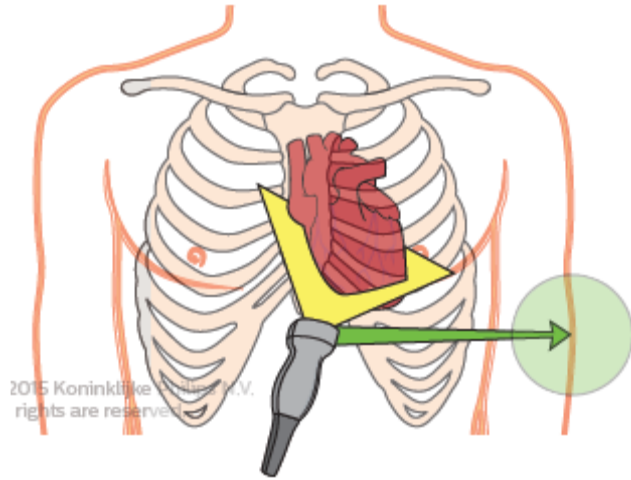
Hypo/hyper-volemia

Ejection

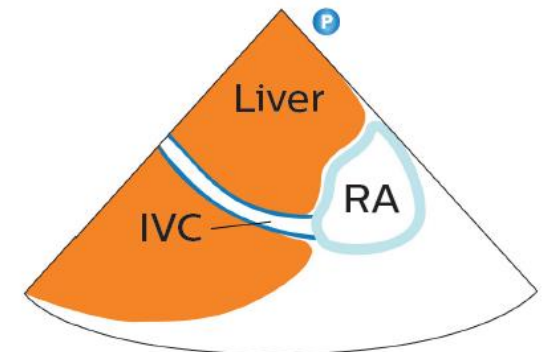
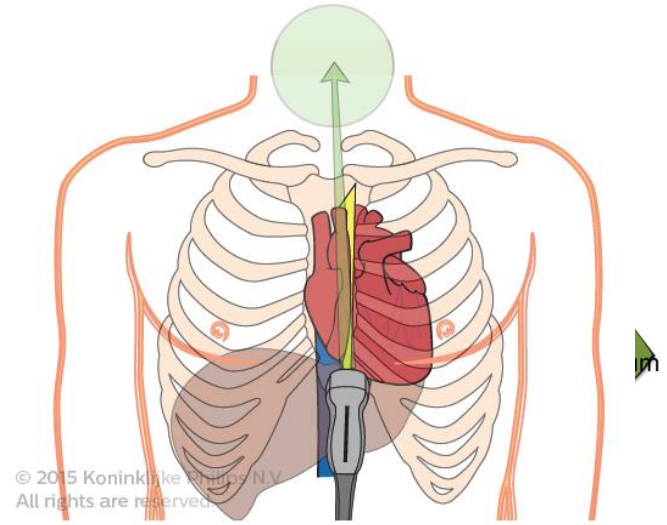
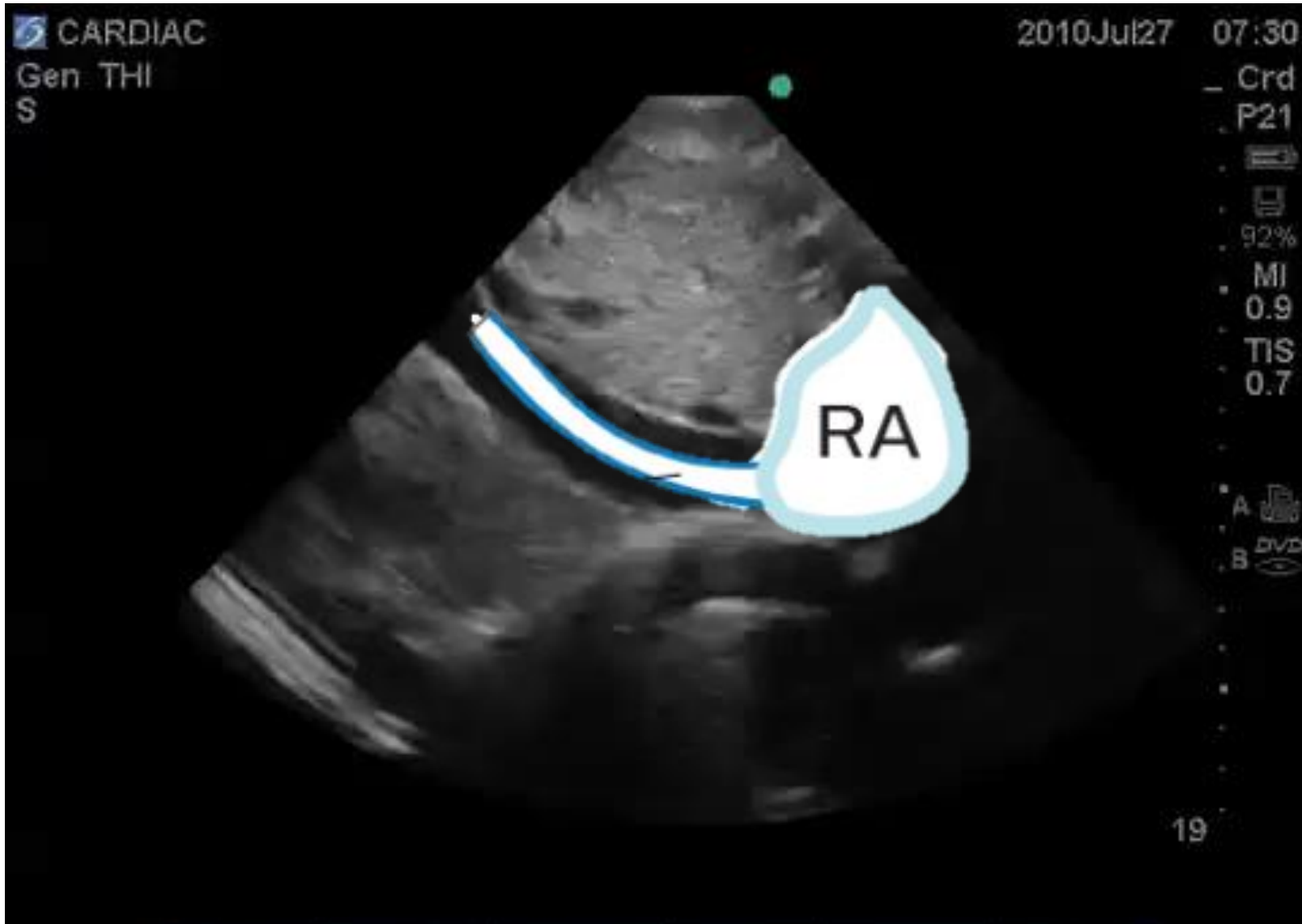
Aorta/valve

Pattern Recognition

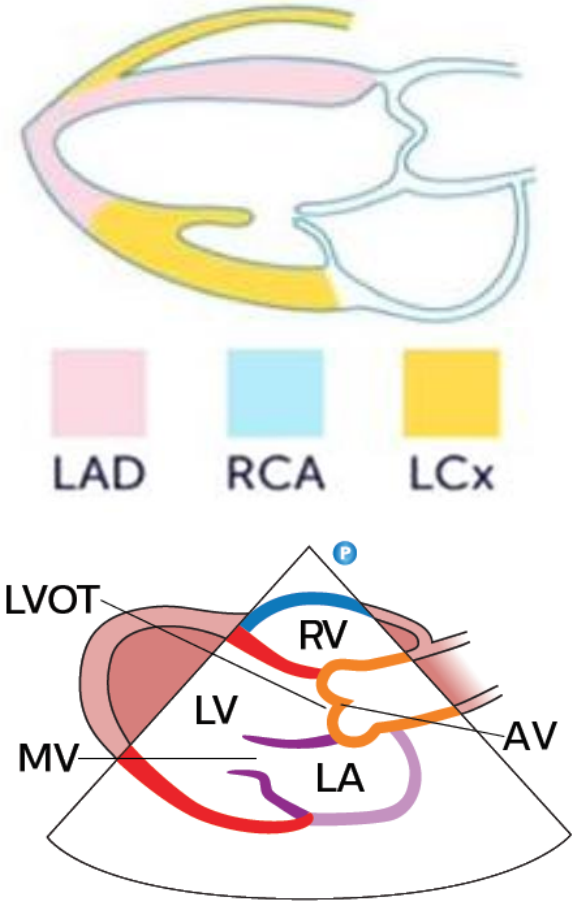
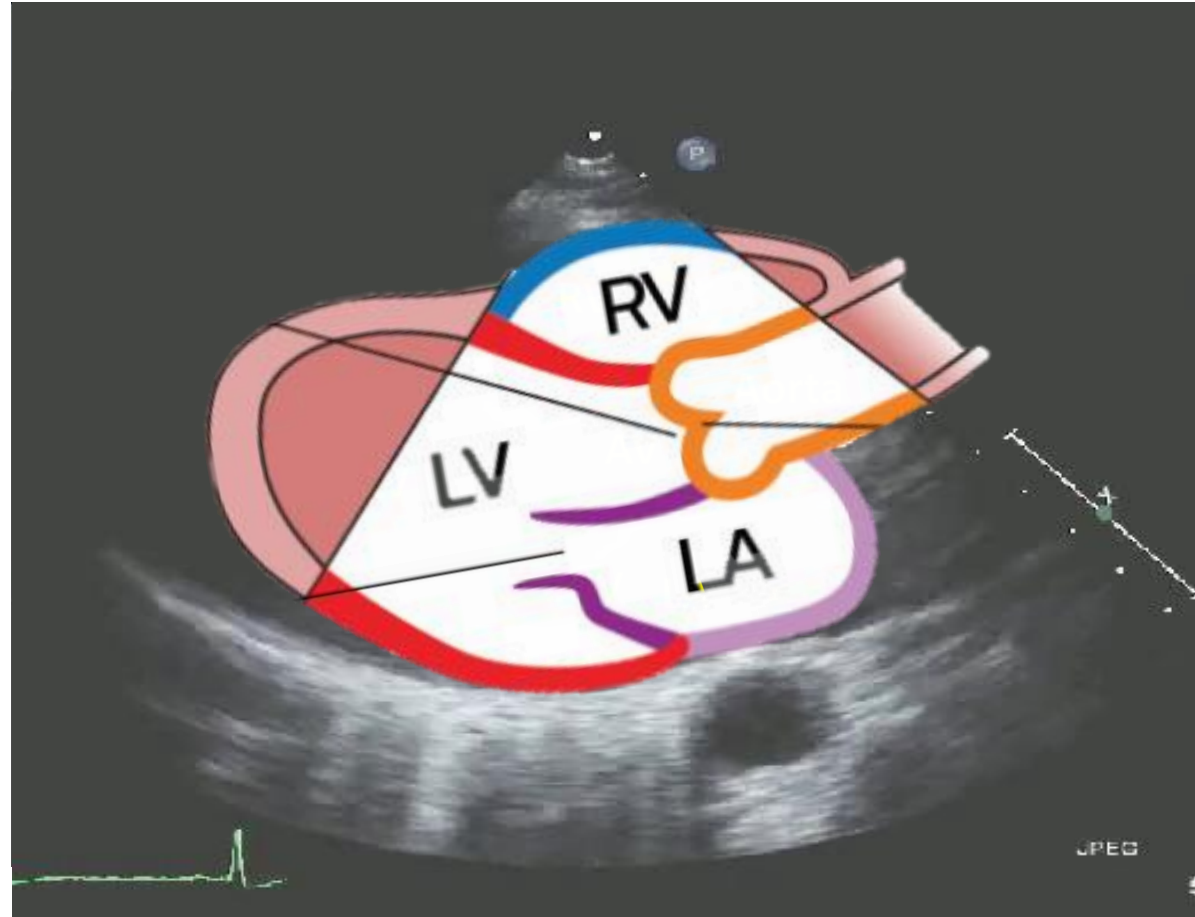

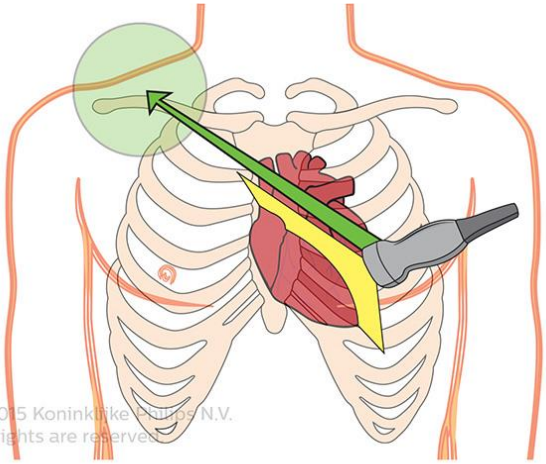
Subcostal Long Axis (SLAX)



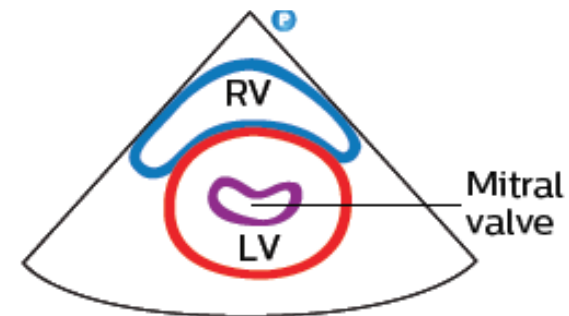
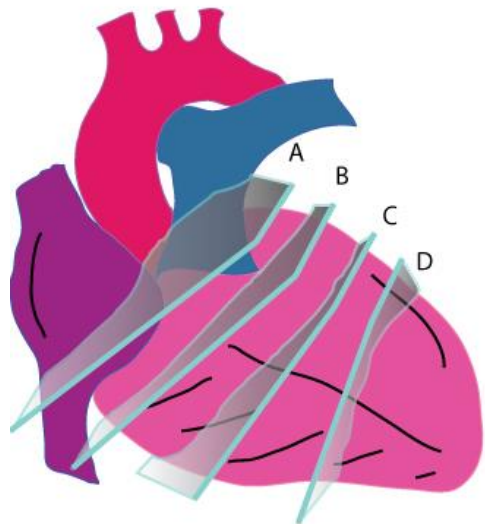
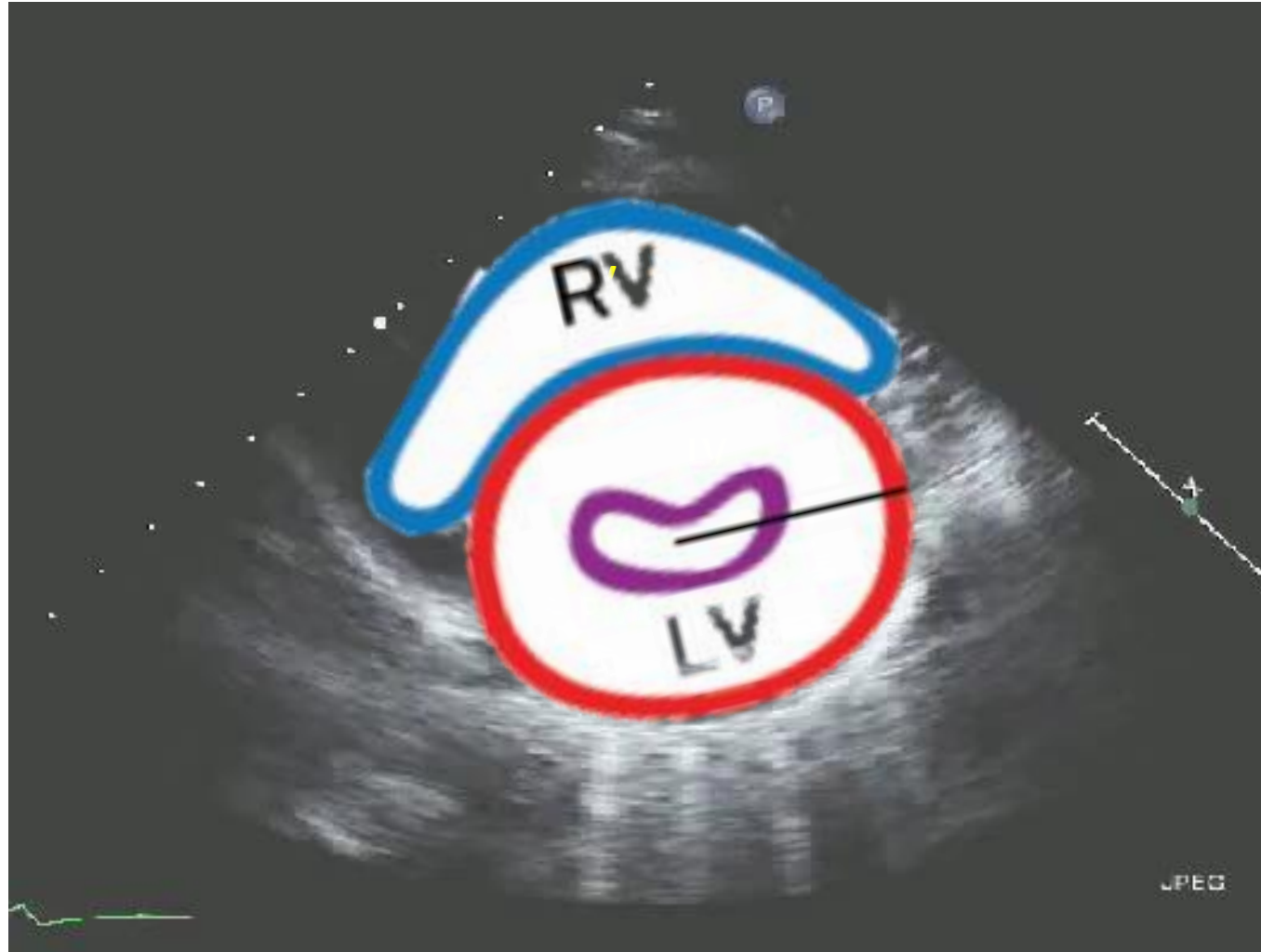
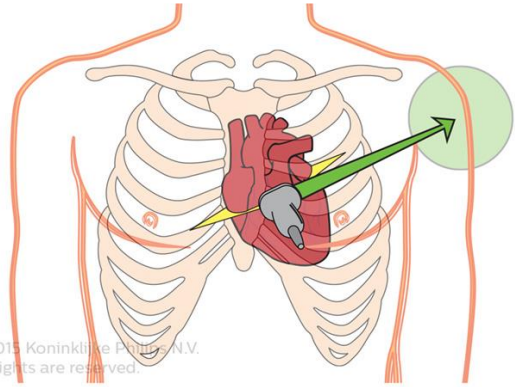
Subcostal IVC (SIVC)



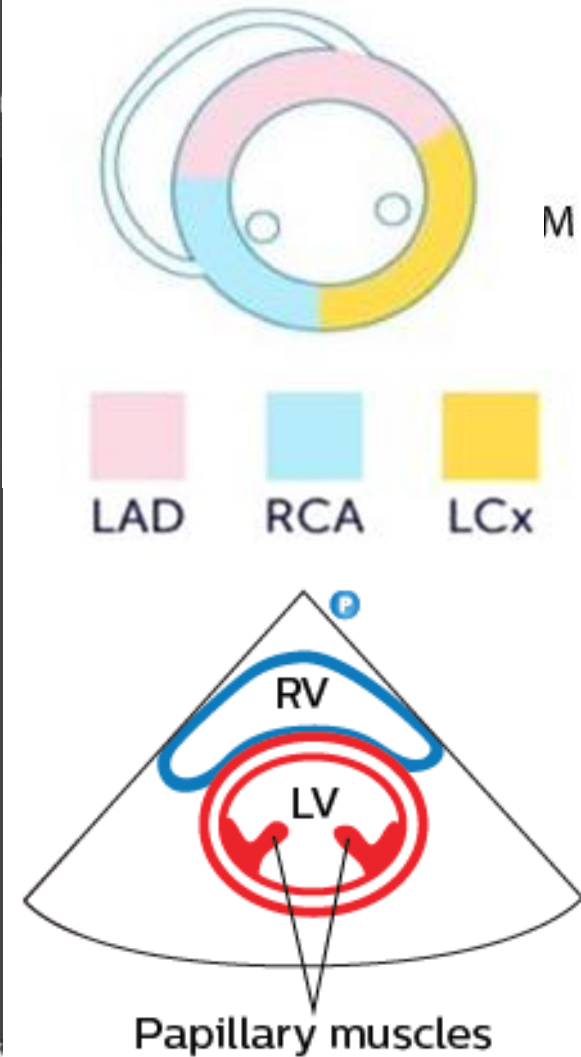
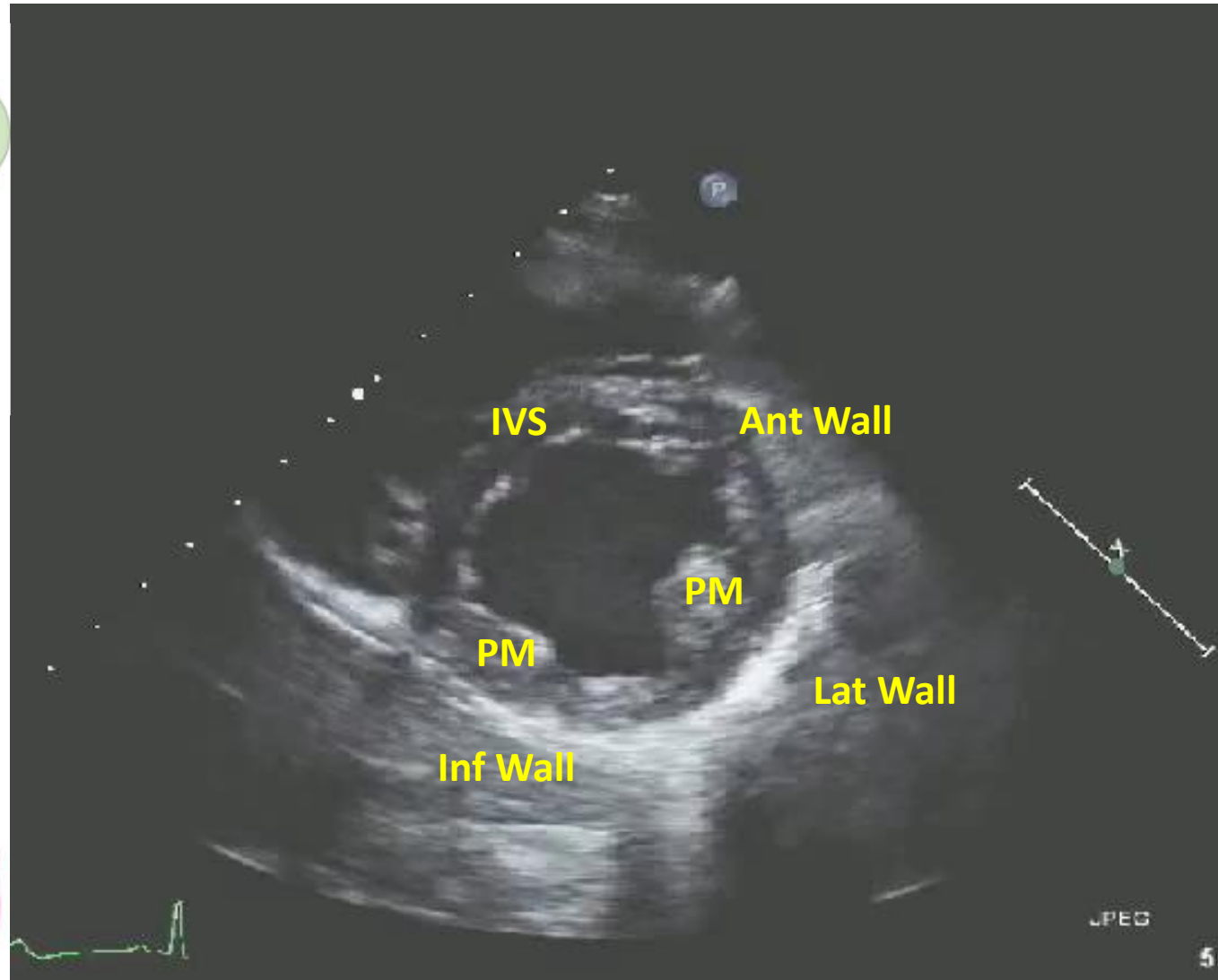
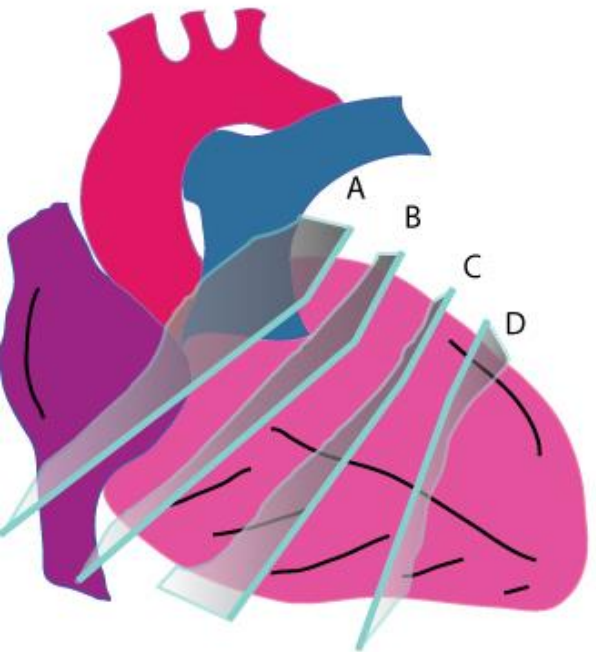
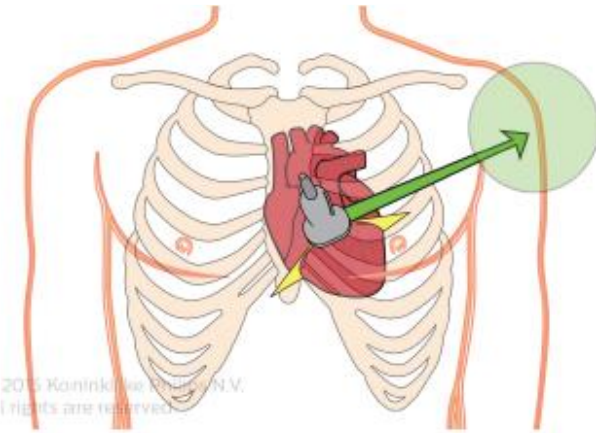
Parasternal Long Axis (PLAX)



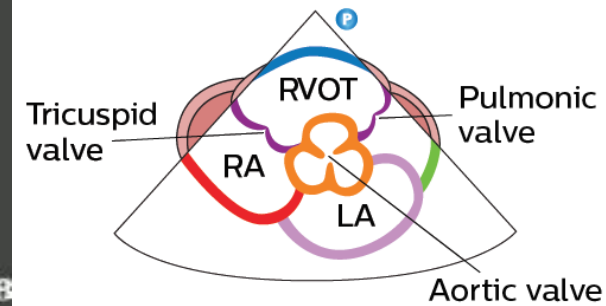
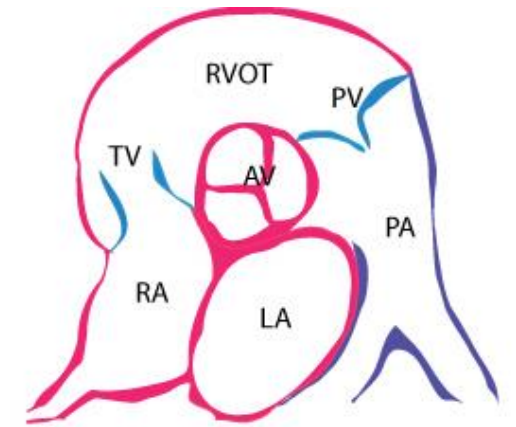
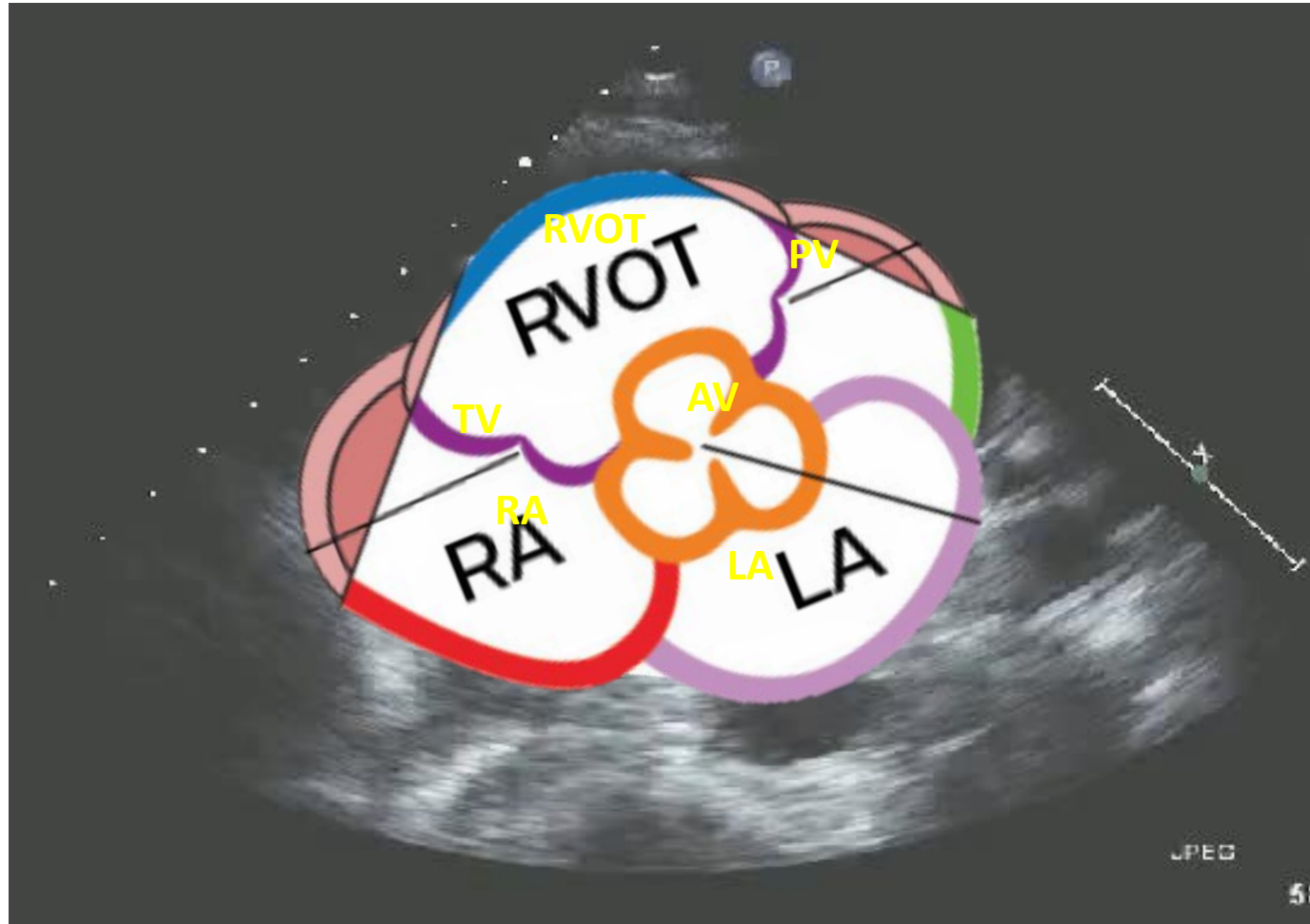
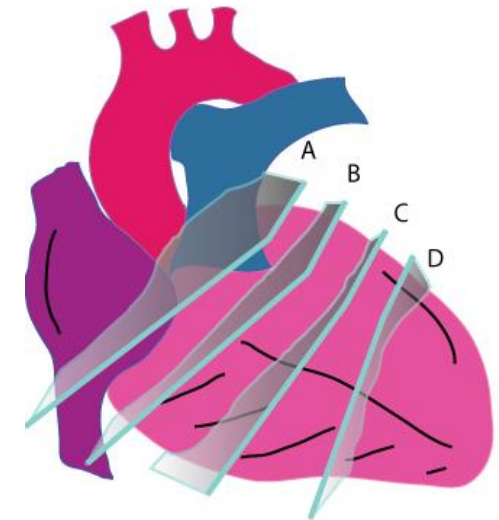
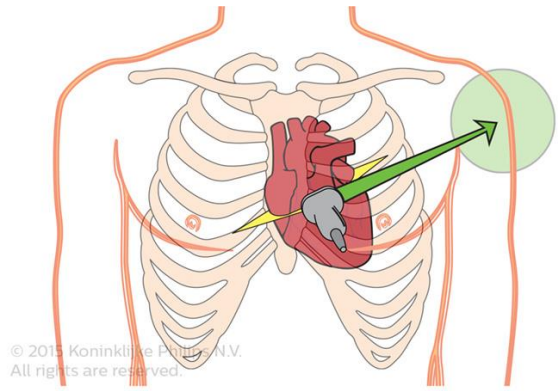
Parasternal Short (PSAX-MV)



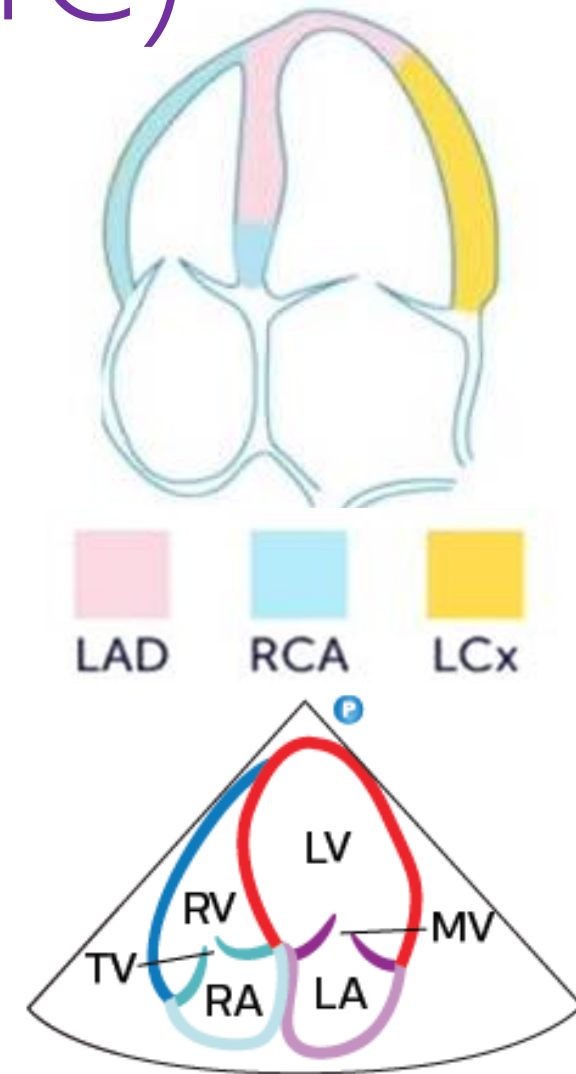
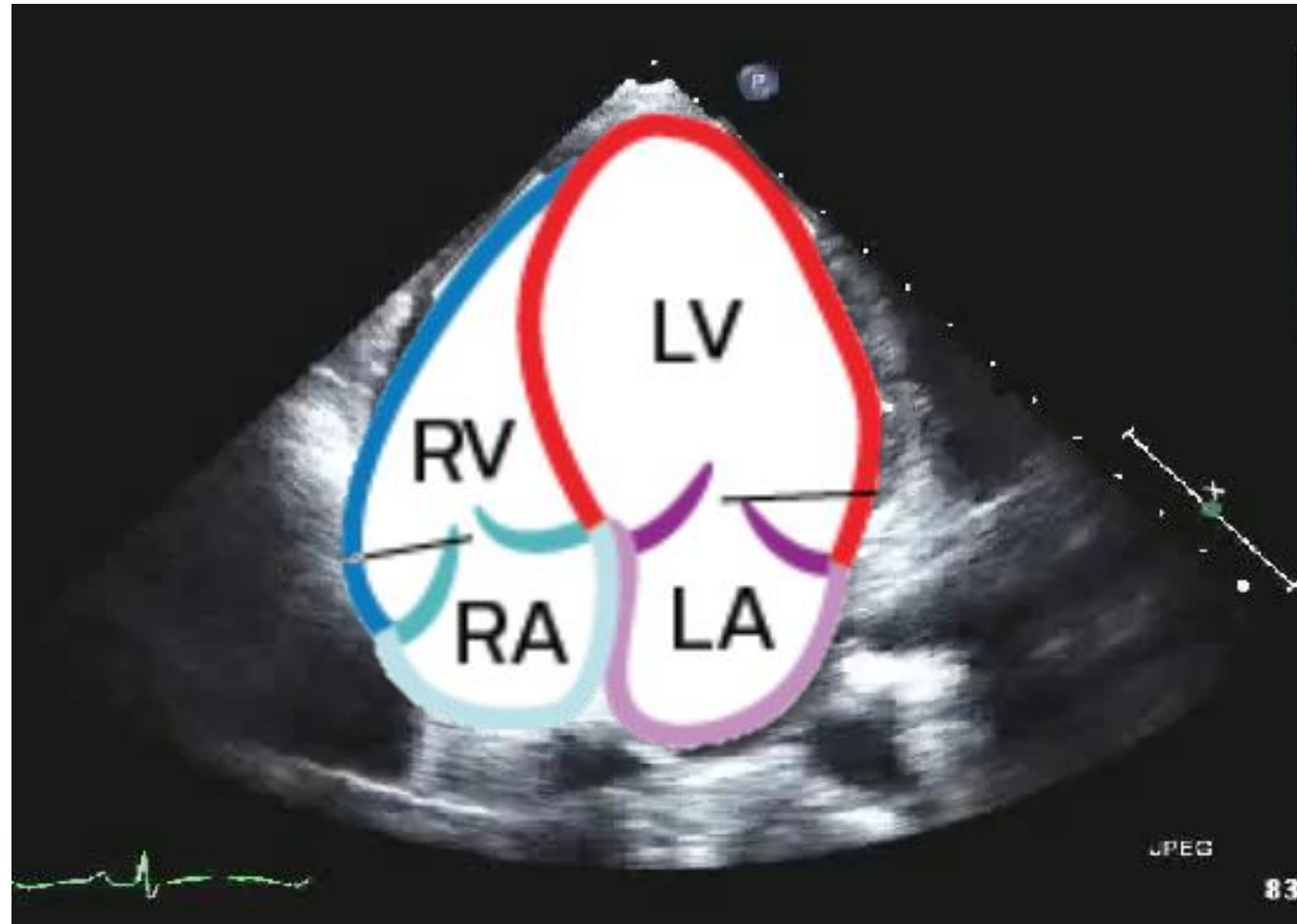

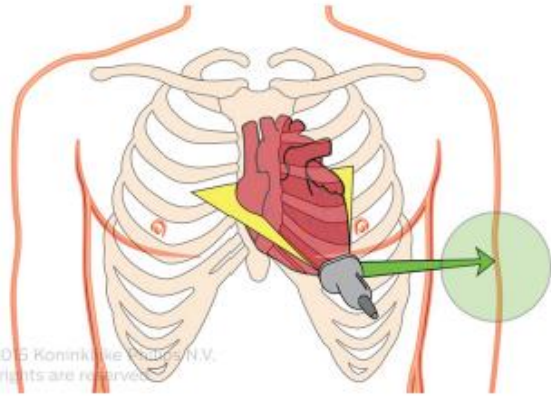
Parasternal Short (PSAX-PM)



Parasternal Short (PSAX-AV)



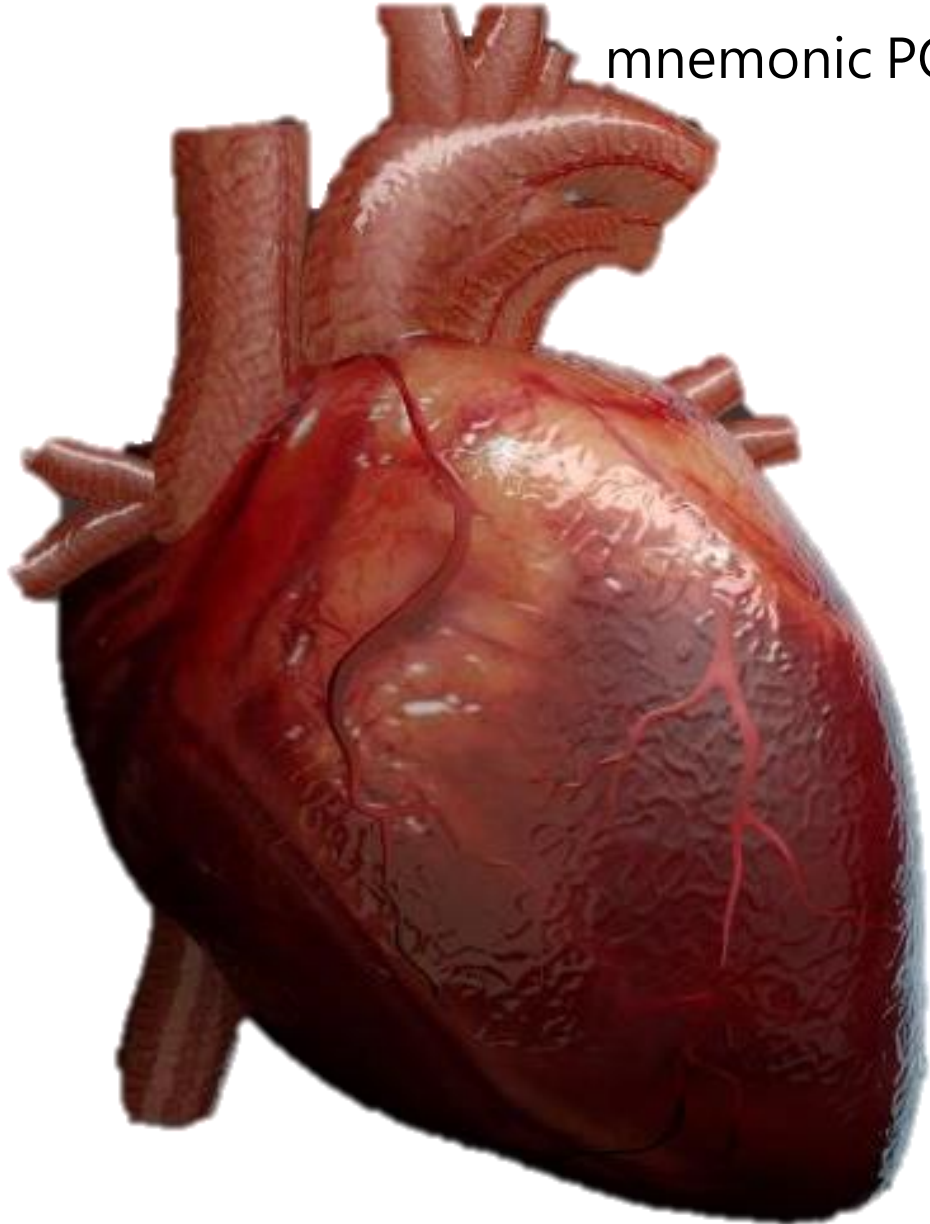
Apical 4-Chamber (A4C)



Interpret

HEART

mnemonic POCUS for Focused Cardiac Ultrasound



Hyper/hypo-volemia

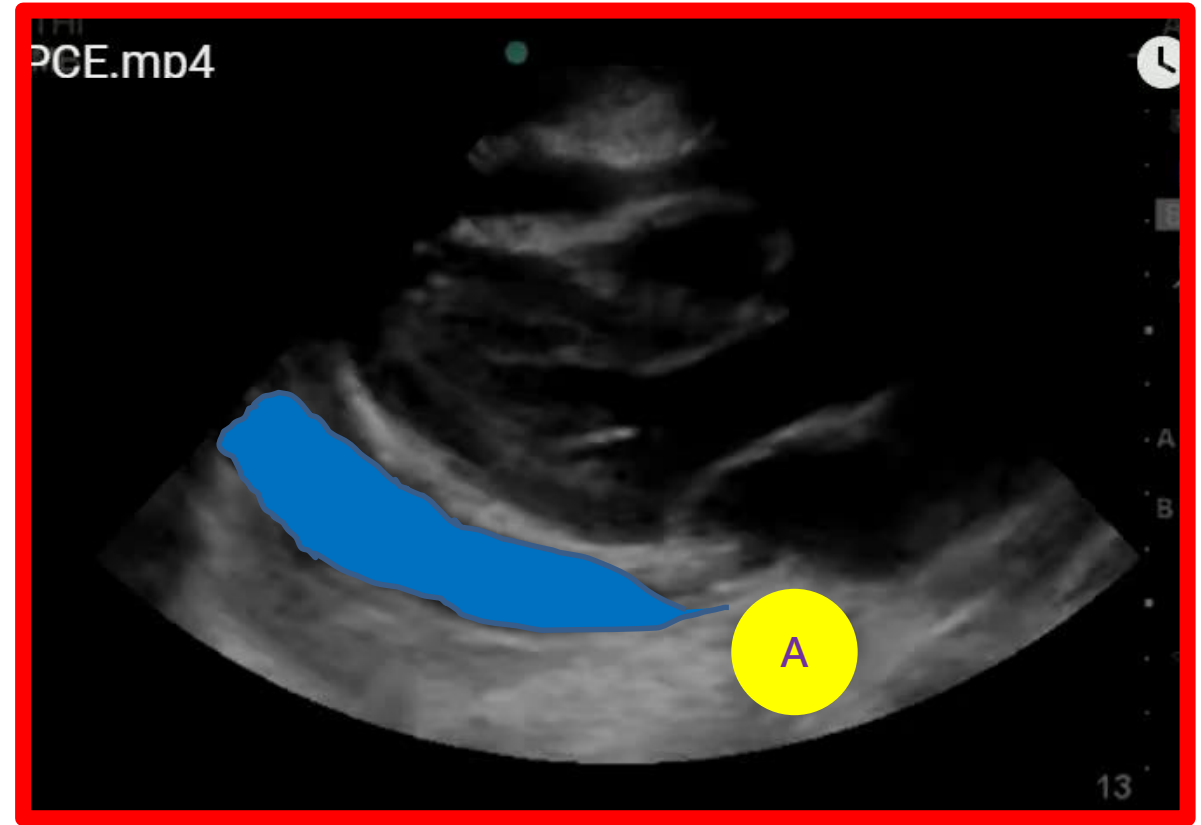
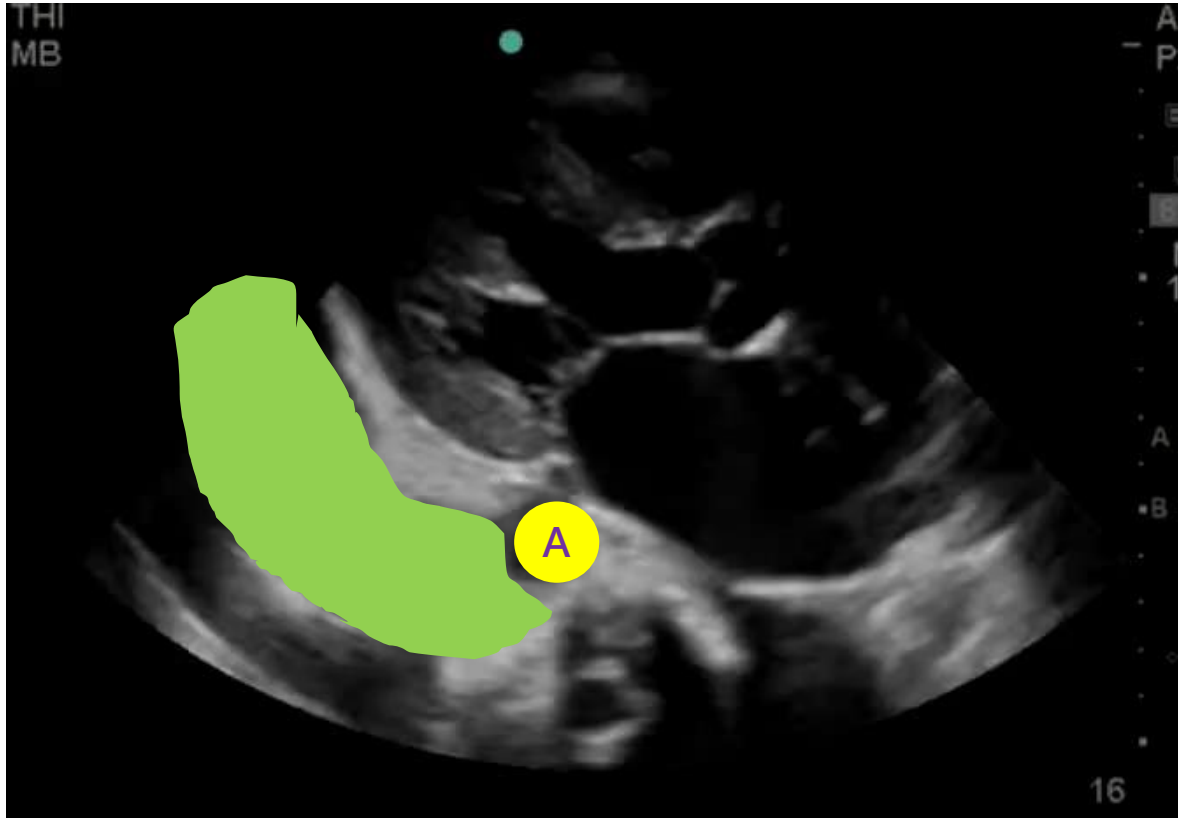
Eejection (LVF)

Aorta/valve

Right chamber

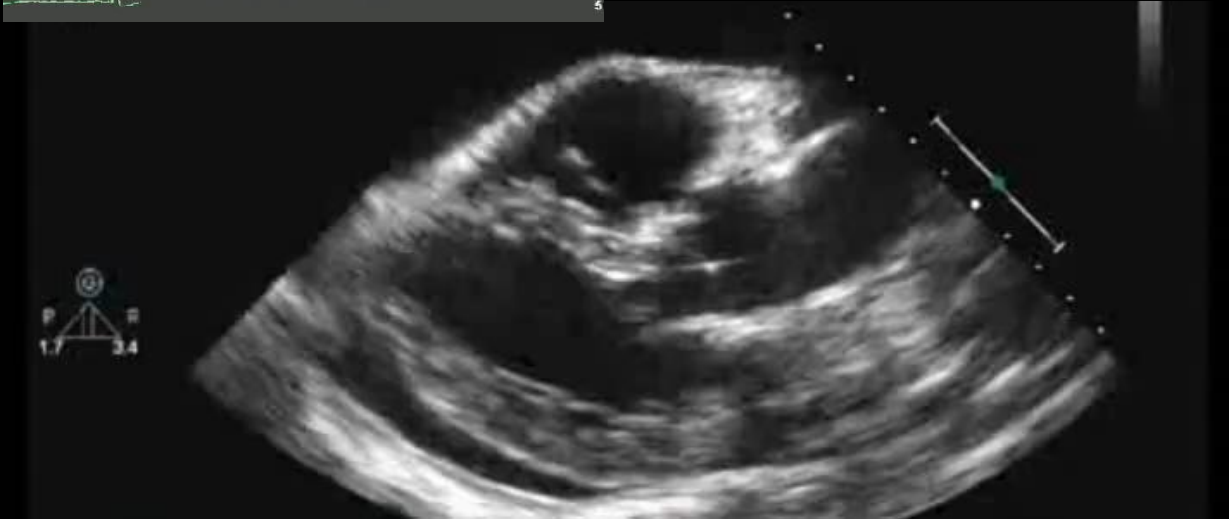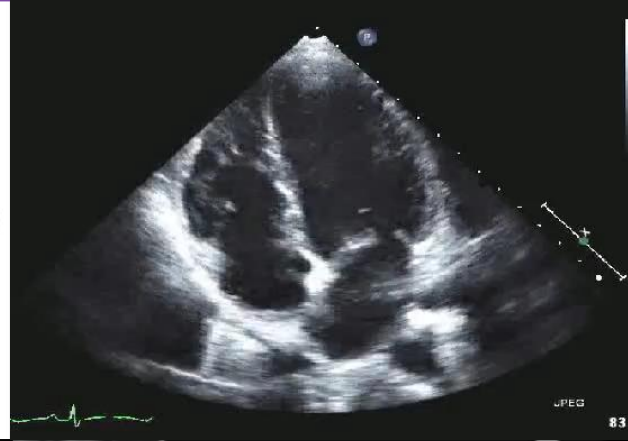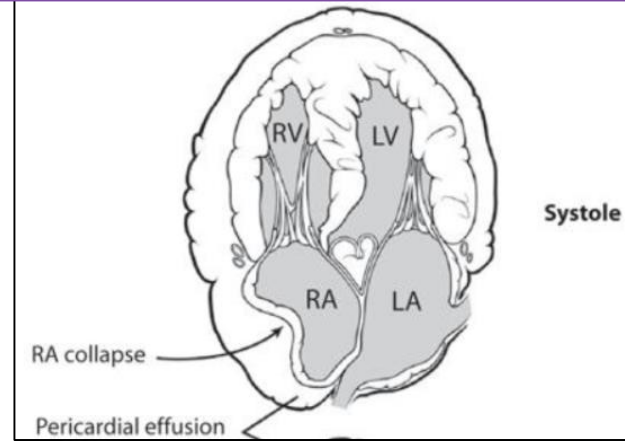
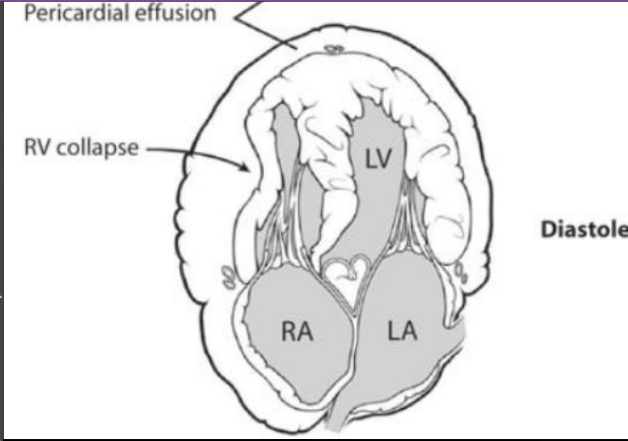
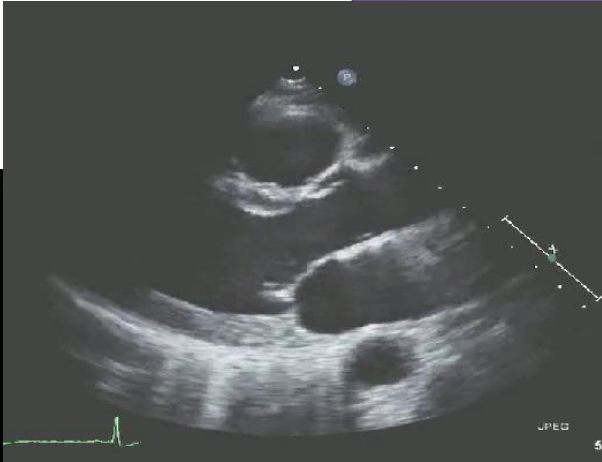
Tamponade

Pericardial Effusion or Pleural Effusion ?

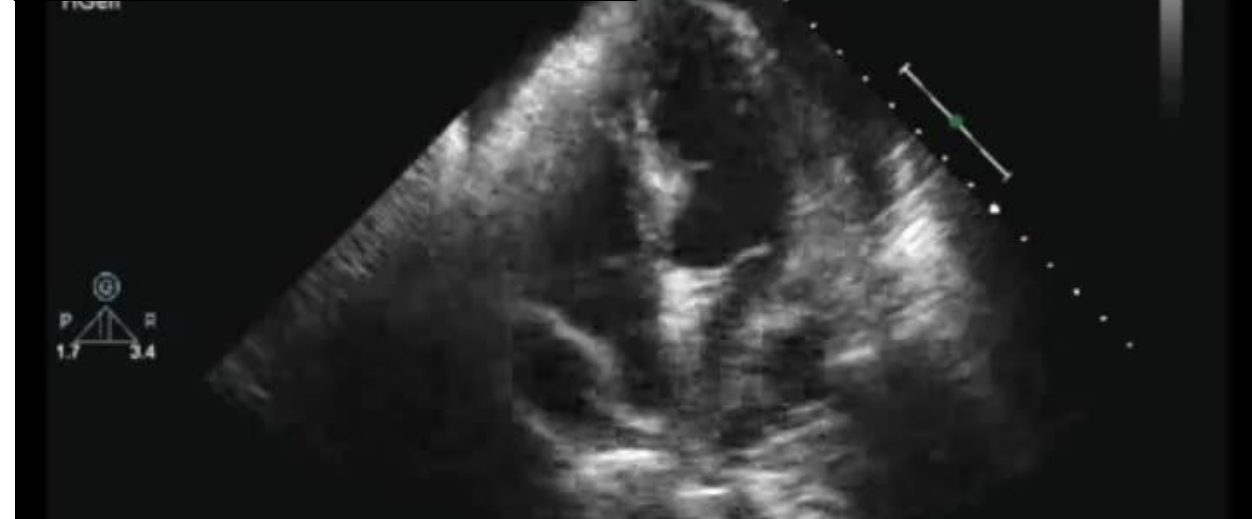

Aorta as a marker

Tamponade is Clinical Diagnosis !



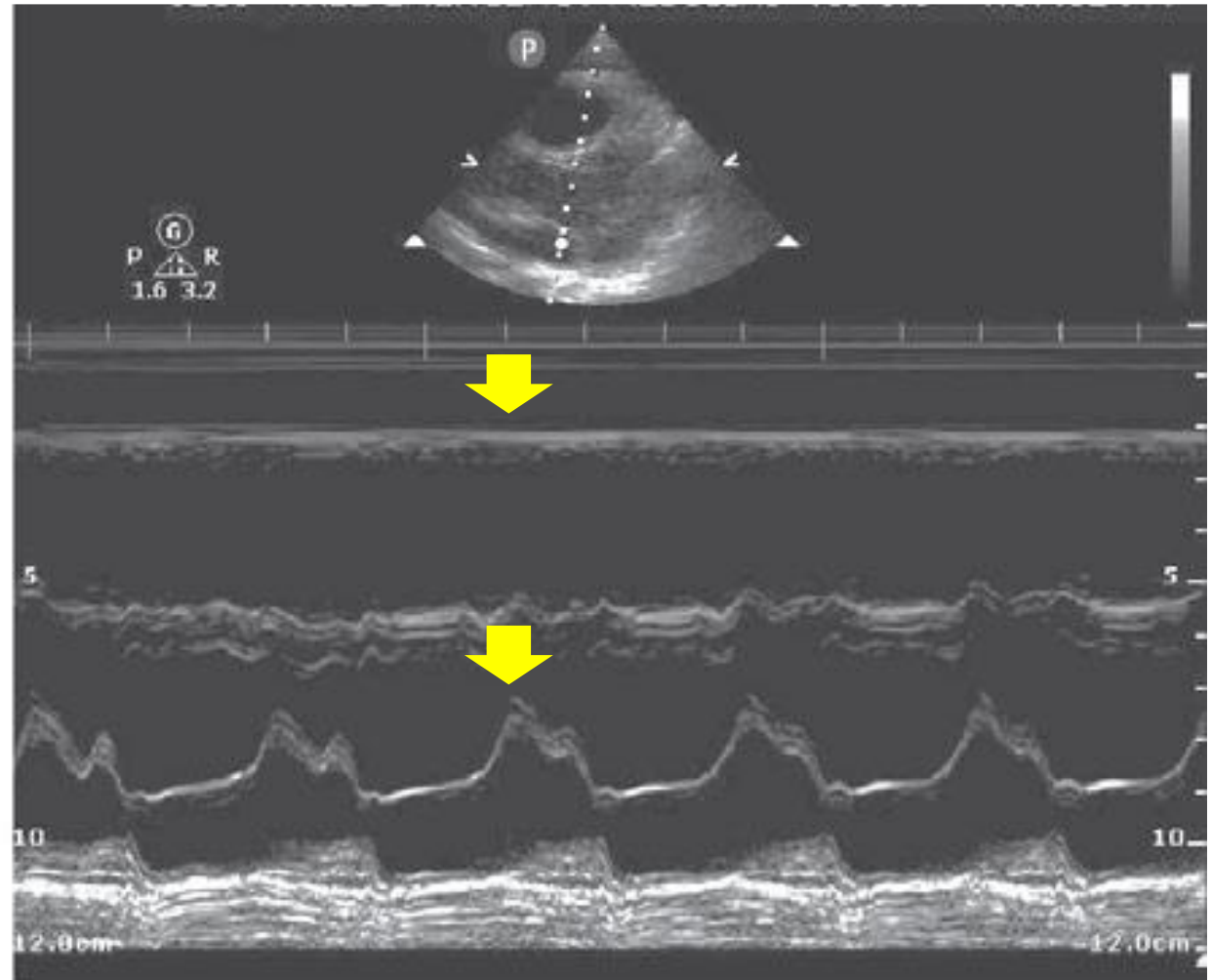
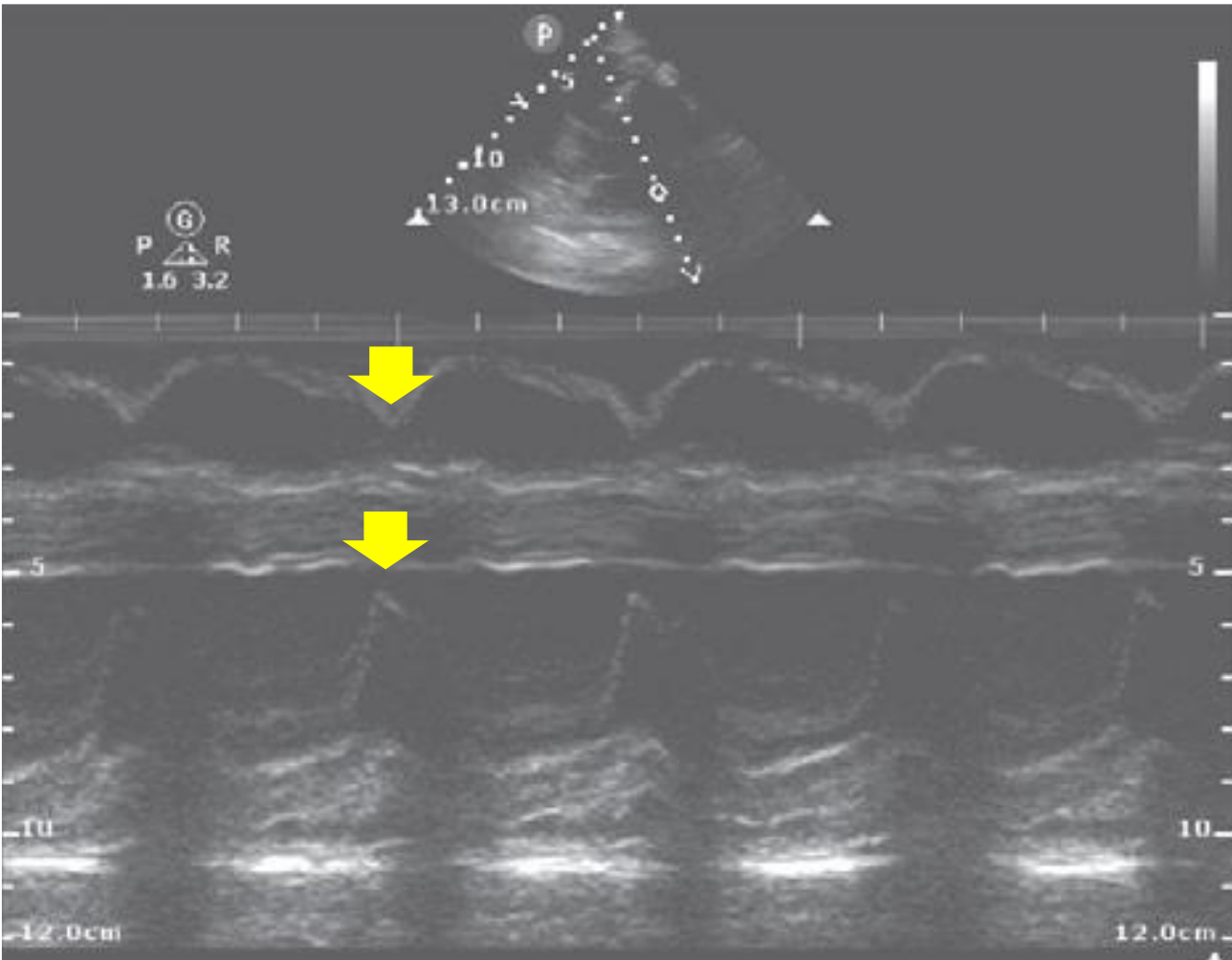
Diastolic
RV collapse

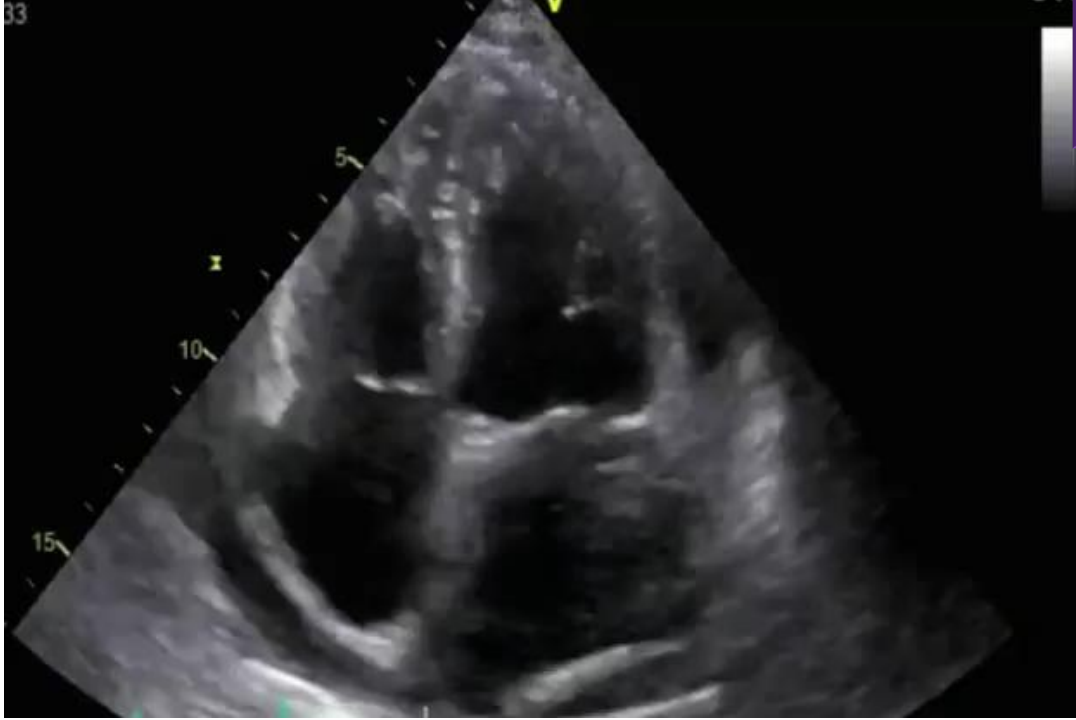

Systolic
RA collapse

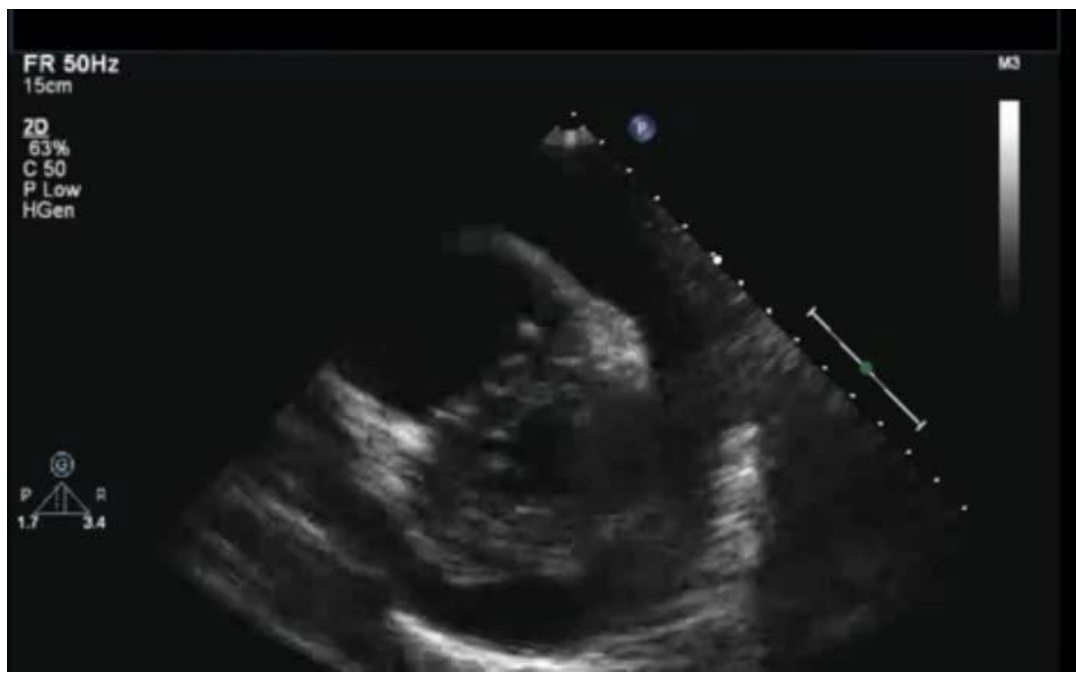
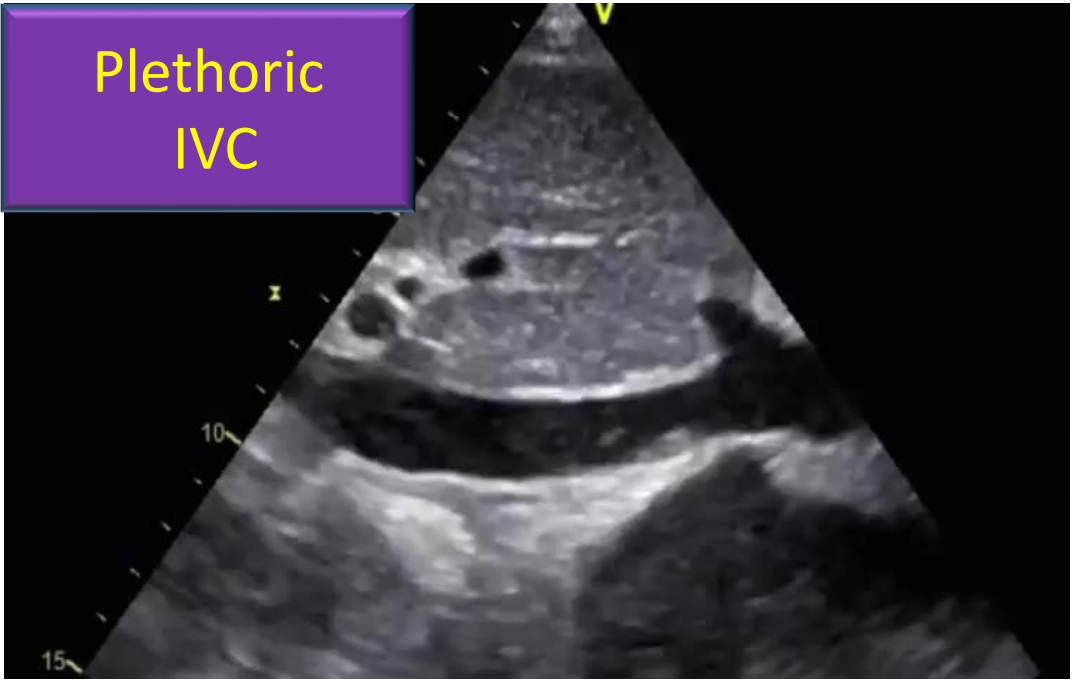
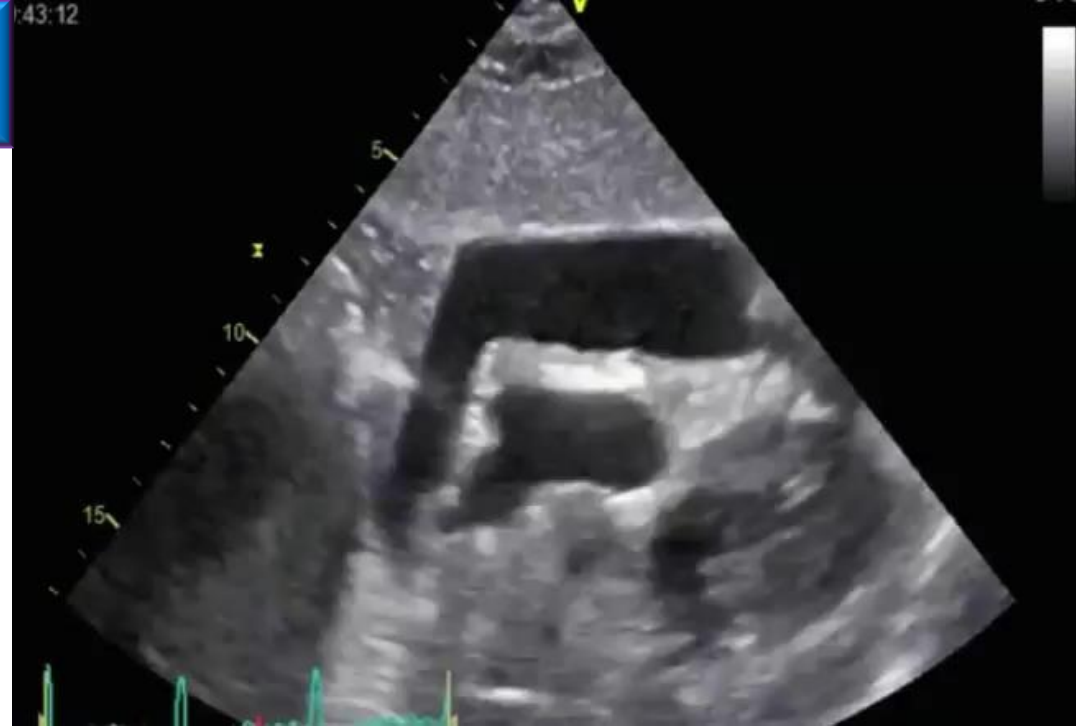PLAX or SLAX

M-mode





Tamponade
Effusion



Pericardial effusion

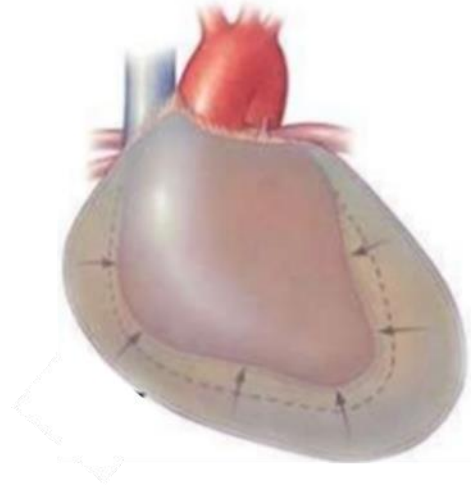
↑
Intra-pericardial pressure

Systolic
RA collapse

Diastolic
RV collapse

Impaired ventricular
filling and increased
interventricular
dependence

Plethoric
IVC



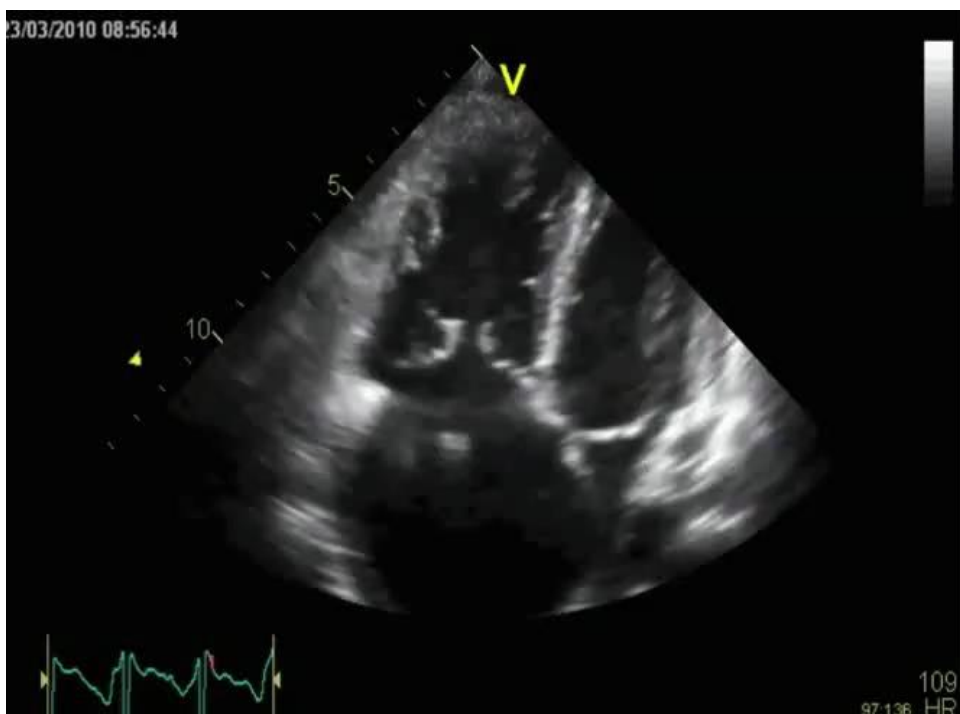
Pericardium

SX4C **P**SLA/**P**SSA **A4C**

1. Pericardial
vs
Pleural effusion

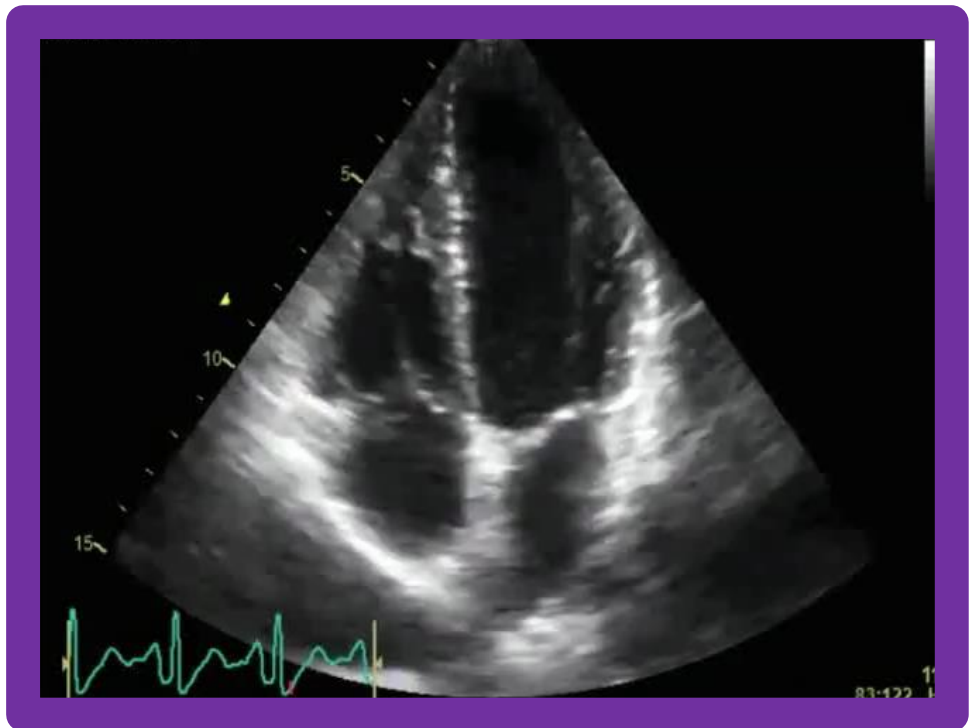
2. Tamponade:
RV Diastolic collapse
RA Systolic collapse
Plethoric IVC

23/03/2010 08:56:44

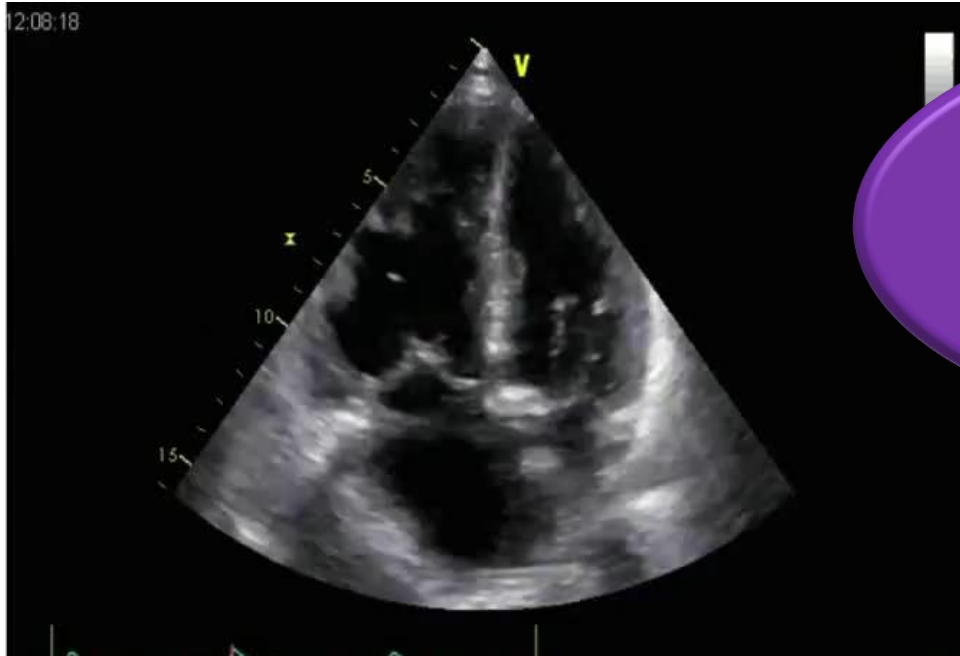


Rt Chamber
Equity

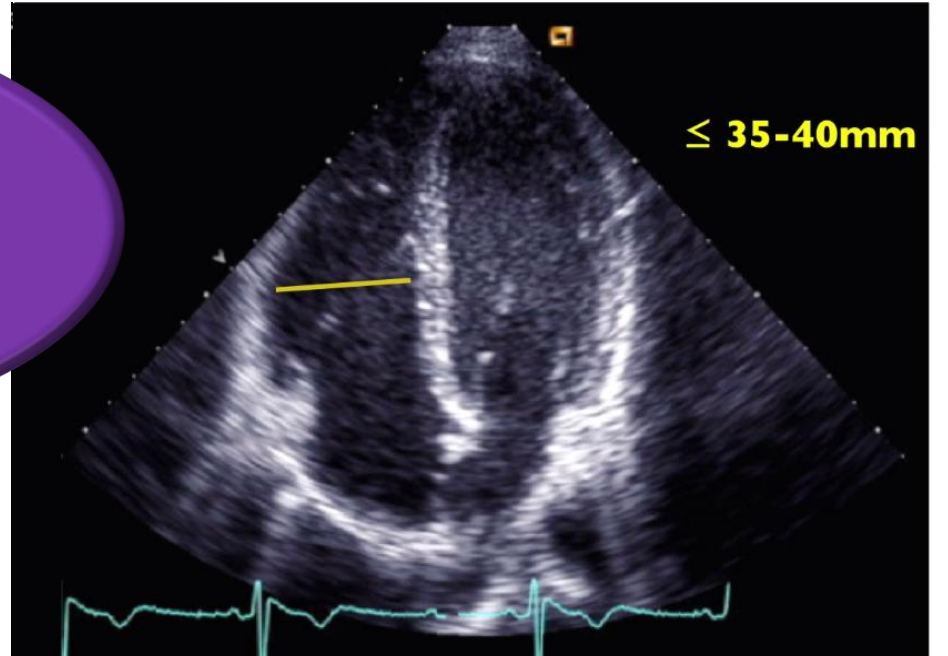
RV:LV
> 1:1

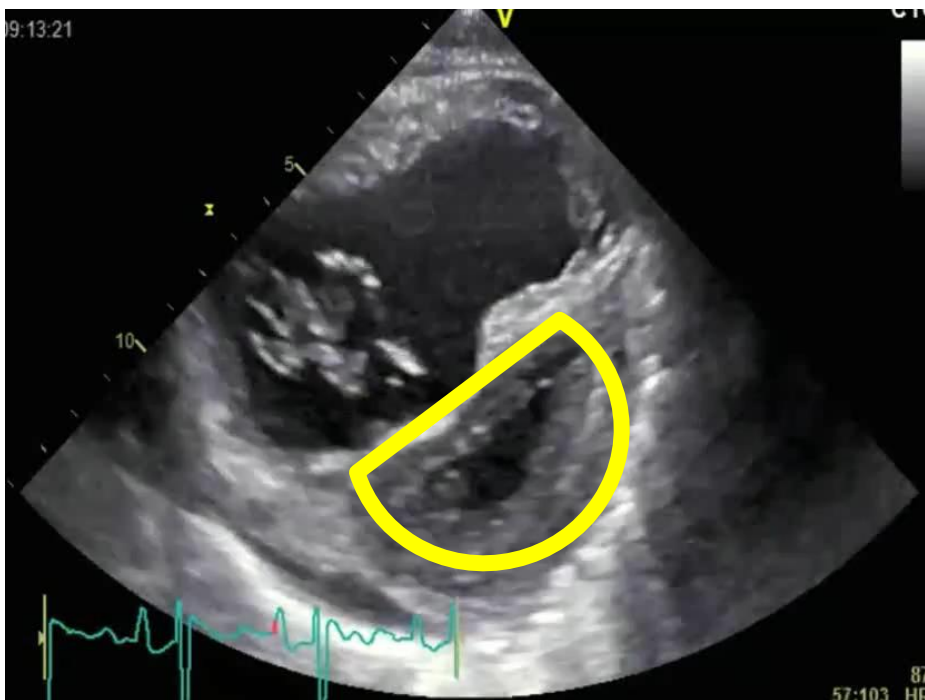


12:08:18



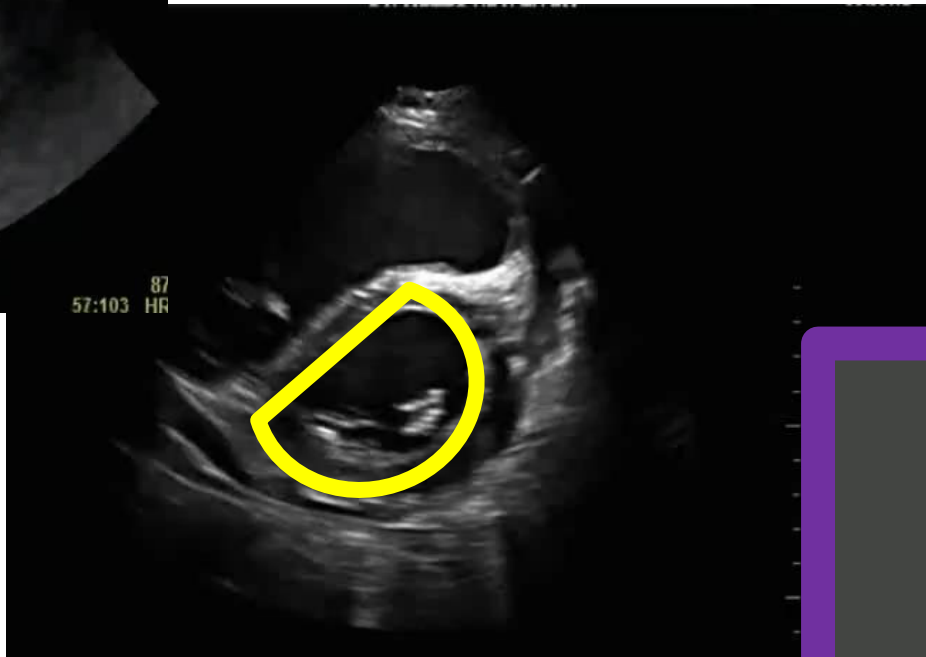
RV Strain



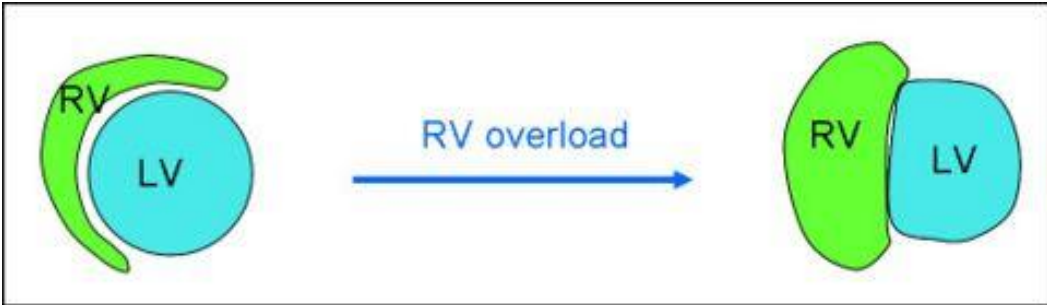
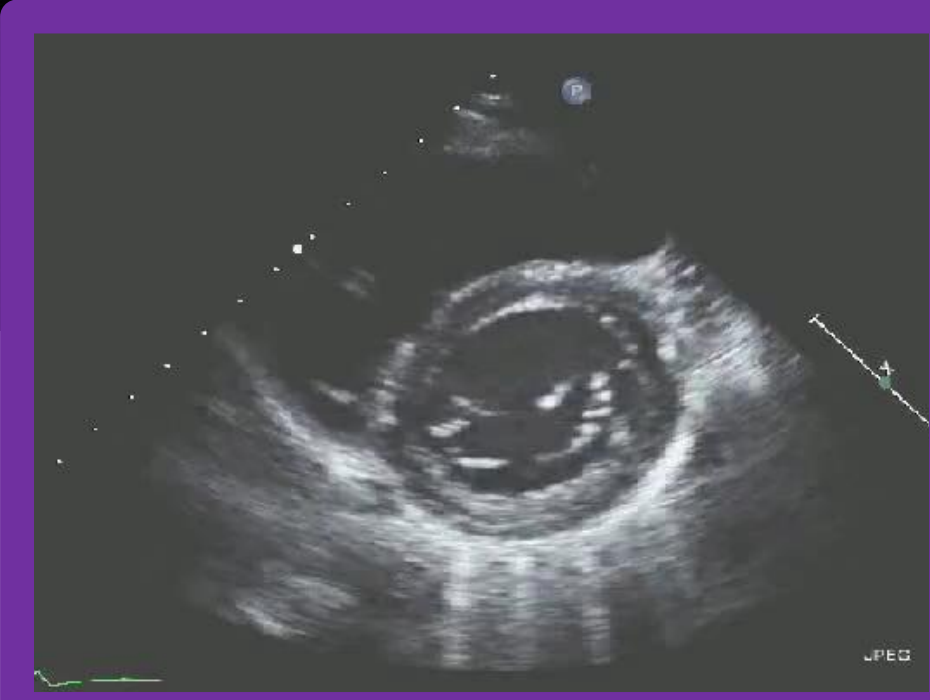


Rt Chamber
Equity

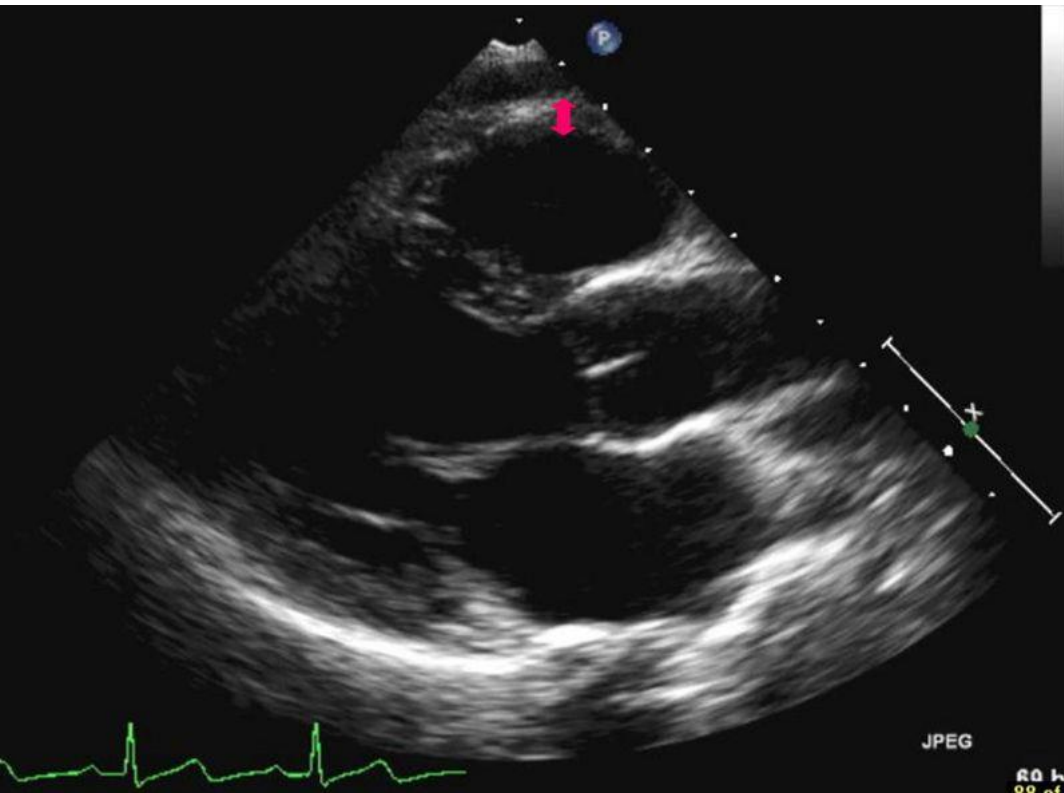
RV Strain



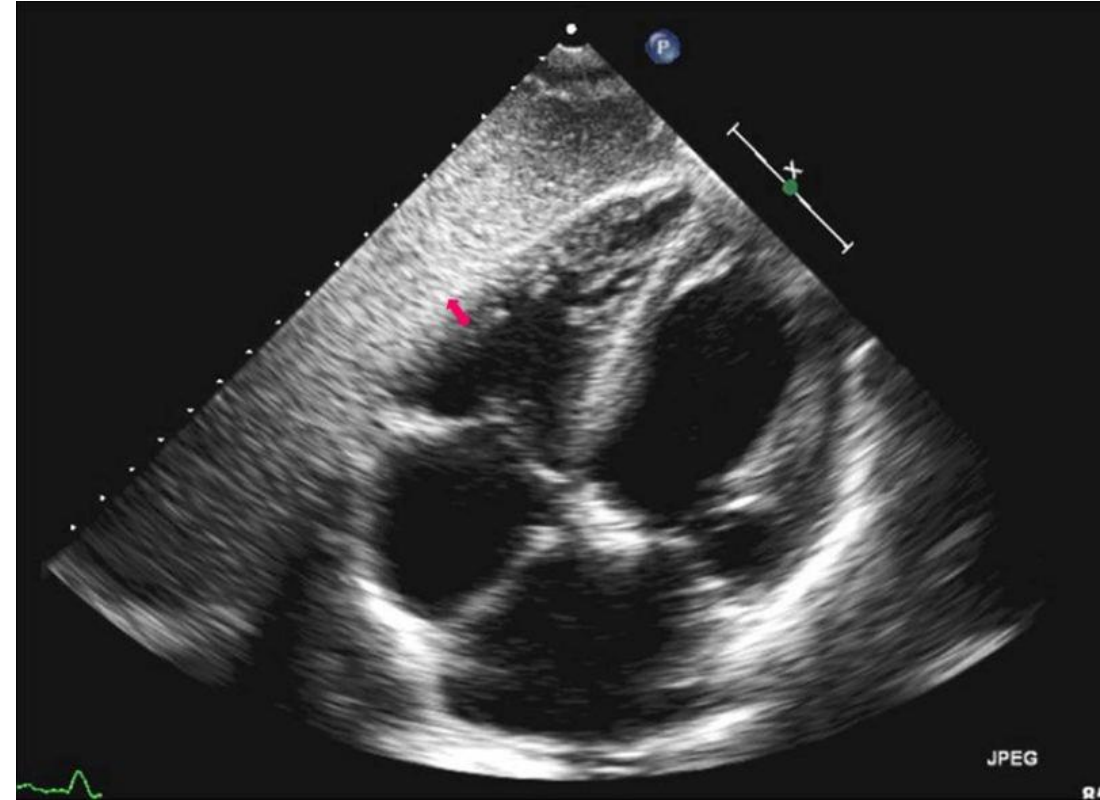
D-sign



RVW Thickness



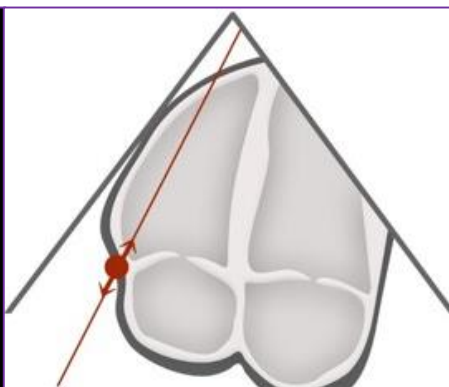
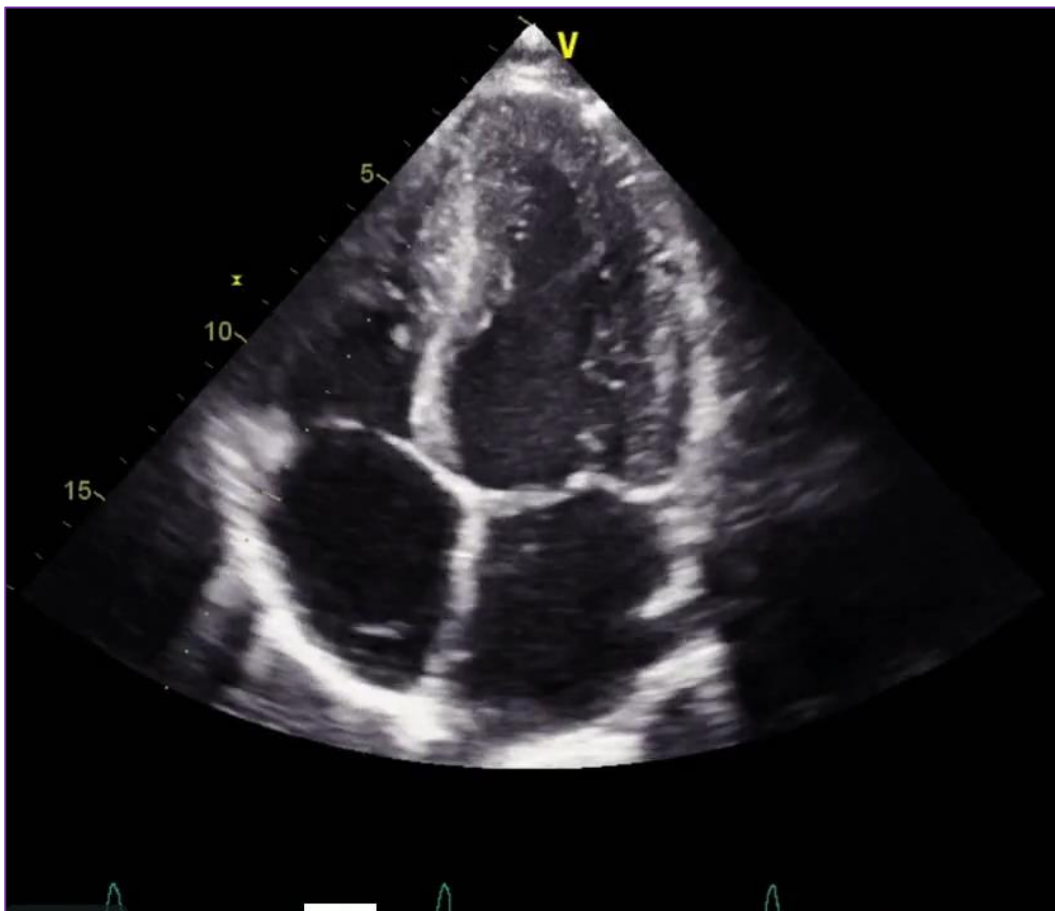
> 5mm



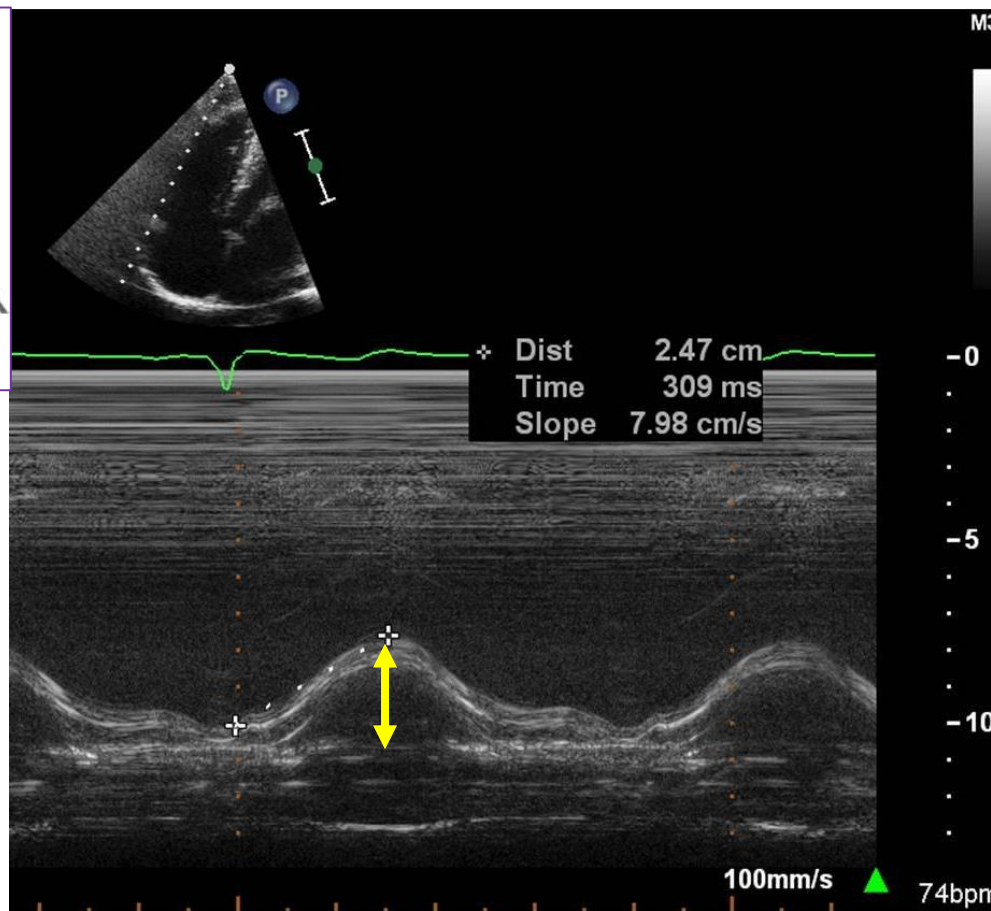
TAPSE

(Tricuspid annular planar systolic excursion)

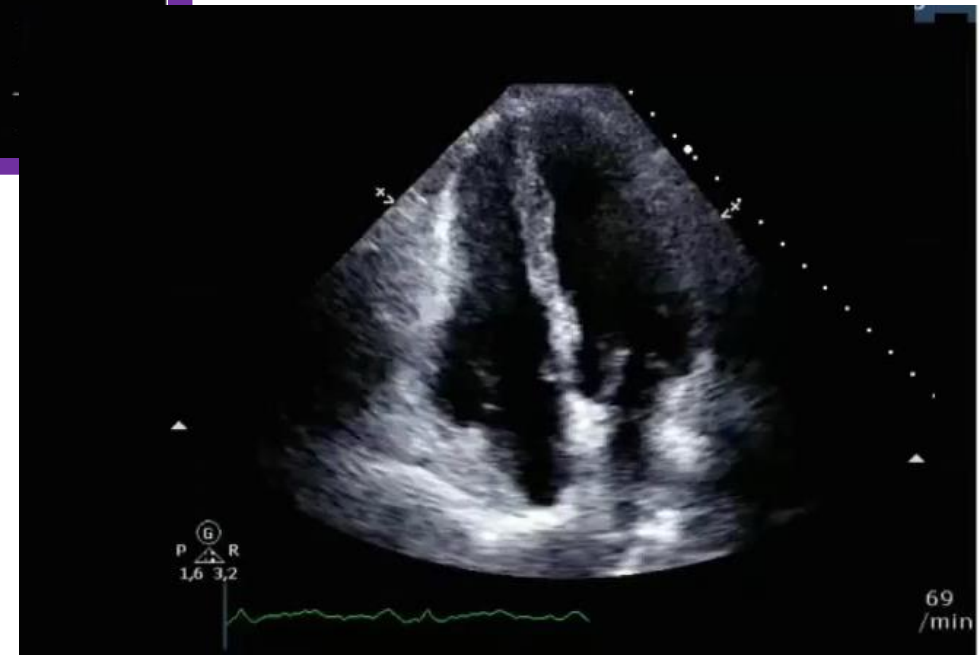
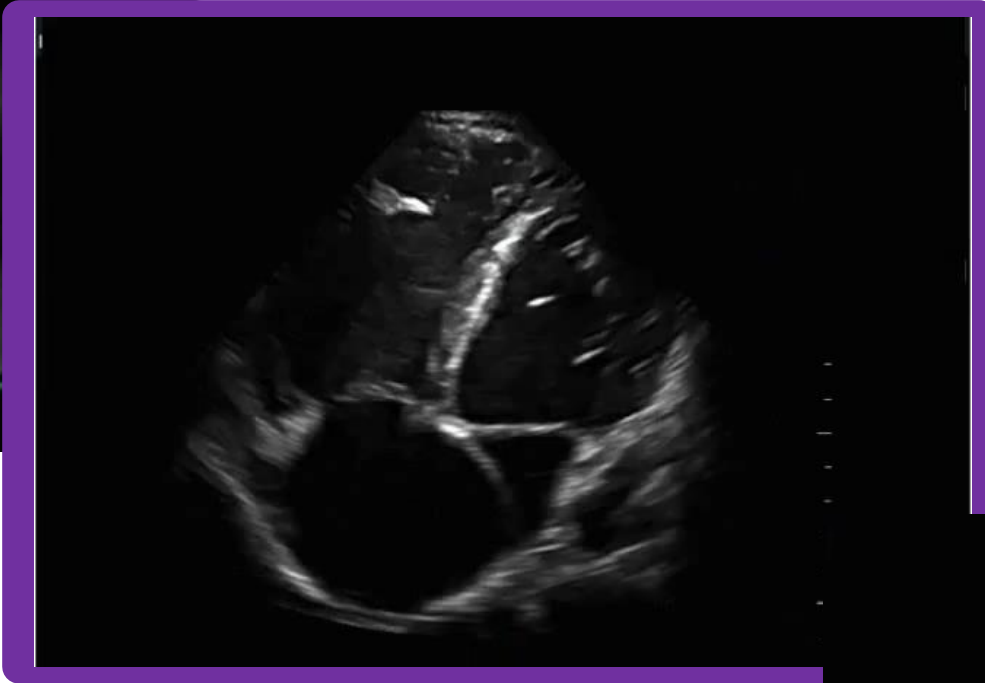
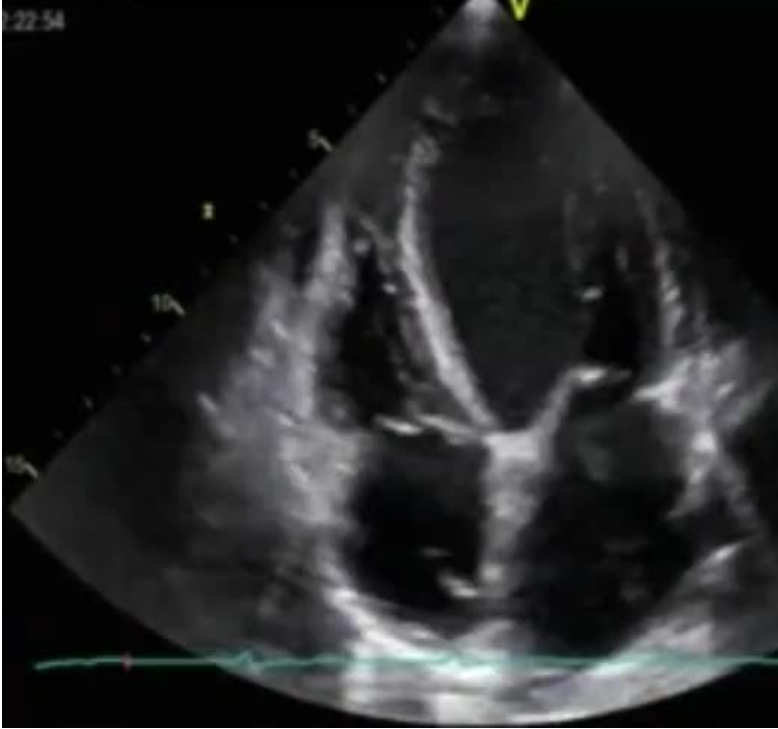
	Abnormal Cutoff
TAPSE	≤ 17 mm



Rt Chamber
Equity

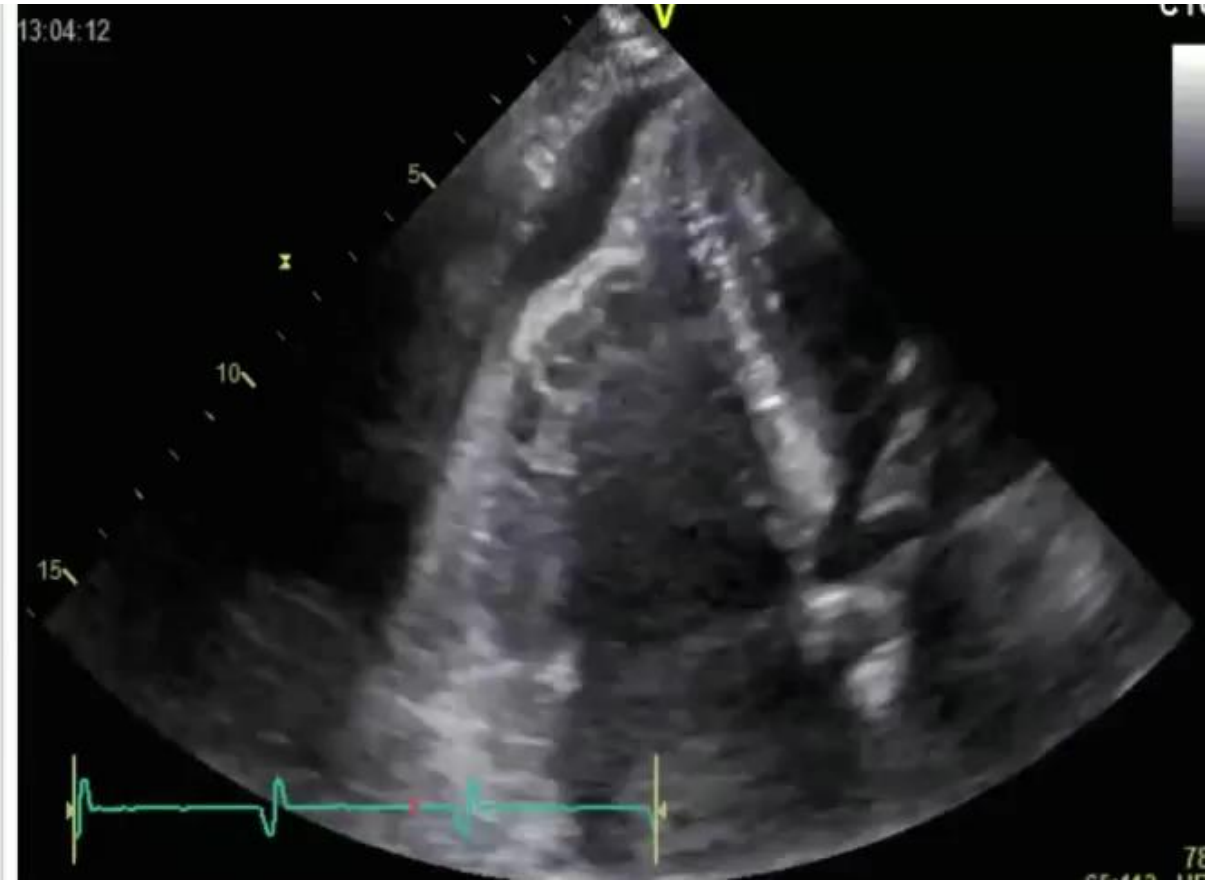
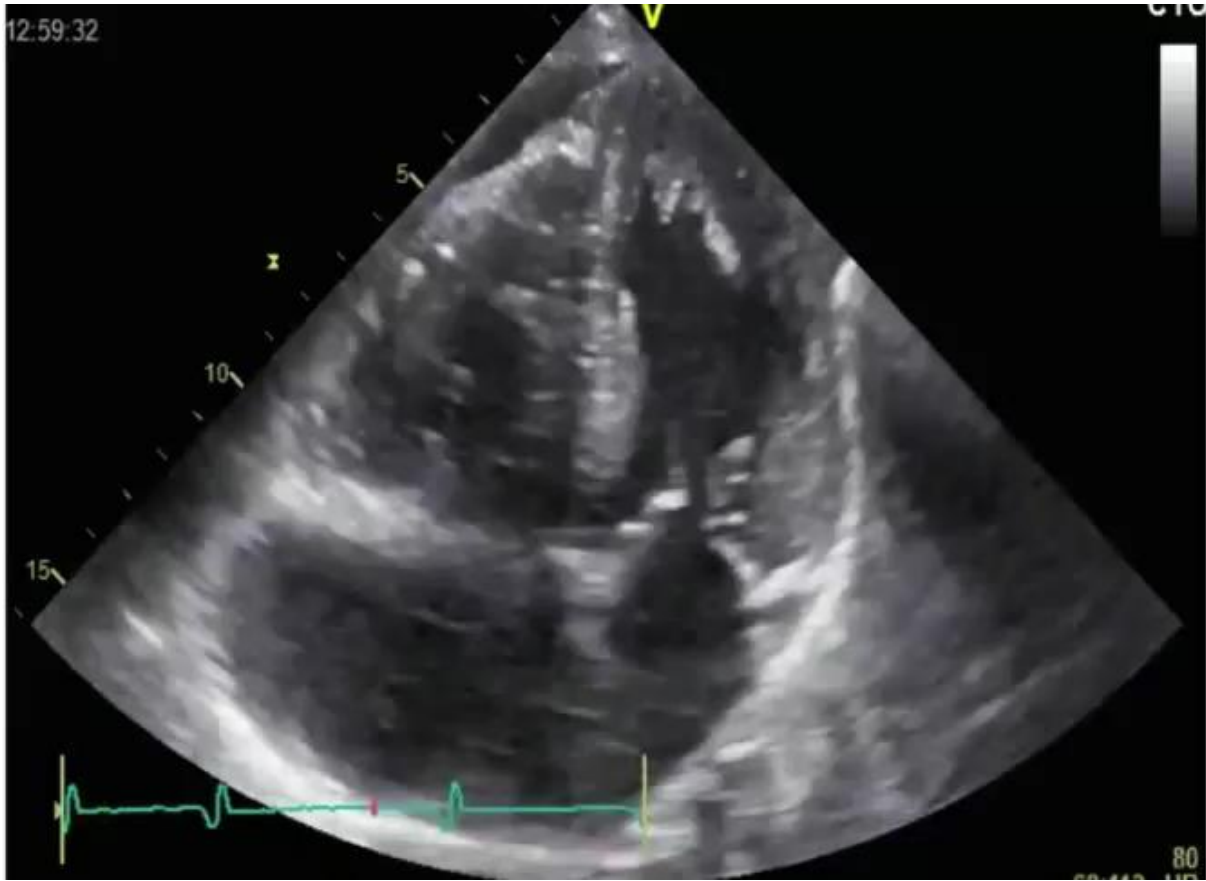


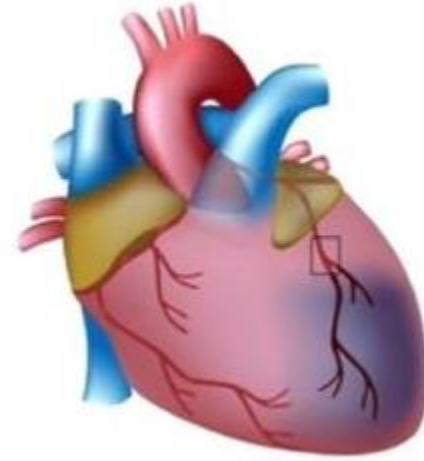
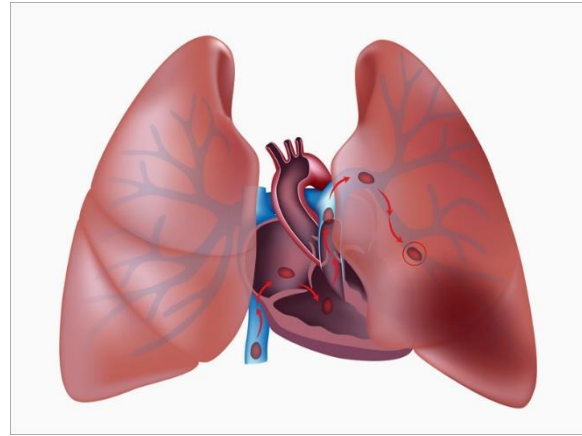TAPSE



Rt Chamber
Equity

McConnell's Sign





Right Chamber

SX4C PSSA PSLA A4C

1. Size & Function:

RV:LV < 1:1;

D-sign;

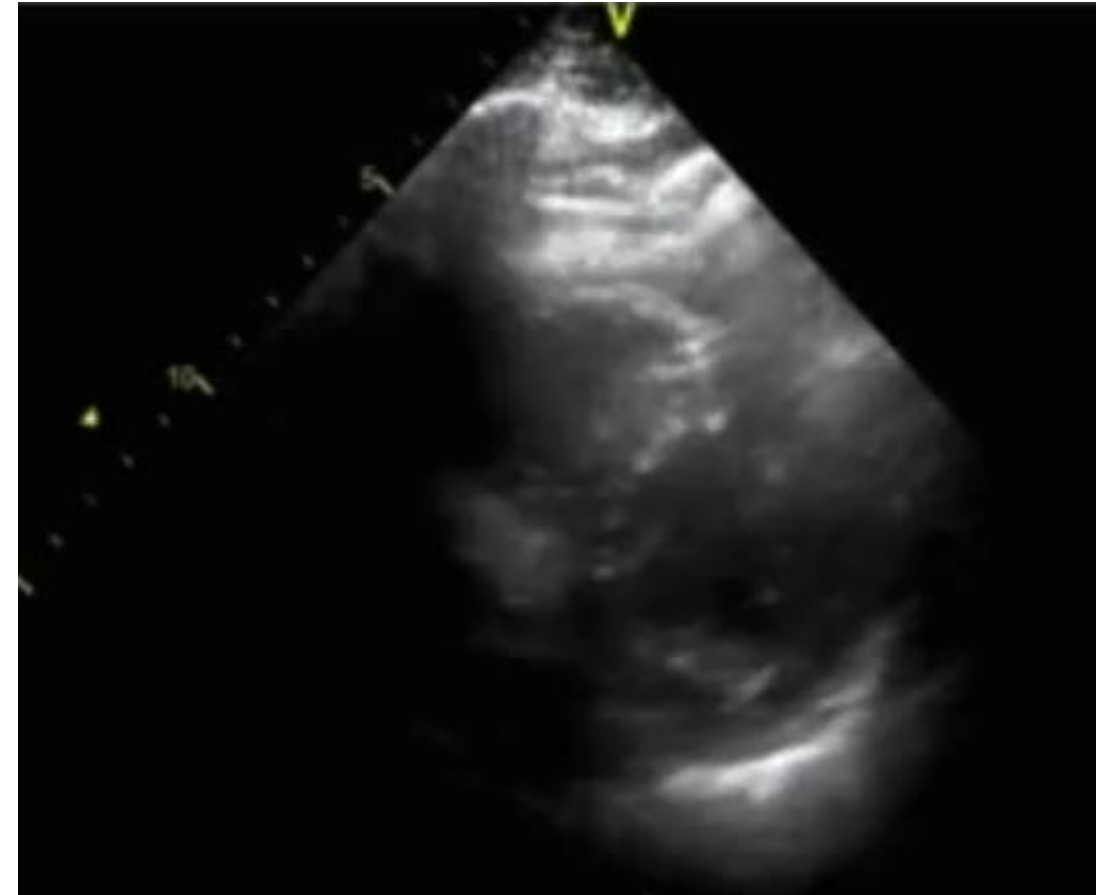
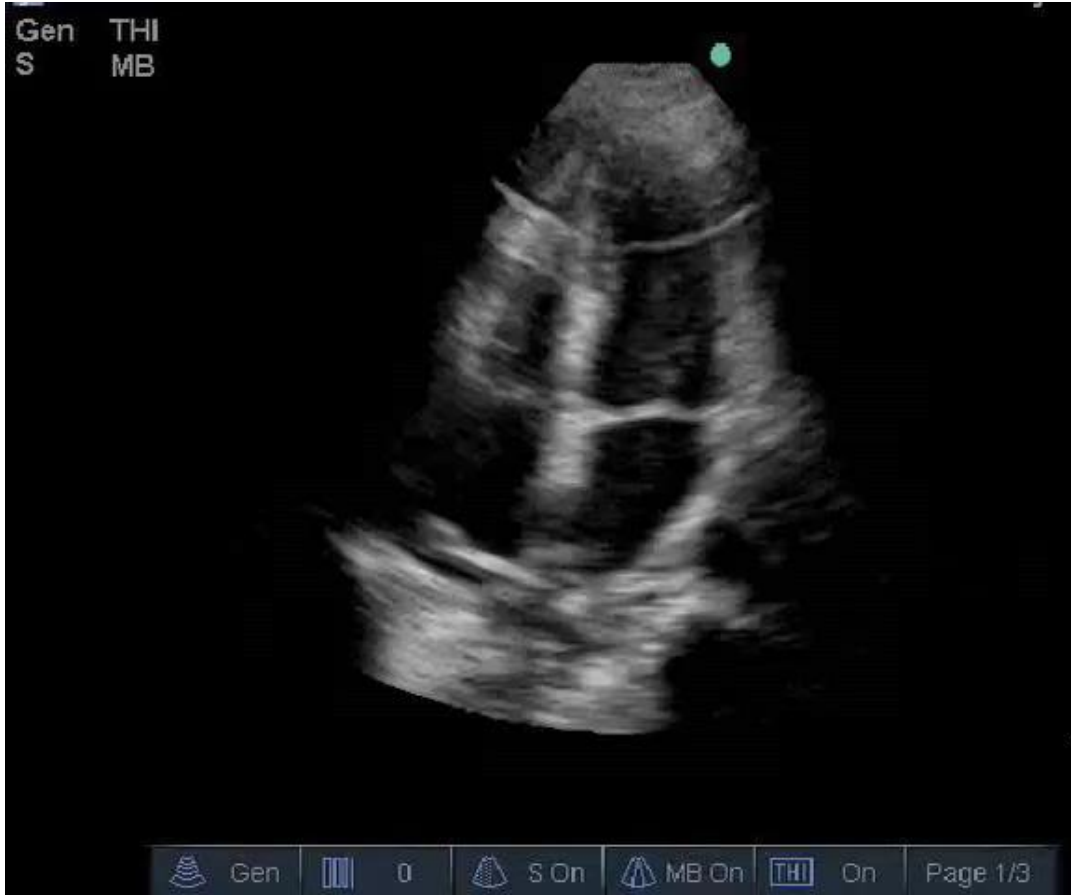TAPSE > 17 mm

2. RV dysfunction:

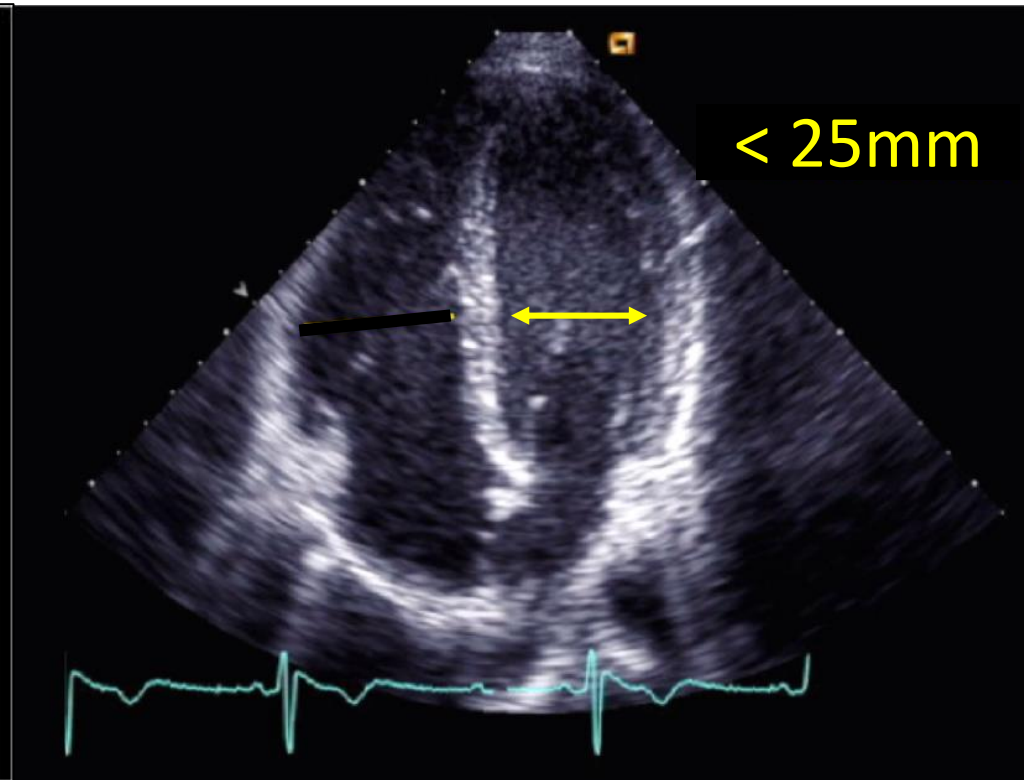
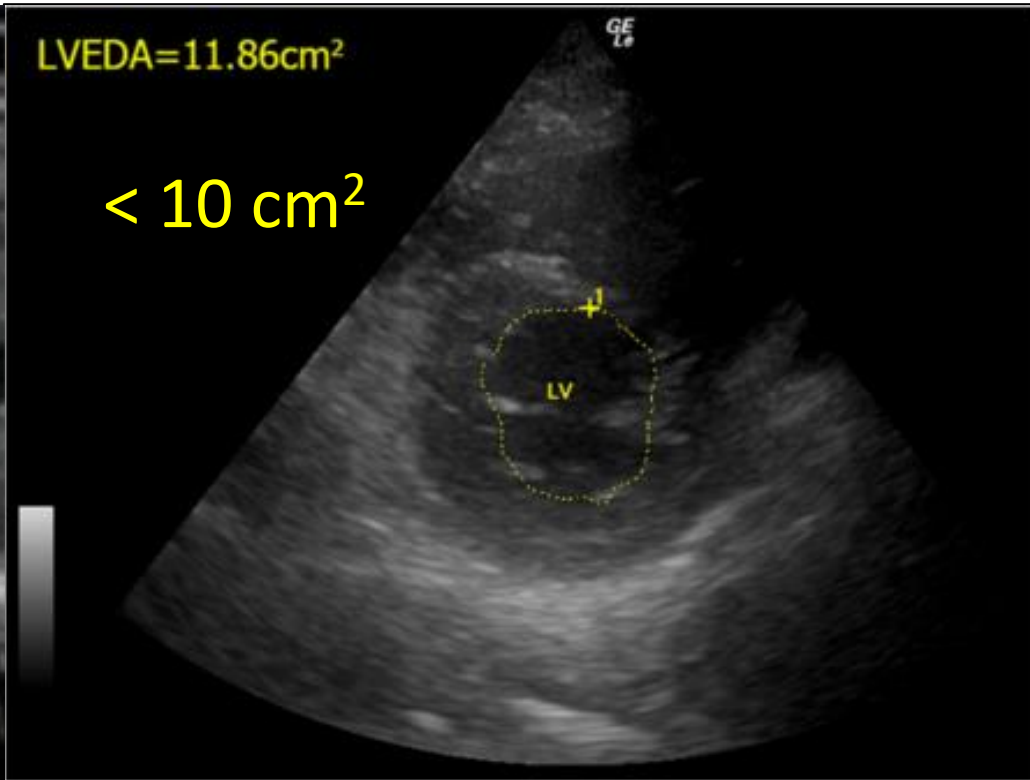
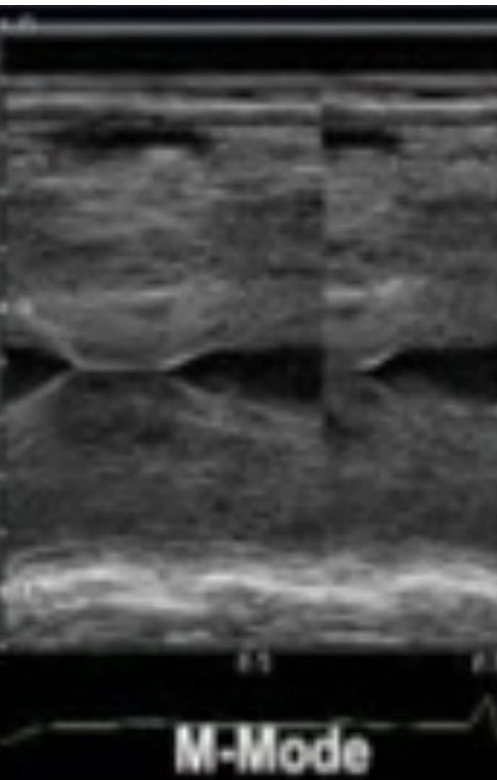
Acute cor pulmonale: PE
(McConnell's sign)

Hypovolemia
Entrance

Eyeballing



Size – 2D/M-mode



Kissing
papillary
muscle sign

LVEDA
(VS > 20 cm²)
LVEDAI < 5.5 cm²/m²
(10-18)

LVEDD

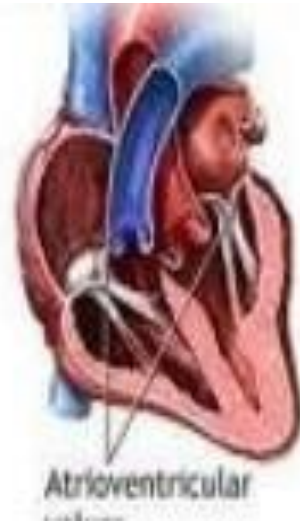Pitfalls-Small LVEDA

- RV dysfunction
- Concentric LV hypertrophy
- Constrictive pericarditis

Small LVEDA \neq Hypovolemia

Hypo-V

Hyper-V



Vasodilation

Fluid/Volume Status

(**S**XIVC **P**SLA **A**4C)

1. Eyeballing:

- A. Chamber size ↓
- B. Hyperdynamic heart (EF > 65%)
- C. Kissing papillary muscle sign

2. 2D/M-mode:

- A. LVED diameter < 2.5cm
- B. LVED area < 10cm² or > 20cm²
- C. IVC size and collapsibility

Ejection

ejection fraction

75%

ejection fraction

60%

ejection fraction

45%

ejection fraction

30%

Ejection Fraction \neq Stroke Volume

hyperdynamic

normal

reduced


very reduced



stroke volume



stroke volume

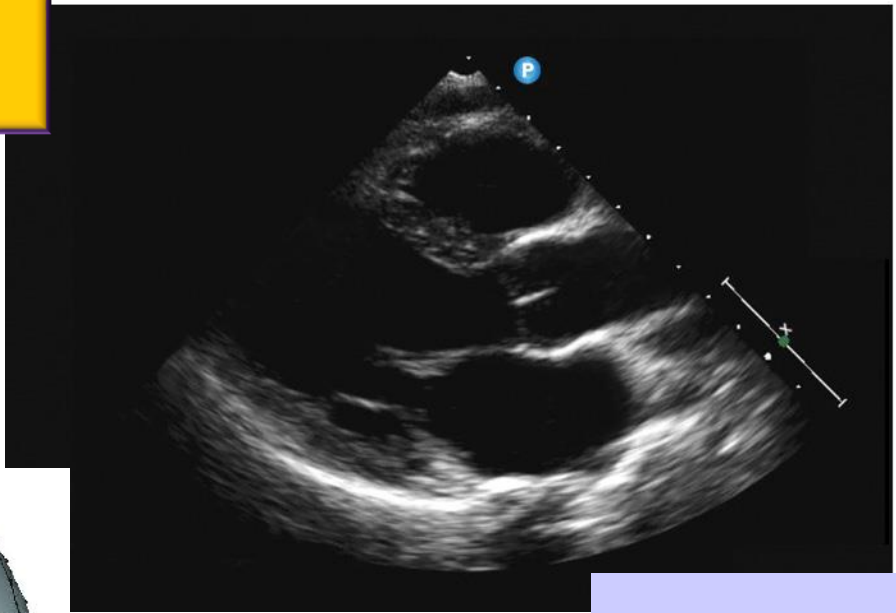


stroke volume

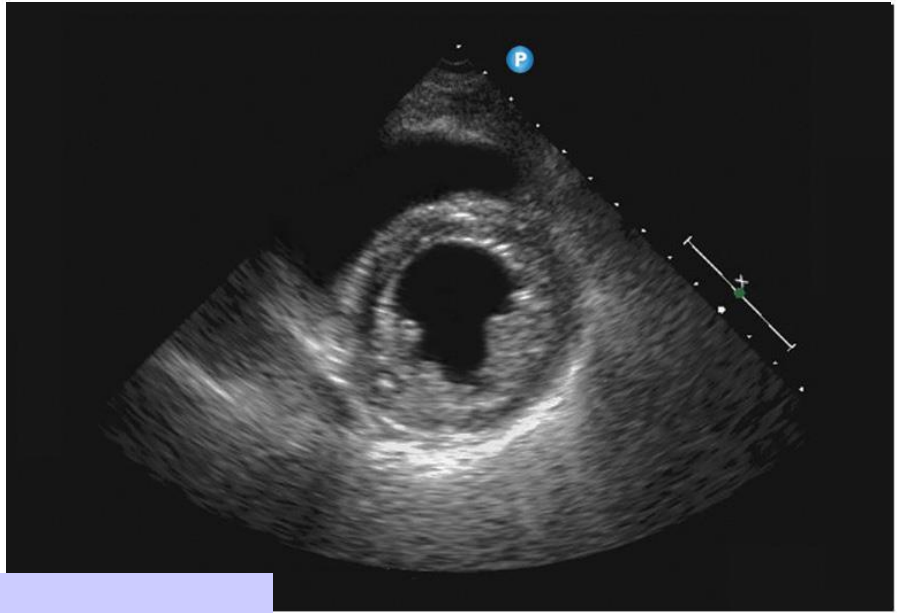


stroke volume

Ejection

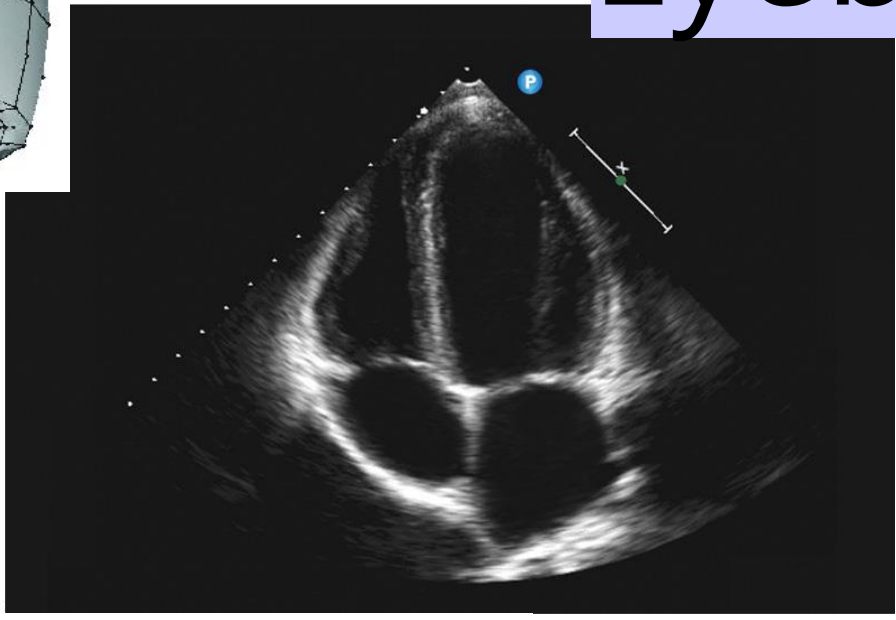


PLAX

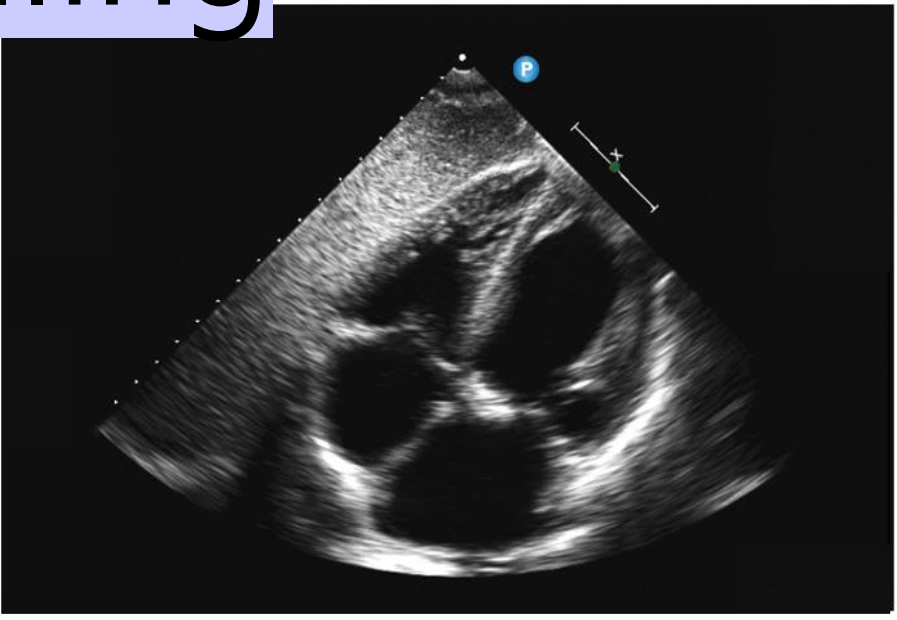


PSAX-PM


Eyeballing



A4CH

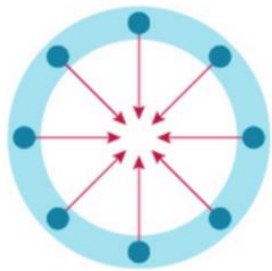


SLAX

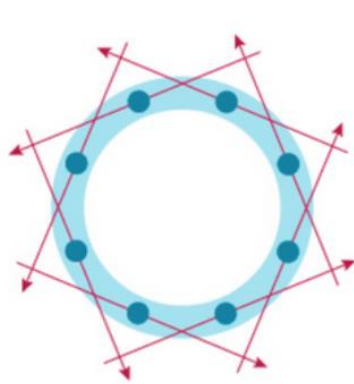


Ejection

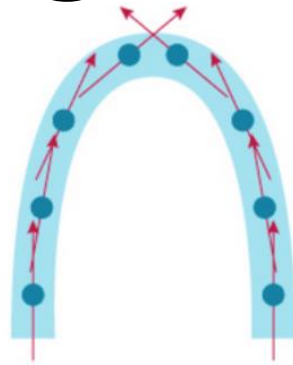
Eyeballing



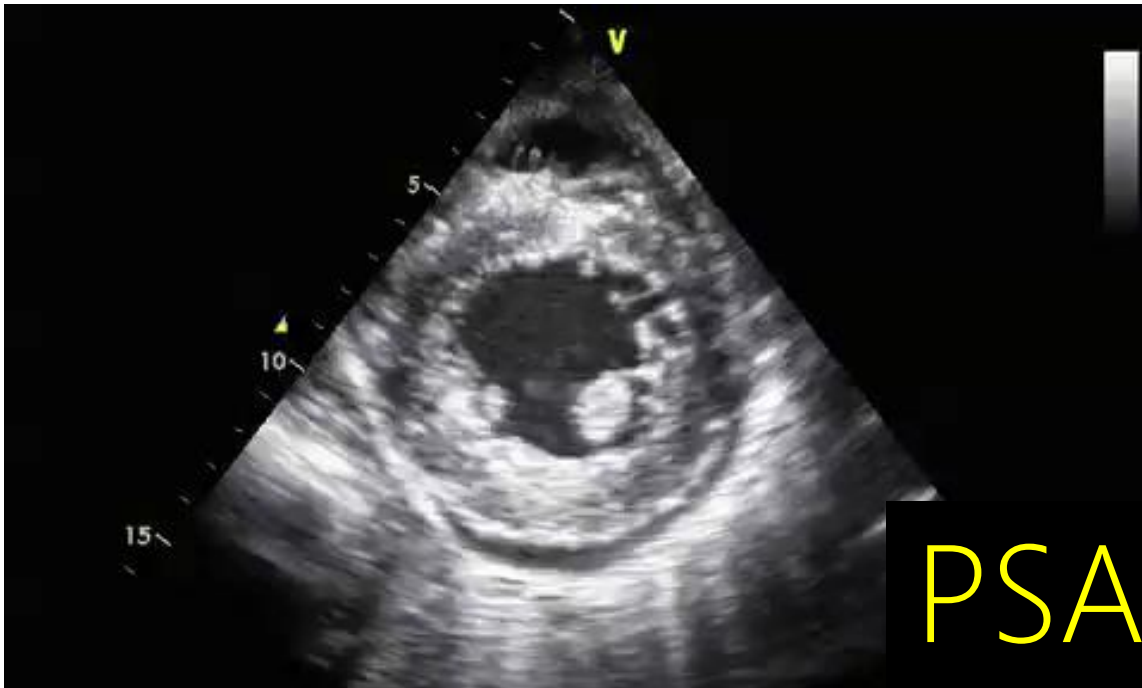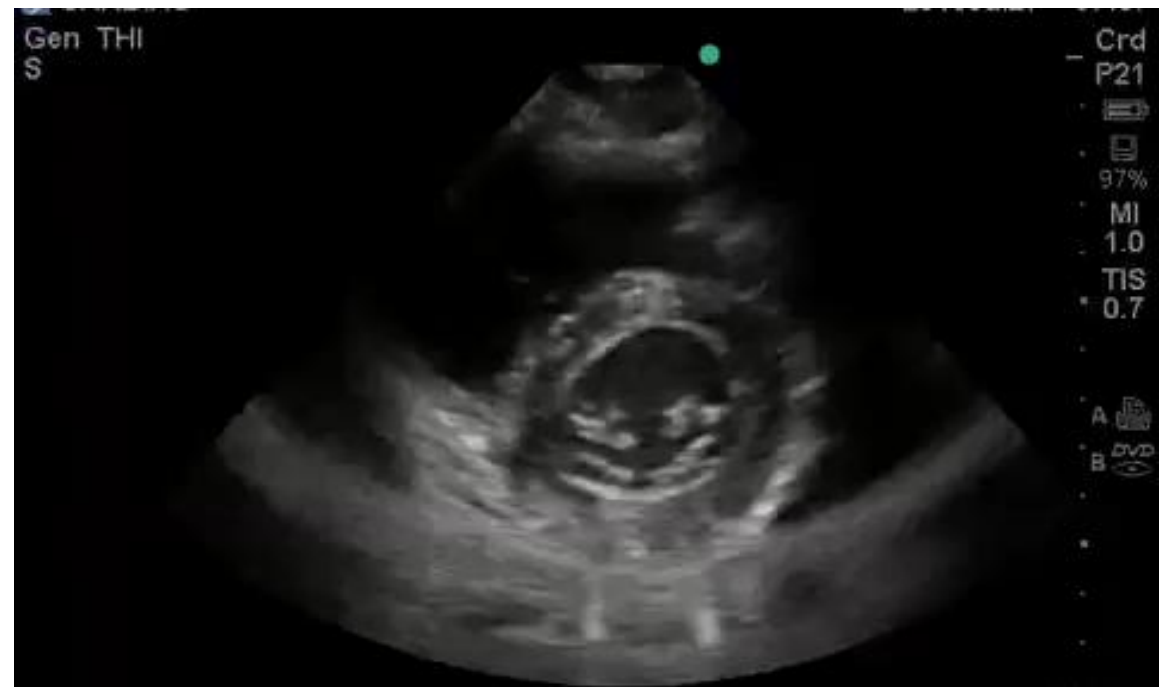radial



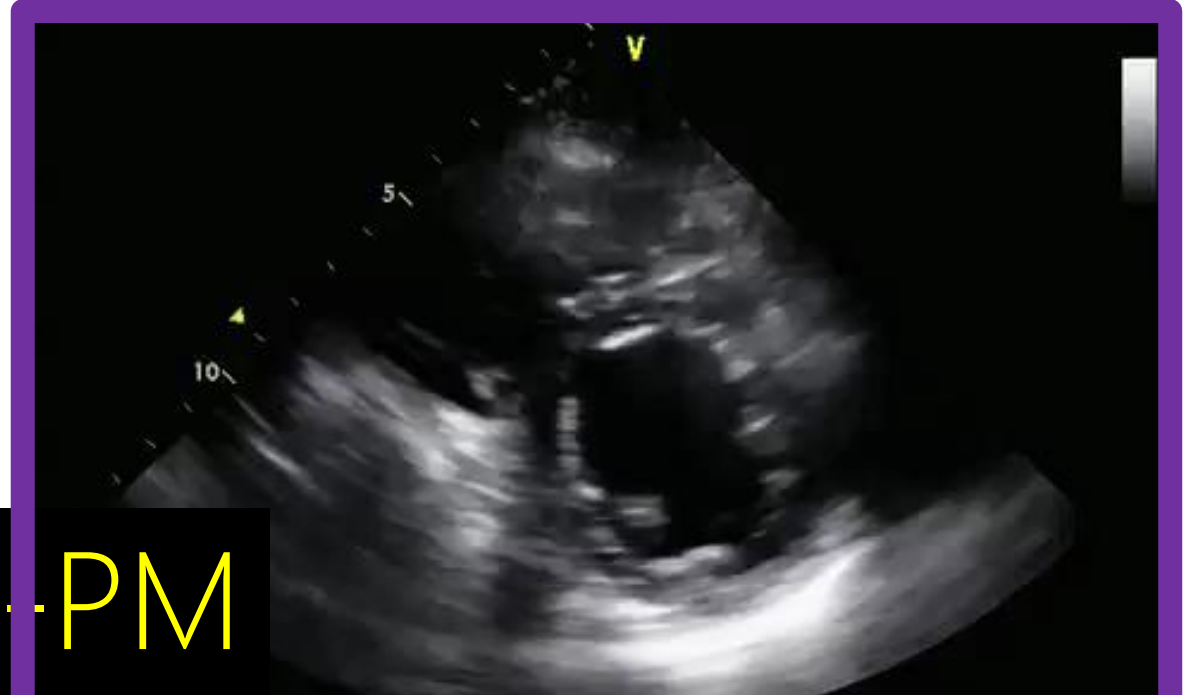circumferential



longitudinal

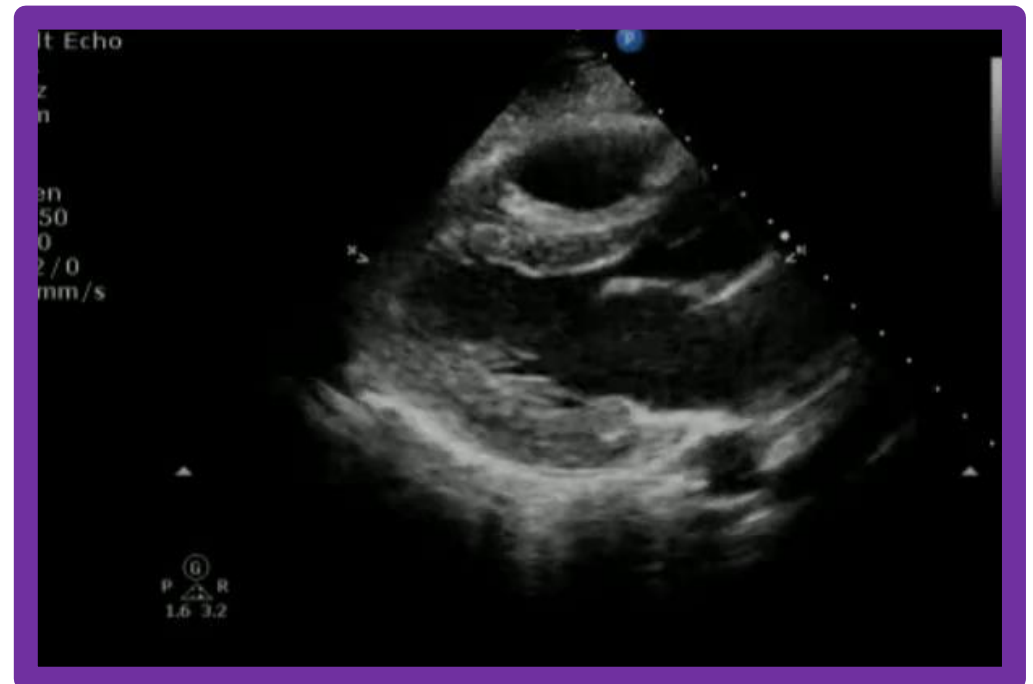
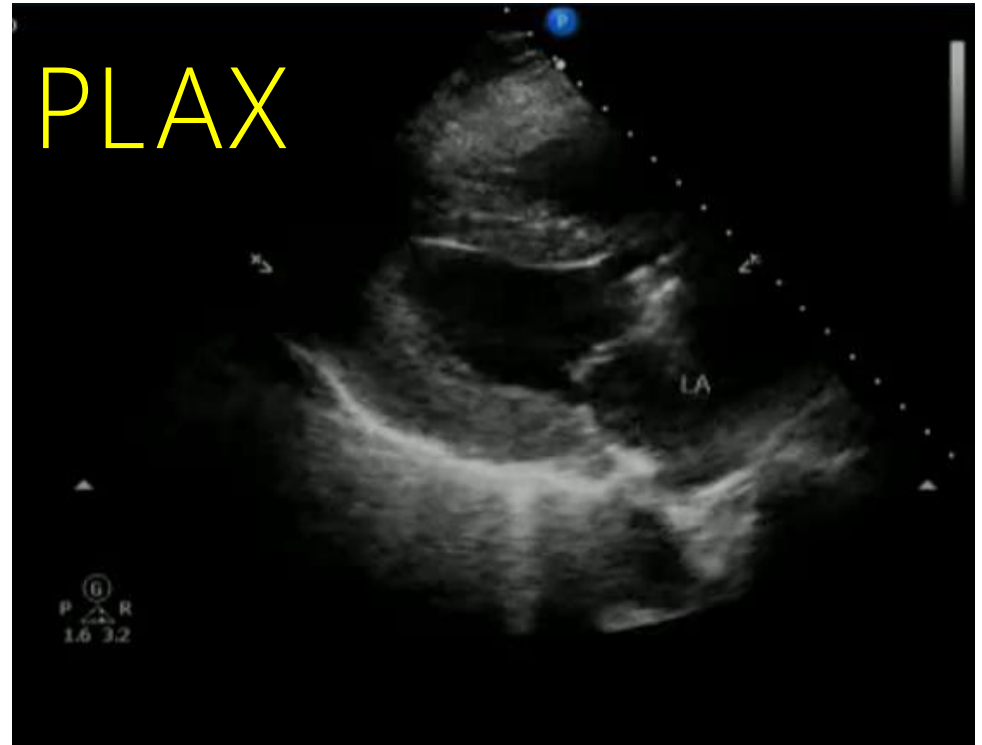
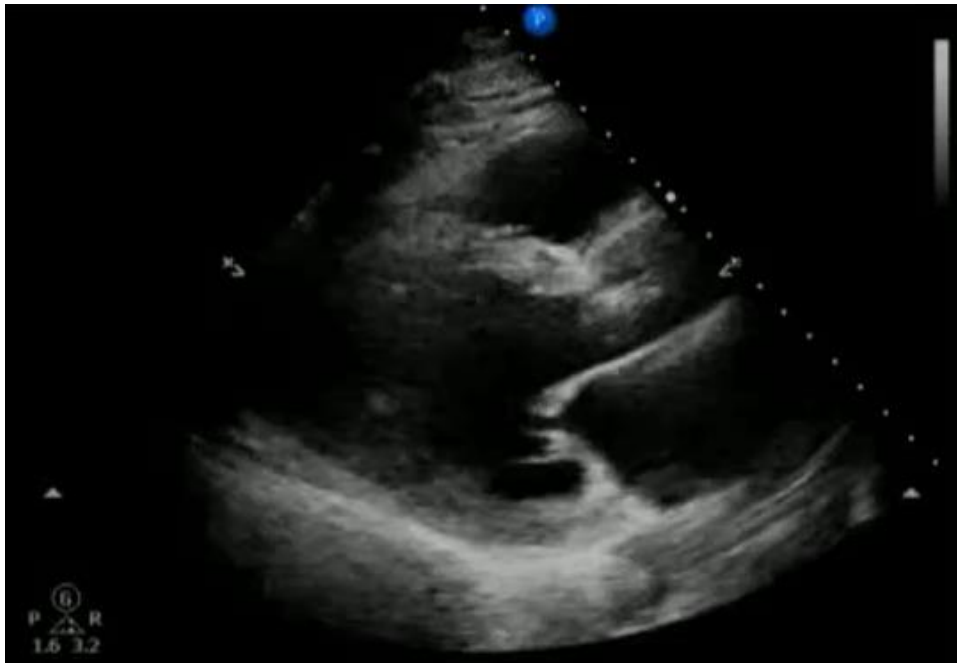

PSAX-PM

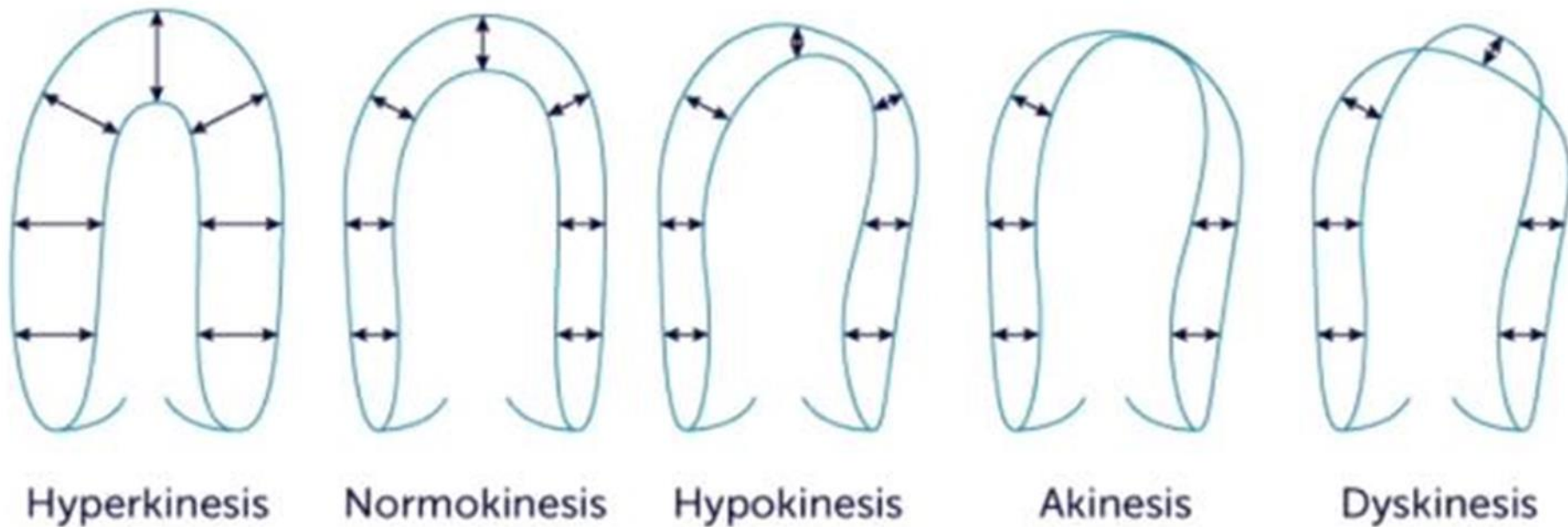


Eyeballing

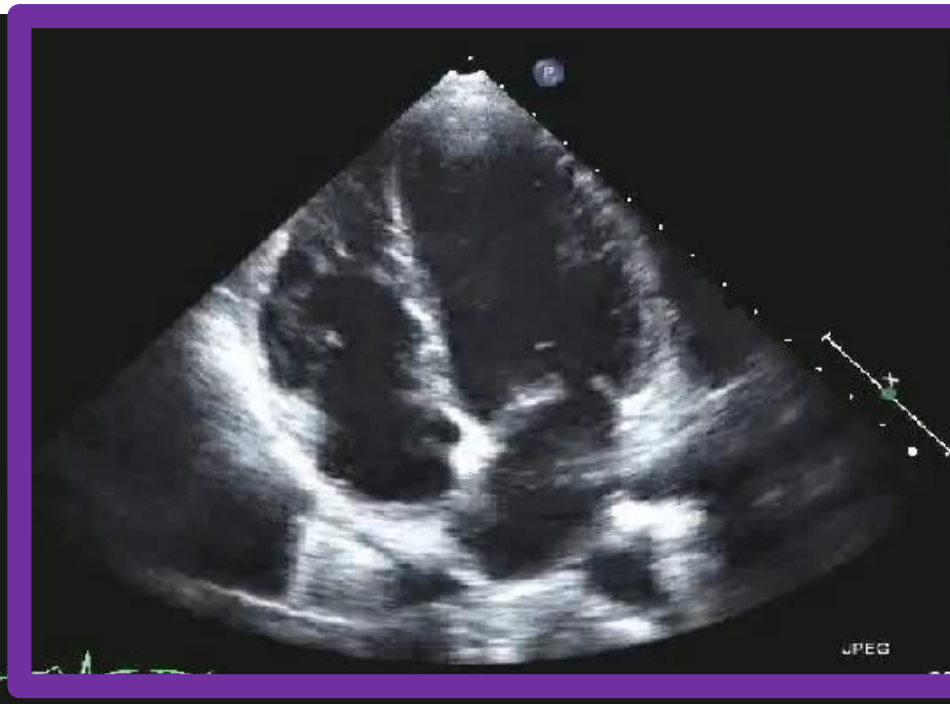
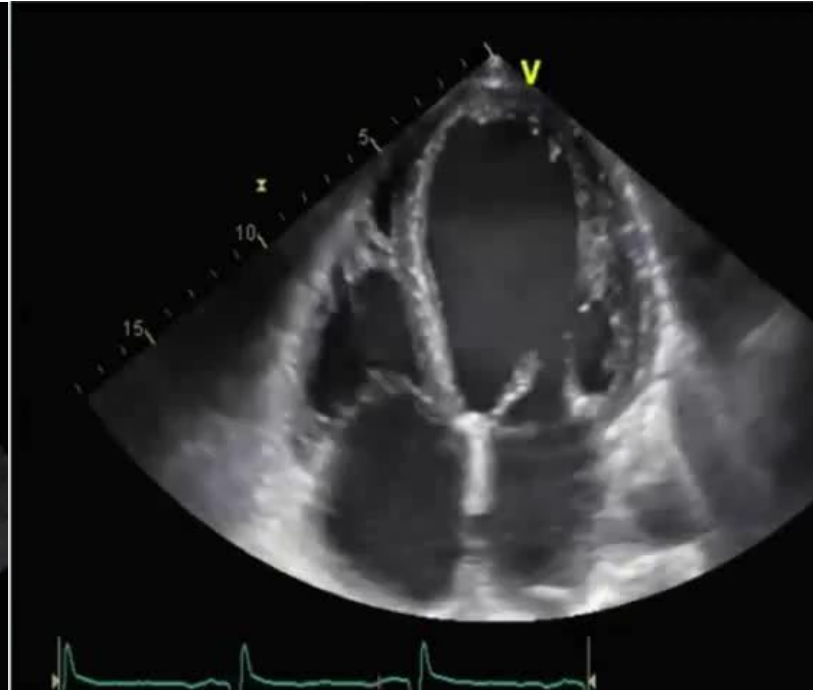
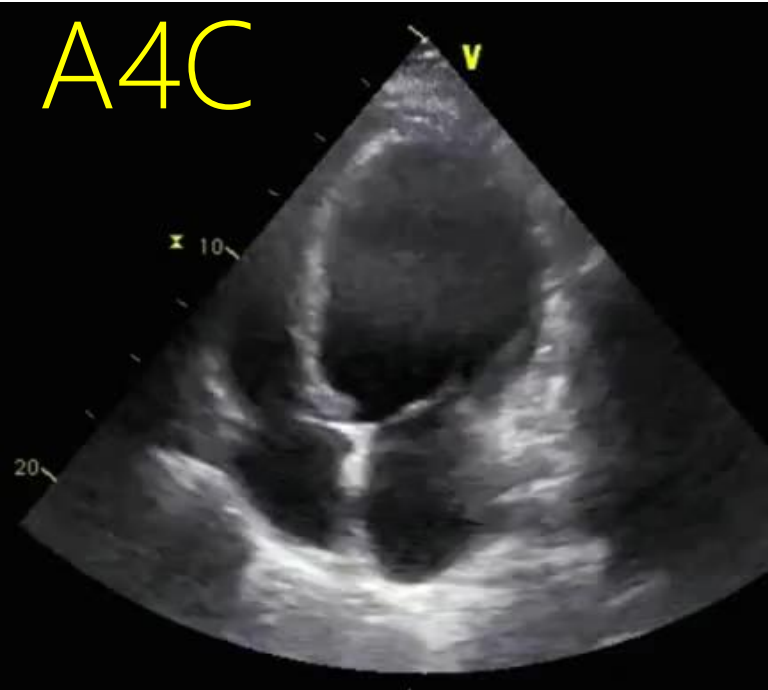
- Regional vs Global
 - Inward Motion
 - Myocardial Thickening
 - Twist
 - Longitudinal shortening



Ejection



A4C

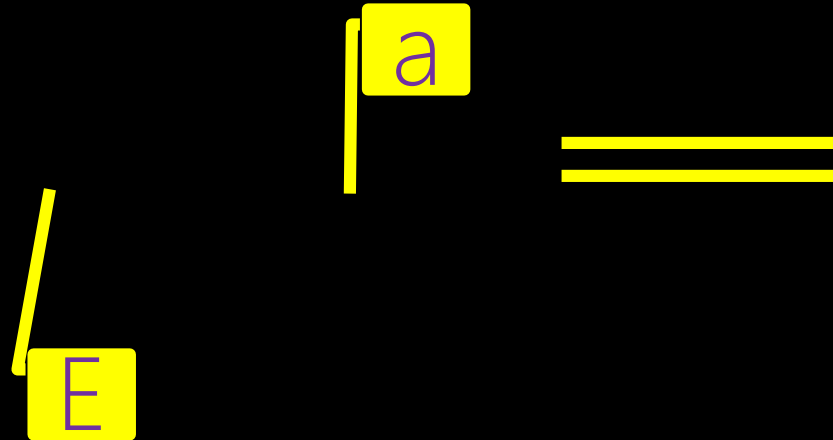
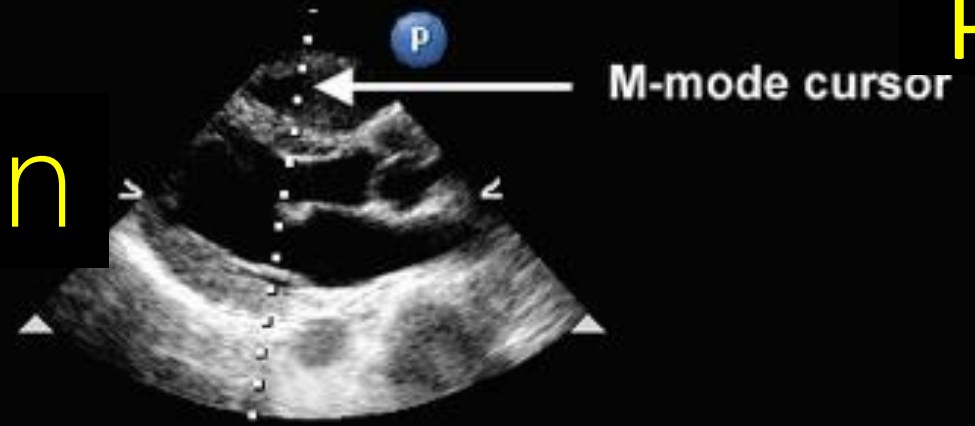


Ejection

PSLA

E-point septal separation

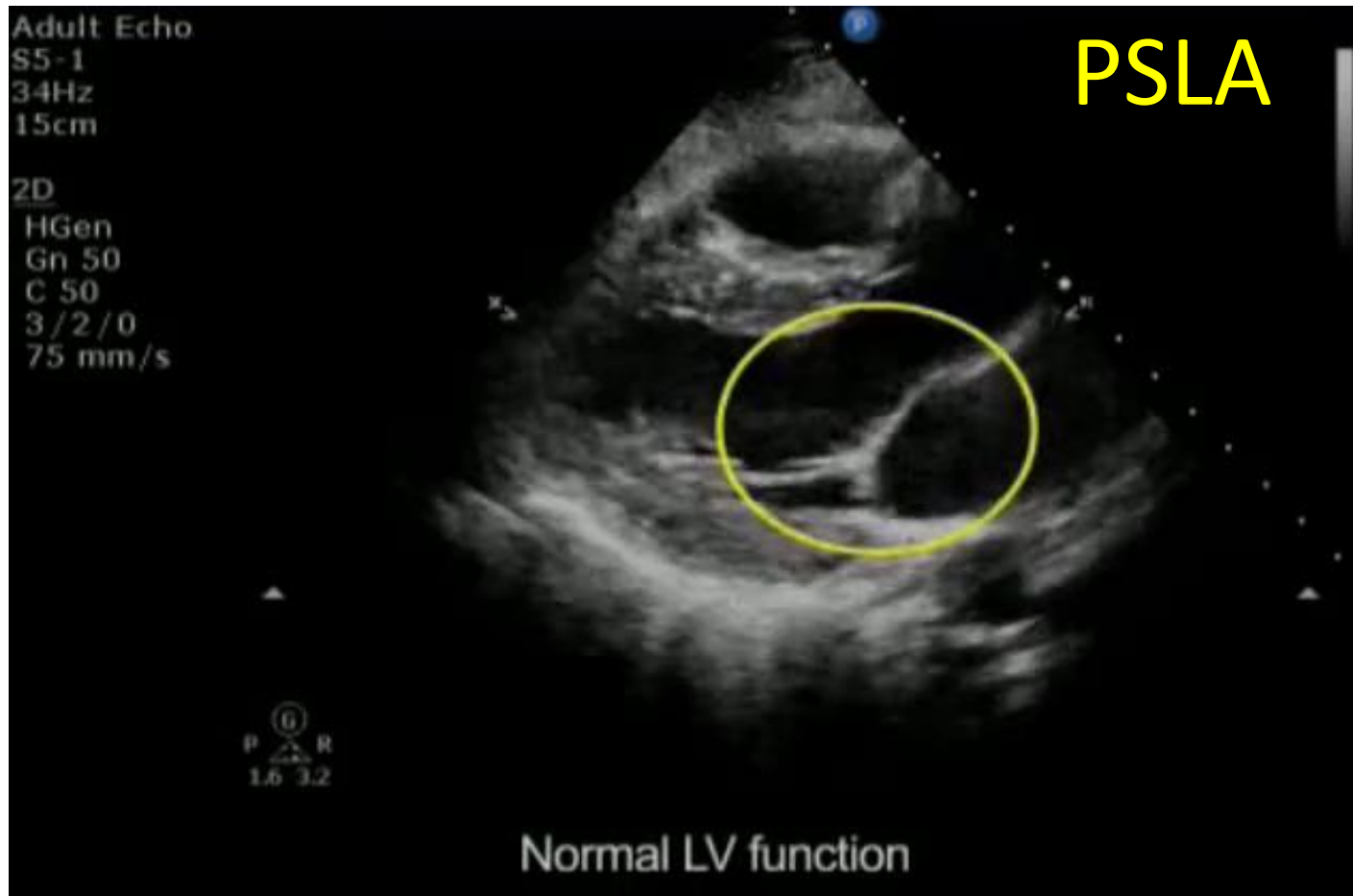
EPSS < 7 mm



Ejection

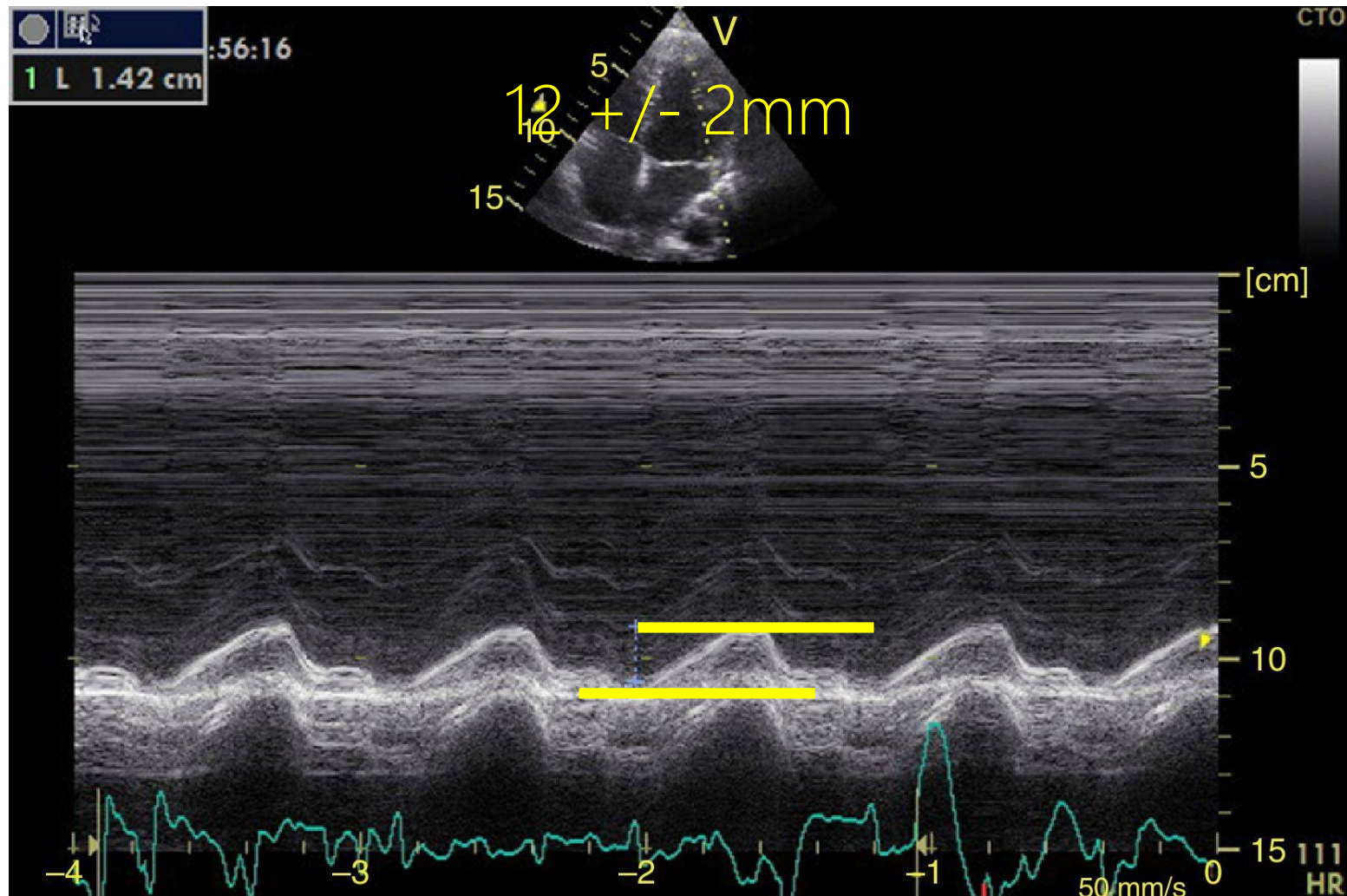
EPSS > 7 mm EF < 50 %

EPSS > 13mm EF < 30%



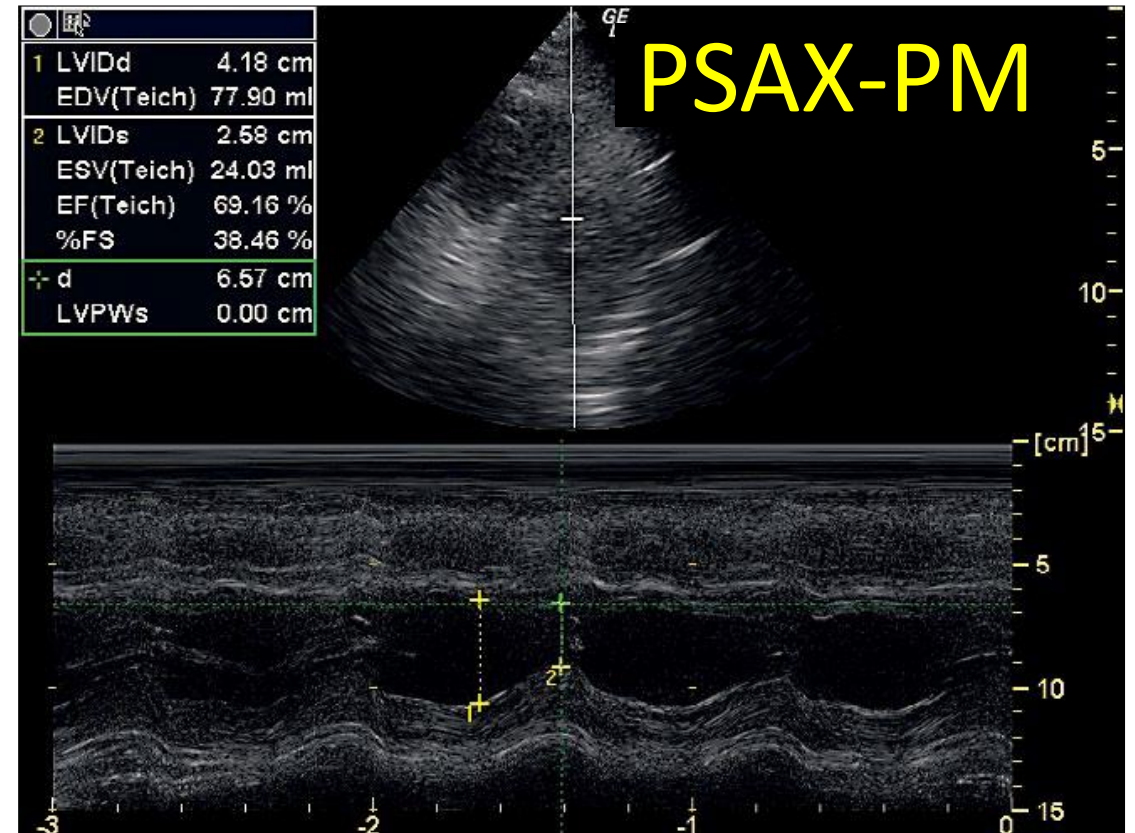
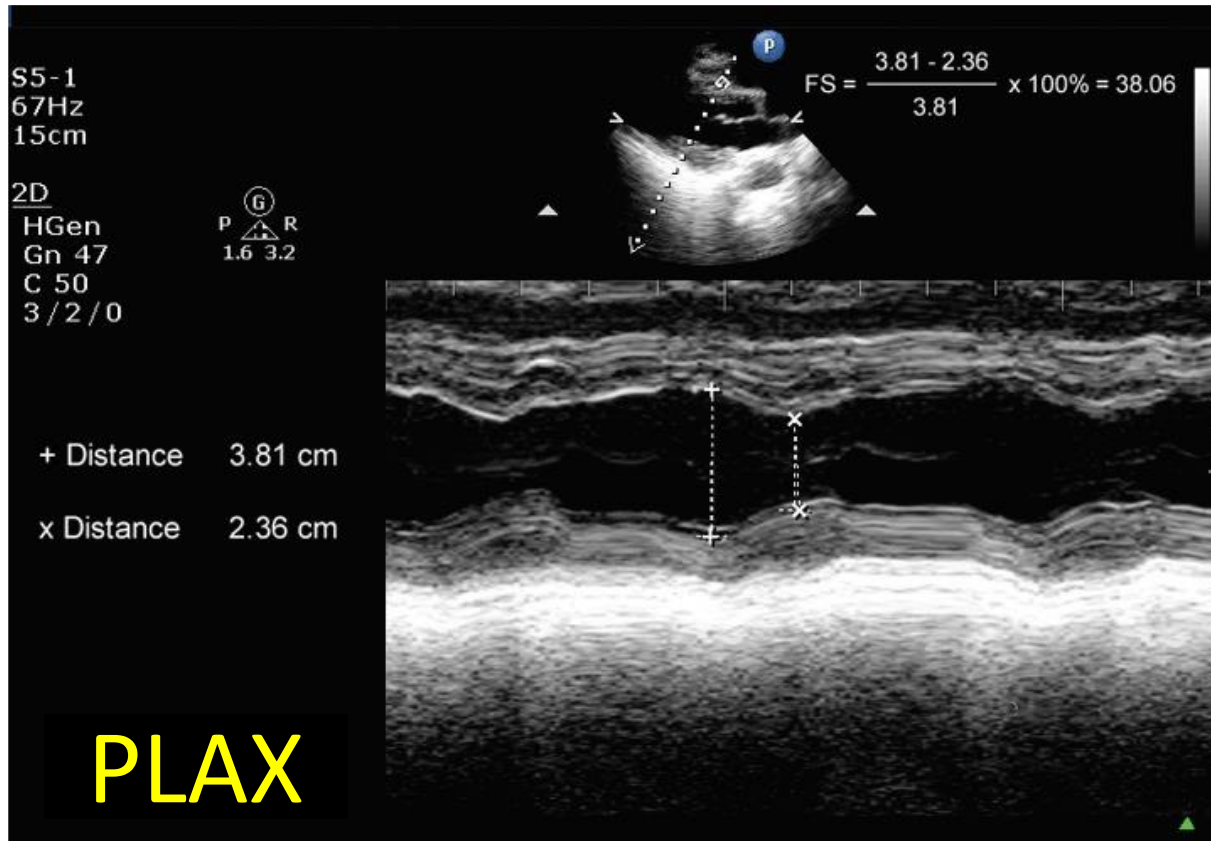
MS/AR; Septal hypertrophy; Paradoxical septal motion

MAPSE < 8 mm \approx EF < 30 %
(Mitral Annular Planar Systolic Excursion)

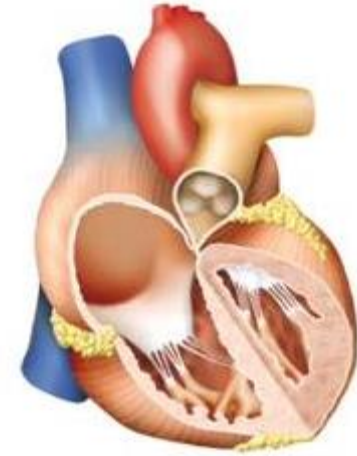
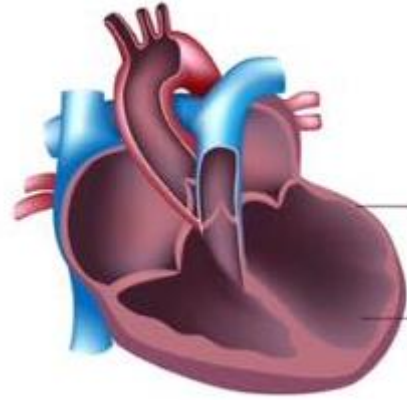
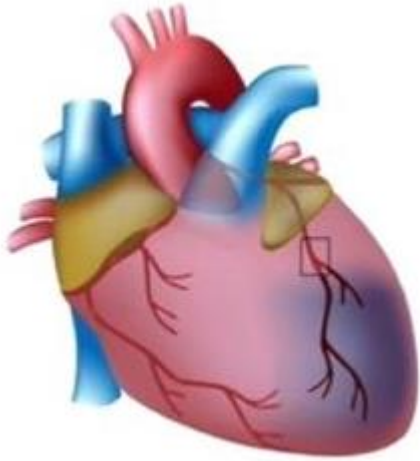

Ejection

$$\text{Fractional Shortening (FS)} = \frac{EDD - ESD}{EDD} \times 100\%$$



LVIDs & LVIDd



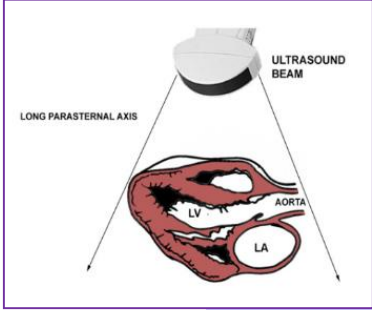
LV Function

PSLA **P**SSA **A**4C **A**5C

1. Qualitative:
Eyeballing
(Visual Estimation Method)

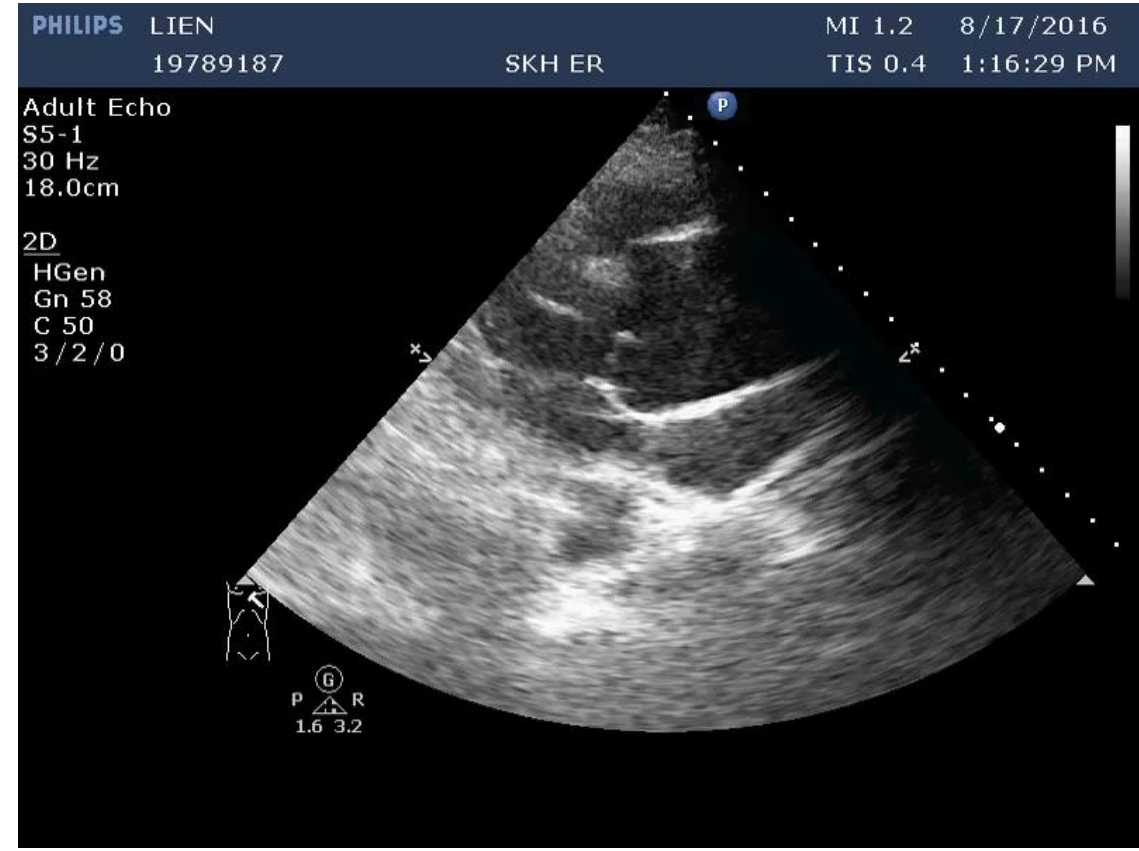
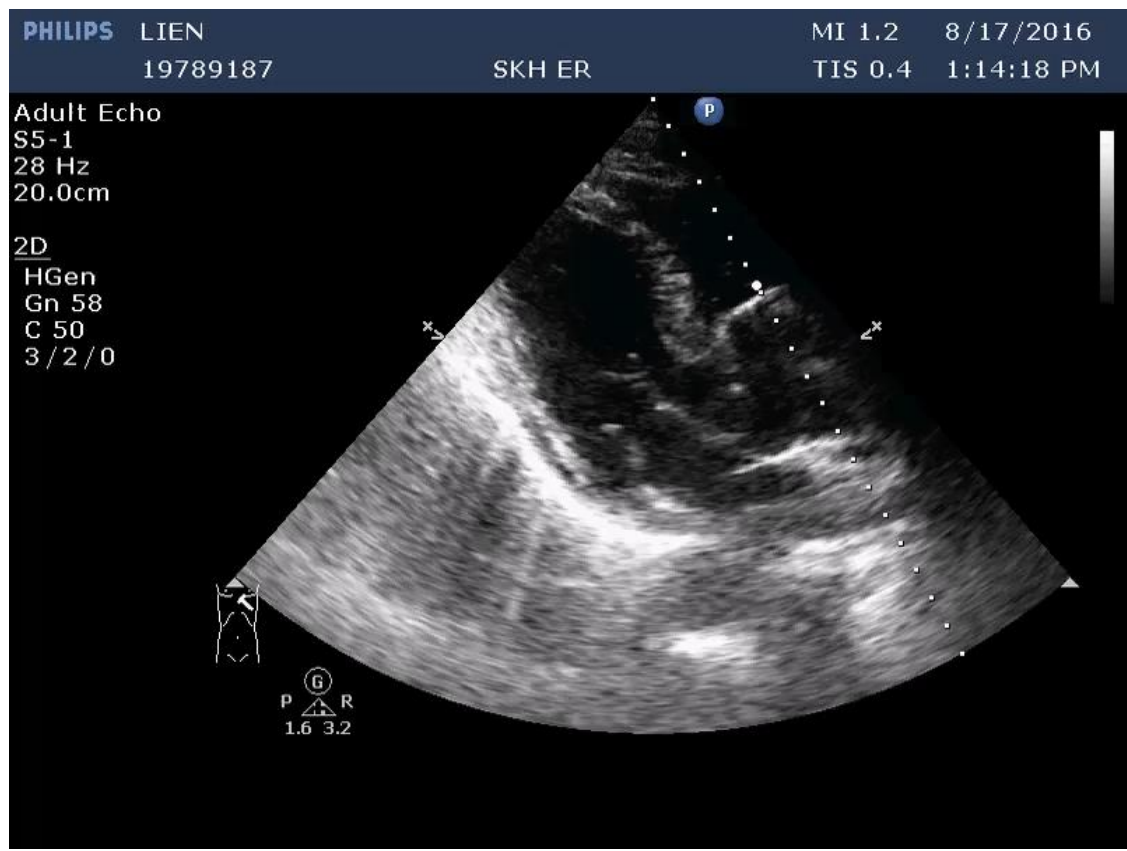
2. Semi-Quantitative
EPSS
MAPSE
FS
(Simpson's)

Aorta/Valve Exit

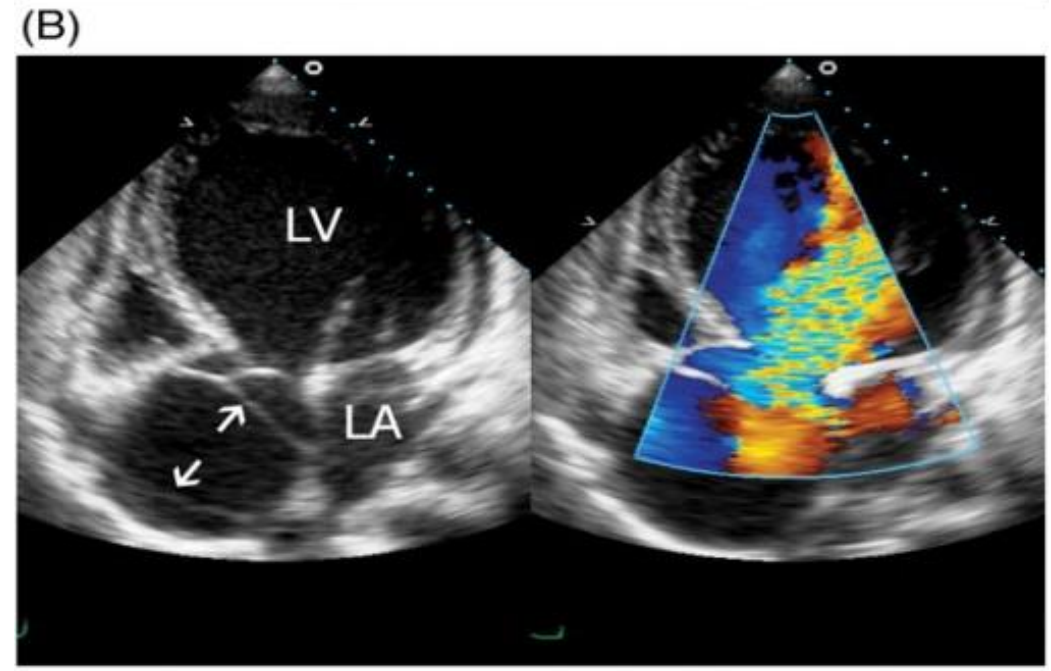
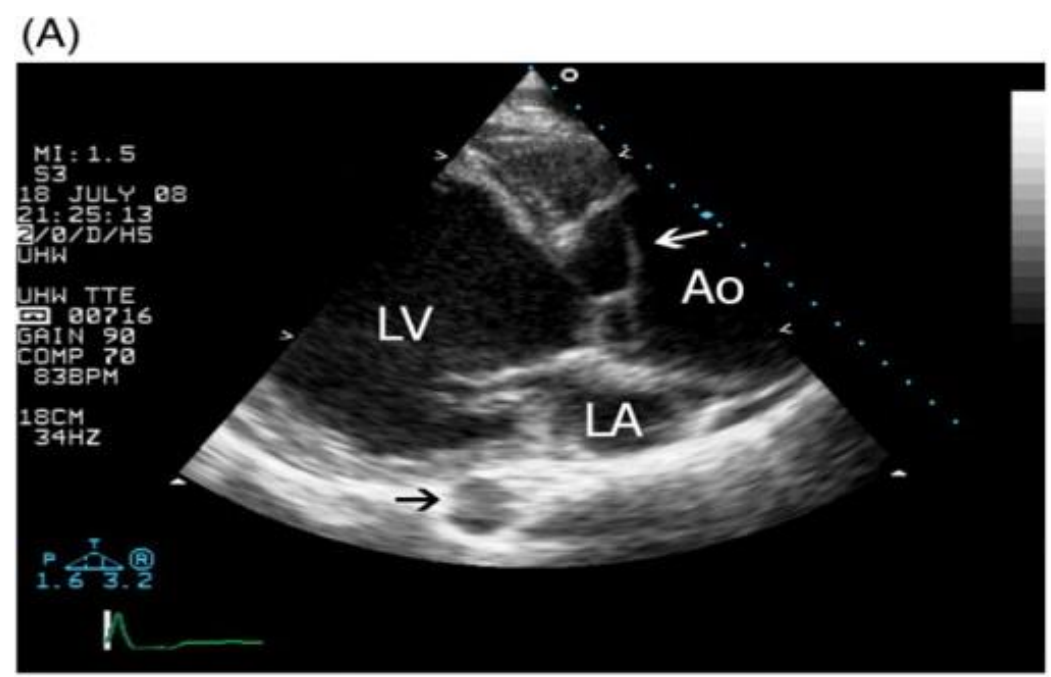
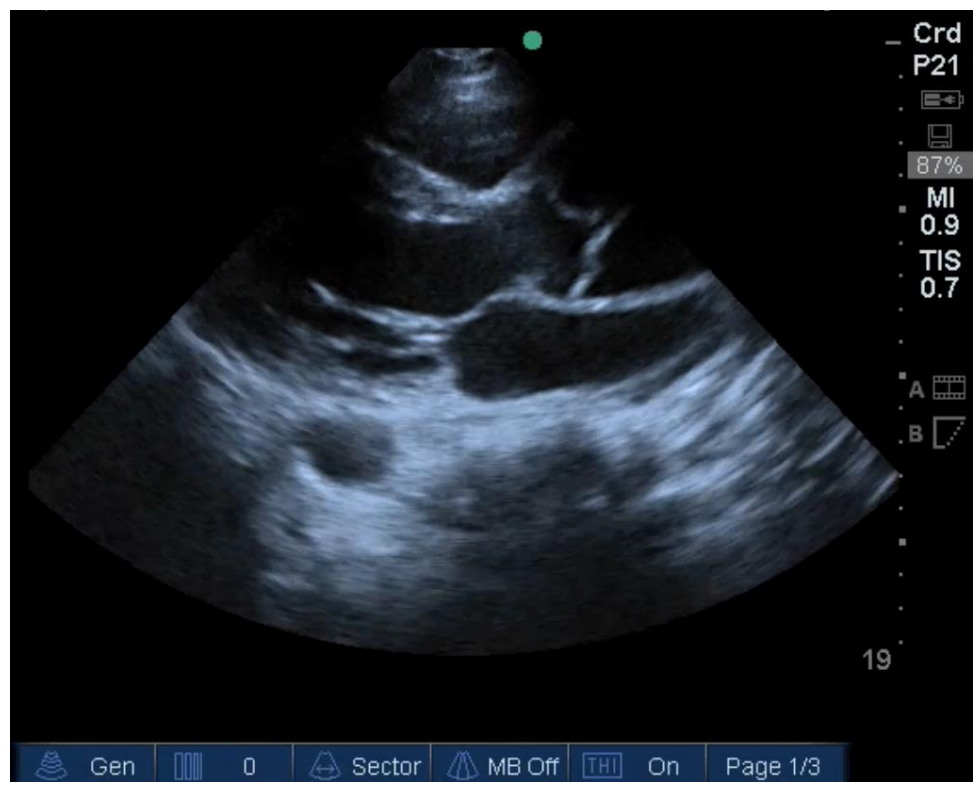


PLAX

Aortic Root Dilatation + Intimal Flap



Aortic Regurgitation



US for Aortic Dissection

Direct Signs

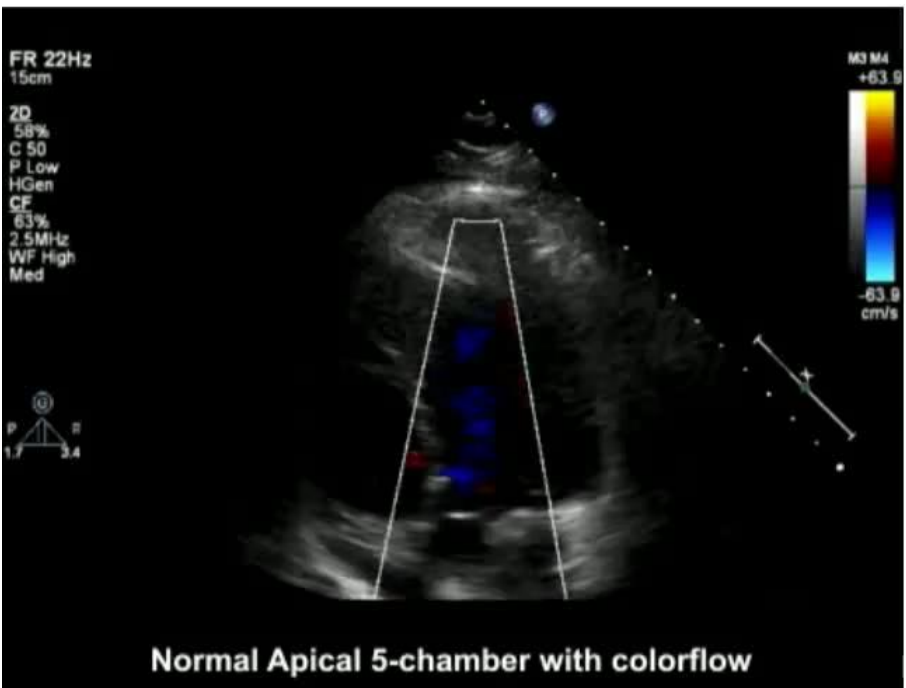
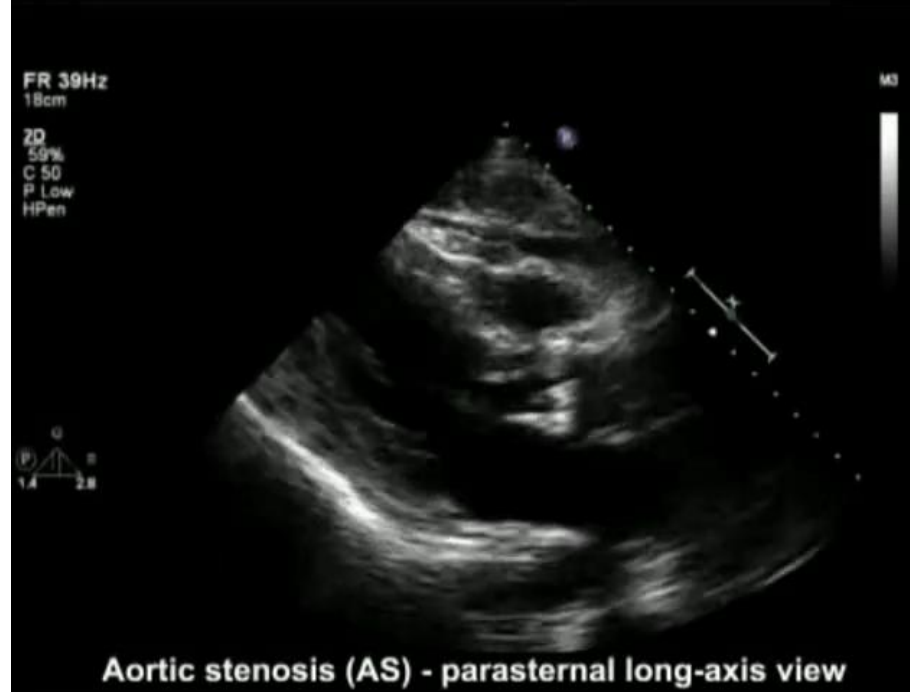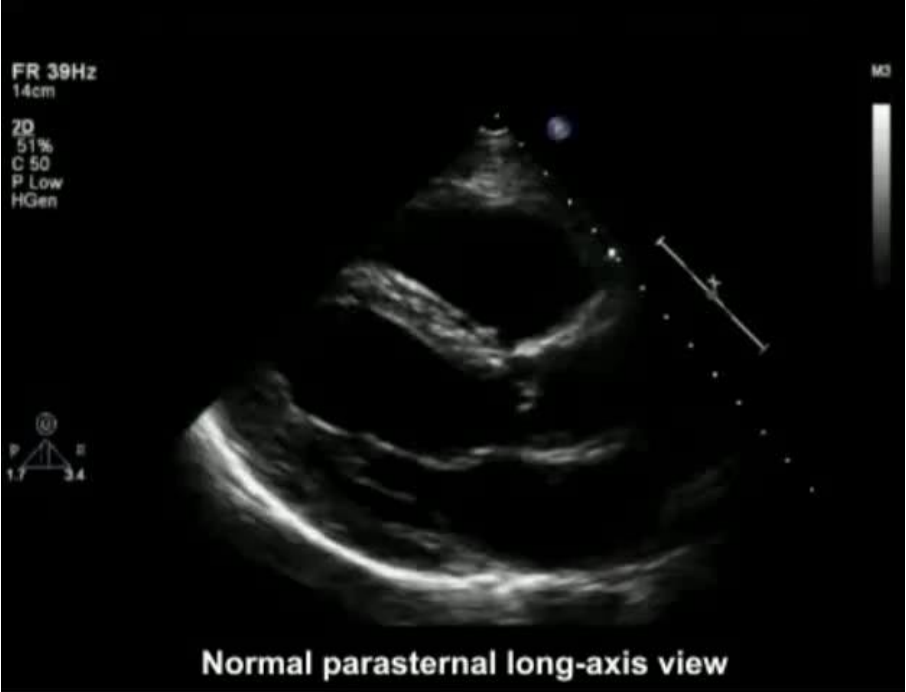Intimal flap
Intramural hematoma

Indirect Signs

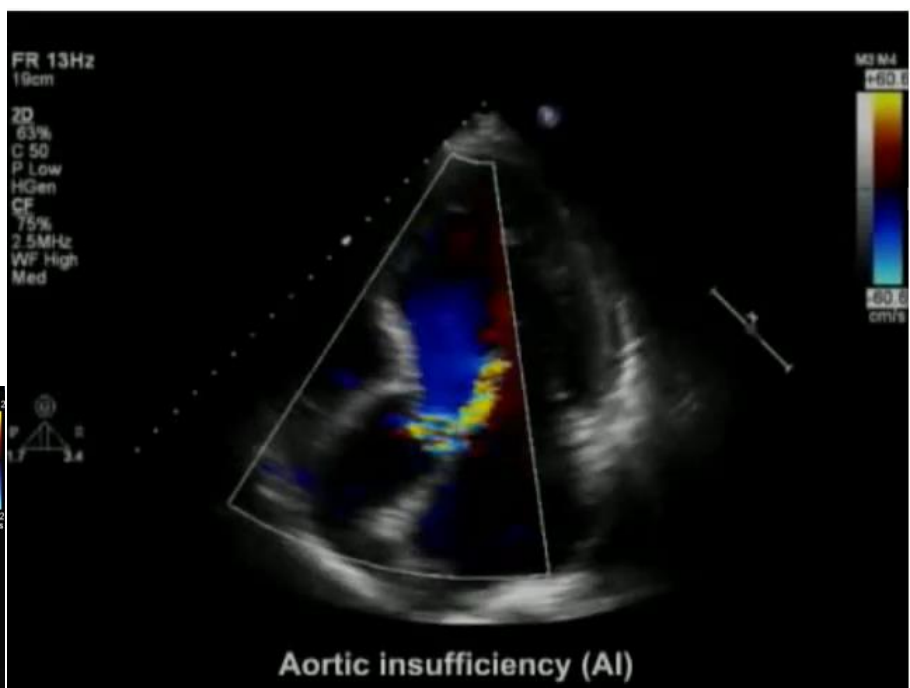
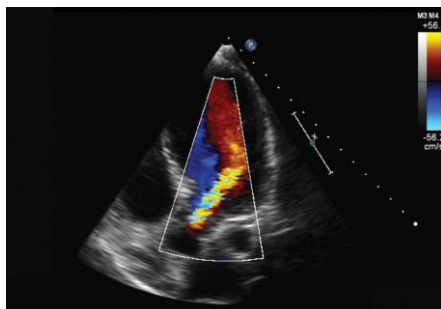
Ascending aorta Dilatation
Aortic valve Insufficiency
Pericardial effusion/ Tamponade

Aorta/Valve
Exit

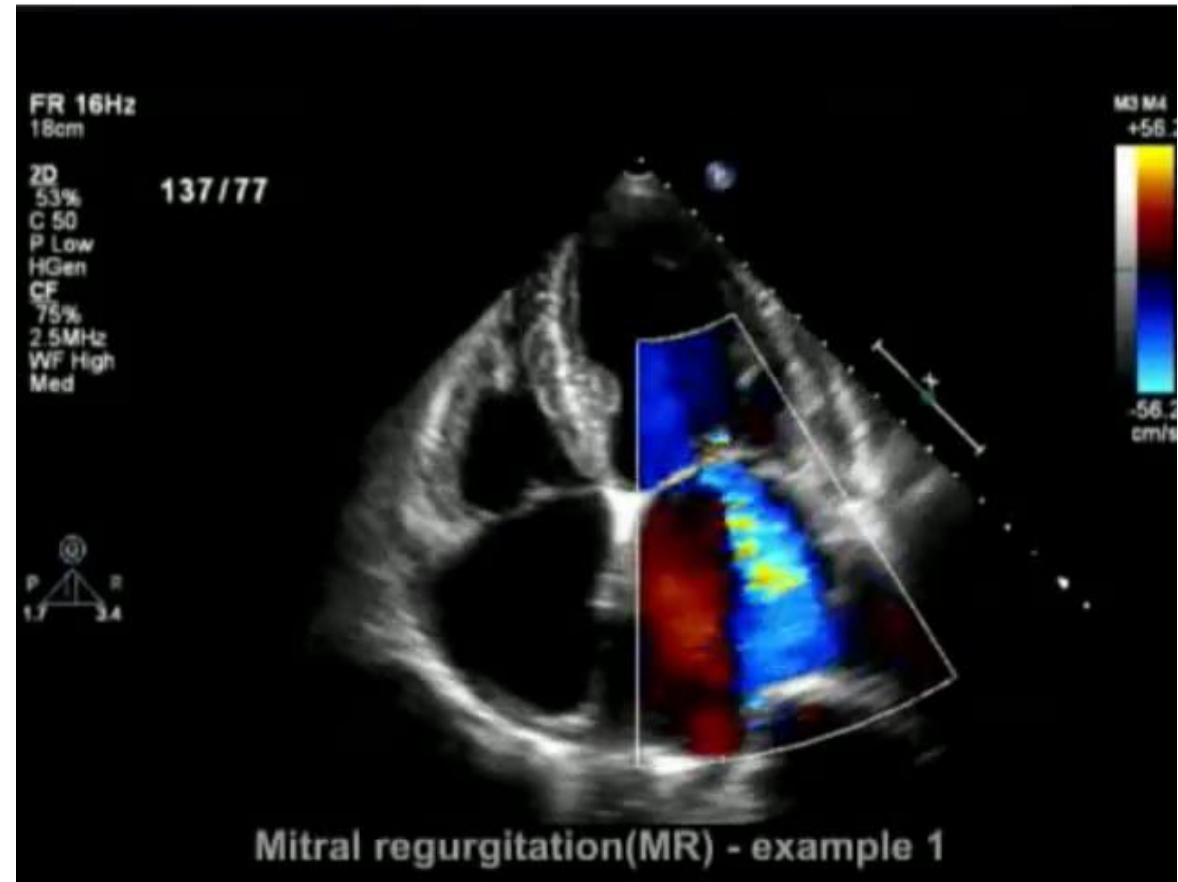
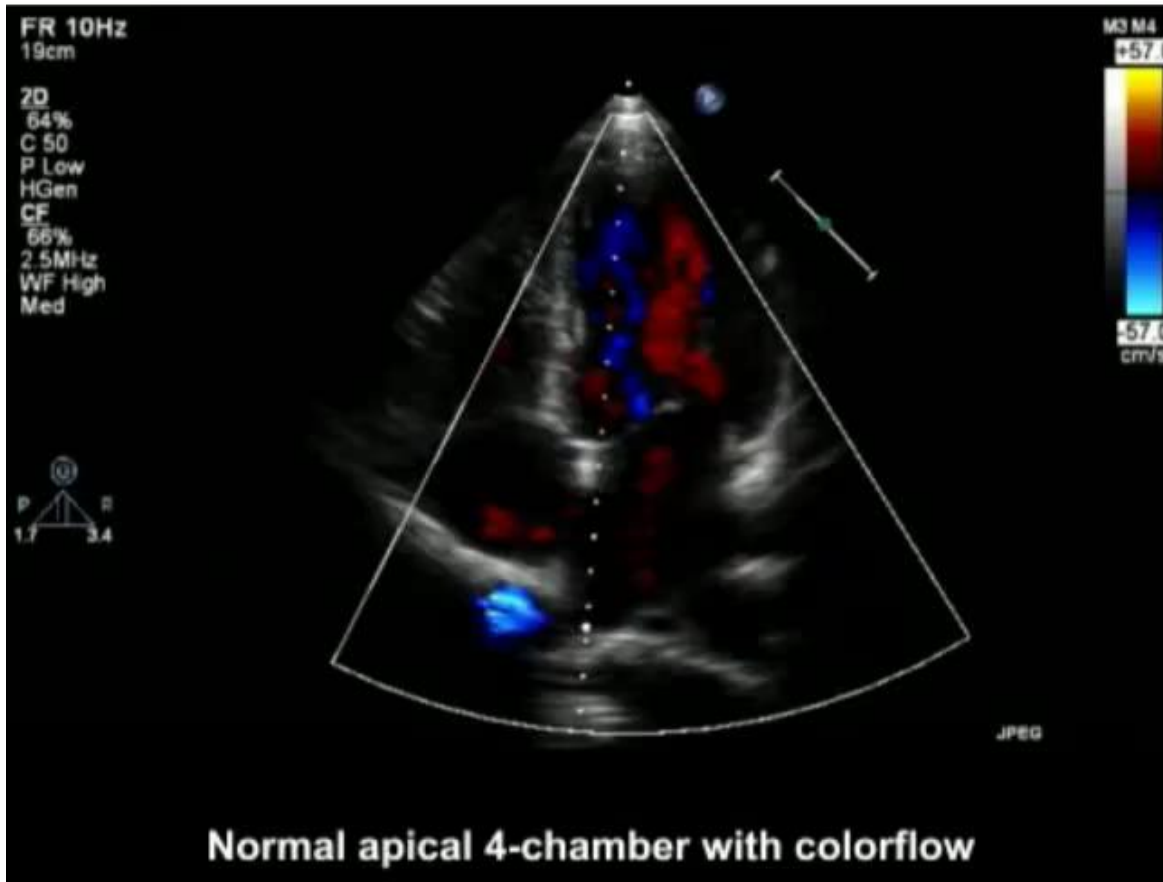
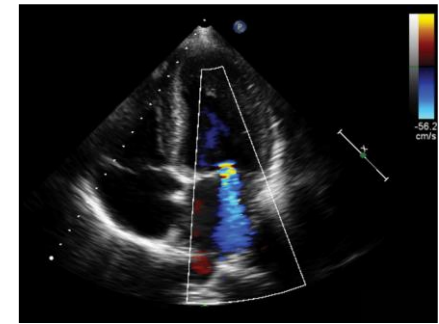
AS



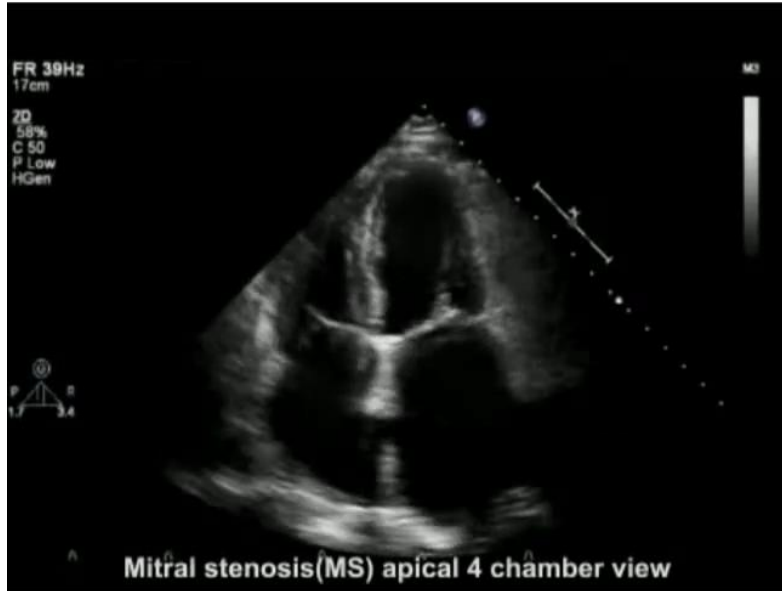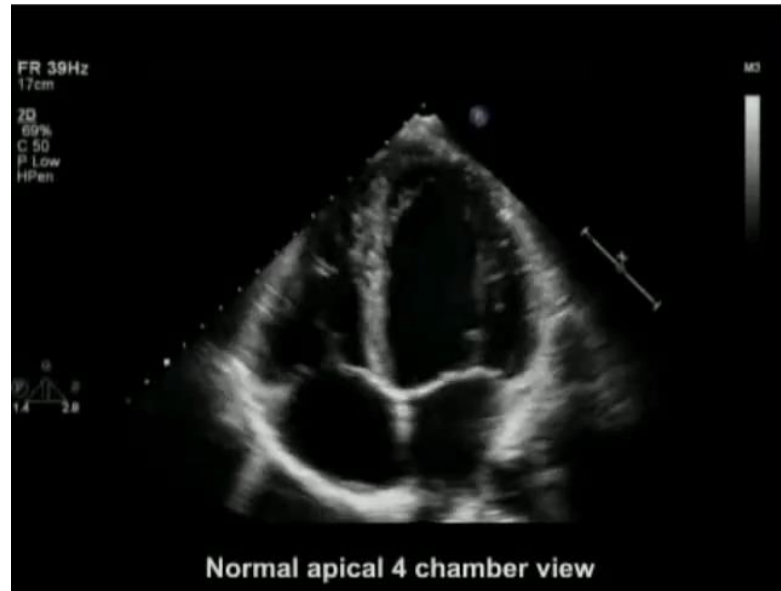
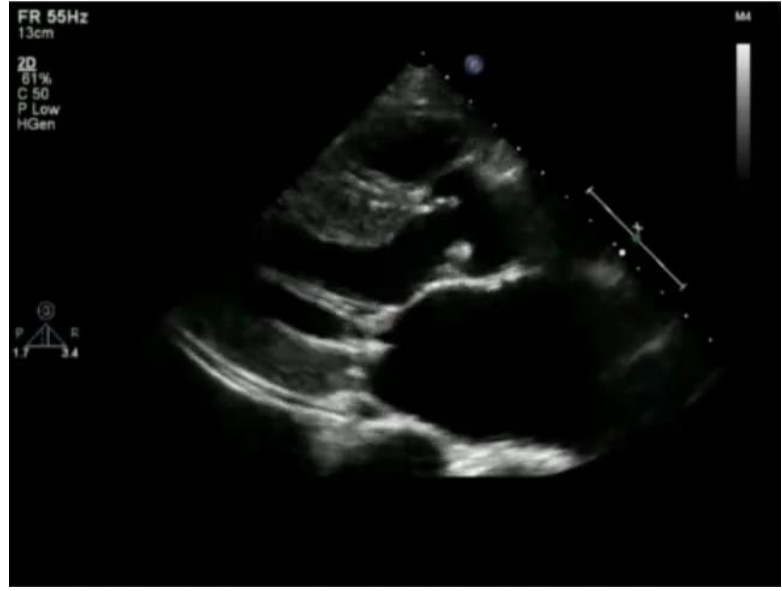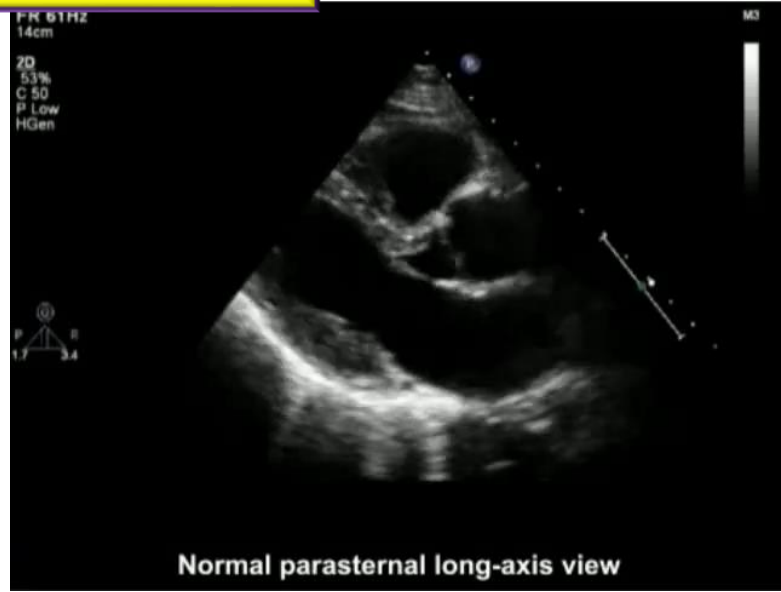AR



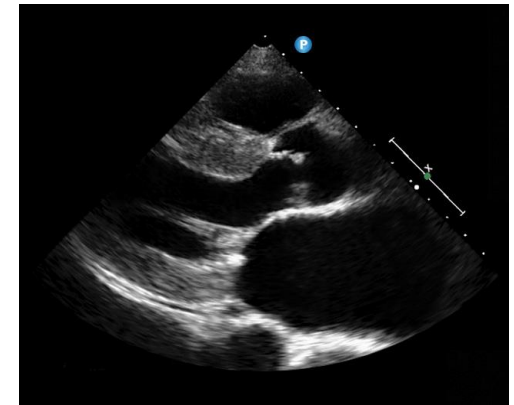
MR



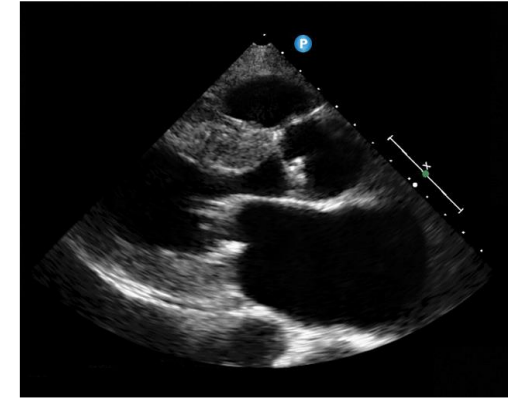
Aorta/Valve Exit



Thickening and calcification

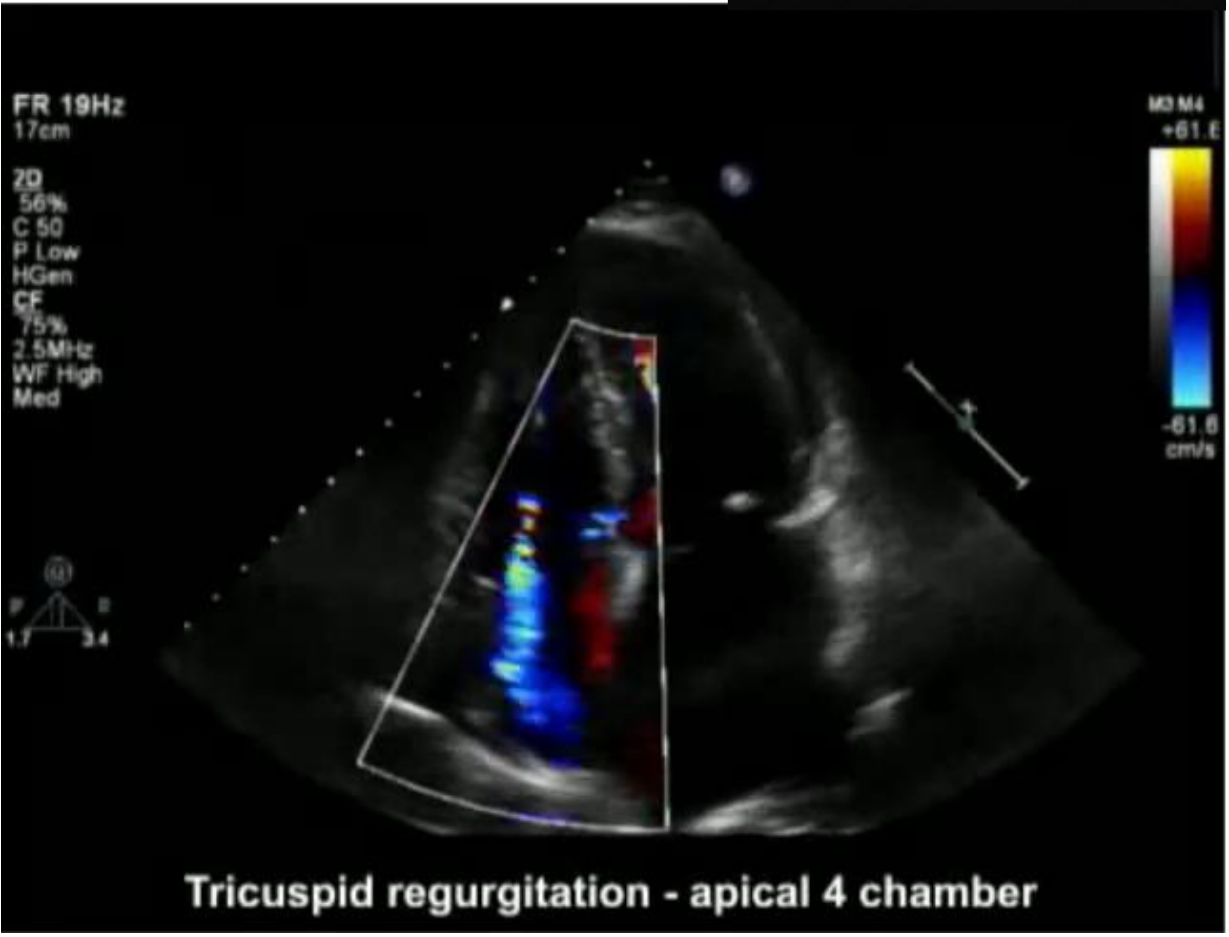
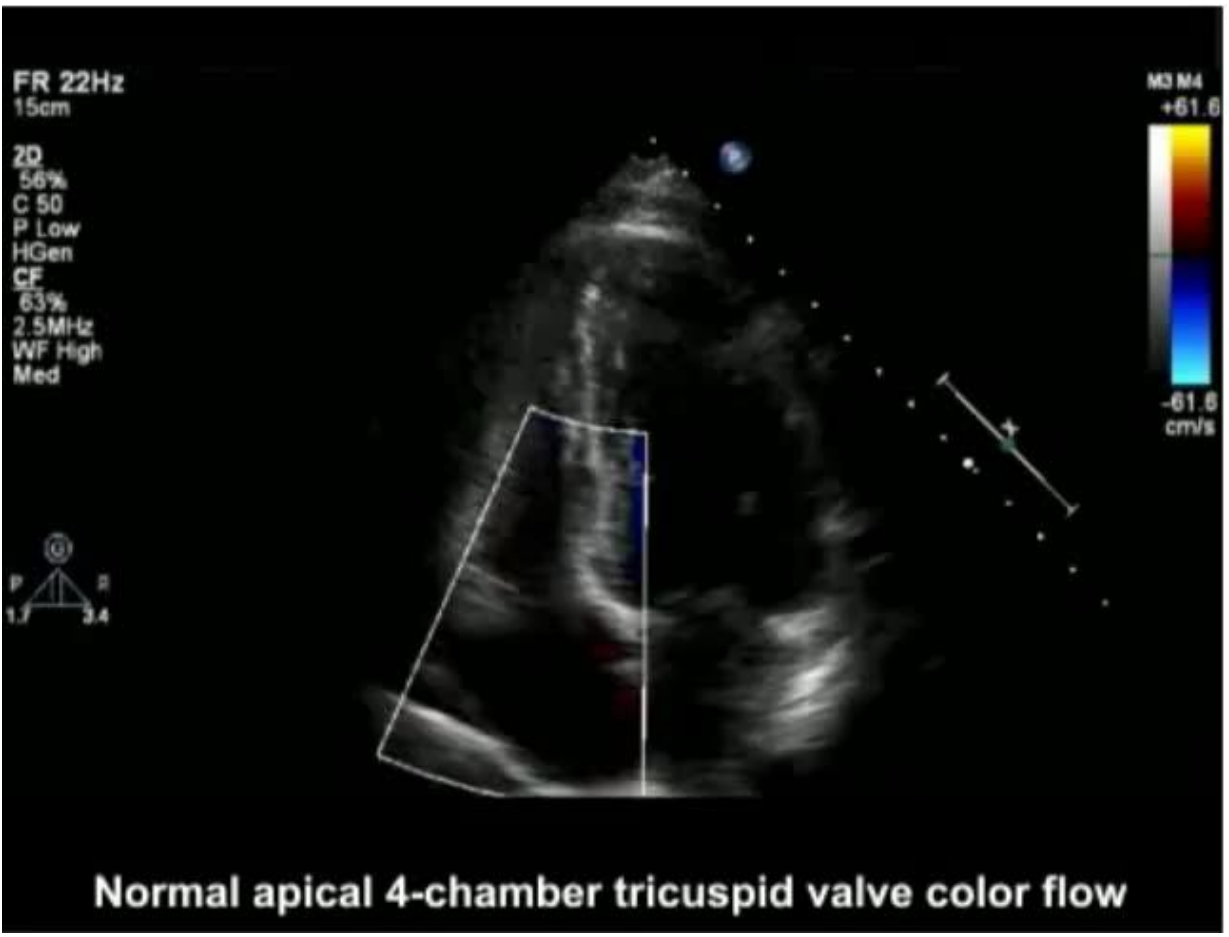
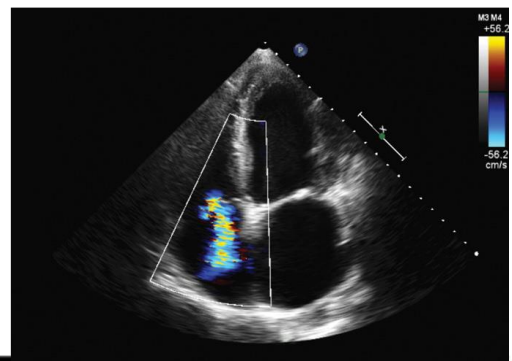


MS

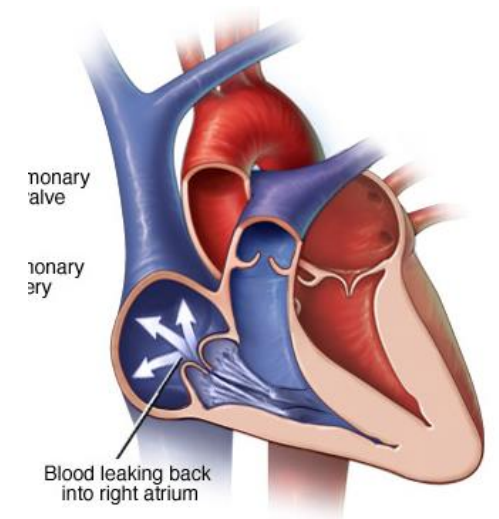
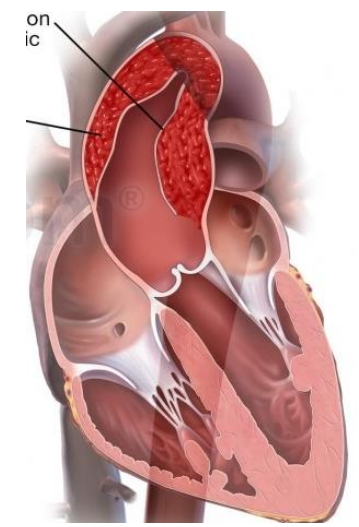
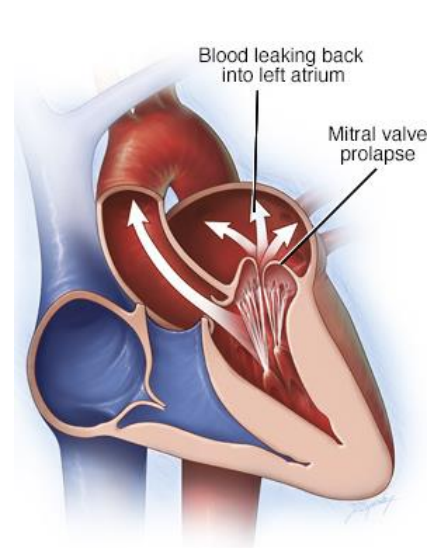


Doming of the anterior MV leaflet

TR



Aorta/Valve Exit



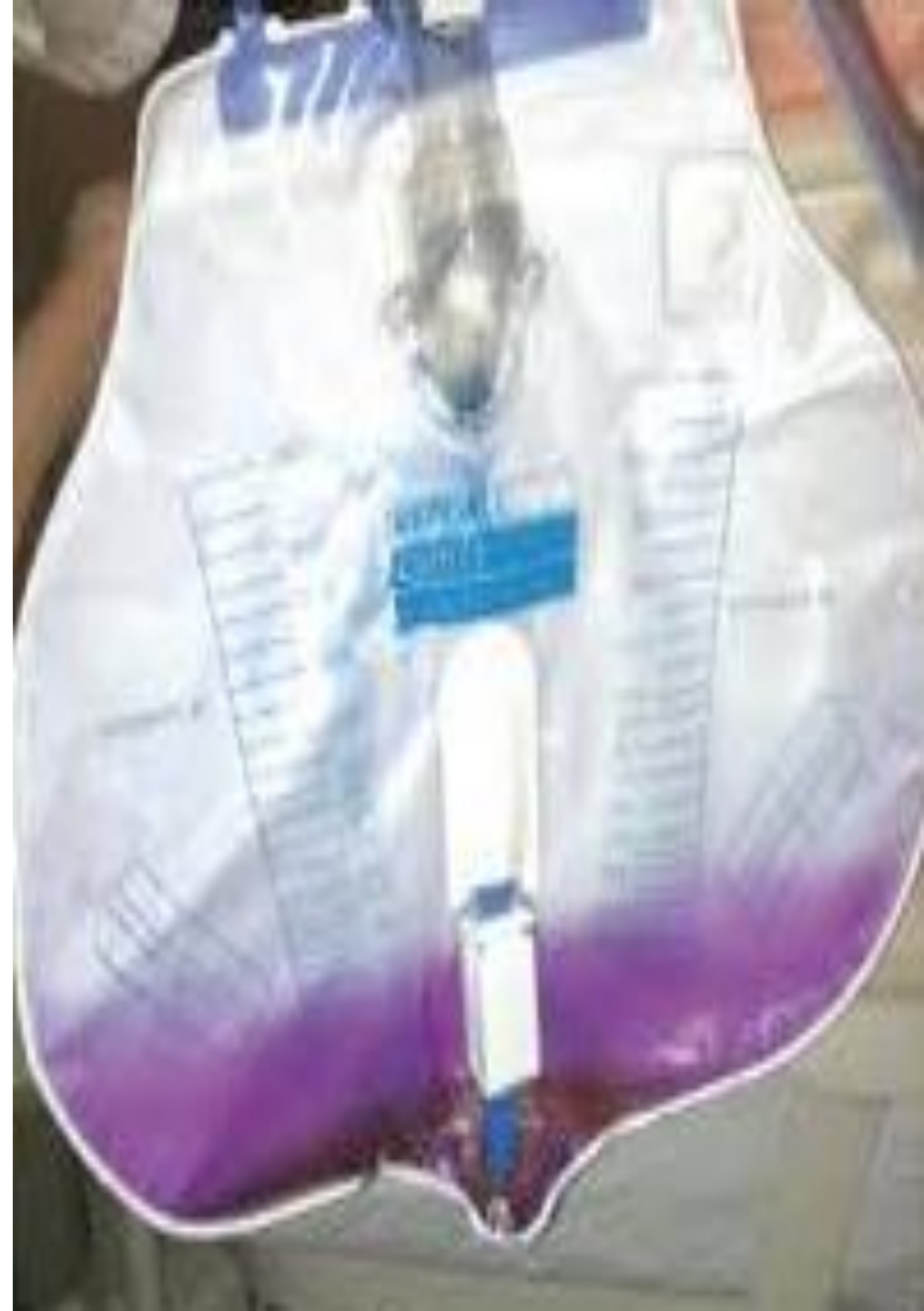Aorta & Valve

- PLAX A4CH SLAX
1. Aorta: Dissection, Aneurysm
 2. MV: MS, MR
 3. AV: AS, AR
 4. TV: TR

案例

- 69 y/o 女性
- BP 70/40 mmHg, PR 117 bpm
- 3L NS + CVC + Norepinephrine
- Post-6 h ICU admission

還是低血壓



Obstructive

- Tamponade
- Rt Chamber
- Aorta/Valve




Hypovolemic

- Hypovolemia
- Aorta/Valve

Cardiogenic

- Ejection

Distributive



Rush Exam Protocol

Rapid Ultrasound for Shock and Hypotension

HI-MAP

Use the mnemonic **HIMAP-ED** to remember...

Heart

- 1 Parasternal long cardiac view
- 2 Apical 4-chamber cardiac view

Ivc

- 3 Inferior Vena Cava View

Morison's

- 4 RUQ Morison's view
- 5 LUQ splenorenal view
- 6 Bladder view

Aorta

- 7 Aortic slide views

Pulmonary

- 8 Left Lung zone #1
- 9 Right Lung zone #5

心包膜

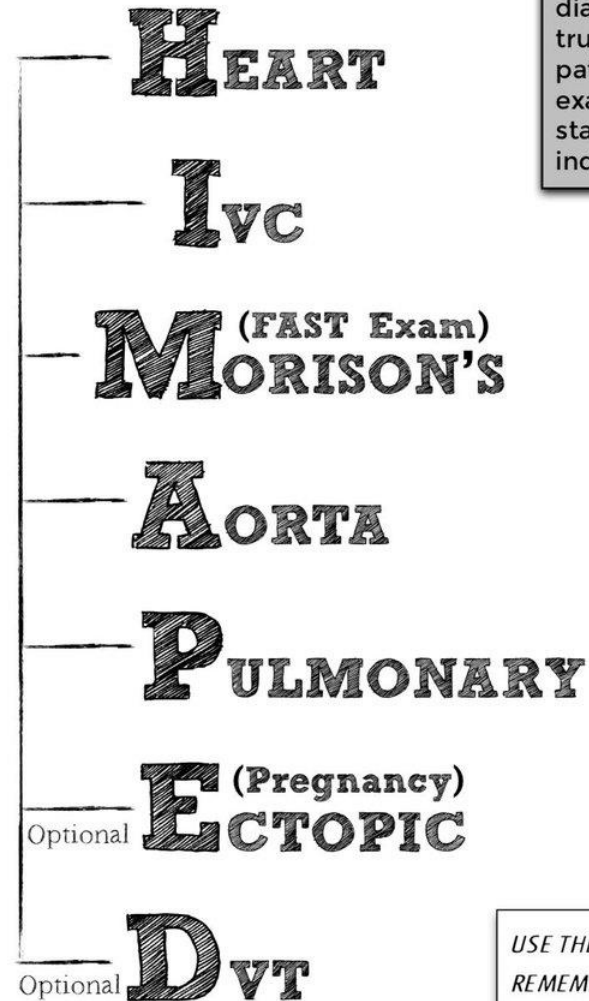
右心

左心

Rapid Ultrasound for Shock and Hypotension (RUSH)

Patients who have unexplained tachycardia, tachypnea, hypotension or are in cardiac arrest may benefit from the RUSH exam to identify potentially treatable causes such as: **AAA, pulmonary embolism, CHF, sepsis, ruptured ectopic pregnancy, hypovolemia, pneumothorax, hemothorax, and hemoperitoneum.**

Tip: The complete RUSH exam is a standardized diagnostic approach for the truly undifferentiated shock patient. Use more focused exams such as the serial fluid status assessment or other individual exams when possible.



USE THE MNEMONIC "HIMAP-ED" TO REMEMBER THE STEPS OF THE RUSH EXAM

✓ Use a curvilinear array for all views.
 ✓ Add in a search for **ectopic** pregnancy and **DVT** depending upon clinical circumstances.

The CASA Exam

(Cardiac Arrest Sonographic Assessment)

1. Cardiac Tamponade?

≤10 seconds

2min ACLS

2. Right heart strain?

≤10 seconds

2min ACLS

3. Cardiac activity?

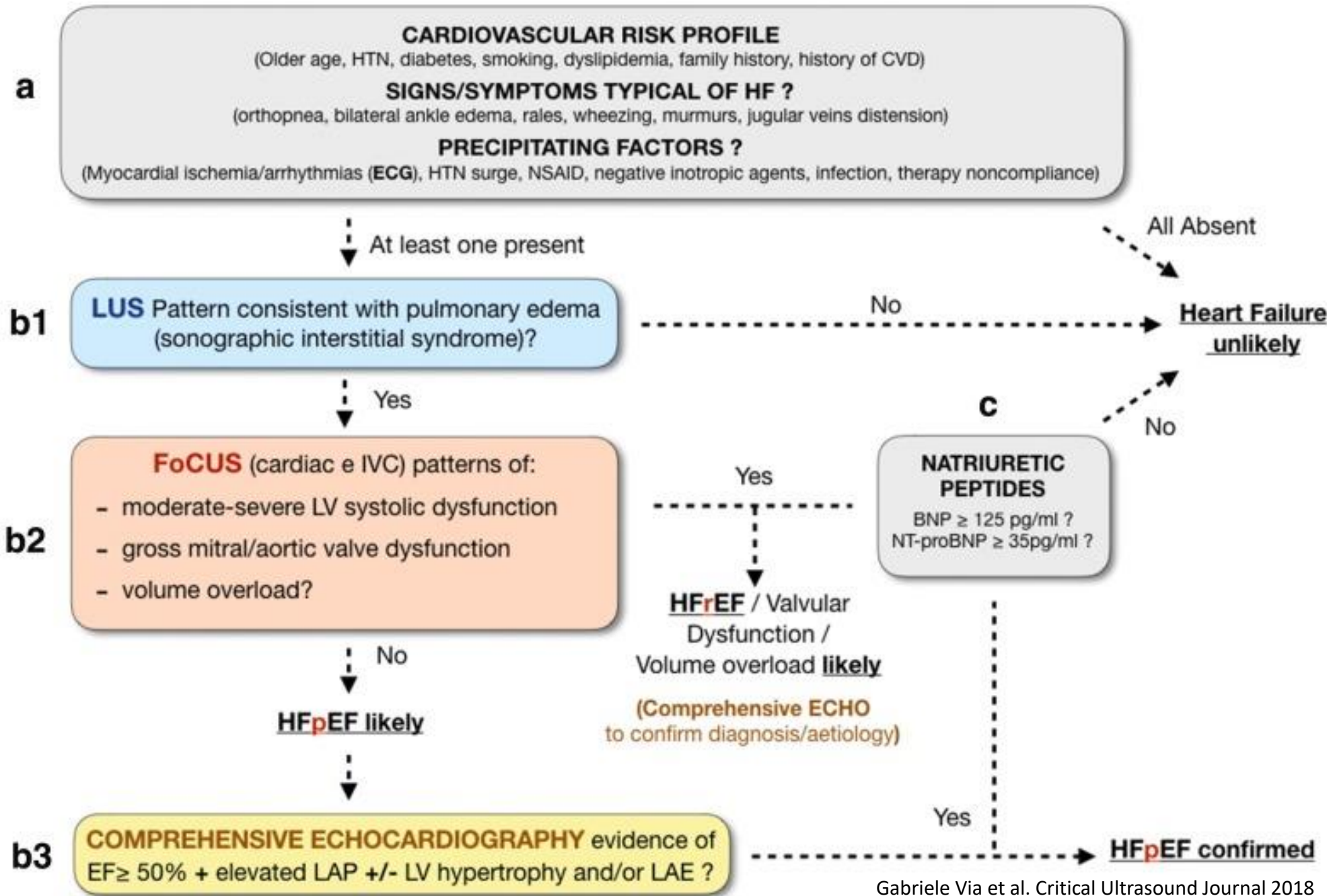
≤10 seconds

PNX/FAST

(As indicated)

Respiratory failure, suspected Congestive Heart Failure. Assess:

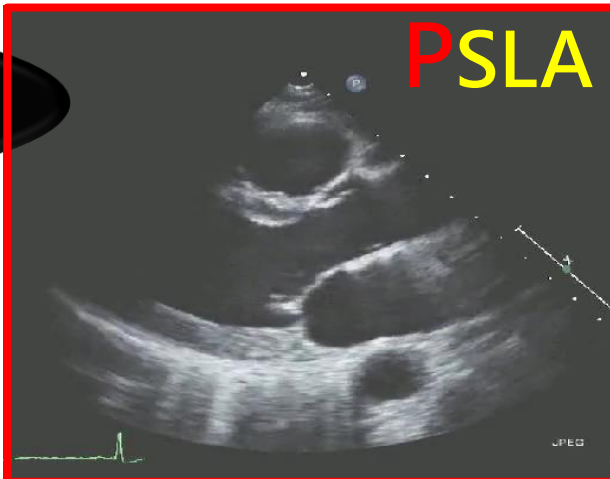
Congestive
Heart
Failure



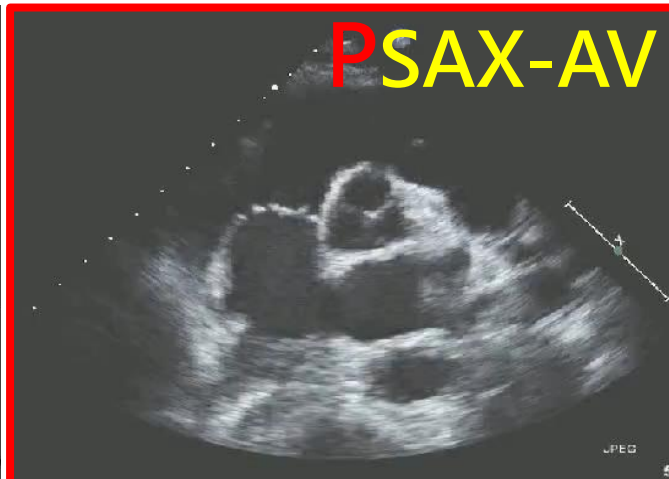Acquire

Scan

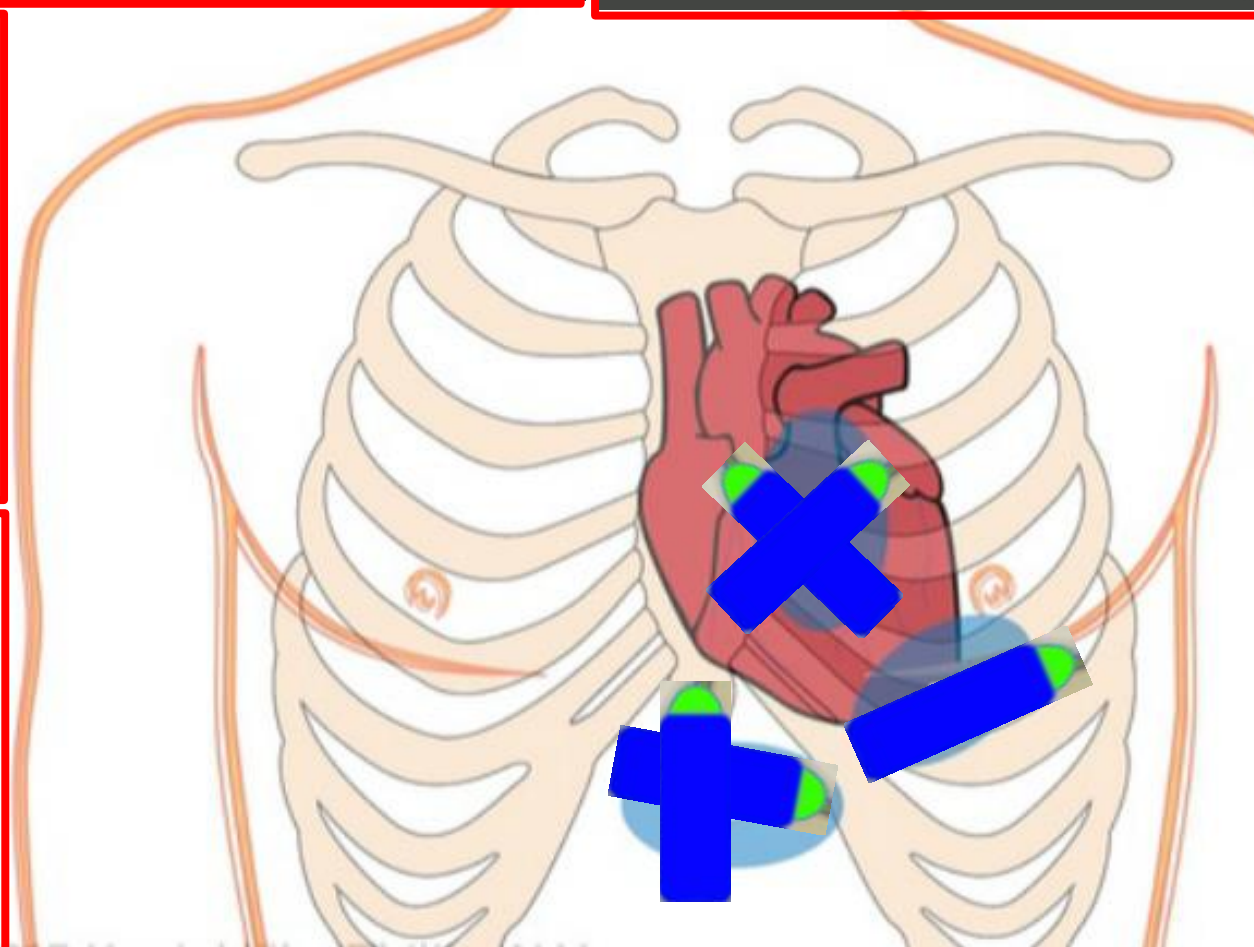
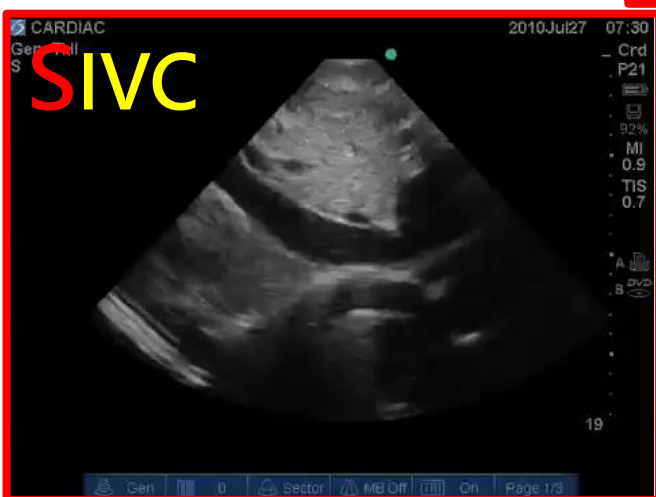
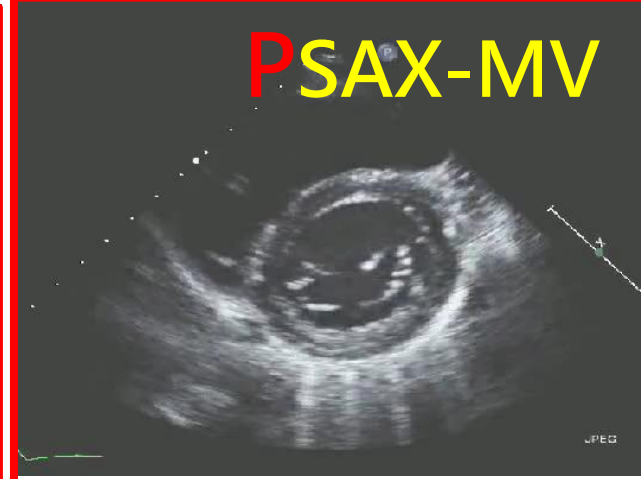PSLA



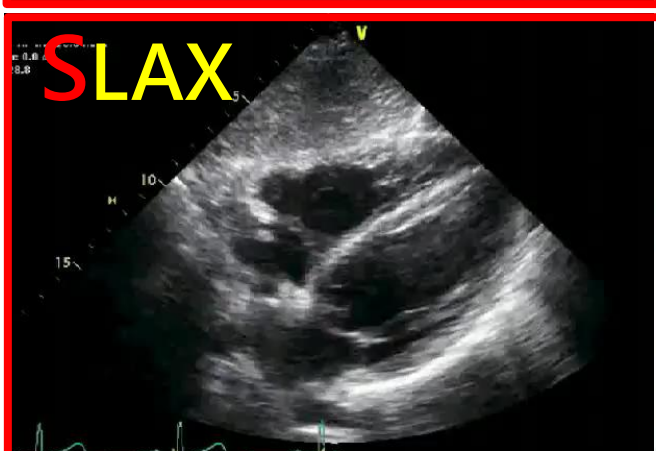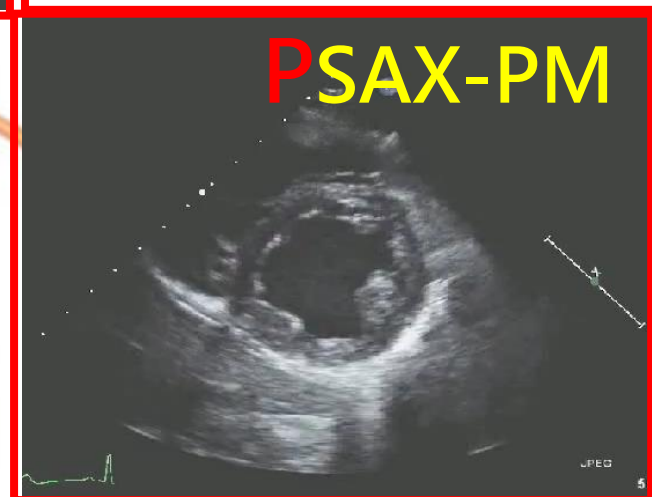PSAX-AV



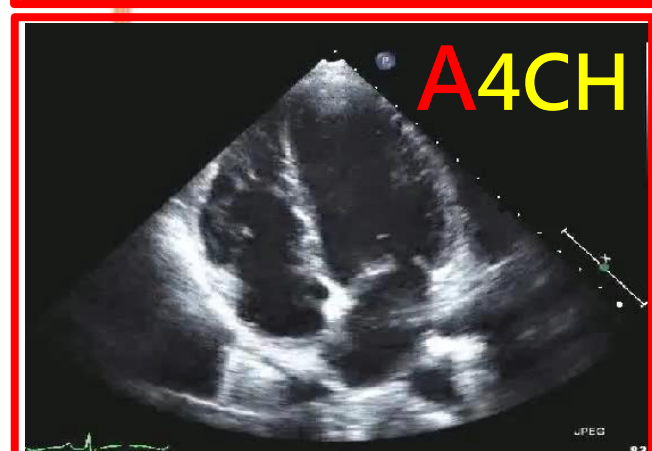
PSAX-MV



PSAX-PM



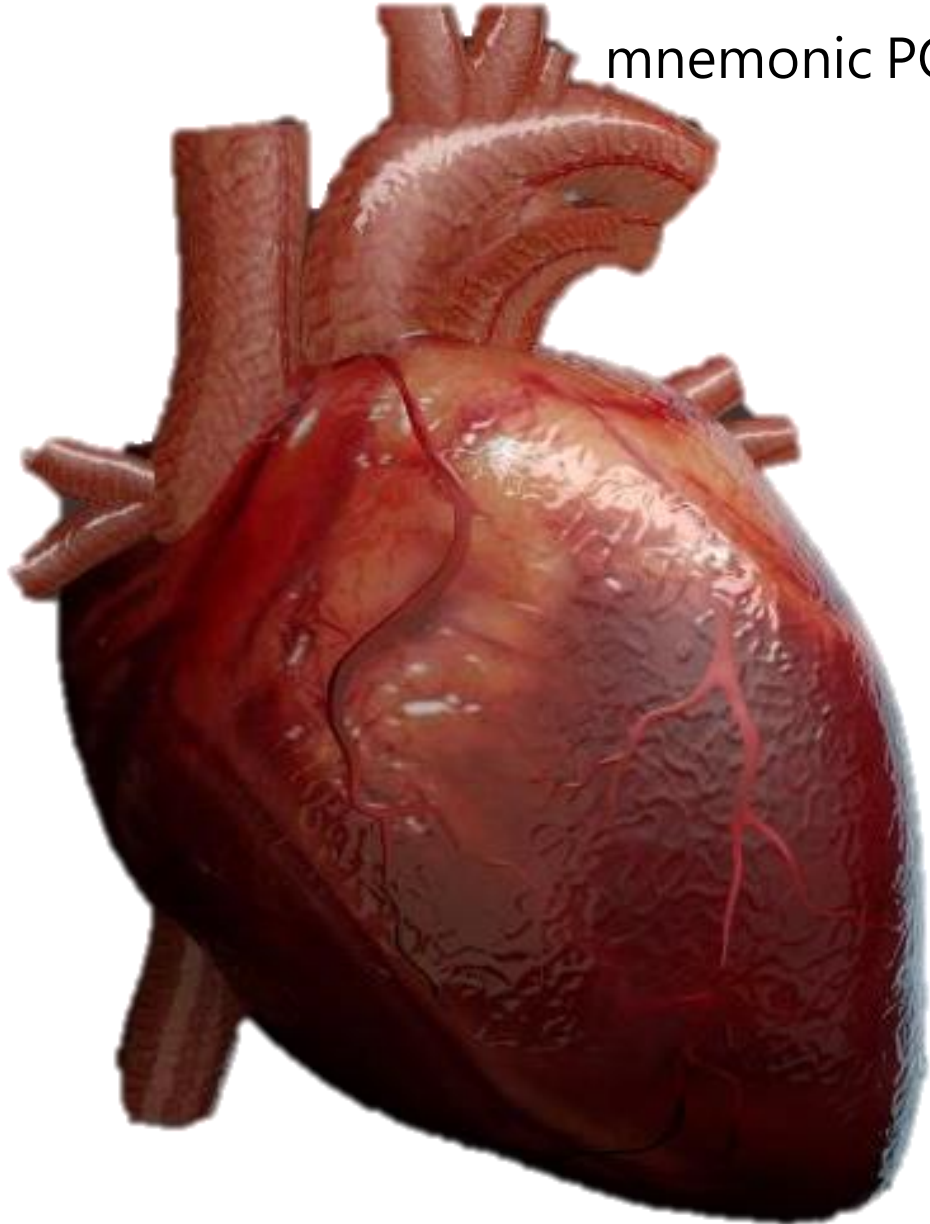
A4CH



Interpret

HEART

mnemonic POCUS for Focused Cardiac Ultrasound



Hyper/hypo-volemia

Eejection (LVF)

Aorta/valve

Right chamber

Tamponade

I

A

I

M

FOCUS

POCUS

SPA1

SPA2

HEART

PLAN