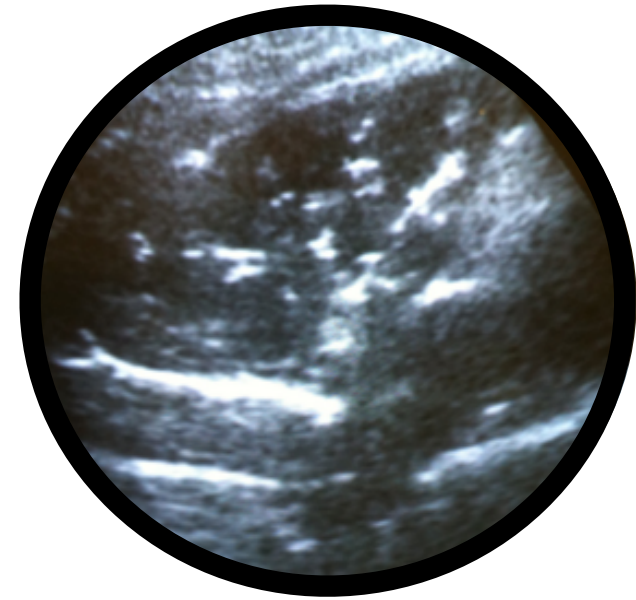
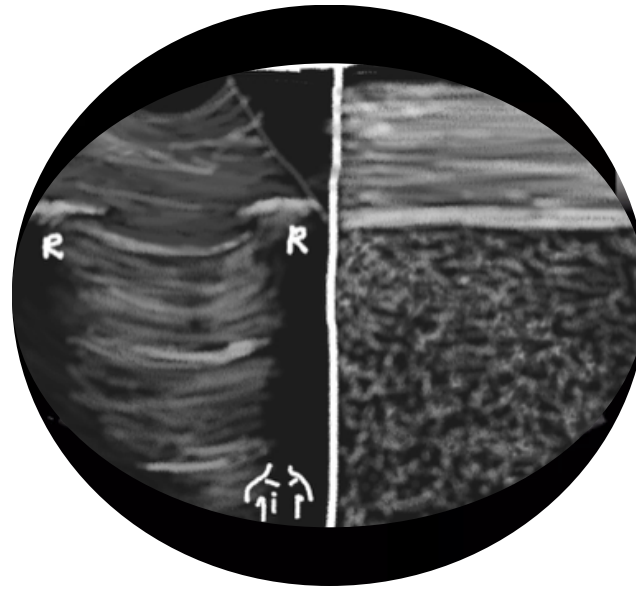


POCUS for acute dyspnea evaluation in ICU

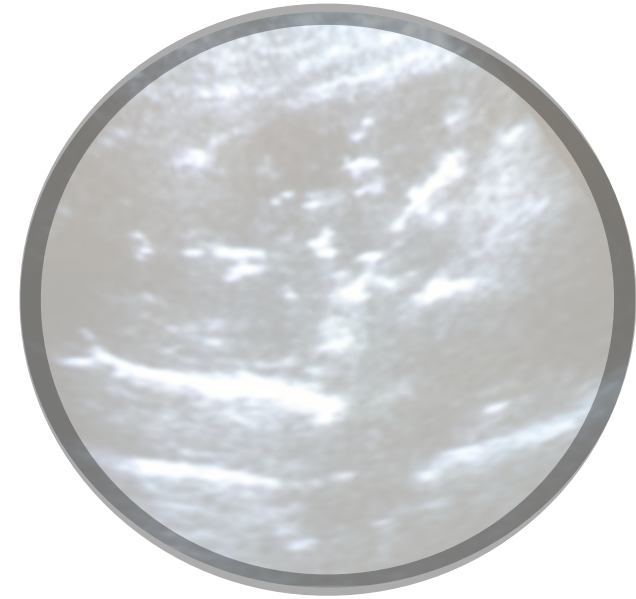
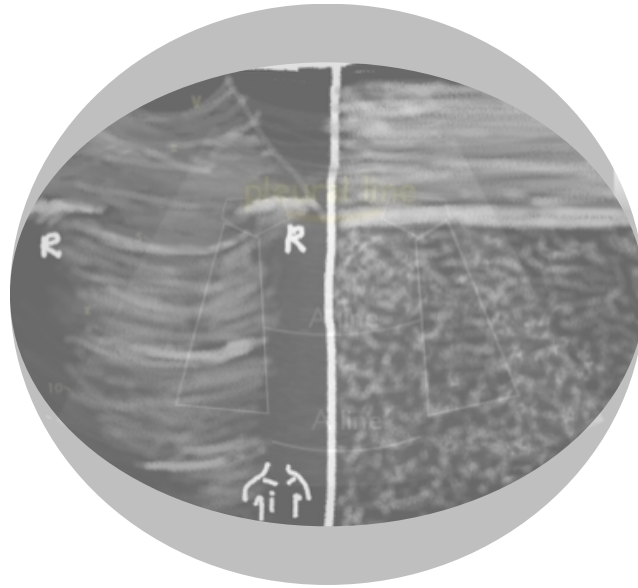



Jen-Tang, Sun MD
Emergency Department
Far East Memorial Hospital

Lung ultrasound




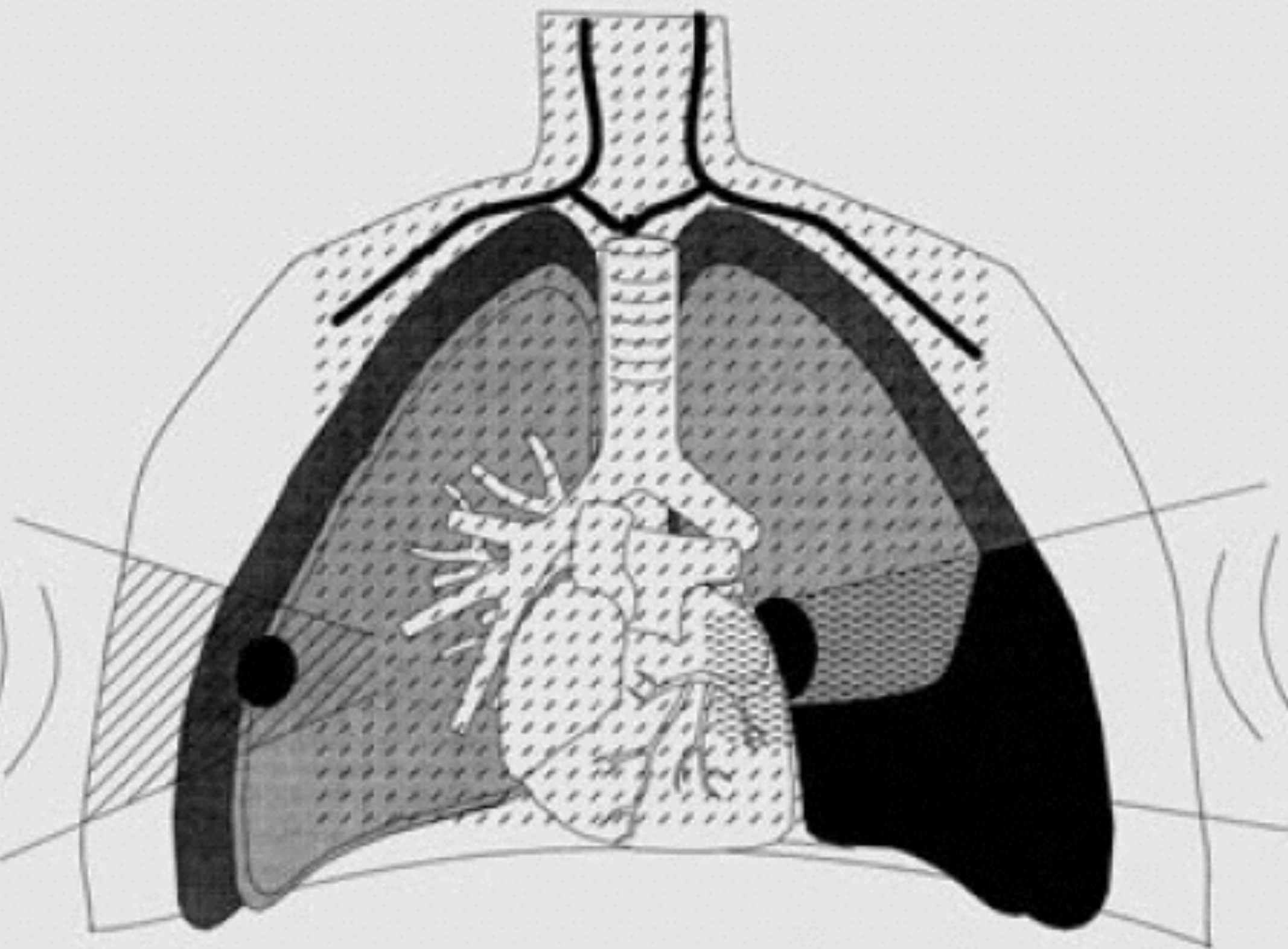
Lung ultrasound

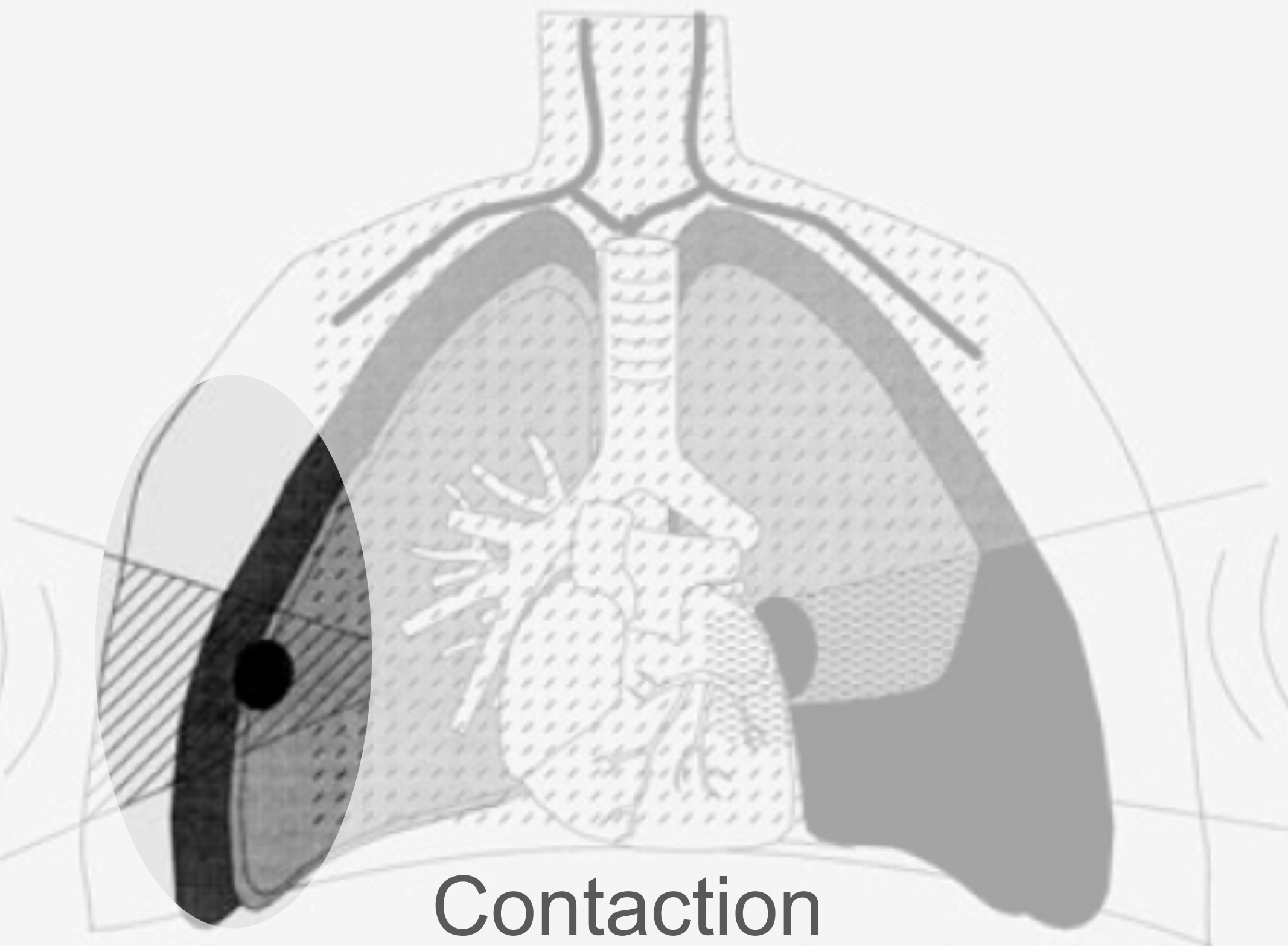


Lung ultrasound

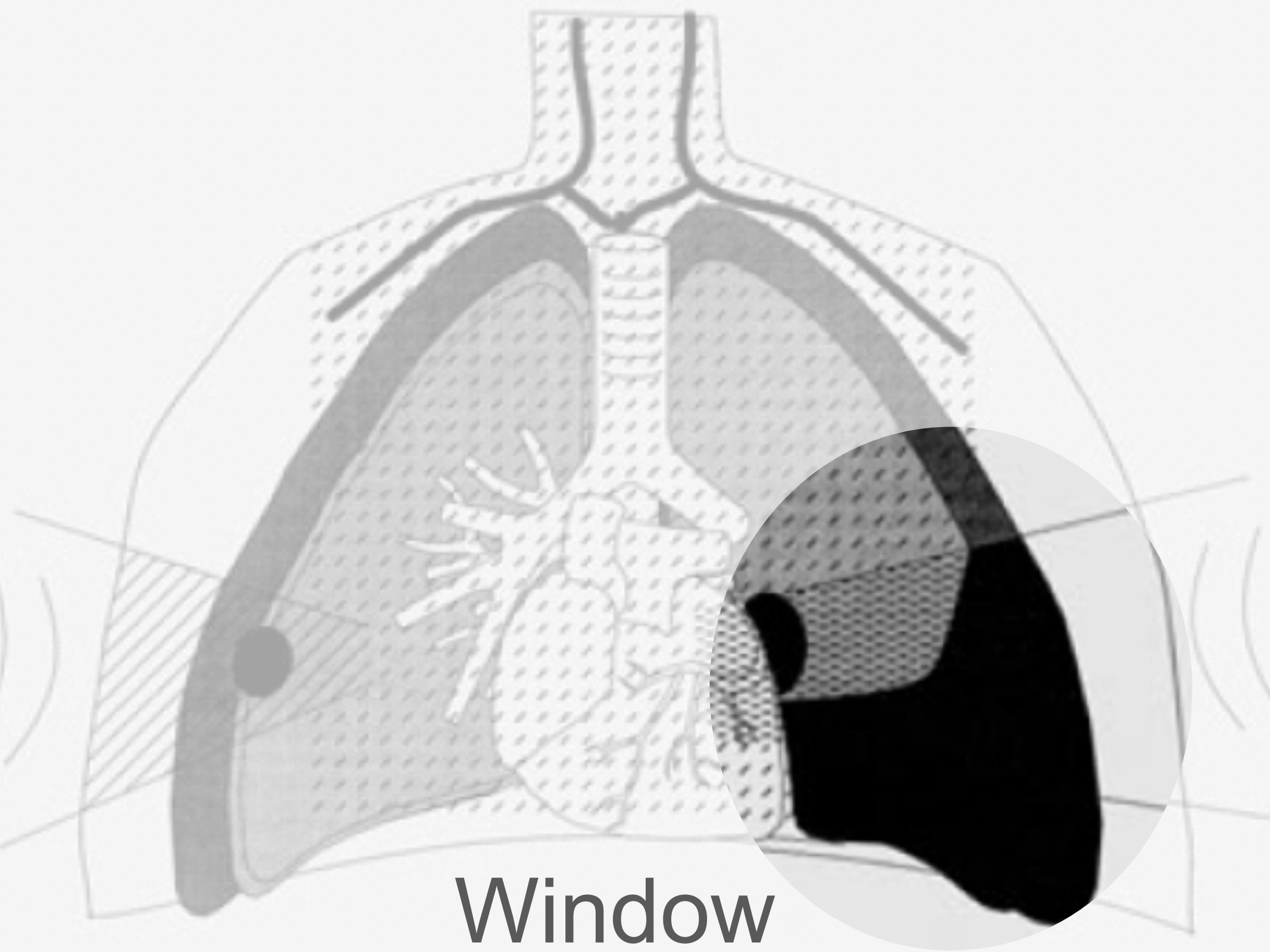
() Could detect all lesion.







Contraction





Window

Lung ultrasound

(X) Could detect all lesion.

() Depends on artifact.



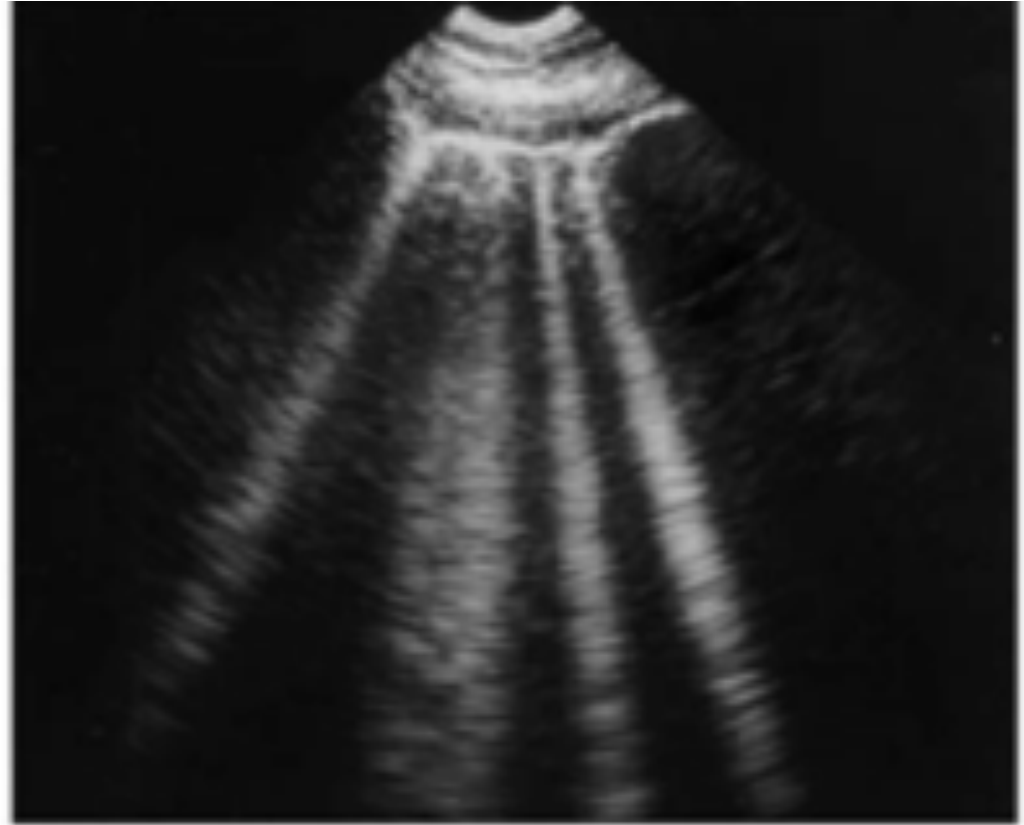
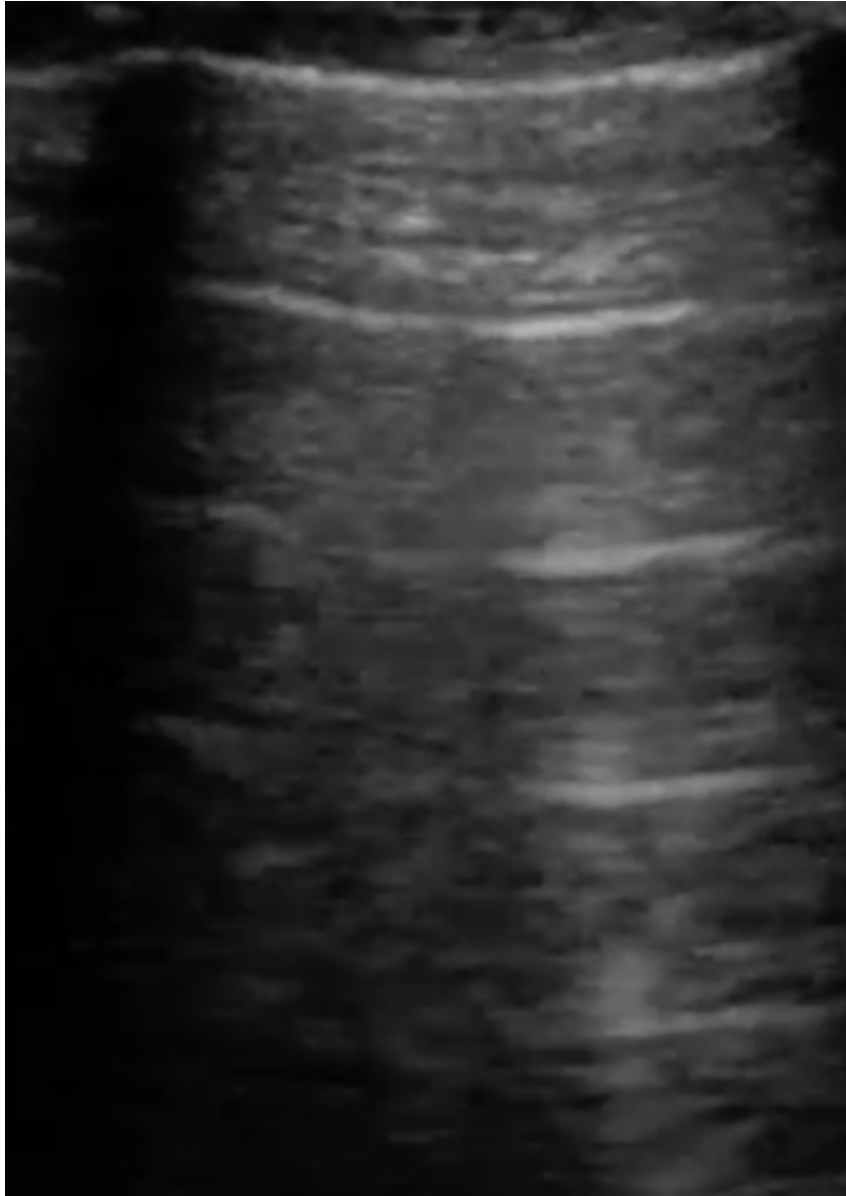
A Buddhist monk with a shaved head and glasses, wearing a yellow robe, is speaking into a microphone. He has his right hand raised in a gesture. Behind him is a large, stylized yellow and white figure, possibly a deity or a large Buddha statue, against a red background.

24 海濤法師

少林寺 / 先生有外遇？練習當假的看妳就不苦

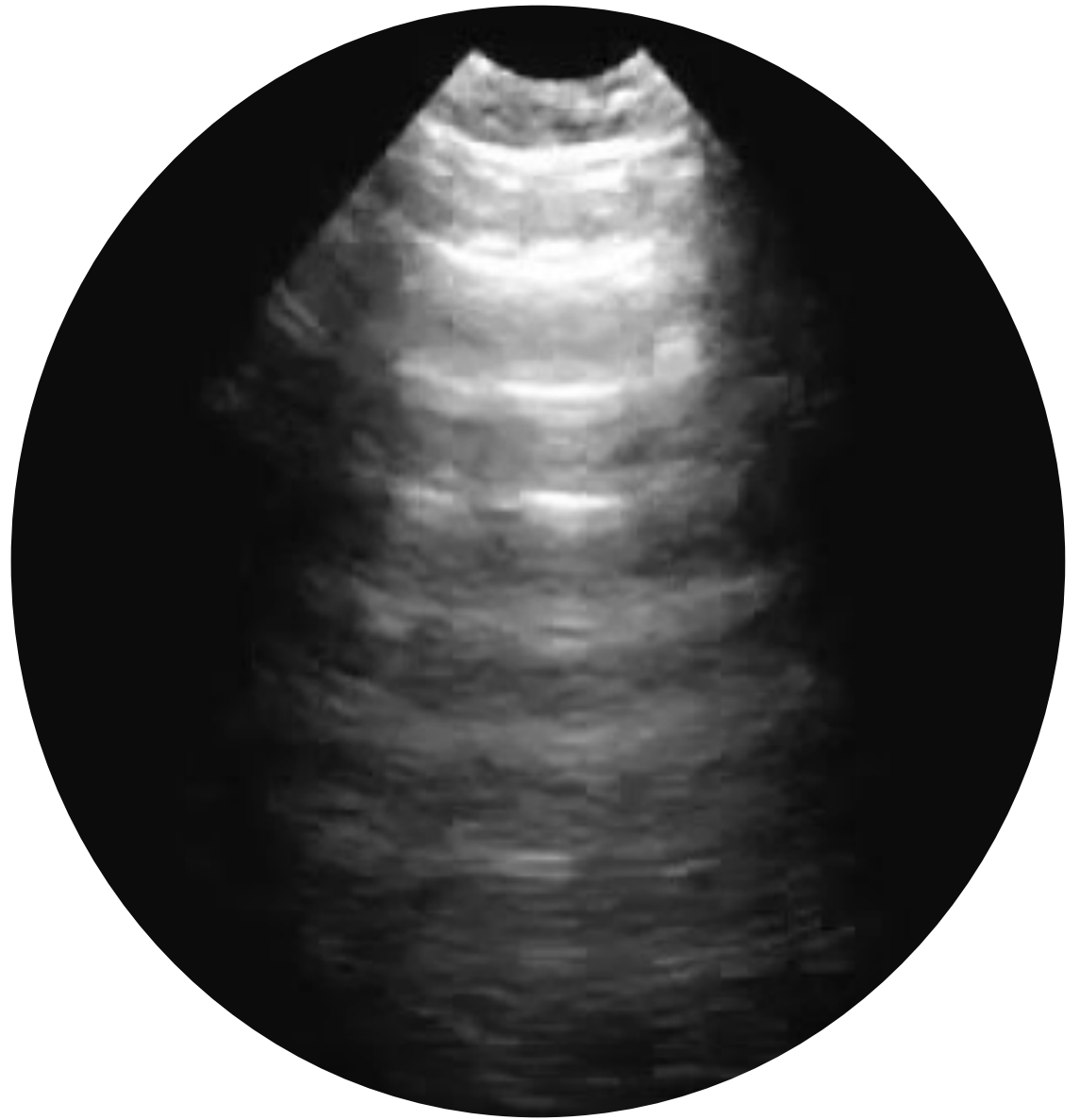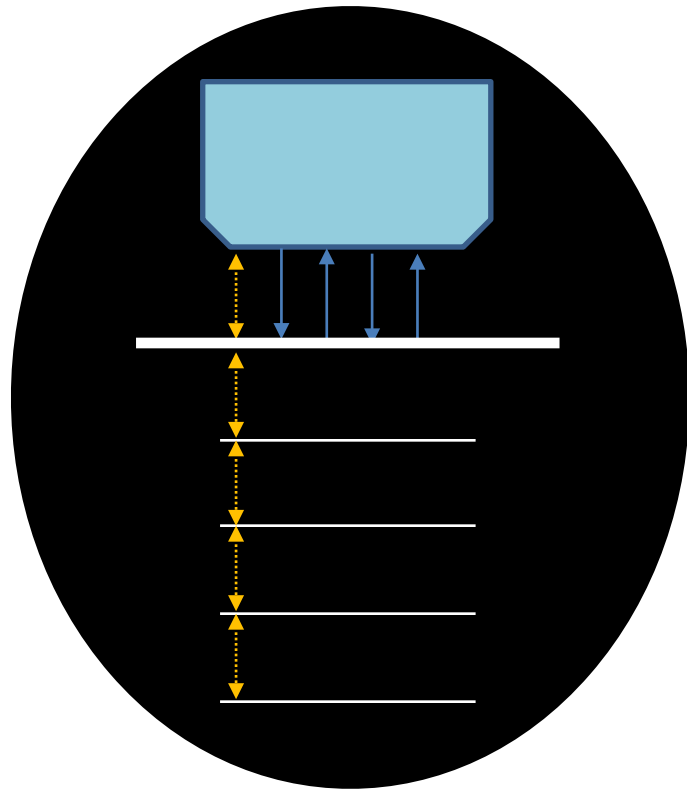
「假的！」

Artifacts



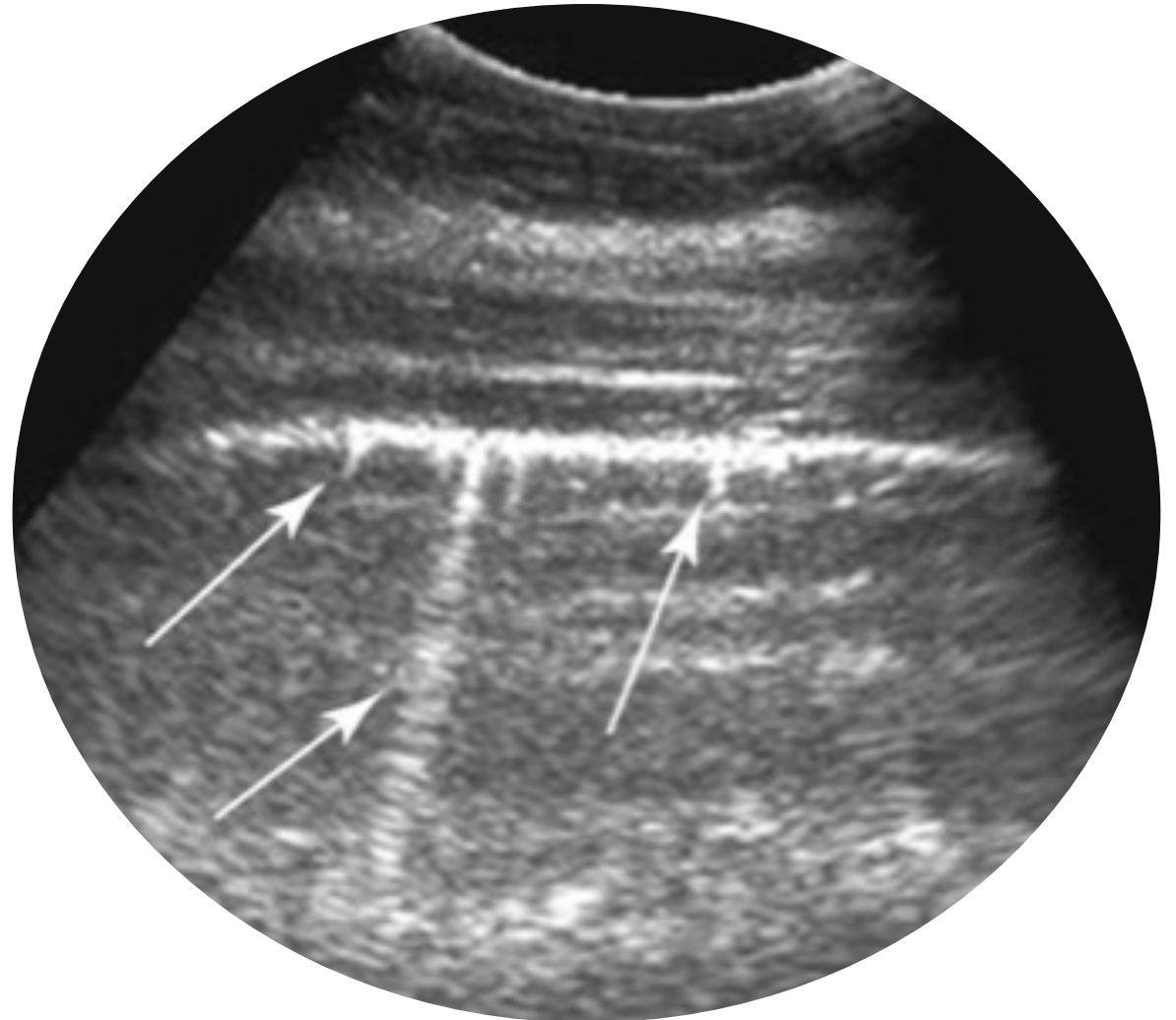
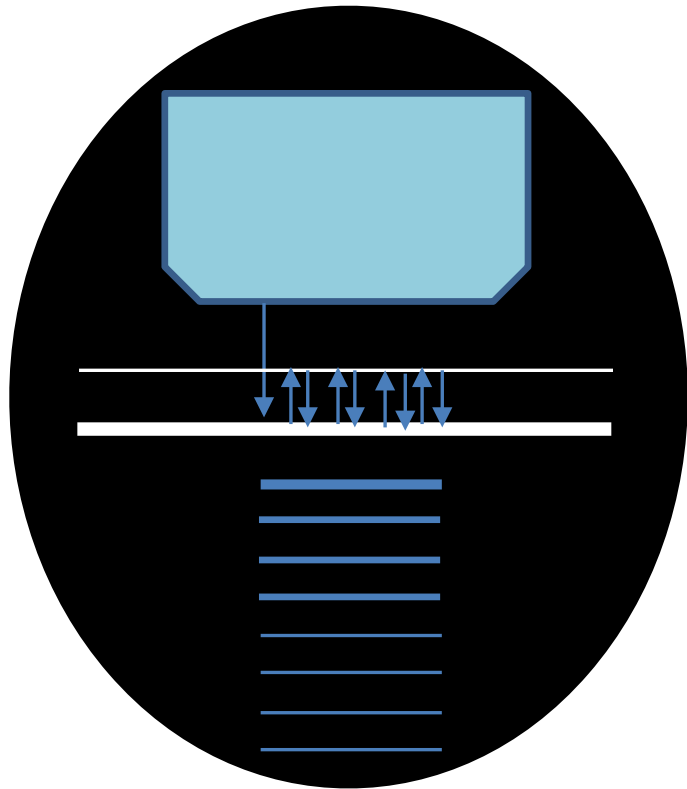
Artifacts

Repetition



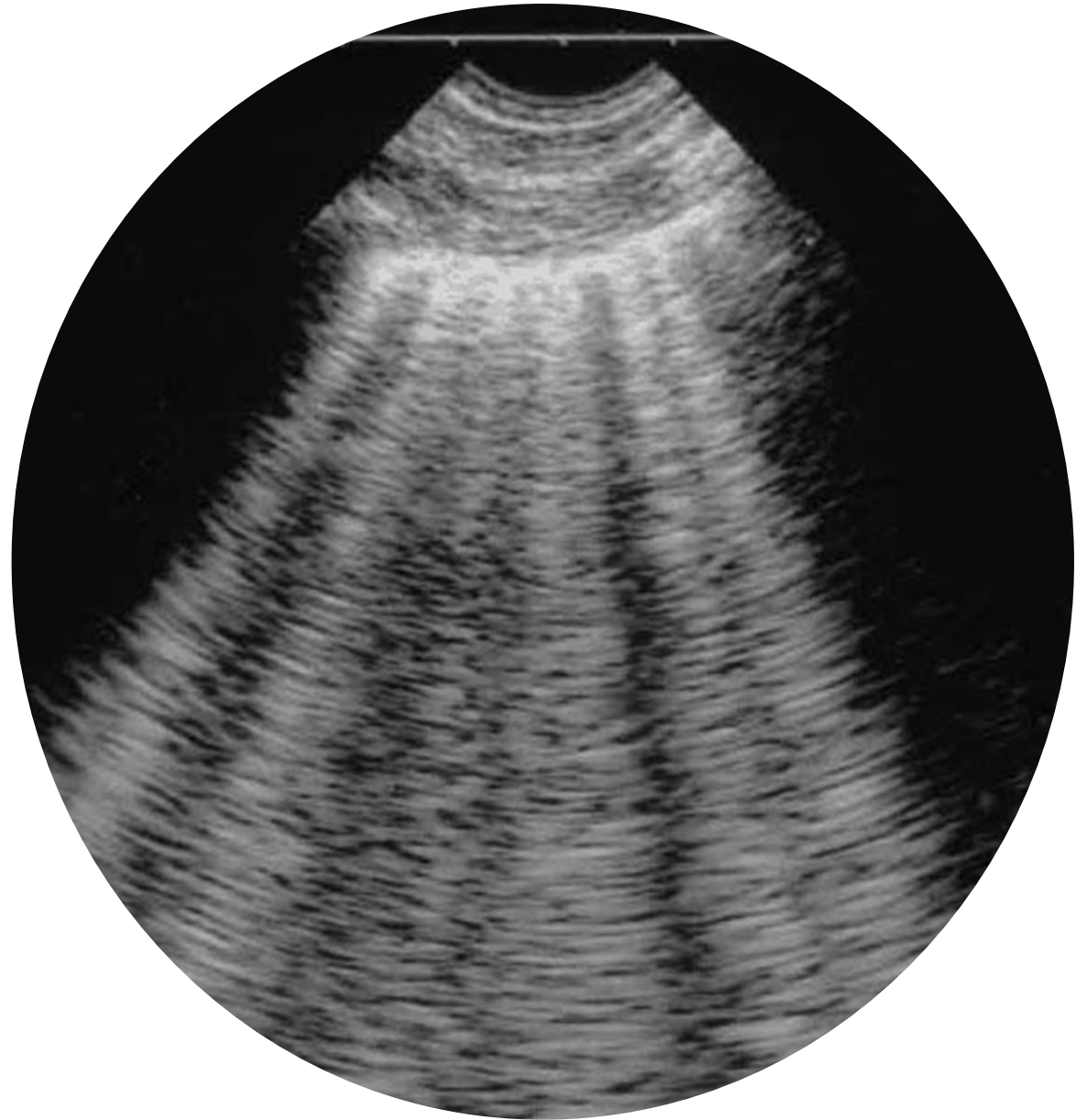
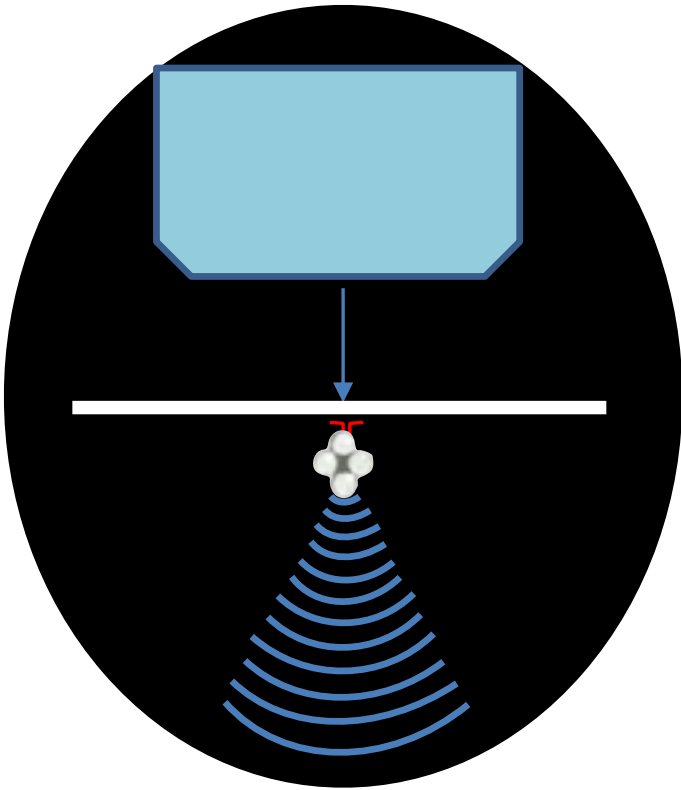
Artifacts

Reverberation



Artifacts

Ring-down



Dr Francis Lee

Lung ultrasound

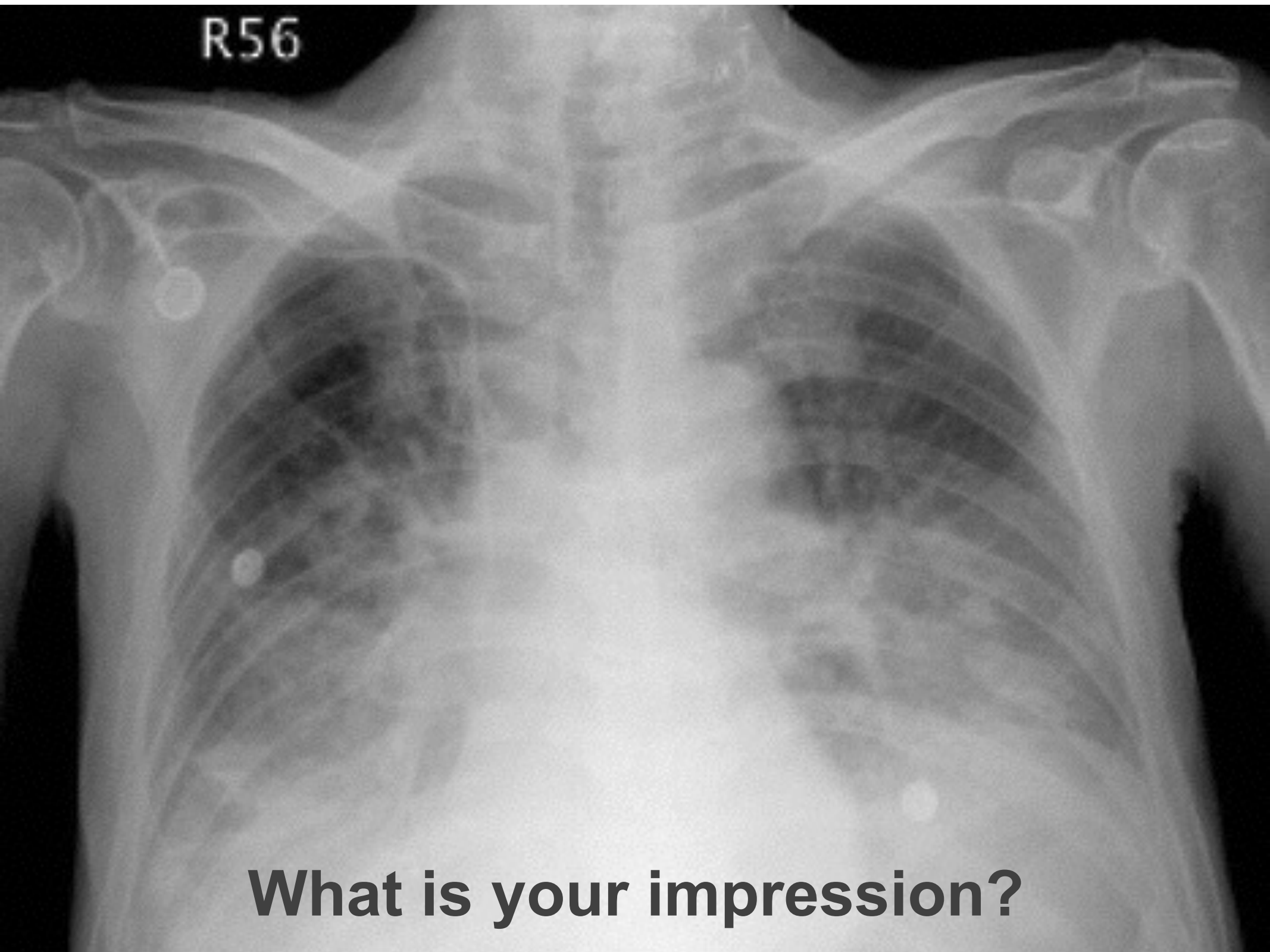
(X) Could detect all lesion.

(O) Depends on artifact.

() Is operator dependent



R56

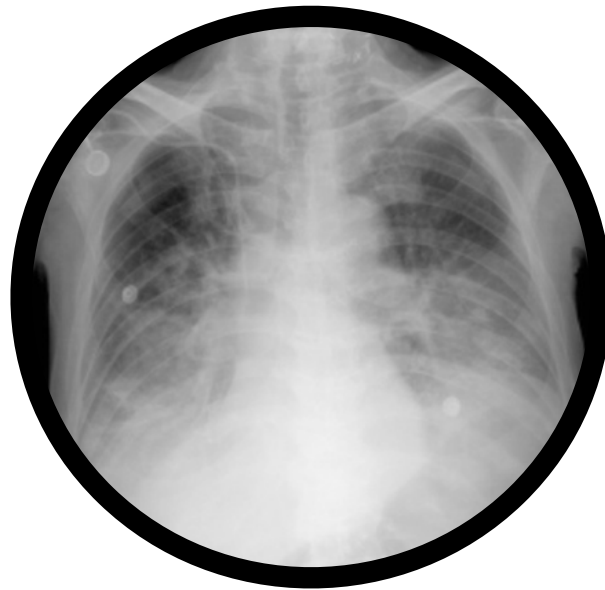

What is your impression?

Interobserver agreement of pneumonia



Kappa
0.30



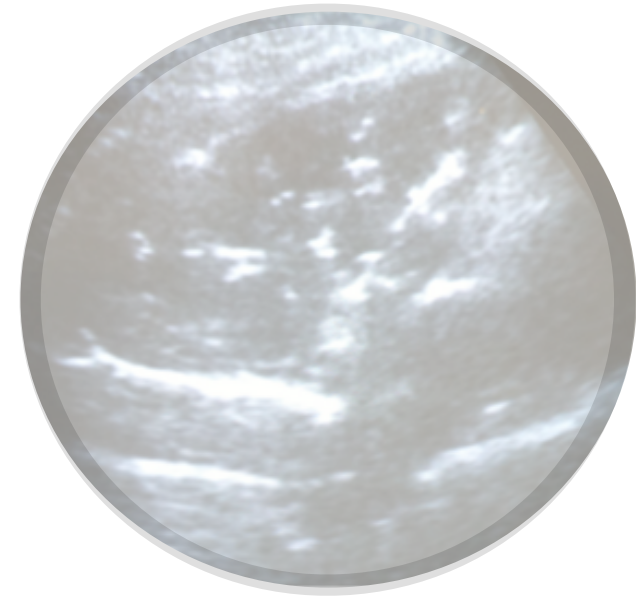
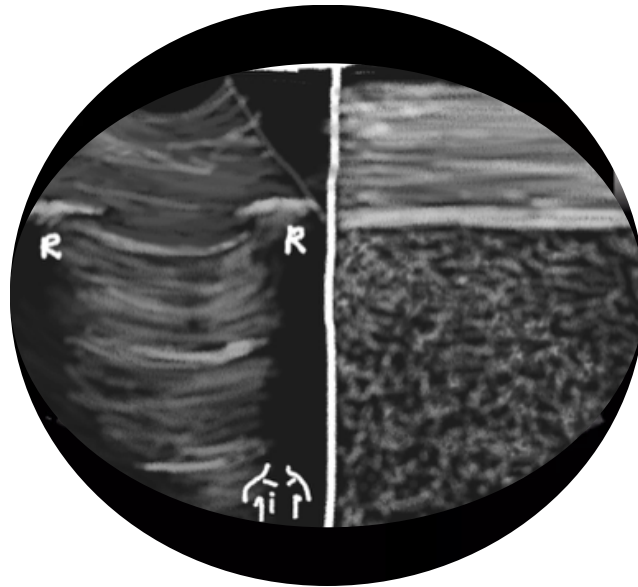
Kappa
0.51



Kappa
0.93

Higher Kappa value, less operator dependent !

Lung ultrasound



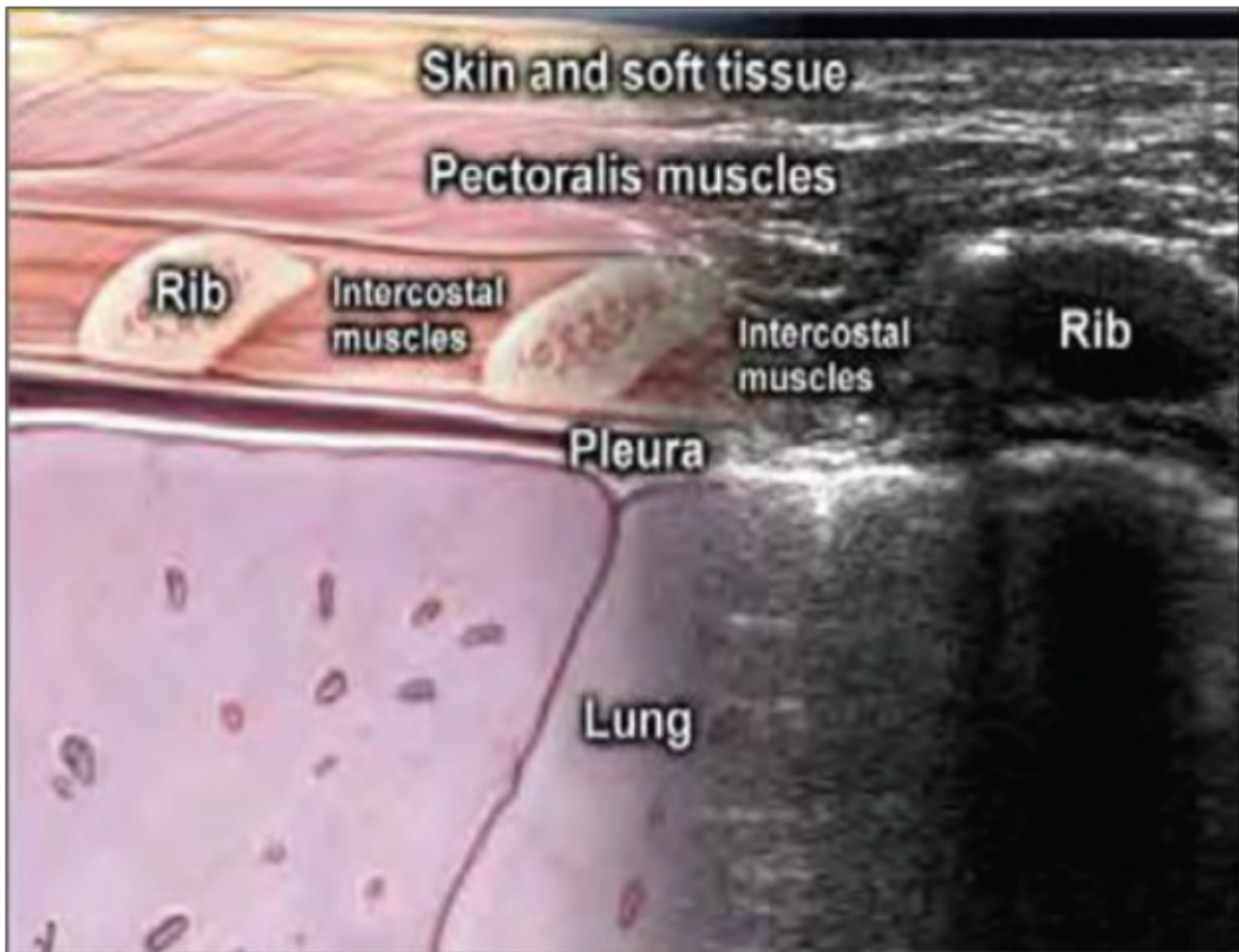
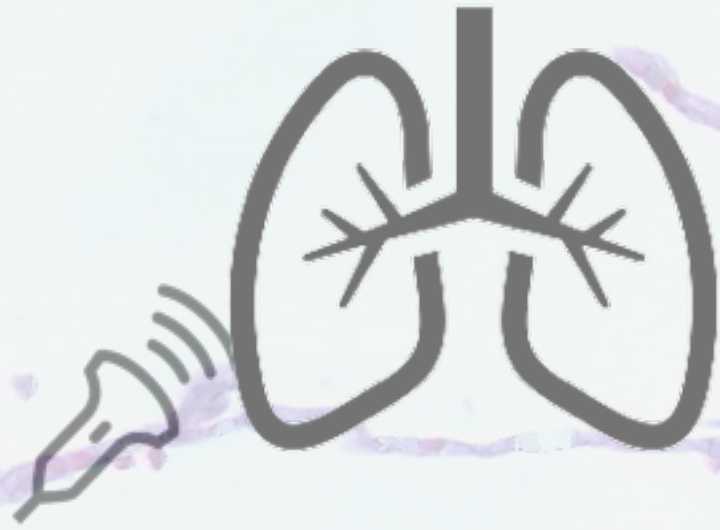

Figure 1: Anatomical drawing fused with corresponding ultrasound image demonstrating the superficial chest wall structures. (www.philips.com/CCEMeducation)

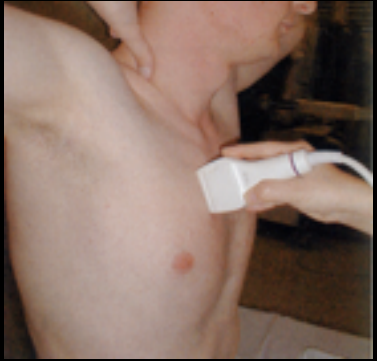

Static

- Pleural line
- A-line
- Comet tail sign/B line

Dynamic

- Lung sliding
- Lung pulse



Rib Plerual Rib

A

A


A



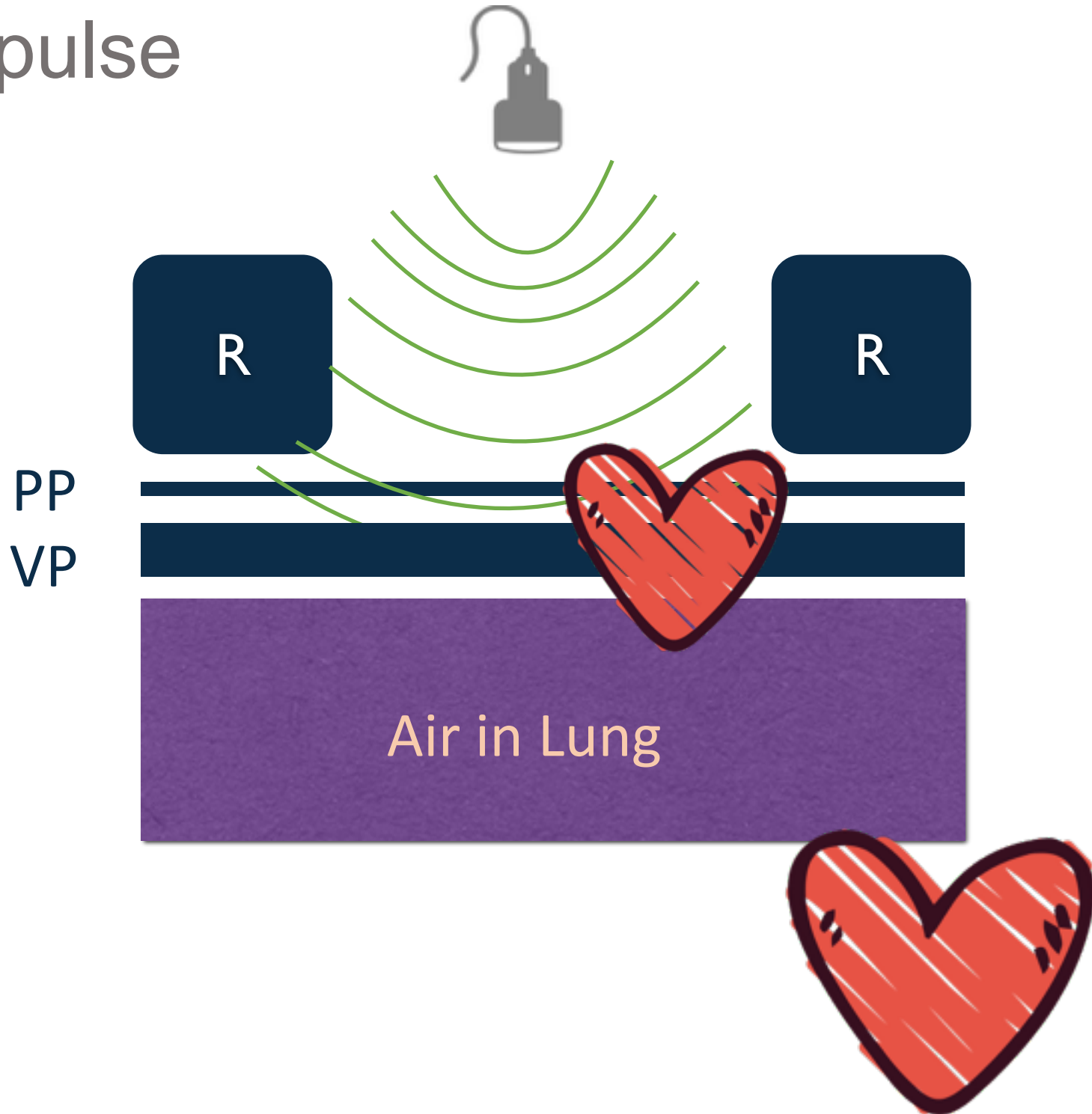
GE

Subcutaneous


P



Lung pulse

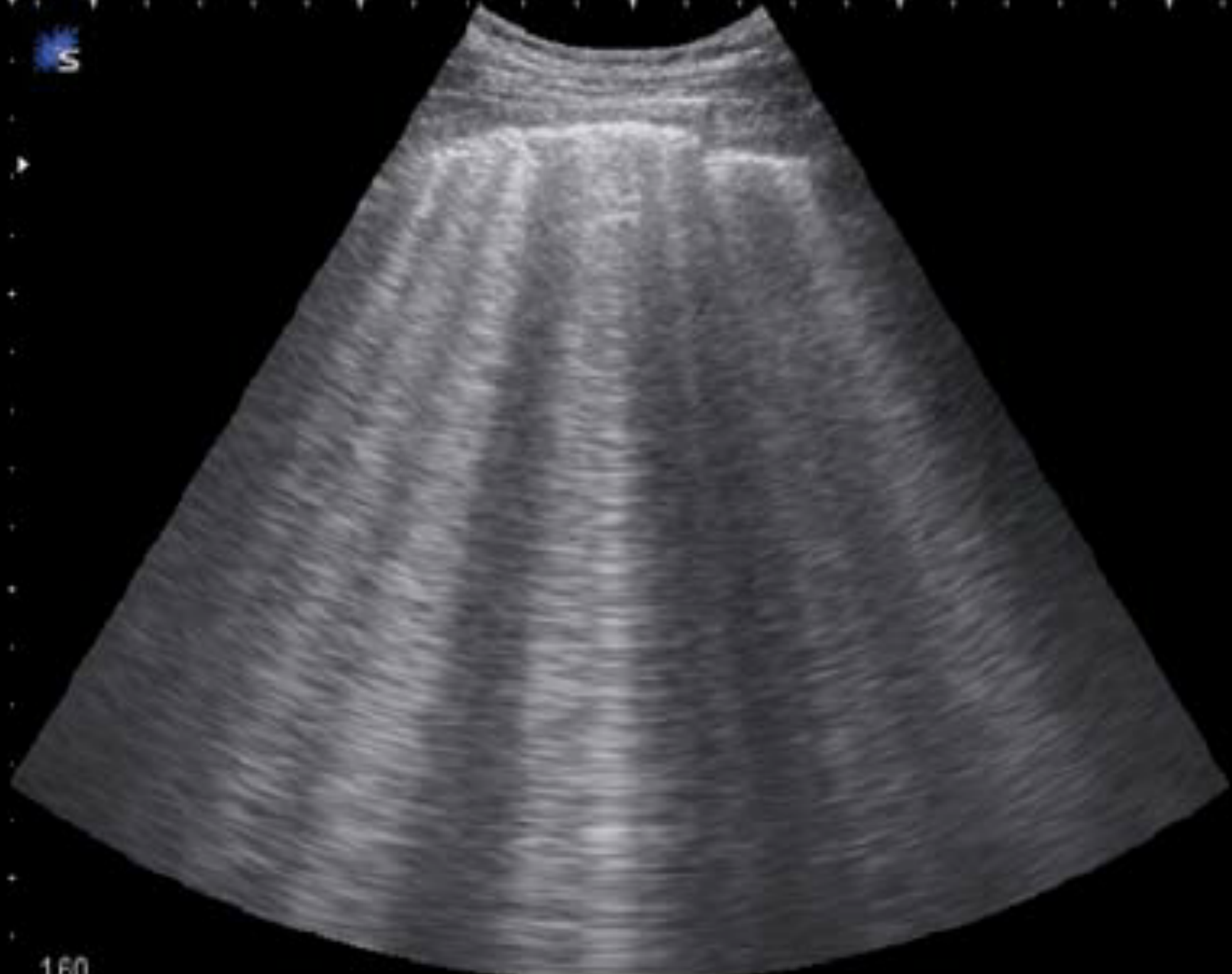

P10
6C
4.
MD5



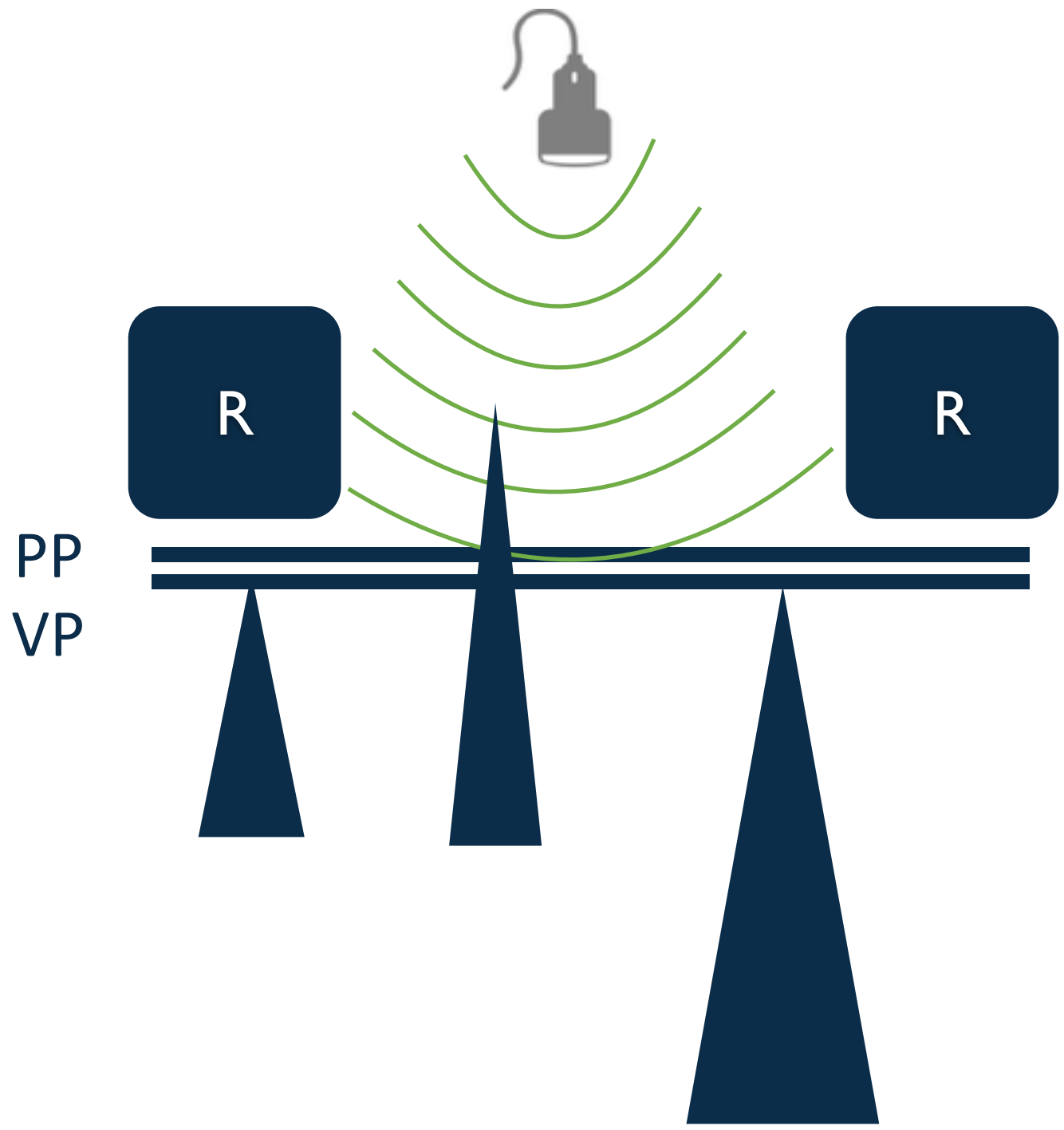
Free 32

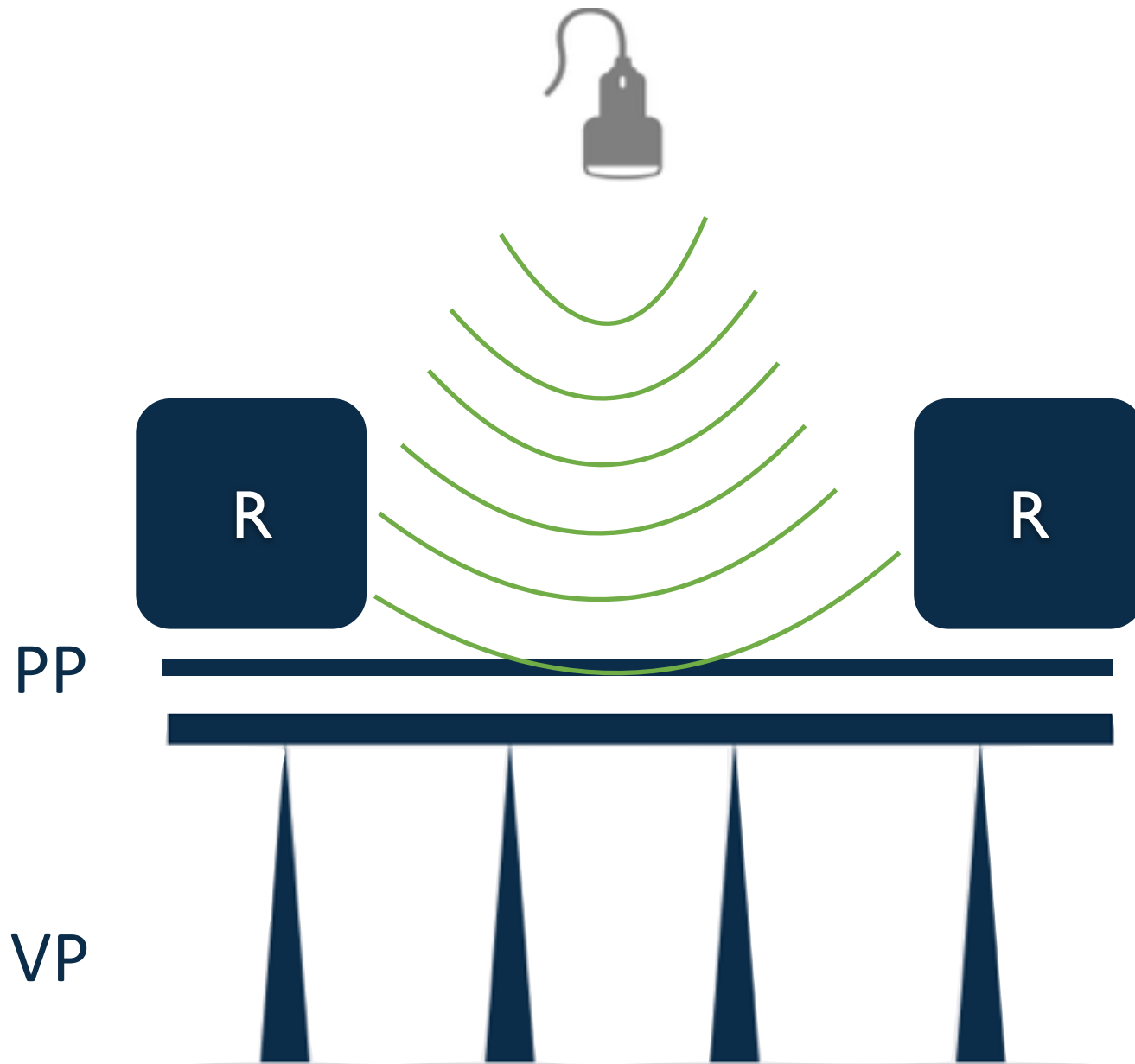
S



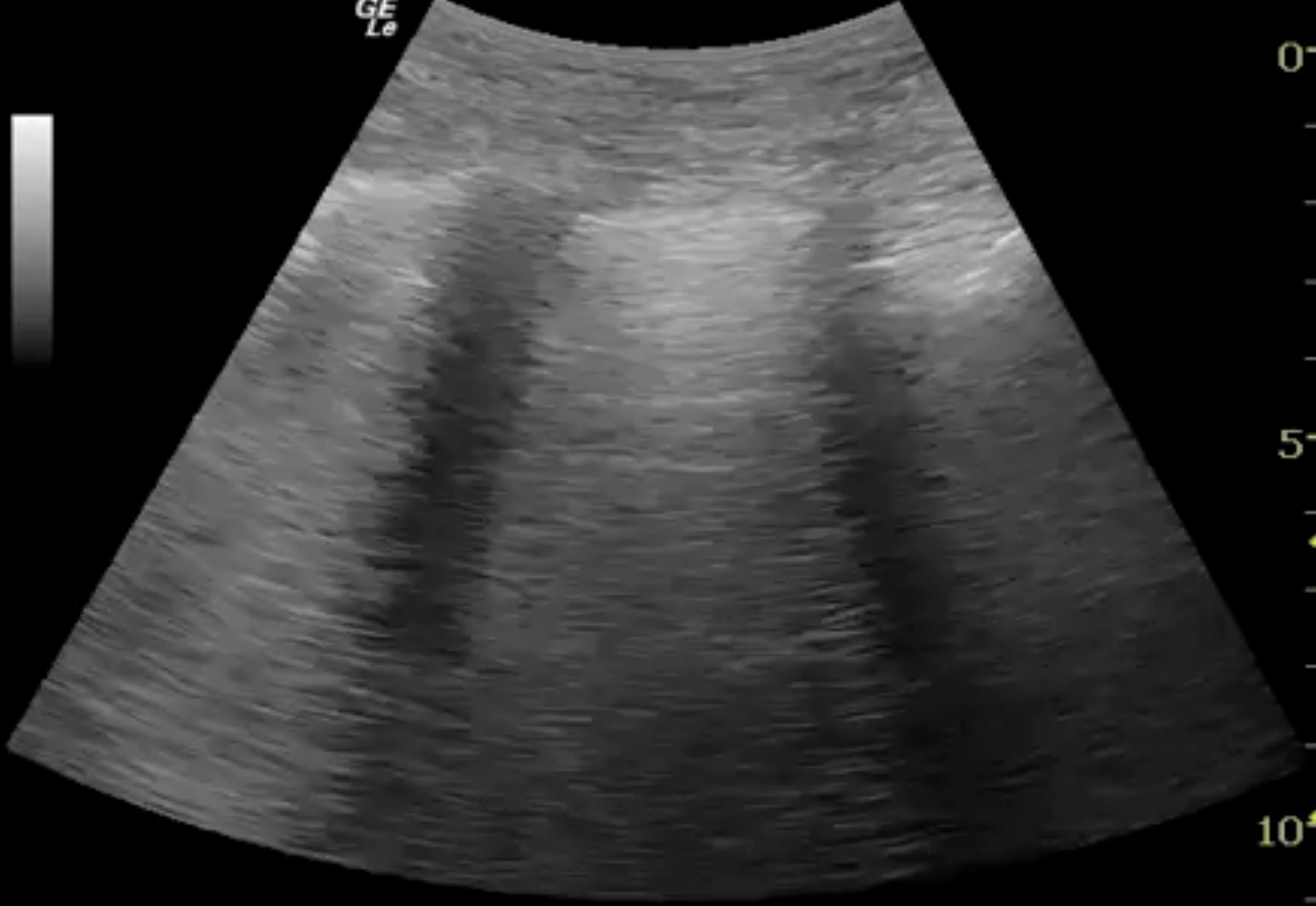L

160





GE
Le

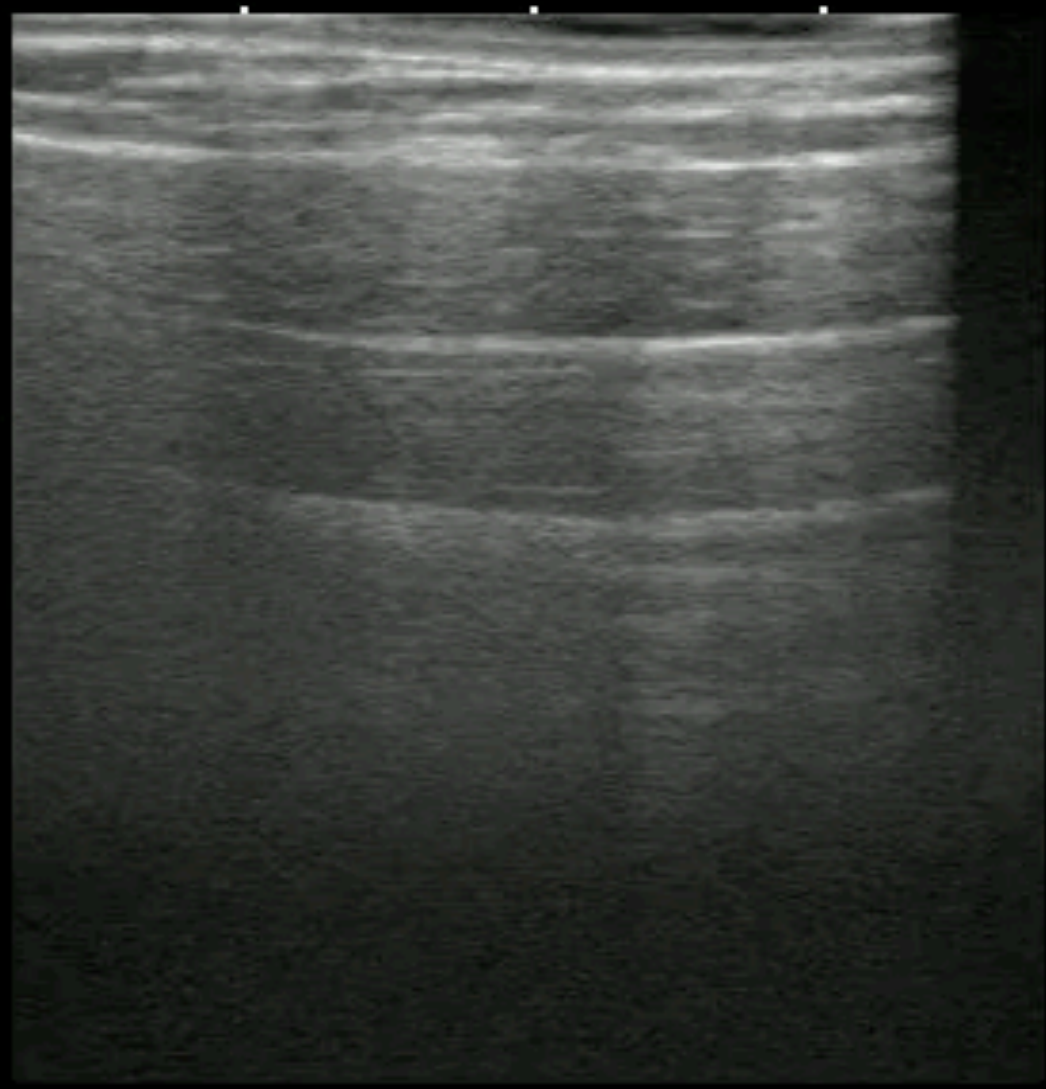

0
-
-
-
-
5
-
-
-
-
10
-

0 ◆

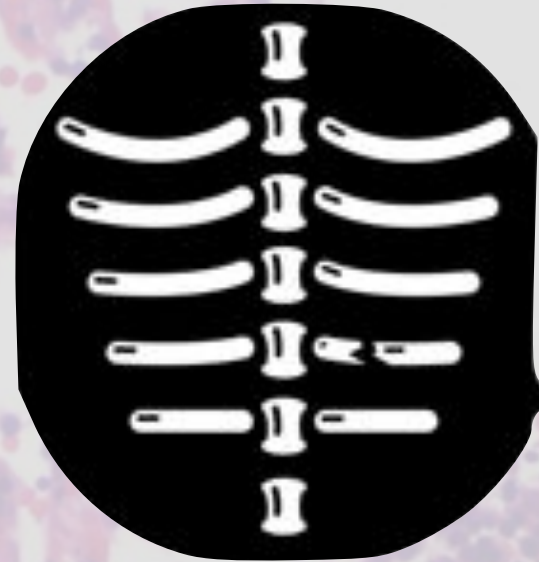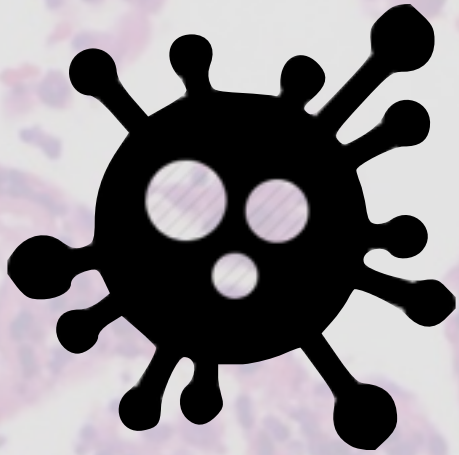

T

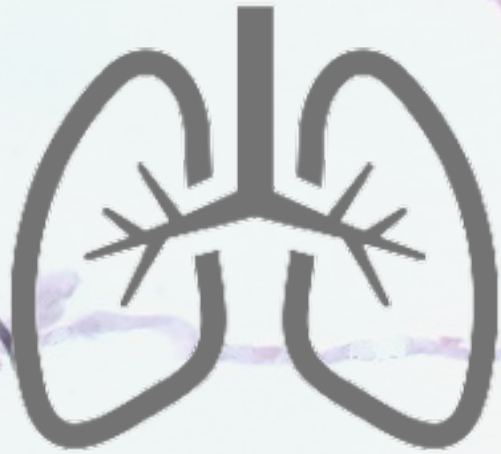P100
14L8
14.0
32fps
DR65
2DG
92



MI
0.4
TIS
0.1
TIB
0.1
TIC
0.3

B line Interstitial syndrome

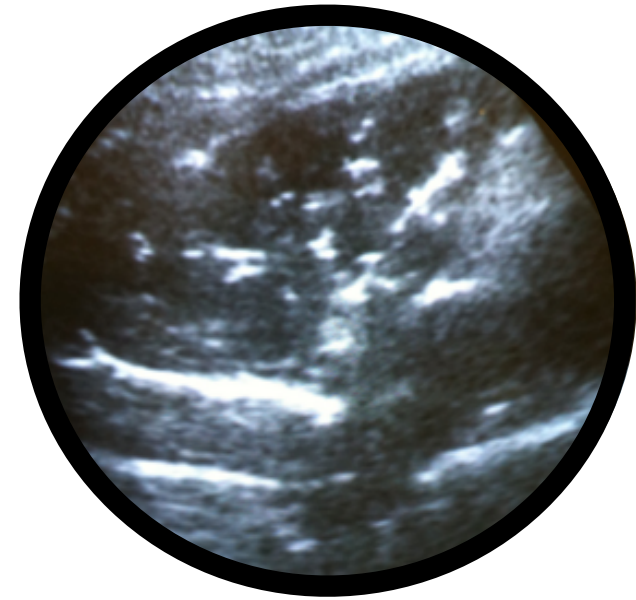
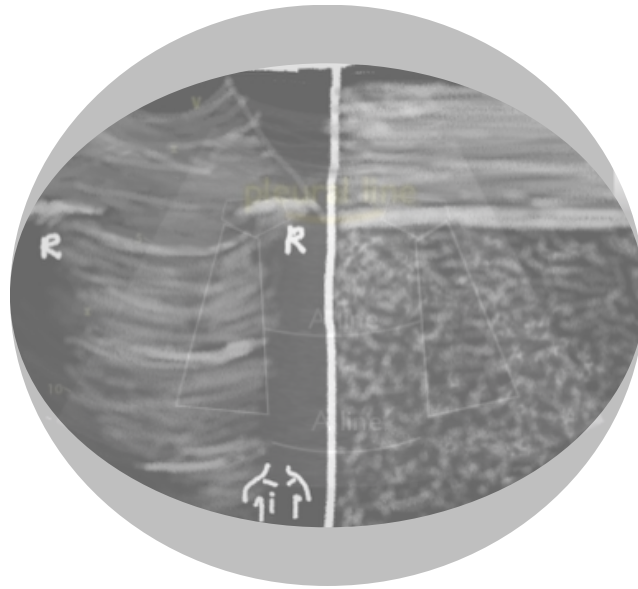


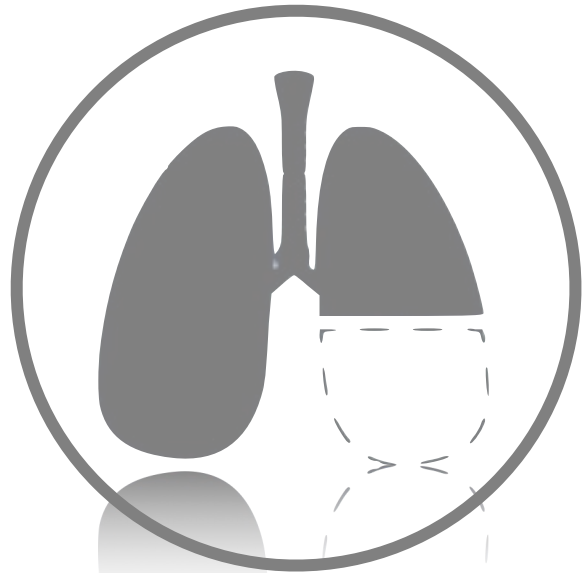


Normal lung

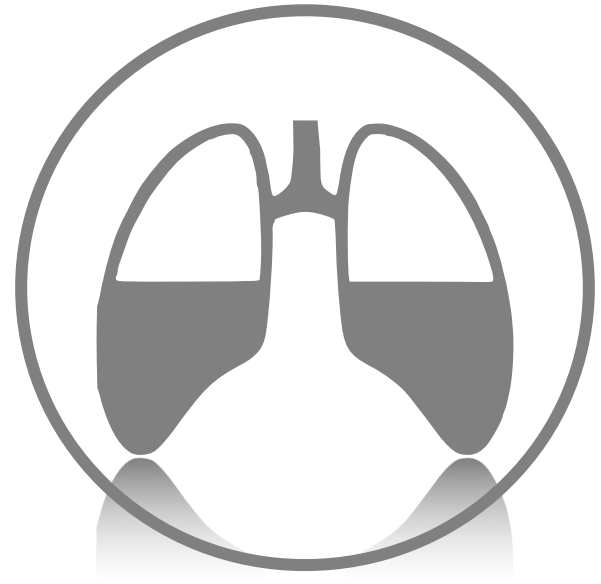
- Basal lung
- 25% of healthy people
- <3 per intercostal space

Lung ultrasound





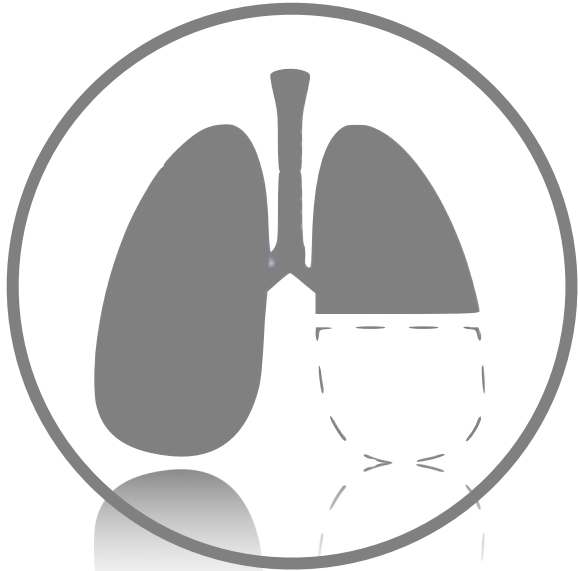Pneumothorax



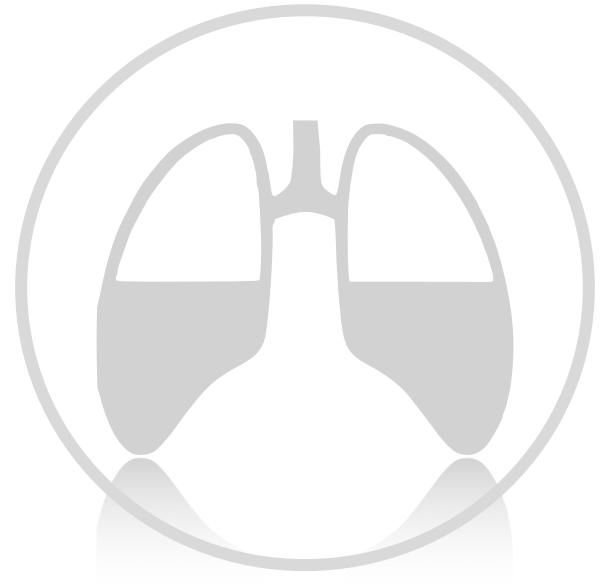Pleural effusion



interstitial lung



Pneumothorax



Pleural effusion



Interstitial lung

Pneumothorax

Signs indicate pneumothorax

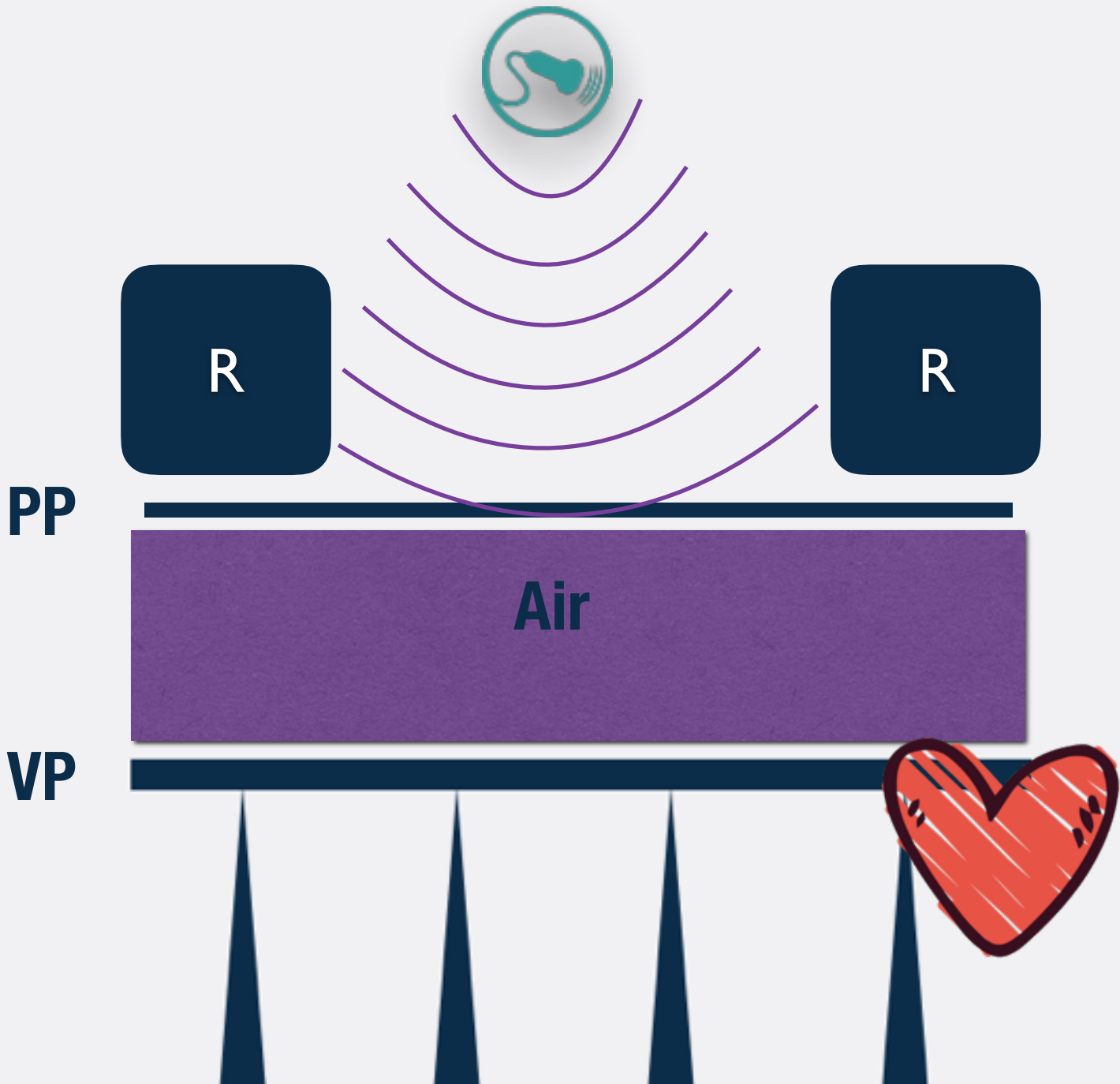
- Barcode sign in Non arrest patient
- Lung point

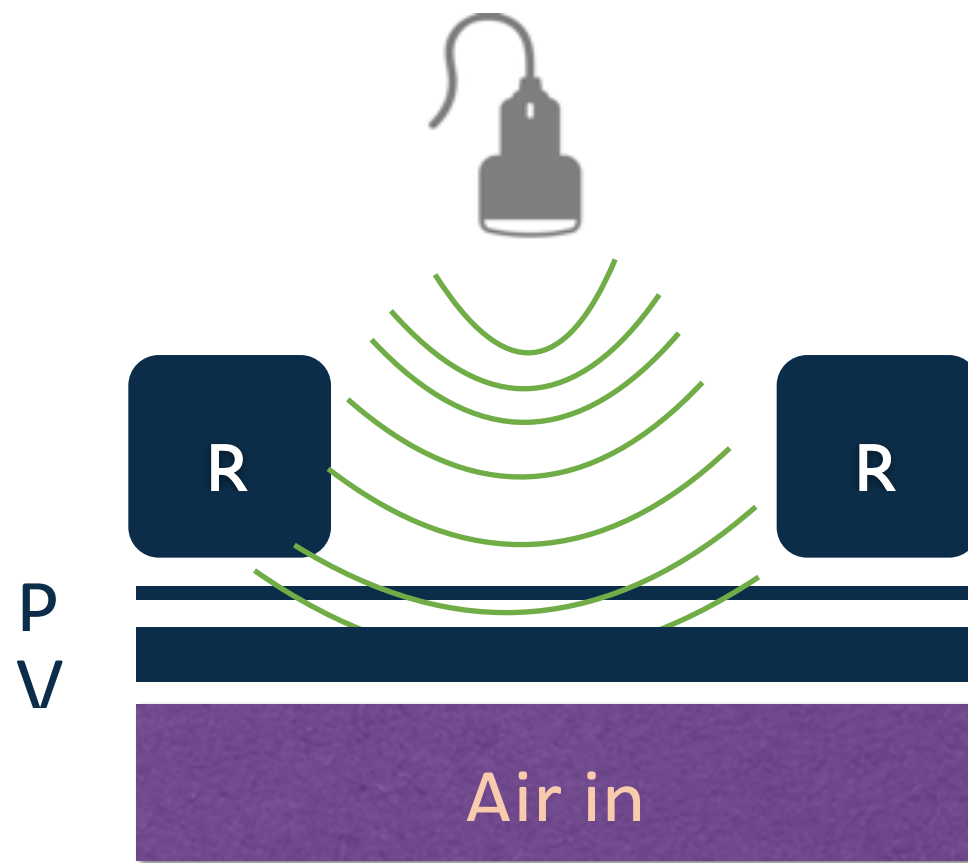
Signs exclude pneumothorax

- Lung sliding sign
- B-line, Comet tail sign
- Lung Pulse

Barcode sign



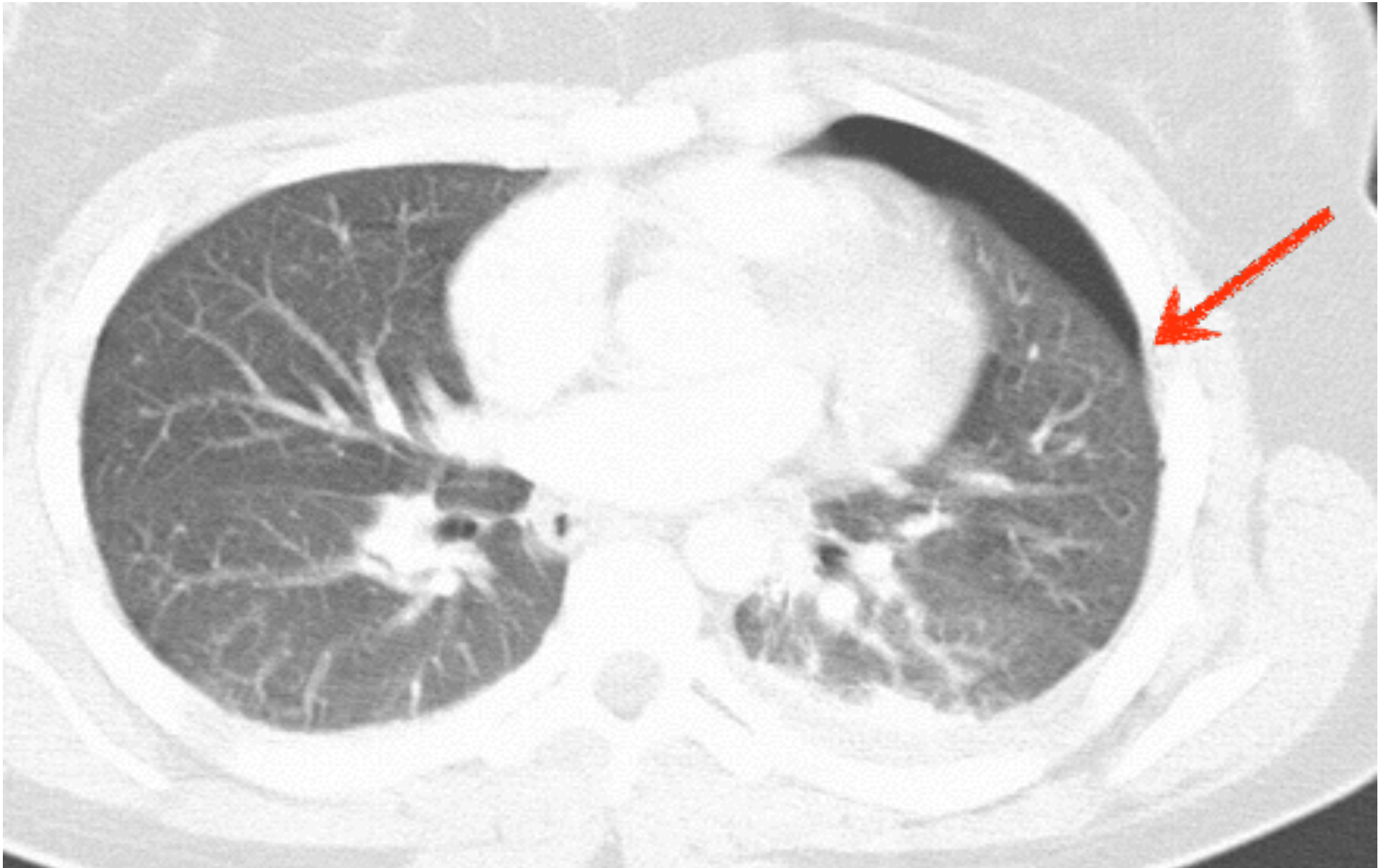




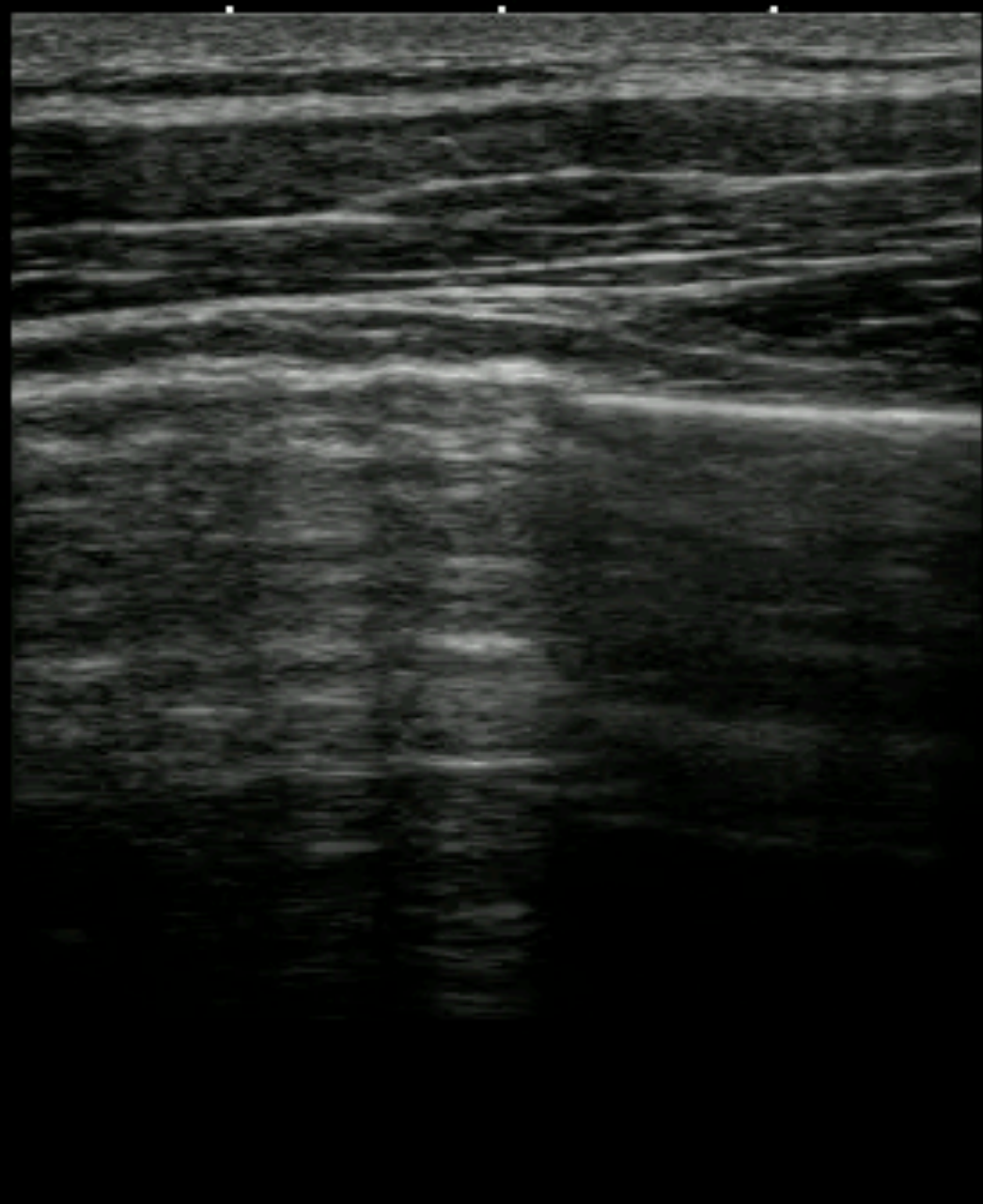
Adhesion



Lung point



0 +



T

P100

14L8

14.0

32fps

DR65

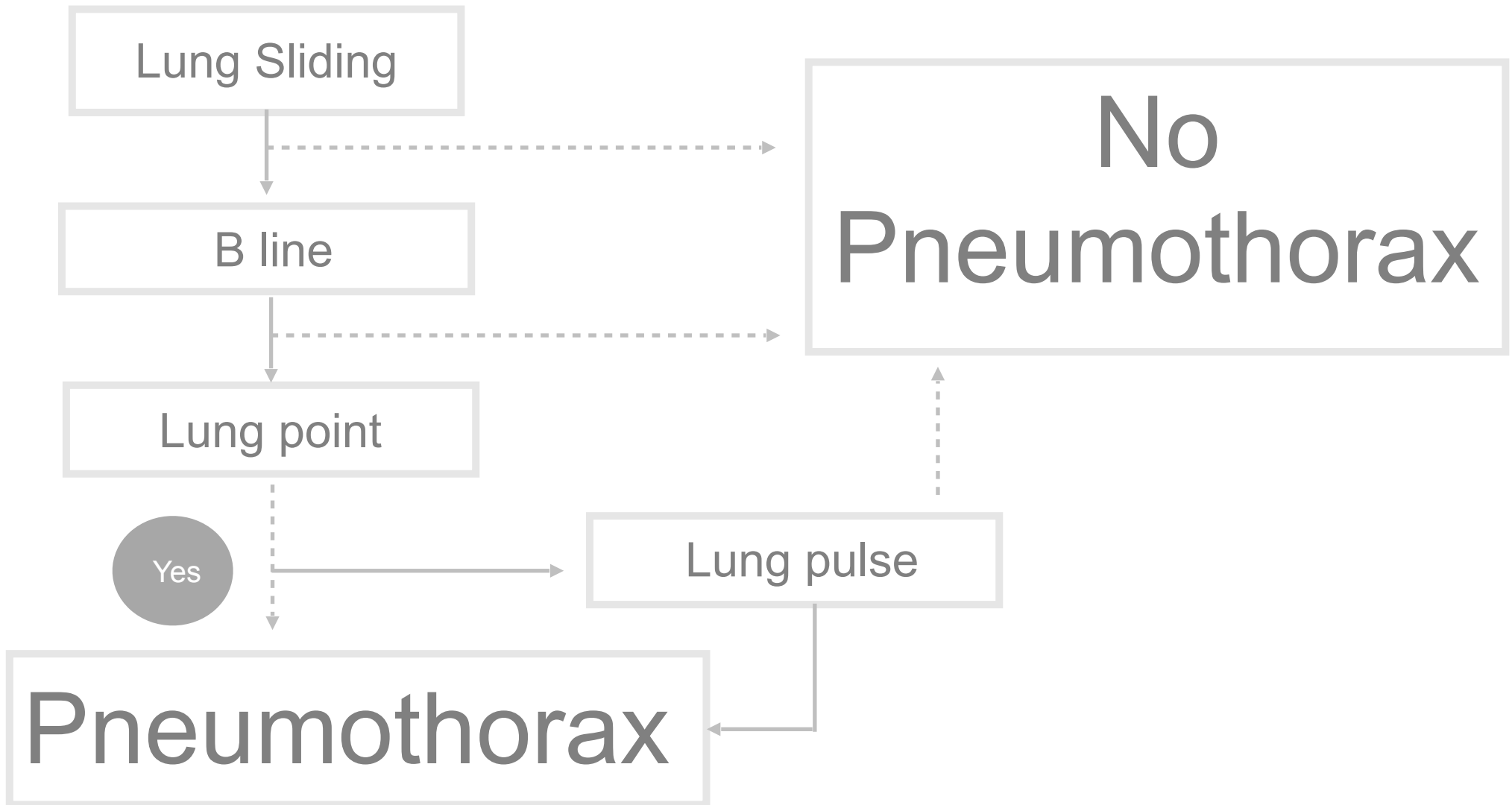
2DG

92

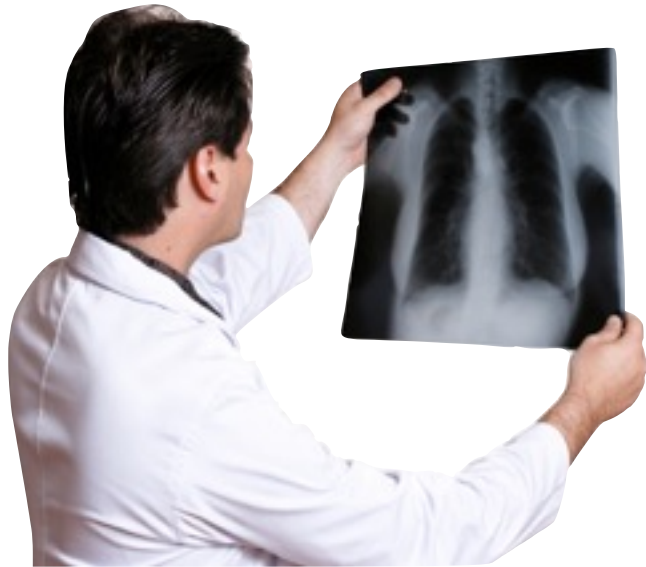

MI
0.4
TIS
0.1
TIB
0.1
TIC
0.3

Pneumothorax



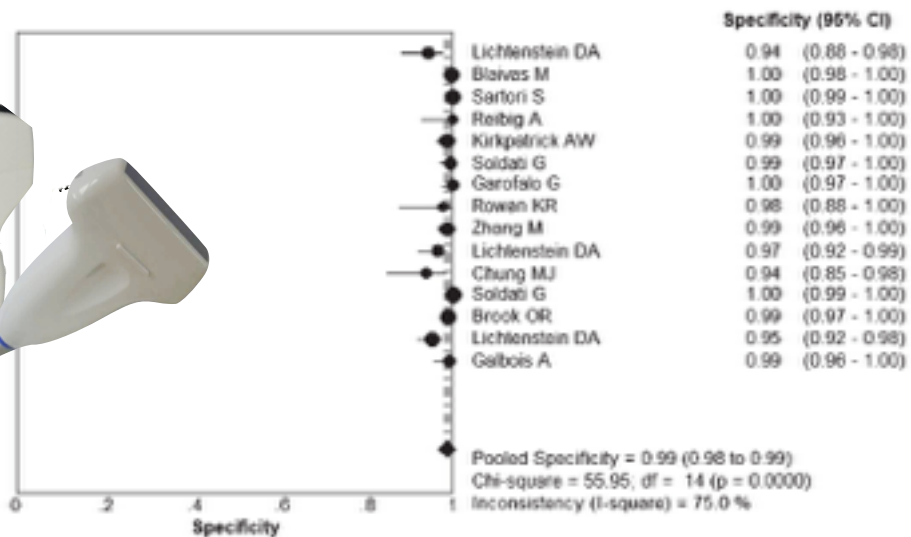
Diagnosis of pneumothorax



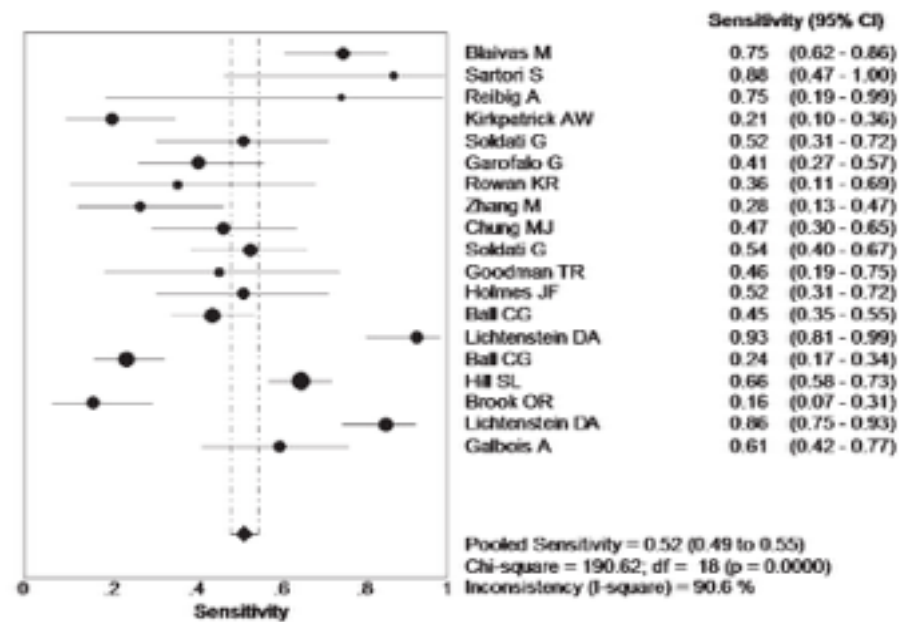
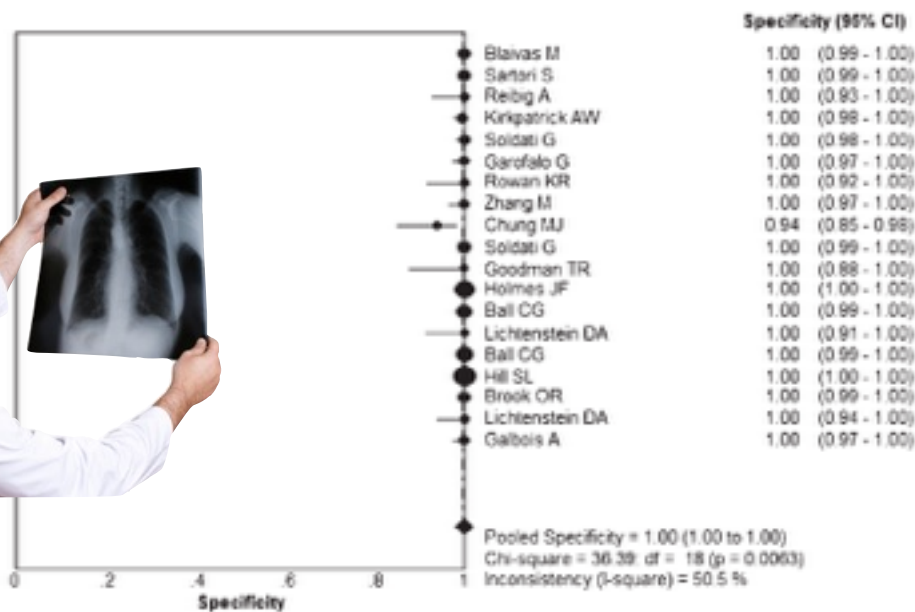
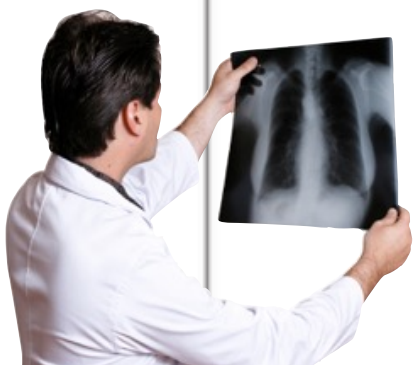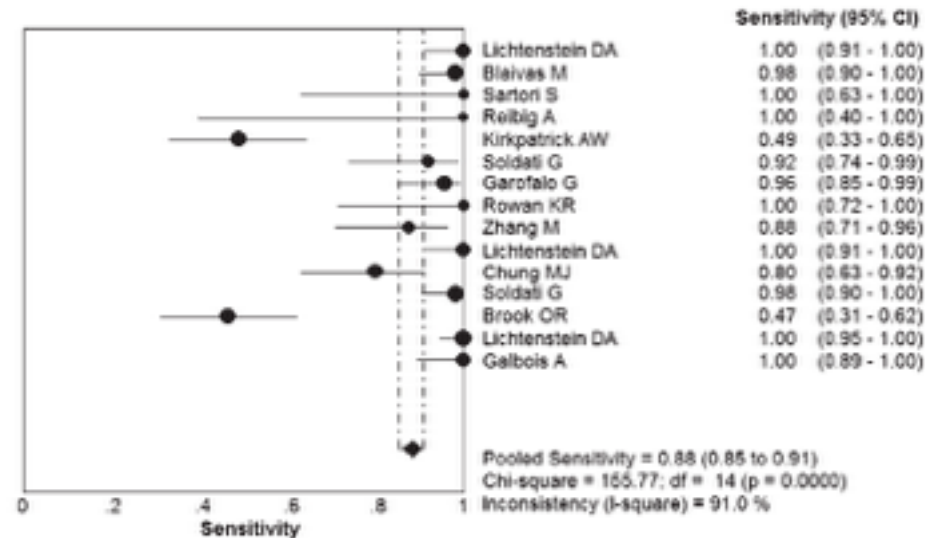
or



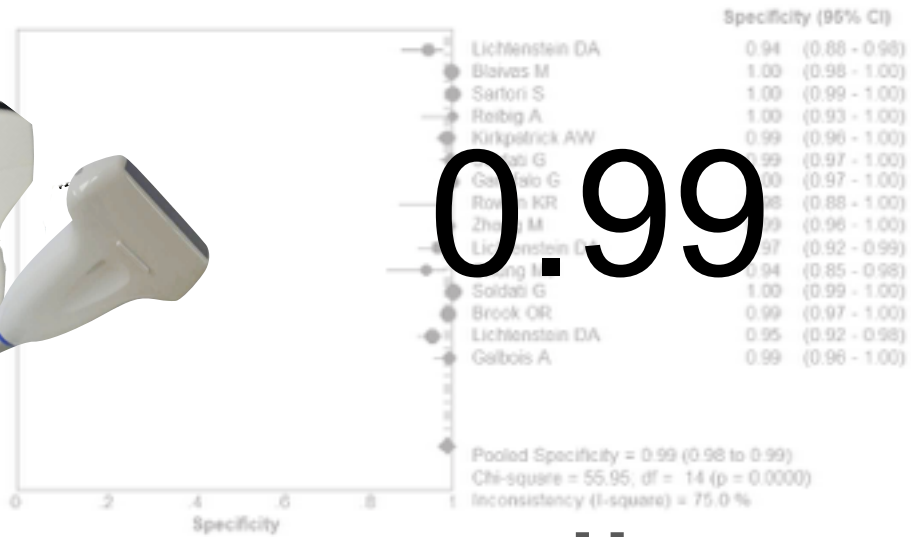
Specificity



Sensitivity

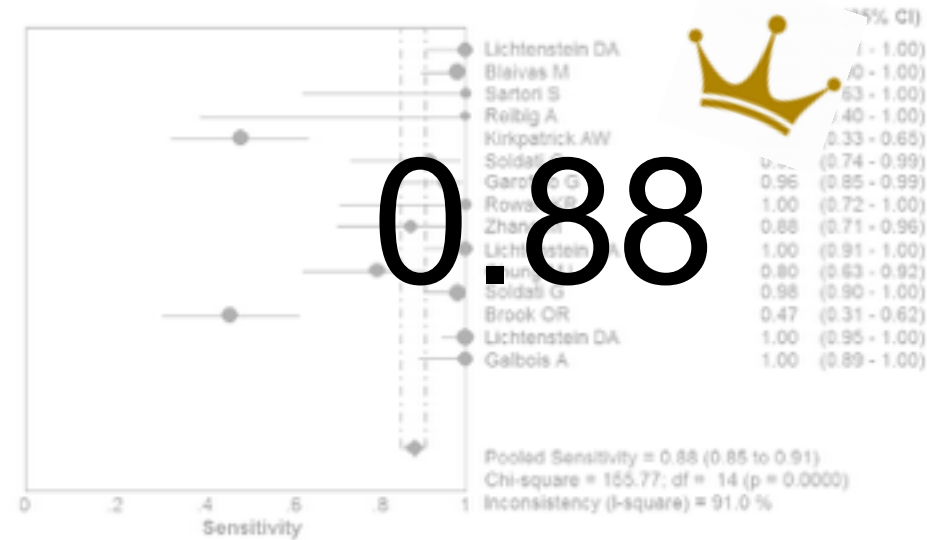


Specificity



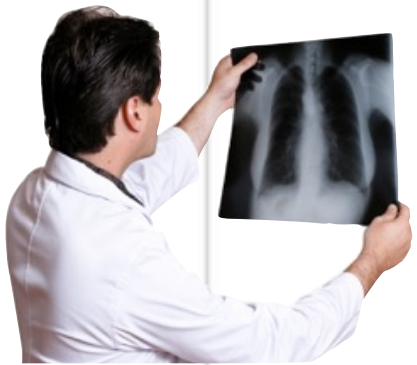
0.99

Sensitivity

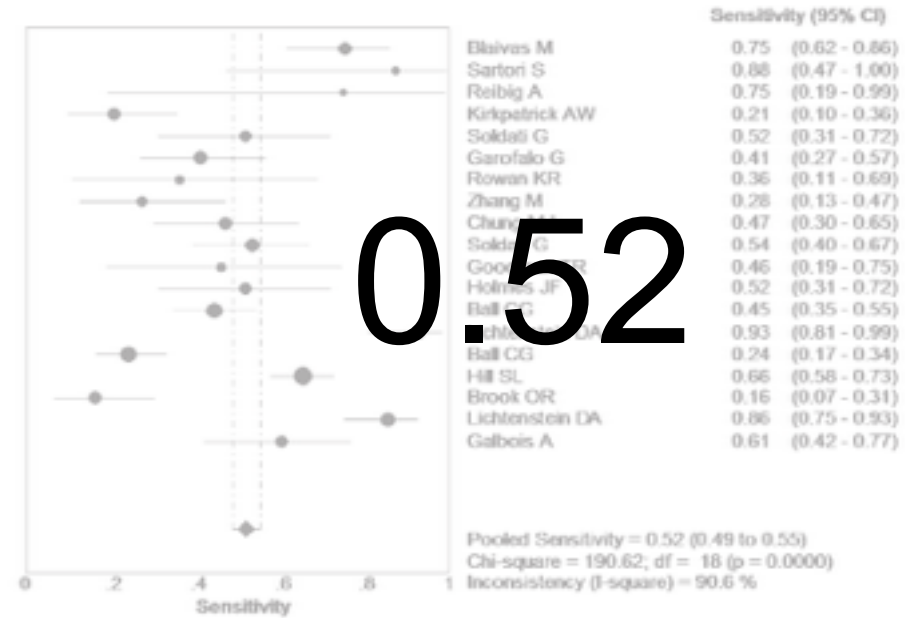


0.88

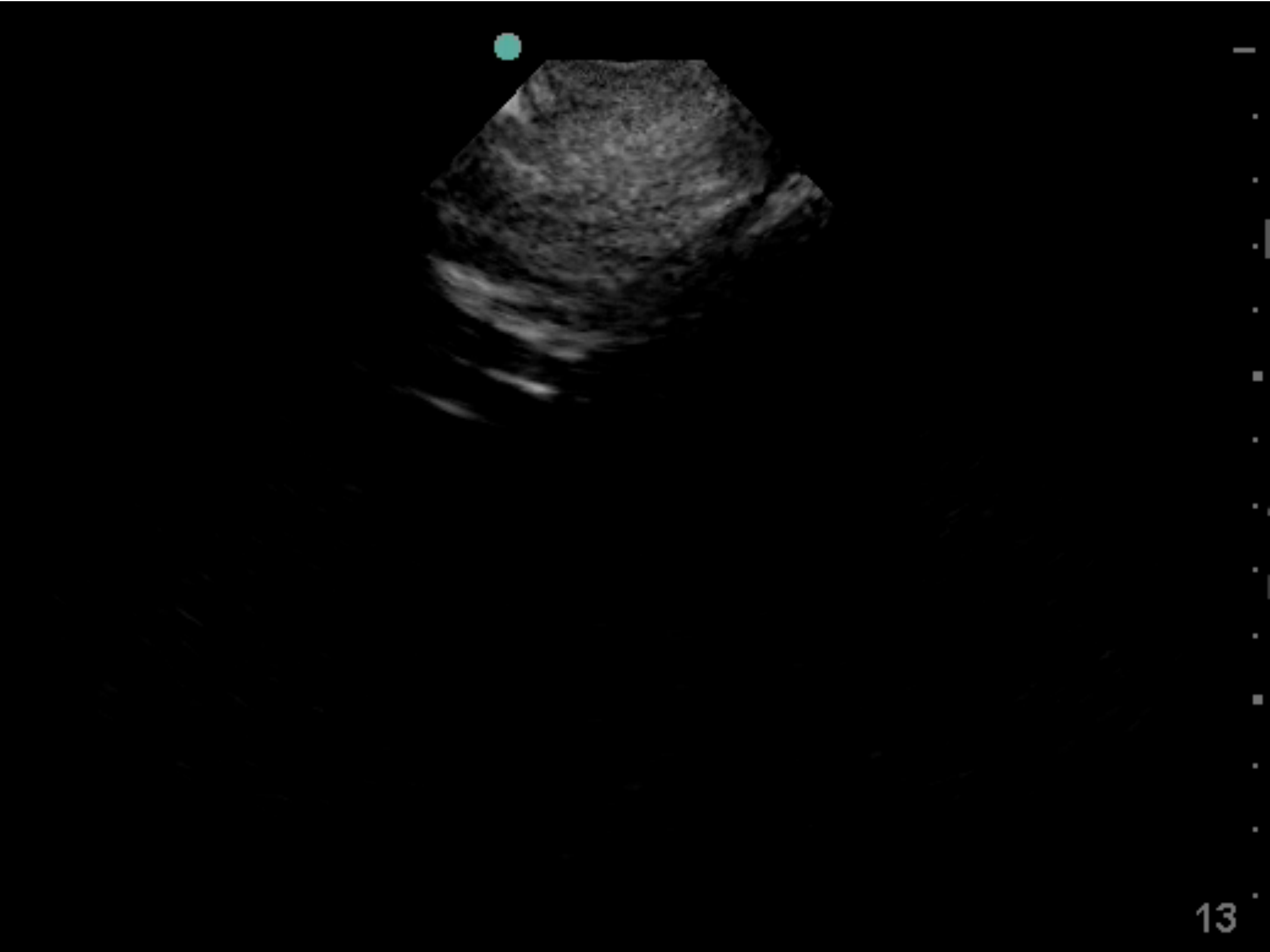
||



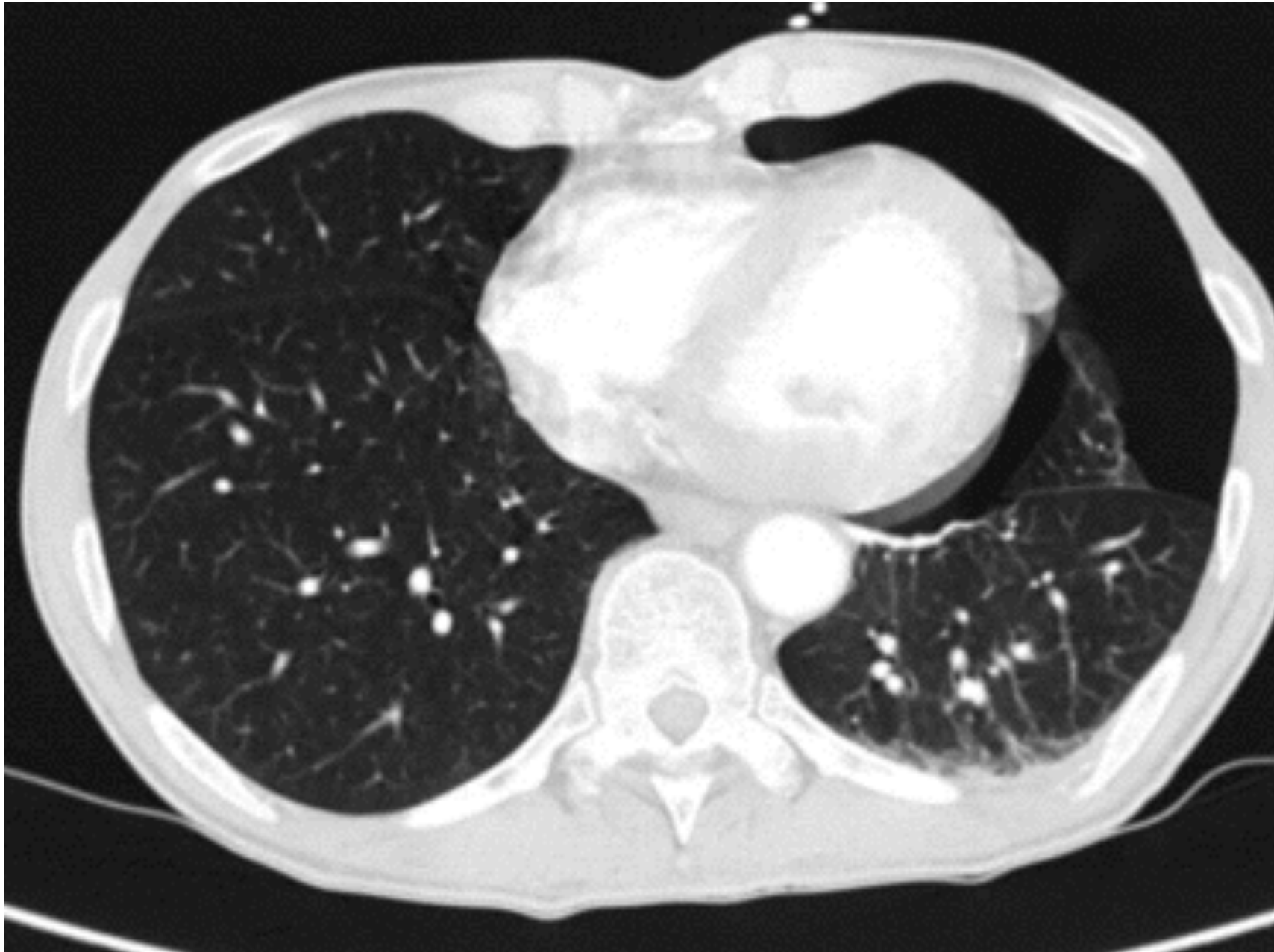1.00



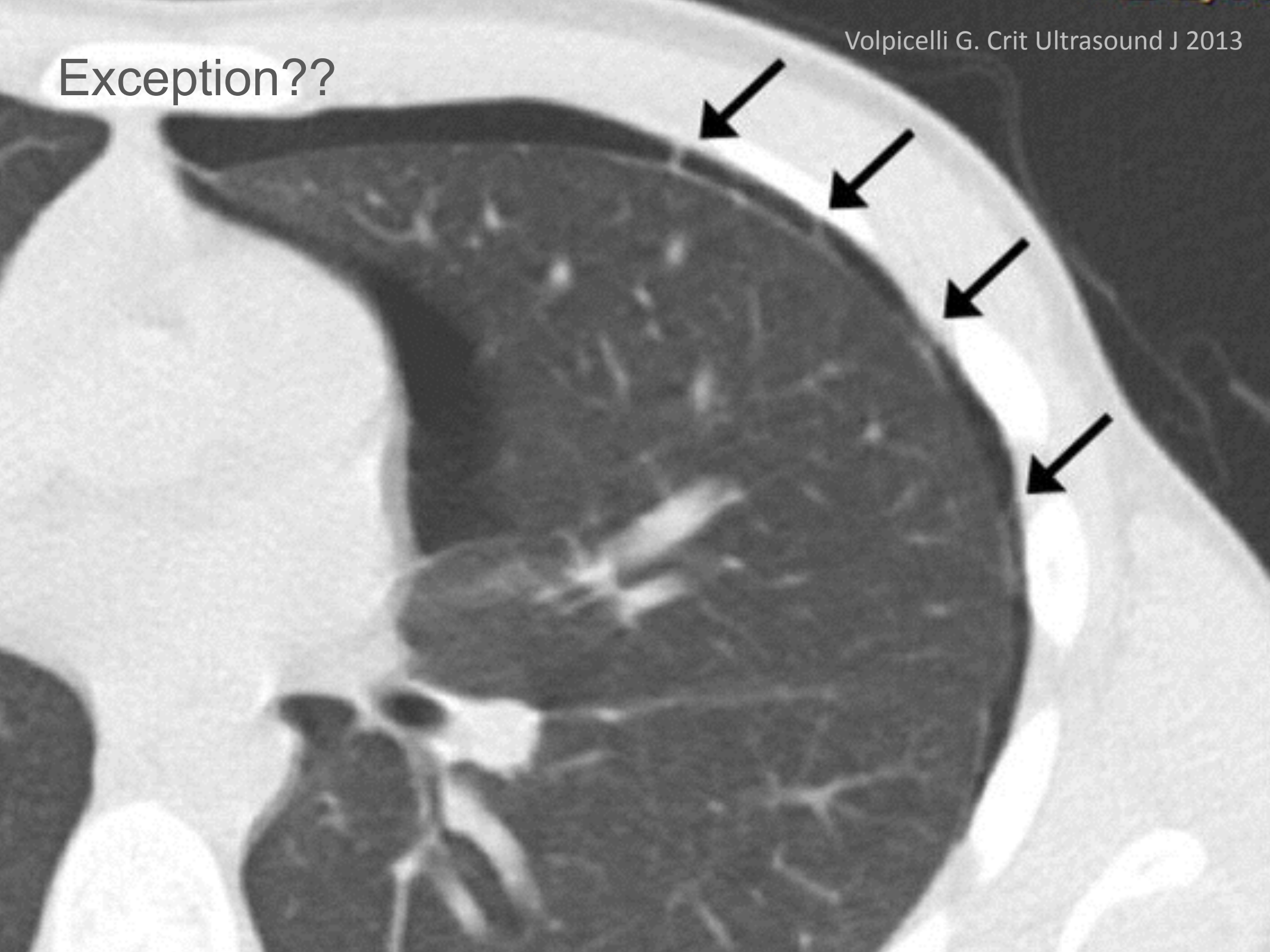
0.52

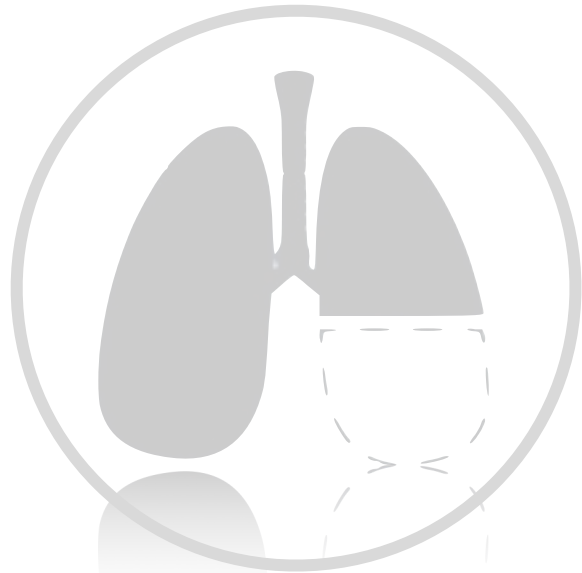


Heart point



Exception??





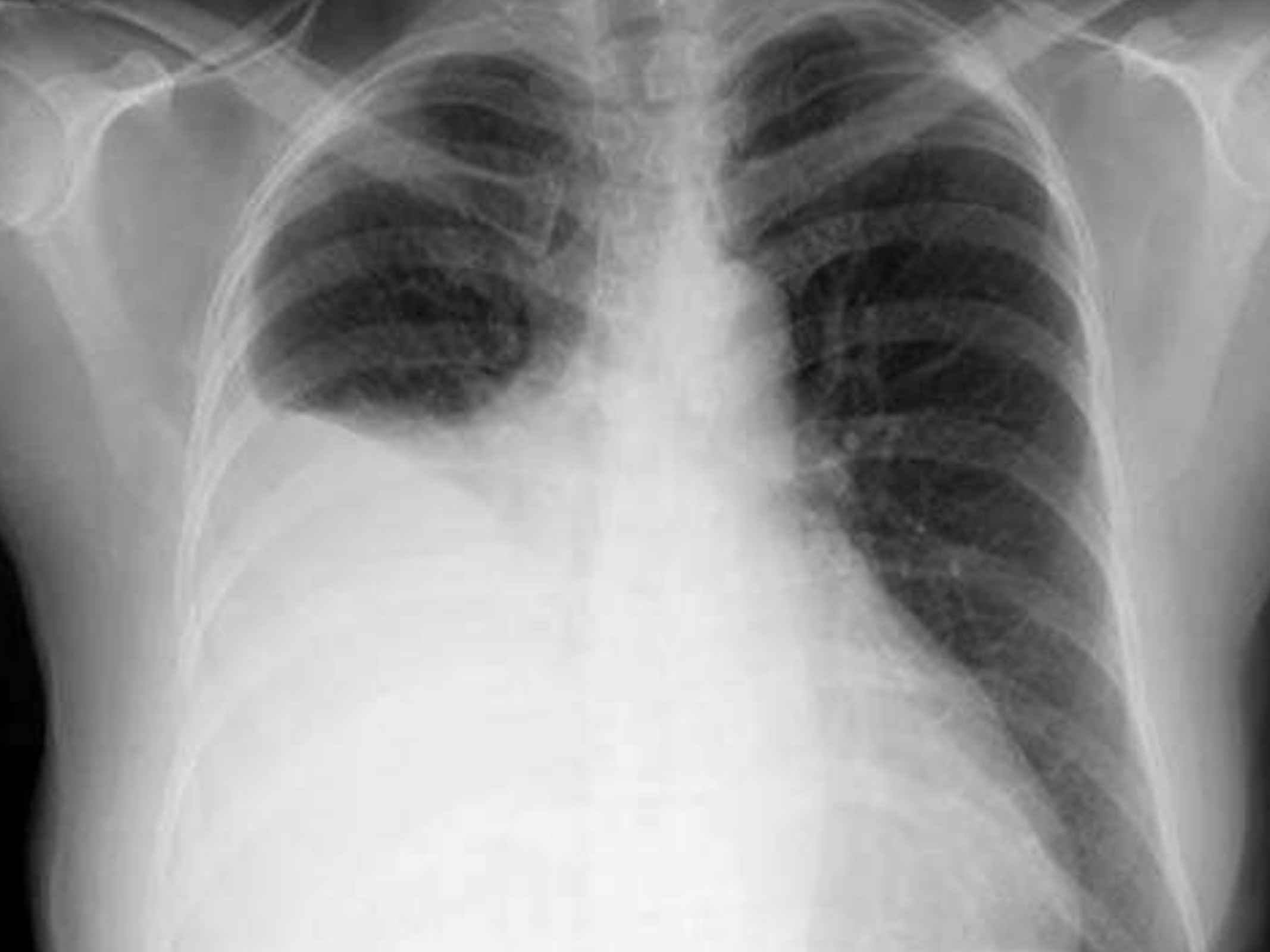Pneumothorax



Pleural effusion



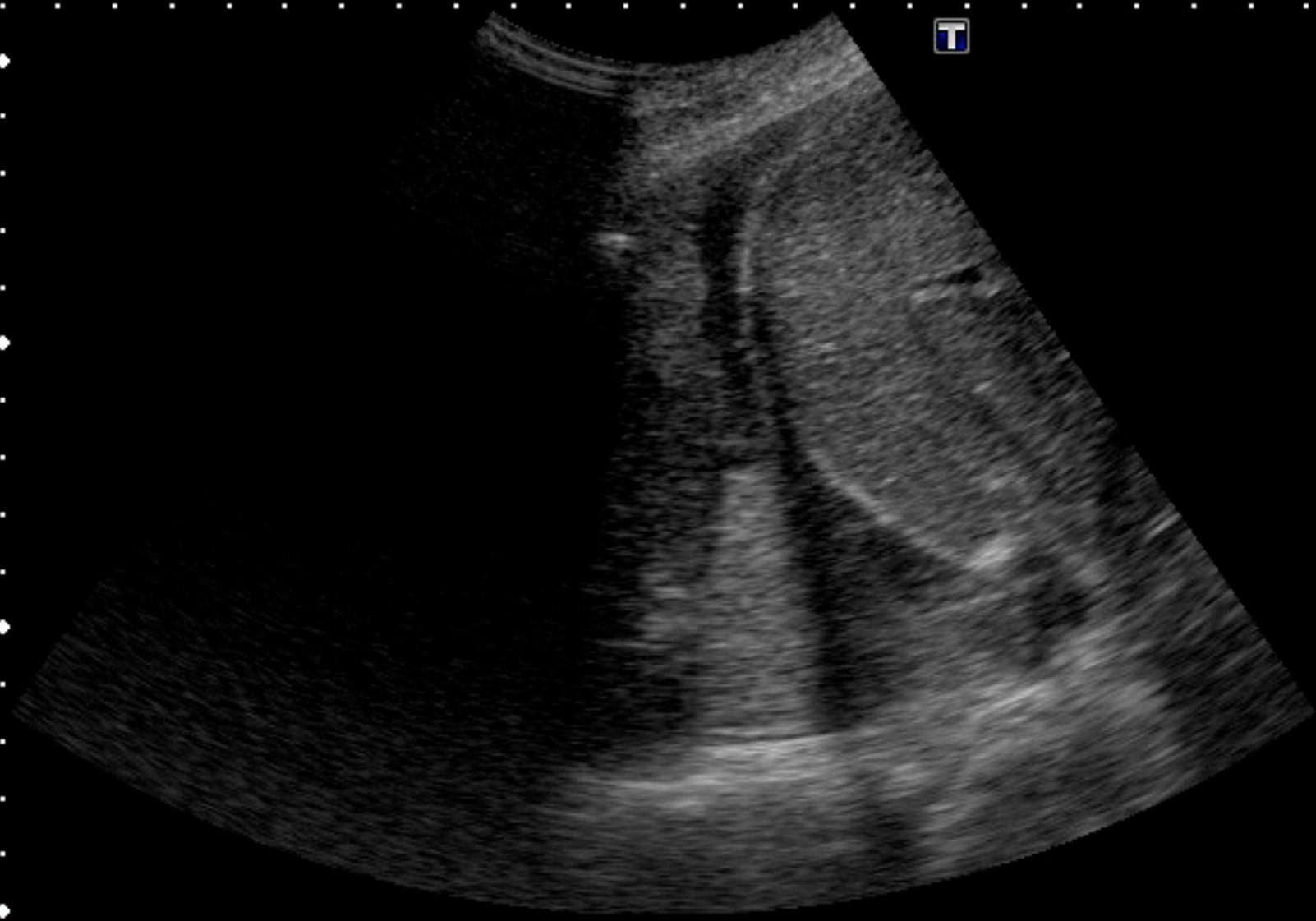
Interstitial lung





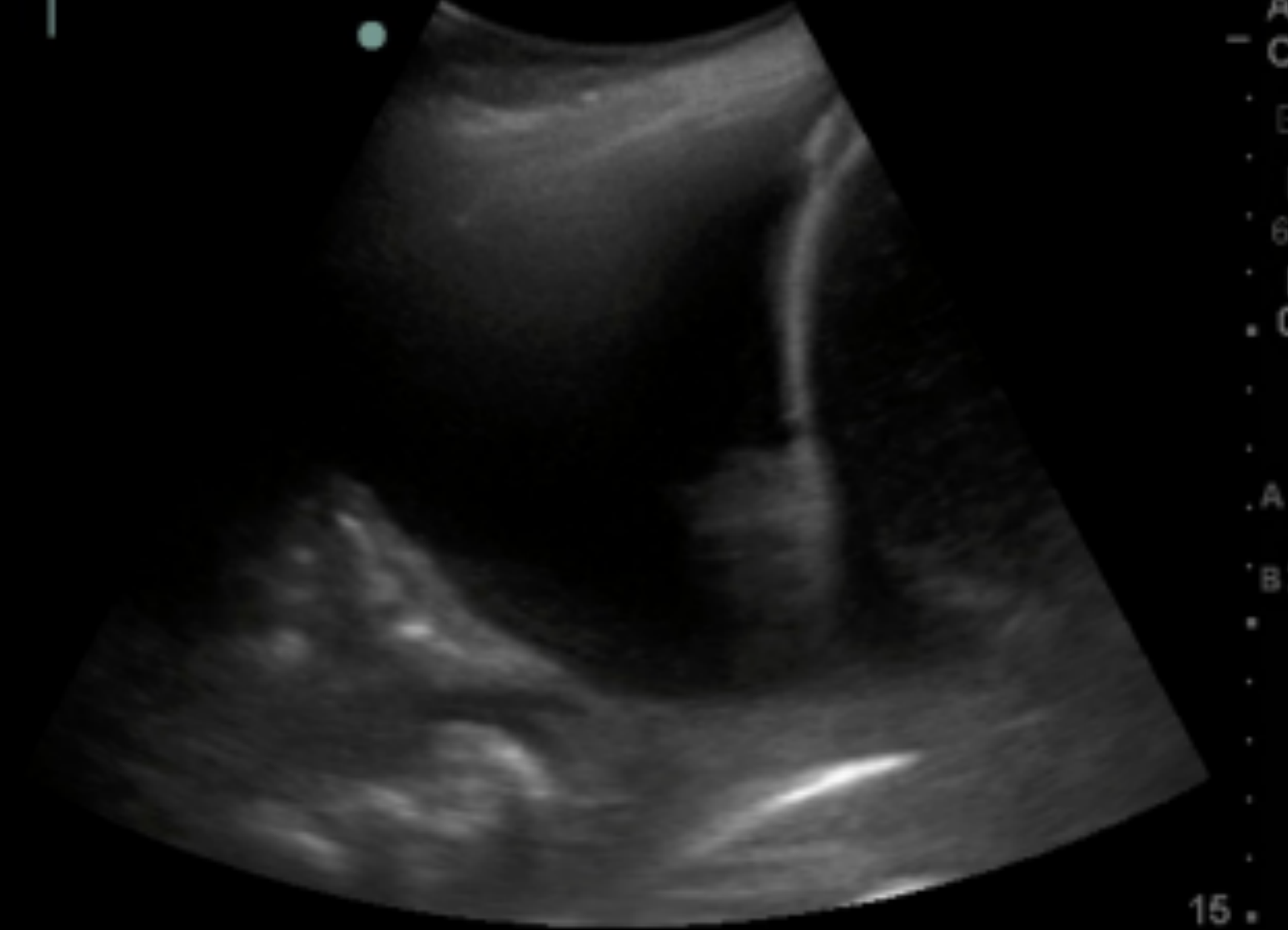0 ♦
5 ♦
10 ♦
15 ♦

T

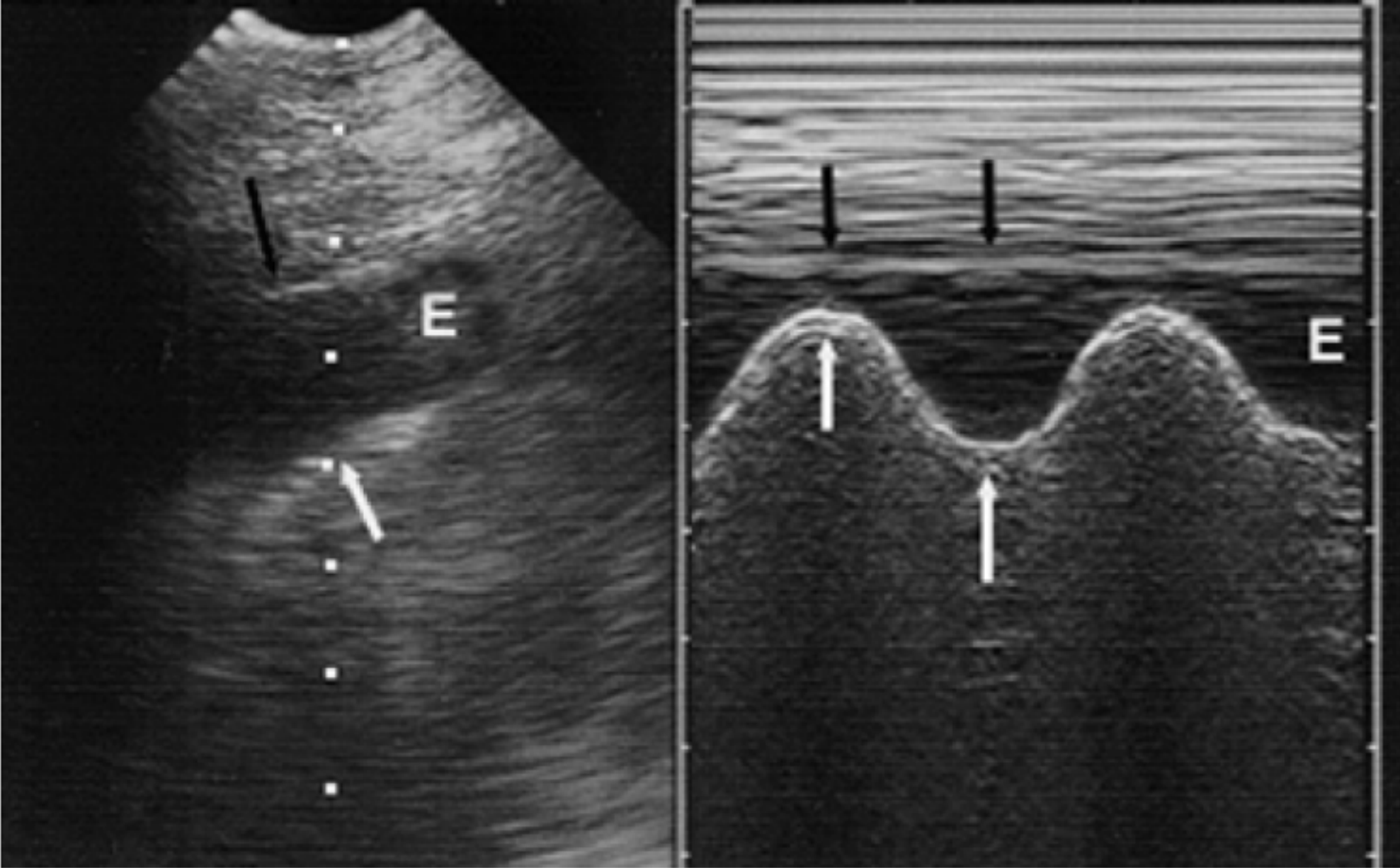


MI:1.6
2DG
83
DR
65

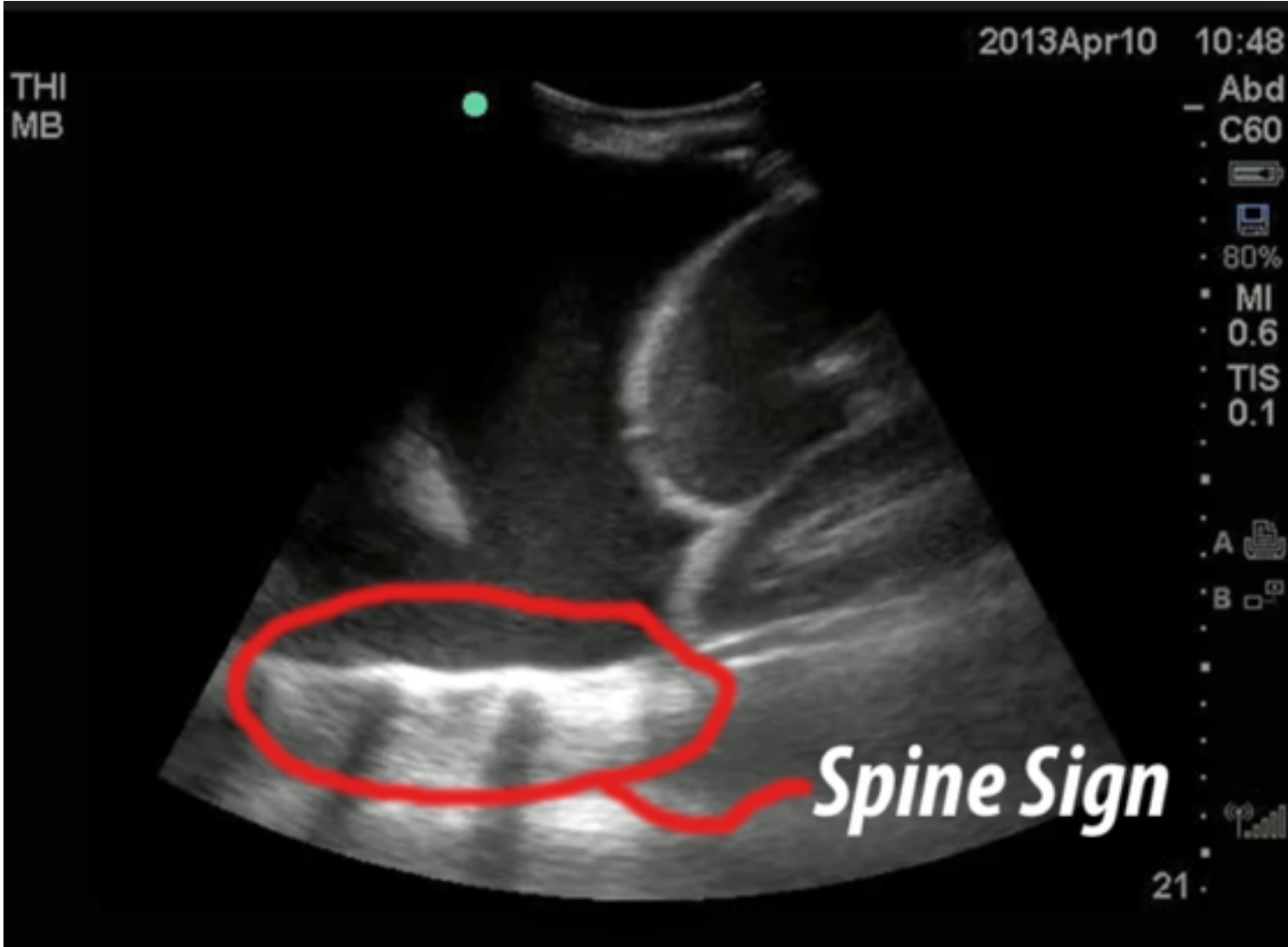
6C1
T5.0
18 fps



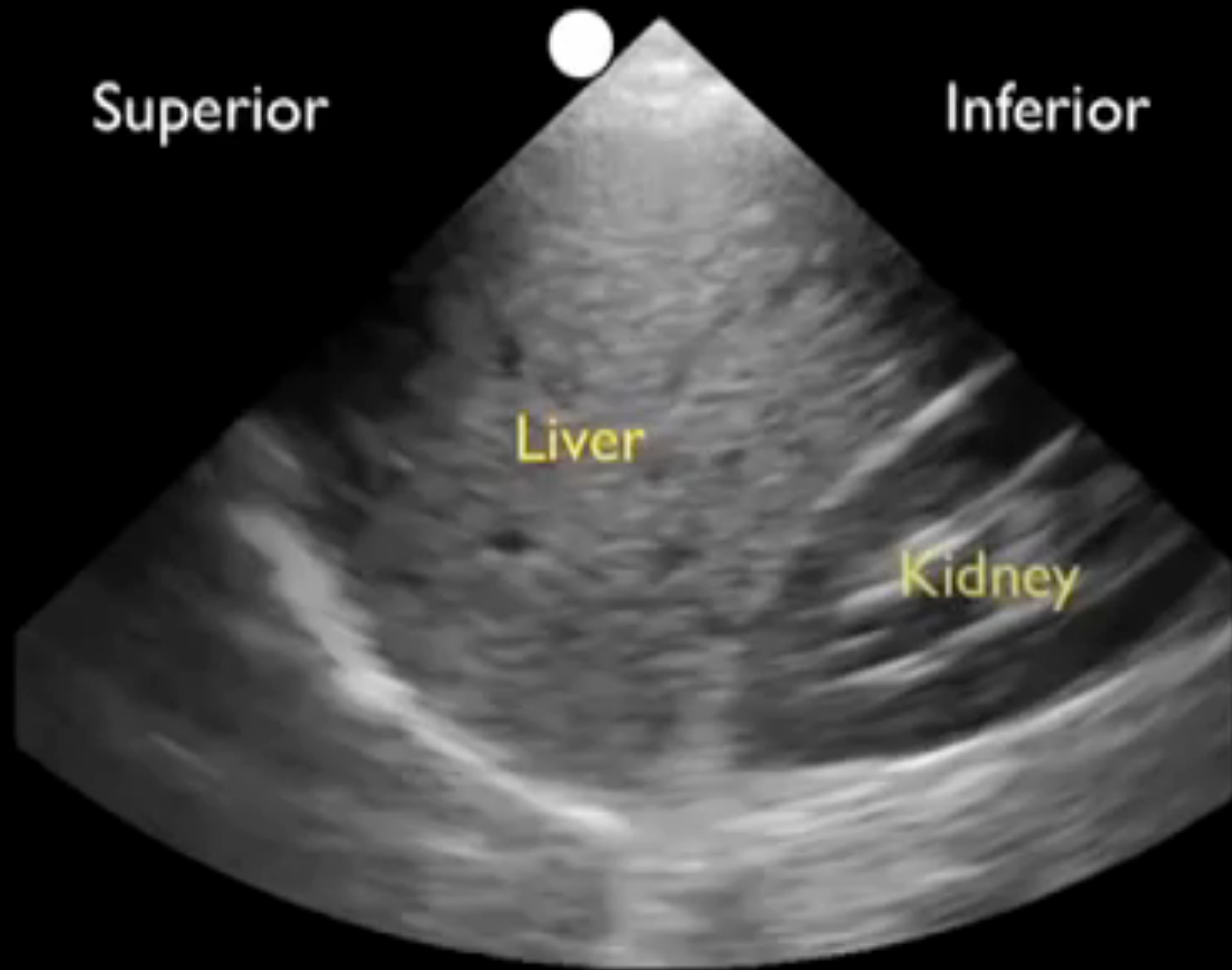
Sinusoid sign



Continuous spine sign



Normal Right Upper Quadrant / Pleural Exam

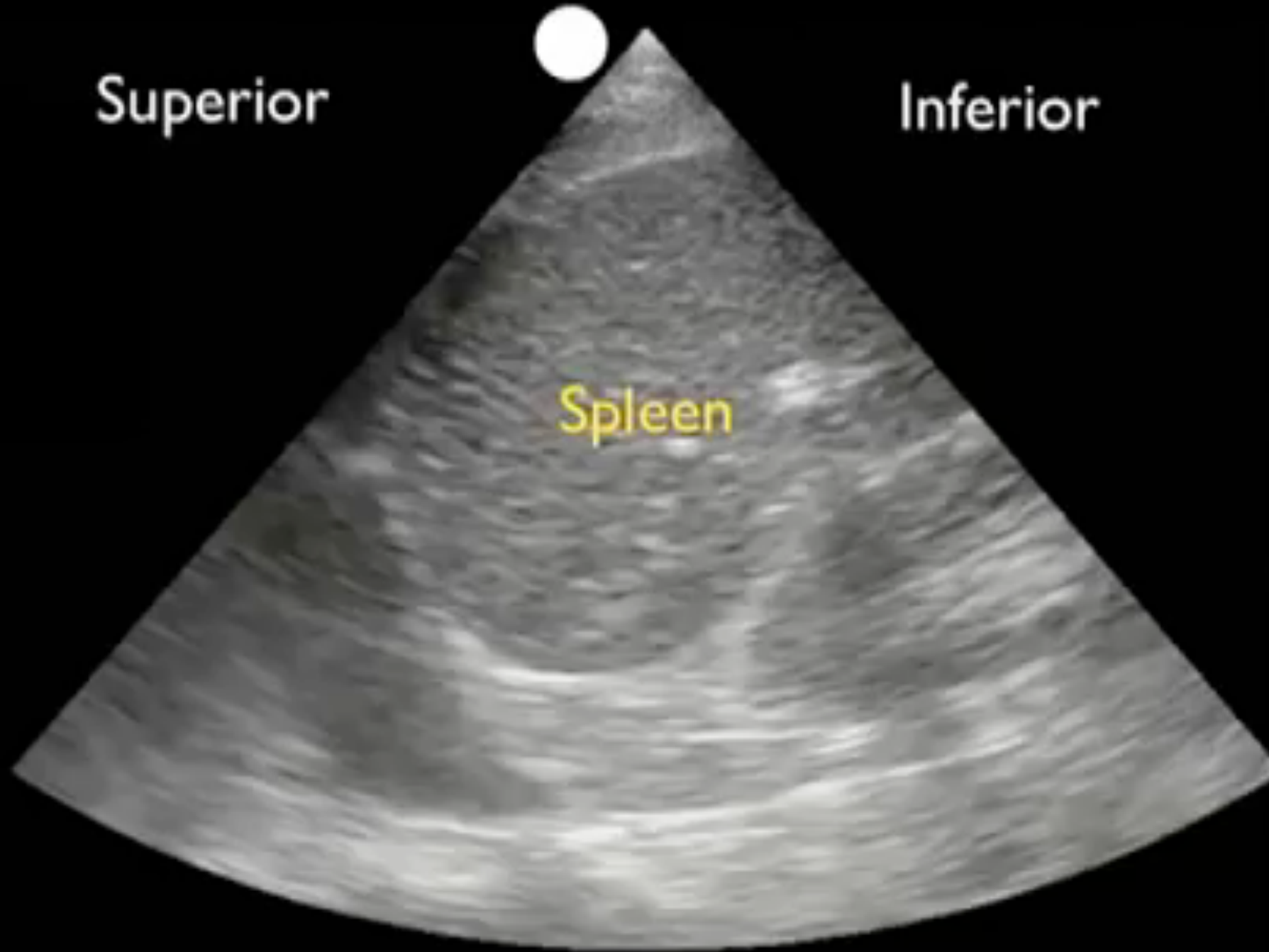


Small Pleural Effusion

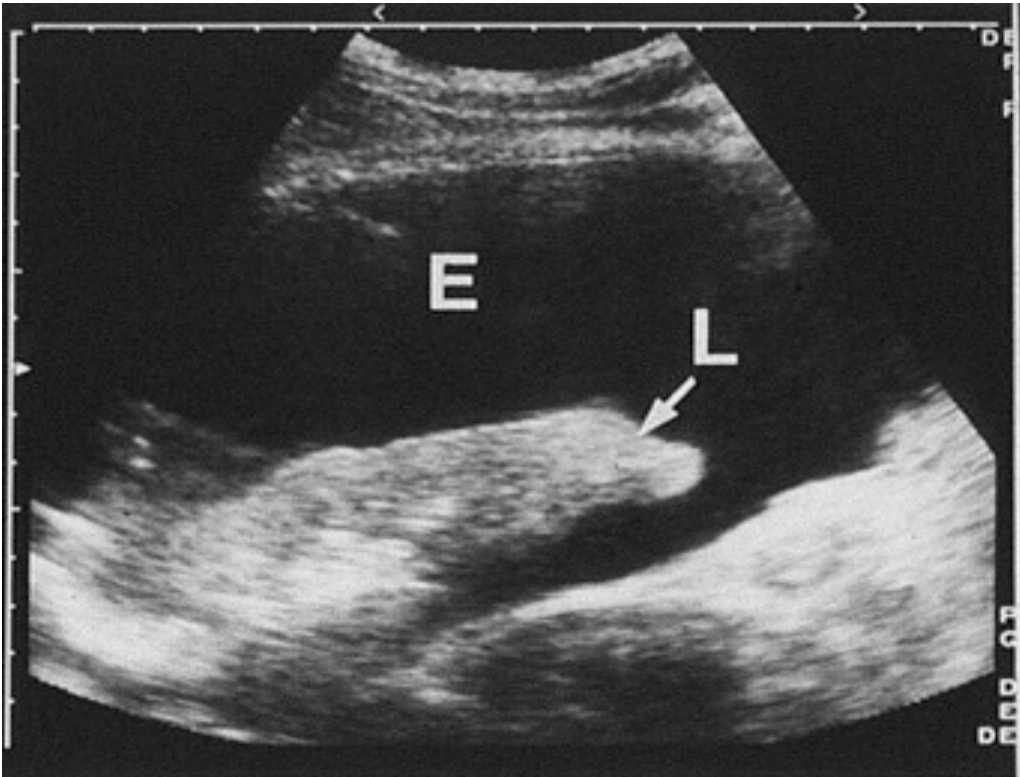
Superior

Inferior

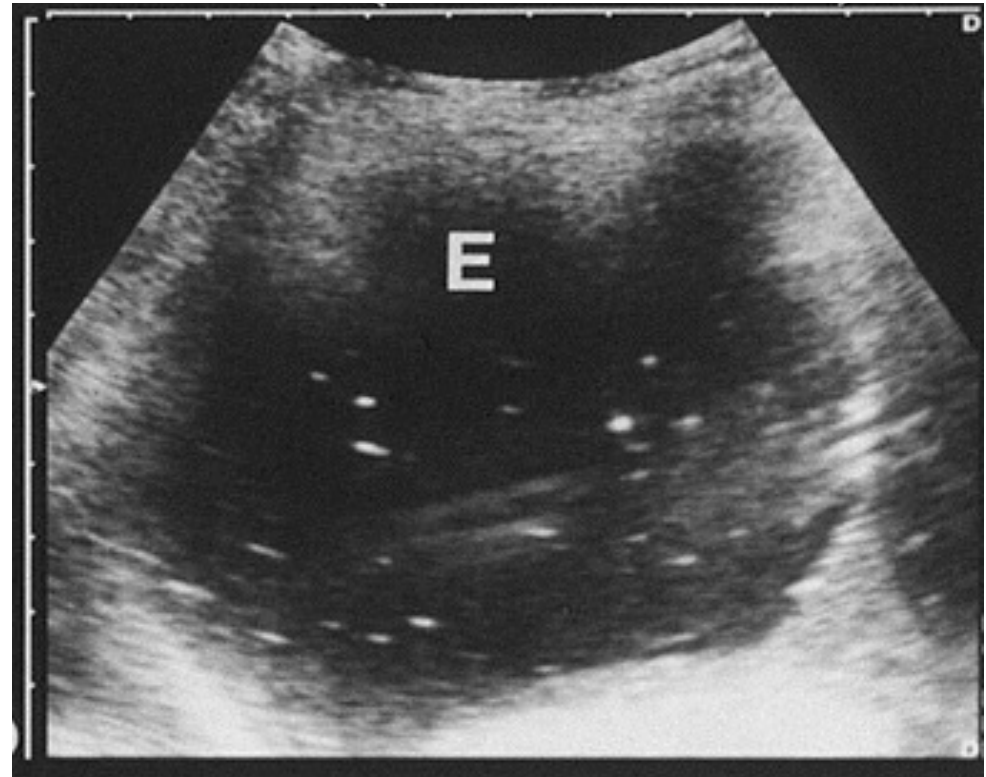
Spleen



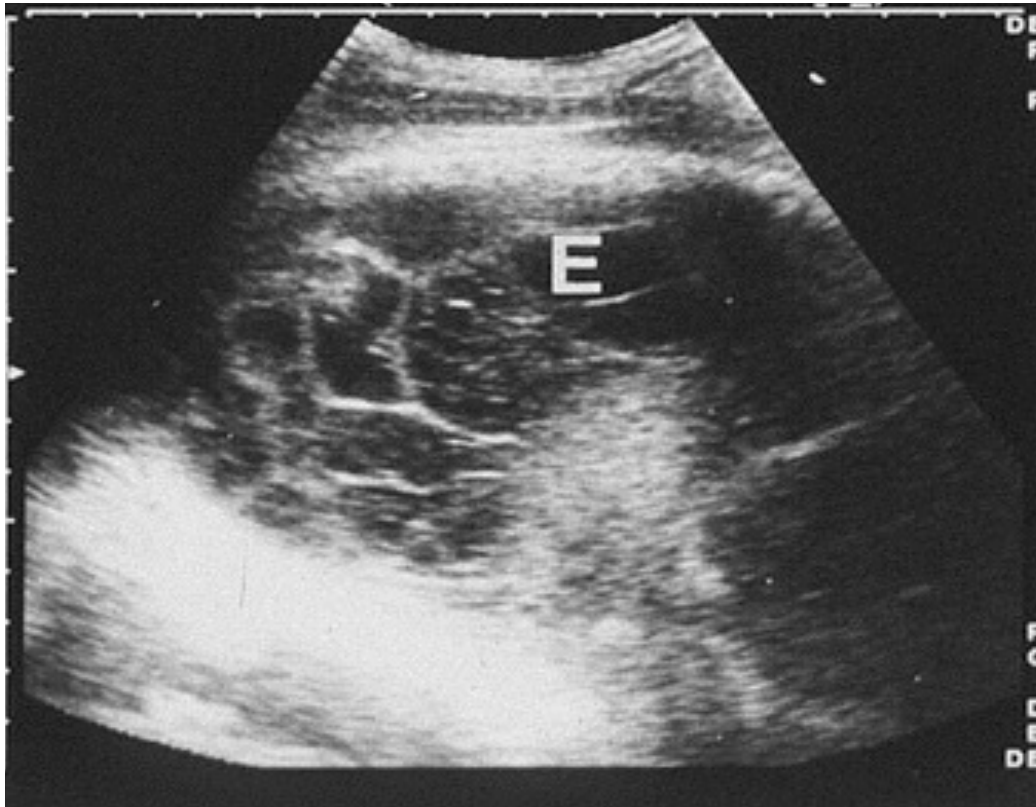
Echo picture of pleural effusion



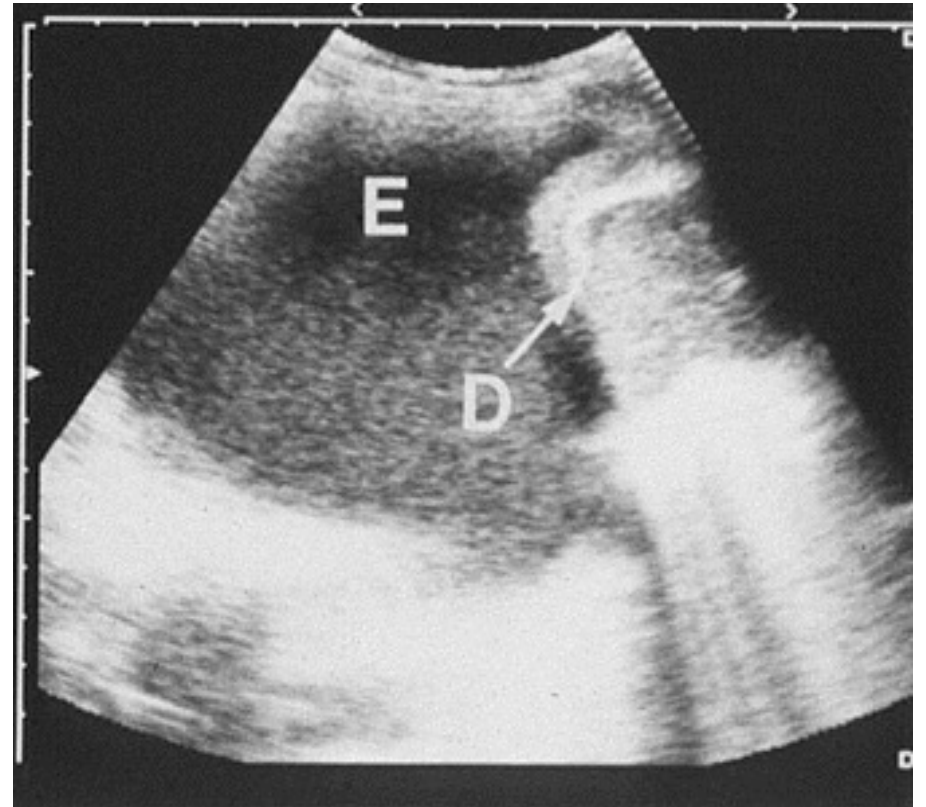
- Anechoic



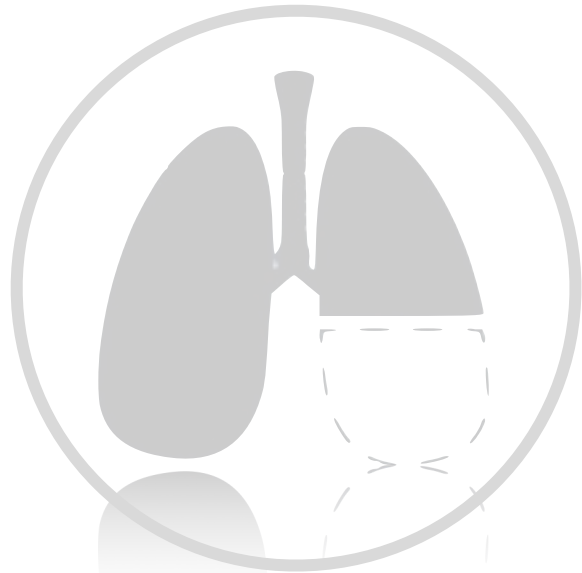
- Complex but non-septated



- Complex and septated



- echogenic



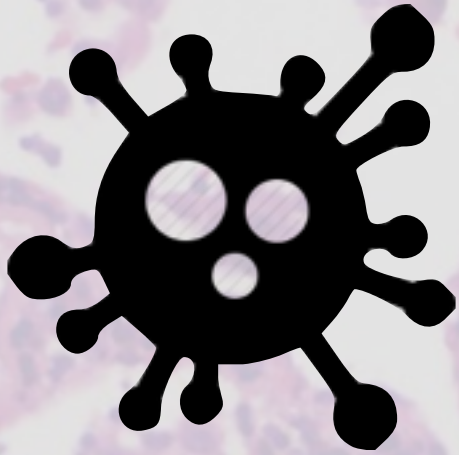

Pneumothorax

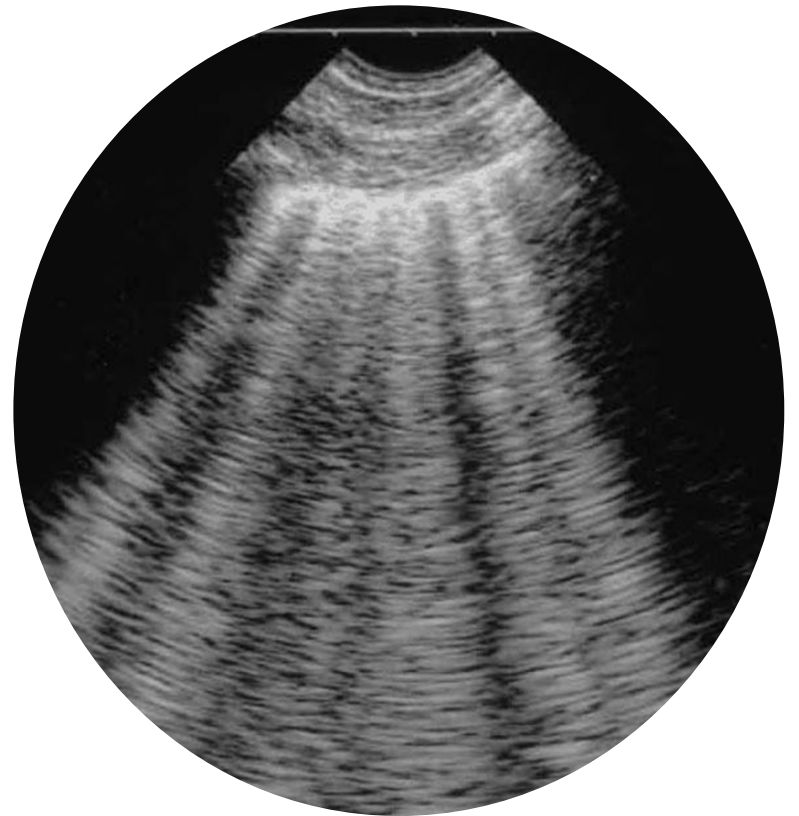
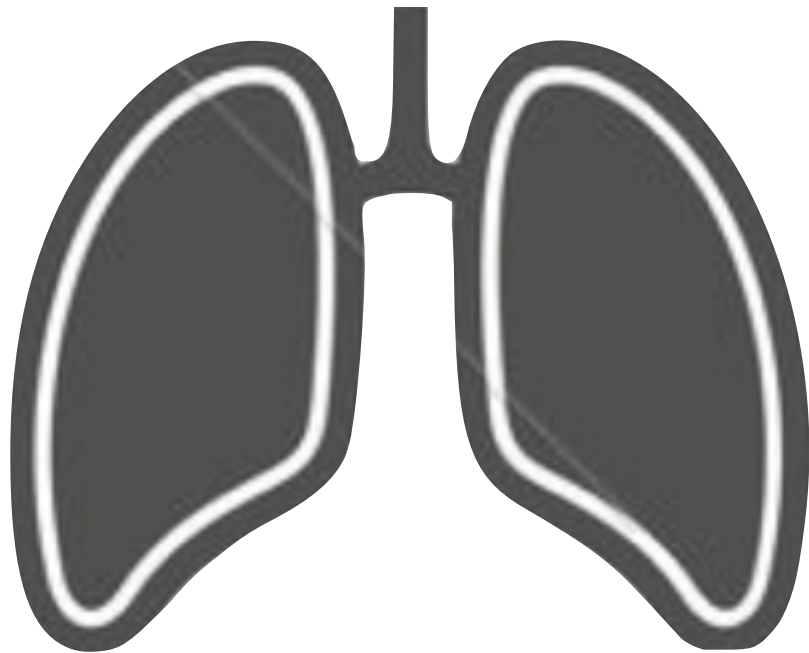


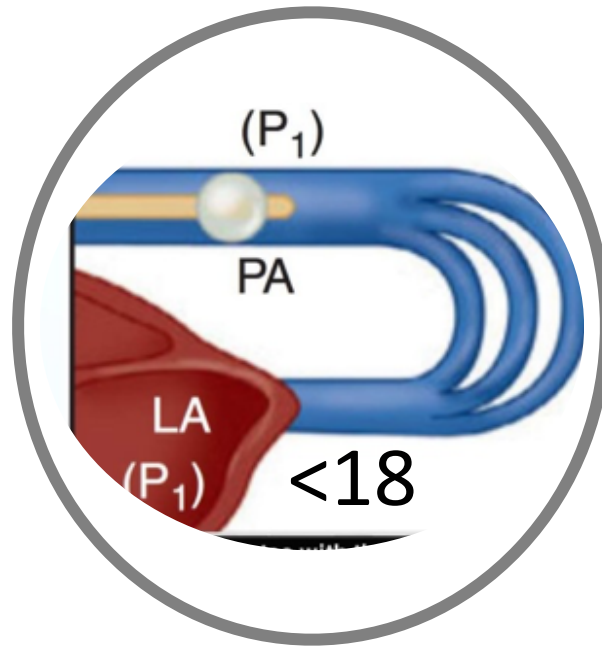
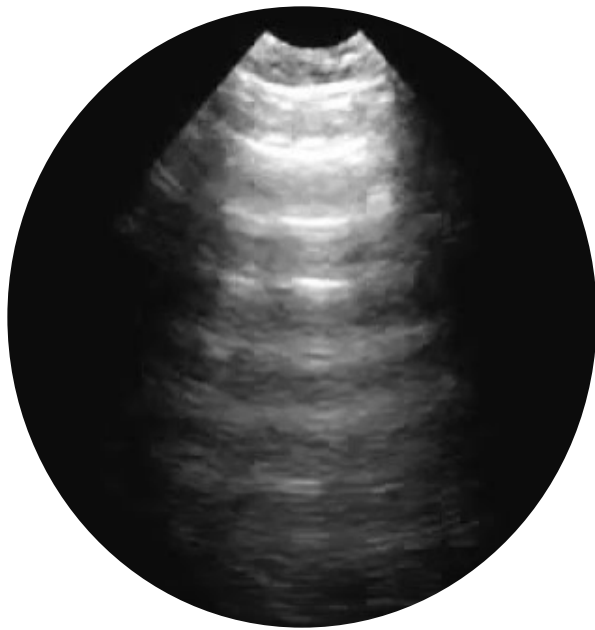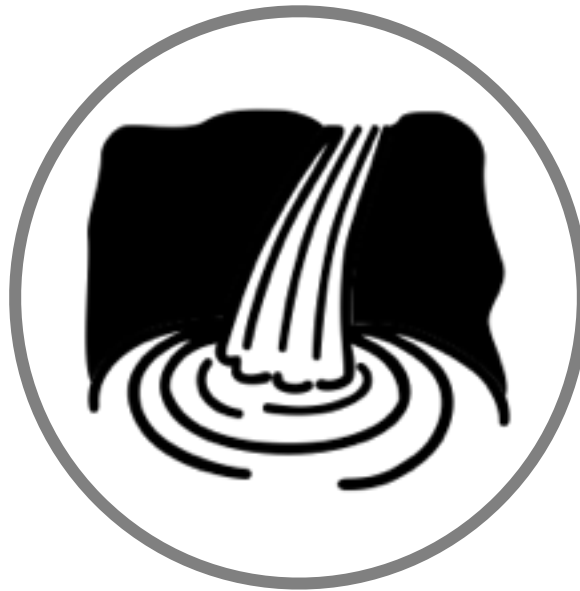Pleural effusion



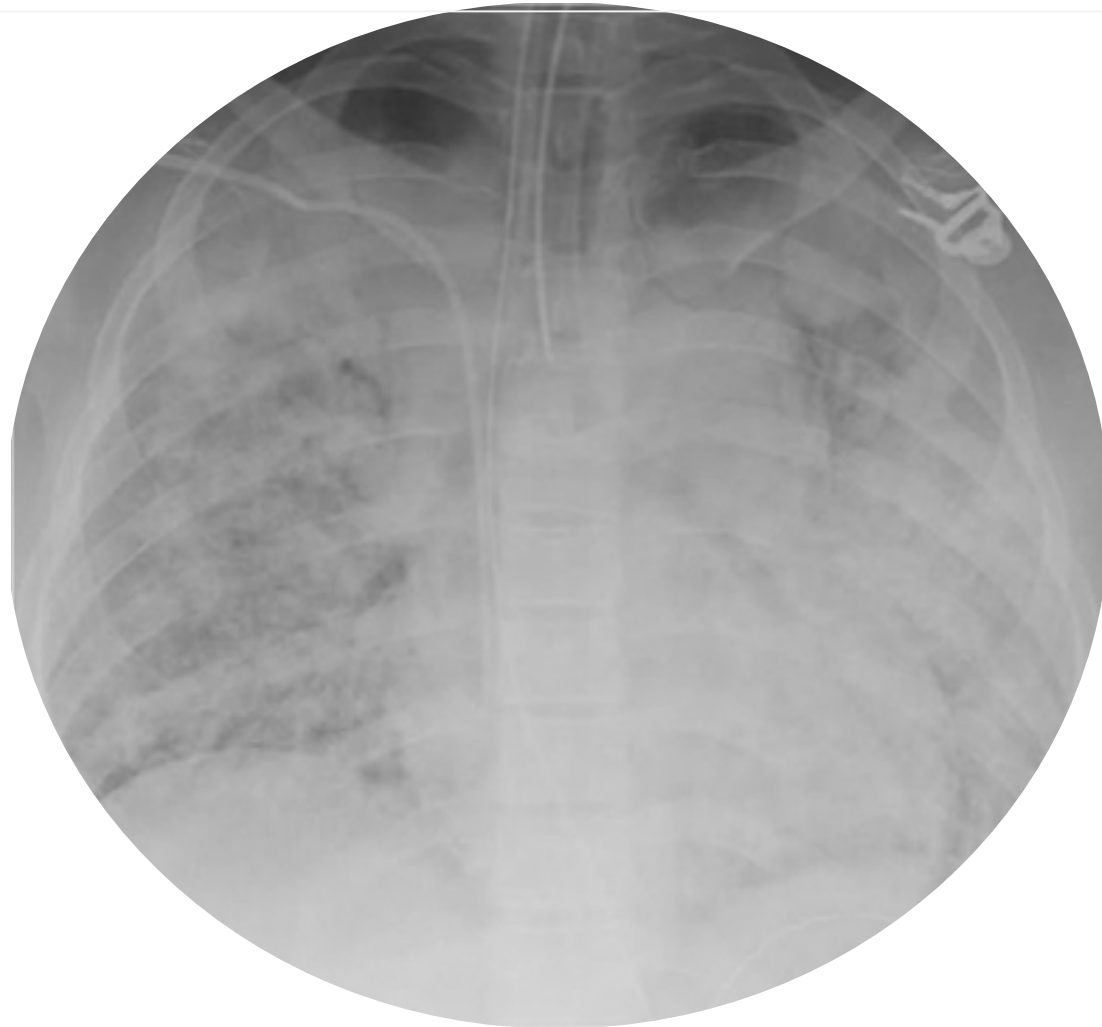Interstitial lung

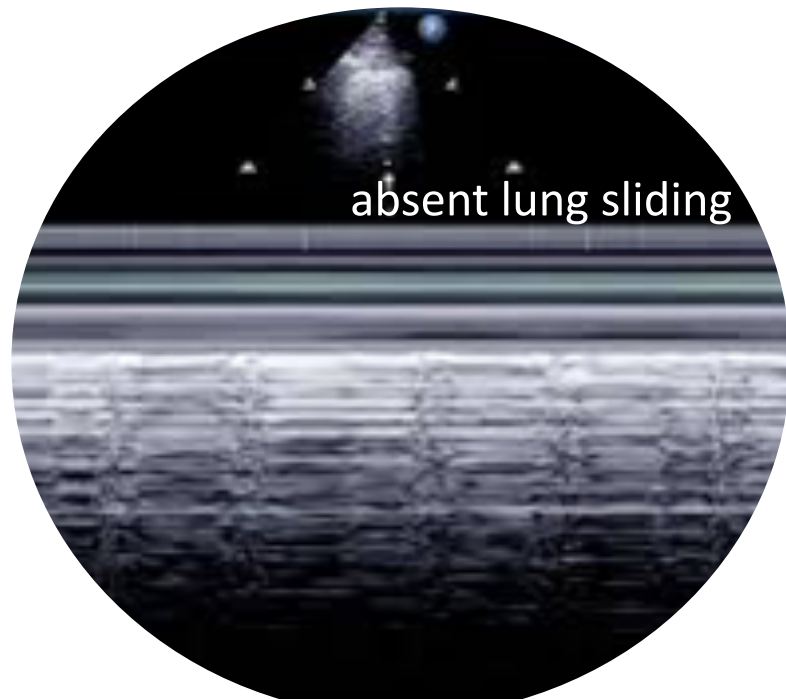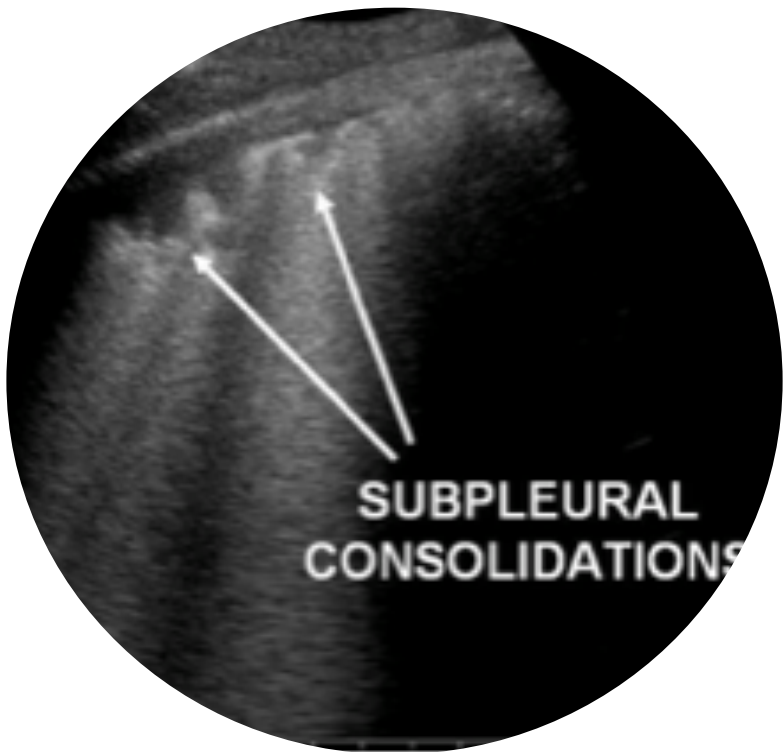
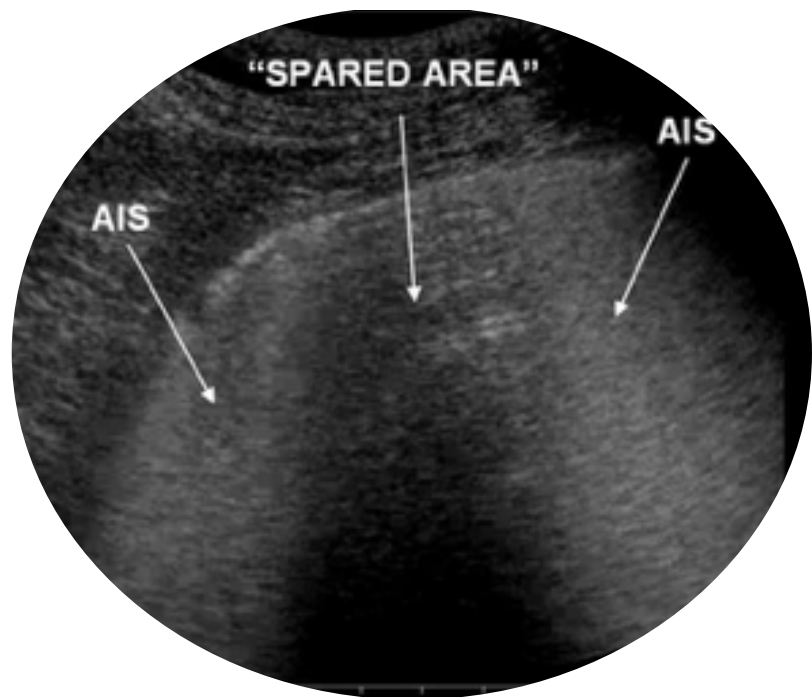
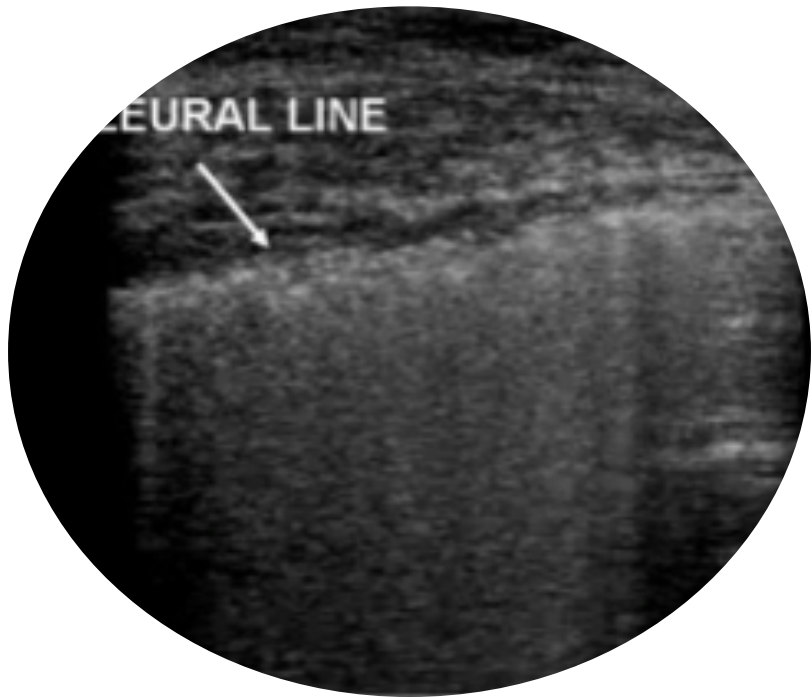



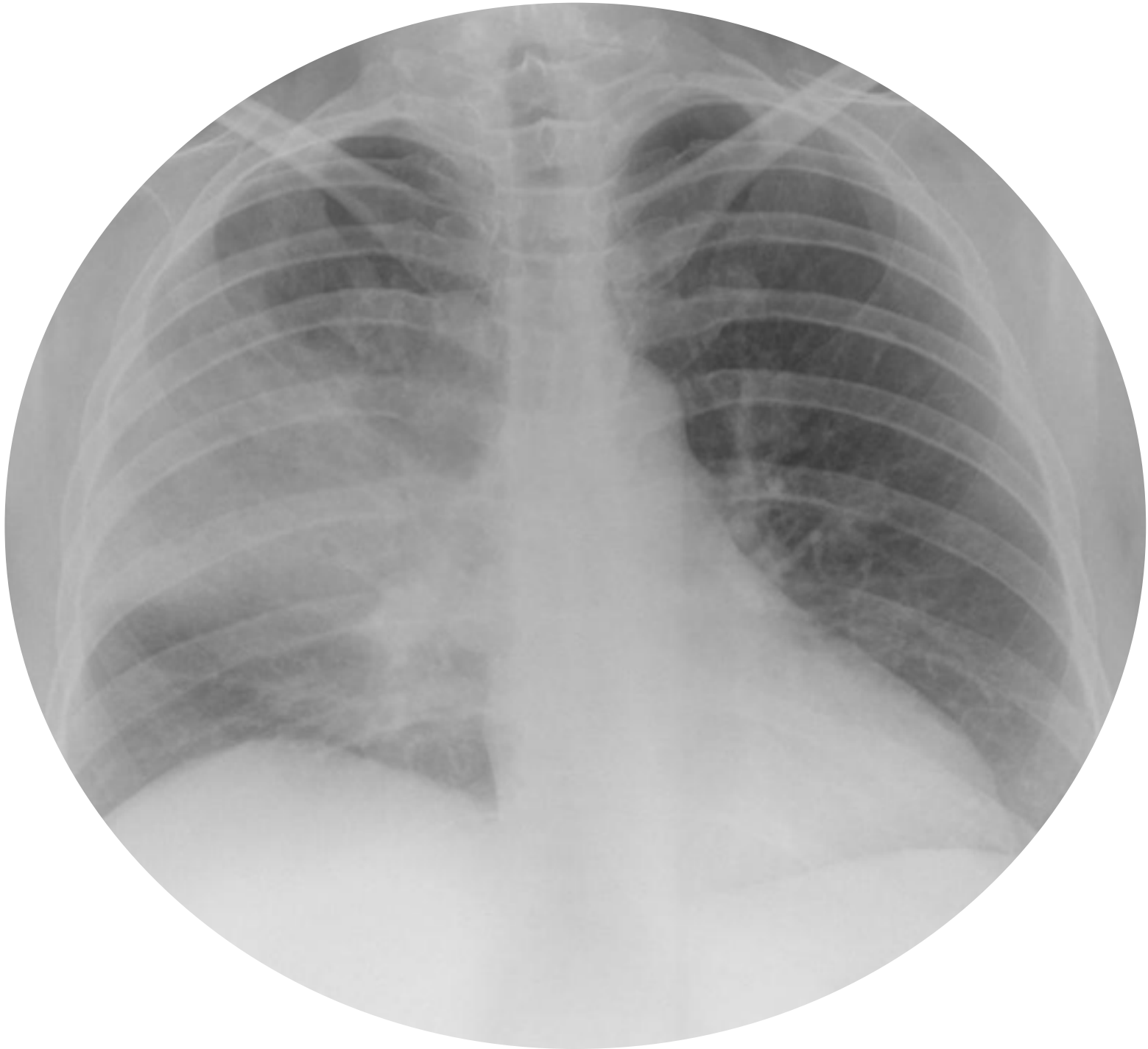
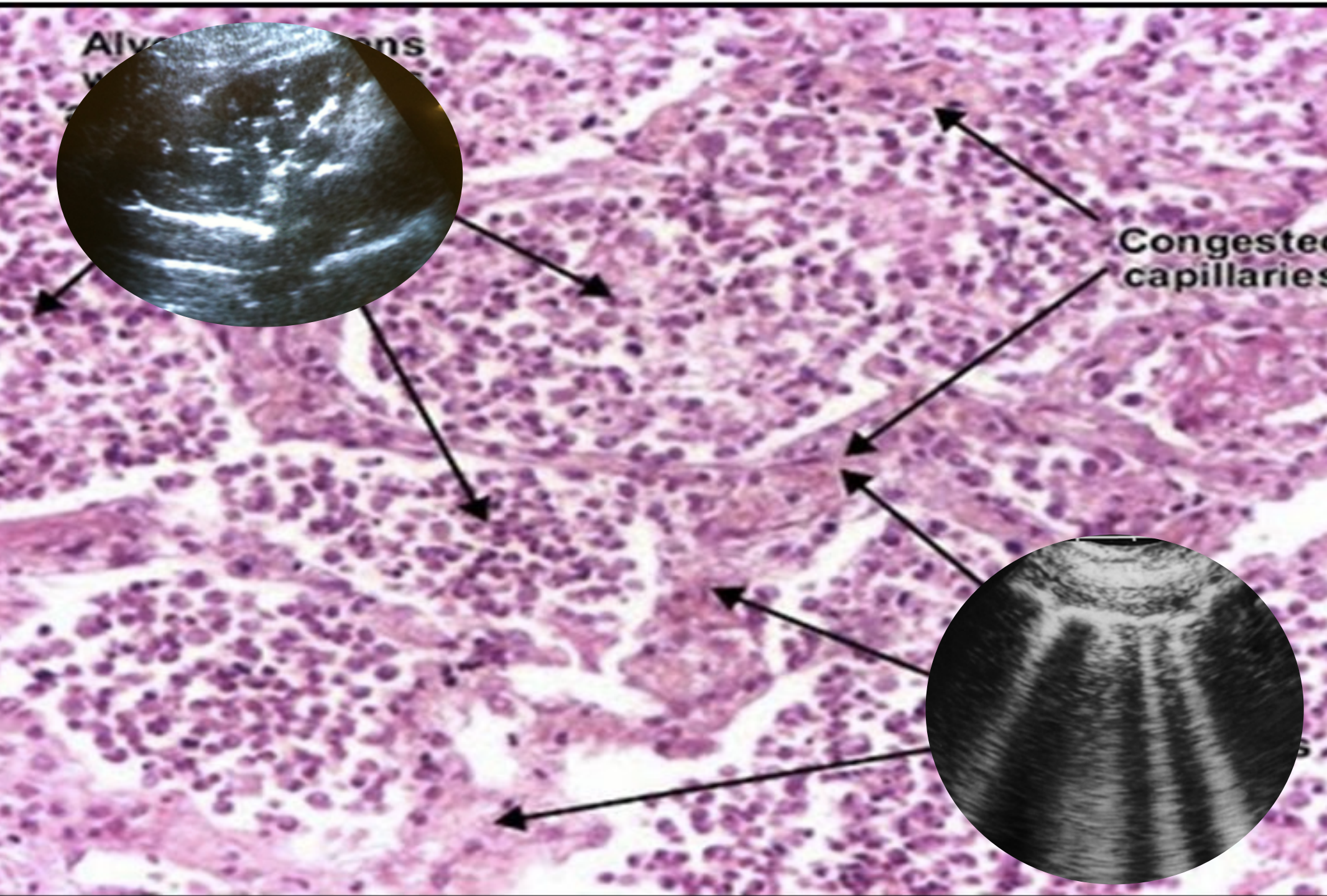


NON CARDIOGENIC LUNG EDEMA



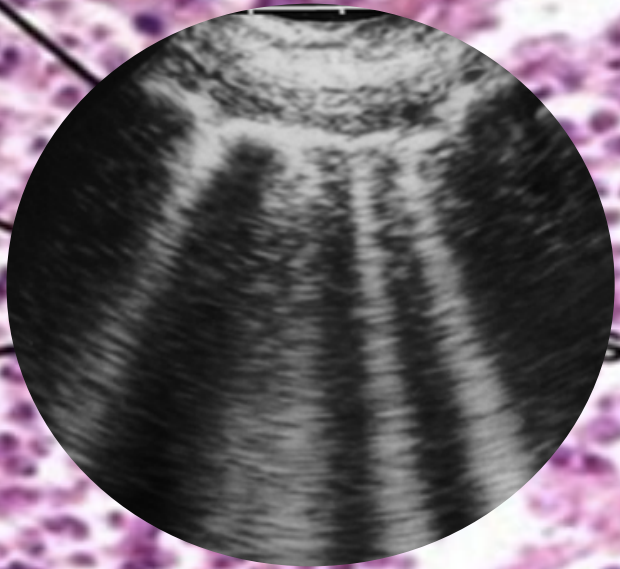
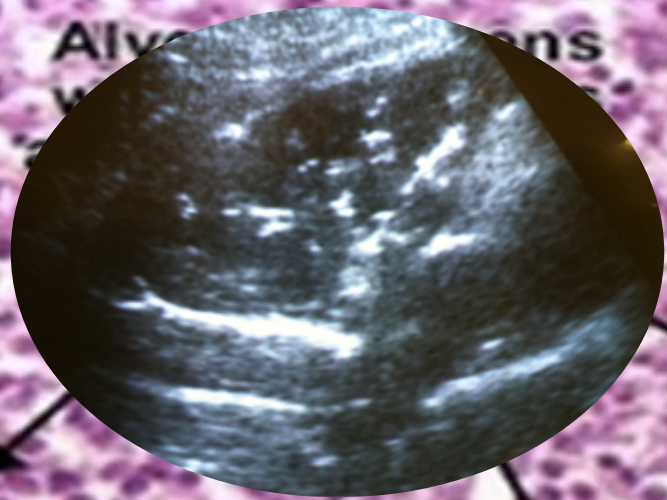


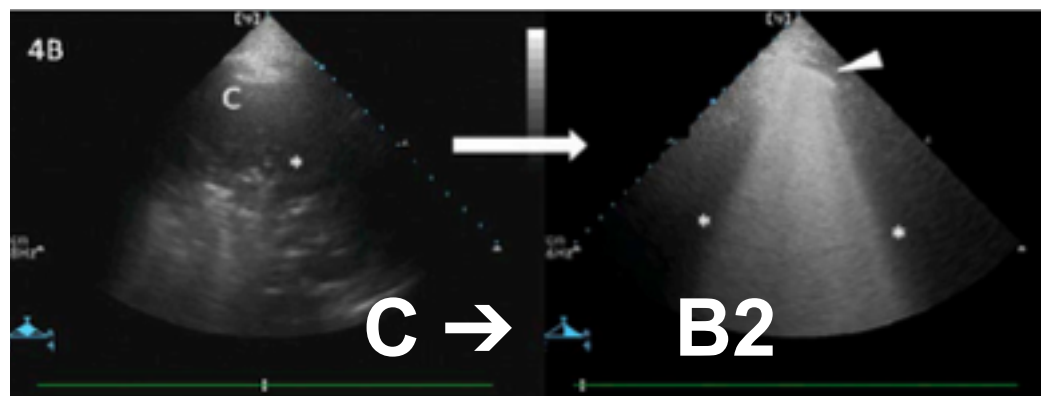
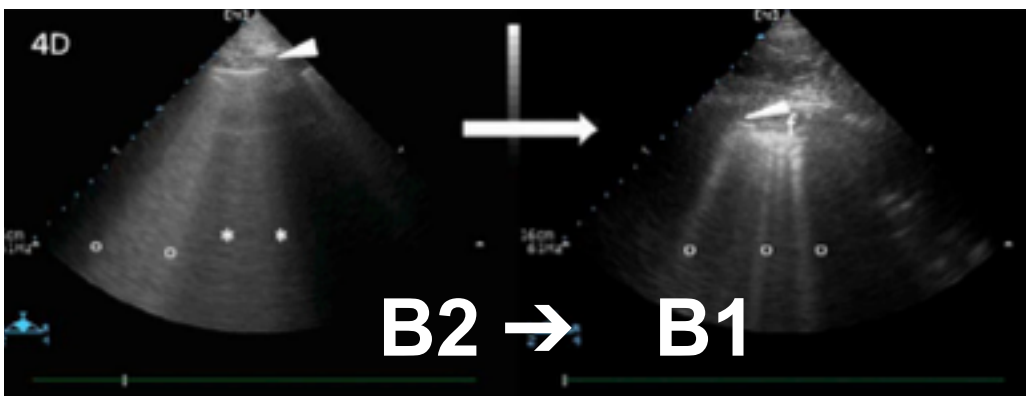
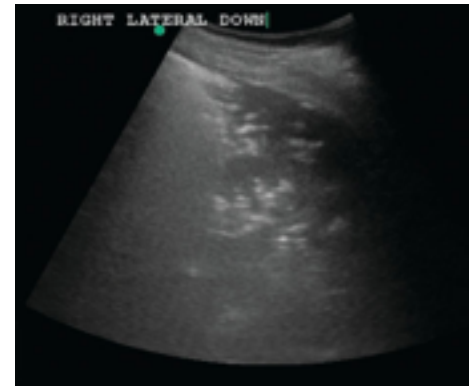
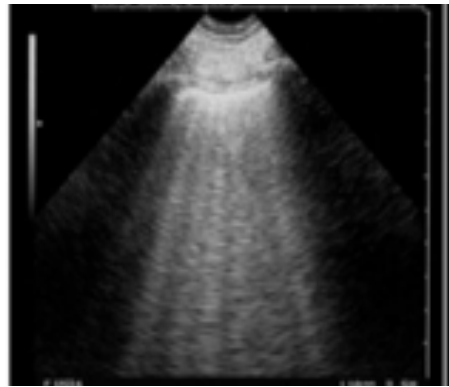
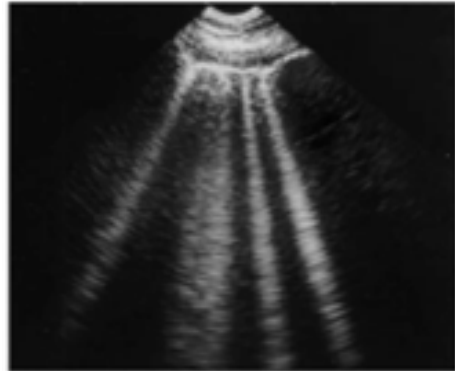
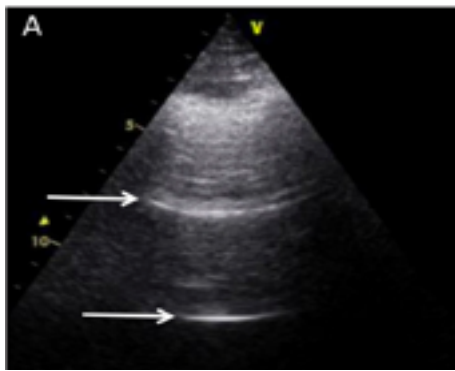




Alveoli

Congested capillaries







SonoSite

C60xp/5-2 Abdomen

6.0 cm

2D: G:

DR

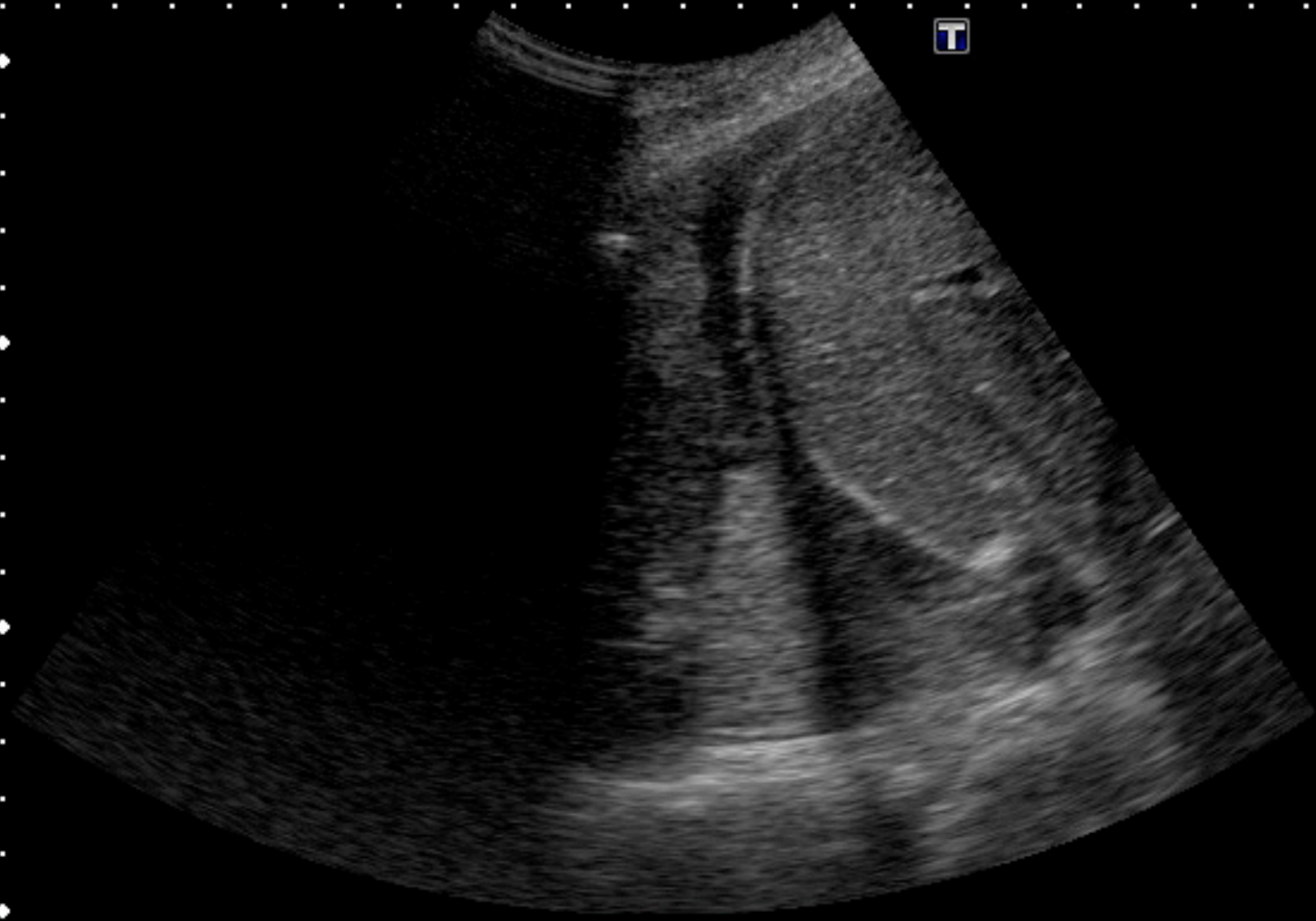
MB





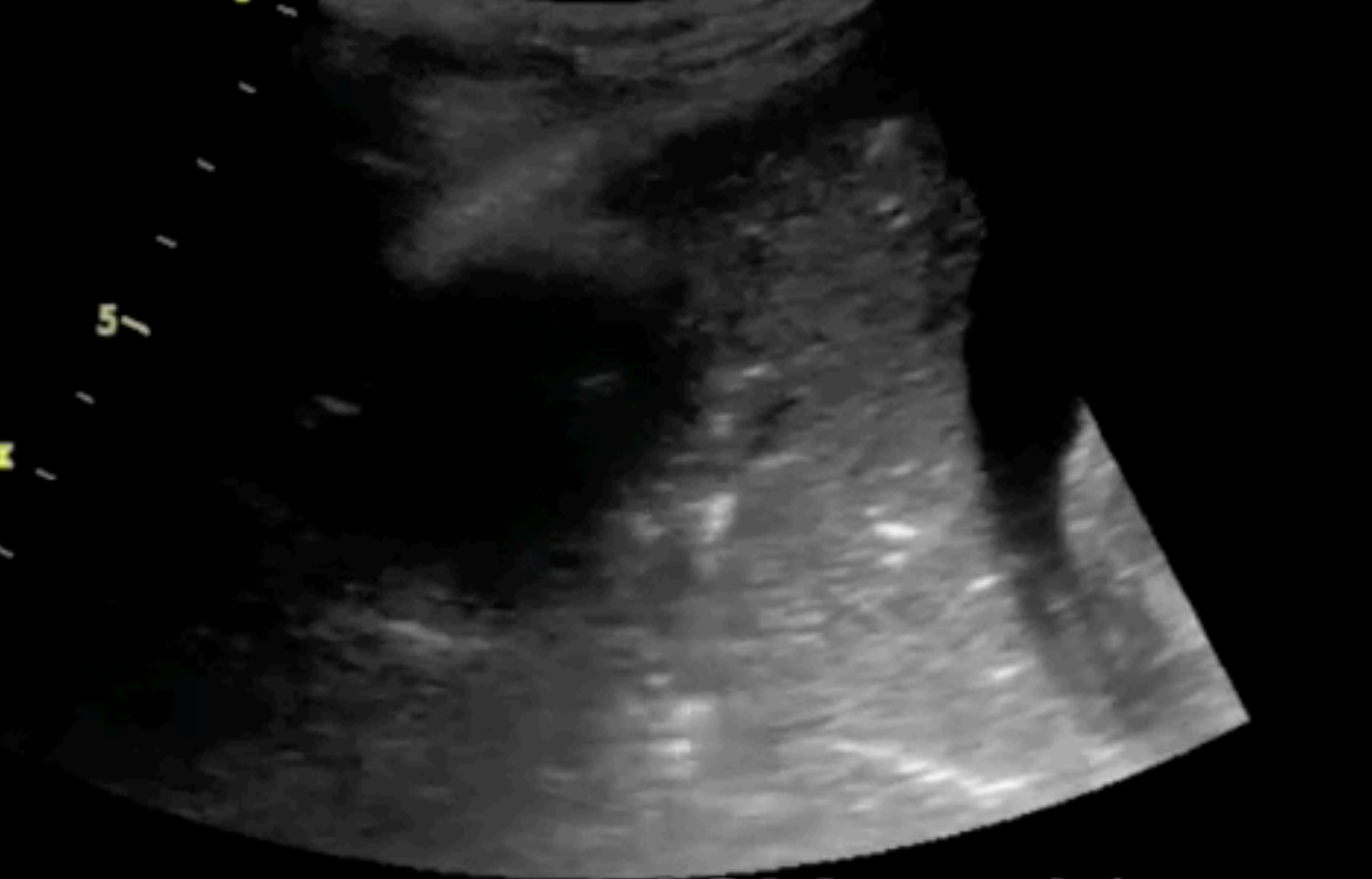0 ♦
5 ♦
10 ♦
15 ♦

T

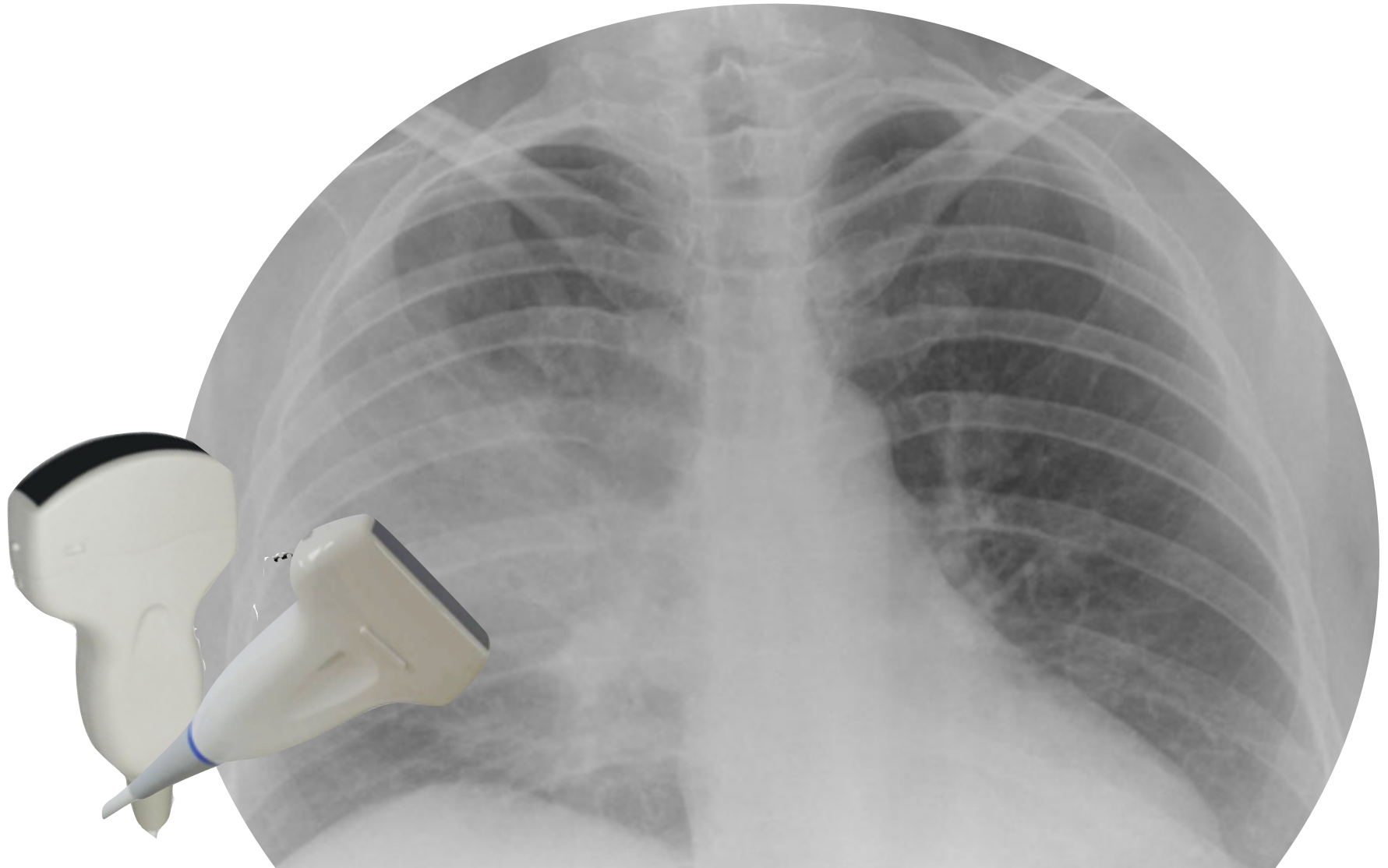


MI:1.6
2DG
83
DR
65

6C1
T5.0
18 fps

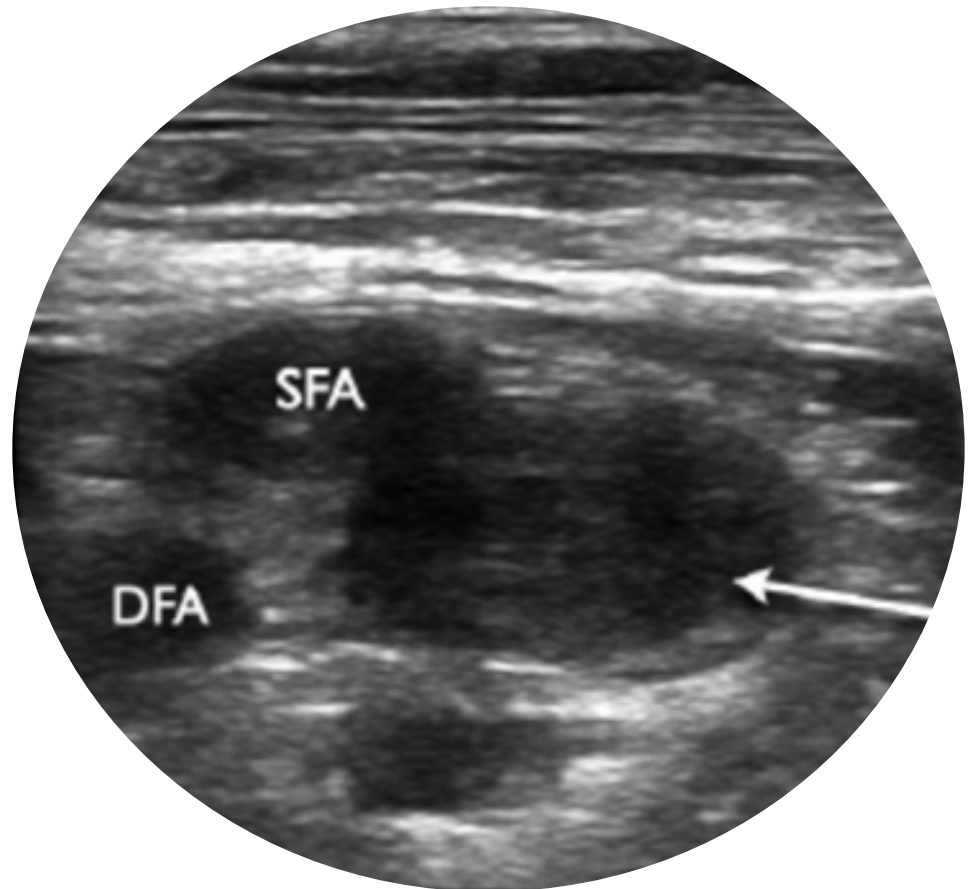
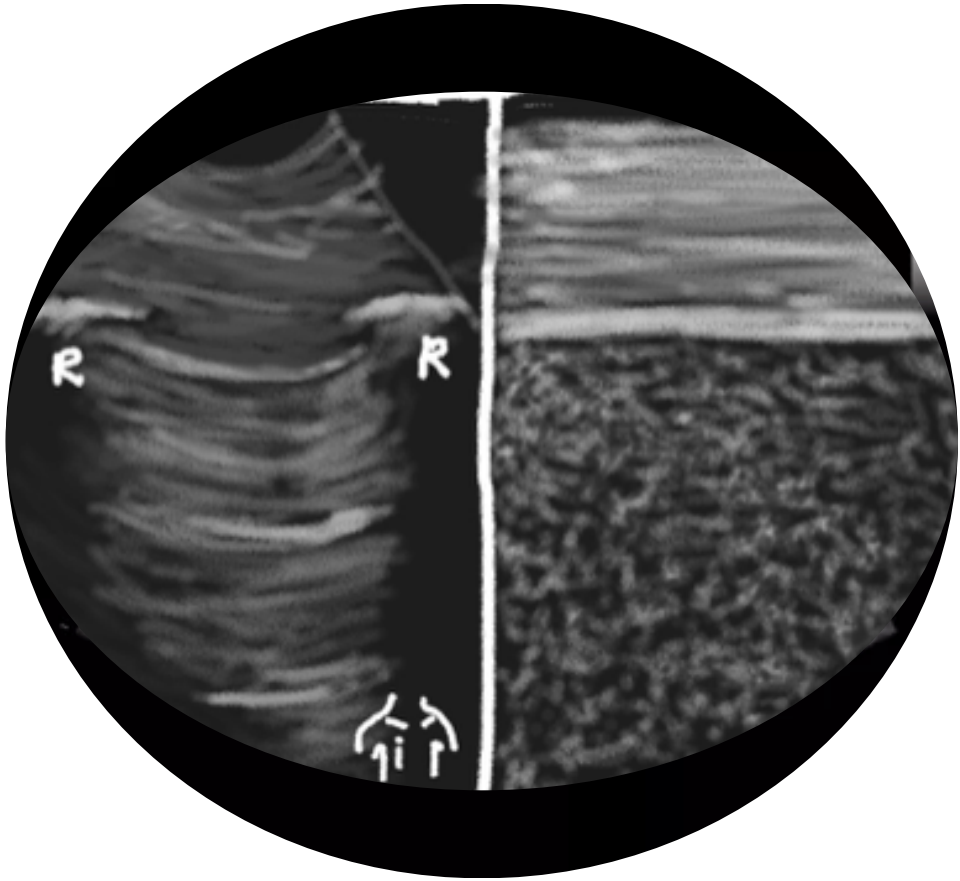


ICMteaching.co

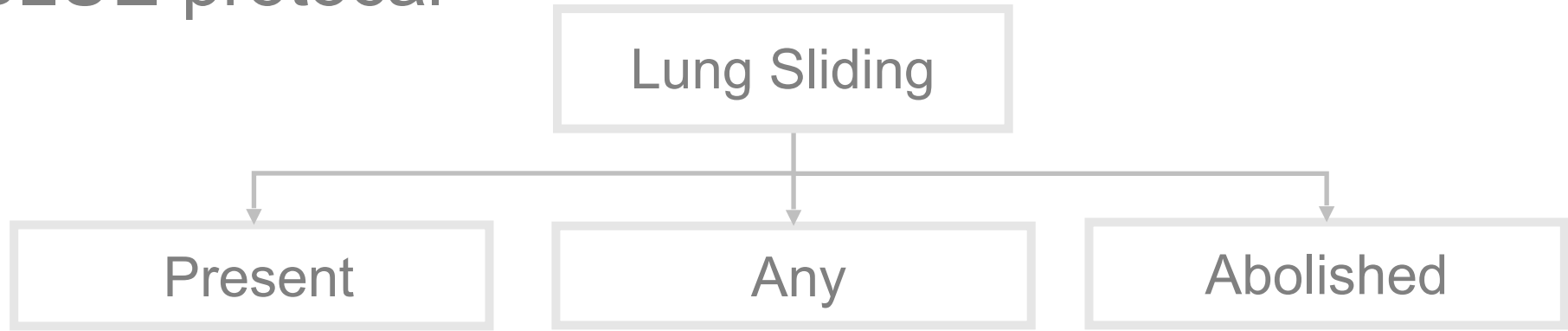


Sensitivity: 91%
Specificity: 98%

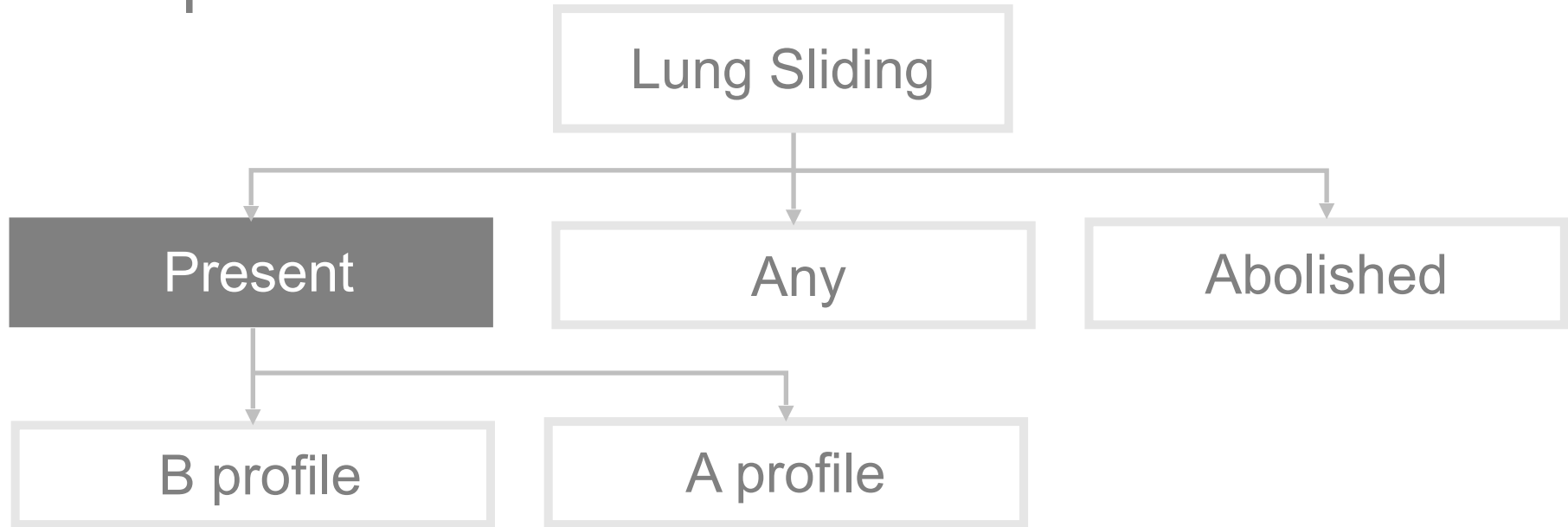




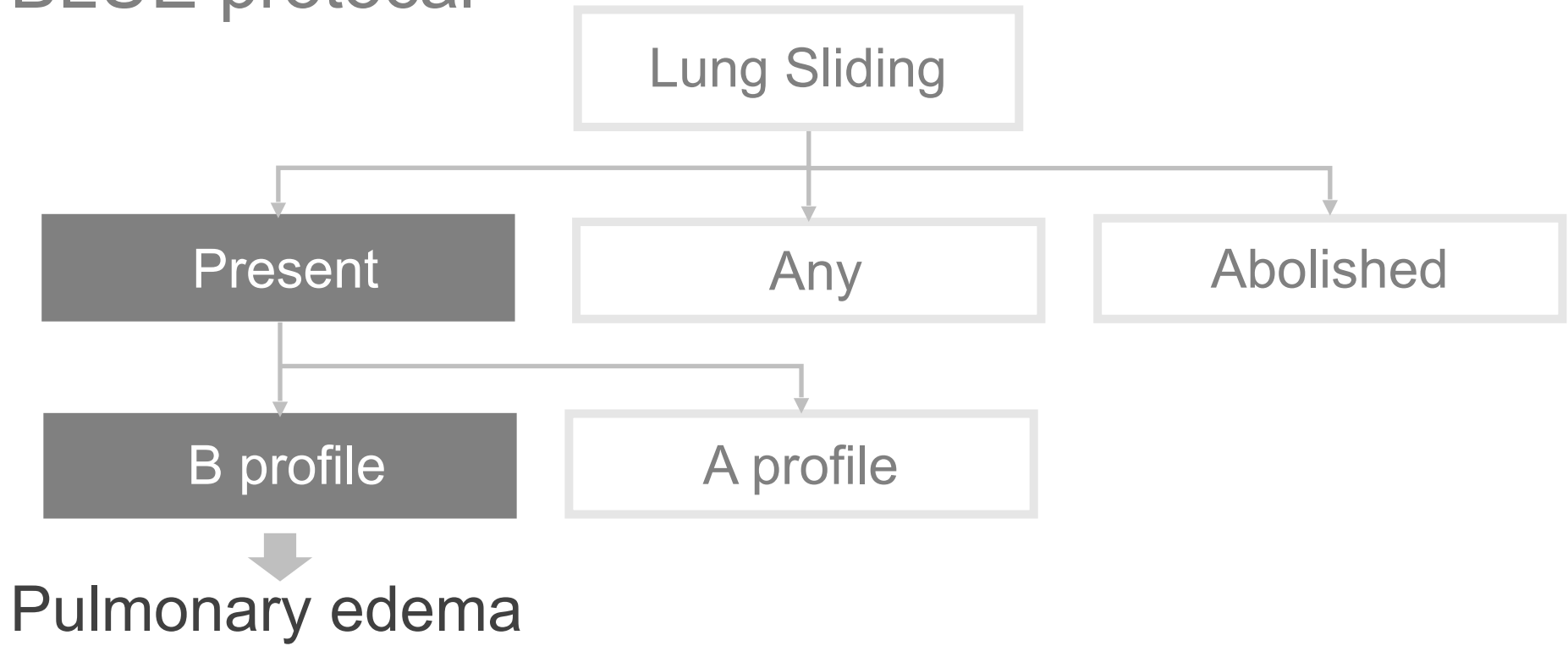
BLUE protocol



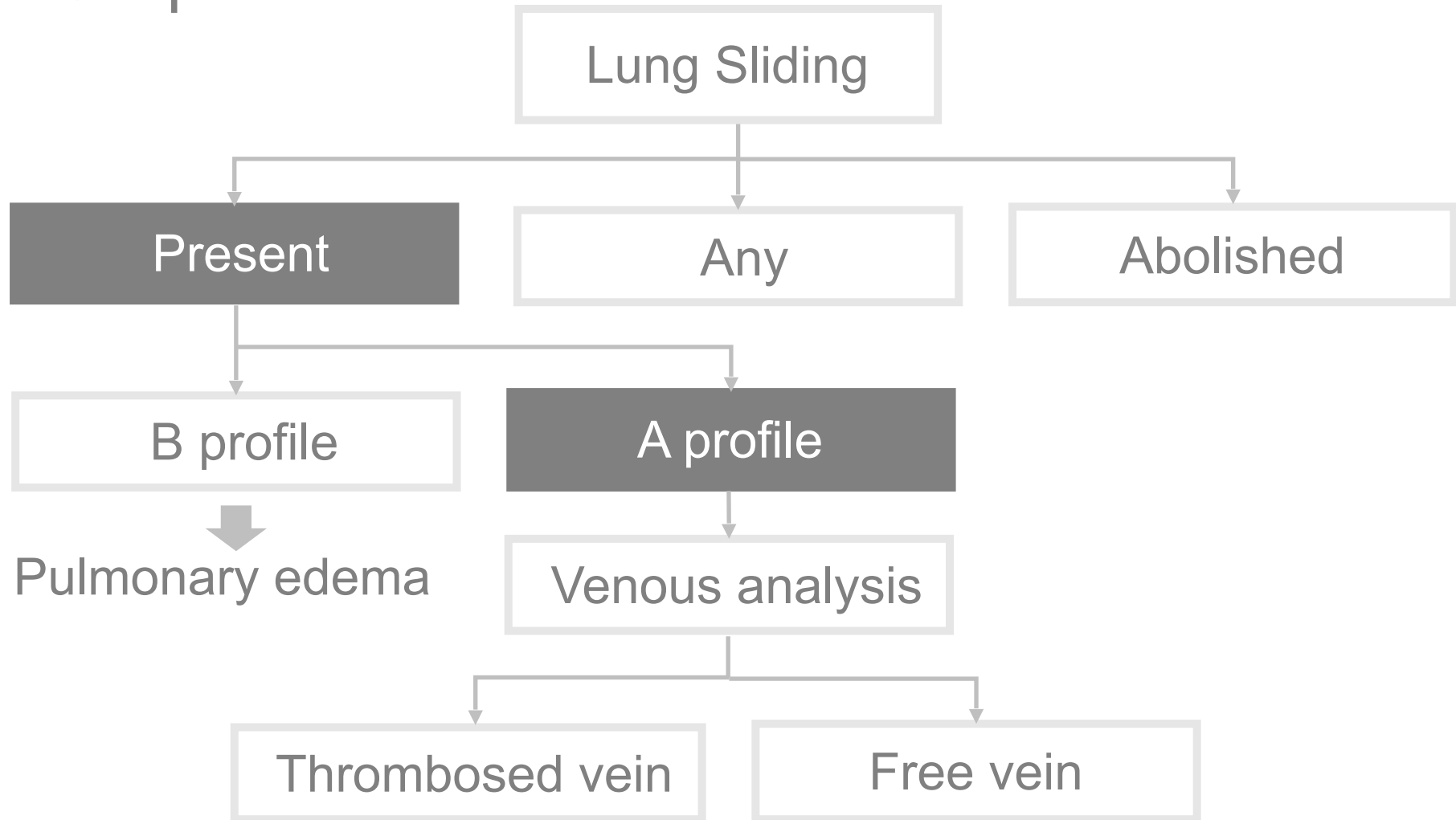
BLUE protocol



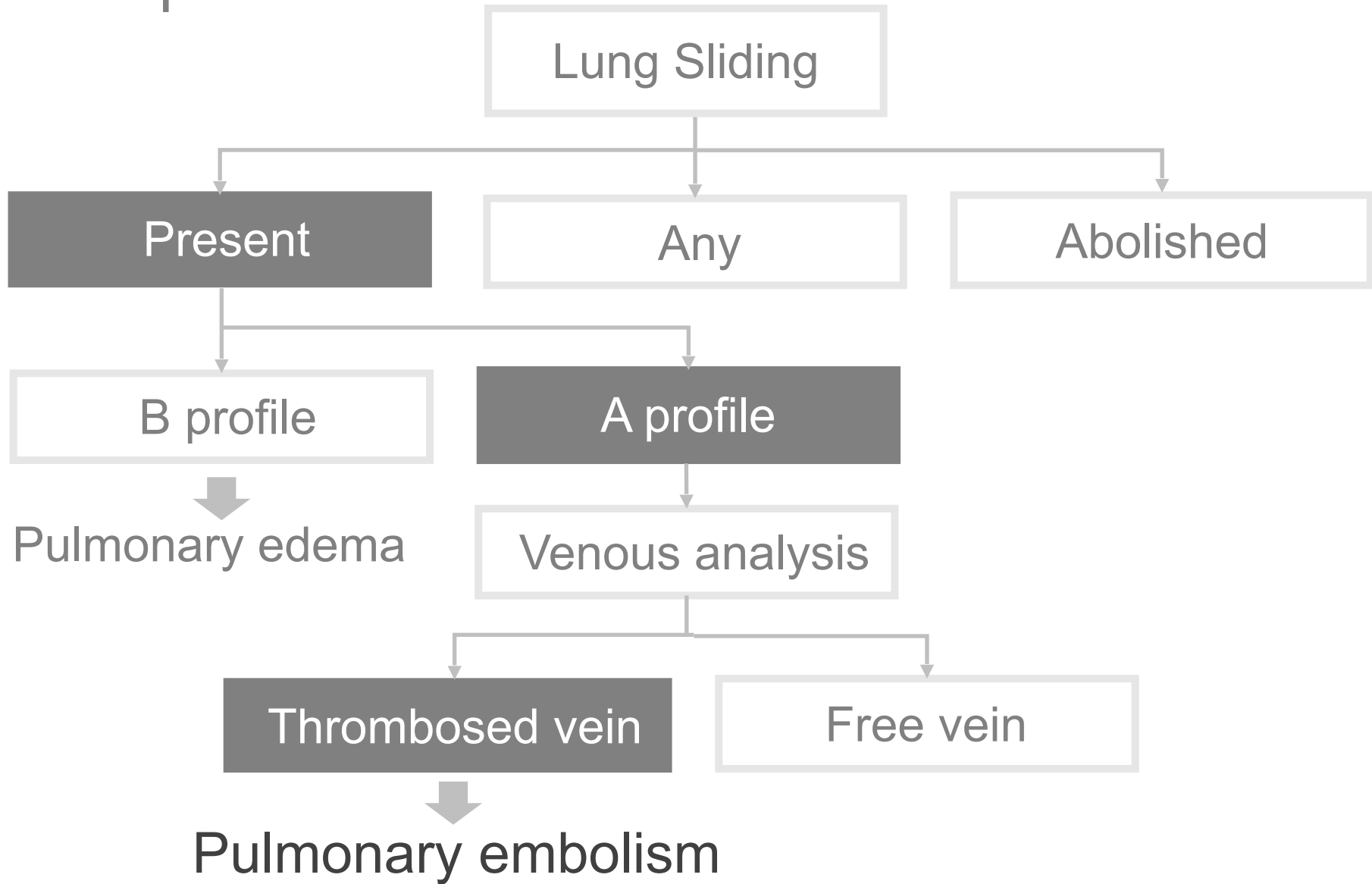
BLUE protocol



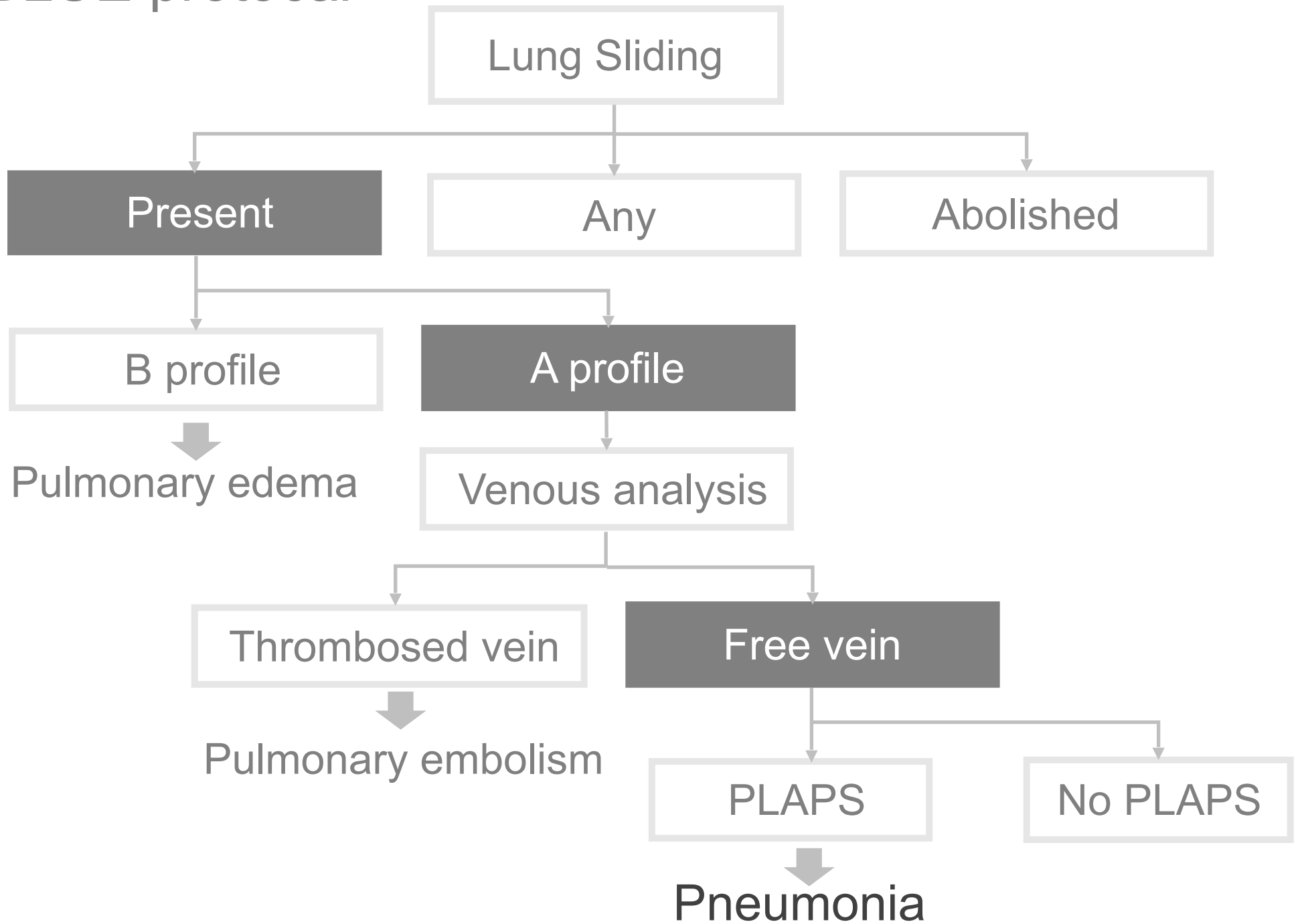
BLUE protocol



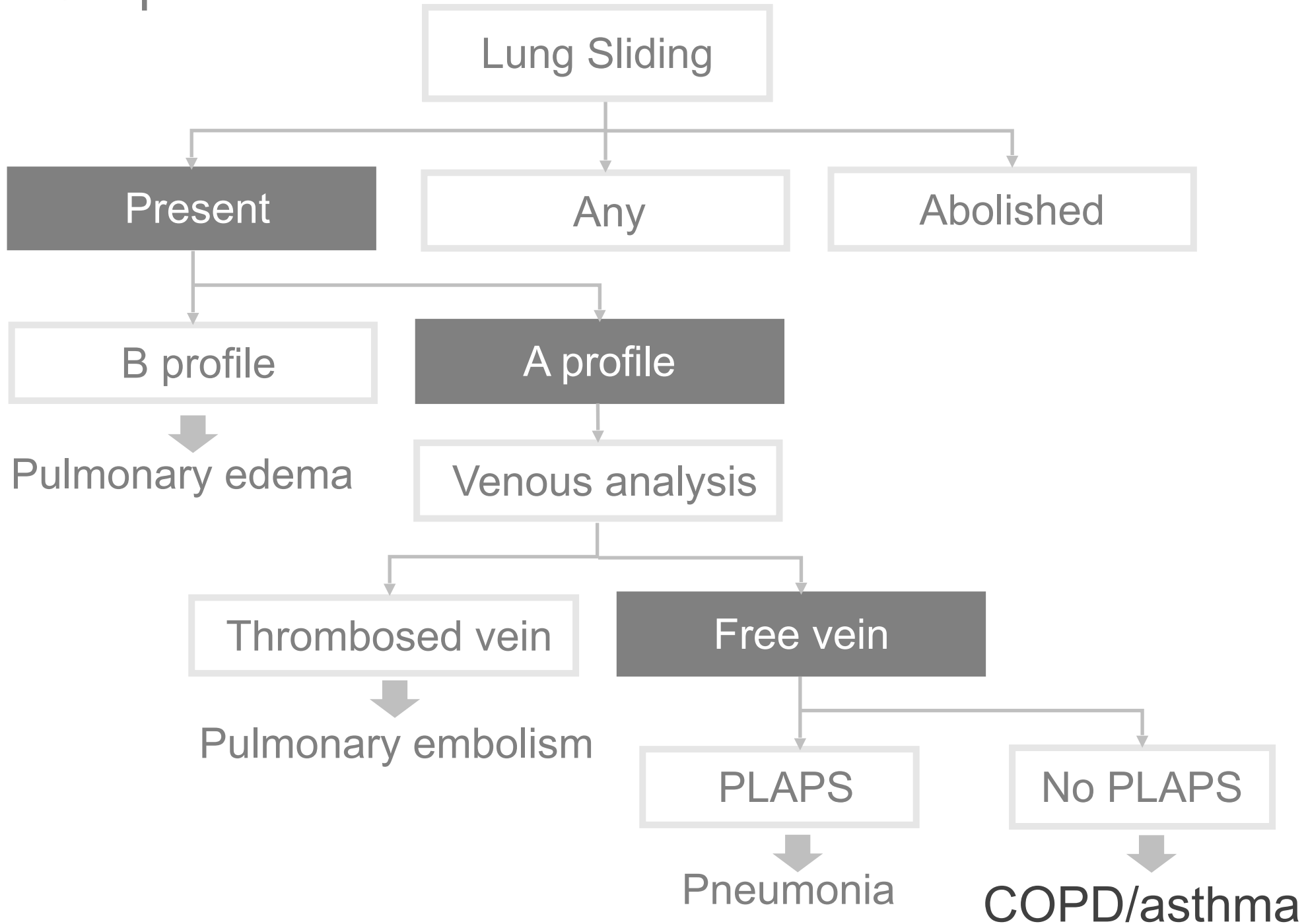
BLUE protocol



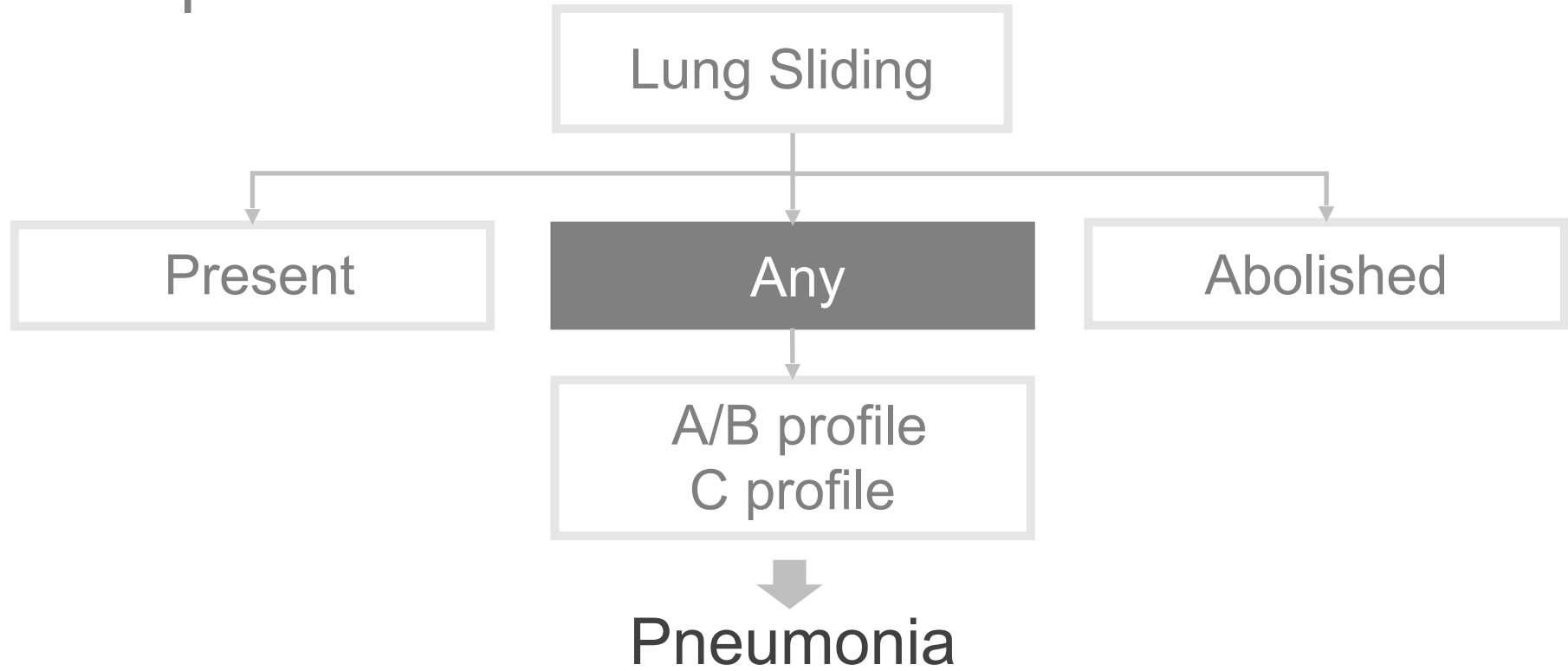
BLUE protocol



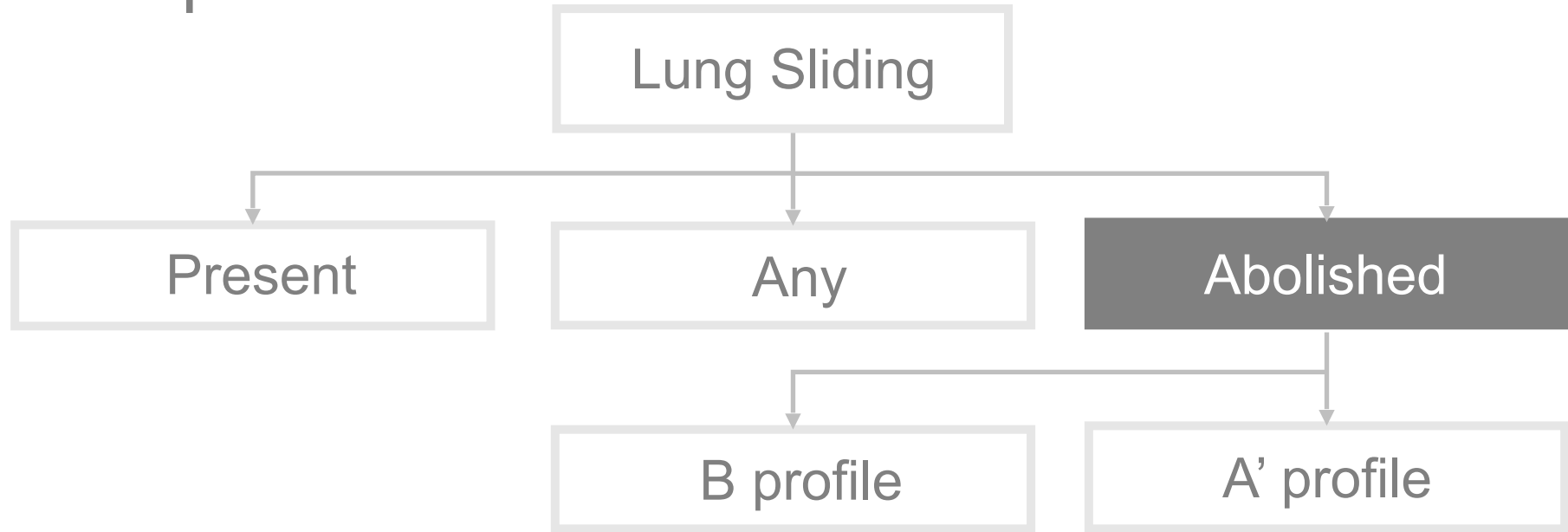
BLUE protocol



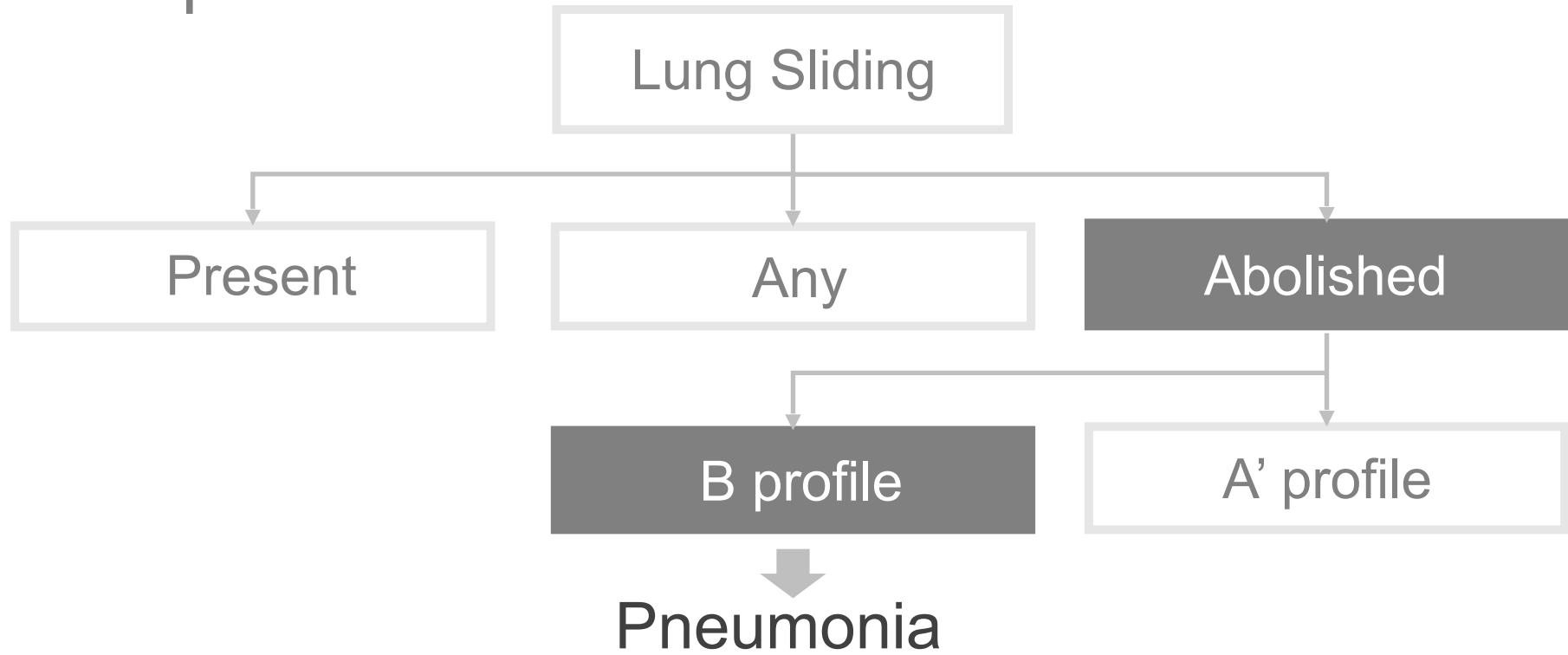
BLUE protocol



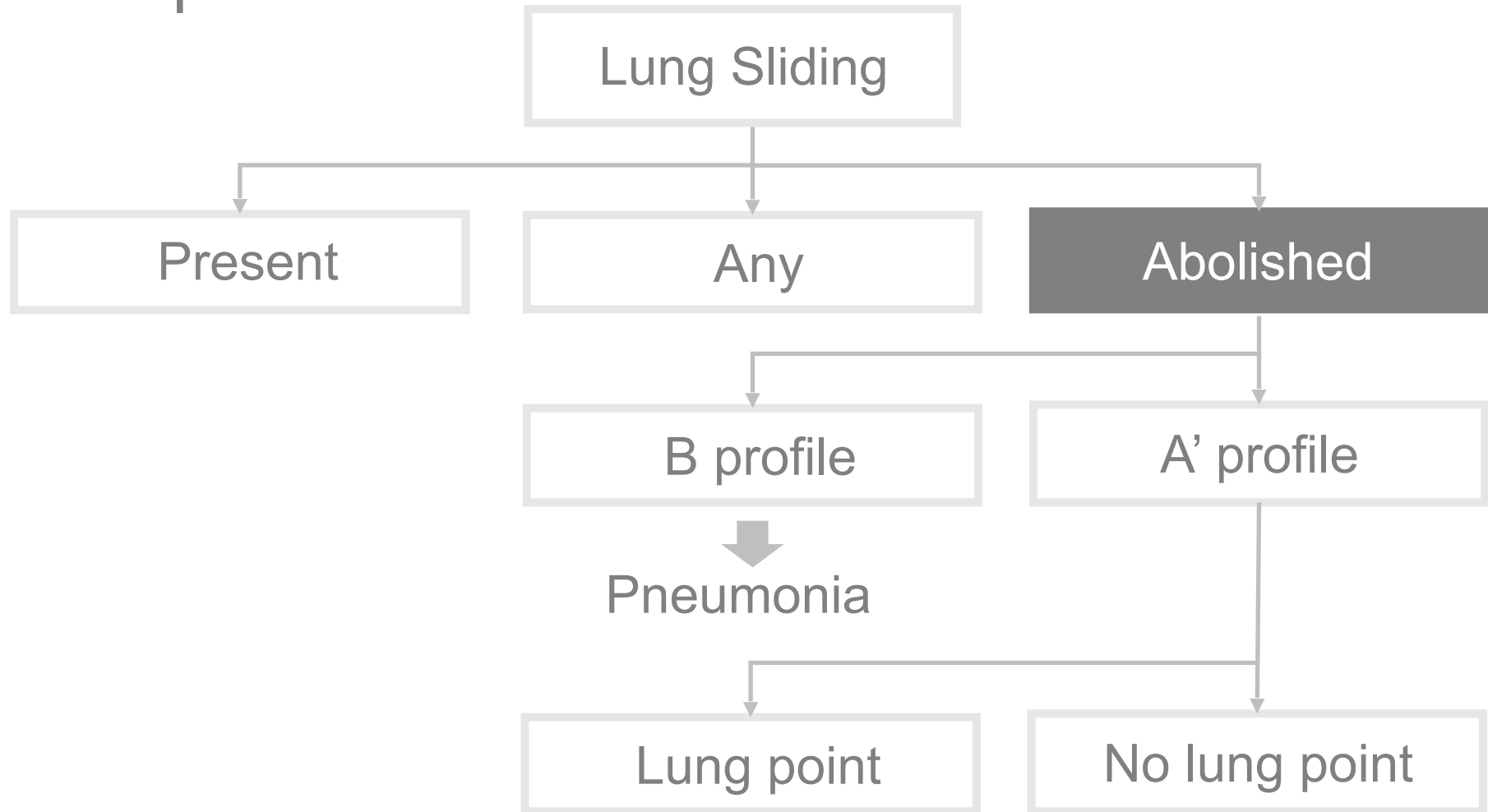
BLUE protocol



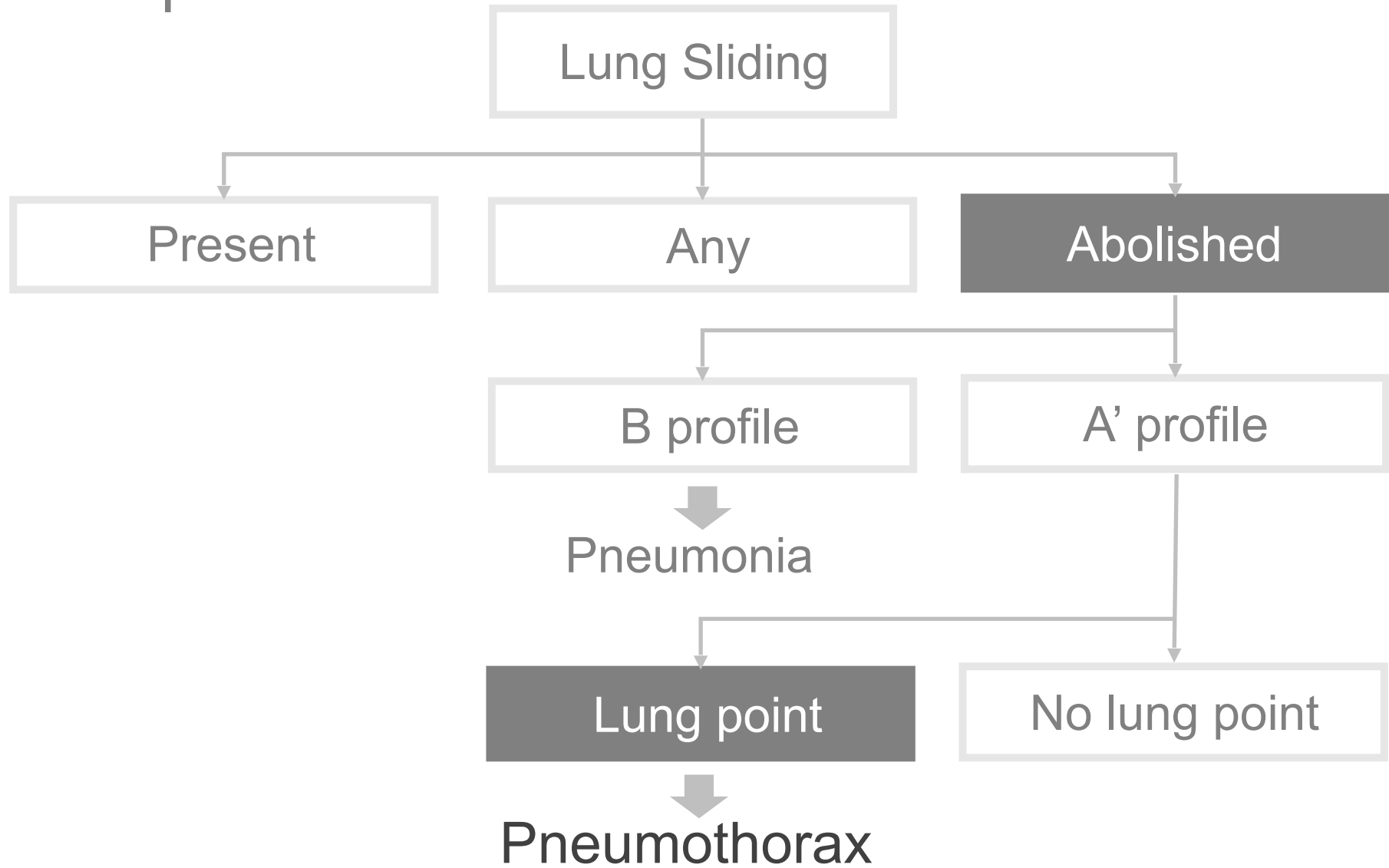
BLUE protocol



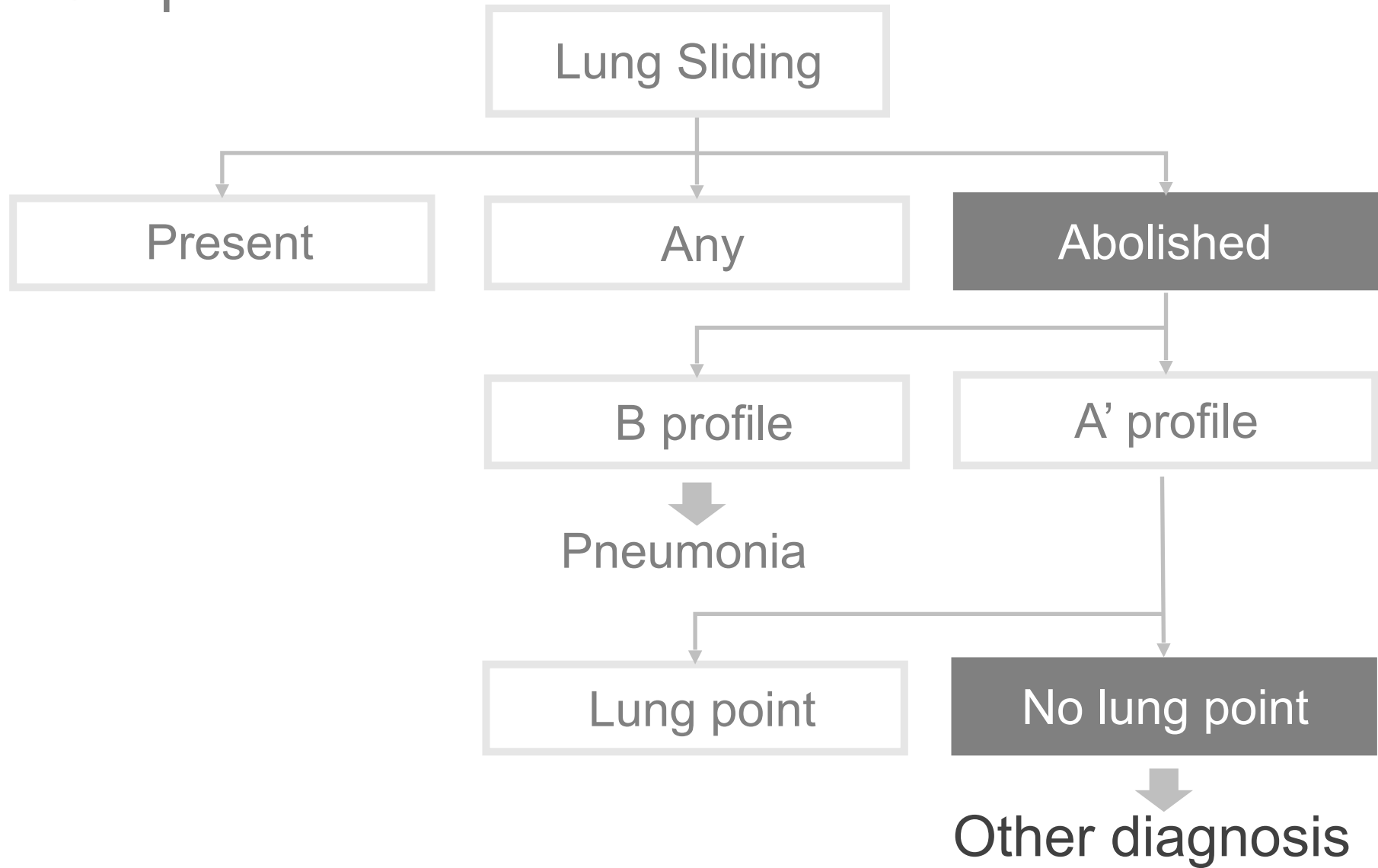
BLUE protocol

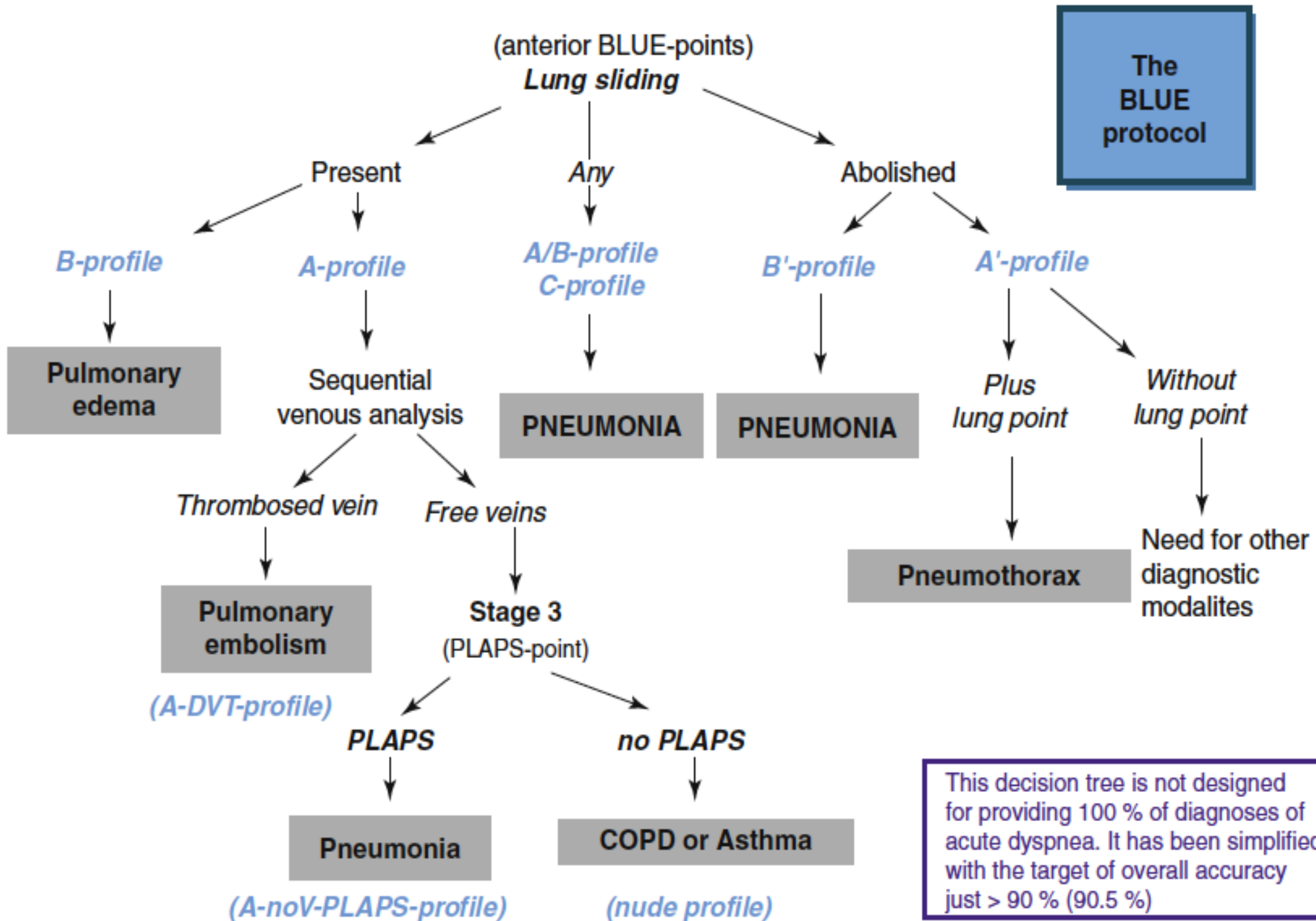


BLUE protocol



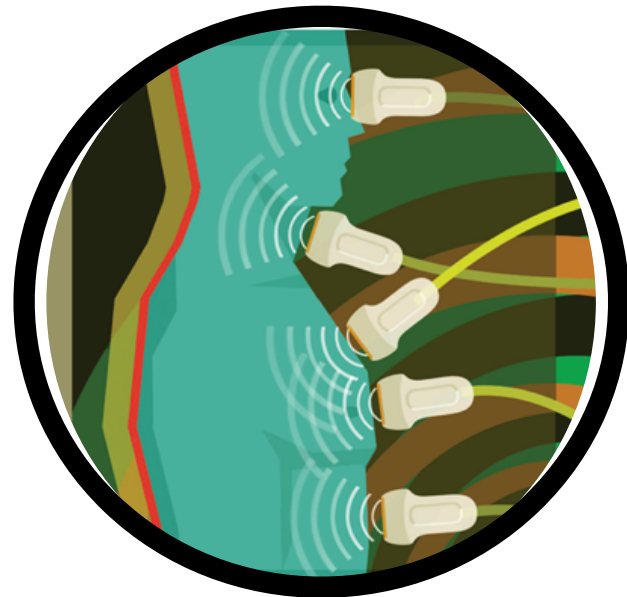
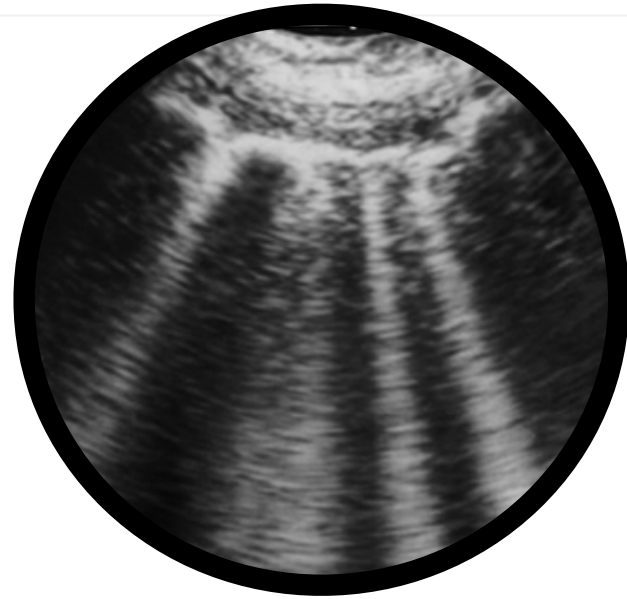
BLUE protocol





This decision tree is not designed for providing 100 % of diagnoses of acute dyspnea. It has been simplified with the target of overall accuracy just > 90 % (90.5 %)

SUMMARY



Thanks for your attention



E-mail: tangtang05231980@hotmail.com

Jen-Tang, Sun MD
Department of emergency medicine,
Far East Memorial Hospital