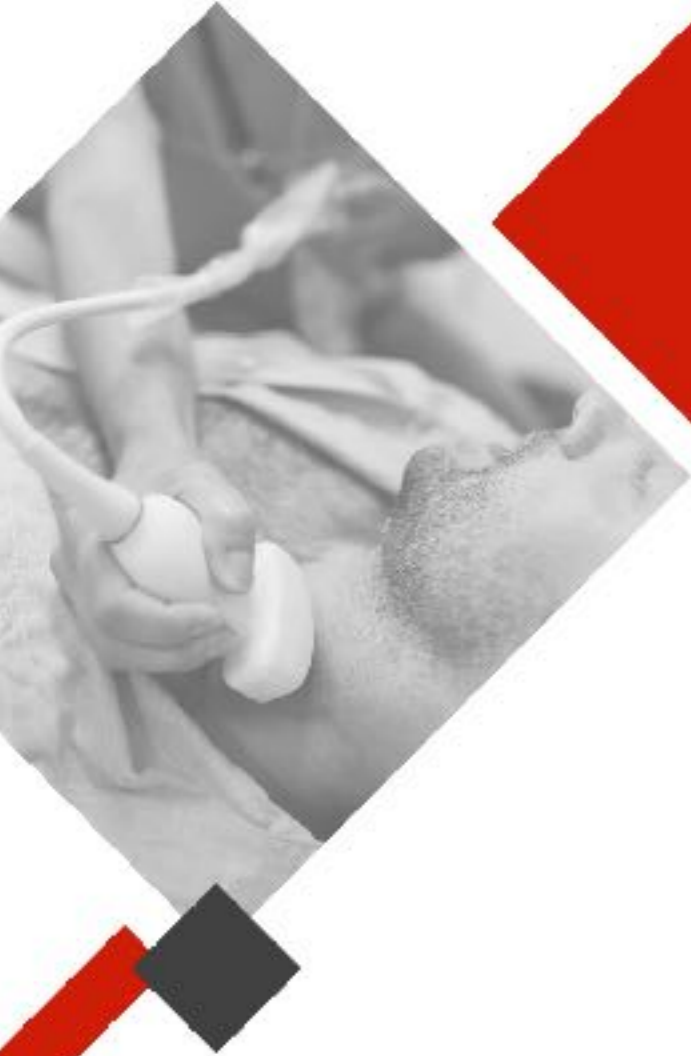



ULTRASOUND
PROGRAM



POCUS

急重症超音波應用

陳國智醫師 西園急診

POCUS

Ultrasound in Med. & Biol., Vol. ■, No. ■, pp. 1–10, 2016
Copyright © 2016 World Federation for Ultrasound in Medicine & Biology
Printed in the USA. All rights reserved
0301-5629/\$ - see front matter



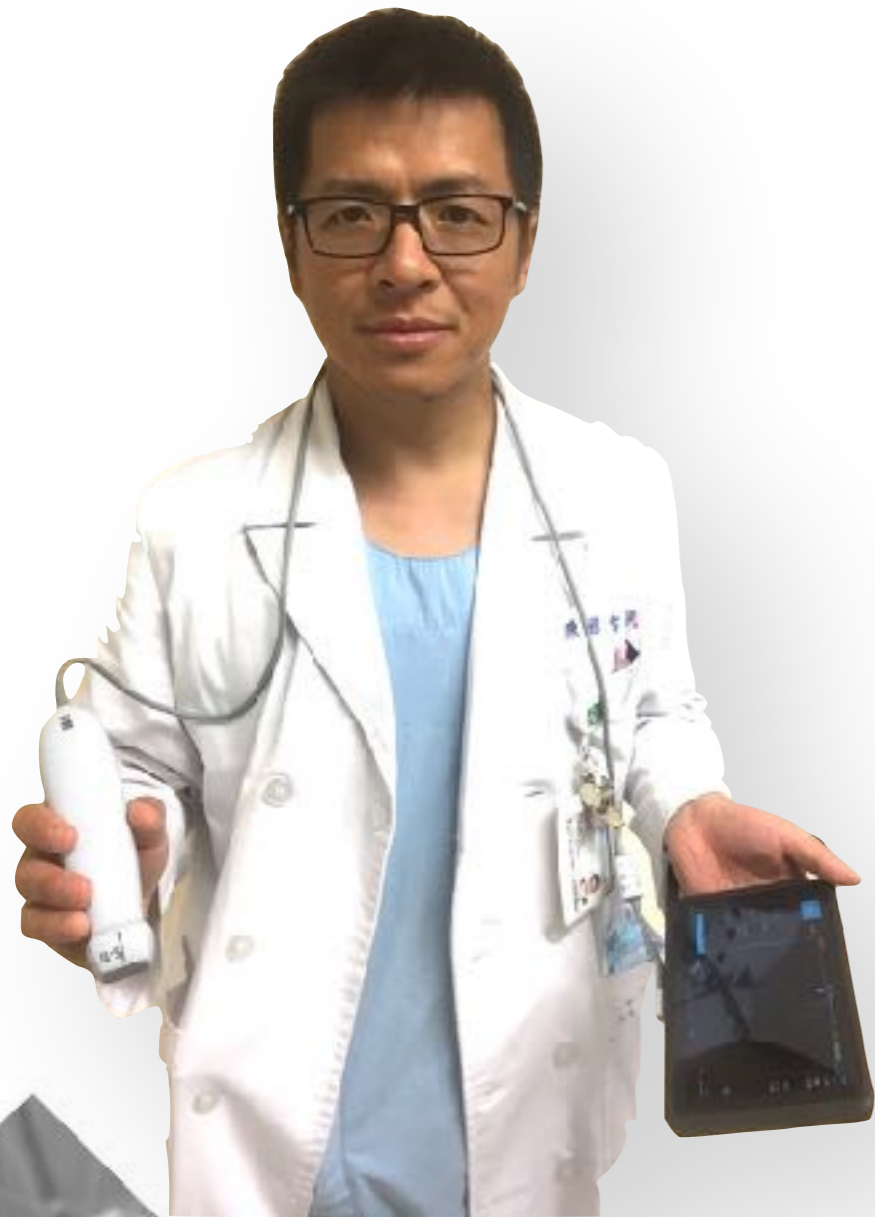ELSEVIER

<http://dx.doi.org/10.1016/j.ultrasmedbio.2016.06.021>

POINT OF CARE ULTRASOUND: A WFUMB POSITION PAPER

CHRISTOPH F. DIETRICH,^{*†} ADRIAN GOUDIE,[‡] LILIANA CHIOREAN,[§] XIN WU CUI,^{*†} ODD HELGE GILJA,[¶]
YI DONG,^{*||} JACQUES S. ABRAMOWICZ,[#] SUDHIR VINAYAK,^{**} SUSAN CAMPBELL WESTERWAY,^{††}
CHRISTIAN PÁLLSON NOLSØE,^{‡‡} YI-HONG CHOU,^{§§} and MICHAEL BLAIVAS^{¶¶}





急救加護重症超音波工作坊負責人
AEACUS Network President
前急診超音波委員會主委

Faculty

-WINFOCUS, PERCUSS, WFPICC

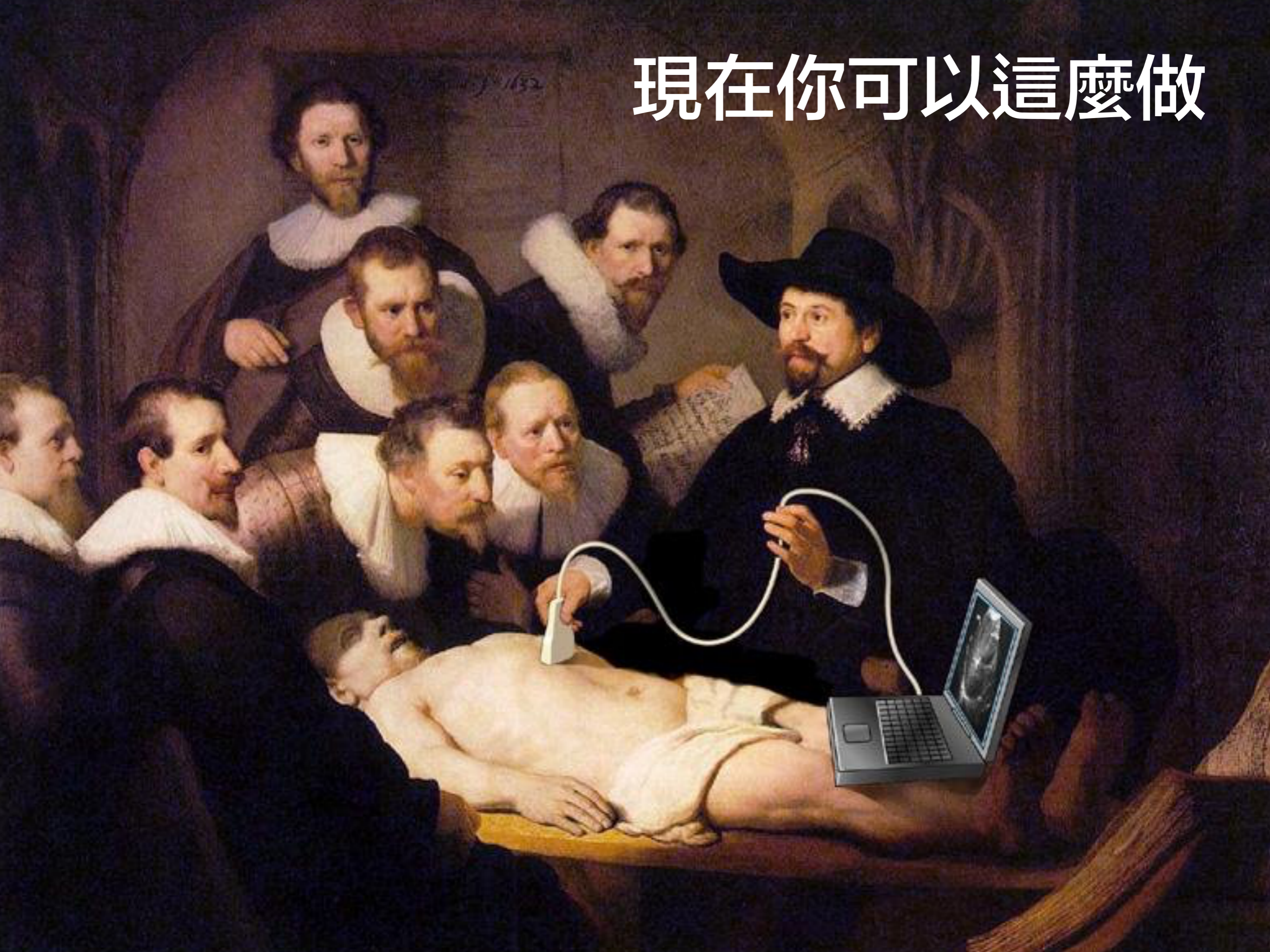
POCUS Academy

Emergency Ultrasound Training Center

The Anatomy Lesson of Dr. Nicolaes Tulp
How Our Muscles Work
林布蘭 1632



現在你可以這麼做

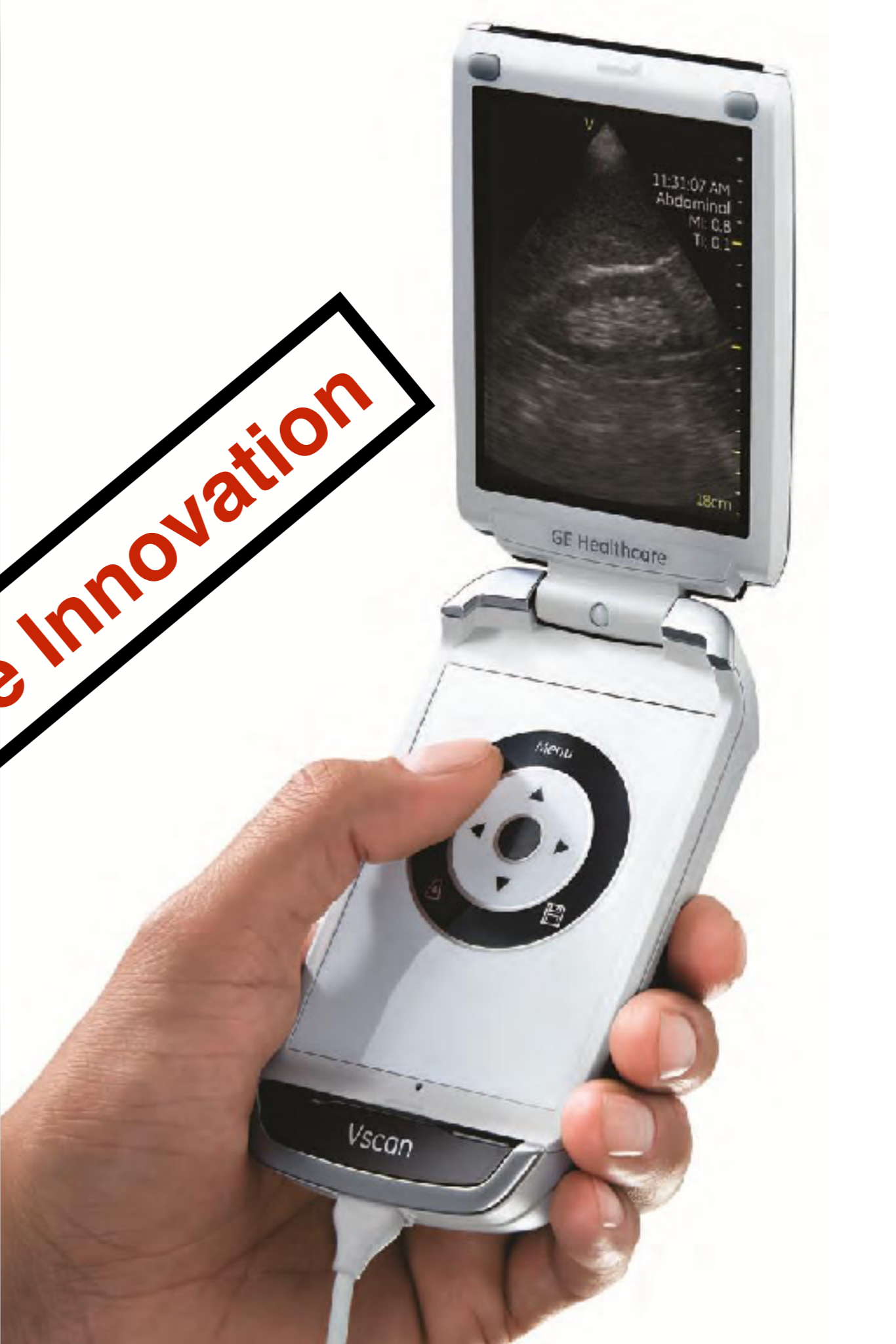
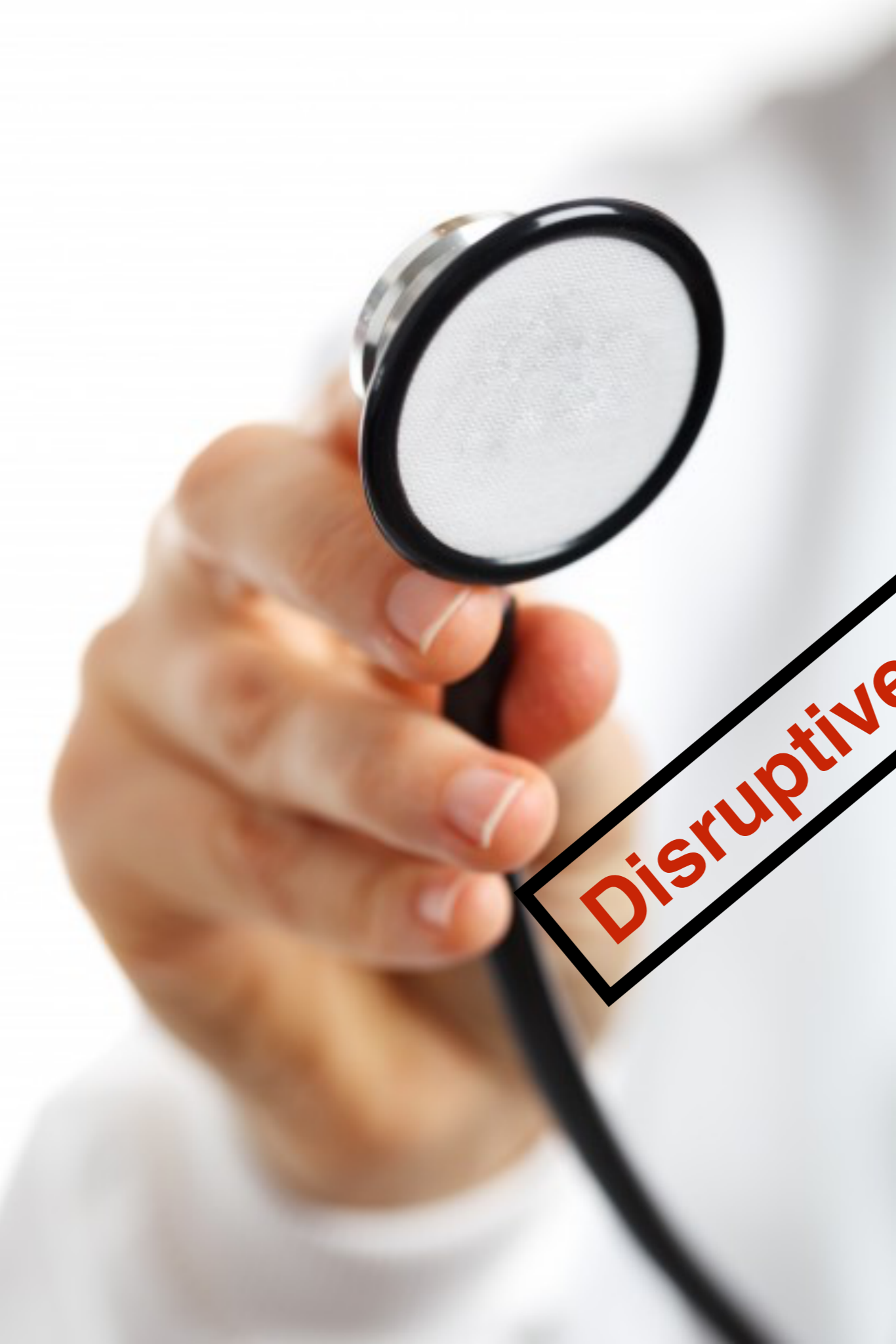
POCUS

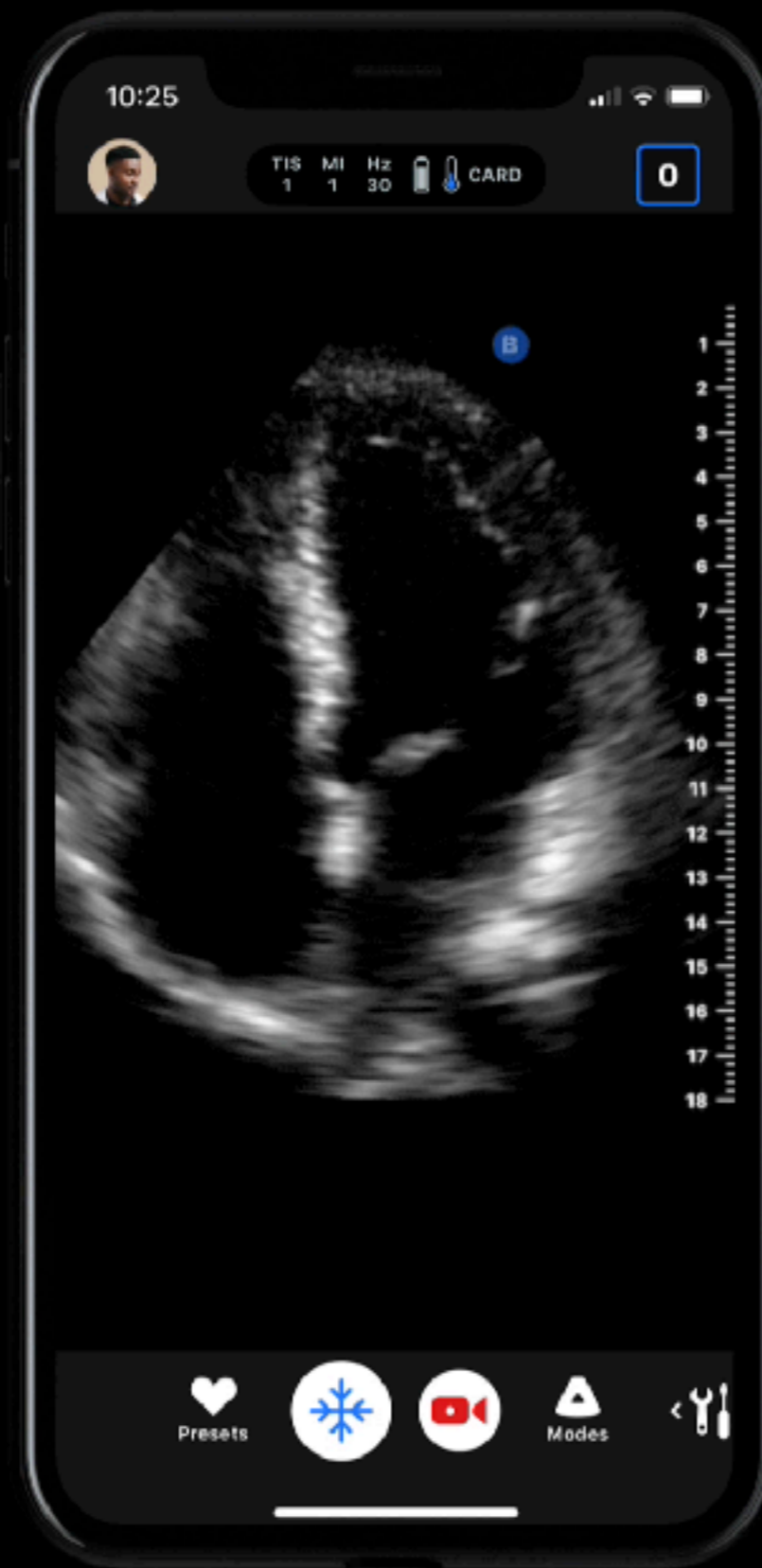Point-of-Care Ultrasound

“ultrasonography brought to
the patient and performed by
the provider in real time”


Moore, C. L., & Copel, J. A. NEJM 2011



Disruptive Innovation



Butterfly iQ



POCUS-急診緣由

症狀
問題

線索
時間

診斷
治療

雜

少

快



病史詢問

理學檢查



Y

POCUS

N

熟悉操控 6 大技巧

X

Sweep

Fan/
Tilt

Y

Slide

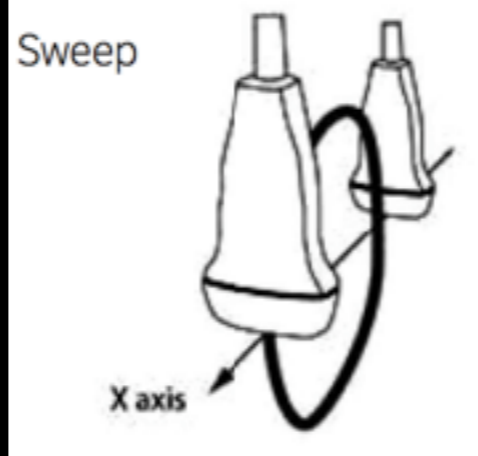
Rock

Z

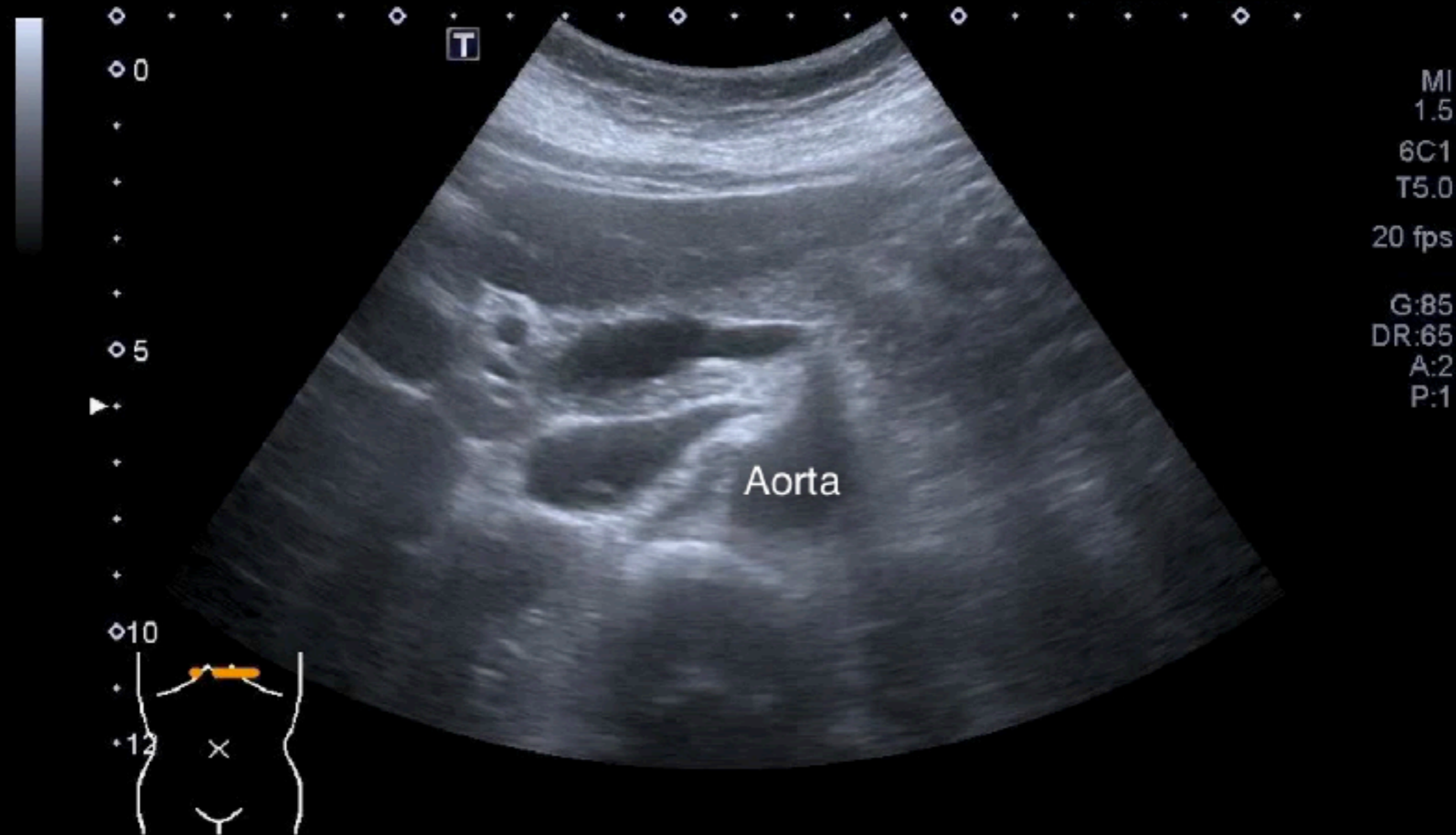Rotate

Compress

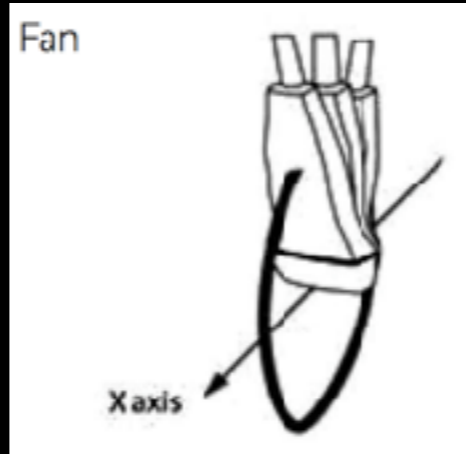
掃



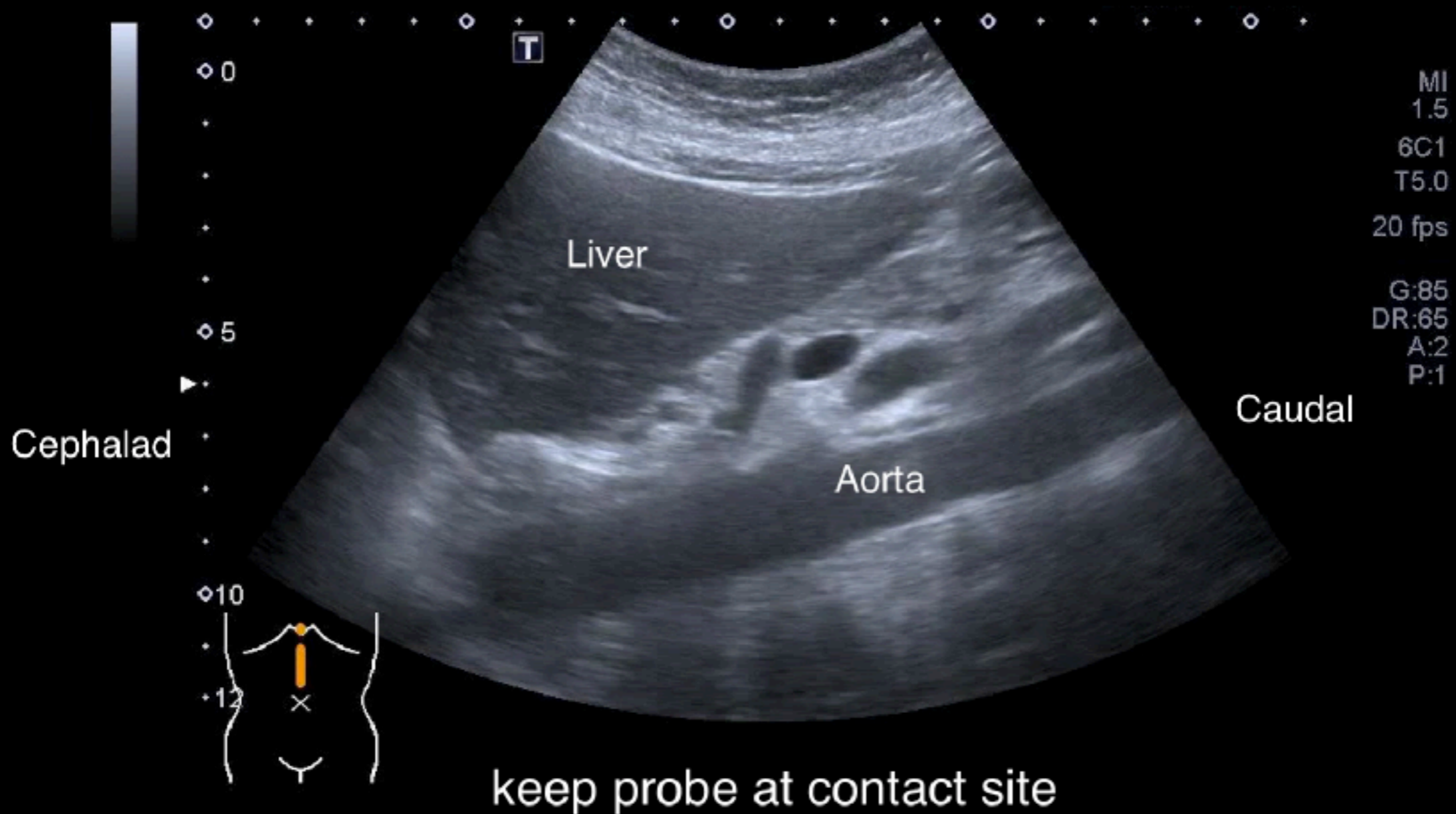Sweep



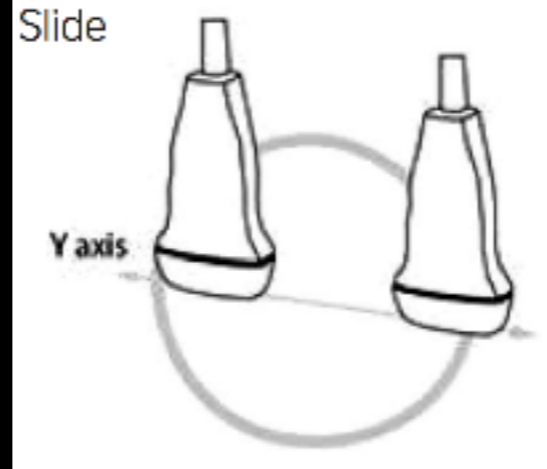
傾



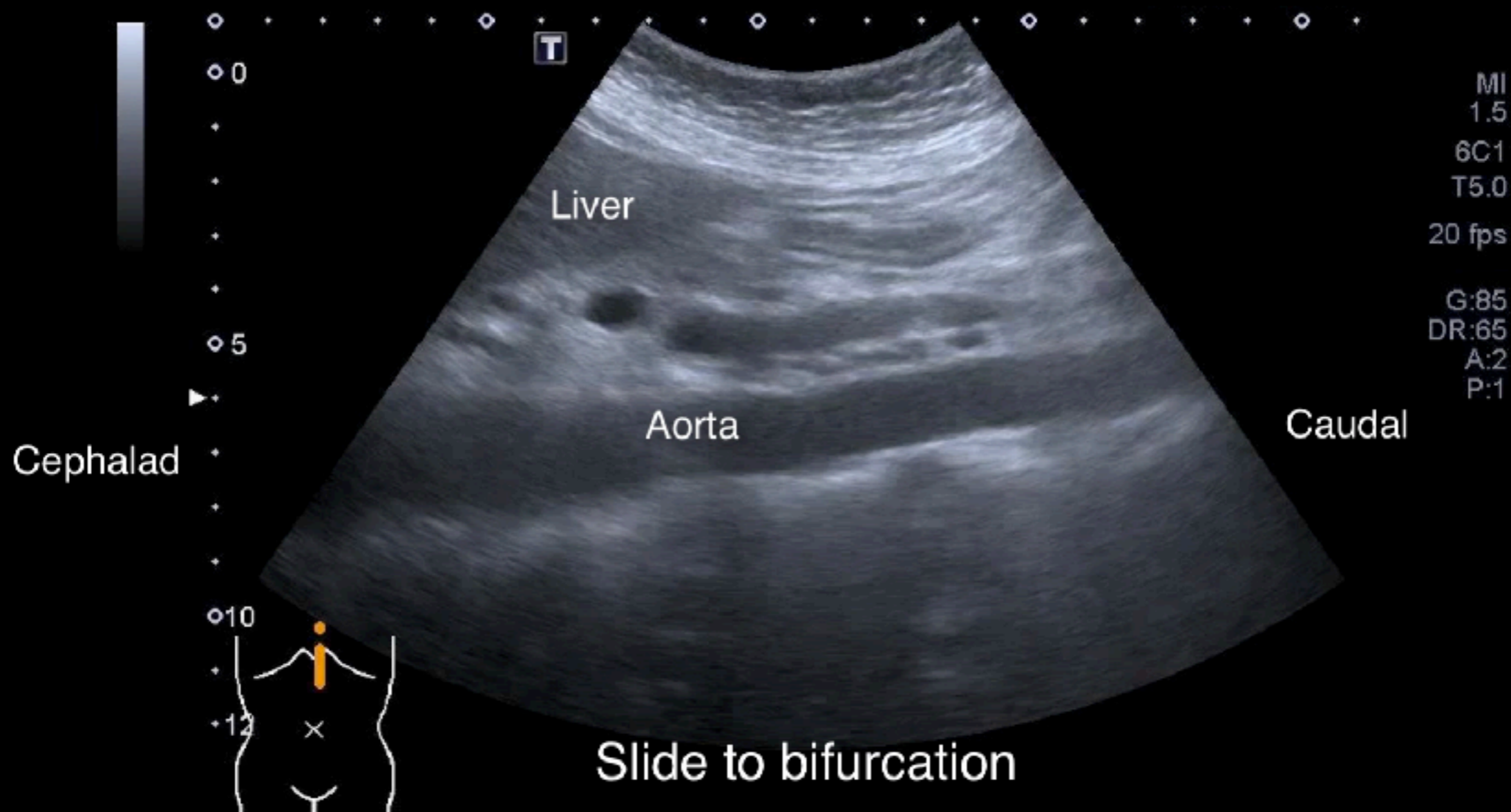
Fan



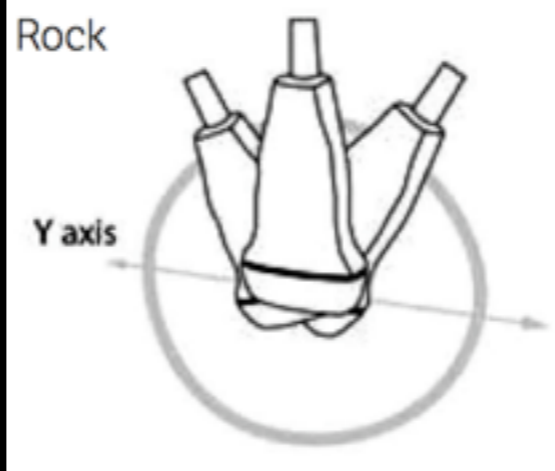
滑



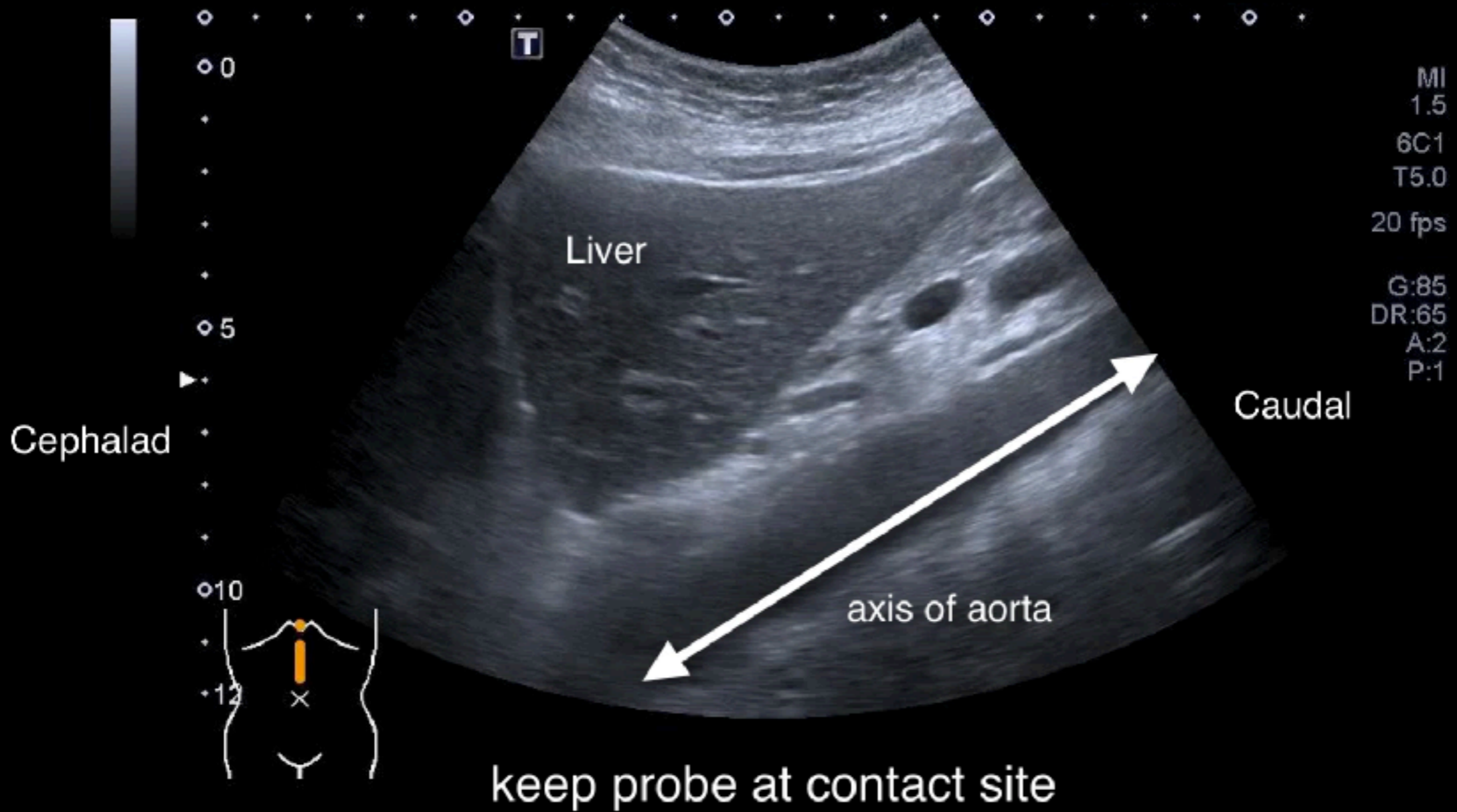
Slide



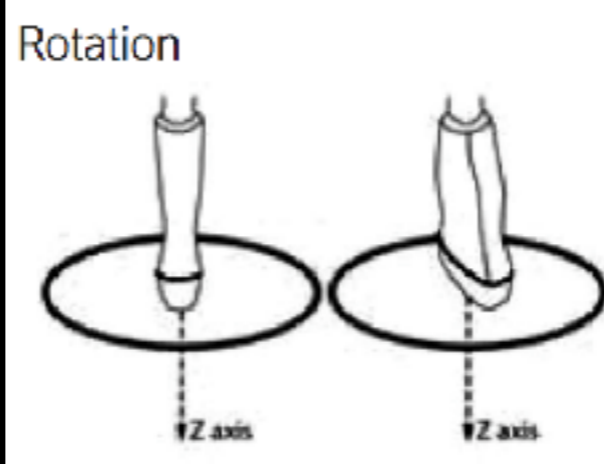
搖



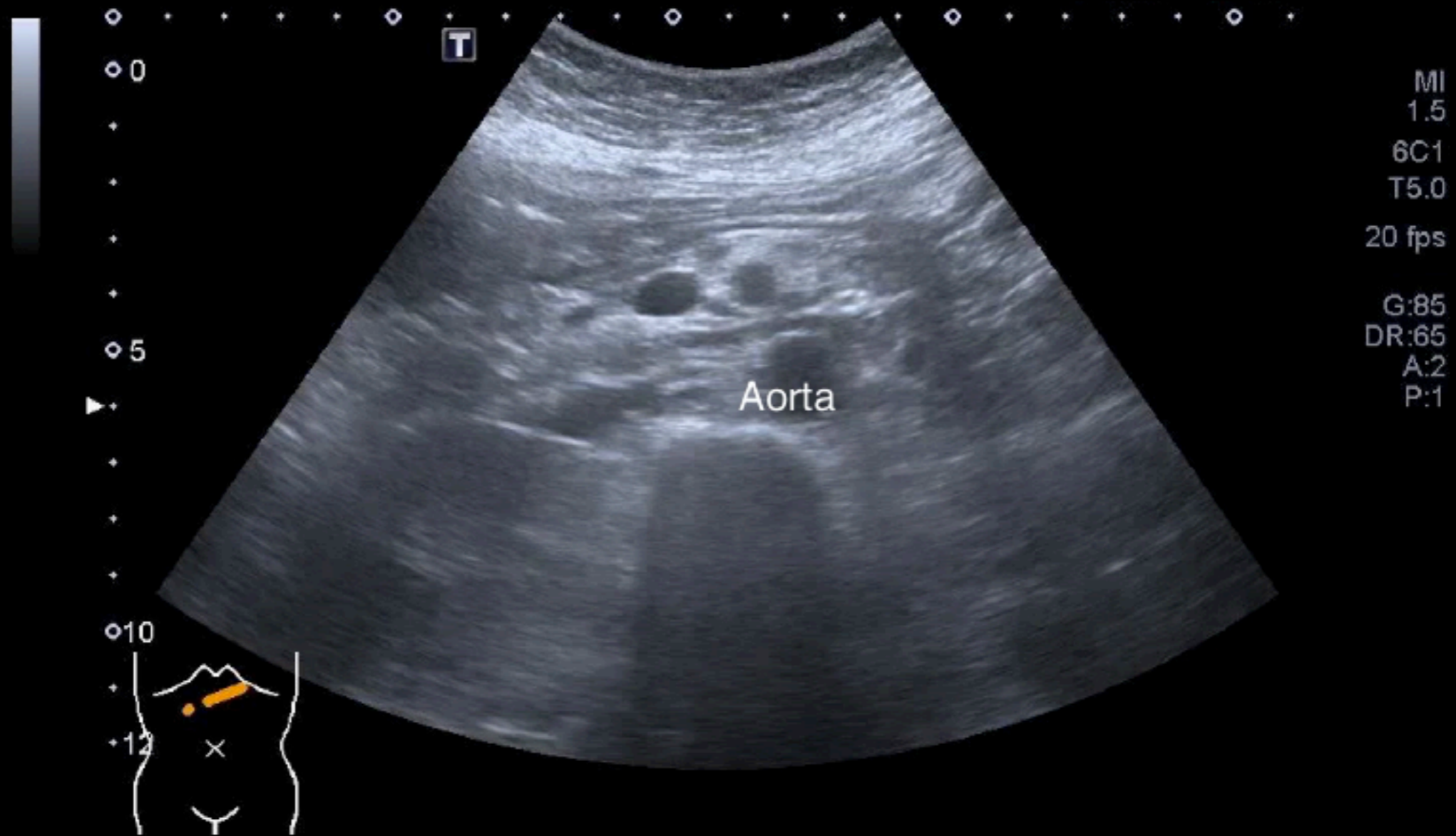Rock



轉

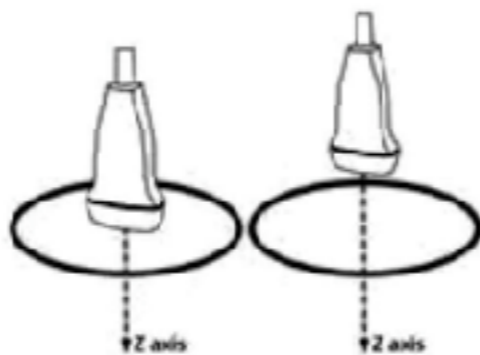


Rotation

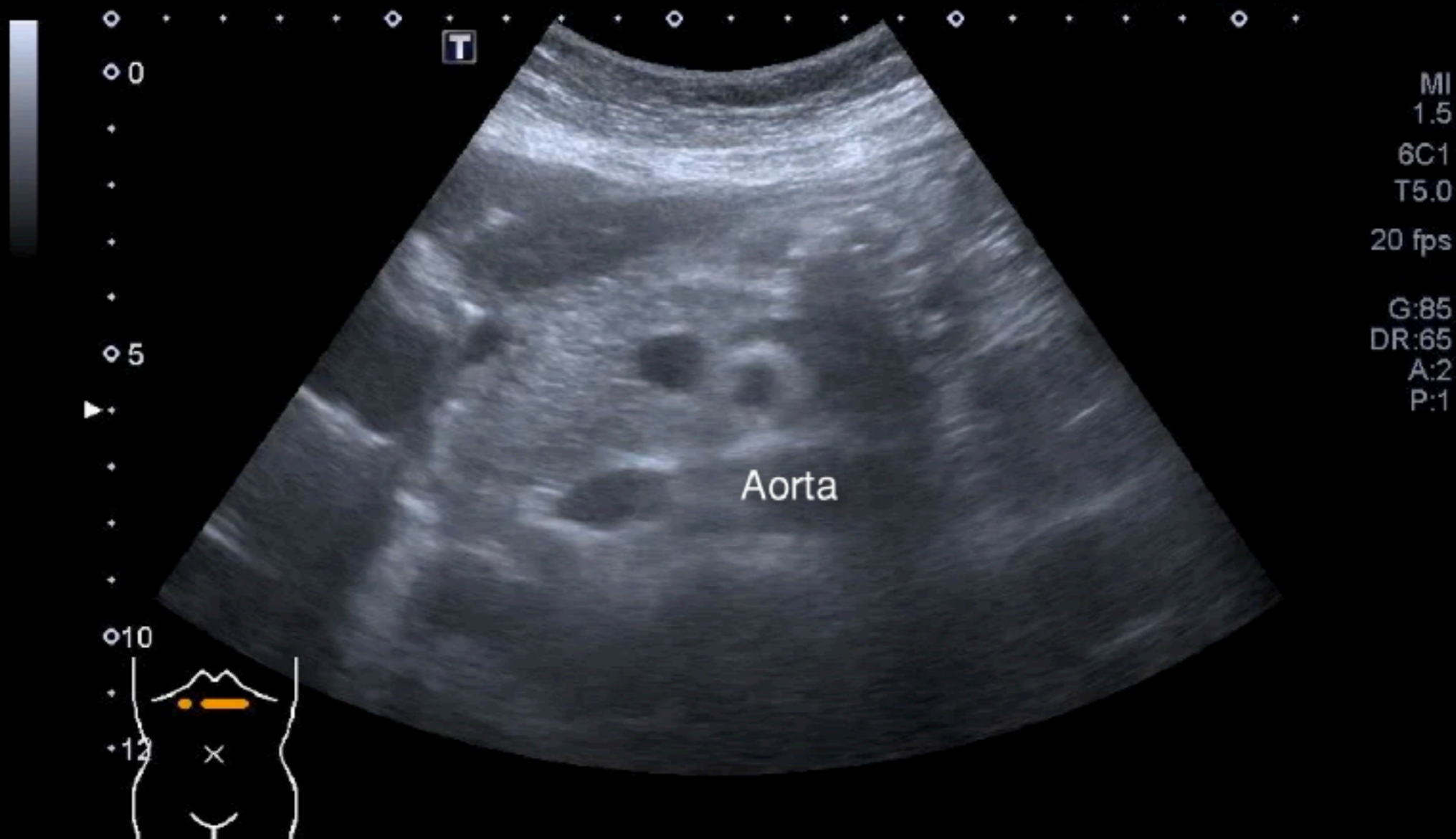


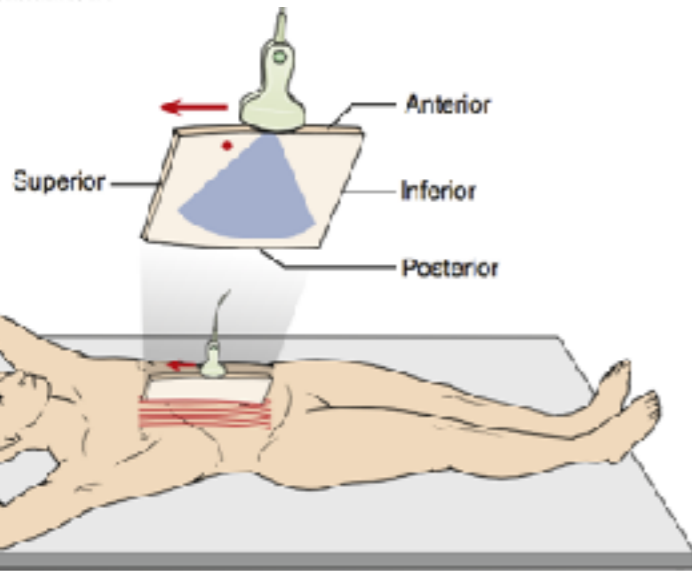
壓

Pressure/compression

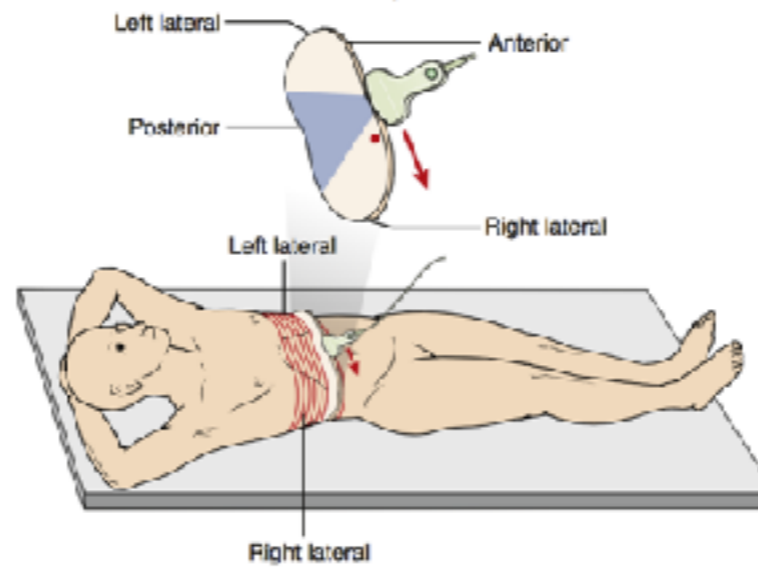


Compression

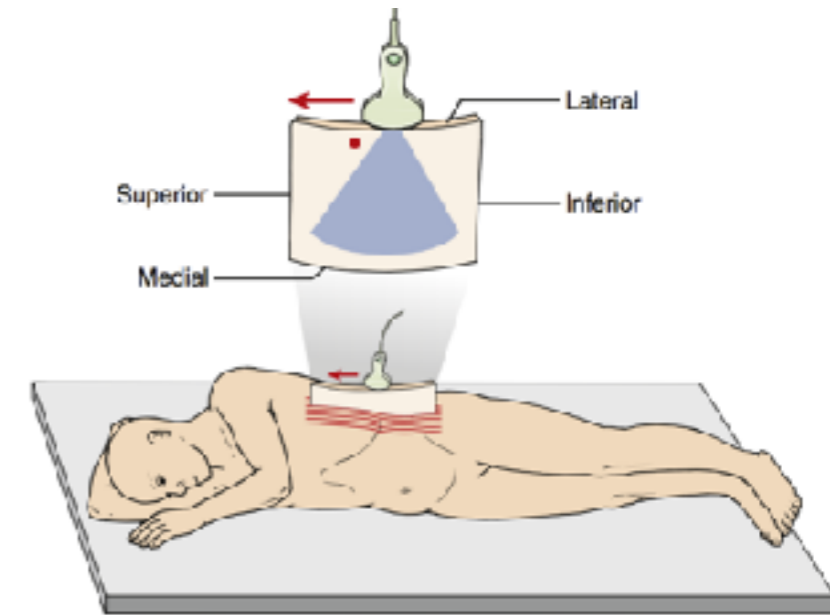




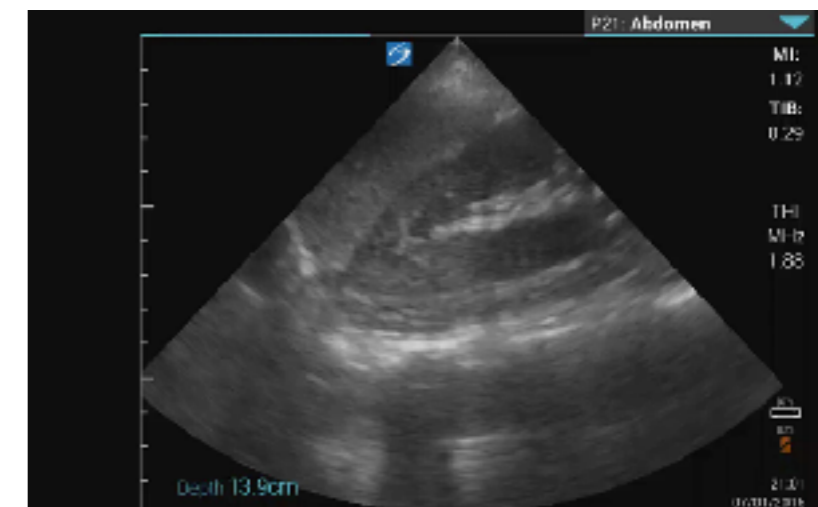
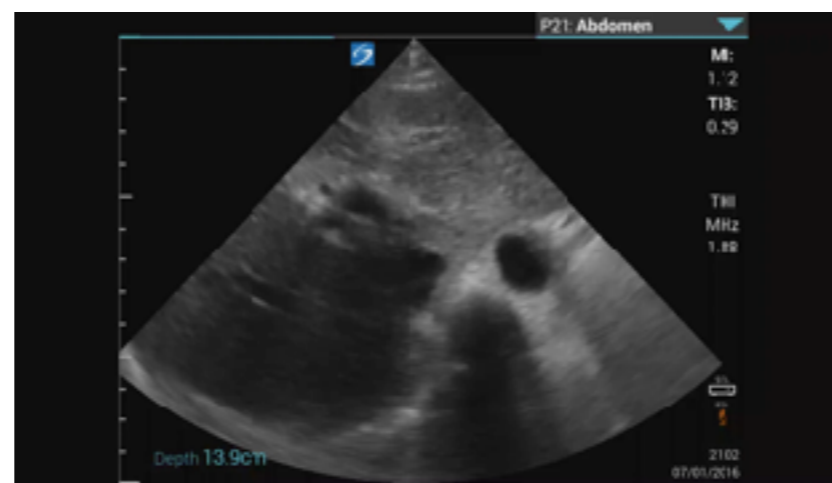
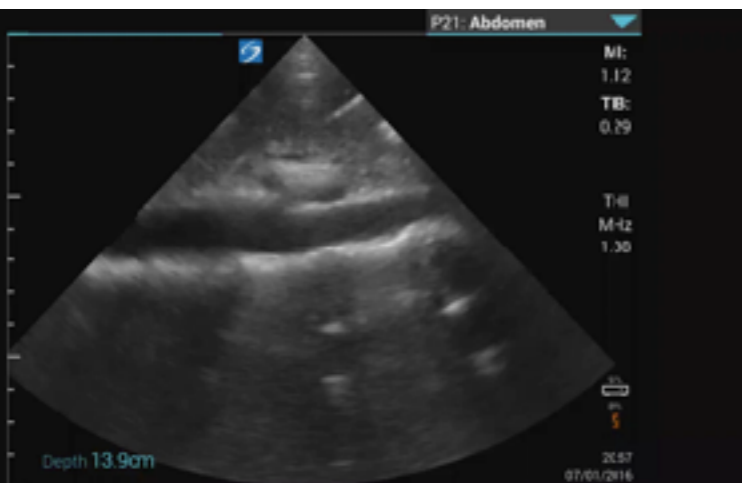Sagittal



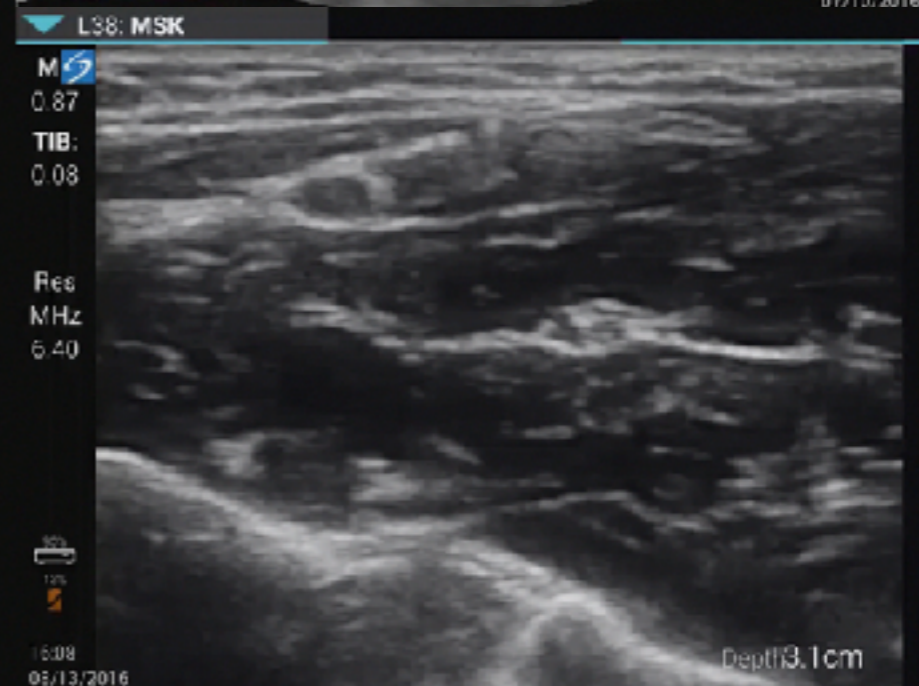
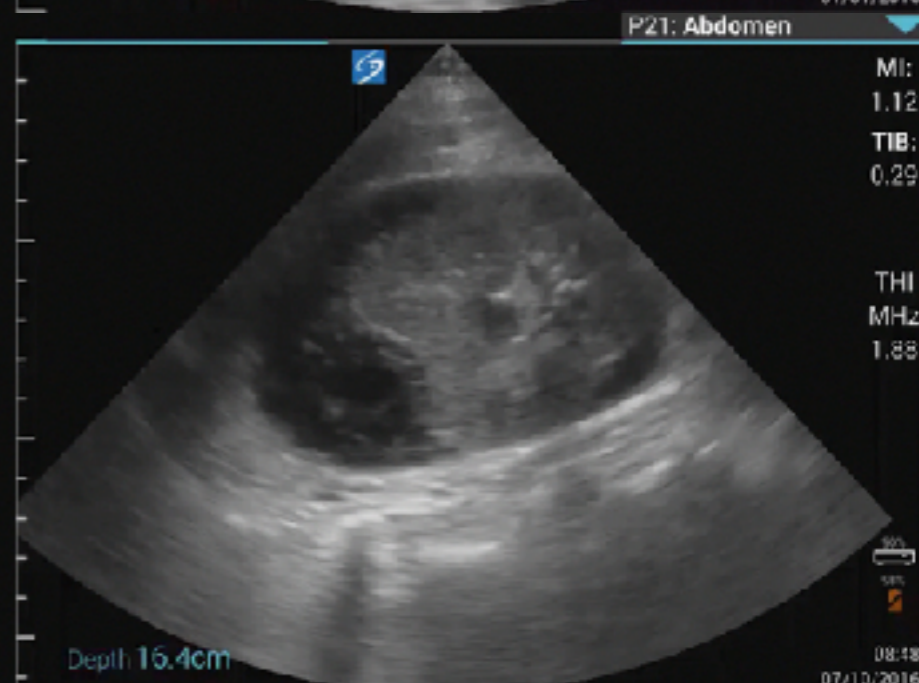
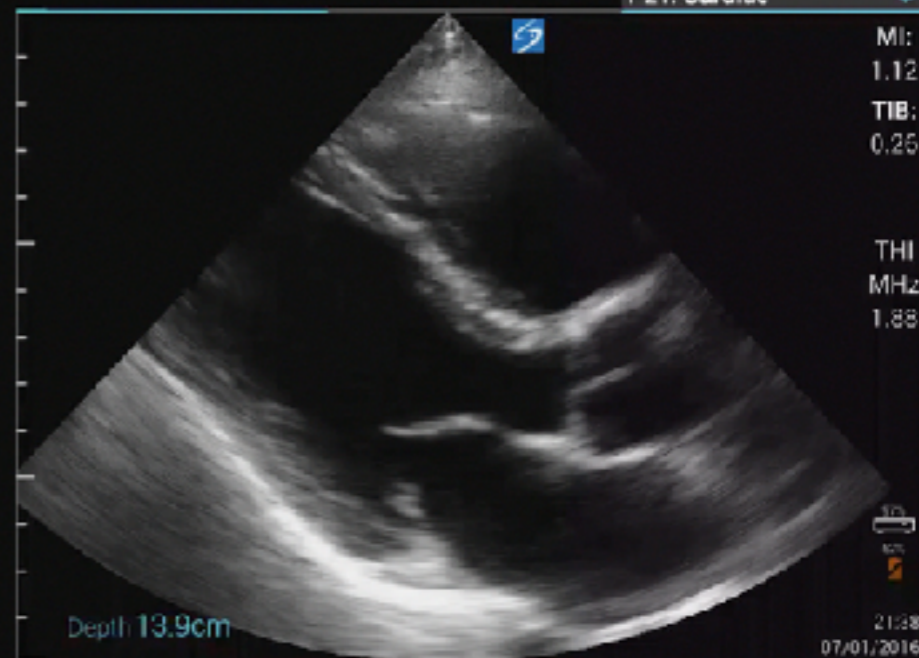
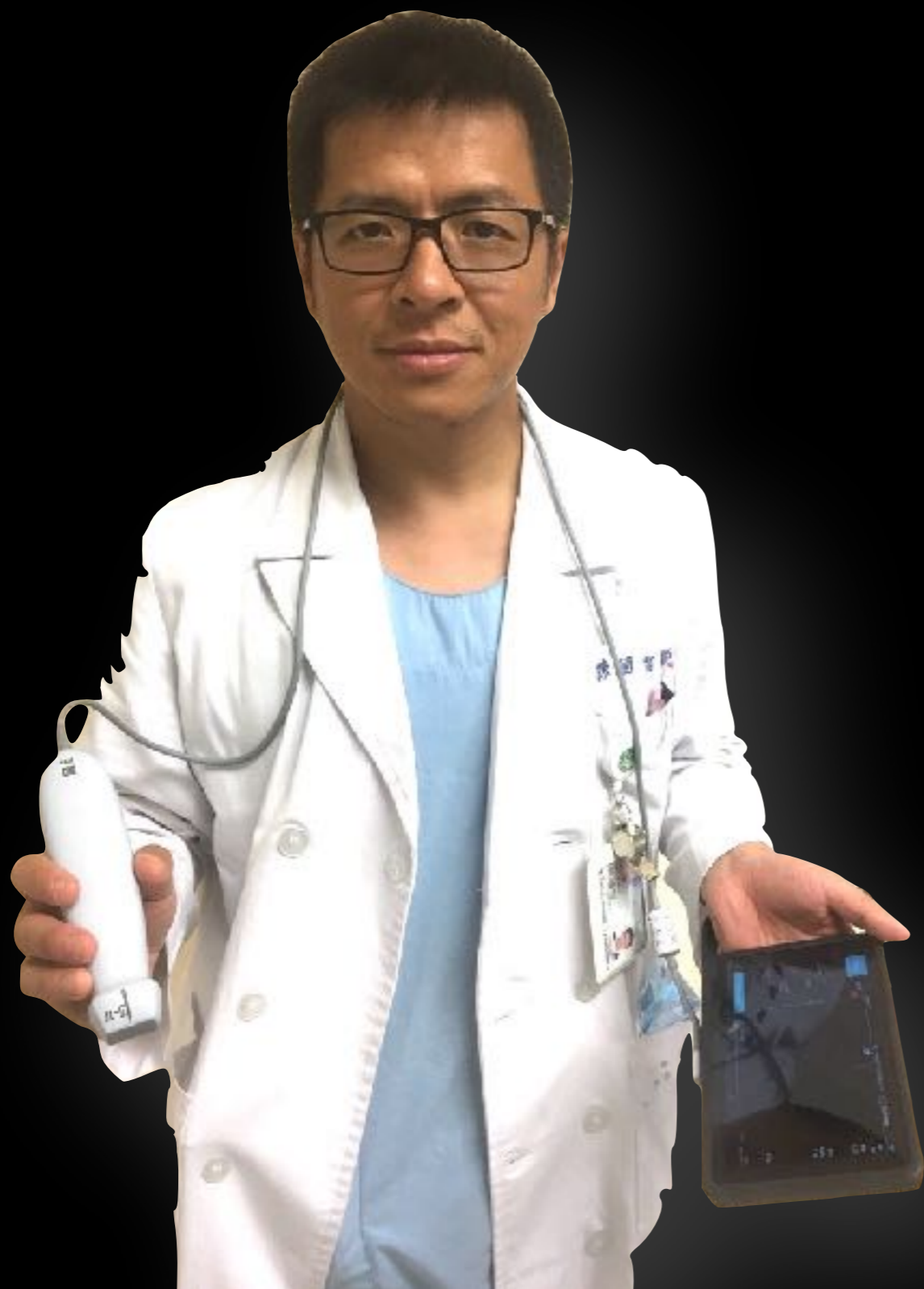
Transverse

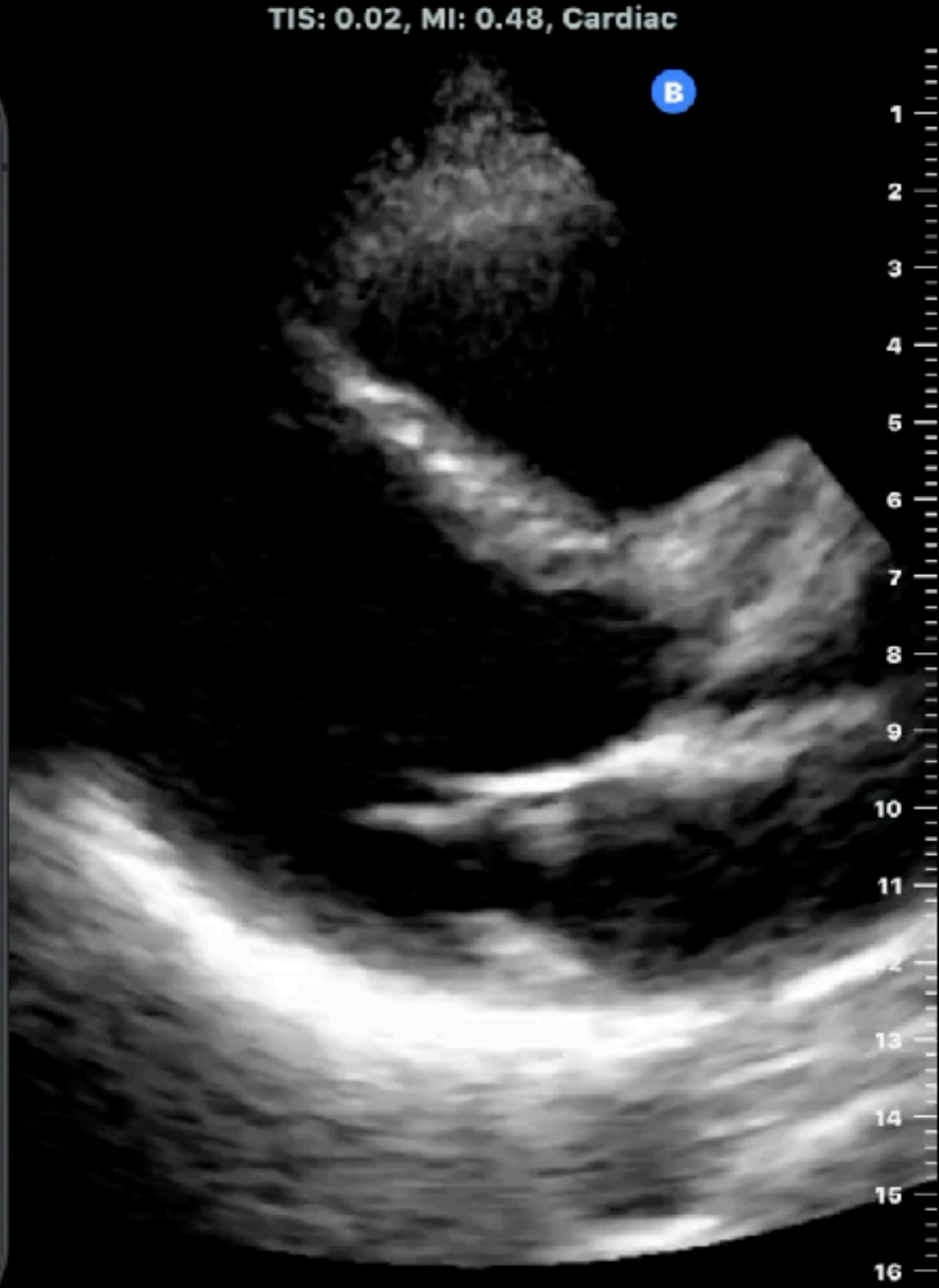
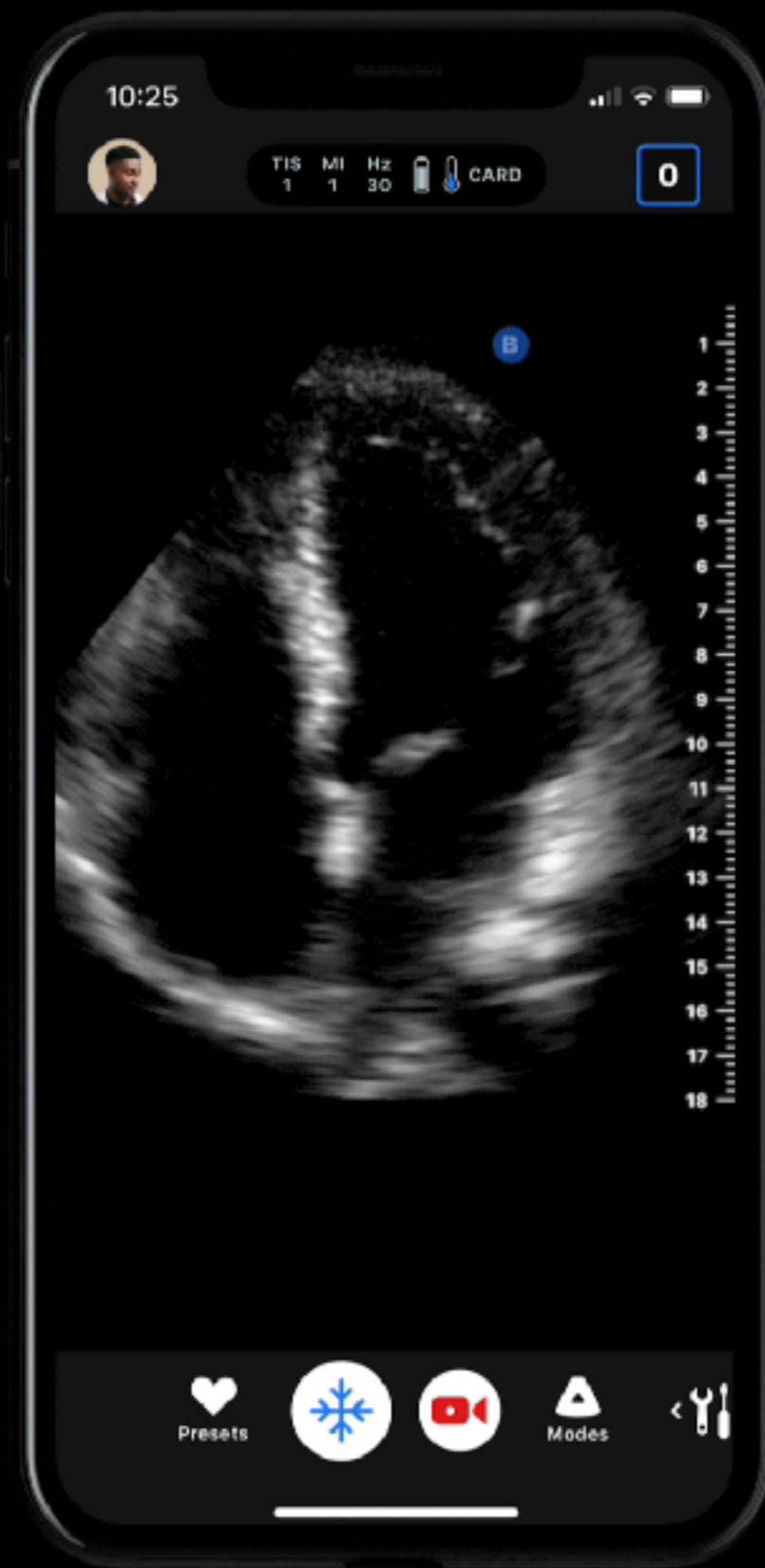

Coronal



設備和能力成反比





I-AIM

Indication



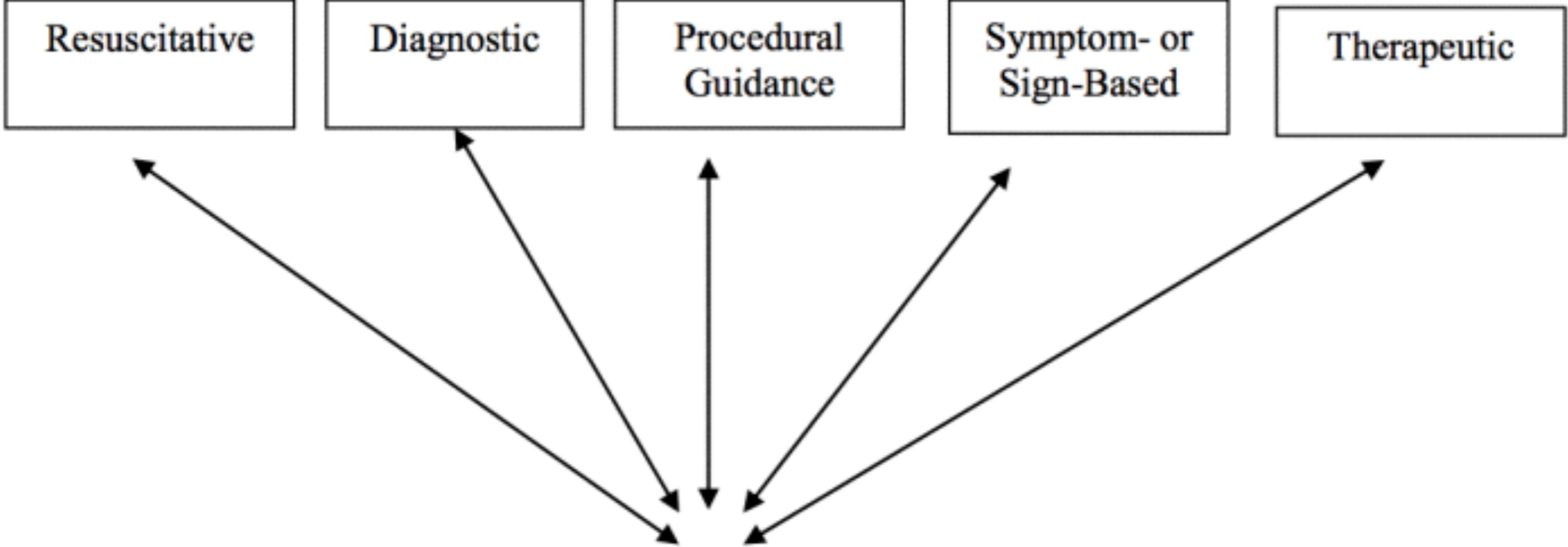
Acquire



Interpret



**Make
decision**



- Core Applications
Trauma
Intrauterine Pregnancy
AAA
Cardiac/HD Assessment
Biliary
Urinary Tract
DVT
Soft-tissue/Musculoskeletal
Thoracic/Airway
Ocular
Bowel
Procedural Guidance

**ACEP
2016**

POCUS for better Airway management

插對了嗎

插不上時

Tracheal tube placement assessment

2015 CPR & ECC guidelines

Continuous waveform Capnography is recommended in addition to clinical assessment as the most reliable method of confirming and monitoring correct placement of an ETT.

(Class I, LOE C-LD)

If continuous waveform capnometry is not available, a nonwaveform CO₂ detector, esophageal detector device, or **ULTRASOUND** used by an experienced operator is a reasonable alternative.

(Class IIa, LOE C-LD)

Systematic Review

TAKE-HOME MESSAGE

During emergency intubations, transtracheal ultrasonography can be used to assess endotracheal tube placement before confirmation with capnography.

Outcome Measure	Sensitivity (95% CI)	Specificity (95% CI)	Number of Studies (Number of Patients)
Pooled data	0.98 (0.97–0.99)	0.98 (0.95–0.99)	11 (969)
Emergency intubations	0.98 (0.97–0.99)	0.94 (0.86–0.98)	8 (713)

CI, Confidence interval.

Dynamic

Fast

Accurate

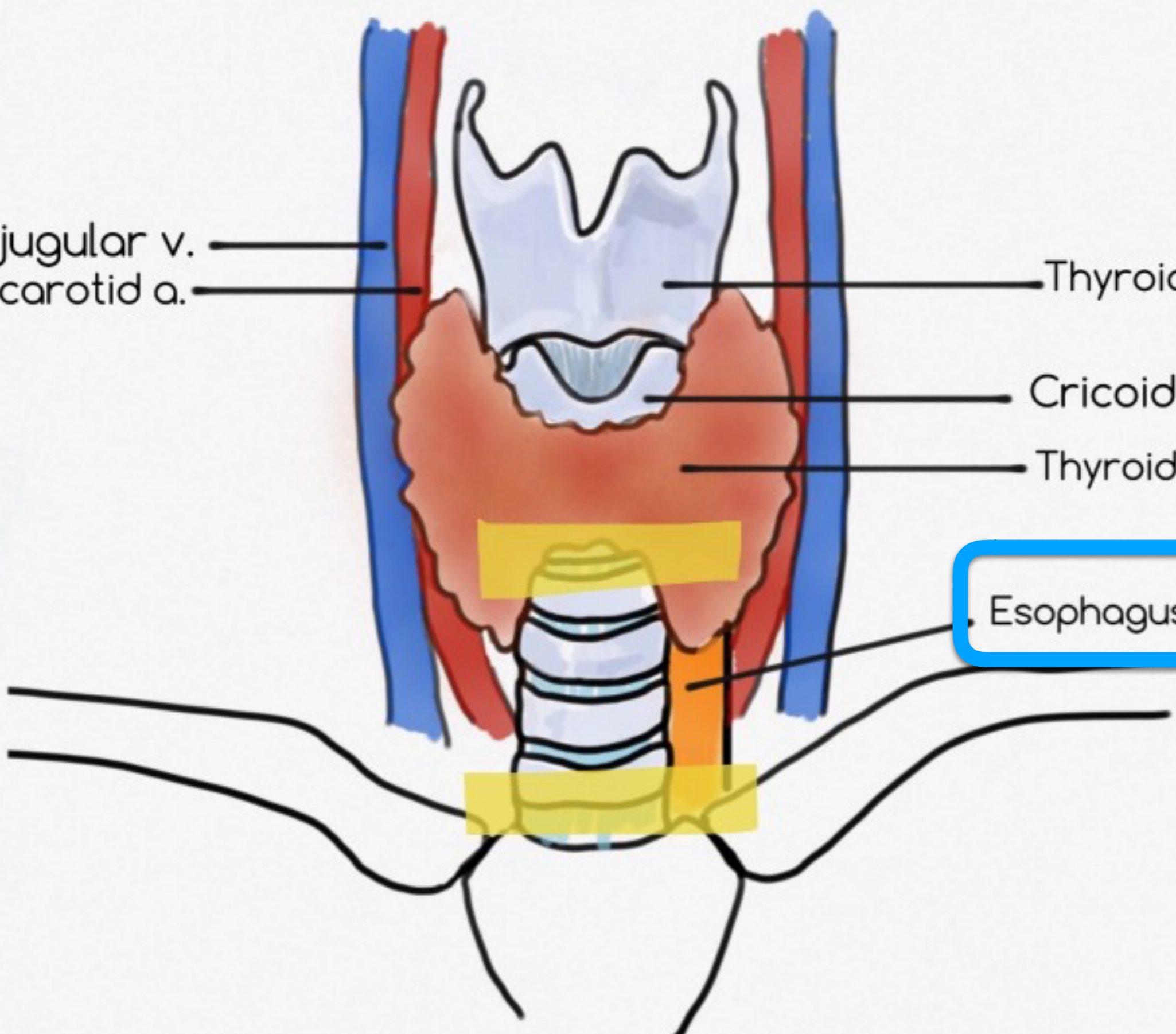
Internal jugular v.
Common carotid a.

Thyroid cartilage


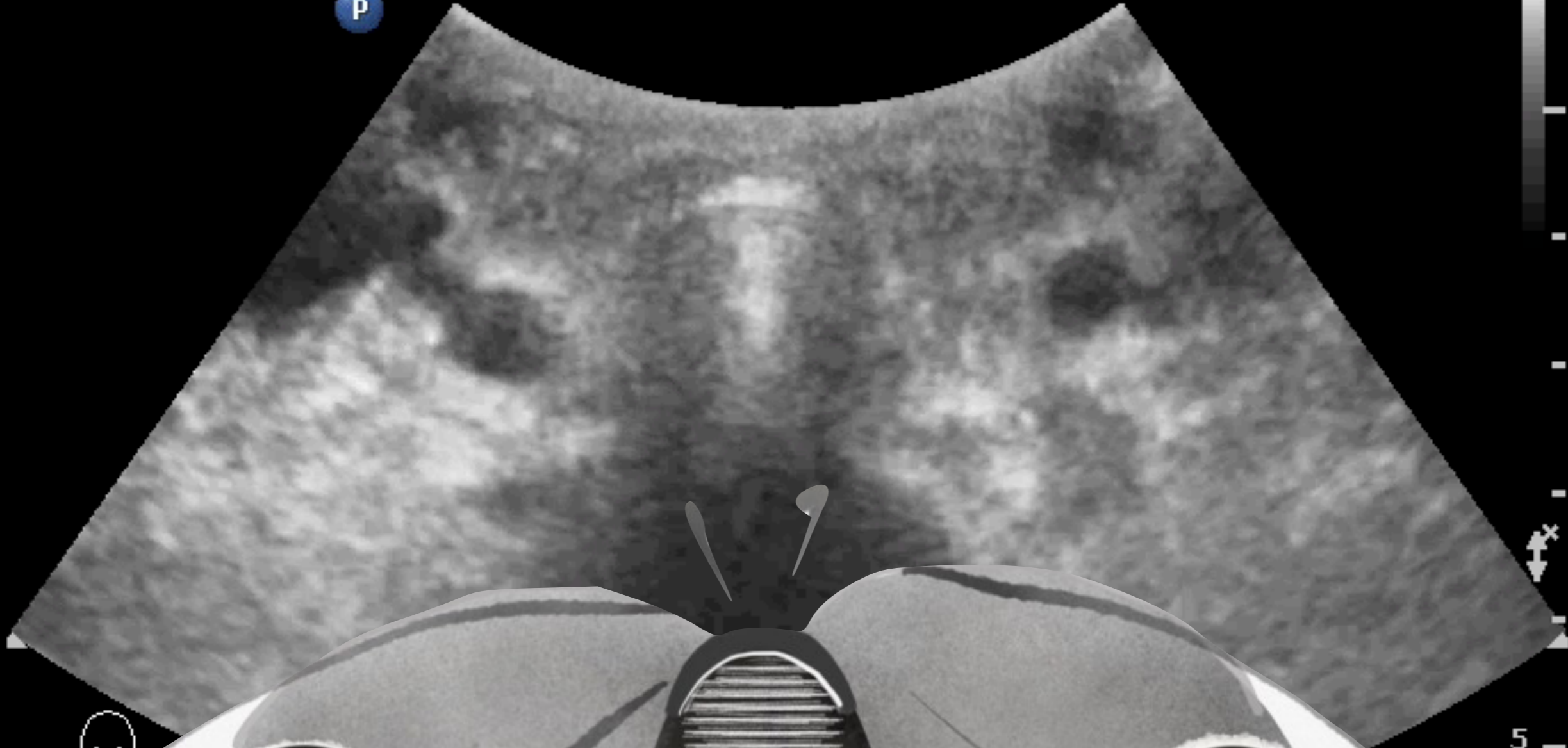
Cricoid cartilage

Thyroid gland

Esophagus



P

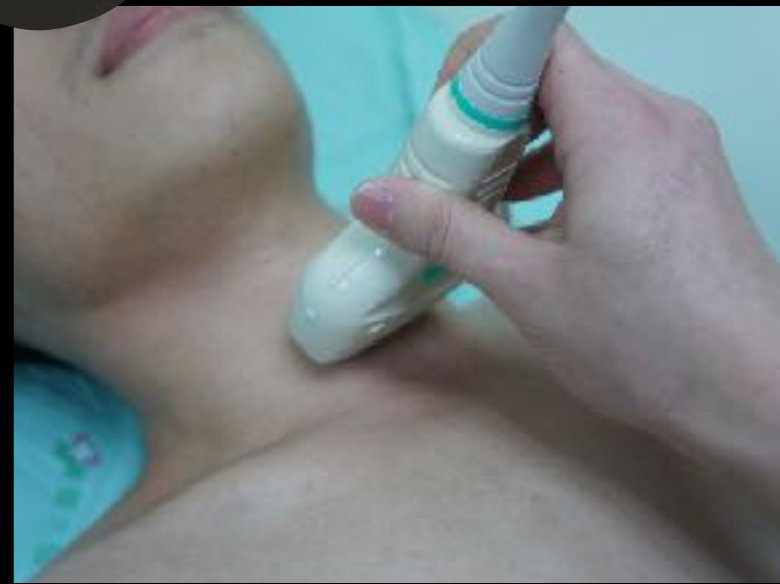

5

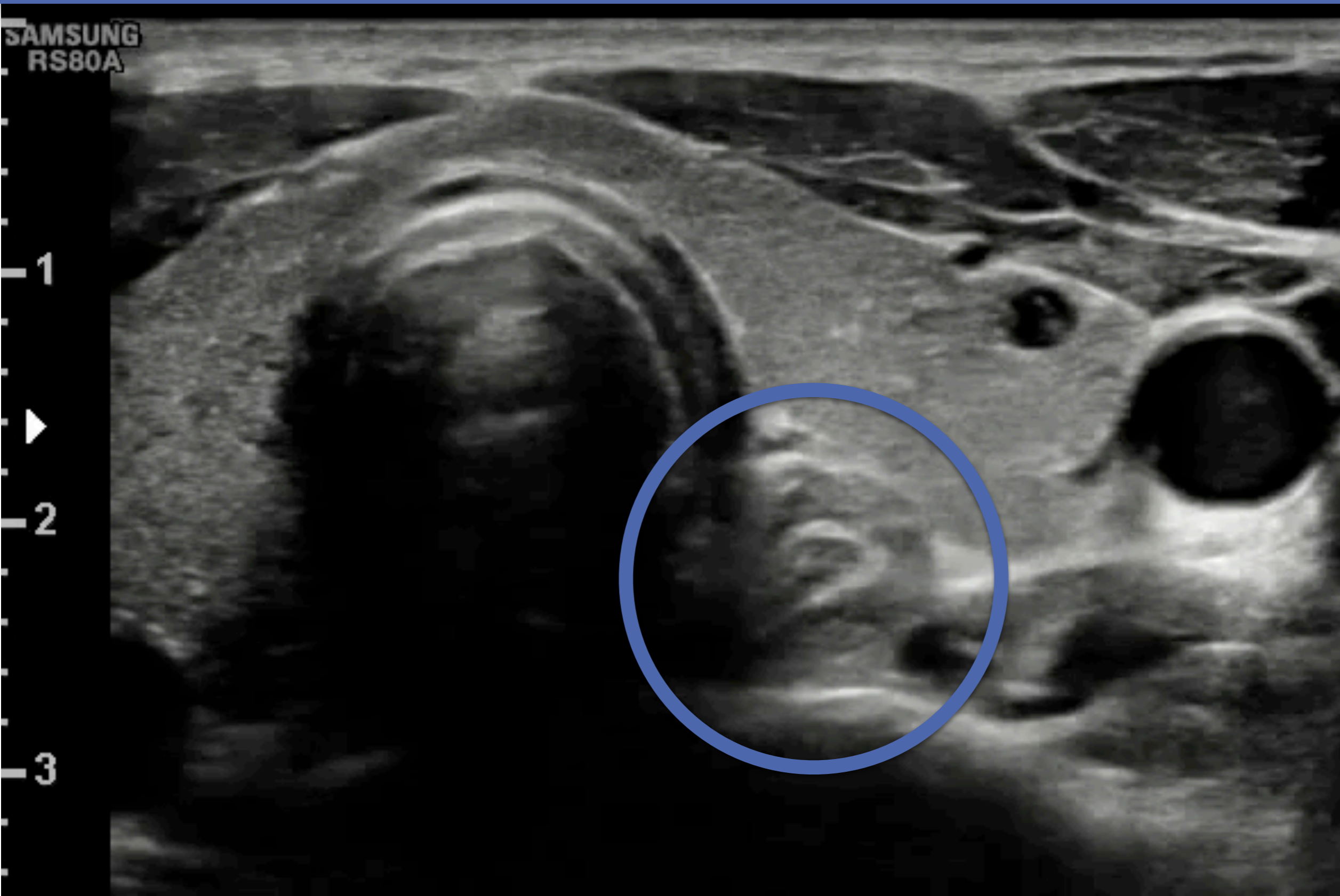
6.0cm



P
1.8 3.6



Find esophagus



Double tract sign ?

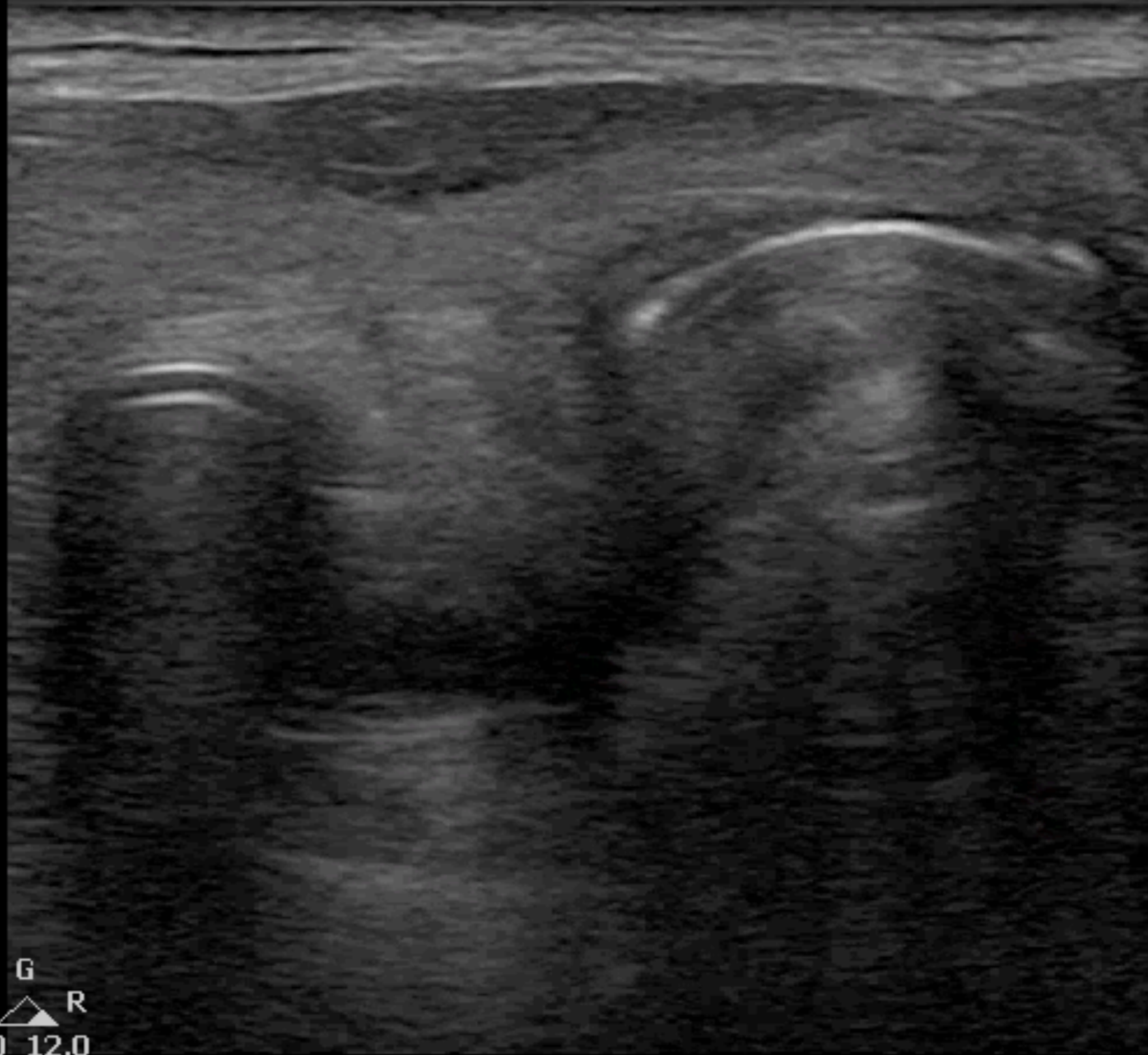
Superficial
L12-3
46 Hz
3.5cm

2D

Res
Gn 60
C 56
3 / 2 / 1



G
P R
3.0 12.0



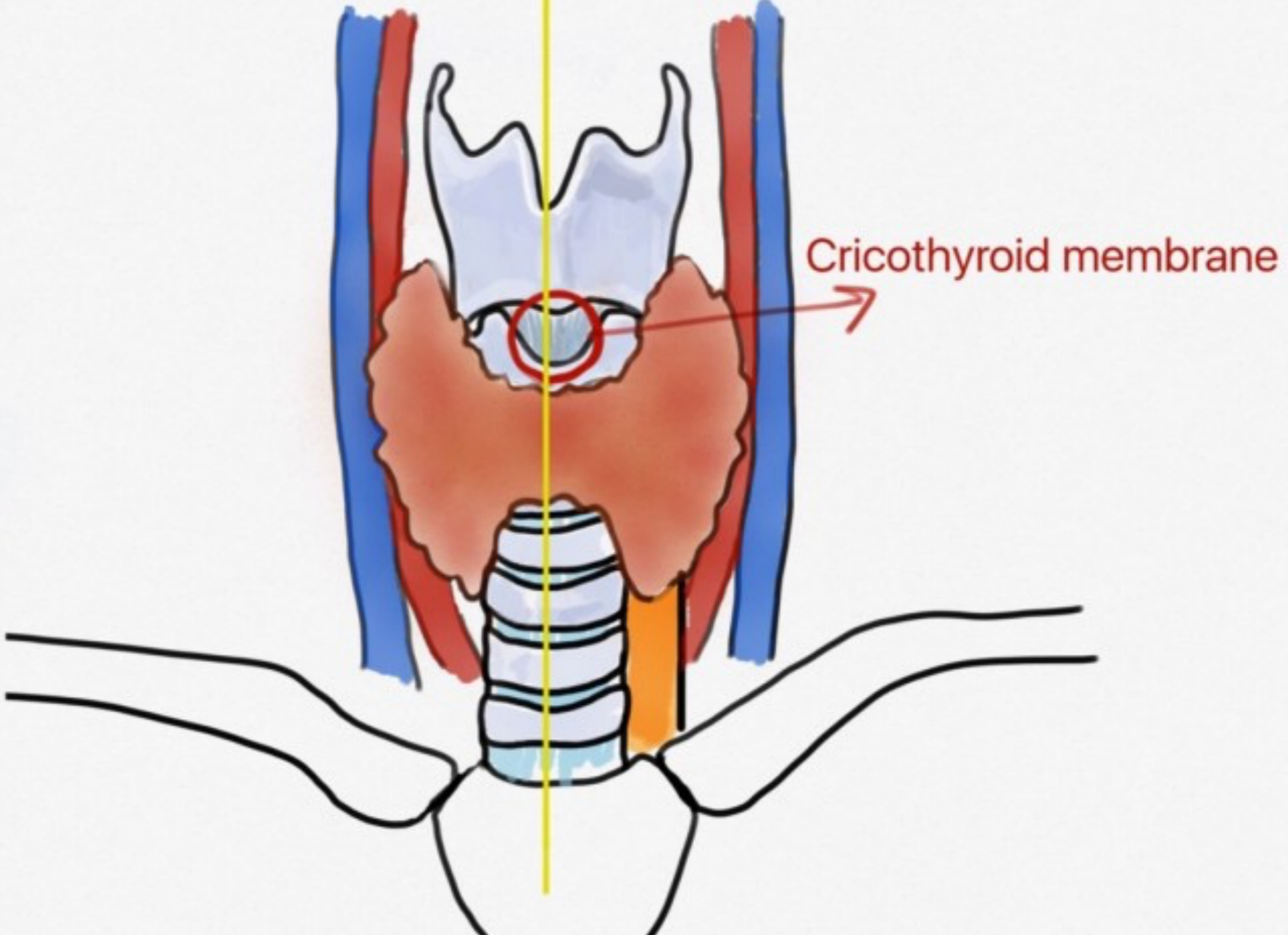
3.5cm

POCUS for better Airway management

插對了嗎

插不上時

1 v.s. 2



Cricothyroid membrane


INT L1
TIS 0.1

B
FH12
DR 110
FR 27
D 2.0
G 53



TC

CC



← -1



POCUS for better Airway management

插對了嗎


插不上時

1 v.s. 2


CTM



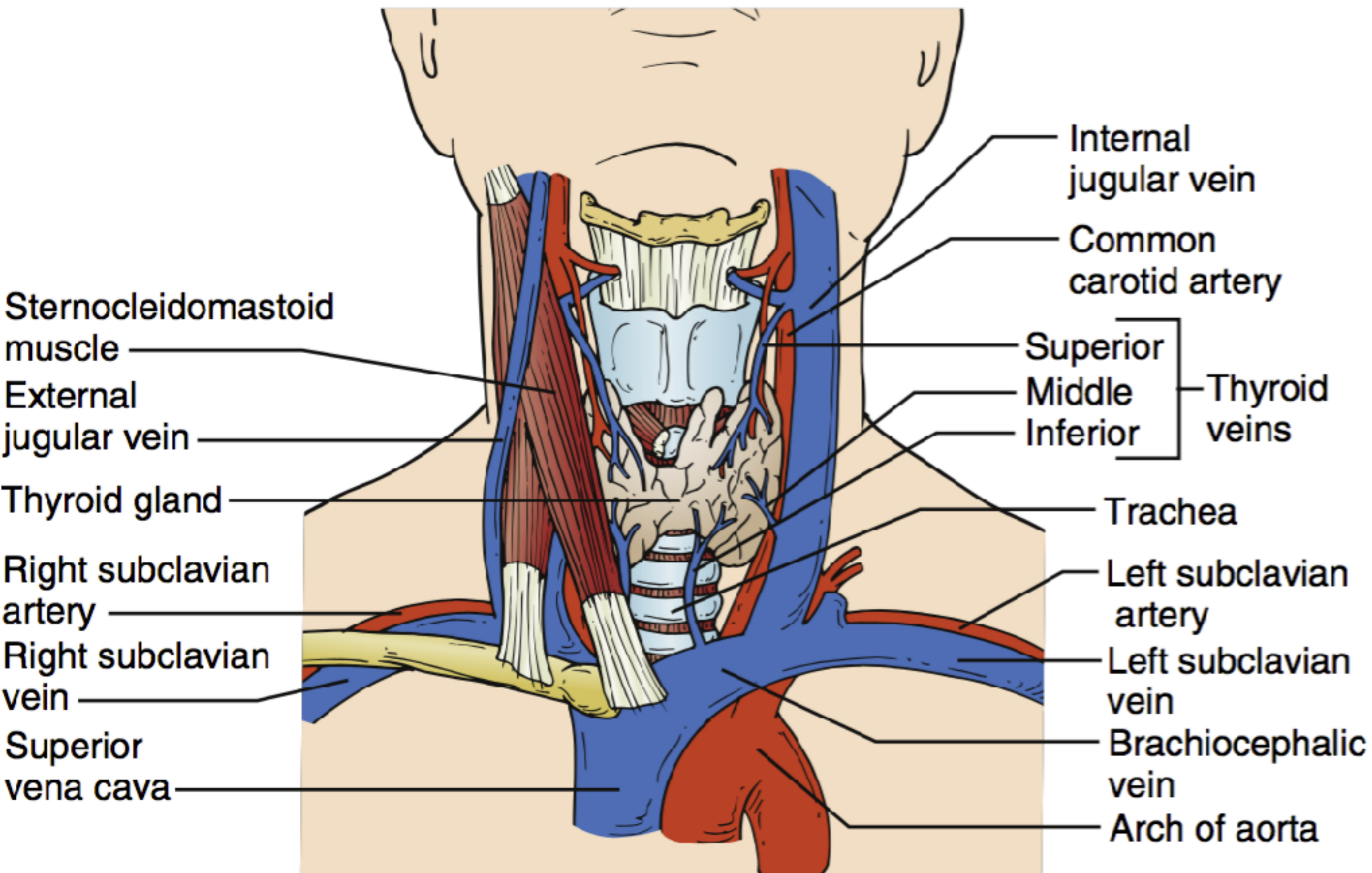
Success rates



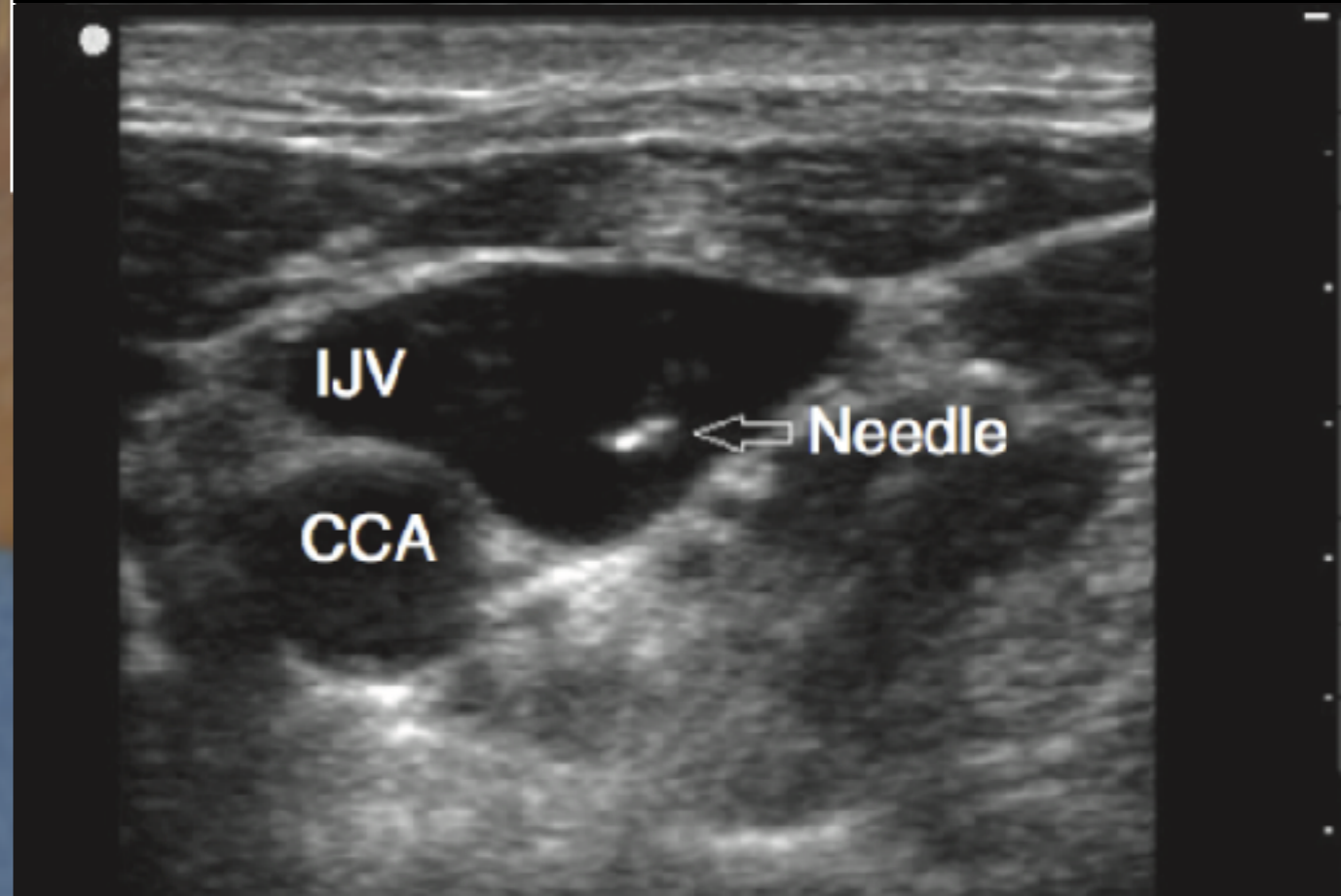
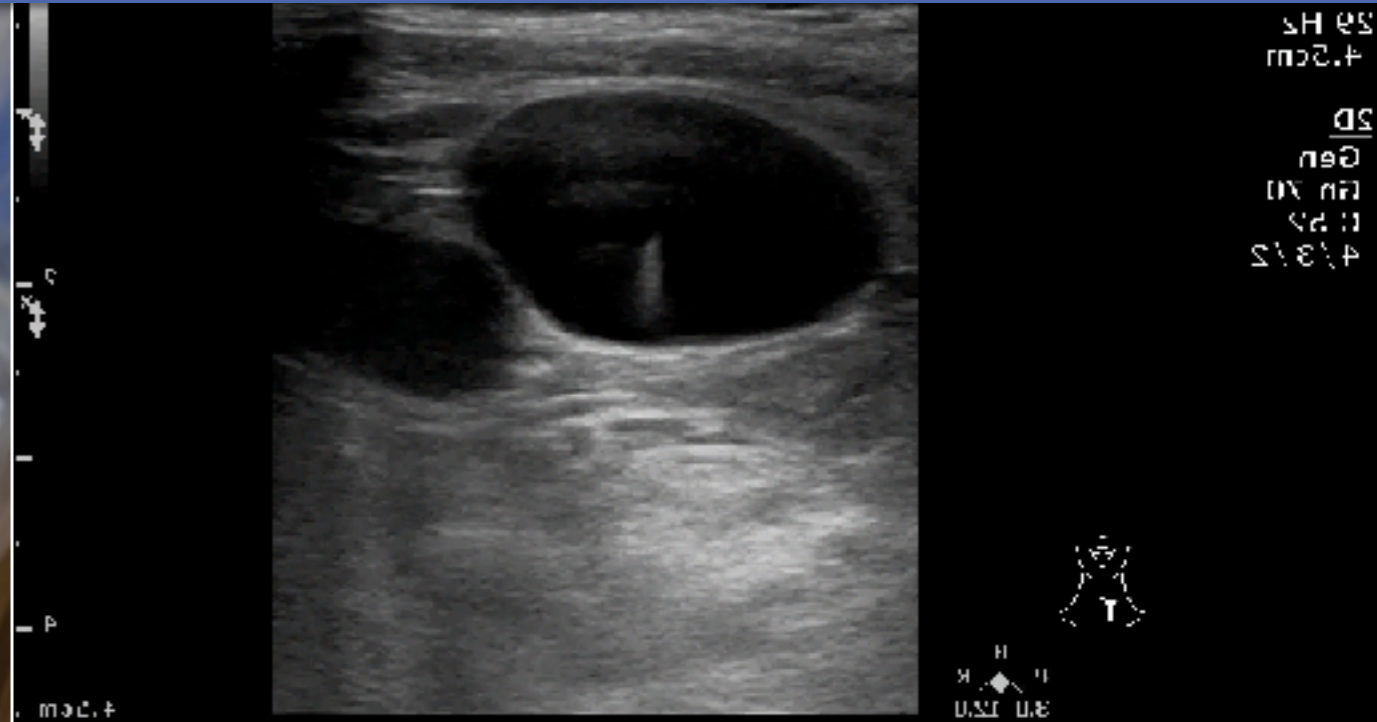
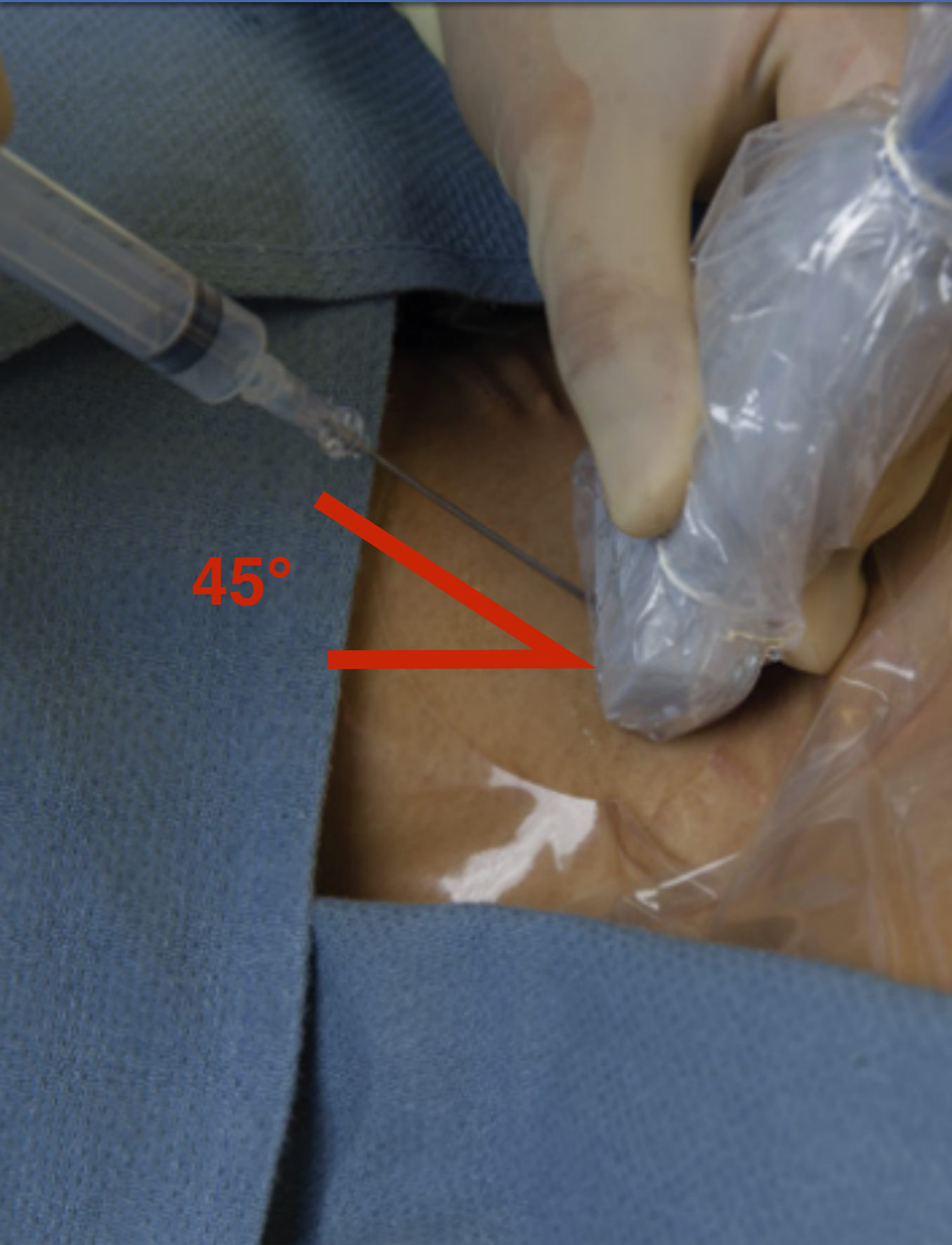Mechanical complications



Neck Vascular Structure



Transverse approach

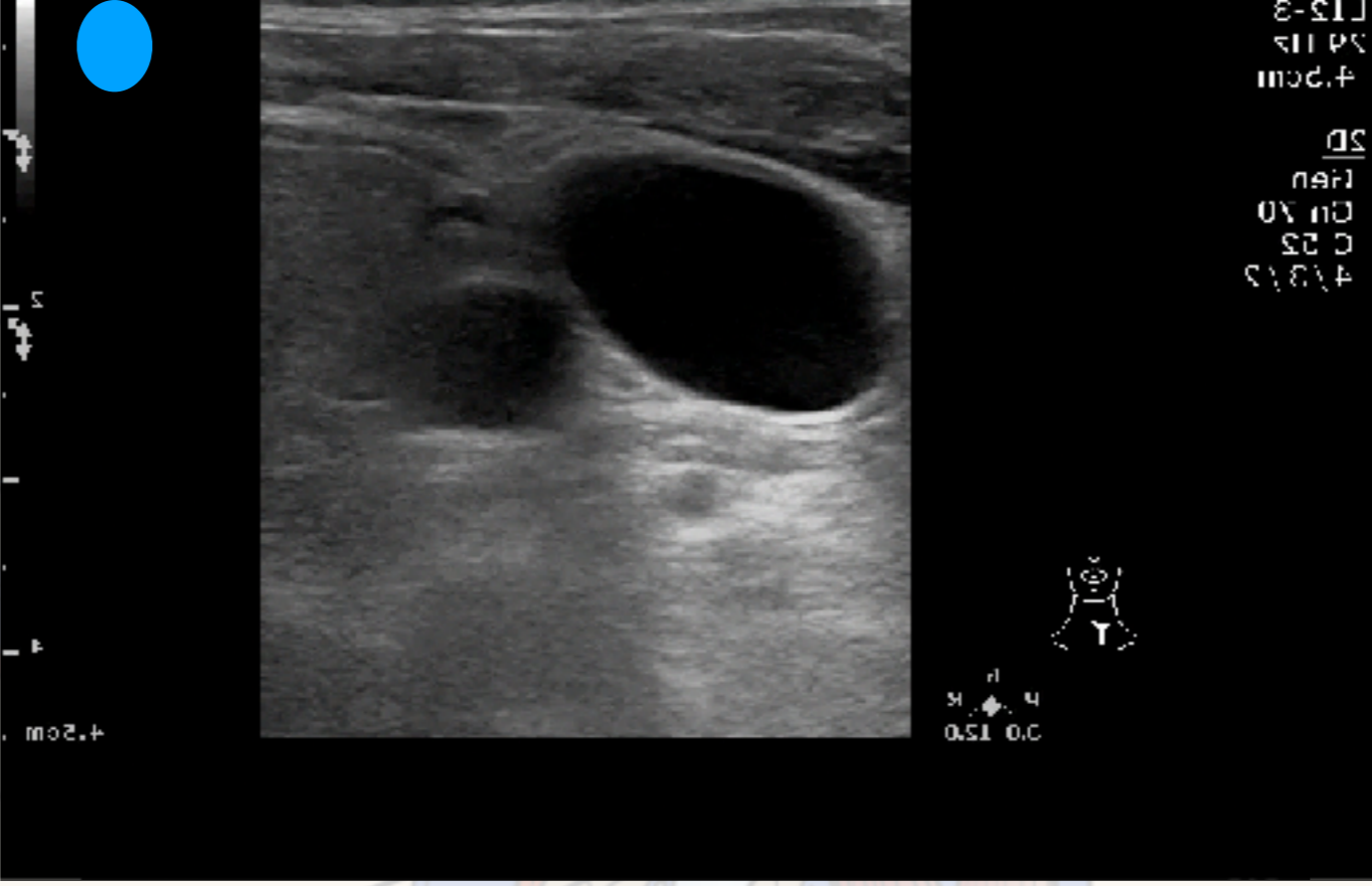


Longitudinal approach



L

R



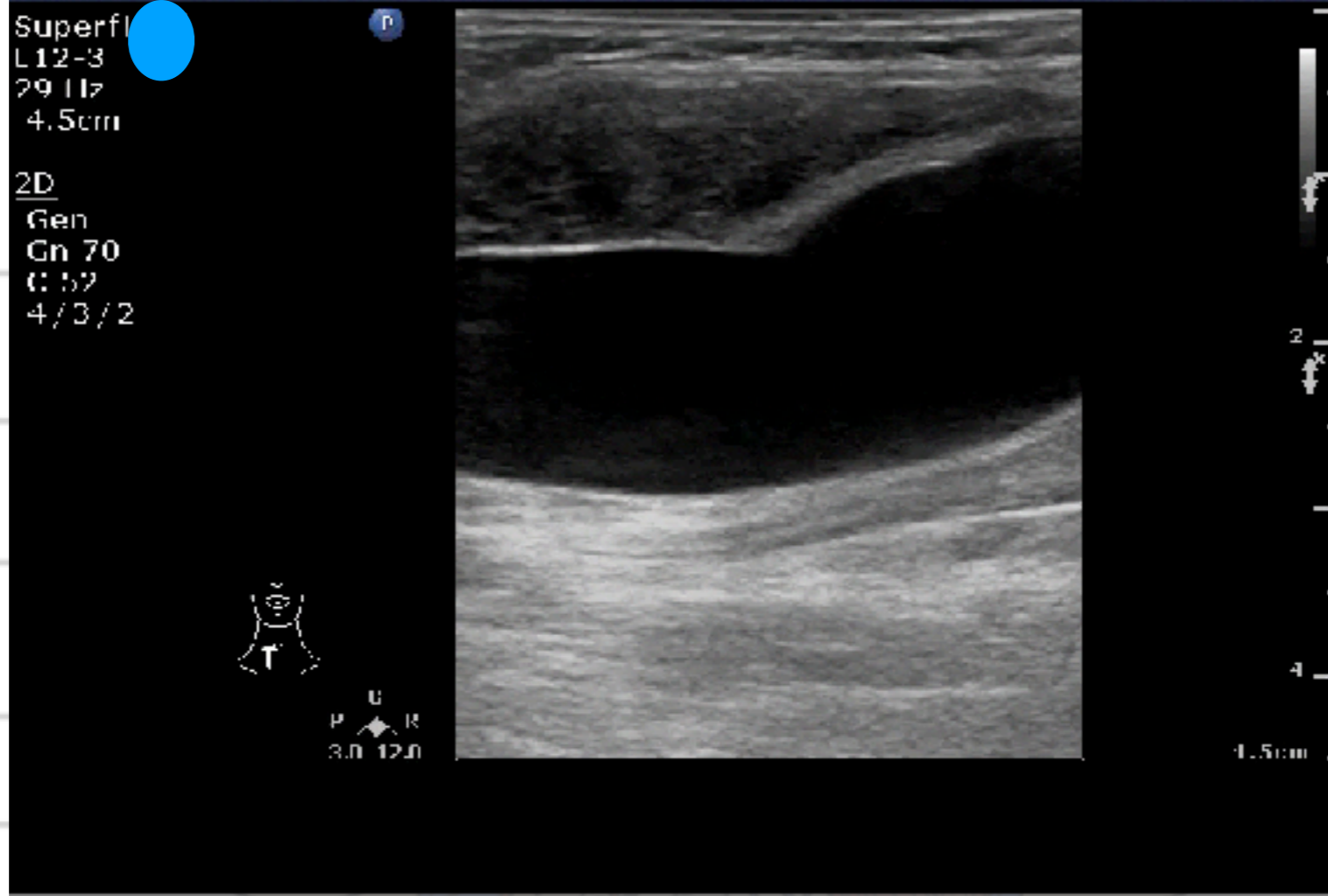
- Arch of aorta
- vein
- Brachiocephalic
- vein
- Left subclavian
- artery
- Left subclavian
- Trachea
- Thyroid
- Superior
- Middle
- Inferior
- veins
- carotid artery
- Common
- jugular vein
- Internal

- Vena cava
- Superior
- vein
- Right subclavian
- artery
- Right subclavian
- Thyroid gland
- External
- muscle
- Sternocleidomastoid
- jugular vein

Operator

L

R

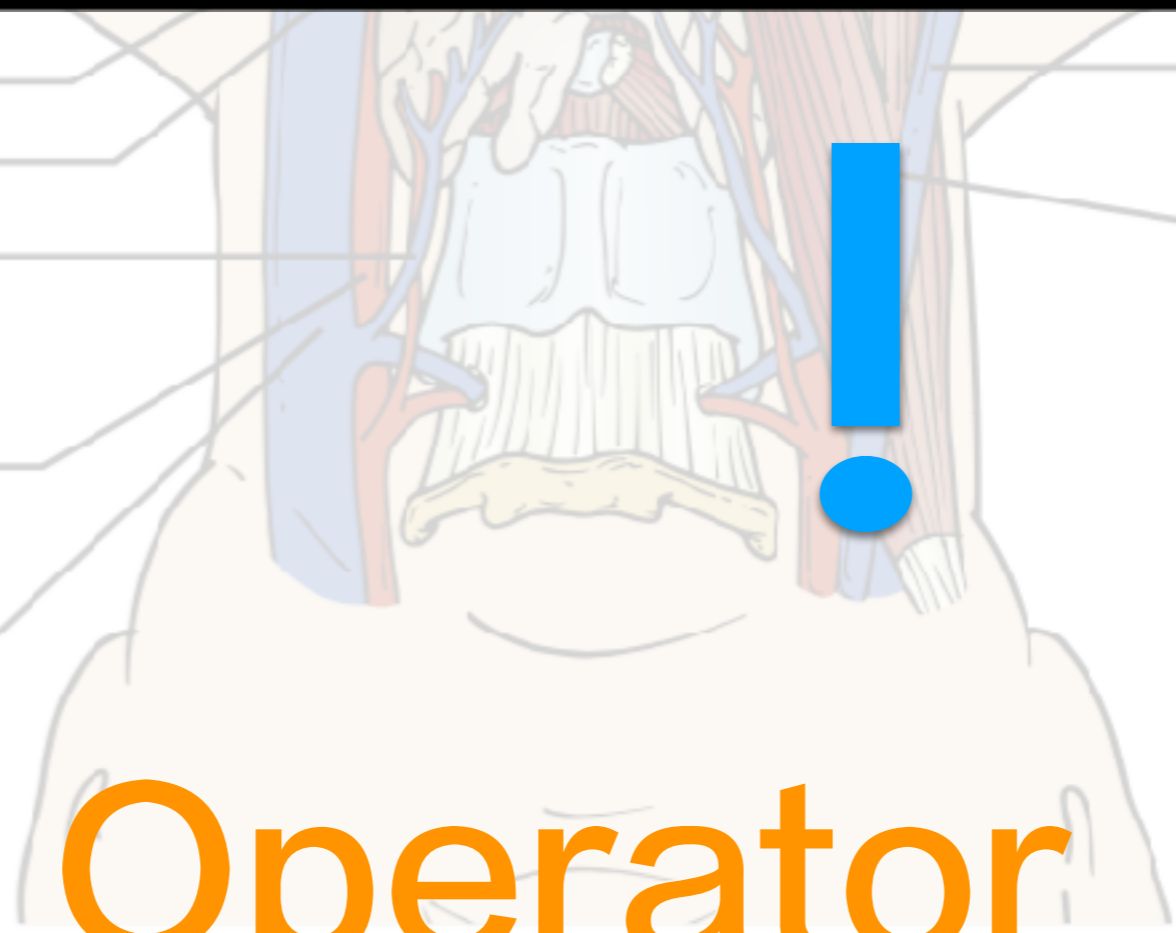


Arch of aorta
 vein
 Brachiocephalic
 vein
 Left subclavian
 artery
 Left subclavian
 Trachea

vena cava
 Superior
 vein
 Right subclavian
 artery
 Right subclavian
 Thyroid gland

Thyroid
 Superior
 Middle
 Inferior
 veins
 Common
 carotid artery
 Internal
 jugular vein

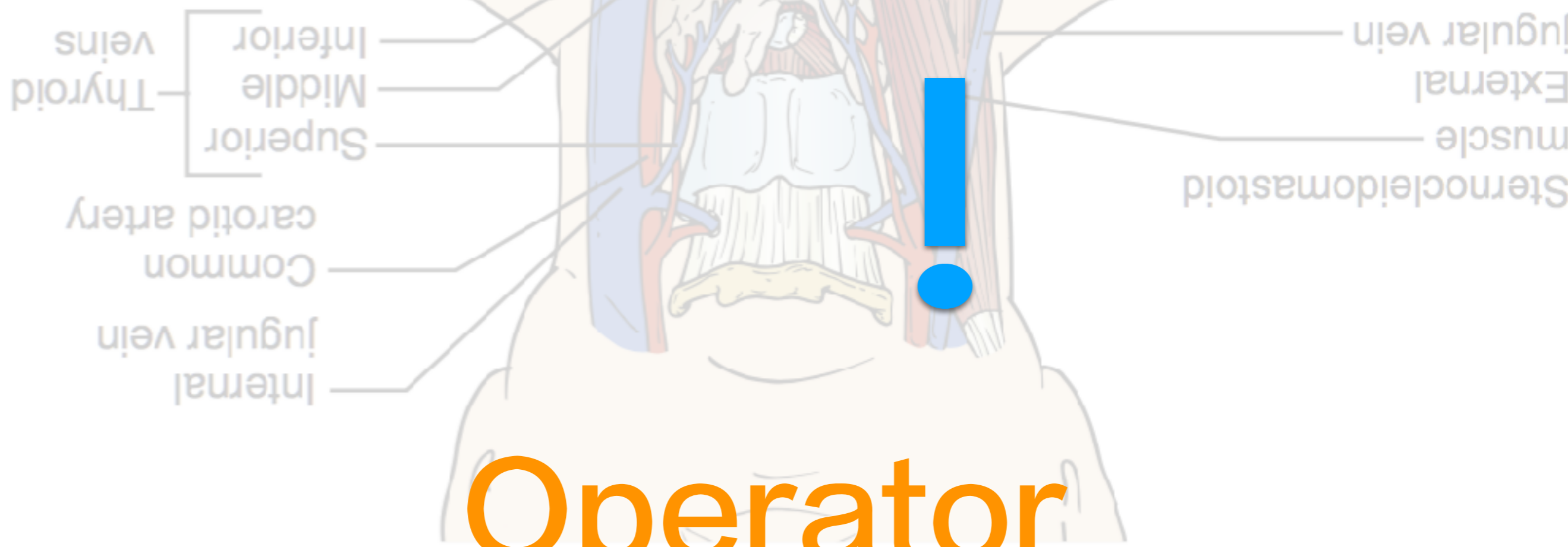
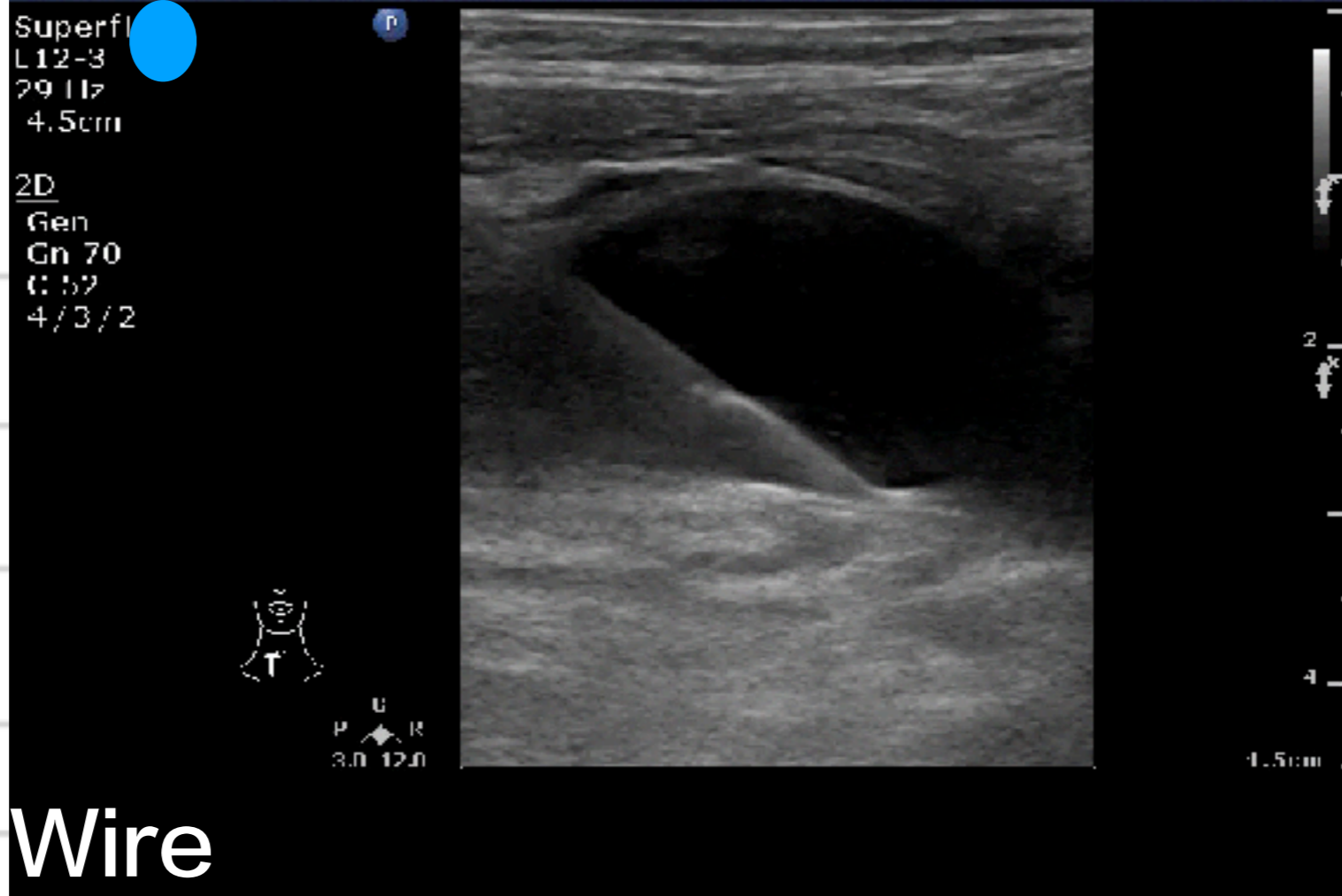
External
 muscle
 Sternocleidomastoid
 jugular vein



Operator

L

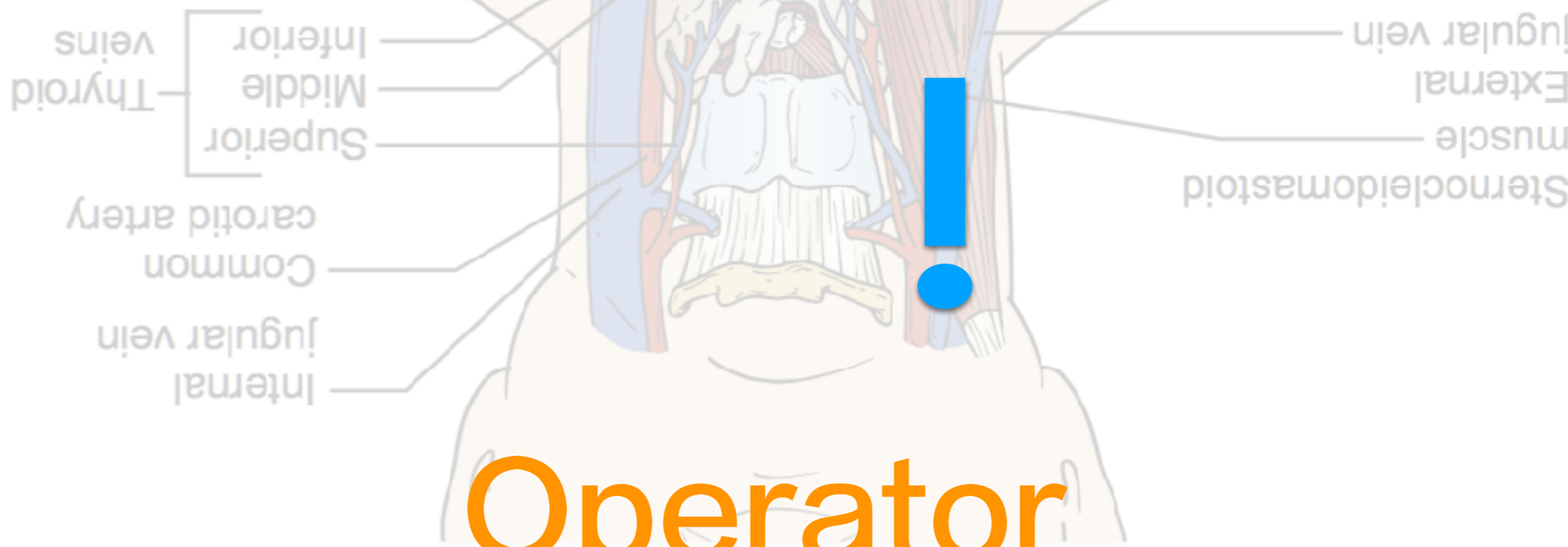
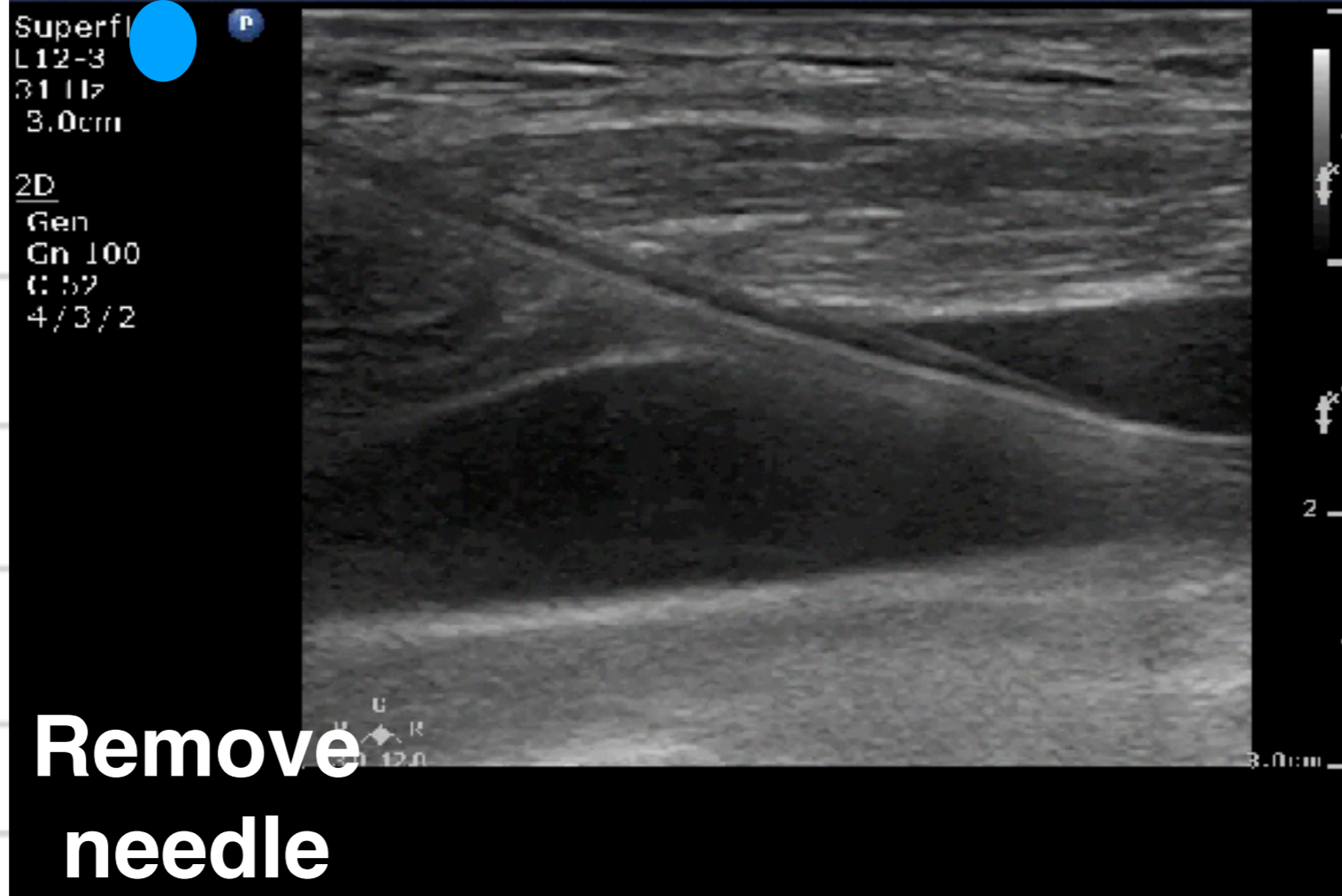R



Operator

L

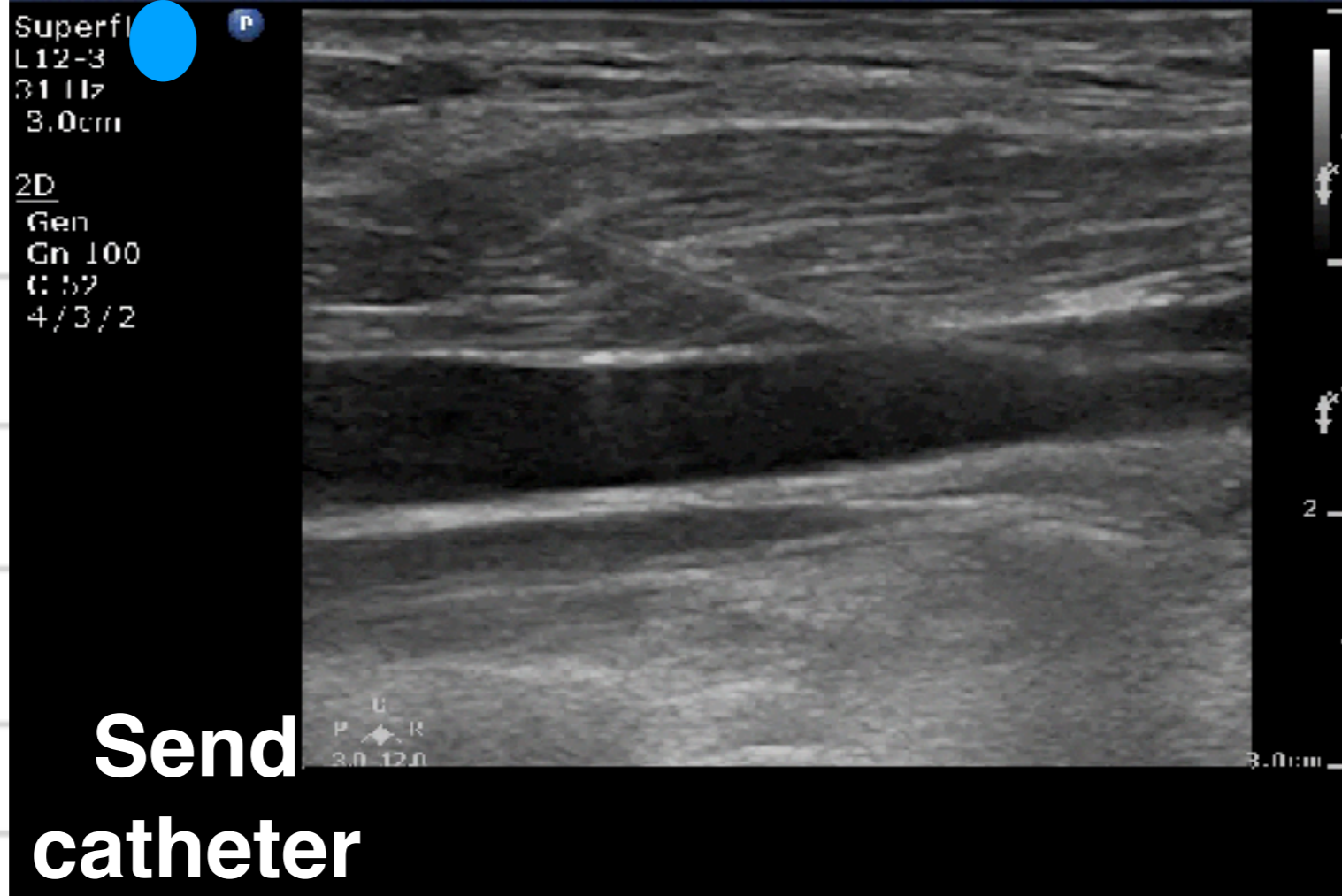
R



Operator

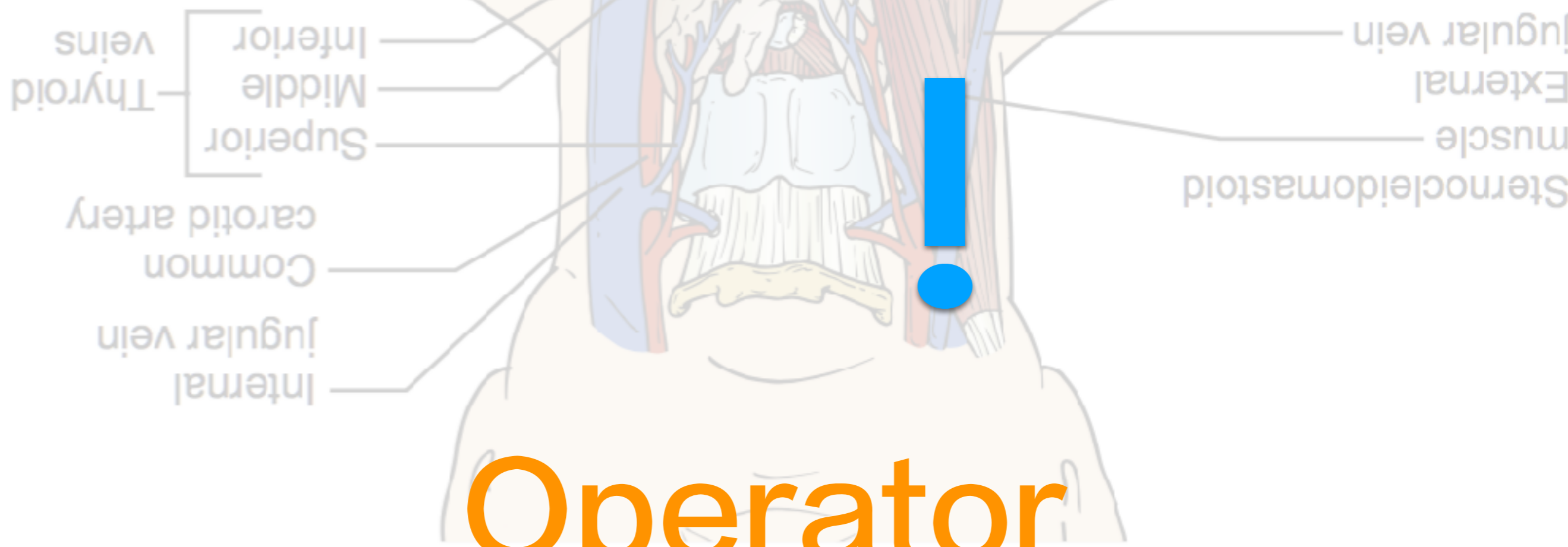
L

R



Arch of aorta
vein
Brachiocephalic
vein
Left subclavian
artery
Left subclavian
artery
Trachea

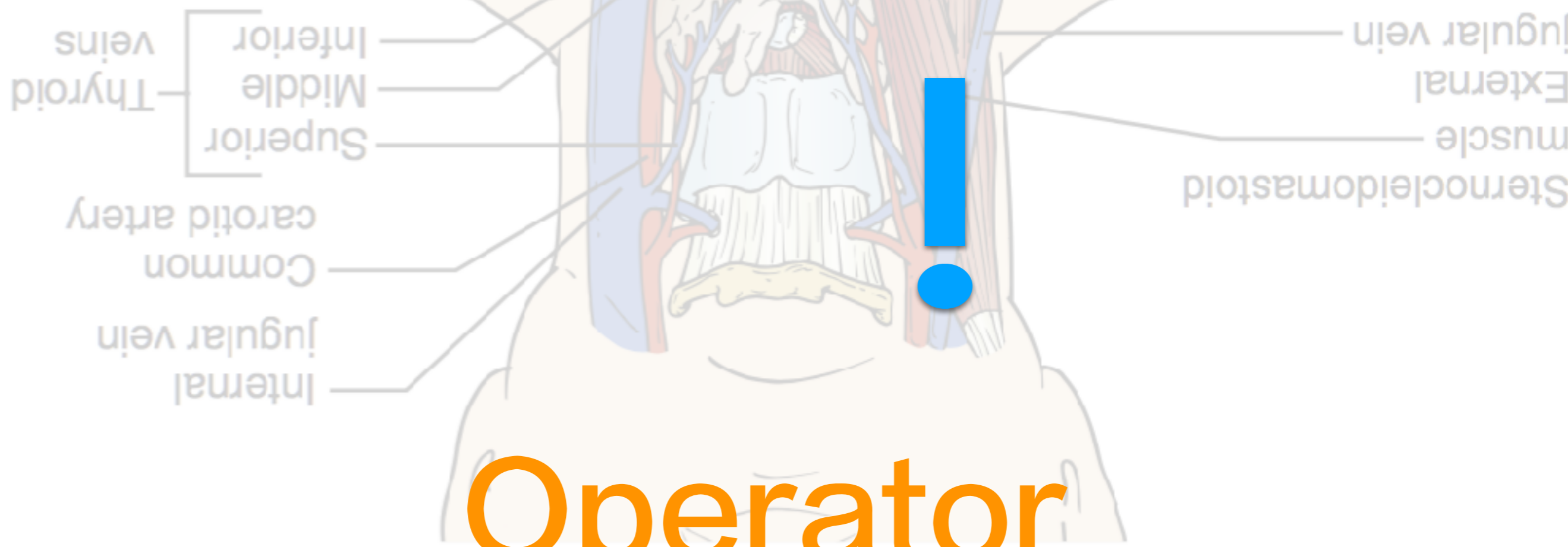
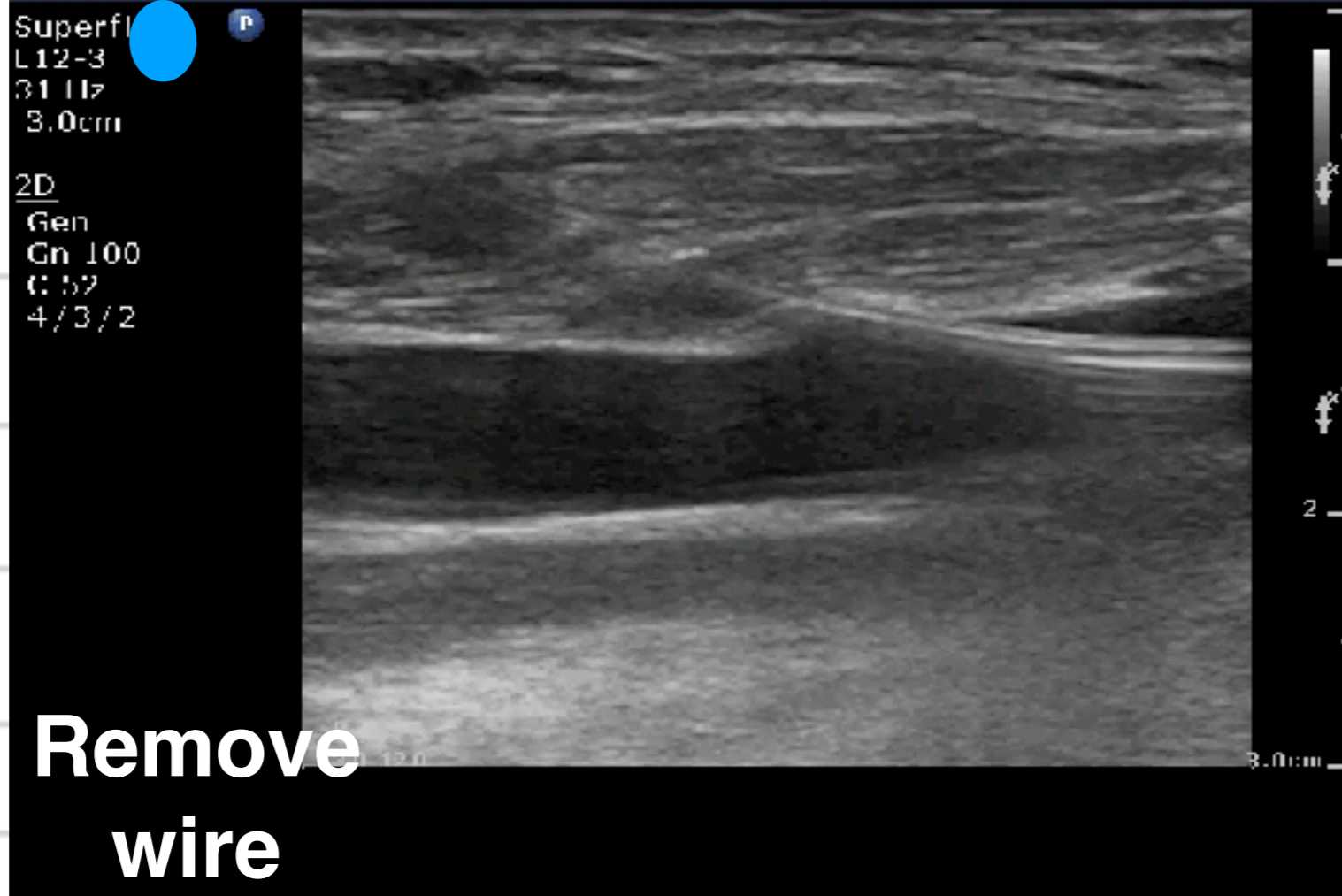
vena cava
Superior
vein
Right subclavian
artery
Right subclavian
artery
Thyroid gland



Operator

L

R

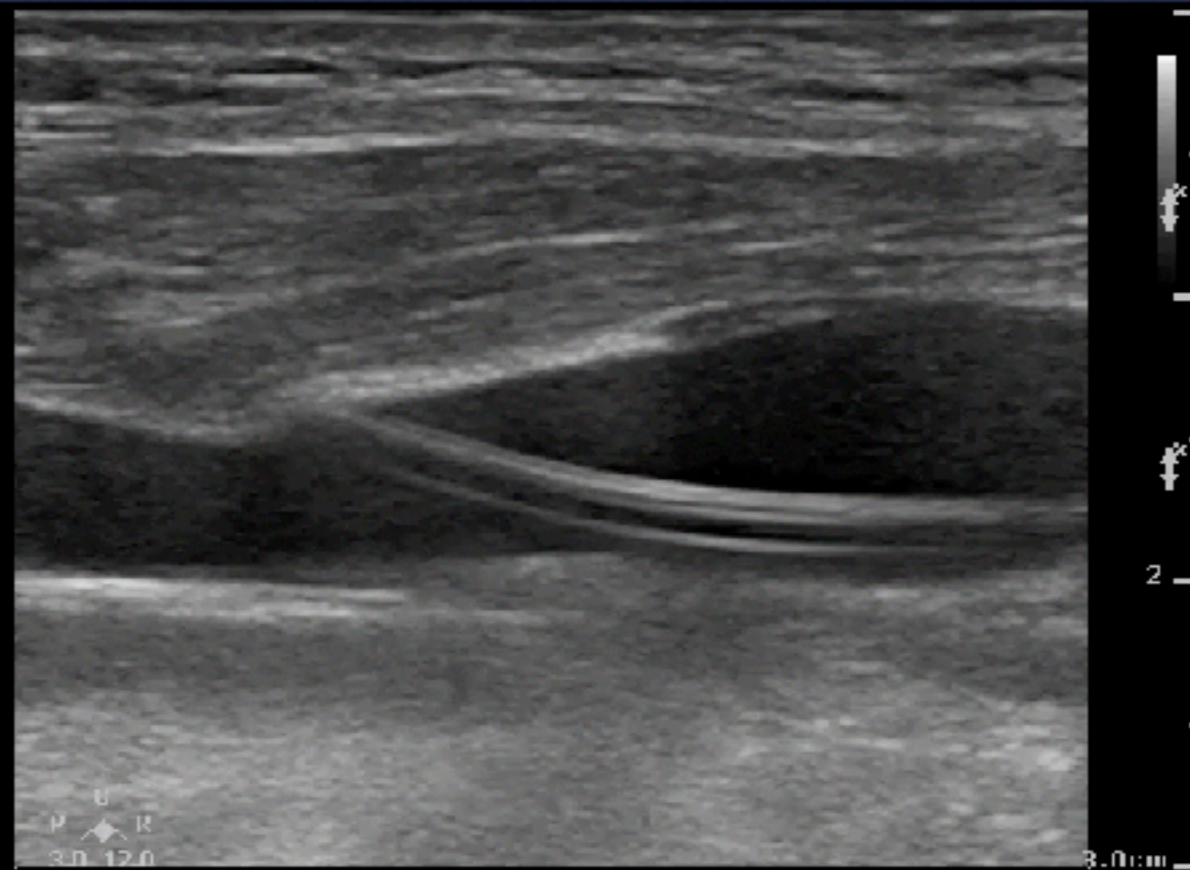


Operator

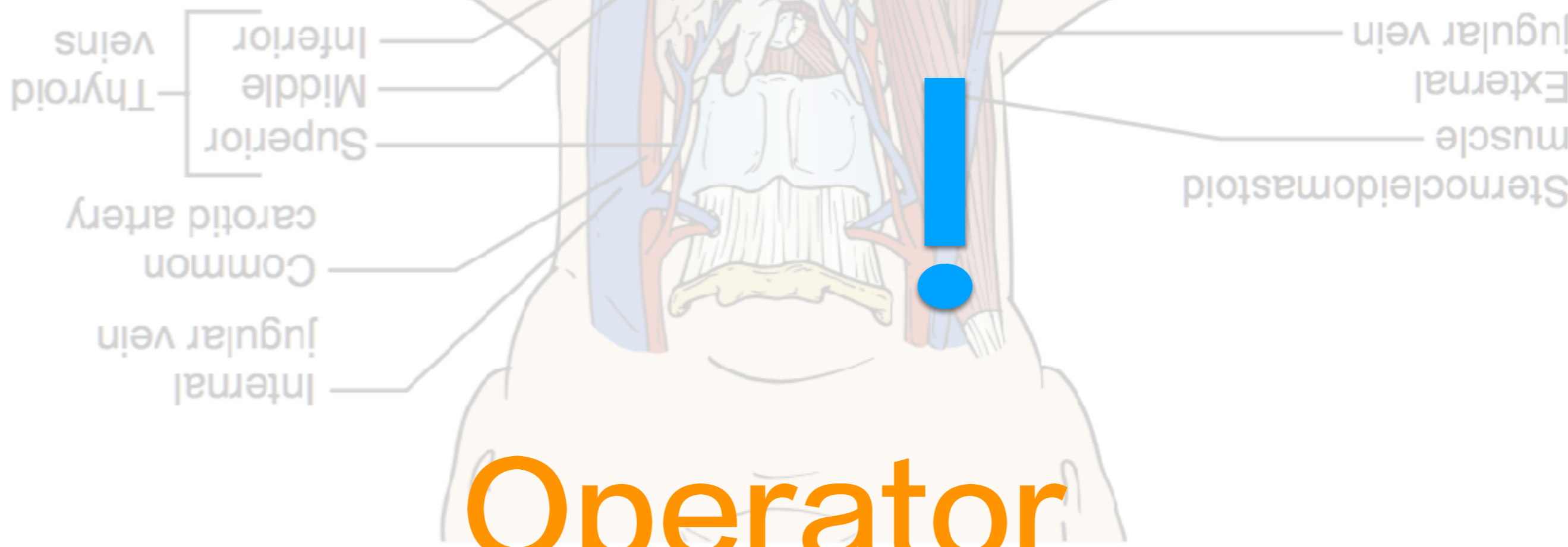
L

R

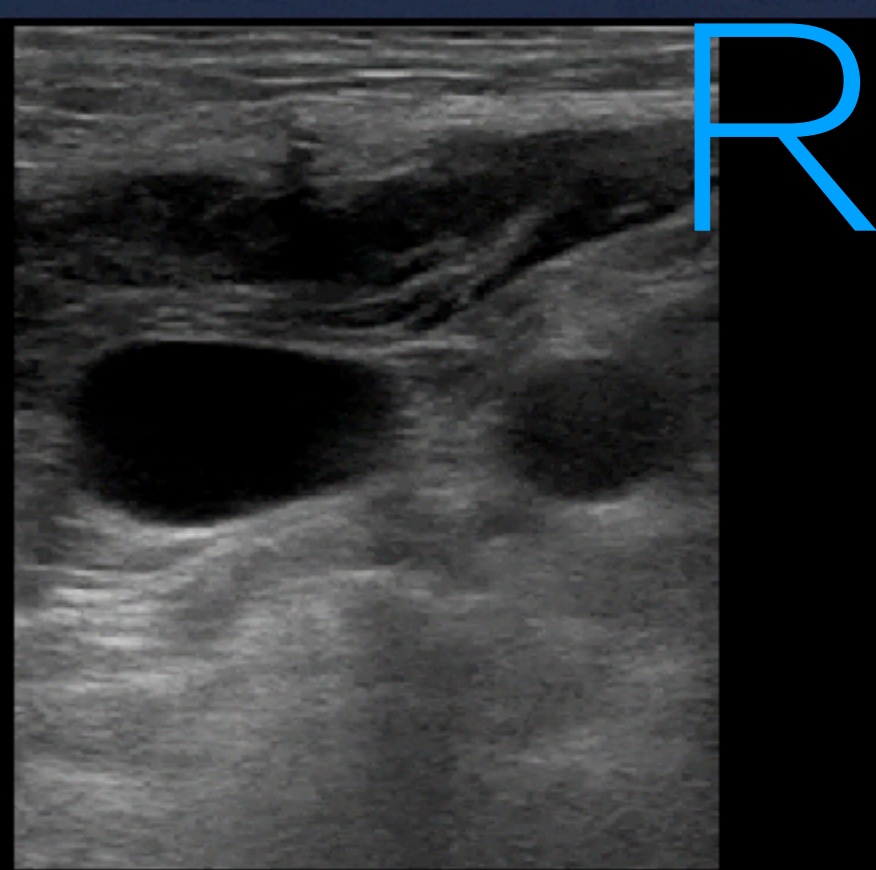
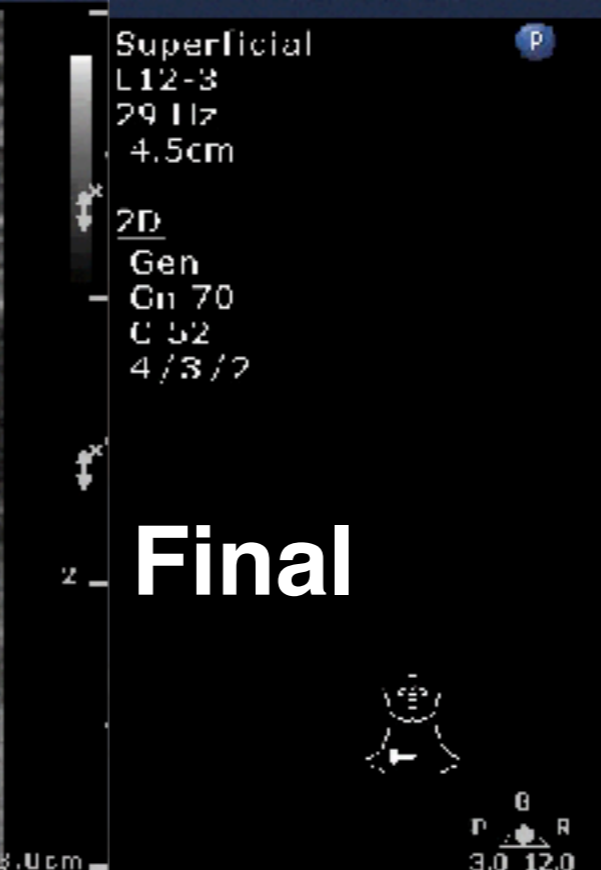
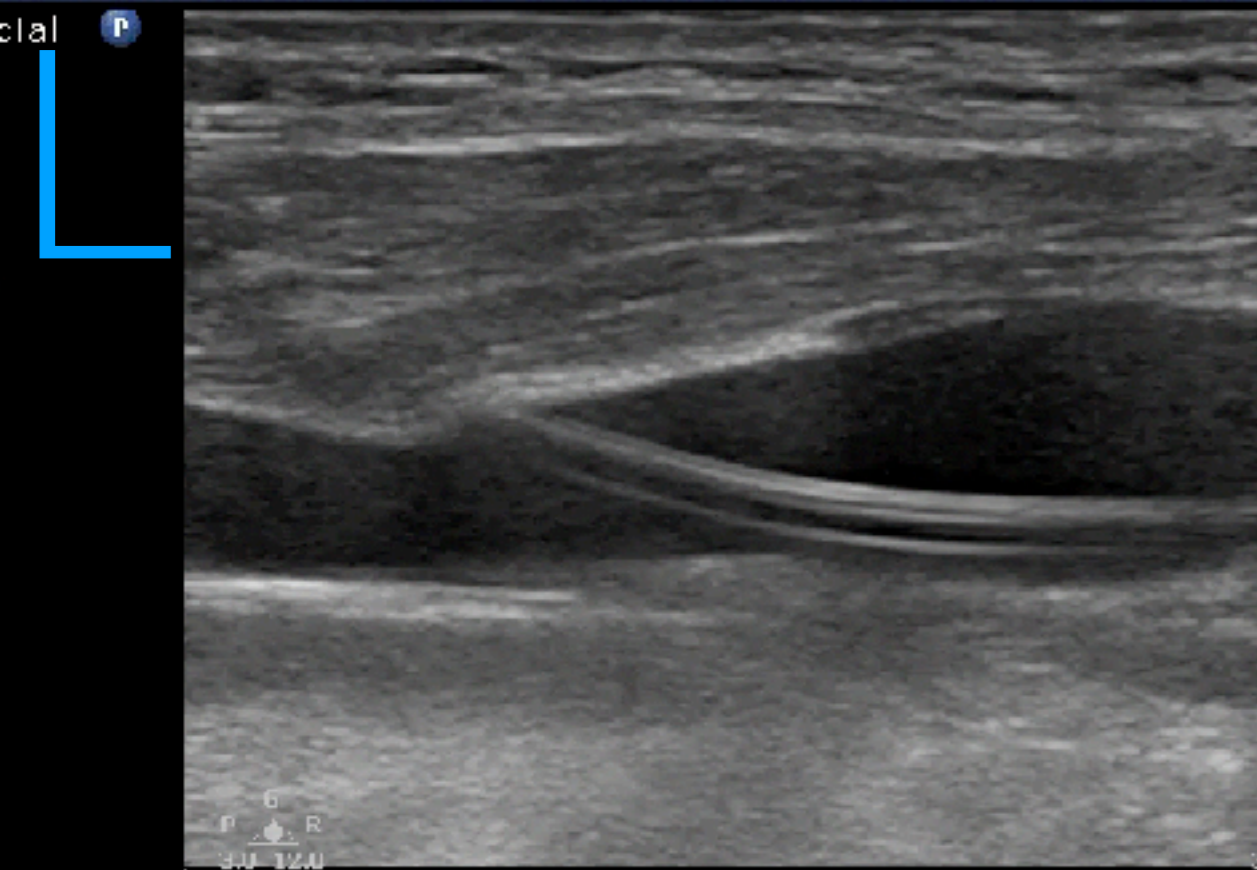
Superf
 L12-3
 31 117
 3.0cm
 2D
 Gen
 Gn 100
 4/3/2



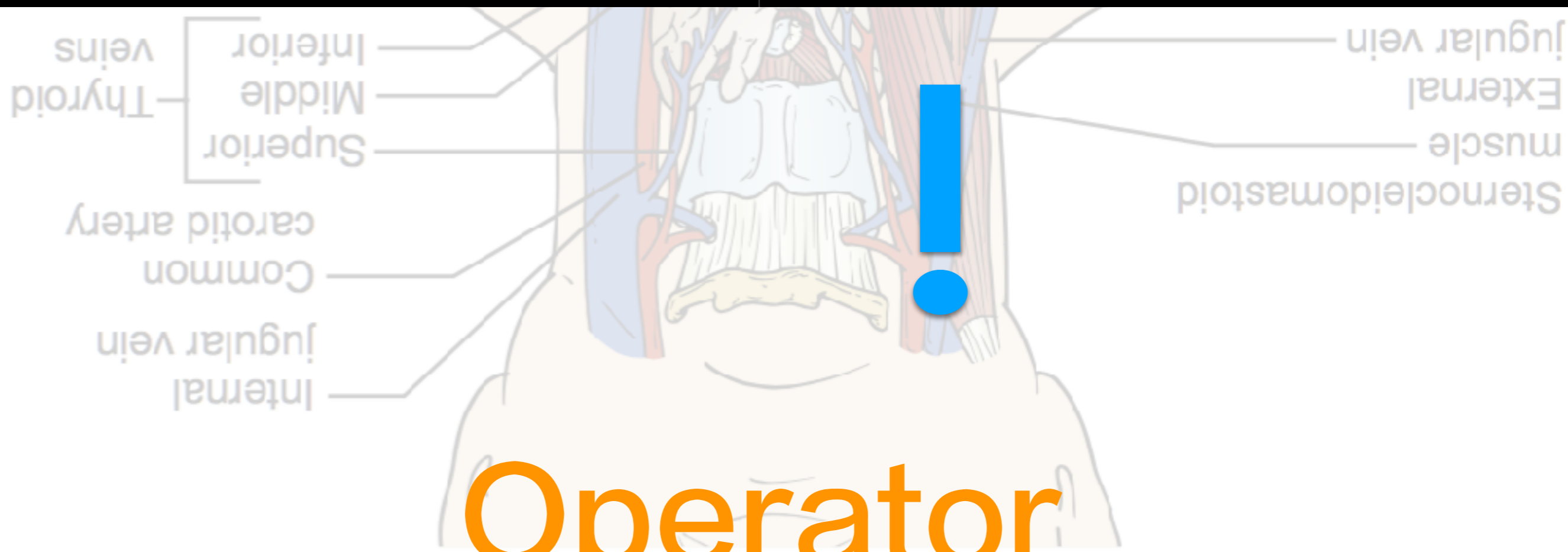
Catheter



Operator

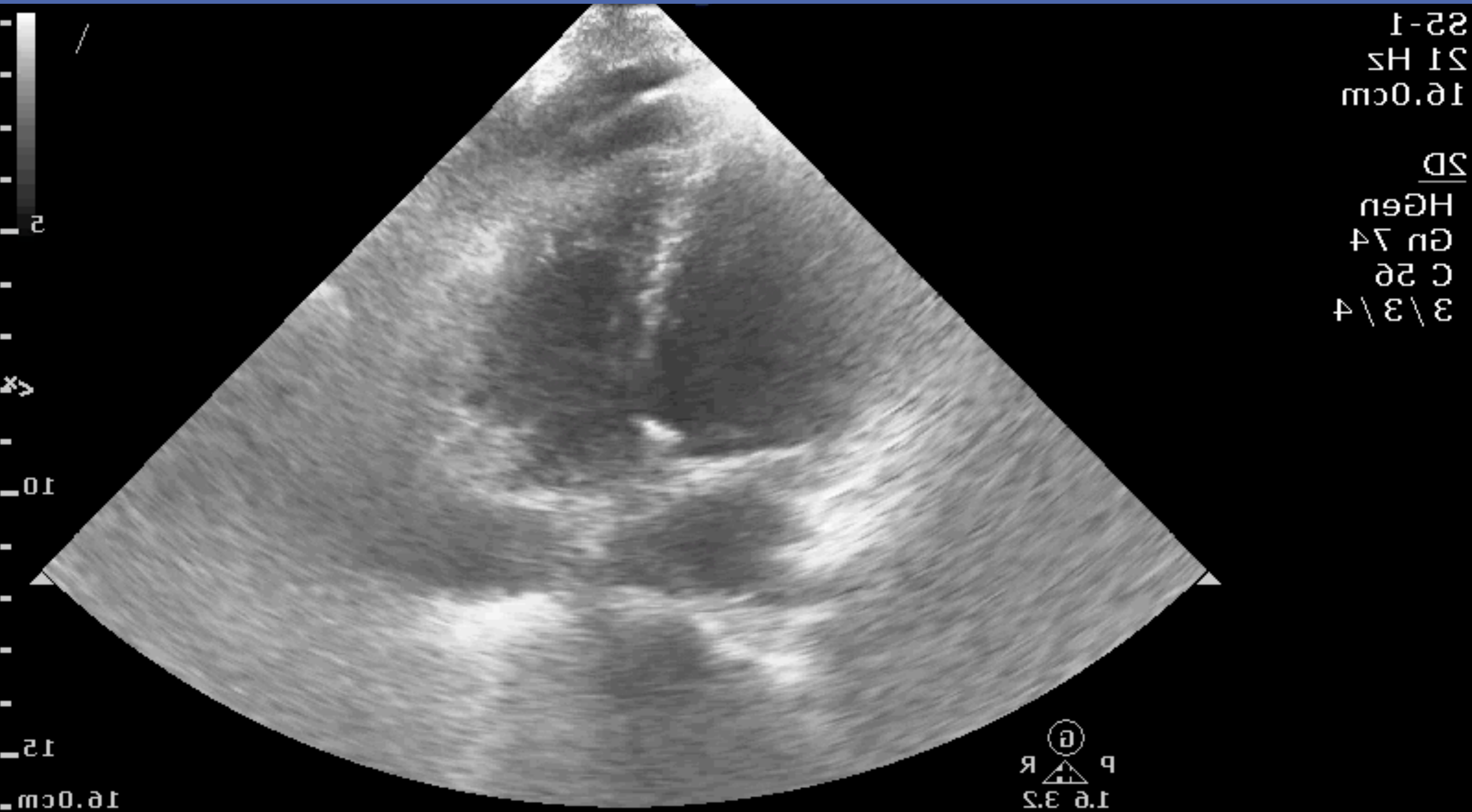


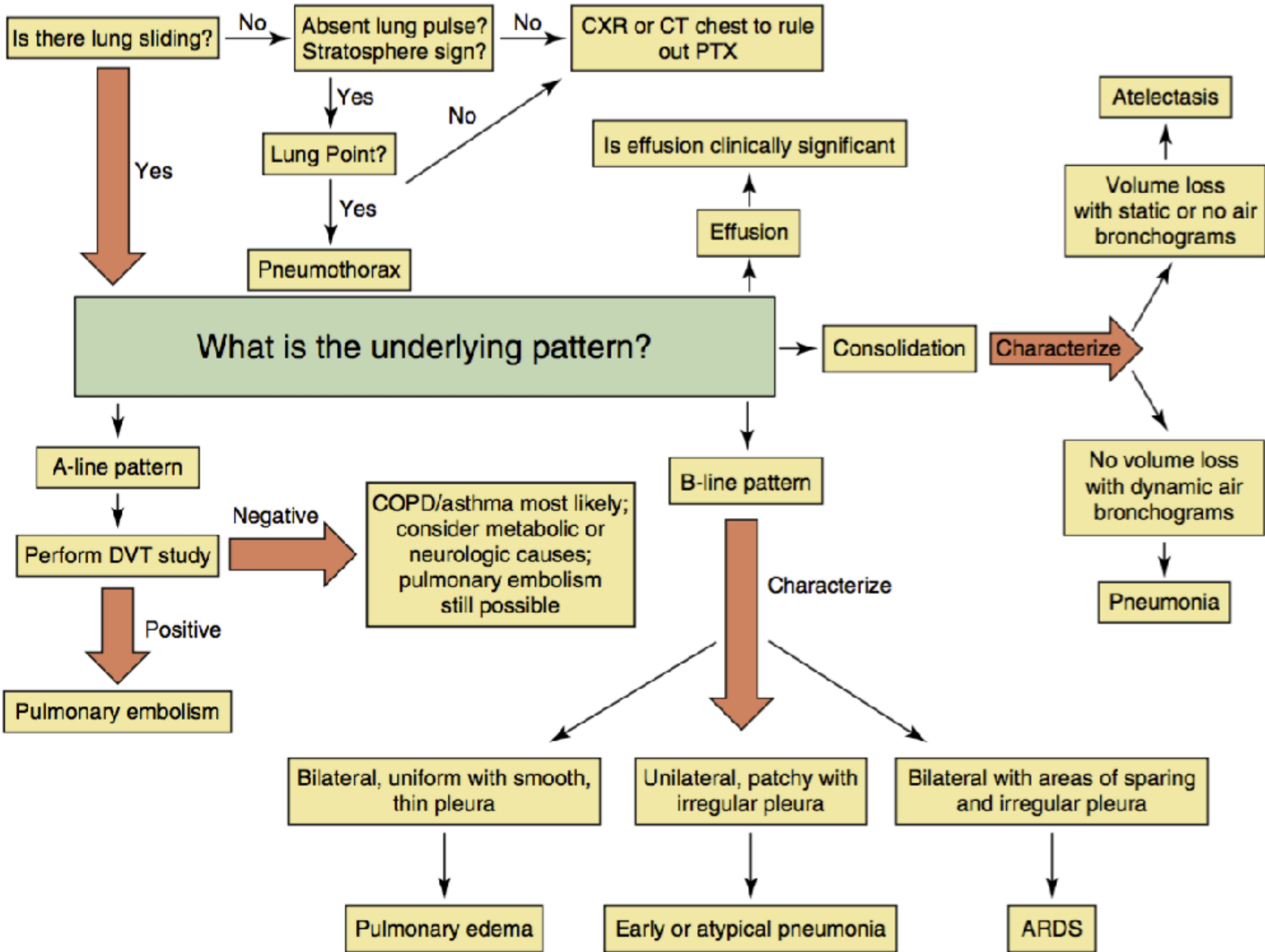
Final



Operator

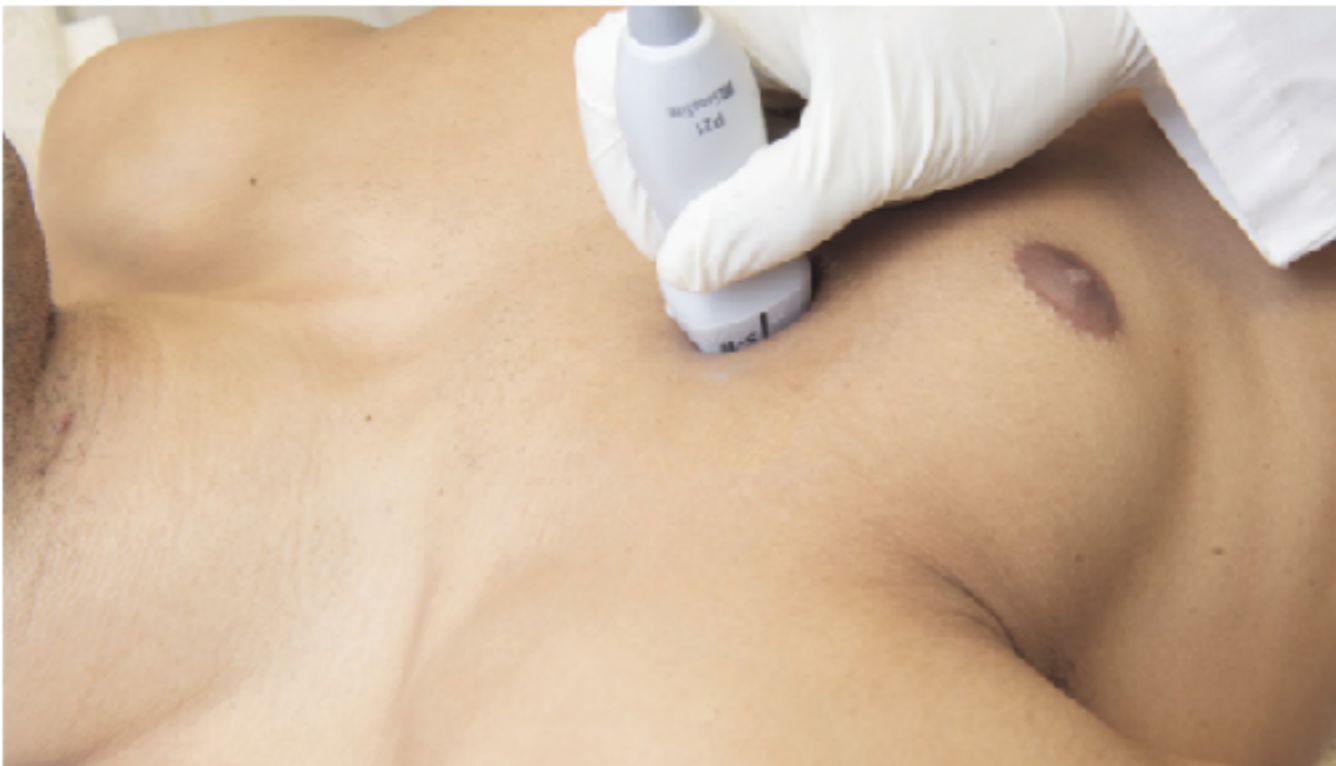Bubble test /Subcostal 4



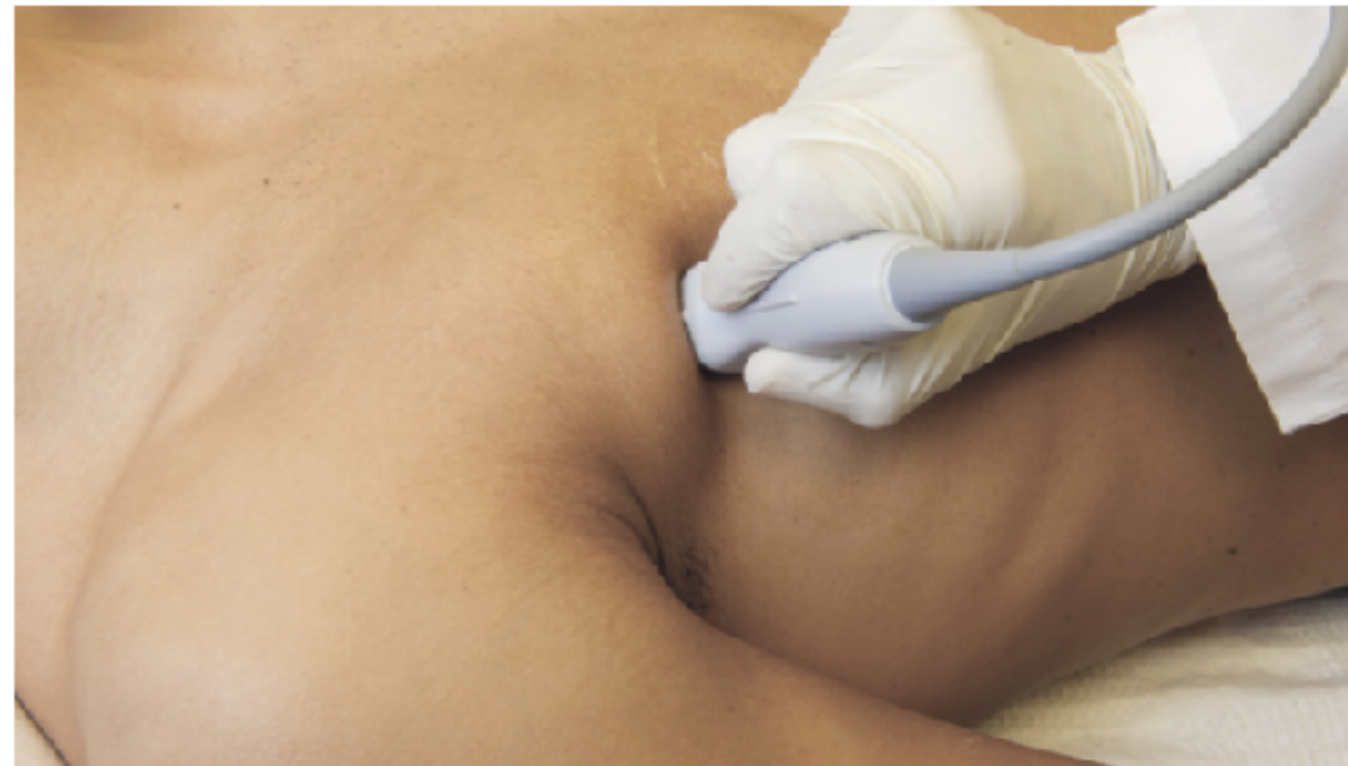

BLUE 4 points

Point 1



Point 2

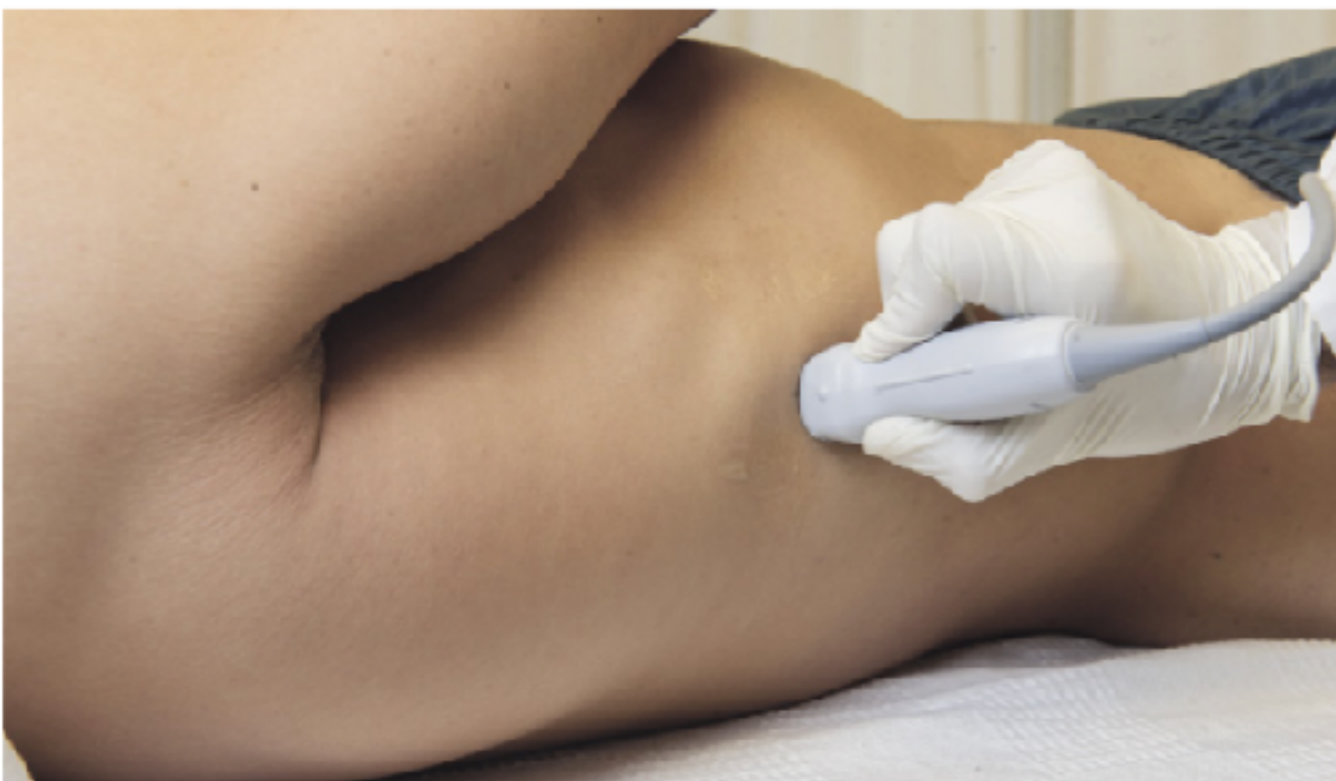

Head <<<<<

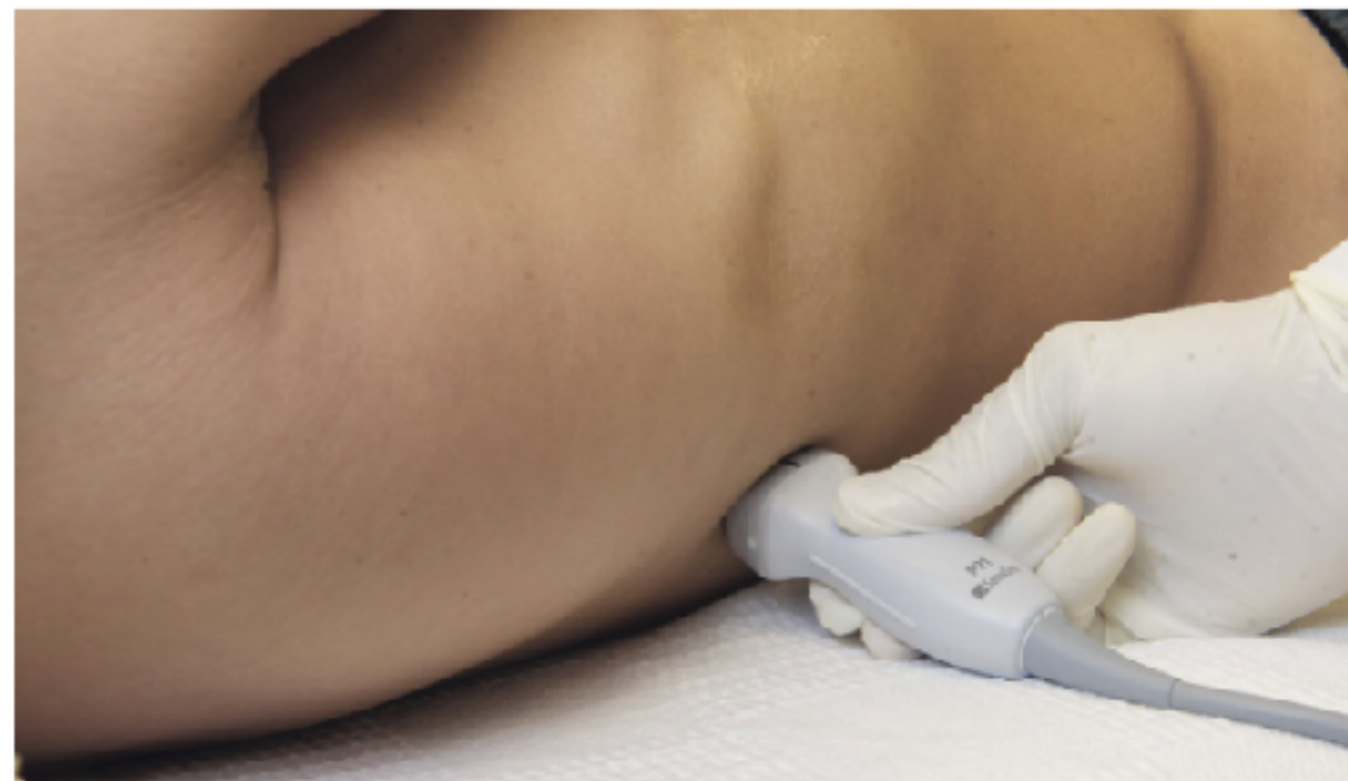Sagittal view

>>>>> Toe

Point 3

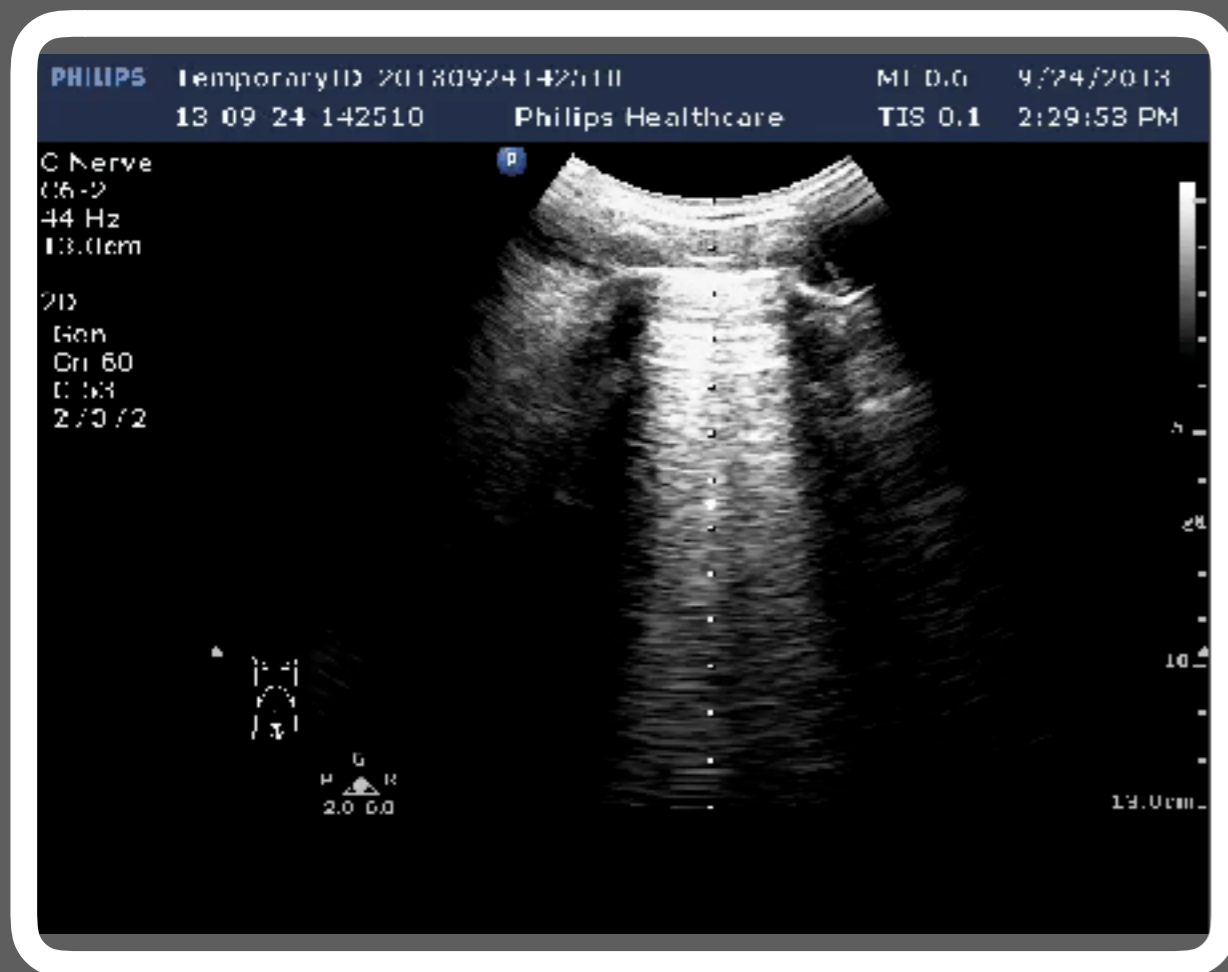


Point 4

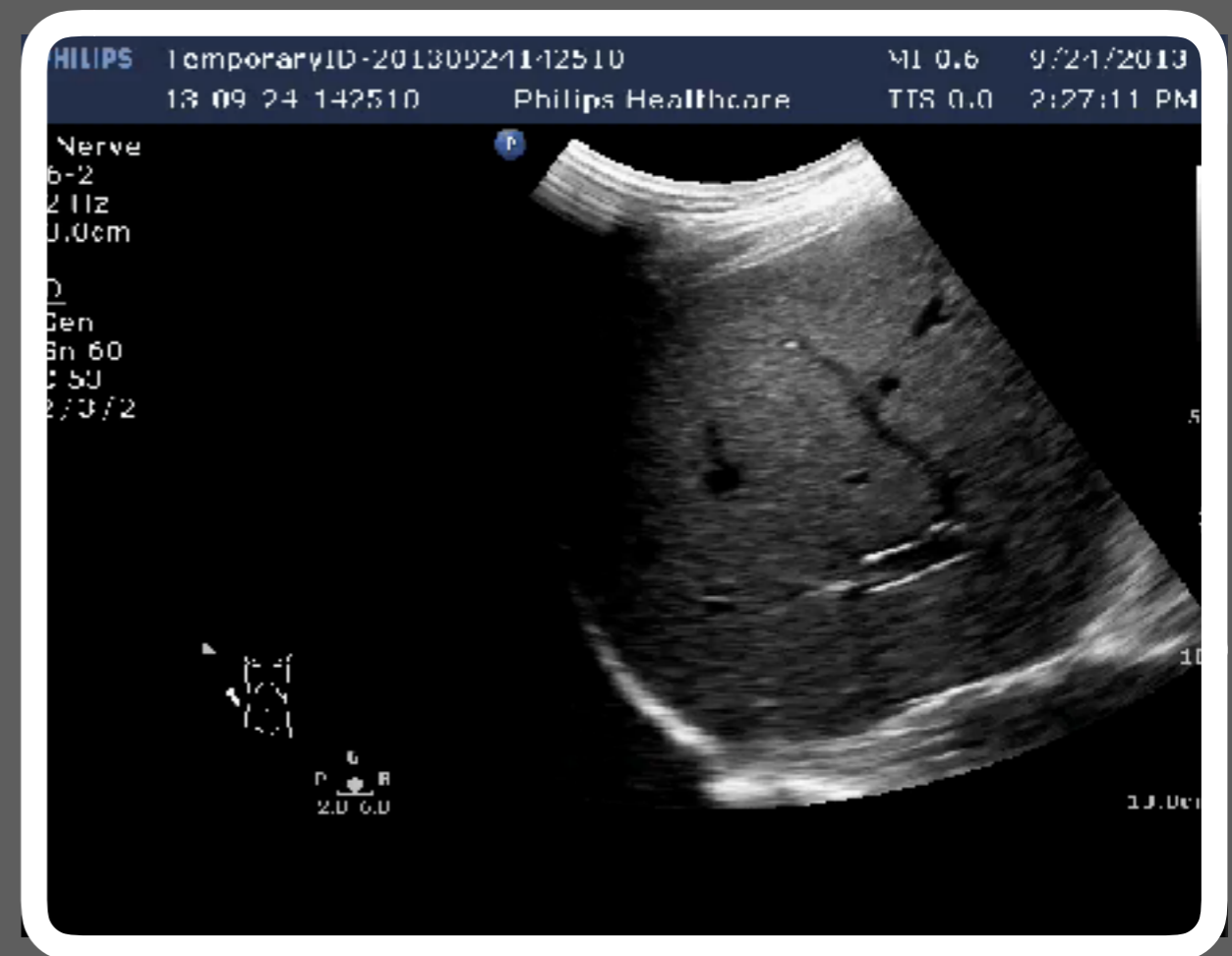


Principle

Air

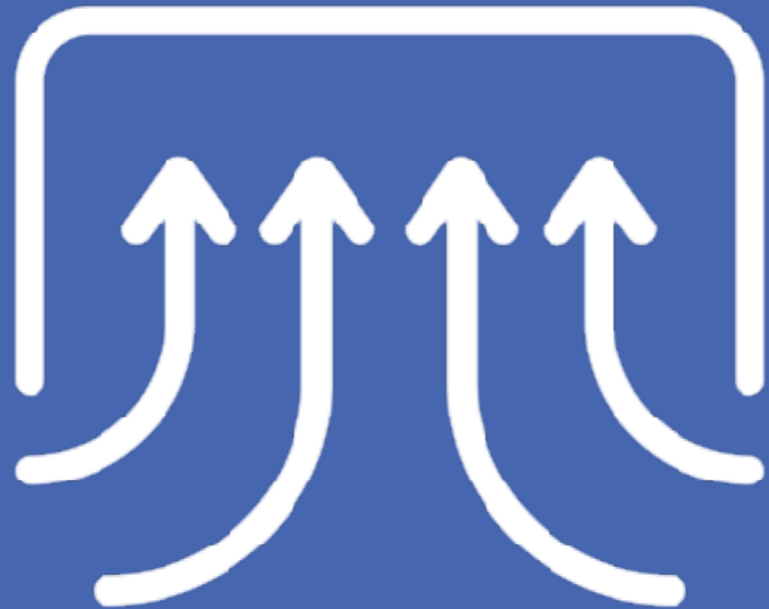


Fluid



Principle

Air 100%



Pneumothorax

Fluid 100%



Pleural effusion

Principle

True

Pneumonia
Pleural effusion
Pleural mass

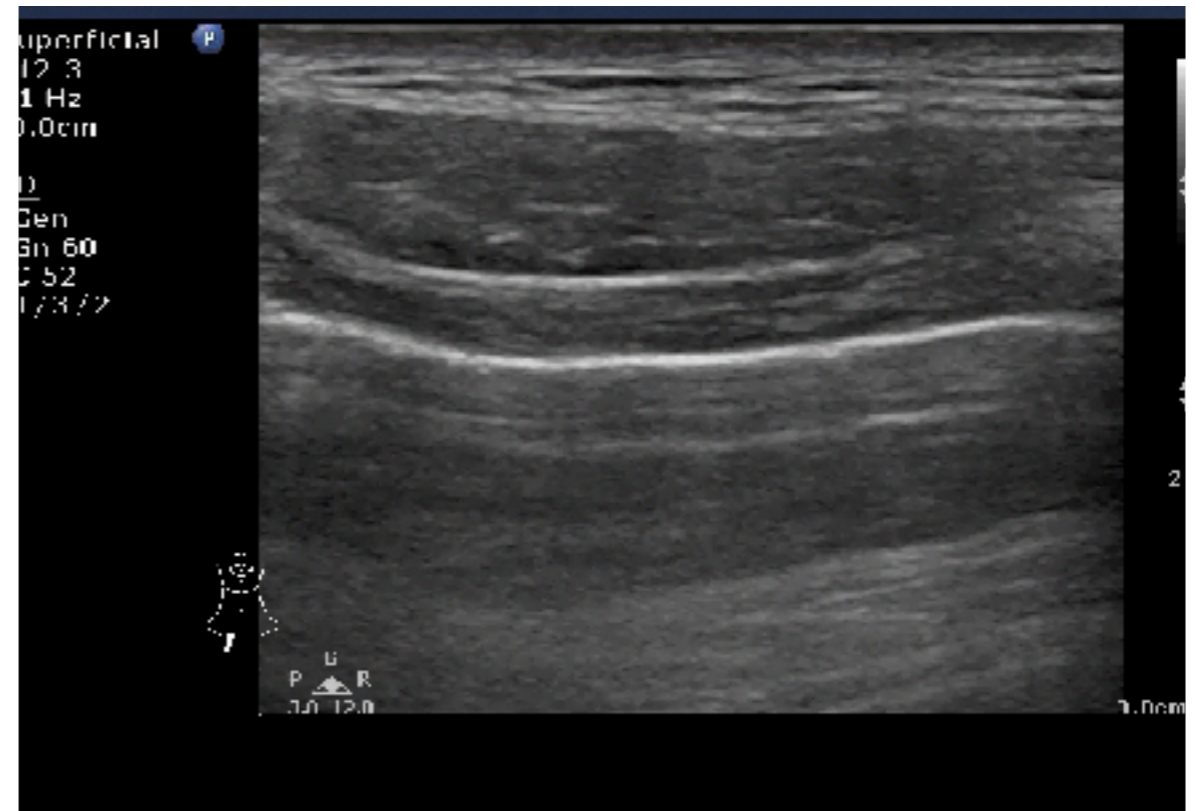
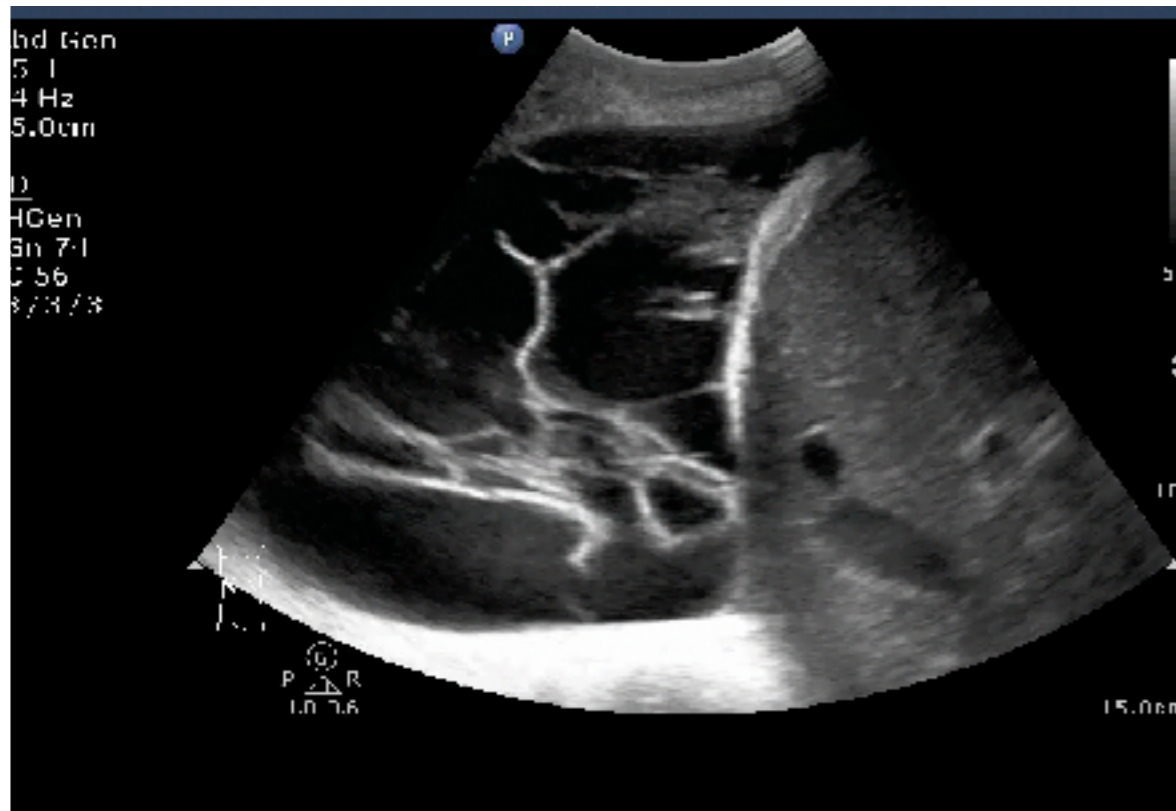
Artifact

Normal lung
Pneumothorax
AIS

Principle

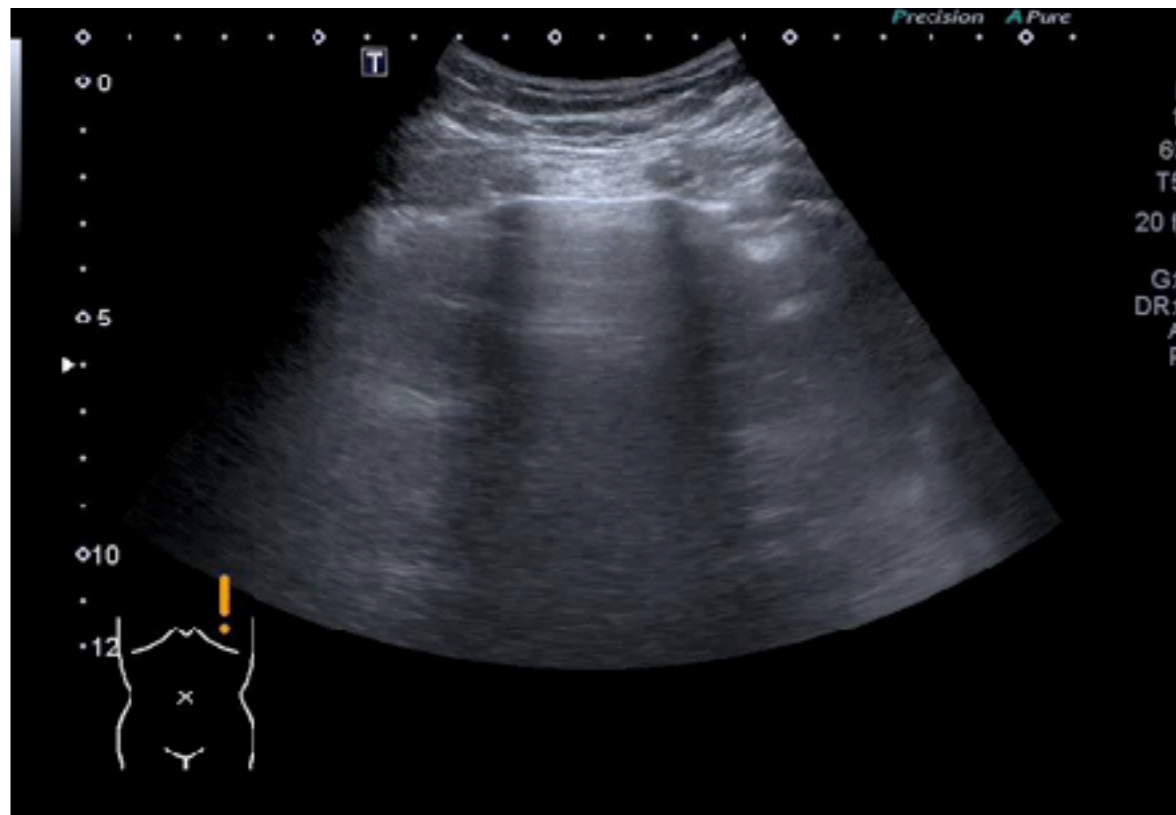
True

Artifact



Artifact

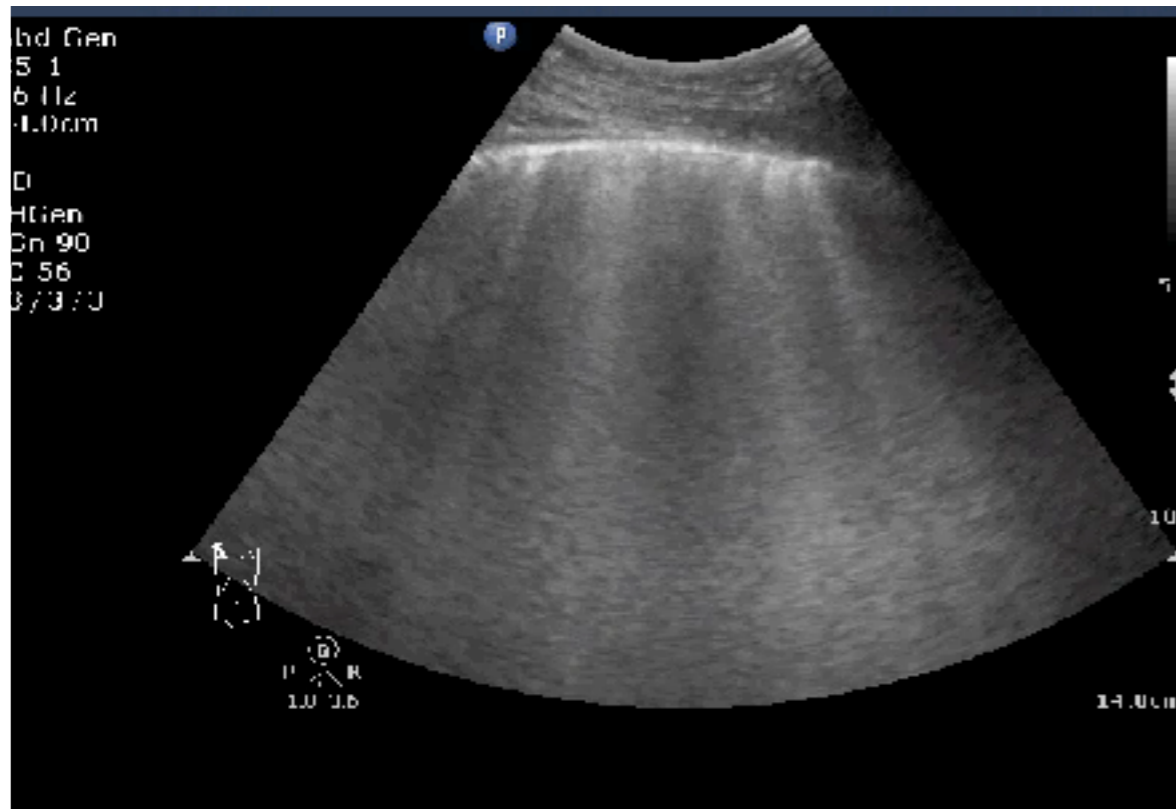
A lines



Pleural
Equal
Horizontal

Artifact

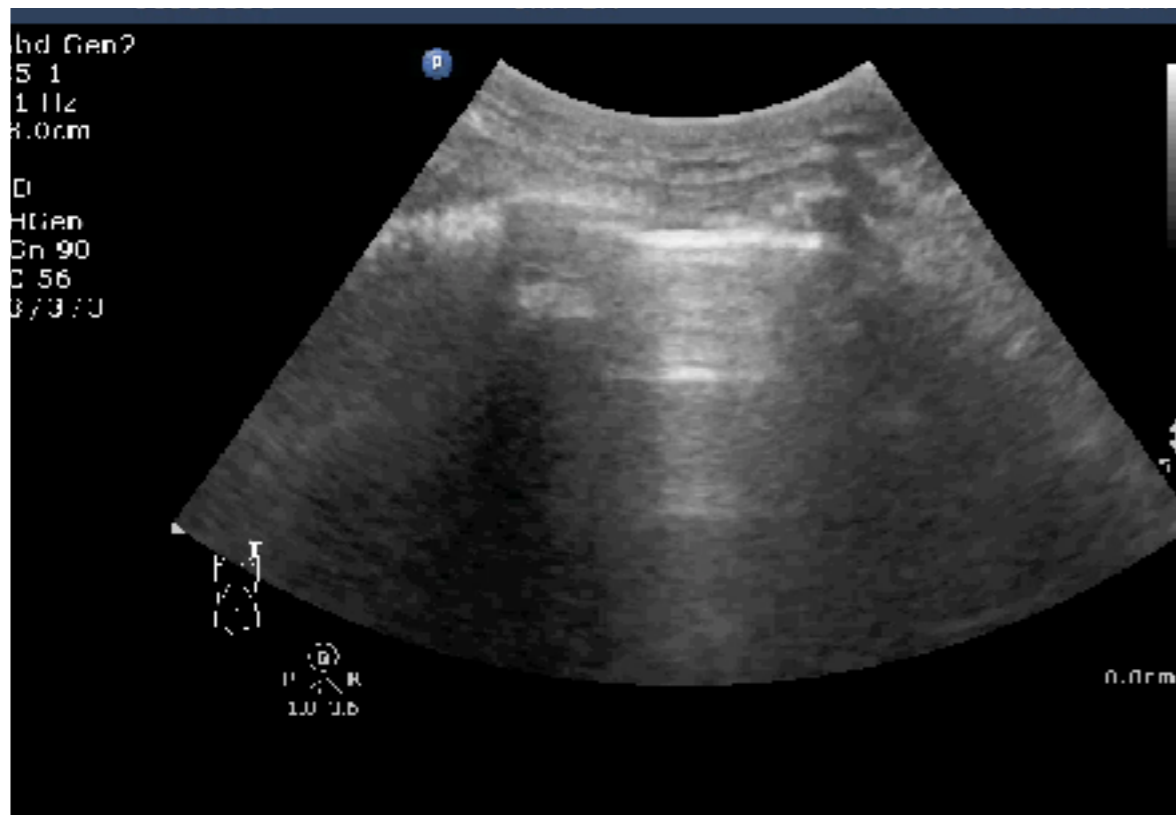
B lines



Pleural
Vertical
 > 3 in ICS

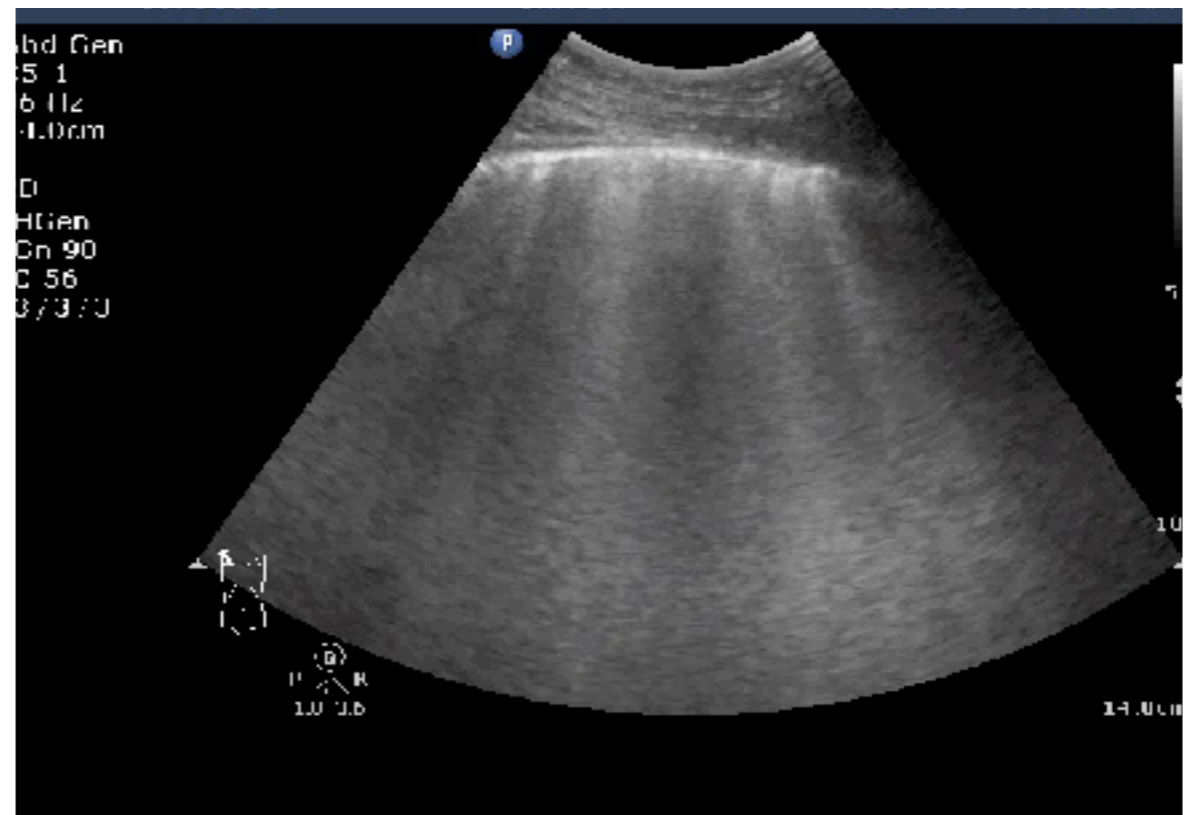
Artifact

A lines



No sliding

B lines



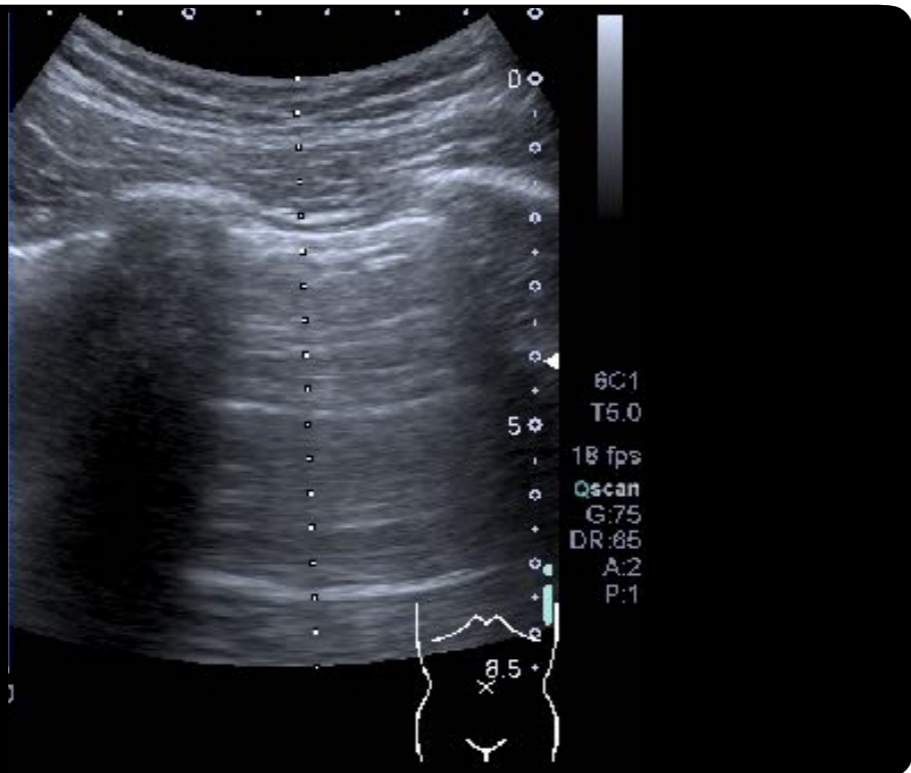Sliding

Normal Lung


Static

Dynamic

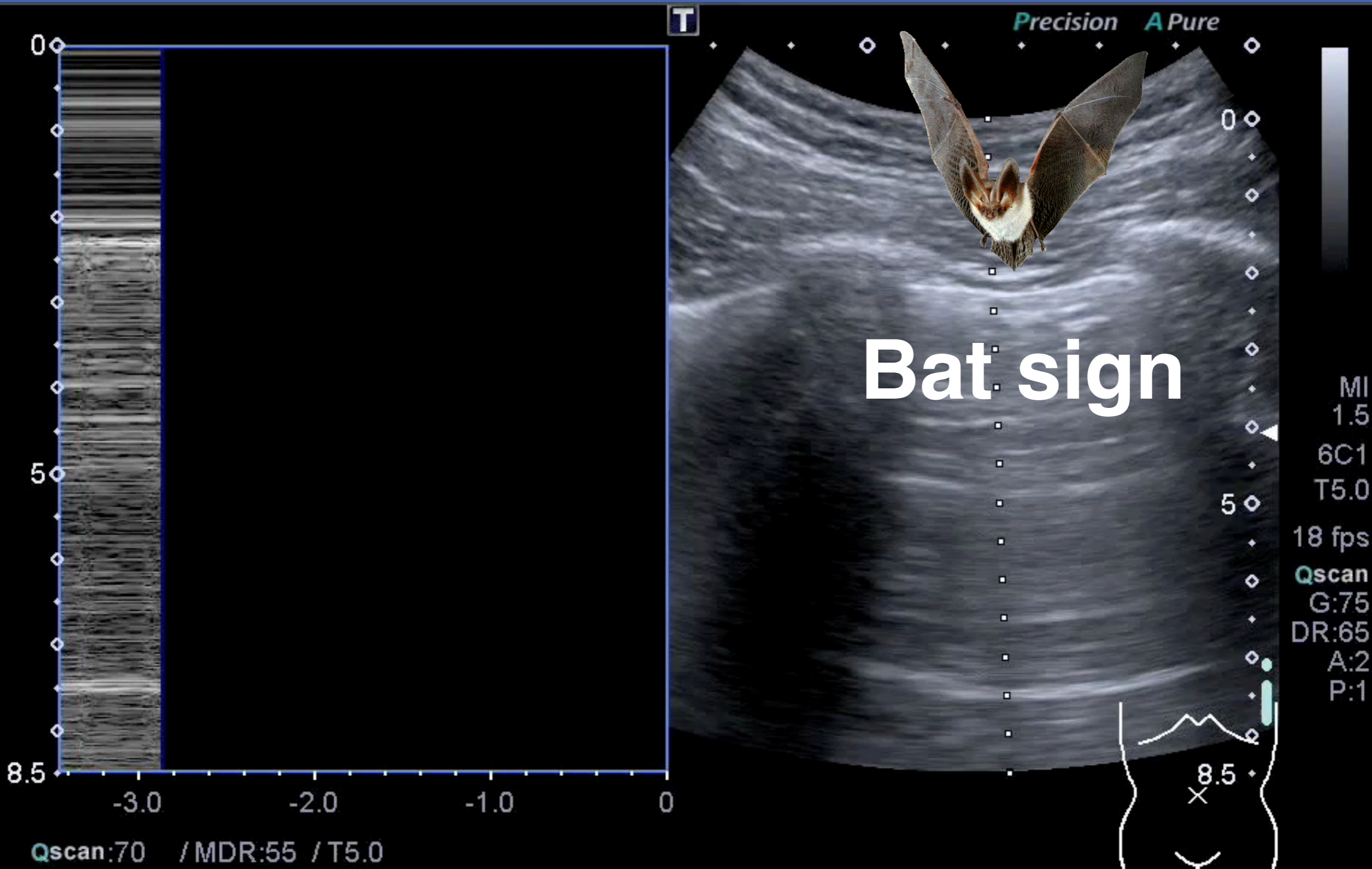
B



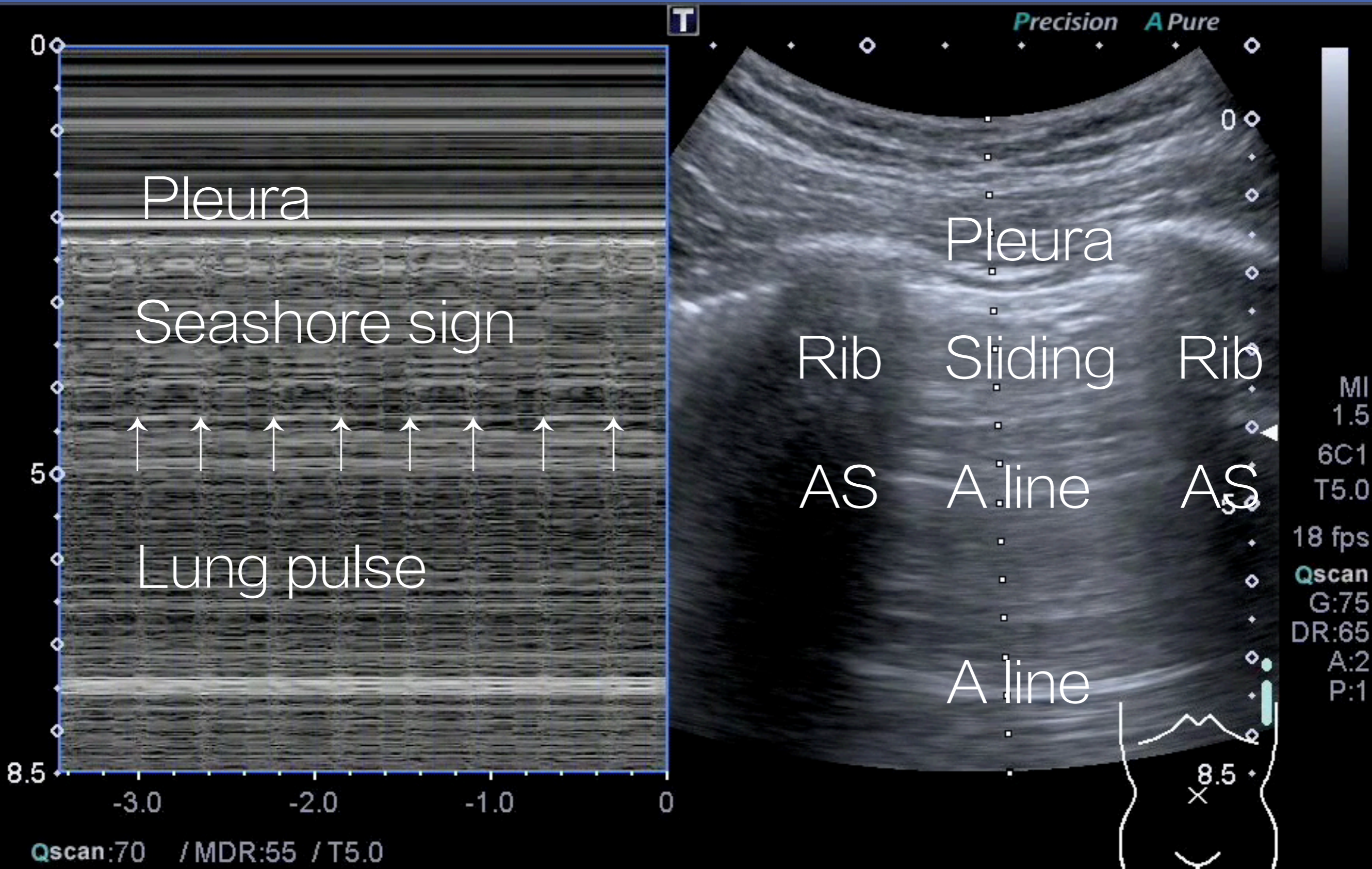
M



Normal Lung



Normal Lung



Interpretation

氣
水

真
假

A
B

動
靜

PLUS for PAP

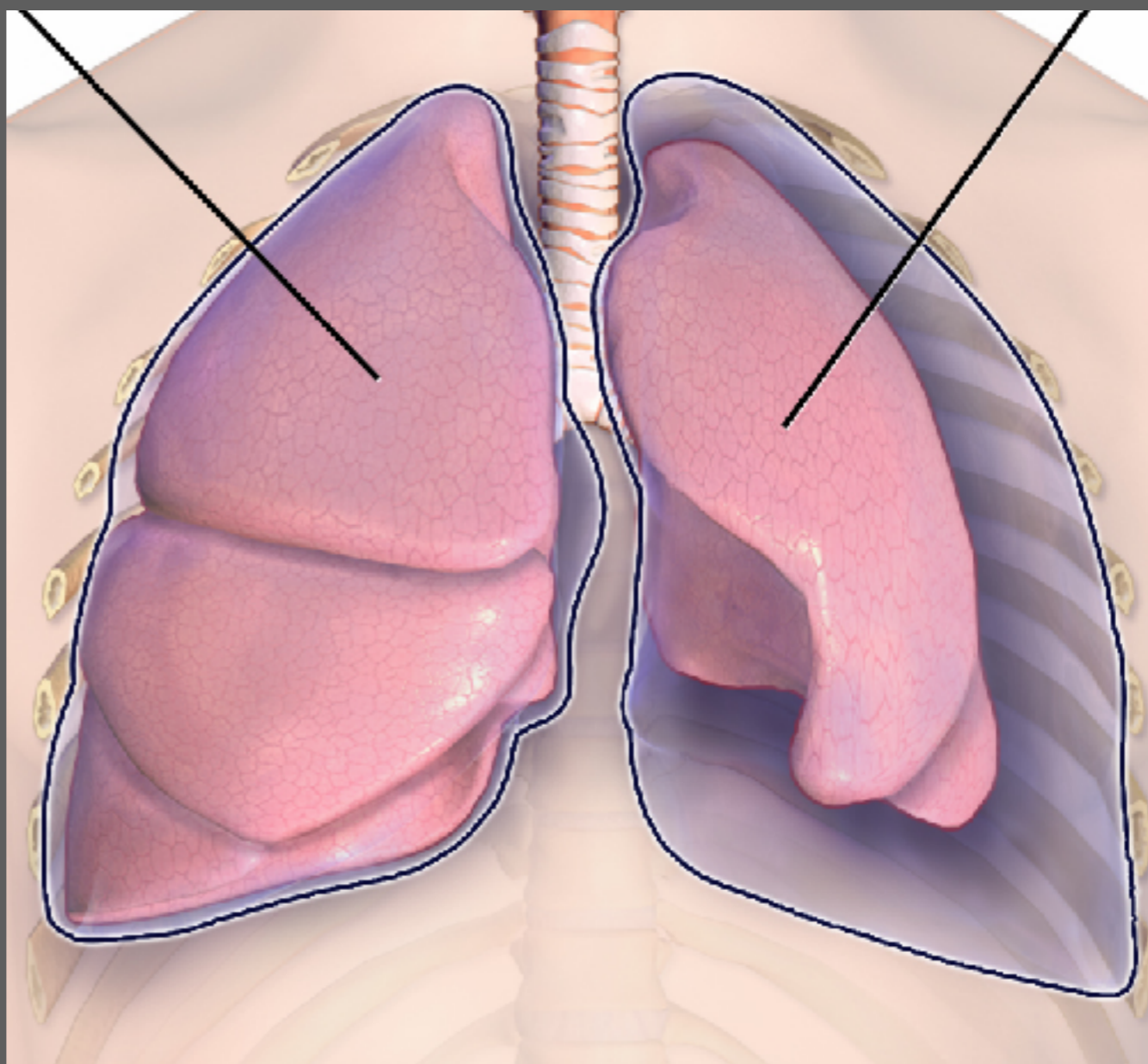
PTX

AIS

PLE

PLUS for PAP

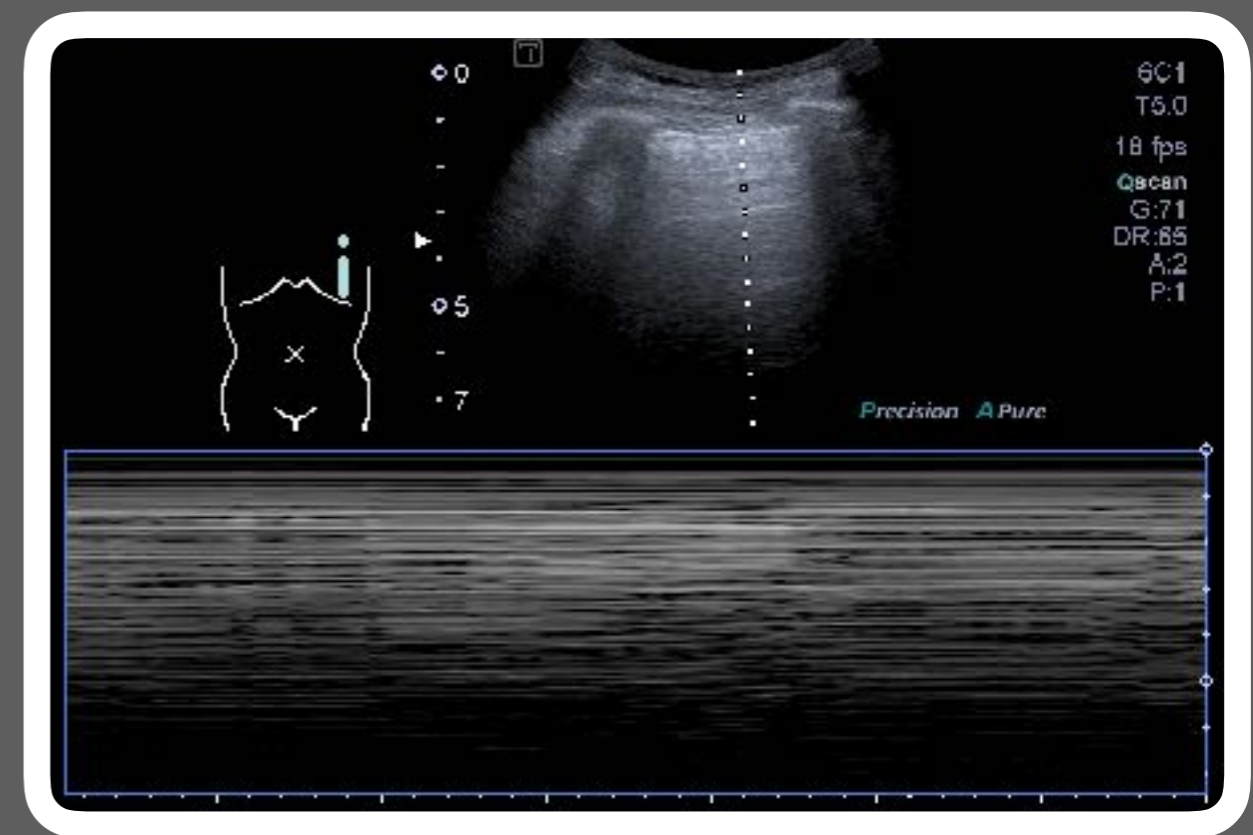
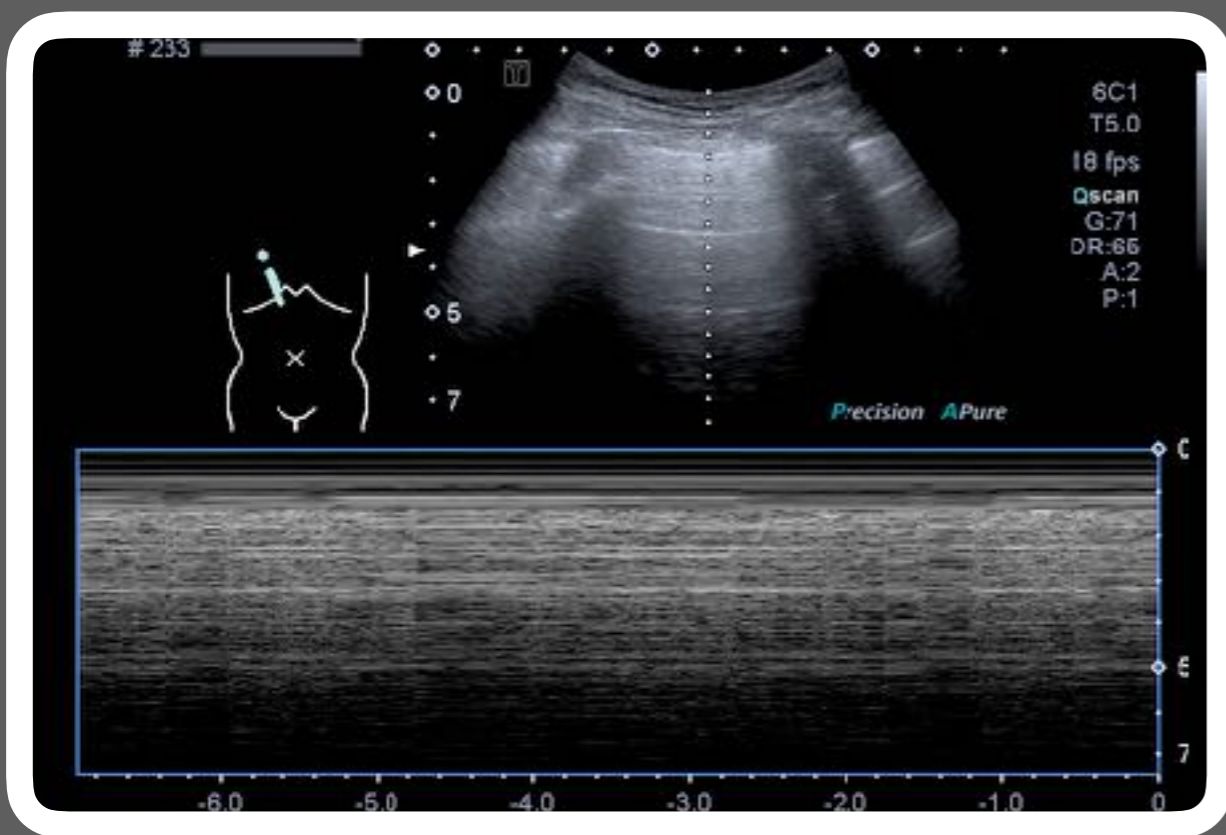
PTX



Pneumothorax

Normal

Pneumothorax



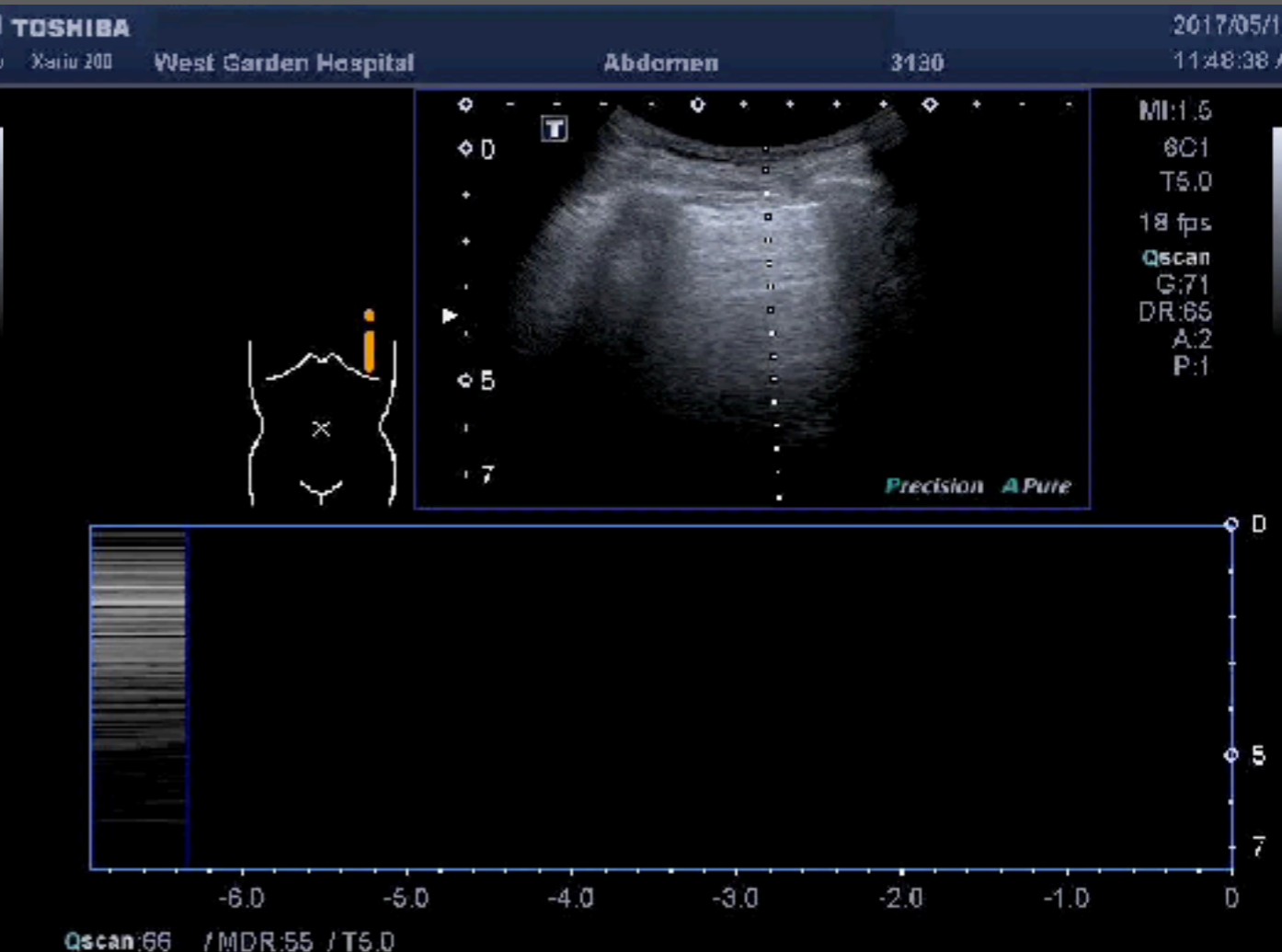
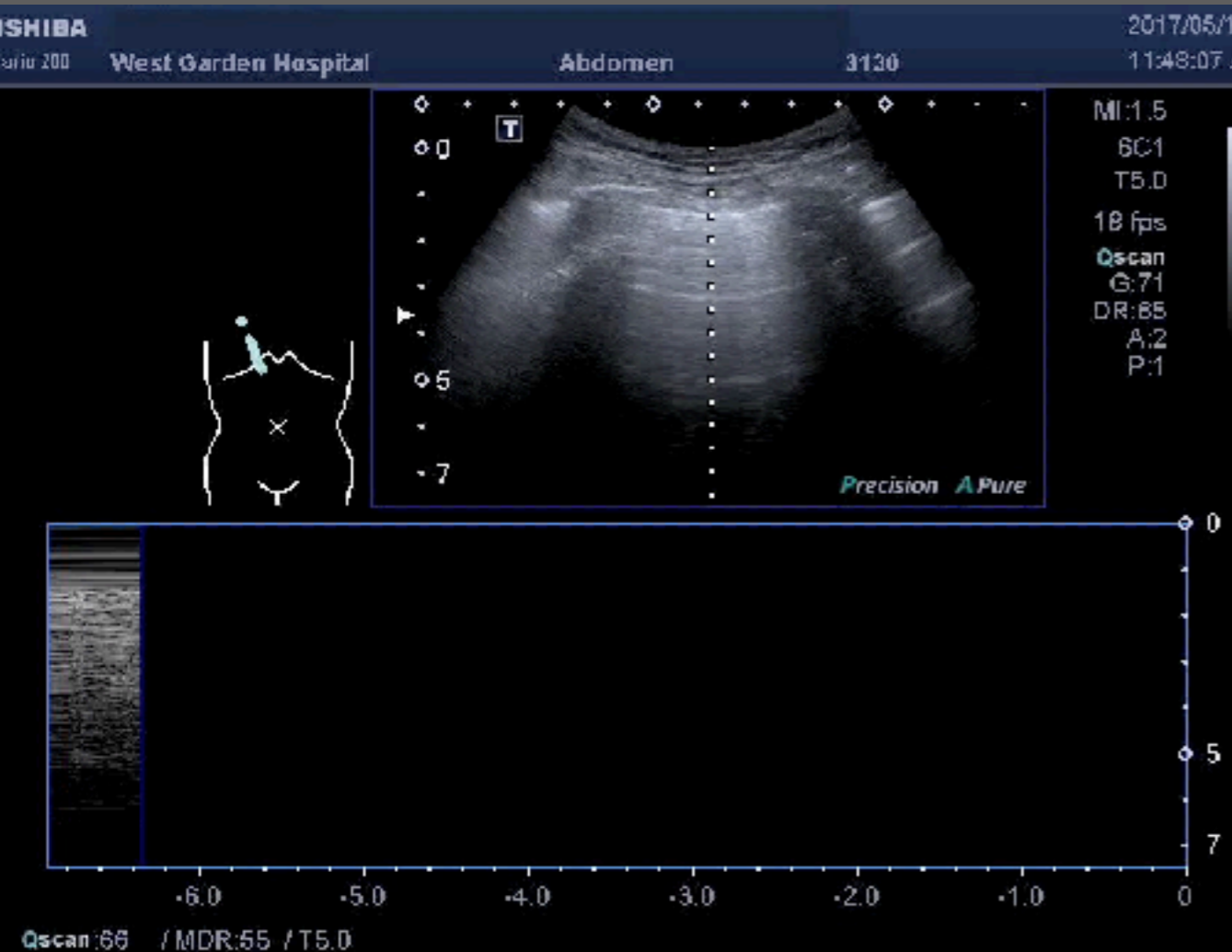
Seashore sign

Stratosphere sign

Pneumothorax

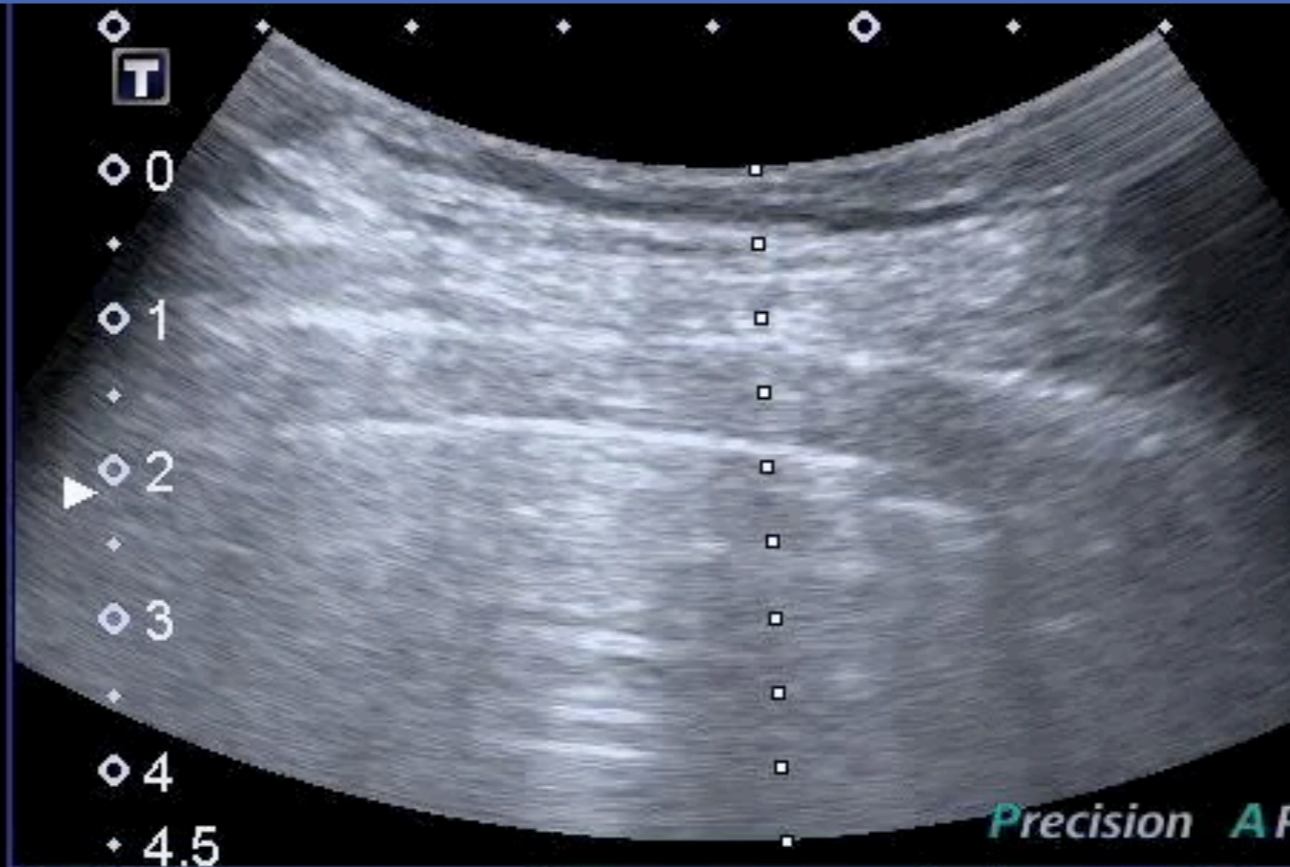
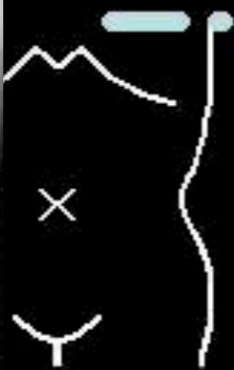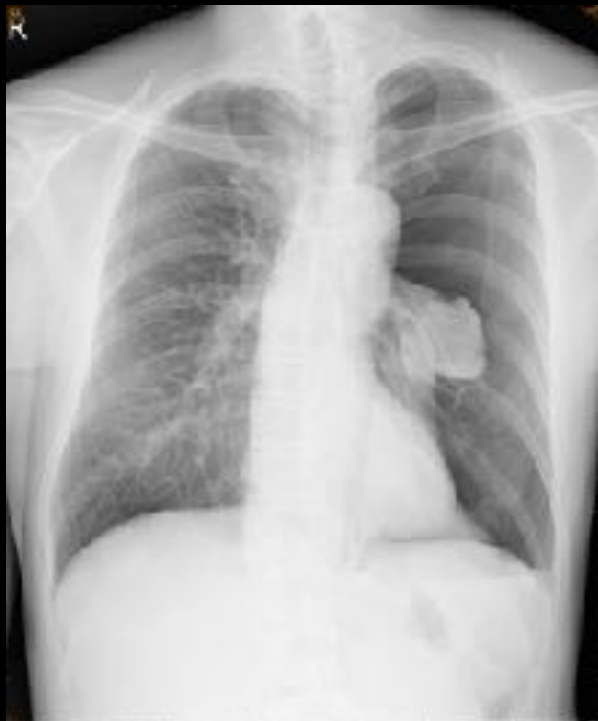Normal

Pneumothorax

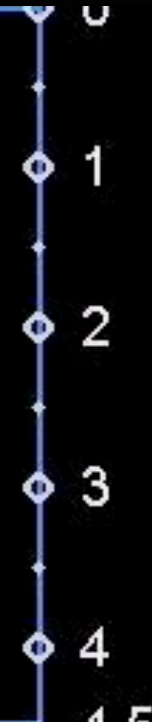
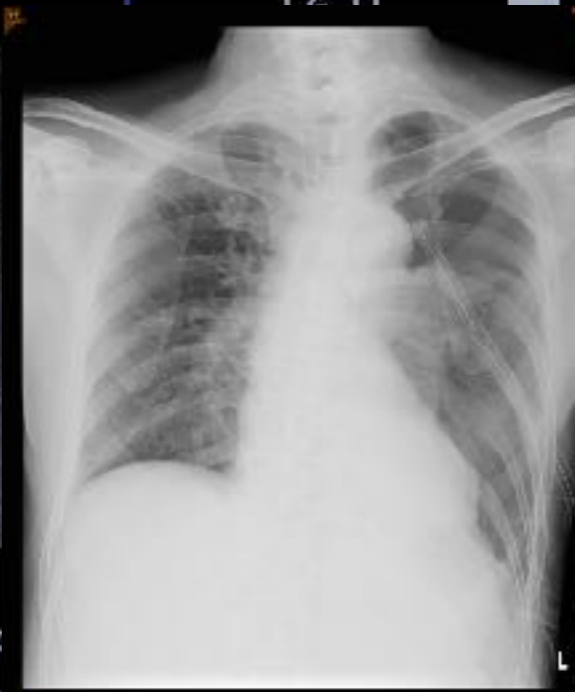

Lung point

A



B



PLUS for PAP

PTX

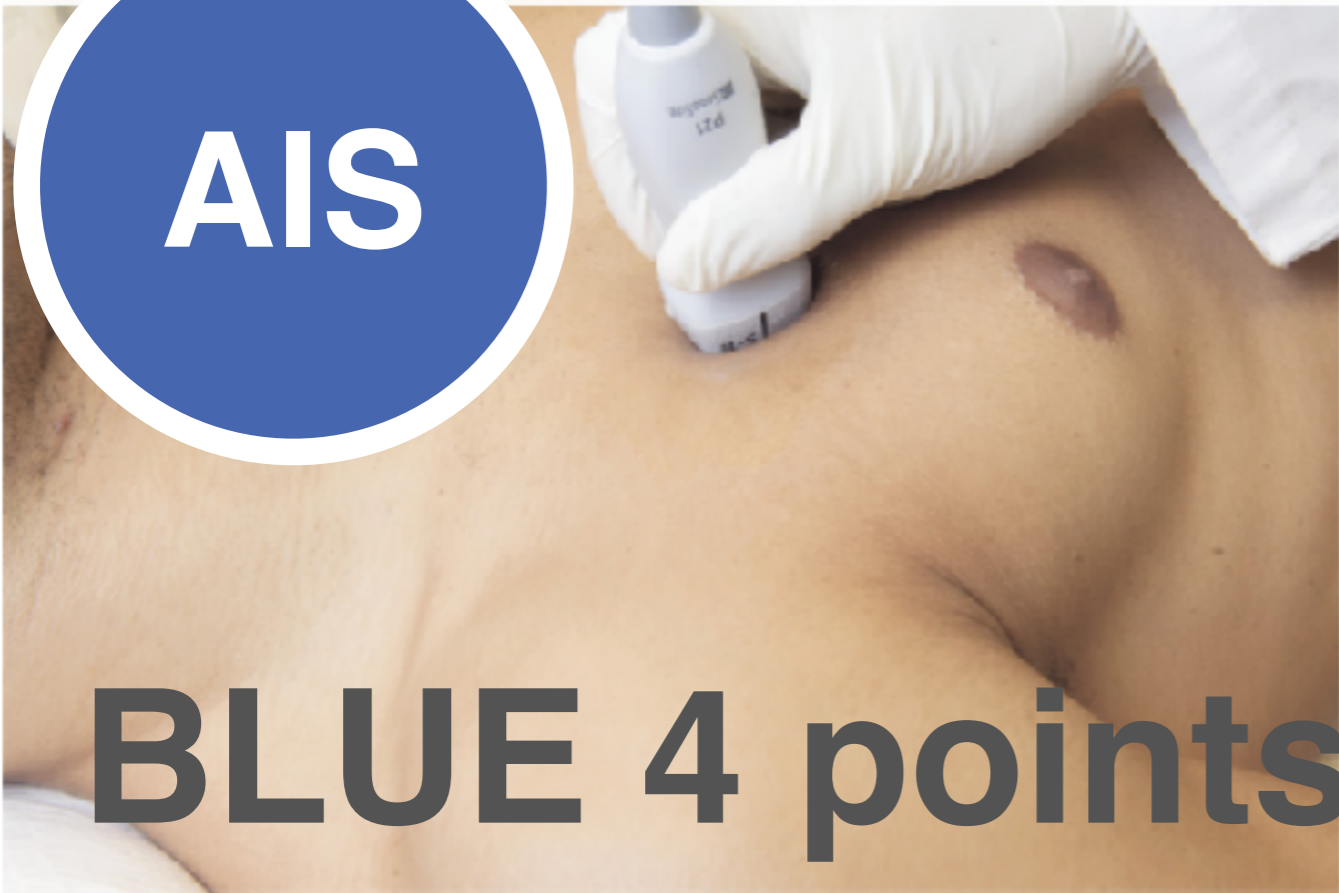AIS

3

2

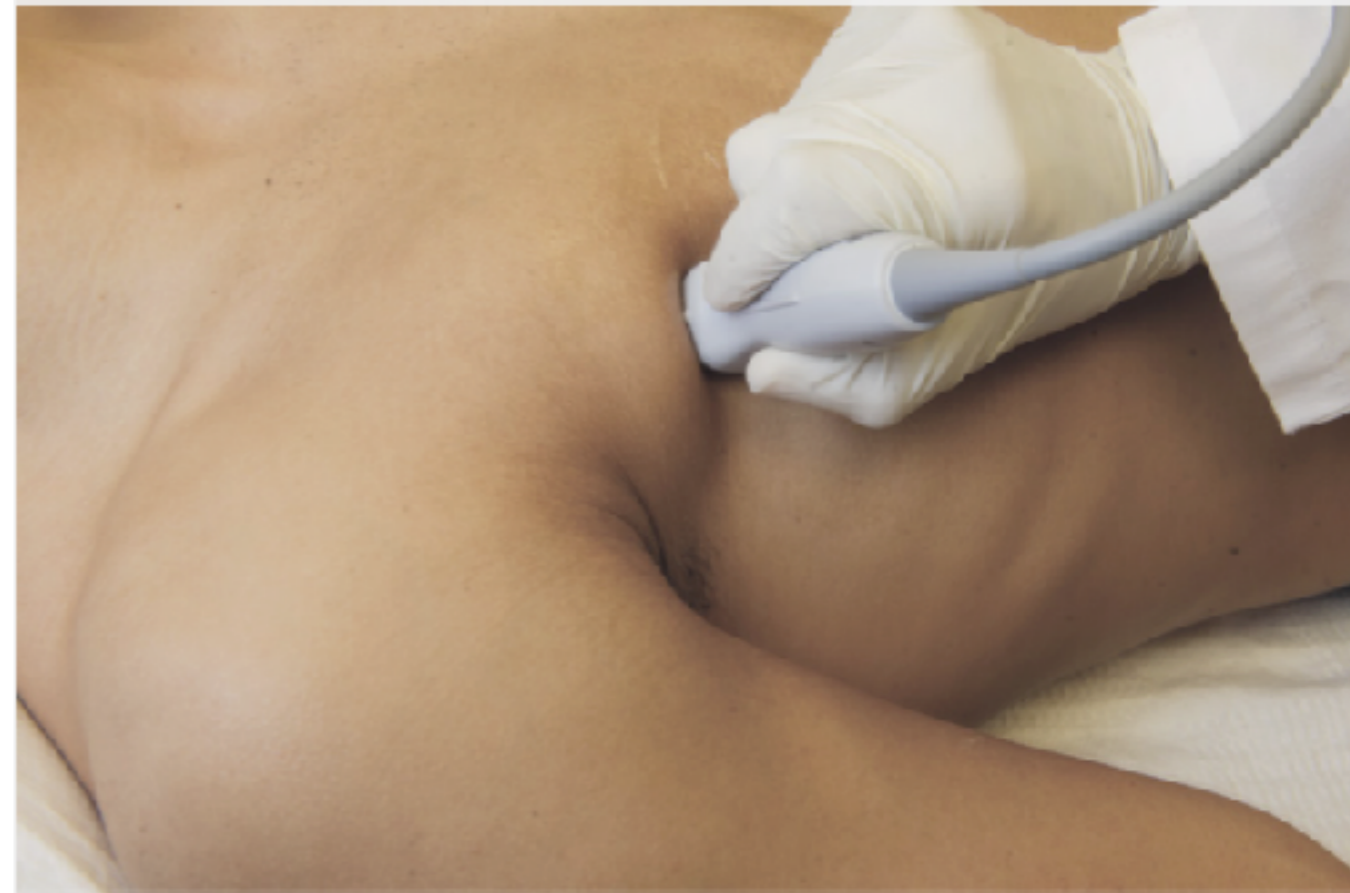3

Point 1

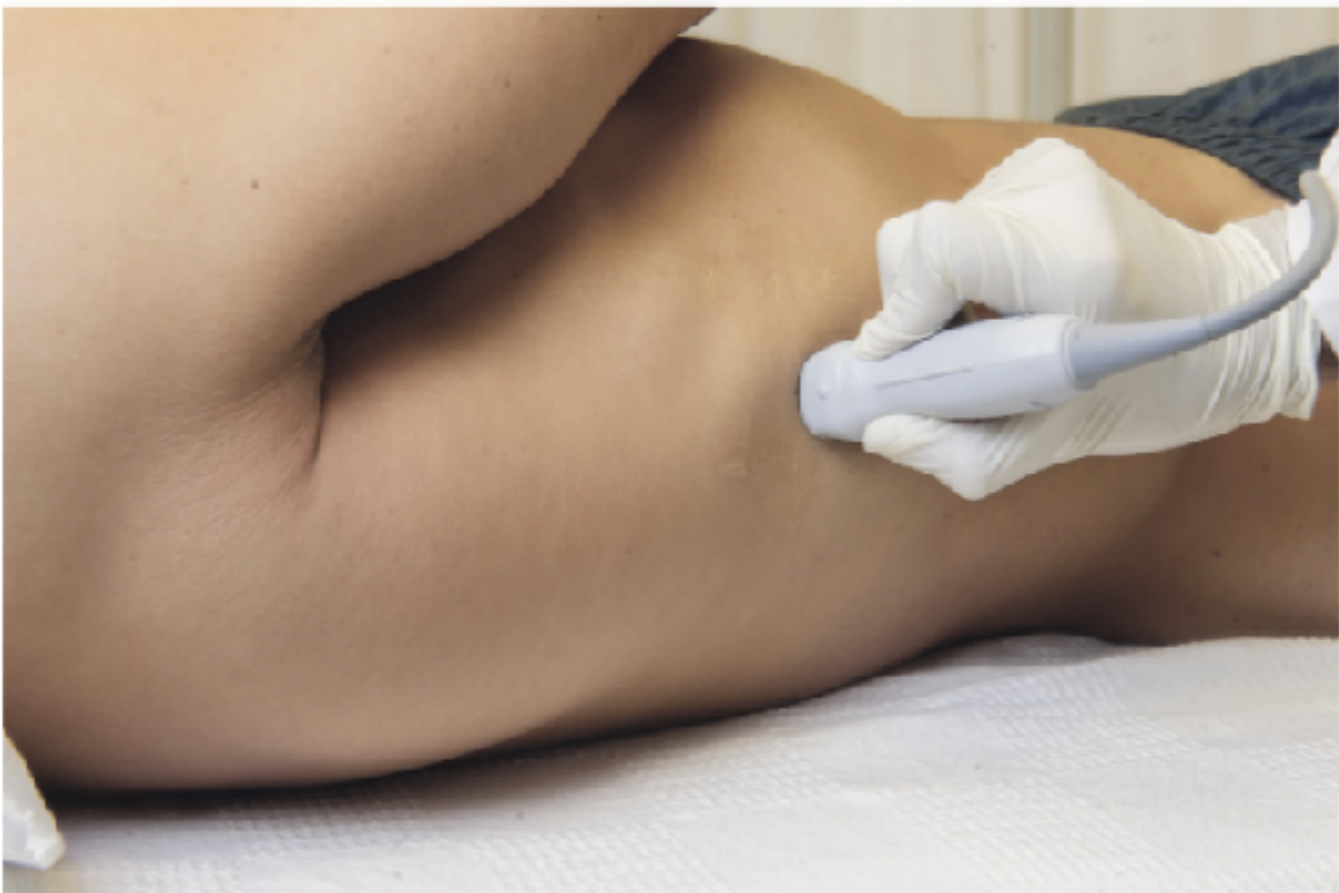

BLUE 4 points

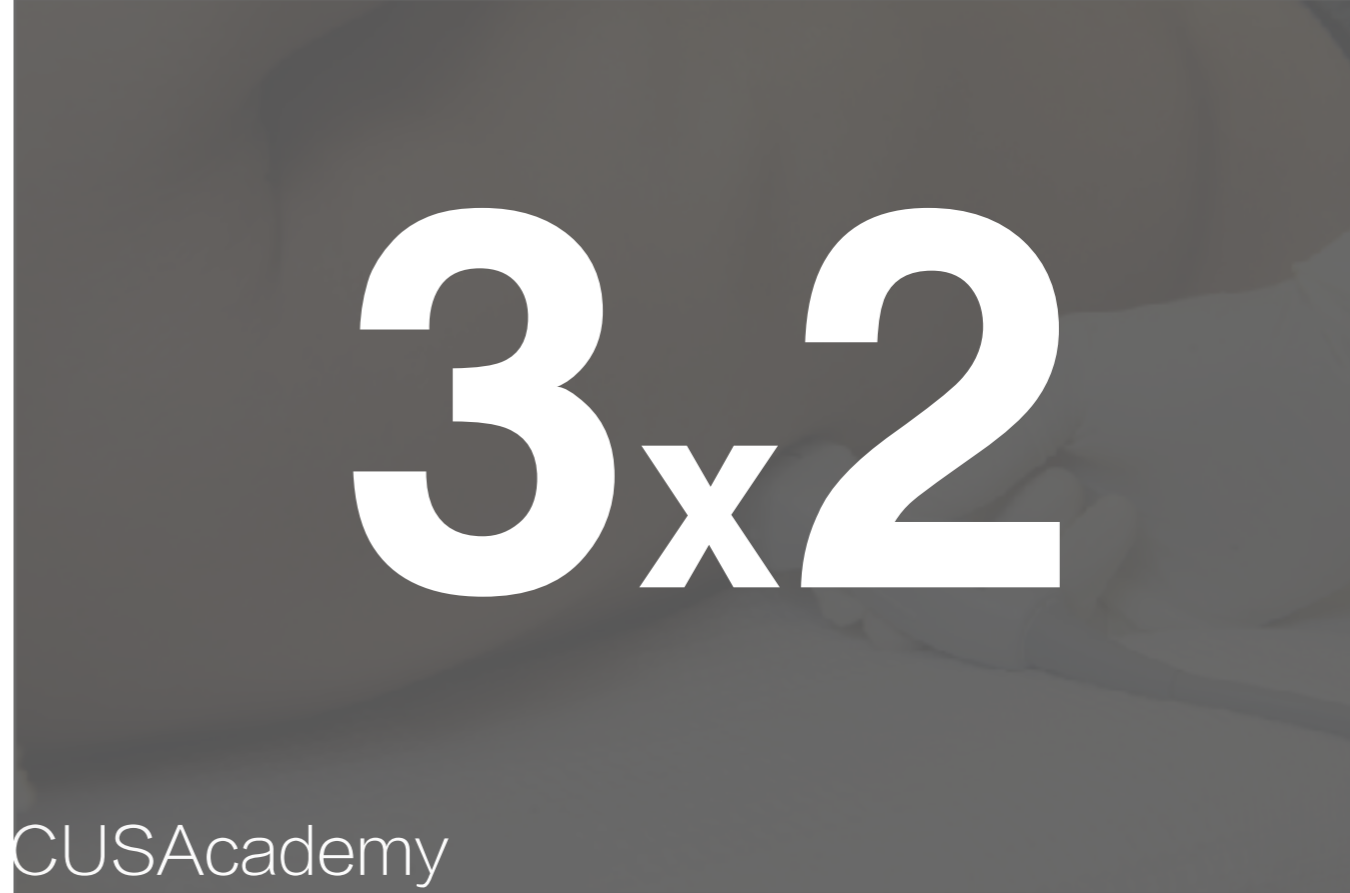
Point 2



Point 3



Point 4



3x2

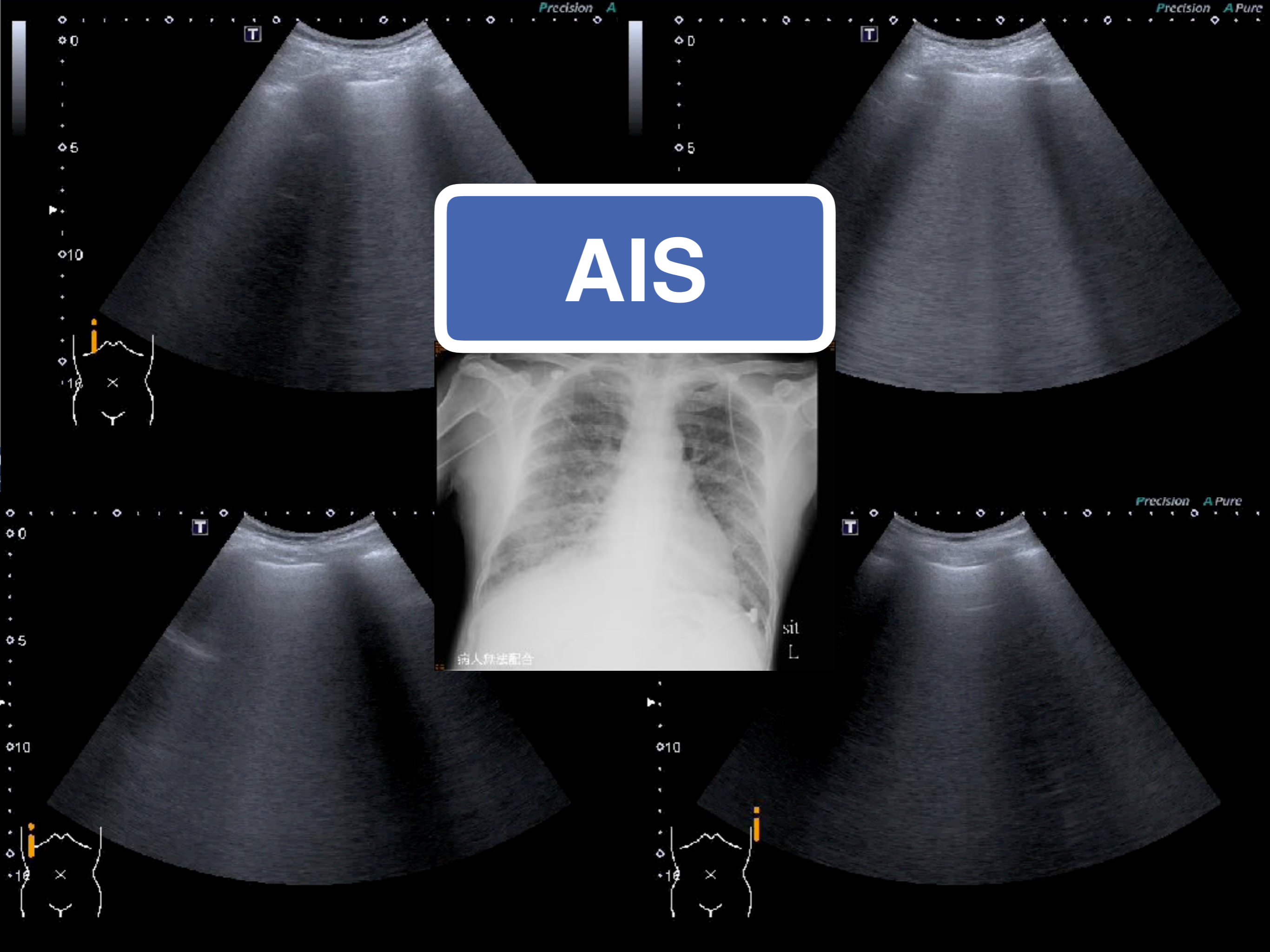
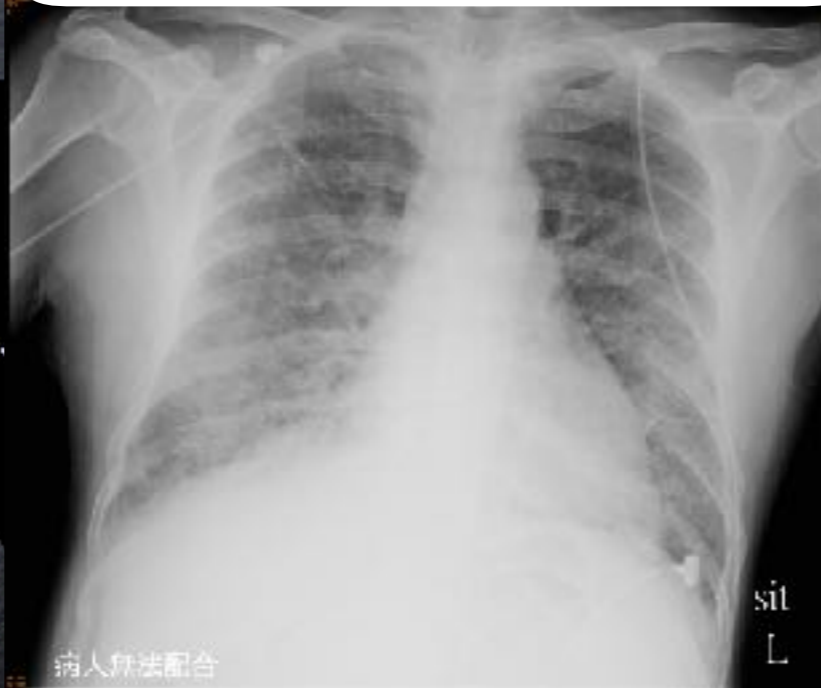

AIS

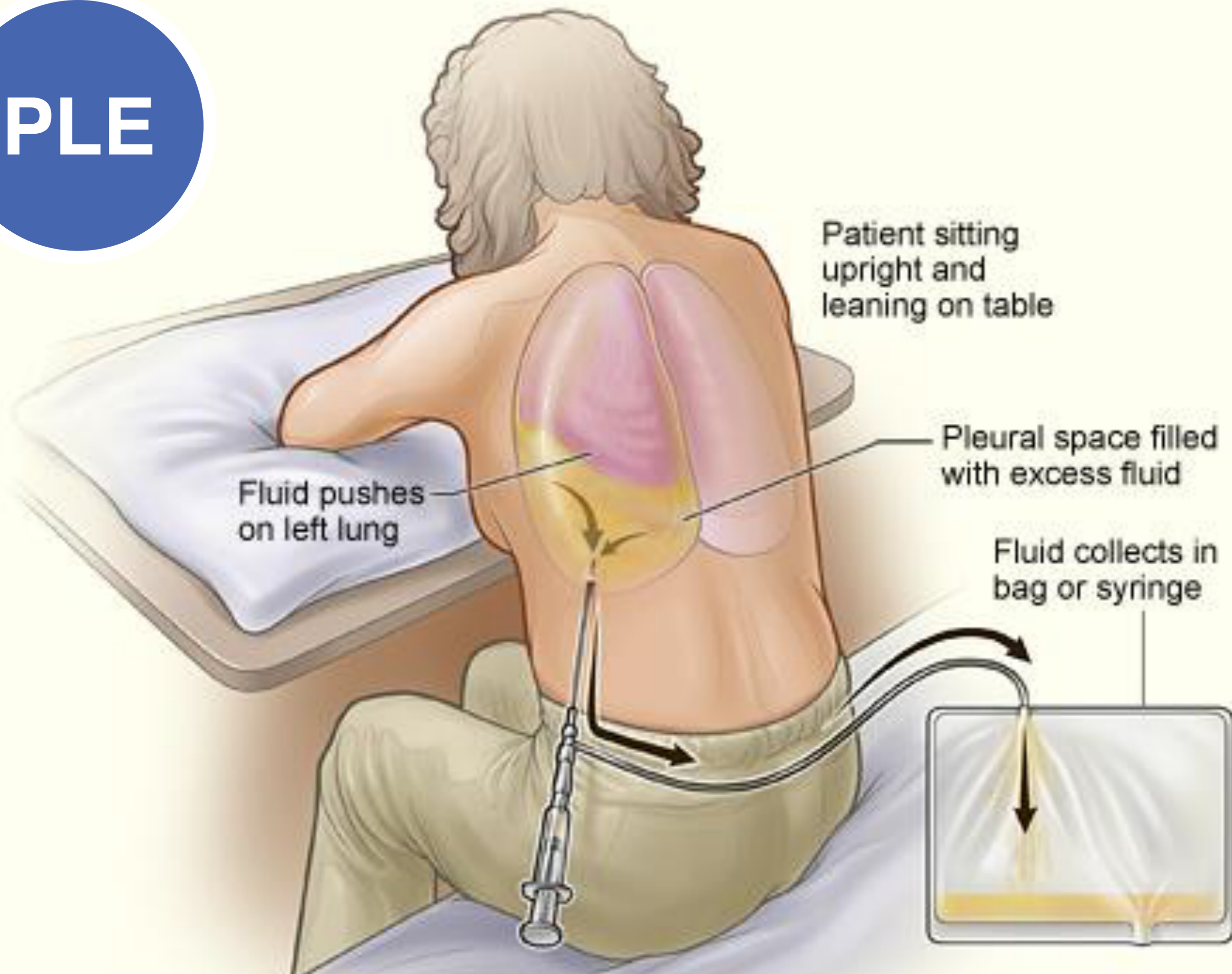
3

15.12

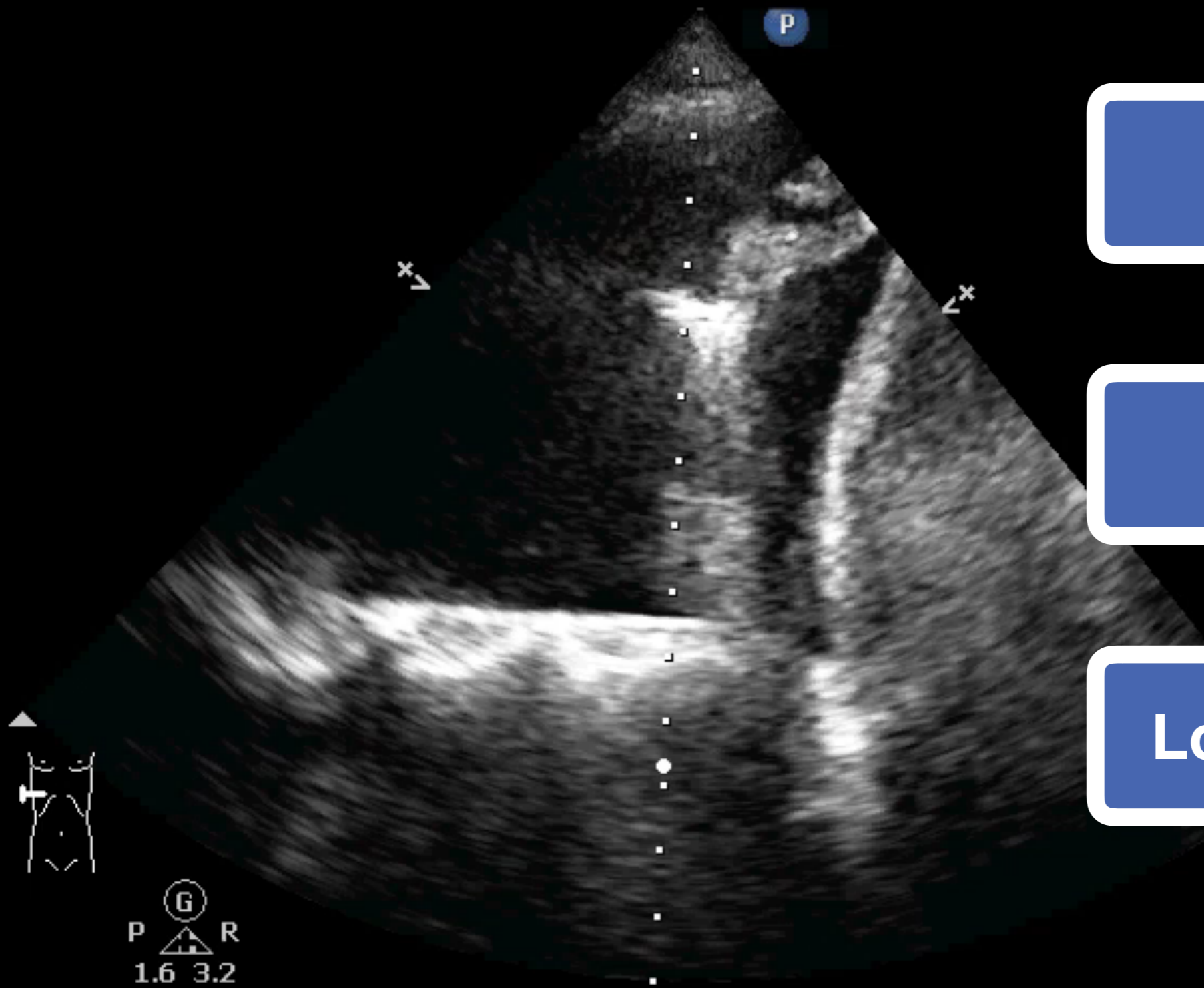
AIS



PLE



SKH-EUTC©ChenKC



Jellyfish sign

Spine sign

Loss of curtain sign

Focused Cardiac Ultrasound in the Emergent Setting:
A Consensus Statement of the American Society of
Echocardiography and American College of
Emergency Physicians

2010

Pericardial effusion
Global systolic function
Marked RV & LV enlargement
Volume assessment
Pericardiocentesis
TVP wire confirmation

FoCUS

Focus Cardiac UltraSound for critically ill patients

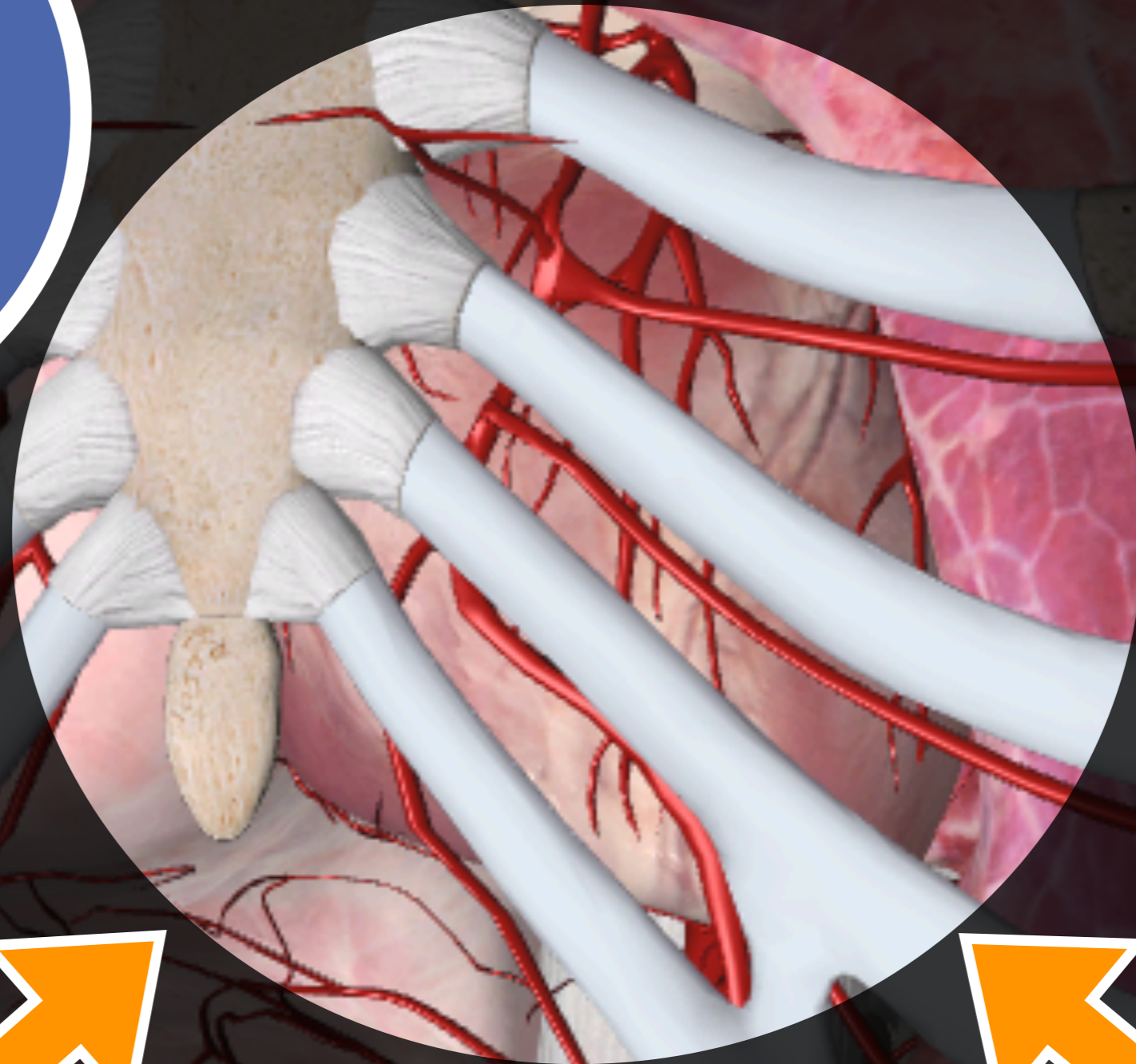

International Evidence-Based Recommendations for Focused Cardiac Ultrasound
J Am Soc Echocardiogr 2014;27:683.e1-e33

Parasternal



SPA



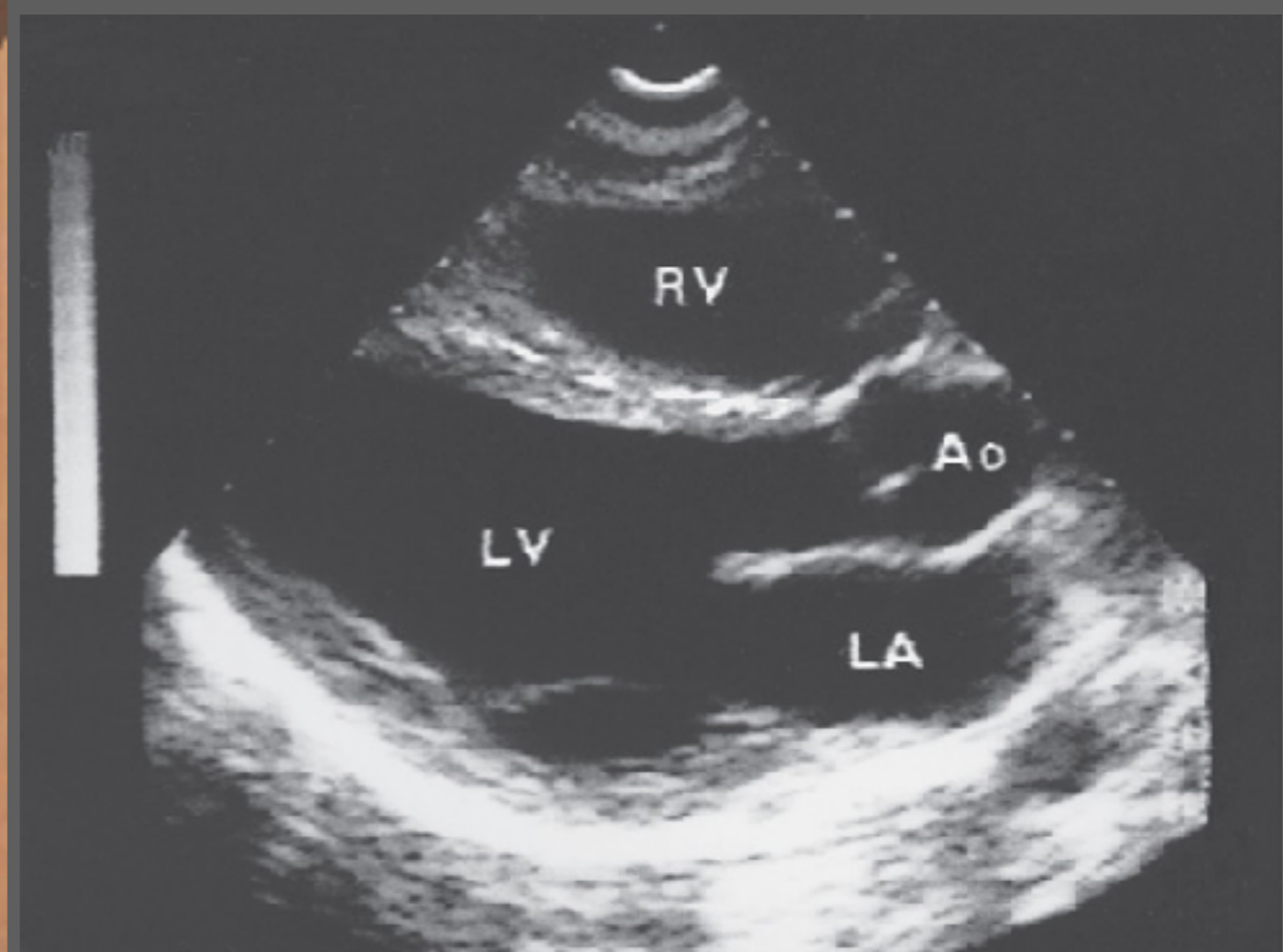
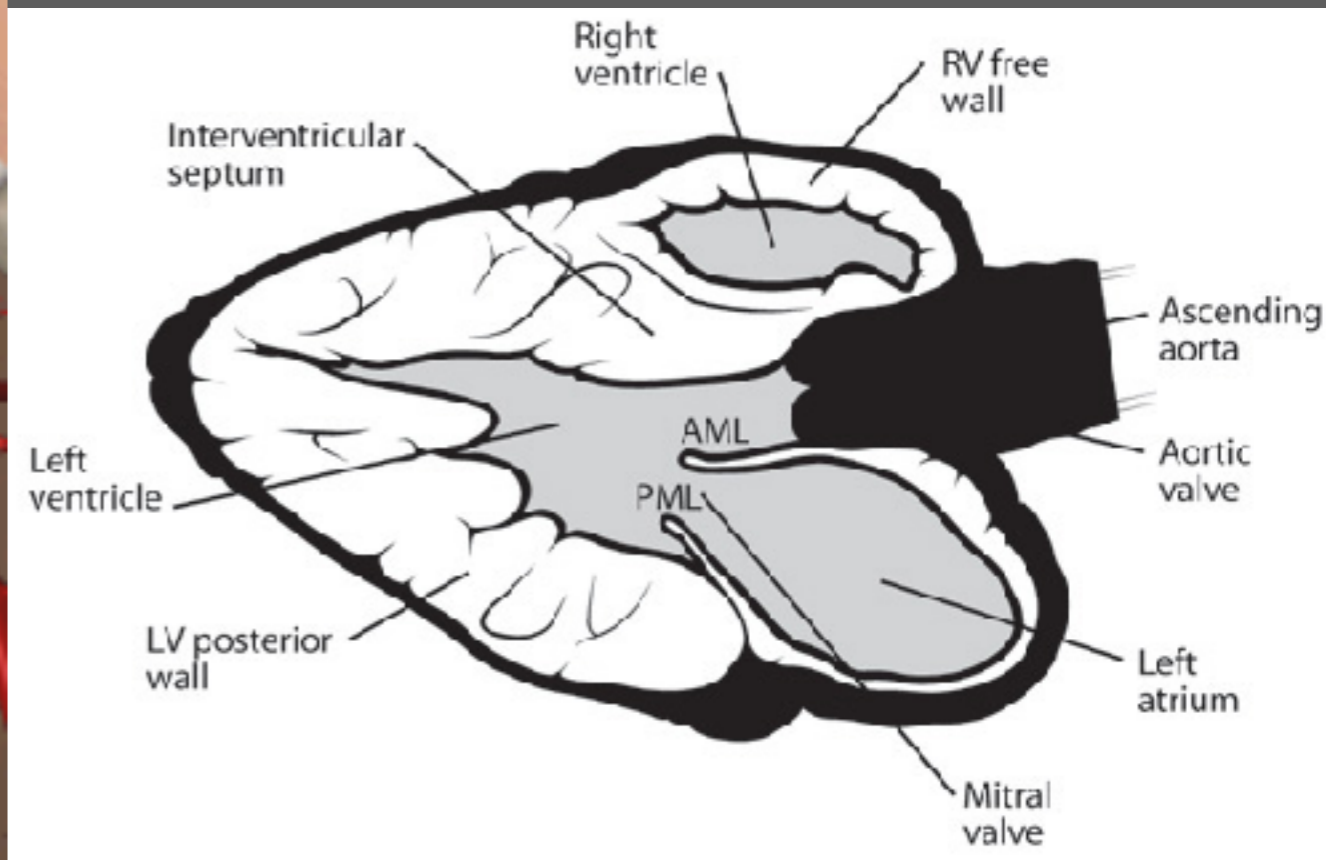
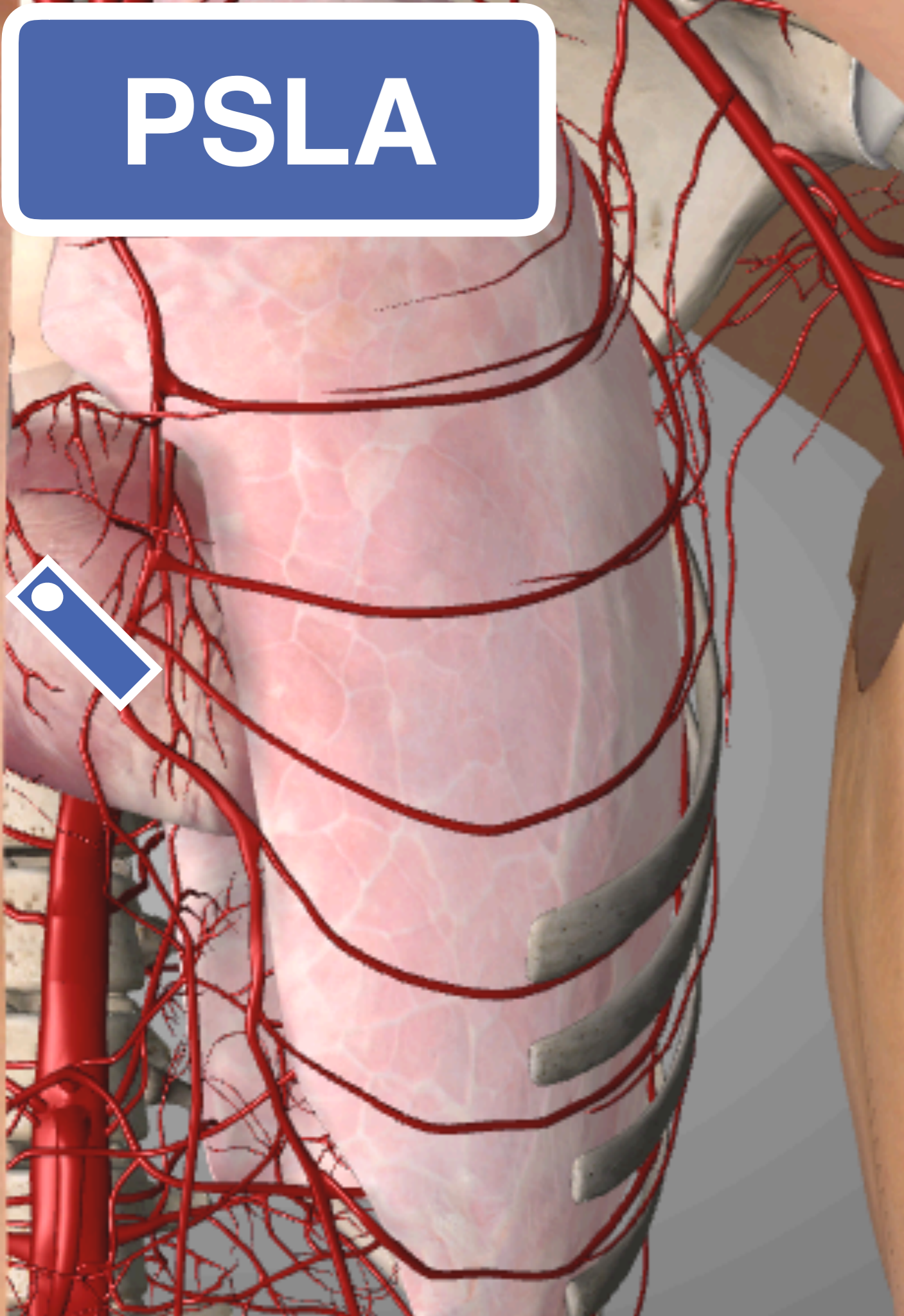
Subcostal



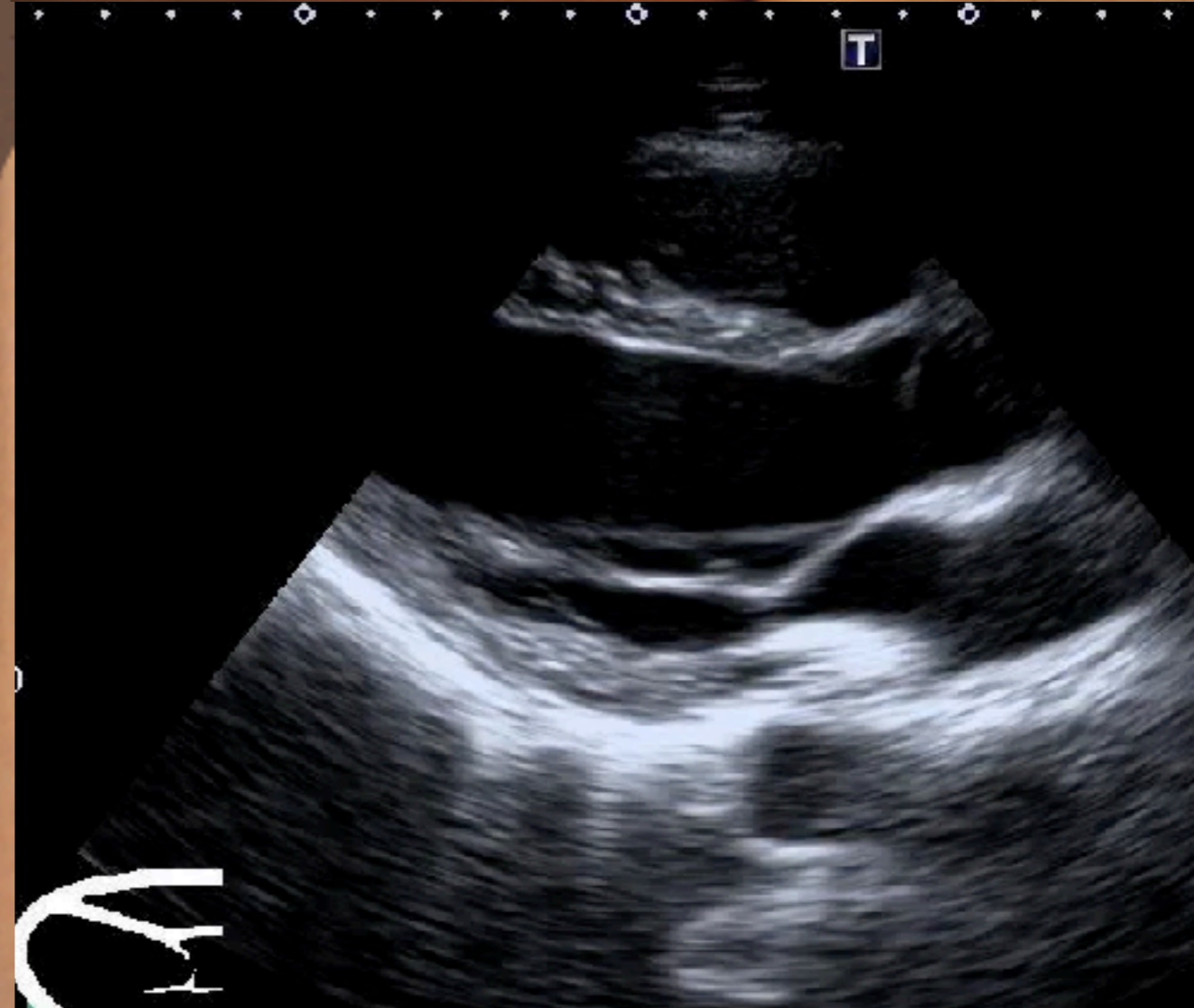
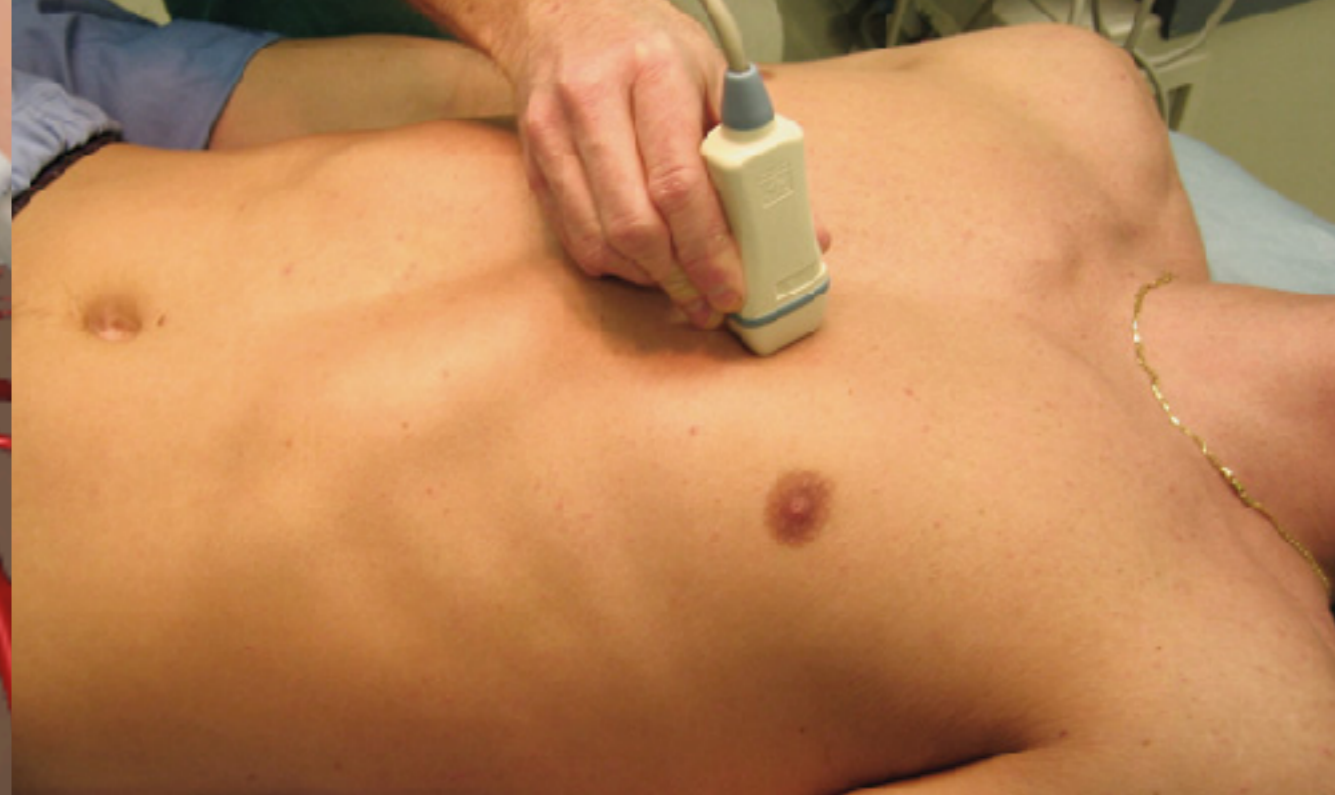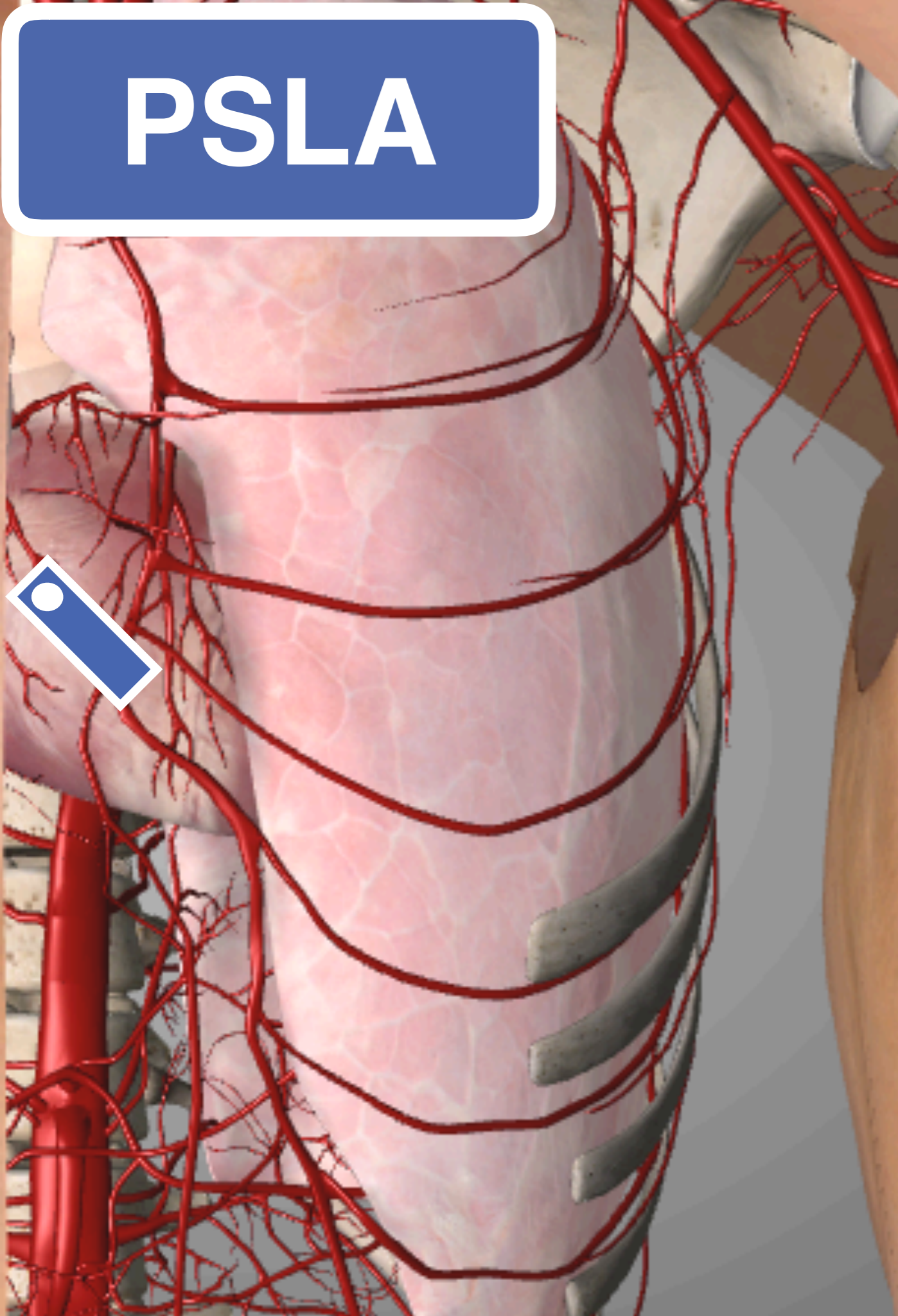
Apical

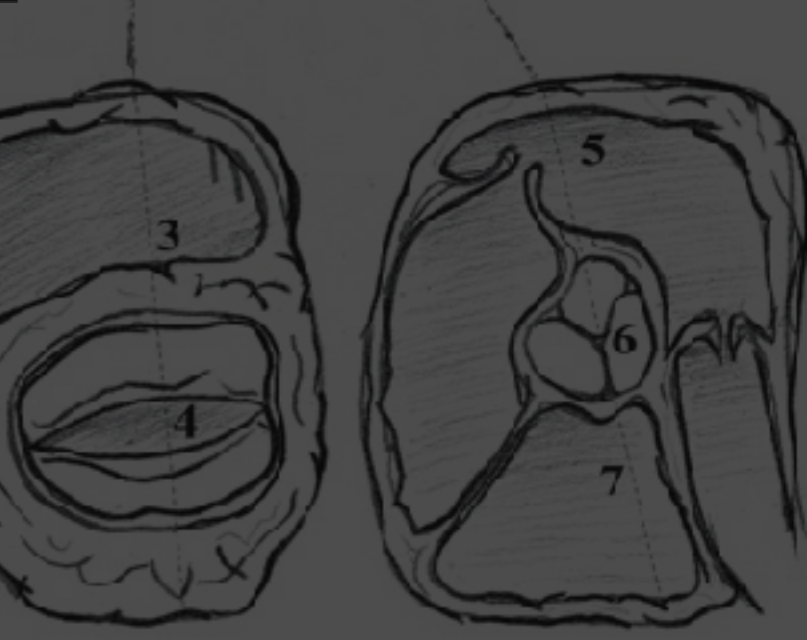
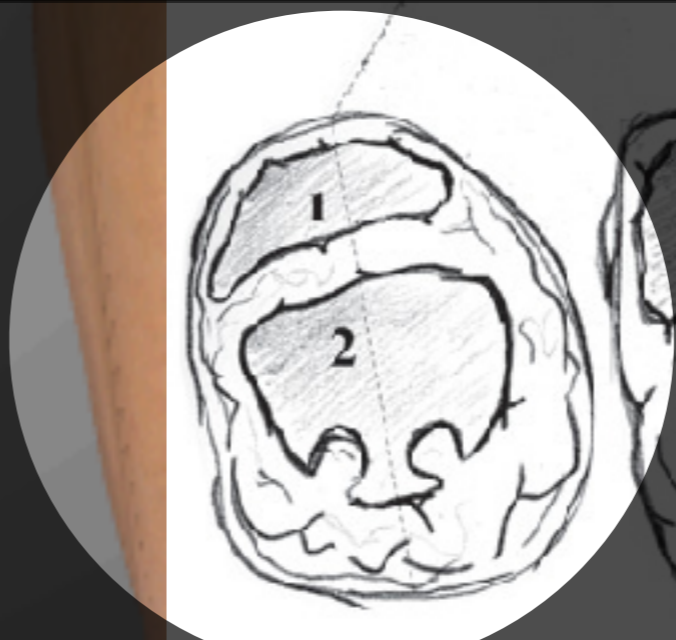
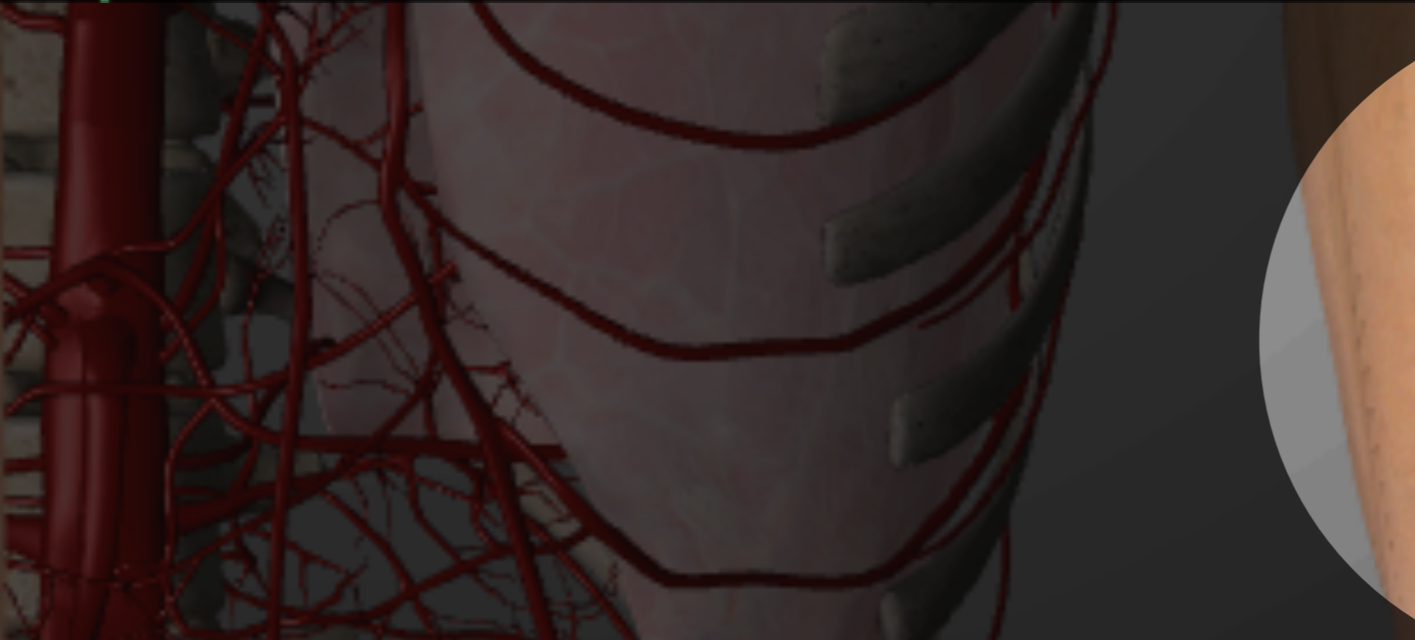
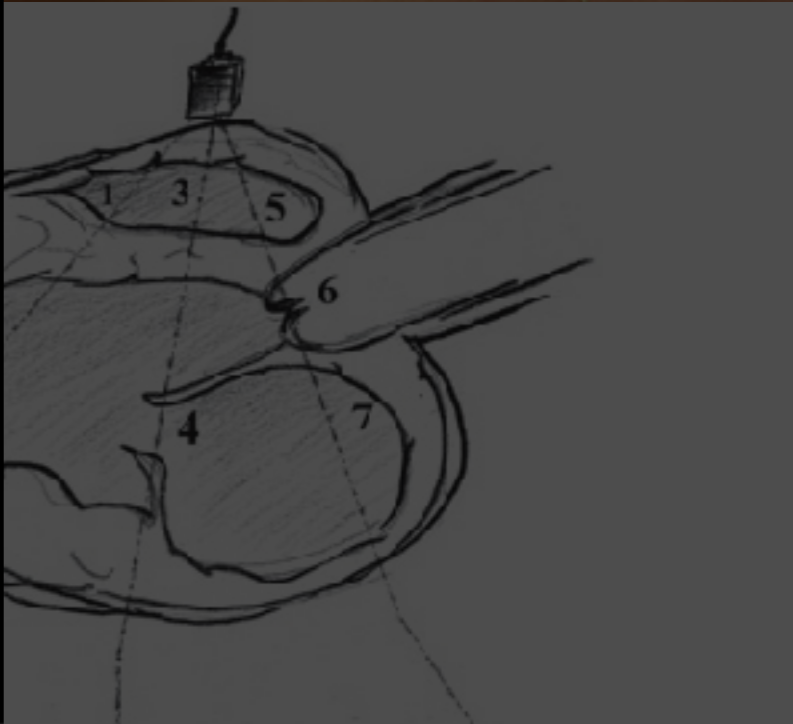
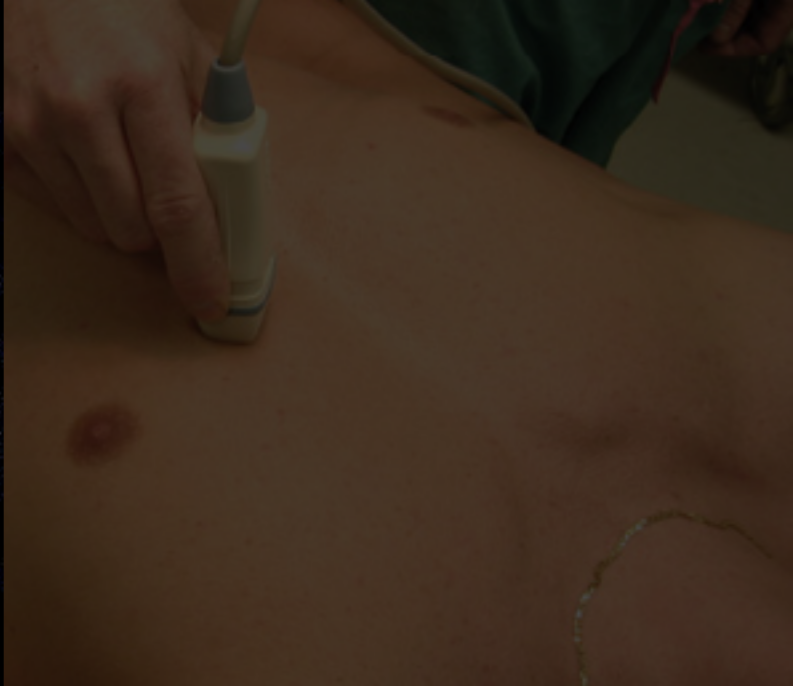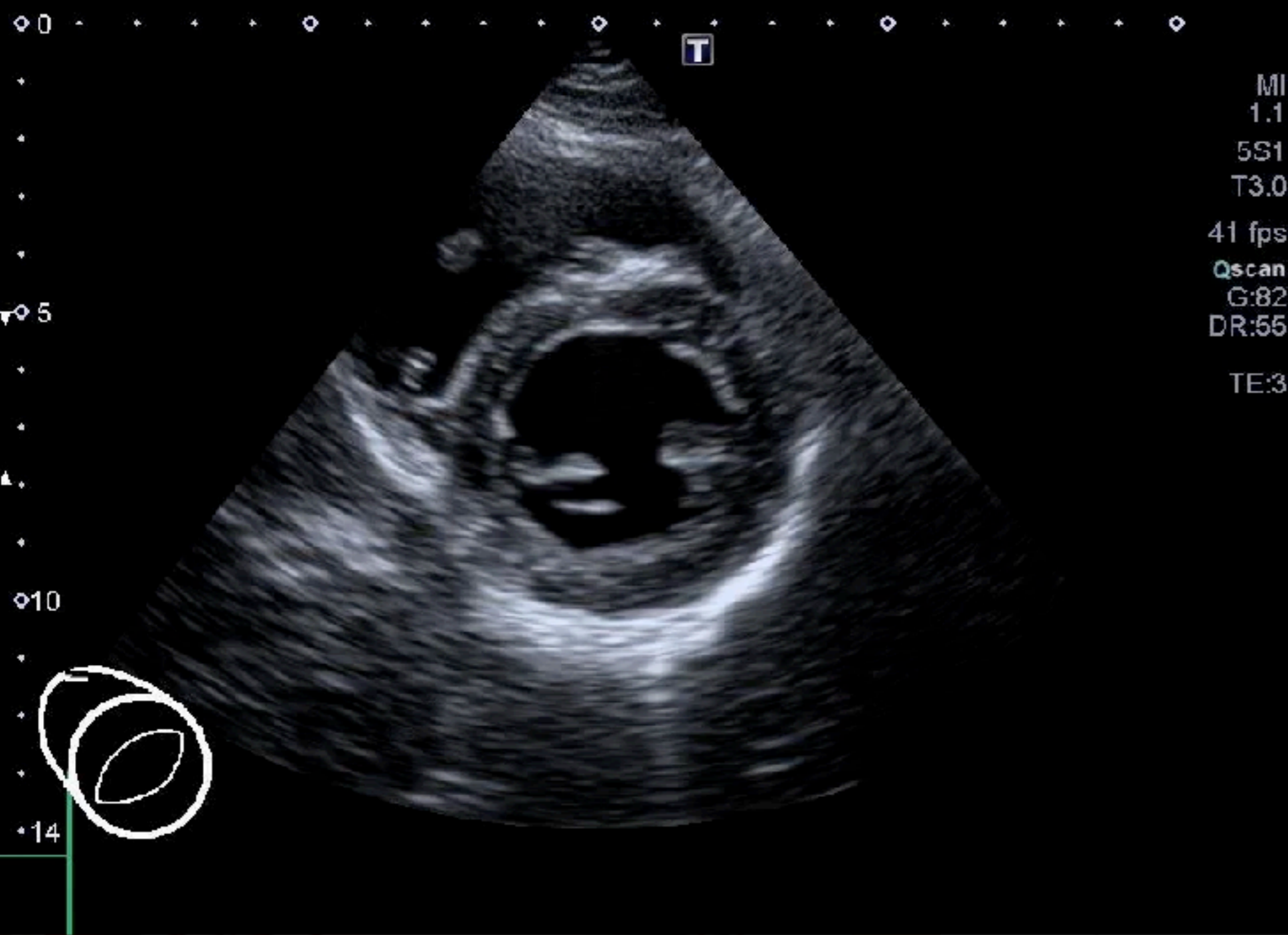


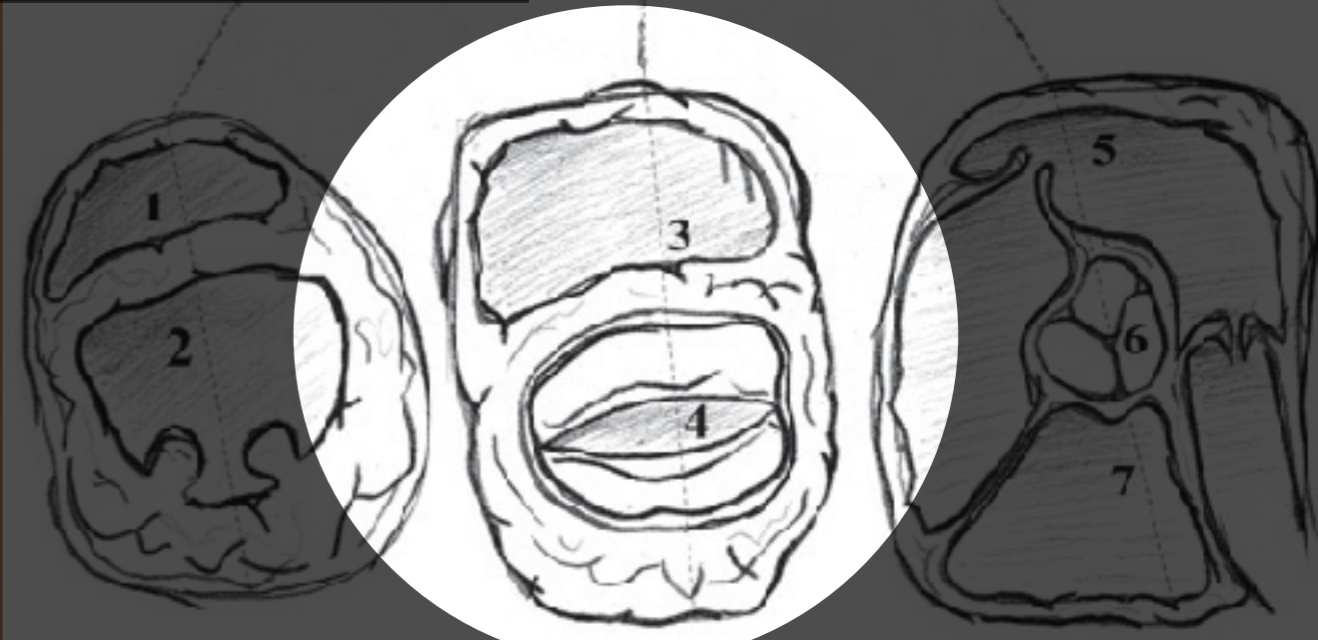
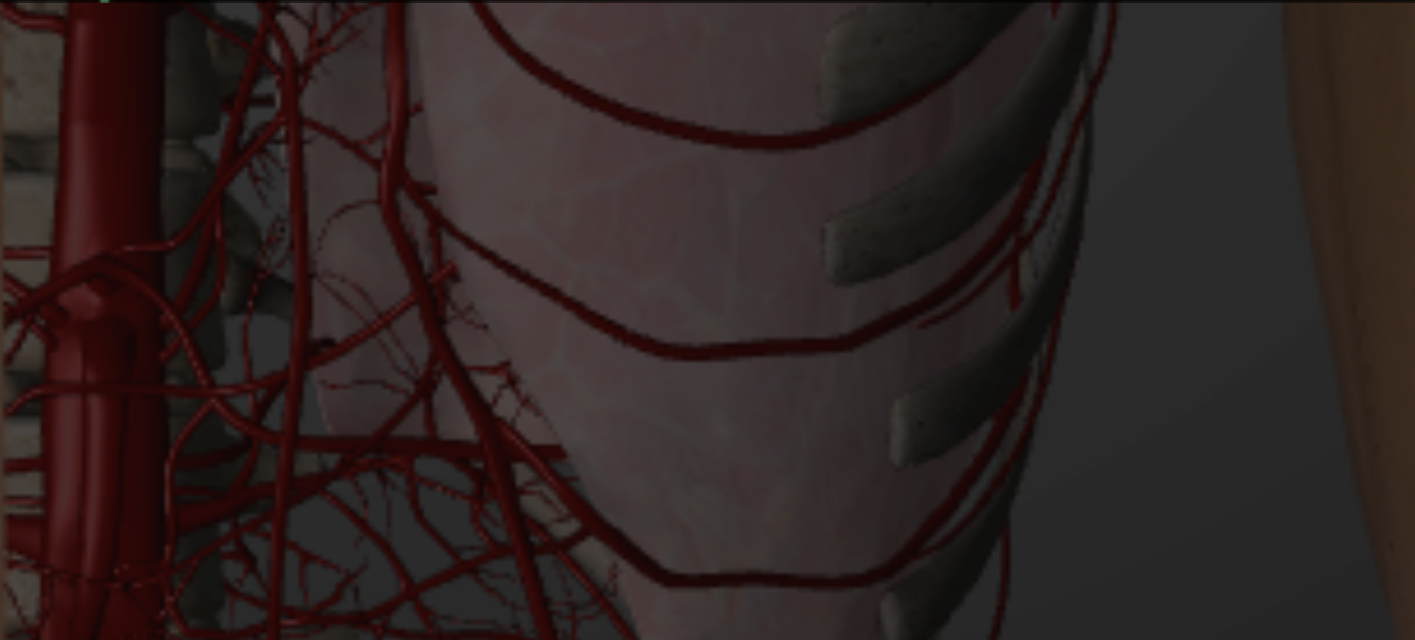
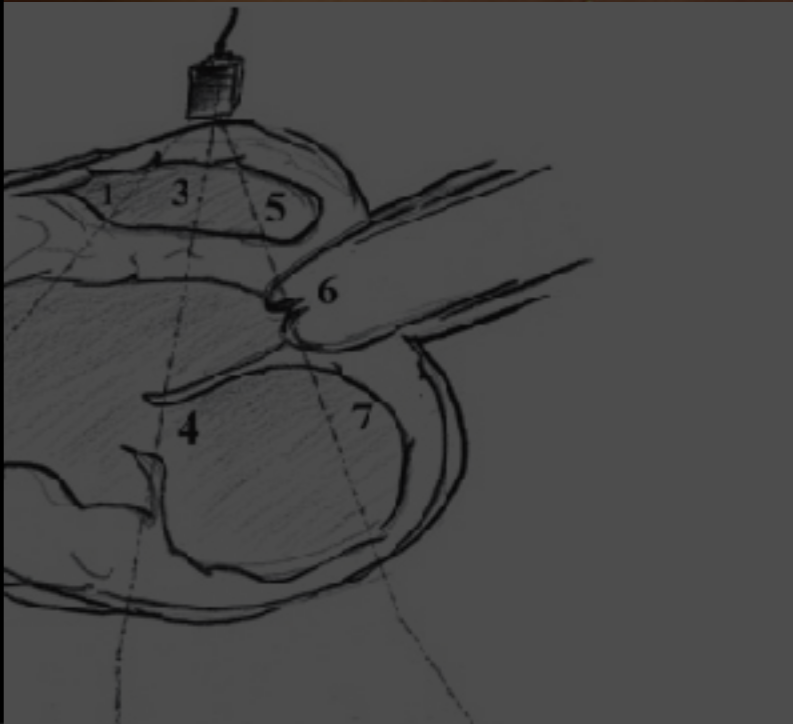
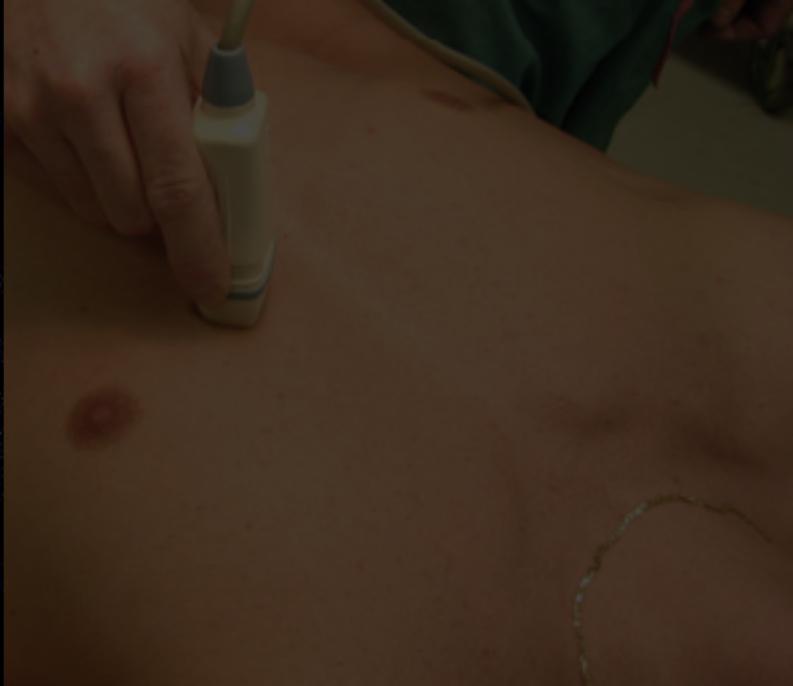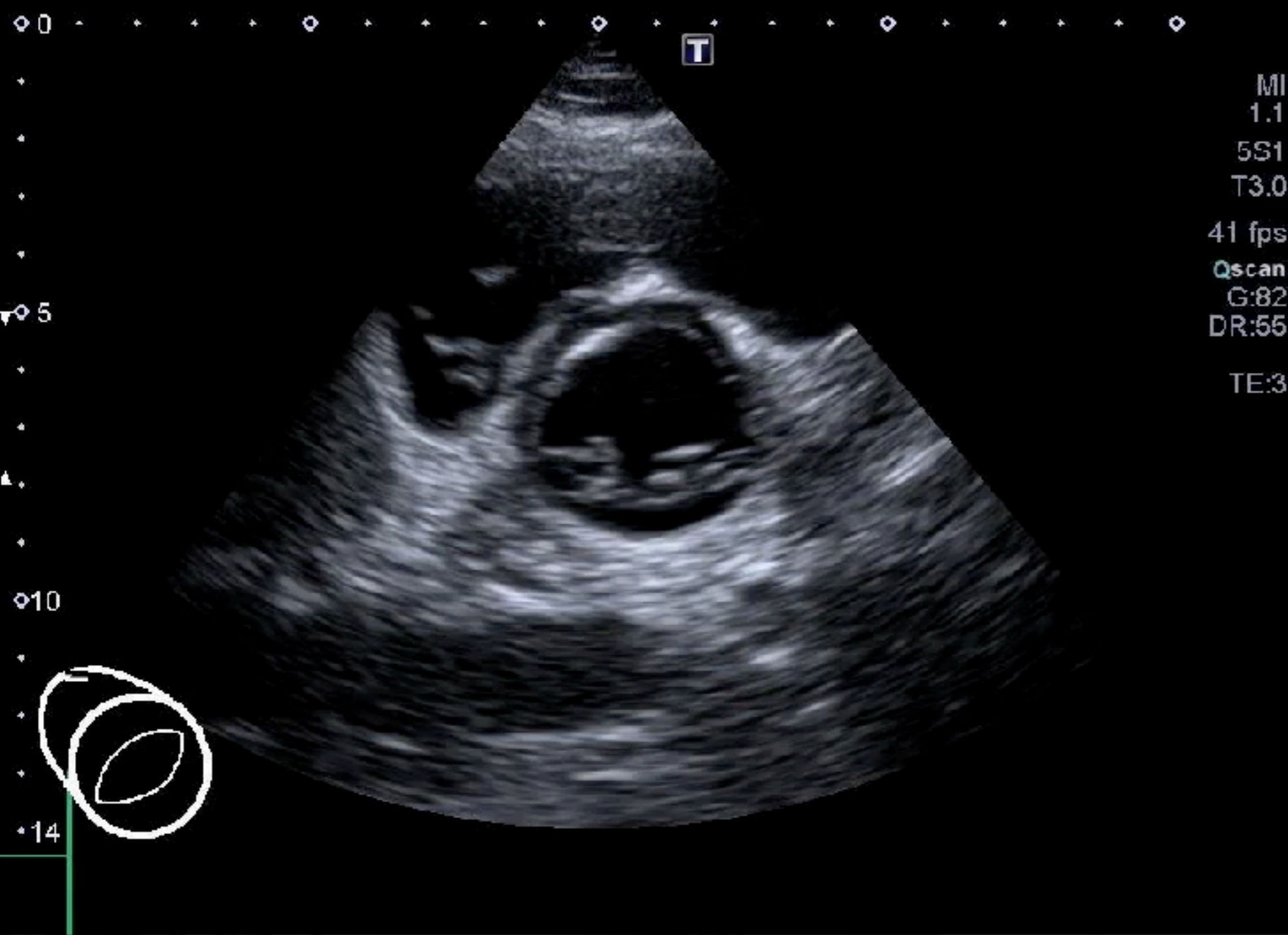
PSLA

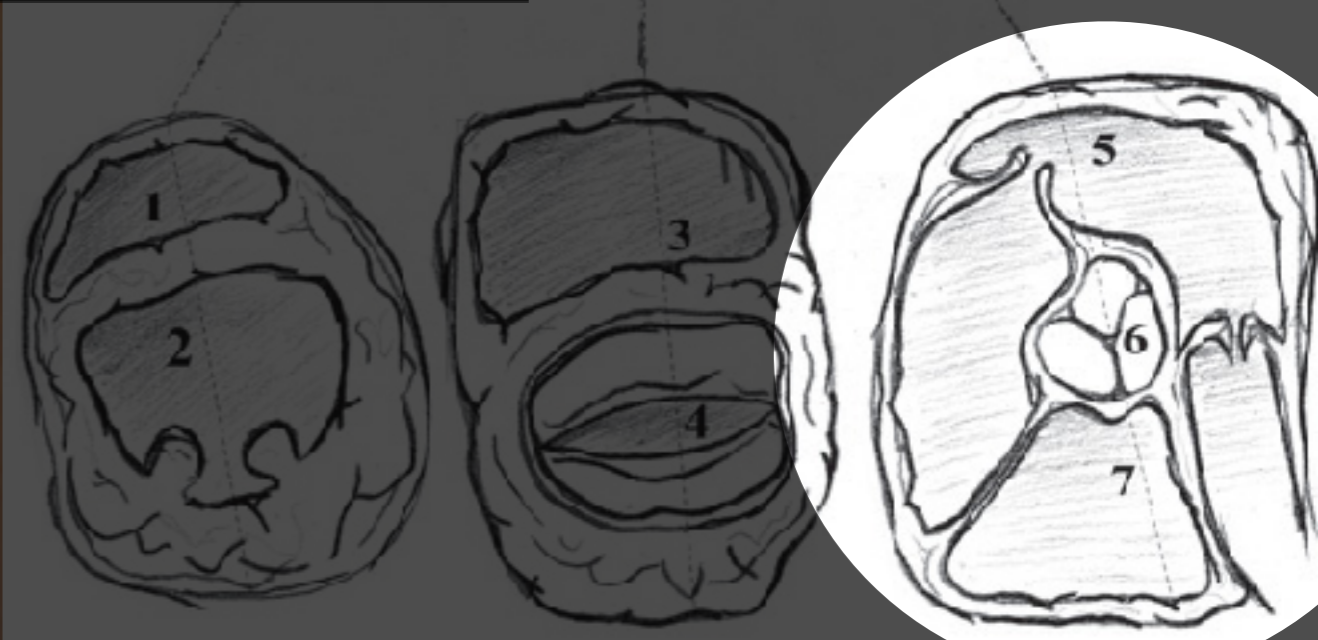
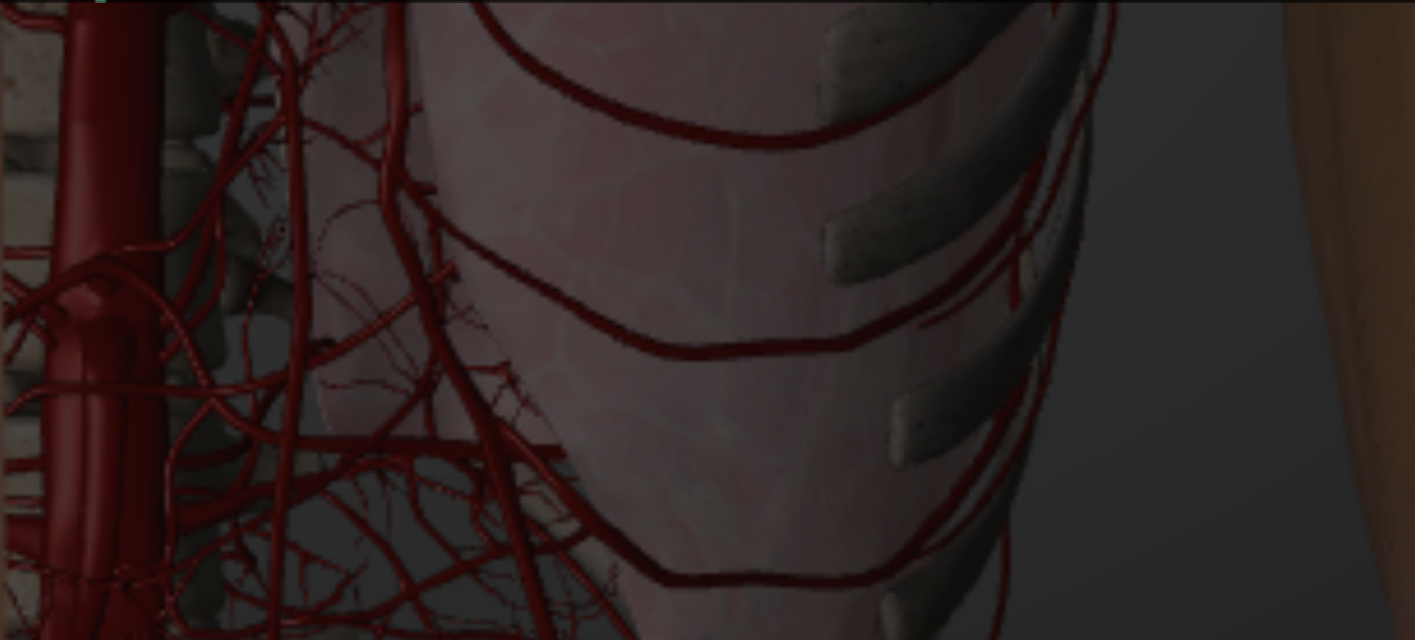
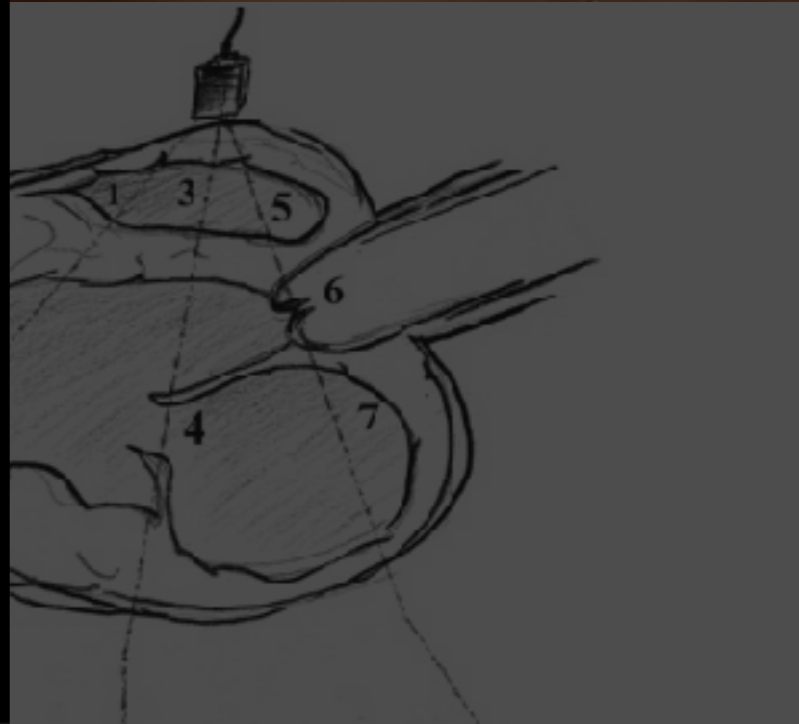
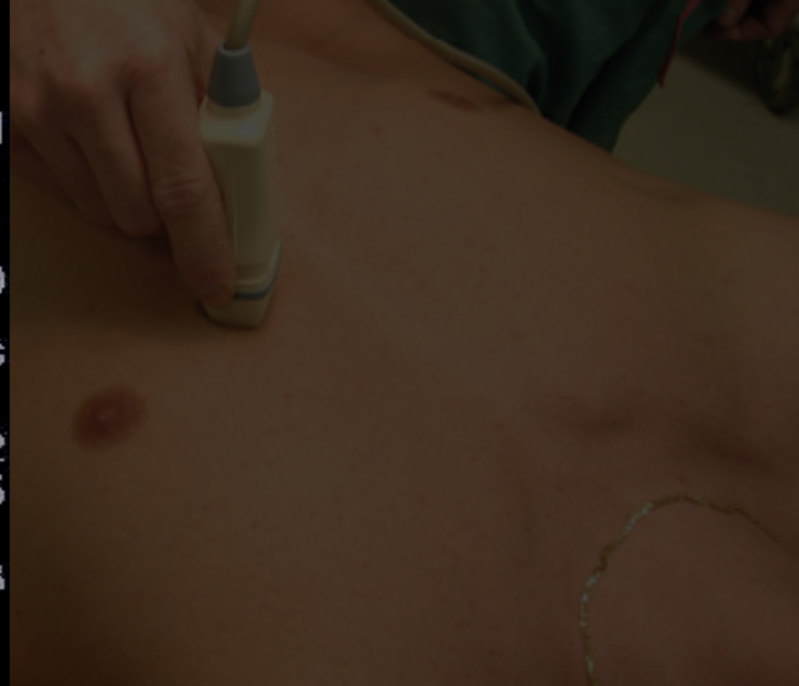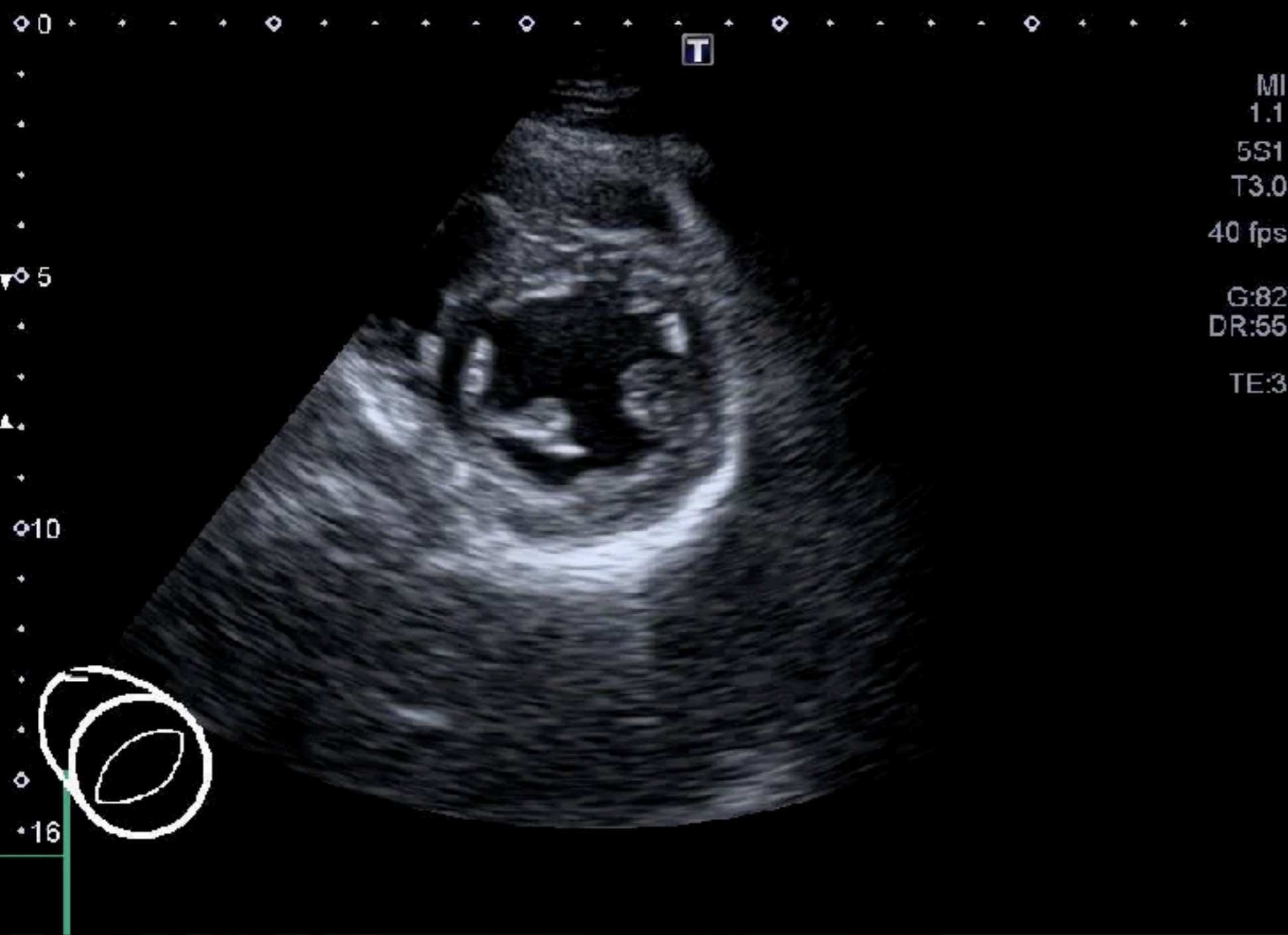


PSLA

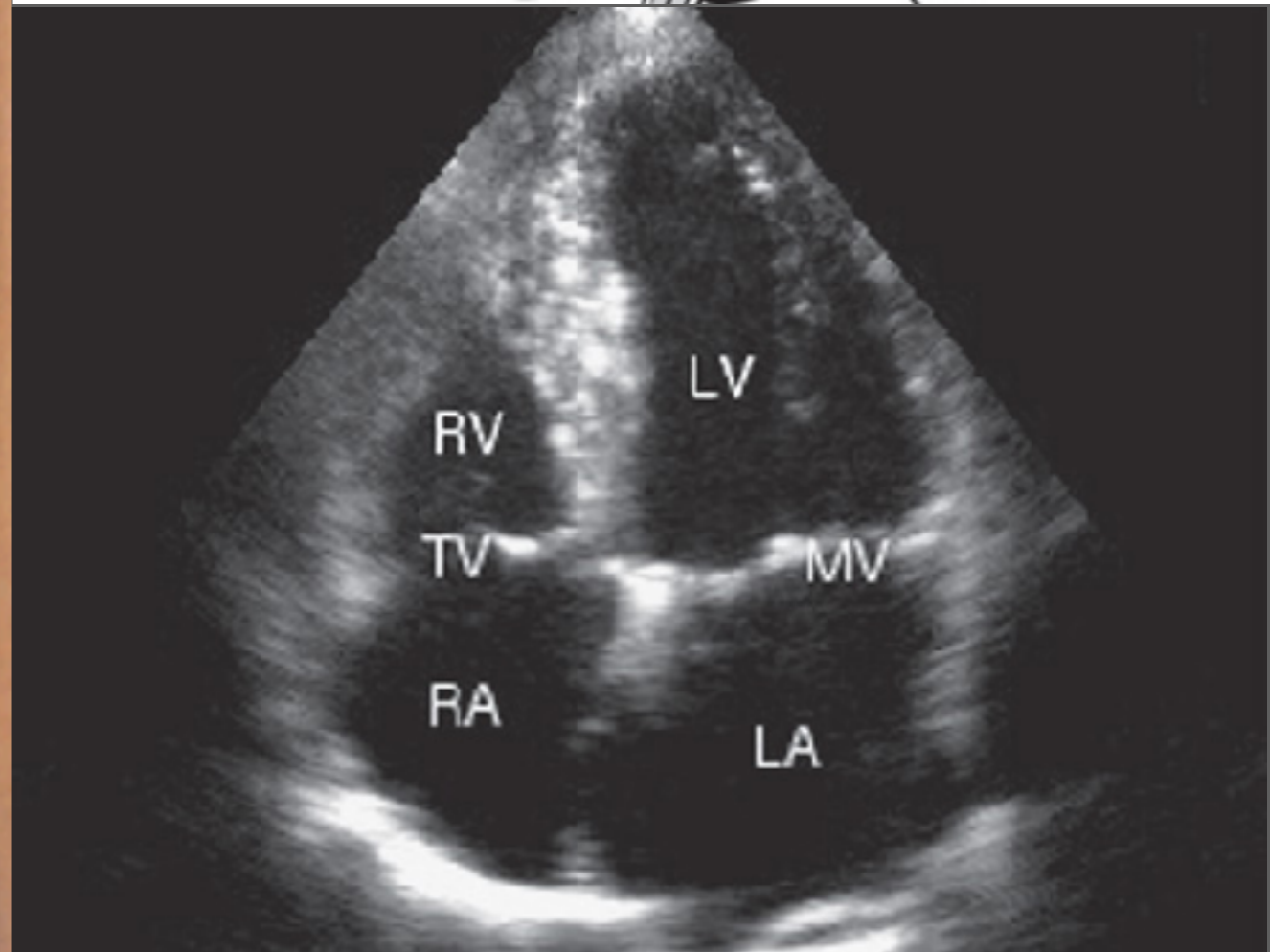
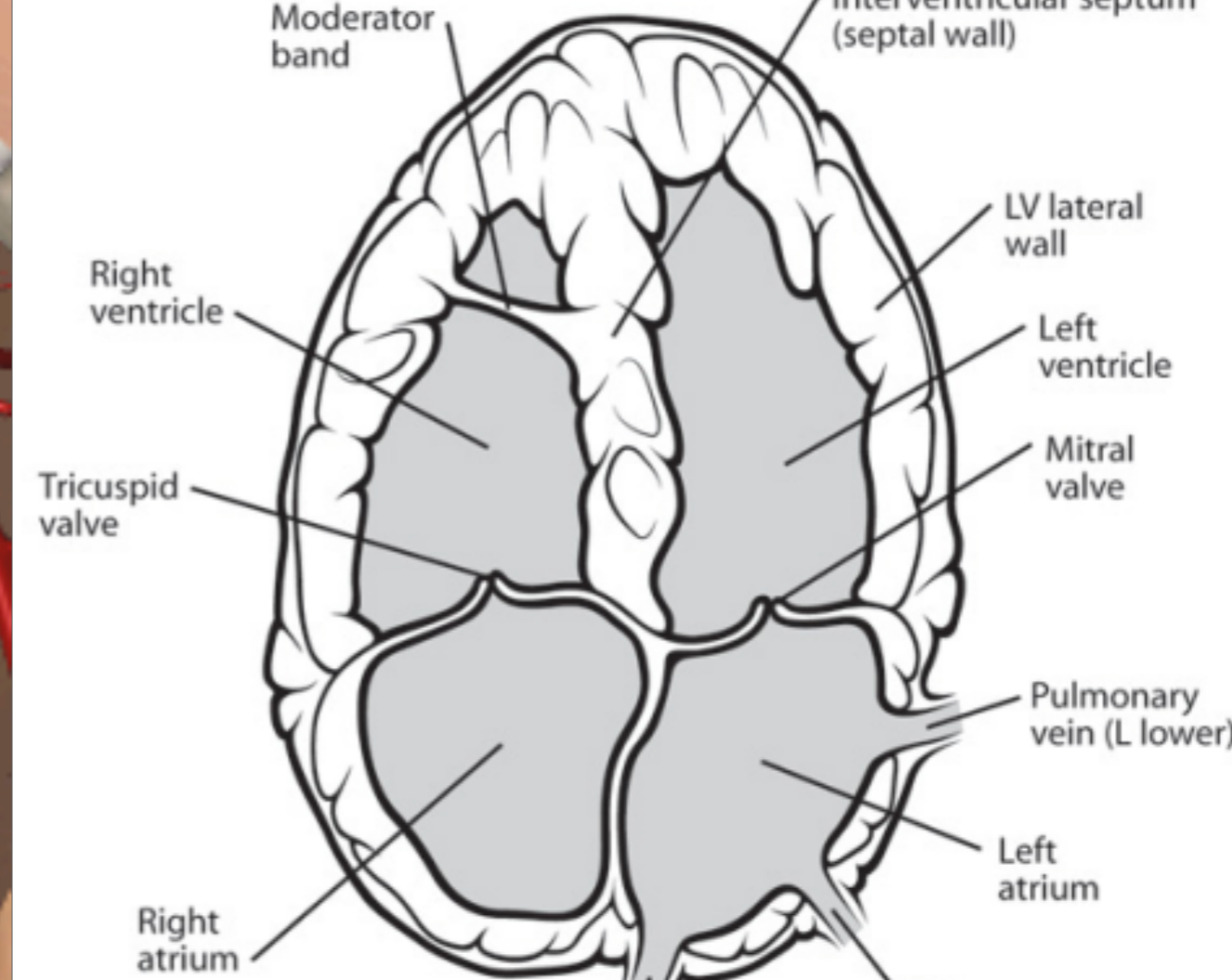
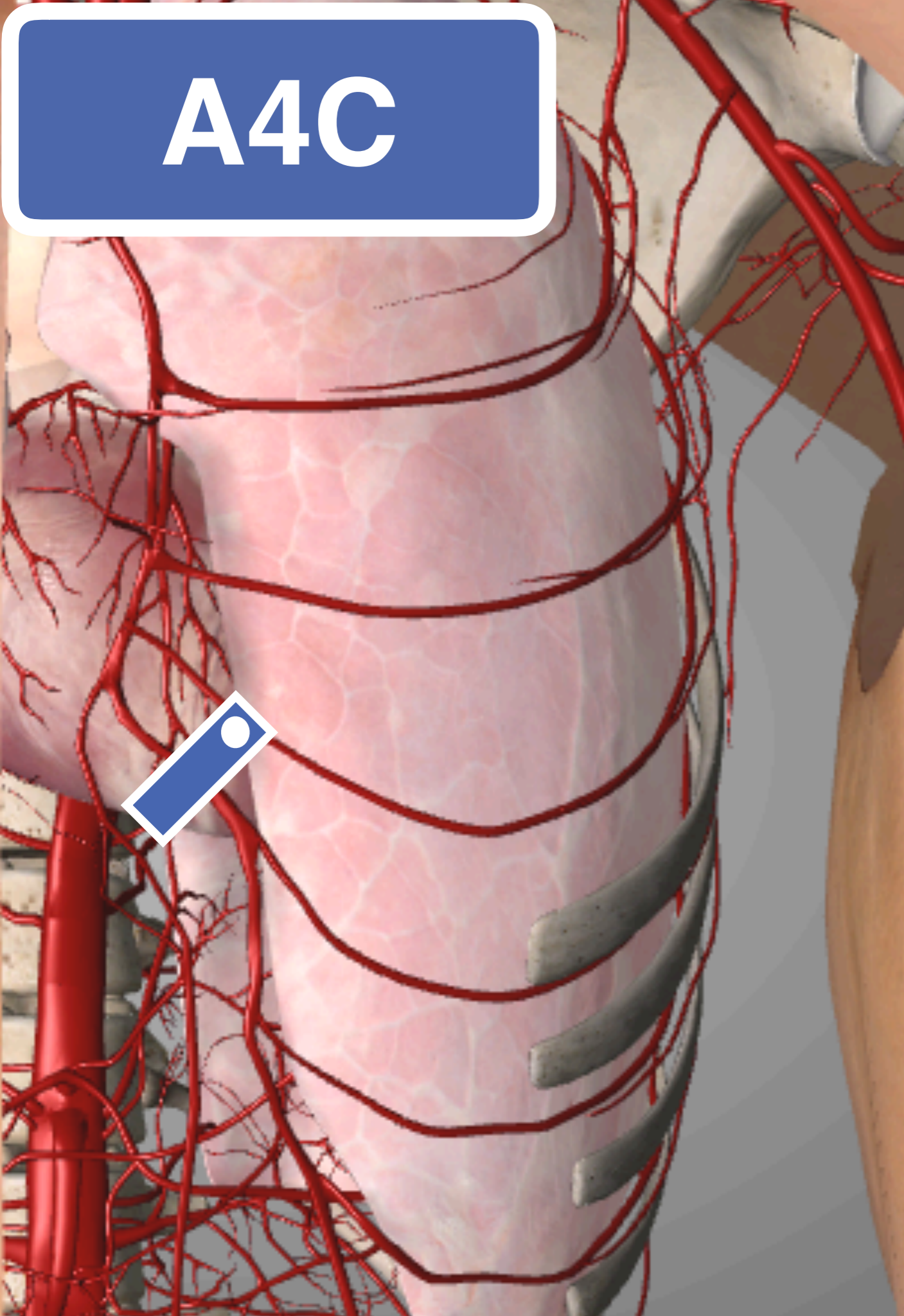




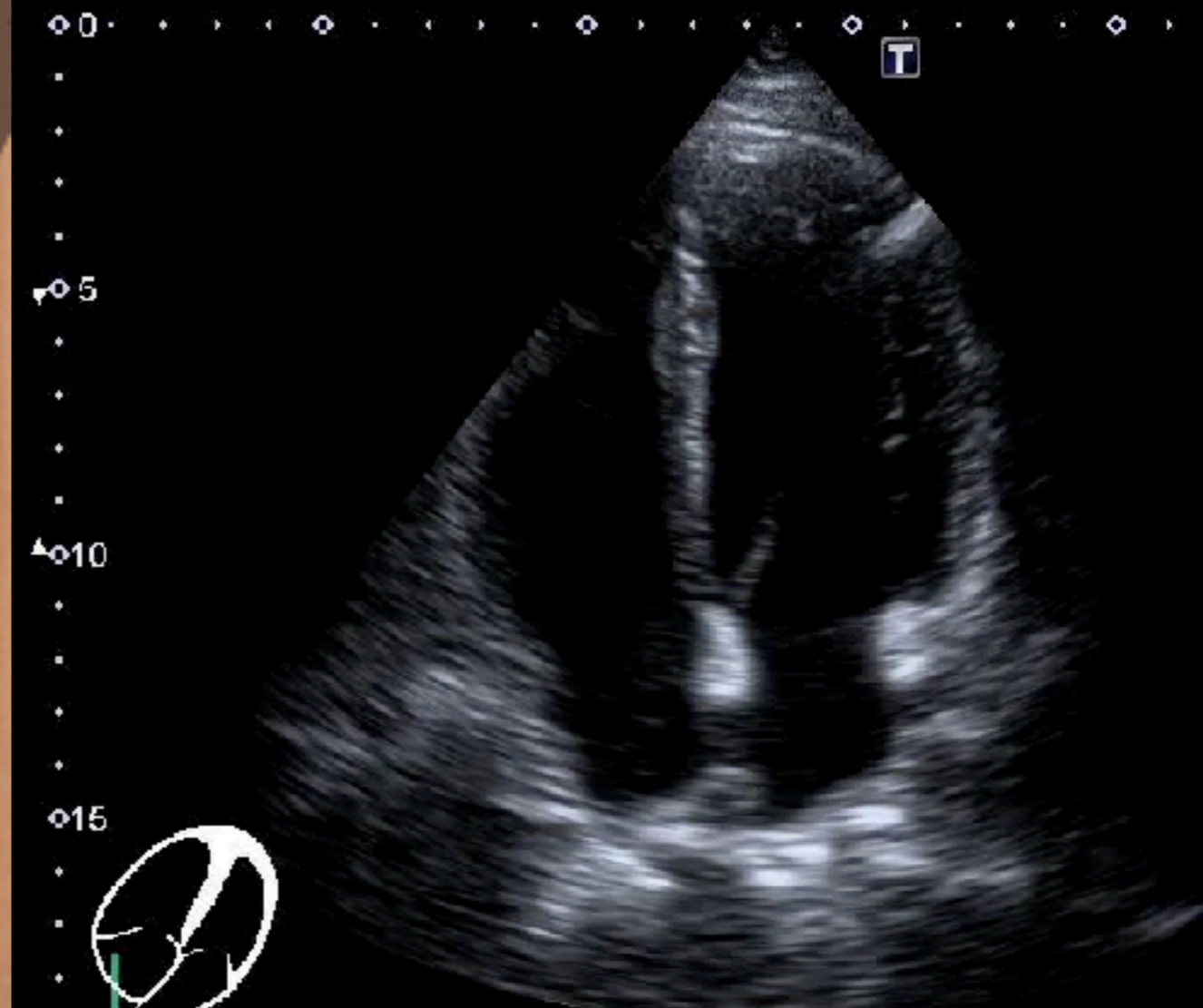
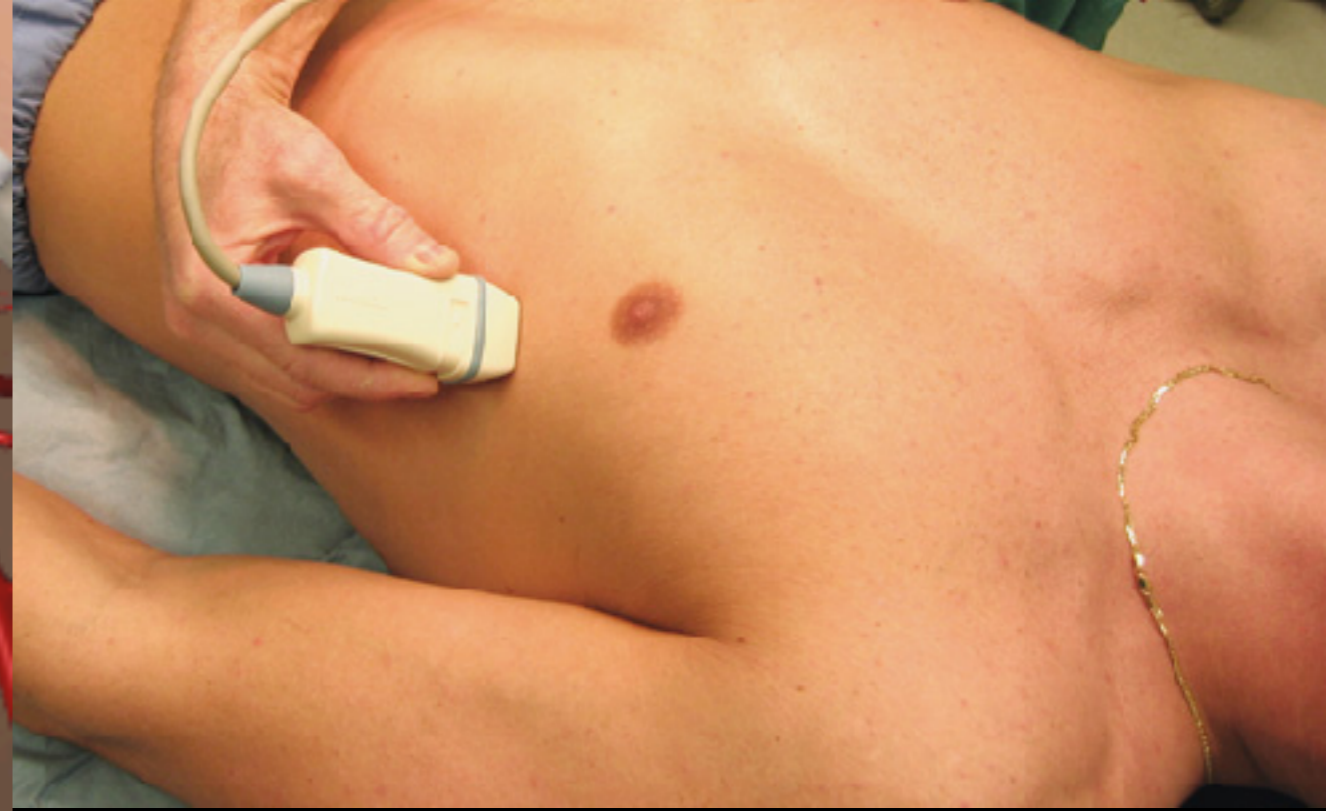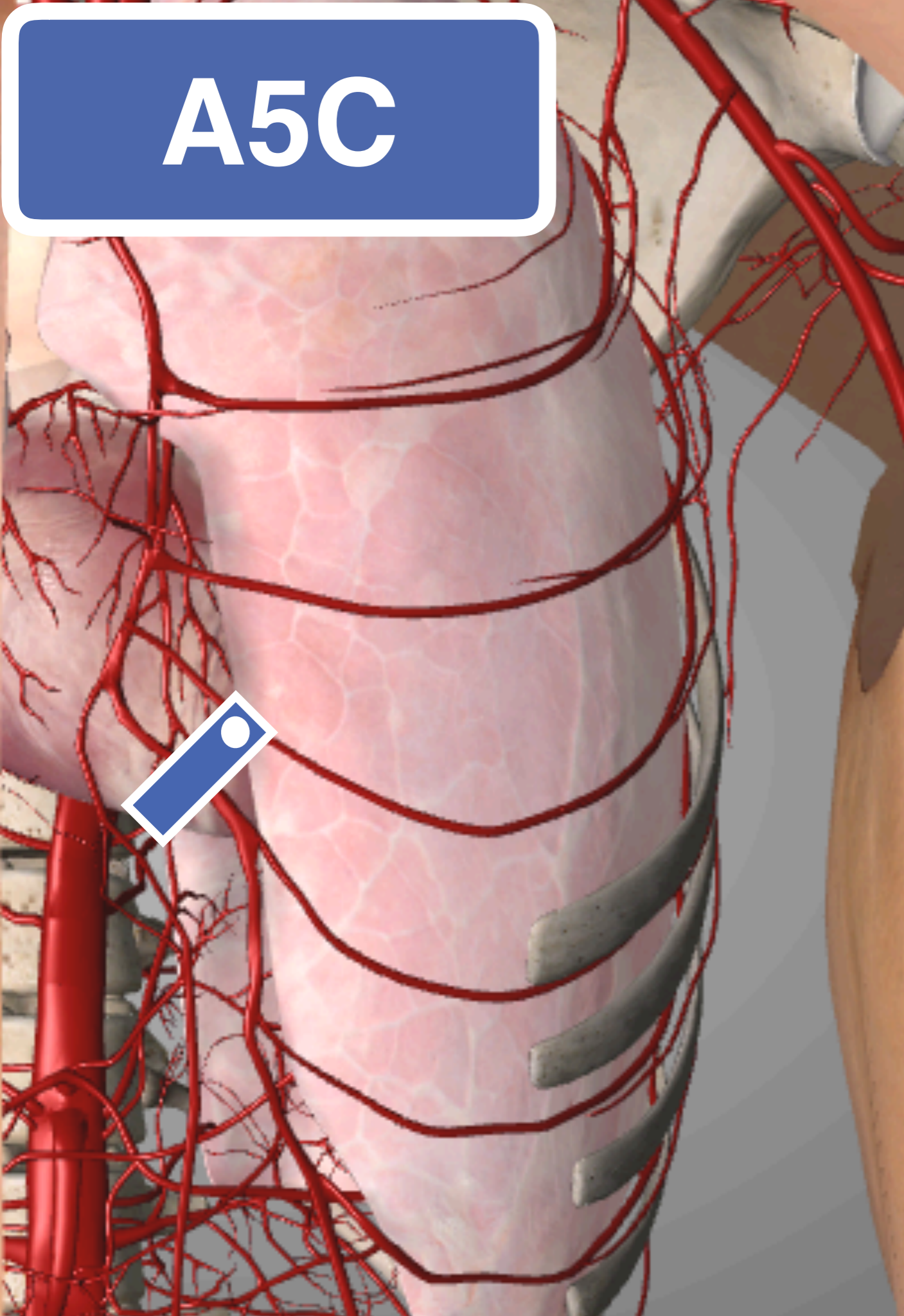




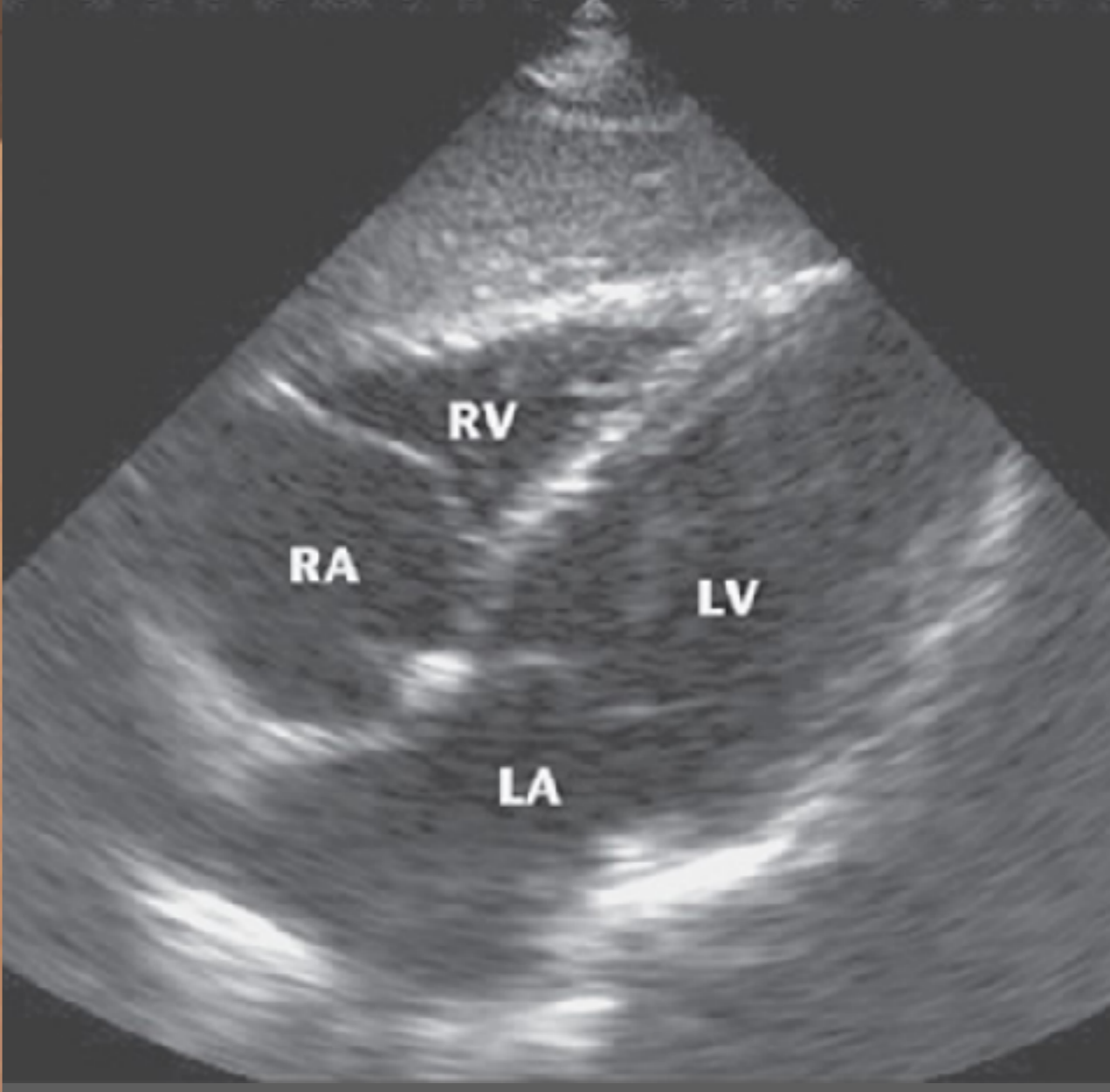
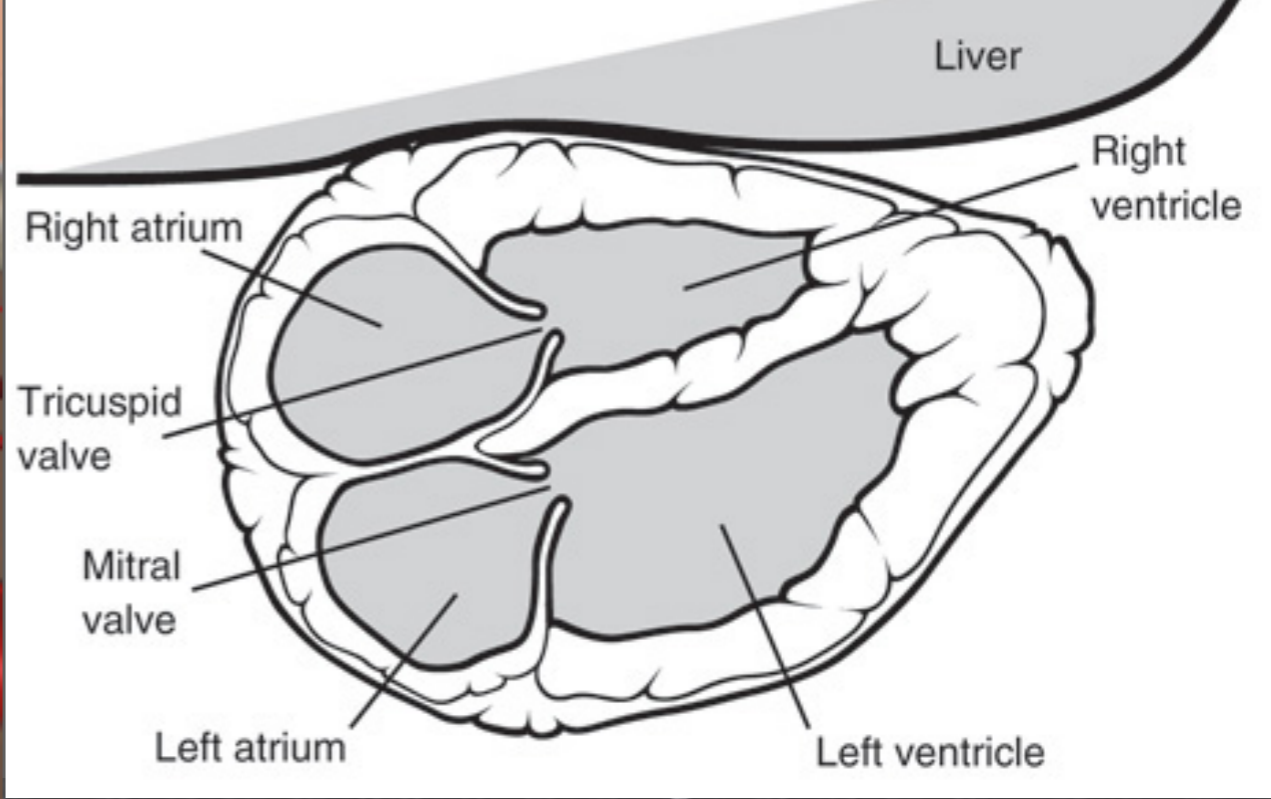
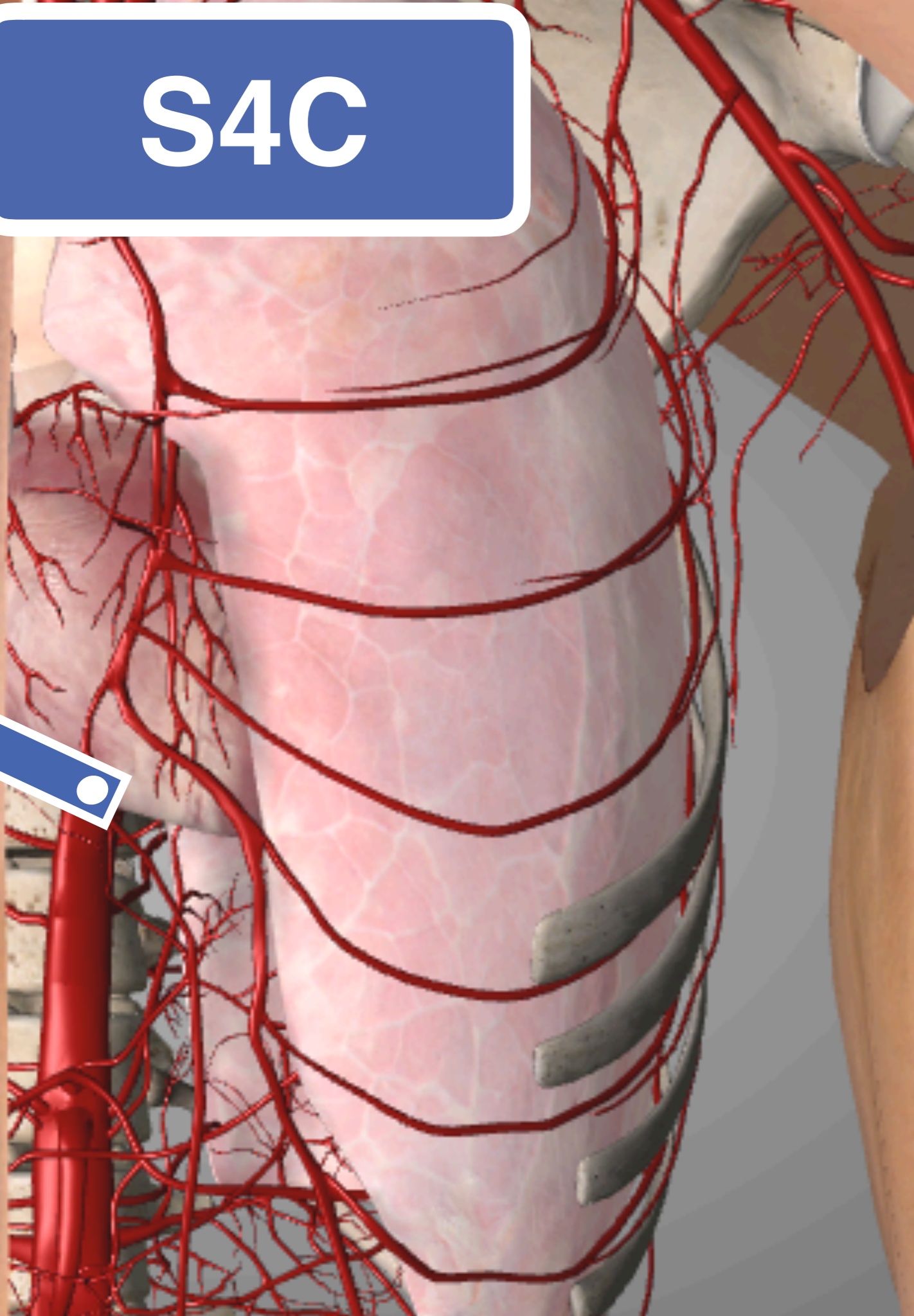
A4C



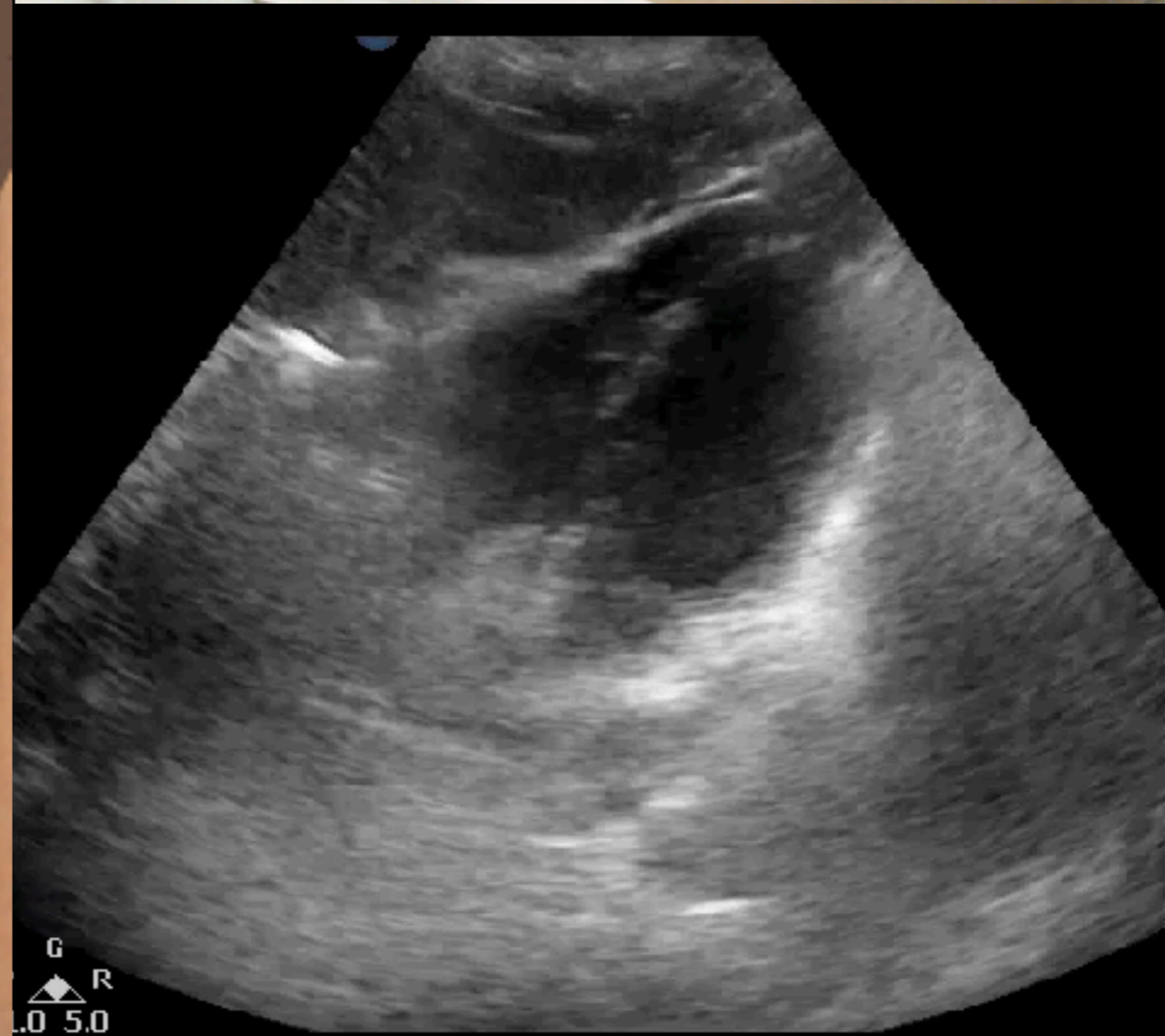
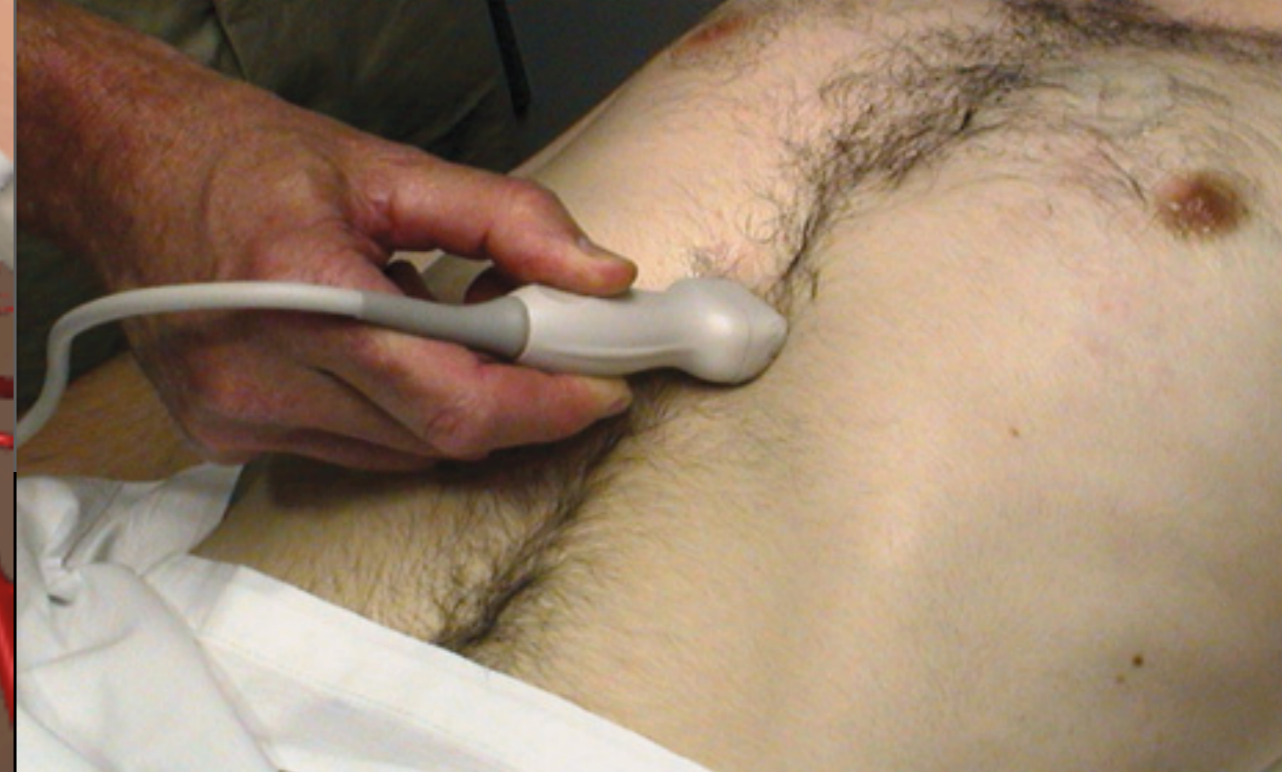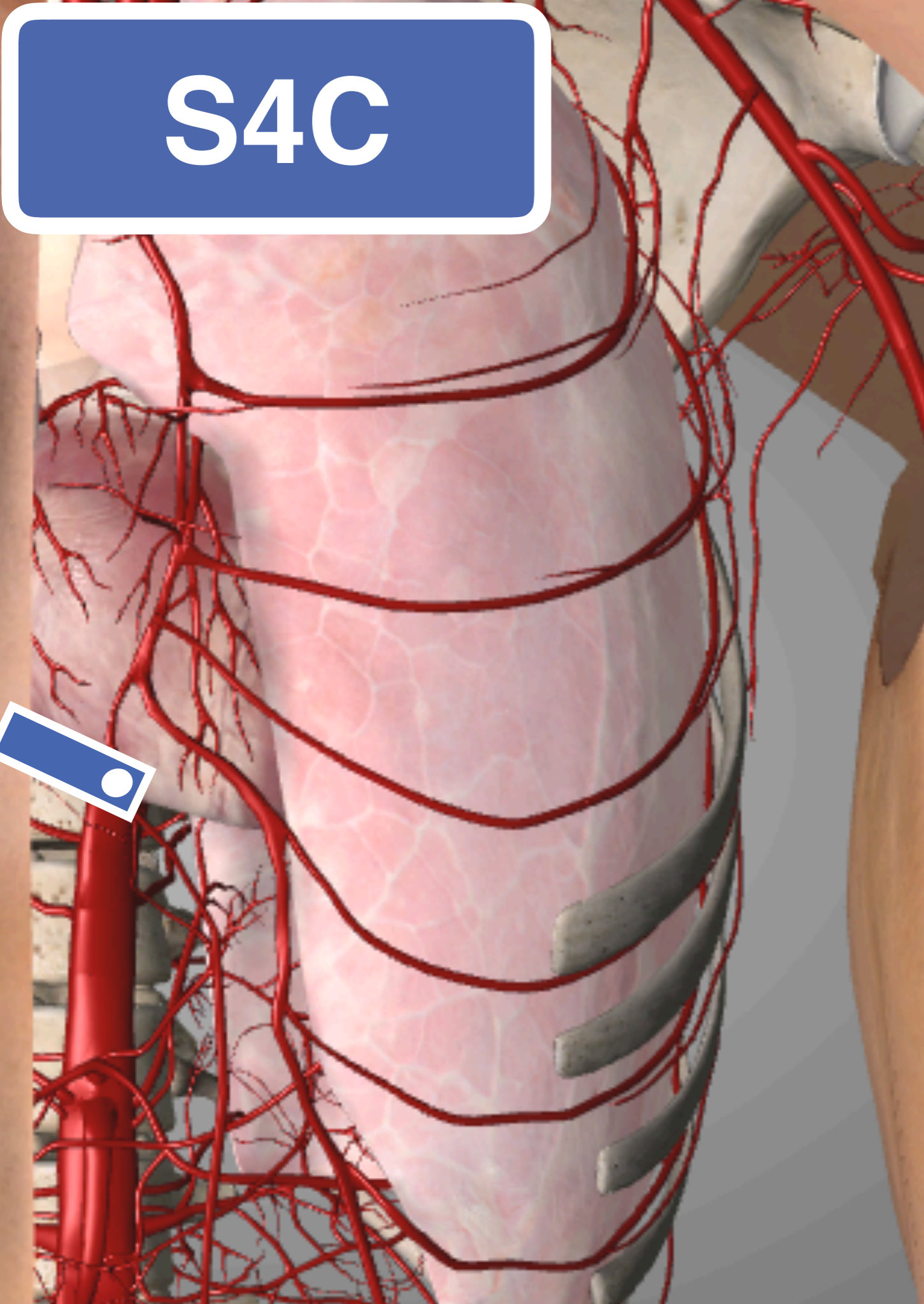
A5C



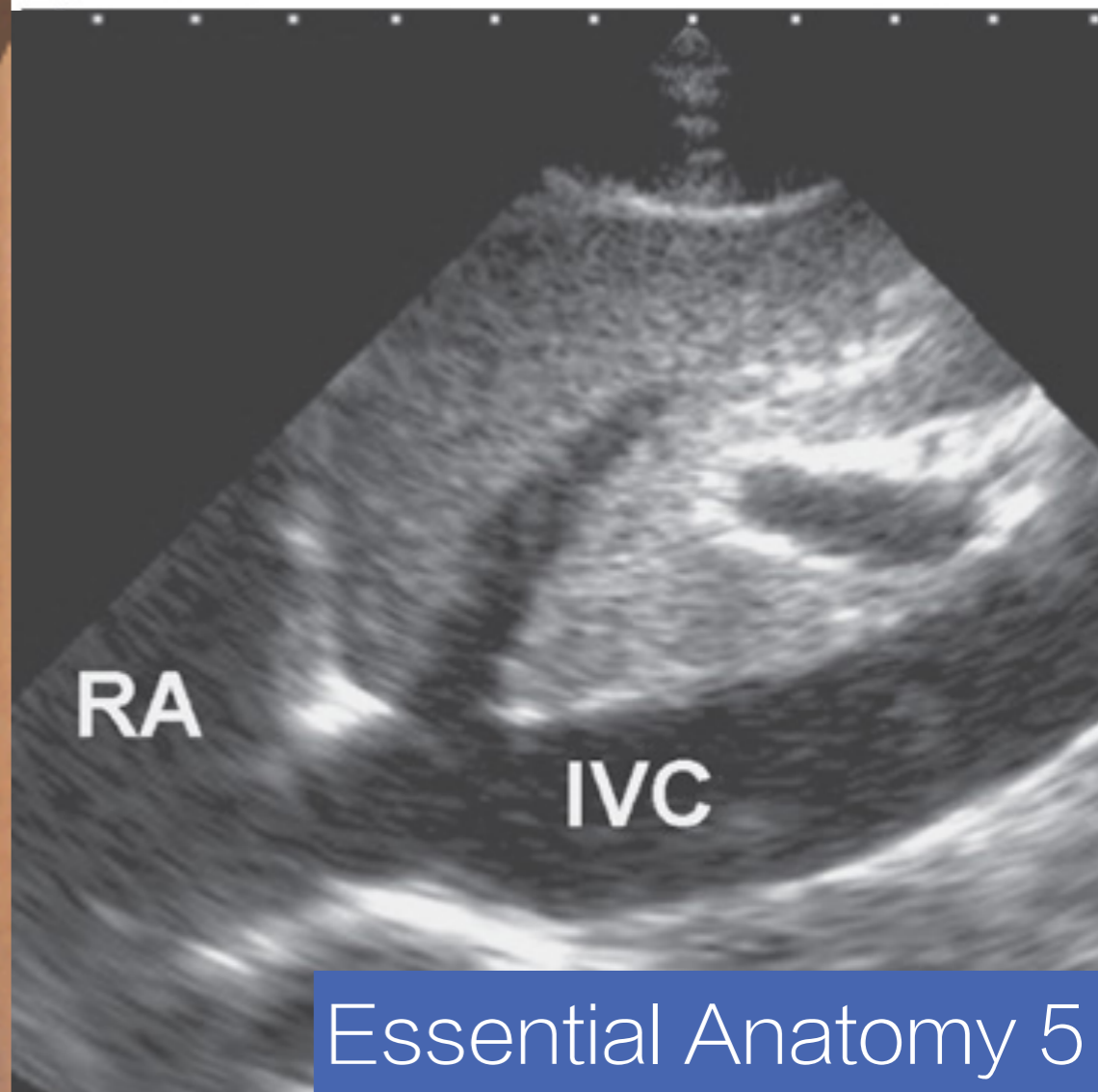
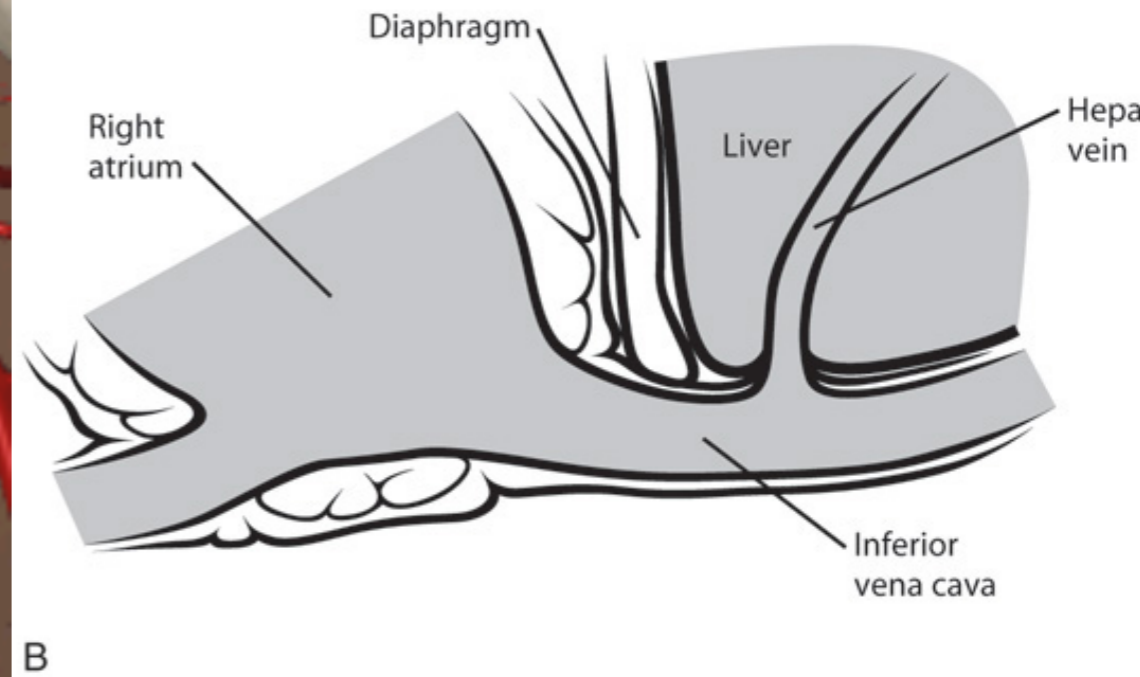
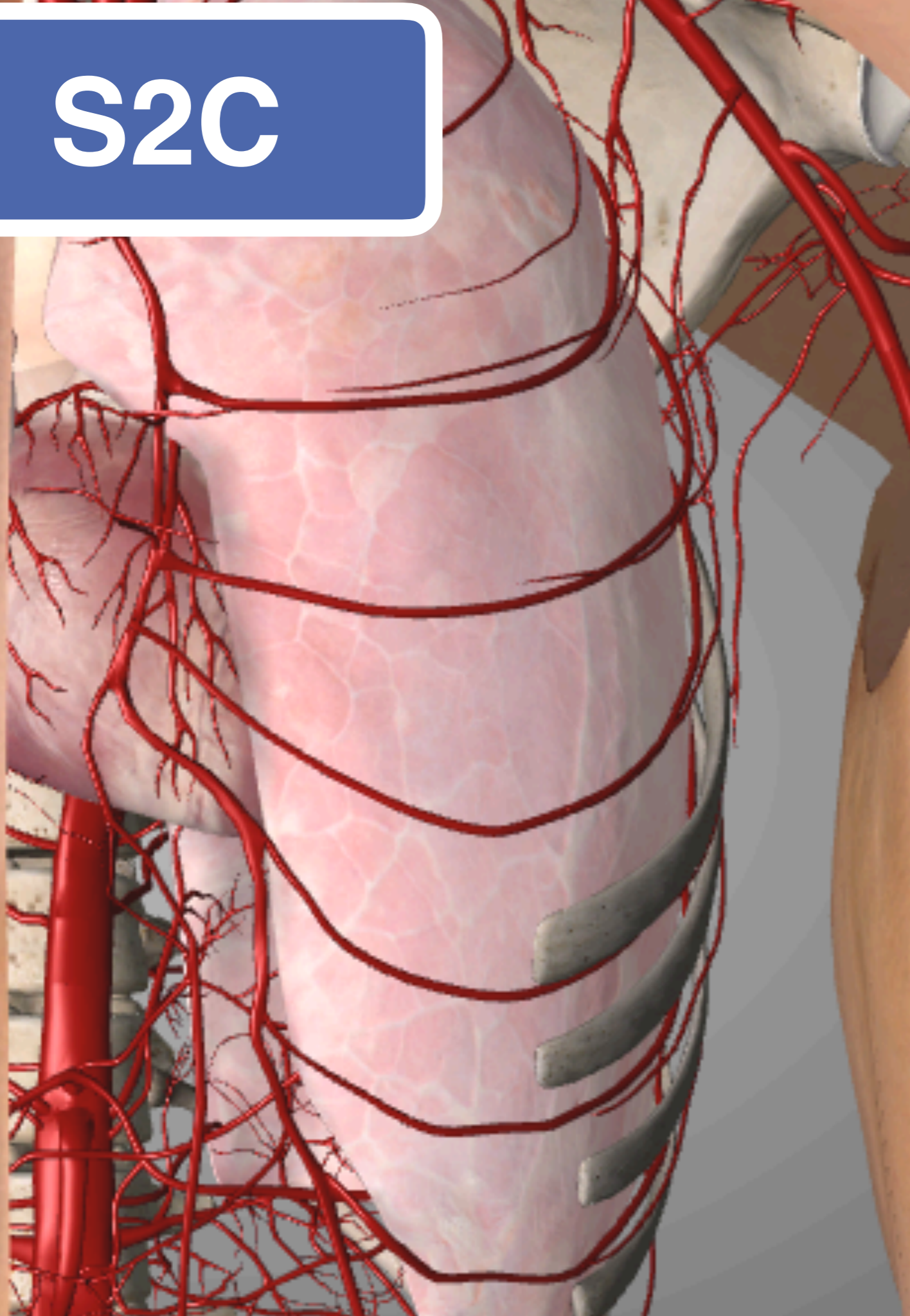
S4C



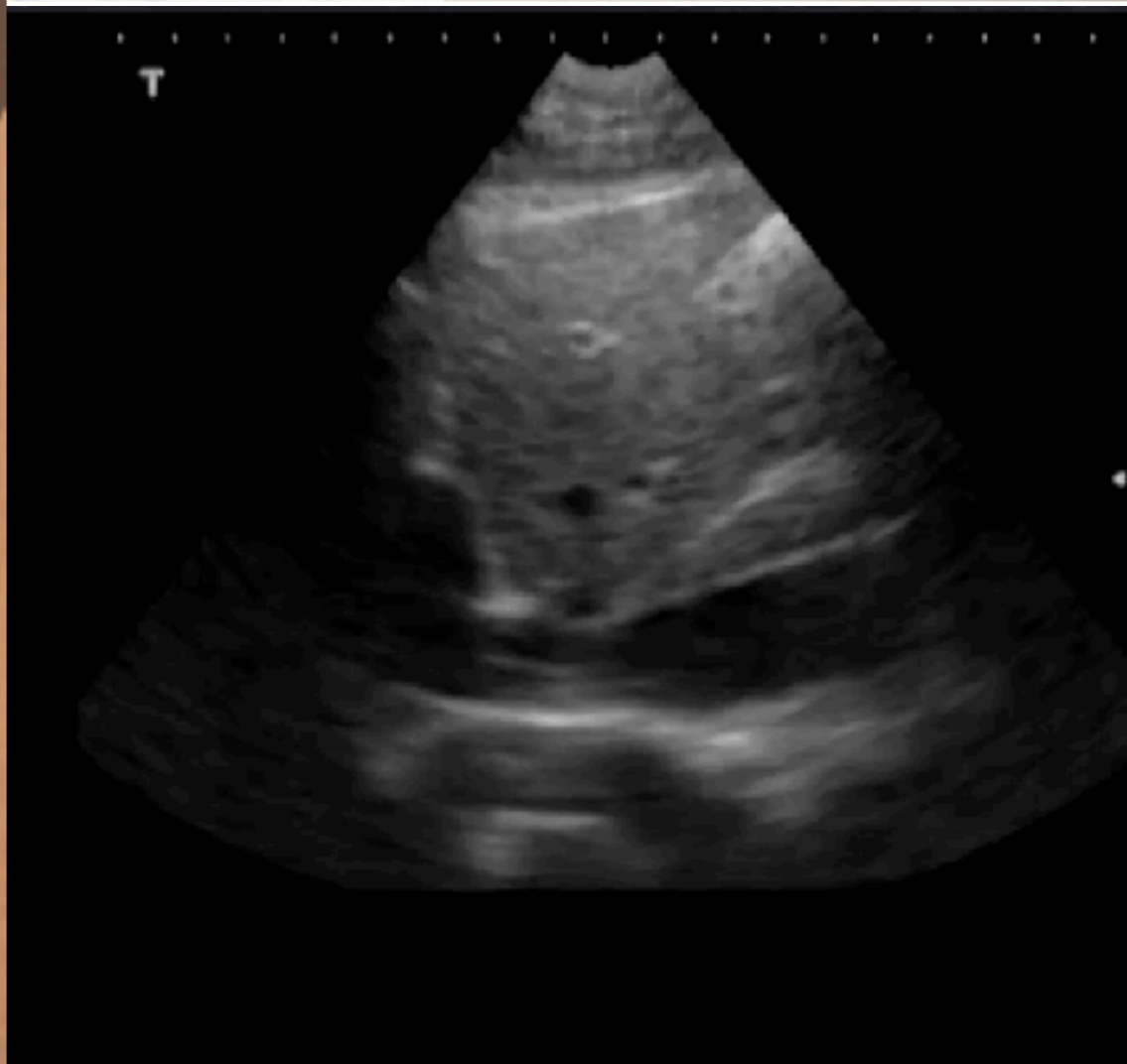
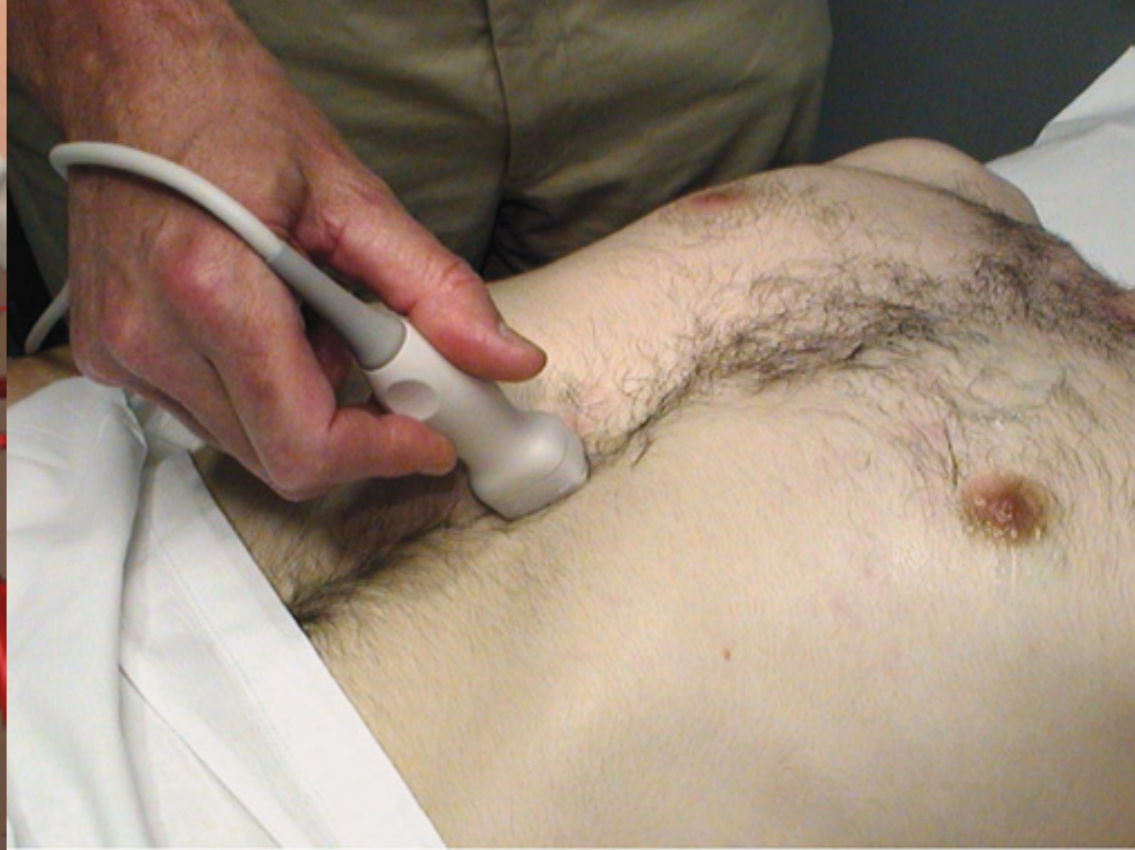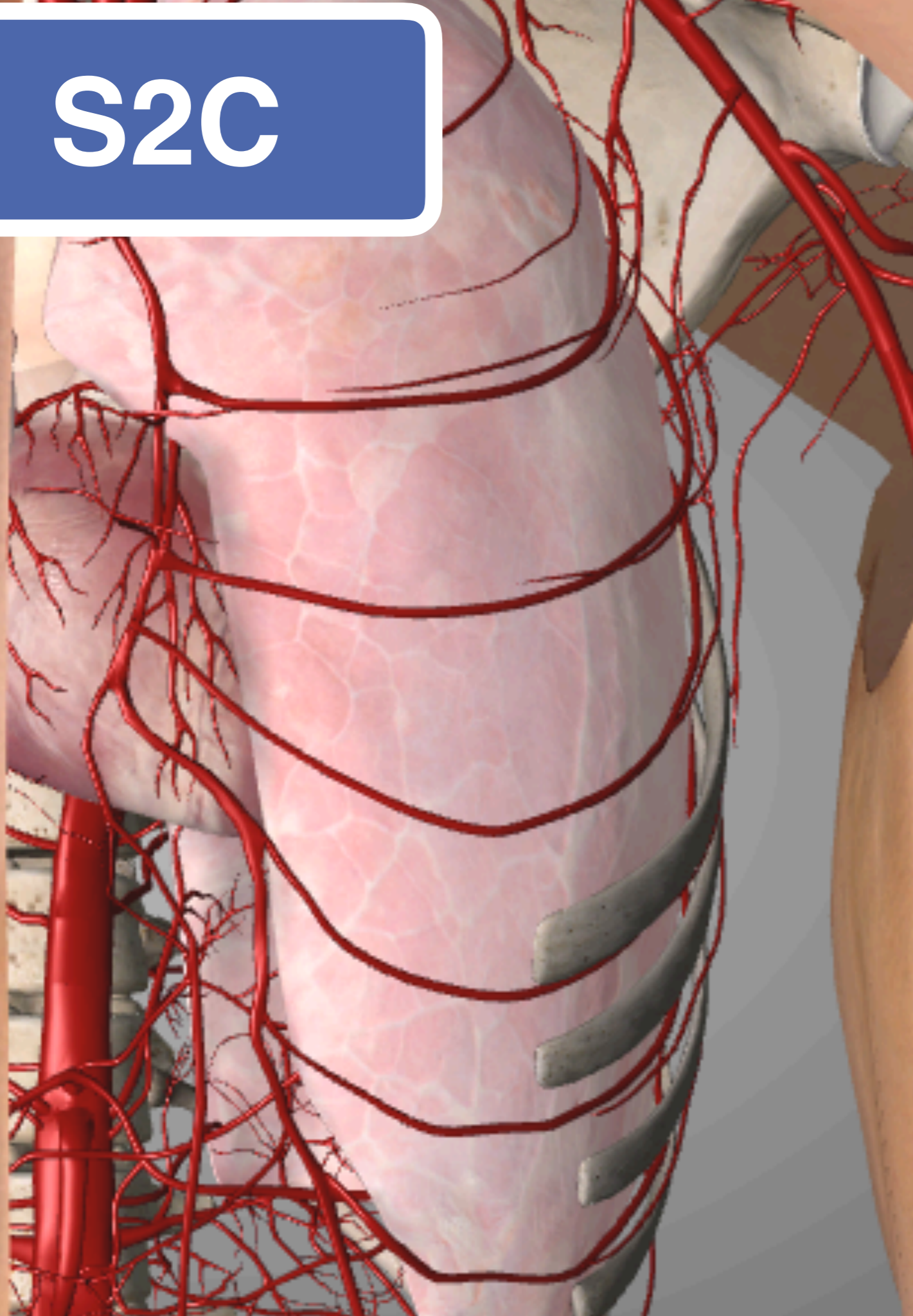
S4C



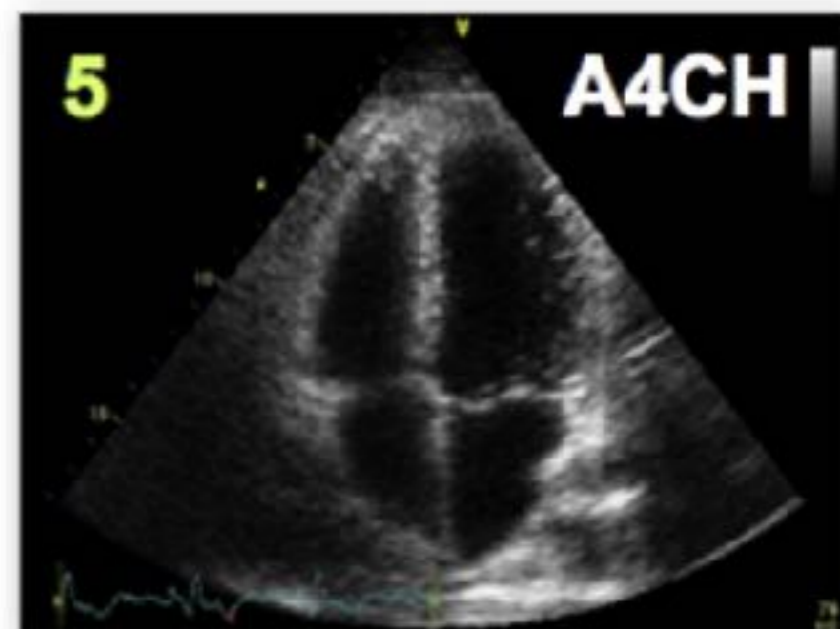
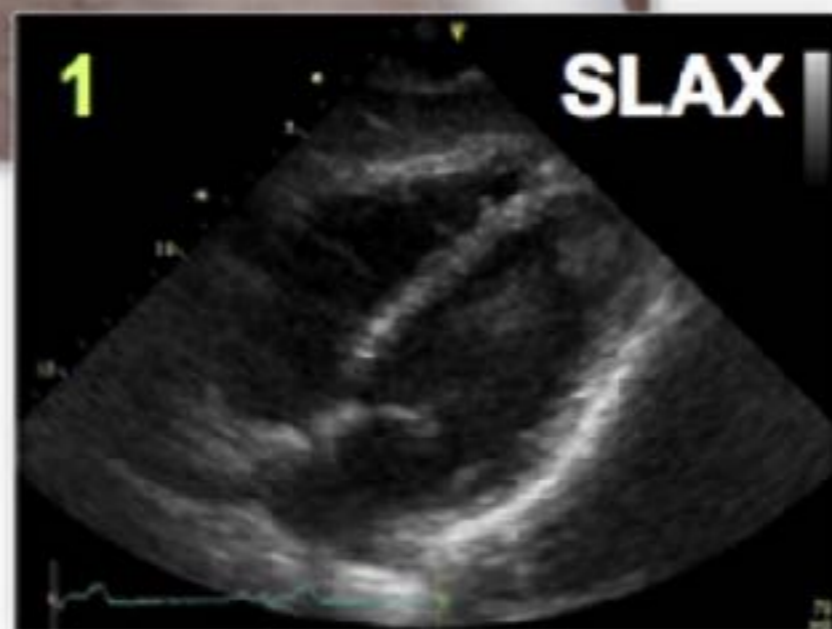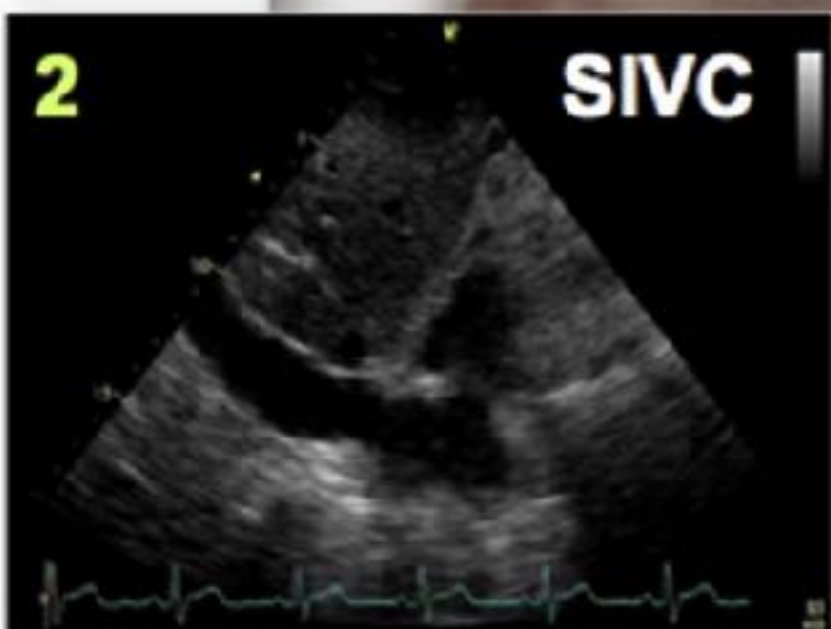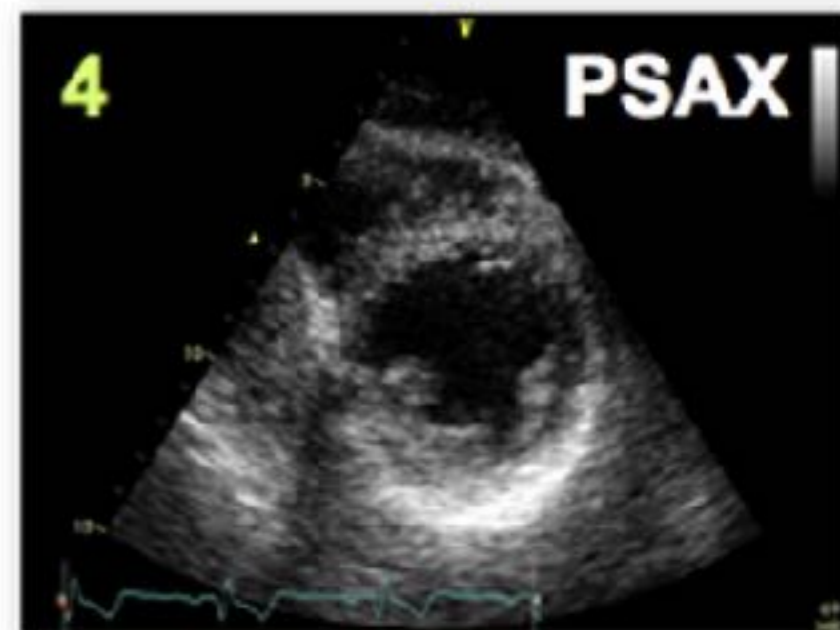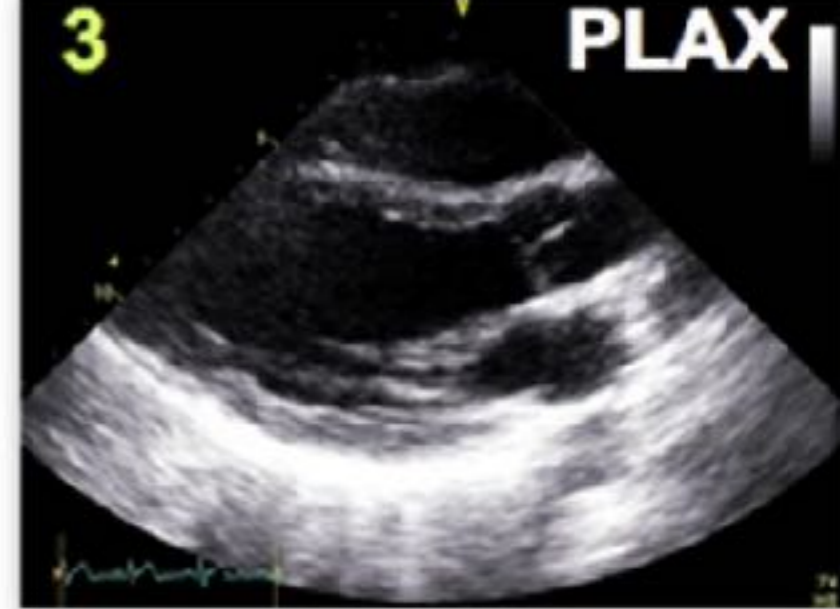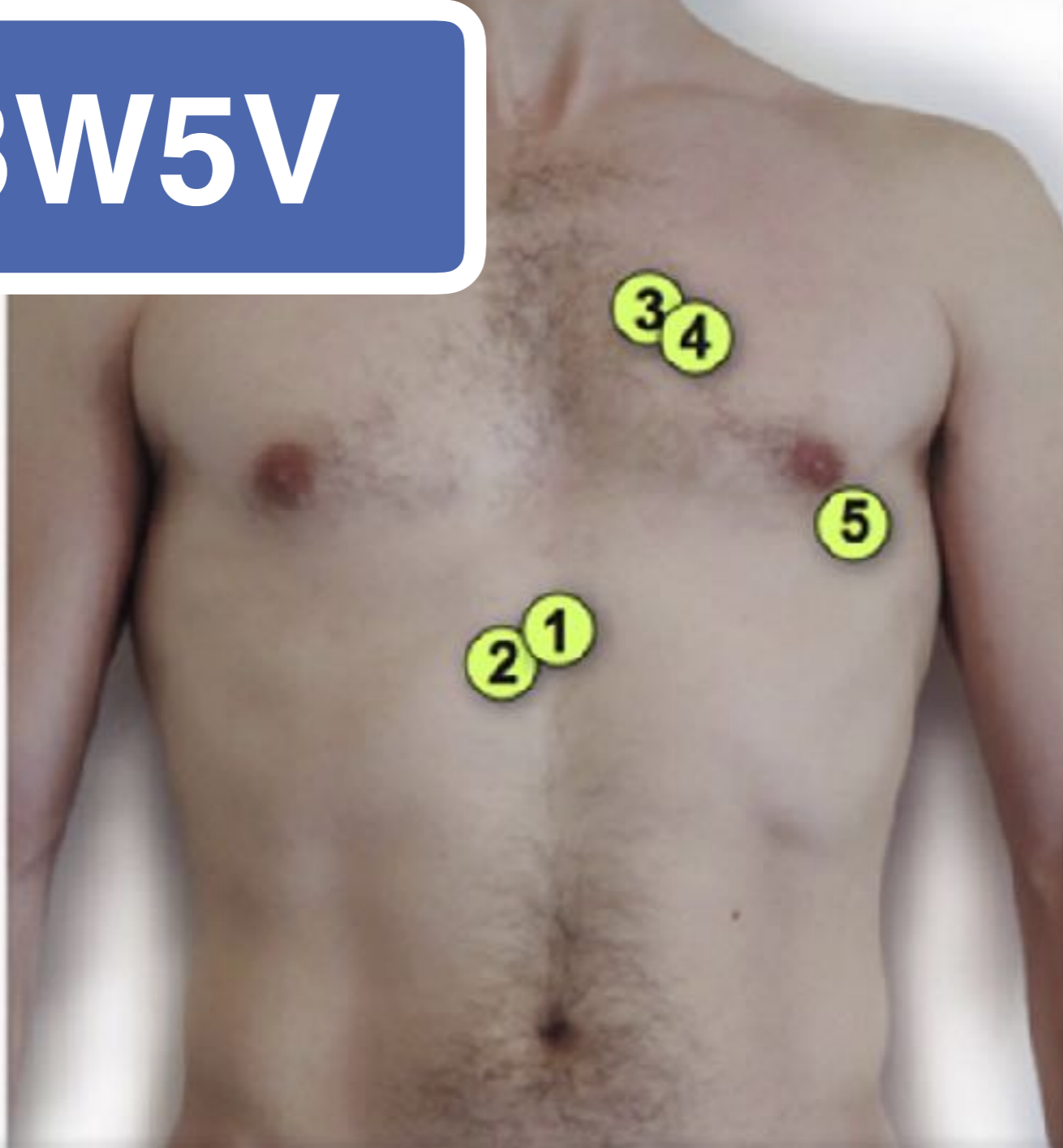
S2C



S2C

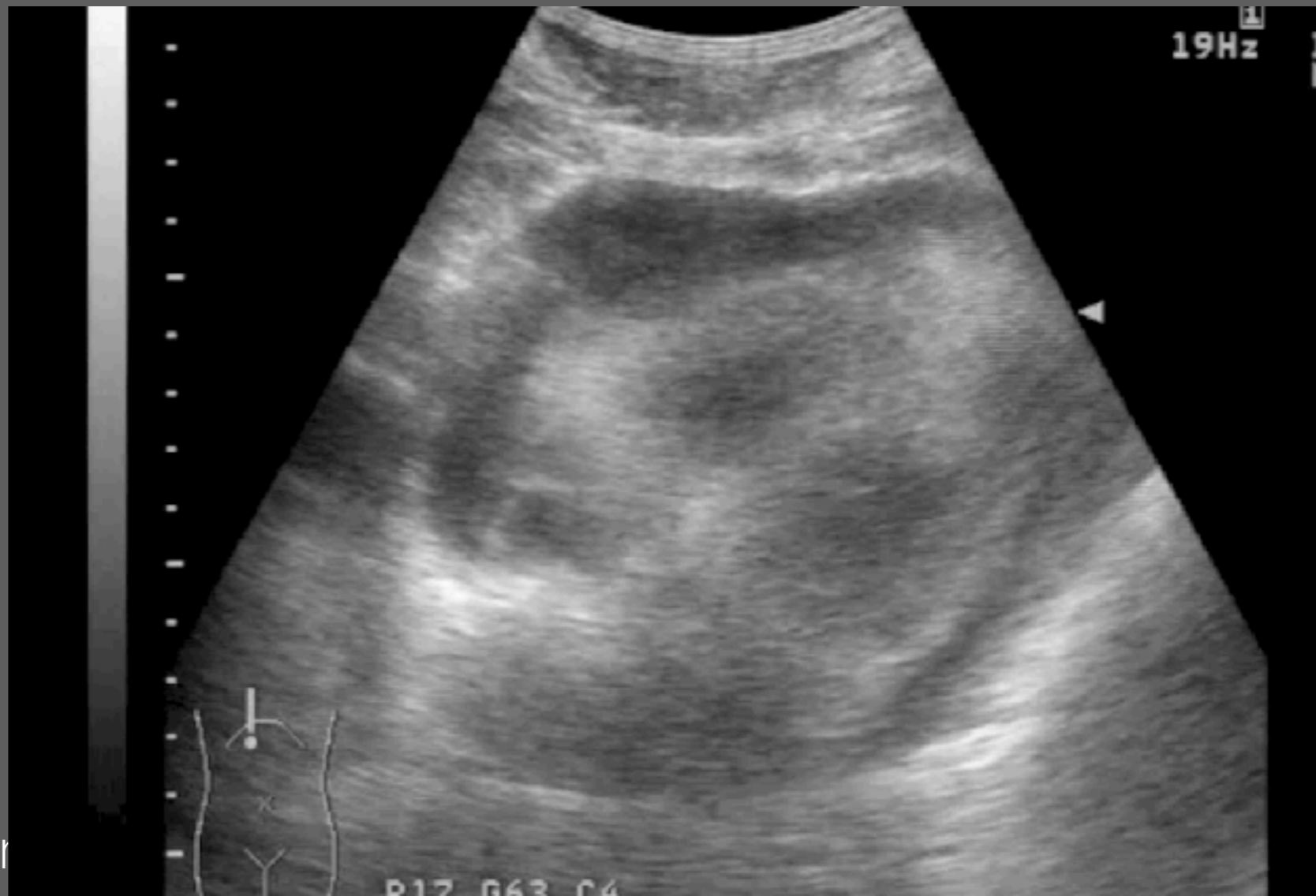

3W5V



Pericardial effusion

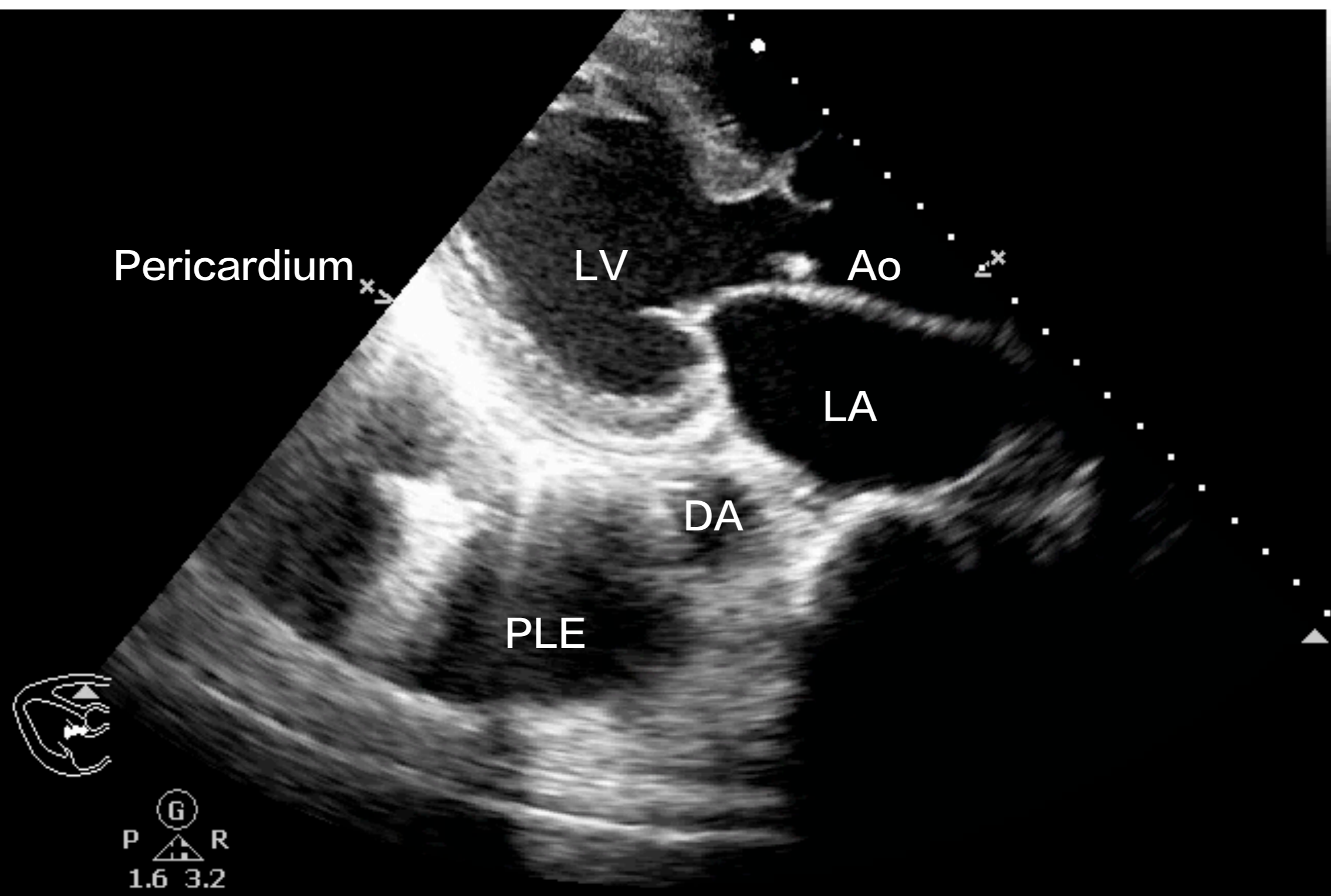
1 ~ 2 cm



Cher

DA as a good reference

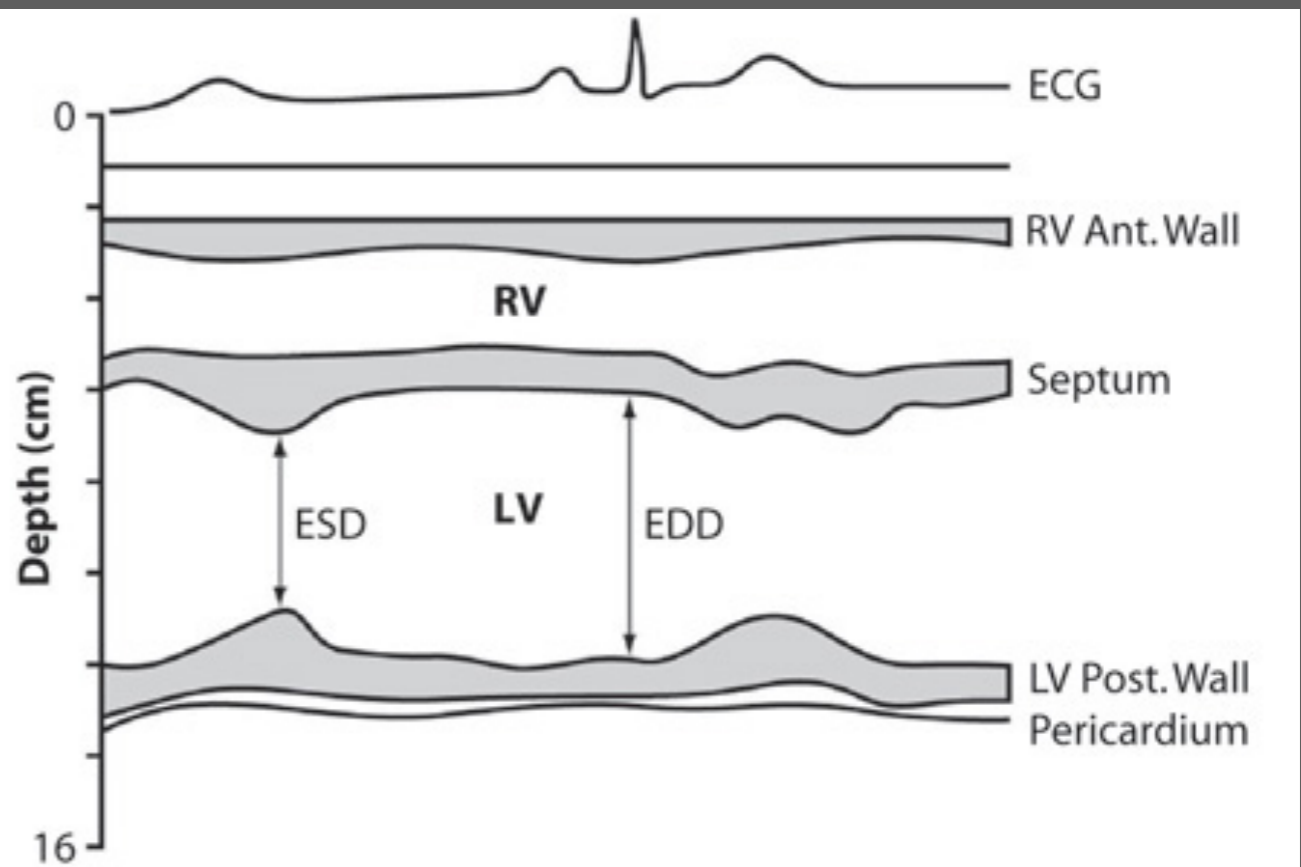
35-1
25 Hz
21.0cm
2D
HGen
Gn 31
C 50
3/2/0



G
P R
1.6 3.2

Fraction shortening

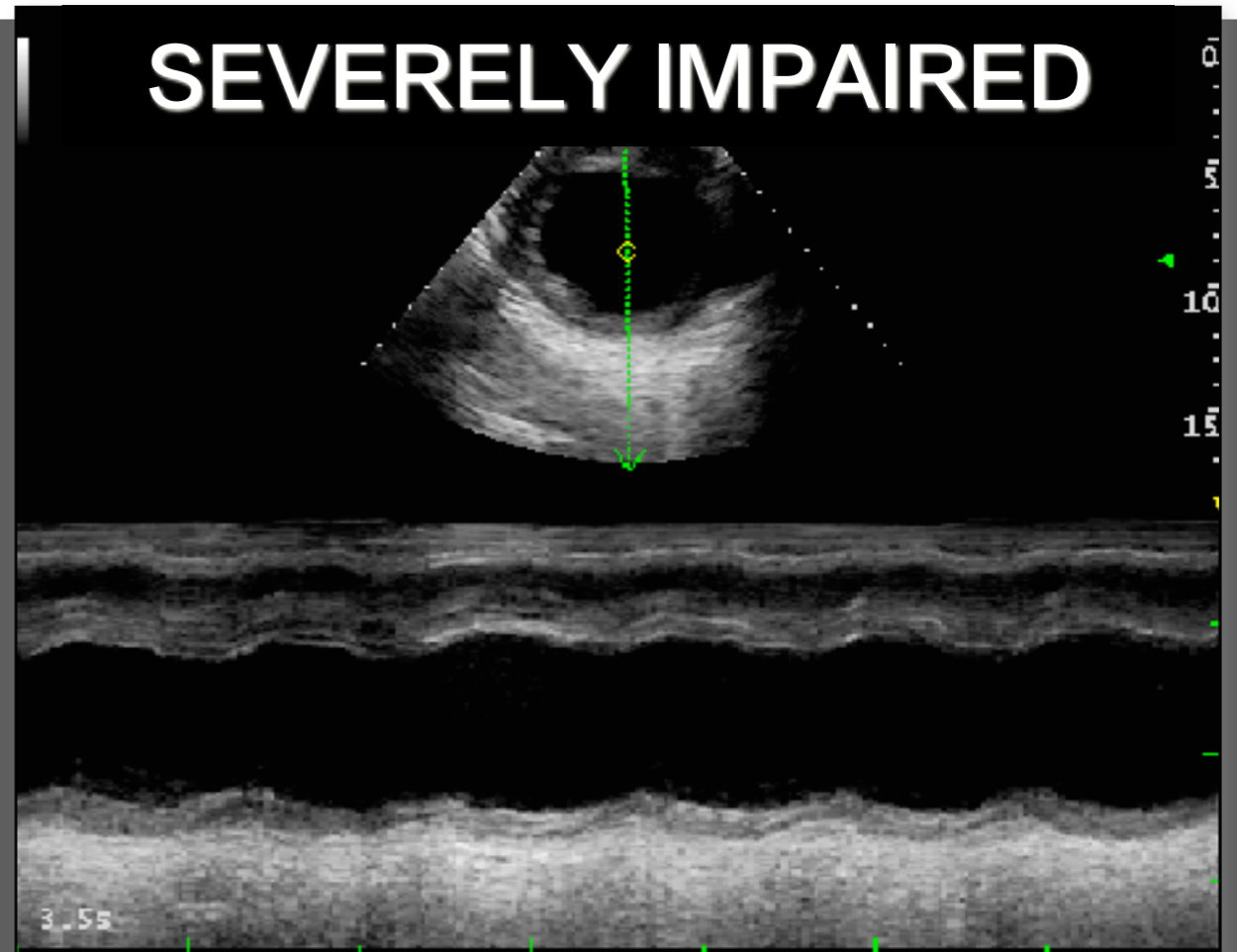
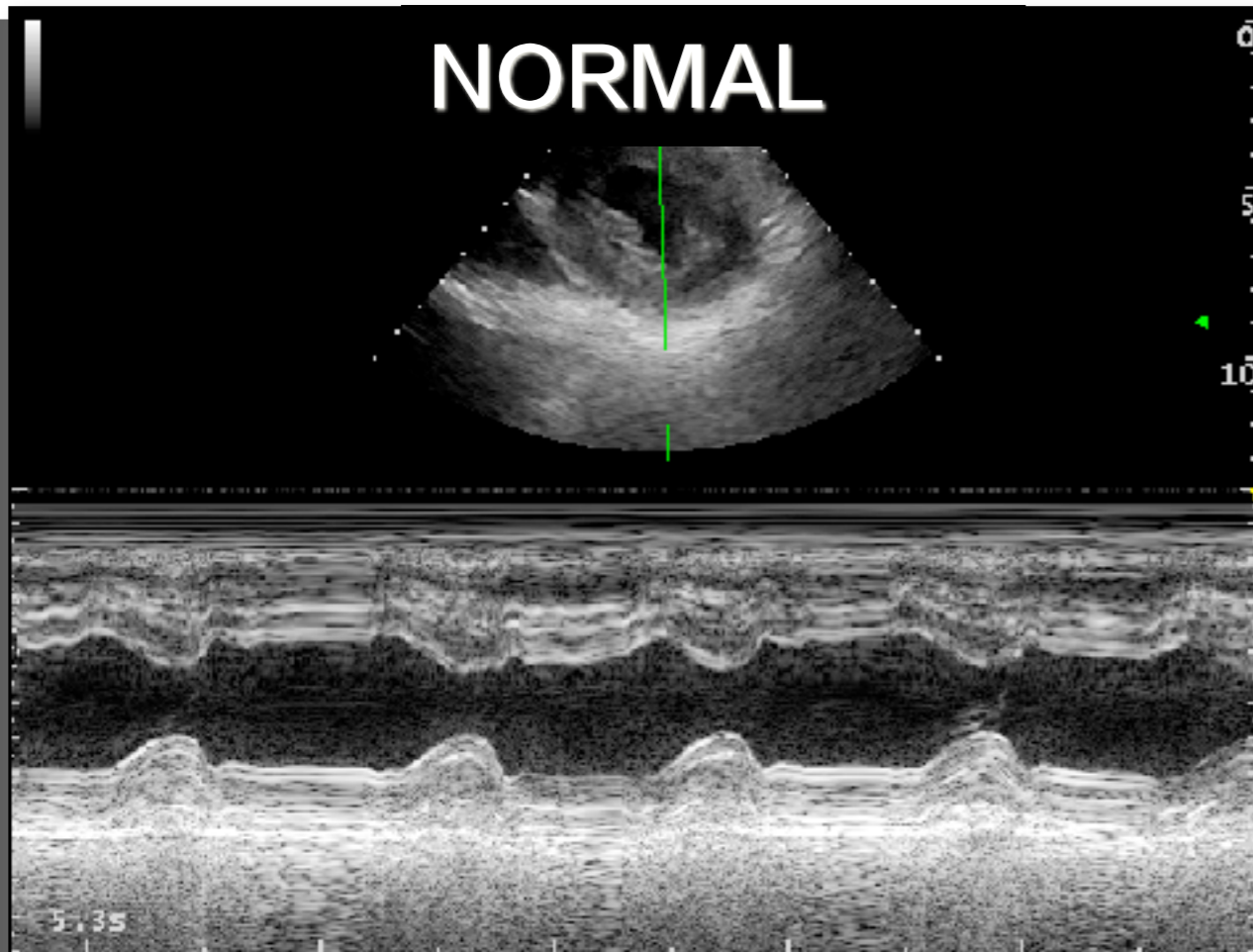
$$FS (\%) = 100 \times \frac{(LVEDD - LVESD)}{LVEDD}$$



NORMAL $\geq 30\%$

SEVERELY IMPAIRED $< 20\%$

FS



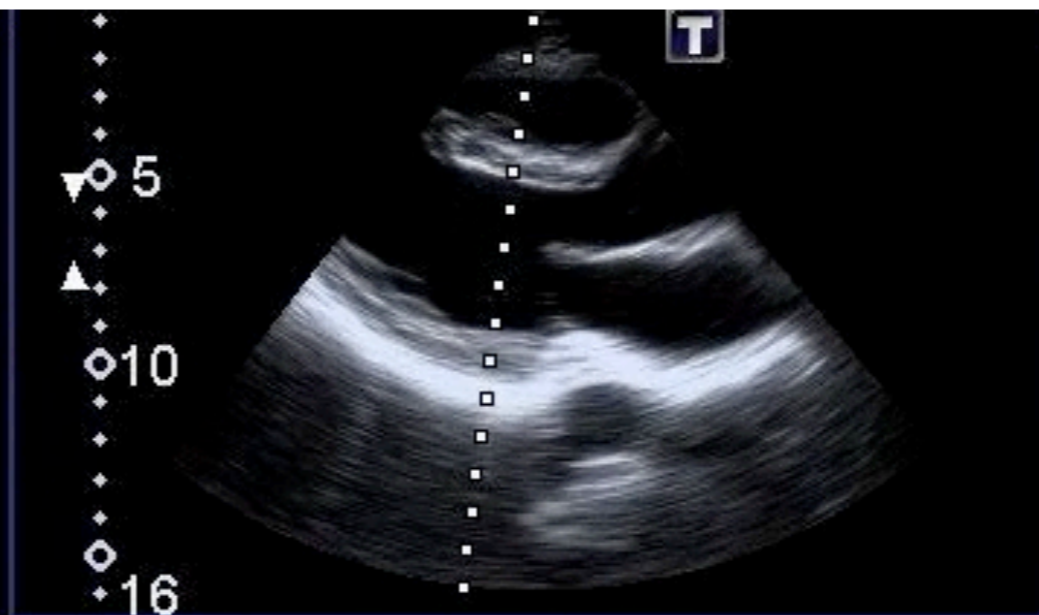
$$EF(\%) \approx FS(\%) \times 2 \quad (\text{ex. FS } 30\% \approx EF \text{ } 60\%)$$

(Simplification of Teicholz method)

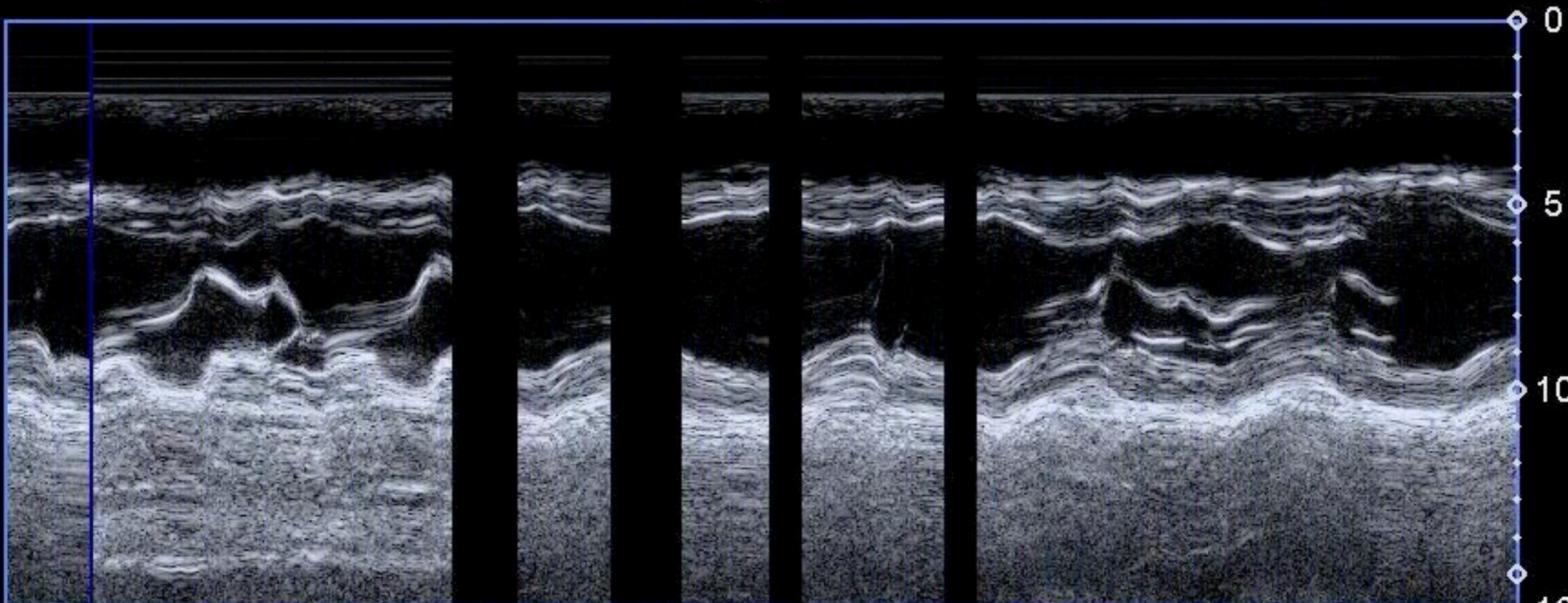
FS

G:82
DR:55
TE:3

5
10
16

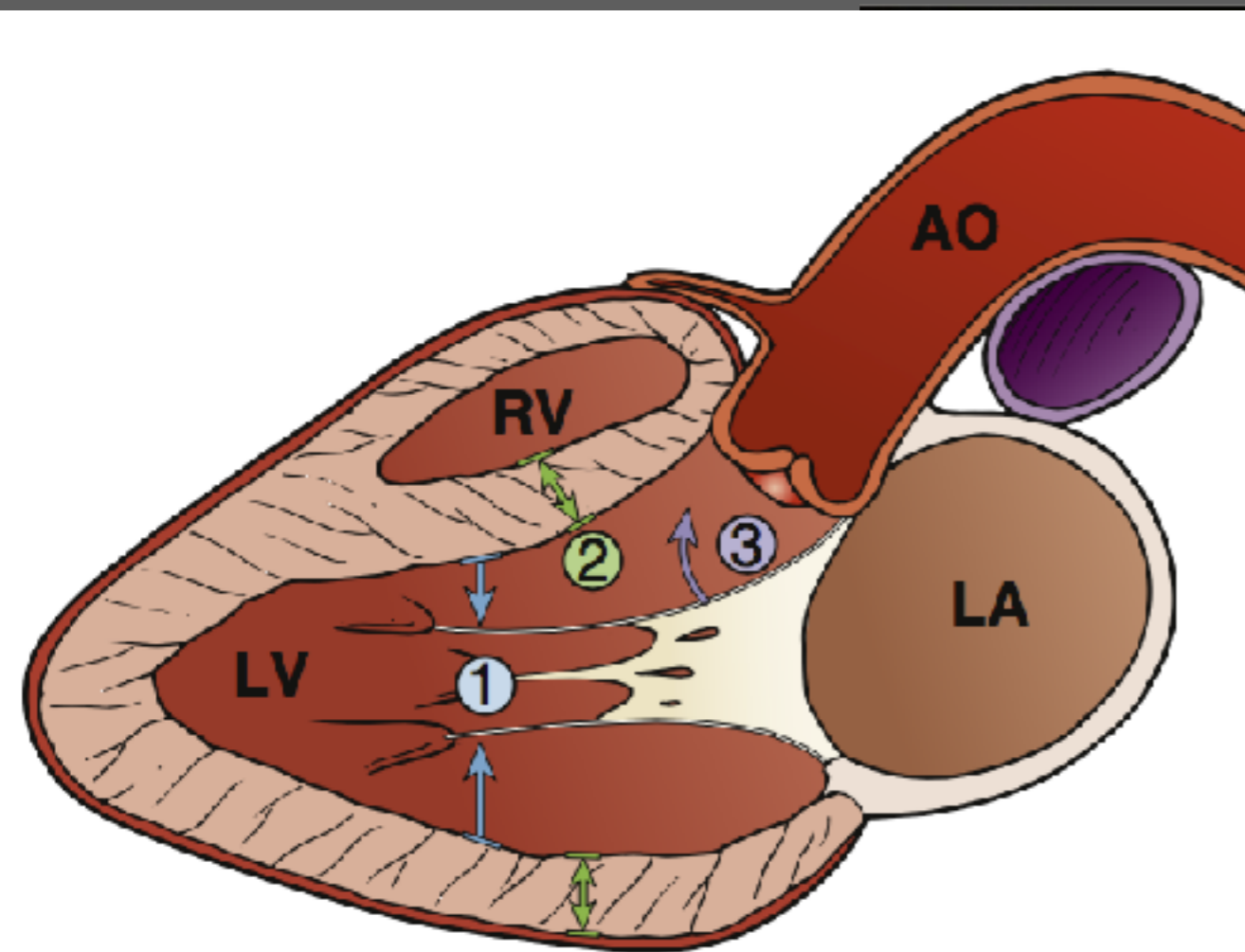


5S1
T3.0
32 fps

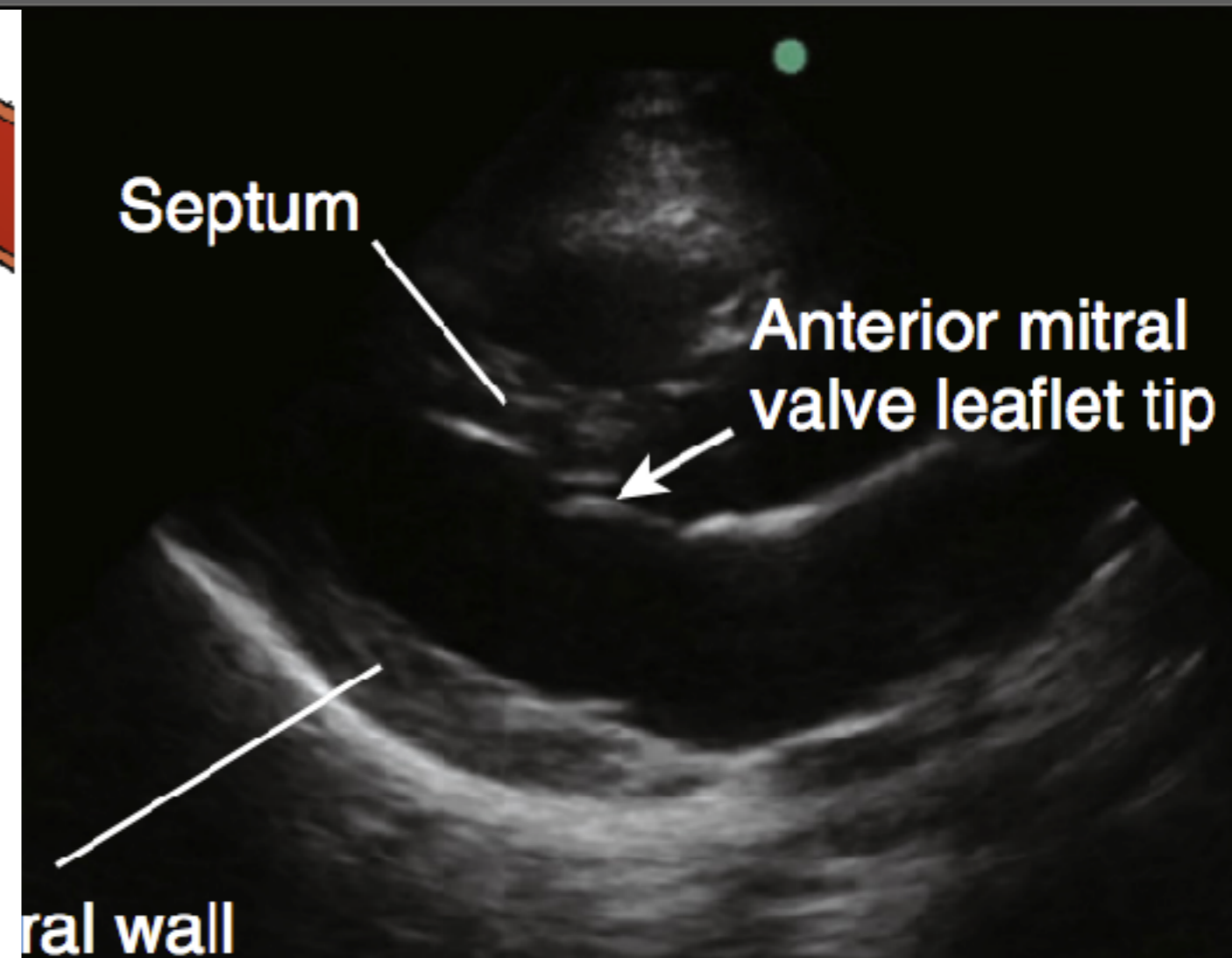


EPSS

E-point septal separation $>7\text{mm}$: LVEF $< 30\%$

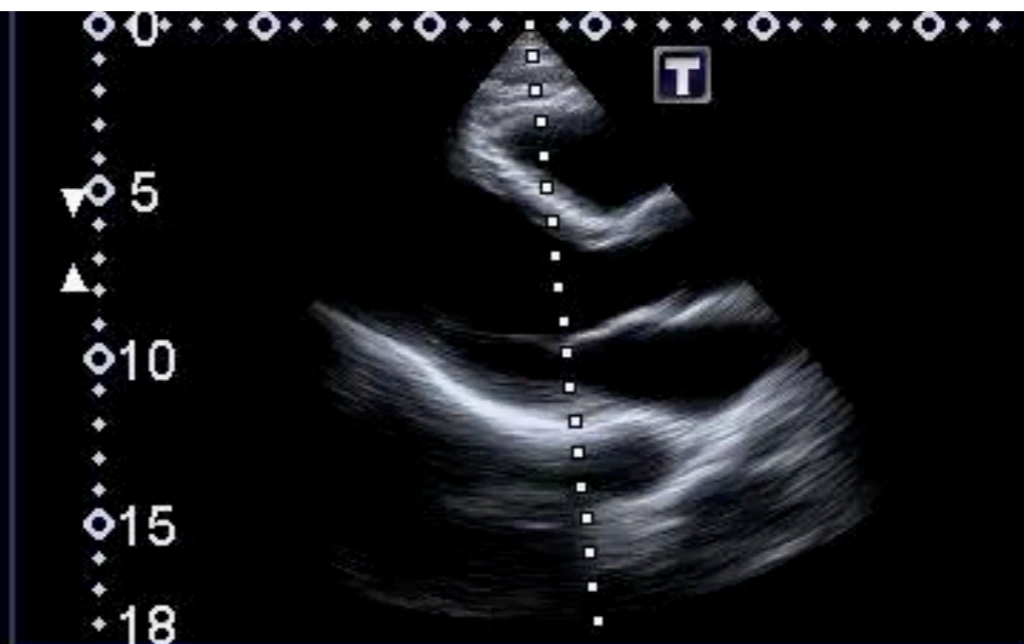


- 1 - Endocardial excursion
- 2 - Myocardial thickening
- 3 - Septal motion of anterior leaflet of mitral valve

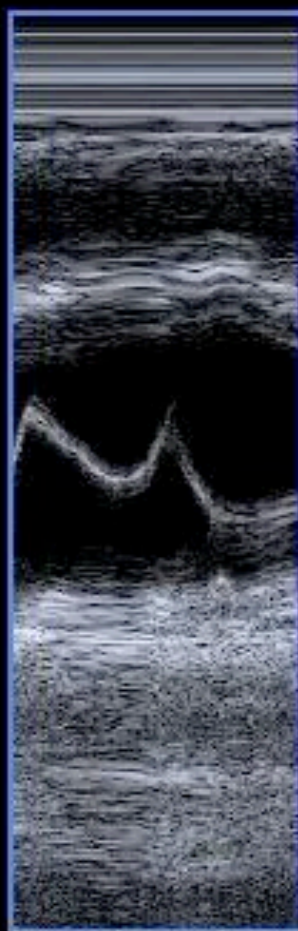


EPSS

Qscan
G:91
DR:55
TE:3



MI:1.5
5S1
T3.0
25 fps



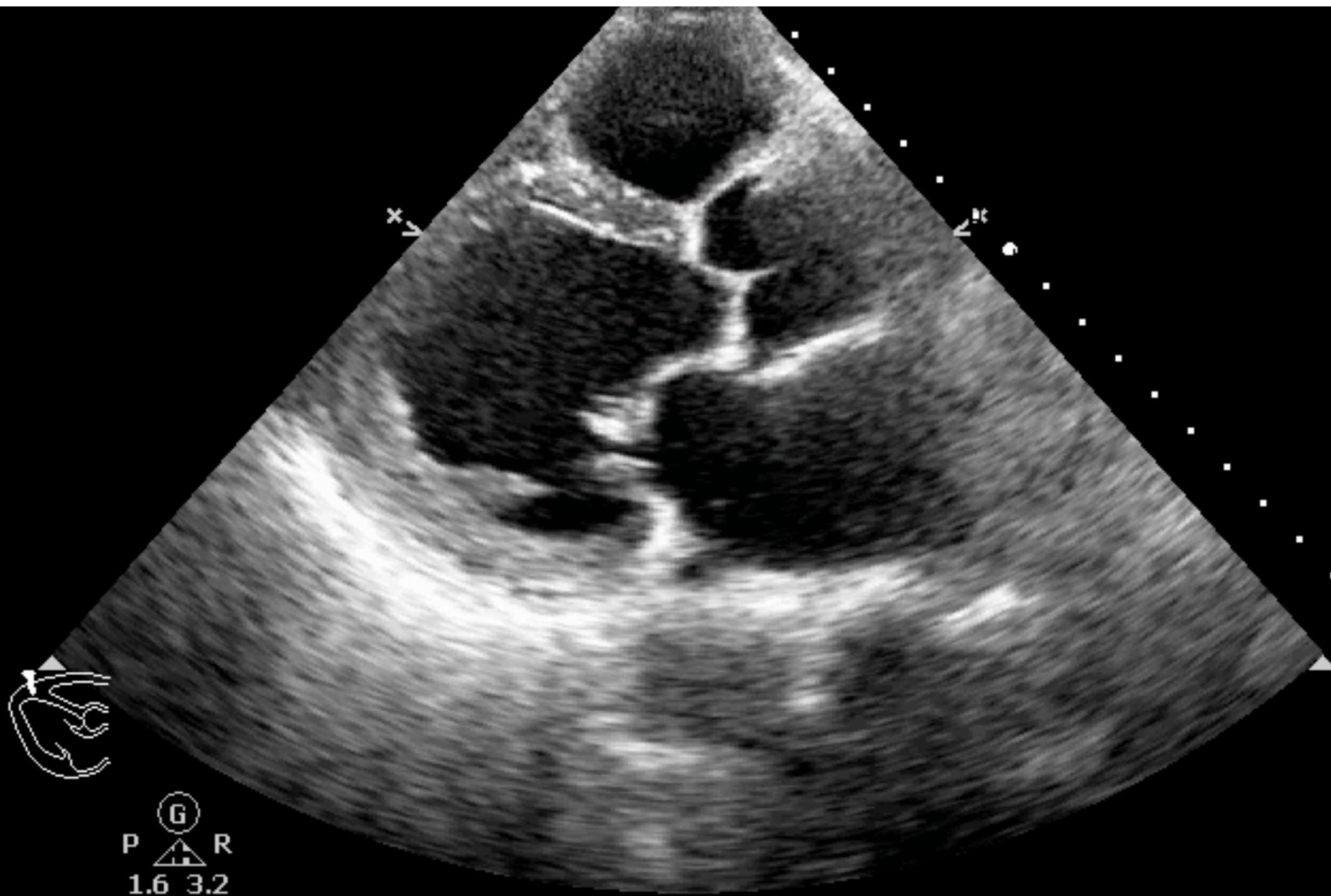Qscan:86 / MDR:50 / T3.0

0
5
10
15
18

Heart failure ?

AS
S5
28 Hz
19.0cm

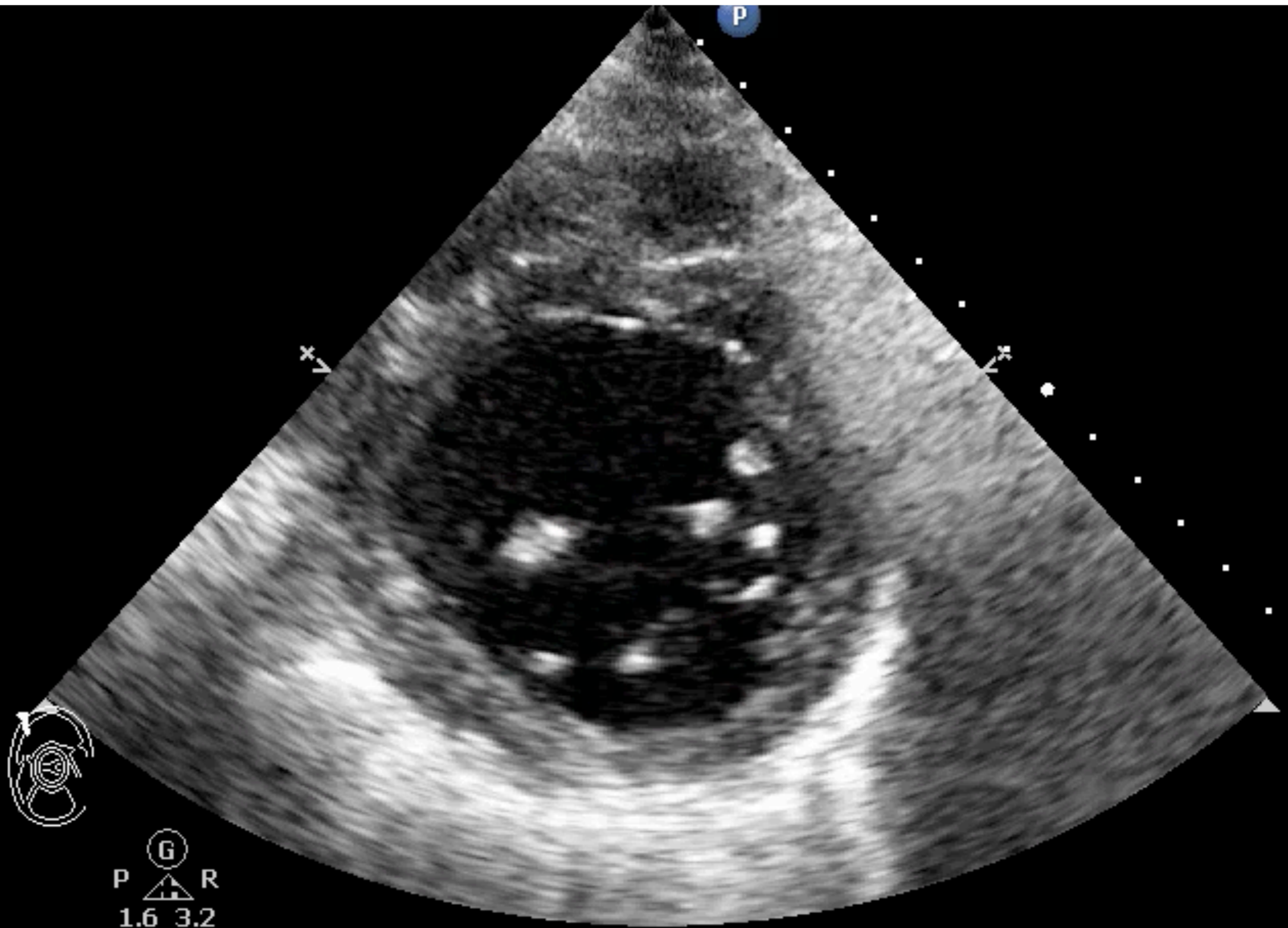
2D
HGen
Gn 34
C 50
3 / 2 / 0



Heart failure ?

Adult Echo2
S5-1
34 Hz
15.0cm

2D
HGen
Gn 34
C 50
3/2/0

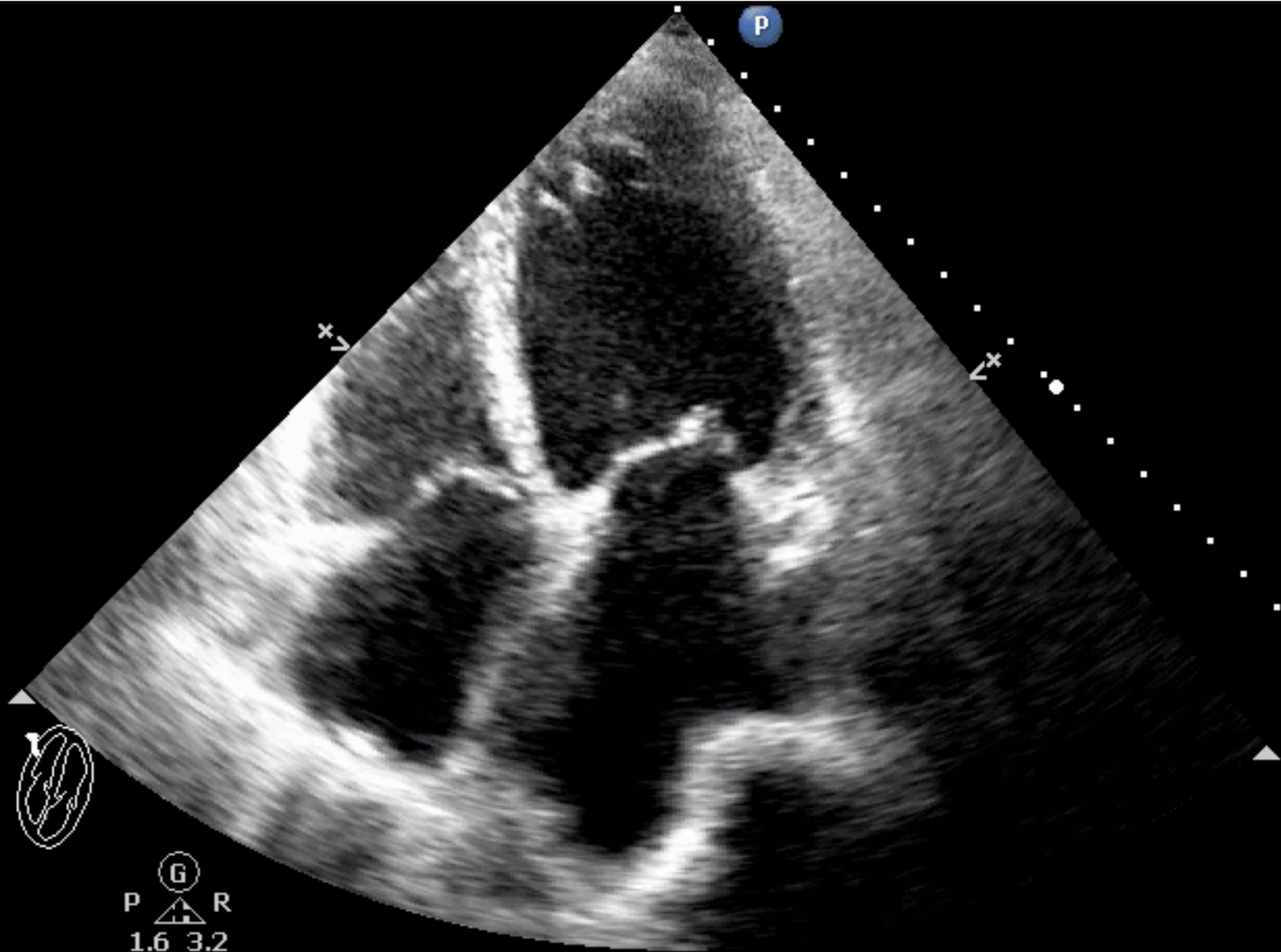


Heart failure ?

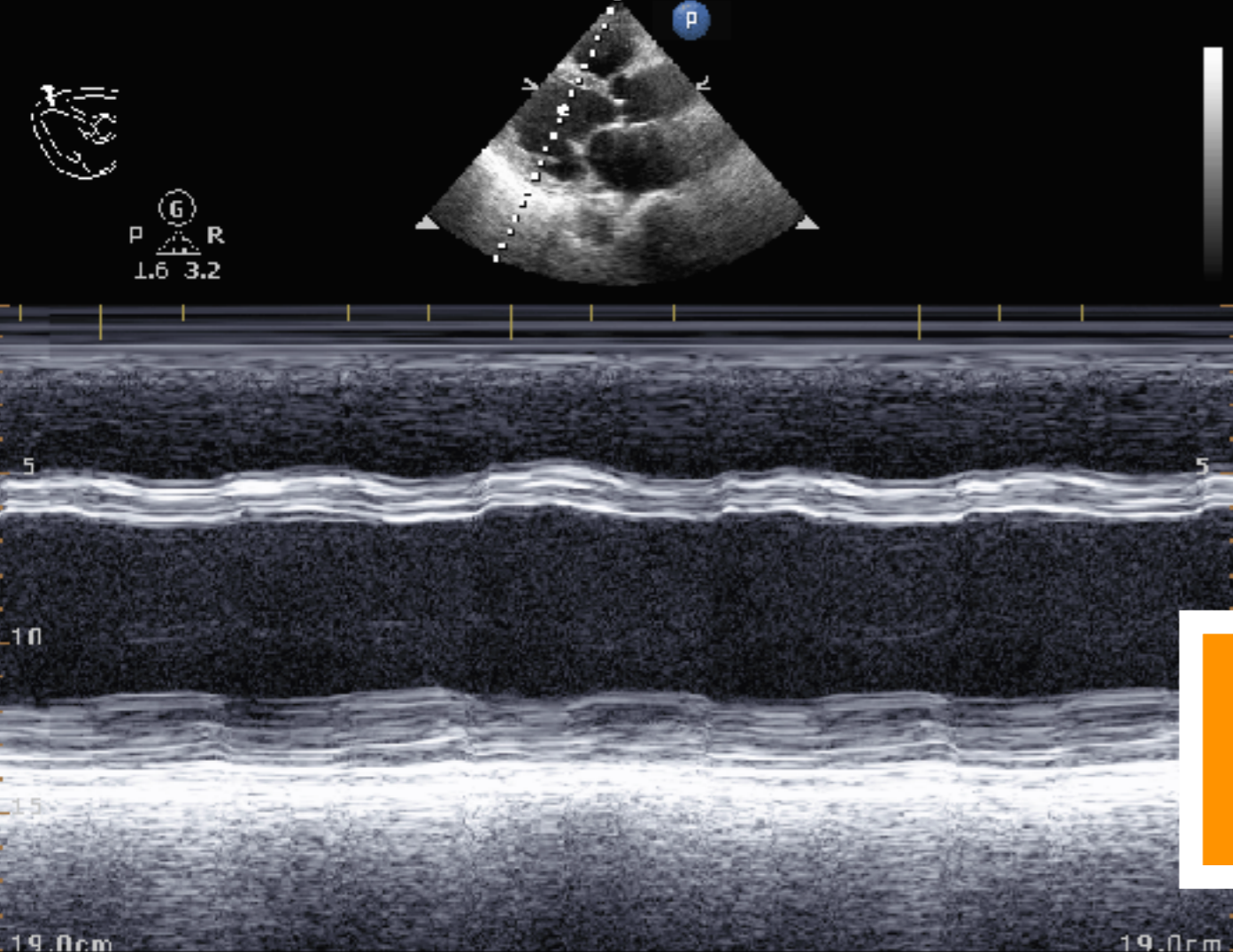
Adult Echo2
S5-1
27 Hz
20.0cm

2D

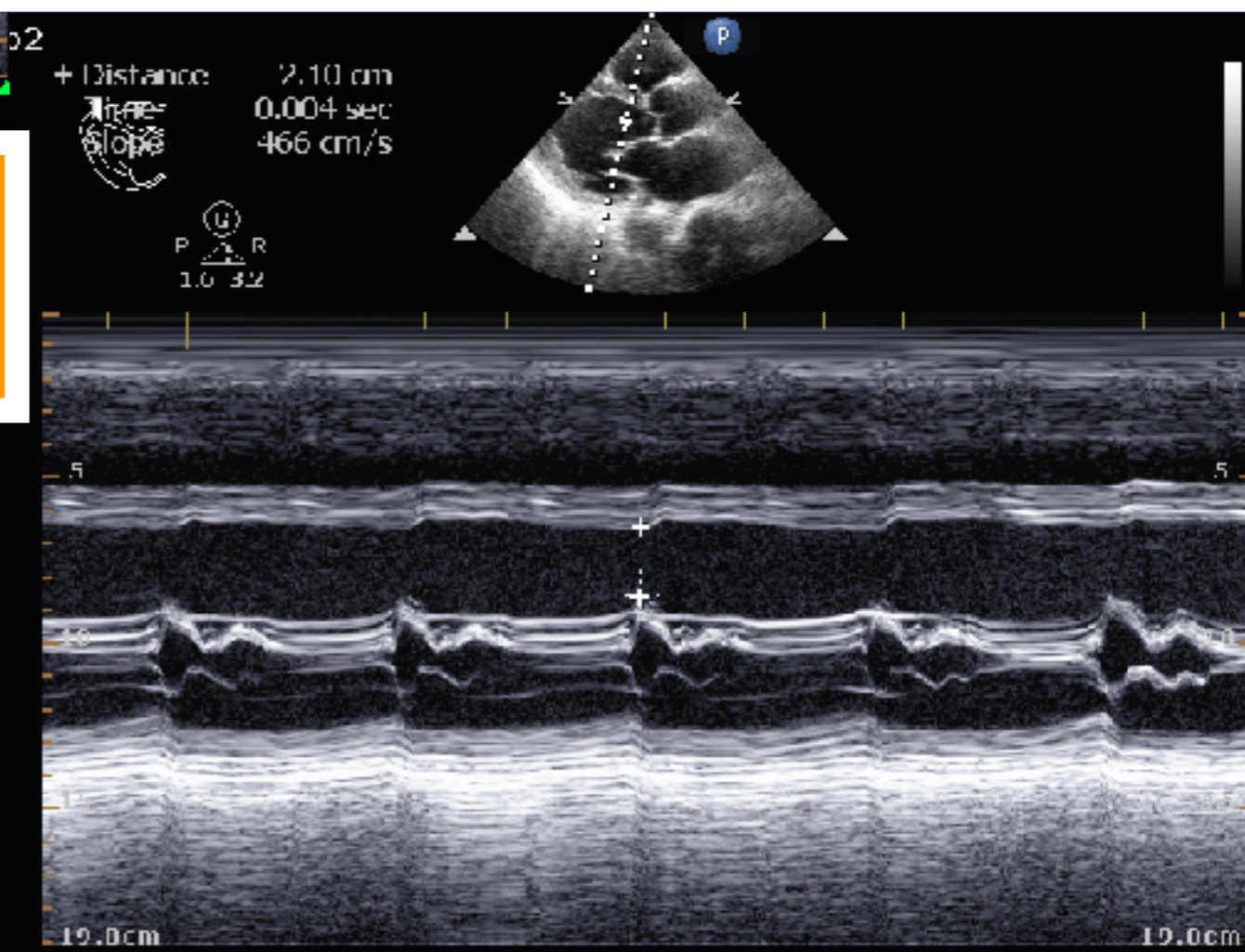
HGen
Gn 41
C 50
3 / 2 / 0



G
P R
1.6 3.2



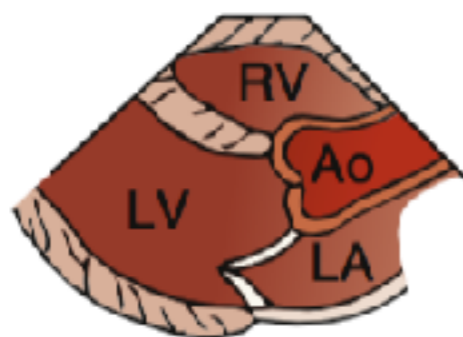
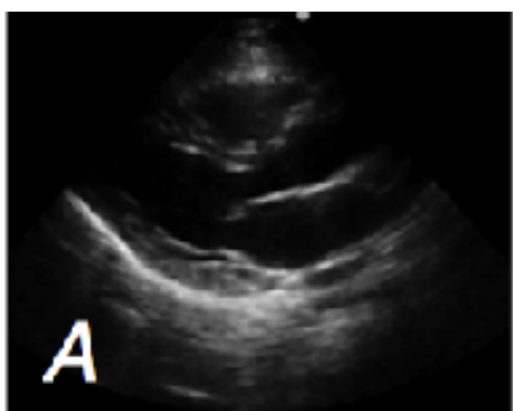
EF/FS



EPSS

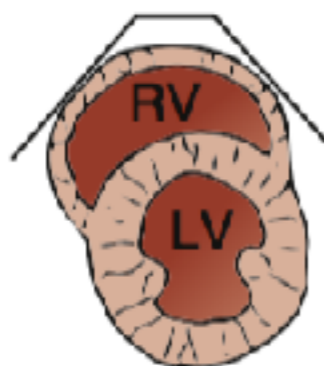
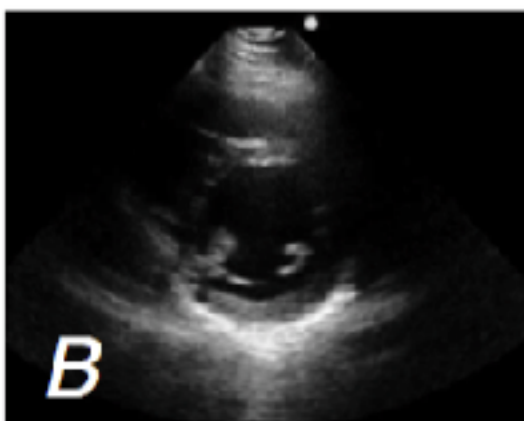
M mode
3/3
75 mm/s

RV evaluation



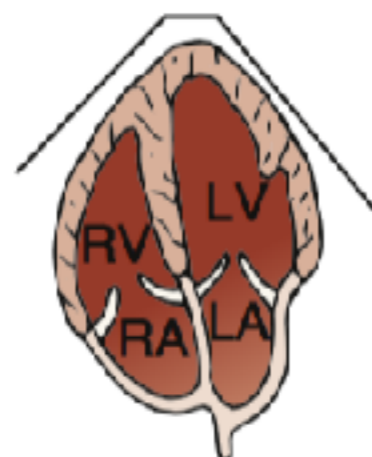
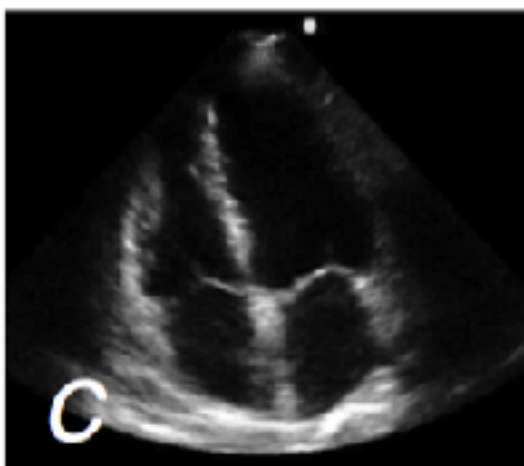
Parasternal long-axis view

- Only RVOT visible in the near field
- Only gross RV size or function abnormalities detectable



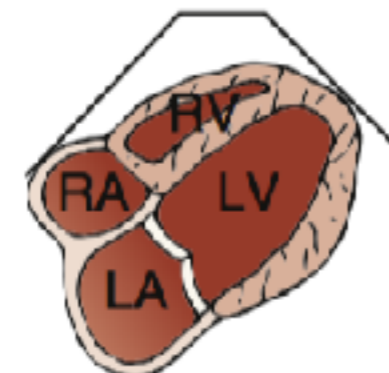
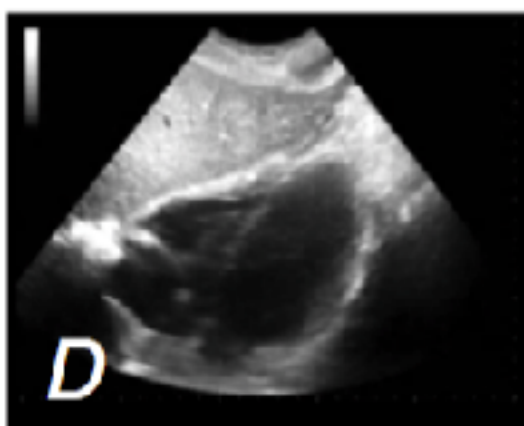
Parasternal short-axis view

- Crescentic RV adjacent to the circular LV
- Look for RV>LV size and septal kinetics or flattening



Apical 4-chamber view

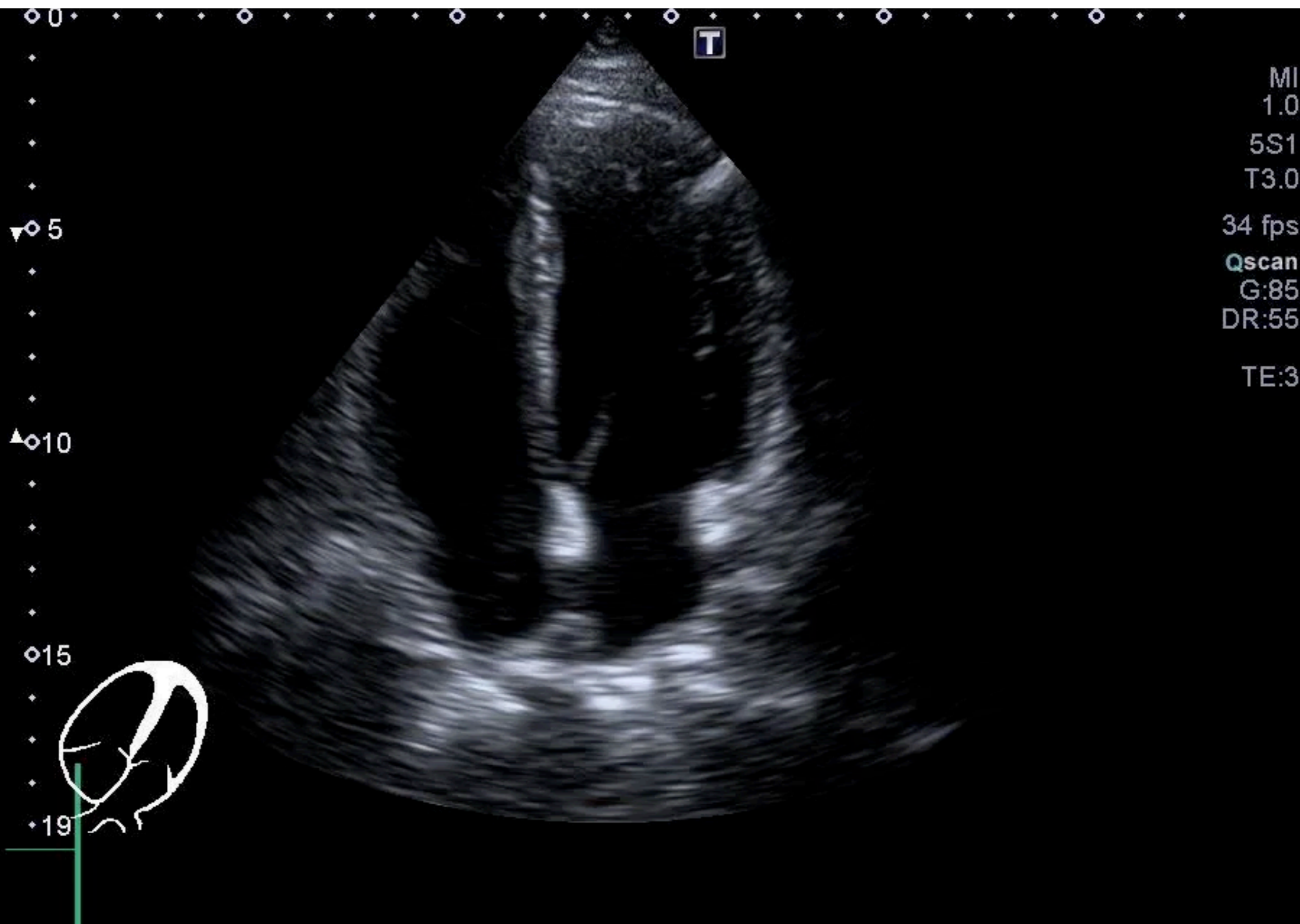
- Triangular RV seen adjacent to the LV
- Ideal view for RV size and systolic function assessment



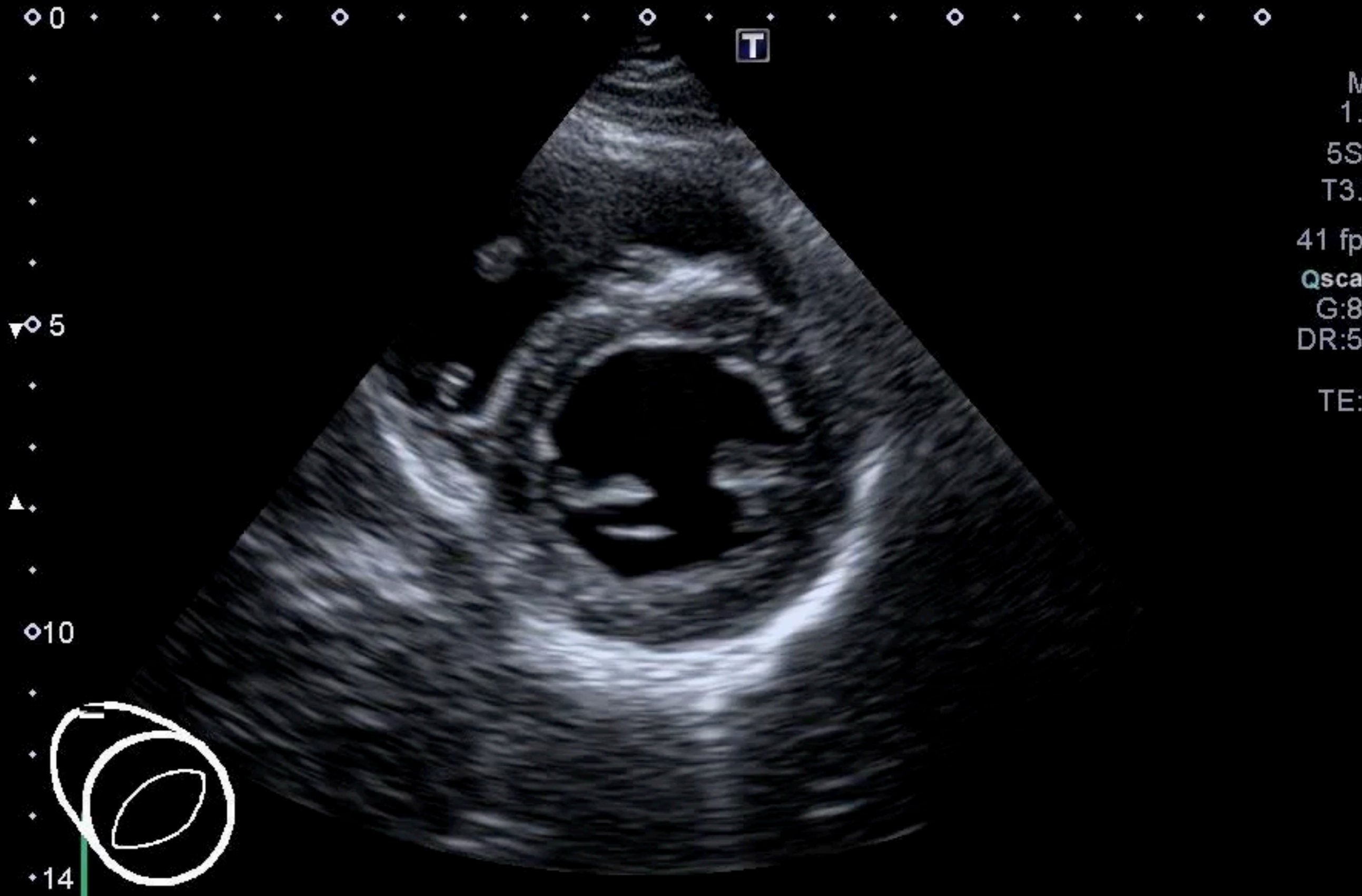
Subcostal 4-chamber view

- Triangular RV in the near field
- May assess RV size, systolic function, and wall thickness

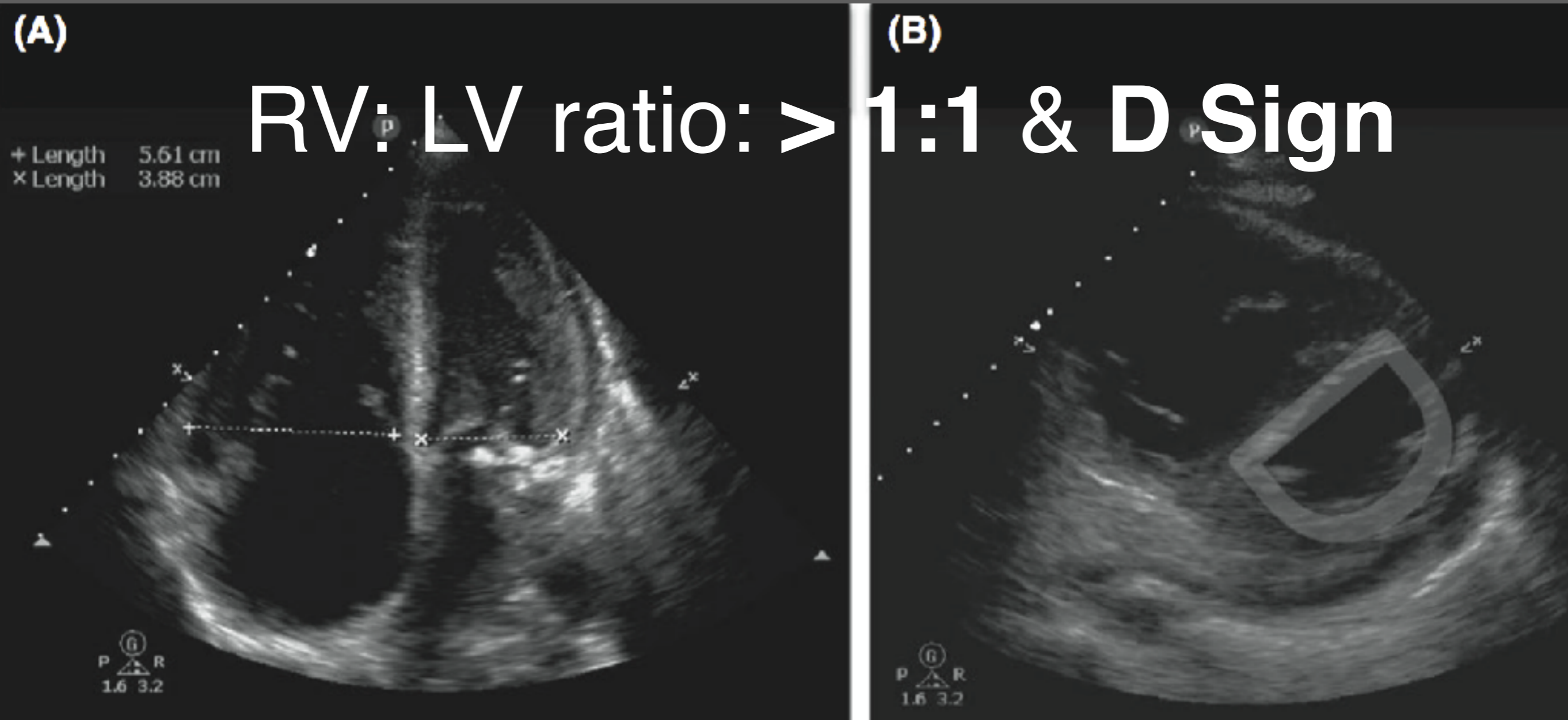
RV: LV = 0.6 : 1



Crescent & Doughnut



Equality (PSSA)



RV: LV ratio: $0.6 : 1$

McConnell's sign

Acute RV strain

mindray

oguz,suleyman 20121105-122652-B5AC

05/11/2012

12:29:22

AP 97%

MI 0.3 TIS 0.2

P4-2s

Adult Cardiac

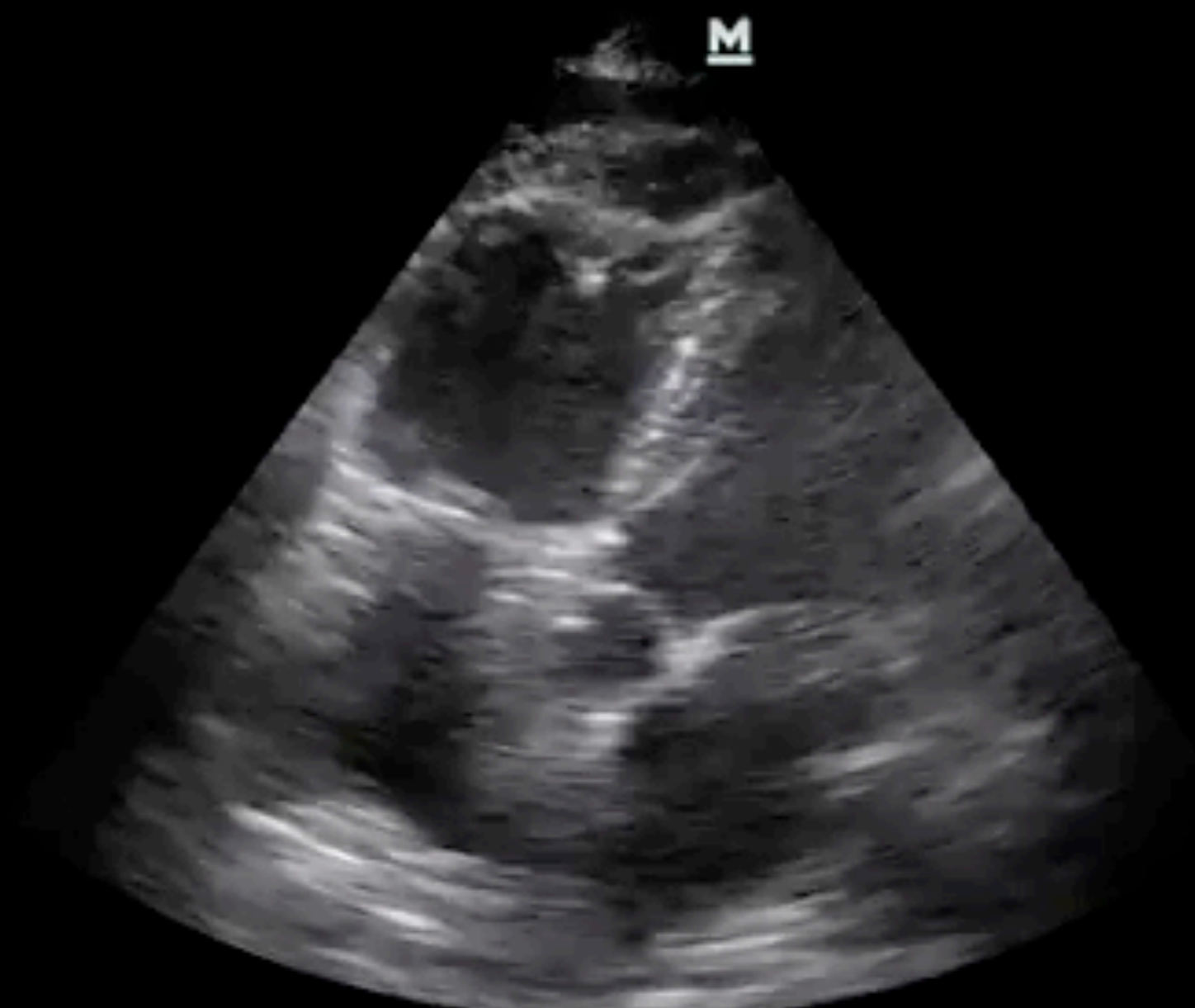
M7

B1

FH3.2 /D18.2

G54 /FR75

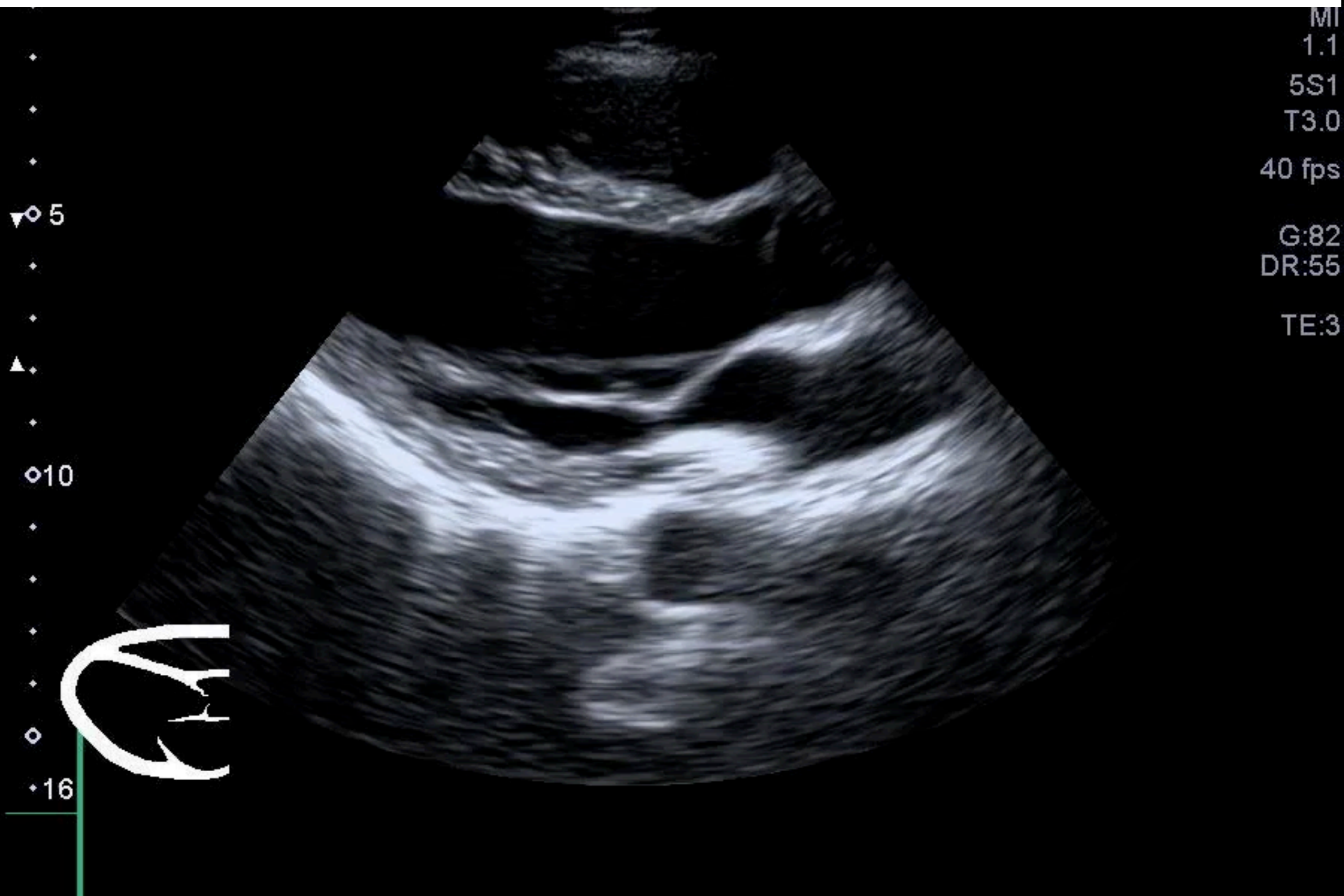
IP4 /DR75



5
10
15

1/373

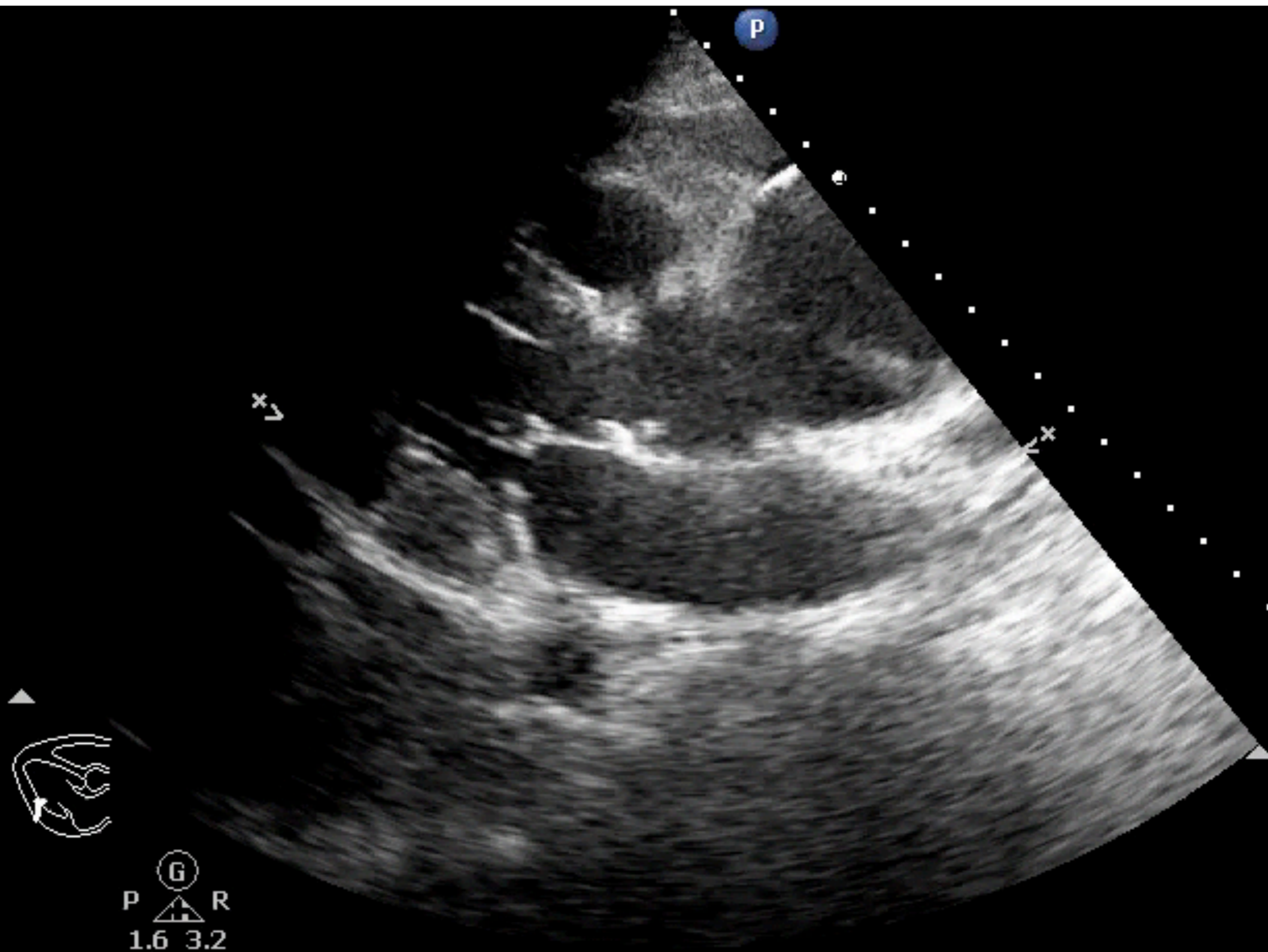
PSLA (root & DA)

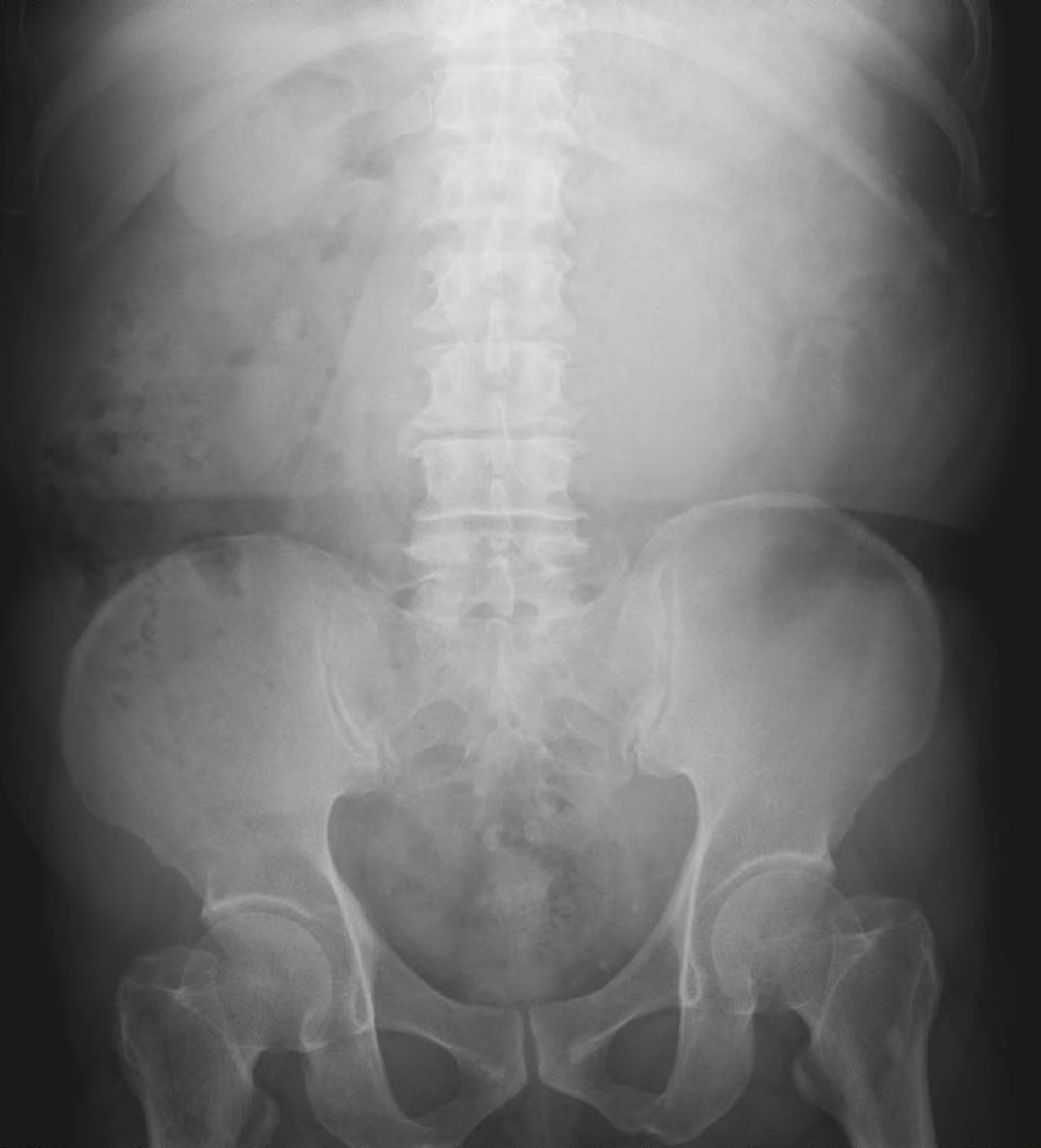

Exit (Aorta)

Adult Echo
S5-1
27 Hz
20.0cm

2D
HGen
Gn 41
C 50
3/2/0





64M,
左下腹痛

1小時

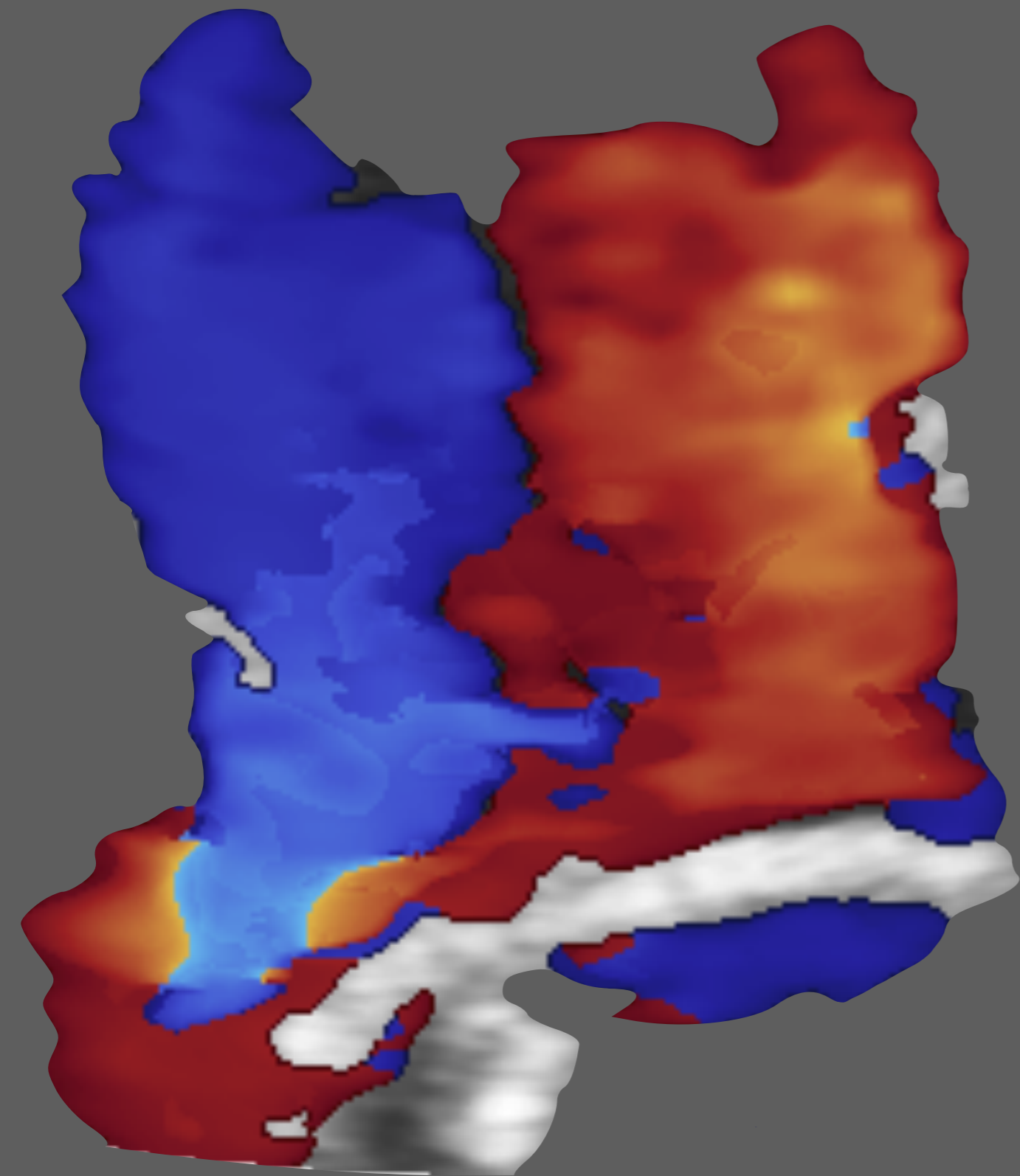
冒冷汗

結石病史

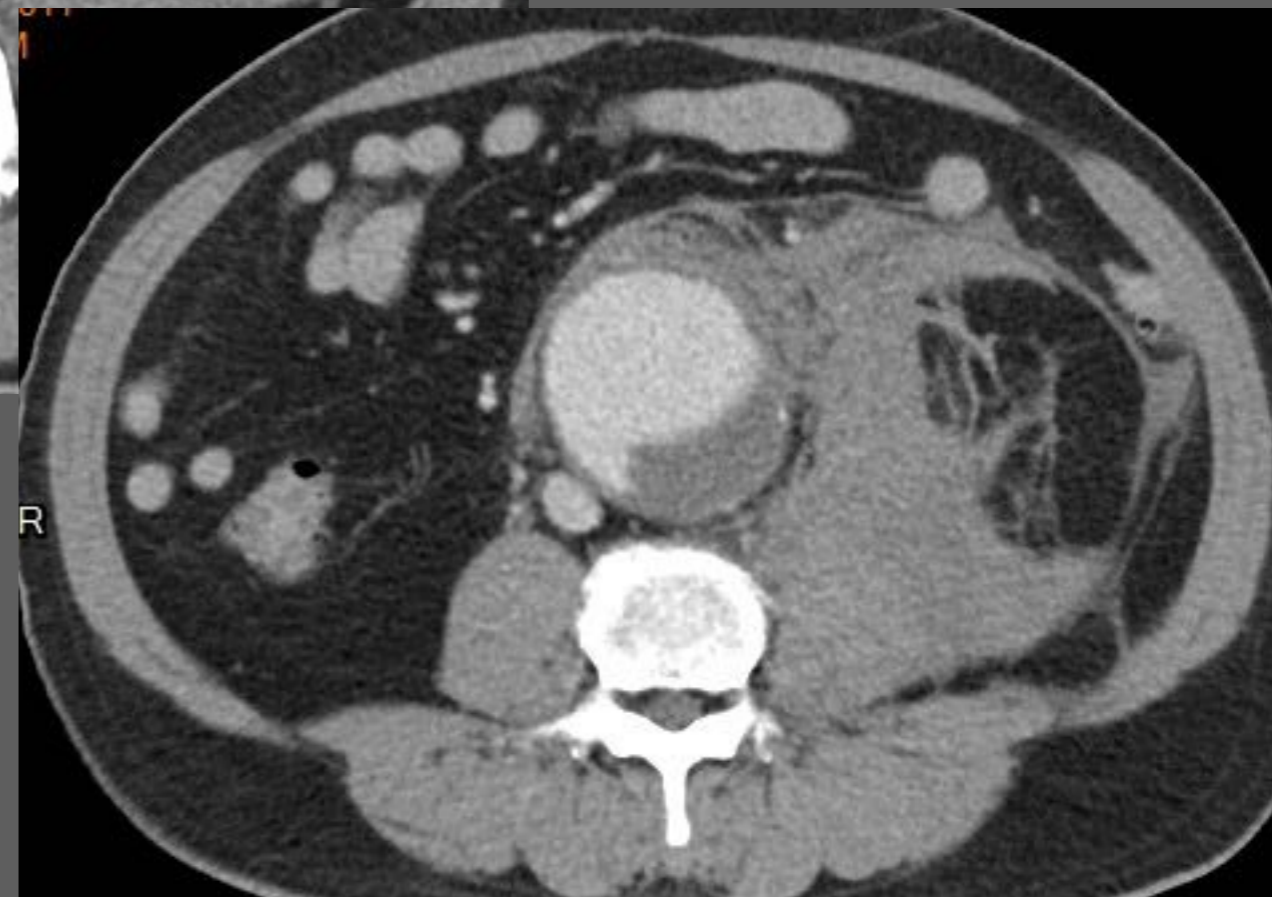
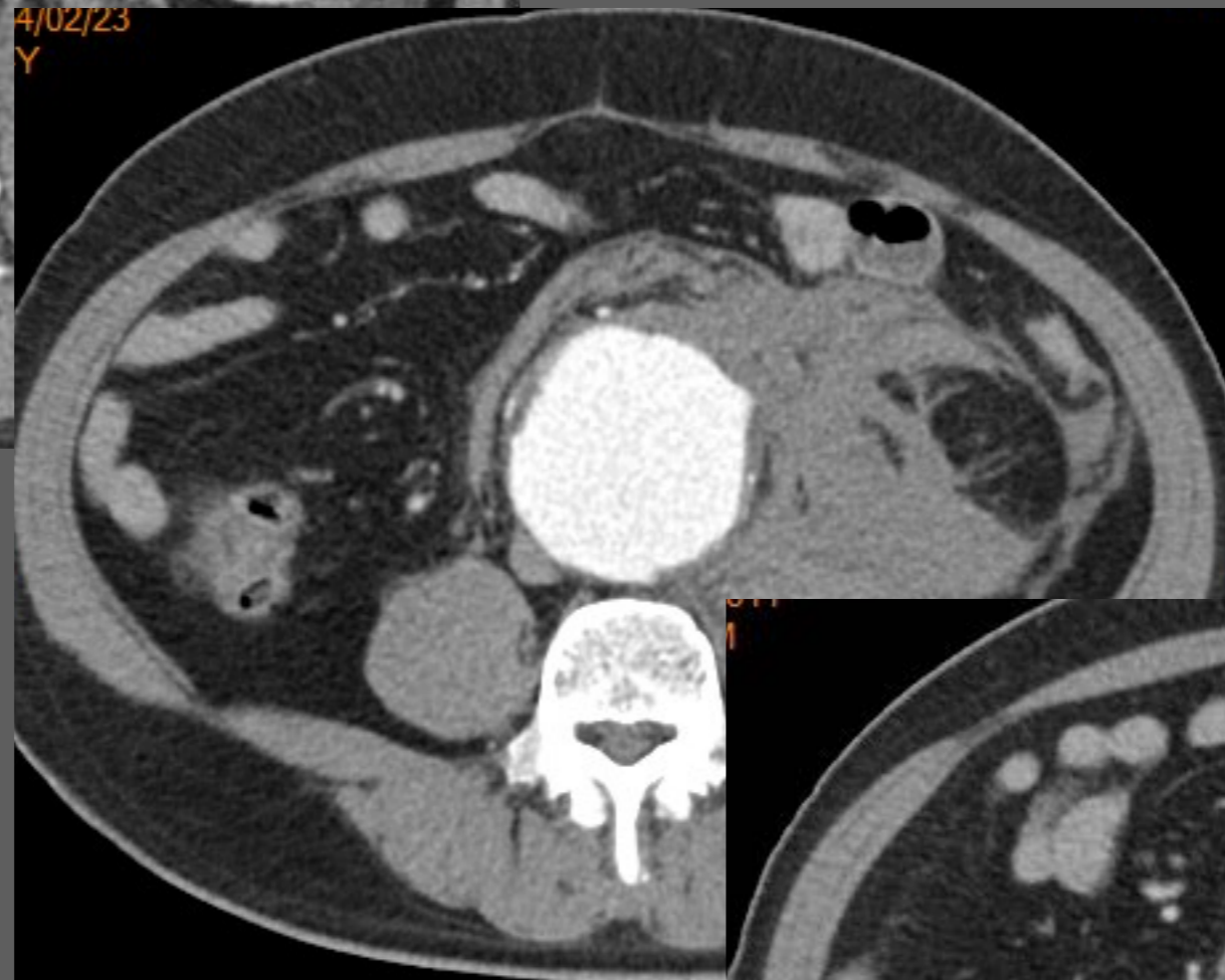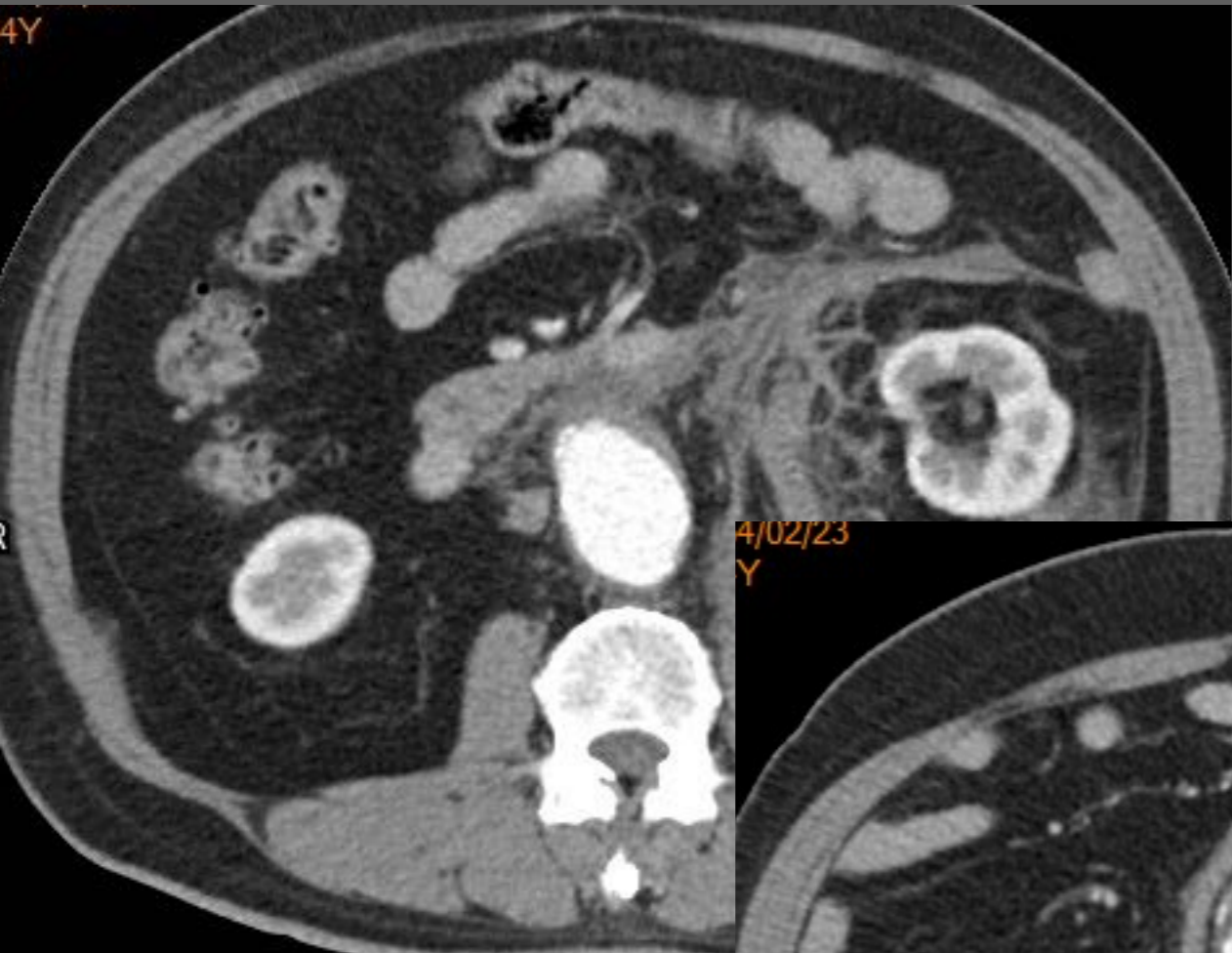PR 117

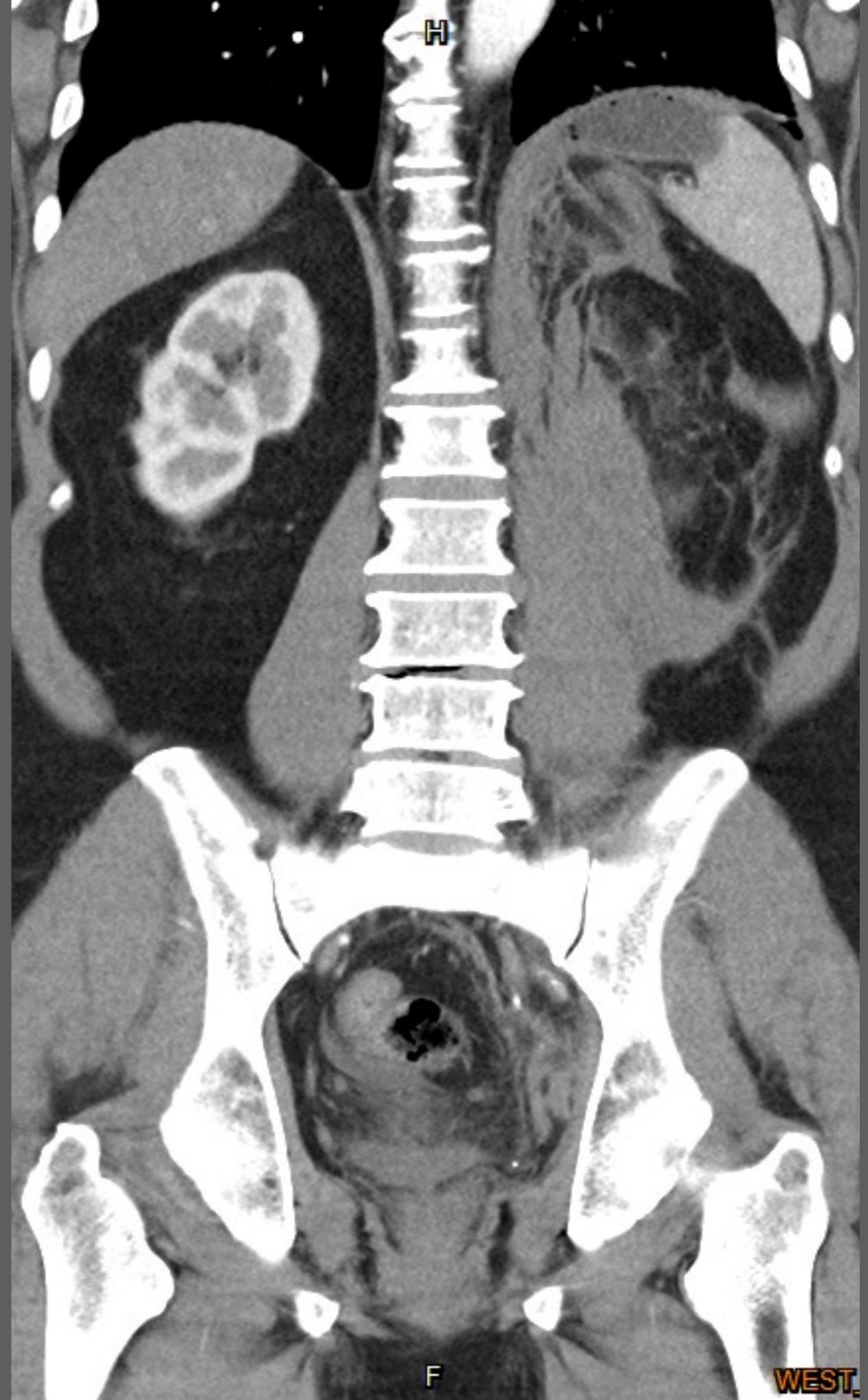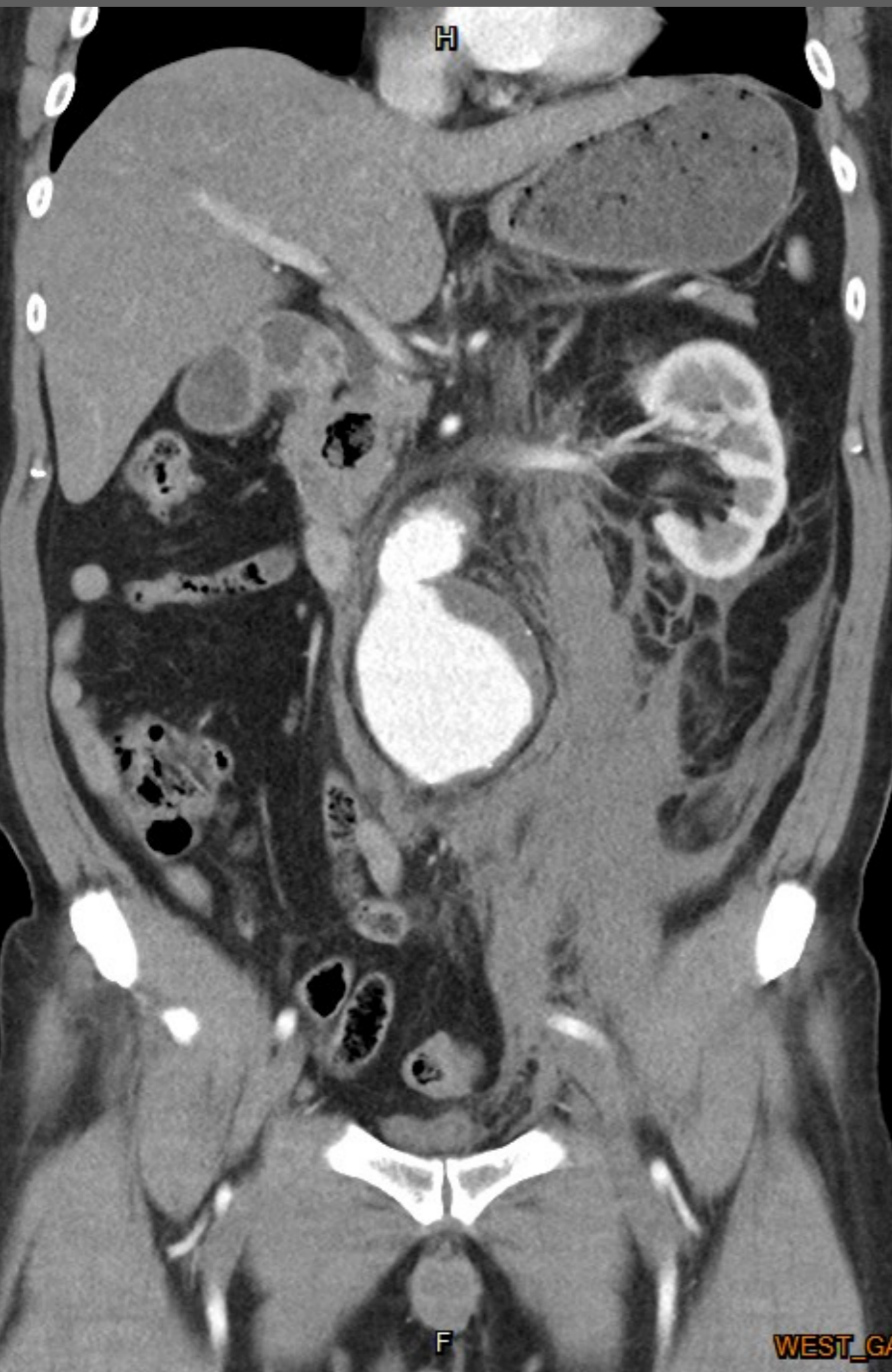BP

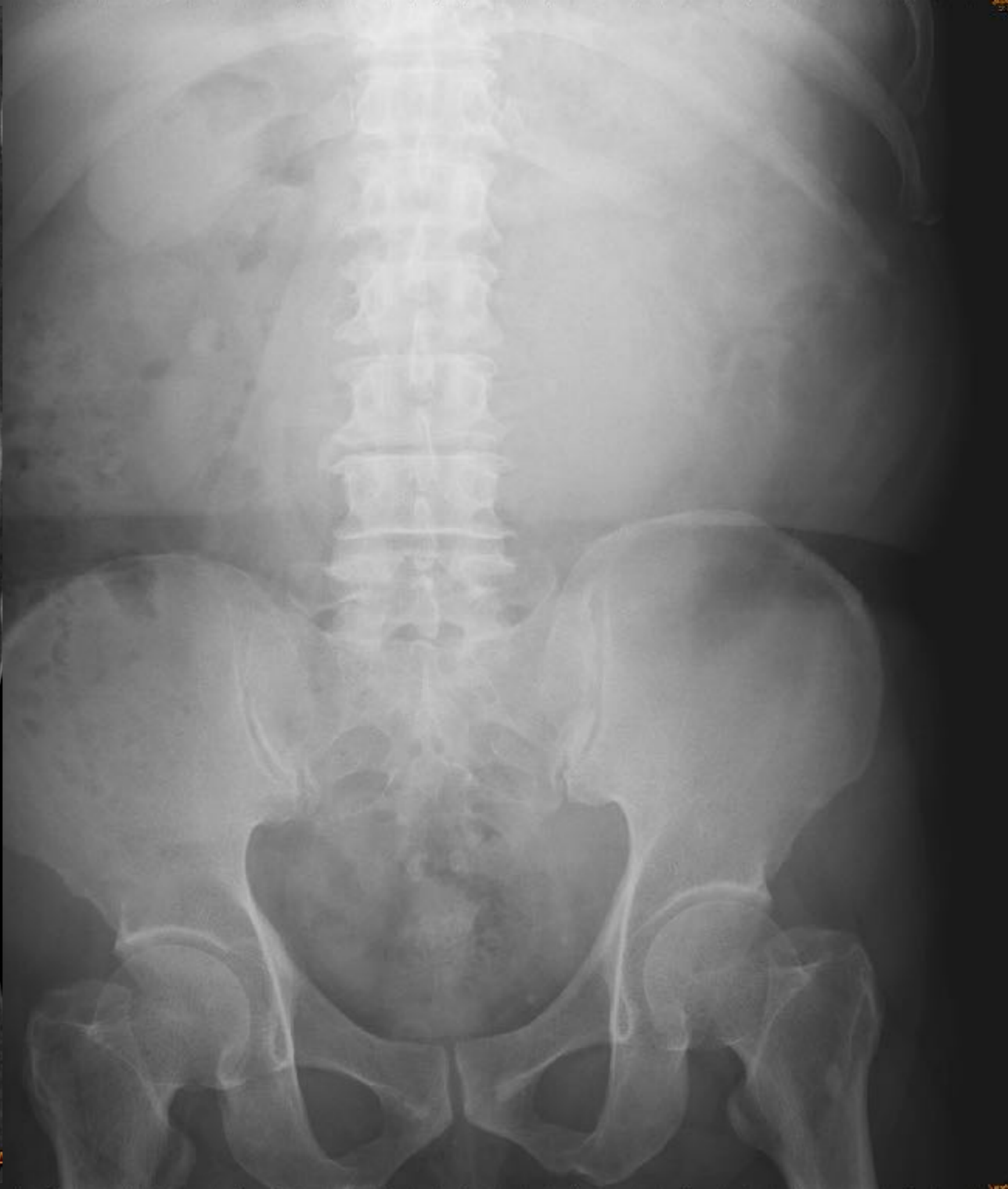
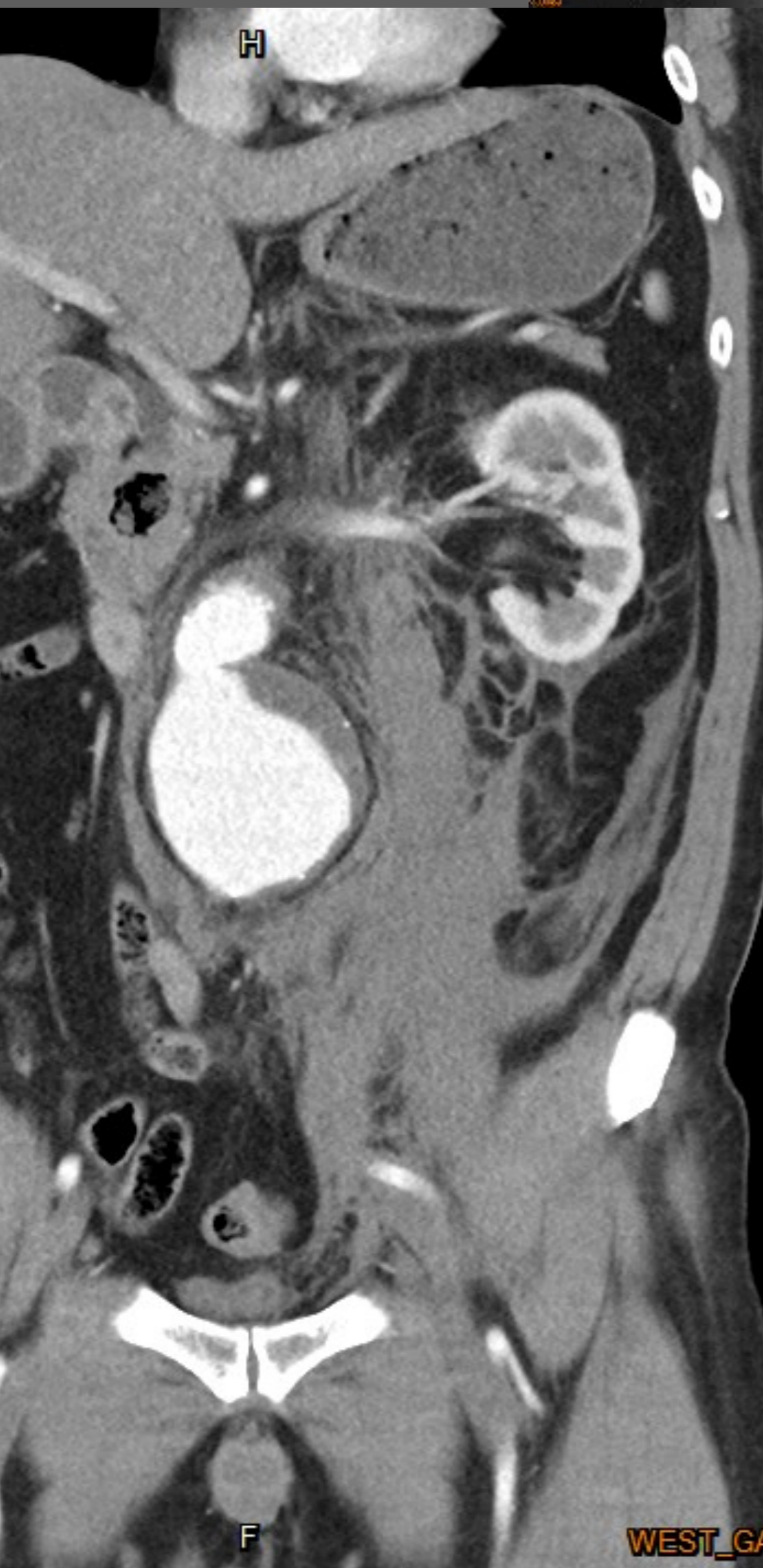
88/62



腰痛 + 冒冷汗，
我的病人可能是
主動脈瘤破裂？



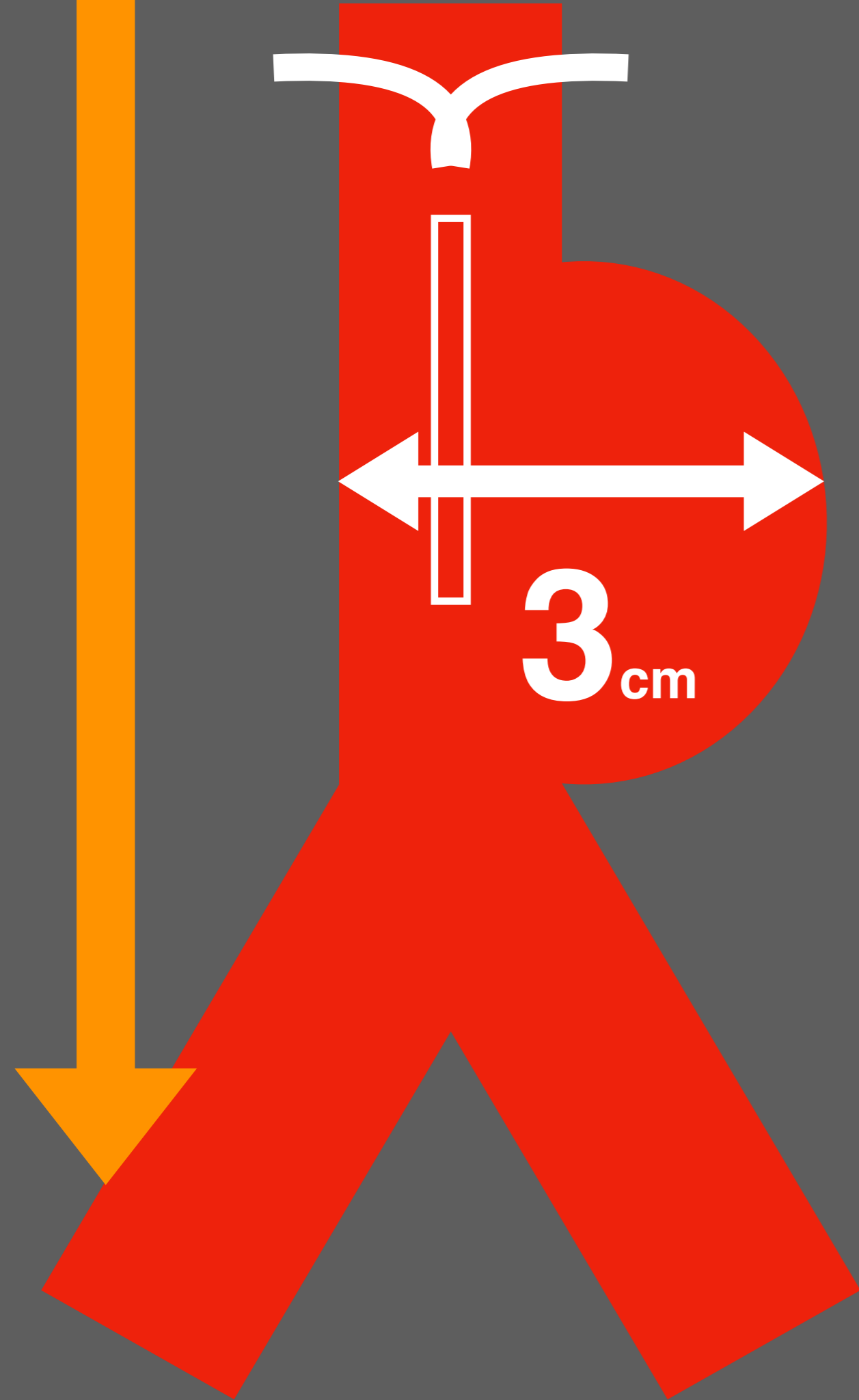


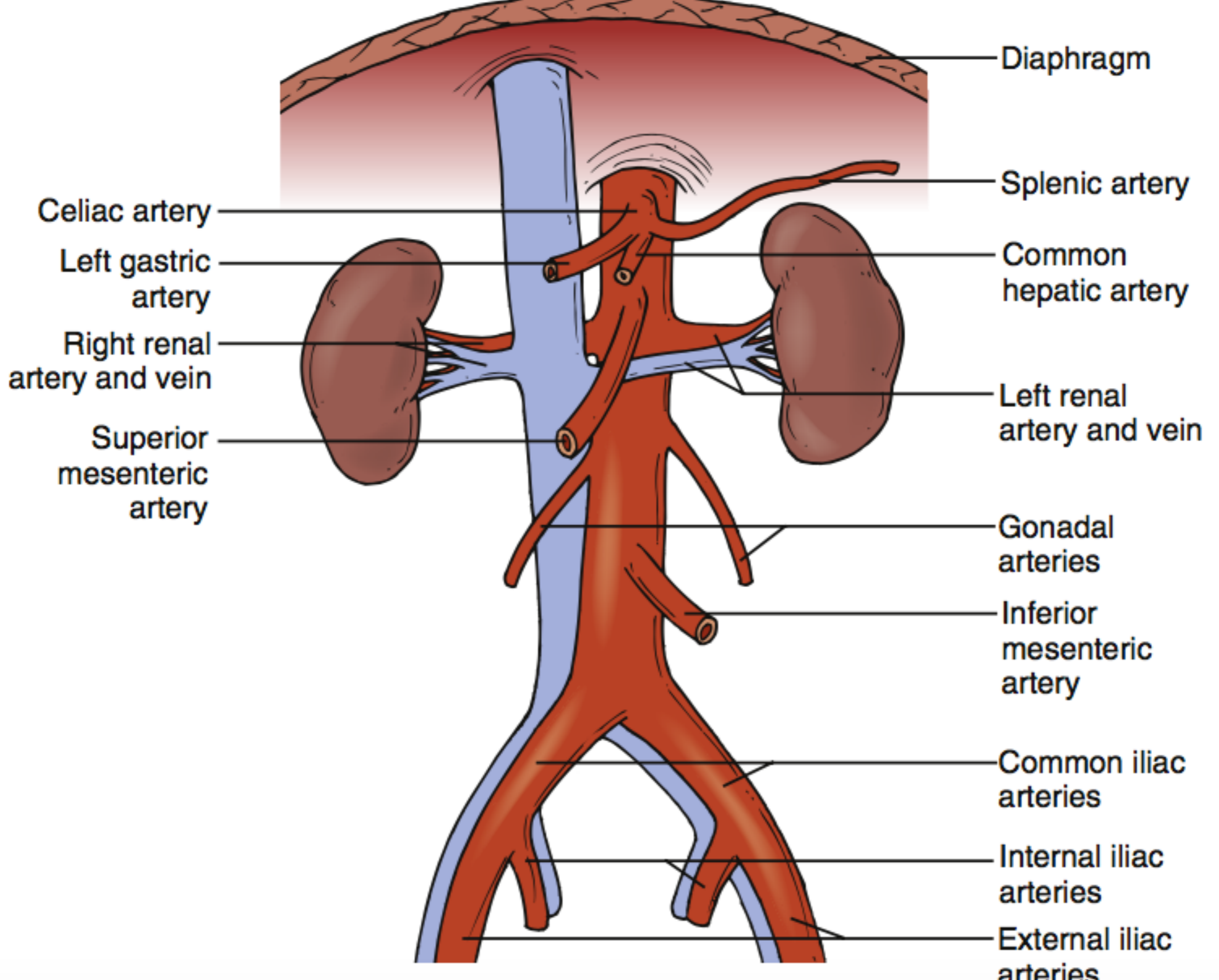


AAA

> 50 y/o
Syncope
Hypotension
ABD/Flank/Back/Groin

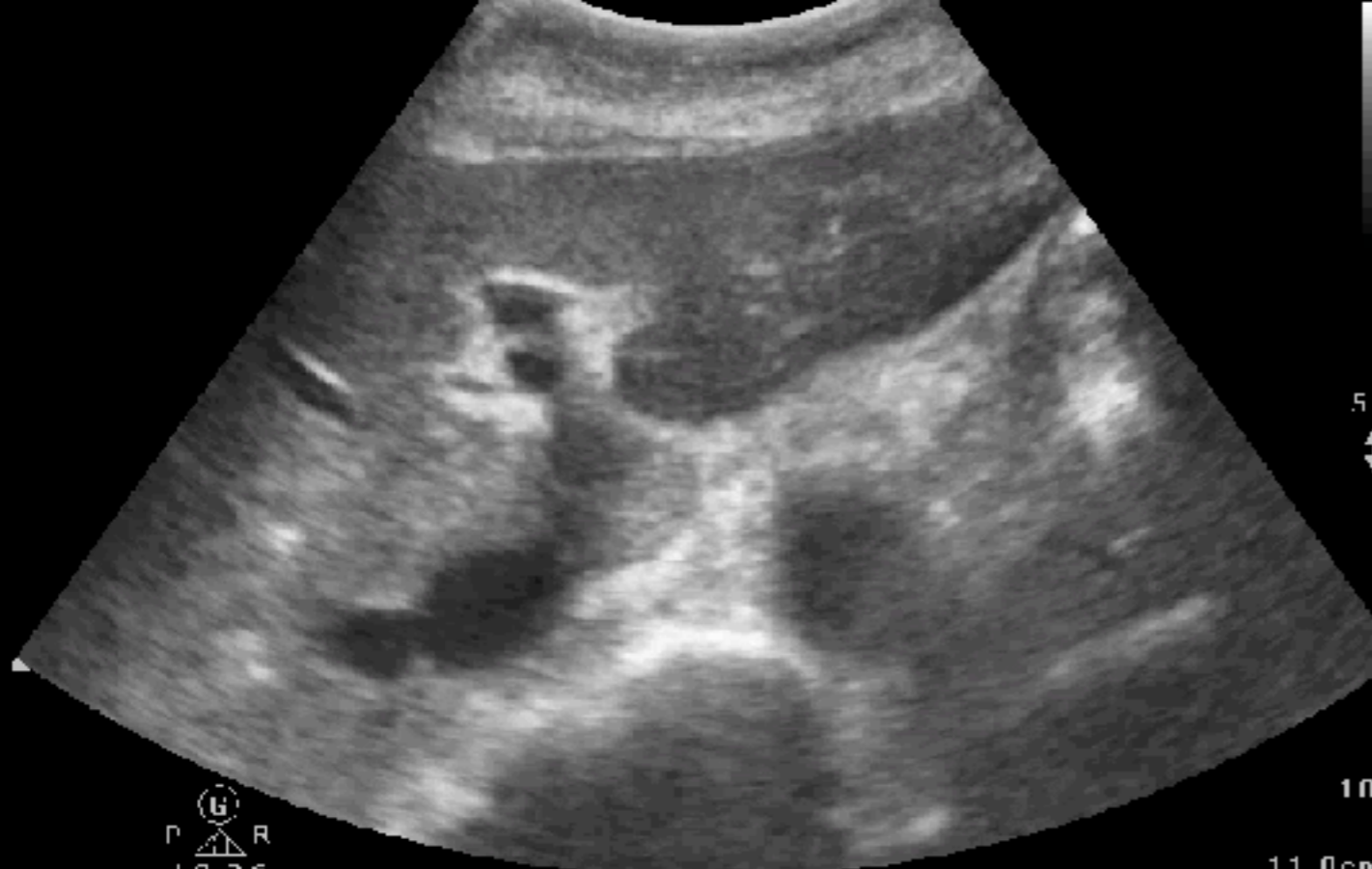
Sensitivity 97.5–100%
Specificity 94.1–100%





1
Hz
0cm

en
66
56
3/3



Seagull Sign

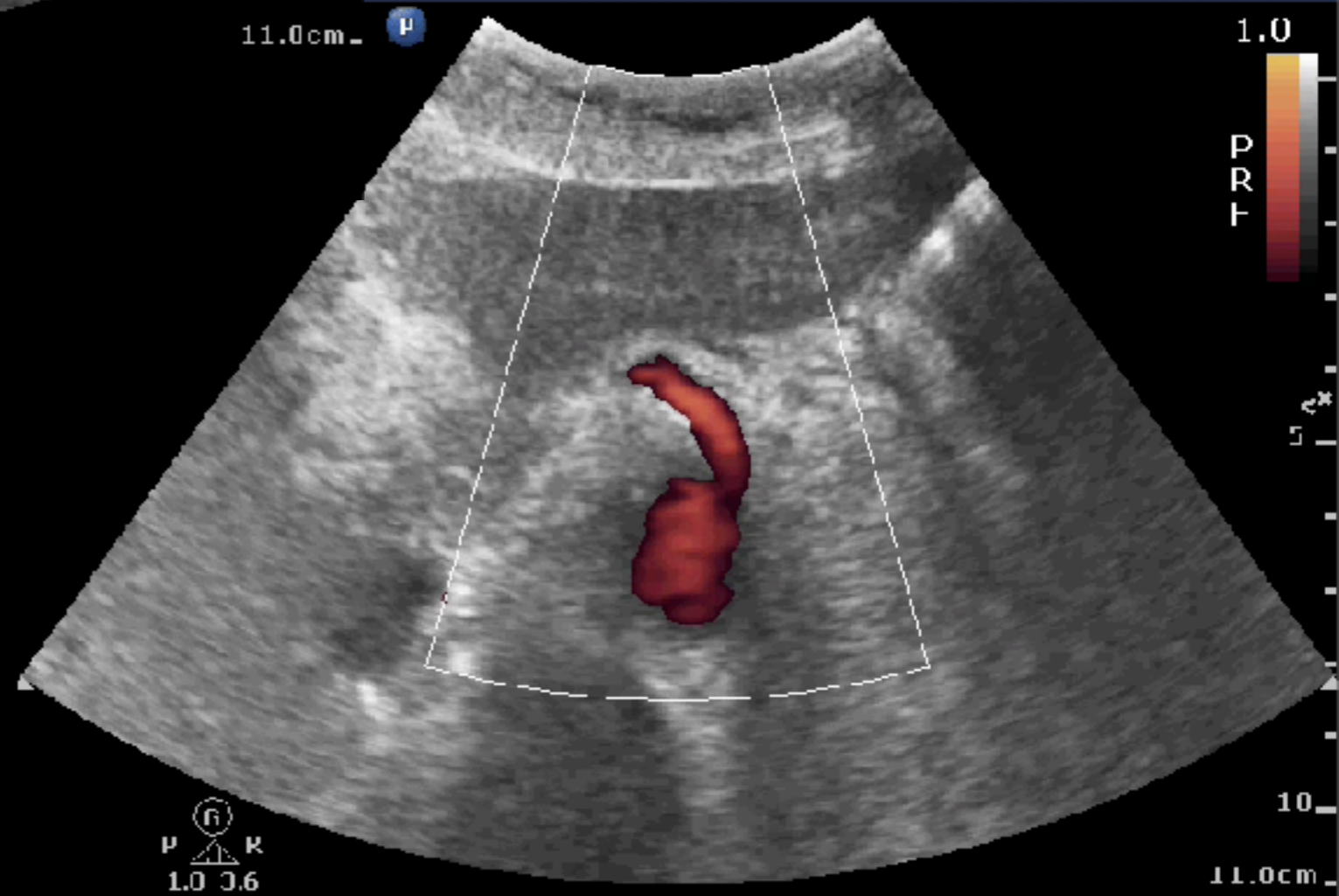
1.8 3.6

11.0cm

Celiac trunk

2D
HGen
Gn 56
C 56
3/3/3

CPA
2.5 MHz
Gn 66
1/8/4
Ftr High
Baseln 8



1.0
PRT

1.0 3.6

11.0cm

Eyeballing

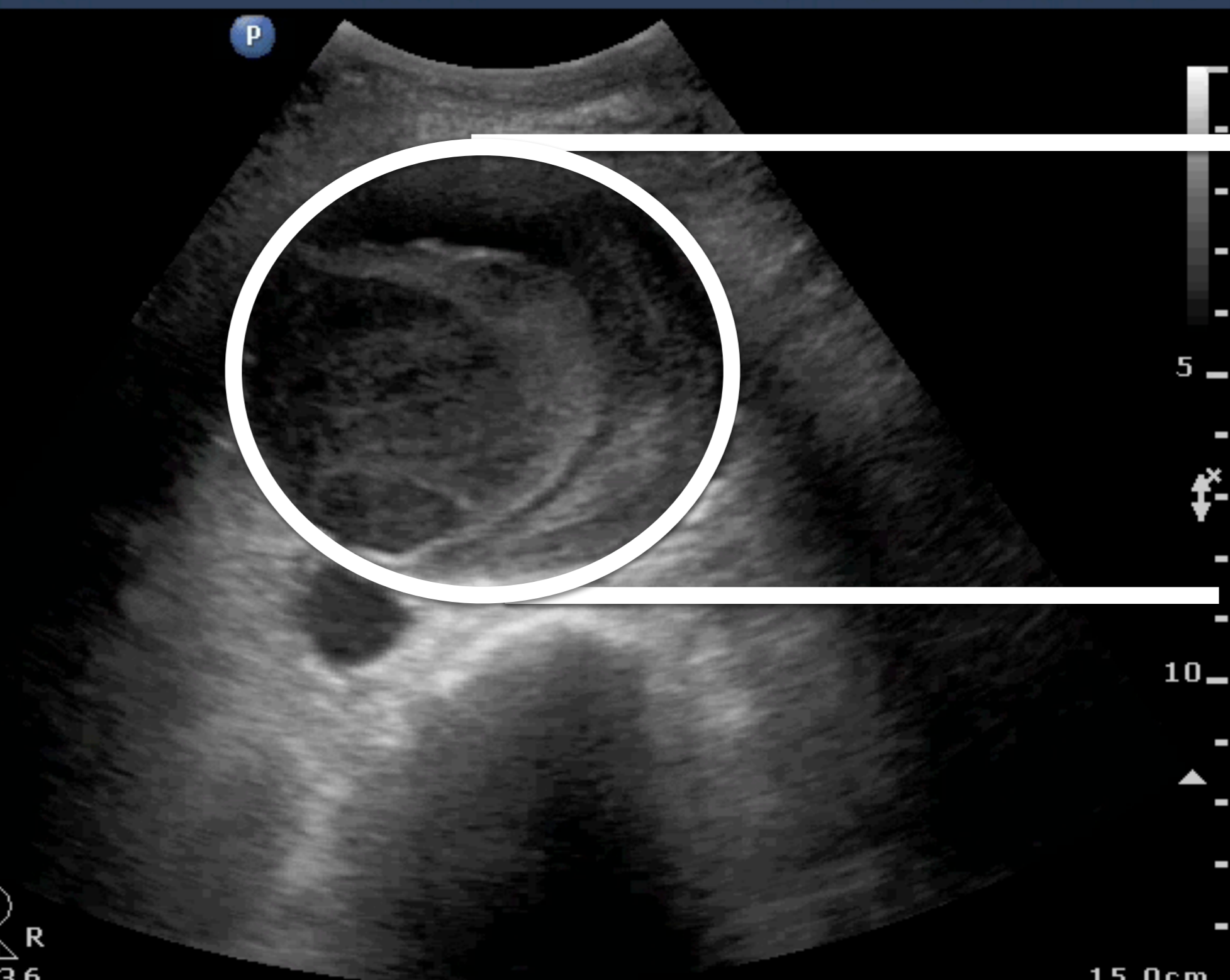
Abd Gen
C5-1
34 Hz
15.0cm

2D

HGen
Gn 57
C 56
3 / 3 / 3

P  R
1.8 3.6

15.0cm

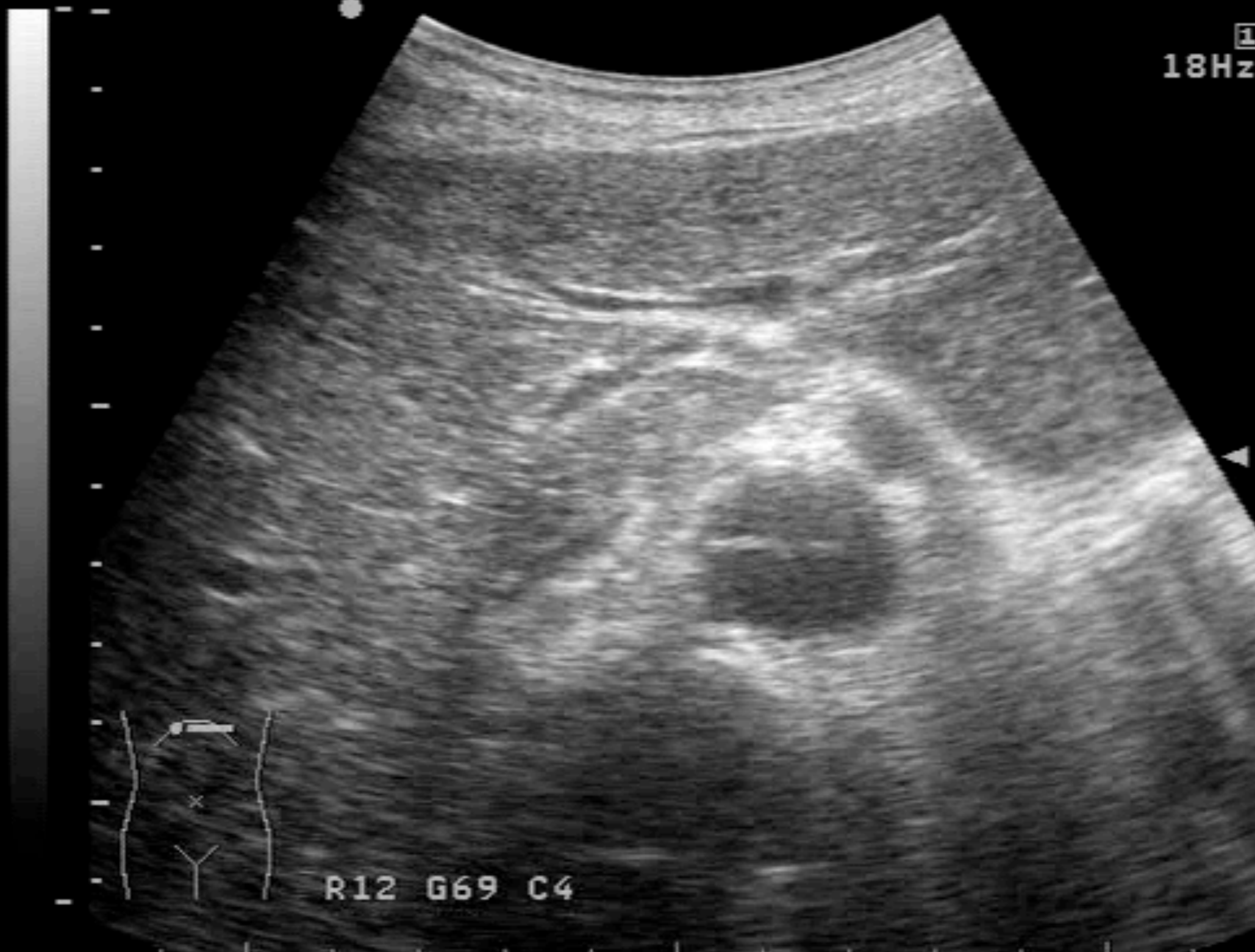

65M, epigastric pain after dinner

SHIN KONG HOSPITAL ER IDI
[

: YJ : 11 OCT. 28, 10
20:33:03

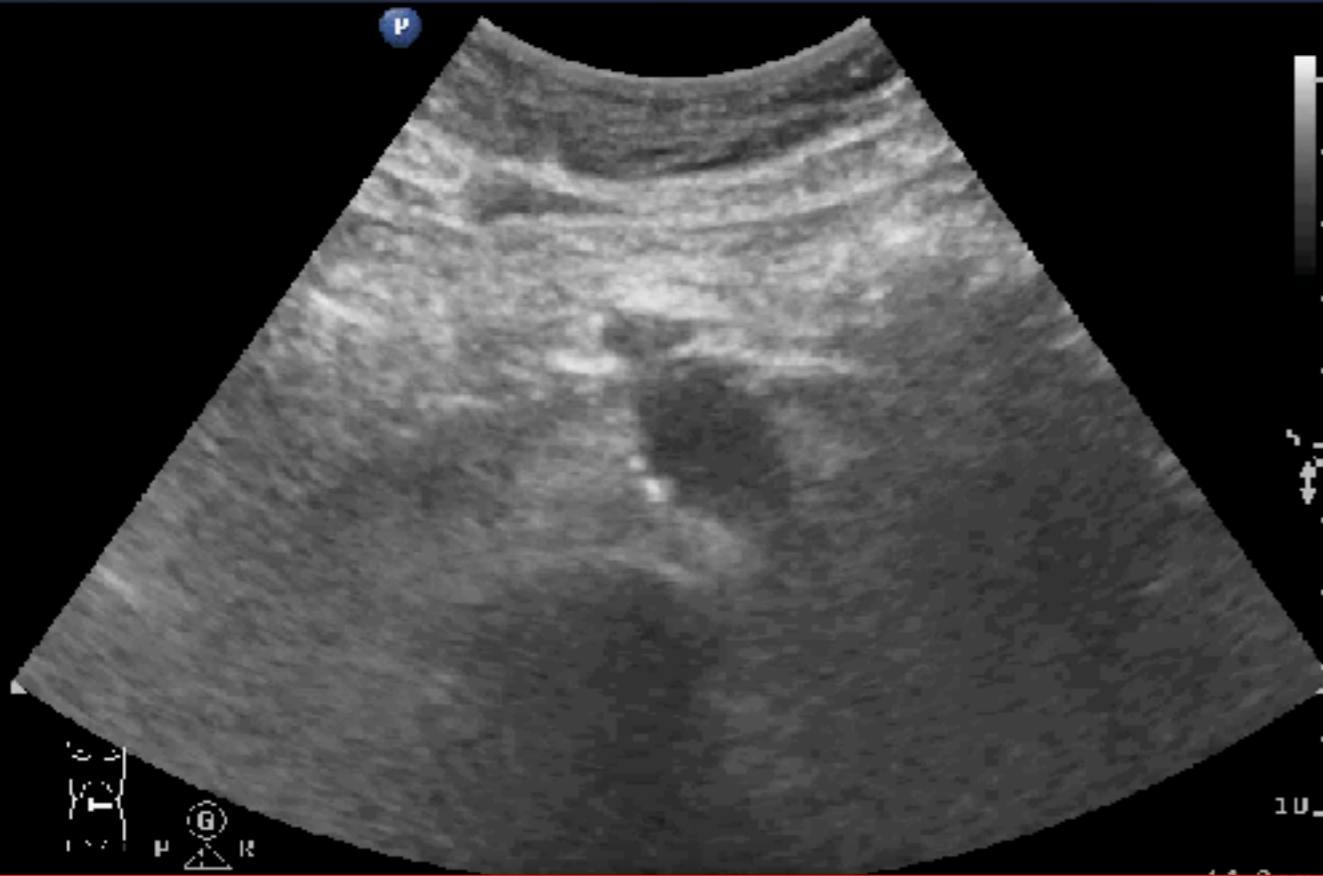
18Hz 3.5M S-H
DVA: 100%
MI = 0.6



R12 G69 C4

1: Abdomen

Ahd Gen2
15-1
42 Hz
11.0cm
2D
11Gen
Gn 89
C 56
3/3/3

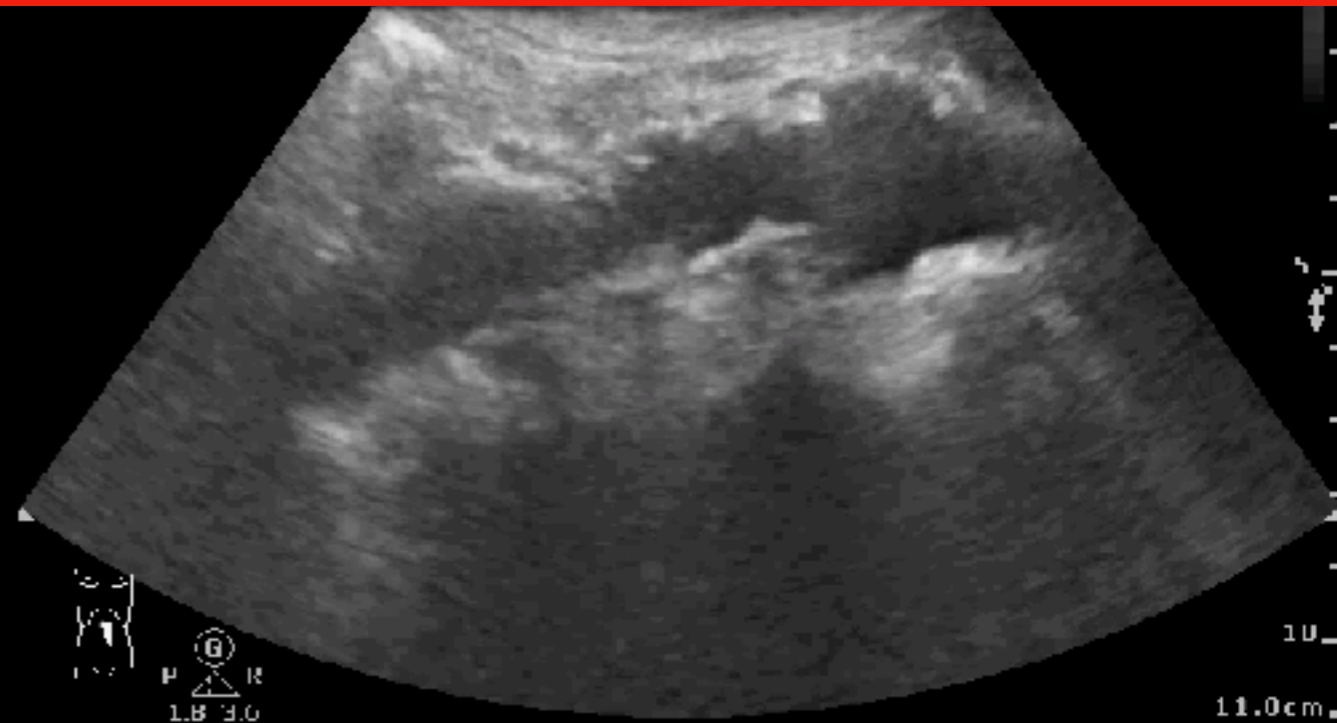

要追蹤

老人結石不掃AAA，你就要倒大楣

量對點

2D
11Gen
Gn 89
C 56
3/3/3



Entrance (IVC)

Volume responsiveness

Central venous pressure

Pericardial effusion

Right heart failure

Intra-abdominal hypertension

Entrance (IVC)

Diameter 1~2 cm

Collapse index 50%

IVC diameter (cm)

Collapse (%)

CVP (mean)mmHg

<1

> 50

0-5 (3)

1-2

NA

5-10 (8)

>2

<50

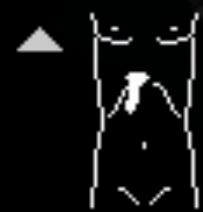10-20 (15)

Small & CI > 50%

36 Hz
14.0cm

2D

HGen
Gn 61
C 56
3 / 3 / 3



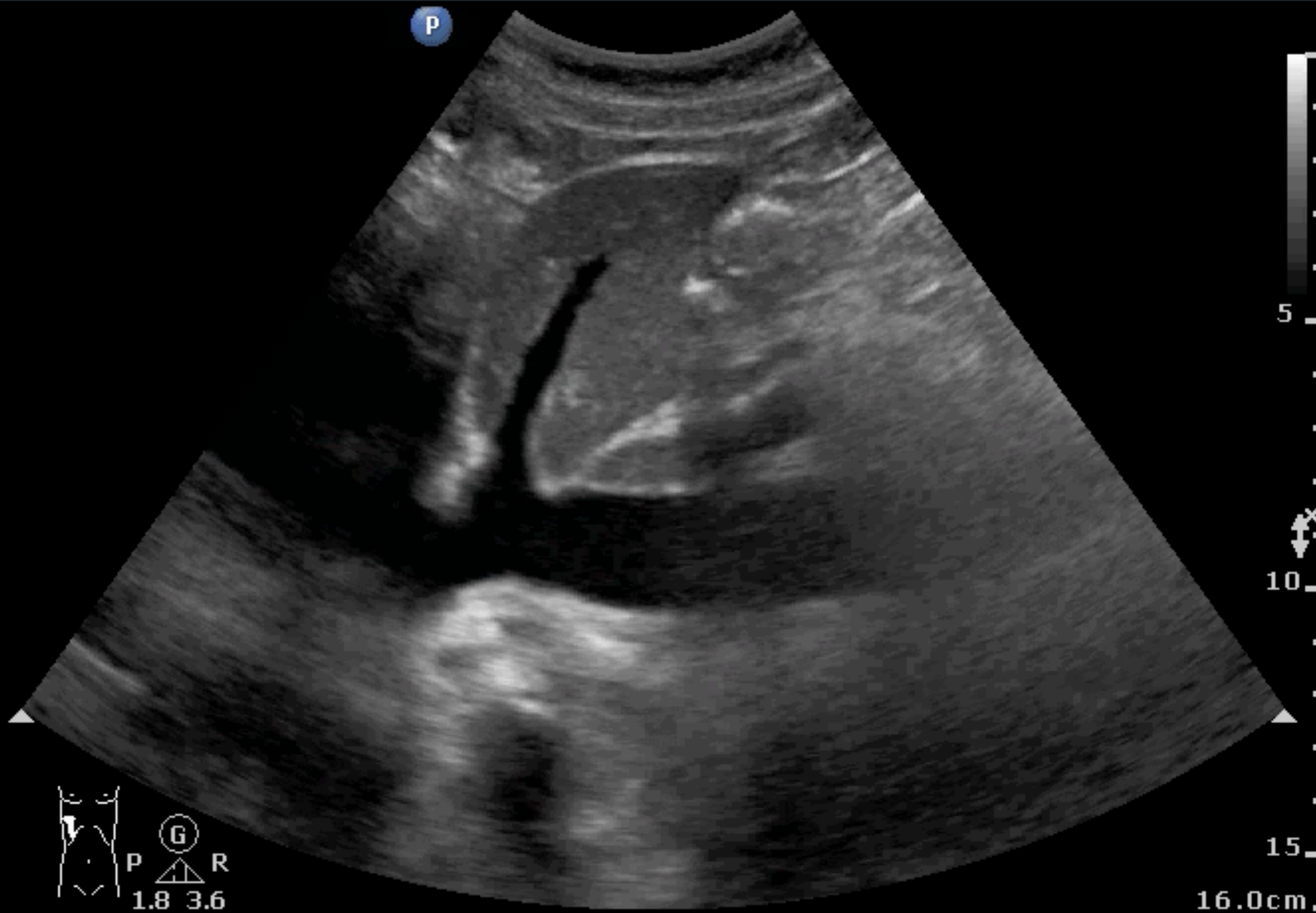14.0cm

Large & CI < 50%

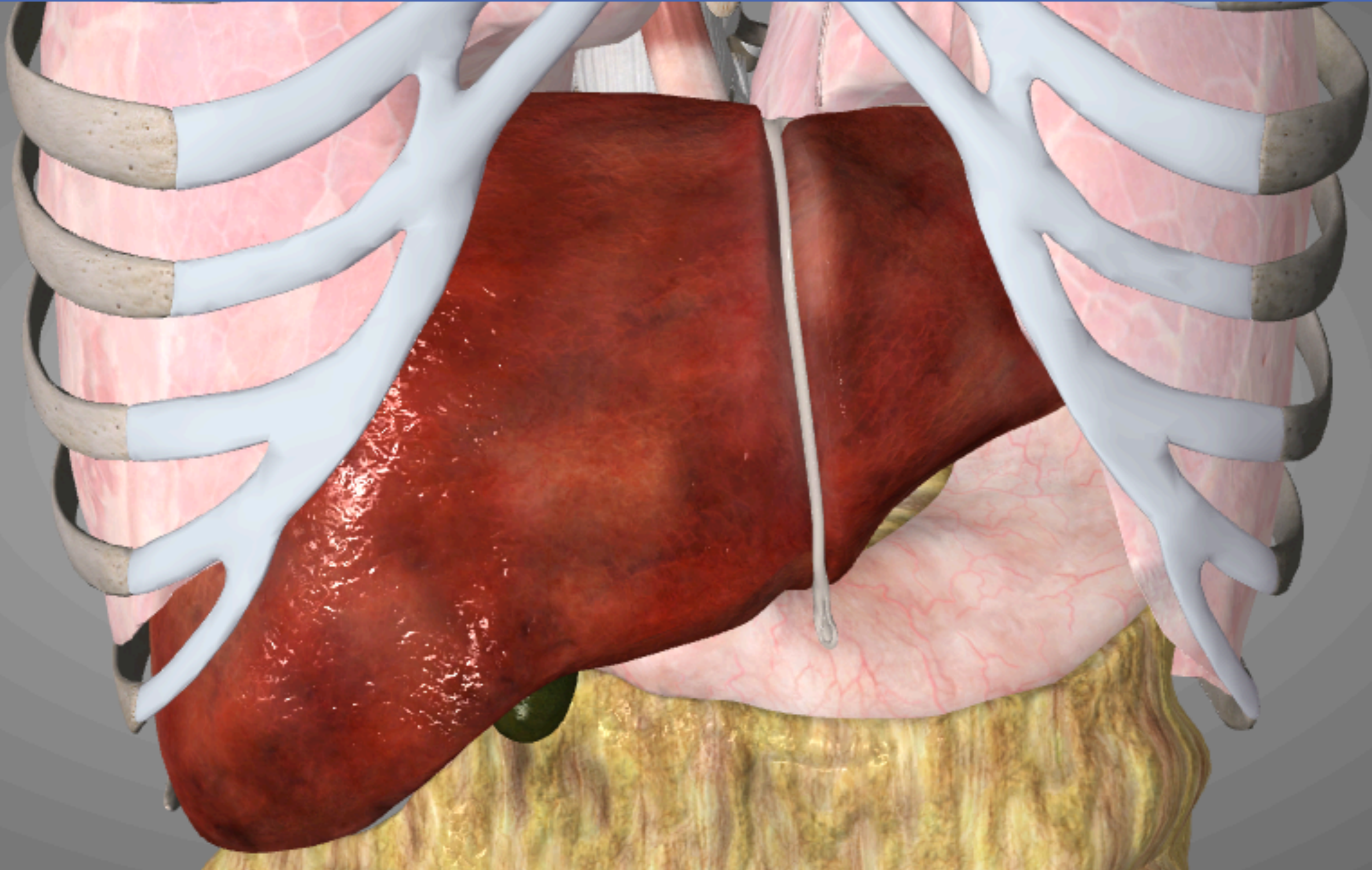
Abd Gen2
C5-1
32 Hz
16.0cm

2D

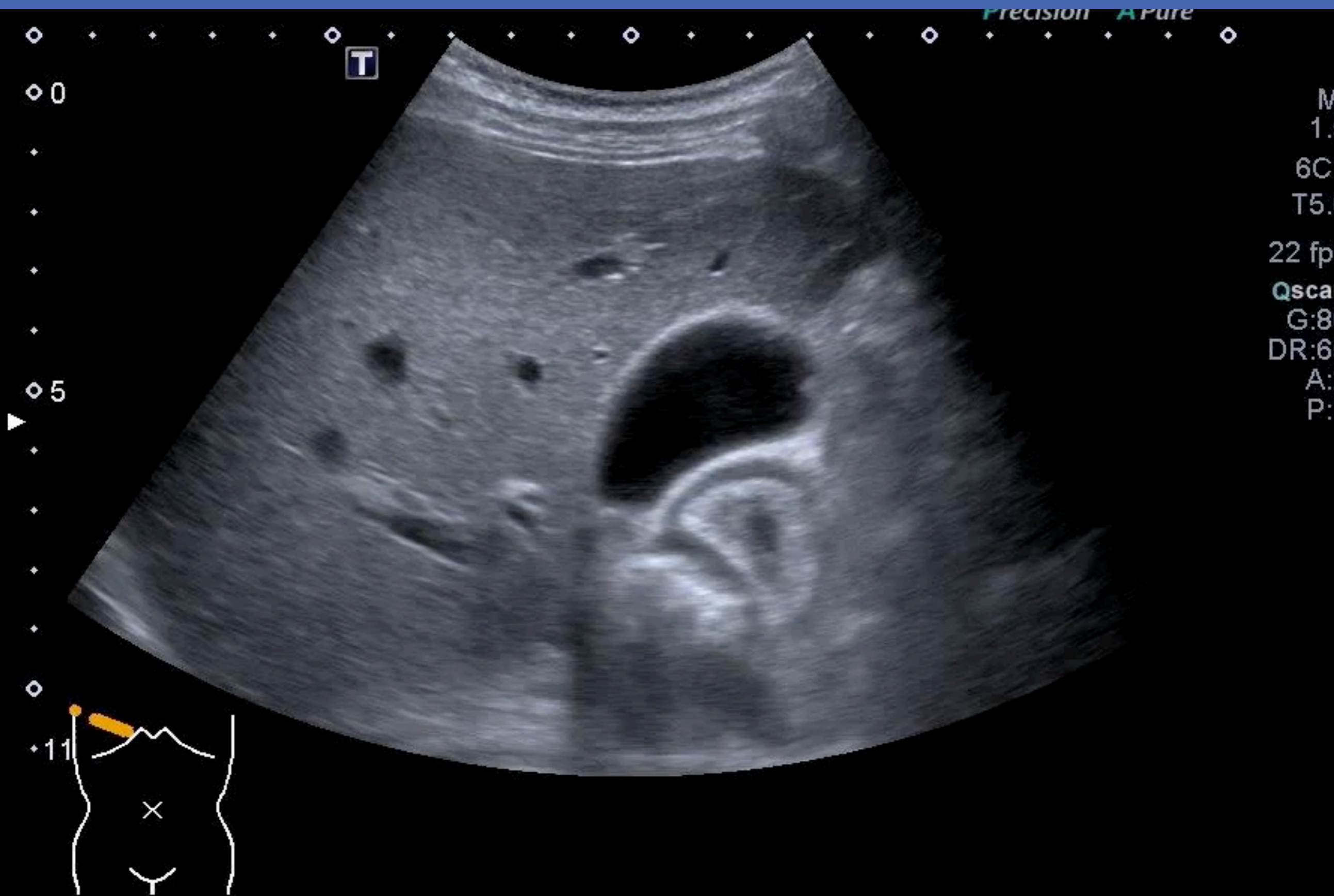HGen
Gn 60
C 55
3/3/3



Liver & GB



讀讀看，你看到了什麼？

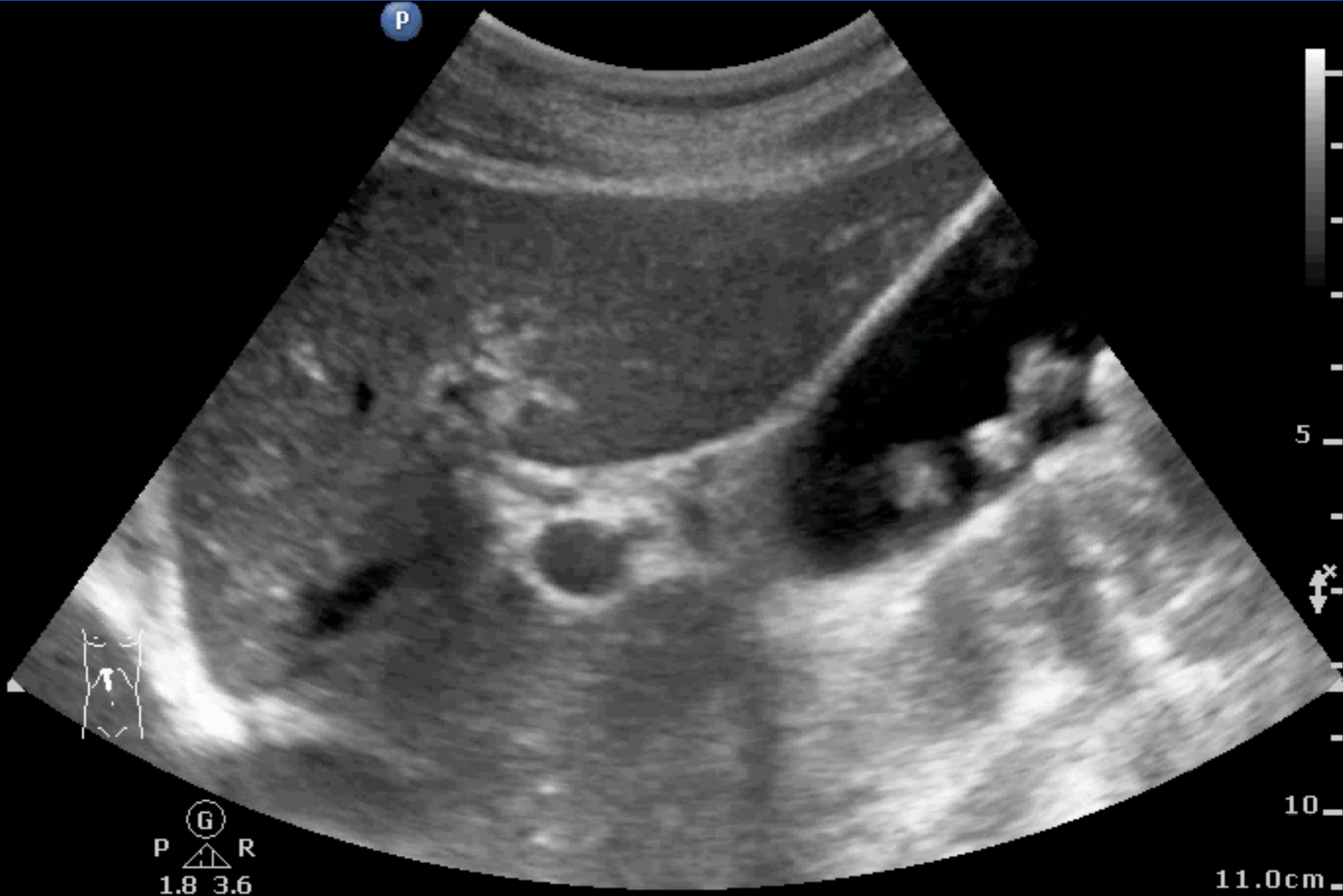


讀讀看，你看到了什麼？

Abd Gen
C5-1
42 Hz
11.0cm

2D

HGen
Gn 80
C 56
3 / 3 / 3



G
P R
1.8 3.6

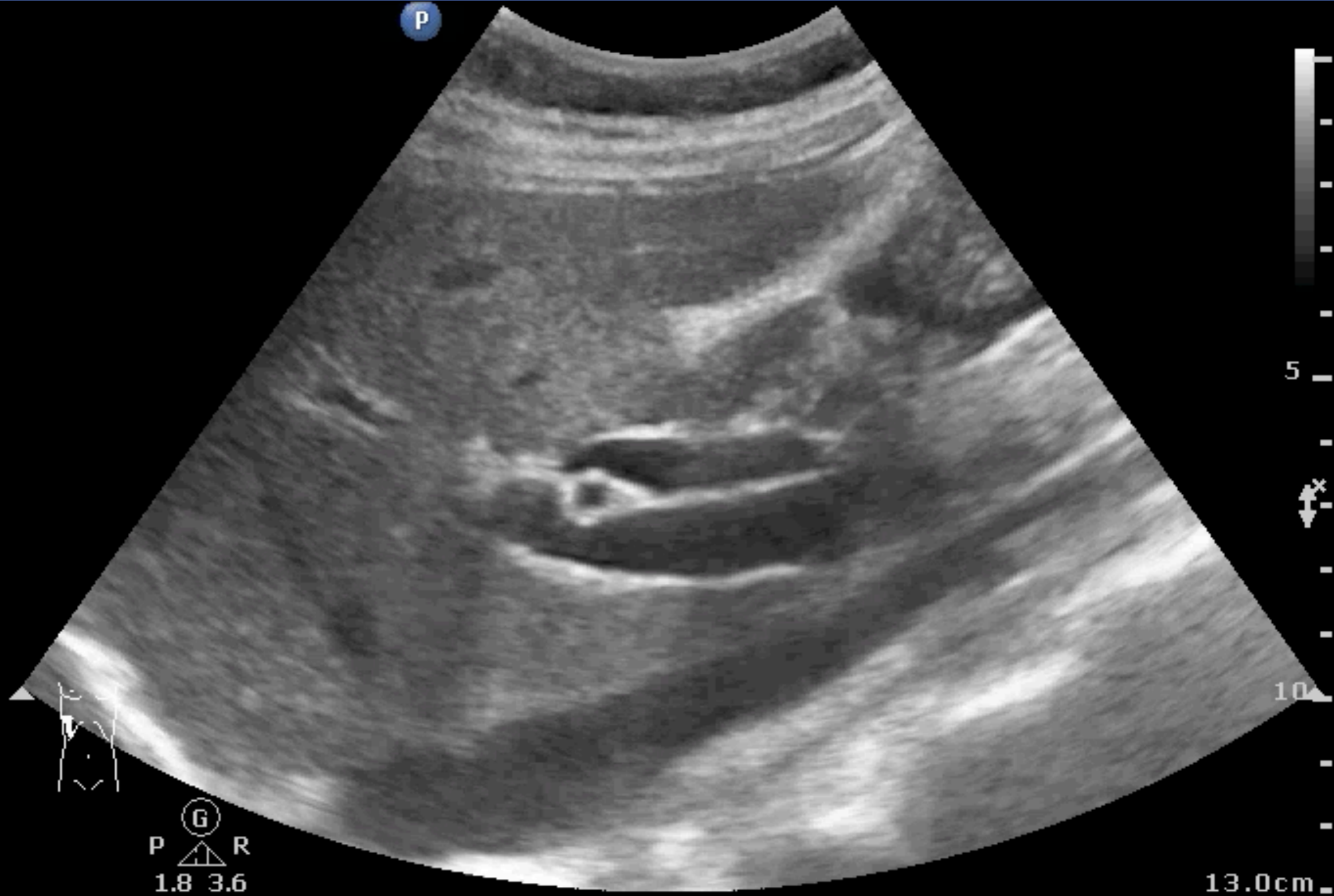
11.0cm

讀讀看，你看到了什麼？

Abd Gen
C5-1
38 Hz
13.0cm

2D

HGen
Gn 82
C 56
3 / 3 / 3

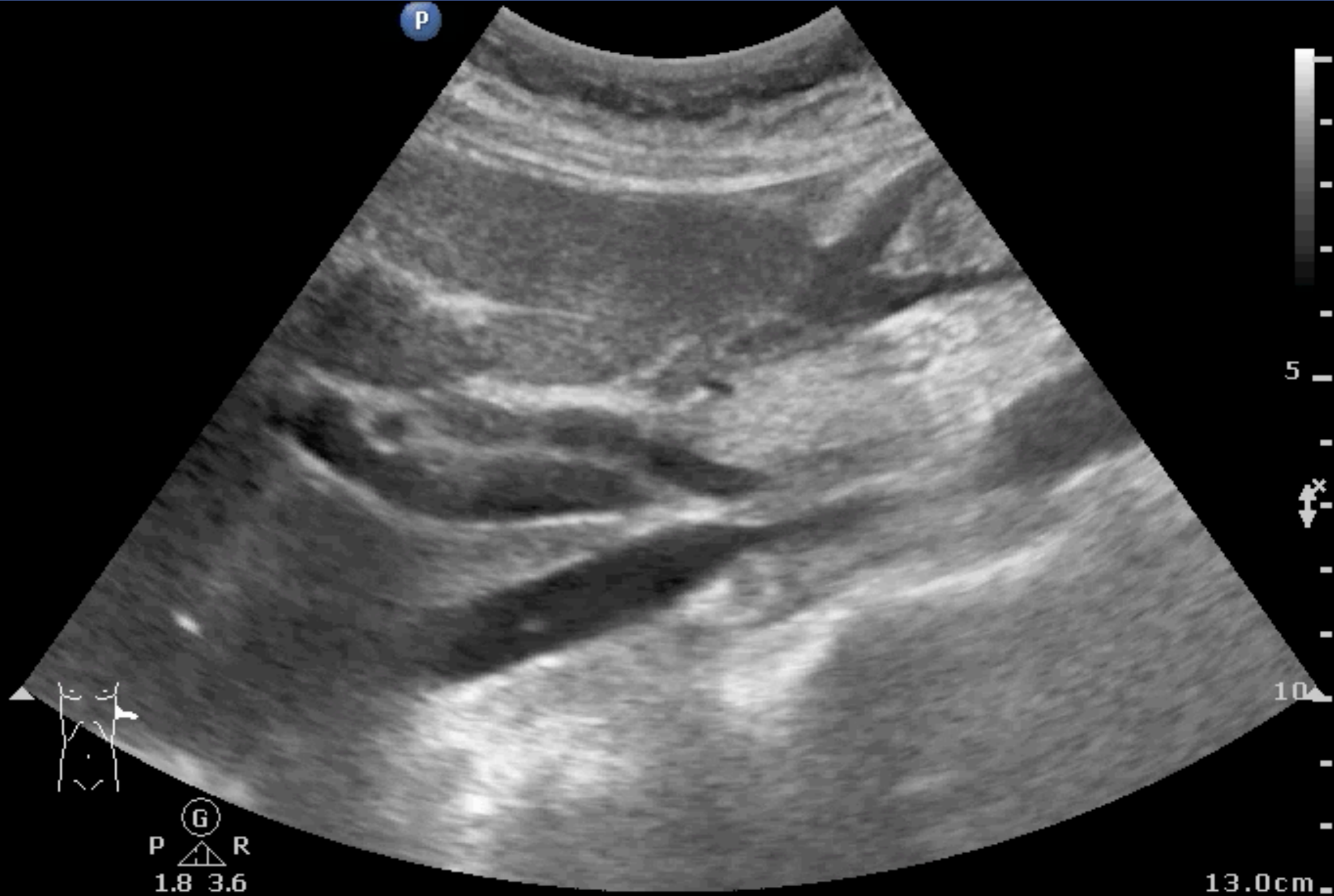

讀讀看，你看到了什麼？

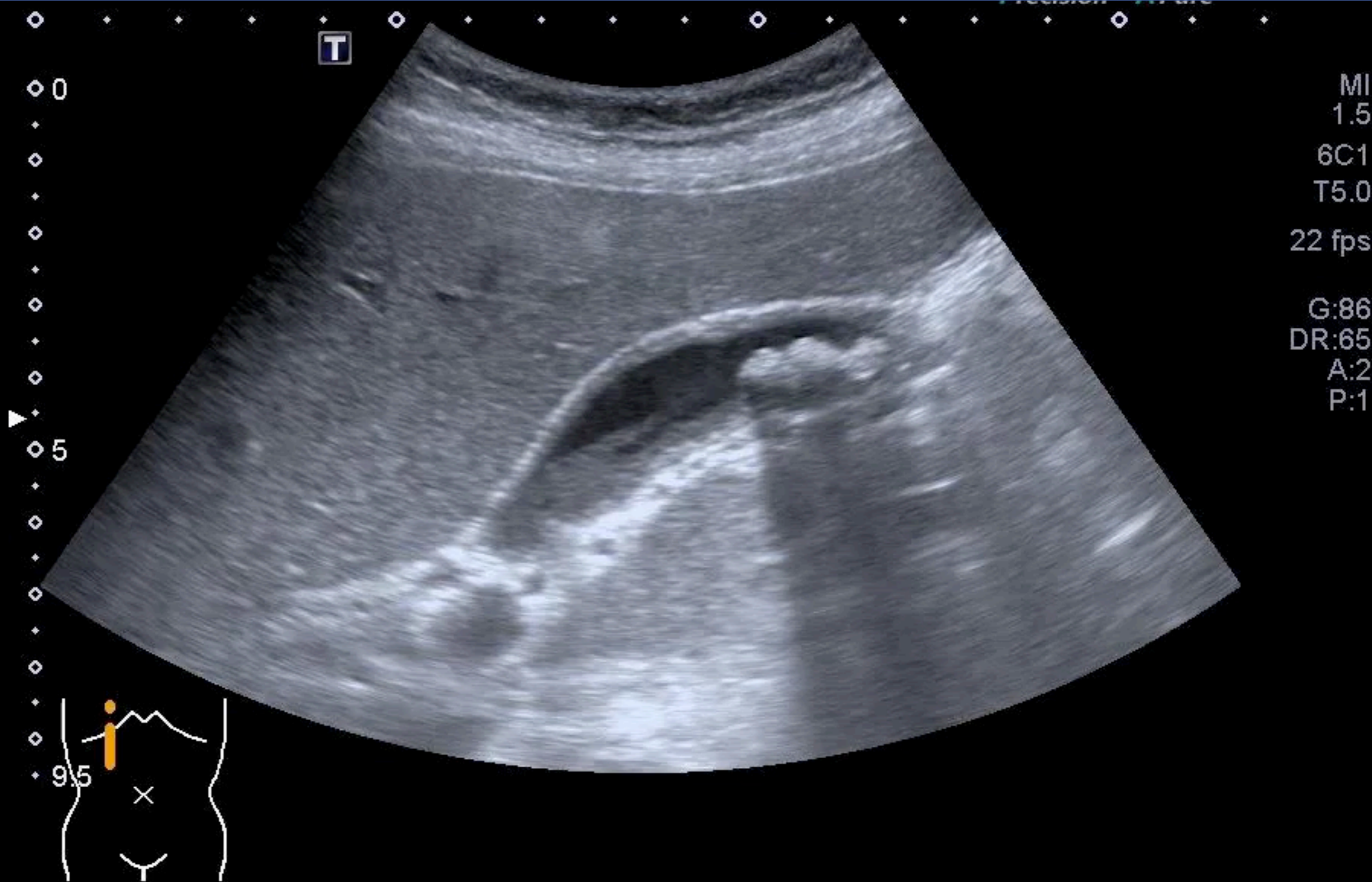Abd Gen
C5-1
38 Hz
13.0cm

2D

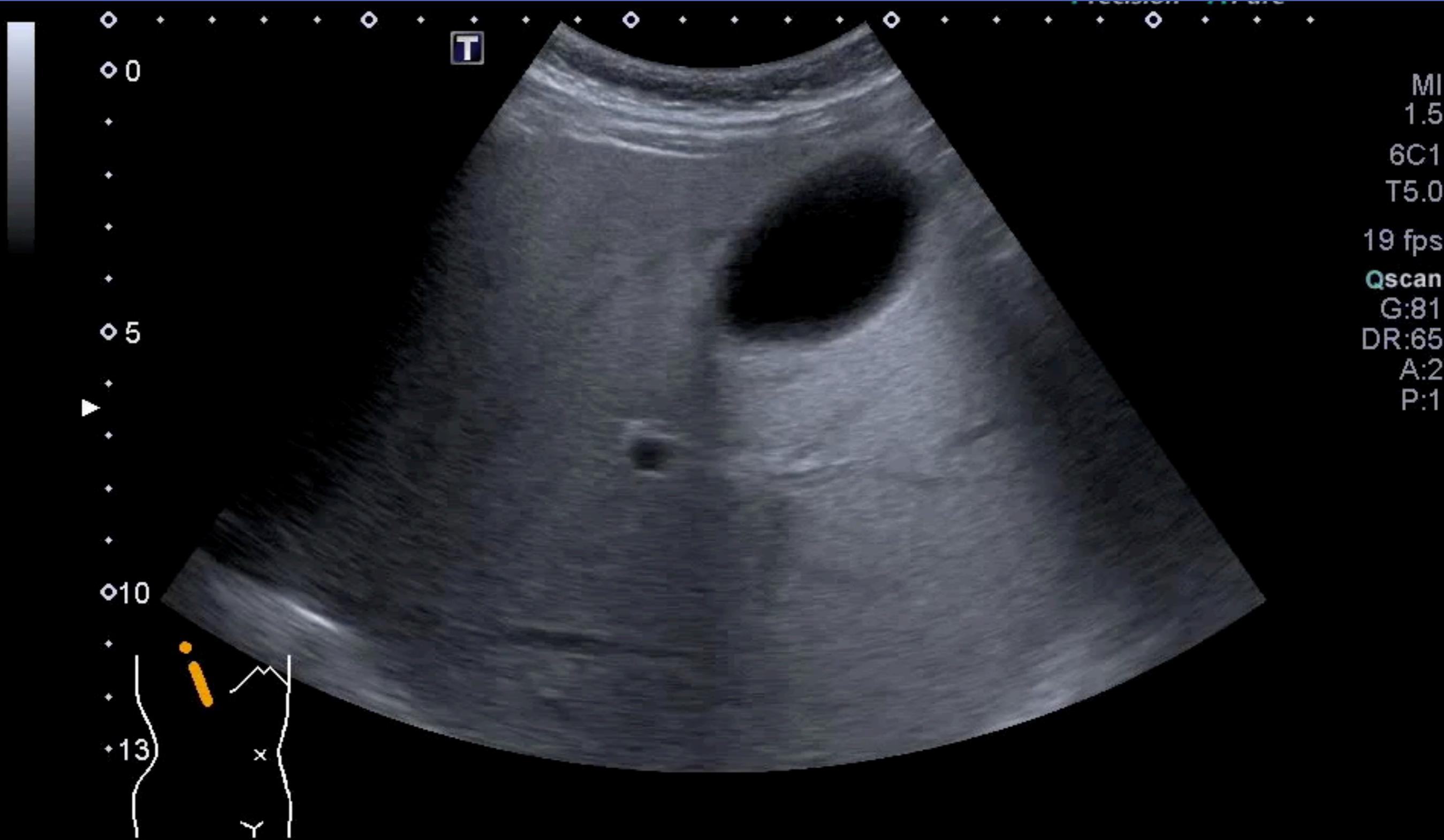
HGen
Gn 82
C 56
3 / 3 / 3



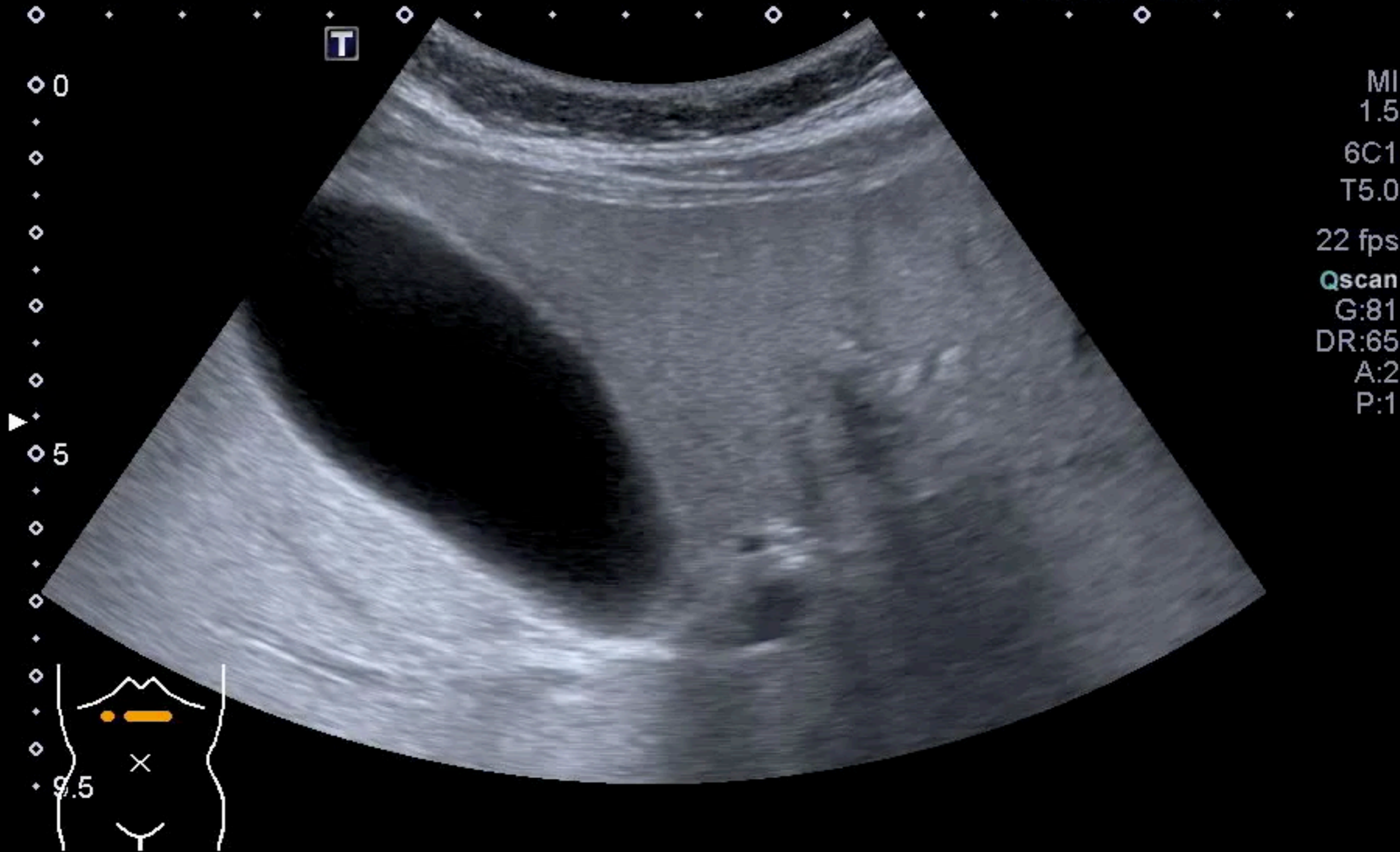
讀讀看，你看到了什麼？



61F , ABD pain for 3-4 days



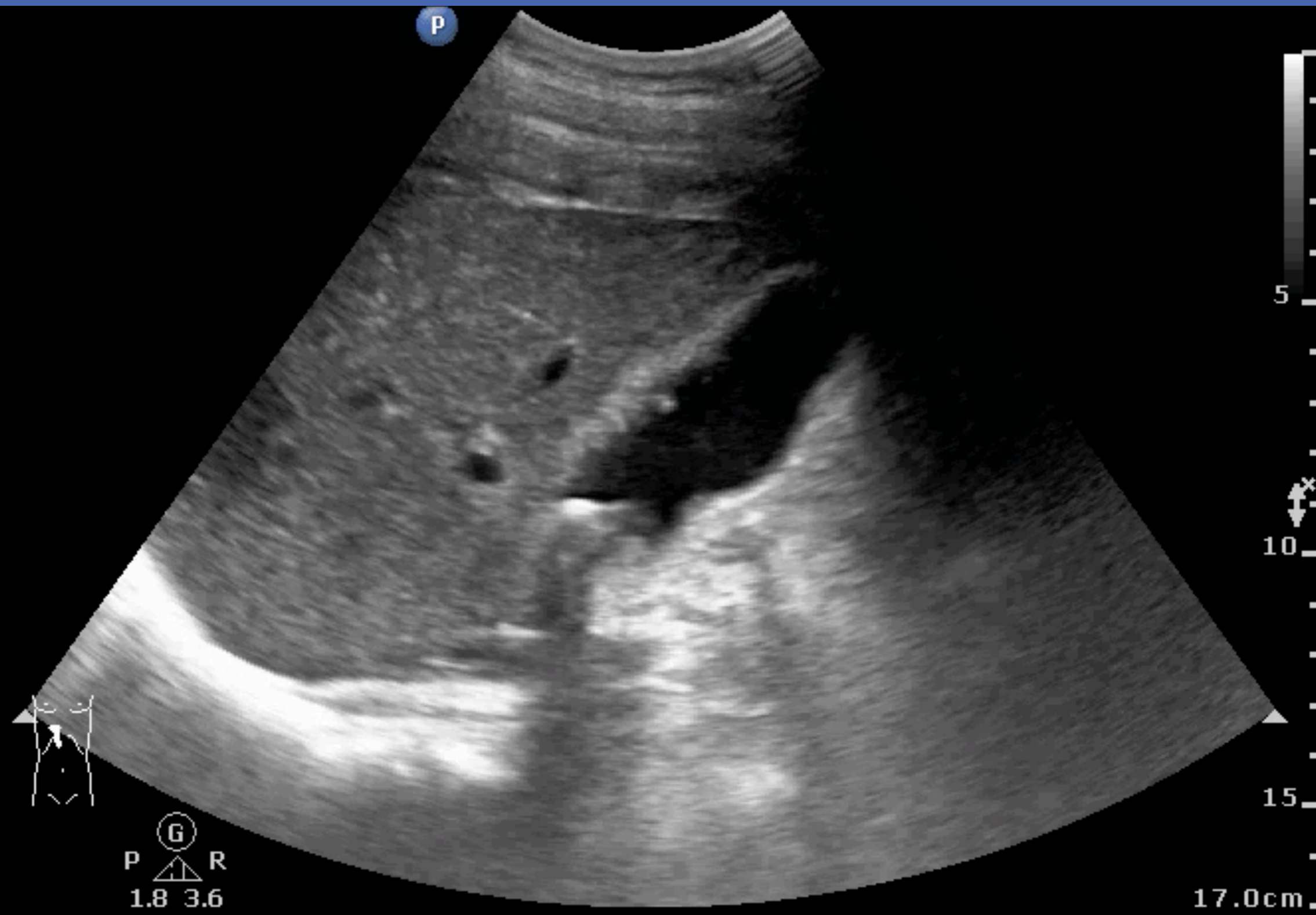
GB stones & Cholecystitis



52M, RUQ pain

Abd Gen2
C5-1
31 Hz
17.0cm

2D
HGen
Gn 86
C 56
3 / 3 / 3

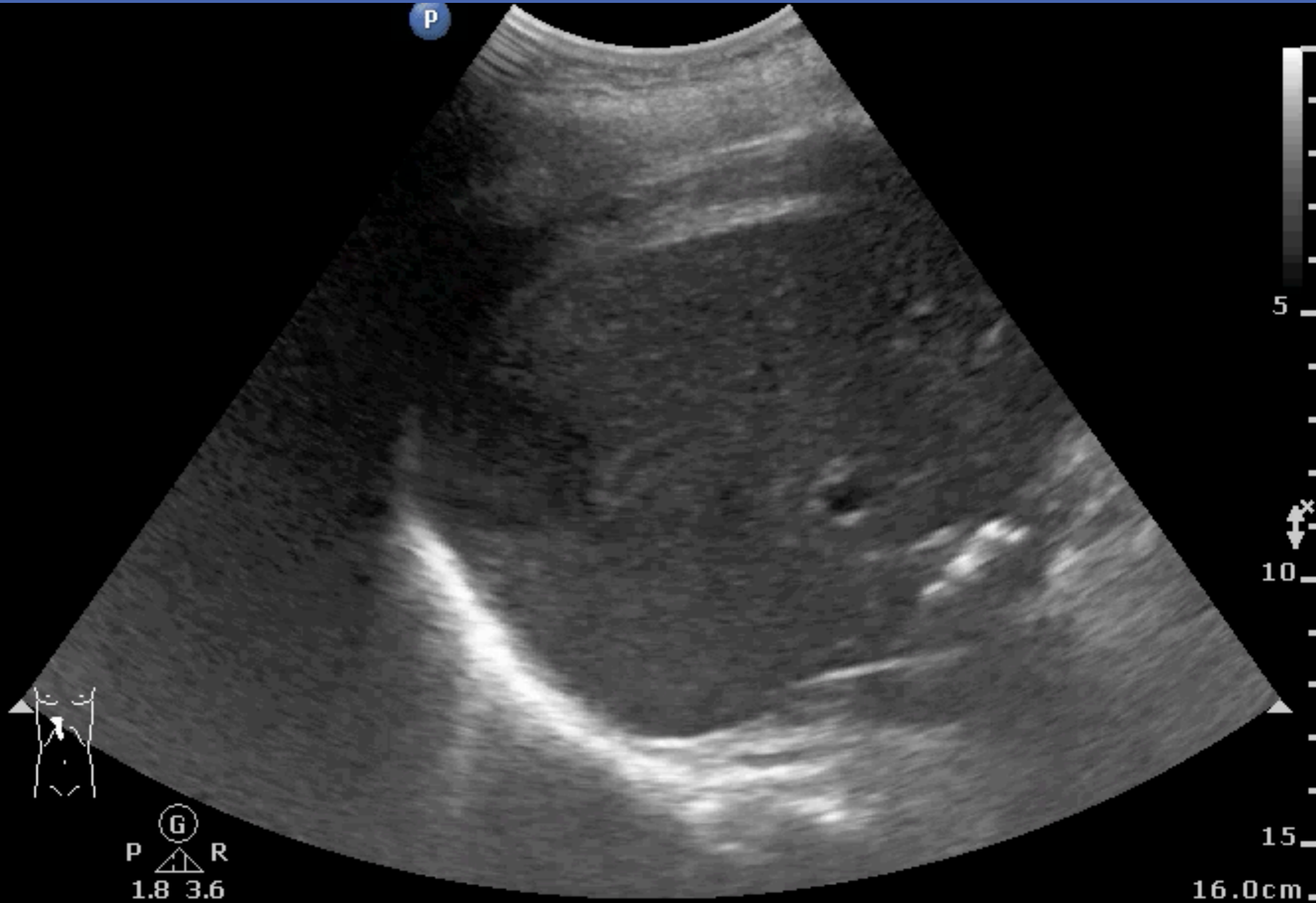


讀讀看，你看到了什麼？

Abd Gen2
C5-1
32 Hz
16.0cm

2D

HGen
Gn 100
C 56
3 / 3 / 3



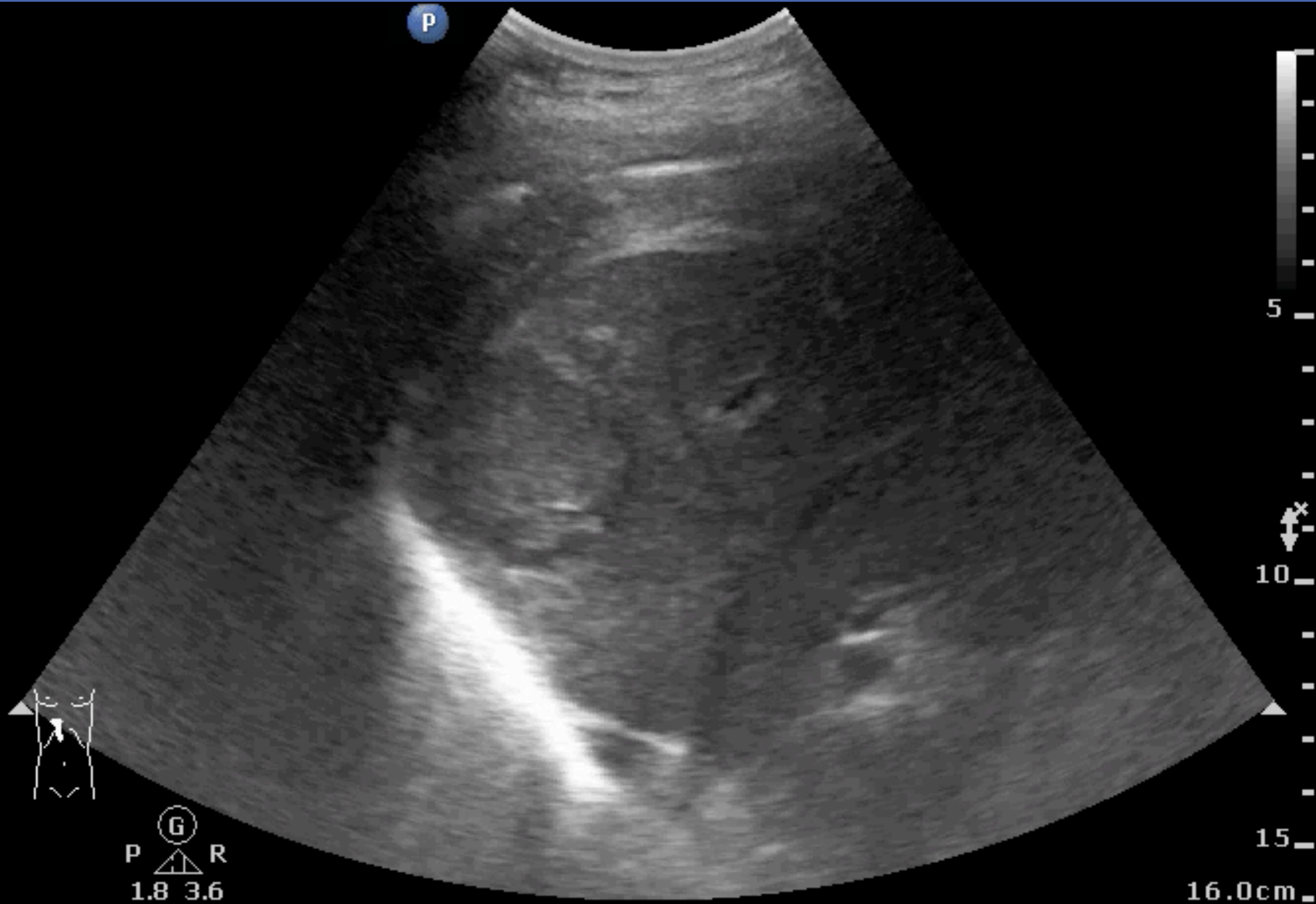
G
P R
1.8 3.6

16.0cm

讀讀看，你看到了什麼？

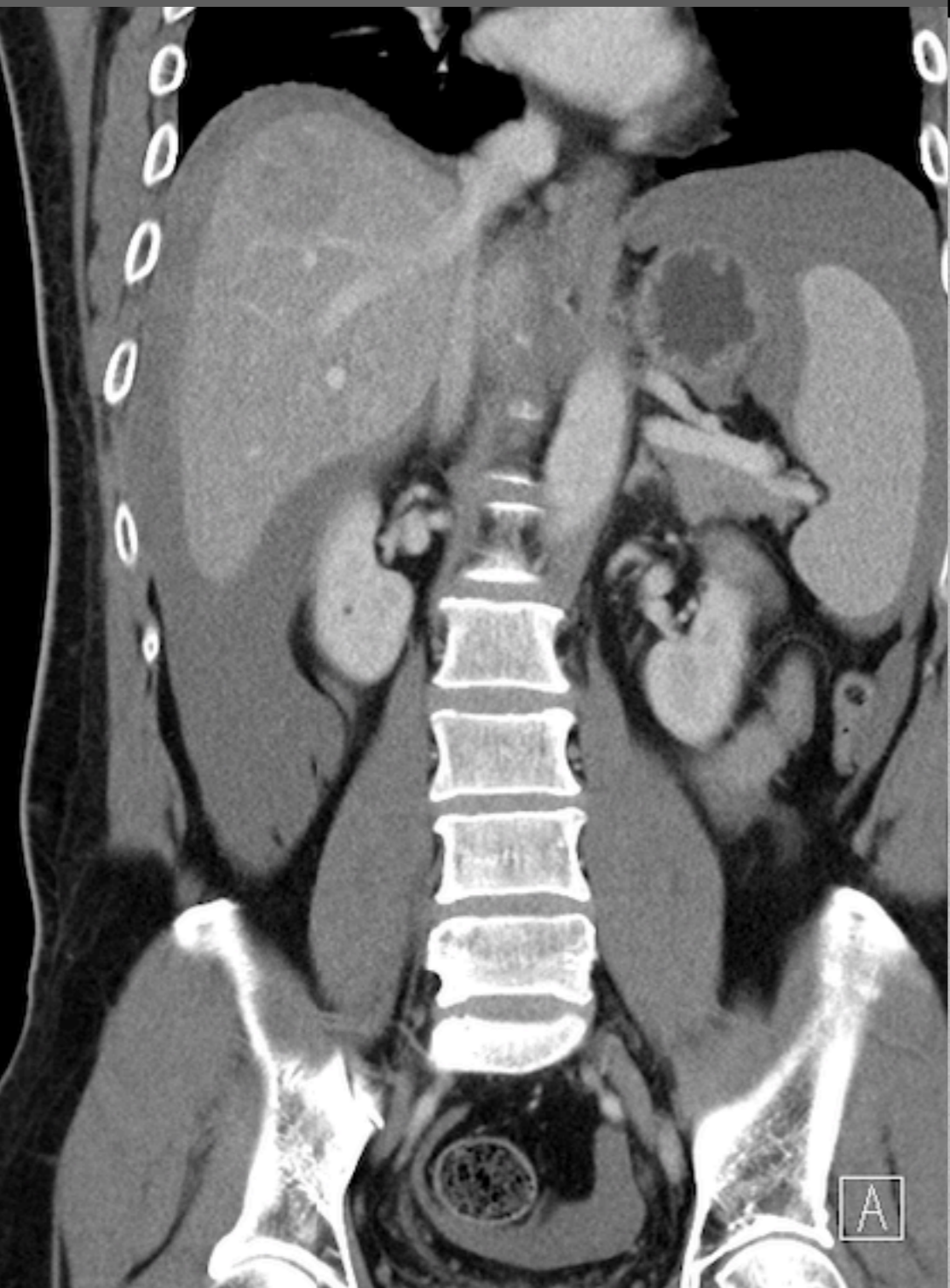Abd Gen2
C5-1
32 Hz
16.0cm

2D
HGen
Gn 100
C 56
3 / 3 / 3

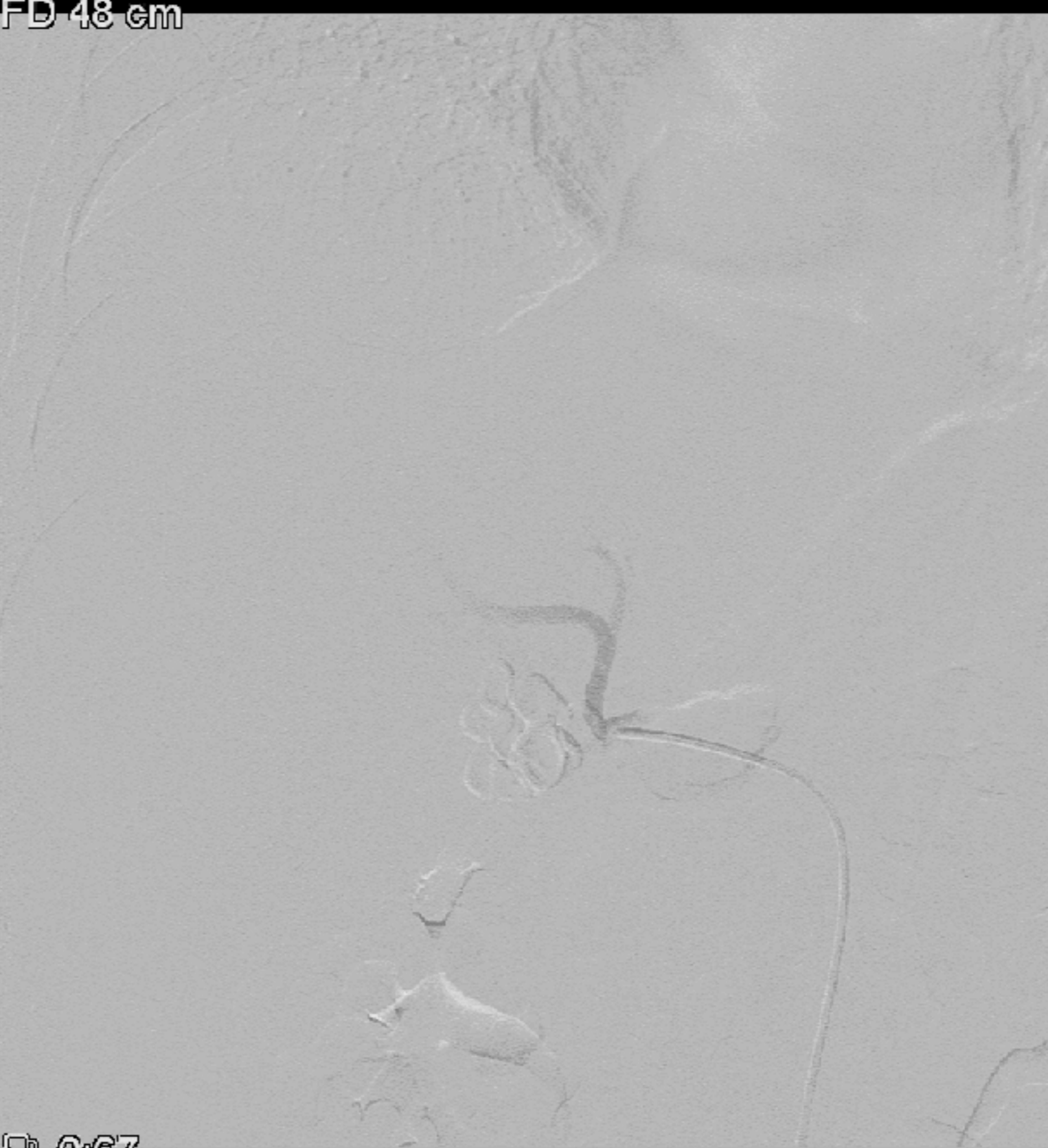


G
P R
1.8 3.6

16.0cm

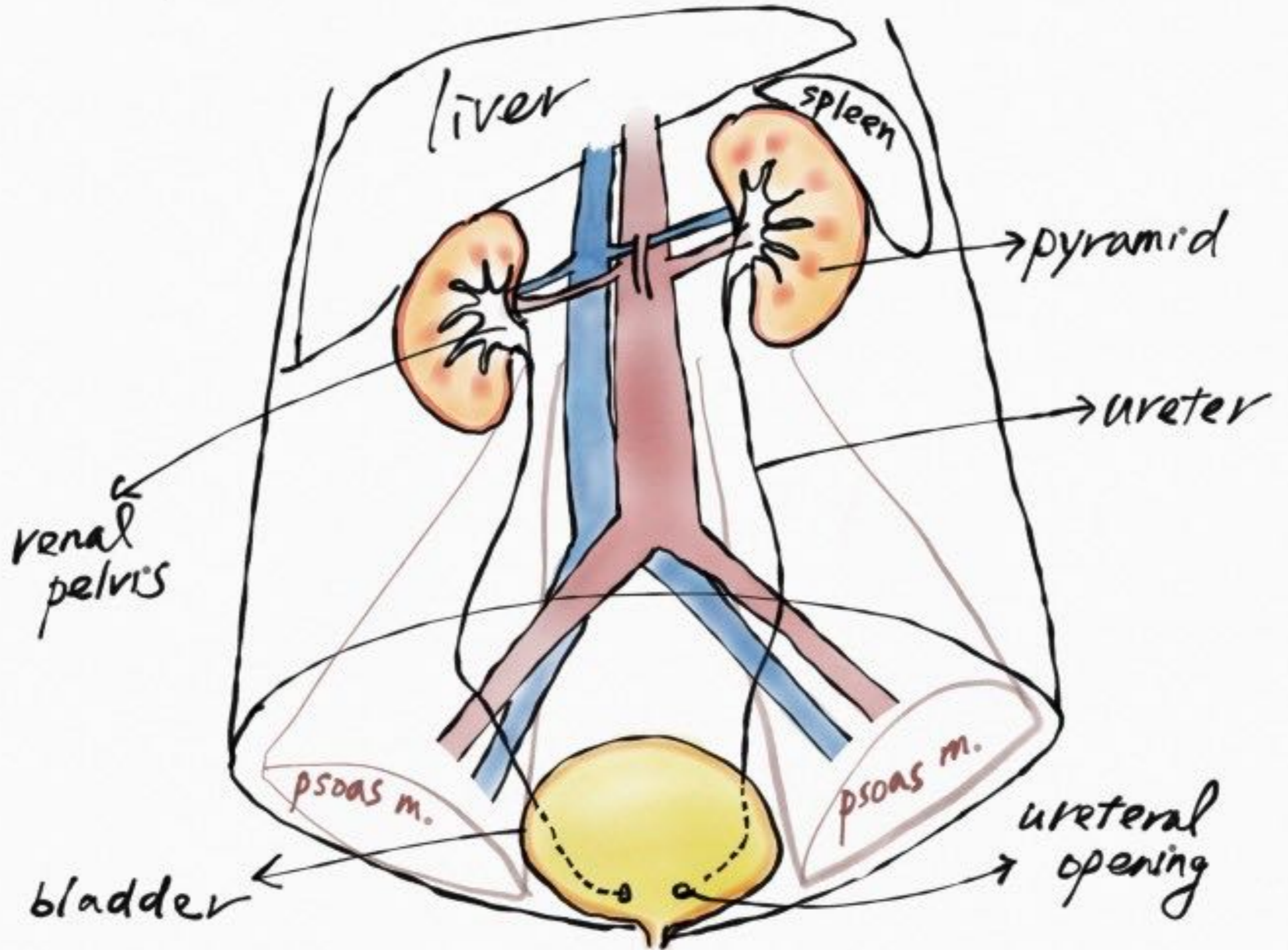


FD 48 cm



0:67
1:00
9:49:03

Copyright © 2016 HSU CHZ CHAN ET. All rights reserved





Where ?




K



u



B



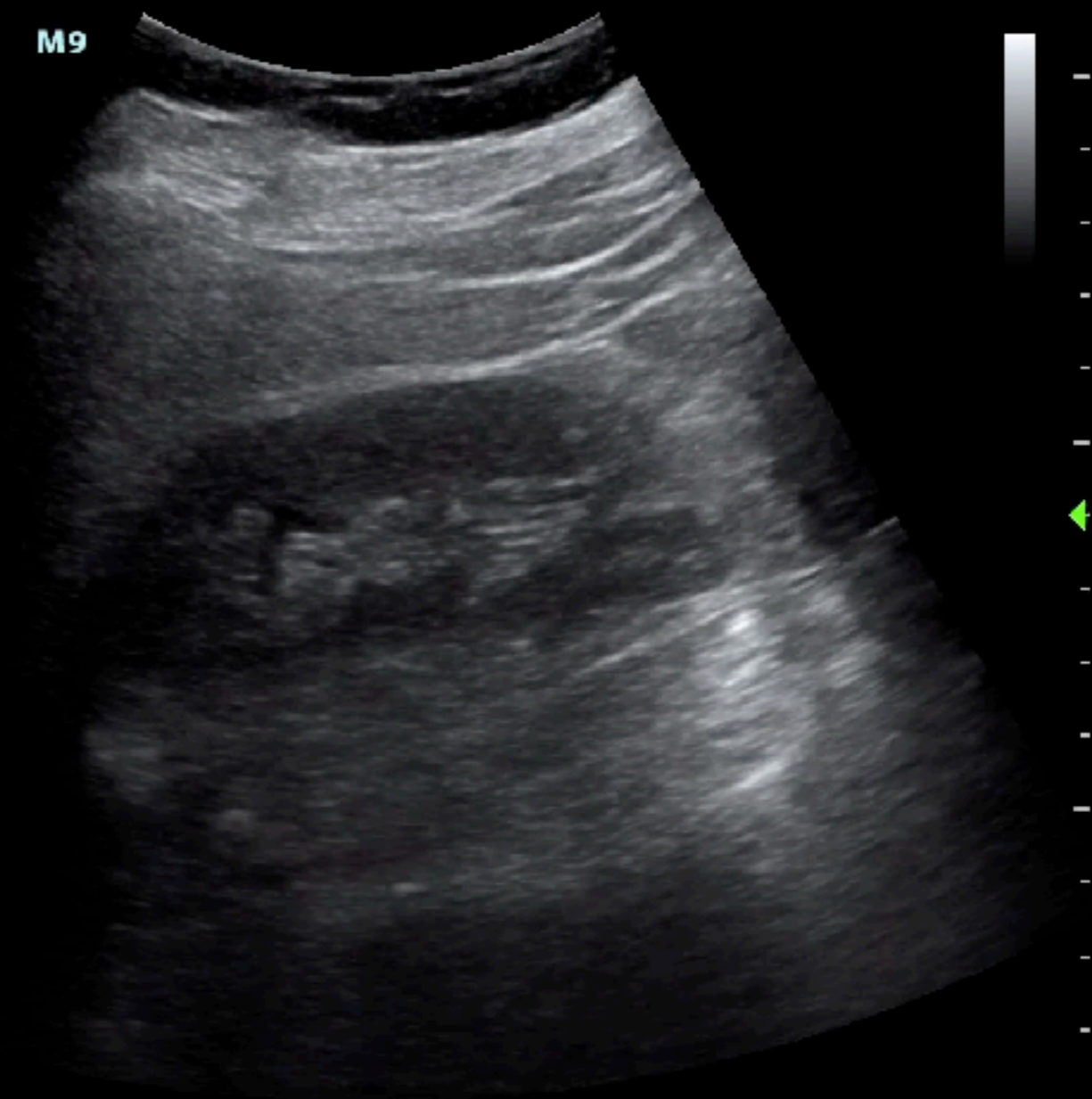
13-03-2016 16:07:02

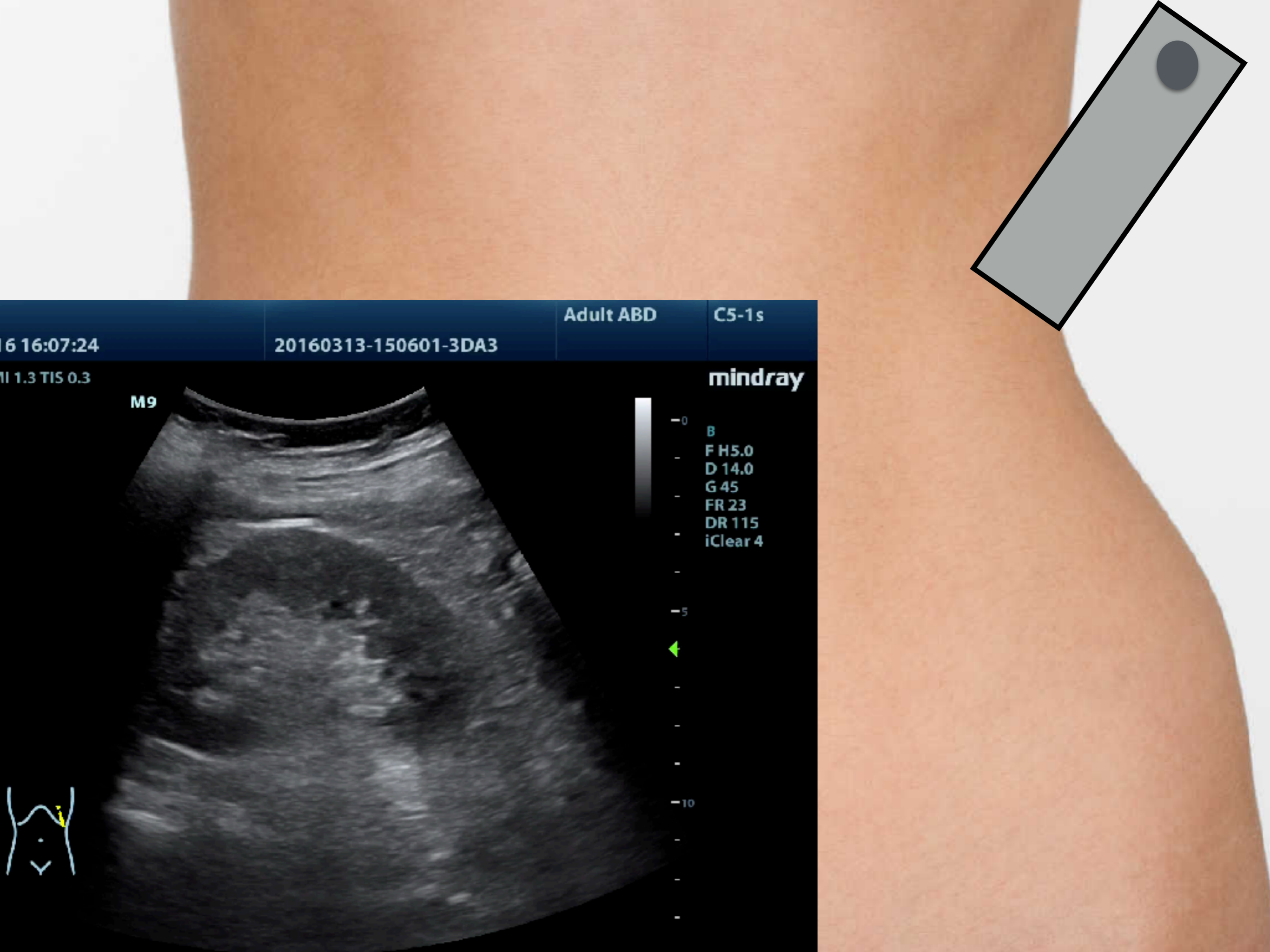
20160313-150601-3DA3

Adult ABD

AP 96.6% MI 1.3 TIS 0.3

M9





16 16:07:24 20160313-150601-3DA3 Adult ABD C5-1s

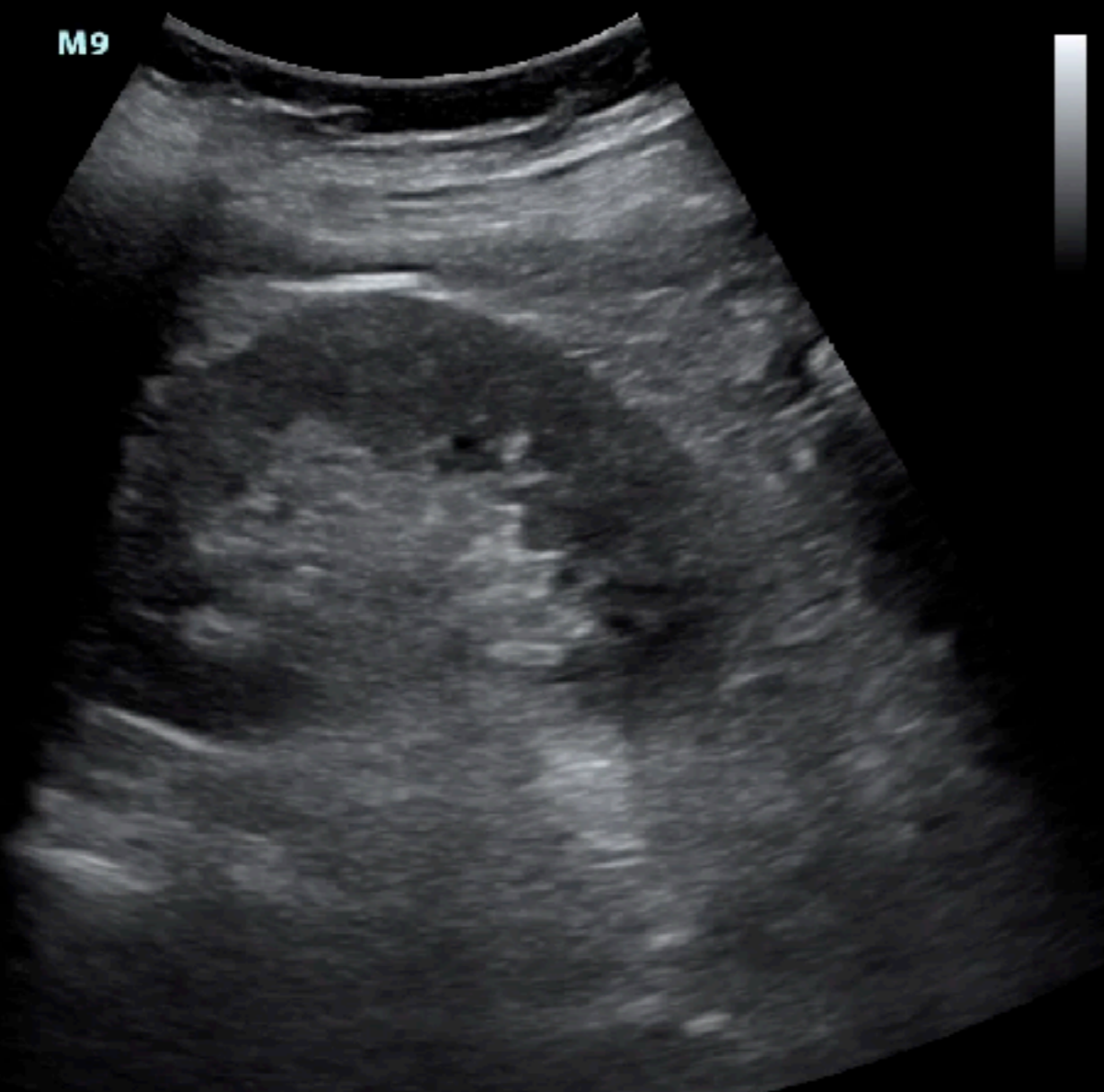MI 1.3 TIS 0.3 **mindray**

M9

-0
B
F H5.0
D 14.0
G 45
FR 23
DR 115
iClear 4

-5


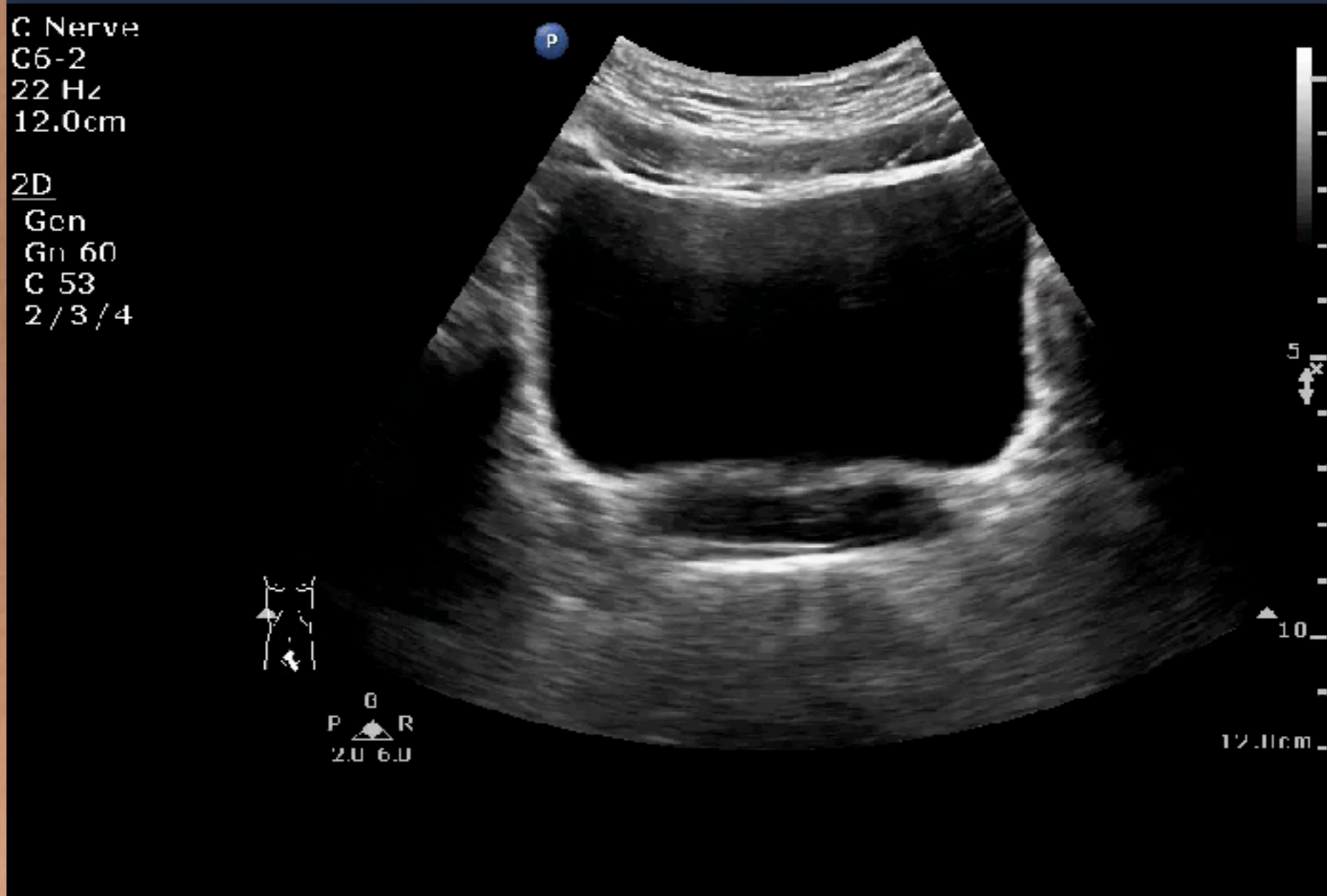
-10



C. Nerve
C6-2
22 Hz
12.0cm


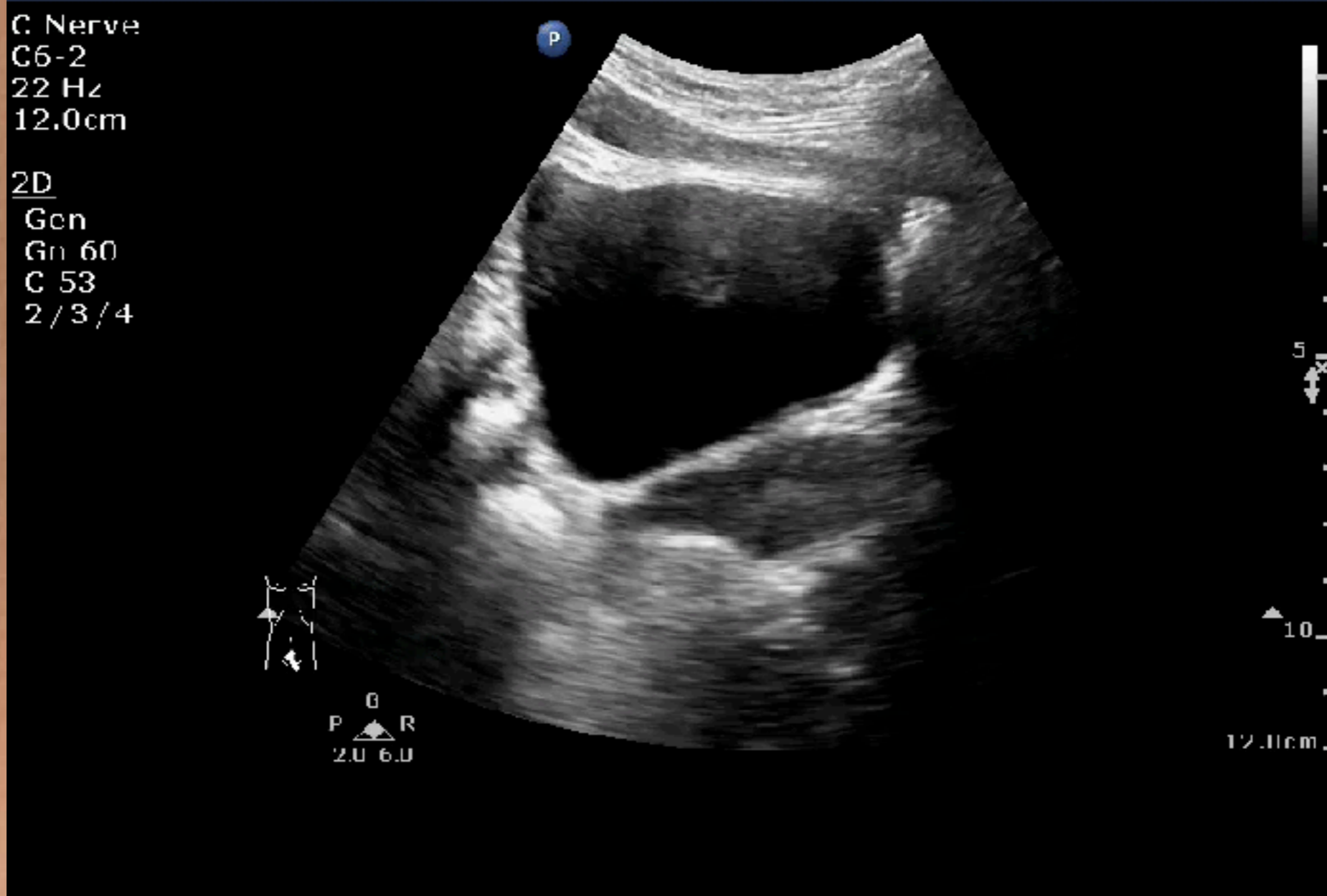
2D

Gen
Gn 60
C 53
2/3/4

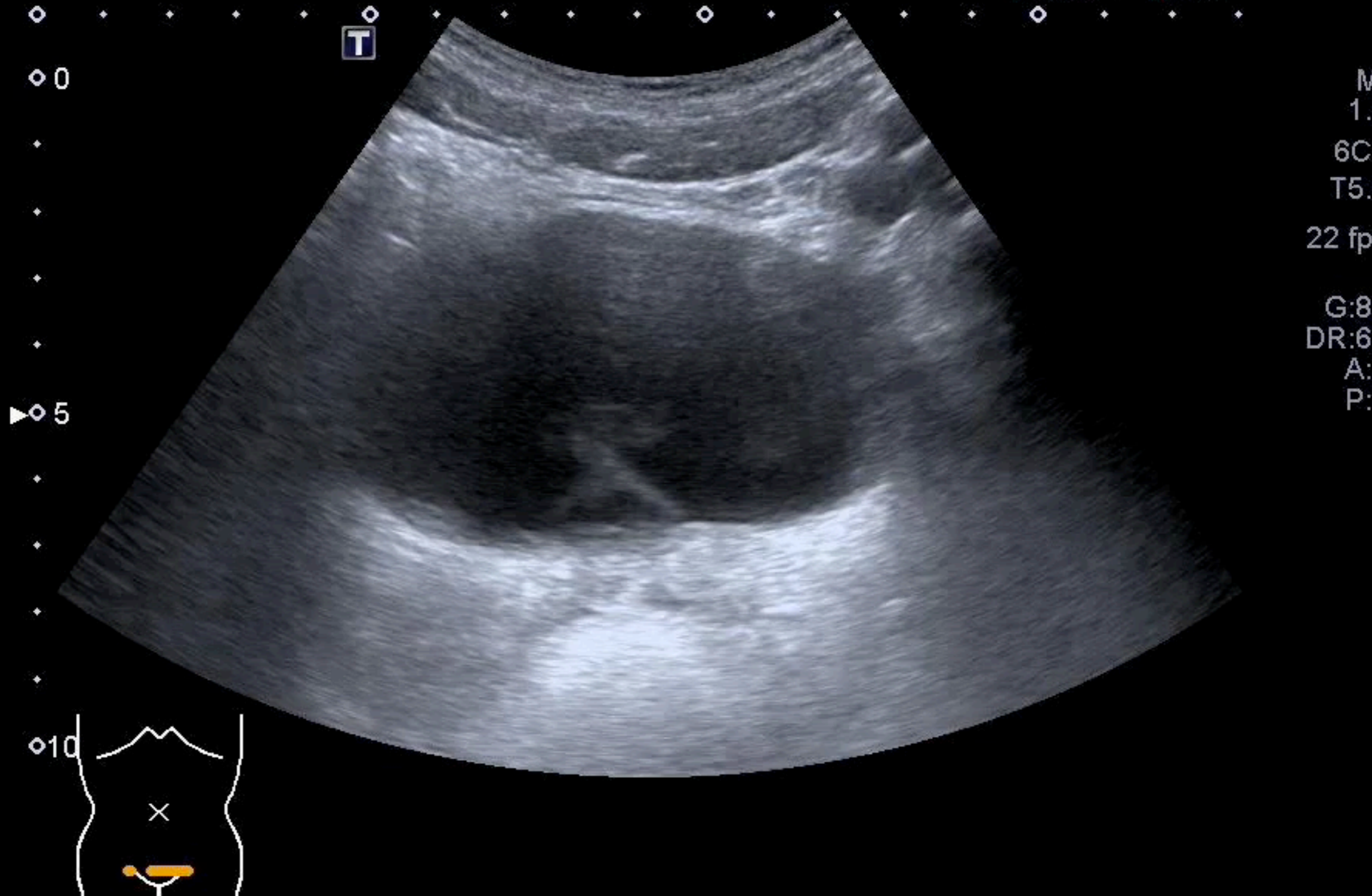


C. Nerve
C6-2
22 Hz
12.0cm

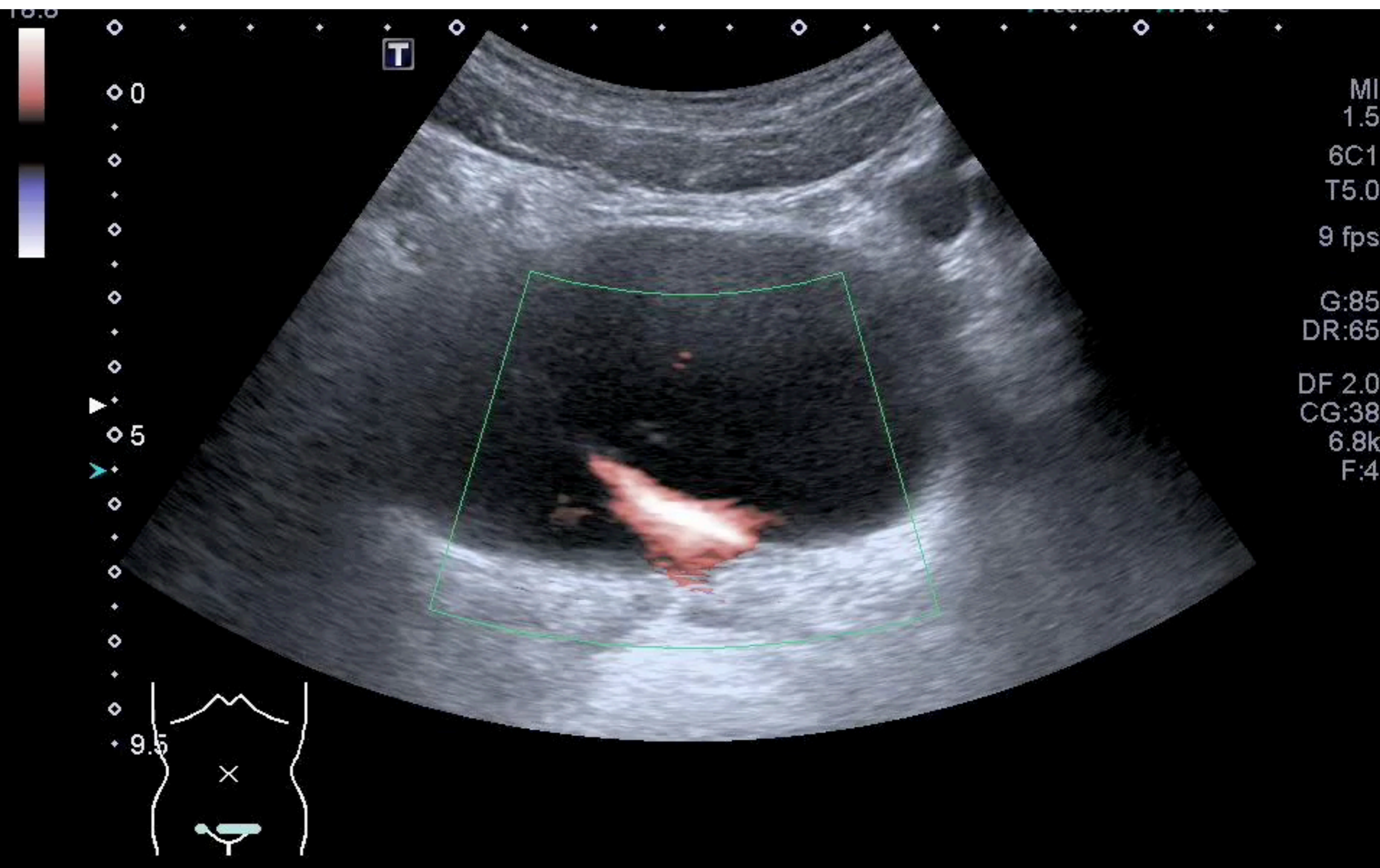
2D
Gen
Gn 60
C 53
2/3/4



Urinary jet



Urinary jet



When will you use US ?

Pain

Infection

Failure

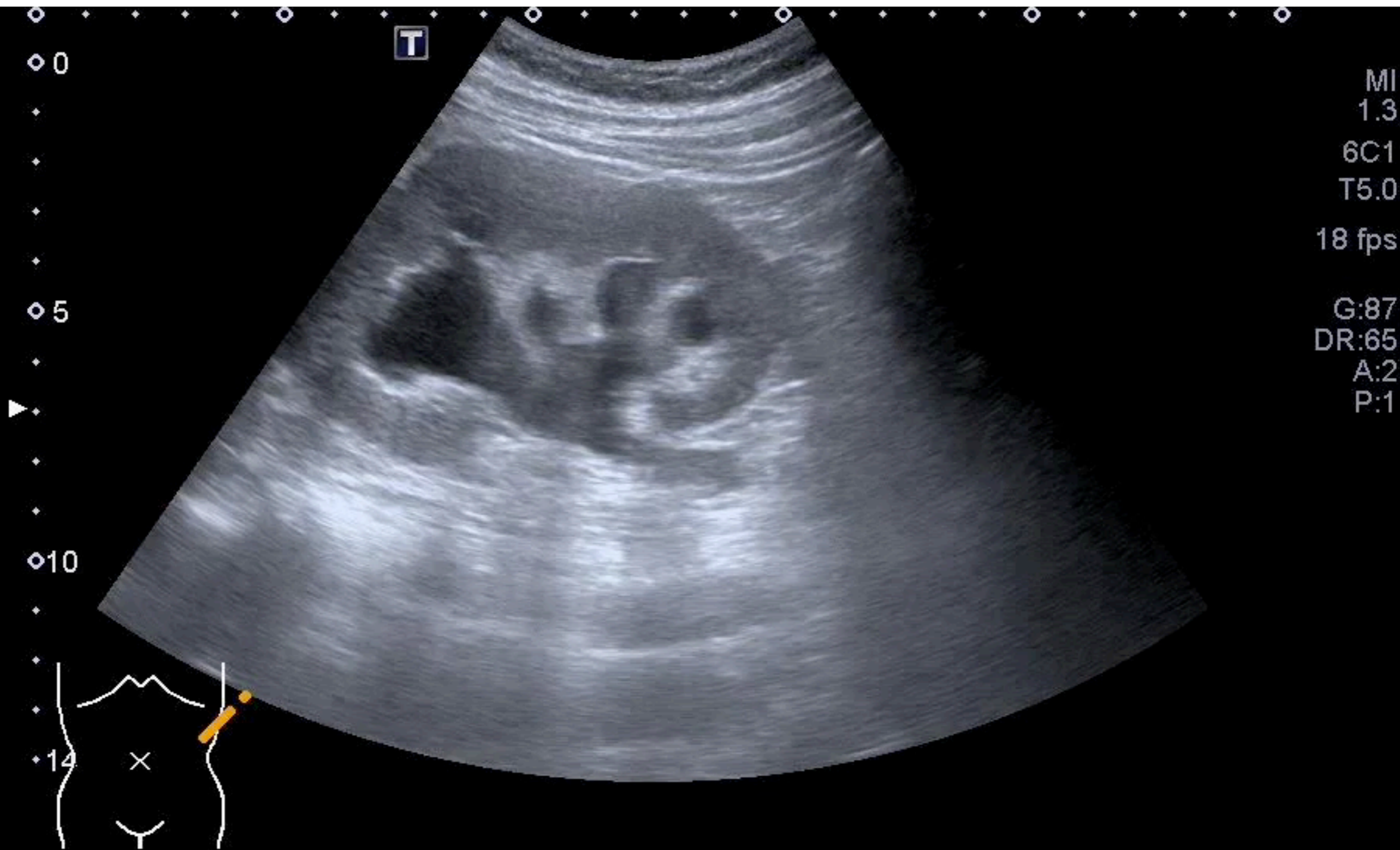GU emergency

POCUS first

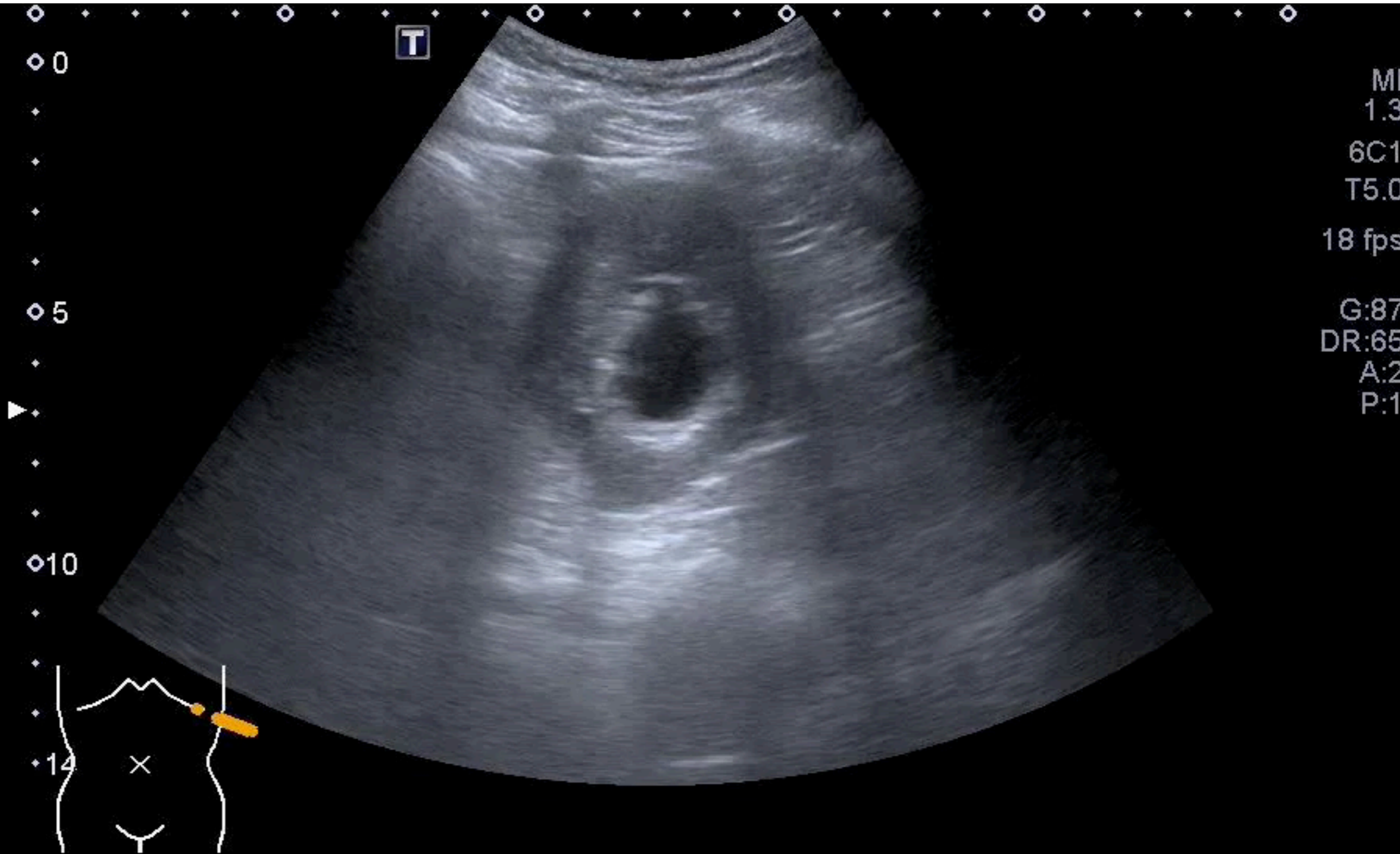
or

Urine first

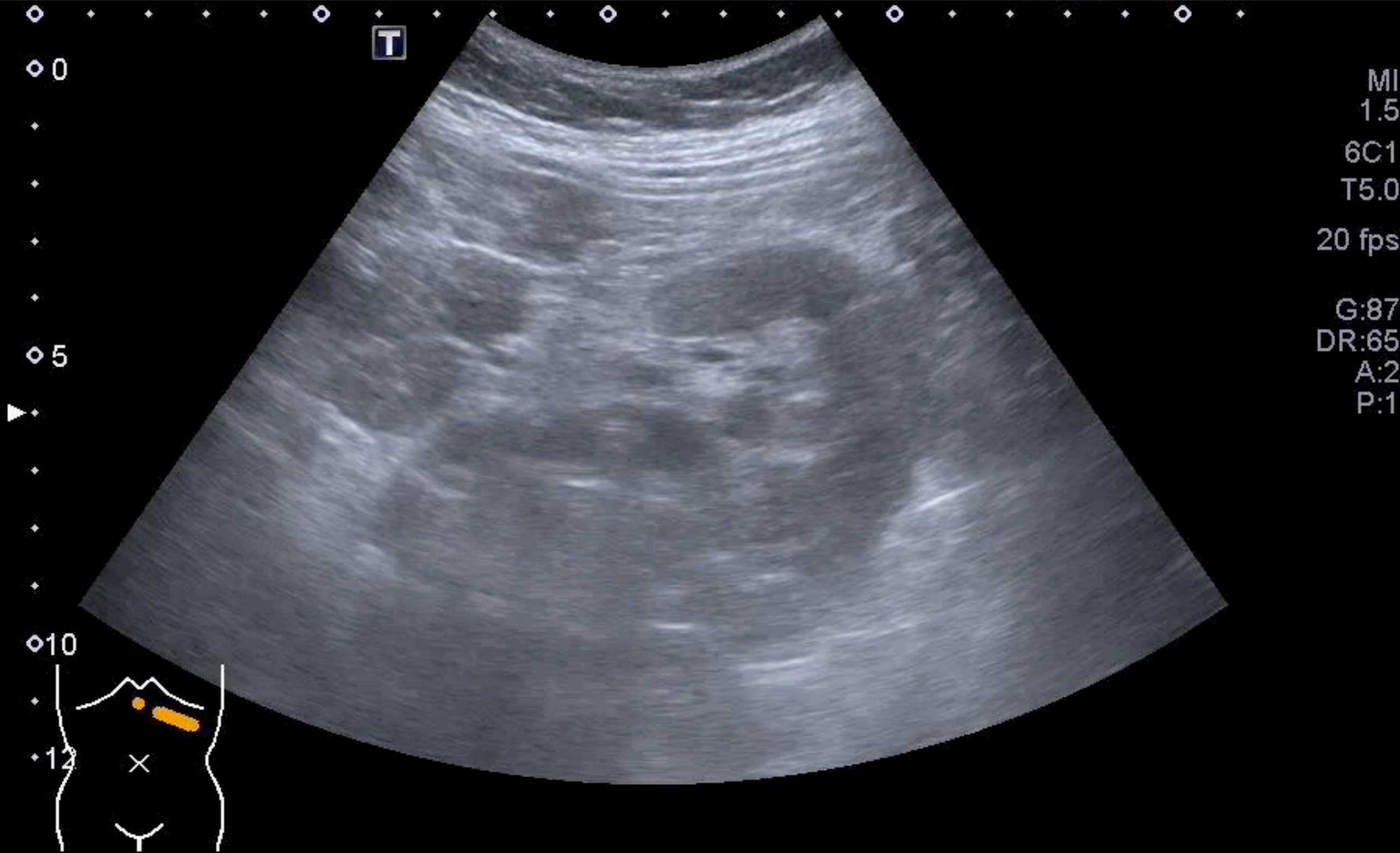
What do you see ?



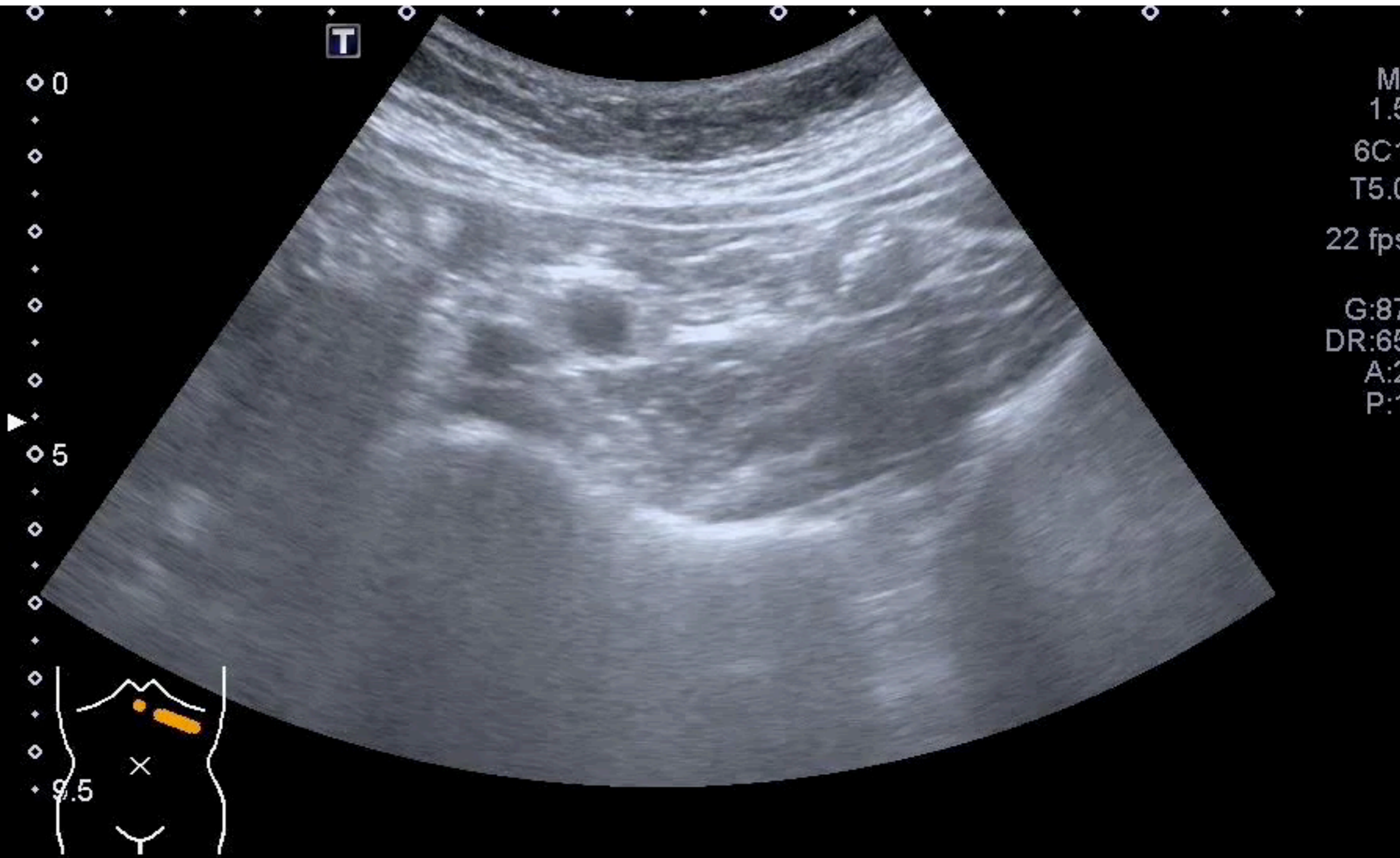
Where is ureter ?



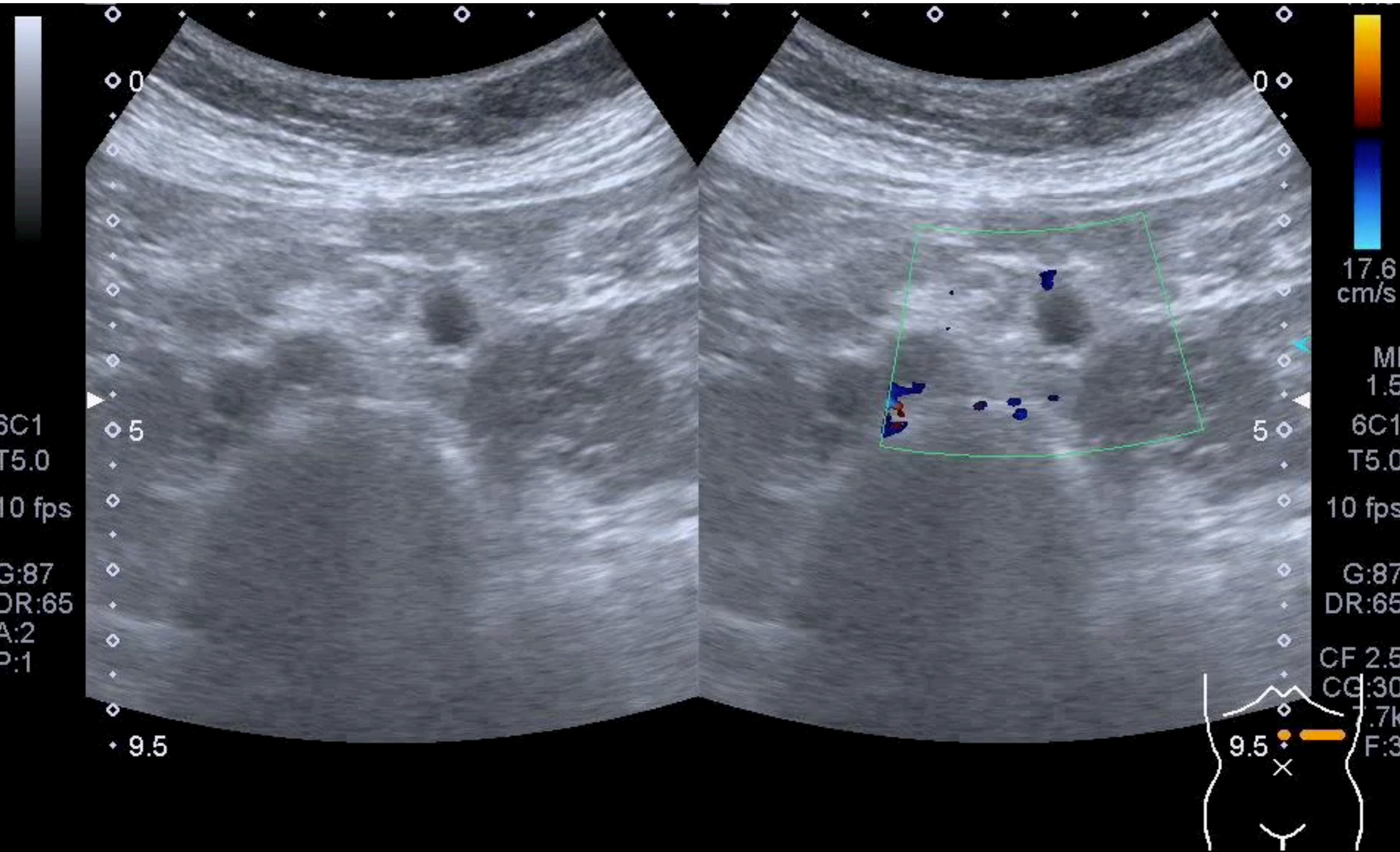
How to move the probe ?

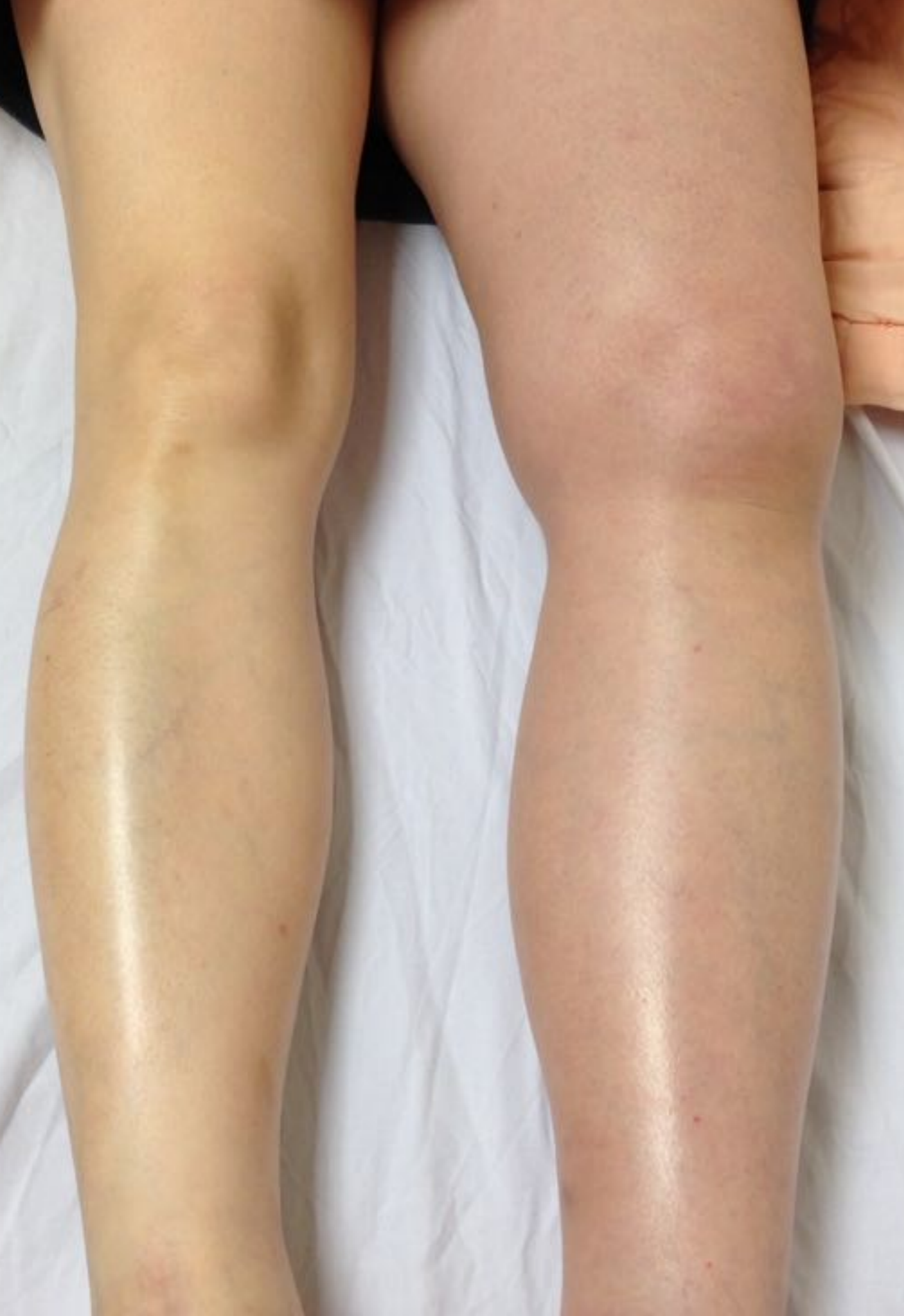

What is the skill ?



Twinkling artifact





A swollen leg,
what will you
do ??



Cellulitis

Abscess

N.F.

DVT

Others ?



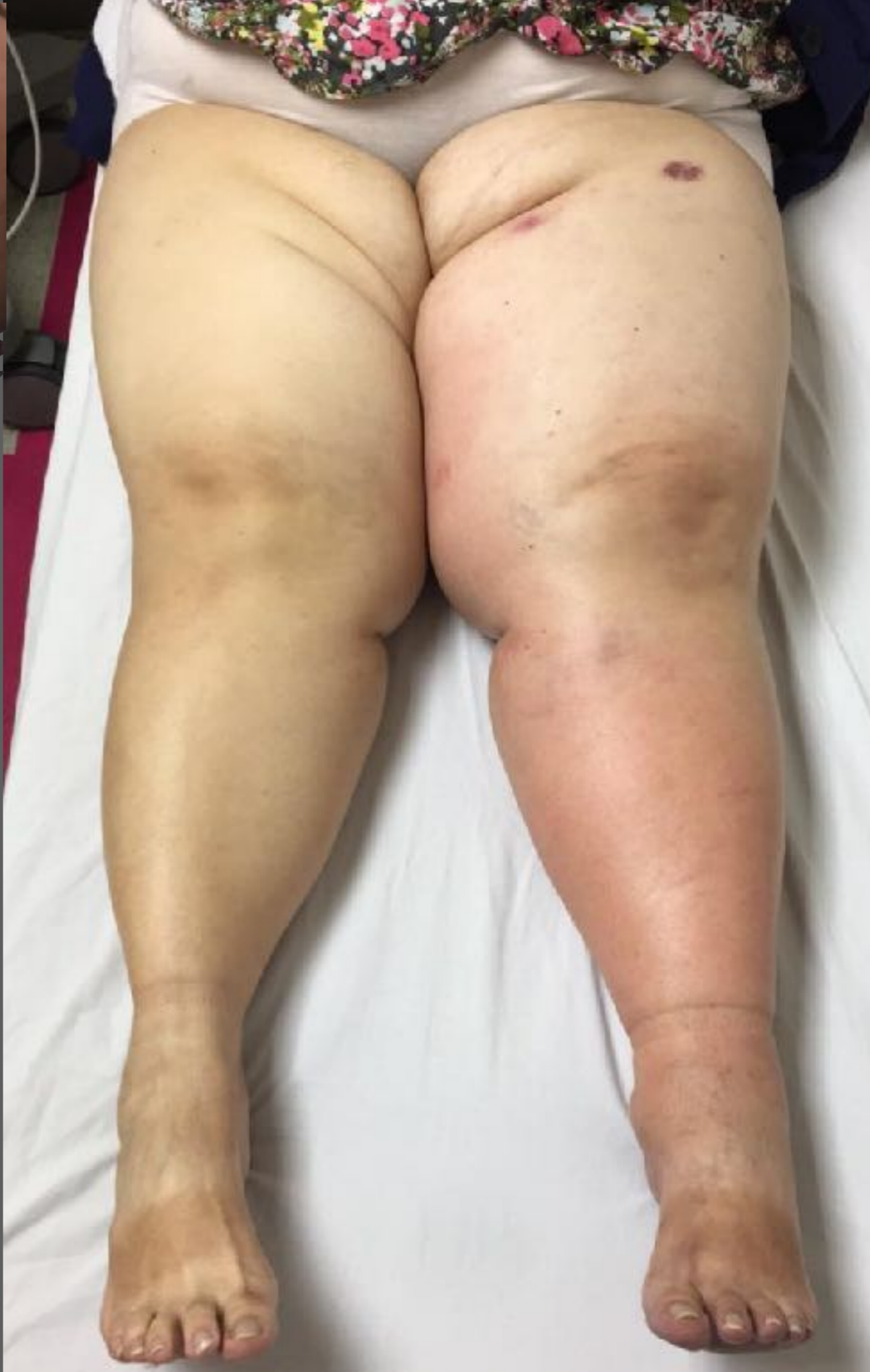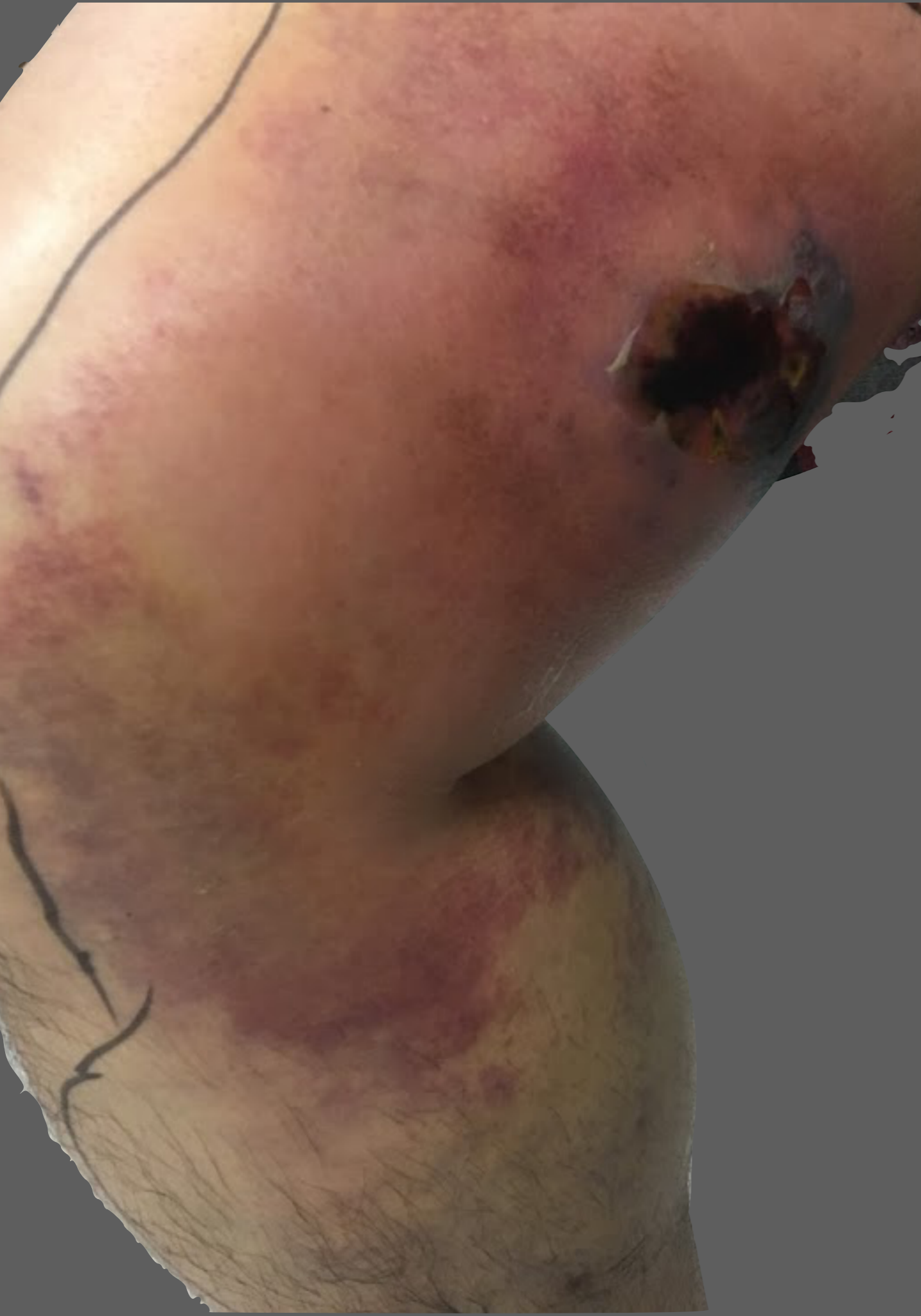Cellulitis

Abscess

N.F.

DVT

Others ?



Wells score for DVT assessment

Active cancer (patient receiving treatment for cancer within the previous 6 months or currently receiving palliative treatment)	1
Paralysis, paresis, or recent plaster immobilization of the lower extremities	1
Recently bedridden for ≥ 3 days, or major surgery within the previous 12 weeks requiring general or regional anesthesia	1
Localized tenderness along the distribution of the deep venous system	1
Entire leg swollen	1
Calf swelling at least 3 cm larger than the asymptomatic side (measured 10 cm below the tibial tuberosity)	1
Pitting edema confined to the symptomatic leg	1
Collateral superficial veins (nonvaricose)	1
Previously documented deep venous thrombosis	1
Alternative diagnosis at least as likely as deep venous thrombosis	-2

≥ 2

Pretest <
2

+

D-dimer
-ve





Likely

+ve D

US

Transducers

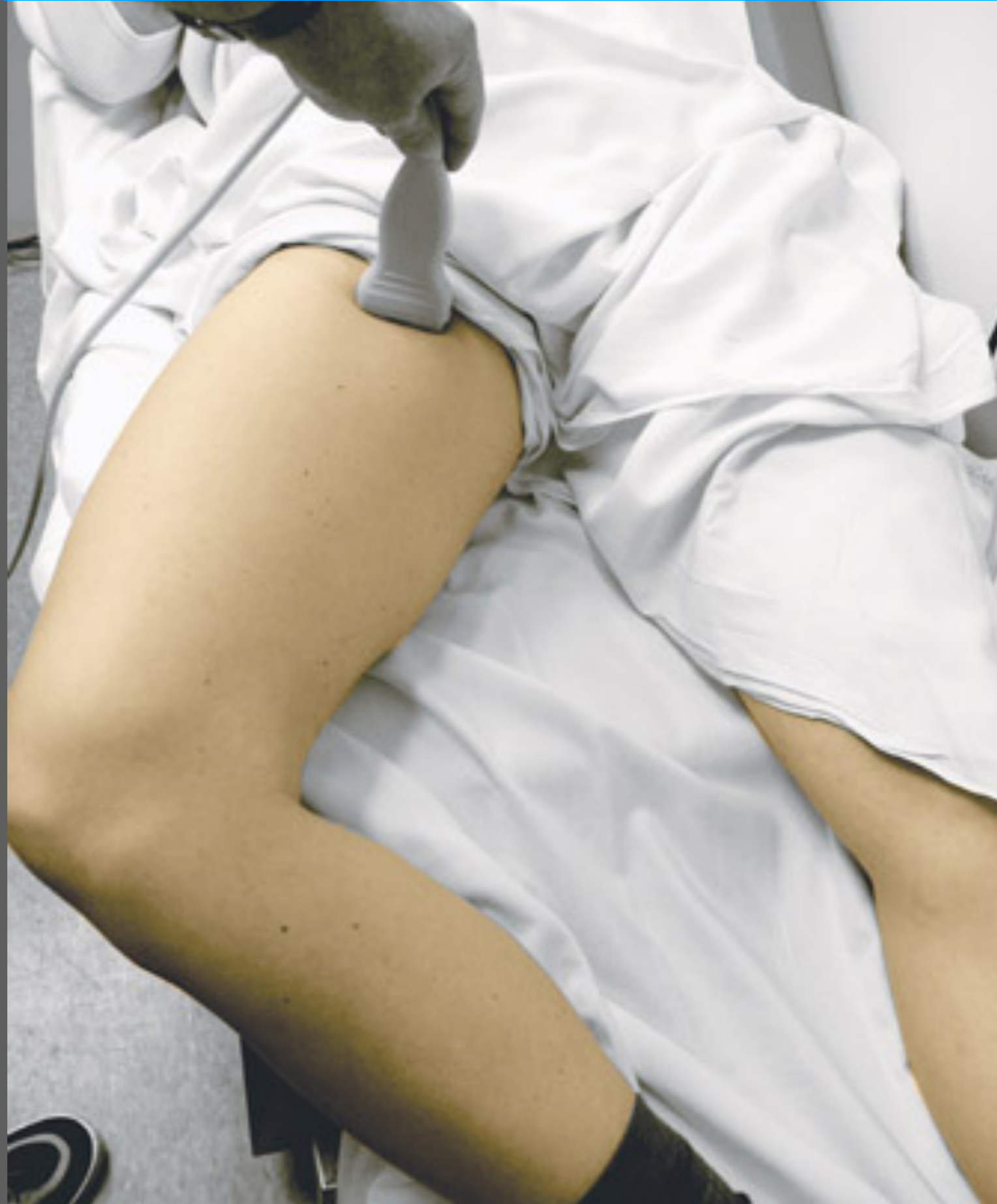

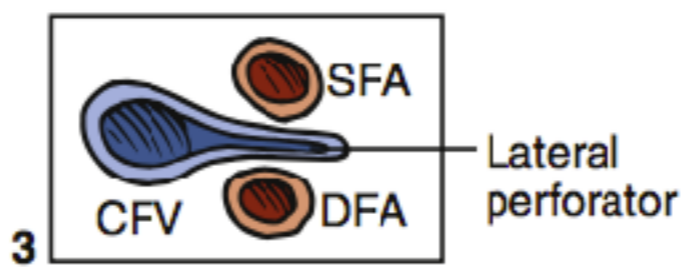
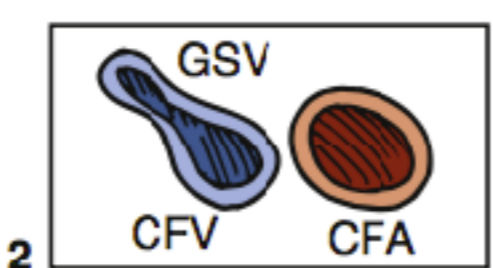
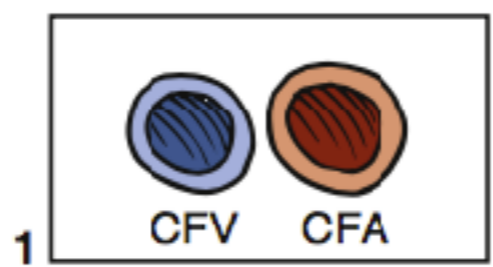
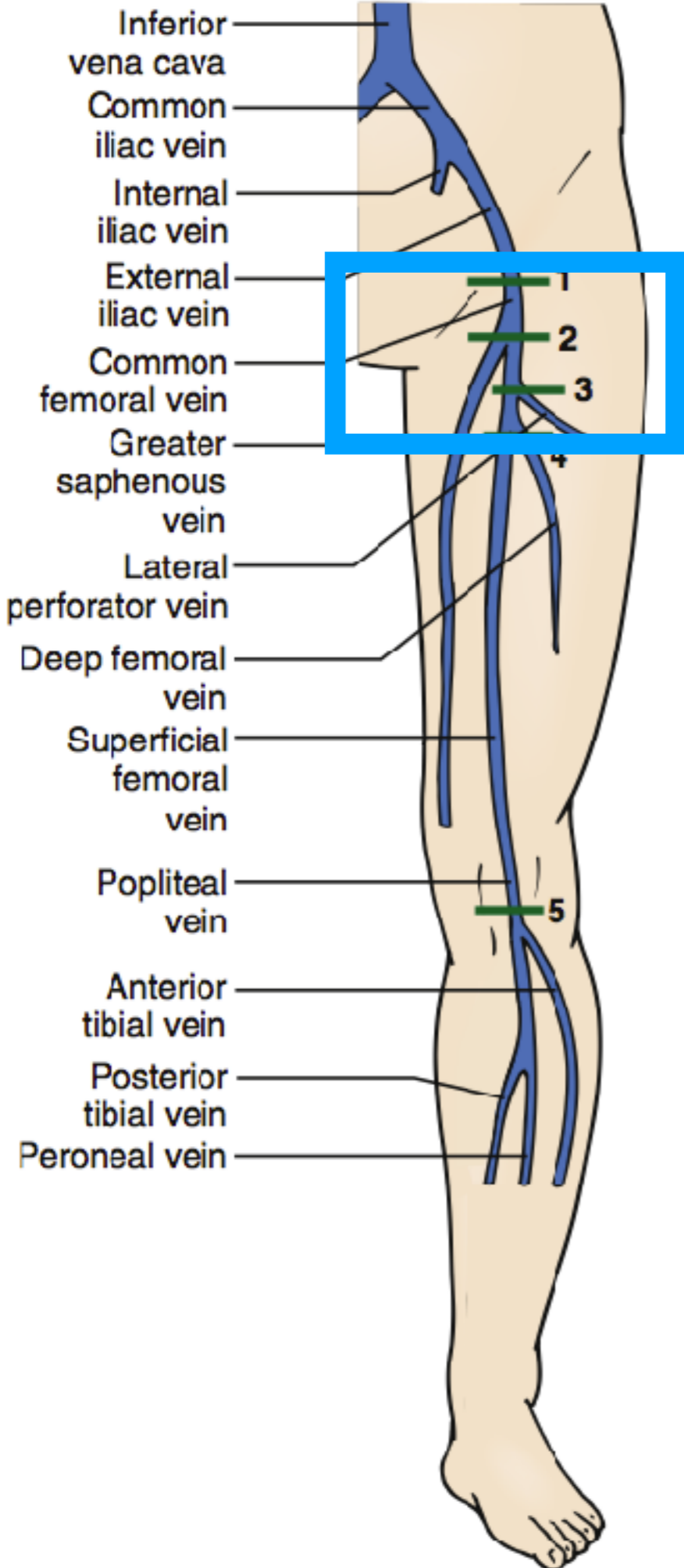
Transverse

Compression

3 regions

Position



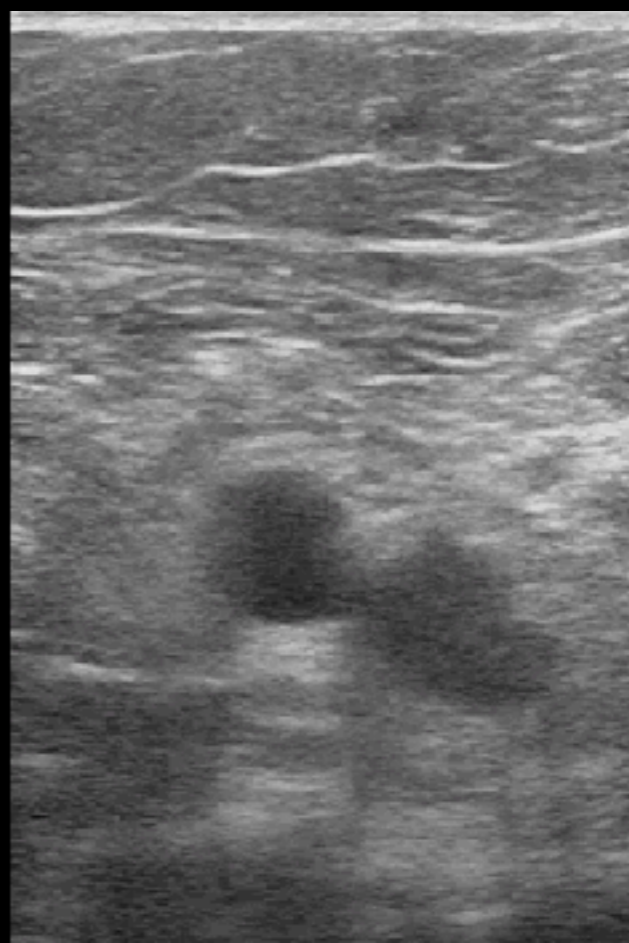


4

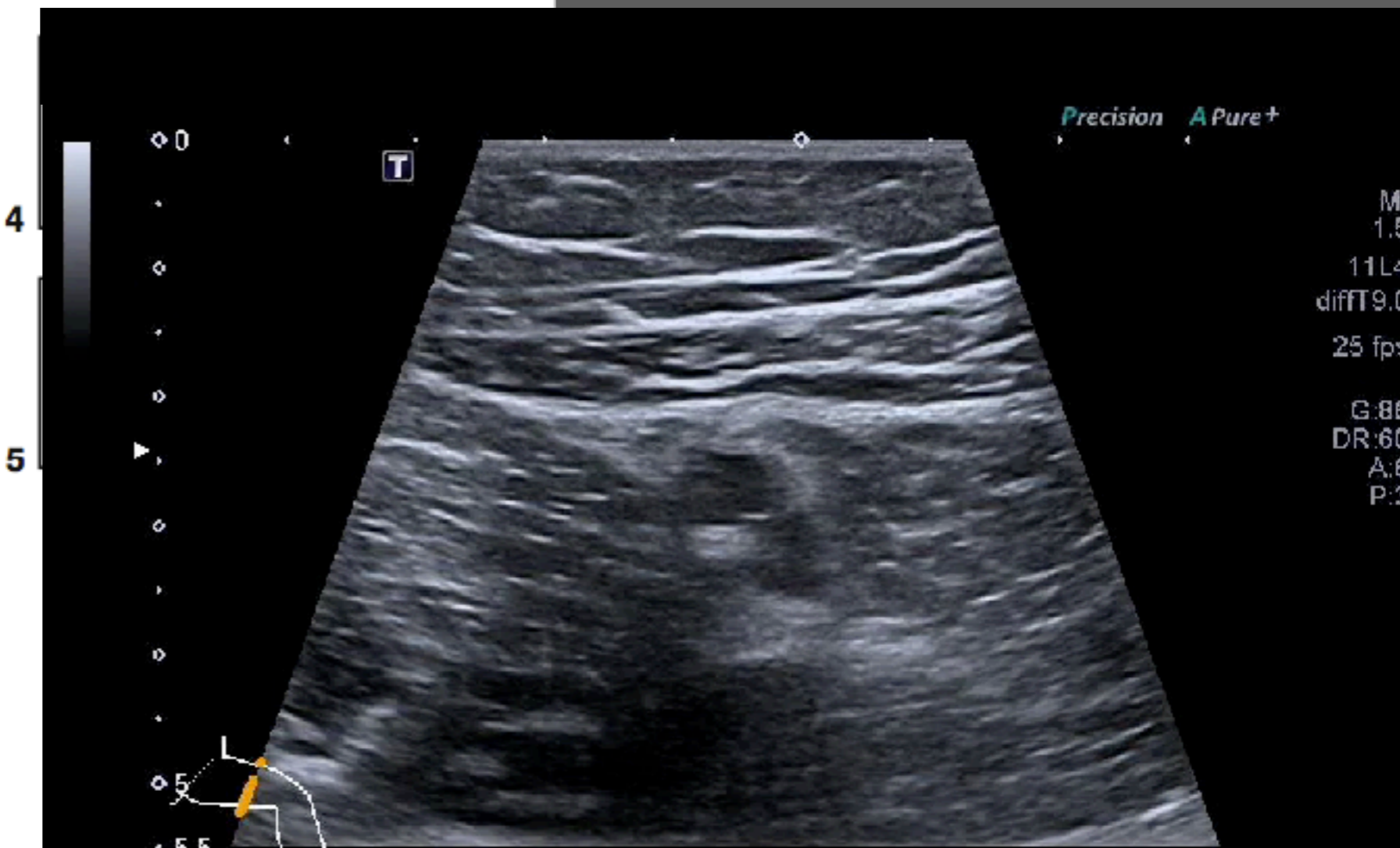
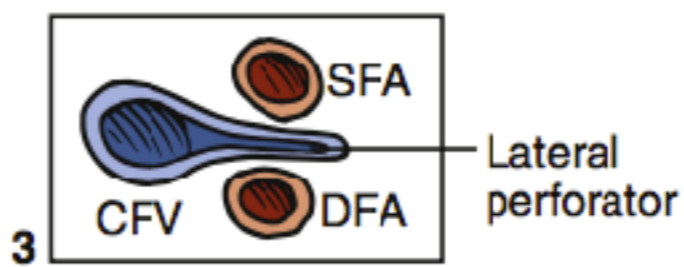
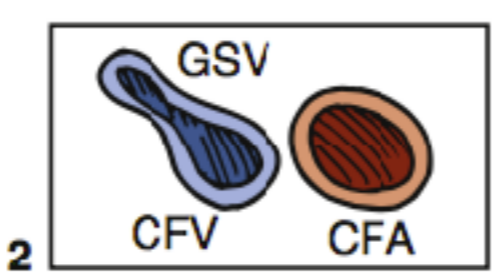
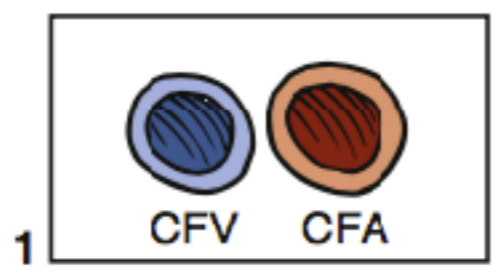
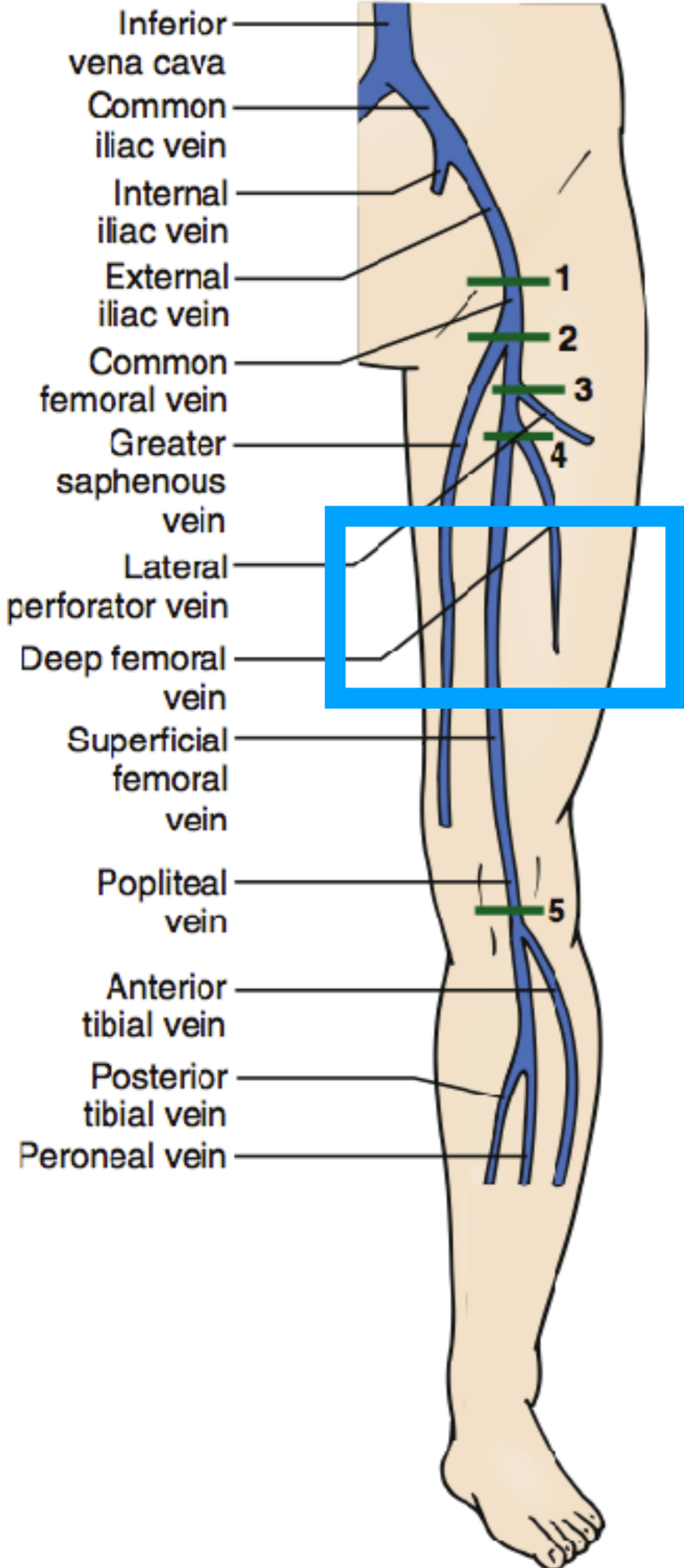
Venous
L12-3
31 Hz
6.0cm

5D
HGen
(in 11)
C 41
3/3/2

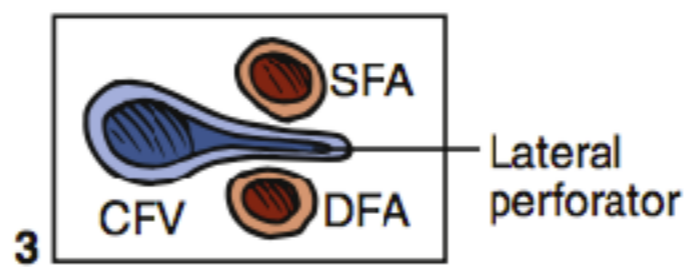
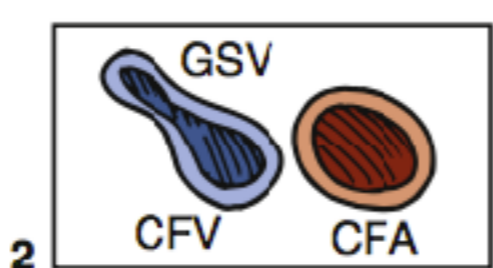
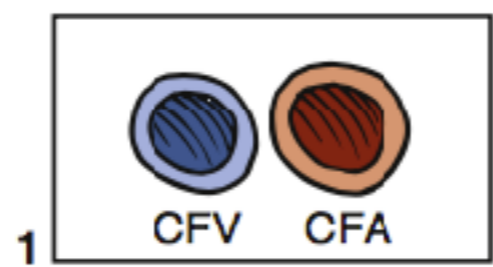
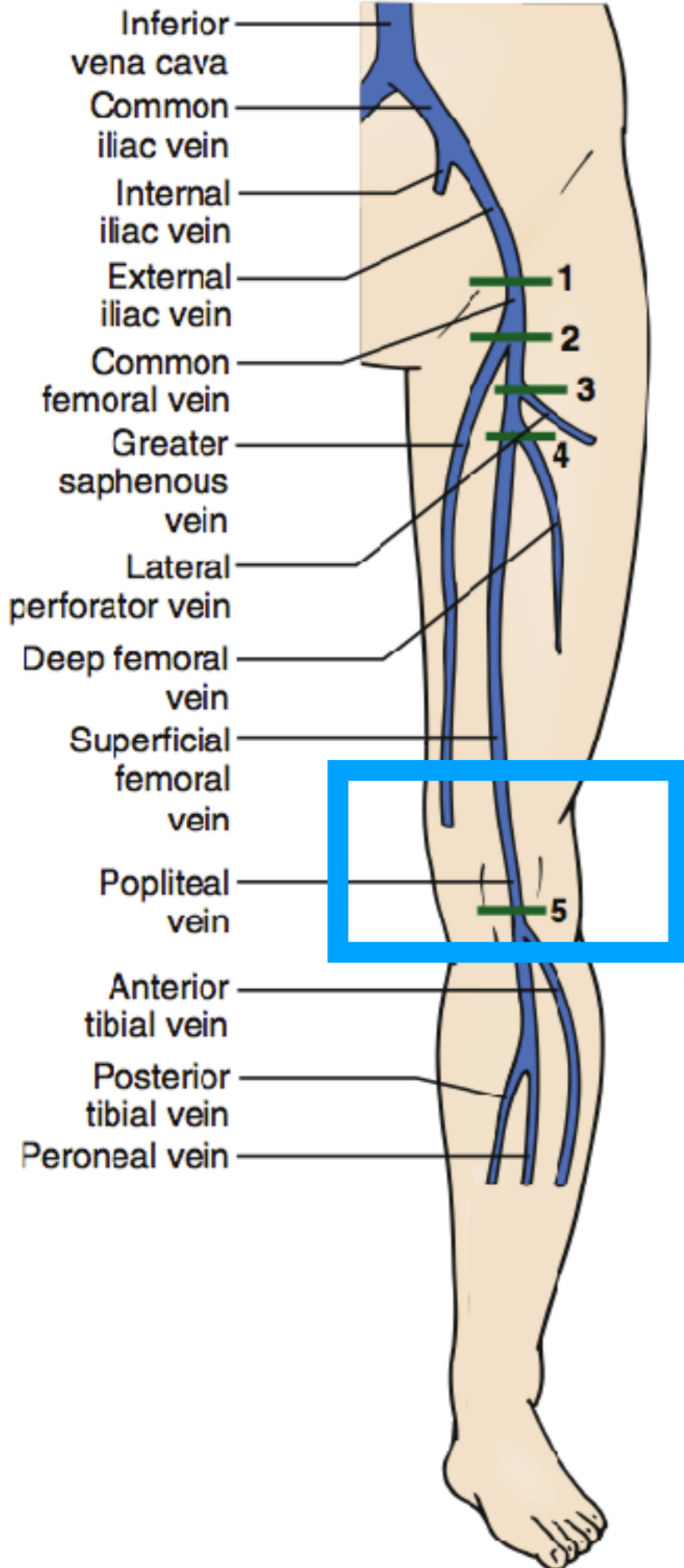
5



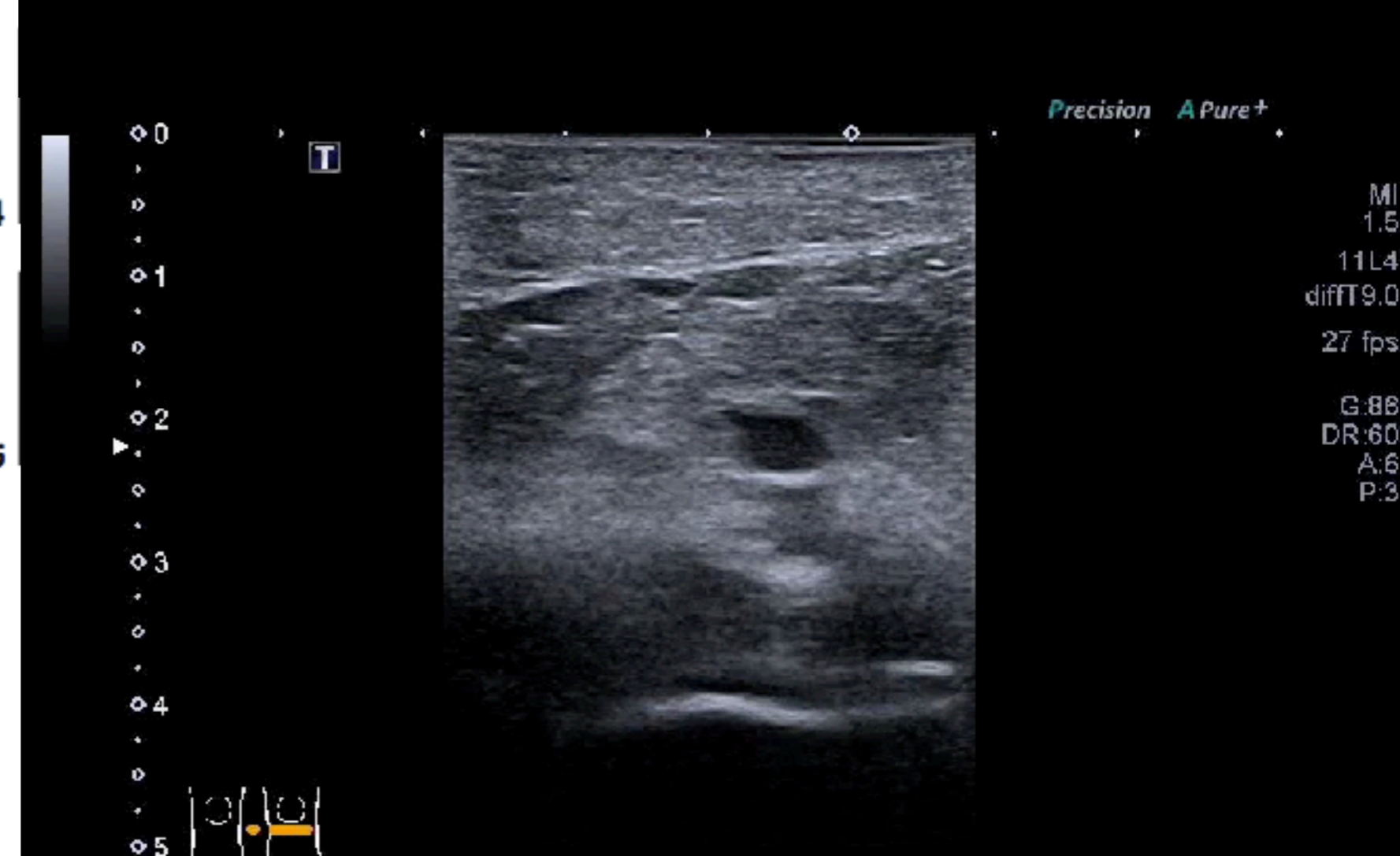3



3

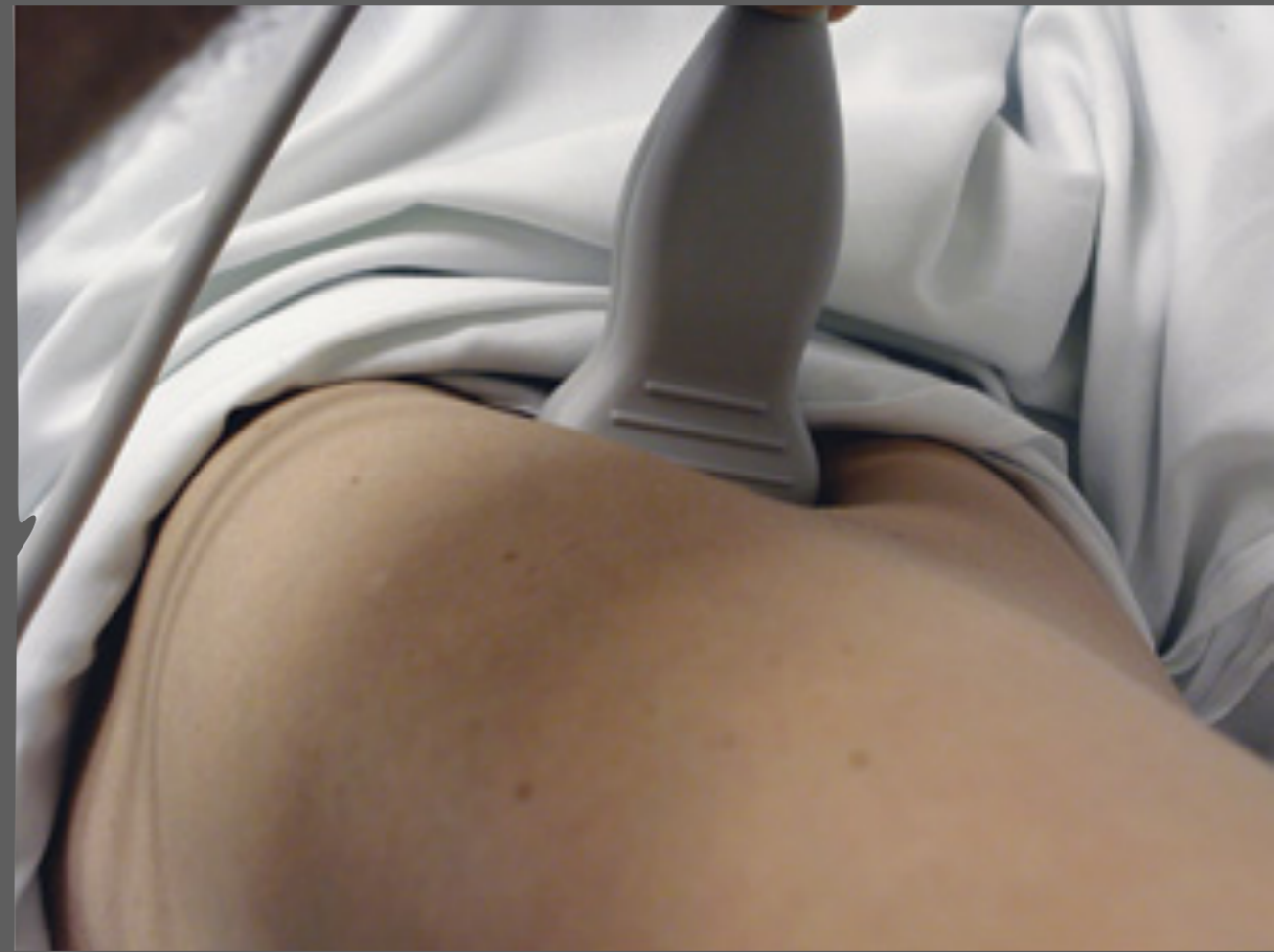
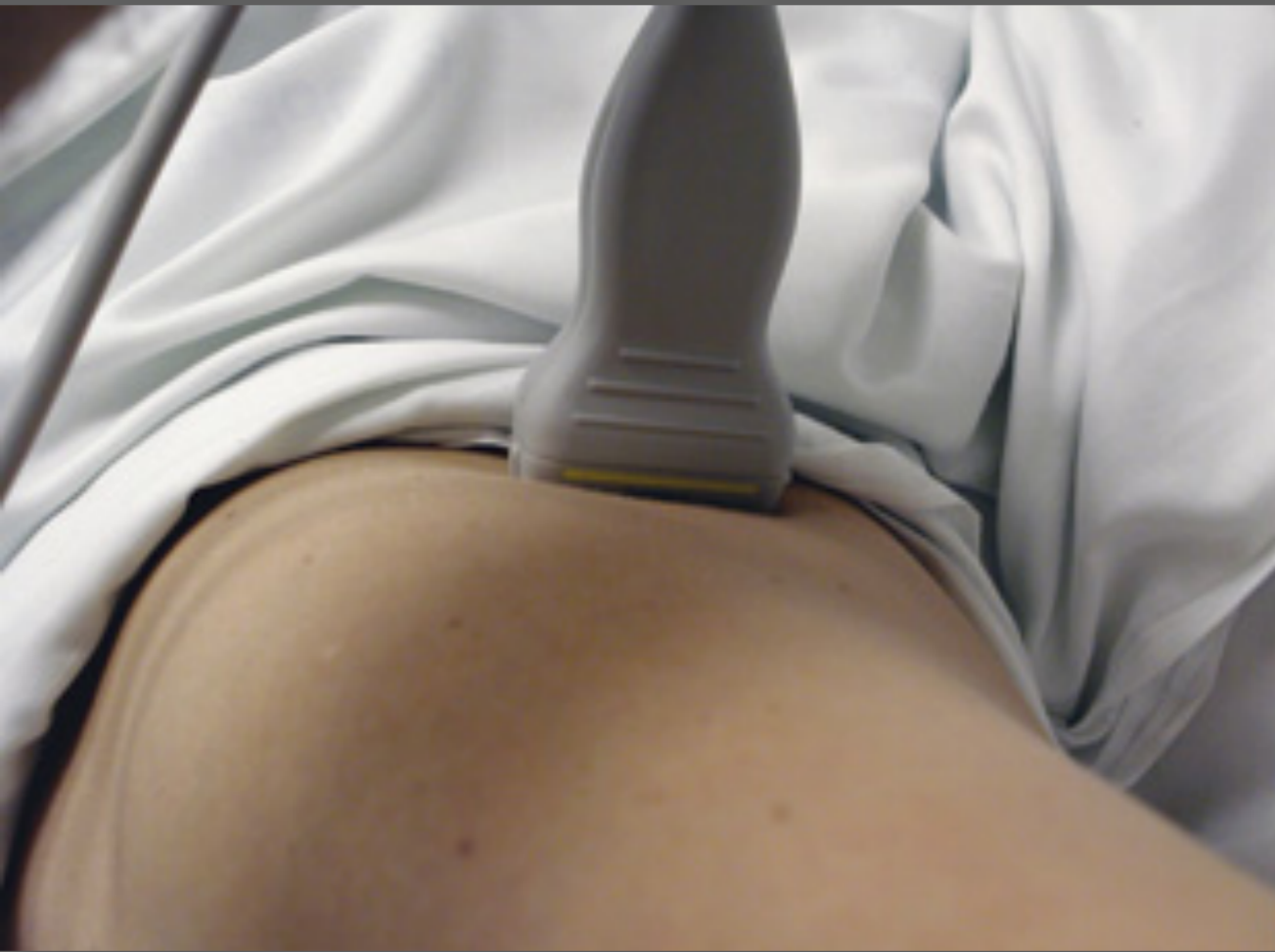
3



Compression

Pressure ?
No vessels ?



Inability to **completely compress** the venous lumen

Presence of a clot

Inadequate position or pressure

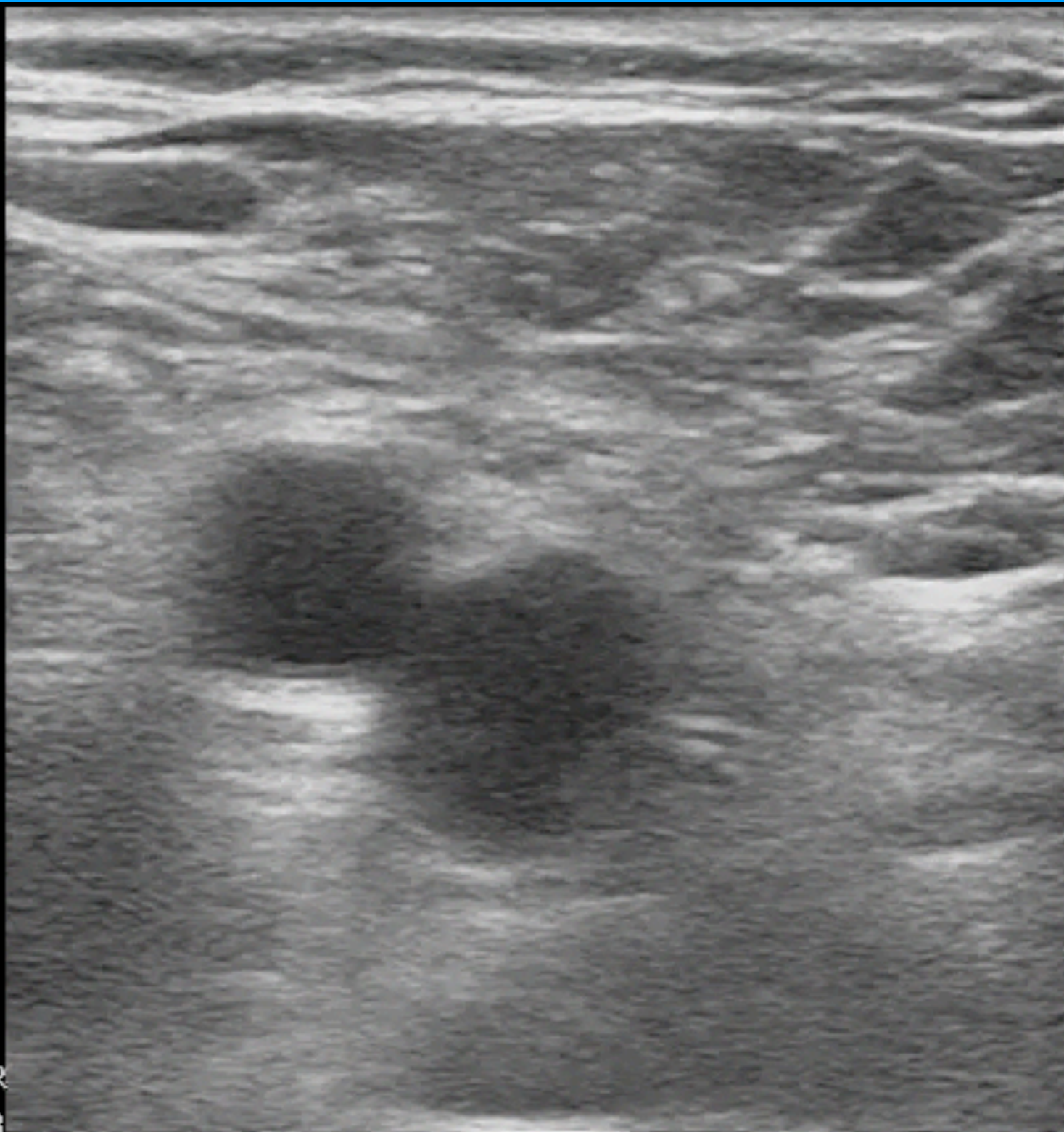
CFV

Venous
L12-3
37 Hz
4.0cm

2D

HGen
Gn 96
C 41
3/3/2

P



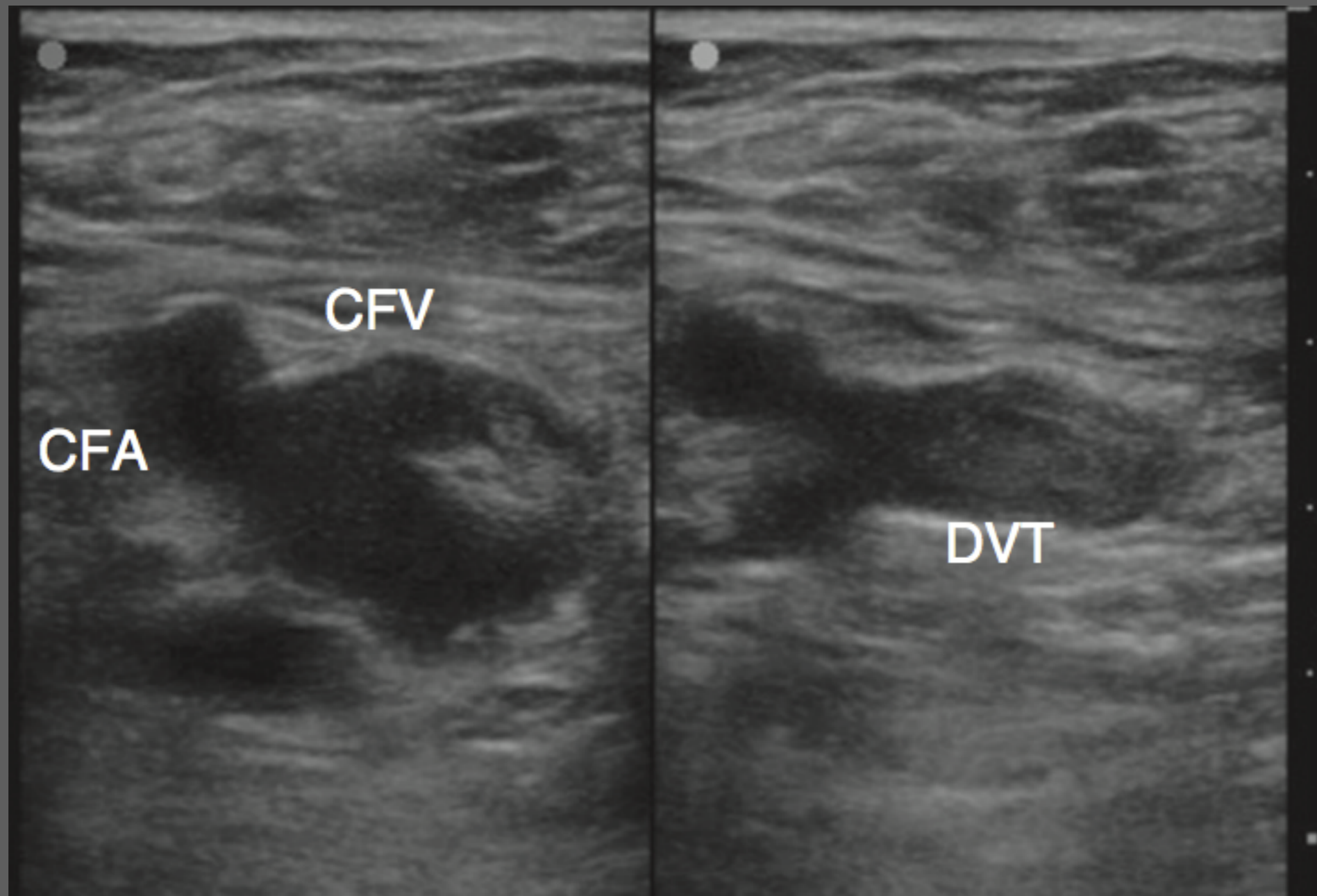
G
P R
4.4 8.8

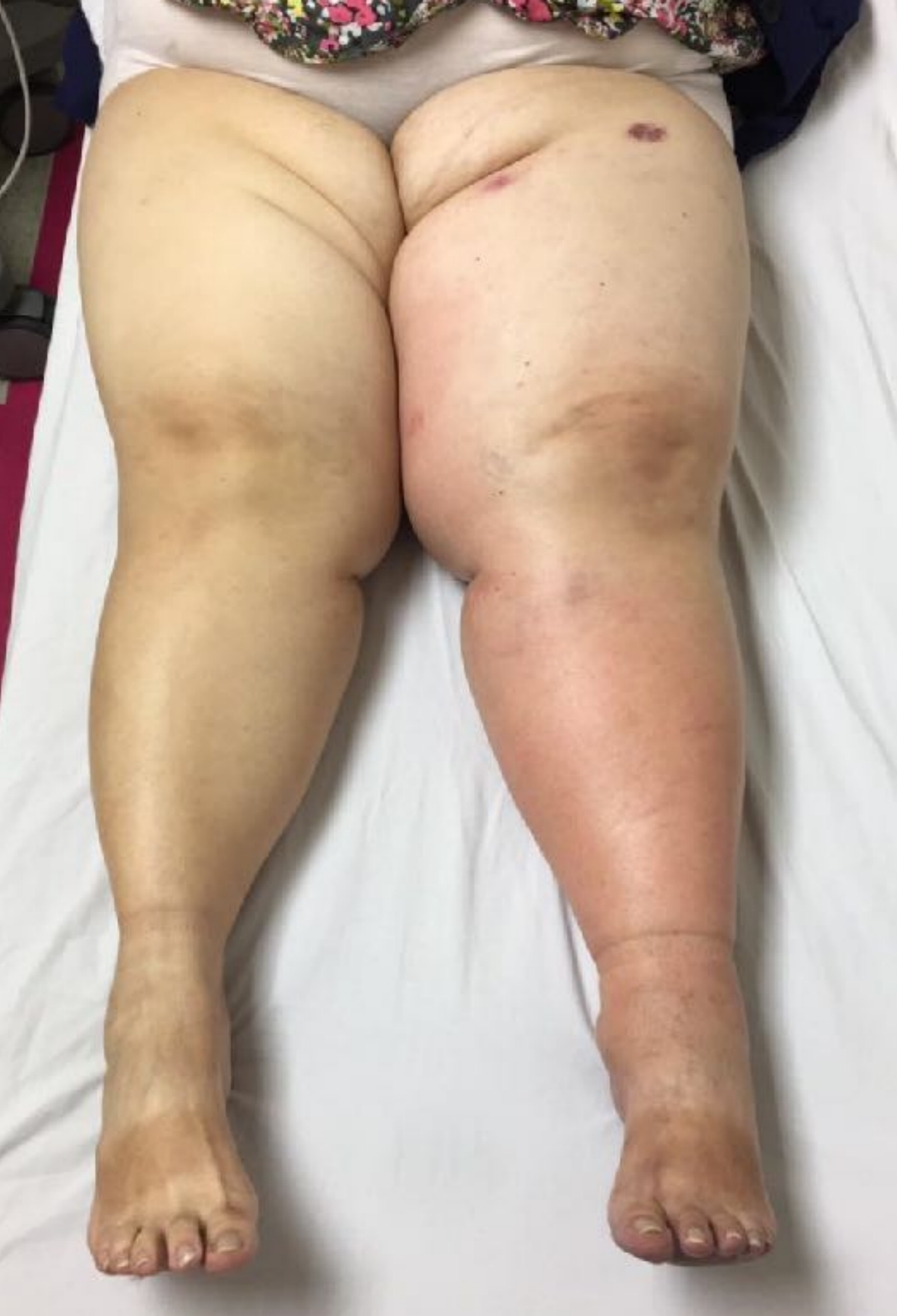2

4.0cm

Document

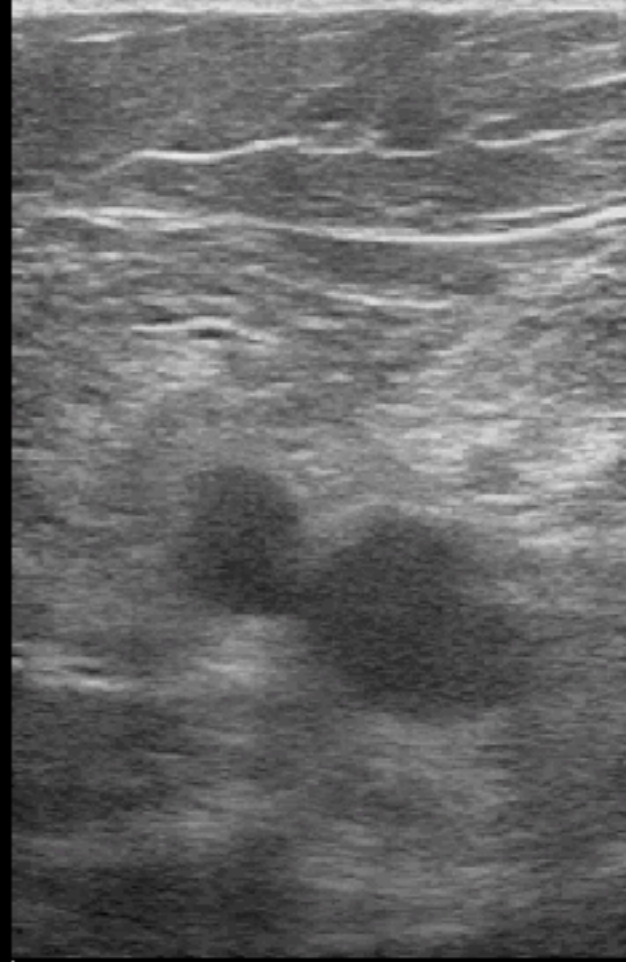
Dual images: w/ & w/o compression



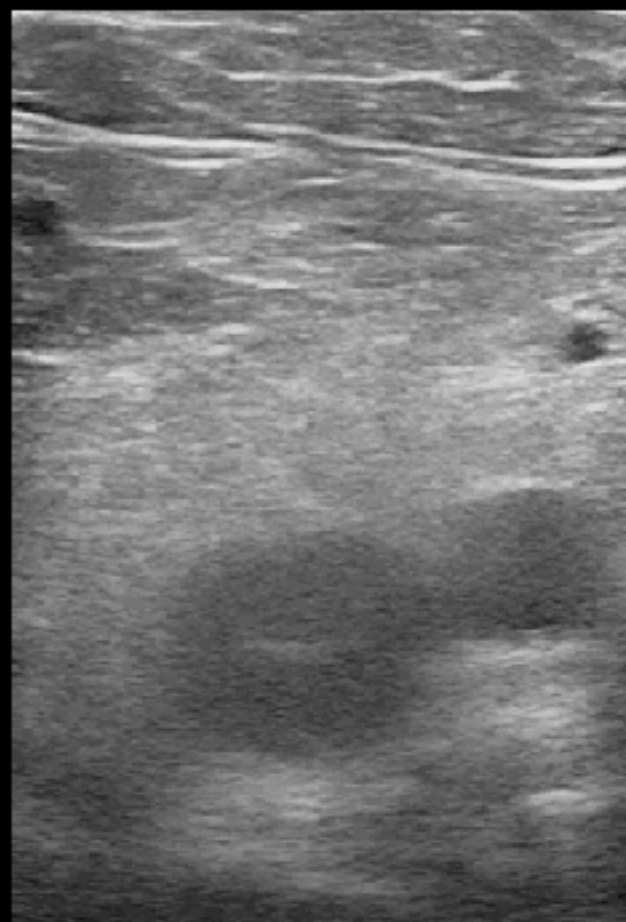


P
R
4.4 8.8

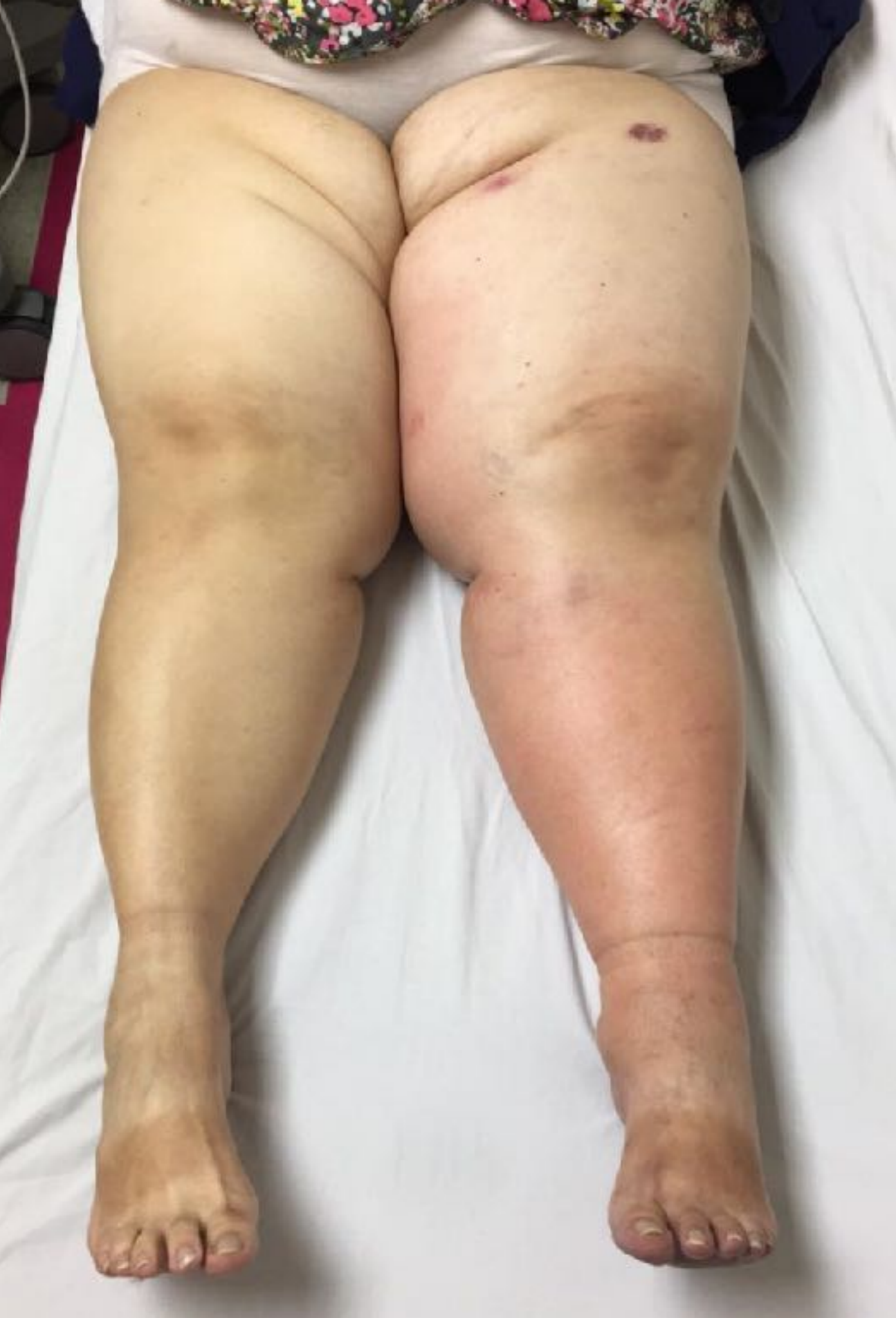P
R
4.4 8.8



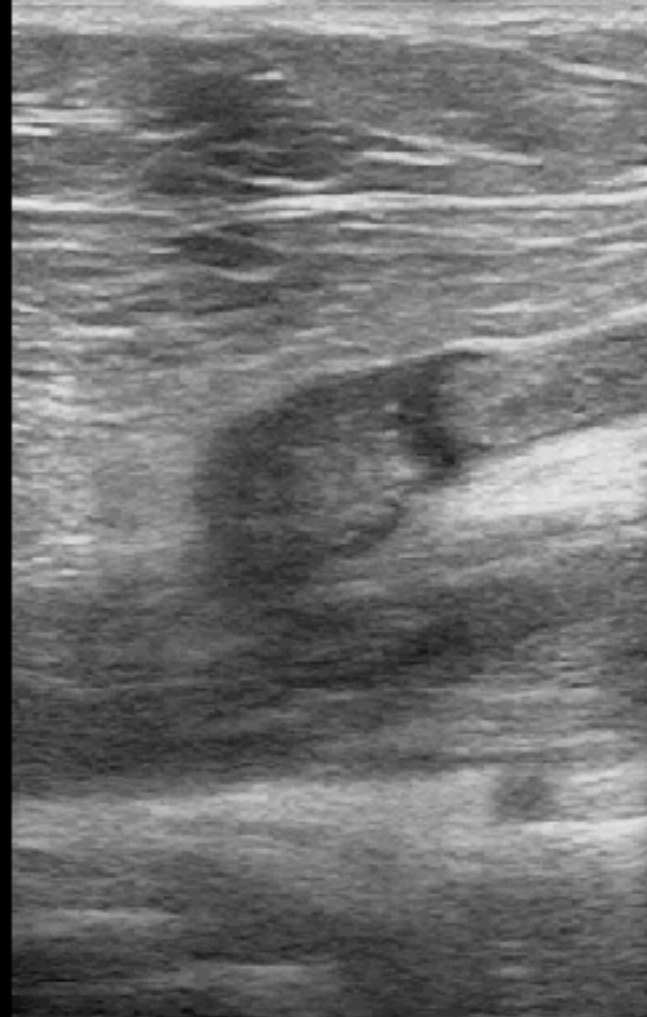
5.1
6.0cm



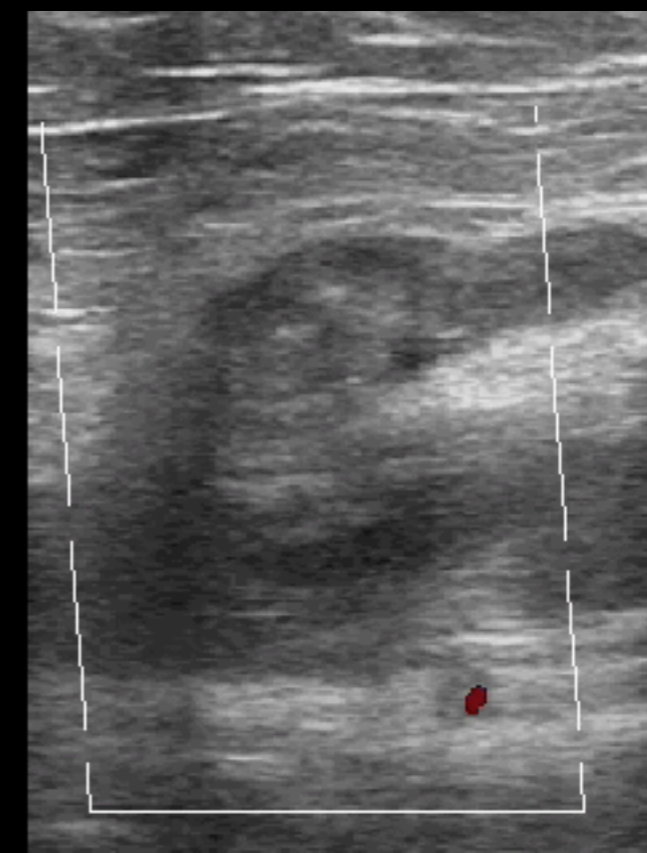5.1



© R
+ 8.8



6.0cm

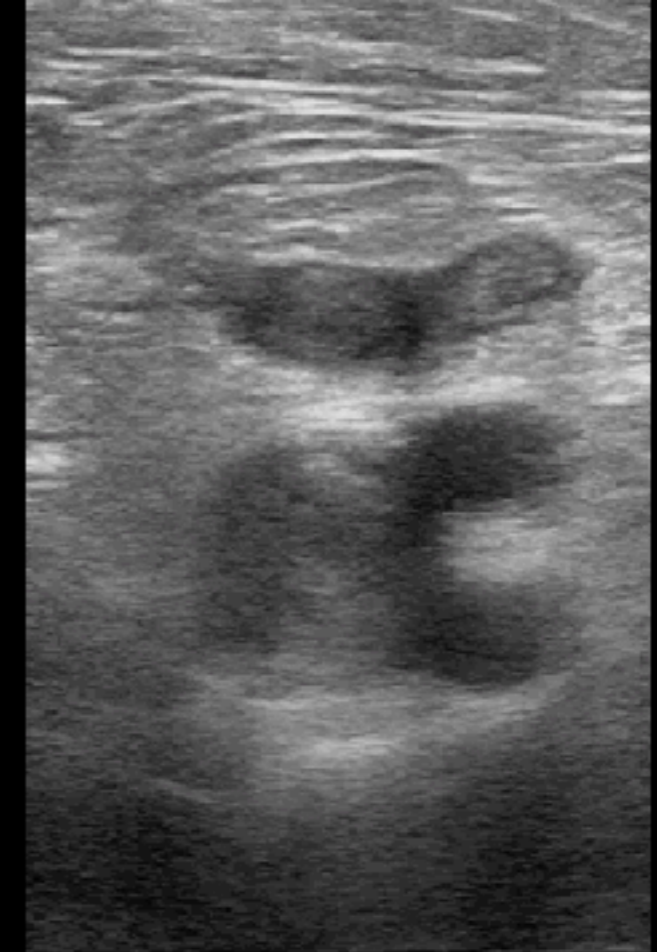

cm/s
-7.0

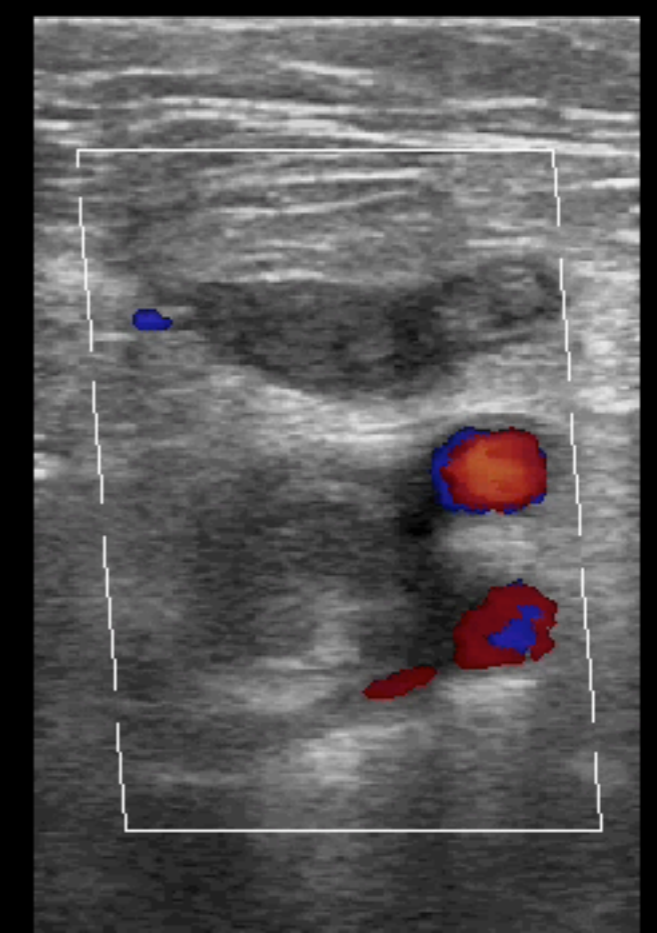
© P



Ⓞ
P R
4.4 8.8



6.0cm



7.0
cm/s
7.0

Ⓞ



DVT assessment

3 regions

Collapse 100%

Proximal only

POCUS Academy

Let's transform EM practice



juice119@gmail.com

FB: Emergency Ultrasound Training Center

