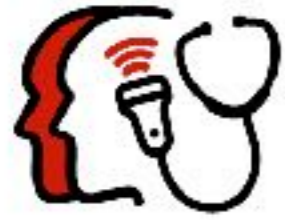



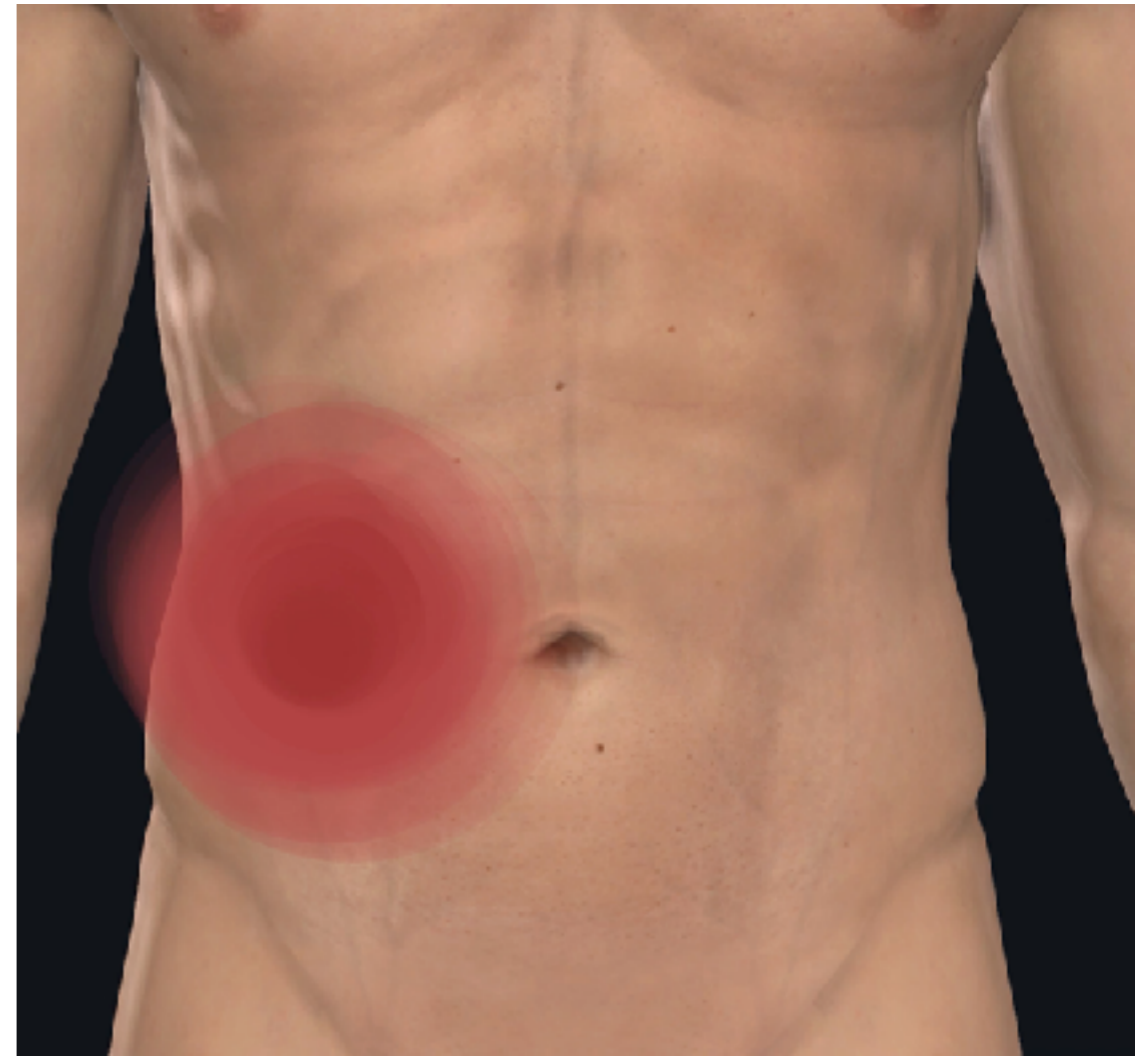
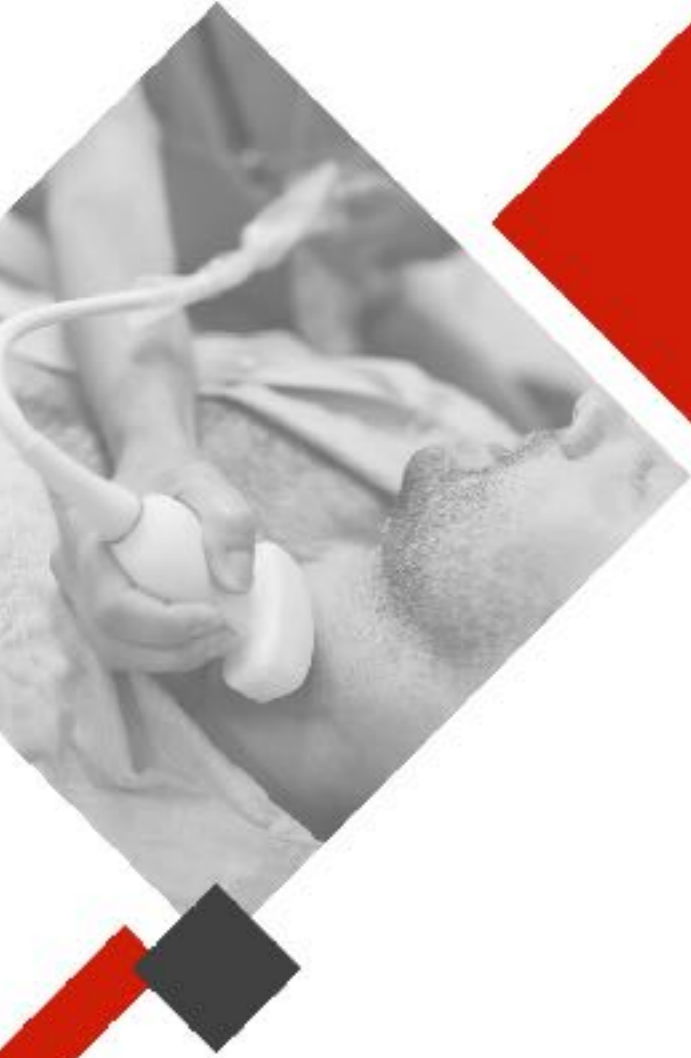臺中榮民總醫院

POCUS 訓練工作坊

急性腹痛超音波介紹



ULTRASOUND
PROGRAM



POCUS 在急性腹痛的應用

陳國智醫師 西園醫院急診

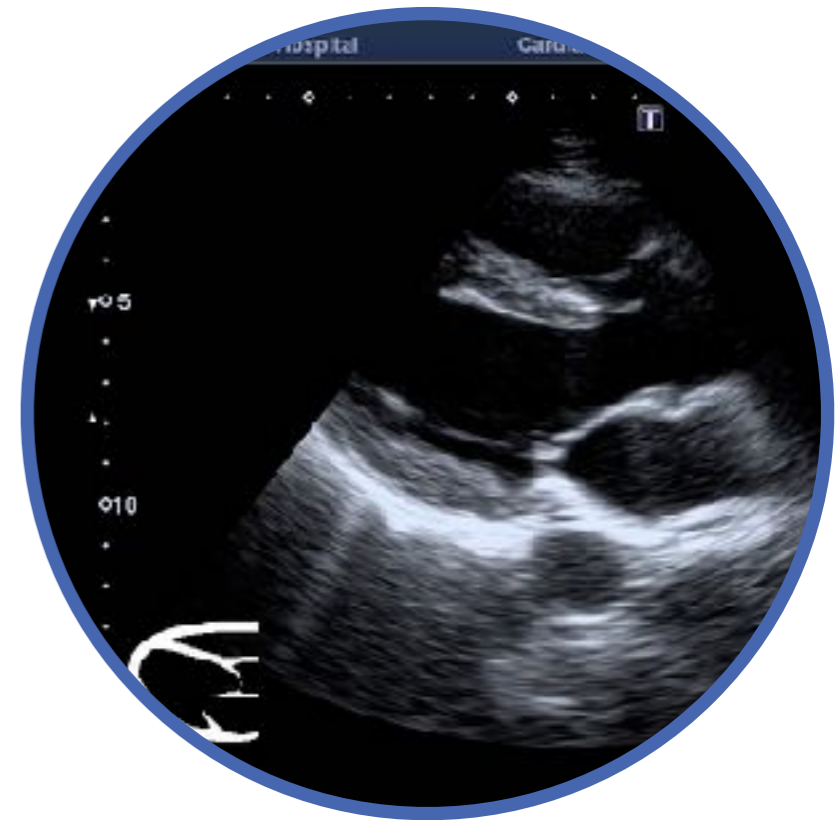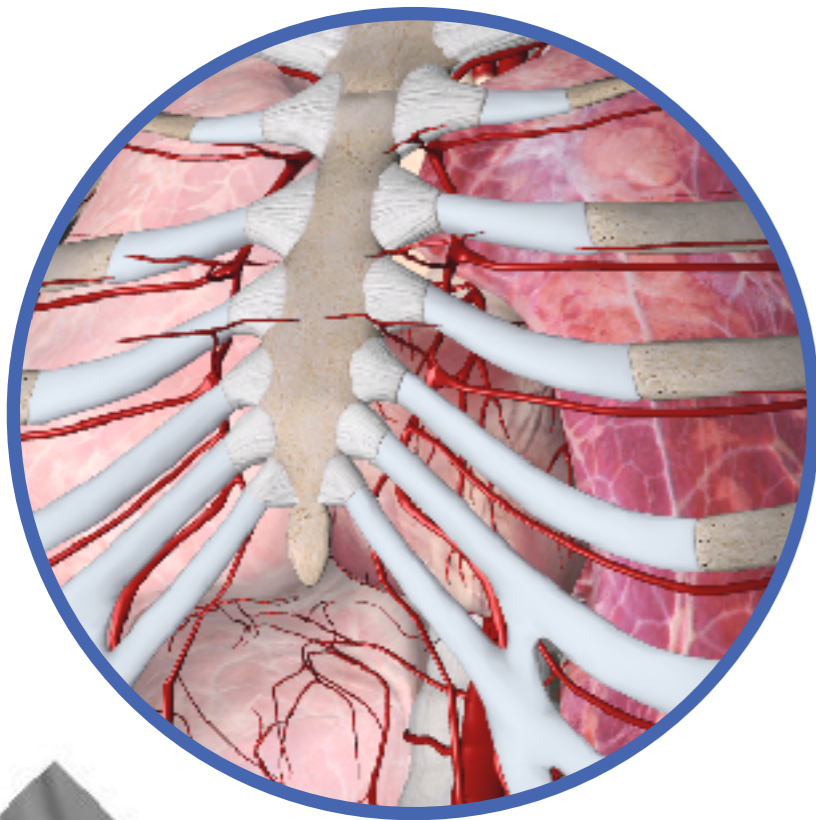
POCUS

Point-of-Care Ultrasound

“ultrasonography brought to
the patient and performed by
the provider in real time”

Moore, C. L., & Copel, J. A. NEJM 2011

POCUS



POCUS-急診緣由

症狀
問題

線索
時間

診斷
治療

雜

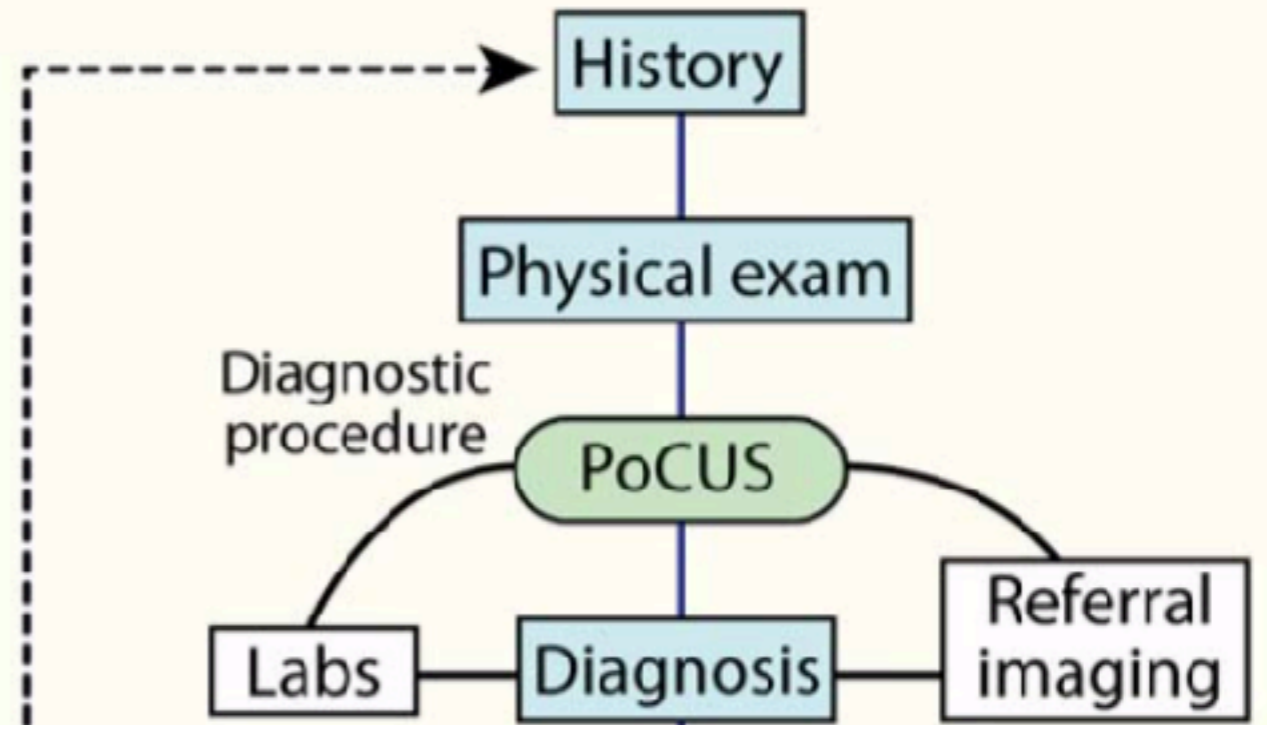
少

快

POCUS

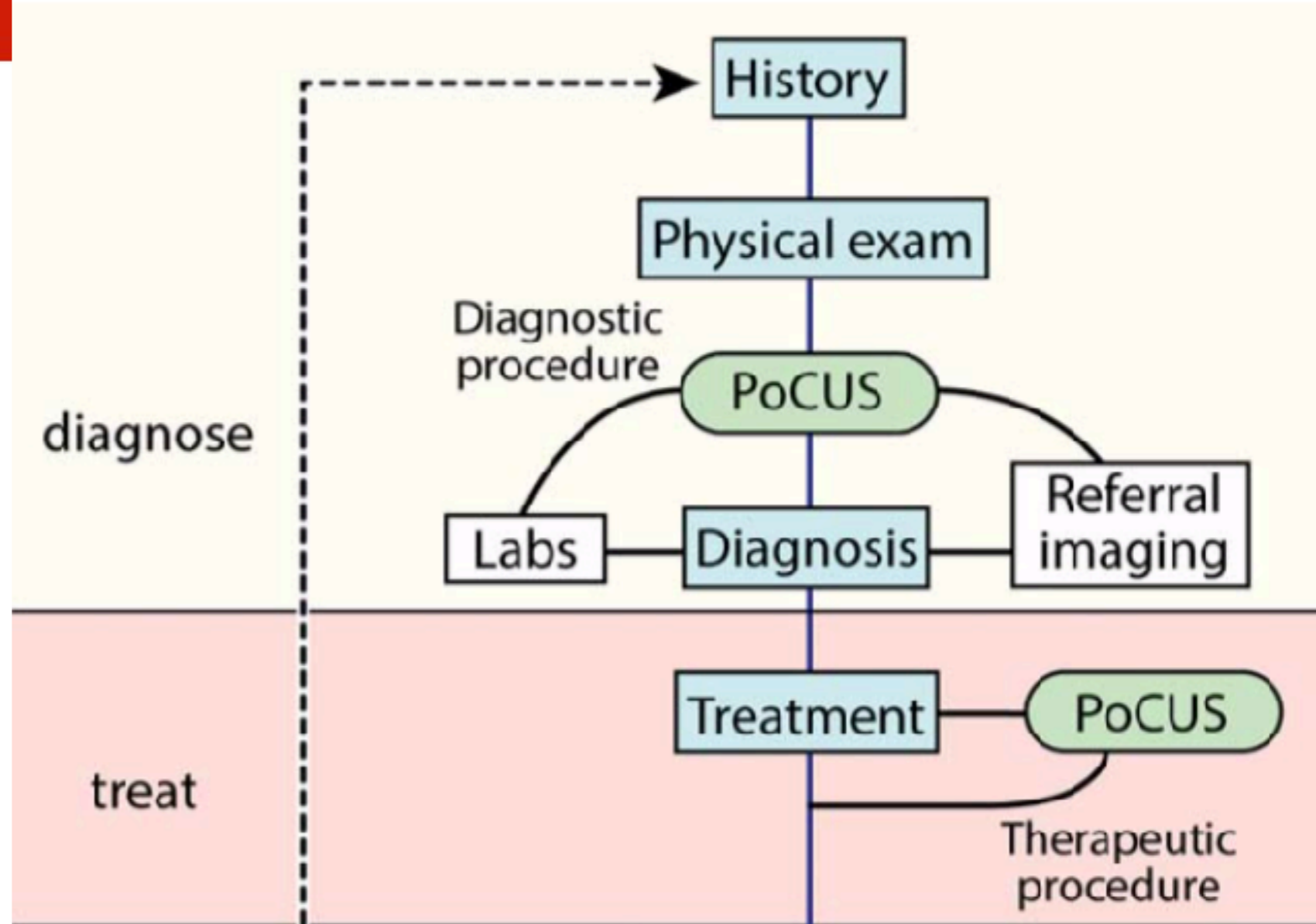
住院病人

diagnose



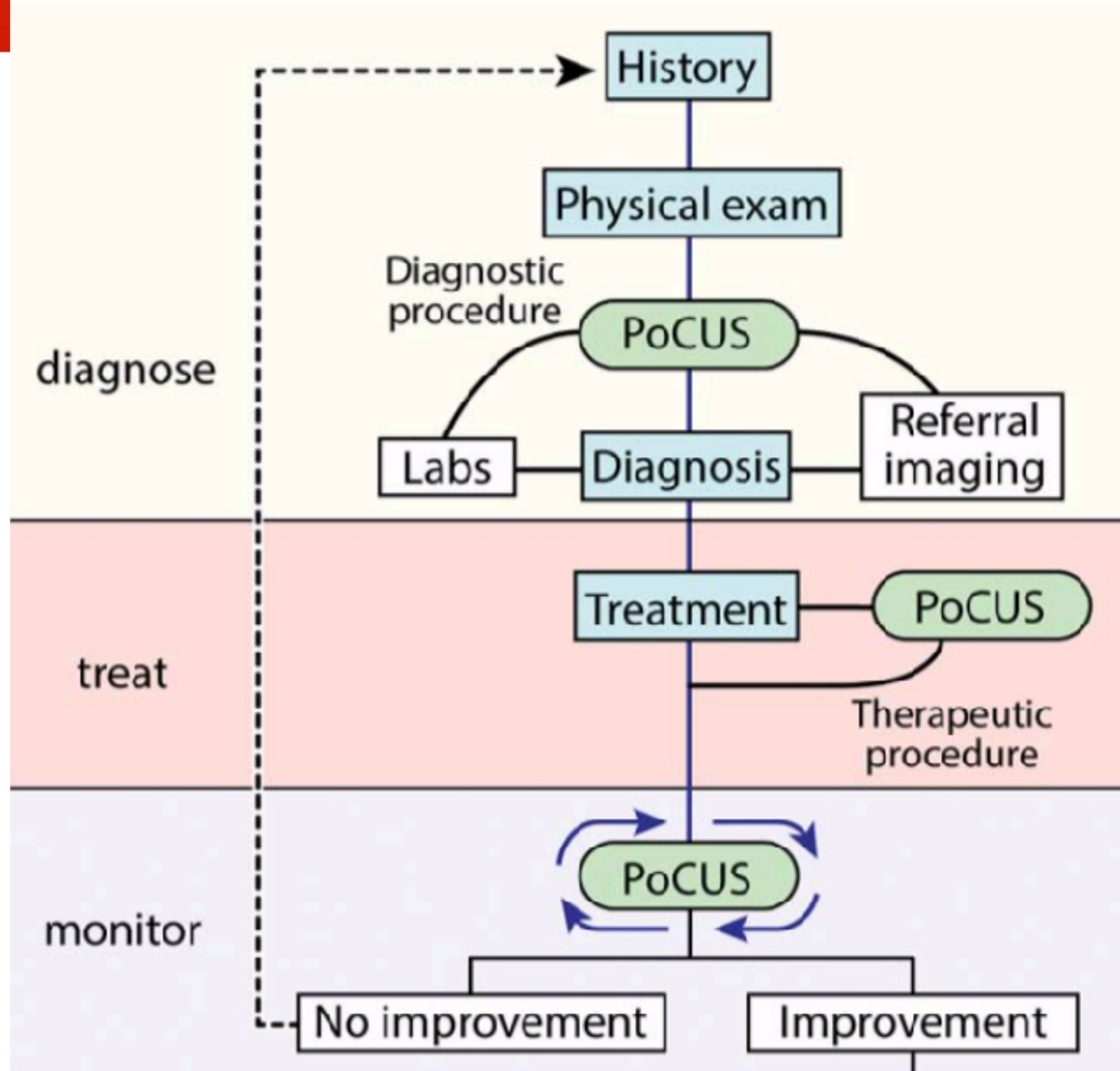
POCUS

住院病人



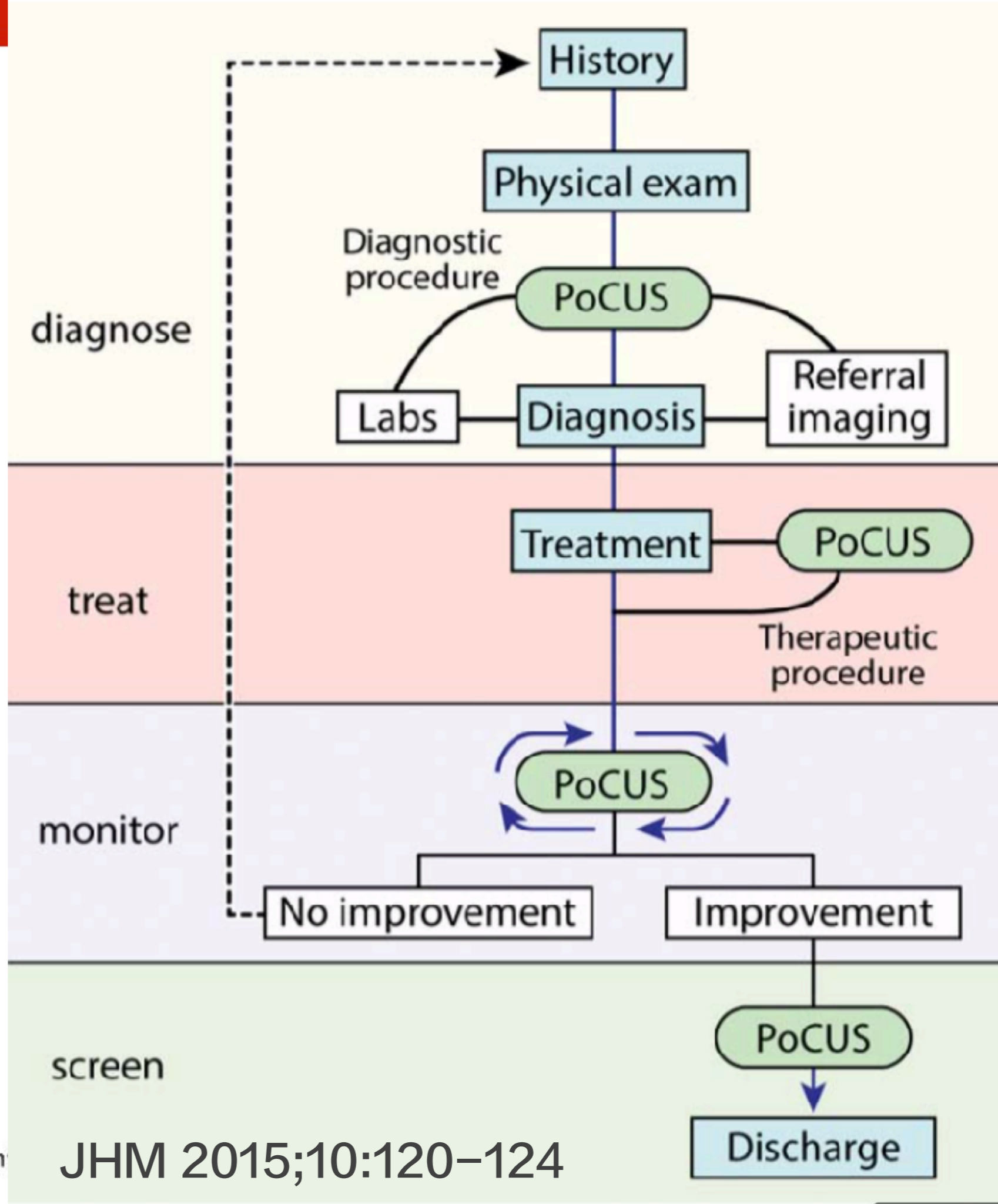
POCUS

住院病人



POCUS

住院病人



I-AIM

Indication



Acquire



Interpret



**Make
decision**

常用的探頭



弧

線

扇

探頭操控 6 大技巧

X

Sweep

**Fan/
Tilt**

Y

Slide

Rock

Z

Rotate

Compress

探頭操控 6 大技巧

X

掃

傾

Y

滑

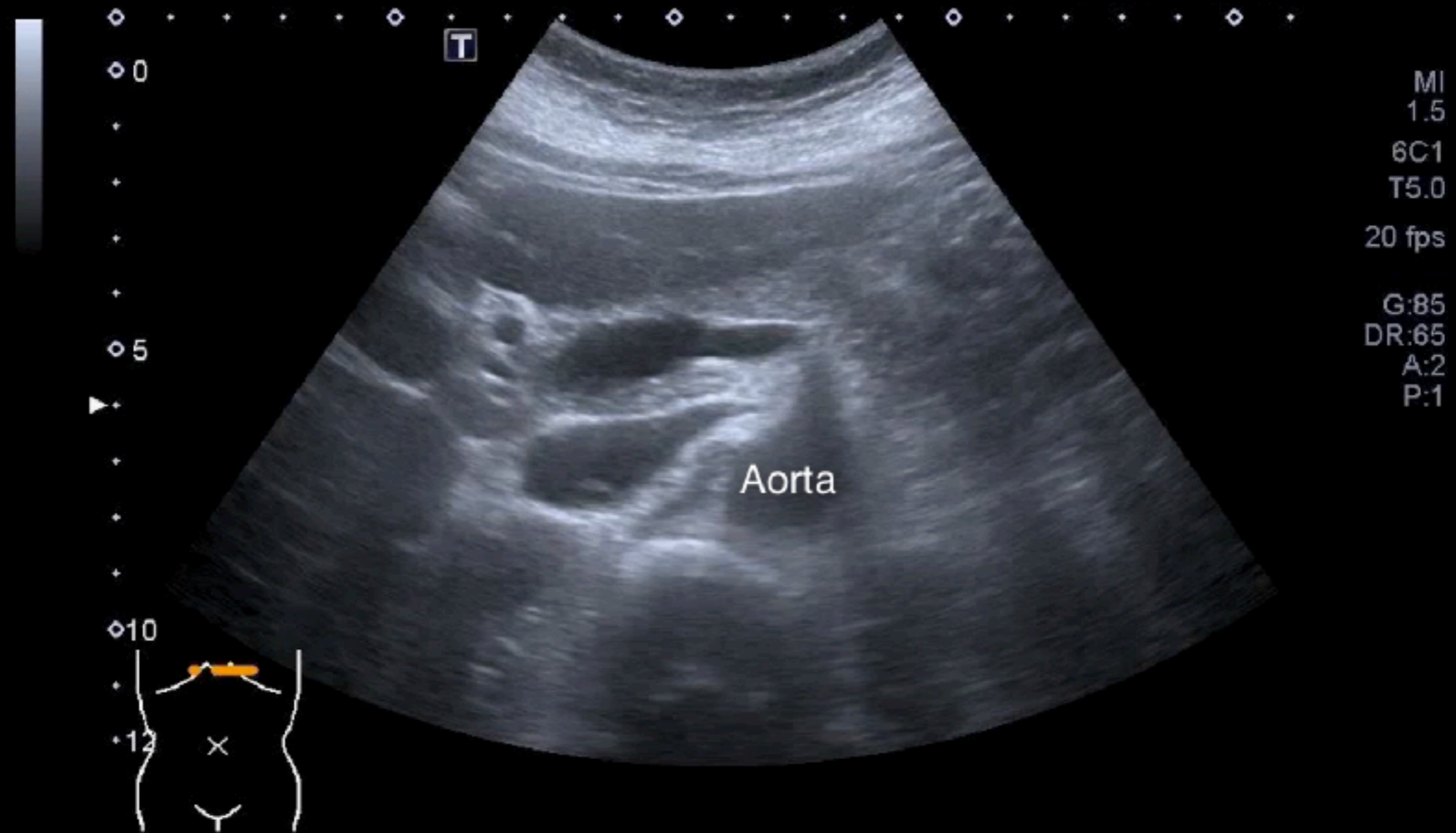搖

Z

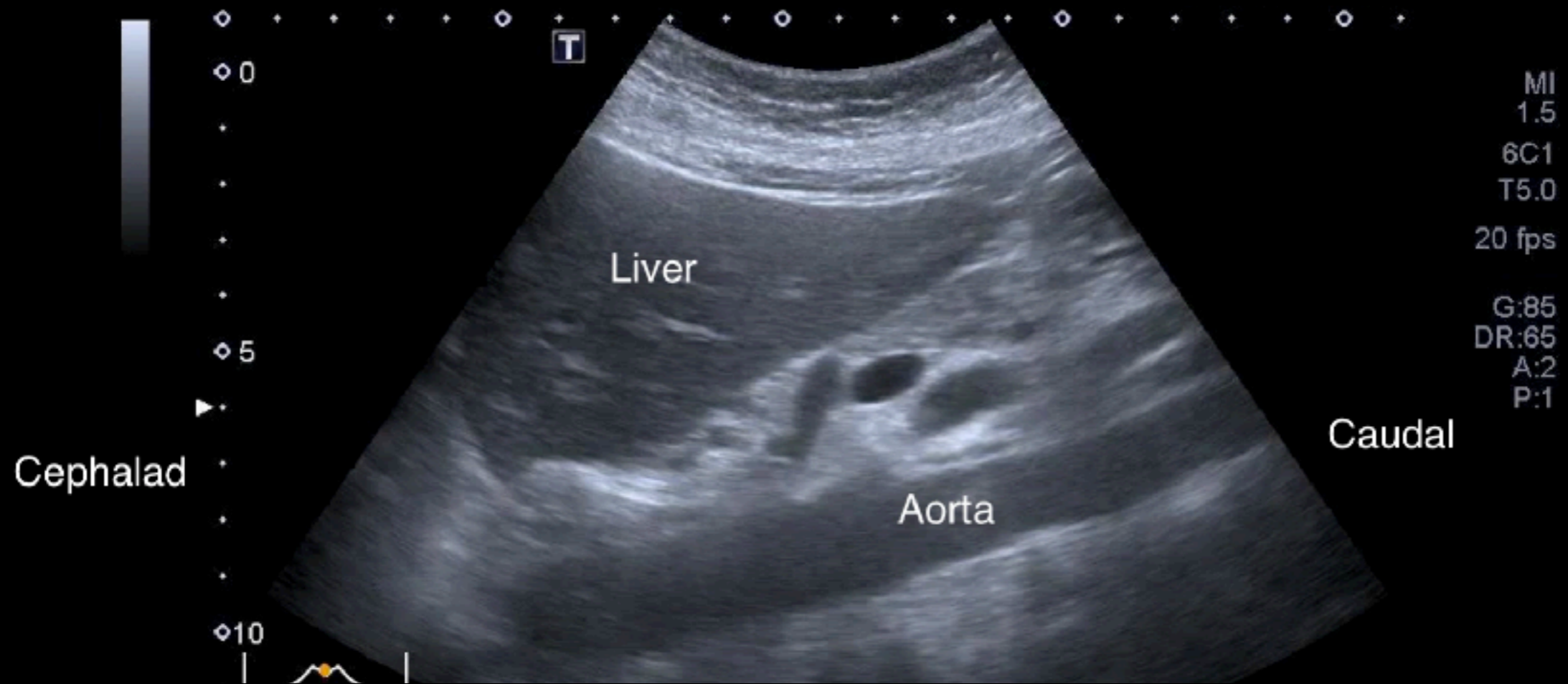轉

壓

這是那一種探頭操作手法??

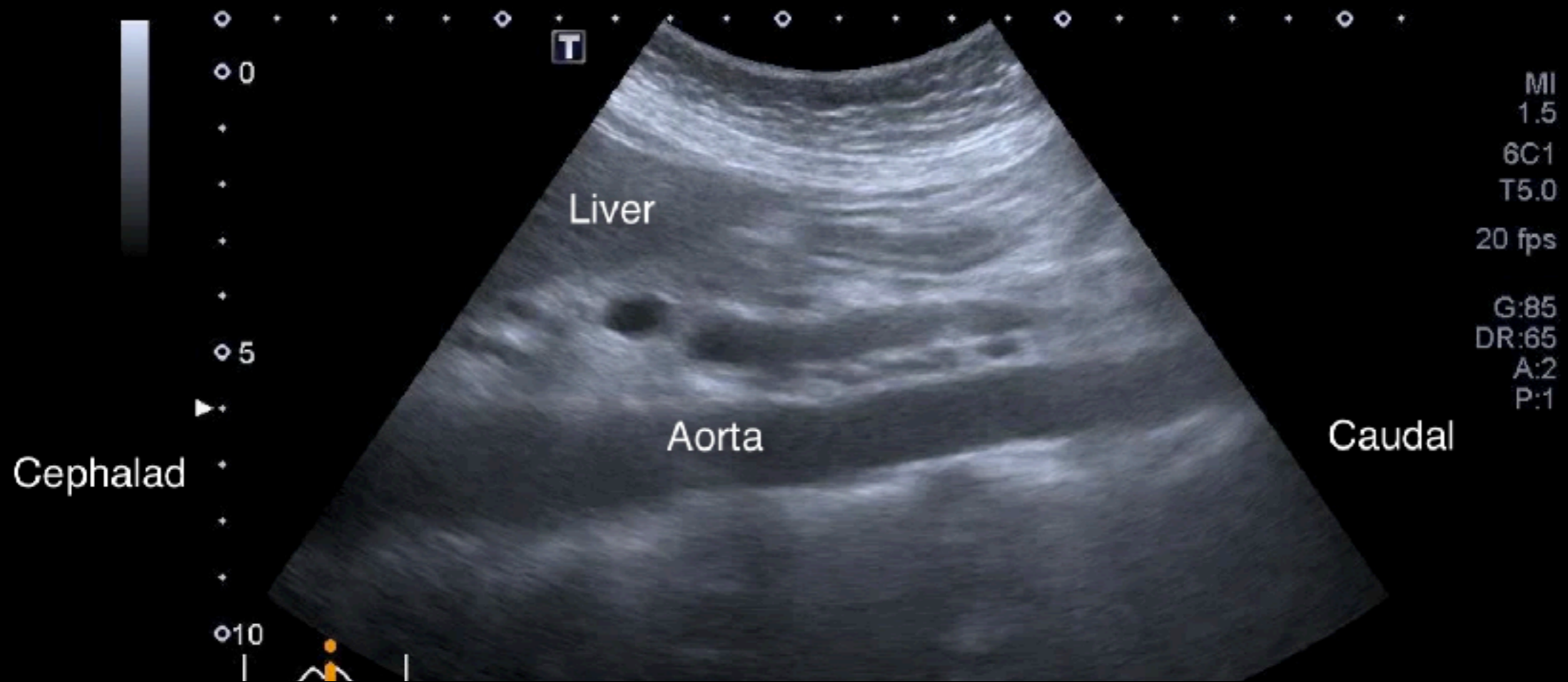

這是那一種探頭操作手法??

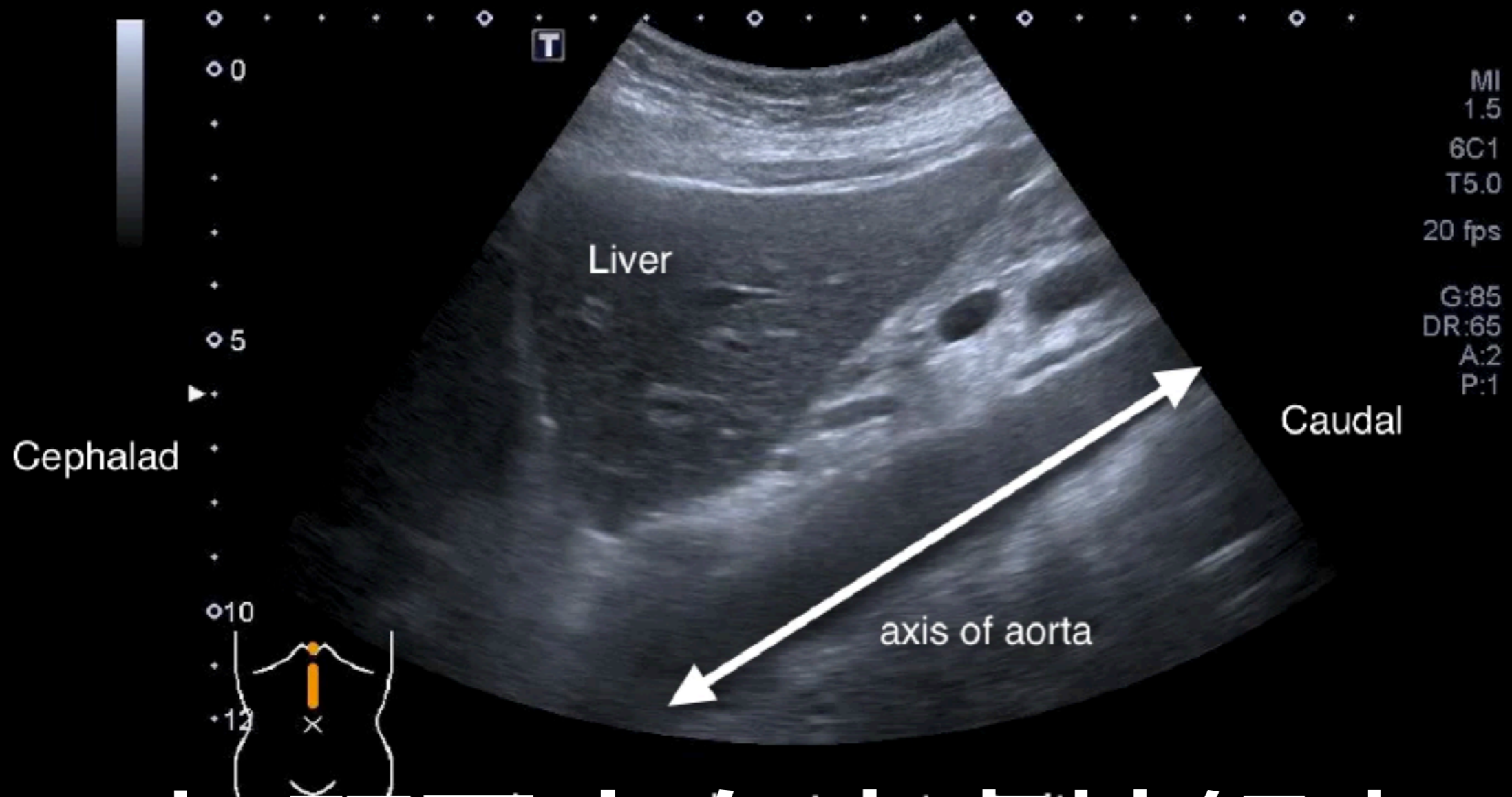


探頭固定在皮膚接觸處

這是那一種探頭操作手法??

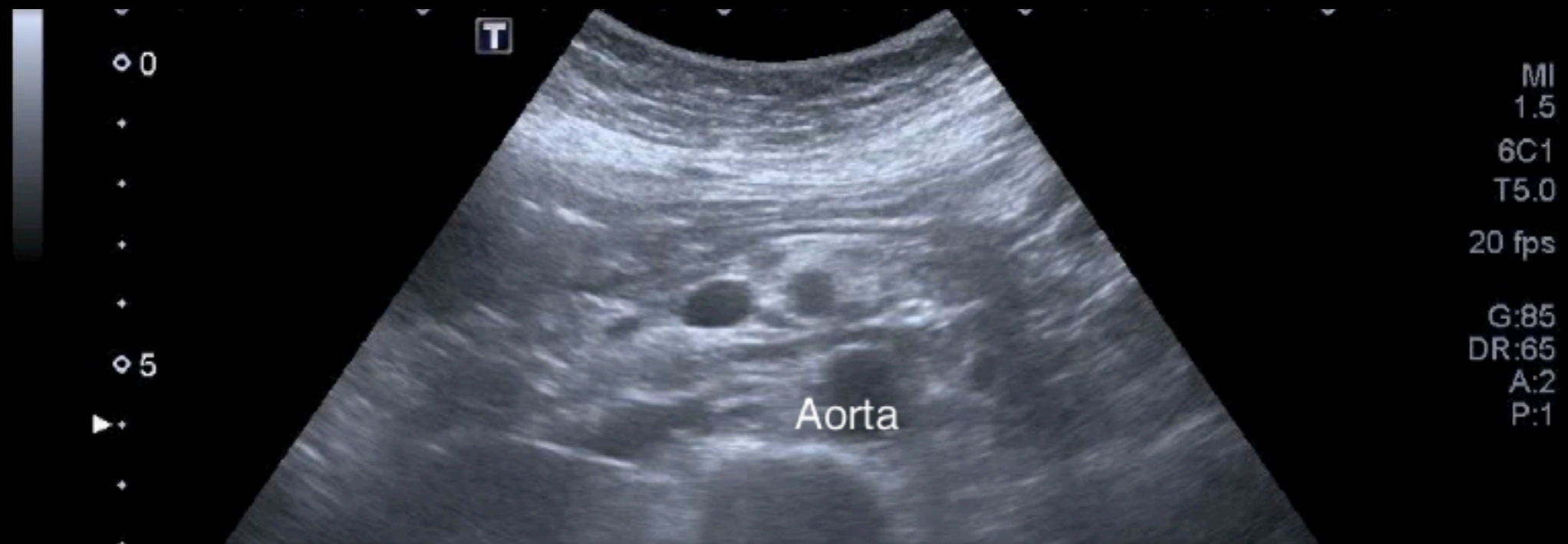

這是那一種探頭操作手法??

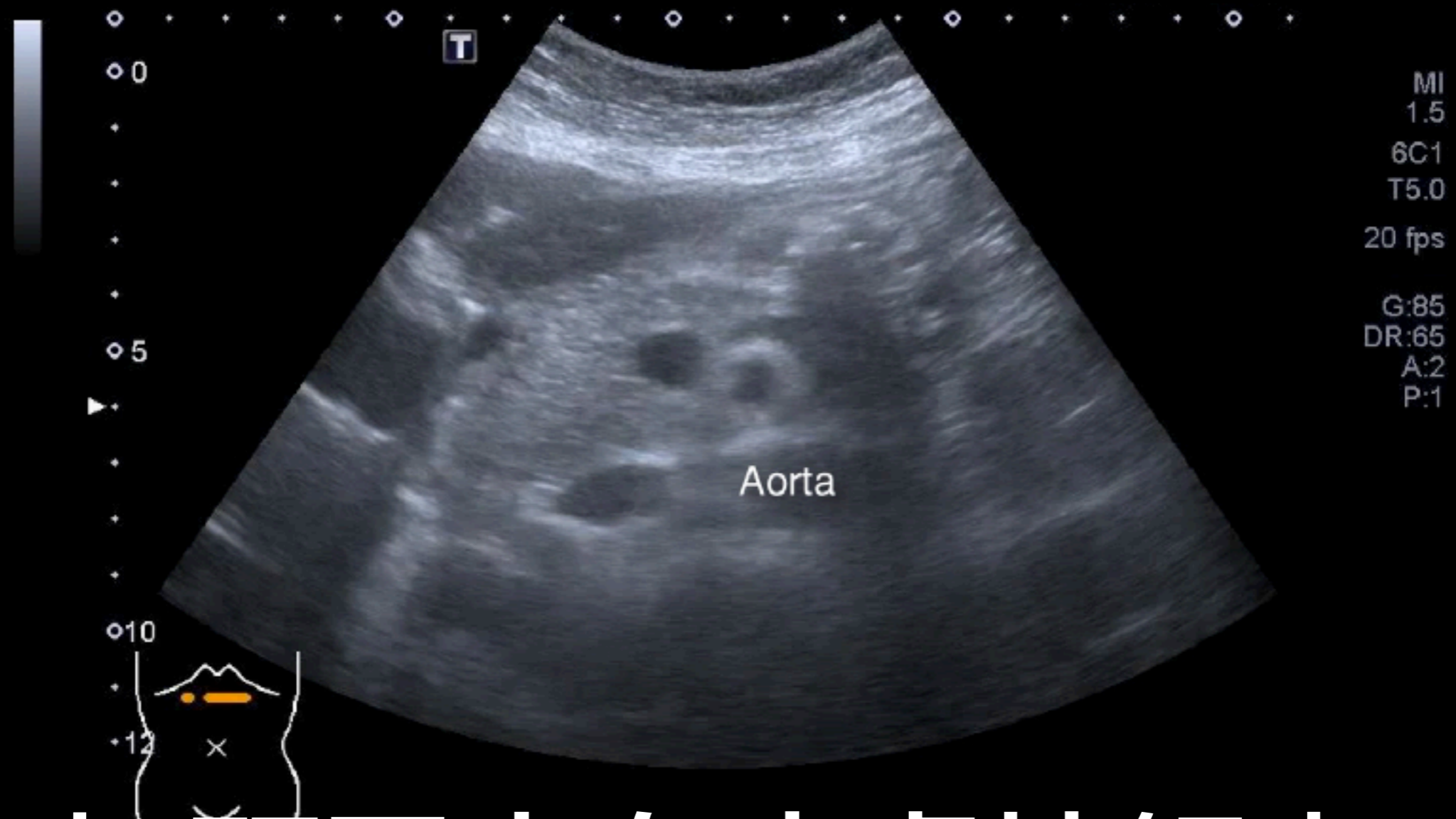

探頭固定在皮膚接觸處

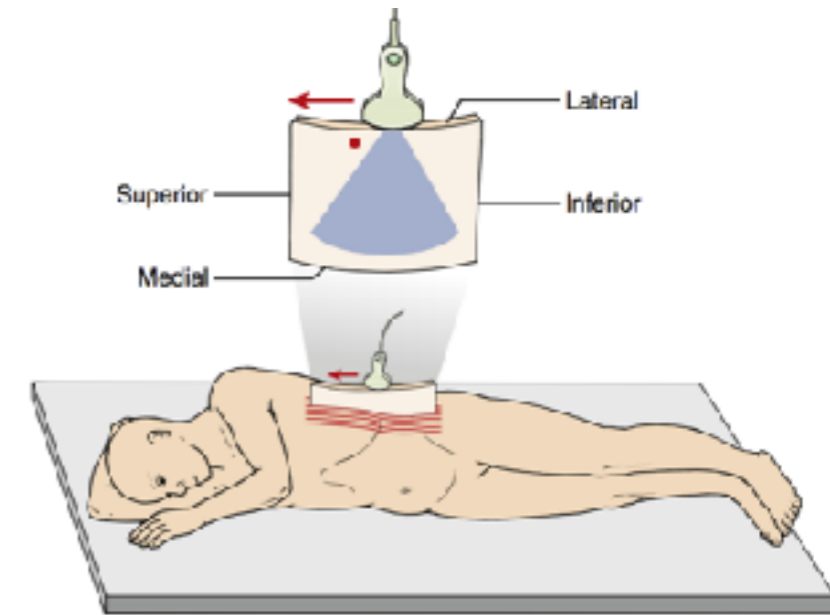
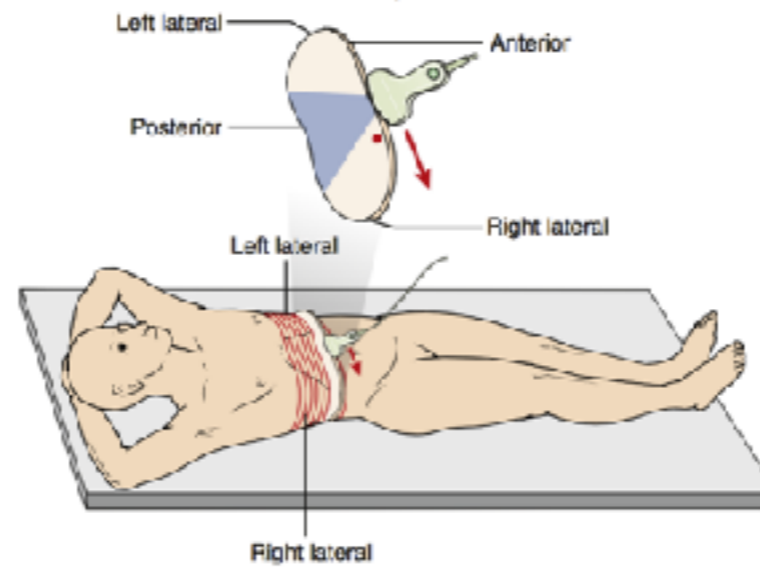
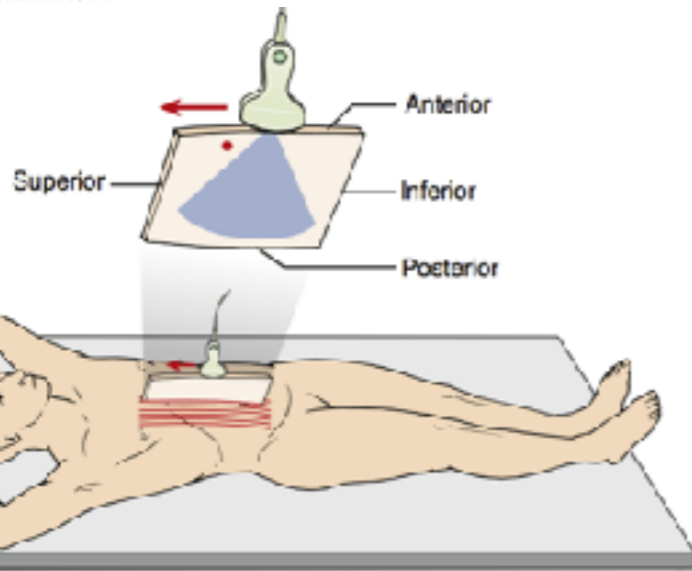
這是那一種探頭操作手法??



這是那一種探頭操作手法??



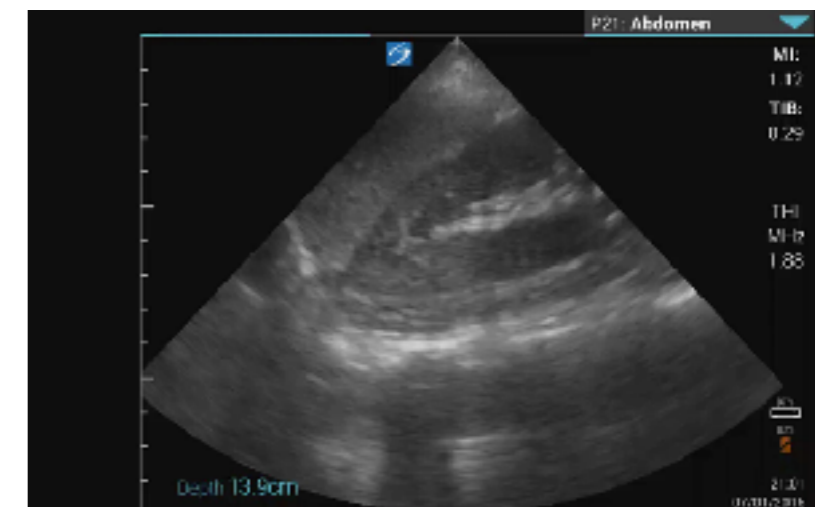
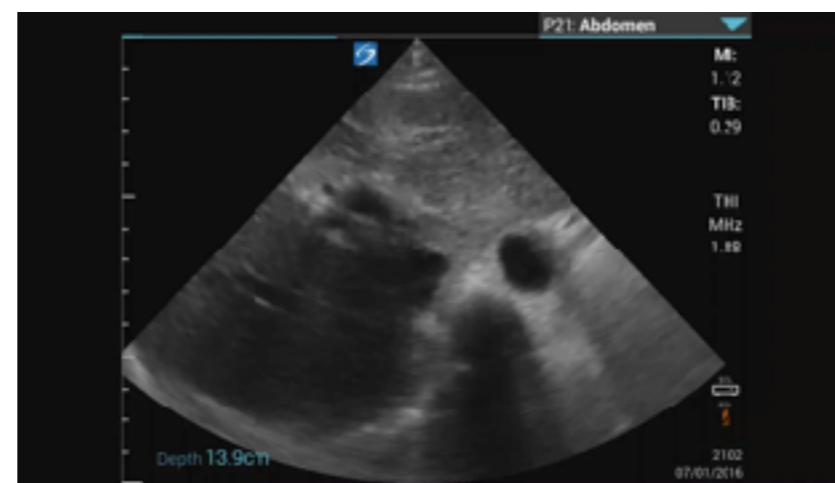
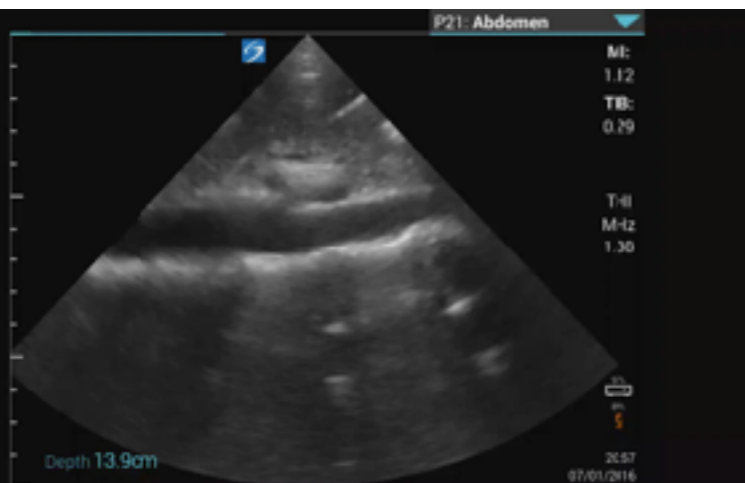探頭固定在皮膚接觸處



Sagittal

Transverse

Coronal



Approach to Abdominal Pain

Location

Onset

Type

Severity

Other locations (radiation)

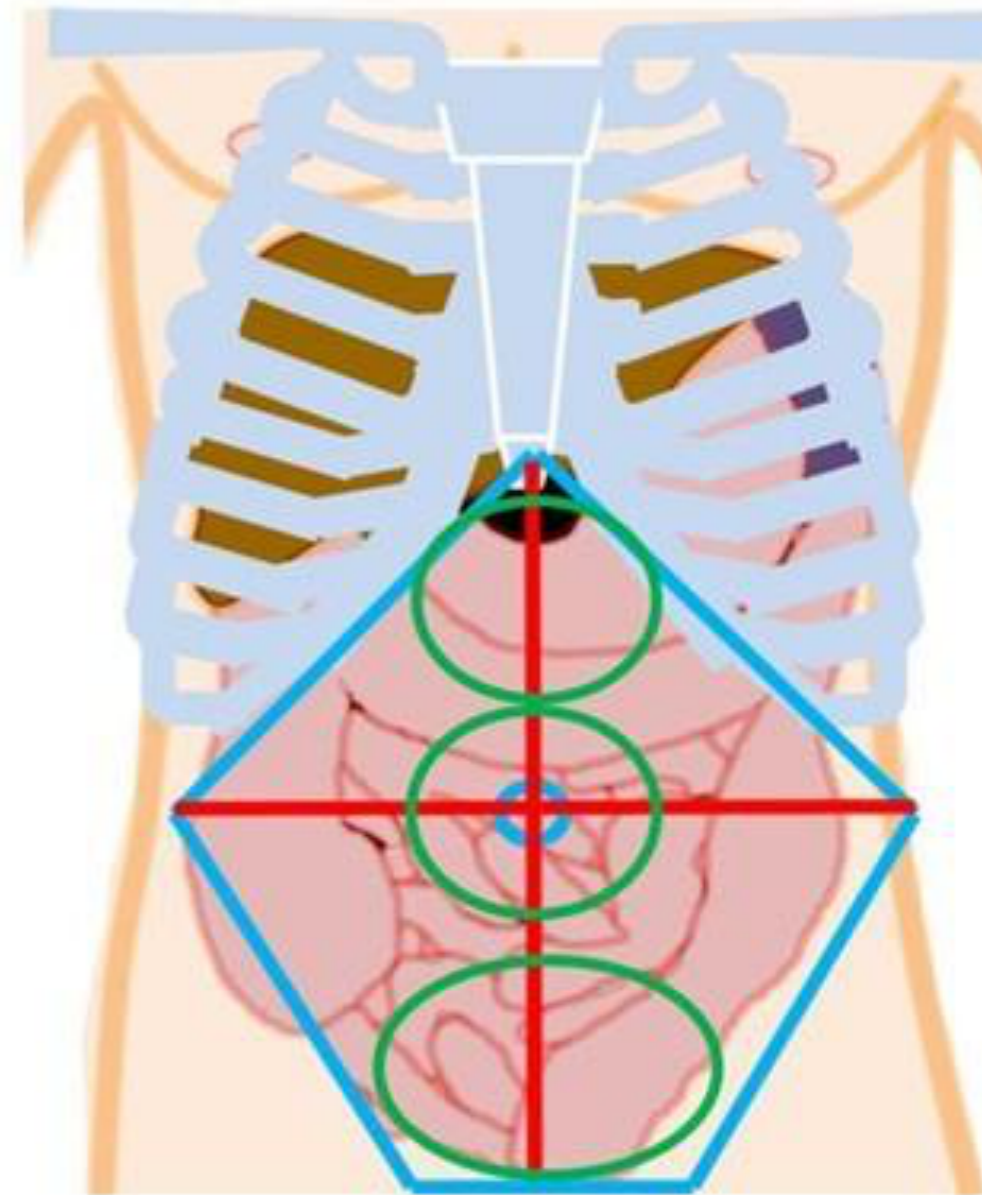
Factors (aggravating / alleviating)

Progression

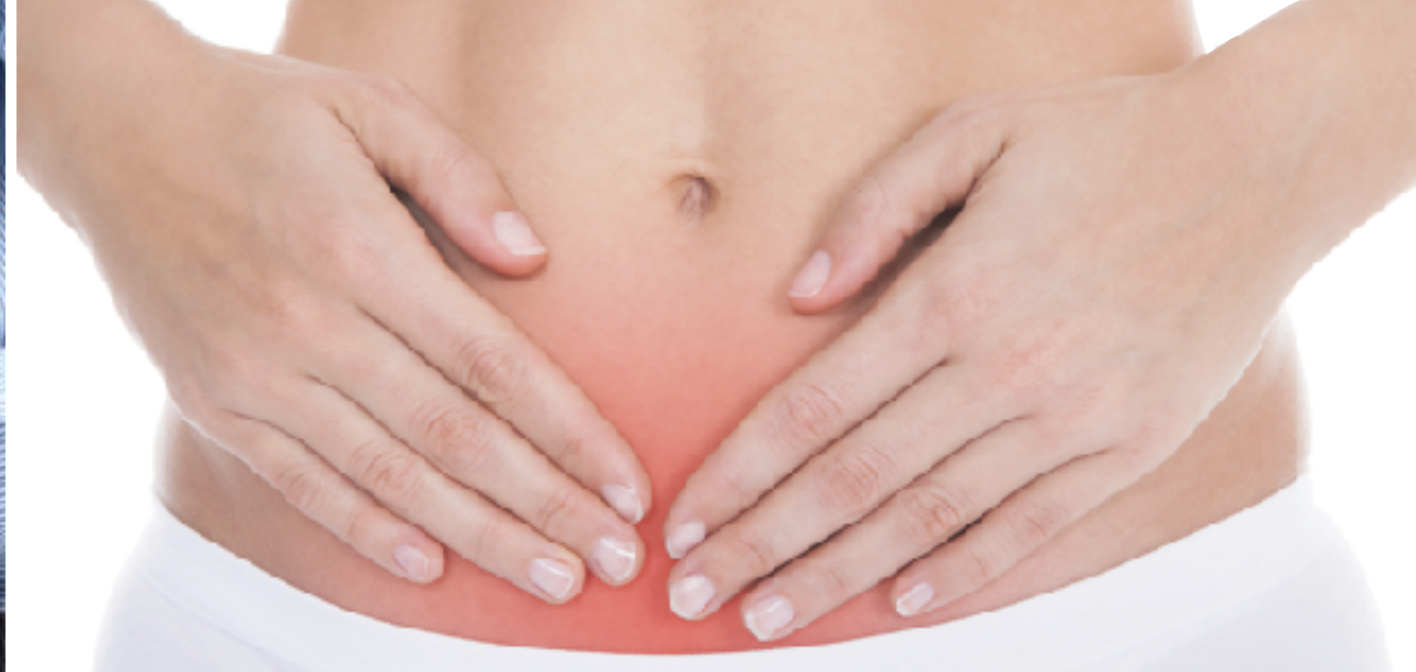Associated symptoms

Insight (what do they think it is)

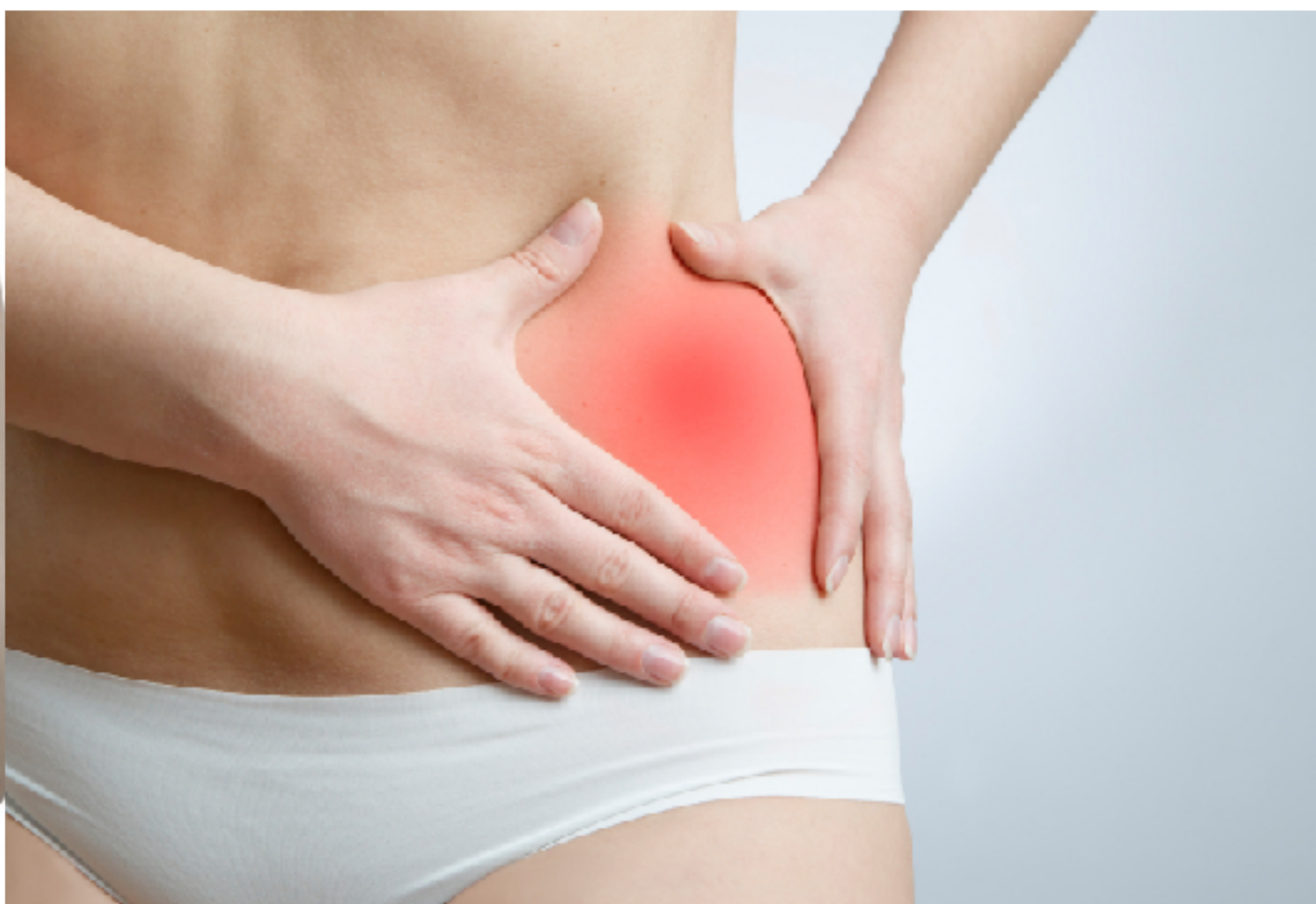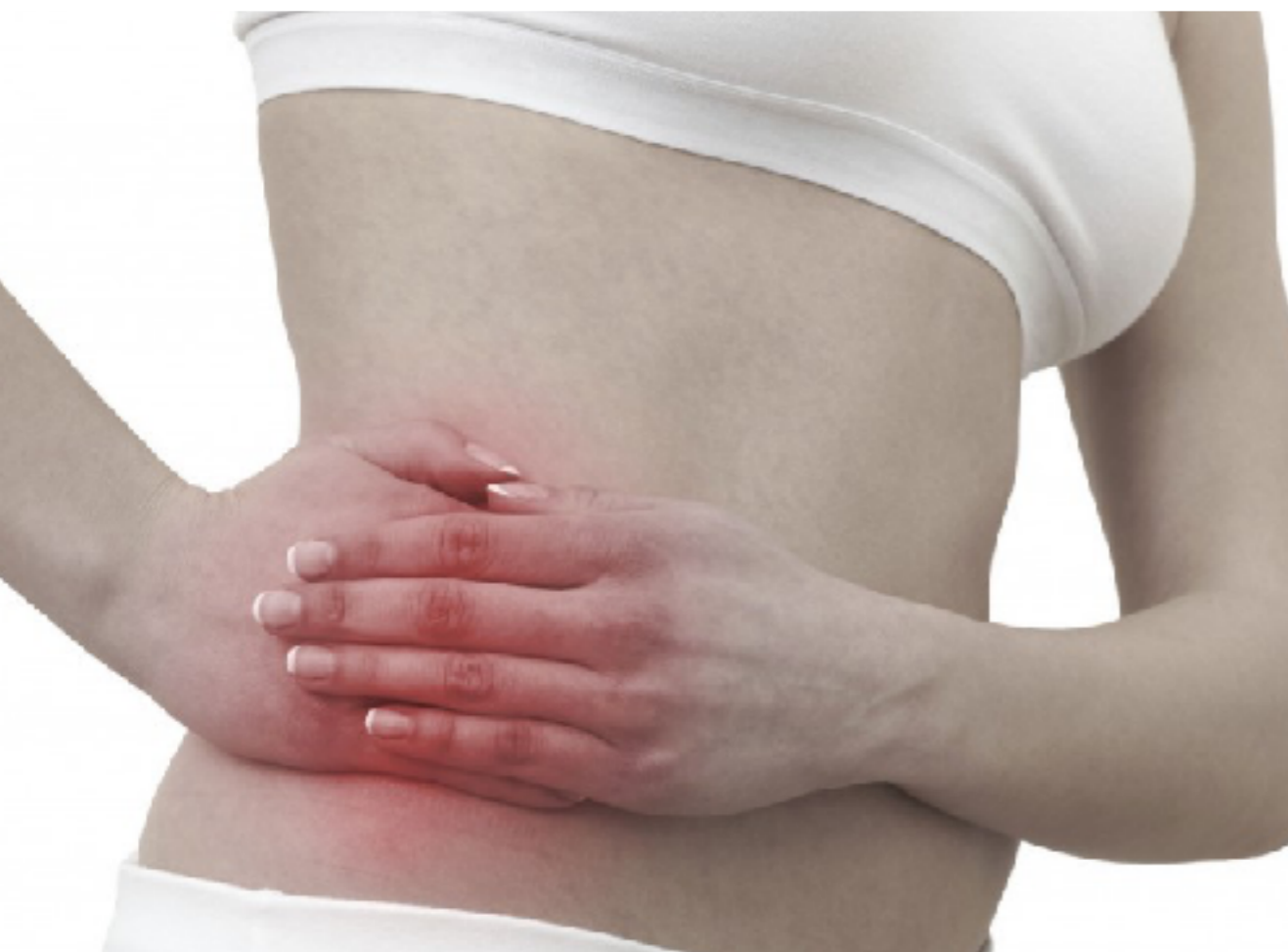Need relief (what have they taken)



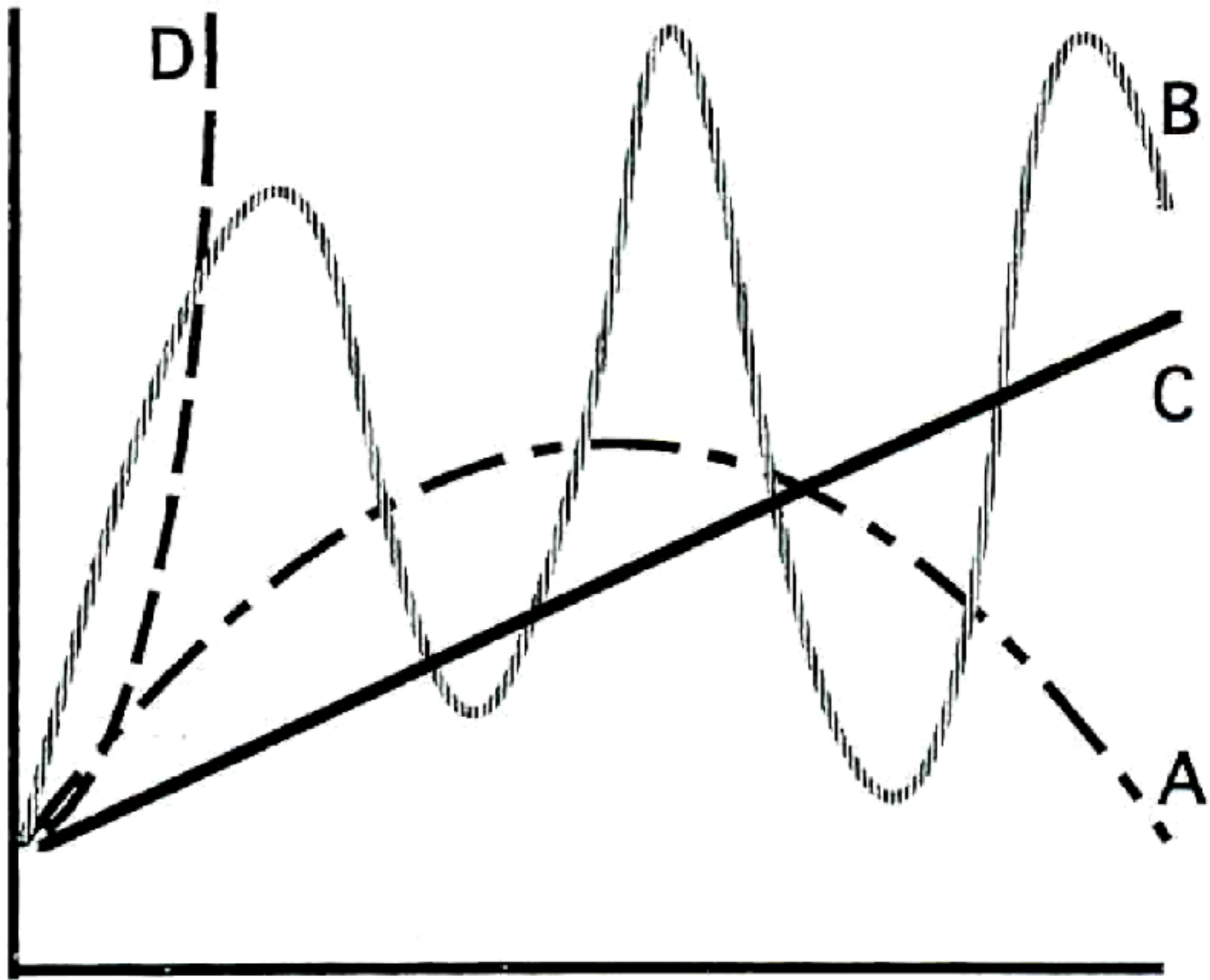
@kwburak



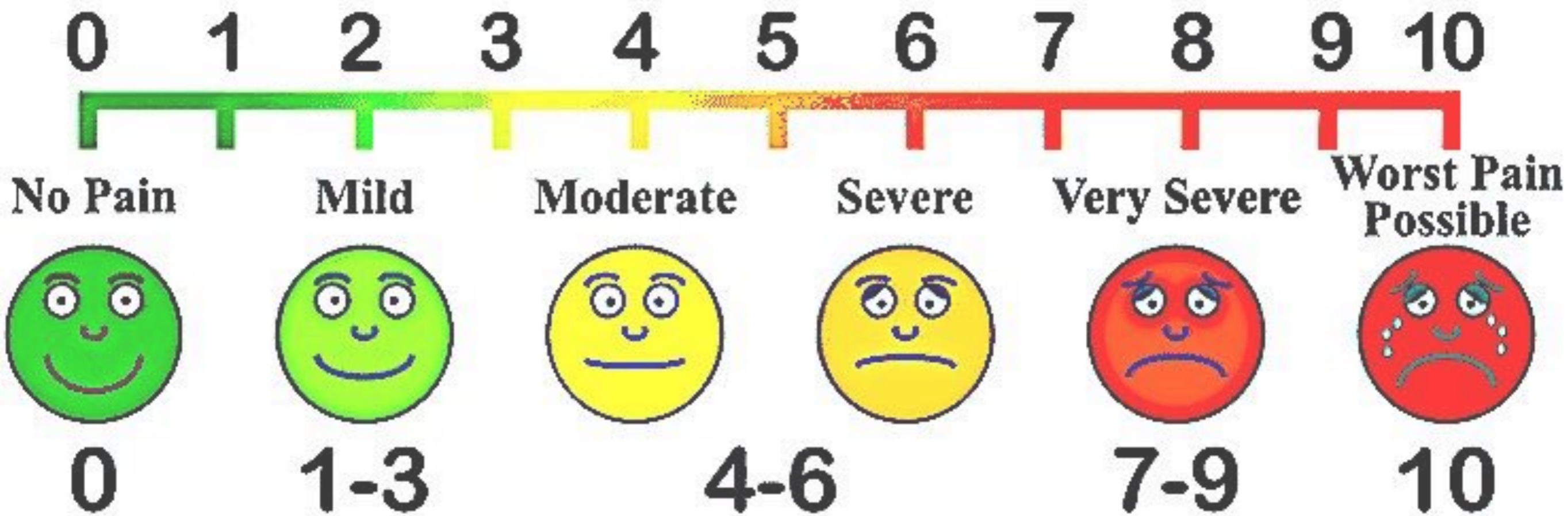
該如何下手???



Severity



Time





病史詢問



理學檢查



Y

POCUS

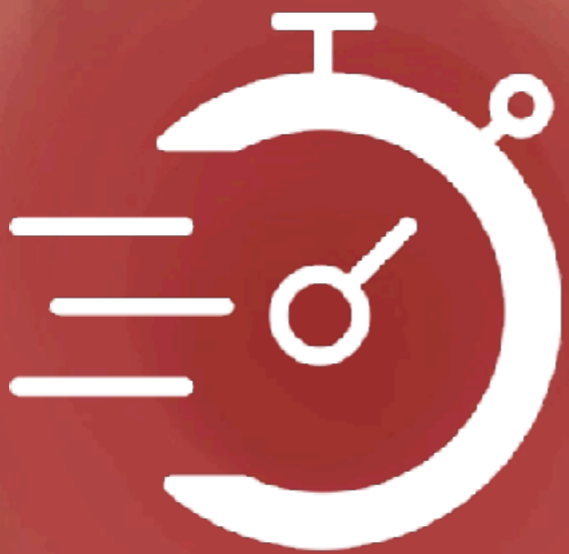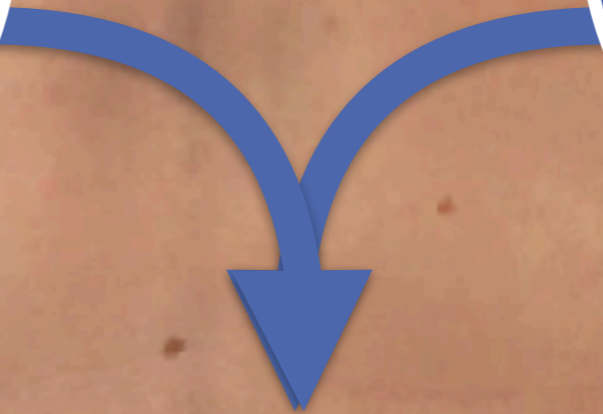N



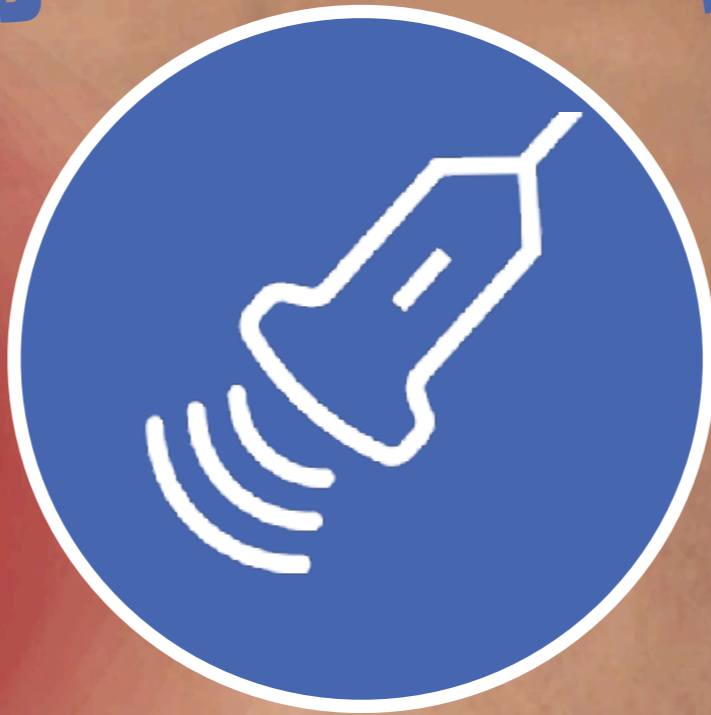病史詢問



理學檢查



POCUS





ULTRASOUND
PROGRAM

POCUS

for

Acute

ABDOMEN

A for aorta

B for biliary

D for diaphragm

O for obstruction

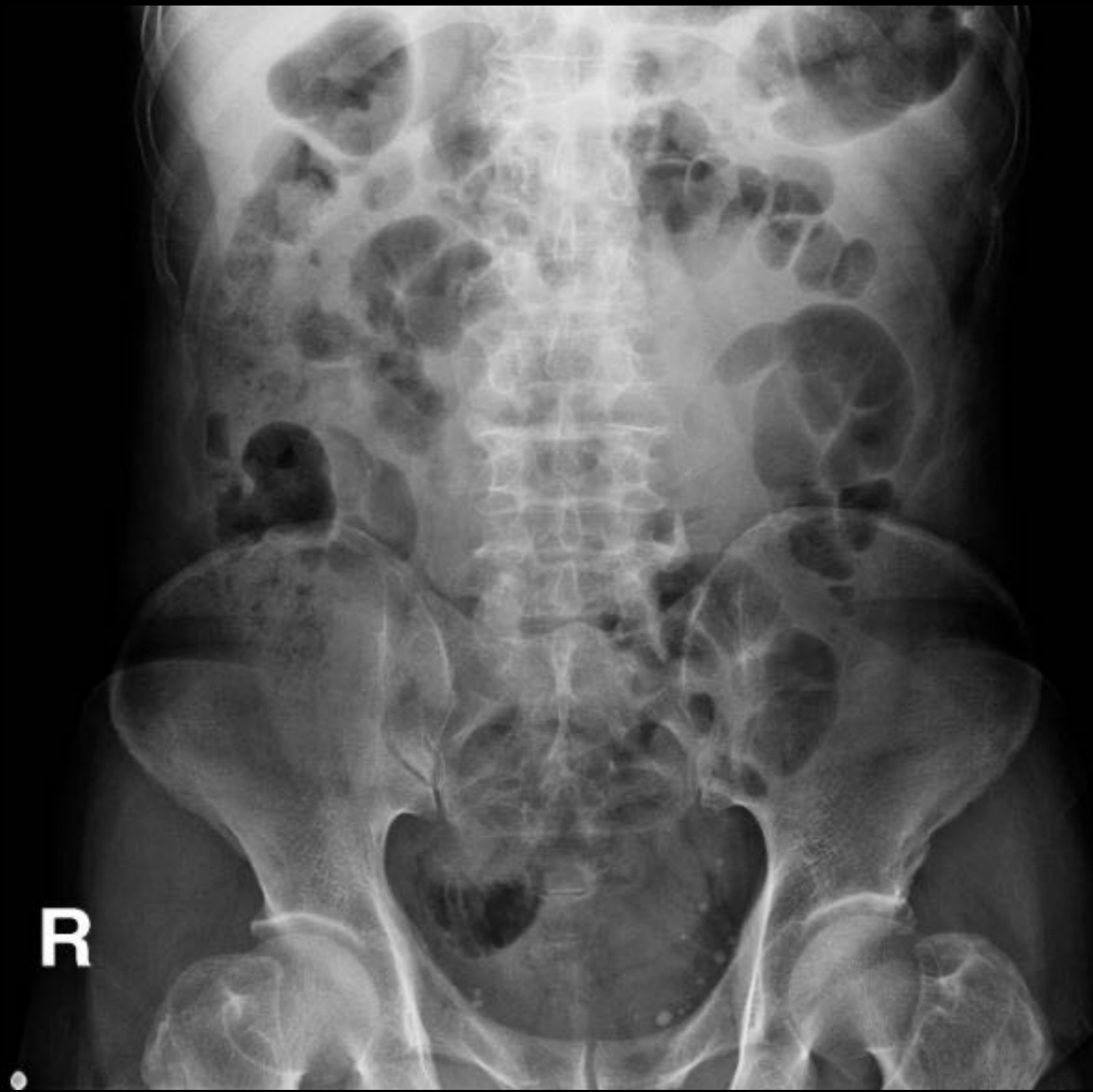M for moving fluid or gas

E for ectopic pregnancy

N for nephropathy

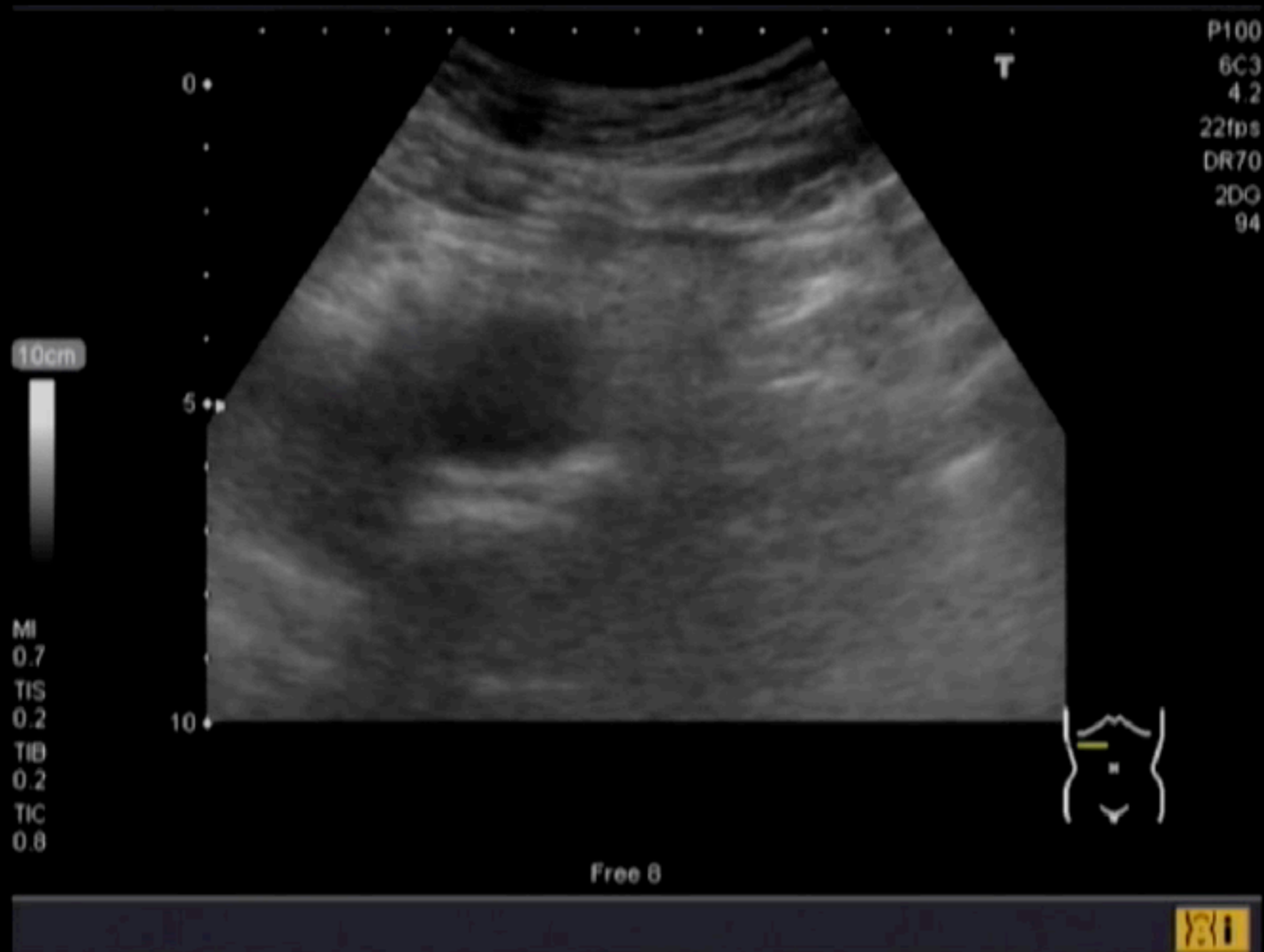

59M, Abd pain & hematuria



59M, Abd pain & hematuria

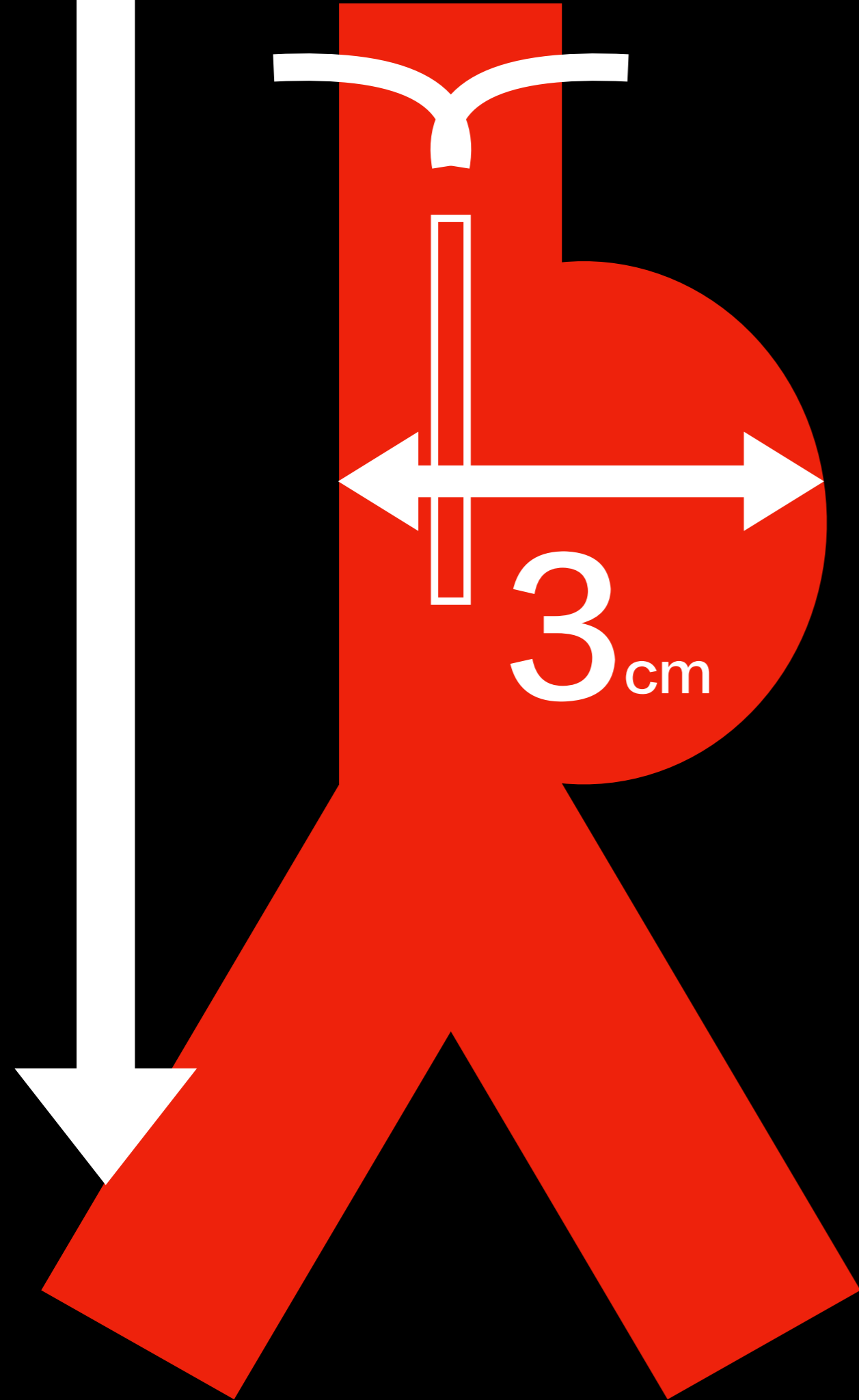
POCUS Academy©ChenKC



ABDOMEN

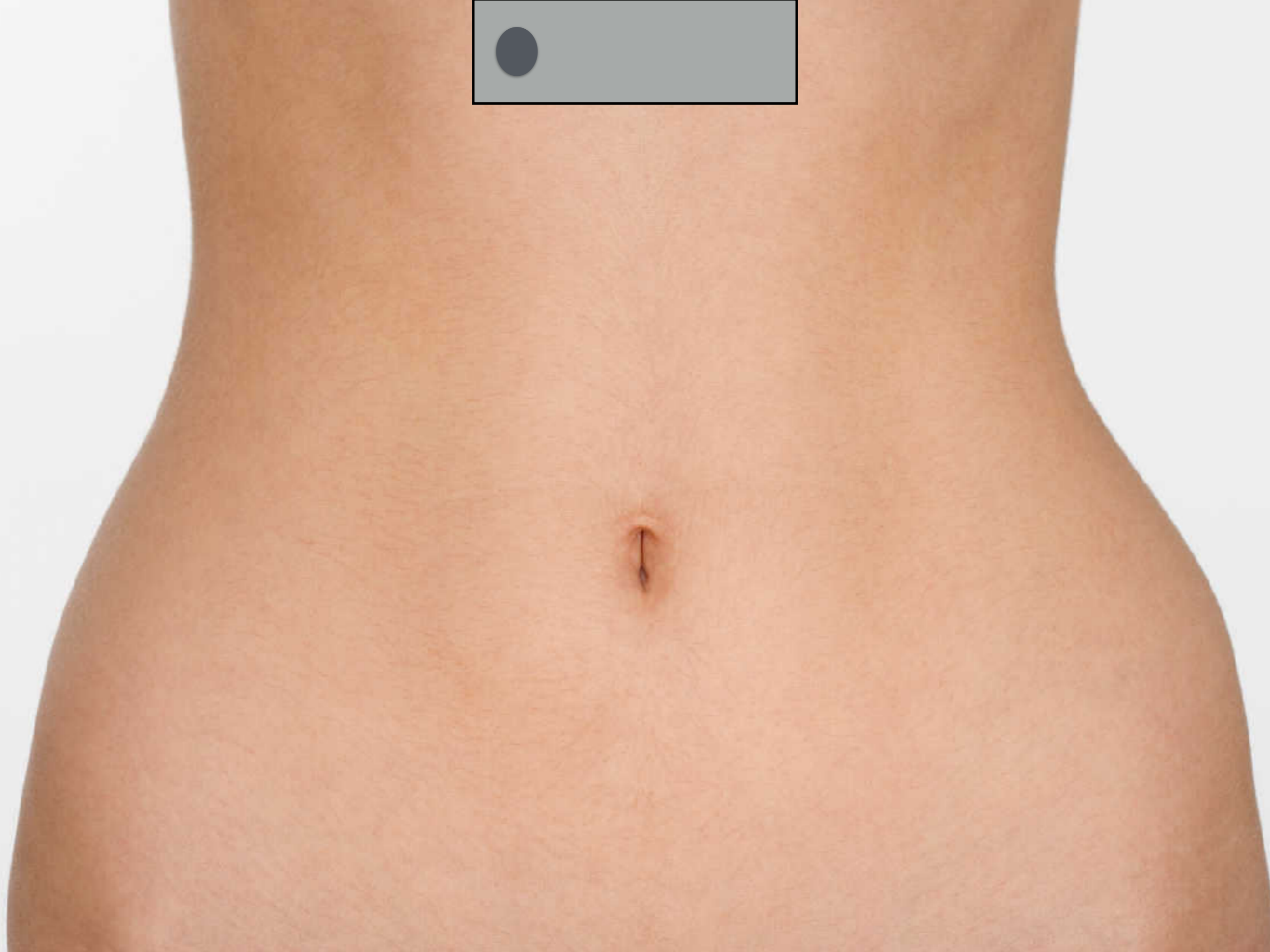
A for AAA & AD

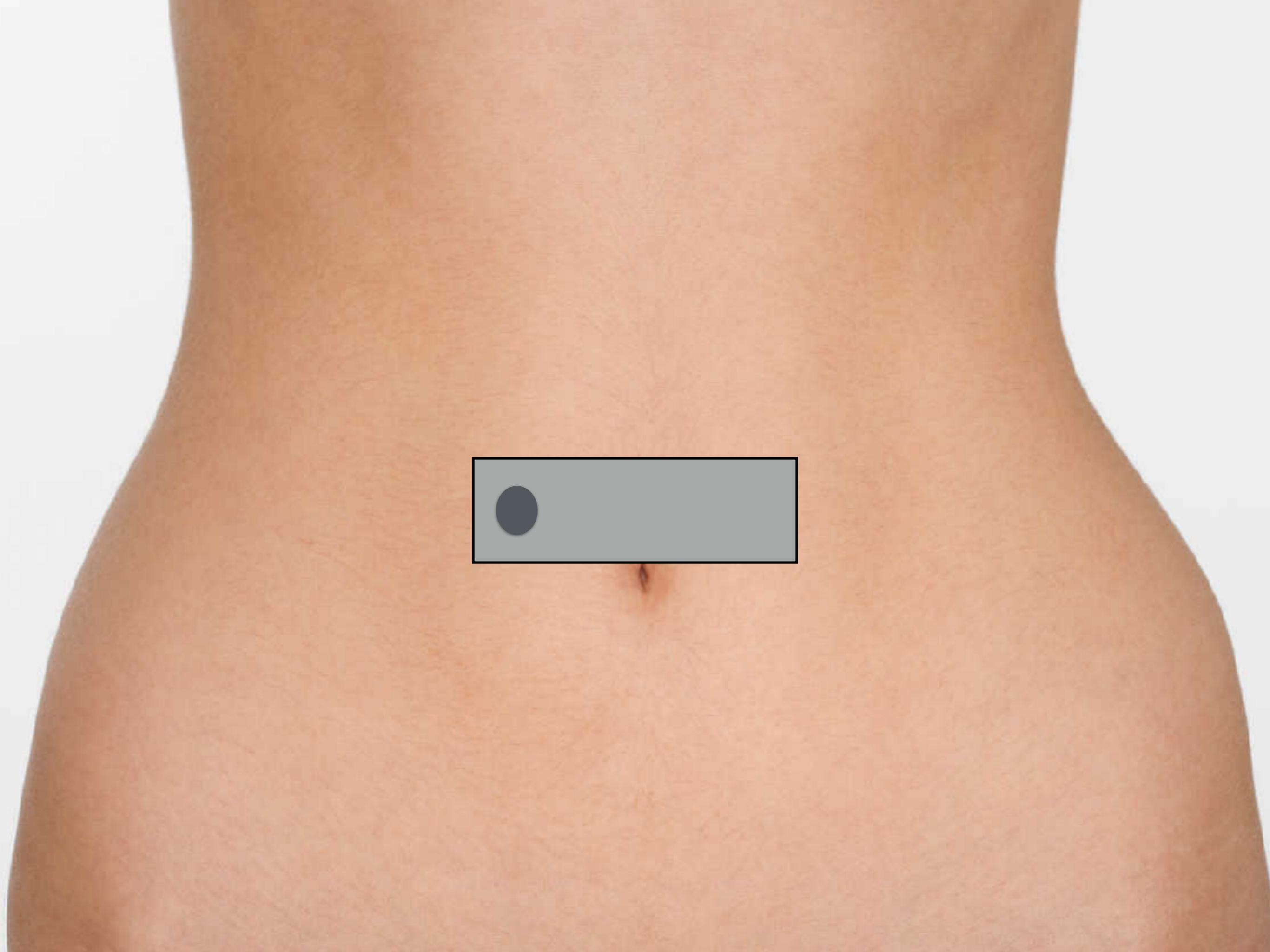
3_{cm}



AAA

- > 50 y/o
- Syncope
- Hypotension
- ABD/Flank/Back/Groin



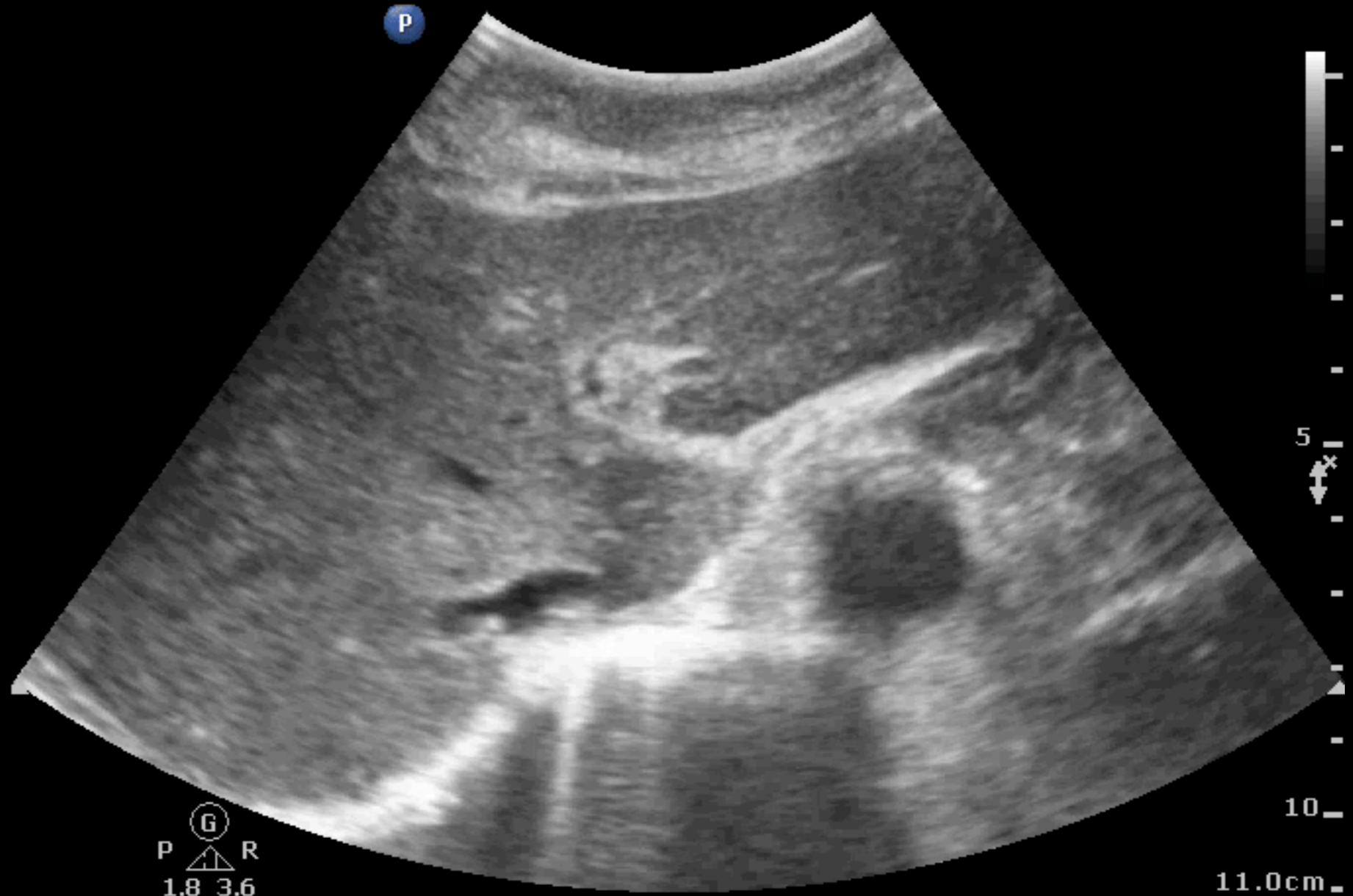

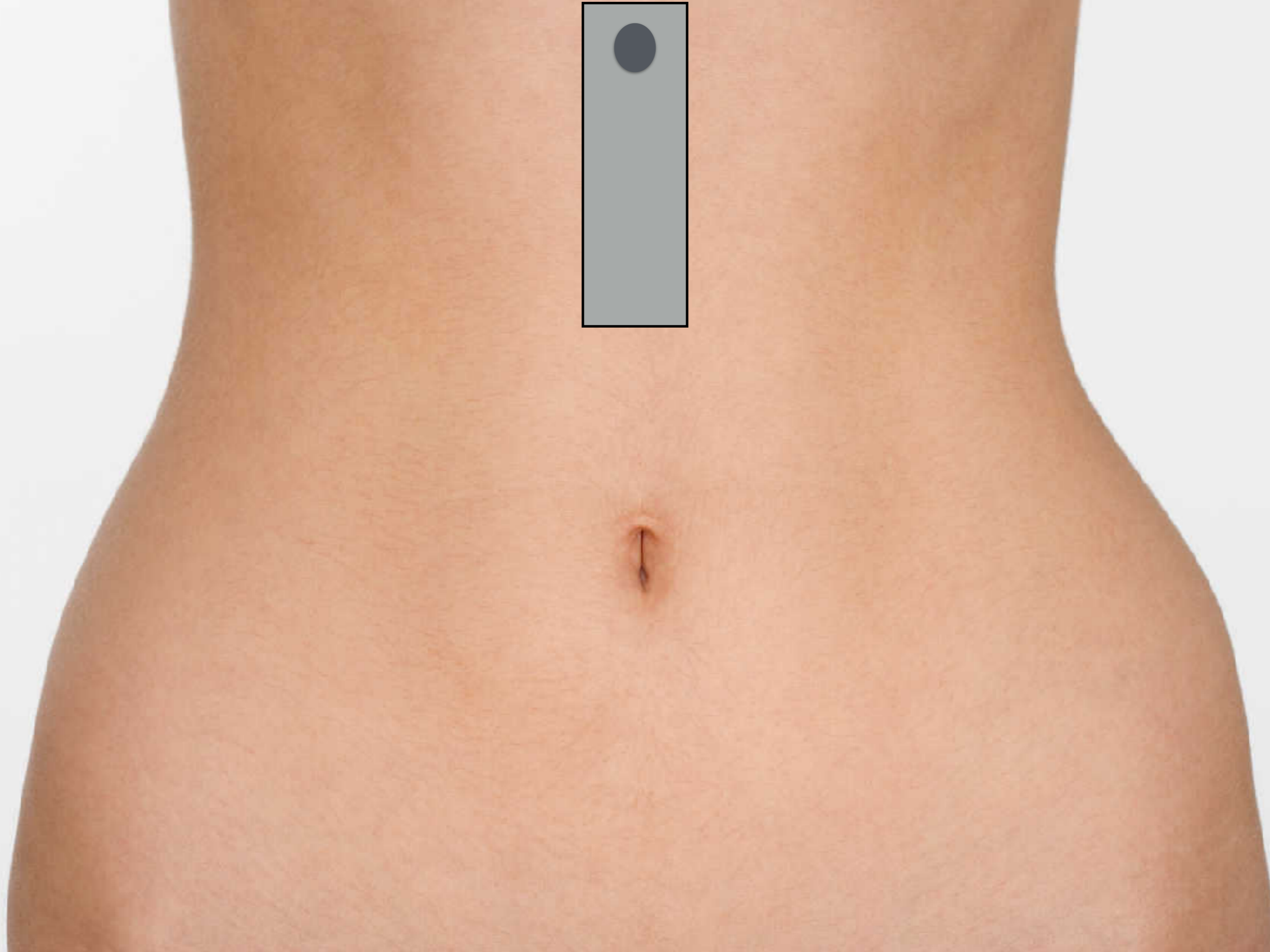
ABDOMEN

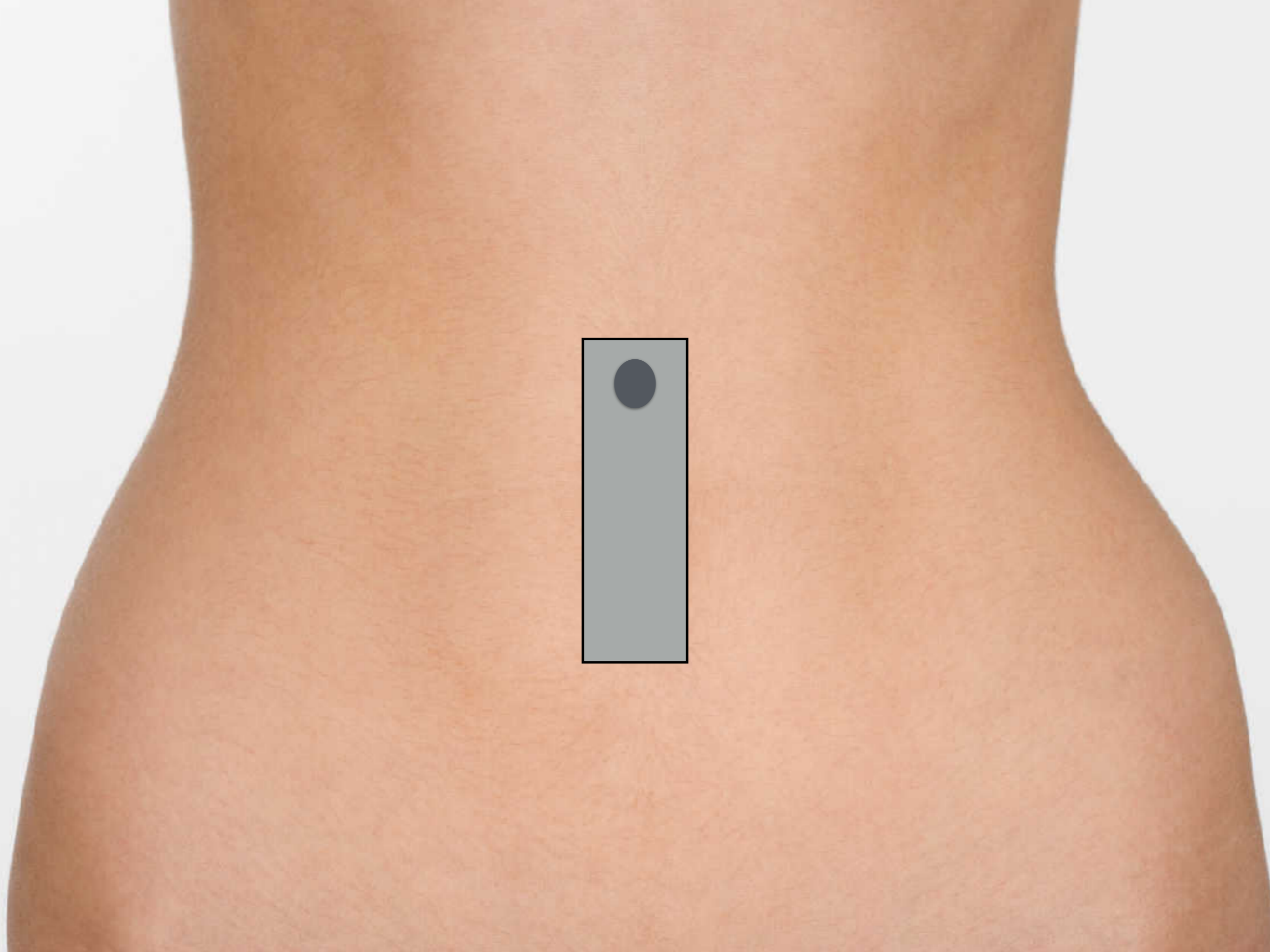
PHILIPS

Abd Gen
C5-1
42 Hz
11.0cm

2D
HGen
Gn 66
C 56
3 / 3 / 3





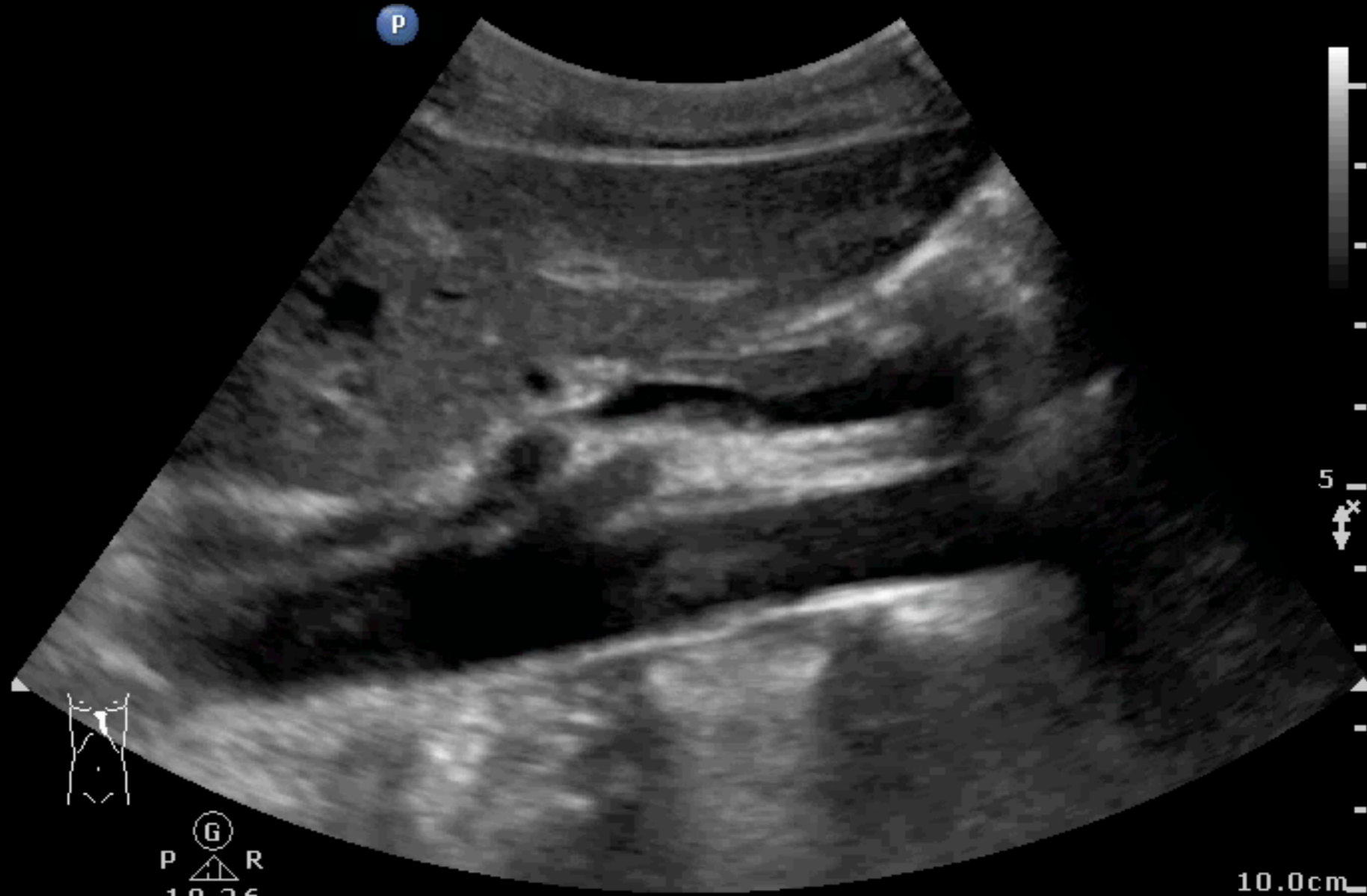

ABDOMEN

PHILIPS

Abd Gen
C5-1
45 Hz
10.0cm

2D
HGen
Gn 60
C 56
3/3/3

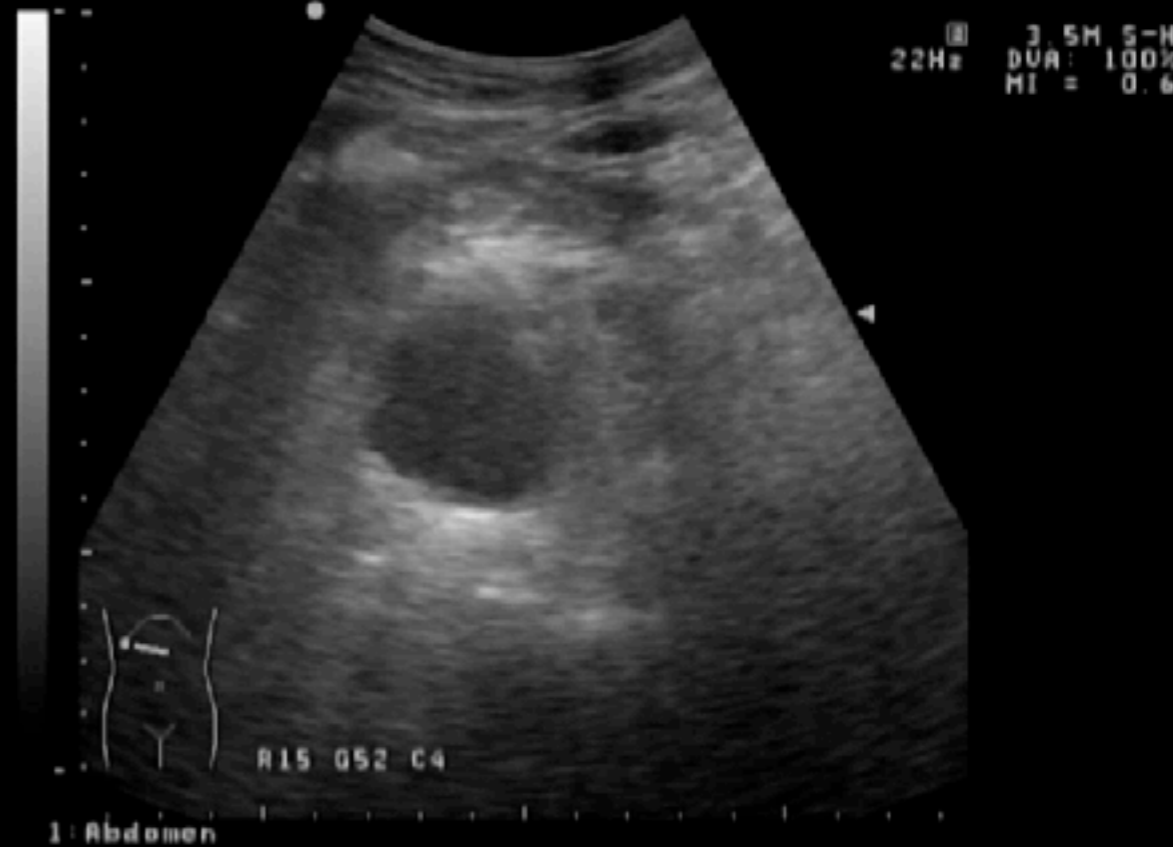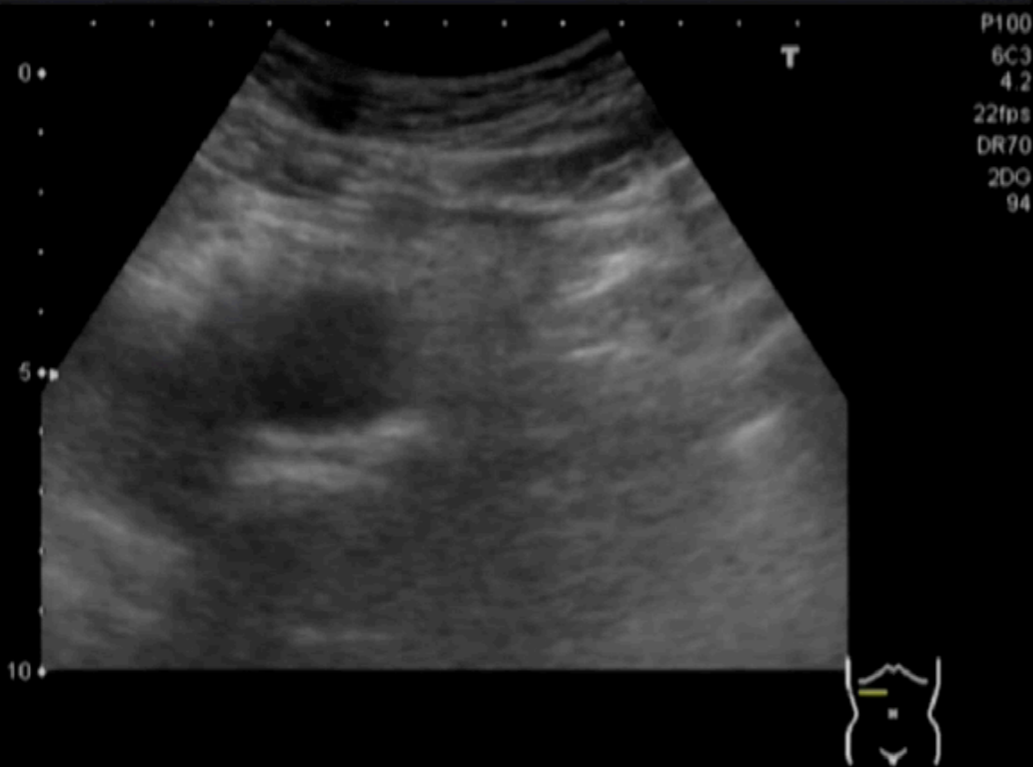


ABDOMEN

A for AAA, not for rupture

POCUS Academy©ChenKC

POCUS Academy©ChenKC

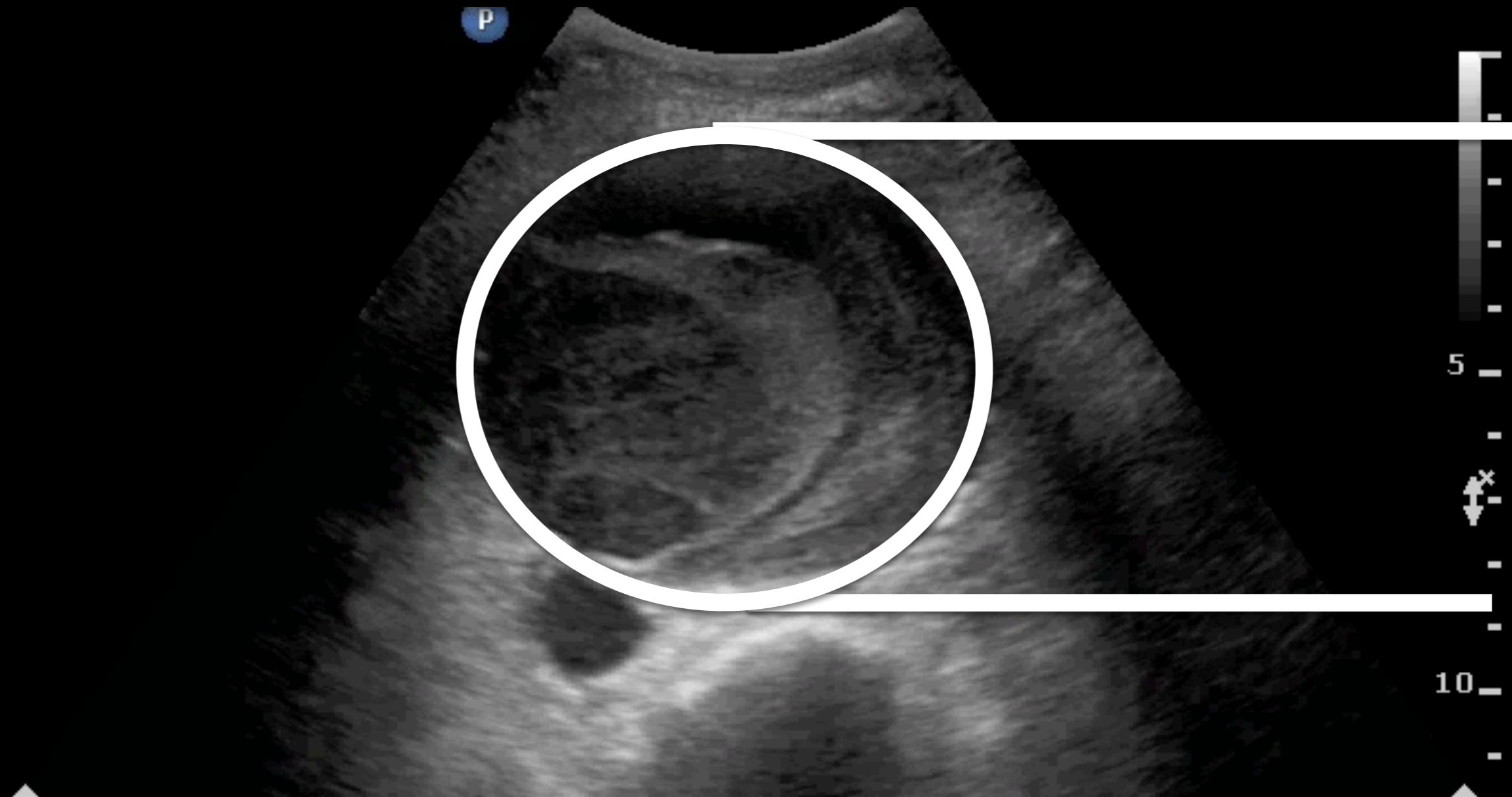


ABDOMEN

Abd Gen
C5-1
34 Hz
15.0cm

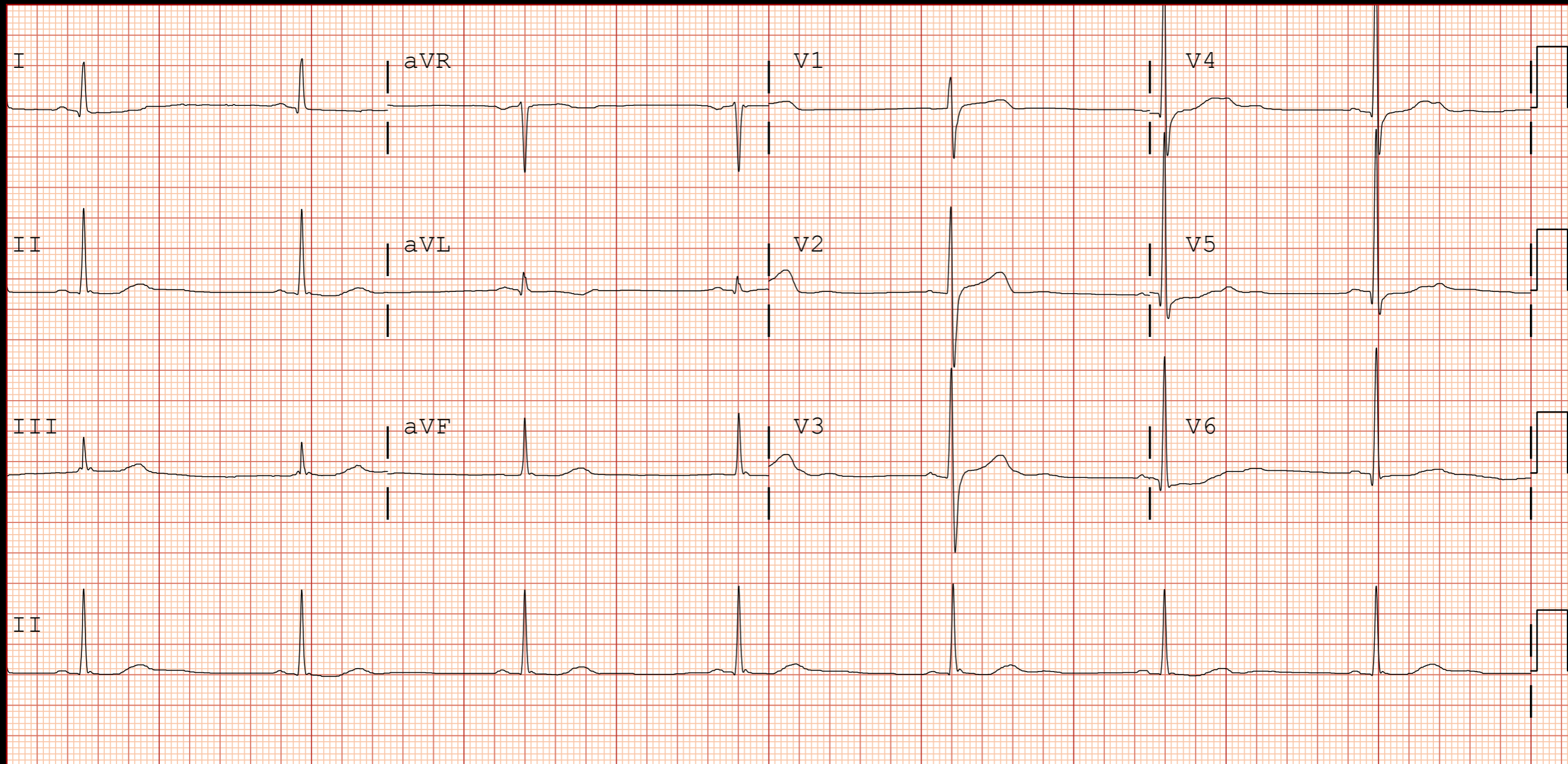
2D

HGen
Gn 57
C 56
3/3/3



Eyeballing

63M, chest/abd pain & low BP

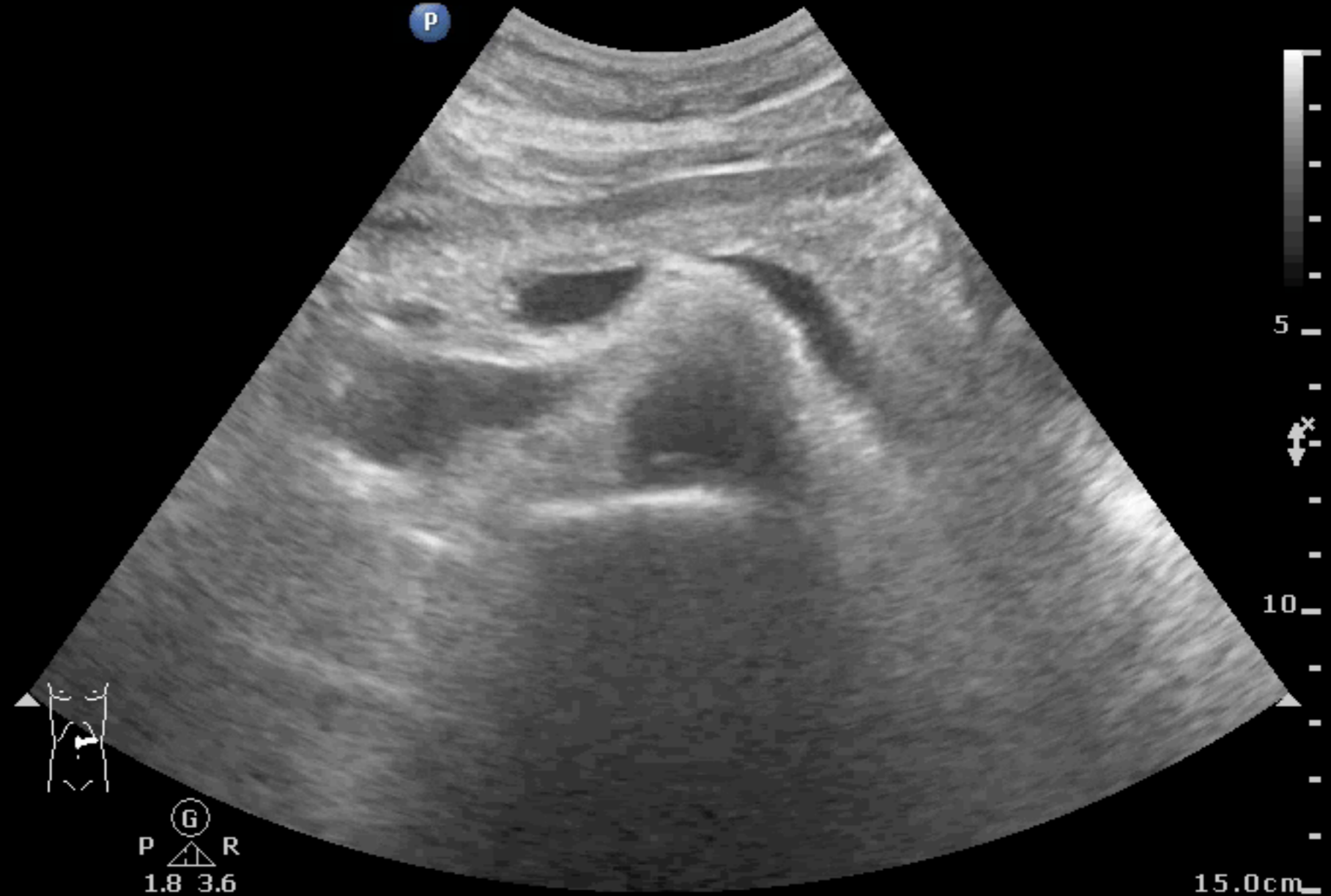

63M, chest/abd pain & low BP

PHILIPS

Abd Gen2
C5-1
34 Hz
15.0cm

2D
HGen
Gn 100
C 56
3/3/3

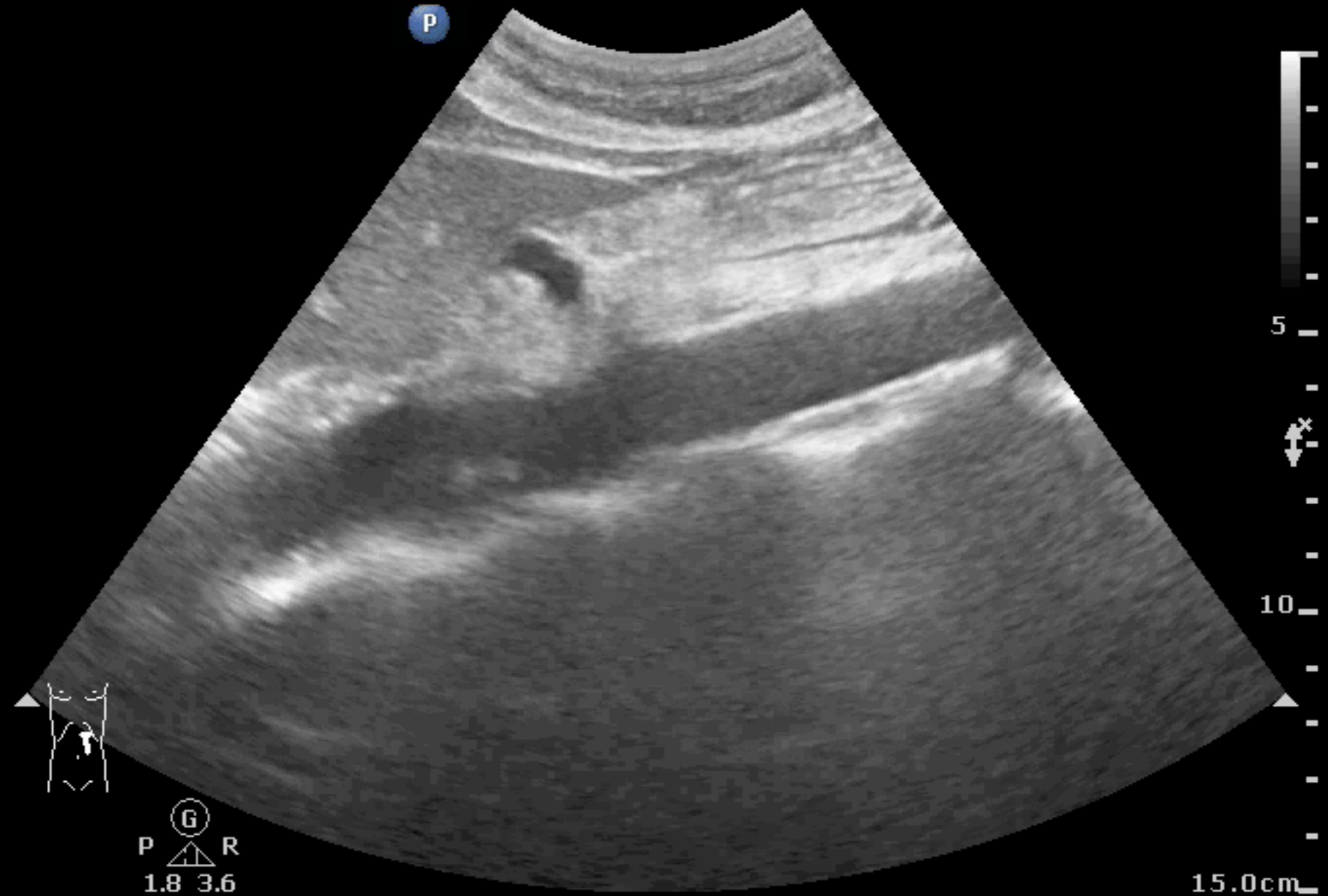

63M, chest/abd pain & low BP

PHILIPS

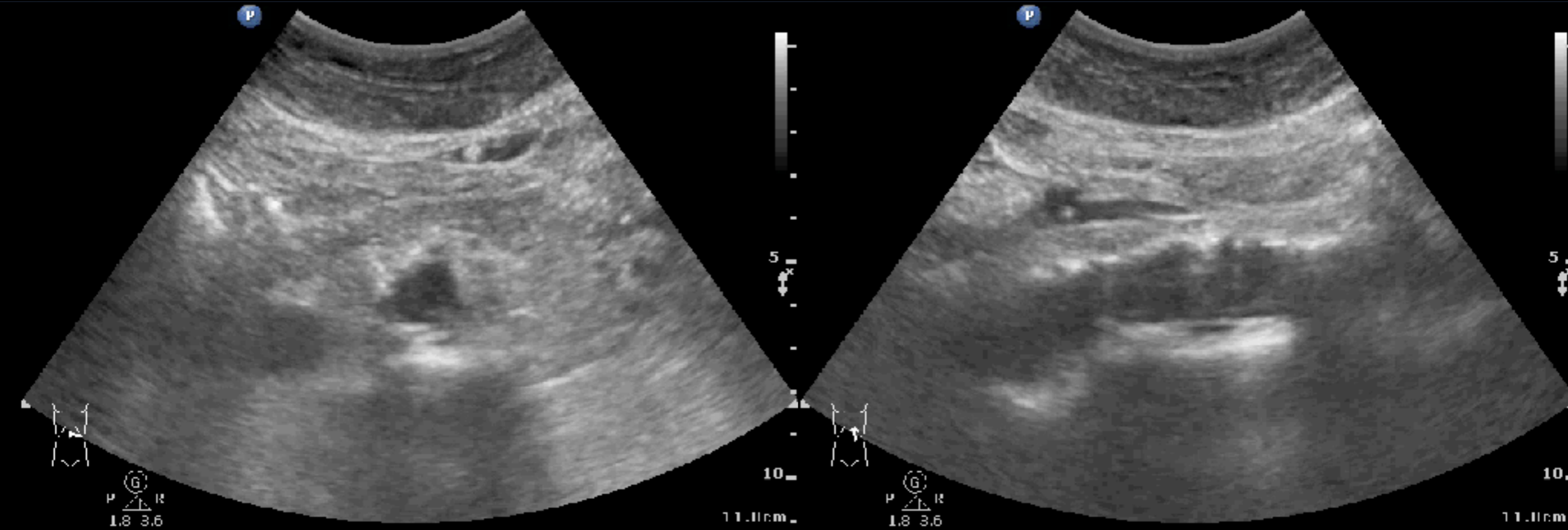
Abd Gen2
C5-1
34 Hz
15.0cm

2D
HGen
Gn 100
C 56
3 / 3 / 3



ABDOMEN

Aortic dissection

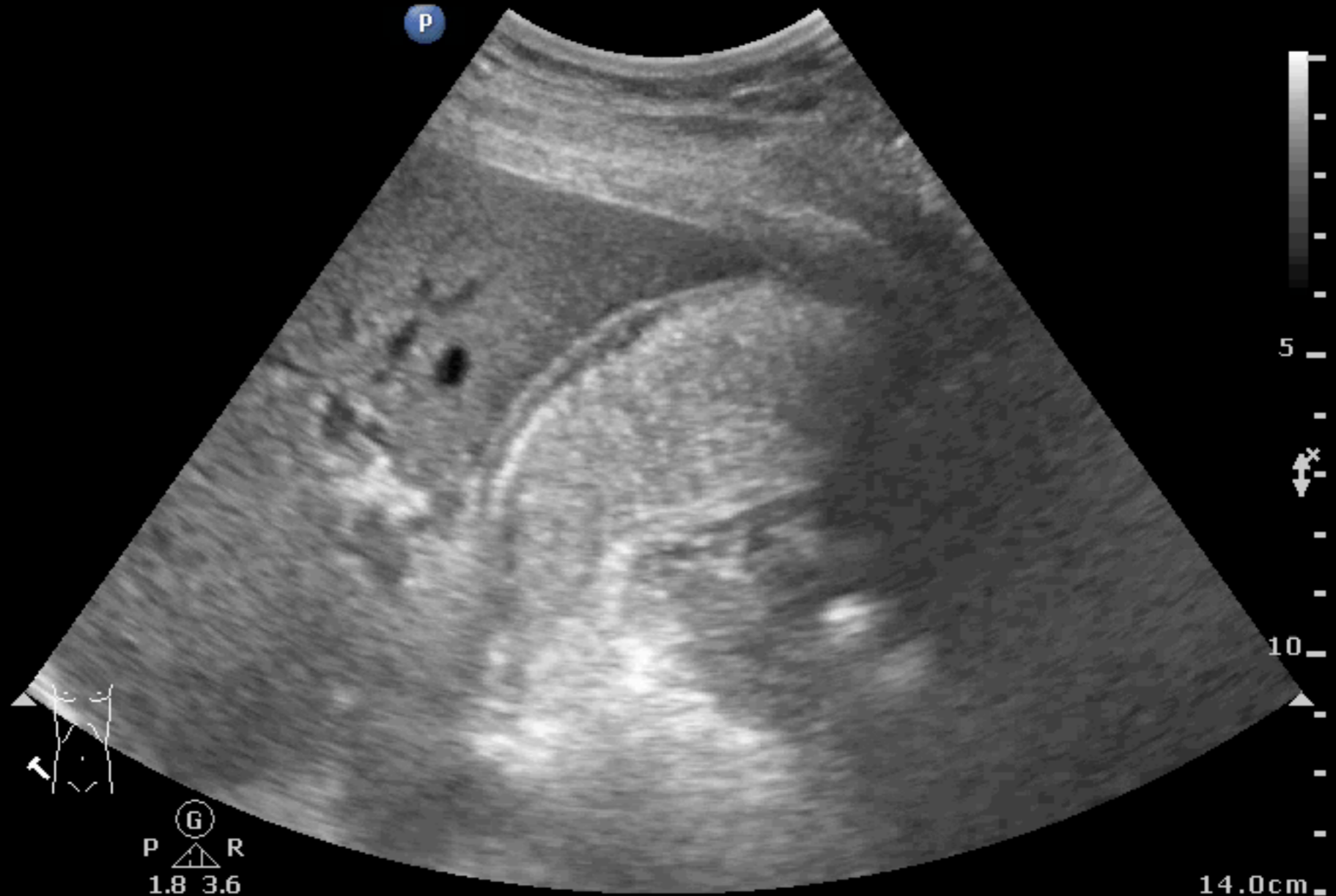

59M, epigastric pain at midnight

PHILIPS

Abd Gen2
C5-1
36 Hz
14.0cm

2D
HGen
Gn 100
C 56
3/3/3



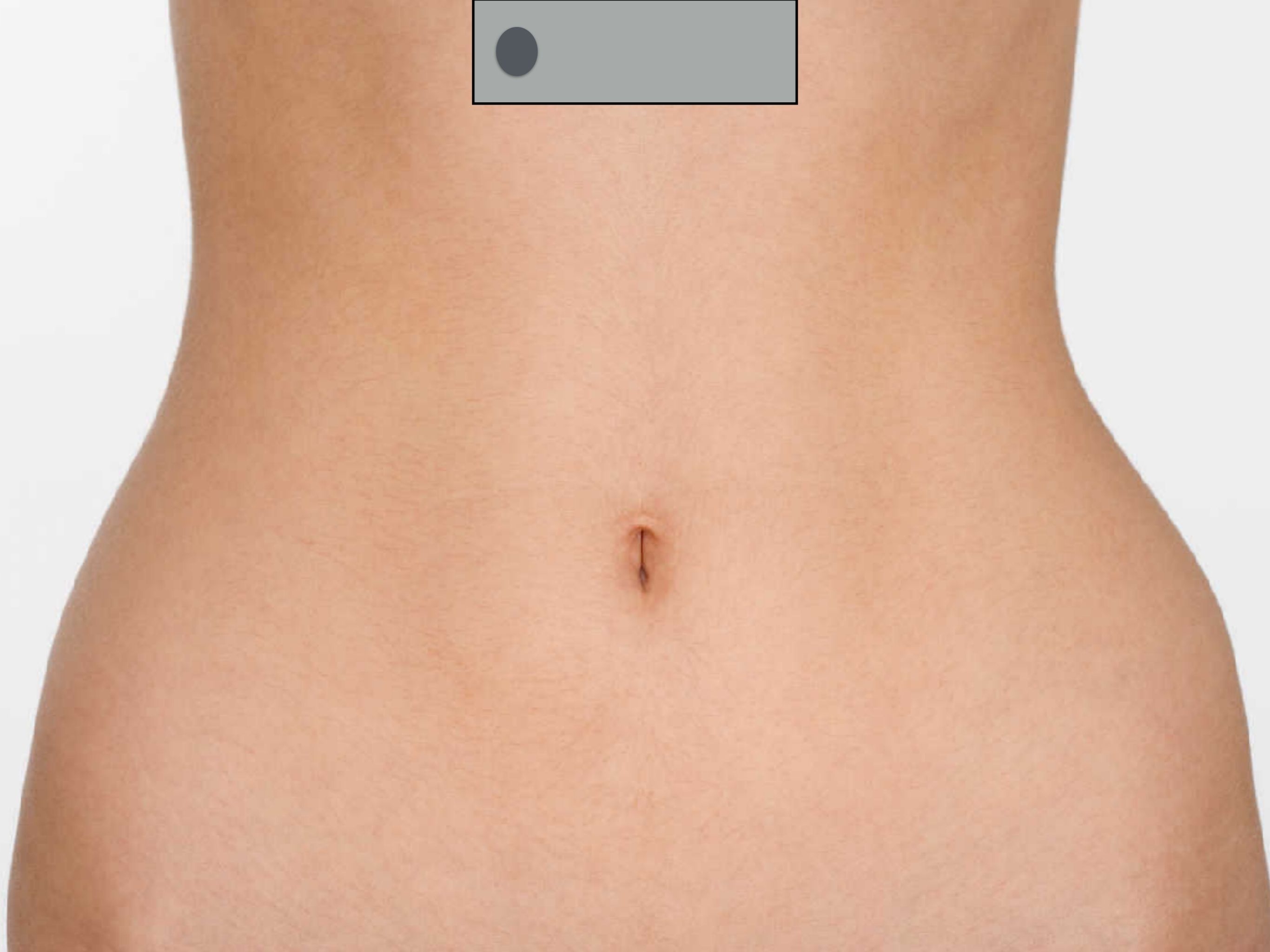
ABDOMEN

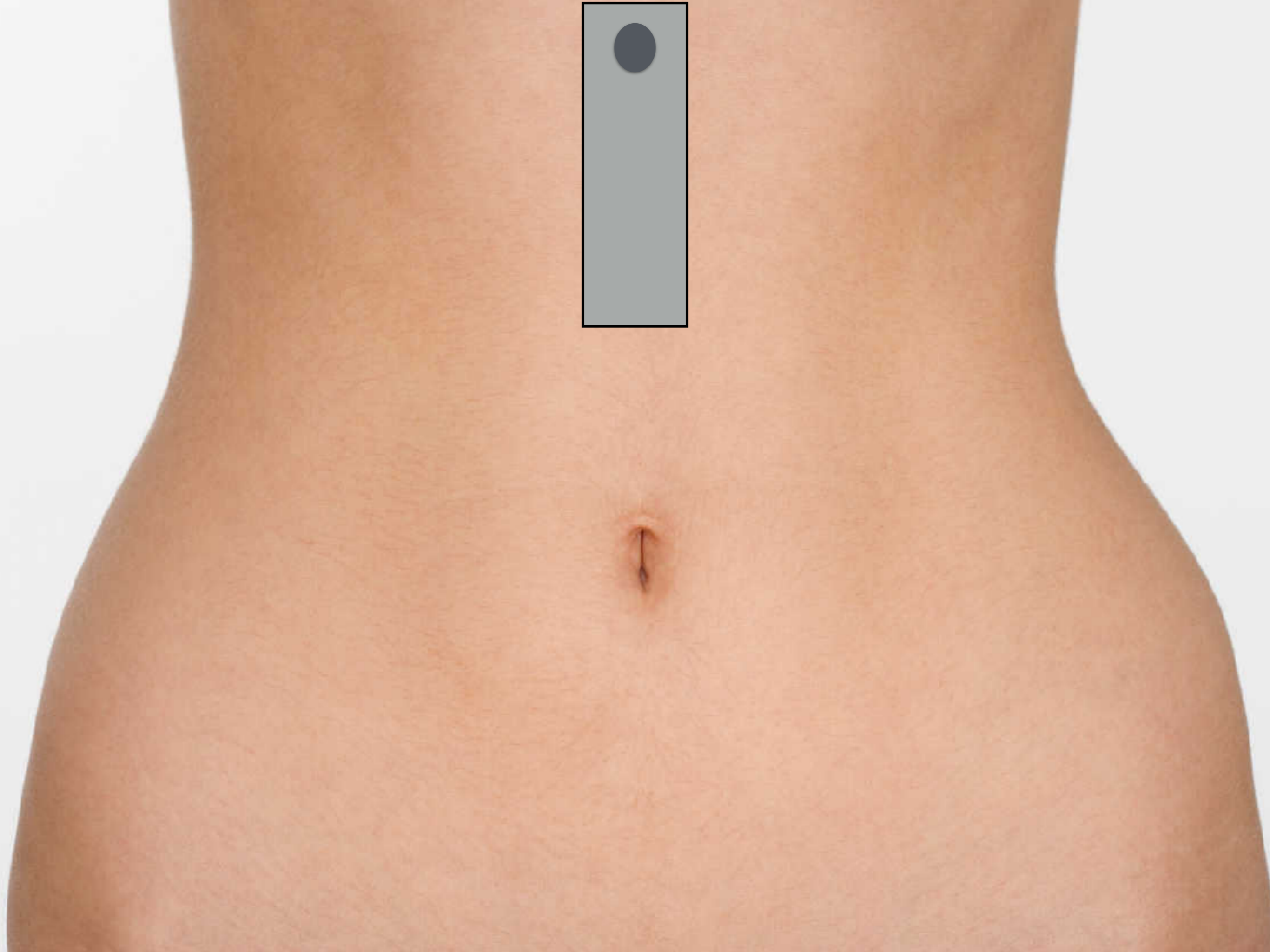
B for GB stone & dilatation

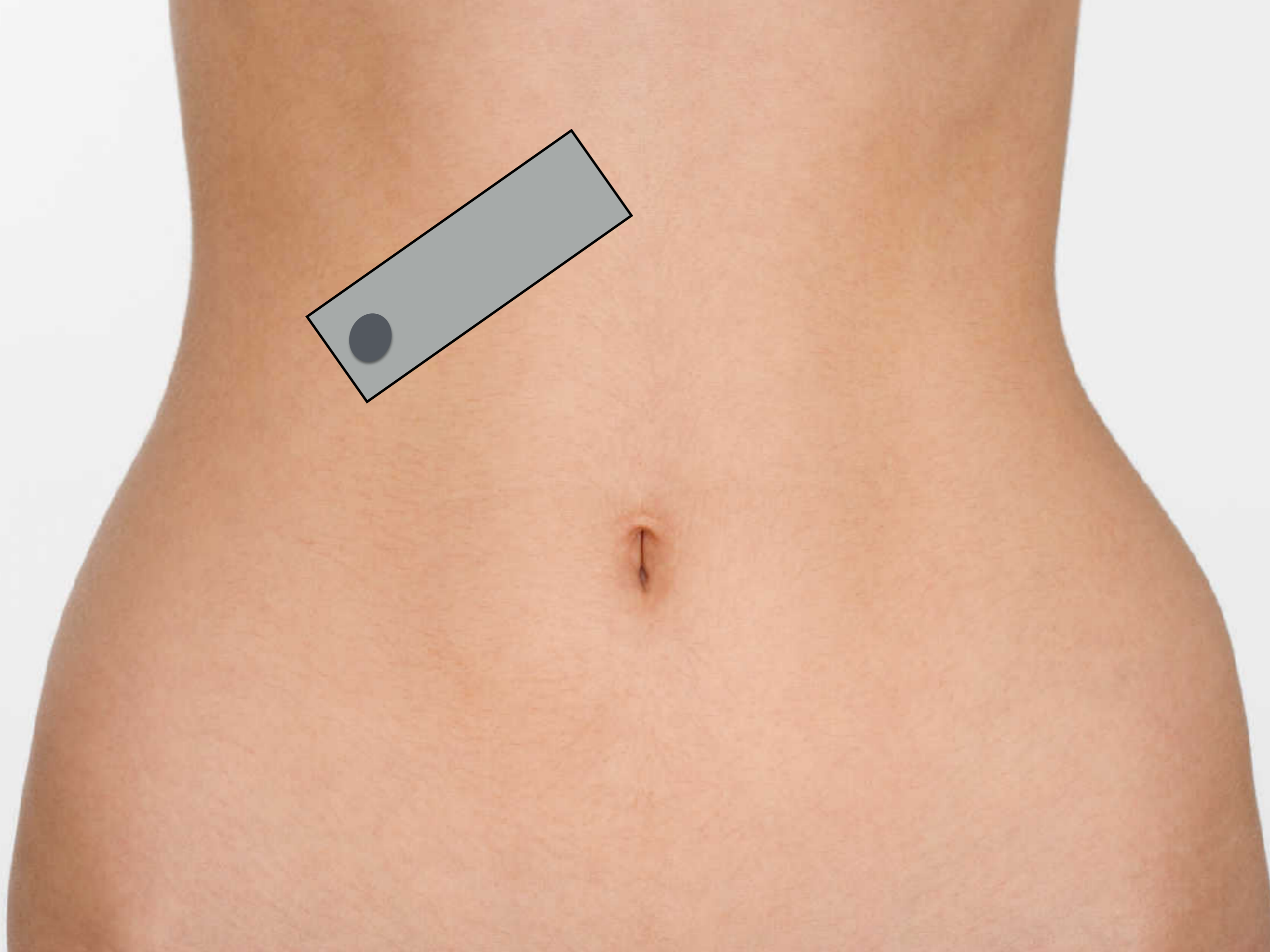
3 mm


7 mm

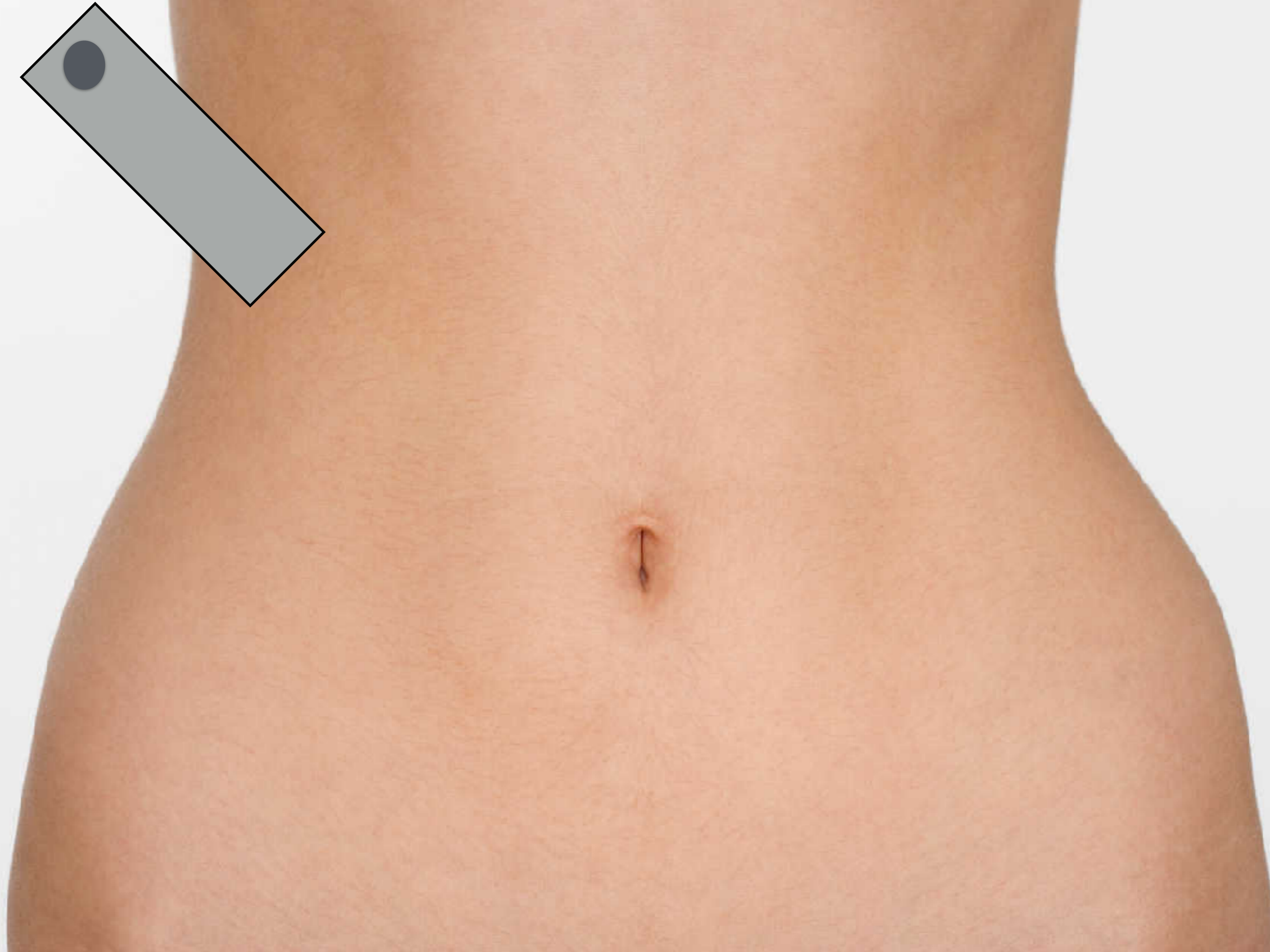11 mm











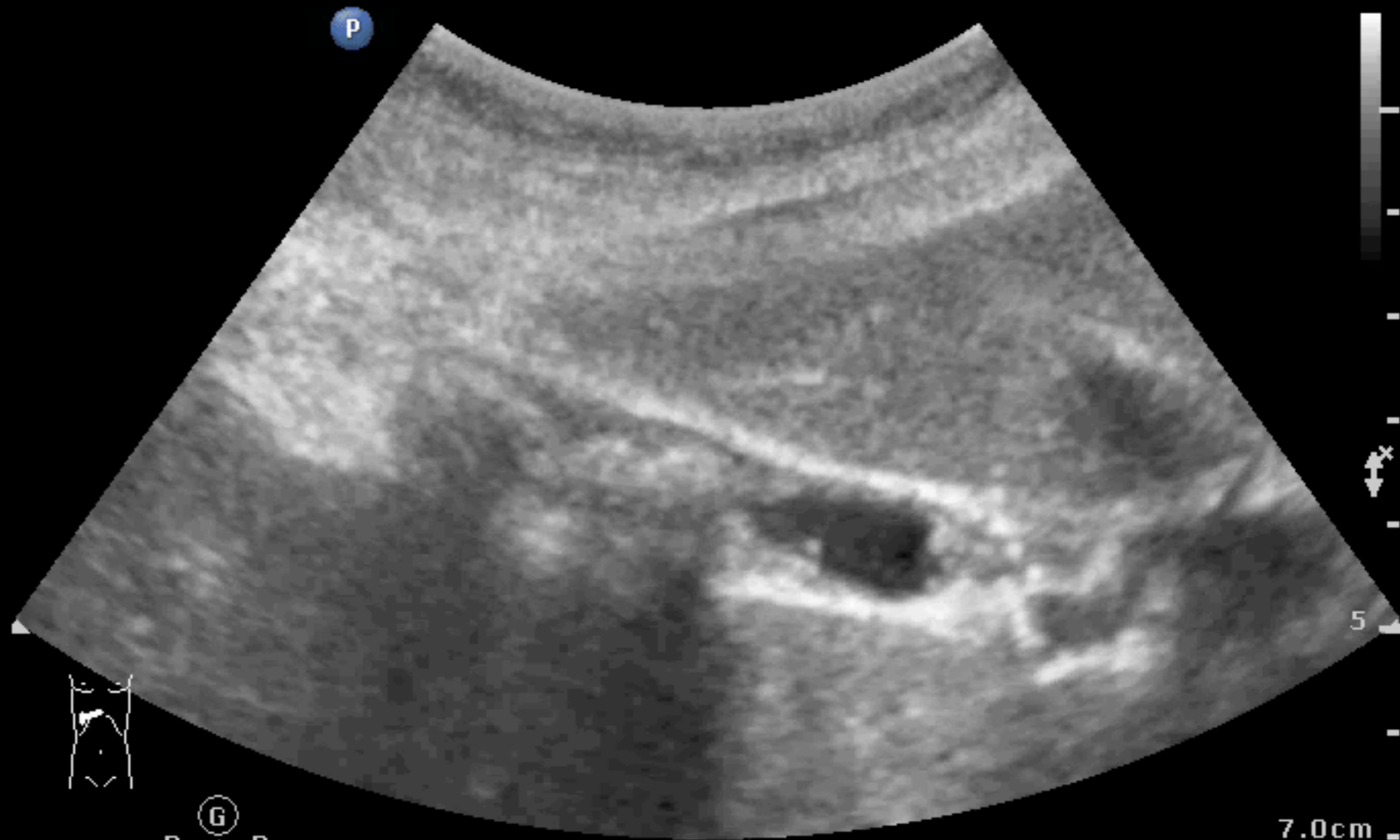ABDOMEN

PHILIPS

40F, RUQ pain

Abd Gen
C5-1
55 Hz
7.0cm

2D
HGen
Gn 100
C 56
3/3/3



G
P R
1.8 3.6

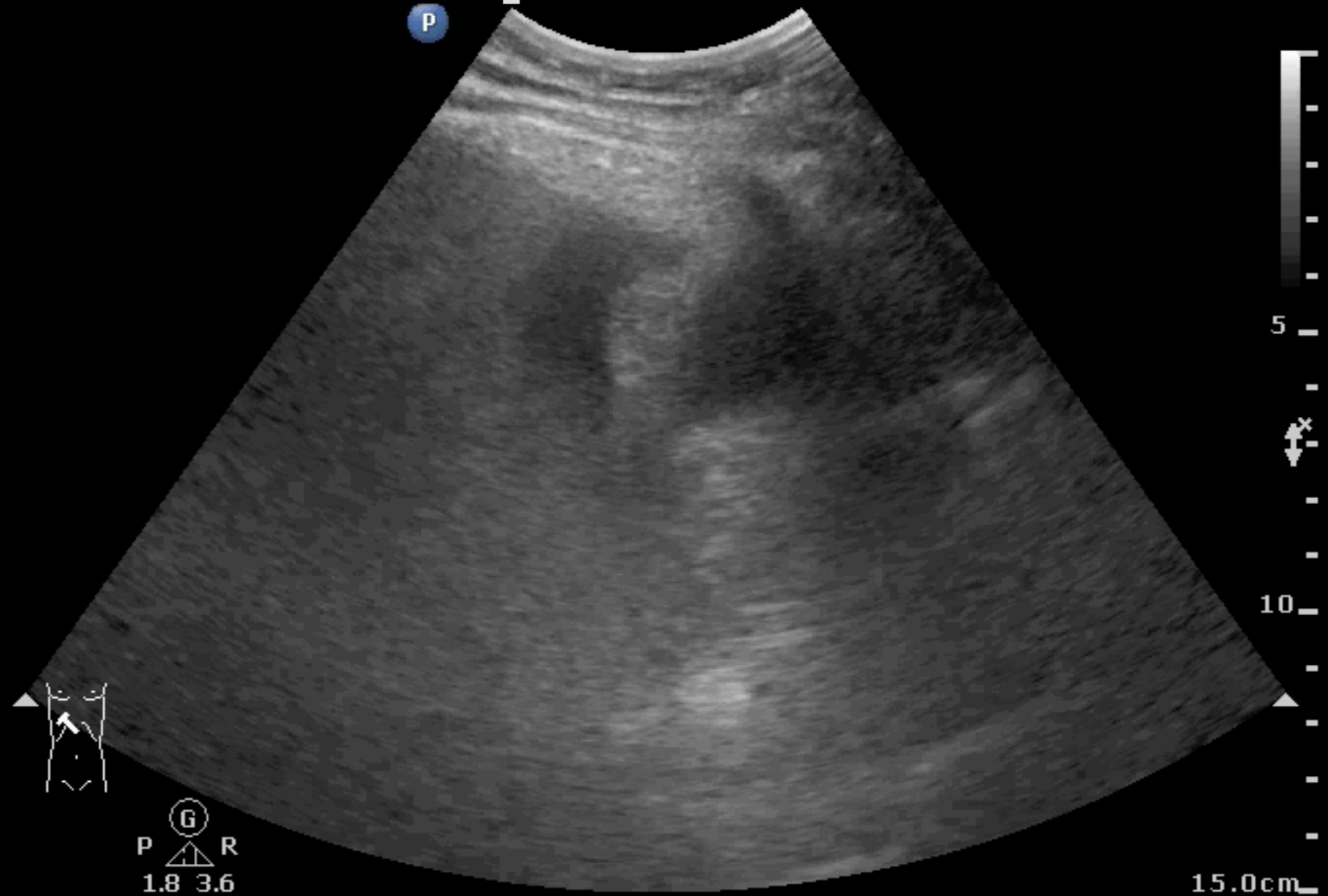7.0cm

ABDOMEN

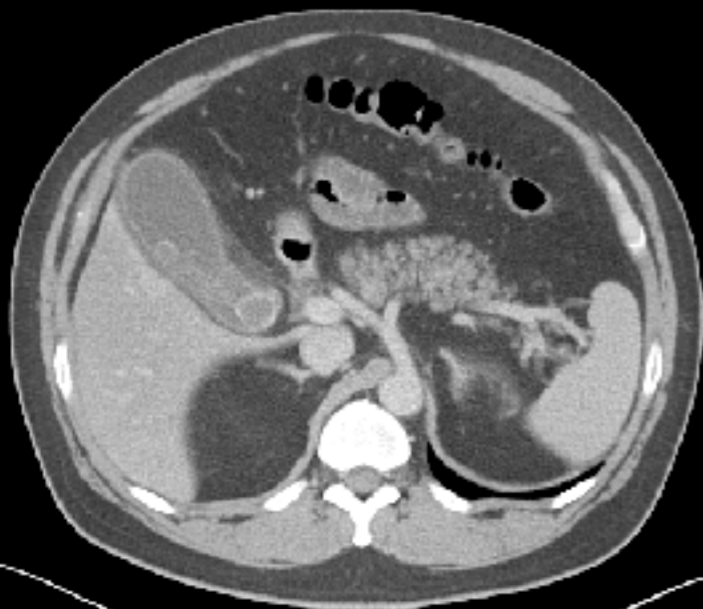
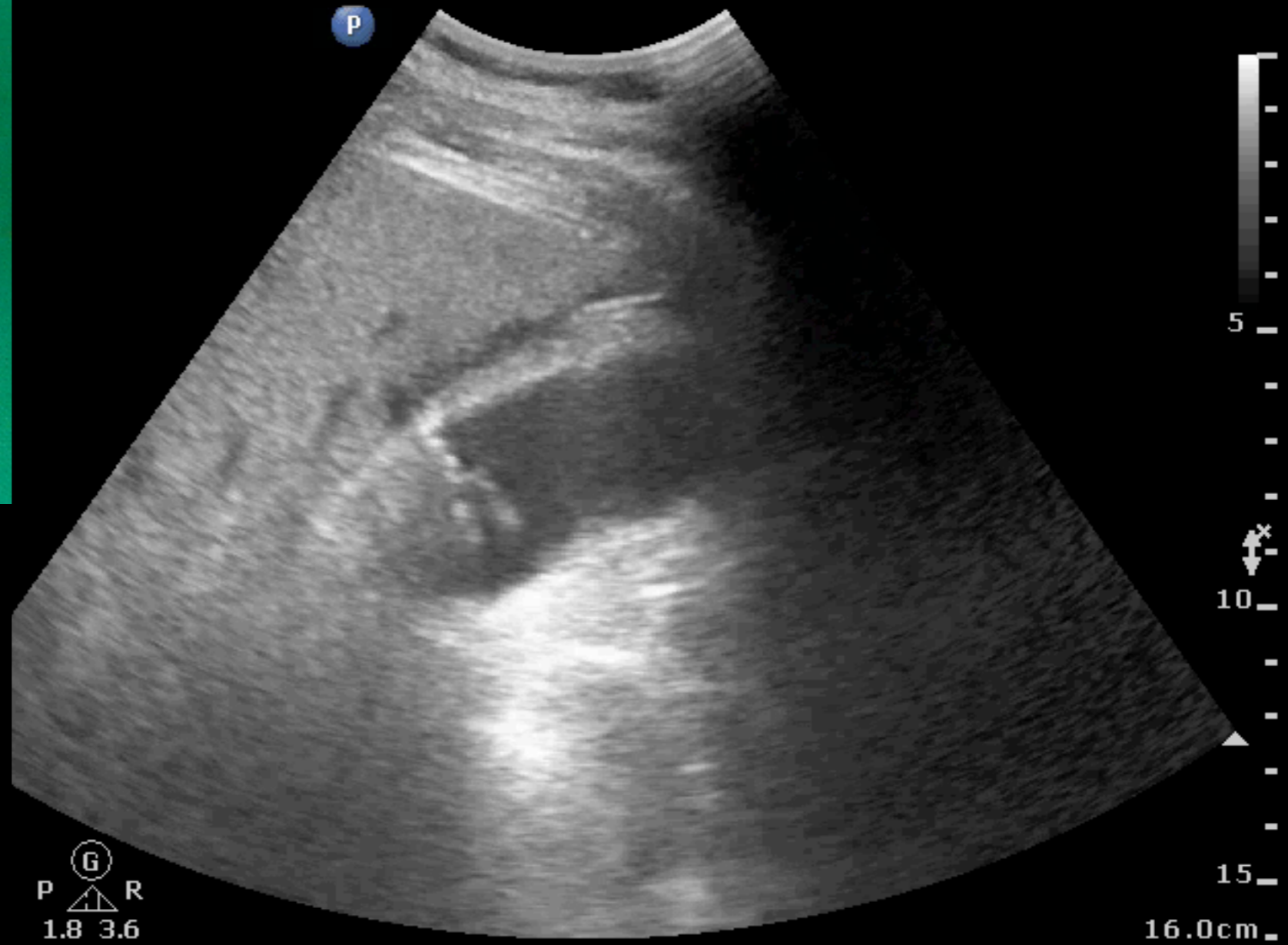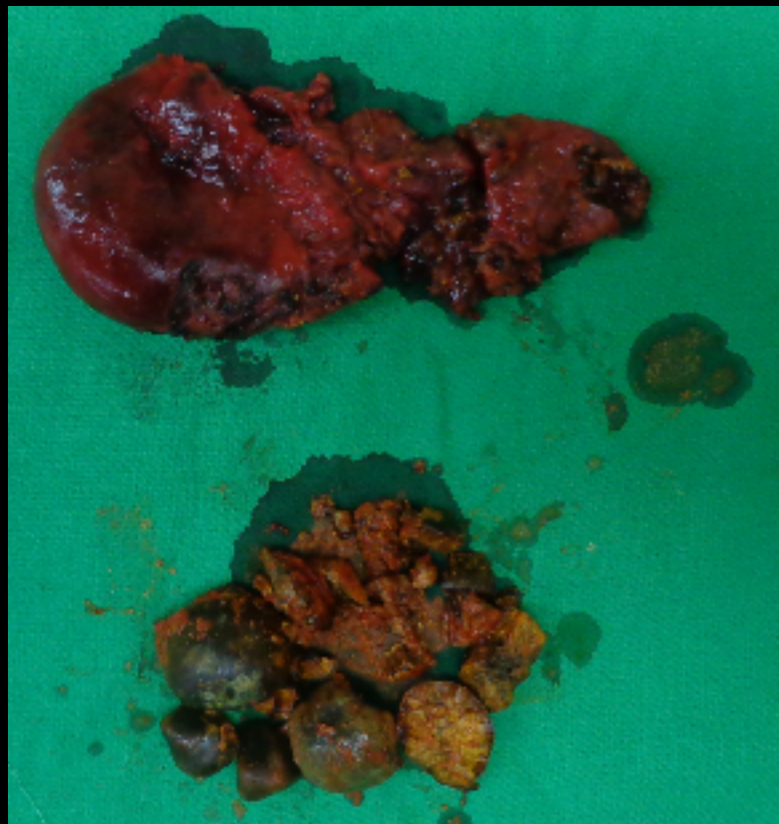
45M, RUQ pain & fever

Abd Gen2
C5-1
34 Hz
15.0cm

2D
HGen
Gn 100
C 56
3/3/3



Acute calculous cholecystitis



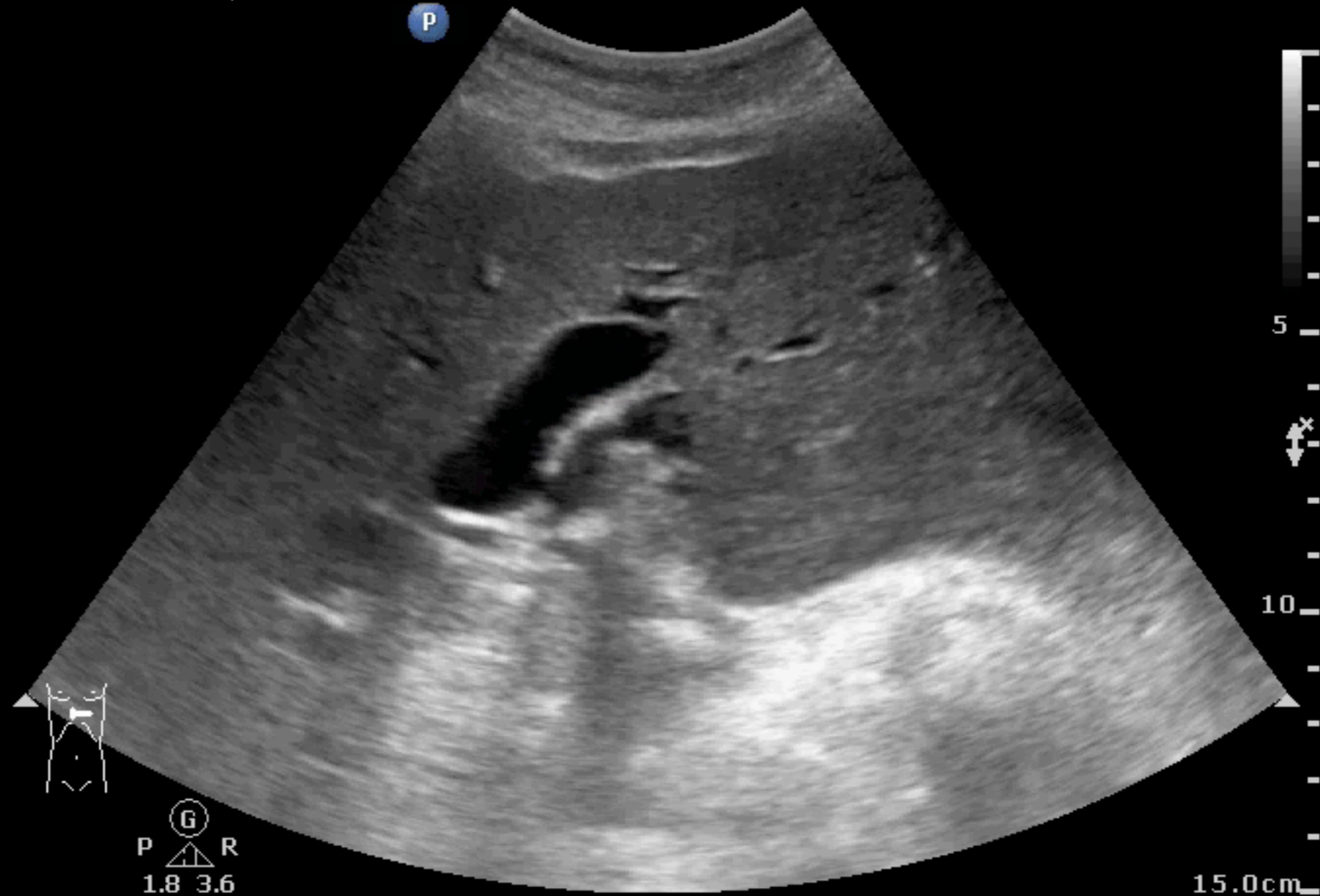⊙
P ⊙ R
1.8 3.6

ABDOMEN

76F, Fever & Chills

Abd Gen2
C5-1
34 Hz
15.0cm

2D
HGen
Gn 78
C 56
3 / 3 / 3



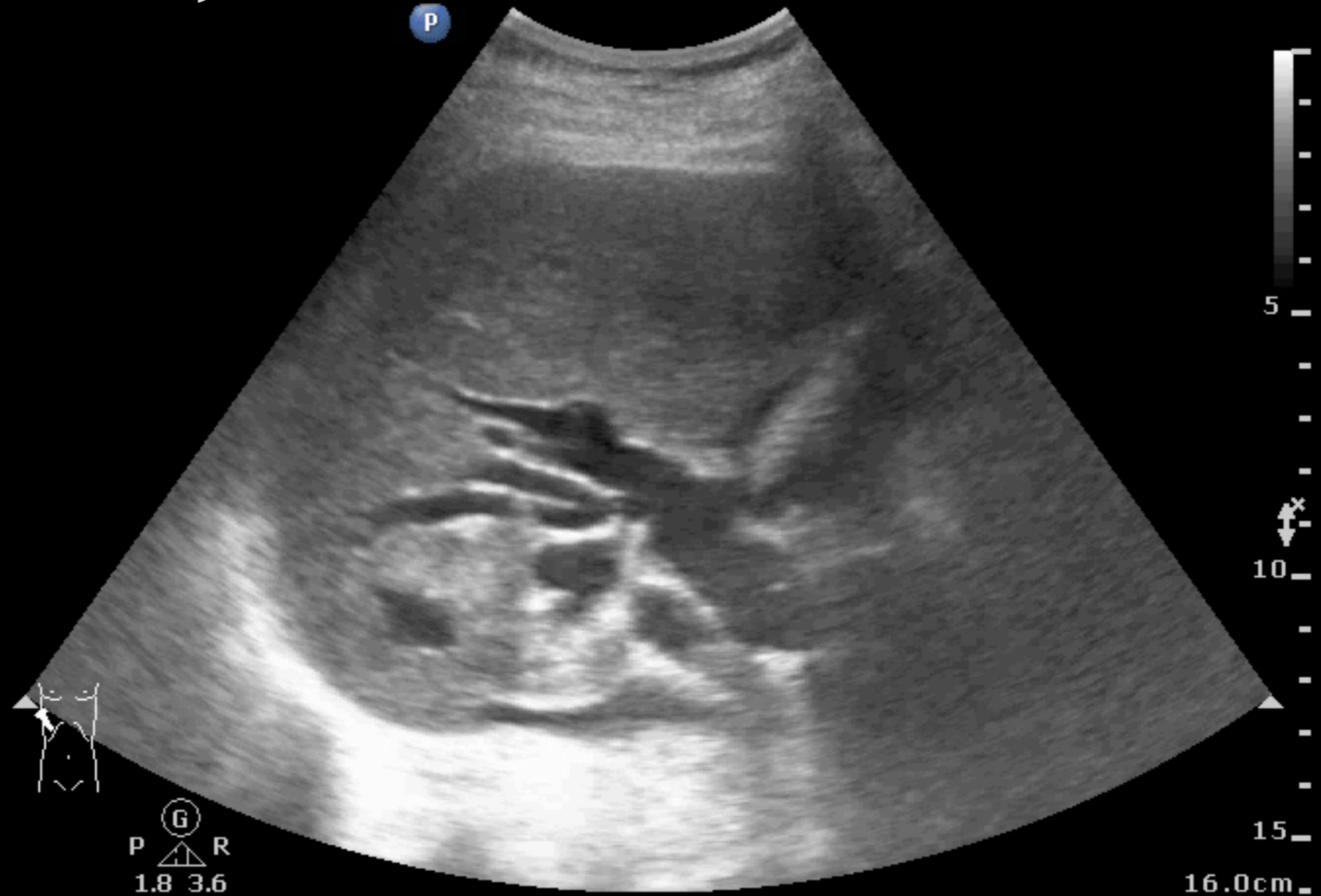ABDOMEN

PHILIPS

76F, Fever & Chills

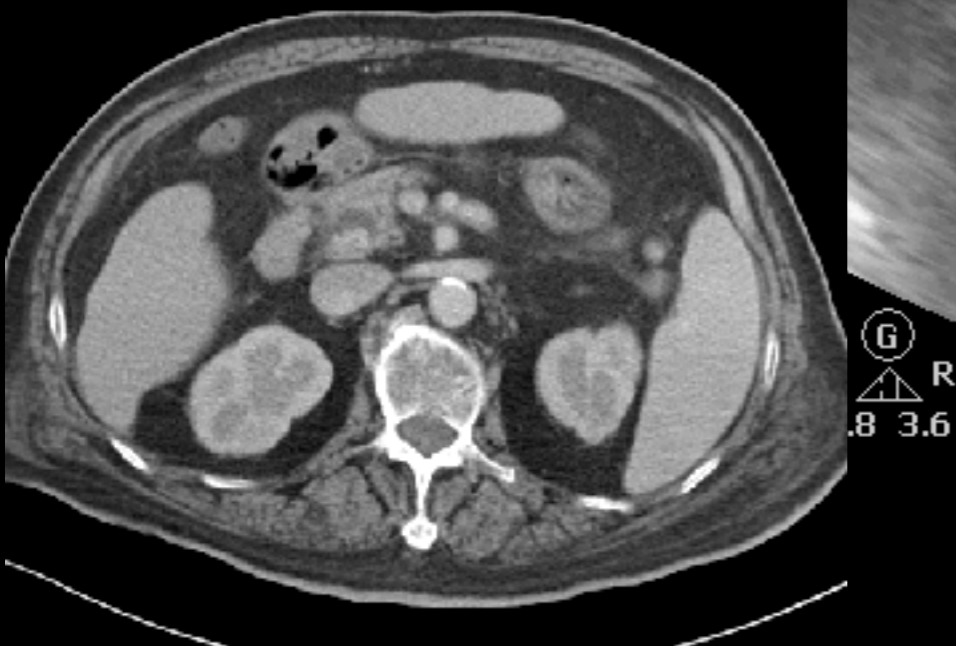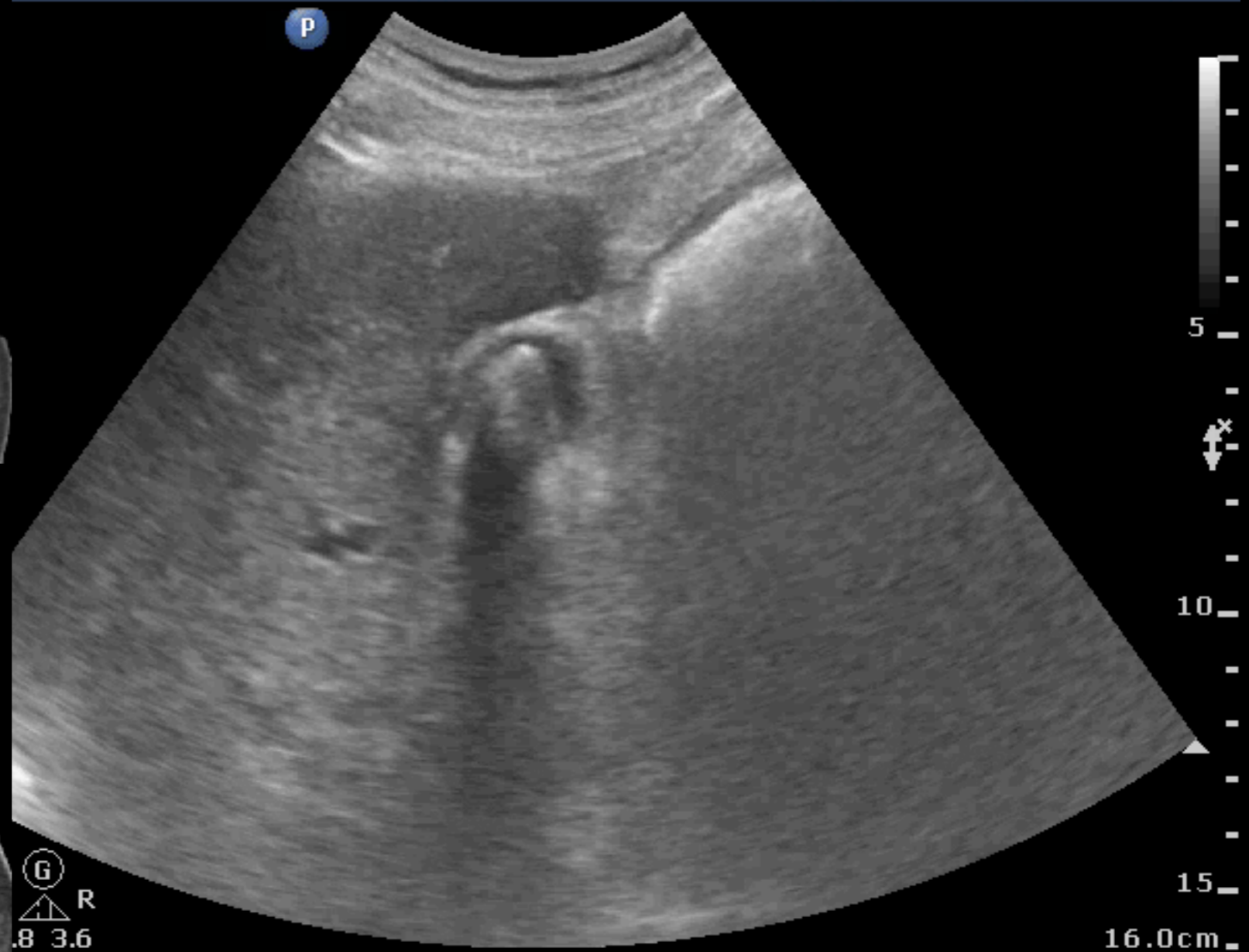
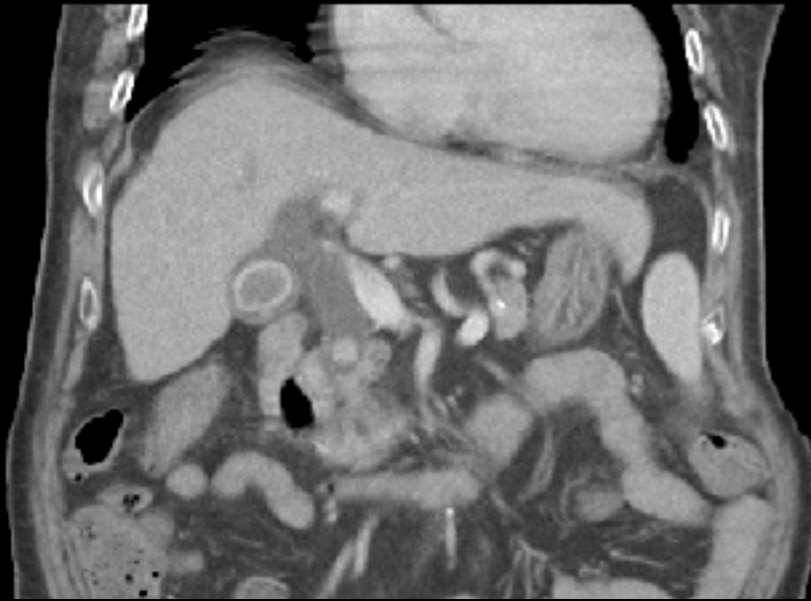
Abd Gen2
C5-1
32 Hz
16.0cm

2D
HGen
Gn 100
C 56
3 / 3 / 3

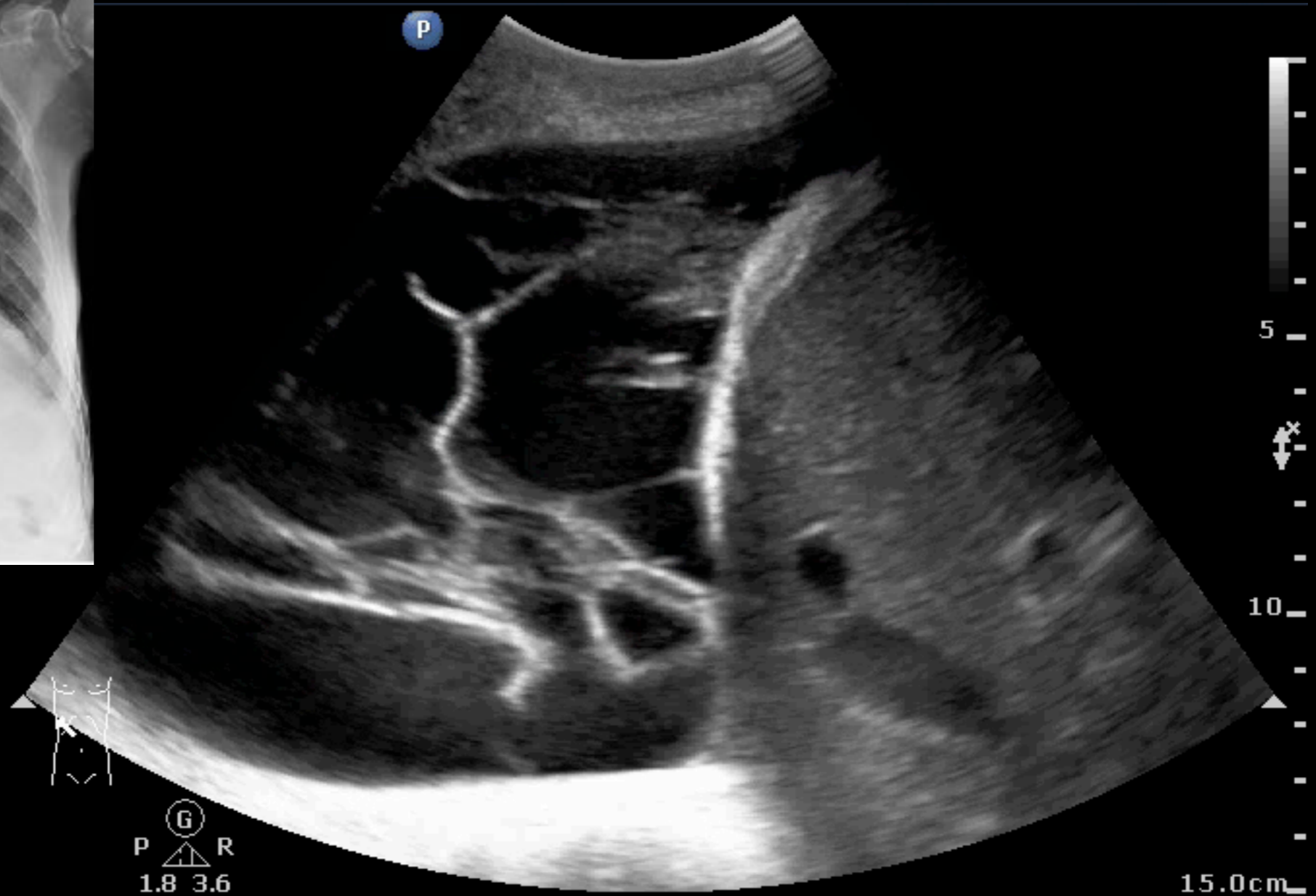
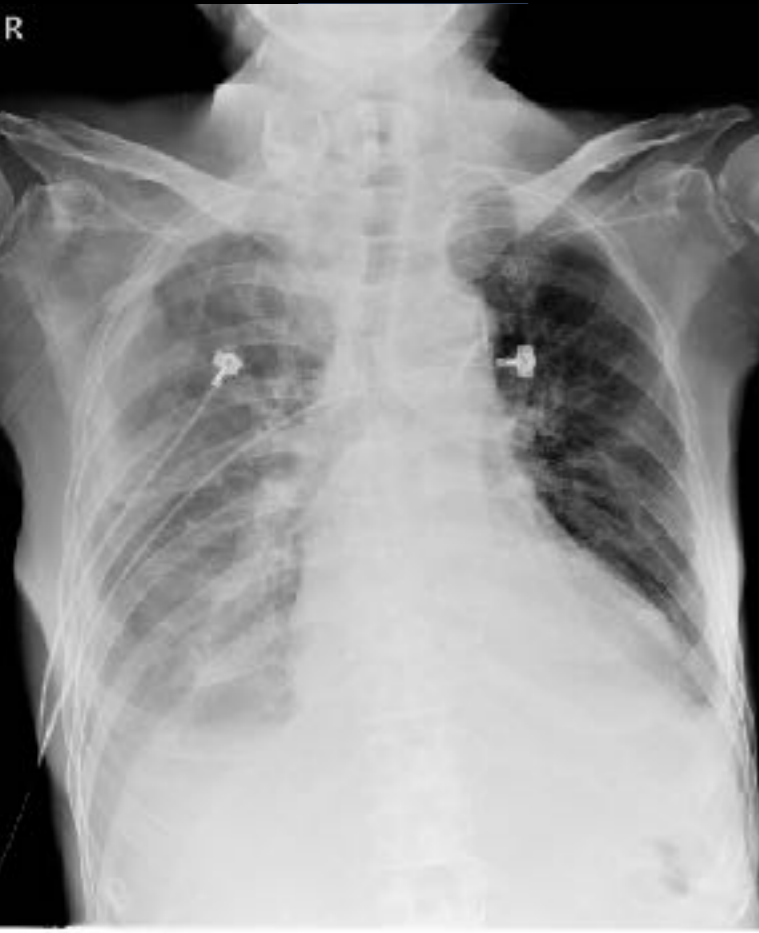

ABDOMEN

CBD dilatation & stone



73M, chest/abd pain & SOB

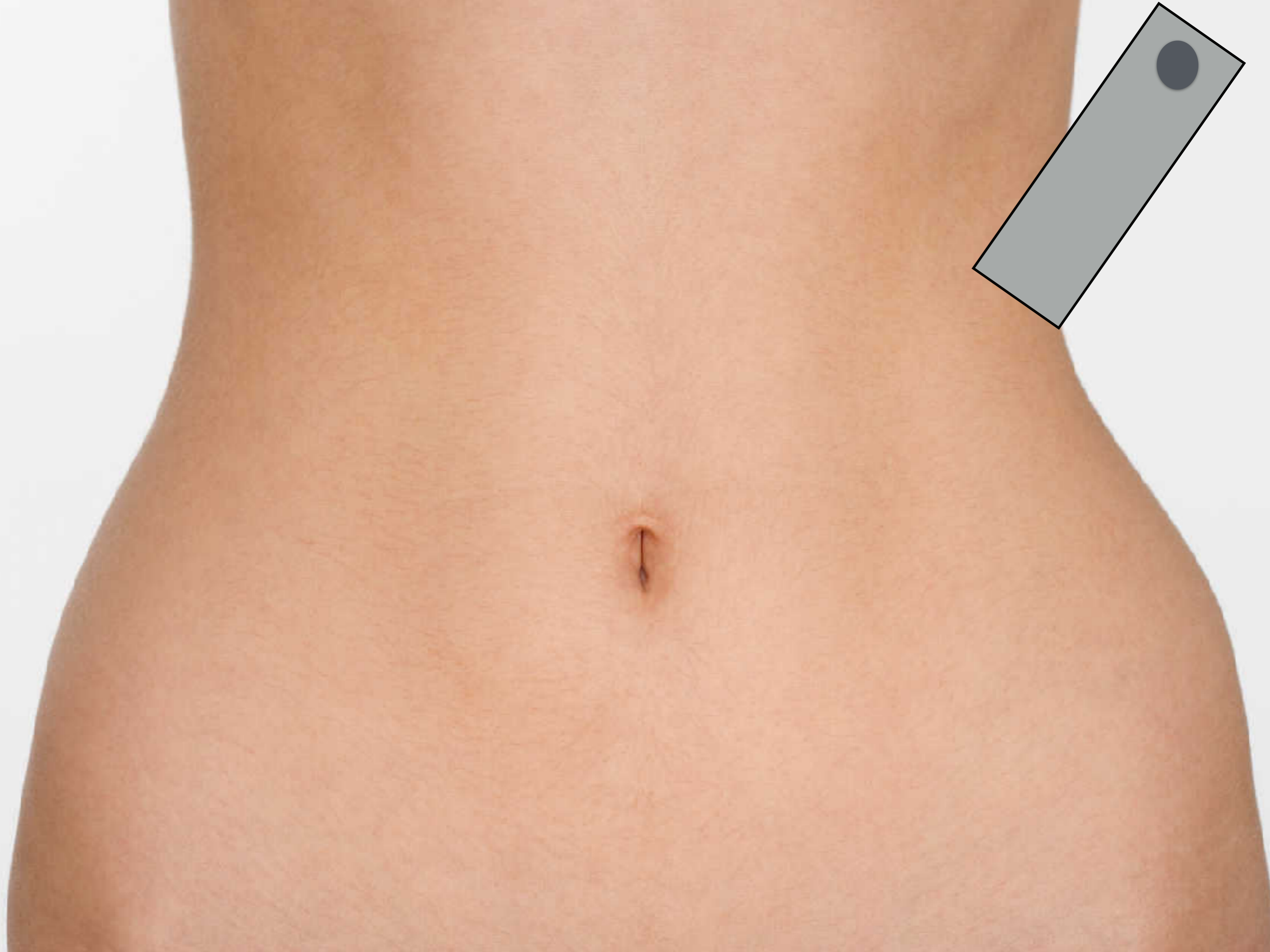

ABDOMEN

D for diaphragm

Outsider



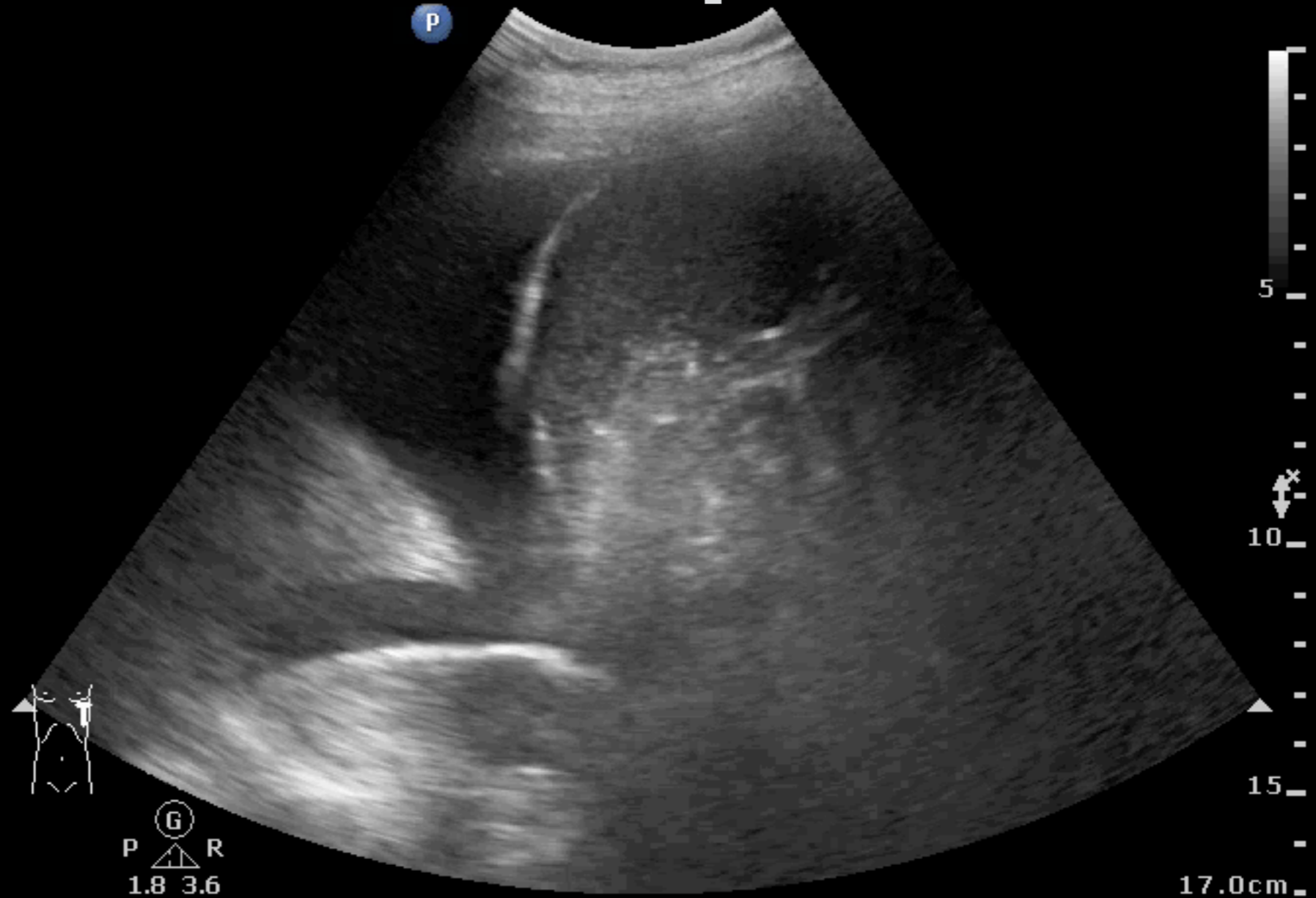

ABDOMEN

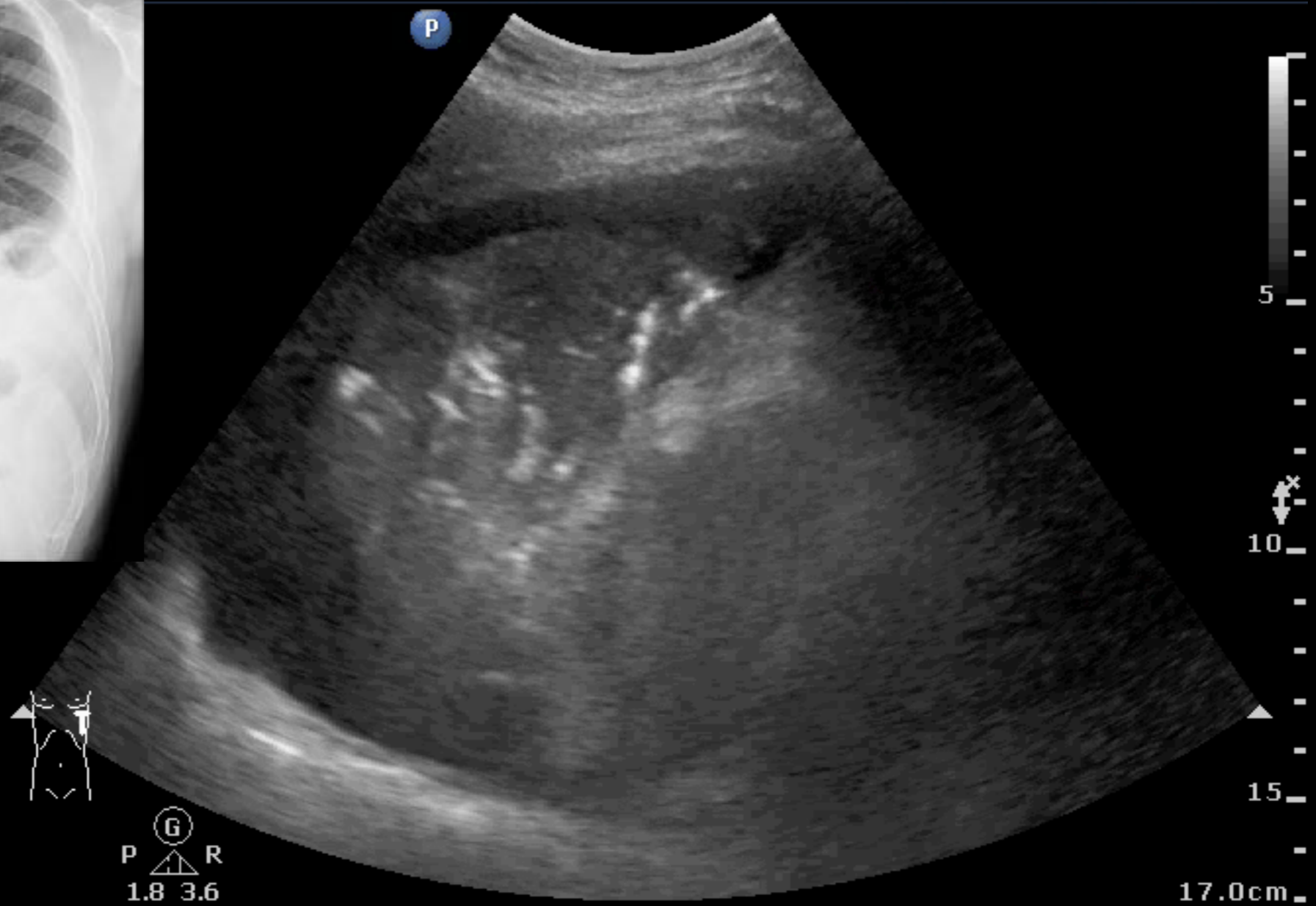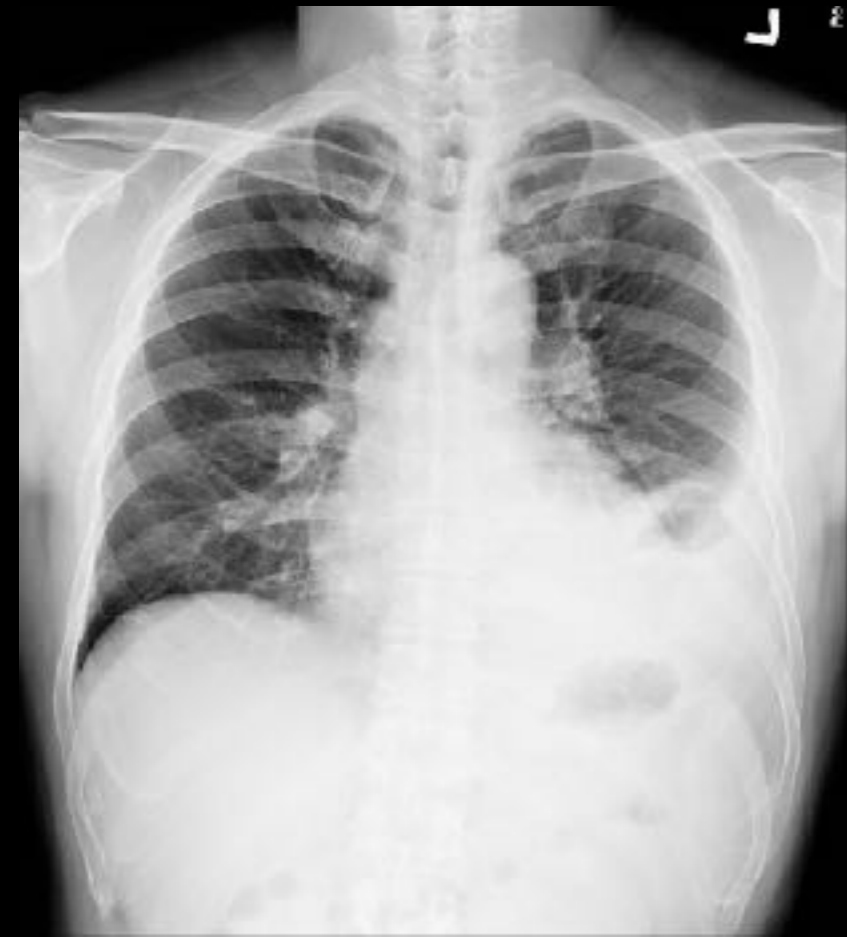45M, LUQ pain

Abd Gen
C5-1
31 Hz
17.0cm

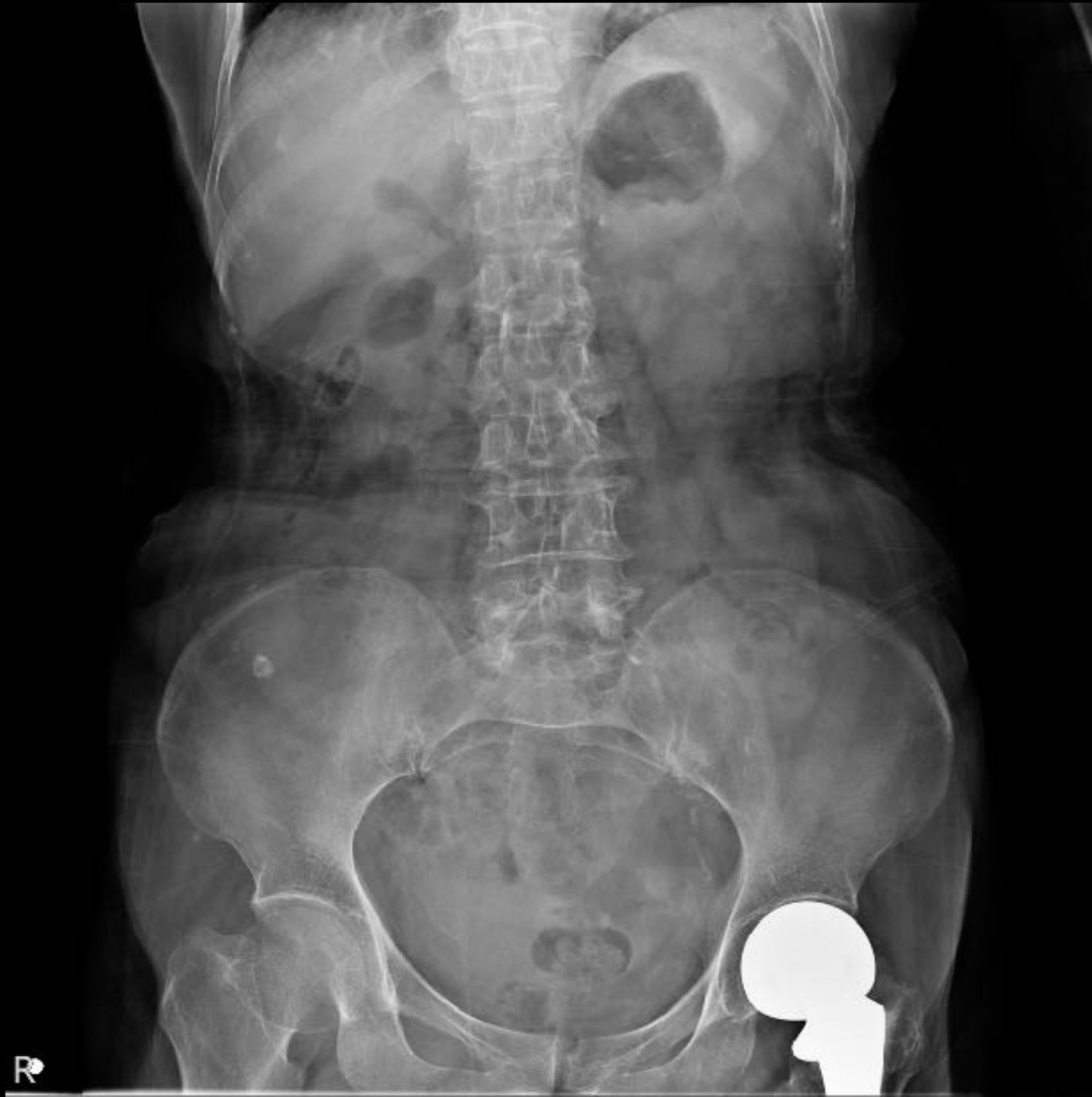2D
HGen
Gn 100
C 56
3/3/3



PN & parapneumonic effusion



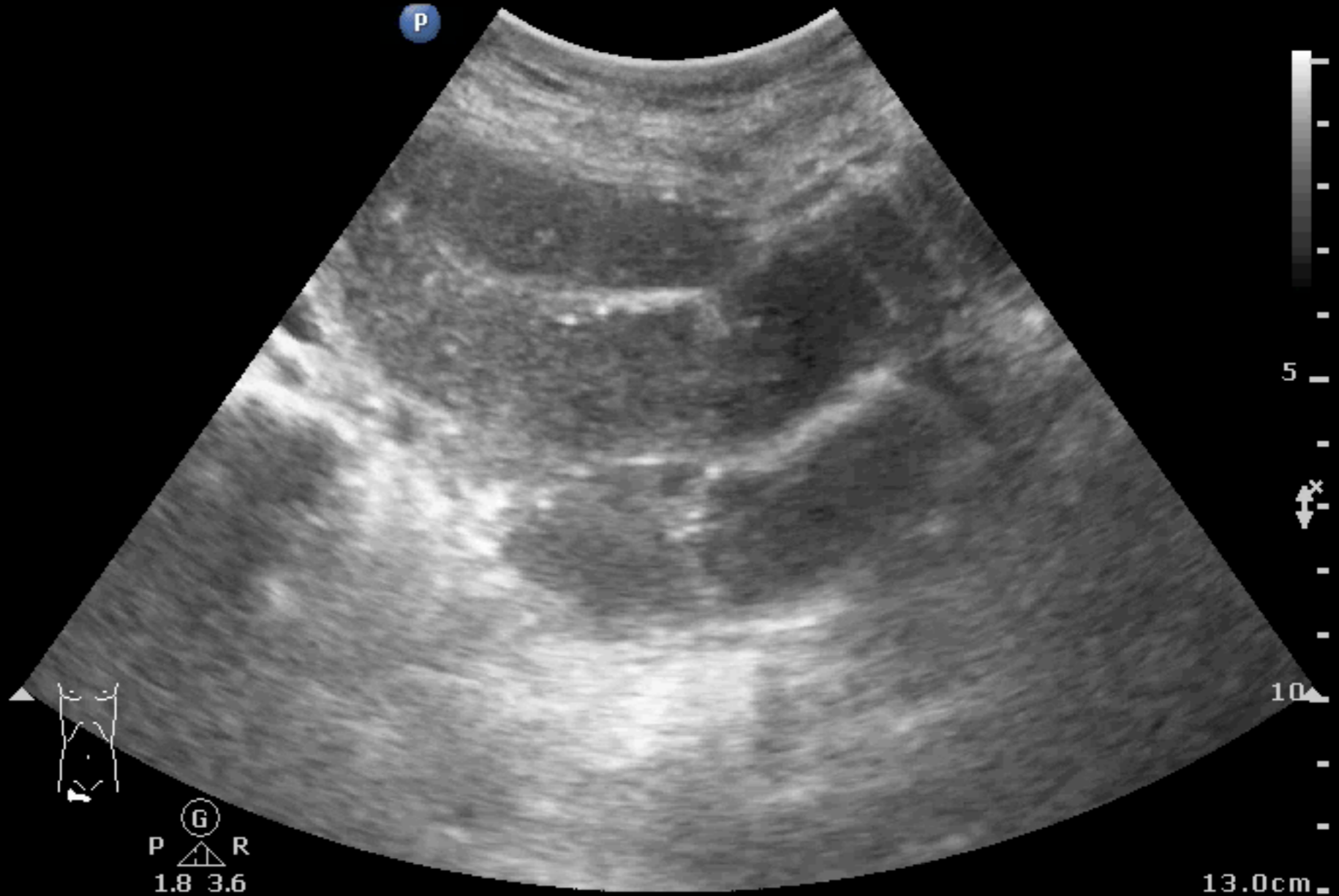88F, diffuse abdominal pain



88F, diffuse abdominal pain

Abd Gen2
C5-1
38 Hz
13.0cm

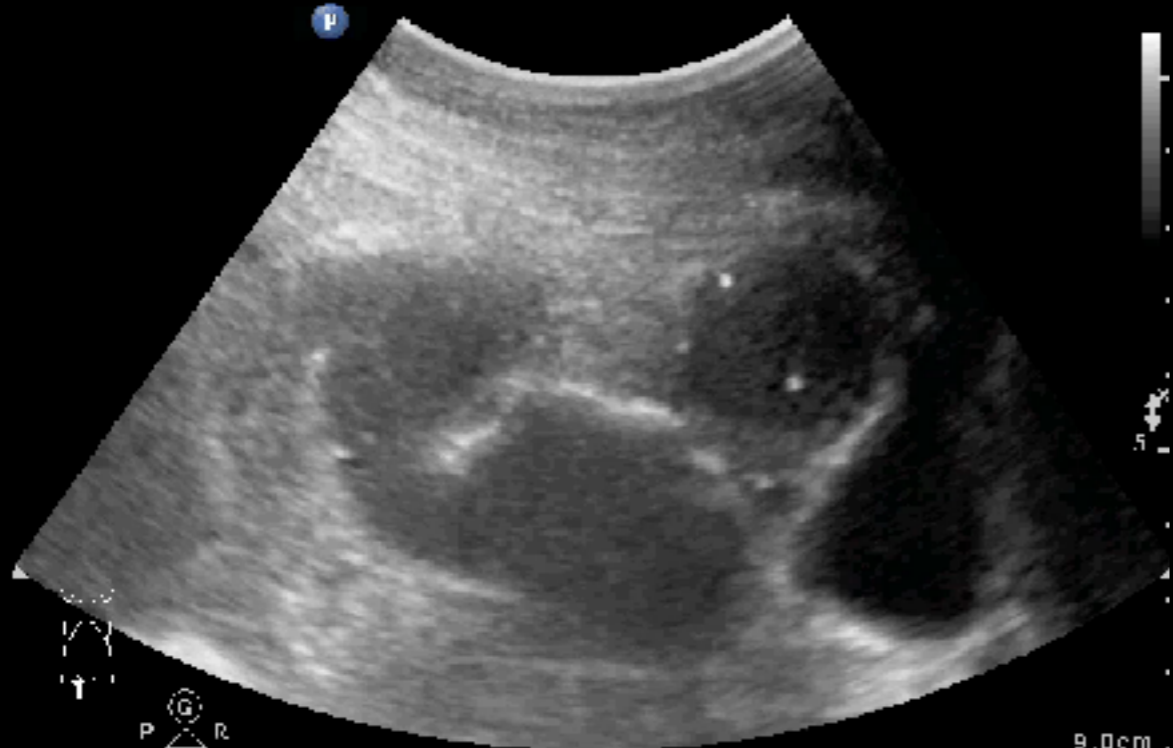
2D
HGen
Gn 99
C 51
3/3/3



Small Bowel Obstruction

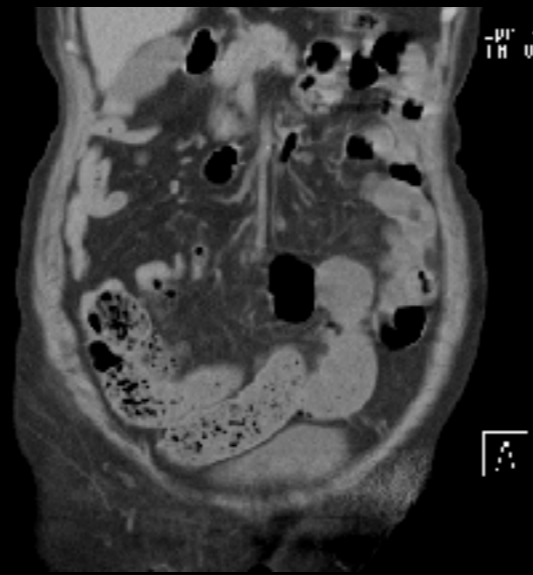
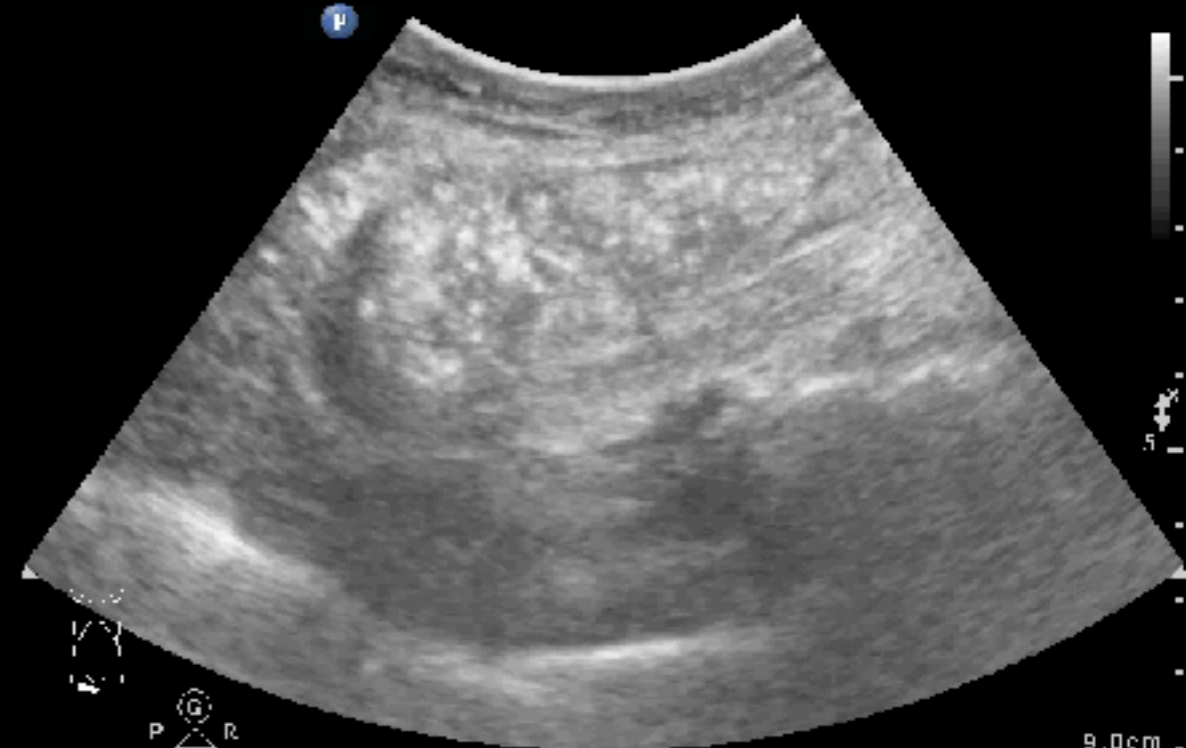Abd Gen2
05 1
47 Hz
9.0cm

2D
111ien
Gr 99
C 51
3/3/3



Abd Gen2
05 1
47 Hz
9.0cm

2D
111ien
Gr 99
C 51
3/3/3

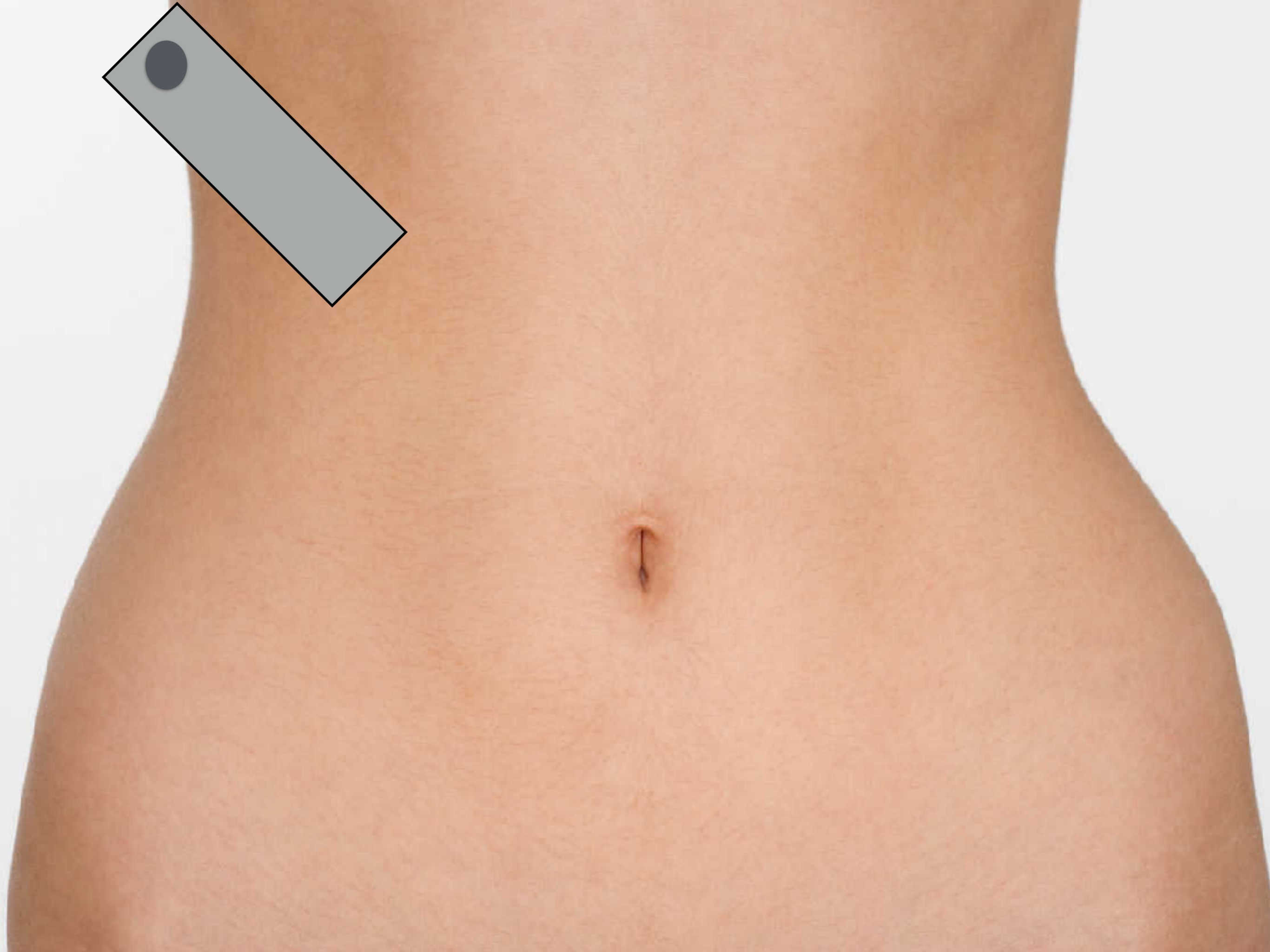

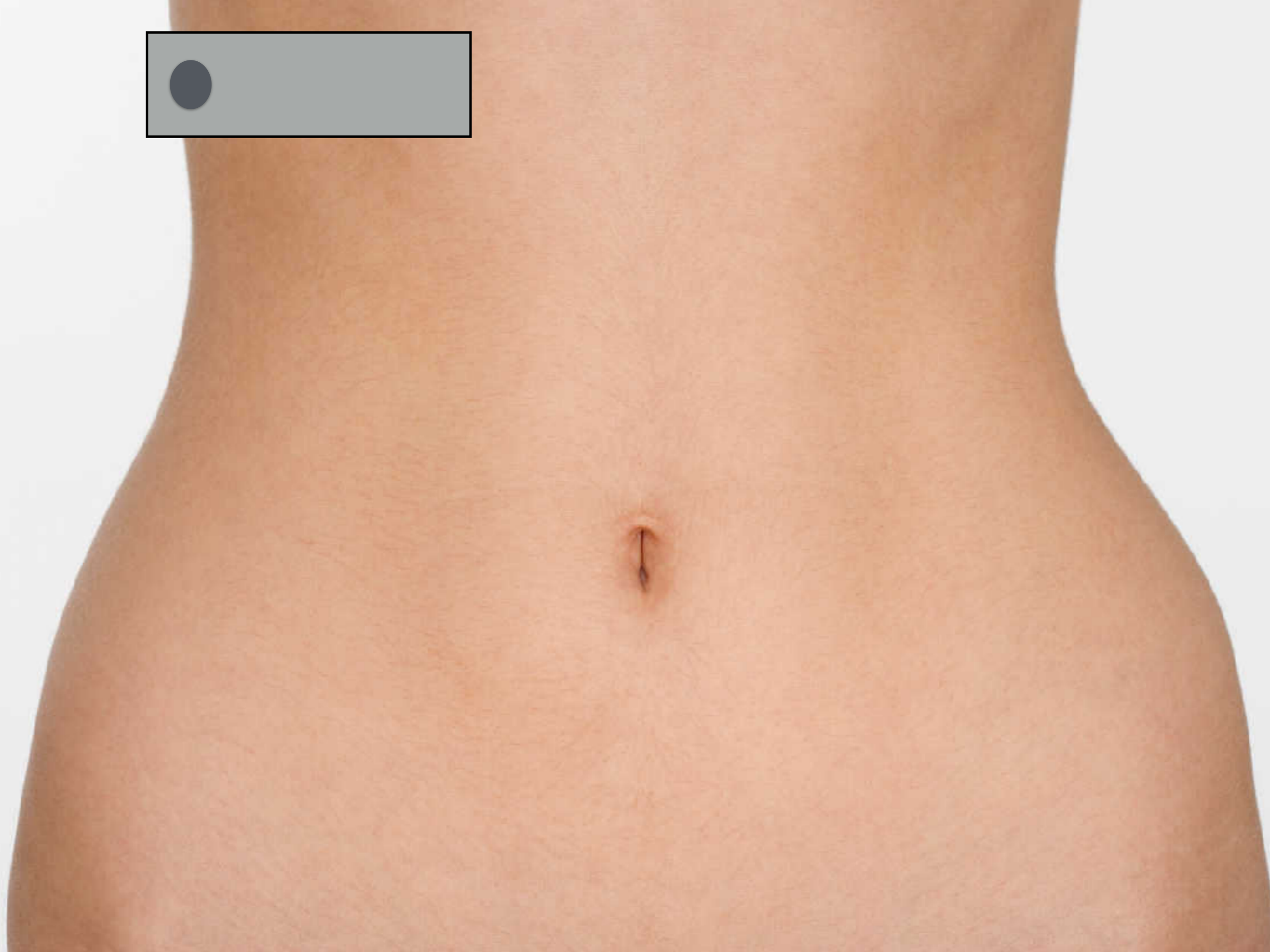ABDOMEN

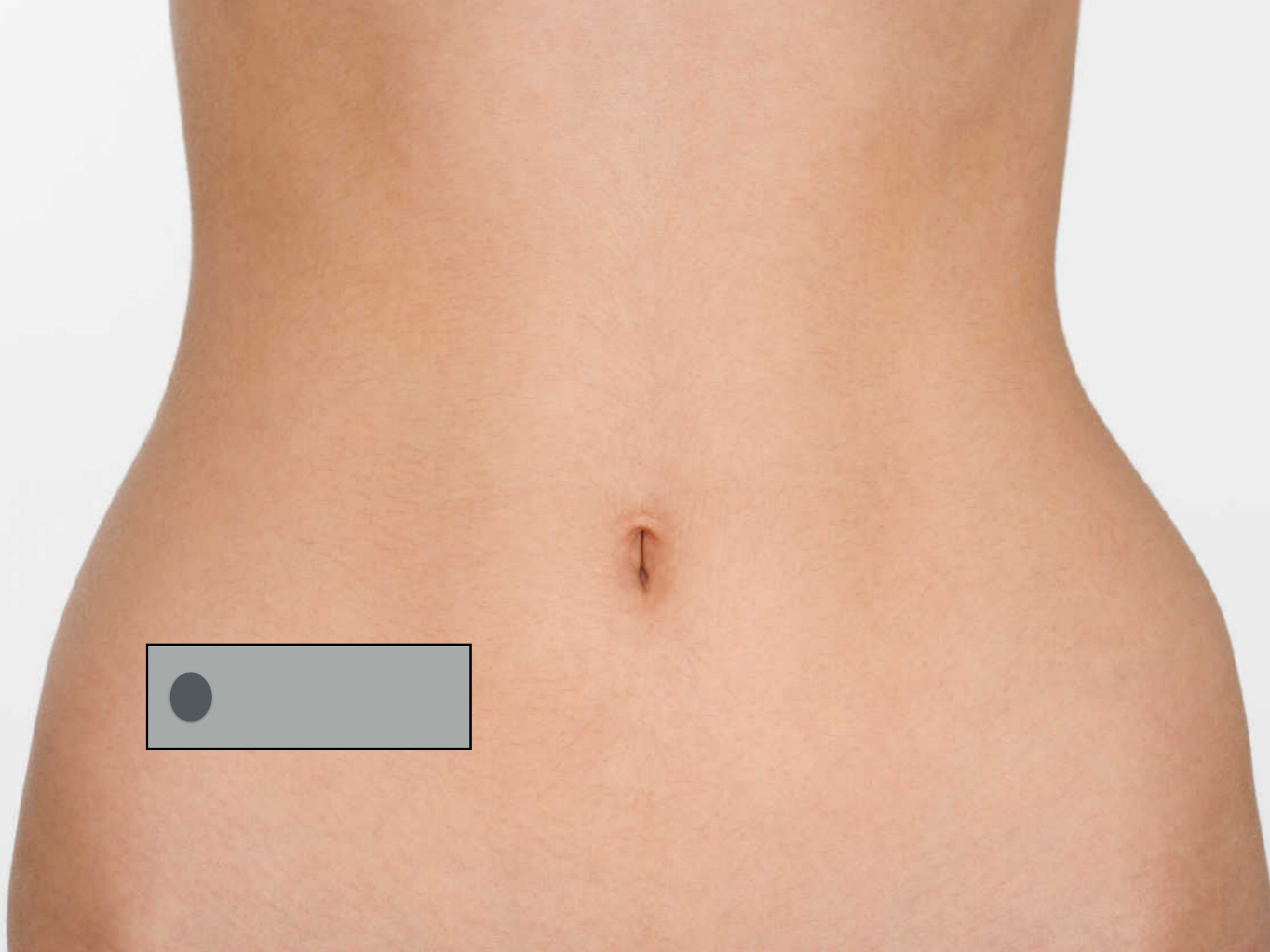
O for obstruction
(SBO & Intussusception)

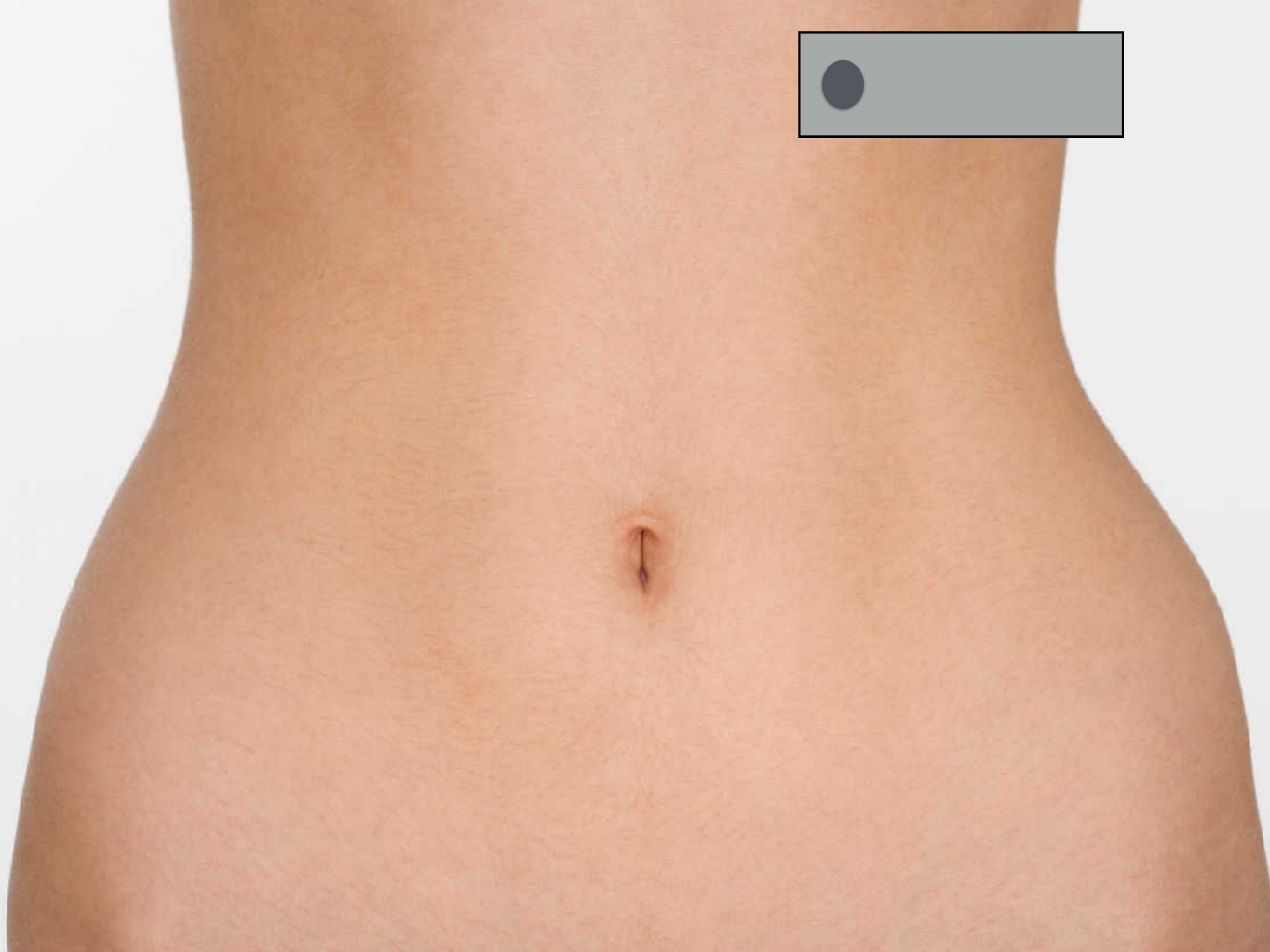3
cm

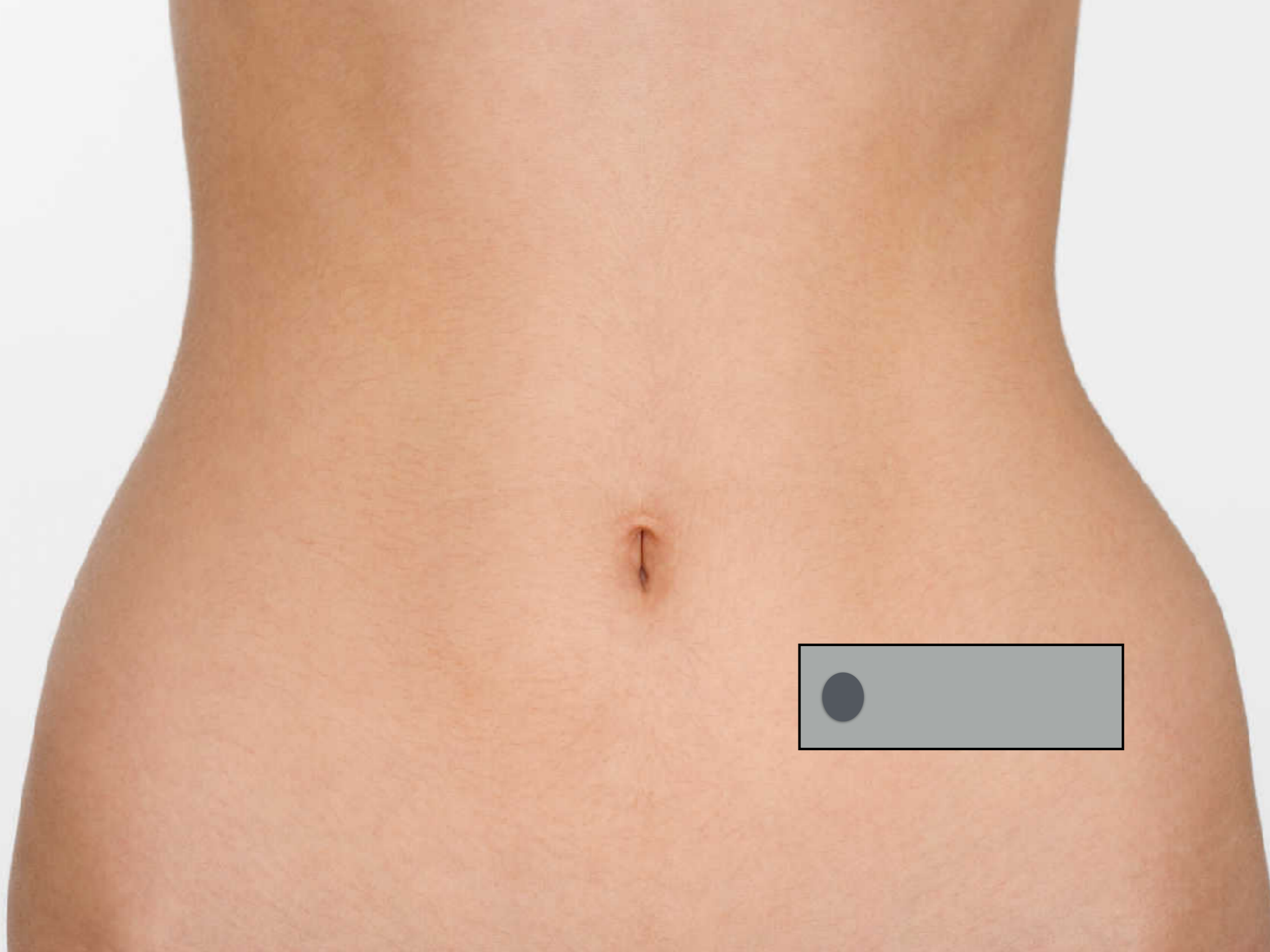
5
cm

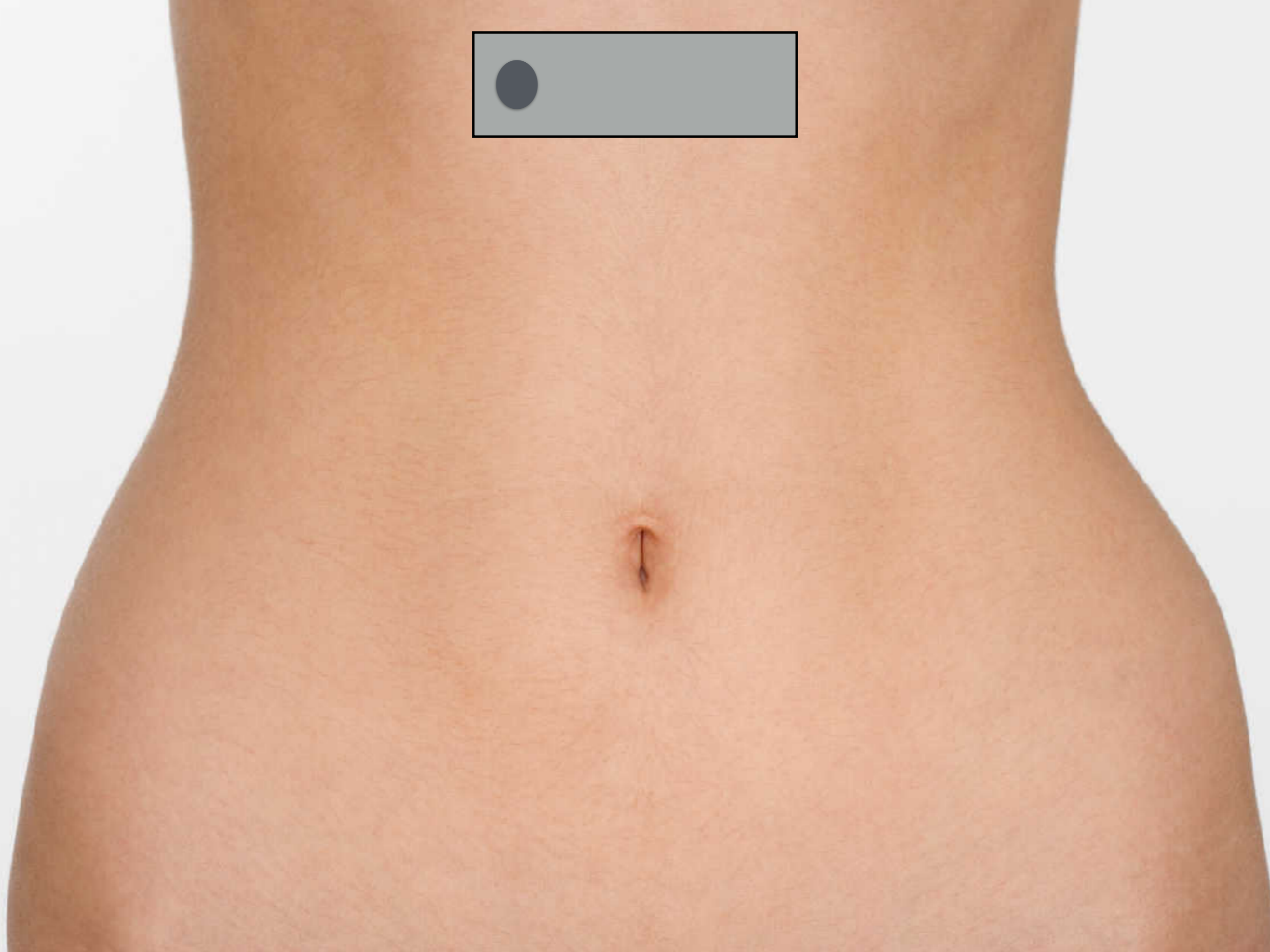


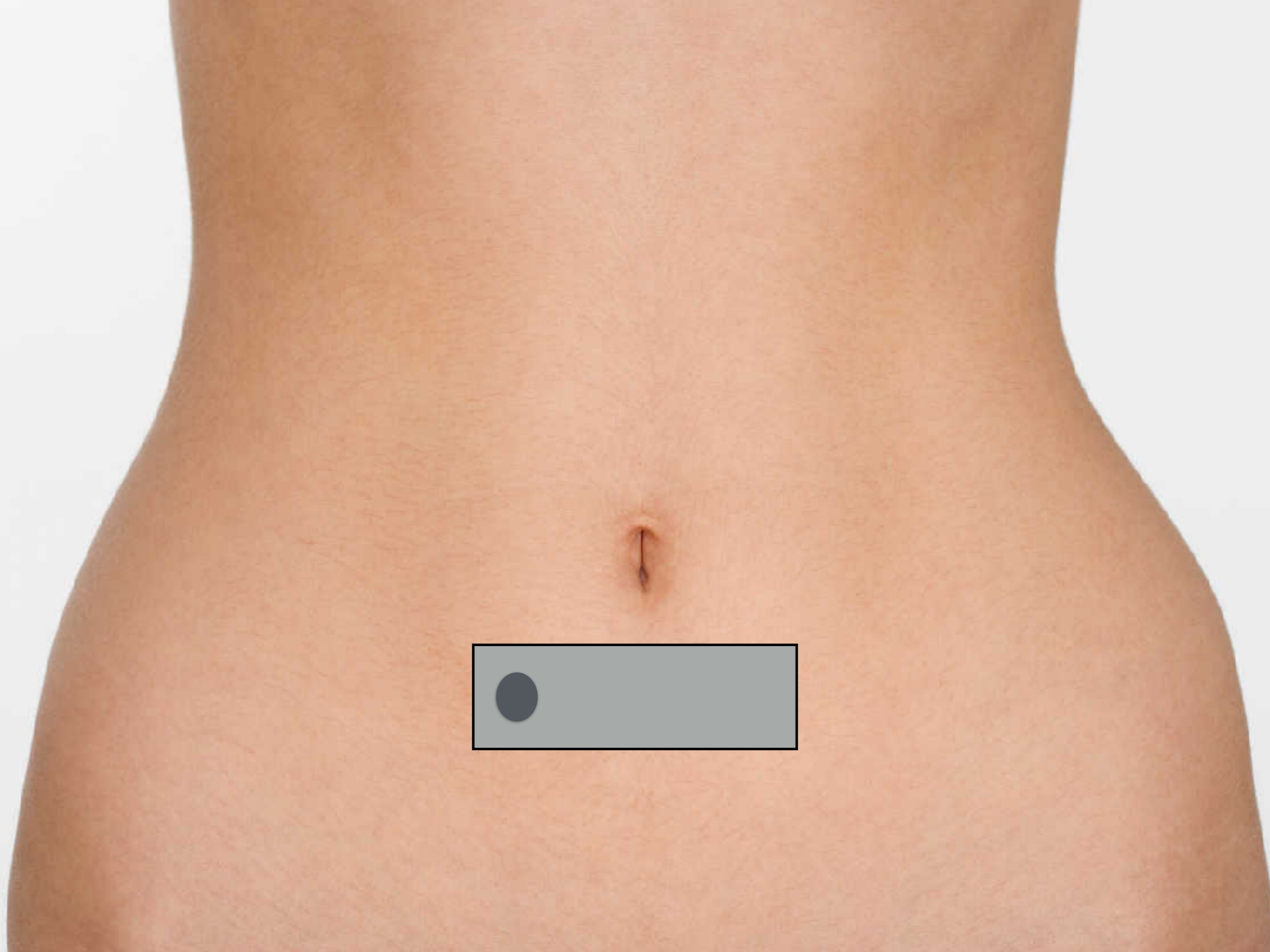




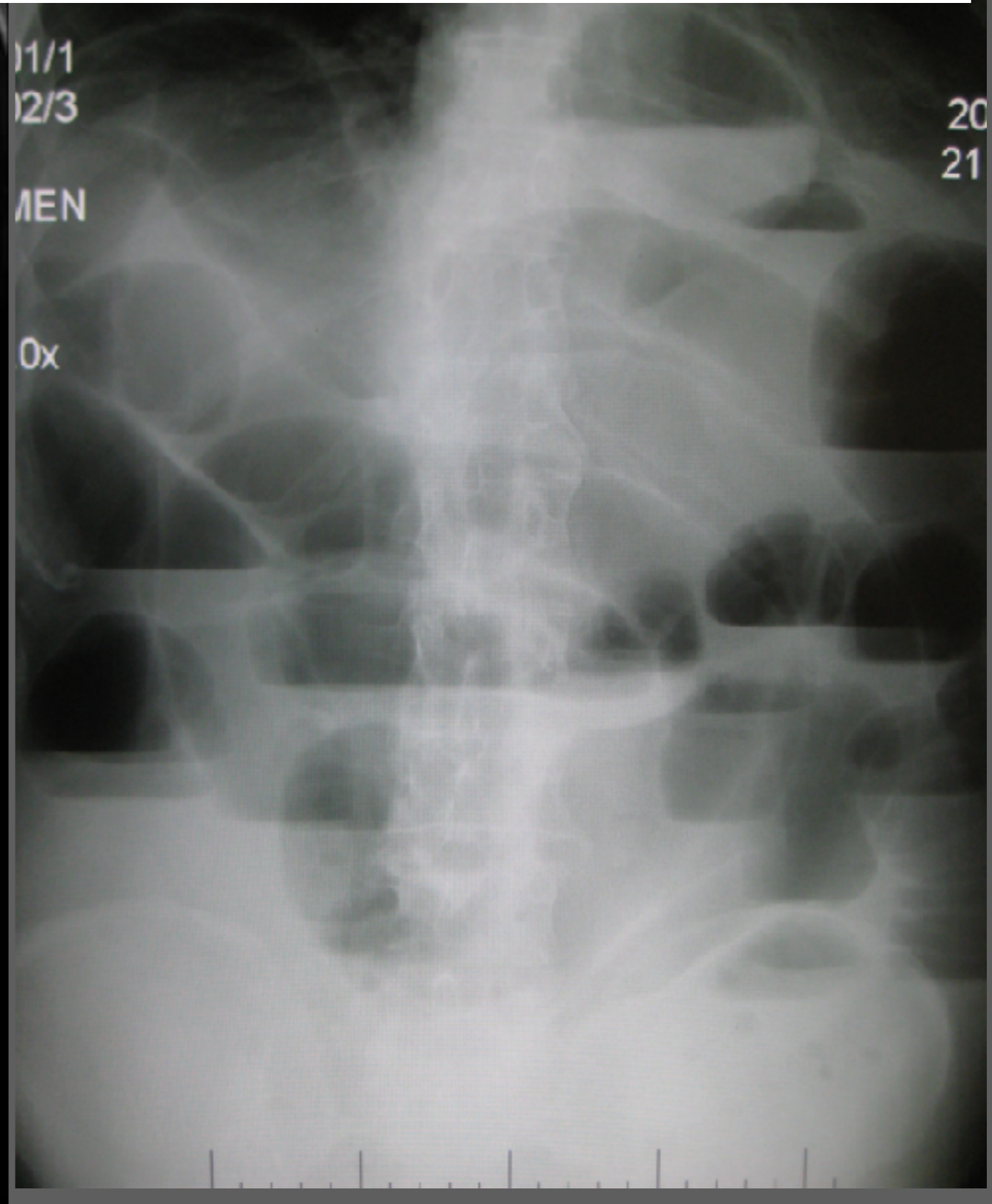
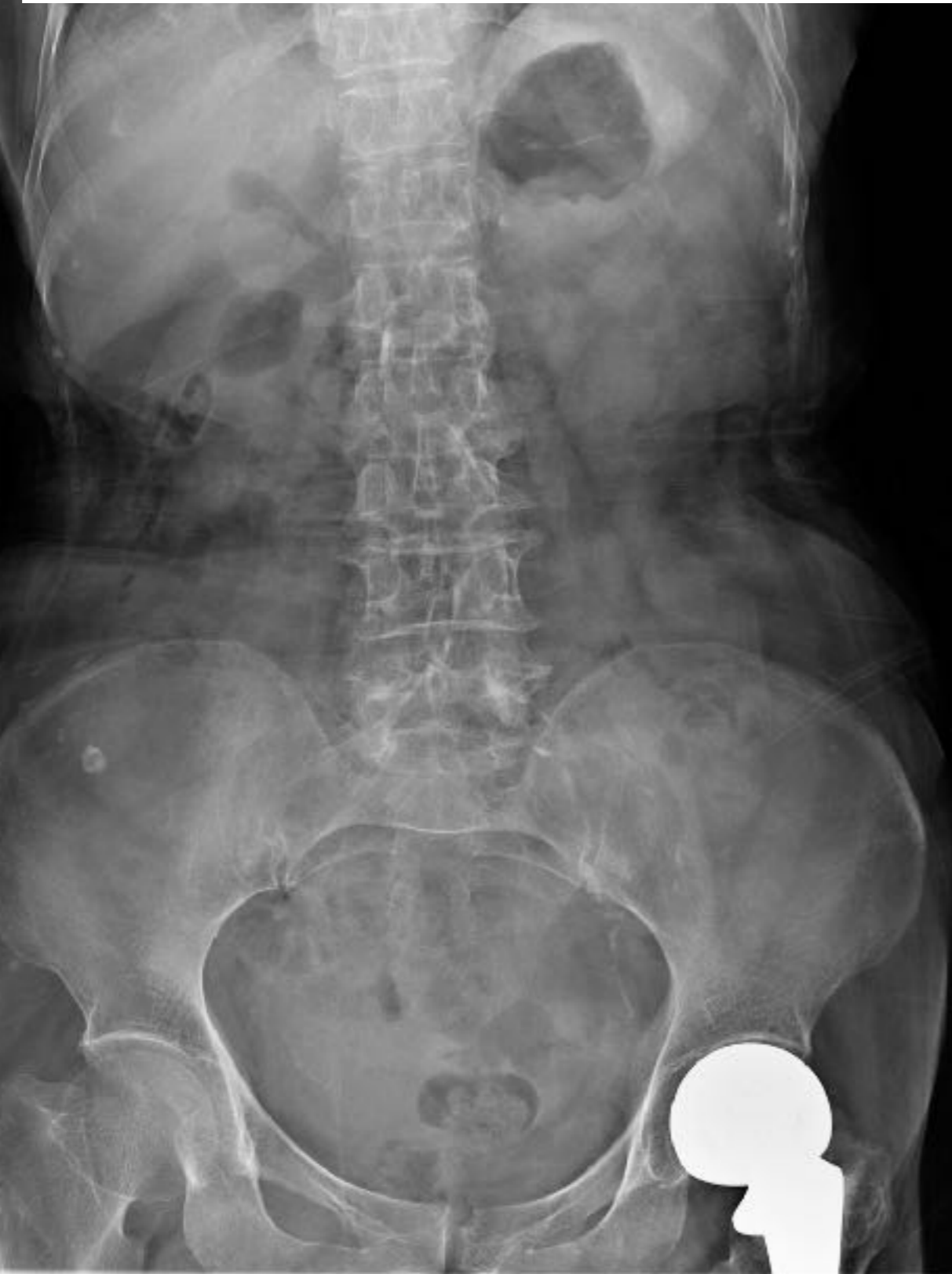




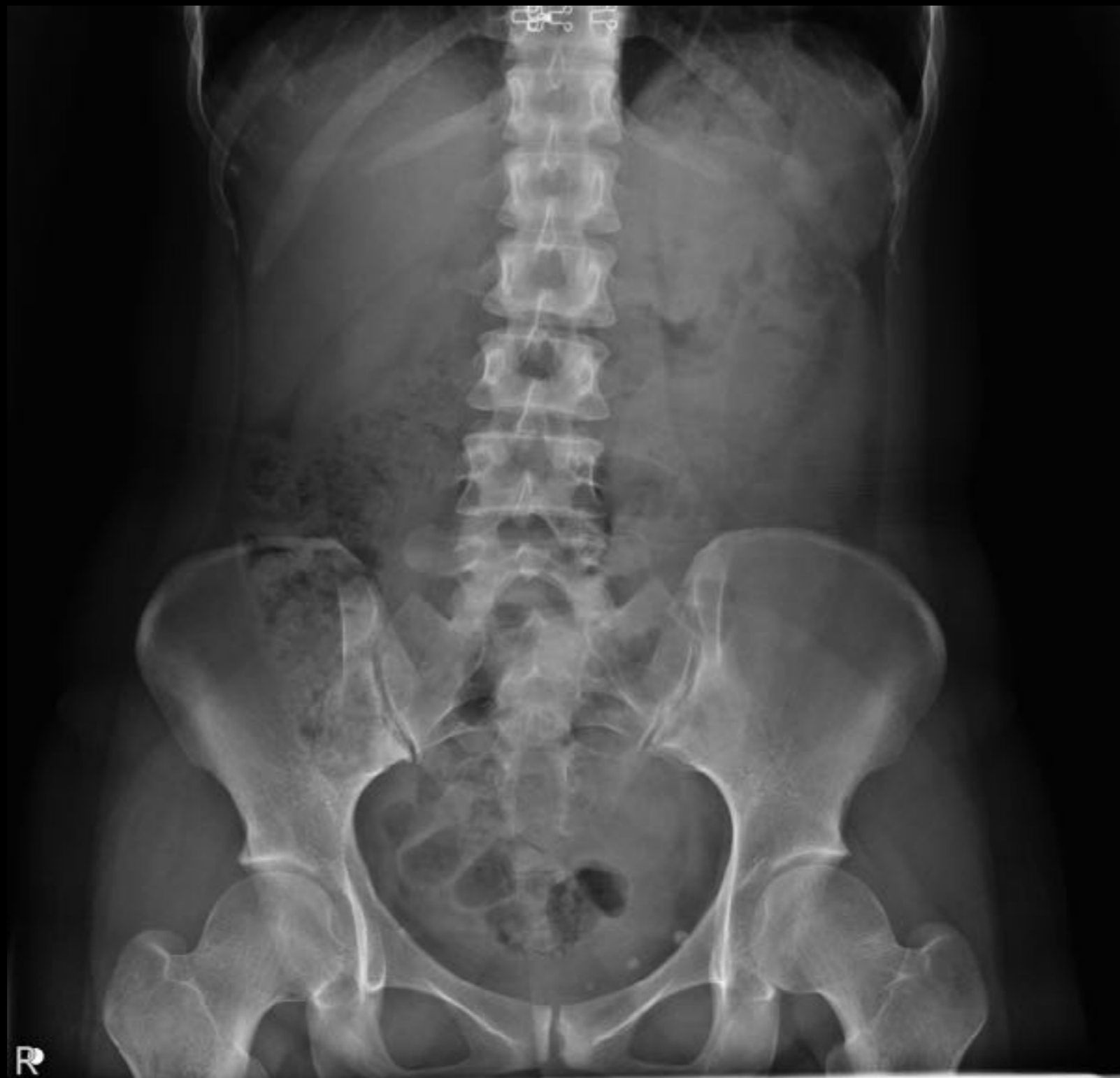


Bowel Obstruction

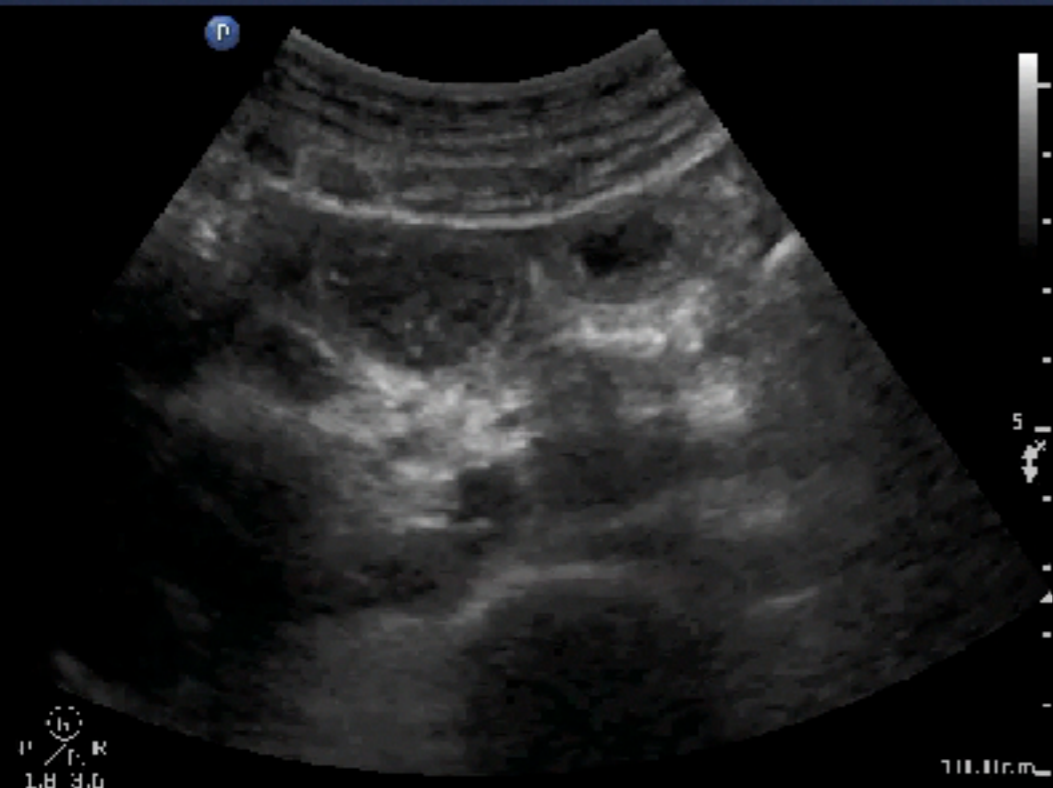


31F with abdominal pain & vomiting for 2 days



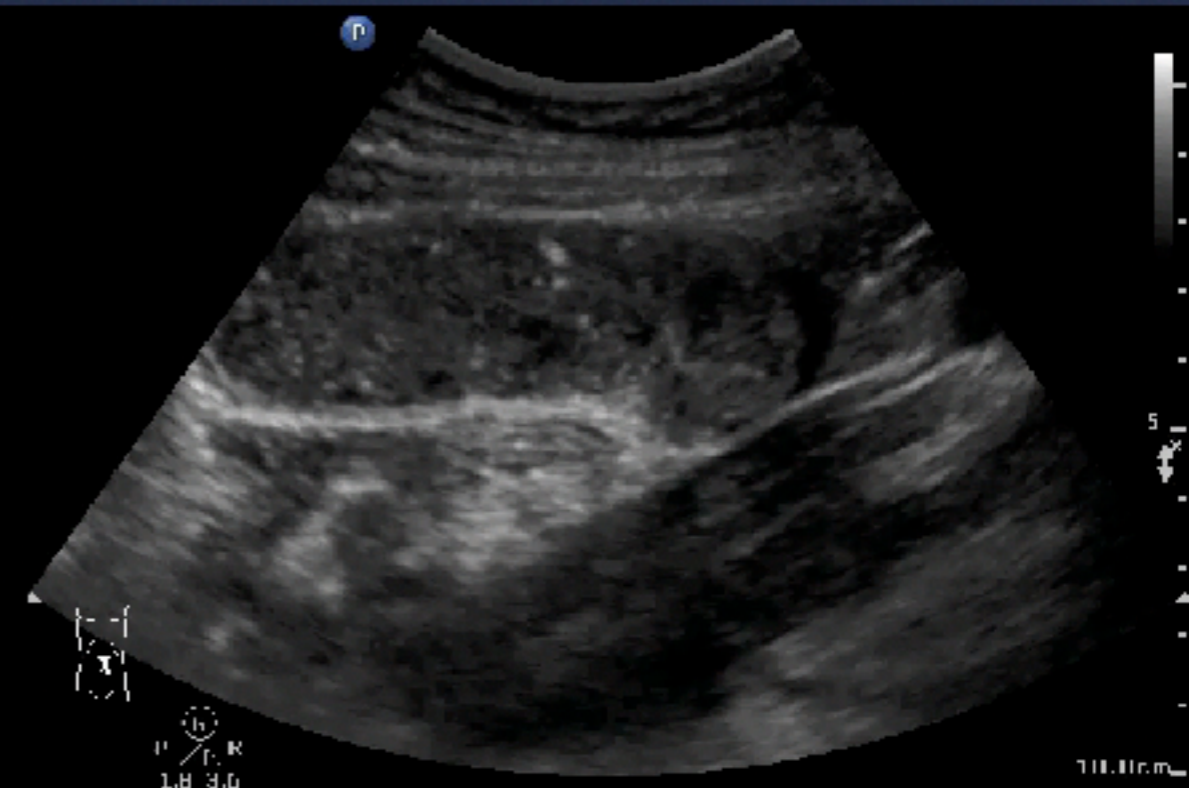
Abd Gen
C5-1
45 Hz
10.0cm

2D
HGen
Gn 51
C 56
3/3/3



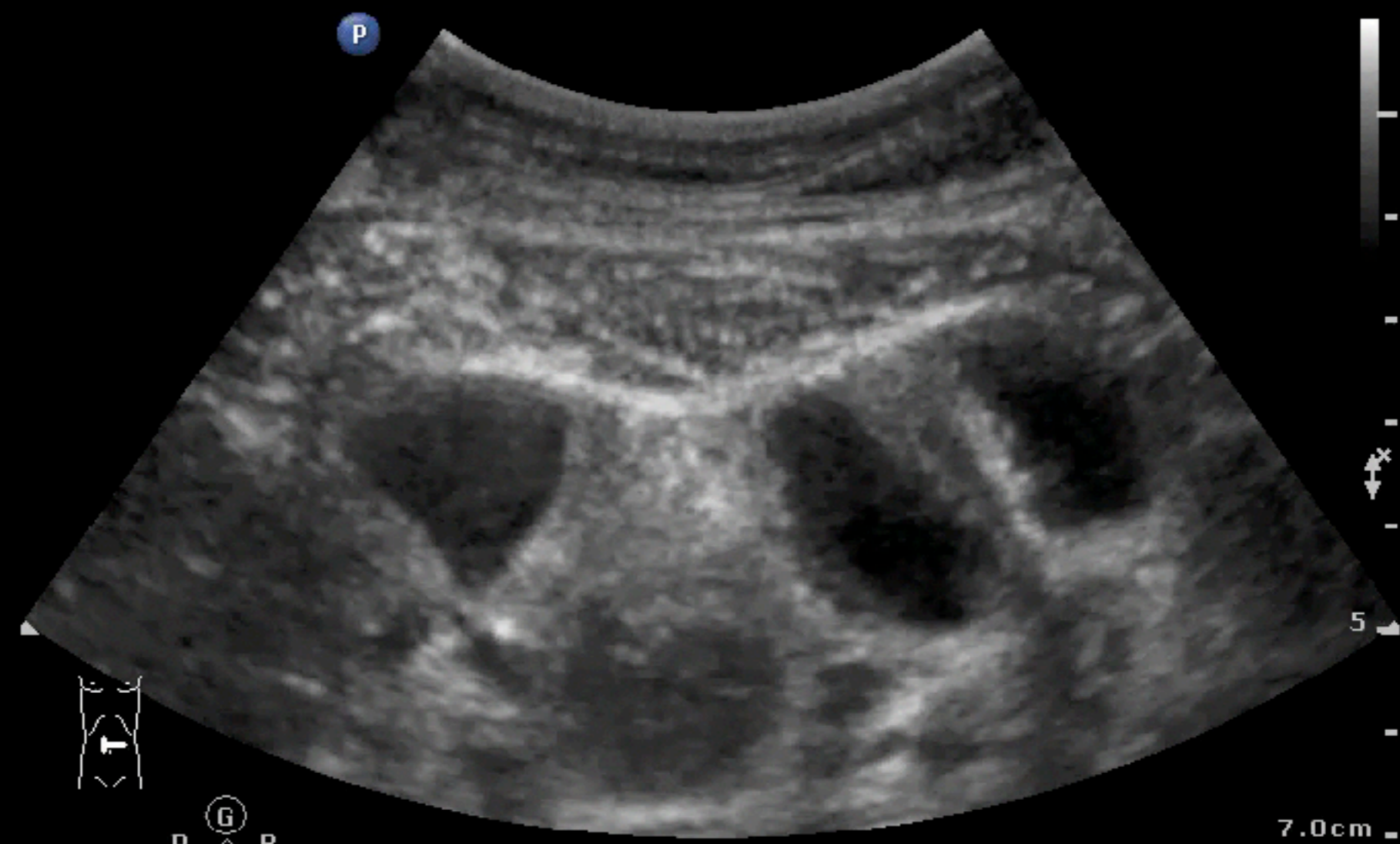
Abd Gen
C5-1
45 Hz
10.0cm

2D
HGen
Gn 45
C 56
3/3/3

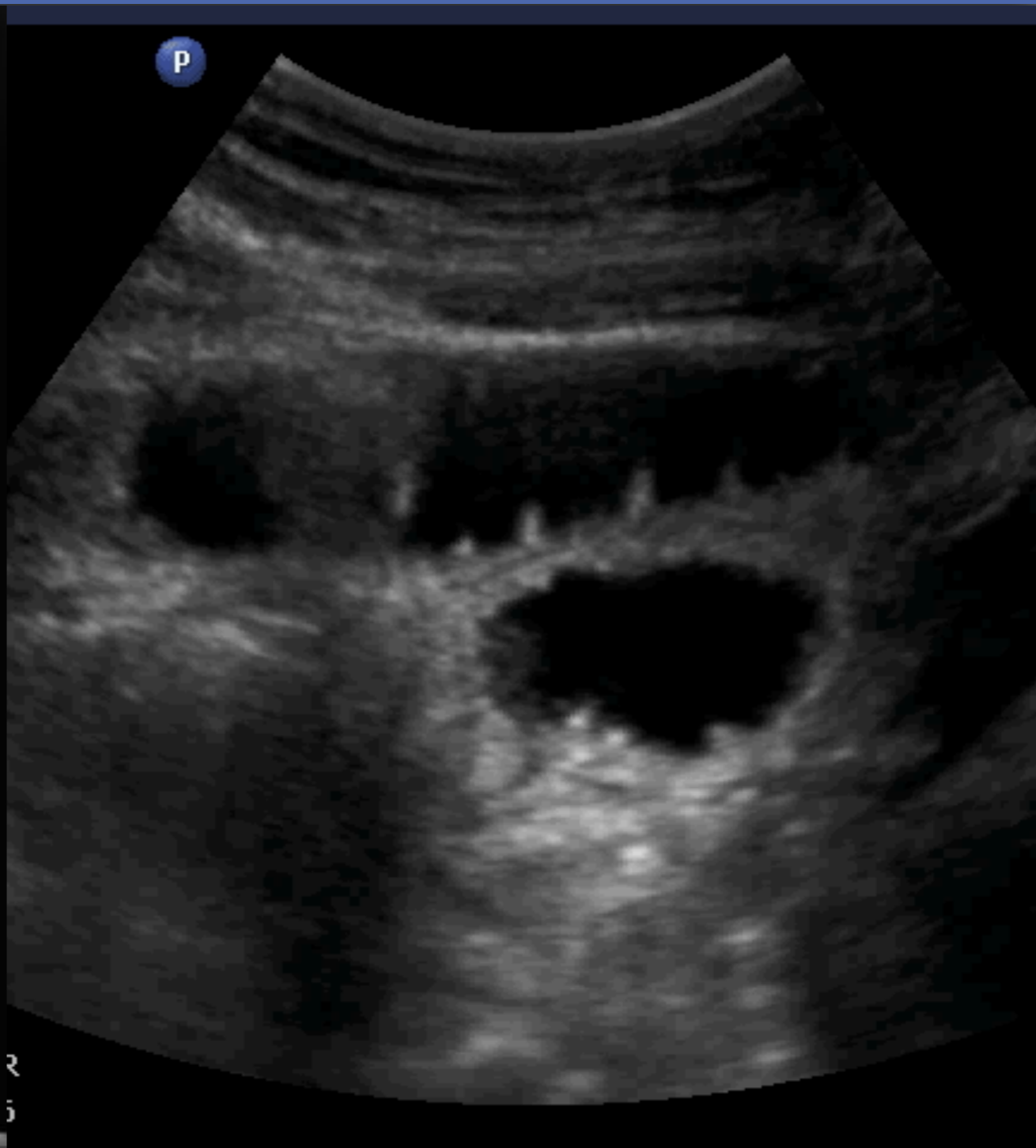
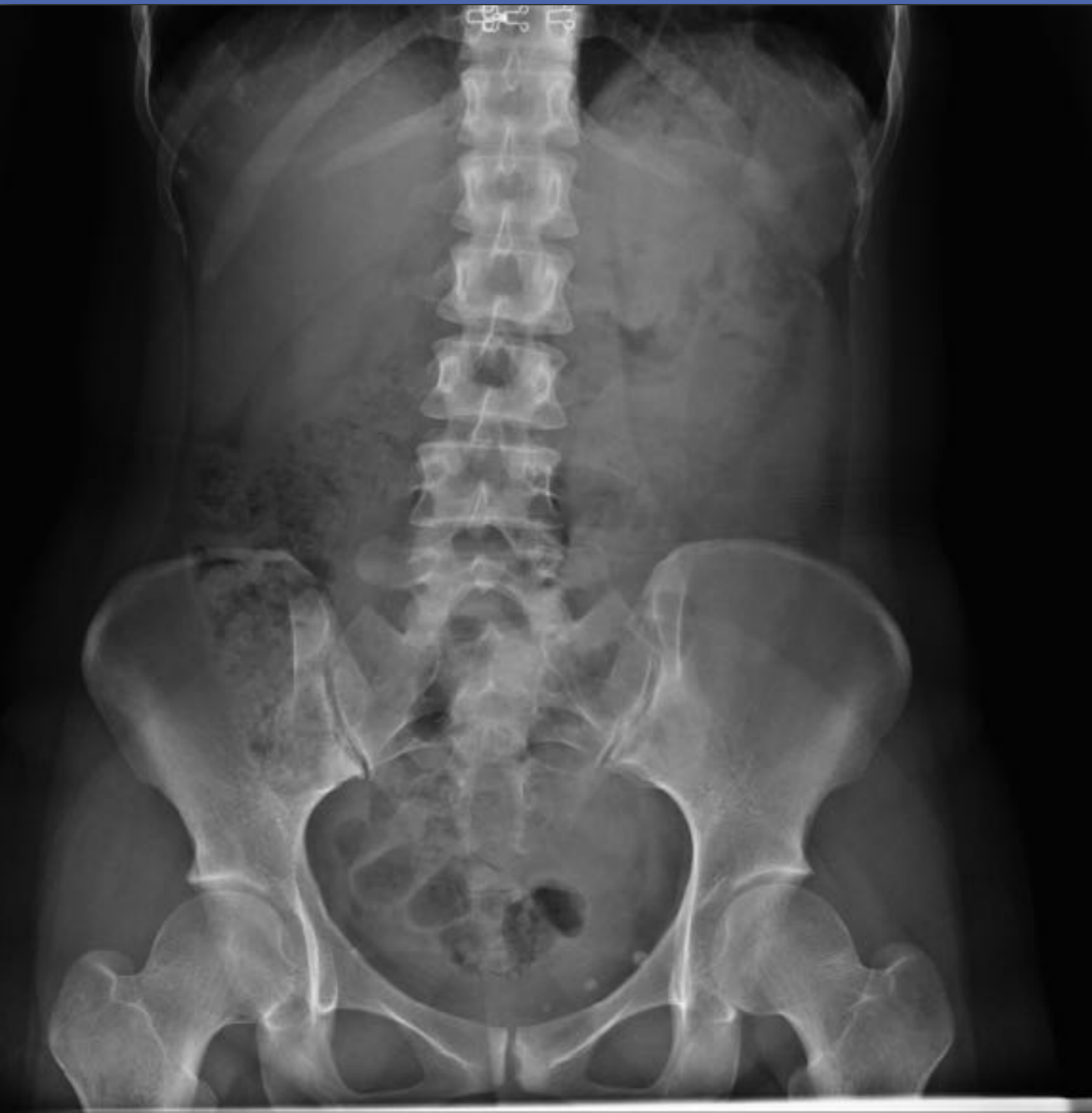

Abd Gen
C5-1
55 Hz
7.0cm

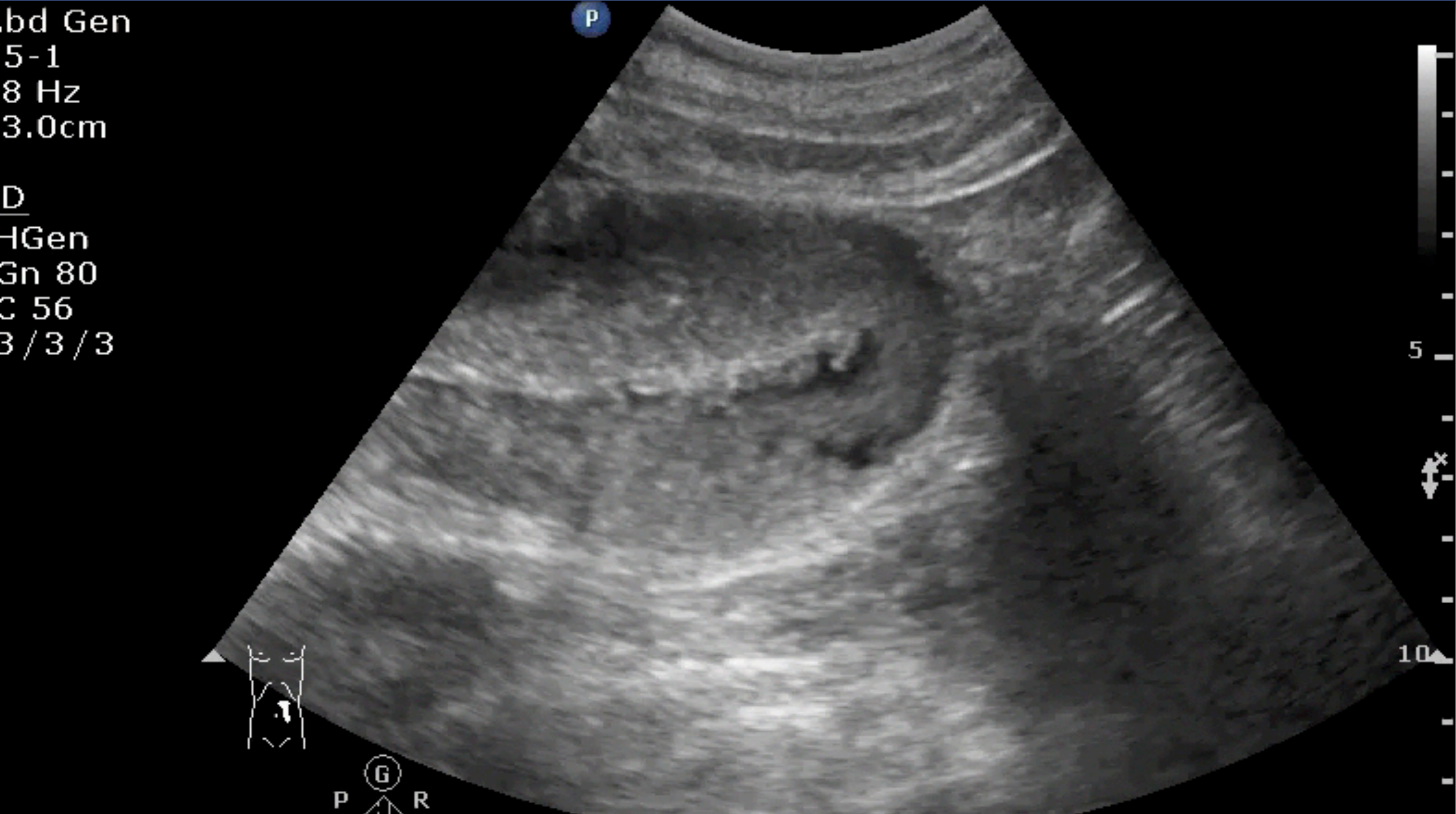
2D
HGen
Gn 67
C 56
3/3/3



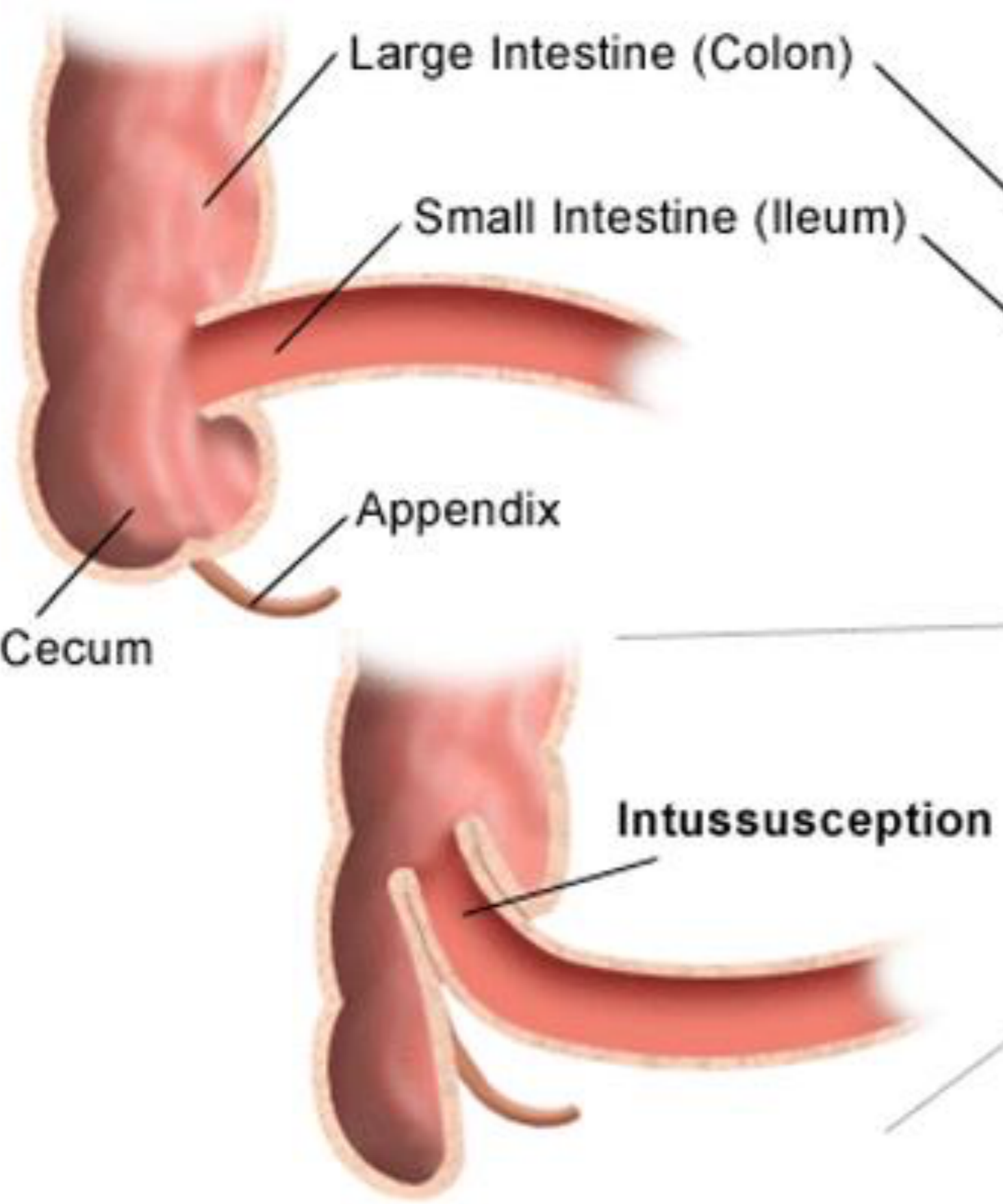
POCUS is useful for gasless ileus detection



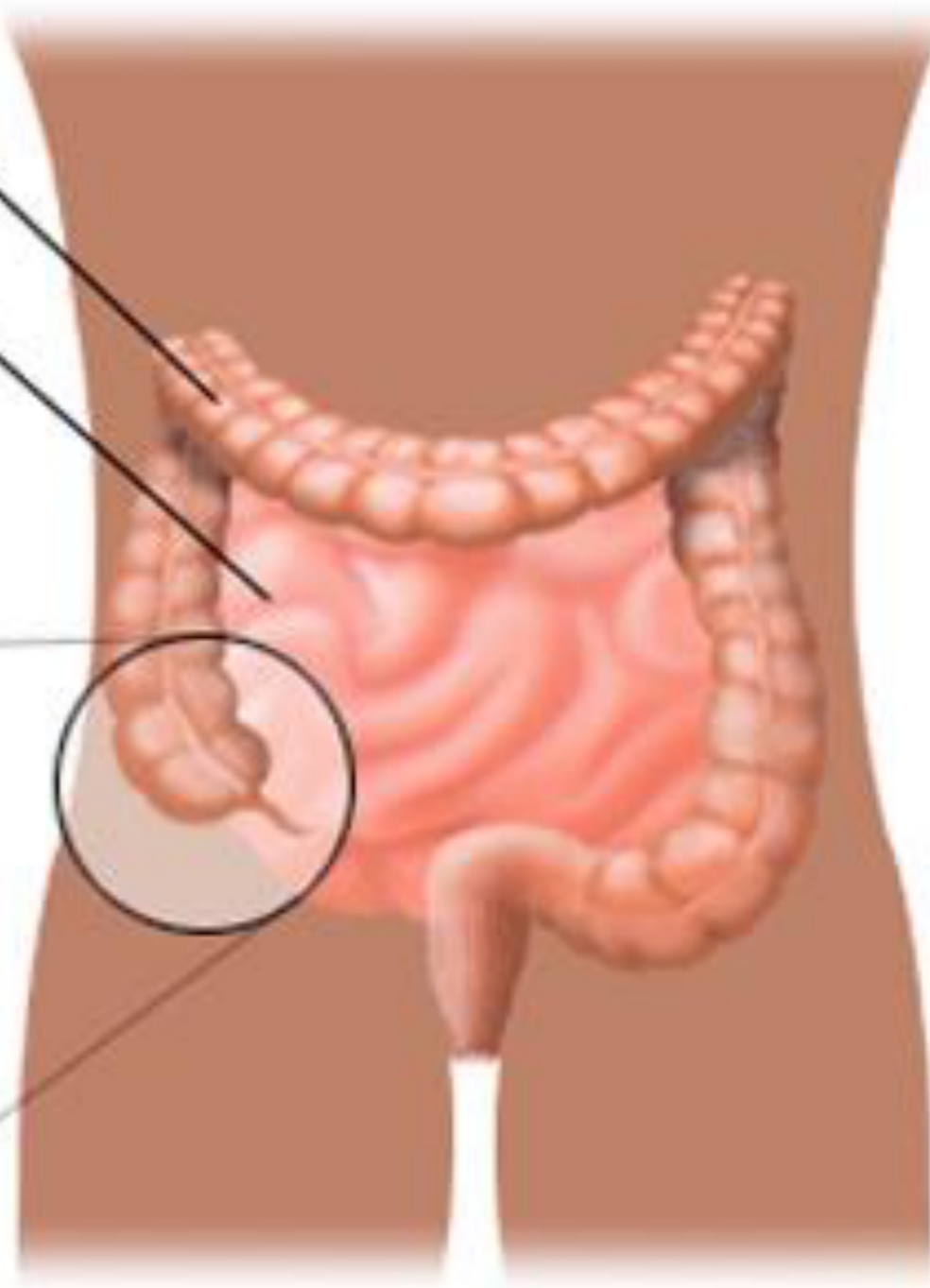
To-and-fro movement Keyboard sign / Tanga sign



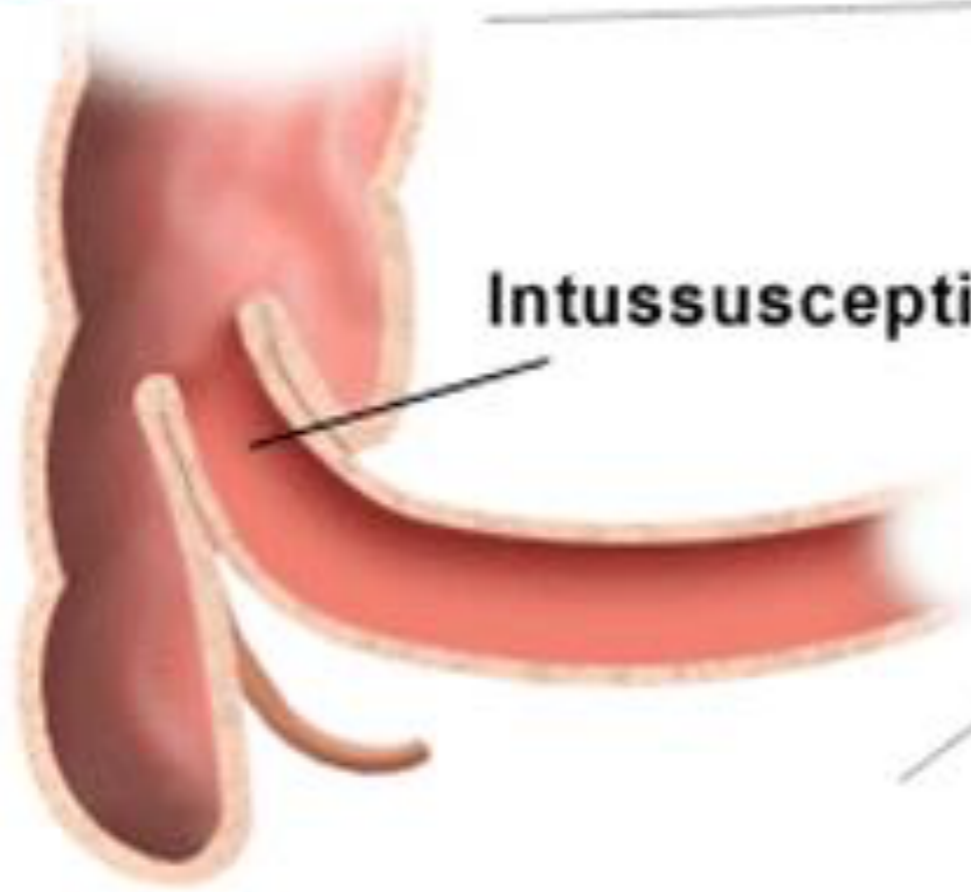
Normal



Intussusception



Intussusception



Ileum "telescopes" inside ascending colon, obstructing passage of intestinal contents.

Bleeding → "Currant jelly stools"

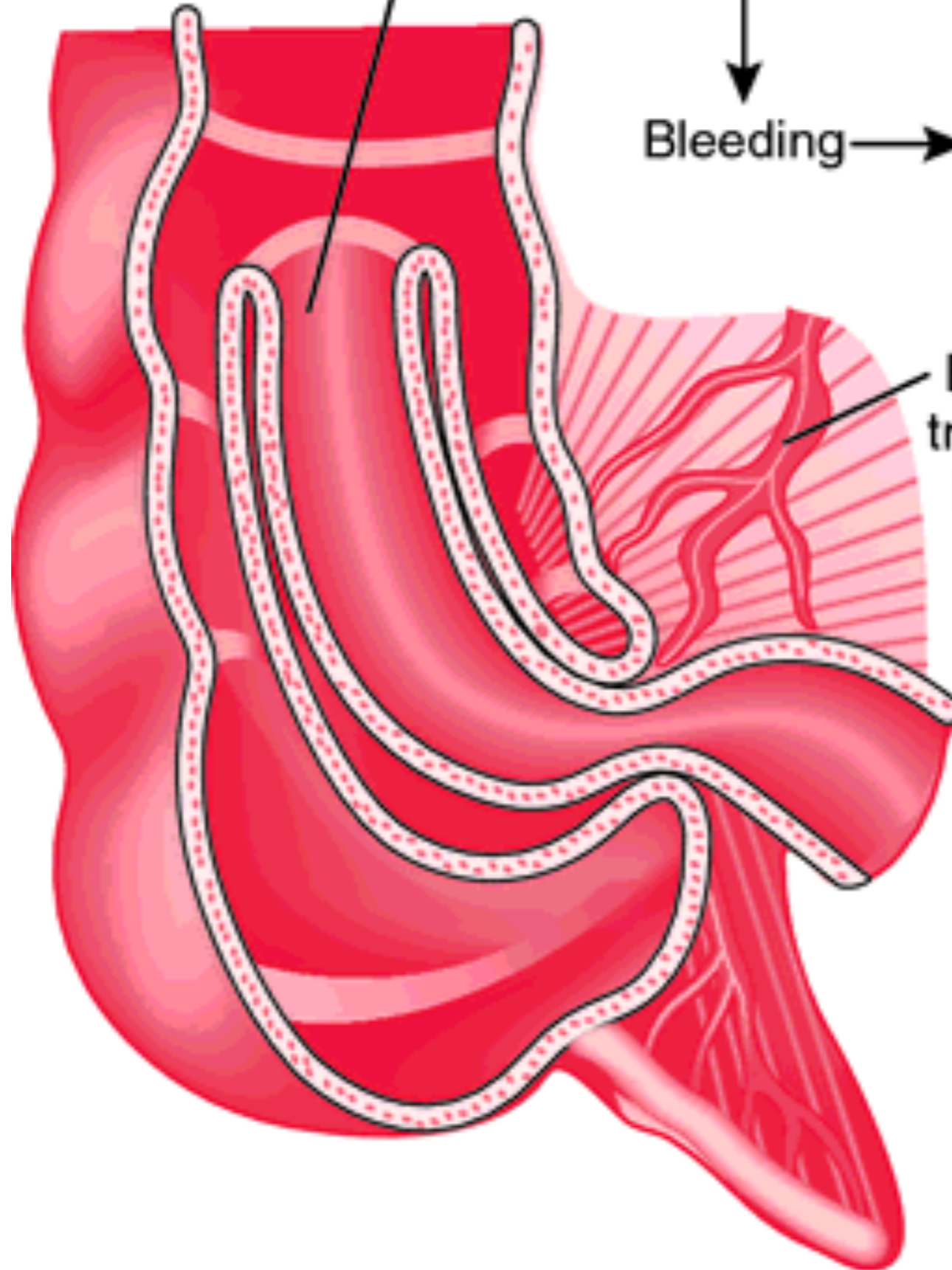
Blood vessels become trapped between layers; blood flow decreases.

Edema

Strangulation of bowel

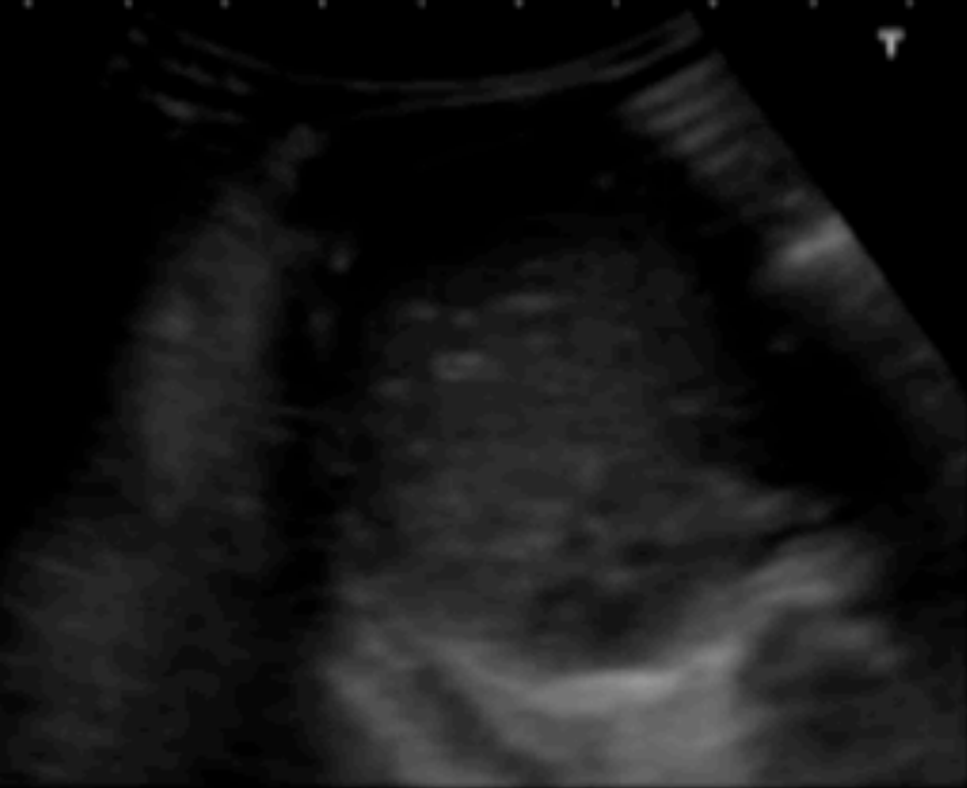Gangrene, sepsis, shock

Death



1F, irritable crying

KCChen@SKH-ED

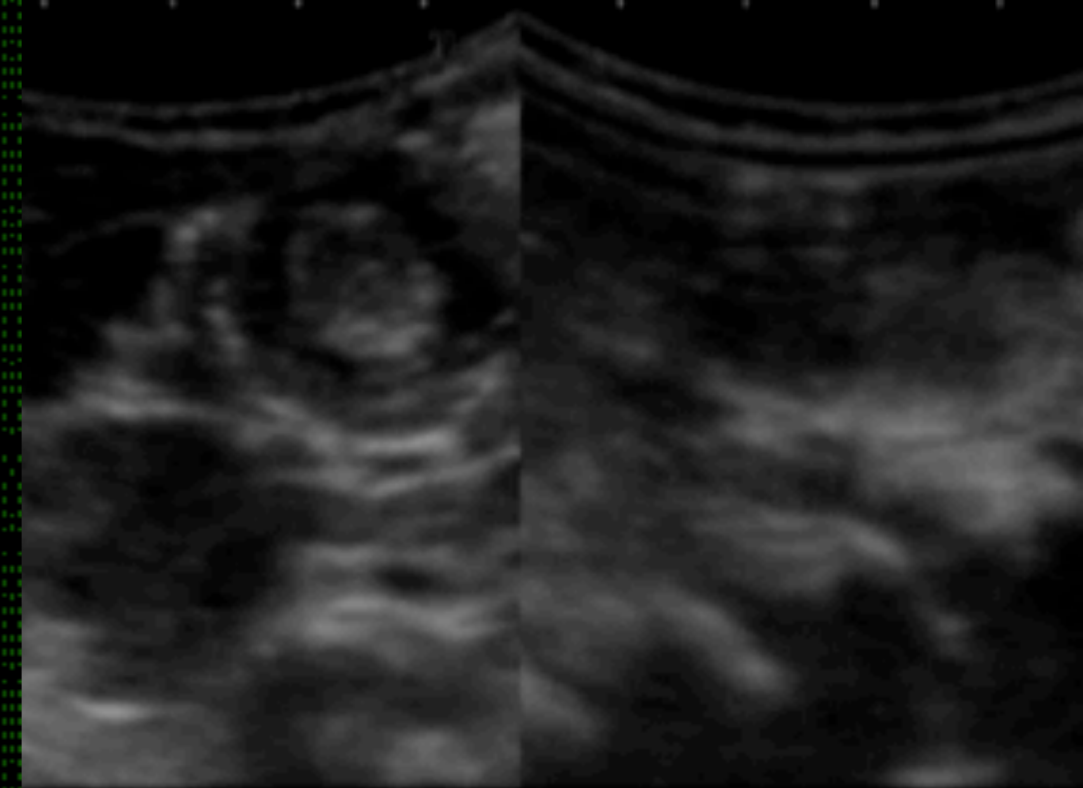


T

F100
6C3
4.2
27fps
DR70
200
06

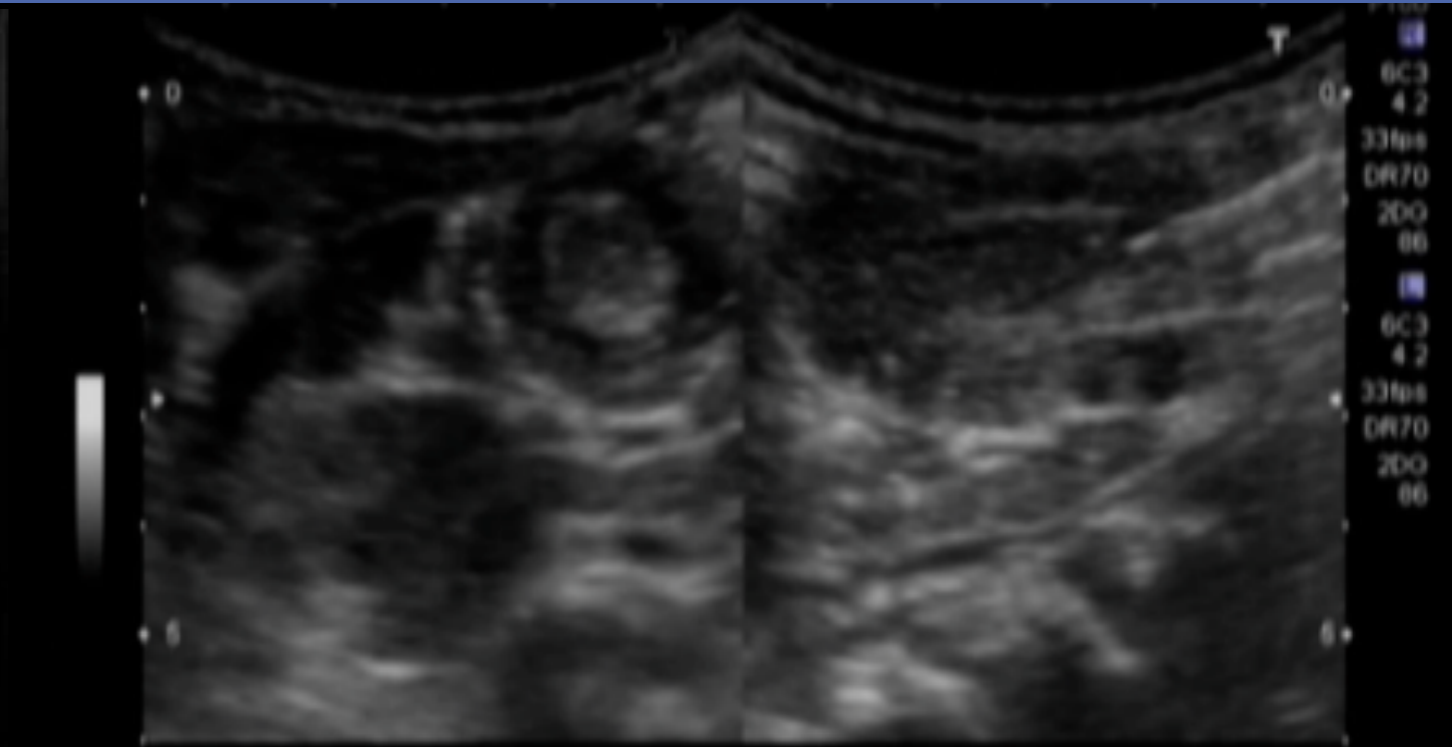
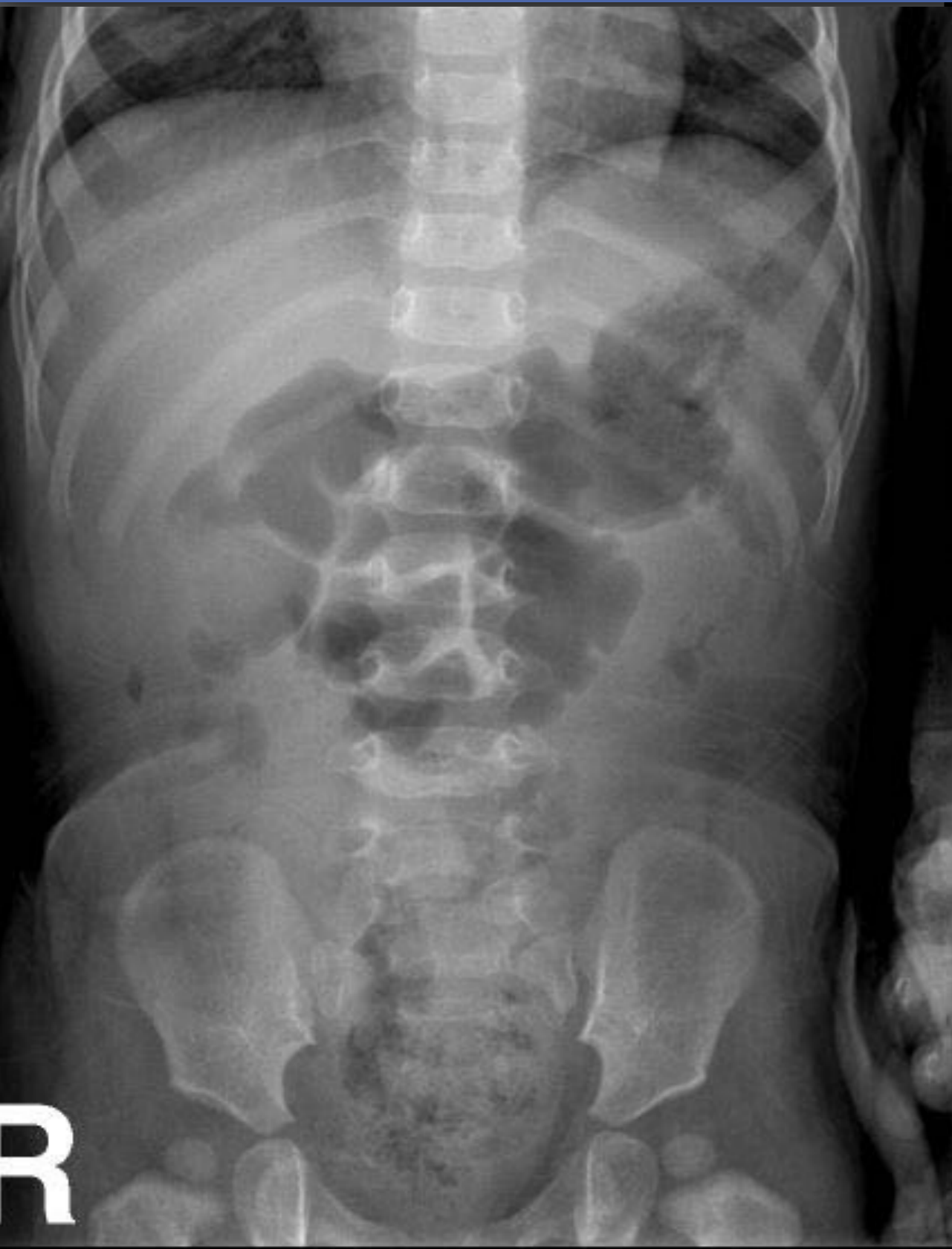Free 0

KCChen@SKH-ED



Free 0

Intussusception



Target sign

Pseudokidney sign

Sandwich sign

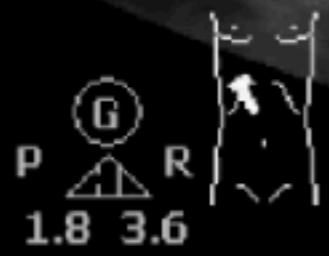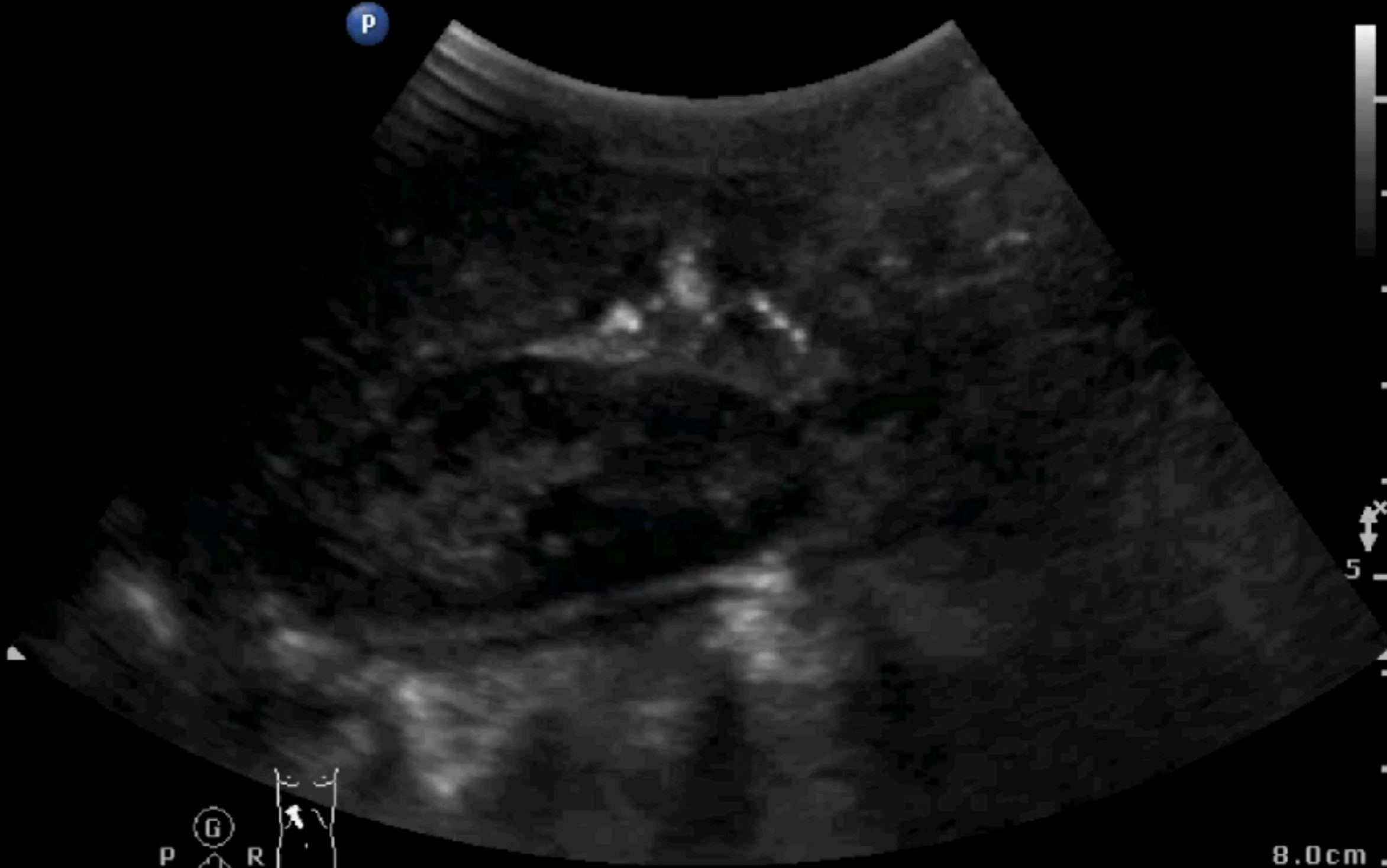
Hayfork sign

ABDOMEN

Abd Gen2
C5-1
51 Hz
8.0cm

2D

HGen
Gn 60
C 56
3/3/3



8.0cm

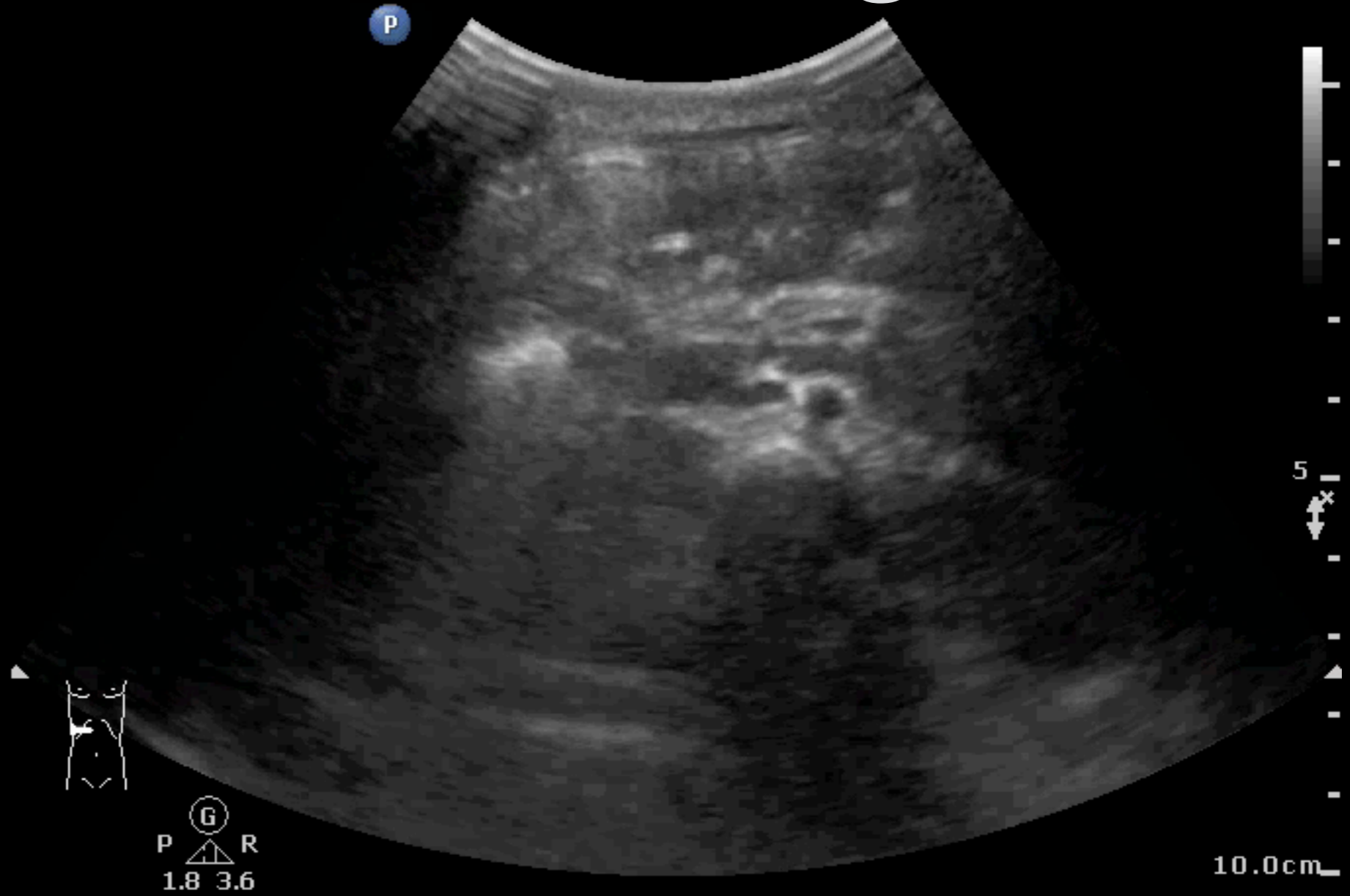
ABDOMEN

PHILIPS

7m, retching

Abd Gen
C5-1
45 Hz
10.0cm

2D
HGen
Gn 72
C 56
3 / 3 / 3

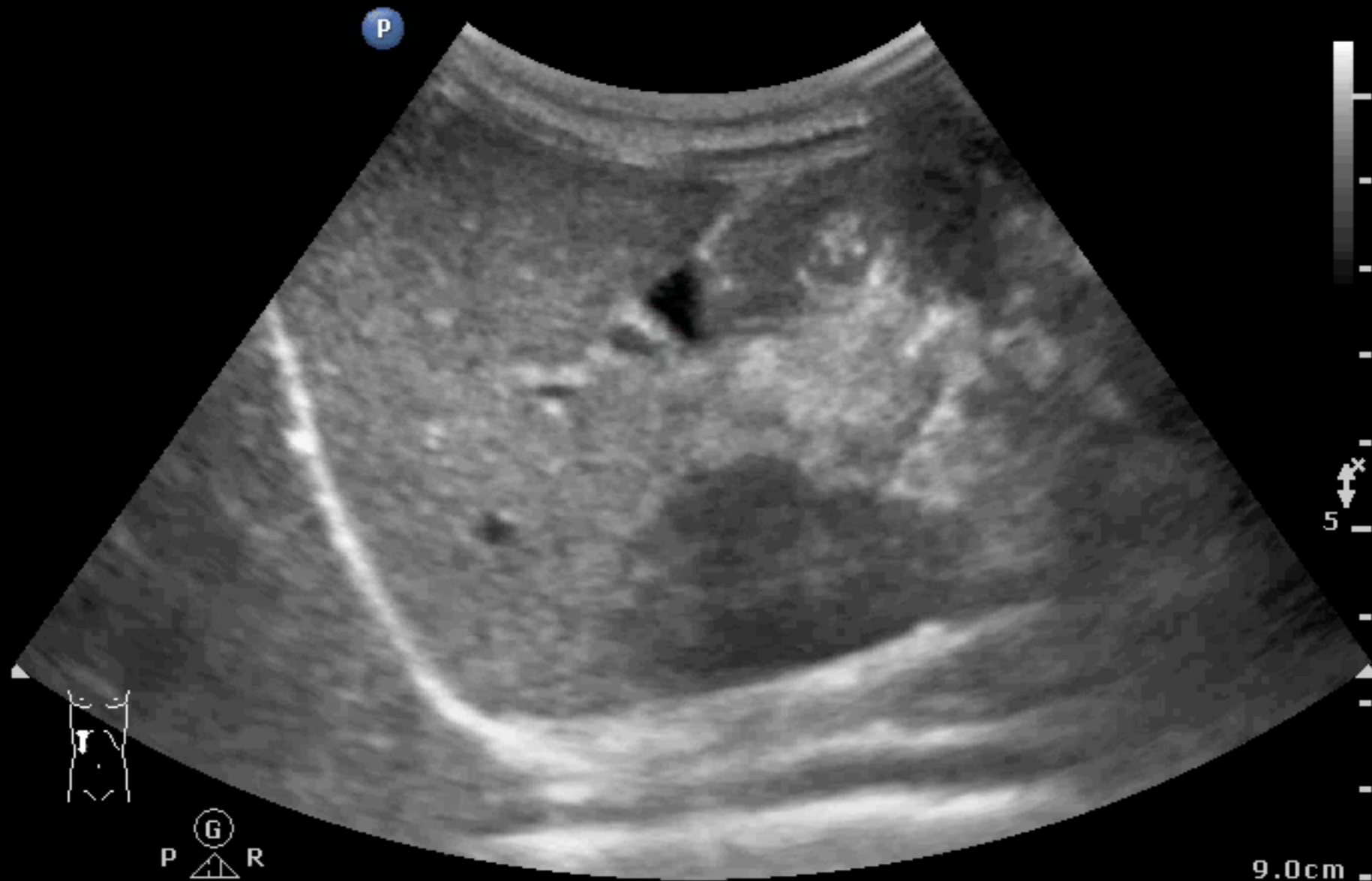

ABDOMEN

Intussusception

Abd Gen
C5-1
47 Hz
9.0cm

2D
HGen
Gn 72
C 56
3 / 3 / 3




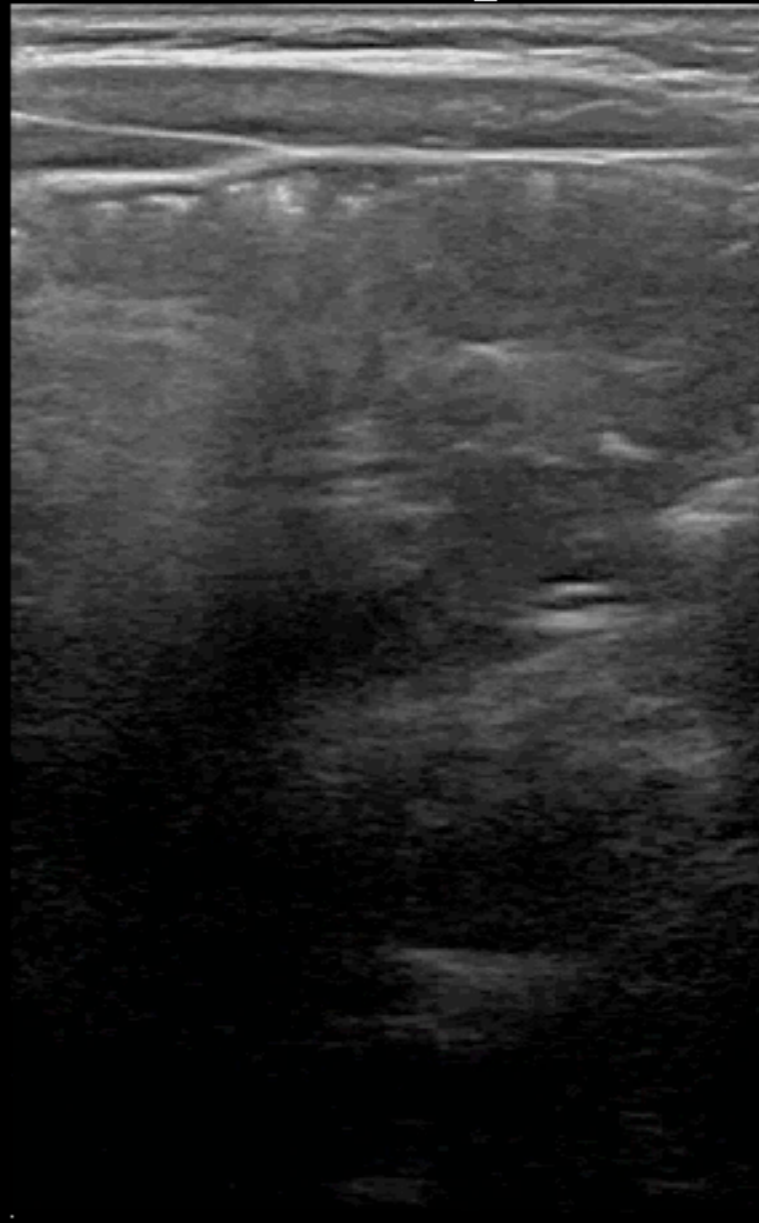
ABDOMEN

Intussusception

Superficial
L12-3
39 Hz
6.0cm

2D
Res
Gn 100
C 56
3 / 2 / 1

P

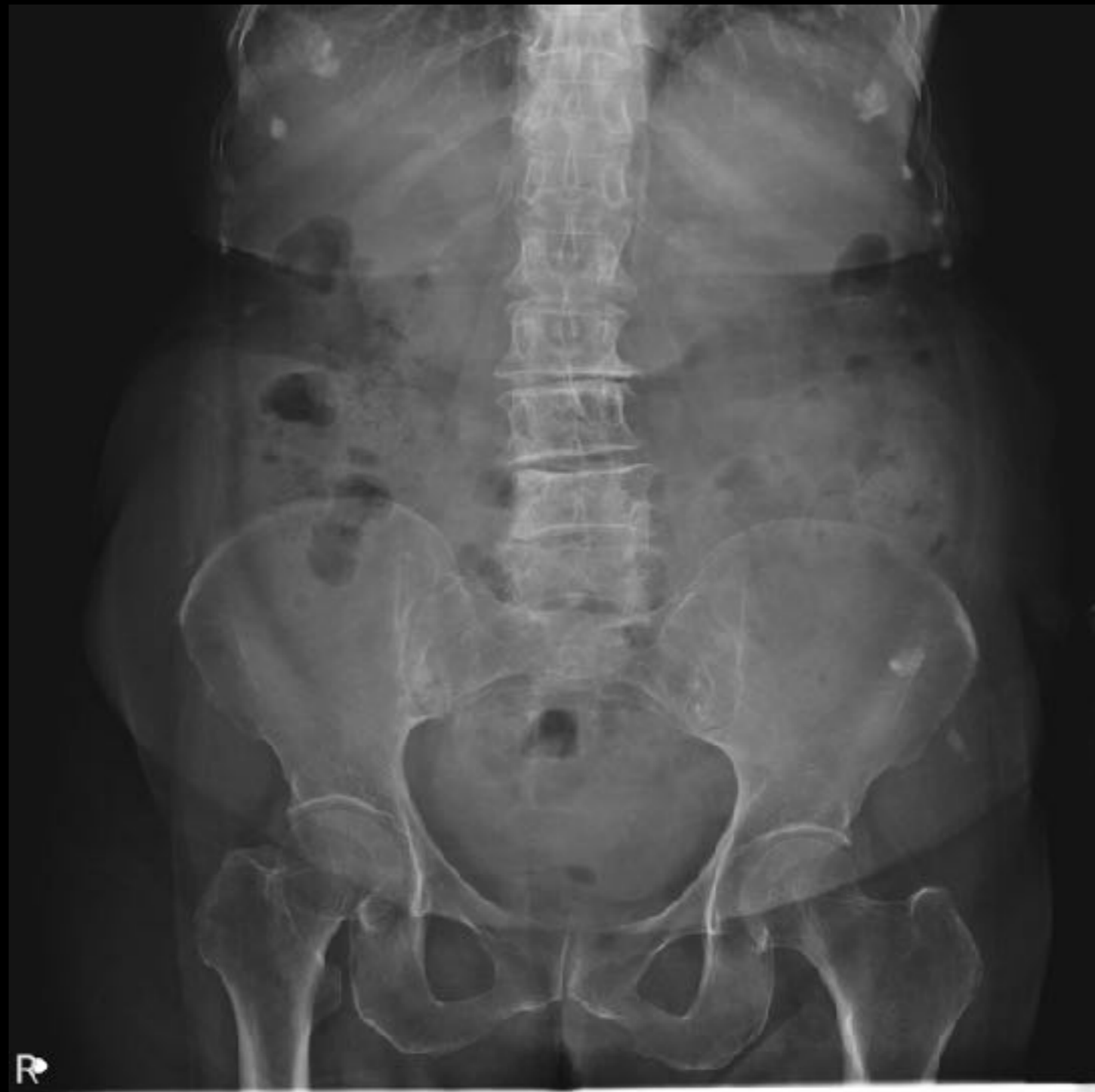
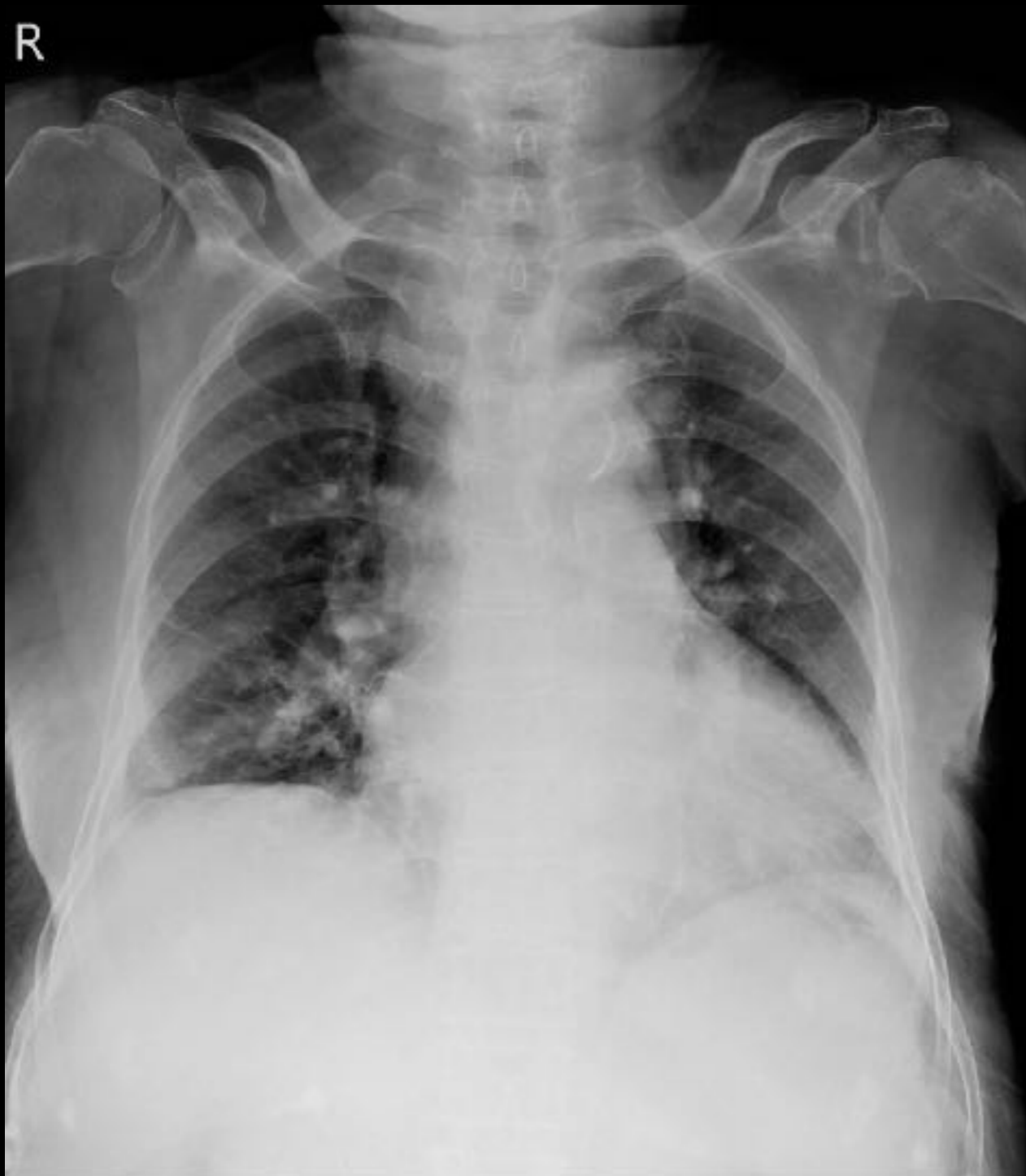
G
P R
3.0 12.0

5

6.0cm

80F, diffuse abdominal pain

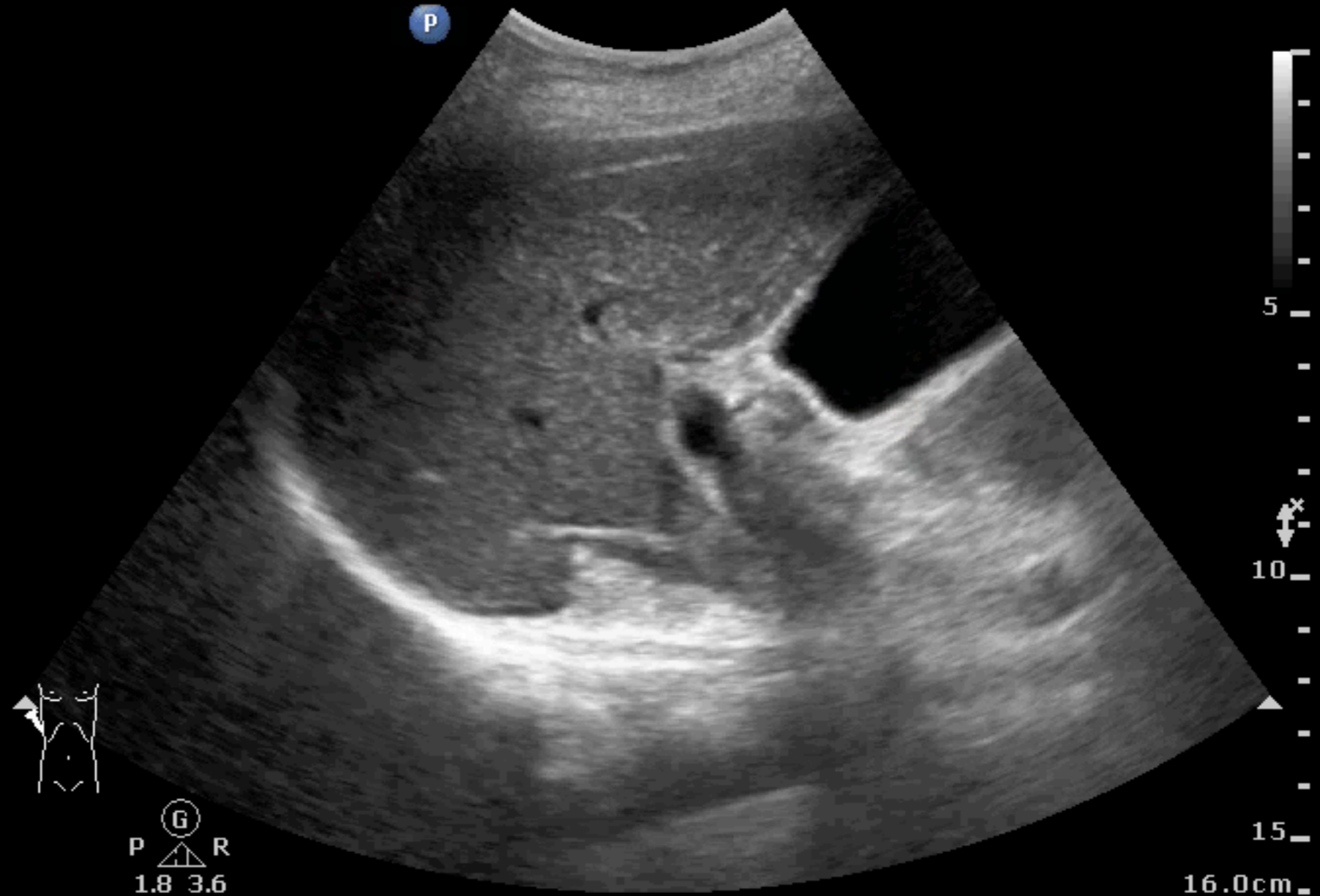

80F, diffuse abdominal pain

PHILIPS

Abd Gen2
C5-1
32 Hz
16.0cm

2D
HGen
Gn 90
C 56
3/3/3



ABDOMEN

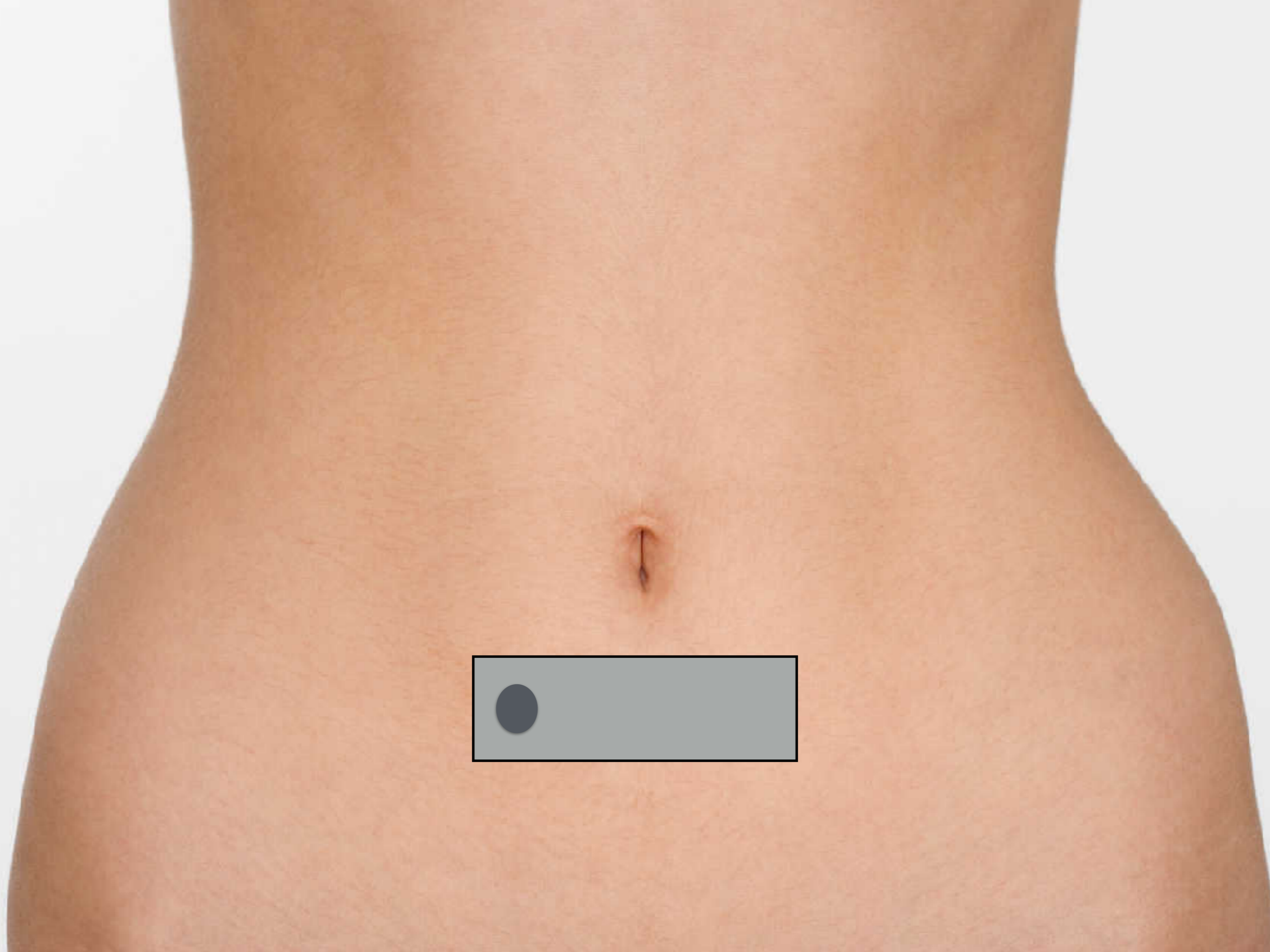
M for moving fluid or air

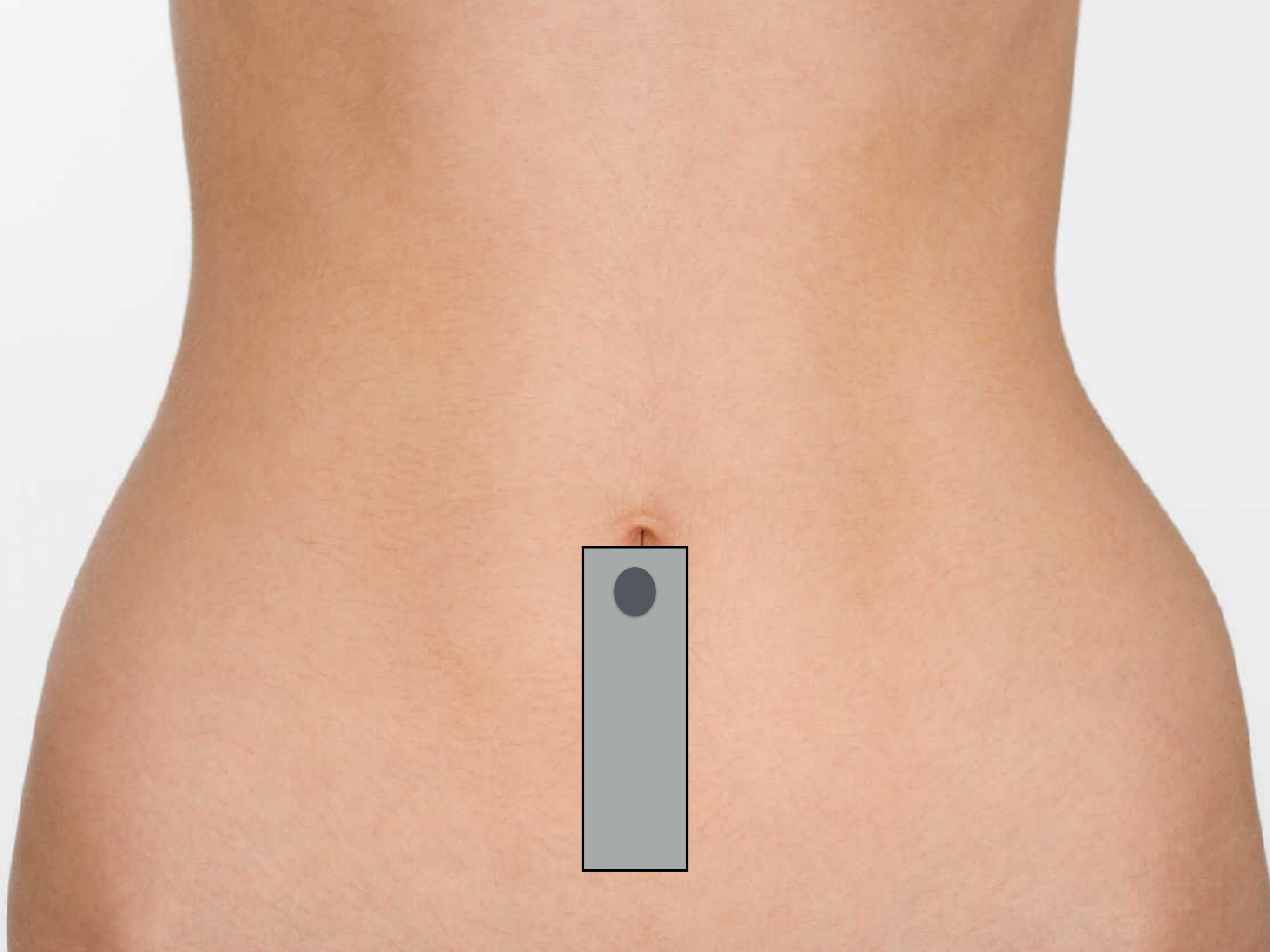
FAST / Liver surface

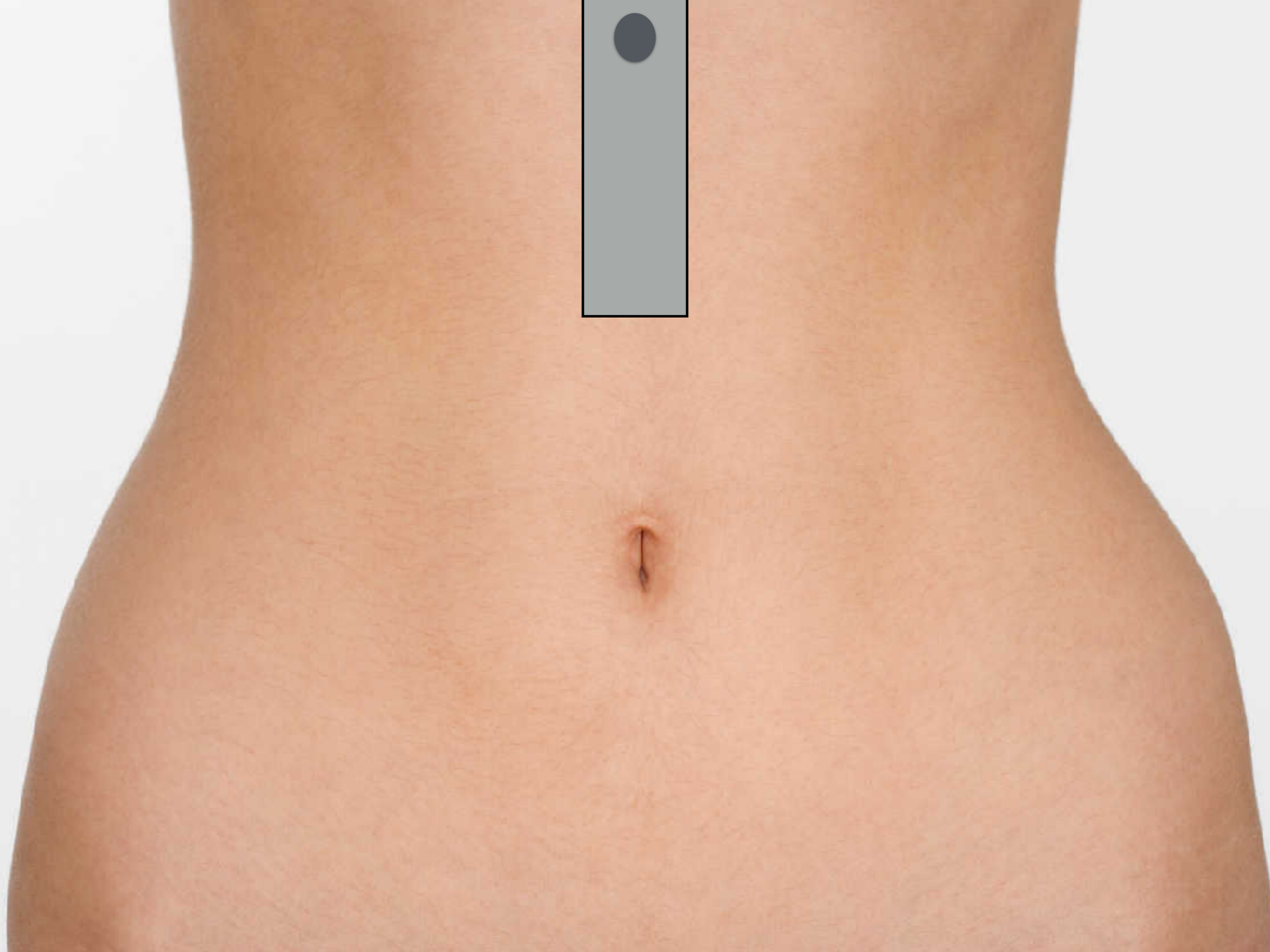








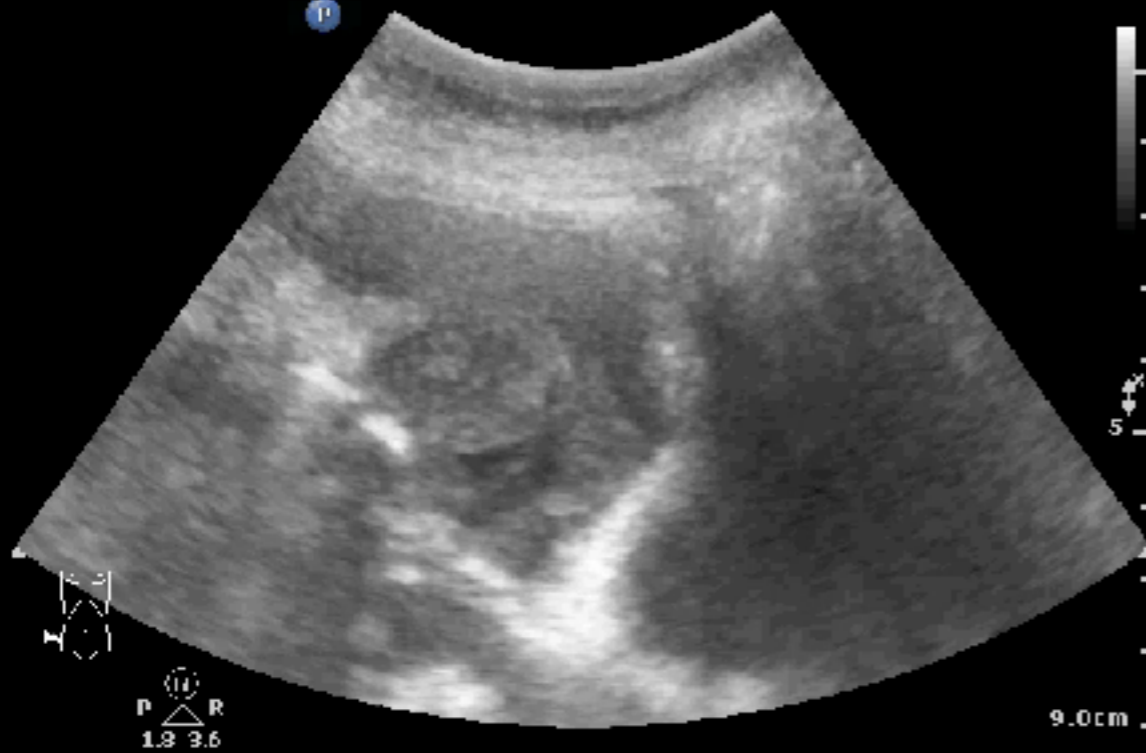




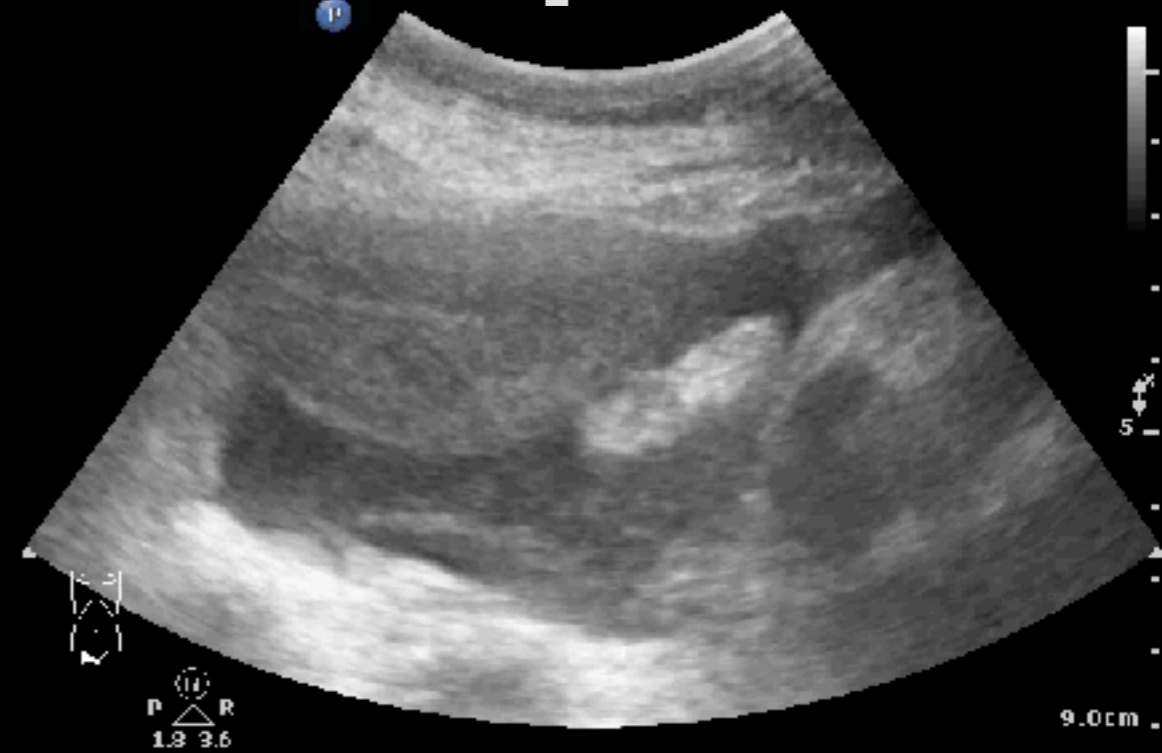ABDOMEN

80F, diffuse abdominal pain

Abd Gen2
C5-1
47 Hz
9.0cm
2D
HGen
Gn 100
C. 56
3/3/3



Abd Gen2
C5-1
47 Hz
9.0cm
2D
HGen
Gn 100
C. 56
3/3/3

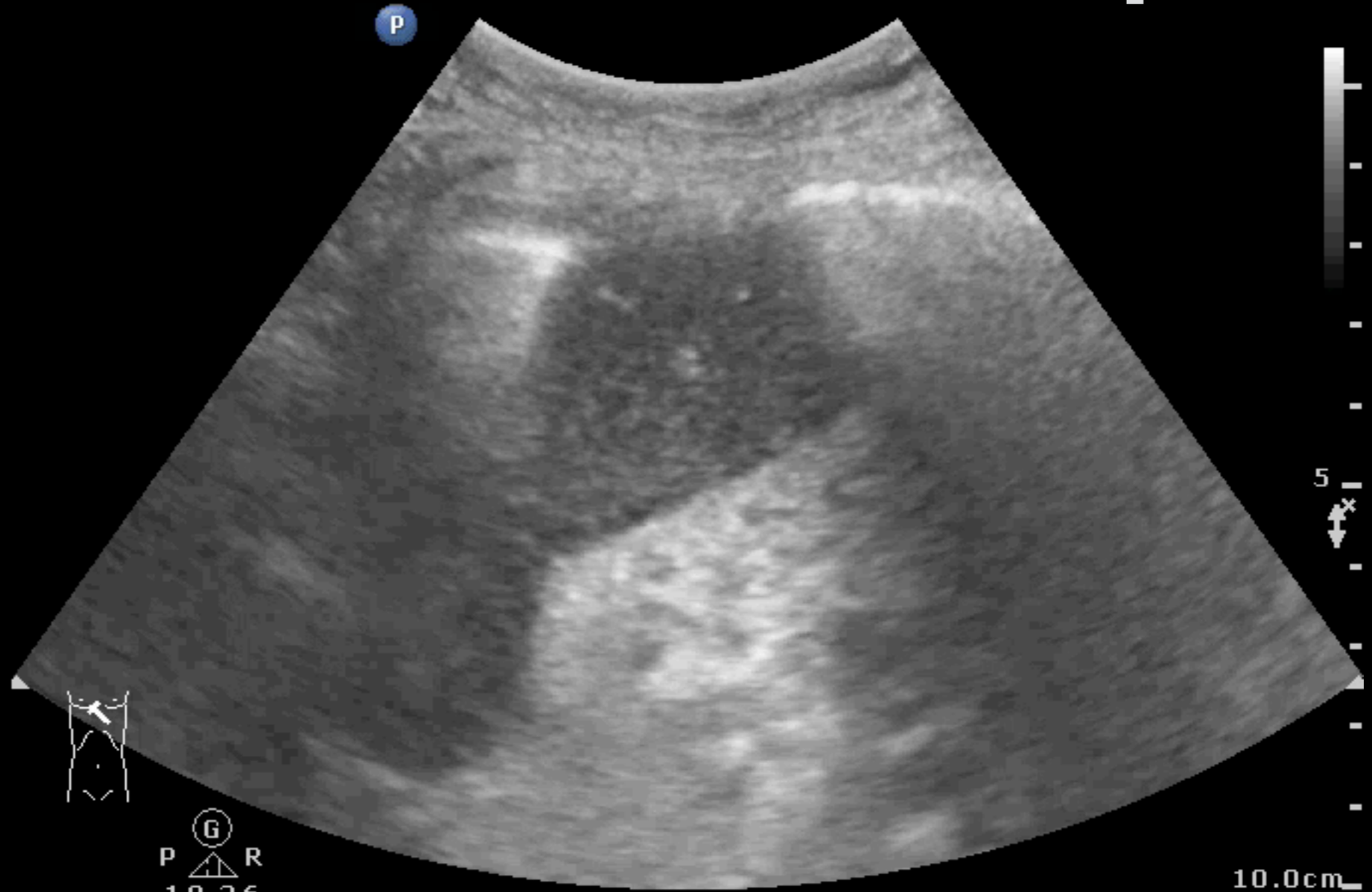

ABDOMEN

80F, diffuse abdominal pain

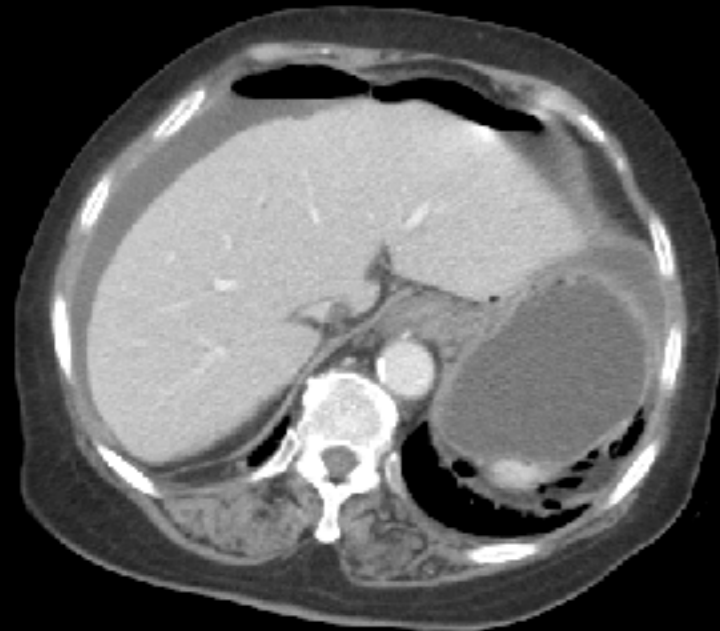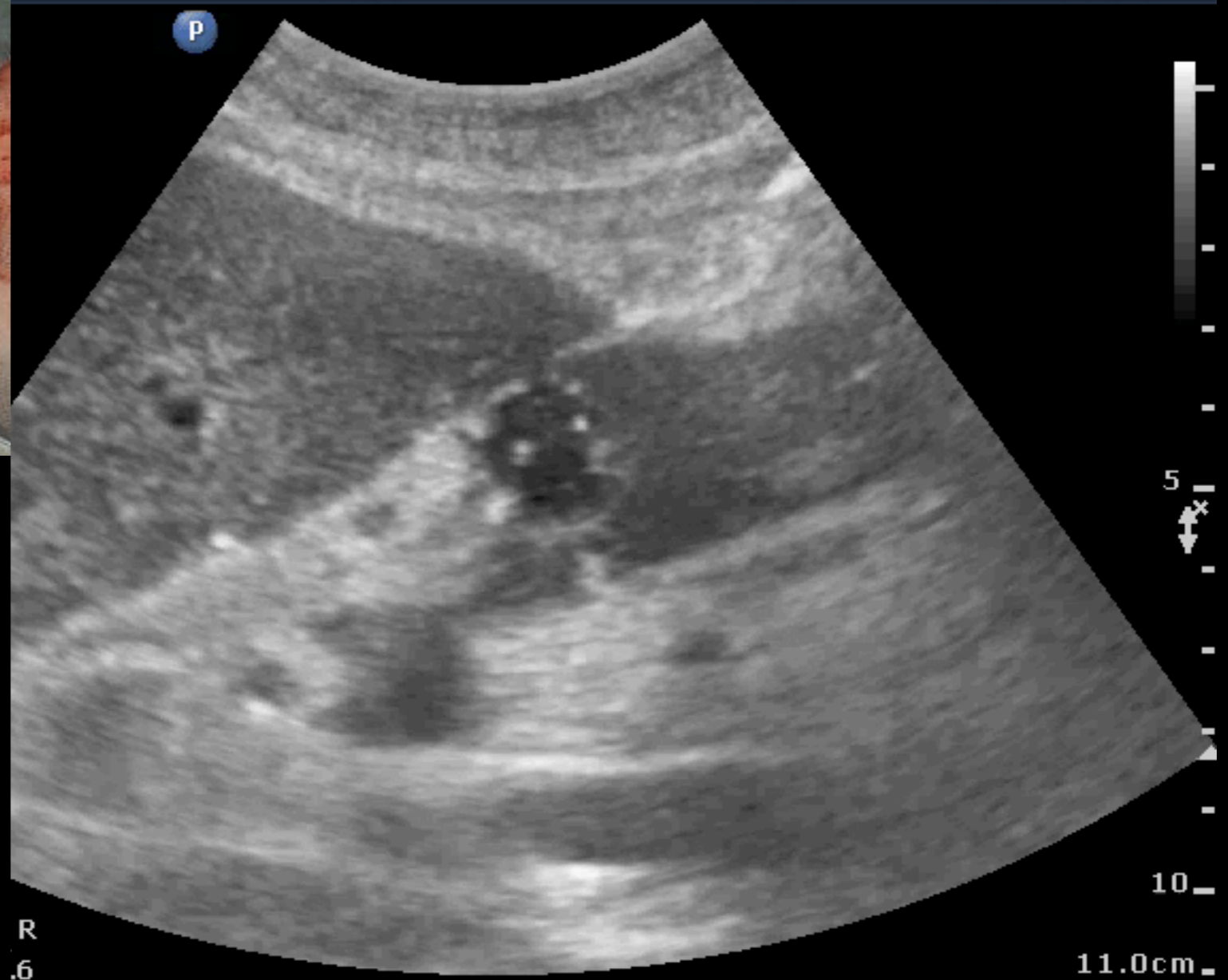
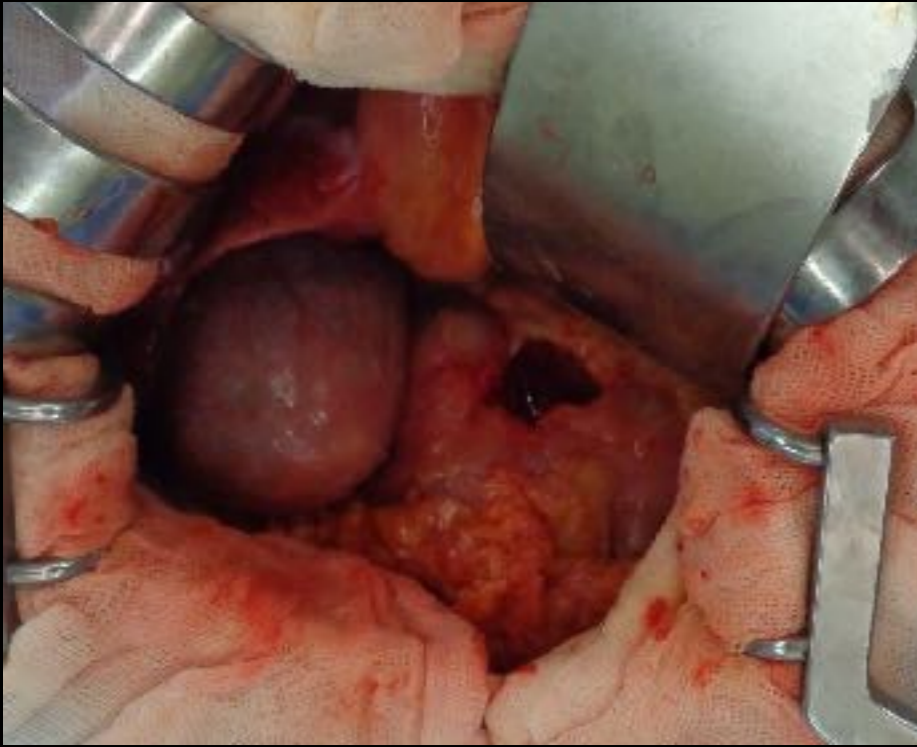
Abd Gen2
C5-1
45 Hz
10.0cm

2D
HGen
Gn 100
C 56
3 / 3 / 3



ABDOMEN

PPU



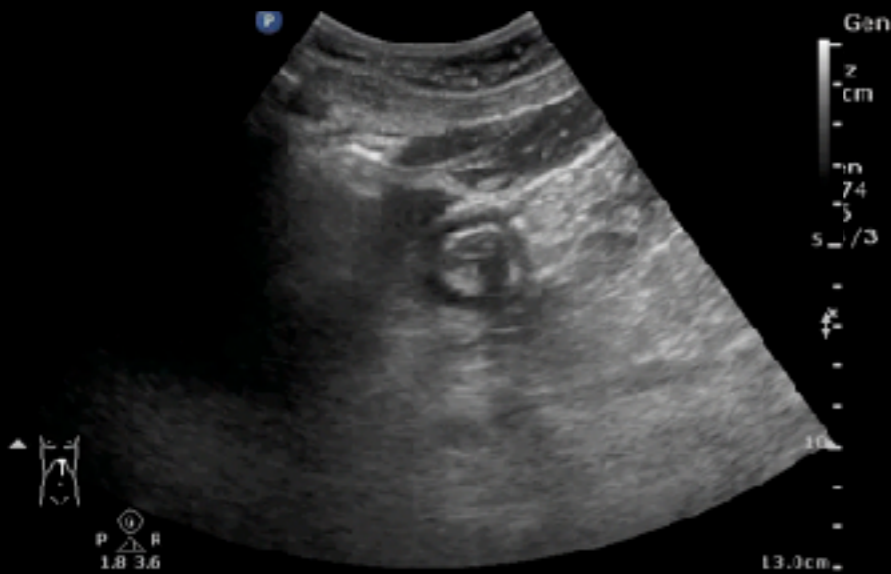R
.6

11.0cm

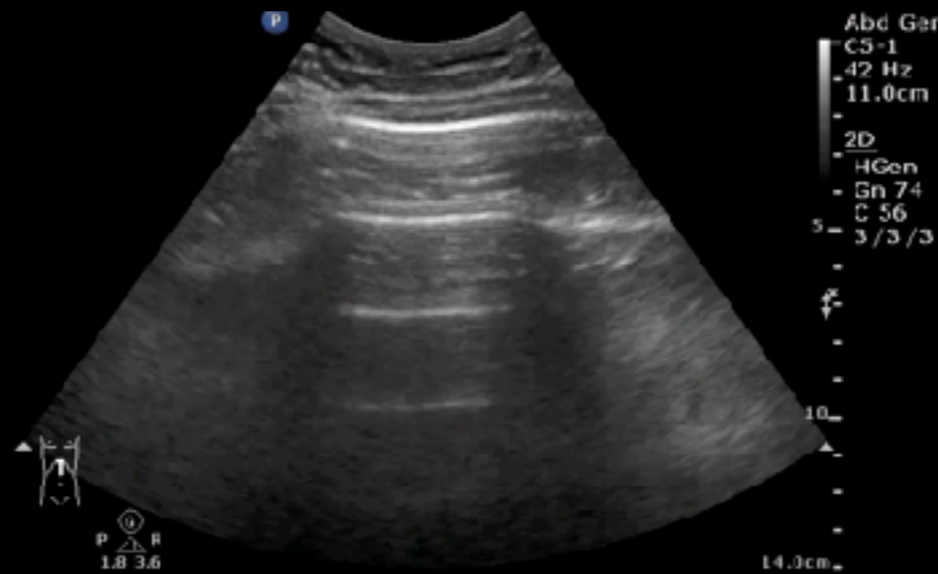ABDOMEN

Free air: 往上找

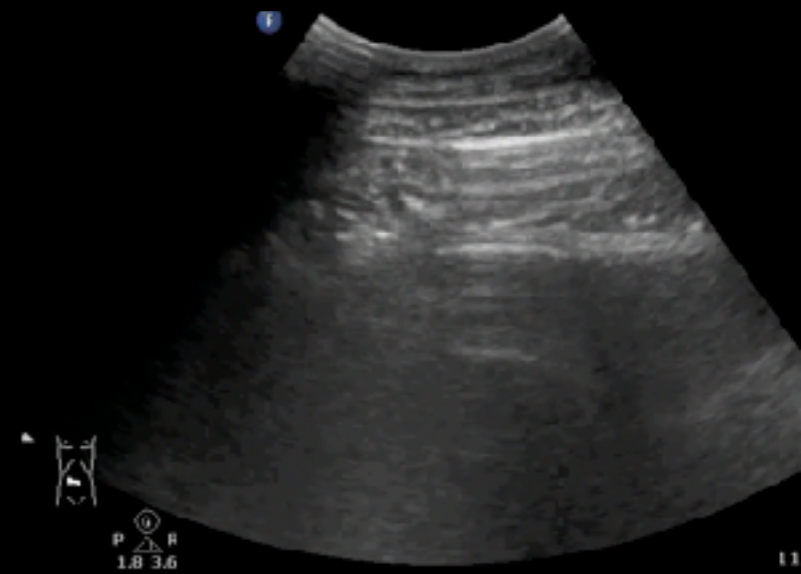Liver surface



Curtain sign



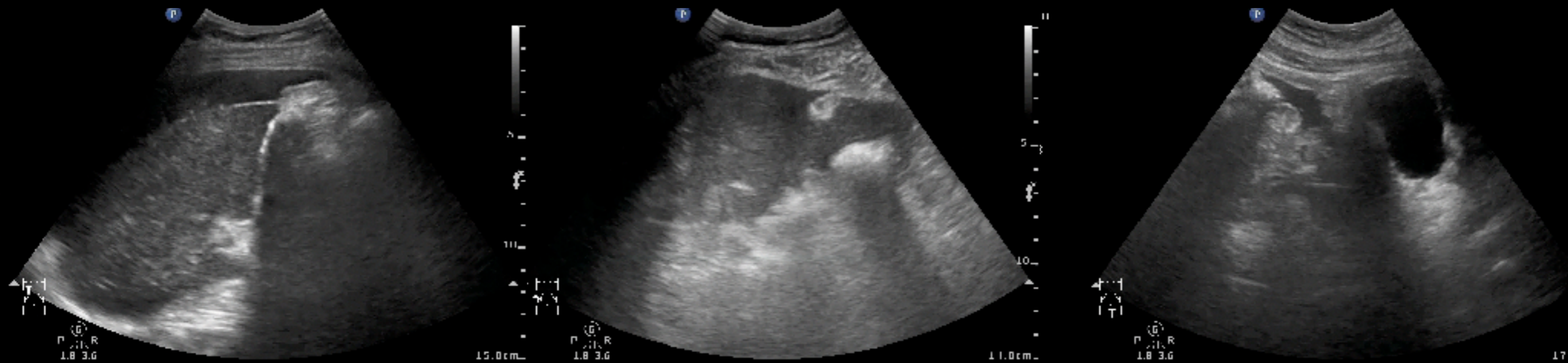
EPSS



EPSS: Enhanced peritoneal strip sign

ABDOMEN

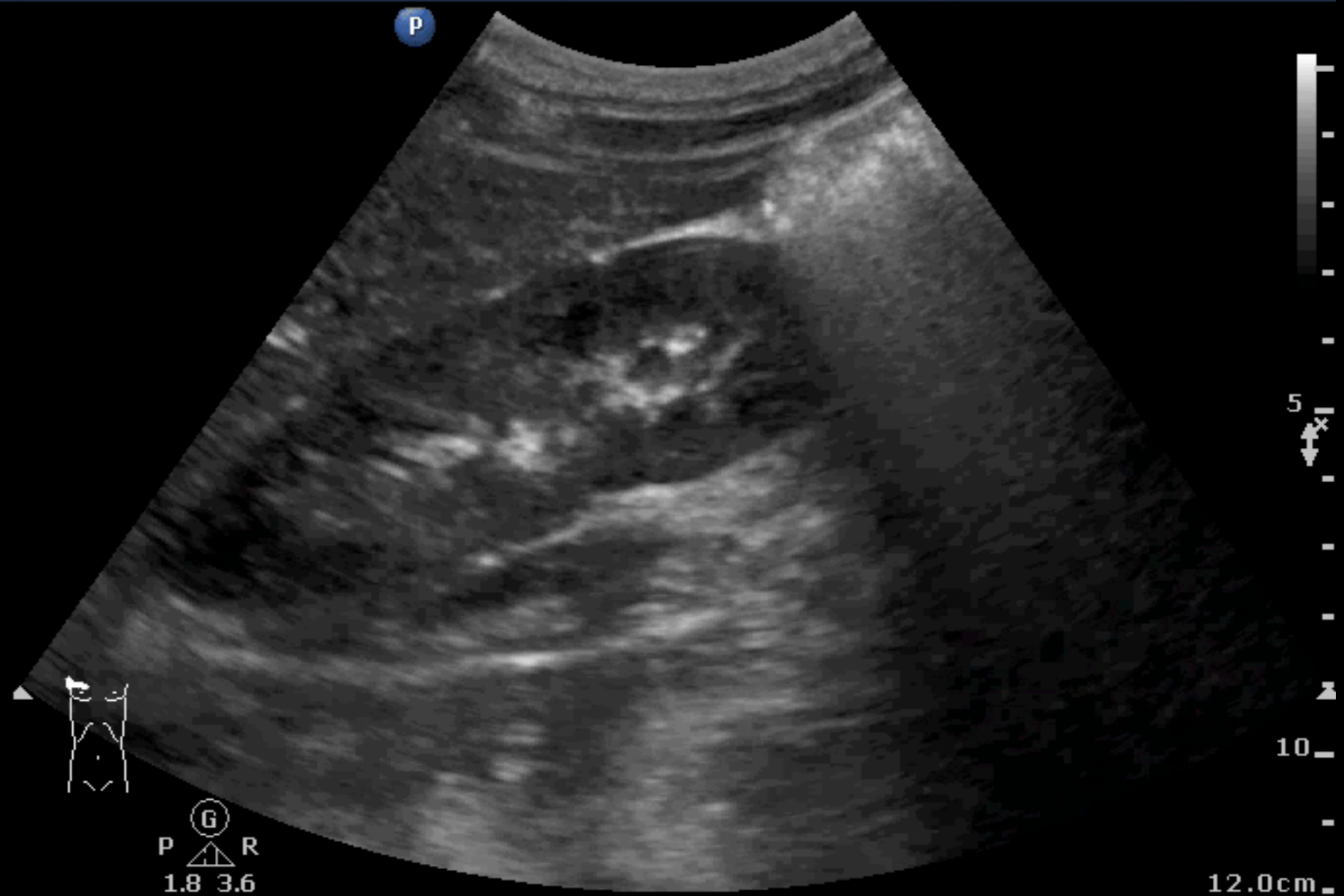
Dirty ascites: 往下流



33F, low abdominal pain & shock

Abd Gen
C5-1
39 Hz
12.0cm

2D
HGen
Gn 71
C 56
3 / 3 / 3



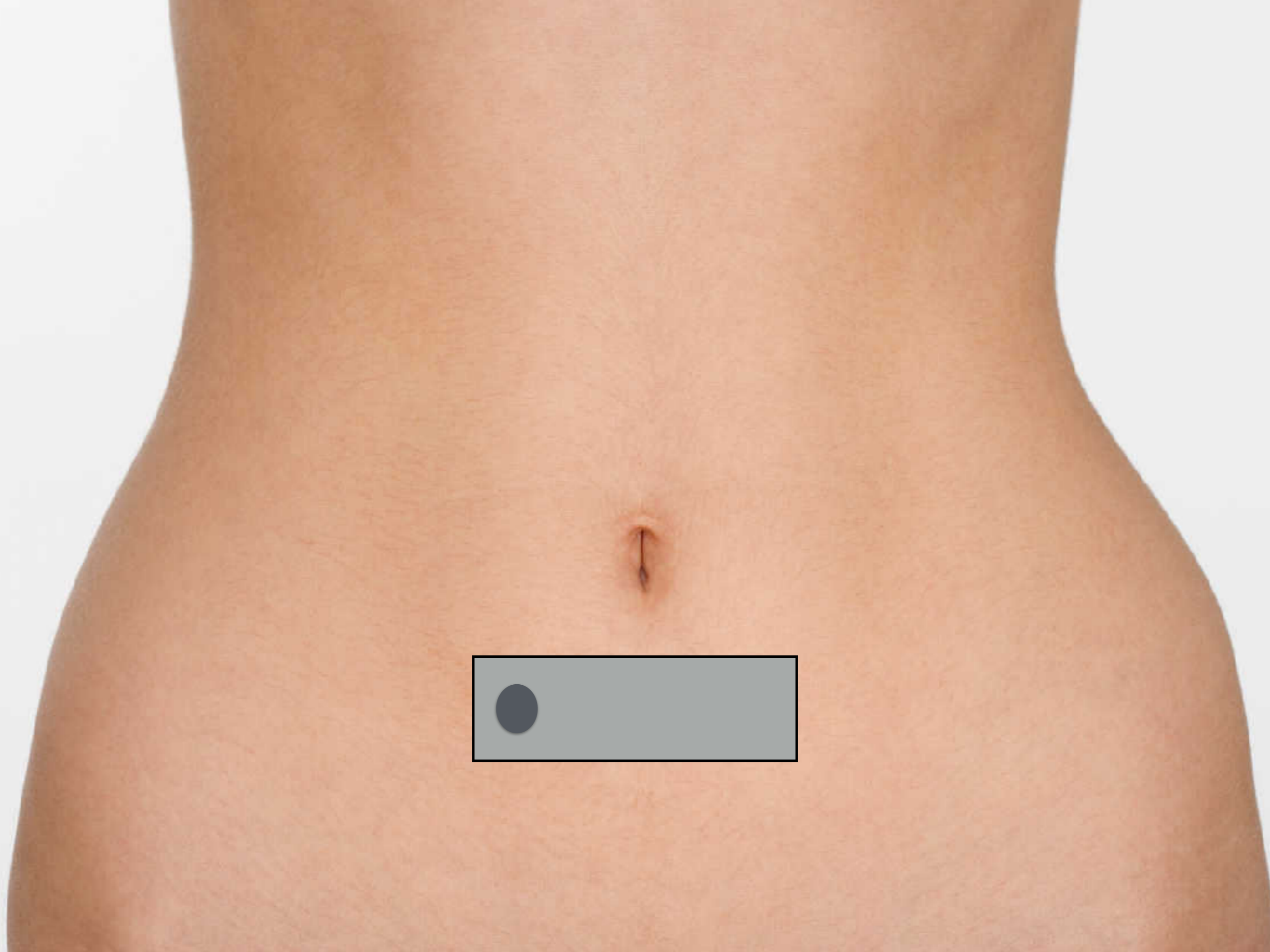
12.0cm

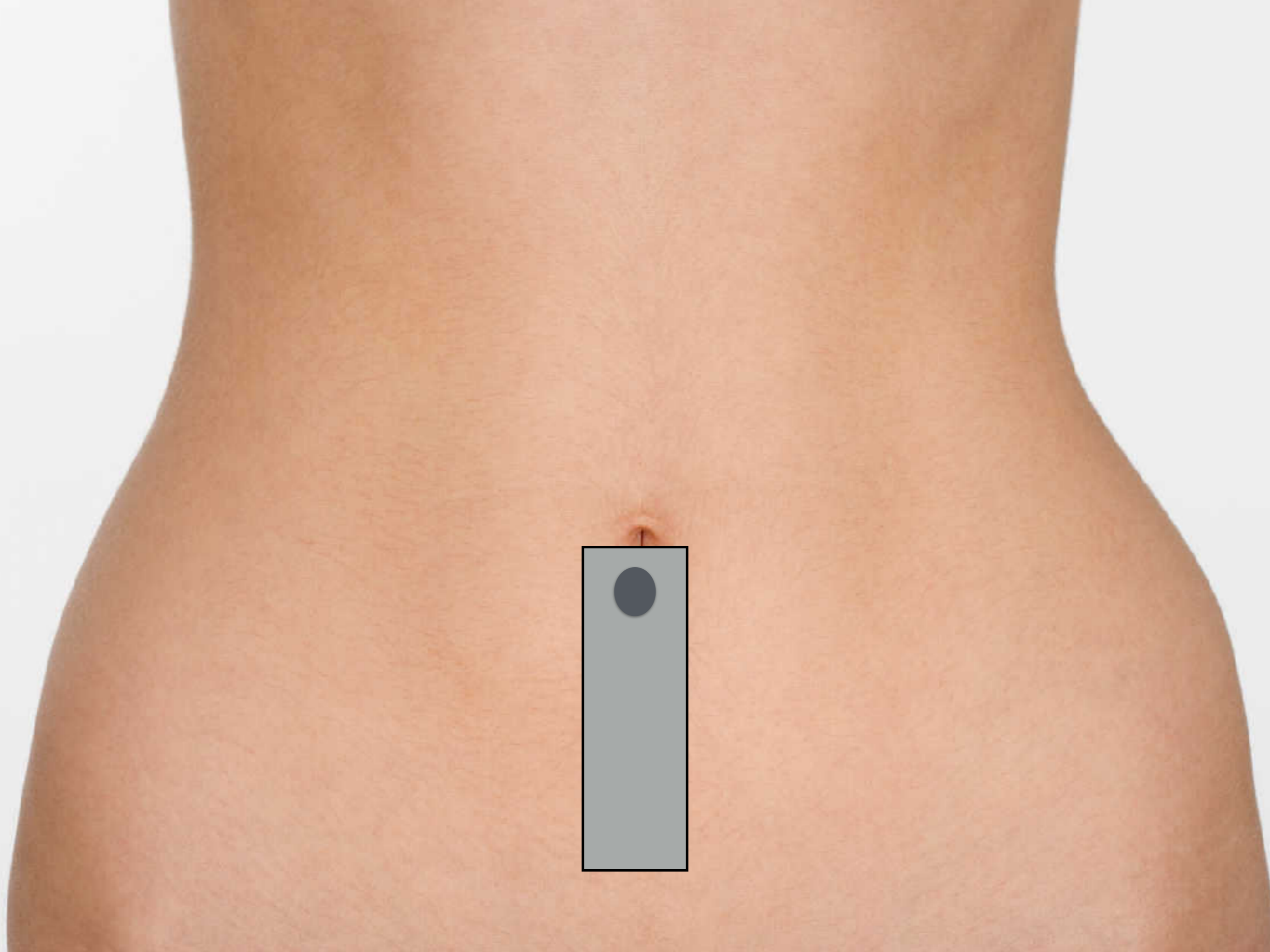
ABDOMEN

E for ectopic pregnancy

Ascites & IUUP





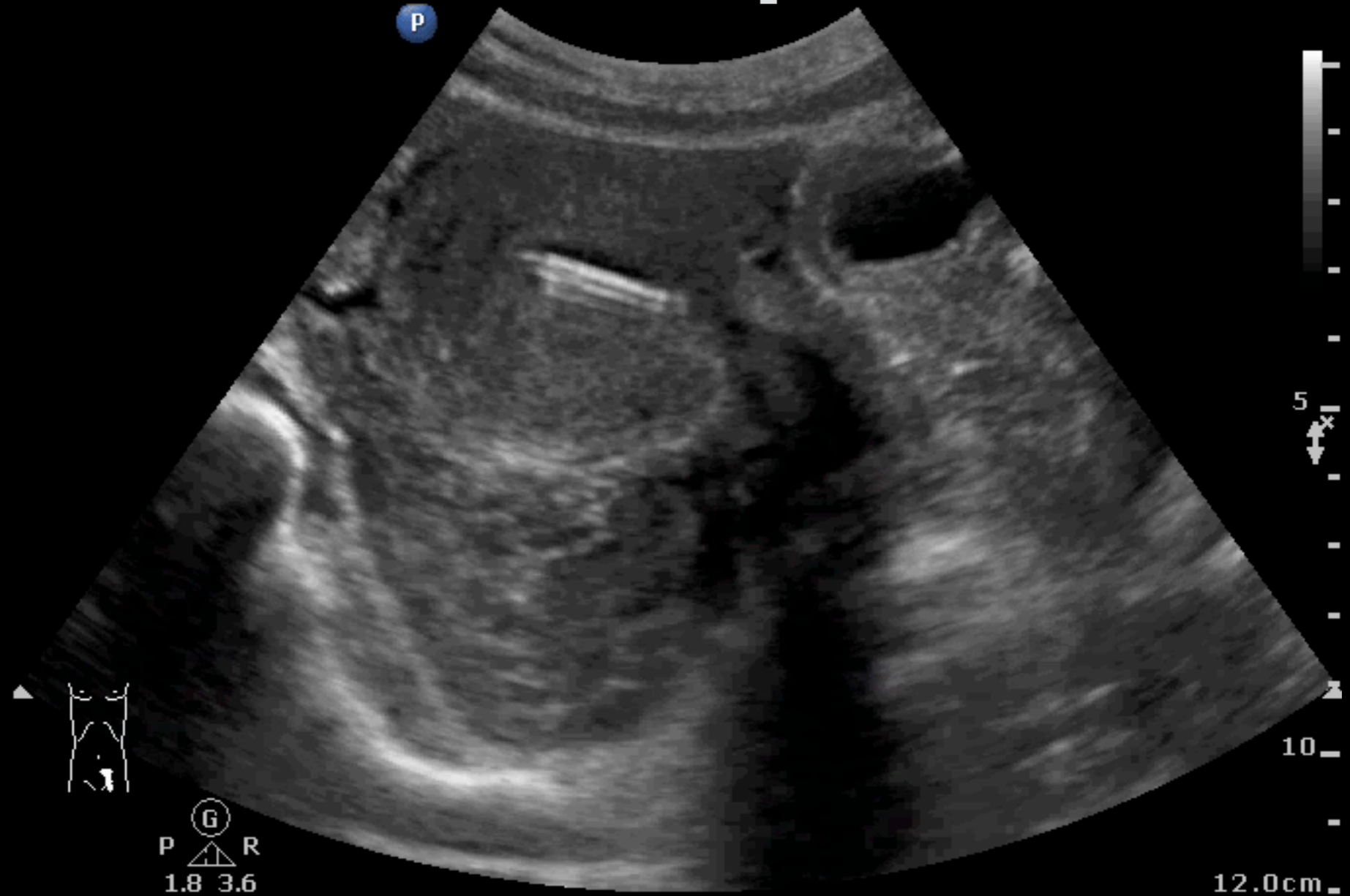


ABDOMEN

33F, low abdominal pain & shock

Abd Gen
C5-1
39 Hz
12.0cm

2D
HGen
Gn 71
C 56
3/3/3

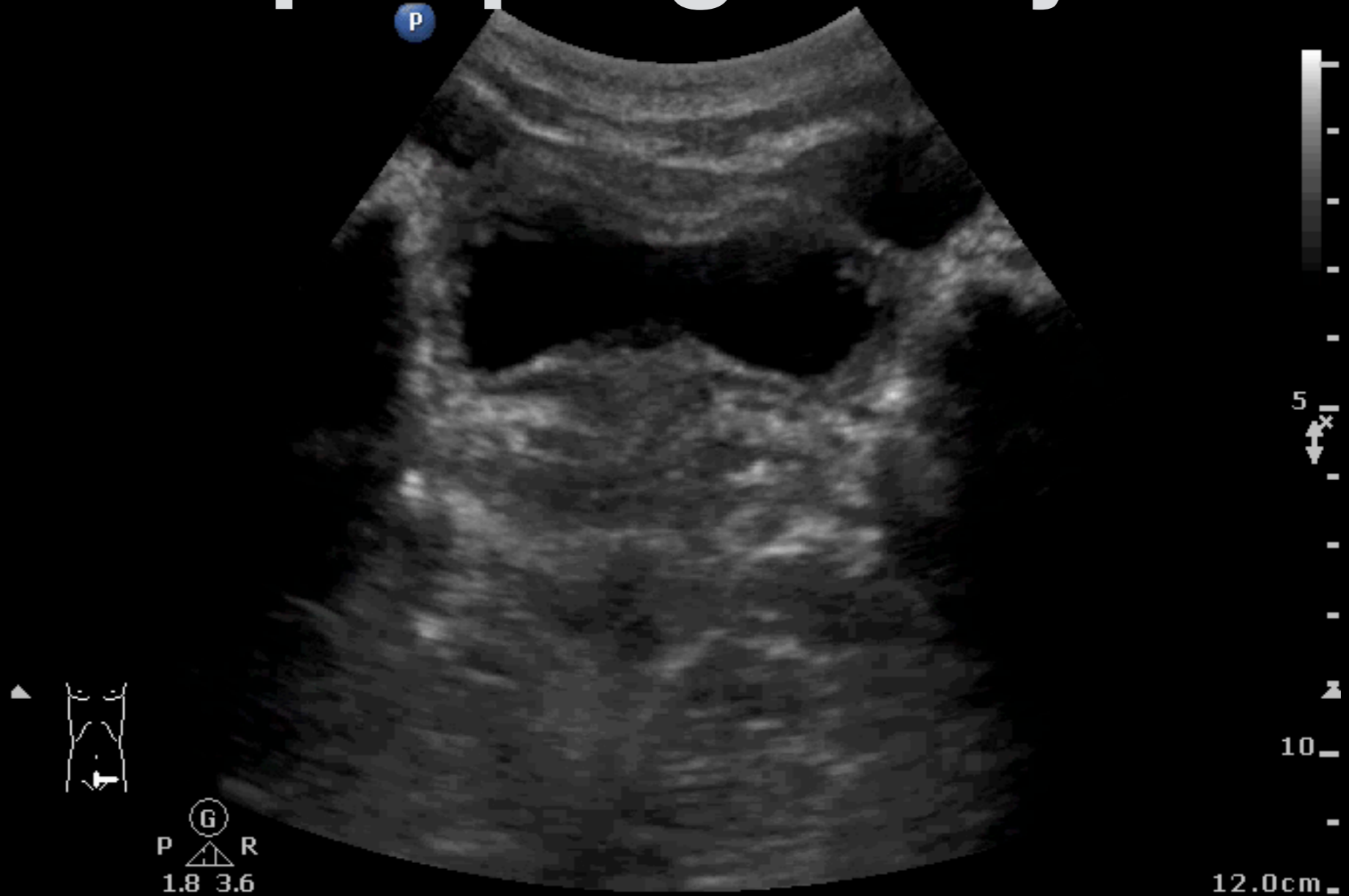

ABDOMEN

Ectopic pregnancy

Abd Gen
C5-1
39 Hz
12.0cm

2D
HGen
Gn 63
C 56
3 / 3 / 3

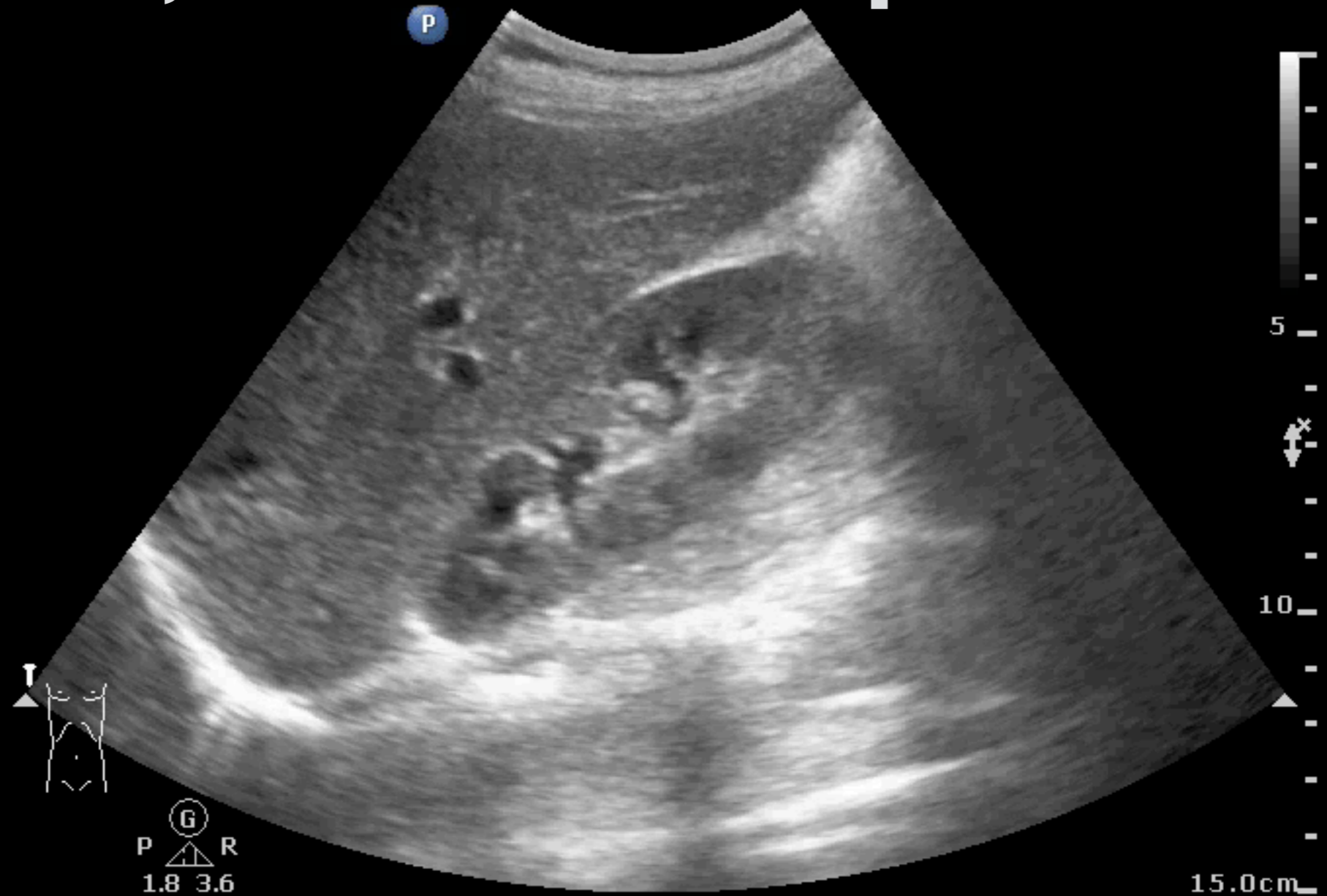


ABDOMEN

25F, abdominal pain

Abd Gen
C5-1
34 Hz
15.0cm

2D
HGen
Gn 95
C 56
3 / 3 / 3

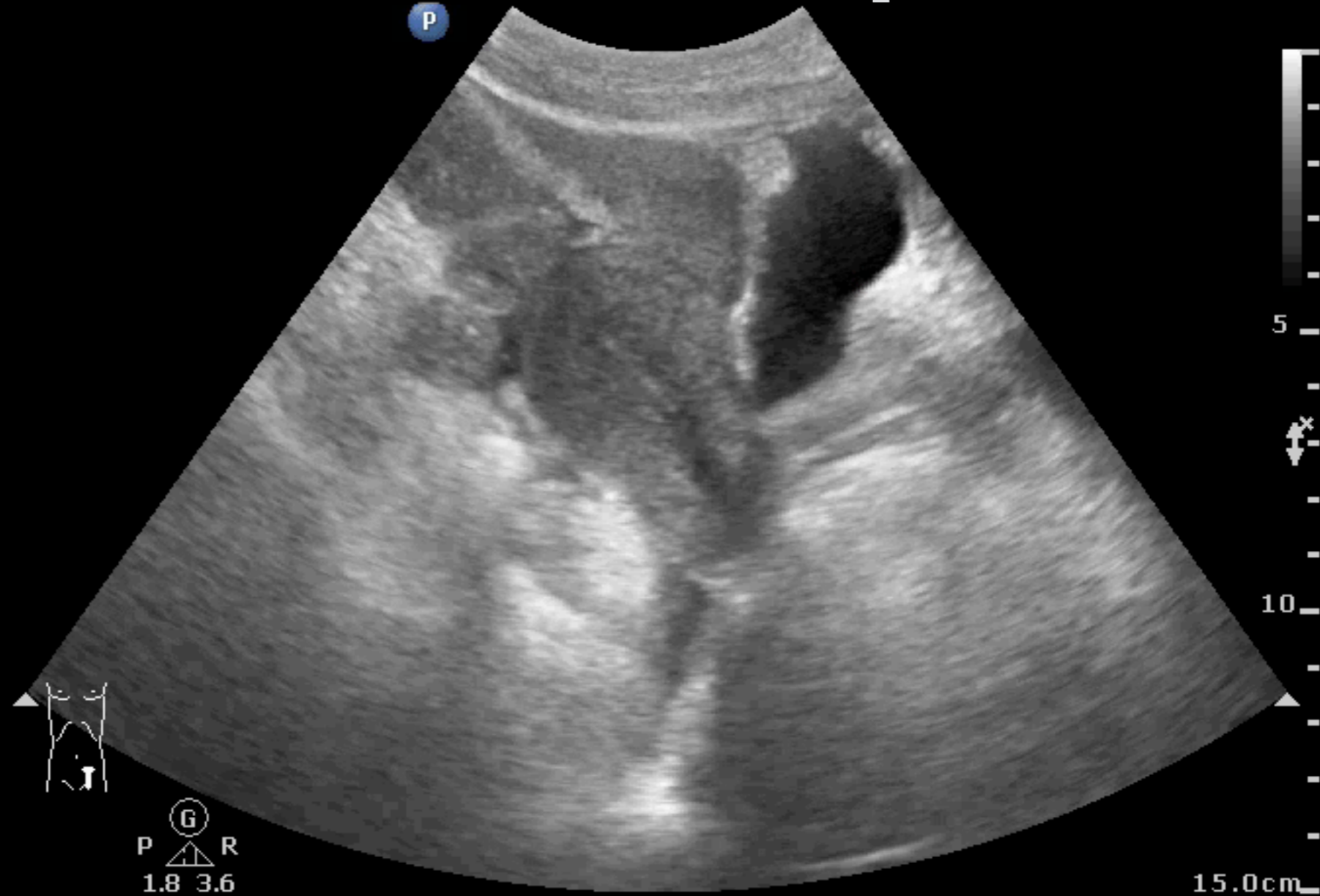

ABDOMEN

25F, abdominal pain

Abd Gen
C5-1
34 Hz
15.0cm

2D
HGen
Gn 95
C 56
3/3/3



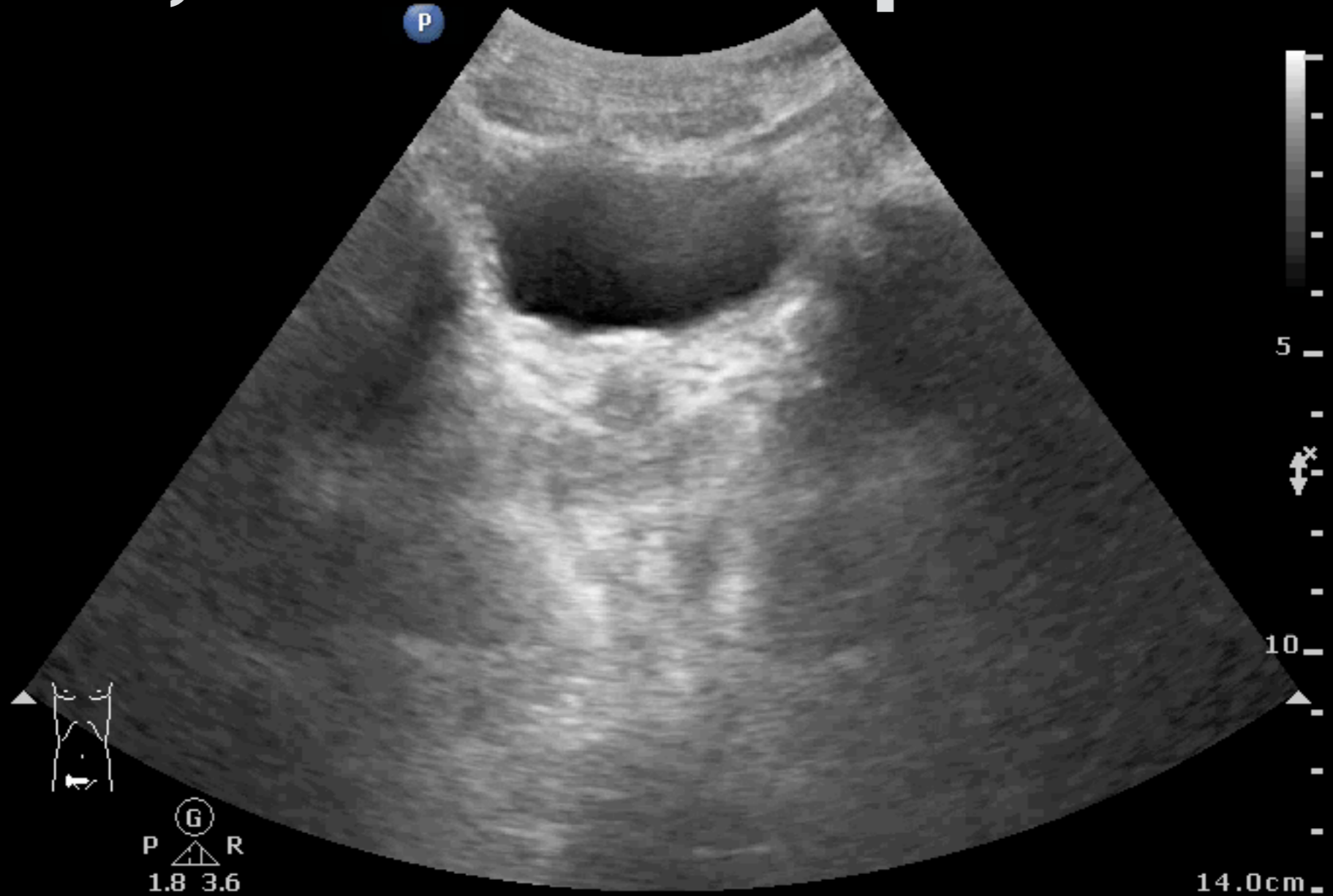ABDOMEN

PHILIPS

25F, abdominal pain

Abd Gen
C5-1
36 Hz
14.0cm

2D
HGen
Gn 95
C 56
3/3/3



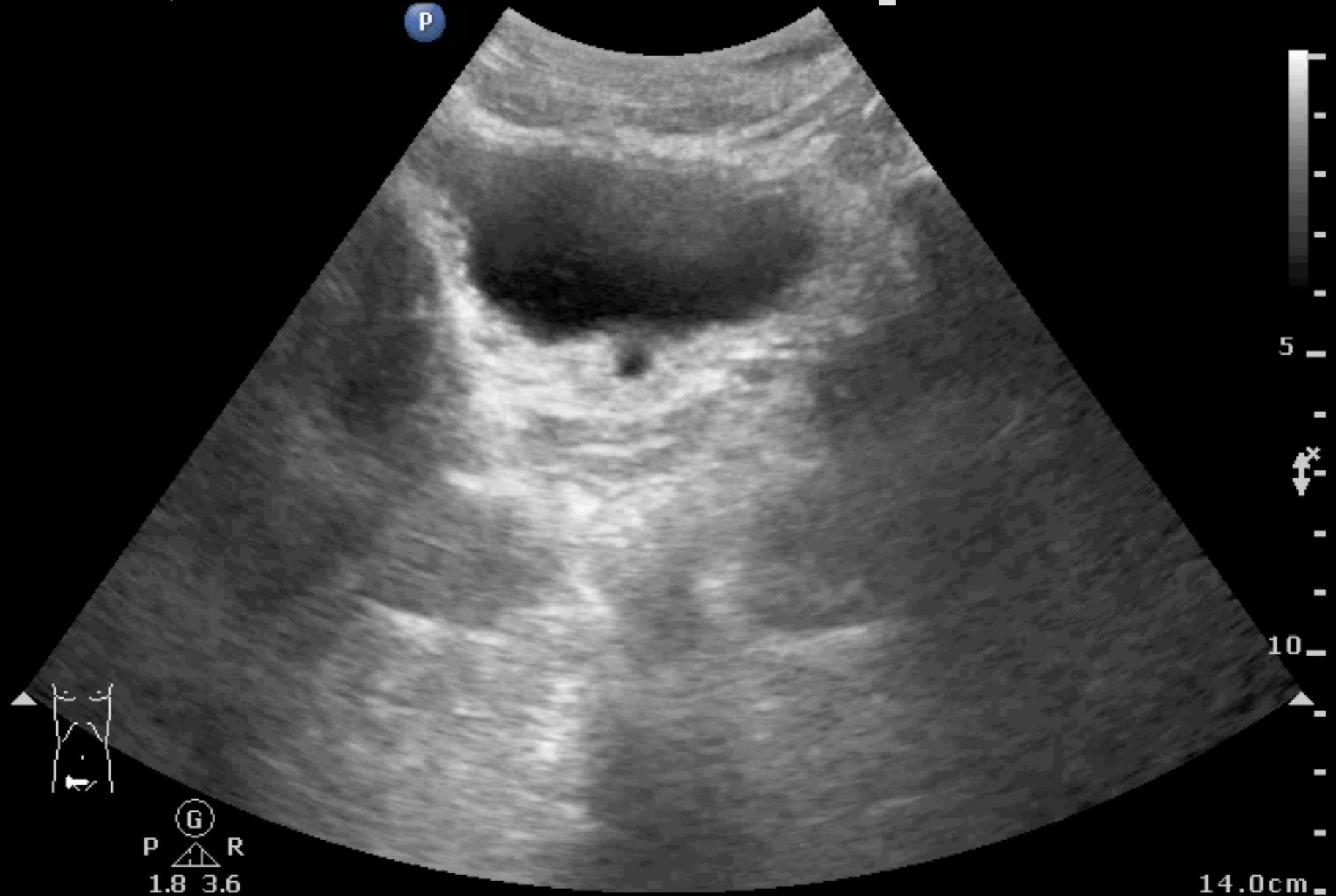
ABDOMEN

PHILIPS

25F, abdominal pain

Abd Gen
C5-1
36 Hz
14.0cm

2D
HGen
Gn 95
C 56
3 / 3 / 3



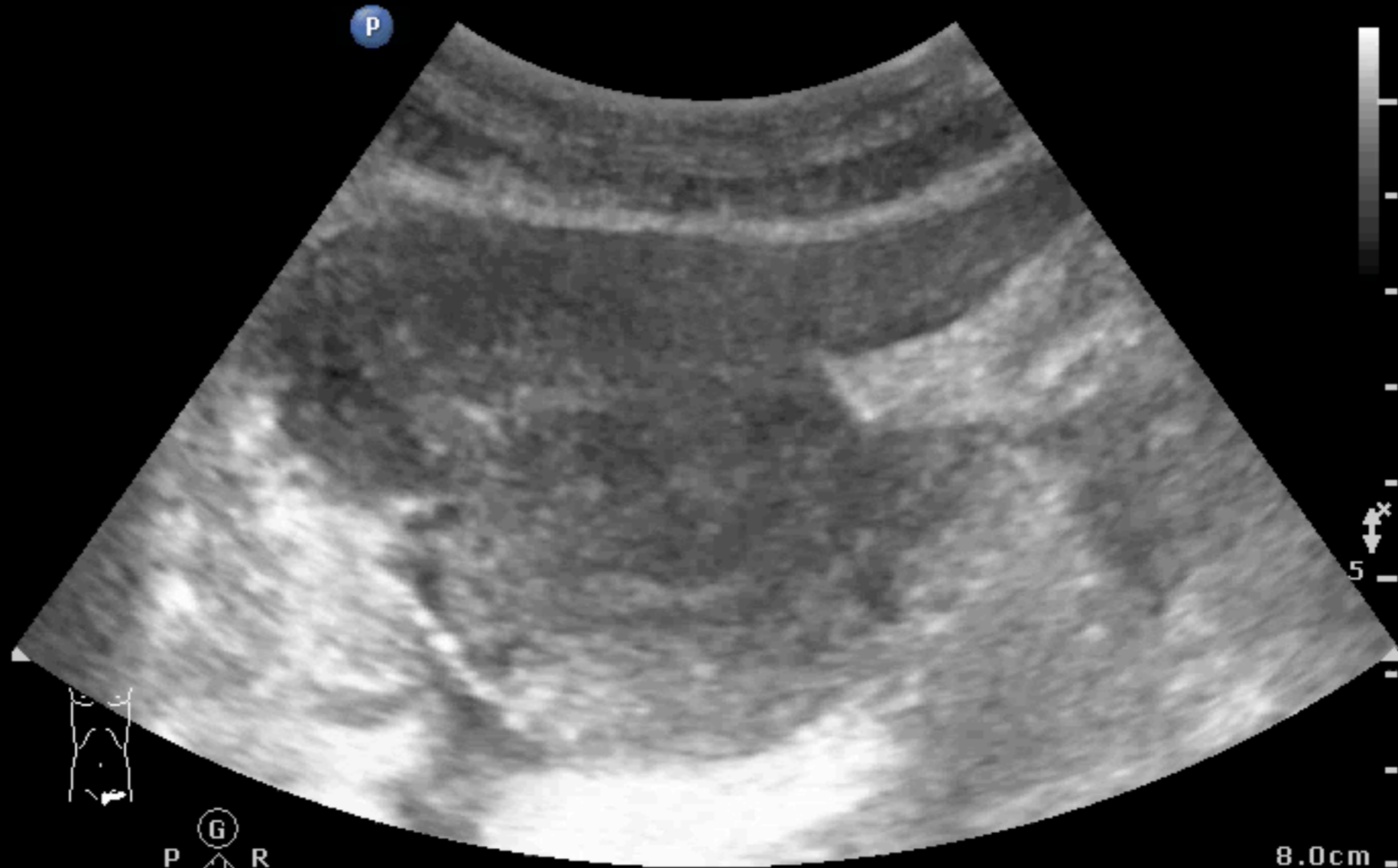
ABDOMEN

PHILIPS

25F, abdominal pain

Abd Gen
C5-1
51 Hz
8.0cm

2D
HGen
Gn 60
C 56
3 / 3 / 3



G
P R
1.8 3.6

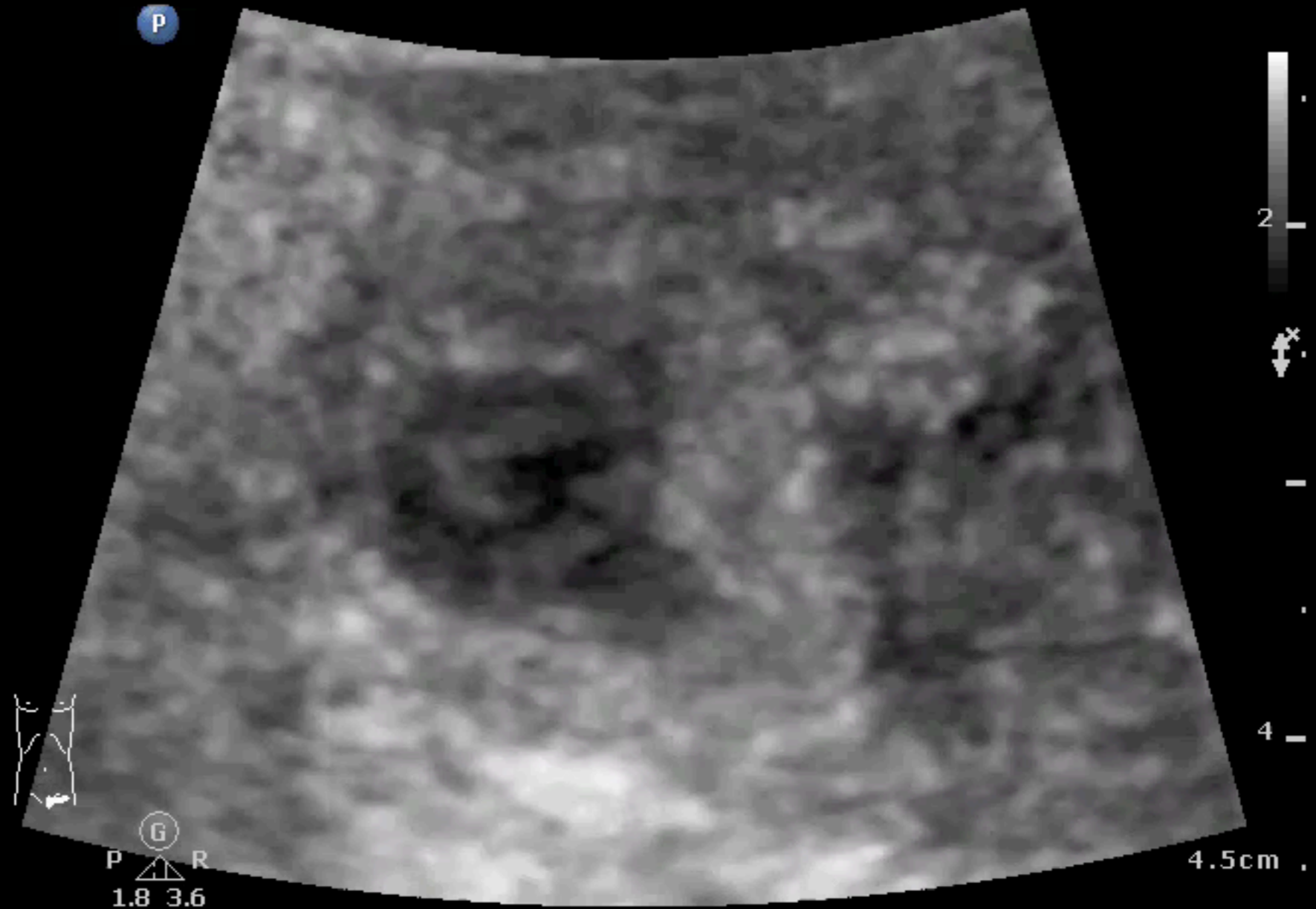8.0cm

Ectopic fetus

PHILIPS

Abd Gen
C5-1
90 Hz
HD Zoom

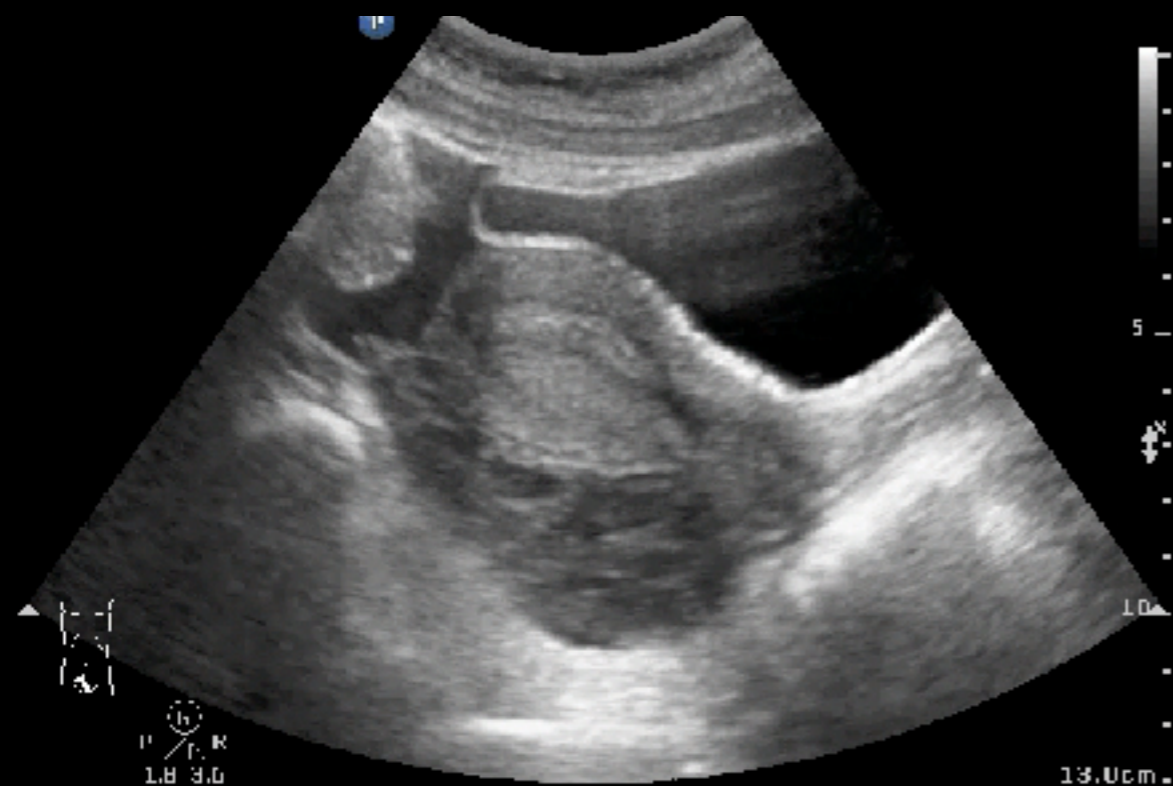
2D
HGen
Gn 60
C 56
3 / 3 / 3



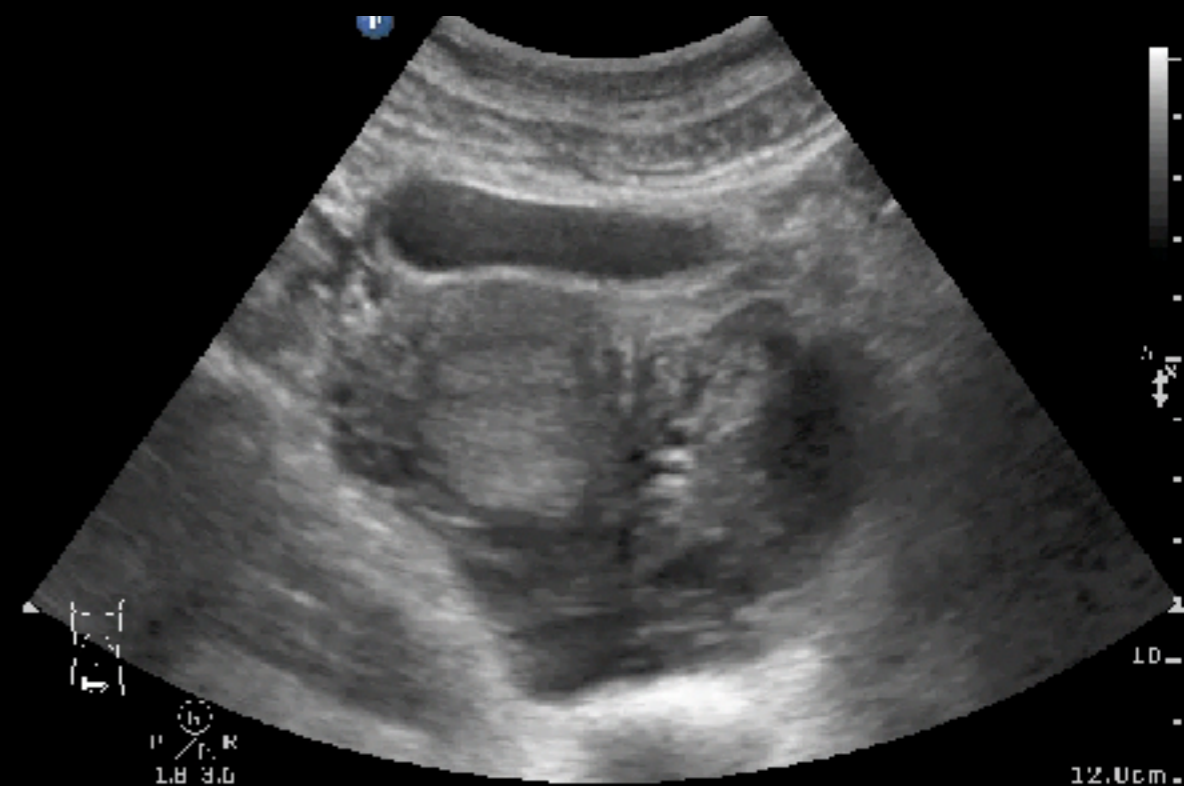
14F, acute lower abdominal pain with cold sweating

Female acute abdomen or shock consider **ovarian cyst rupture**

Abd Gen
[15 1
38 Hz
13.0cm
2D
11Gen
[1n 7/8
[1 56
3/3/3



Abd Gen
[15 1
39 Hz
12.0cm
2D
11Gen
[1n 7/8
[1 56
3/3/3

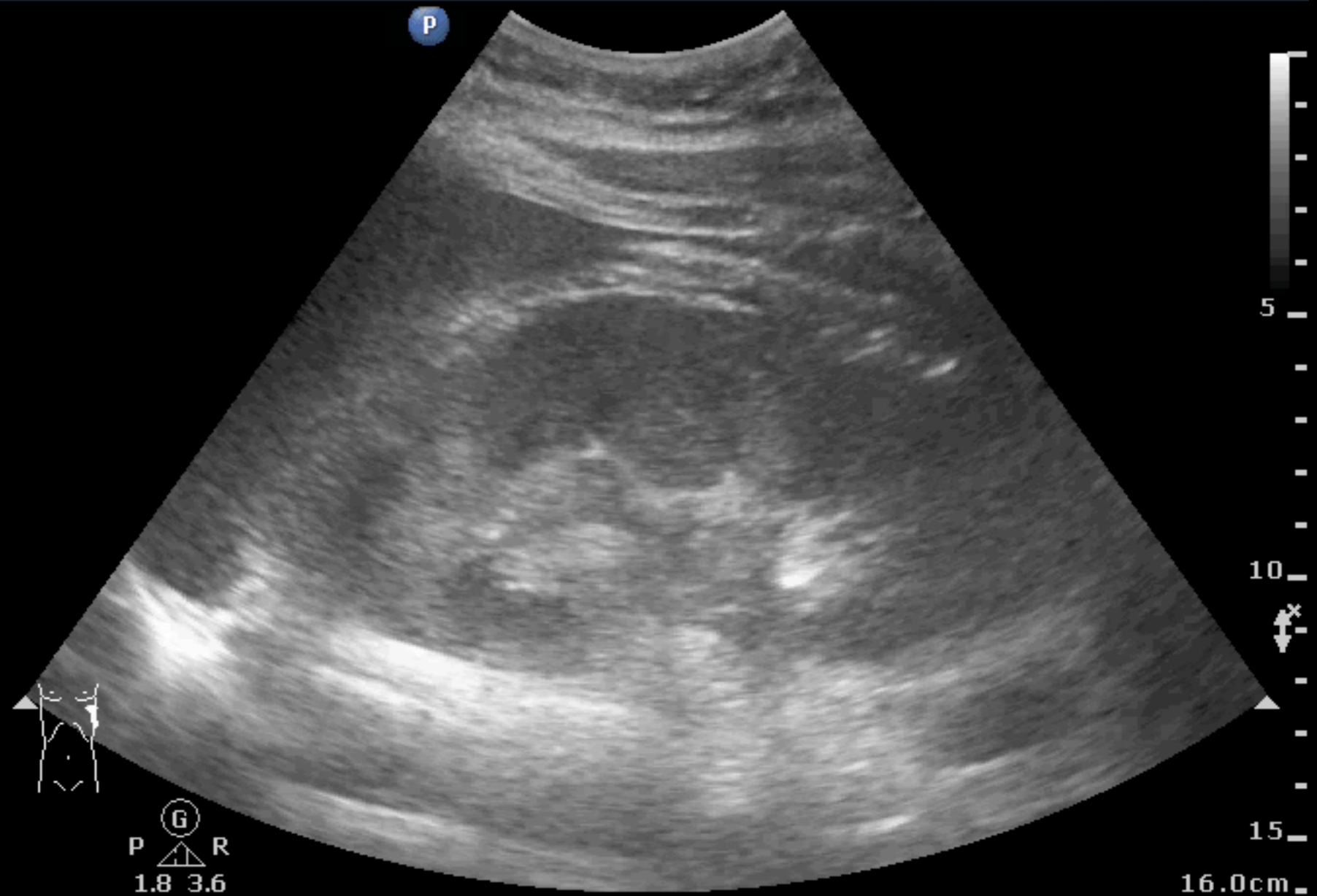

Echo first then Urine pregnancy test

25M, left flank pain

Abd Gen2
C5-1
32 Hz
16.0cm

2D
HGen
Gn 93
C 56
3 / 3 / 3



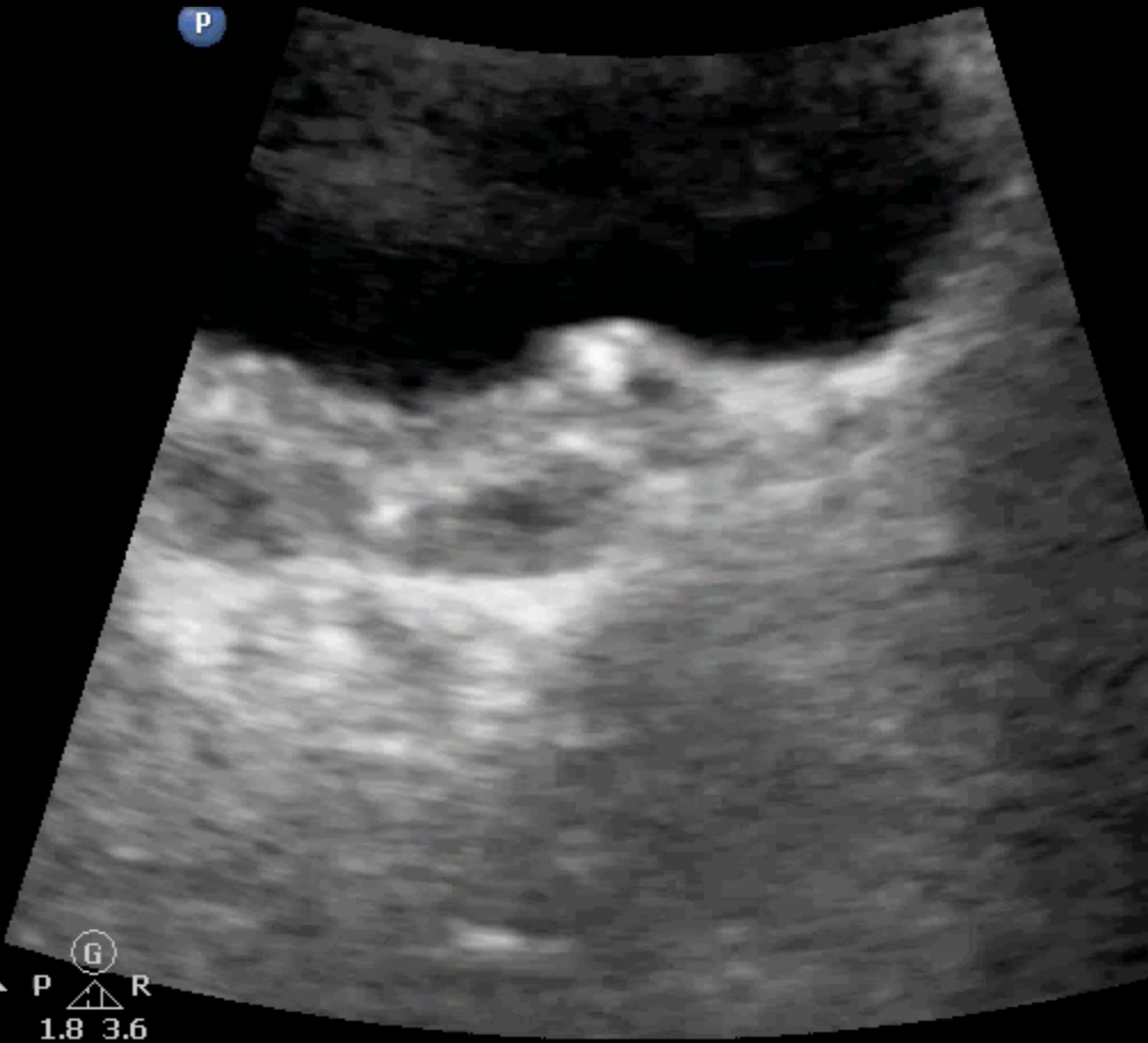
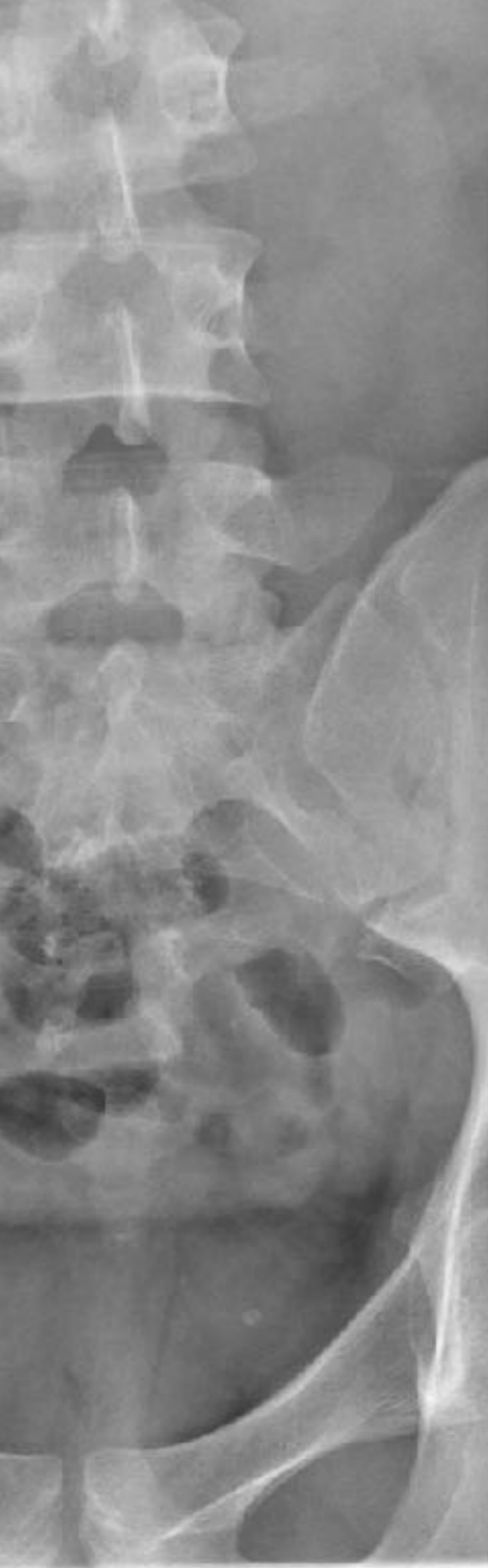
16.0cm

L UJV stone

Abd Gen2
C5-1
73 Hz
HD Zoom

2D

HGen
Gn 58
C 56
3 / 3 / 3



▲ P R
1.8 3.6

ABDOMEN **N**

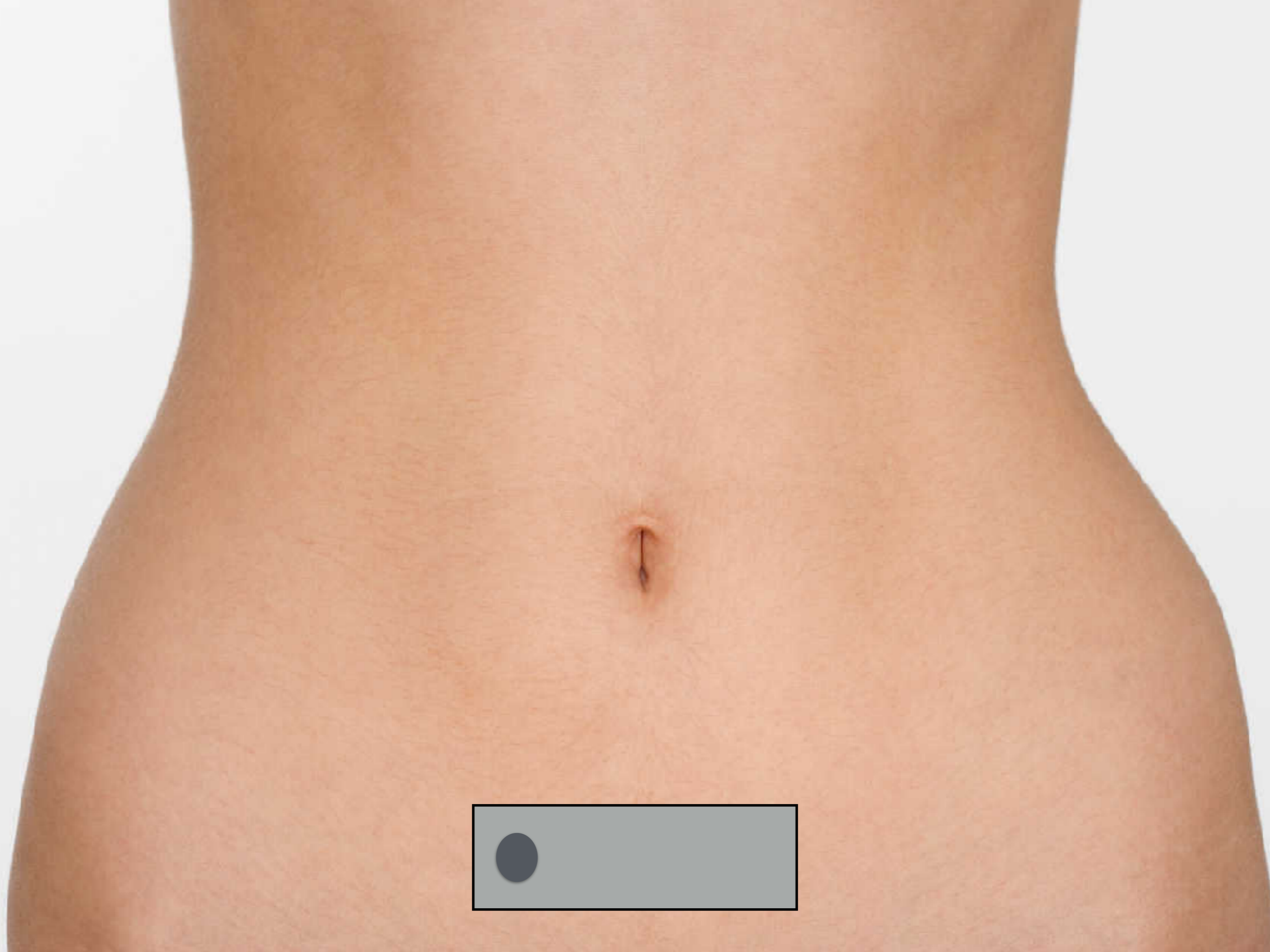
N for nephropathy

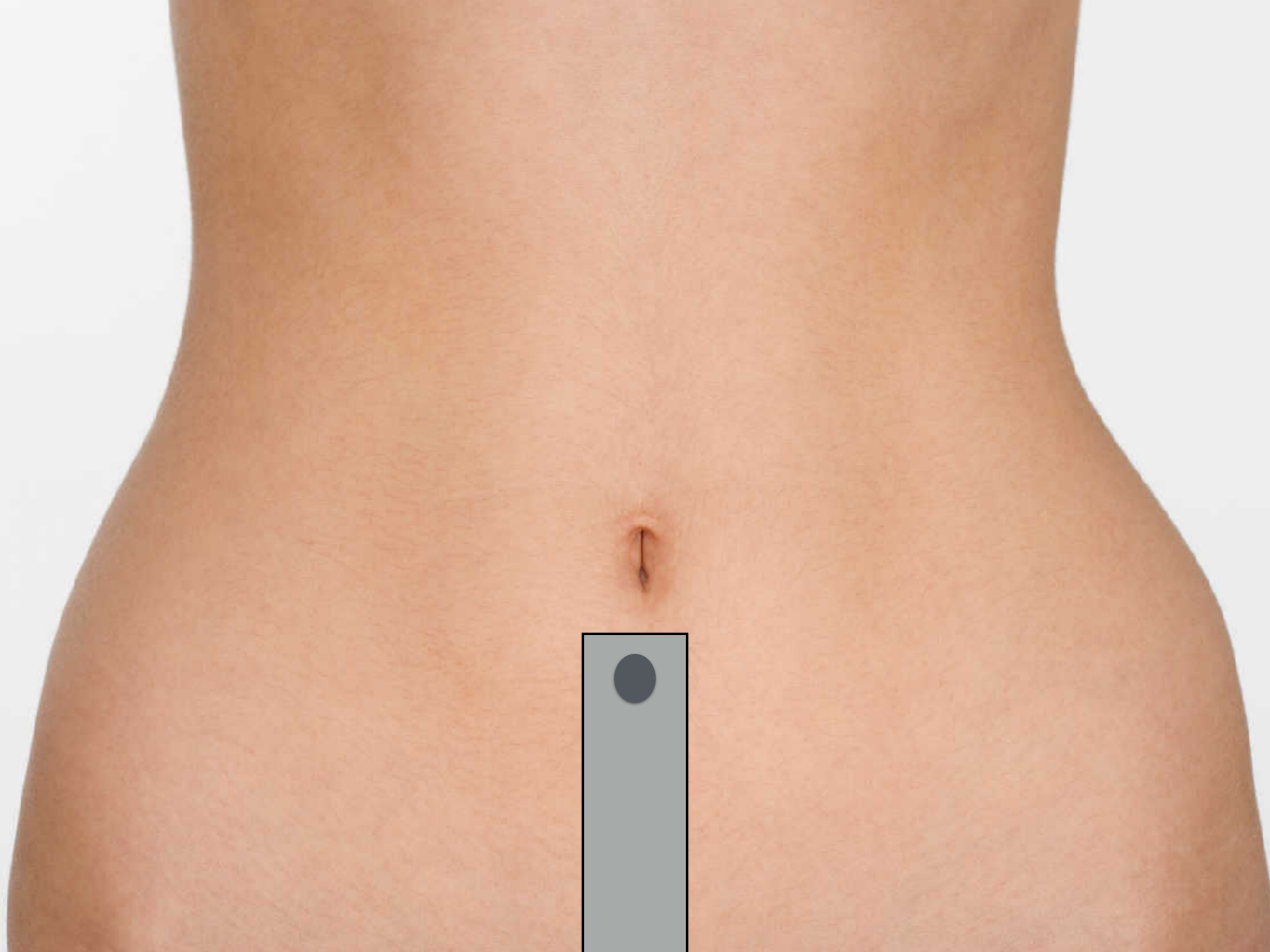
Hydronephrosis & KuB

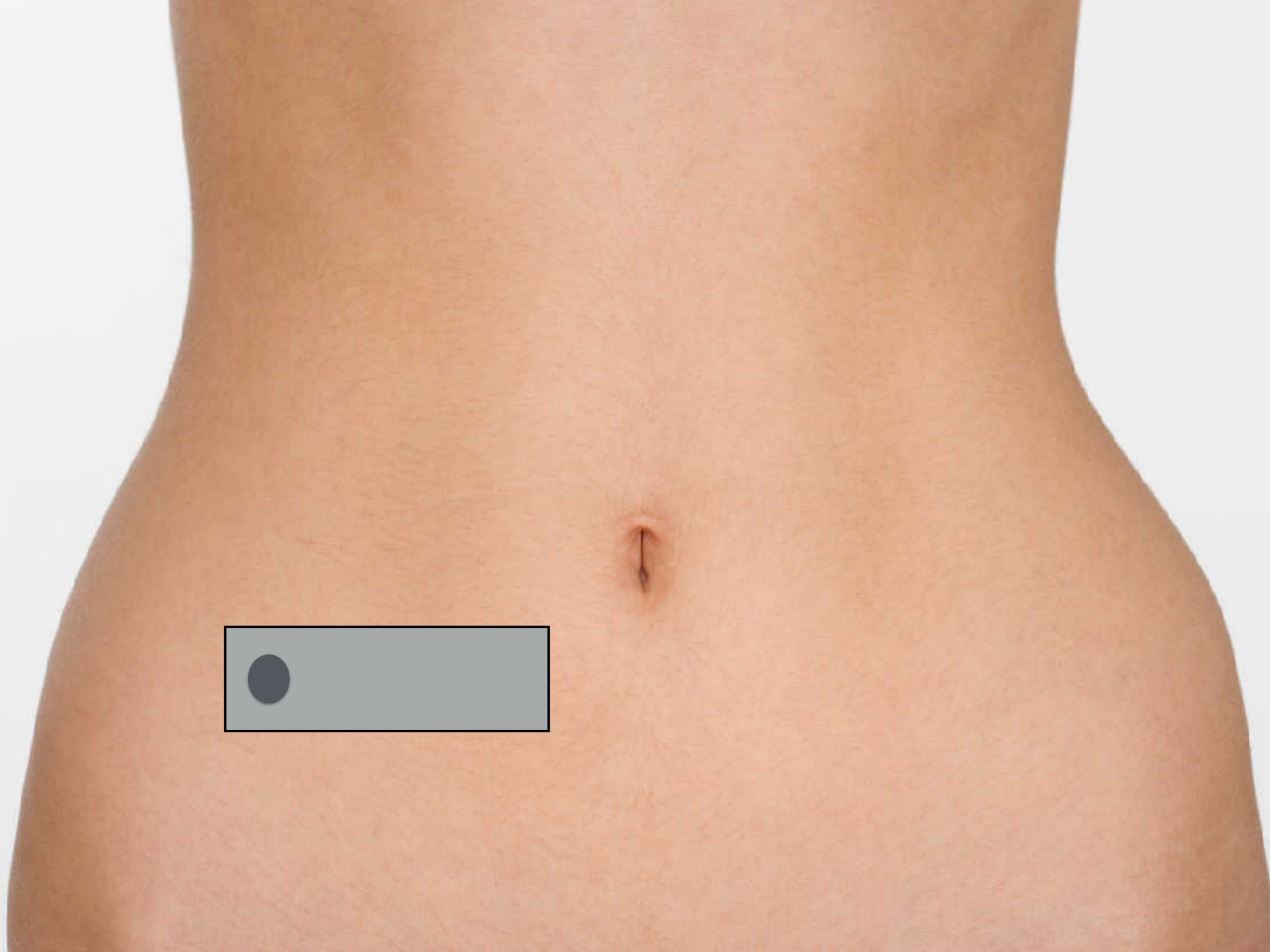


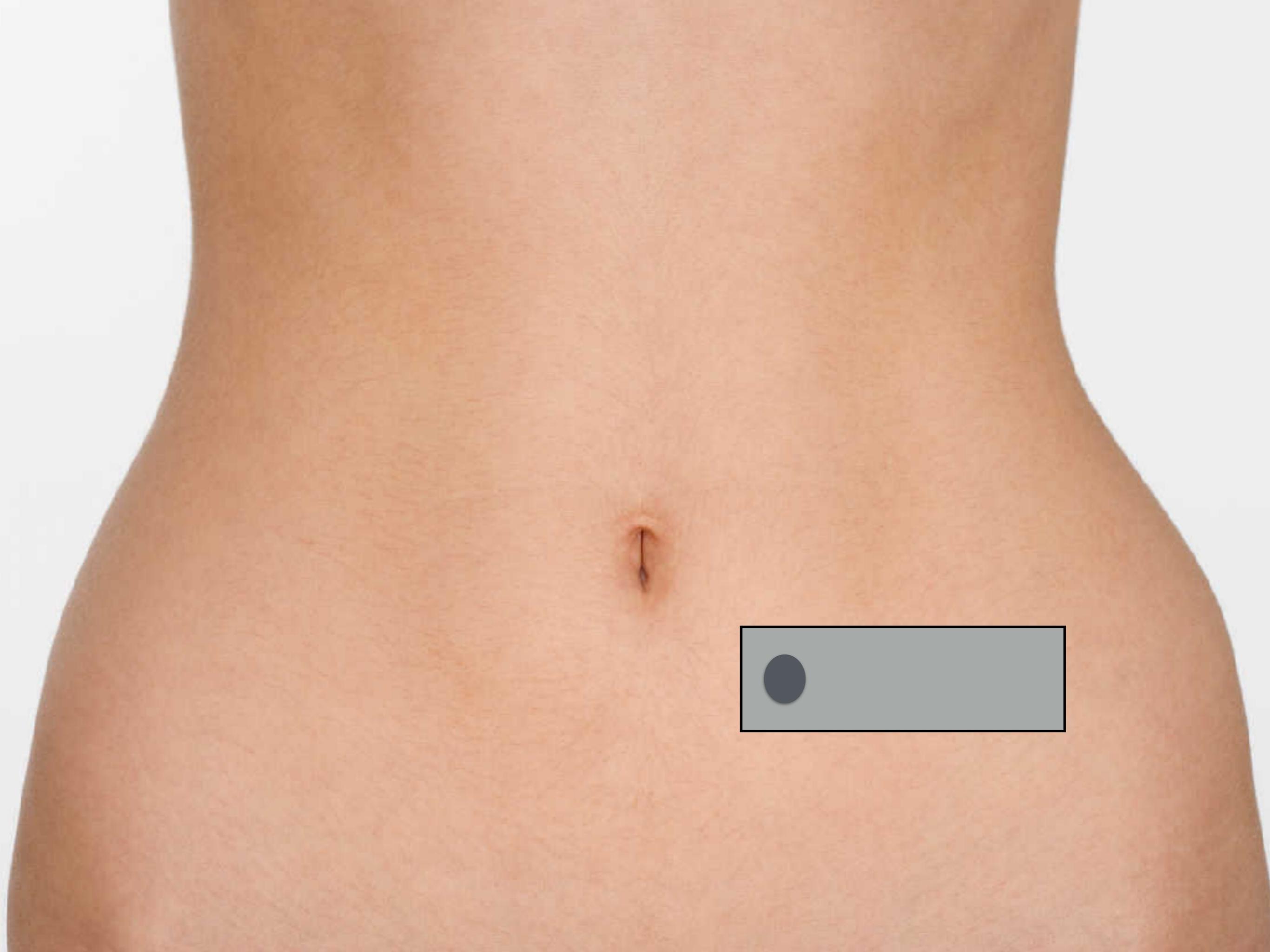


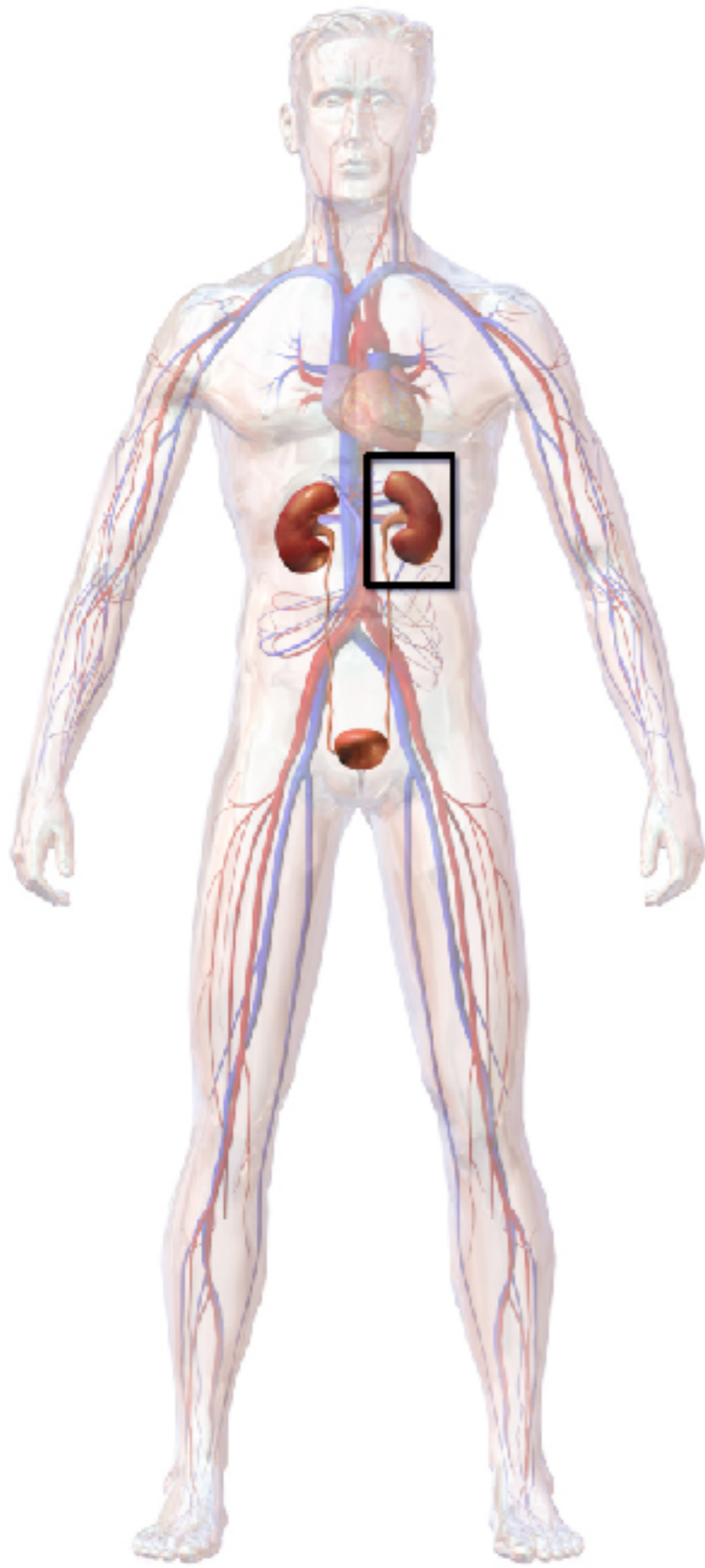




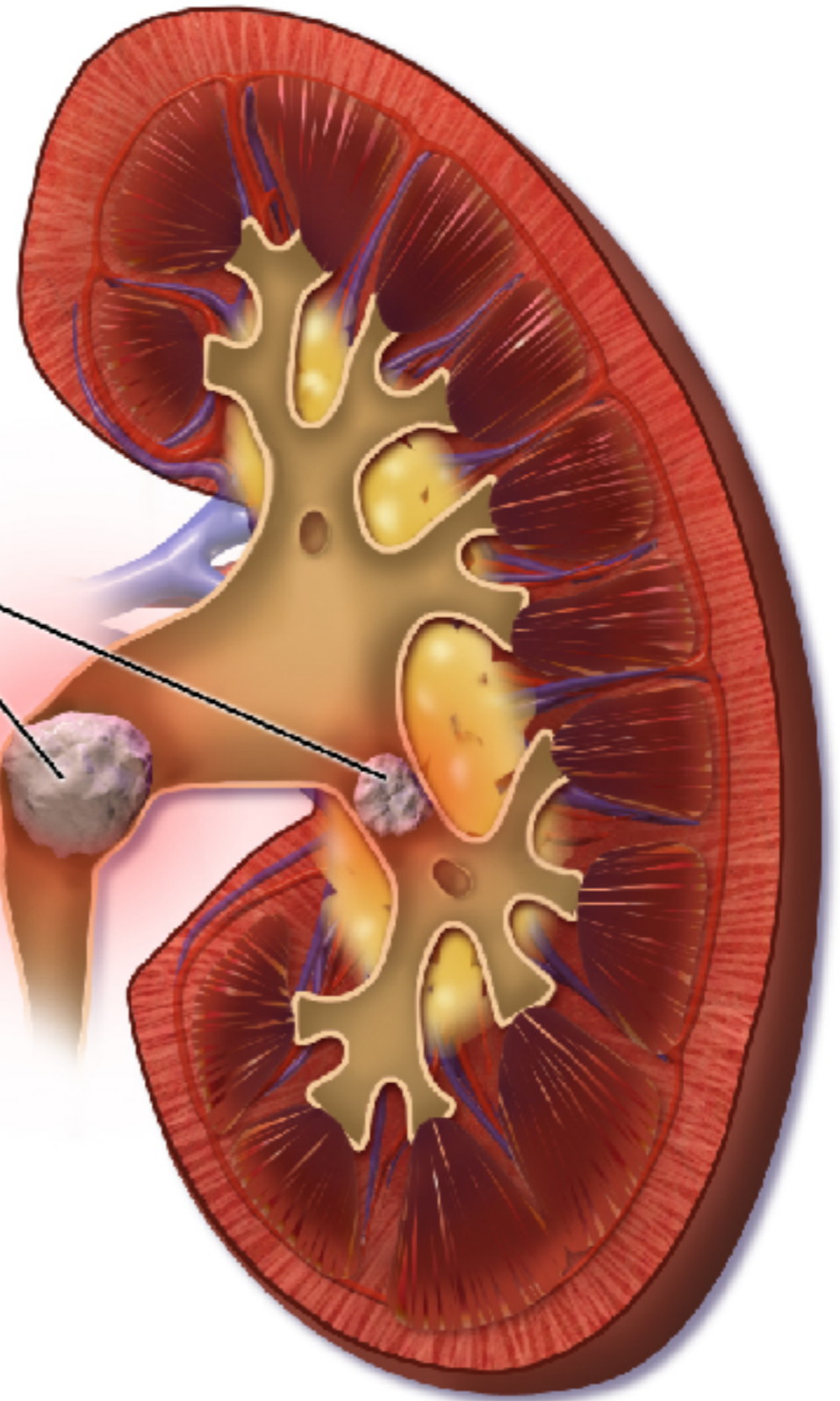




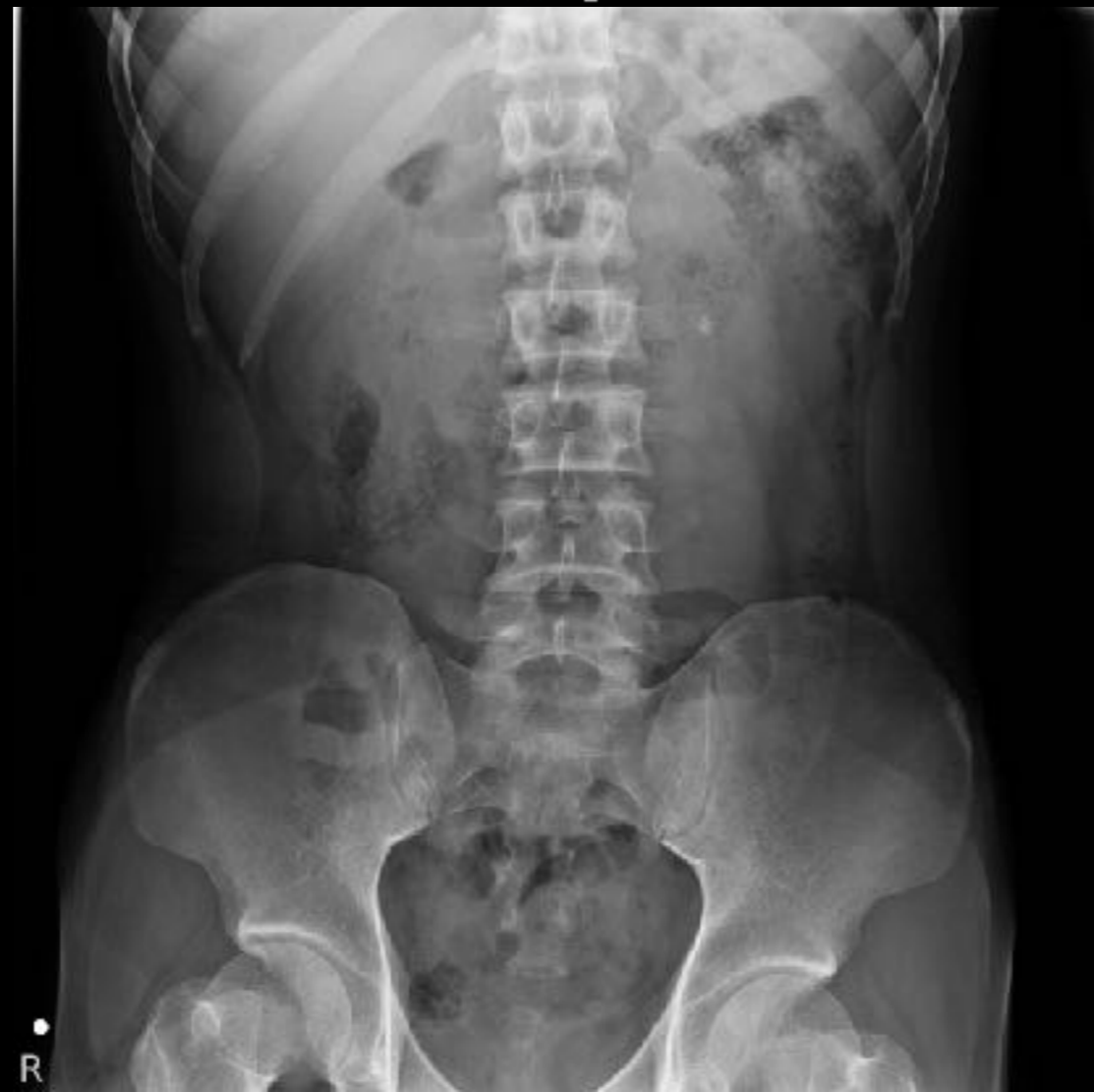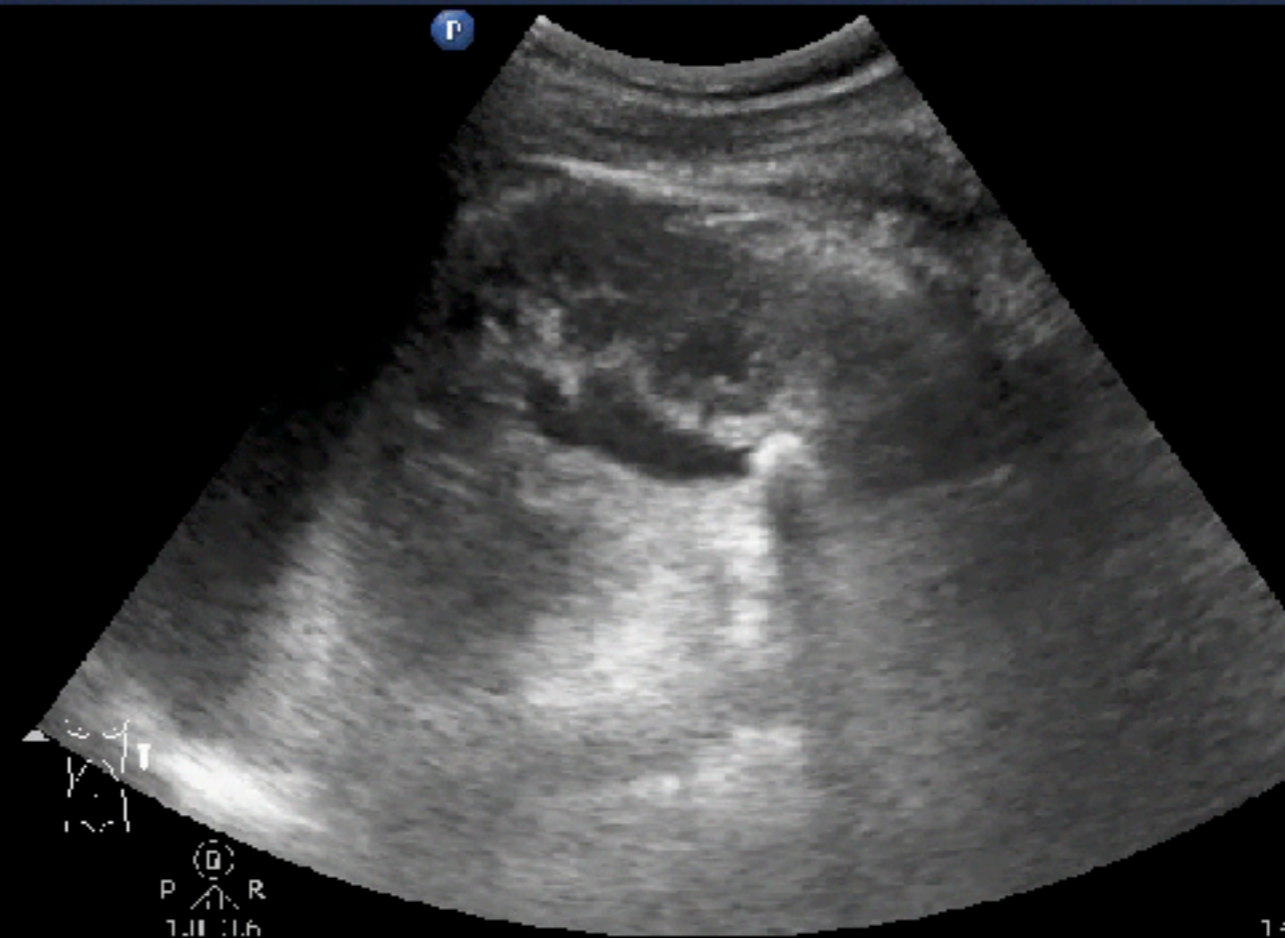
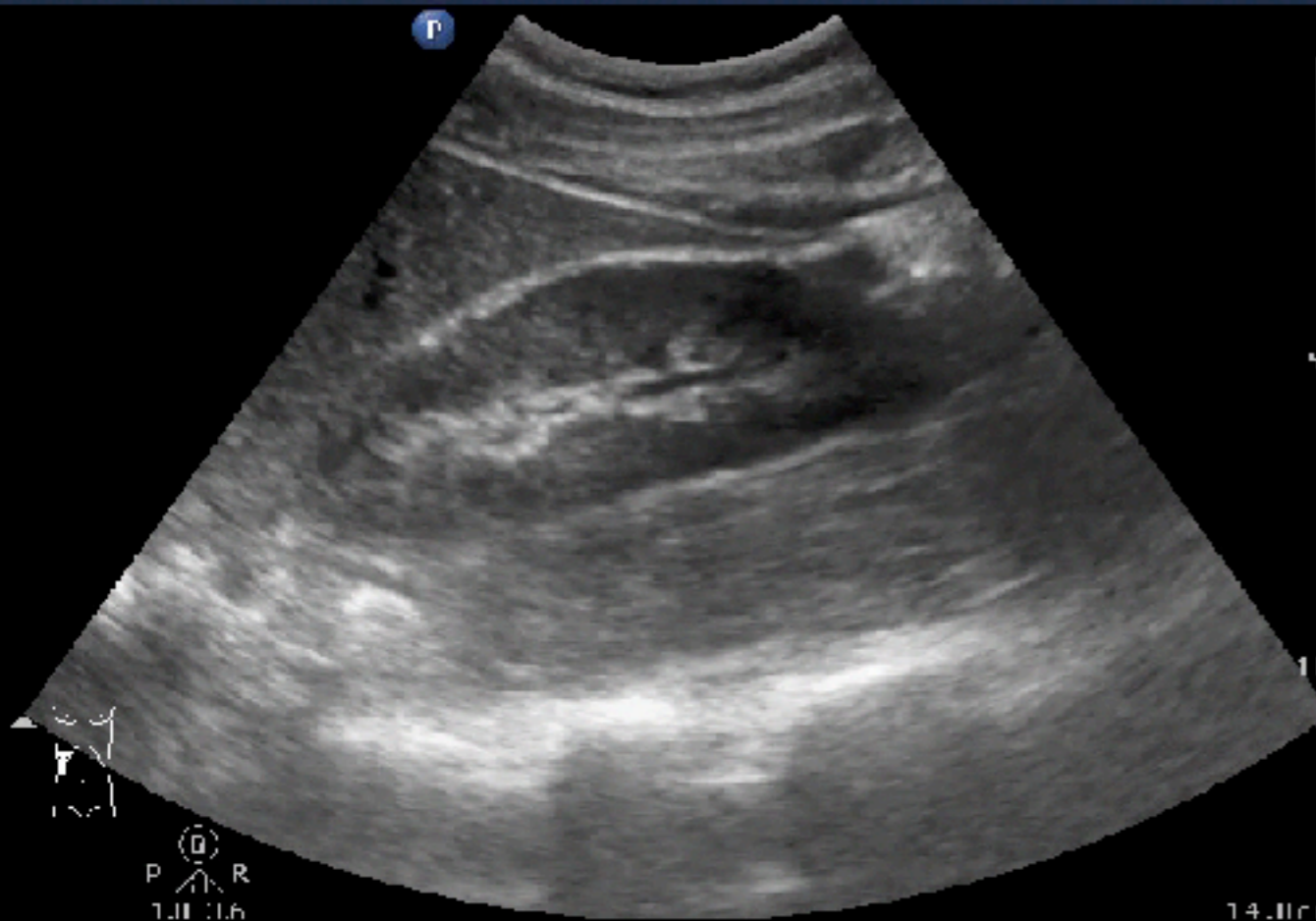




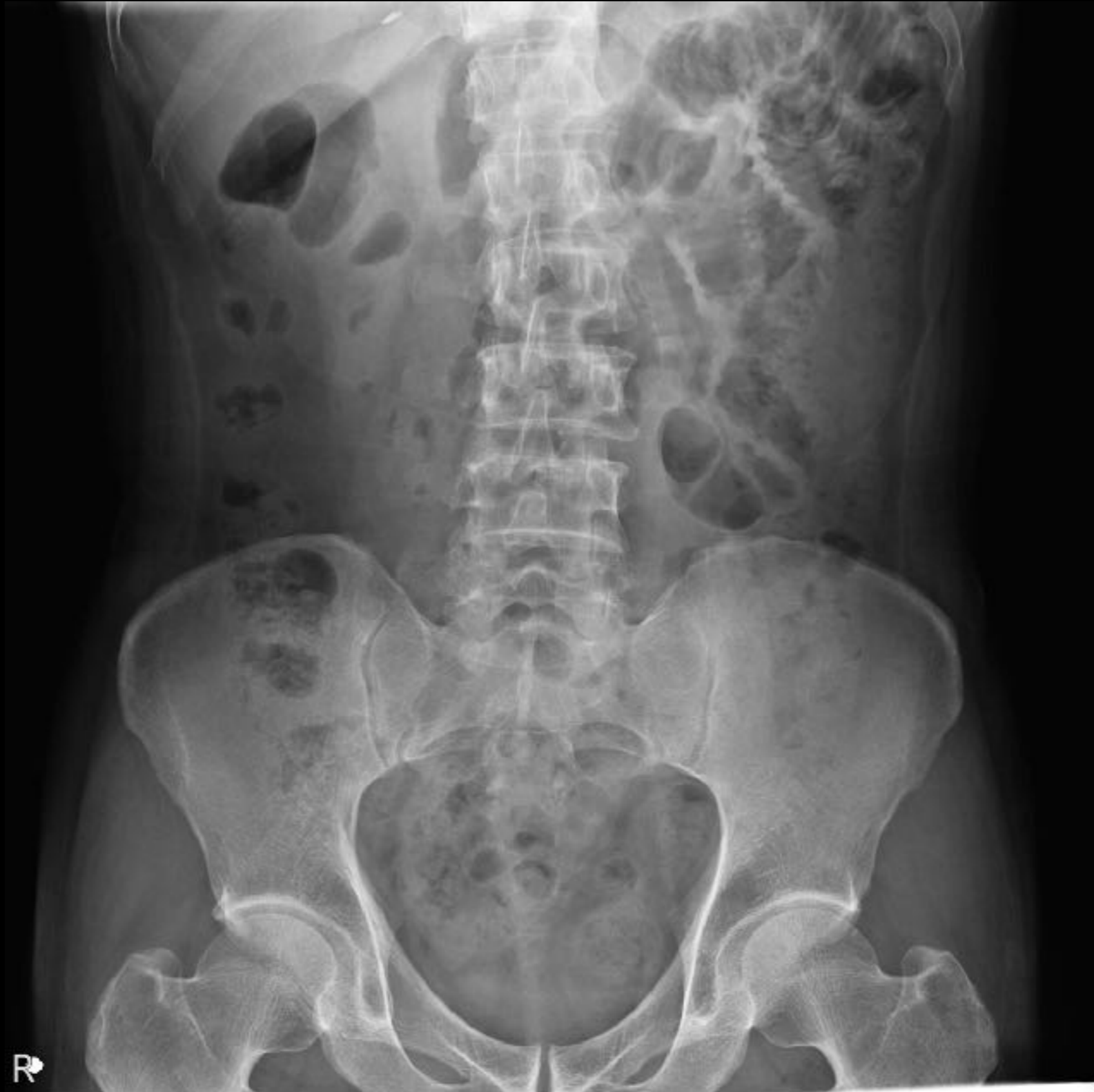Kidney stones



Kidney Stones



54M, right flank/abd pain

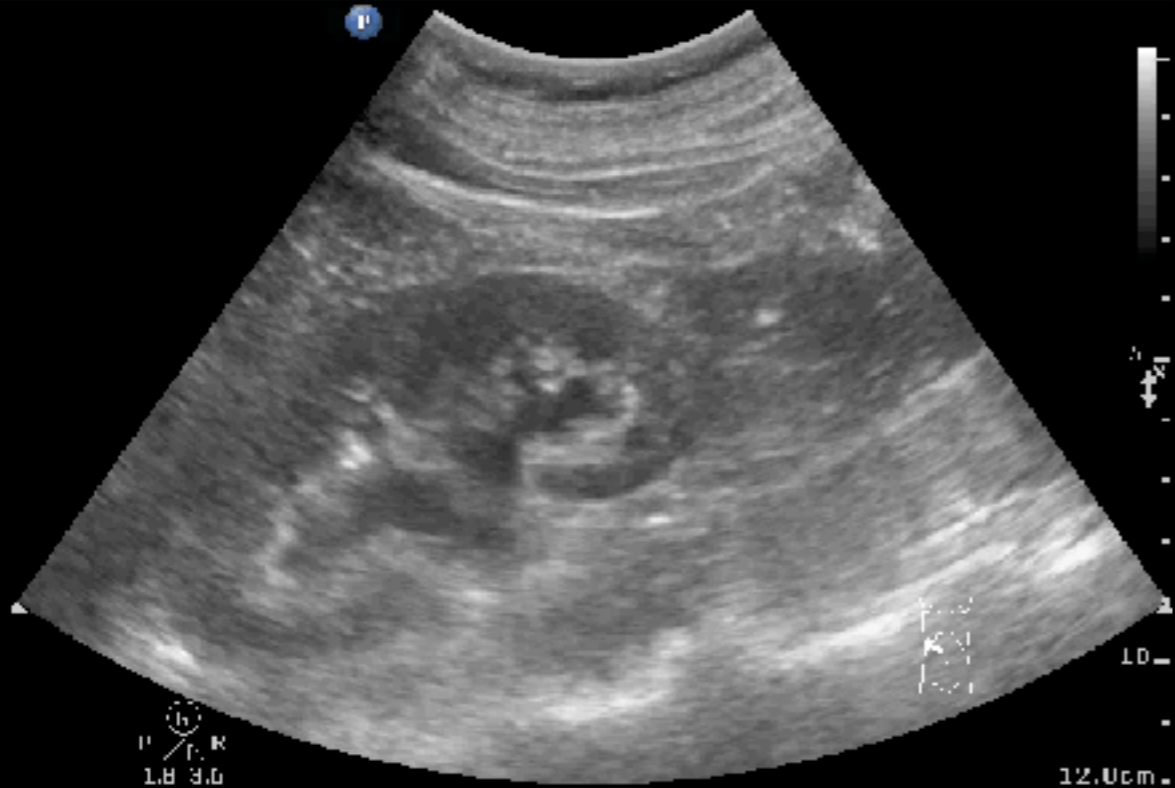


ABDOMEN **N**

54M, right flank/abd pain

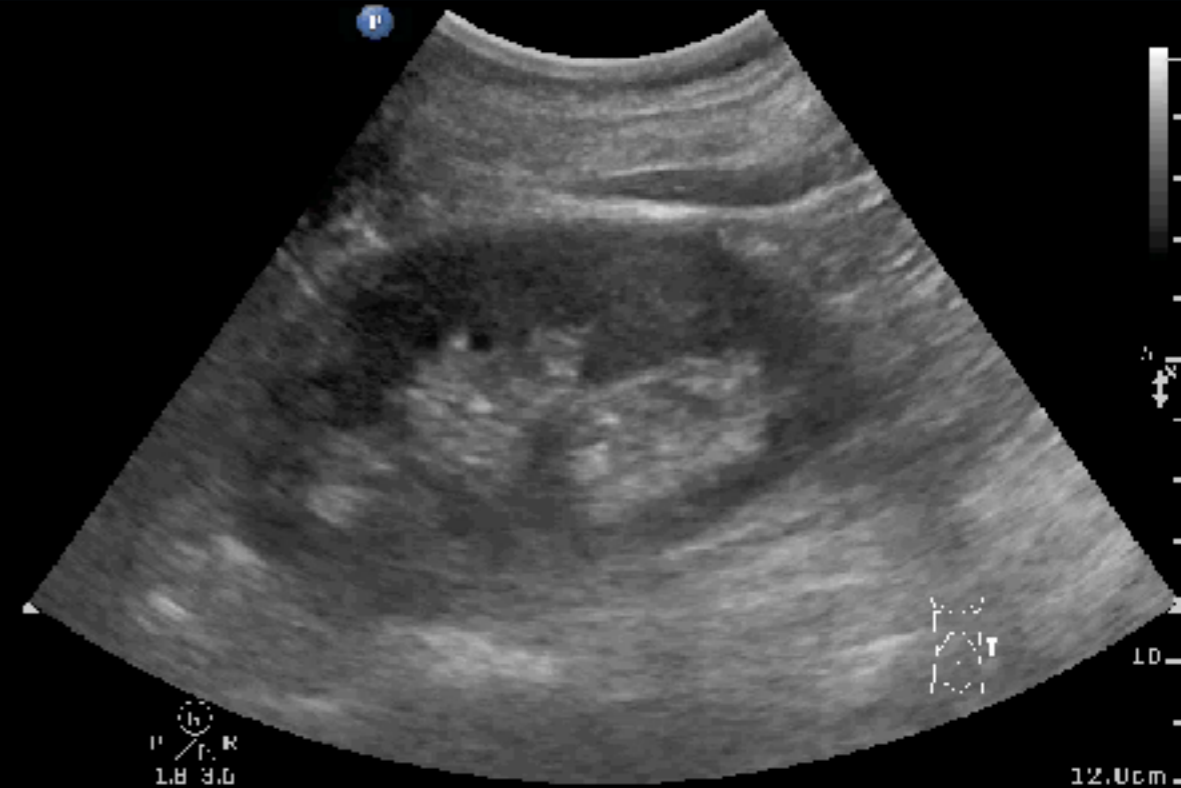Abd Gen2
11.5 1
39 Hz
12.0cm

2D
11Gen
11.5 1
11.55
3/3/3



Abd Gen2
11.5 1
39 Hz
12.0cm

2D
11Gen
11.5 1
11.55
3/3/3

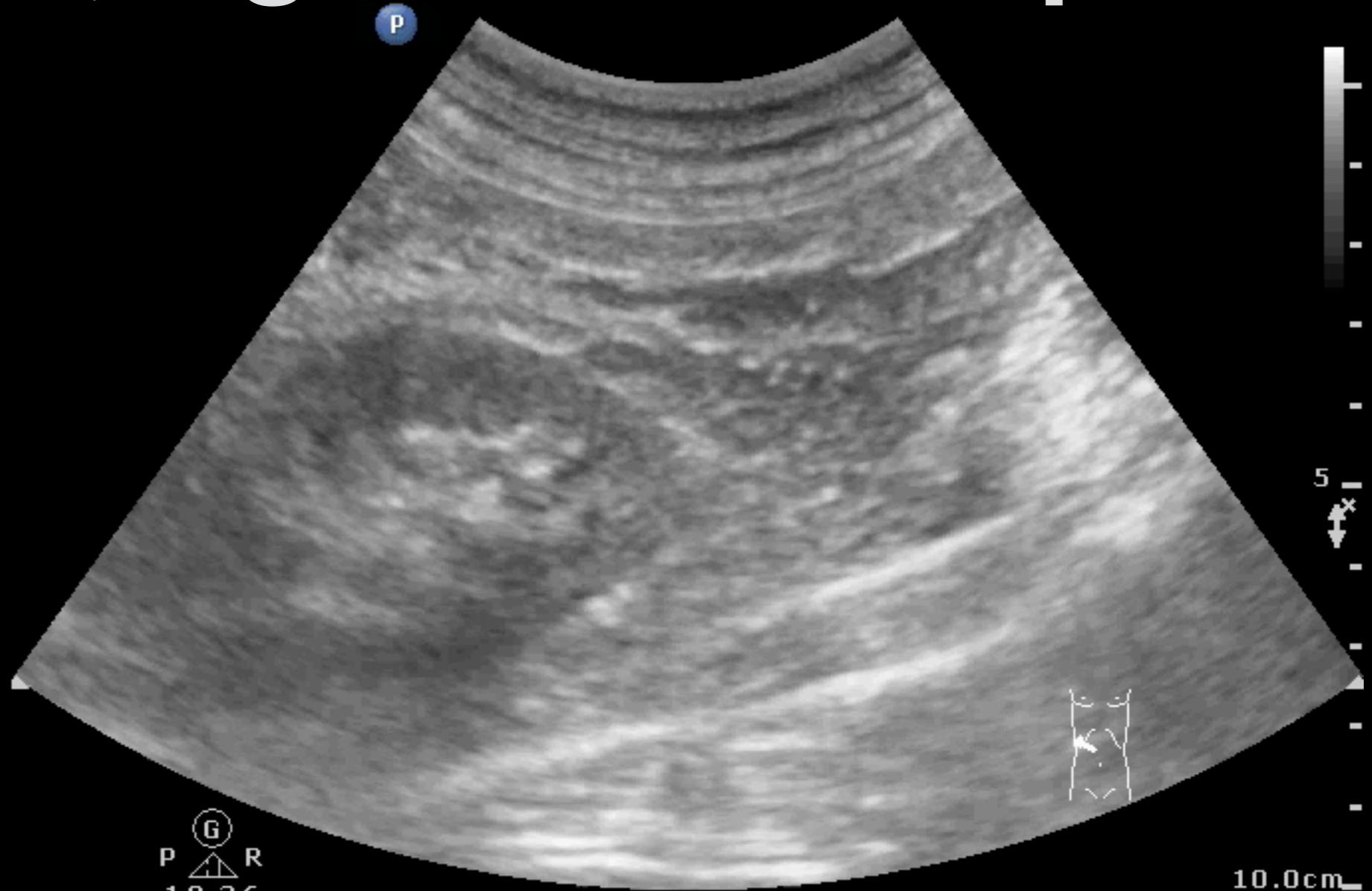

ABDOMEN **N**

54M, right flank/abd pain

Abd Gen2
C5-1
45 Hz
10.0cm

2D
HGen
Gn 84
C 56
3 / 3 / 3

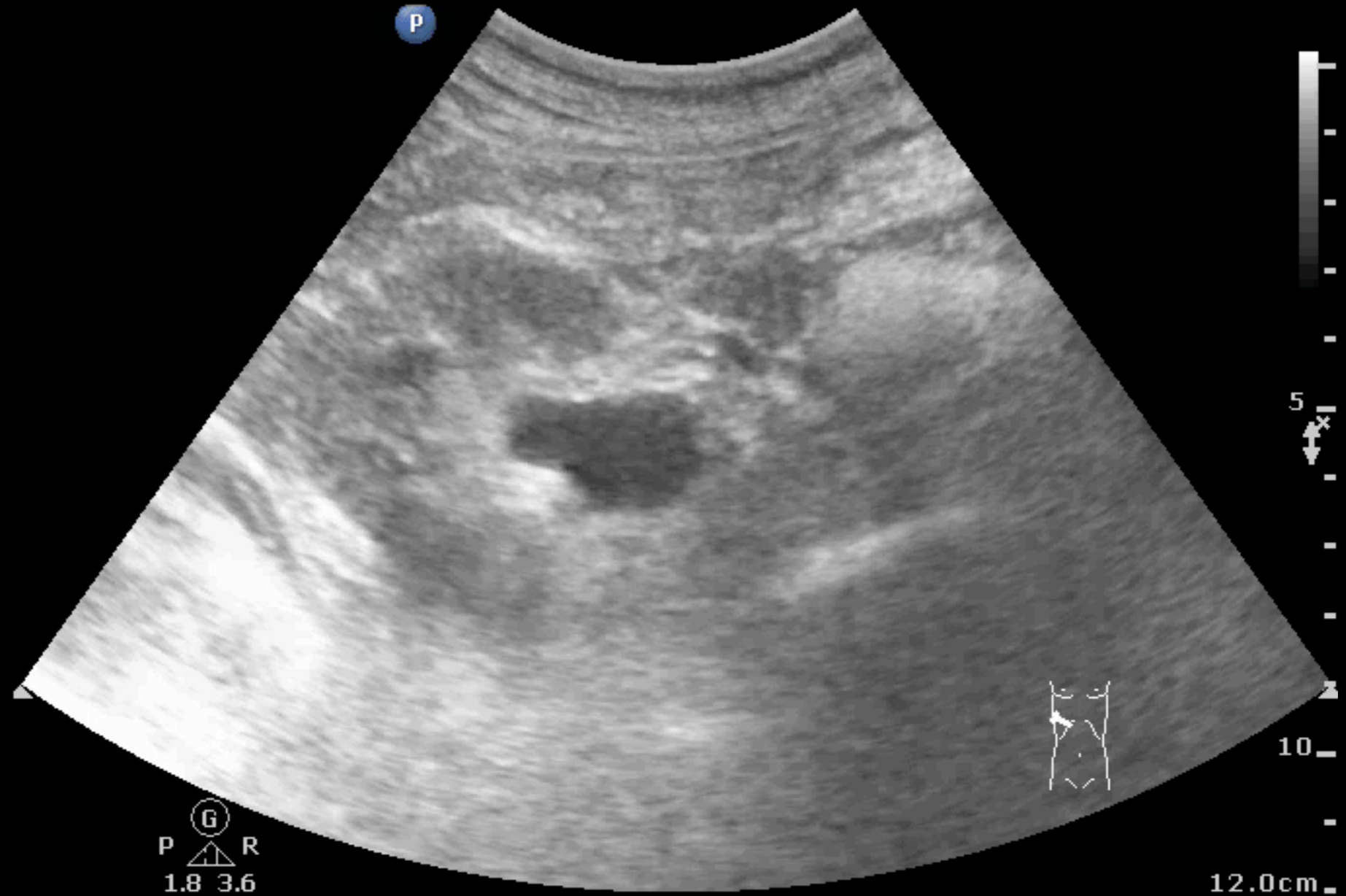

ABDOMEN

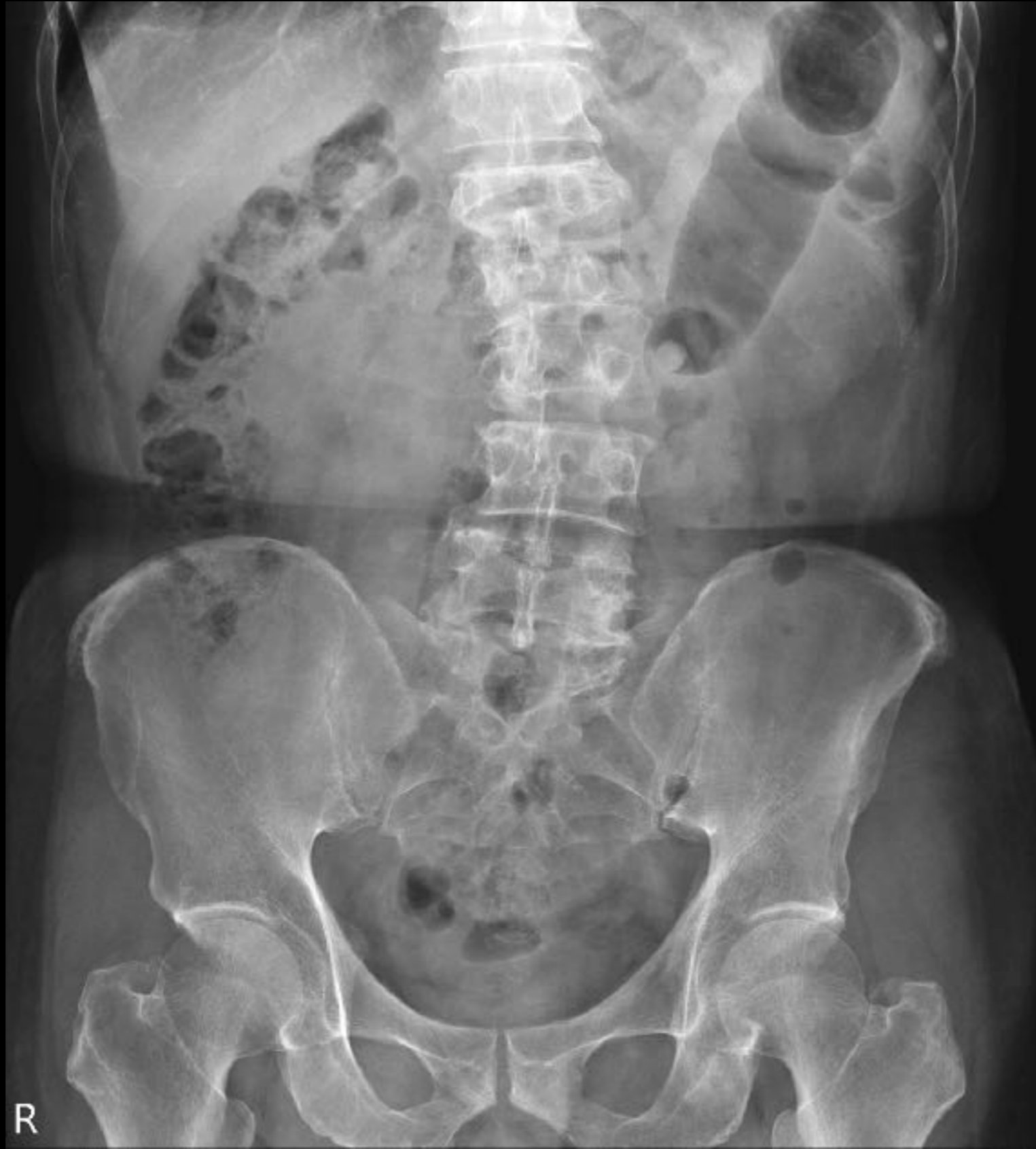Ureteral stone

Abd Gen2
C5-1
39 Hz
12.0cm

2D
HGen
Gn 100
C 56
3 / 3 / 3



63M, left flank pain



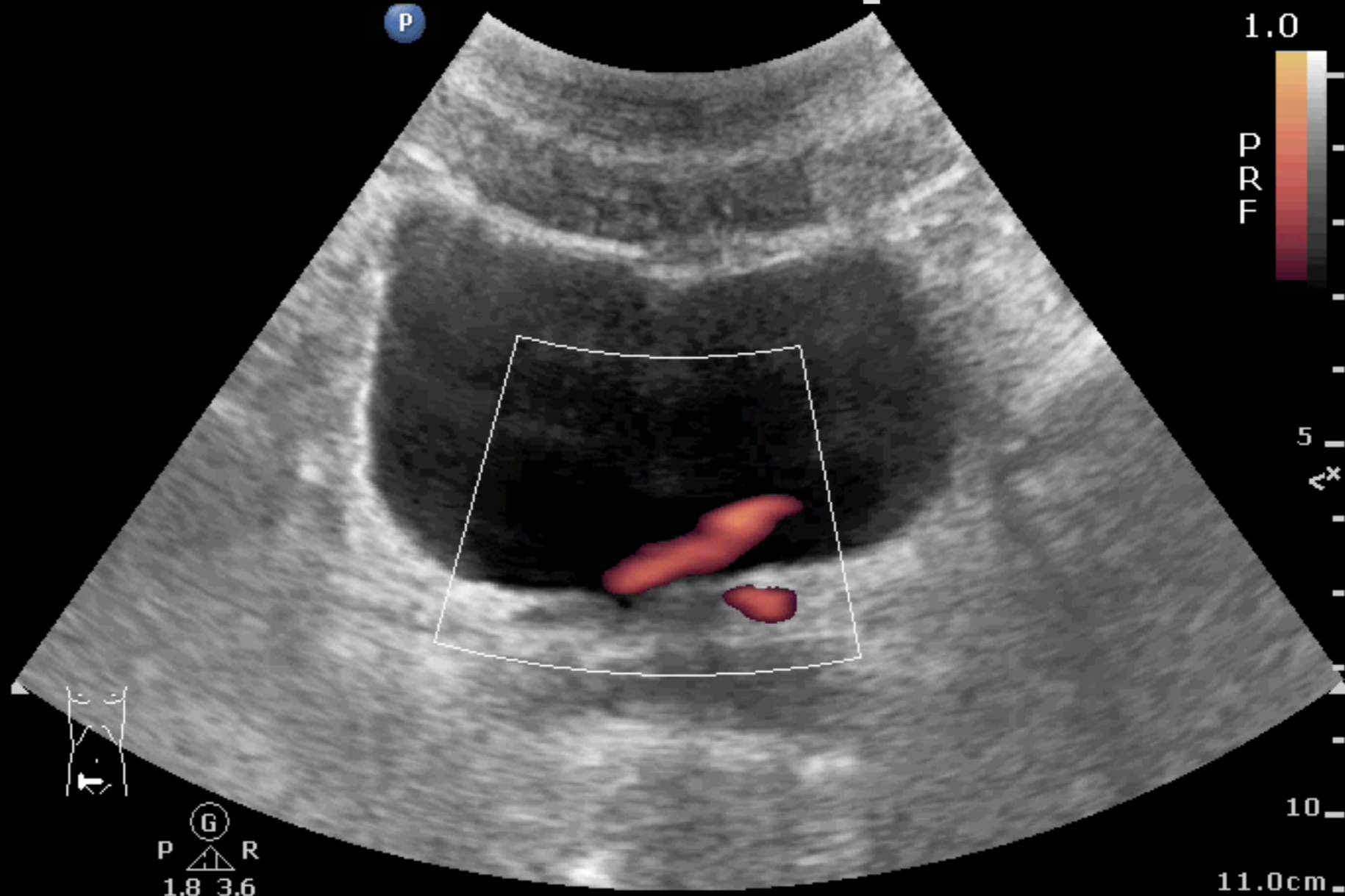
ABDOMEN

63M, left flank pain

Abd Gen
C5-1
12 Hz
11.0cm

2D
HGen
Gn 70
C 56
3/3/3

CPA
2.5 MHz
Gn 72
1/8/4
Fltr High
Baseln 8



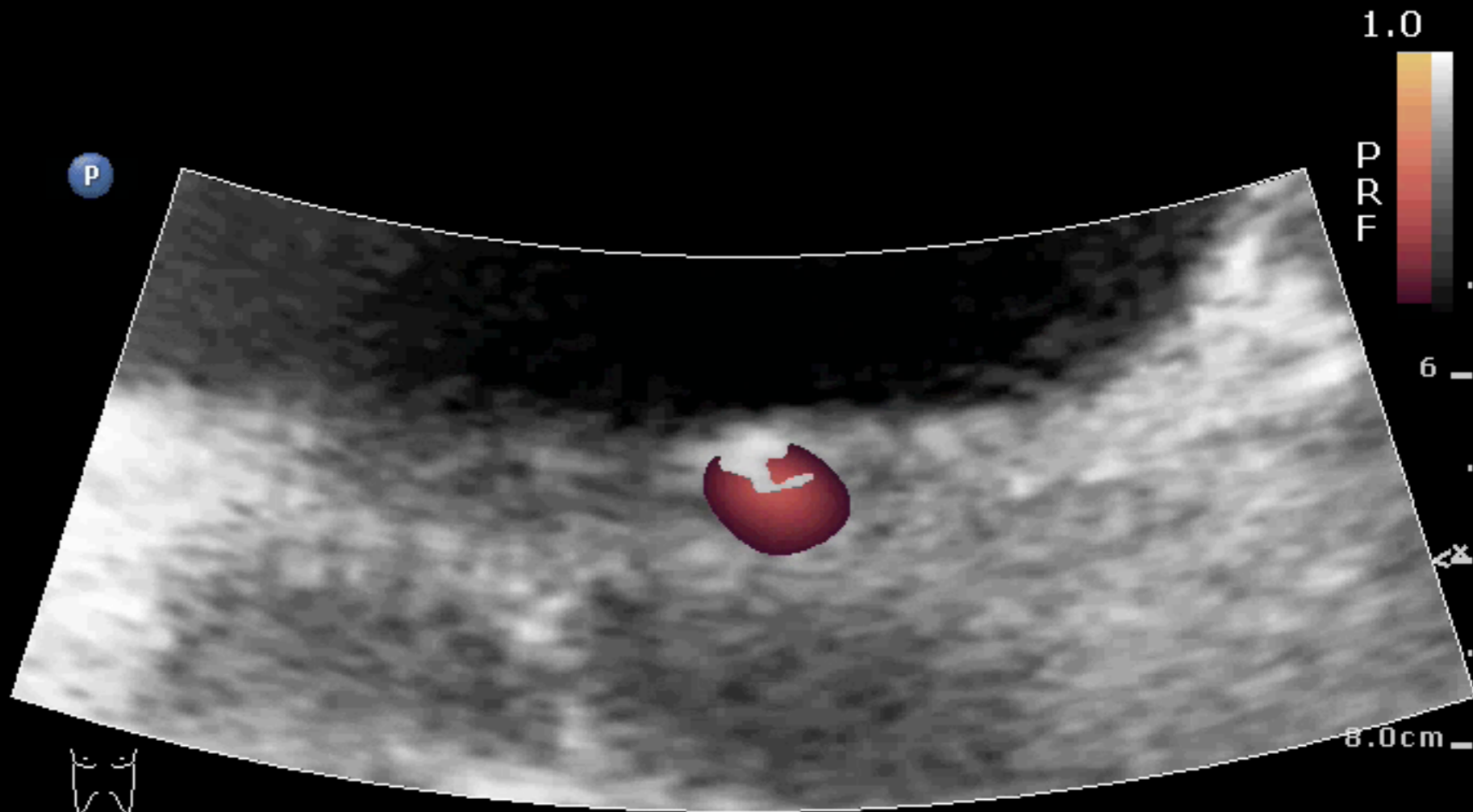
Twinkling artifact

PHILIPS

Abd Gen
C5-1
12 Hz
HD Zoom

2D
HGen
Gn 70
C 56
3/3/3

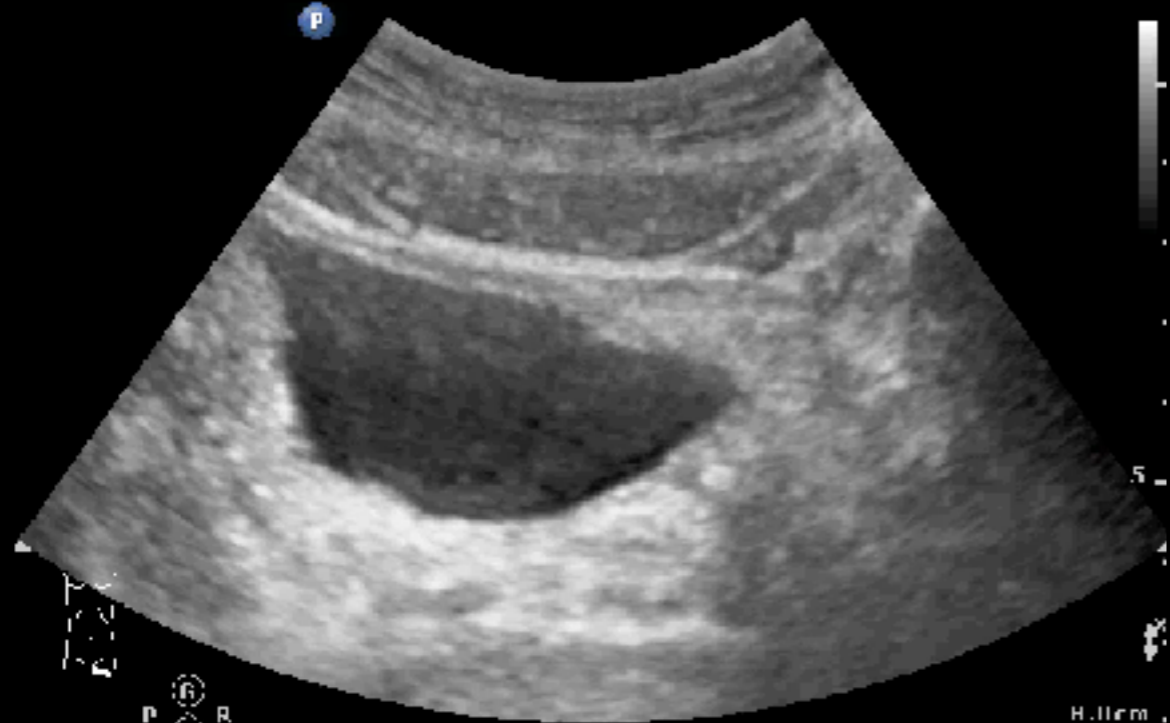
CPA
2.5 MHz
Gn 72
1/8/4
Filtr High
Baseln 8



Twinkling artifact

Abd Gen
C5-1
51 117
8.0cm

2D
HGen
Gn 71
C 56
3/3/3



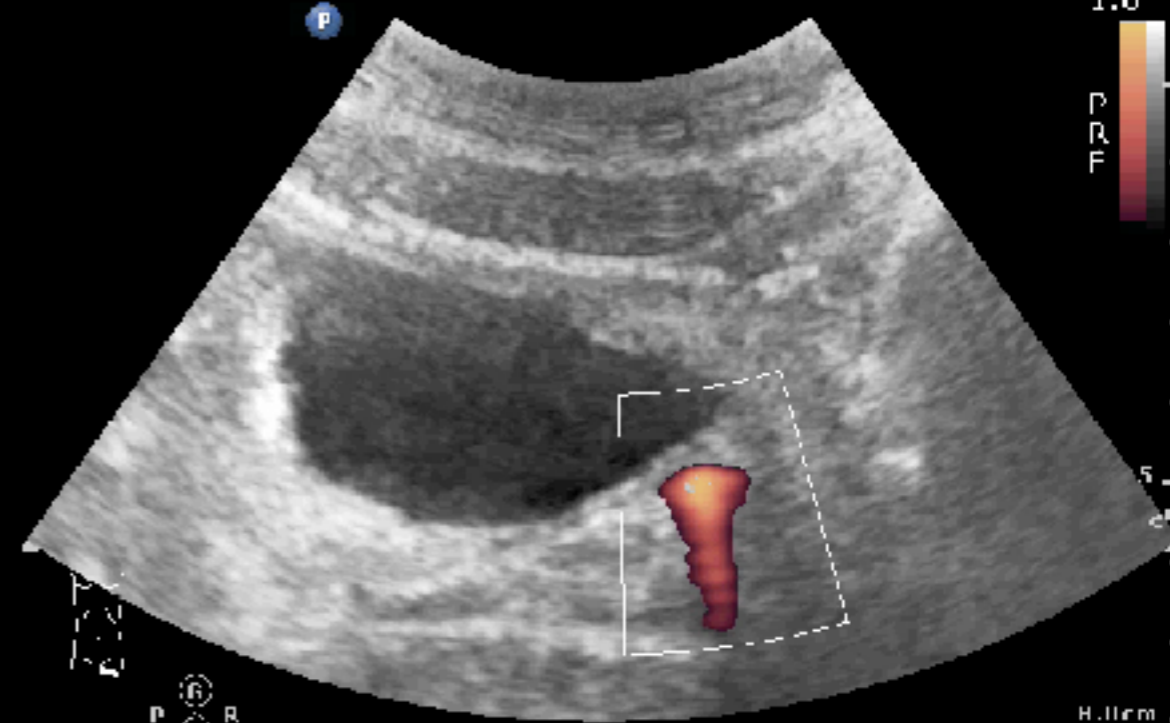
1.8 3.6

Abd Gen
C5-1
51 117
8.0cm

2D
HGen
Gn 71
C 56
3/3/3

CPA
2.5 MHz
Gn 66
1/8/4
Filtr High
Baseln 8

H.11cm



1.8 3.6

H.11cm



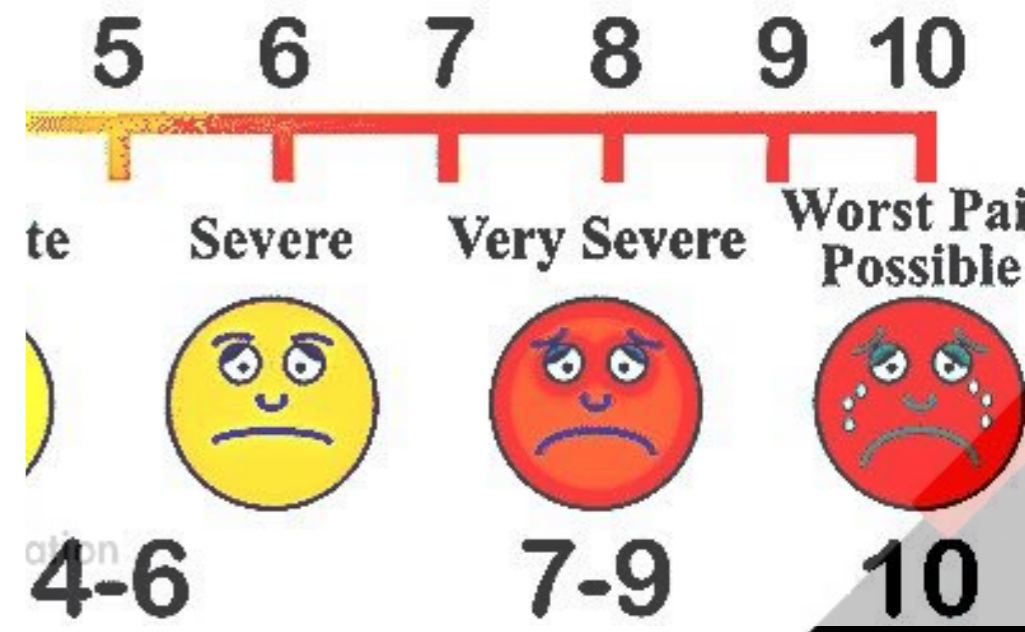
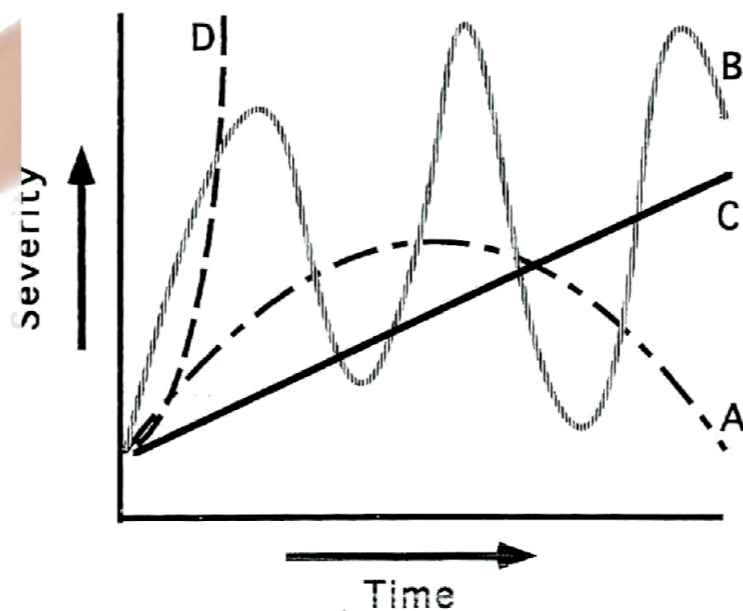
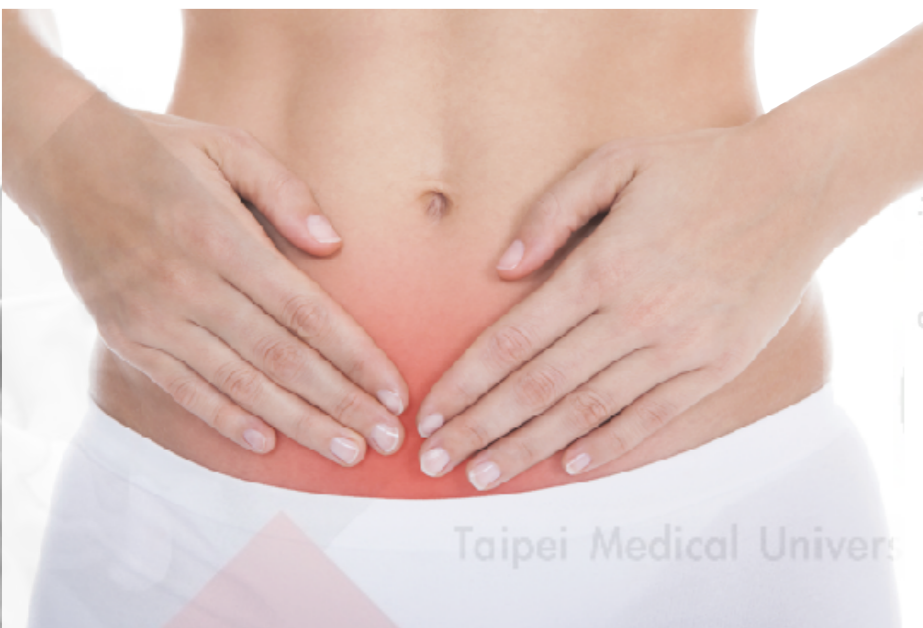病史詢問



POCUS



理學檢查





ULTRASOUND
PROGRAM

POCUS

for

Acute

ABDOMEN

A for aorta

B for biliary

D for diaphragm

O for obstruction

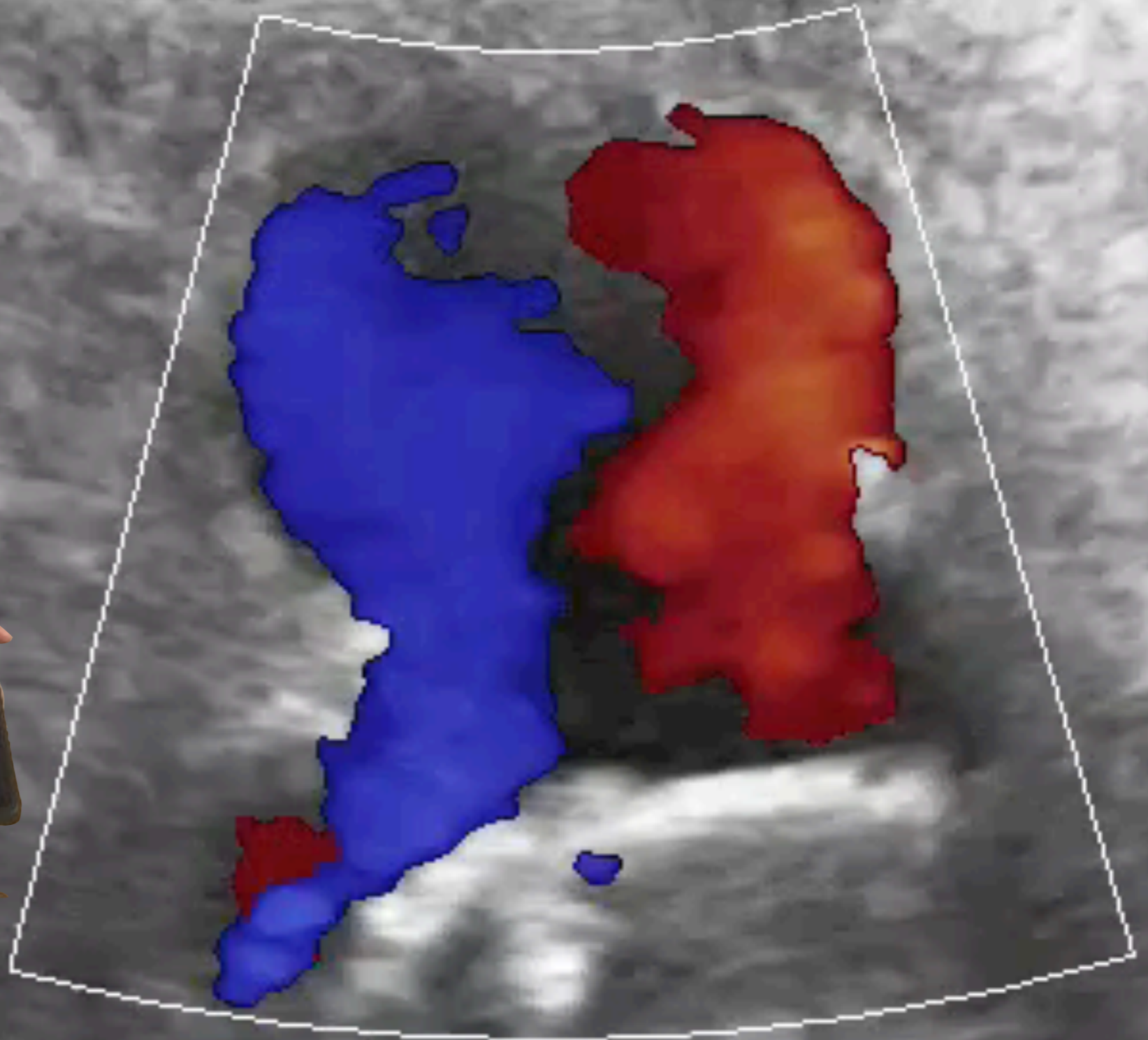
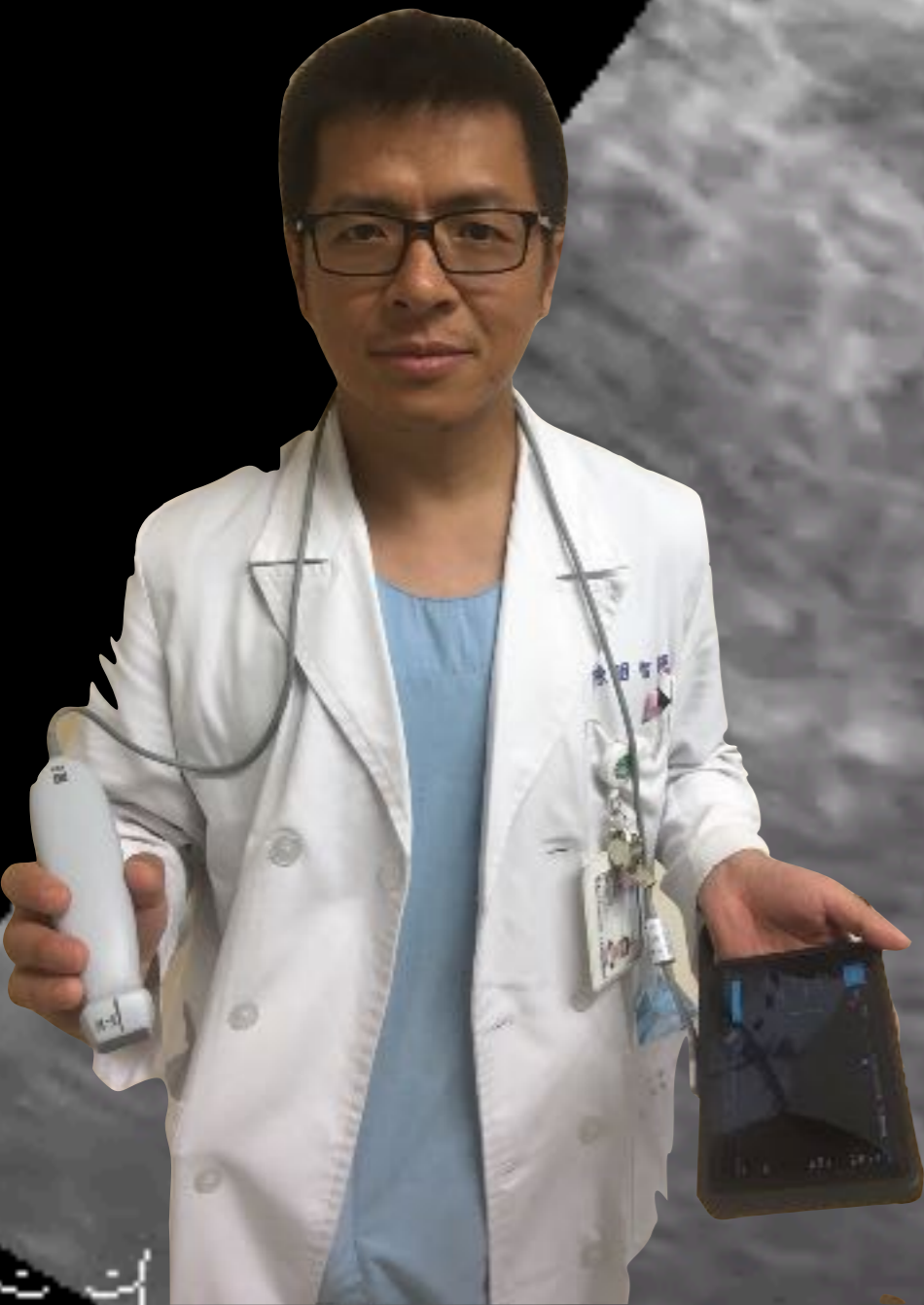
M for moving fluid or gas

E for ectopic pregnancy

N for nephropathy



POCUS幫你【透視】急性腹痛



POCUS Academy

Point-of-care ultrasound is the visual stethoscope in the 21st century

Password: 20200104



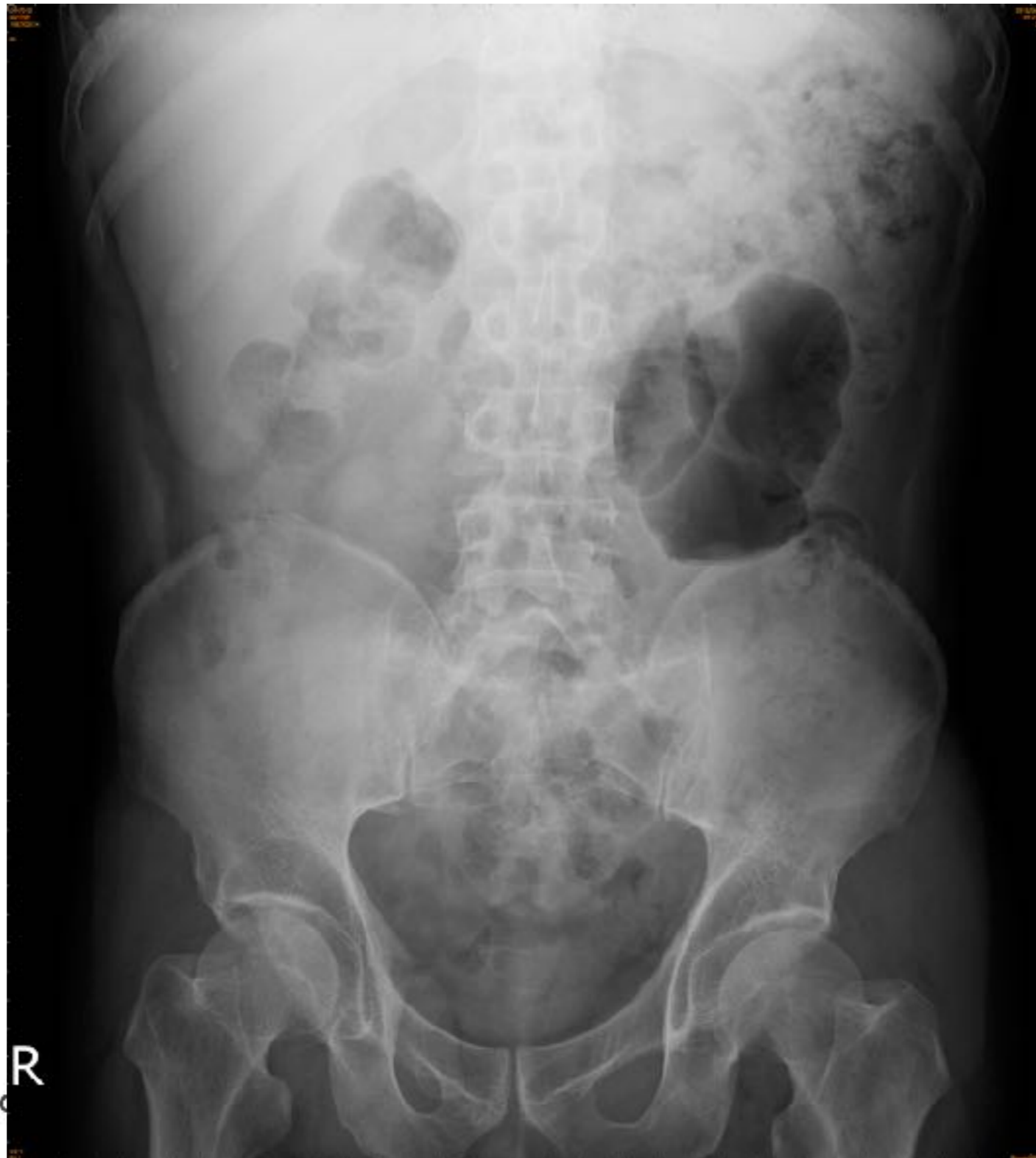juice119@gmail.com

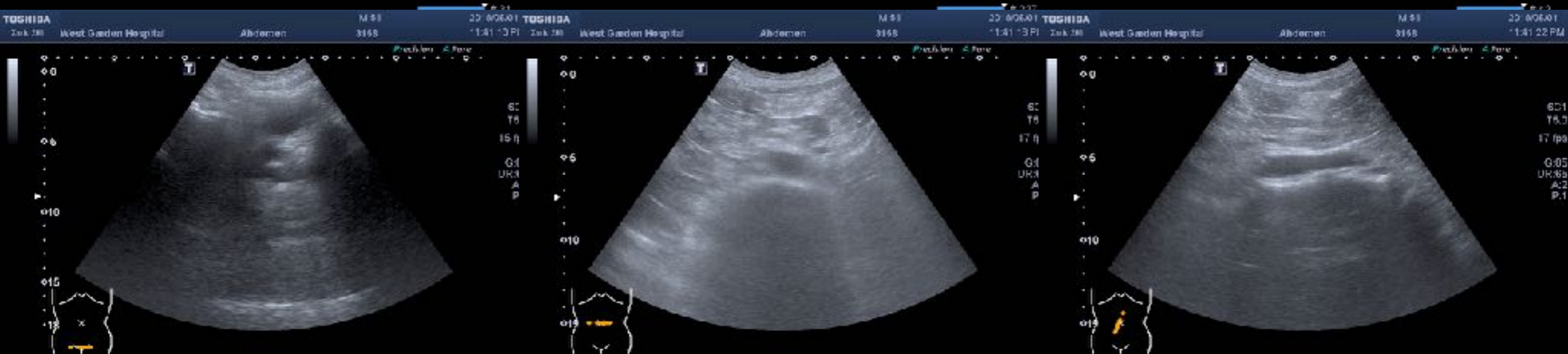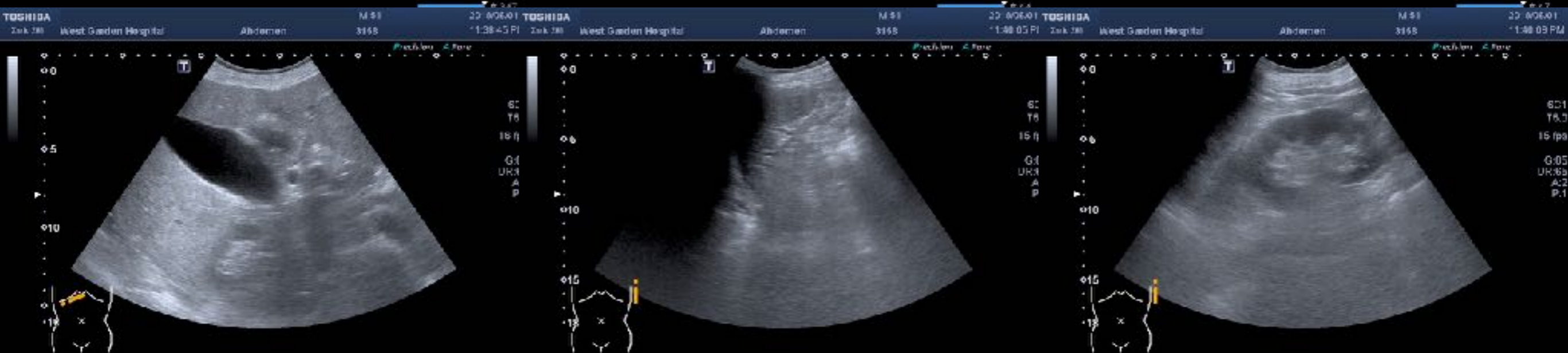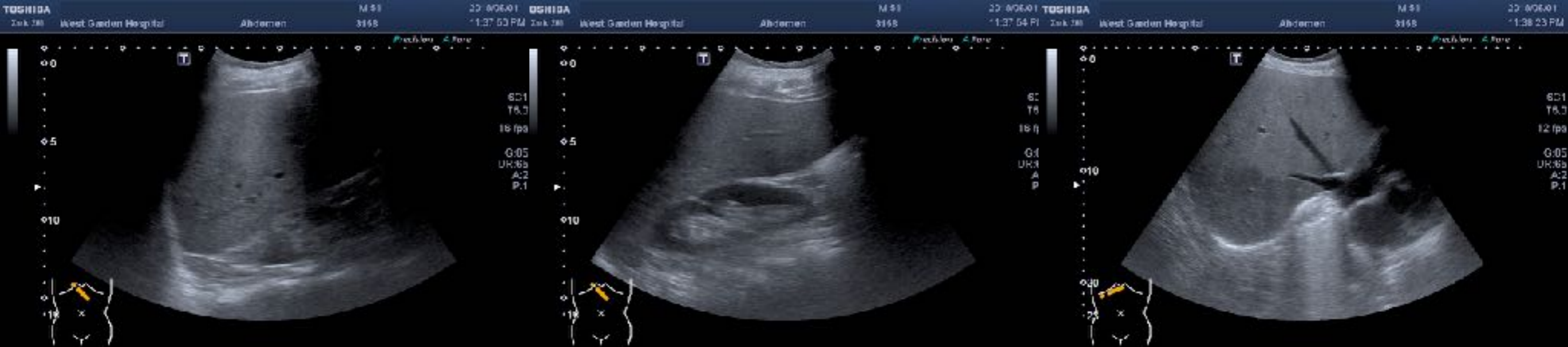FB: Emergency Ultrasound Training Center

Taipei Medical University Center for Education in Medical Simulation

51M, RUQ pain

WBC 13000; CRP 8.5





T

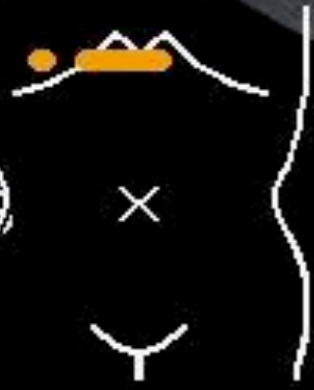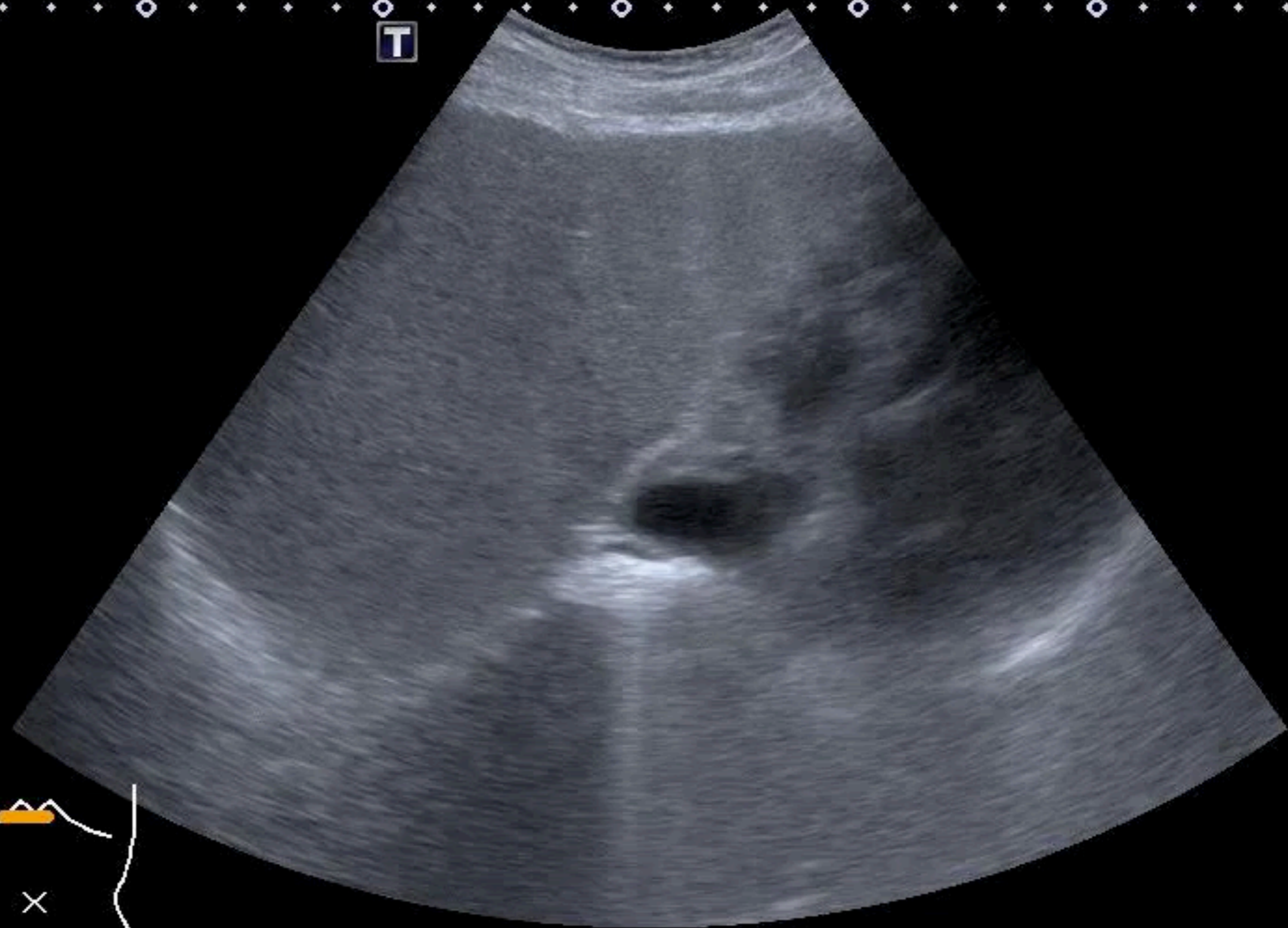
0

5

10

15

18

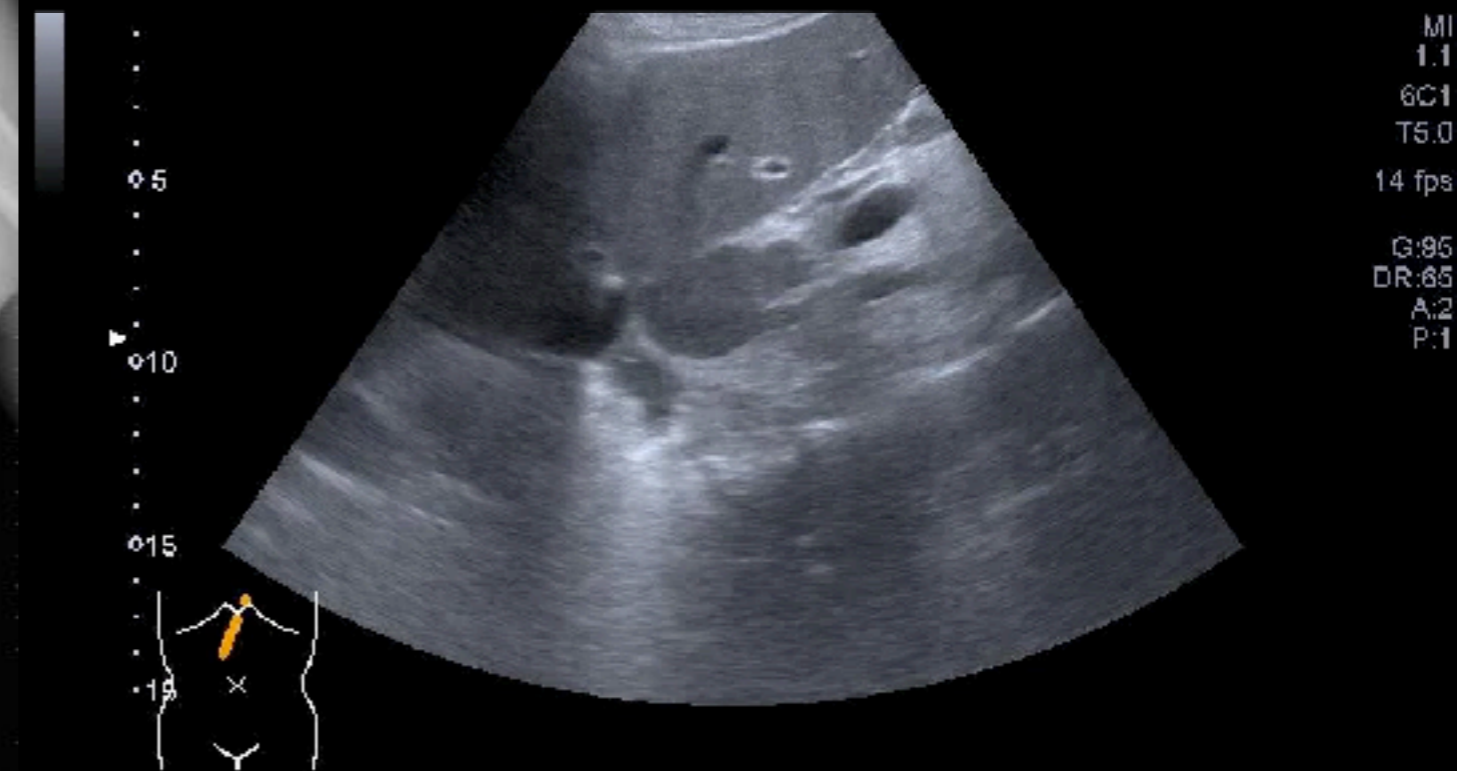
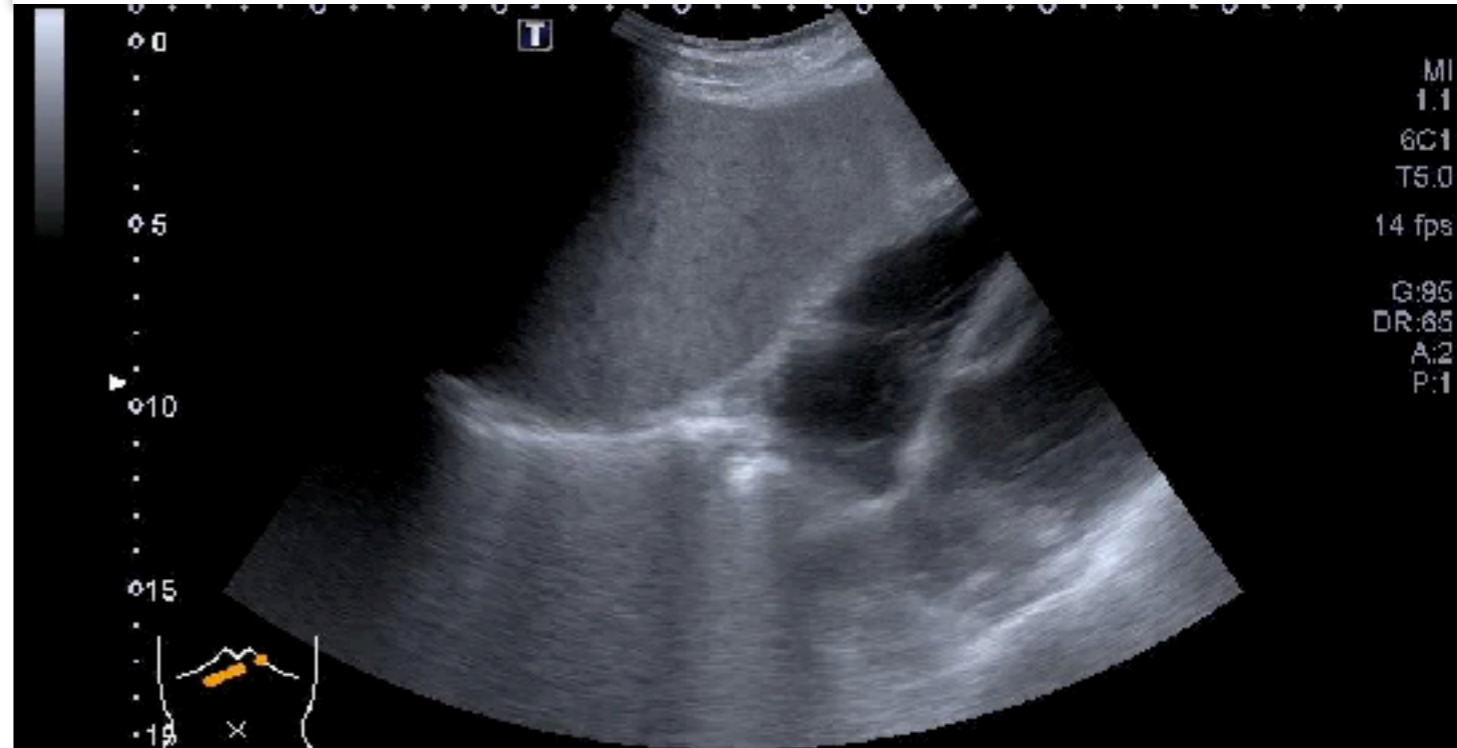
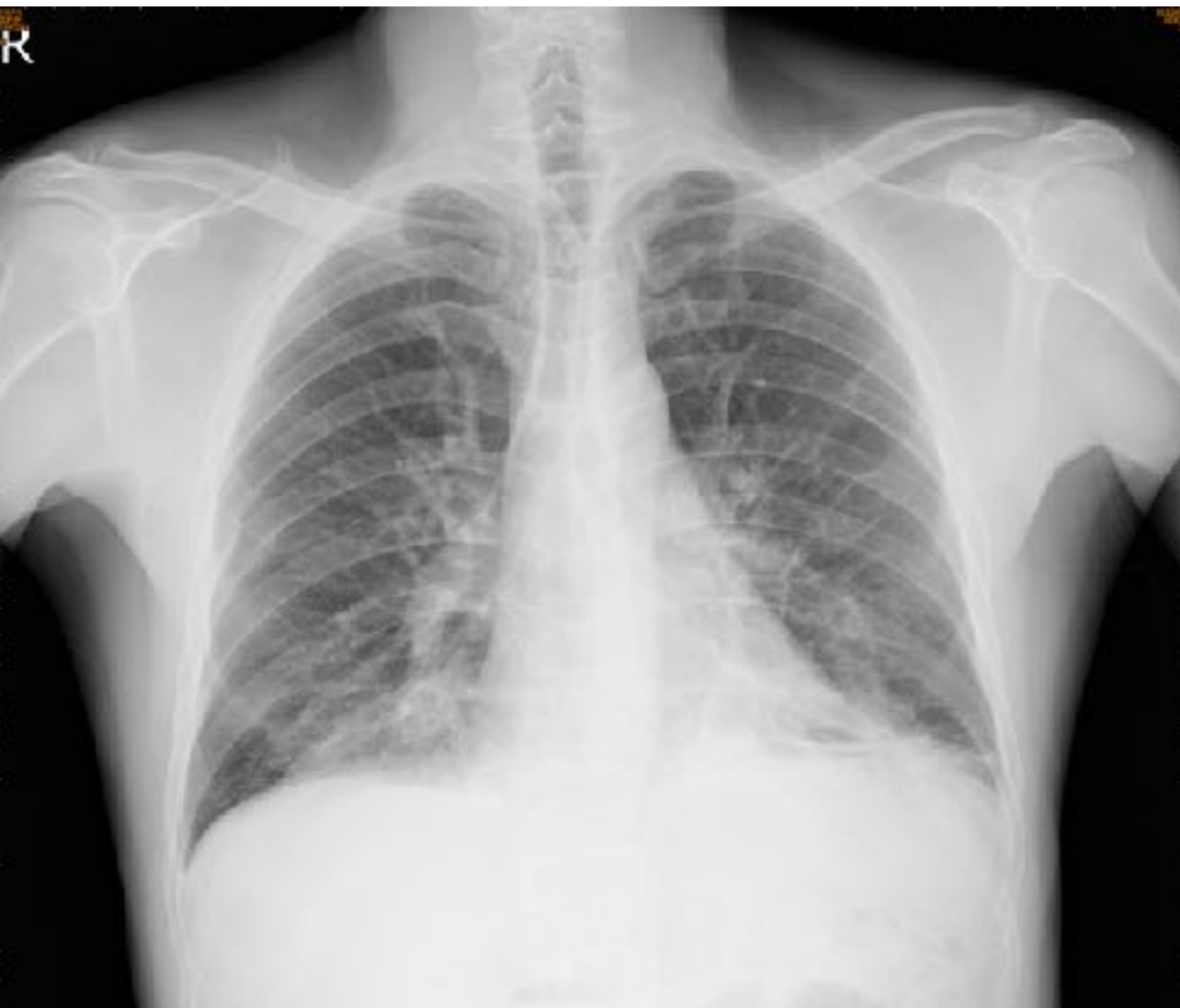



ULTRASOUND
PROGRAM

2nd WINDOW

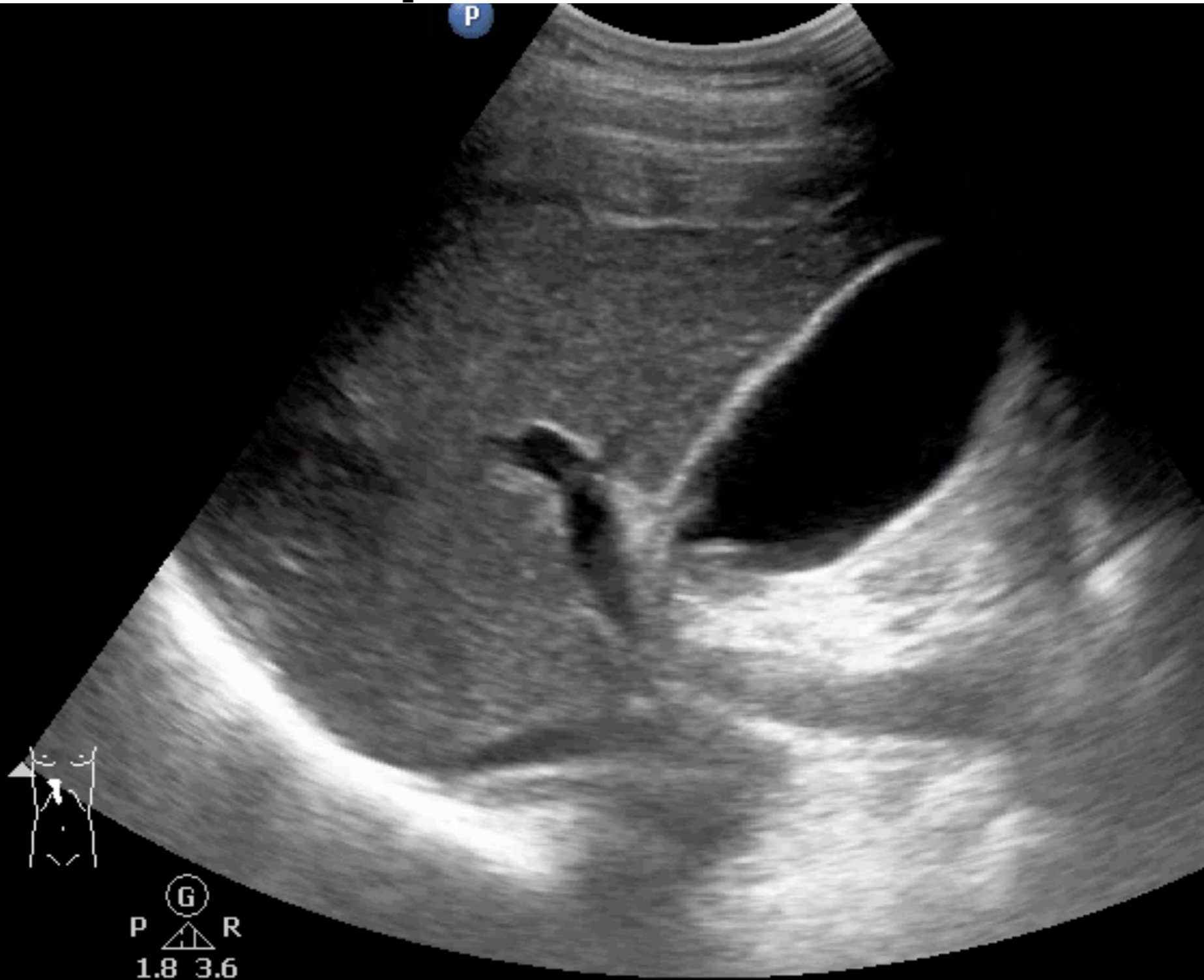(肝 & 背)

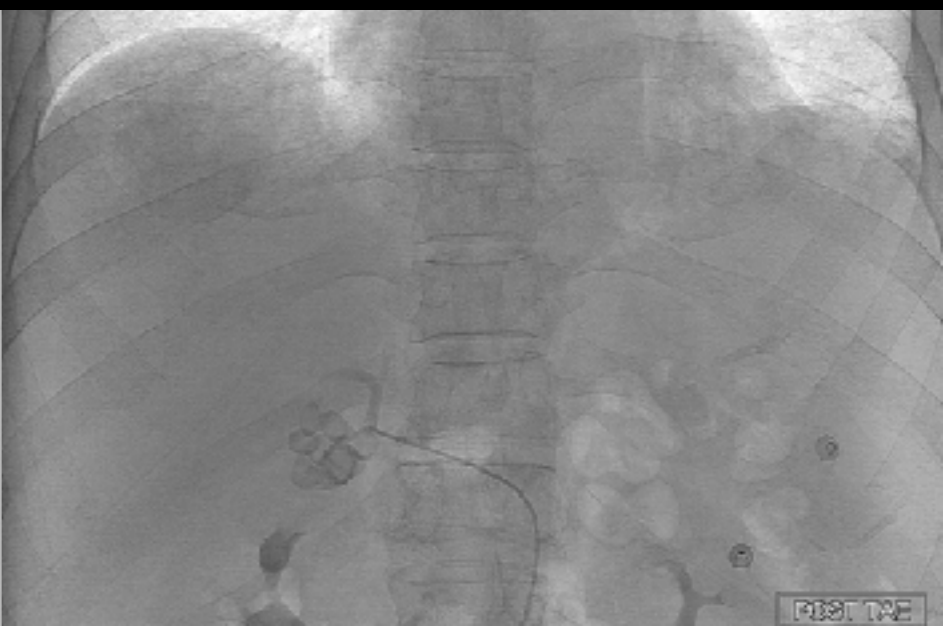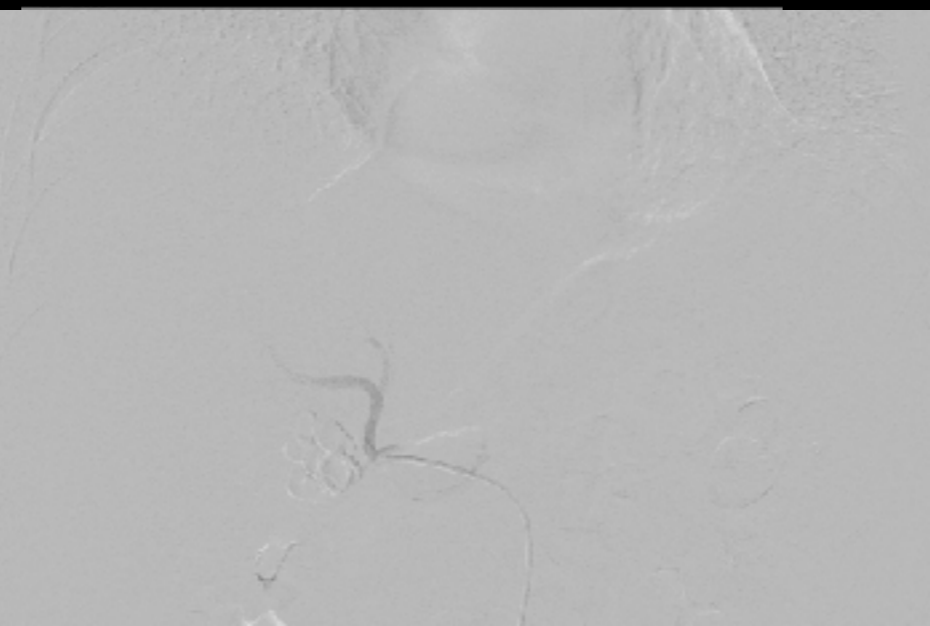
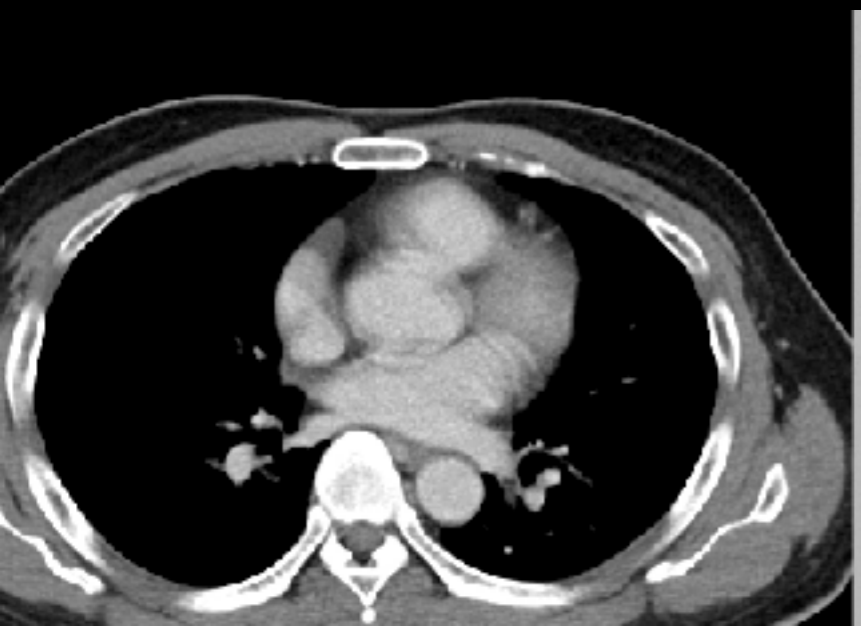
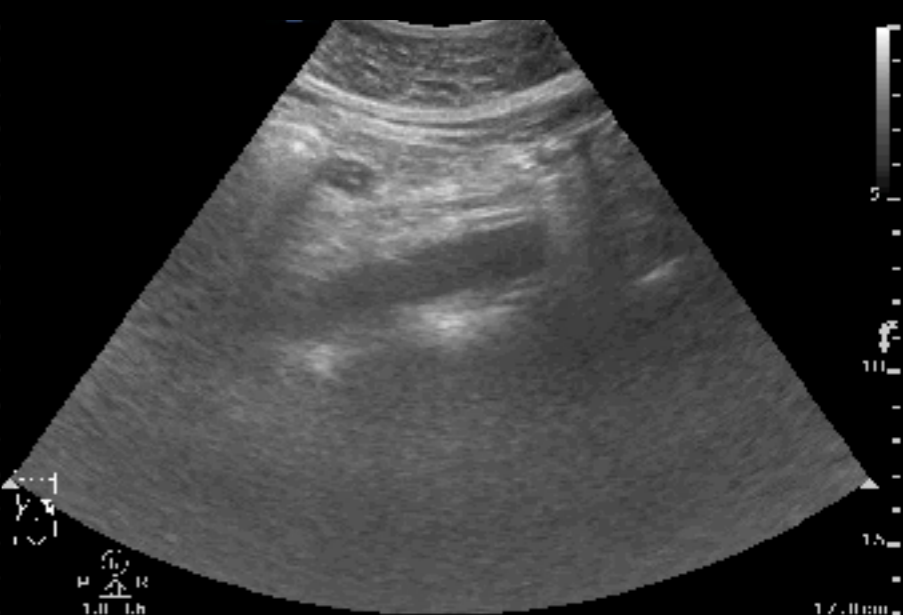

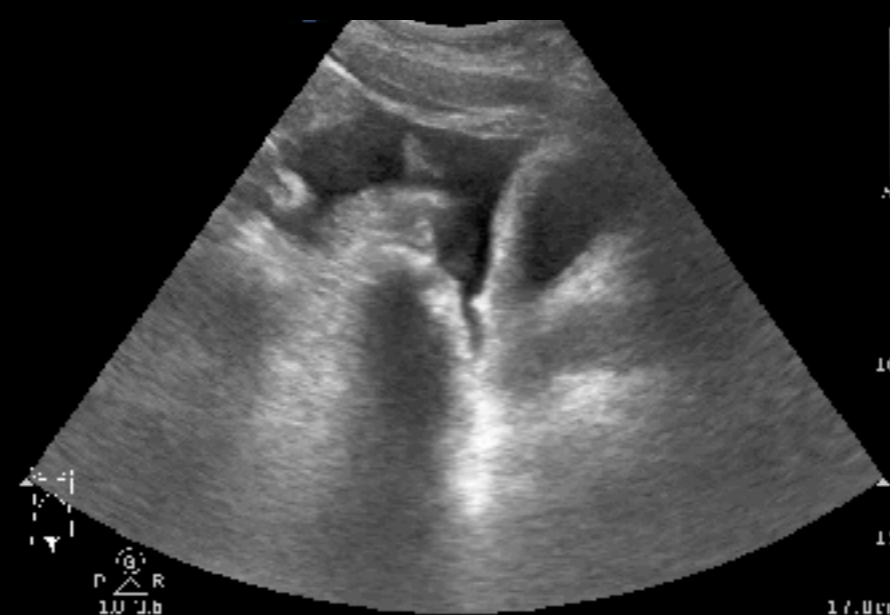
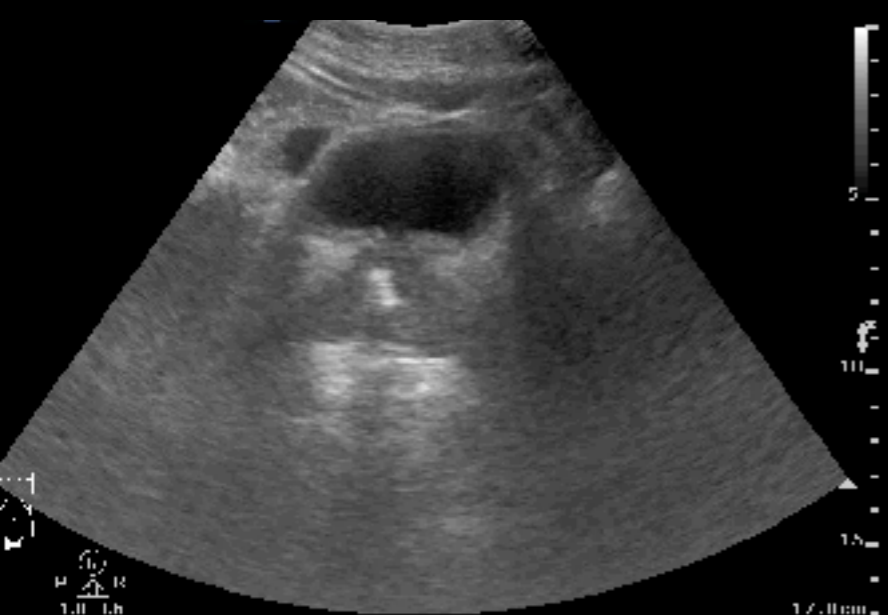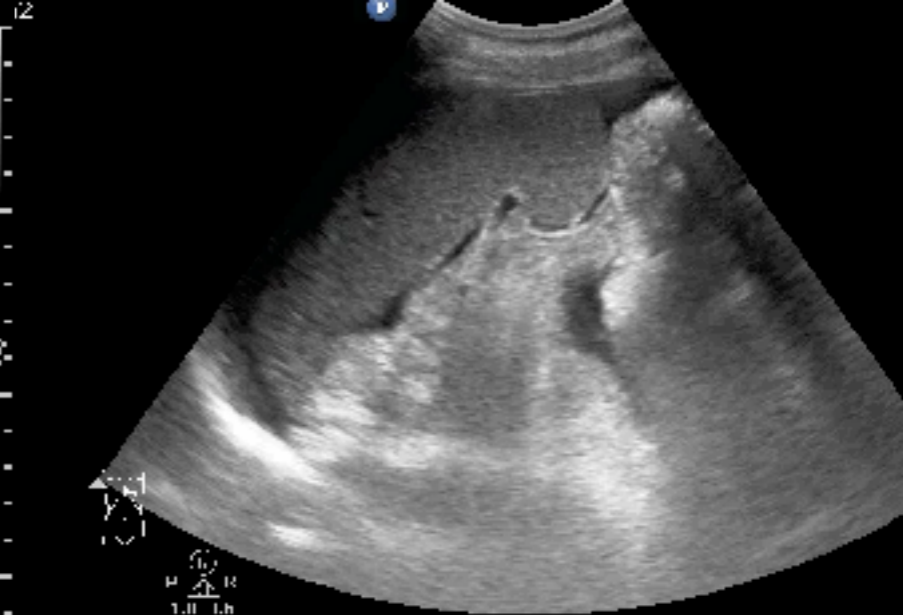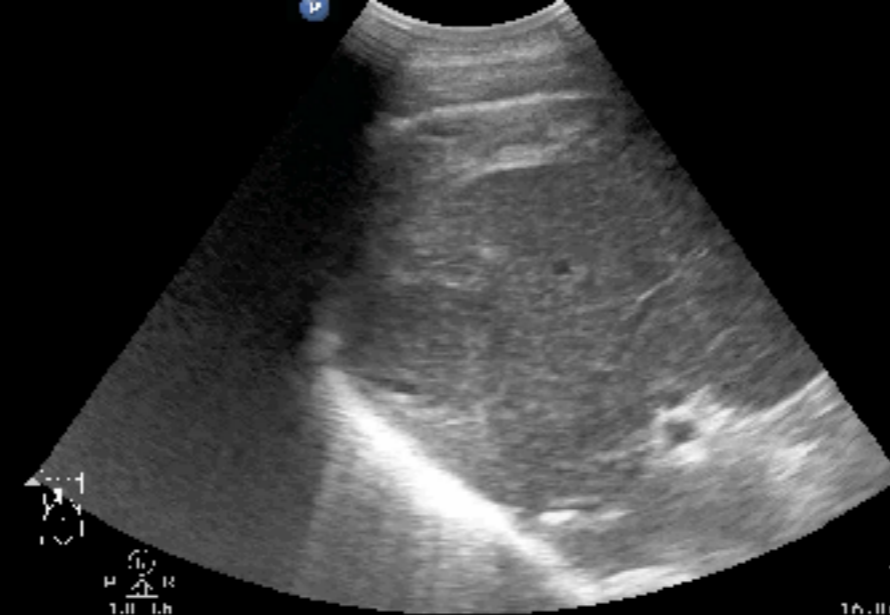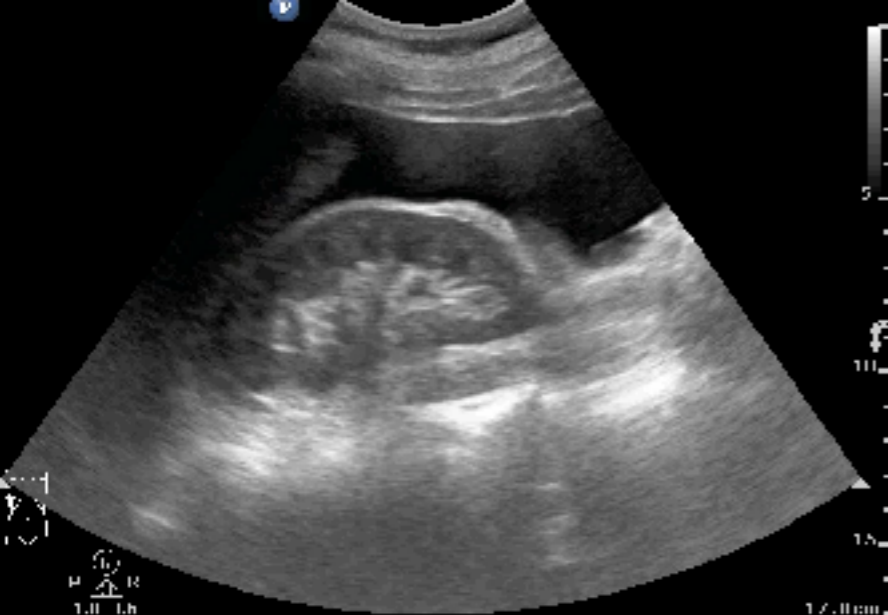52M, RUQ pain

Abd Gen2
C5-1
31 Hz
17.0cm

2D
HGen
Gn 86
C 56
3 / 3 / 3

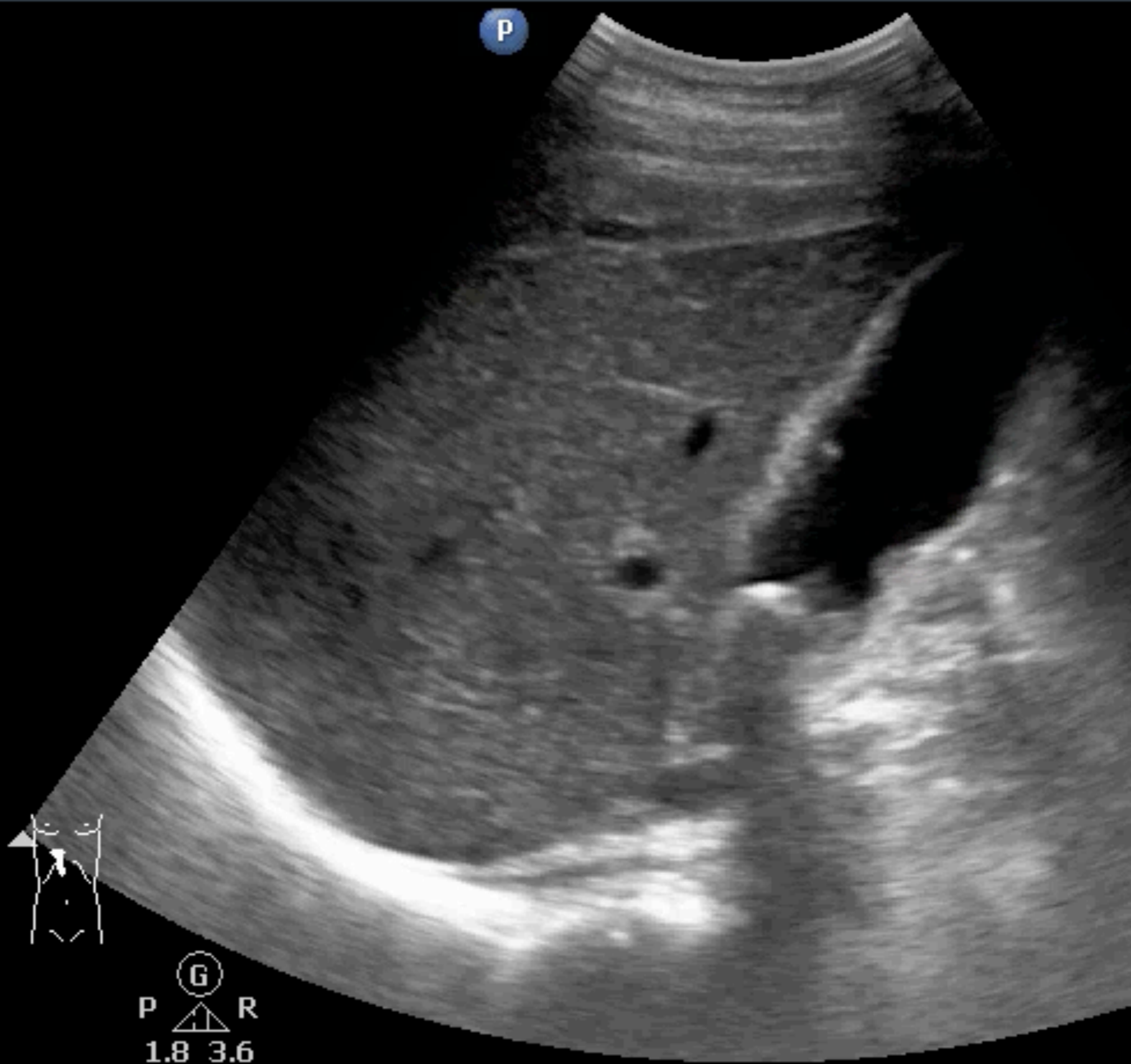



What else ?

Abd Gen2
C5-1
31 Hz
17.0cm

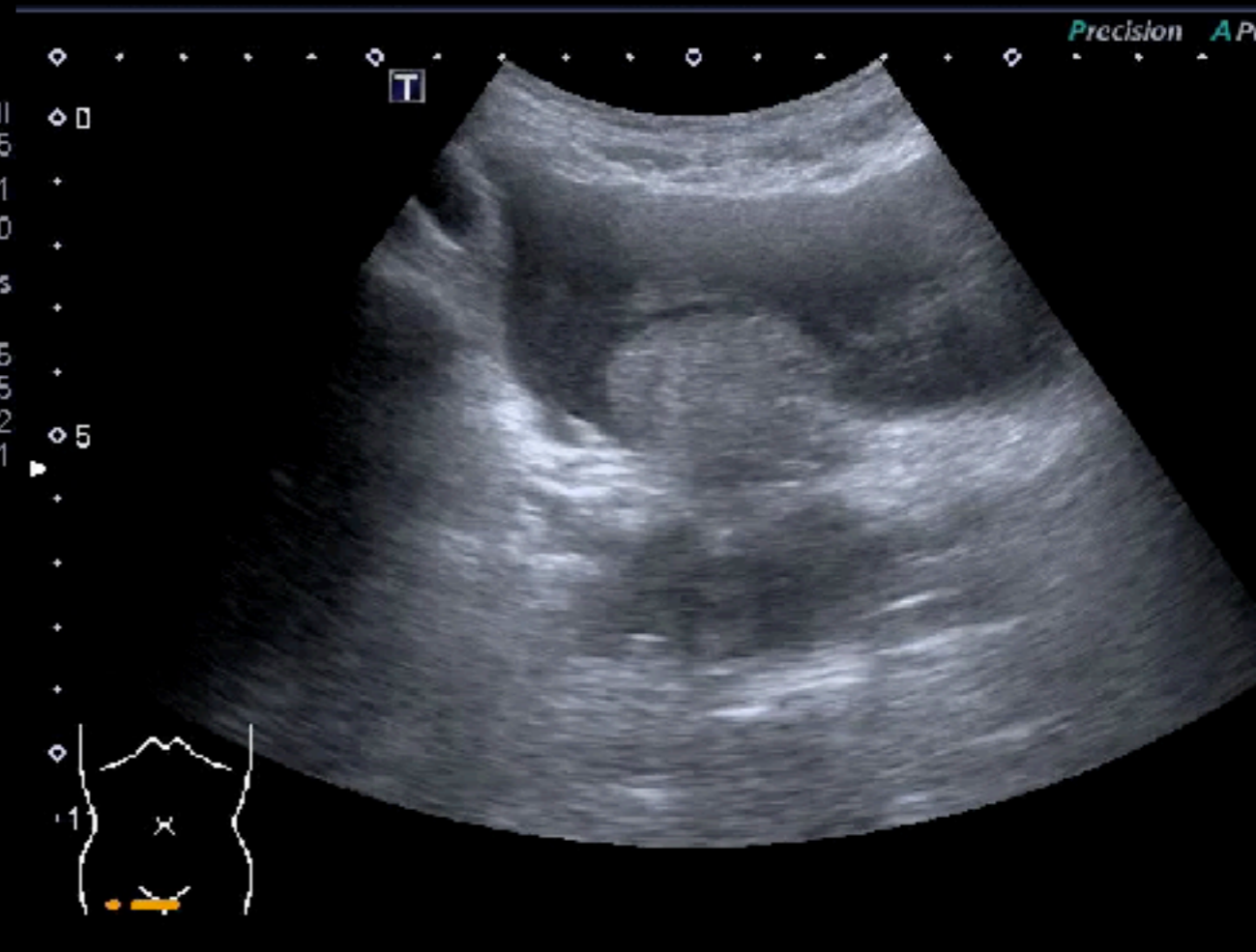
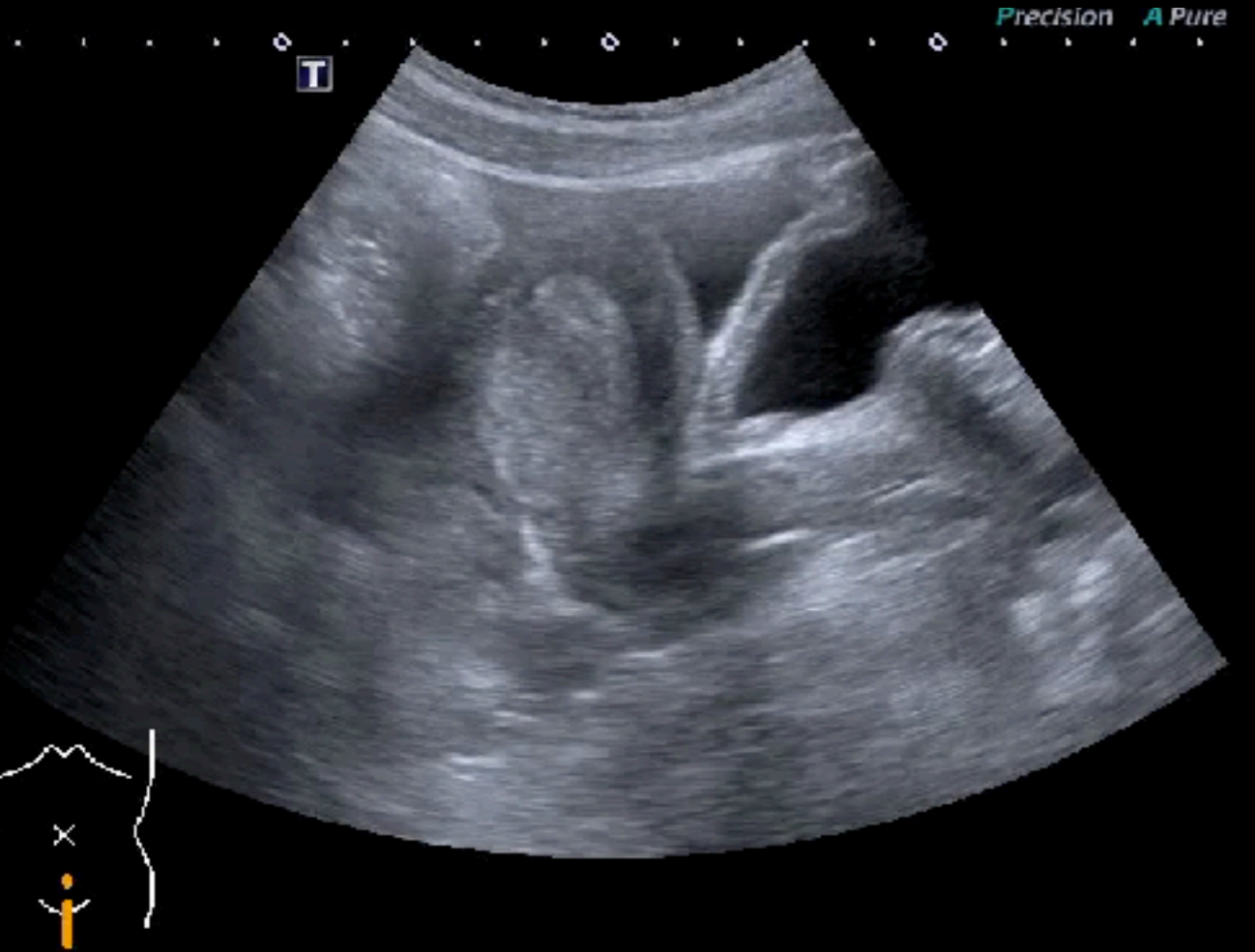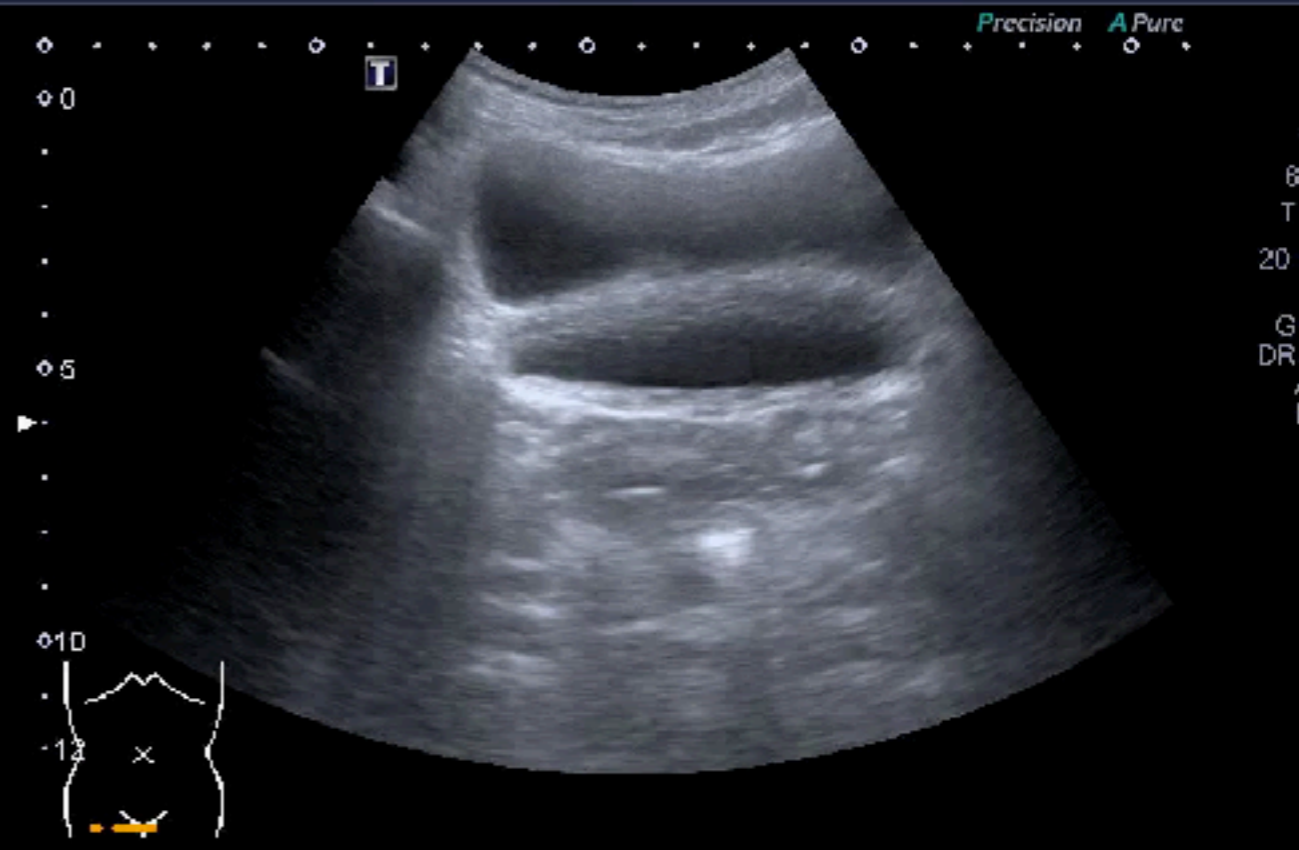
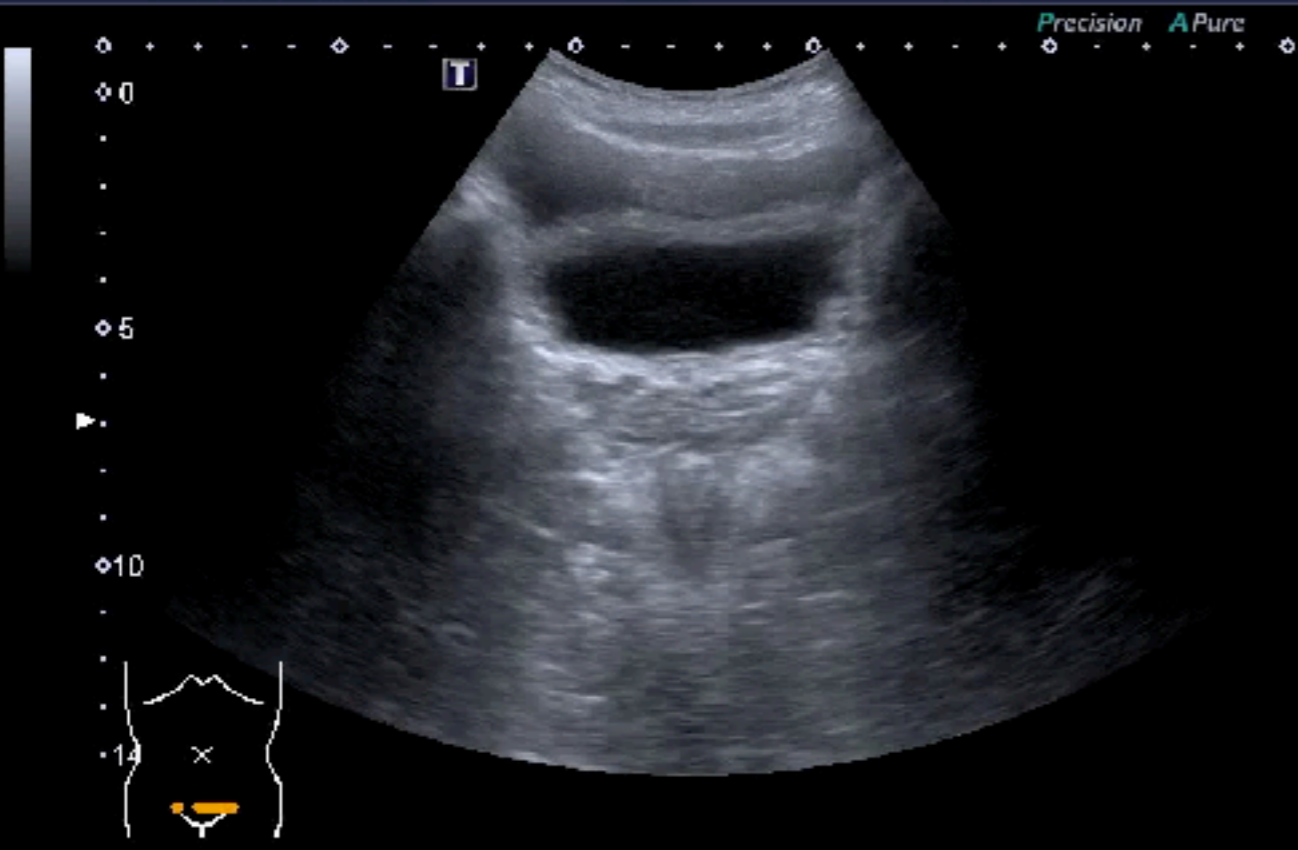
2D
HGen
Gn 86
C 56
3 / 3 / 3



25F , AGE s/s

腹痛三天、水瀉完後改善，
今天覺得想解便解不出、
腹部絞痛

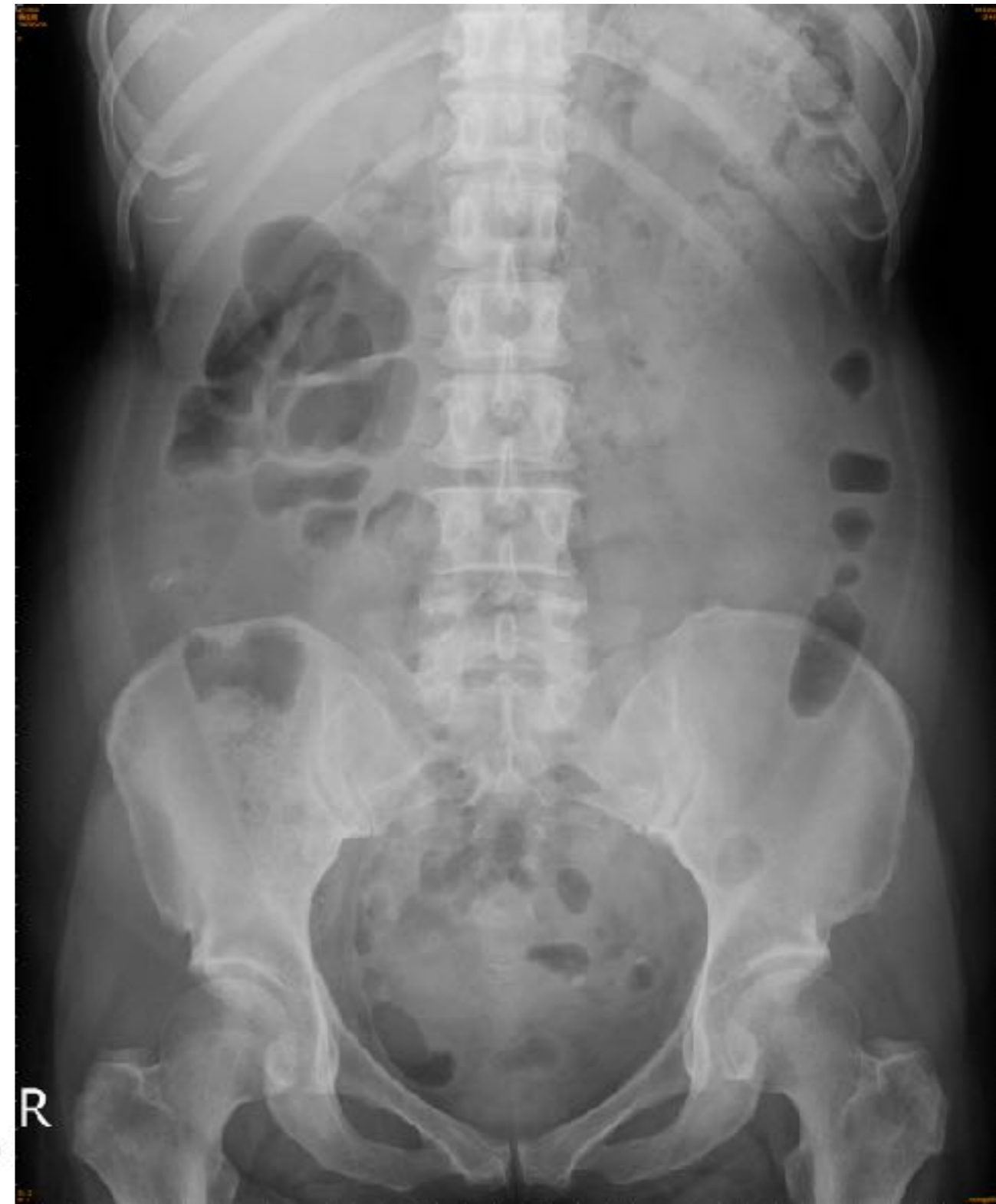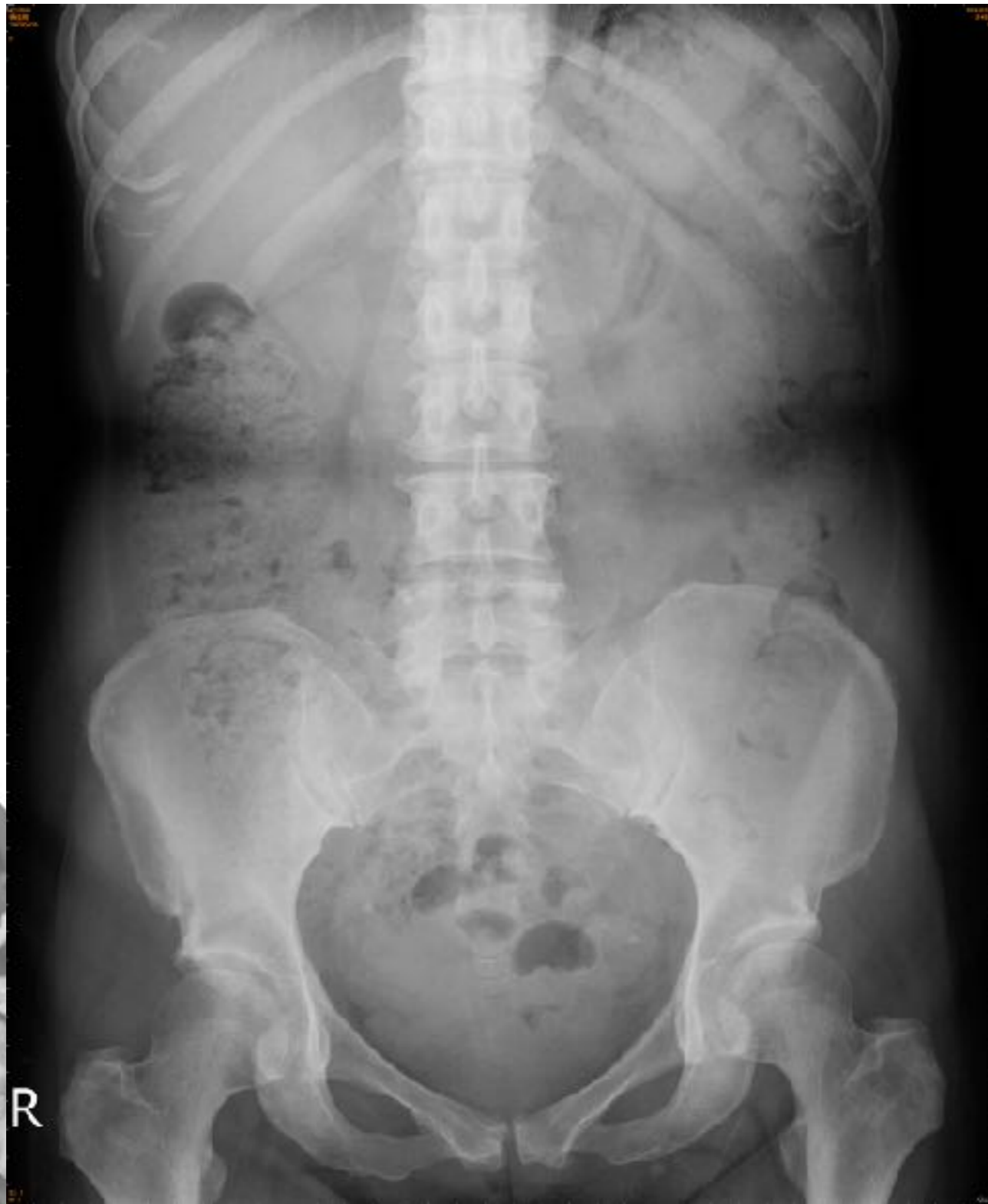PE: lower ABD tenderness

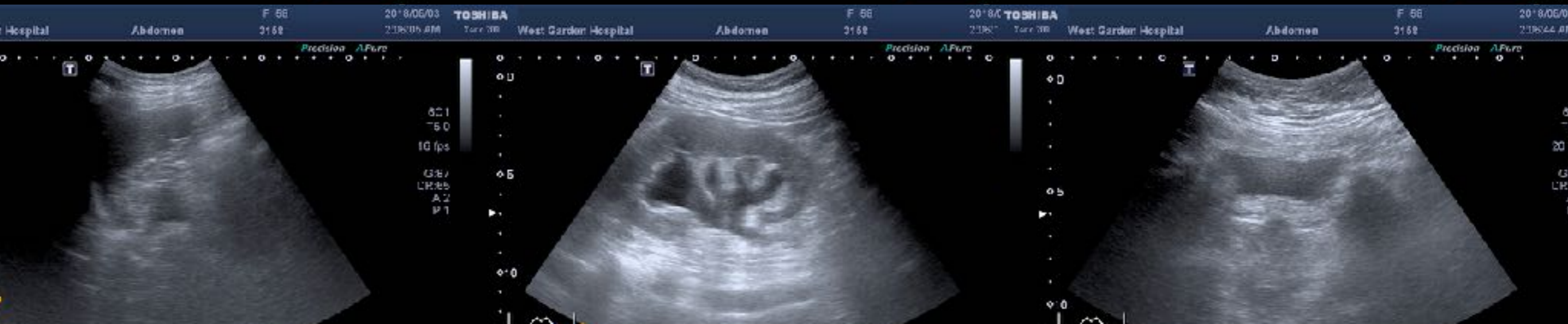
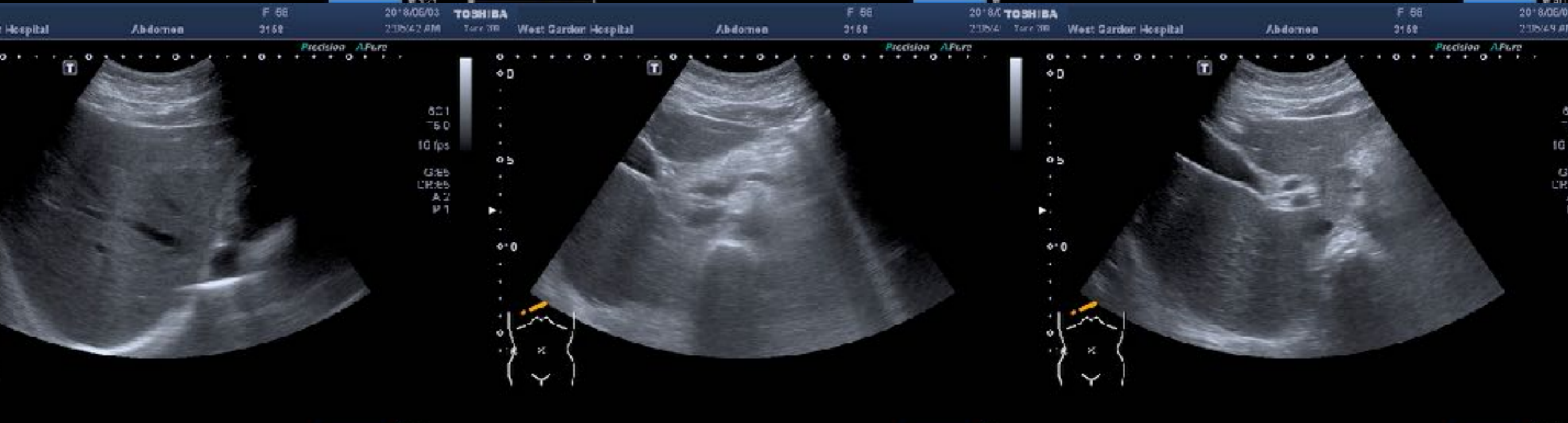
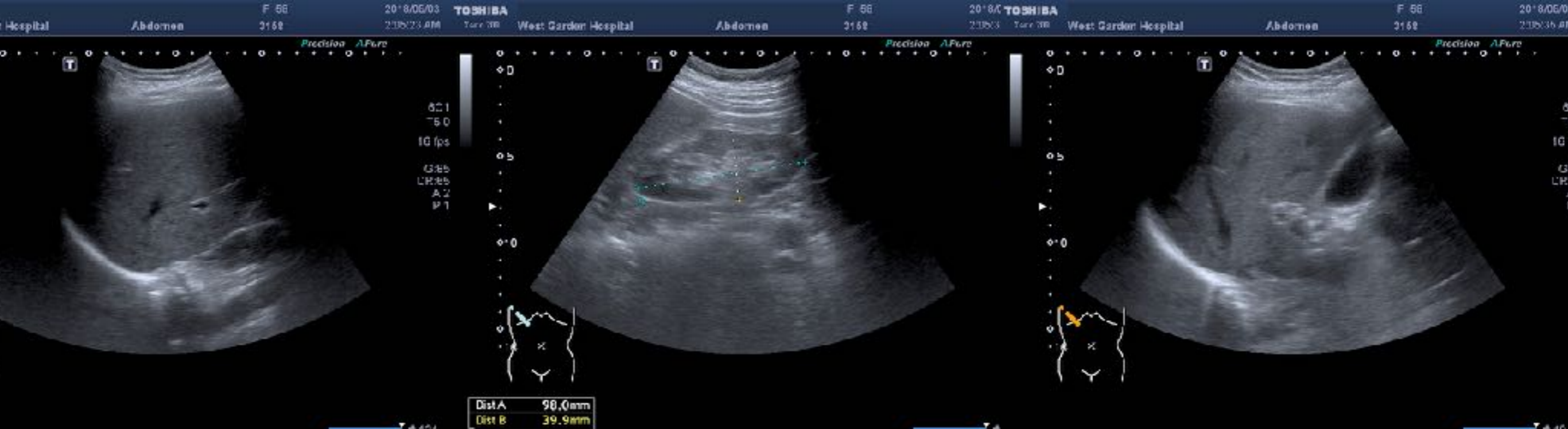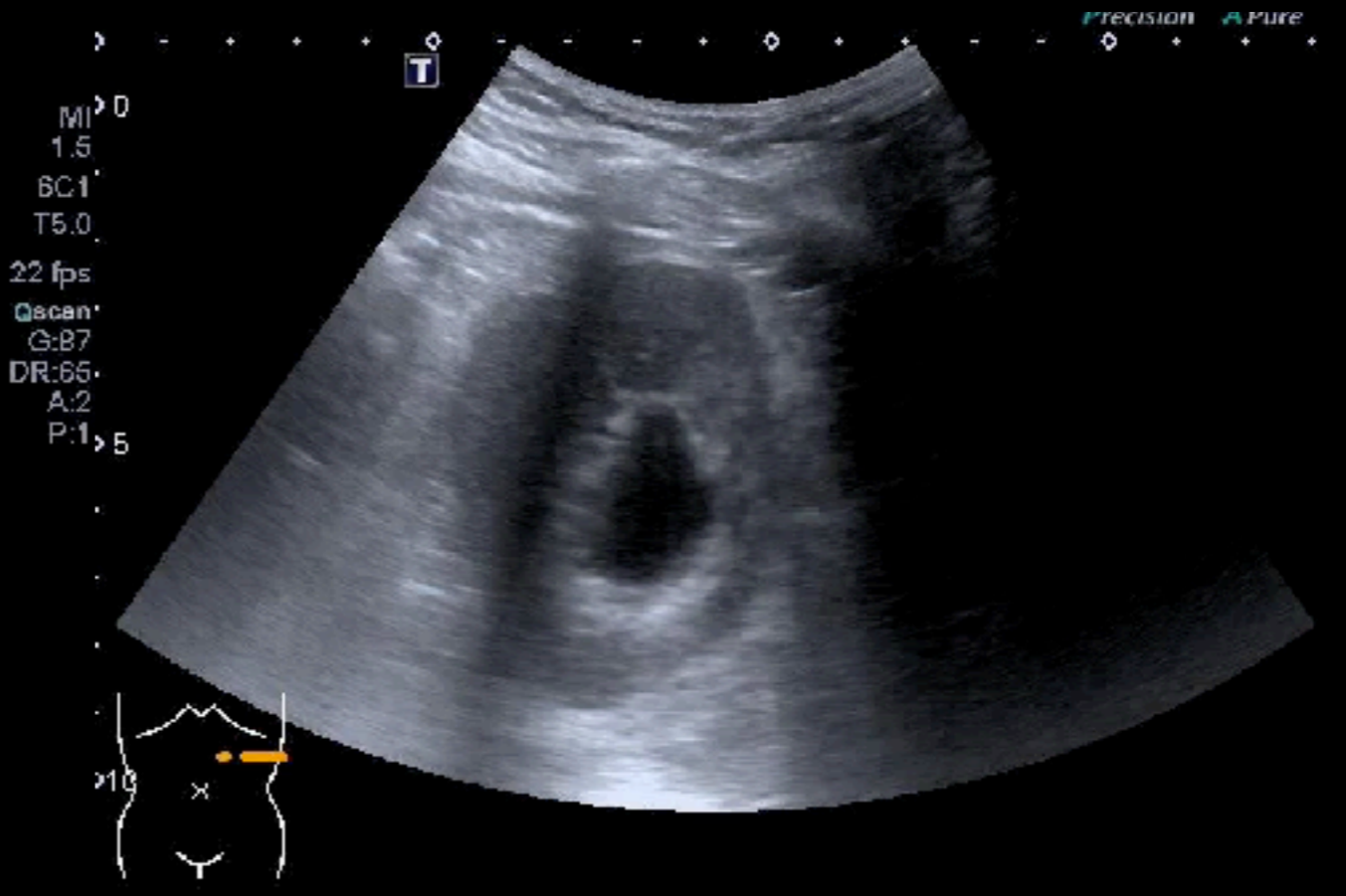
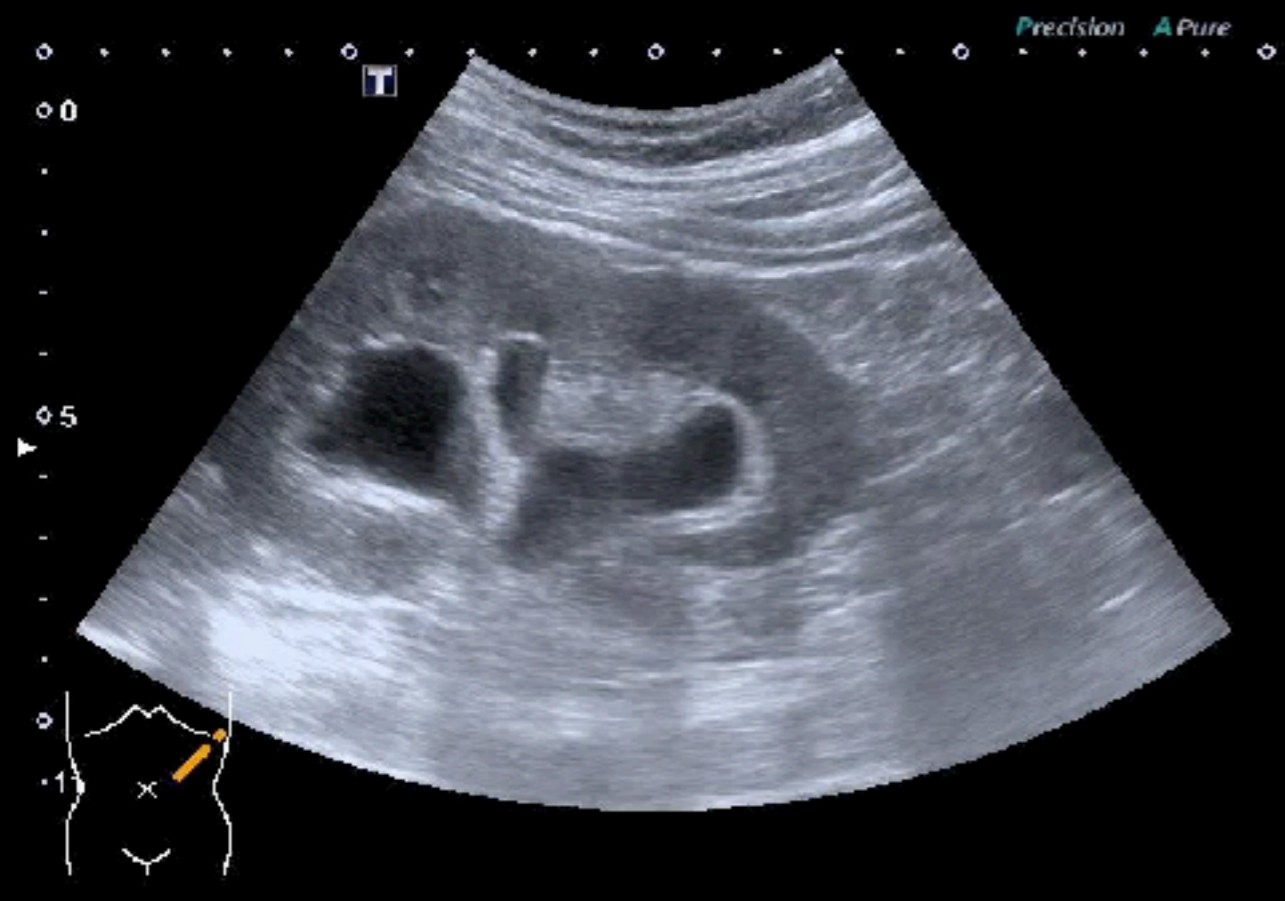
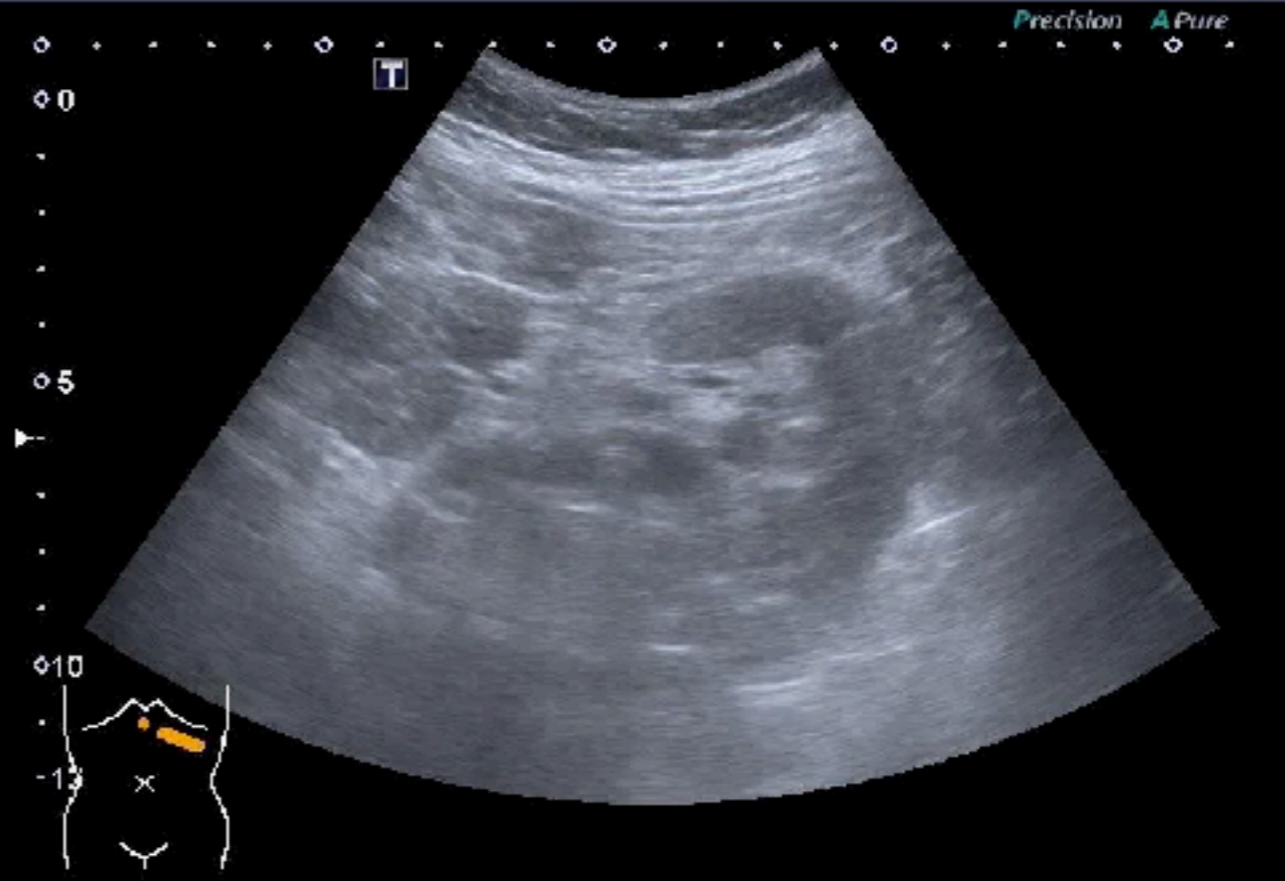
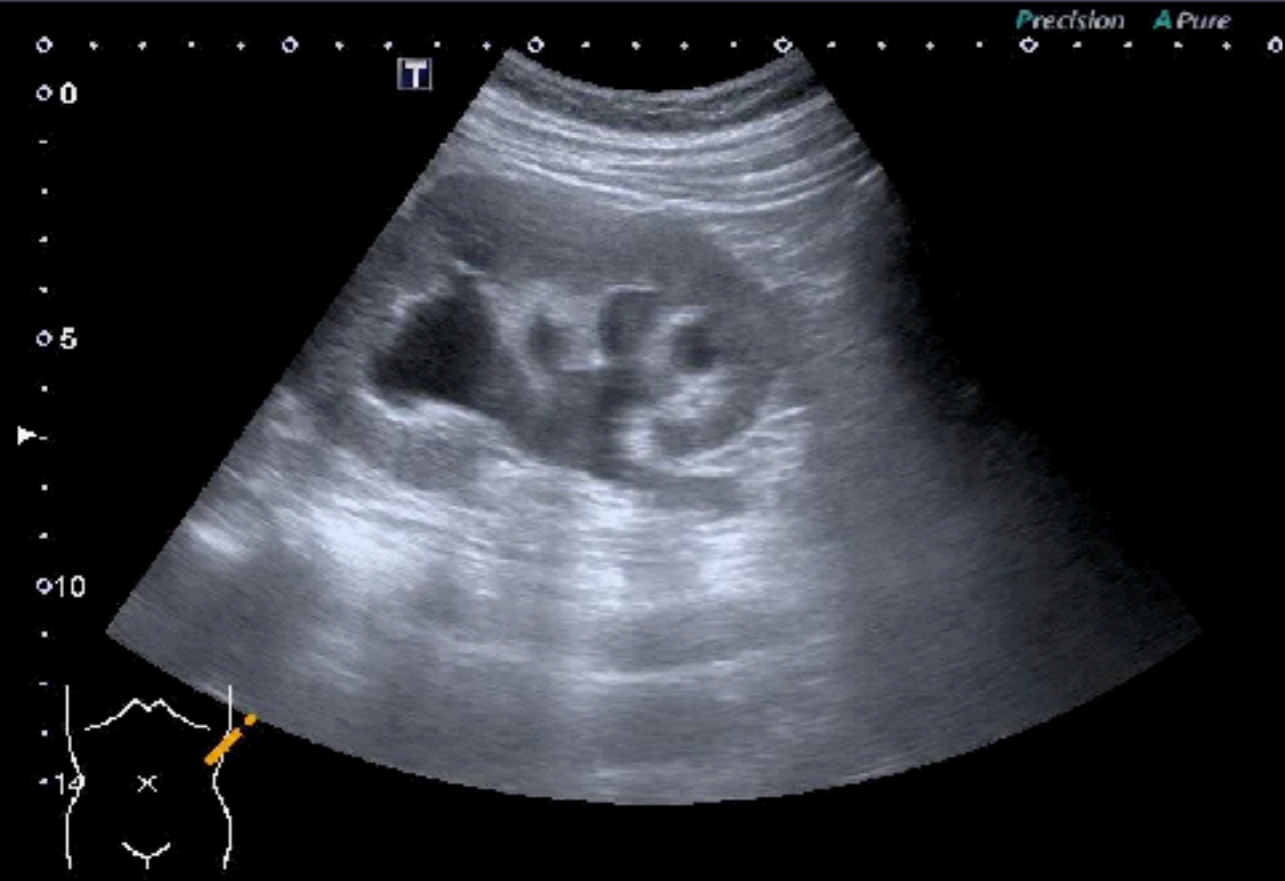
58F, 左腰腹痛併發燒2天

20160726

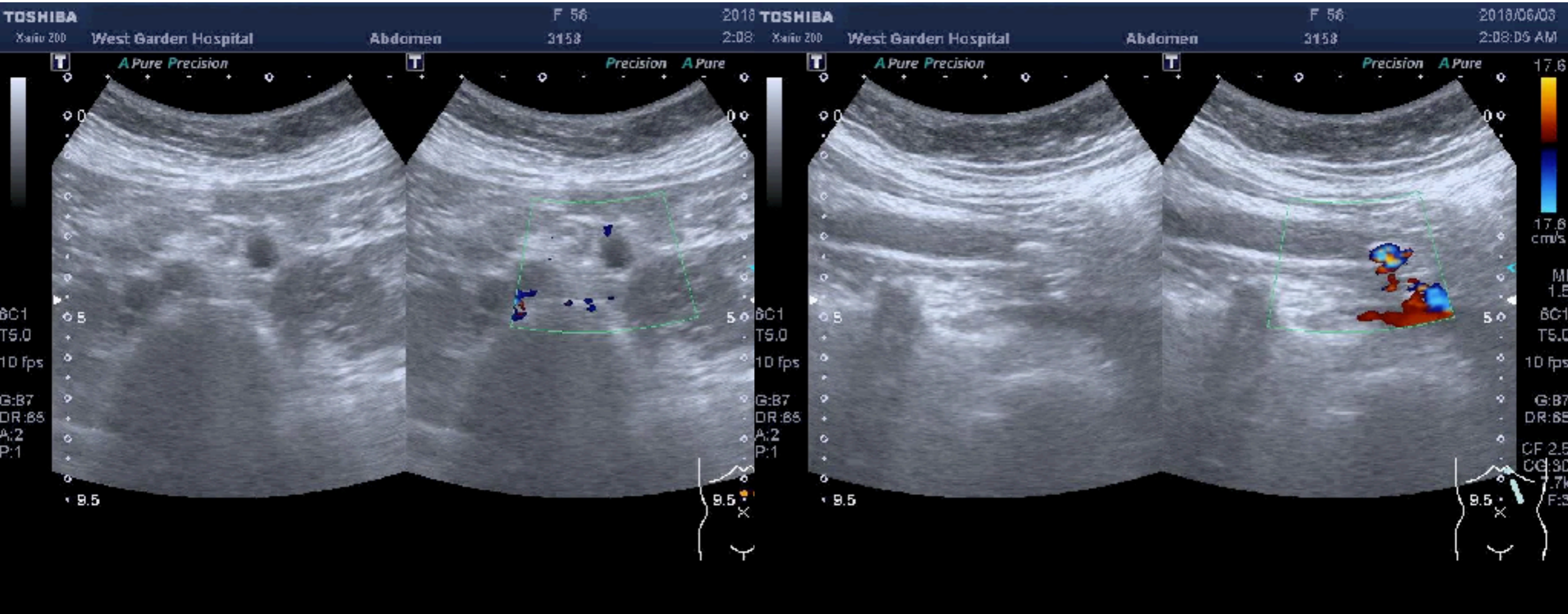
20180603







Hydro is a good guide



90M, RLQ pain * 2days

Need POCUS ??

Where to star?

Why ?

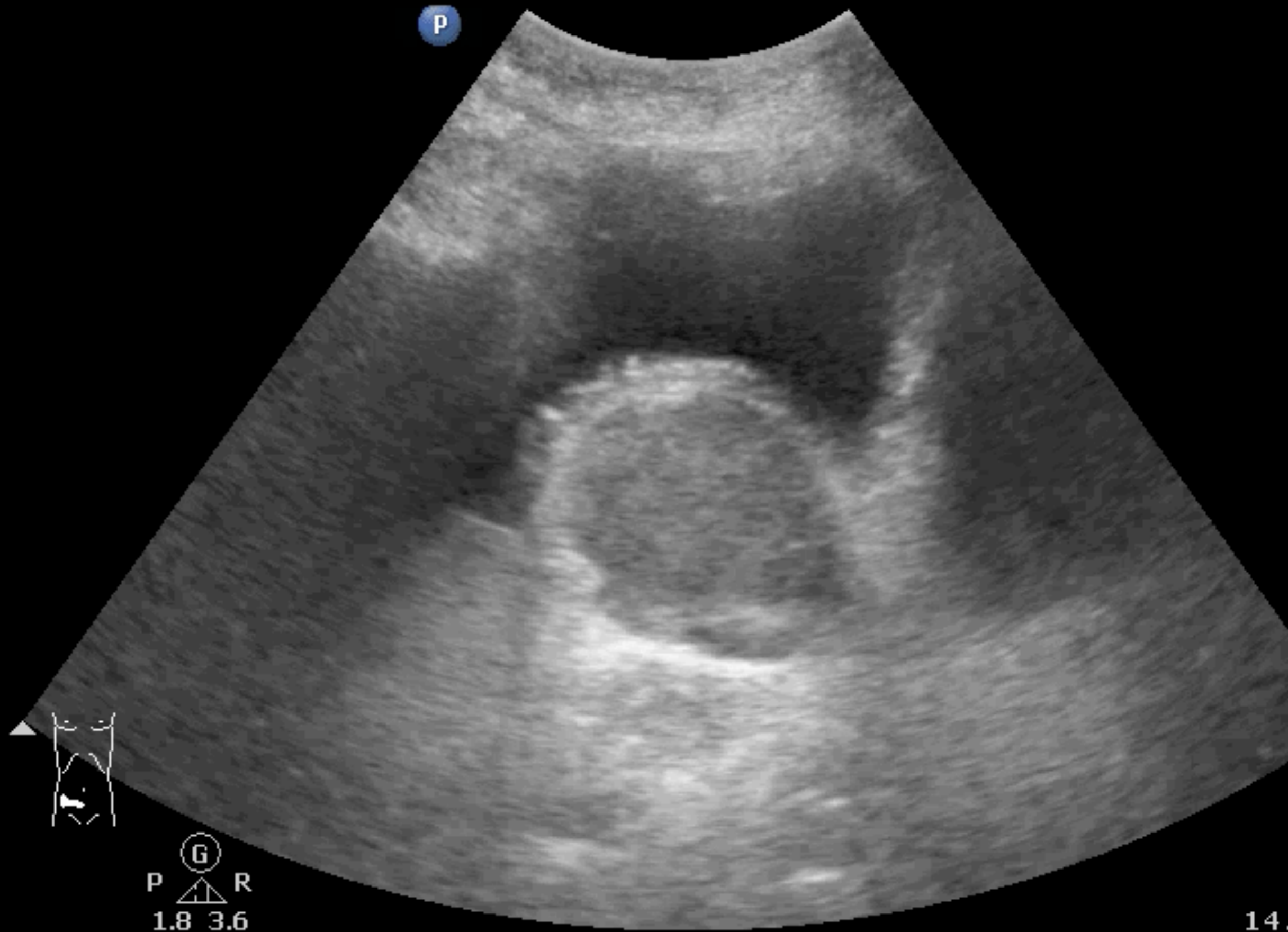


Gen2

Hz
cm

en
97
6
3/3

P



G
P R
1.8 3.6

Mechanical obstruction

