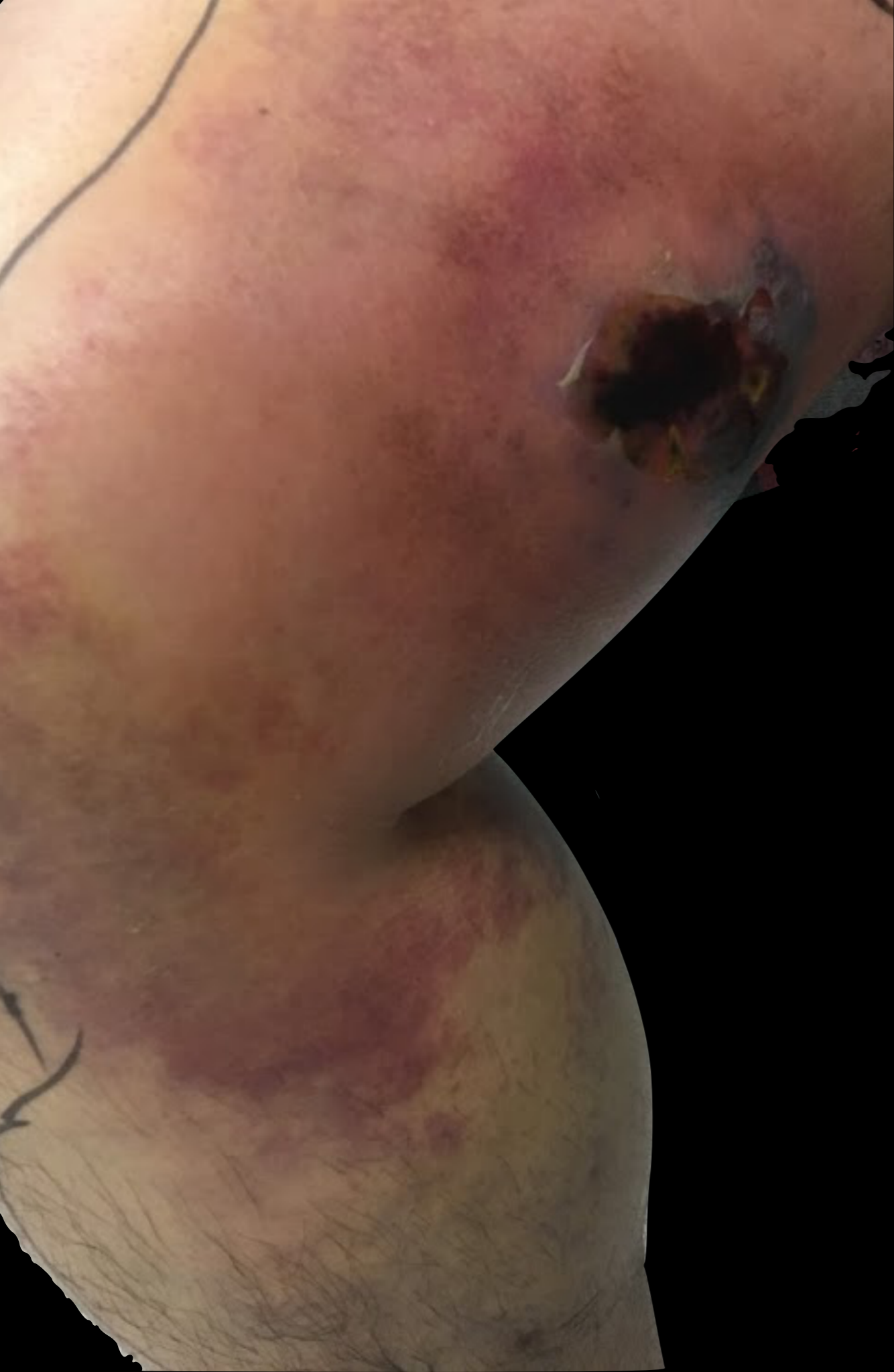



ST-MSK

POCUS

in **ER**

陳國智

西園醫院急診醫學科

REVIEW

Open Access



An overview of point-of-care ultrasound for soft tissue and musculoskeletal applications in the emergency department

Kuo-Chih Chen^{1,2}, Aming Chor-Ming Lin^{1,2*}, Chee-Fah Chong^{1,2} and Tzong-Luen Wang^{1,2}

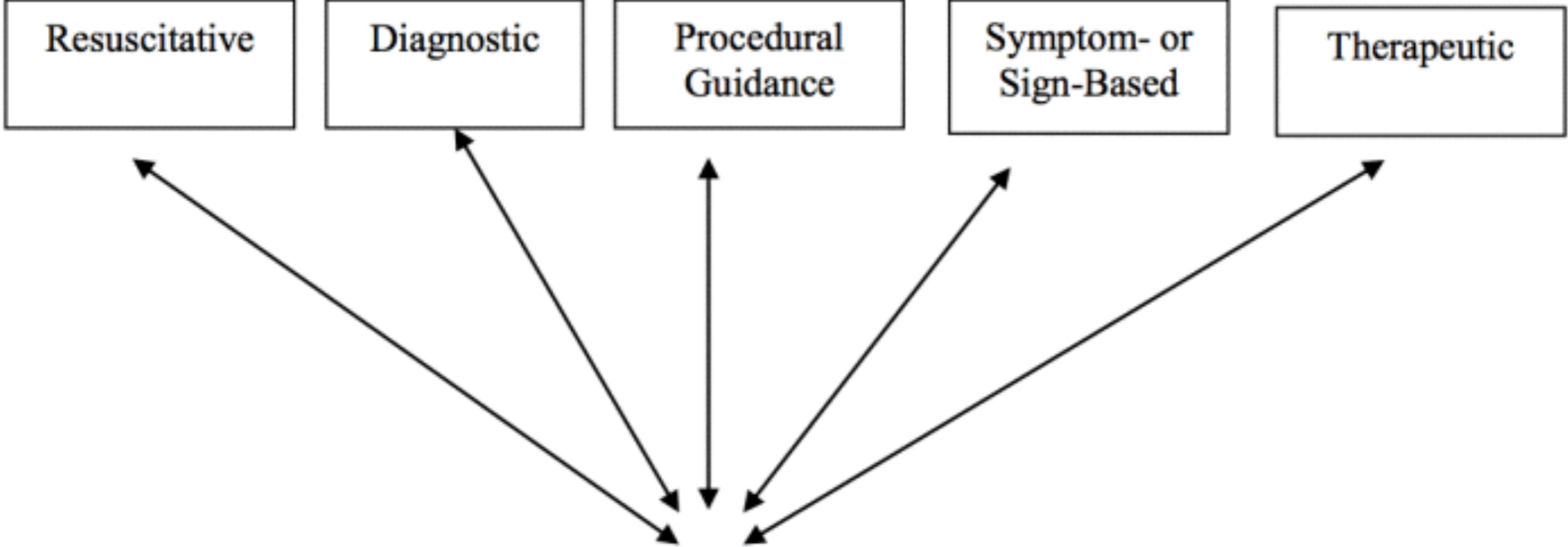
Abstract

Background: The skin, soft tissue, and most parts of the musculoskeletal system are relatively superficial anatomical structures and ideal targets for ultrasound examination in the emergency departments. Soft tissue and musculoskeletal ultrasound applications are relatively underused compared to traditional emergency applications, such as trauma, abdominal aortic aneurysm, and chest and cardiovascular systems.

Main text: It is important to have knowledge about sonoanatomy and landmarks within the skin, soft tissue, and musculoskeletal systems. Portable machines equipped with high-resolution transducers are now available to fulfill this field of applications in many emergency departments. After needling practice, emergency physicians can not only diagnose and identify pathological findings but also provide interventional procedures and treatments. In this review, we will introduce point-of-care ultrasound (POCUS) applications regarding the soft tissue and musculoskeletal systems: soft tissue infections, joint effusions, foreign bodies, long bone fractures, muscle and tendon injuries, vascular occlusions, and procedures.

Conclusions: With POCUS, emergency physicians can visualize the structures beneath the skin and provide better and safer cares in the emergency departments.

Keywords: Point-of-care, Ultrasound, Soft tissue, Musculoskeletal, Emergency medicine



- Core Applications
Trauma
Intrauterine Pregnancy
AAA
Cardiac/HD Assessment
Biliary
Urinary Tract
DVT
Soft-tissue/Musculoskeletal
Thoracic/Airway
Ocular
Bowel
Procedural Guidance

ACEP 2016

I-AIM

Indication

Acquisition

Interpretation

**Making
decision**

3

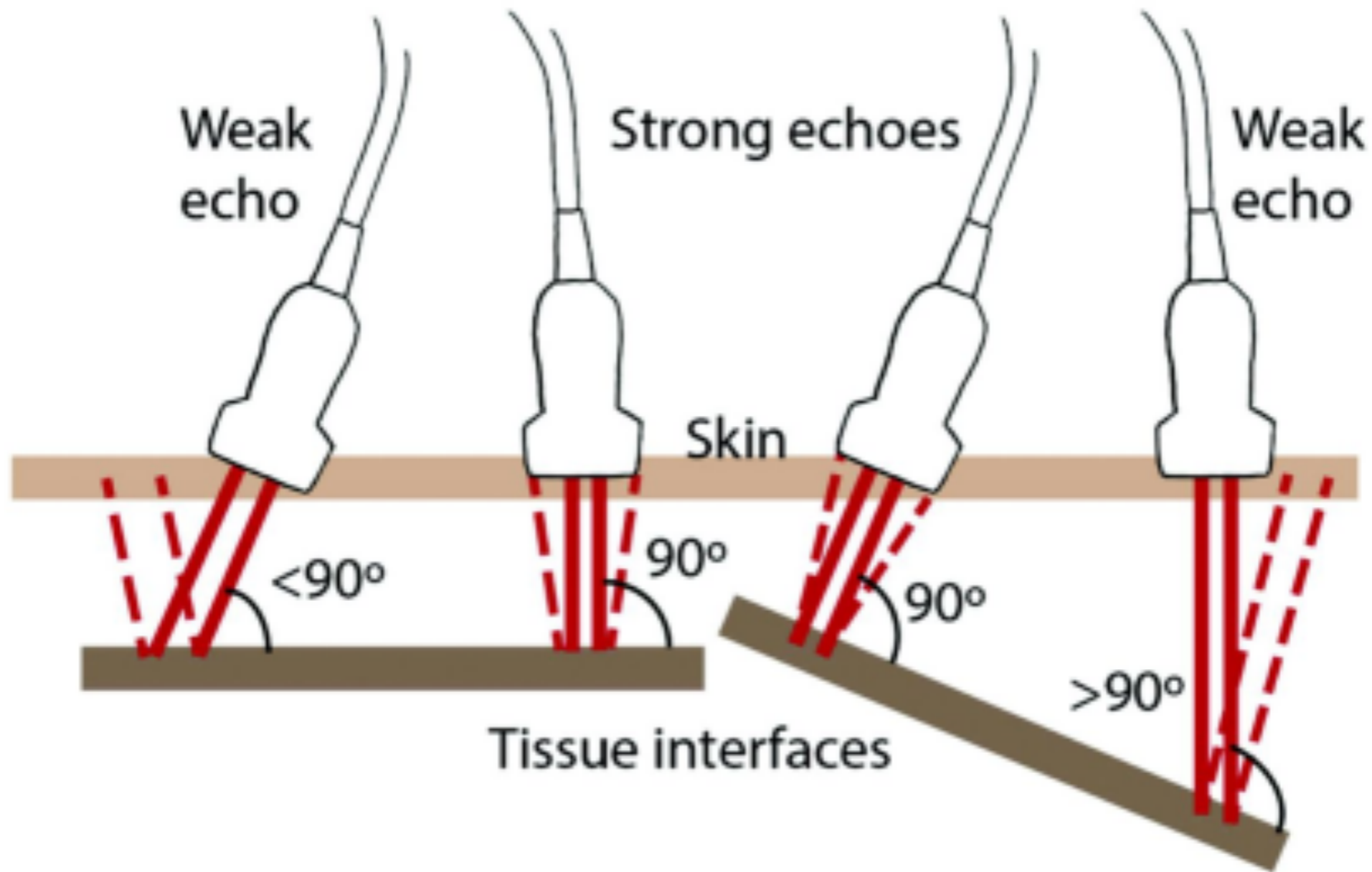
ST-MSK

Infection

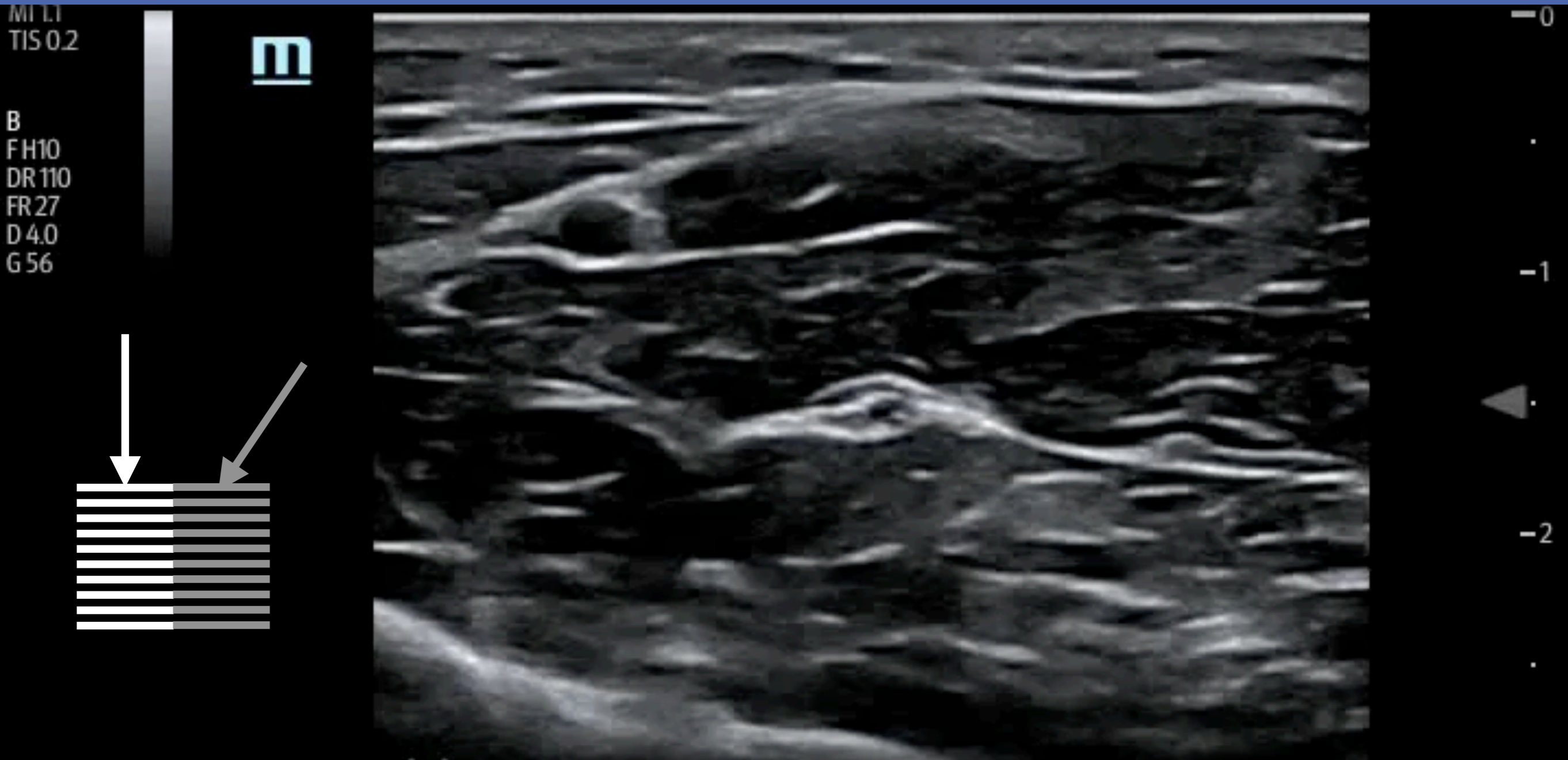
Effusion

Fracture

Principle



Anisotropy



Tendon

Nerve

Muscle

Principle 1



2 view

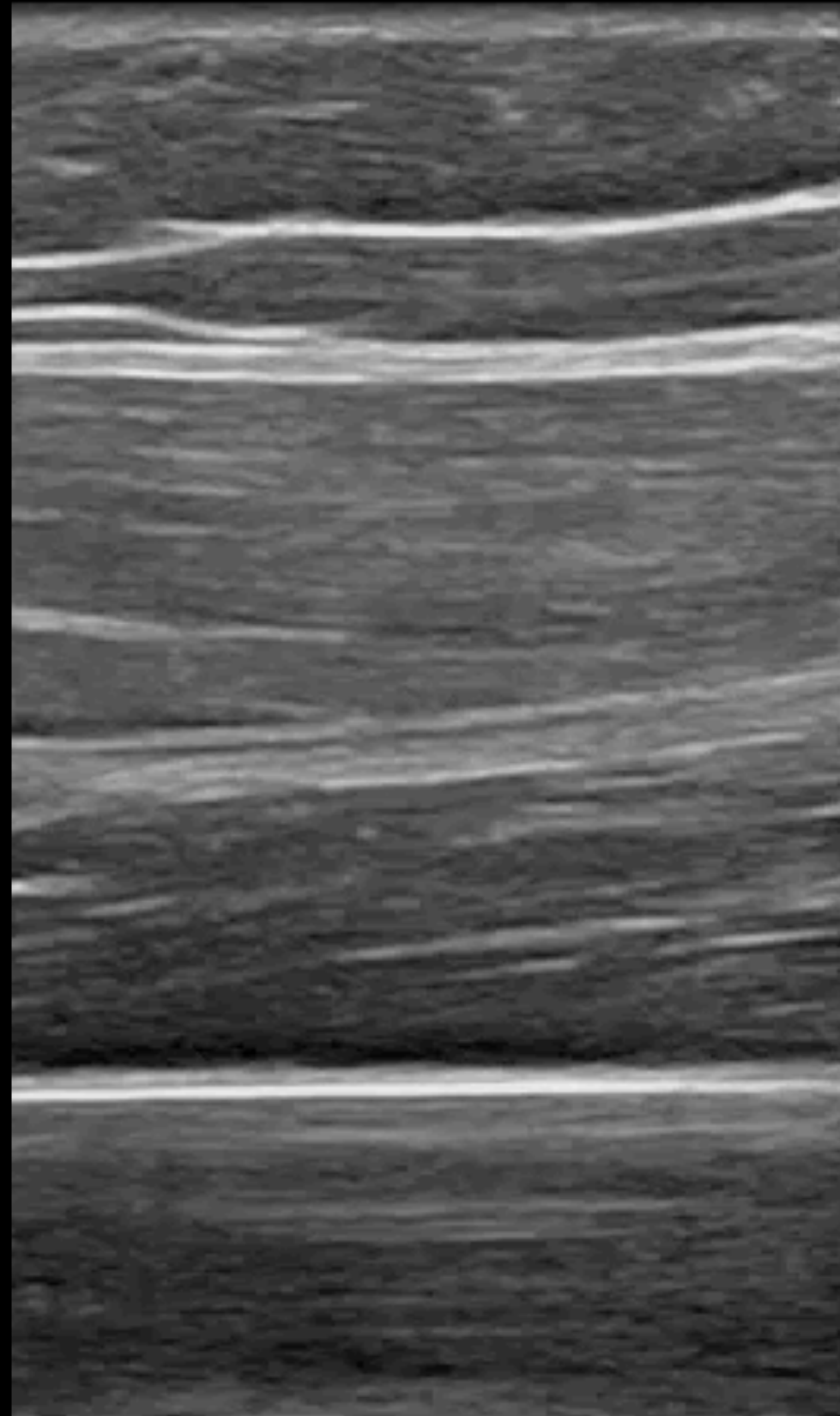
SonoAnatomy

Superficial
2-3
Hz
0cm

es
n 95
56
/2/1



G
P F
3.0 12.1



4.0c

管狀結構由橫向掃描開始

Superficial
2-3
Hz
5cm

es
n 95
56
/2/1



G
P R
3.0 12.0

Skin

Fascia

Femur



SonoAnatomy

Skin

Subcutaneous tissue

Lymph nodes

Fascia

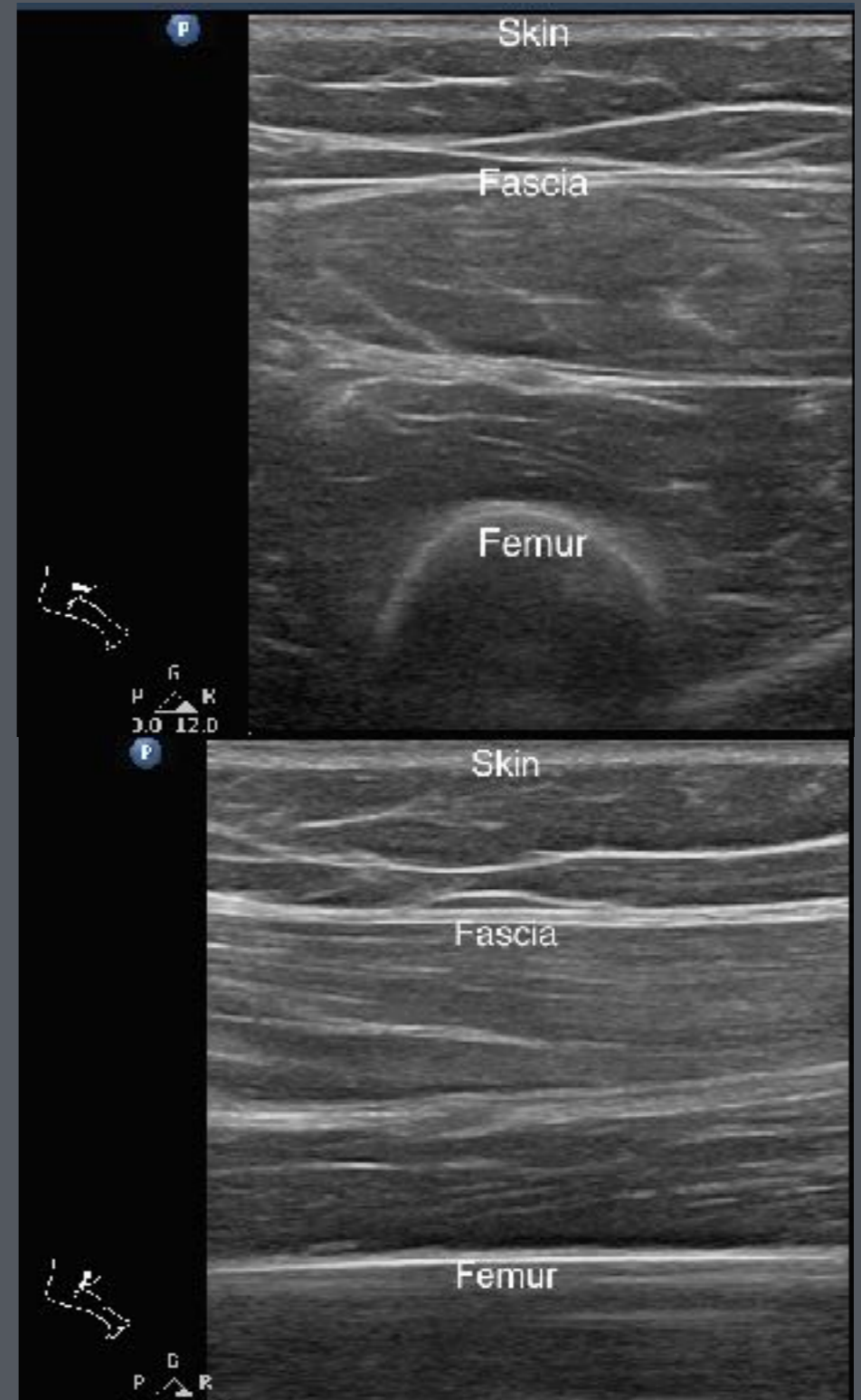
Muscles

Tendon

Vascular structures

Bone

3



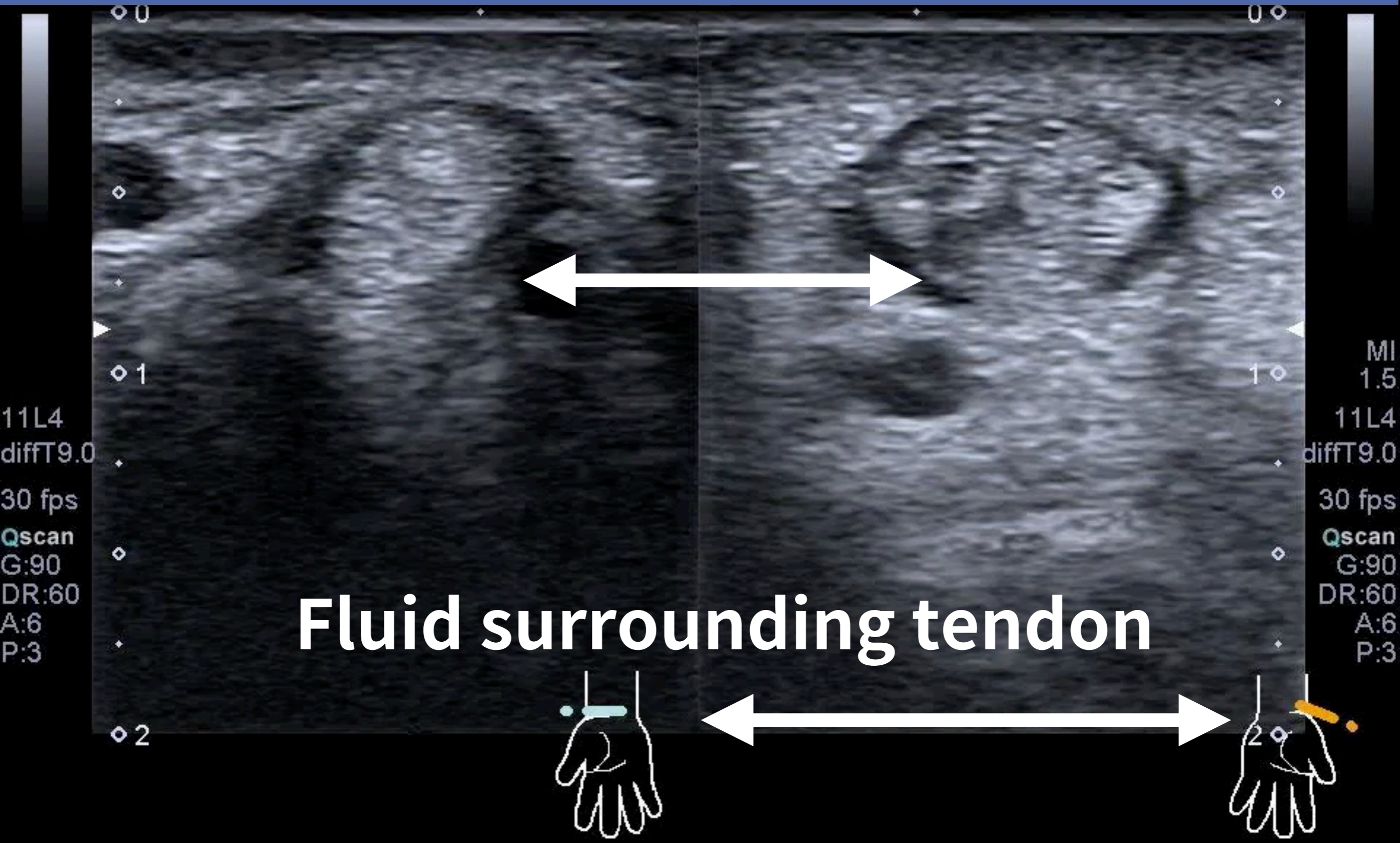
Principle 2



Compare

2 Views

De Quervain's Tenosynovitis



Principle 3



Compare

2 Views

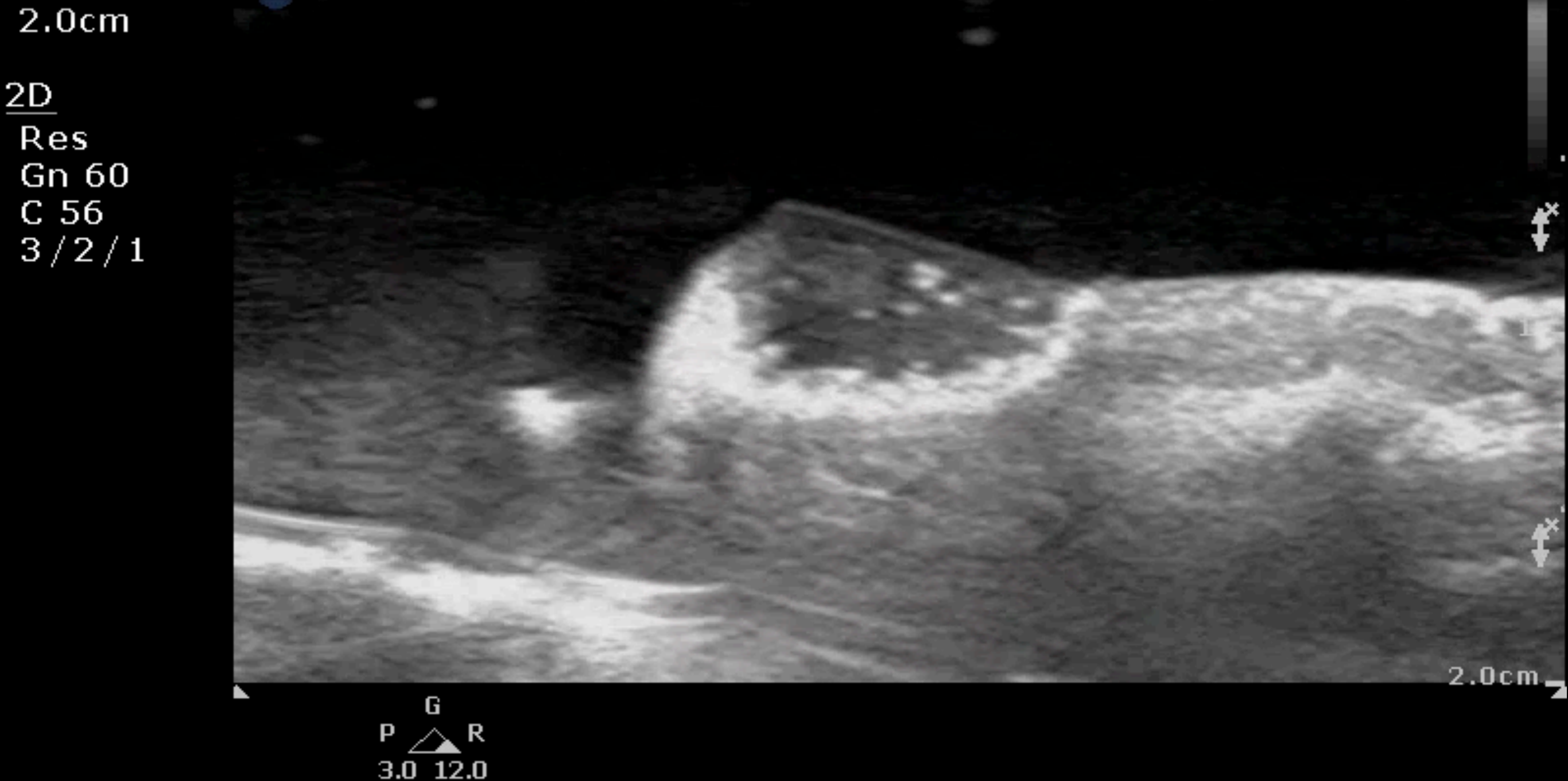
Window

Copious Gel



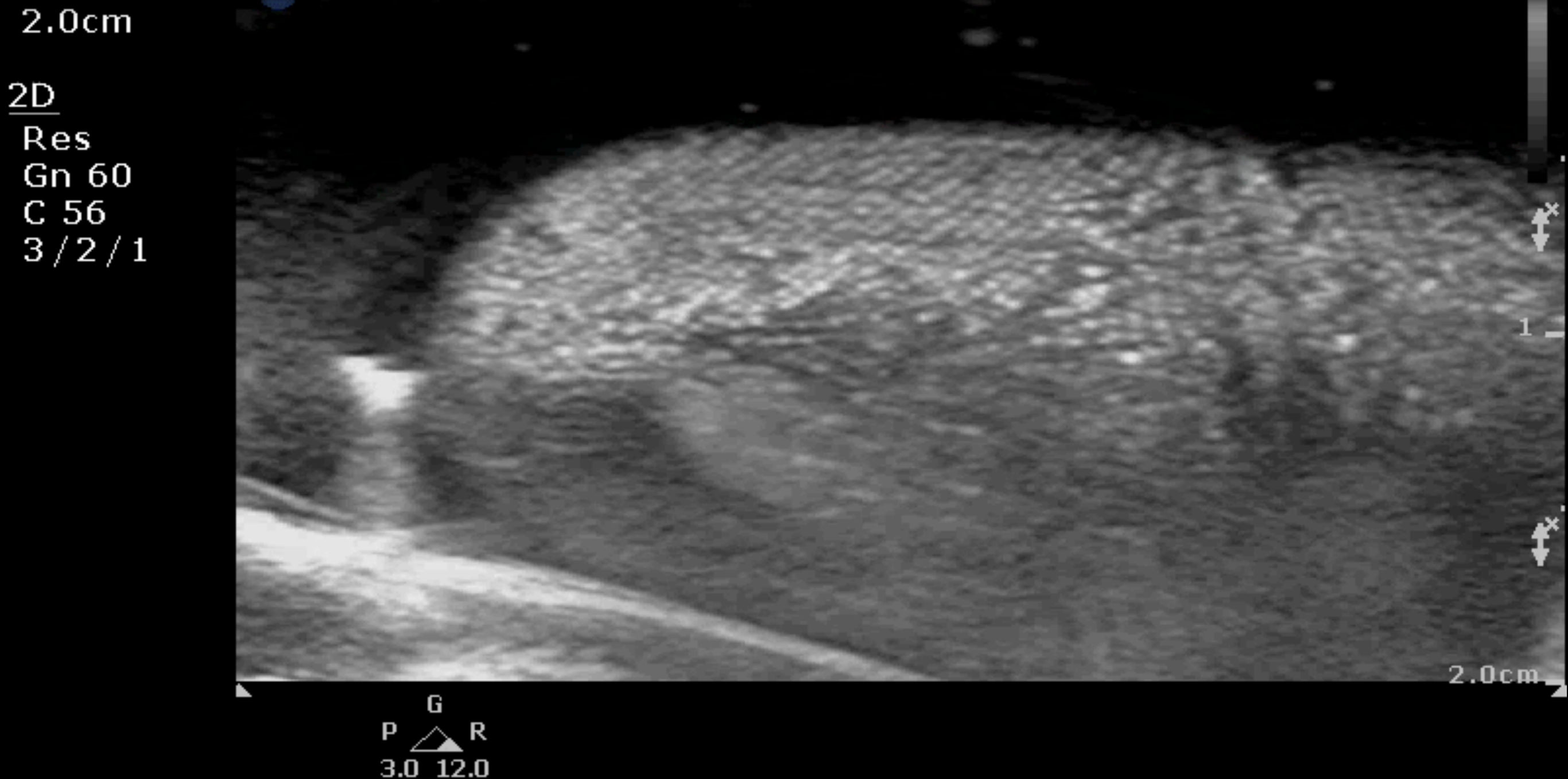
for small parts & superficial evaluation

Water bath method



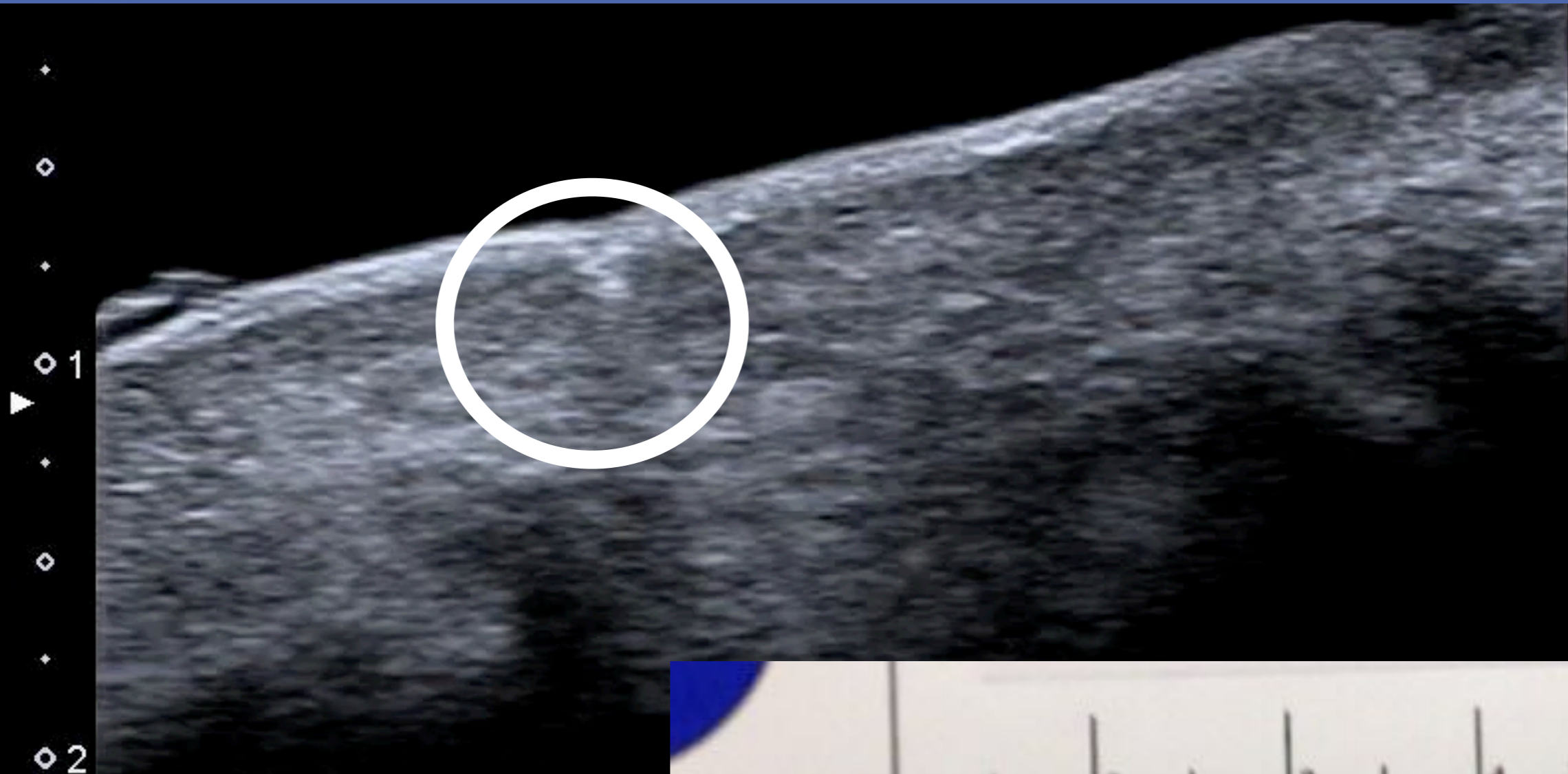
for small parts & superficial evaluation

Water bath method

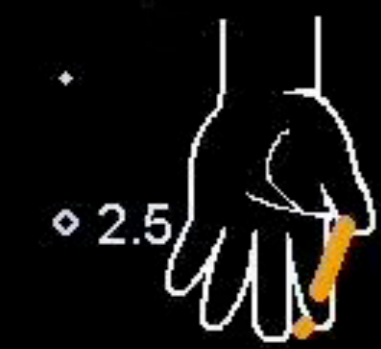


for small parts & superficial evaluation

Water bath



M
1.5
11L4
diffT9.0
30 fps
G:86
DR:60
A:6
P:3



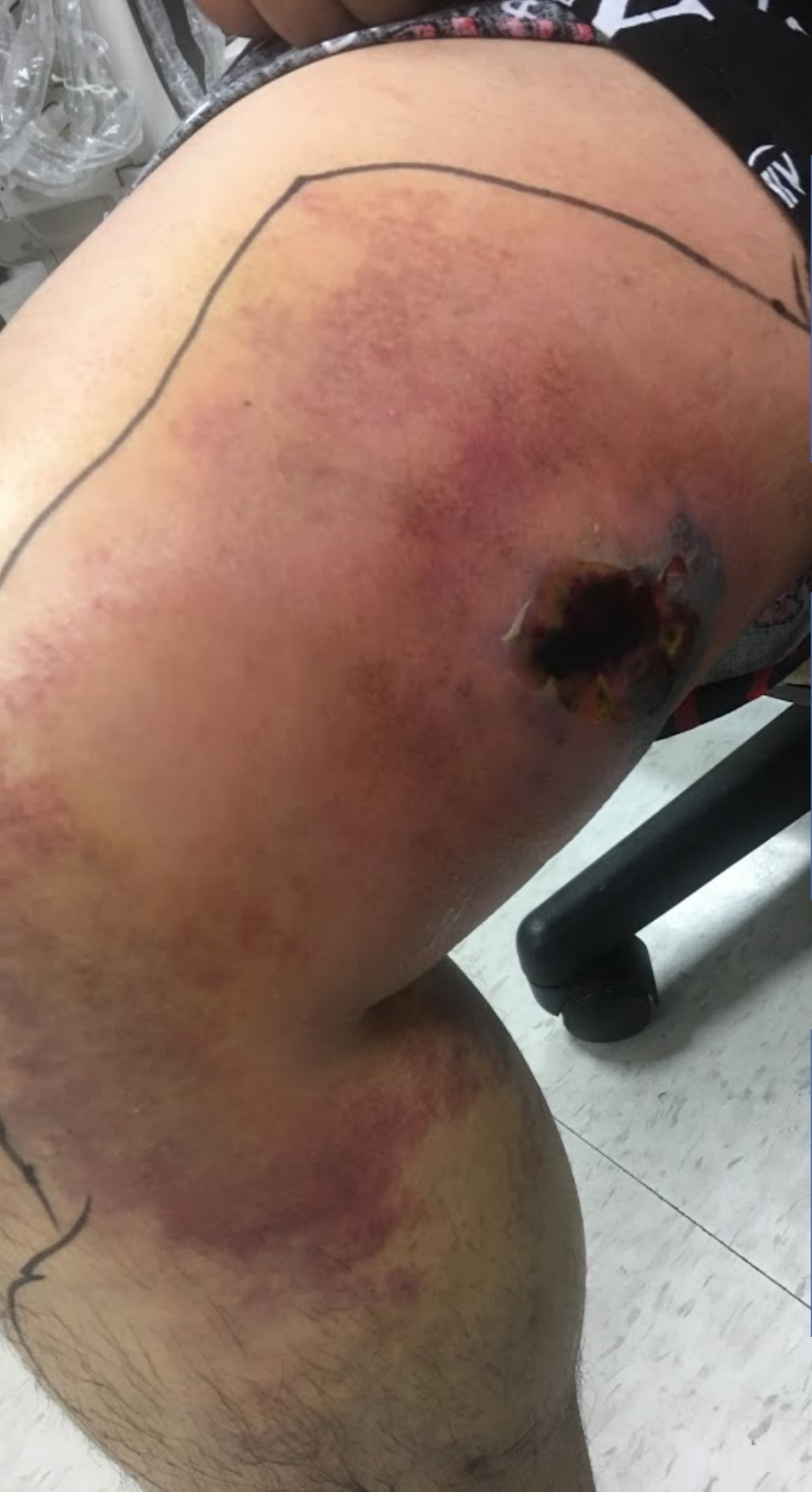1

ST-MSK US

Infection

Effusion

Fracture



Cellulitis

Abscess

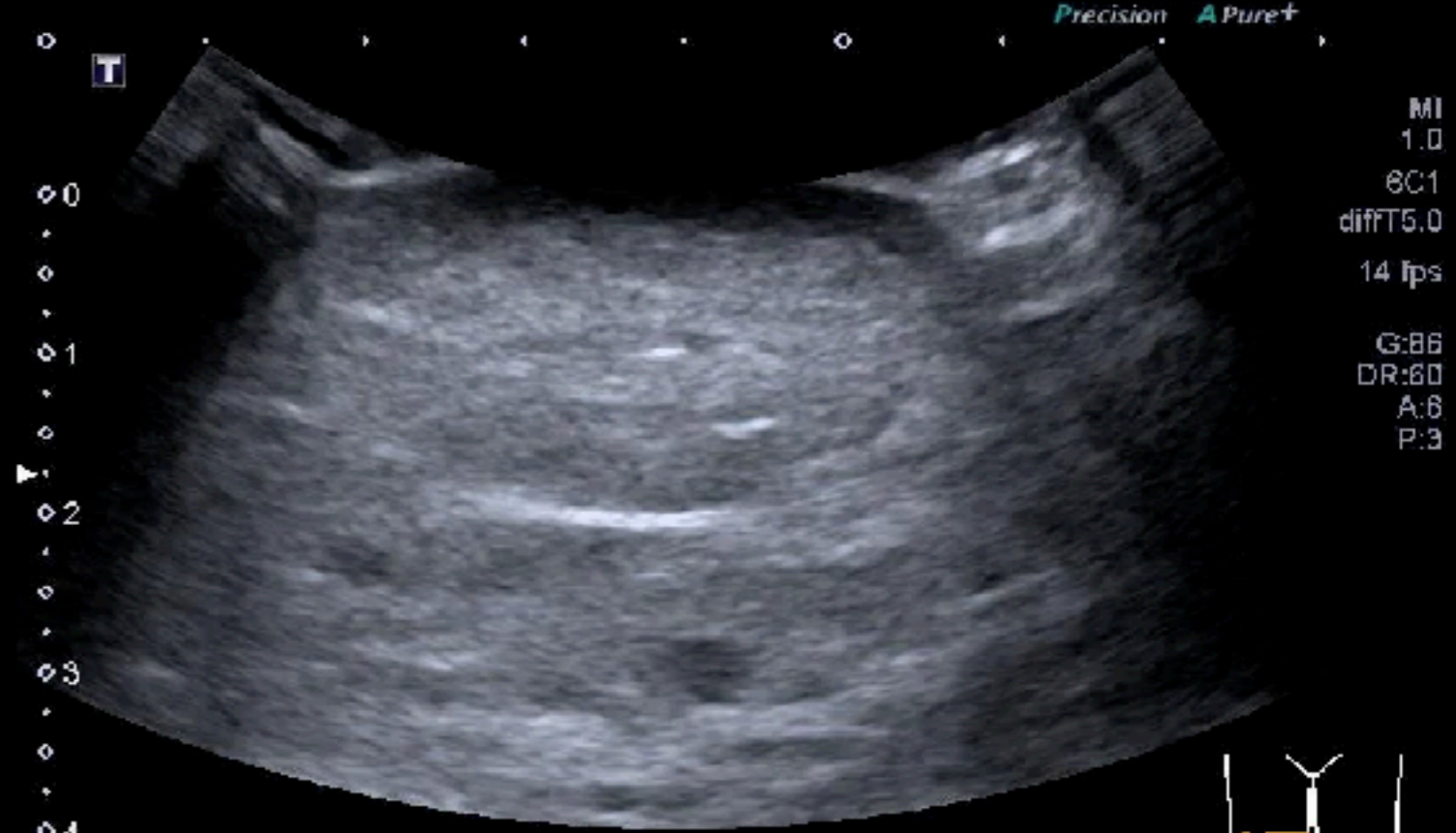
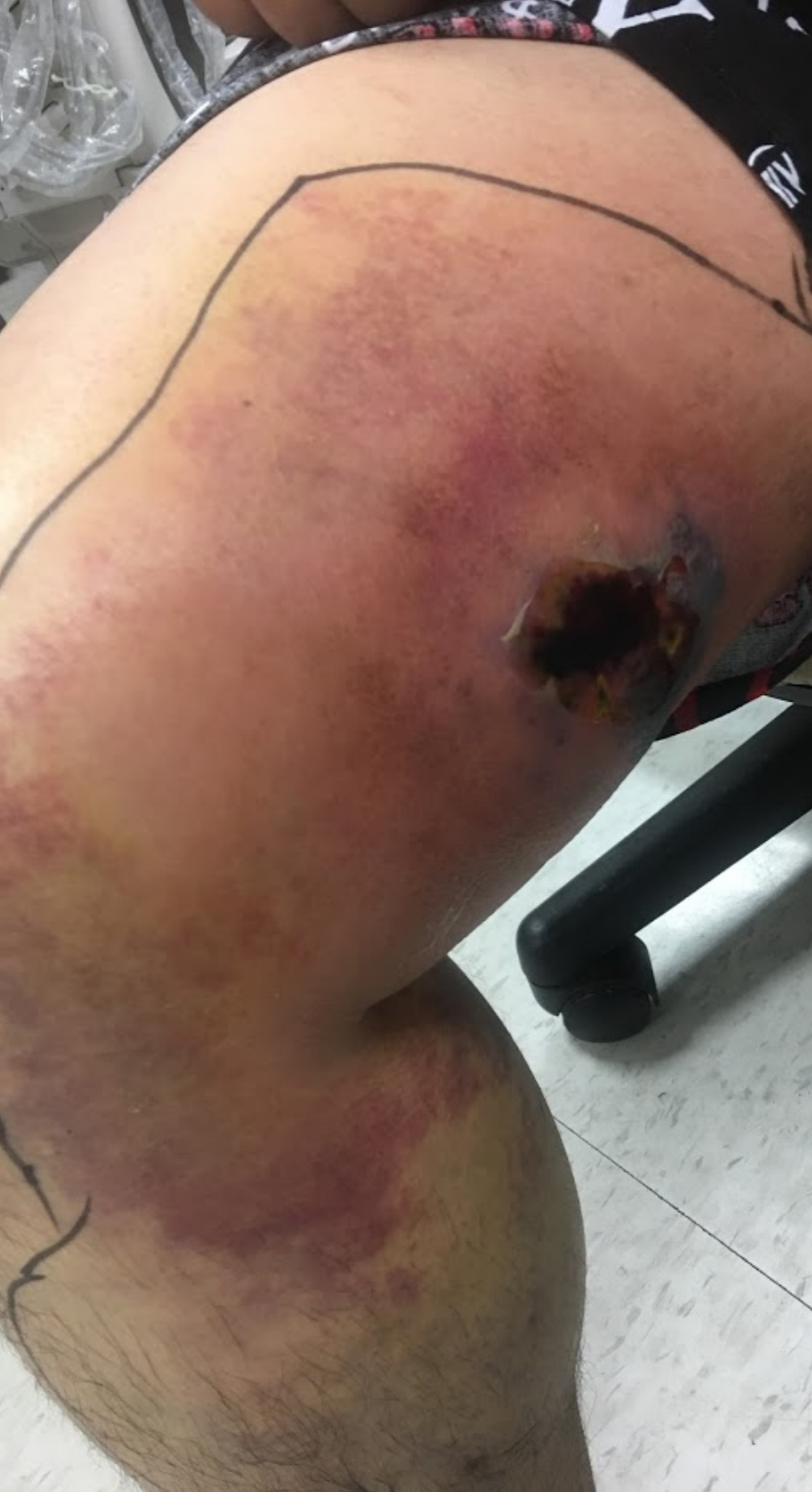Necrotizing Fasciitis



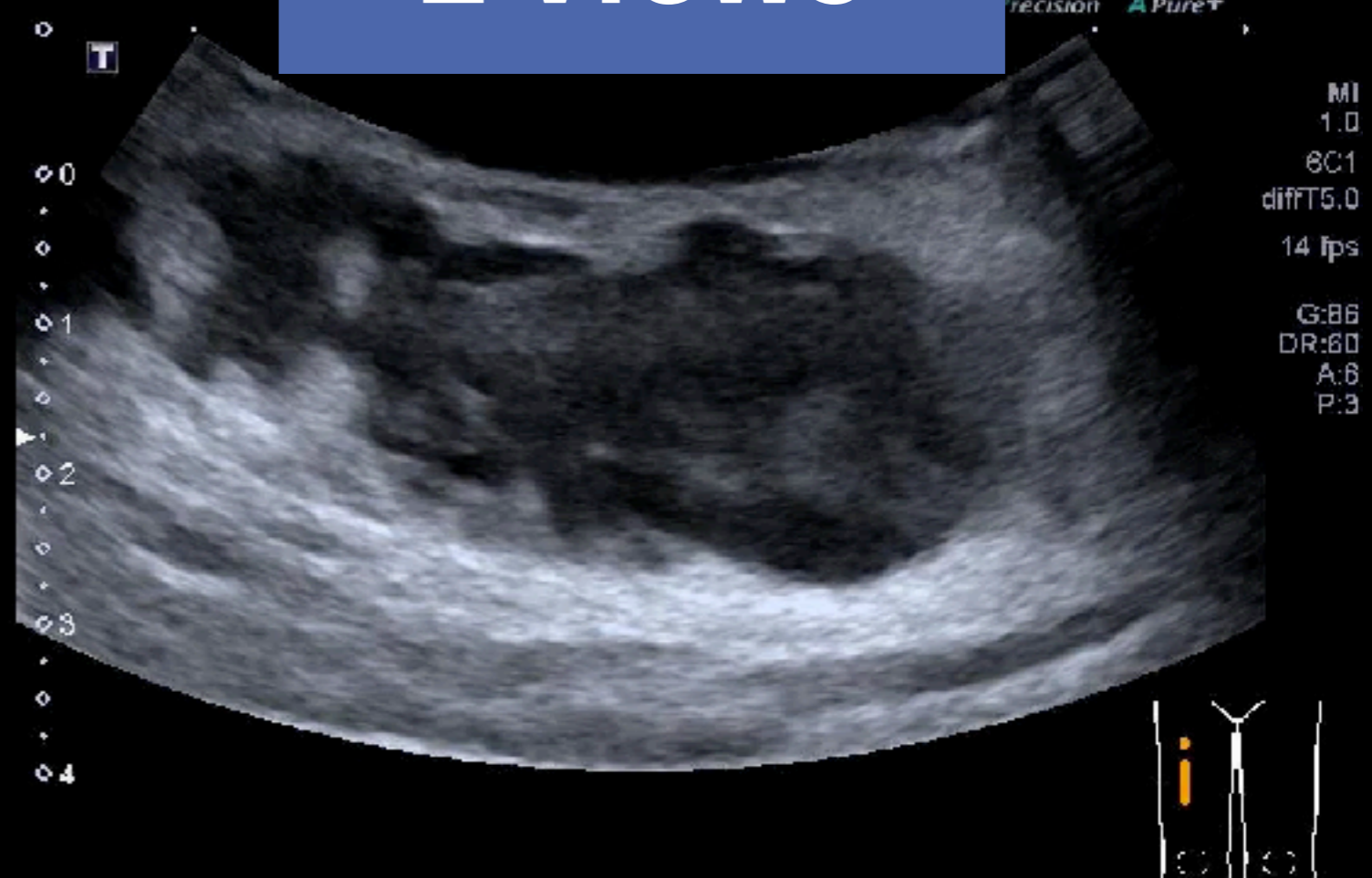Cellulitis

Abscess

Necrotizing Fasciitis



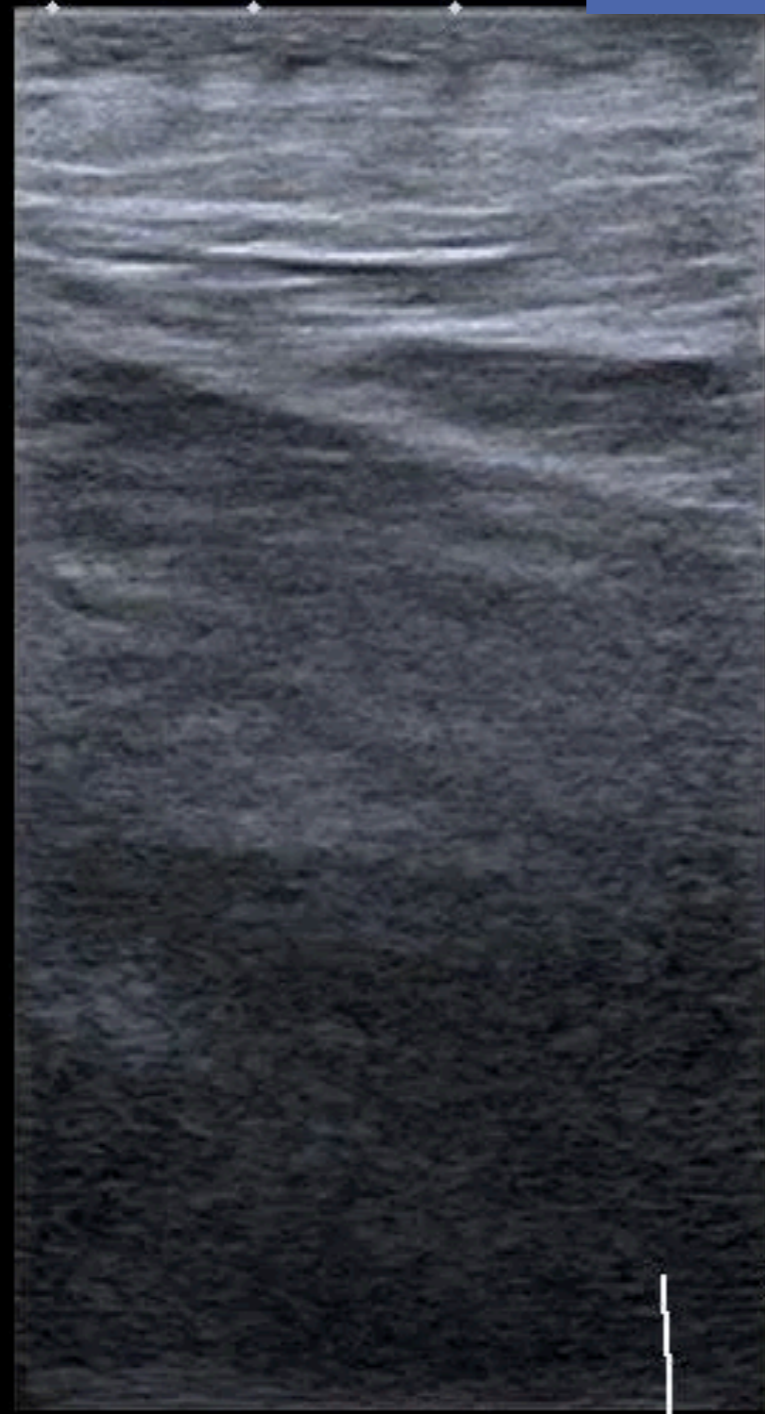
2 Views



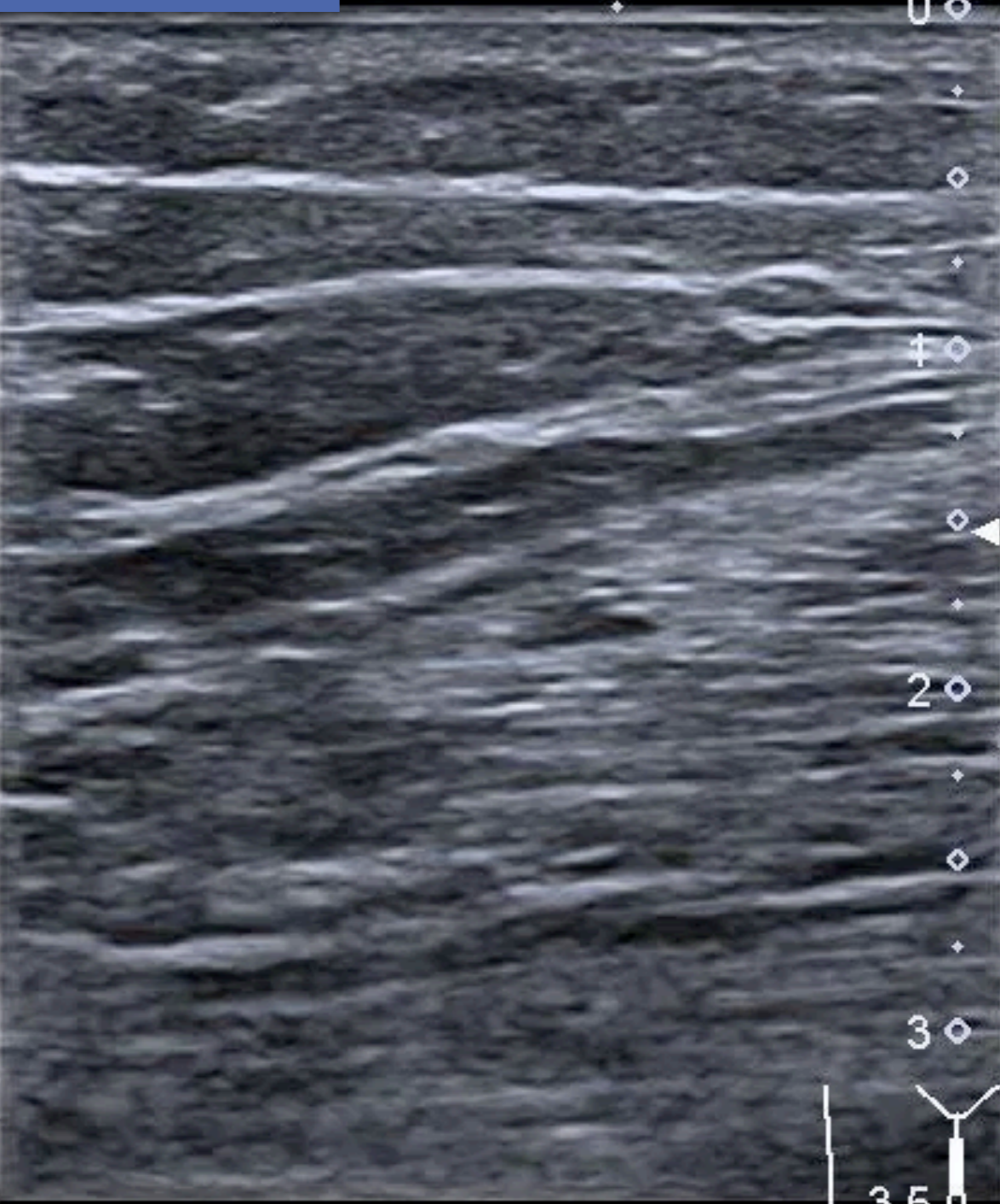
Compare

T
0
MI
1.5
11L4
diffT9.0
21 fps
5
G:86
DR:60
A:6
P:3
7

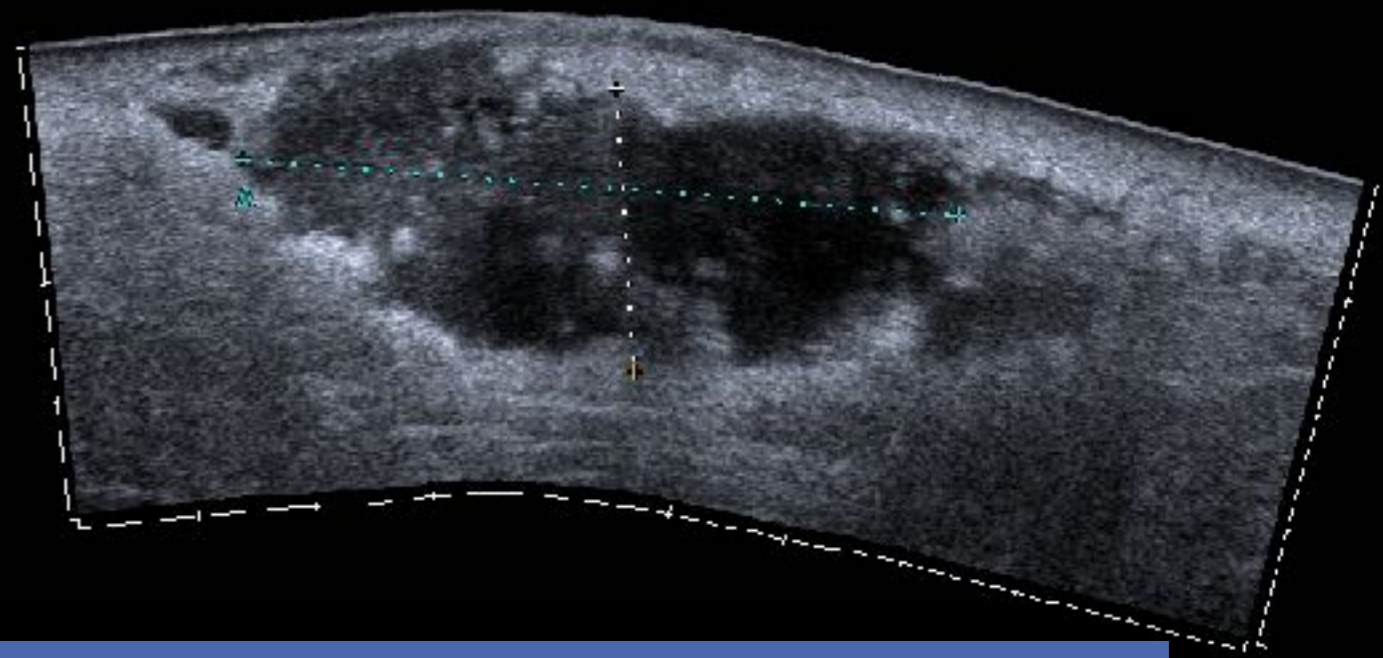
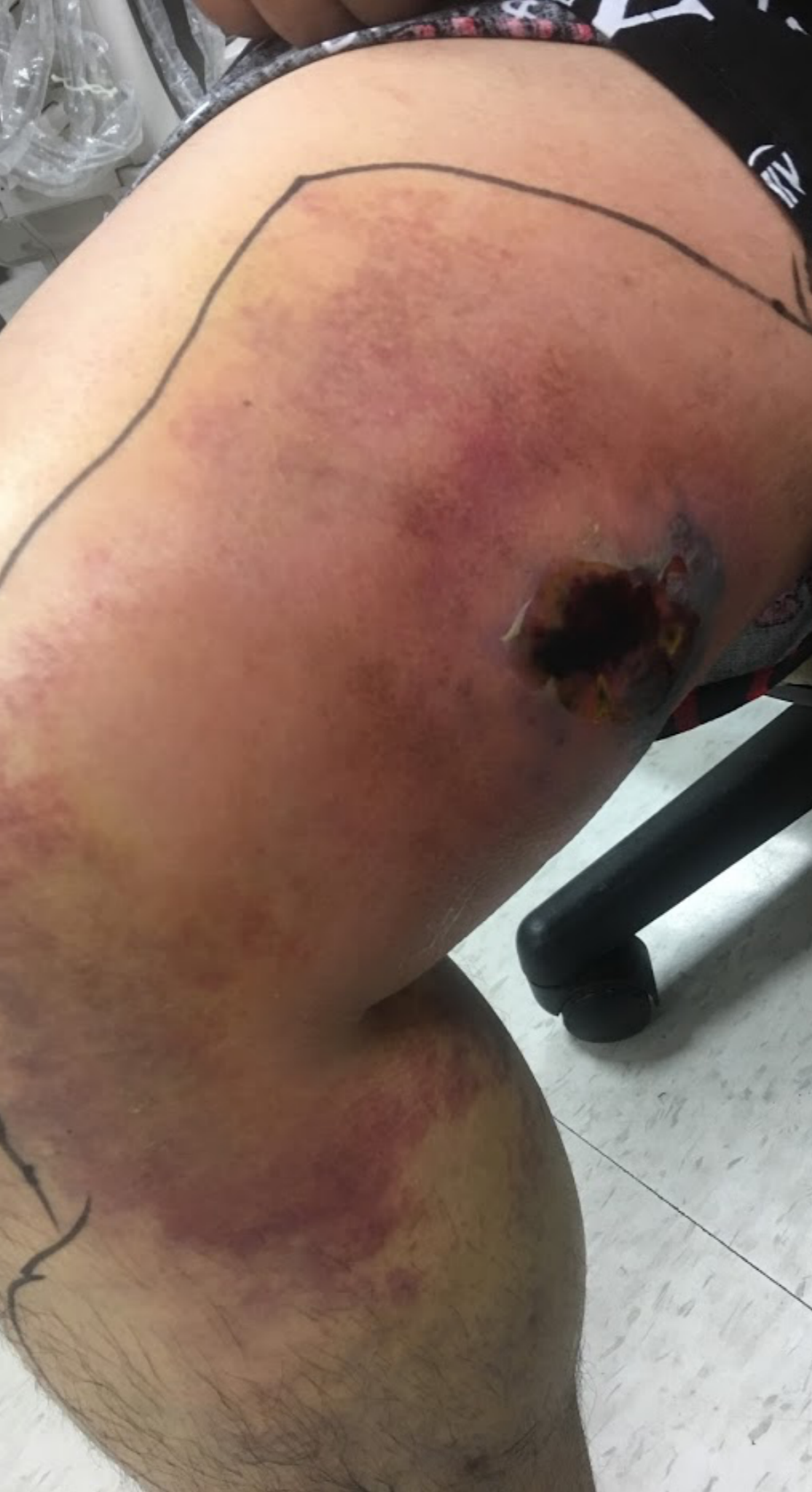A Pure+ Precision



Precision A Pure+
0
1
2
3
3.5
11L4
diffT9.0
30 fps
G:86
DR:60
A:6
P:3

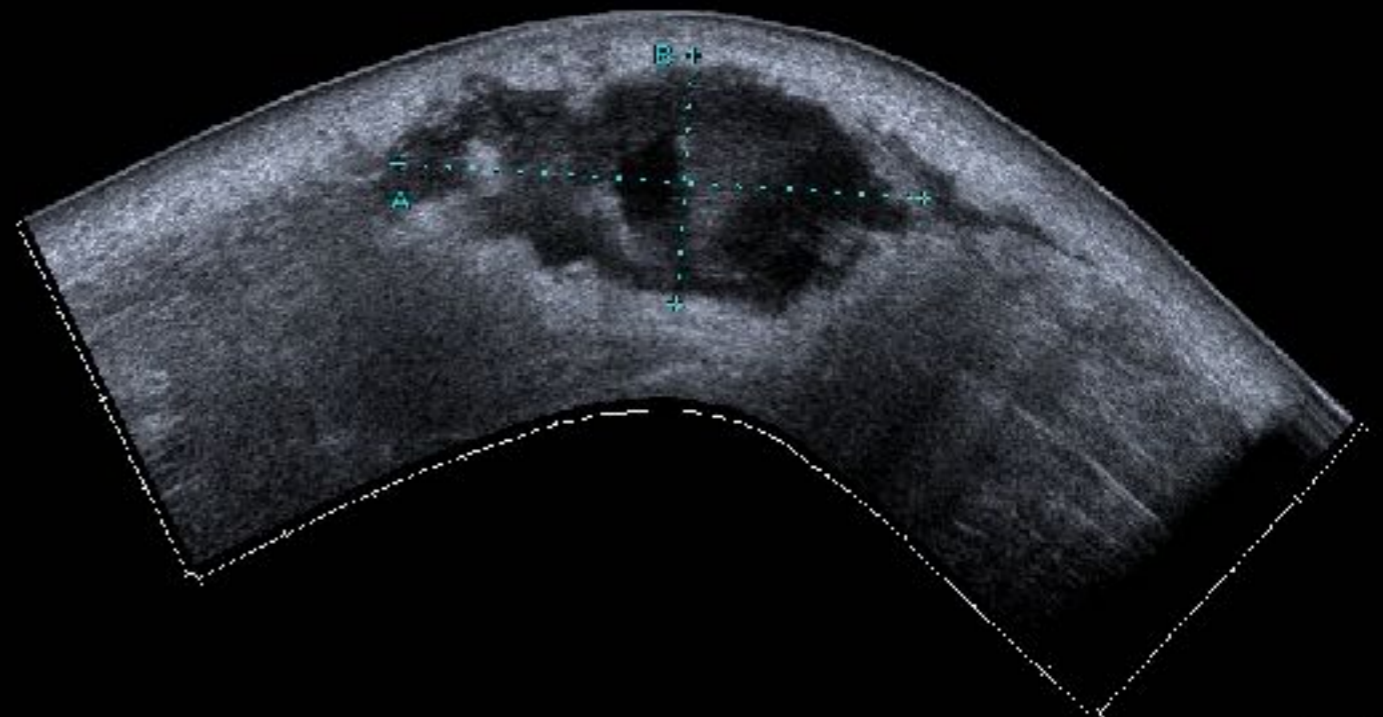


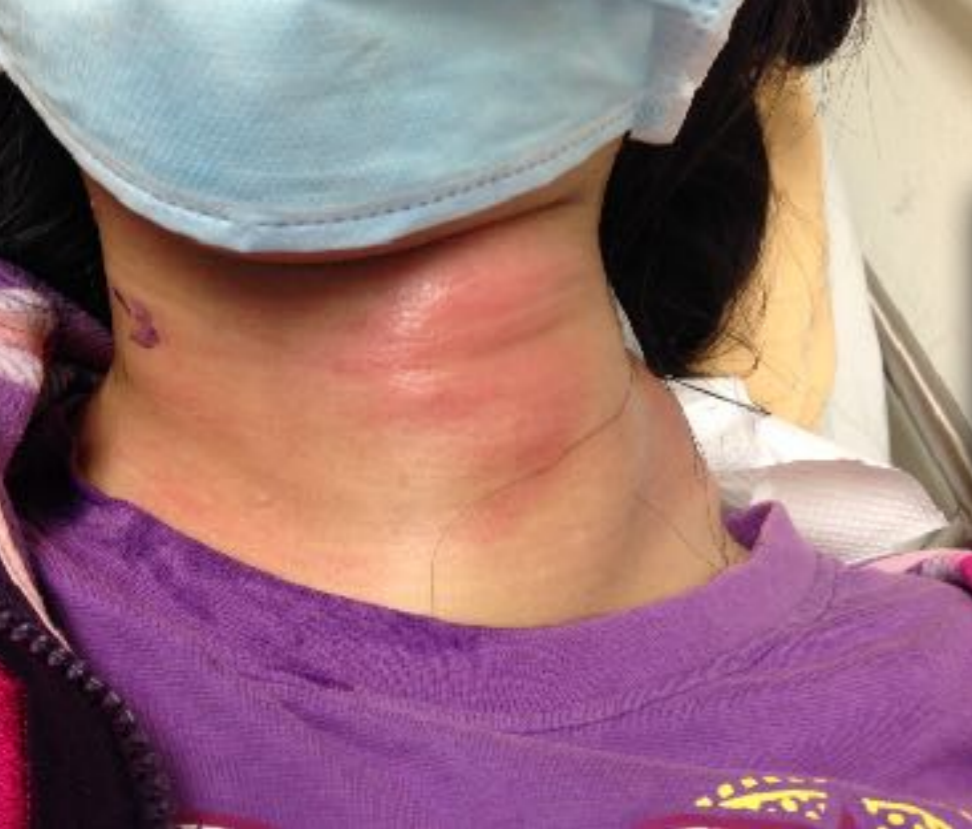113



Panoramic view

Dist A	60.6mm
Dist B	23.9mm

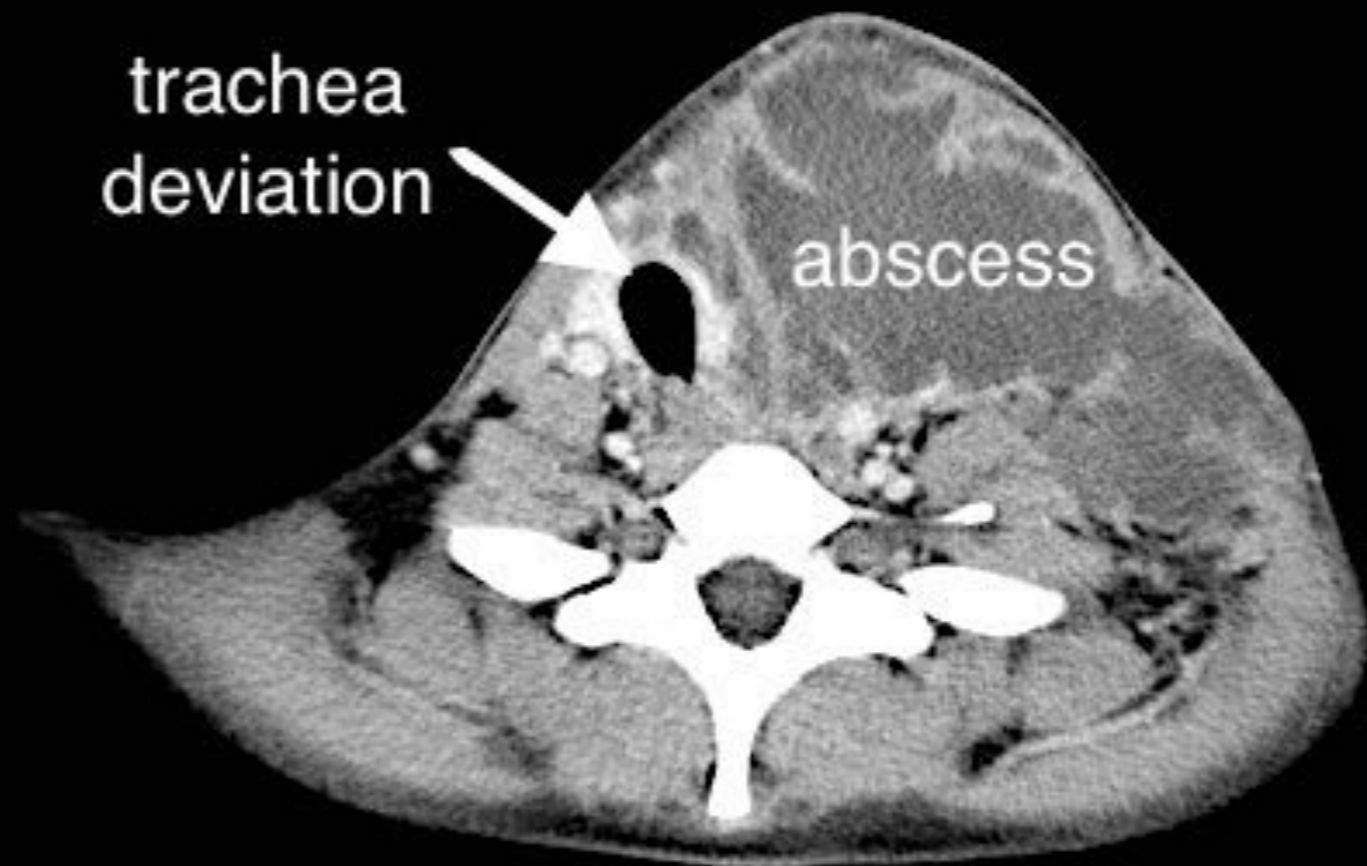
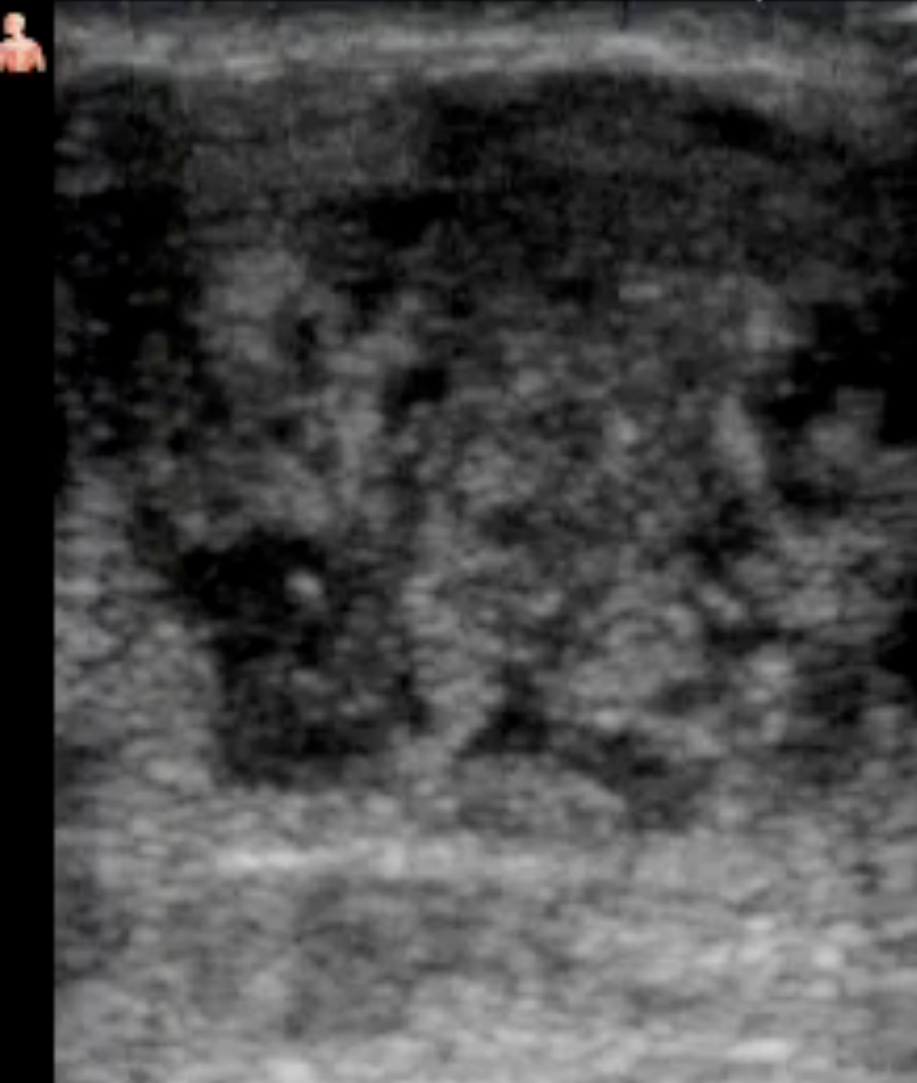



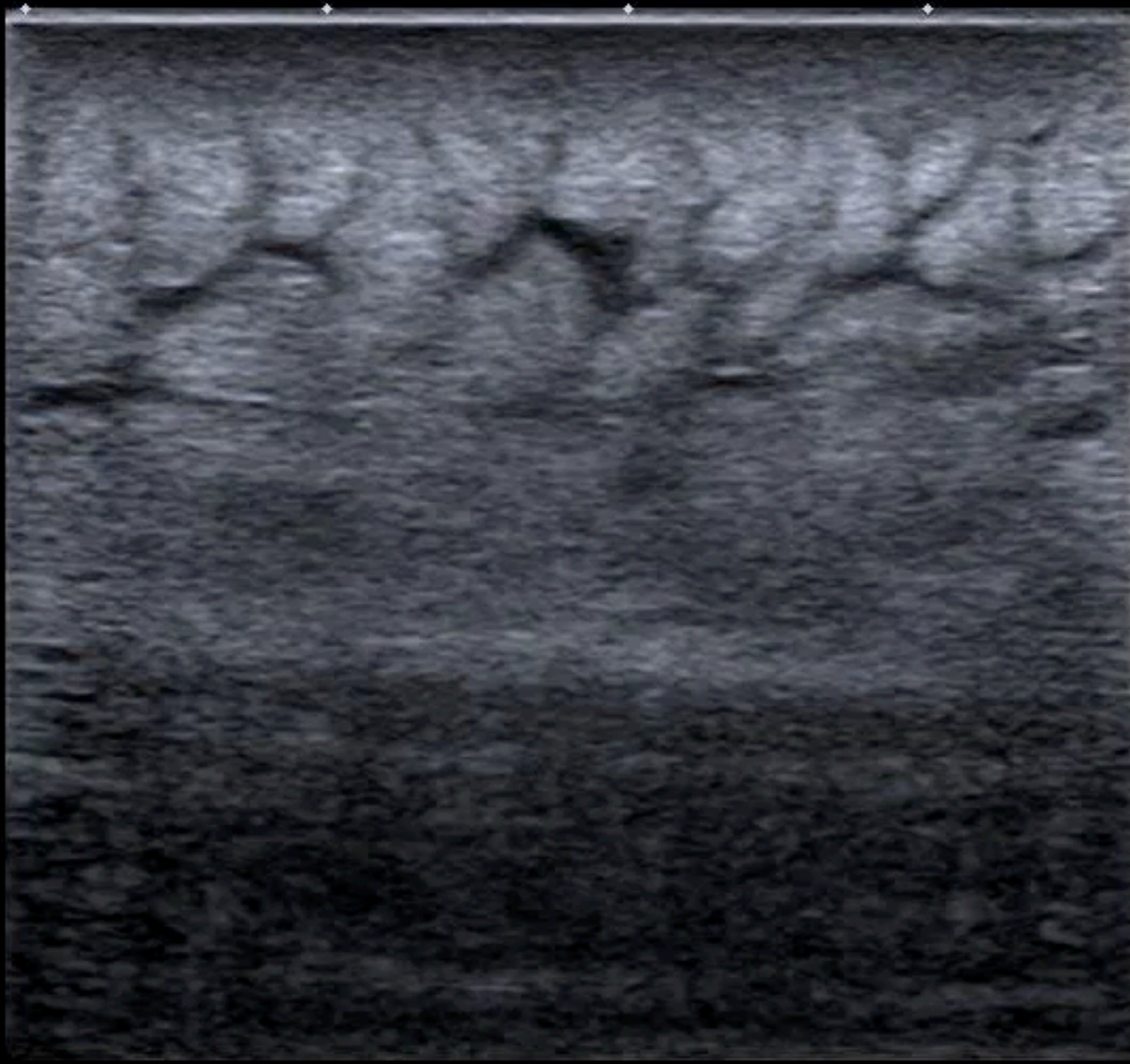
Squish sign

Moving particles or fluid

MI: 0.8 TI: 0.2 #: 359 14:23:59
25/Apr/2015

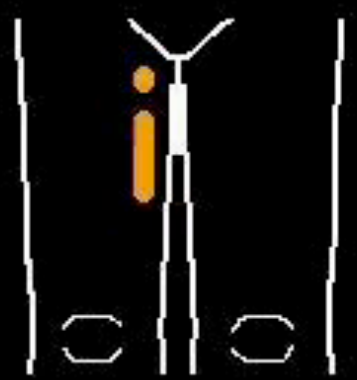



0
T
1
2
3
3.5



Resolution 4.0mm
11L
diffT9
30 fr
G:8
DR:6
A
P

Above or below fascial level ?



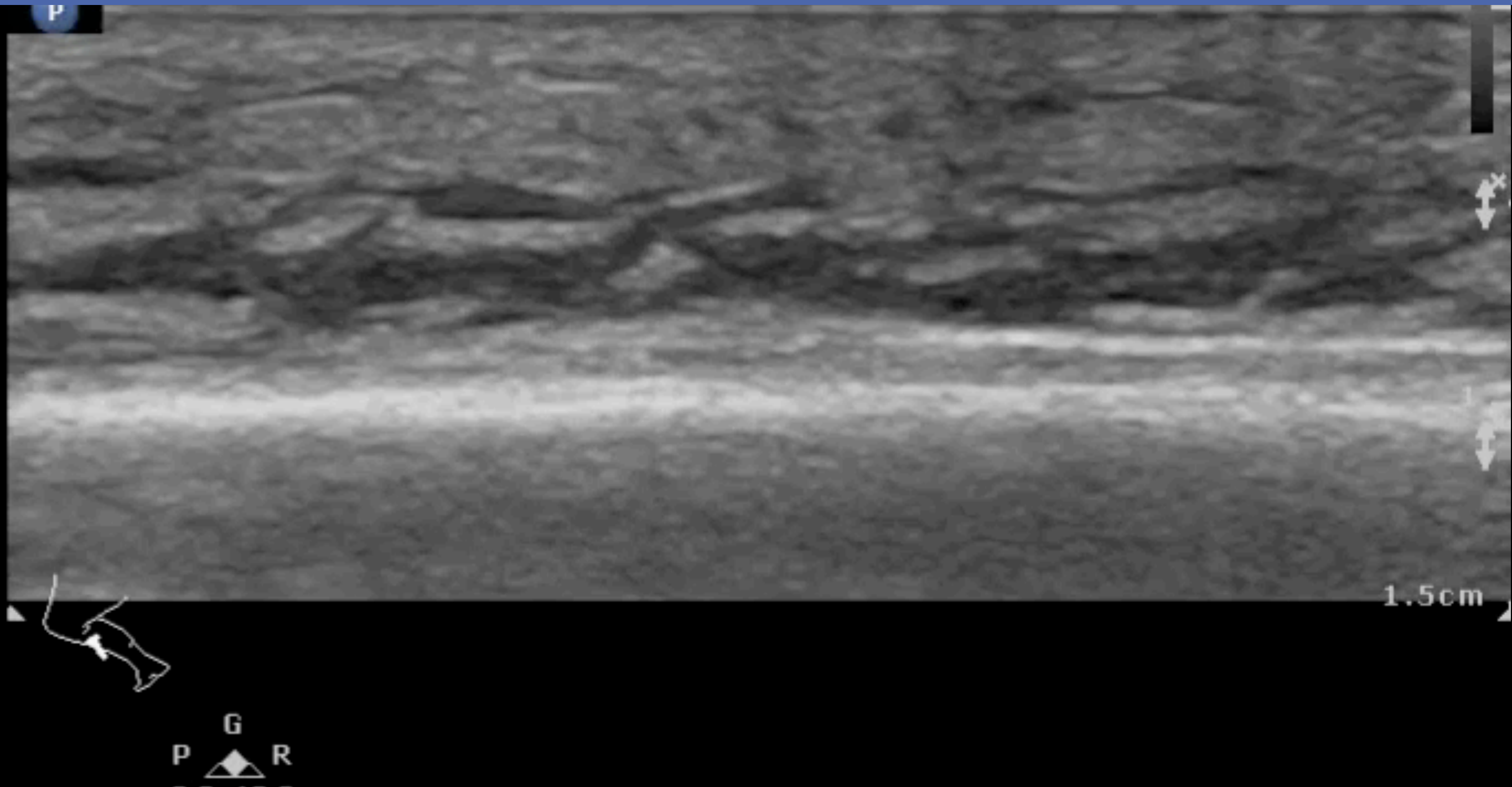


Fat

Cobblestone-like appearance

Fluid

Tissue edema



POCUS for diagnosis of abscess in SSTI

6 observational studies (4A / 2P) for 800 patients

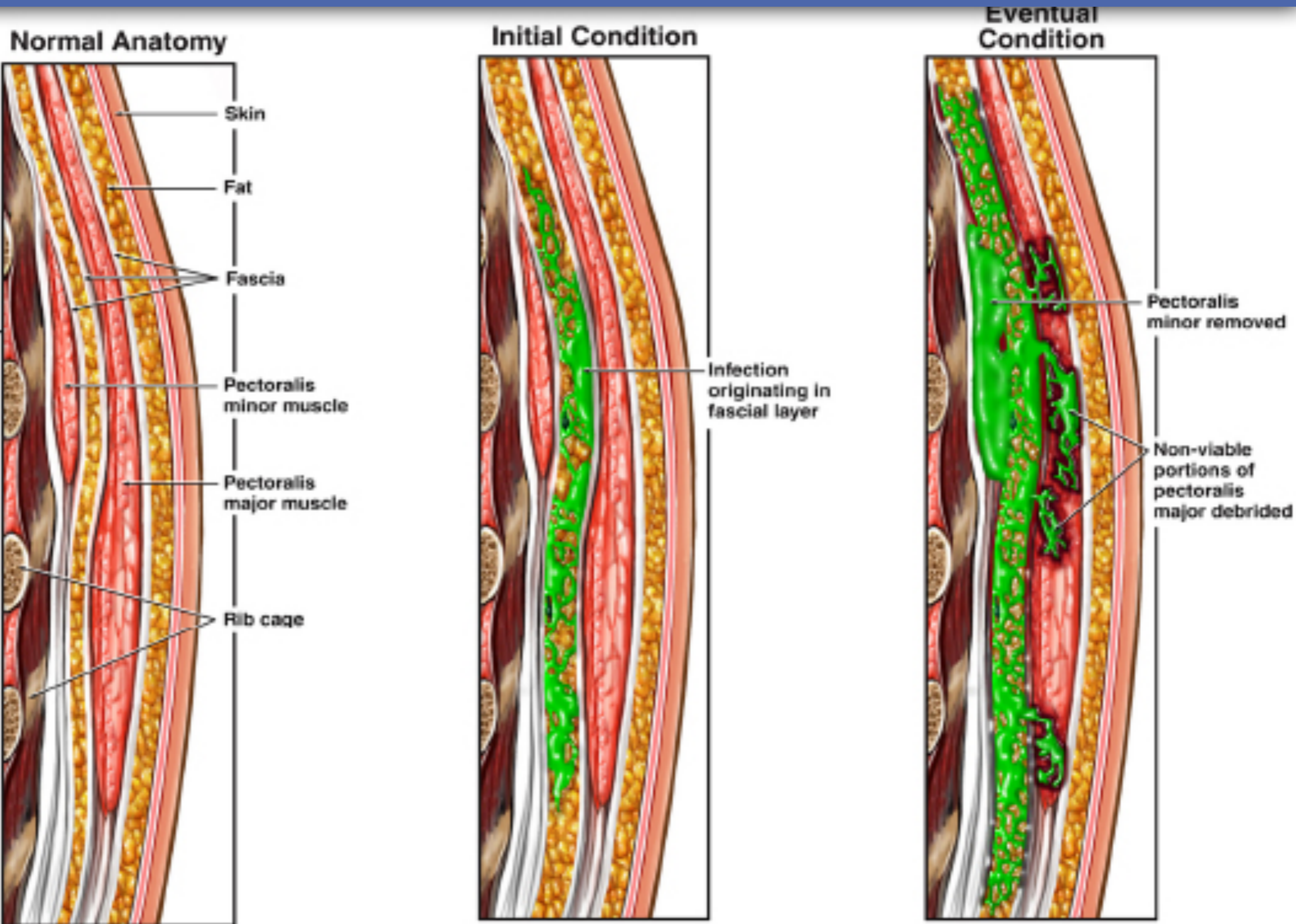
Sensitivity 97% (95% CI = 94-98%)

Specificity 83% (95% CI = 75-88%)

LR+ 5.5 (95% CI = 3.7-8.2)

LR- 0.04 (95% CI = 0.02-0.08)

Finger test



NTUH experience on Necrotizing fasciitis

Diffuse thickening of the SC tissue

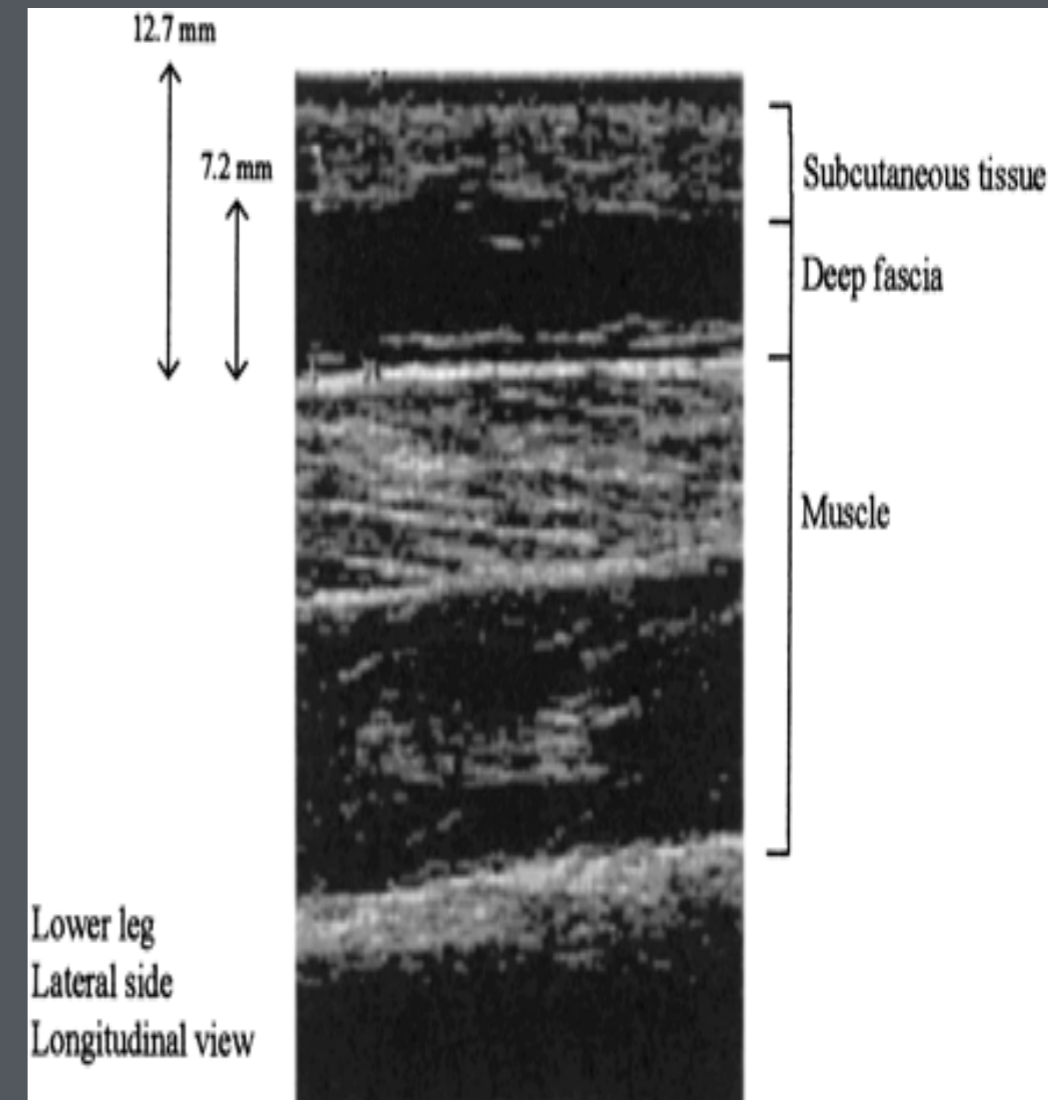
Fascial fluid > 4 mm

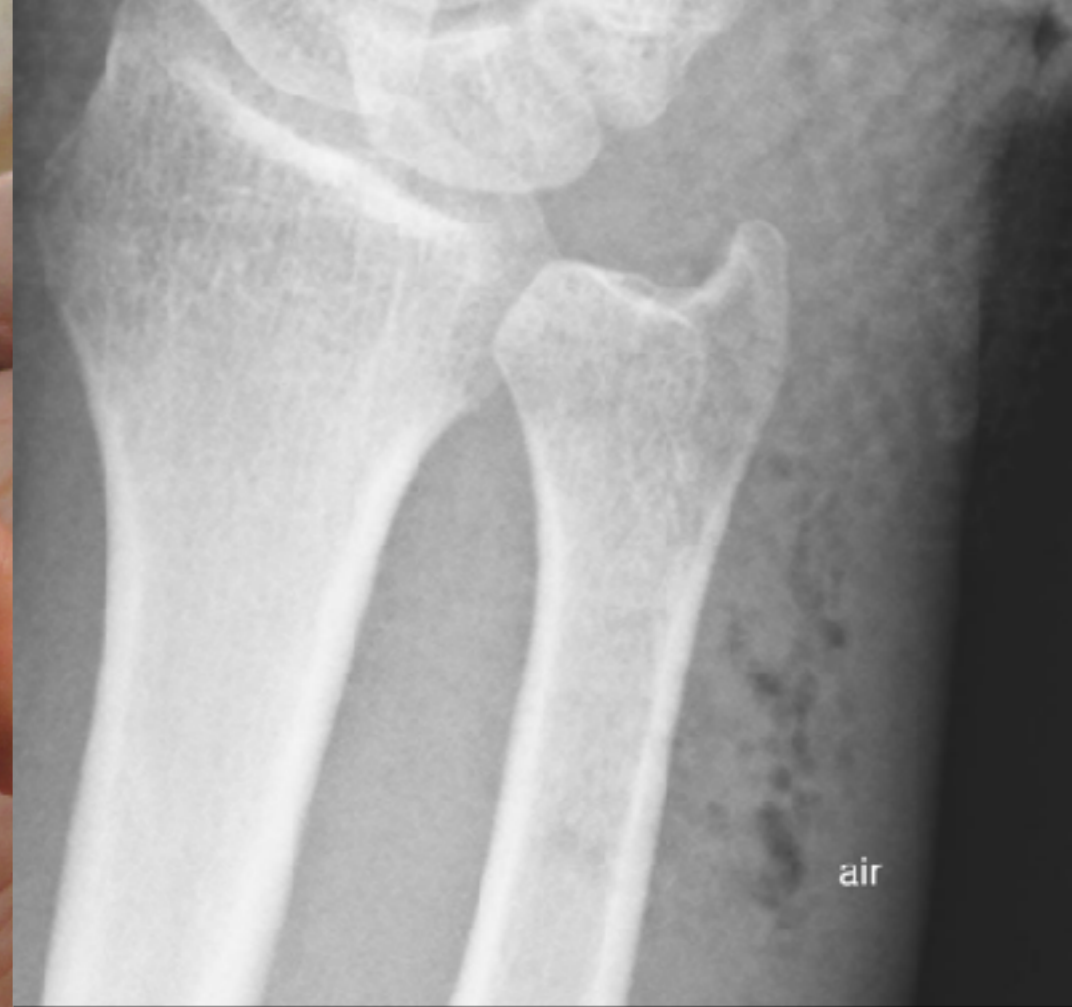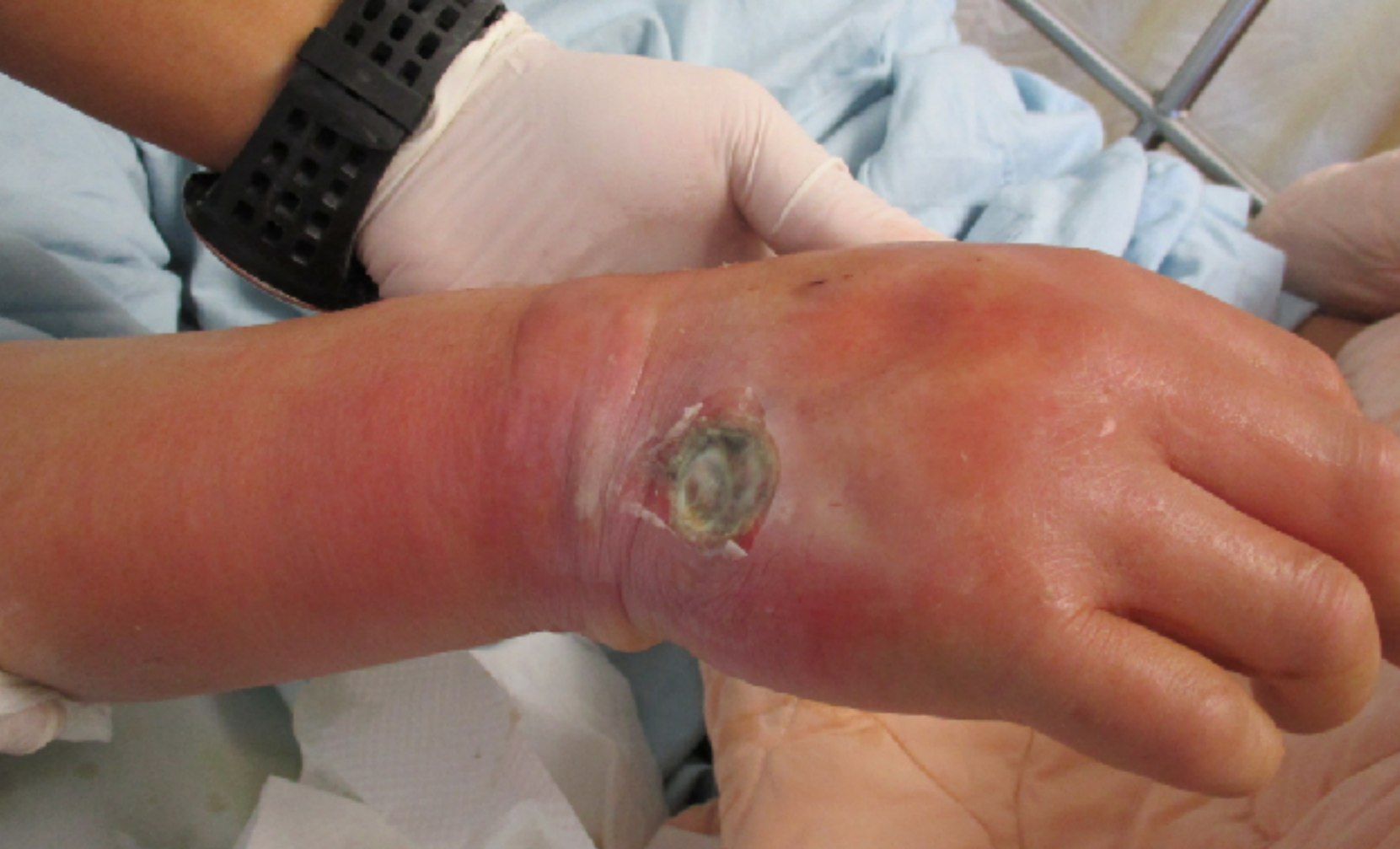66 patients (17,NF)

Sensitivity: 88.2%; Specificity: 93.3%

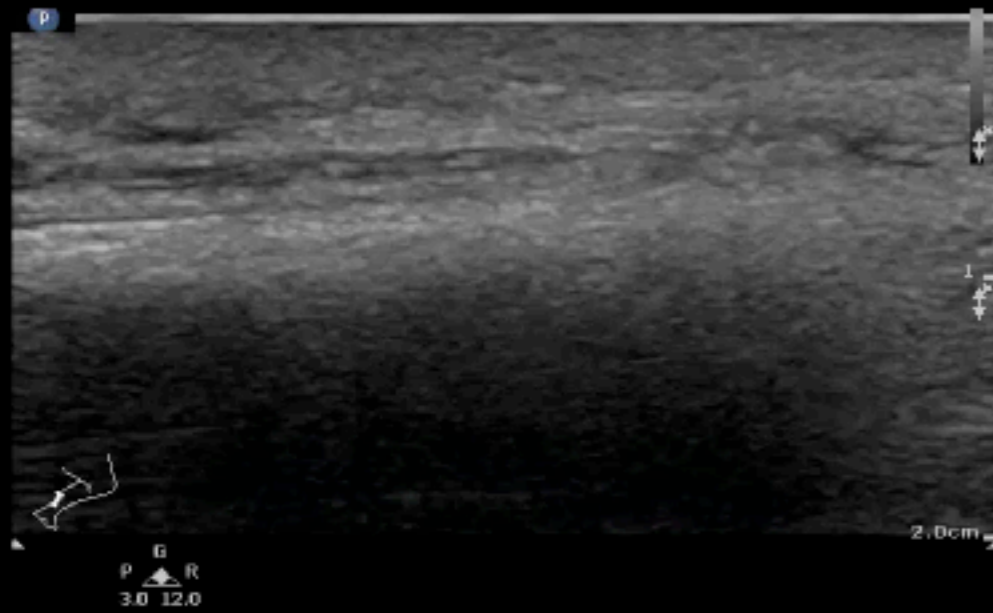
PPV: 83.3%; NPV: 95.4%

Accuracy: 91.9 %





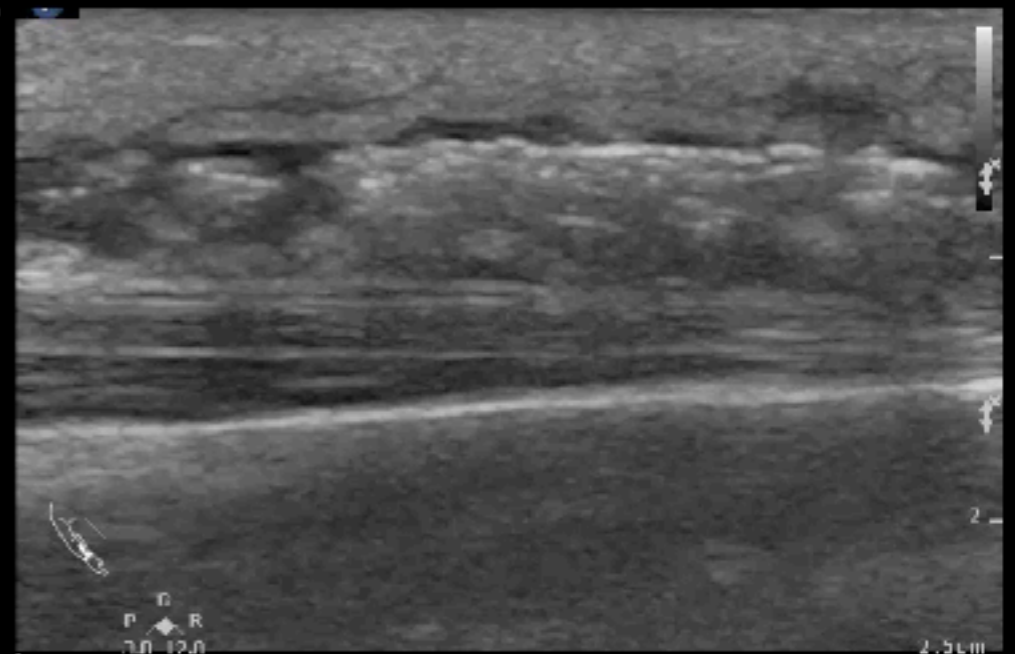
SKH-EUTC



SKH-EUTC

Superficial
L12-3
3-4 Hz
2.5cm

2D
Gen
Gn 100
C 52
4/3/2



STAFF exam (3)

Subcutaneous Thickening

Air

Fascial Fluid

59.1 km

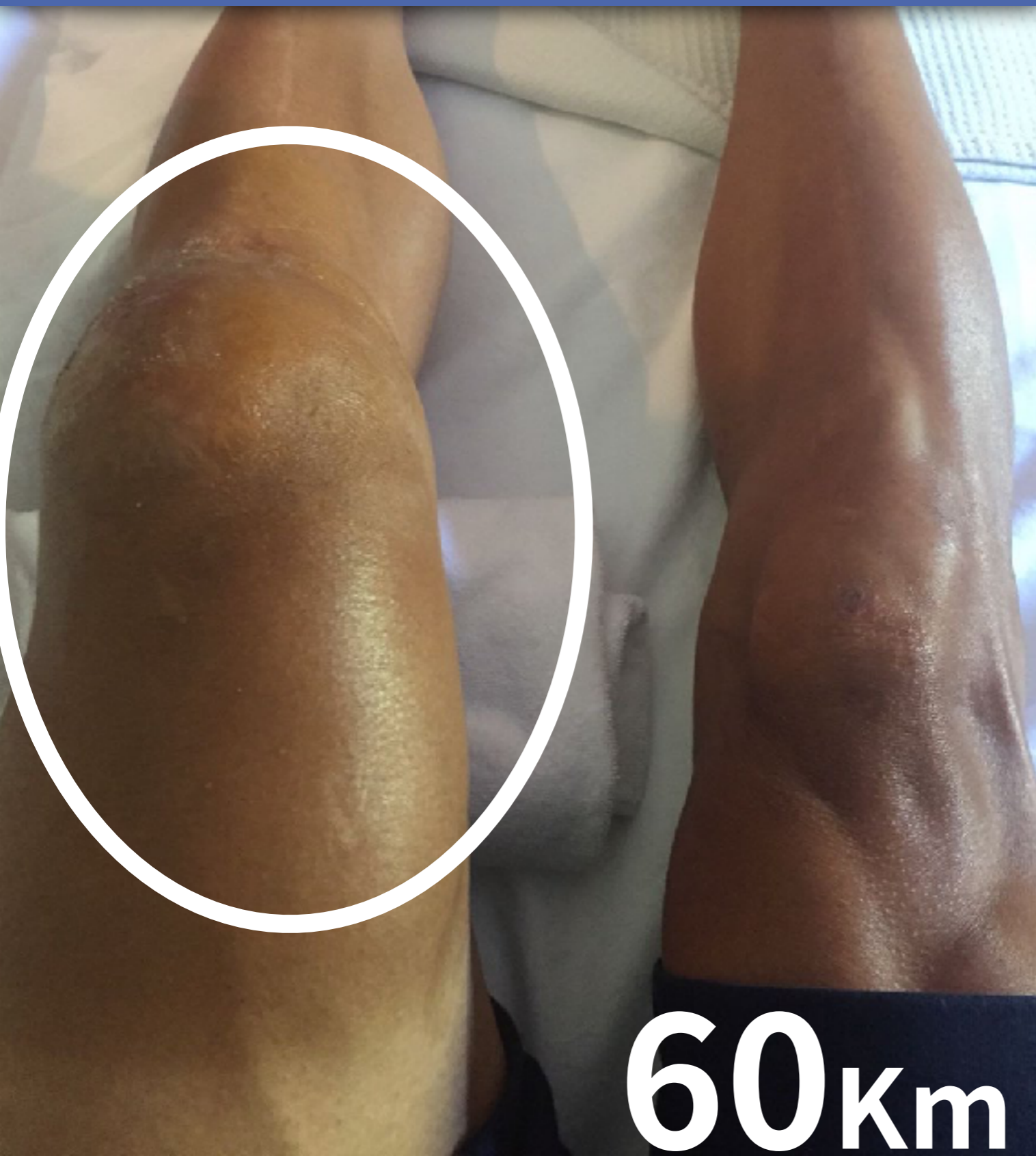

3 

10'24"



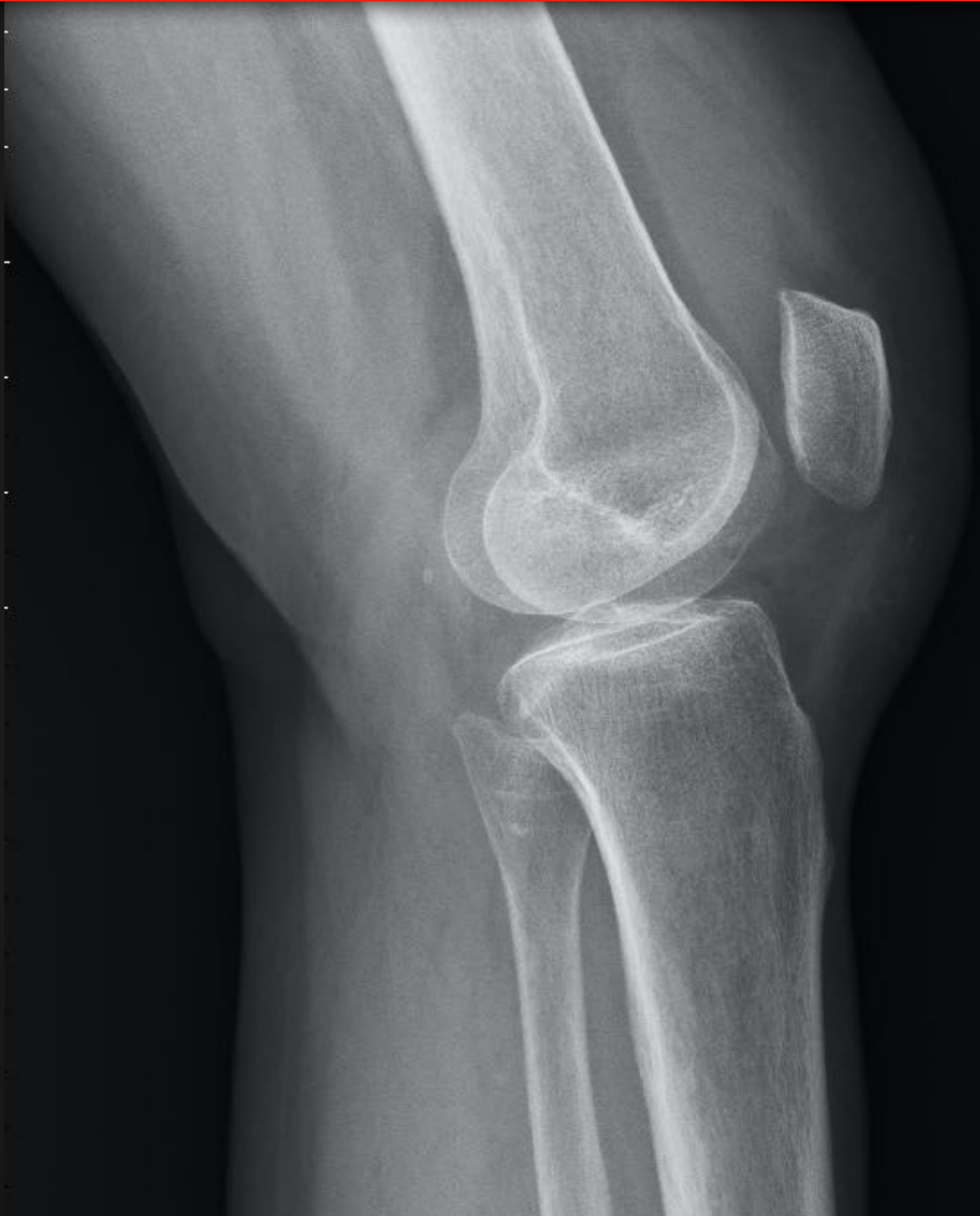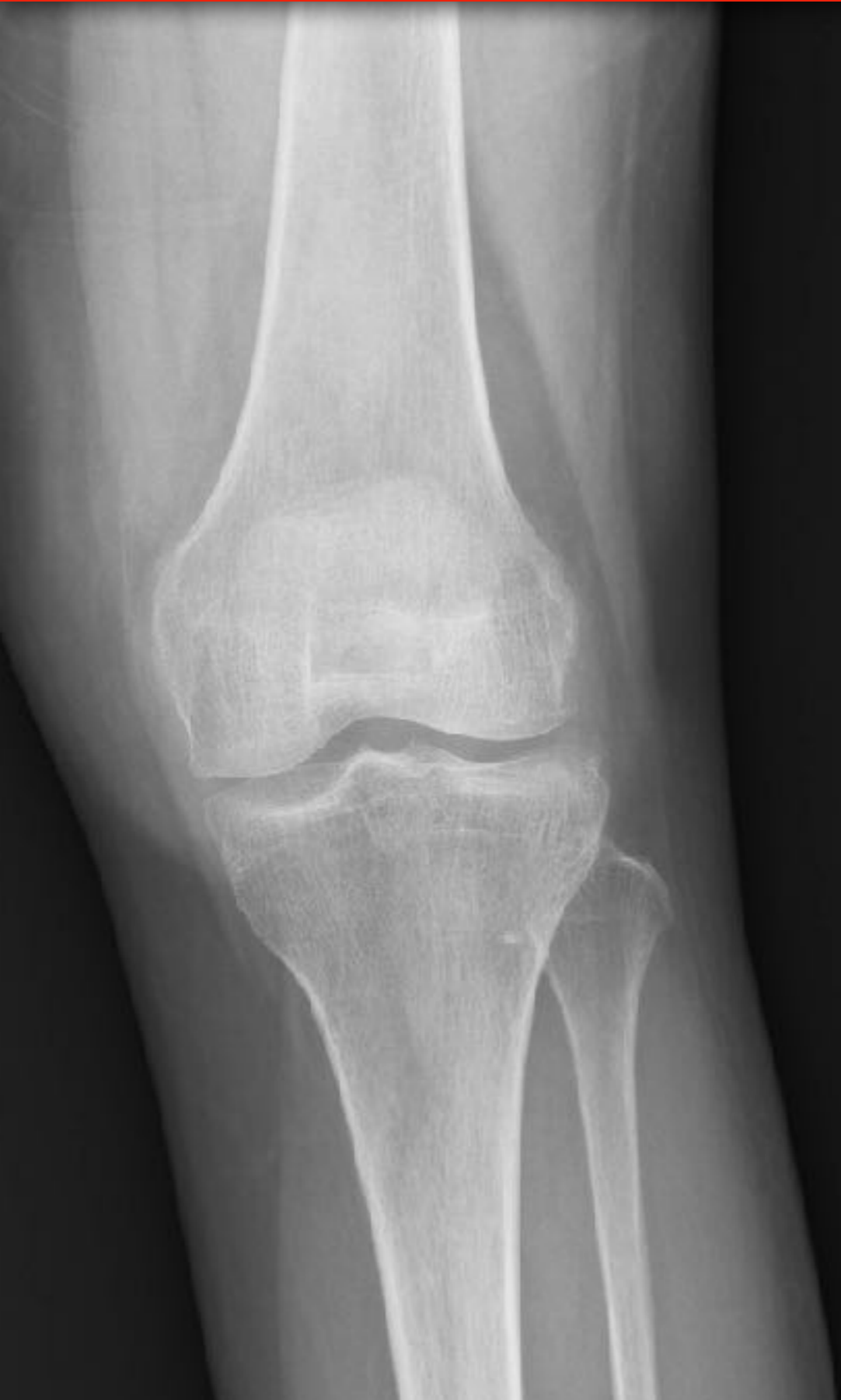Knee cap fracture



60Km



膝蓋很腫，無法彎也無法站



2

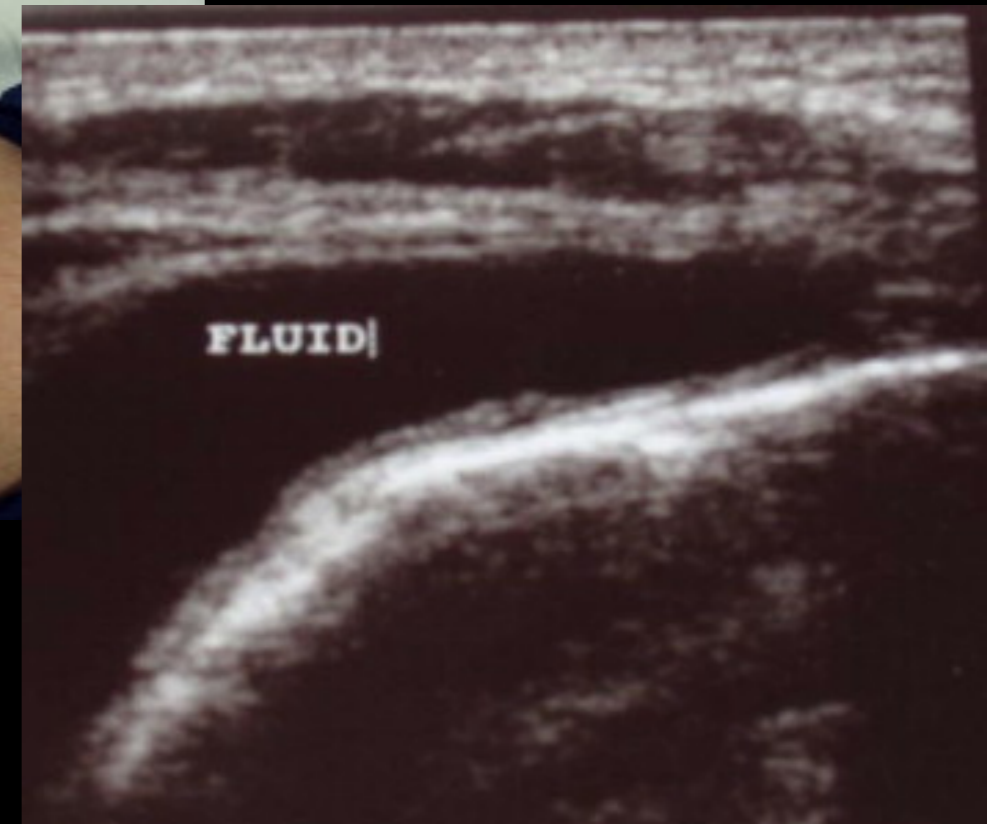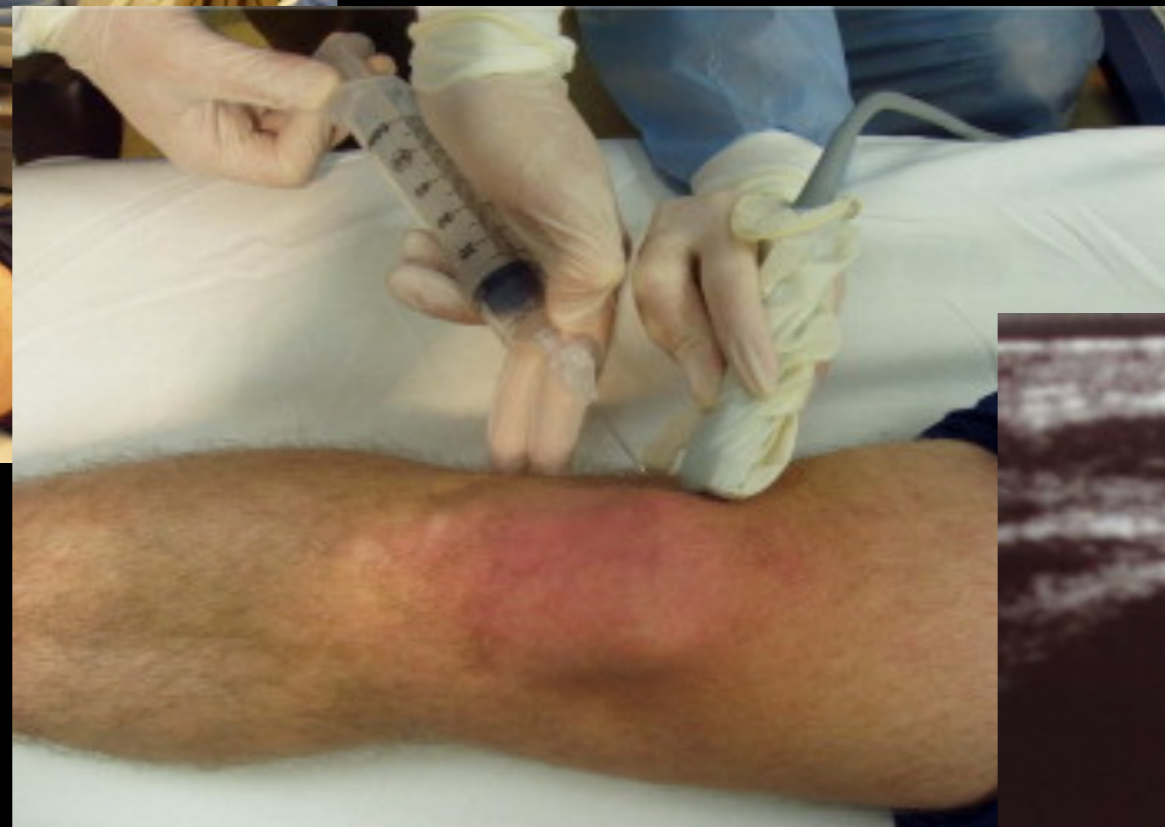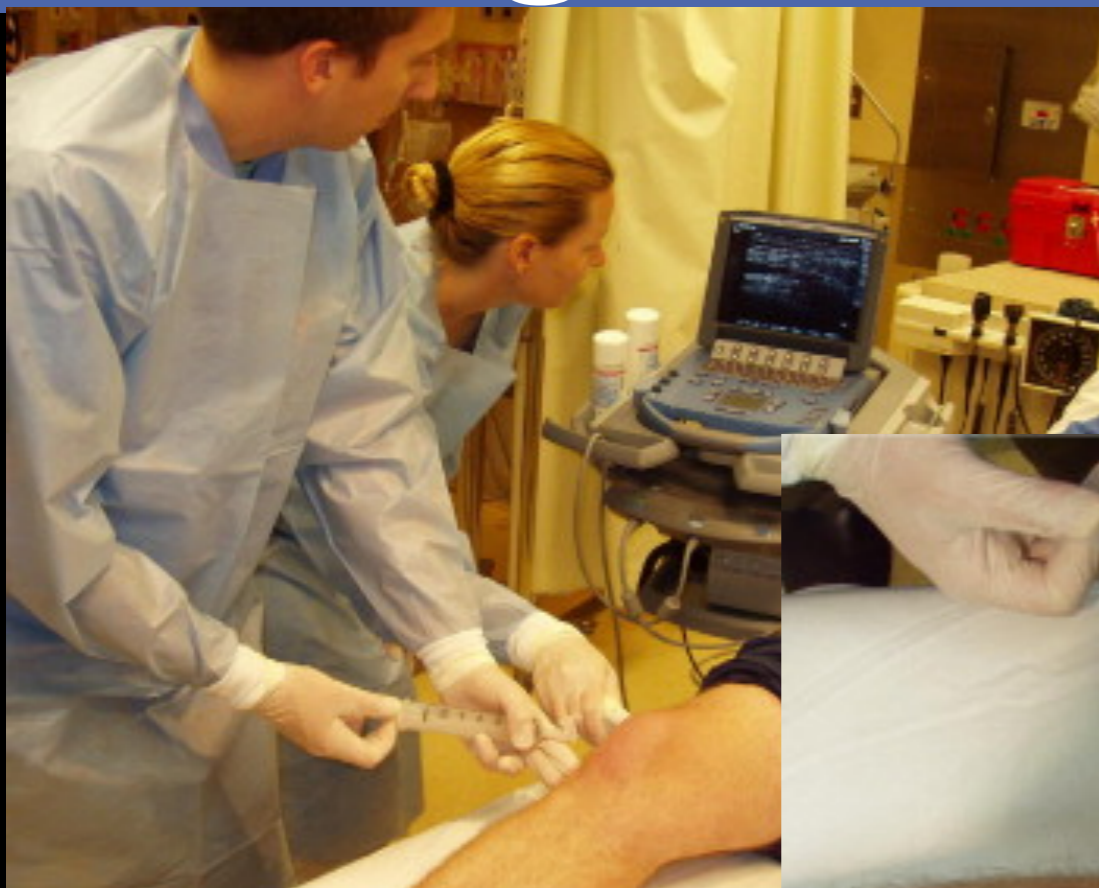ST-MSK US

Infection

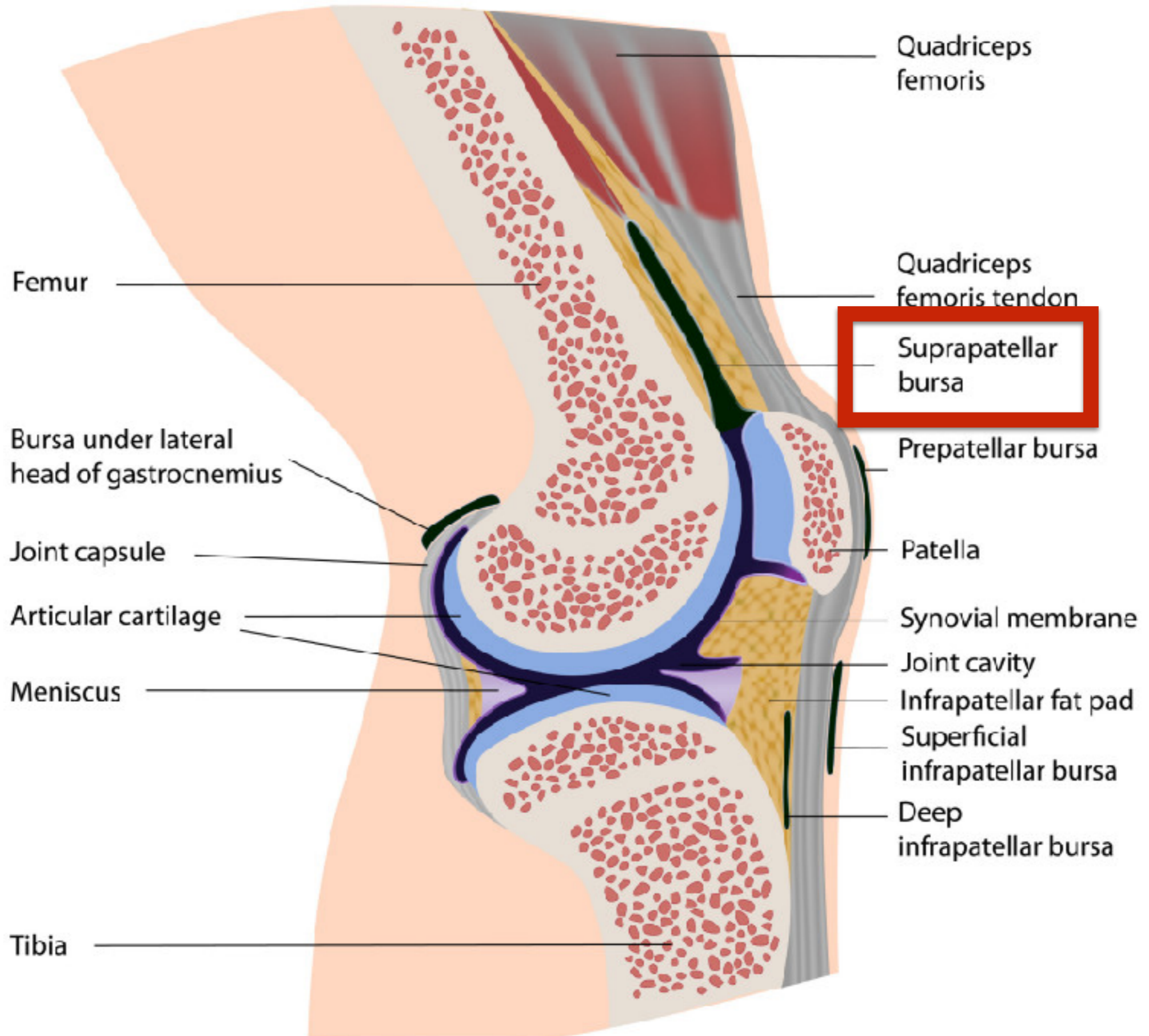
Effusion

Fracture

US guided **joint effusion** diagnosis & arthrocentesis



Anatomy of the Knee Joint



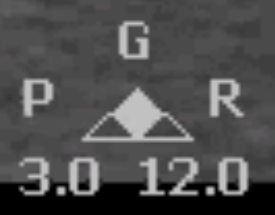
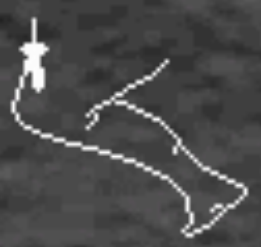P

QT

Patella

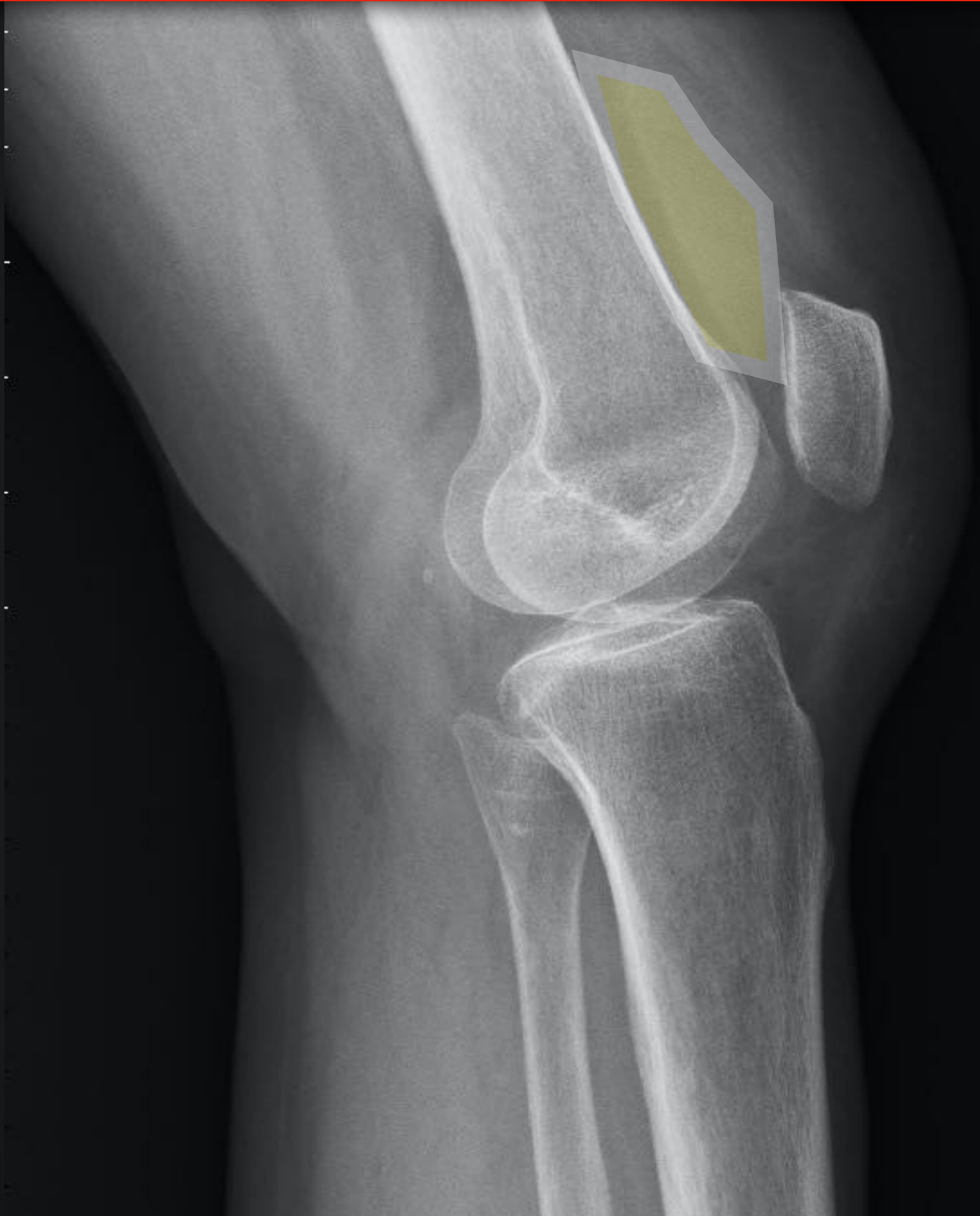Fat

Femur

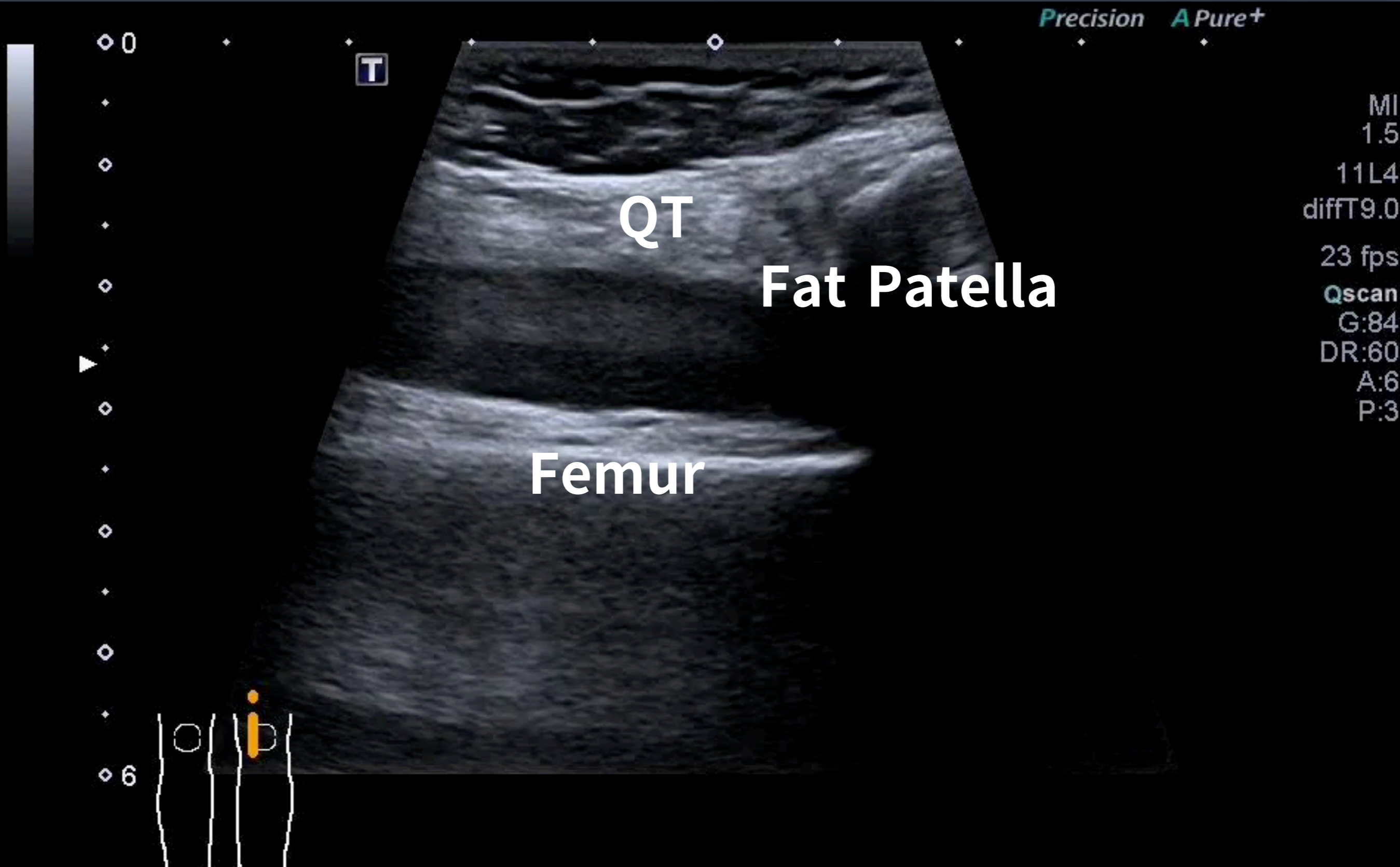


2.5cm

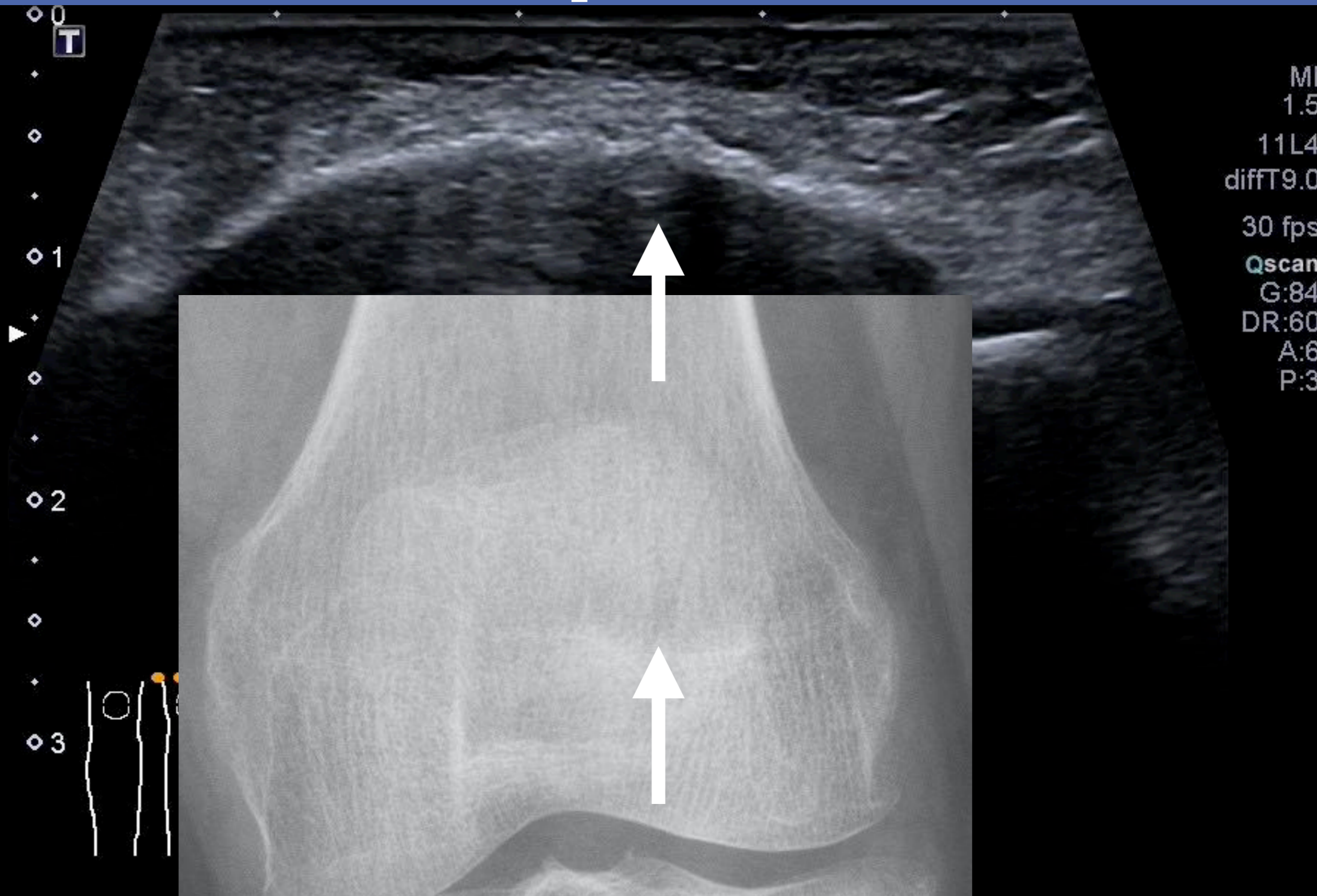
膝蓋很腫，無法彎也無法站



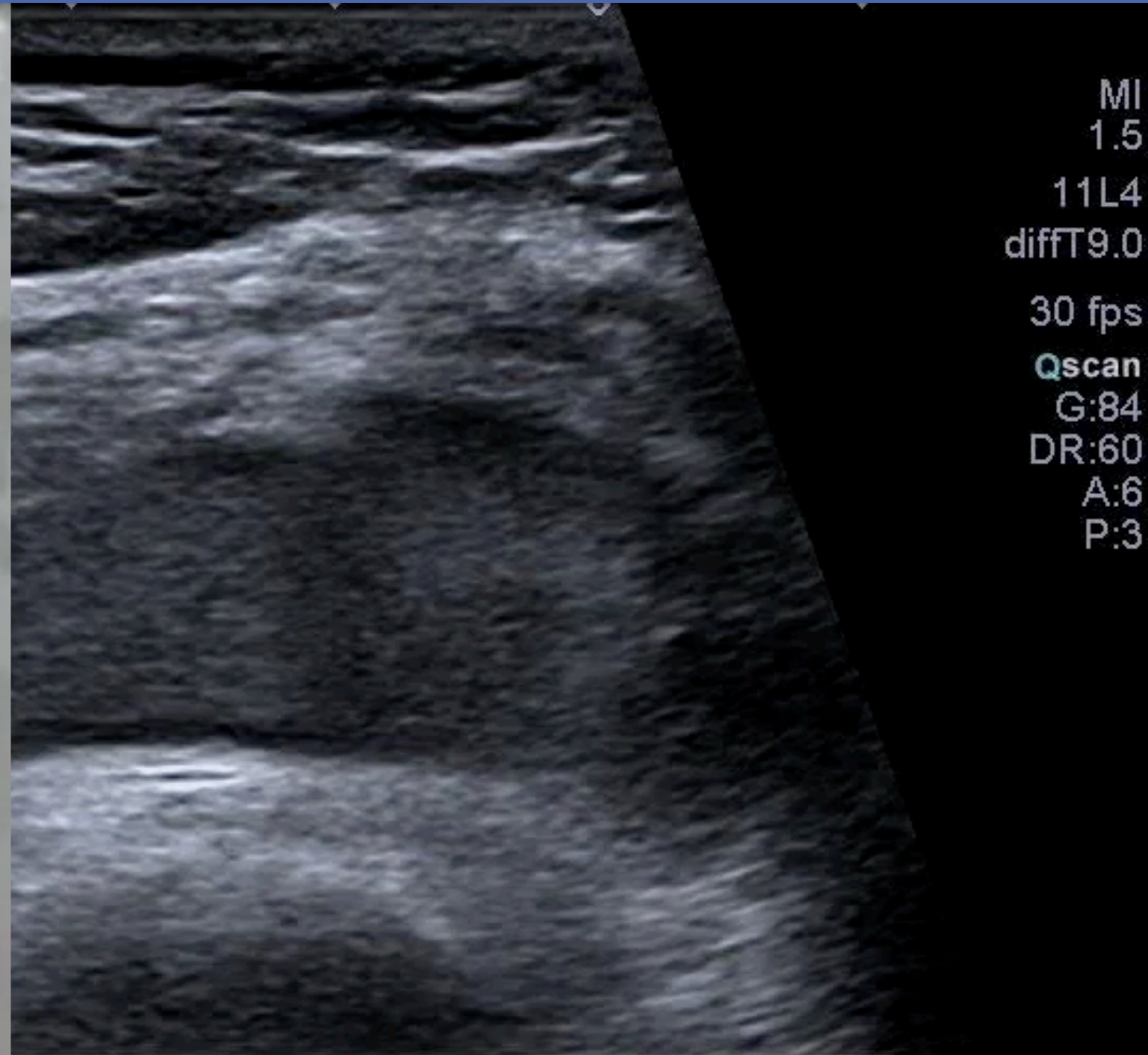
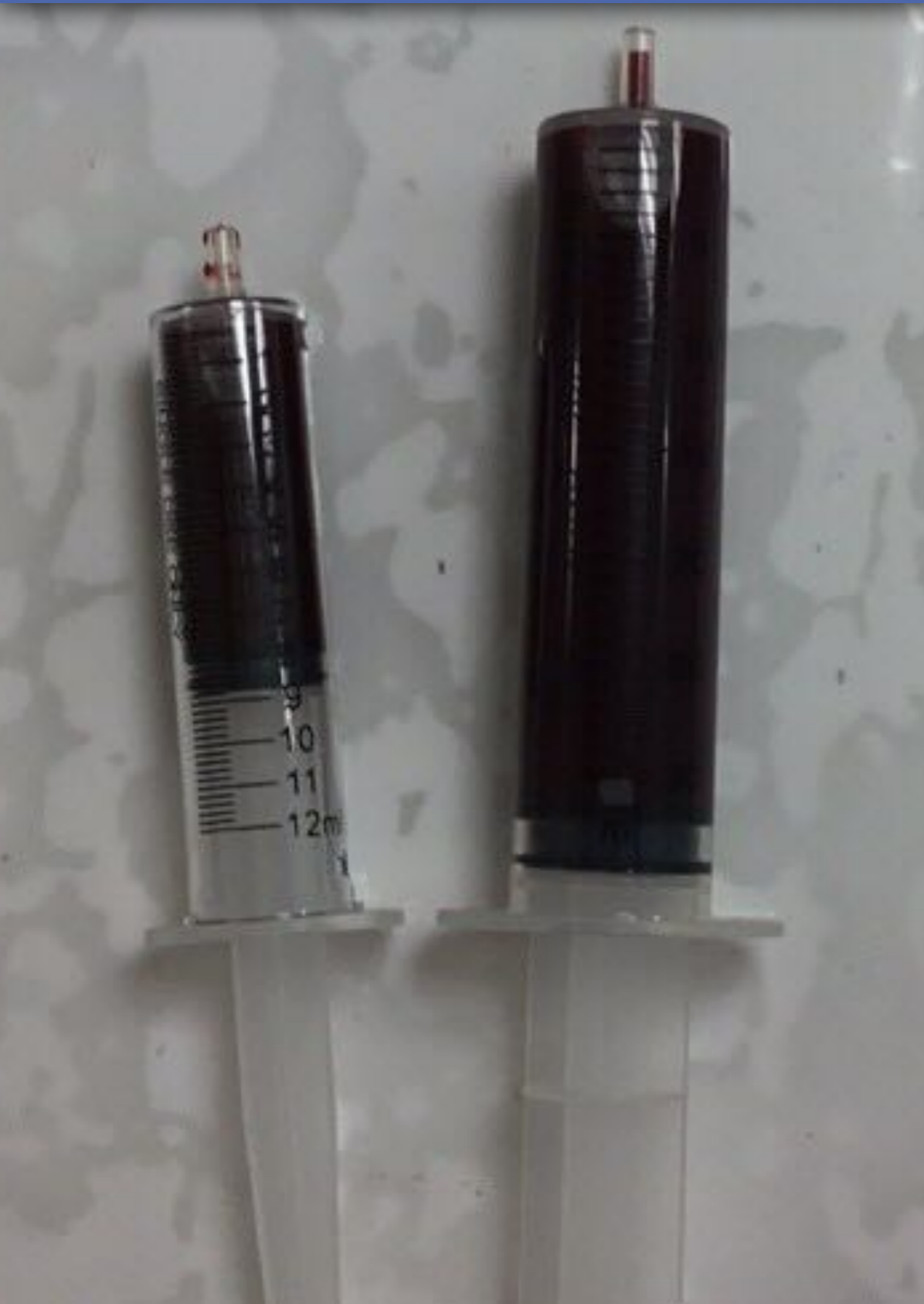Knee hemarthrosis



Knee cap fracture

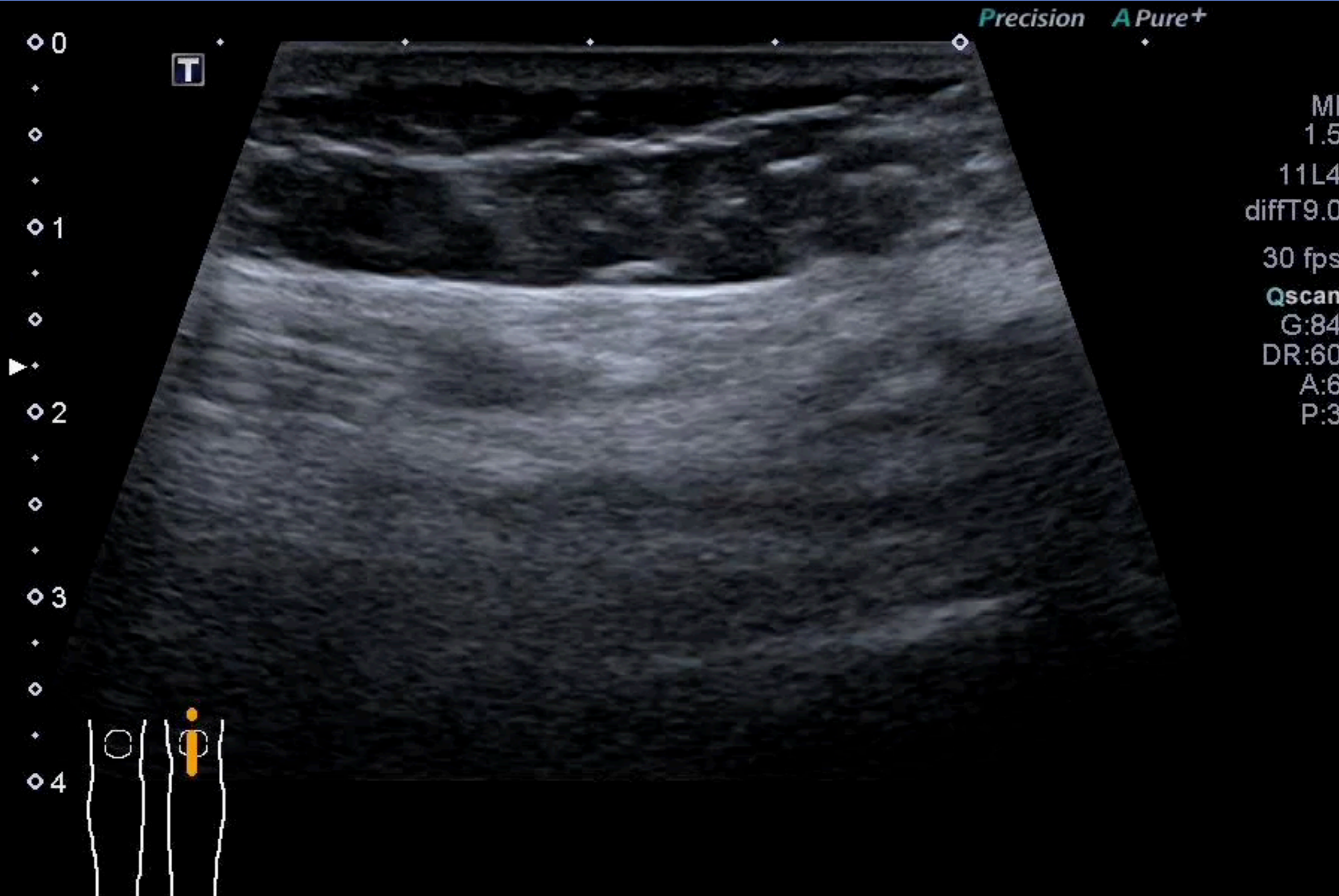


Knee hemarthrosis

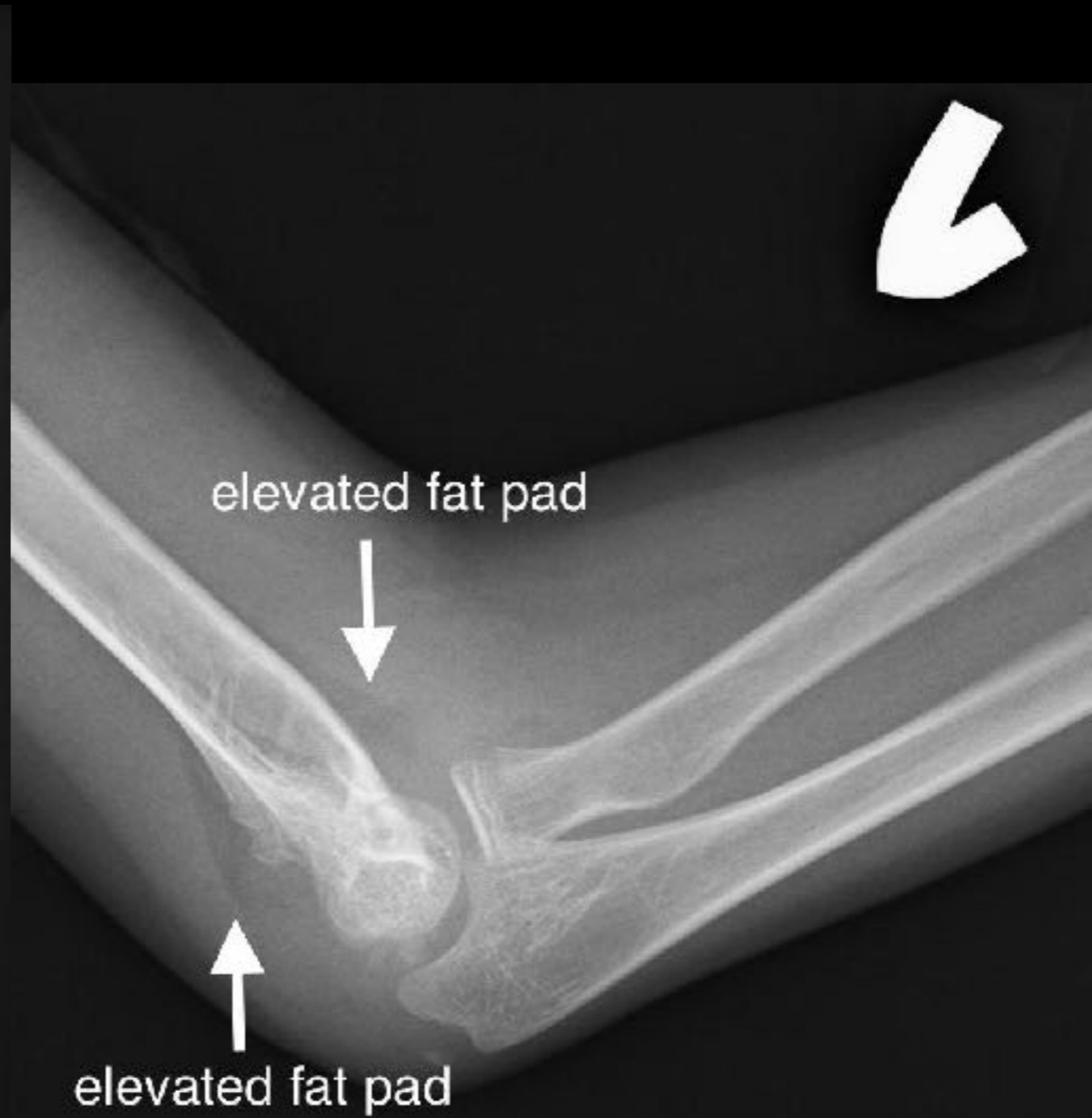
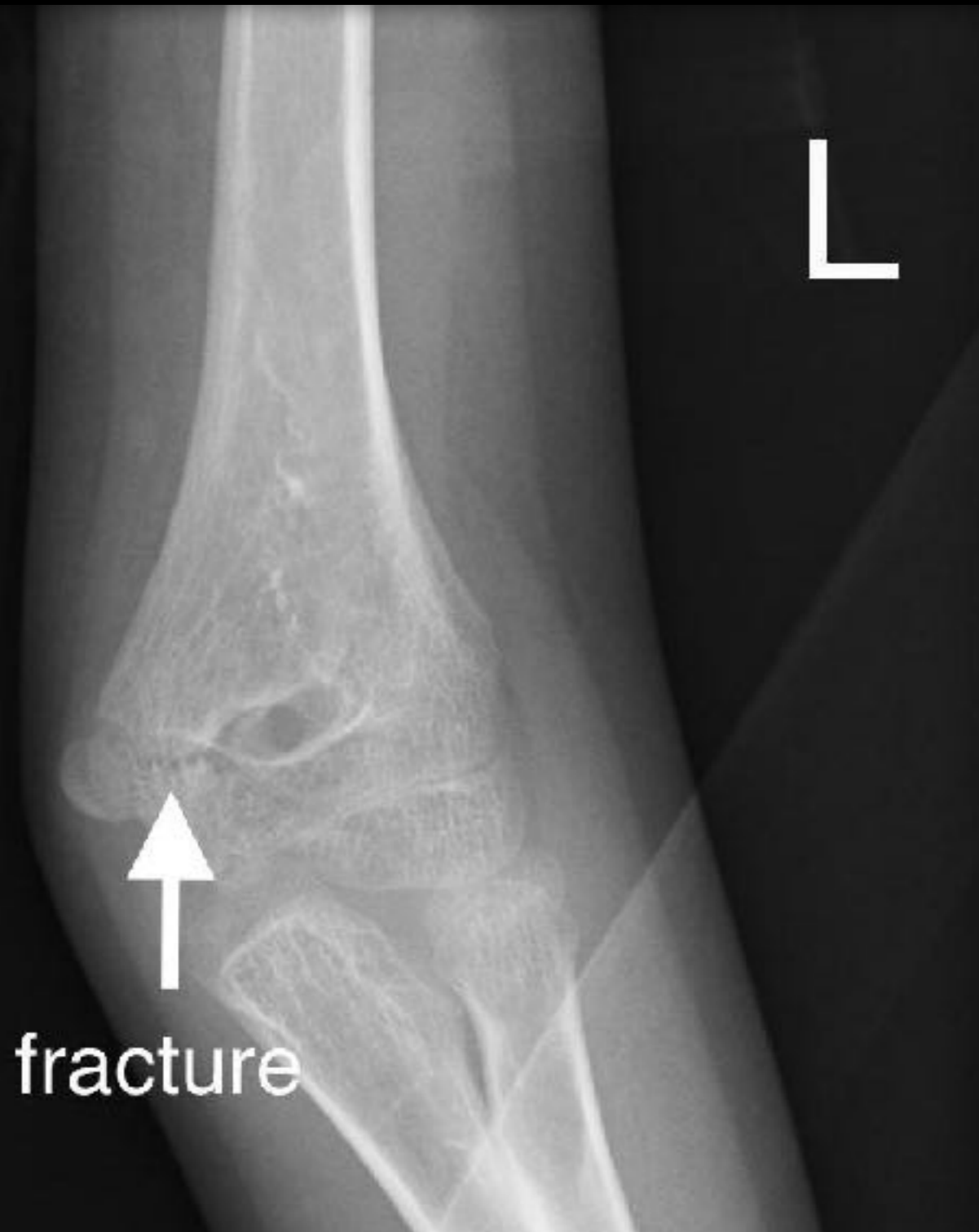

MI
1.5
11L4
diffT9.0
30 fps
Qscan
G:84
DR:60
A:6
P:3

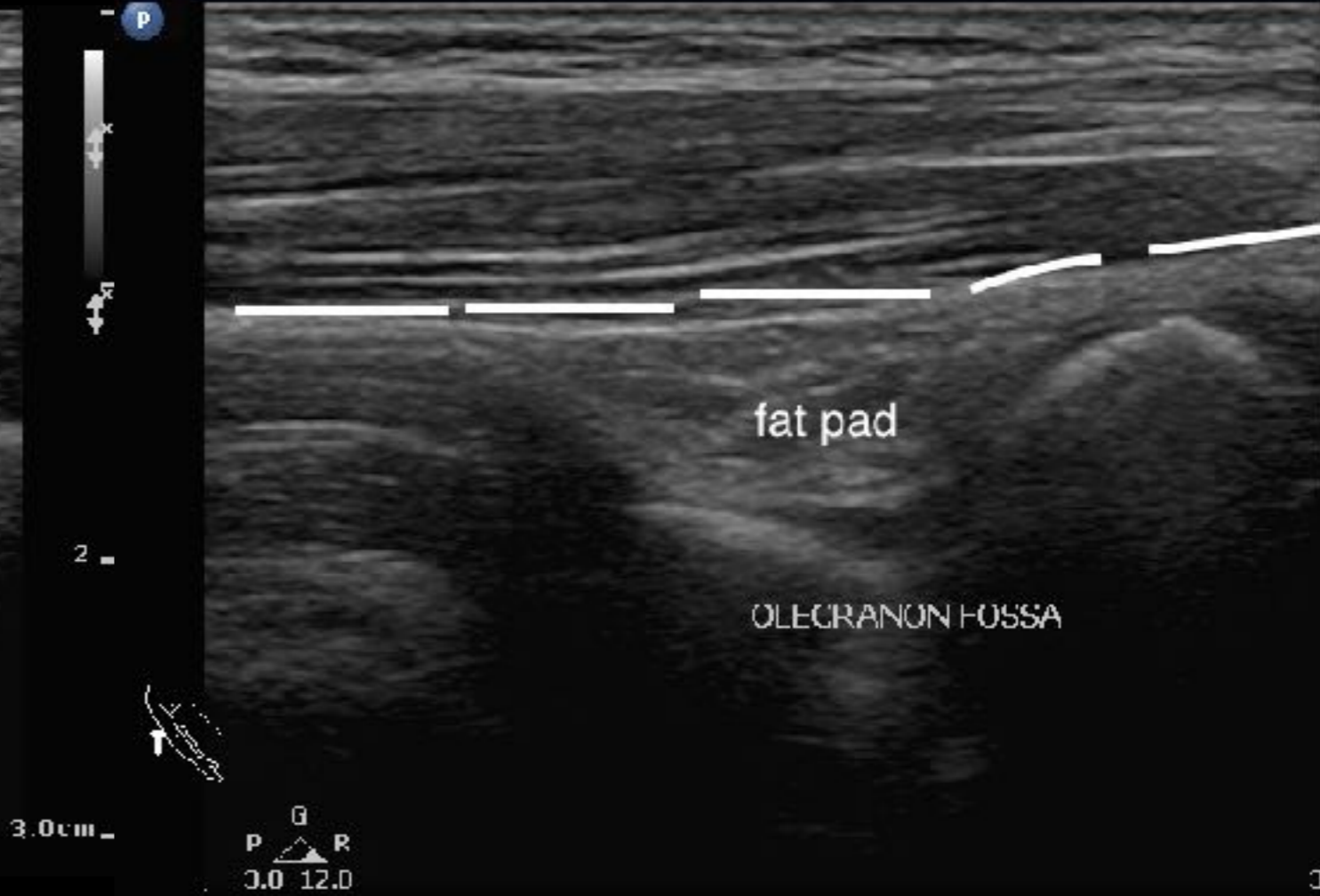
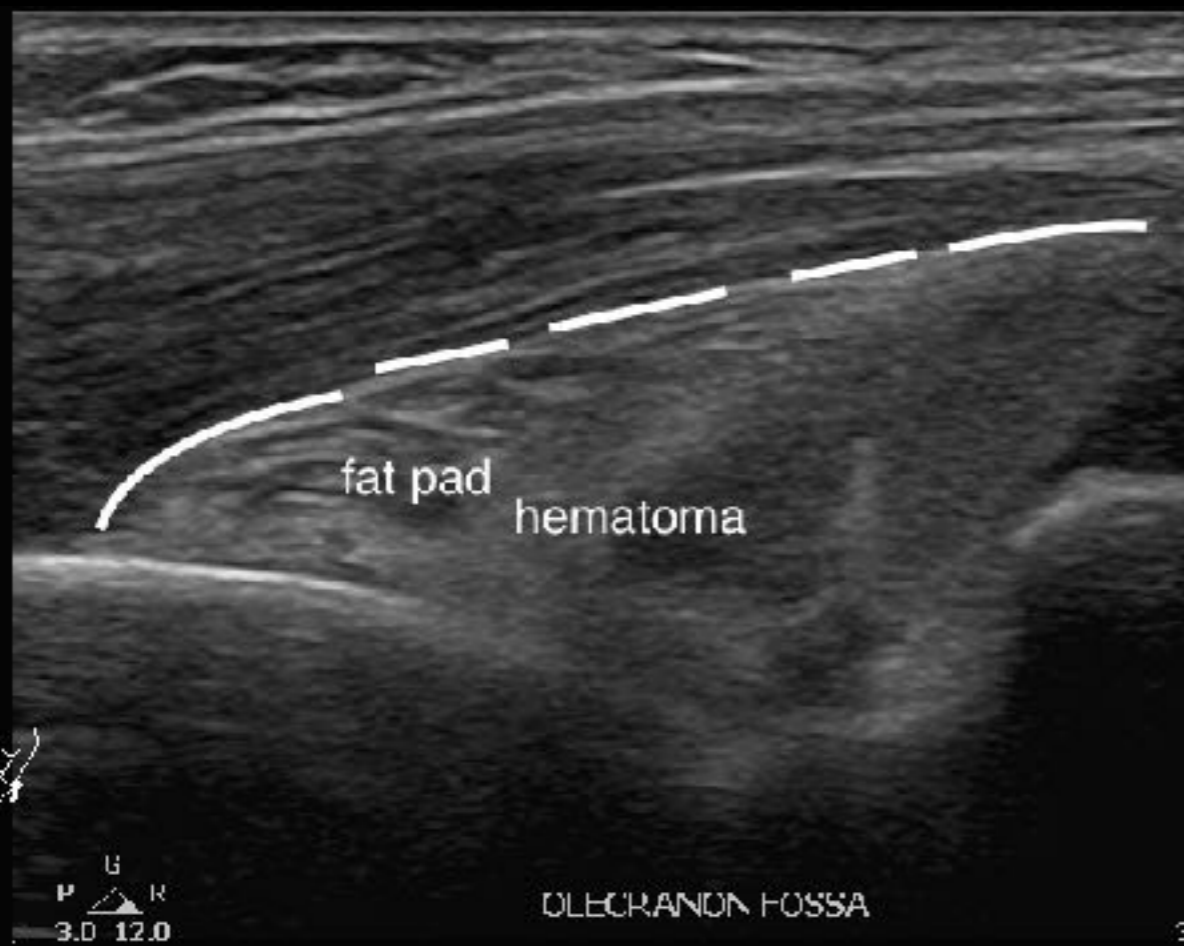
Post aspiration



Fat pad sign



Elevated fat pad sign



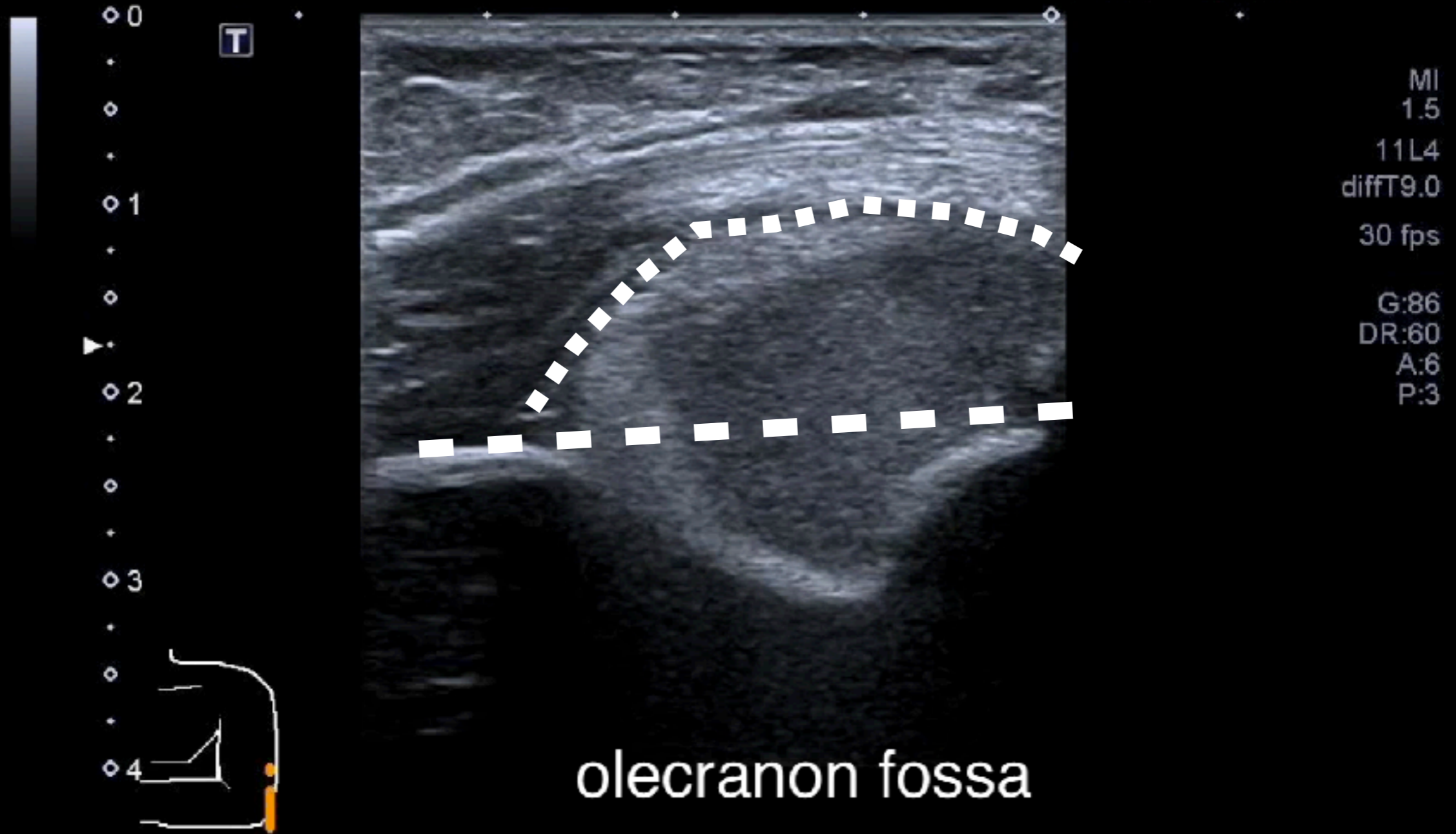
Olecranon

Radial

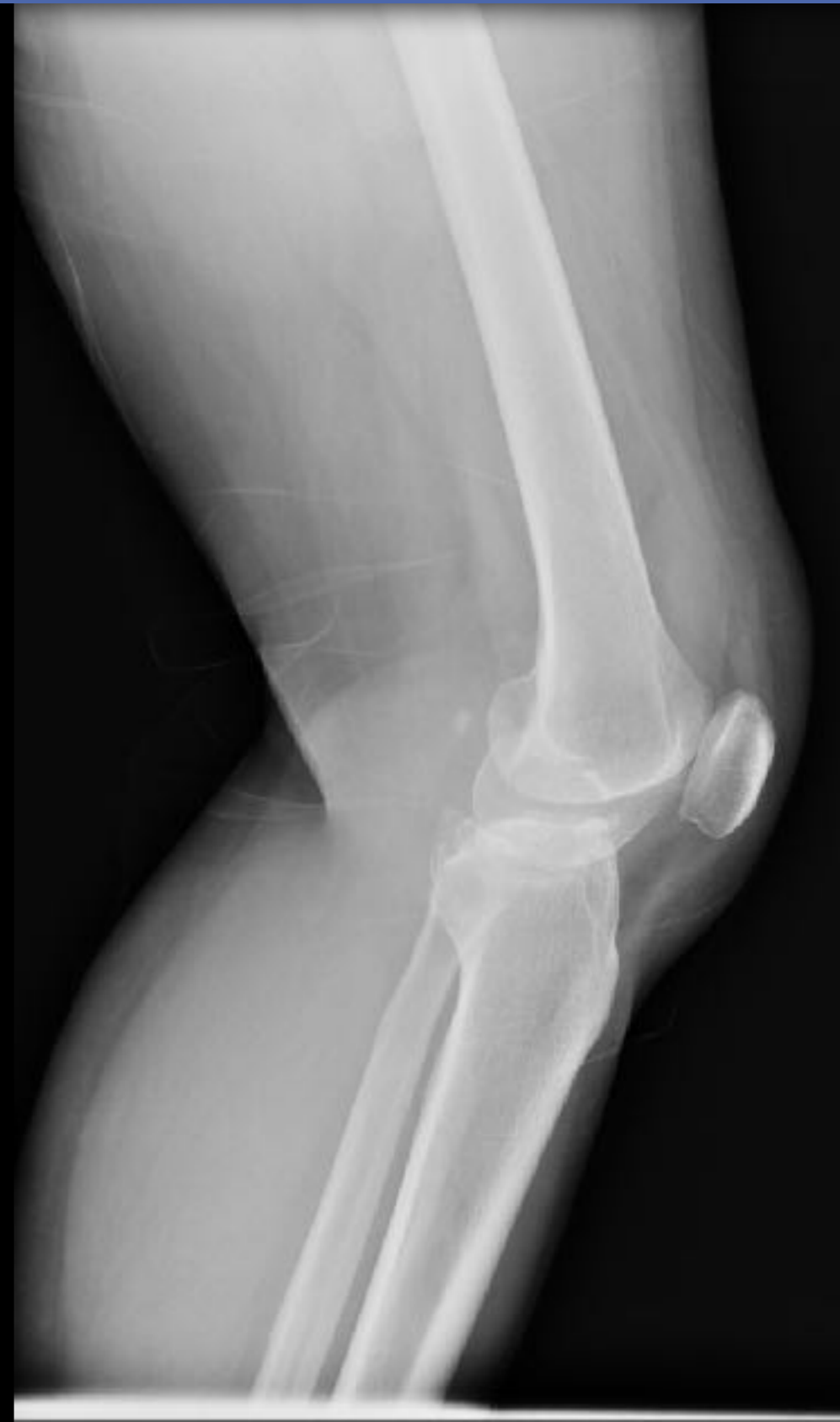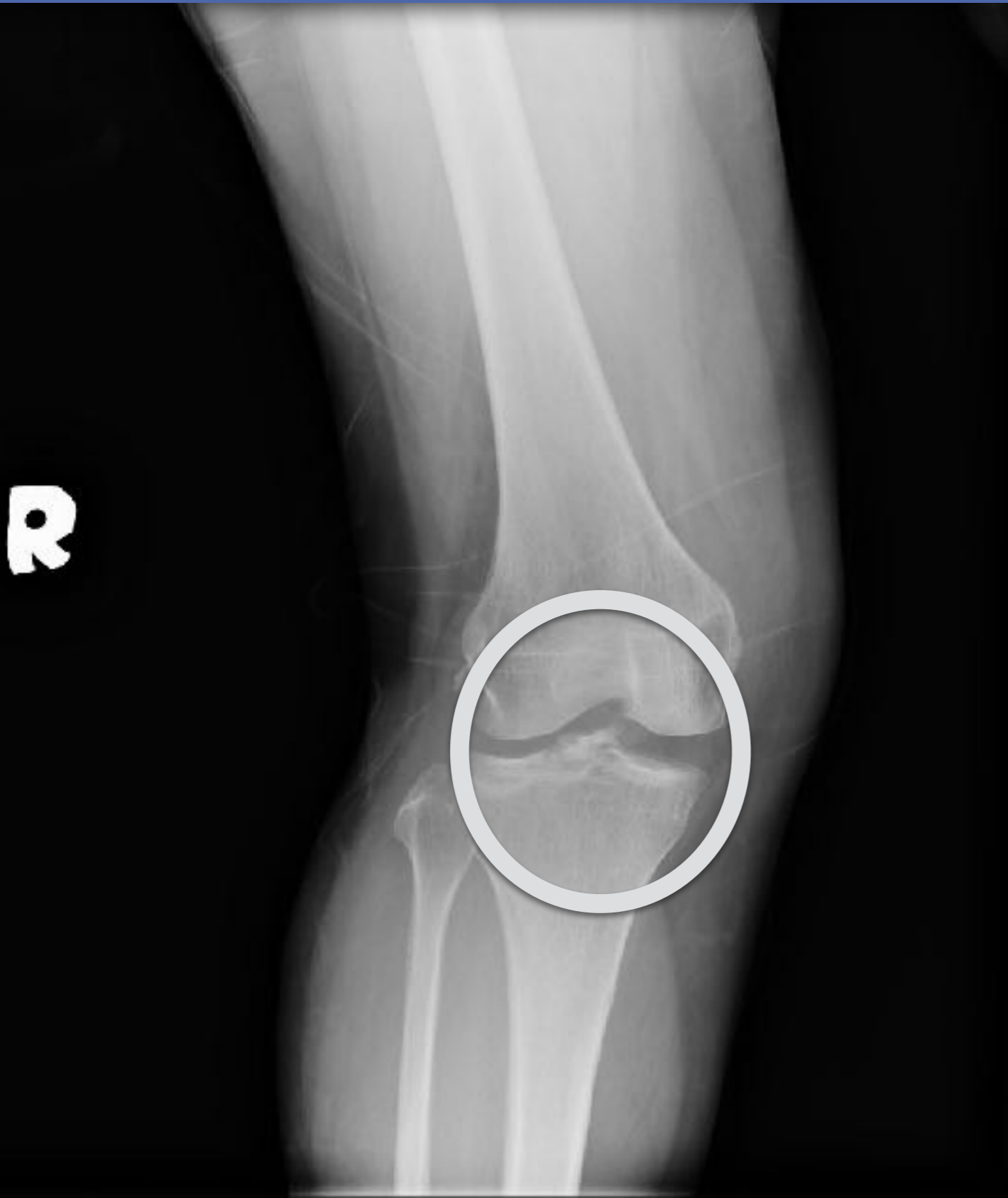
Coronoid

Posterior fat pad sign

POCUSAcademy©ChenKC



Plateau fracture



Lipohemarthrosis

TE7 Ultrasound System

27-02-2018

27-02-2018

20180227-175129-34EA

MSK1

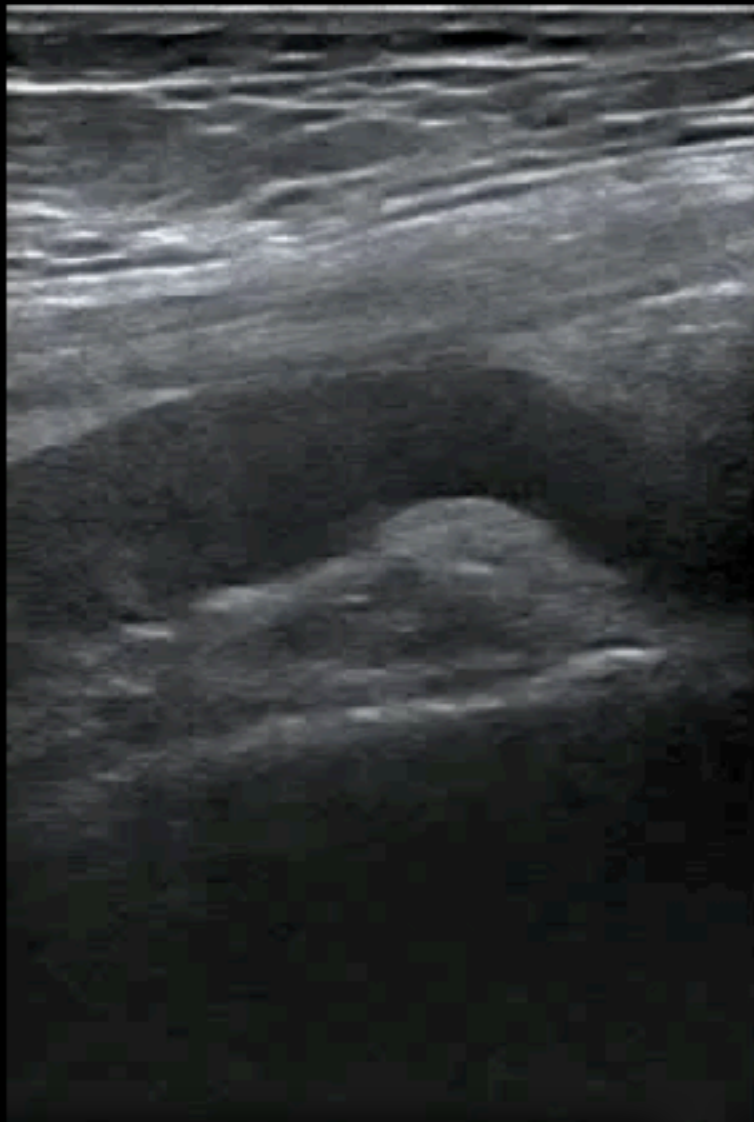17:38:36

17:38:01

20180227-175129-34EA

MSK1

m

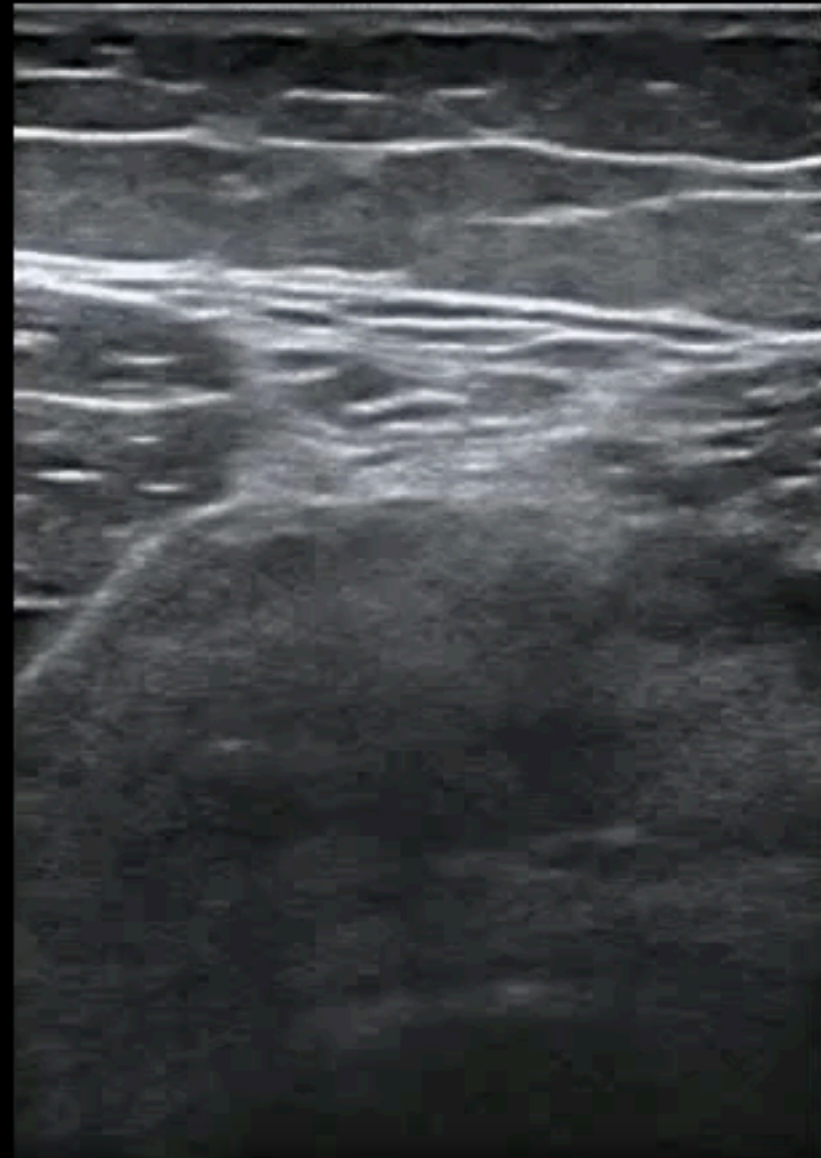


-0

m



-5



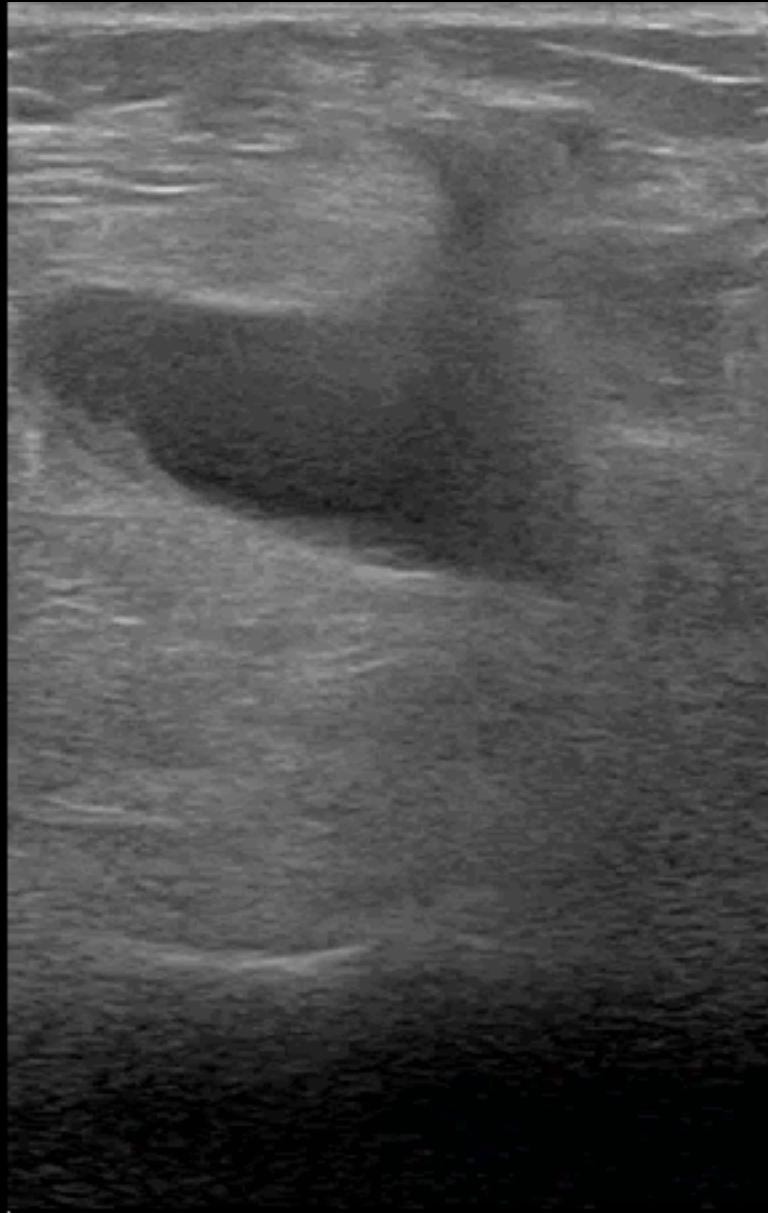
骨頭標記

兩側對比

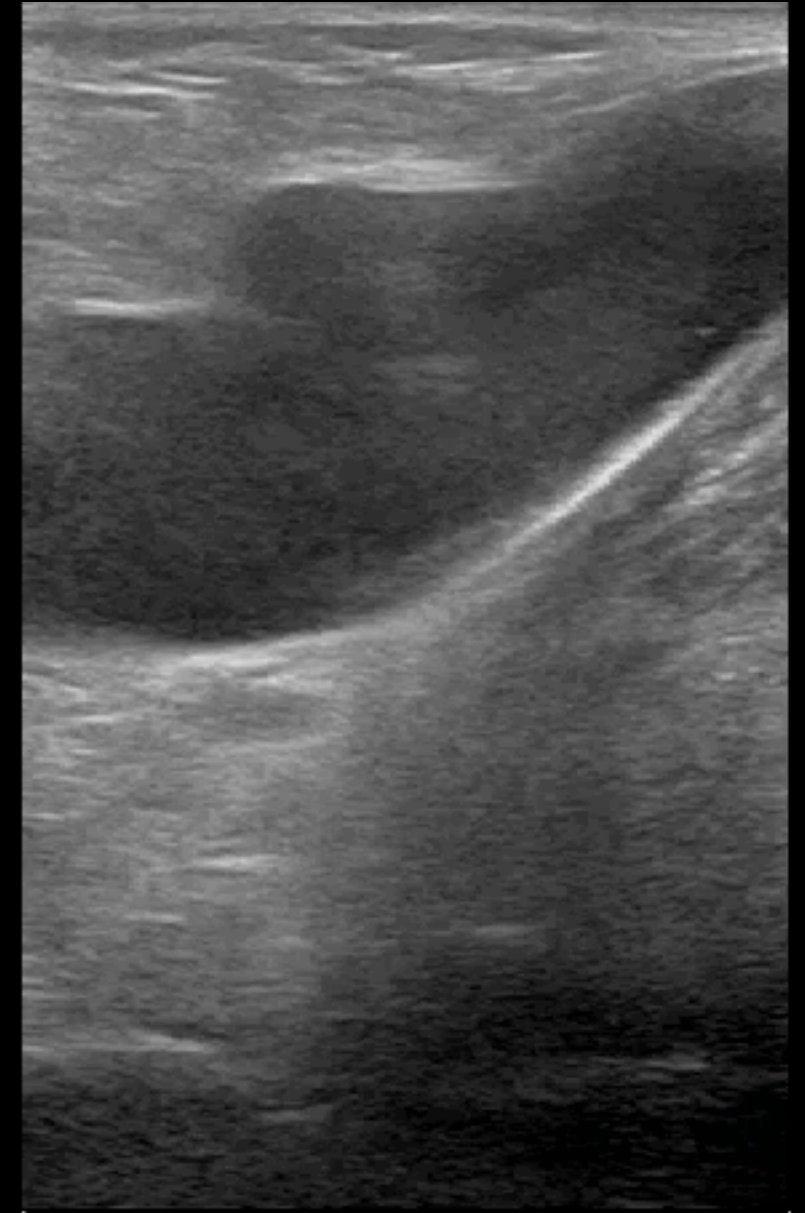流動液體

Baker's cyst

P



P

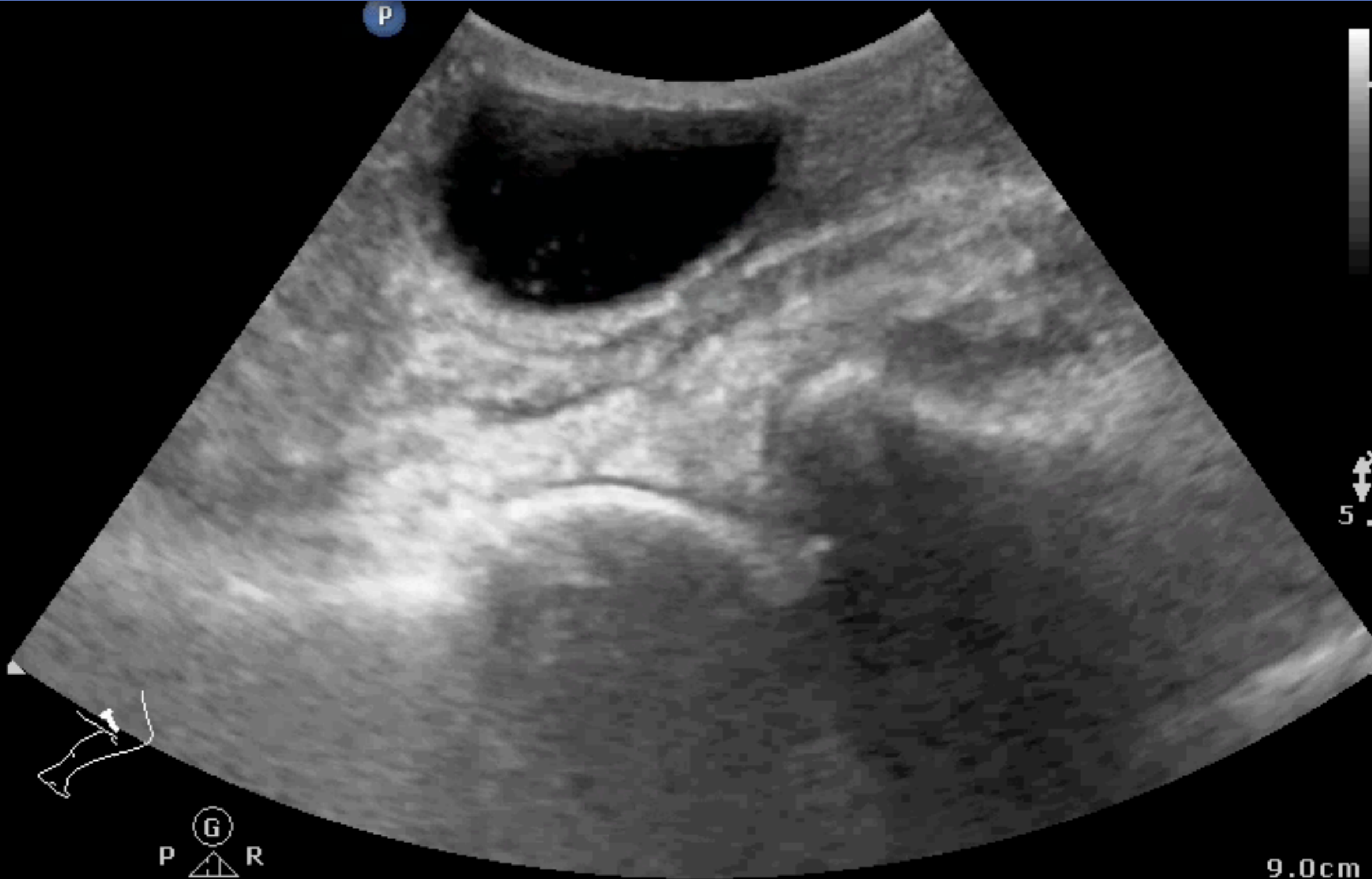


G
P R
3.0 12.0

R
6.0cm 0

Baker's cyst

Abd Genz
C5-1
47 Hz
9.0cm
2D
HGen
Gn 85
C 56
3/3/3



P (G) R
1.8 3.6

9.0cm

3

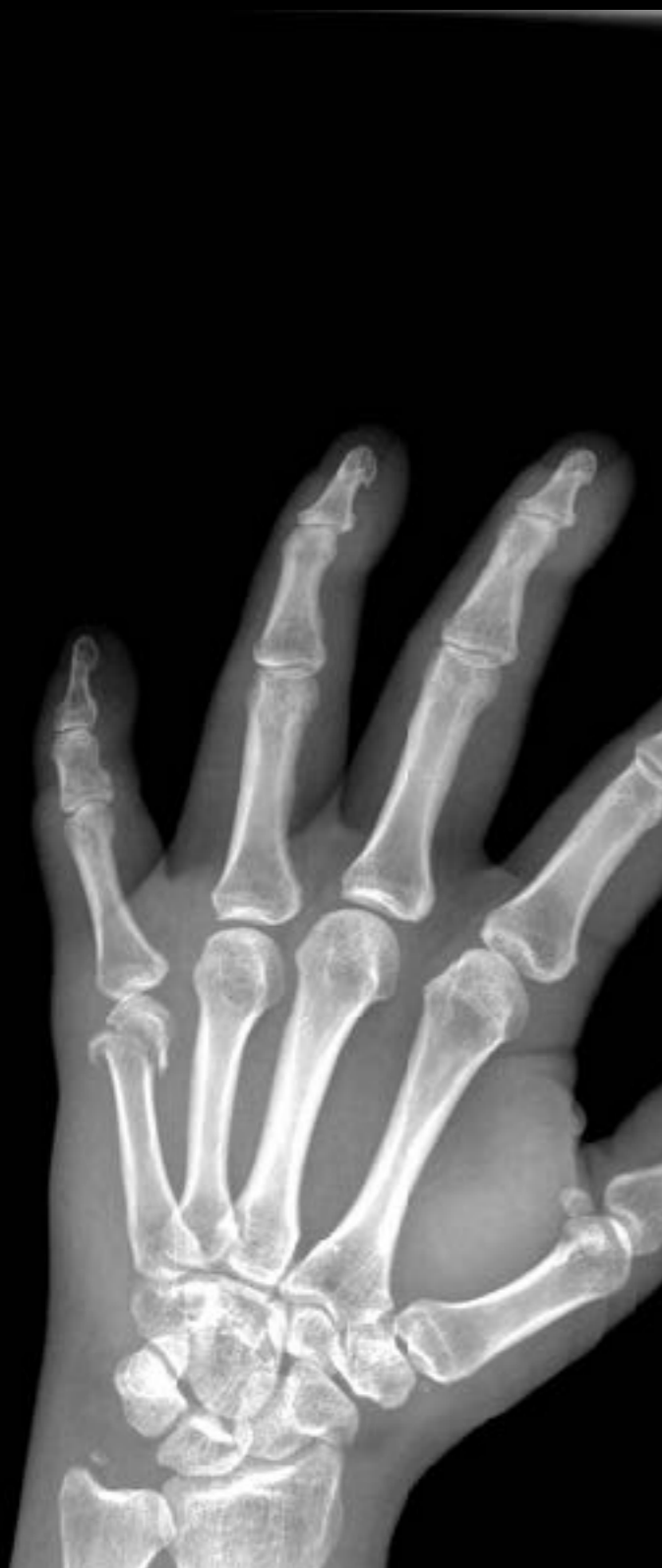ST-MSK US

Infection

Effusion

Fracture

53F, left hand pain after MBA

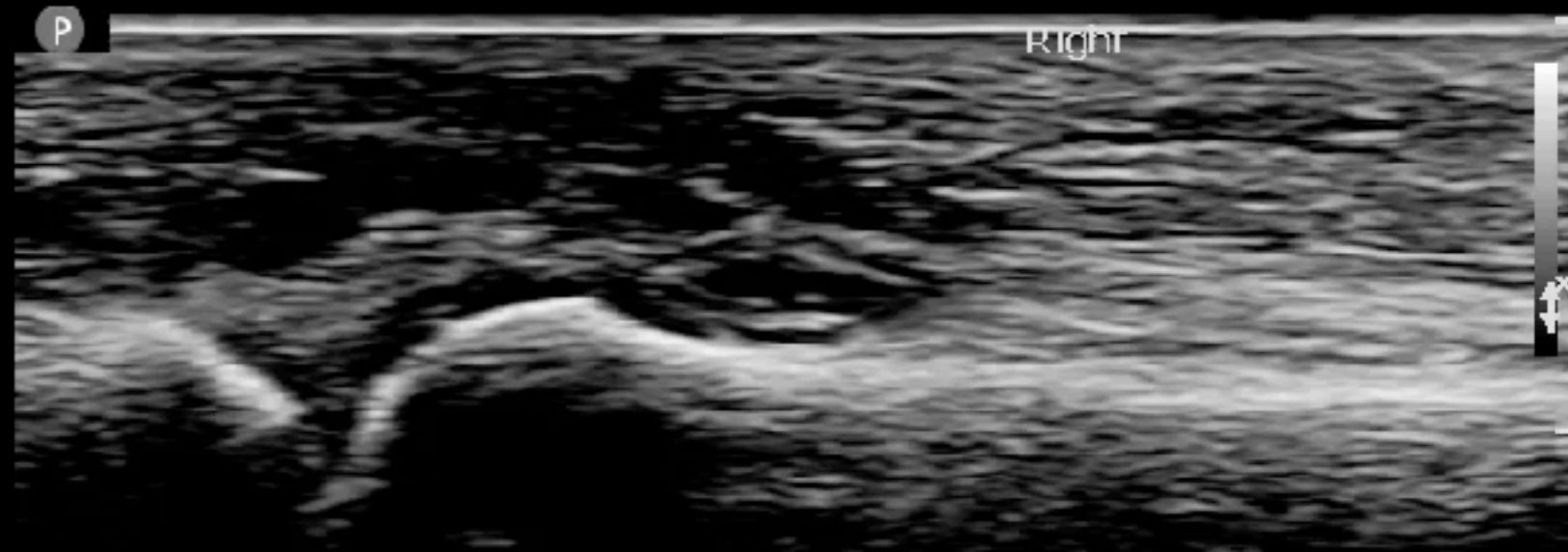

PHILIPS
Venous1
L12-4
41Hz
2.5cm

2D
Gen
Gn 70
50
1/1/2

TemporaryID-20141101125116
14 11 01 125116 Philips Healthcare

MI 0.5 11/1/2014
TIS 0.0 12:51:22 PM

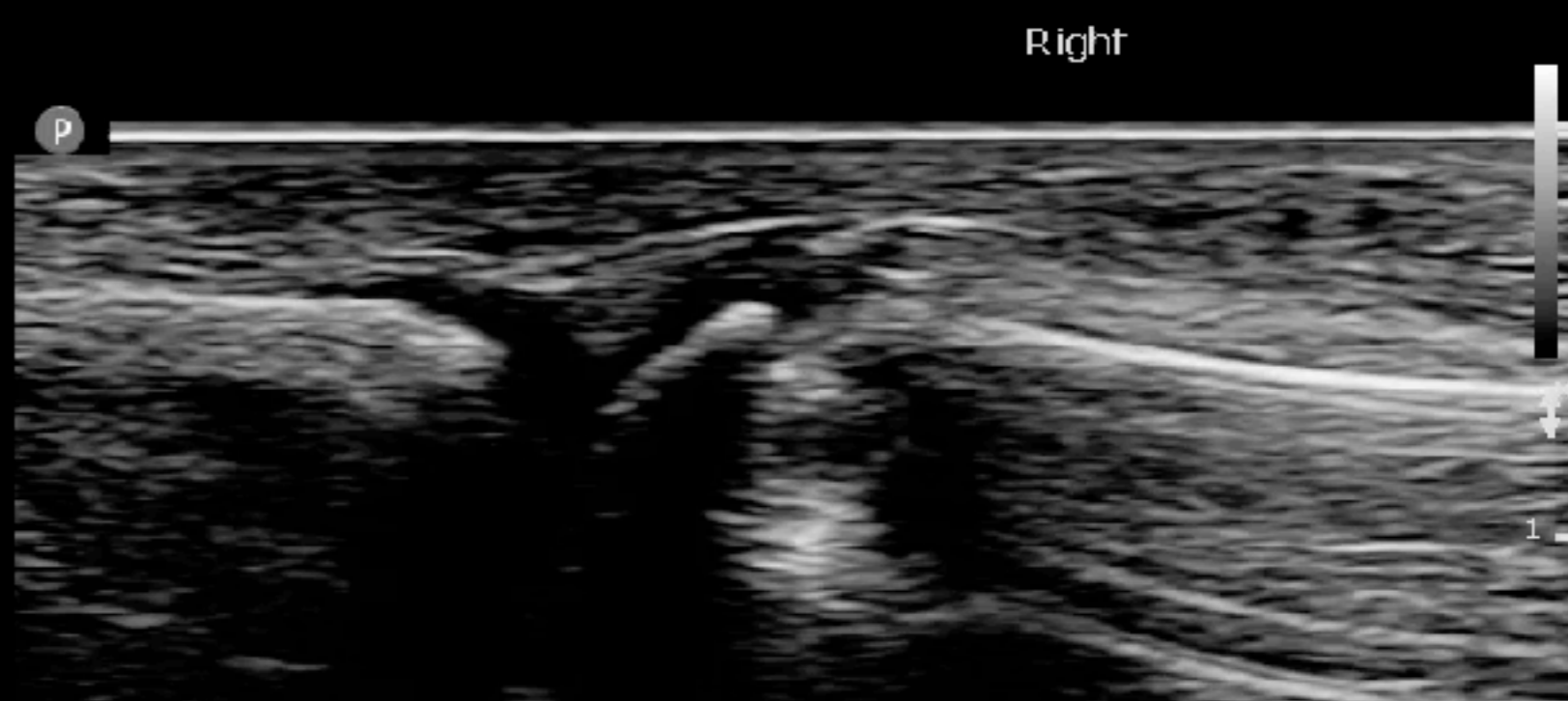


PHILIPS
Venous1
L12-4
41Hz
2.0cm

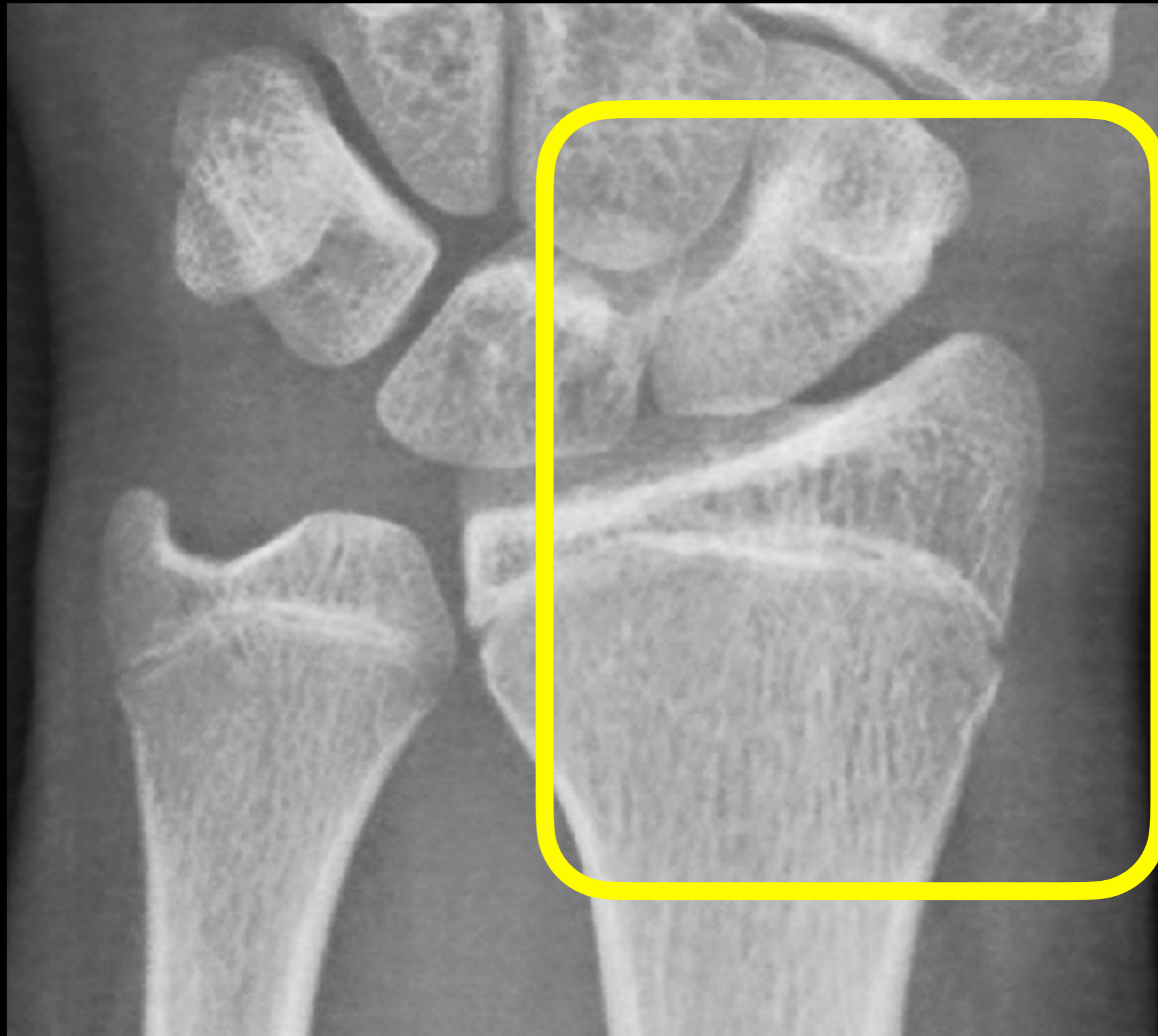
2D
Gen
Gn 72
50
1/2/2

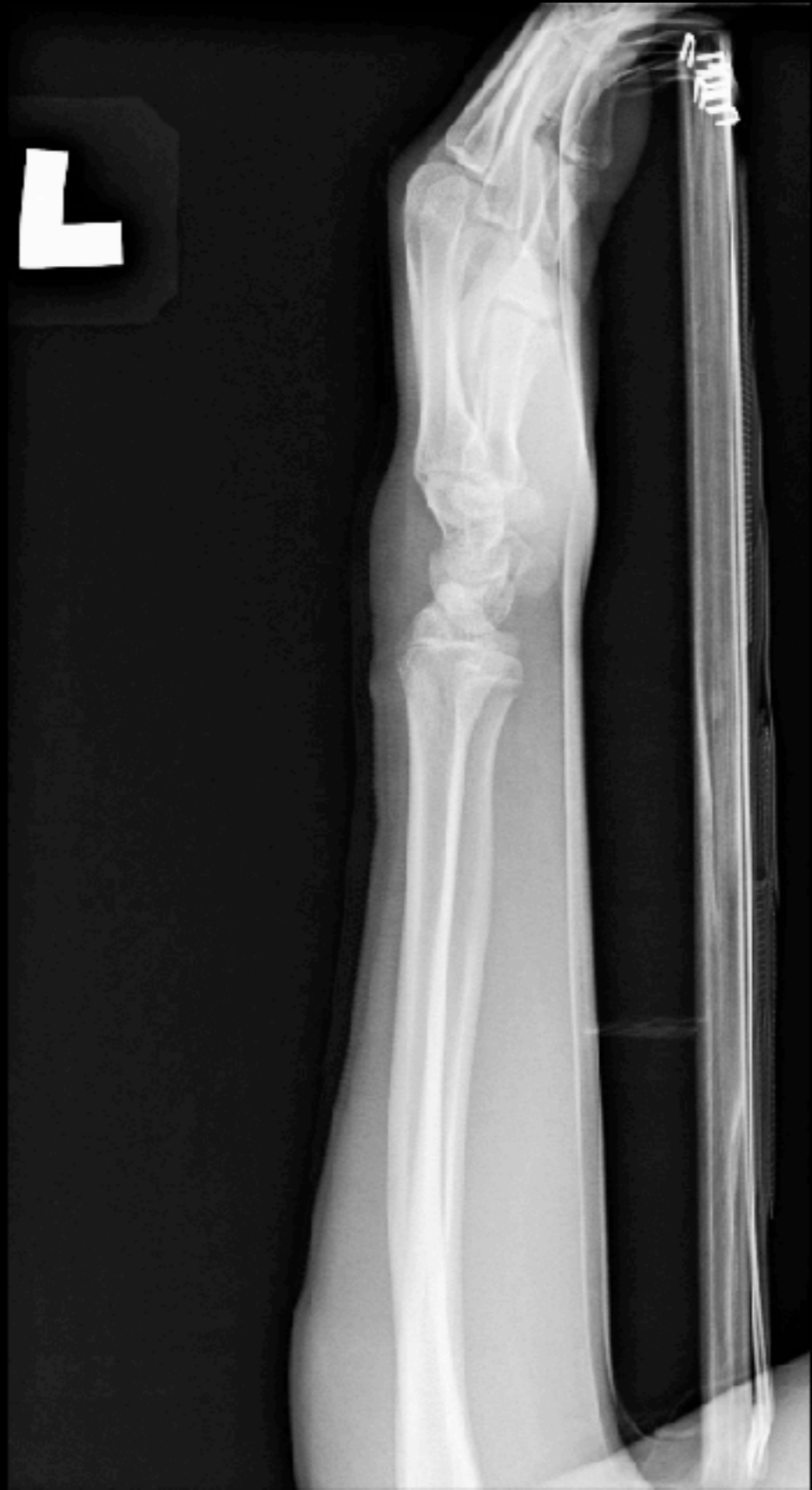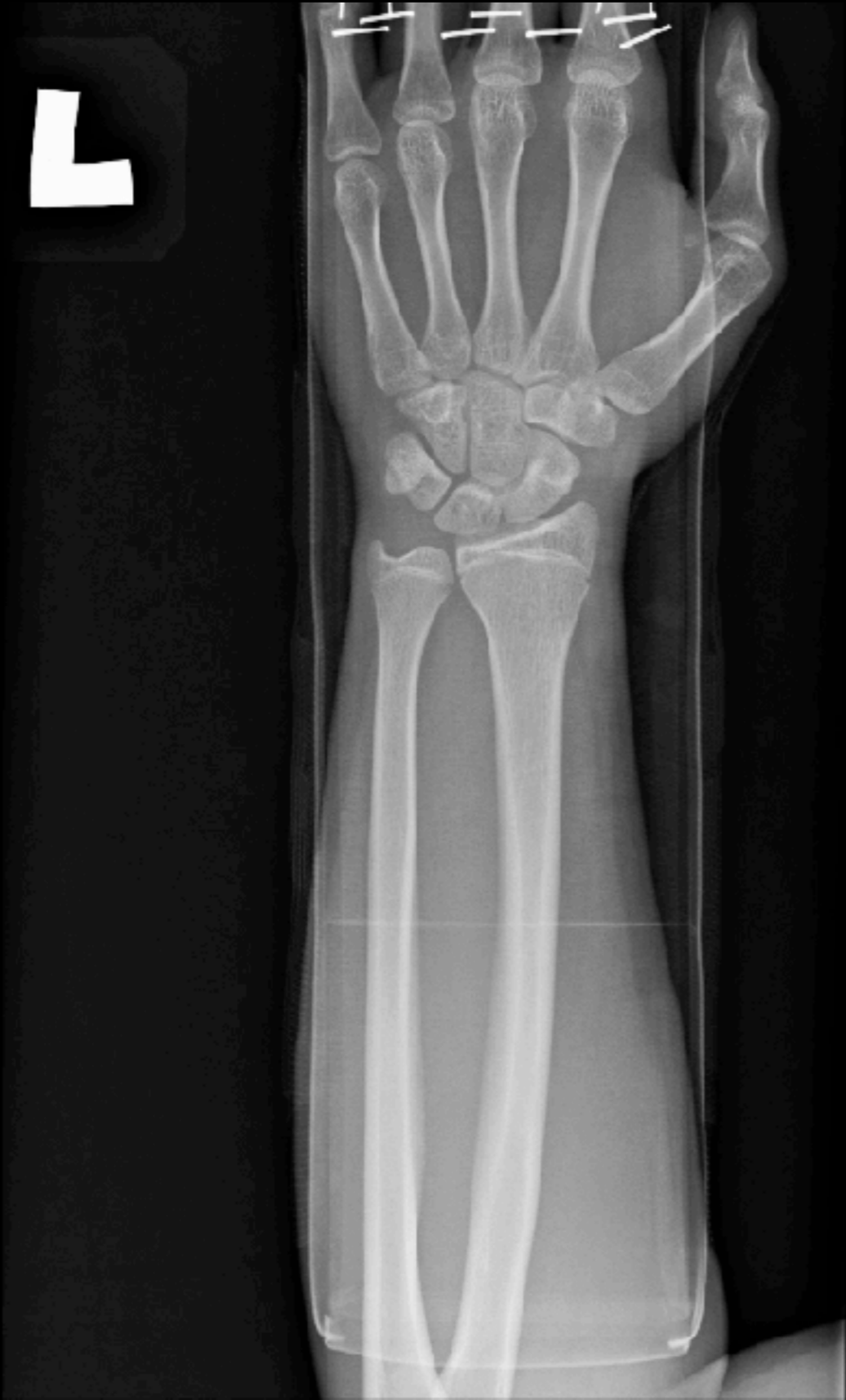TemporaryID-20141101125116
14 11 01 125116 Philips Healthcare

MI 0.5 11/1/2014
TIS 0.0 12:55:40 PM




15M with left wrist pain





POCUS for occult fracture



POCUS for occult fracture



POCUS for occult fracture



Sweep/掃

POCUS for occult fracture



Sweep/掃

Rotate/轉

POCUS for occult fracture



Sweep/掃

Rotate/轉

POCUS for occult fracture



Sweep/掃

Rotate/轉

POCUS for occult fracture

Flat

Long

Sweep/掃

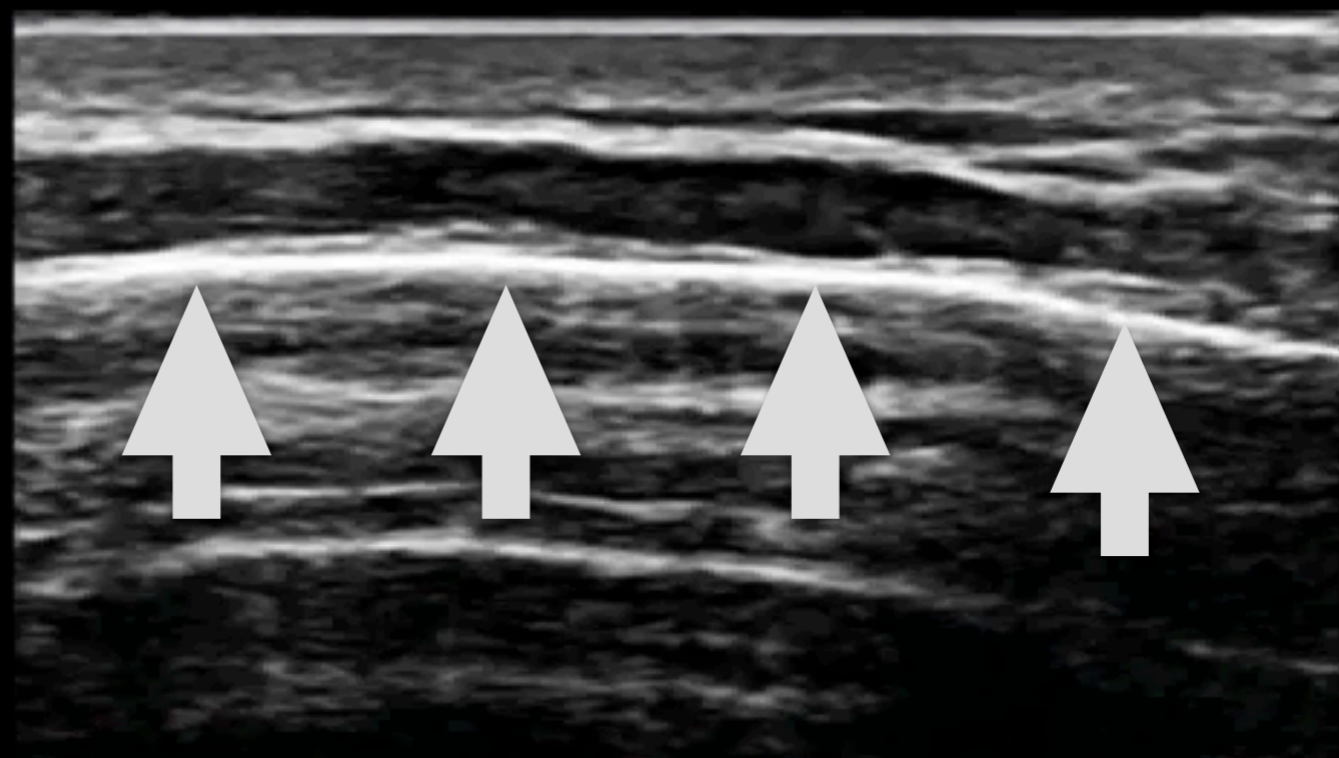
Rotate/轉

Slide/滑



SHIH-Linear
L12-4
27 Hz
3.5cm

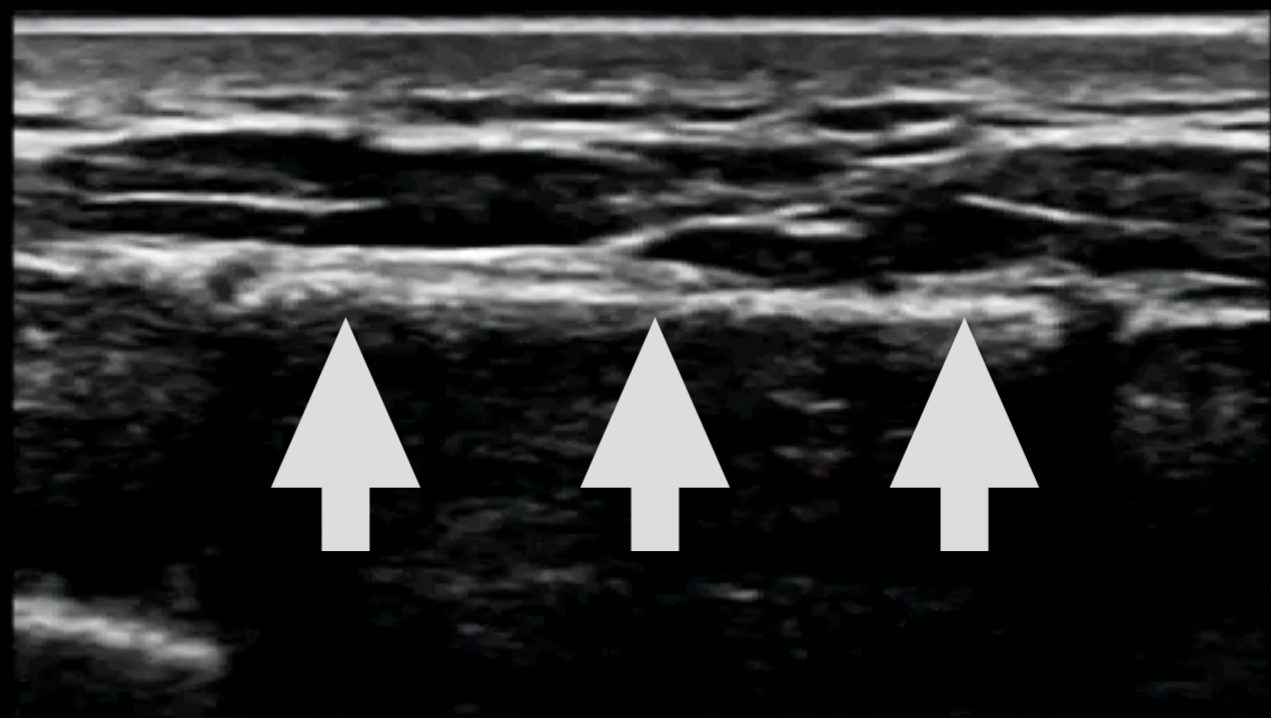
P





Smooth & Hyperechoic Cortical Surface

SHIH-Linear
L12-4
27 Hz
3.5cm

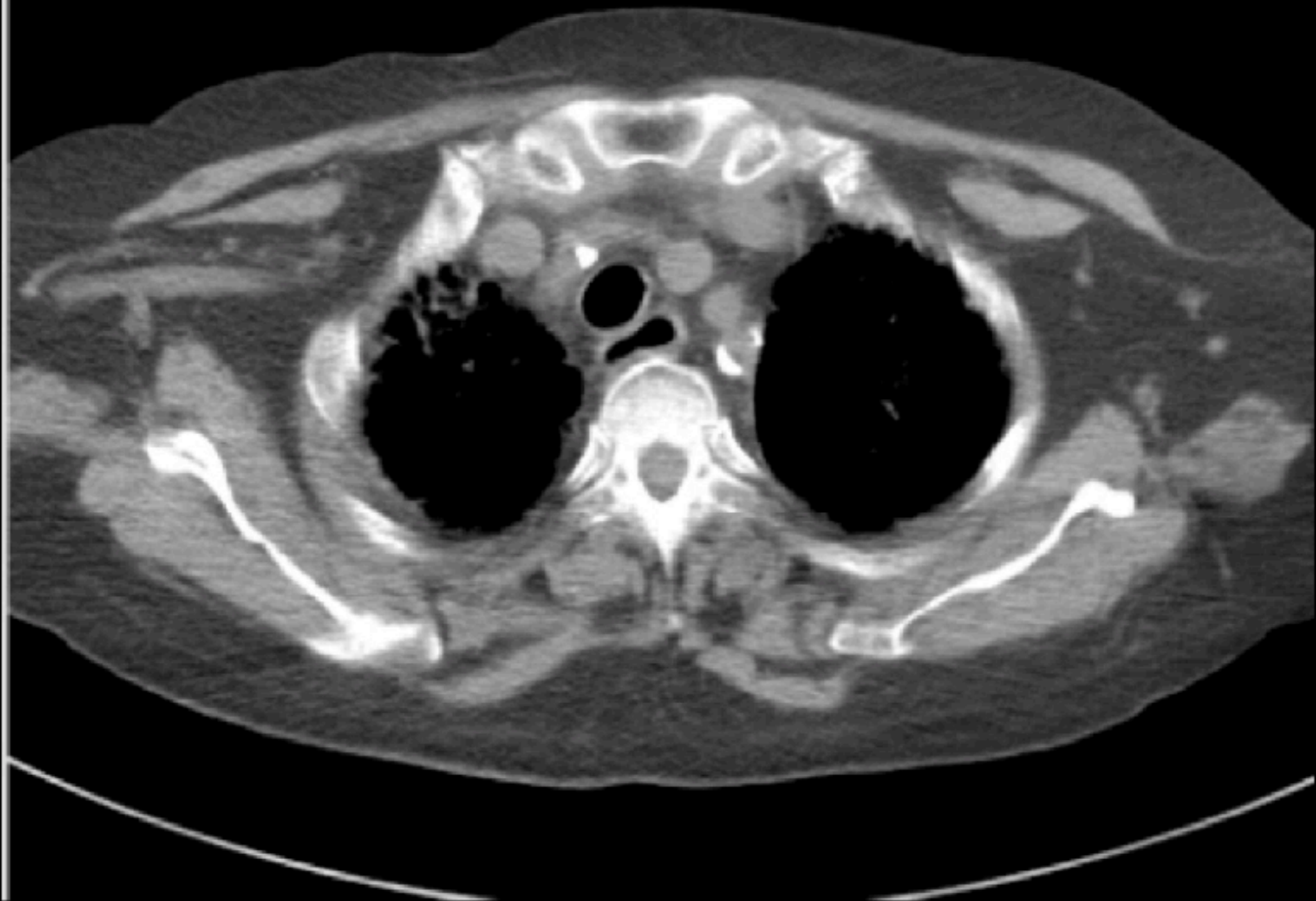P

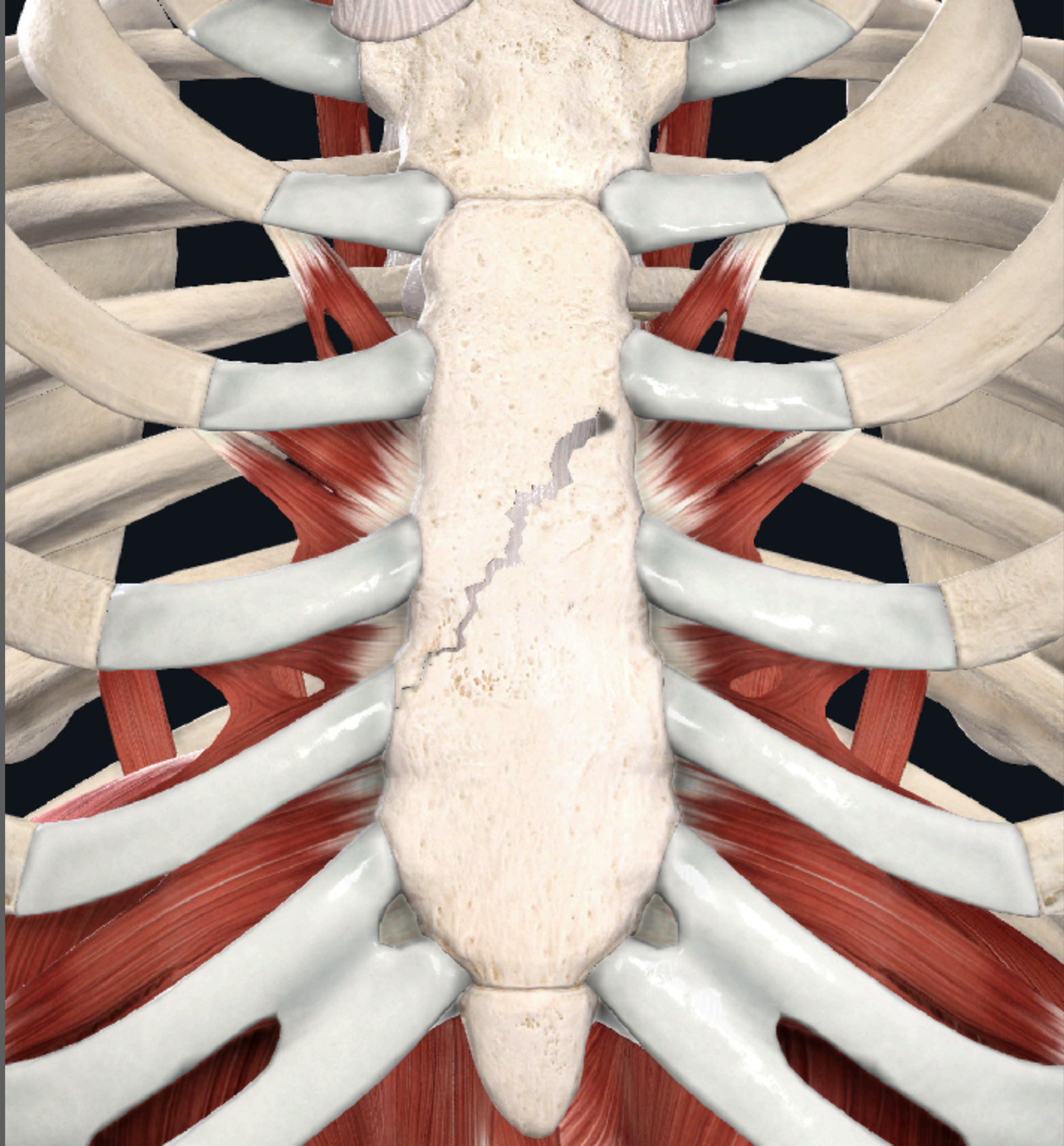

2D
Gen
Gn 55
C 53
6 / 3 / 3

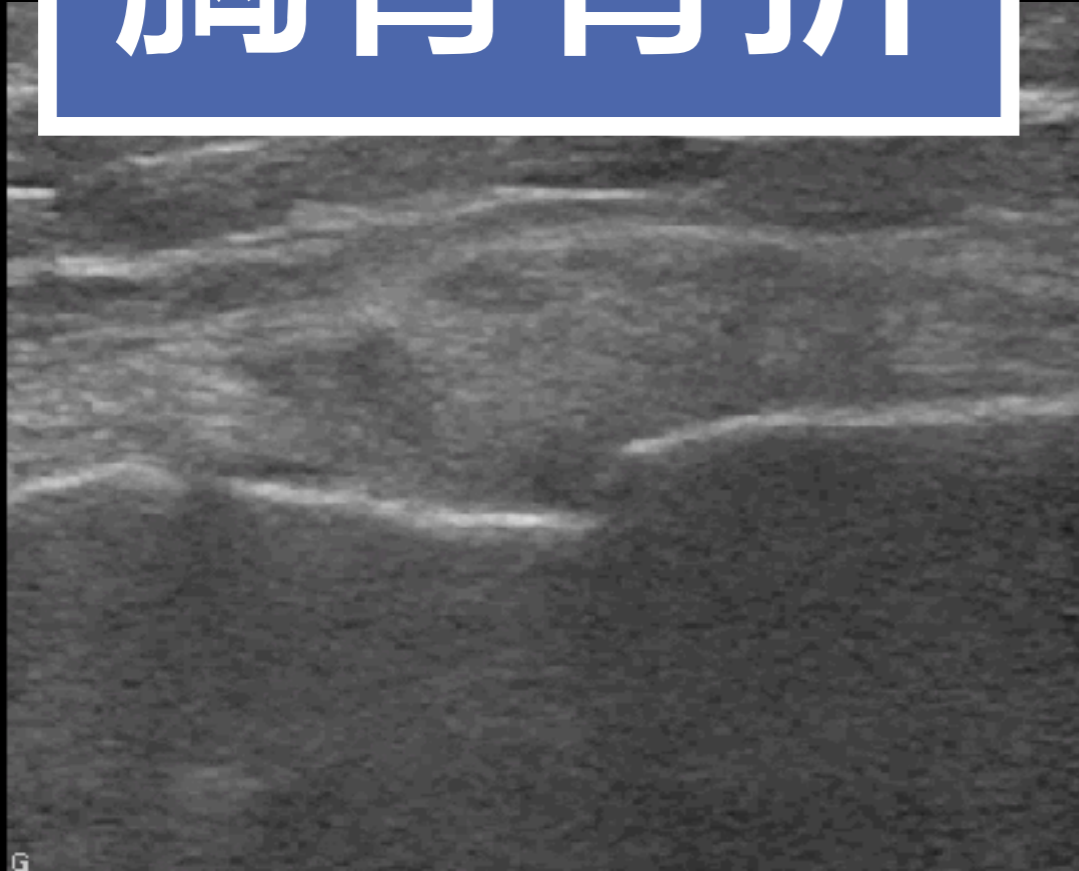
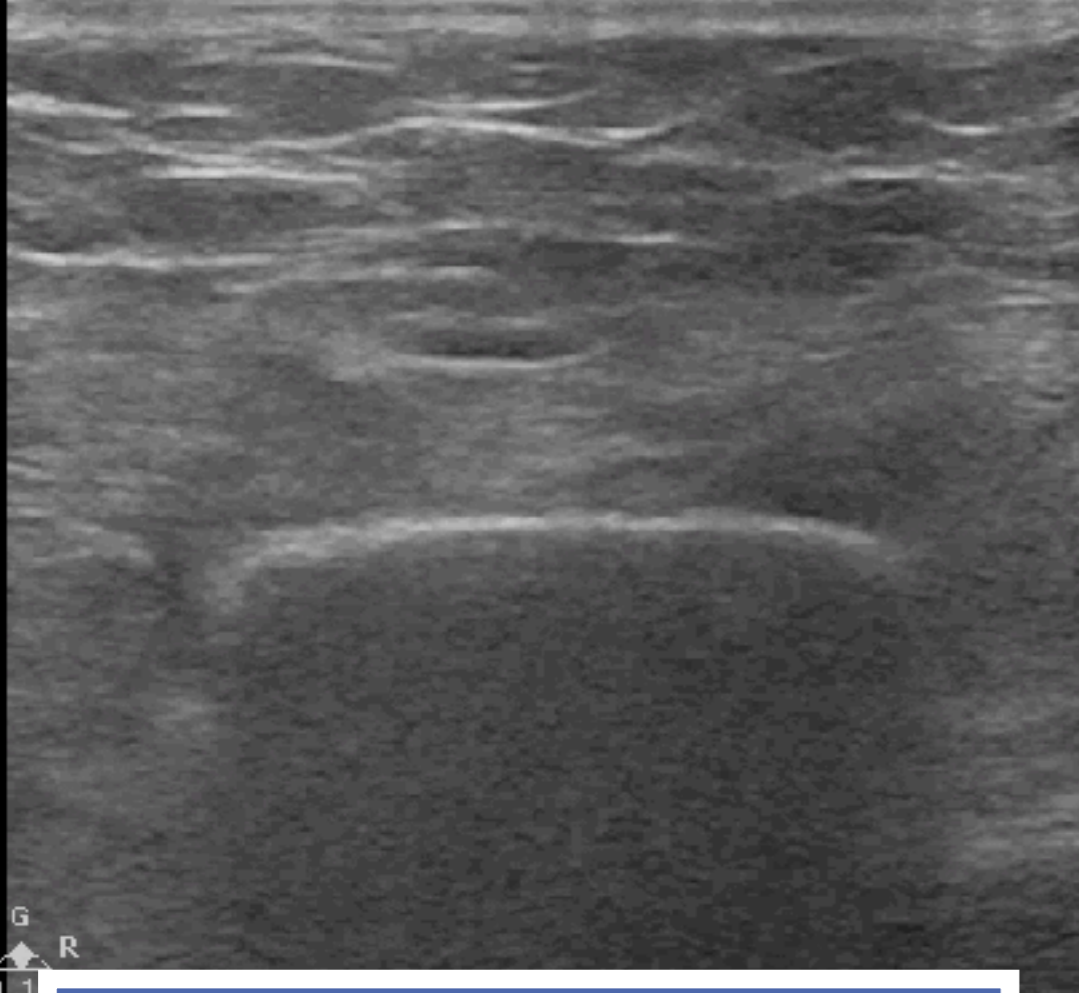
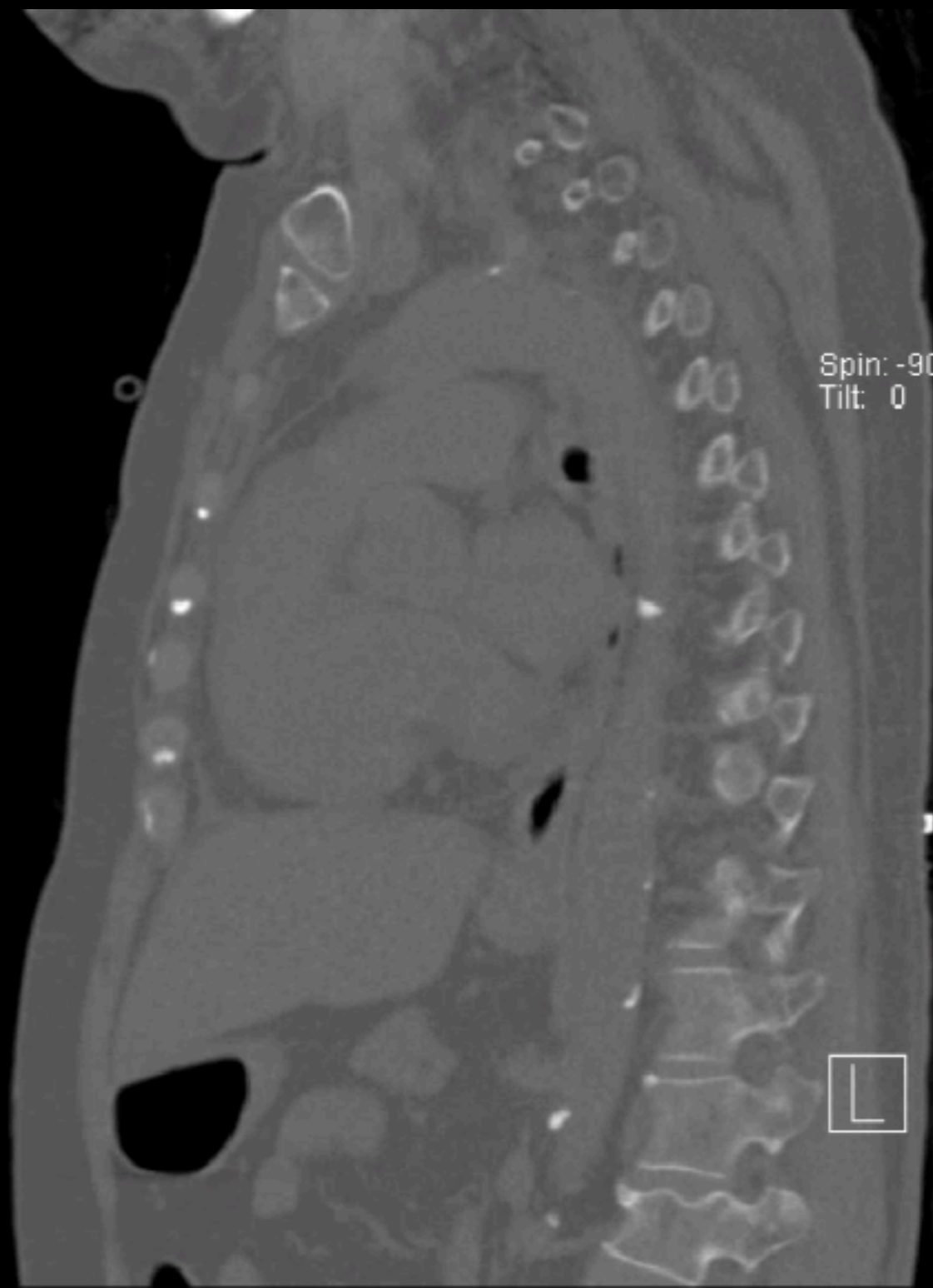你看到胸骨骨折了嗎？

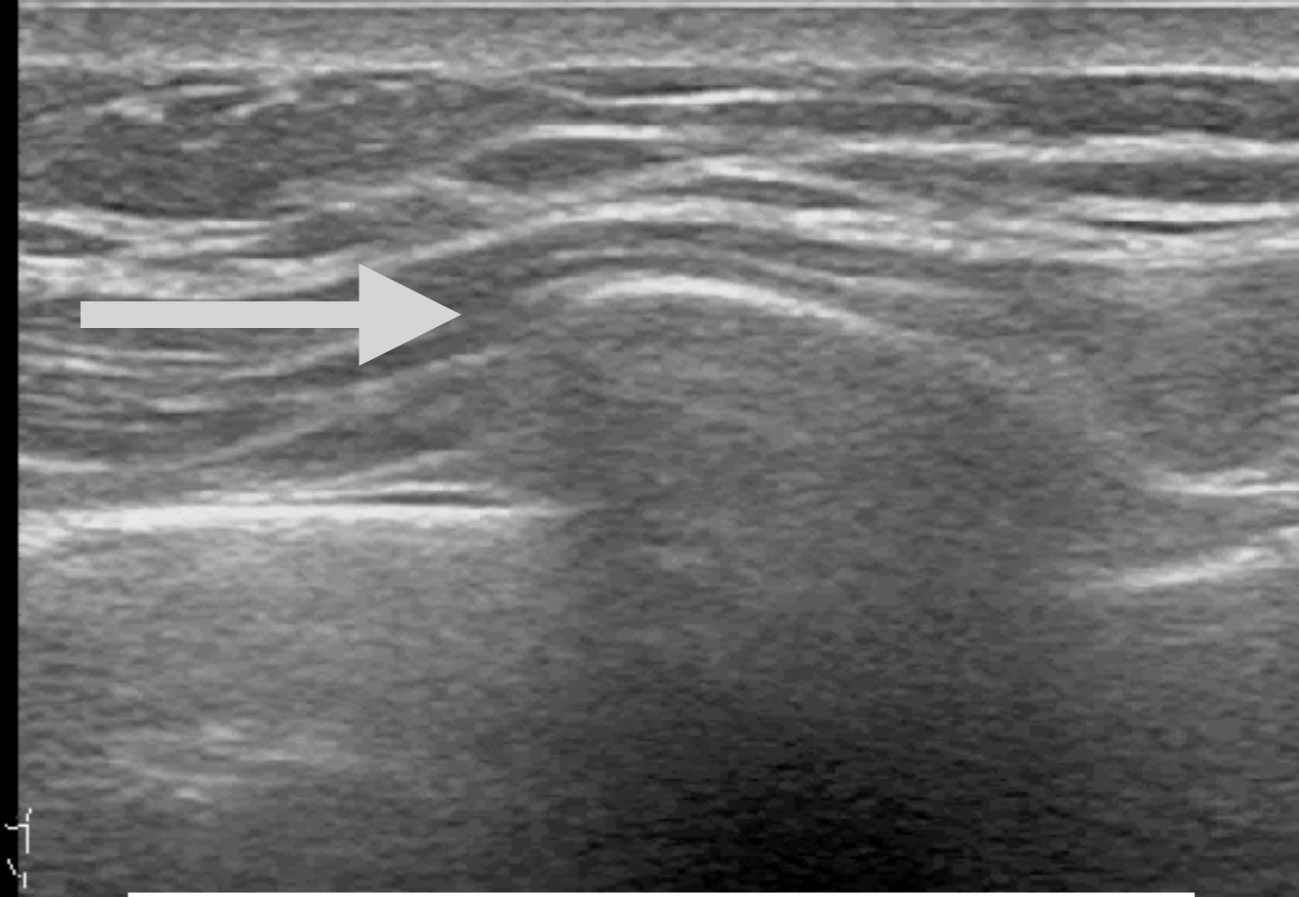
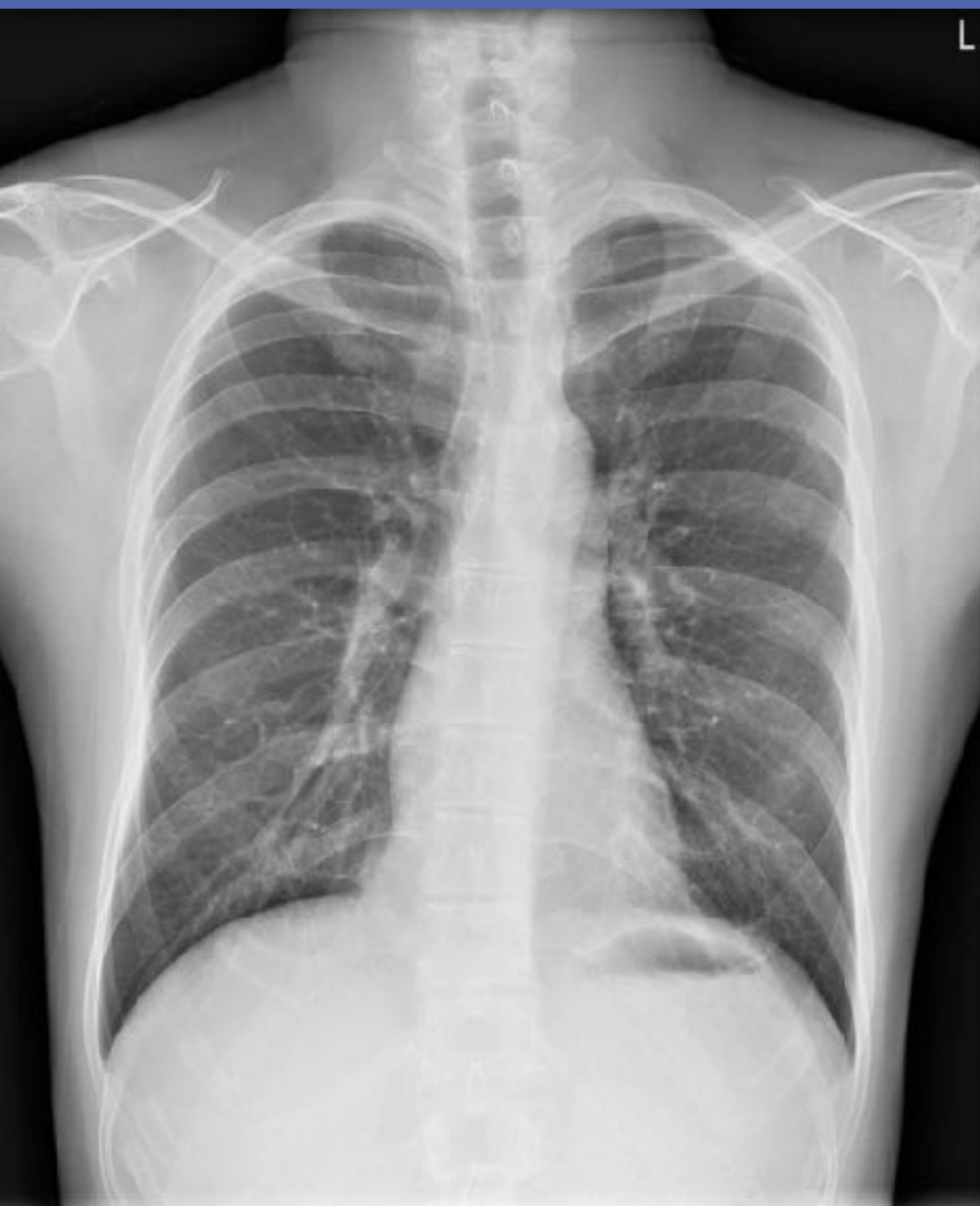



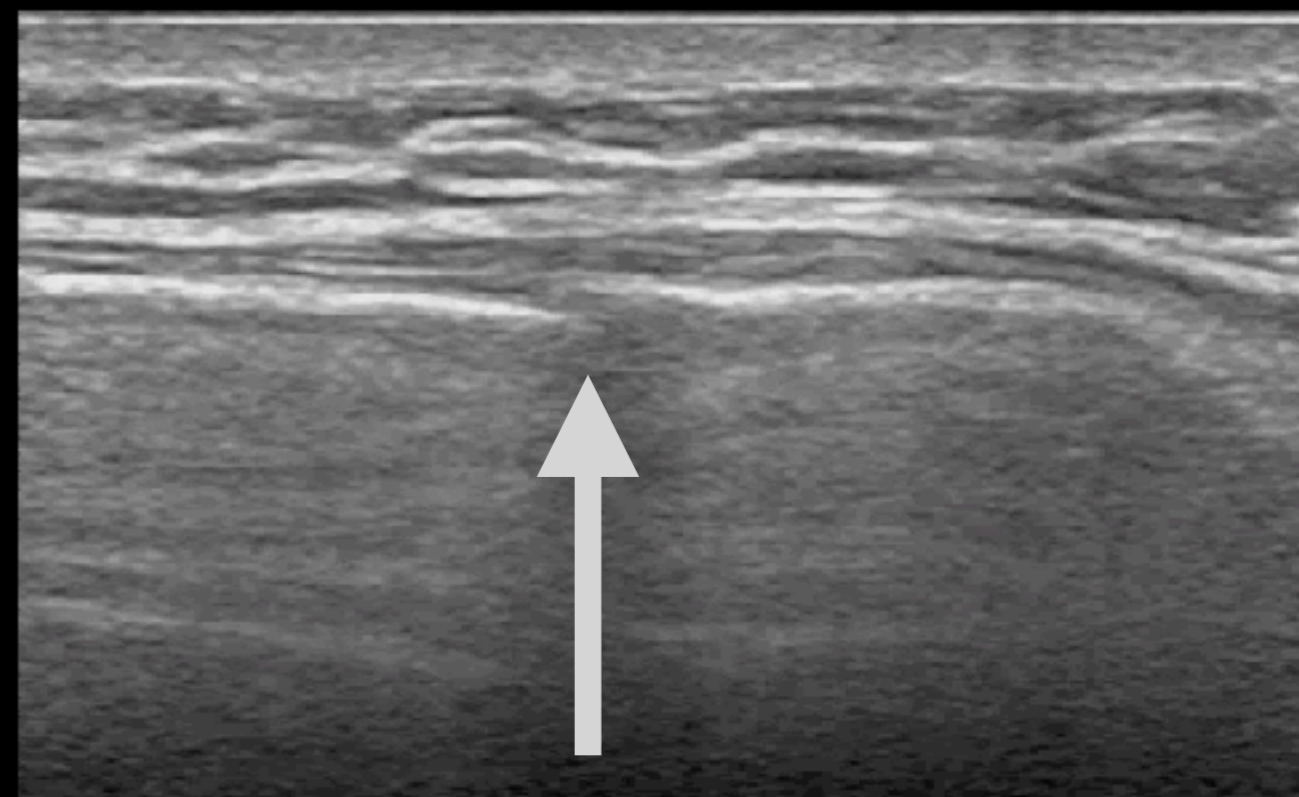
胸骨骨折



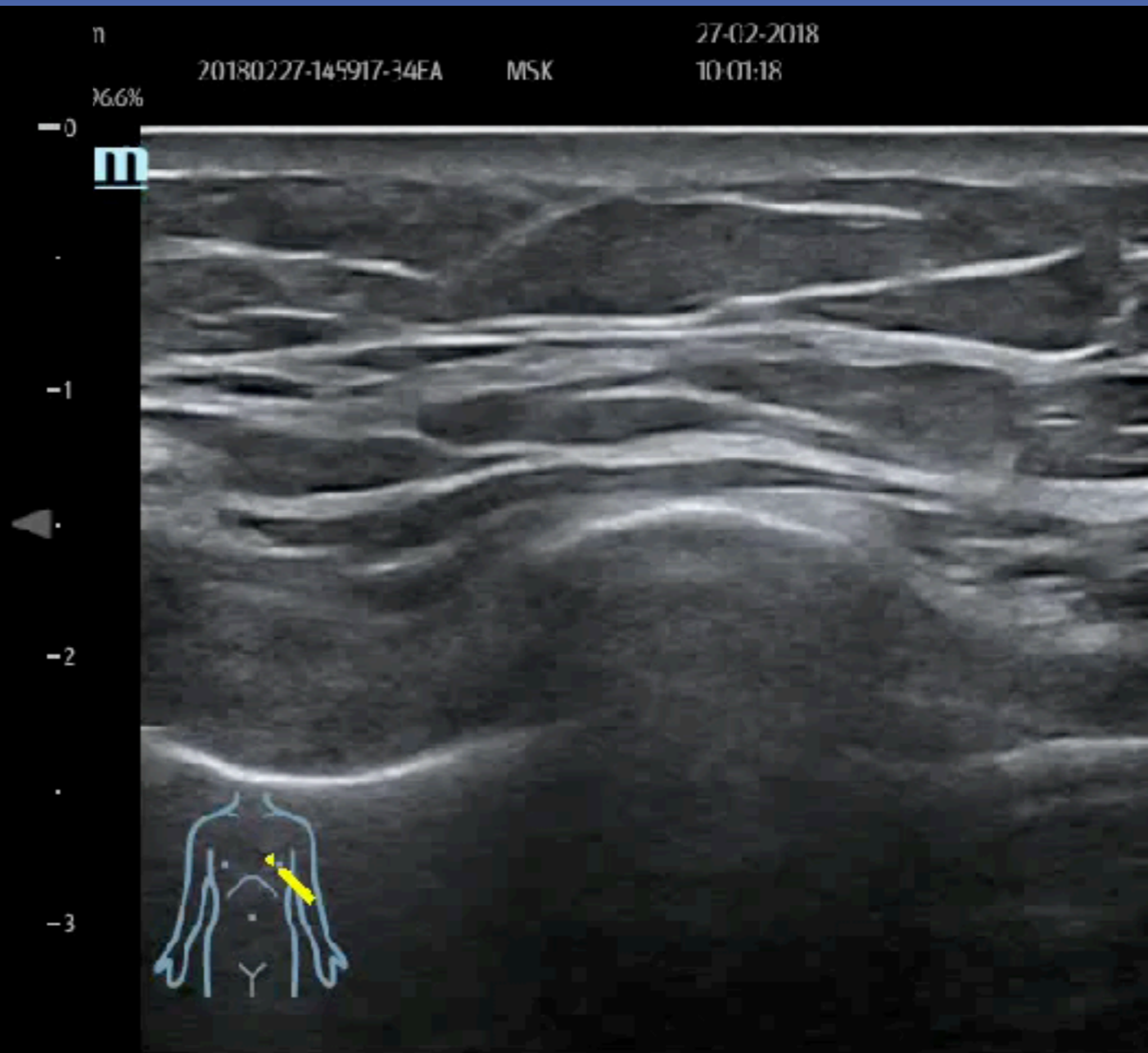
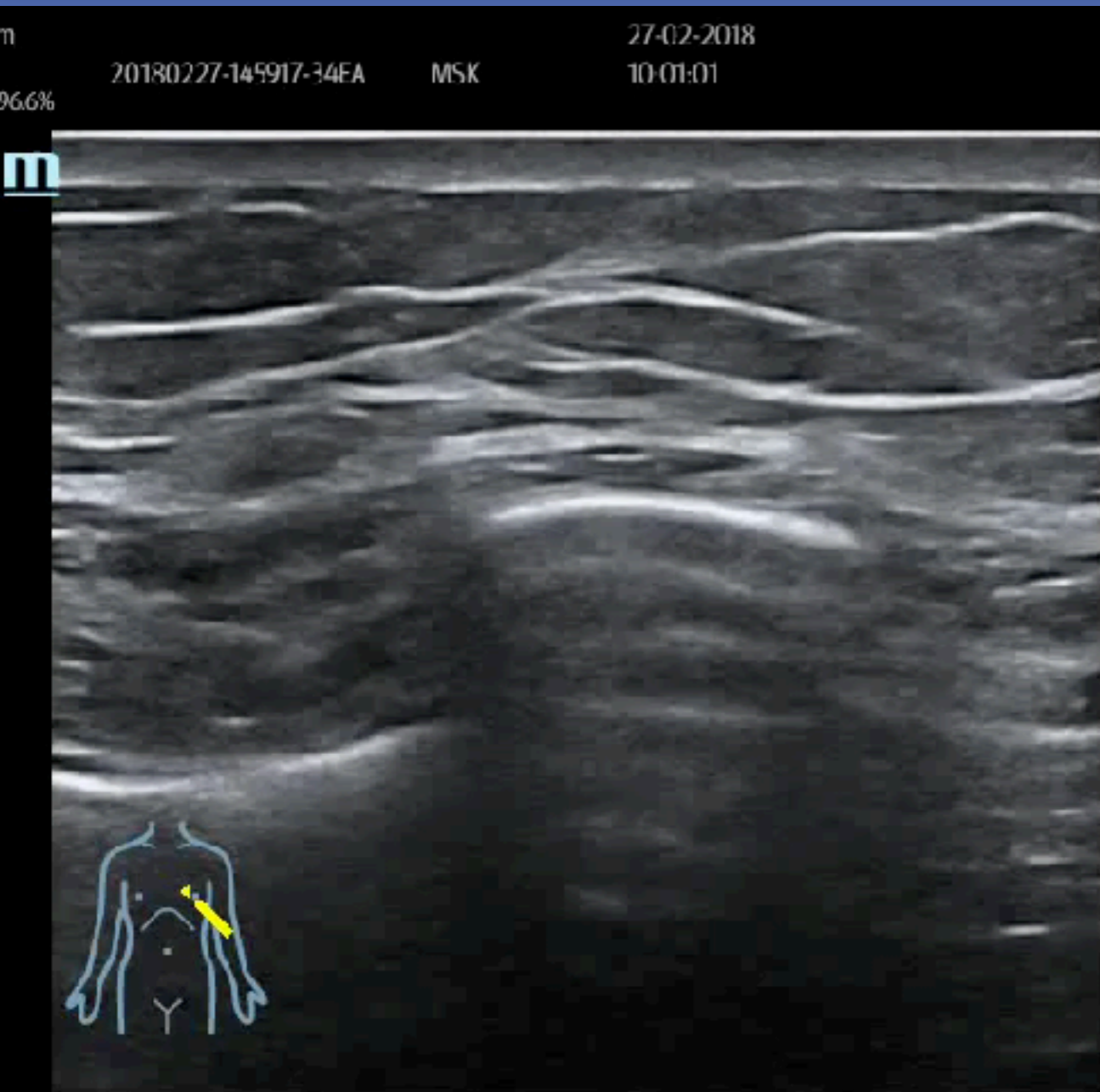
BAT & R chest pain



右第5肋骨骨折



POCUS for Occult fracture

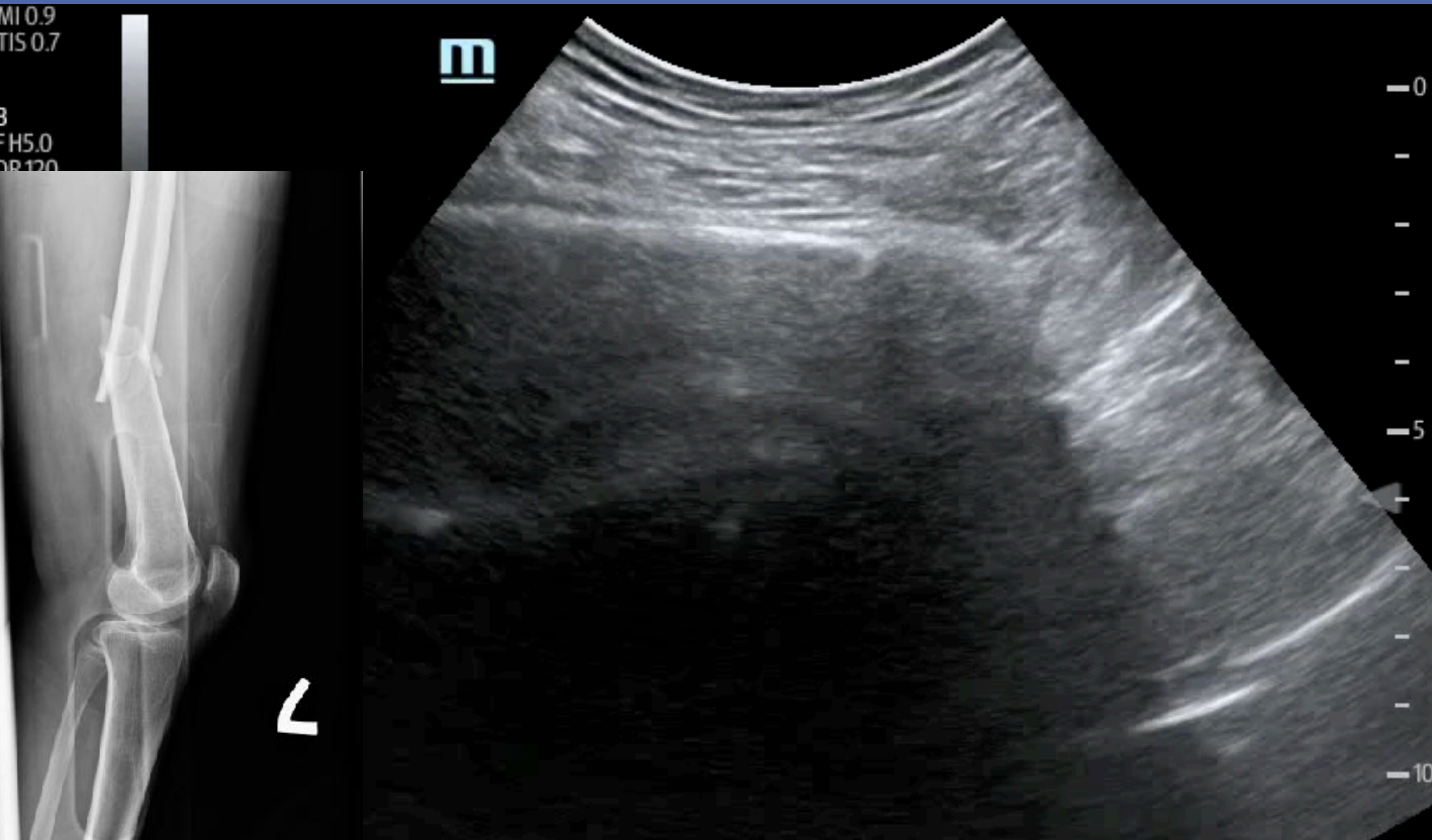


高低差

不連續

有血腫

Major trauma, deformed thigh



Bonus 1

ST-MSK US

FB

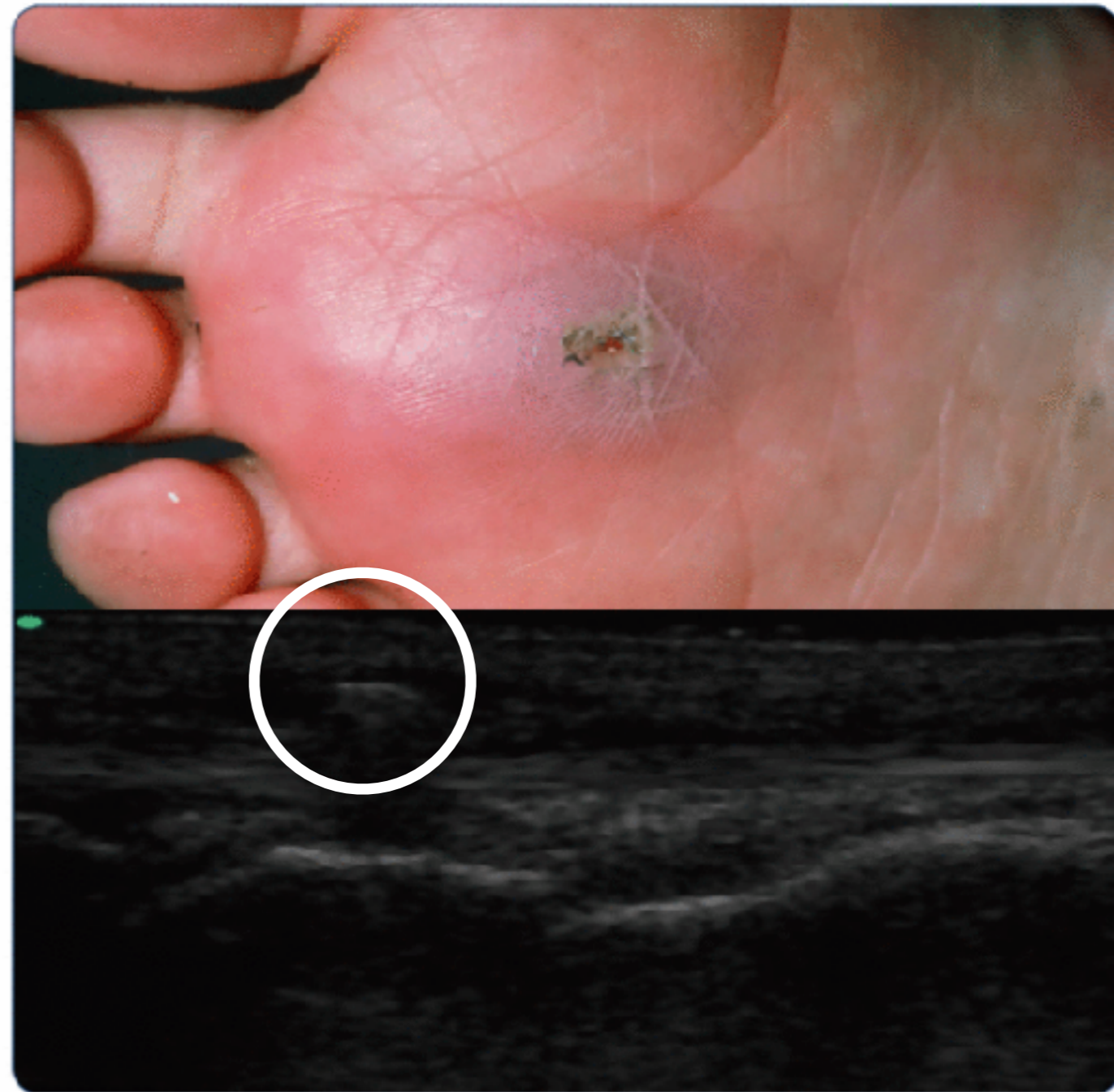Foreign body

Complication

Difficult

38% missed

Malpractice



Detection of soft tissue foreign bodies by nurse practitioner-performed ultrasound

Atkinson *et al.*

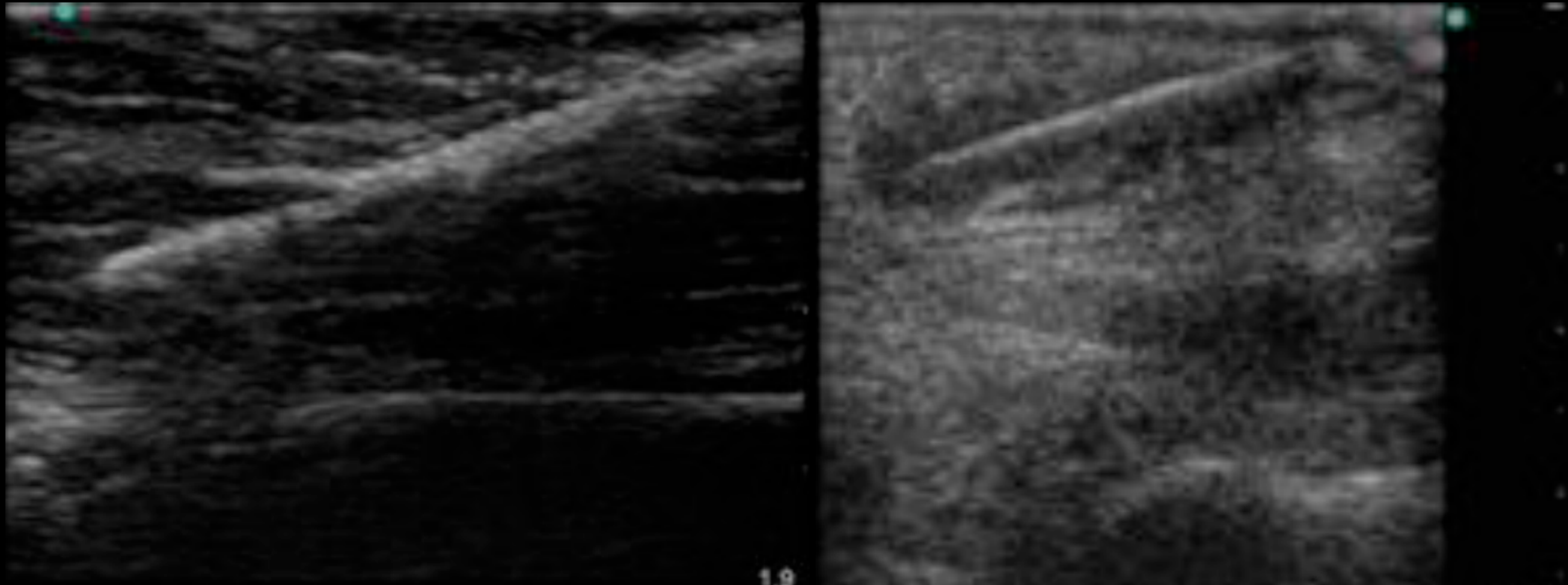
Foreign body

Size; Material; Period

Hyperechoic

Variable shadow

Time matters



Retained FBs for longer than 24-48hrs

Hypoechoic halo

Clinical applications

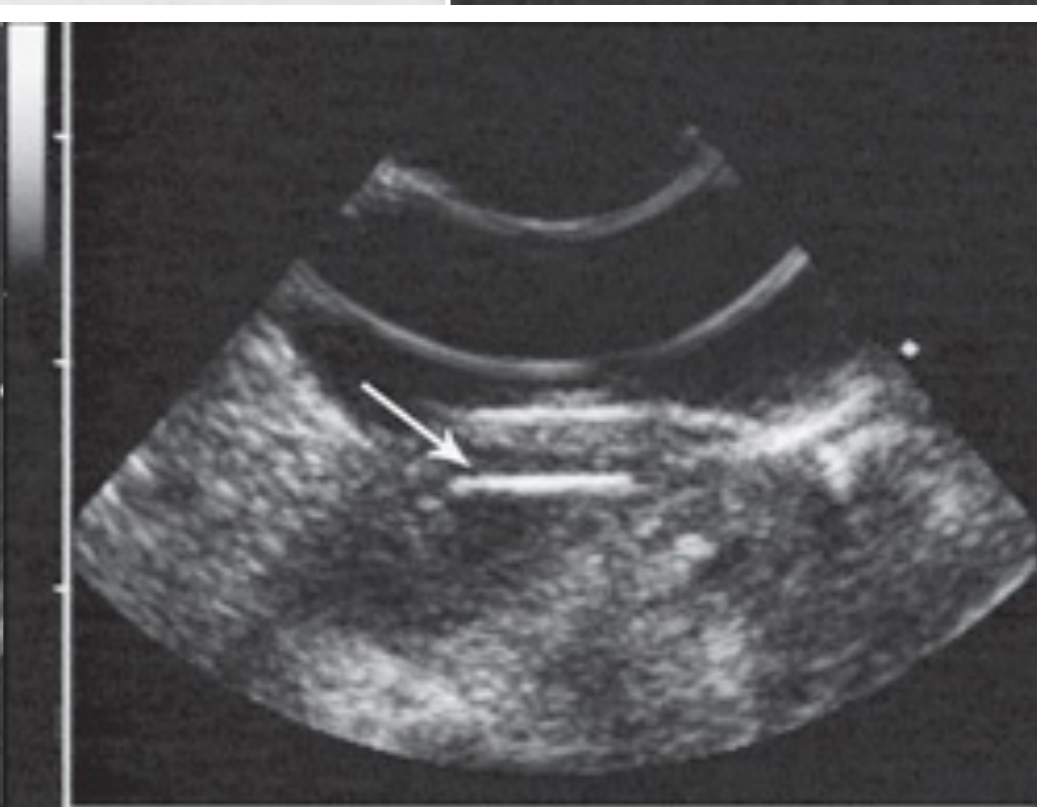
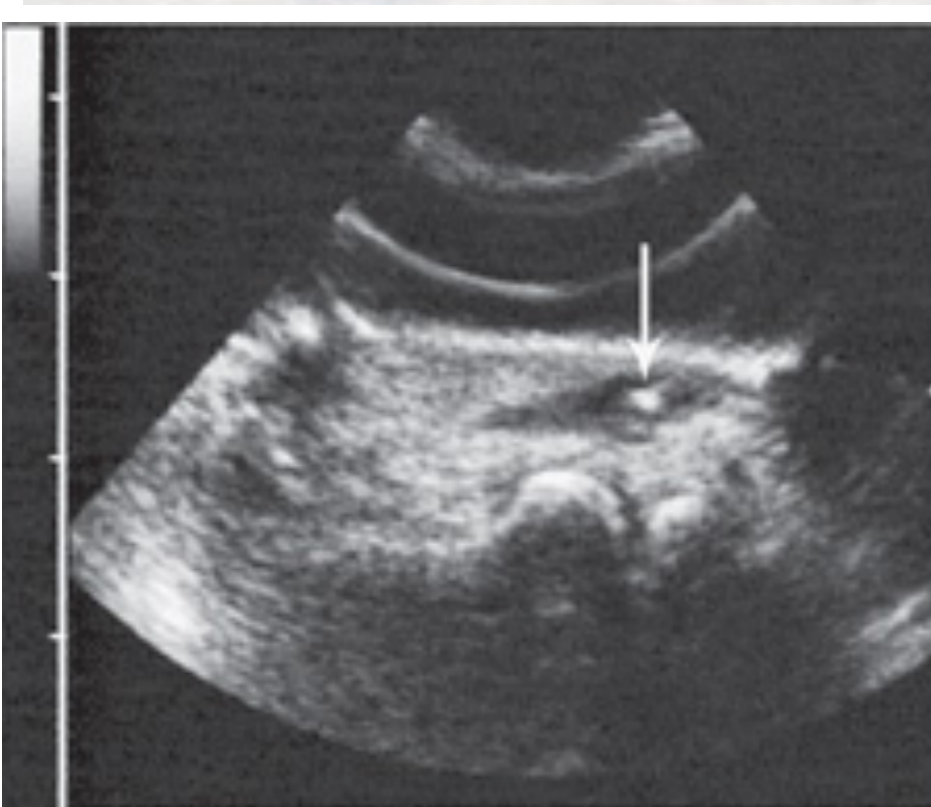
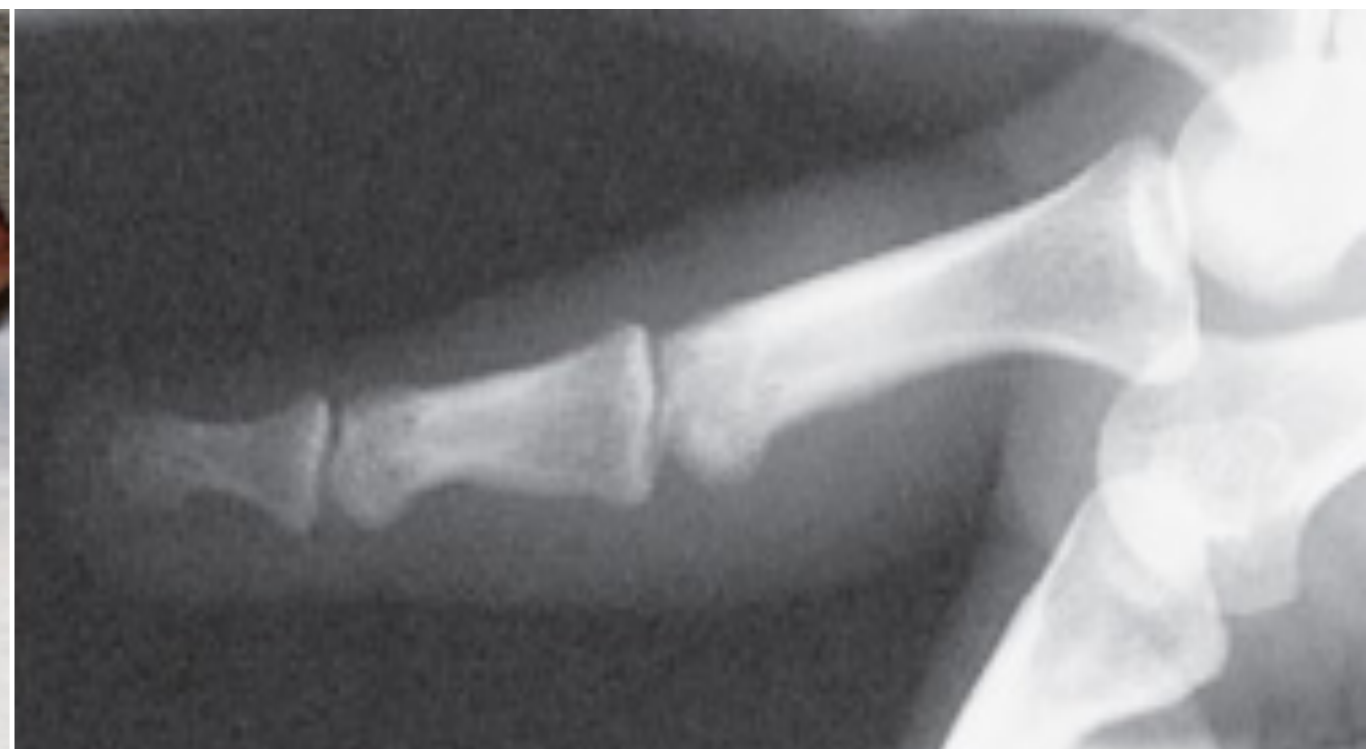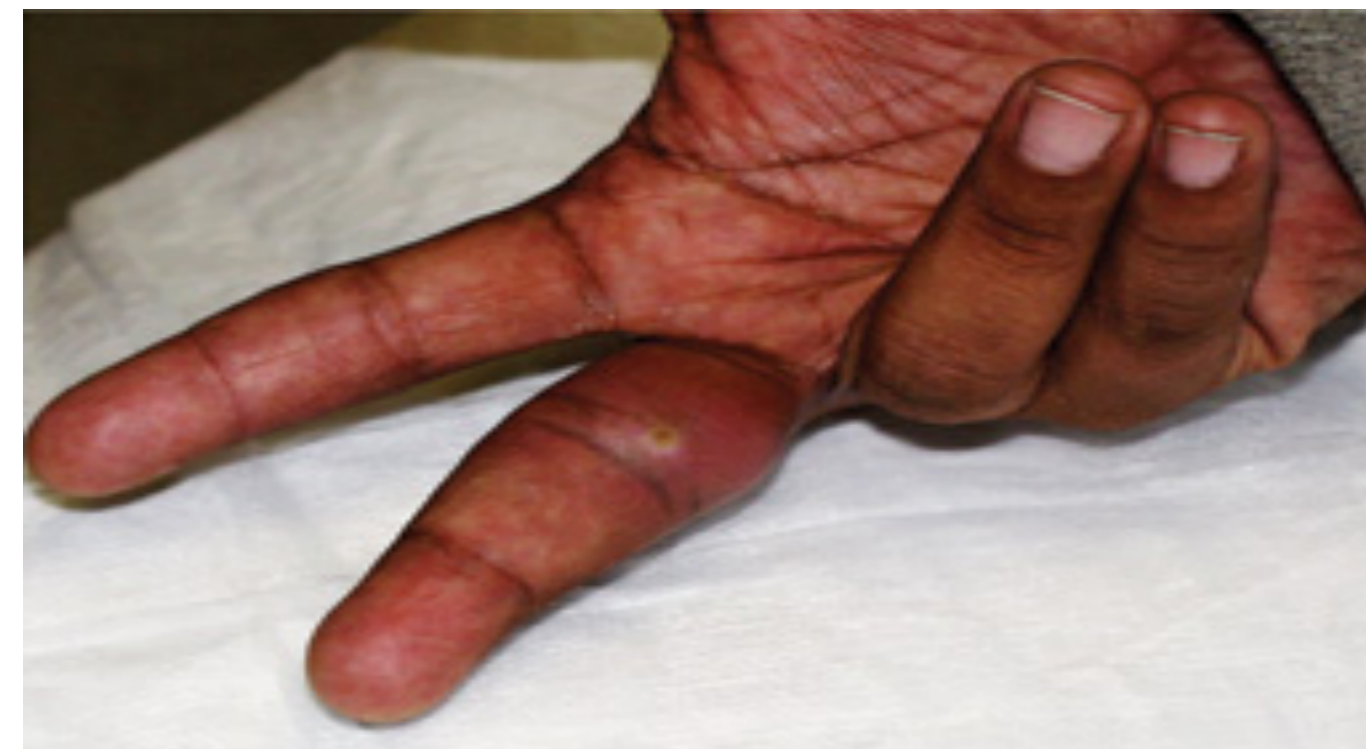Radiolucent FBs

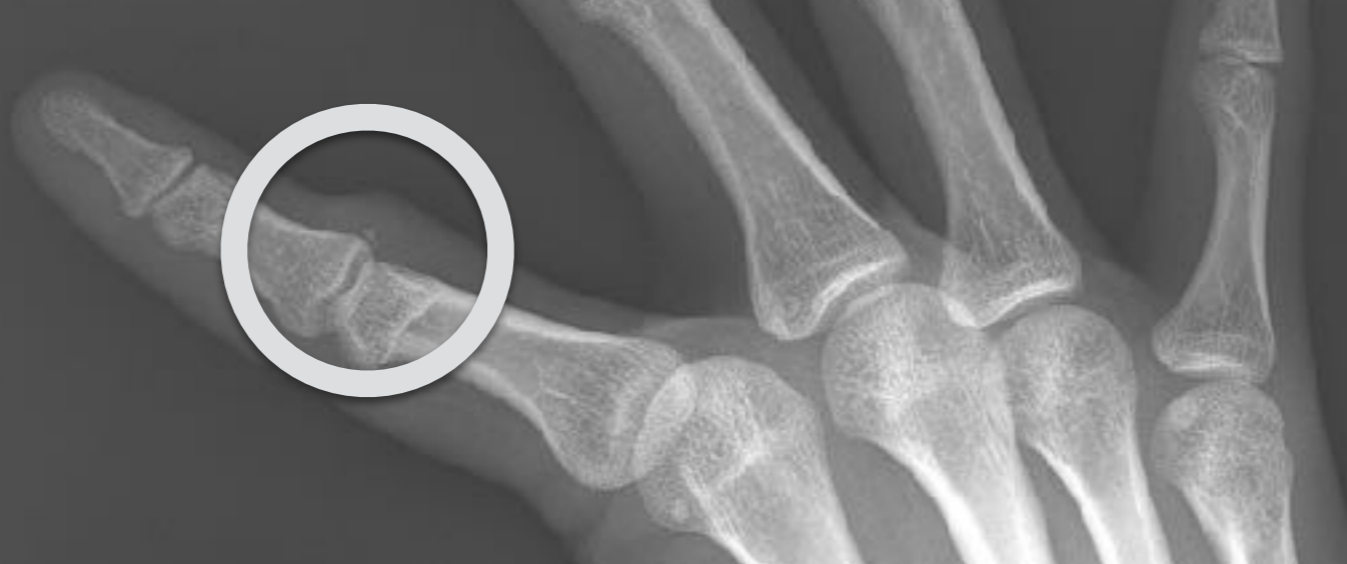Localize & Identify

Surrounding structures

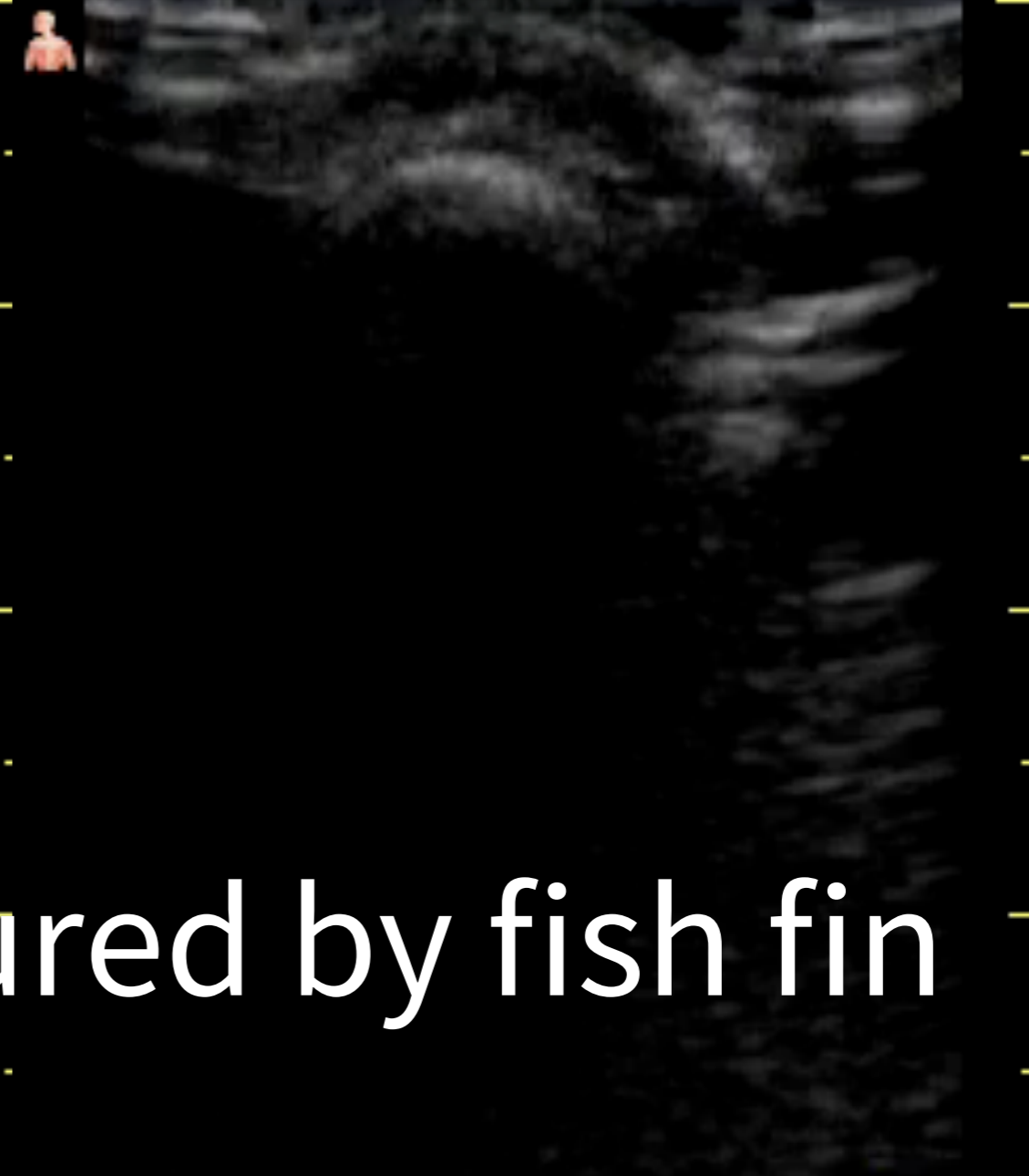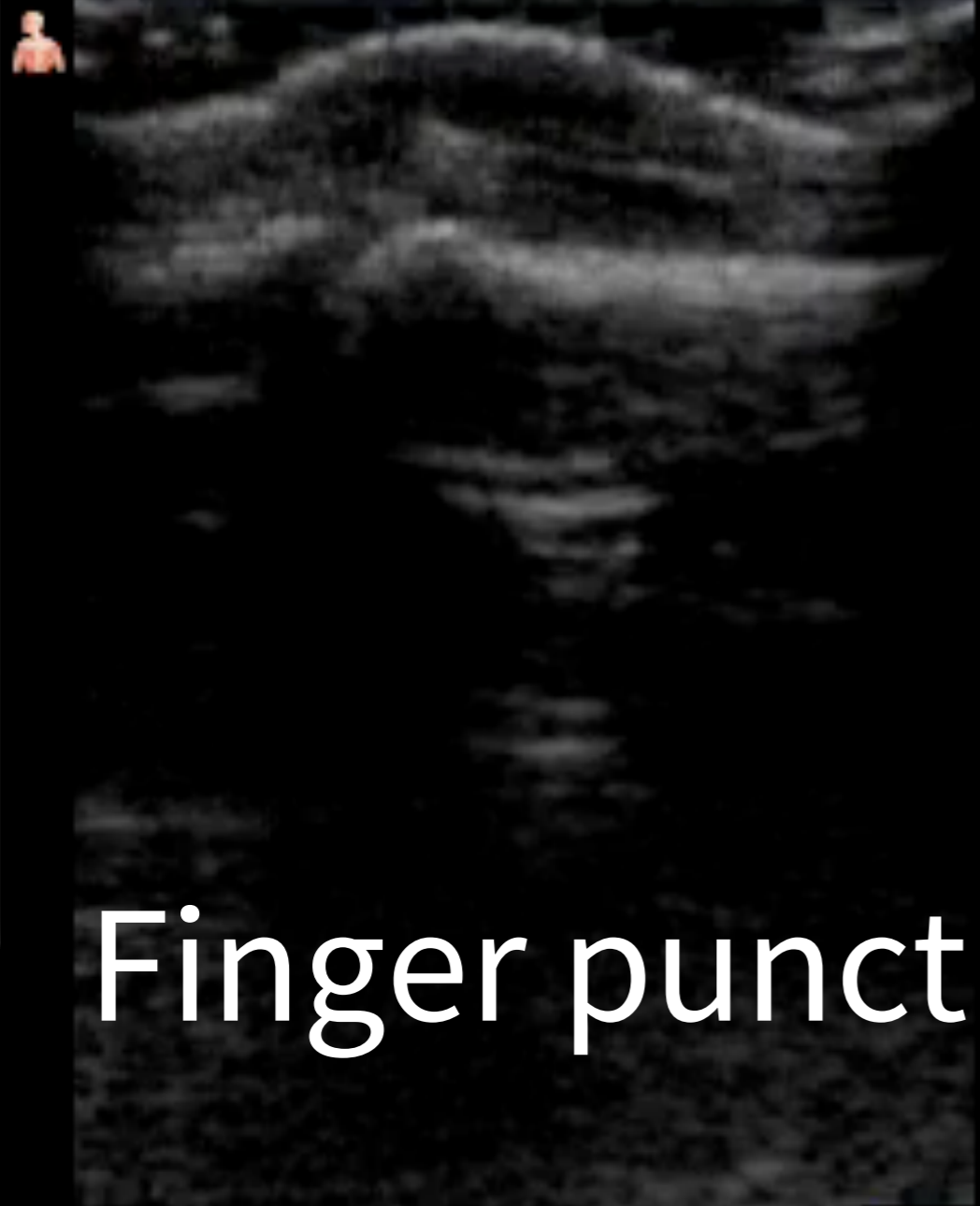Facilitate FB removal

Clinical Scenario



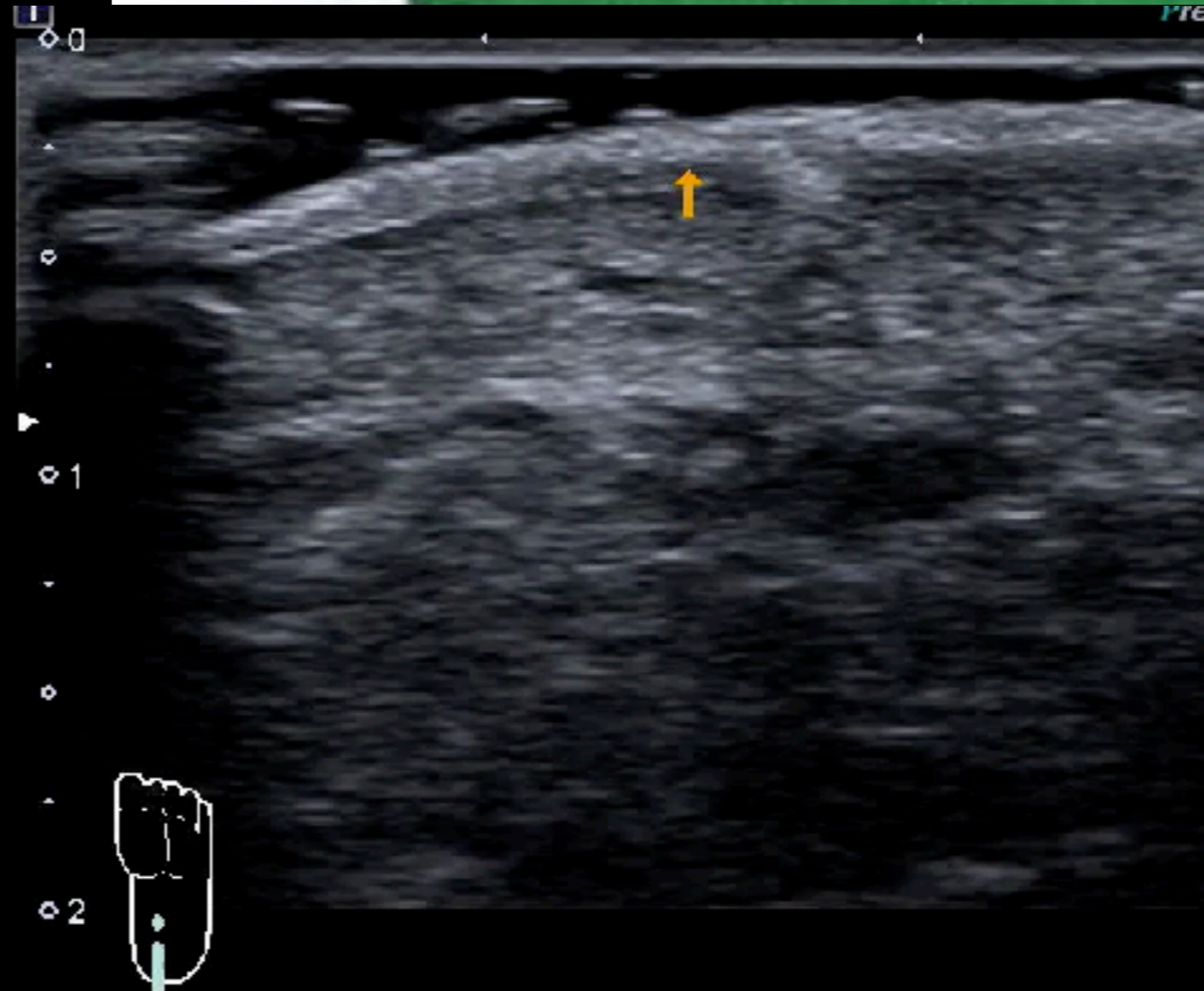
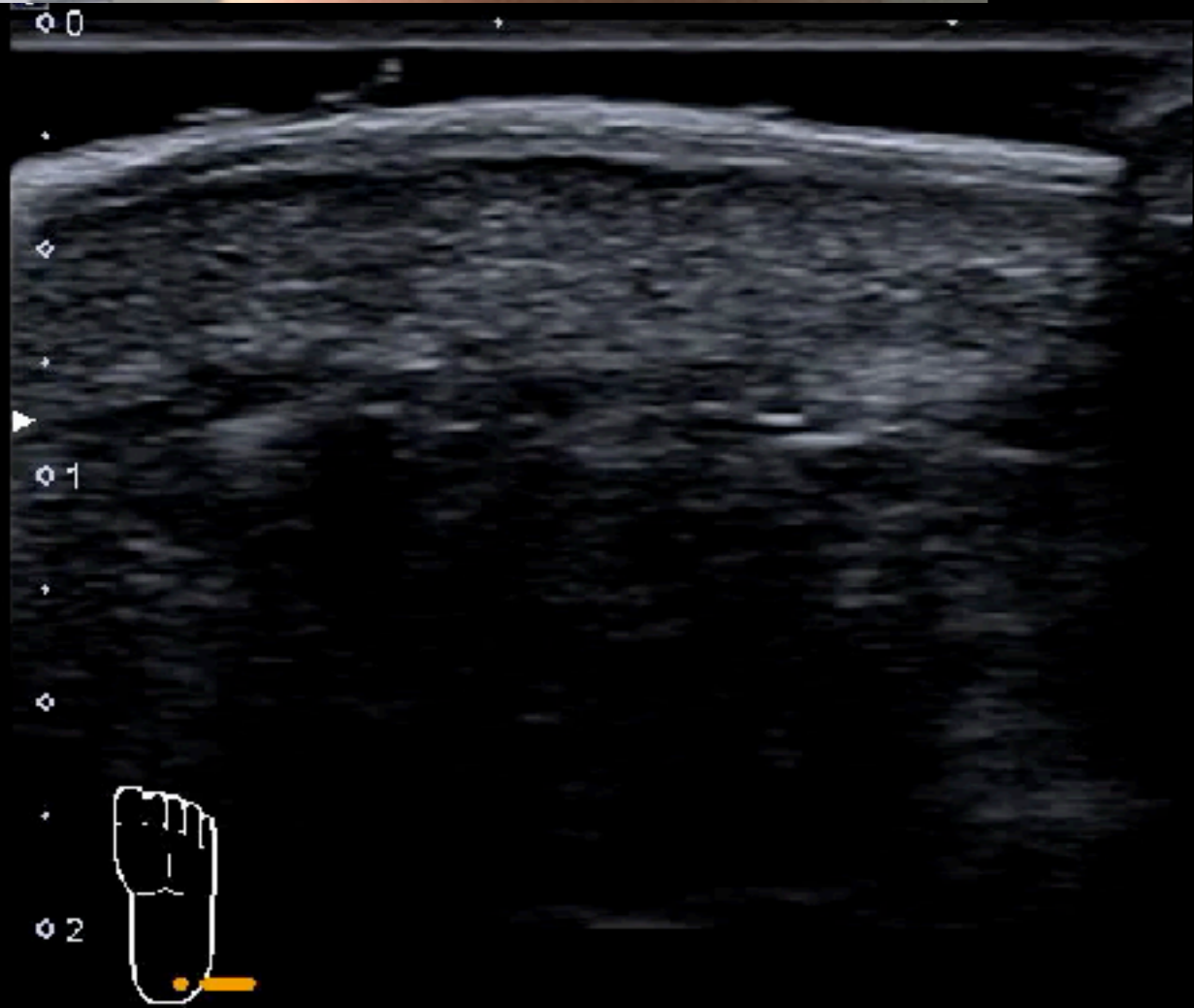
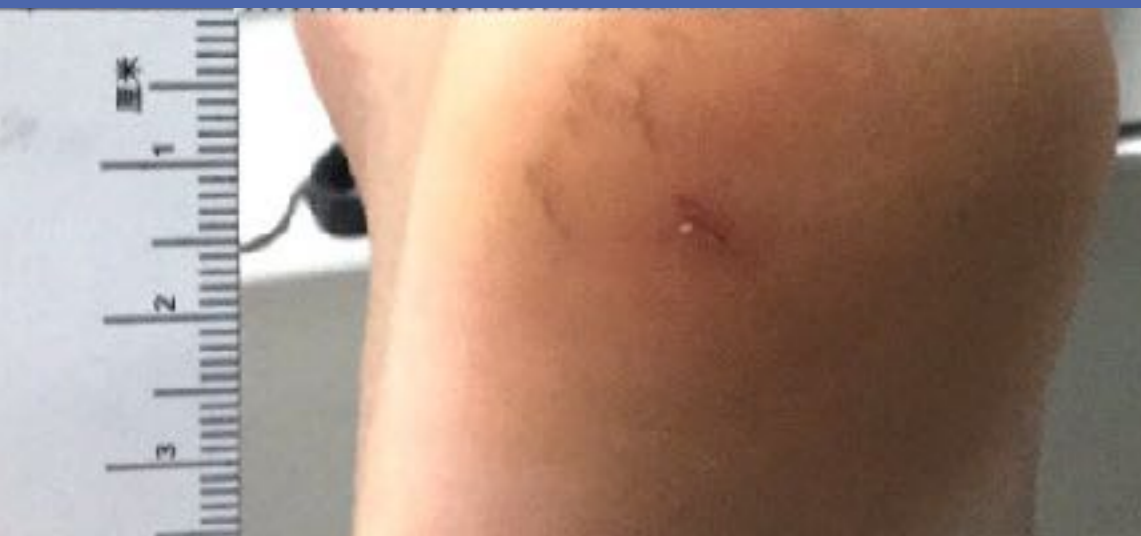


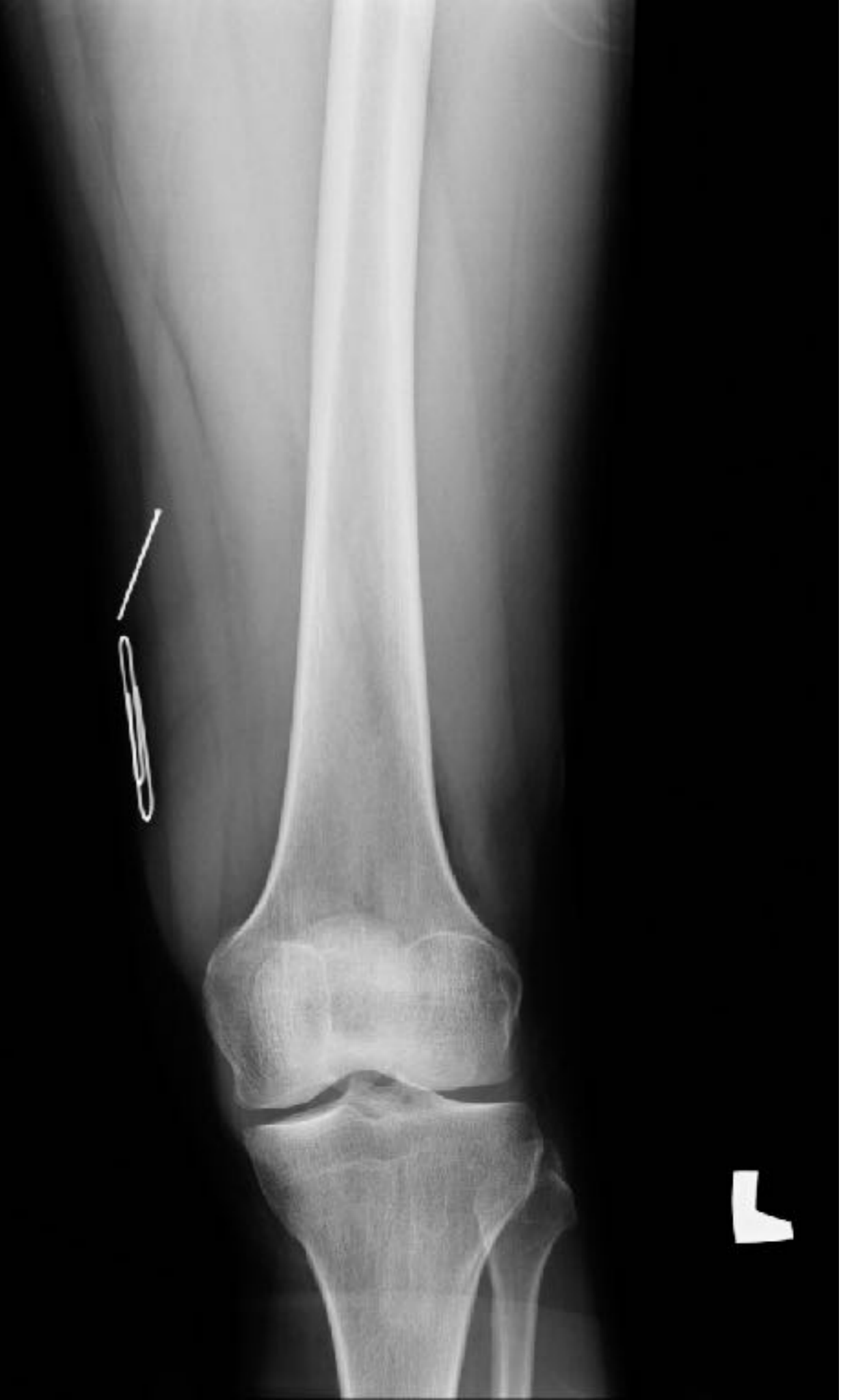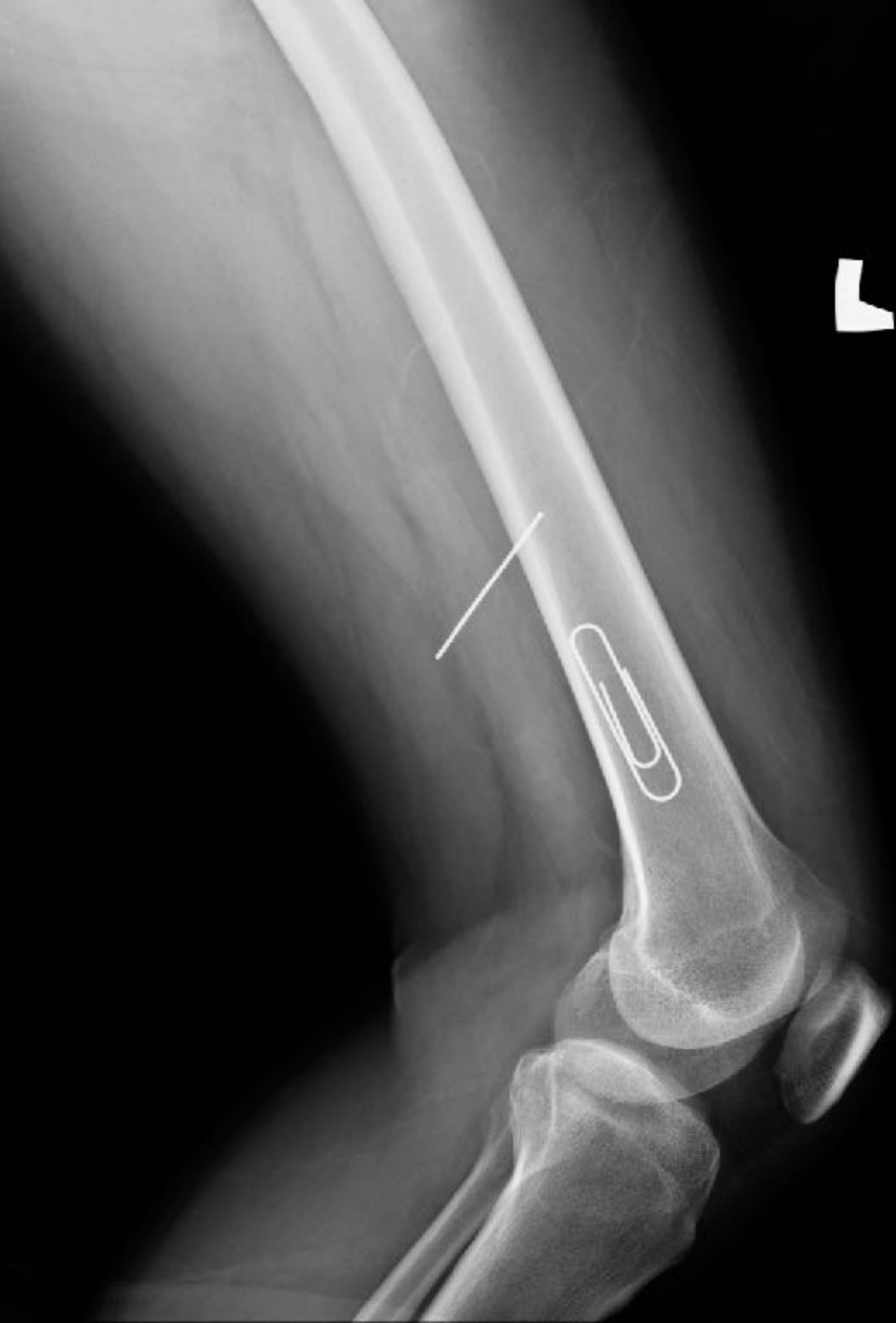#: 35 2:16:02 PM #: 35 2:17:09 PM
MI: 0.8 TI: 0.2 28/Mar/2015 MI: 0.8 TI: 0.2 28/Mar/2015



Finger punctured by fish fin

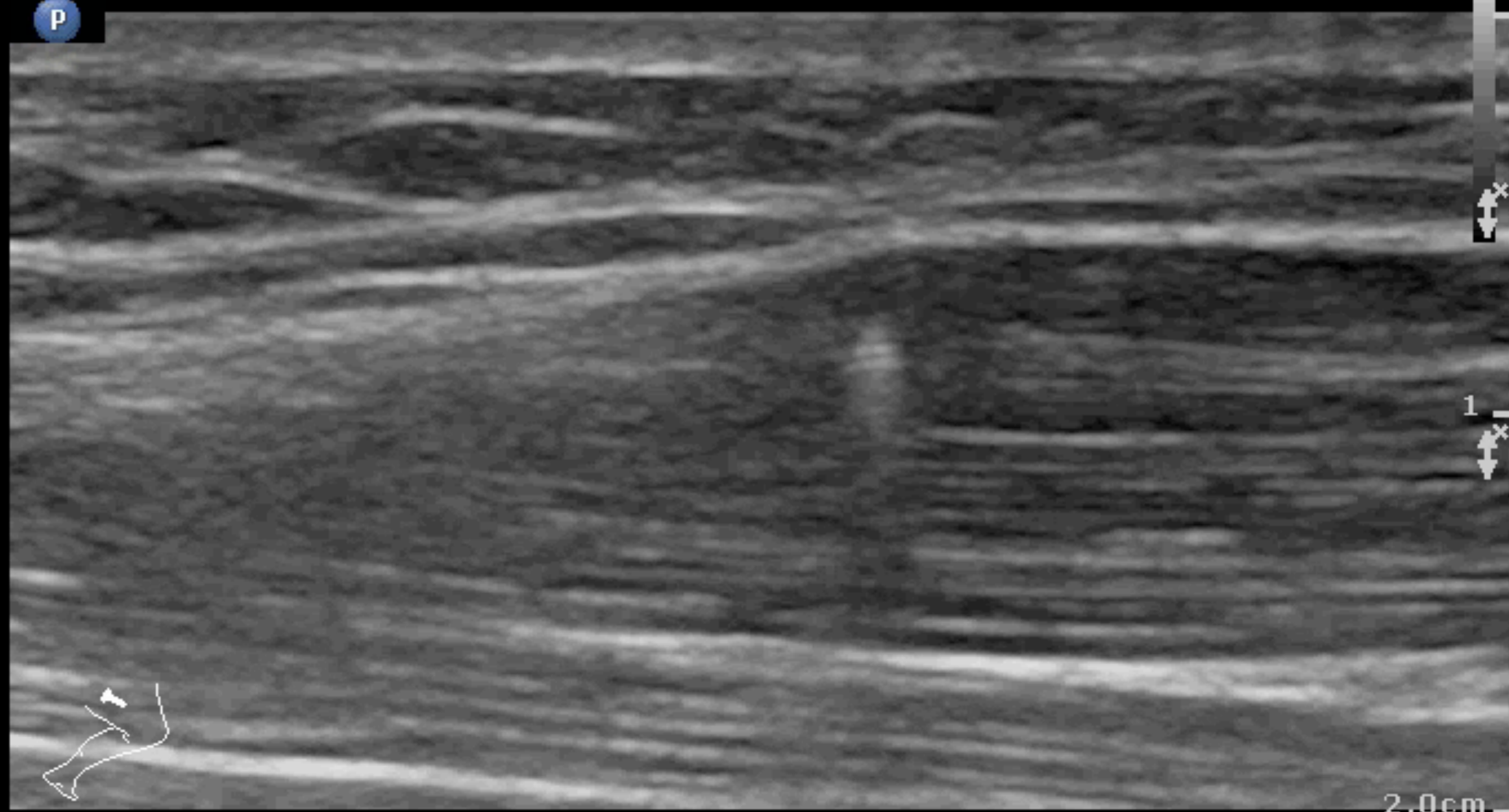
踩到碎玻璃，覺得有異物







superficial
L12-3
34 Hz
2.0cm

2D
Gen
Gn 60
C 52
4/3/2



P

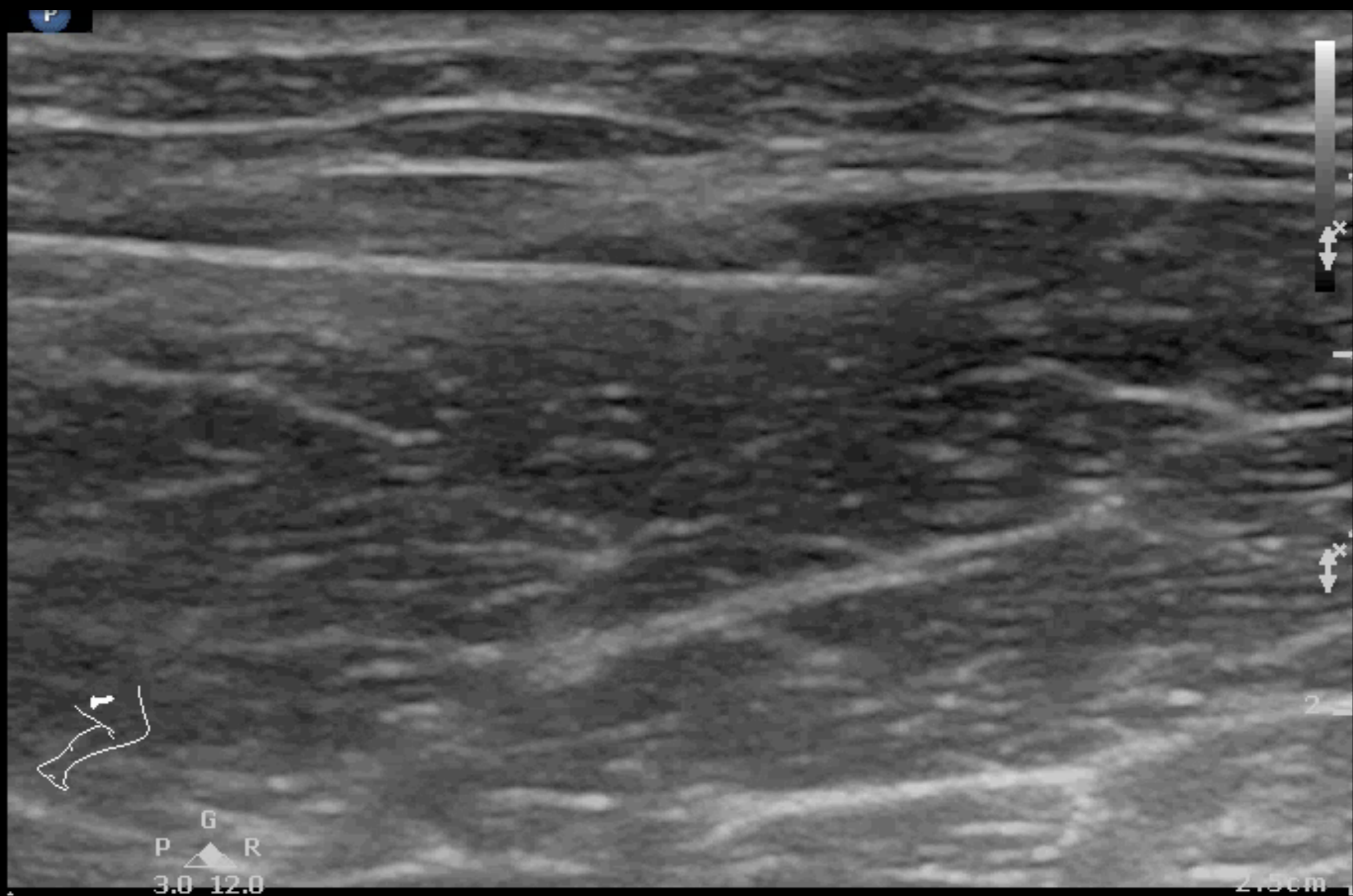


2.0cm

G
P R
3.0 12.0

superficial
L12-3
34 Hz
2.5cm

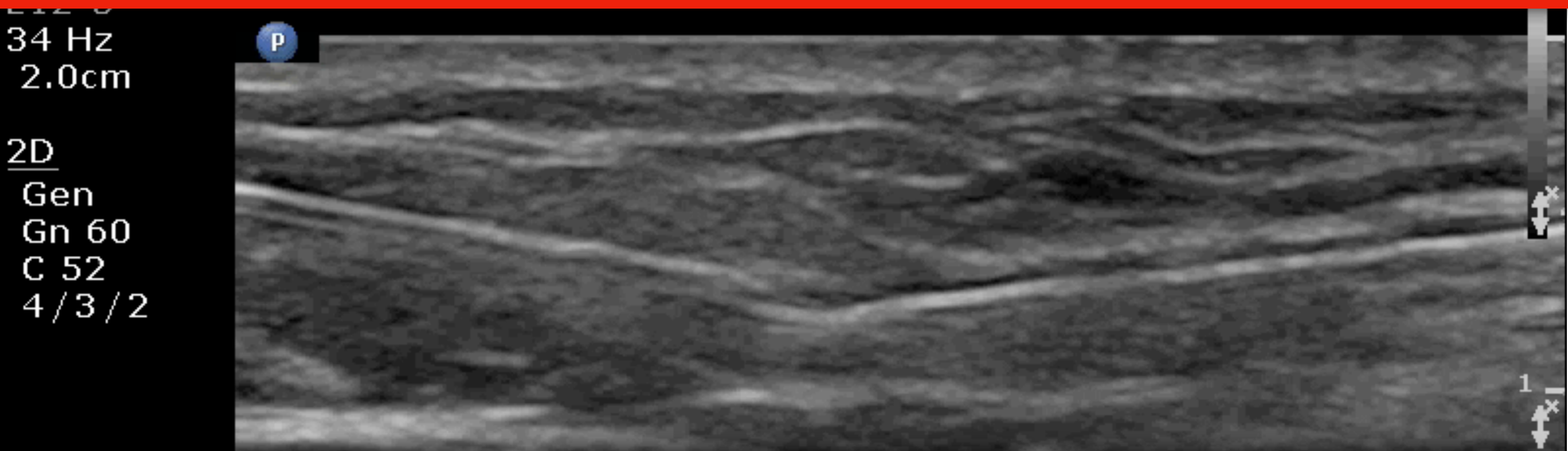
2D
Gen
Gn 60
C 52
4/3/2



P G R
3.0 12.0

2.5cm


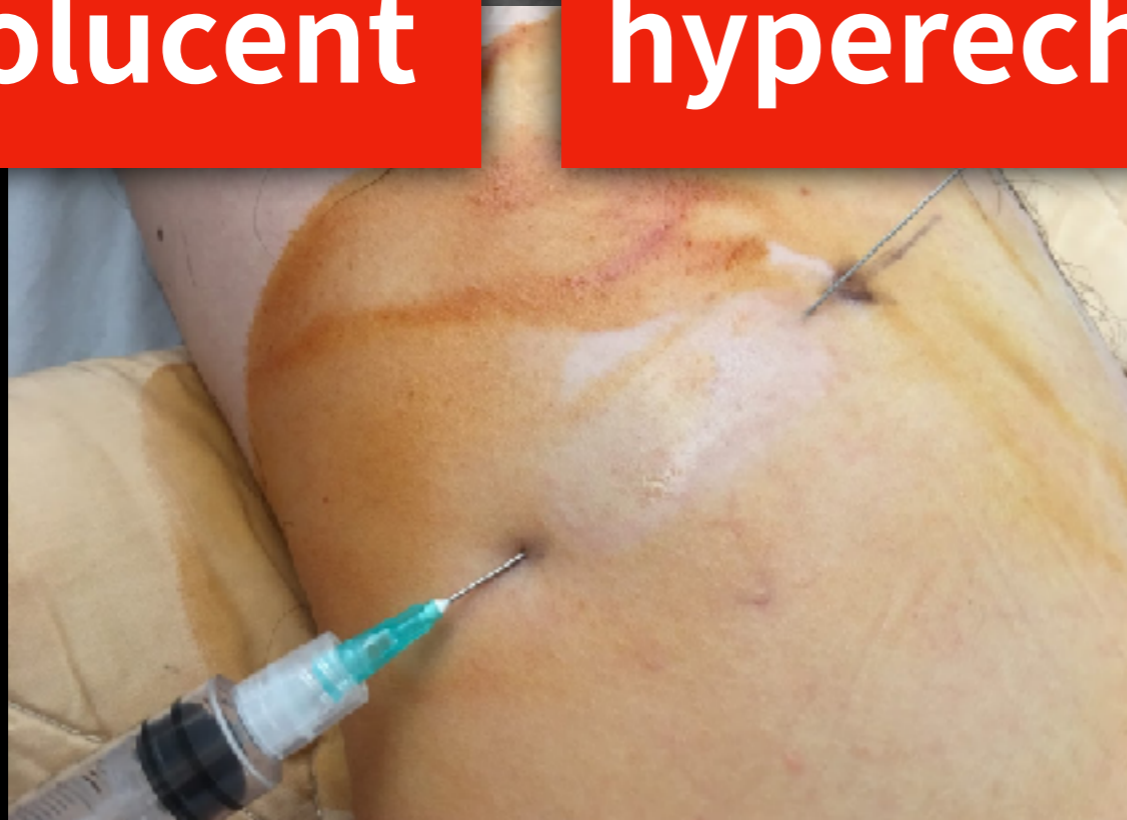
POCUS for Foreign Body



radiolucent

hyperechoic

localization



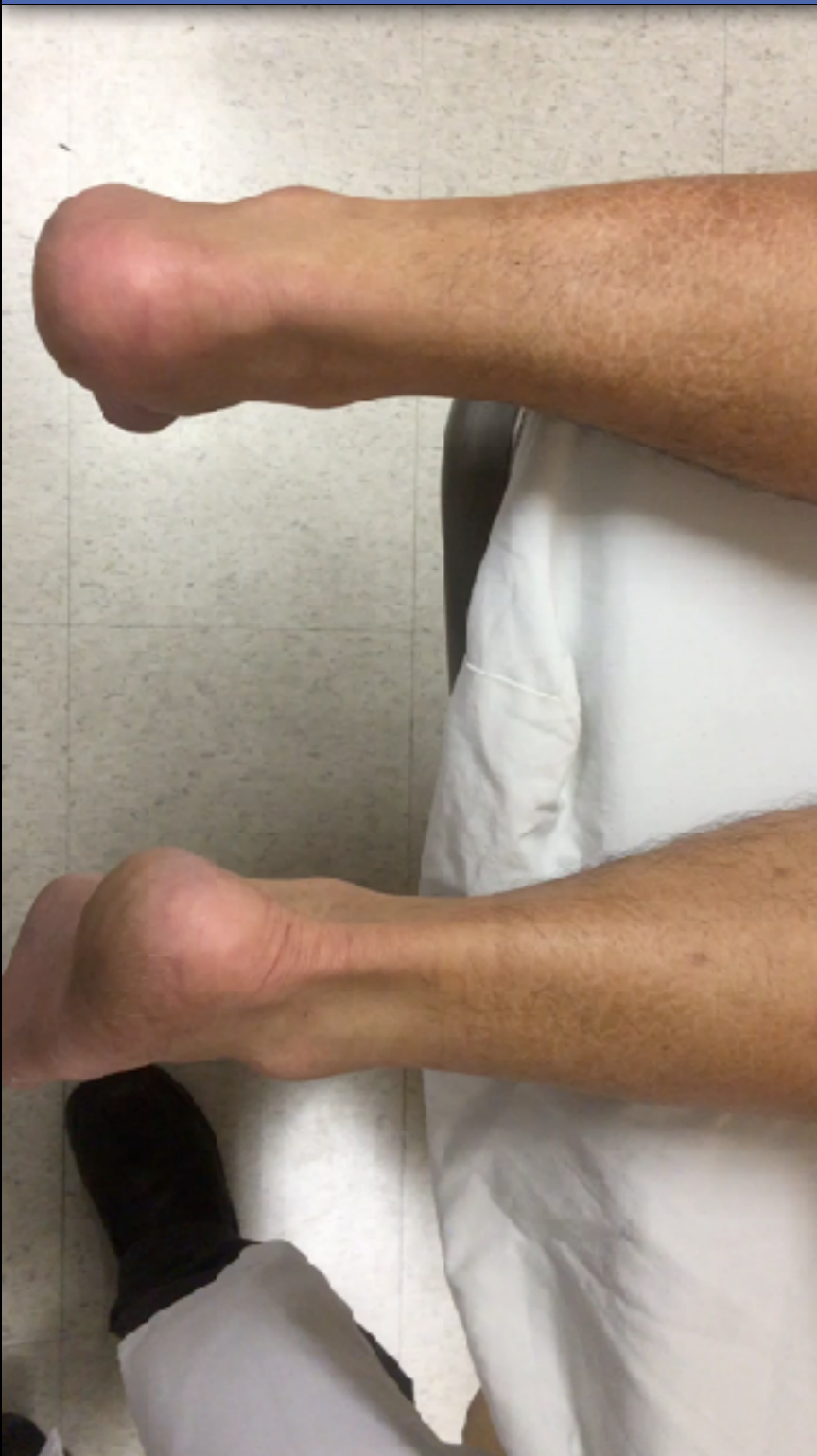Bonus 2

ST-MSK US

FB

Tendon

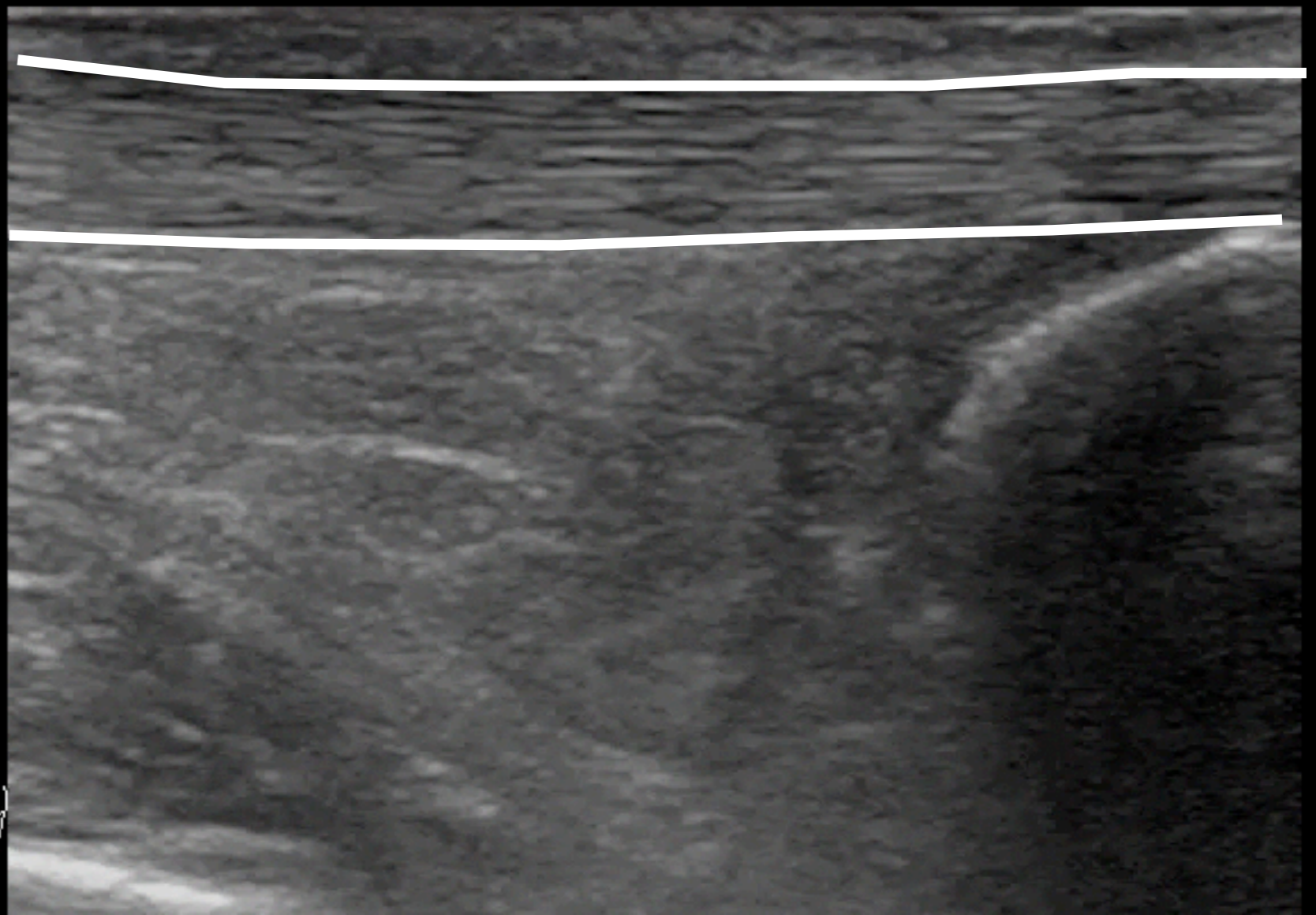
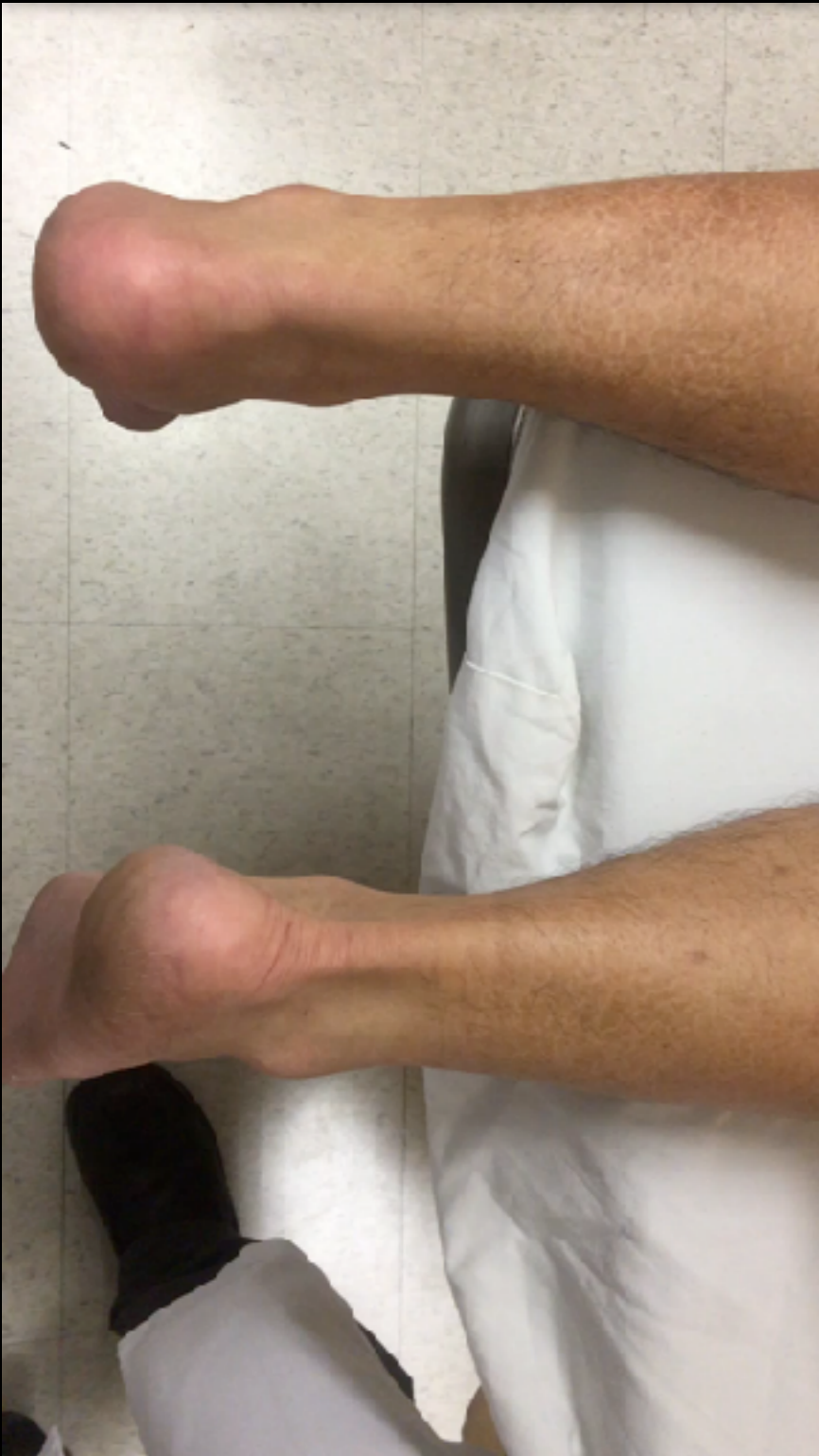47M, left leg pain after jumping
during badminton

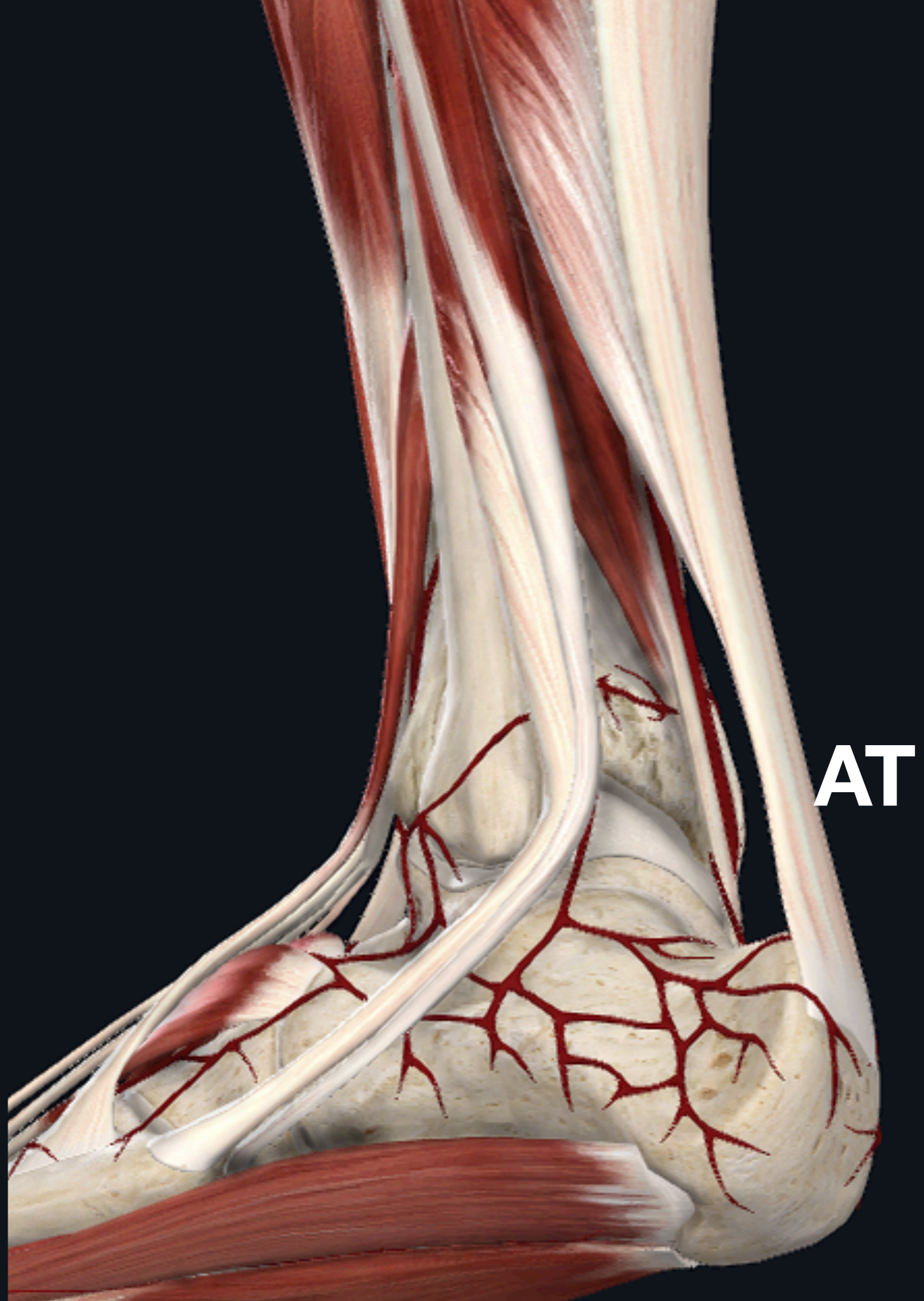
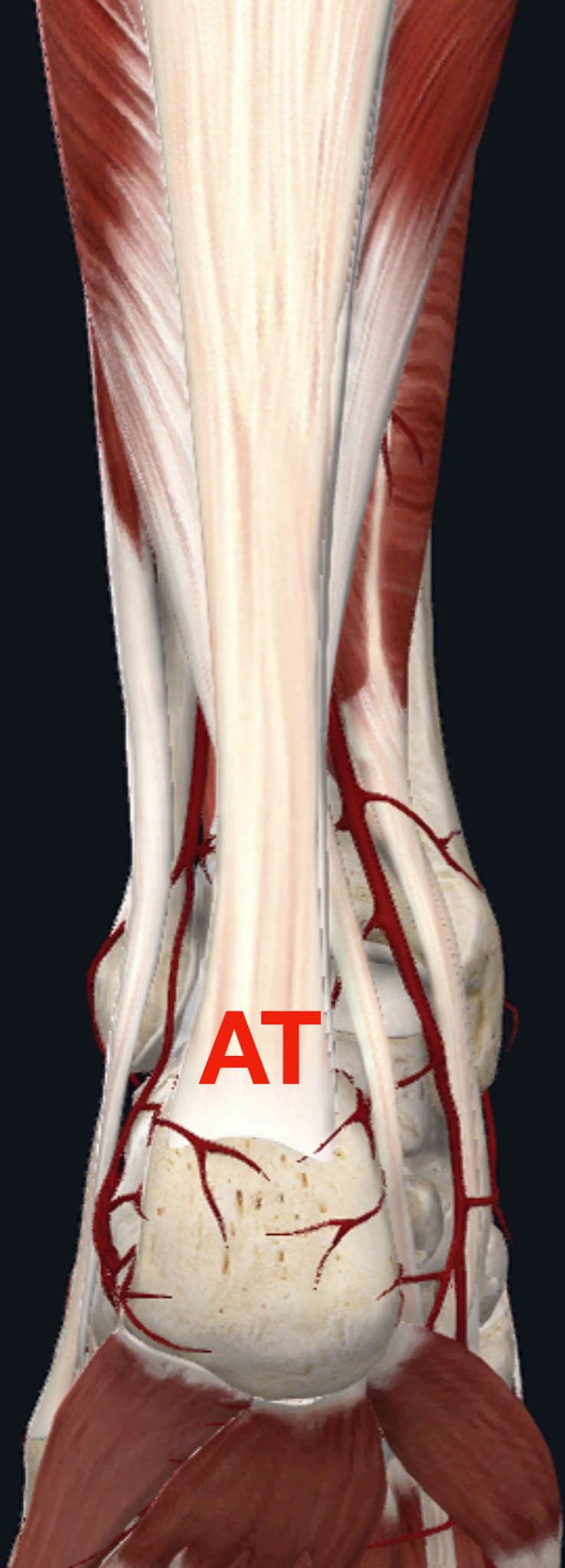
Thompson test

47M, left leg pain after jumping during badminton

Achilles tendon



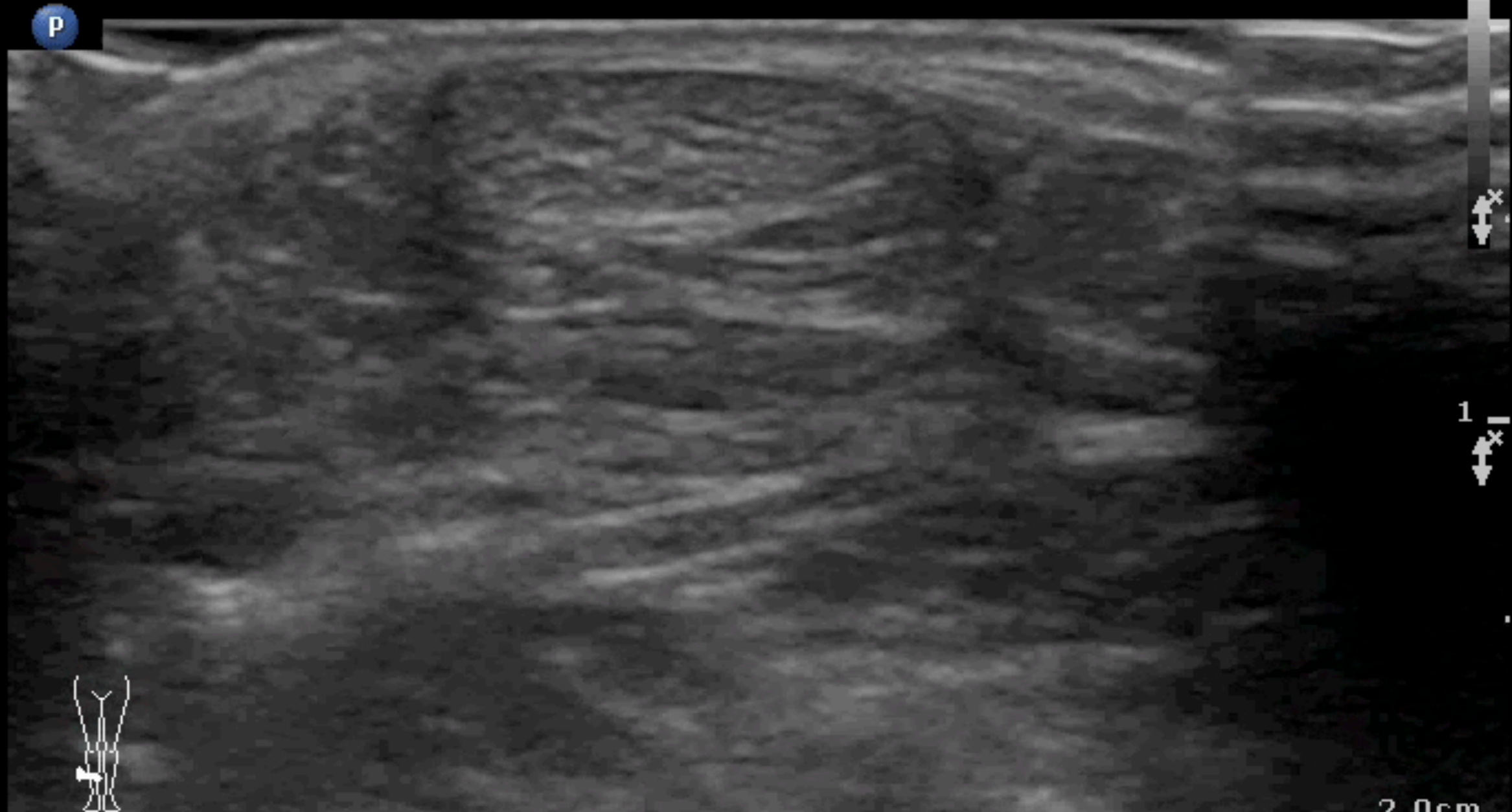


Achilles tendon rupture

34 Hz
2.0cm

2D

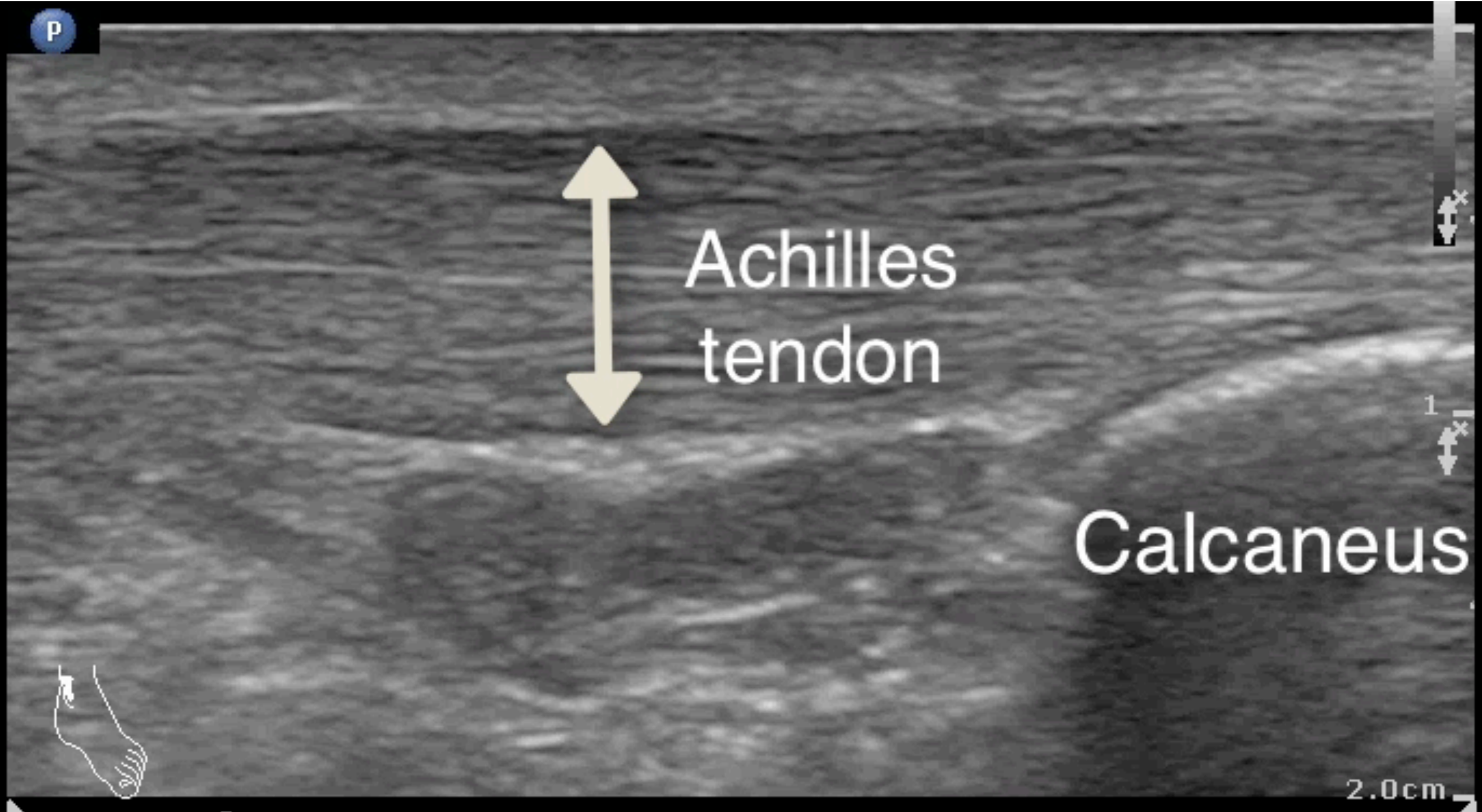
Gen
Gn 94
C 52
4/3/2



G
P R
3.0 12.0

2.0cm

Achilles tendon rupture



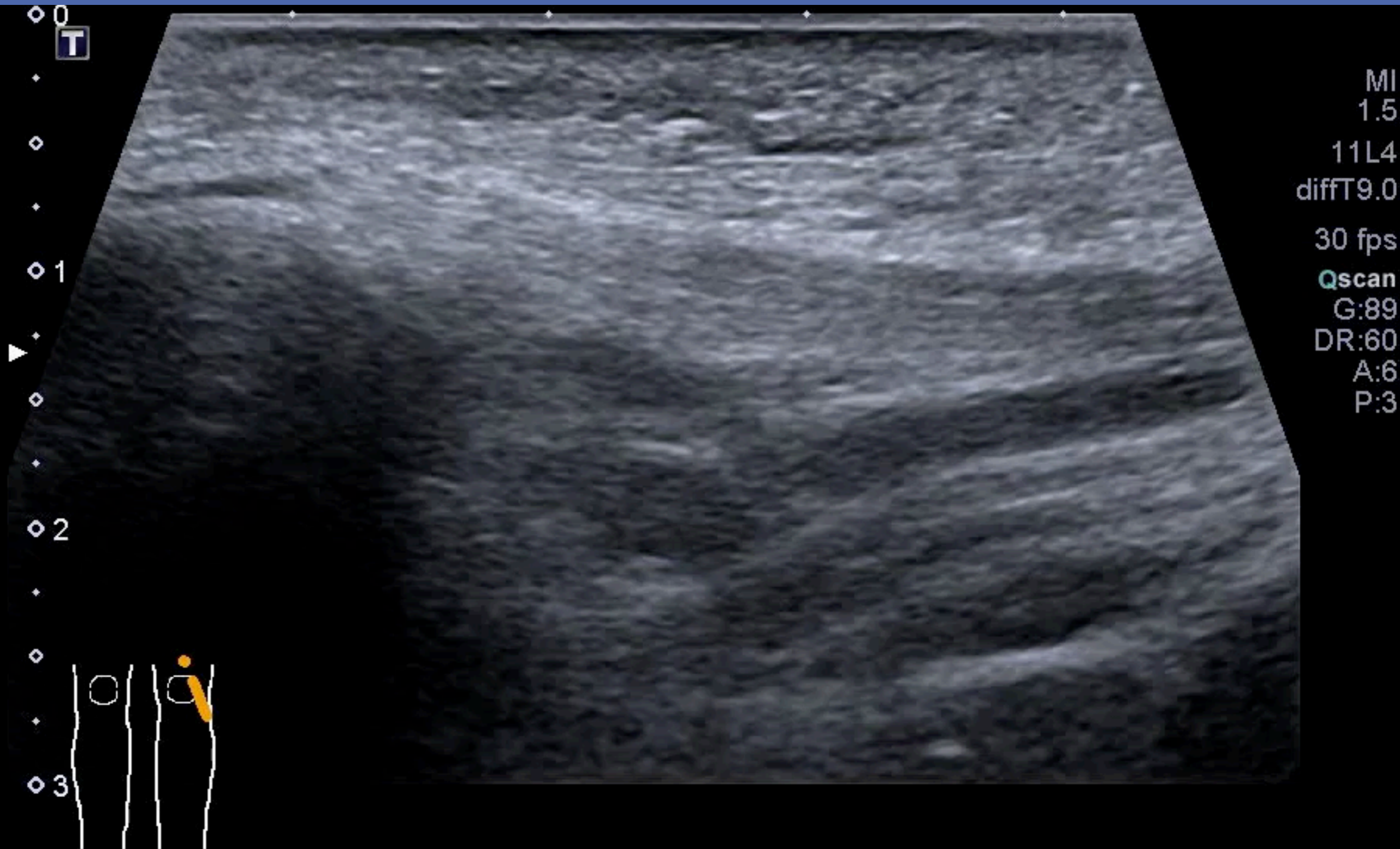P



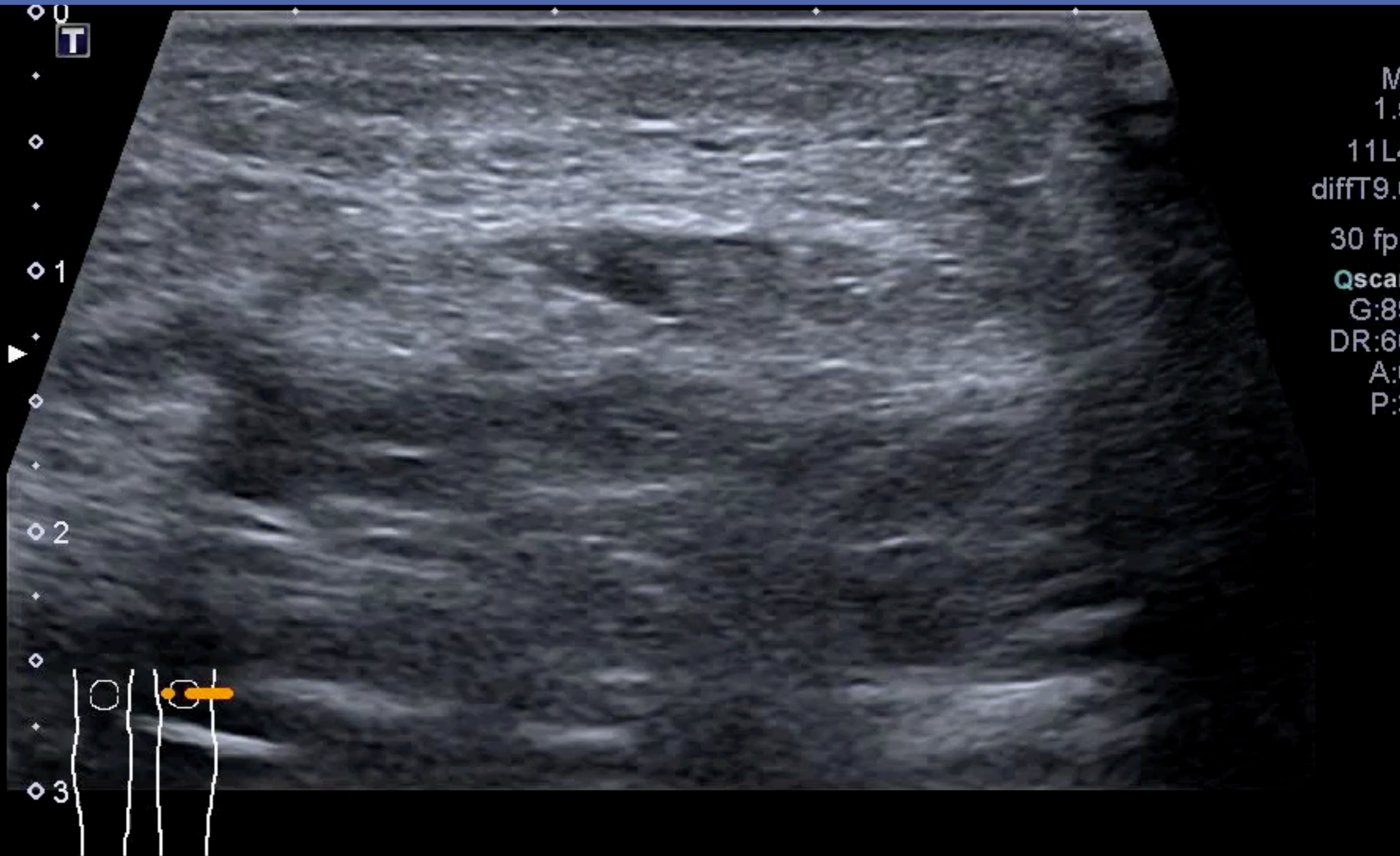G
P R
30 120

2.0cm

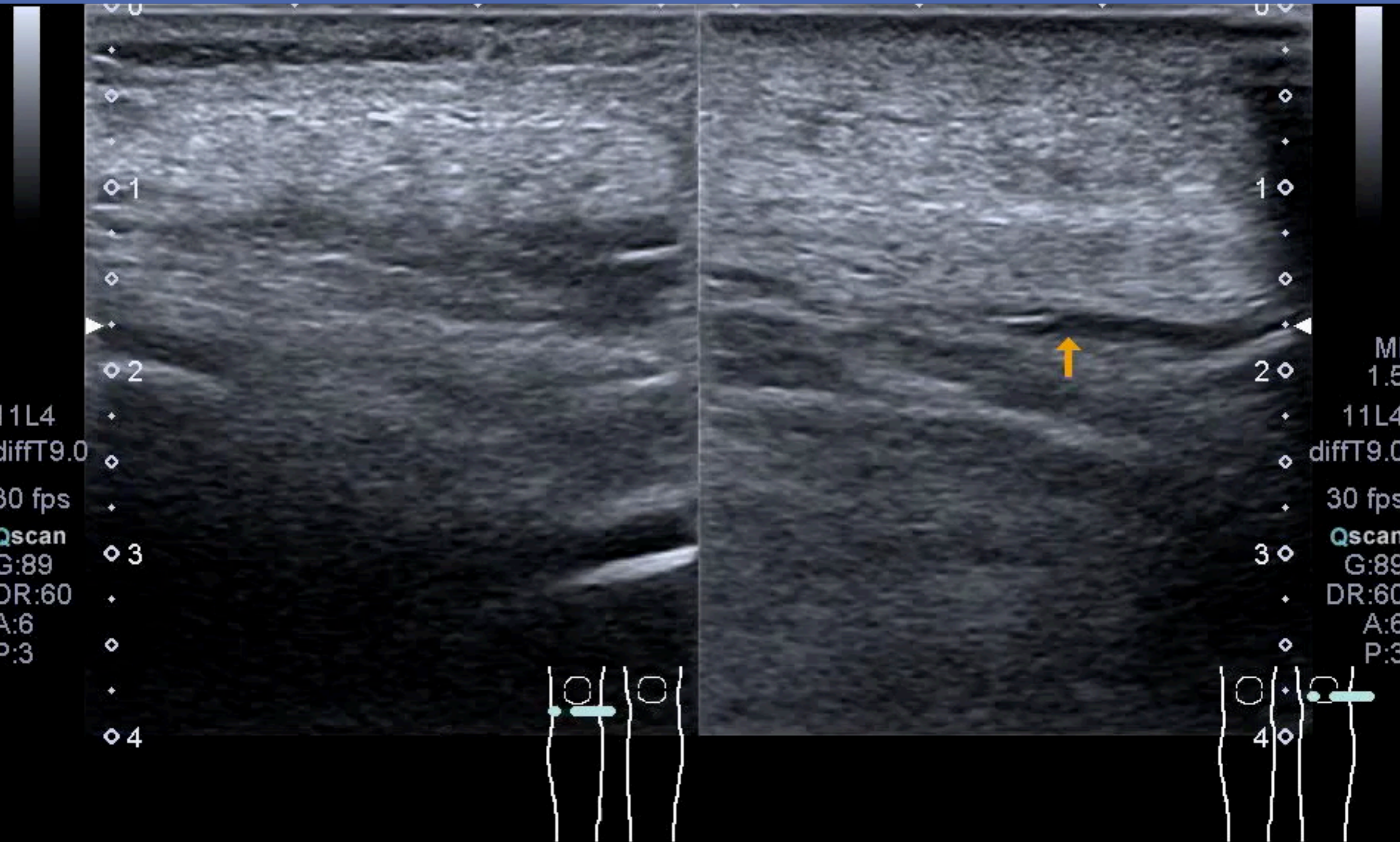
Patellar tendon injury ?



Patellar tendon injury ?



Patellar tendon injury



Bonus 3

ST-MSK US

FB

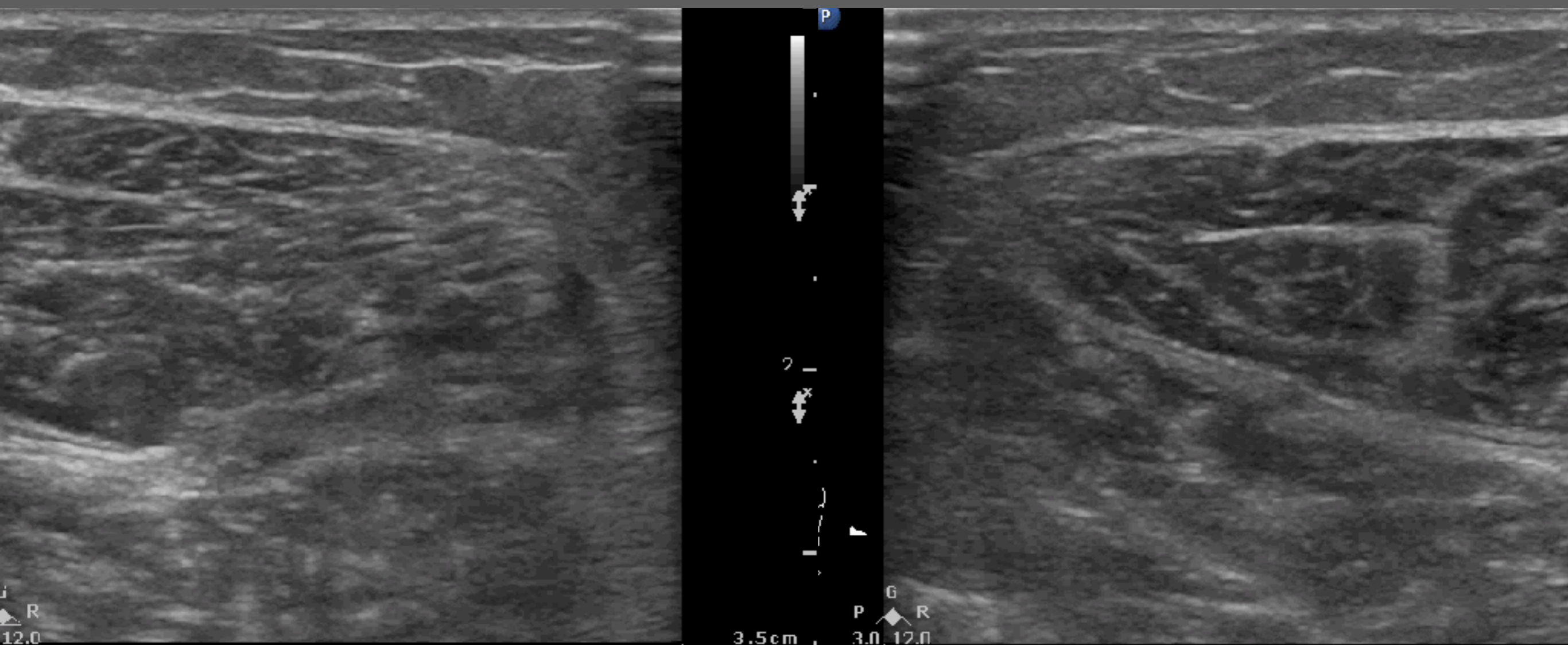
Tendon

Muscle

請問那一邊的小腿有問題？

Left calf

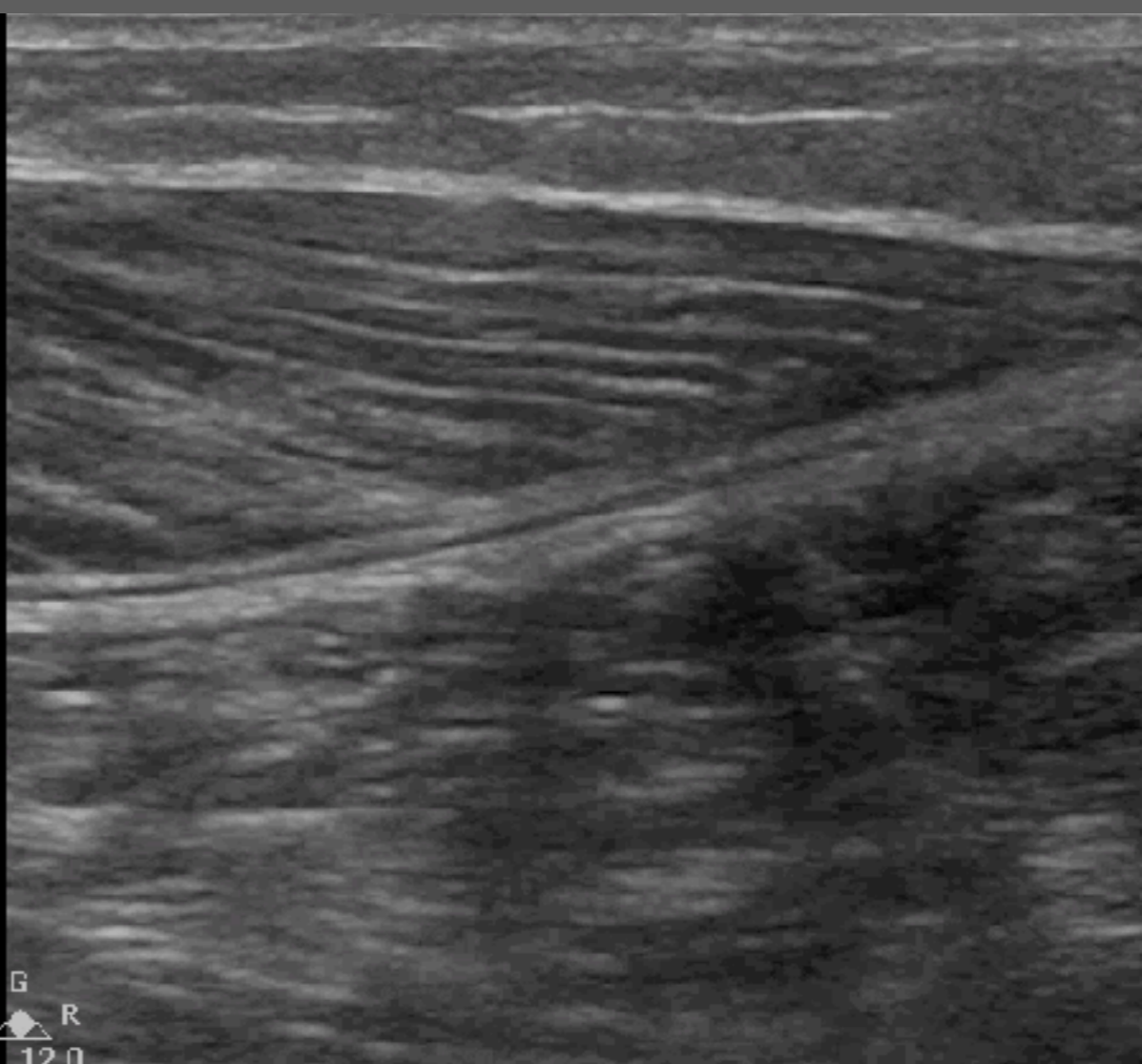

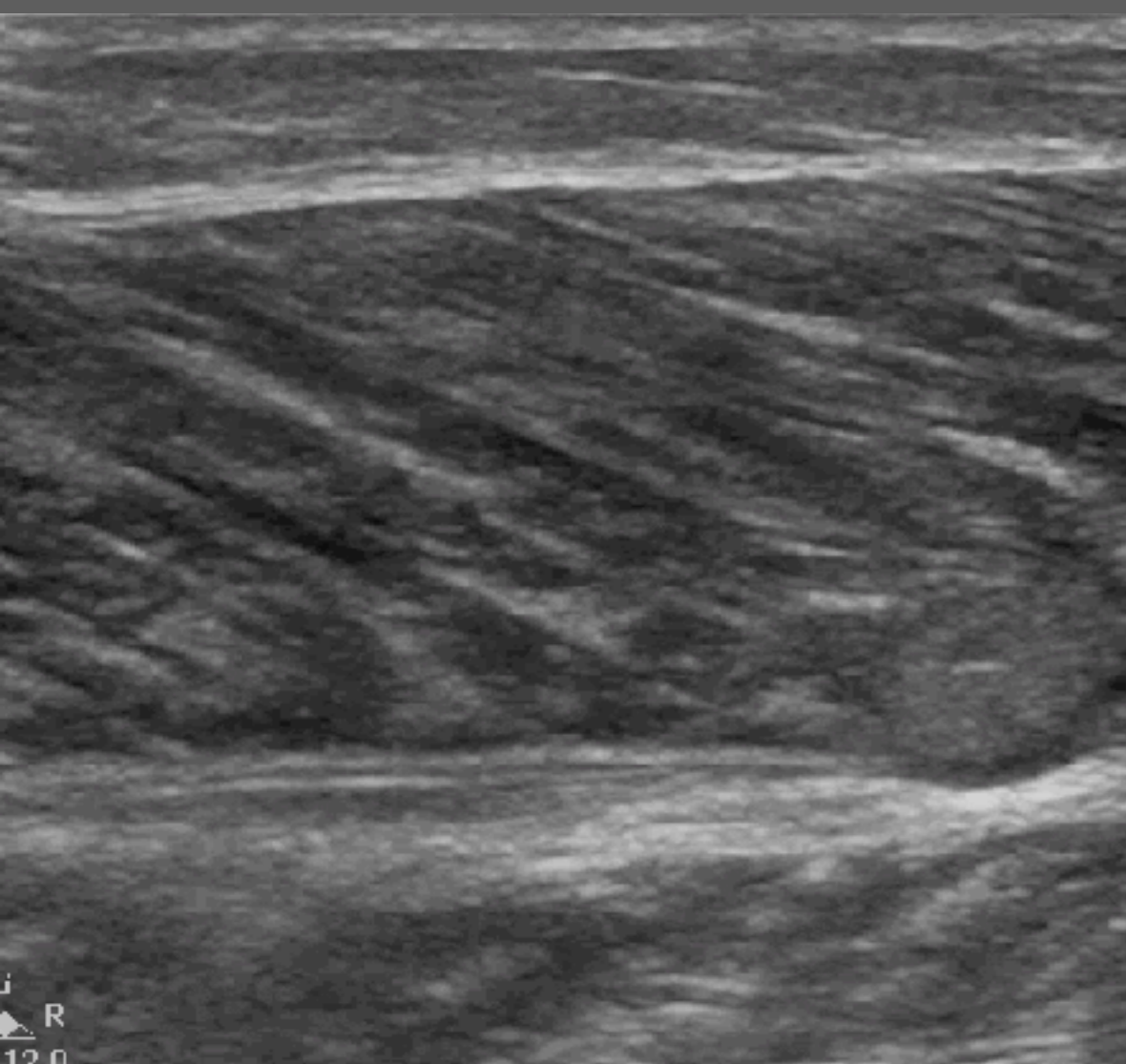
Right calf



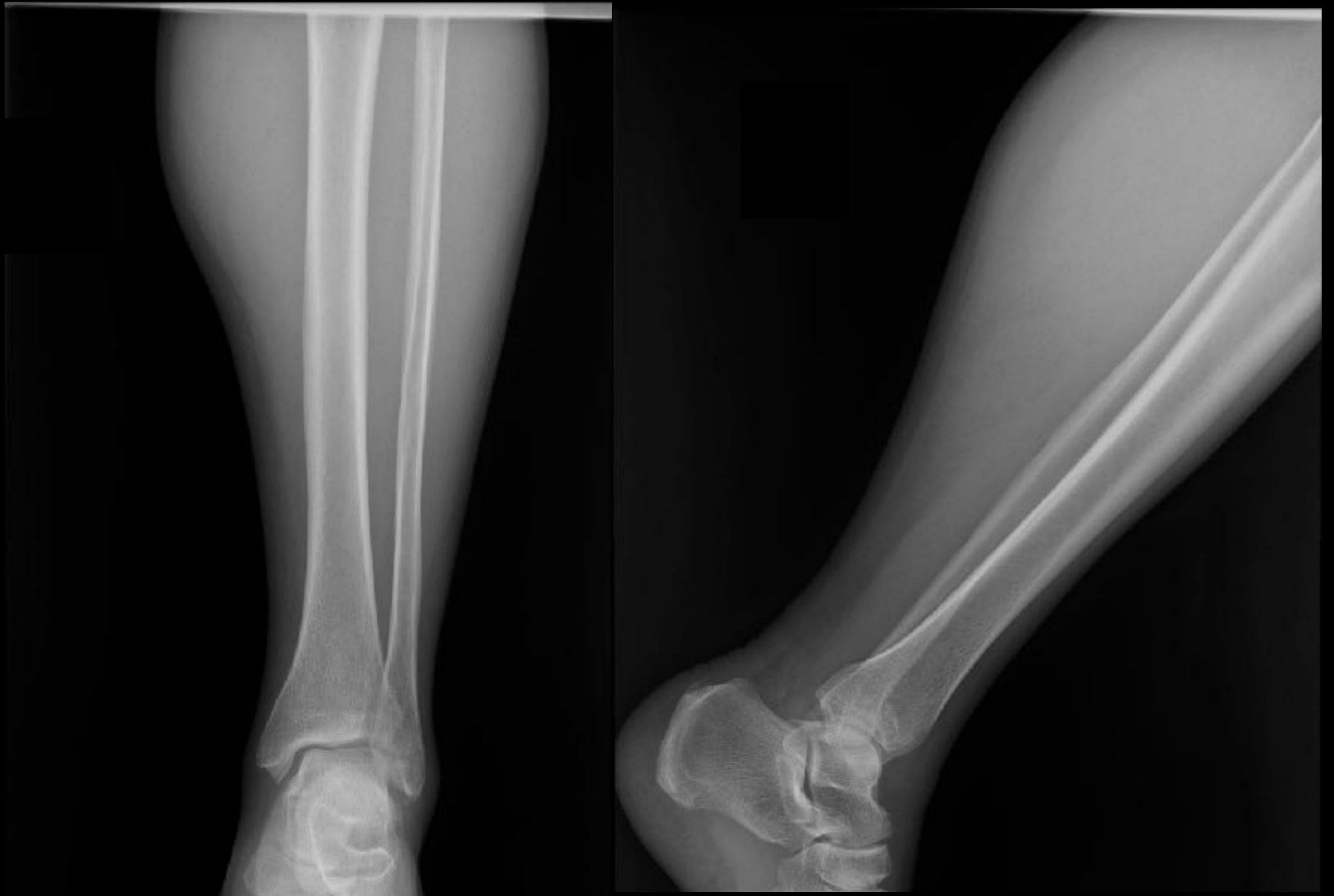Gastrocnemius M tear

Left calf

Right calf



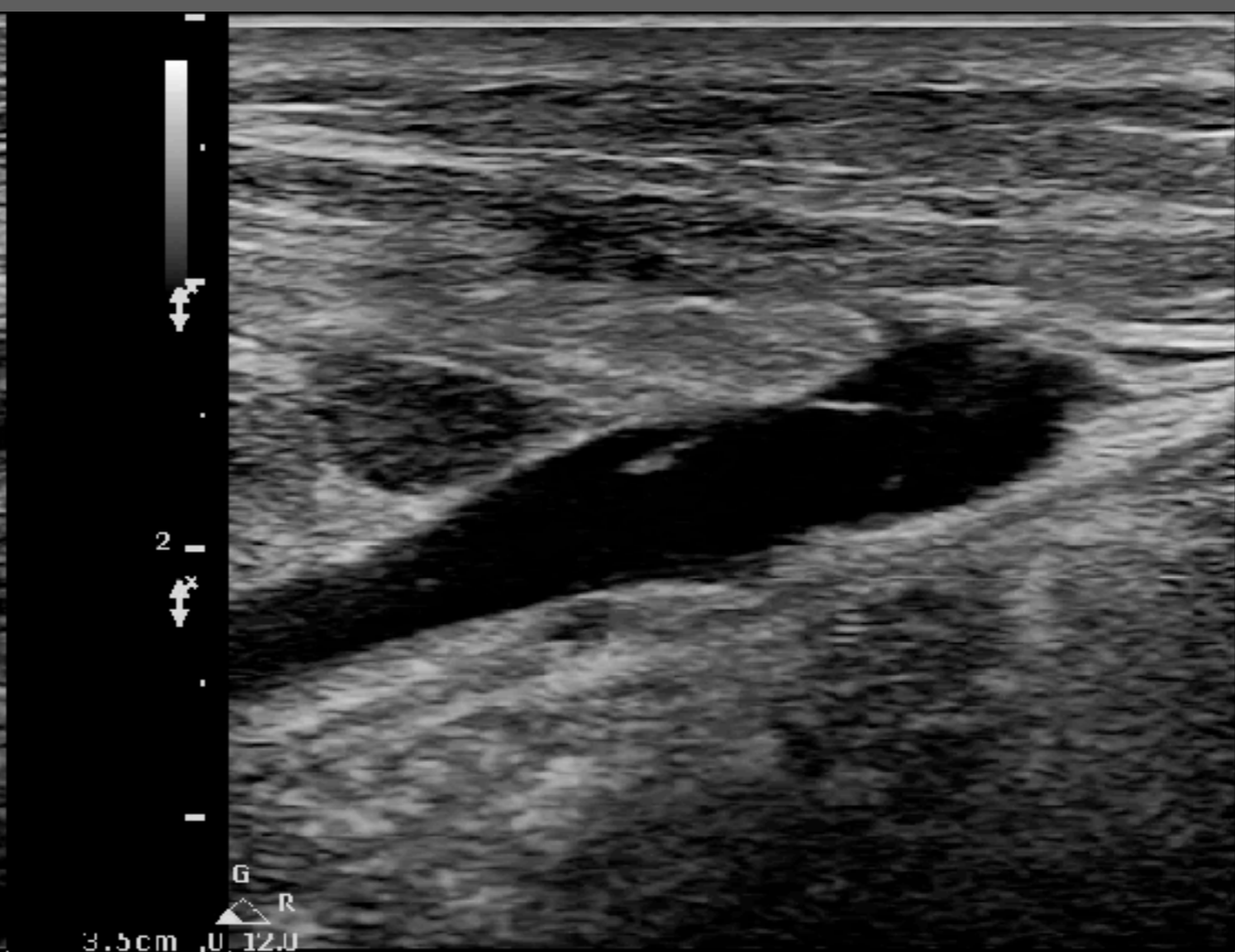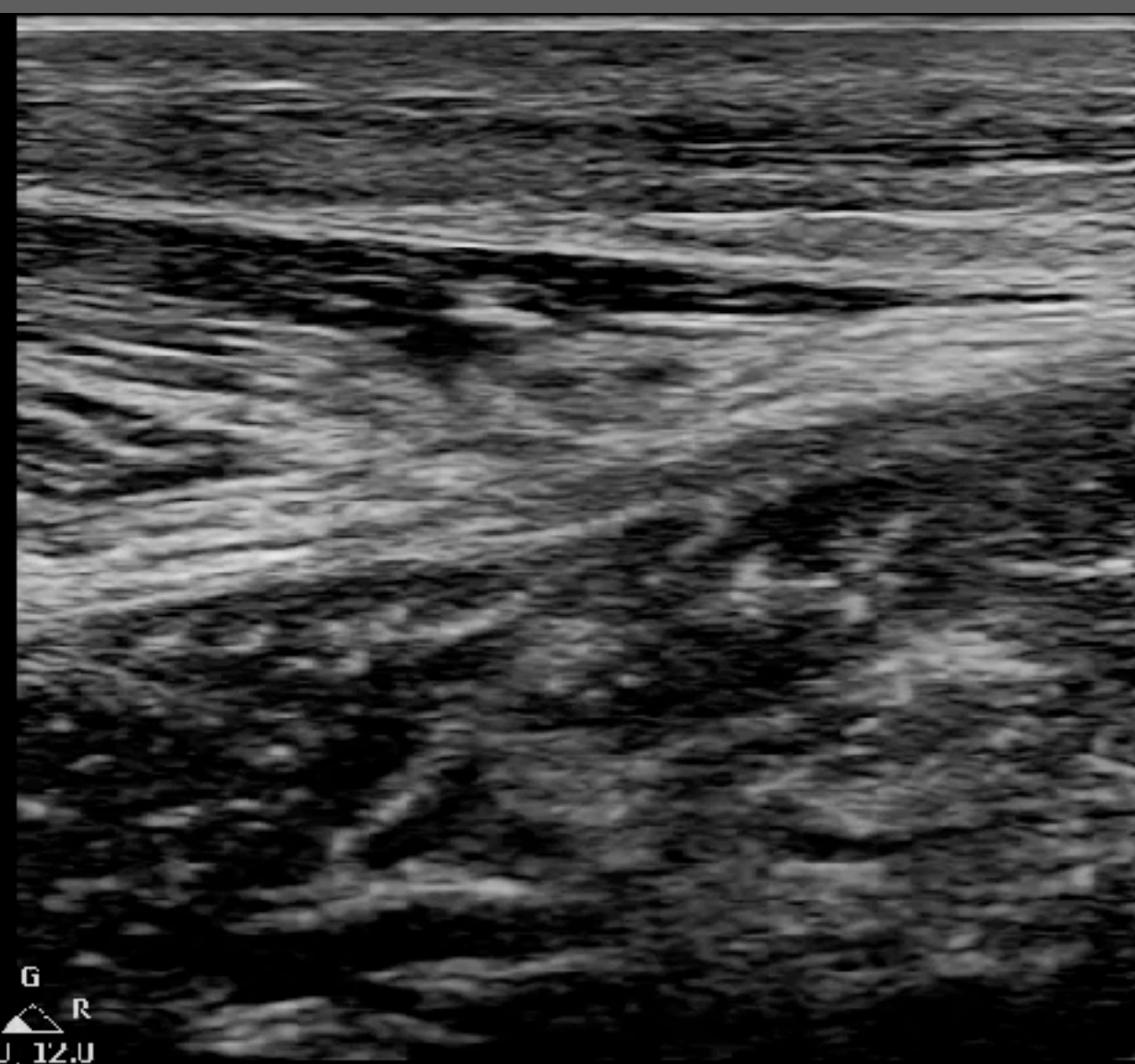
58M, right leg pain while running



Calf muscle tear

Left calf

Right calf



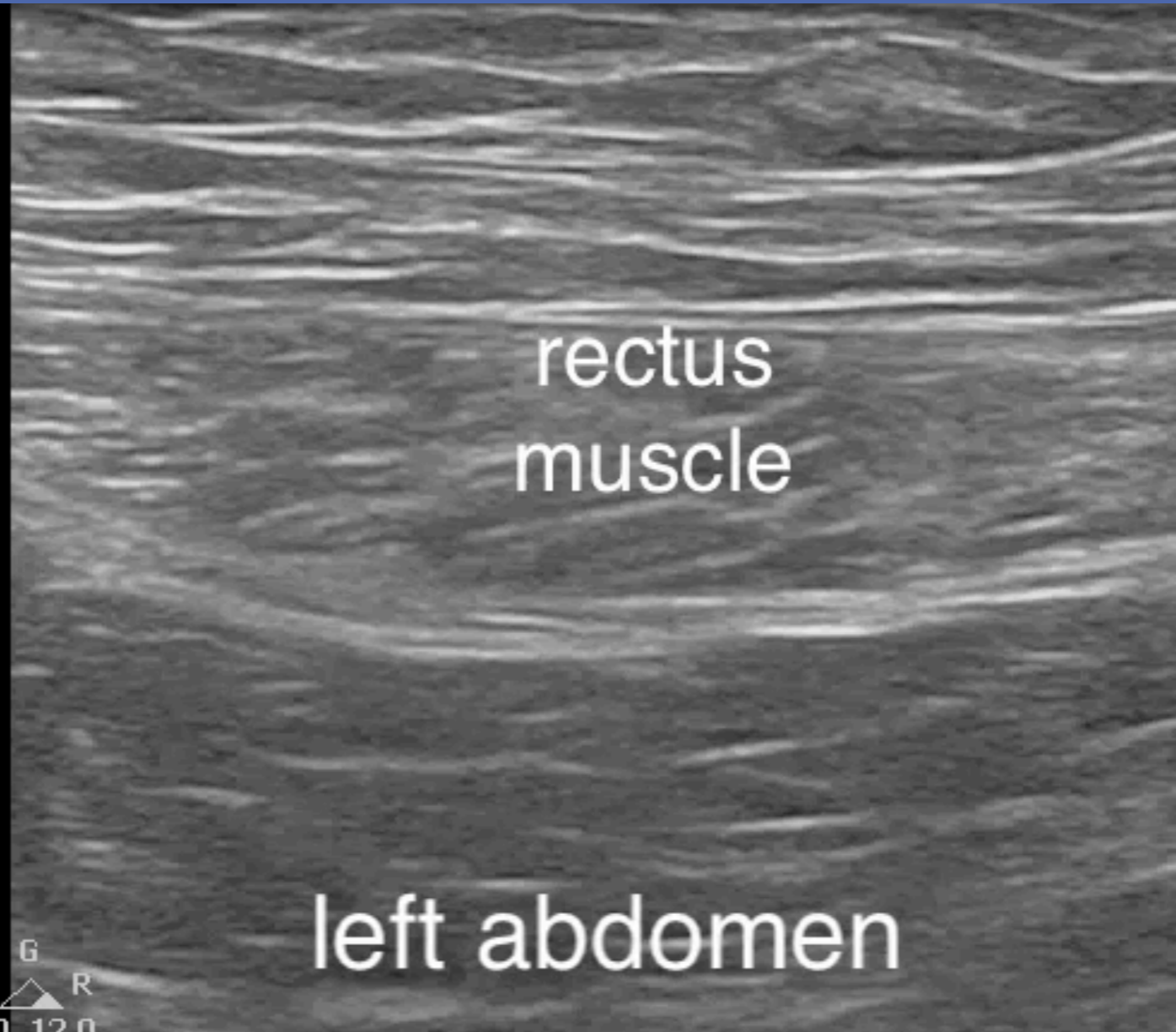Rectus sheath muscle hematoma

L12-3
46 Hz
3.5cm

2D
Res
Gn 100
C 56
3 / 2 / 1



P G R
3.0 12.0



2

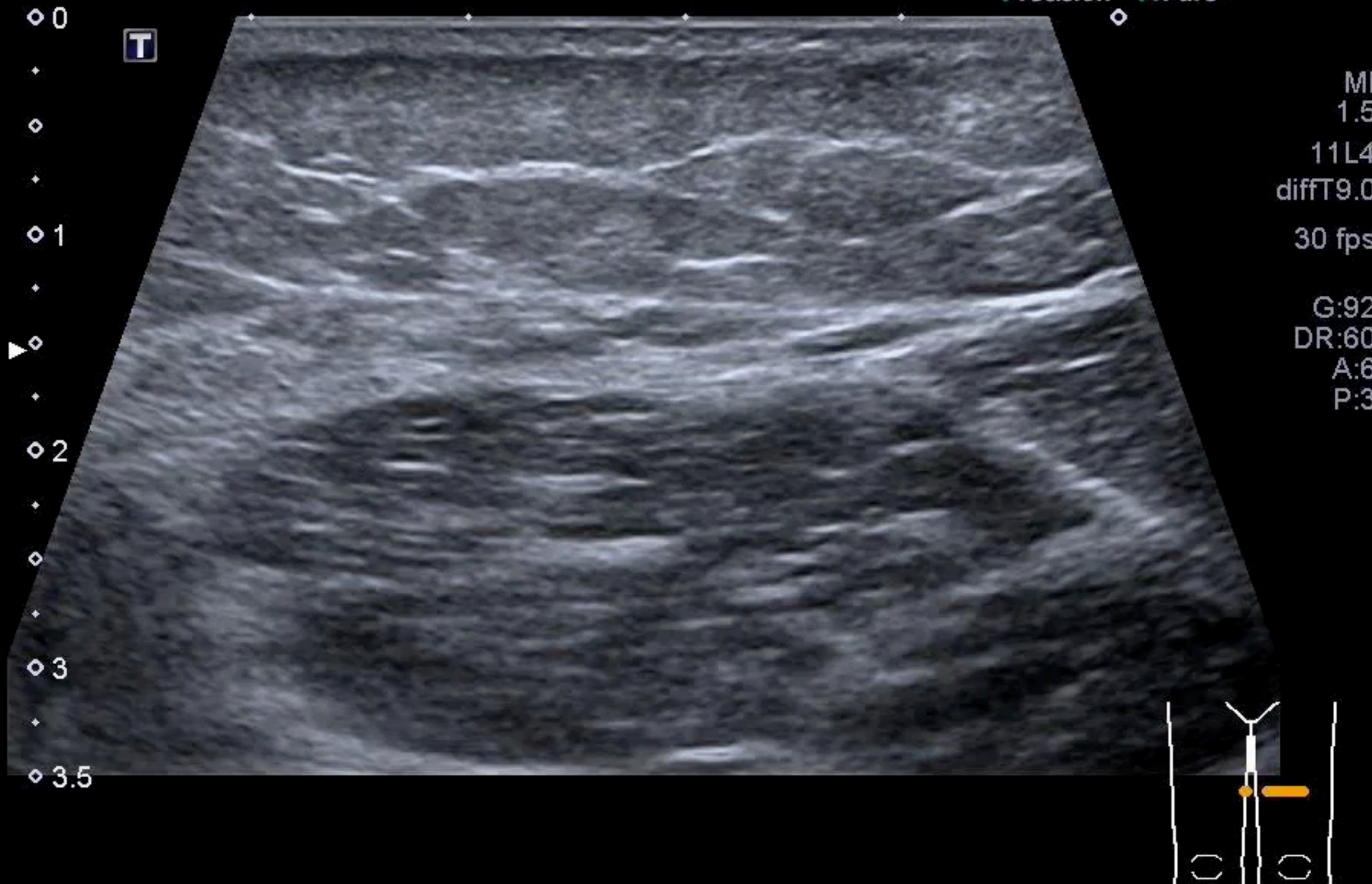
3.5cm

Outline

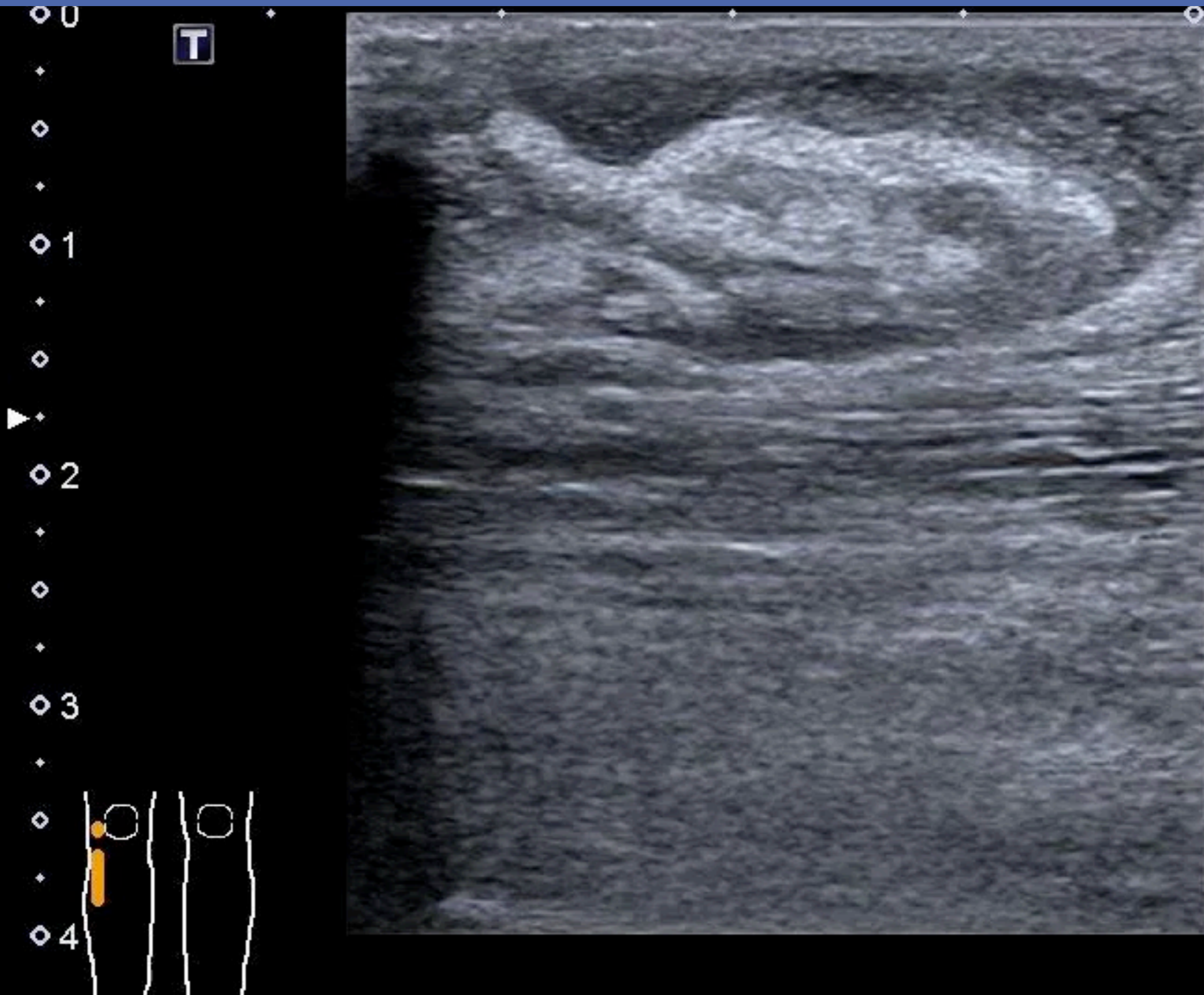
Texture

Content

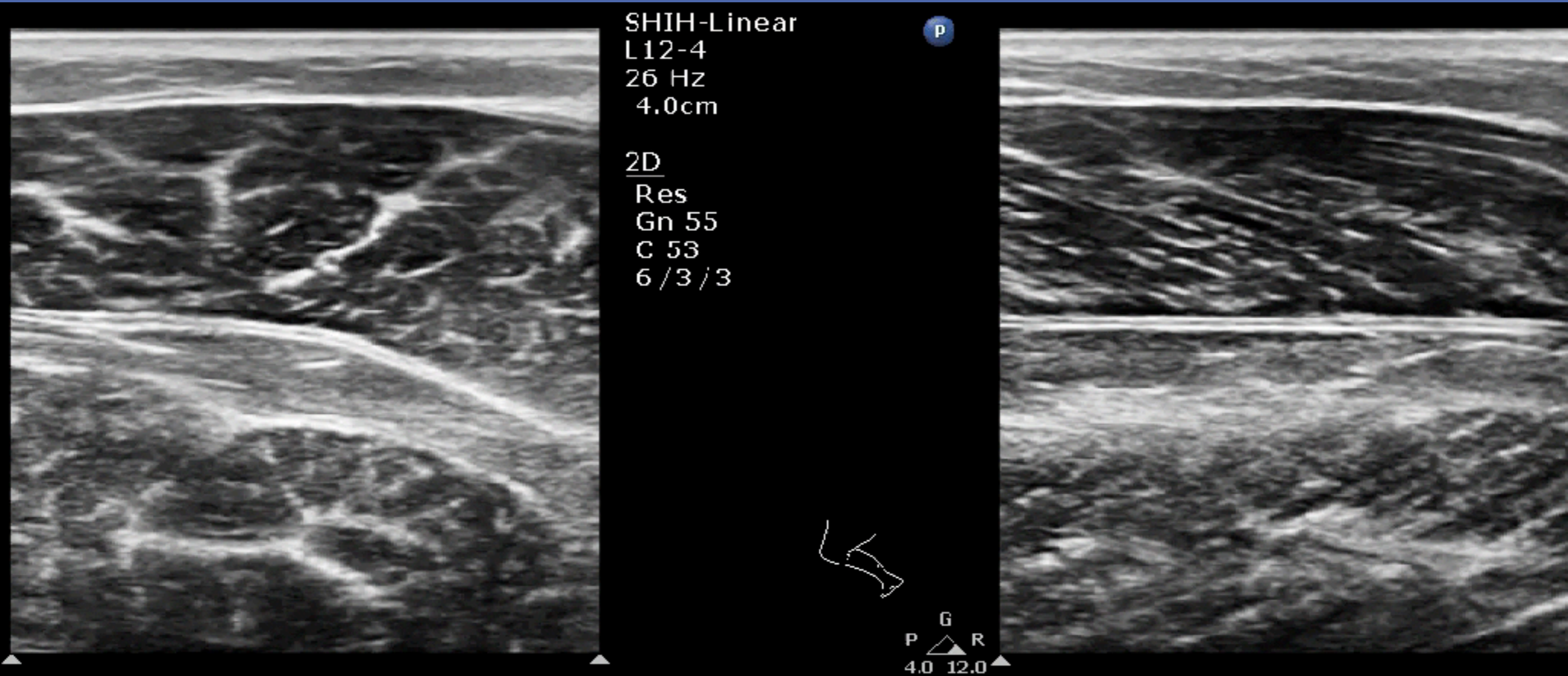
Left thigh contusion



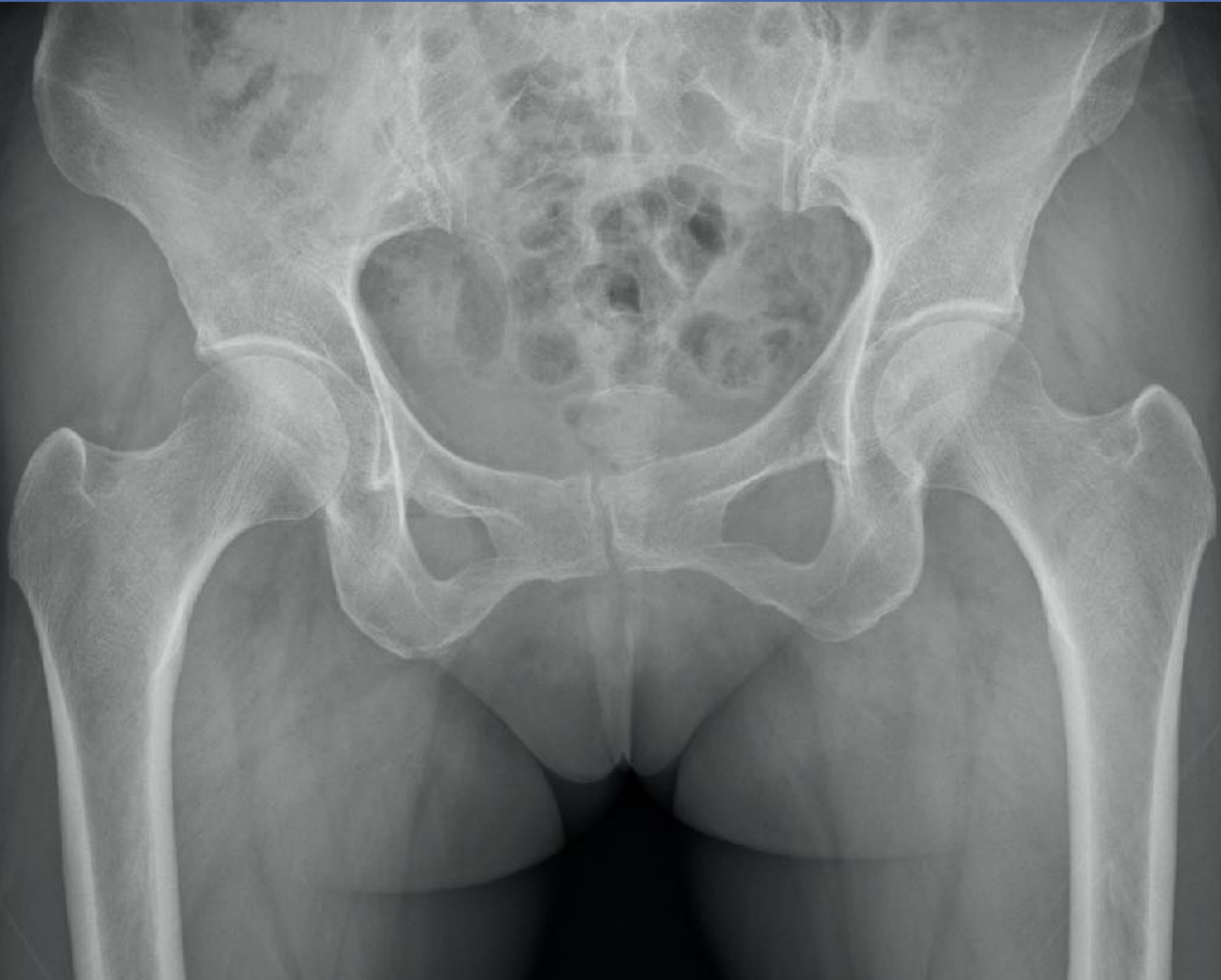Knee contusion



26F with thigh contusion

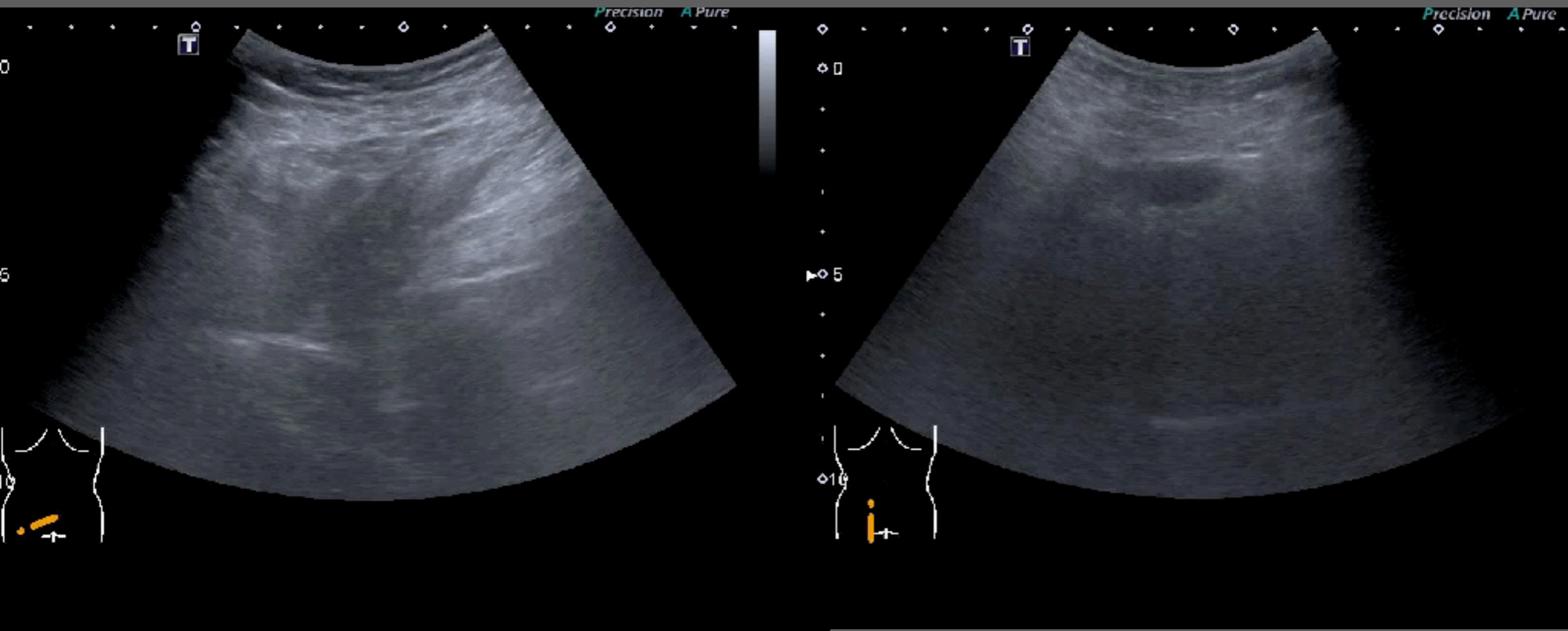


跌坐後左臀部痛，返家後腫起來



R

跌坐後左臀部痛，返家後腫起來



Take Home



Abscess

Effusion

Occult Fx

Radiolucent FB

Tendon

Muscle

juice119@gmail.com
POCUSAcademy.com

FB: Emergency Ultrasound Training Center