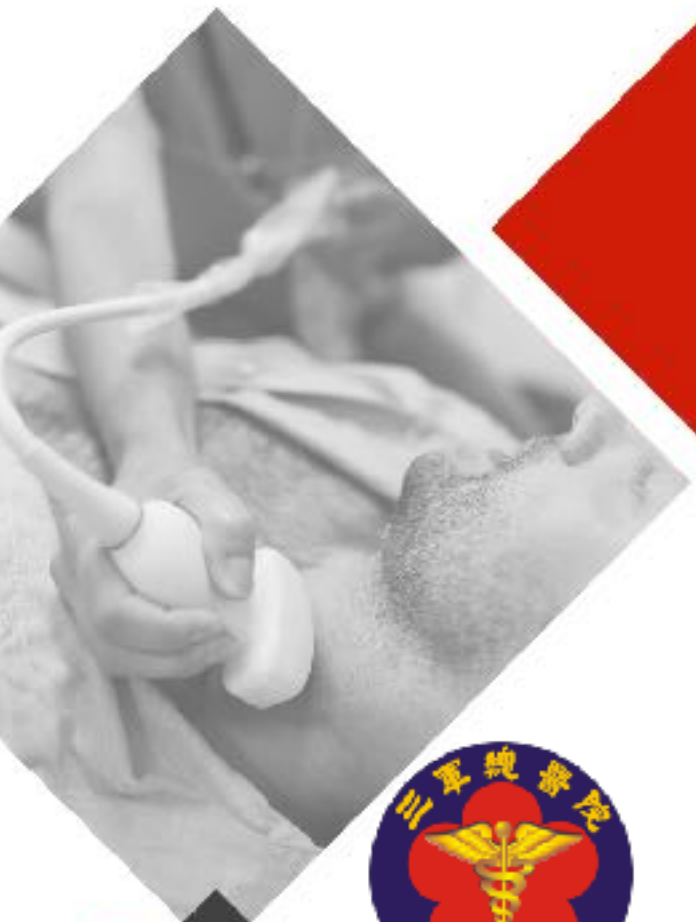



ULTRASOUND
PROGRAM



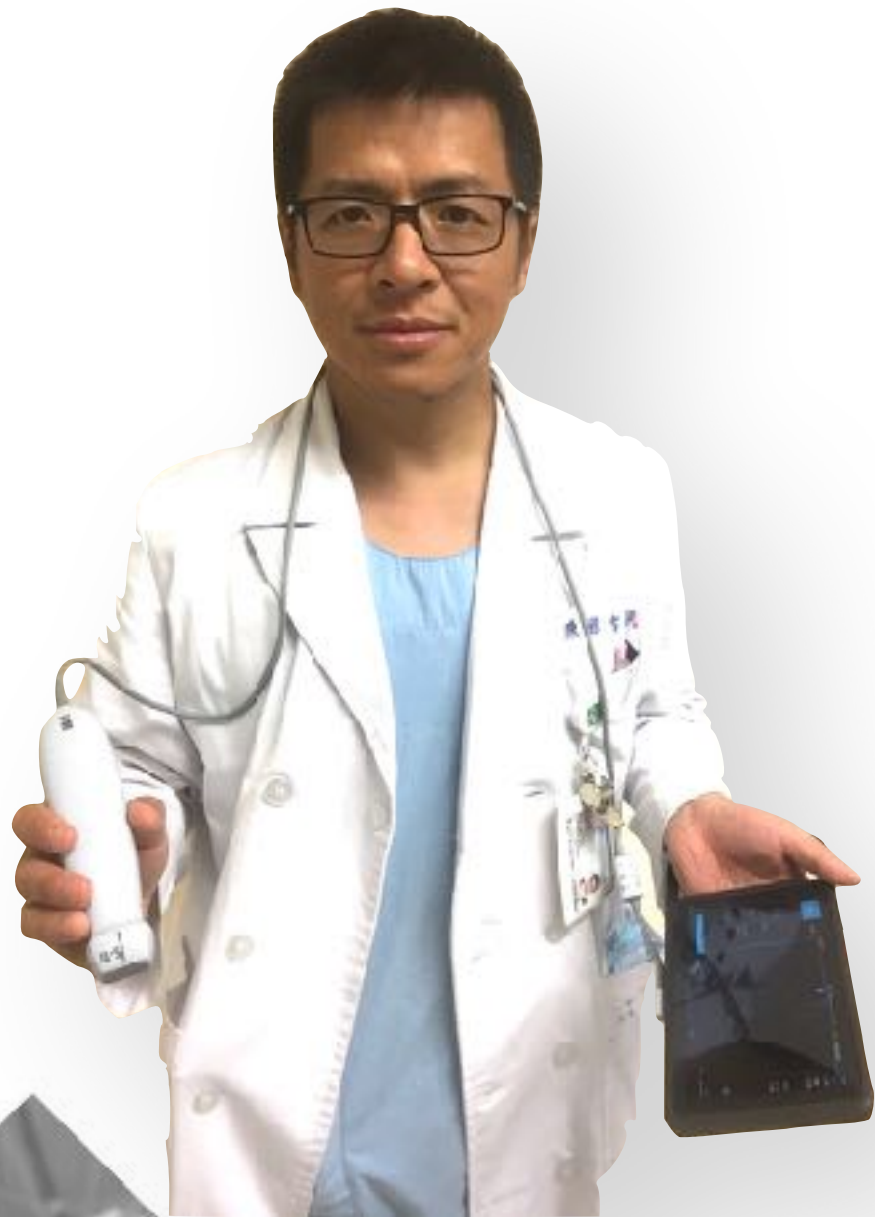三軍總醫院

Wholehearted, Holistic Care
全 心 三 總 · 全 人 照 護

POCUS

急重症超音波應用
2020/07/18

陳國智醫師 西園急診



急救加護重症超音波工作坊負責人
AEACUS Network President
前急診超音波委員會主委

Faculty

-WINFOCUS, PERCUSS, WFPICC

POCUS Academy

Emergency Ultrasound Training Center

POCUS Academy

Point-of-care ultrasound is the visual stethoscope in the 21st century

POCUSACADEMY

POCUSWORLD



CATEGORY

[POCUS Case \(83\)](#)

[POCUS Course \(71\)](#)

[POCUS Education \(129\)](#)

[POCUS Issue \(75\)](#)

[SonoAnatomy \(29\)](#)

[Teaching video \(64\)](#)

MOST VIEWED POSTS

- [1 外傷超音波的基本報告 \(Trauma EUS\)](#)
- [2 \[Sonoanatomy\] Liver, Portal vein, hepatic vein](#)
- [3 \[Sonoanatomy\] IVC](#)
- [4 22歲女性，右下腹痛2天](#)
- [5 \[Sonoanatomy\] Pancreas, splenic vein, SMV](#)
- [6 iViz 手持式超音波全台初體驗](#)

RECENT POSTS

[受保護的文章：POCUS在急性腹痛的應用](#)

[2019 4th POCUS Game](#)

[Pain Management](#)

[超音波基礎原理和影像](#)

[漲大的膀胱、放不進的導尿管](#)

[急診進階超音波課程@新光\(已額滿\)](#)

[AACES: Abdomen & PED US Courses](#)

[Sonographic Evaluation of Aetiology for](#)



POCUS Academy

1,073 位訂閱者

訂閱

首頁

影片

播放清單

社群

頻道

簡介



上傳 全部播放

排序依據

POCUS-急診緣由

症狀問題 線索時間 診斷治療

15:44

20181221@雙和急診基礎課程簡介(15分鐘精華)
觀看次數：366次 · 3 個月前

POCUSAcademy@ChenKC

1:44

Ureteral stone 張簡世新醫師提供
觀看次數 Ureteral stone 張簡世新醫師提供

POCUSAcademy@ChenKC

0:40

Paracentesis (off plane)
觀看次數：81次 · 7 個月前

POCUSAcademy@ChenKC

1:38

Diverticulitis
觀看次數：247次 · 1 年前

POCUSAcademy@ChenKC

0:49

Saphenous thrombophlebitis
觀看次數：122次 · 1 年前

1:00:48

20191018_Focused Cardiac USG@SKHED
觀看次數：327次 · 1 年前

Appendicitis

51:00

P-ABDOMEN for pediatric diseased abdomen @ SKH-...
觀看次數：174次 · 1 年前

1:06:19

POCUS for male genital emergency
觀看次數：159次 · 1 年前

POCUSAcademy@ChenKC

0:50

84M, sudden onset of epigastric pain
觀看次數：212次 · 1 年前

0:11

Right adrenal gland tumor
觀看次數：318次 · 1 年前

KCChen@SKHED

1:48

Torsion 解說
觀看次數：177次 · 1 年前

CHEST

T for tamponade

PSLA & SC4C & I 1:15:34

POCUS for acute dyspnea
觀看次數：336次 · 1 年前

20170322 新光急診教學實錄 RUSH
觀看次數：264次 · 1 年前

20161012 Basic EUS
觀看次數：950次 · 1 年前

POCUS for Acute dyspnea (CHEST)
觀看次數：340次 · 1 年前

第一卷第二期

刊登日期：2018/04/30

Taiwan Emergency Medicine Bulletin 1(2) : e2018010211

重點式超音波教學：活用手中探頭的6個技巧

第一卷第四期

刊登日期：2018/08/03

Taiwan Emergency Medicine Bulletin 1(4) : e2018010410

重點式超音波個案解析：中年女性胸痛

第一卷第六期

刊登日期：2018/12/07

Taiwan Emergency Medicine Bulletin 1(6) : e2018010610

台灣急診醫學里程碑中的重點式超音波

POCUS

Ultrasound in Med. & Biol., Vol. ■, No. ■, pp. 1–10, 2016
Copyright © 2016 World Federation for Ultrasound in Medicine & Biology
Printed in the USA. All rights reserved
0301-5629/\$ - see front matter



ELSEVIER

<http://dx.doi.org/10.1016/j.ultrasmedbio.2016.06.021>

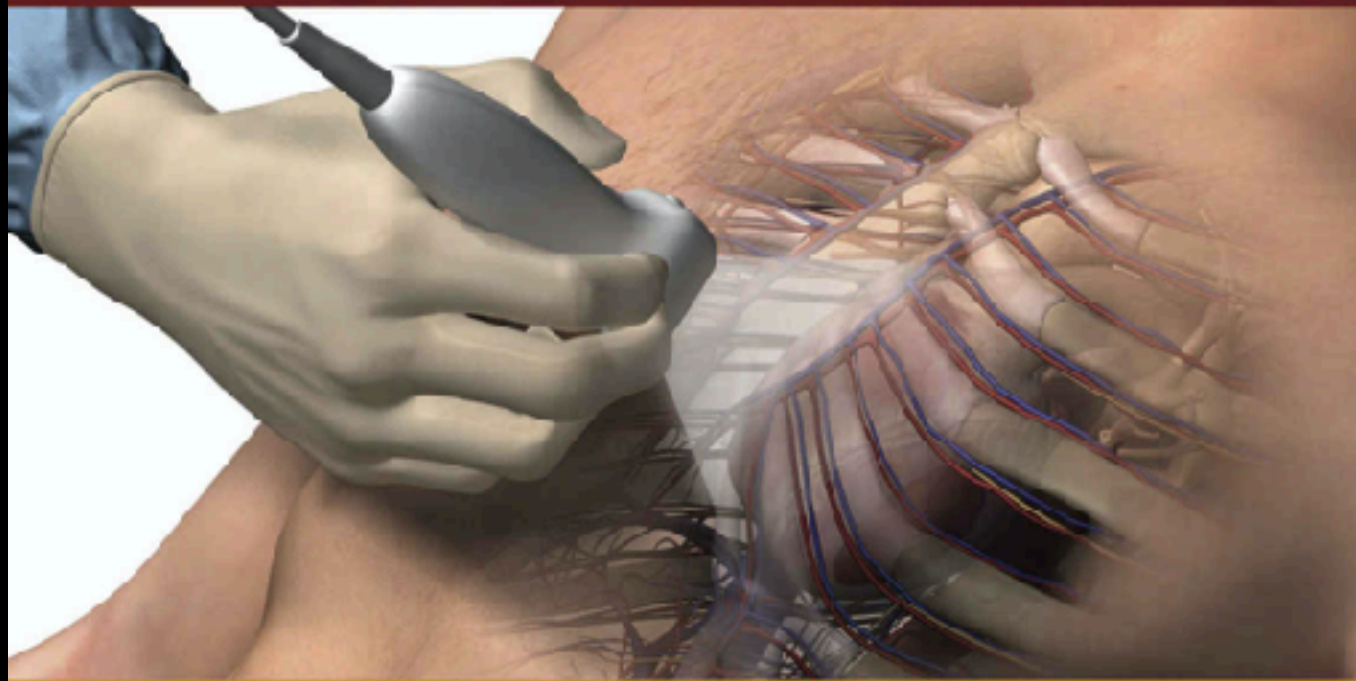
POINT OF CARE ULTRASOUND: A WFUMB POSITION PAPER

CHRISTOPH F. DIETRICH,^{*†} ADRIAN GOUDIE,[‡] LILIANA CHIOREAN,[§] XIN WU CUI,^{*†} ODD HELGE GILJA,[¶]
YI DONG,^{*||} JACQUES S. ABRAMOWICZ,[#] SUDHIR VINAYAK,^{**} SUSAN CAMPBELL WESTERWAY,^{††}
CHRISTIAN PÁLLSON NOLSØE,^{‡‡} YI-HONG CHOU,^{§§} and MICHAEL BLAIVAS^{¶¶}



Second Edition

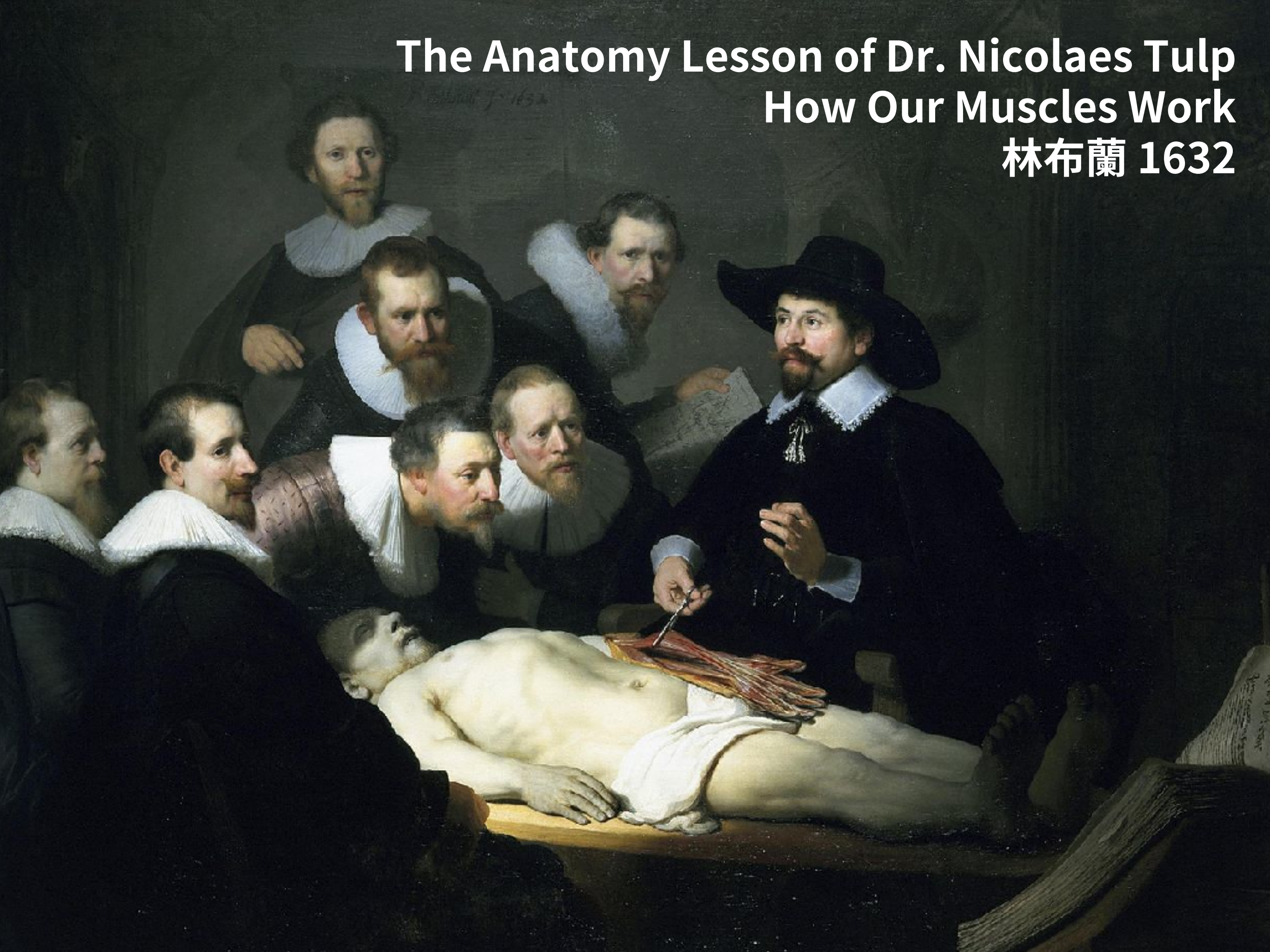
Point-of-Care **ULTRASOUND**



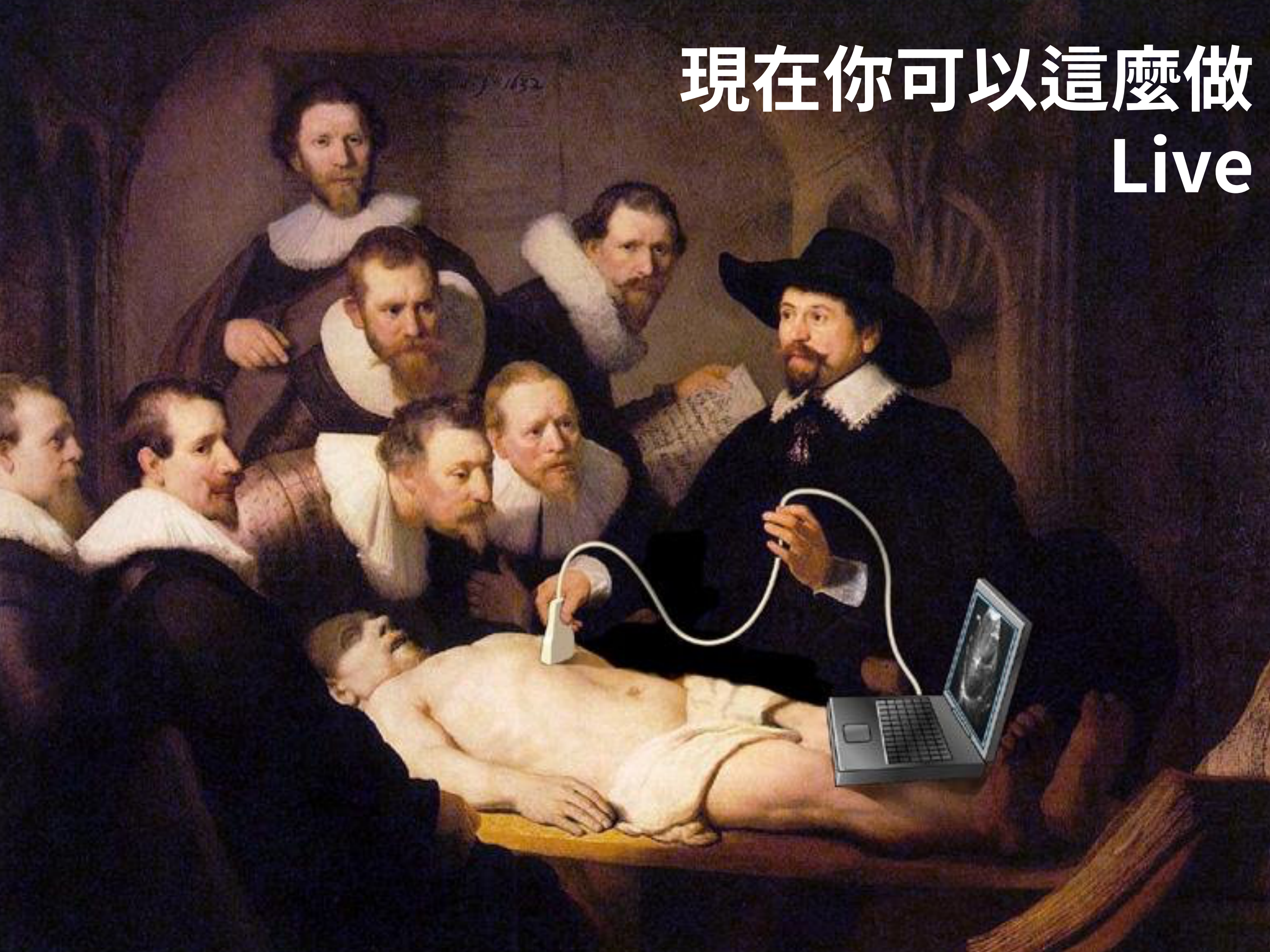
Nilam J. Soni
Robert Arntfield
Pierre Kory



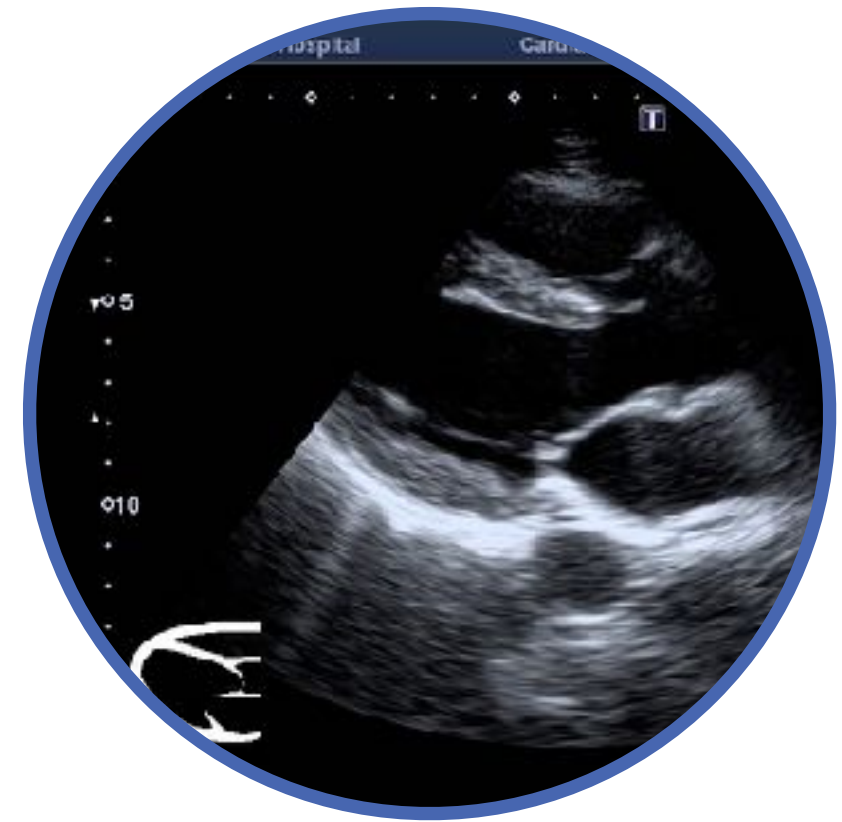
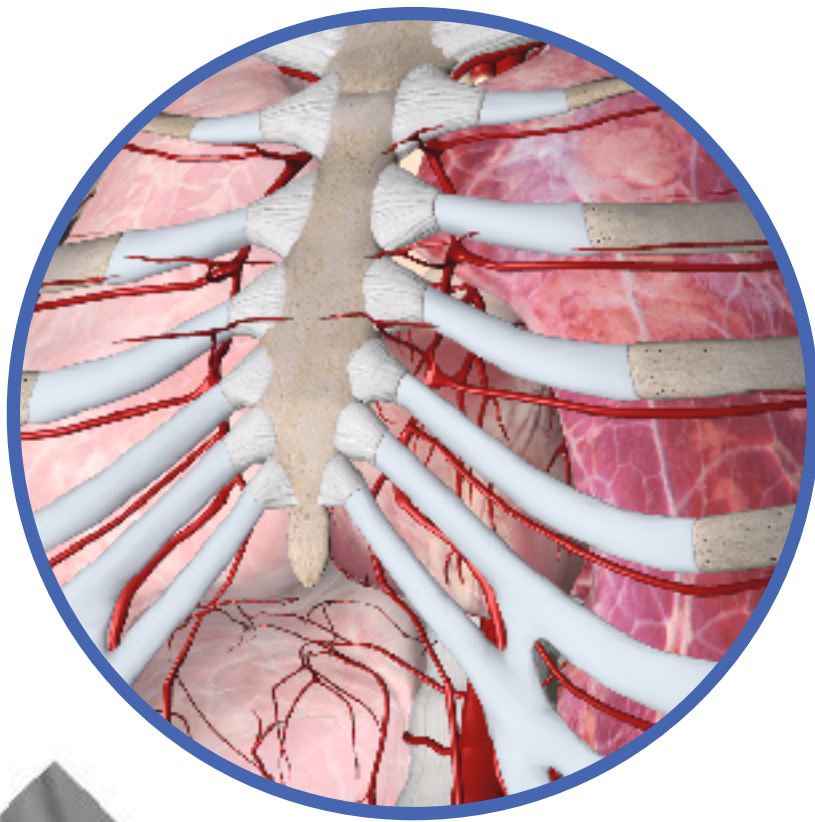
The Anatomy Lesson of Dr. Nicolaes Tulp
How Our Muscles Work
林布蘭 1632



現在你可以這麼做
Live



POCUS

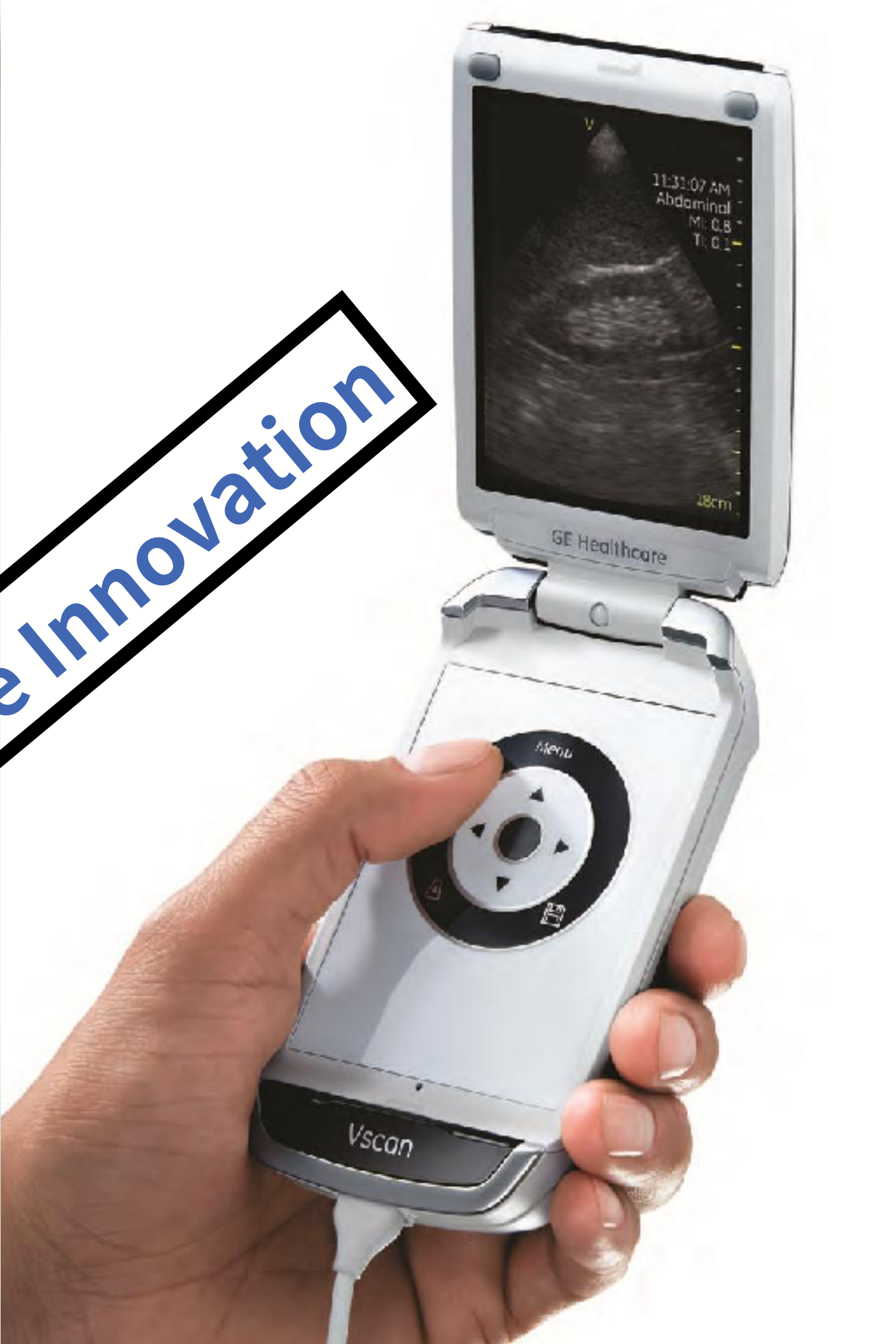
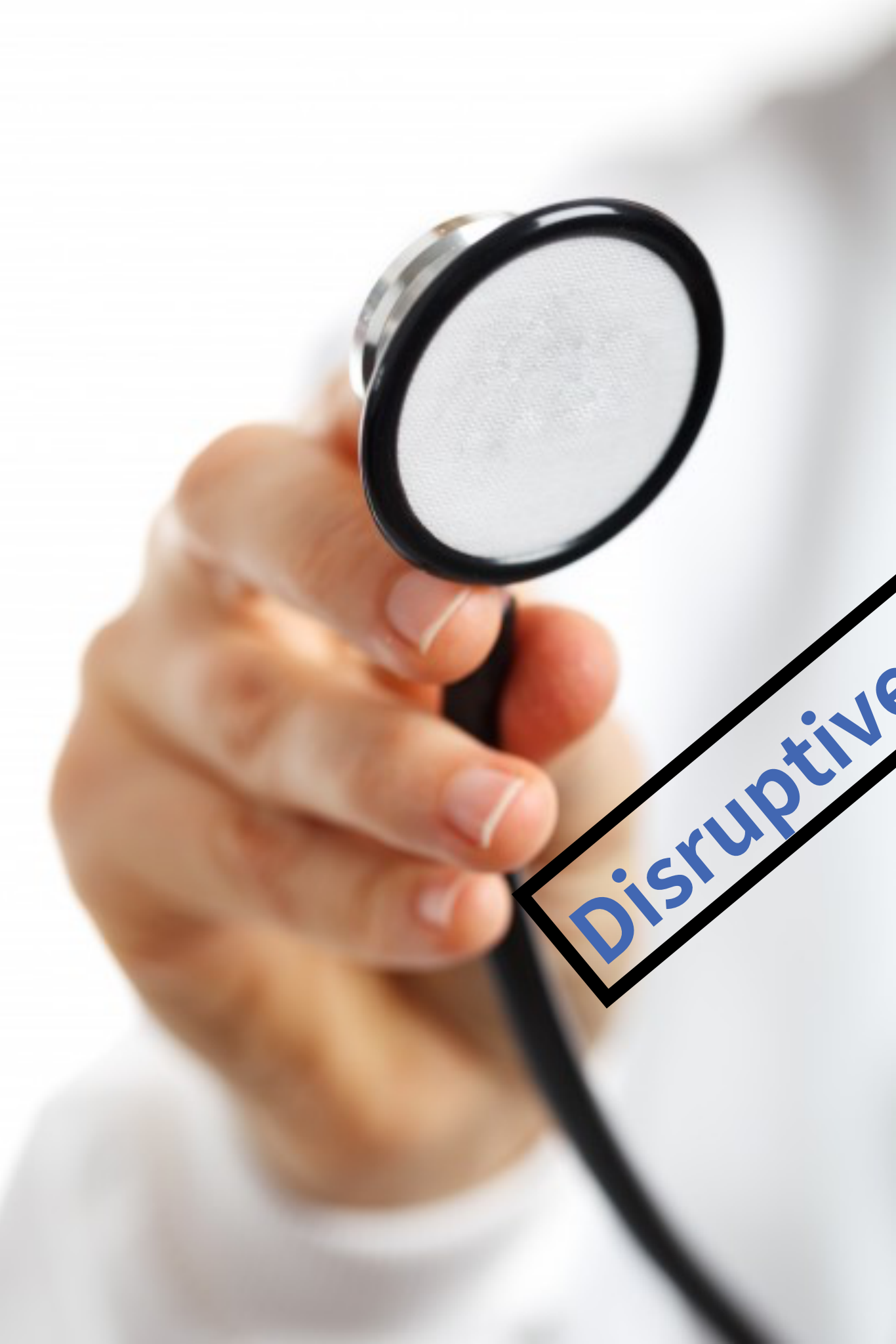
POCUS

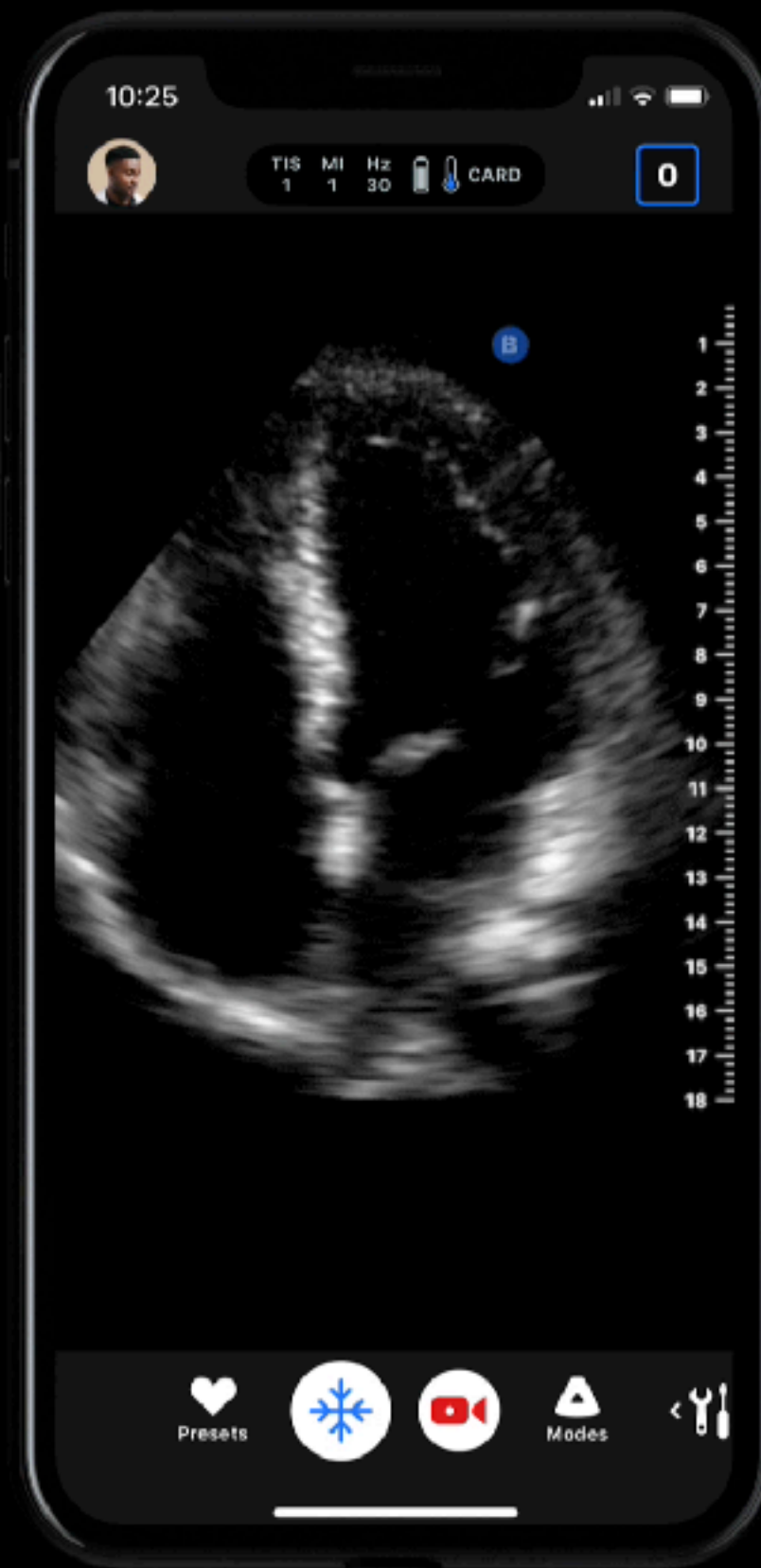Point-of-Care Ultrasound

“ultrasonography brought to
the patient and performed by
the provider in real time”


Moore, C. L., & Copel, J. A. NEJM 2011

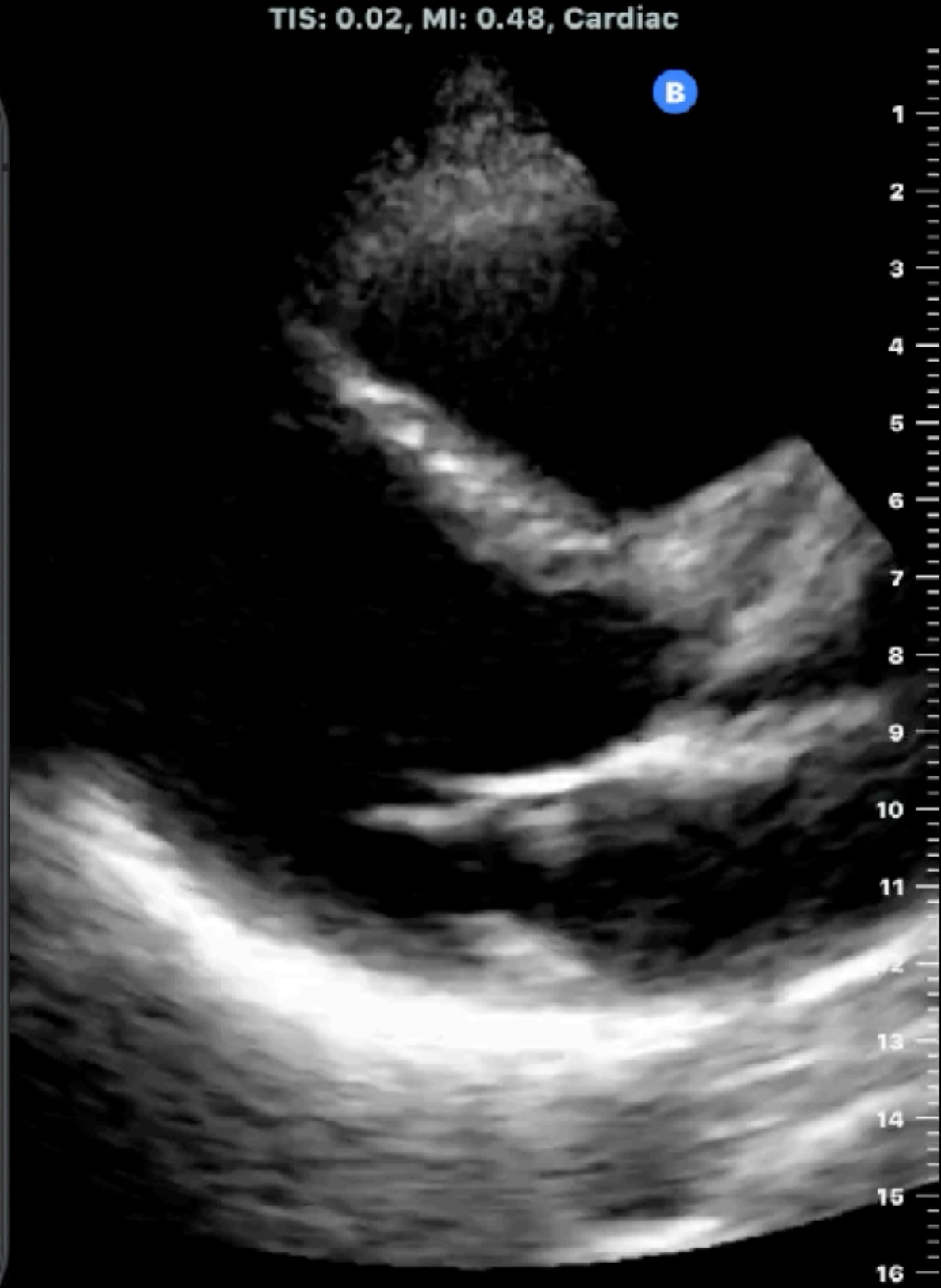
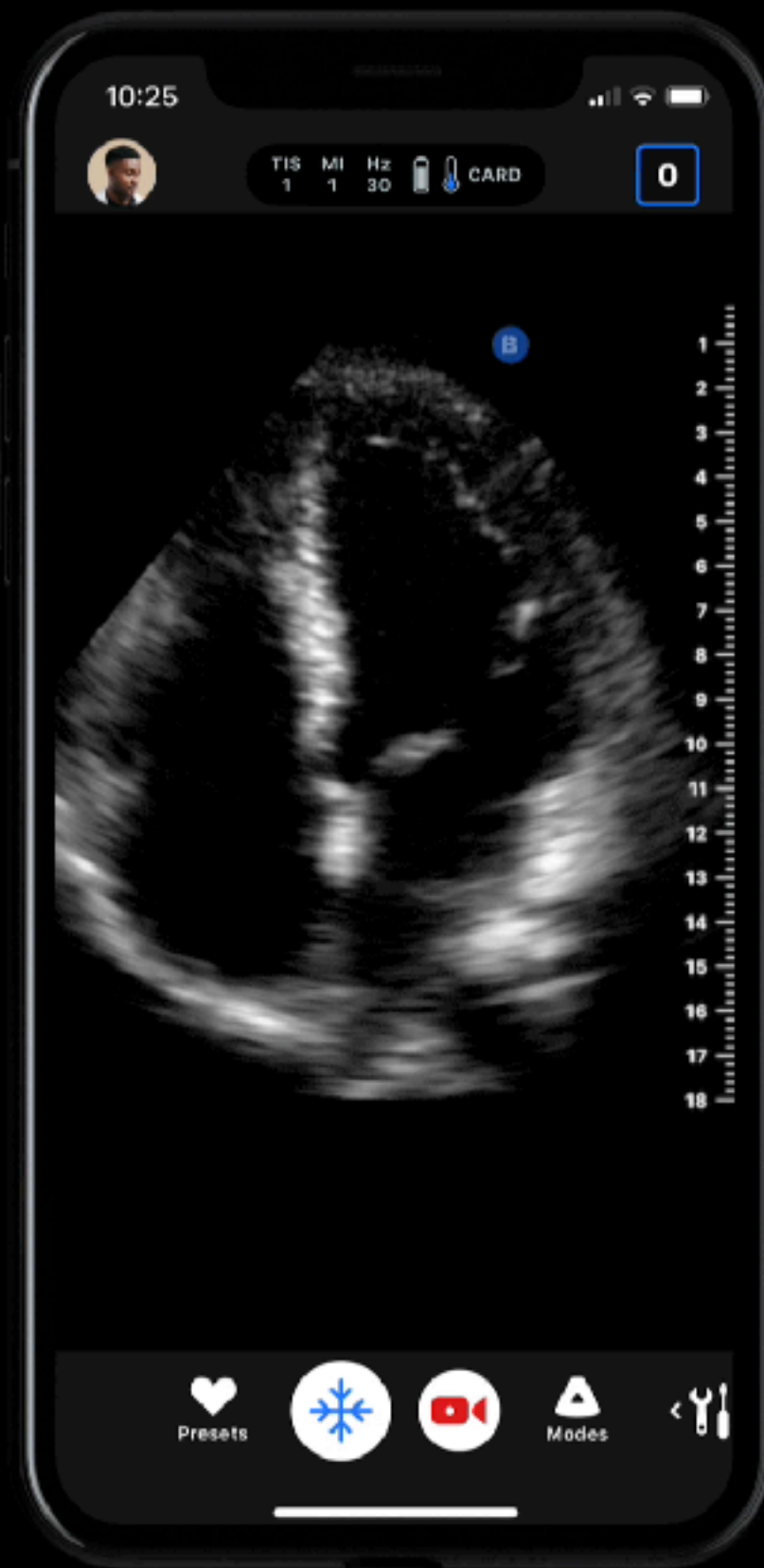

Disruptive Innovation



Butterfly iQ
\$ 2000





POCUS-急診緣由

症狀
問題

線索
時間

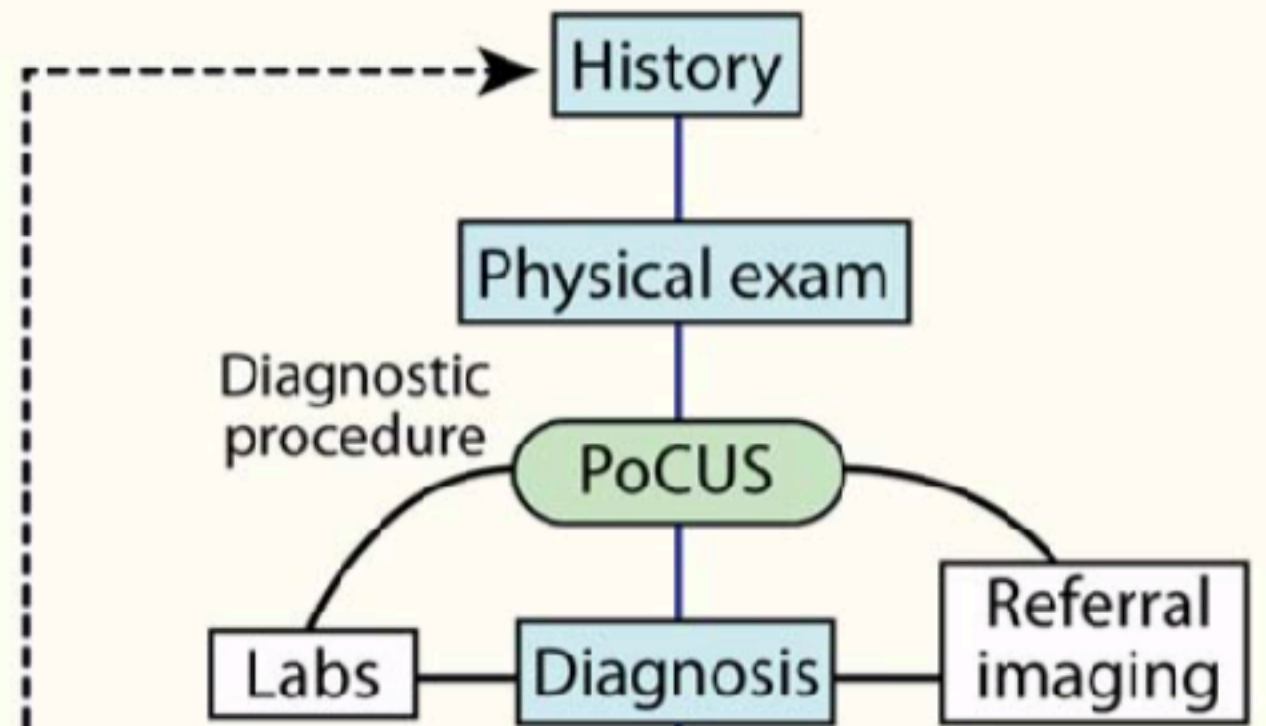
診斷
治療

雜

少

快

diagnose



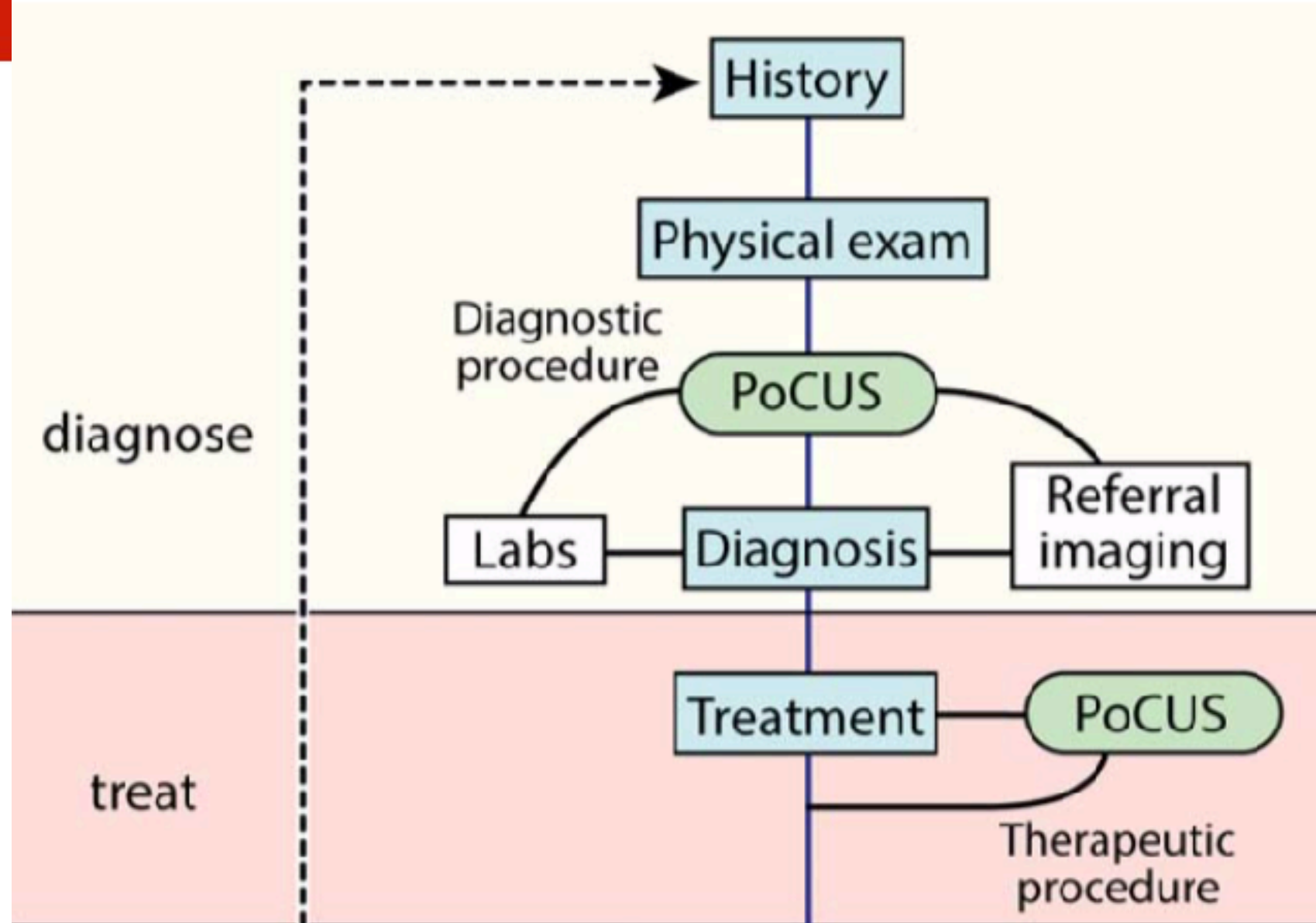
POCUS

處置流程



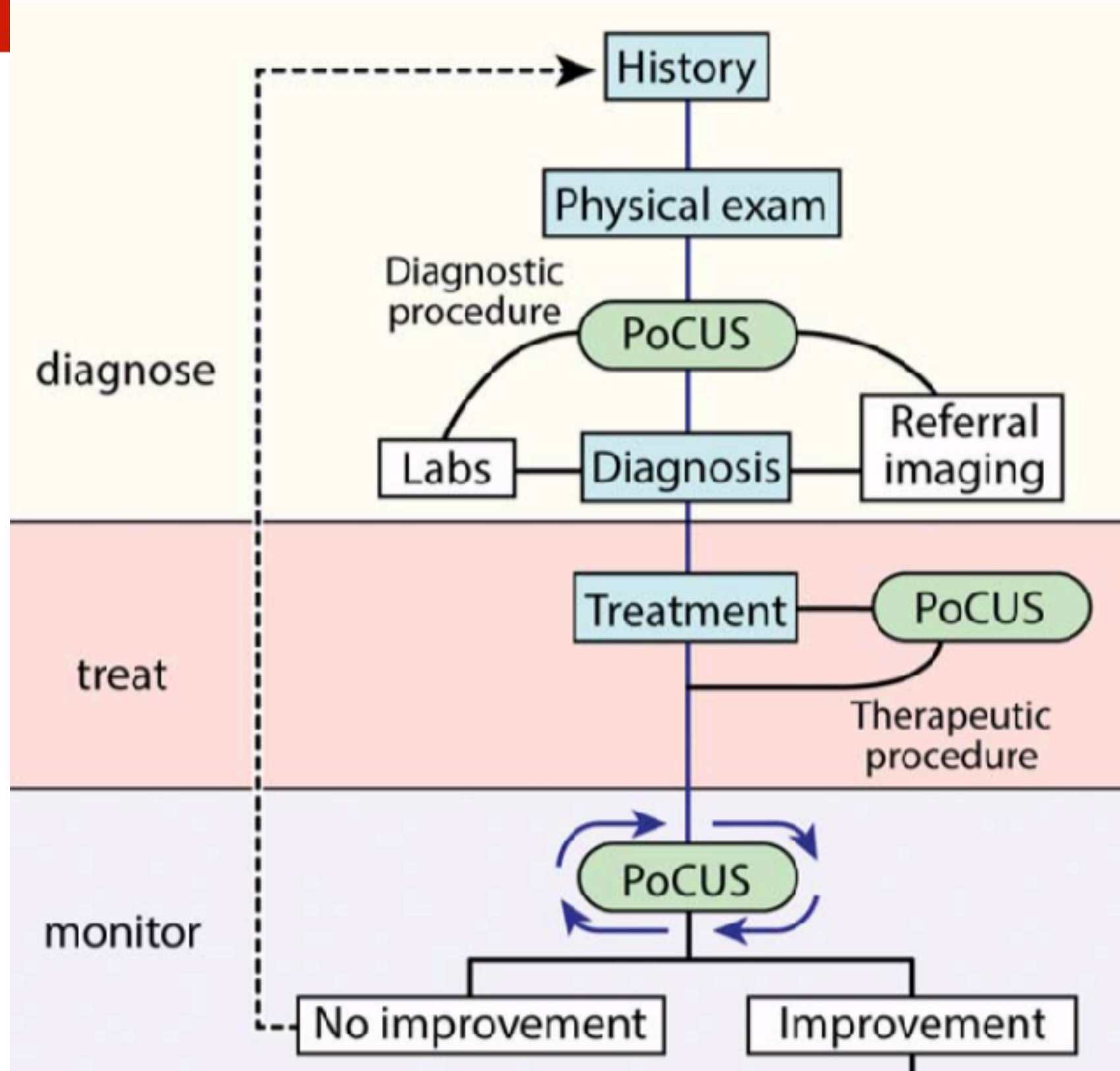
POCUS

處置流程



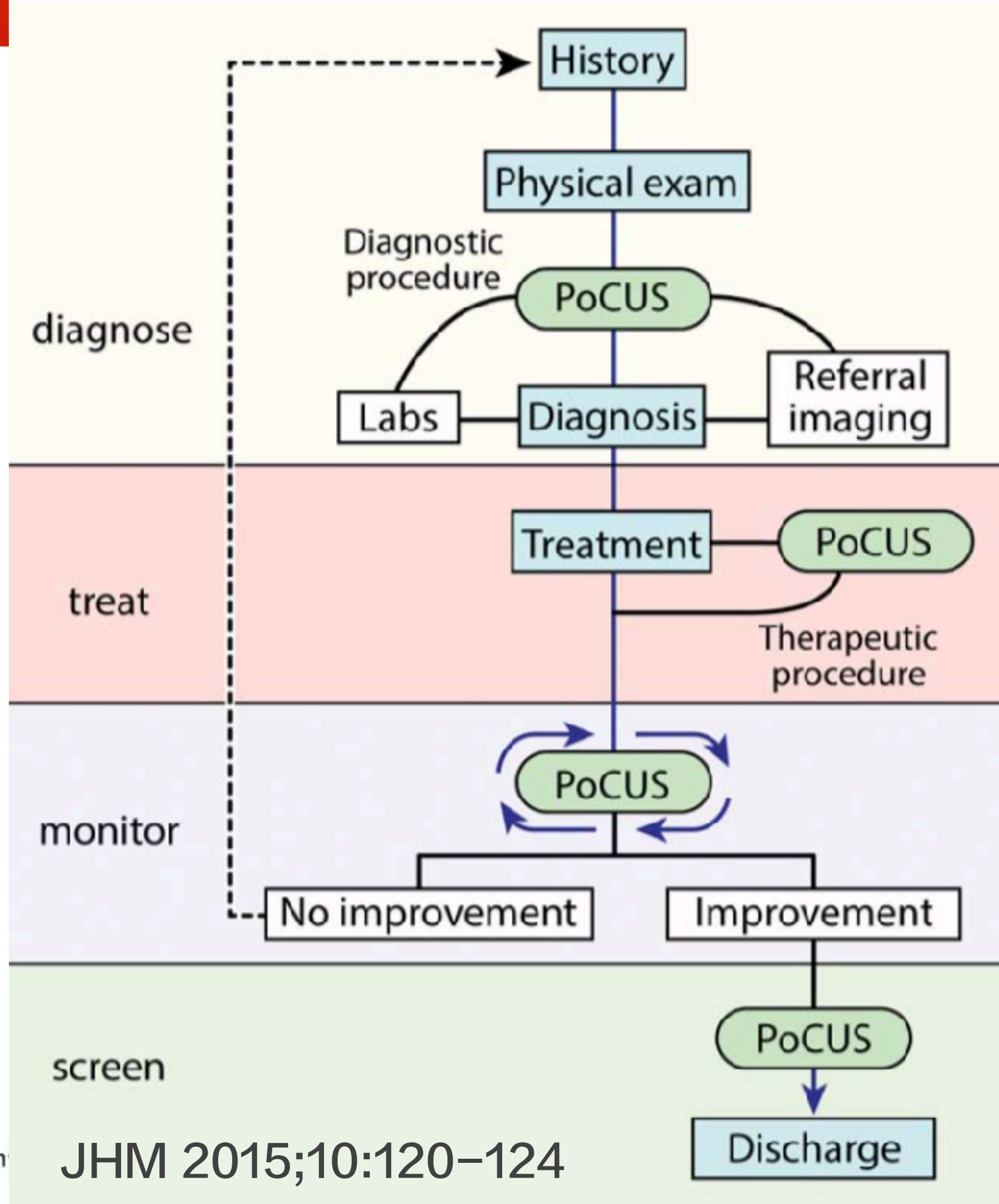
POCUS

處置流程



POCUS

處置流程



I-AIM

Indication (point)



Acquire



Interpret



**Make
decision**

Acute abdomen

Internal bleeding ?



FAST



Fluid



CT/TAE/OP

熟悉操控 6 大技巧

X

Sweep

**Fan/
Tilt**

Y

Slide

Rock

Z

Rotate

Compress

熟悉操控 6 大技巧

X

掃

傾

Y

滑

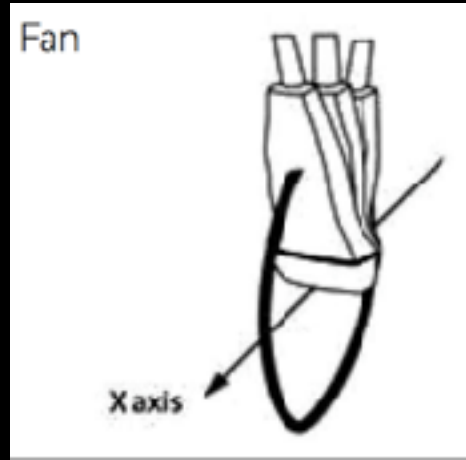
搖

Z

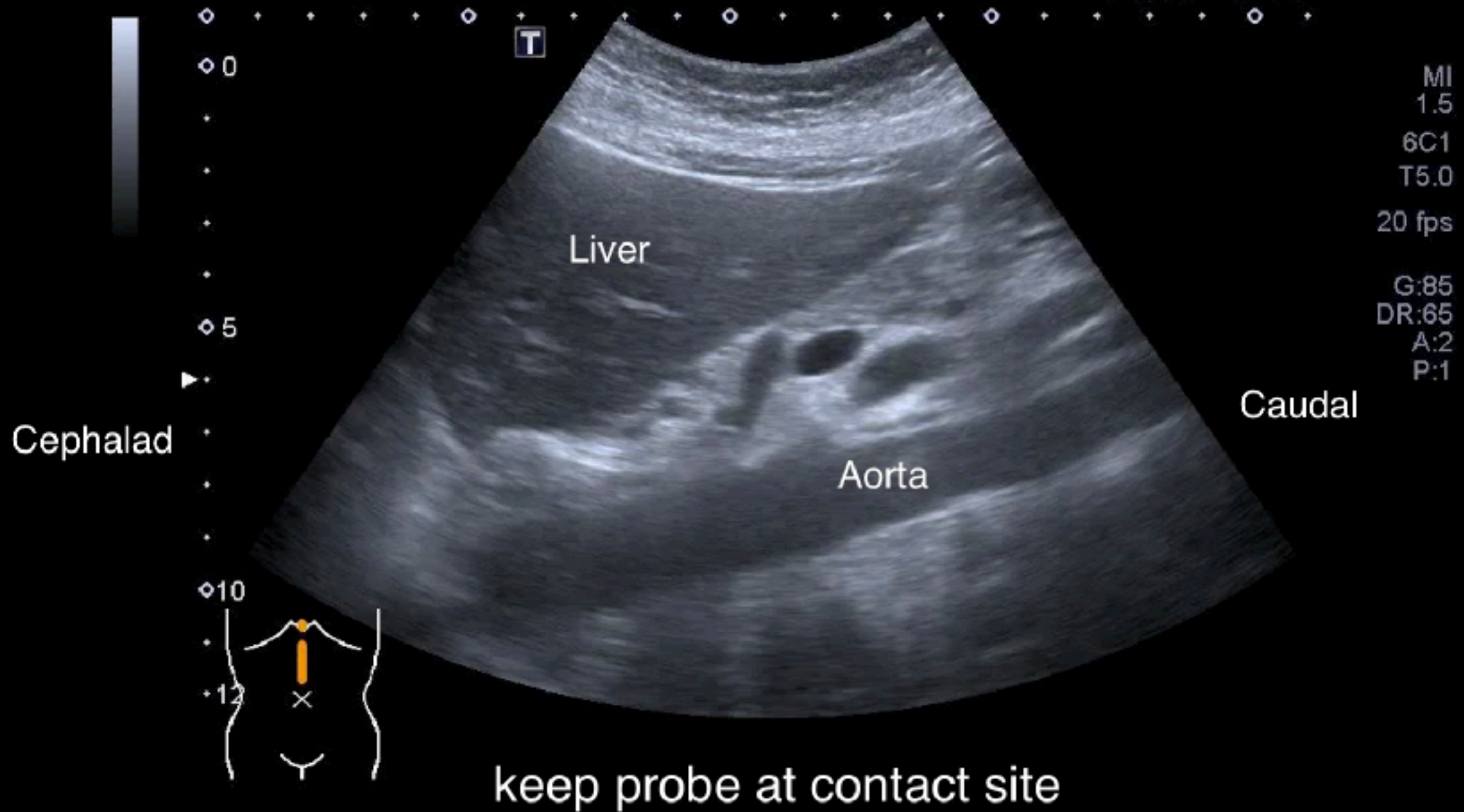轉

壓

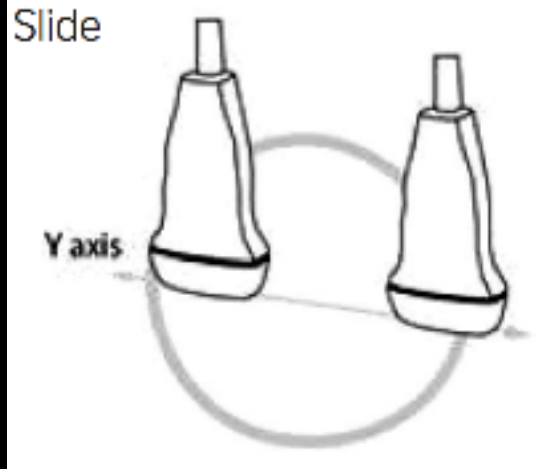
傾



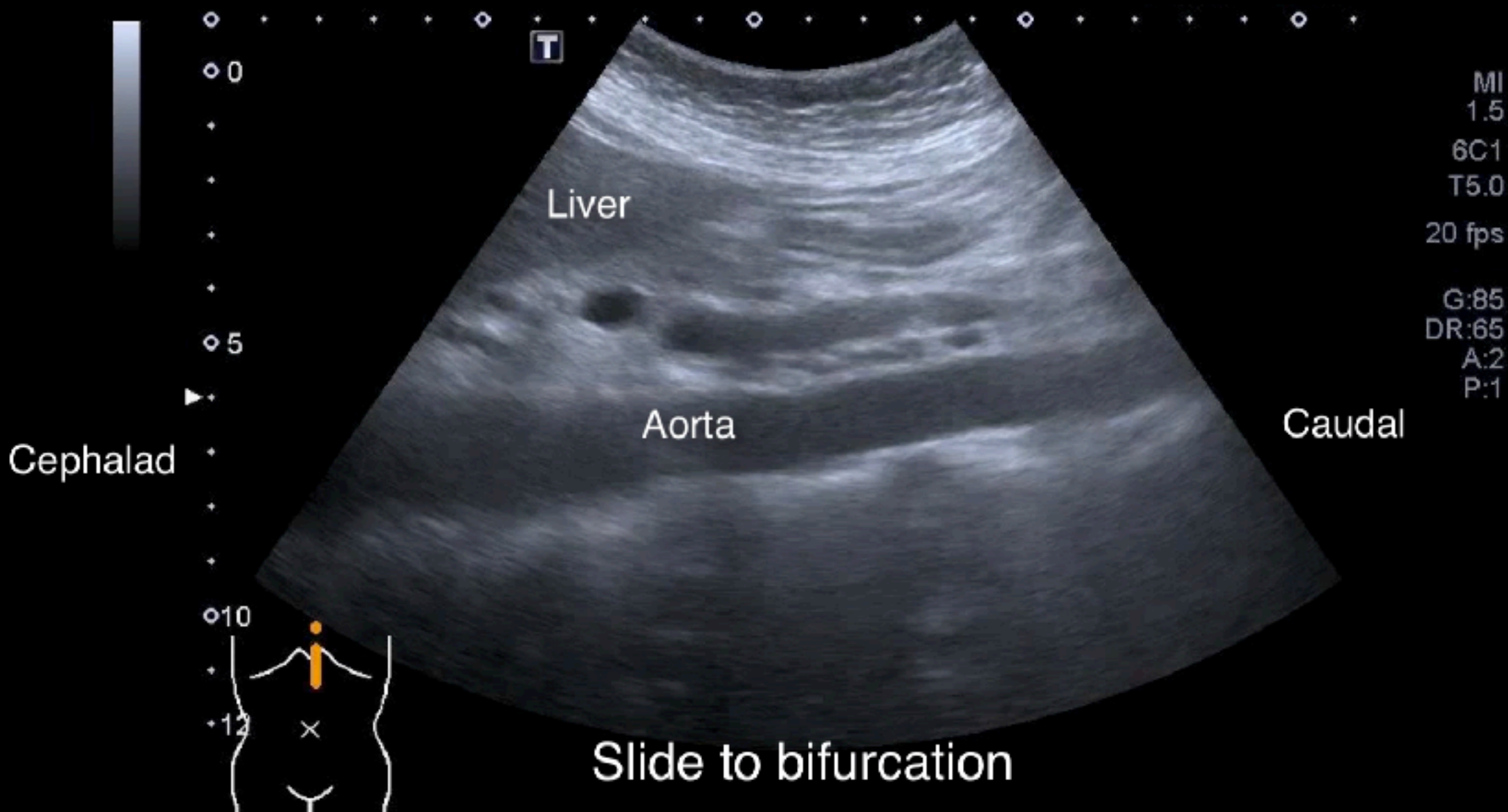
Fan



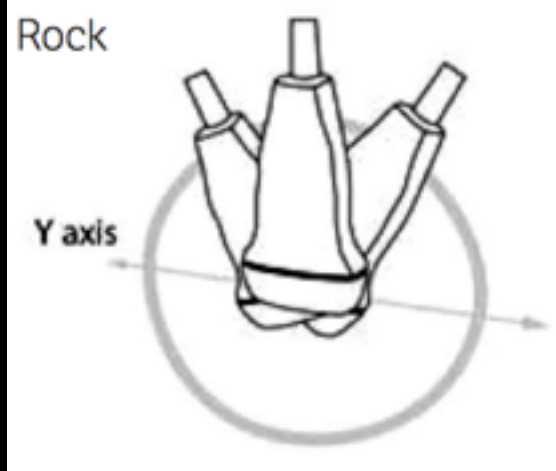
滑



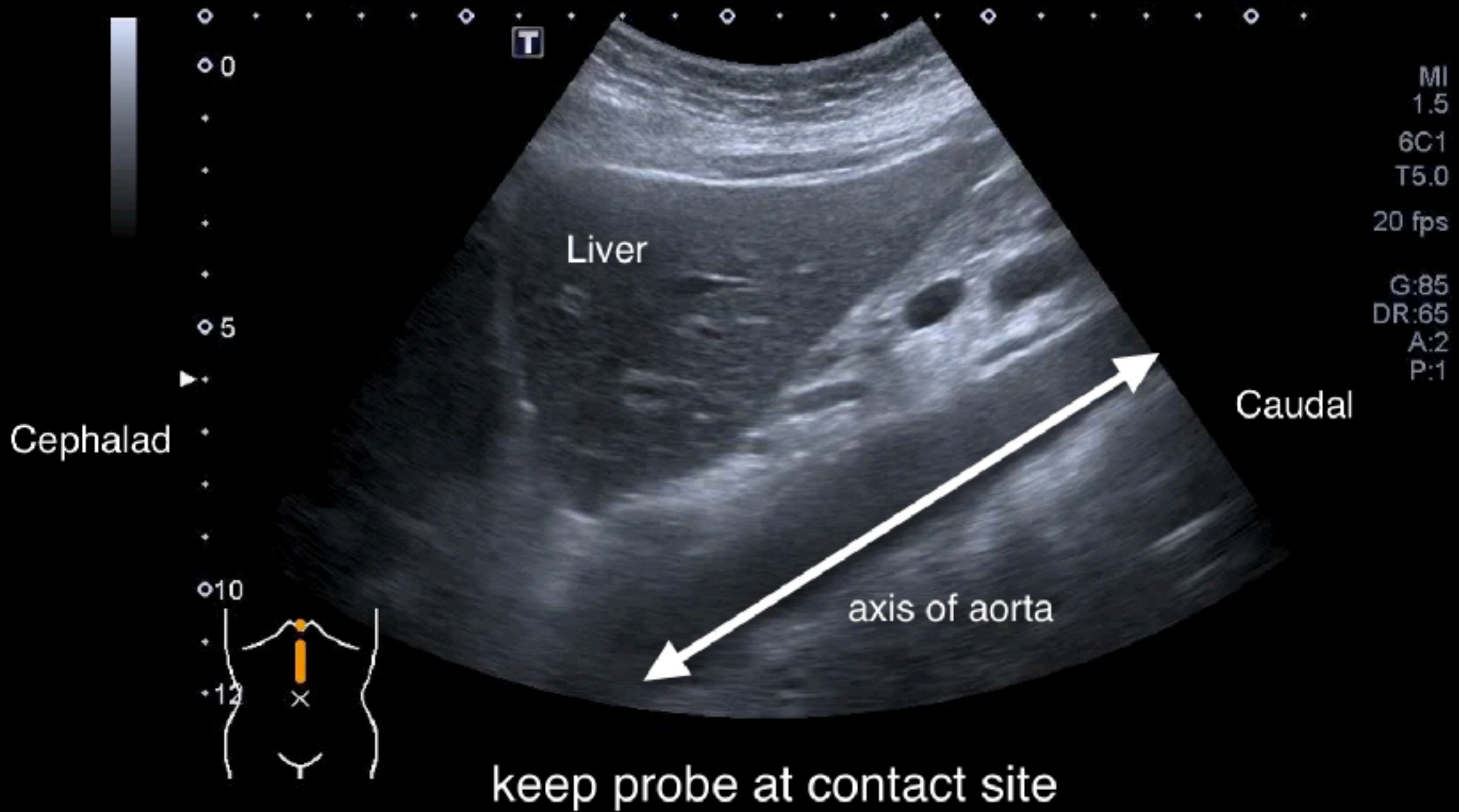Slide



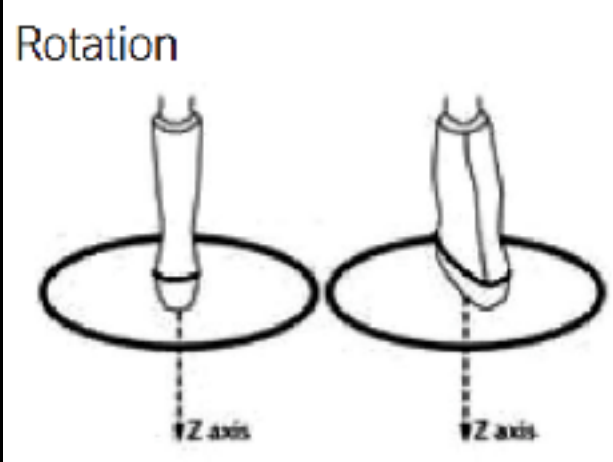
搖



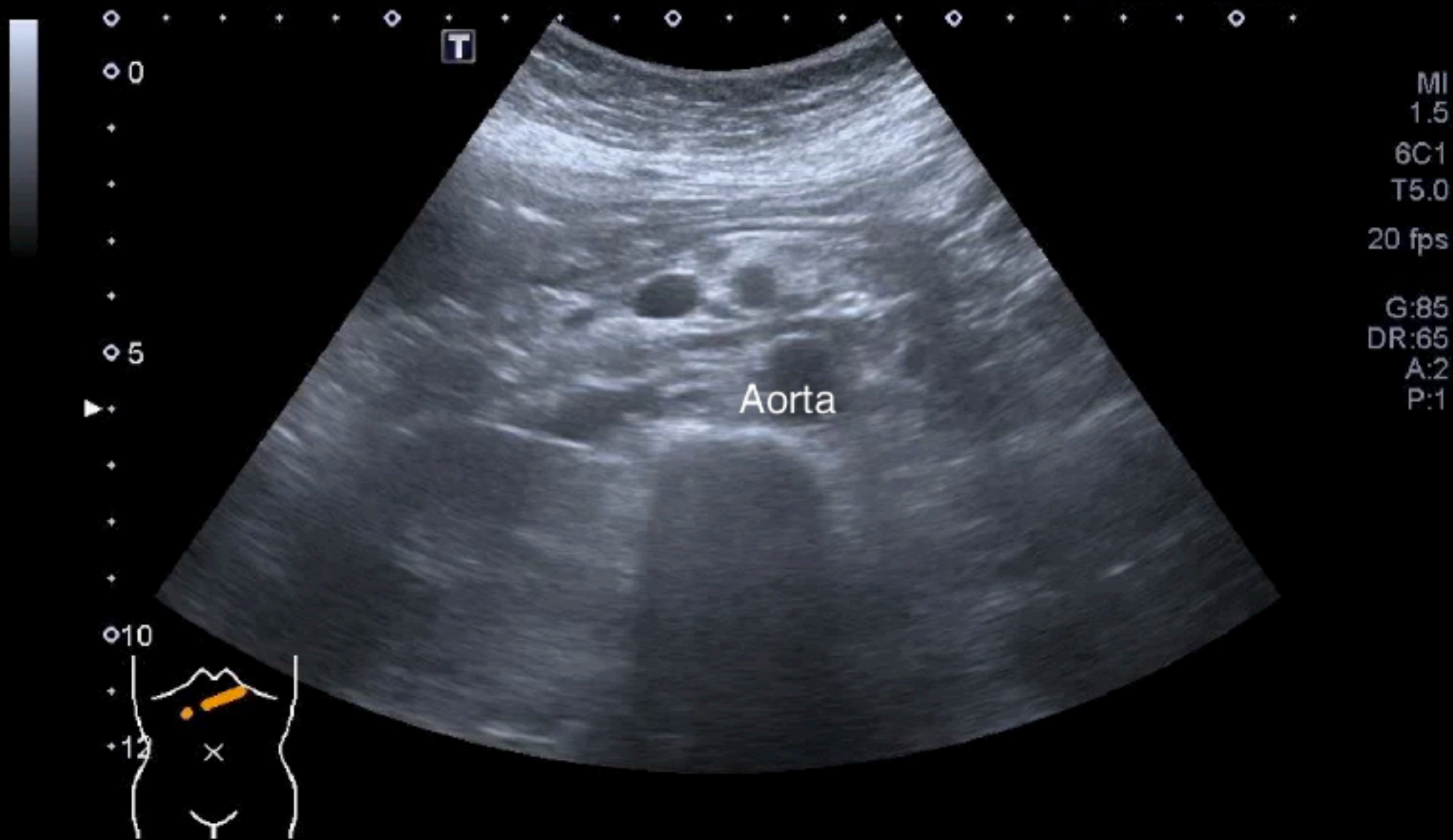Rock



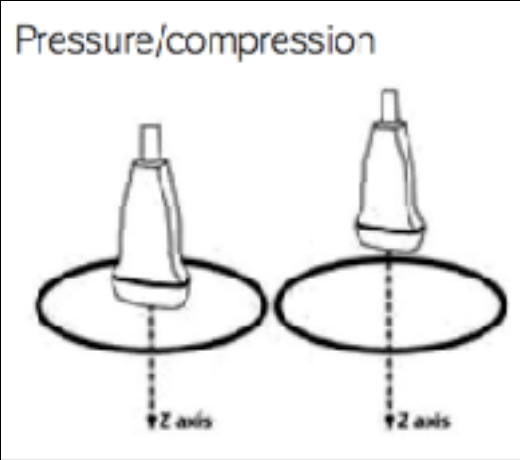
轉



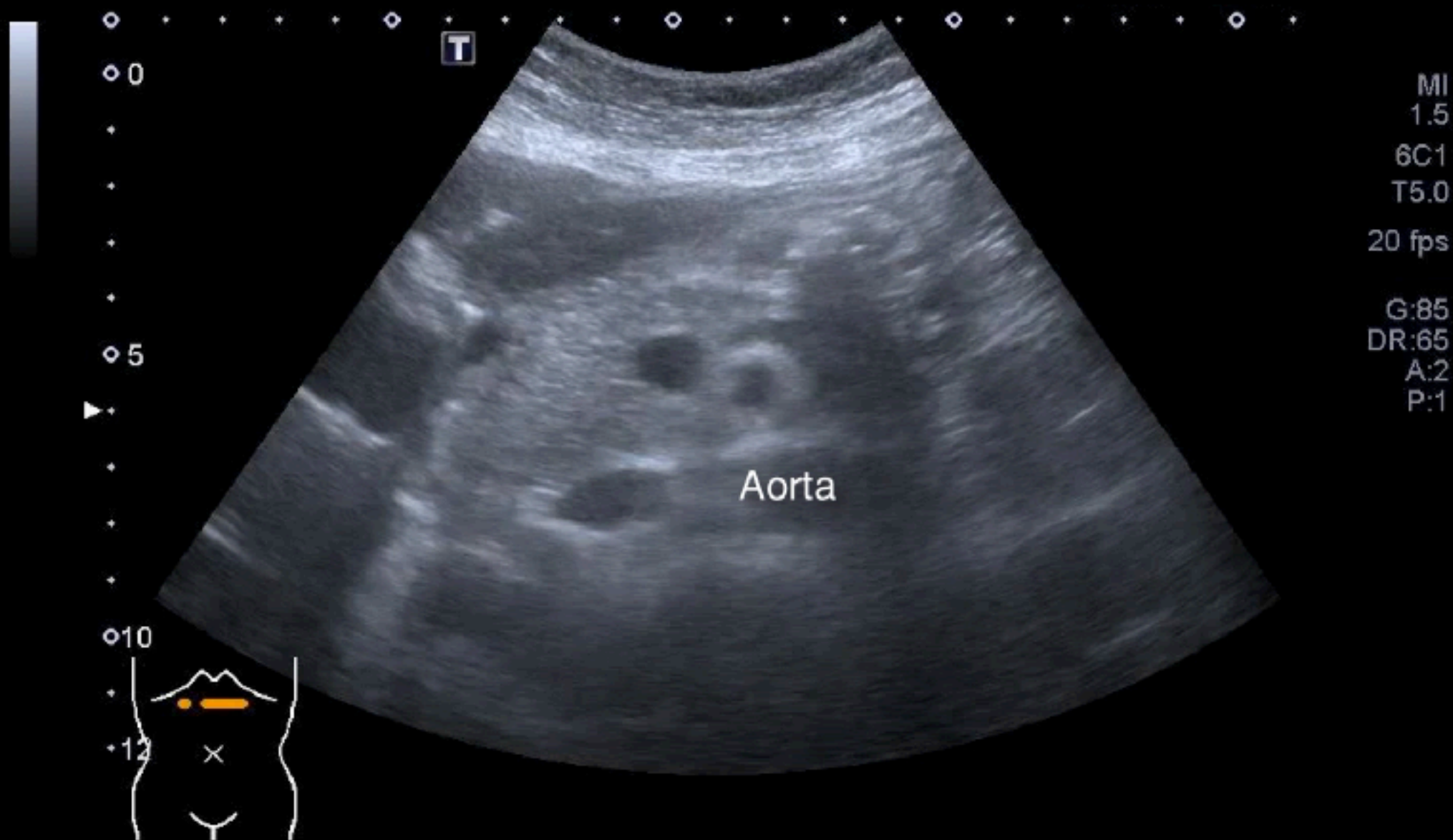
Rotation



壓



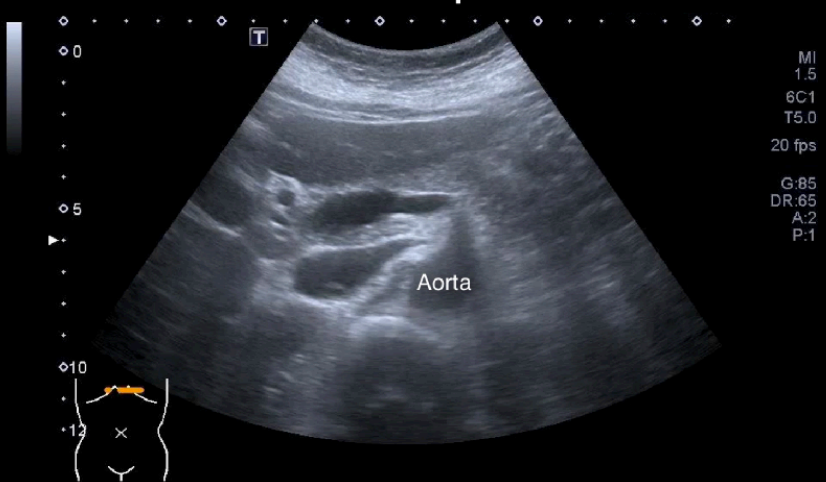Compression



熟悉操控 6 大技巧

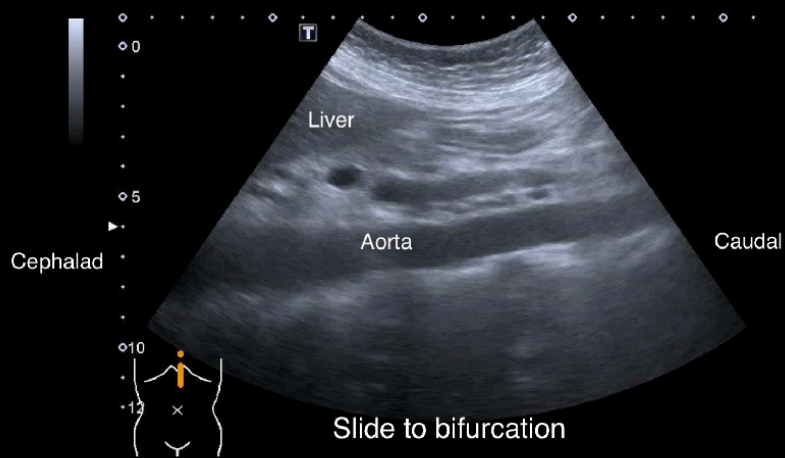
X

Sweep



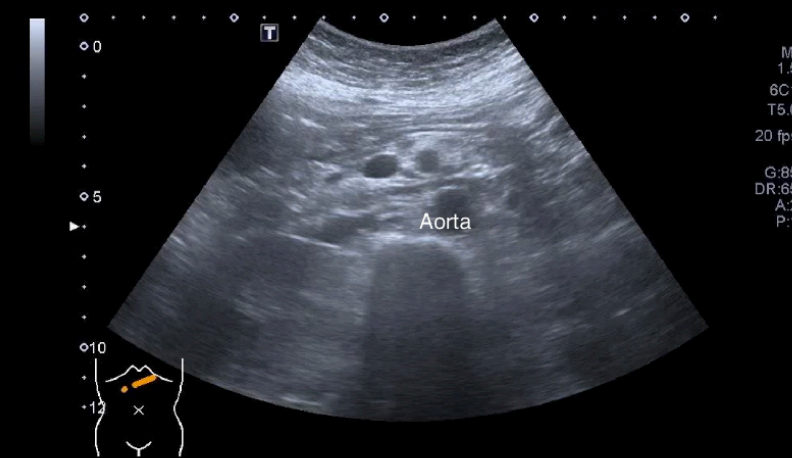
Y

Slide

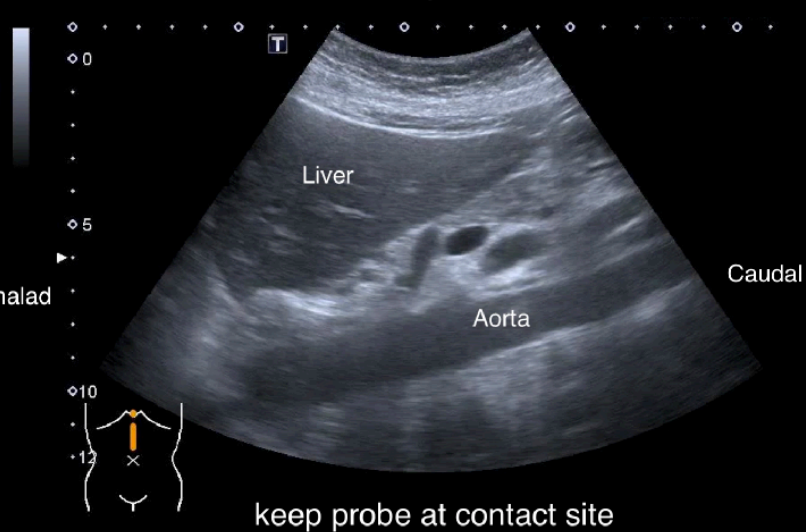

Z

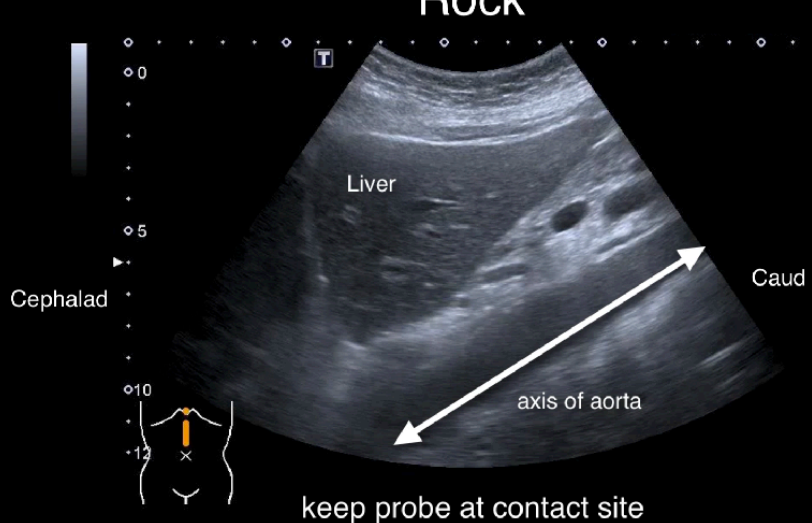
Rotation



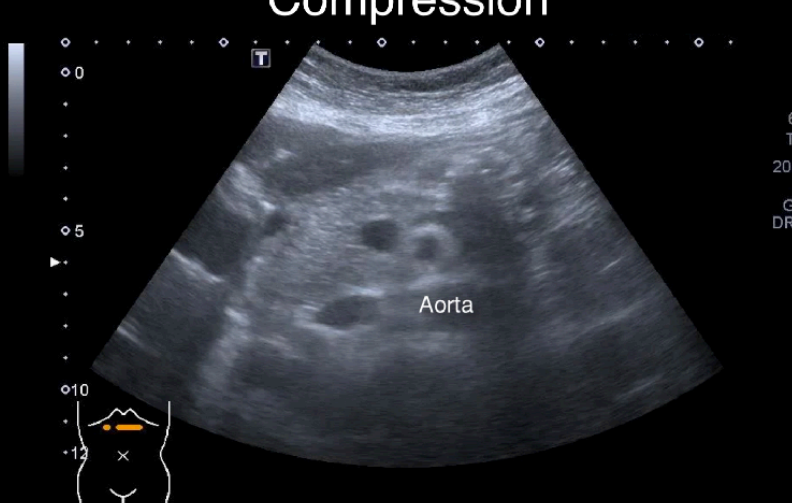Fan



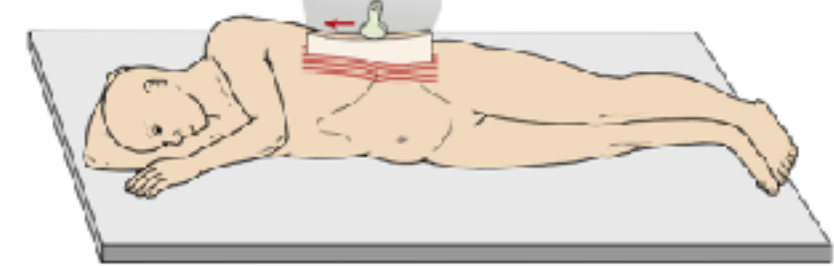
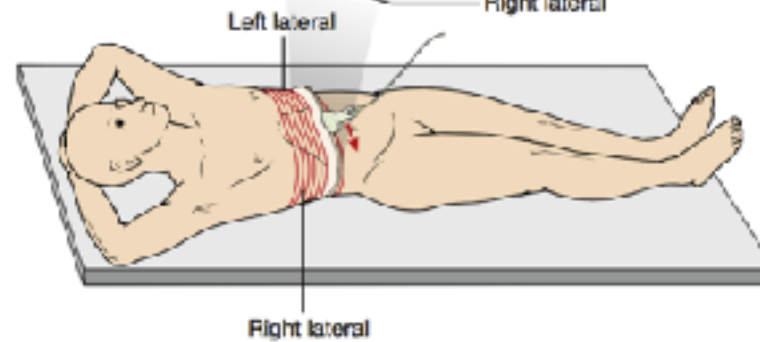
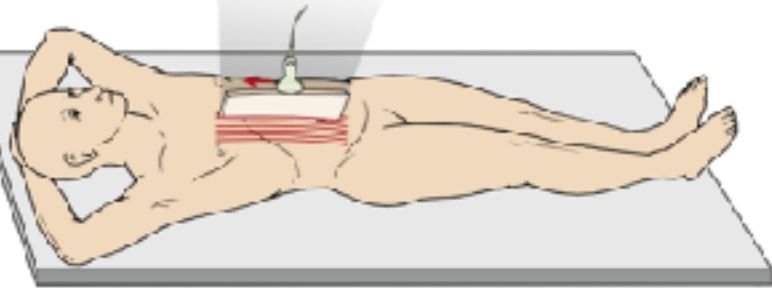
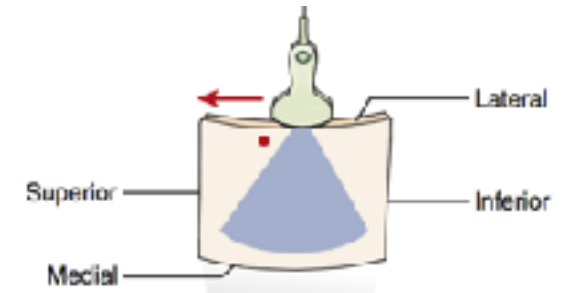
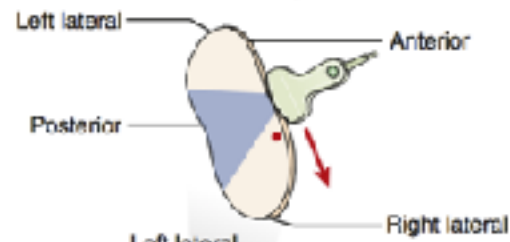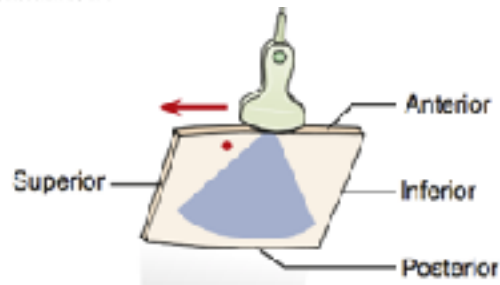
Rock



Compression



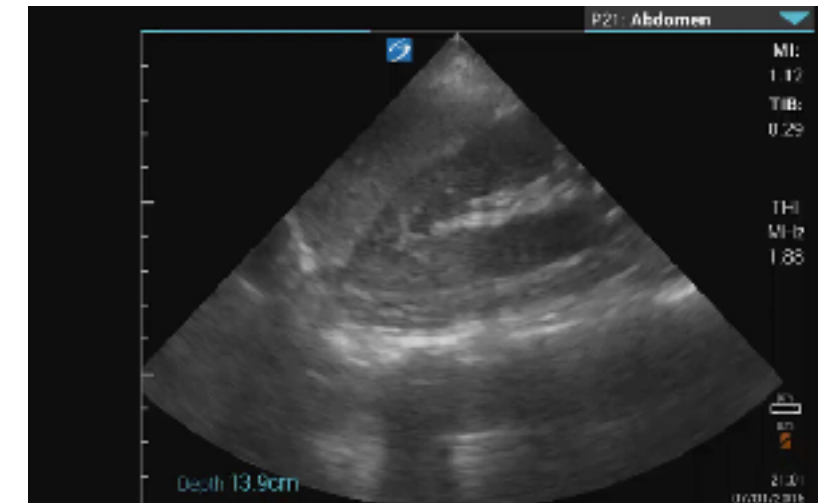
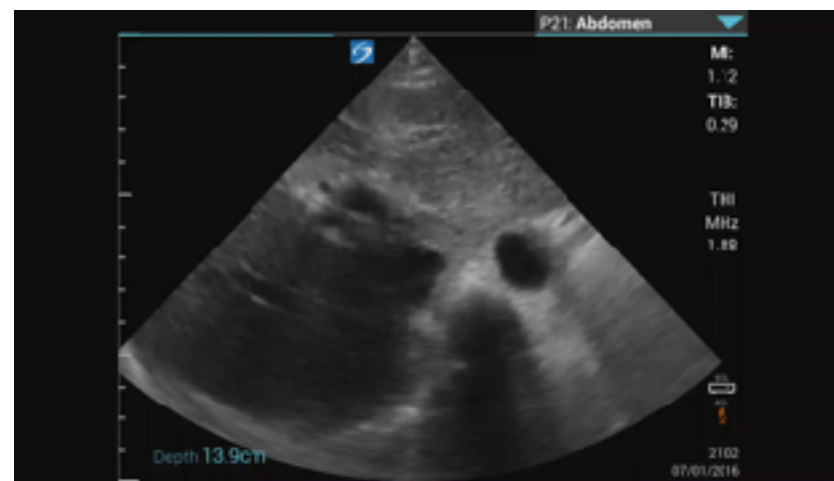
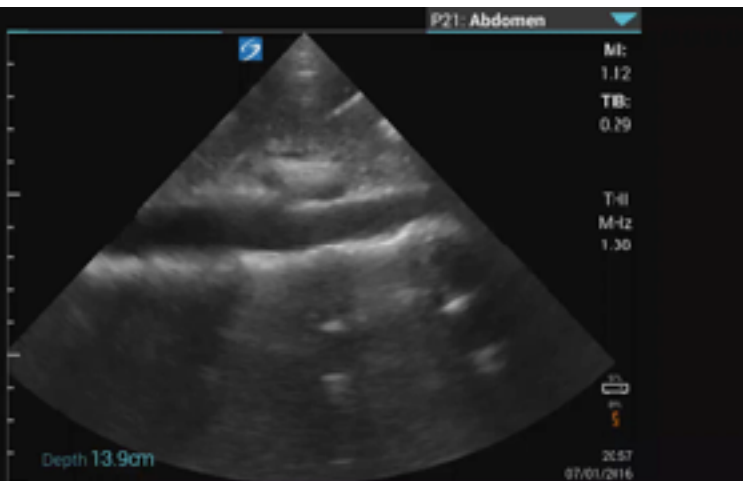3D 立體掃描



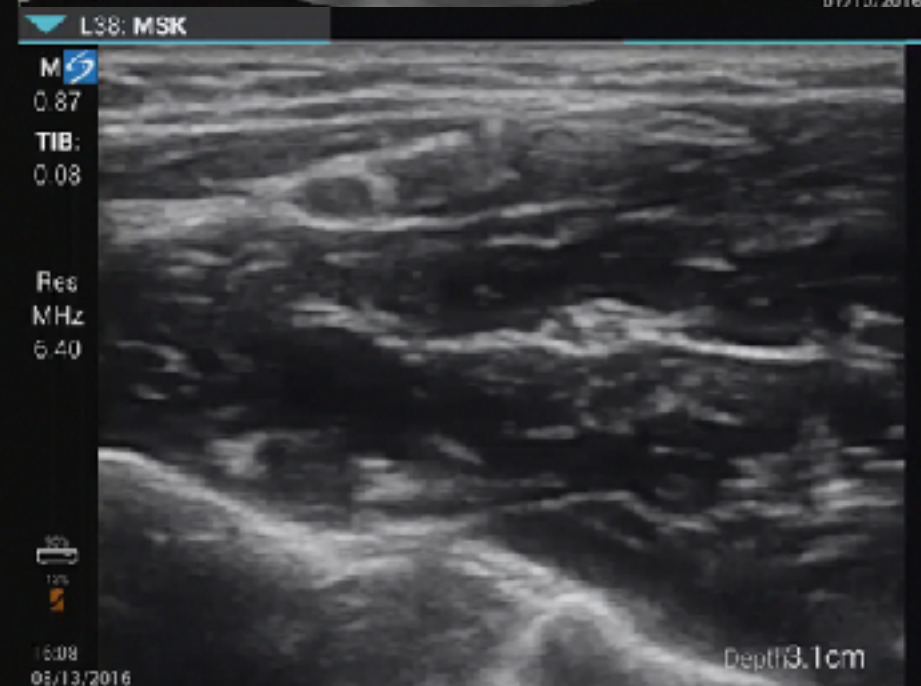
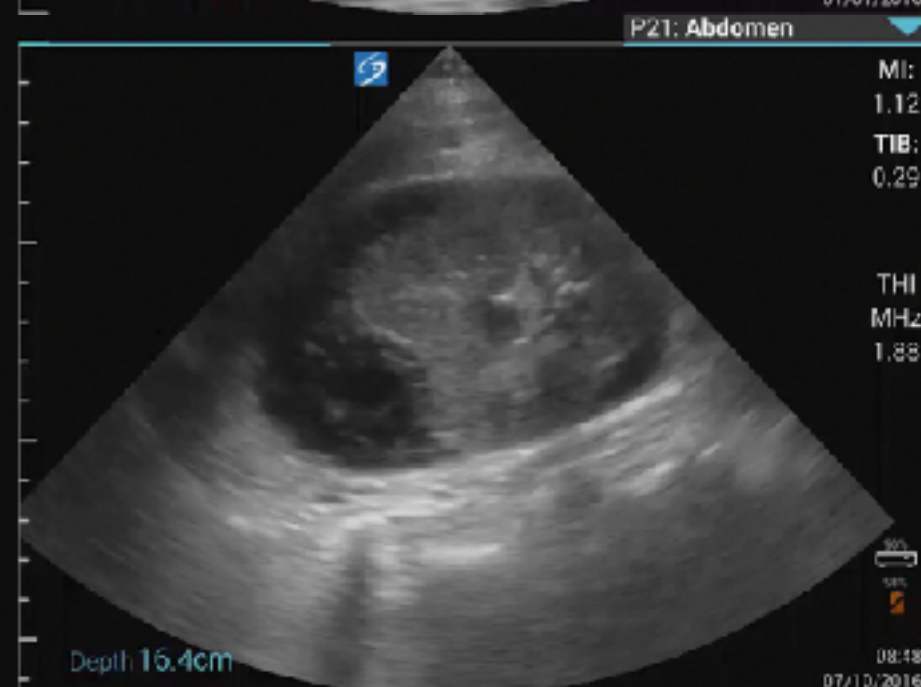
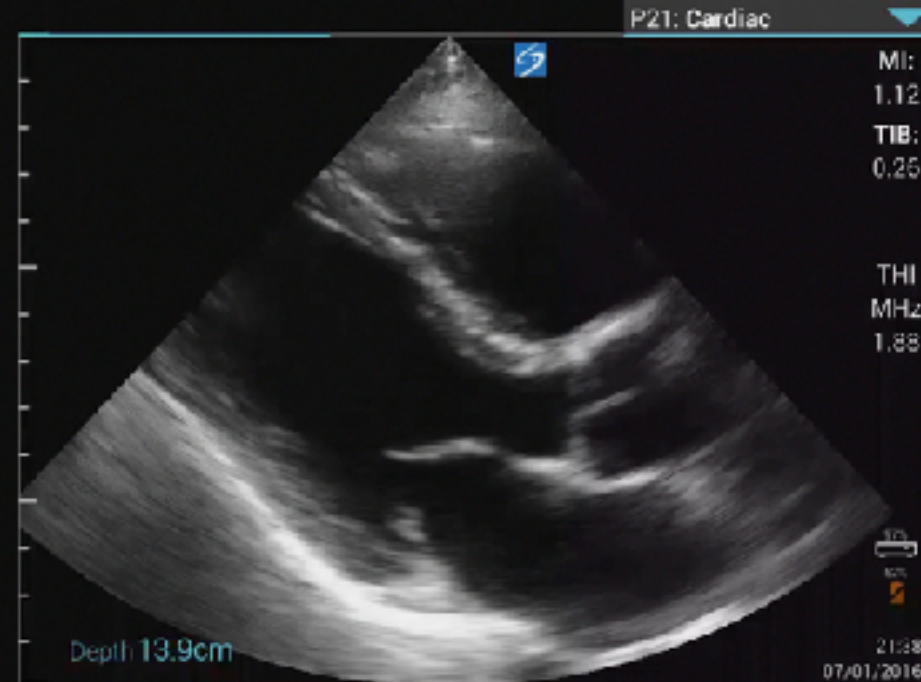
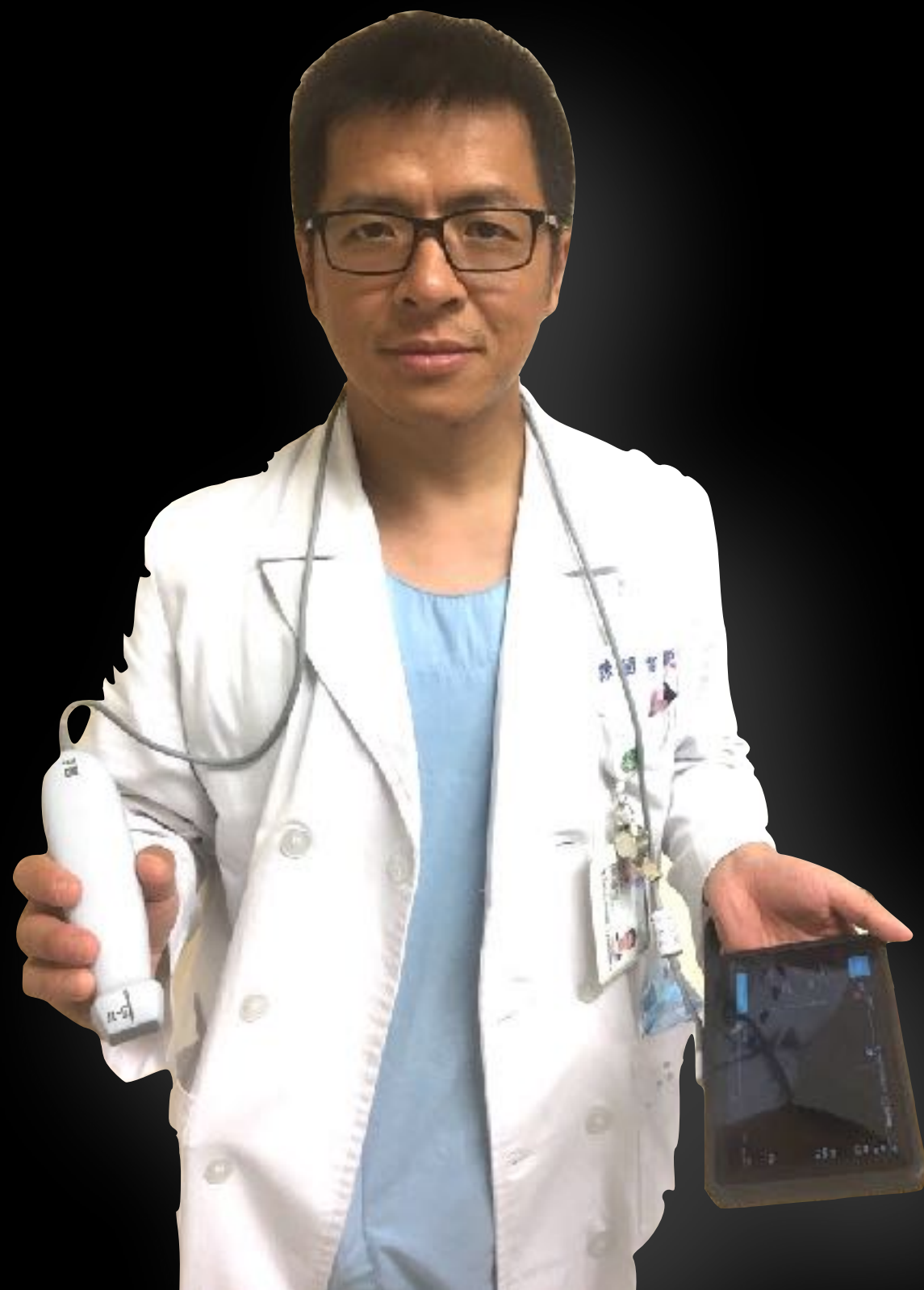
Sagittal 縱

Transverse 橫

Coronal 側



設備和能力成反比



POCUS常用探頭



弧

線

扇

POCUS常用探頭



表面



頻率



深度

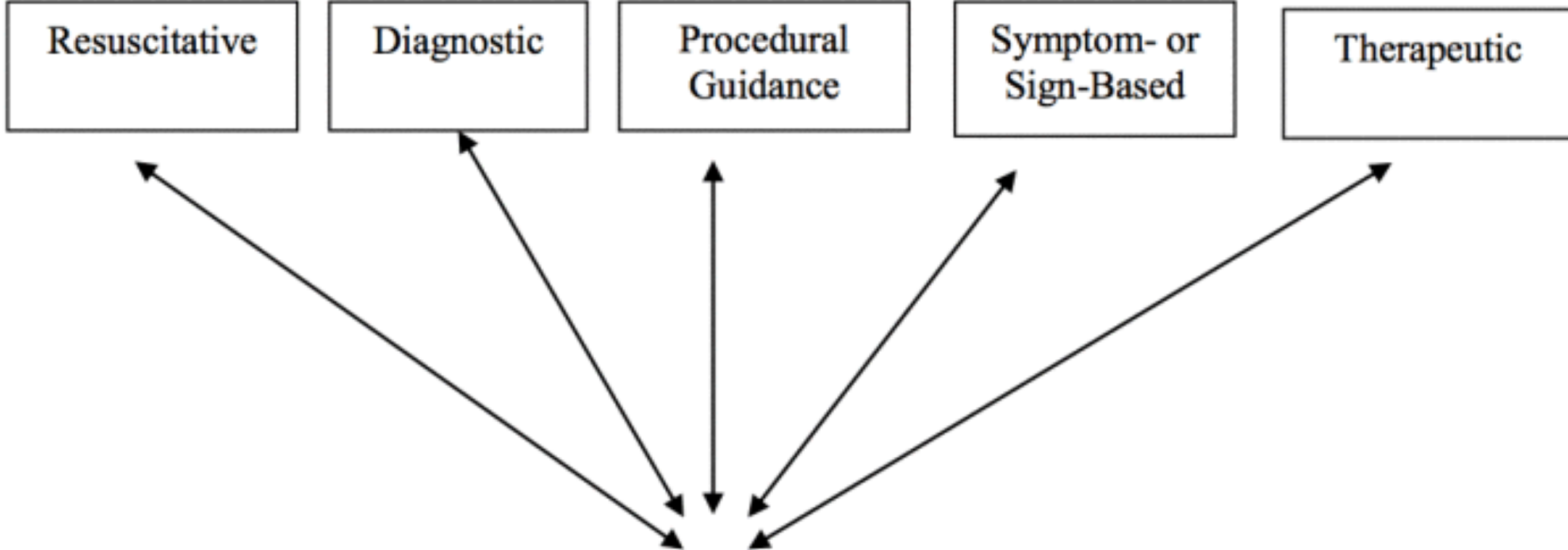


**可以
同步** 病史詢問

理學檢查 **不可
省略**



Y POCUS N



ACEP
2016

- Core Applications
- Trauma
 - Intrauterine Pregnancy
 - AAA
 - Cardiac/HD Assessment
 - Biliary
 - Urinary Tract
 - DVT
 - Soft-tissue/Musculoskeletal
 - Thoracic/Airway
 - Ocular
 - Bowel
 - Procedural Guidance

12 核心

5大應用

POCUS for better Airway management

插對了嗎

插不上時

Tracheal tube placement assessment

2015 CPR & ECC guidelines

Continuous waveform Capnography is recommended in addition to clinical assessment as the most reliable method of confirming and monitoring correct placement of an ETT.

(Class I, LOE C-LD)

If continuous waveform capnometry is not available, a nonwaveform CO₂ detector, esophageal detector device, or **ULTRASOUND** used by an experienced operator is a reasonable alternative.

(Class IIa, LOE C-LD)

Systematic Review

TAKE-HOME MESSAGE

During emergency intubations, transtracheal ultrasonography can be used to assess endotracheal tube placement before confirmation with capnography.

Outcome Measure	Sensitivity (95% CI)	Specificity (95% CI)	Number of Studies (Number of Patients)
Pooled data	0.98 (0.97–0.99)	0.98 (0.95–0.99)	11 (969)
Emergency intubations	0.98 (0.97–0.99)	0.94 (0.86–0.98)	8 (713)

CI, Confidence interval.

Dynamic Fast Accurate

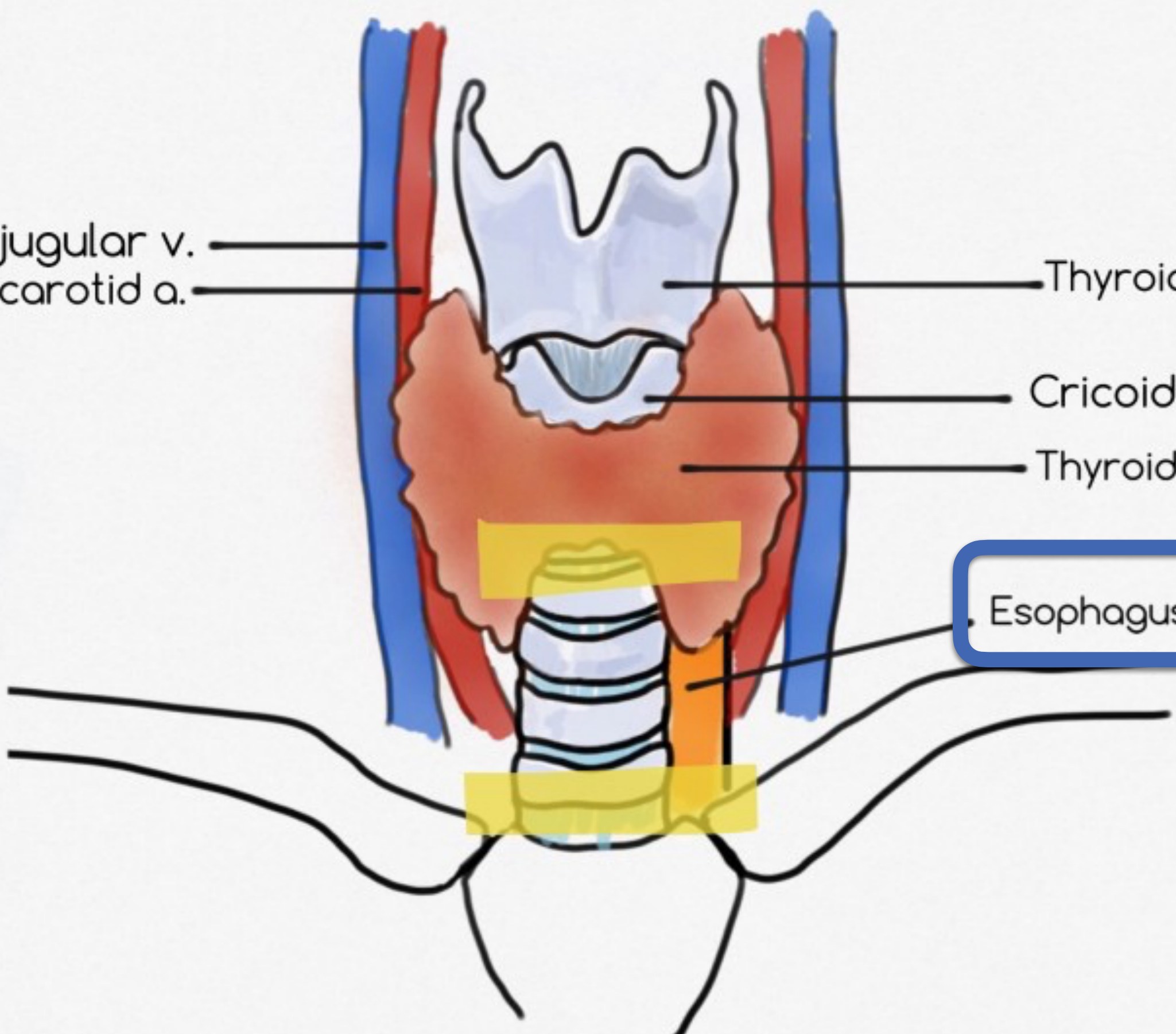
Internal jugular v.
Common carotid a.

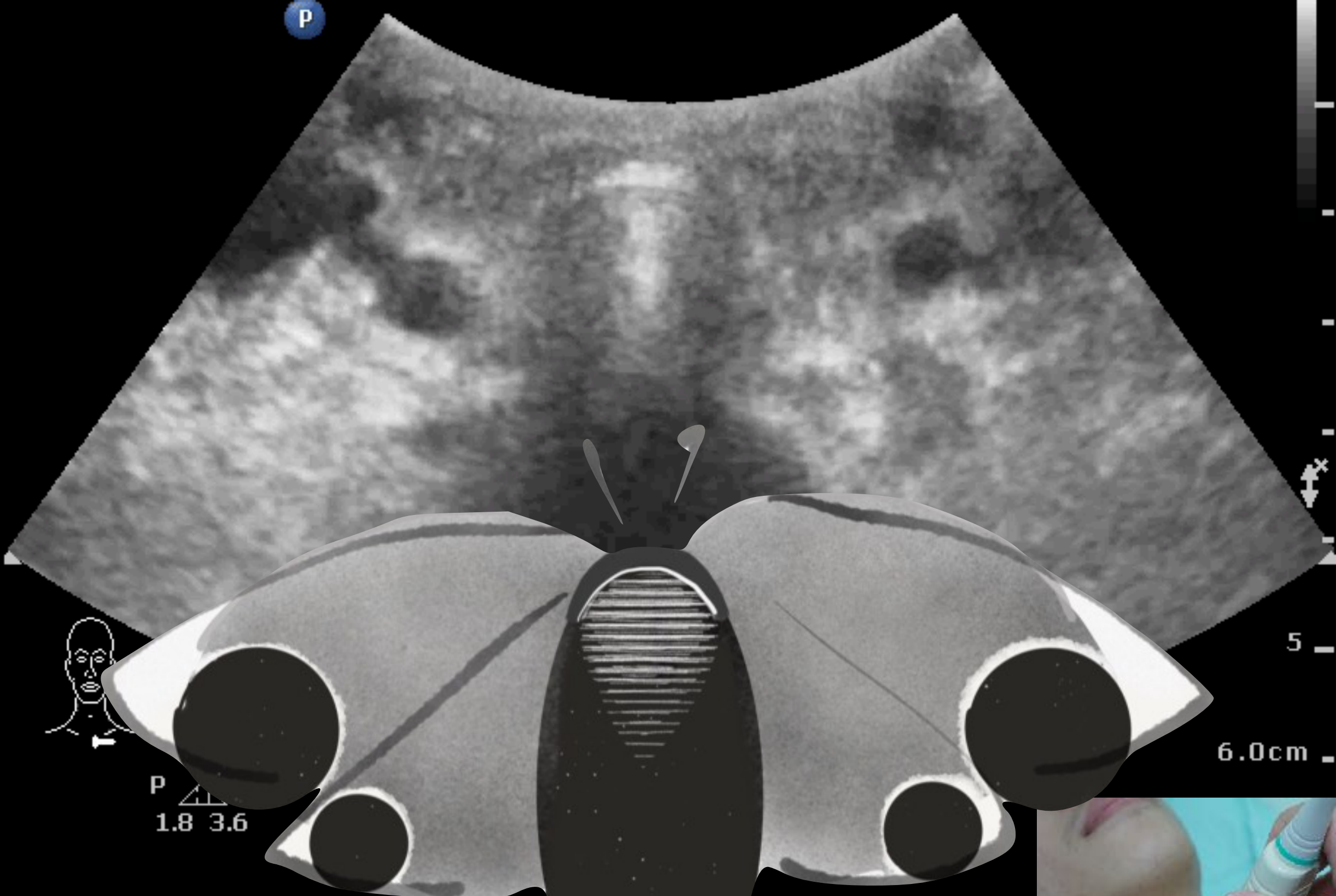
Thyroid cartilage

Cricoid cartilage

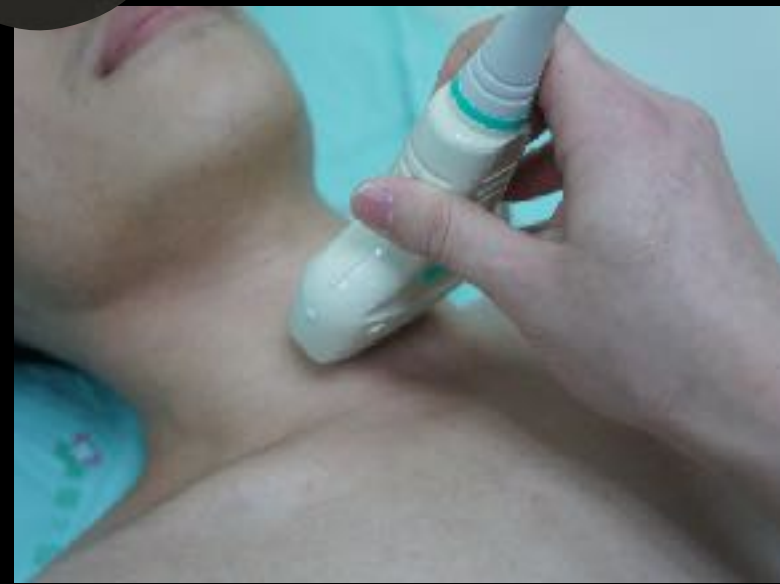Thyroid gland

Esophagus

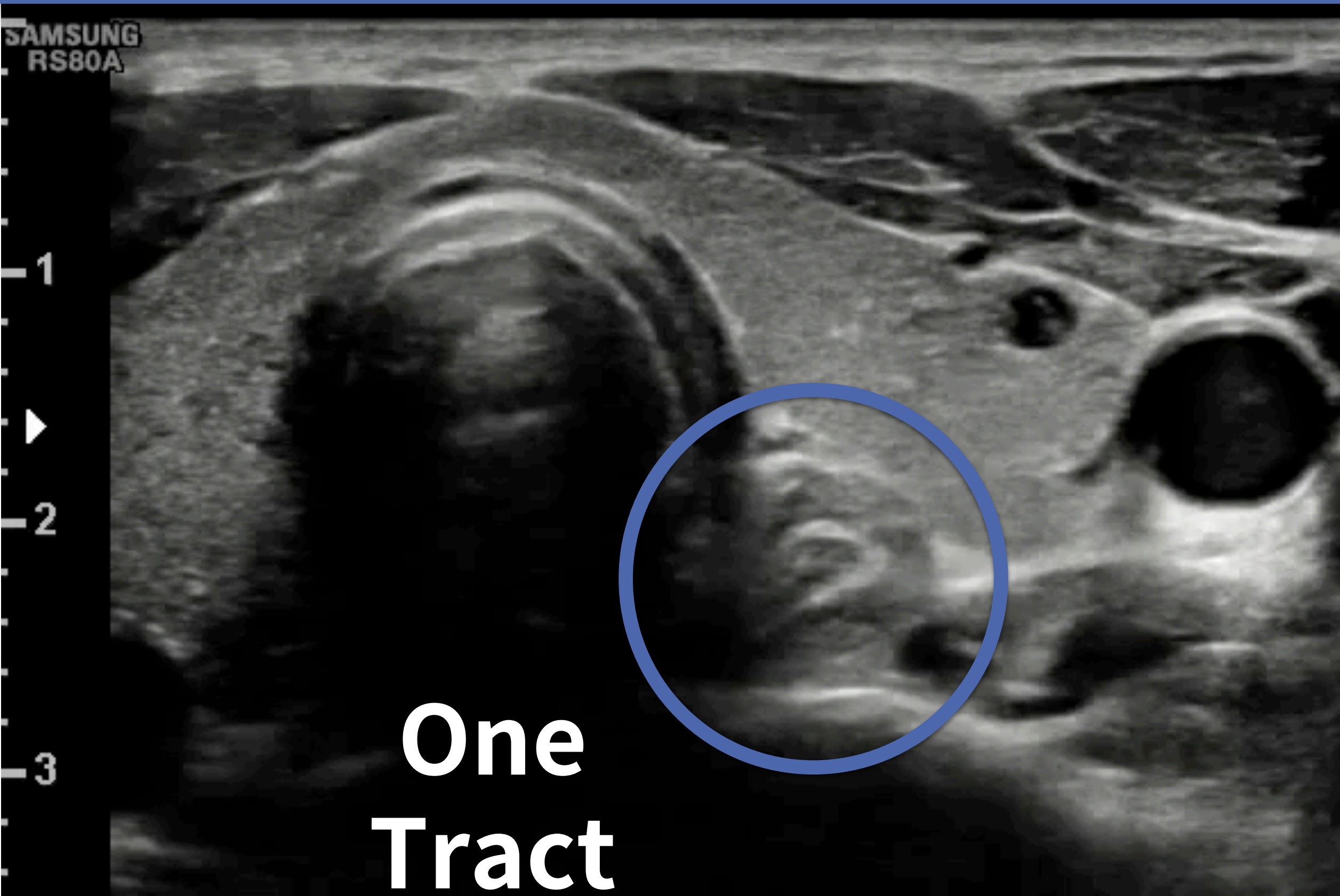




**One
Tract**



Find esophagus



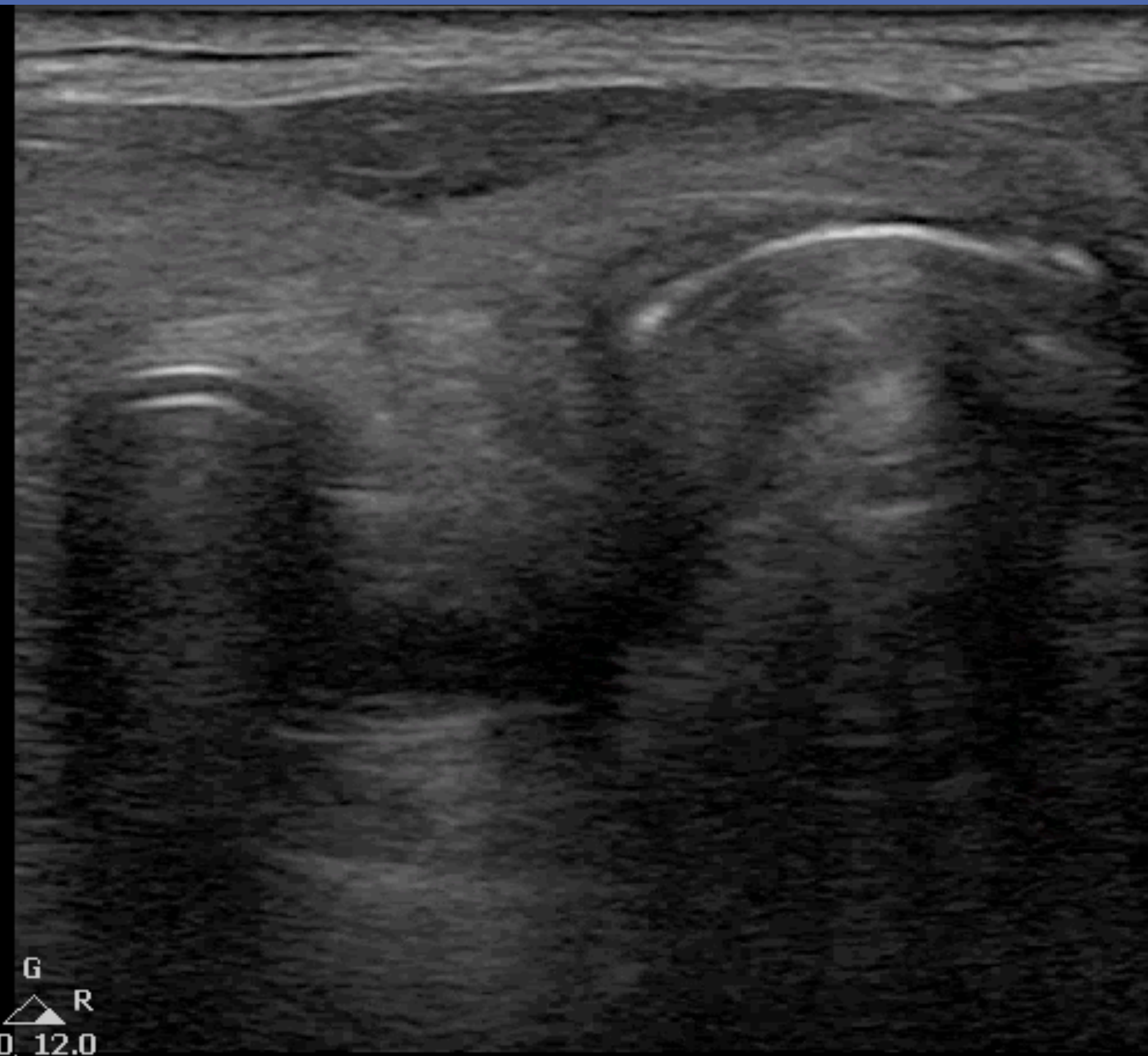
Double tract sign ?

Superficial
L12-3
46 Hz
3.5cm

2D
Res
Gn 60
C 56
3/2/1



G
P R
3.0 12.0



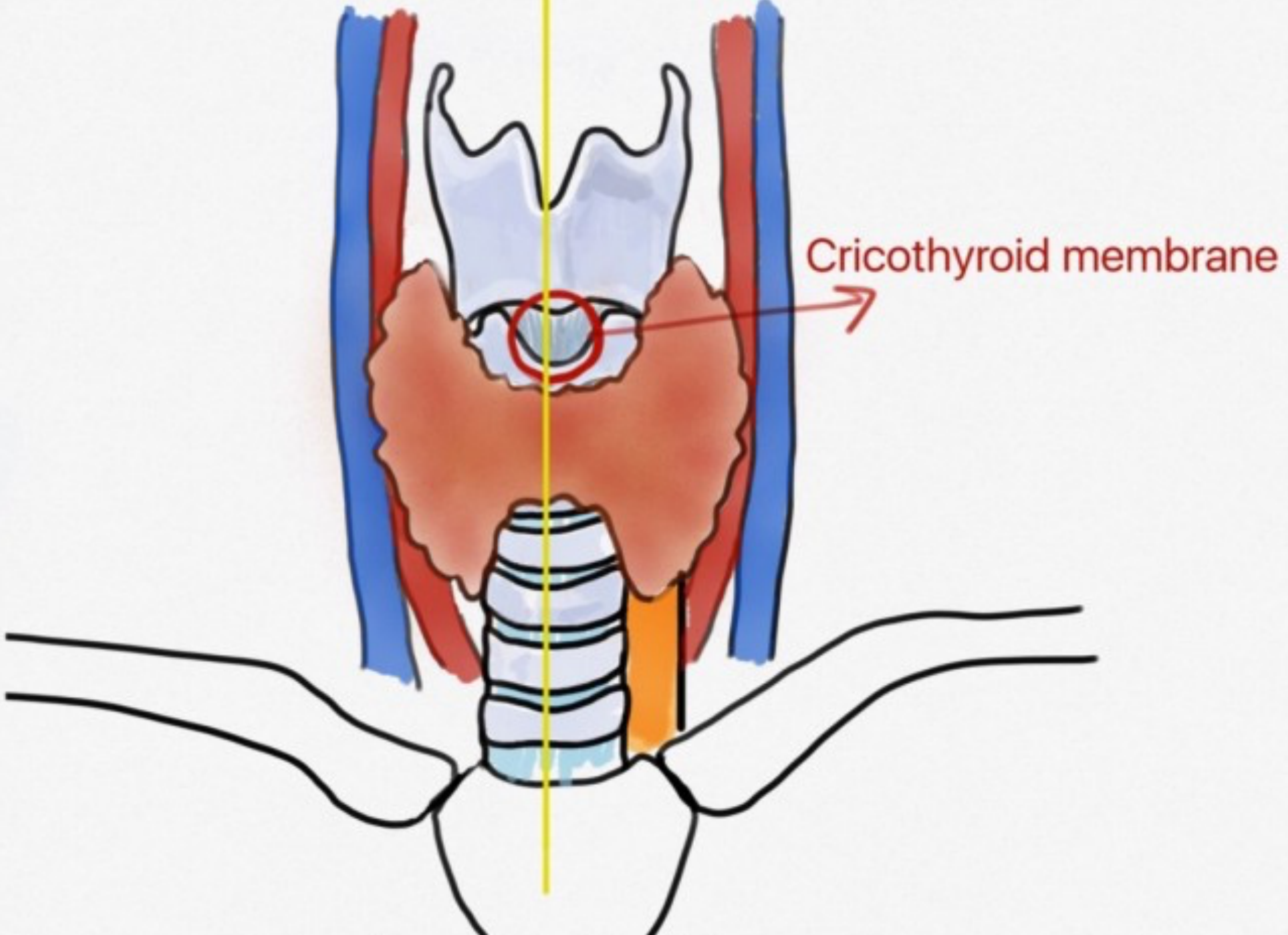
3.5cm

POCUS for better Airway management

插對了嗎

插不上時

1 v.s. 2



Cricothyroid membrane

INT L1
TIS 0.1
B
FH12
DR 110
FR 27
D 2.0
G 53



TC

CC



← -1



POCUS for better Airway management

插對了嗎

插不上時

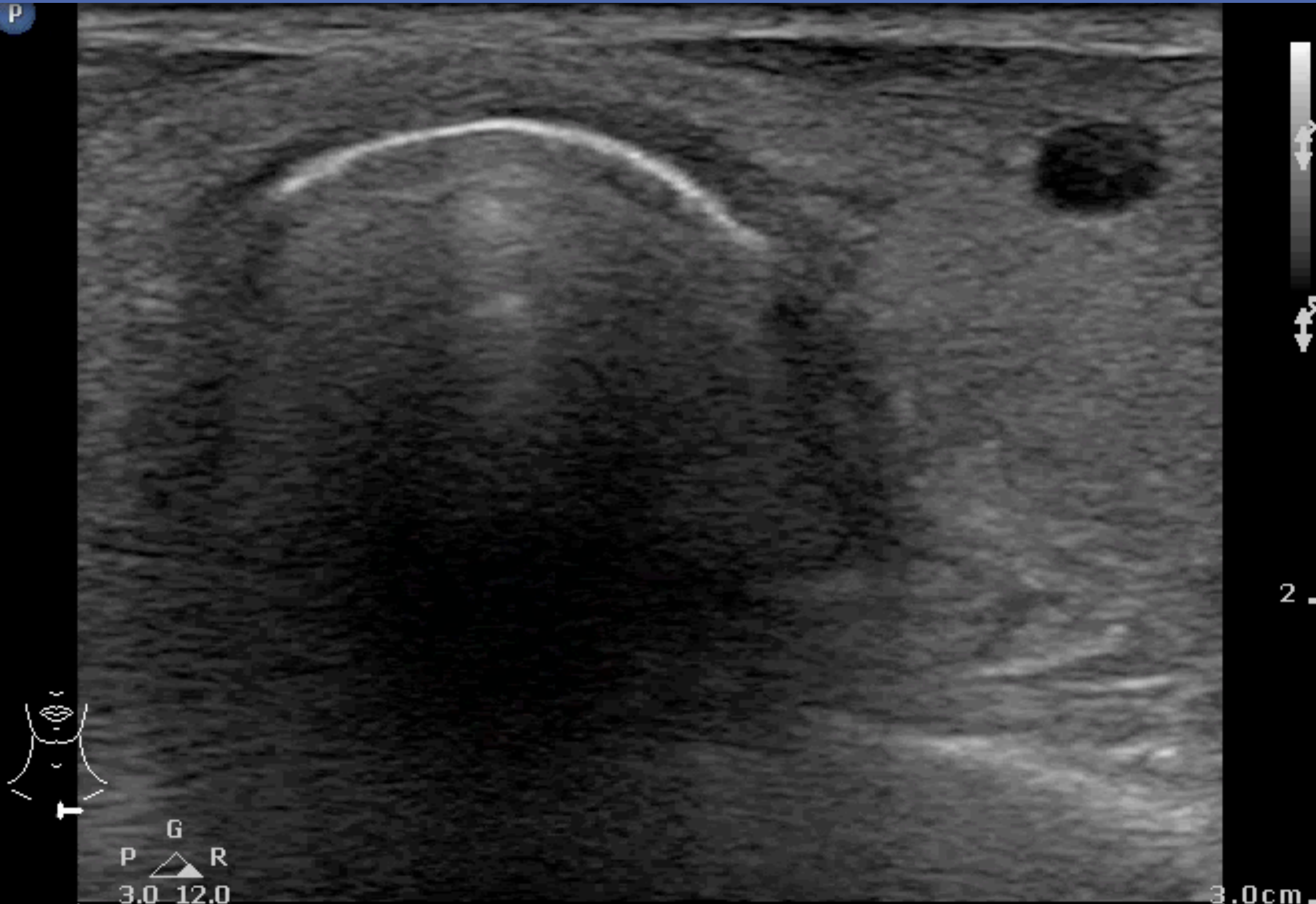
1 v.s. 2

CTM

Tracheal compression

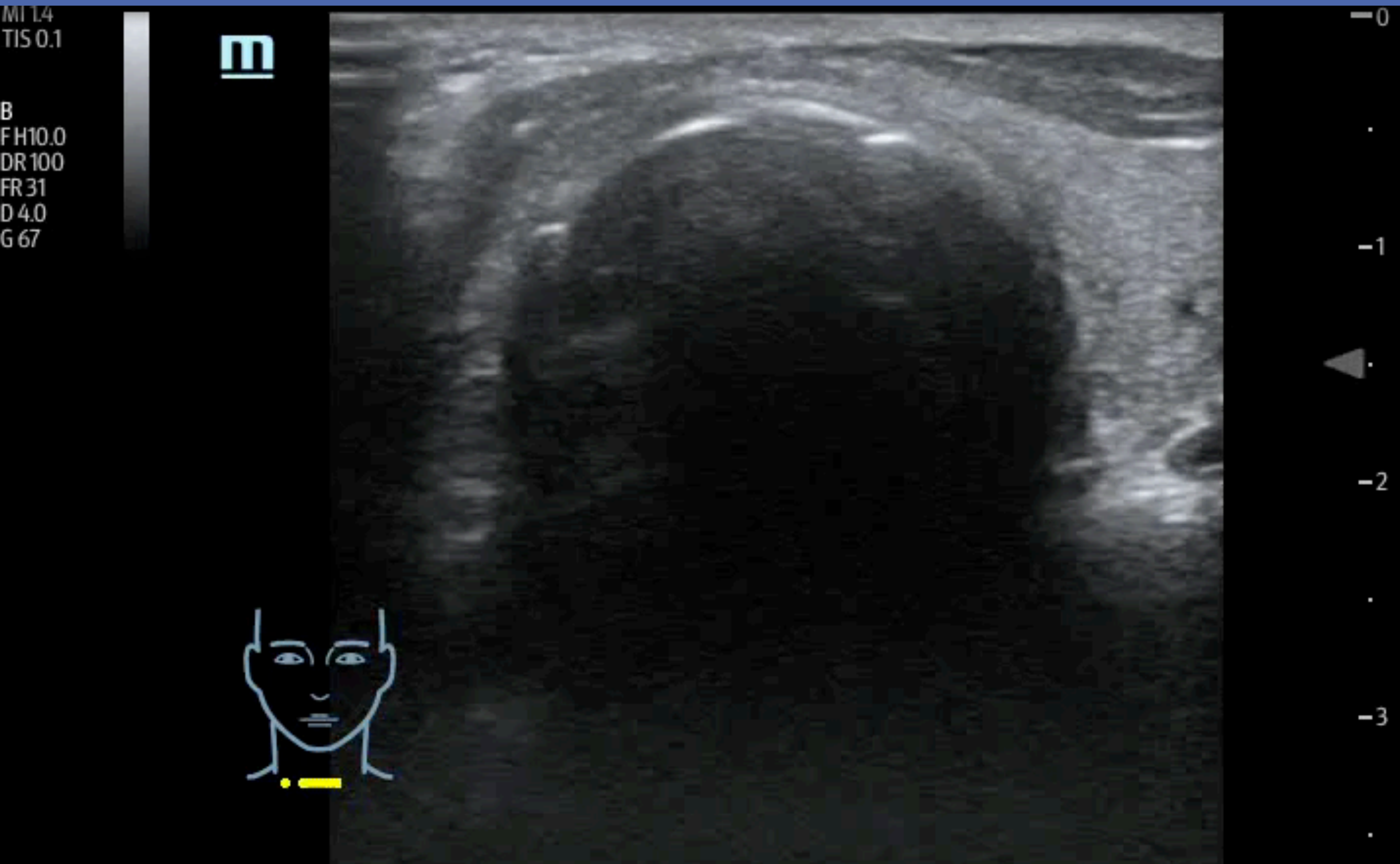
Direct visualization of ETT

Superficial : P
L12-3
46 Hz
3.0cm
2D
Res
Gn 60
C 56
3 / 2 / 1

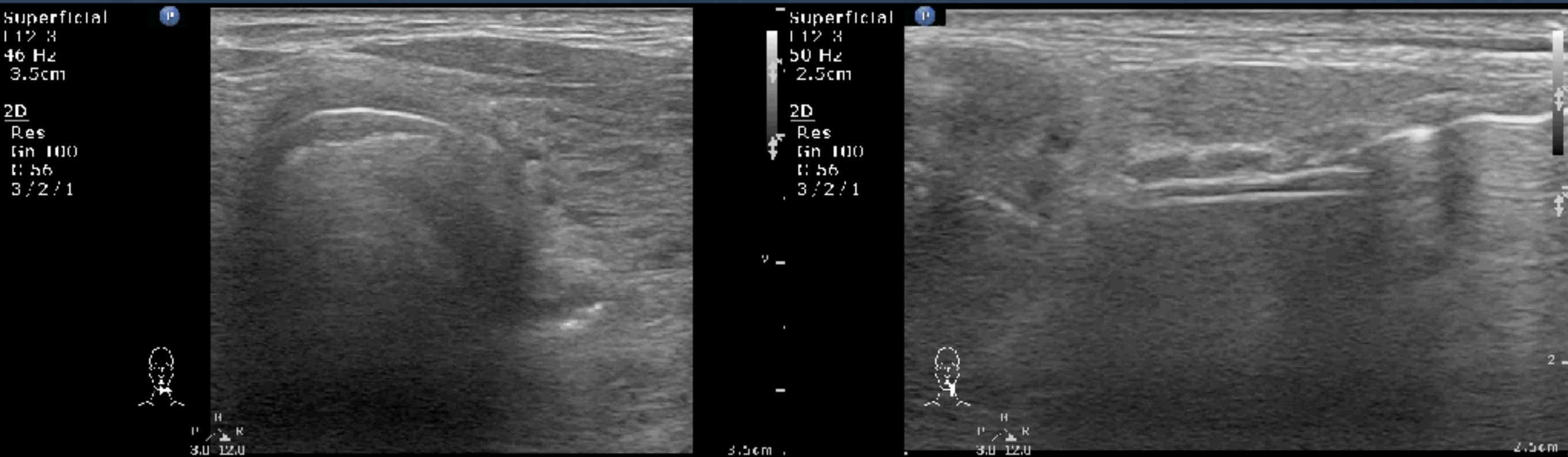


Cuff compression

Direct visualization of ETT



EVB_Airway protection Compression test

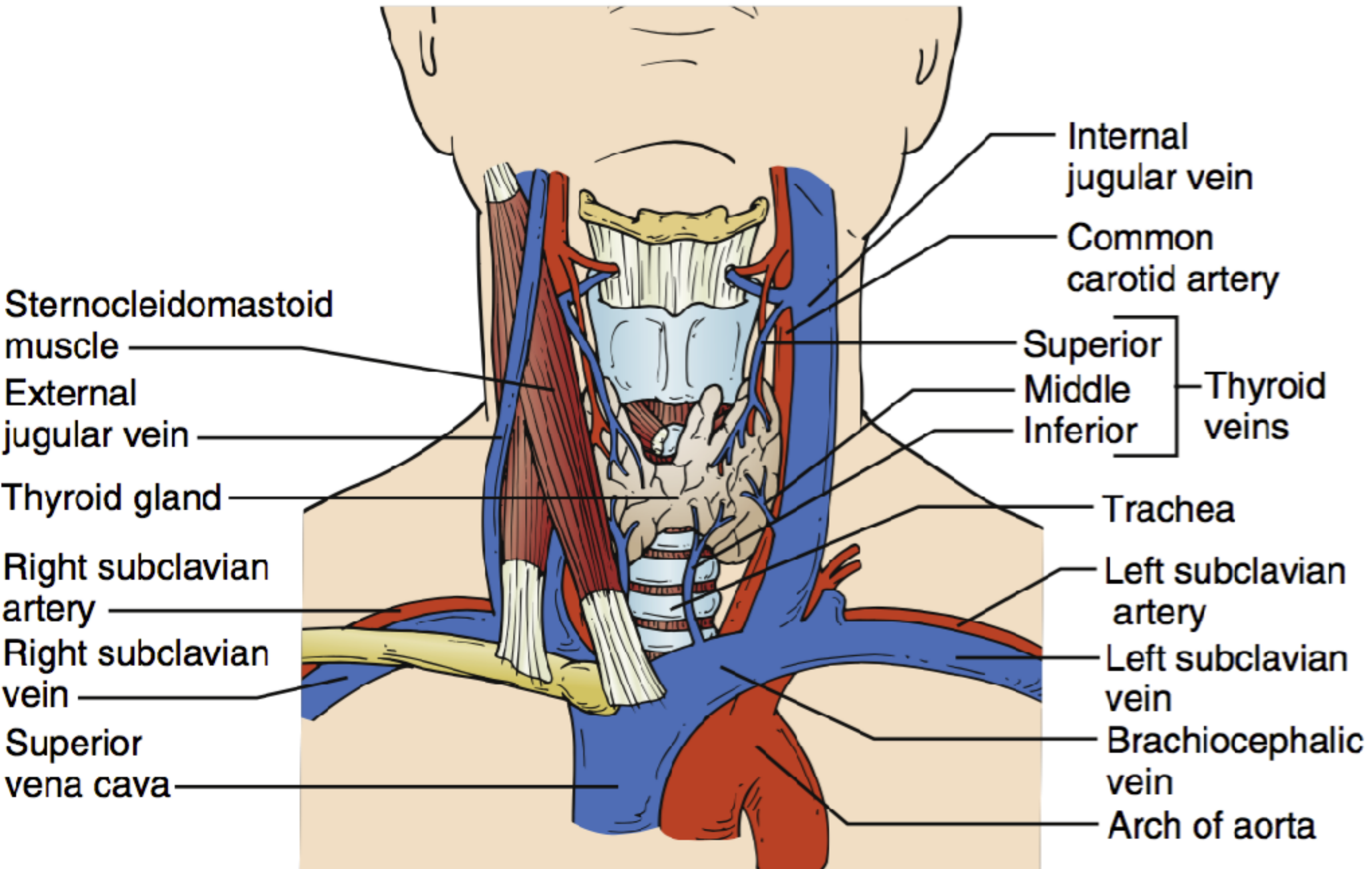


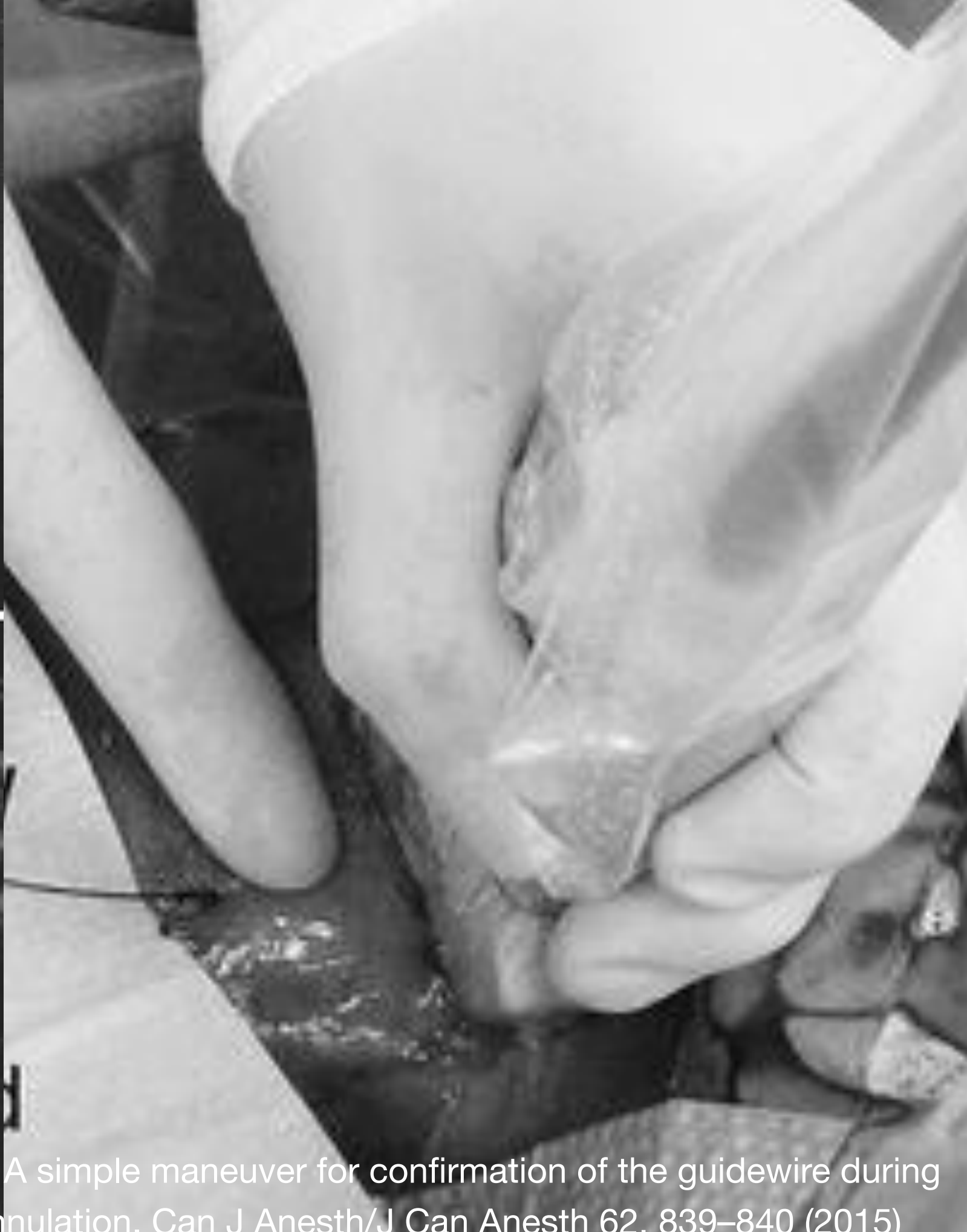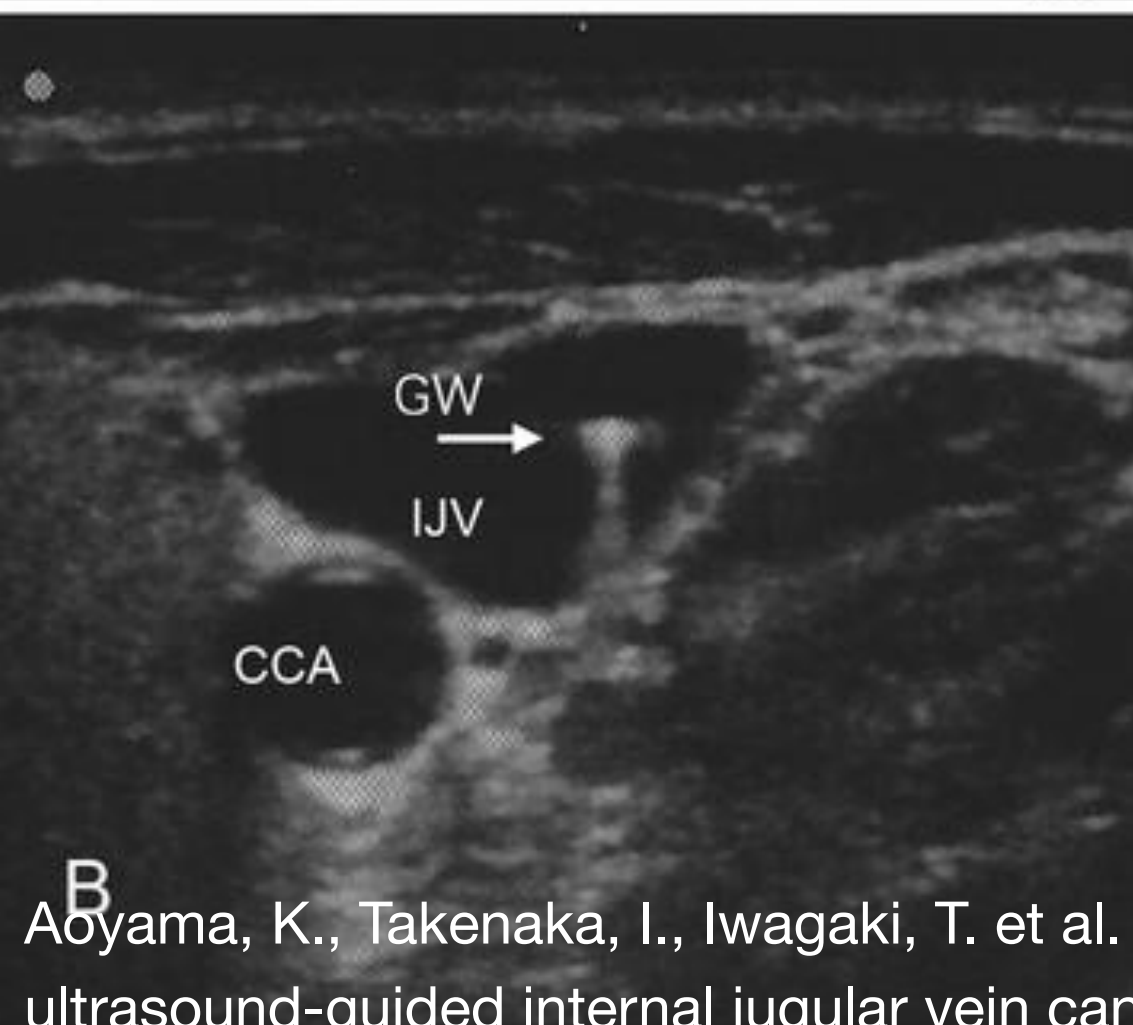
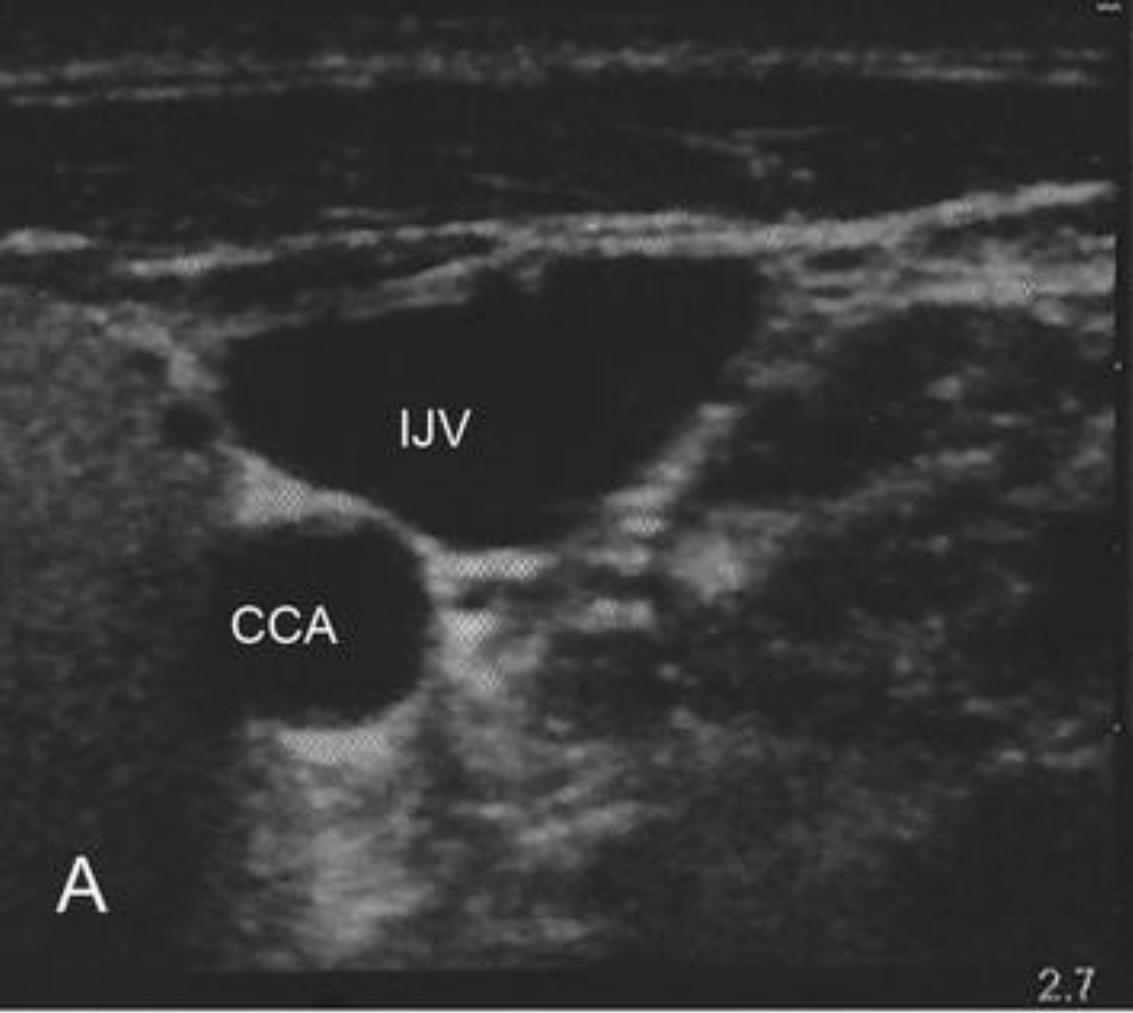


Success rates ↑

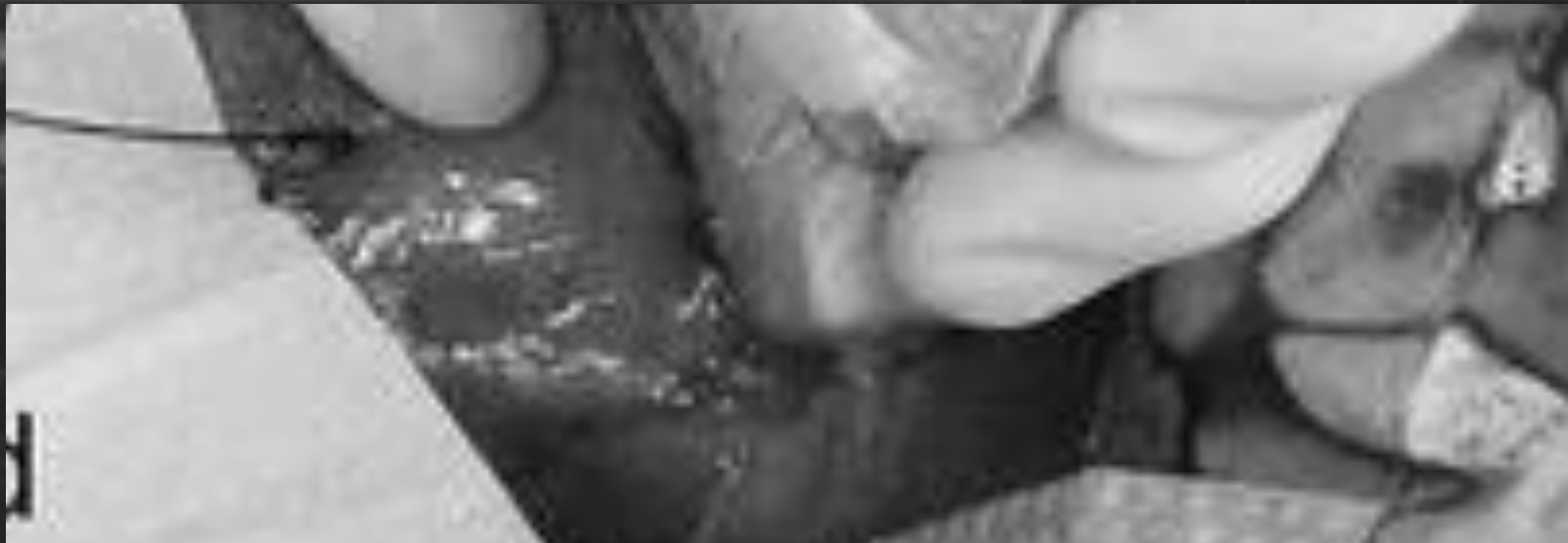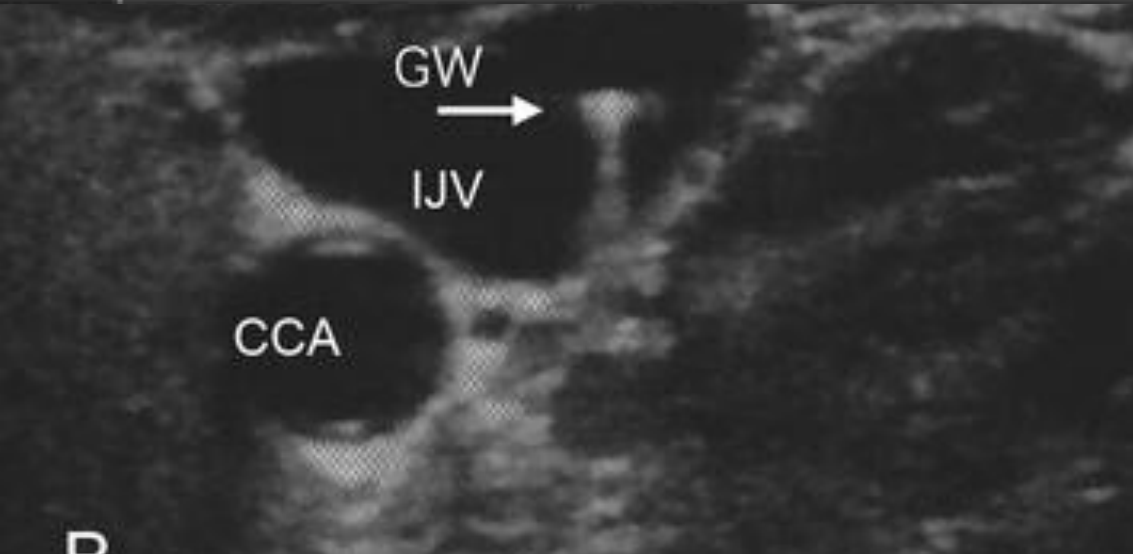
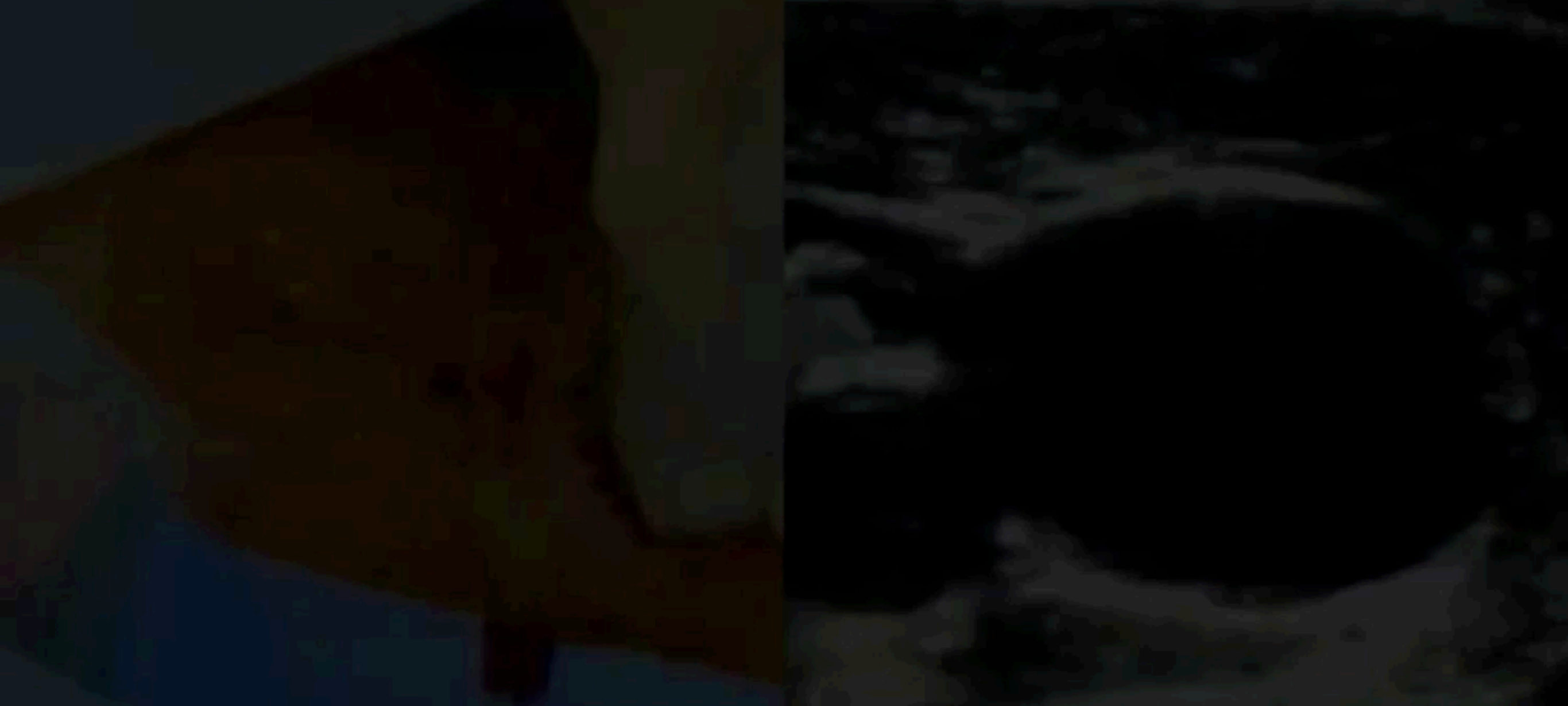Mechanical complications ↓

Neck Vascular Structure





Aoyama, K., Takenaka, I., Iwagaki, T. et al. A simple maneuver for confirmation of the guidewire during ultrasound-guided internal jugular vein cannulation. *Can J Anesth/J Can Anesth* 62, 839–840 (2015)



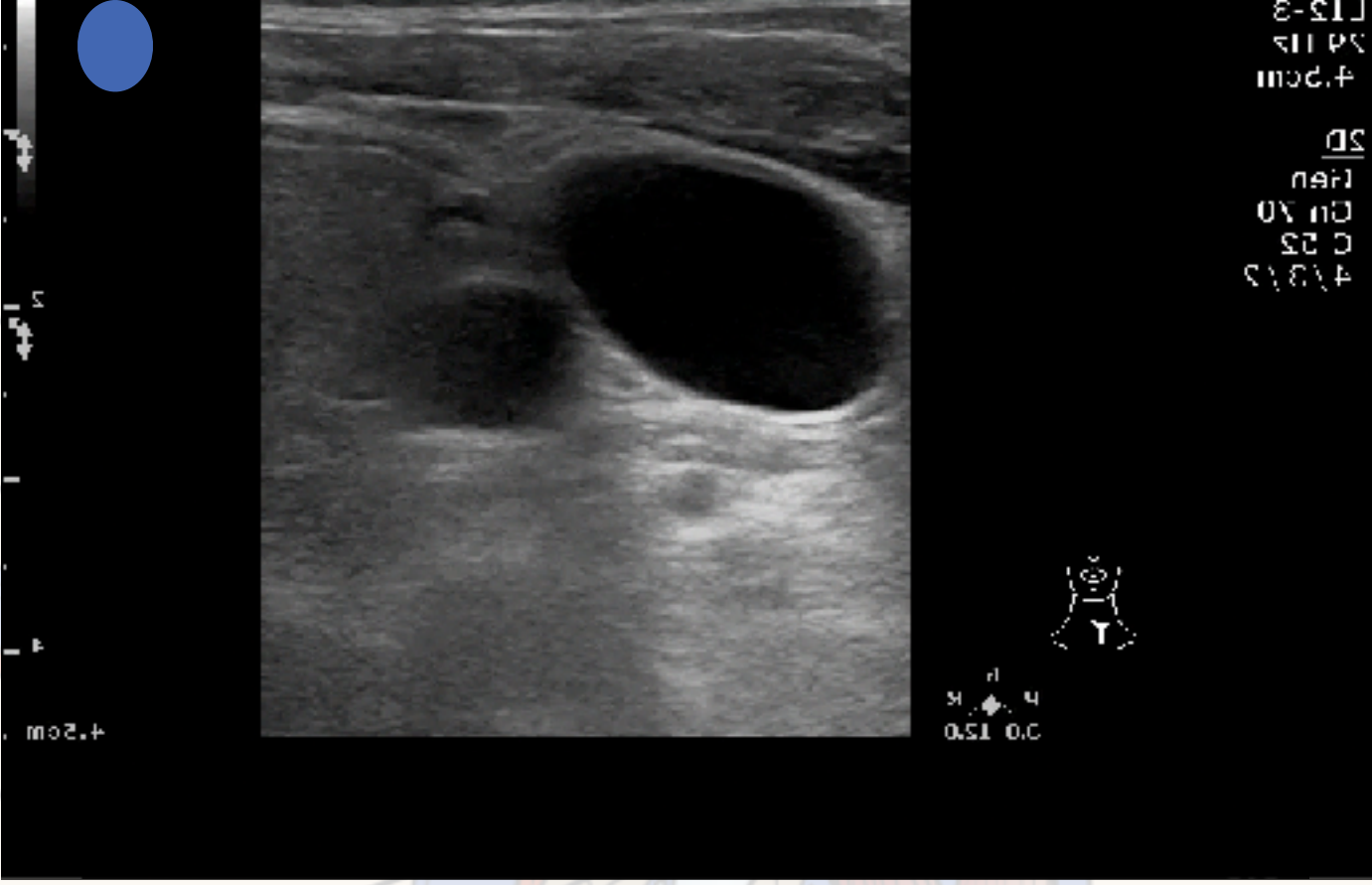
B Aoyama, K., Takenaka, I., Iwagaki, T. et al. A simple maneuver for confirmation of the guidewire during ultrasound-guided internal jugular vein cannulation. *Can J Anesth/J Can Anesth* 62, 839–840 (2015)

Longitudinal approach



L

R



Arch of aorta
vein
Brachiocephalic
vein
Left subclavian
artery
Left subclavian

vena cava
Superior
vein
Right subclavian
artery
Right subclavian

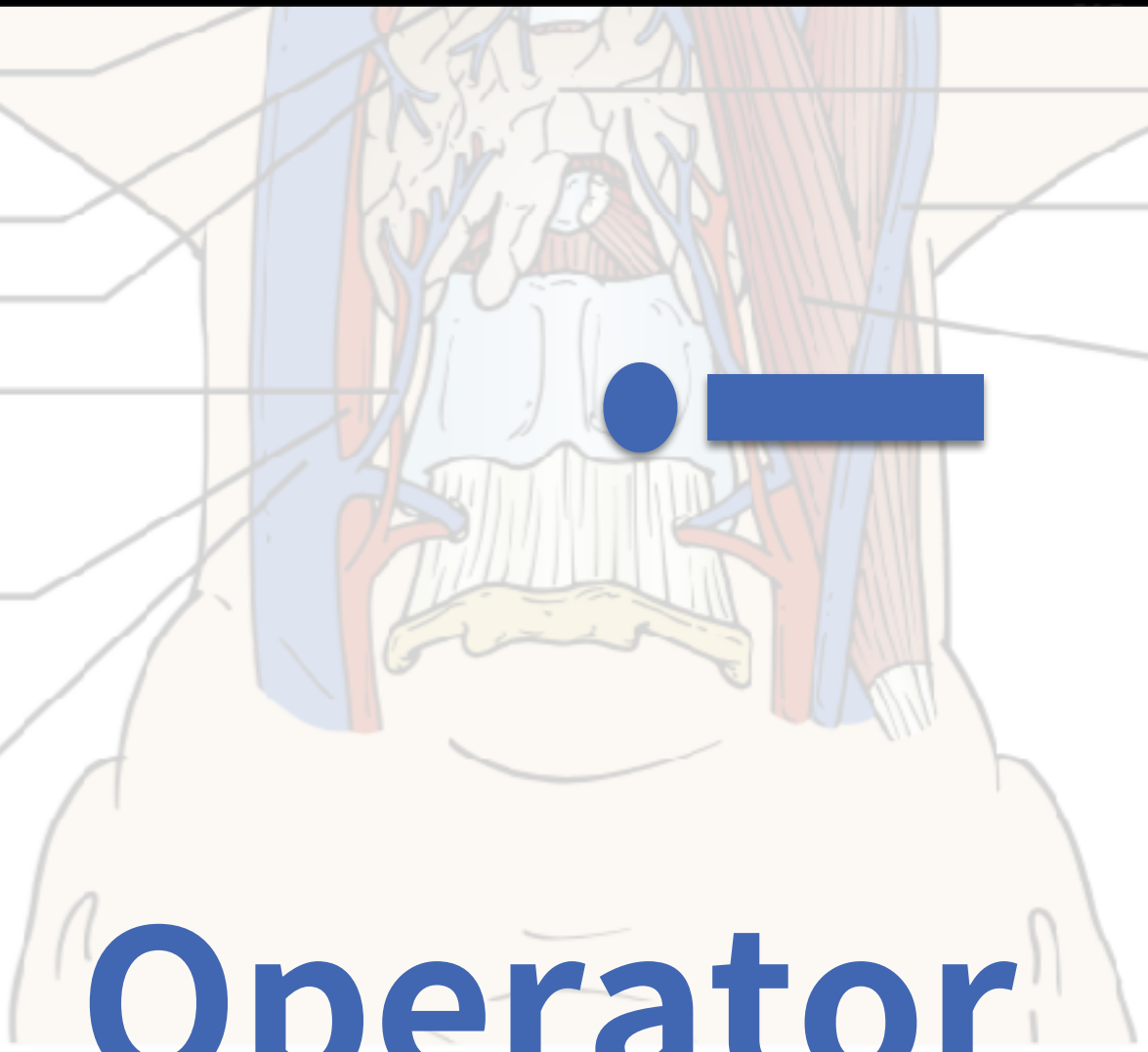
Trachea

Thyroid gland

Thyroid
veins
Superior
Middle
Inferior

External
muscle
Sternocleidomastoid
jugular vein

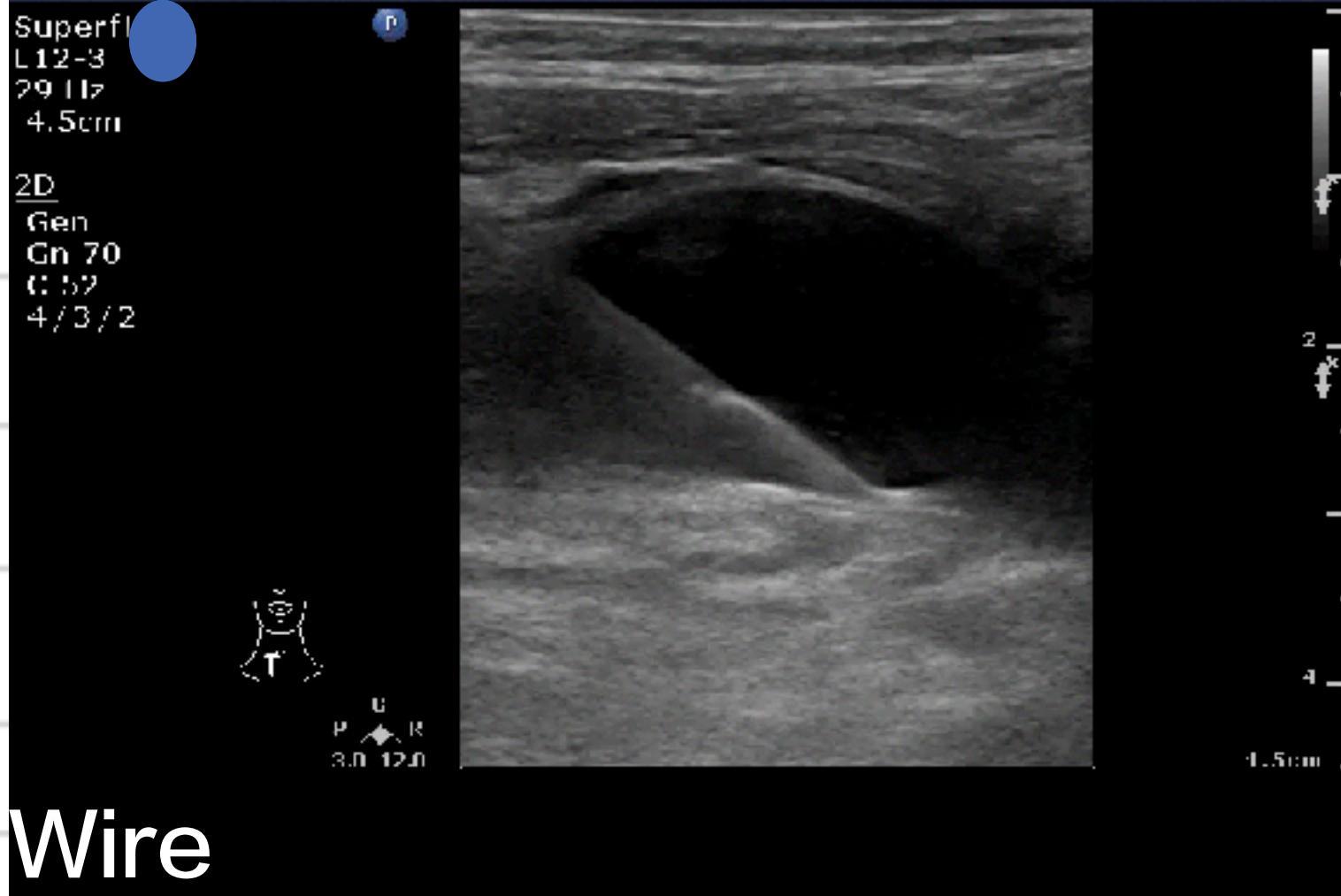
Internal
jugular vein
Common
carotid artery



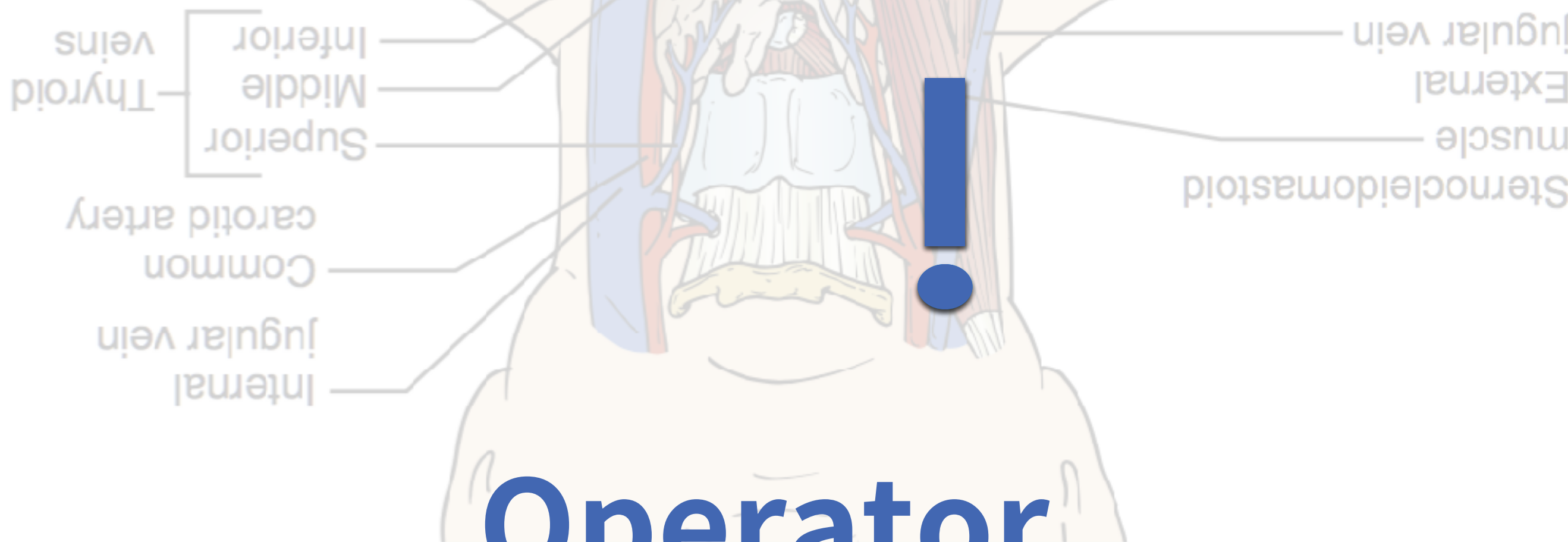
Operator

L

R



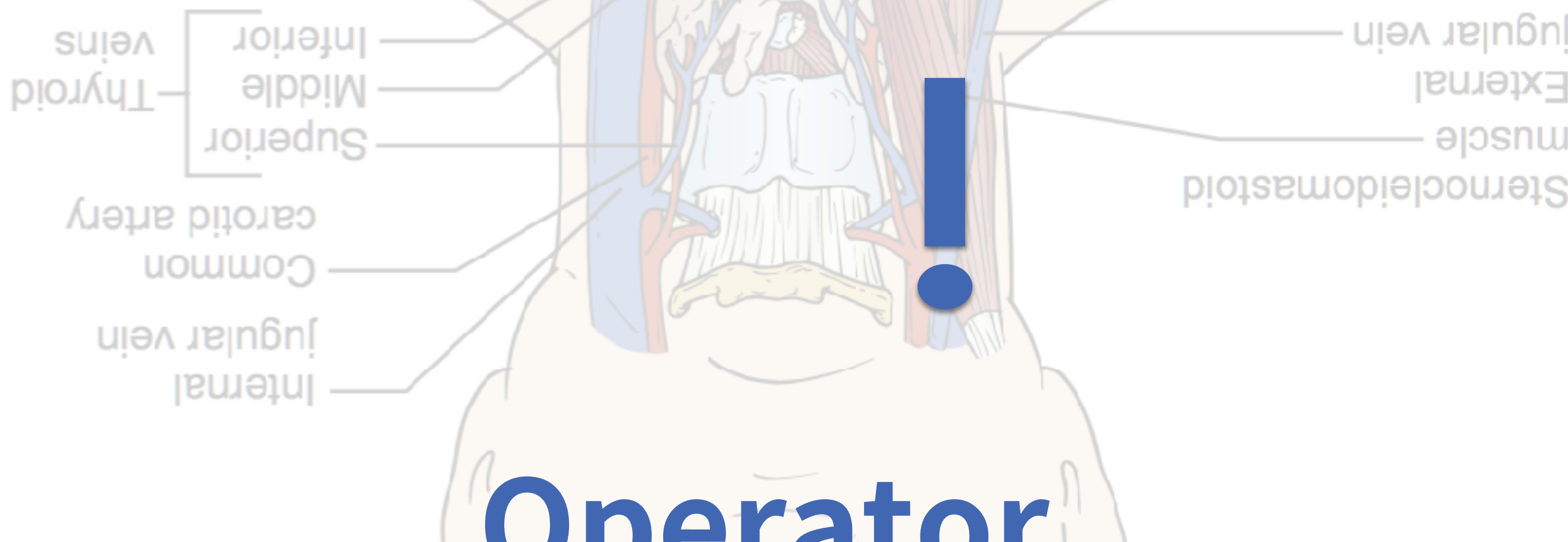
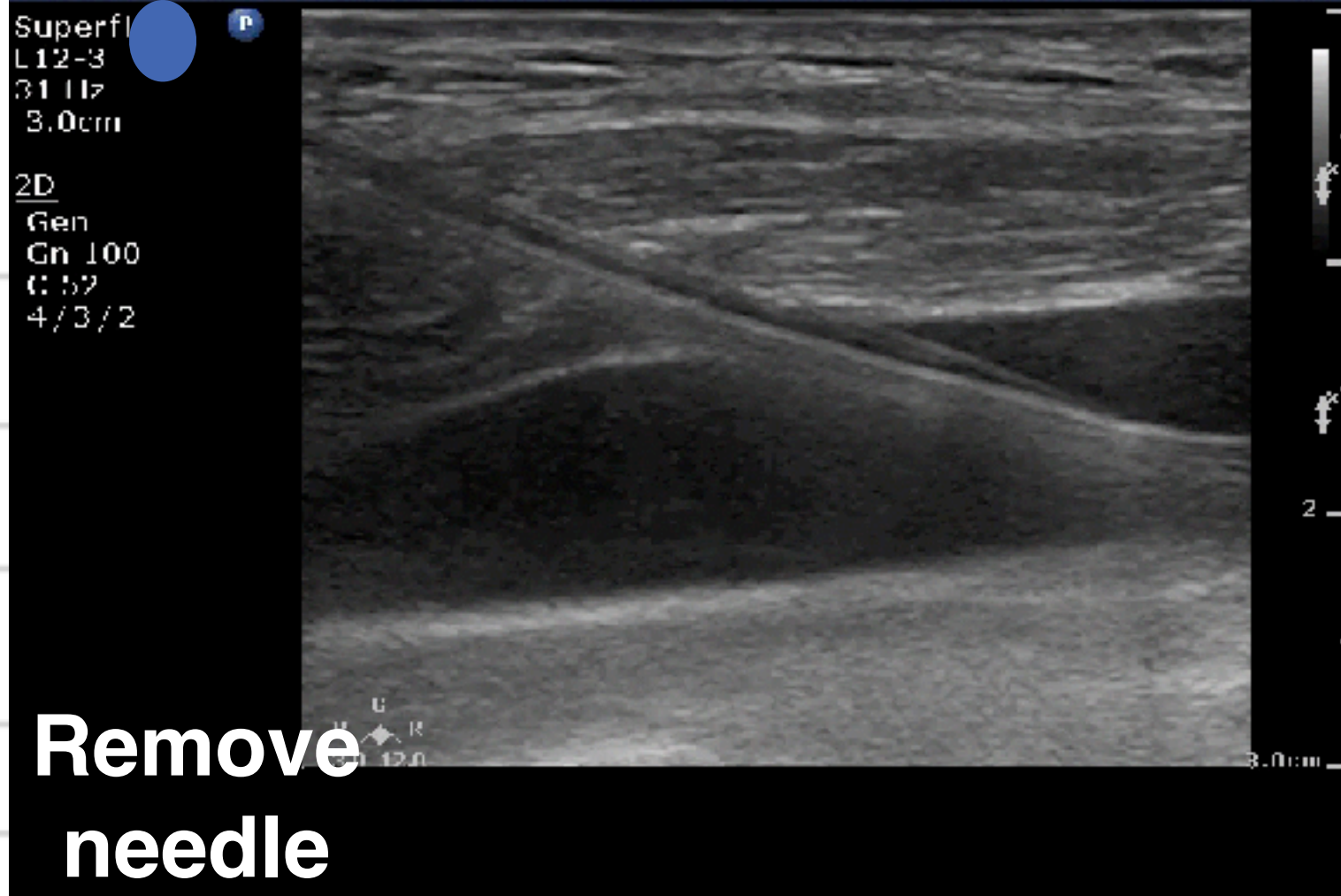Wire



Operator

L

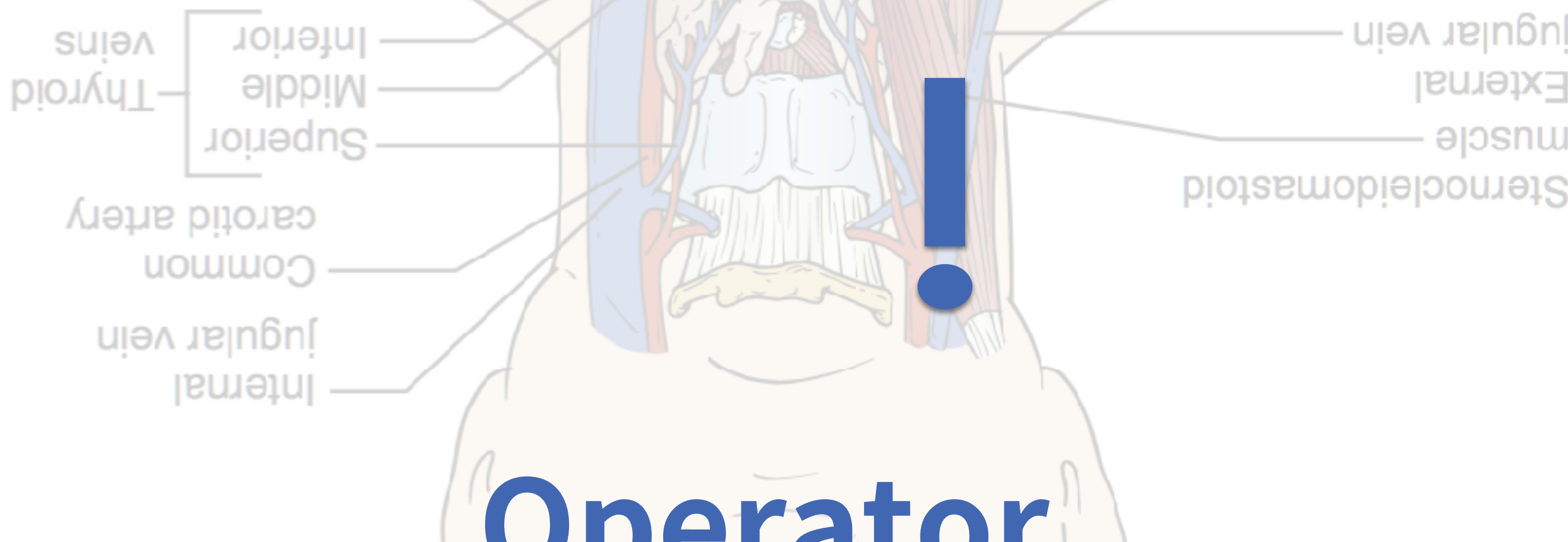
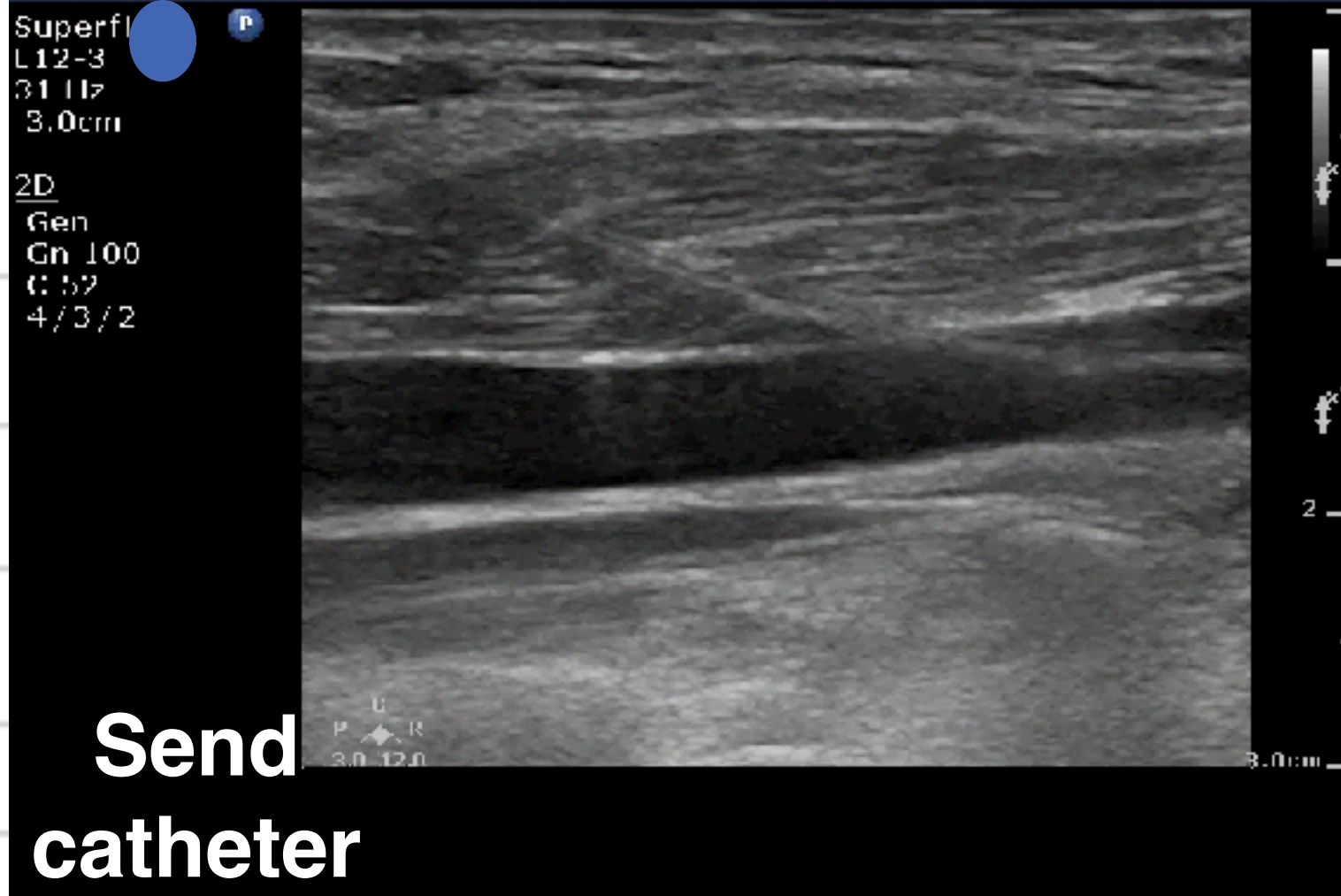
R



Operator

L

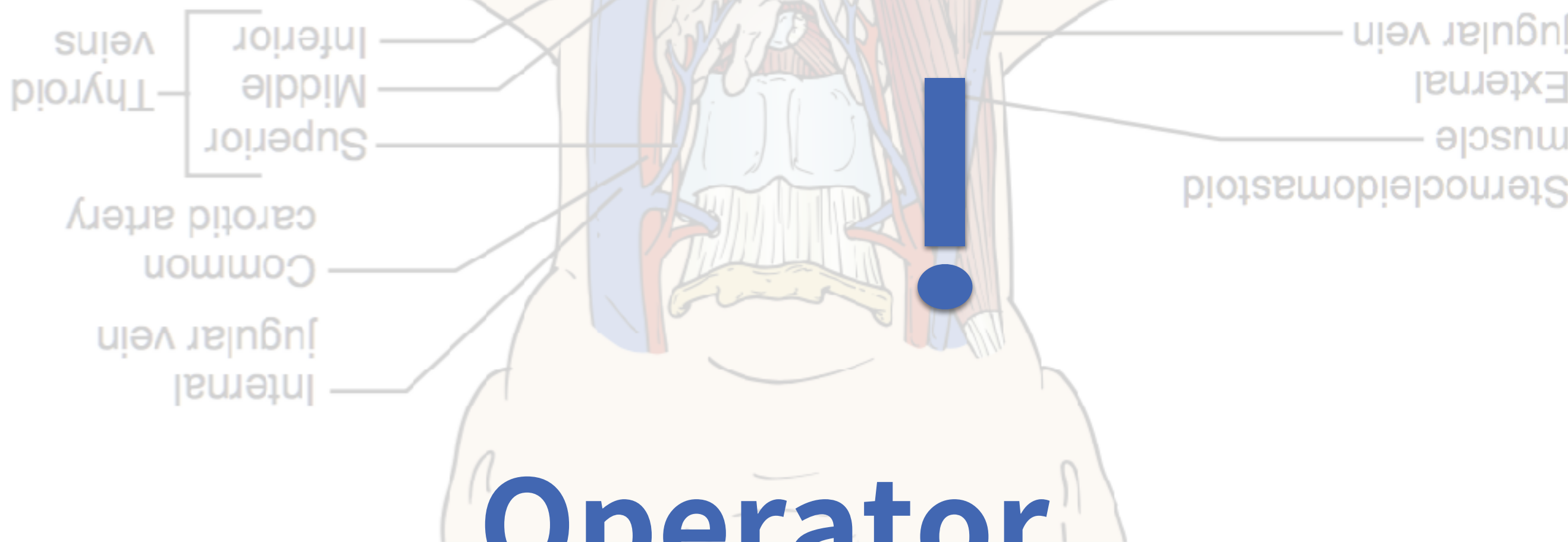
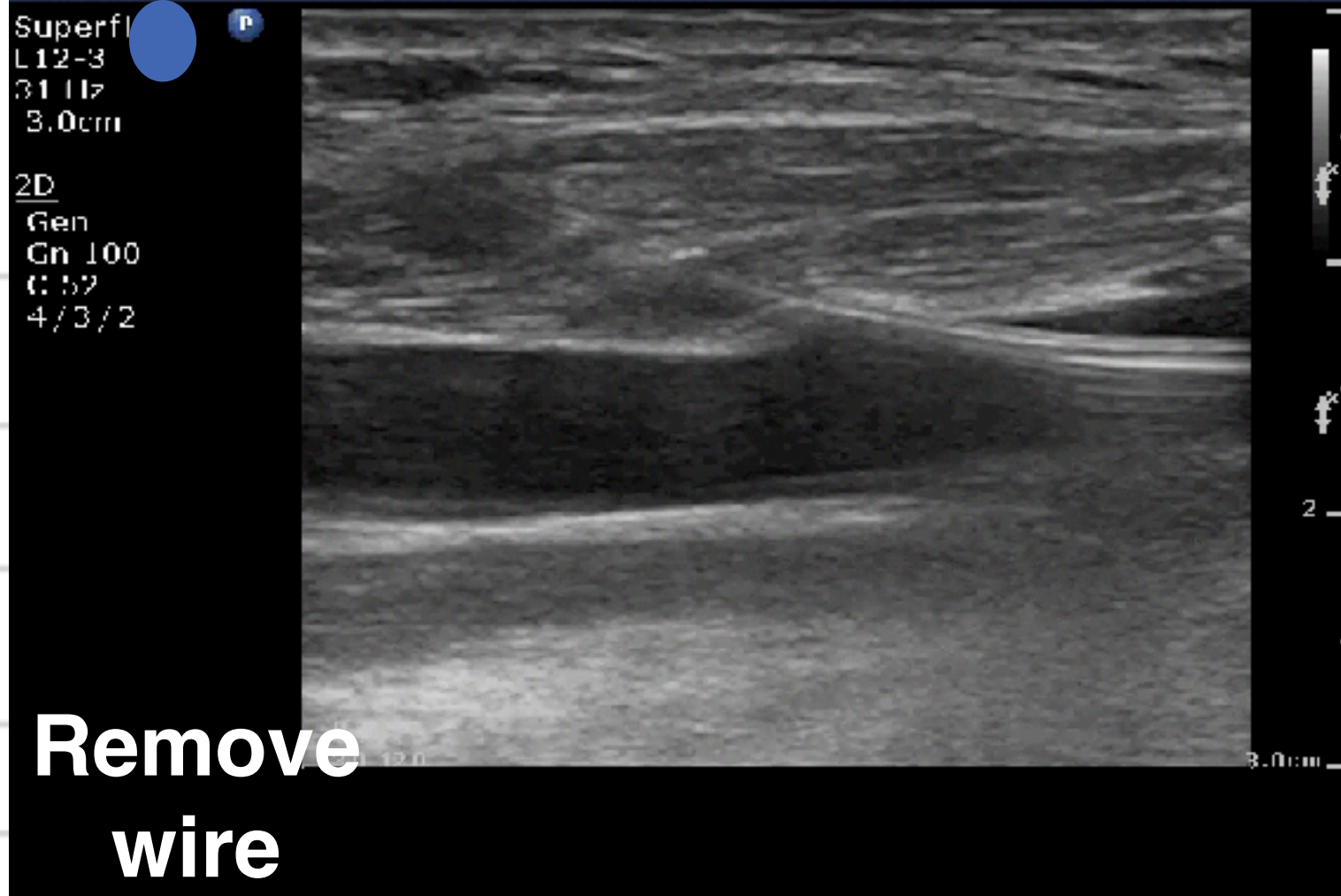R



Operator

L

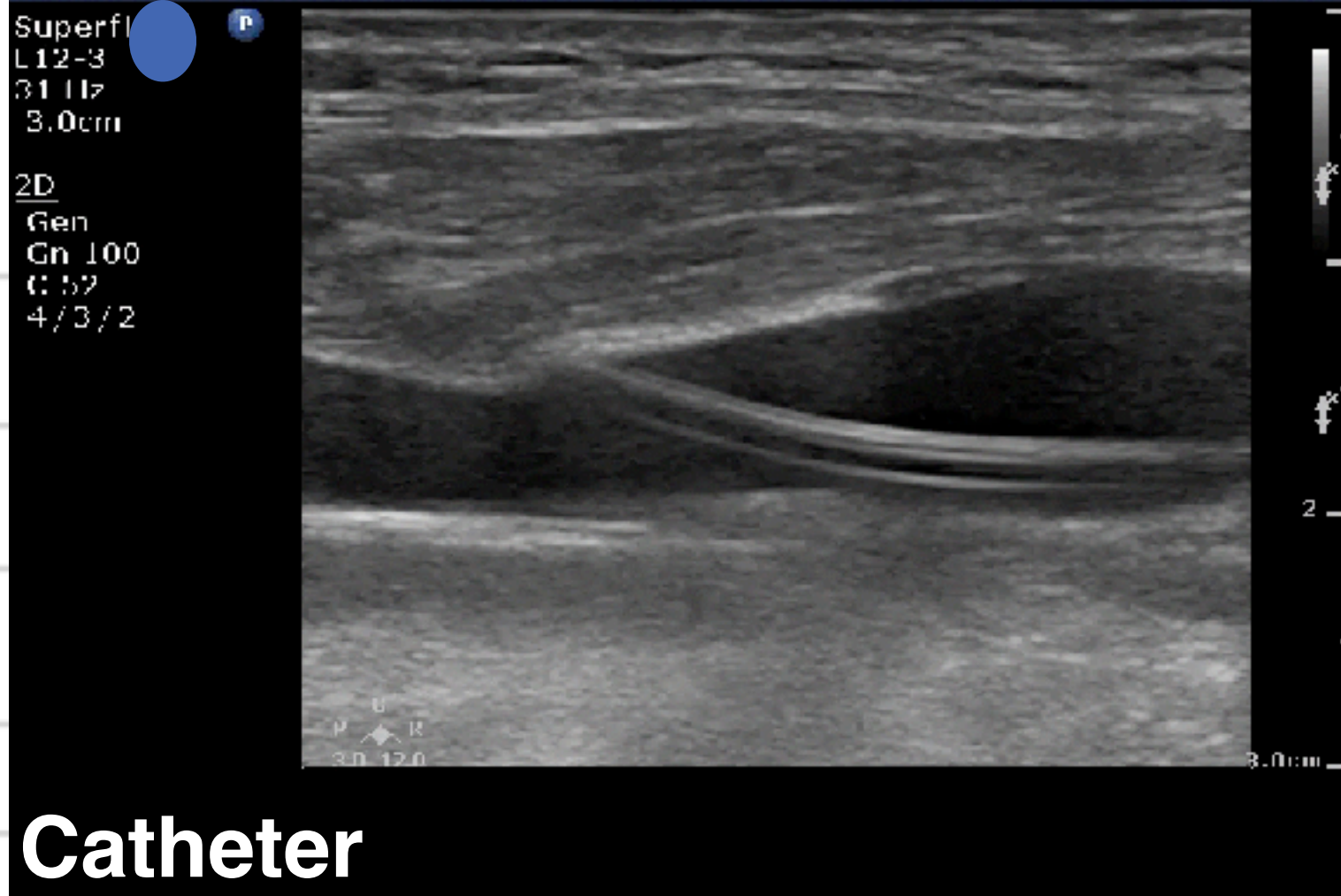
R



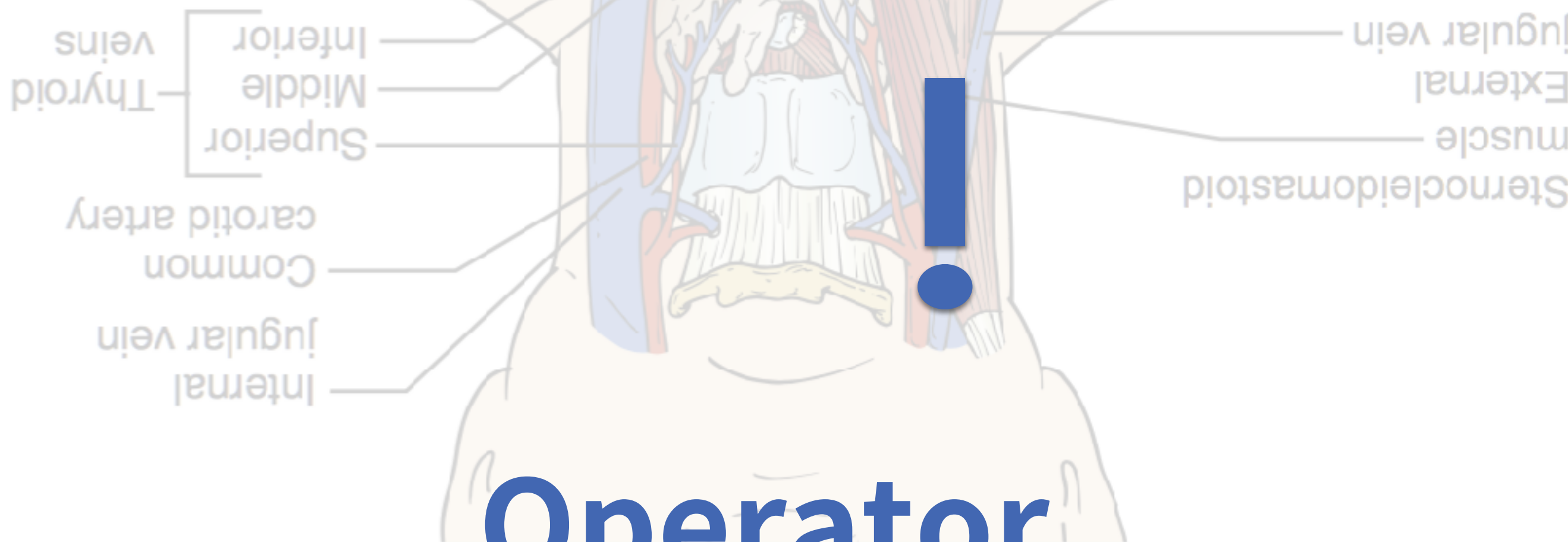
Operator

L

R



Catheter

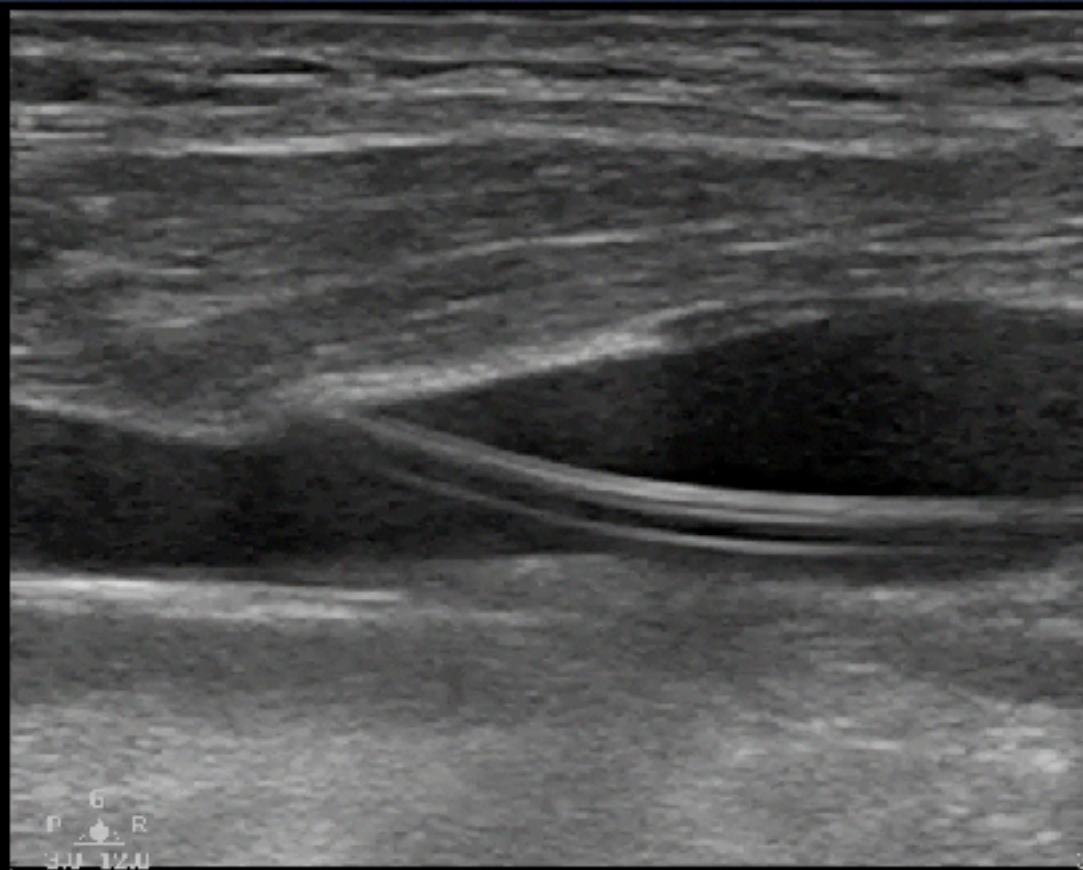


Operator

clal

P

L

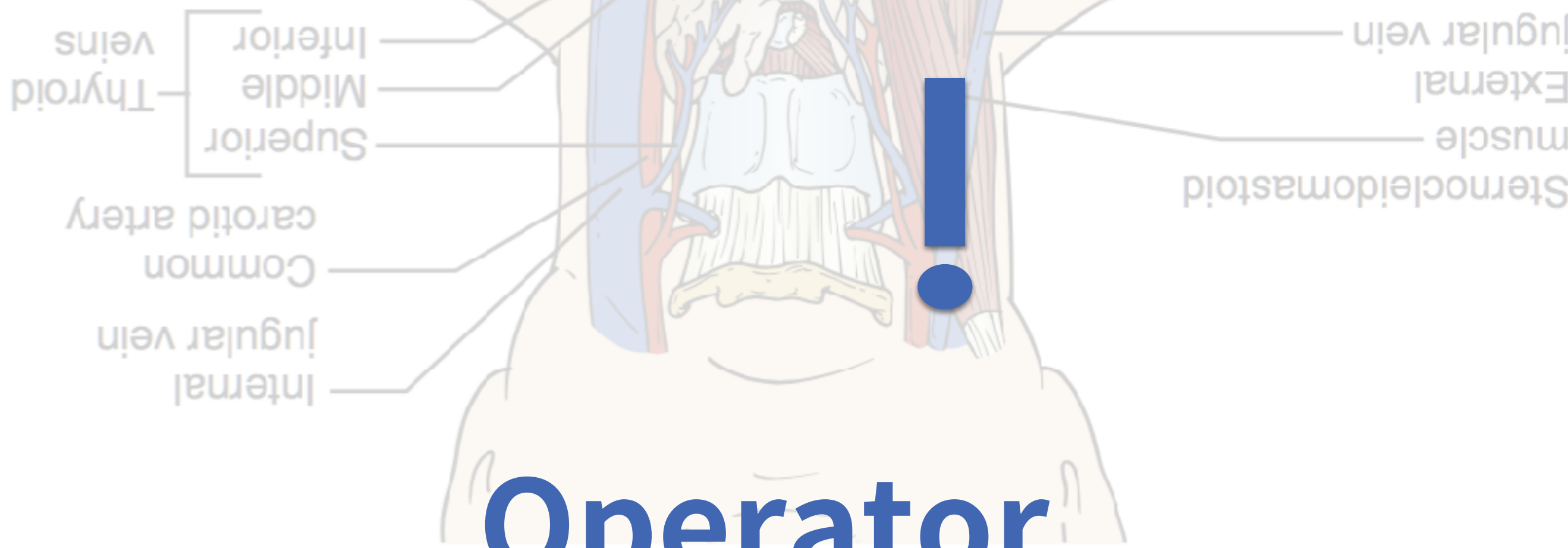
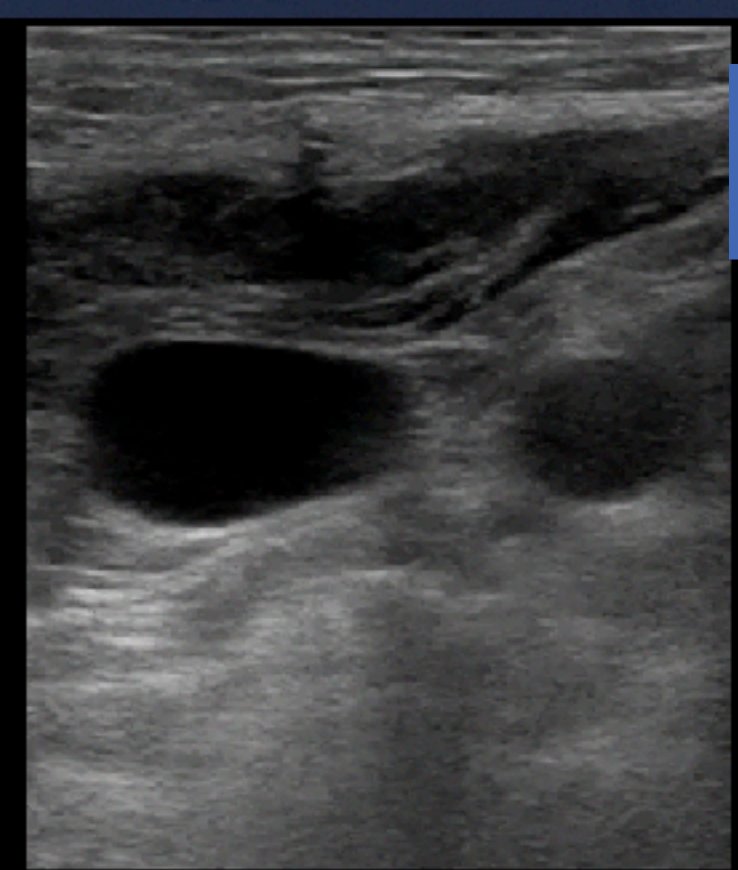


Superficial
 L12-3
 29 Hz
 4.5cm
 2D
 Gen
 Cn 70
 C 52
 4/3/7

Final

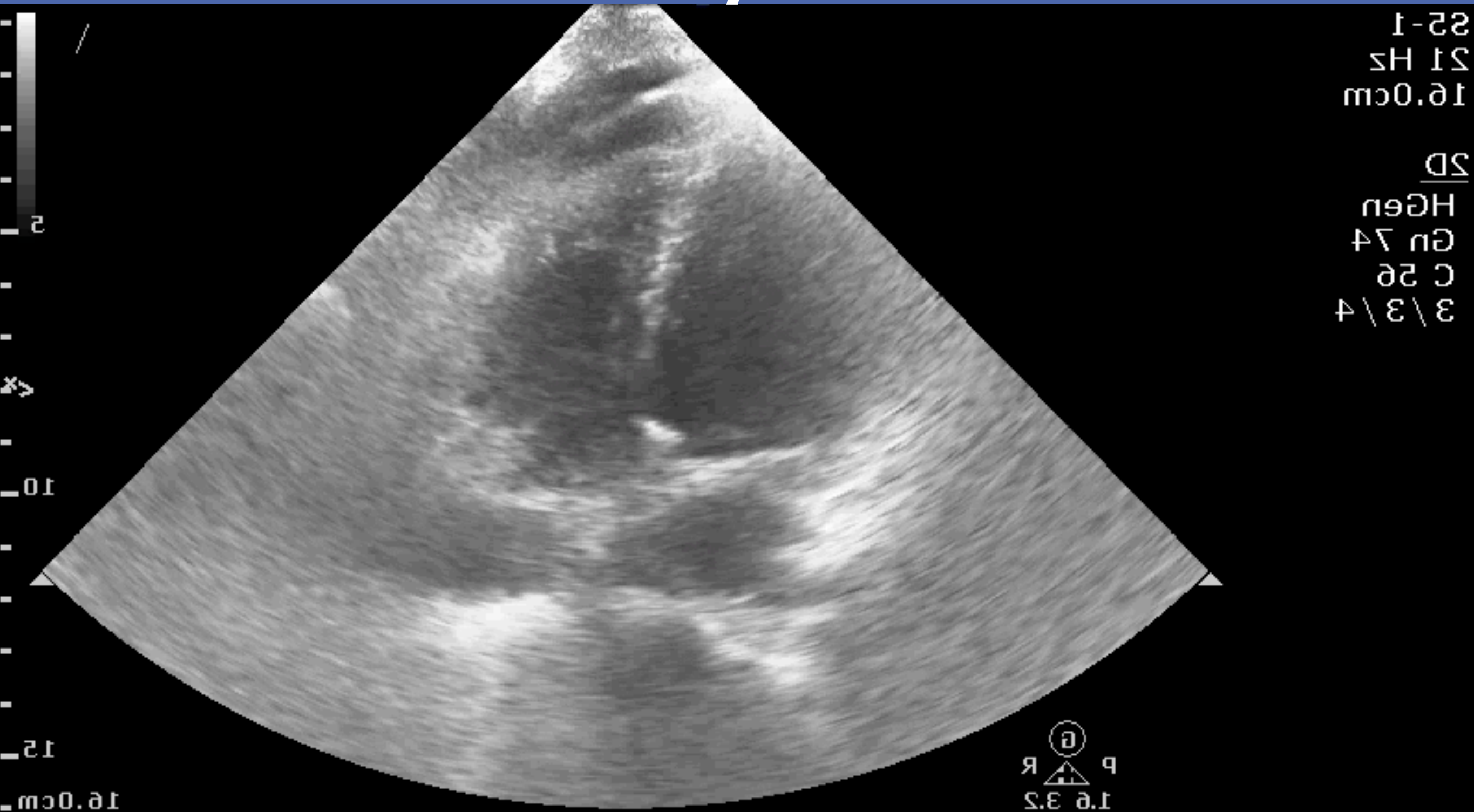
P

R

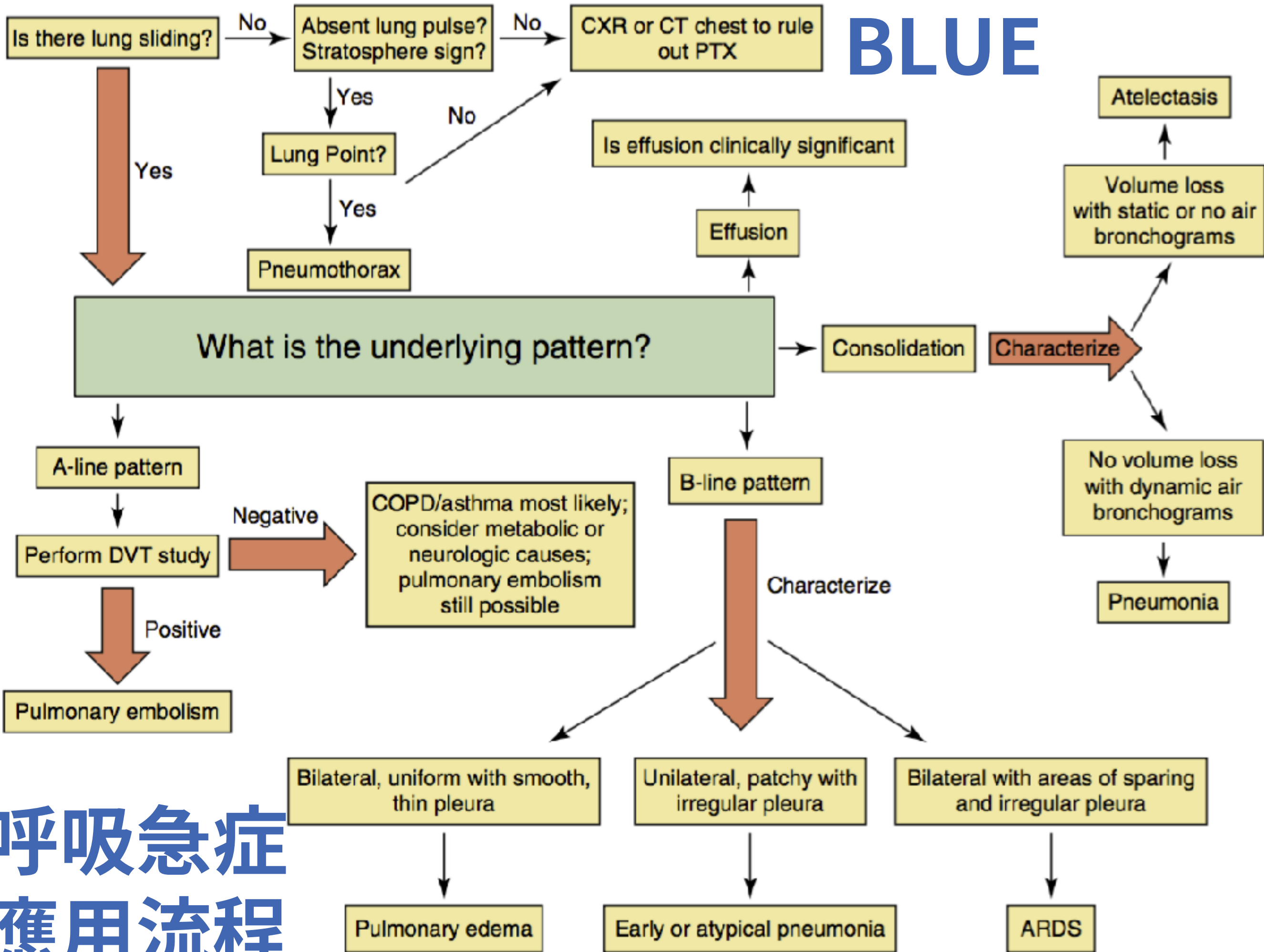


Operator

Bubble test / Subcostal 4



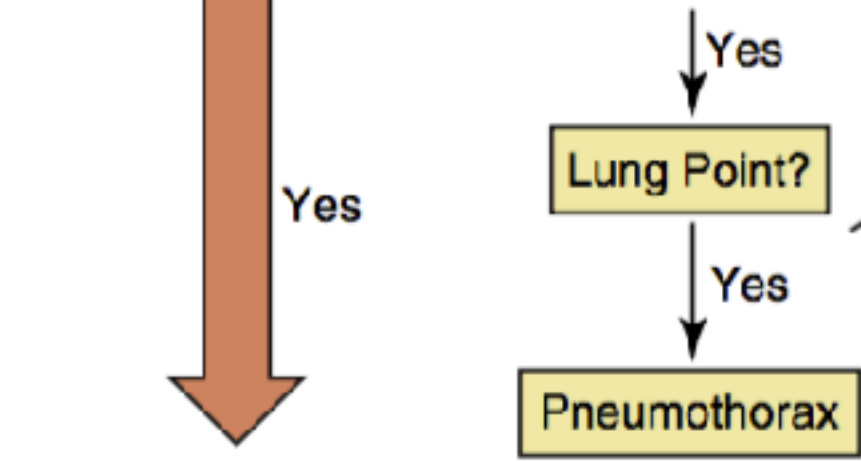
BLUE



呼吸急症 應用流程

Is there lung sliding? No → Absent lung pulse? Stratosphere sign? No → CXR or CT chest to rule out PTX

BLUE



Is effusion clinically significant

Effusion

Consolidation

Characterize

What is the underlying pattern?

A-line pattern

Perform DVT study

Negative

Positive

Pulmonary embolism

COPD/asthma most likely; consider metabolic or neurologic causes; pulmonary embolism still possible

B-line pattern

Characterize

Bilateral, uniform with smooth, thin pleura

Unilateral, patchy with irregular pleura

Bilateral with areolar and irregular

Pulmonary edema

Early or atypical pneumonia

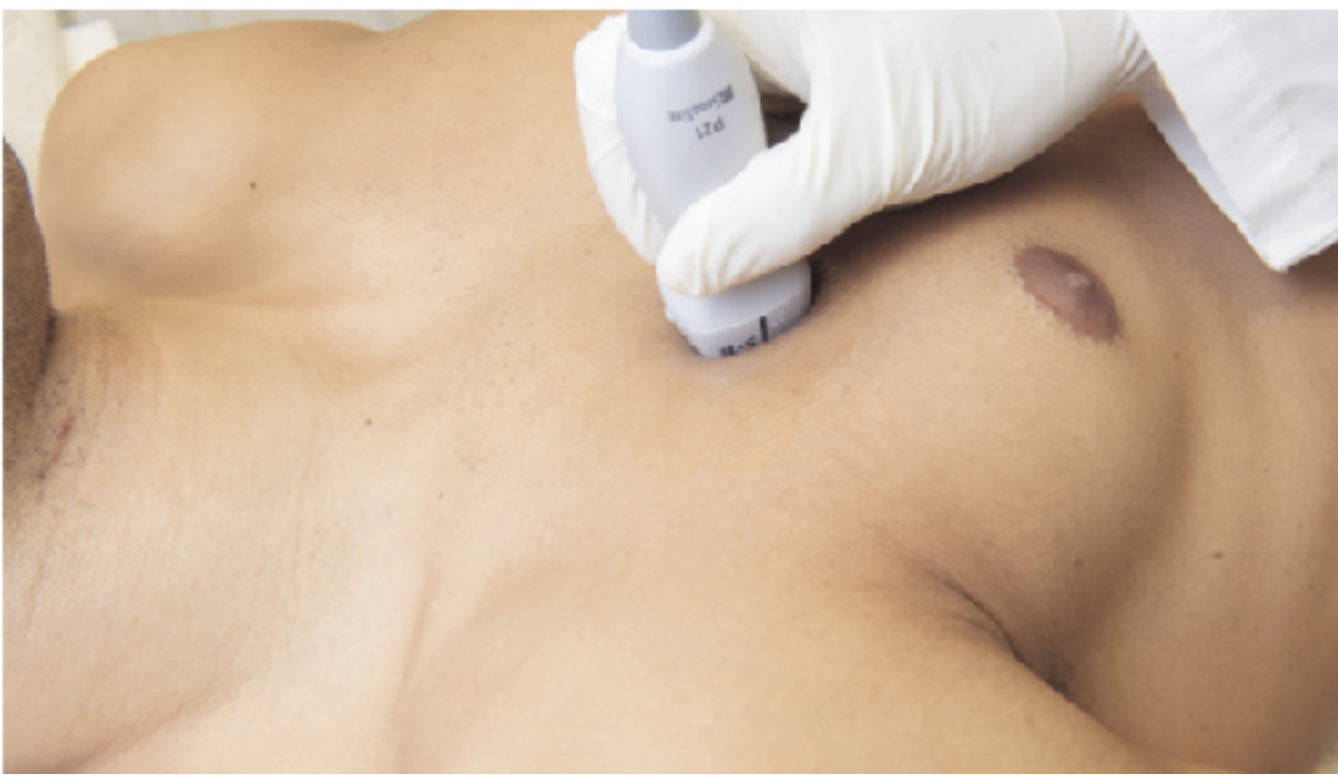ARDS

S
A
B
E
C

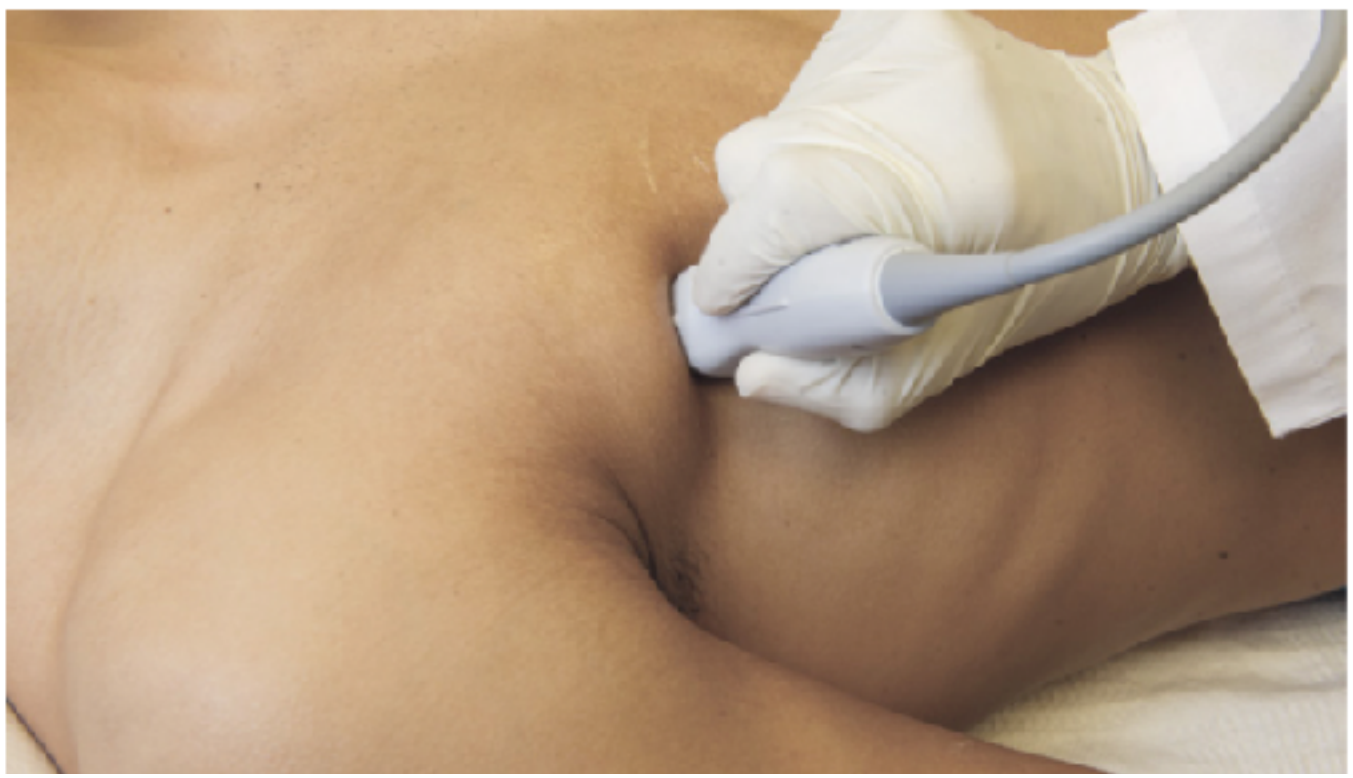呼吸急症
應用流程

BLUE 4 points

Point 1

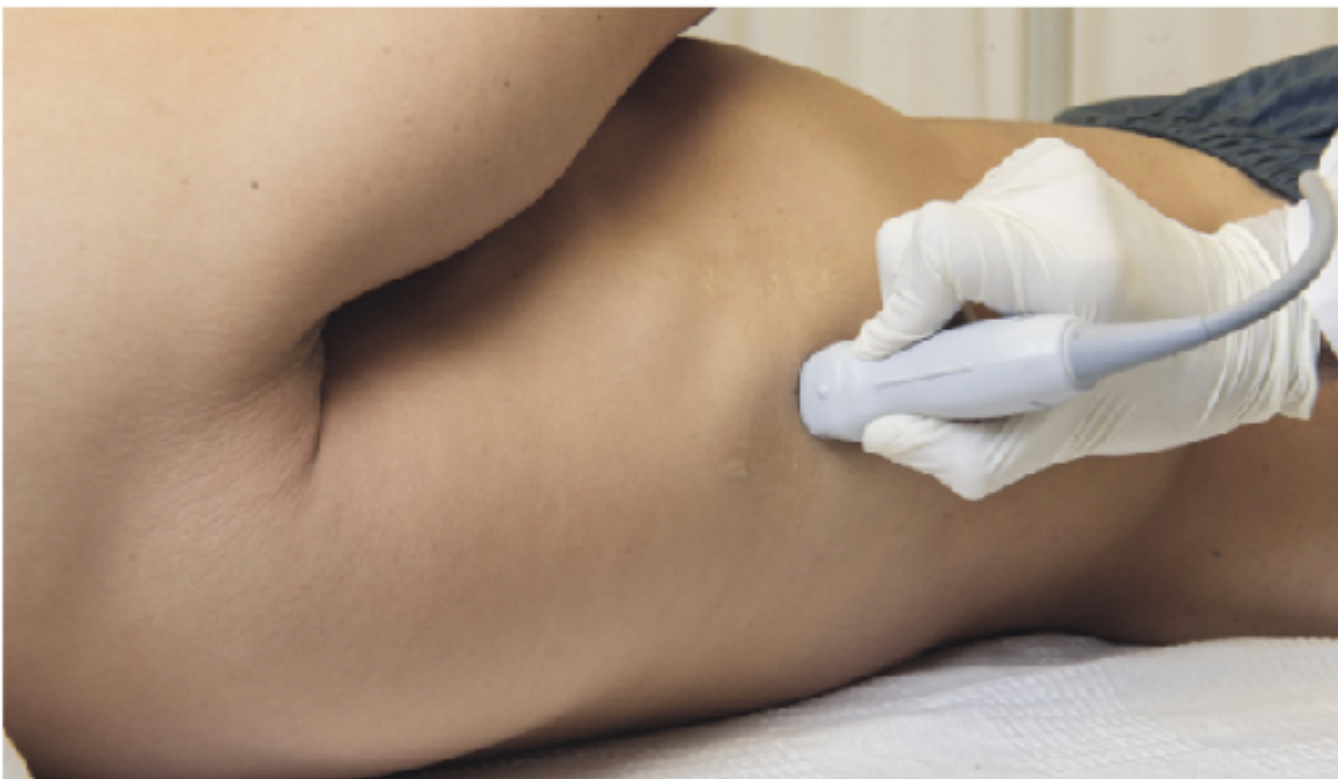

Point 2

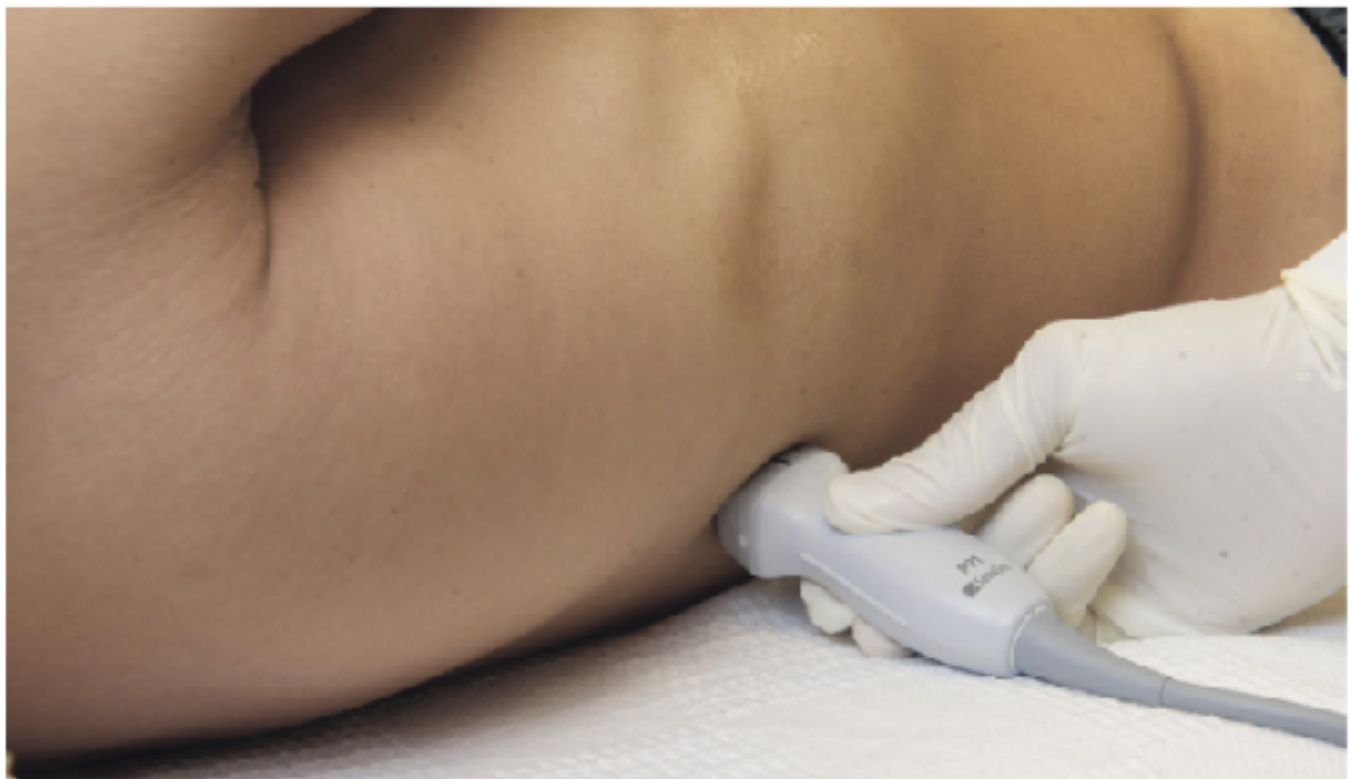

Head <<<<< **Sagittal view** >>>>> Toe

Point 3

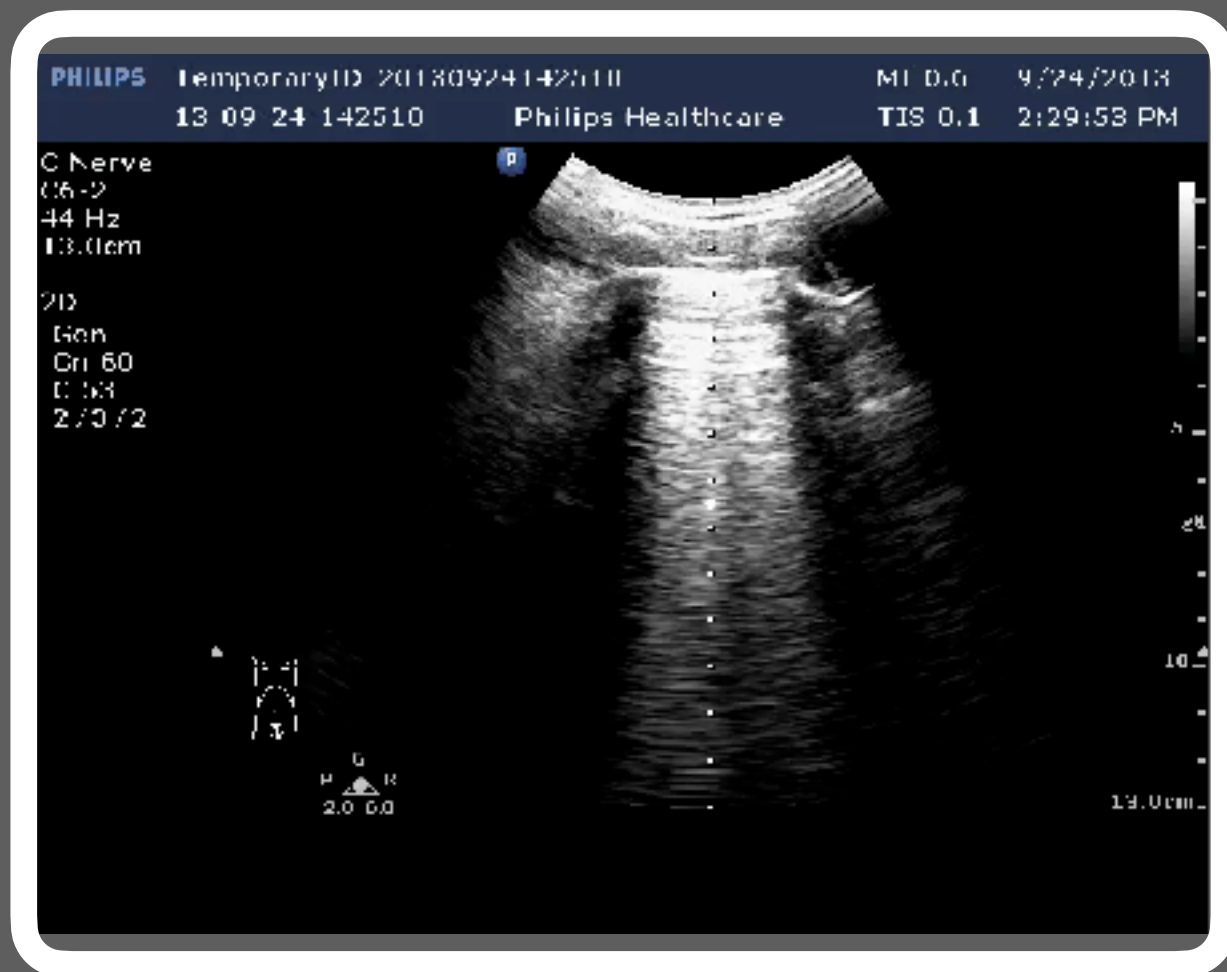


Point 4

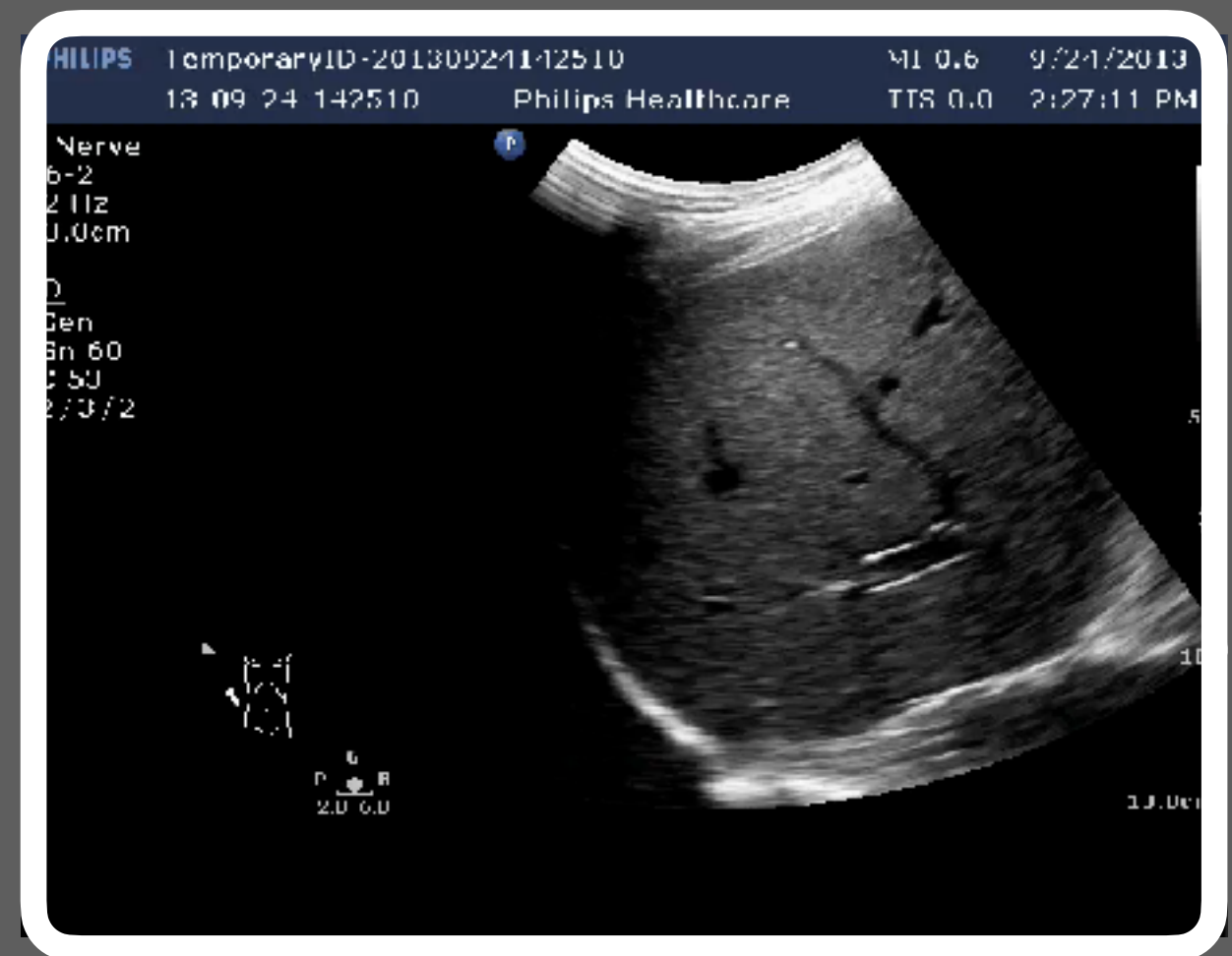


Principle

Air

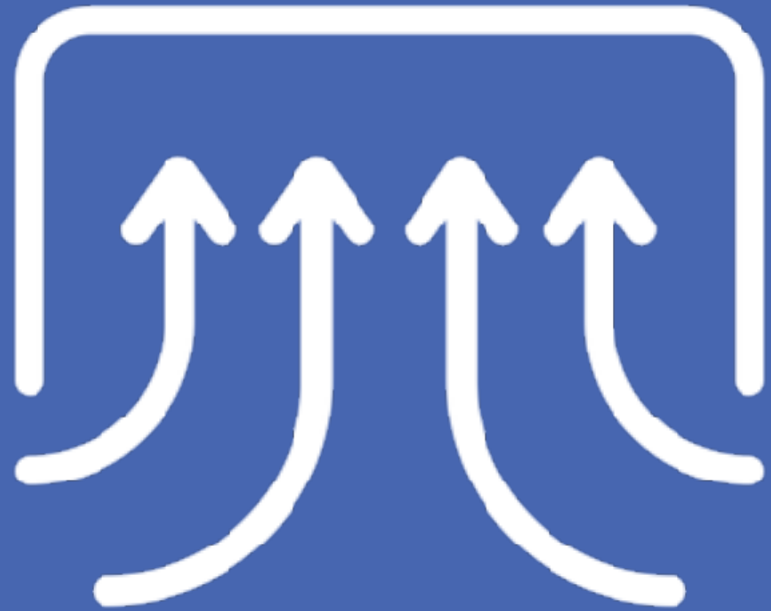


Fluid



Principle

Air 100%



Pneumothorax

Fluid 100%



Pleural effusion

Principle

True

Pneumonia
Pleural effusion
Pleural mass

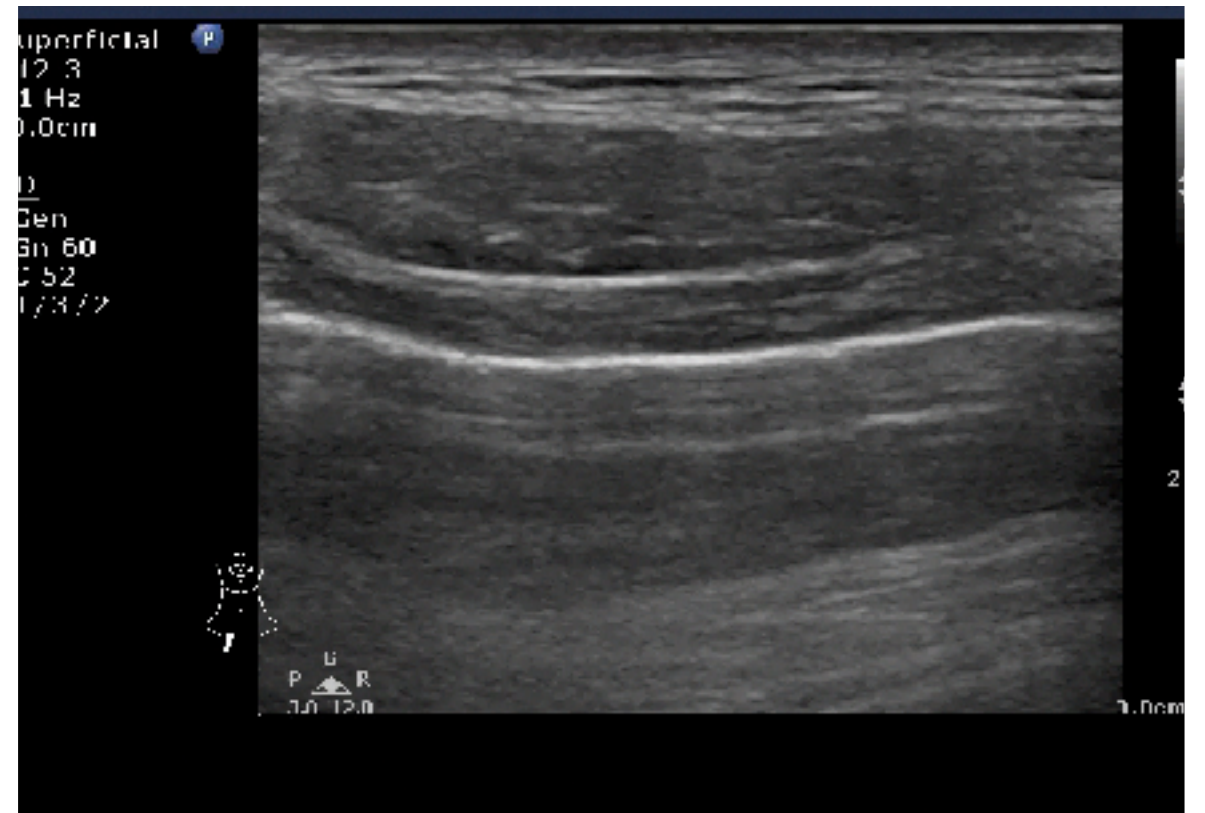
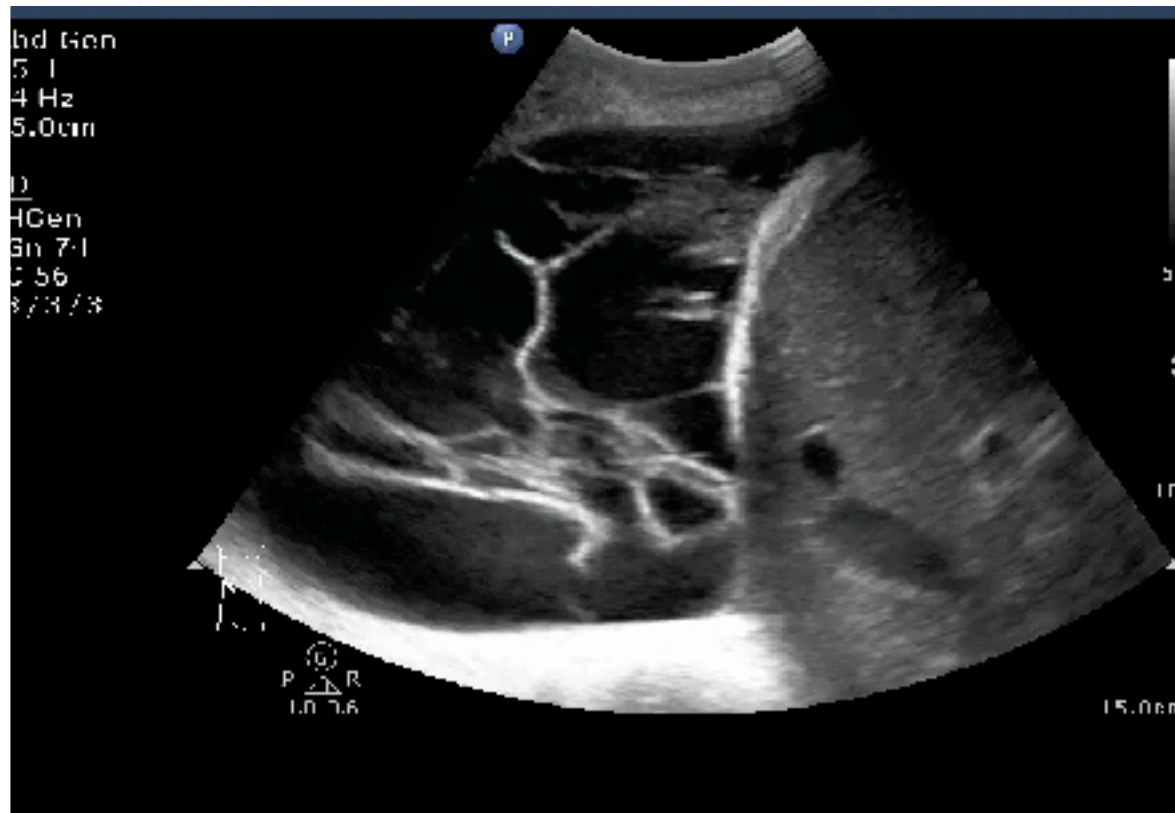
Artifact

Normal lung
Pneumothorax
AIS

Principle

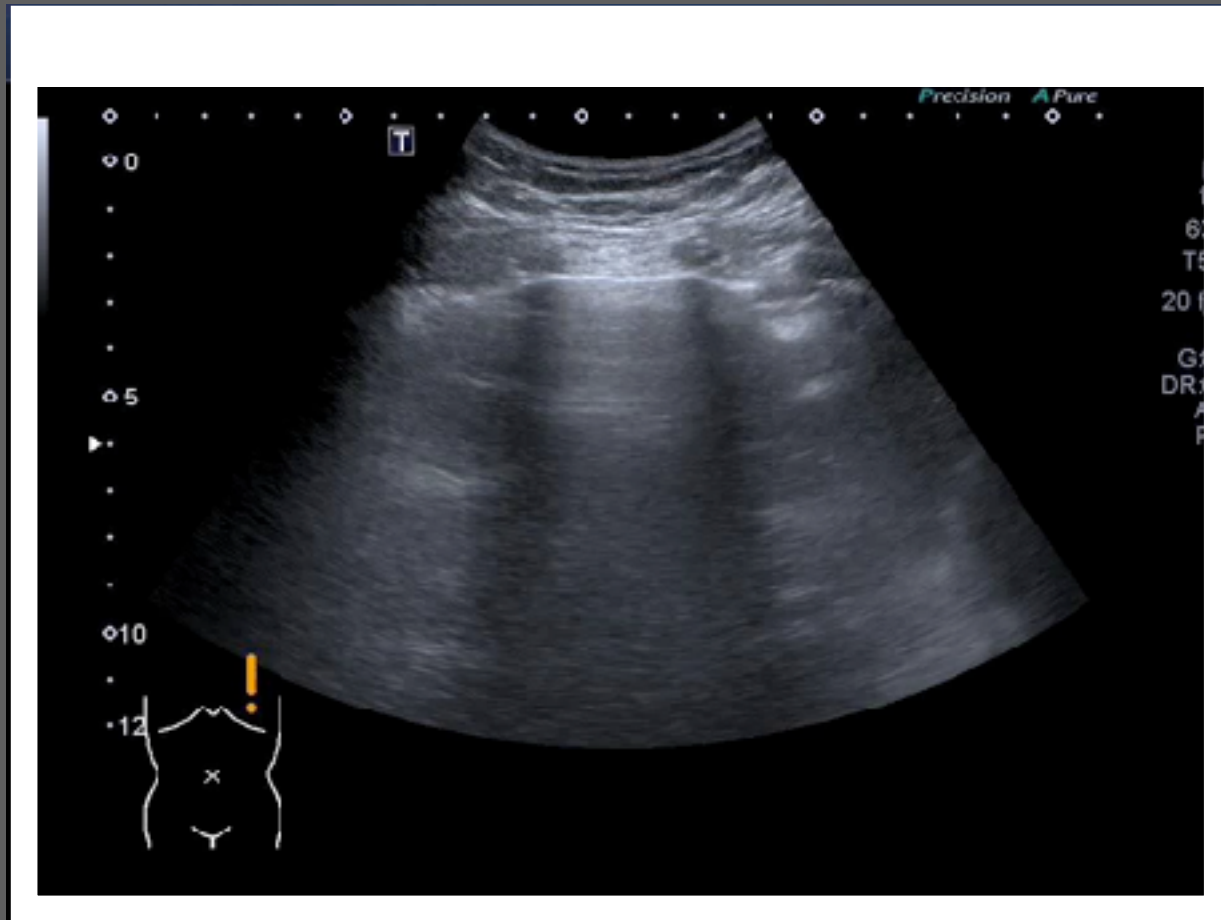
True

Artifact



Artifact

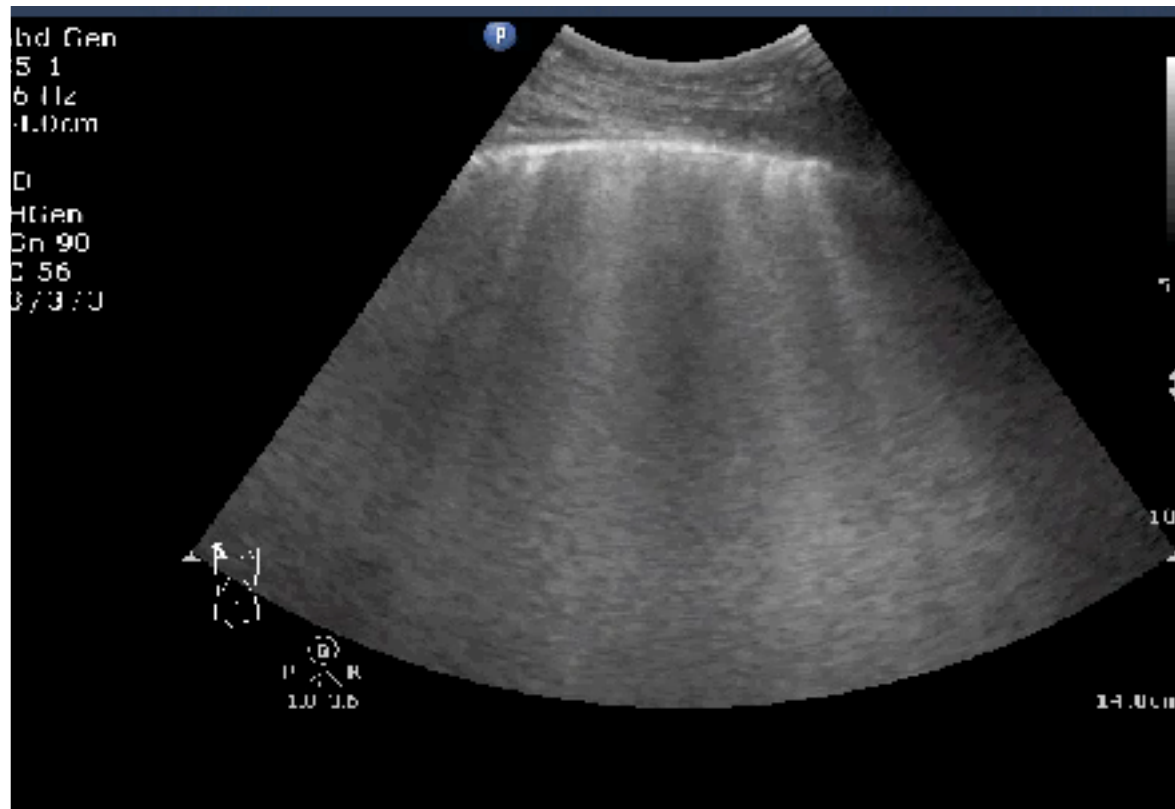
A lines



Pleural
Equal
Horizontal

Artifact

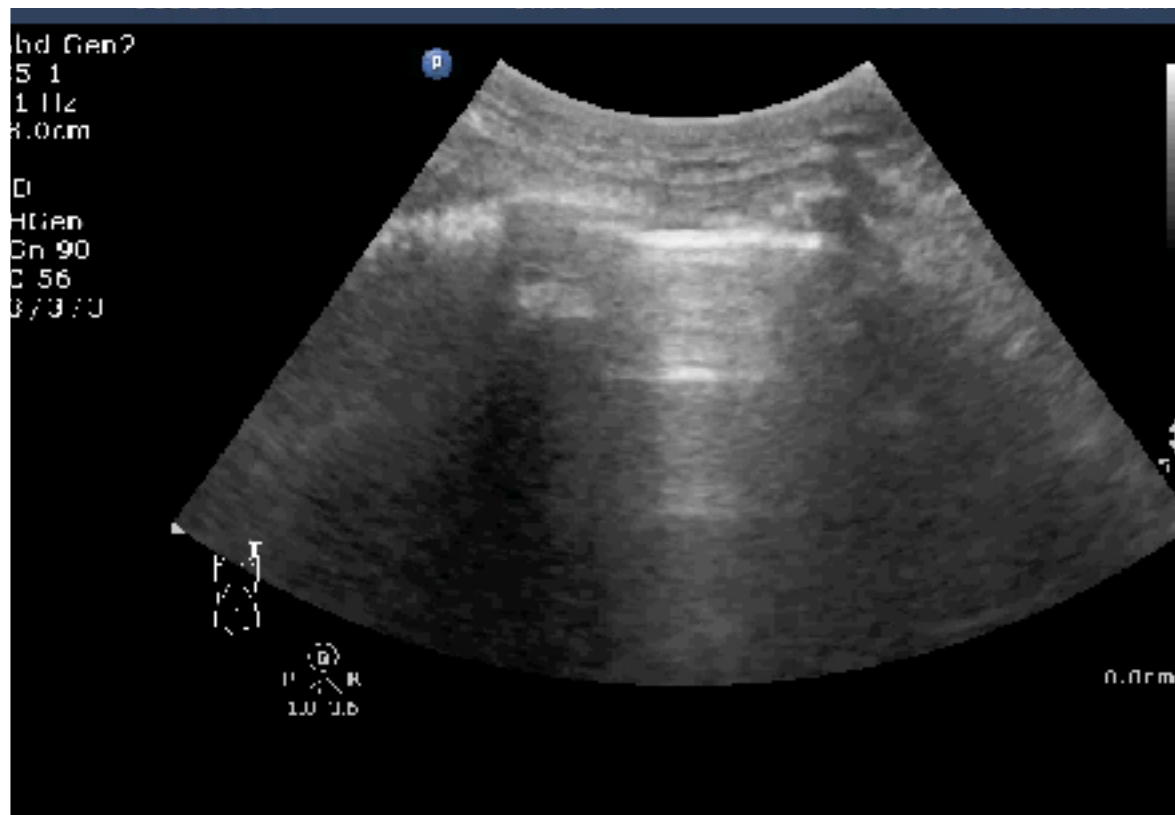
B lines



Pleural
Vertical
> 3 in ICS

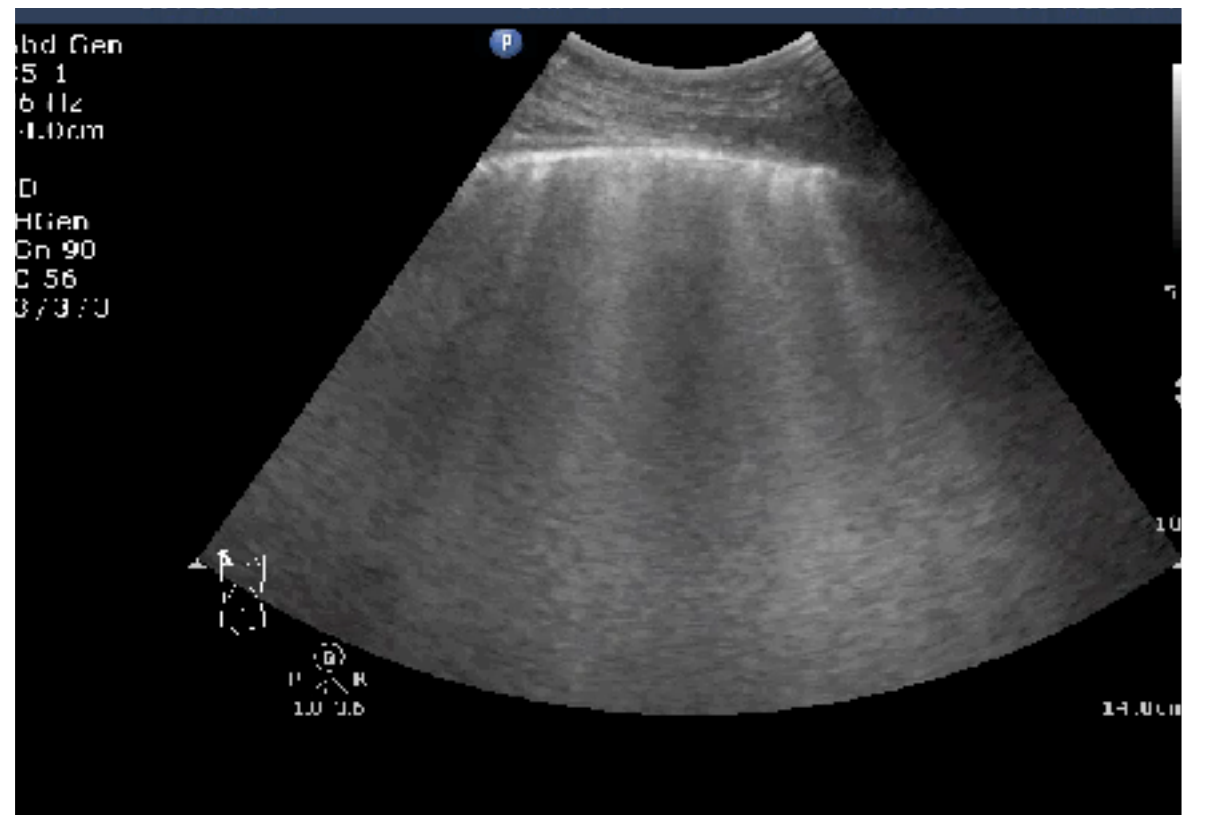
Artifact

A lines



No sliding

B lines



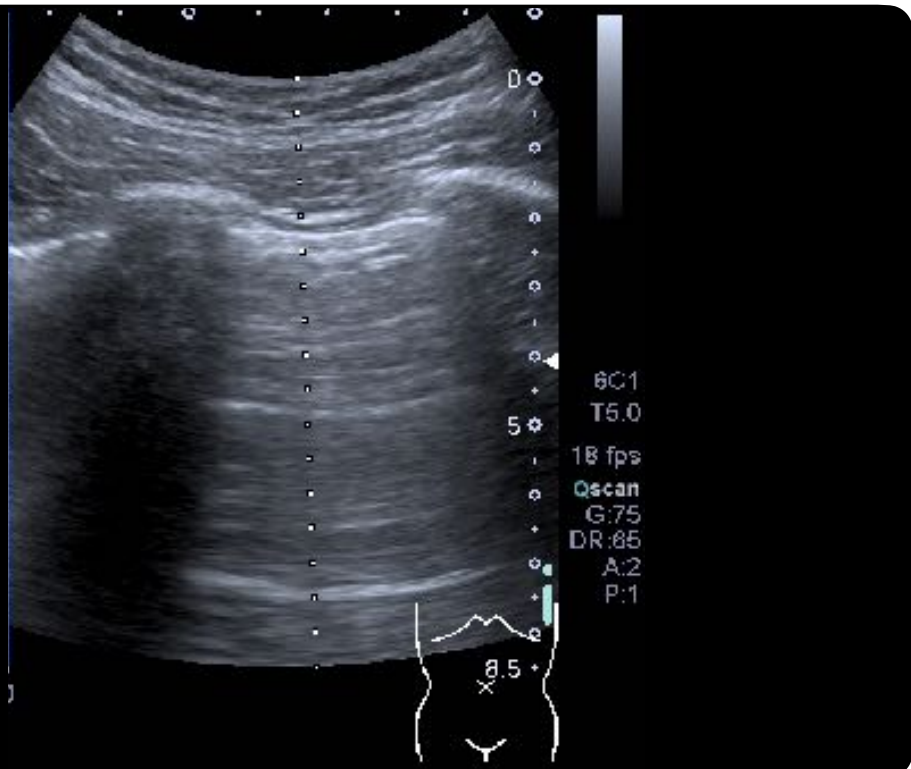Sliding

Normal Lung


Static

Dynamic

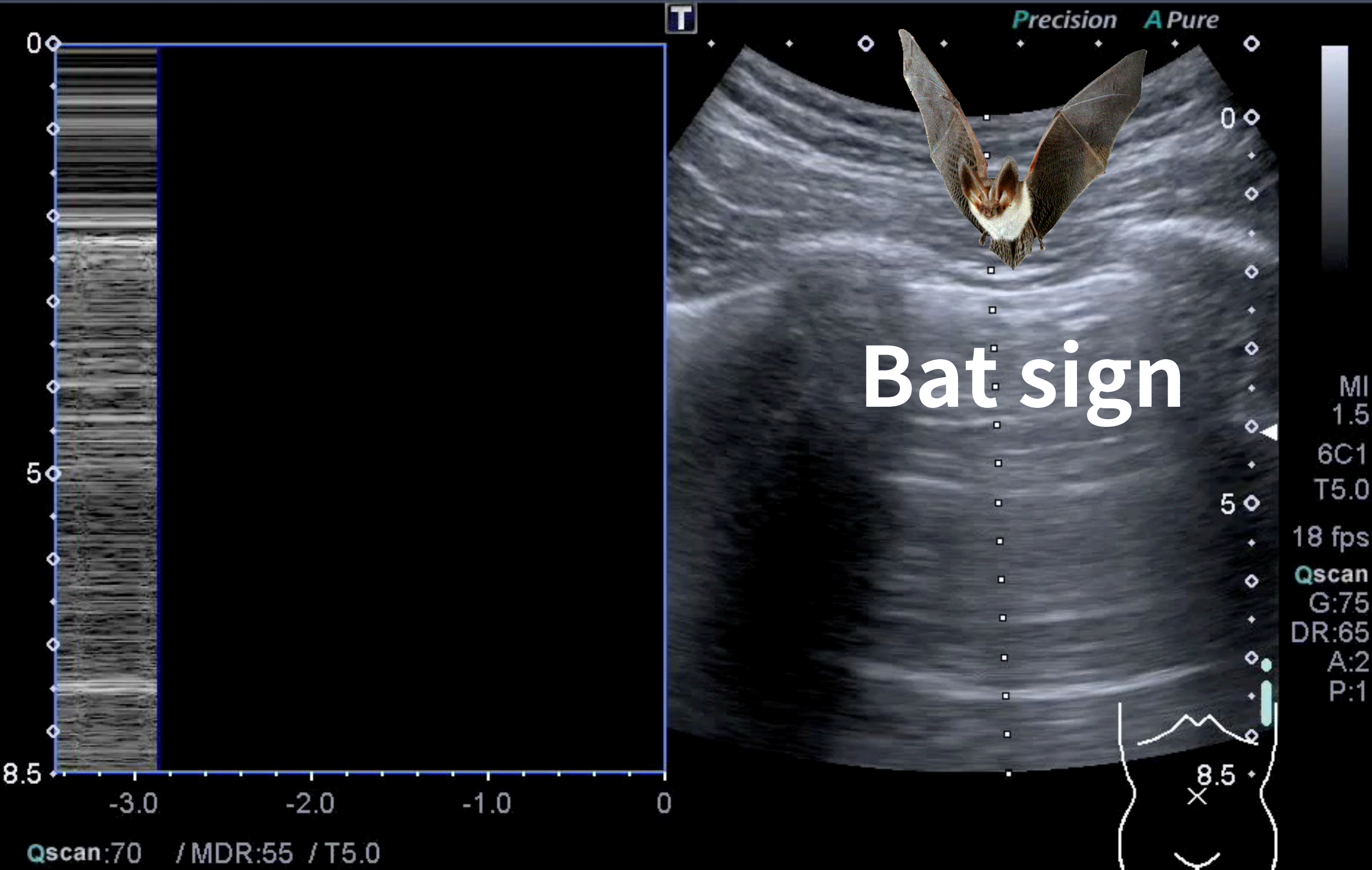B



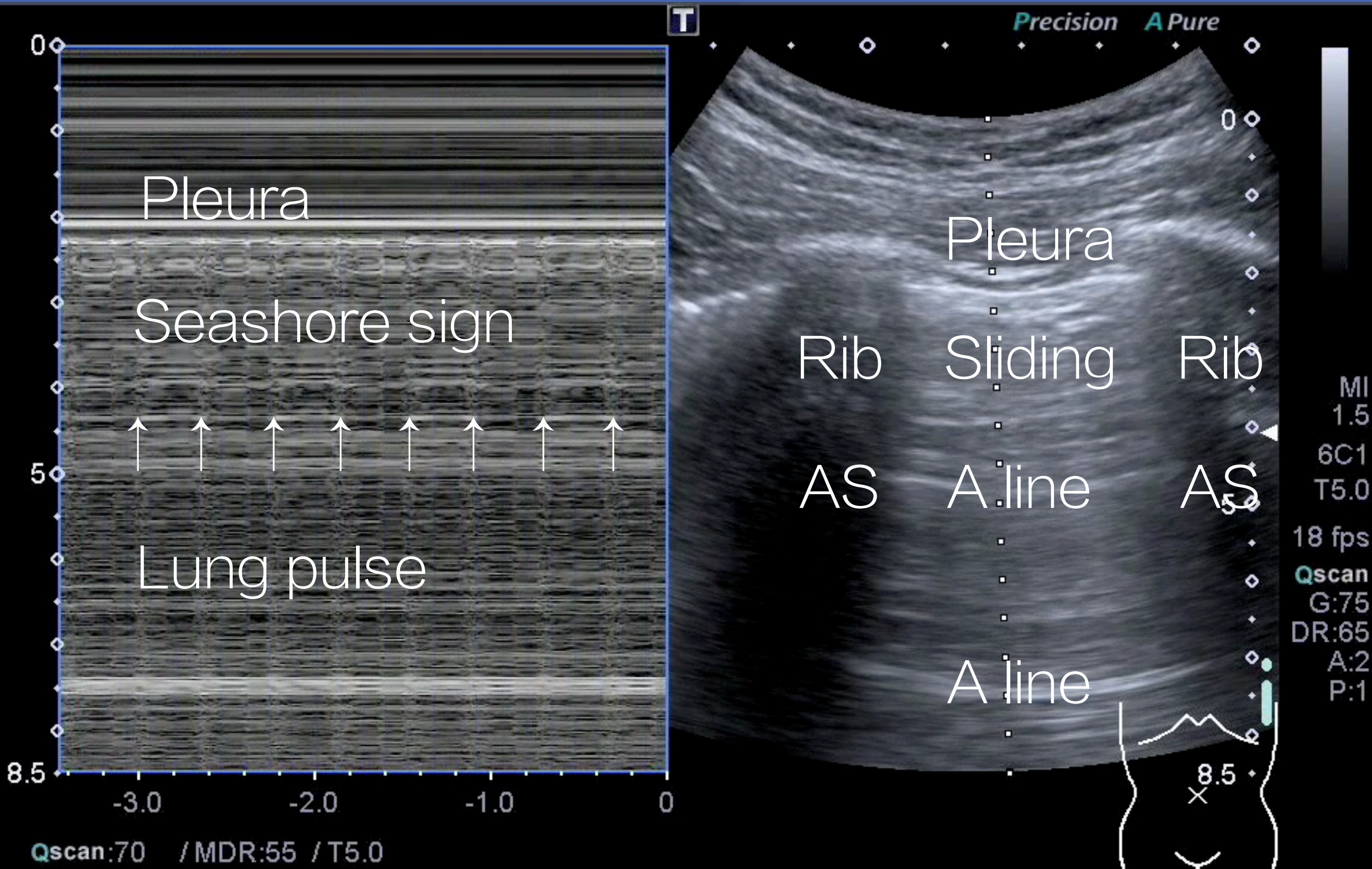
M



Normal Lung



Normal Lung



Interpretation

氣
水

真
假

A
B

動
靜

PLUS for PAP

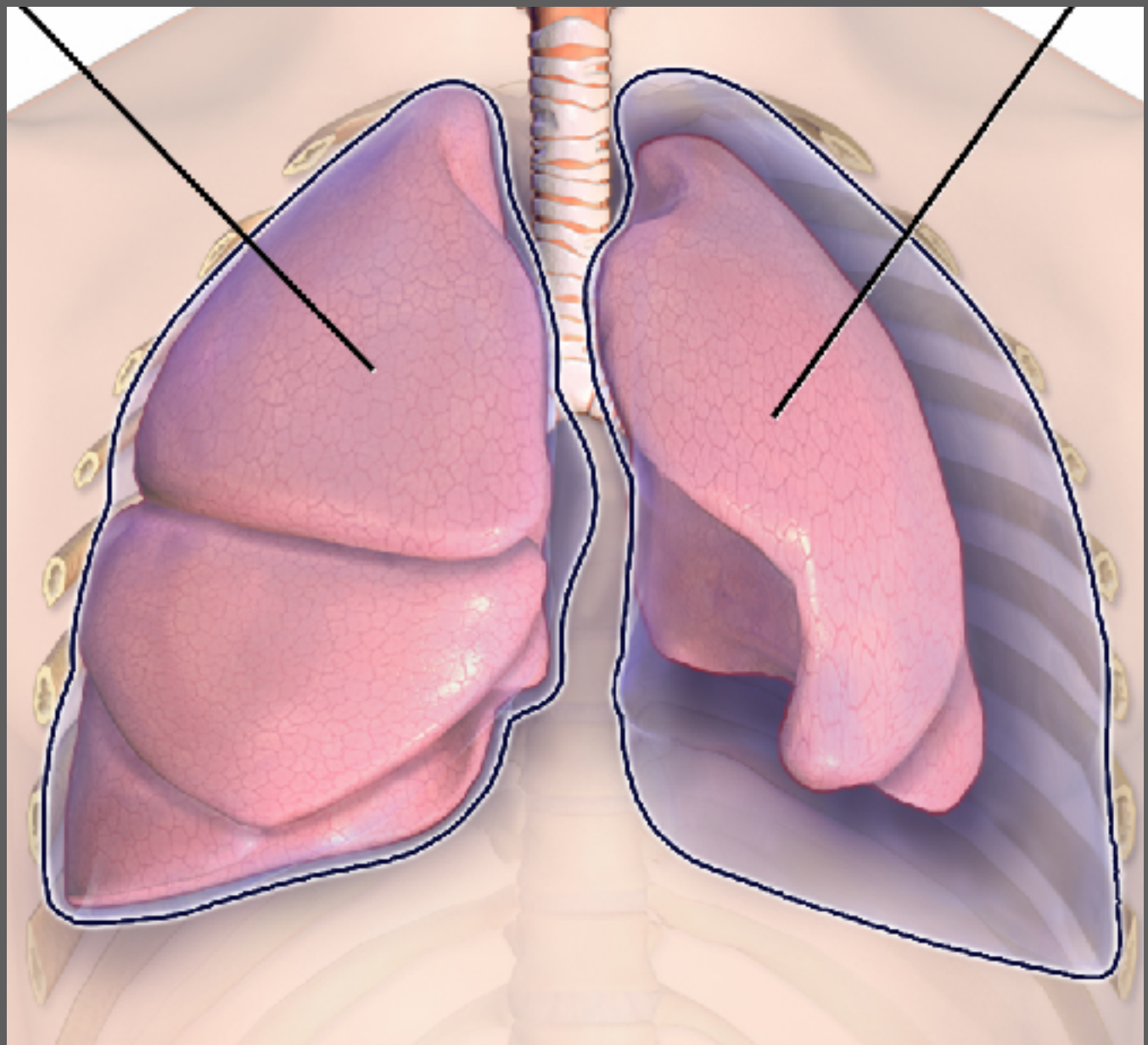
PTX

AIS

PLE

PLUS for PAP

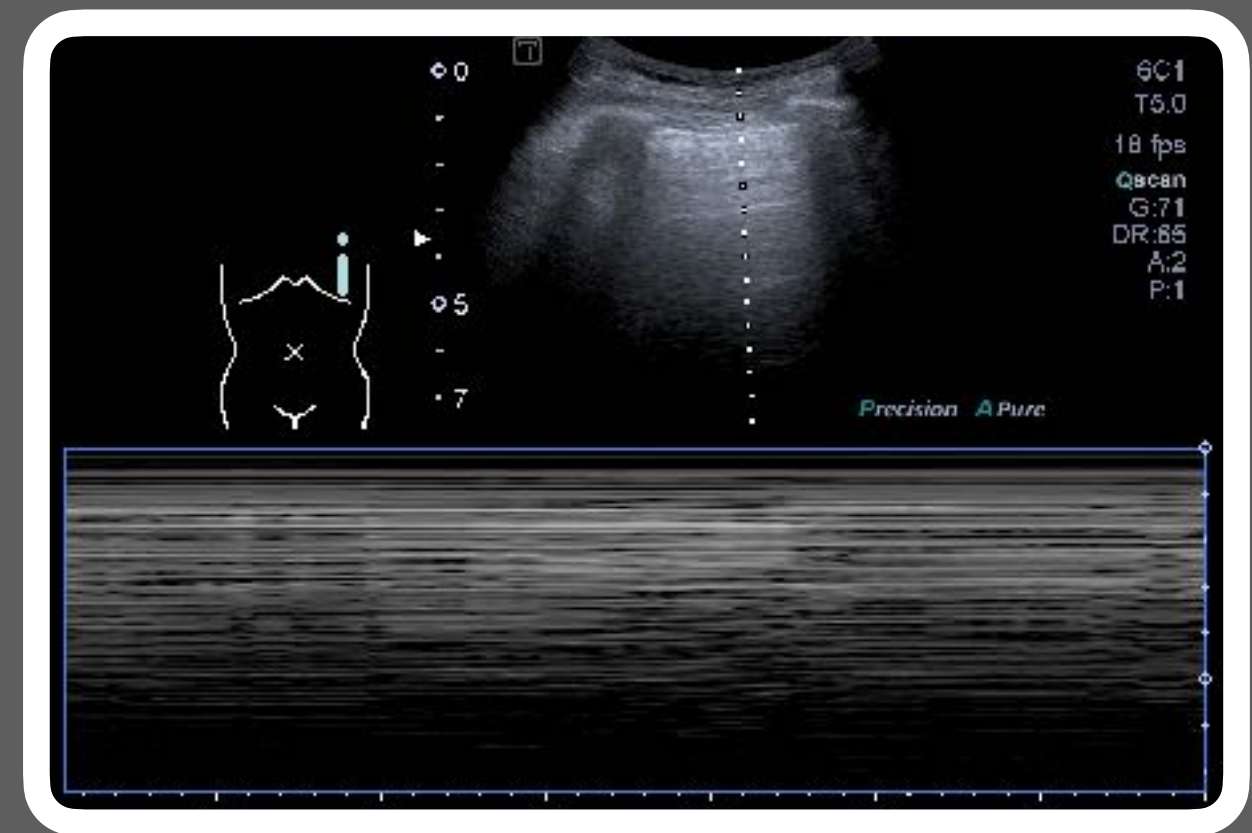
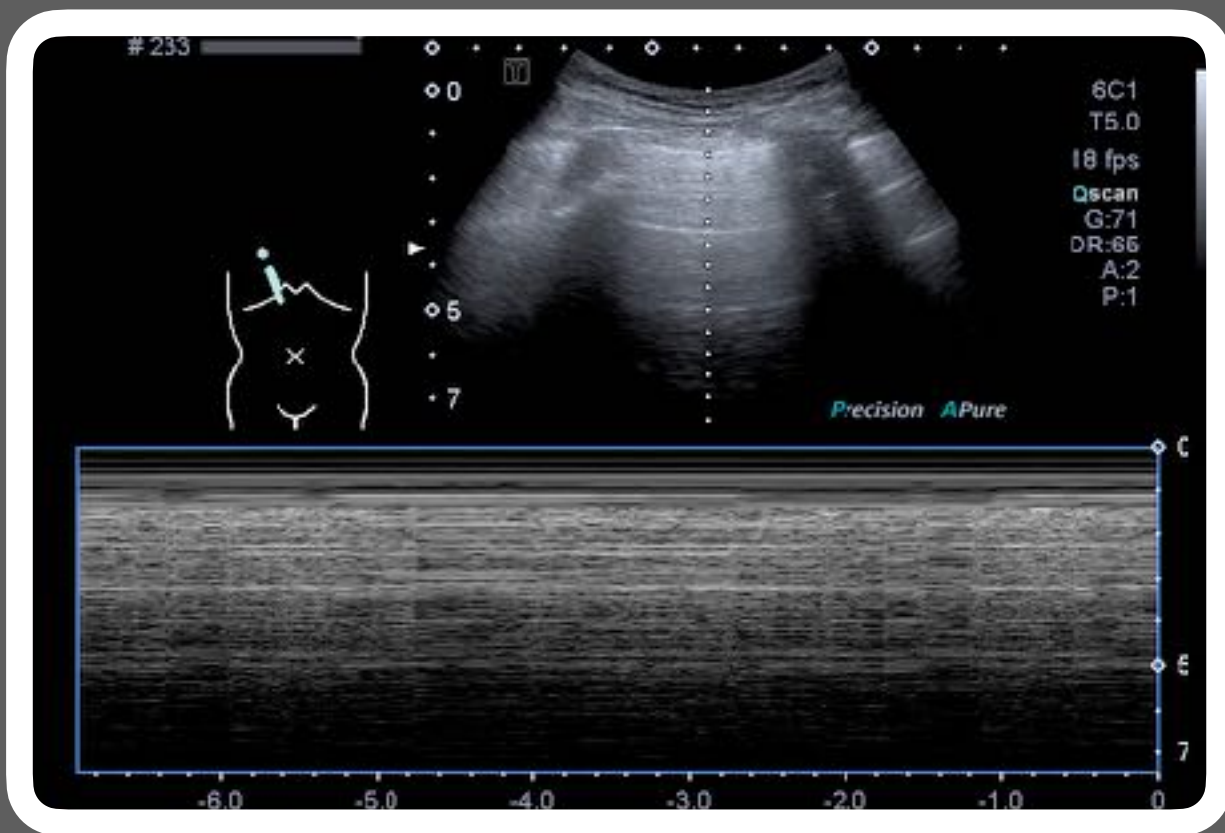
PTX



Pneumothorax

Normal

Pneumothorax



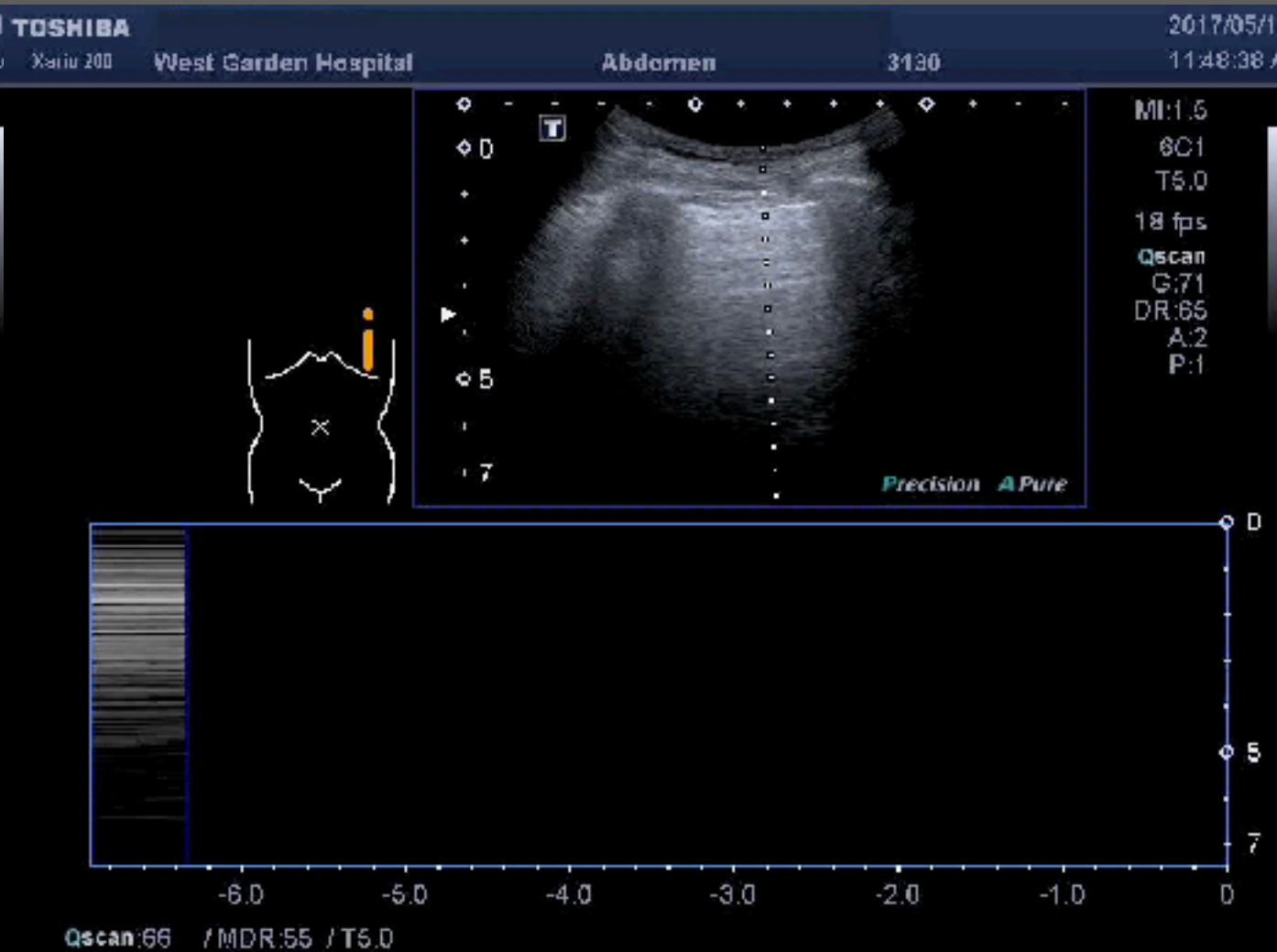
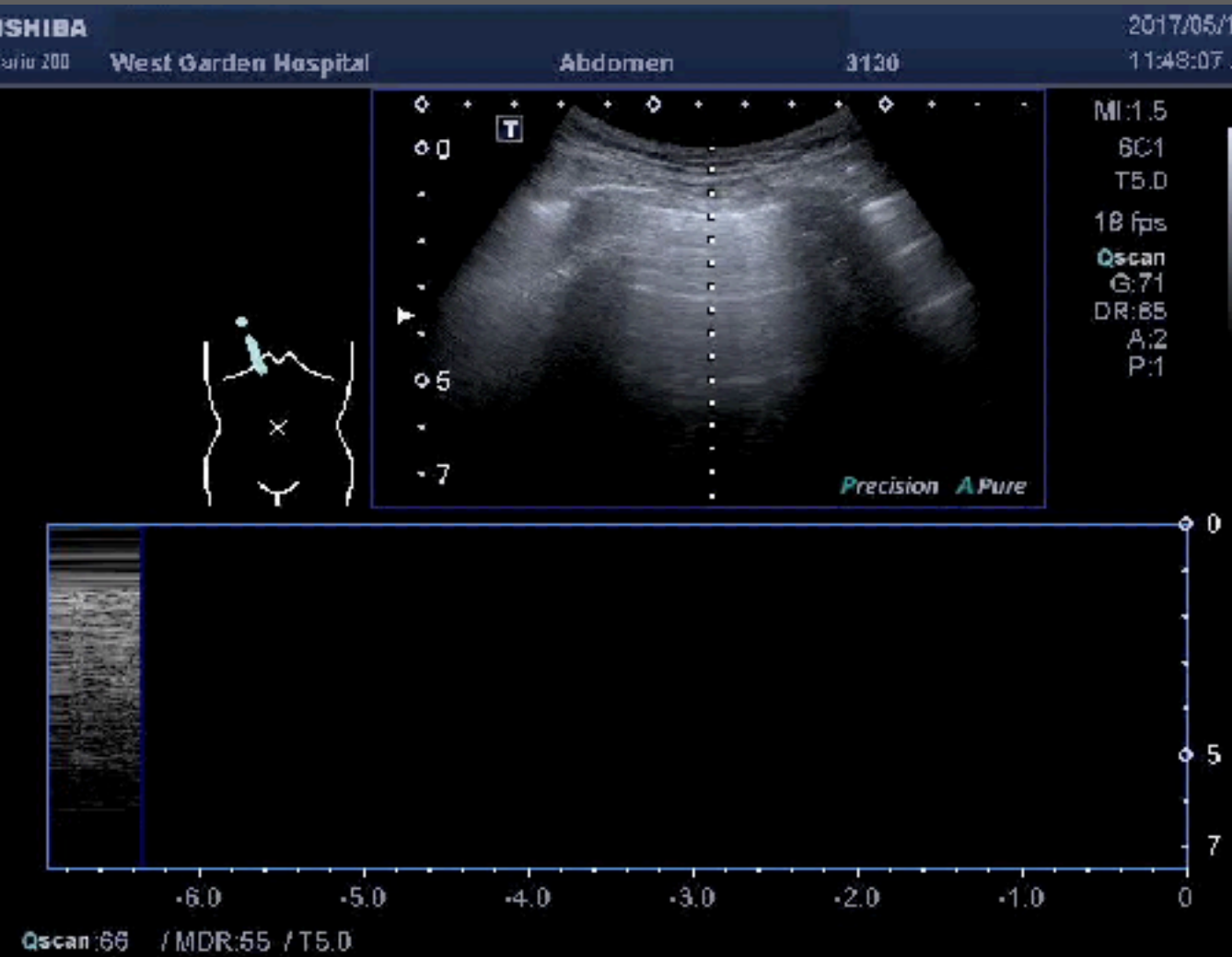
Seashore sign

Stratosphere sign

Pneumothorax

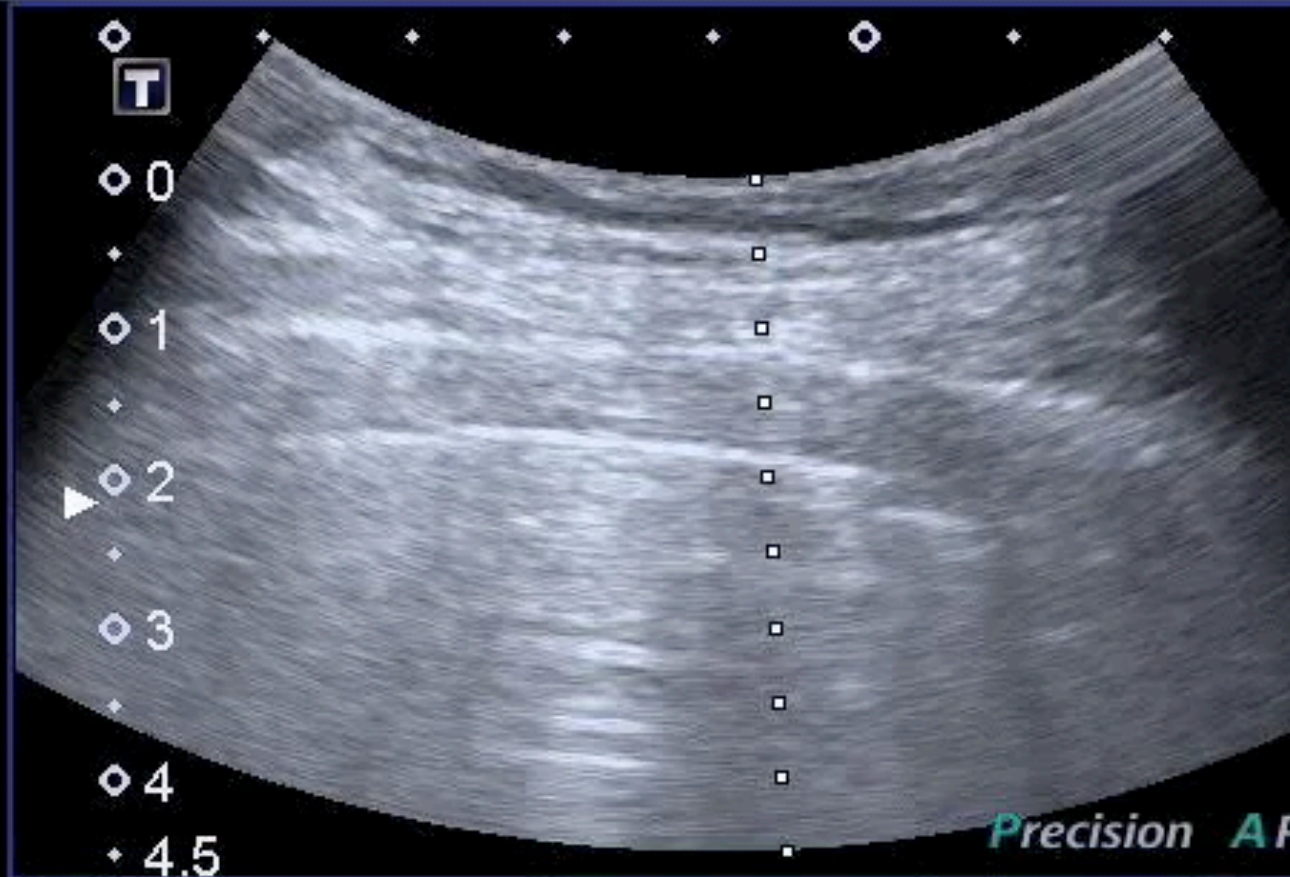
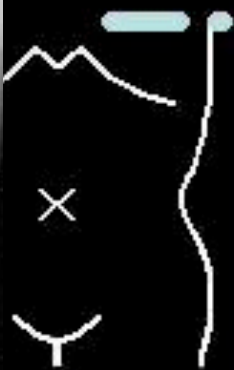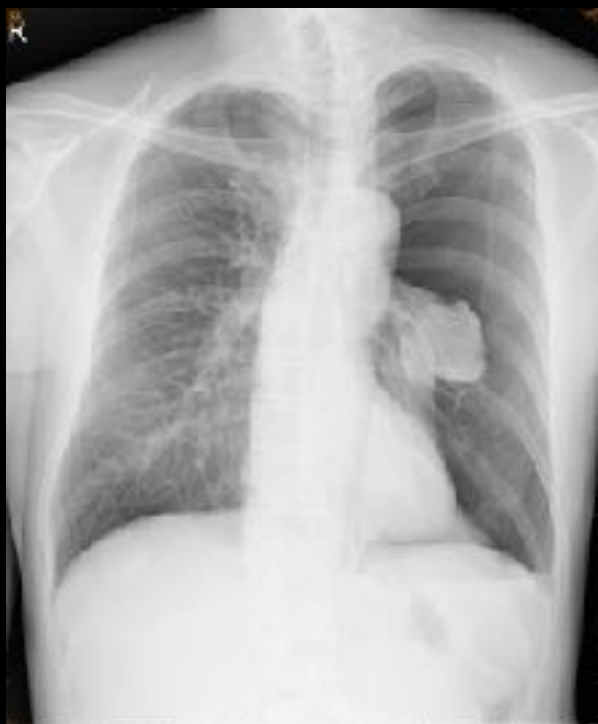Normal

Pneumothorax

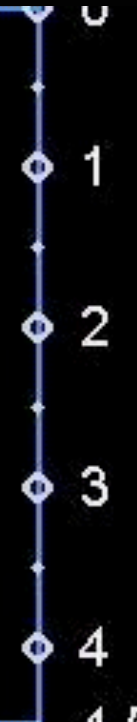
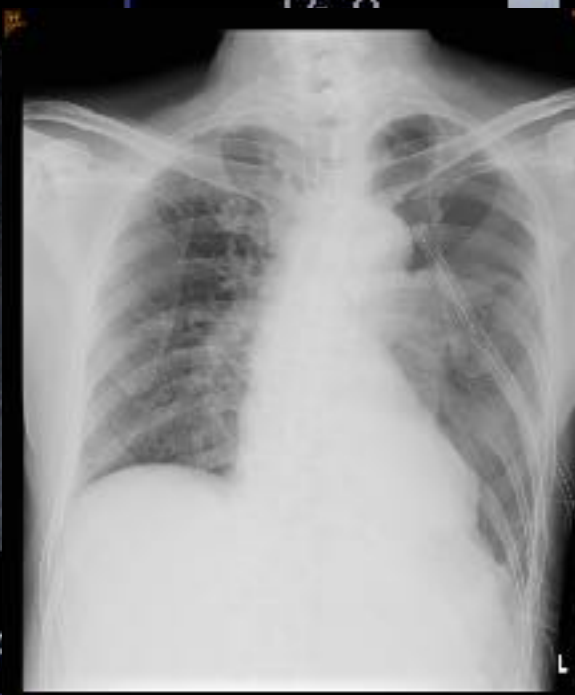

Lung Point

A



B



PLUS for PAP

PTX

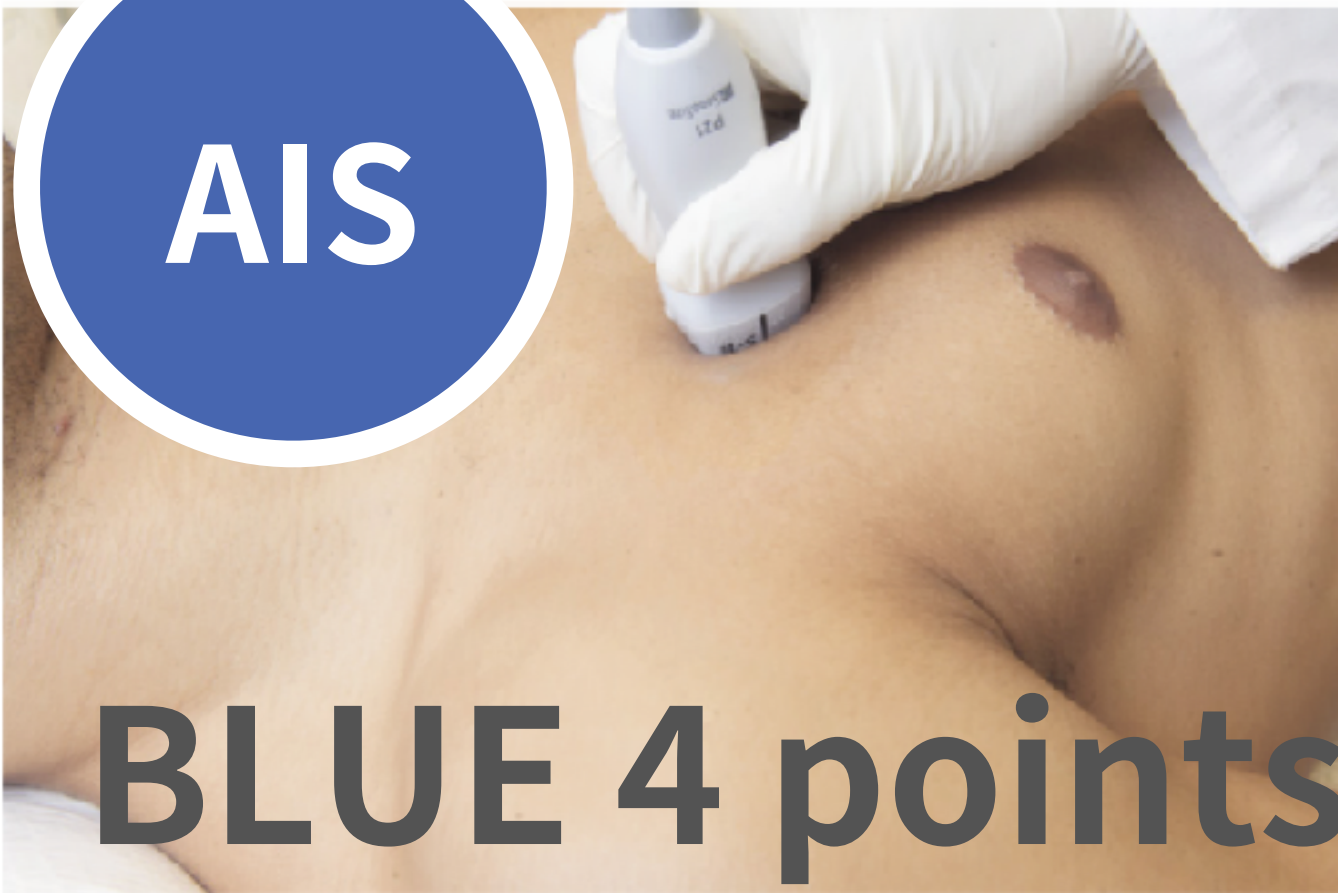AIS

3

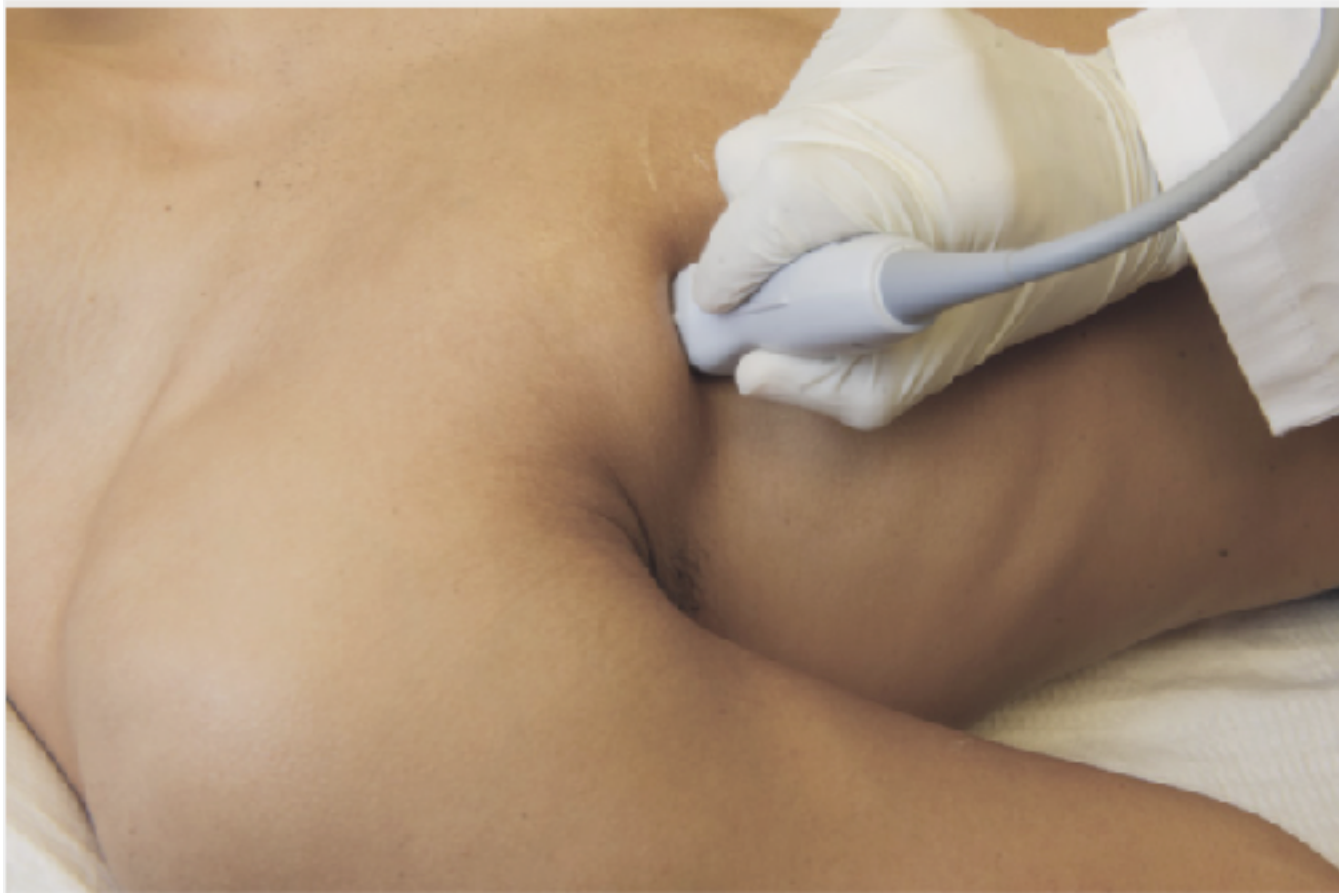2

3

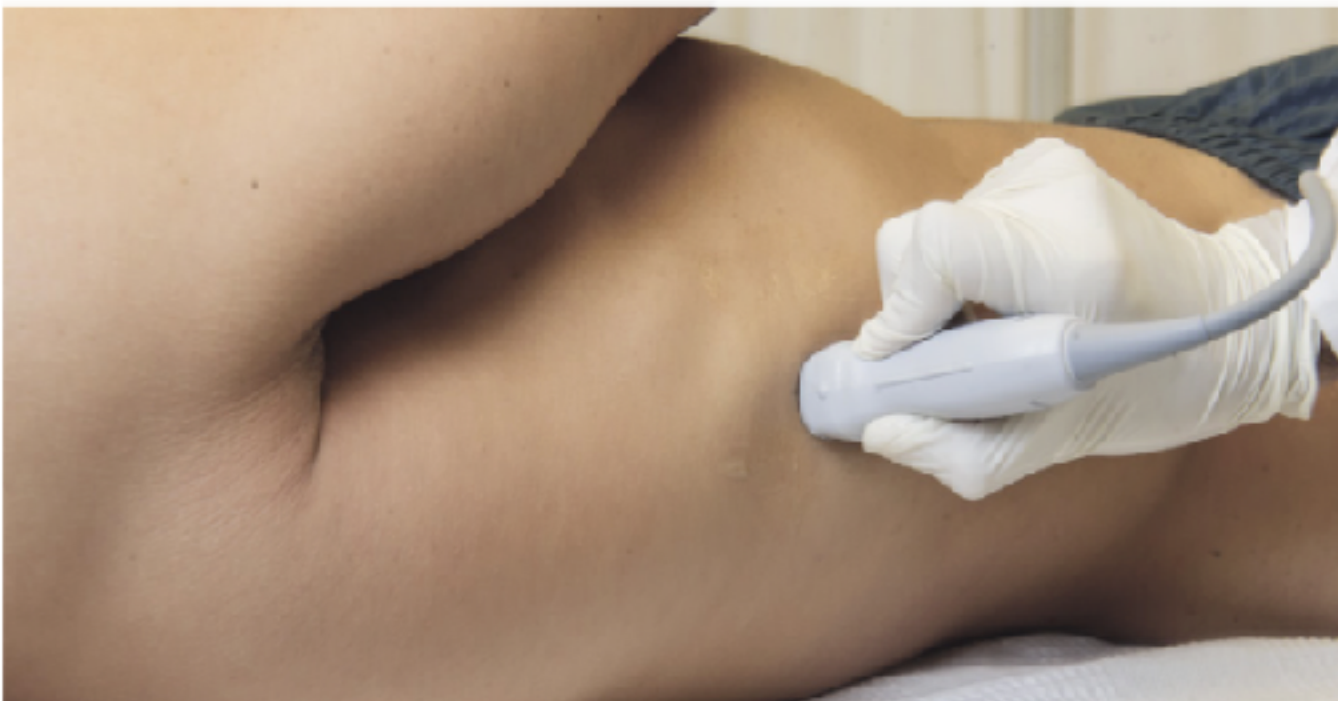Point 1



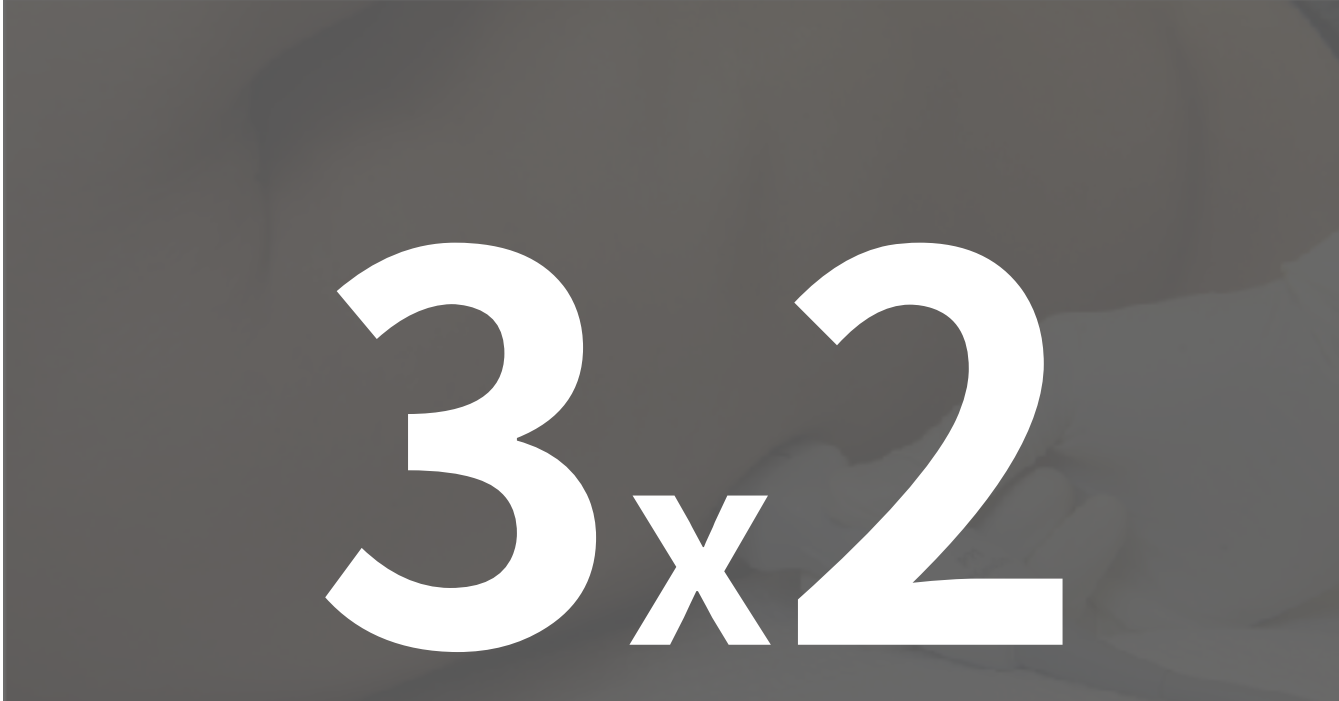Point 2



Point 3



Point 4



BLUE 4 points

3x2

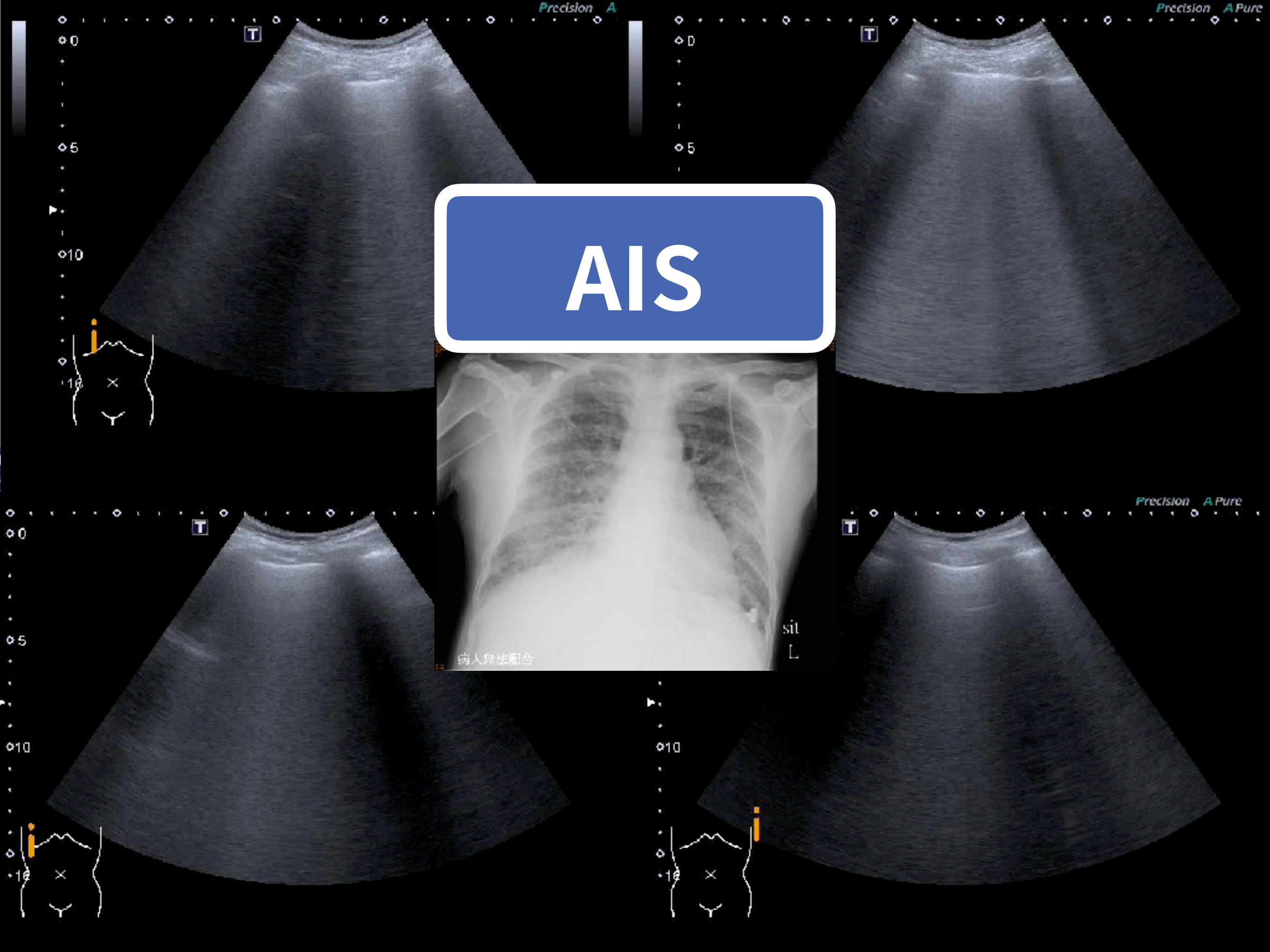
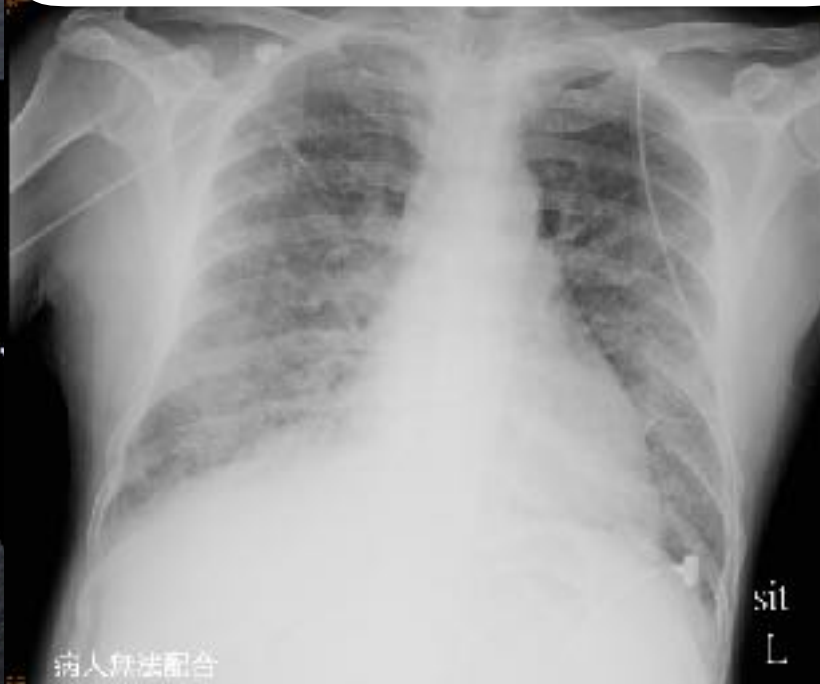Alveolar Interstitial Syndrome



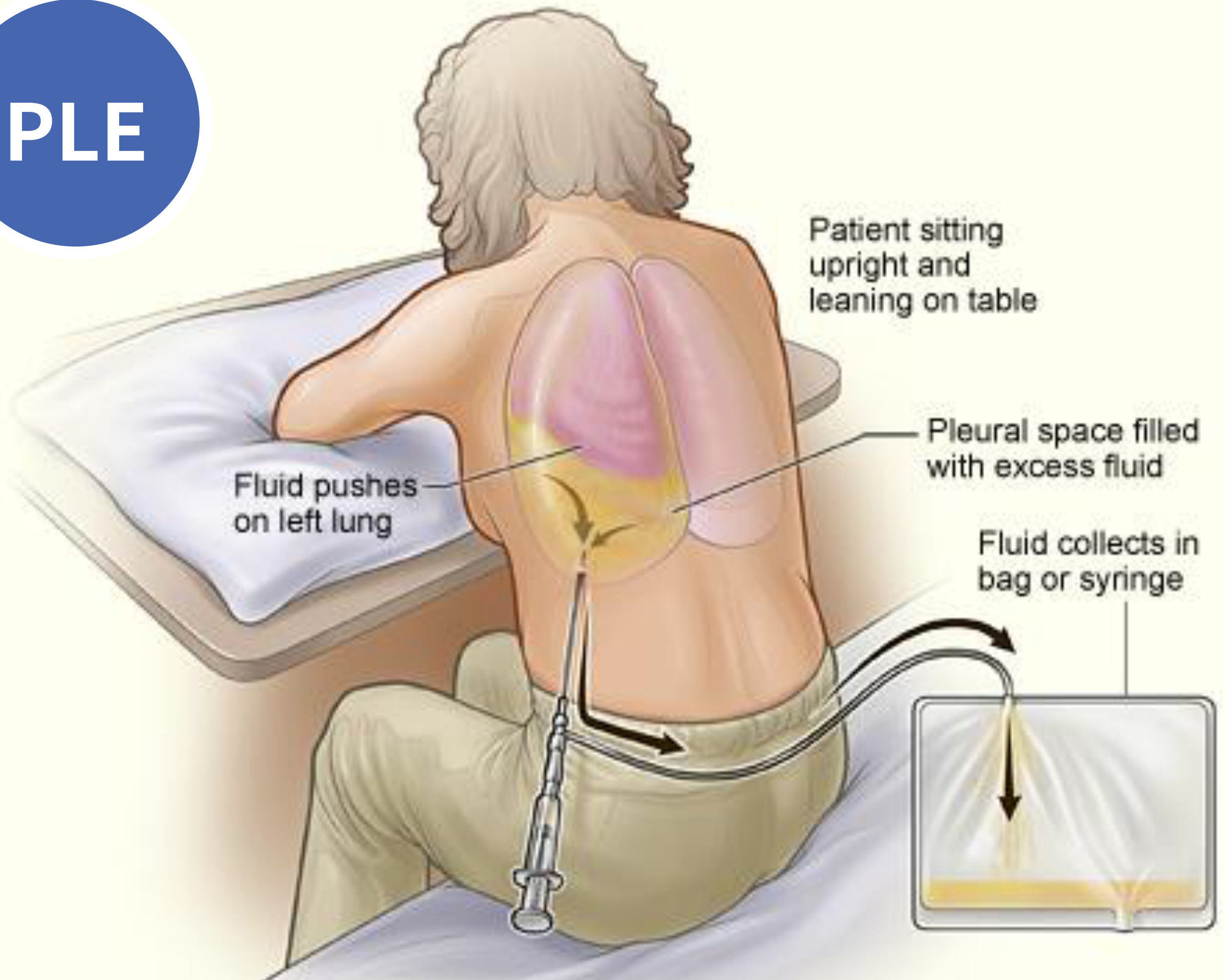
3

15.12

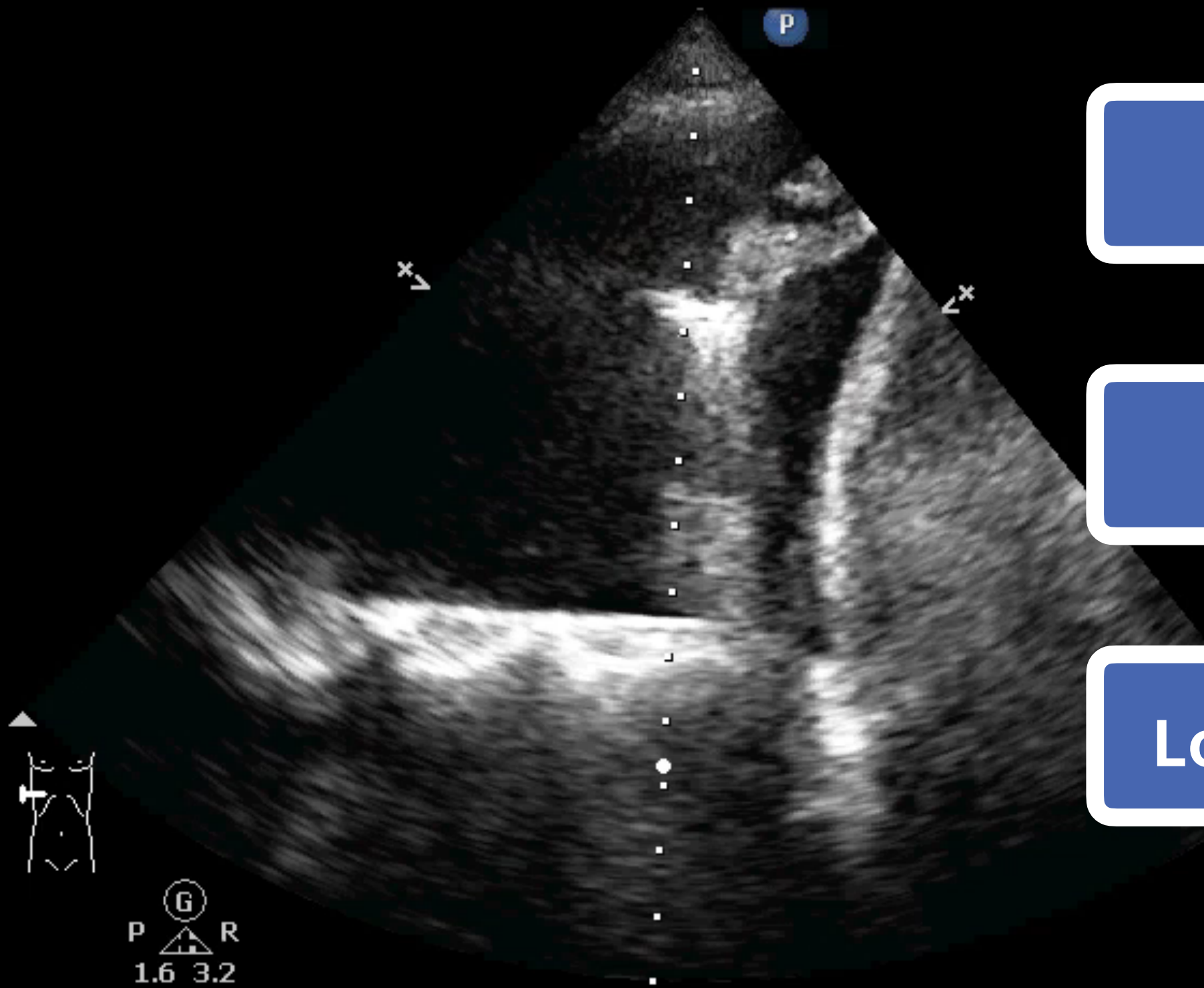
AIS



PLE



SKH-EUTC©ChenKC



Jellyfish sign

Spine sign

Loss of curtain sign

Focused Cardiac Ultrasound in the Emergent Setting:
A Consensus Statement of the American Society of
Echocardiography and American College of
Emergency Physicians

2010

Pericardial effusion
Global systolic function
Marked RV & LV enlargement
Volume assessment
Pericardiocentesis
TVP wire confirmation

FoCUS

Focus Cardiac UltraSound for critically ill patients



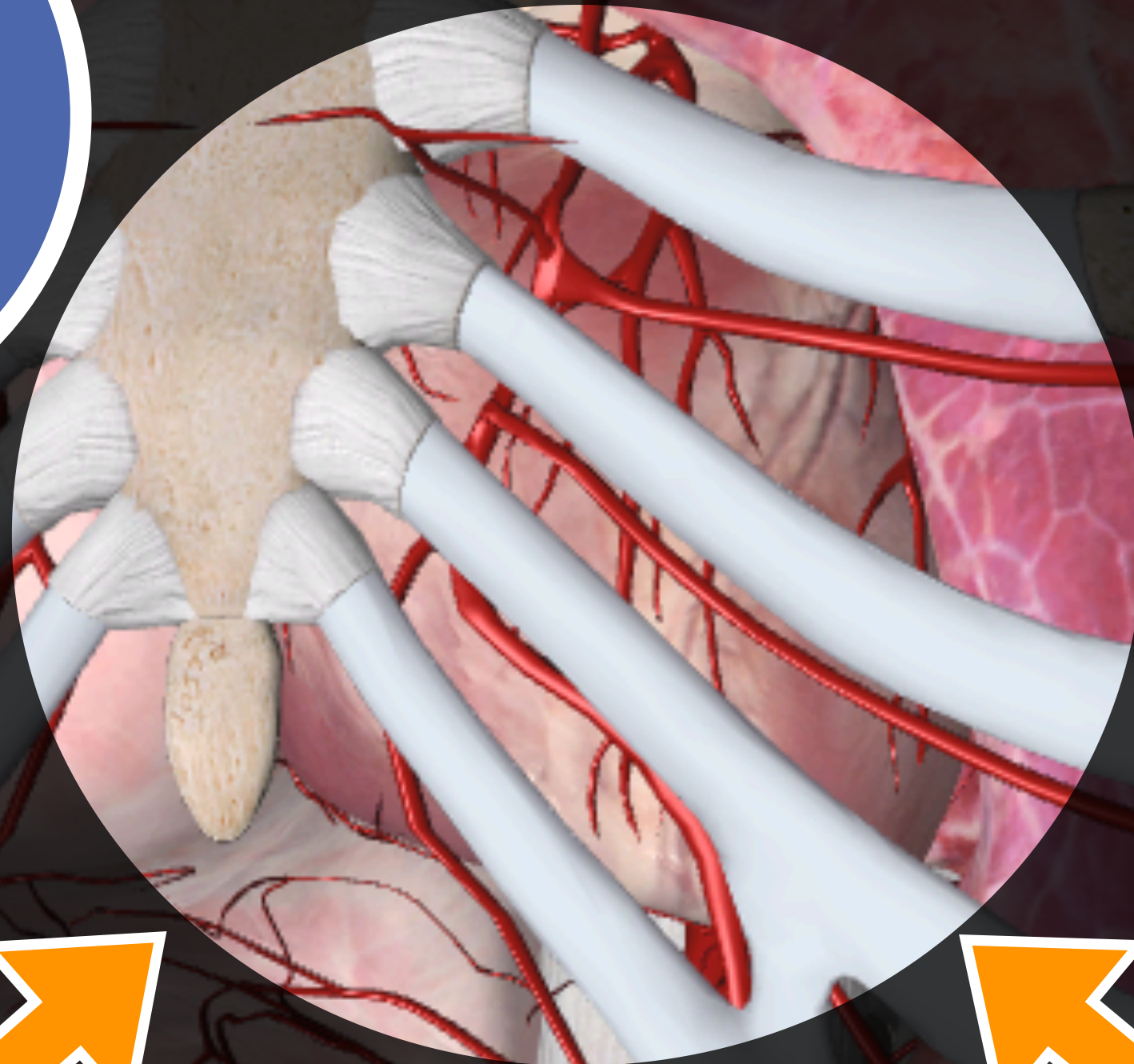Gabriele Via

International Evidence-Based Recommendations for Focused Cardiac Ultrasound
J Am Soc Echocardiogr 2014;27:683.e1-e33

Parasternal



SPA



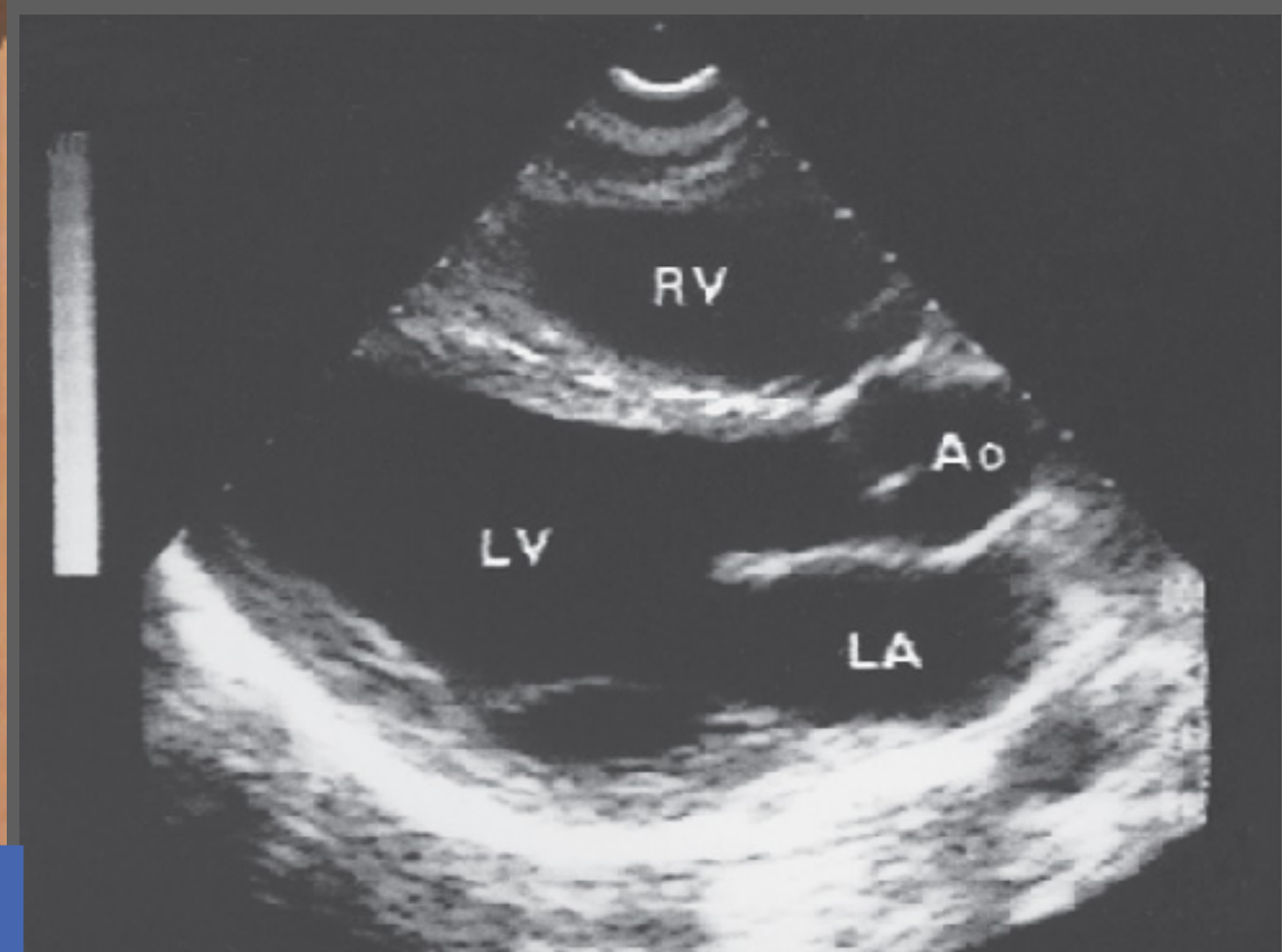
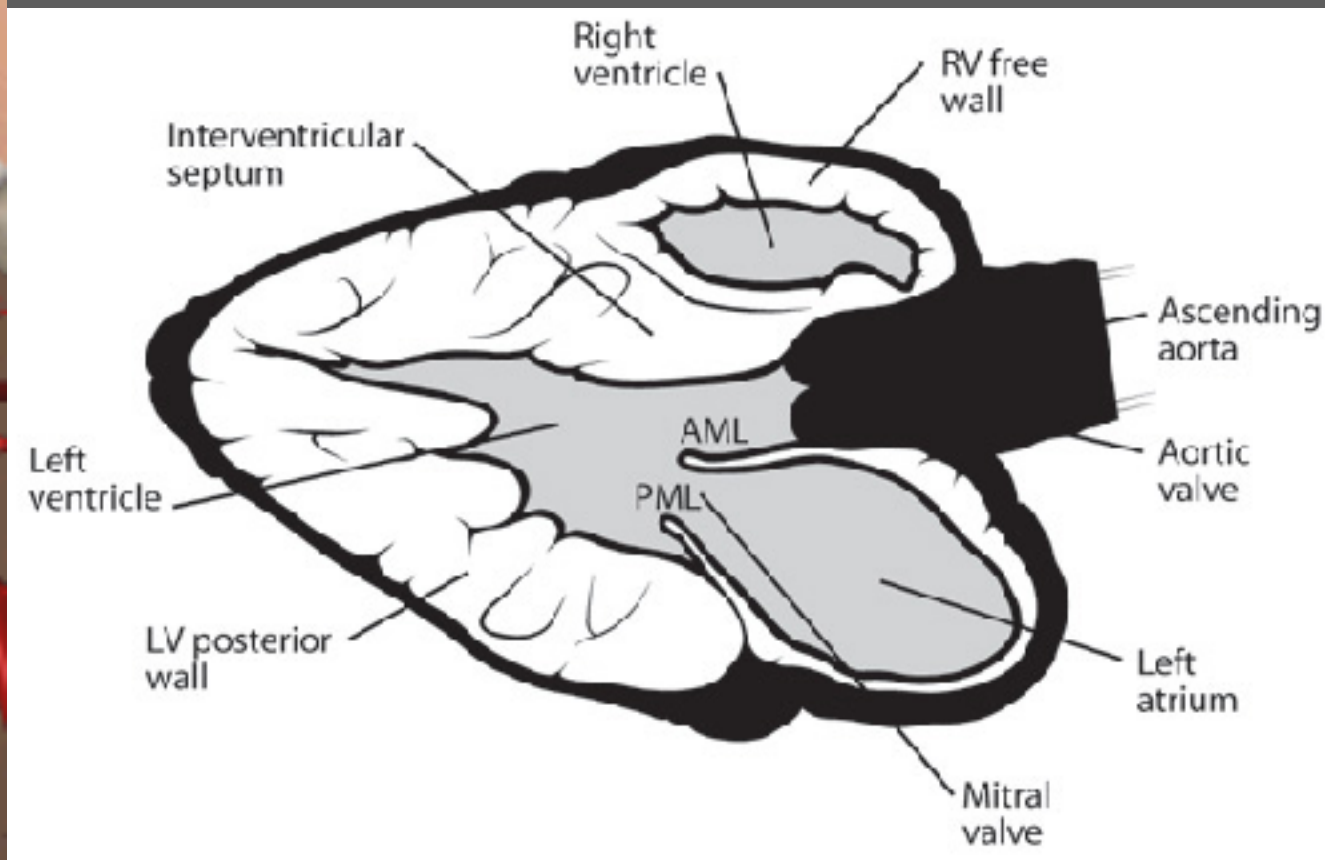
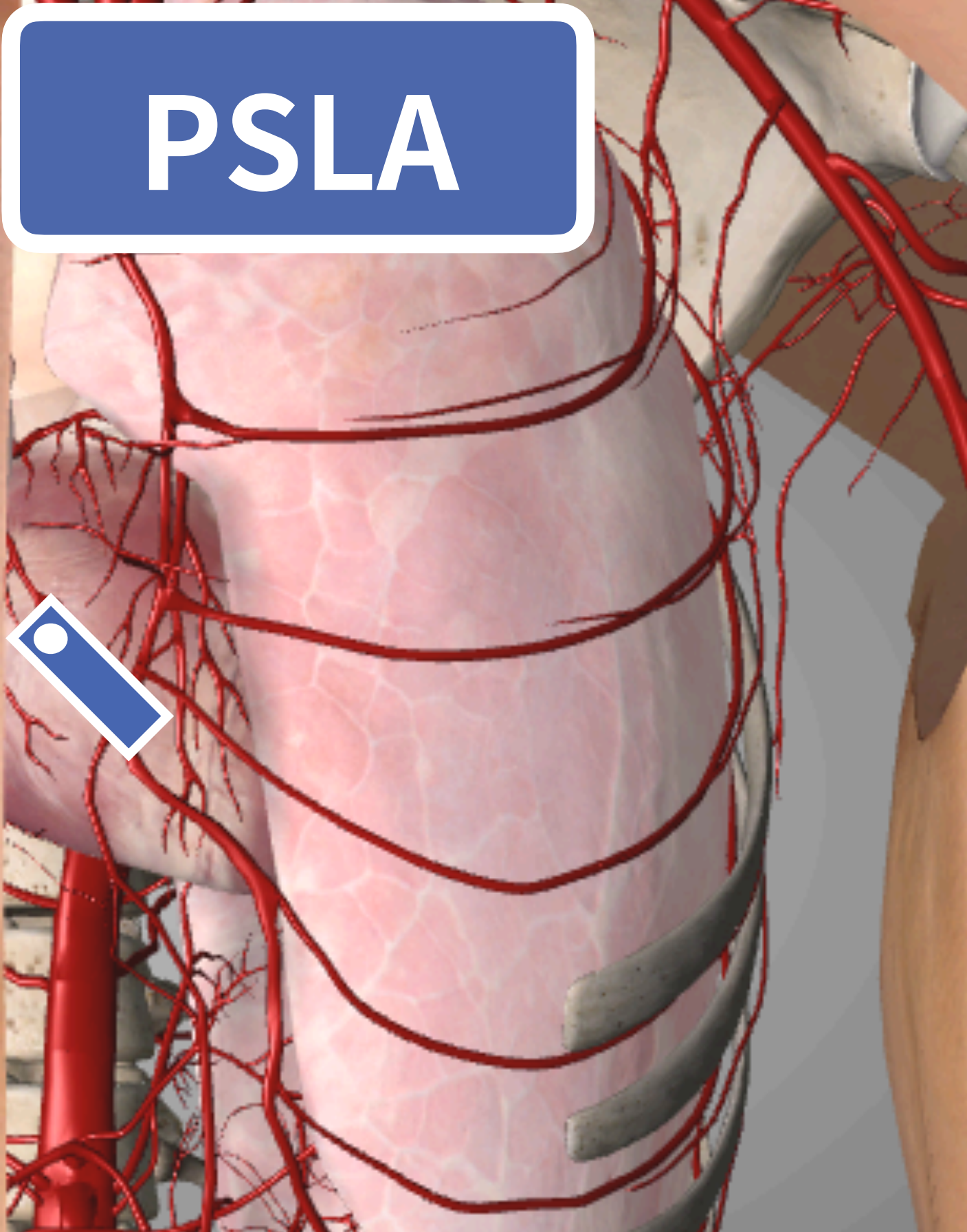
Subcostal



Apical

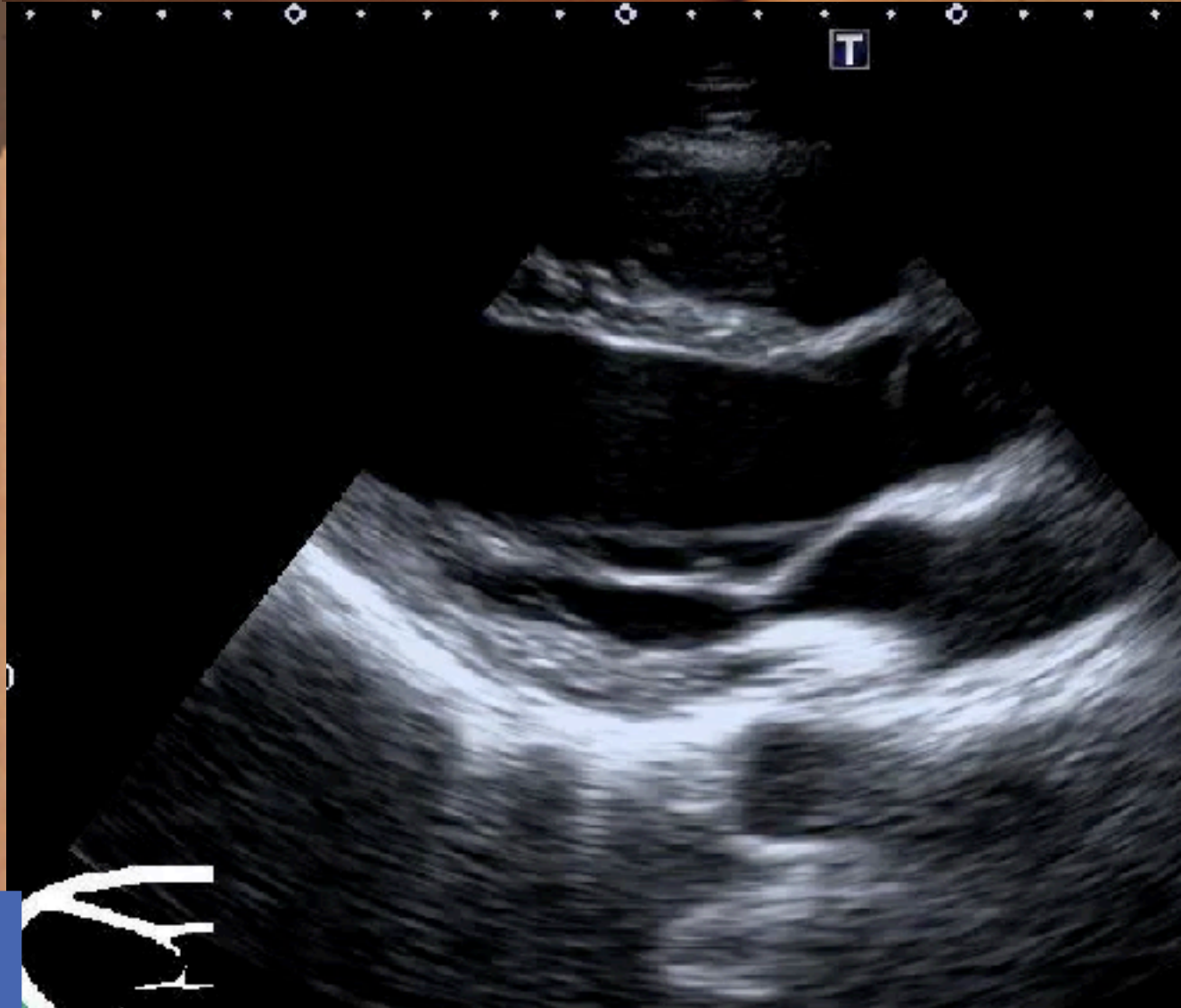
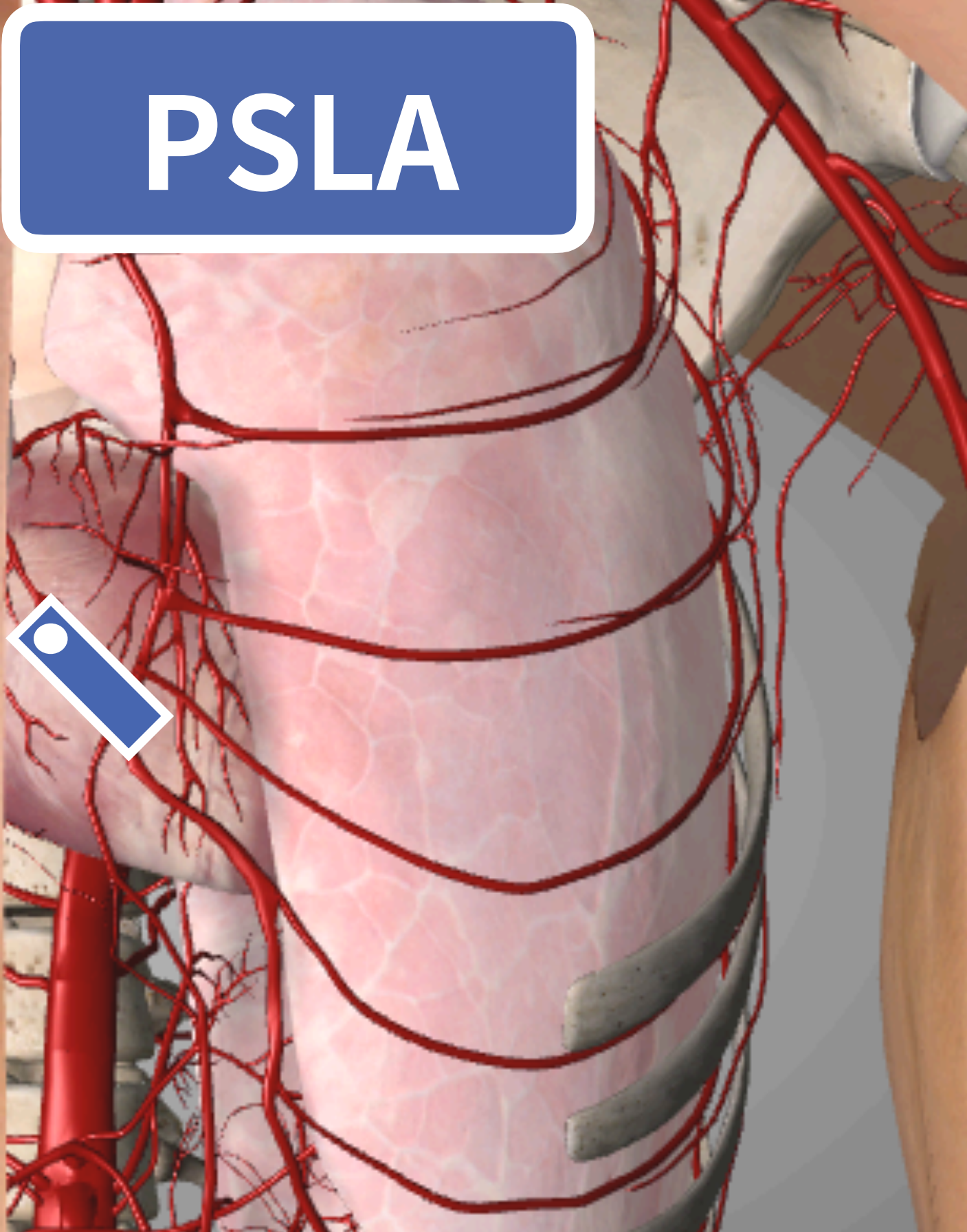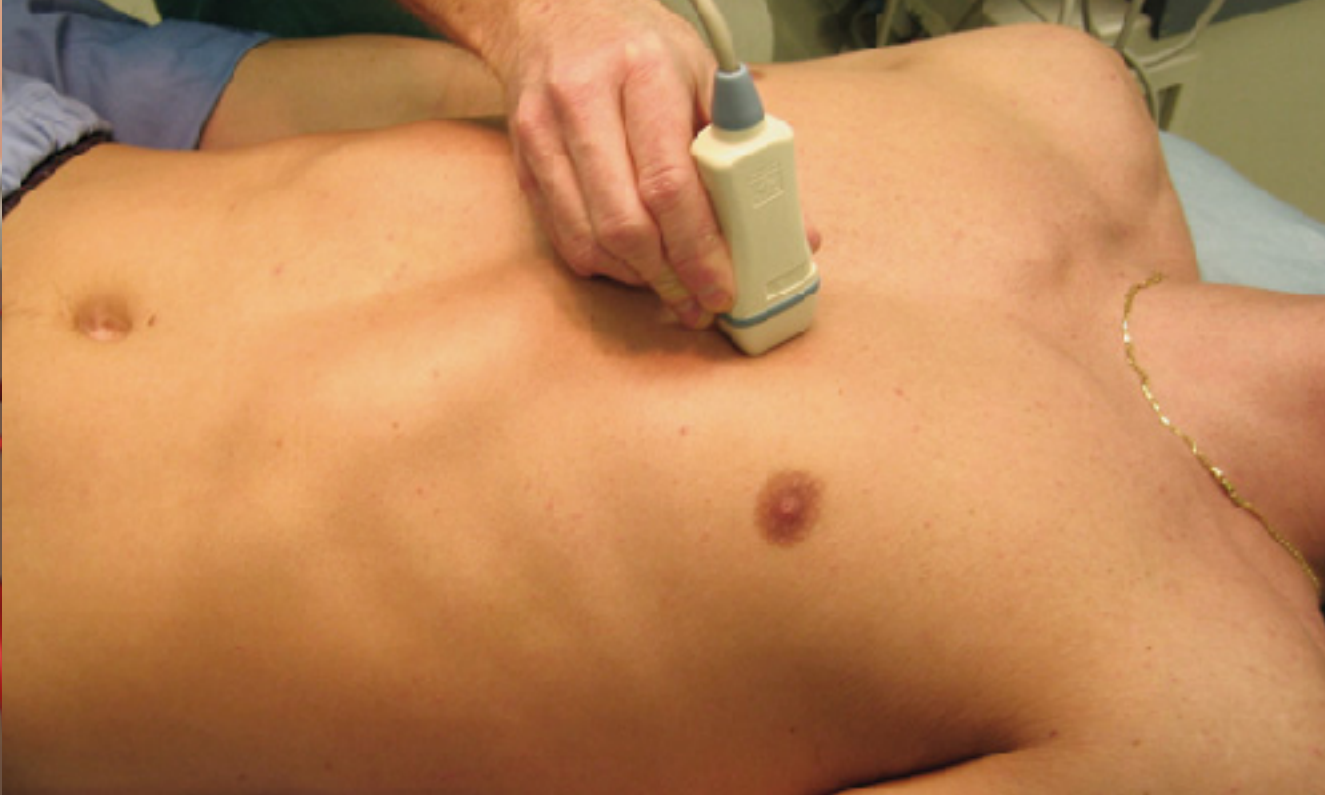


PSLA



Parasternal long axis

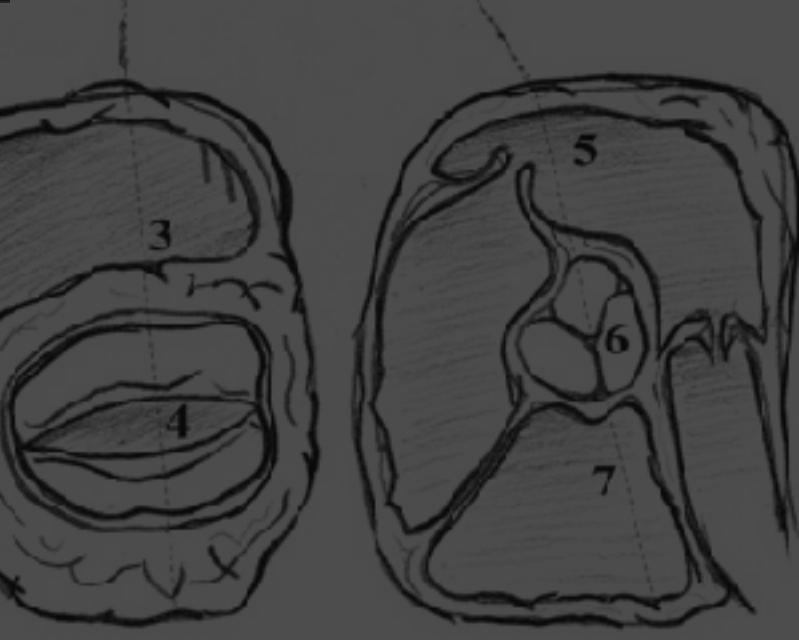
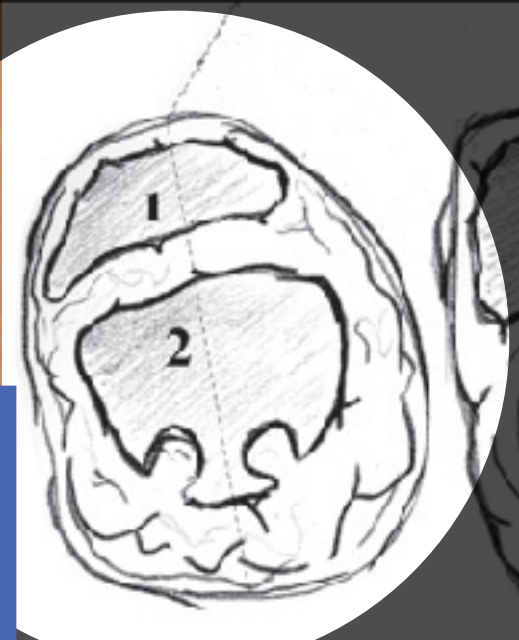
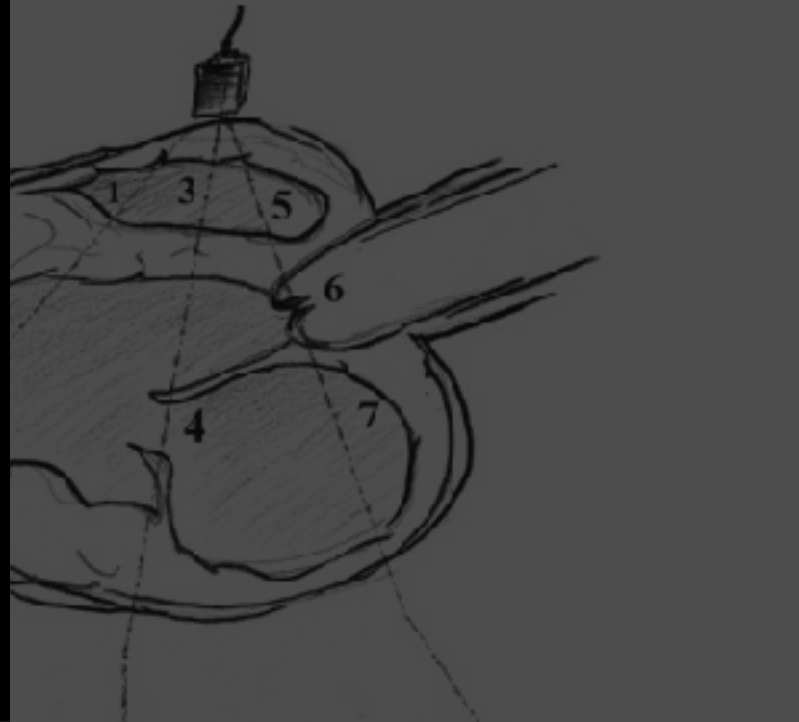
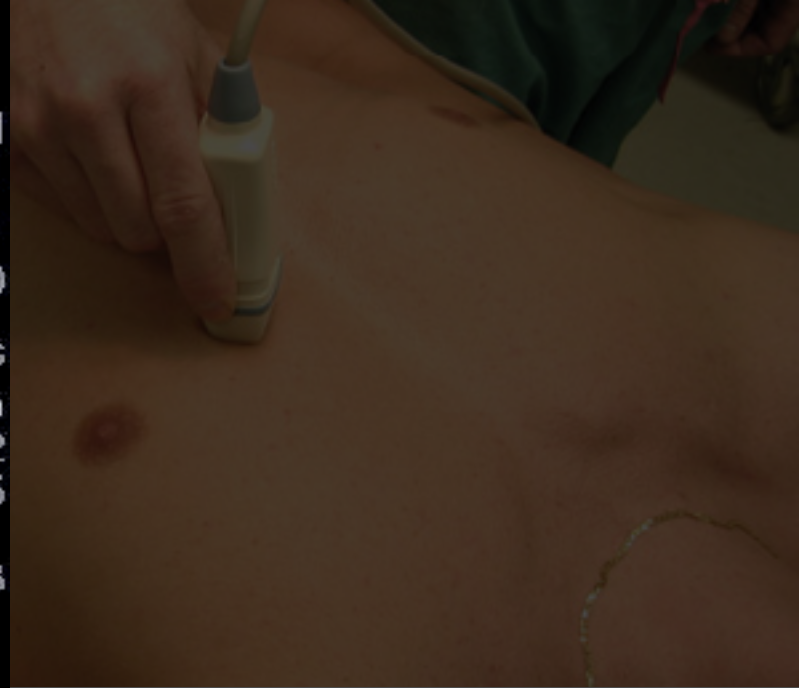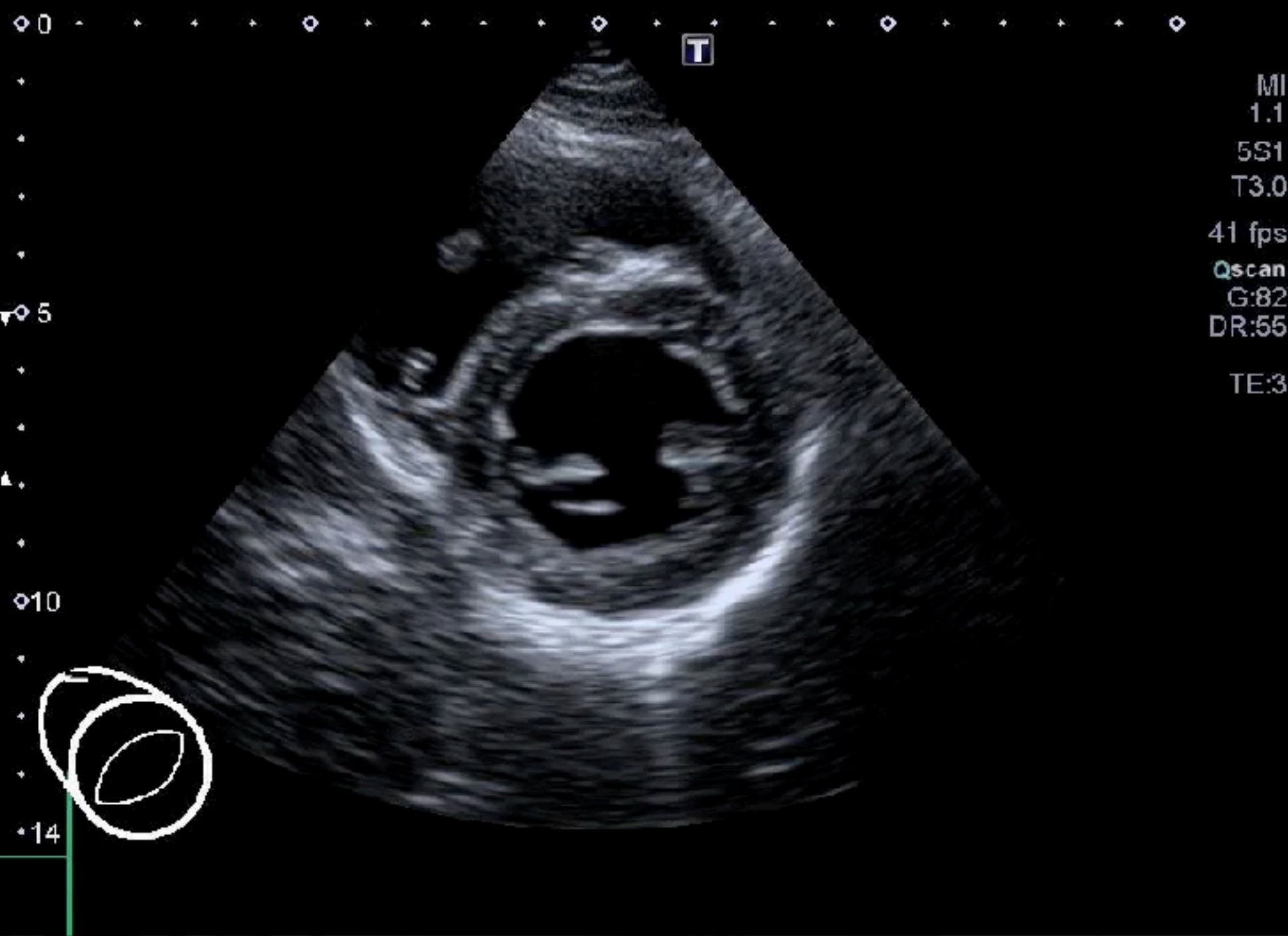
PSLA



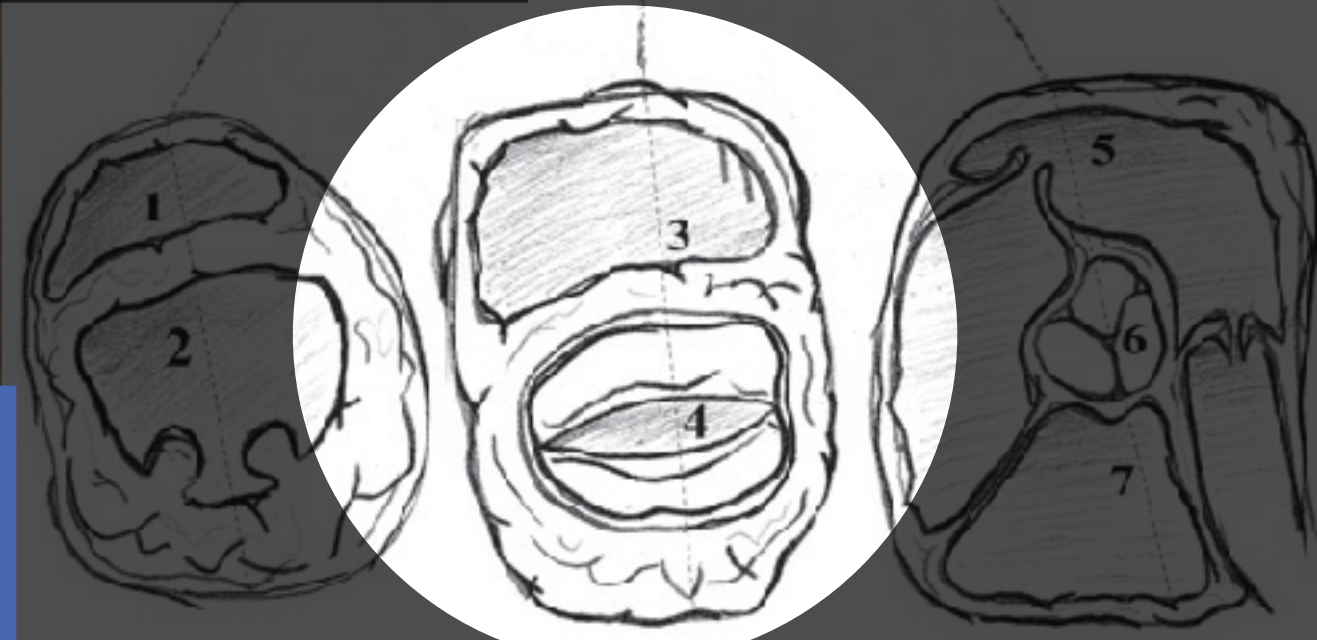
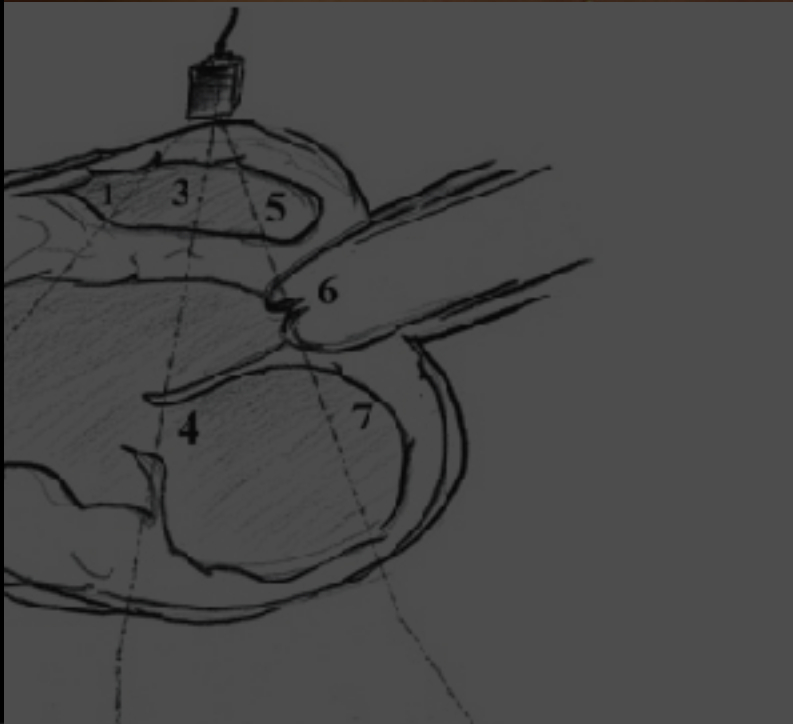
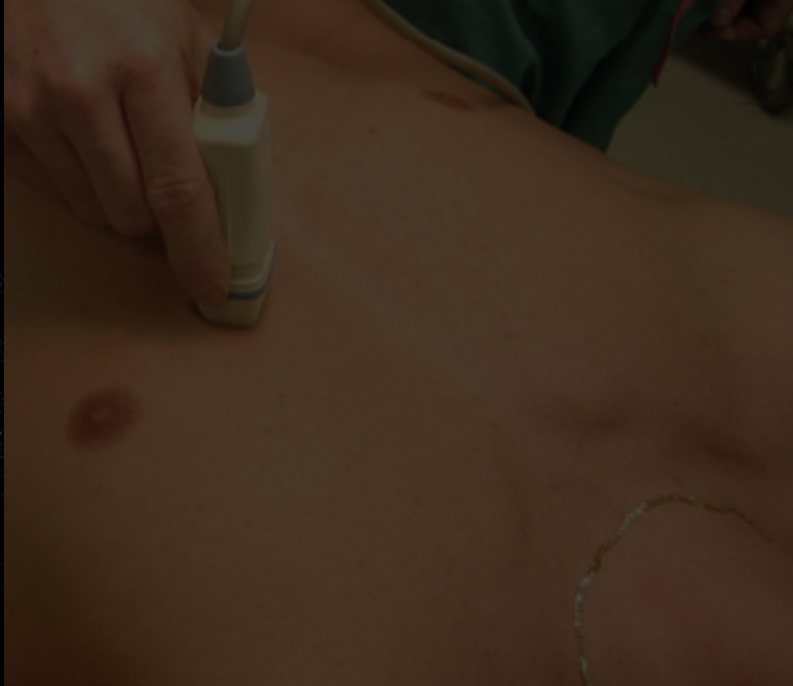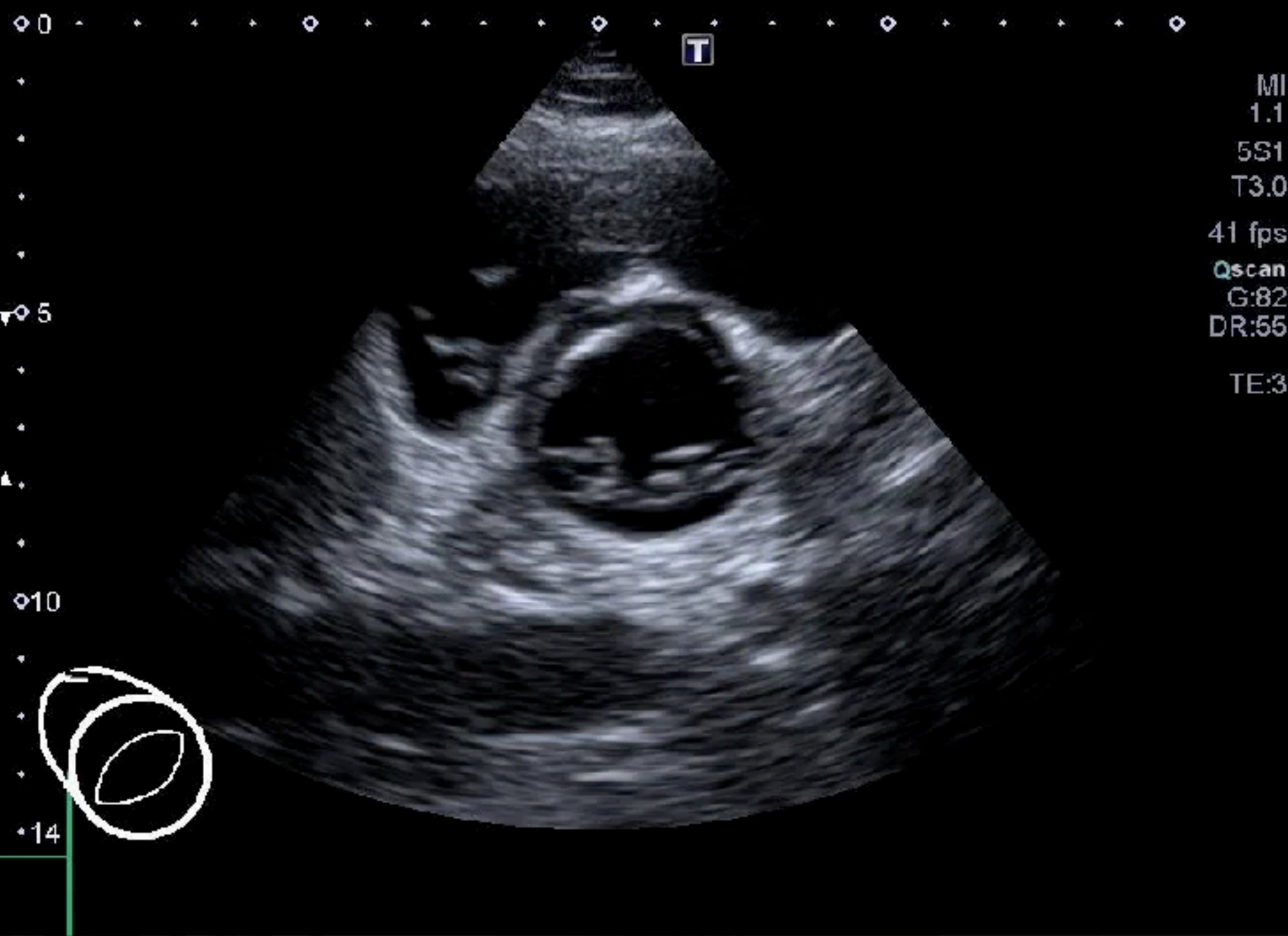
Parasternal long axis



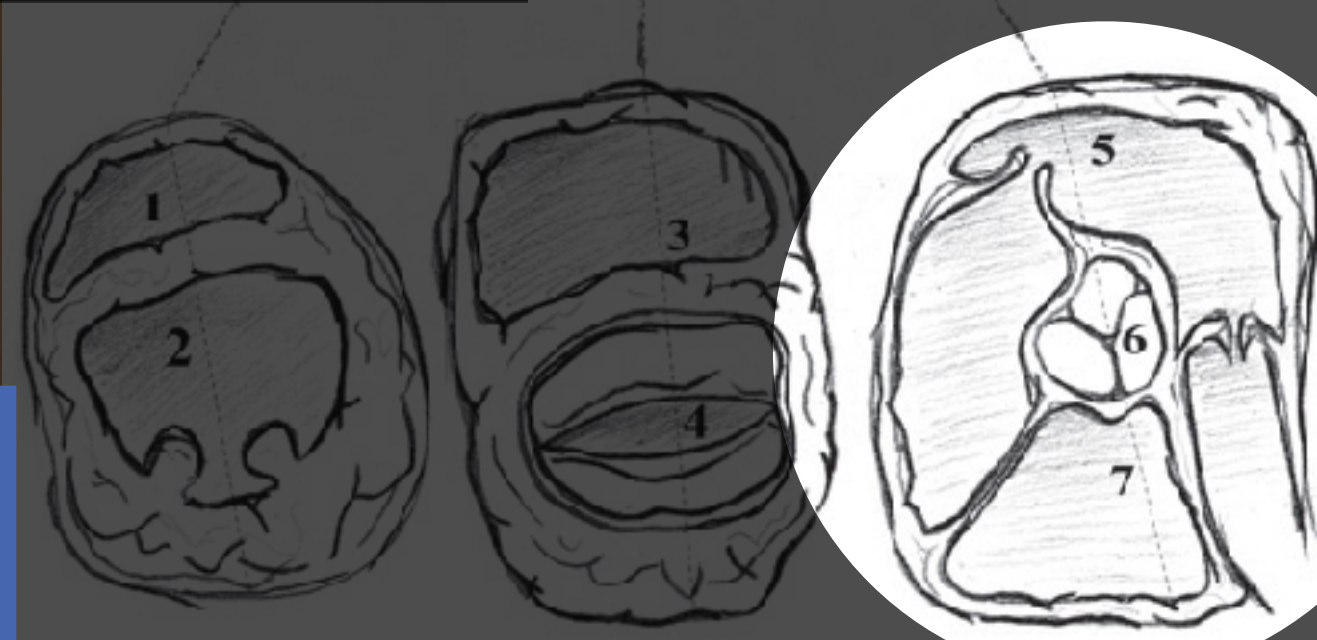
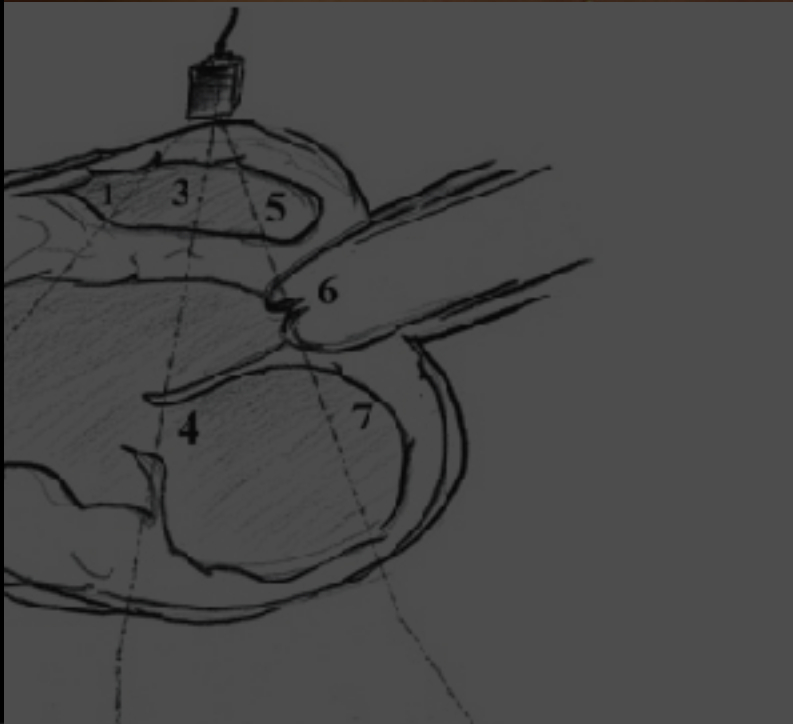
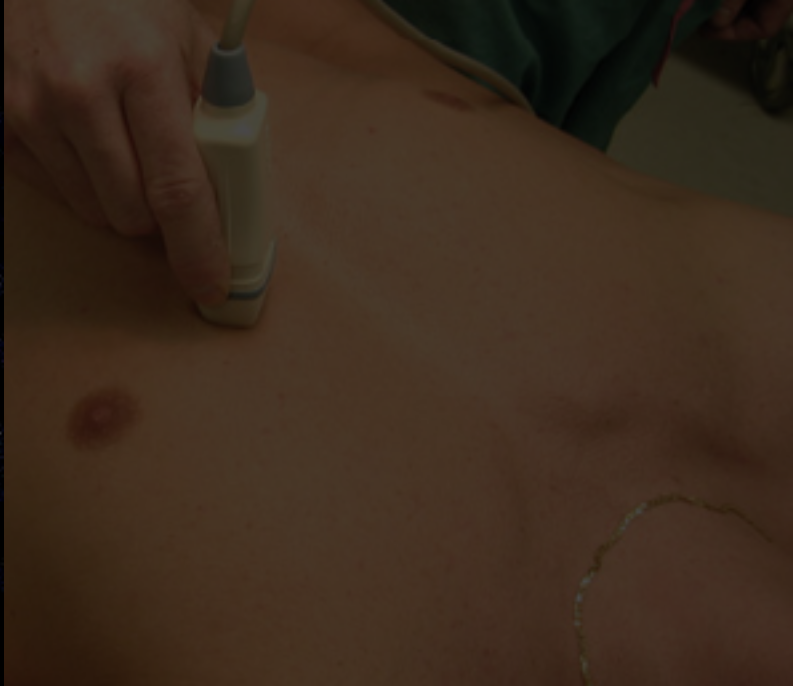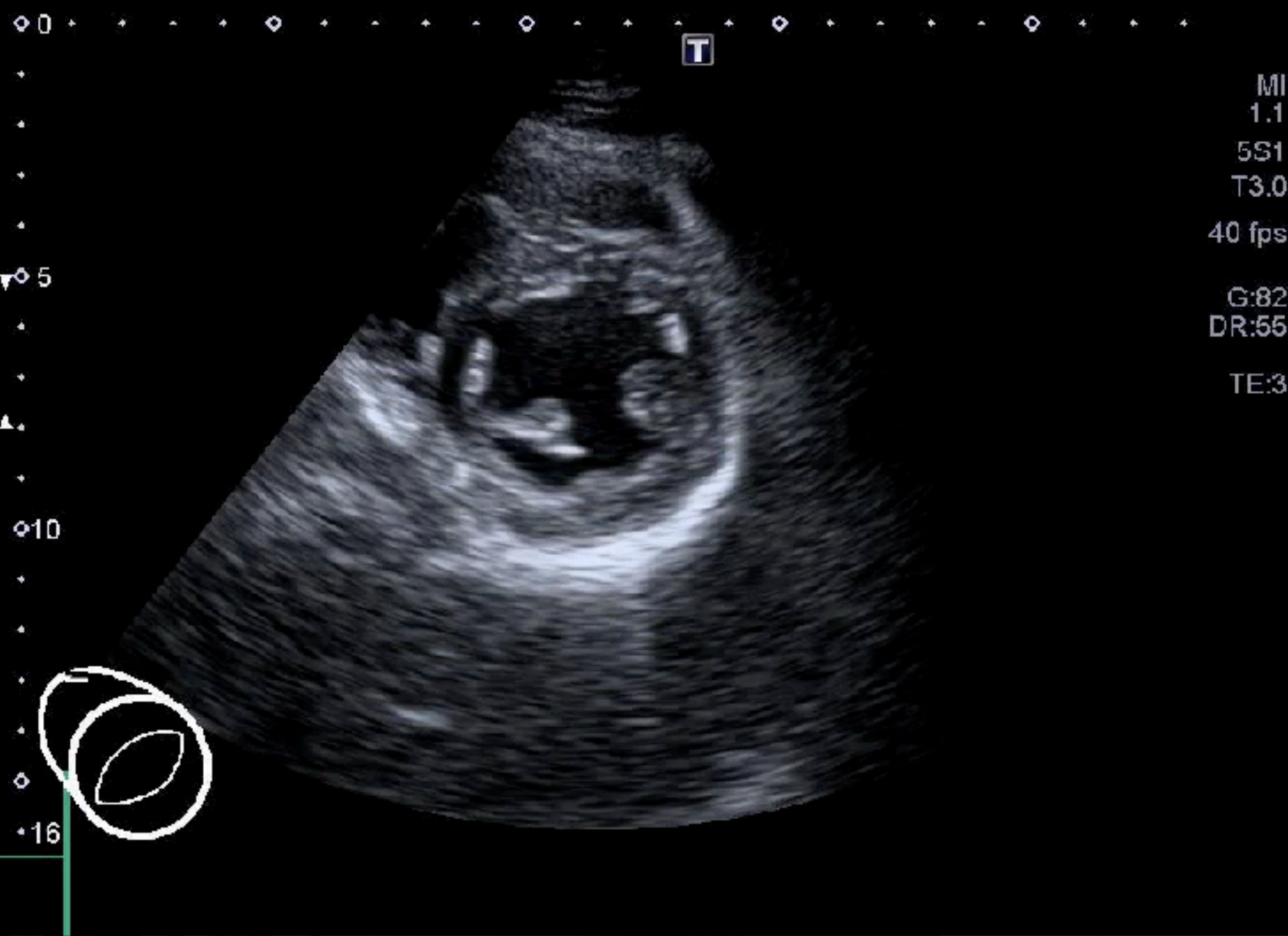
Essential Anatomy 5



Parasternal short axis

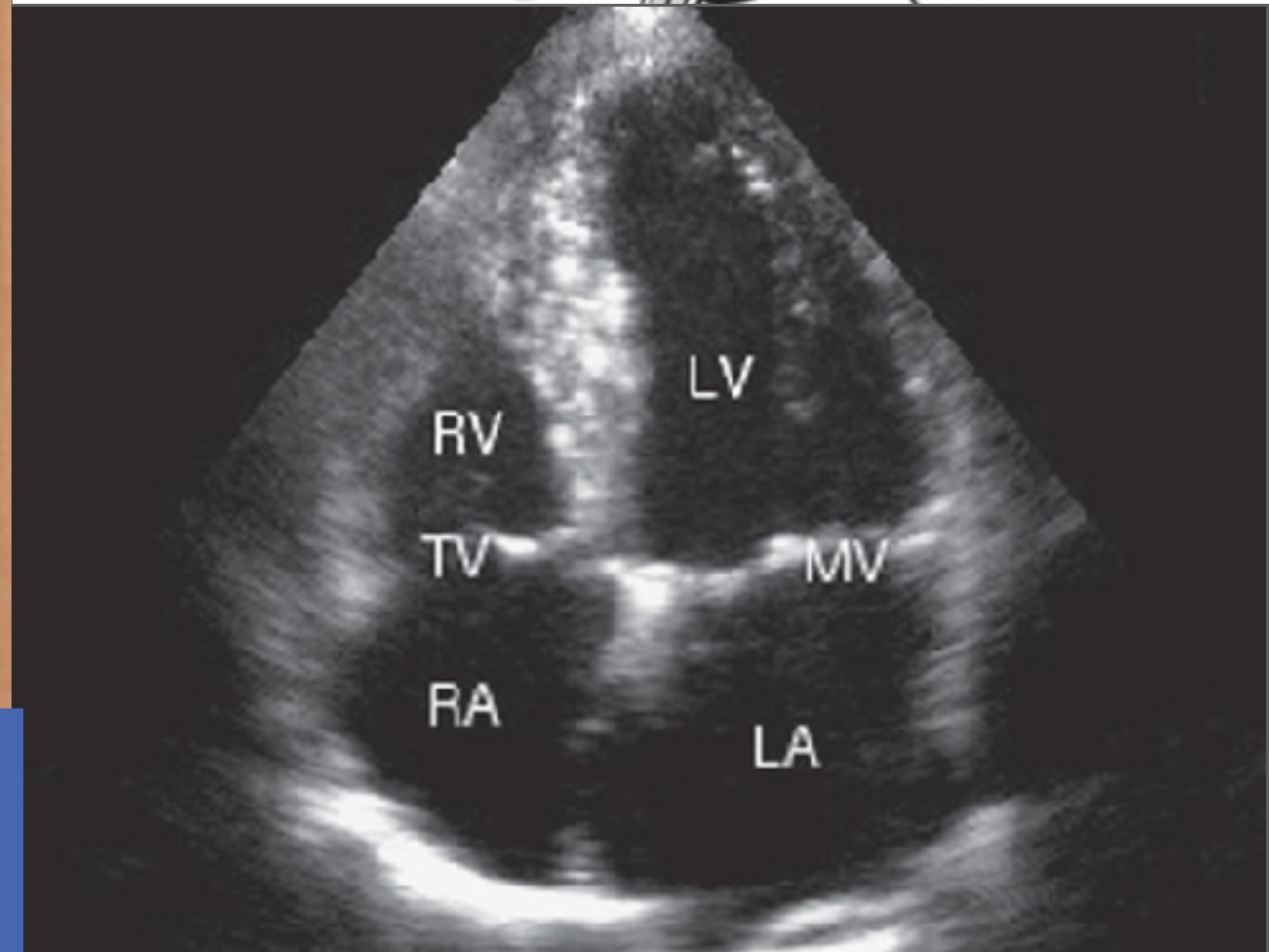
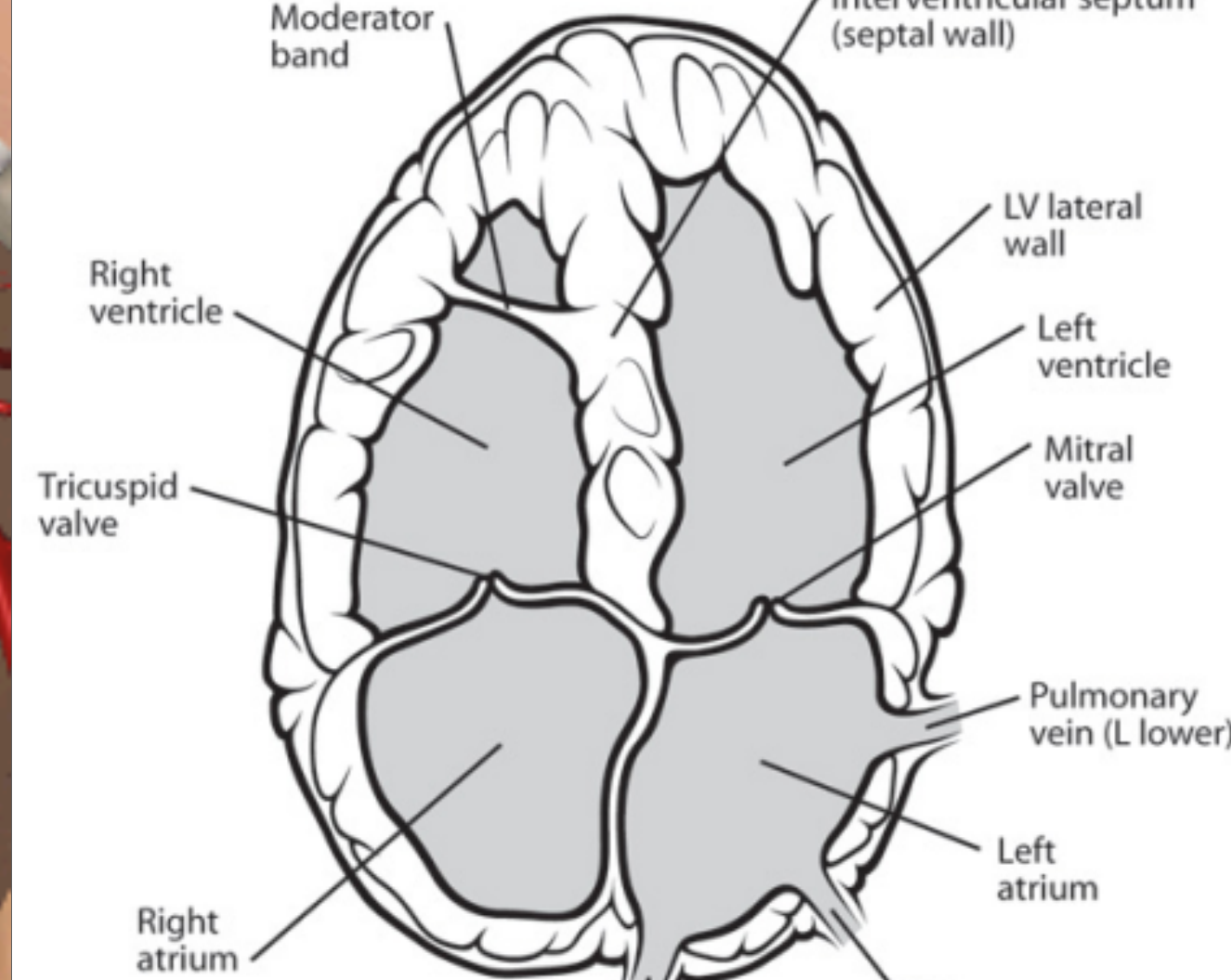
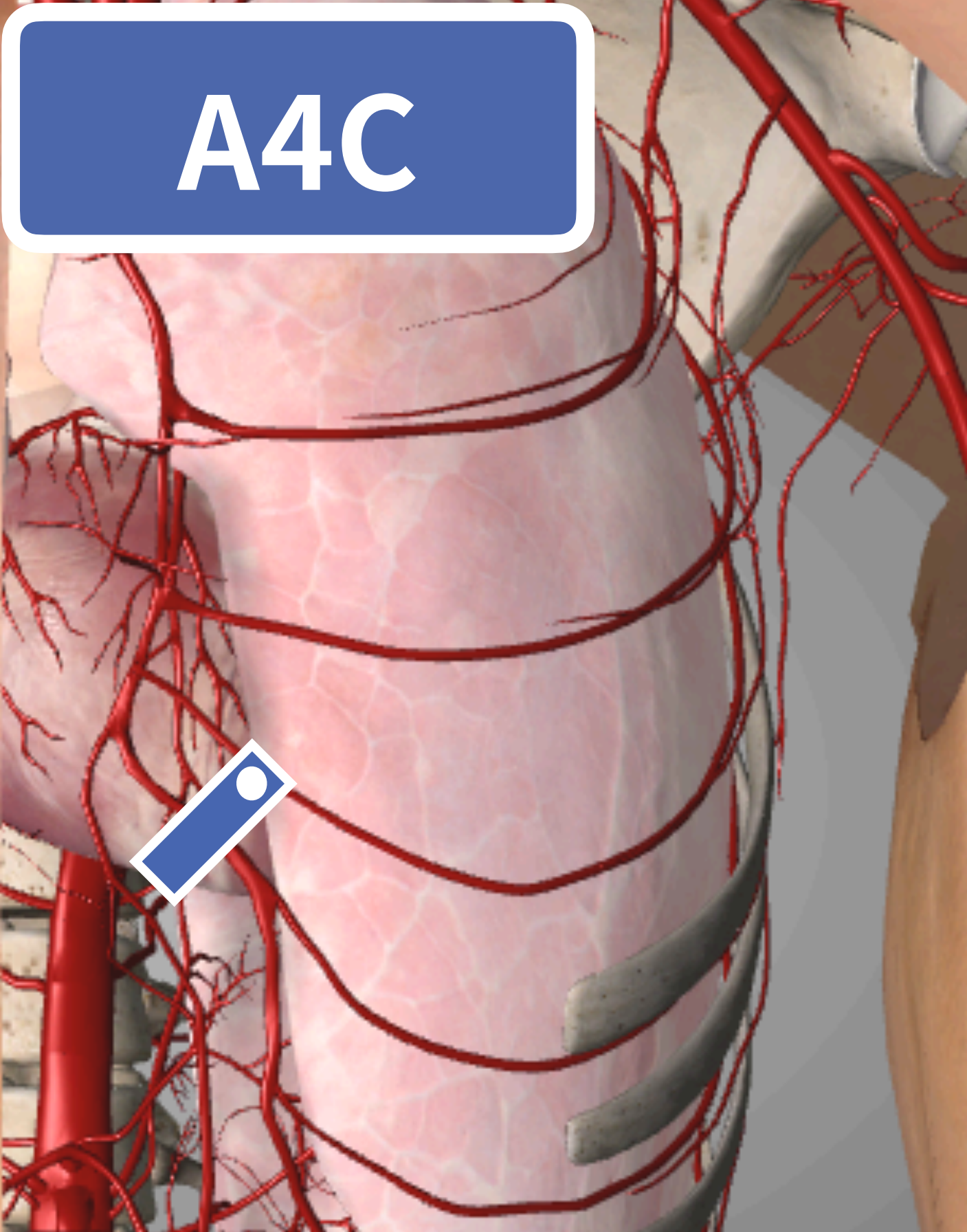


Parasternal short axis



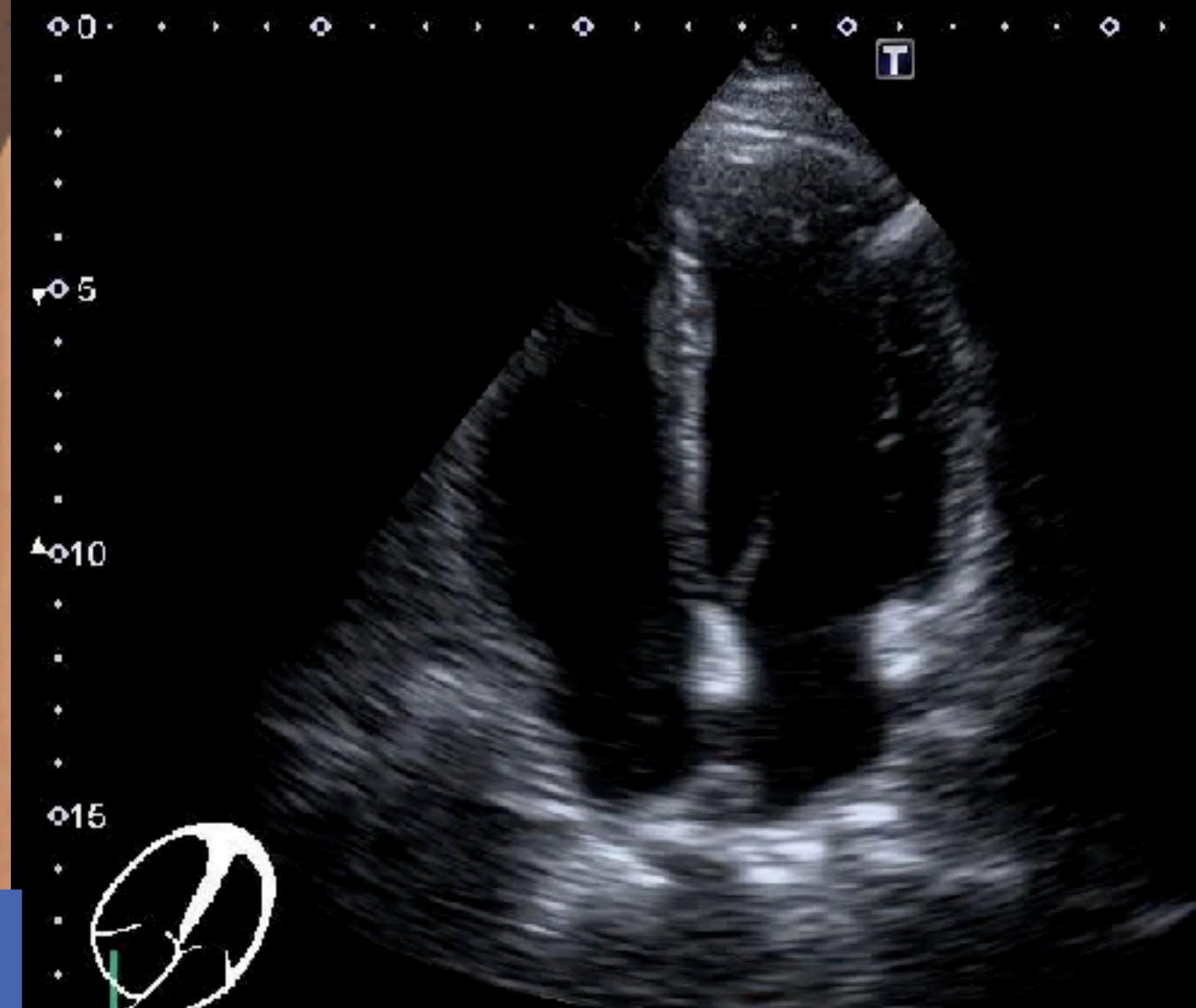
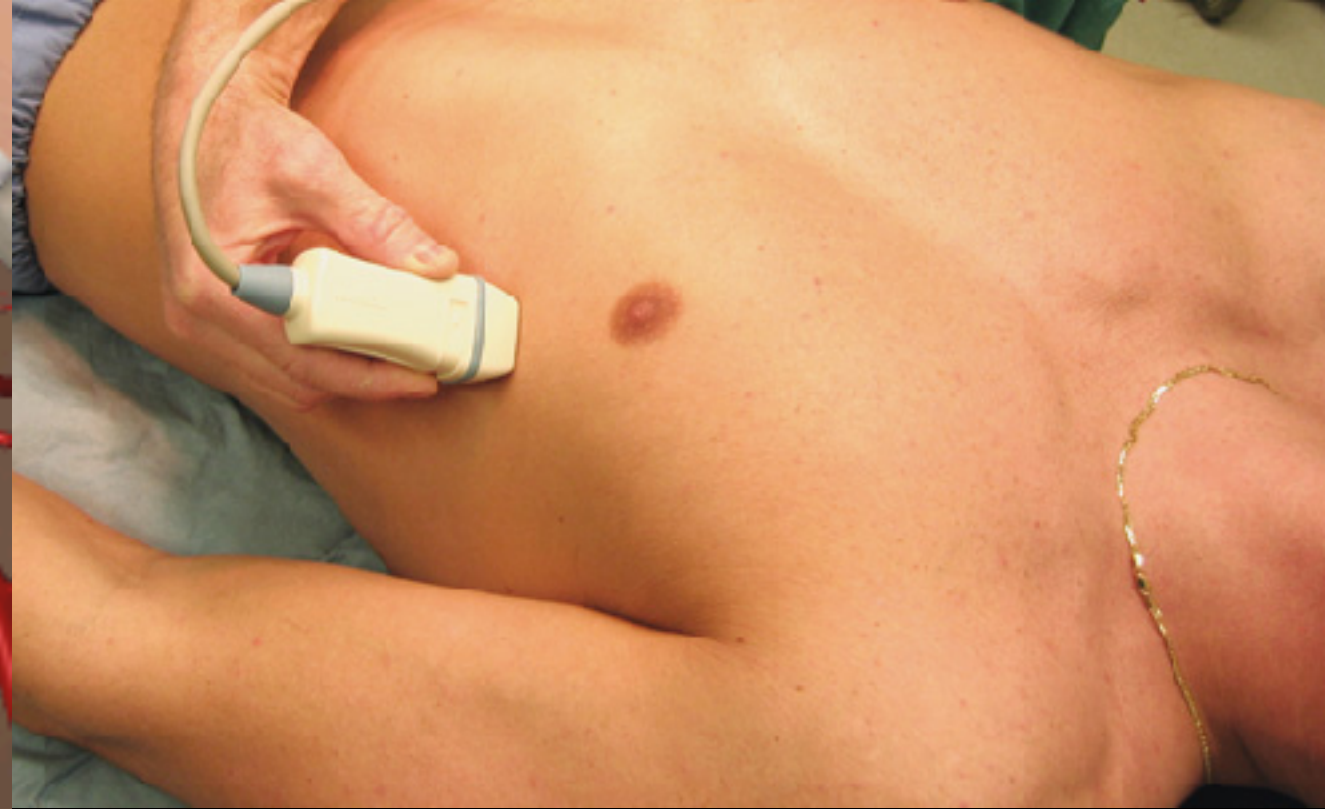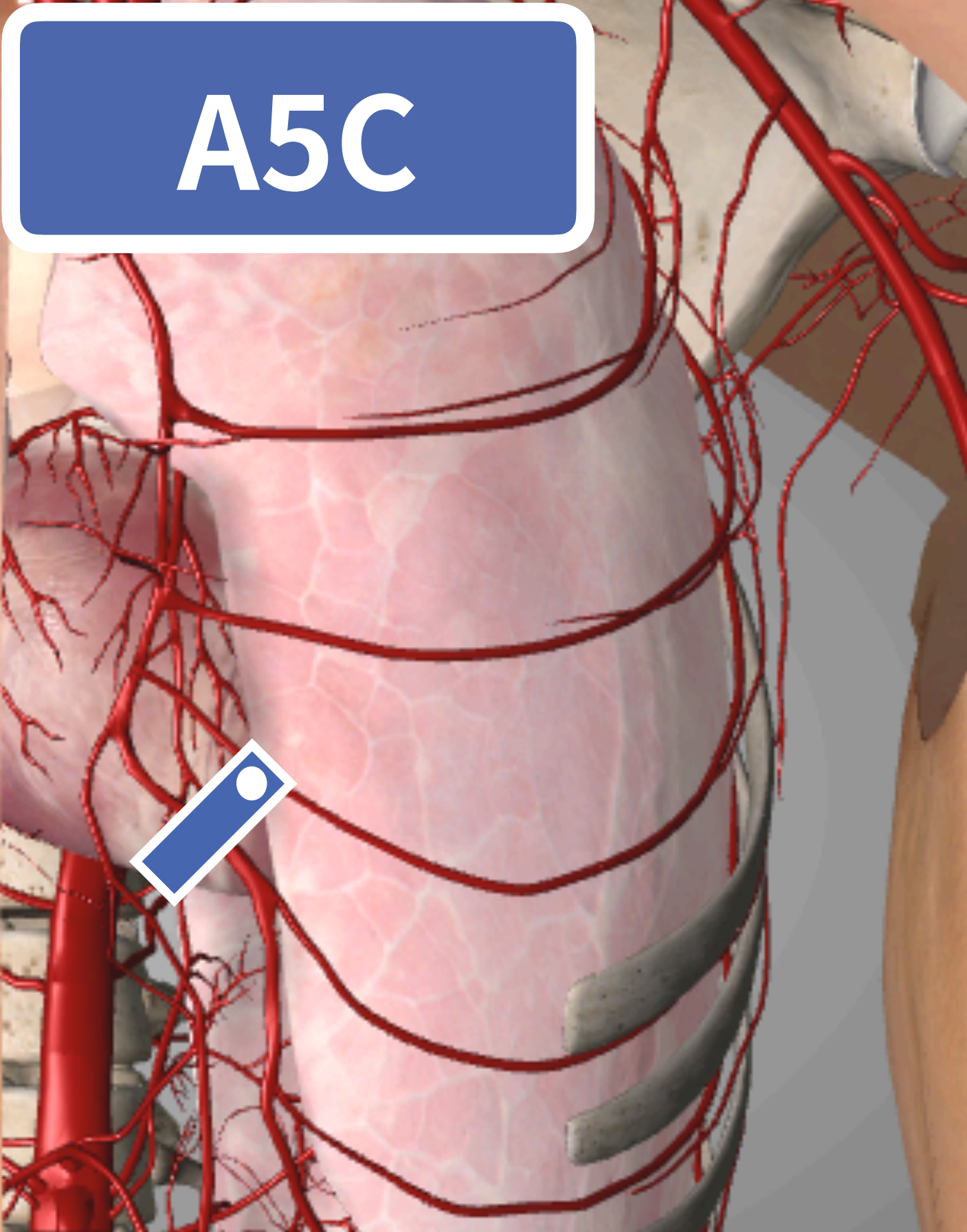
Parasternal short axis

A4C



Apical 4 Chambers

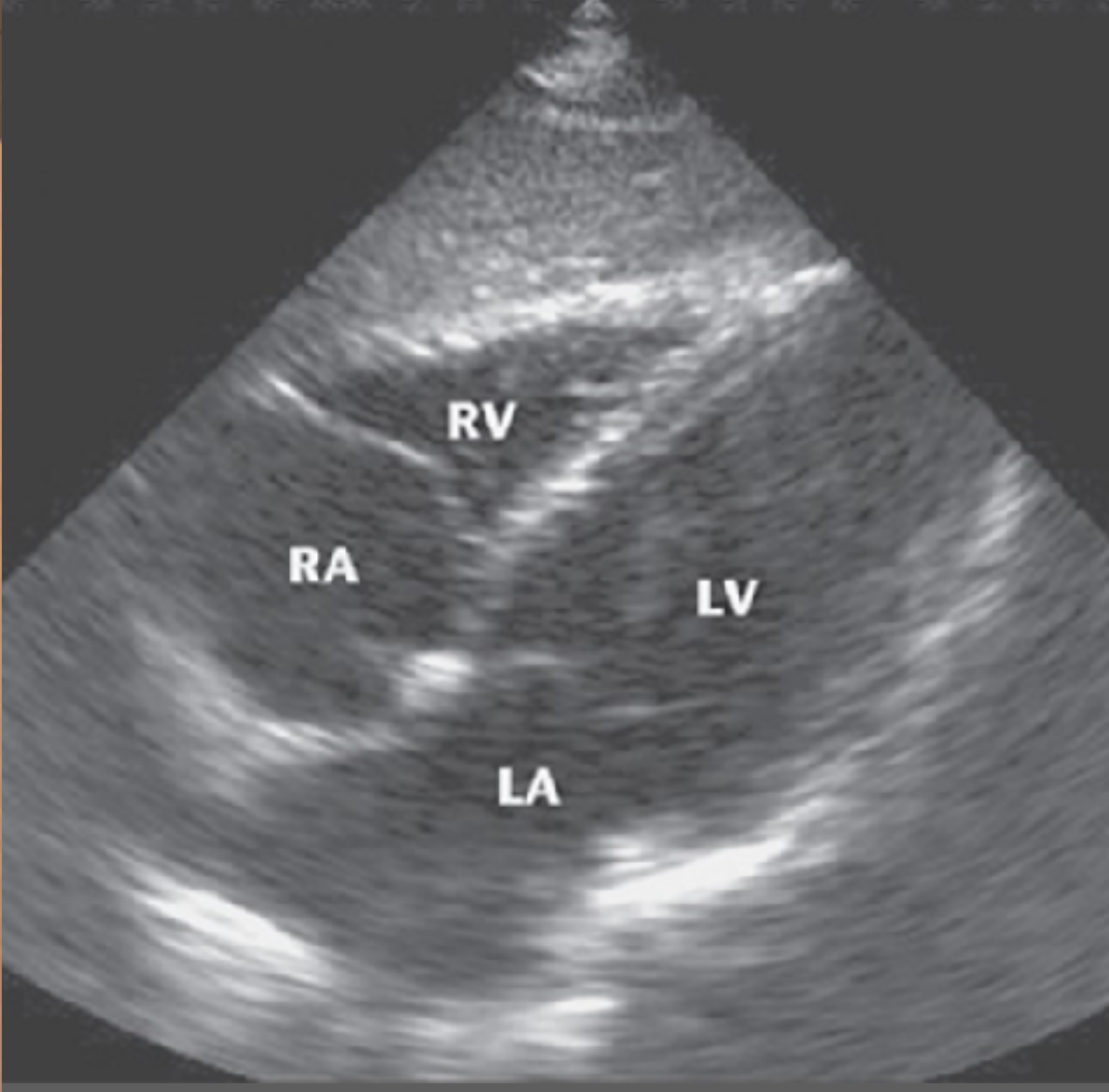
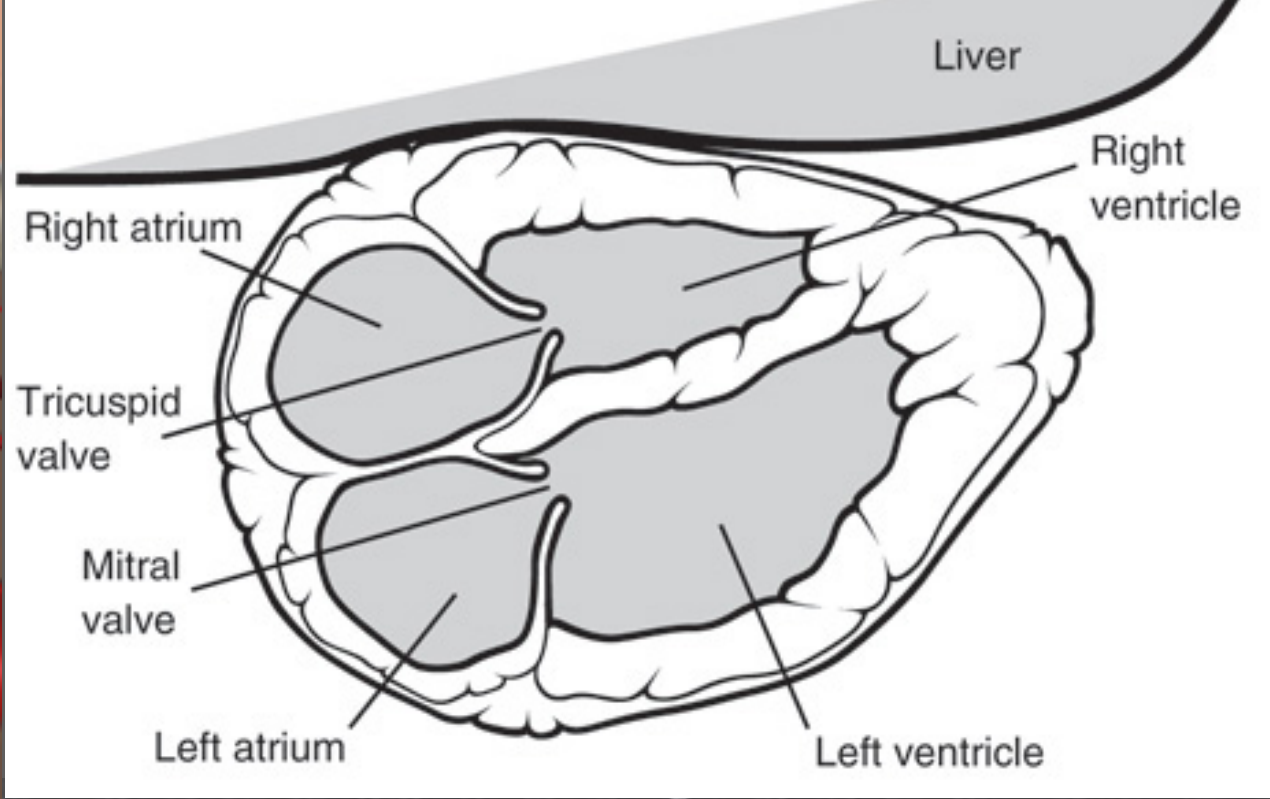
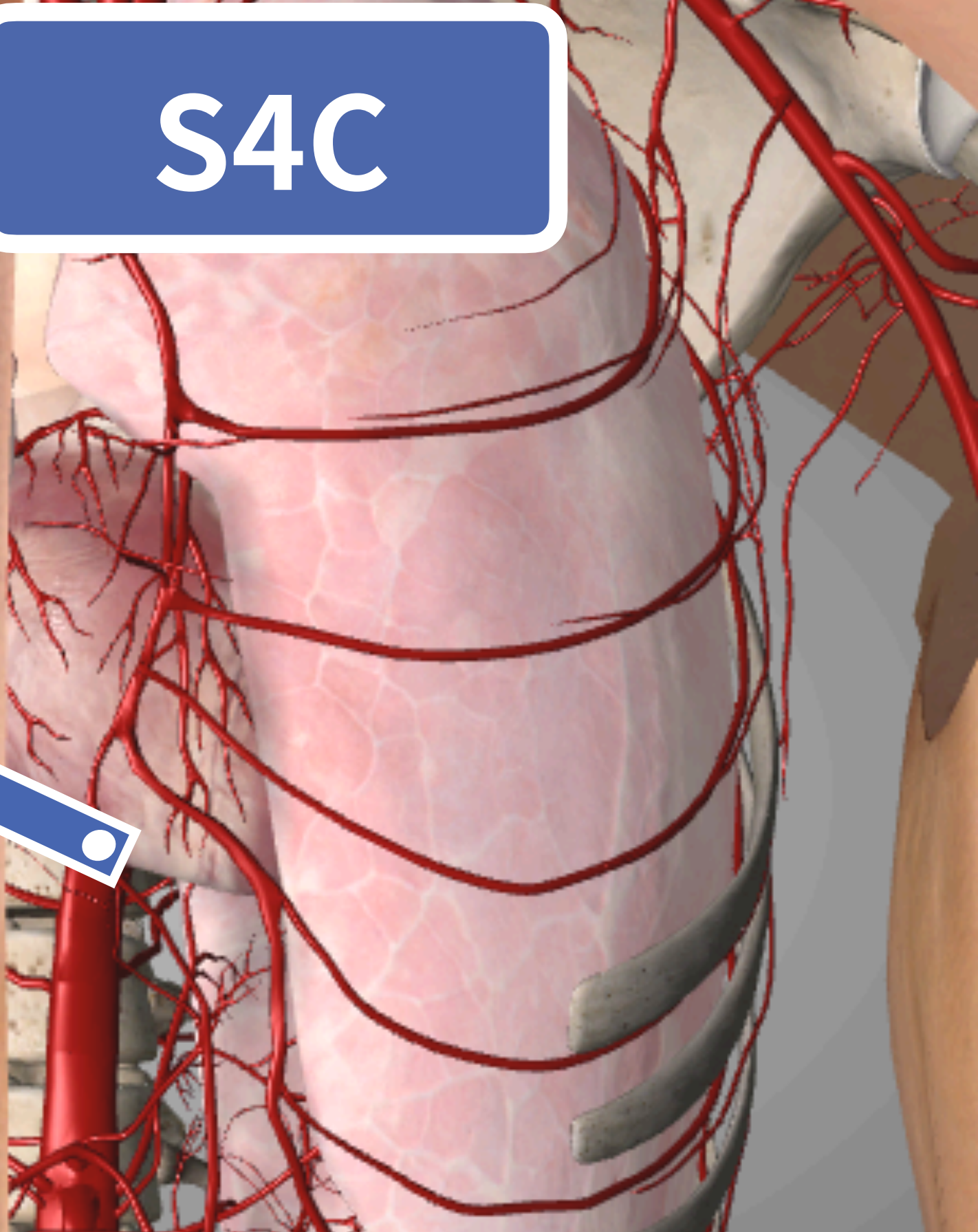
A5C



Apical 5 Chambers

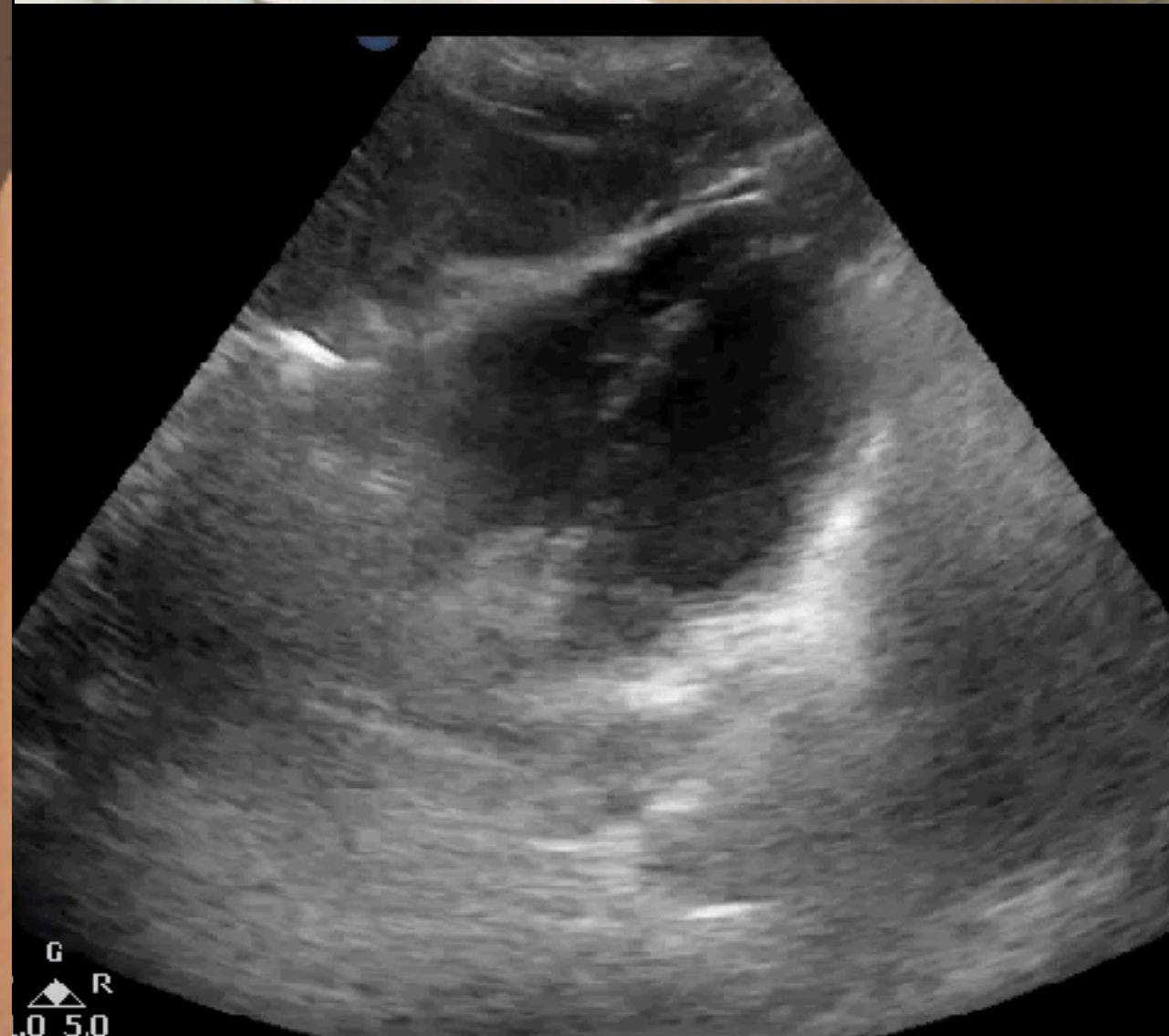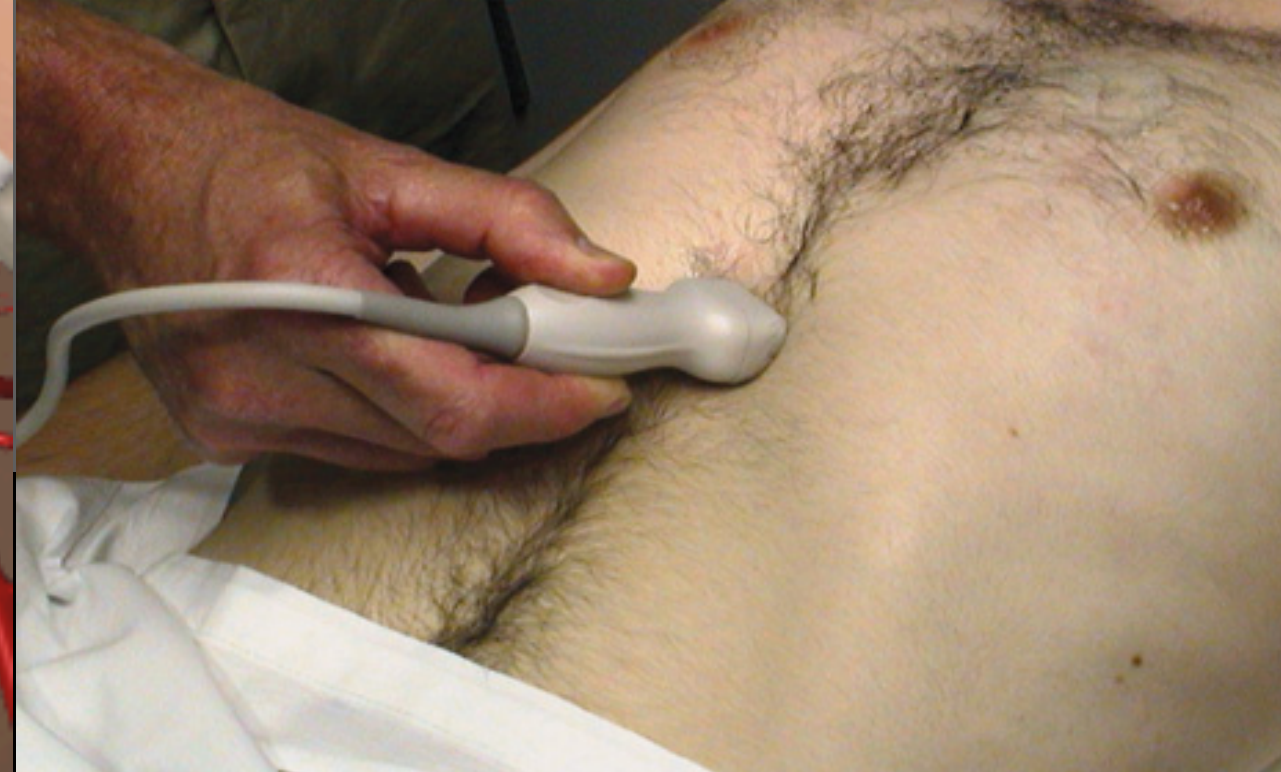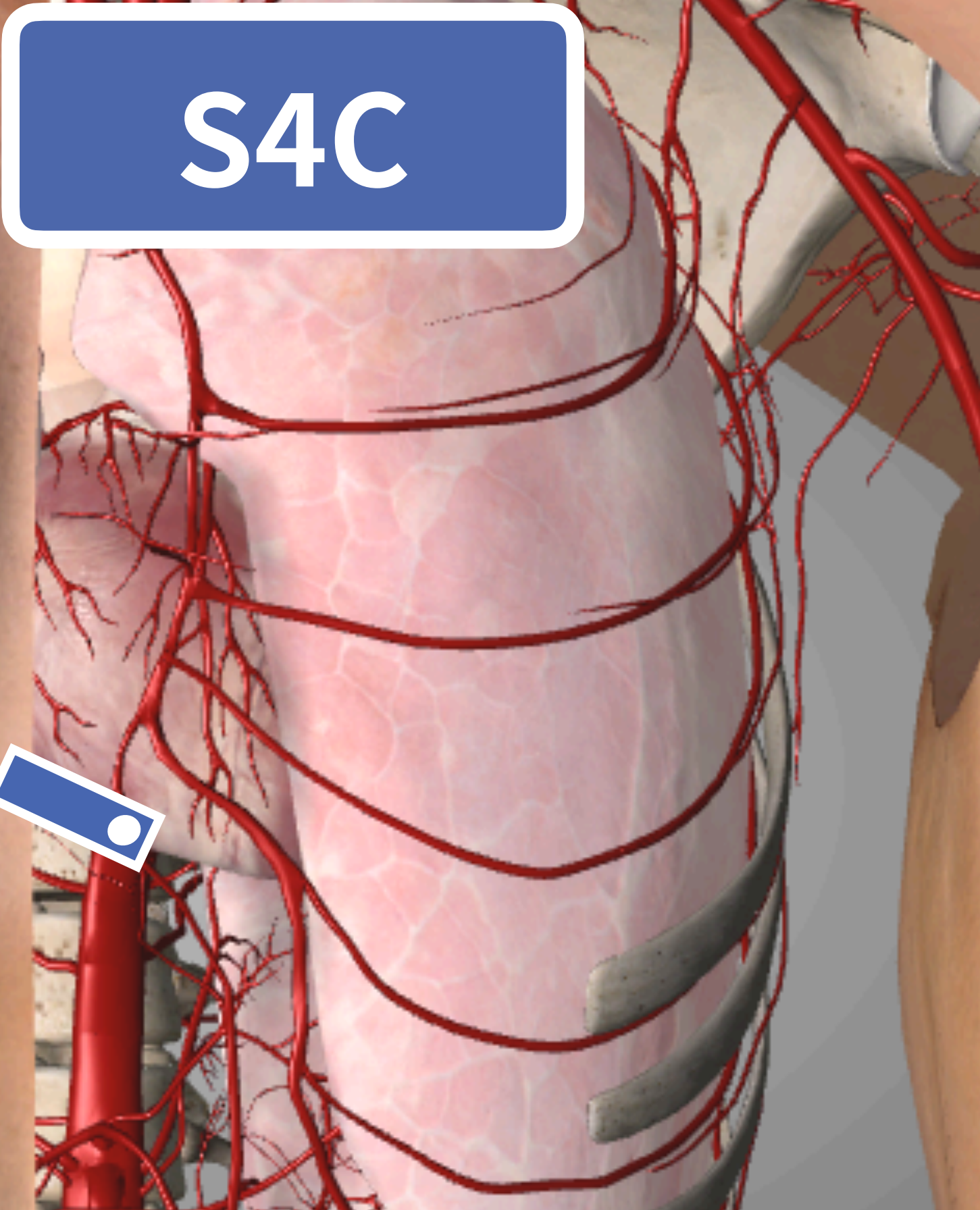
Essential Anatomy 5

S4C



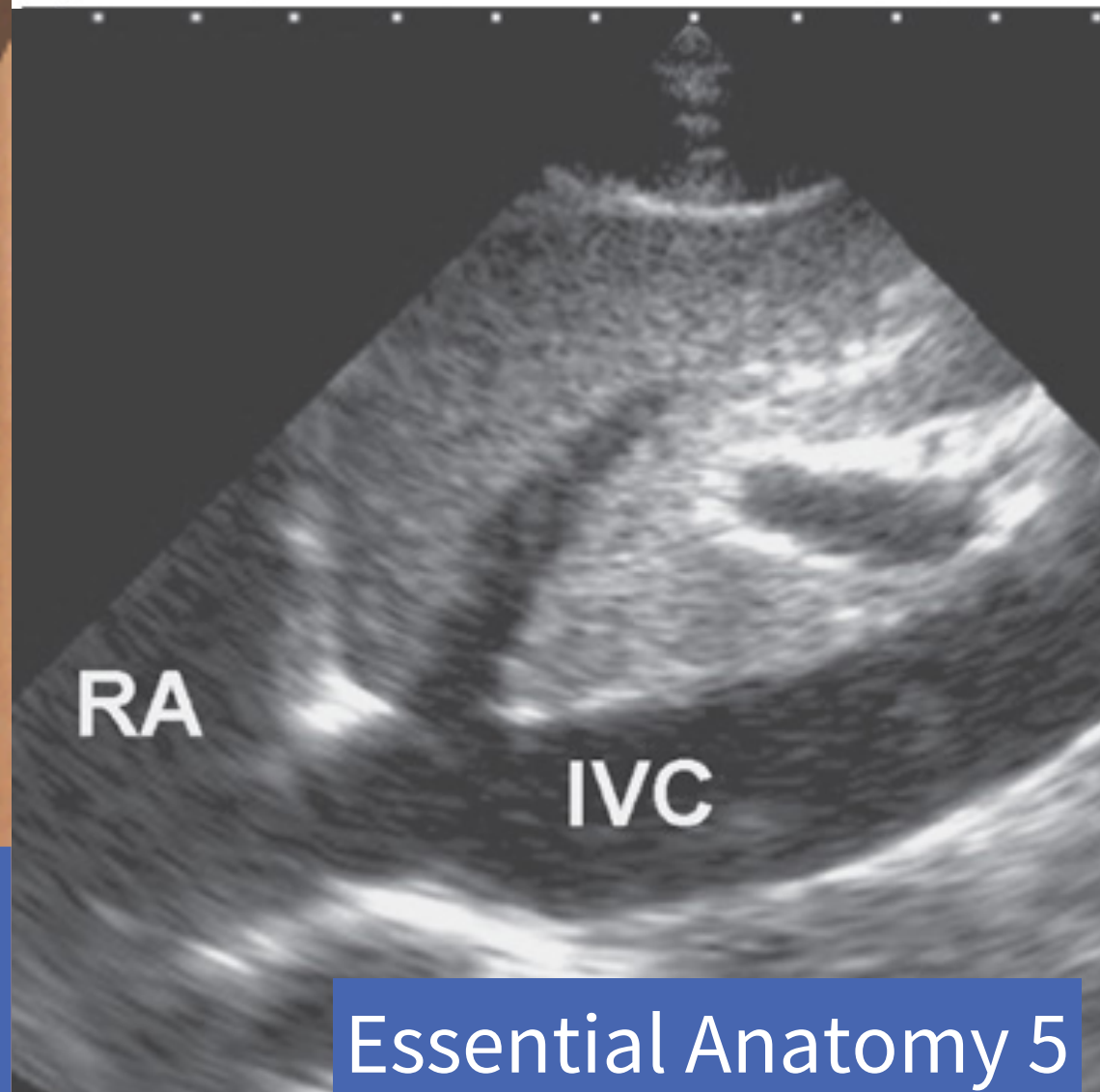
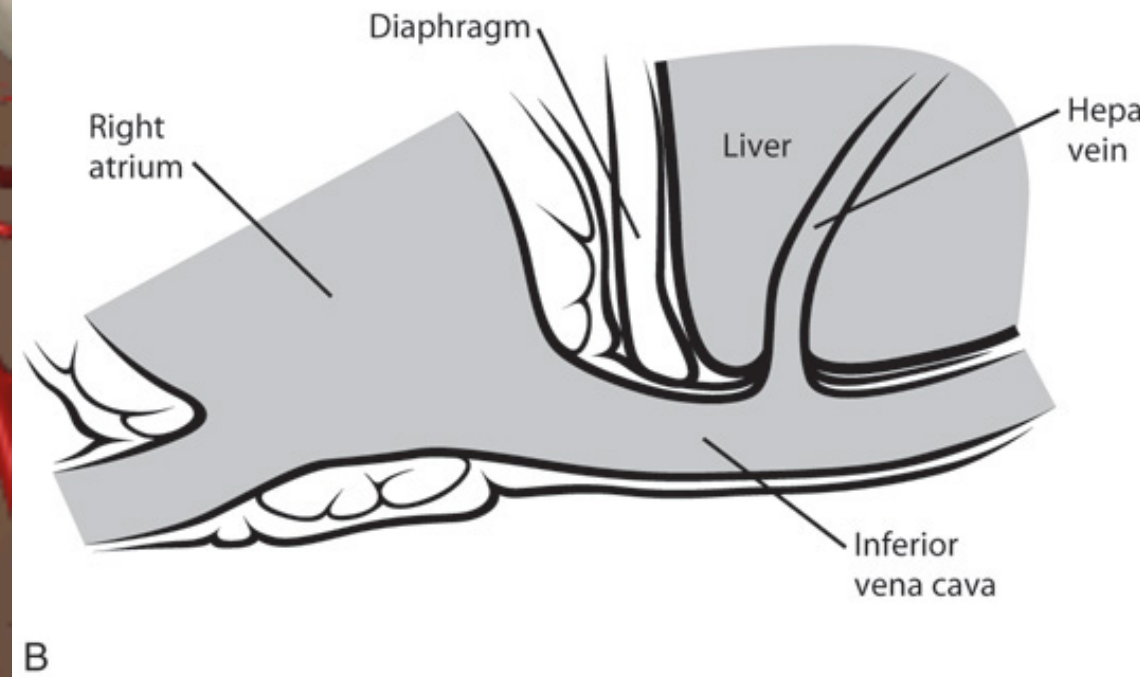
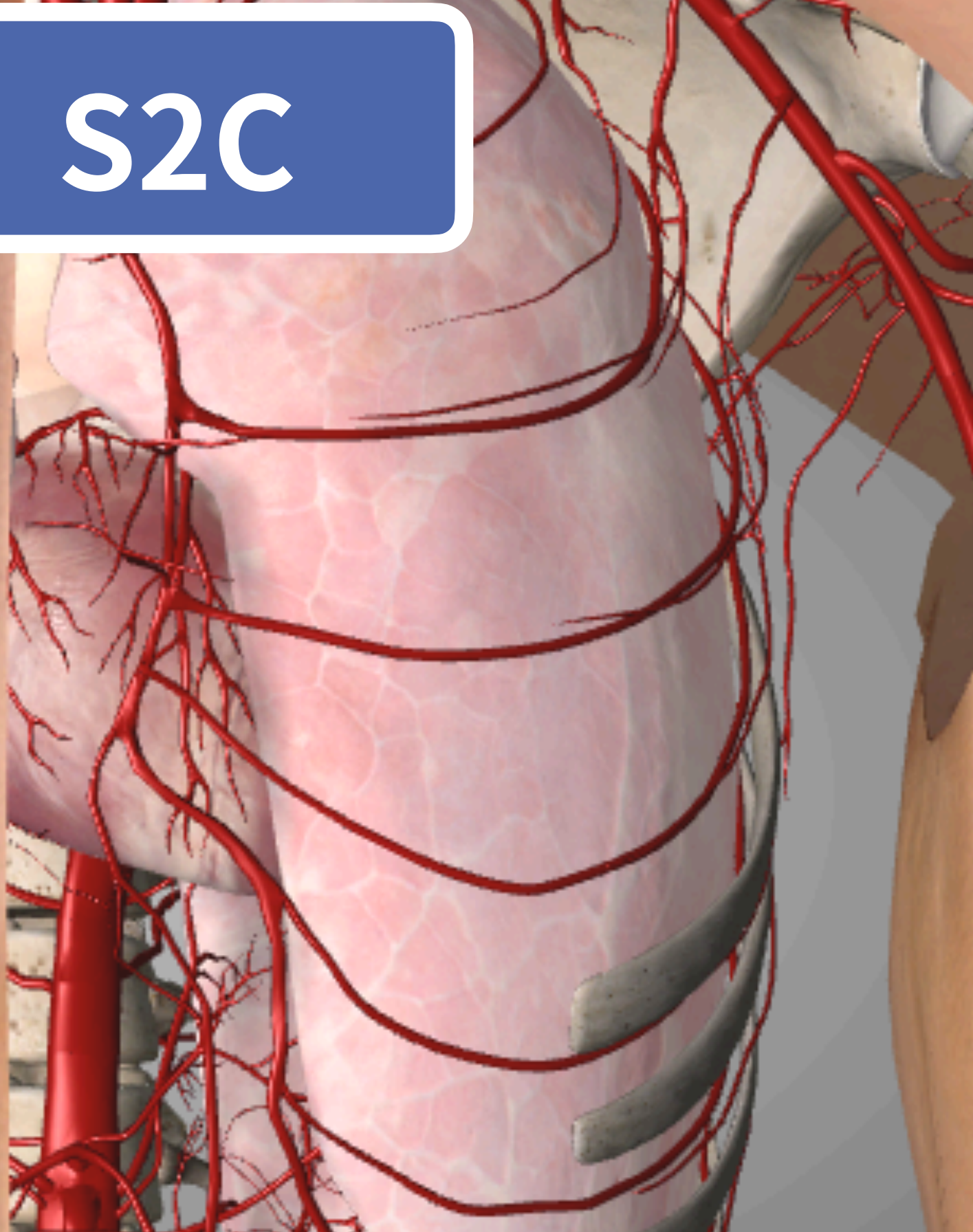
Subcostal 4 Chambers

S4C



Subcostal 4 Chambers

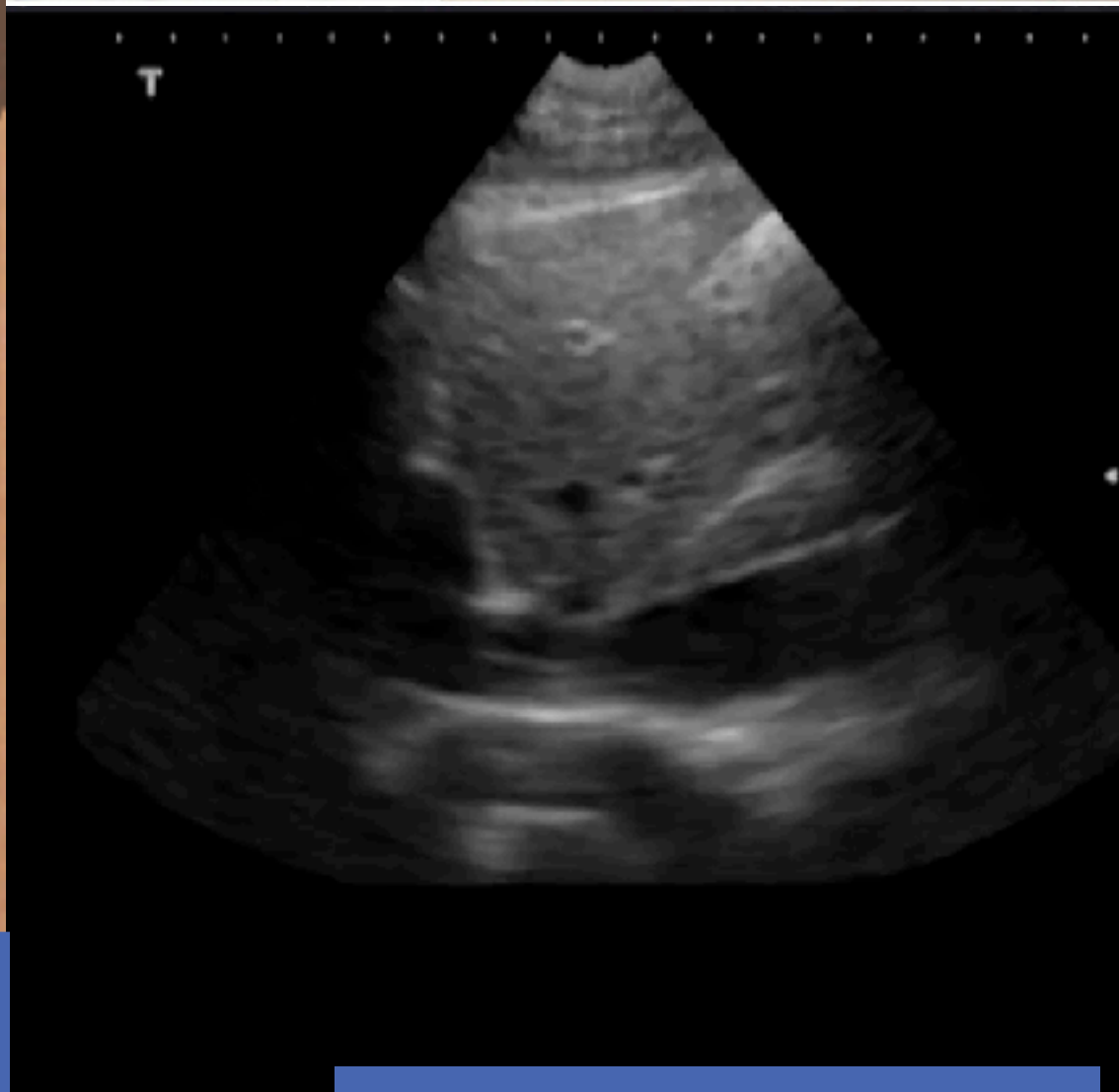
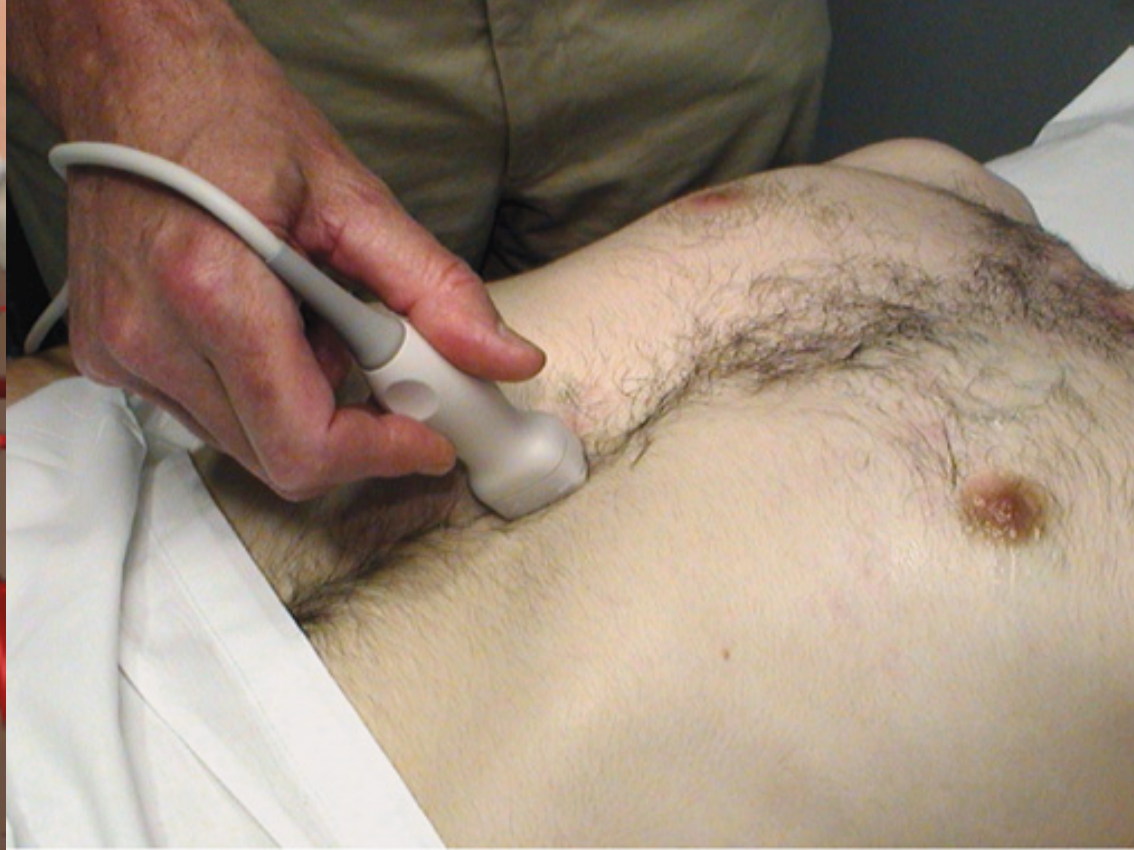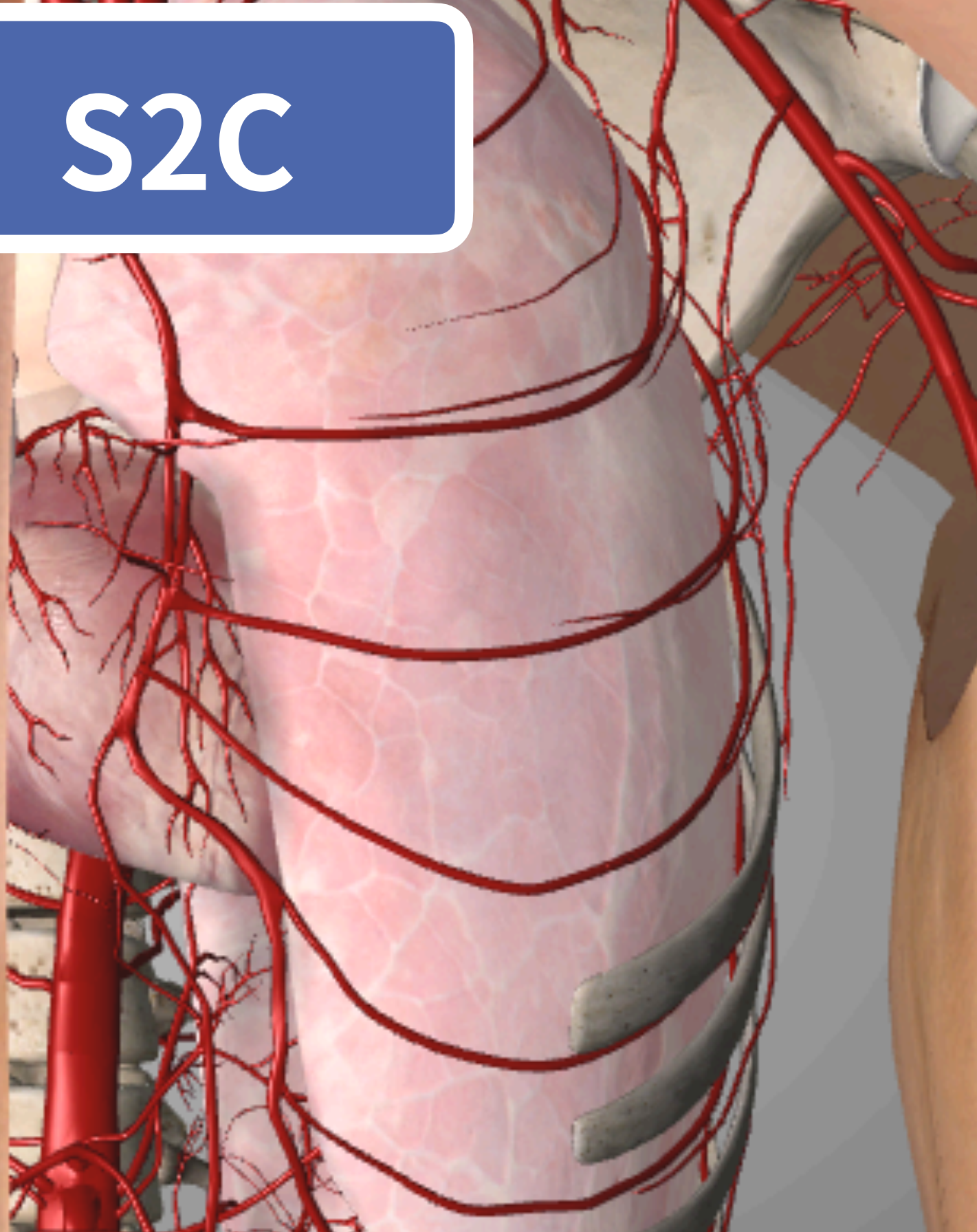
S2C



Subcostal 2 Chambers

Essential Anatomy 5

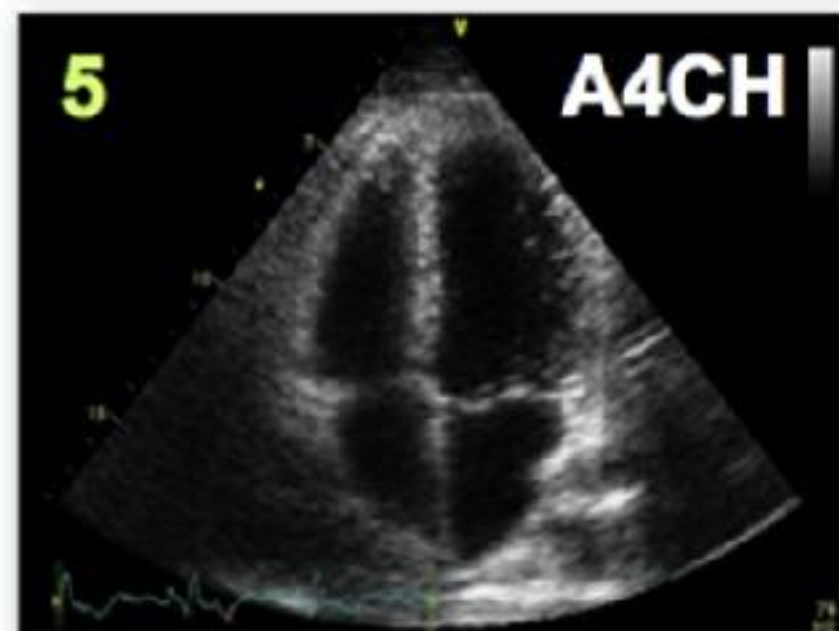
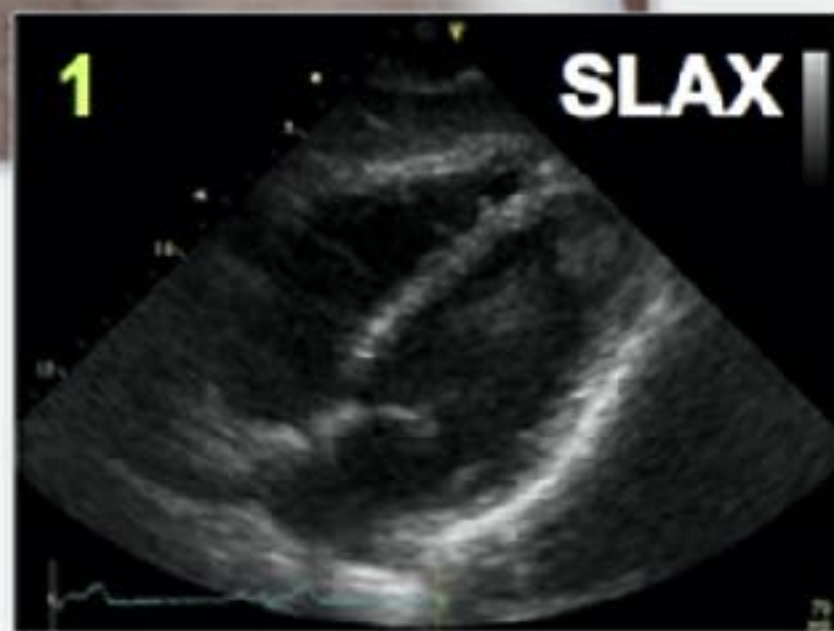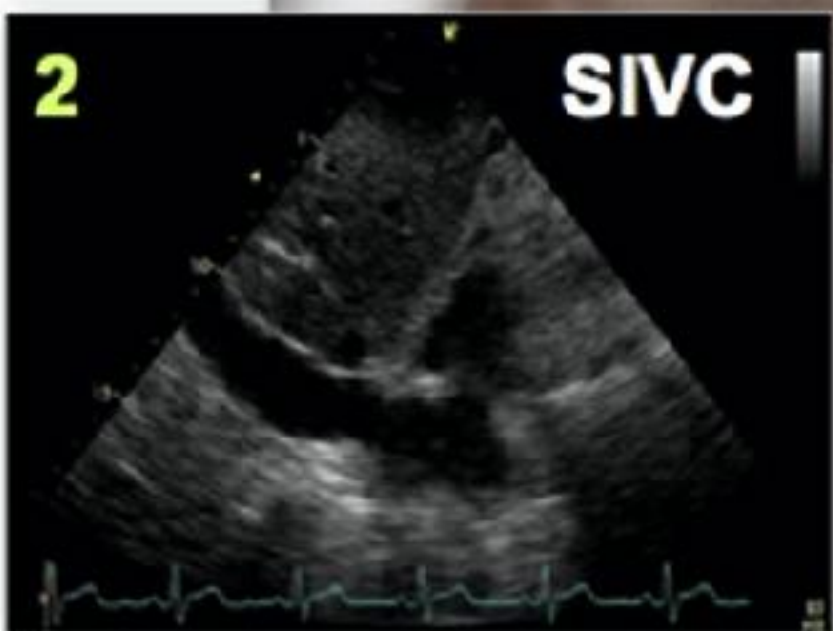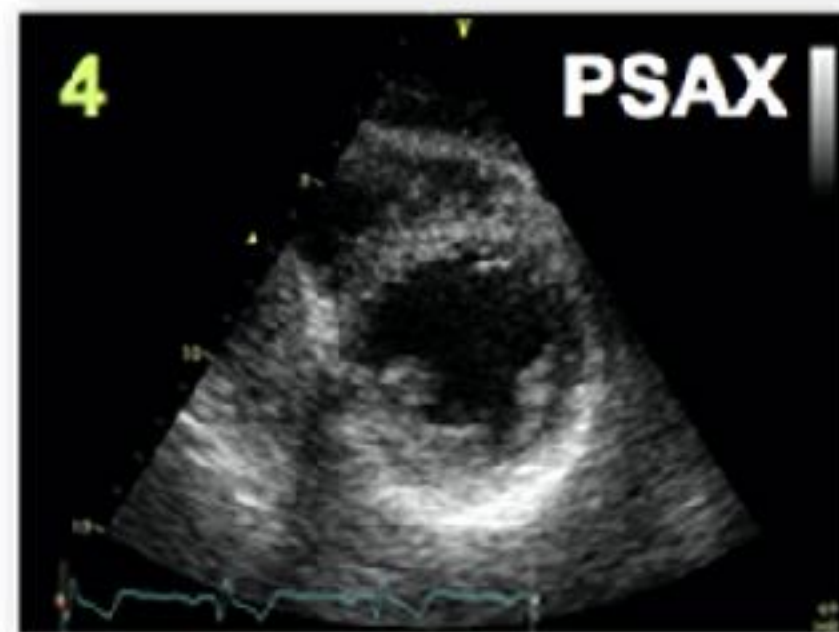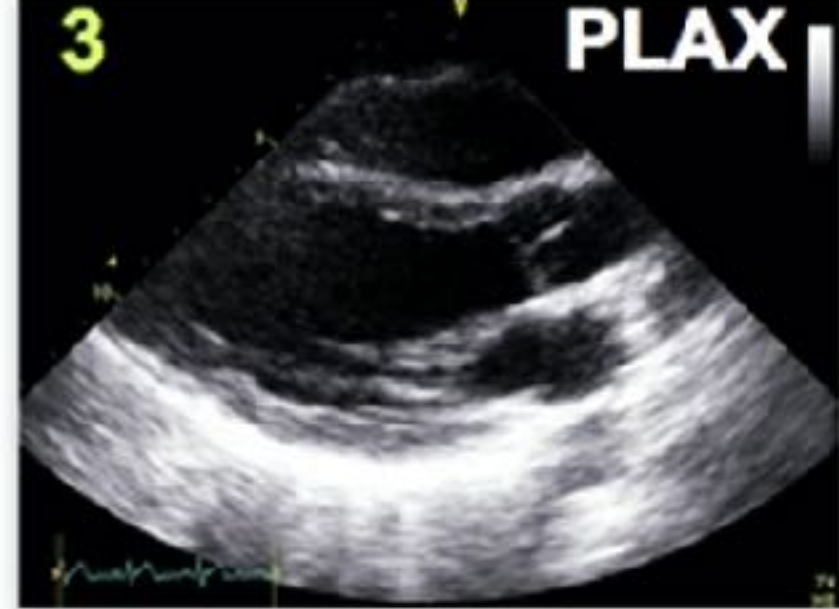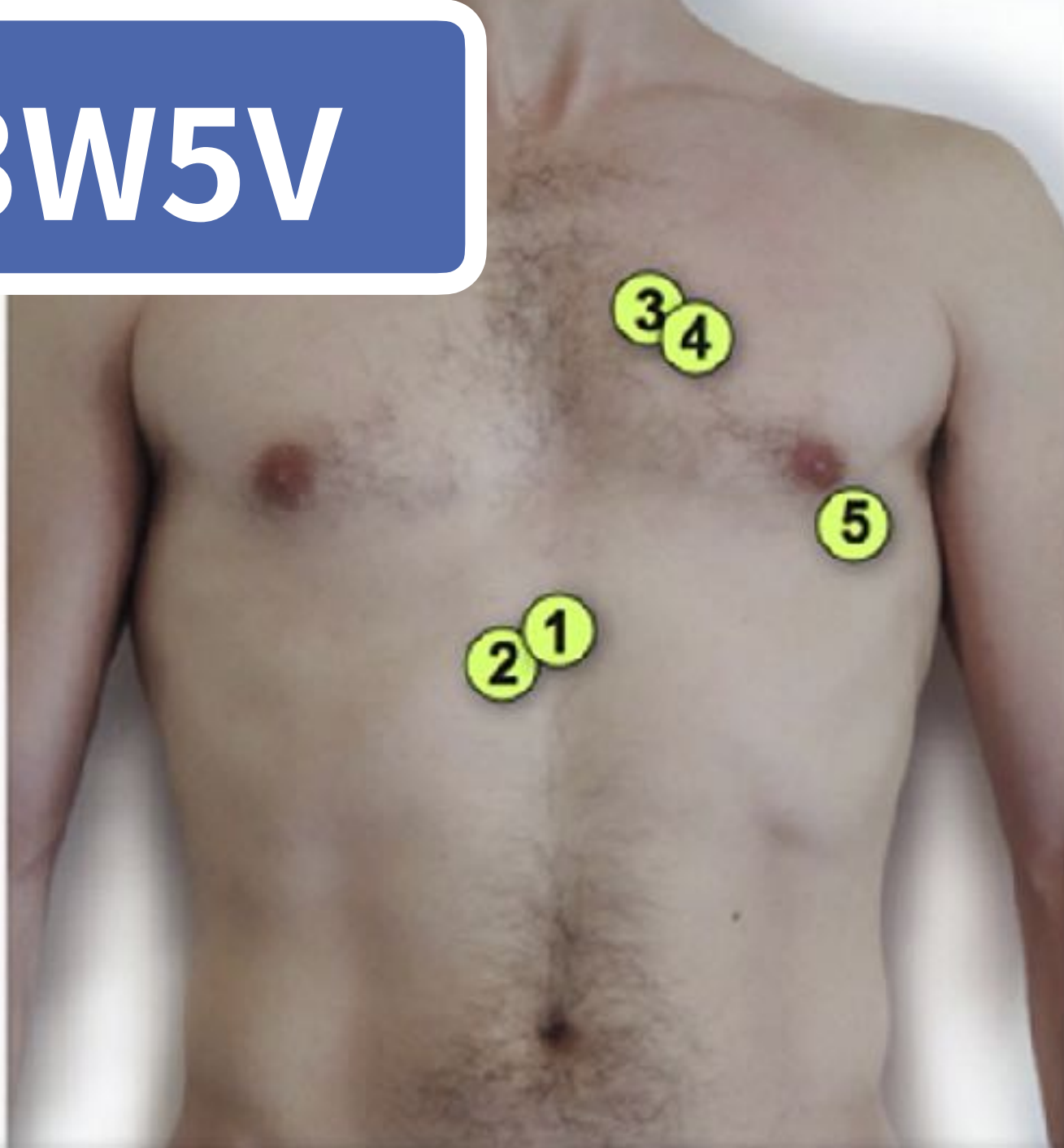
S2C



Subcostal 2 Chambers

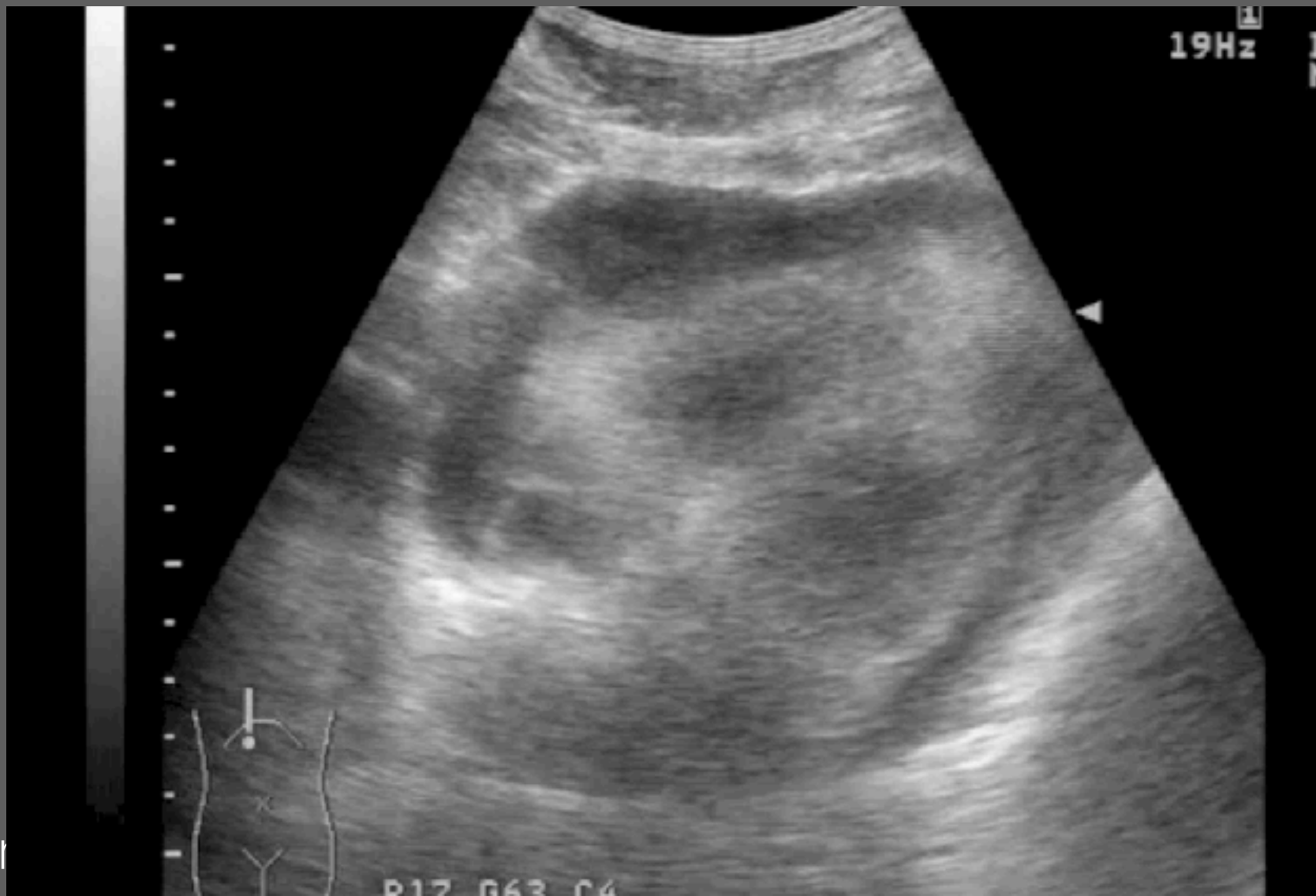Essential Anatomy 5

3W5V



Pericardial effusion

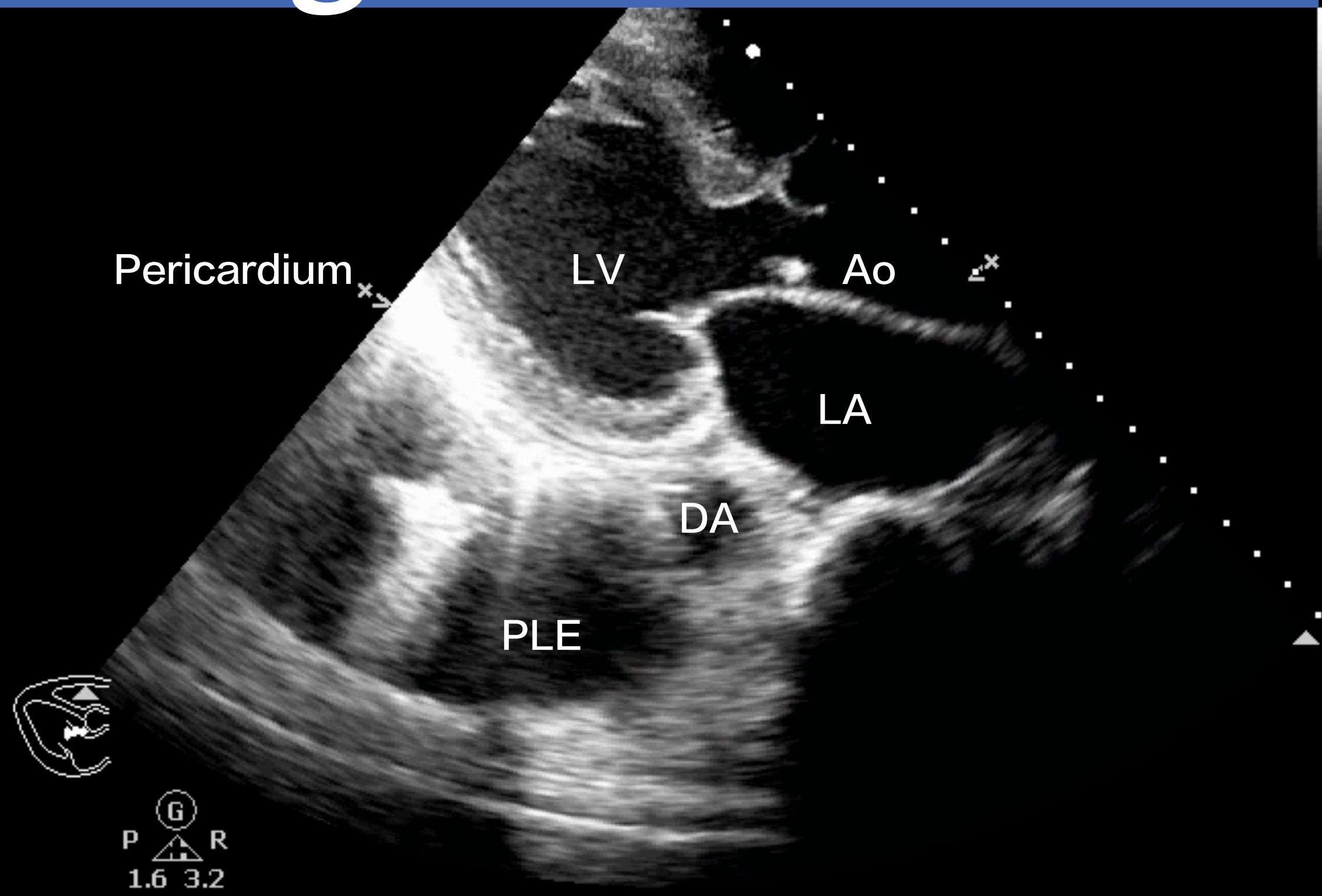
1 ~ 2 cm



Cher

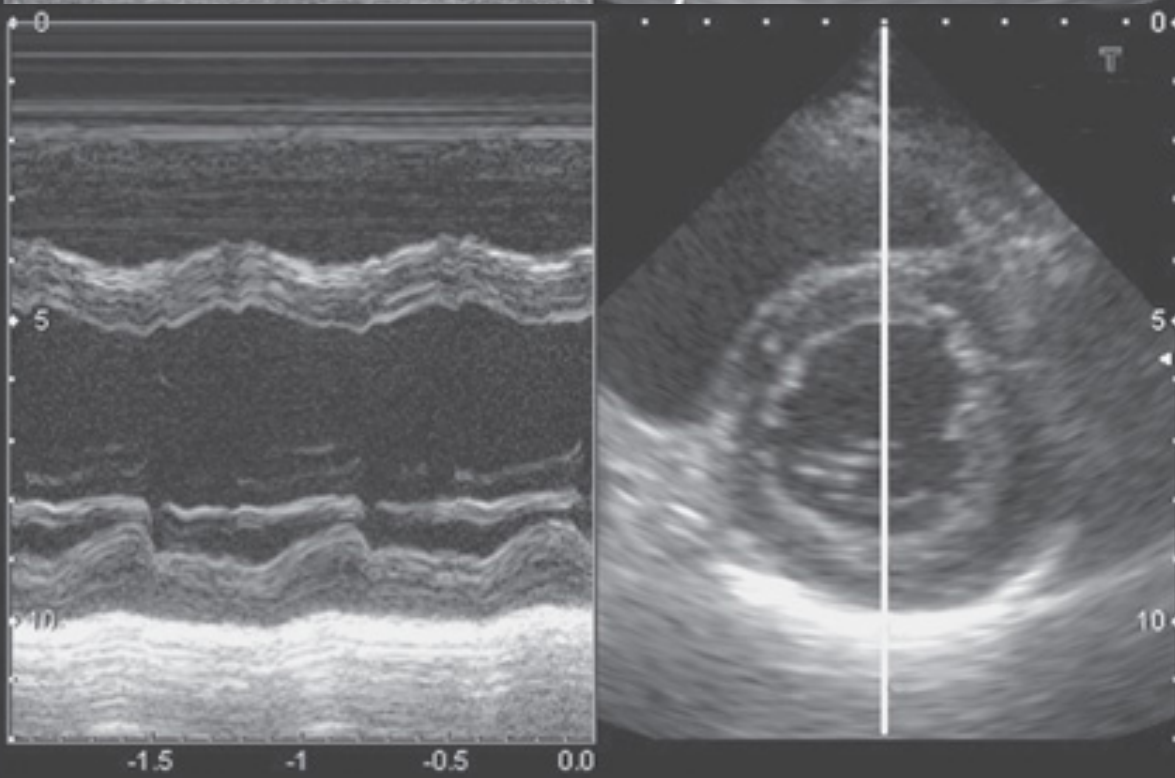
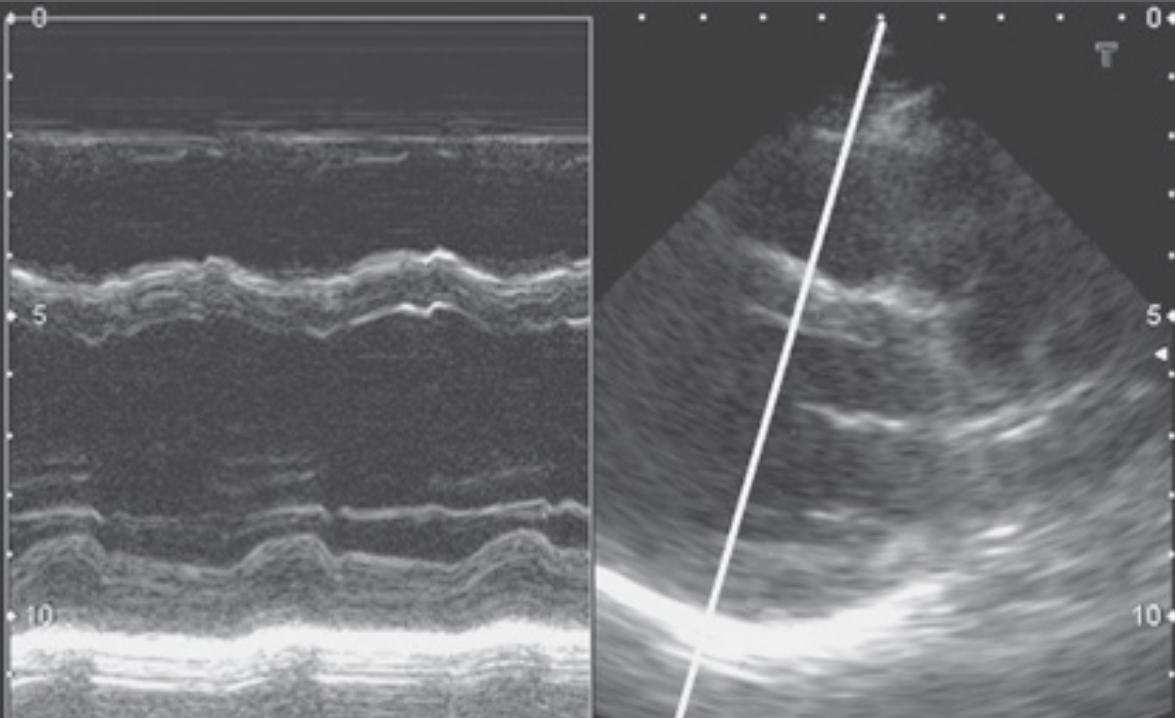
DA as a good reference

35-1
25 Hz
21.0cm
2D
HGen
Gn 31
C 50
3/2/0

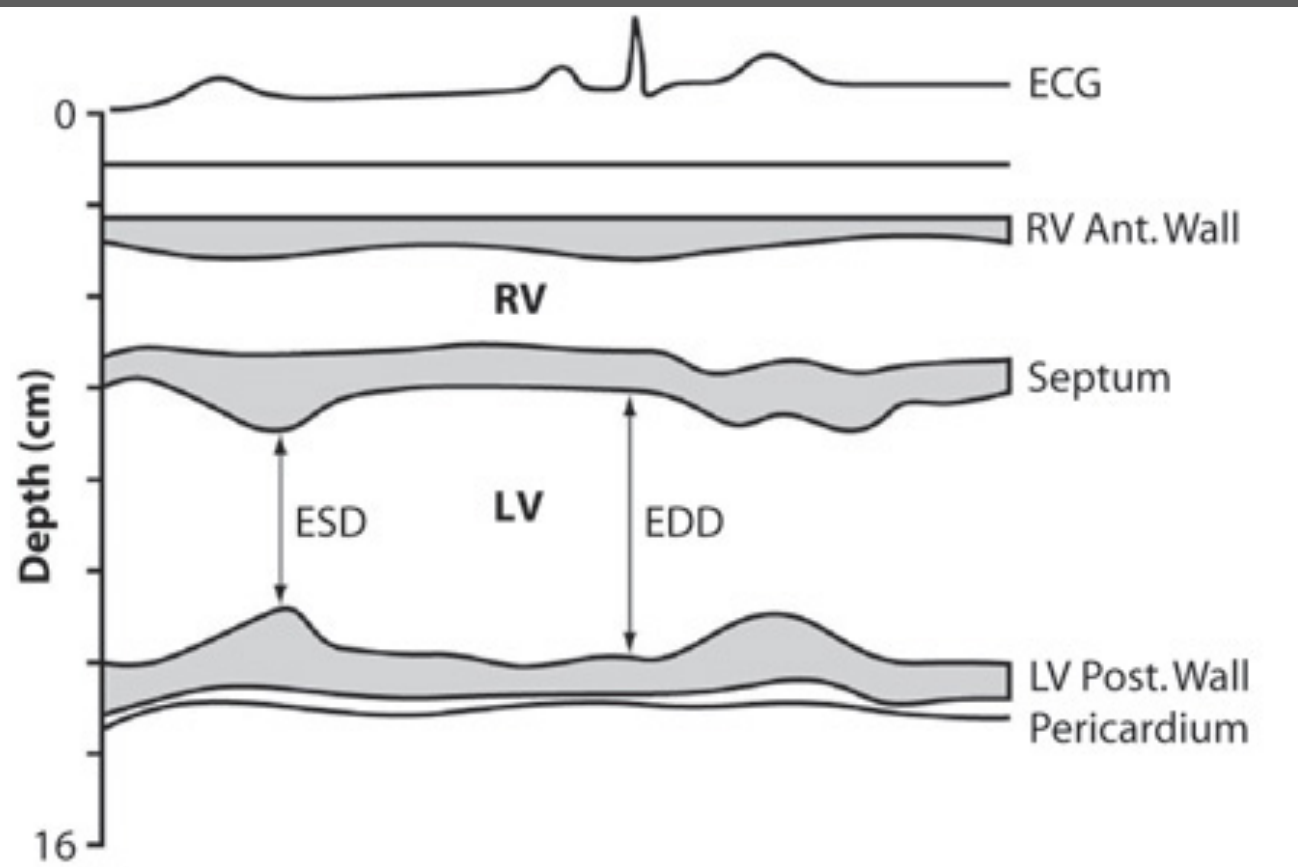


G
P R
1.6 3.2

Fraction shortening



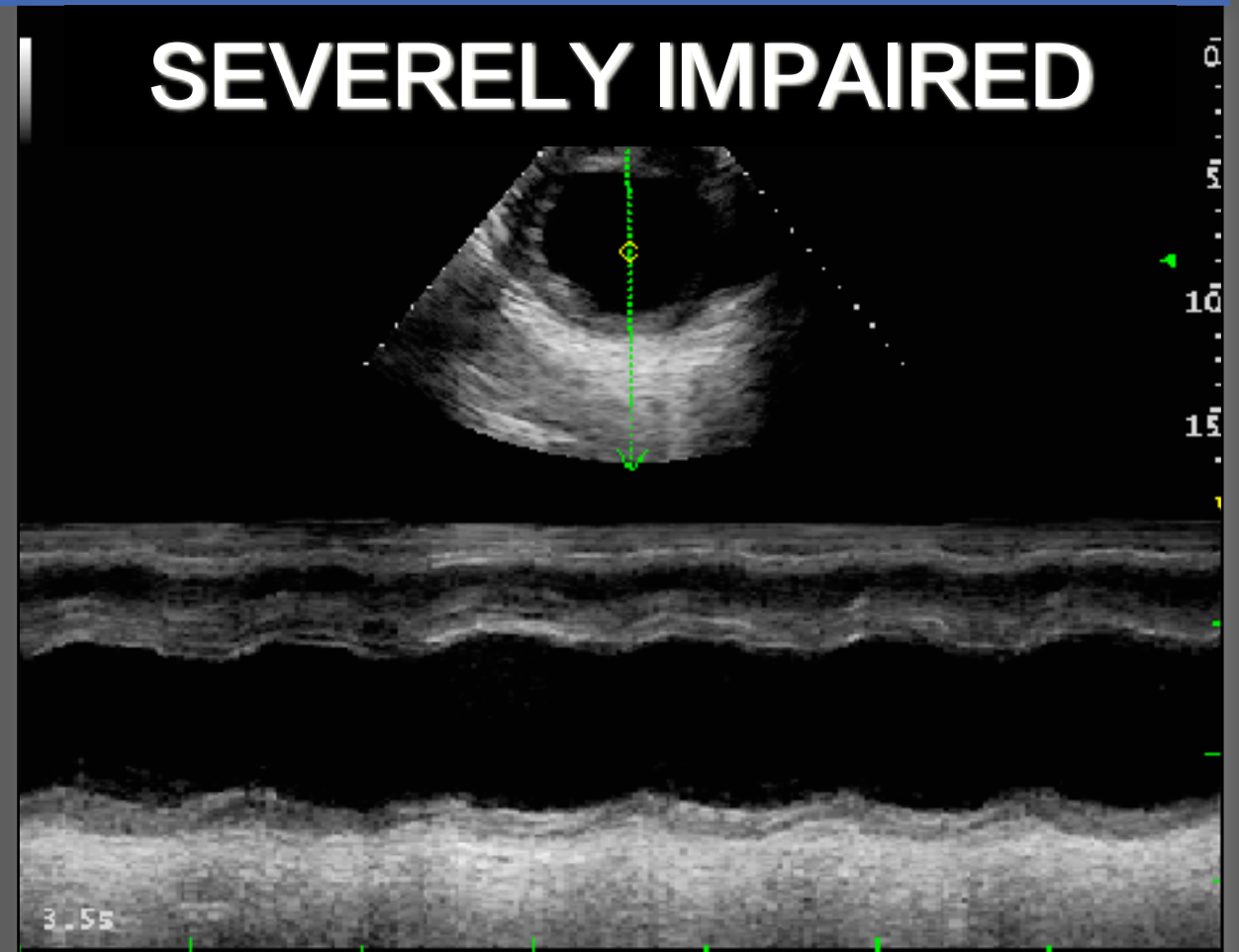
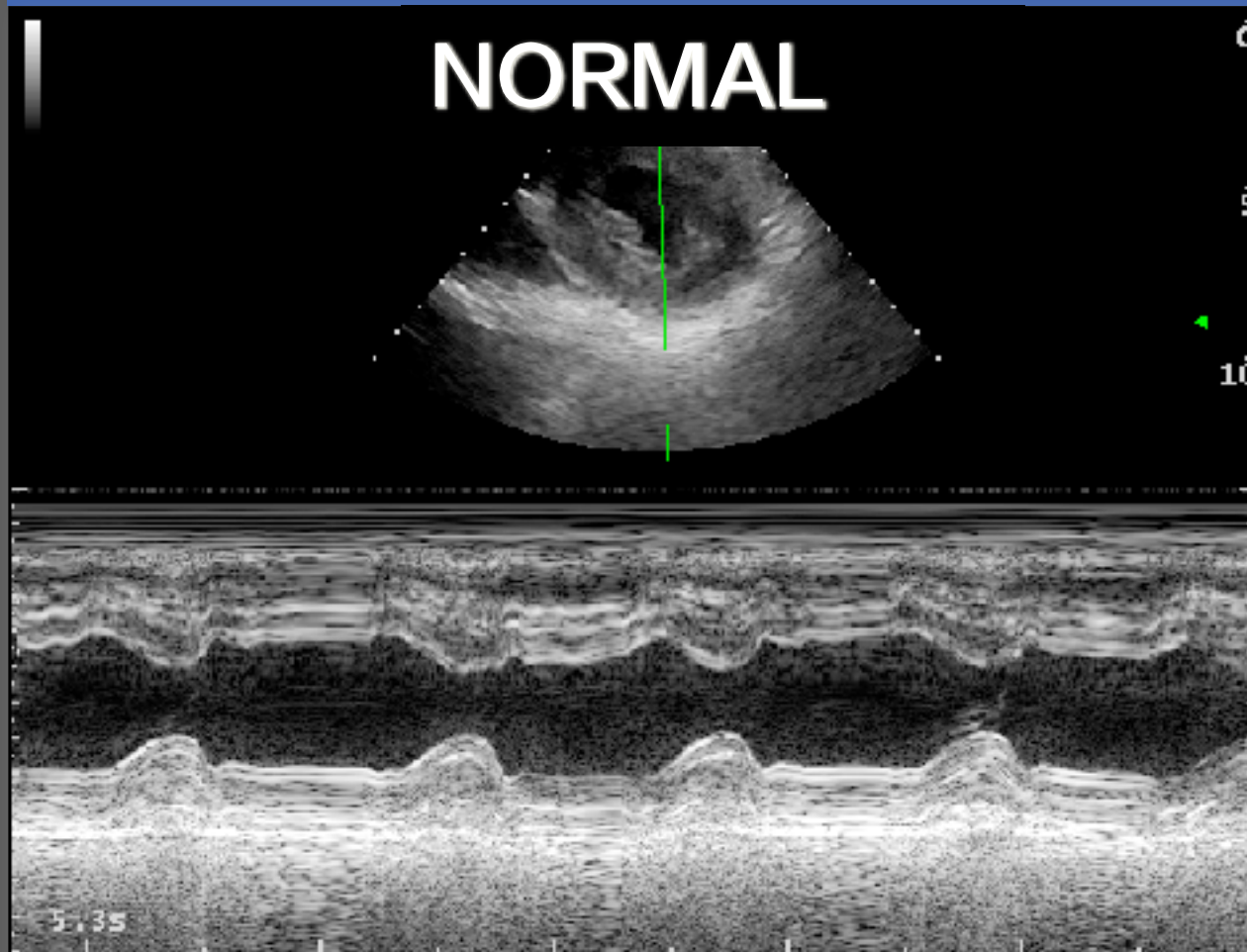
$$FS (\%) = 100 \times \frac{(LVEDD - LVESD)}{LVEDD}$$



NORMAL $\geq 30\%$

SEVERELY IMPAIRED $< 20\%$

FS

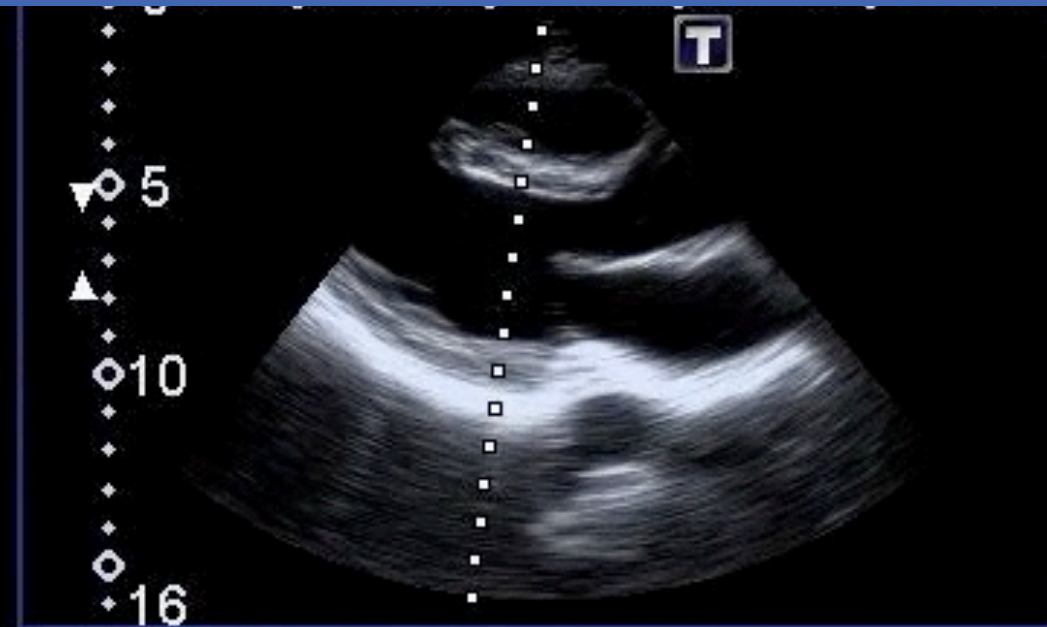


$$EF(\%) \approx FS(\%) \times 2 \quad (\text{ex. FS } 30\% \approx EF \text{ } 60\%)$$

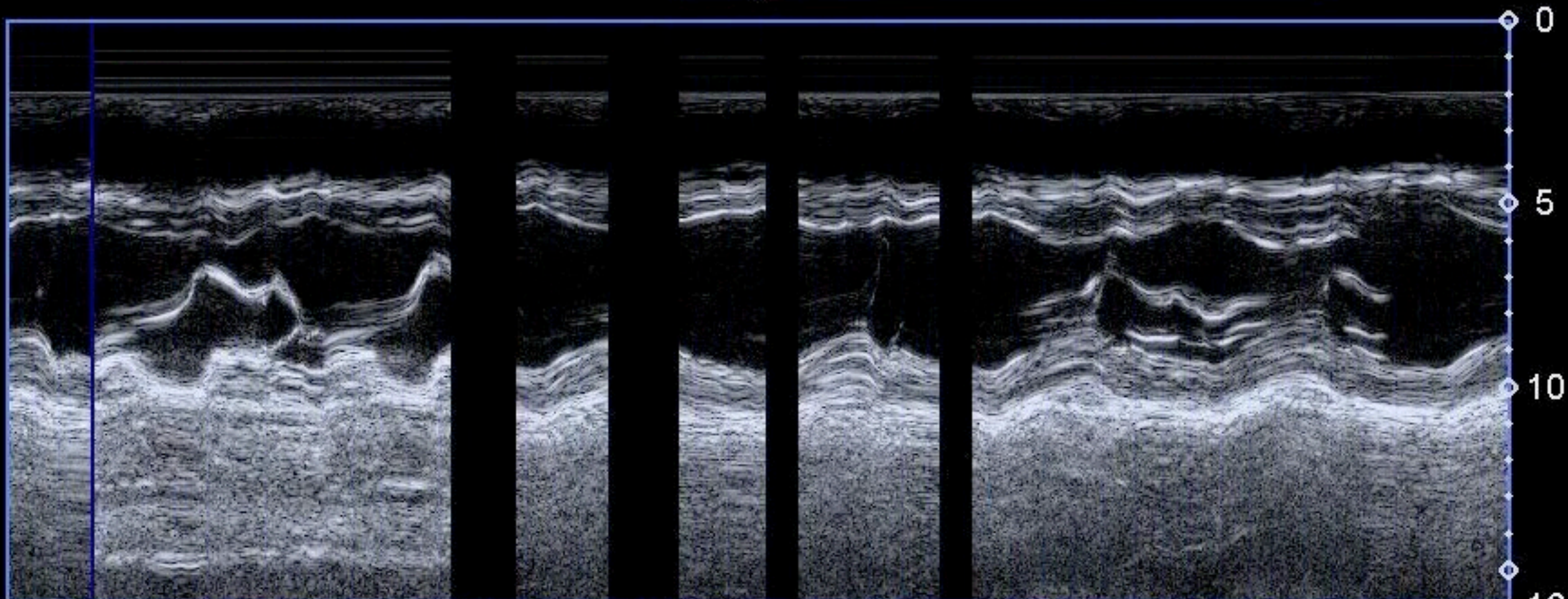
(Simplification of Teicholz method)

FS

G:82
DR:55
TE:3

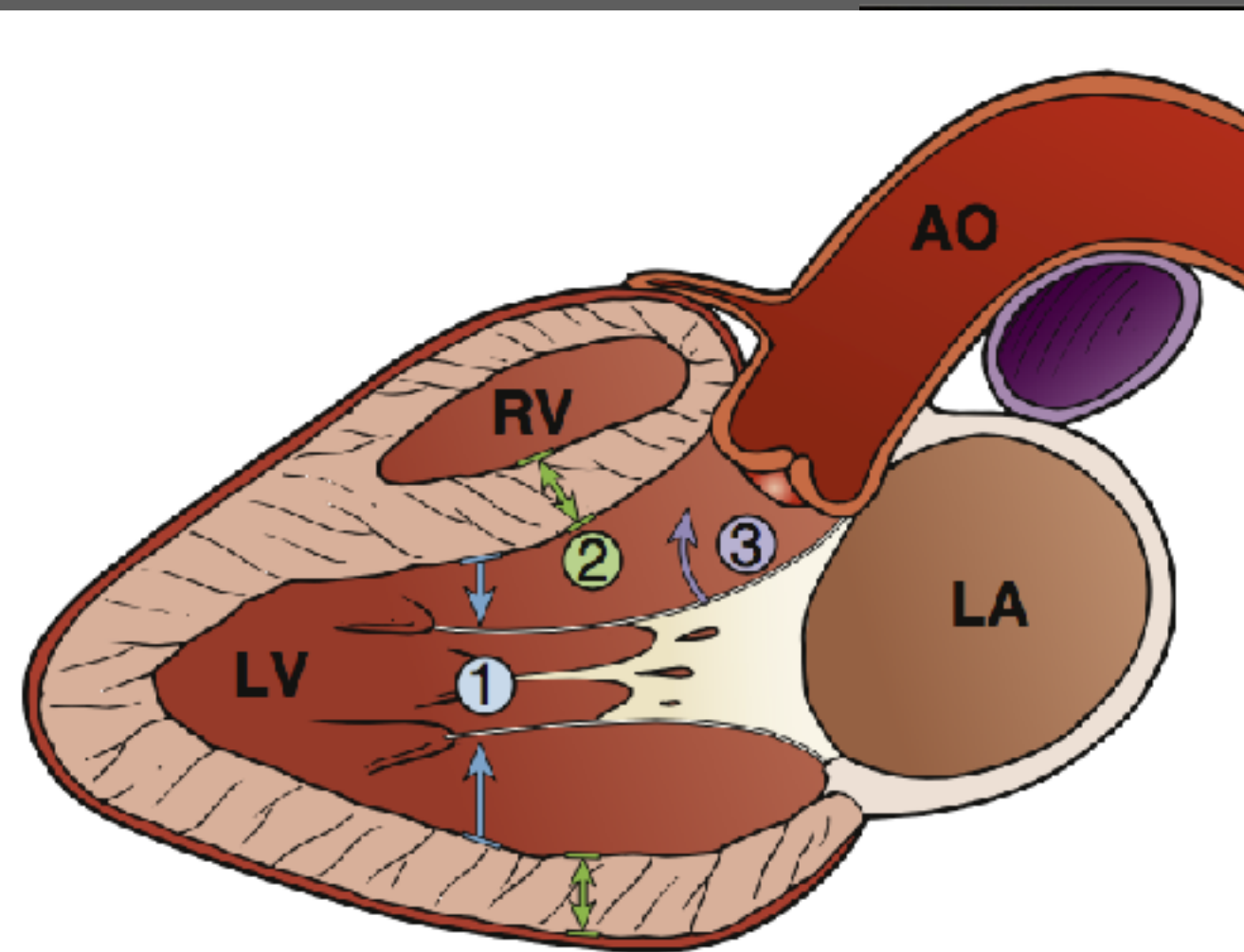


MI:1.5
5S1
T3.0
32 fps

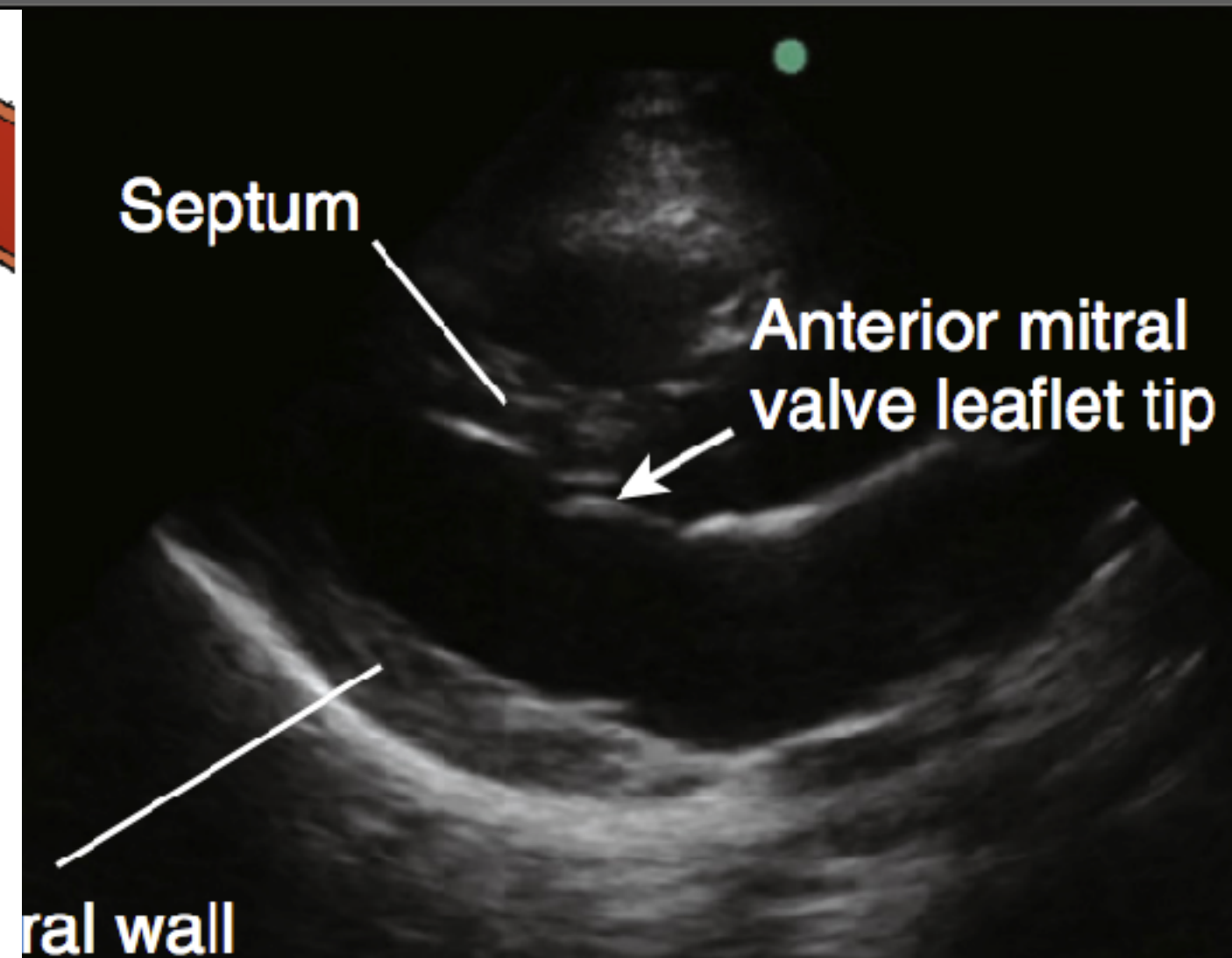


EPSS

E-point septal separation $>7\text{mm}$: LVEF $< 30\%$

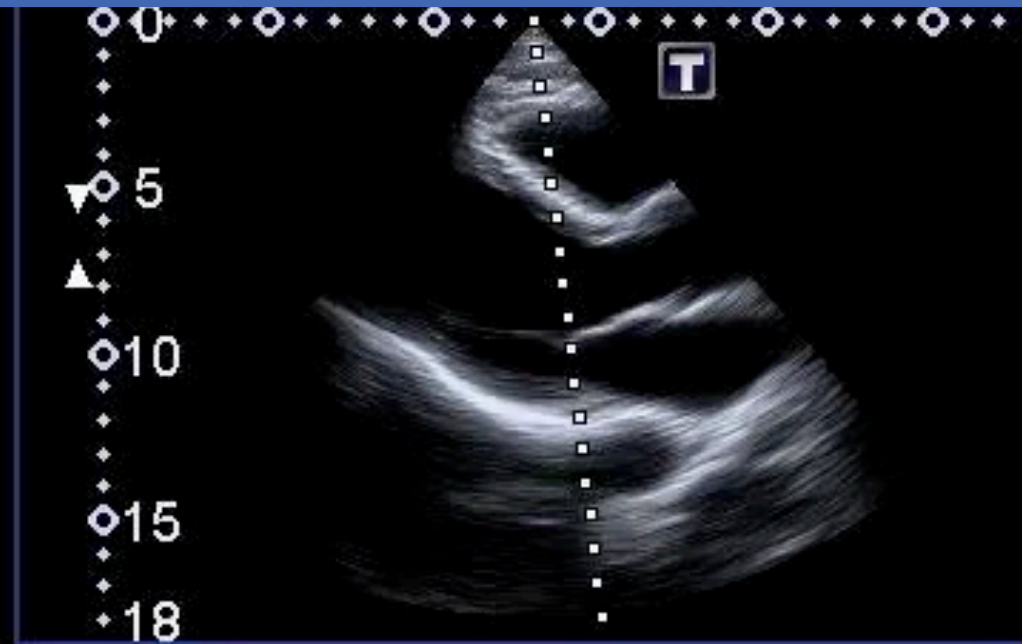

- 1 - Endocardial excursion
- 2 - Myocardial thickening
- 3 - Septal motion of anterior leaflet of mitral valve

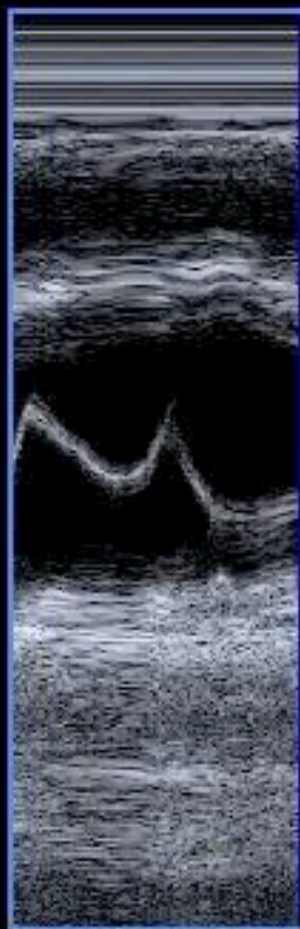


EPSS

Qscan
G:91
DR:55
TE:3



MI:1.5
5S1
T3.0
25 fps



0
5
10
15
18

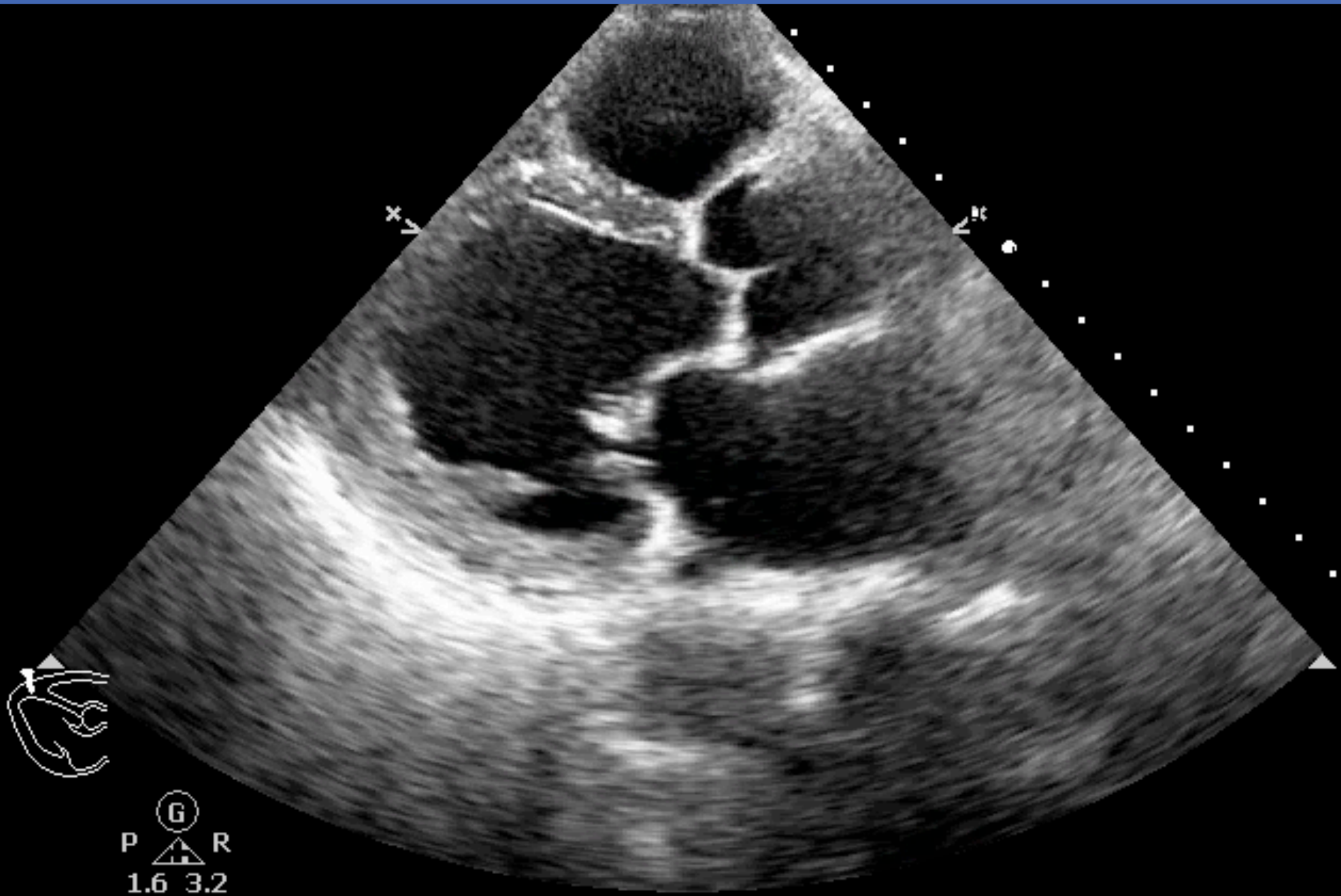
Qscan:86 / MDR:50 / T3.0

Heart failure ?

28 Hz
19.0cm

2D

HGen
Gn 34
C 50
3 / 2 / 0

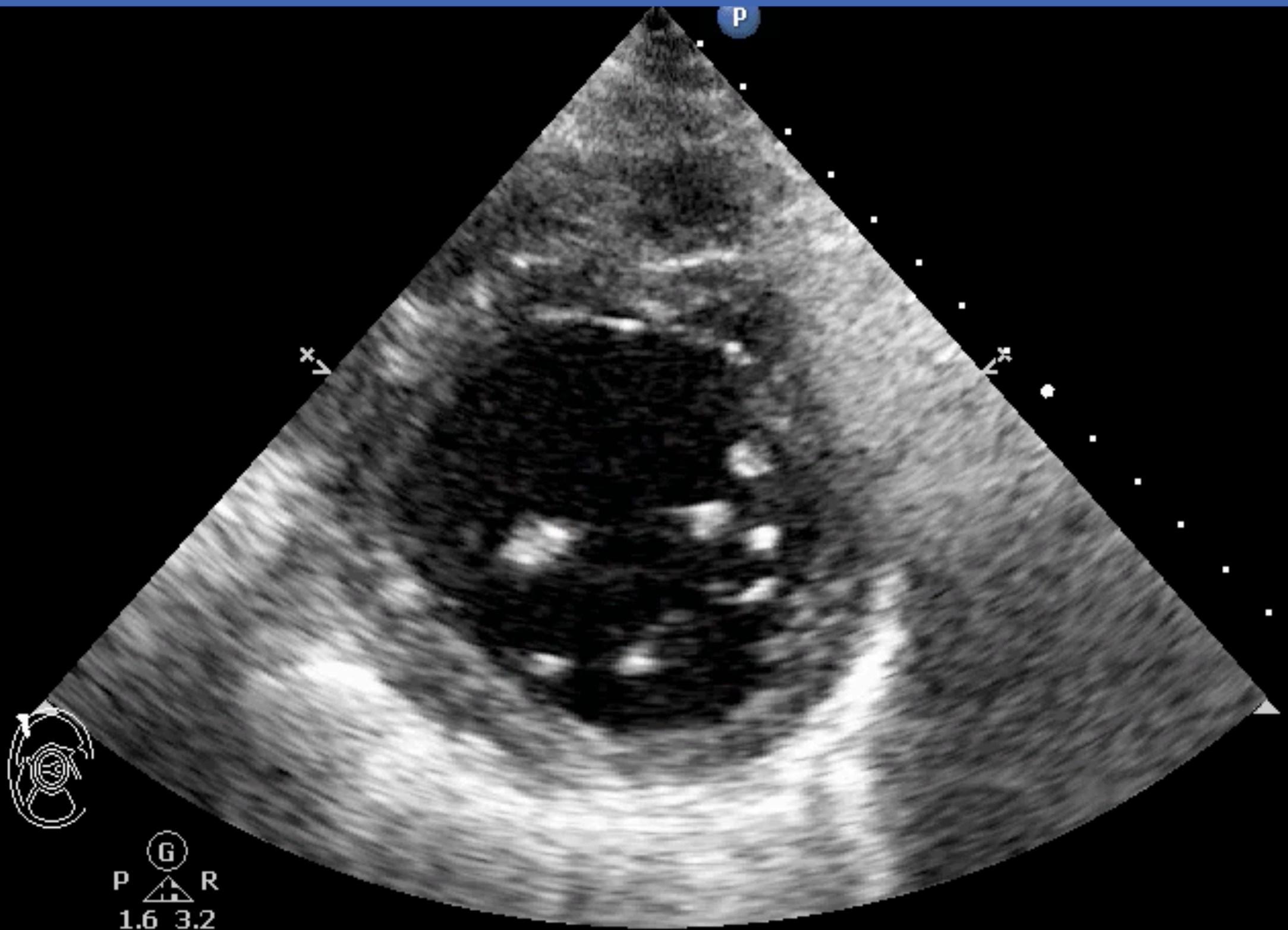


Heart failure ?

Adult Echo2
S5-1
34 Hz
15.0cm

2D

HGen
Gn 34
C 50
3/2/0



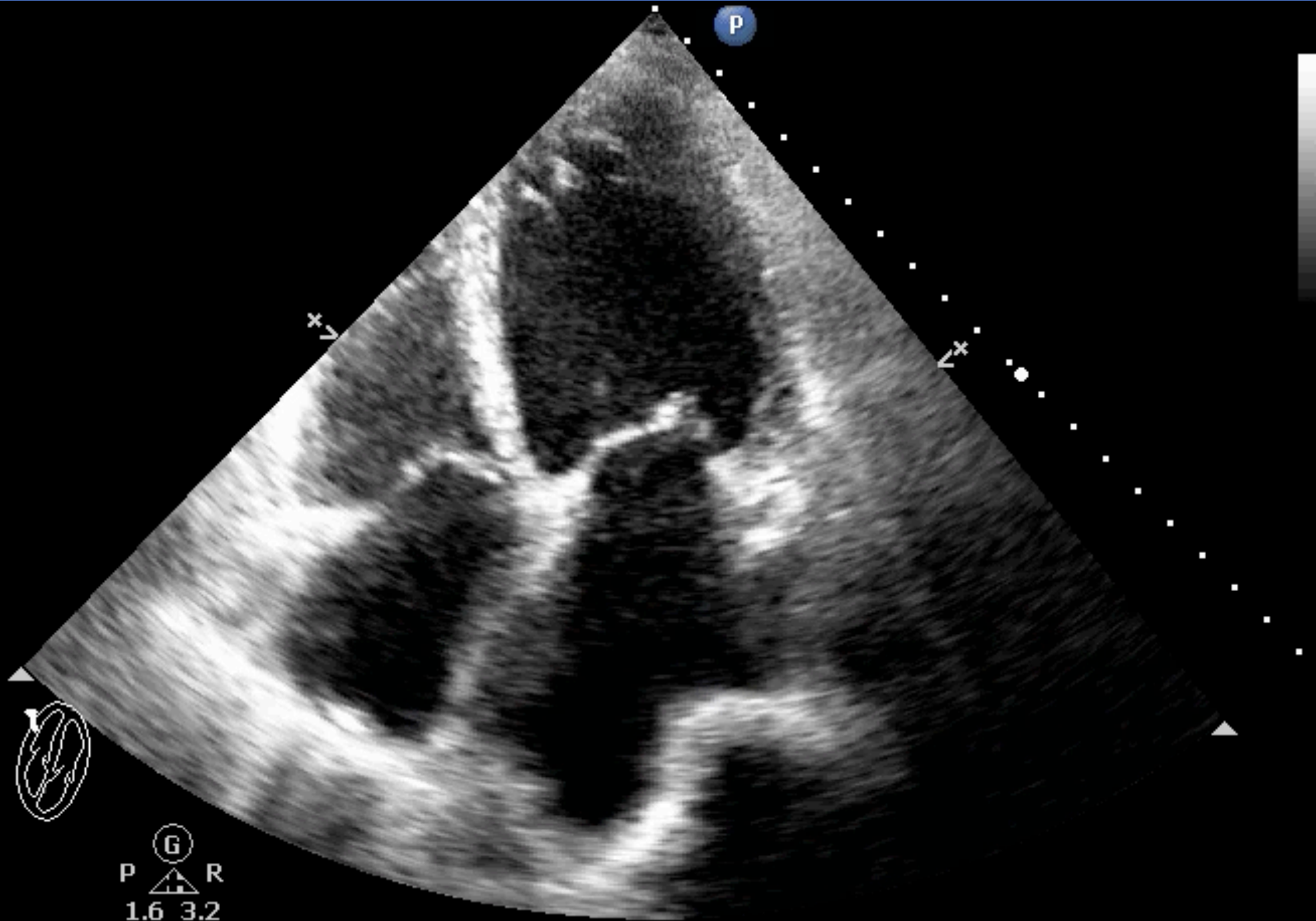
G
P R
1.6 3.2

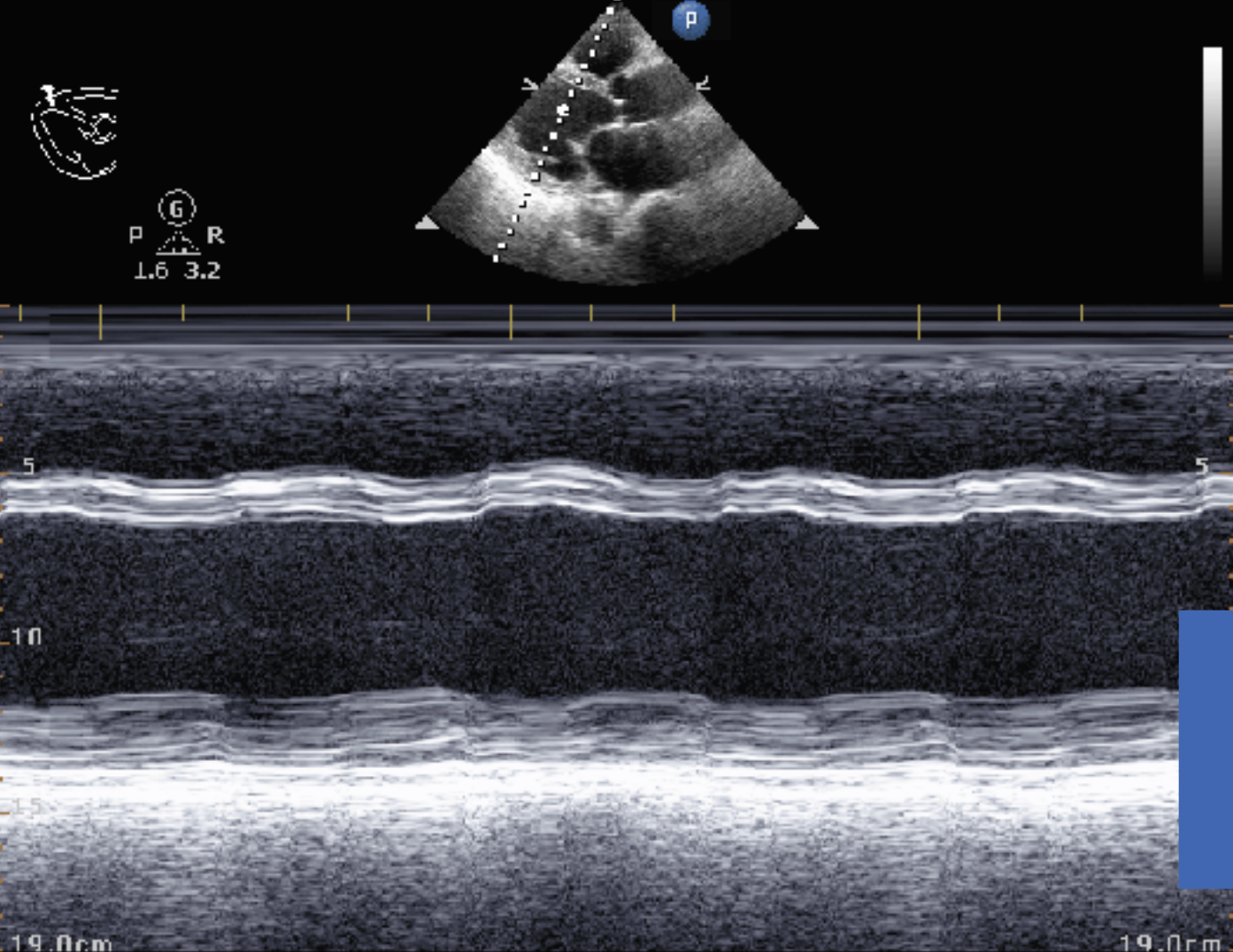
Heart failure ?

Adult Echo2
S5-1
27 Hz
20.0cm

2D

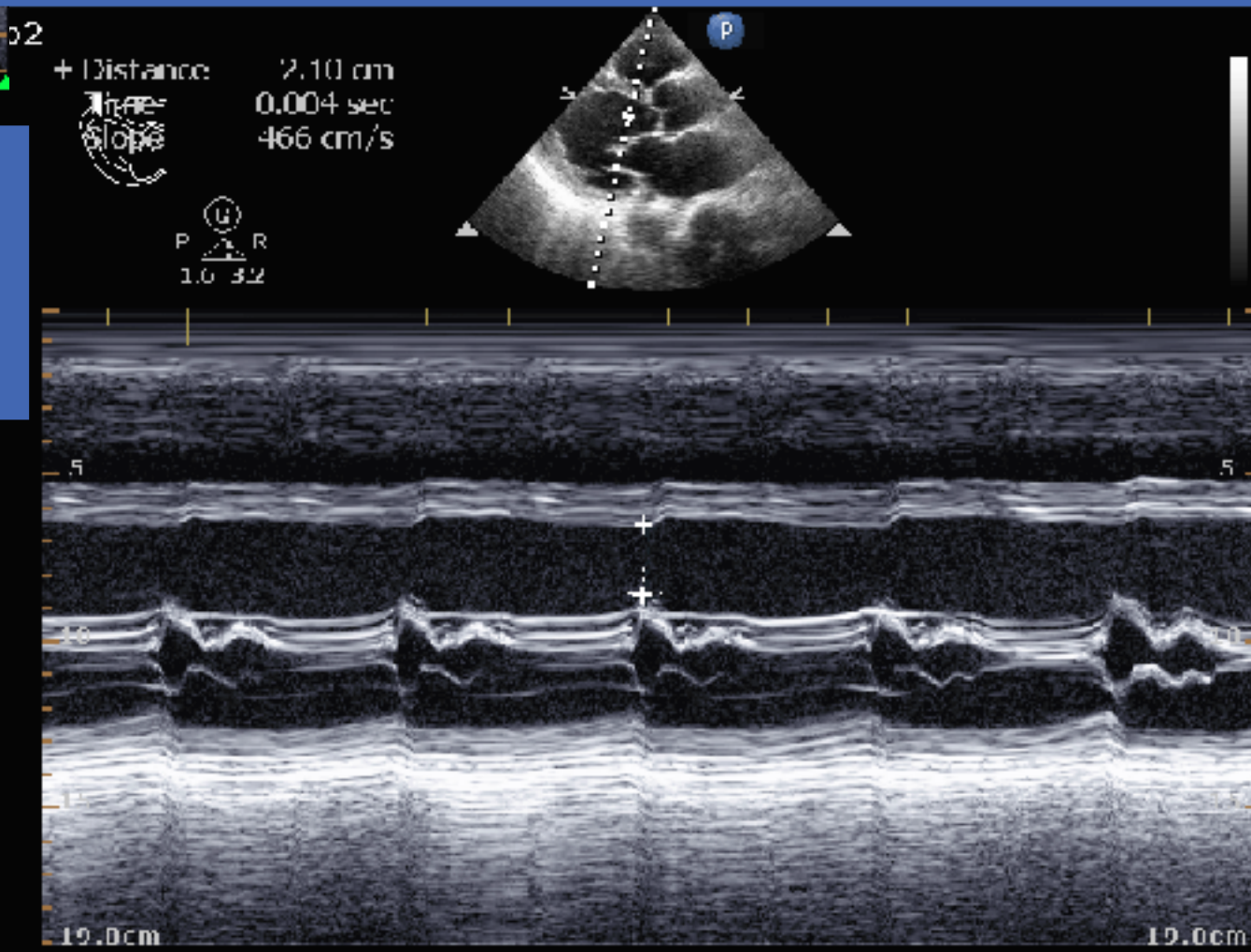
HGen
Gn 41
C 50
3 / 2 / 0



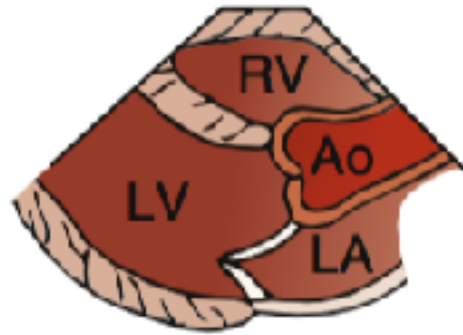
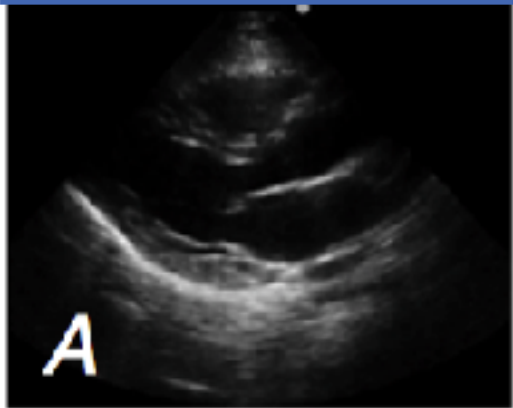


EF/FS

EPSS

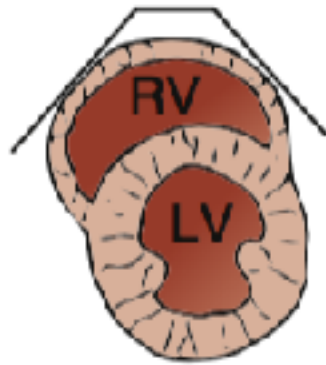
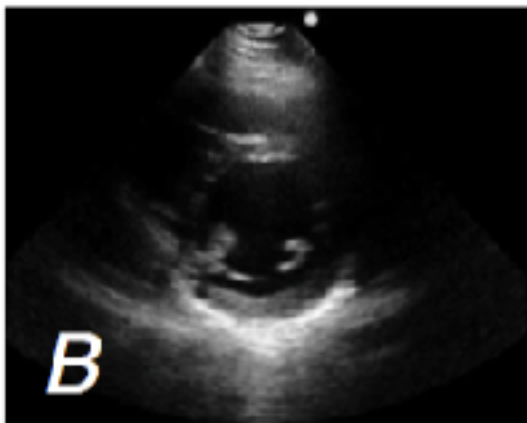


RV evaluation



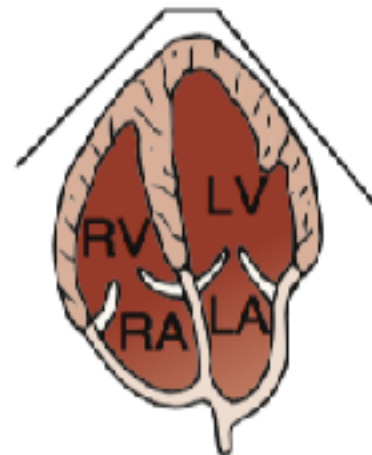
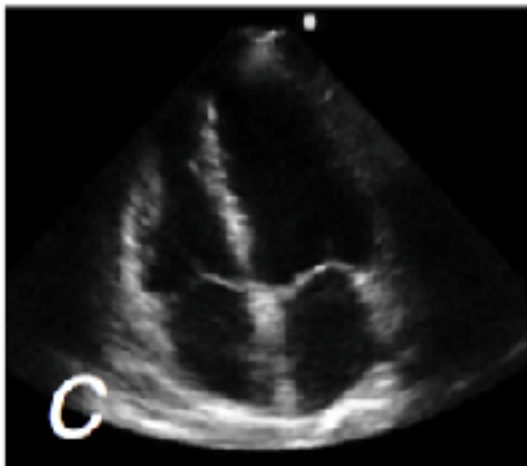
Parasternal long-axis view

- Only RVOT visible in the near field
- Only gross RV size or function abnormalities detectable



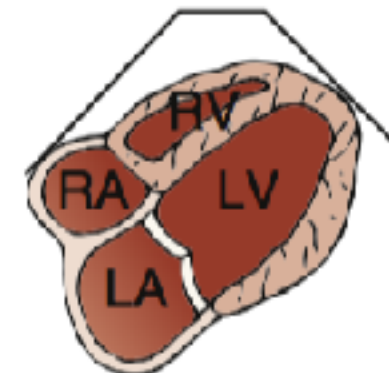
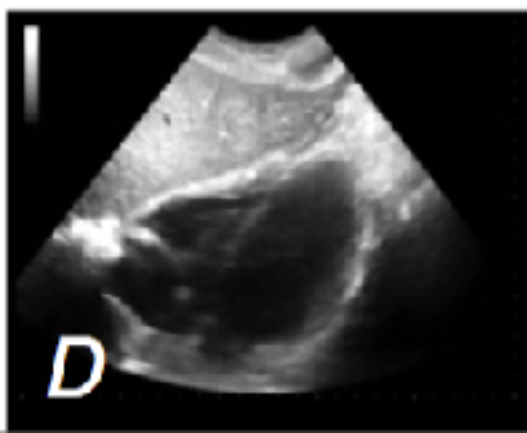
Parasternal short-axis view

- Crescentic RV adjacent to the circular LV
- Look for RV>LV size and septal kinetics or flattening



Apical 4-chamber view

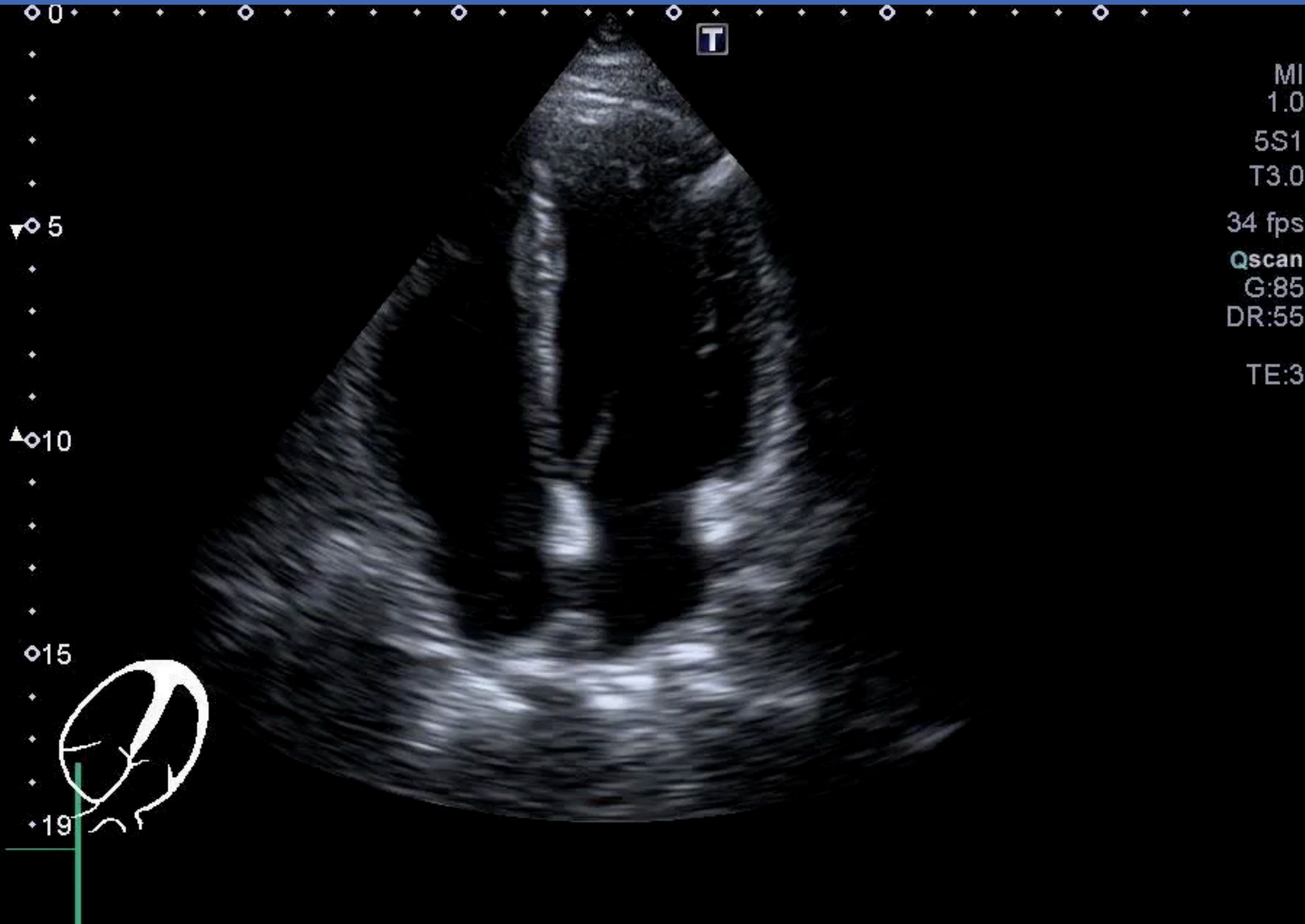
- Triangular RV seen adjacent to the LV
- Ideal view for RV size and systolic function assessment



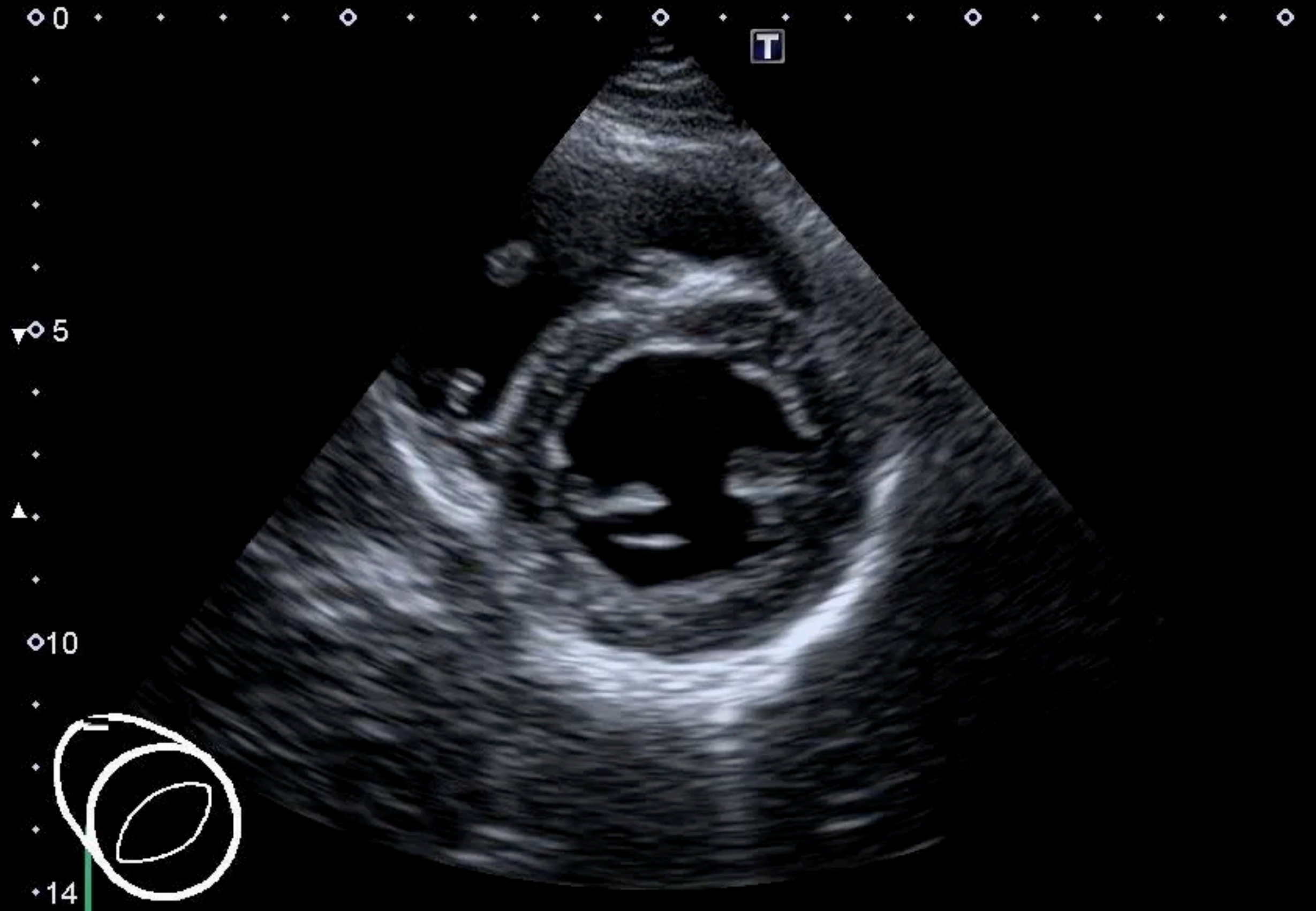
Subcostal 4-chamber view

- Triangular RV in the near field
- May assess RV size, systolic function, and wall thickness

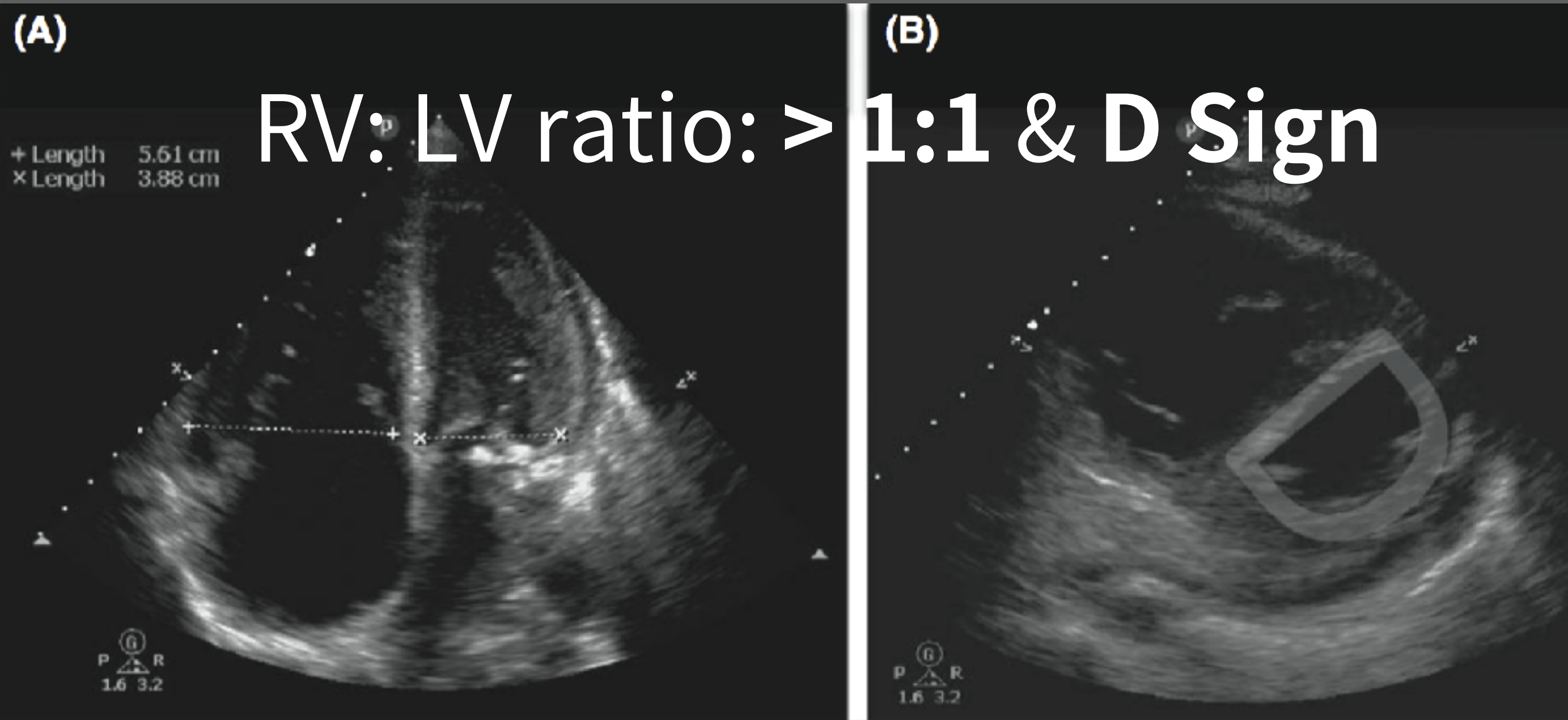
RV: LV = 0.6 : 1



Crescent & Doughnut



Equality (PSSA)



RV: LV ratio: **0.6 : 1**

McConnell's sign

Acute RV strain

mindray

oguz,suleyman 20121105-122652-B5AC

05/11/2012

12:29:22

AP 97%

MI 0.3 TIS 0.2

P4-2s

Adult Cardiac

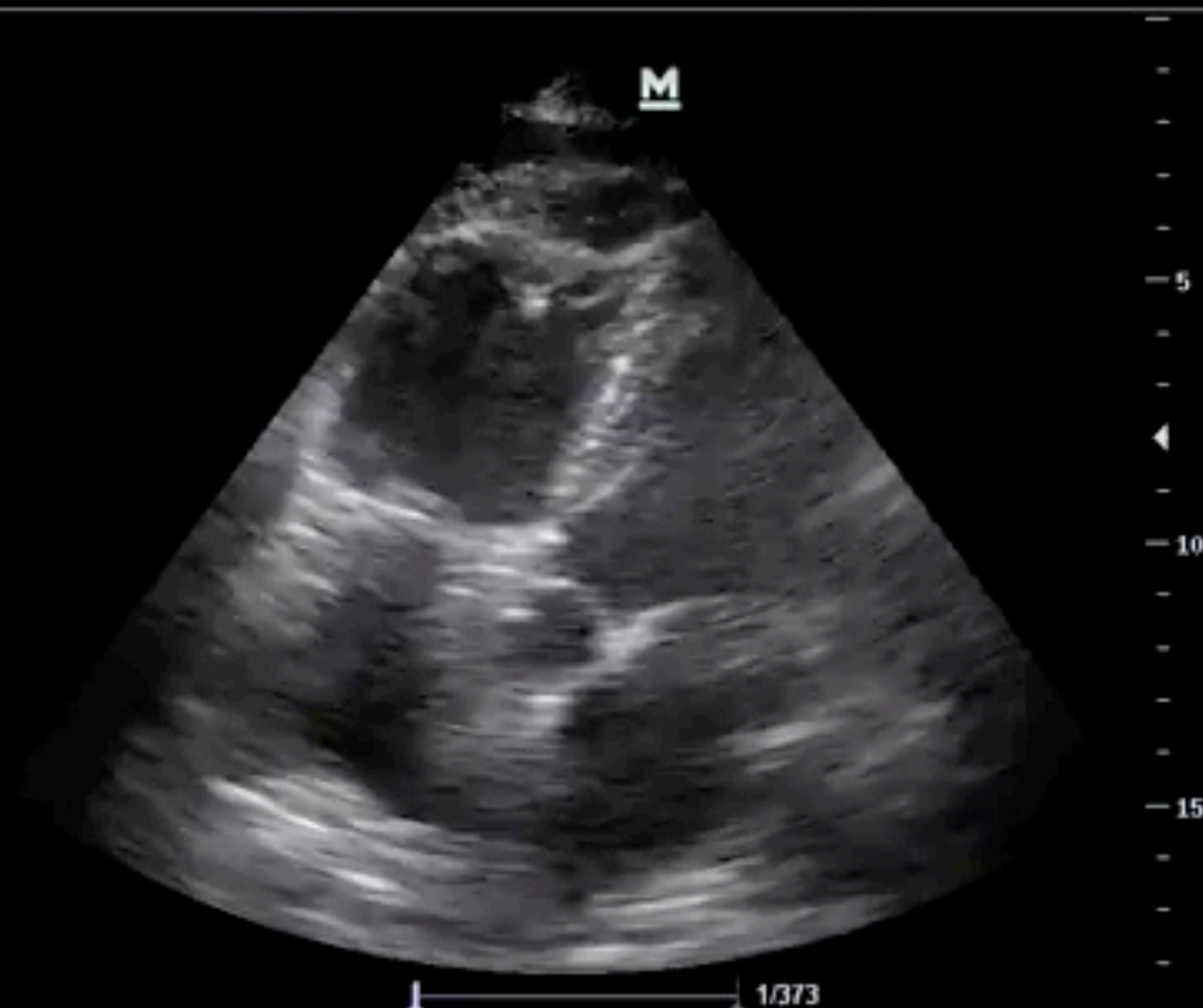
M7

B1

FH3.2 /D18.2

G54 /FR75

IP4 /DR75

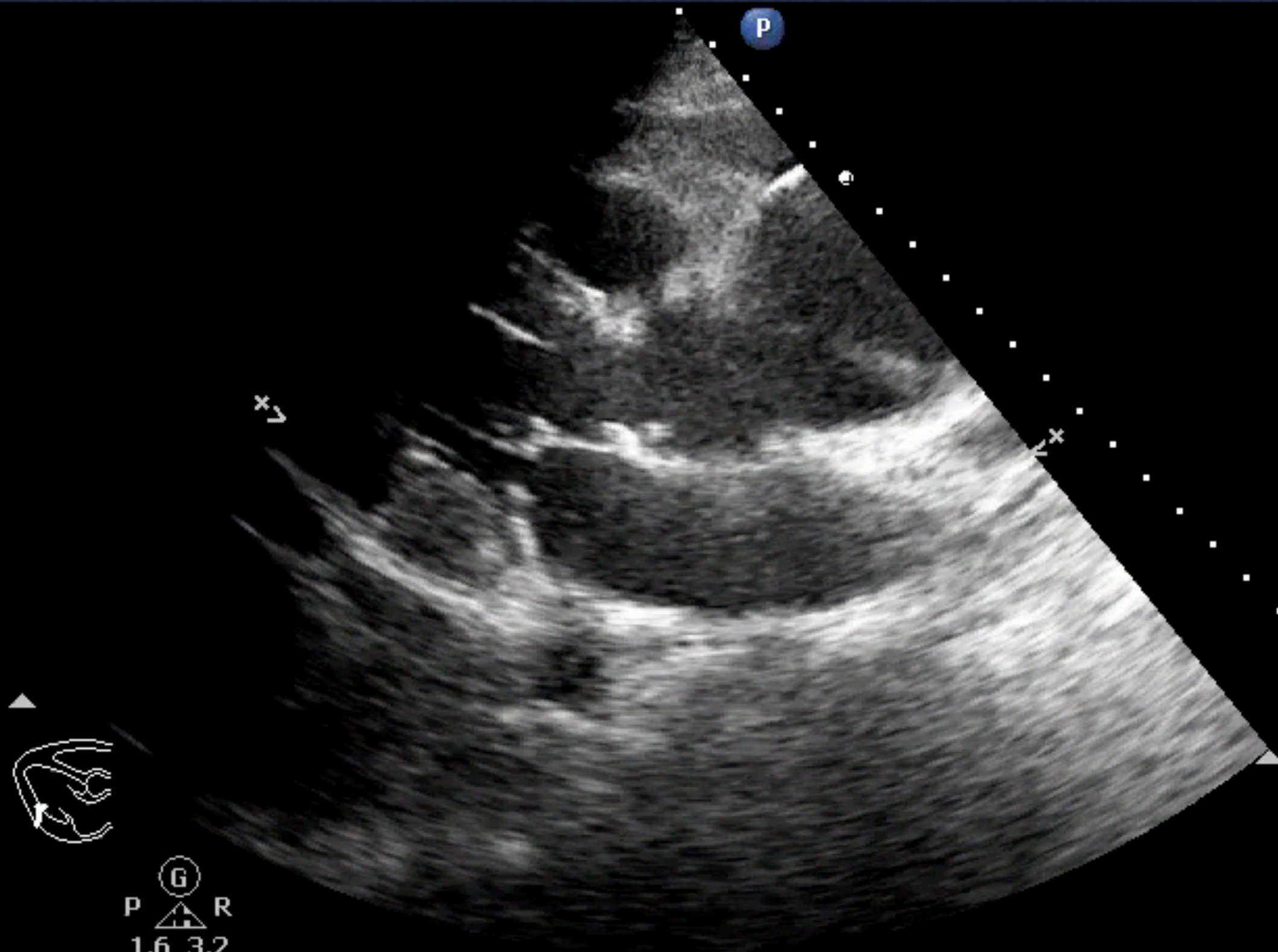


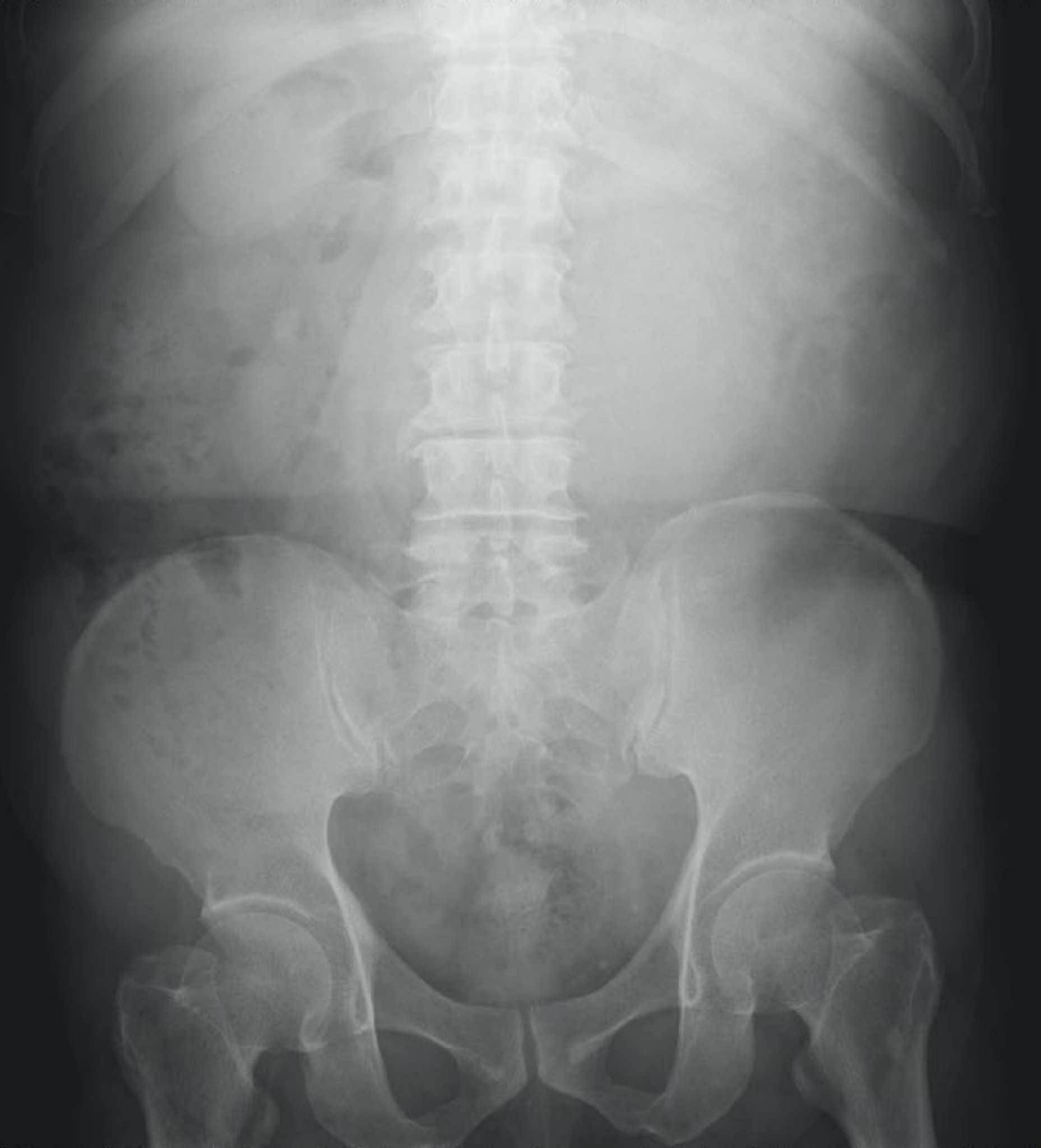1/373

Exit (Aorta)

Adult Echo
S5-1
27 Hz
20.0cm

2D
HGen
Gn 41
C 50
3/2/0



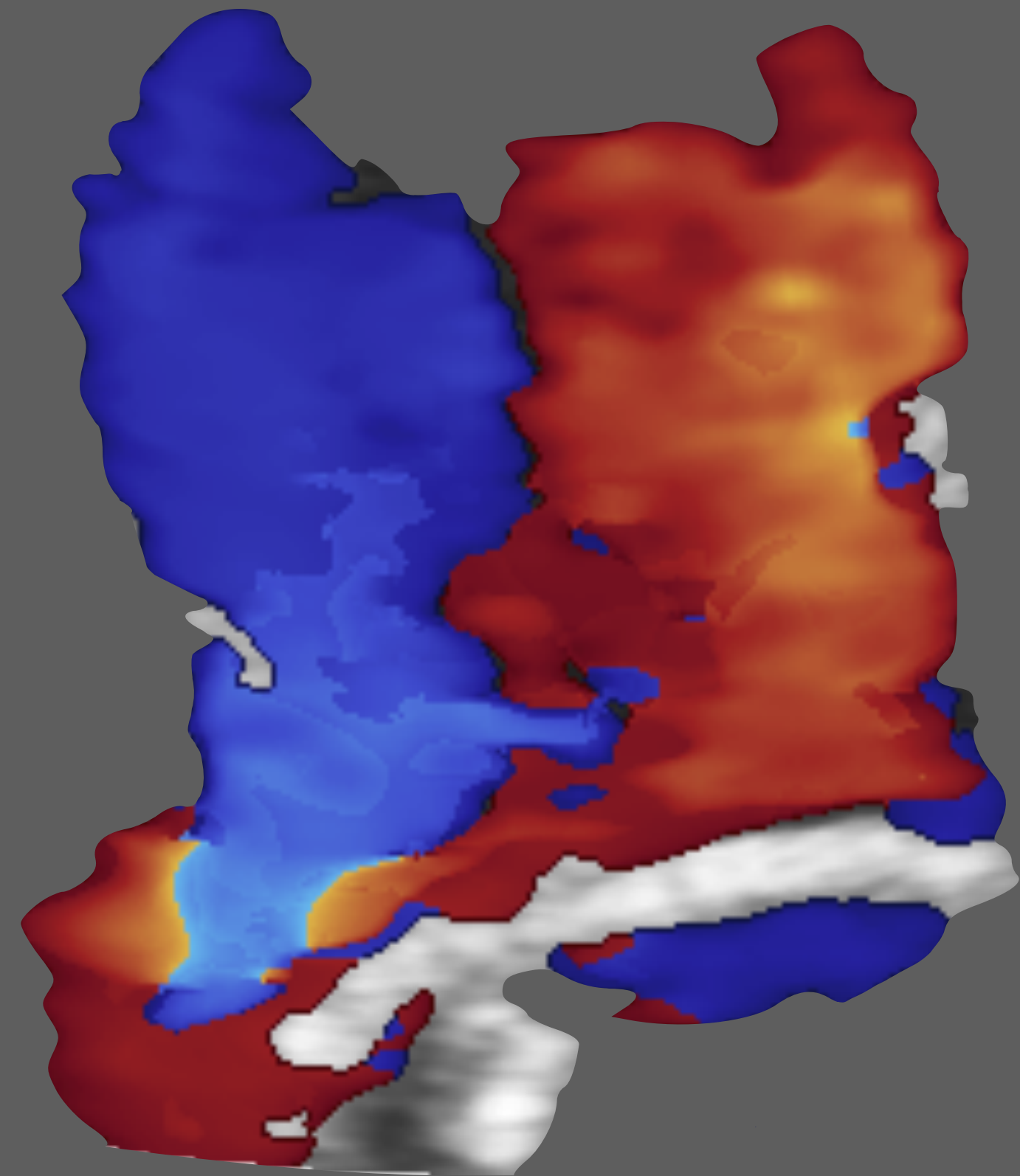


**64M,
左下腹痛
1小時
冒冷汗
結石病史**

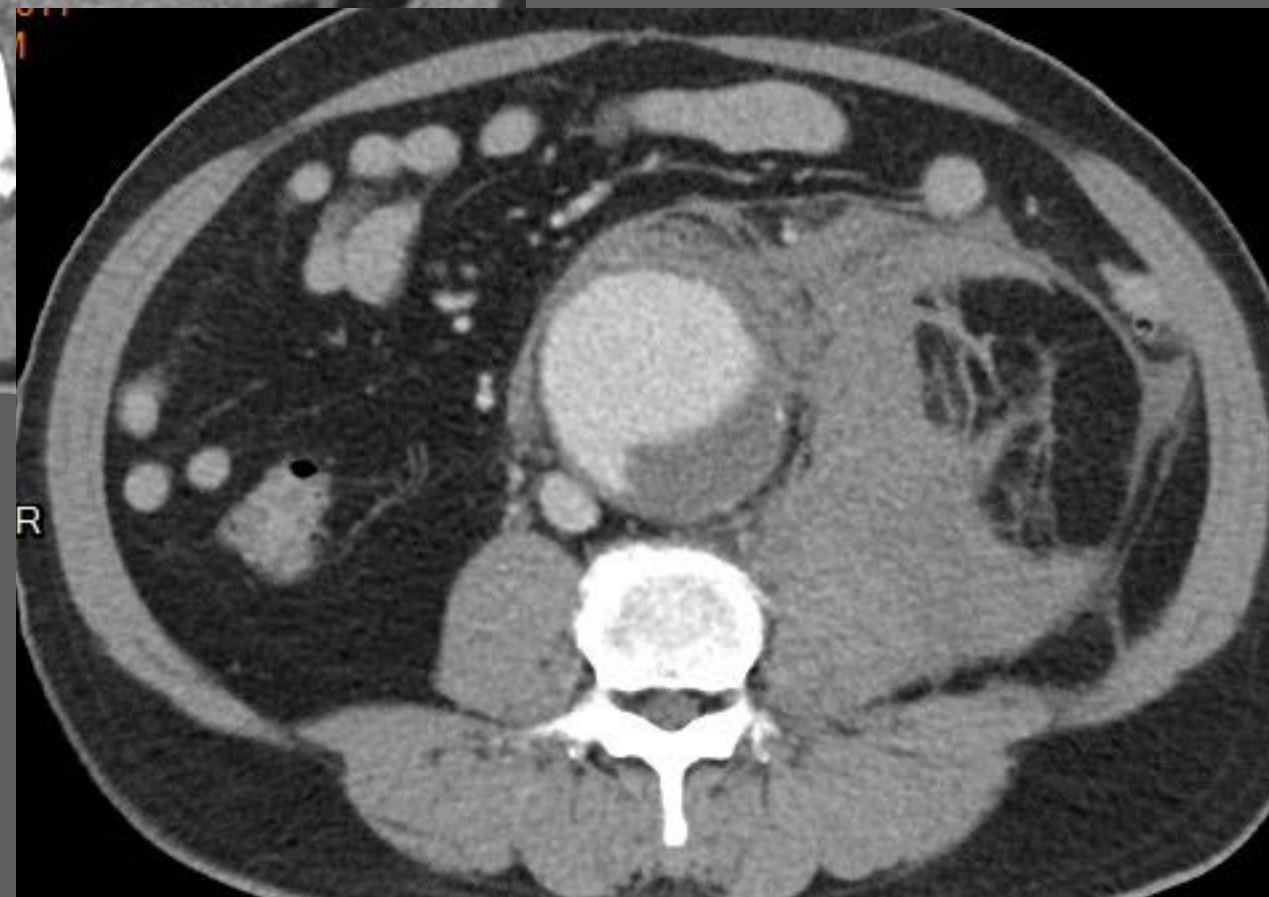
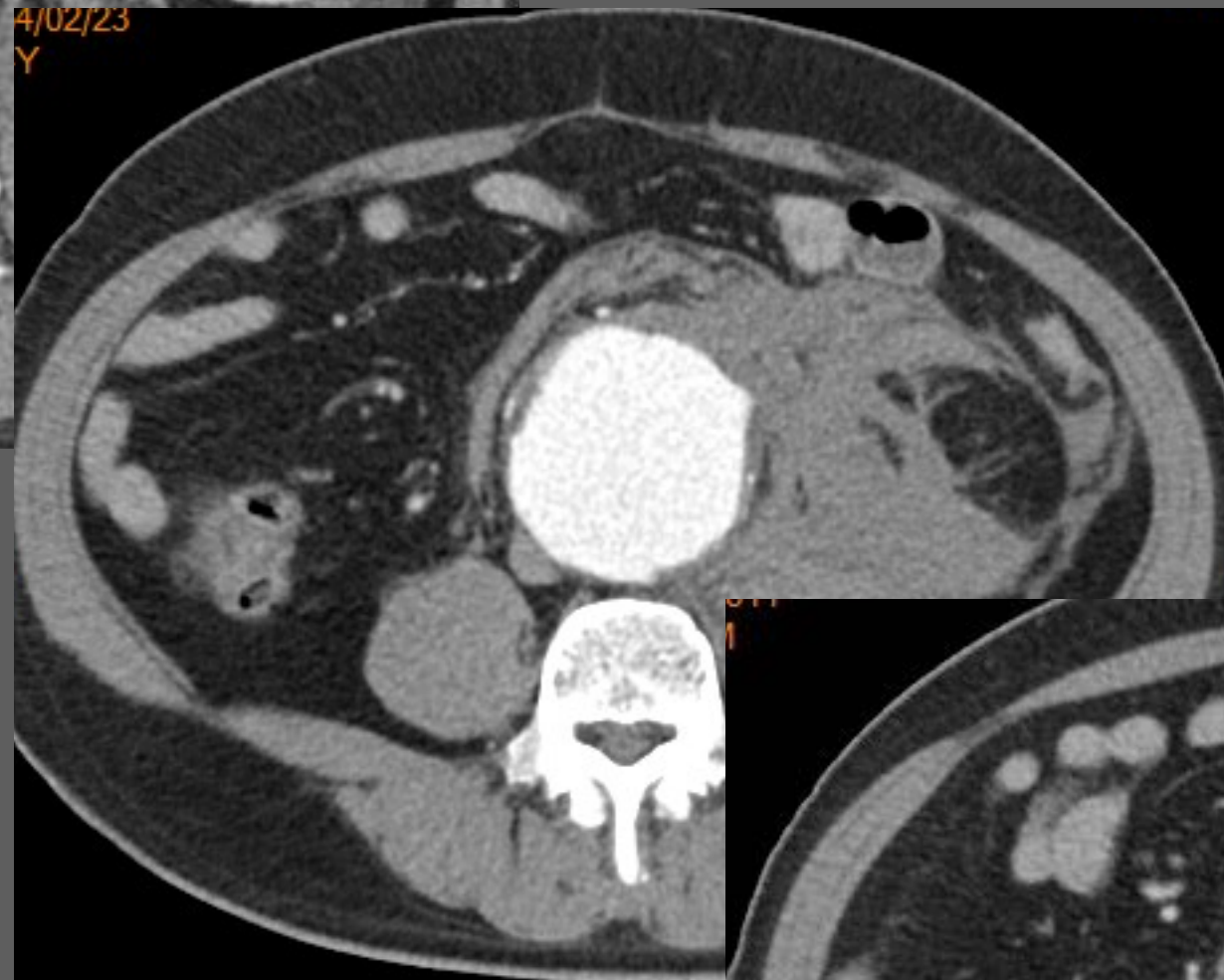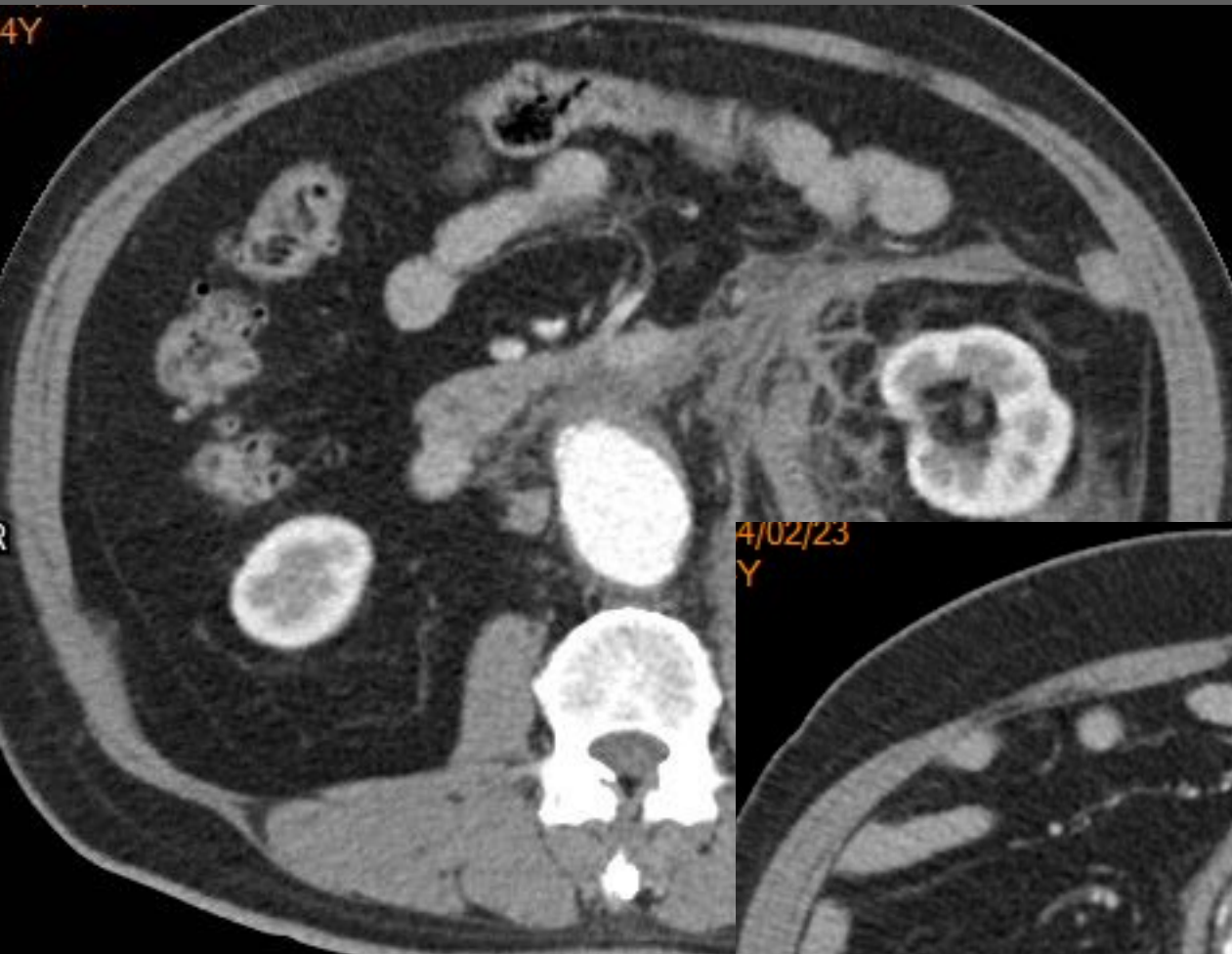PR 117

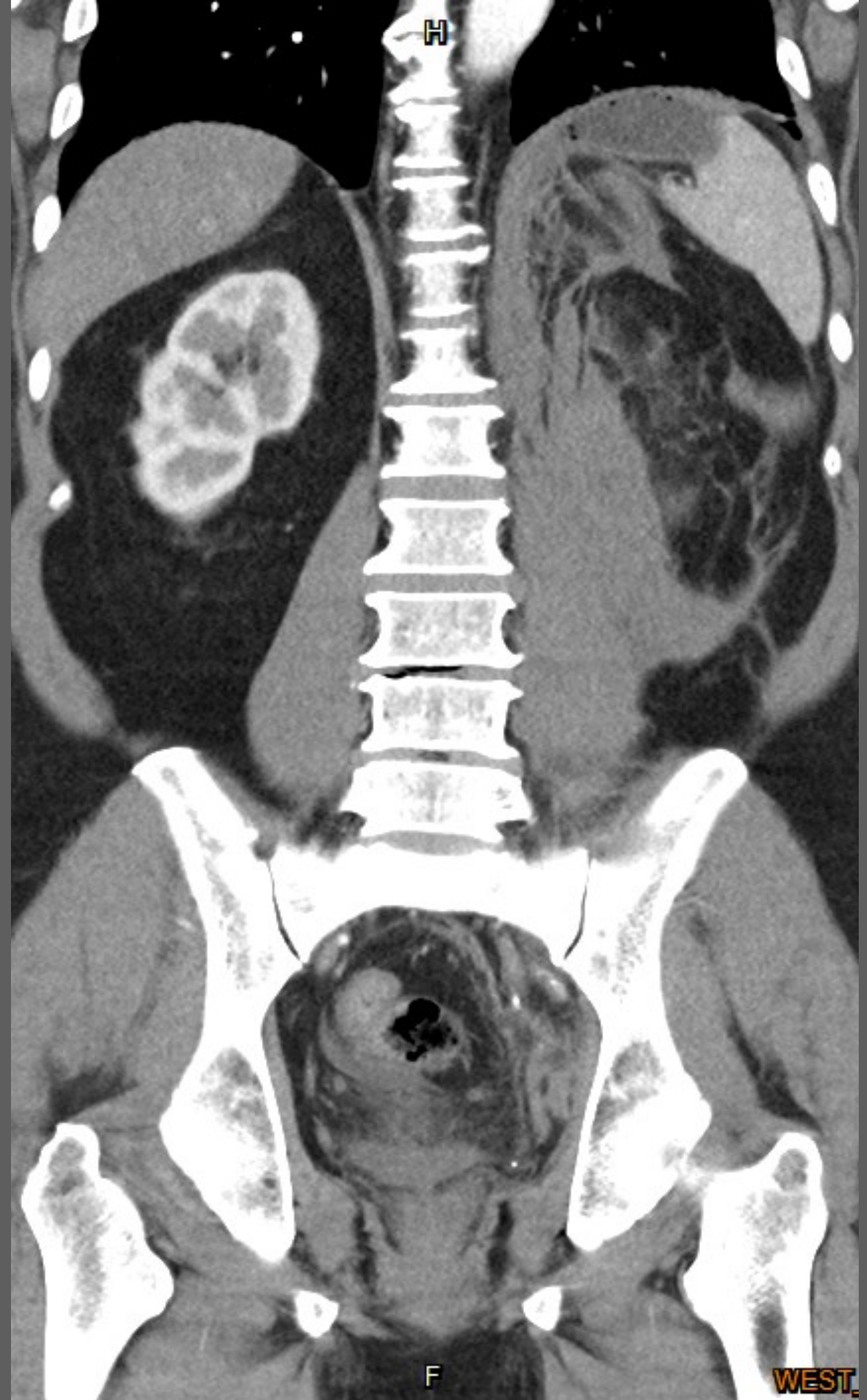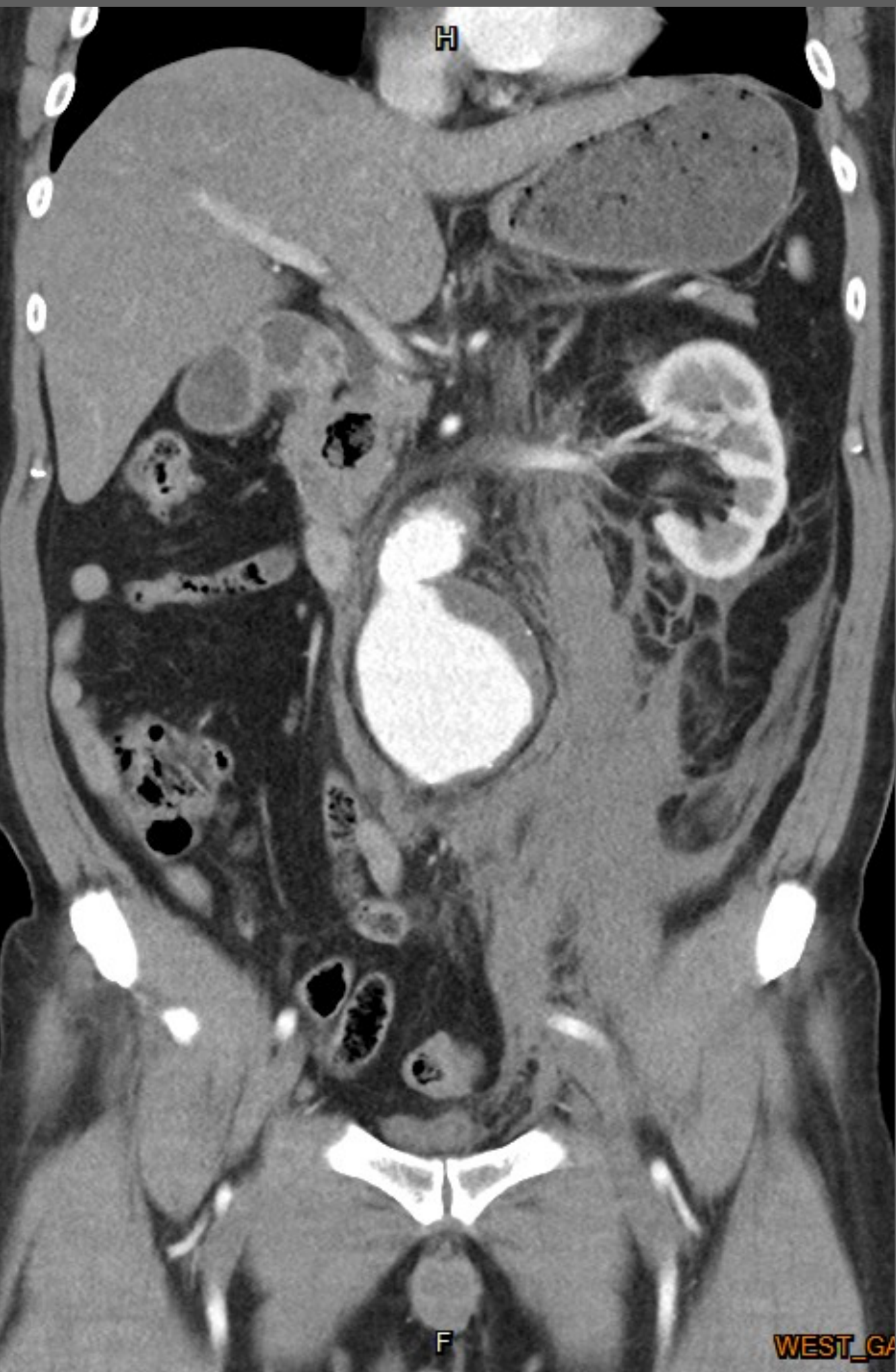BP

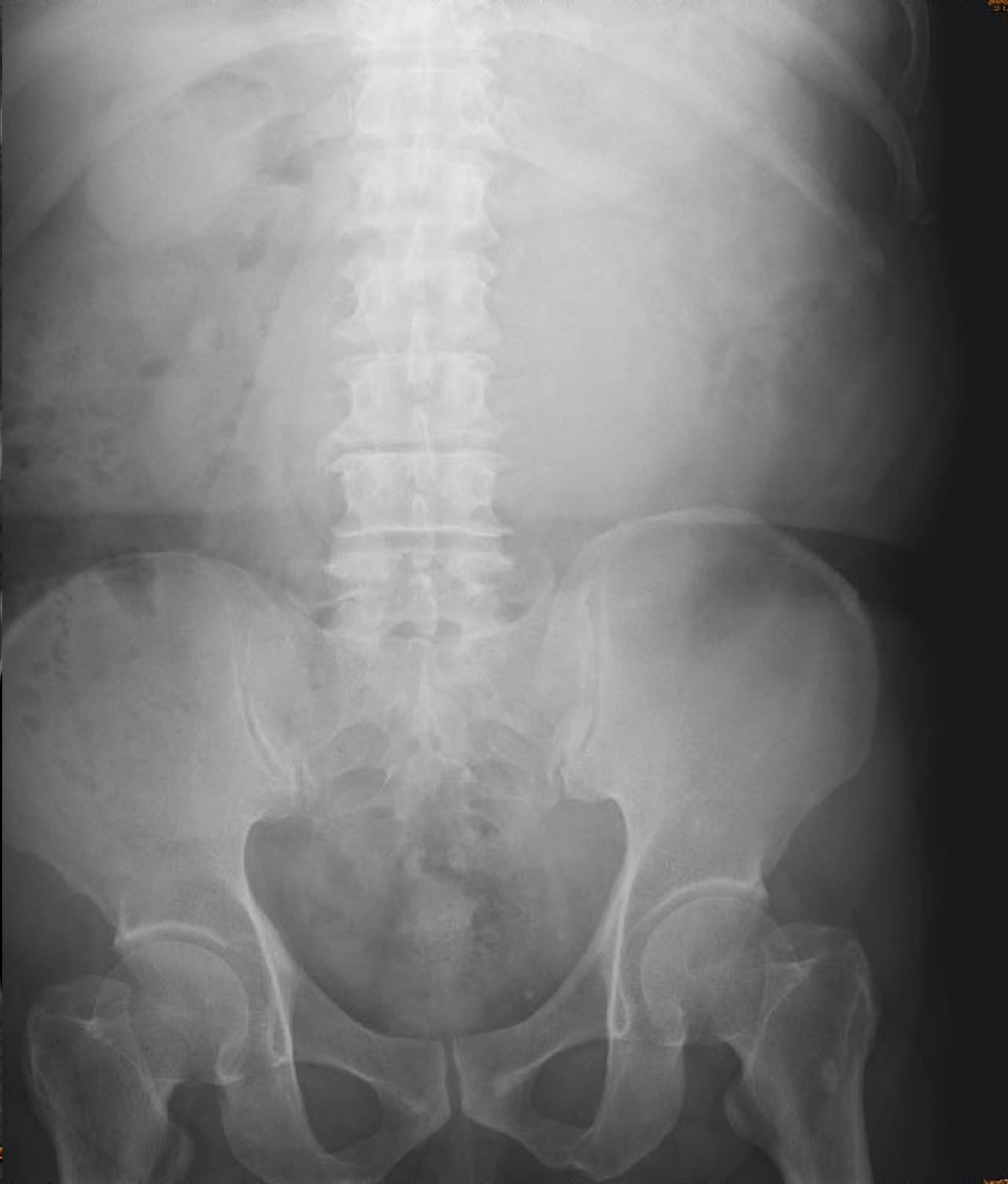
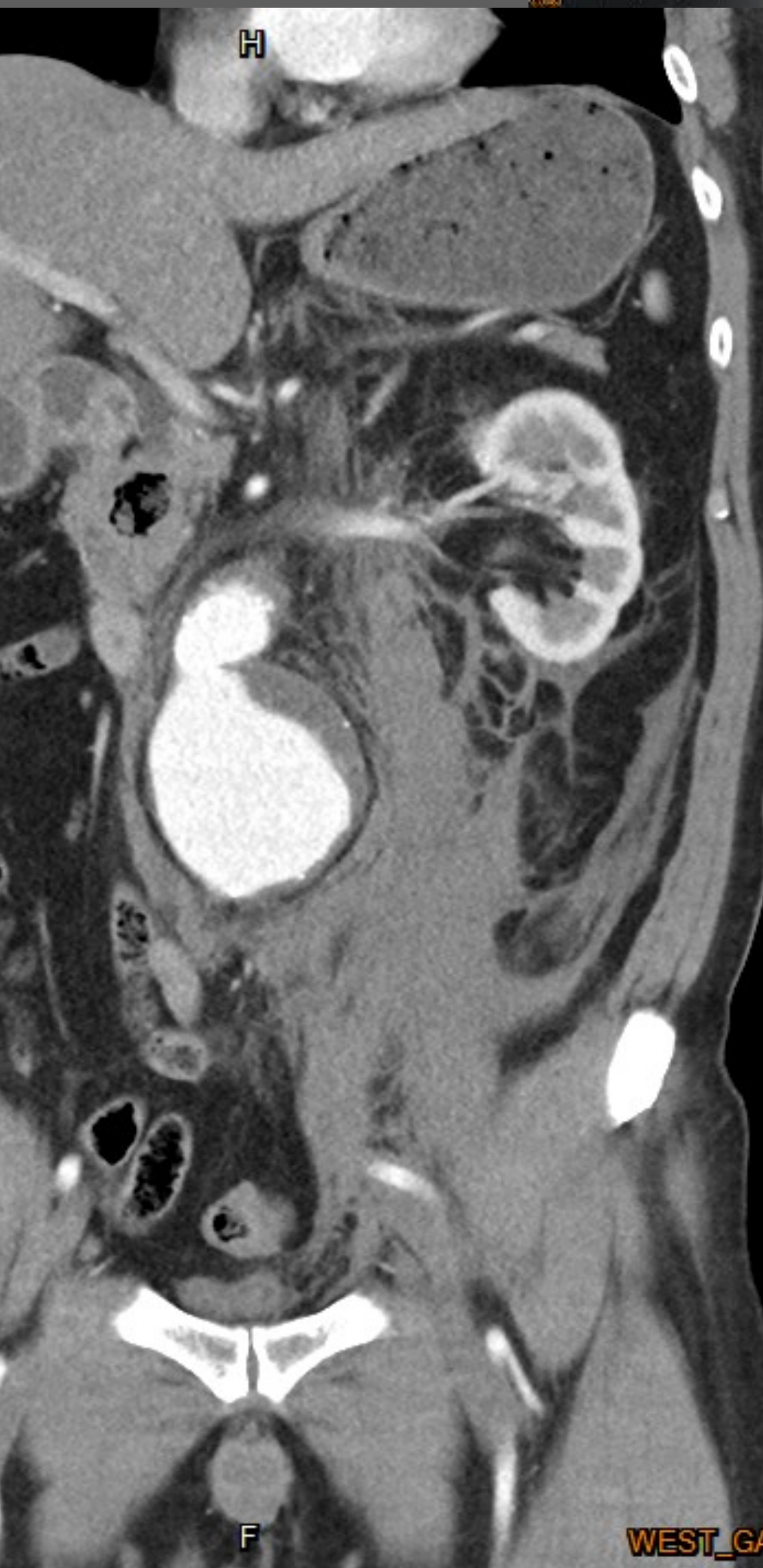
88/62



腰痛 + 冒冷汗，
我的病人可能是
主動脈瘤破裂？







AAA

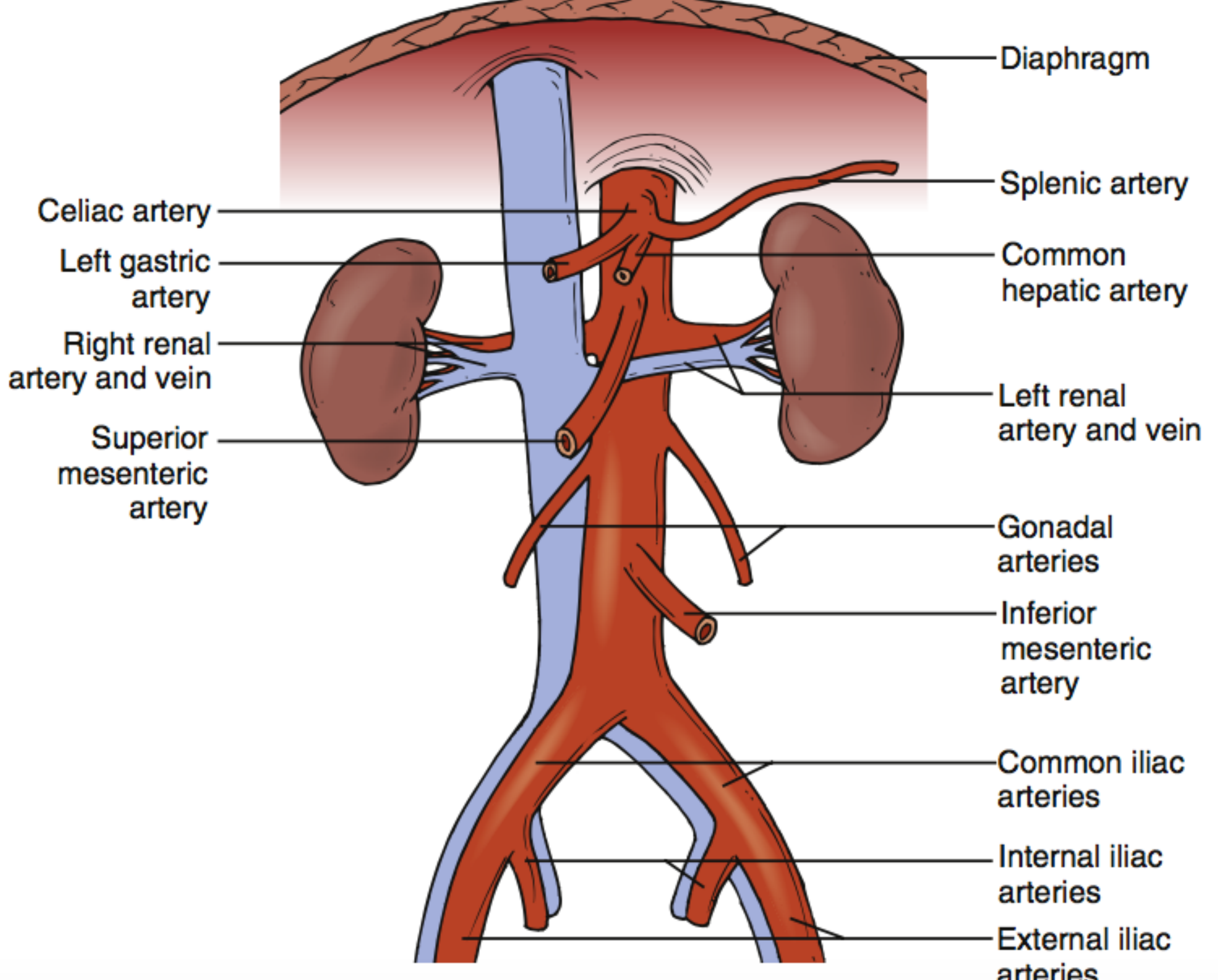
> 50 y/o
Syncope
Hypotension
ABD/Flank/Back/Groin

Sensitivity **97.5-100%**
Specificity **94.1-100%**

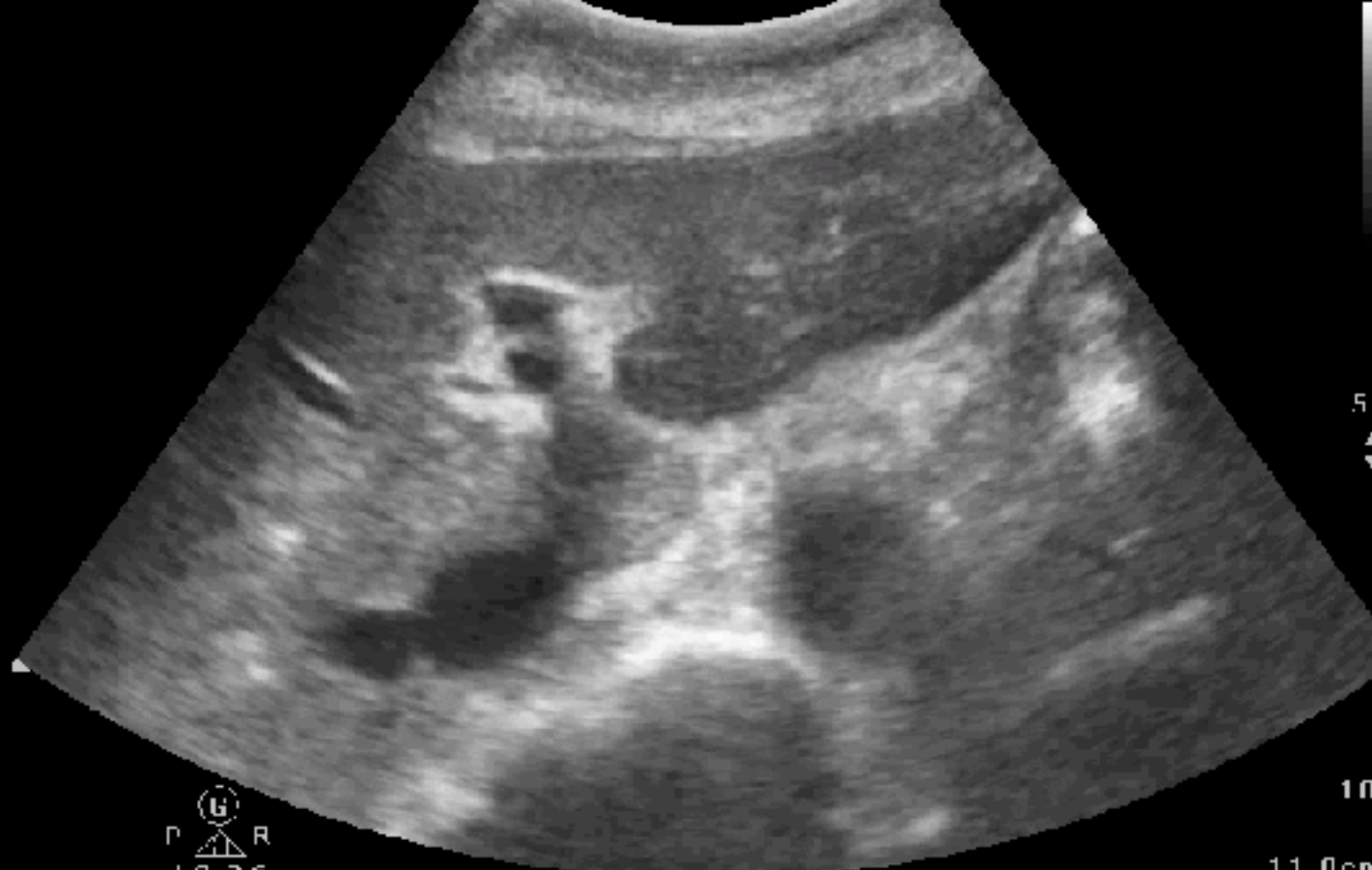


3_{cm}

The diagram shows a stylized human figure in red. A large red circle on the lower back represents an abdominal aortic aneurysm (AAA). A white double-headed arrow indicates the diameter of the aneurysm, which is labeled as 3 cm. A blue arrow on the left points downwards, representing blood flow. A white bracket at the top indicates the location of the aneurysm relative to the aorta.



1
Hz
0cm
en
66
56
3/3



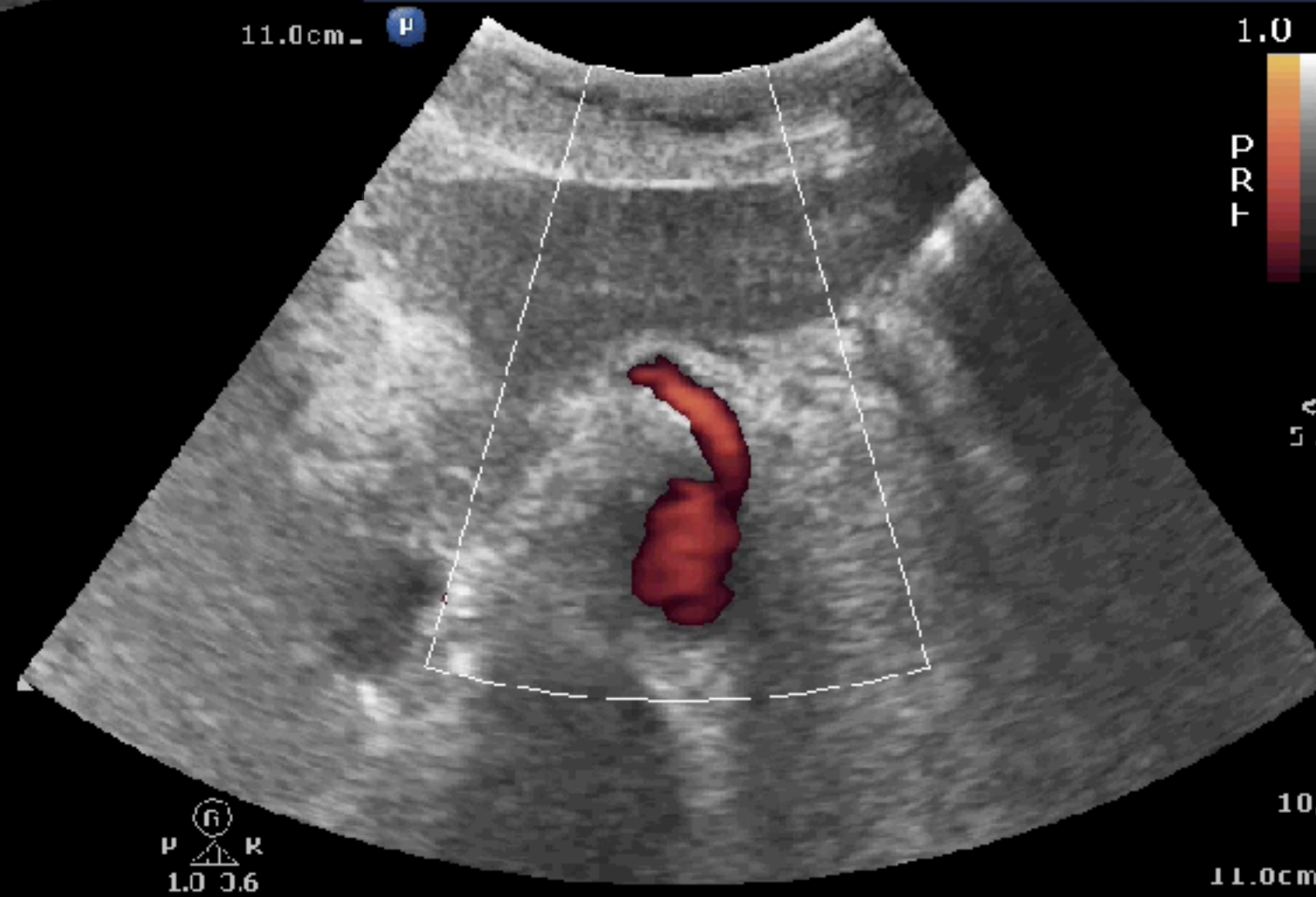
Seagull Sign

1.8 3.6

11.0cm

Celiac trunk

2D
HGen
Gn 56
C 56
3/3/3
CPA
2.5 MHz
Gn 66
1/8/4
Ftr High
Baseln 8



1.0

PRT

10

11.0cm

1.0 3.6

Eyeballing

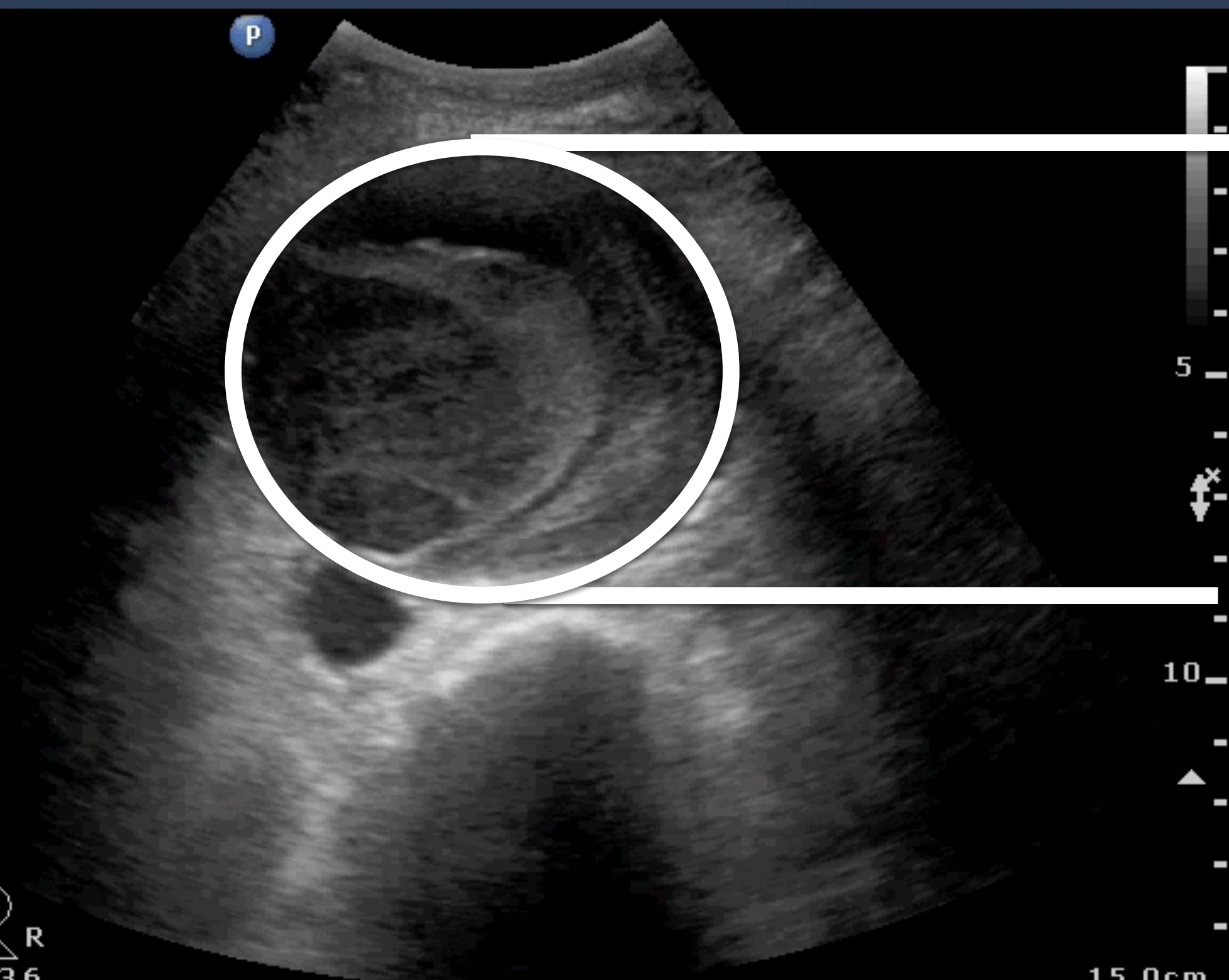
Abd Gen
C5-1
34 Hz
15.0cm

2D

HGen
Gn 57
C 56
3 / 3 / 3

P  R
1.8 3.6

15.0cm

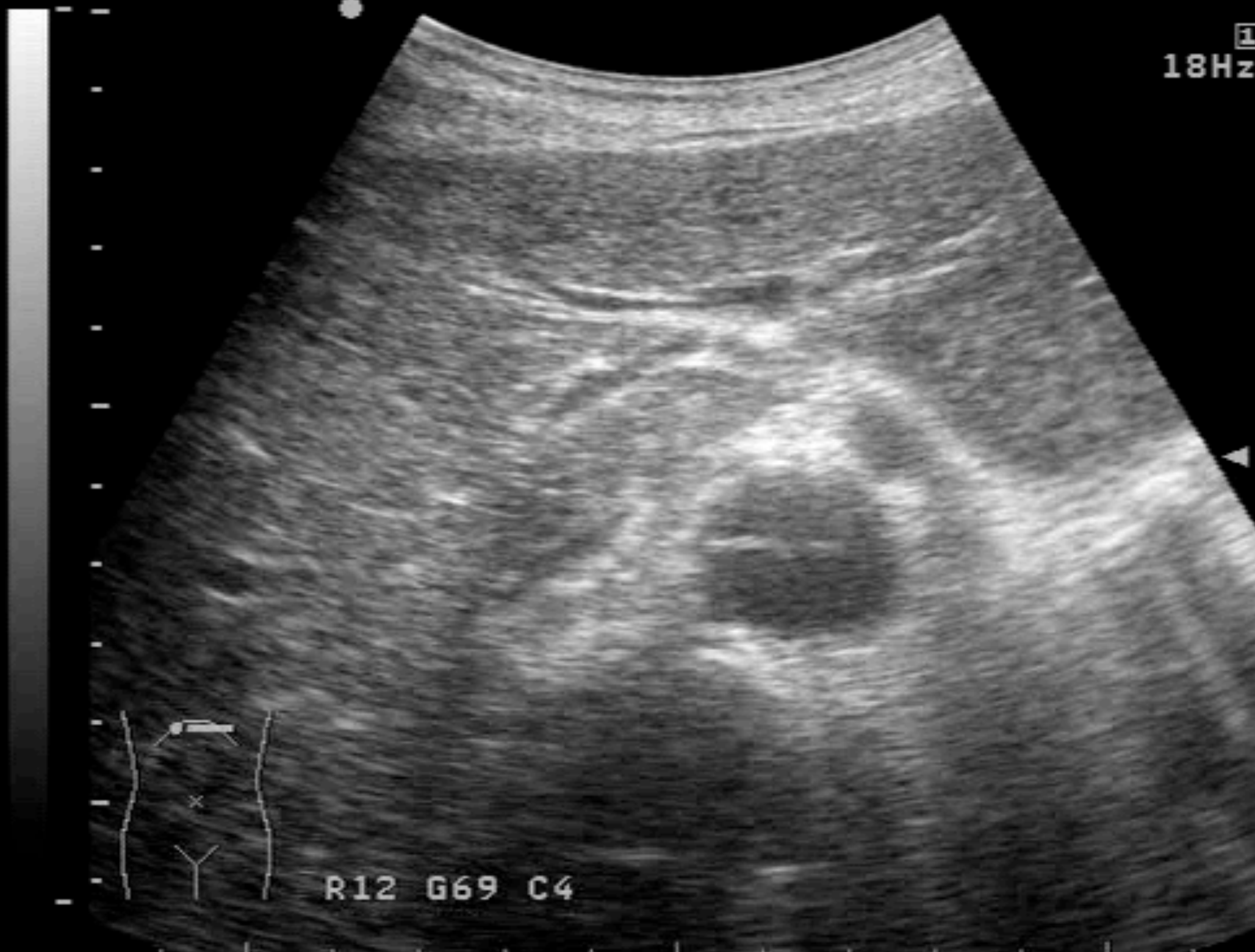

65M, epigastric pain after dinner

SHIN KONG HOSPITAL ER IDI
[

: YJ : 11 OCT. 28, 10
20:33:03

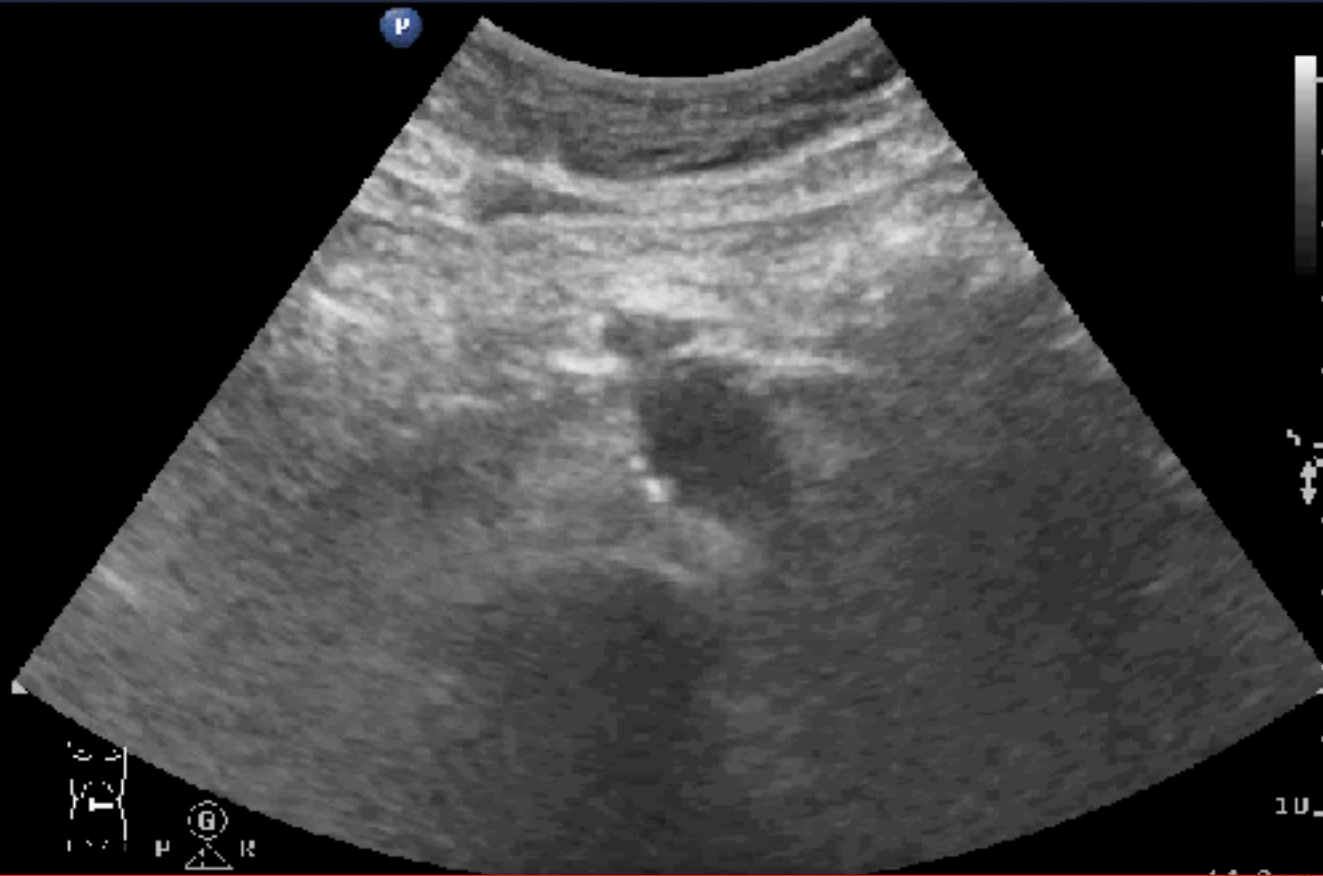
18Hz 3.5M S-H
DVA: 100%
MI = 0.6



R12 G69 C4

1: Abdomen

Abd Gen2
15-1
42 Hz
11.0cm
2D
11Gen
Gn 89
C 56
3/3/3

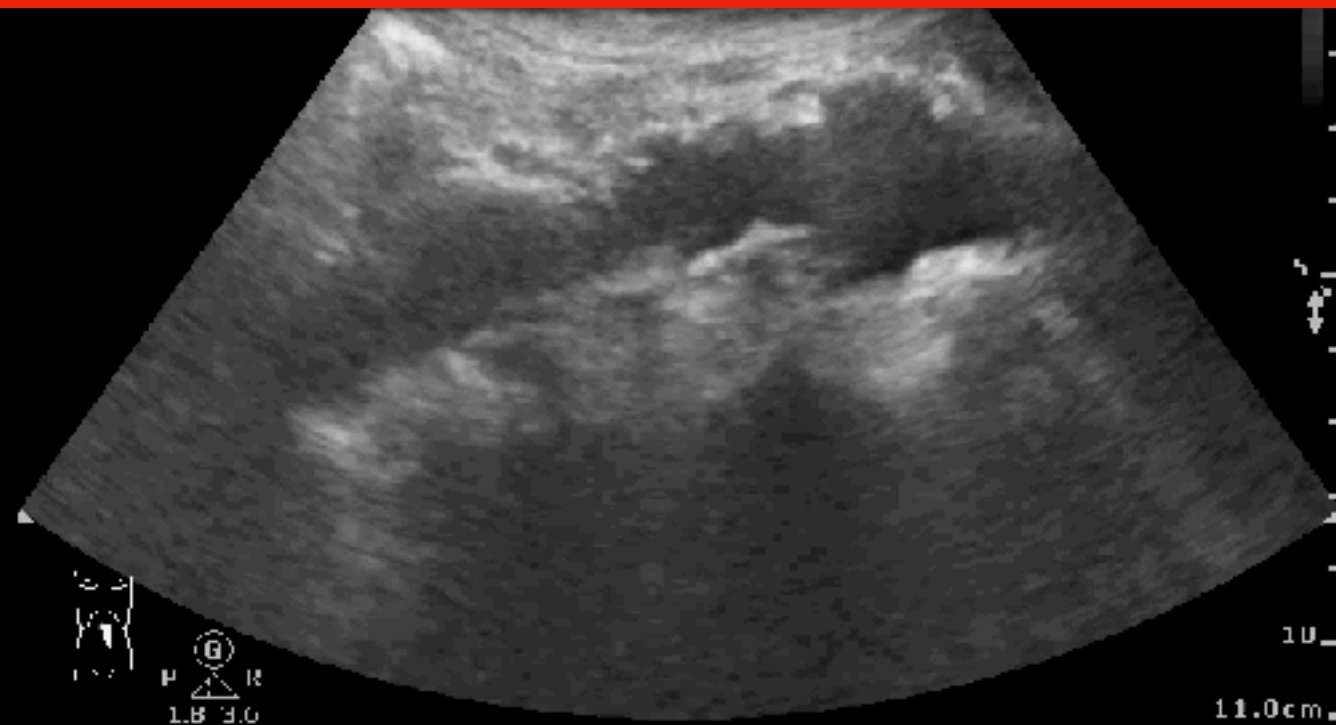

要追蹤

老人結石不掃AAA，你就要倒大楣

量對點

2D
11Gen
Gn 89
C 56
3/3/3



11.0cm

Entrance (IVC)

Volume responsiveness

Central venous pressure

Pericardial effusion

Right heart failure

Intra-abdominal hypertension

Entrance (IVC)

Diameter 1~2 cm

Collapse index 50%

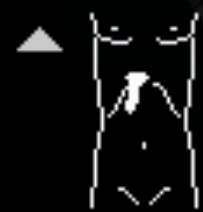IVC diameter (cm)	Collapse (%)	CVP (mean)mmHg
<1	> 50	0-5 (3)
1-2	NA	5-10 (8)
>2	<50	10-20 (15)

Small & CI > 50%

36 Hz
14.0cm

2D

HGen
Gn 61
C 56
3 / 3 / 3



P  R
1.8 3.6

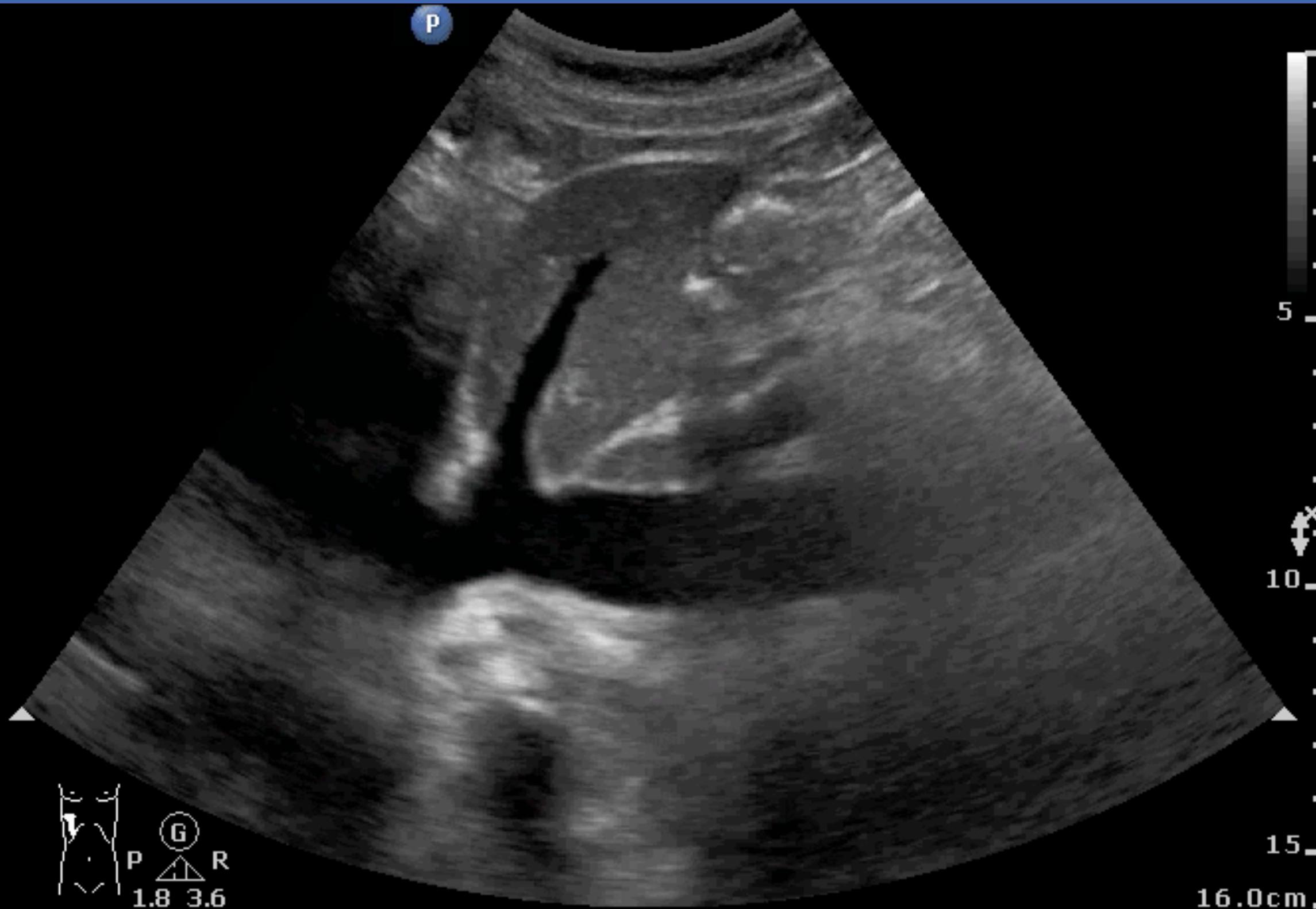
14.0cm

Large & CI < 50%

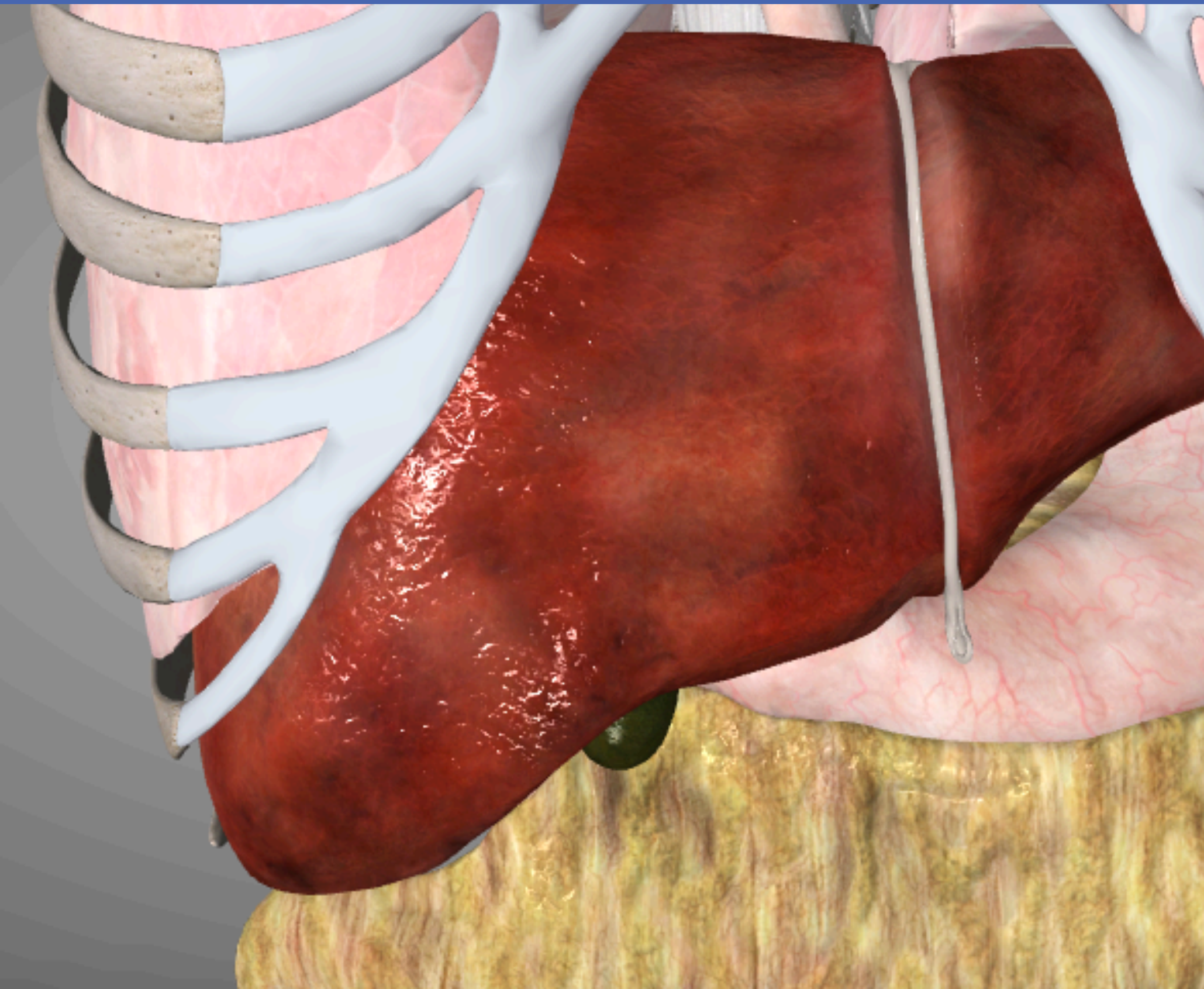Abd Gen2
C5-1
32 Hz
16.0cm

2D

HGen
Gn 60
C 55
3/3/3



Liver & GB

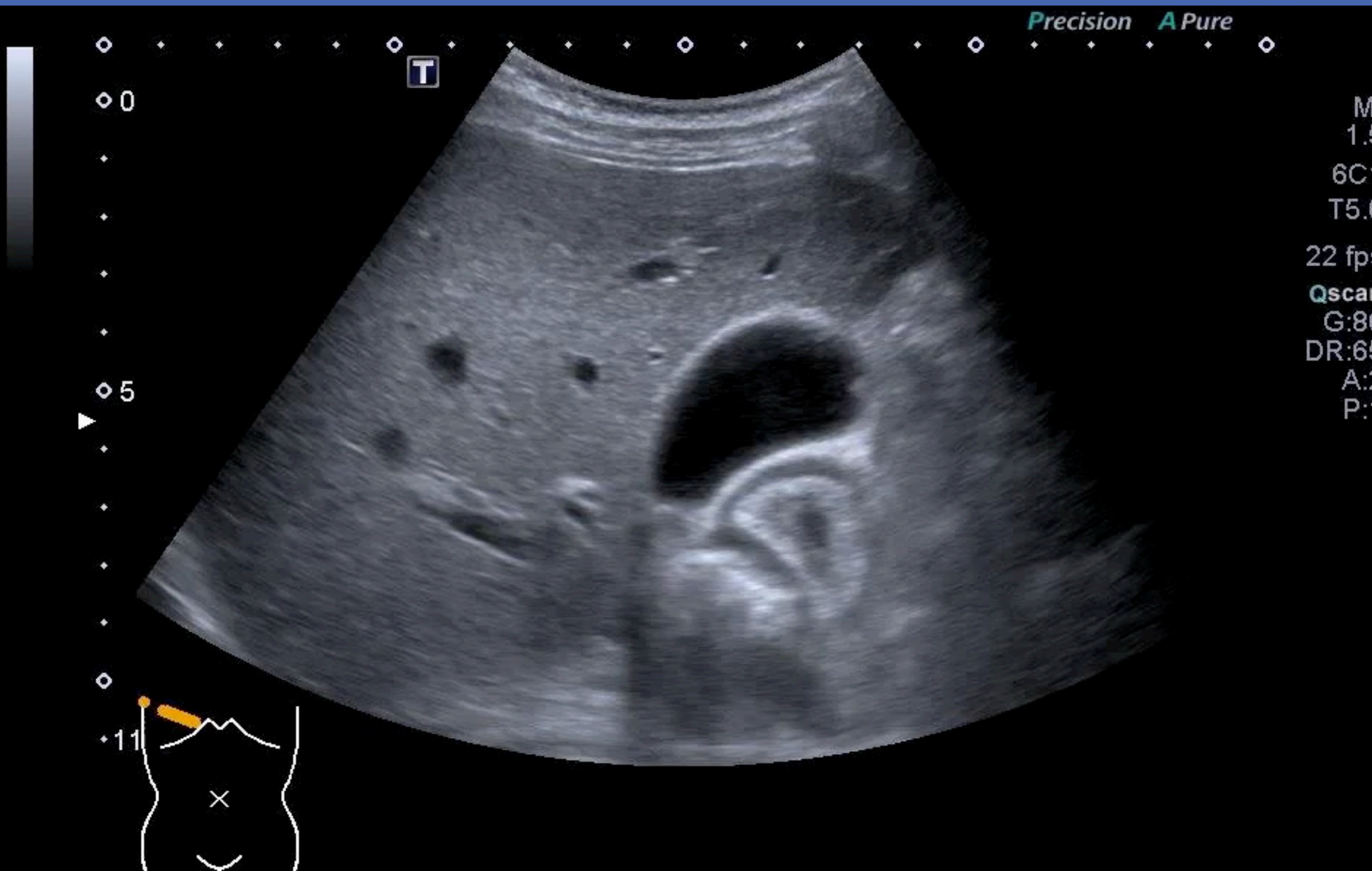

3 mm

7 mm

11 mm

讀讀看，你看到了什麼？

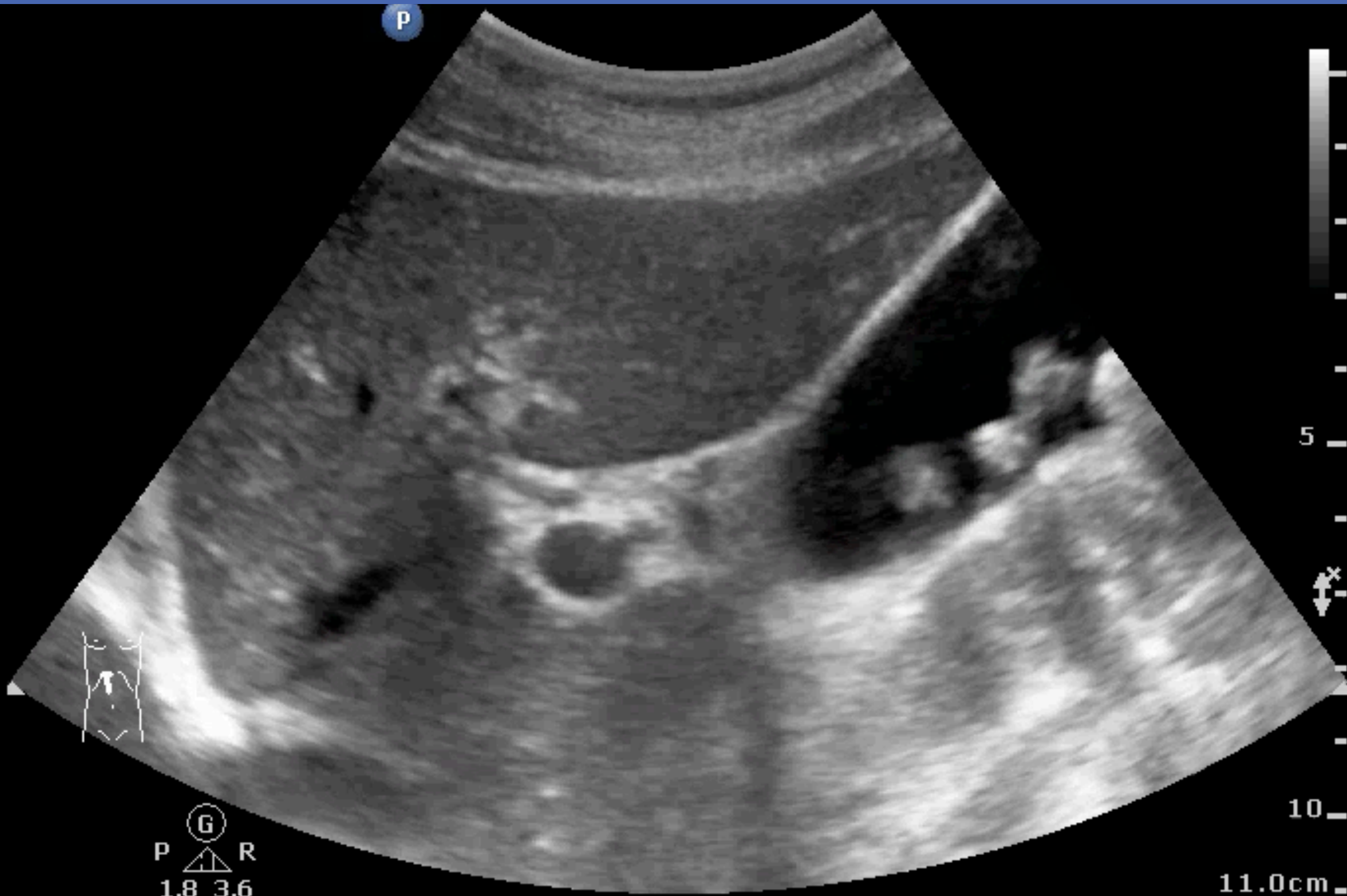


讀讀看，你看到了什麼？

Abd Gen
C5-1
42 Hz
11.0cm

2D

HGen
Gn 80
C 56
3 / 3 / 3



P (G) R
1.8 3.6

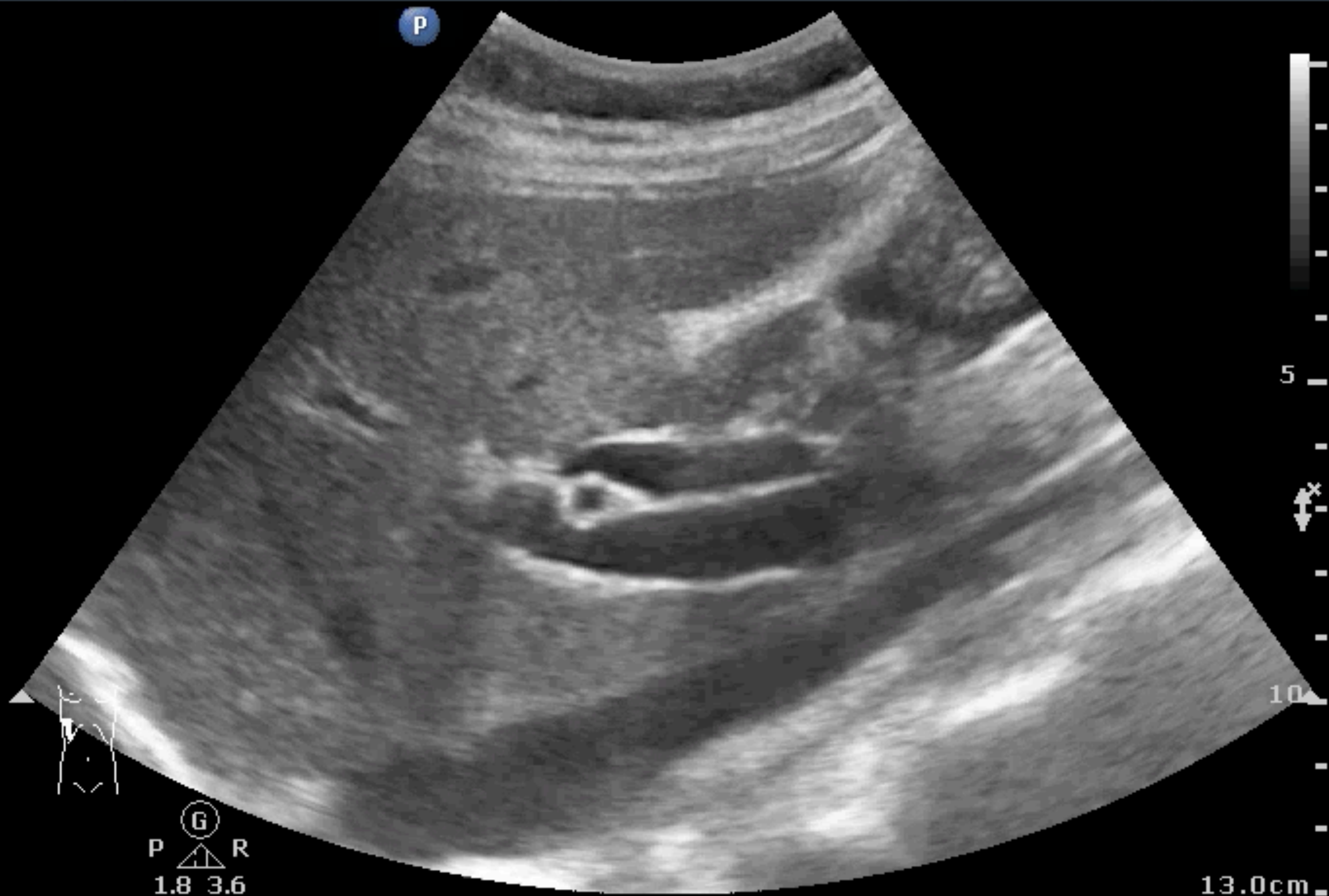11.0cm

讀讀看，你看到了什麼？

Abd Gen
C5-1
38 Hz
13.0cm

2D

HGen
Gn 82
C 56
3 / 3 / 3



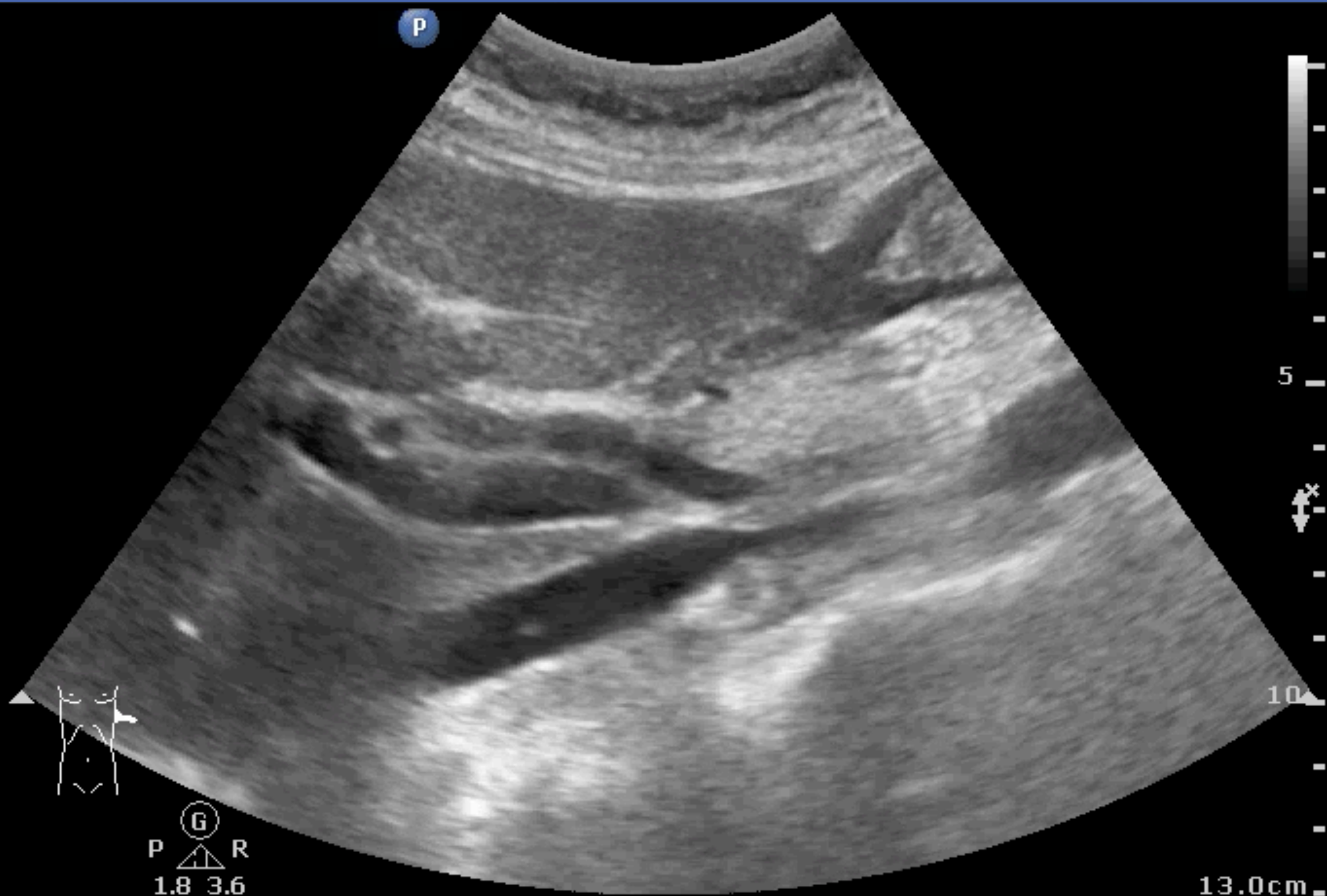13.0cm

讀讀看，你看到了什麼？

Abd Gen
C5-1
38 Hz
13.0cm

2D

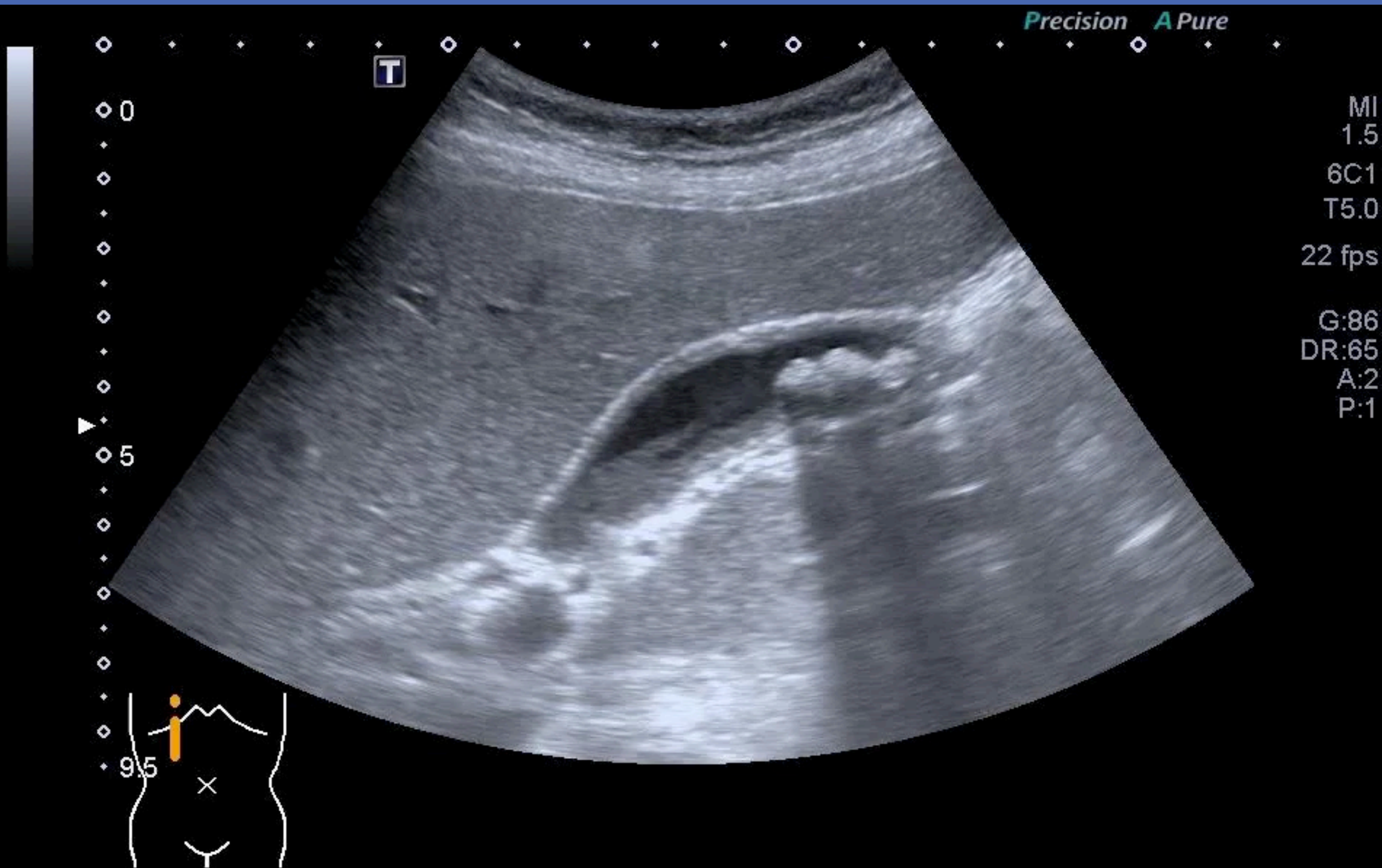
HGen
Gn 82
C 56
3/3/3



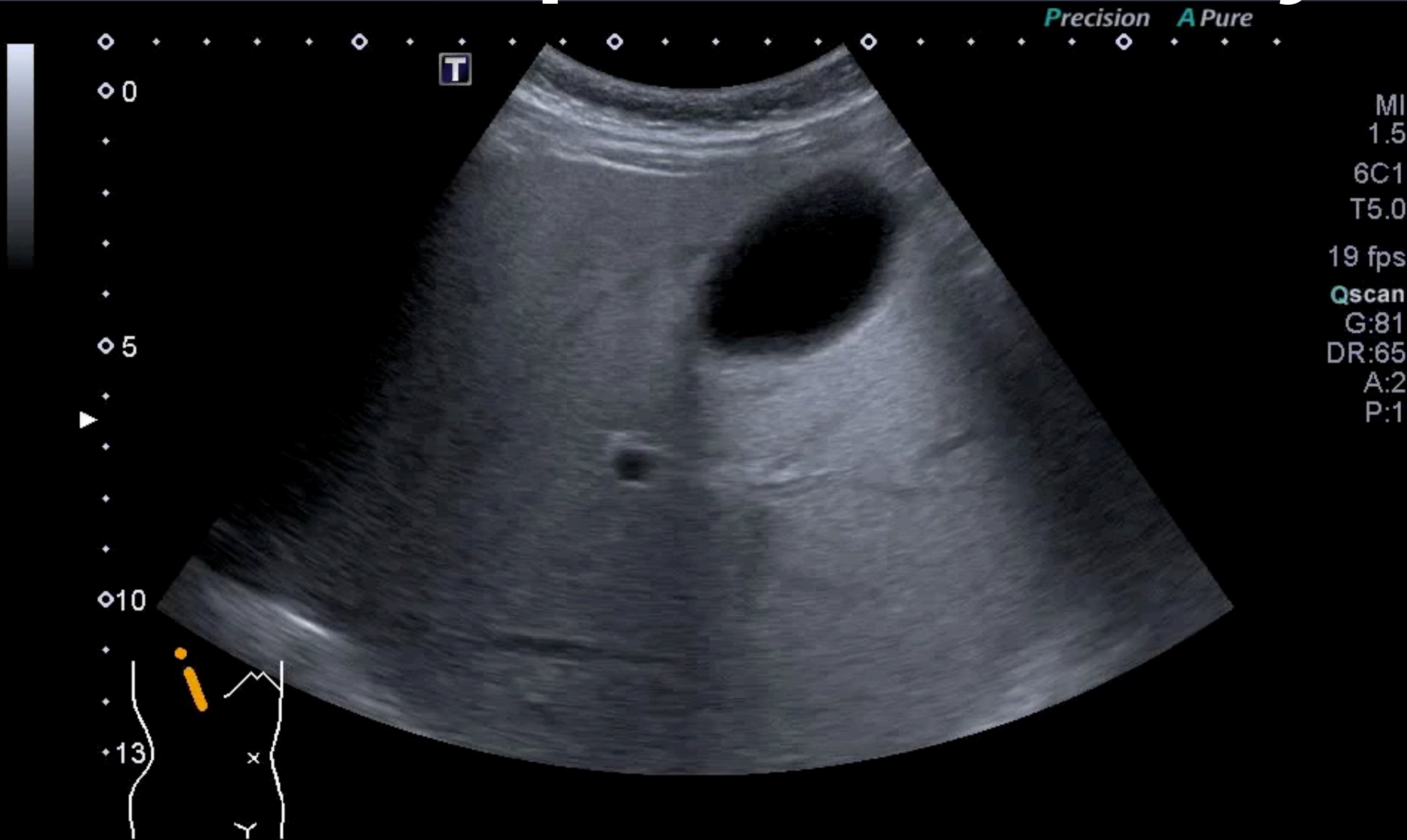
G
P R
1.8 3.6

13.0cm

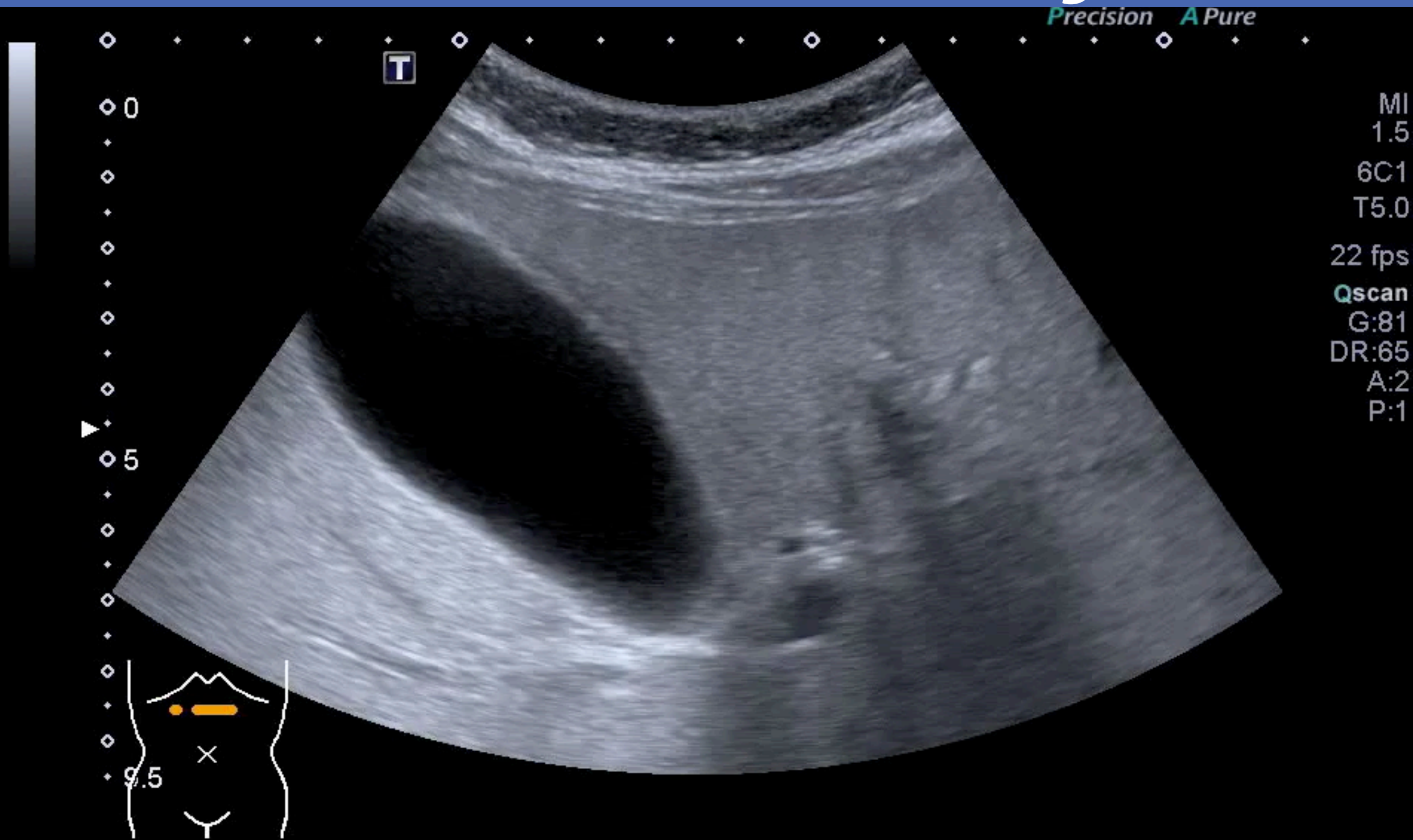
讀讀看，你看到了什麼？



61F , ABD pain for 3-4 days



GB stones & Cholecystitis

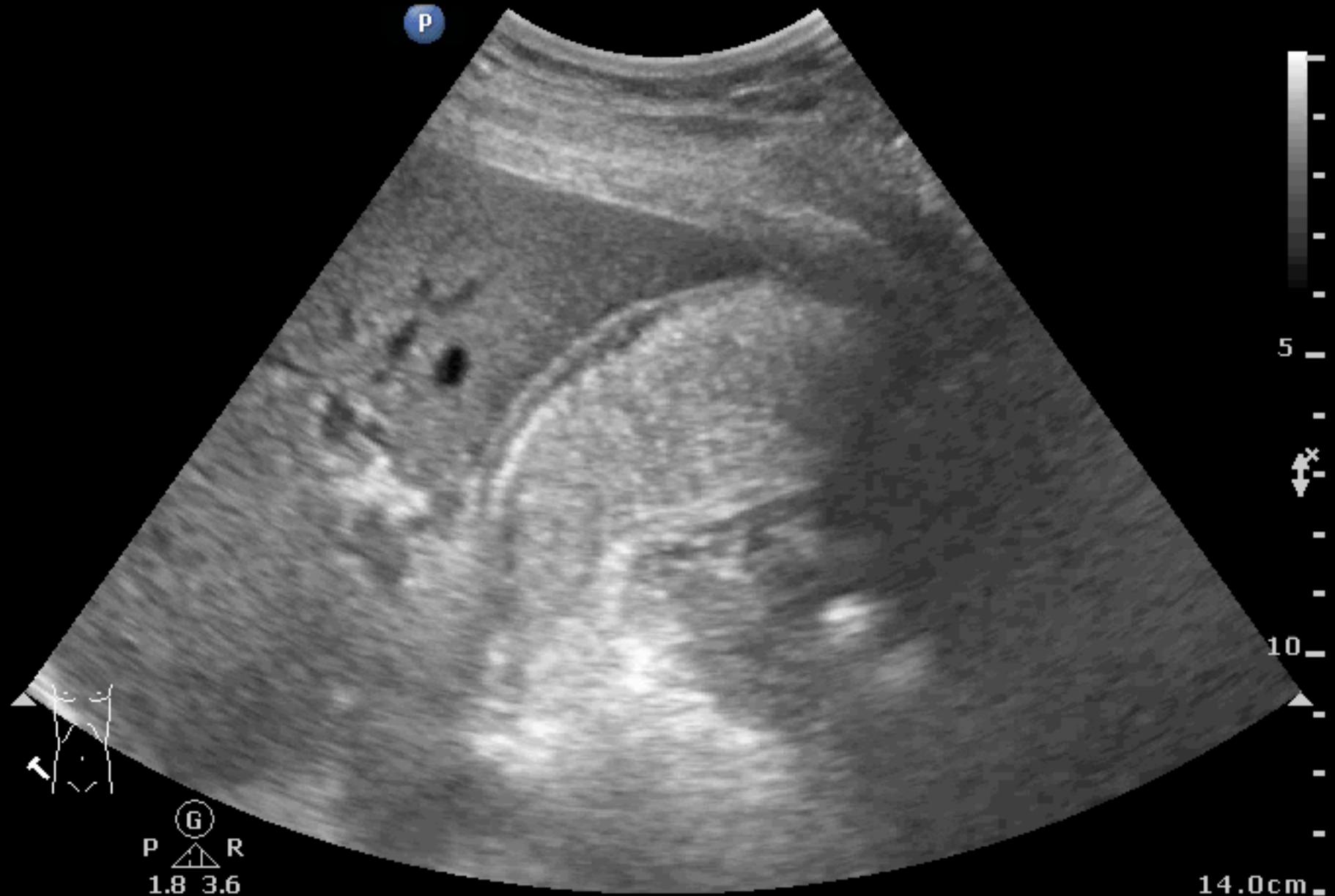


59M, epigastric pain at midnight

PHILIPS

Abd Gen2
C5-1
36 Hz
14.0cm

2D
HGen
Gn 100
C 56
3/3/3

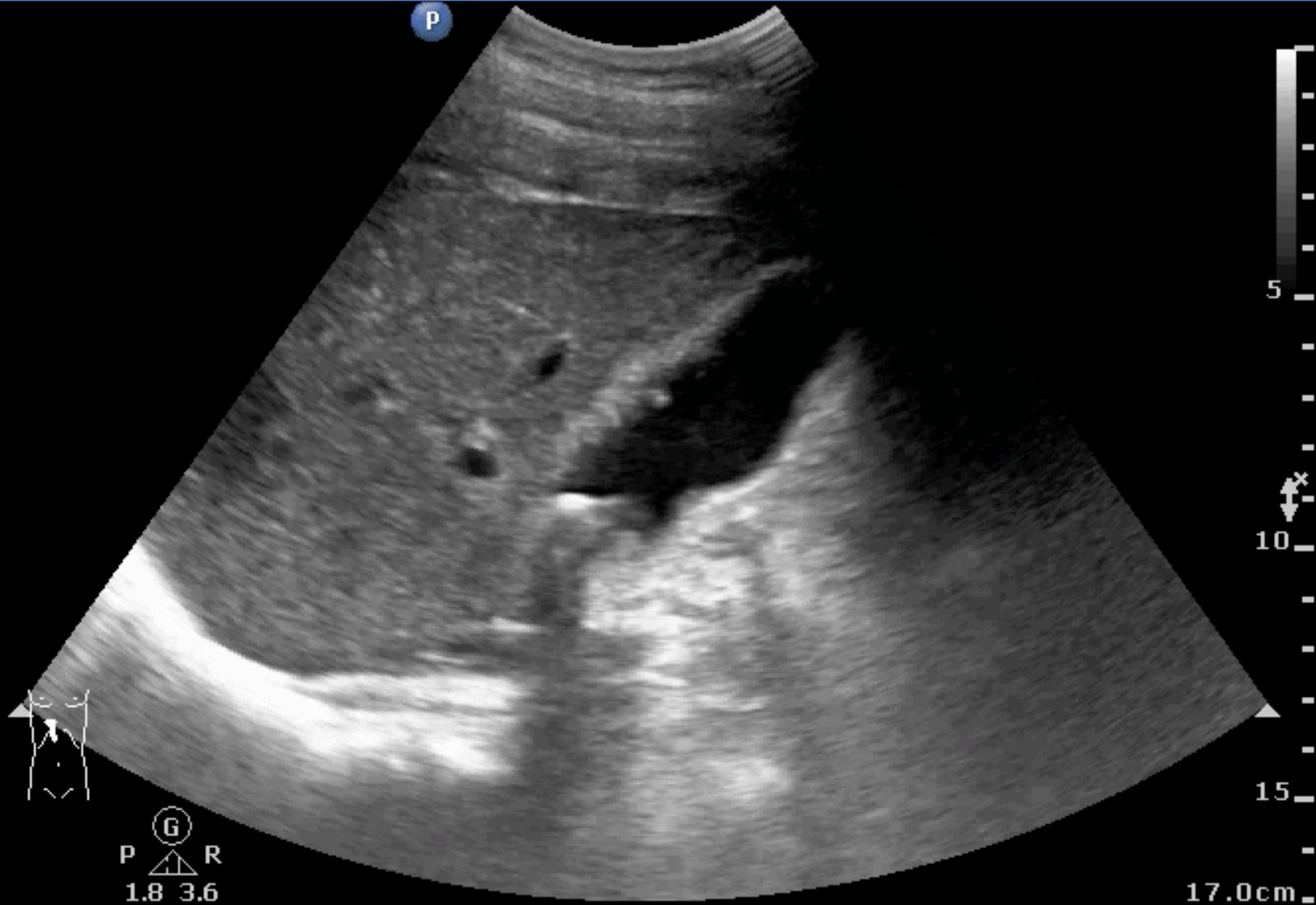


52M, RUQ pain

Abd Gen2
C5-1
31 Hz
17.0cm

2D

HGen
Gn 86
C 56
3/3/3

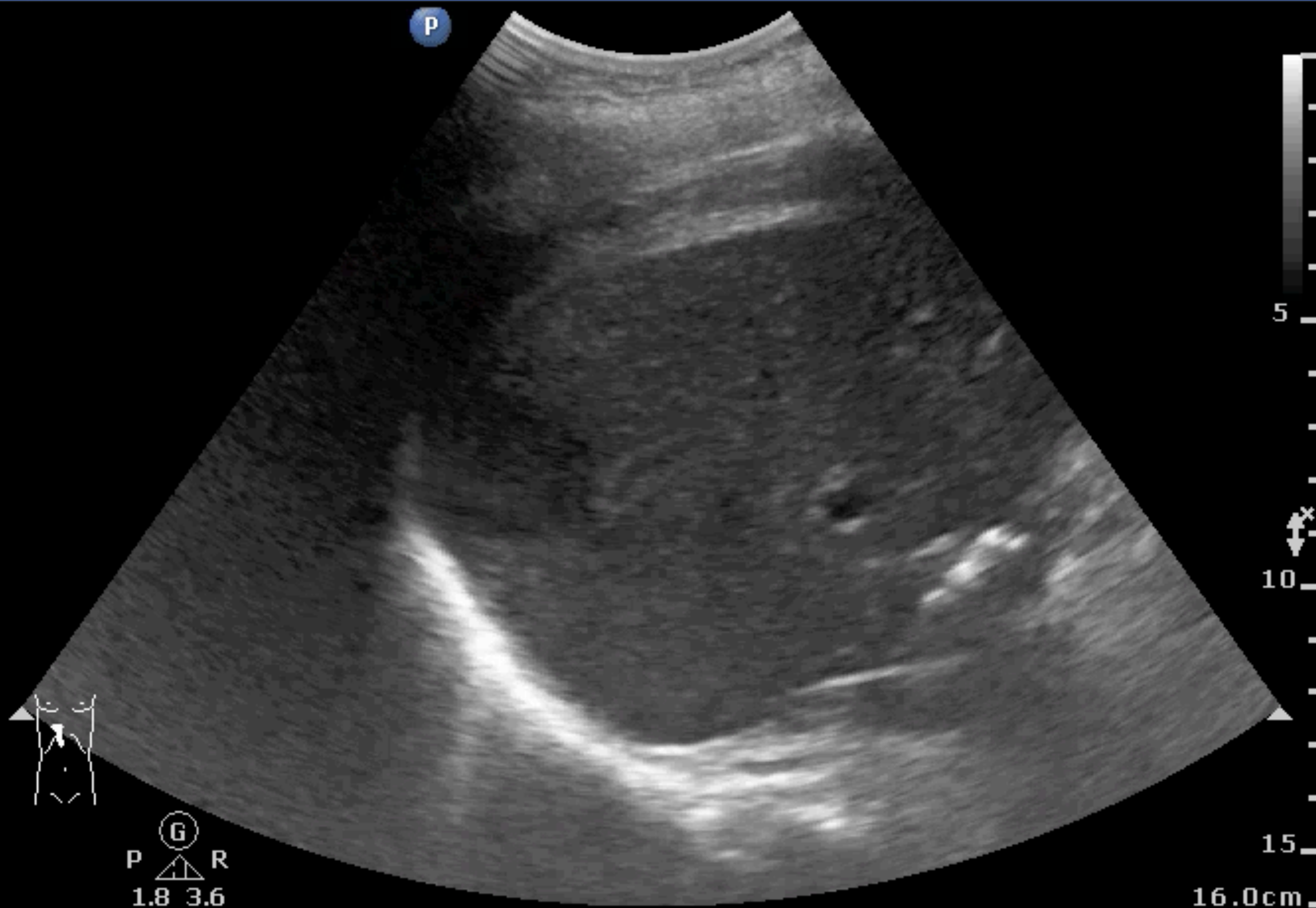


讀讀看，你看到了什麼？

Abd Gen2
C5-1
32 Hz
16.0cm

2D

HGen
Gn 100
C 56
3 / 3 / 3



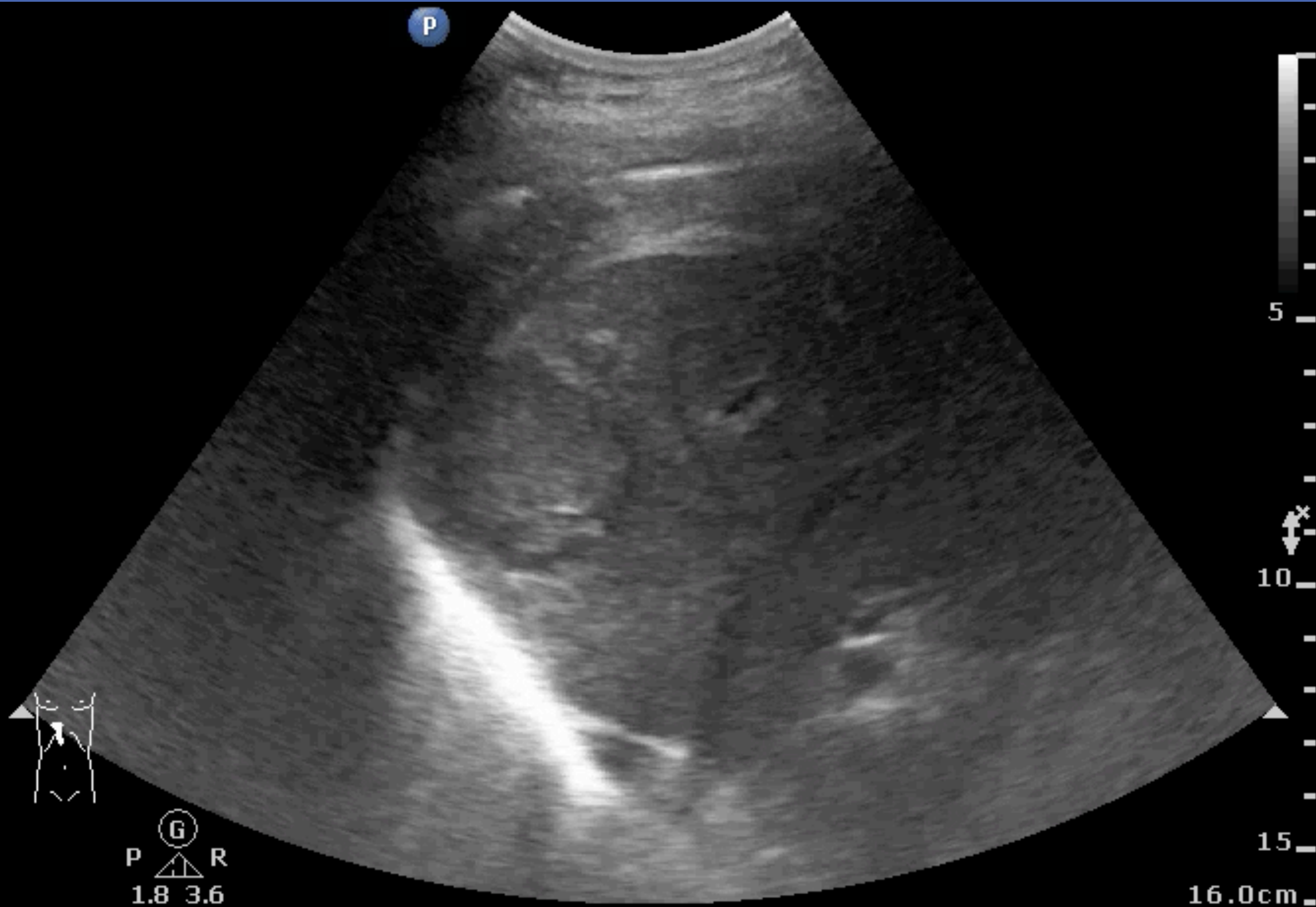
P G R
1.8 3.6

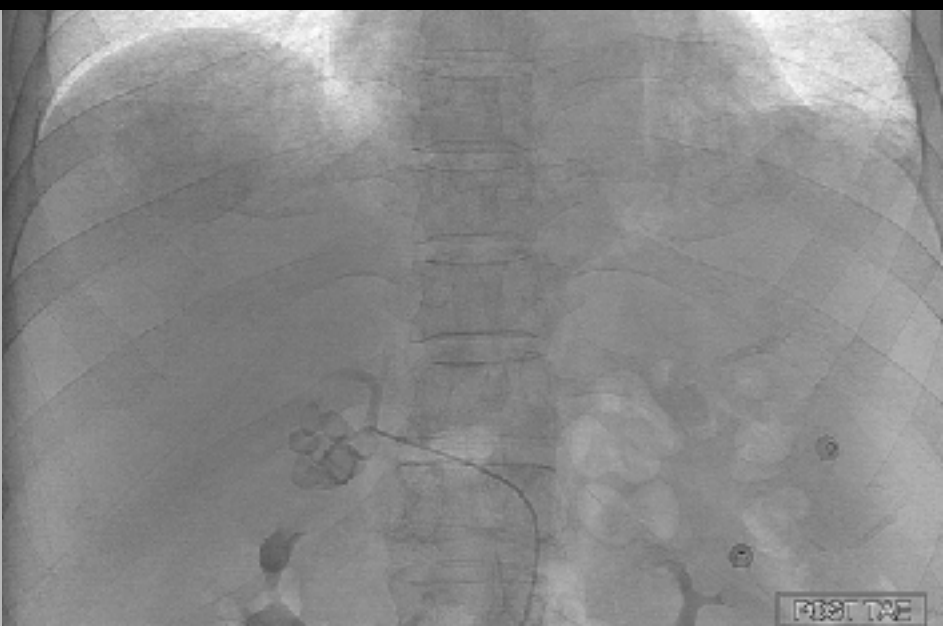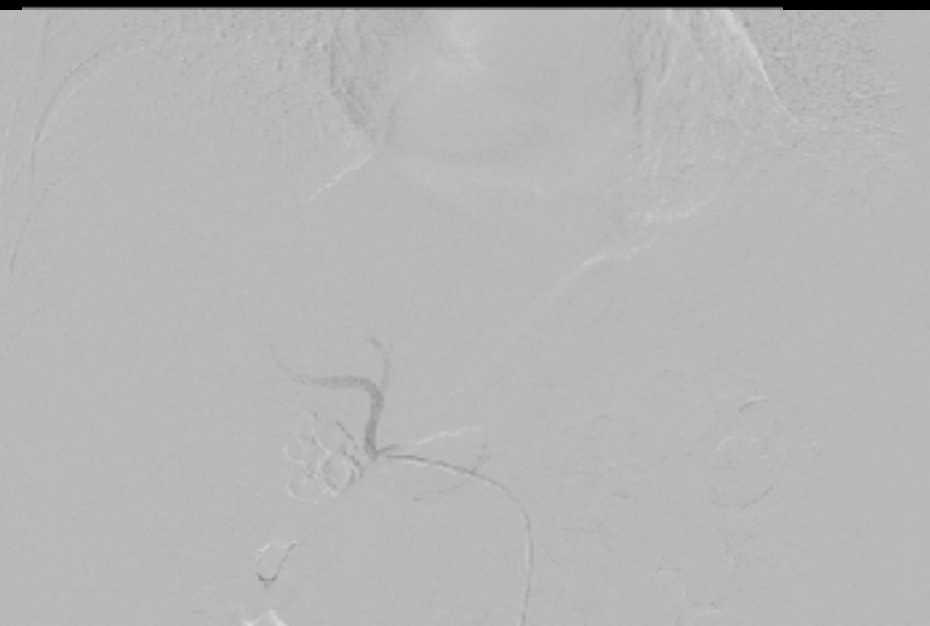
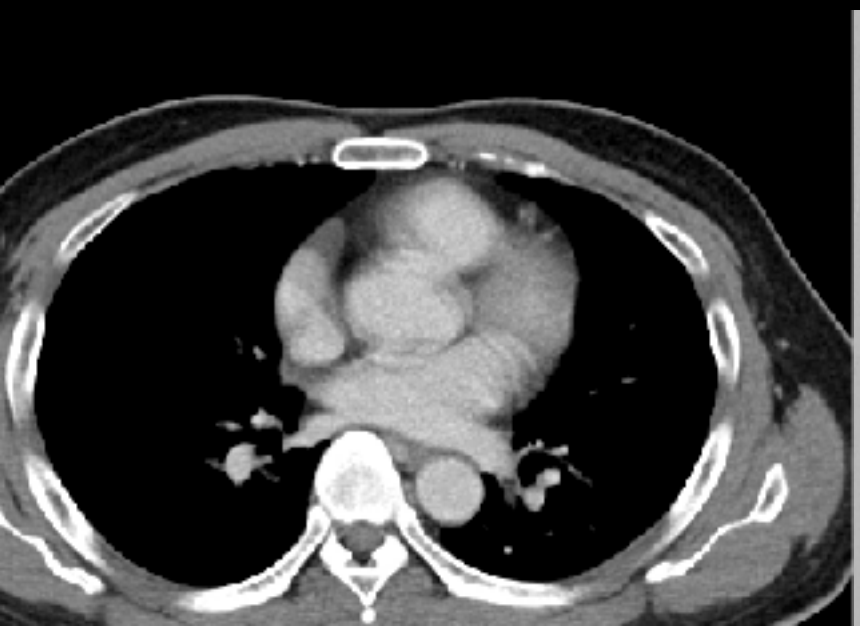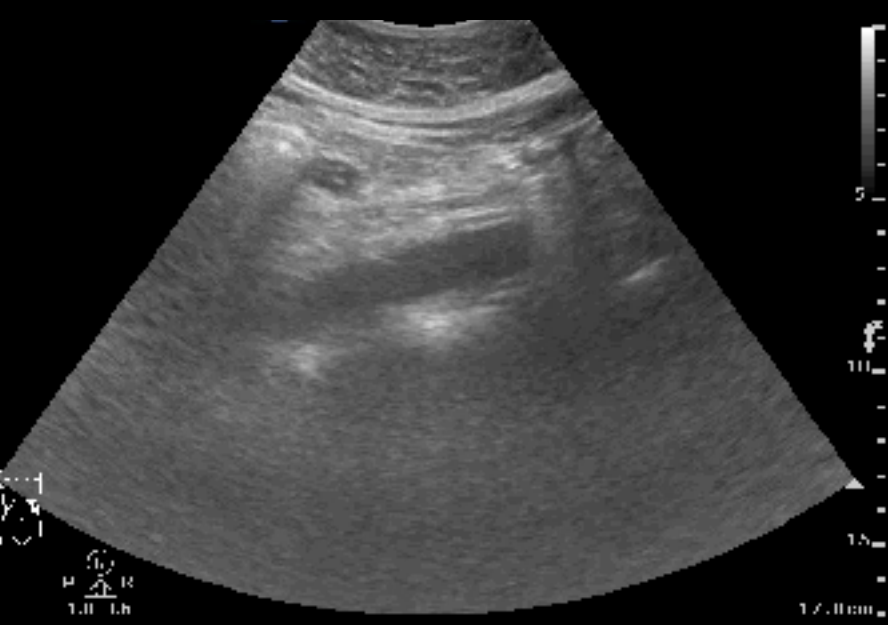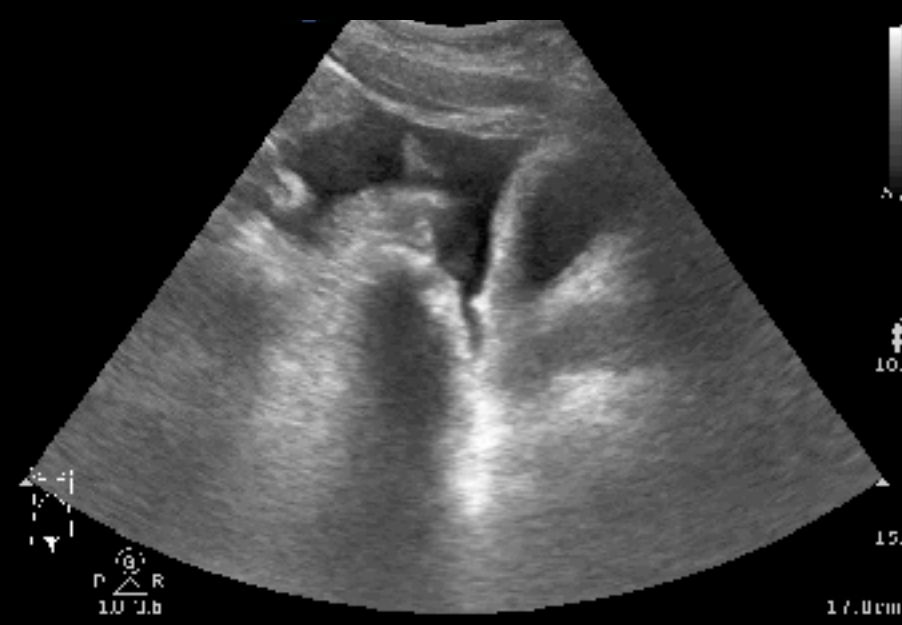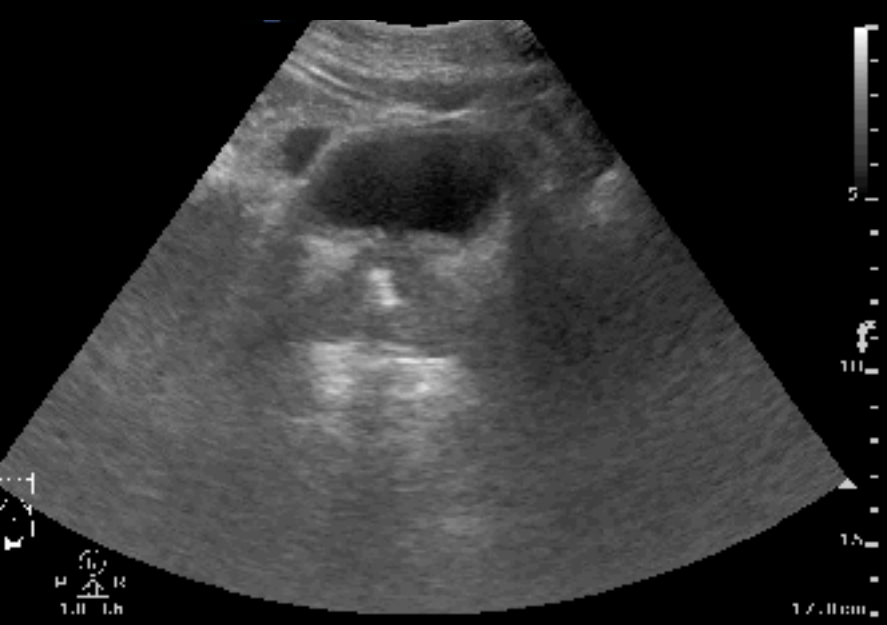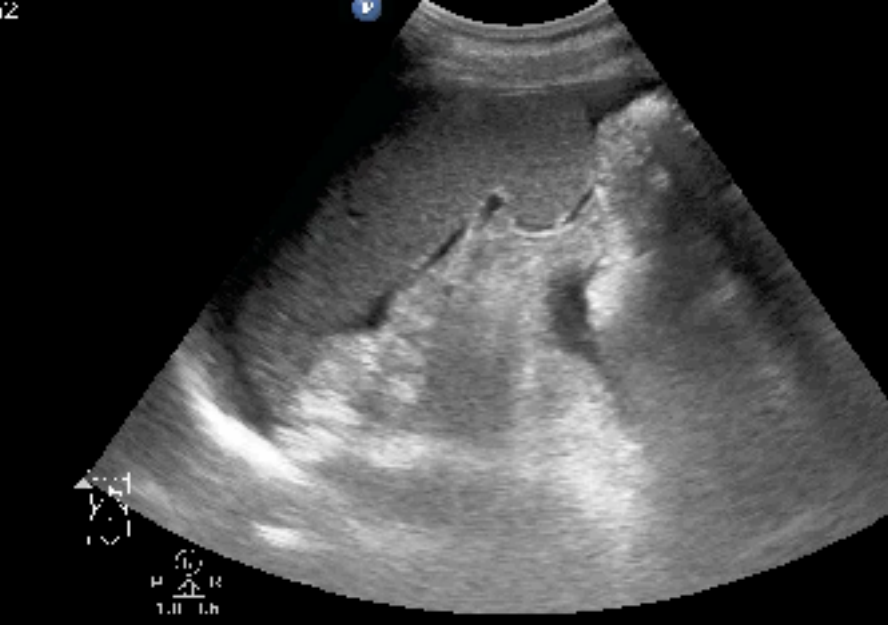
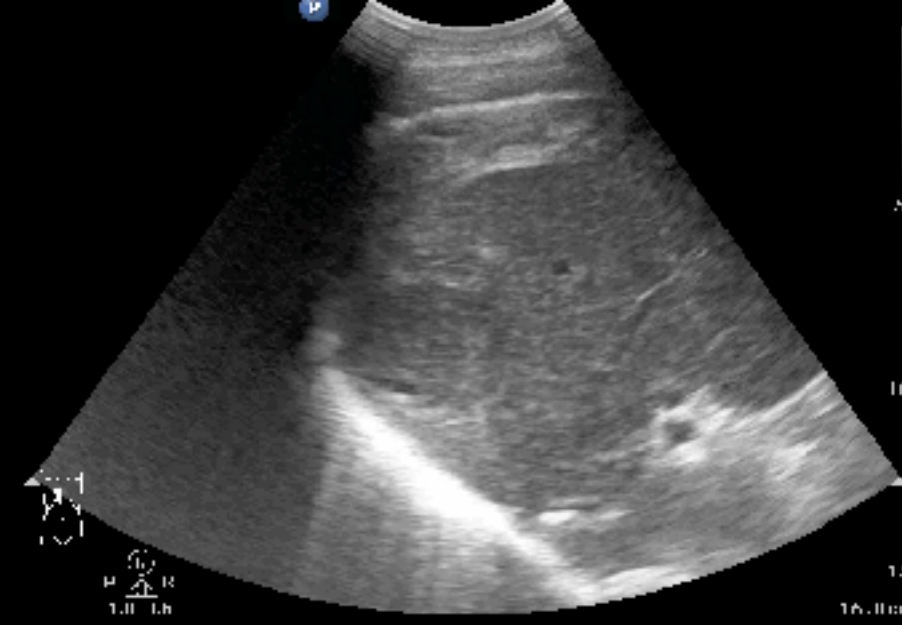
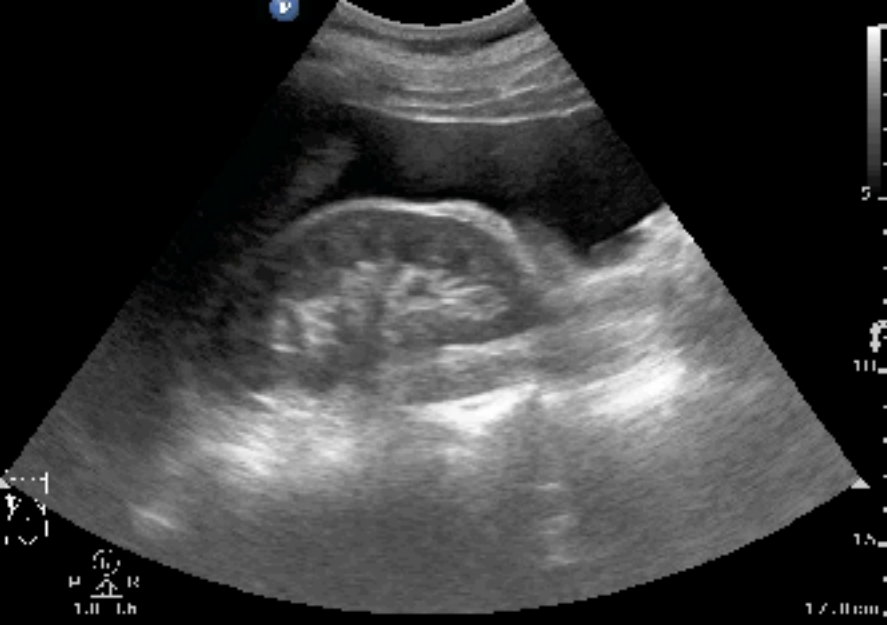16.0cm

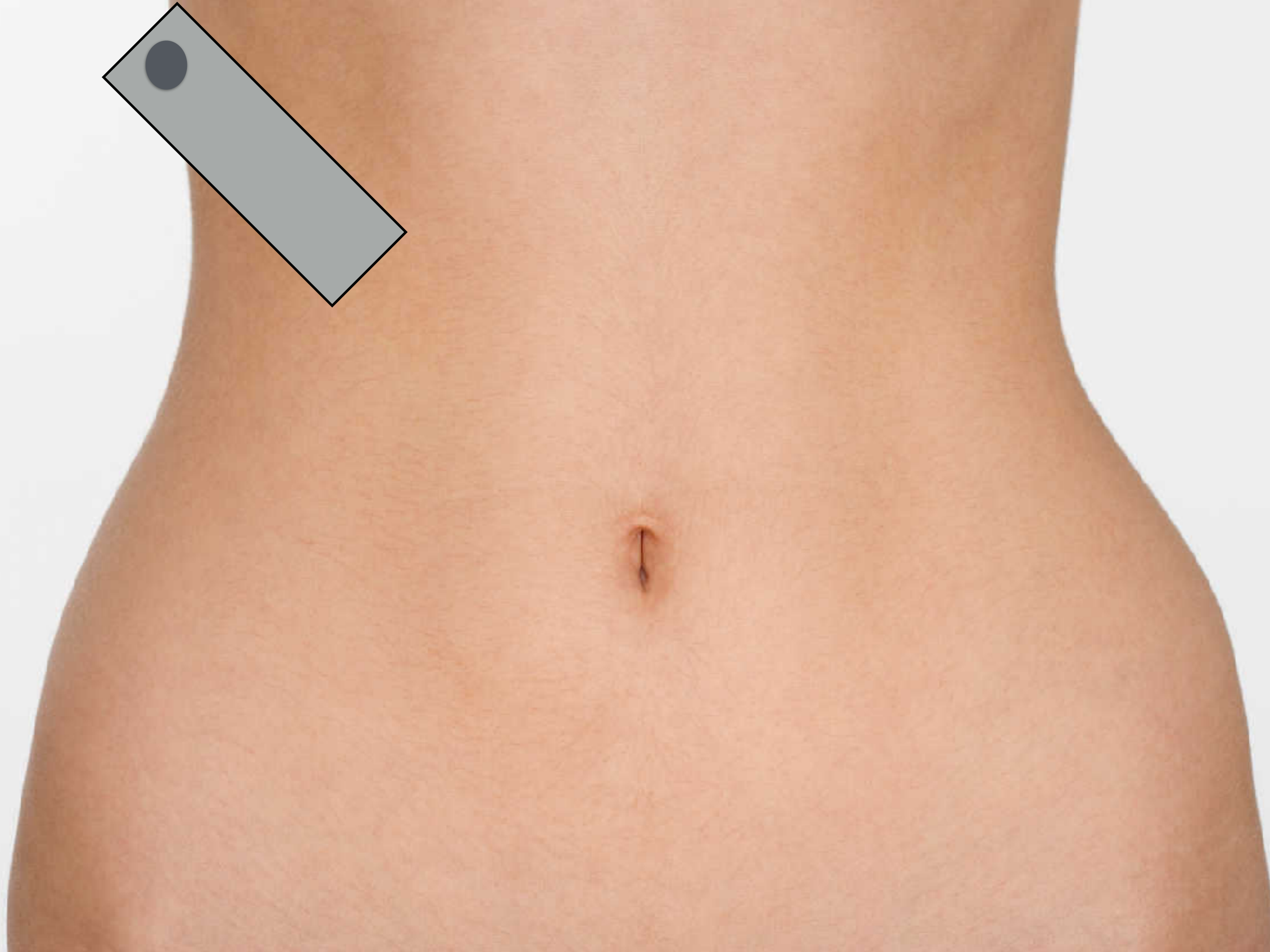讀讀看，你看到了什麼？

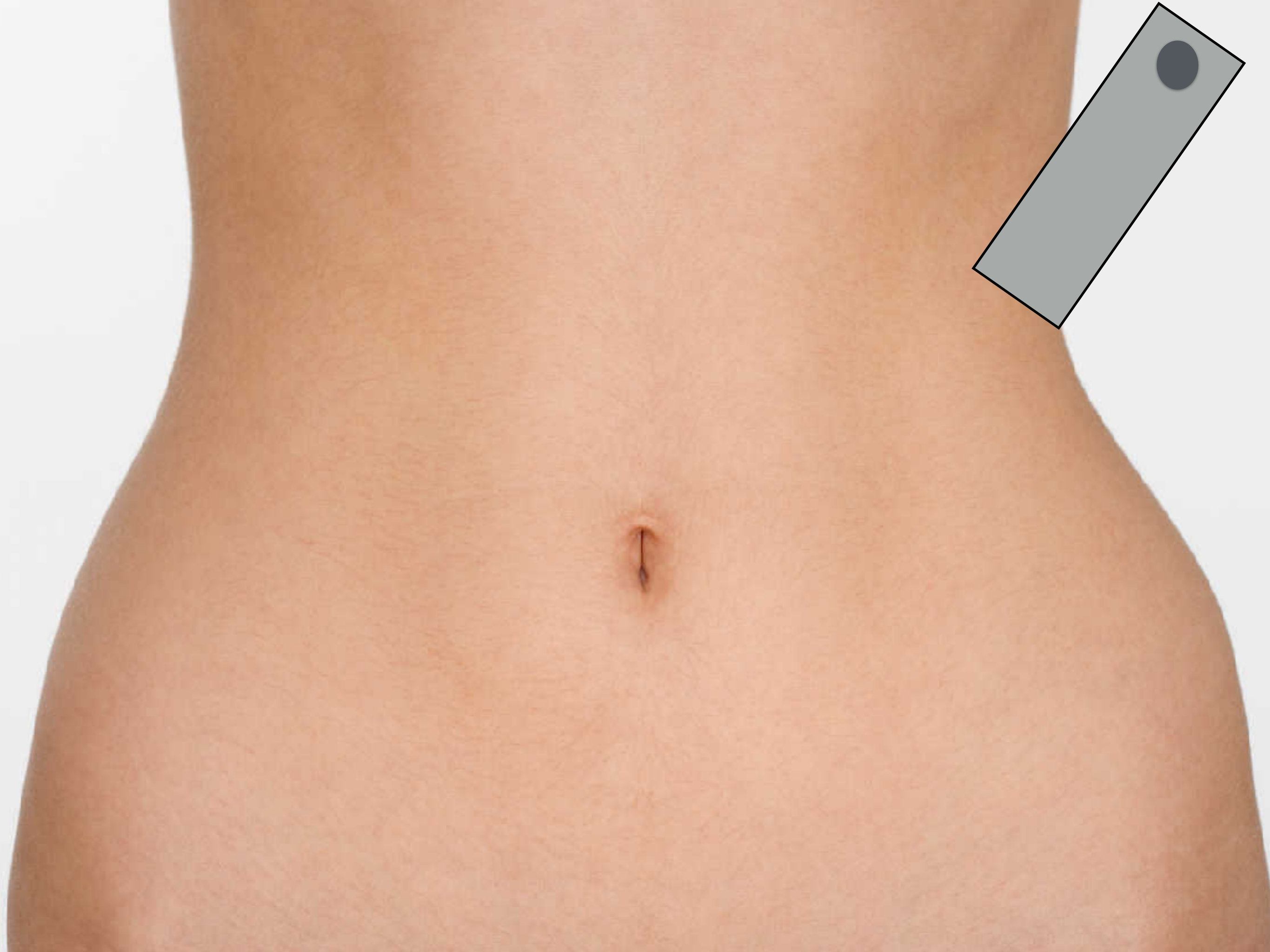Abd Gen2
C5-1
32 Hz
16.0cm

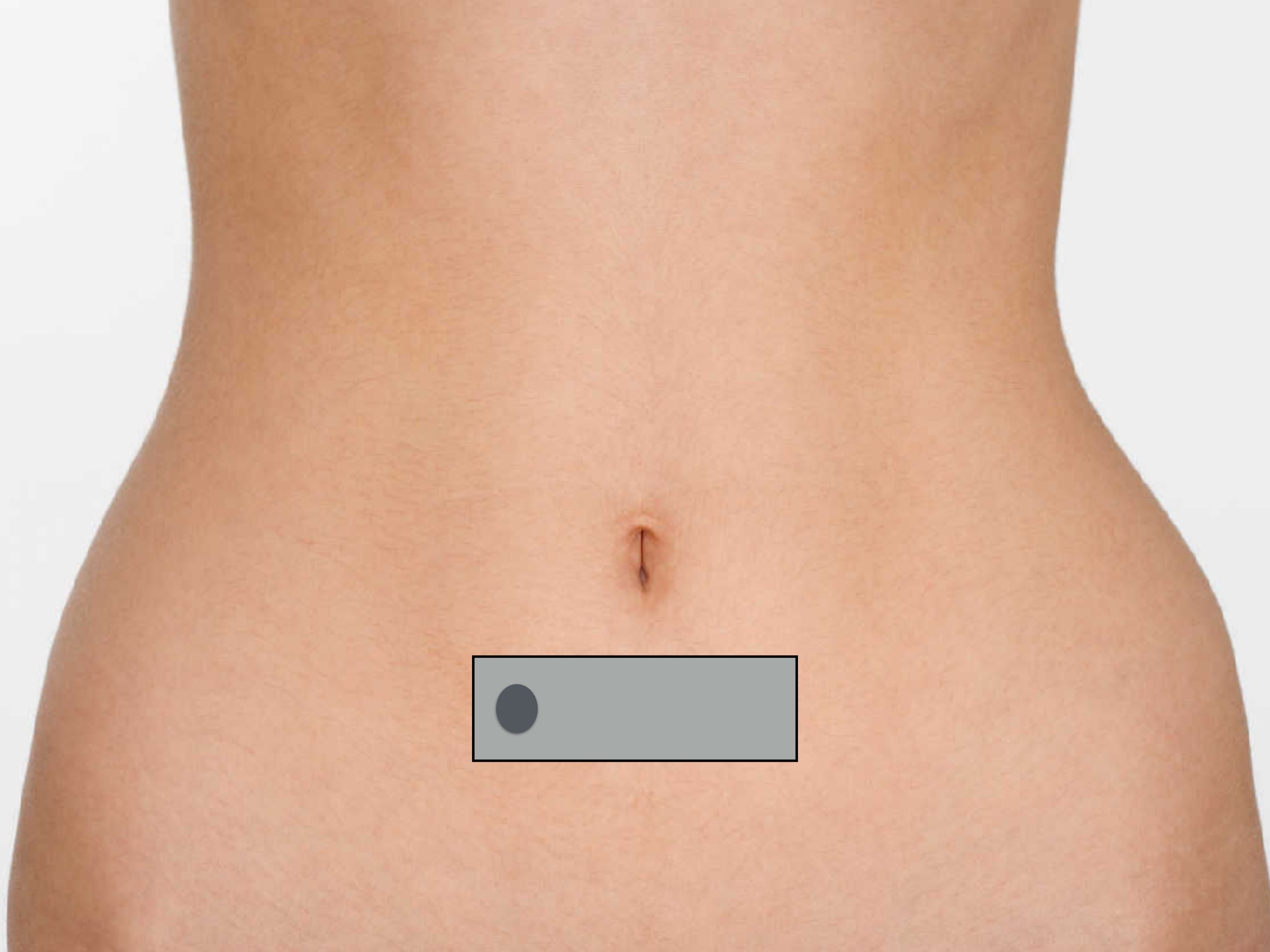
2D
HGen
Gn 100
C 56
3/3/3

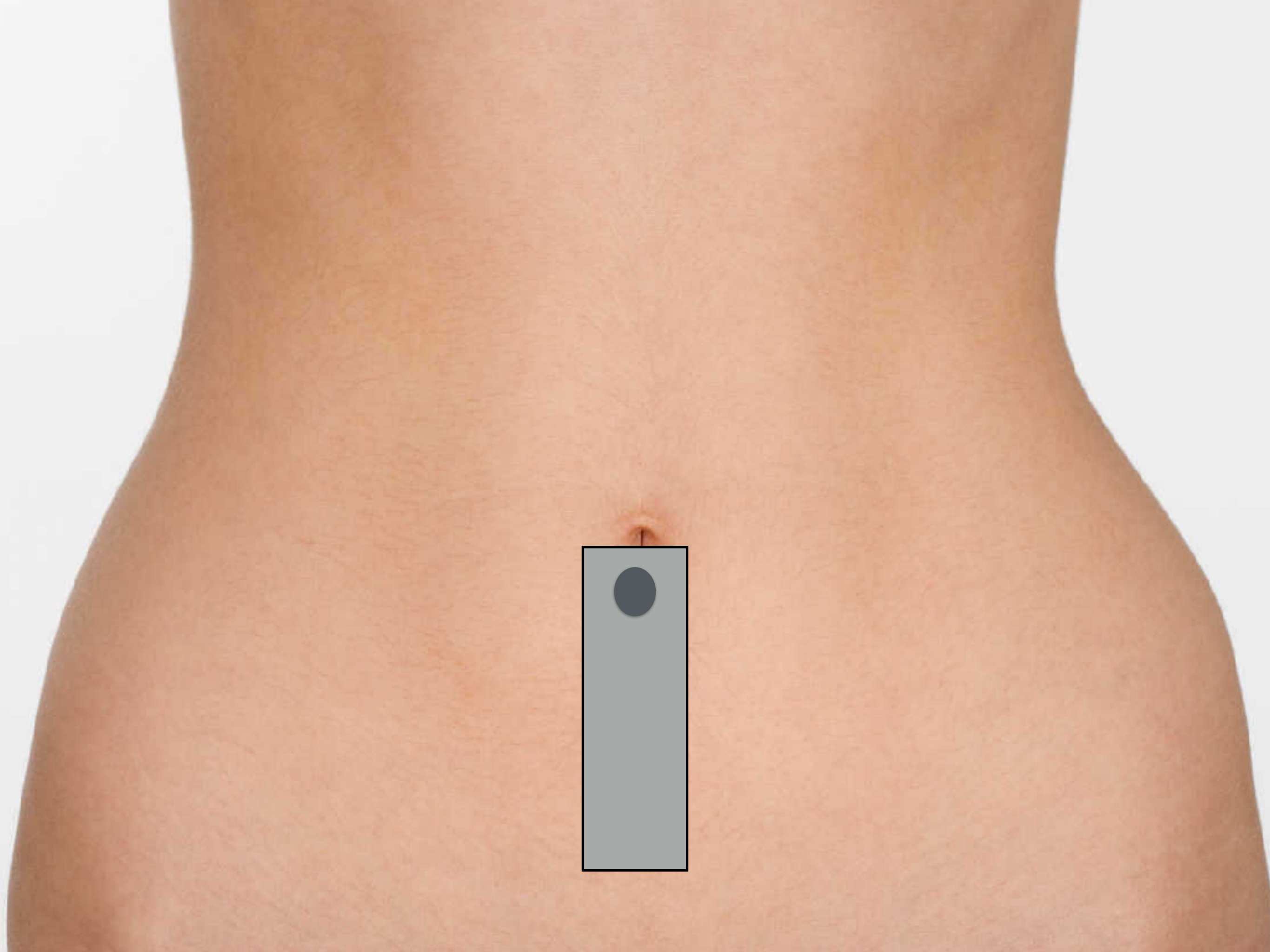








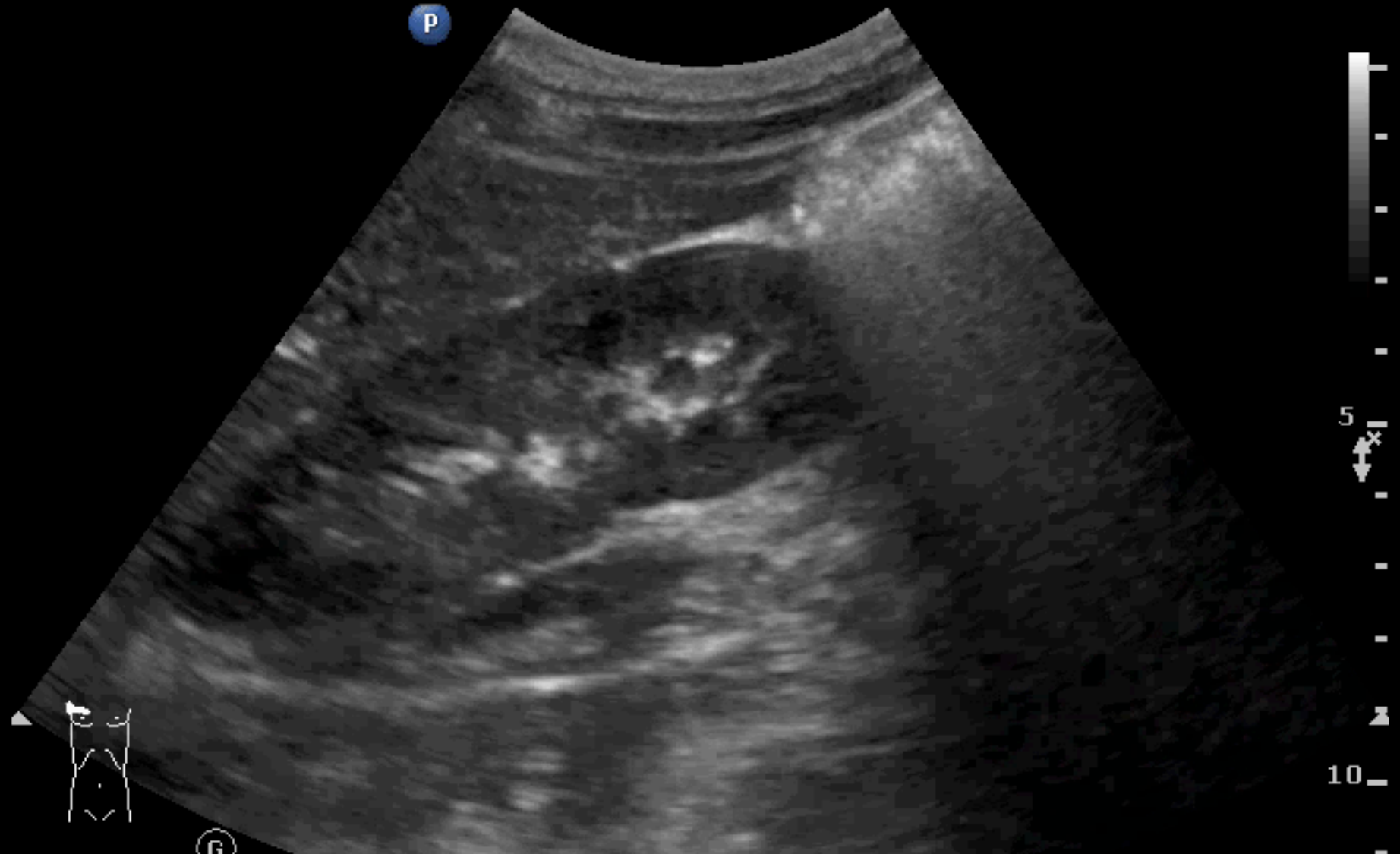




33F, low abdominal pain & shock

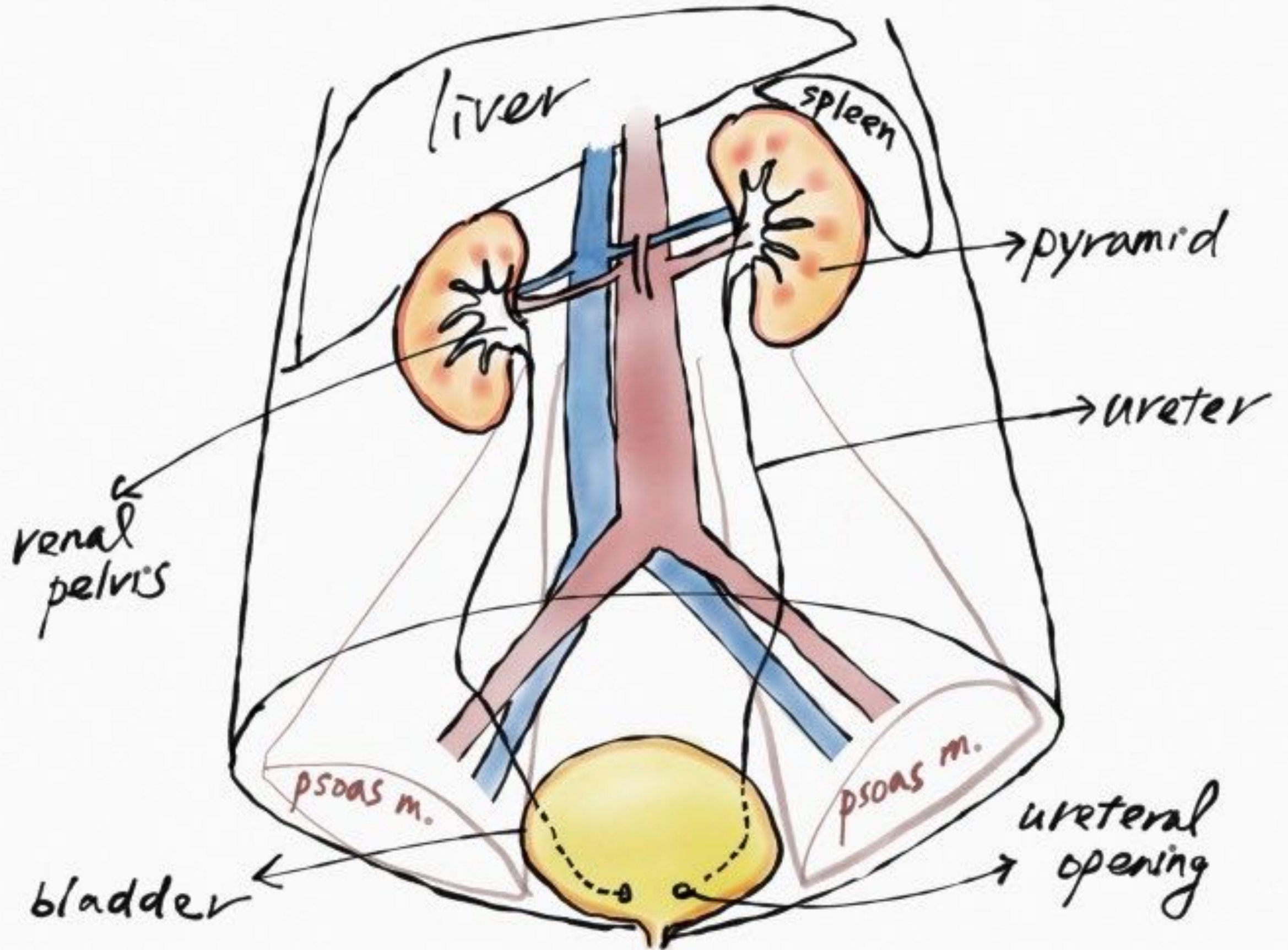
Abd Gen
C5-1
39 Hz
12.0cm

2D
HGen
Gn 71
C 56
3/3/3



FAST for moving fluid

Copyright © 2016 HSU CHZ CHAN ET. All rights reserved





Where ?




K



u



B



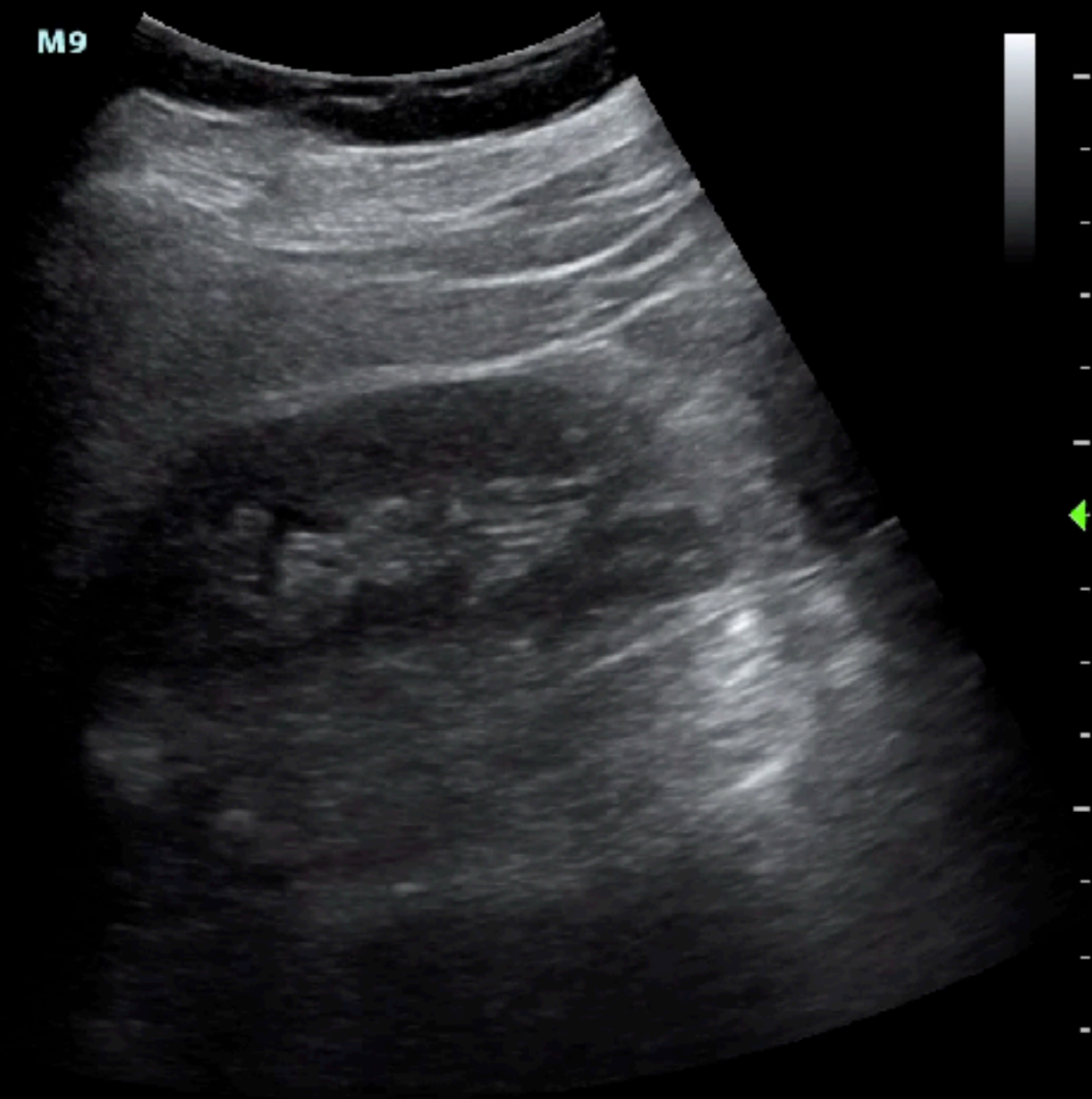
13-03-2016 16:07:02

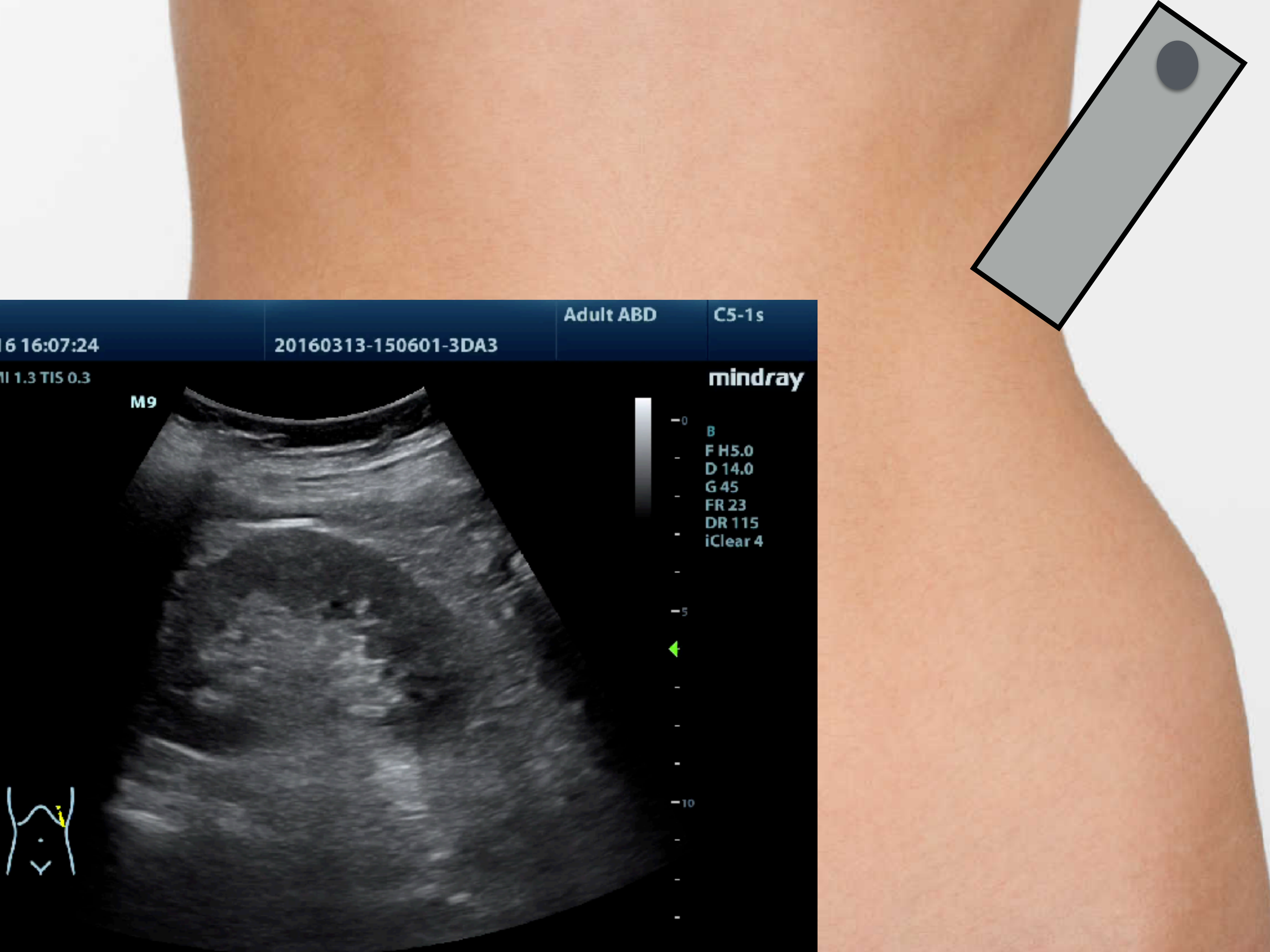
20160313-150601-3DA3

Adult ABD

AP 96.6% MI 1.3 TIS 0.3

M9





16 16:07:24 20160313-150601-3DA3 Adult ABD C5-1s

MI 1.3 TIS 0.3 **mindray**

M9

-0
B
F H5.0
D 14.0
G 45
FR 23
DR 115
iClear 4

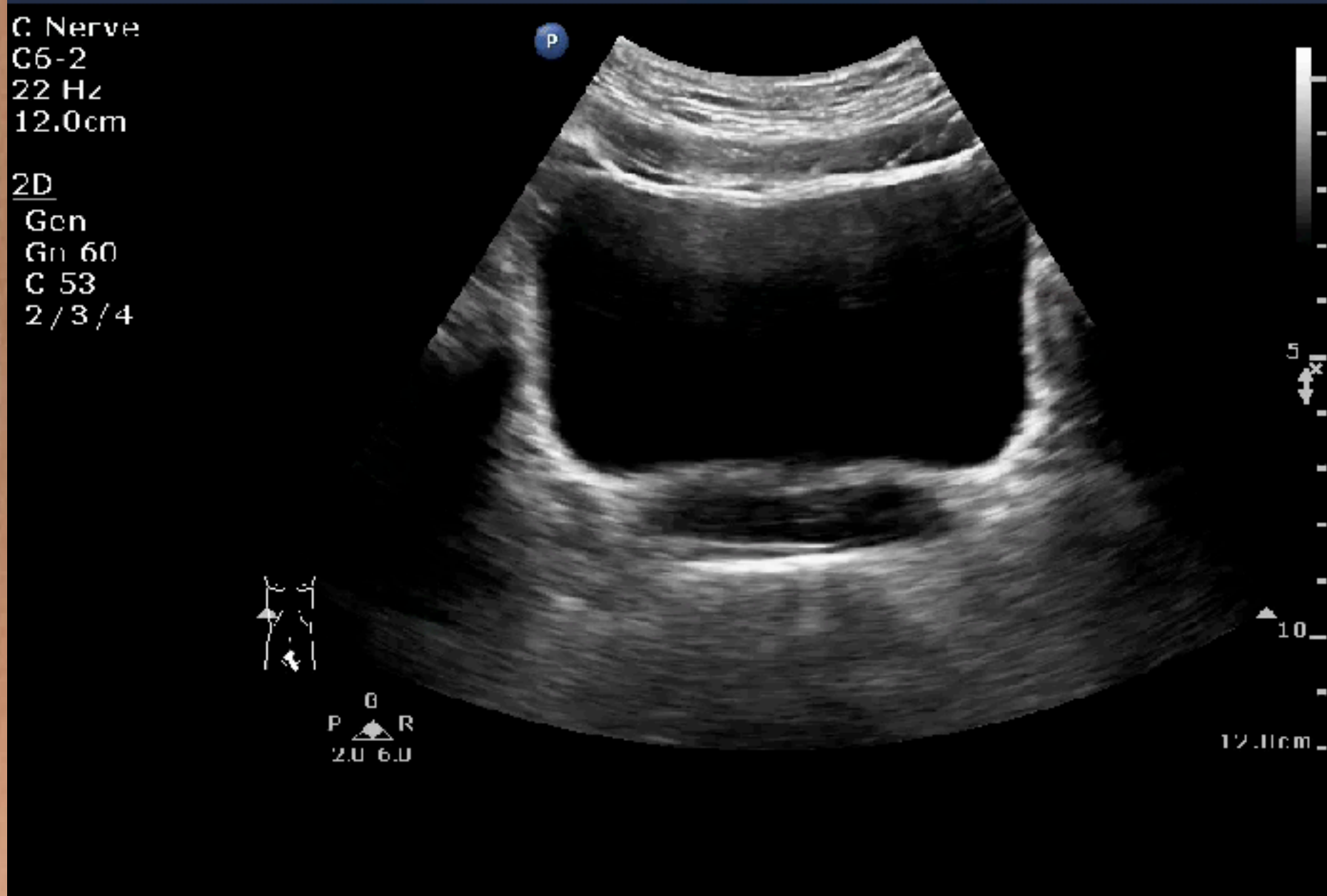
-5

-10




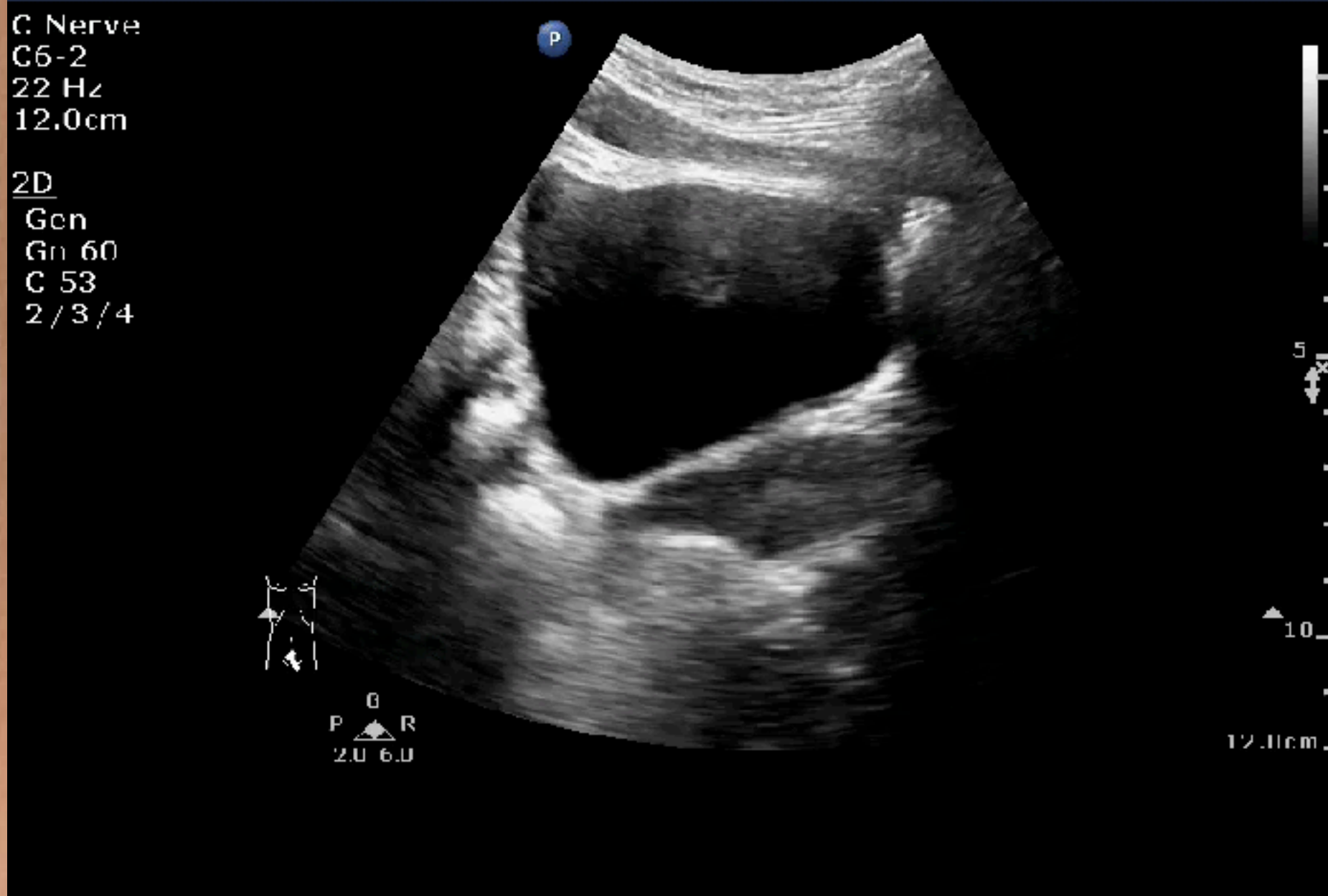
C. Nerve
C6-2
22 Hz
12.0cm

2D
Gen
Gn 60
C 53
2/3/4

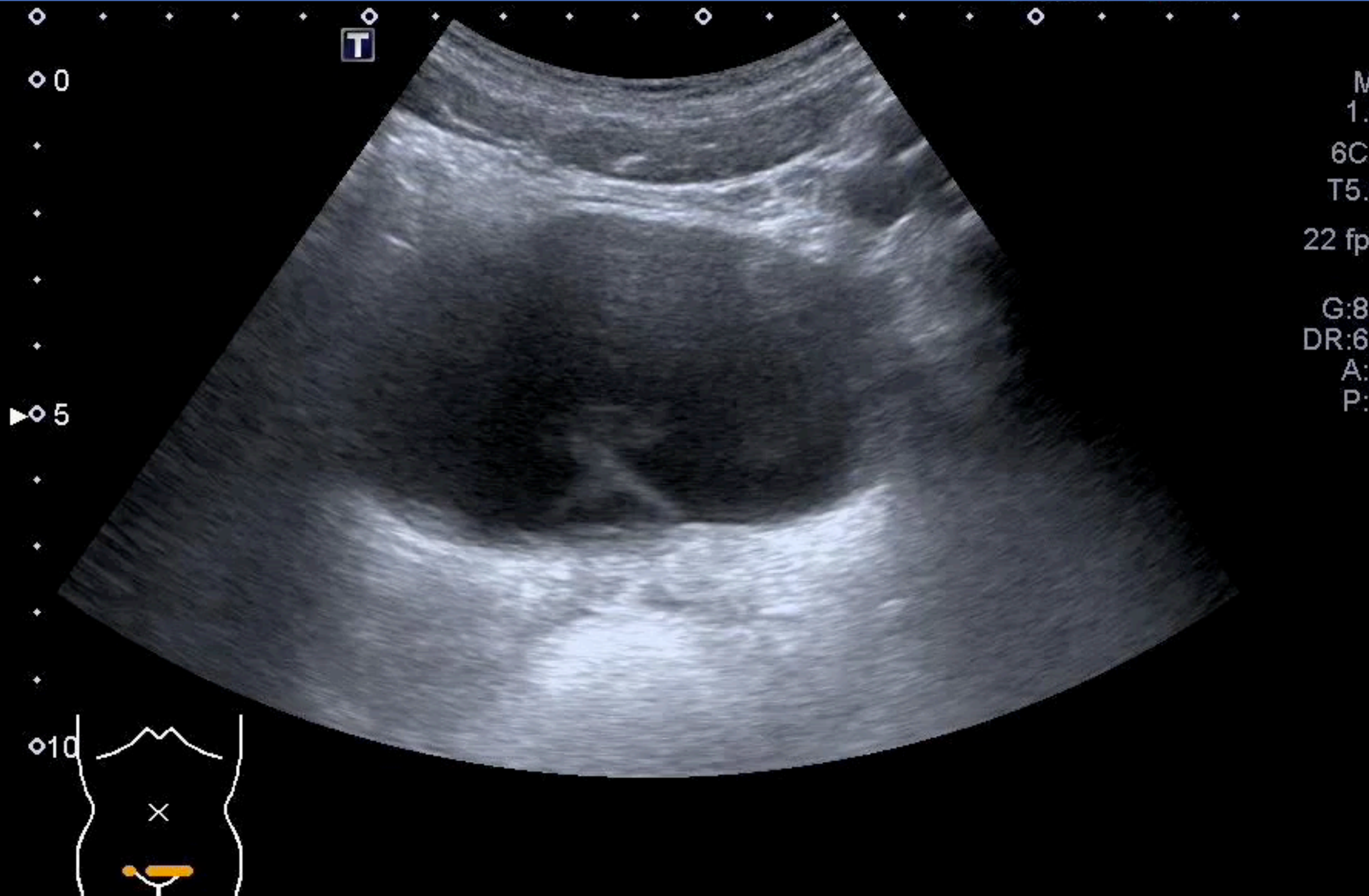


C. Nerve
C6-2
22 Hz
12.0cm

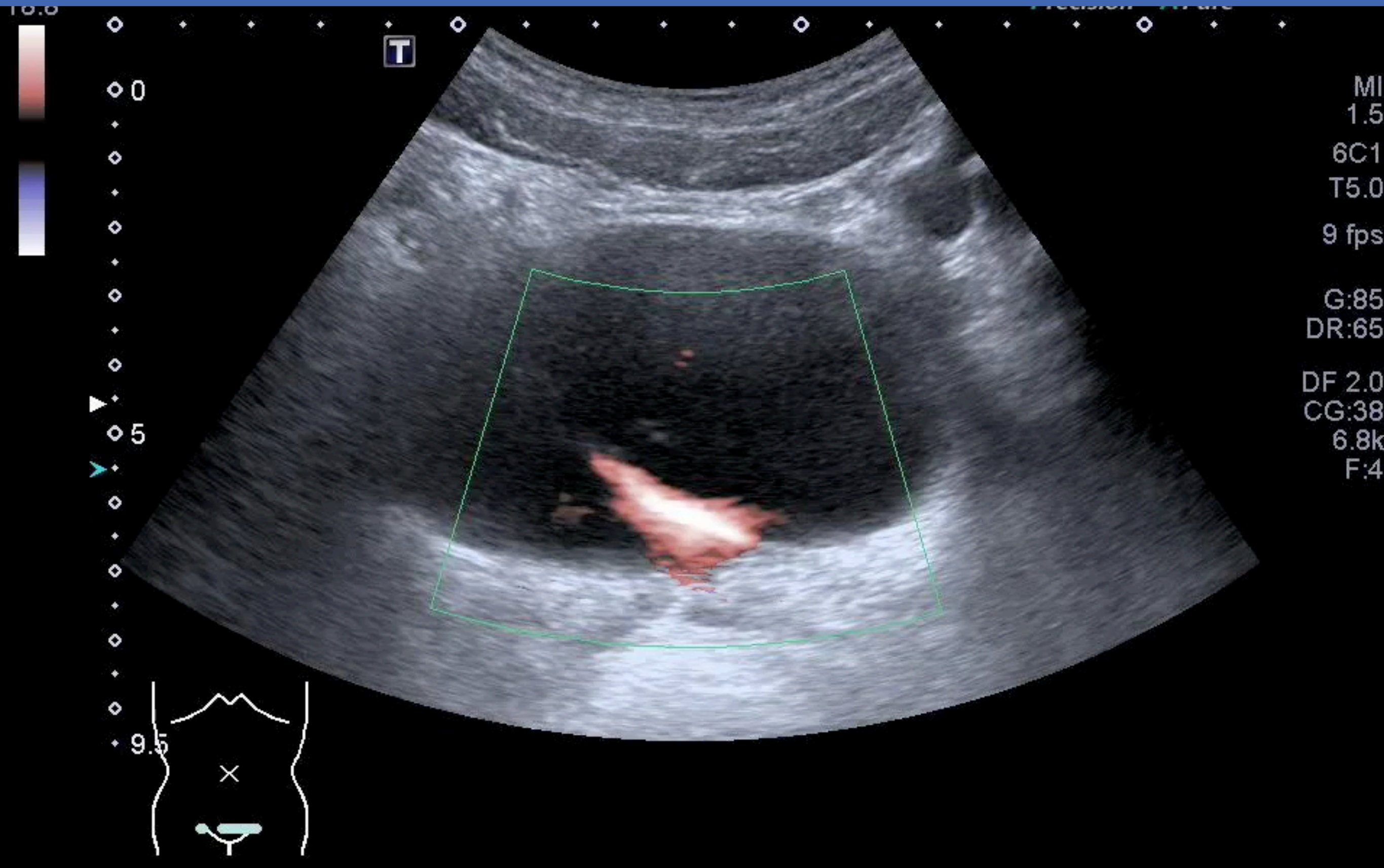
2D
Gen
Gn 60
C 53
2/3/4



Urinary jet



Urinary jet



When will you use US ?

Pain

Infection

Failure

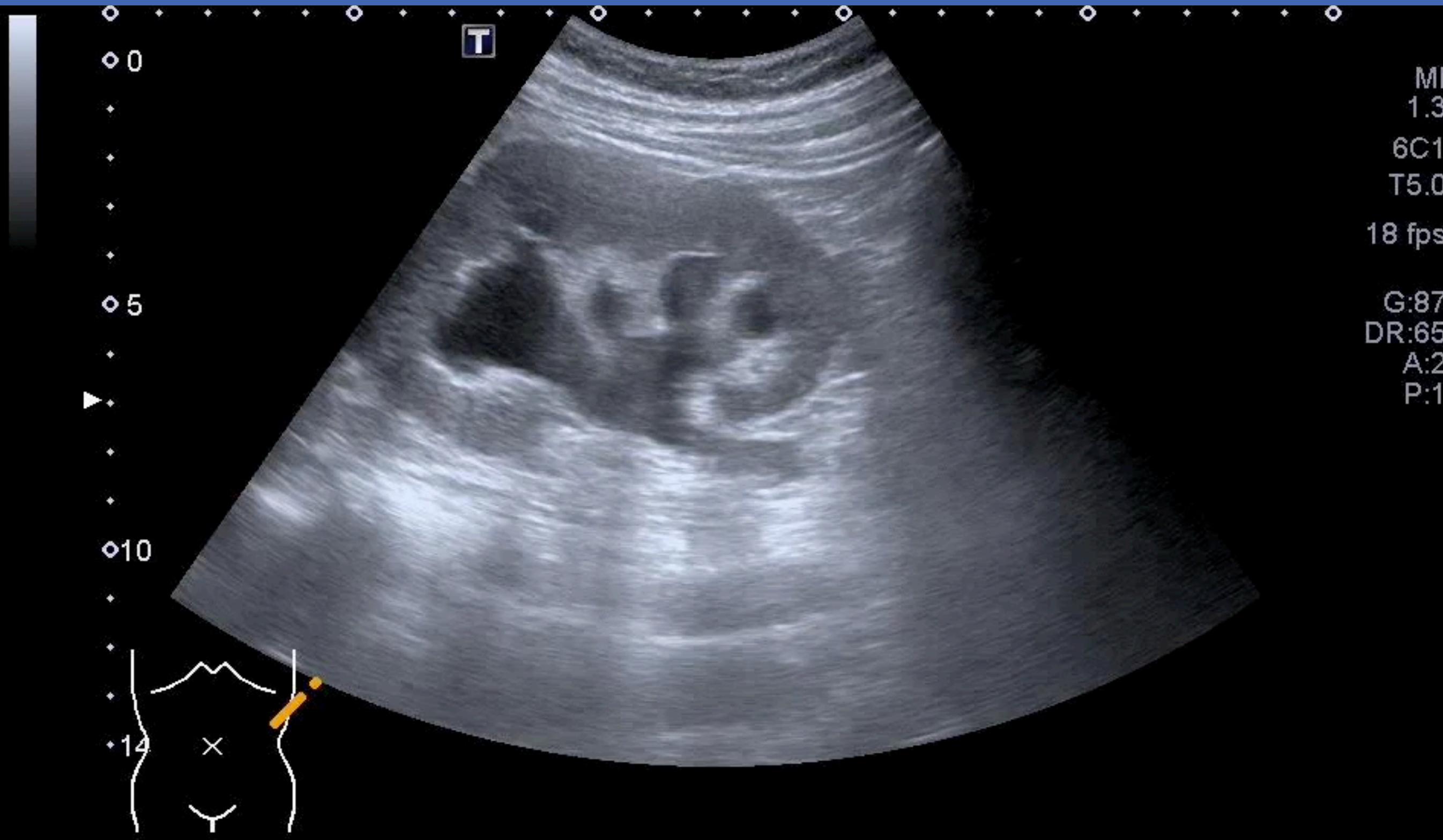
GU emergency

POCUS first

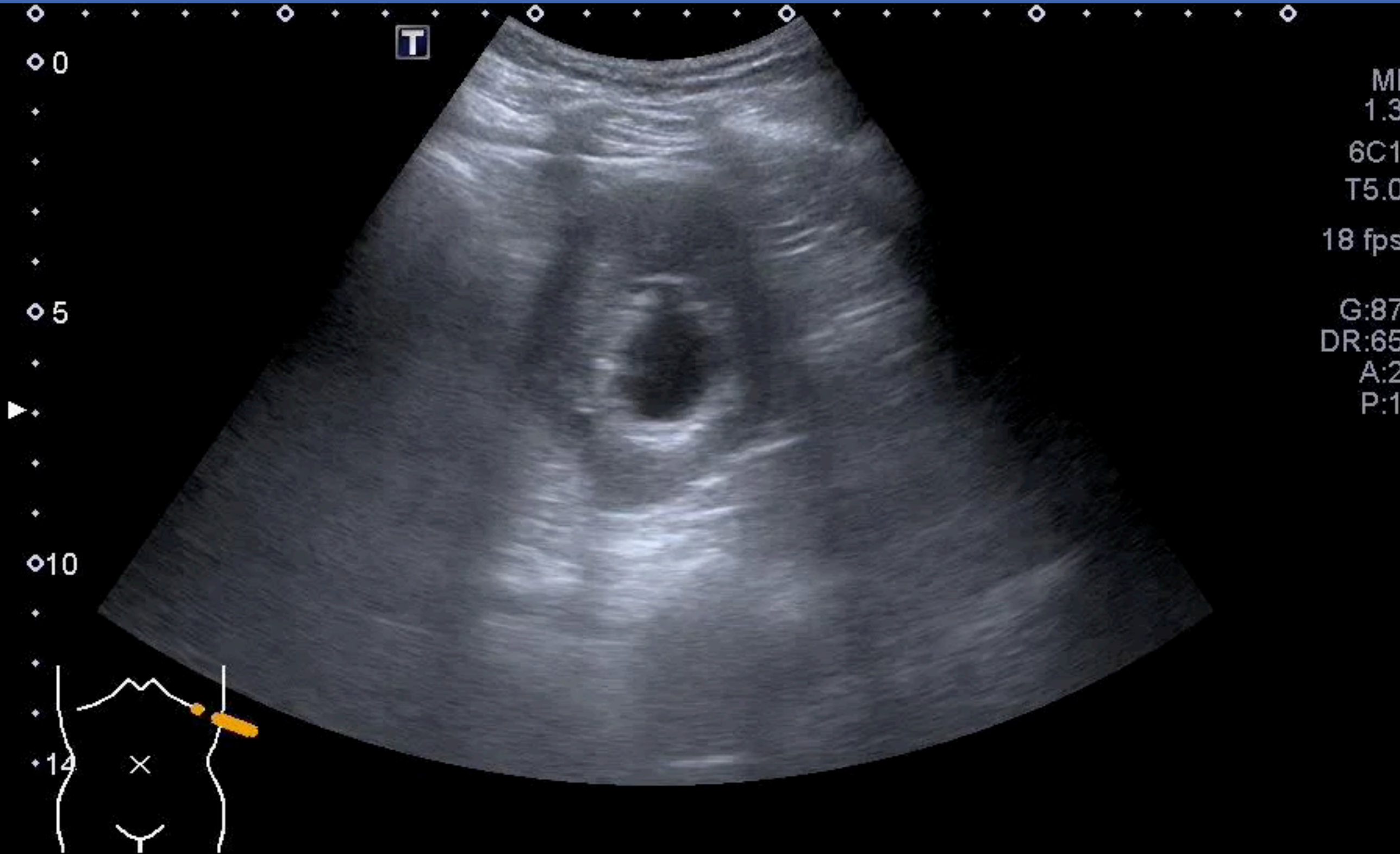
or

Urine first

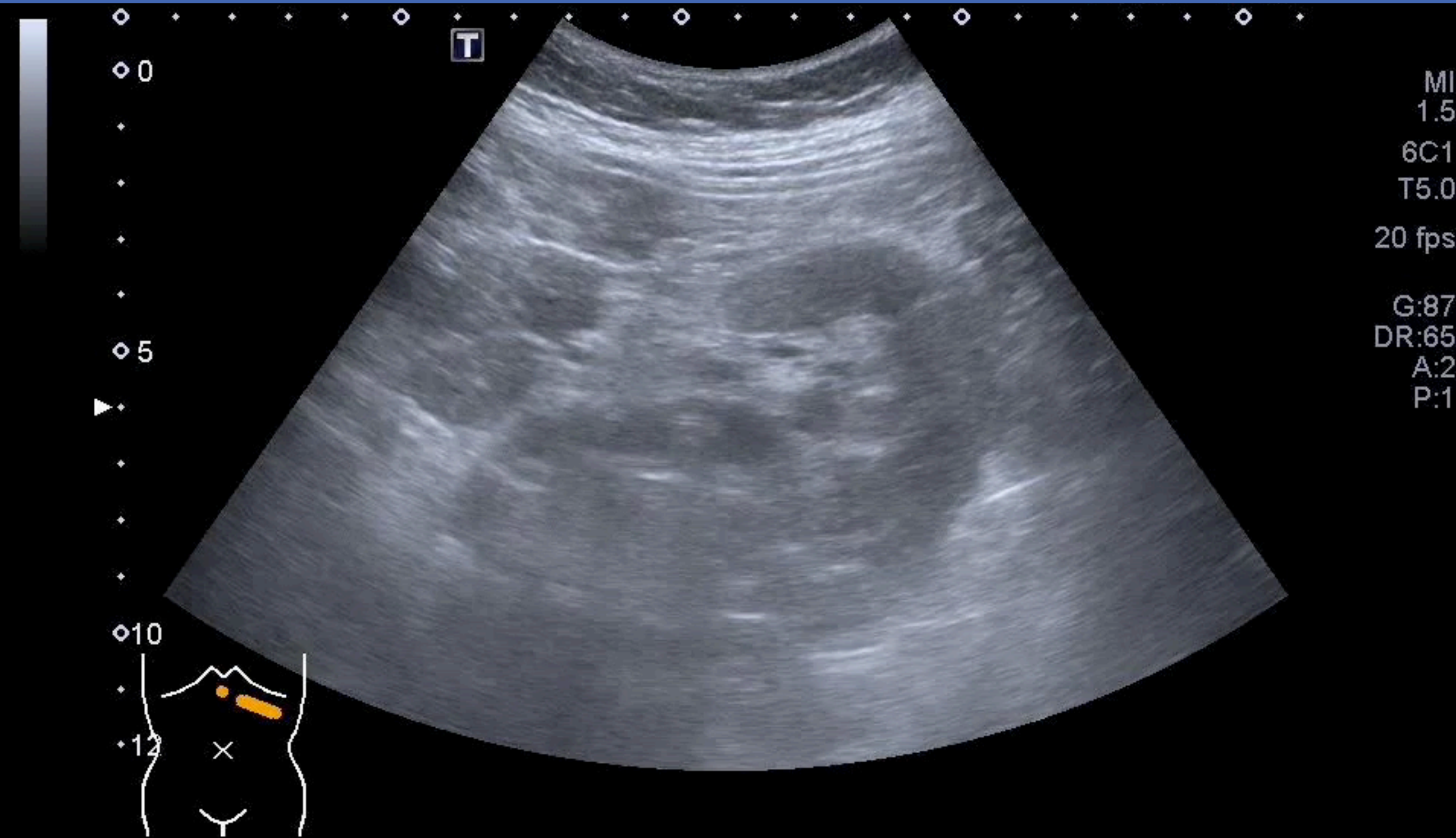
What do you see ?



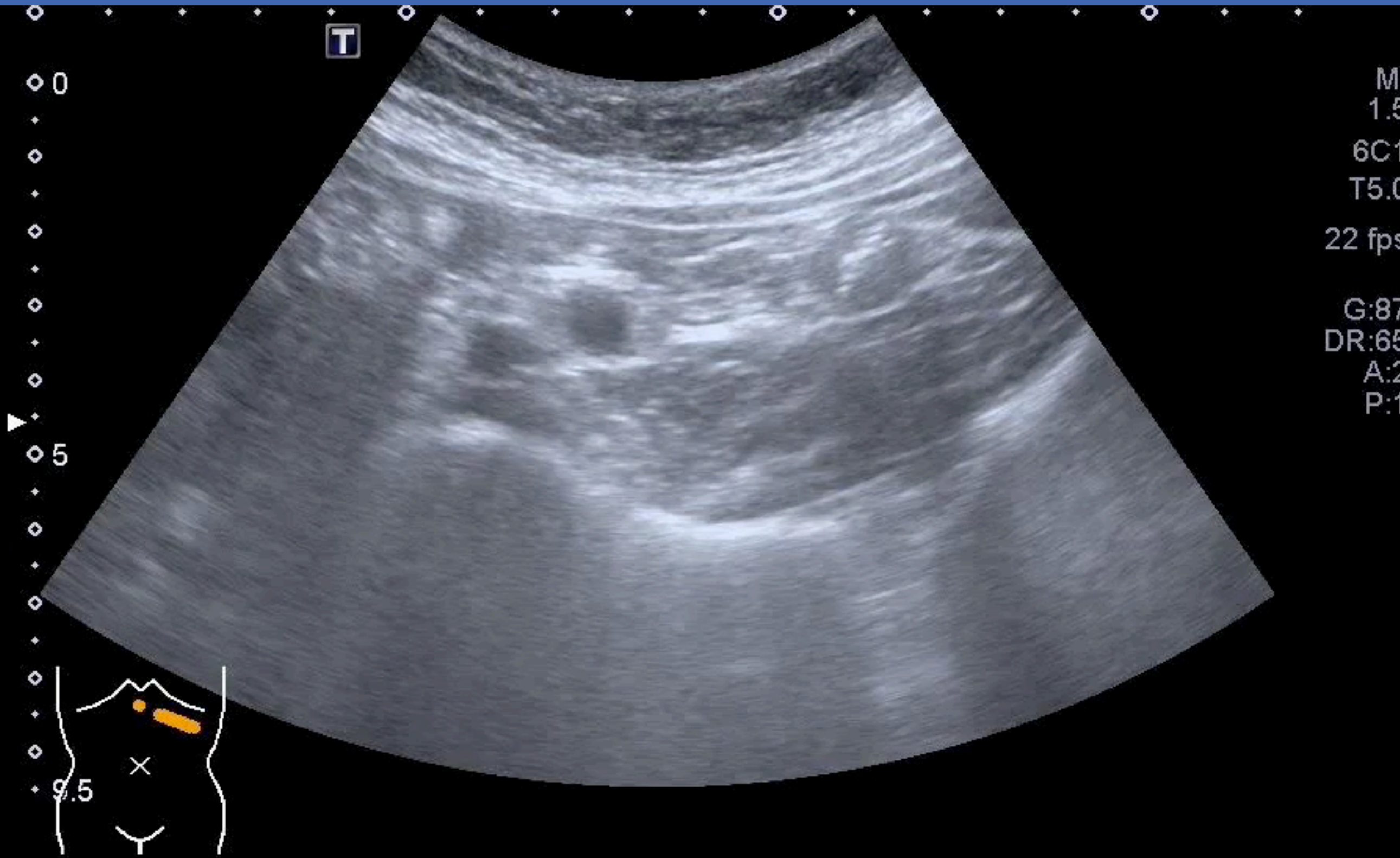
Where is ureter ?



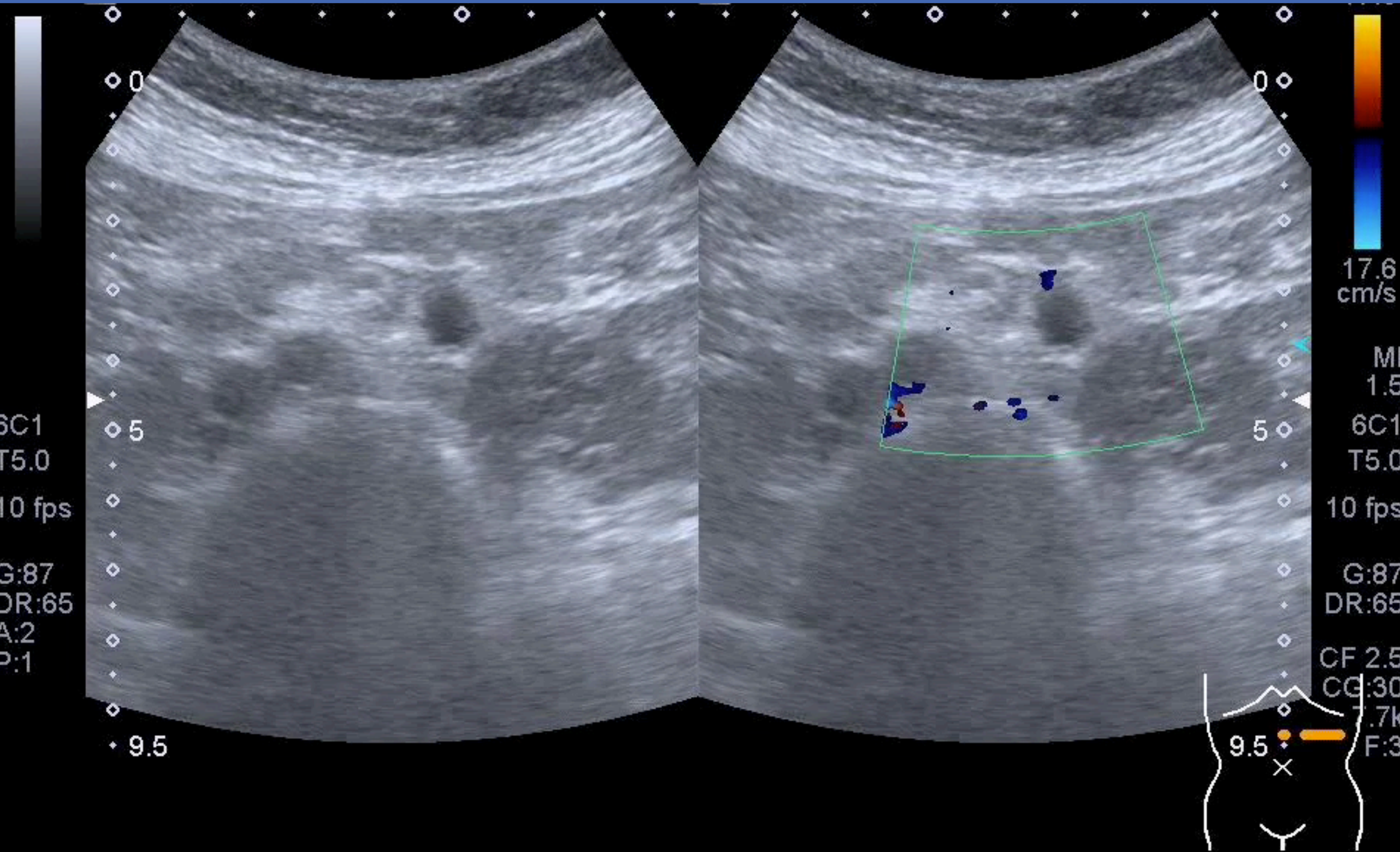
How to move the probe ?

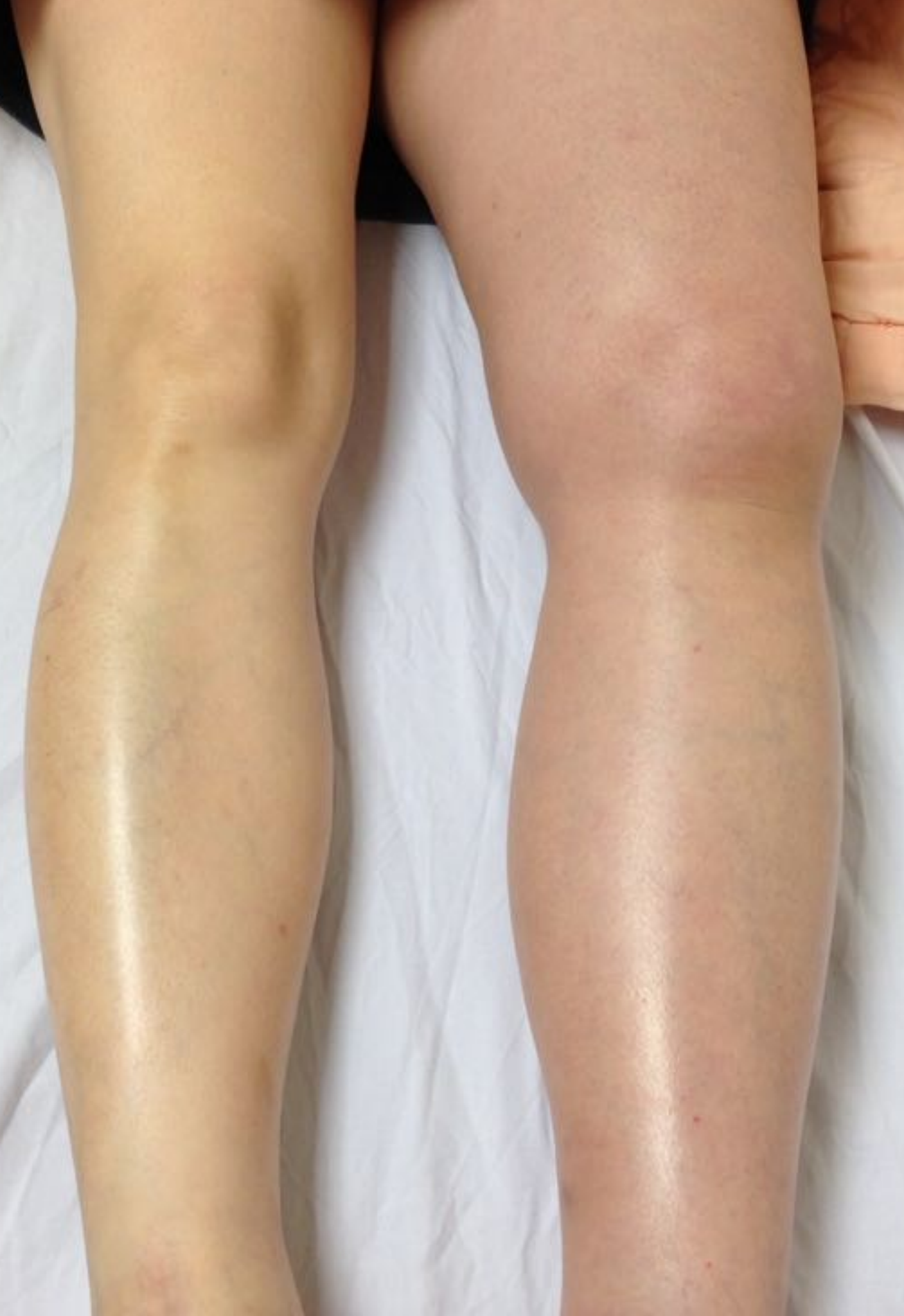

What is the skill ?



Twinkling artifact





**A swollen leg,
what will you do
??**



Cellulitis

Abscess

N.F.

DVT

Others ?



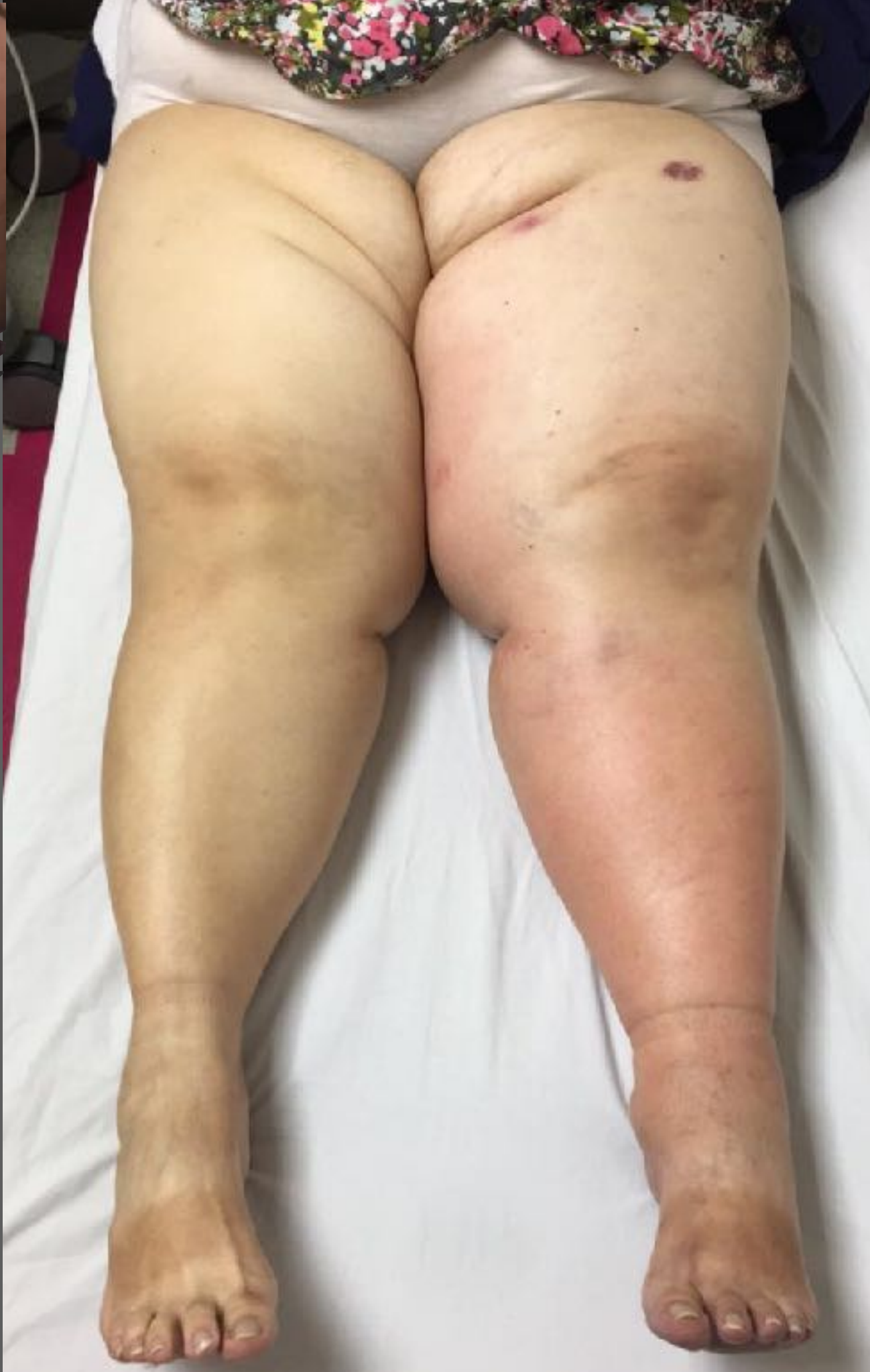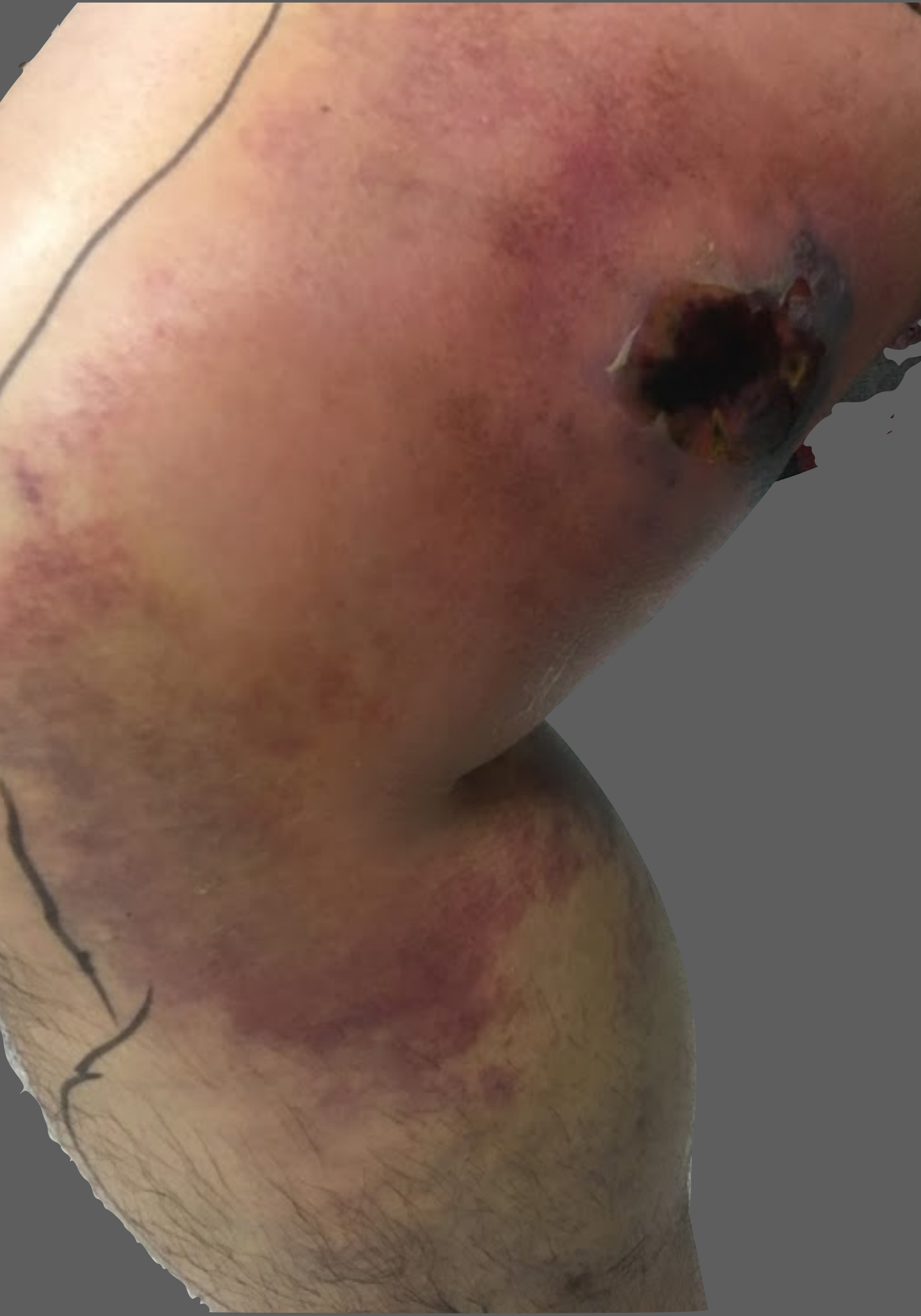Cellulitis

Abscess

N.F.

DVT

Others ?



Wells score for DVT assessment

Active cancer (patient receiving treatment for cancer within the previous 6 months or currently receiving palliative treatment)	1
Paralysis, paresis, or recent plaster immobilization of the lower extremities	1
Recently bedridden for ≥ 3 days, or major surgery within the previous 12 weeks requiring general or regional anesthesia	1
Localized tenderness along the distribution of the deep venous system	1
Entire leg swollen	1
Calf swelling at least 3 cm larger than the asymptomatic side (measured 10 cm below the tibial tuberosity)	1
Pitting edema confined to the symptomatic leg	1
Collateral superficial veins (nonvaricose)	1
Previously documented deep venous thrombosis	1
Alternative diagnosis at least as likely as deep venous thrombosis	-2

≥ 2

Pretest <
2

+

D-dimer
-ve





Likely

+ve D

US

Transducers

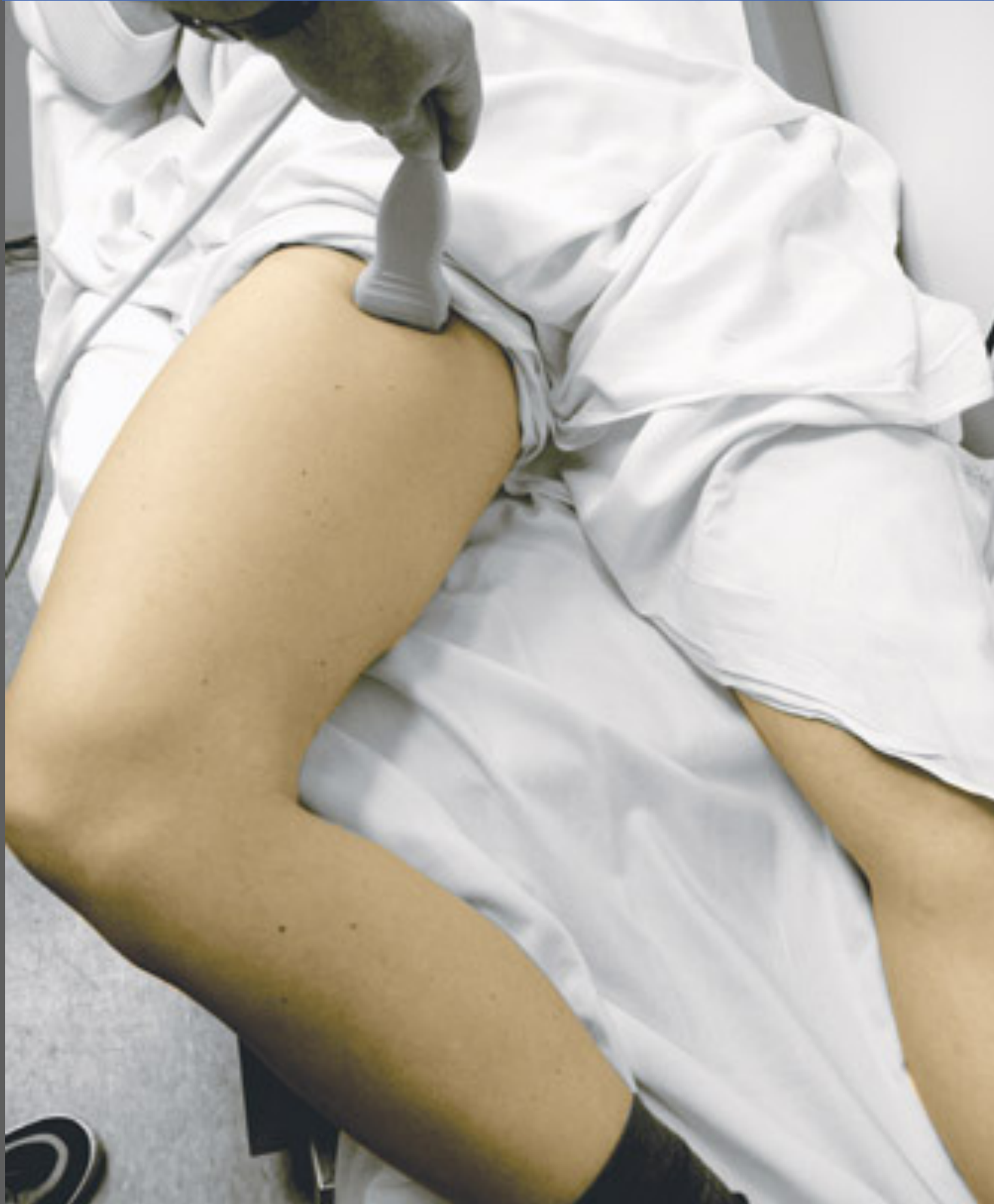

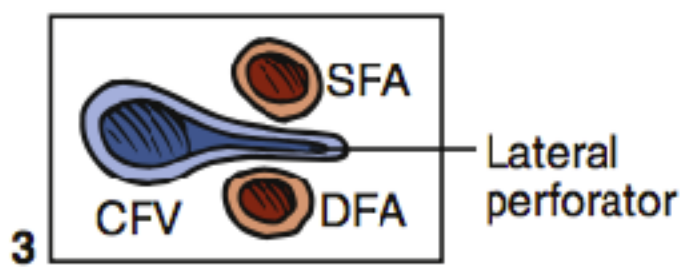
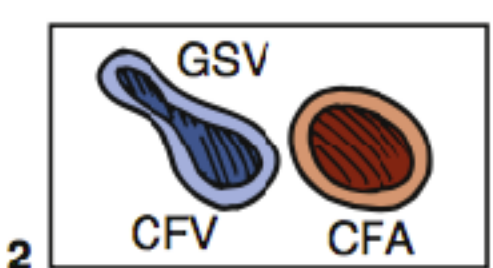
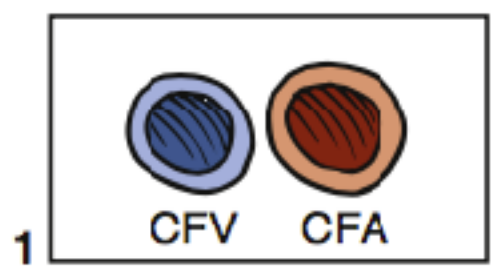
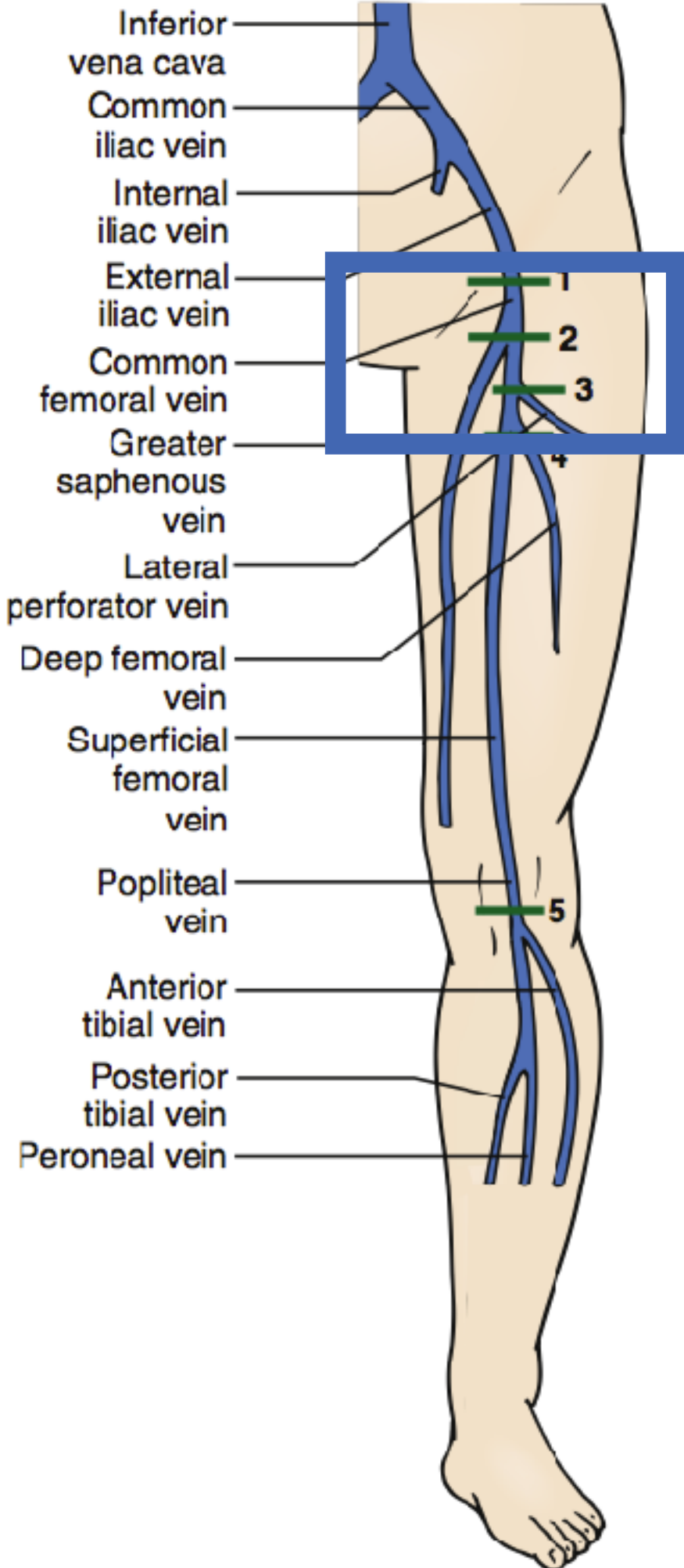
Transverse

Compression

3 regions

Position



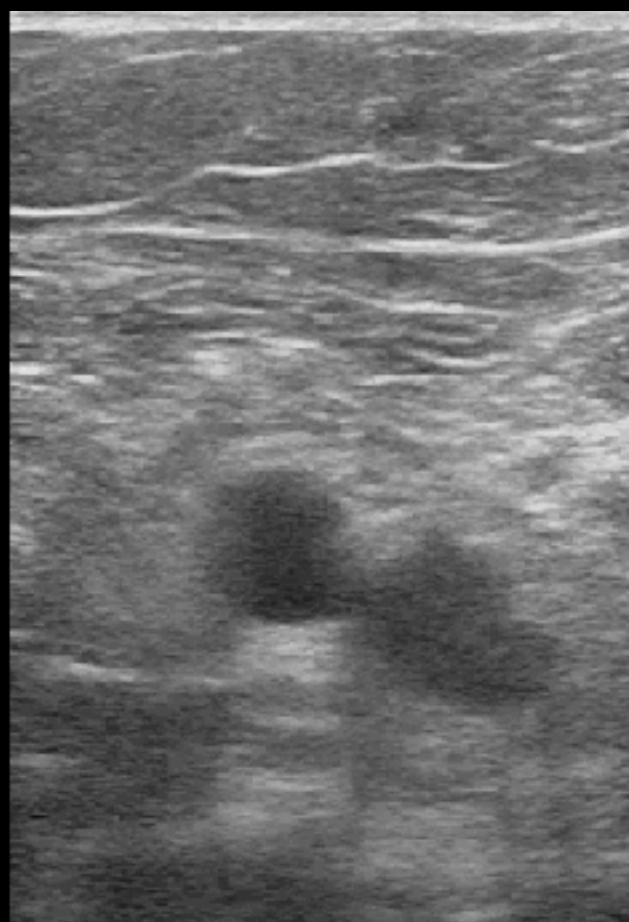


4

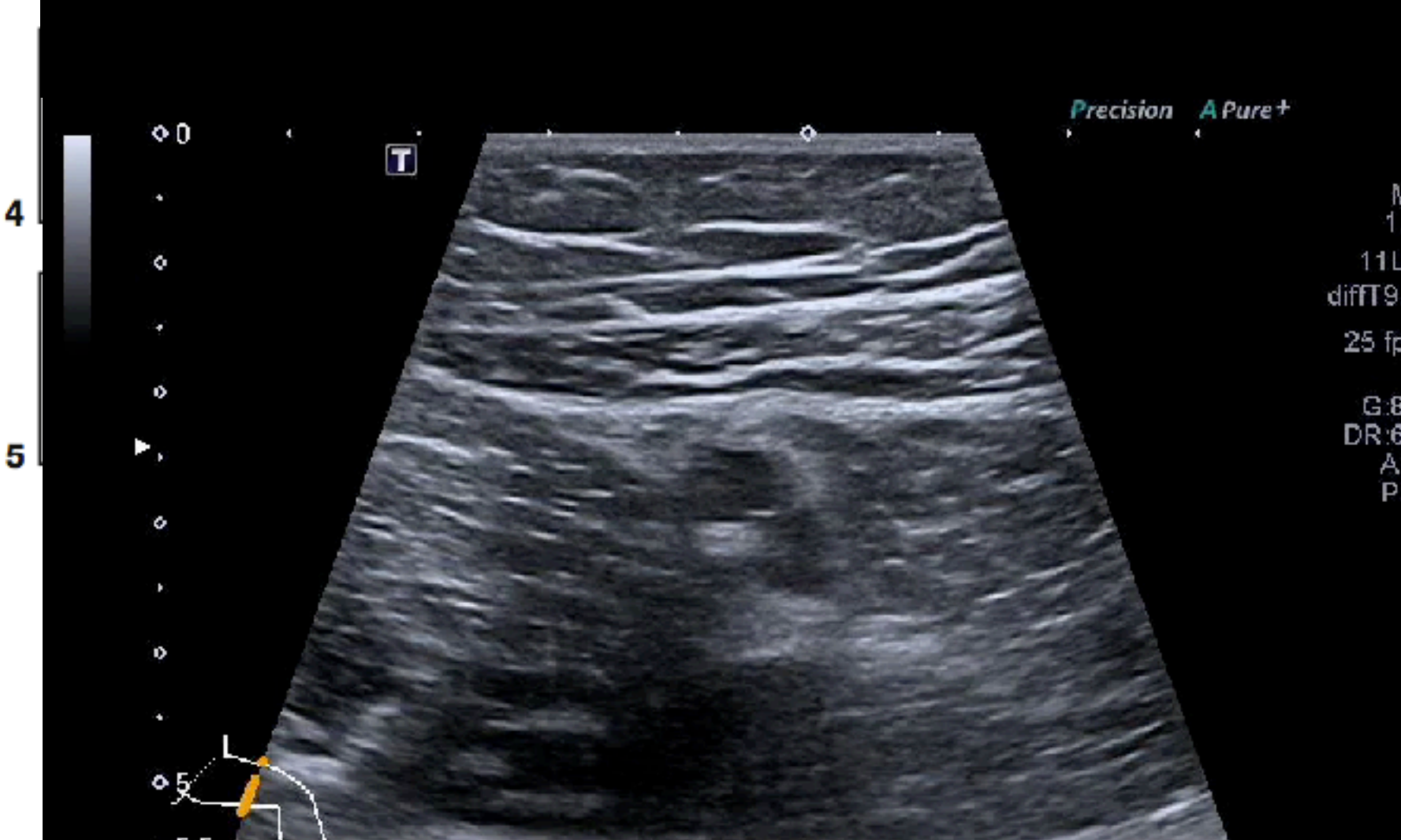
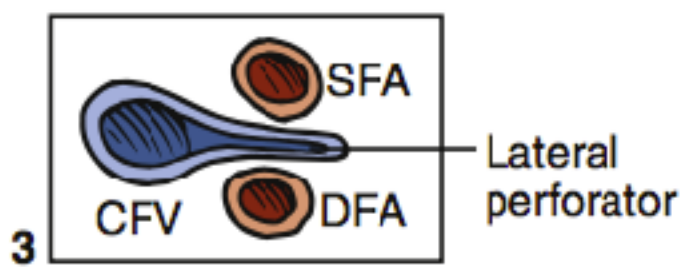
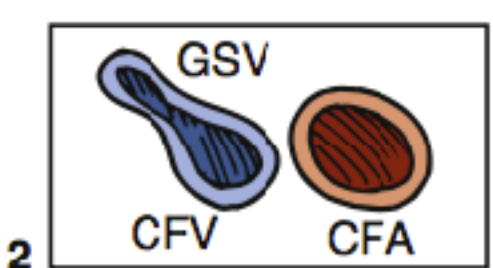
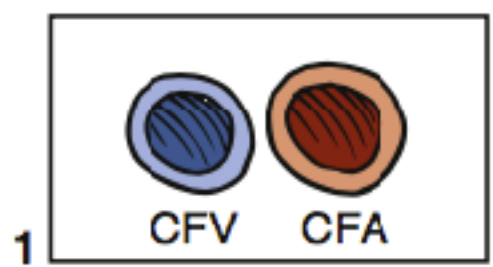
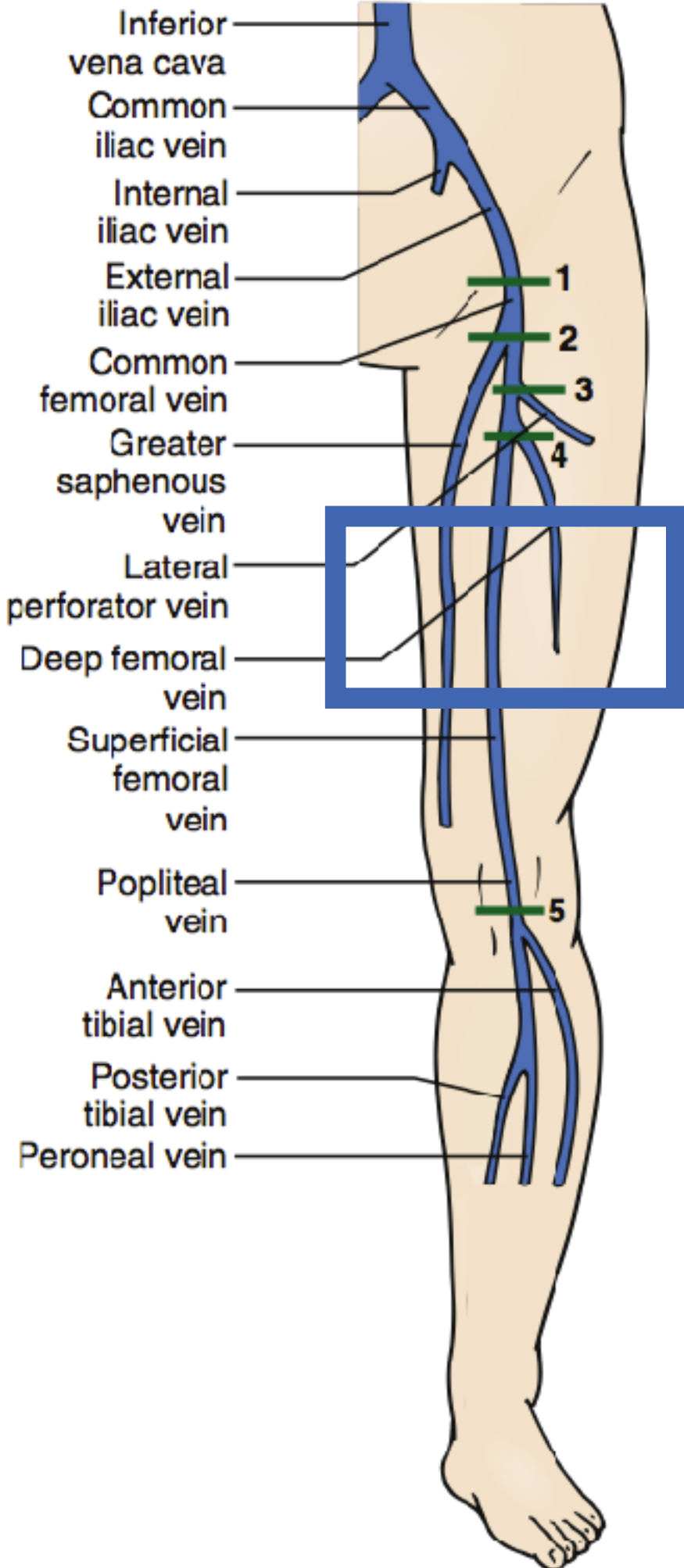
Venous
L12-3
31 Hz
6.0cm

5D
HGen
(in 11)
C 41
3/3/2

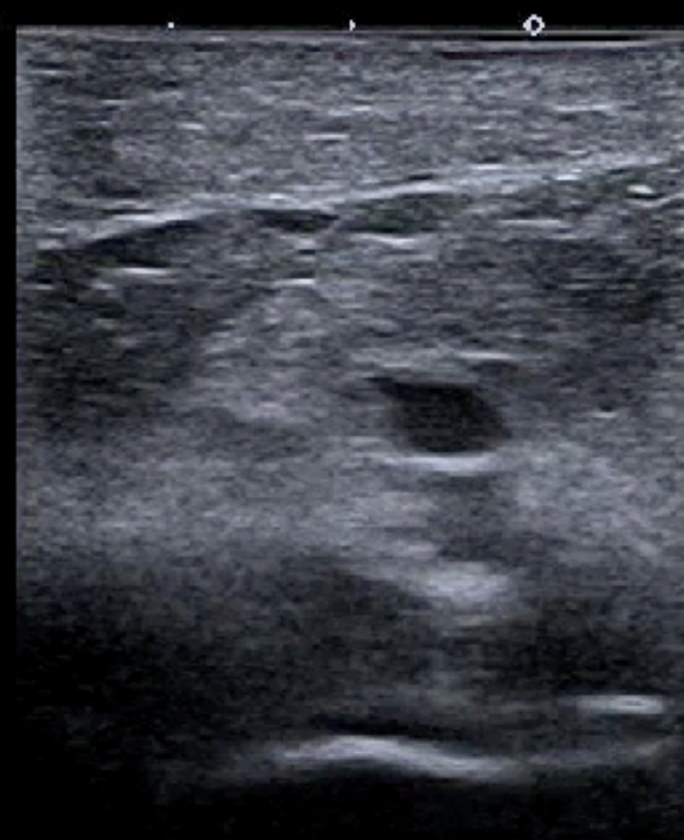

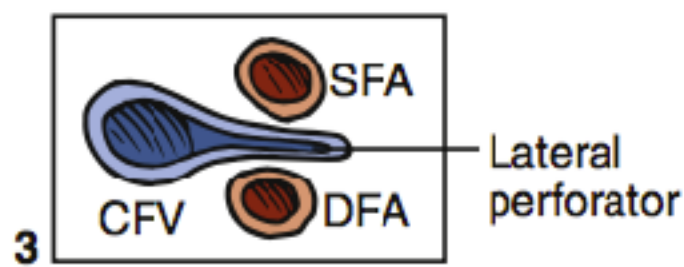
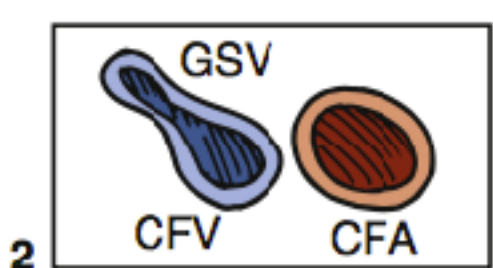
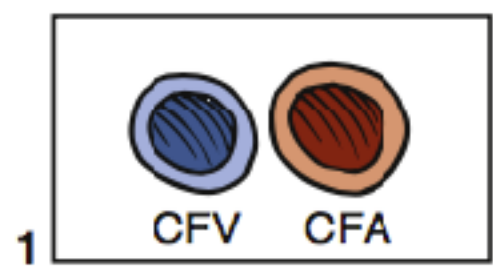
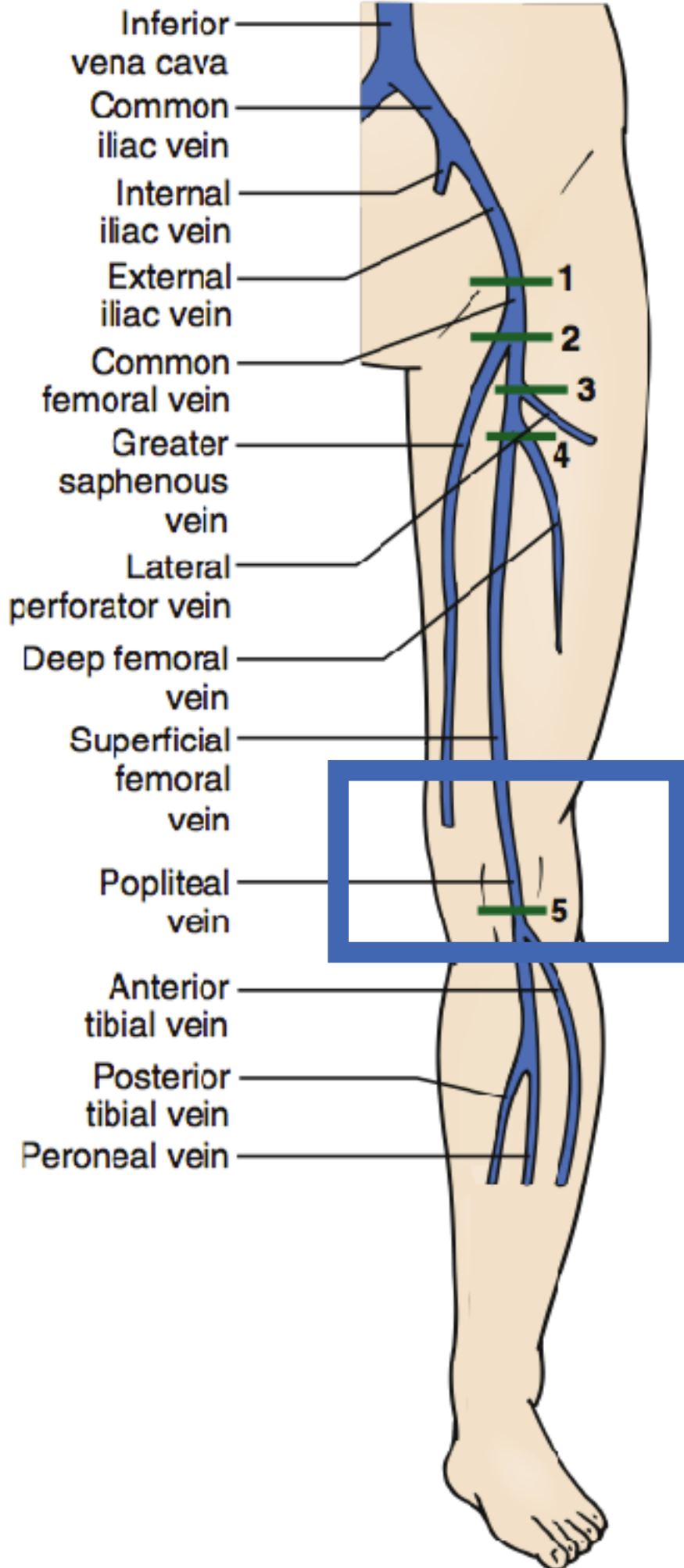
5



3



3



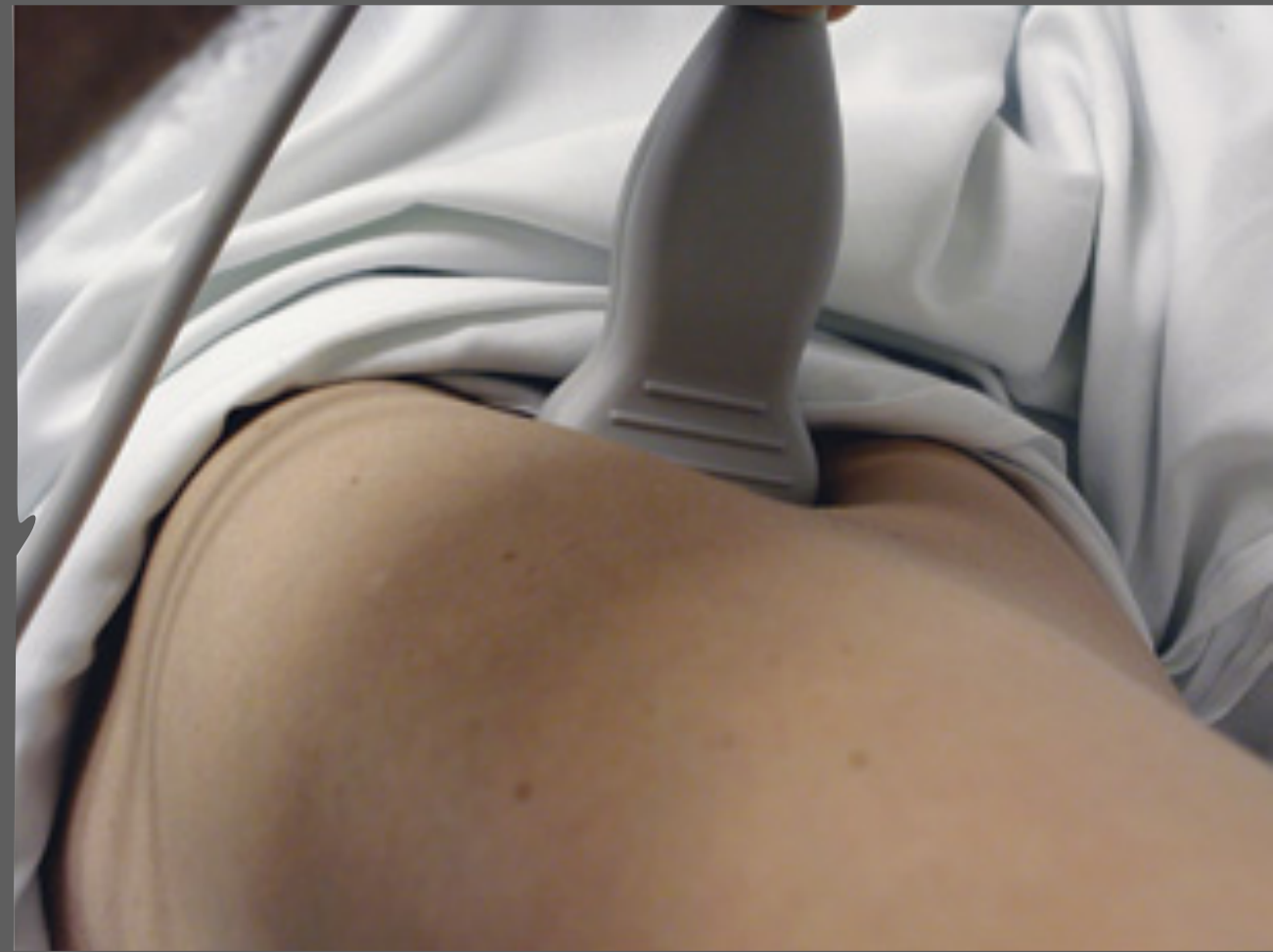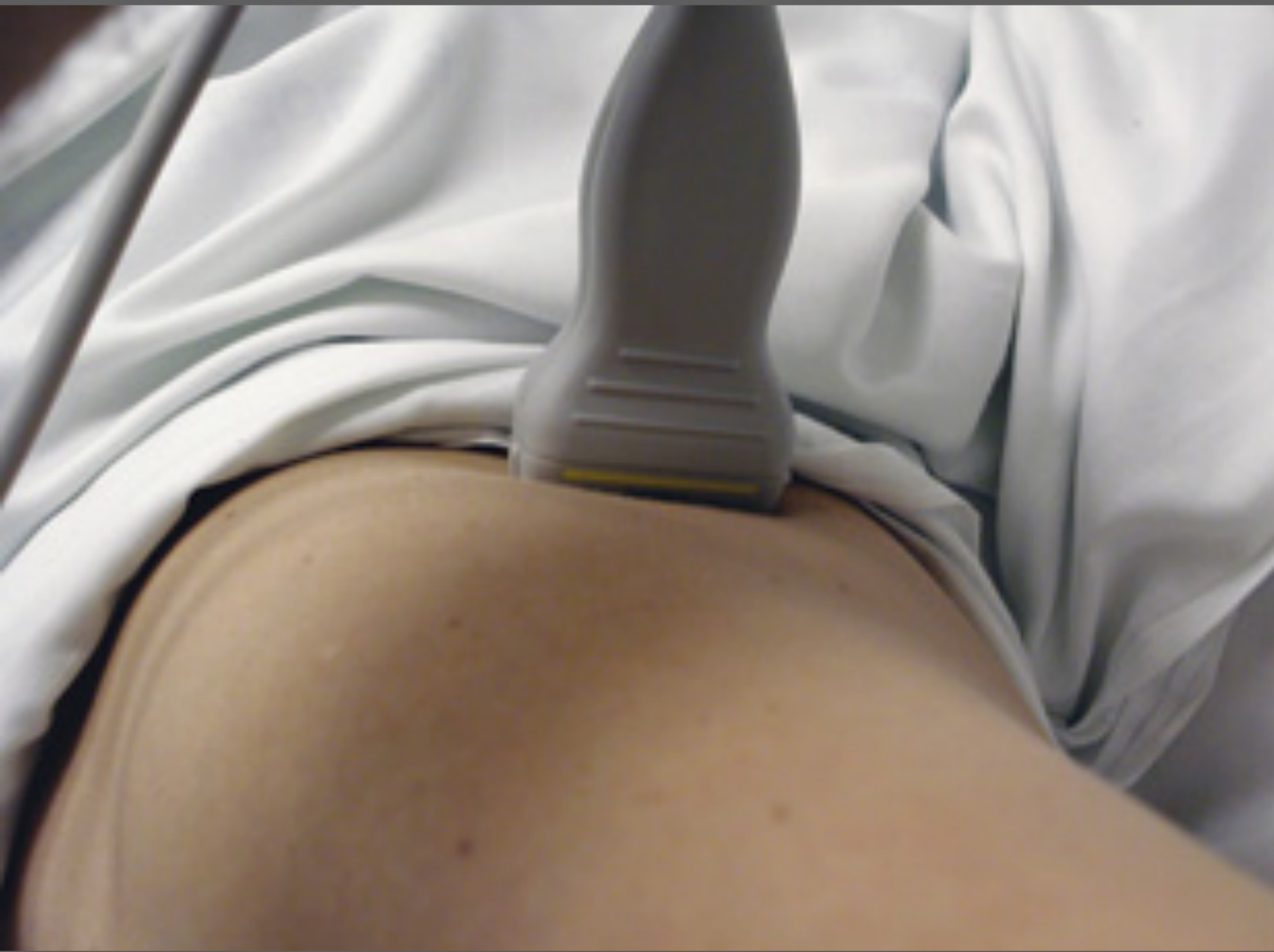Precision APure+

MI 1.5
 11L4
 diffT9.0
 27 fps
 G:88
 DR:60
 A:6
 P:3

3

Compression

Pressure ?
No vessels ?



Inability to **completely compress** the venous lumen

Presence of a clot

Inadequate position or pressure

CFV

Venous
L12-3
37 Hz
4.0cm

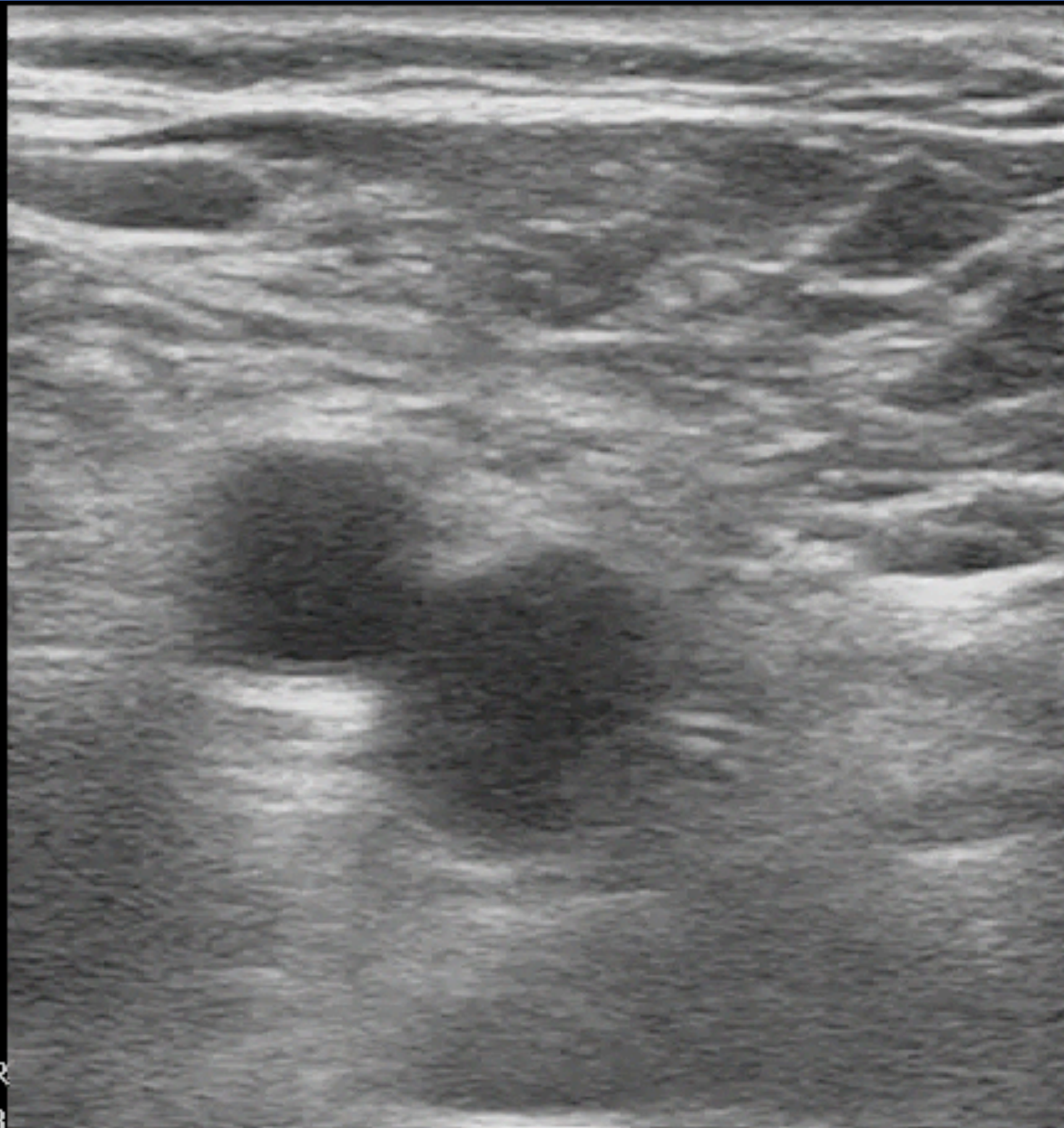
2D

HGen
Gn 96
C 41
3 / 3 / 2

P



G
P R
4.4 8.8

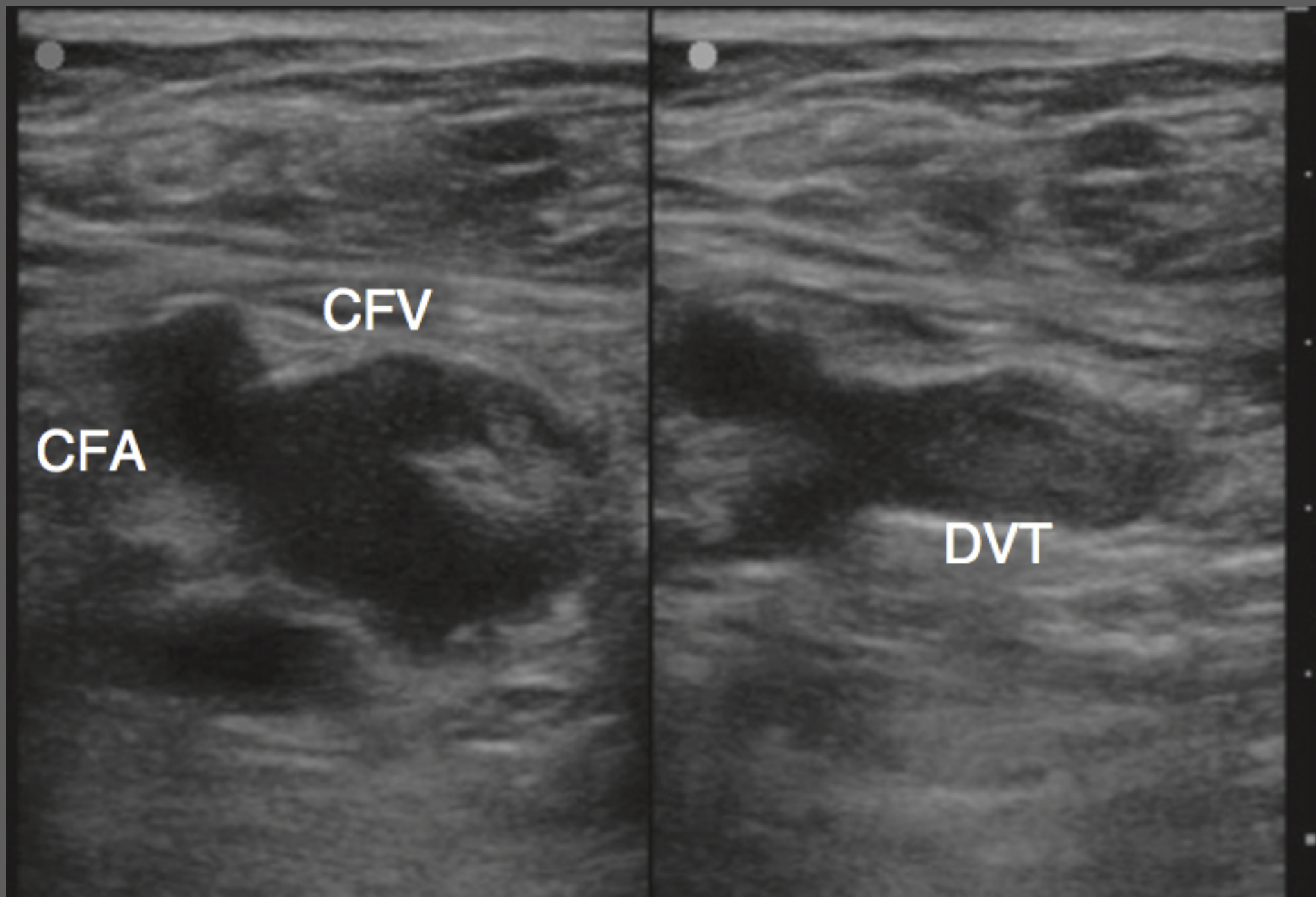


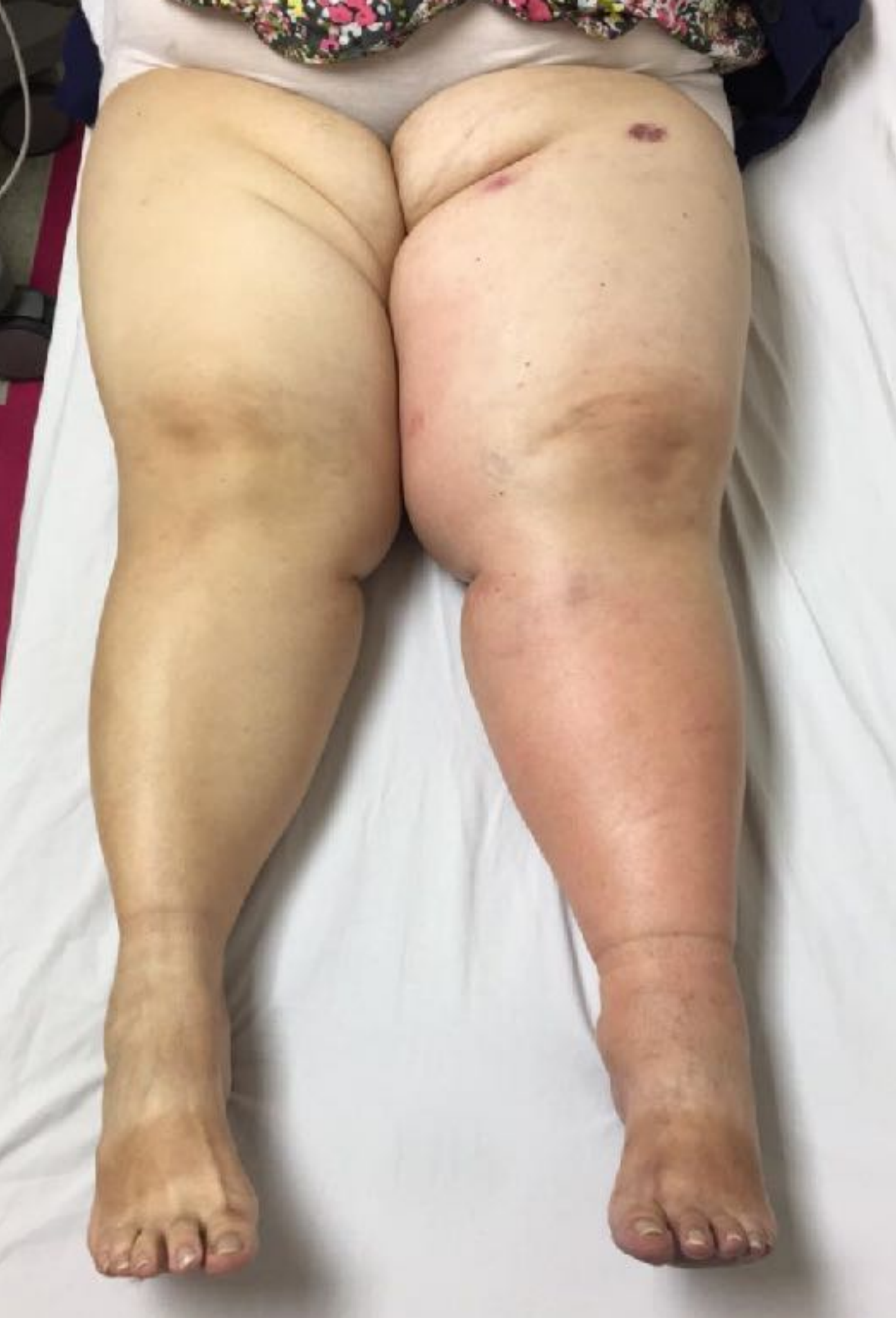2

4.0cm

Document

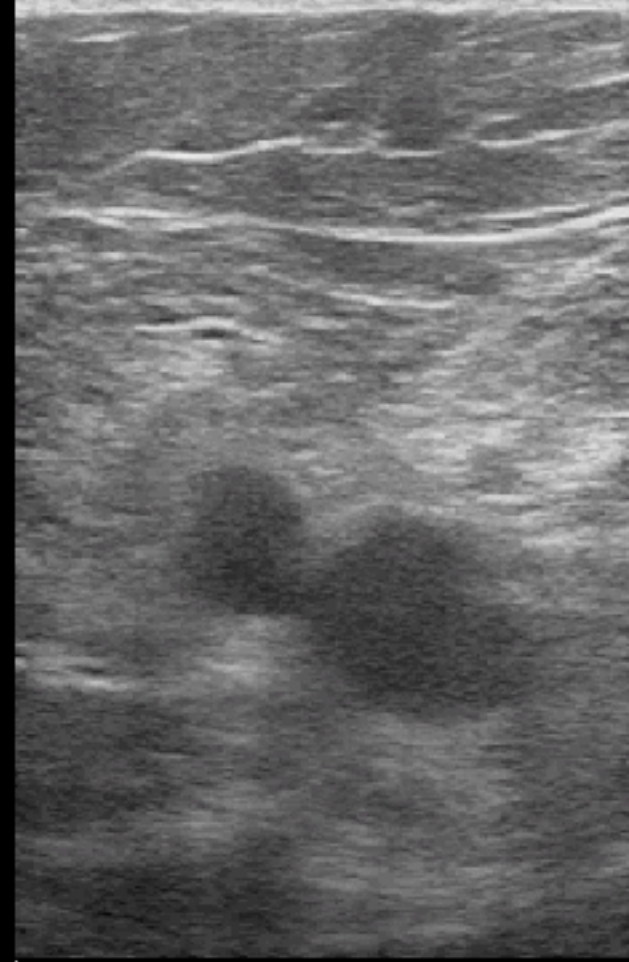
Dual images: w/ & w/o compression



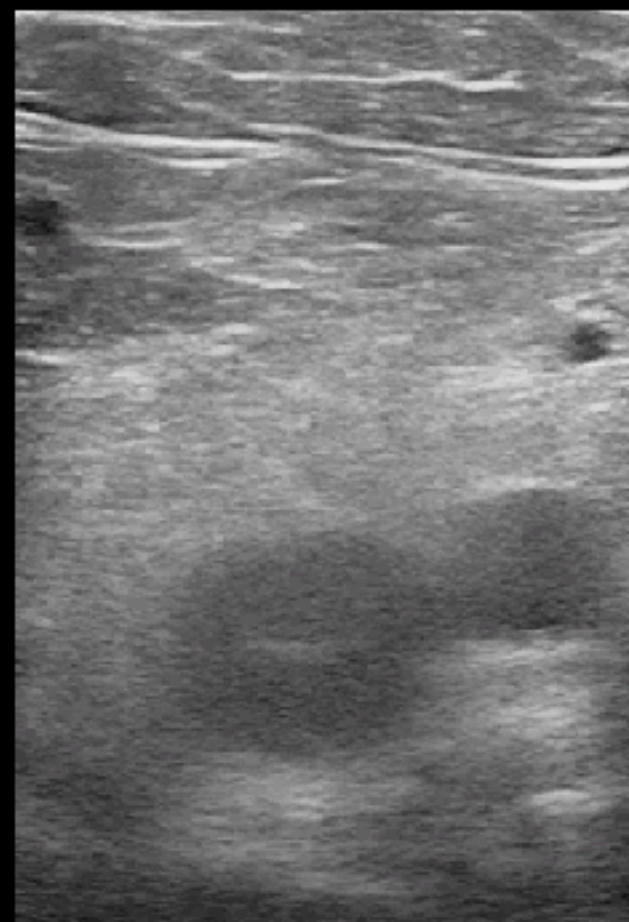


P
R
4.4 8.8

P
R
4.4 8.8



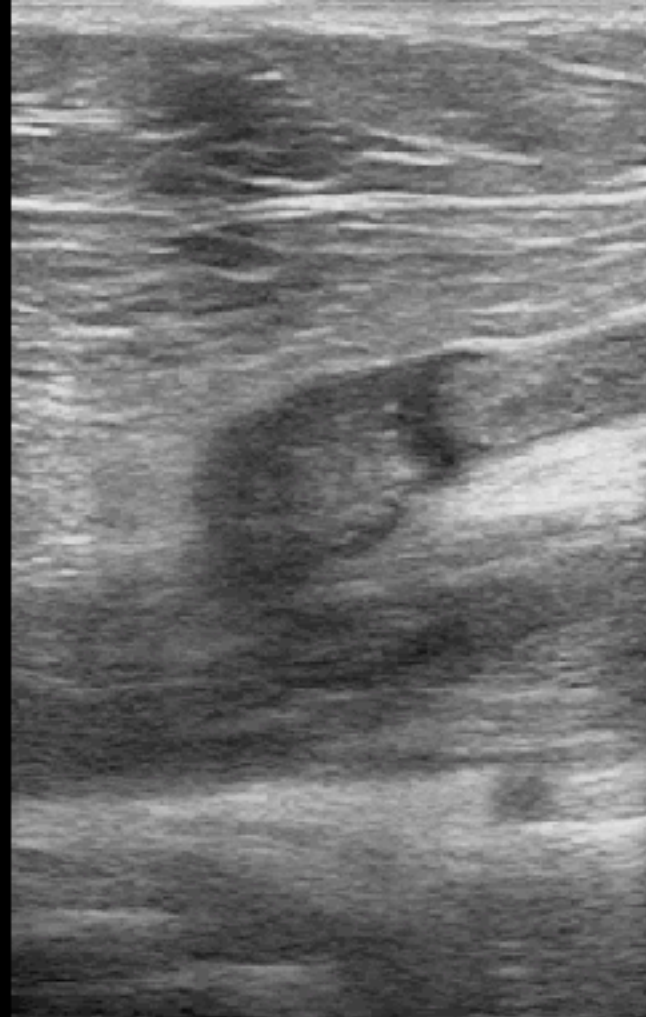
5.1
6.0cm



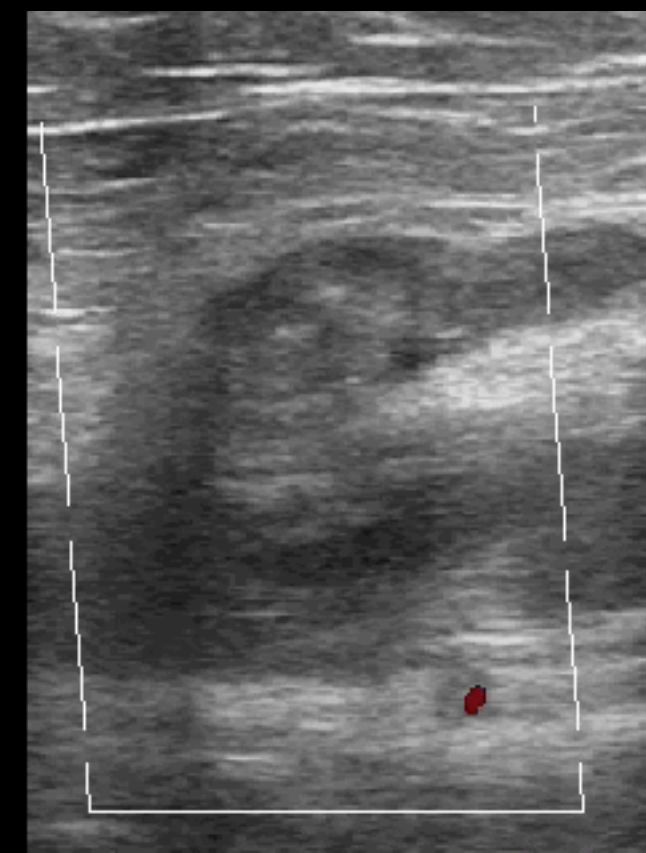5.1



©
R
+ 8.8



6.0cm

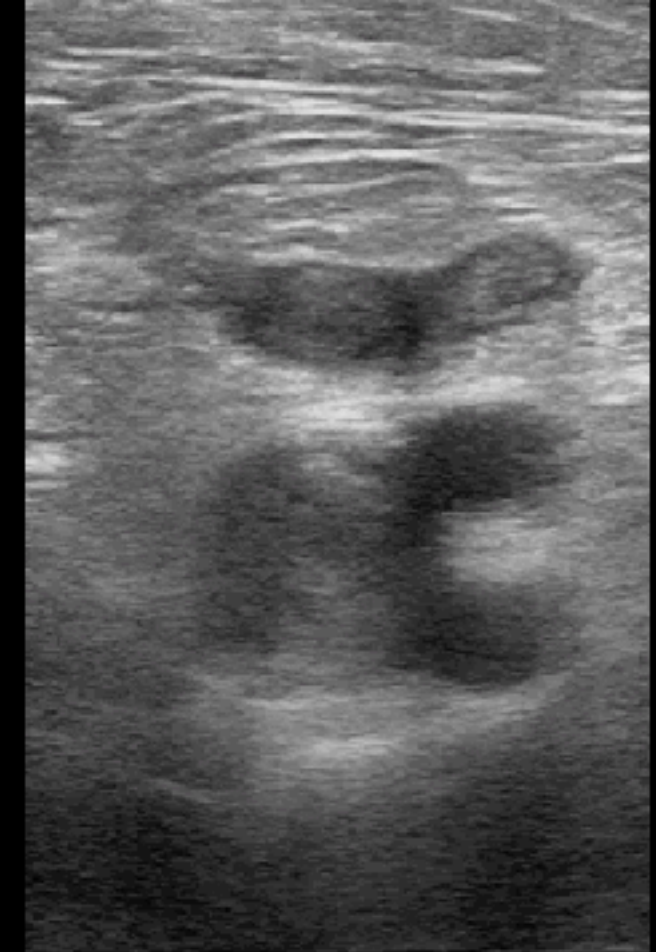

cm/s
-7.0

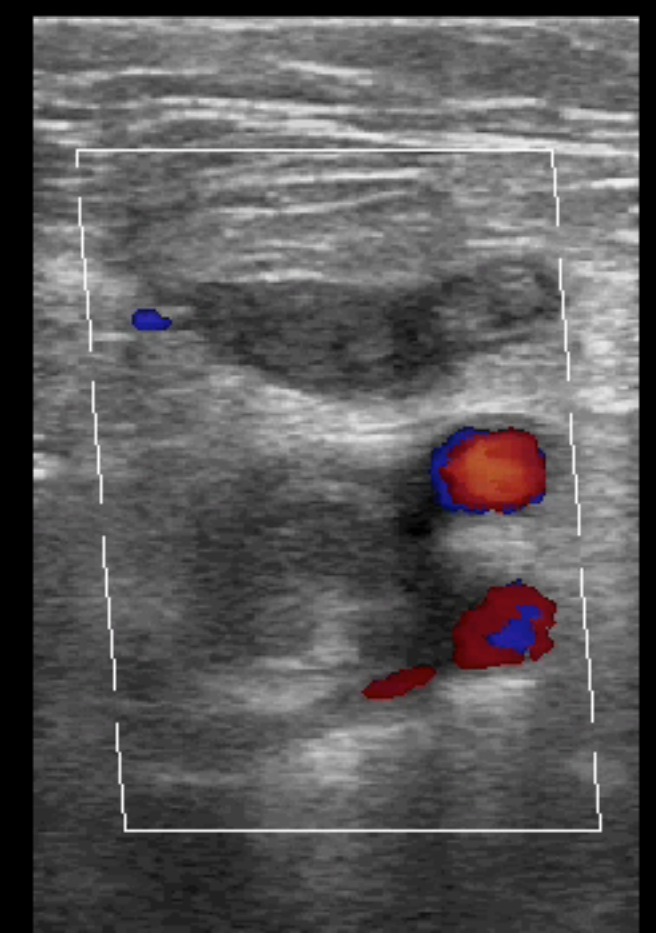
©
P



Ⓞ
P R
4.4 8.8



6.0cm



7.0
cm/s
7.0

Ⓞ



DVT assessment

3 regions

Collapse 100%

Proximal only

3

ST-MSK

Infection

Effusion

Fracture

SonoAnatomy

Skin

Subcutaneous tissue

Lymph nodes

Fascia

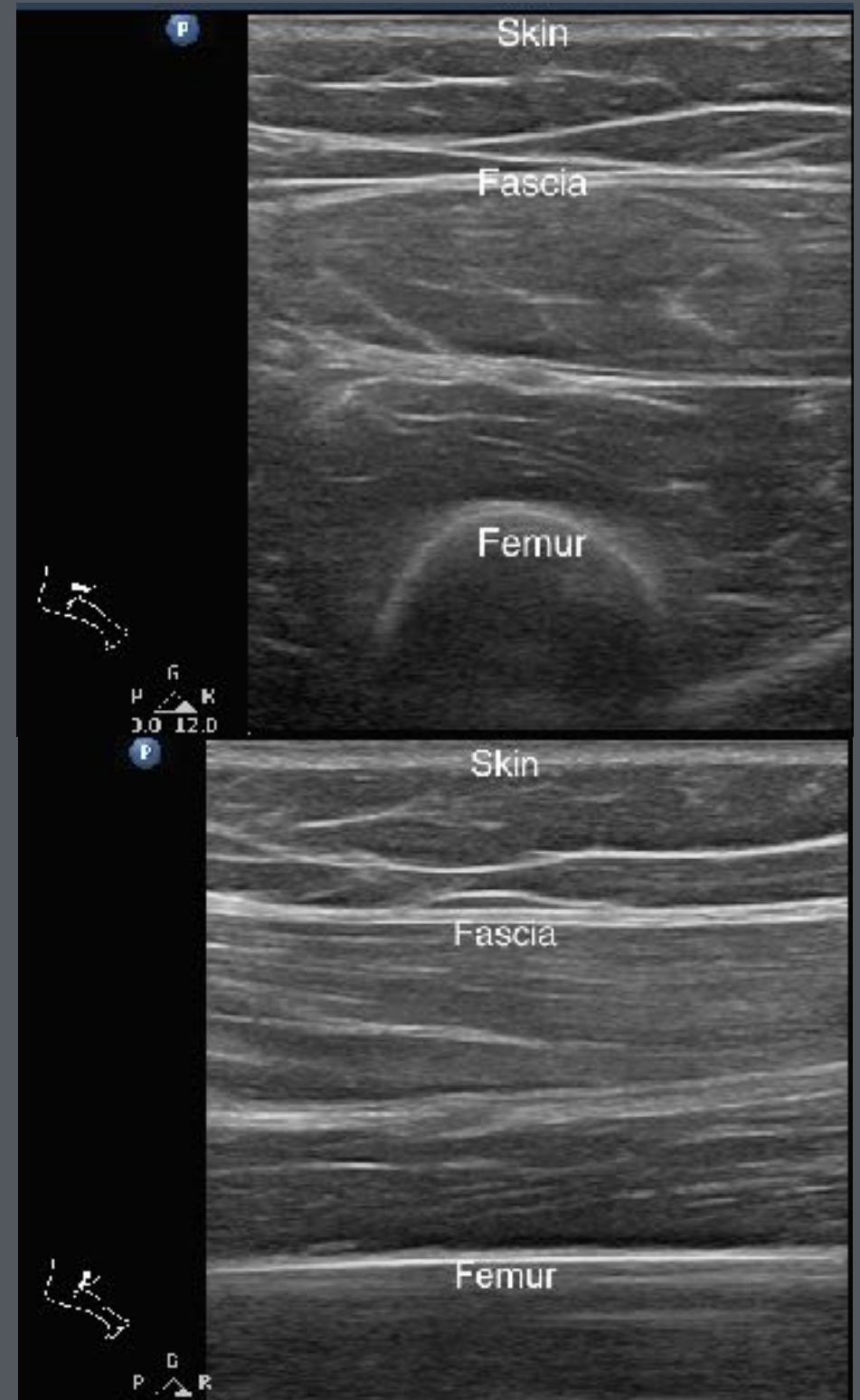
Muscles

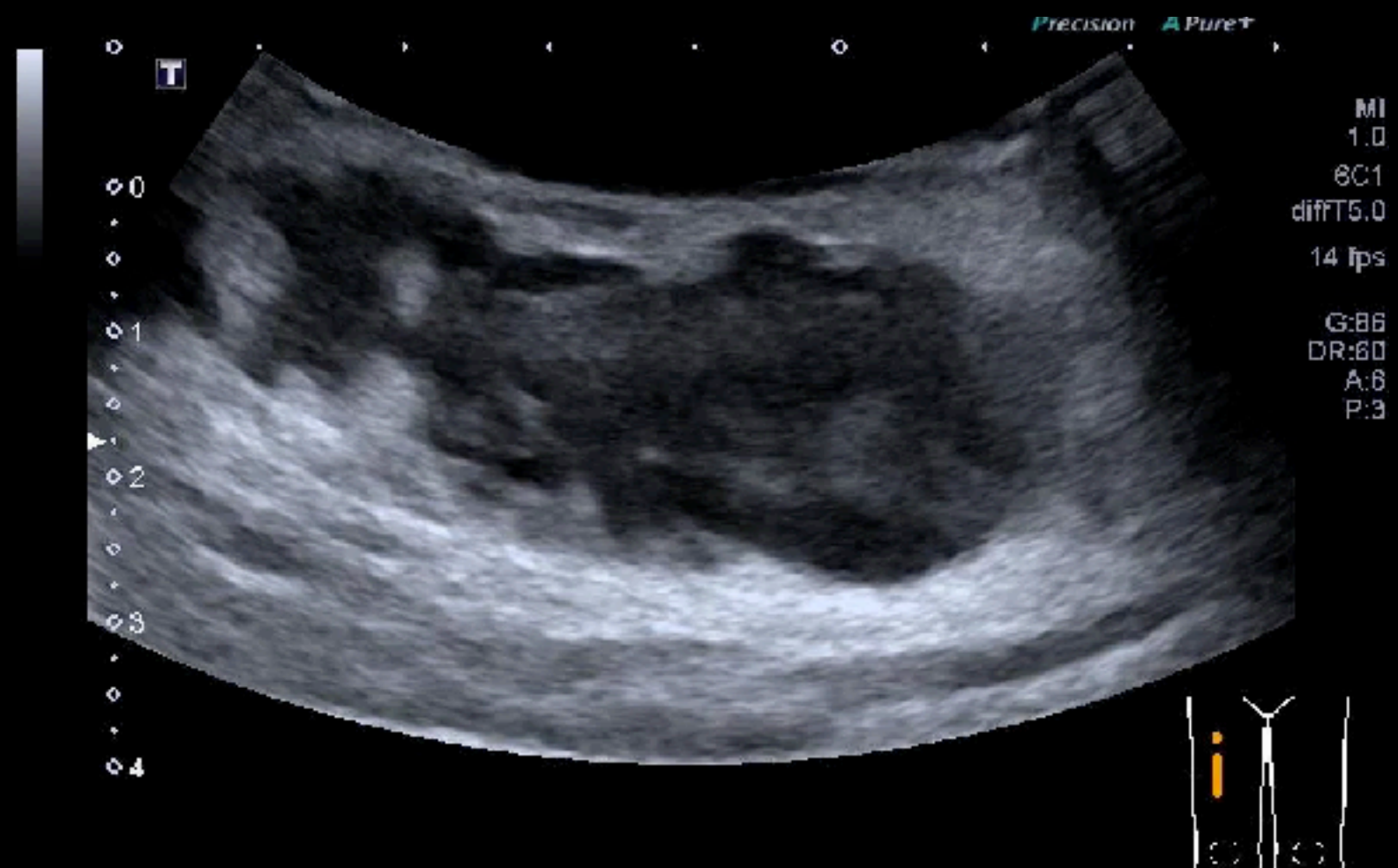
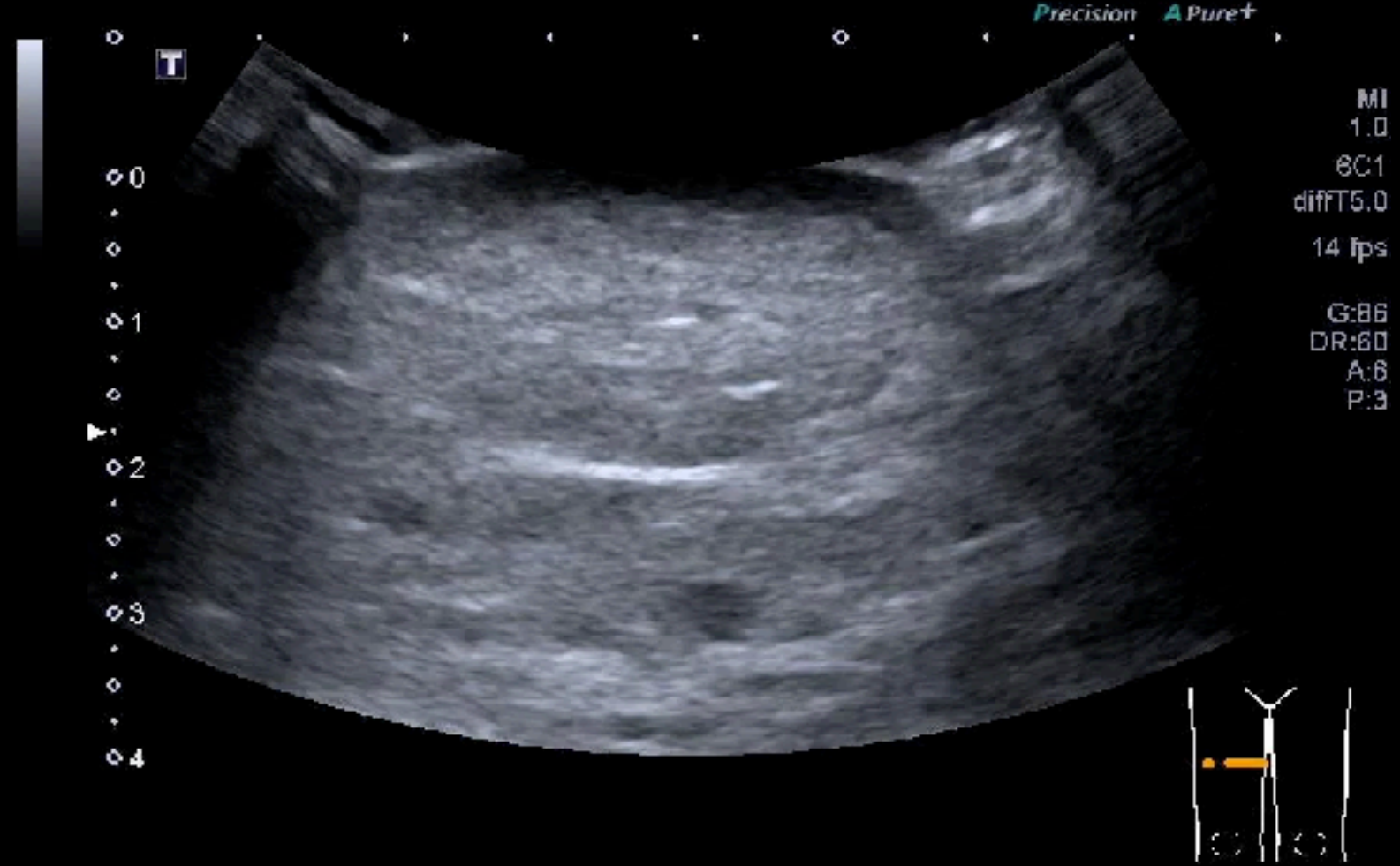
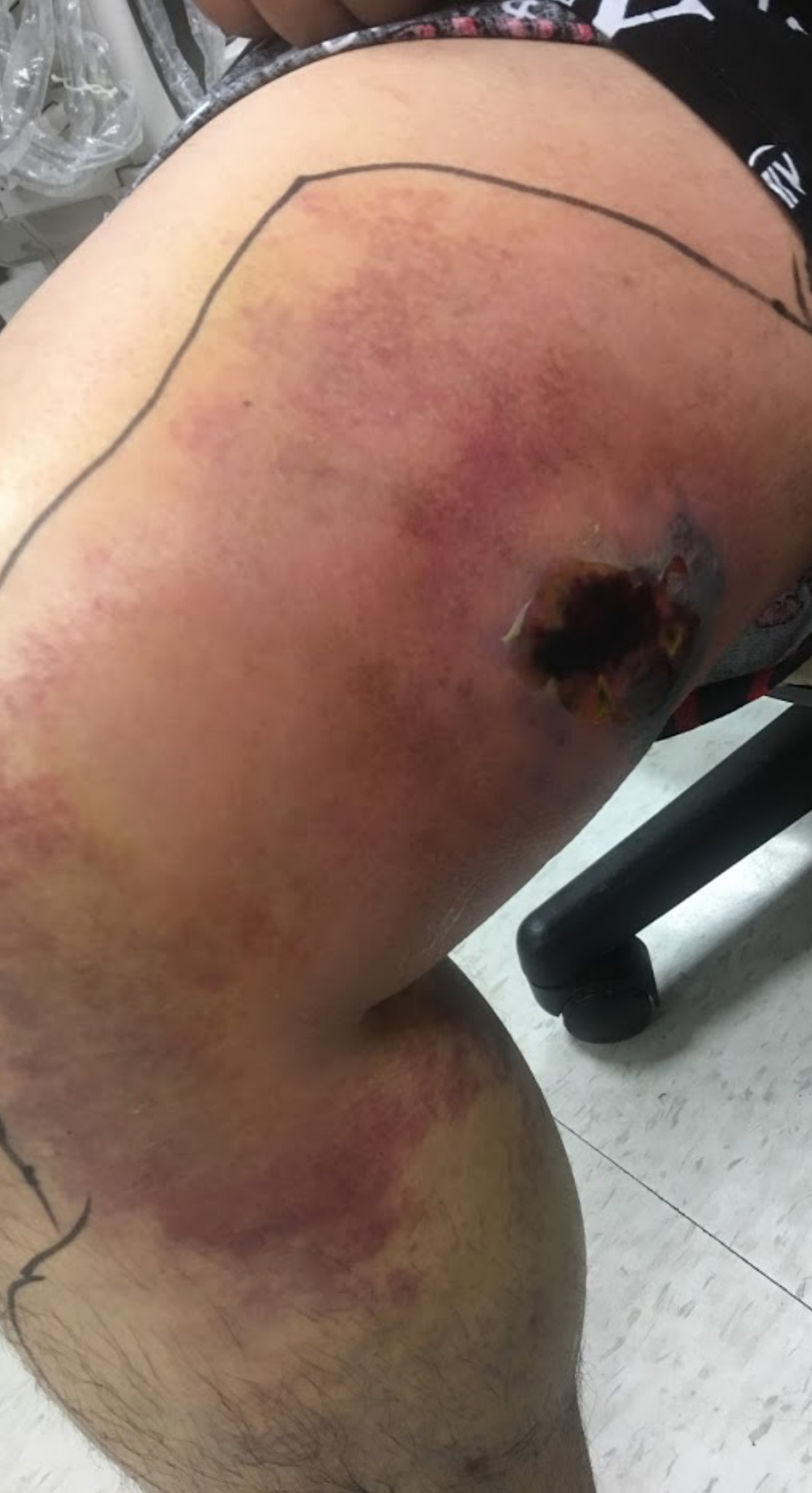Tendon

Vascular structures

Bone

3





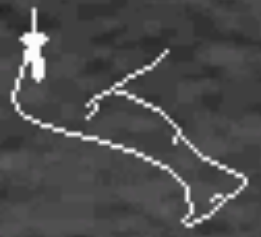
P

QT

Patella

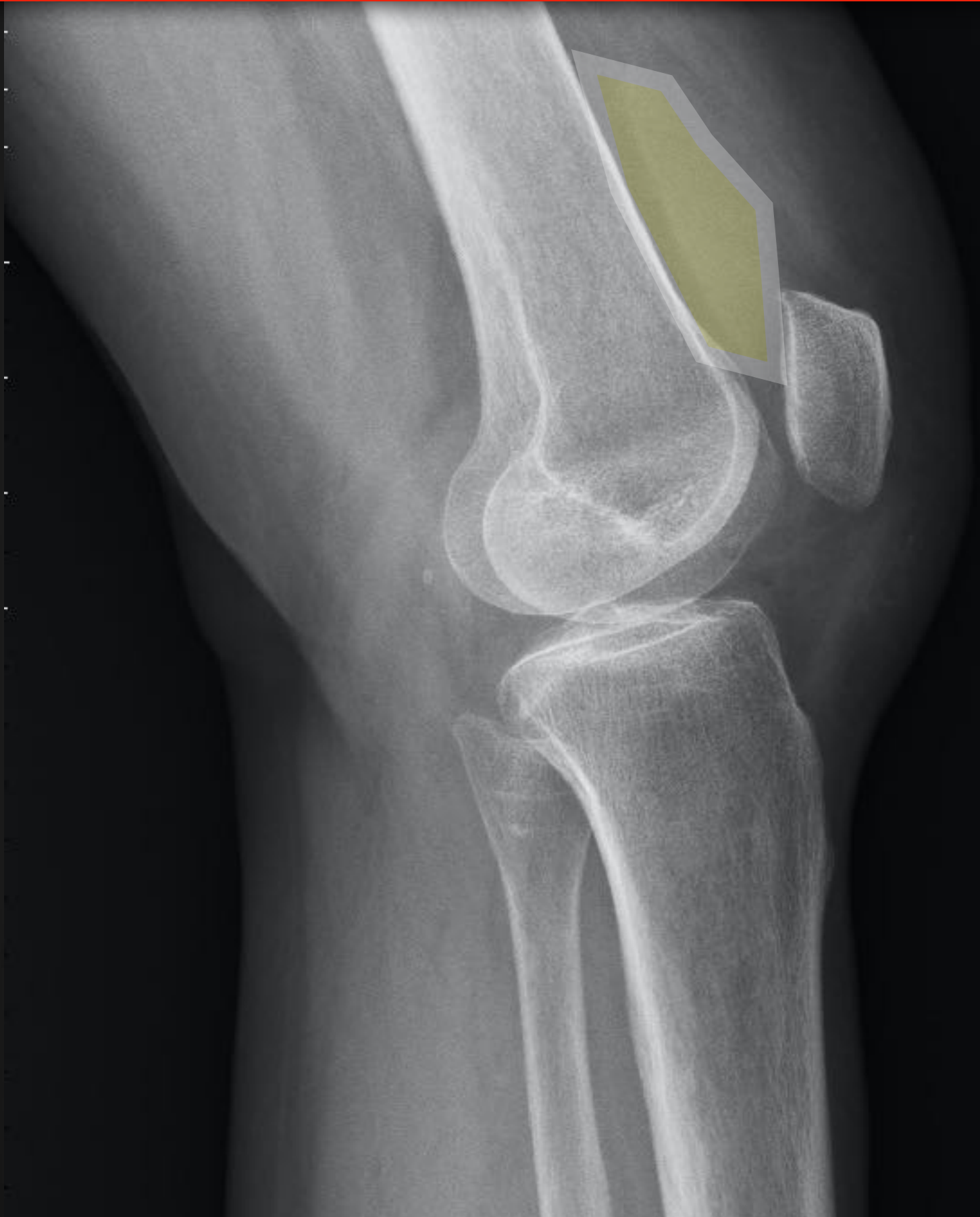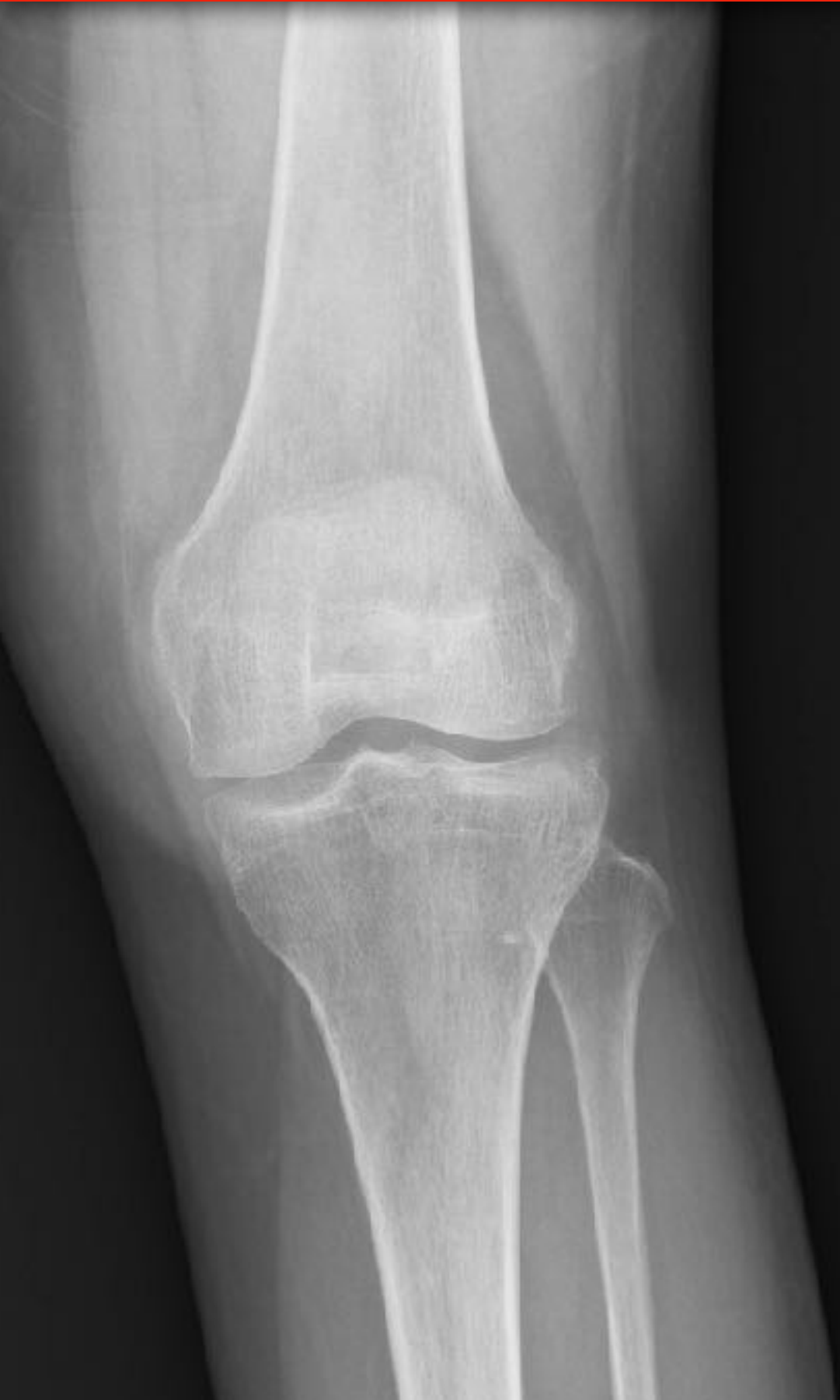Fat

Femur

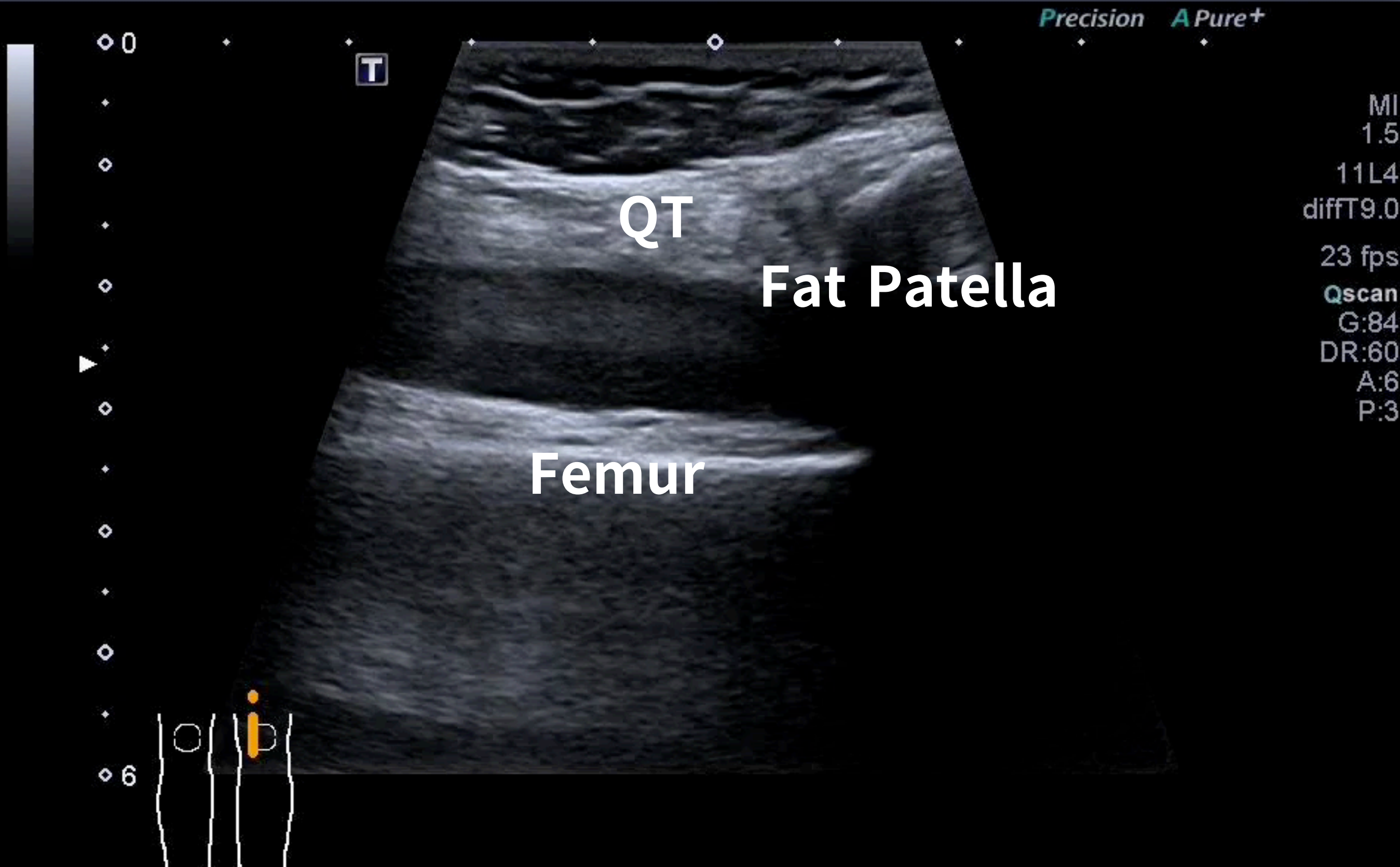


2.5cm

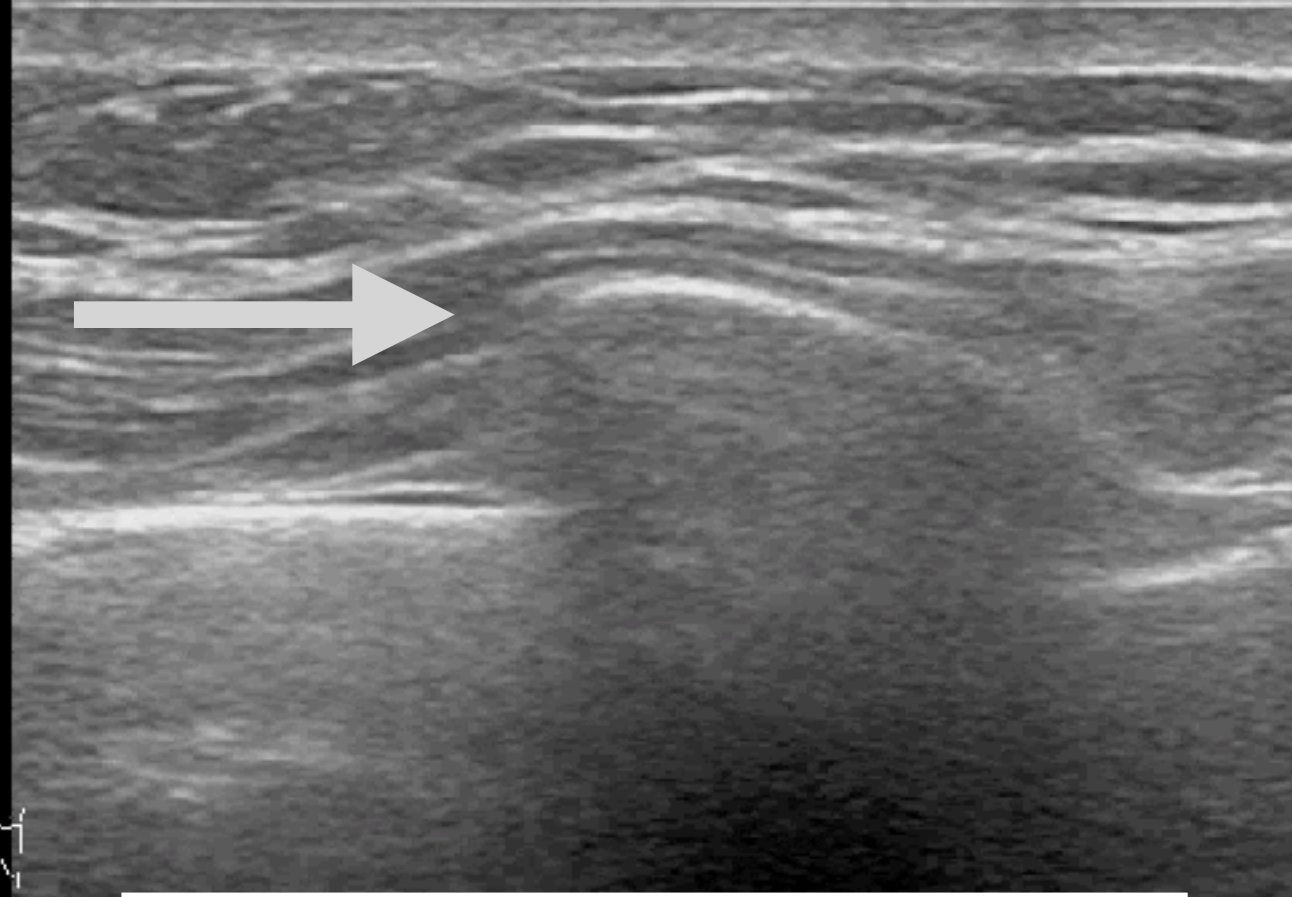
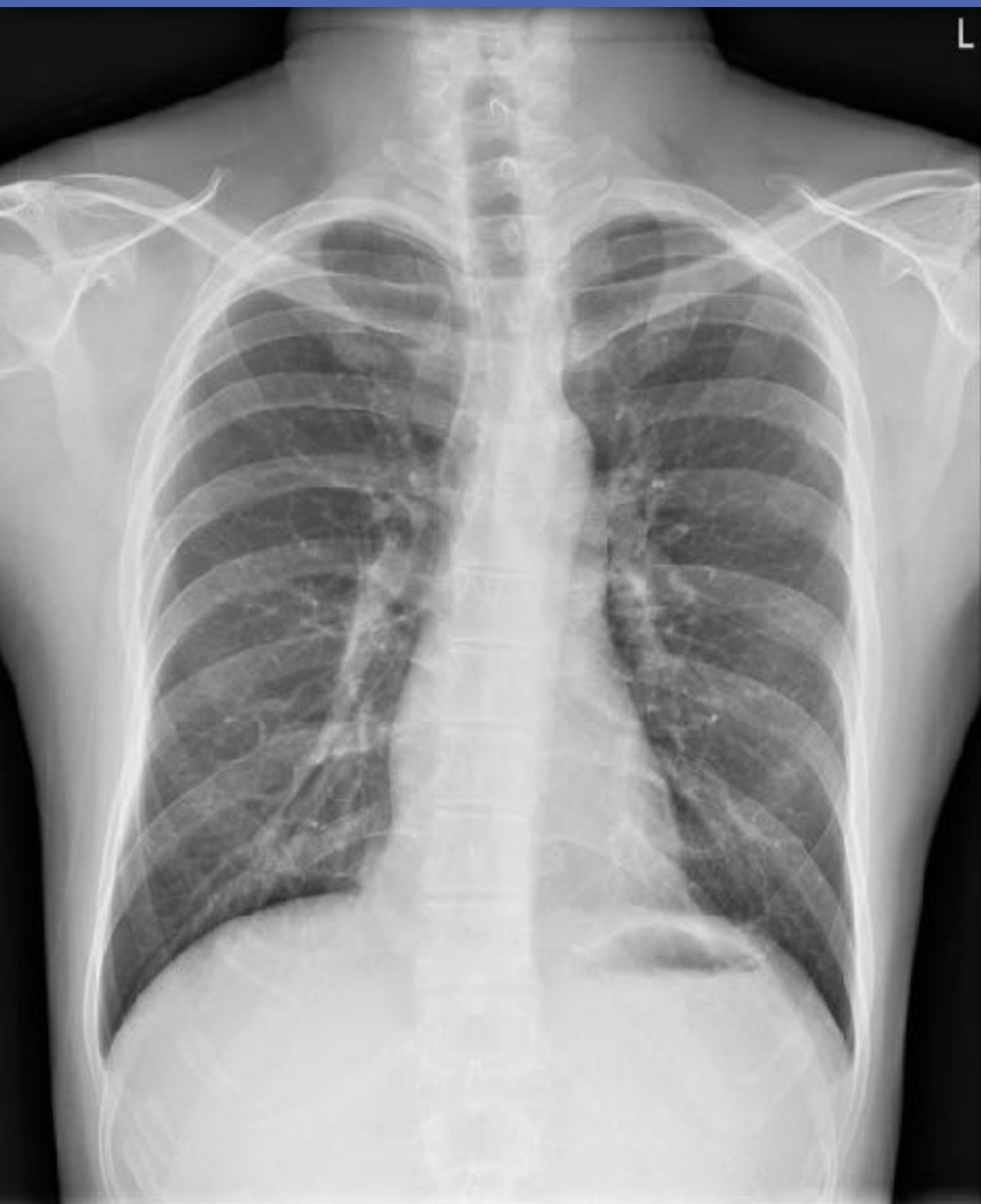膝蓋很腫，無法彎也無法站



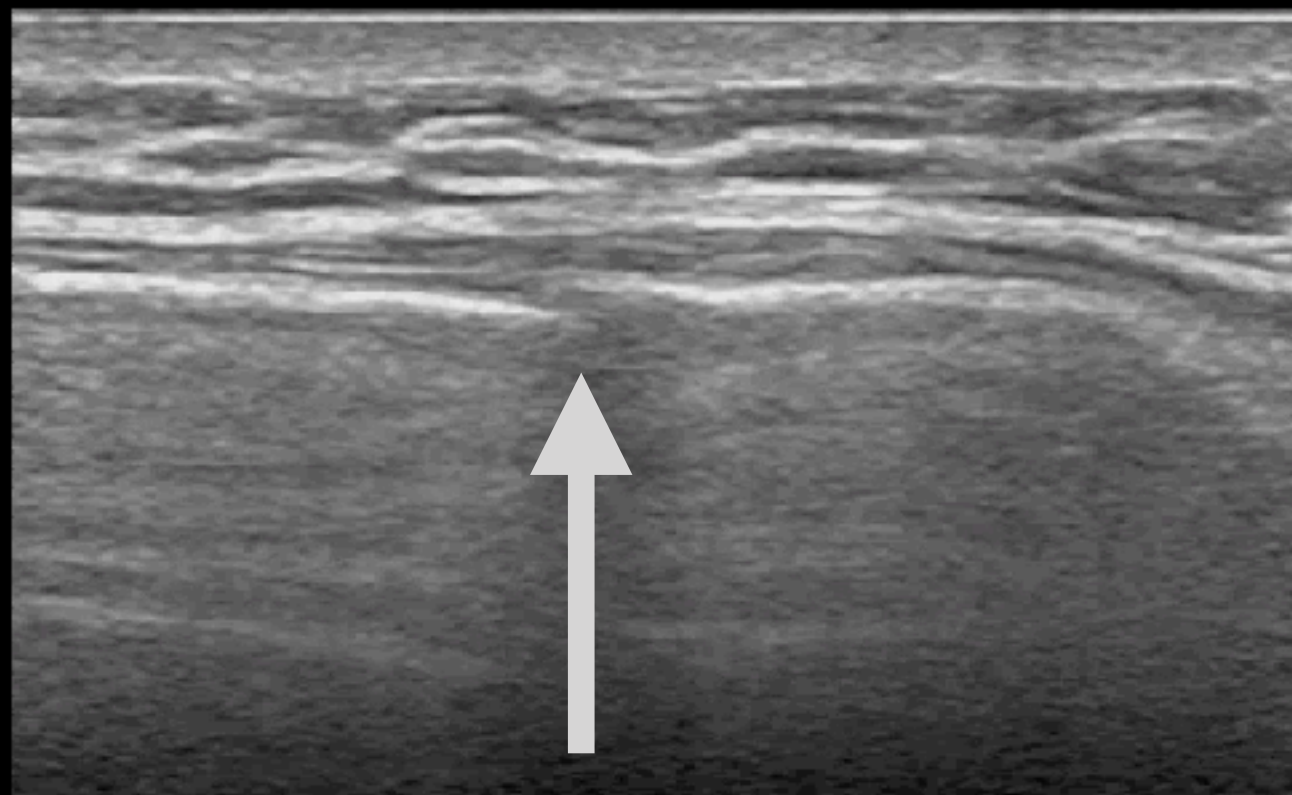
Knee hemarthrosis



BAT & R chest pain



右第5肋骨骨折



POCUS Academy

Let's transform practice today



juice119@gmail.com

FB: Emergency Ultrasound Training Center

