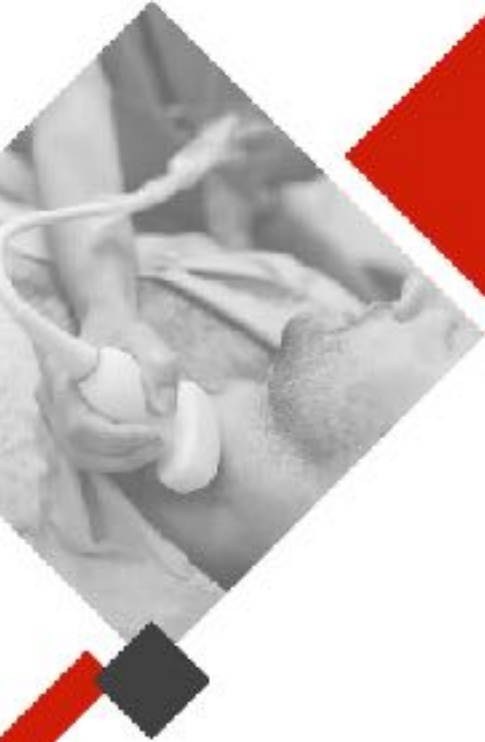
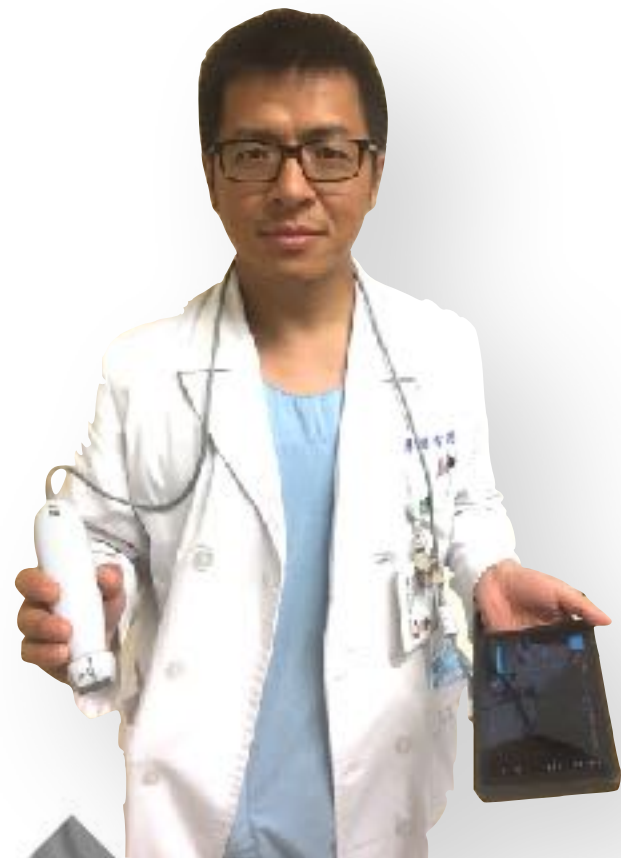


ULTRASOUND
PROGRAM



骨骼肌肉軟組織 POCUS

陳國智 西園醫院急診醫學科



急重症超音波工作坊負責人

POCUS Academy

Emergency Ultrasound Training Center

Faculty

-WINFOCUS, PERCUSS, WFPICC

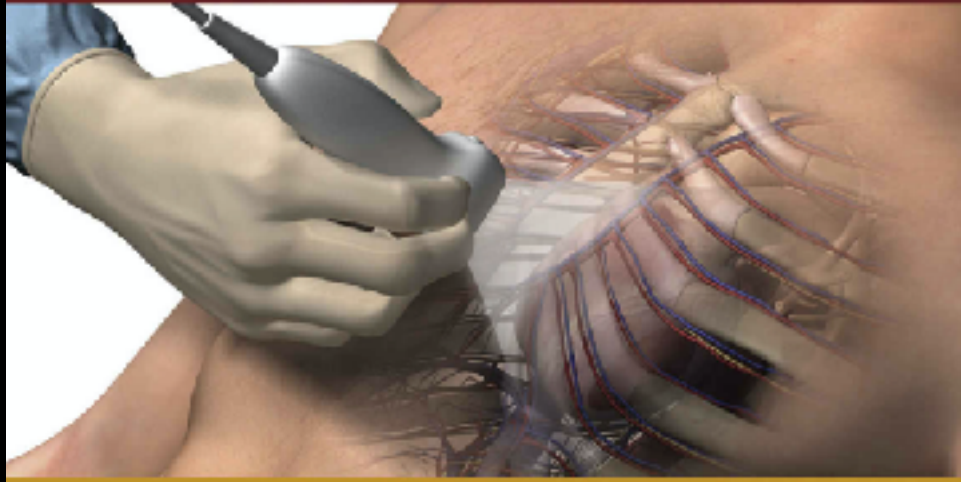-Taiwan Pain Society

前急診超音波委員會主委

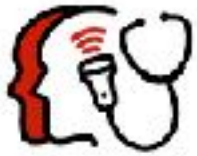

Second Edition

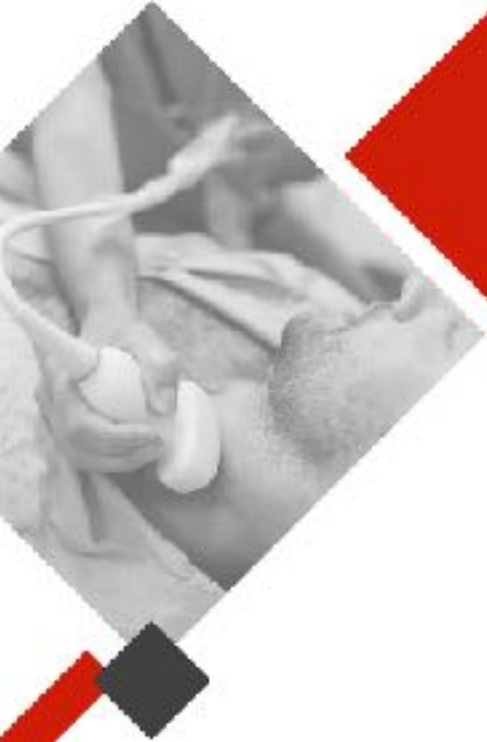Point-of-Care **ULTRASOUND**



Nilam J. Soni
Robert Arntfield
Pierre Kory

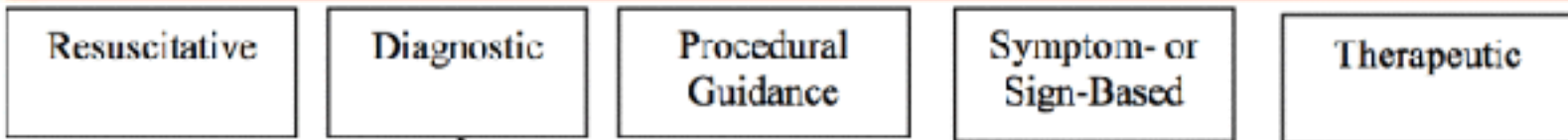


ULTRASOUND
PROGRAM



POCUS

What's the point ?



**Nerve block
TEE
NeuroSono**

**Endocavity
Contrast**

**ACEP
2016**

- Core Applications
Trauma
Intrauterine Pregnancy
AAA
Cardiac/HD Assessment
Biliary
Urinary Tract
DVT
Soft-tissue/Musculoskeletal
Thoracic/Airway
Ocular
Bowel
Procedural Guidance

12 核心

5大應用



I-AIM

Indication (Point)



Acquire



Interpret



**Make
decision**

ST - MSK

Abscess ?



掃得到嗎



看得懂嗎



有差別嗎

POCUS-急診

症狀
問題

線索
時間

診斷
治療

雜

少

快

POCUS for EP

診斷

Diagnosis

監測

Monitoring

介入

Intervention



可以
同步
病史詢問



不可
省略
理學檢查

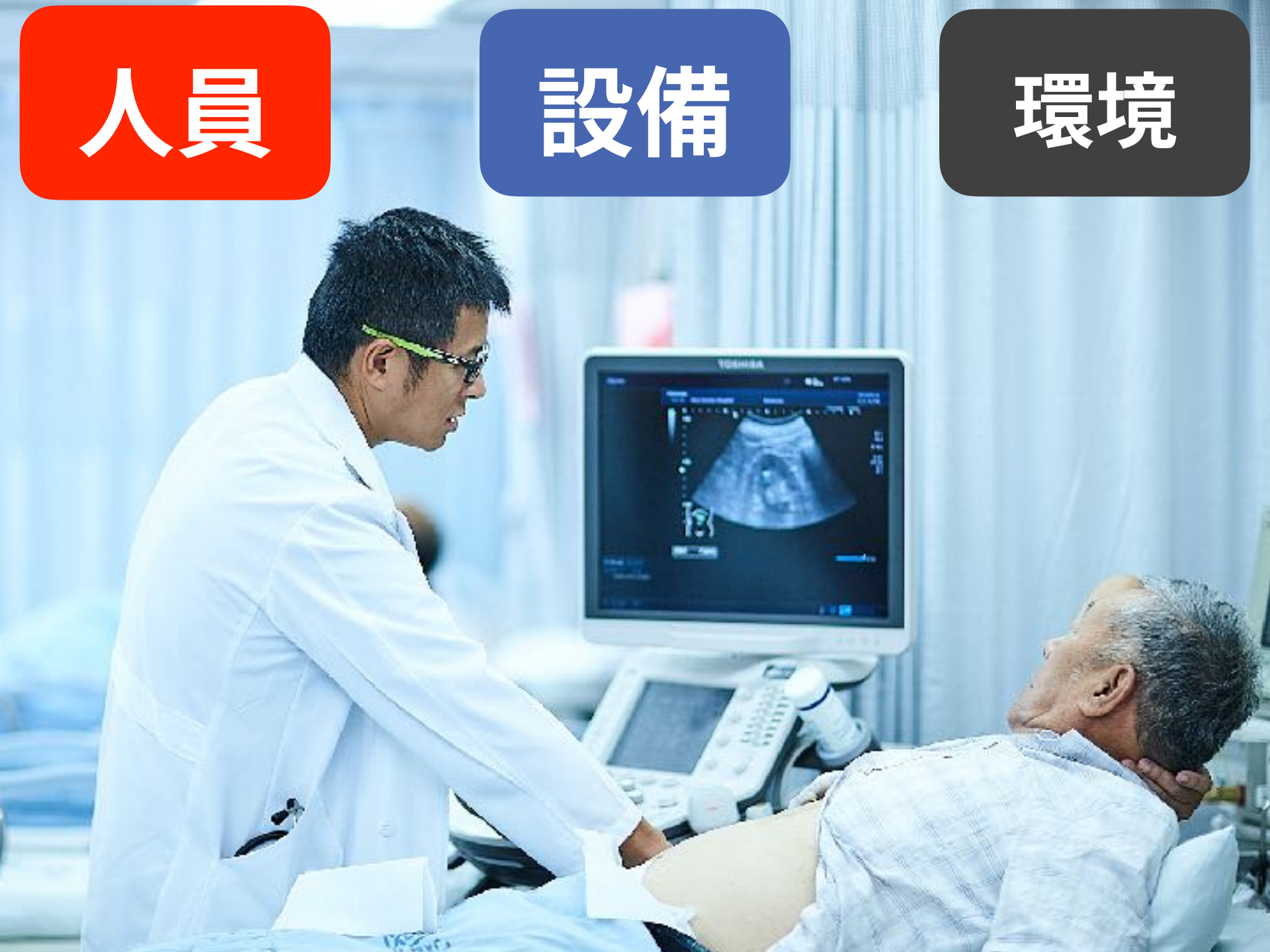

Y POCUS N

人員

設備

環境

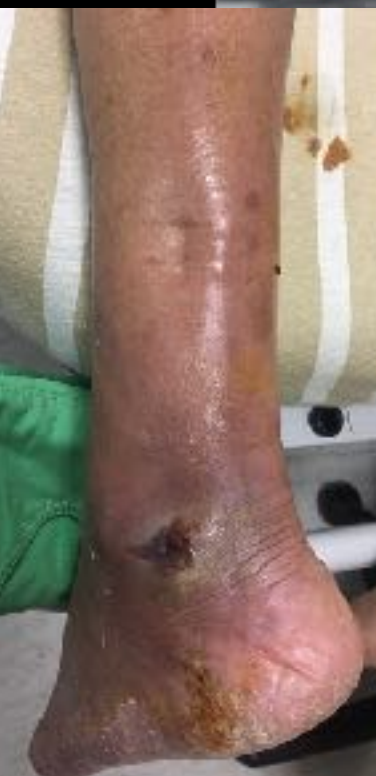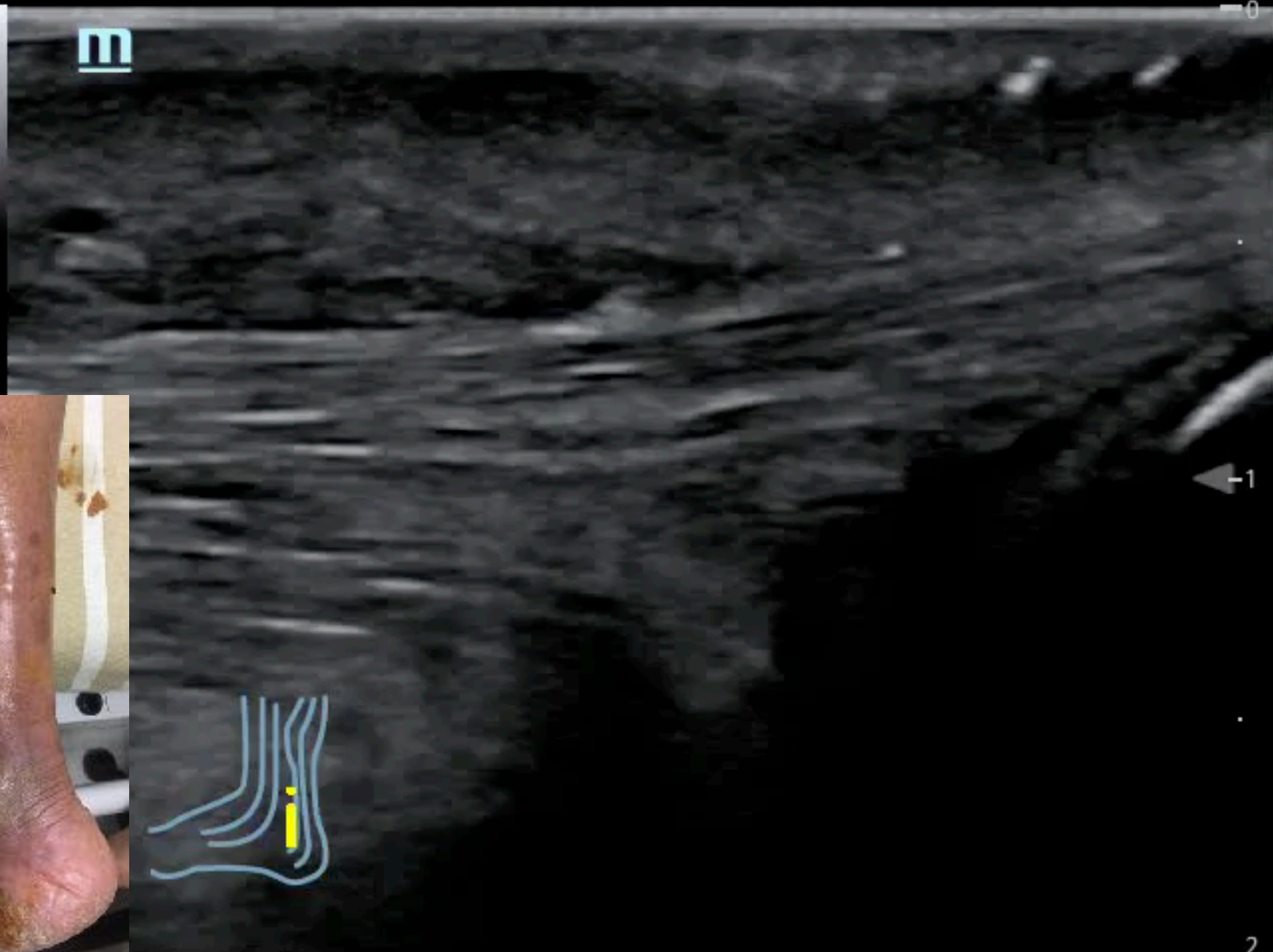


L14-6Ns
MI 13
TIS 0.1

AP 96.6%



B
FH10
DR 110
FR 27
D 2.0
G 46



-1

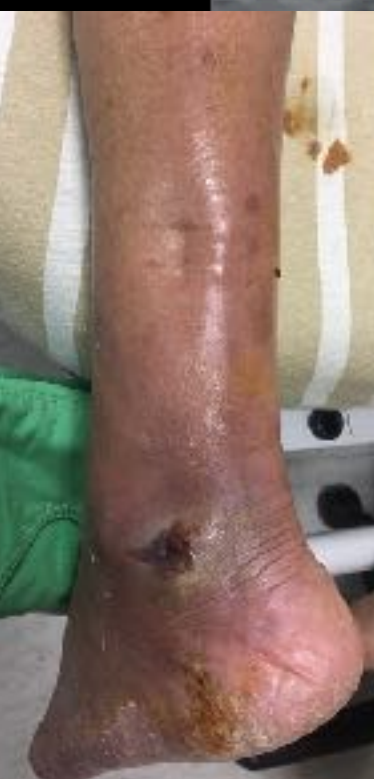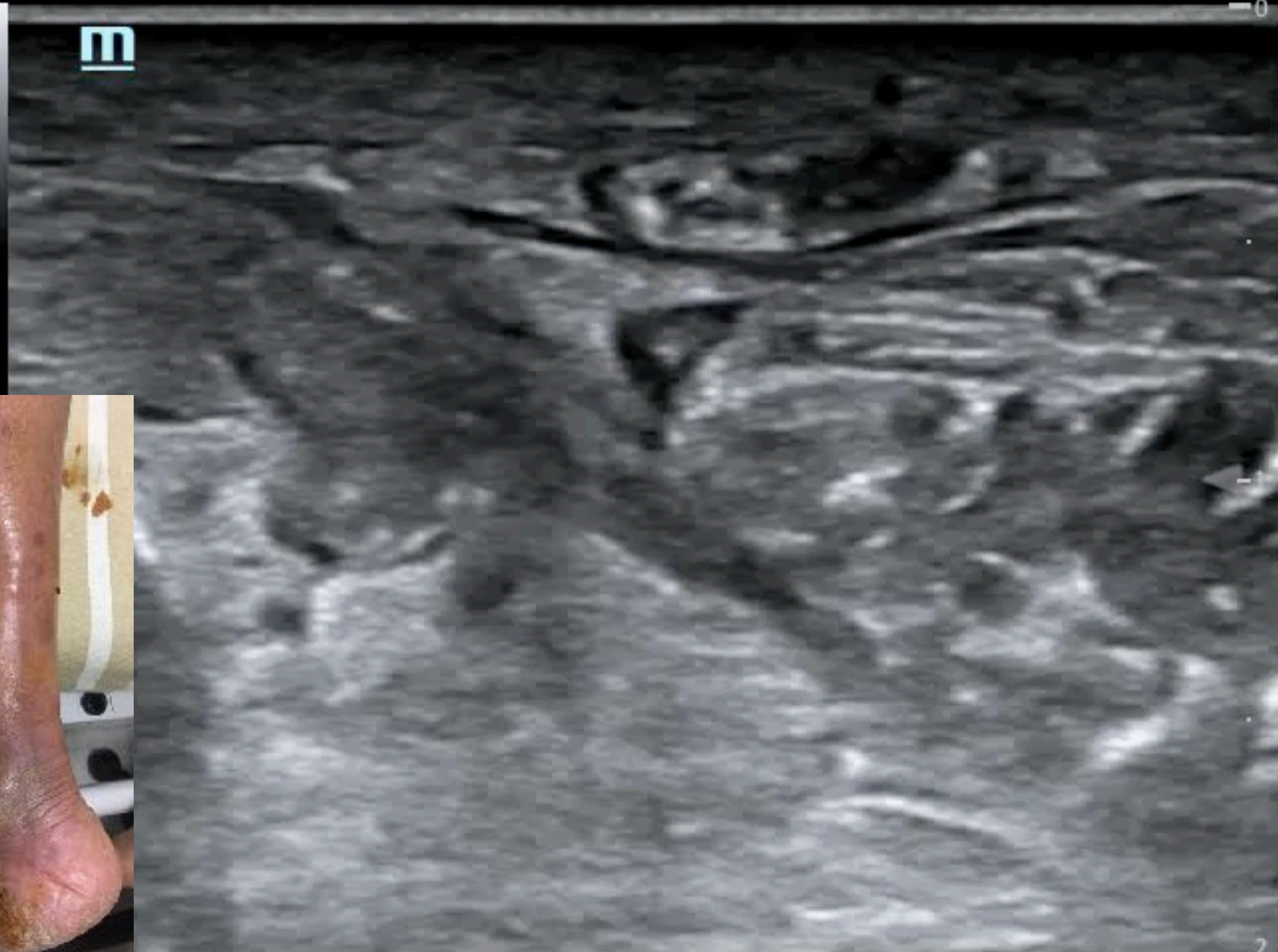
-2

L14-6Ns
MI 0.6
TIS 0.2

AP 96.6%



B
F 6.0~12.6
DR 100
FR 82
D 2.0
G 40



POCUS常用探頭



表面
目標

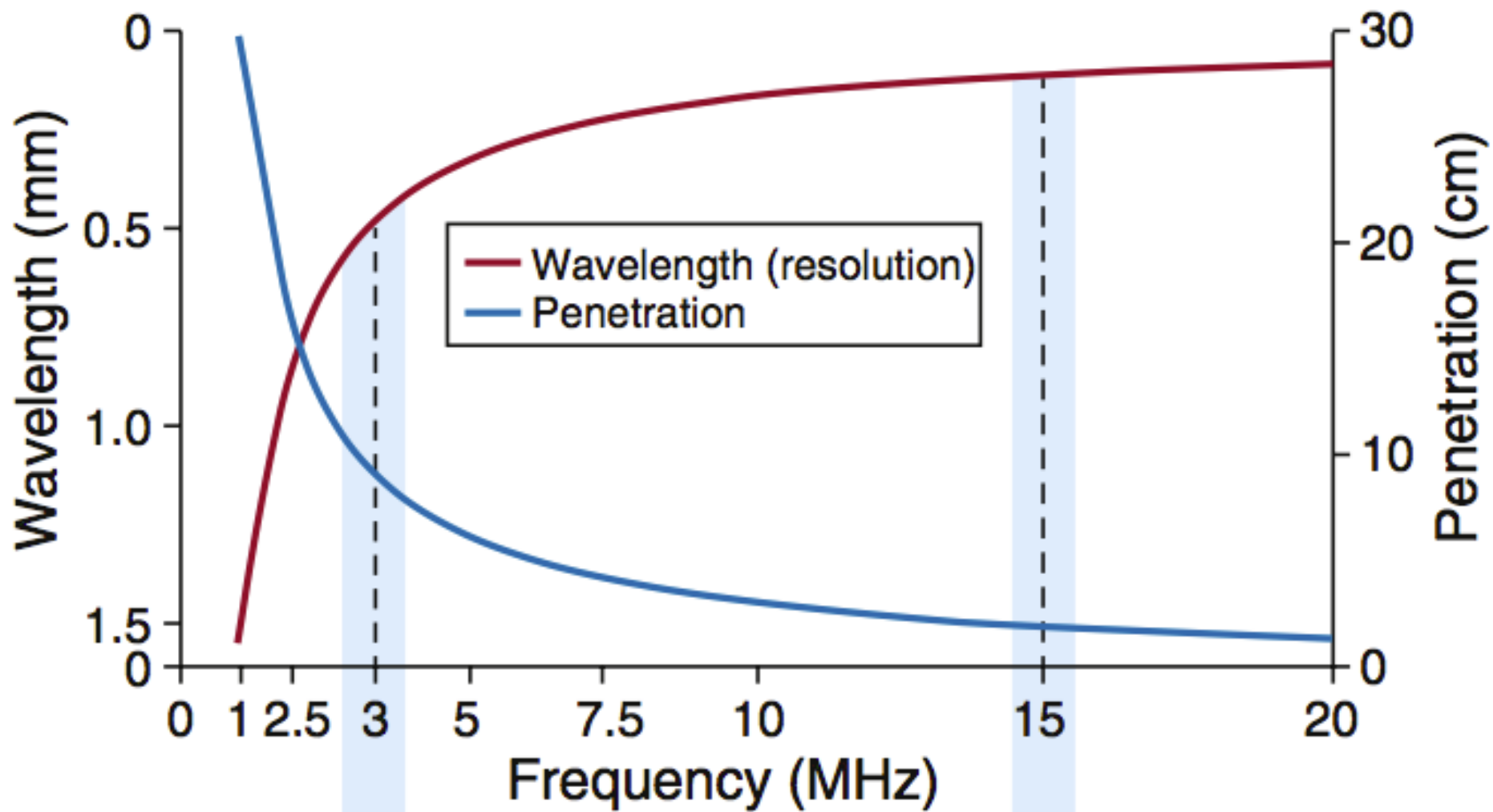


頻率
介面

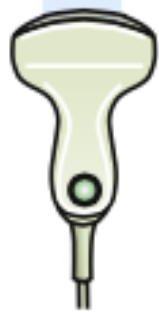

深度
視窗





Low-frequency transducer



High-frequency transducer



影像優化3大重點

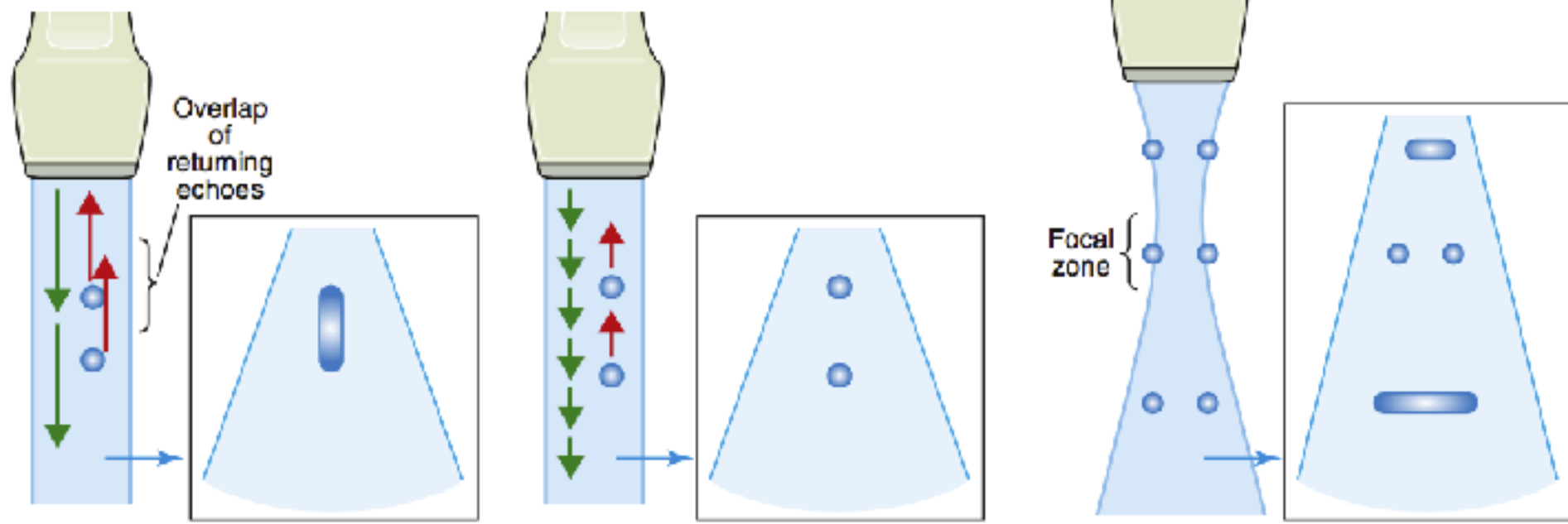
置中 對焦 高頻

Axial resolution

Lateral resolution

Lower frequency

Higher frequency





操控 6 大技巧

X

Sweep

Fan/
Tilt

Y

Slide

Rock

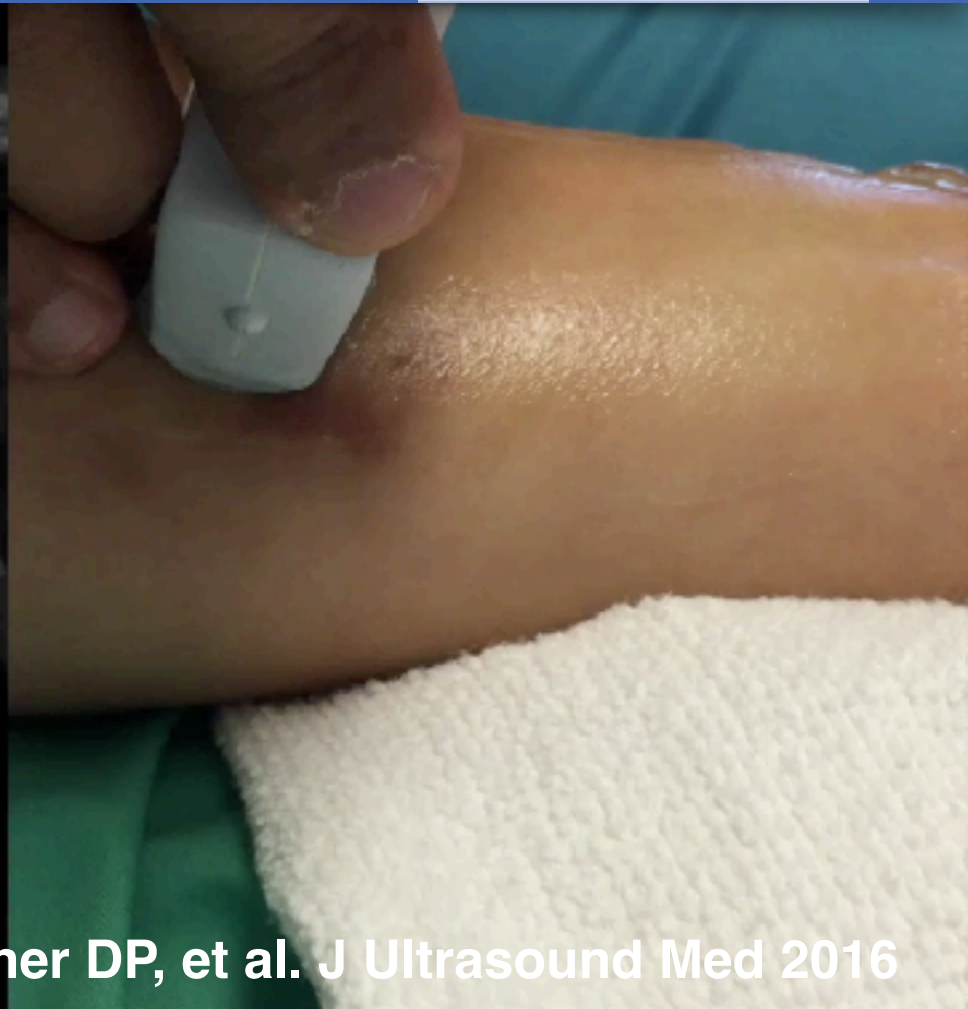
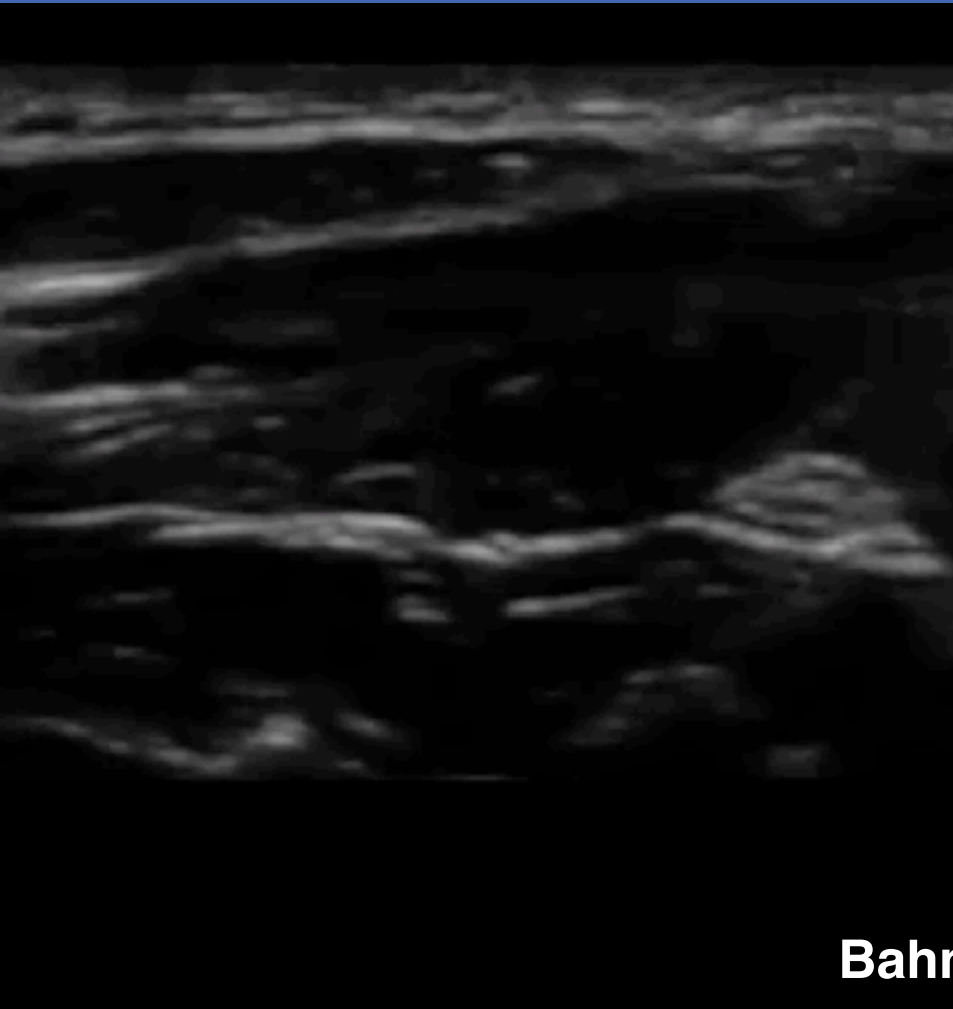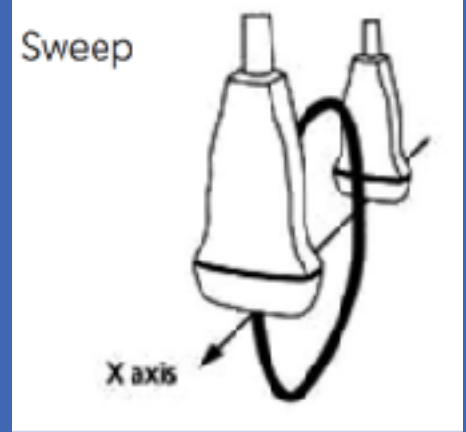
Z

Rotate

Compress

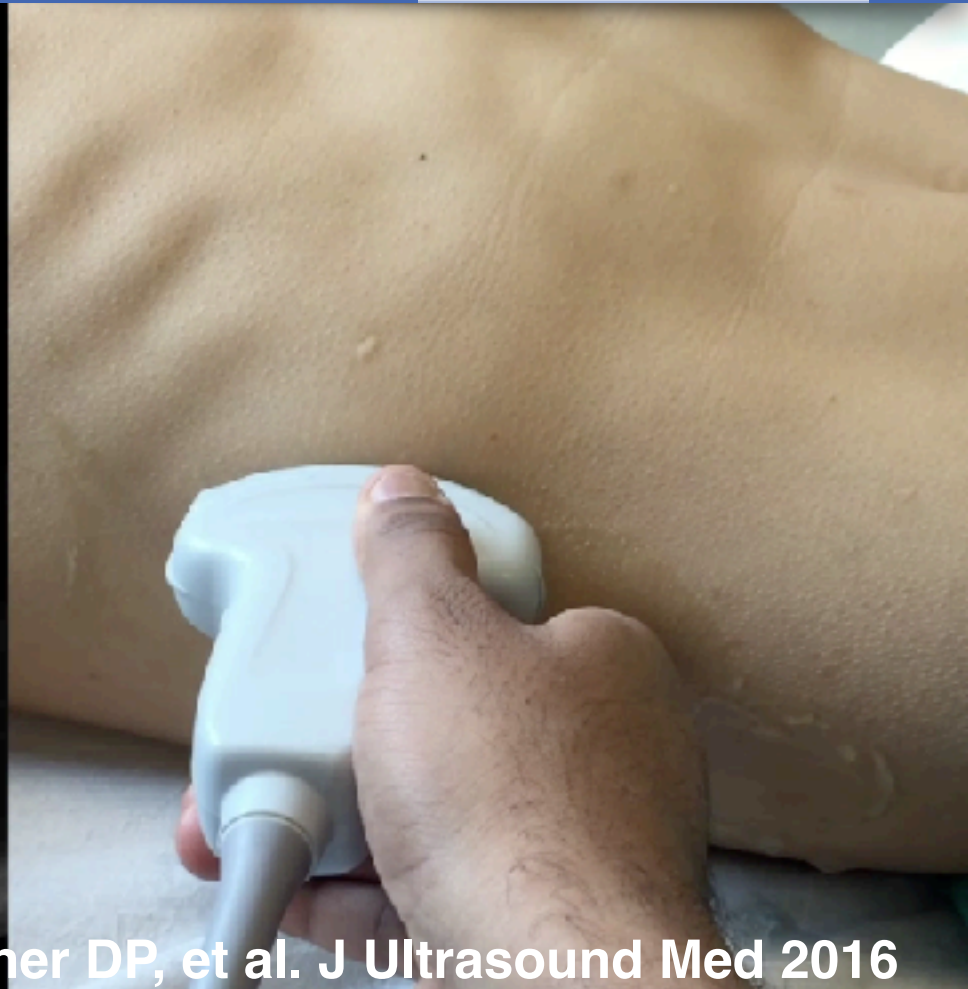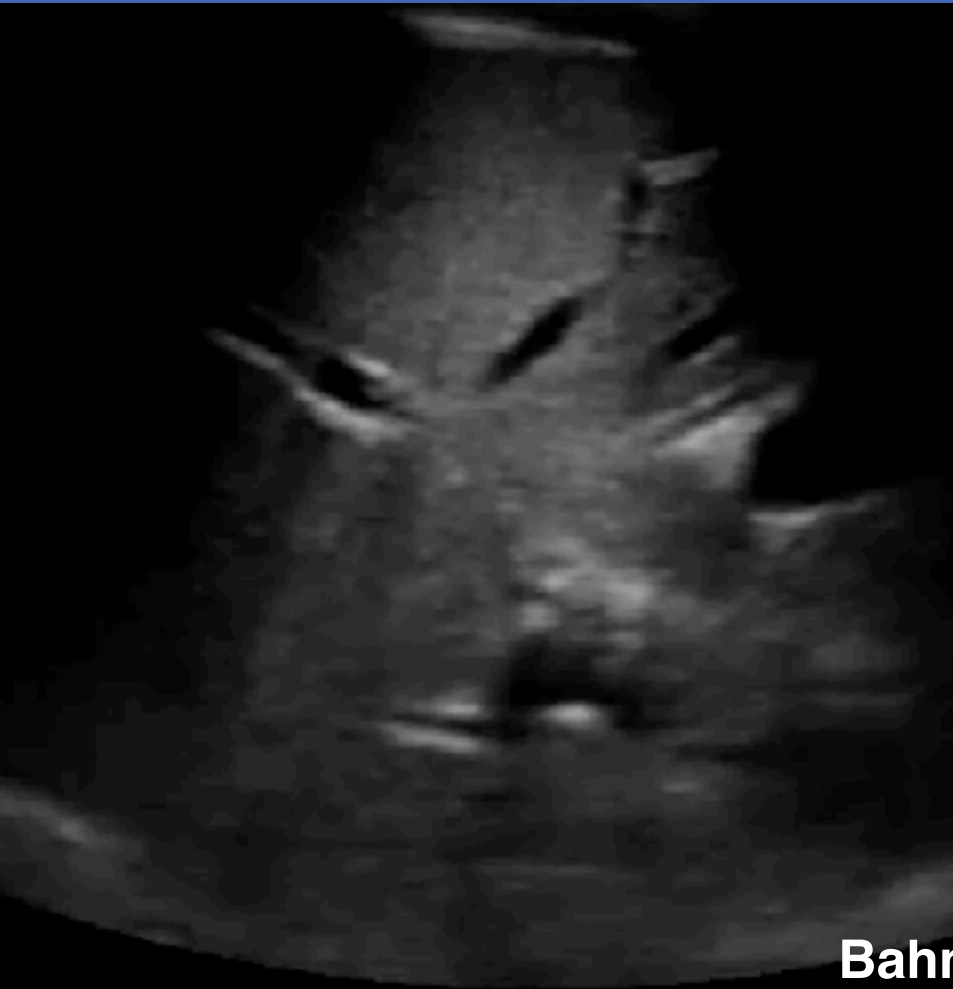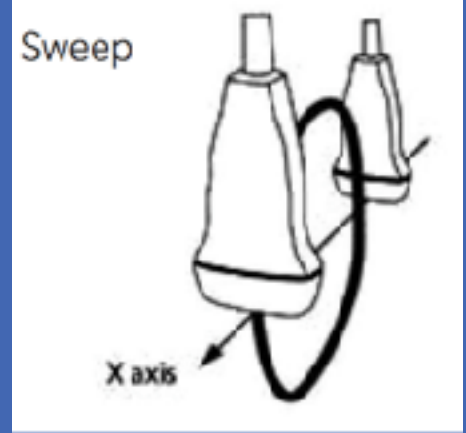
Sweep

X

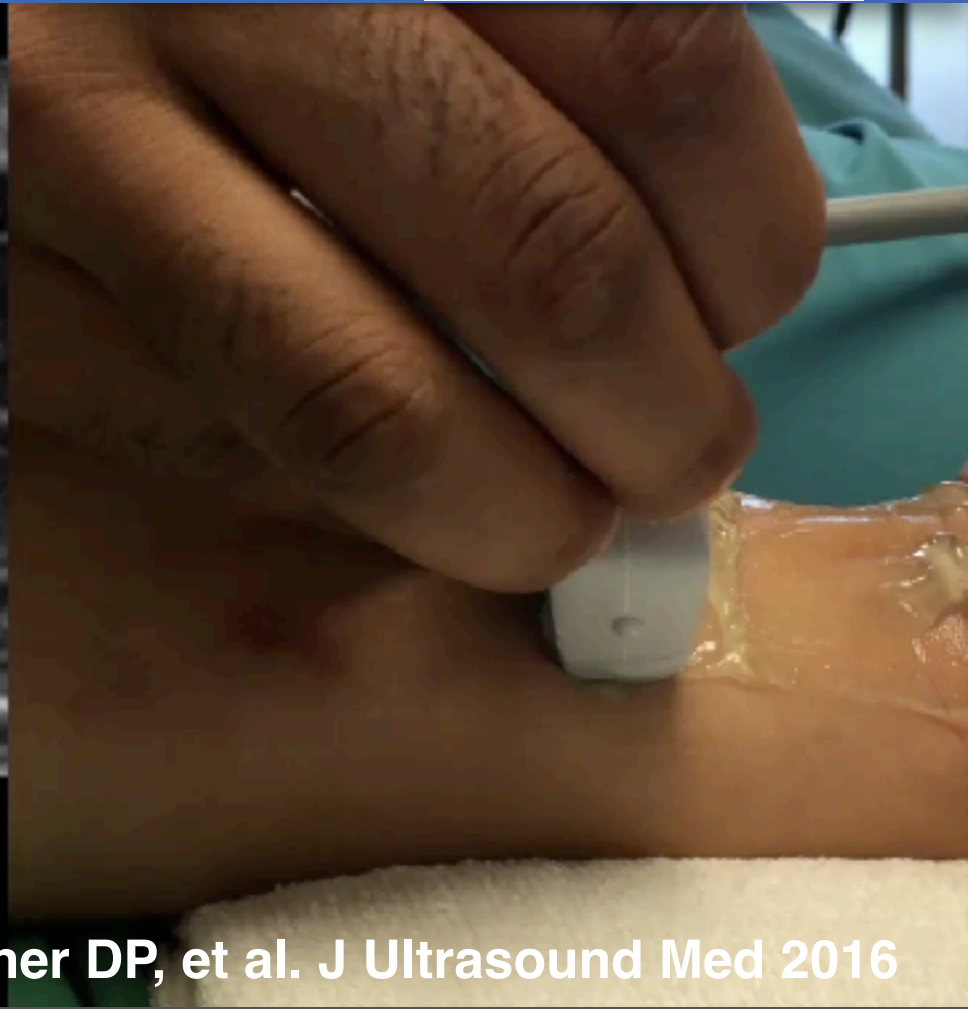
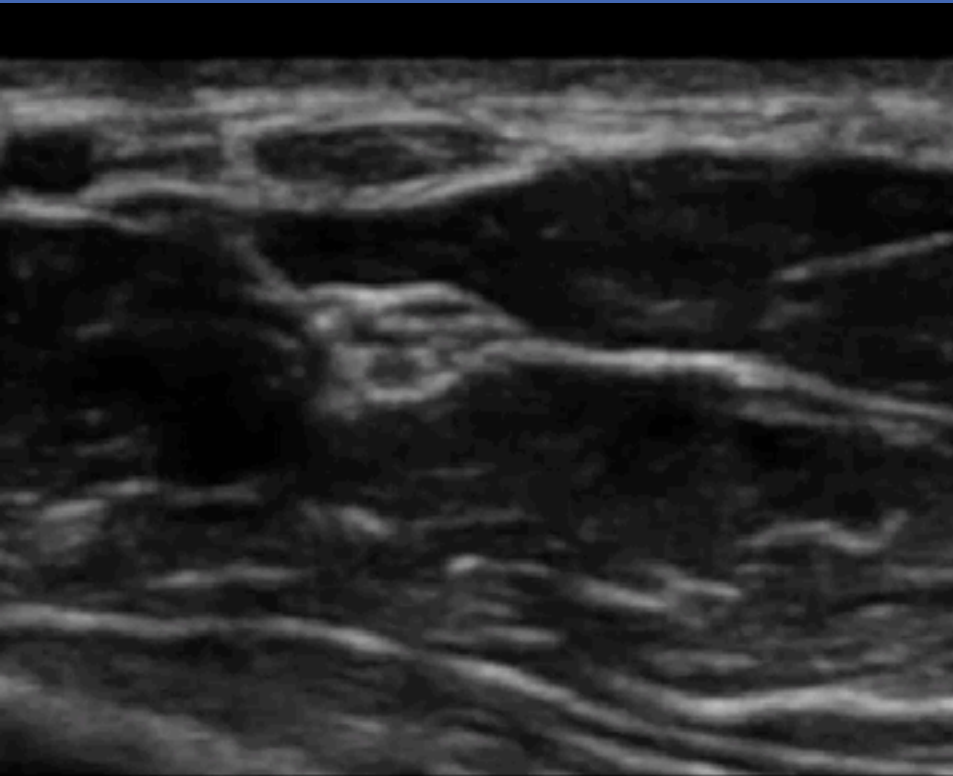
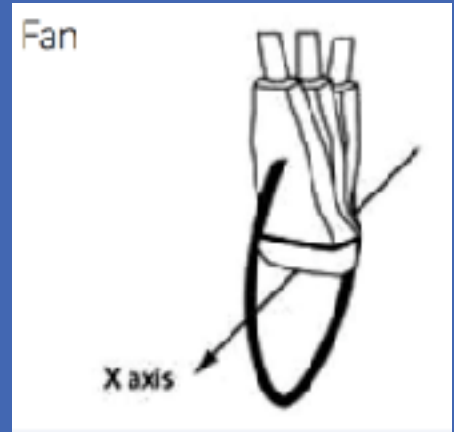


Sweep

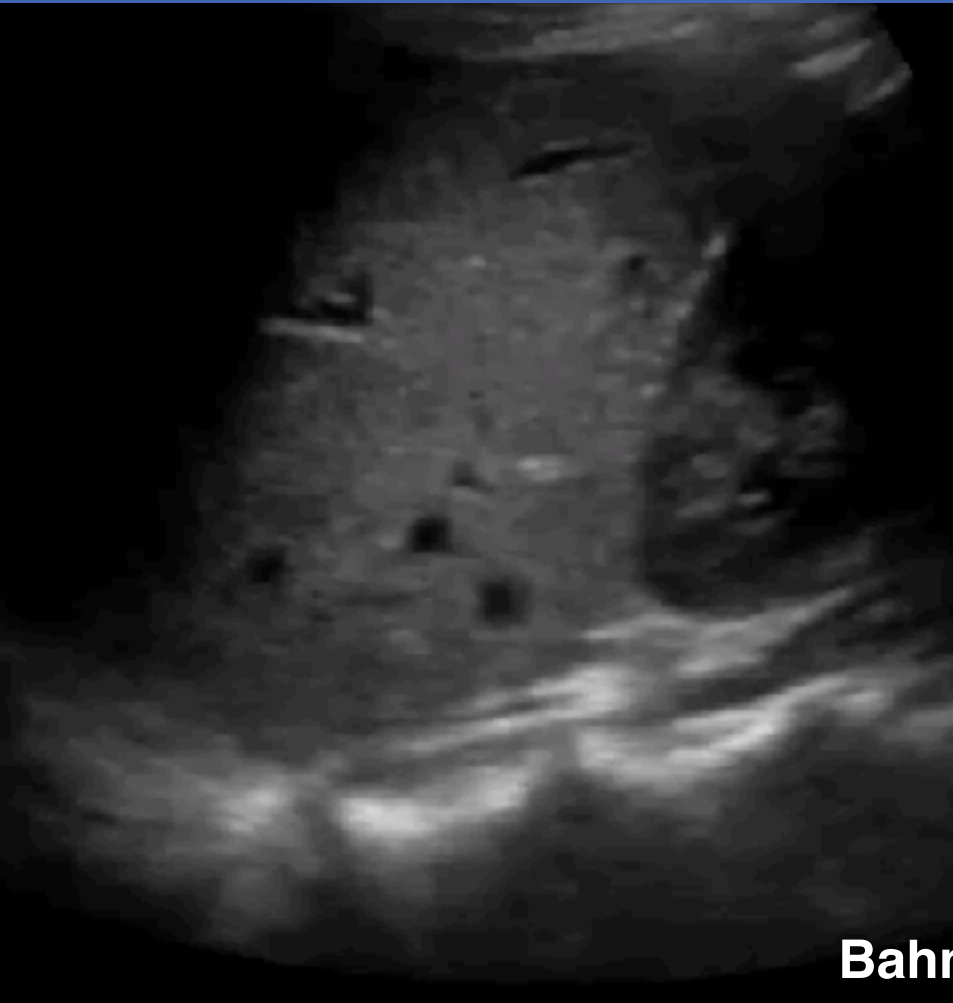
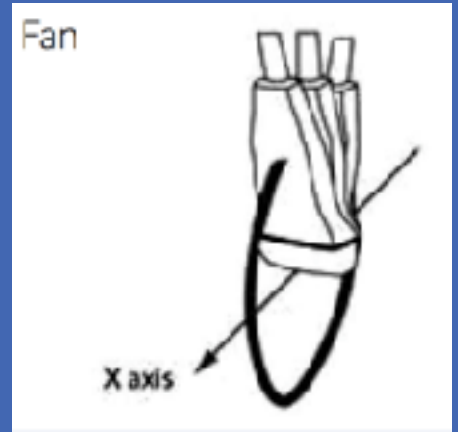
X



Fan/Tilt X

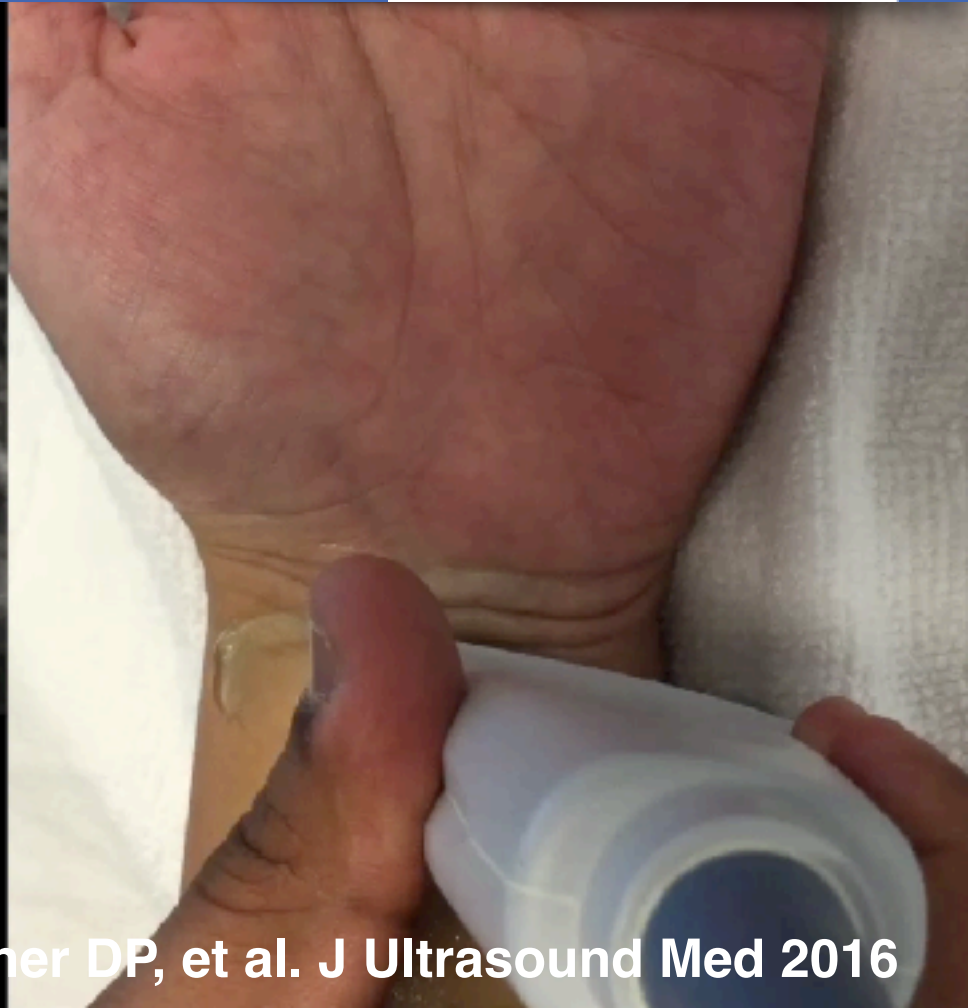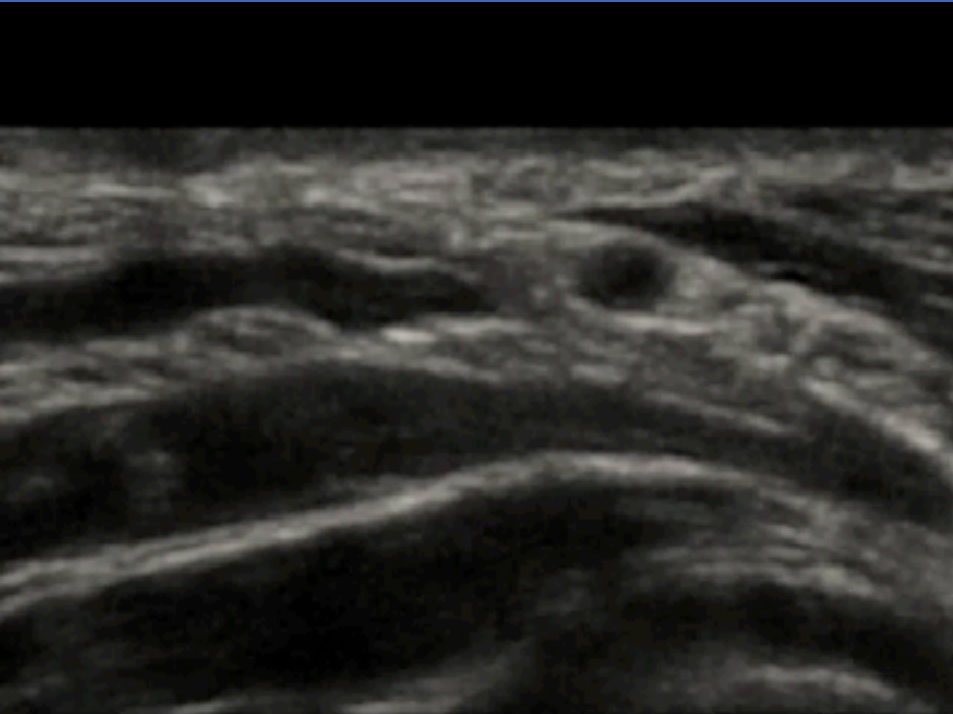
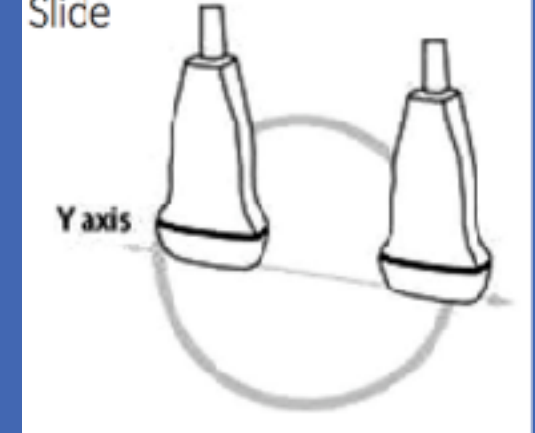


Fan/Tilt X



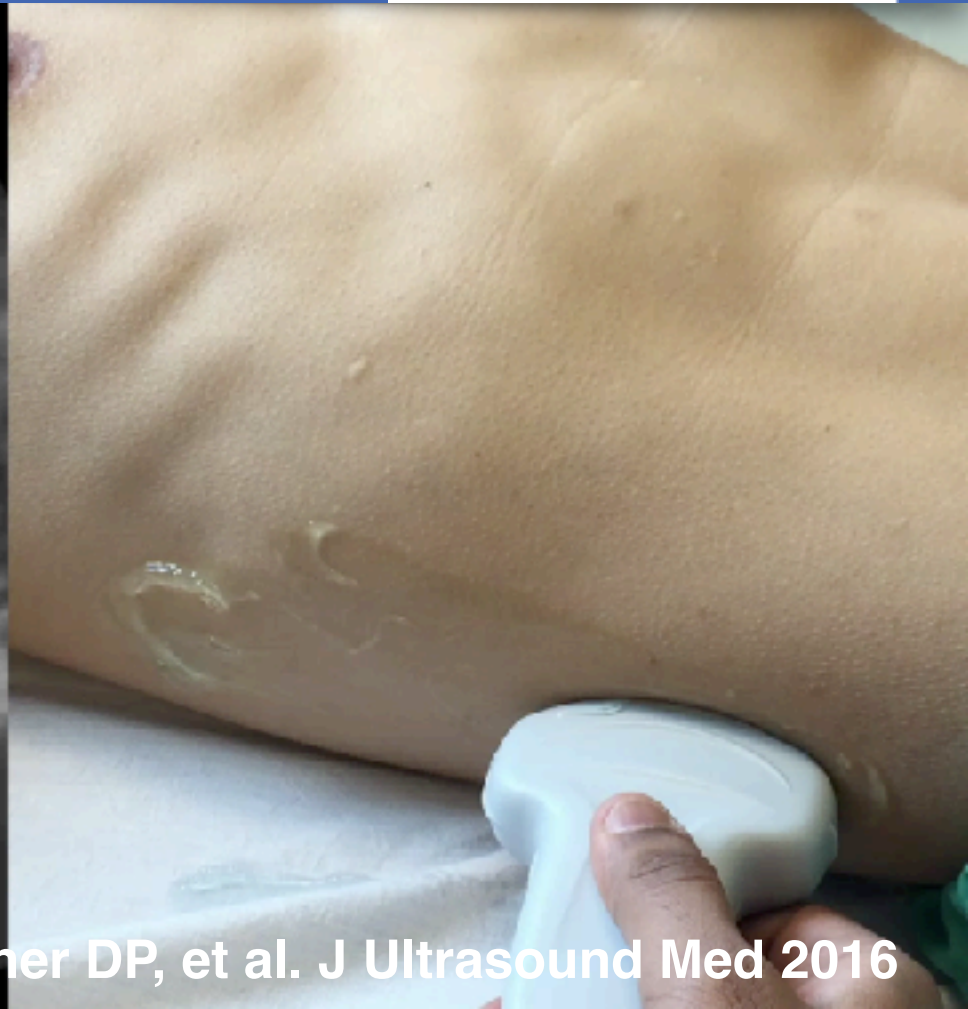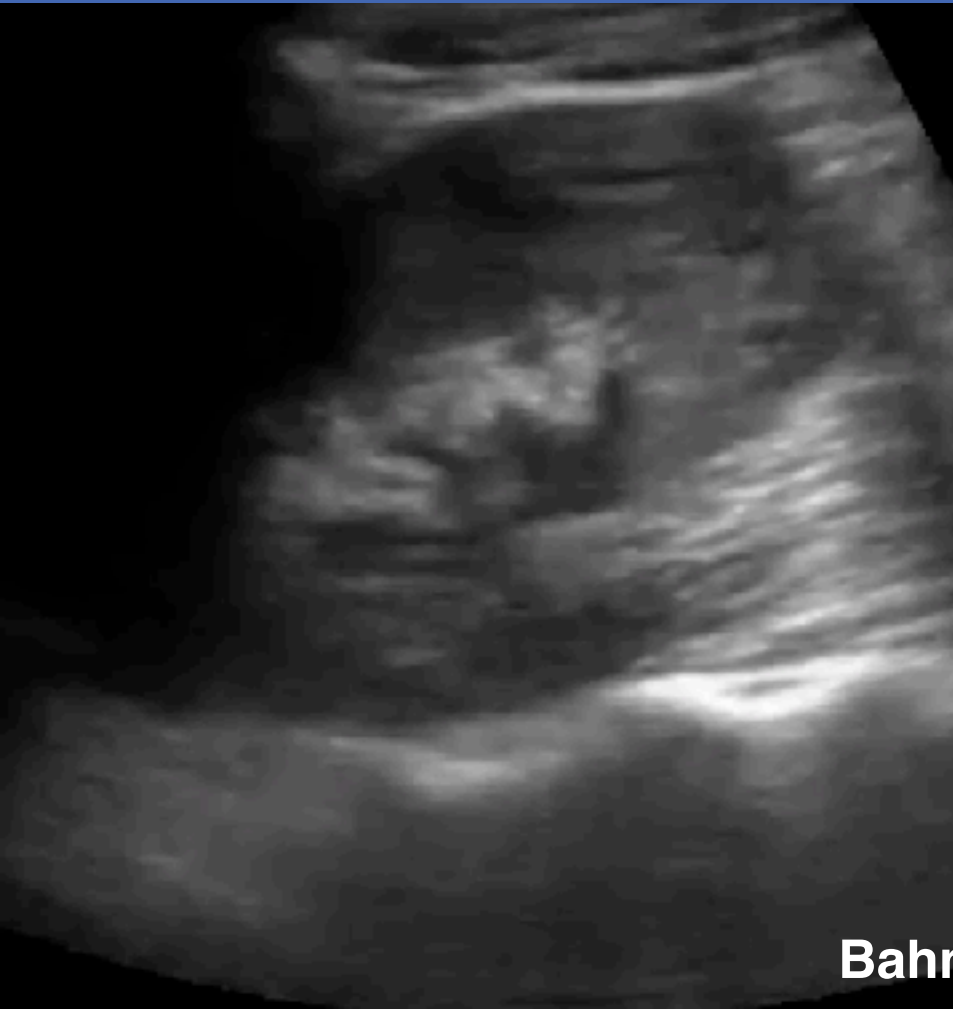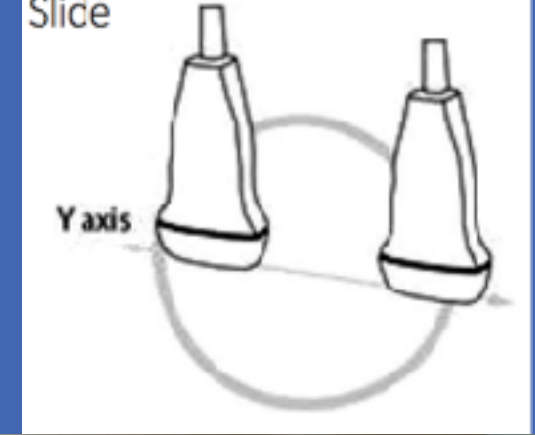
Slide

Y



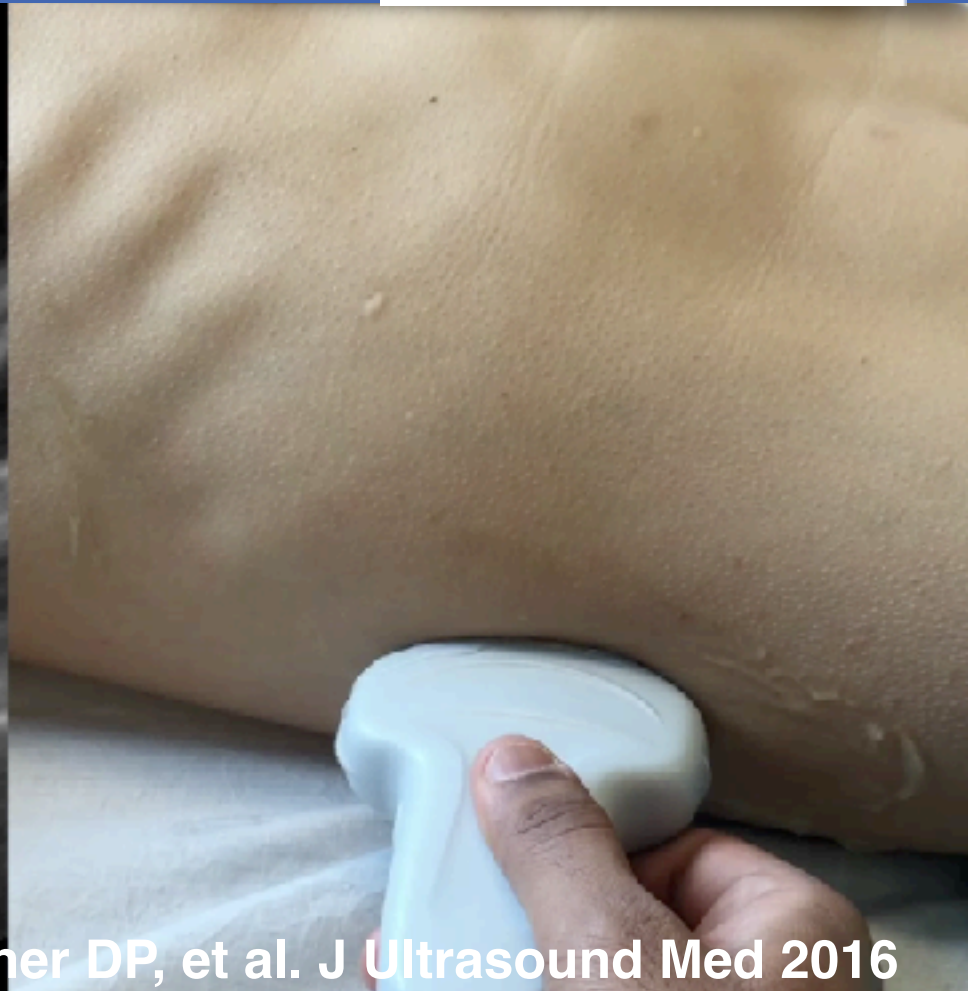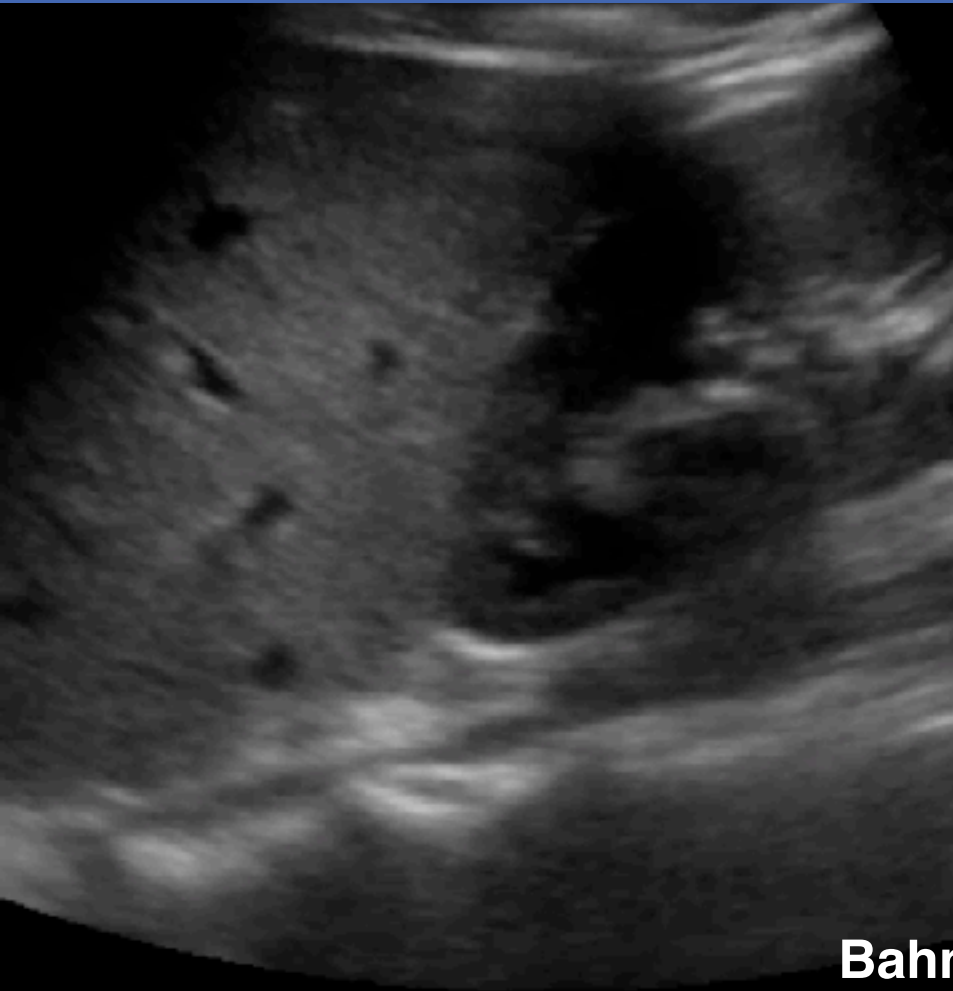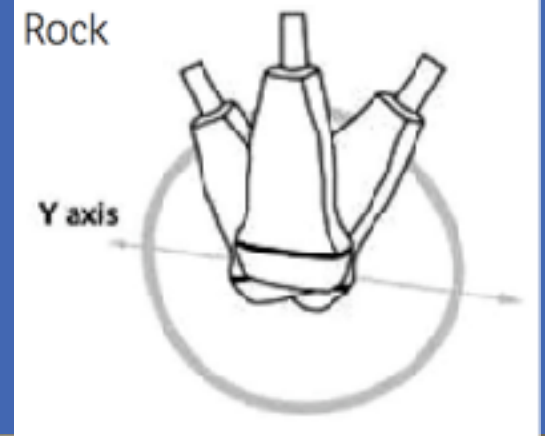
Slide

Y



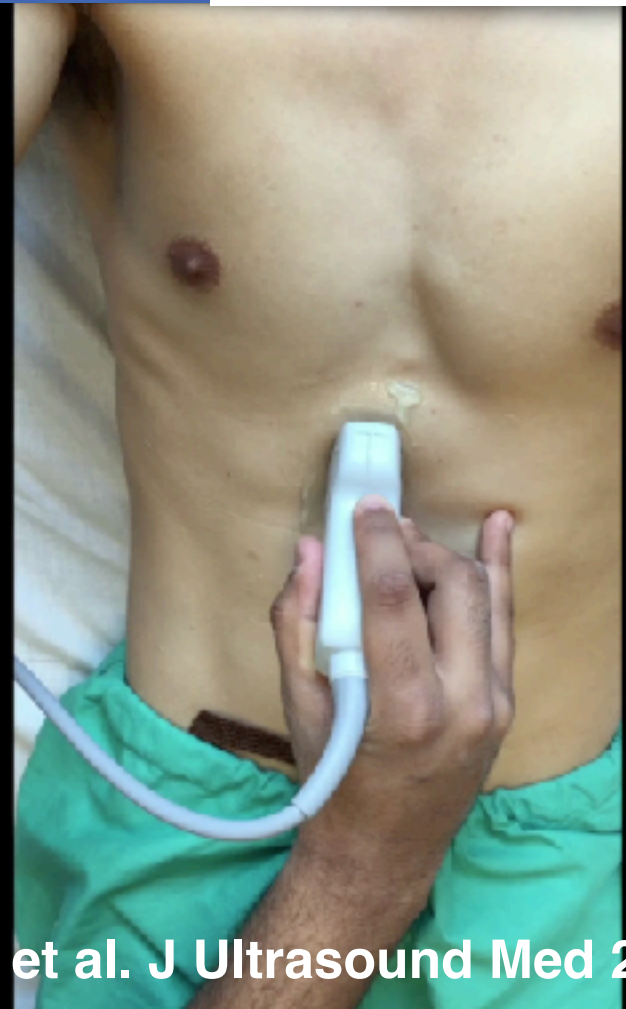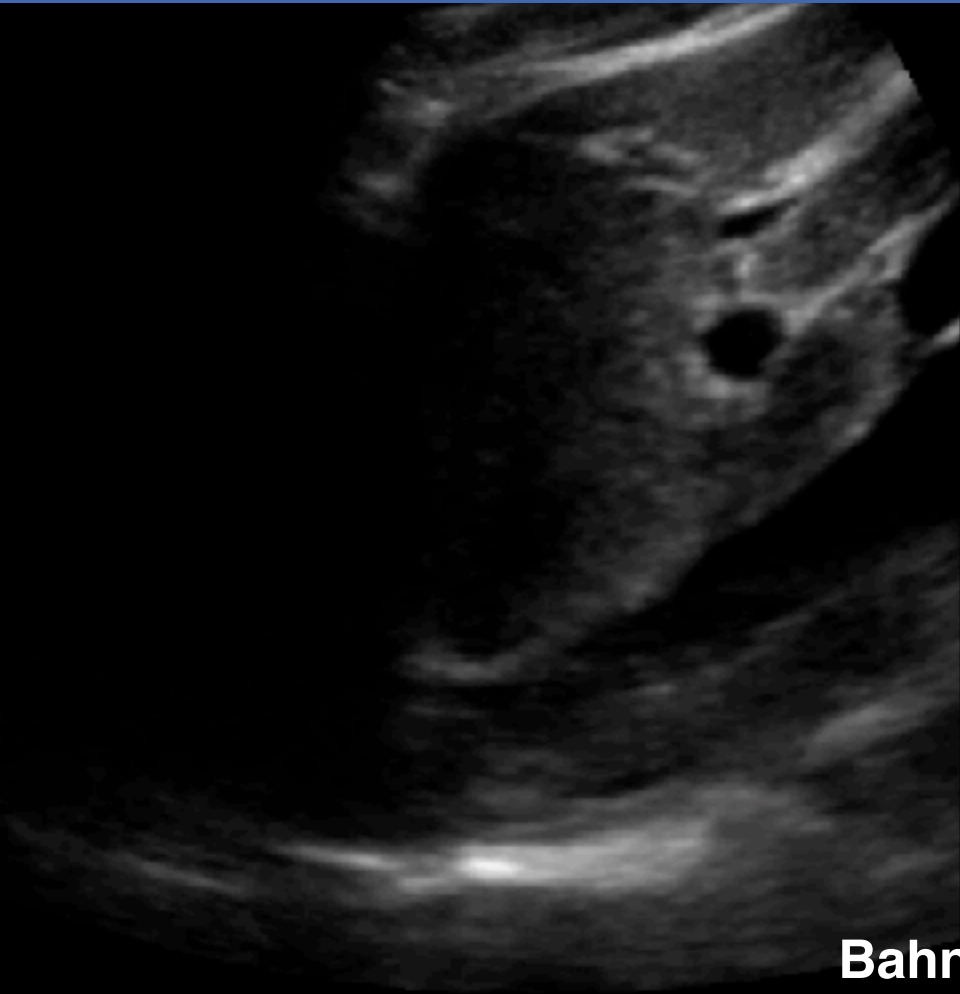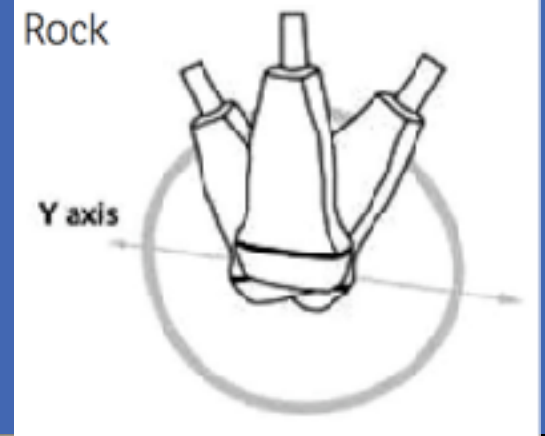
Rock

Y



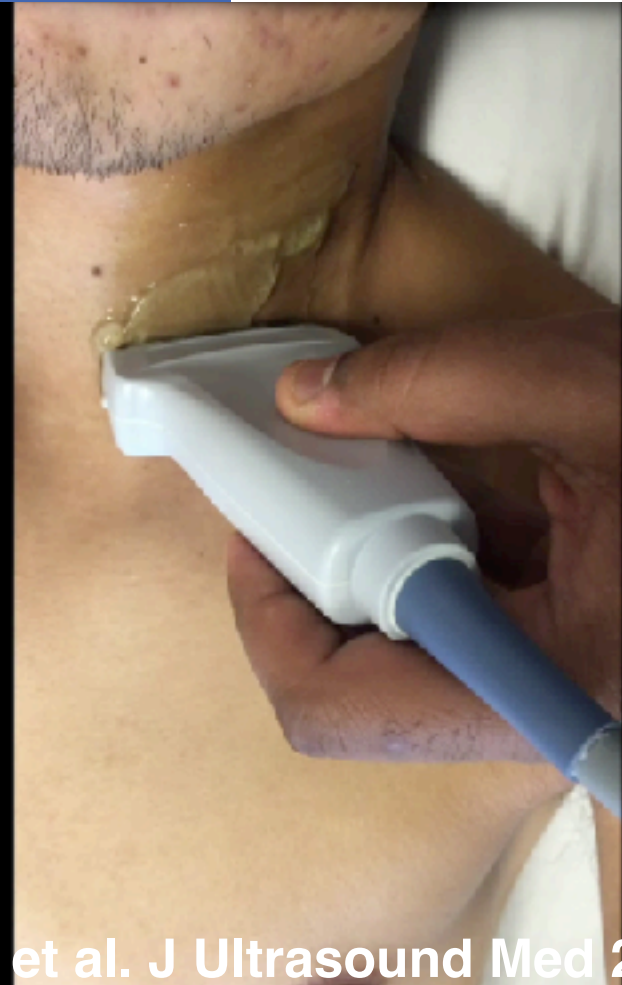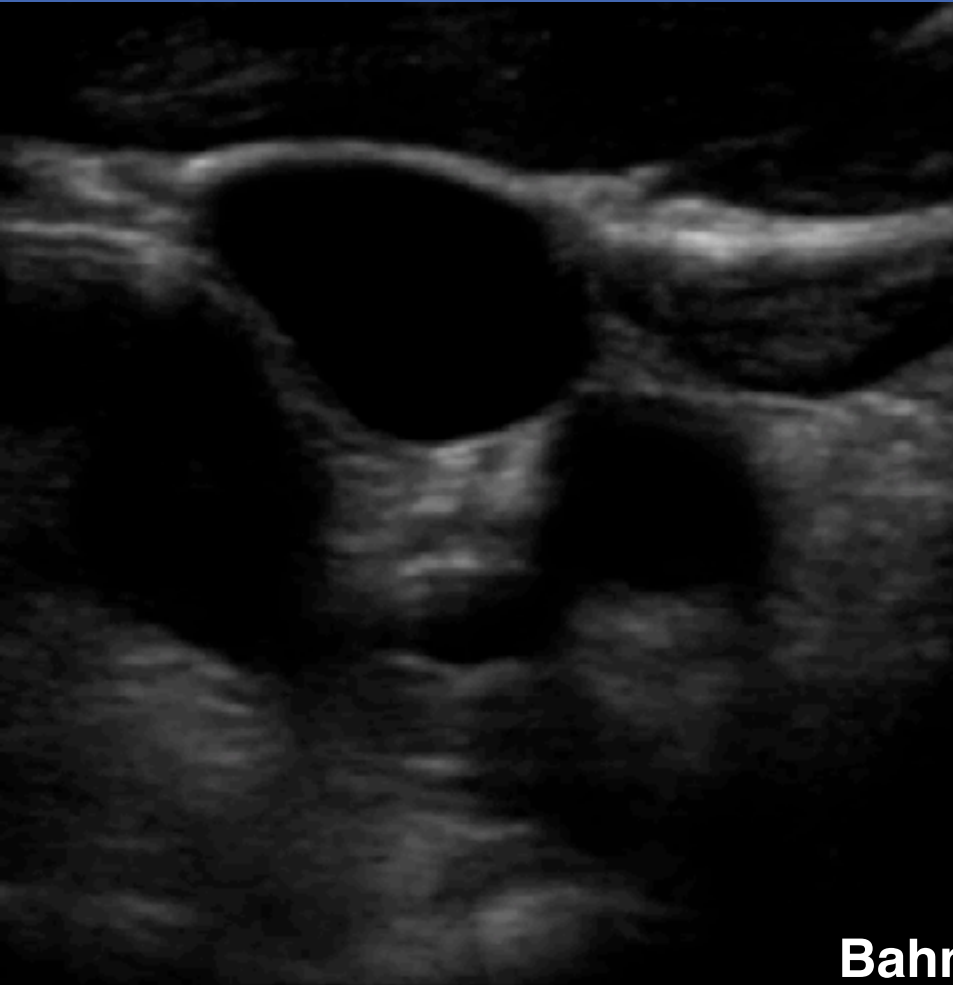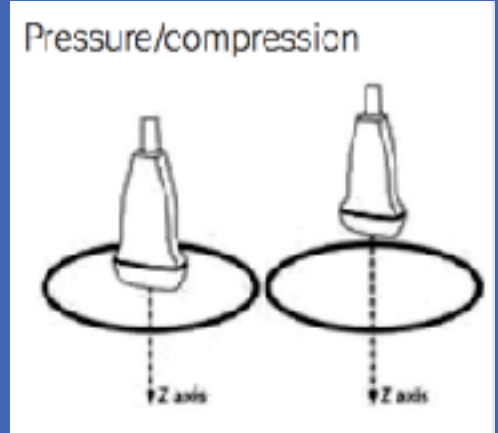
Rock

Y



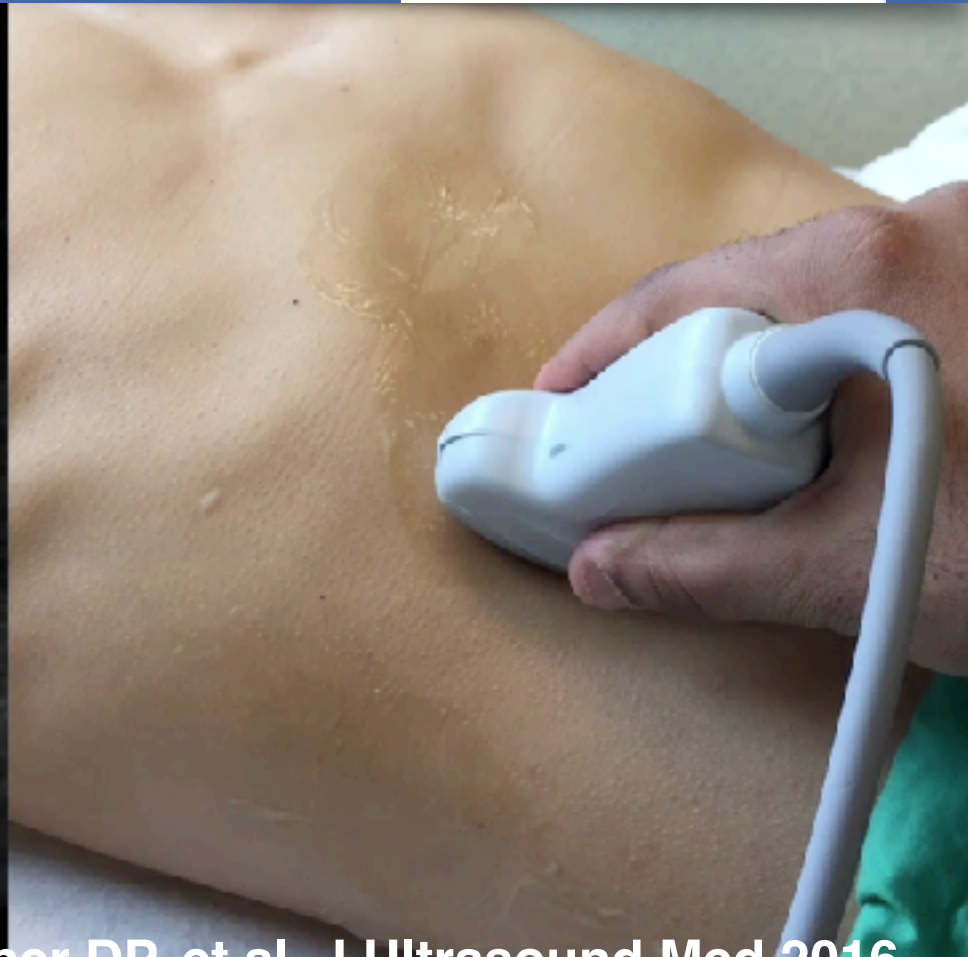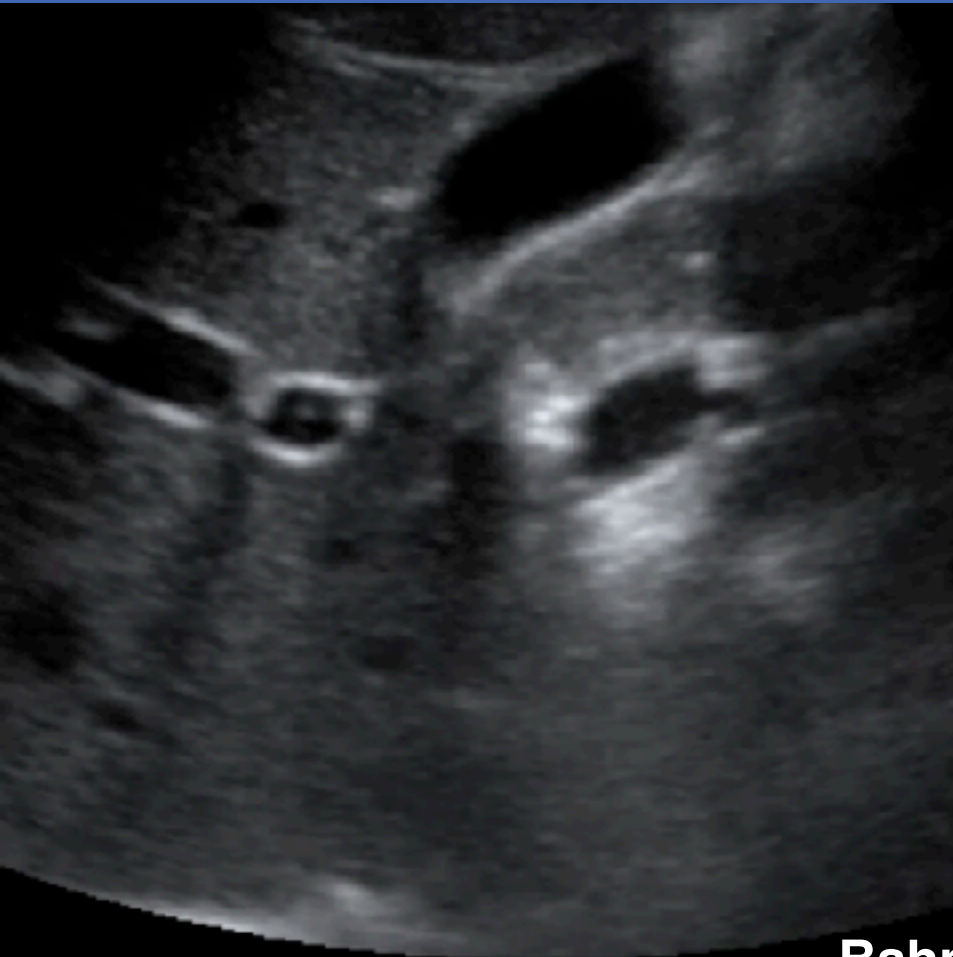
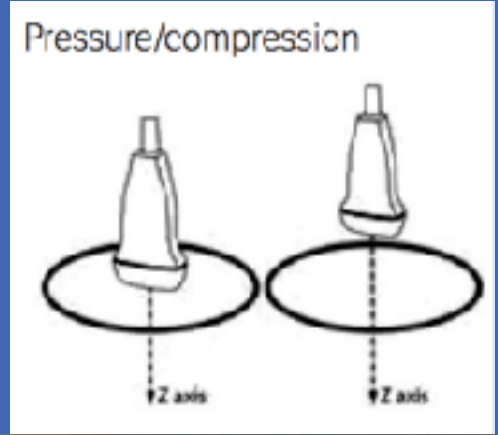
Compress

Z



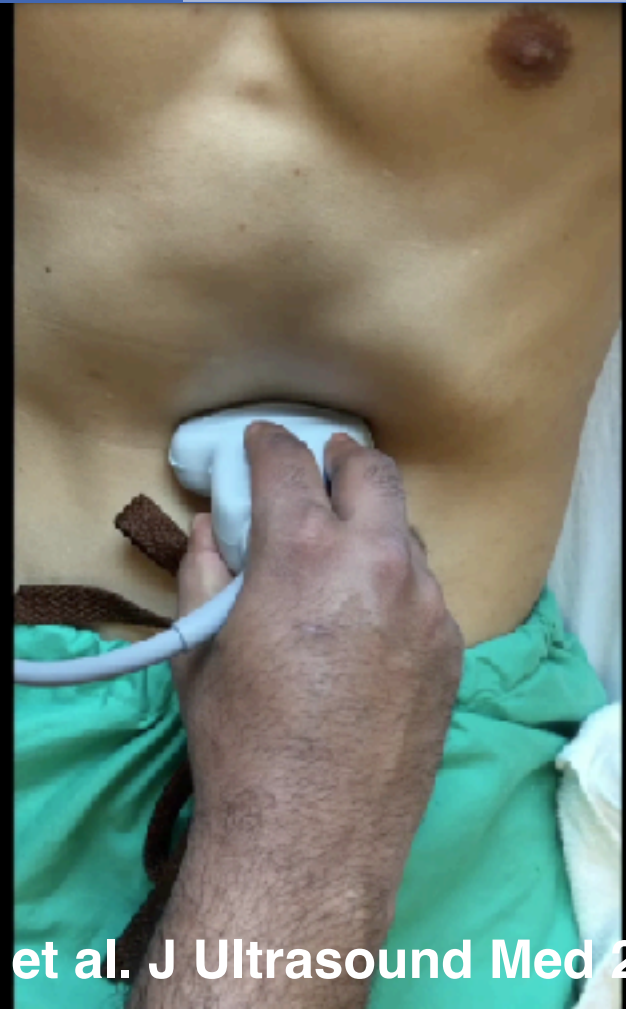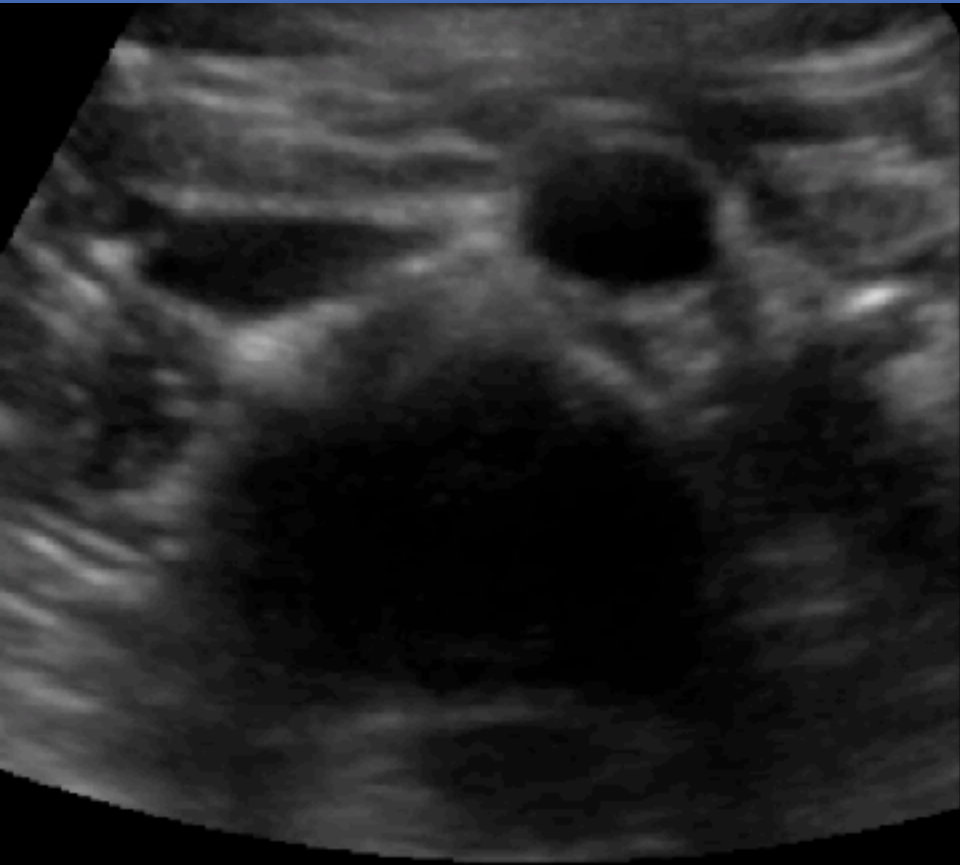
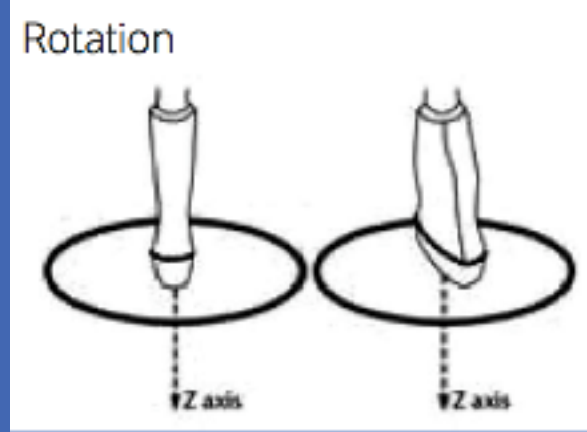
Compress

Z



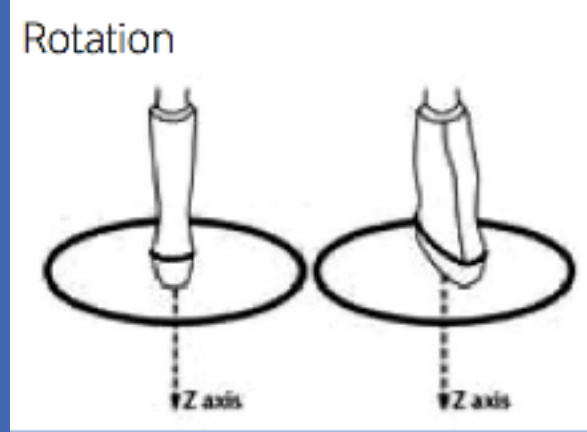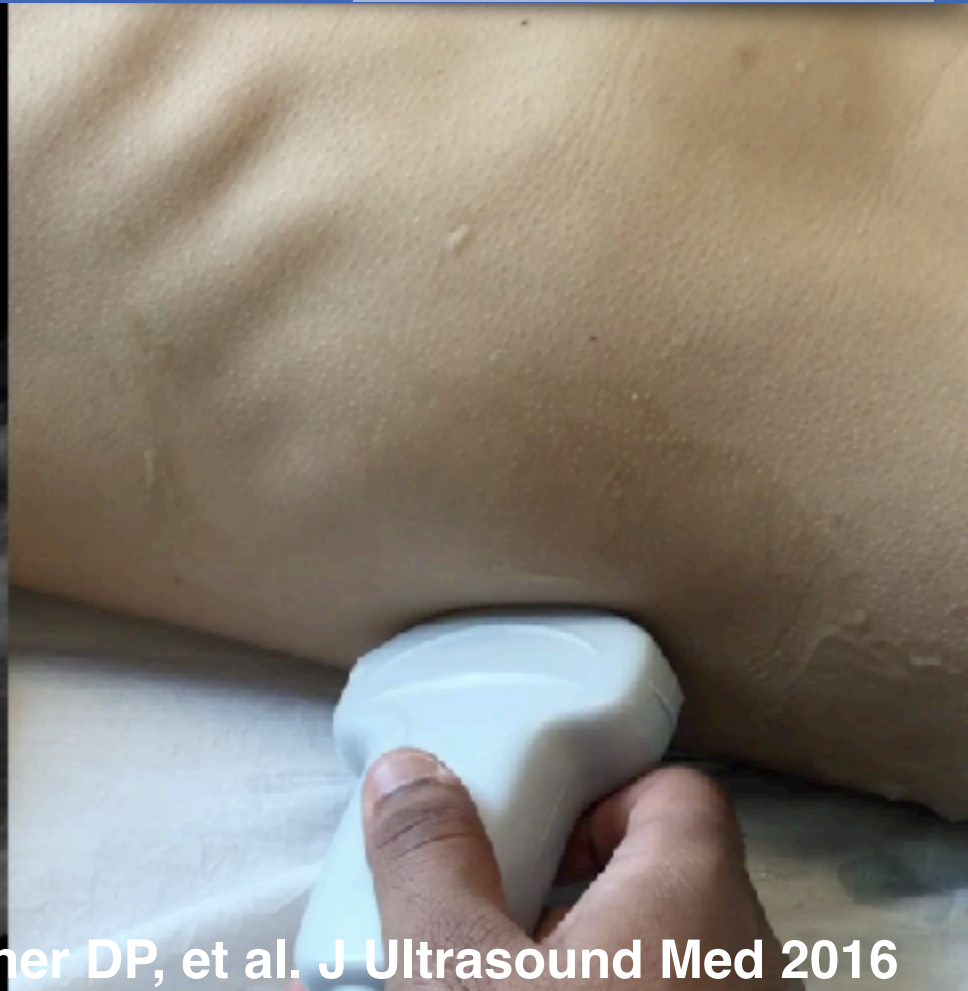
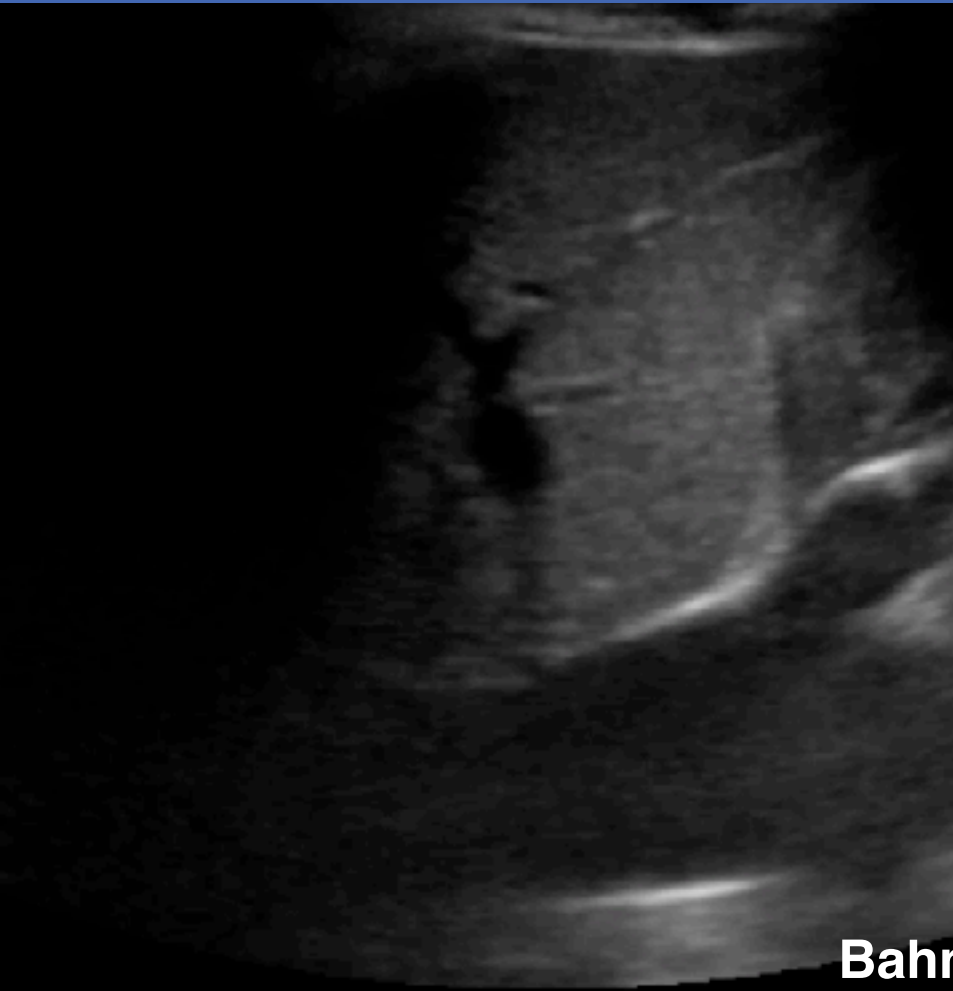Rotate

Z



Rotate

Z





操控 6 大技巧

X

Sweep
掃

Y

Slide
滑

Z

Rotate
轉

Fan/Tilt
傾

Rock
搖

Compress
壓

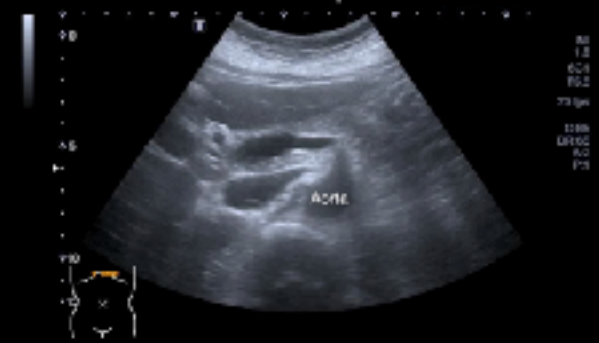Abdominal Aorta

X

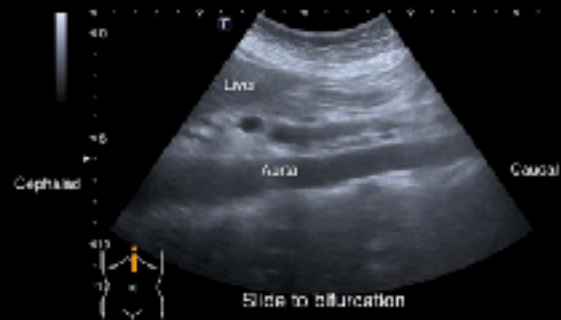Y

Z

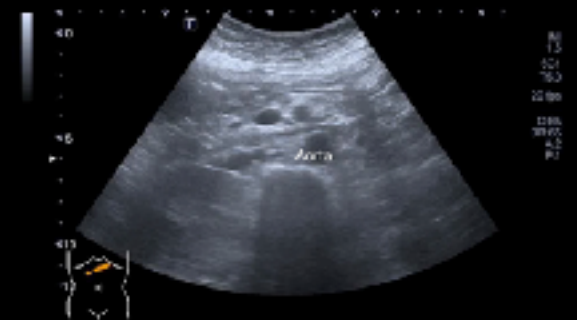Sweep



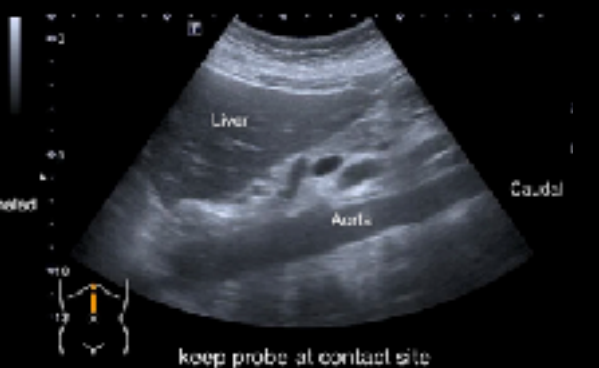Slide



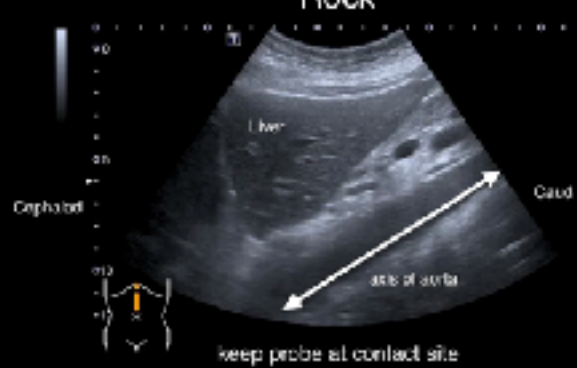
Rotation



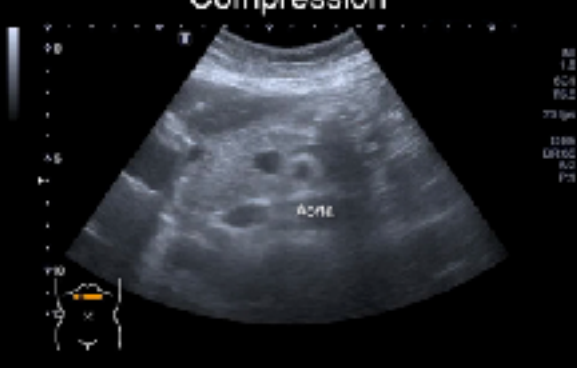Fan



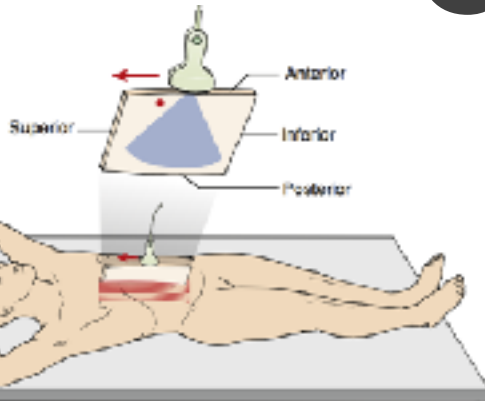
Rock



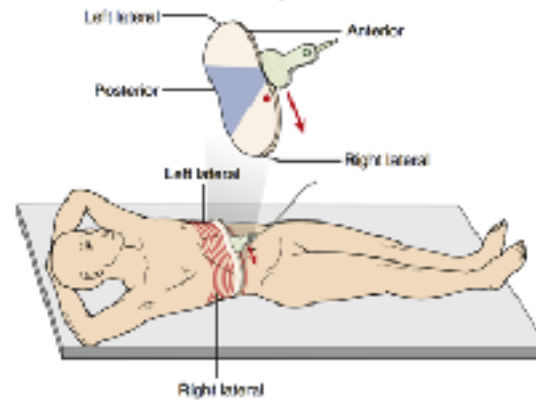
Compression



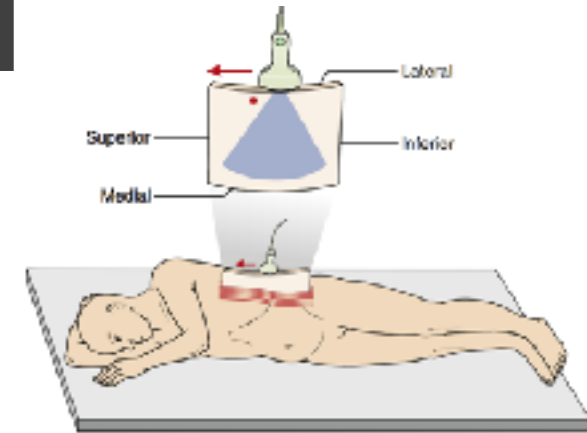
3D 立體掃描



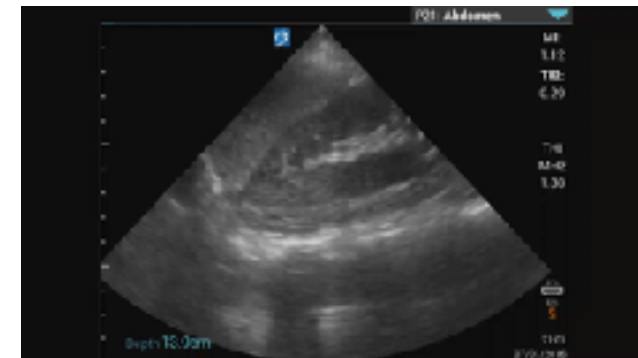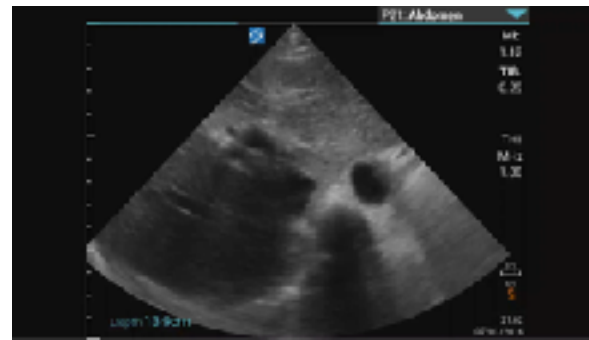
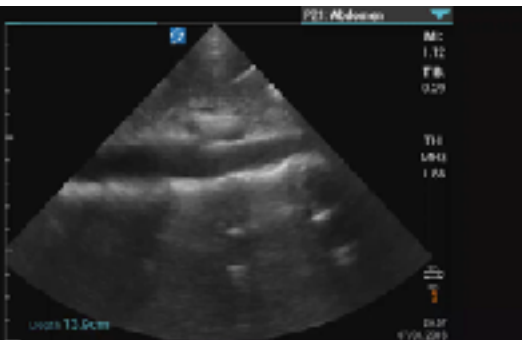
Sagittal 縱



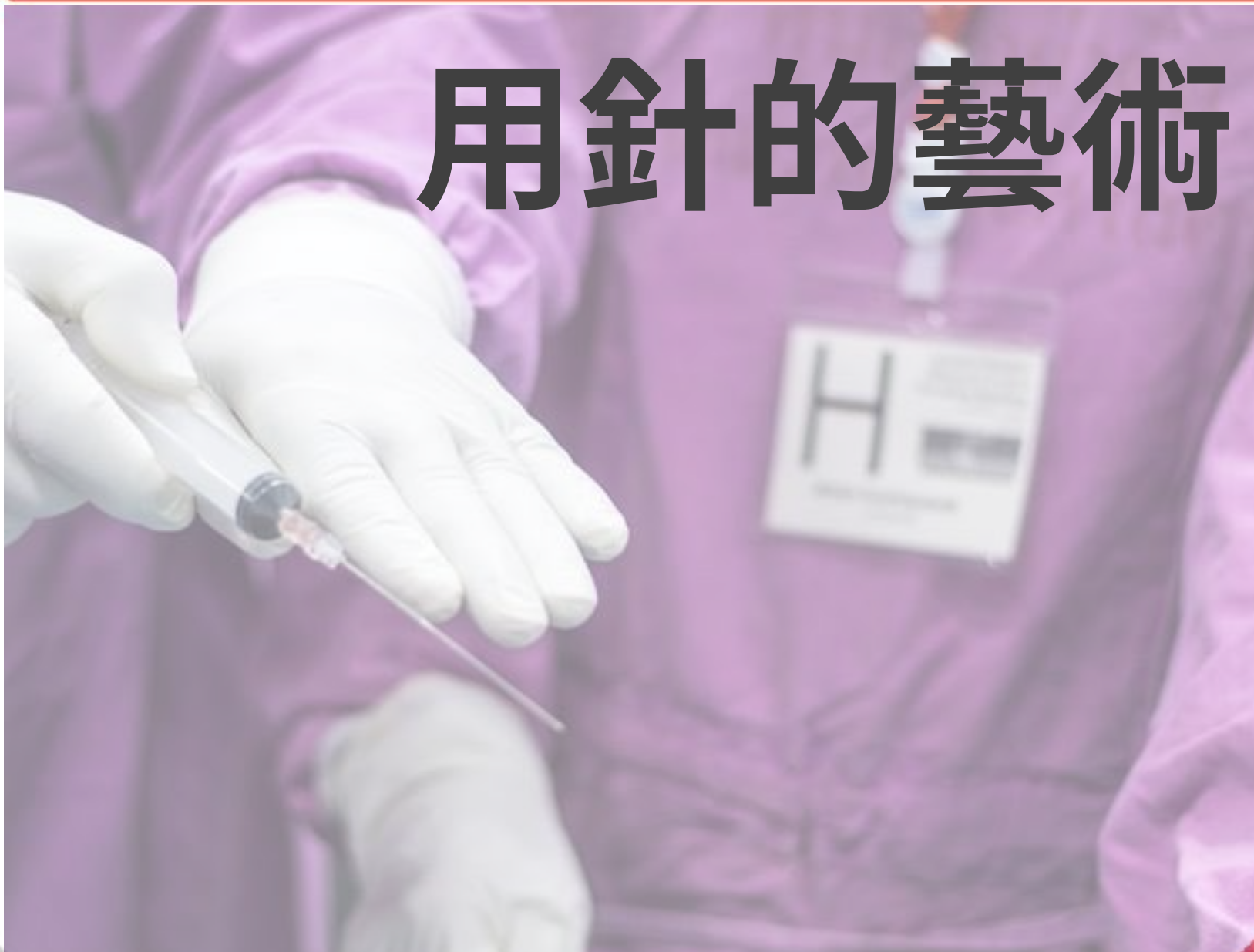Transverse 橫



Coronal 側



用針的藝術



Procedures



Success rates ↑

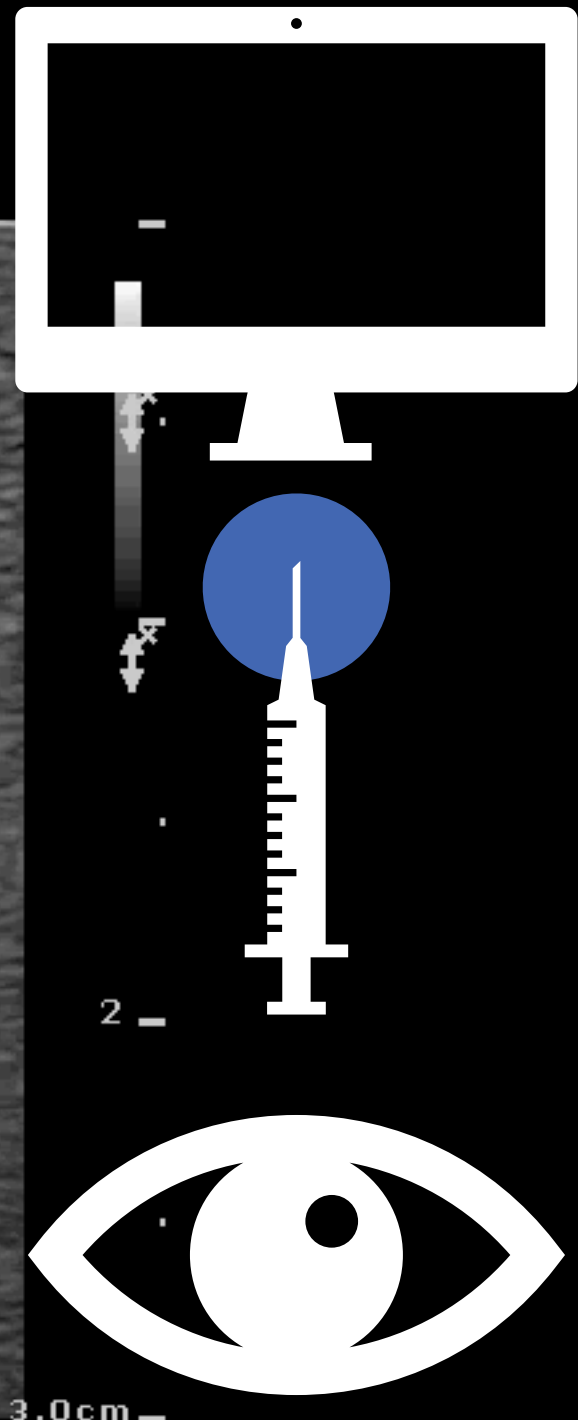
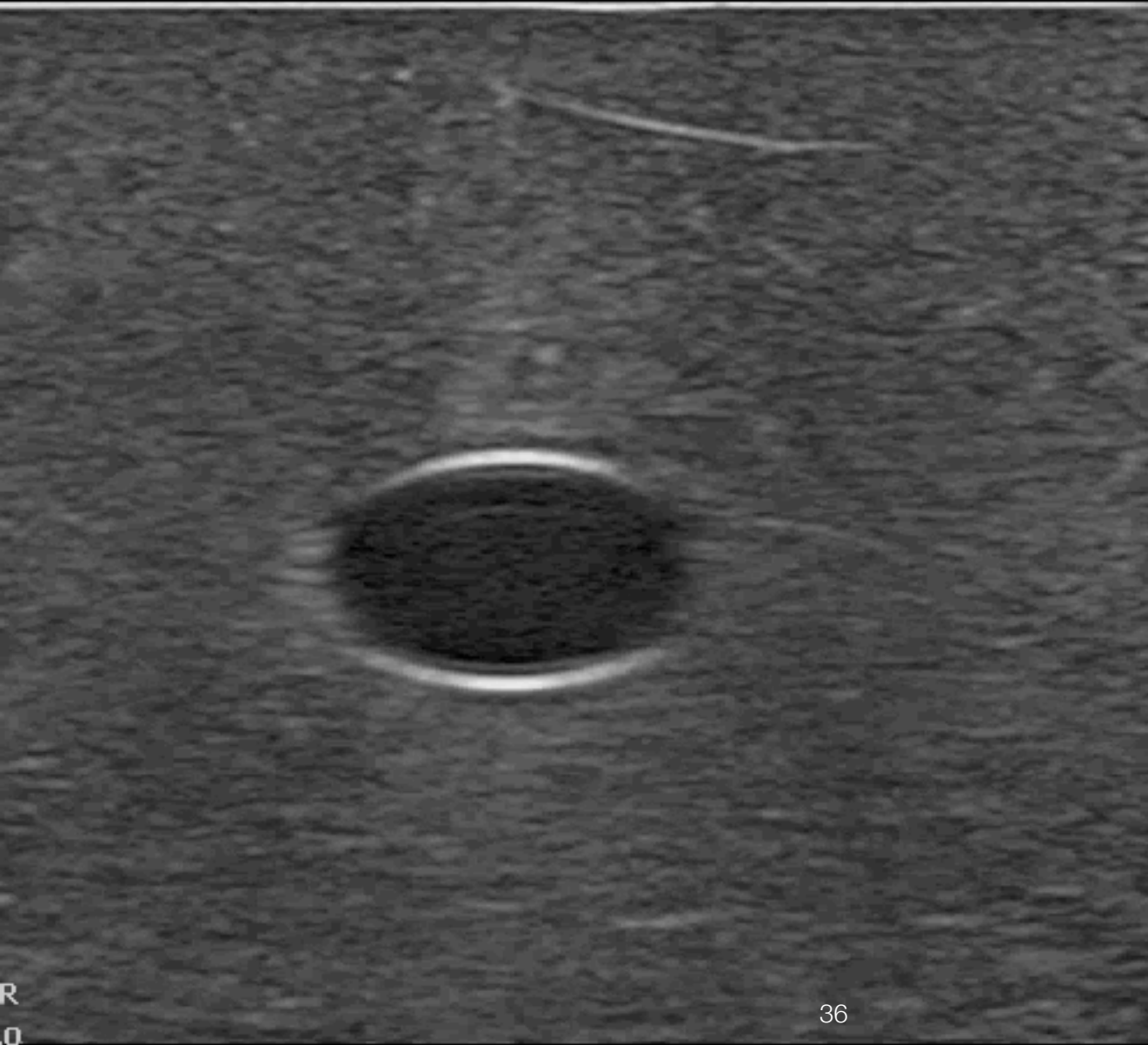
Mechanical complications ↓

Off-plane

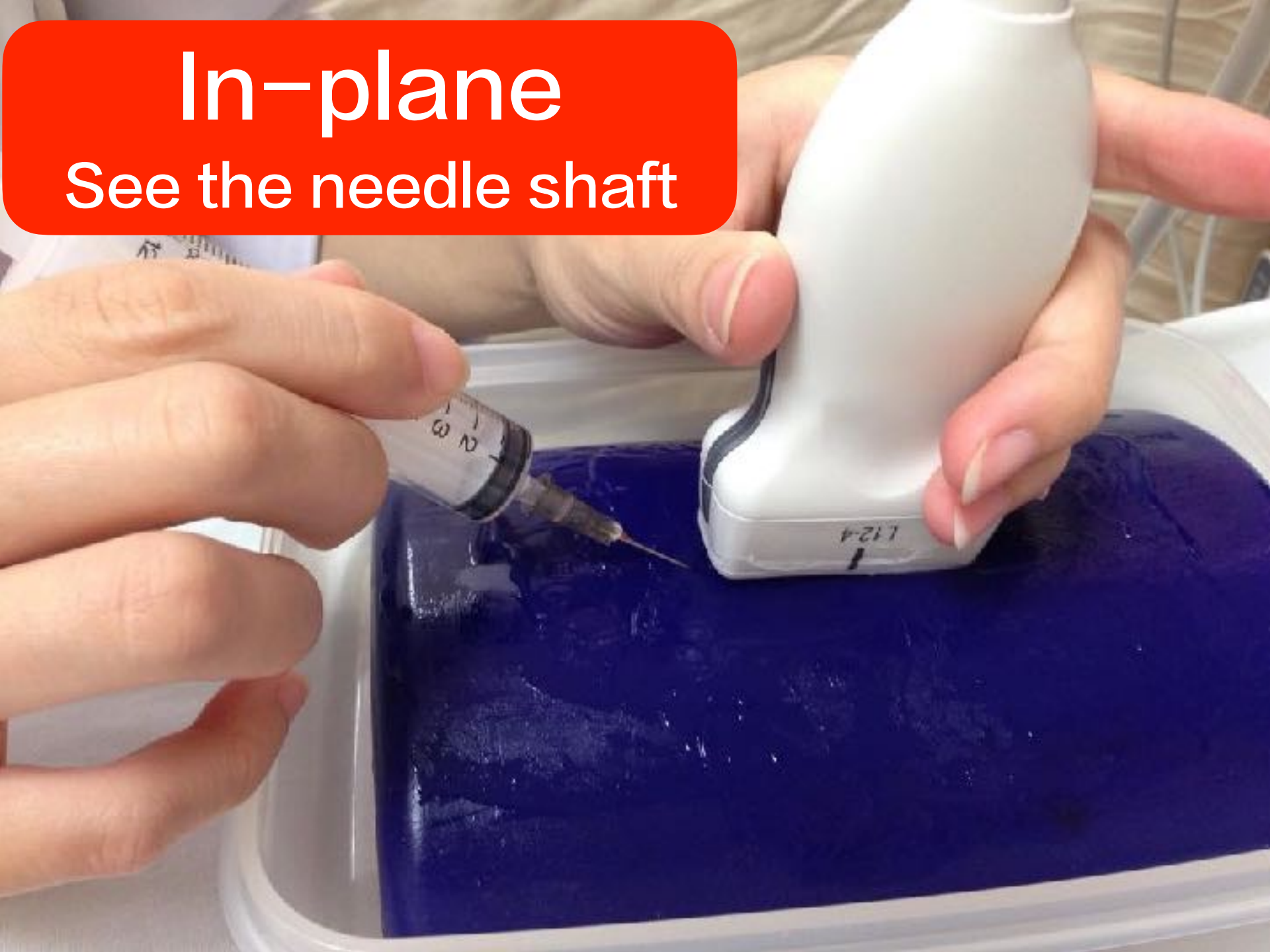Trace the tip



Tilt & Sweep



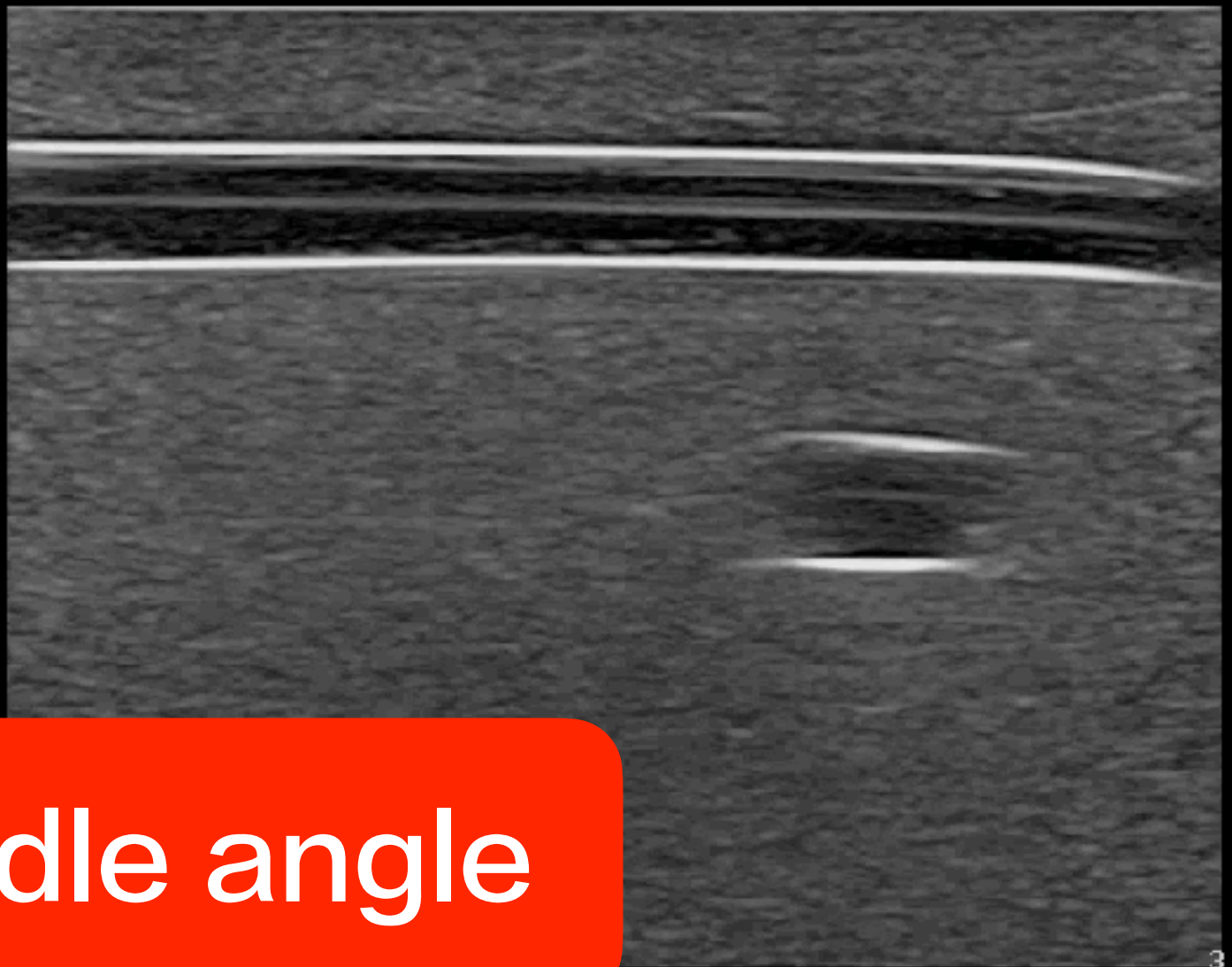
In-plane
See the needle shaft



Needle optimisation

Superficial P
L12-3
46 Hz
3.0cm

2D
Res
Gn 96
C. 56
3 / 2 / 1



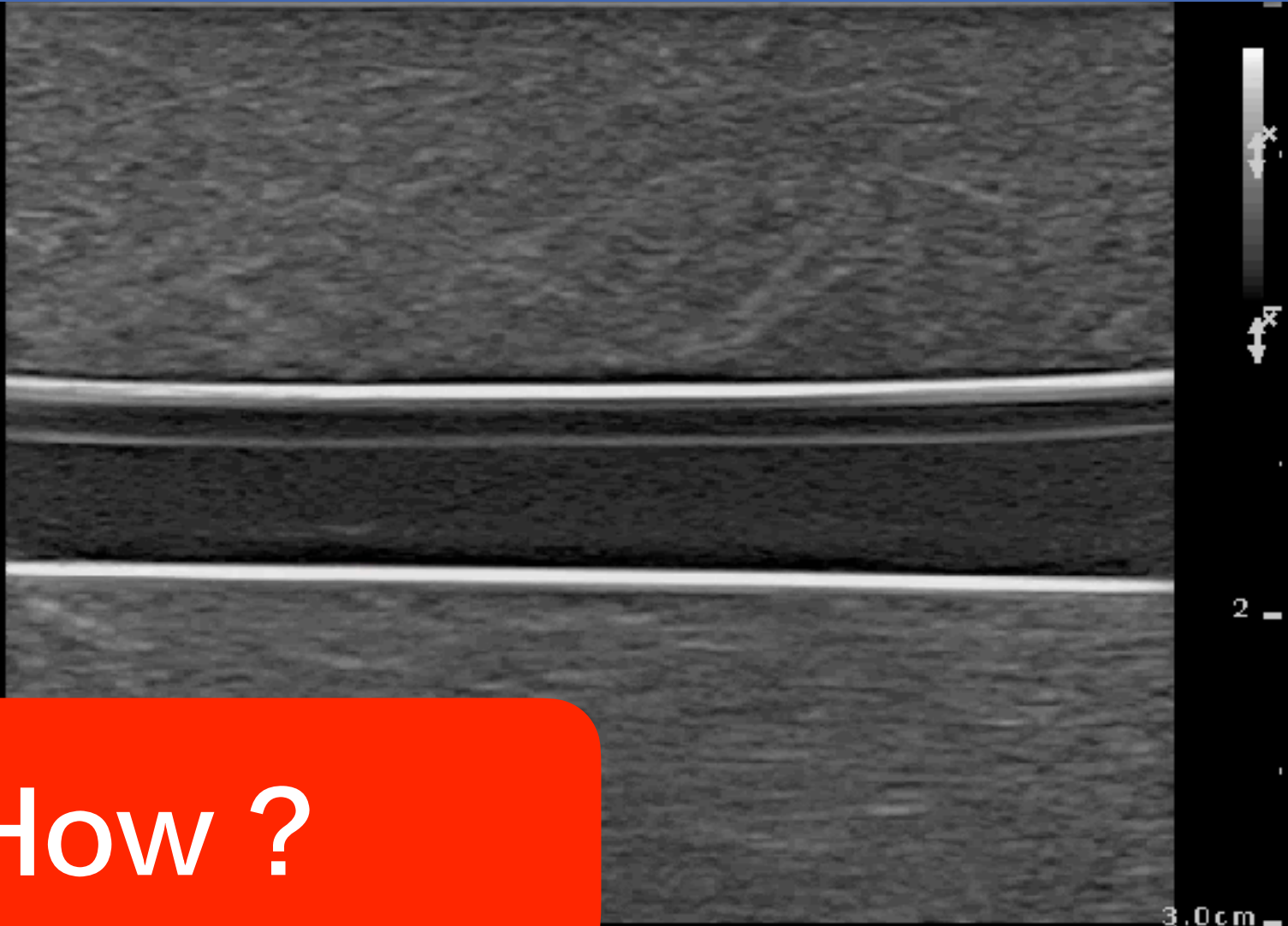
Needle angle

3.0cm

Needle optimisation

Superficial P
L12-3
46 Hz
3.0cm

2D
Res
Gn 96
C 56
3 / 2 / 1

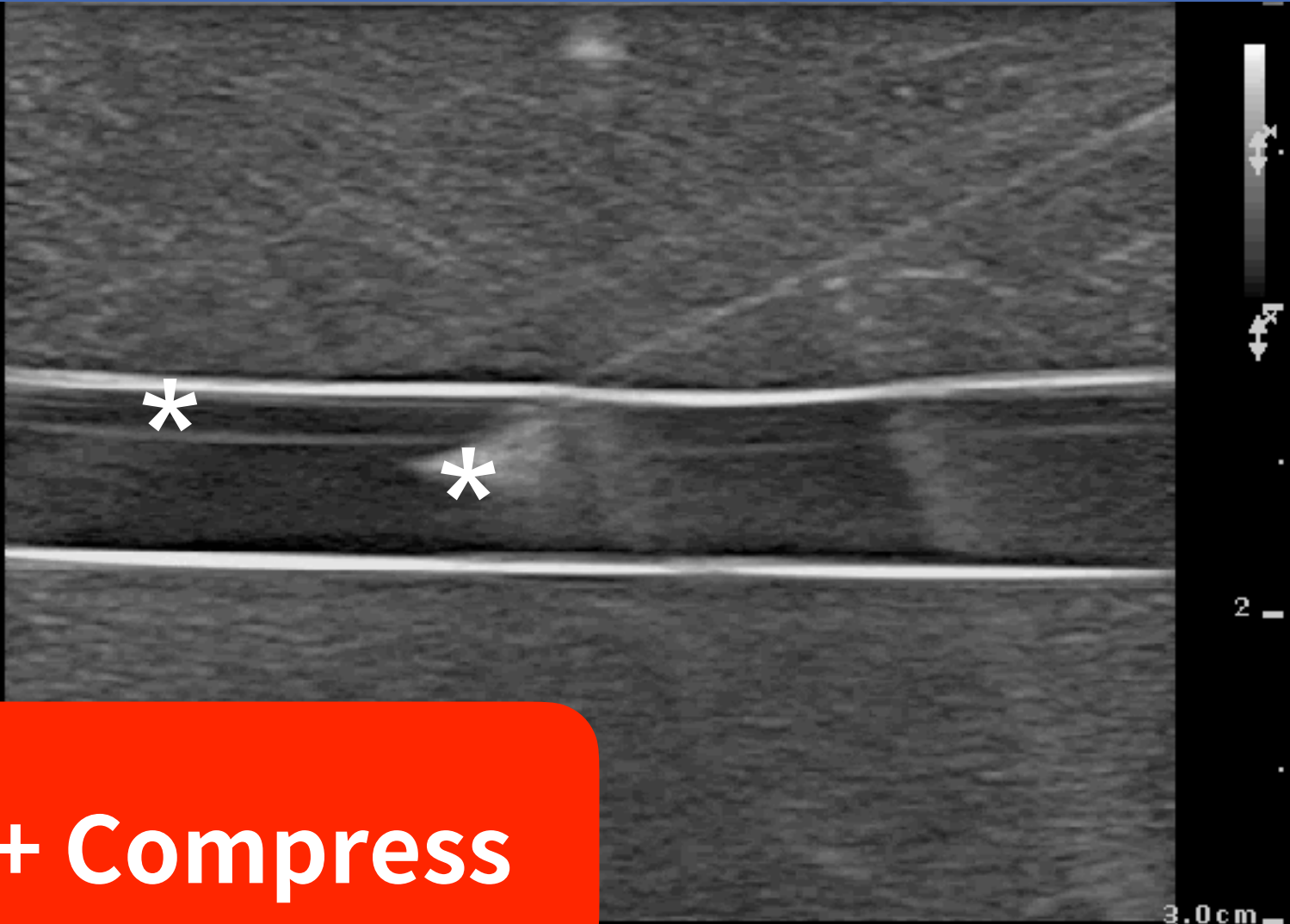


How ?

Needle optimisation

Superficial P
L12-3
46 Hz
3.0cm

2D
Res
Gn 96
C 56
3/2/1

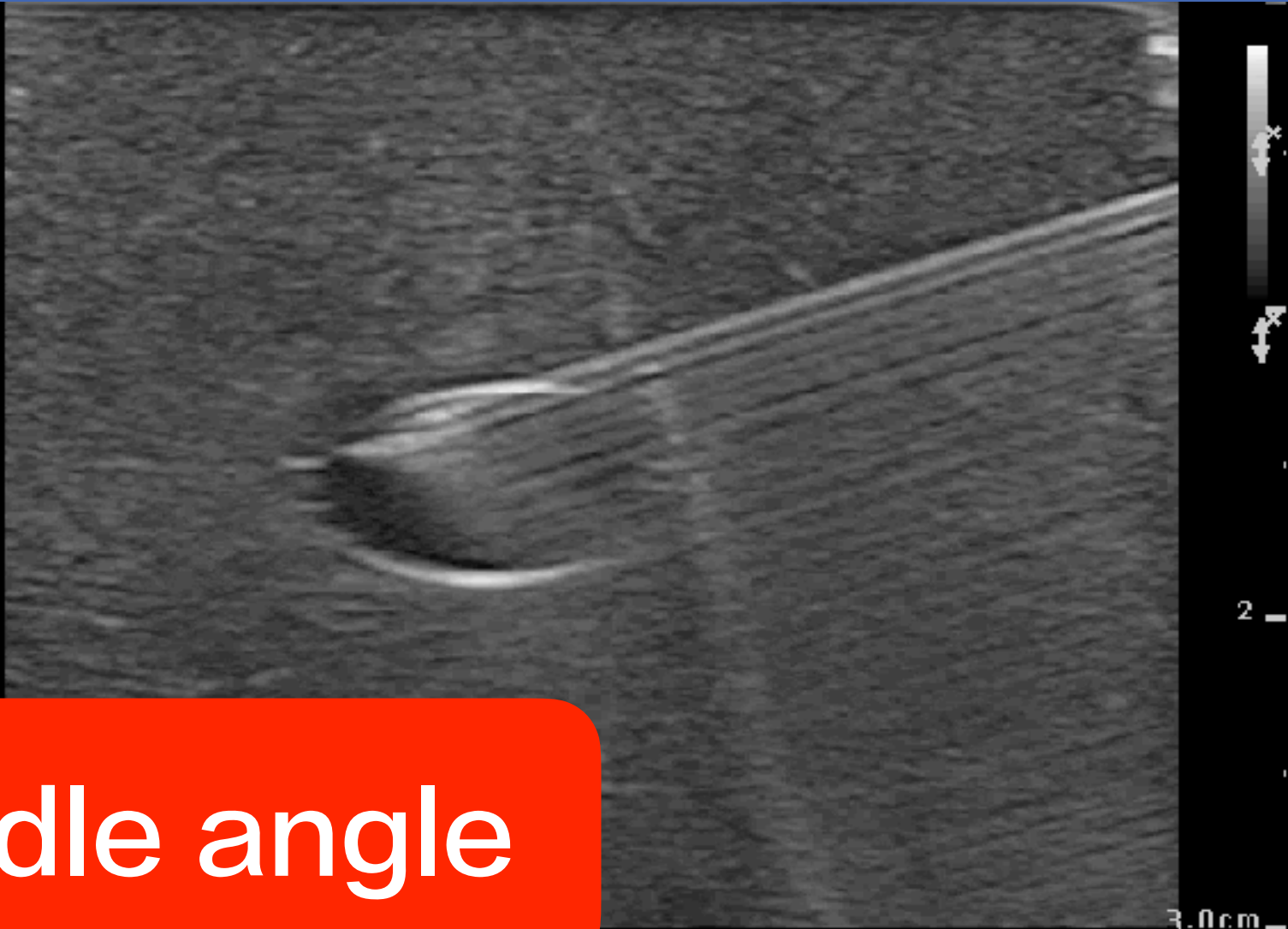


Rock + Compress

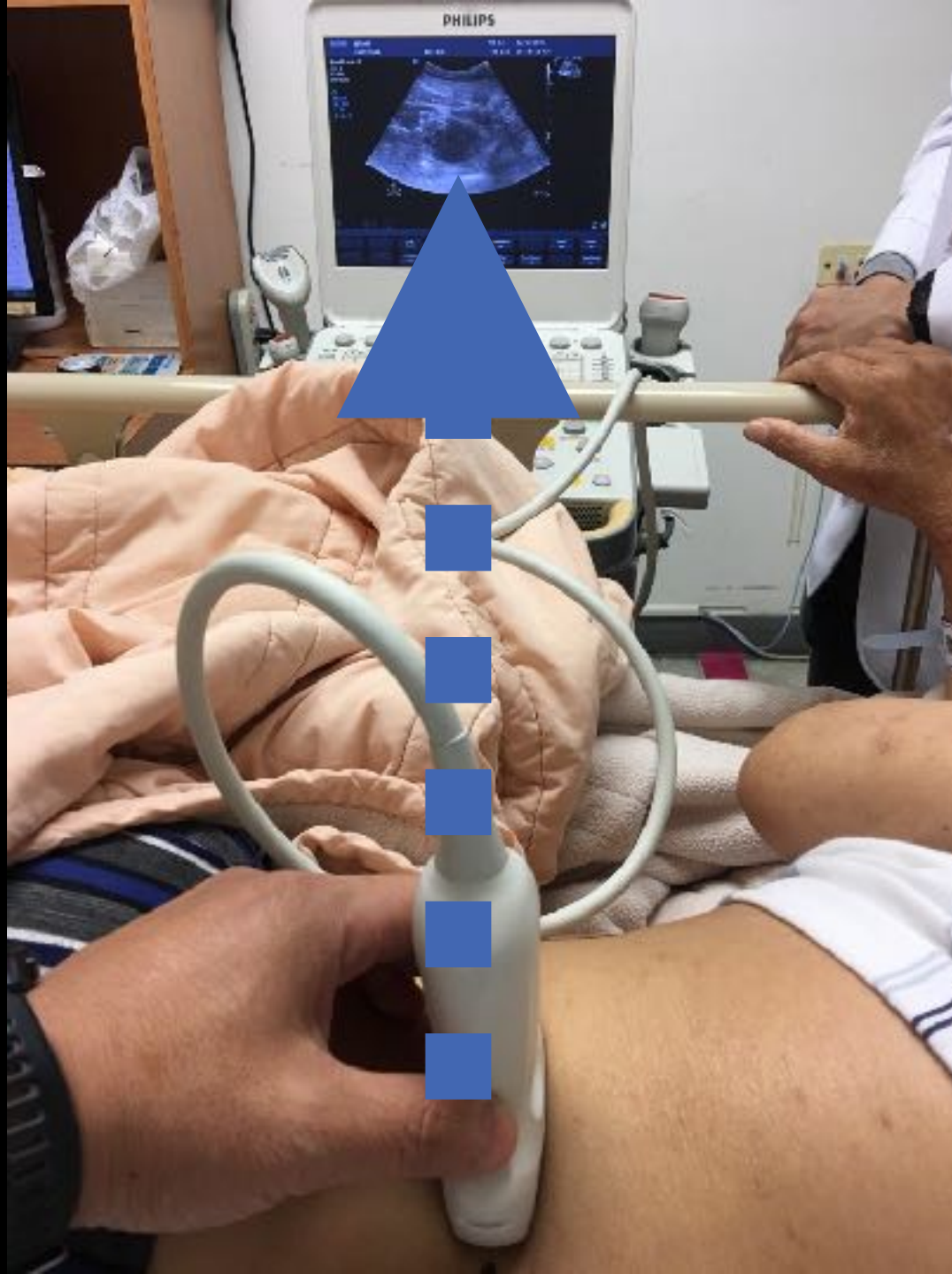Needle optimisation

Superficial P
L12-3
46 Hz
3.0cm

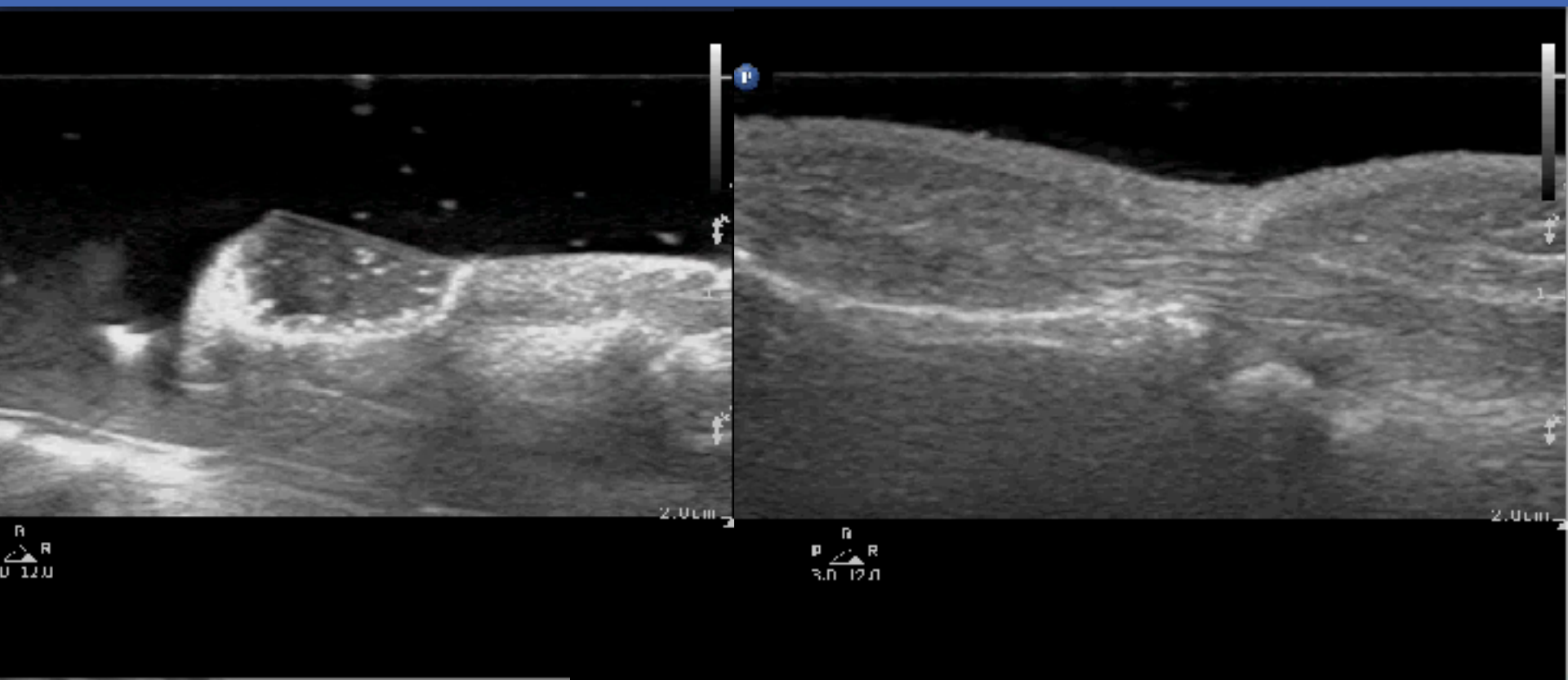
2D
Res
Gn 96
C 56
3/2/1



Needle angle



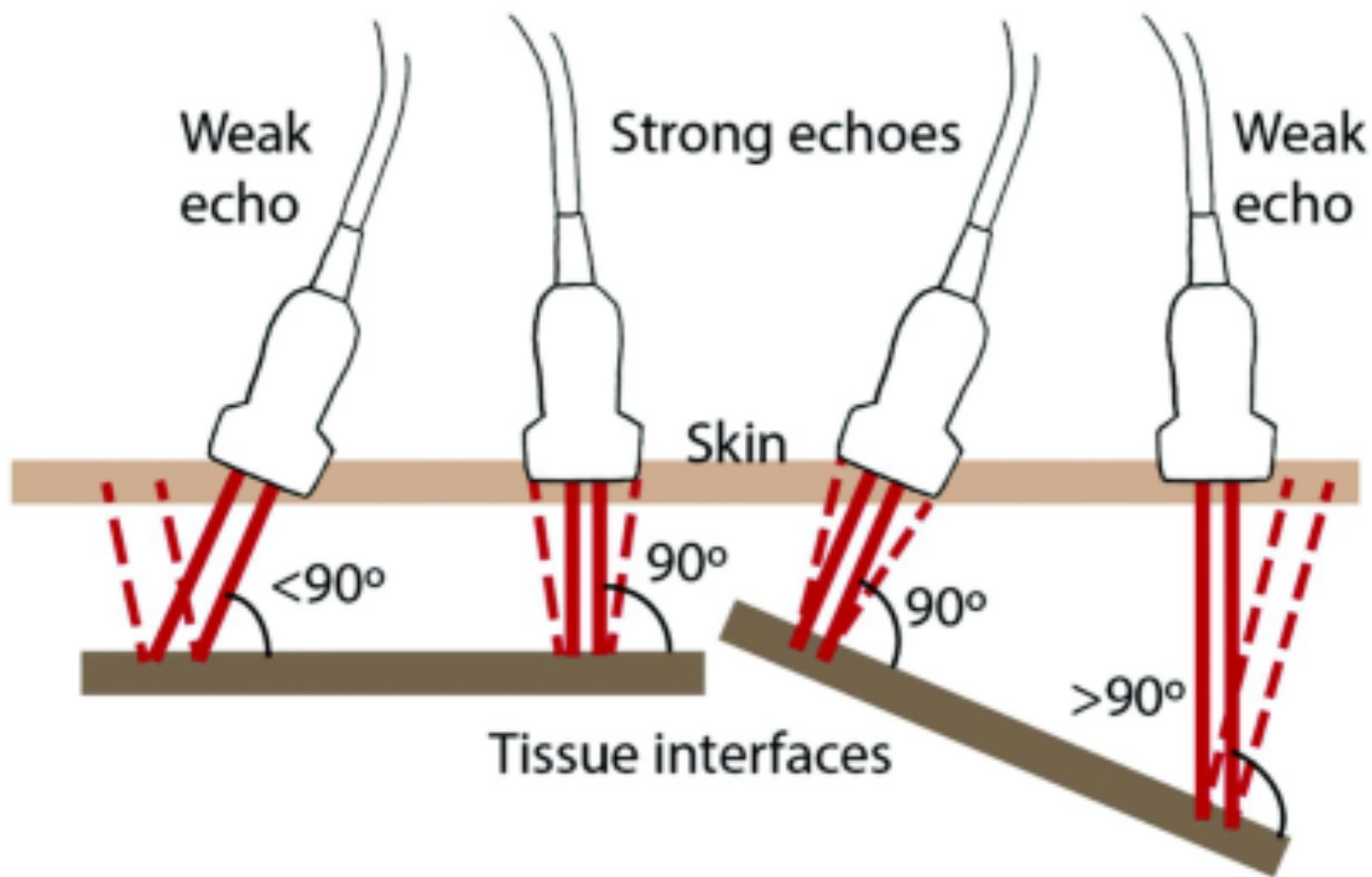
Water Bath



Water Bath



探頭**垂直**於掃描的**目標物**



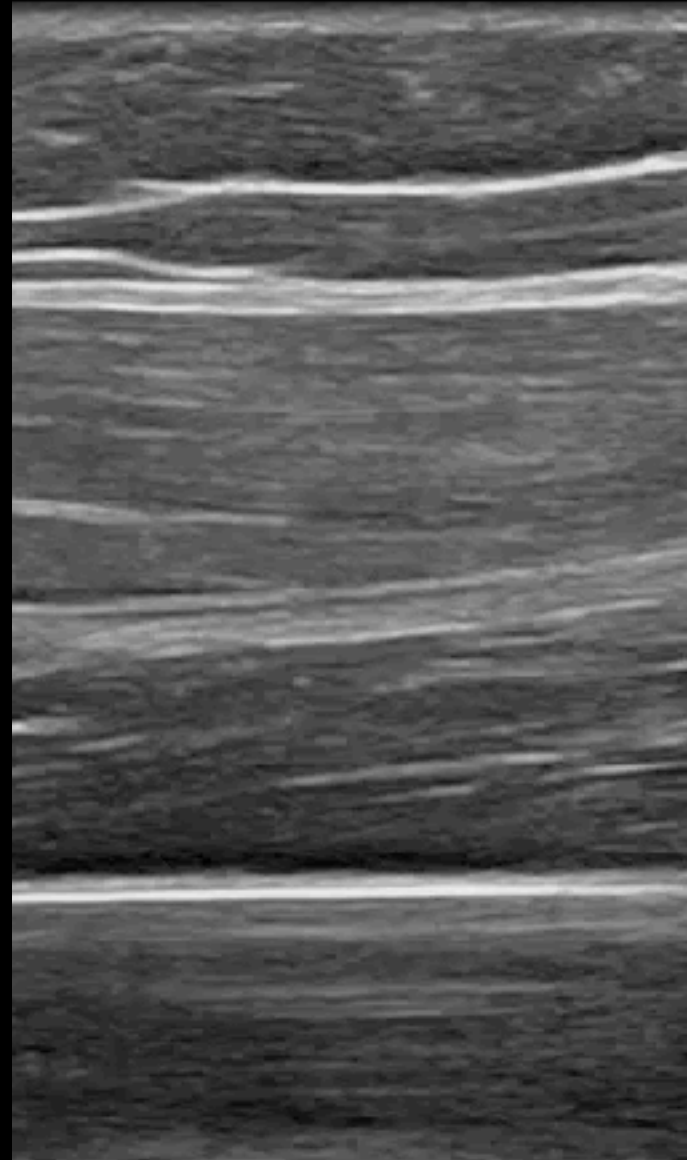
SonoAnatomy

perthical
2-3
Hz
0cm

es
n 95
56
/2/1



G
P I
3.0 12.1



4.0c

管狀結構由橫向掃描開始

Superficial
2-3
Hz
5cm

es
n 95
56
/2/1



G
P R
3.0 12.0

Skin

Fascia

Femur



SonoAnatomy

Skin

Subcutaneous tissue

Lymph nodes

Fascia

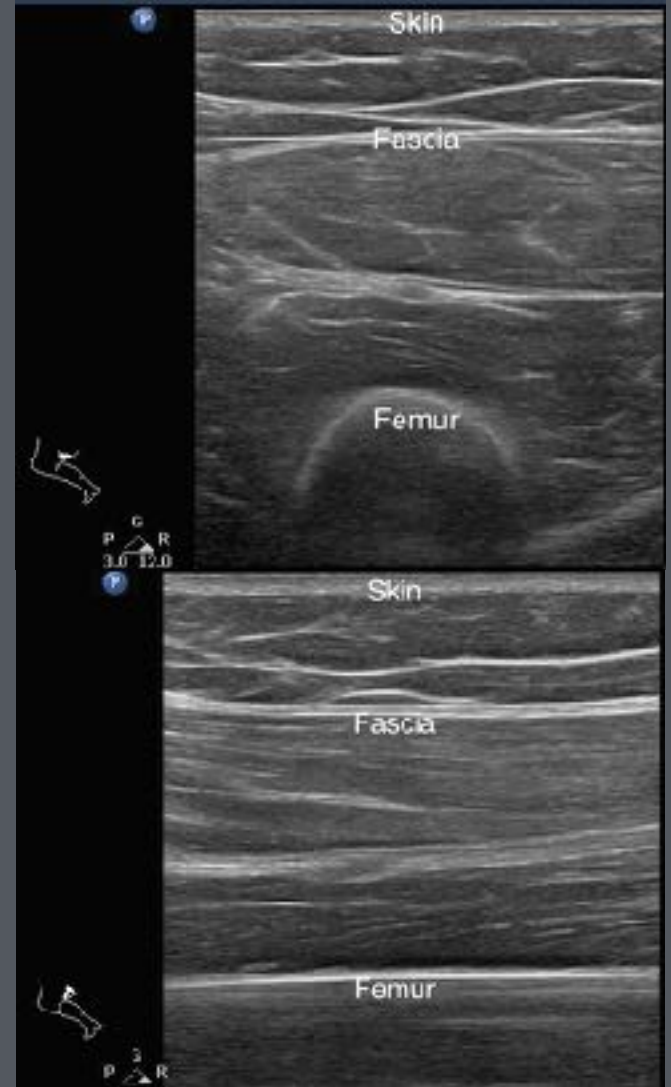
Muscles

Tendon

Vascular structures

Bone

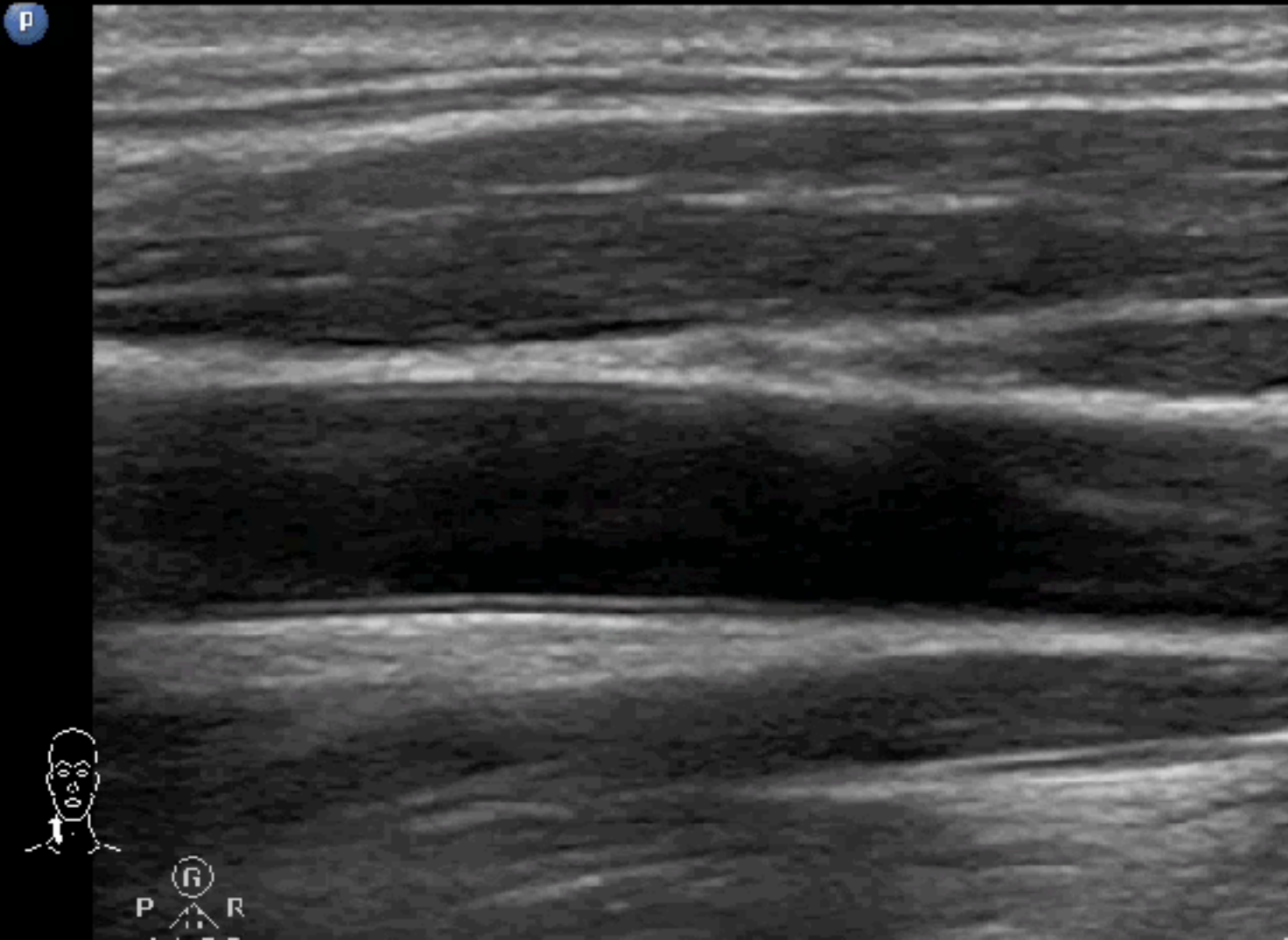3



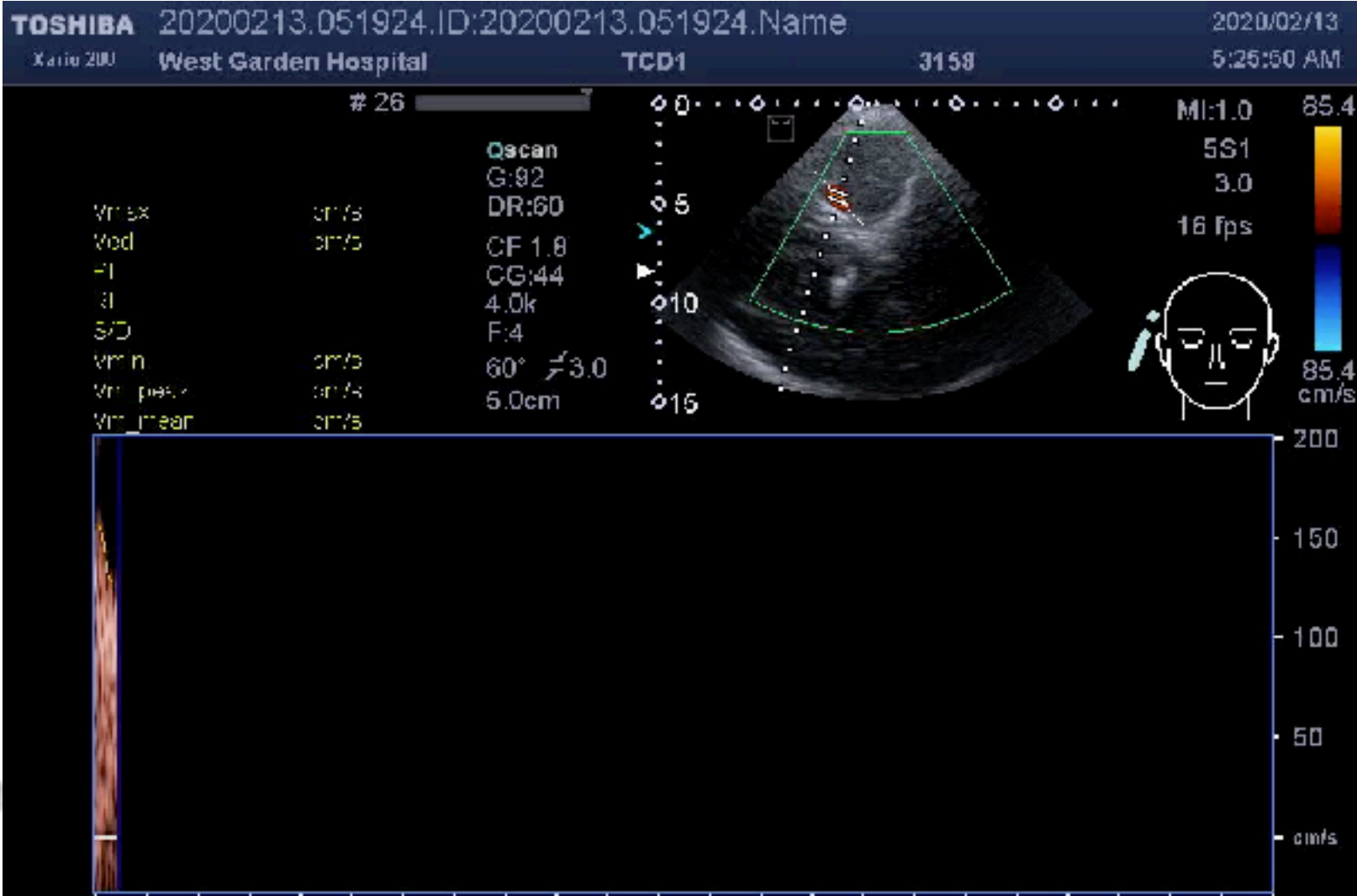影片為動脈最主要的依據

Abd Gen
L12-3
42 Hz
3.0cm

2D
HGen
Gn //
C. 56
3 / 3 / 4



Arterial wave



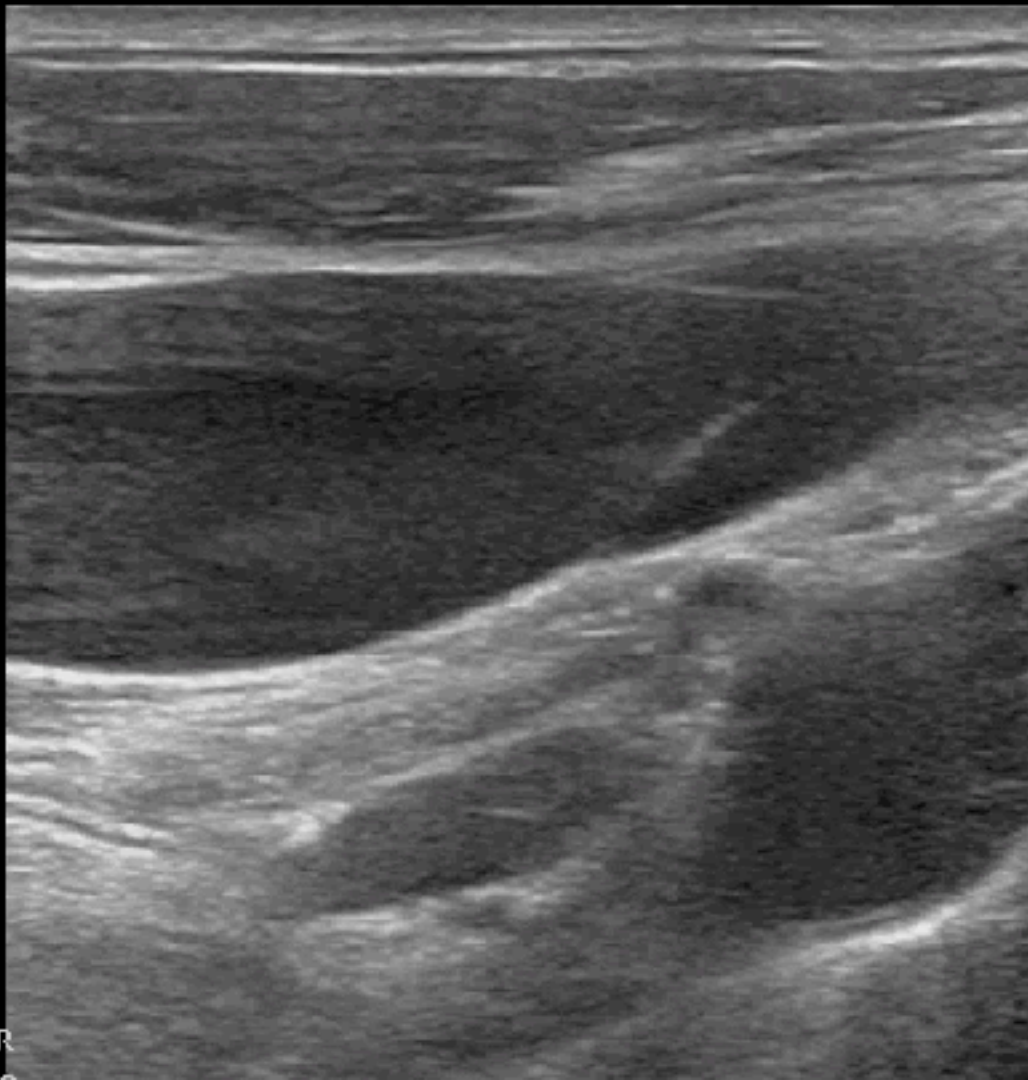
影片中為IJV的依據為何

Superficial
L12-3
43 Hz
4.0cm

2D
Res
Gn 100
C. 56
3/2/1



P R
30 40 50



2
10
100

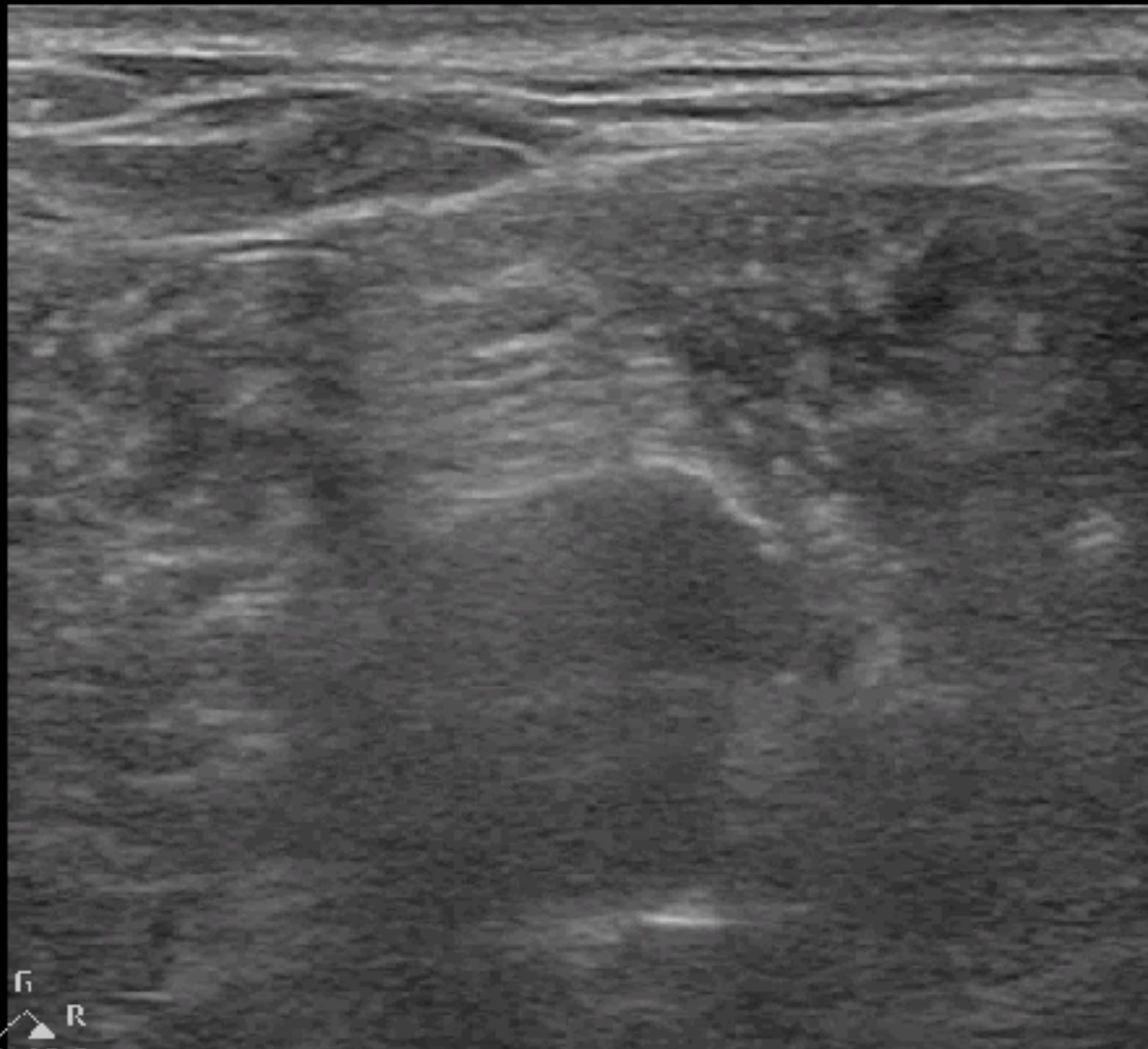
影片中施壓的位置為何

Superficial
L12-3
46 Hz
3.5cm

2D

Res
Gn 100
C. 56
3 / 2 / 1

P

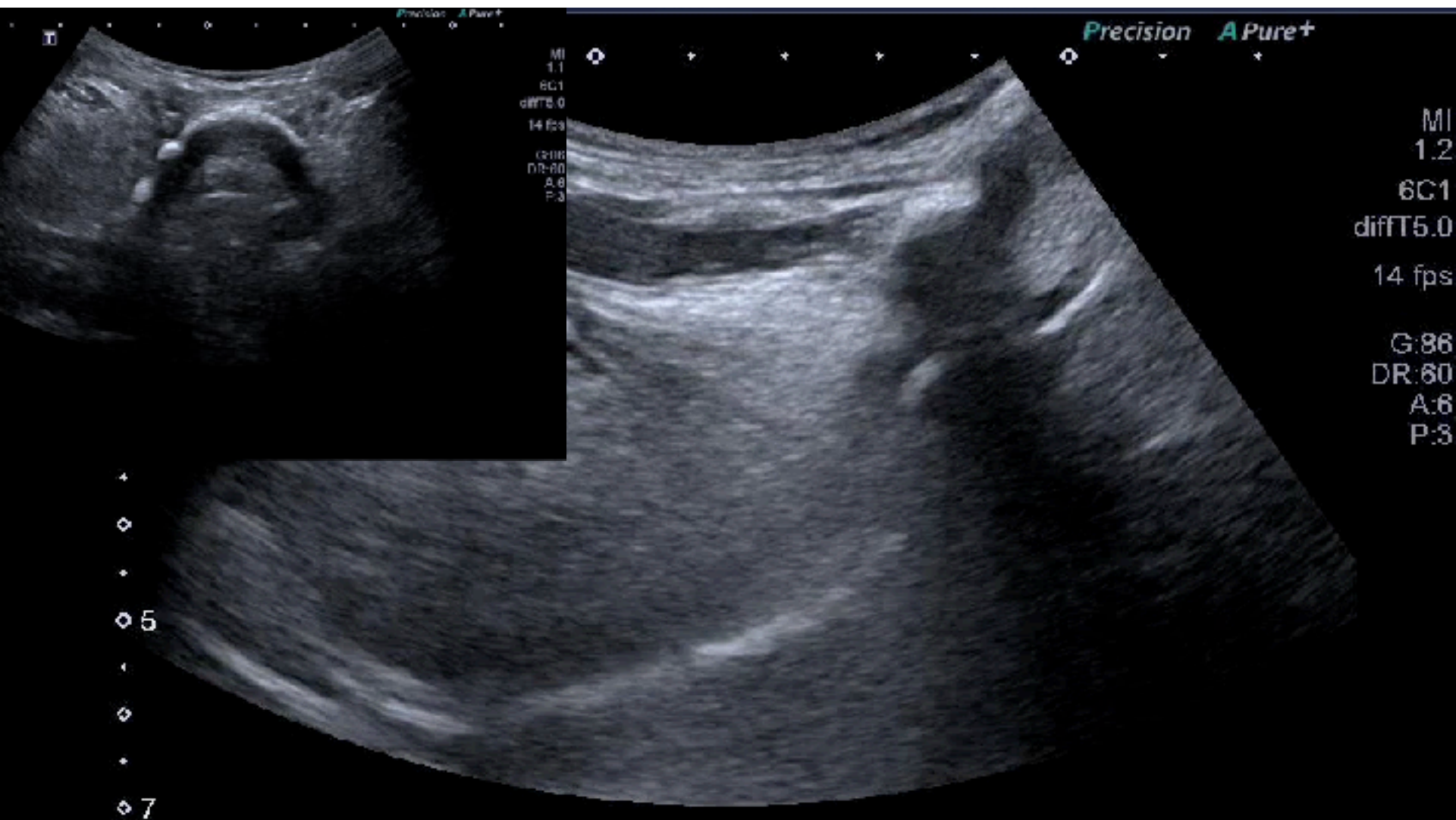


P R
7.0 10.0

2

2.5cm

影片中出現的shadow為何

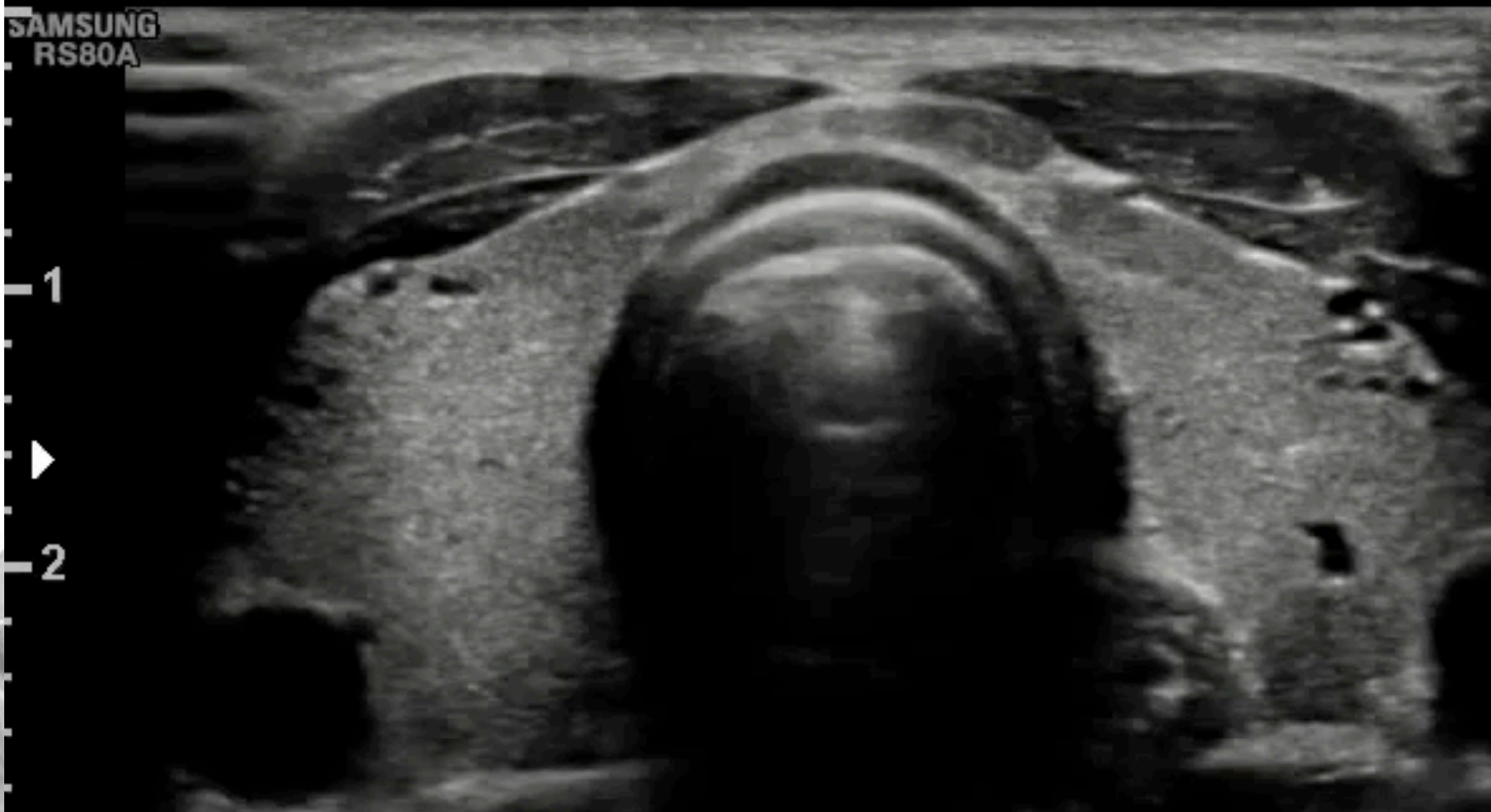

影片中出現mirror為何者

ZD G53/DR58/FA4/P90/2.7/Frq Pen./3.5cm



SAMSUNG
RS80A

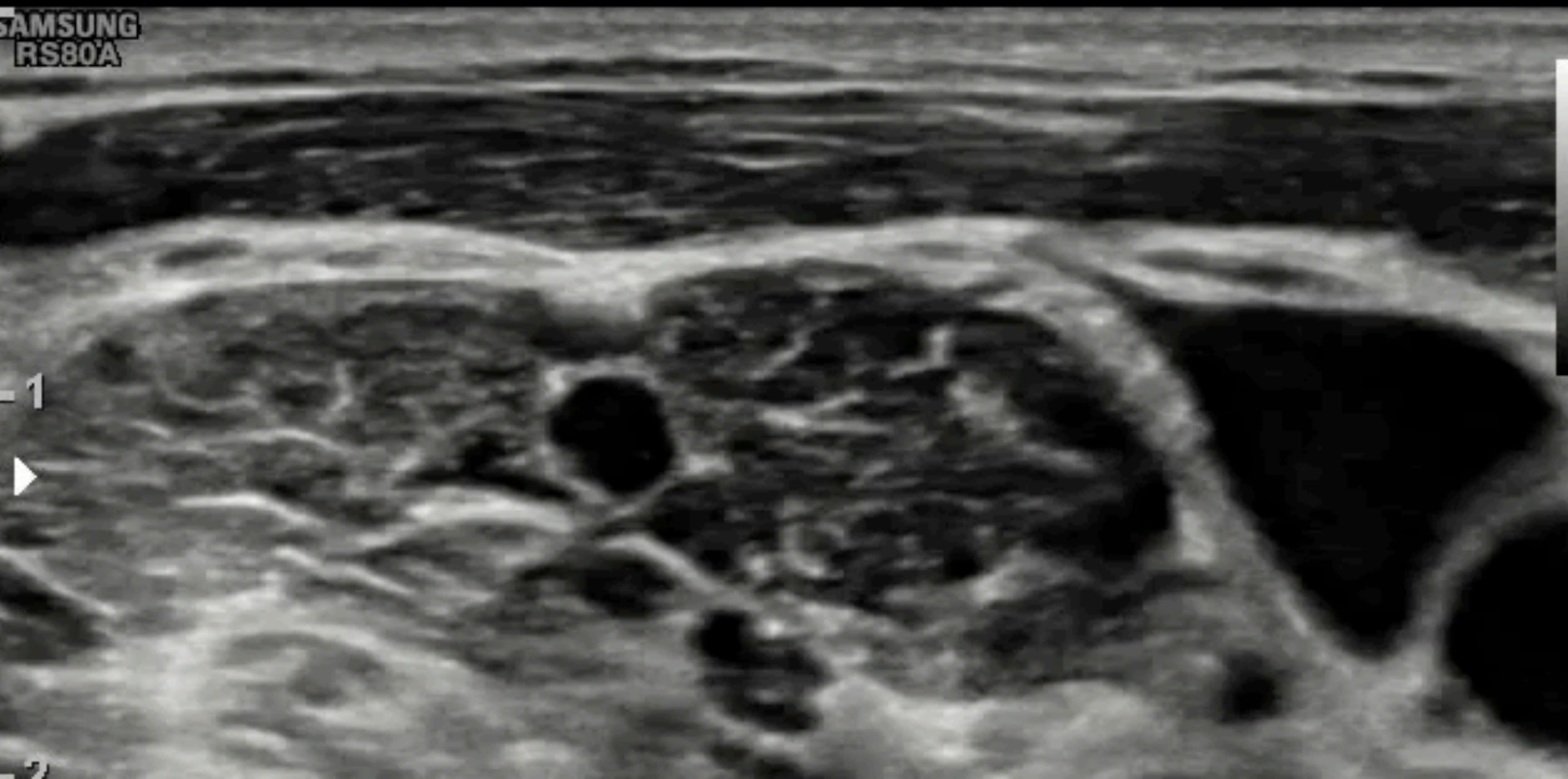


影片中出現的神經叢為何

2D G54/DR58/FA4/P90/2.7/Frq Pen./2.5cm



SAMSUNG
RS80A



-1

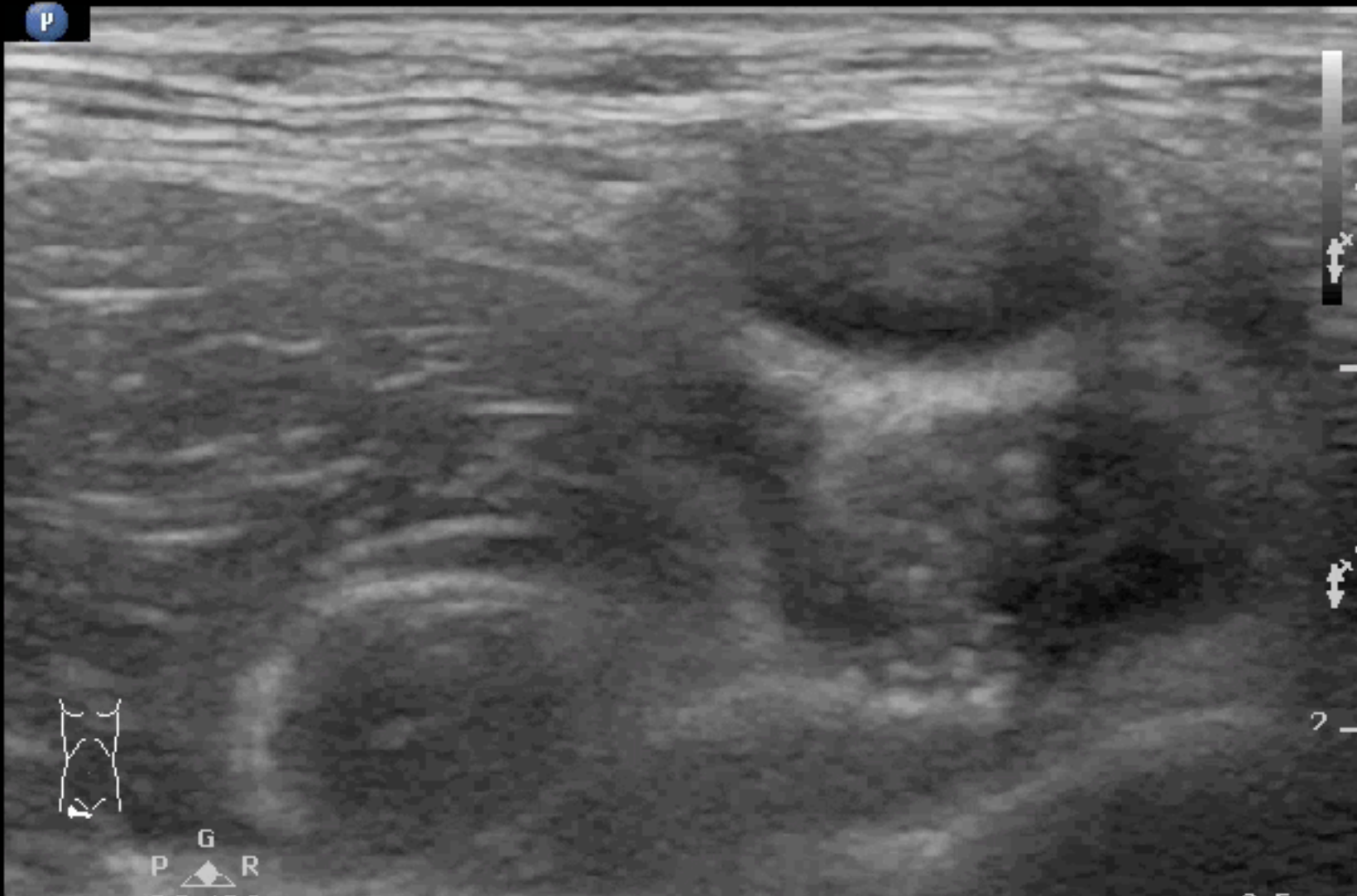-2

影片中出現的神經為何

Superficial
L12-3
34 Hz
2.5cm

2D

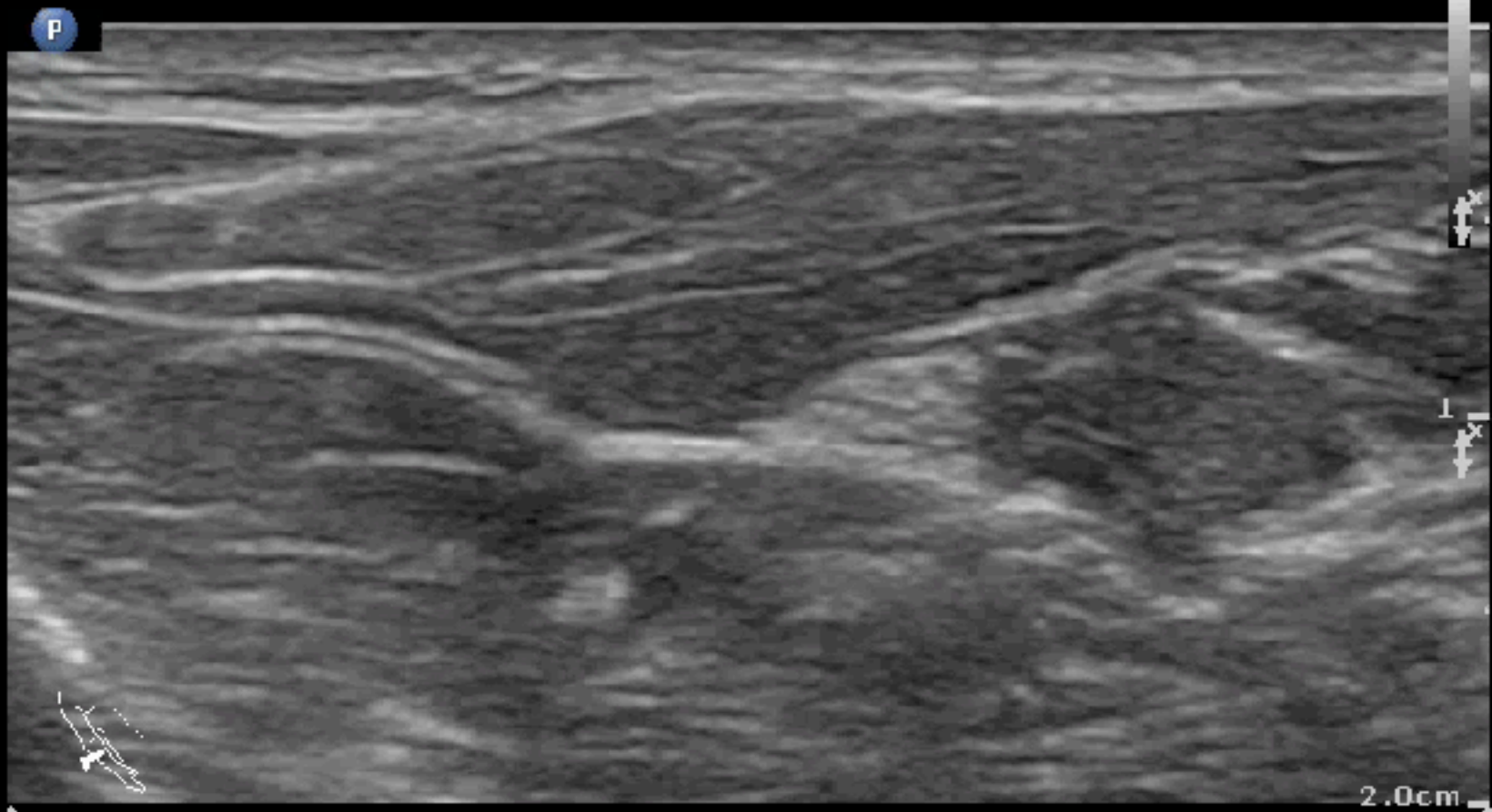
Gen
Gn 90
C 52
4/3/2



影片中掃描的神經為何

Superficial
L12-3
50 Hz
2.0cm

2D
Res
Gn /6
C. 56
3 / 2 / 1



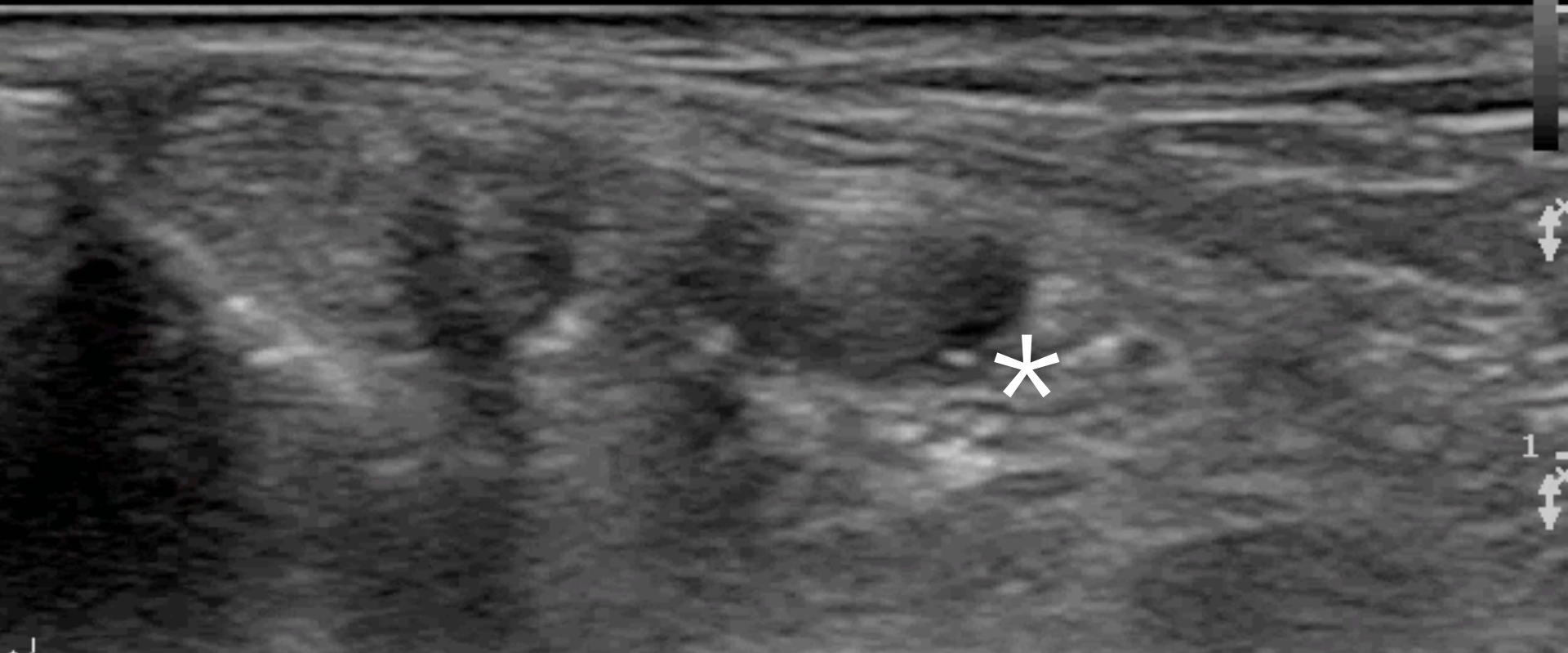
P R

2.0cm



Tom, Dick and Very Nervous Harry

Ant **TP** **FDL** **PTA** **TN** **FHL**
Post



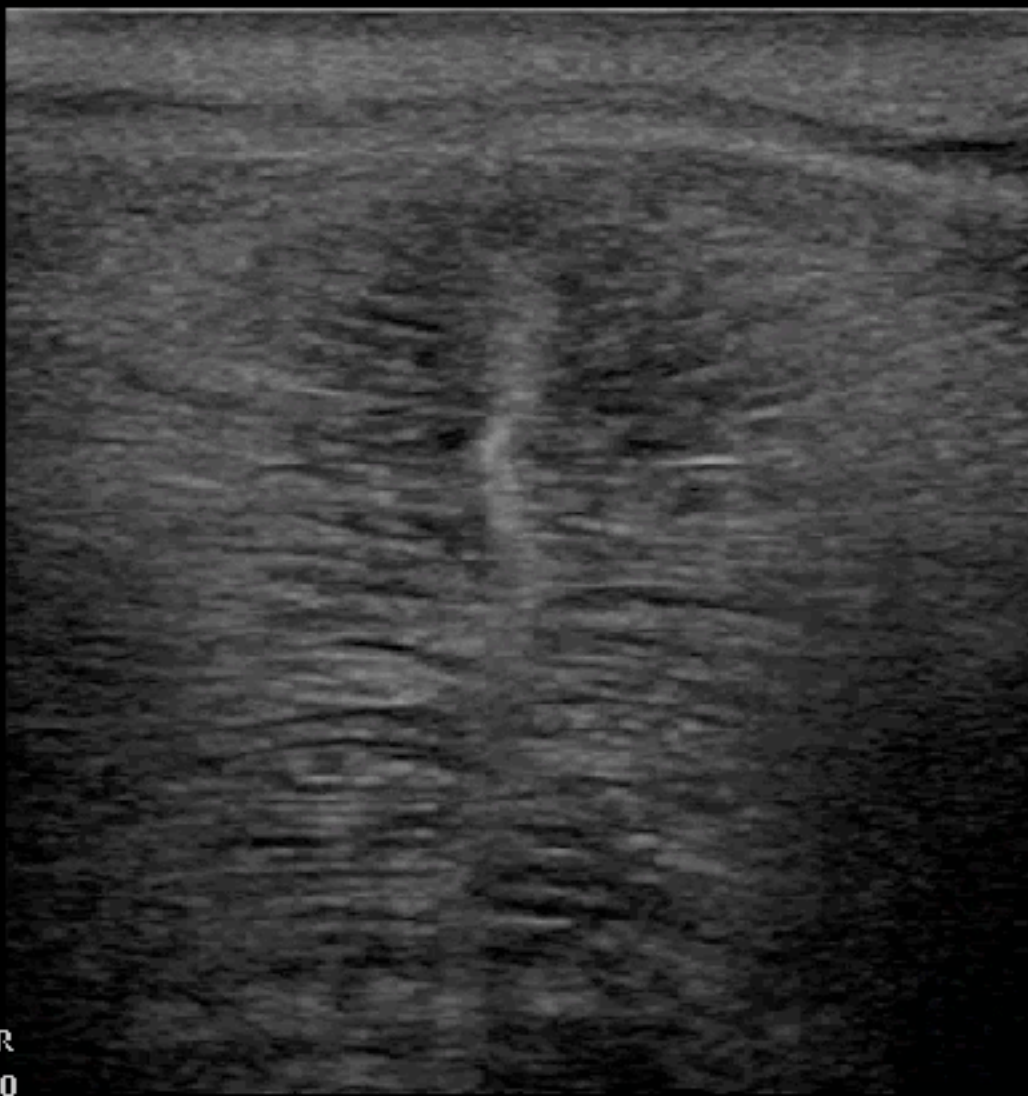
影片中出現的肌肉為何

Superficial
L12-3
43 Hz
4.0cm

2D
Res
Gn 88
C. 56
3 / 2 / 1



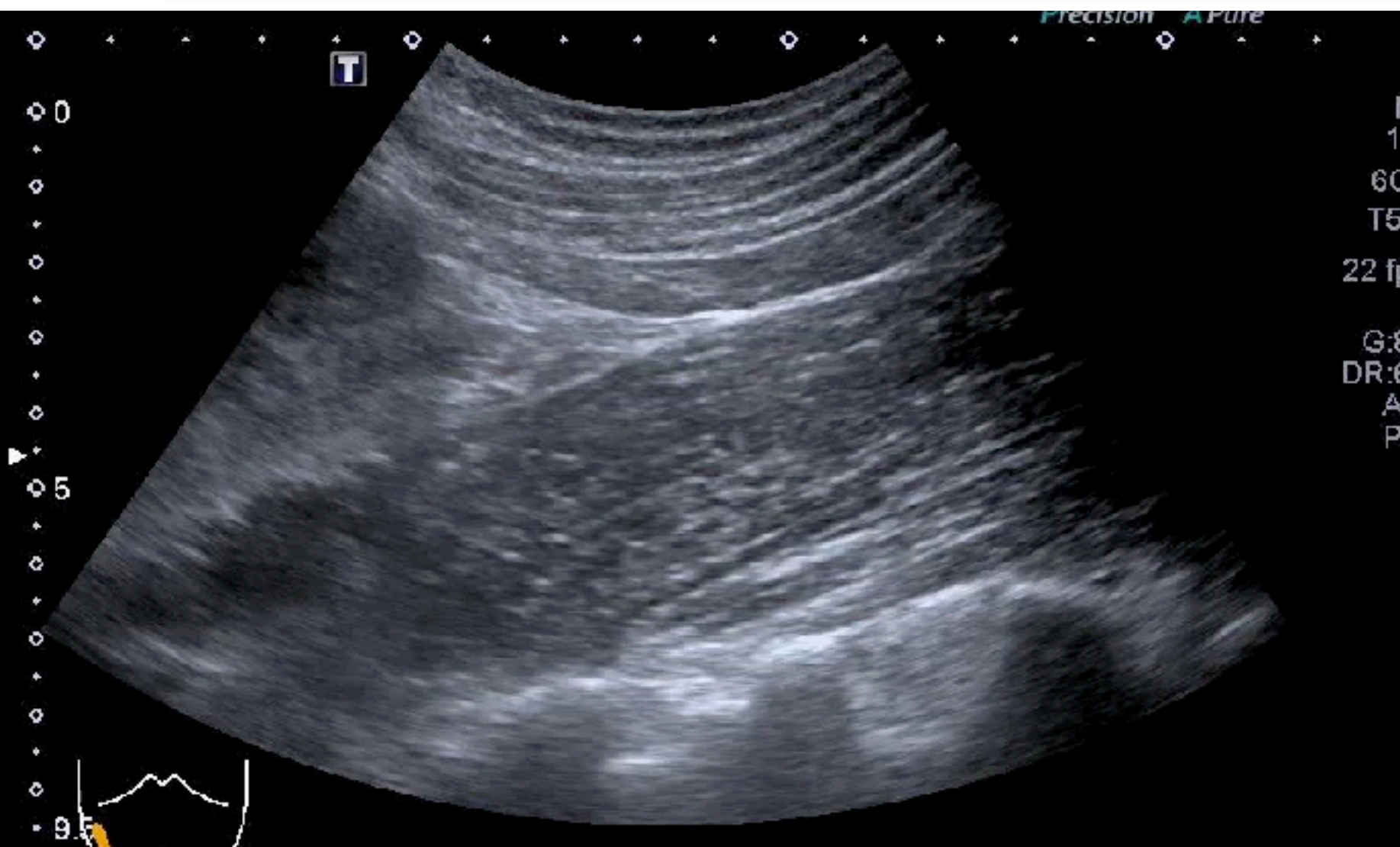
P
G
P R
3.0 12.0



2

1.0cm

影片中最大的肌肉為何



影片中出現的韌帶為何

Superficial

| 12-3

31 Hz

3.0cm

2D

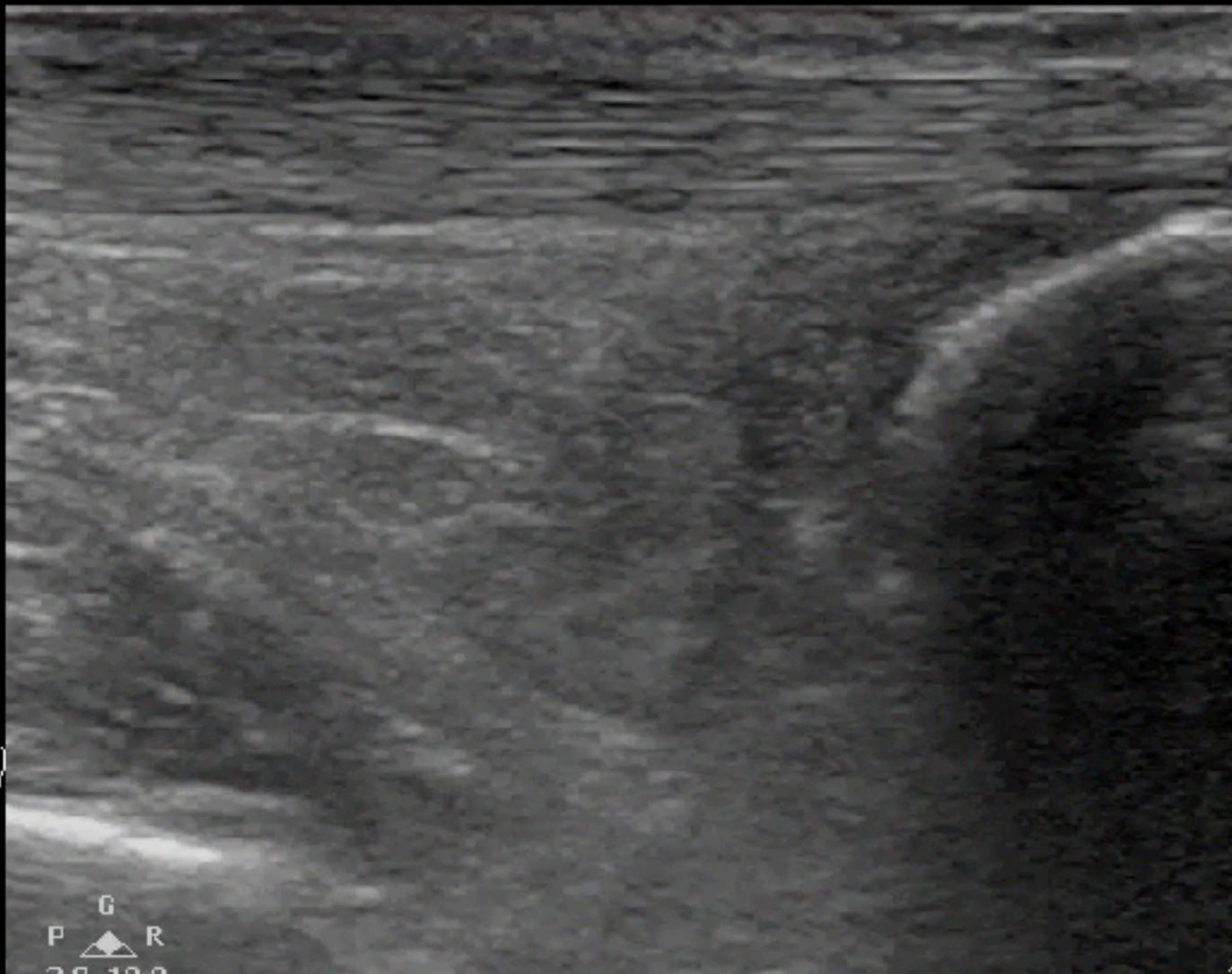
Gen

Gn 100

C 52

4/3/7

P

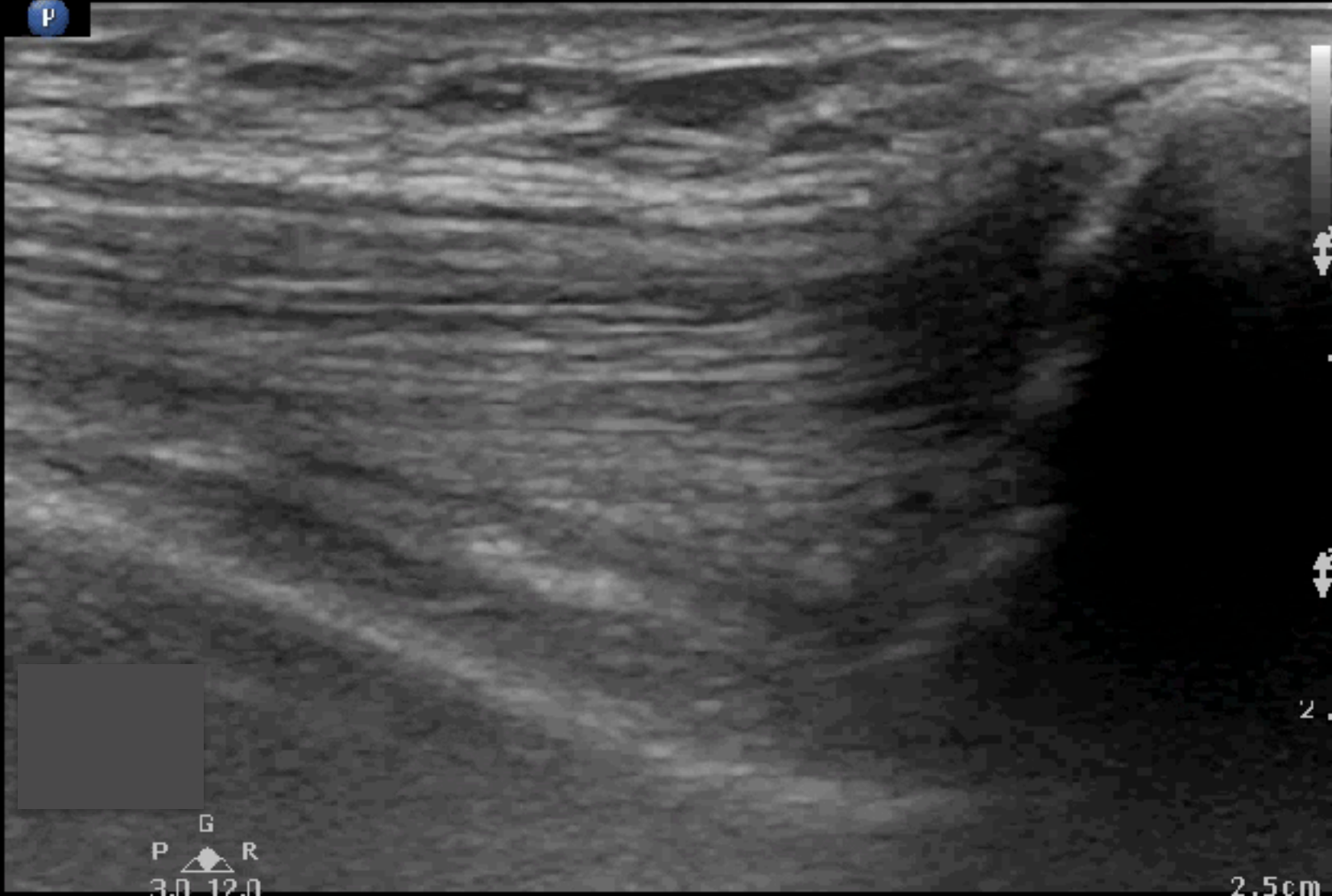

2

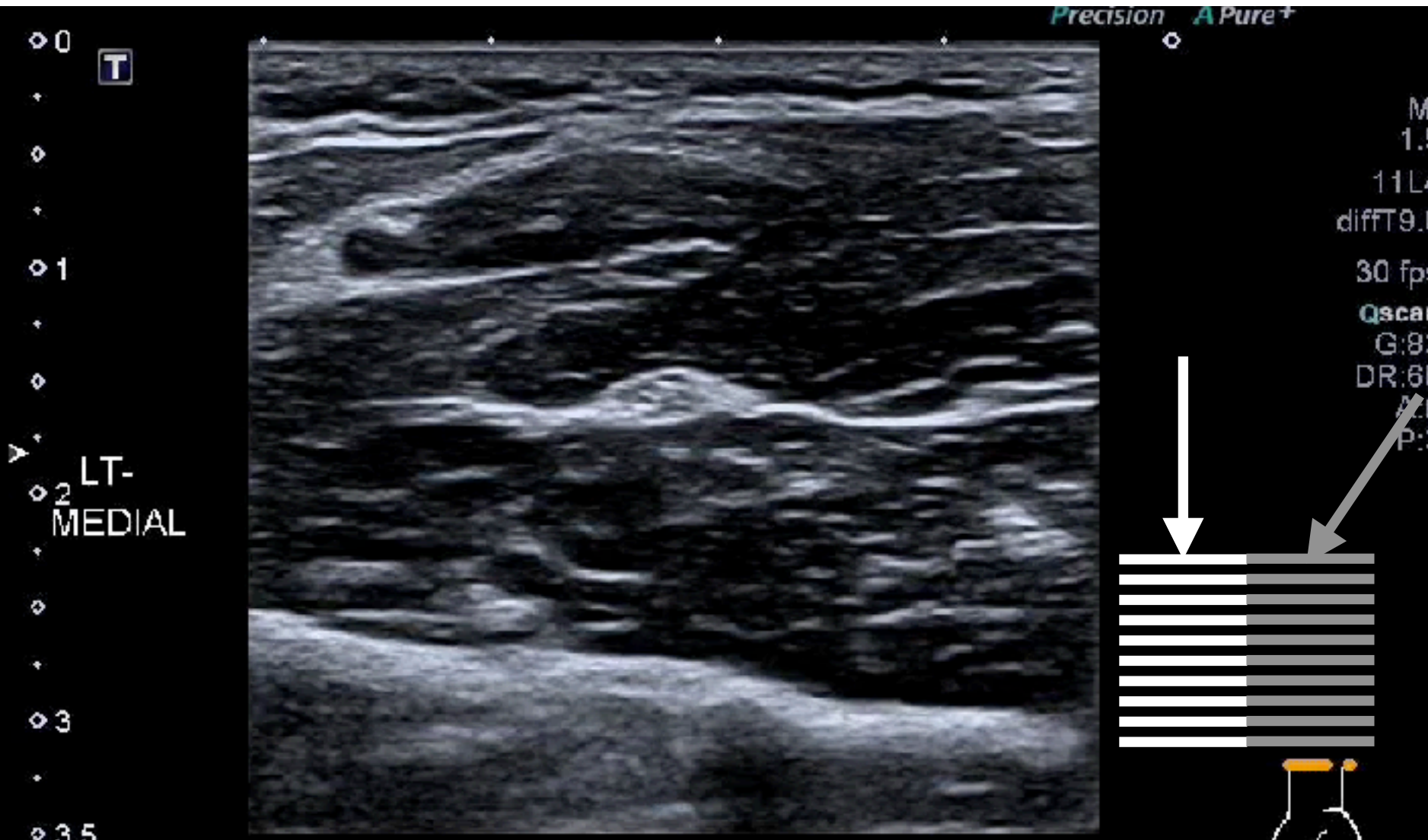
影片中出現的關節為何

Superficial
12 3
34 Hz
2.5cm

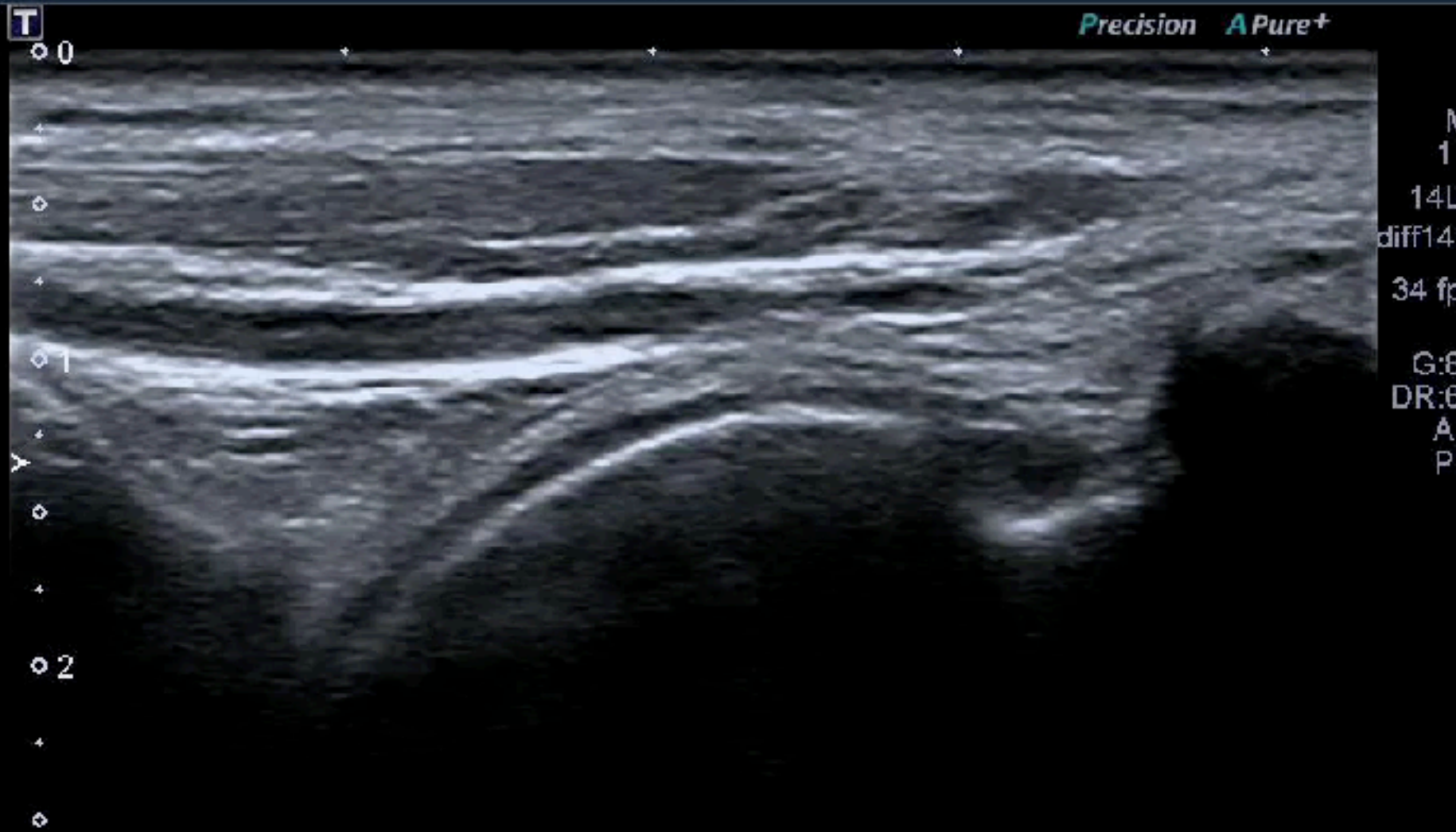2D
Gen
Gn 82
C 52
4/3/2



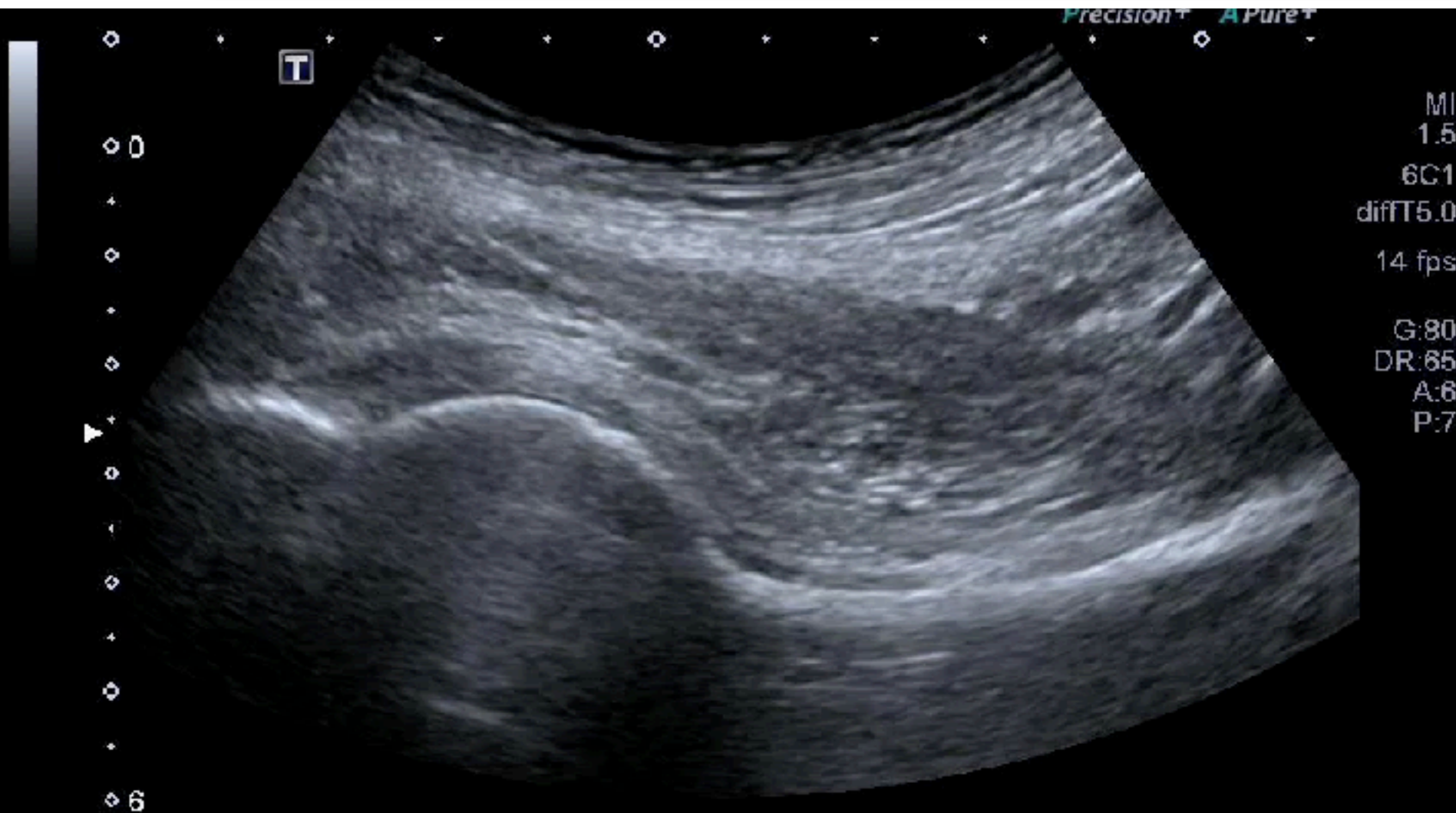
請列舉具有Anisotropy的構造



影片中出現的關節為何



影片中出現的關節為何



依序執行的掃描技巧為何

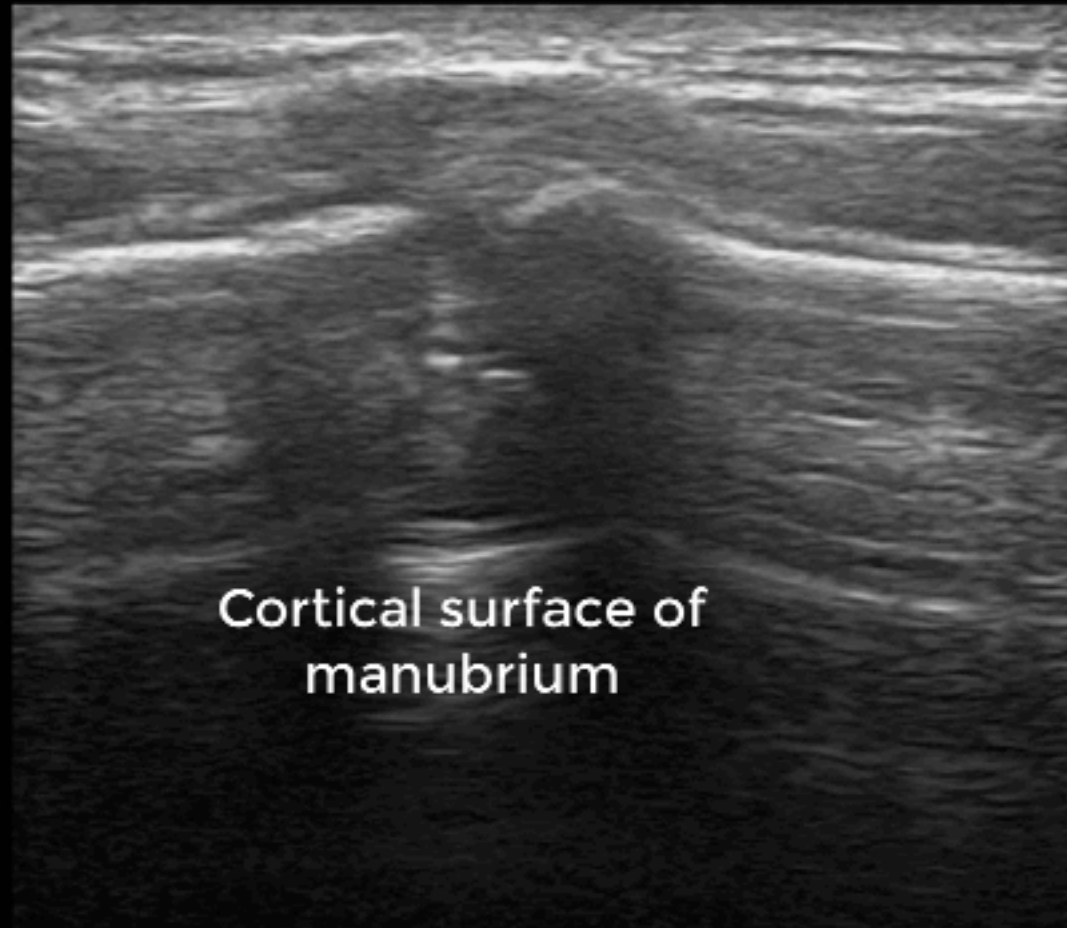PHILIPS TemporaryID-20190311170310 MI 0.9 3/11/2019
19-03-11-170310 SKH ER TIS 0.2 5:40:55 PM

ISK Gen
12-4
2 Hz
3.5cm

D
Res
Gn 100
58
4/3/4

Cephalad

P



Caudal



REVIEW

Open Access

An overview of point-of-care ultrasound for soft tissue and musculoskeletal applications in the emergency department



Kuo-Chih Chen^{1,2}, Aming Chor-Ming Lin^{1,2*}, Chee-Fah Chong^{1,2} and Tzong-Luen Wang^{1,2}

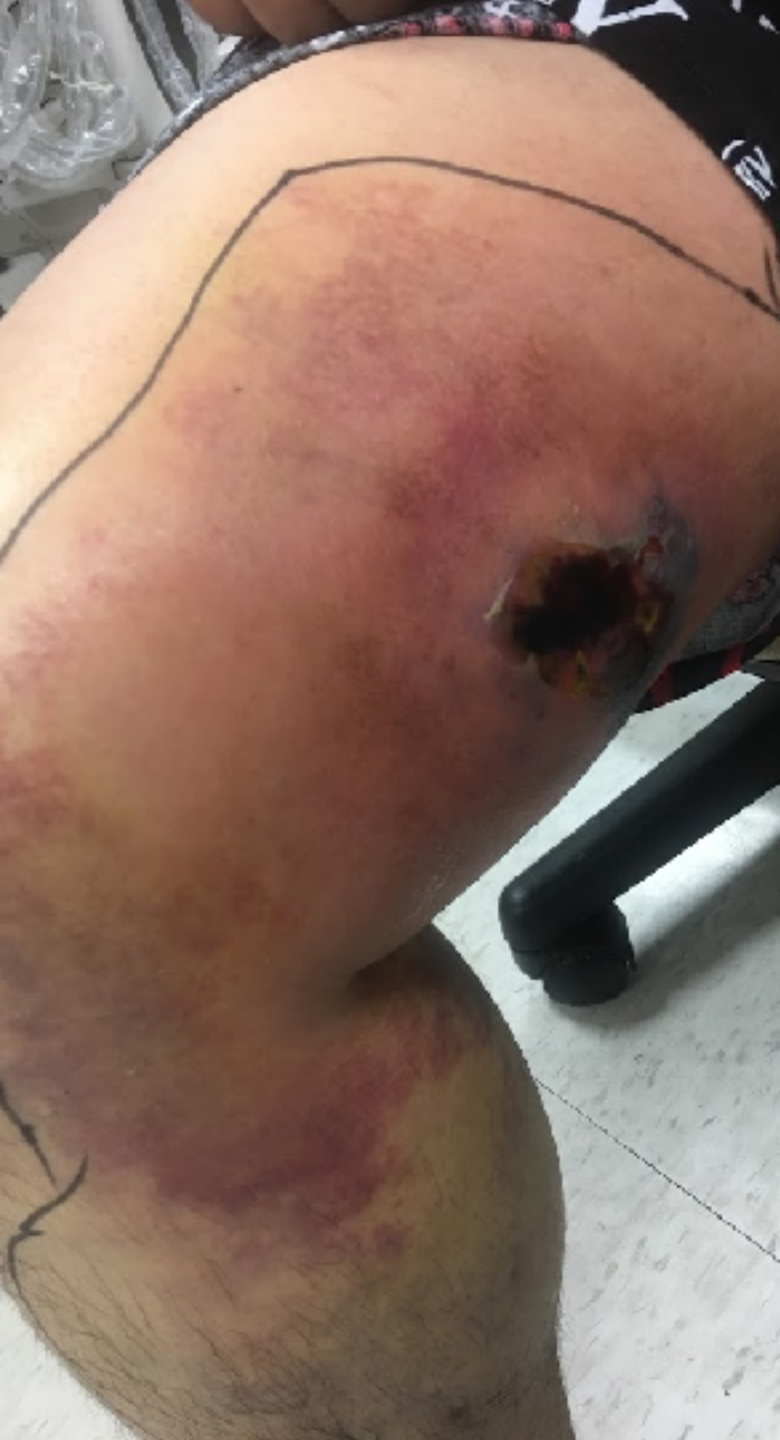Abstract

Background: The skin, soft tissue, and most parts of the musculoskeletal system are relatively superficial anatomical structures and ideal targets for ultrasound examination in the emergency departments. Soft tissue and musculoskeletal ultrasound applications are relatively underused compared to traditional emergency applications, such as trauma, abdominal aortic aneurysm, and chest and cardiovascular systems.

Main text: It is important to have knowledge about sonoanatomy and landmarks within the skin, soft tissue, and musculoskeletal systems. Portable machines equipped with high-resolution transducers are now available to fulfill this field of applications in many emergency departments. After needling practice, emergency physicians can not only diagnose and identify pathological findings but also provide interventional procedures and treatments. In this review, we will introduce point-of-care ultrasound (POCUS) applications regarding the soft tissue and musculoskeletal systems: soft tissue infections, joint effusions, foreign bodies, long bone fractures, muscle and tendon injuries, vascular occlusions, and procedures.

Conclusions: With POCUS, emergency physicians can visualize the structures beneath the skin and provide better and safer cares in the emergency departments.

Keywords: Point-of-care, Ultrasound, Soft tissue, Musculoskeletal, Emergency medicine



Cellulitis

Abscess

Necrotizing Fasciitis



Cellulitis

Abscess

Necrotizing Fasciitis

Point-of-Care Ultrasonography for the Diagnosis of Skin and Soft Tissue Abscesses: A Systematic Review and Meta-analysis

Michael Gottlieb, MD*; Jacob Avila, MD; Mark Chottiner, MD; Gary Peksa, PharmD

Study 14 ; Patients 2656

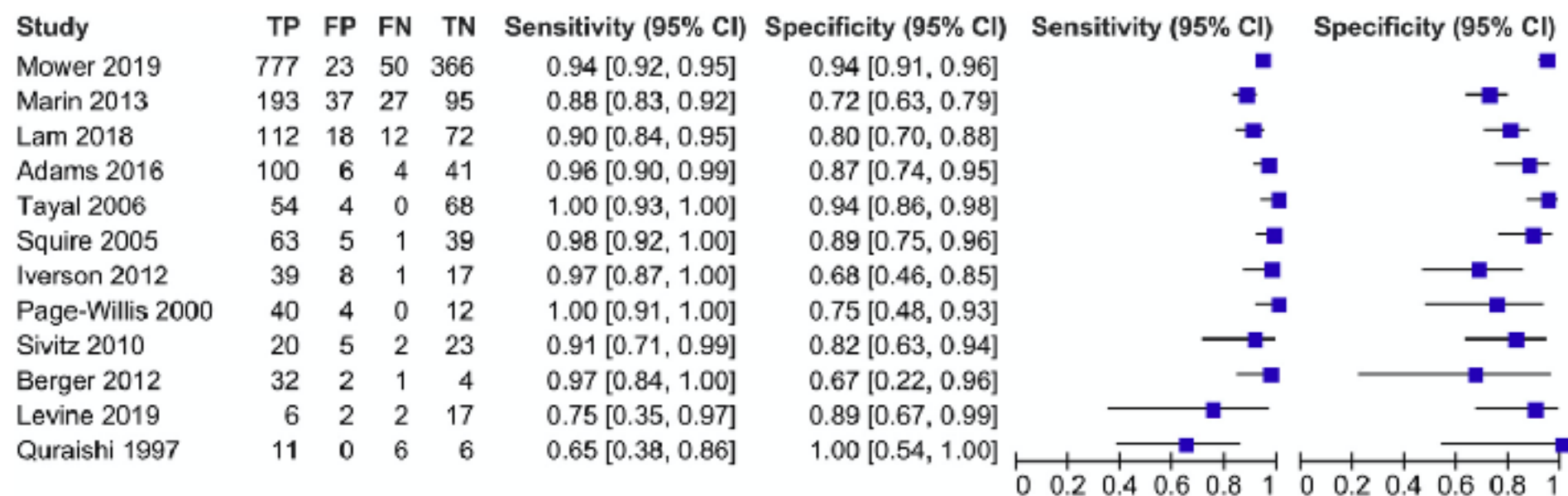


Figure 2. Forest diagram of the overall sensitivity and specificity of ultrasonography for identifying abscesses.



Point-of-Care Ultrasonography for the Diagnosis of Skin and Soft Tissue Abscesses: A Systematic Review and Meta-analysis

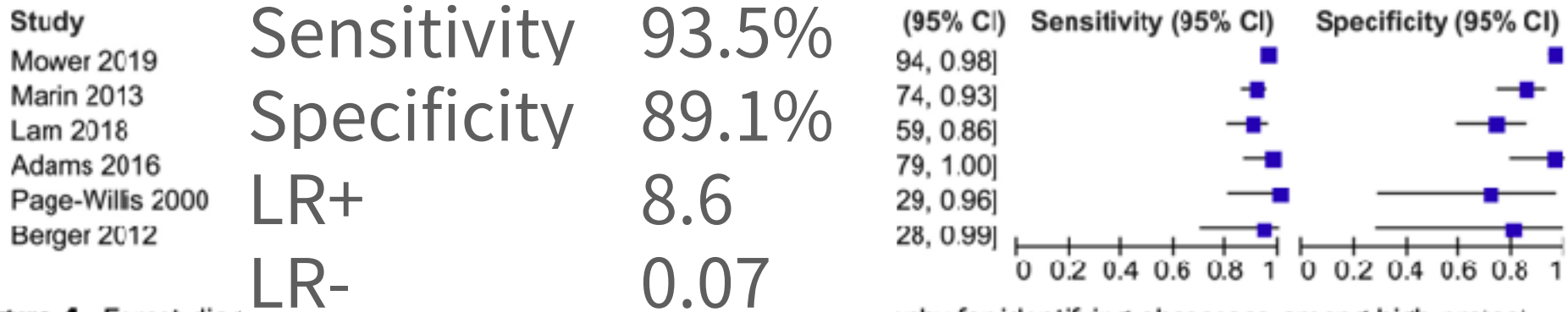


Figure 4. Forest diagram of the sensitivity and specificity of ultrasonography for identifying abscesses among high pretest probability cases.




Figure 5. Forest diagram of the sensitivity and specificity of ultrasonography for identifying abscesses among clinically unclear cases.



Point-of-Care Ultrasonography for the Diagnosis of Skin and Soft Tissue Abscesses: A Systematic Review and Meta-analysis

Michael G
 Sensitivity 98.7%
 Specificity 91.0%
 LR+ 10.9
 LR- 0.01

ottiner, MD; Gary Peksa, PharmD

Study TP
 Tayal 2006 54
 Squire 2005 63
 Berger 2012 32

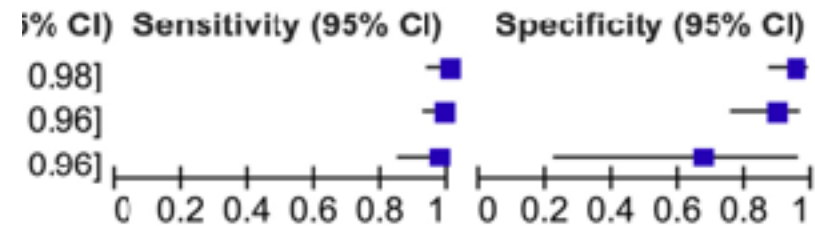


Figure 6. Forest diagram of the sensitivity and specificity of ultrasonography for identifying abscesses among adults.

Study TP FP FN TN
 Marin 2013 19
 Lam 2018 11
 Adams 2016 10
 Iverson 2012 3
 Sivitz 2010 2
 Levine 2019
 Quraishi 1997 1

Sensitivity 89.9%
 Specificity 79.9%
 LR+ 4.5
 LR- 0.13

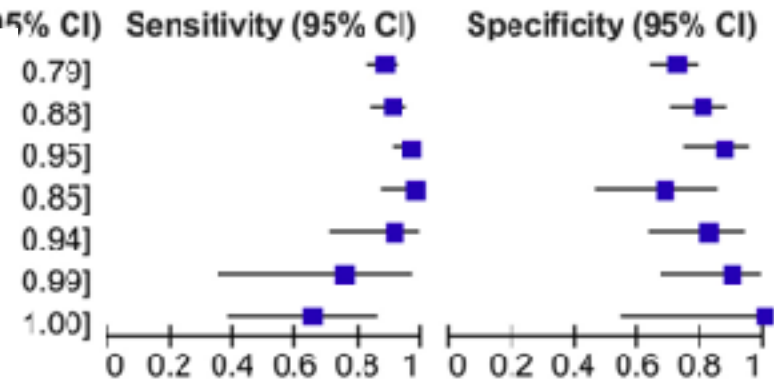


Figure 7. Forest diagram of the sensitivity and specificity of ultrasonography for identifying abscesses among pediatric patients.



Point-of-Care Ultrasonography for the Diagnosis of Skin and Soft Tissue Abscesses: A Systematic Review and Meta-analysis

Michael Gottlieb, MD*; Jacob Avila, MD; Mark Chottiner, MD; Gary Peksa, PharmD

Management change: correct 10.3%; incorrect 0.7%

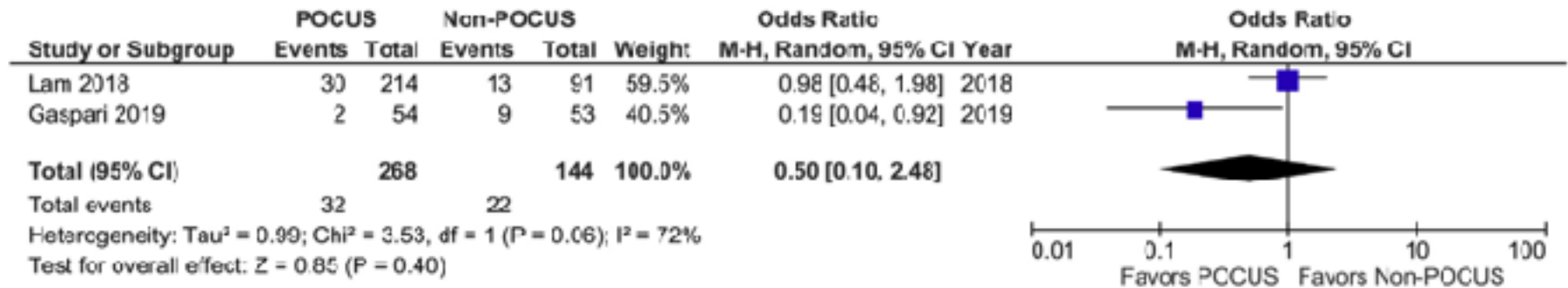
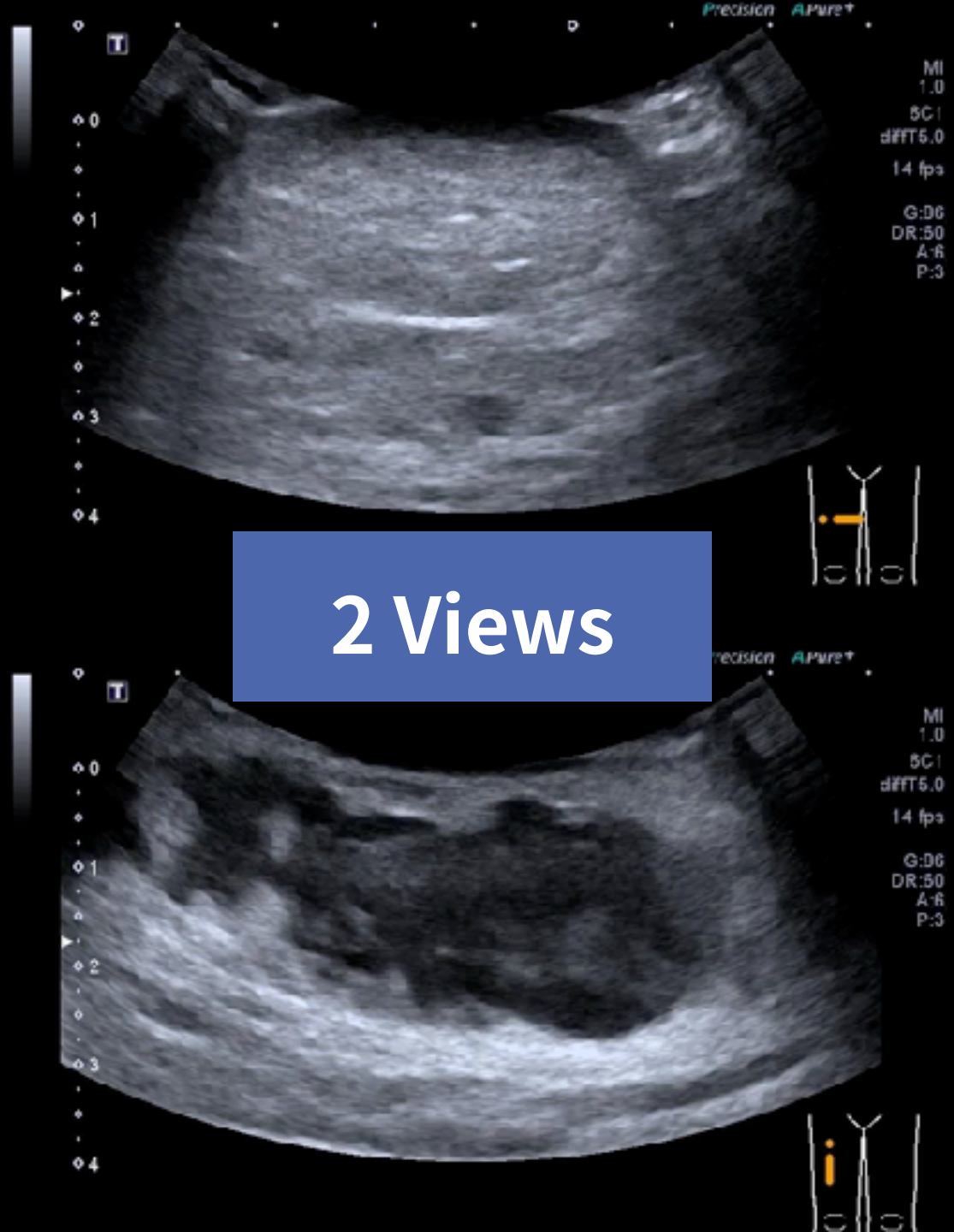
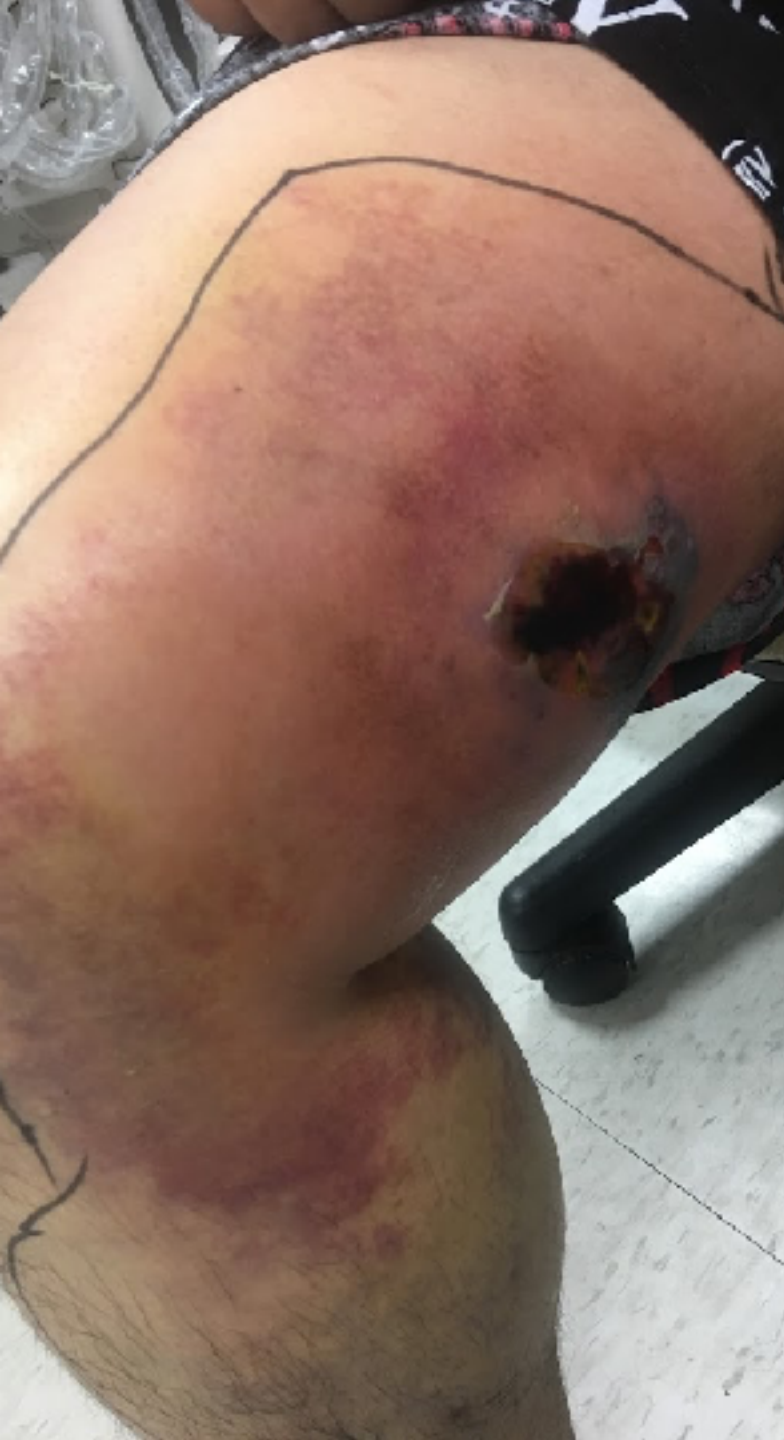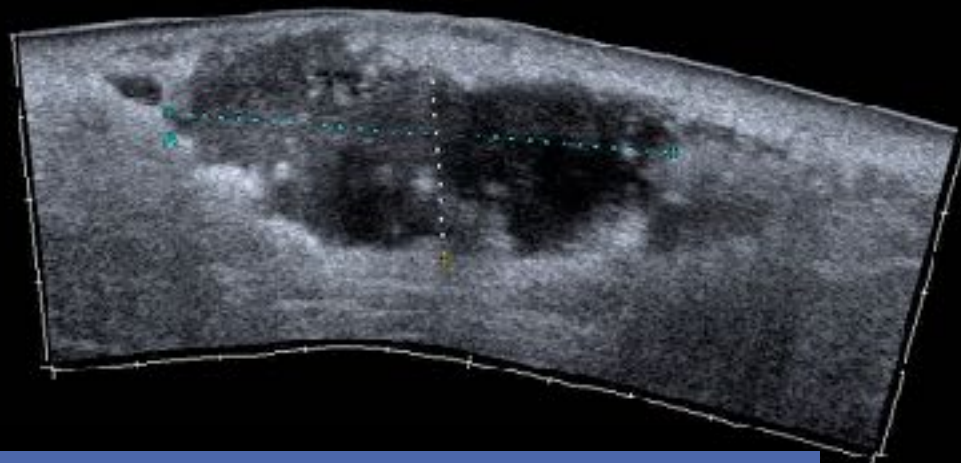

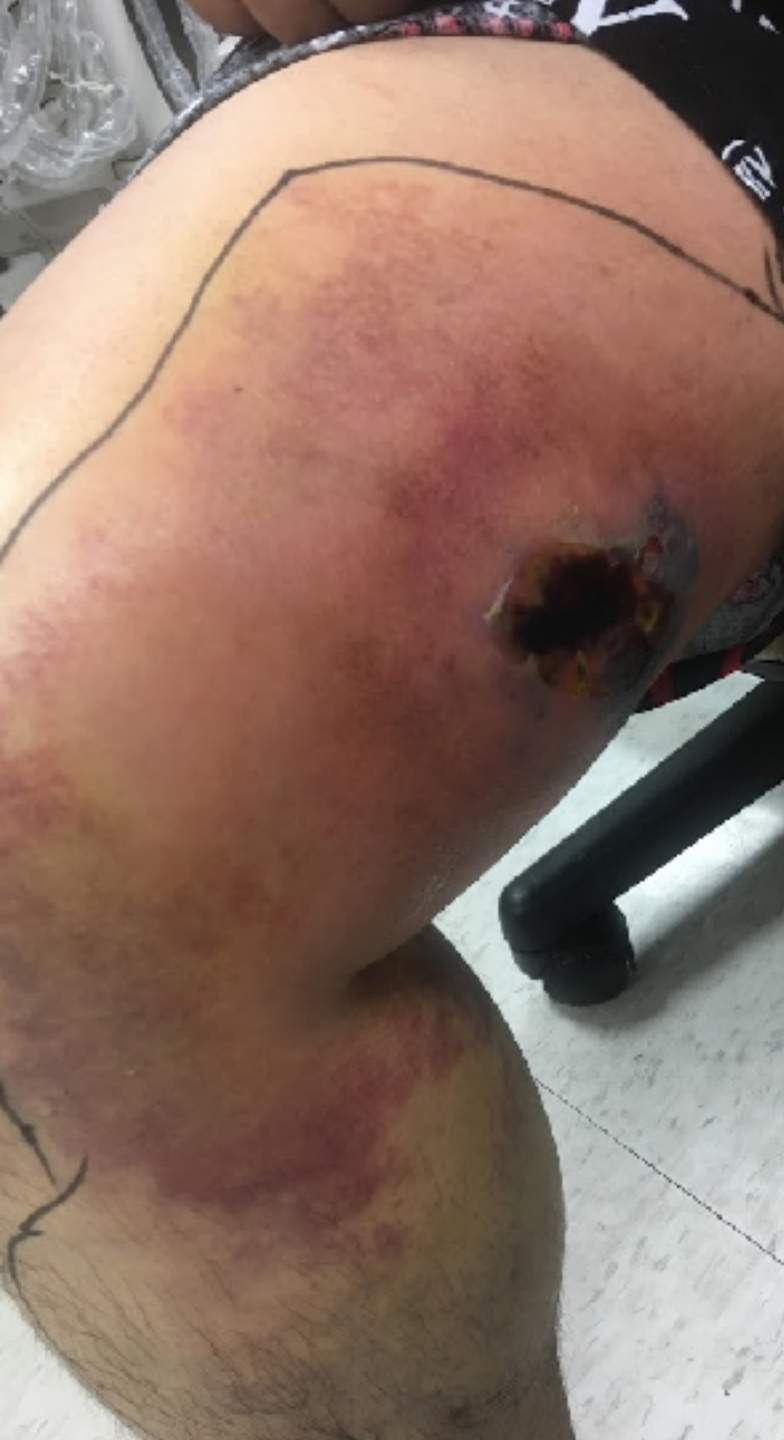
Figure 8. Forest diagram comparing the effect of ultrasonography versus no ultrasonography on treatment failures. *POCUS*, Point-of-care ultrasound; *M-H*, Mantel-Haenszel.

11.9% 15.3%

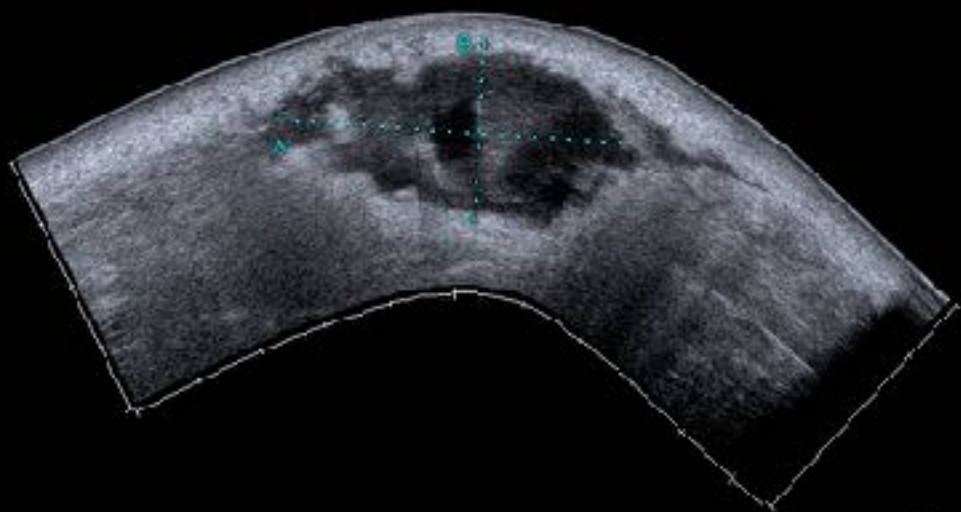


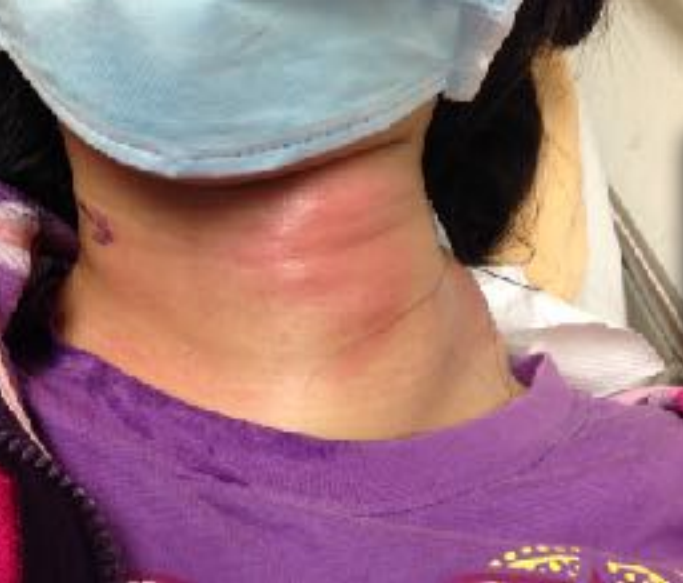



Panoramic view

Dist A	50.6mm
Dist B	23.9mm

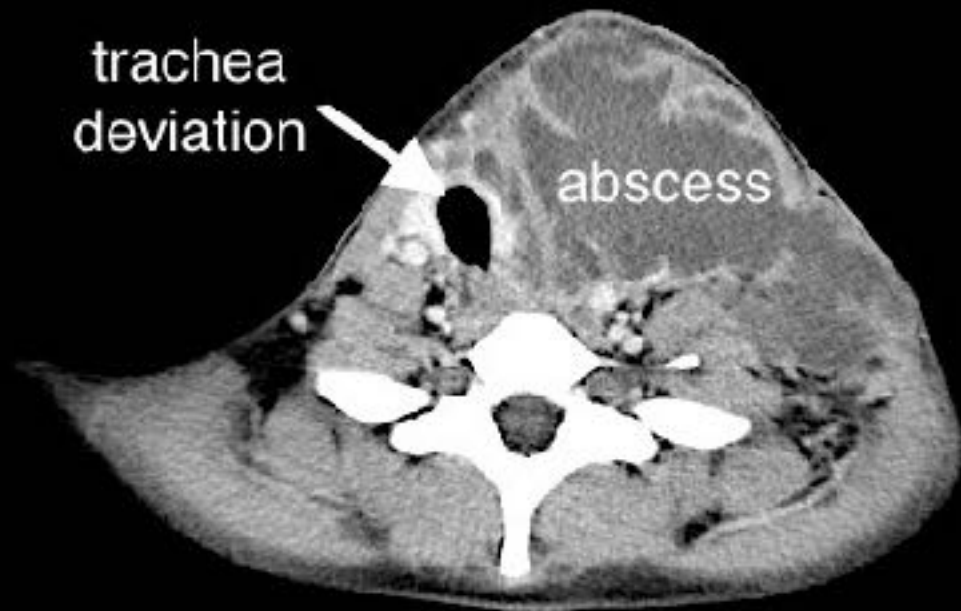
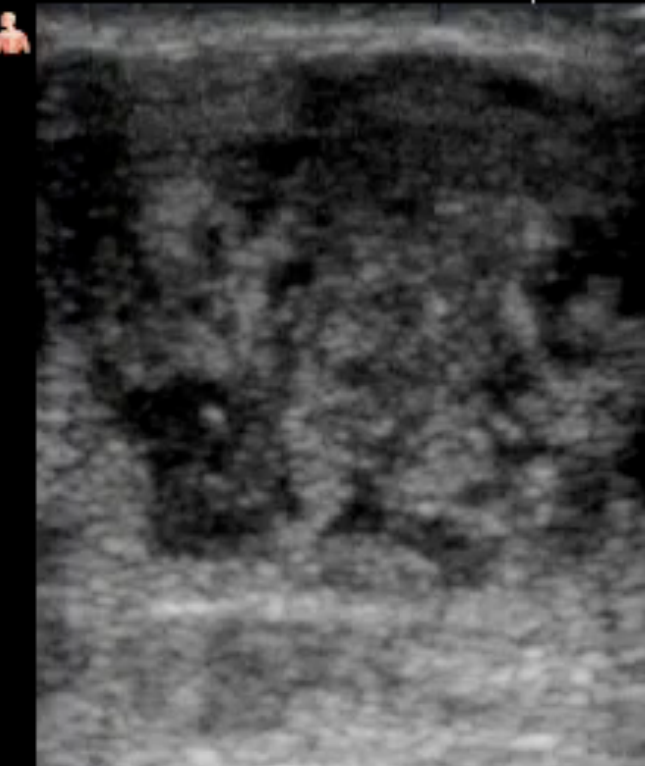




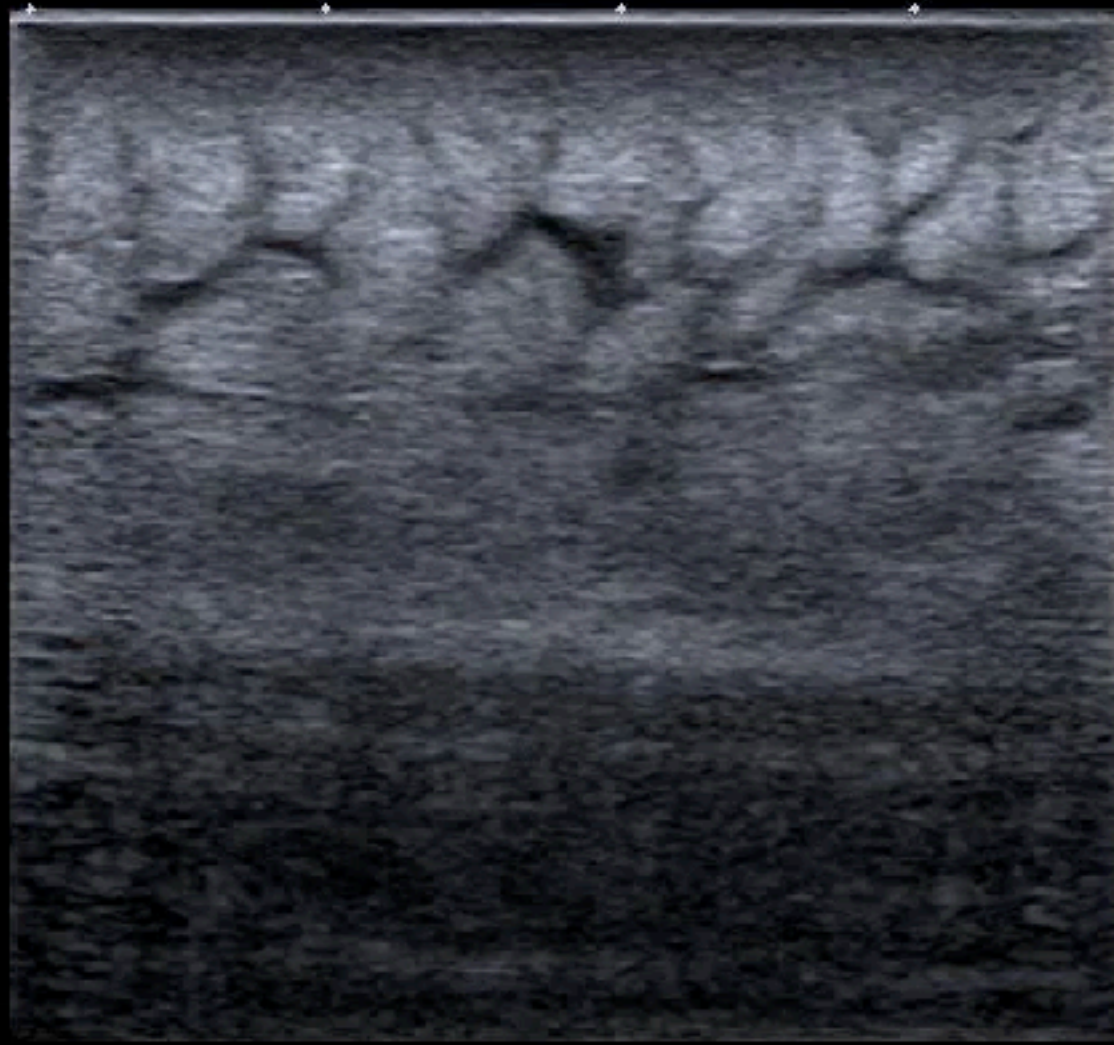
Squish sign

Moving particles or fluid

#: 359 14:23:59
MI: 0.8 TI: 0.2 25/Apr/2015

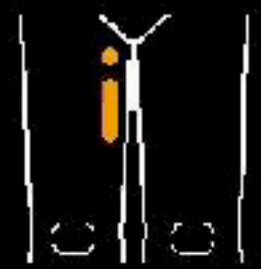

0
T
1
2
3
3.5

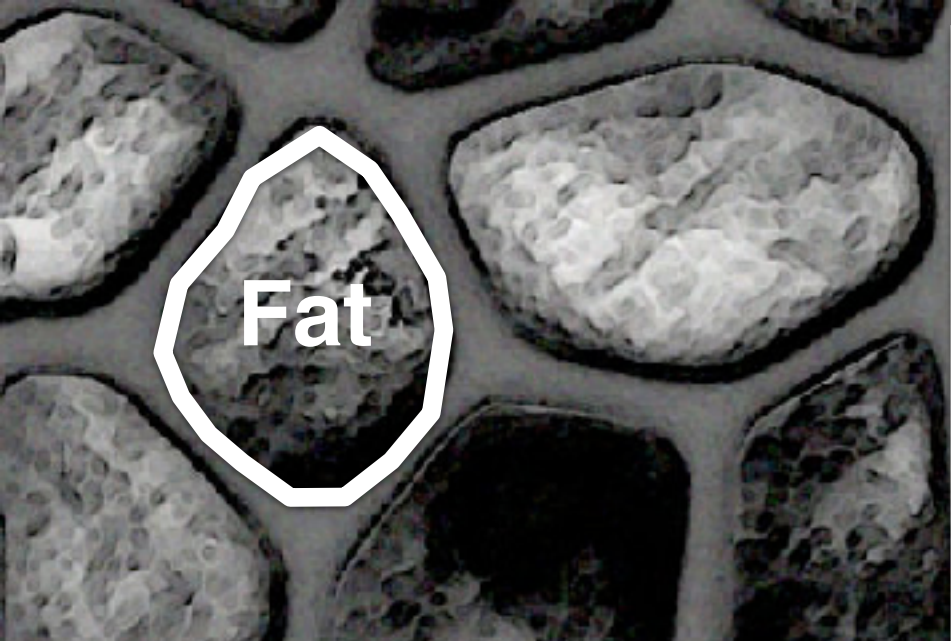


PRECISION

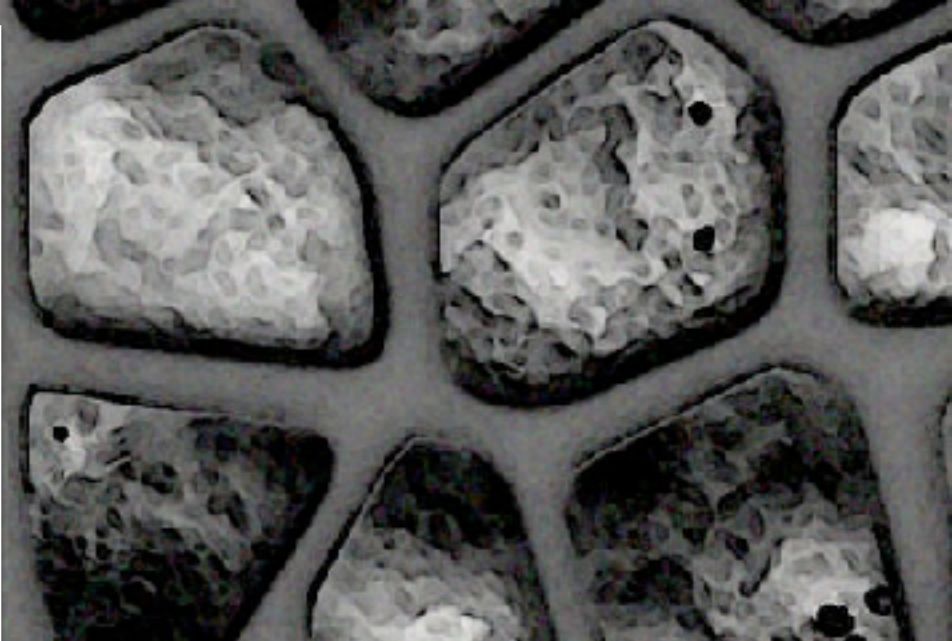
1
11L
diffT9
30 fp
G:8
DR:6
A
P



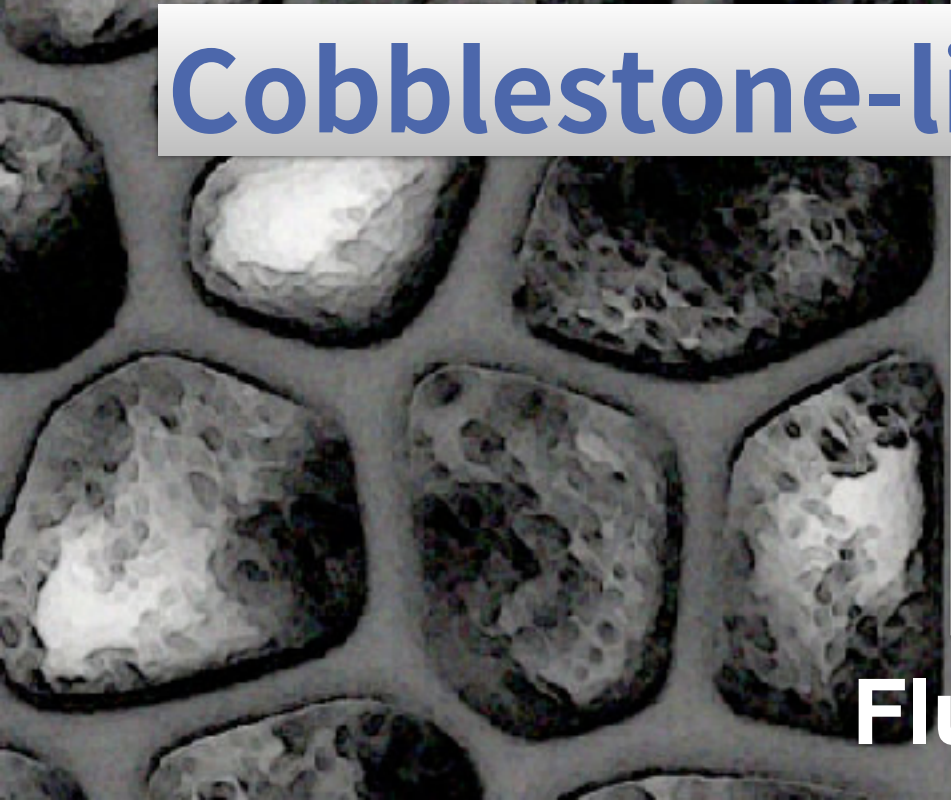
Above or below fascial level ?



Fat



Cobblestone-like appearance

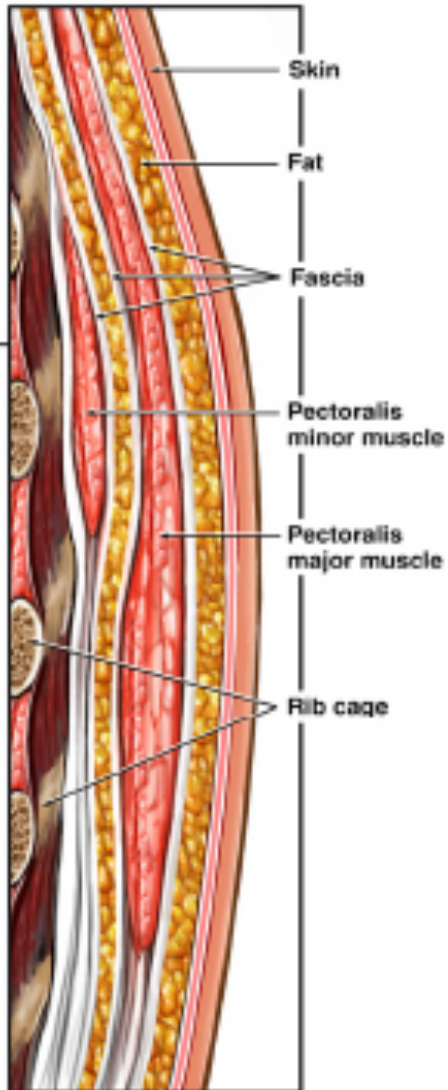


Fluid

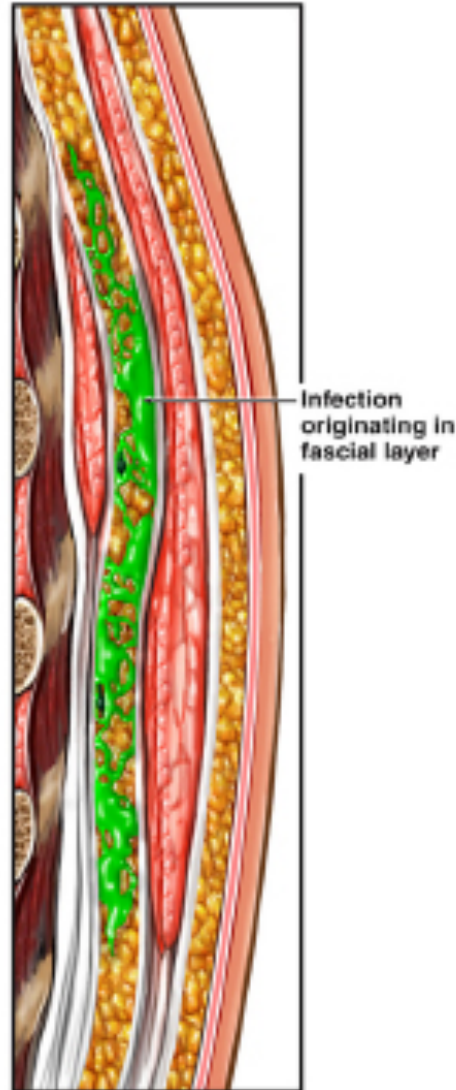


Finger test

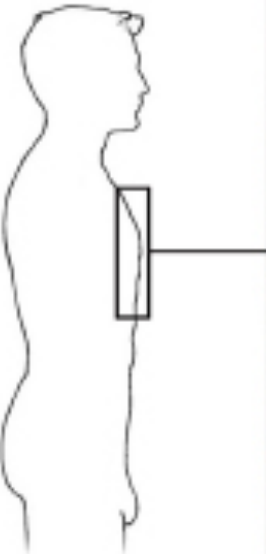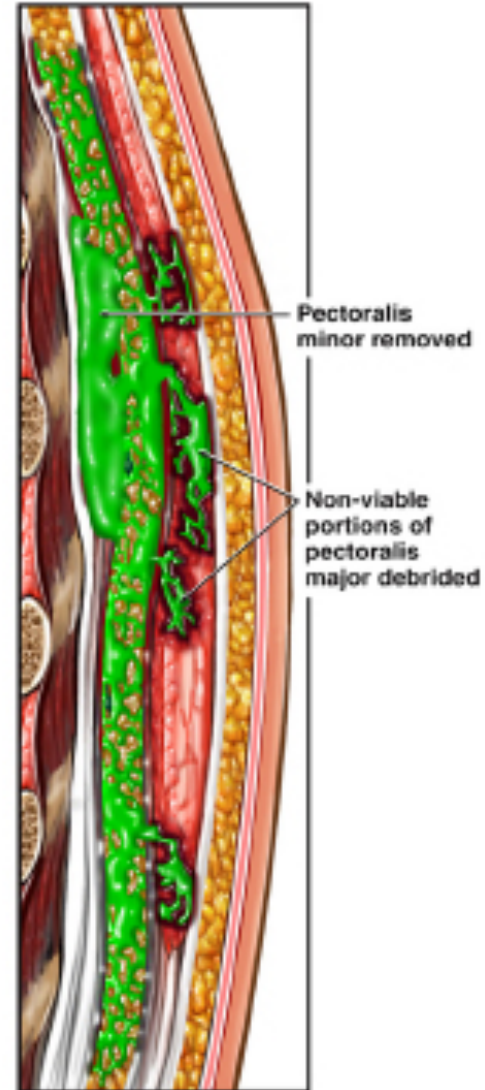
Normal Anatomy



Initial Condition



Eventual Condition



NTUH experience on Necrotizing fasciitis

Diffuse thickening of the SC tissue

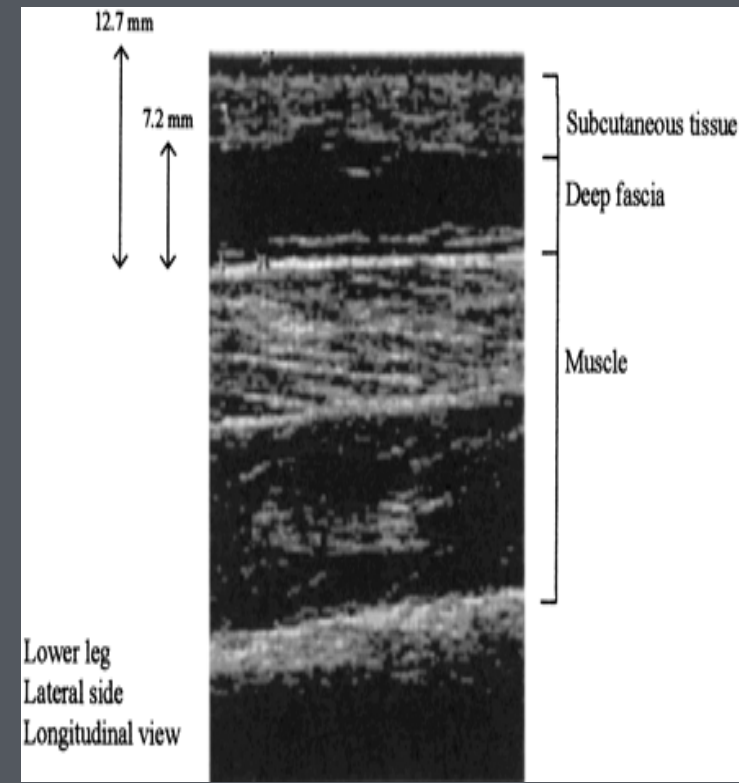
Fascial fluid > 4 mm

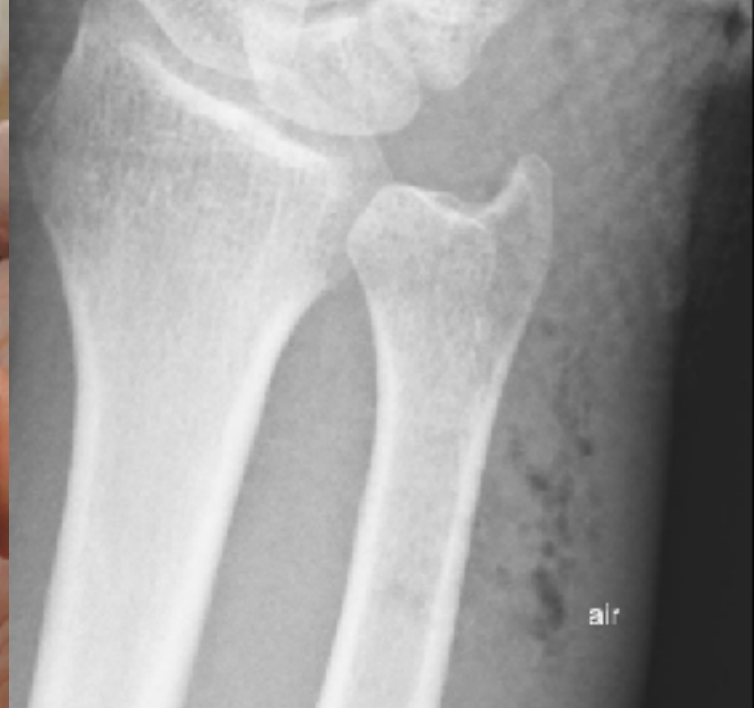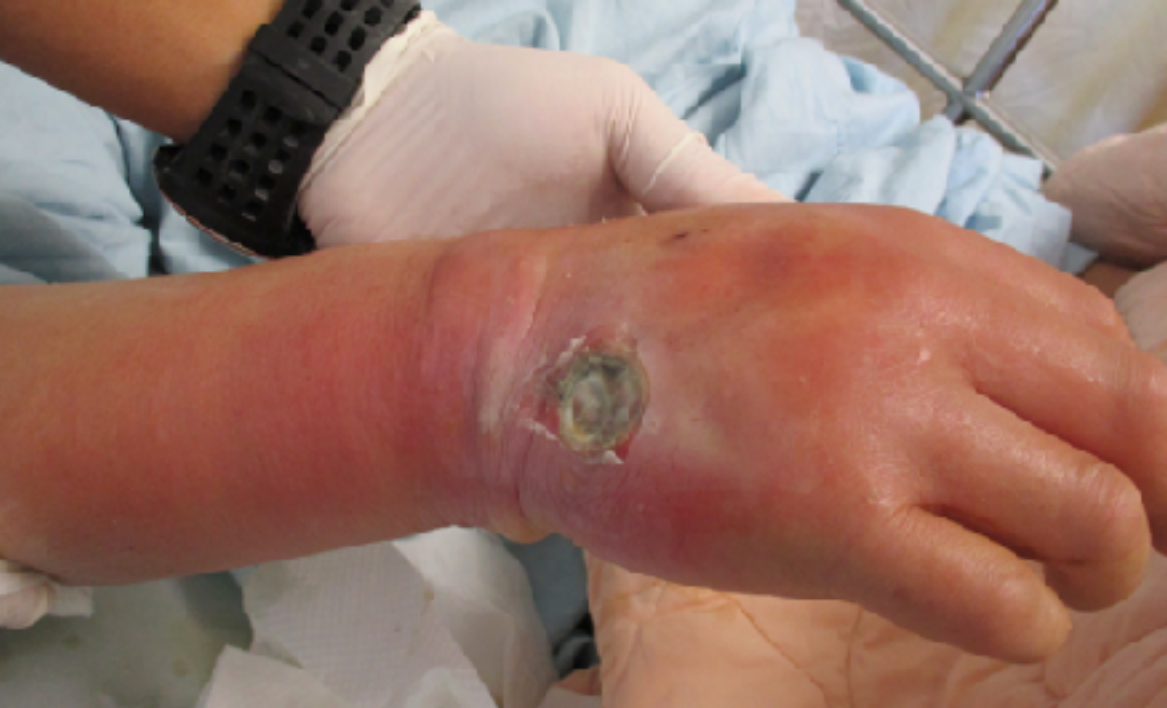66 patients (17,NF)

Sensitivity: 88.2%; Specificity: 93.3%

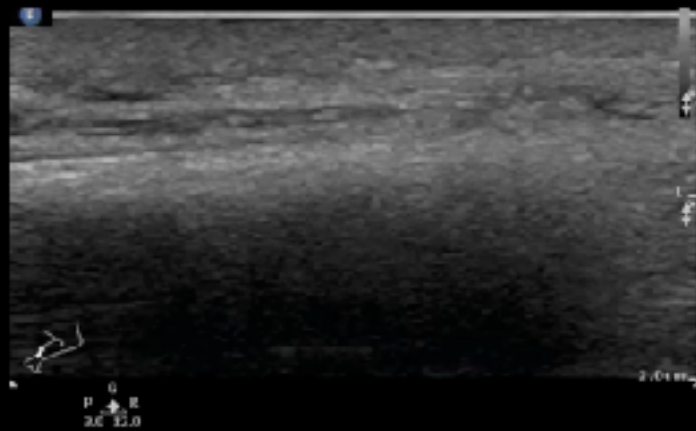
PPV: 83.3%; NPV: 95.4%

Accuracy: 91.9 %

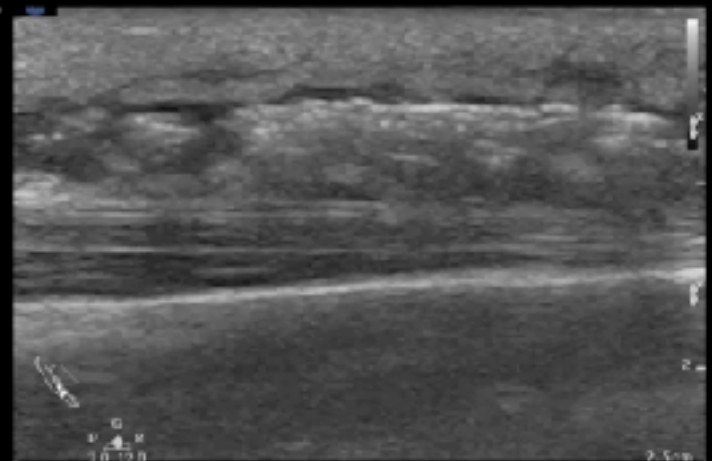




SKH-EUTC



SKH-EUTC

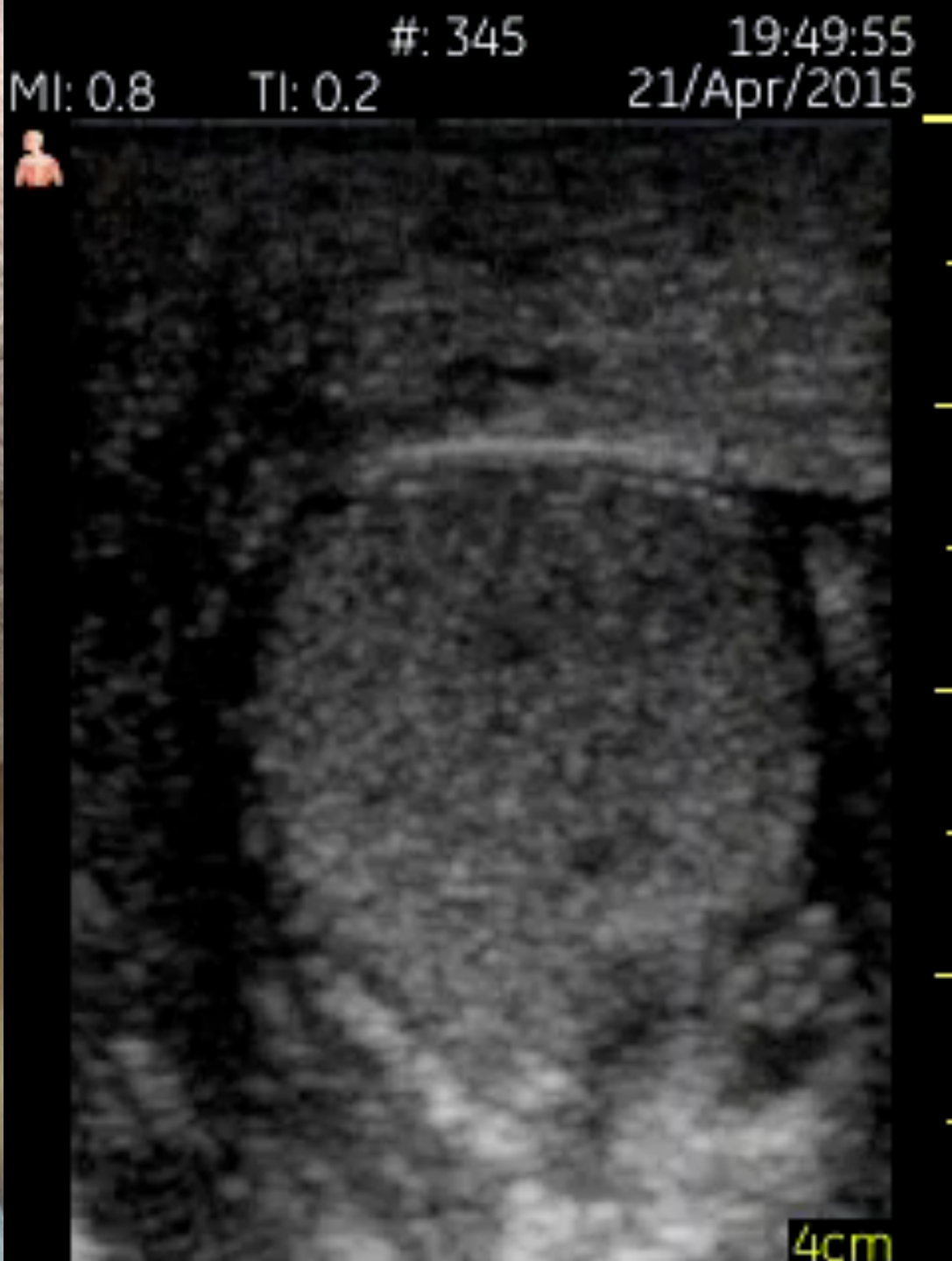
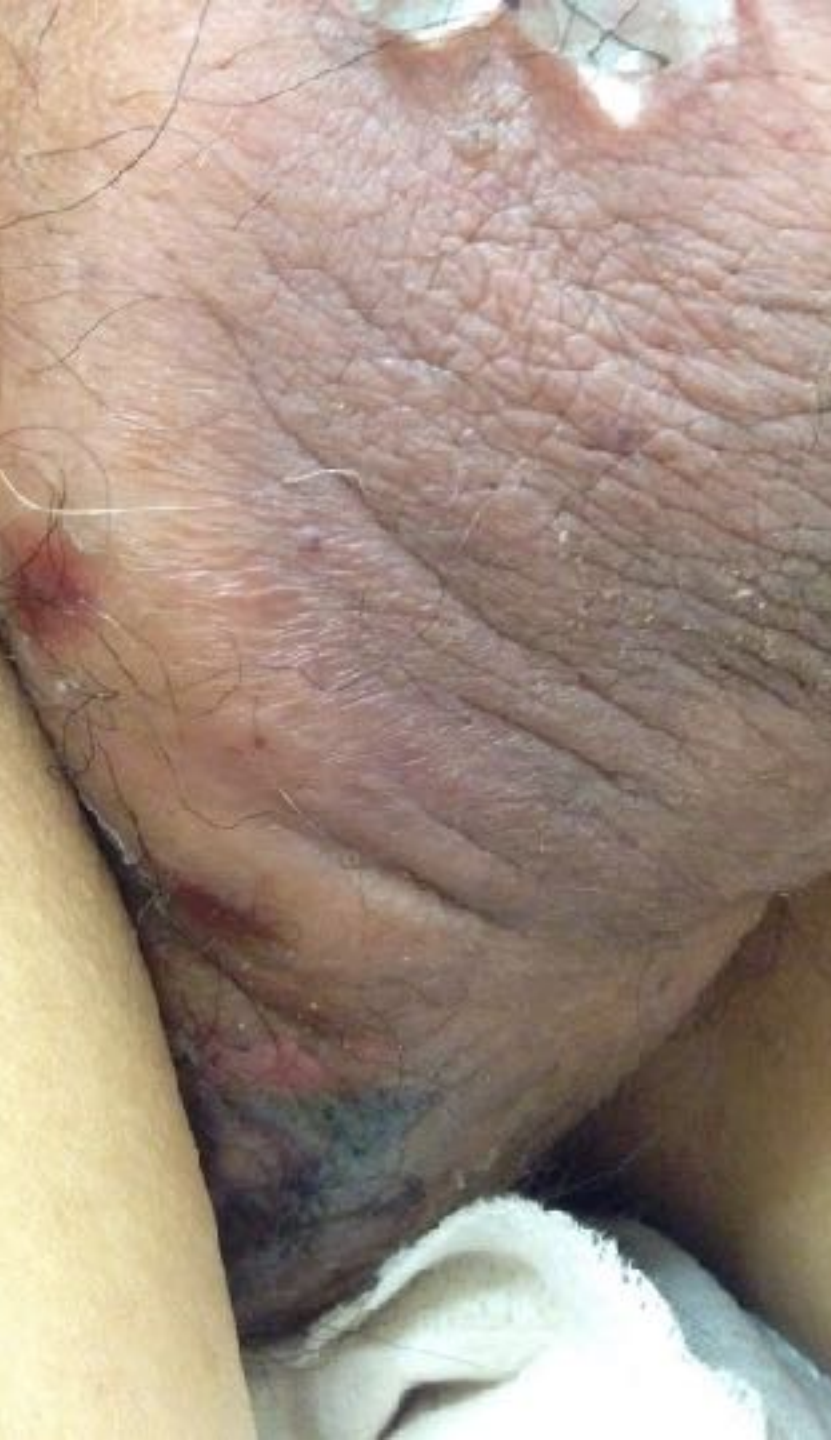
STAFF exam (3)

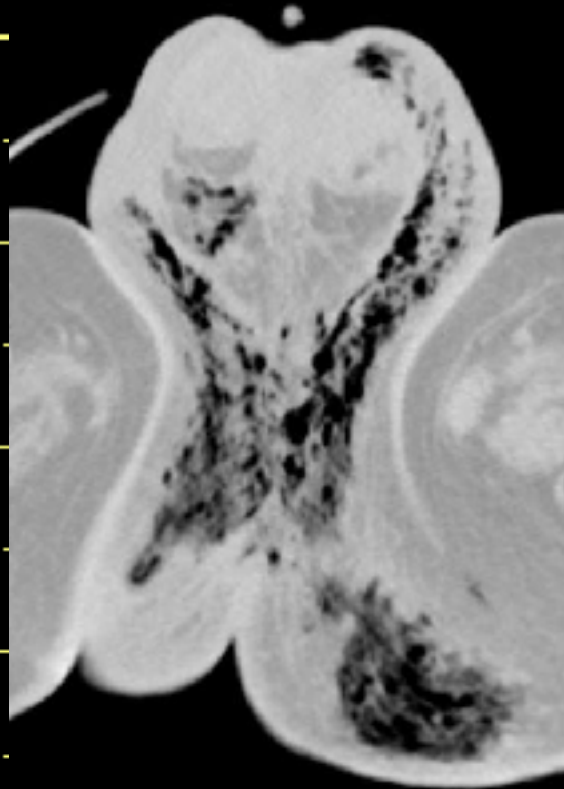
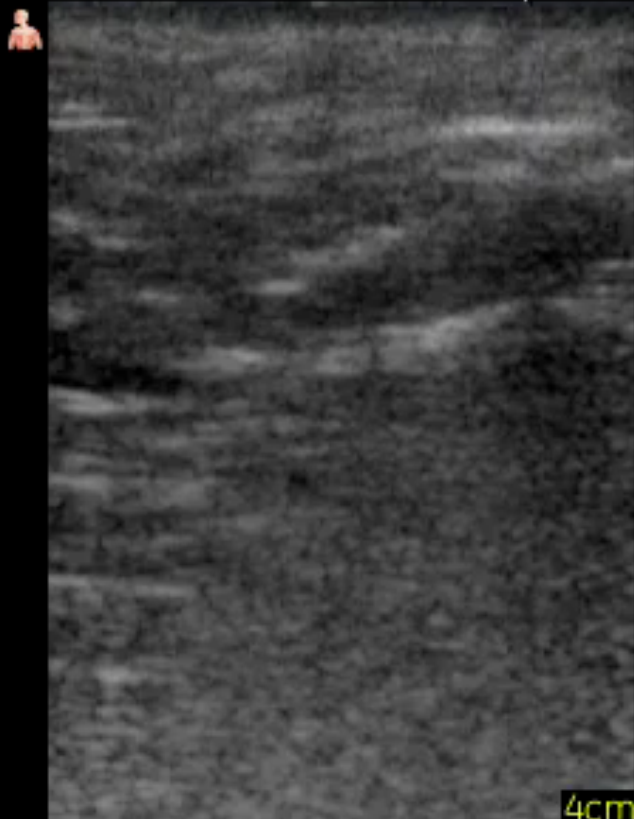Subcutaneous Thickening

Air

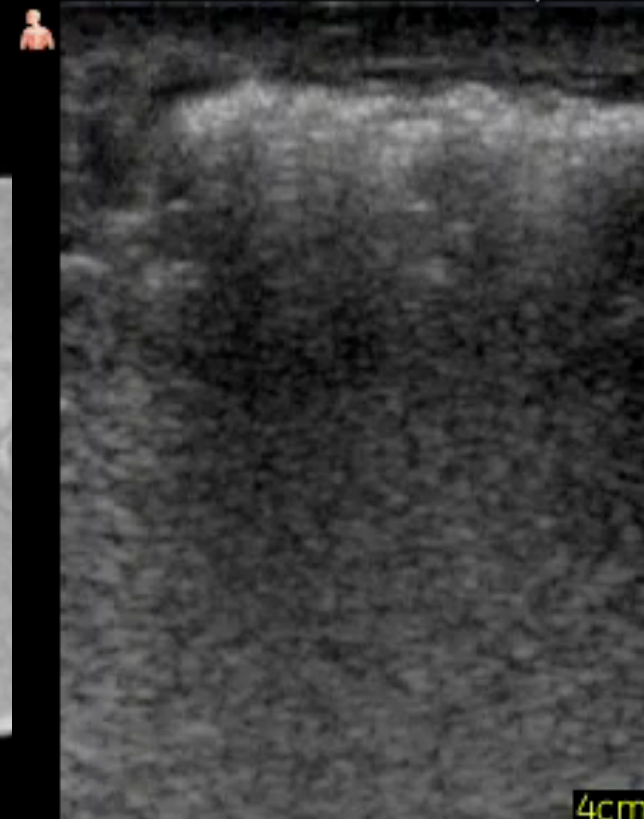
Fascial Fluid



#: 345 19:47:25
MI: 0.8 TI: 0.2 21/Apr/2015



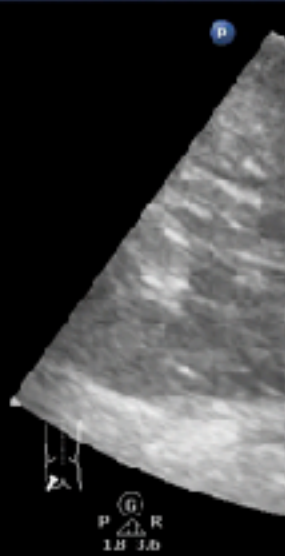
#: 345 19:46:55
MI: 0.8 TI: 0.2 21/Apr/2015



PHILIPS TemporaryID-2016042510
16-04-25-103615

Abd Gen
C5-1
31 Hz
8.0cm

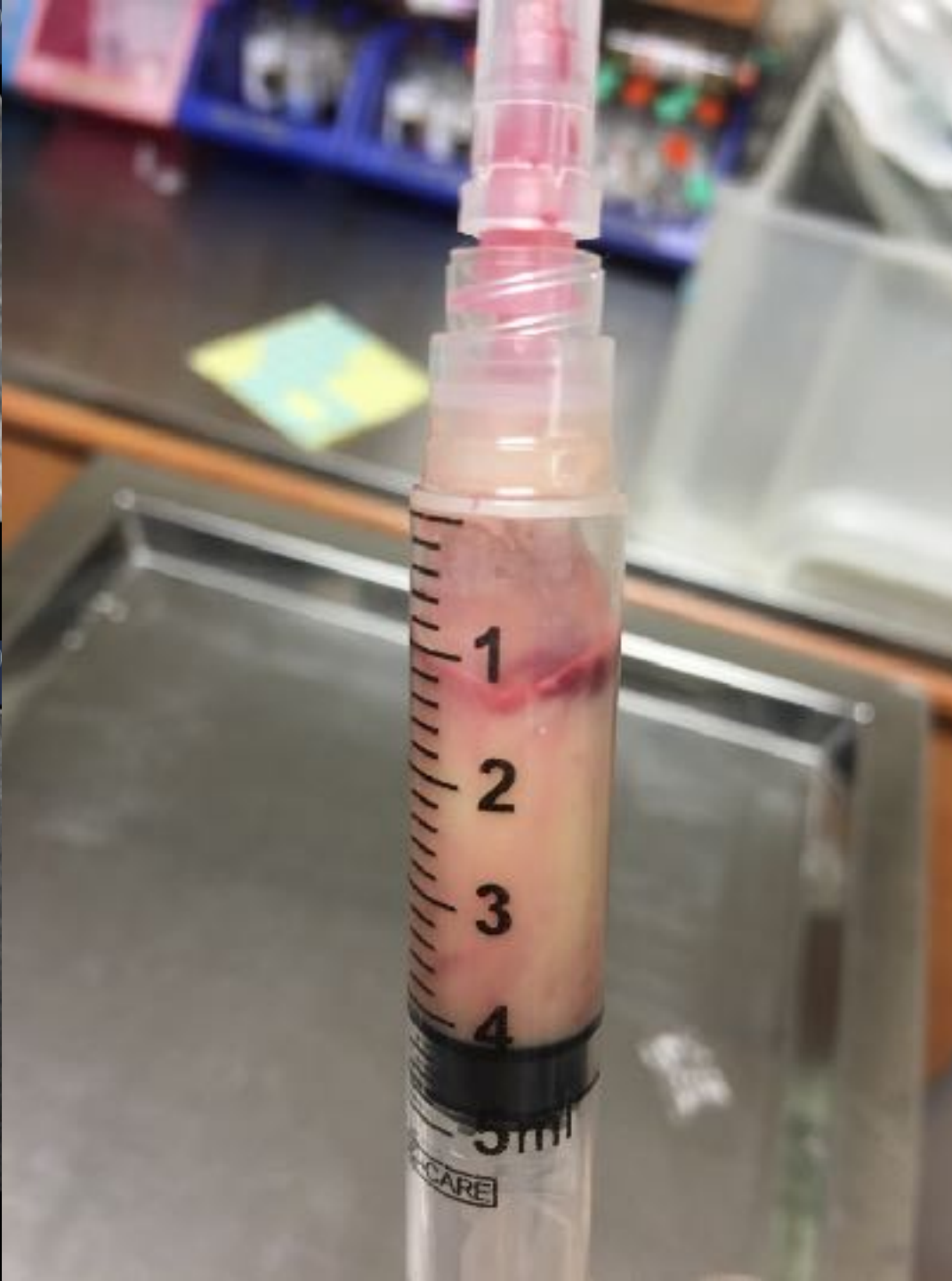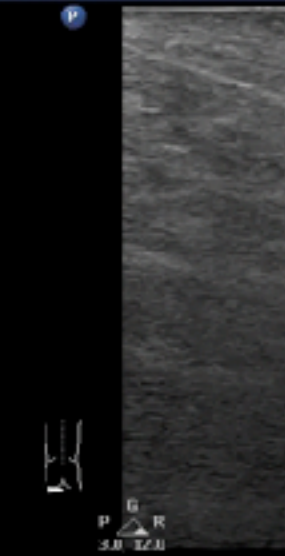
2D
HGen
Gn 100
C 56
3/3/3



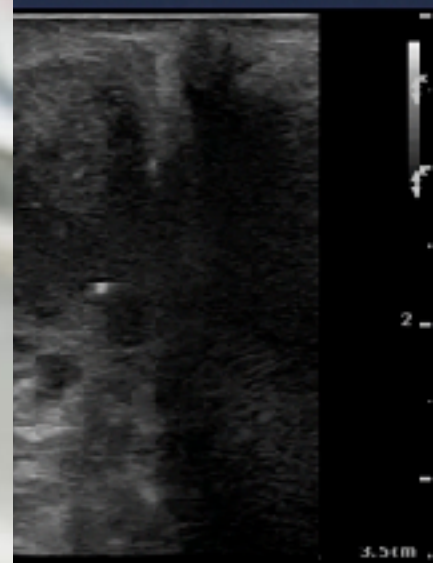
PHILIPS TemporaryID-2016042510
16-04-25-103615

Superficial
L12-3
40 Hz
3.5cm

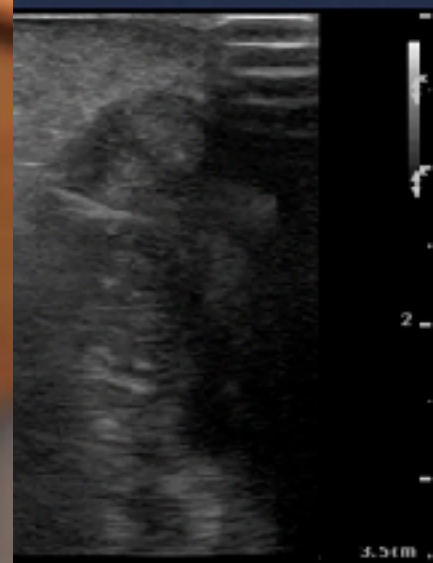
2D
Res
Gn 100
C 56
3/2/1



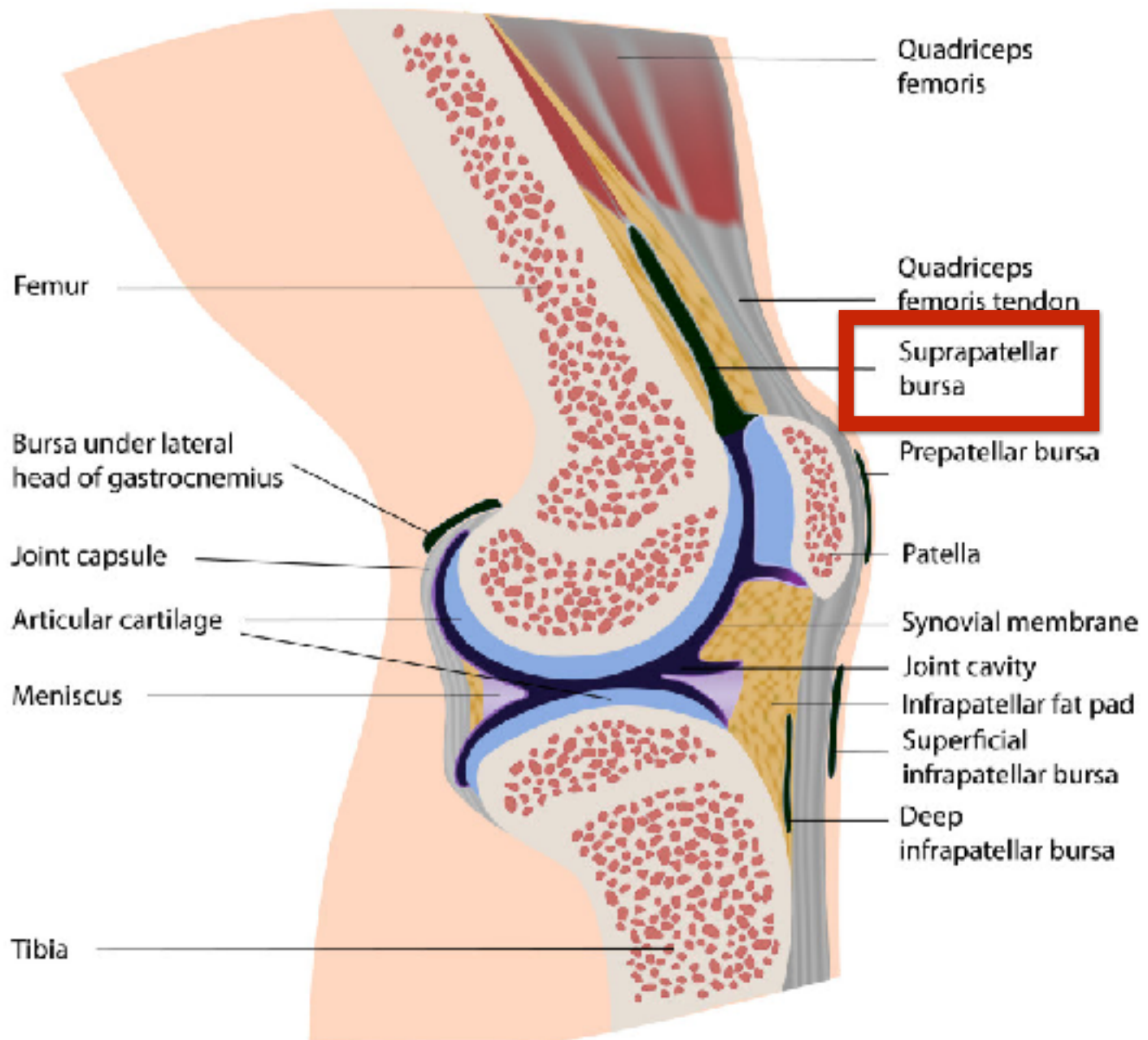
ME 0.5 4/25/2016
TIS 0.1 10:55:14 AM



ME 0.5 4/25/2016
TIS 0.1 11:01:59 AM



Anatomy of the Knee Joint



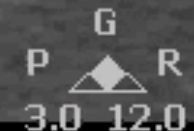
P

QT

Patella

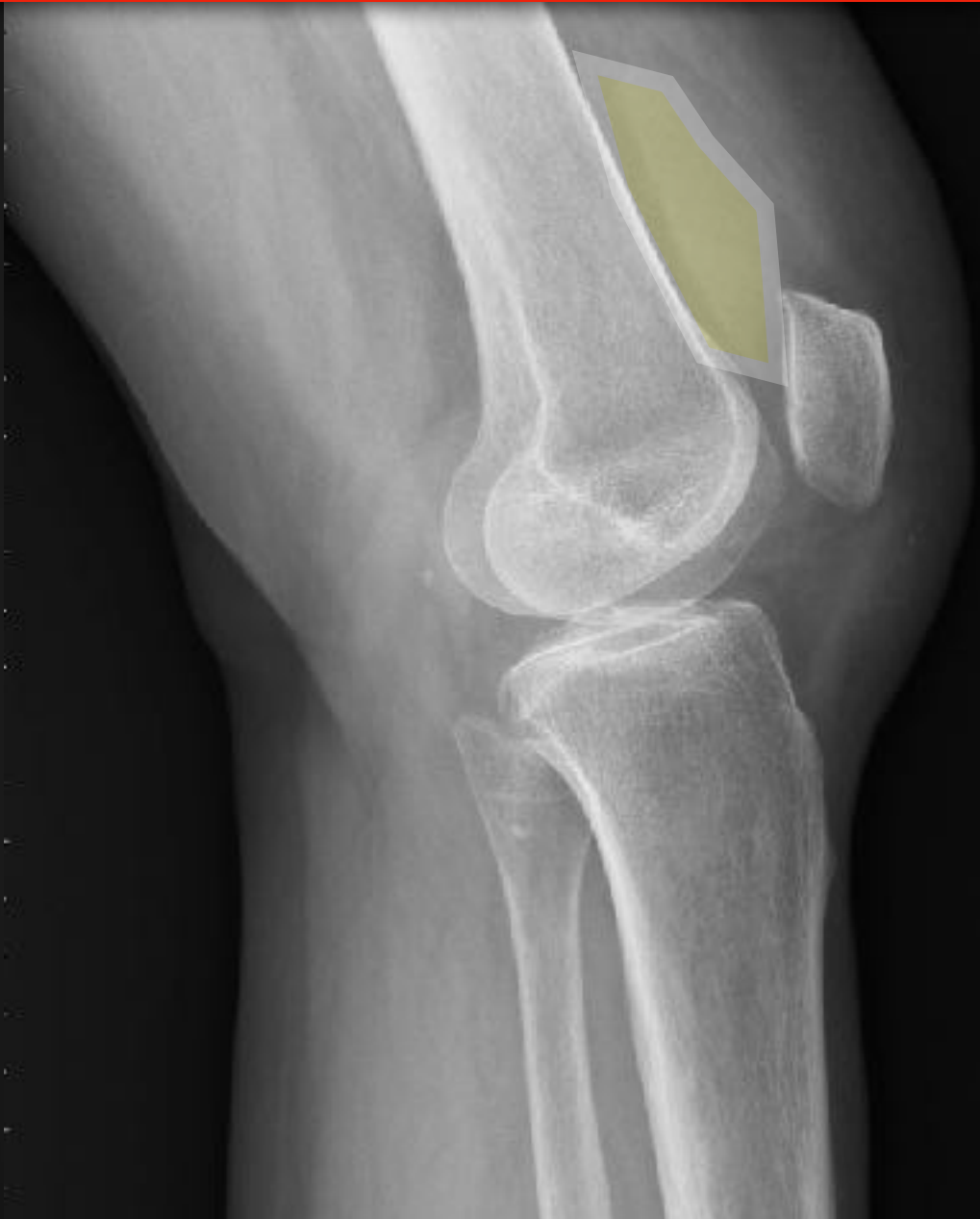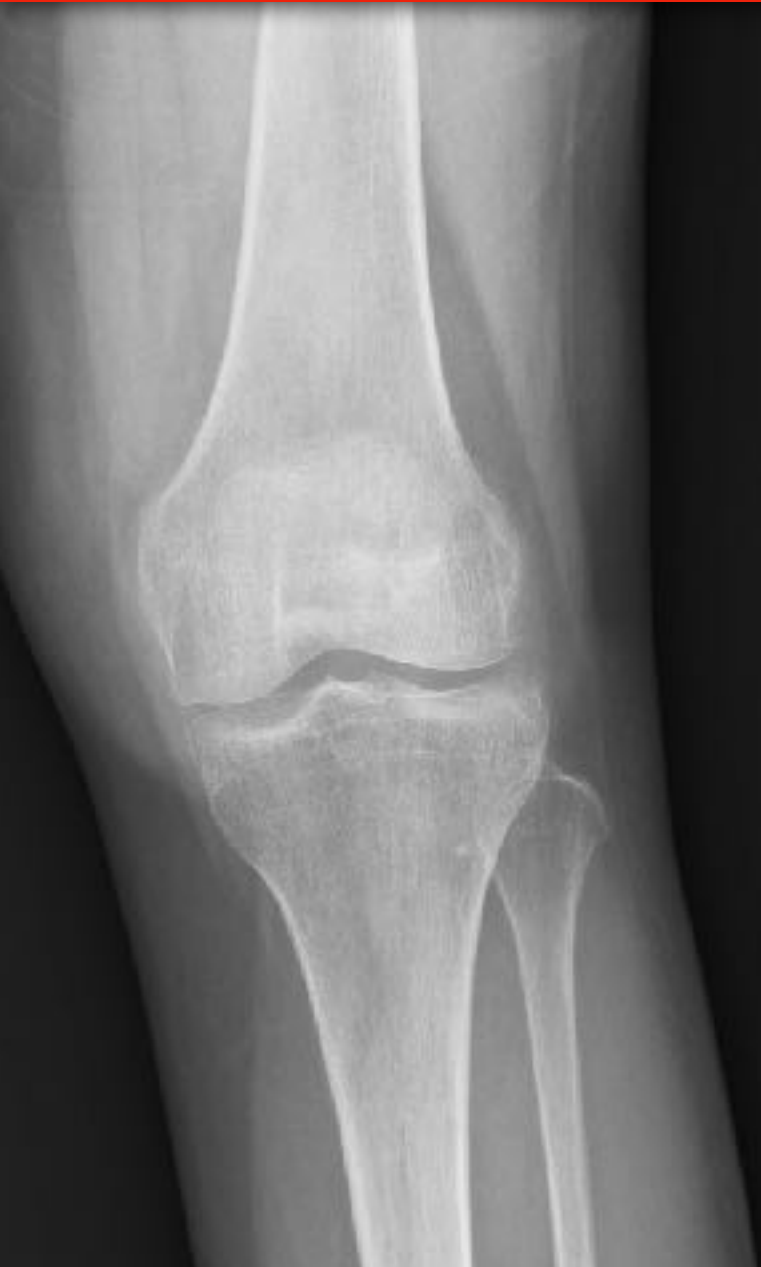Fat

Femur

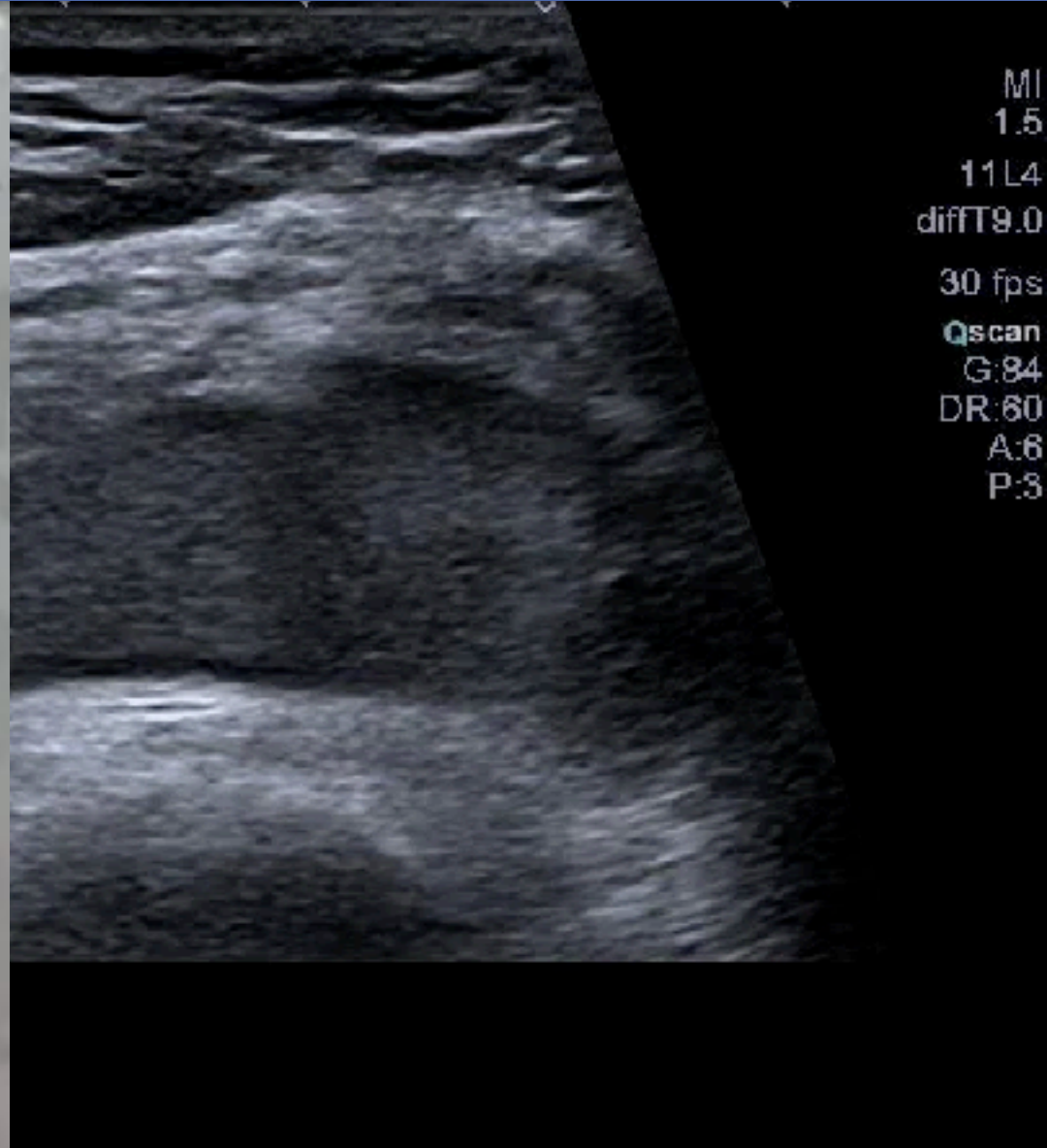
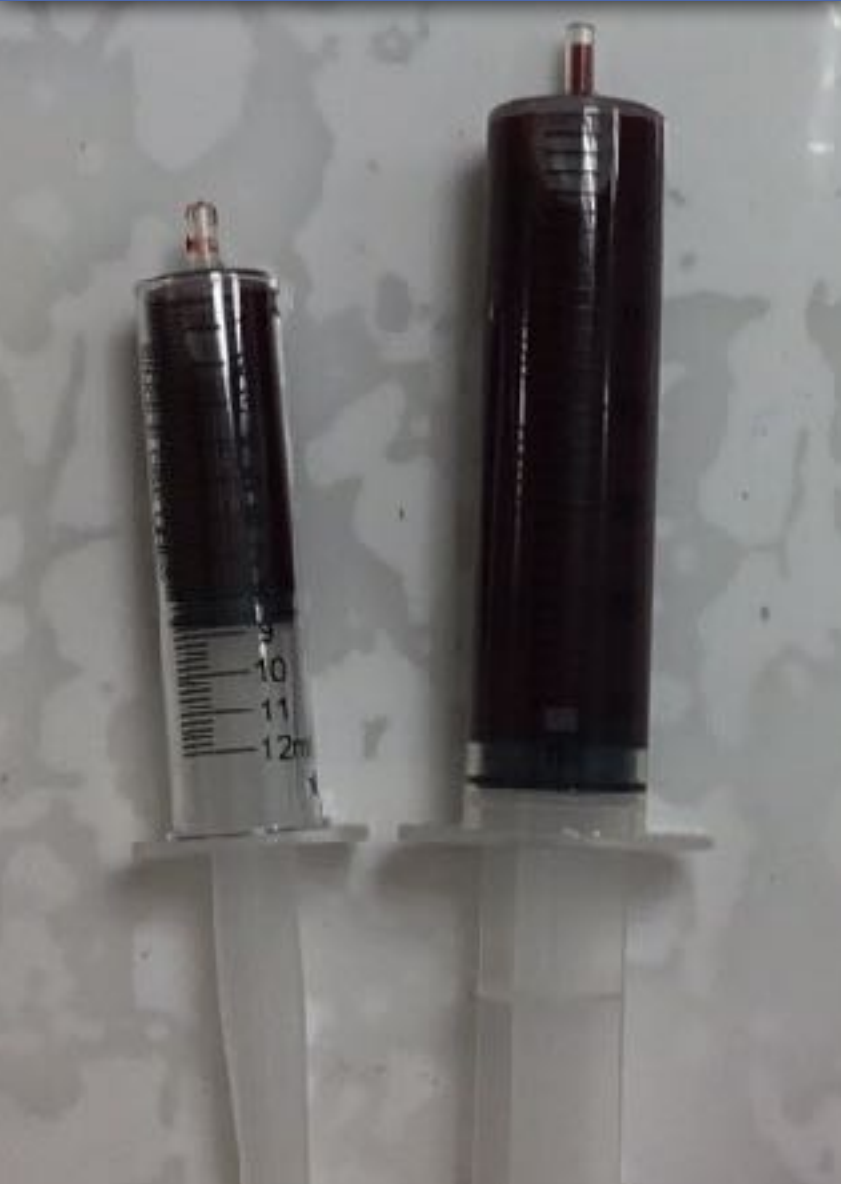

2.5cm

膝蓋很腫，無法彎也無法站

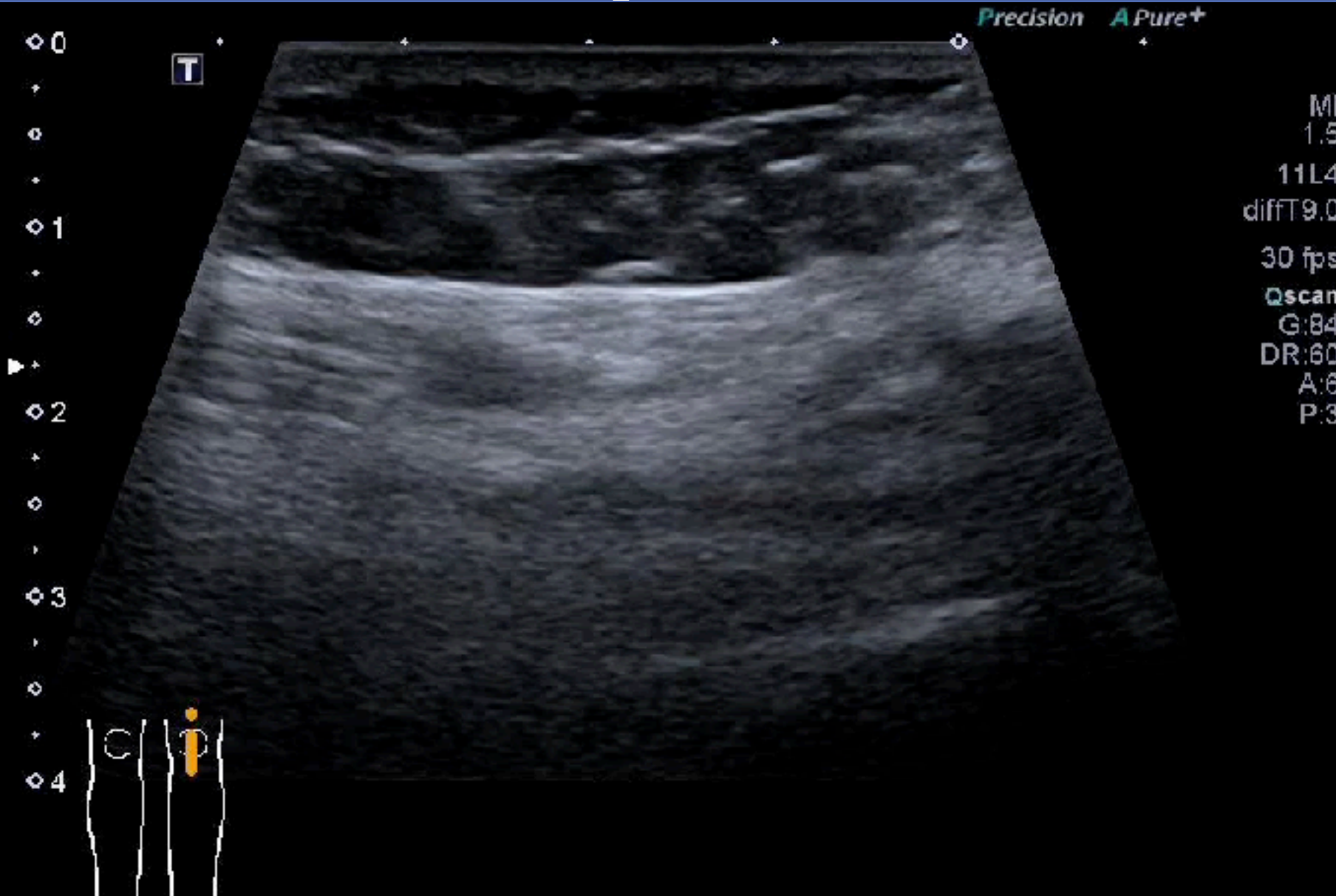


Knee hemarthrosis

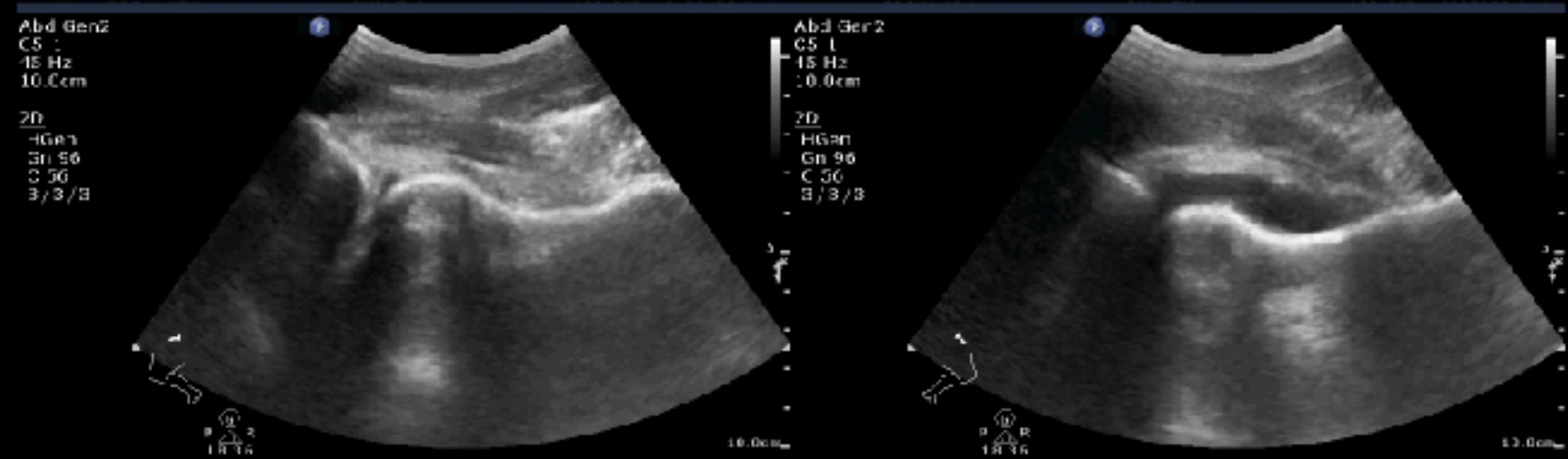

MI
1.5
11L4
diffT9.0
30 fps
Qscan
G:84
DR:60
A:6
P:3

Post aspiration



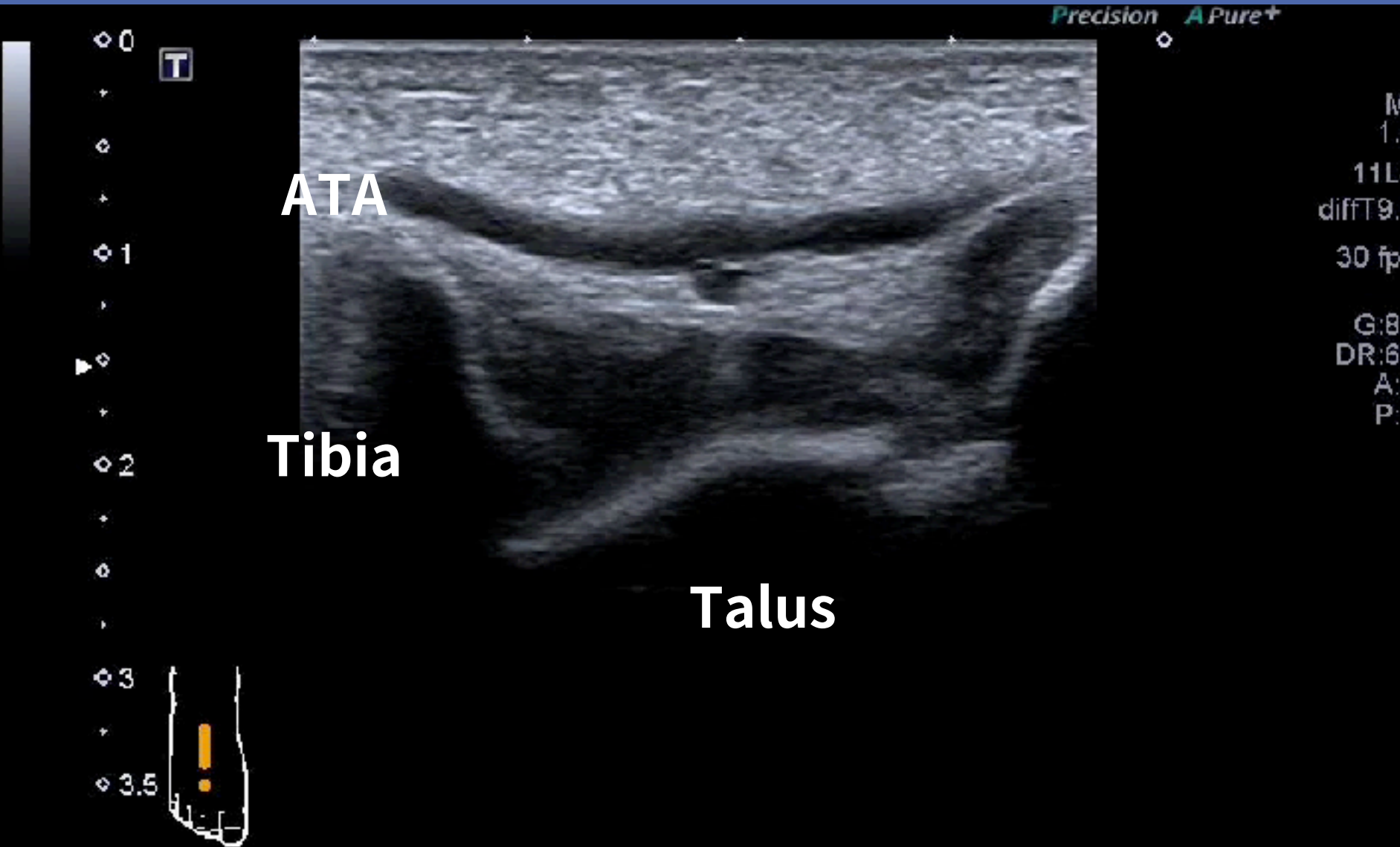
Hip joint effusion



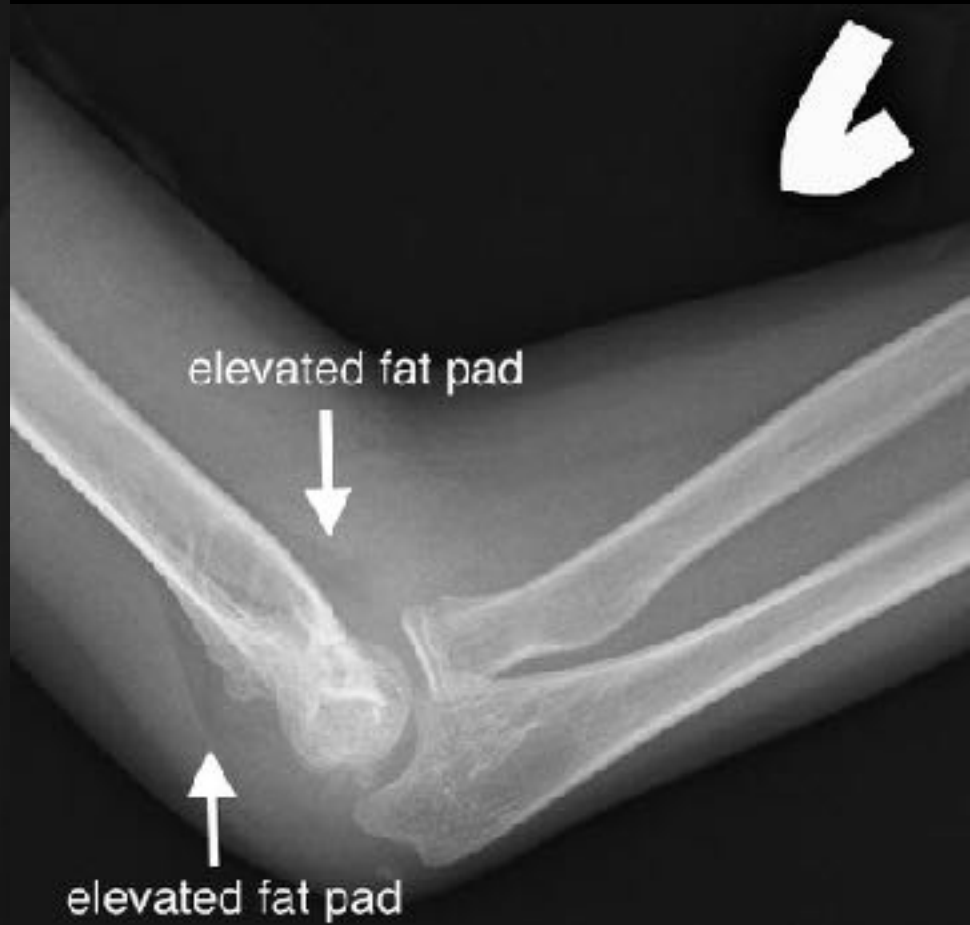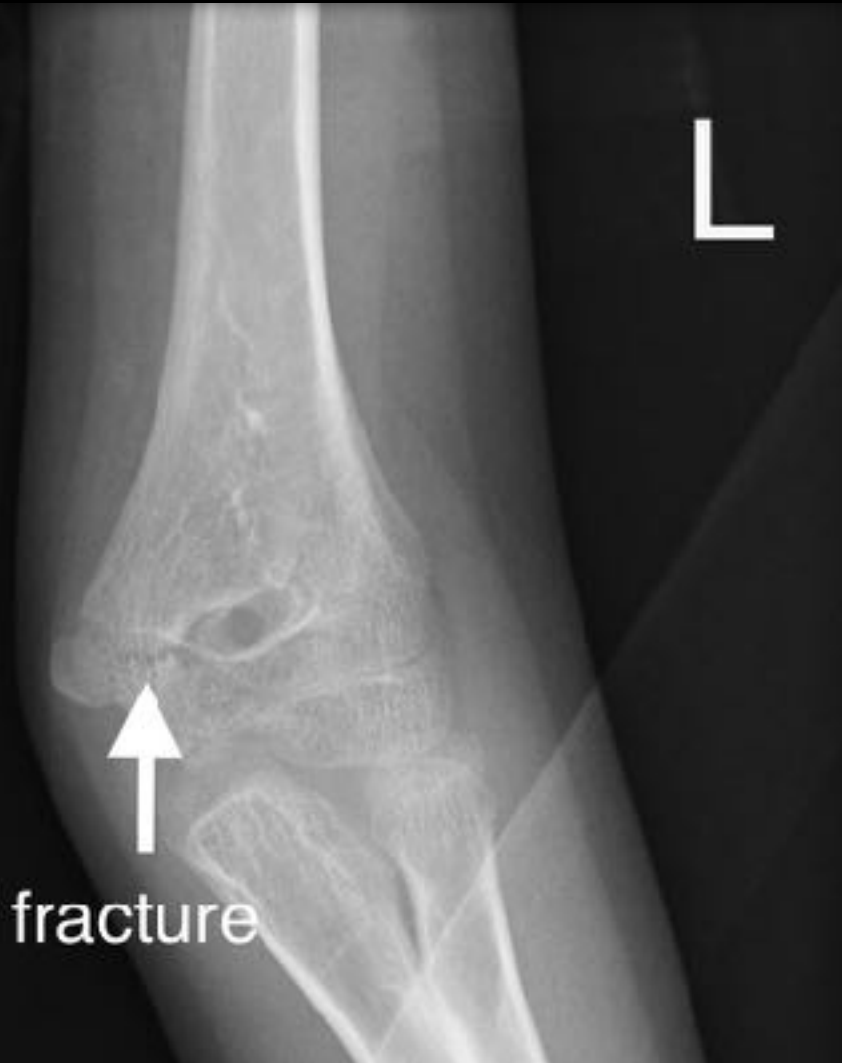right hip

left hip

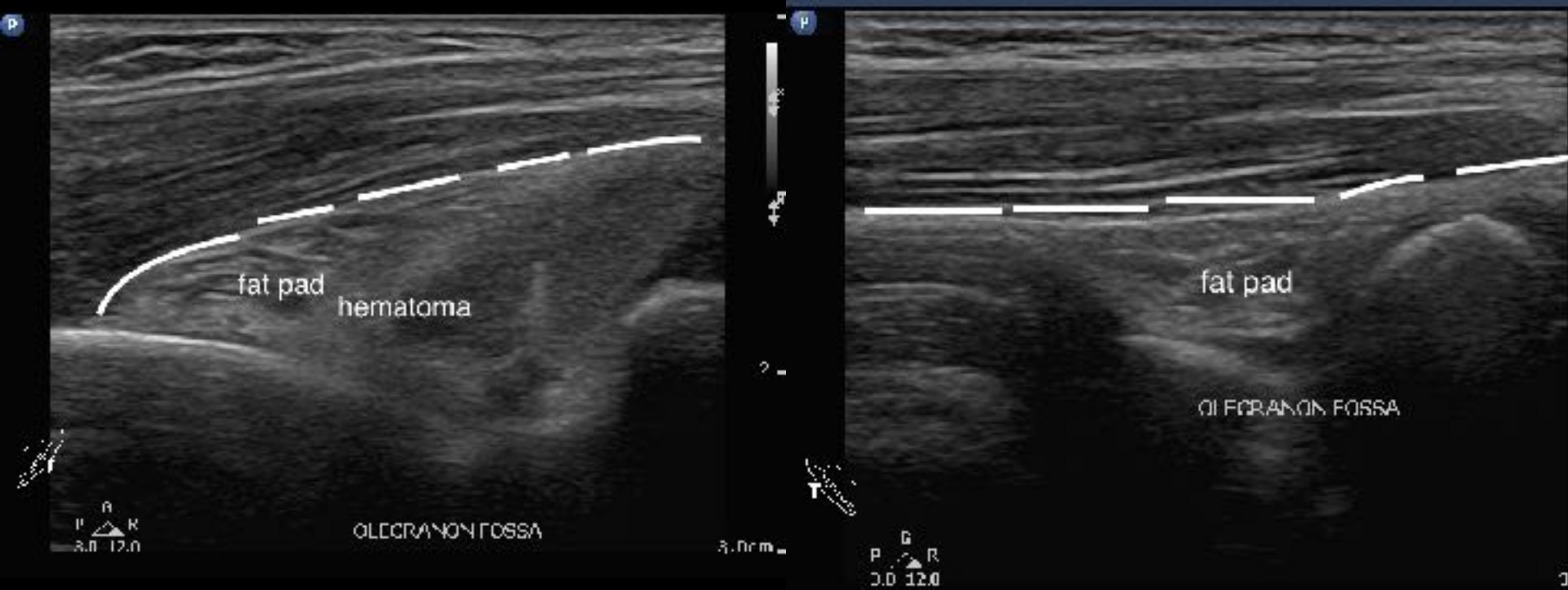Ankle joint effusion



Fat pad sign



Elevated fat pad sign



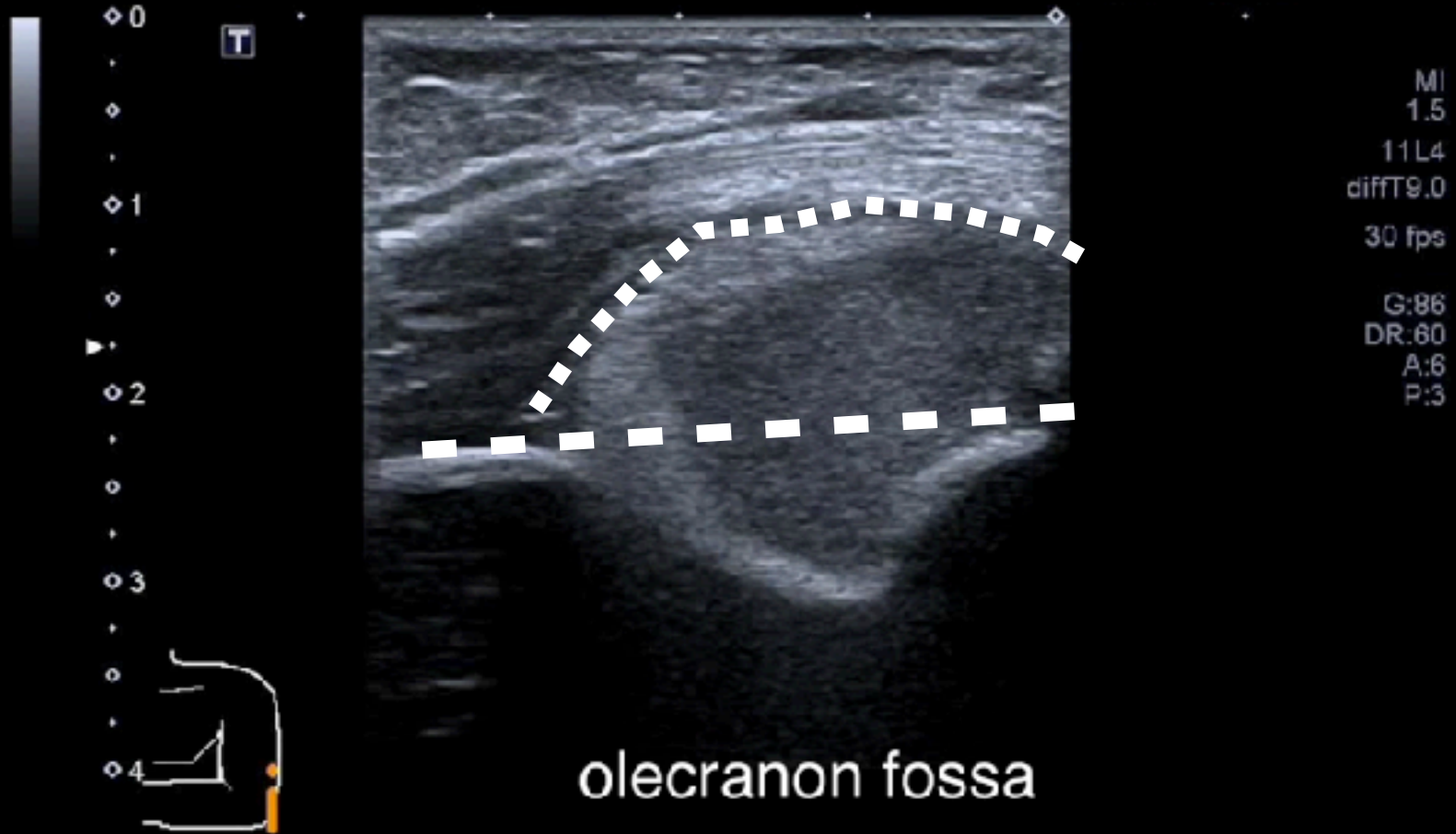
Olecranon

Radial

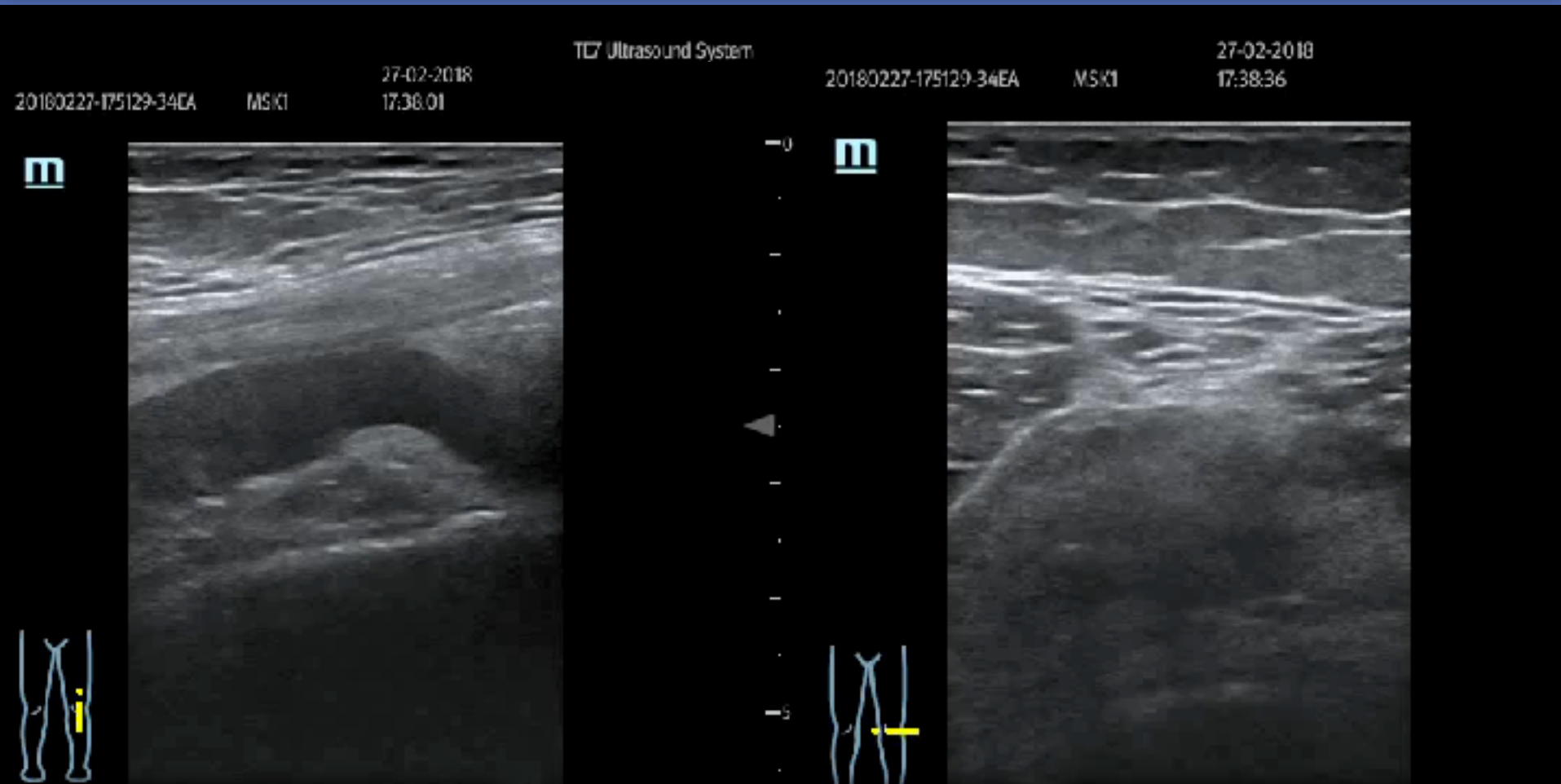
Coronoid

Elevated fat pad sign

POCUSAcademy©ChenKC



Lipohemarthrosis



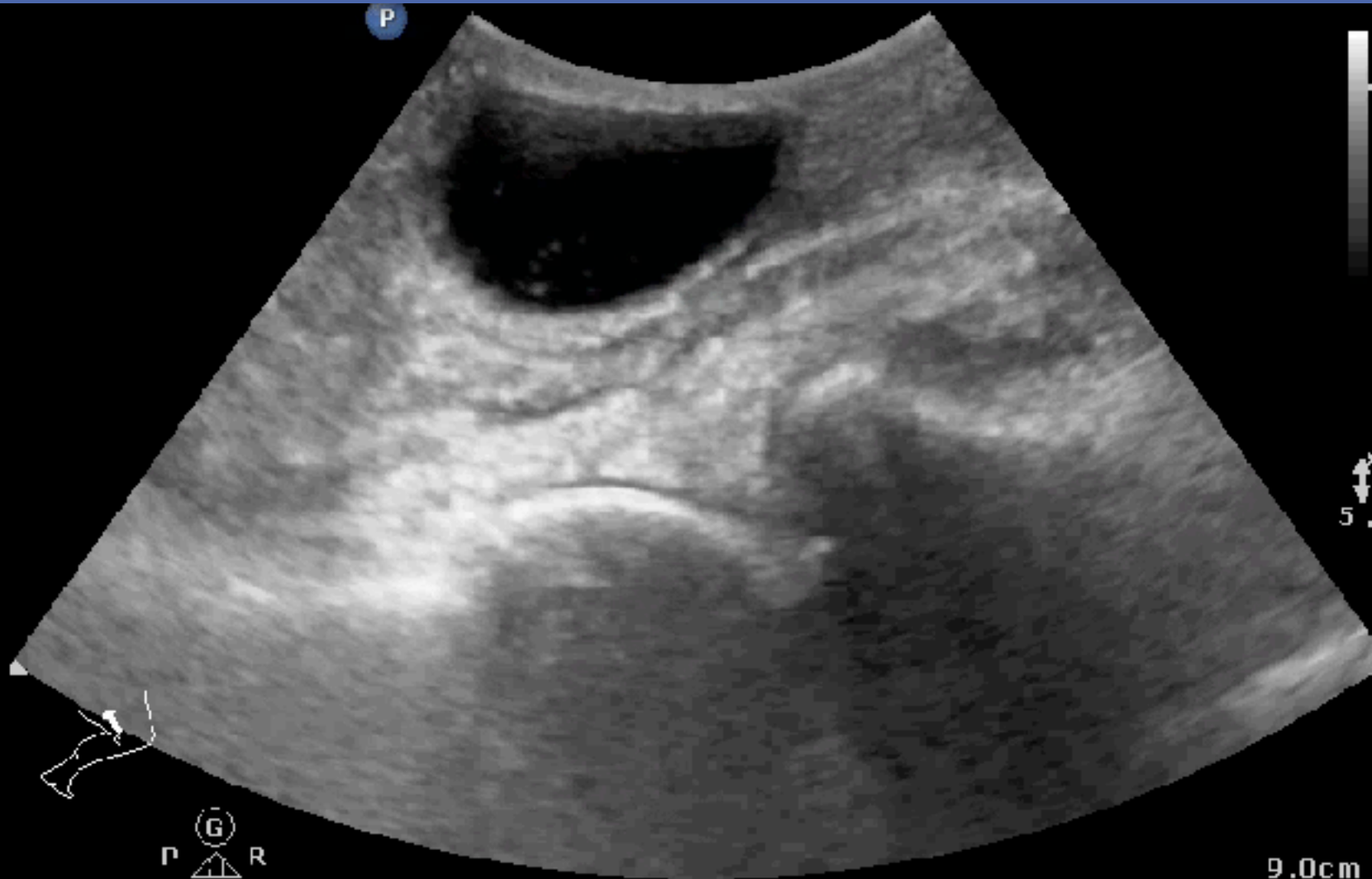
骨頭標記

兩側對比

流動液體

Baker's cyst

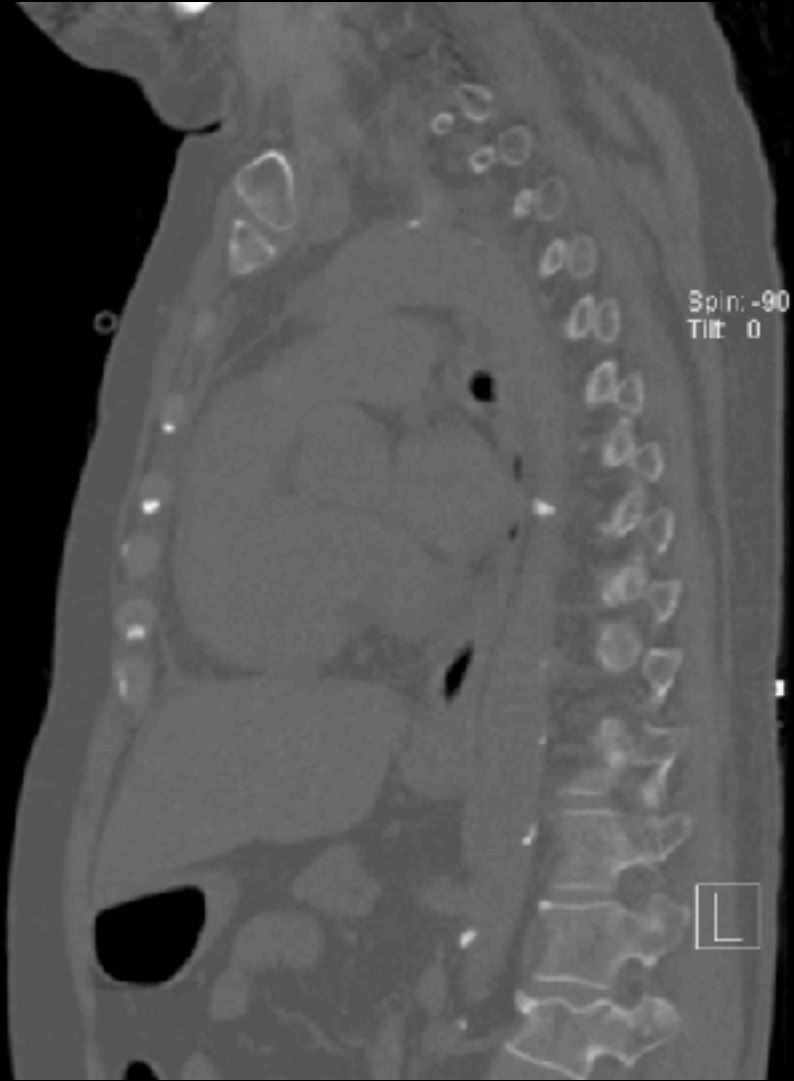ADU Gen7
C5-1
47 Hz
9.0cm
2D
HGen
Gn 85
C 56
3 / 3 / 3



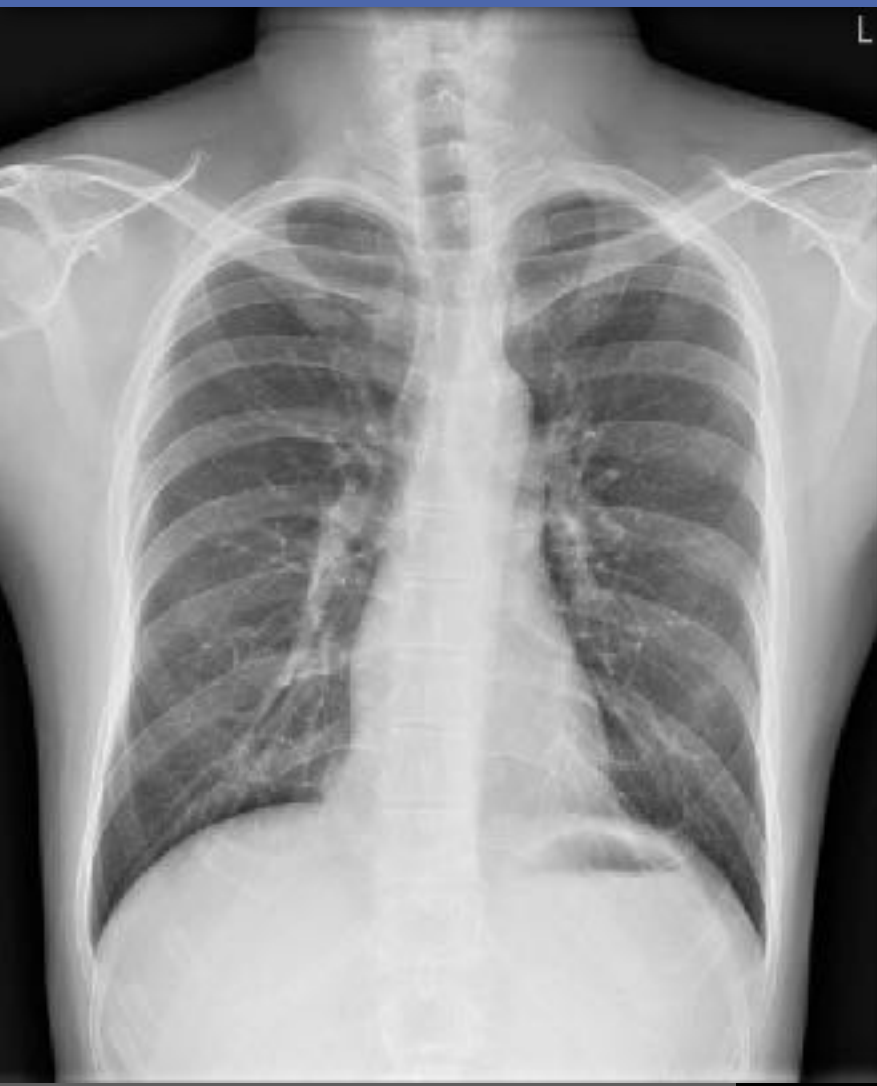Ⓞ
P R
1.8 3.6

9.0cm

胸骨骨折



BAT & R chest pain

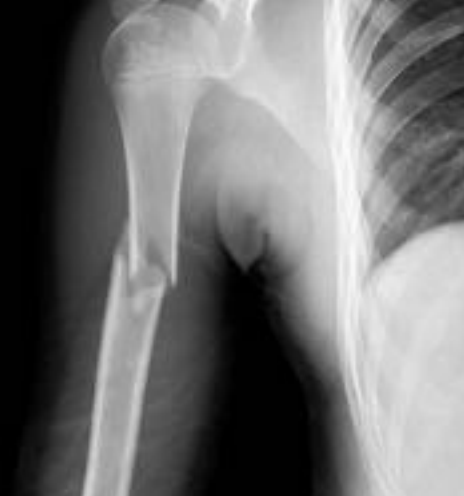

右第5肋骨骨折



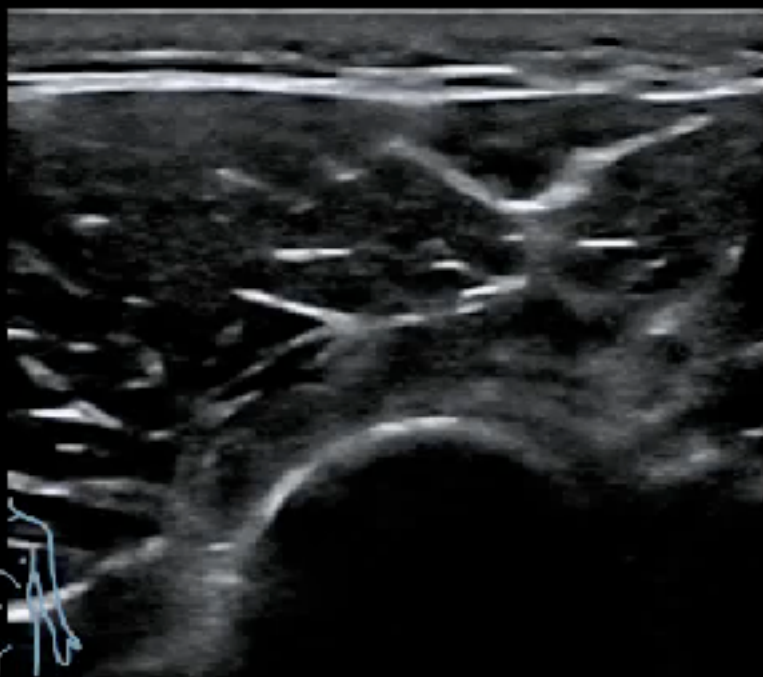
Growth plate

Cartilage

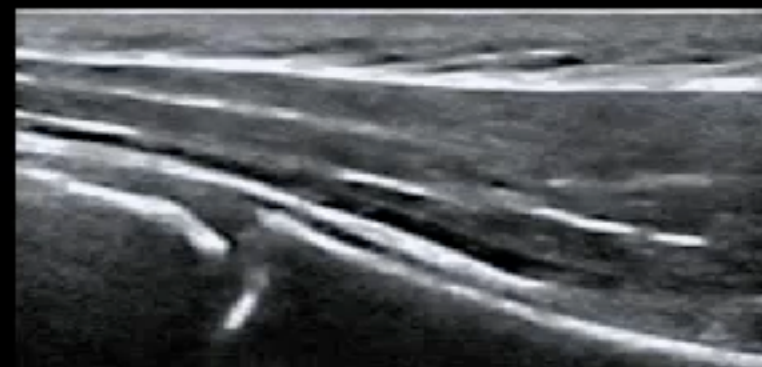


3m 07-02-2018
20180207-164506-34EA NSK 14:41:15

AP 96.0%



3m



-0

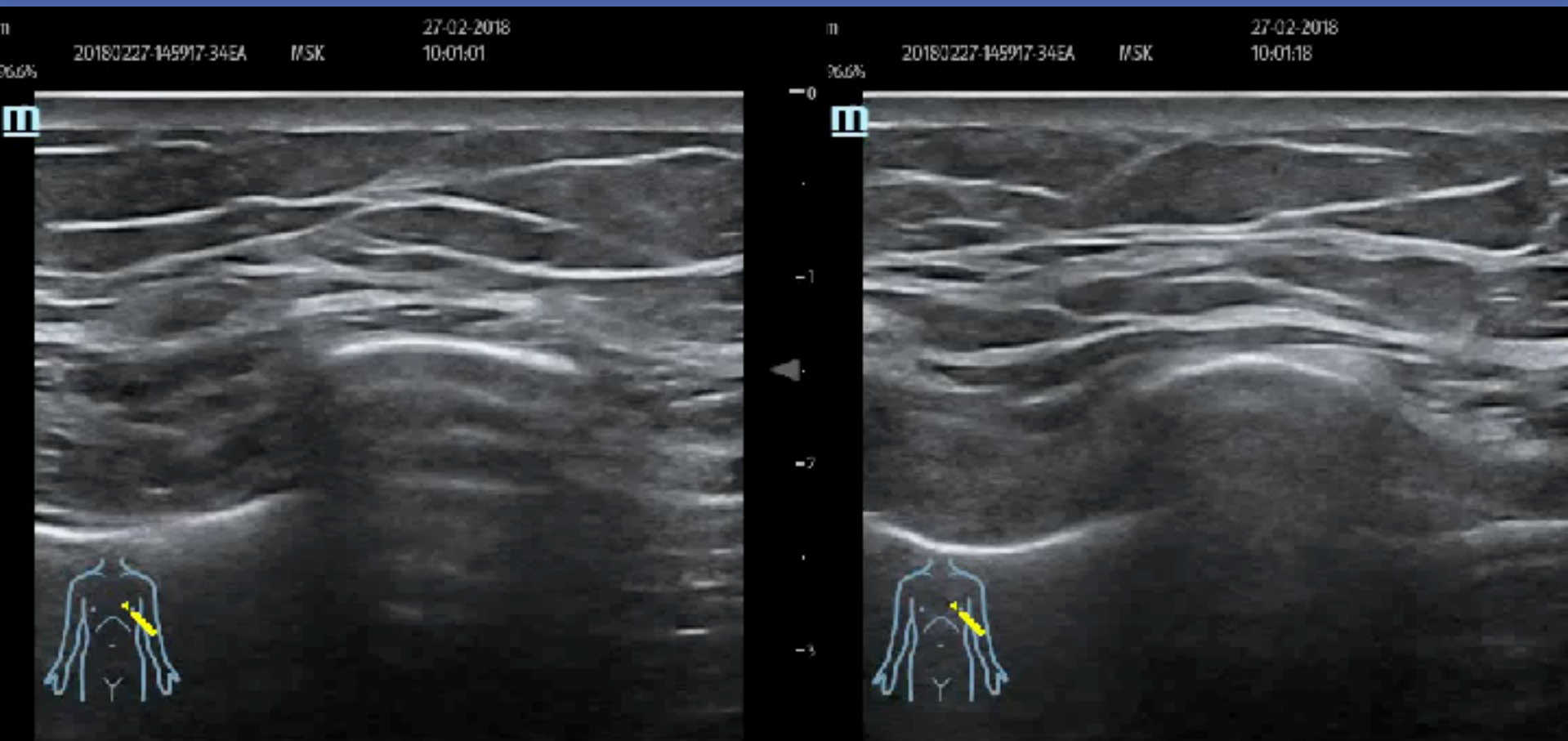
-1

-2

-3

-4

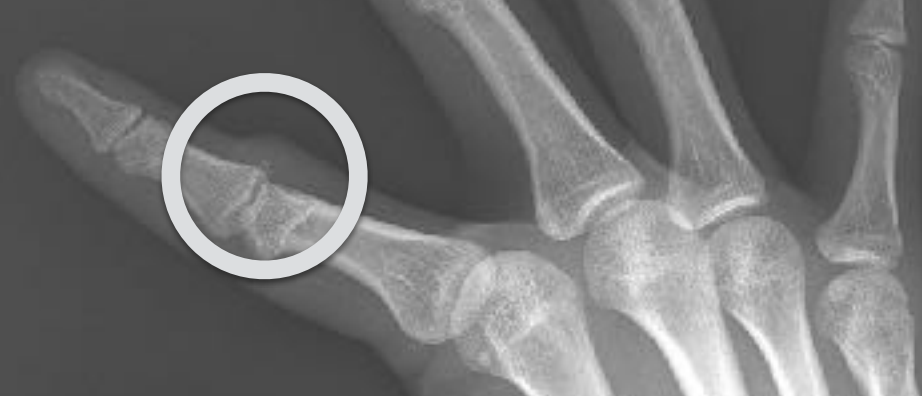POCUS for Occult fracture



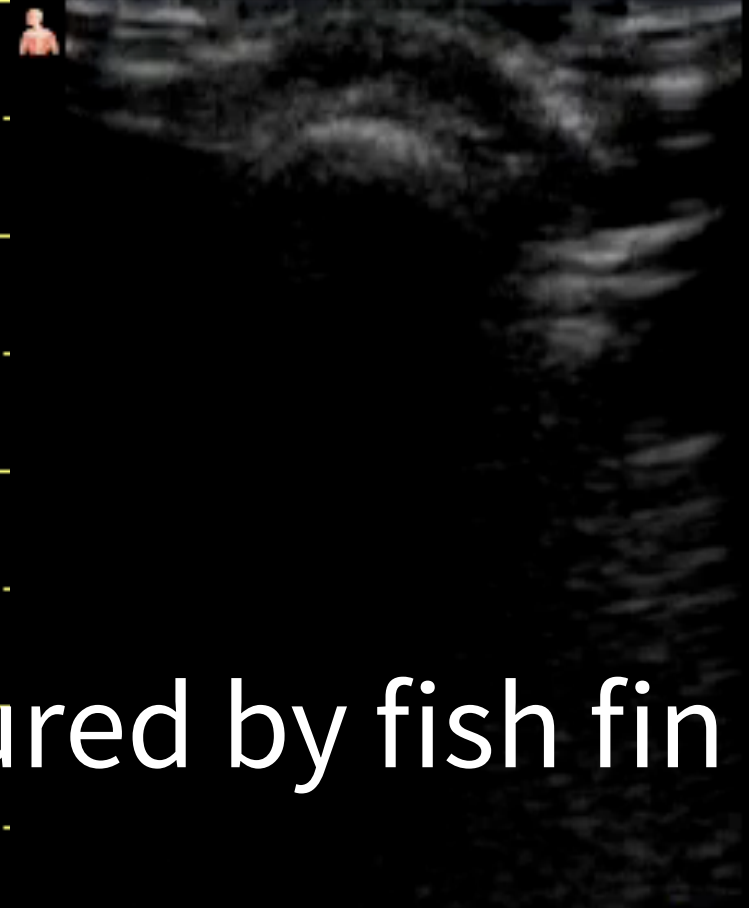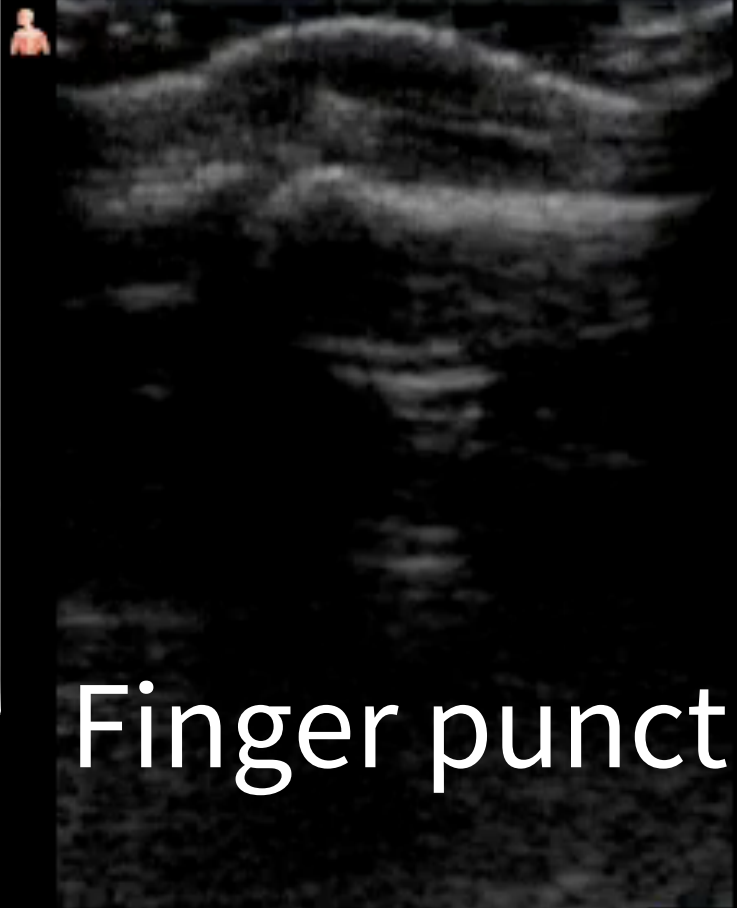高低差

不連續

有血腫



#: 35 2:16:02 PM #: 35 2:17:09 PM
MI: 0.8 TI: 0.2 28/Mar/2015 MI: 0.8 TI: 0.2 28/Mar/2015

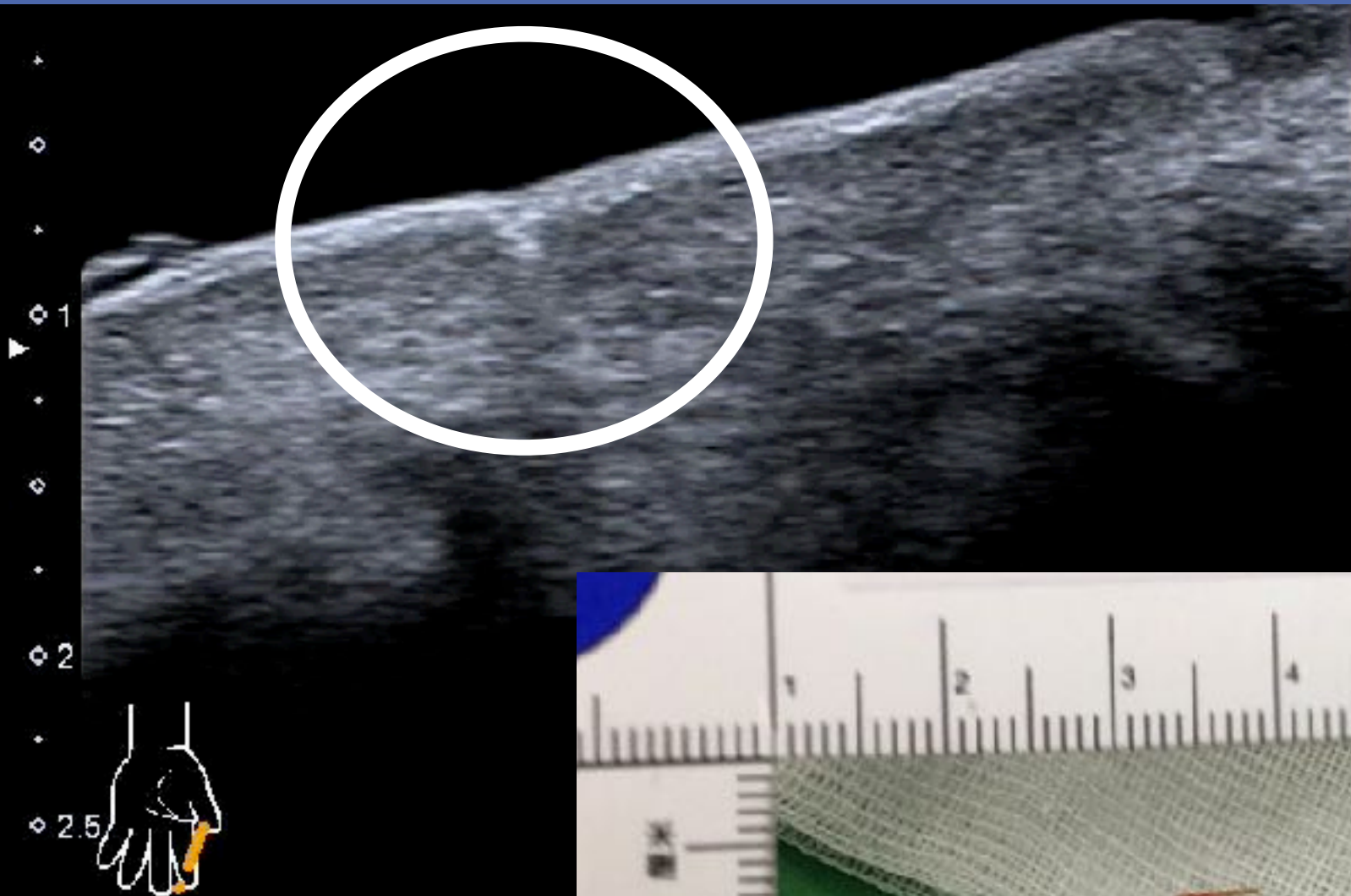


Finger punctured by fish fin


4cm

4cm

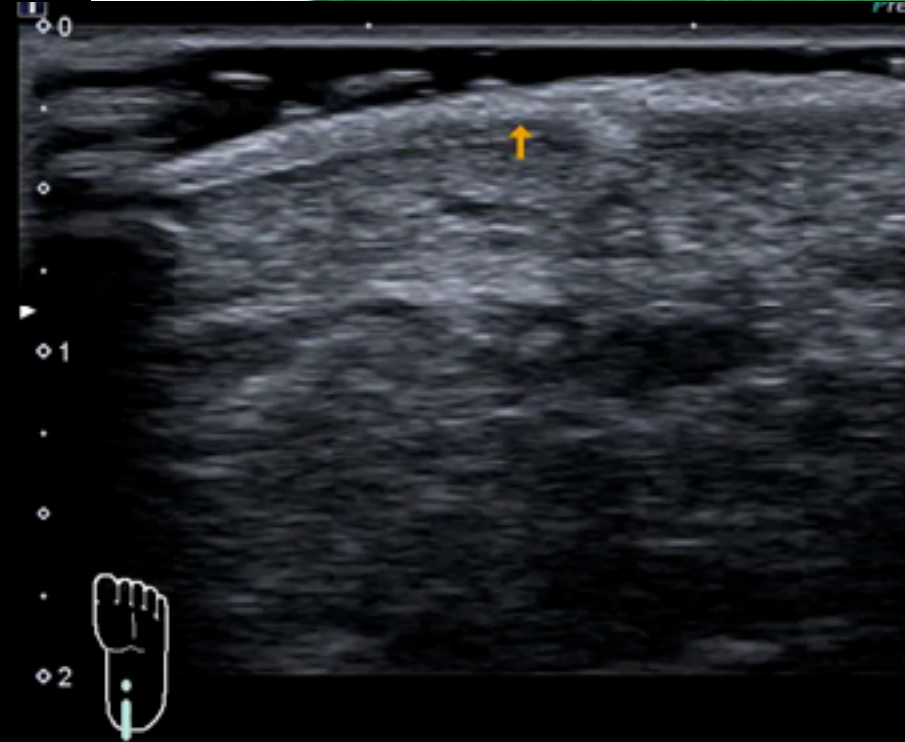
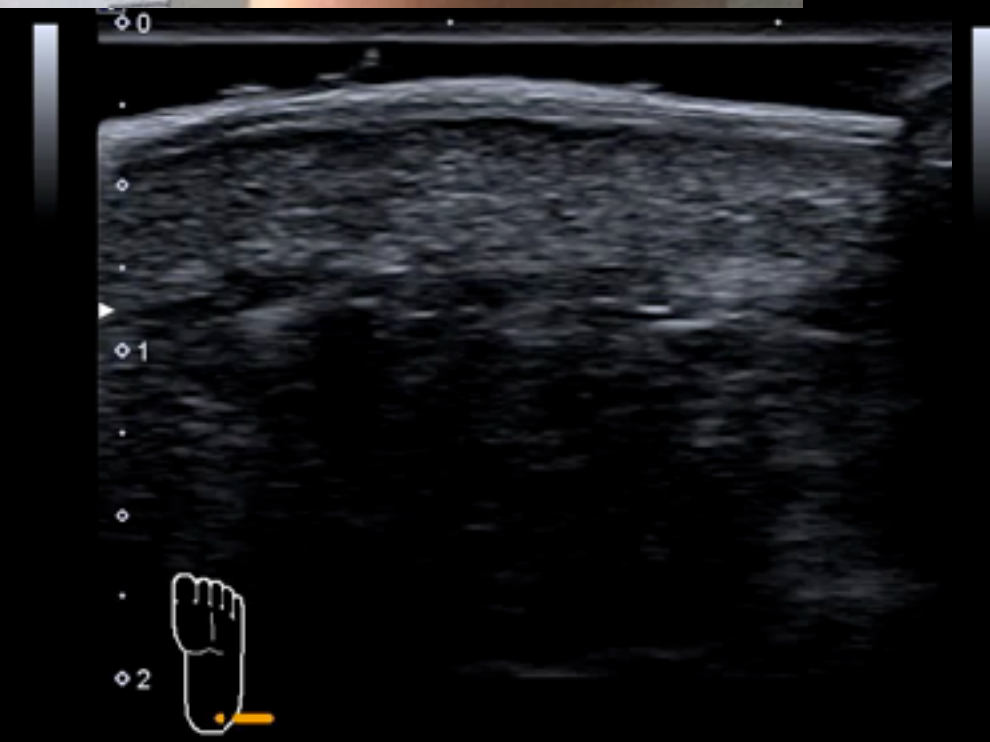
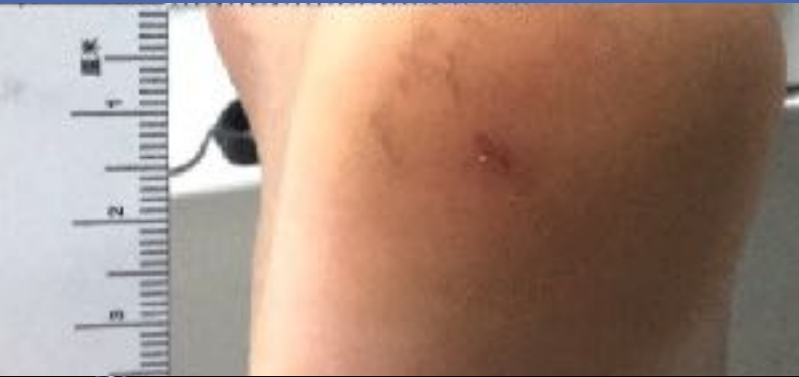Water bath method

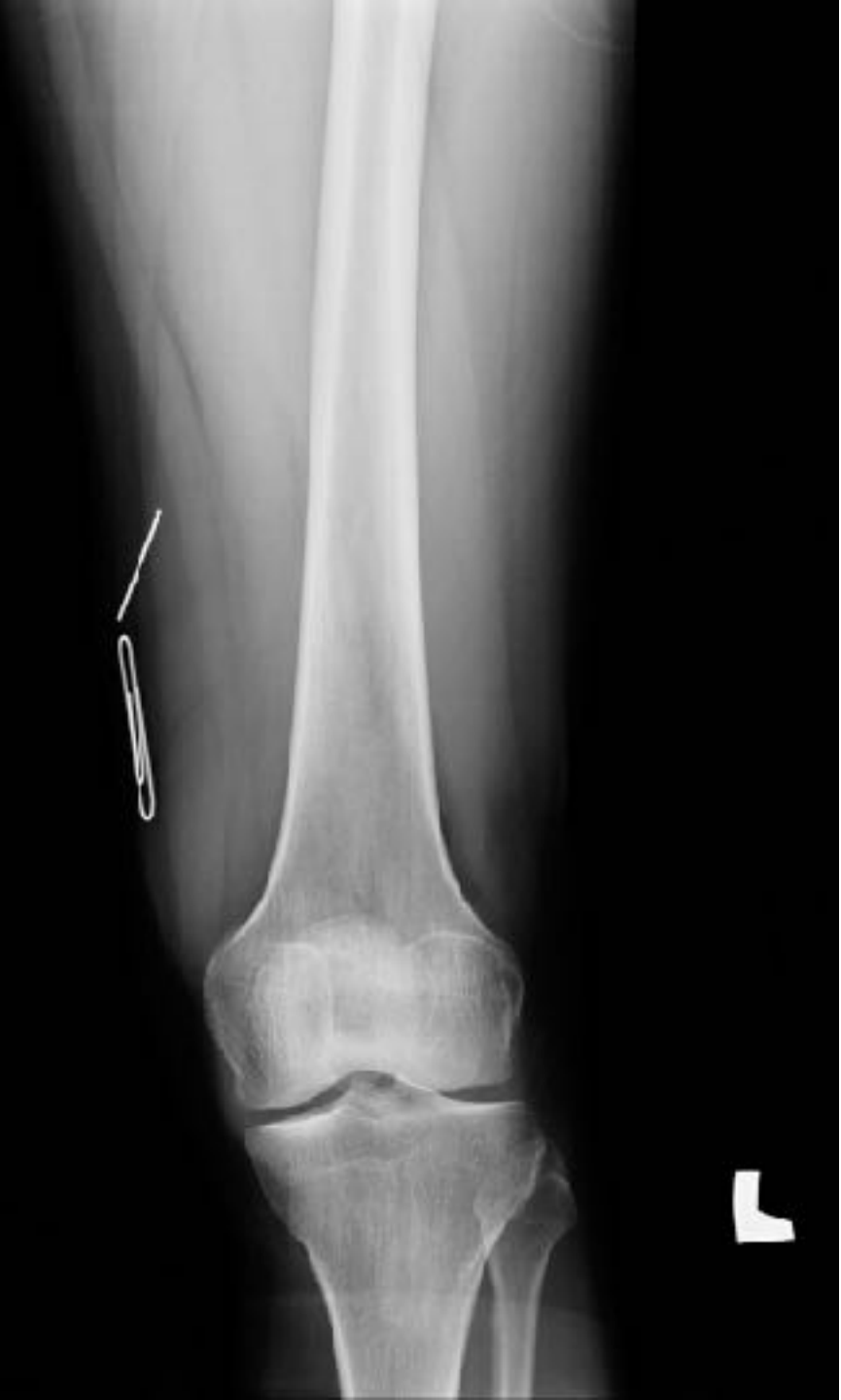
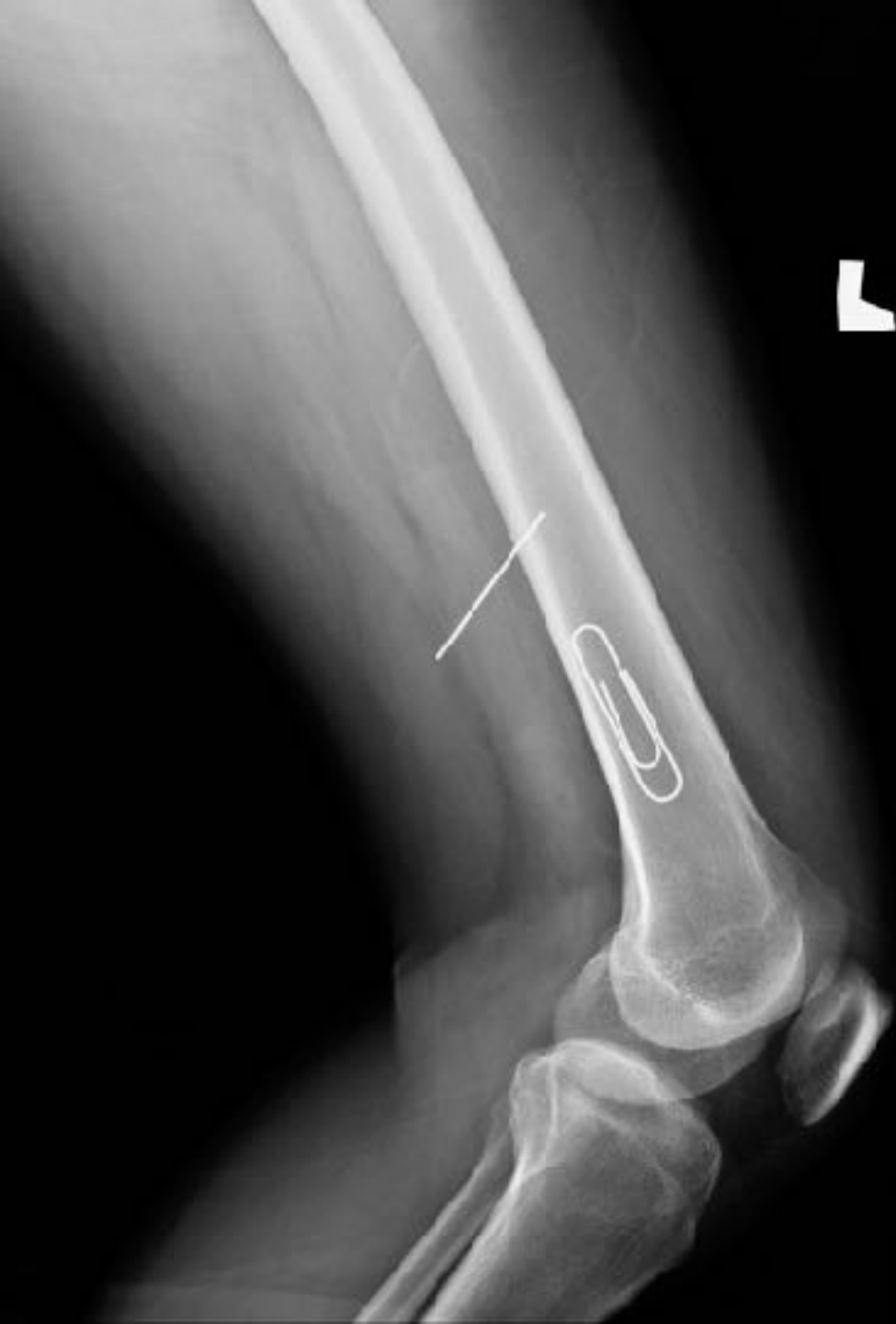
M:
1.5
11L4
diffT9.0
30 fps
G:86
DR:60
A:6
P:3



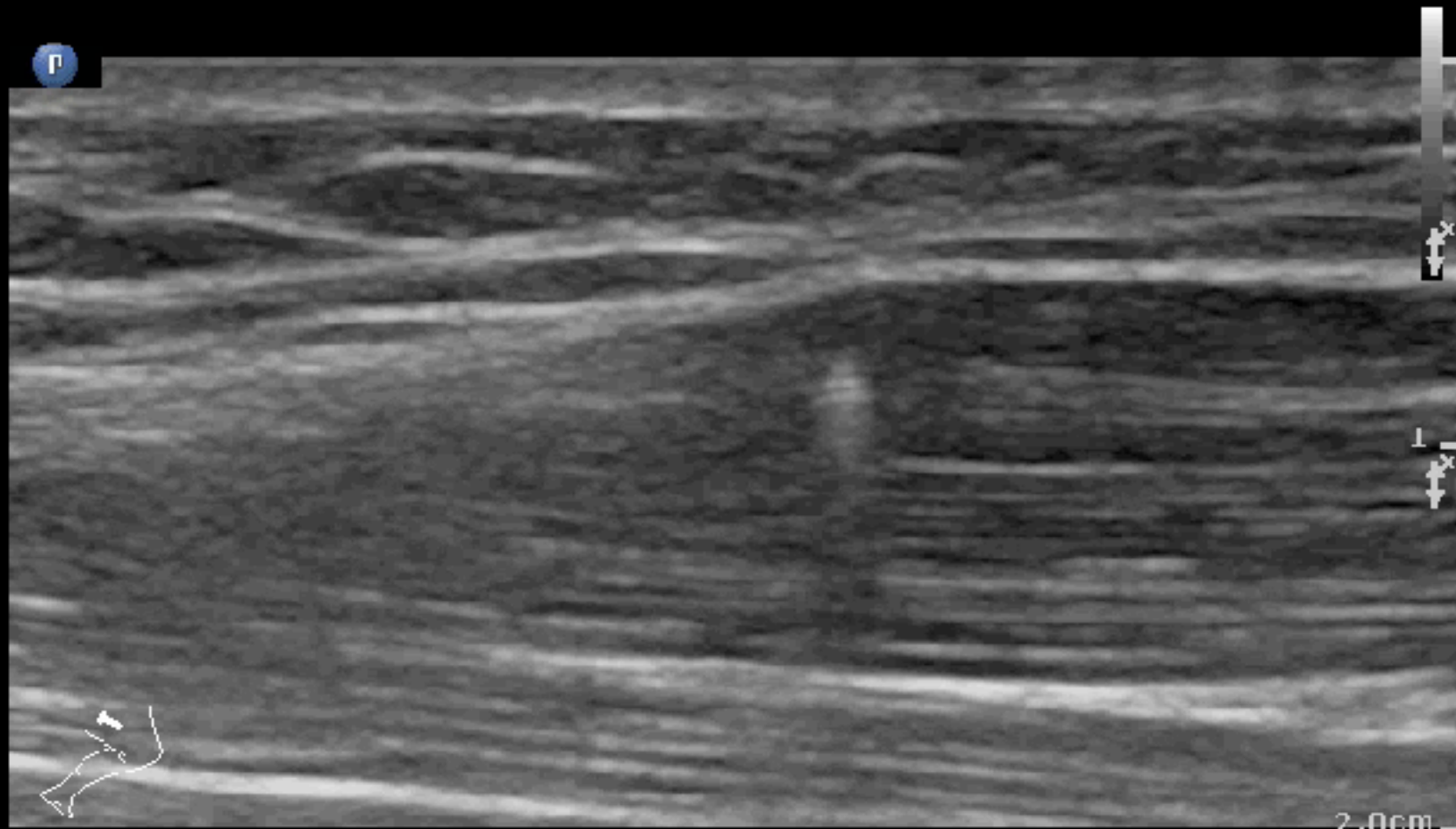
踩到碎玻璃，覺得有異物





superficial
L12-3
34 Hz
2.0cm

2D
Gen
Gn 60
C. 57
4/3/2



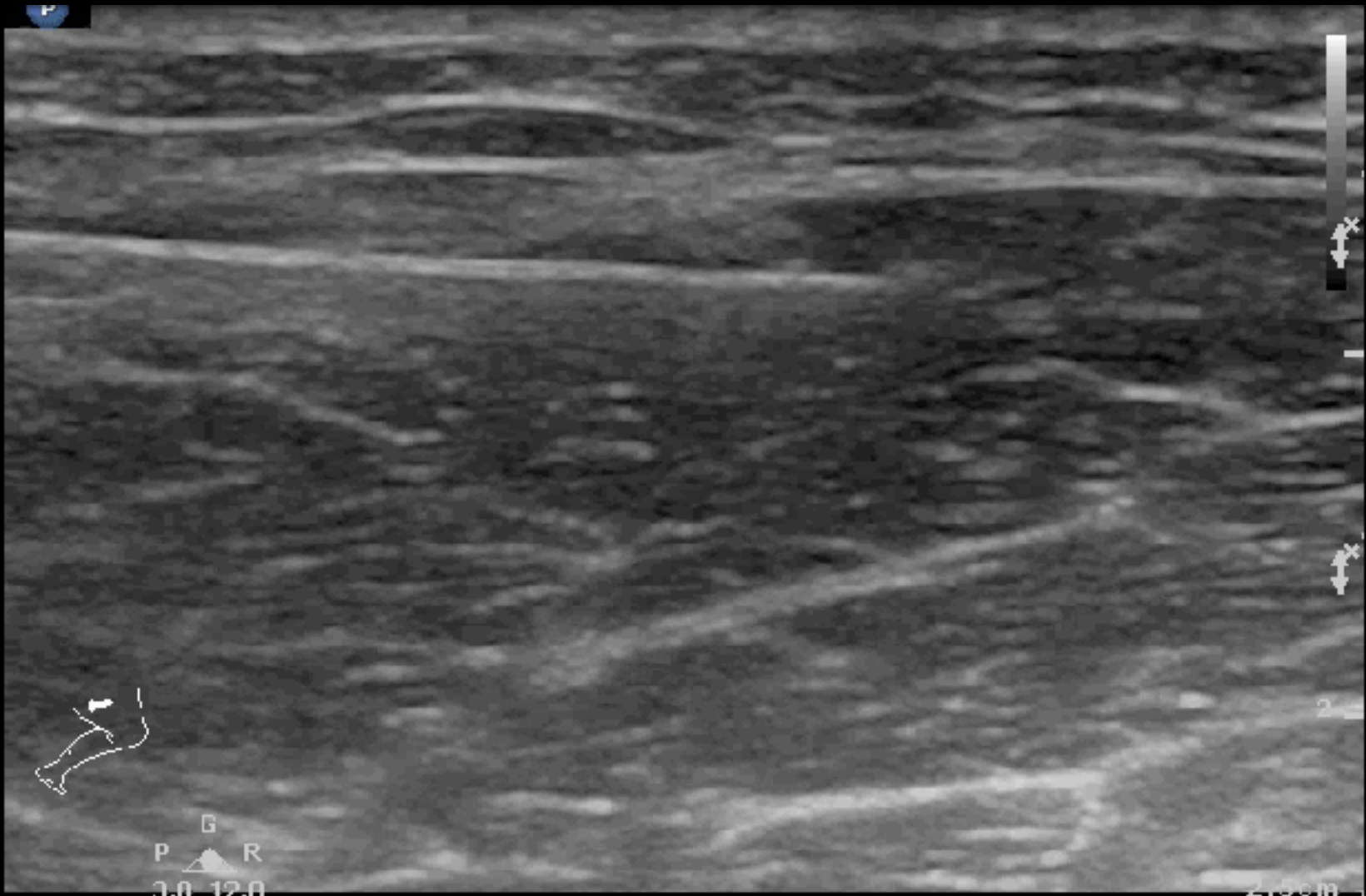
2.0cm

P R
3.0 12.0

Superficial
L12-3
34 Hz
2.5cm

2D

Gen
Gn 60
C 52
1/3/2



G
P R
3.0 12.0

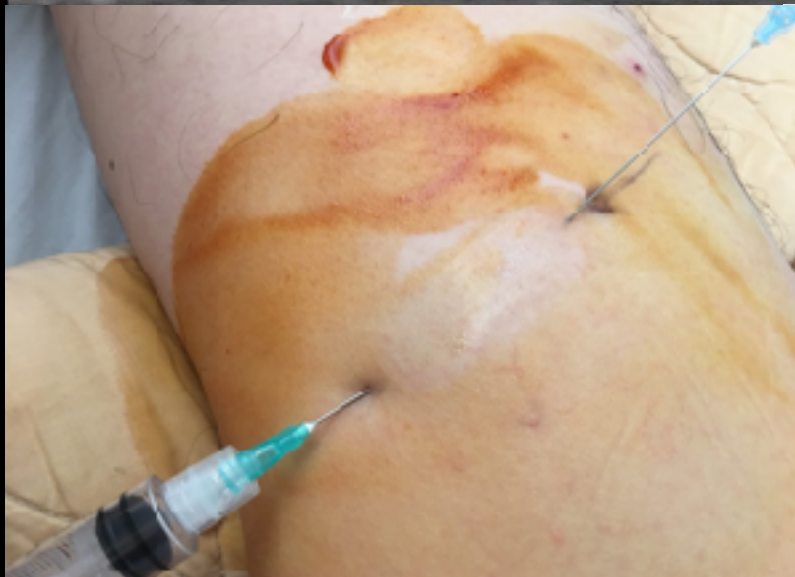
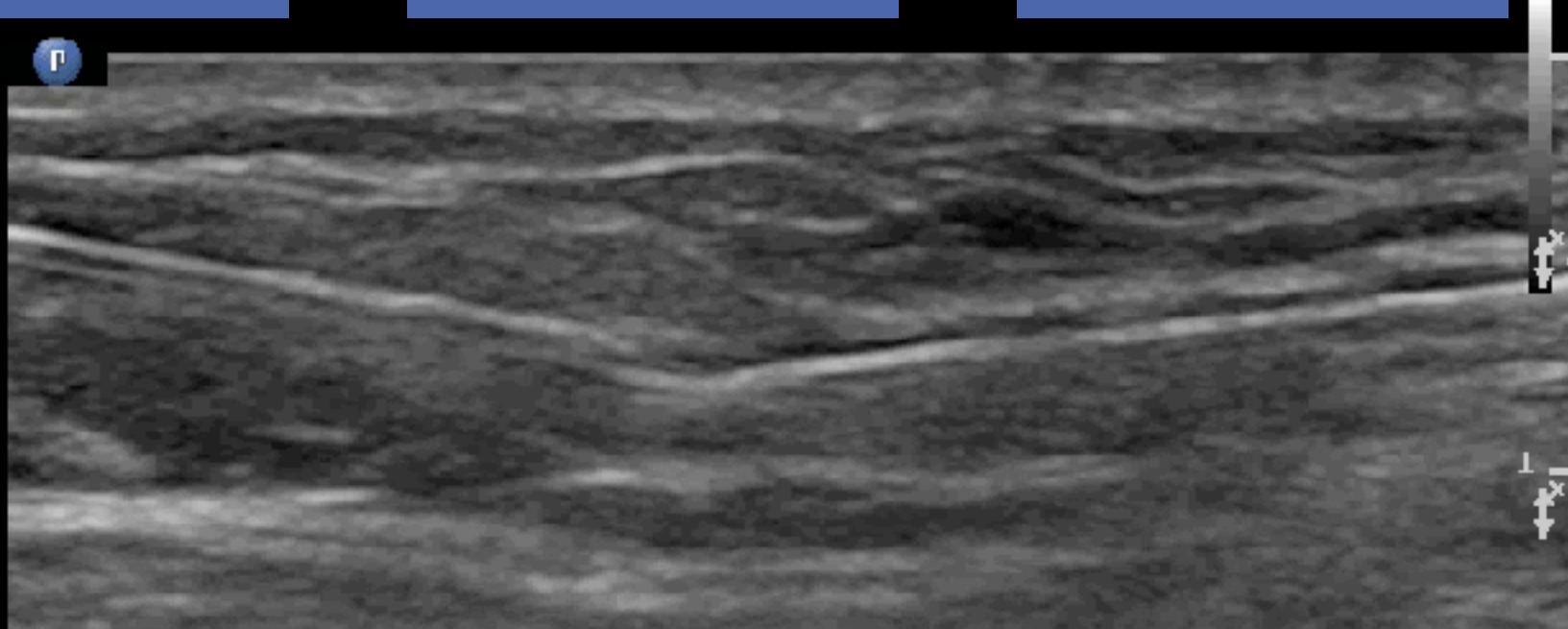
2.5cm

Localization

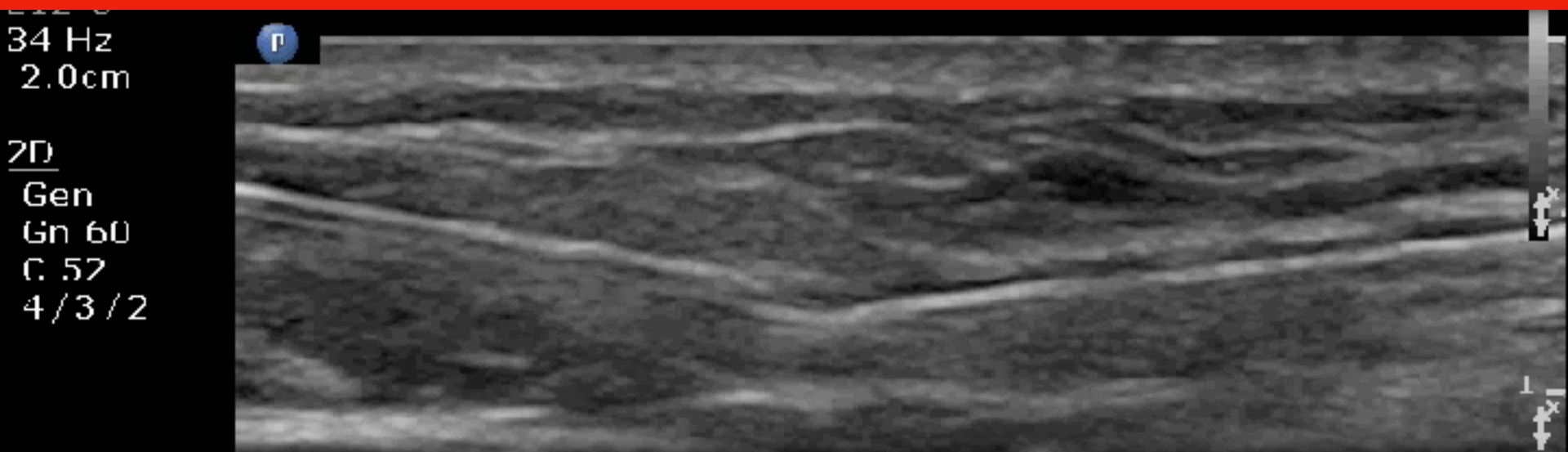
2 needle

Removal

L12
34 Hz
2.0cm
7D
Gen
Gn 60
C. 57
4/3/2




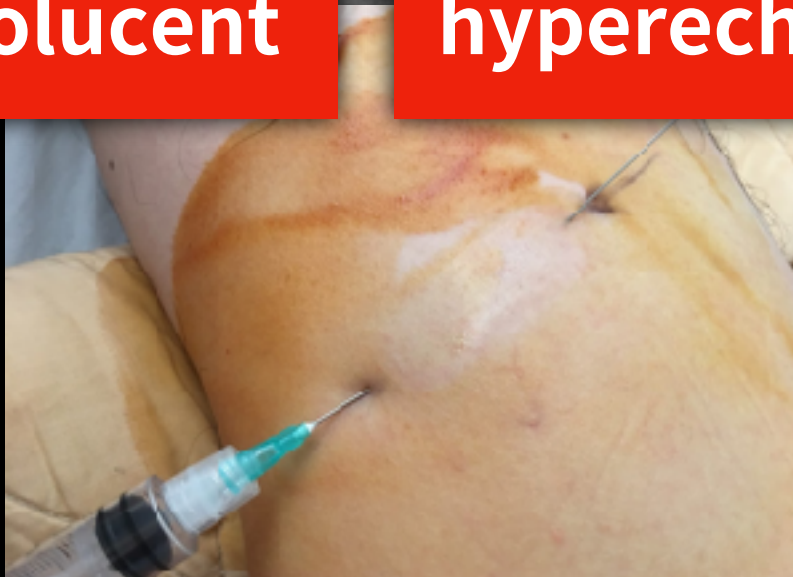
POCUS for Foreign Body



radiolucent

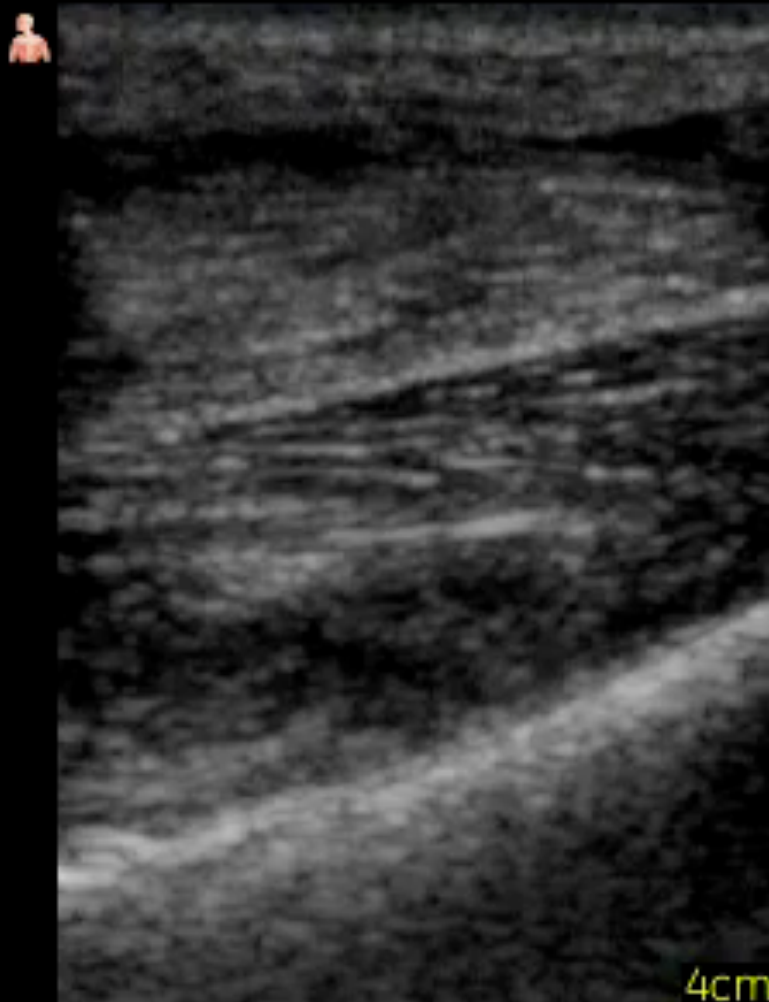hyperechoic

localization

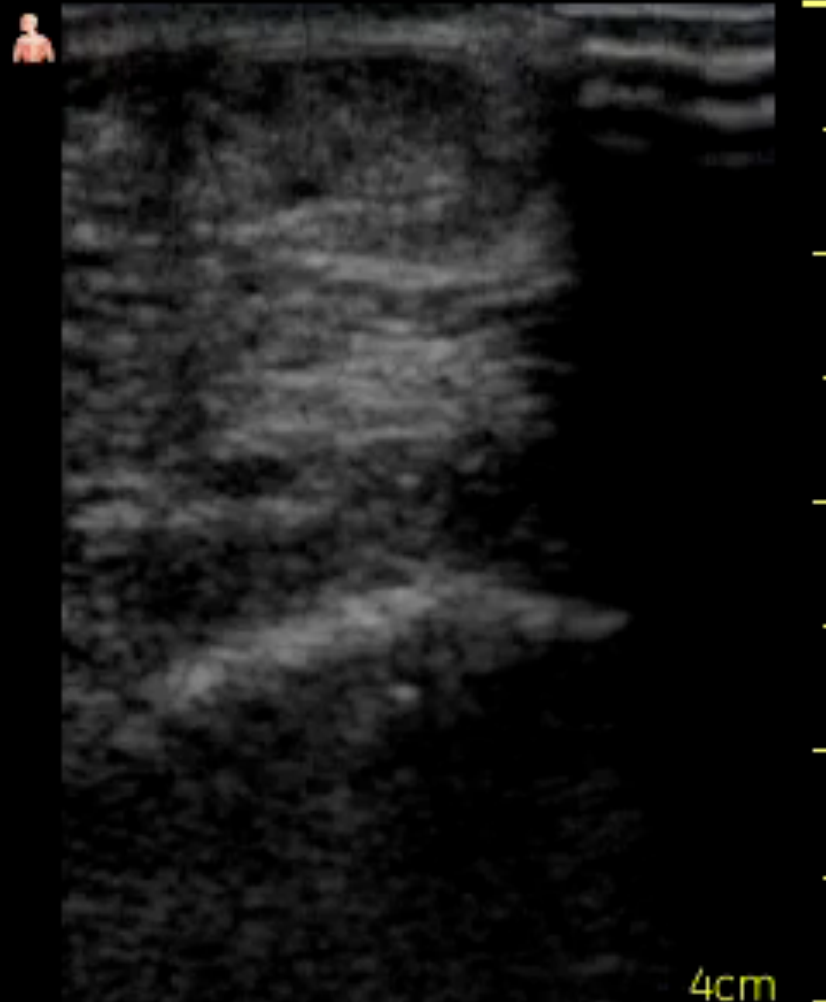


47M, left leg pain after jumping during badminton

#: 168 17:37:36
MI: 0.8 TI: 0.2 20/Mar/2015

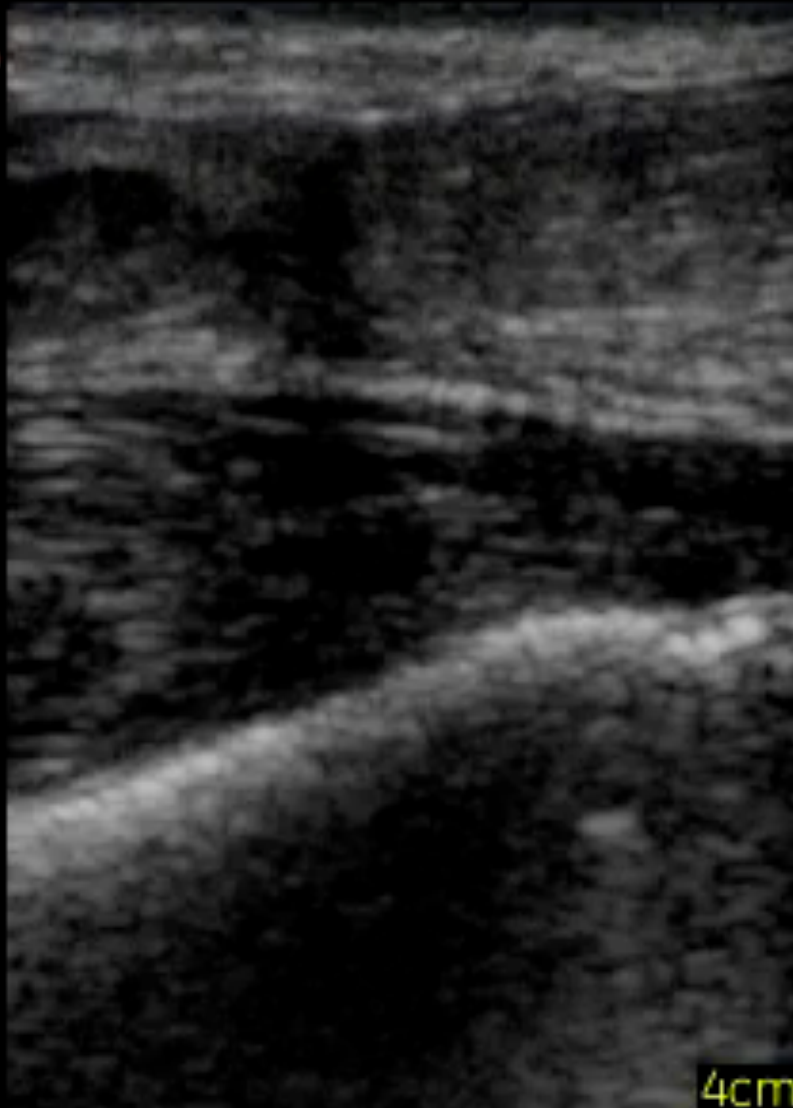


#: 168 17:39:13
MI: 0.8 TI: 0.2 20/Mar/2015



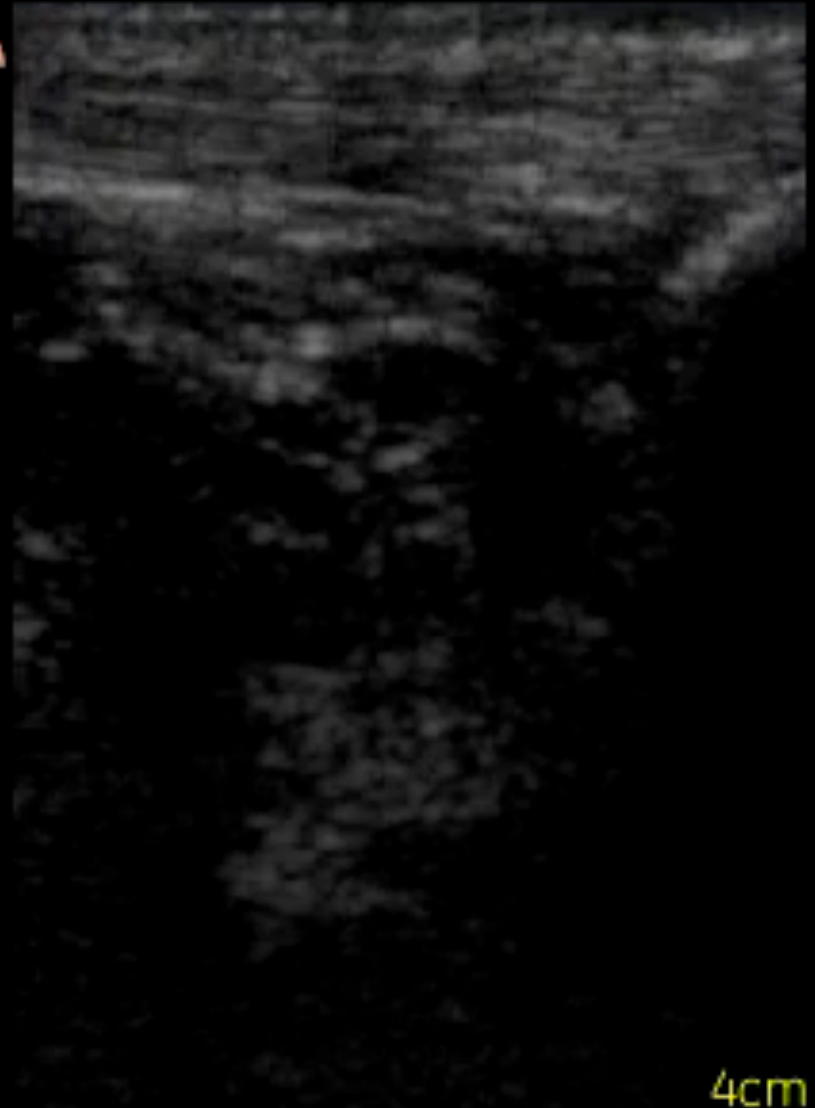
Dynamics & Comparison

#: 168
MI: 0.8 TI: 0.2
17:44:04
20/Mar/2015



4cm

#: 168
MI: 0.8 TI: 0.2
17:40:12
20/Mar/2015



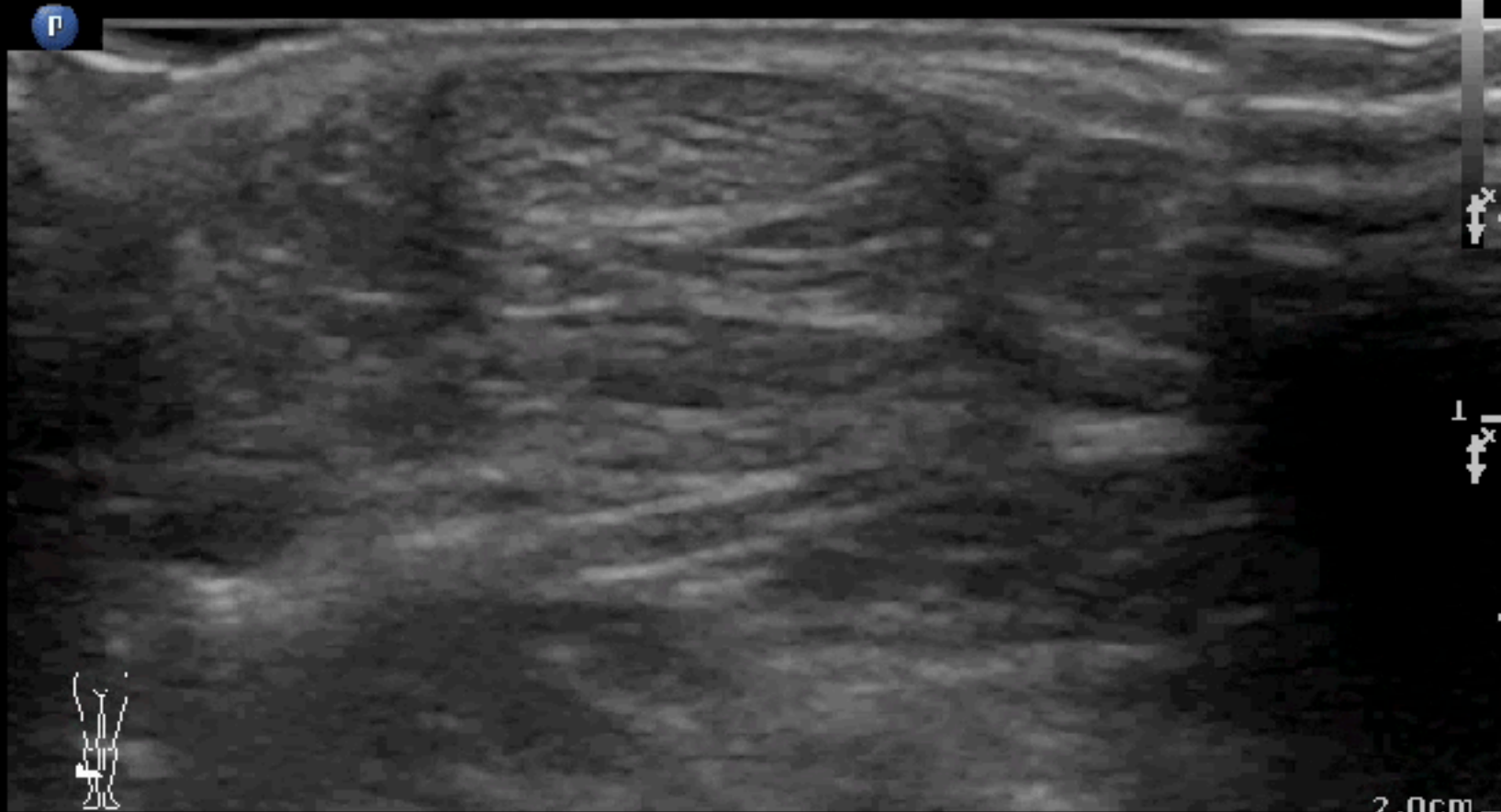
4cm

Achilles tendon rupture

34 Hz
2.0cm

2D

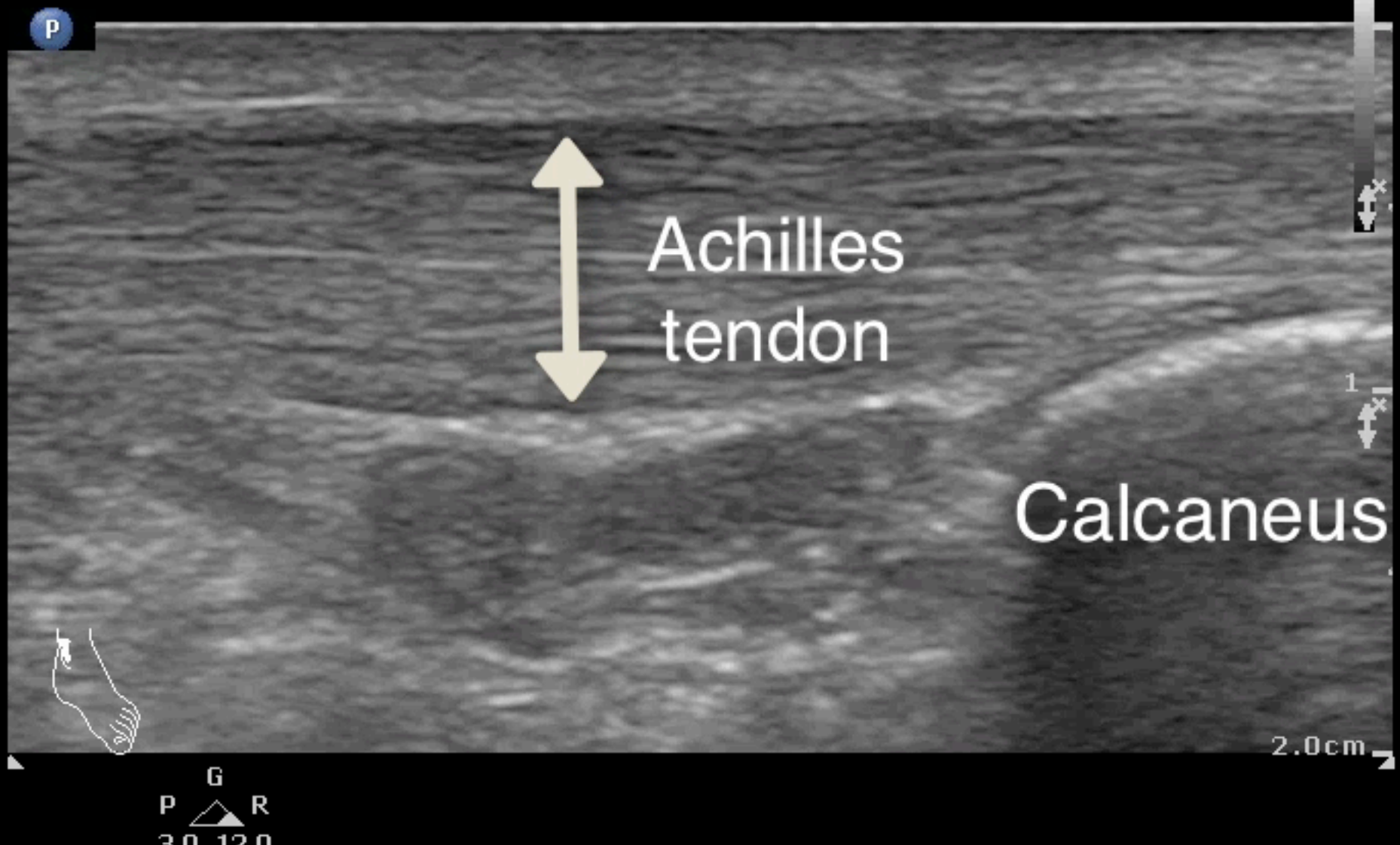
Gen
Gn 94
C. 57
4/3/2



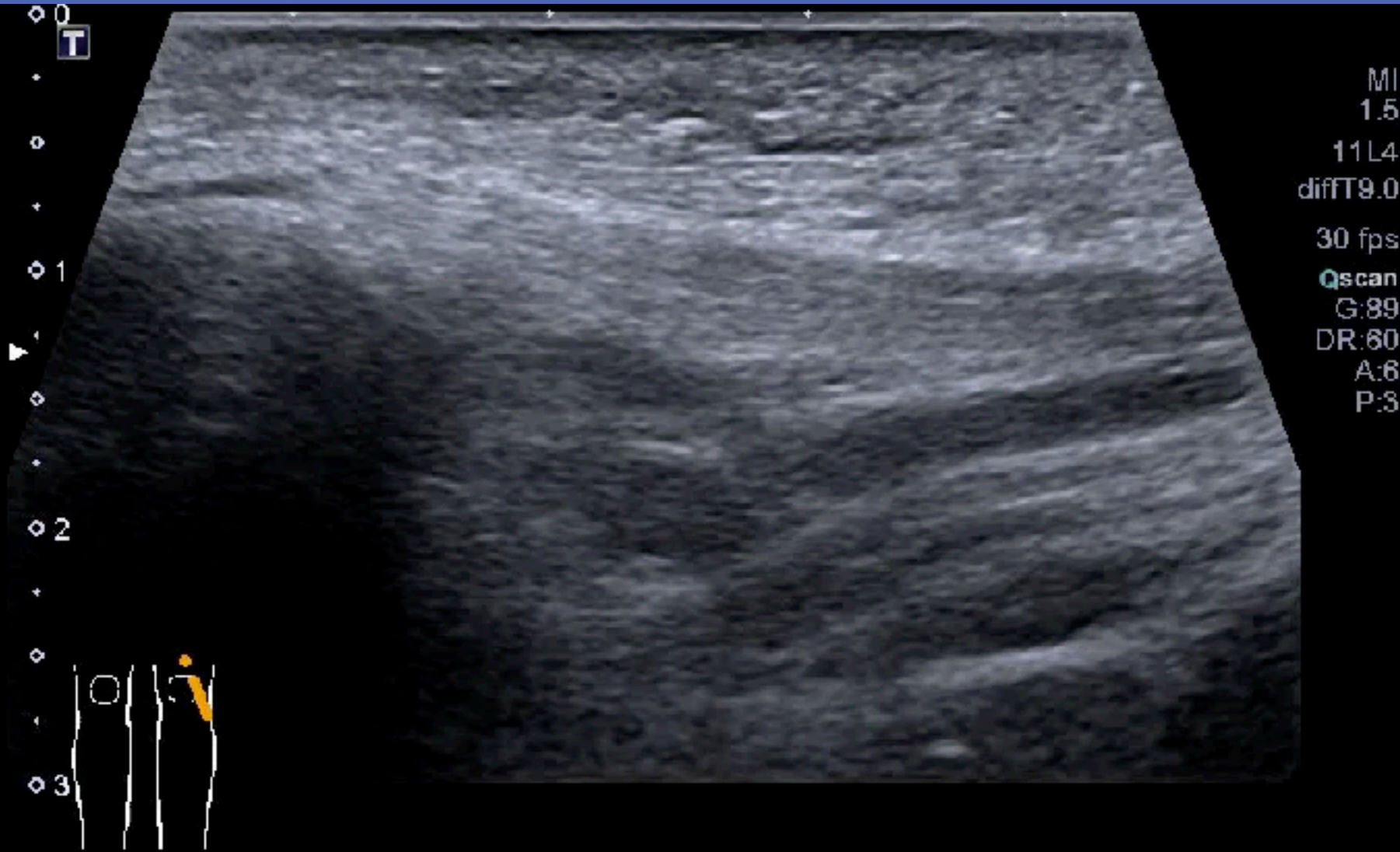
2.0cm

P R
3.0 12.0

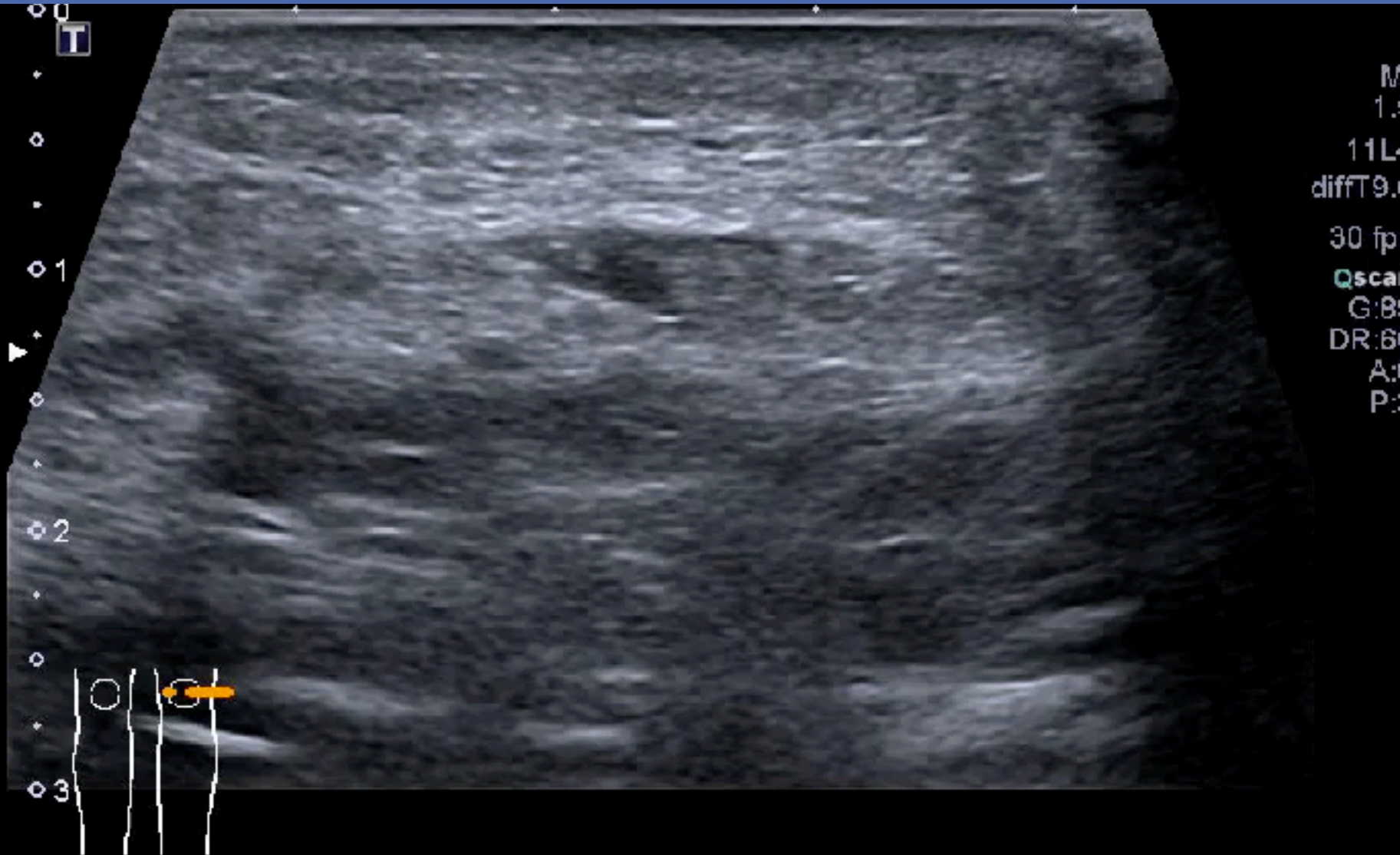Achilles tendon rupture



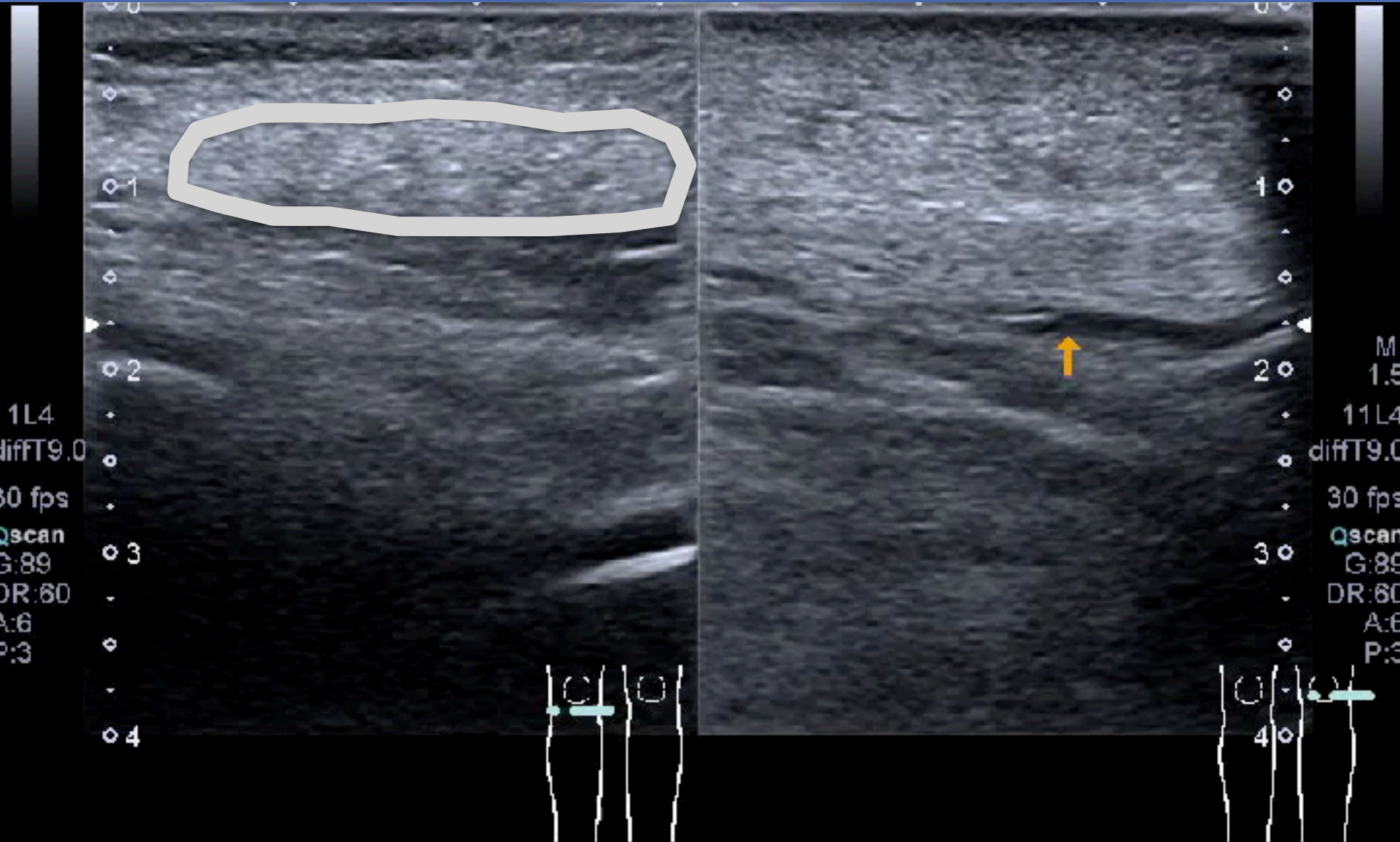
Patellar tendon injury ?



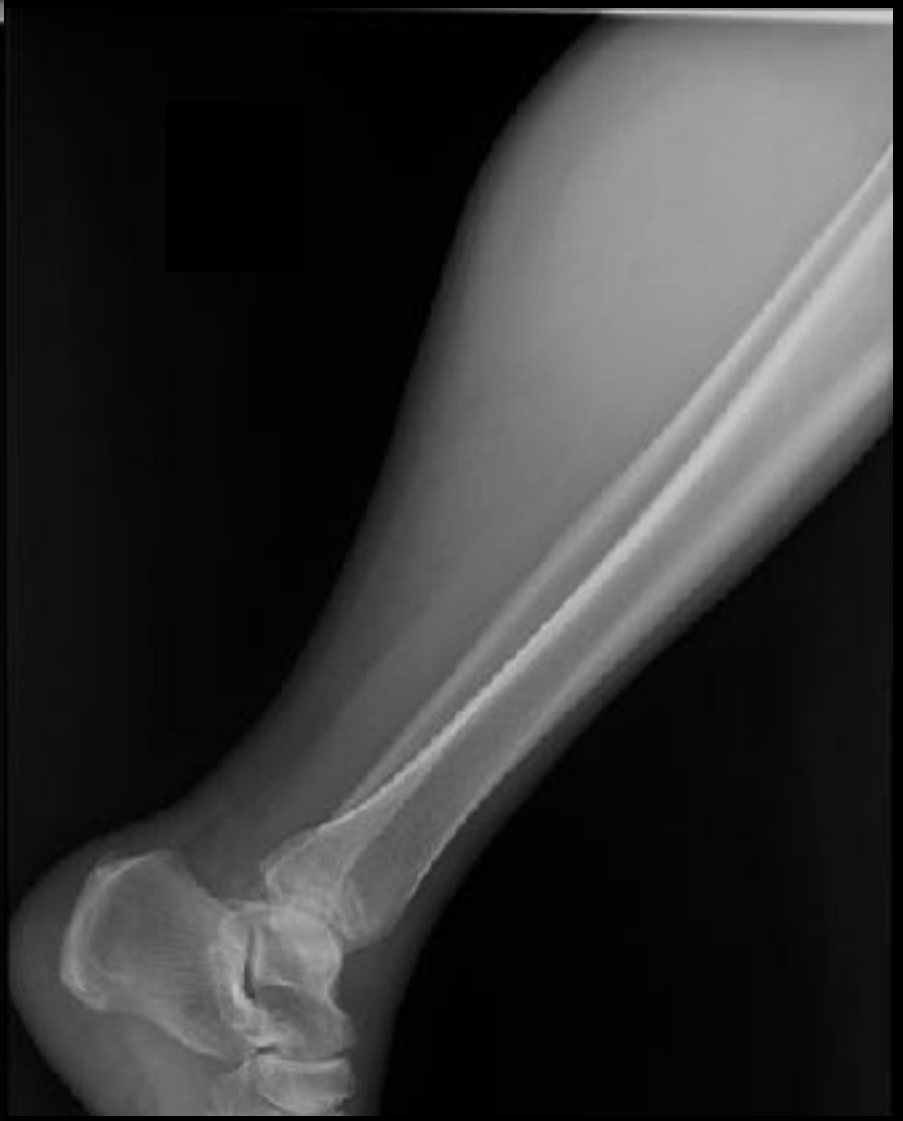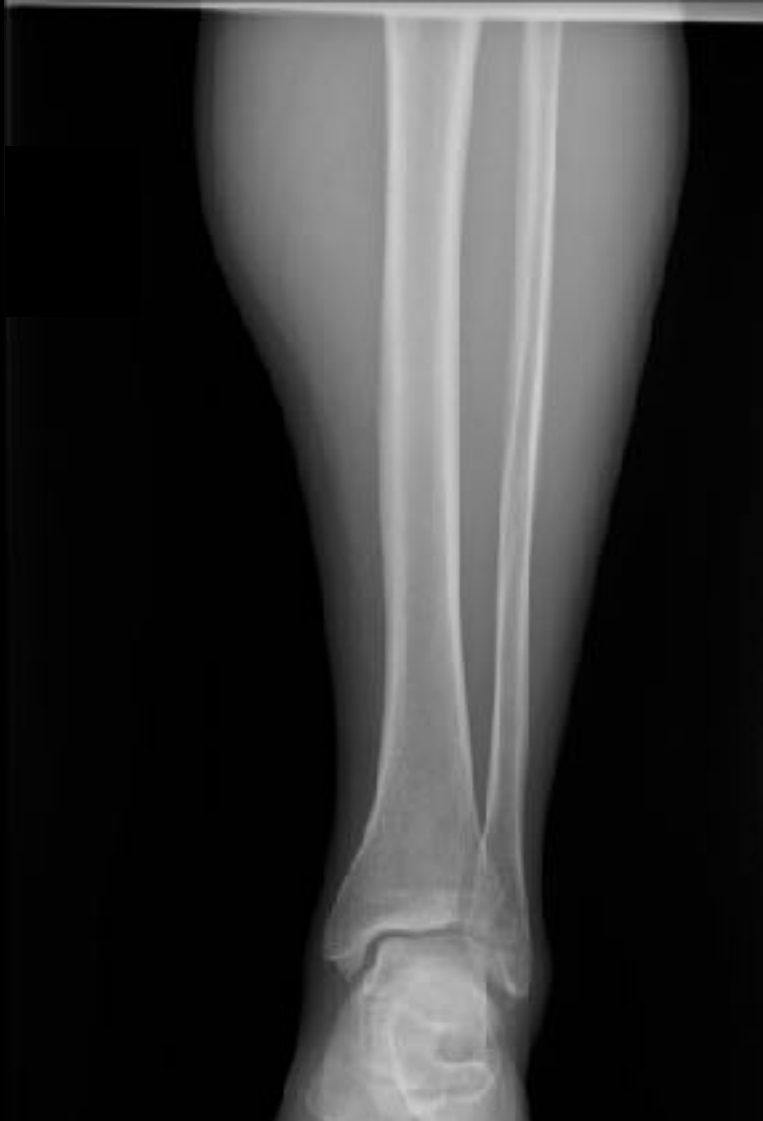Patellar tendon injury ?



Patellar tendon injury

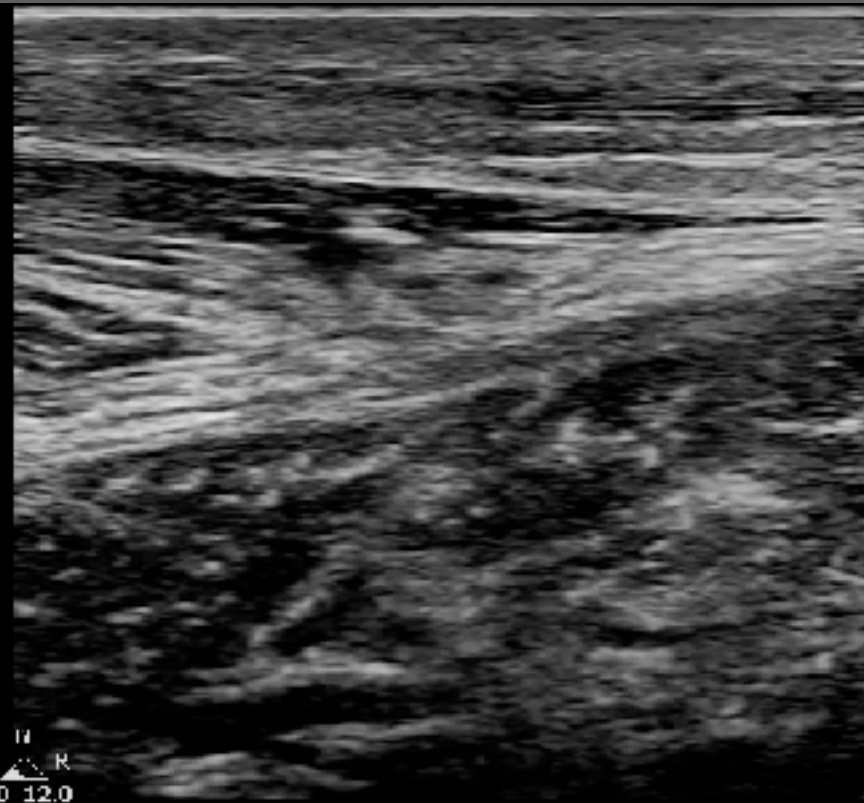

58M, right leg pain while running

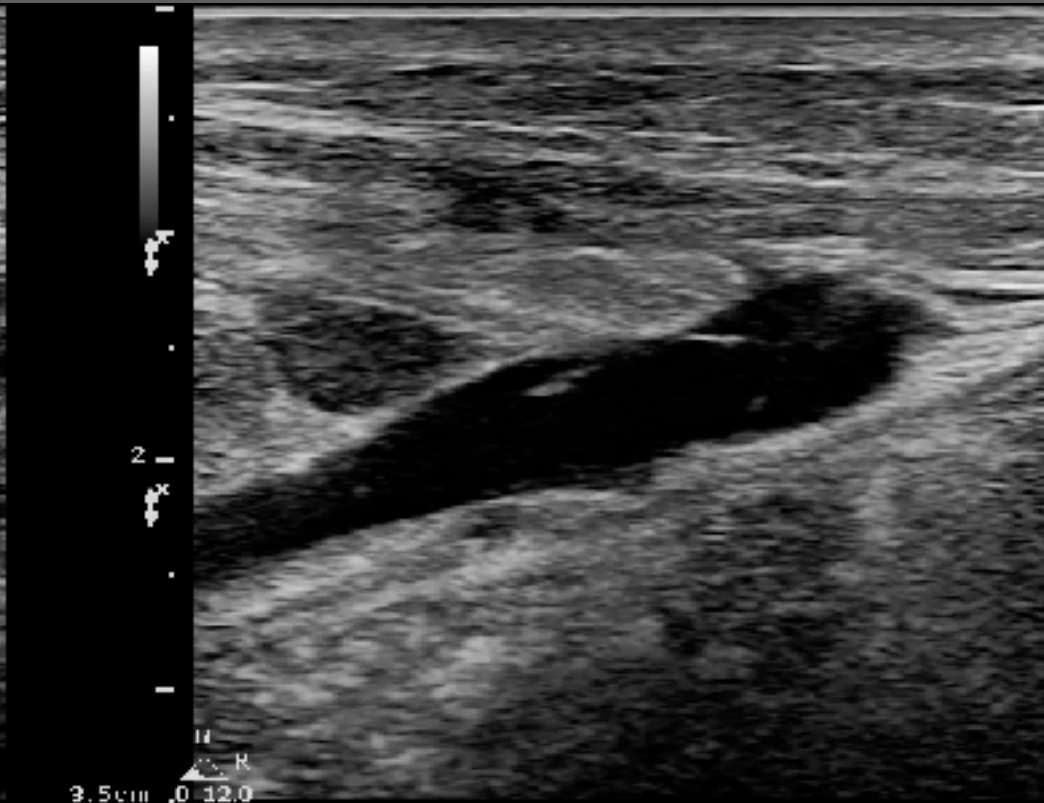


Calf muscle tear

Left calf



Right calf



Dynamic examination

Superficial
12-3
45 Hz
3.0cm

P

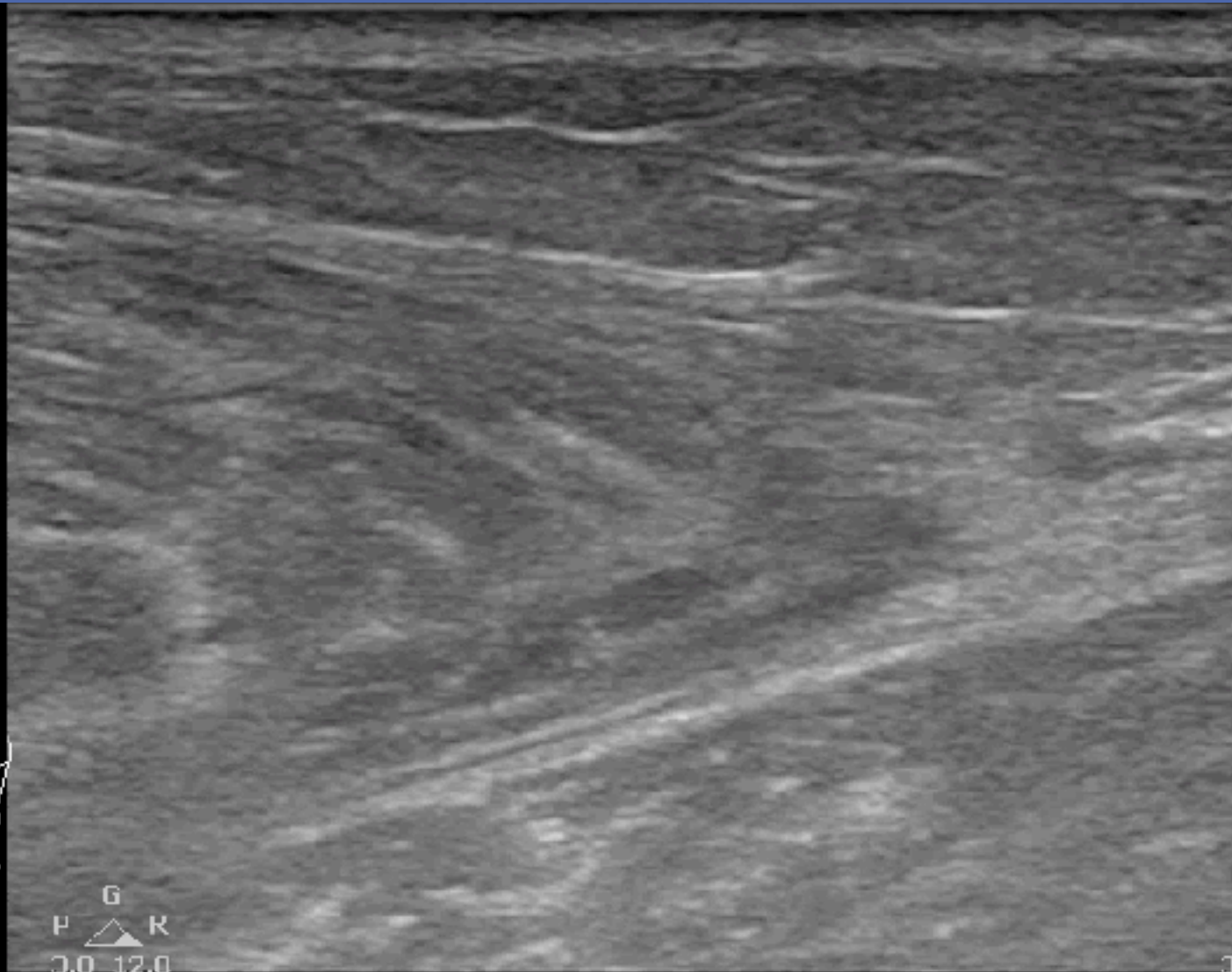
2D

Res
Gn 92
C 56
3 / 2 / 1



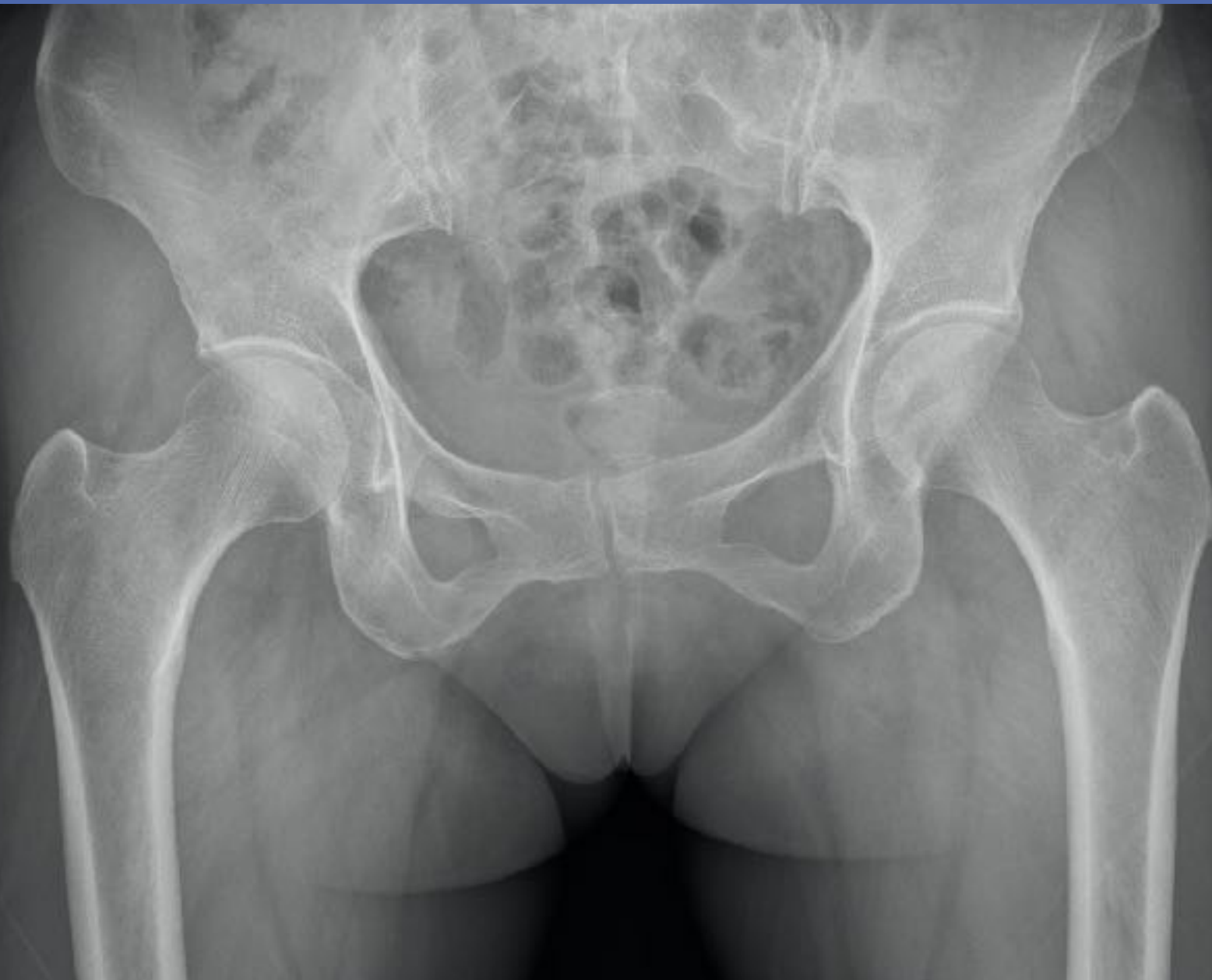G
P R
3.0 12.0

3.0cm



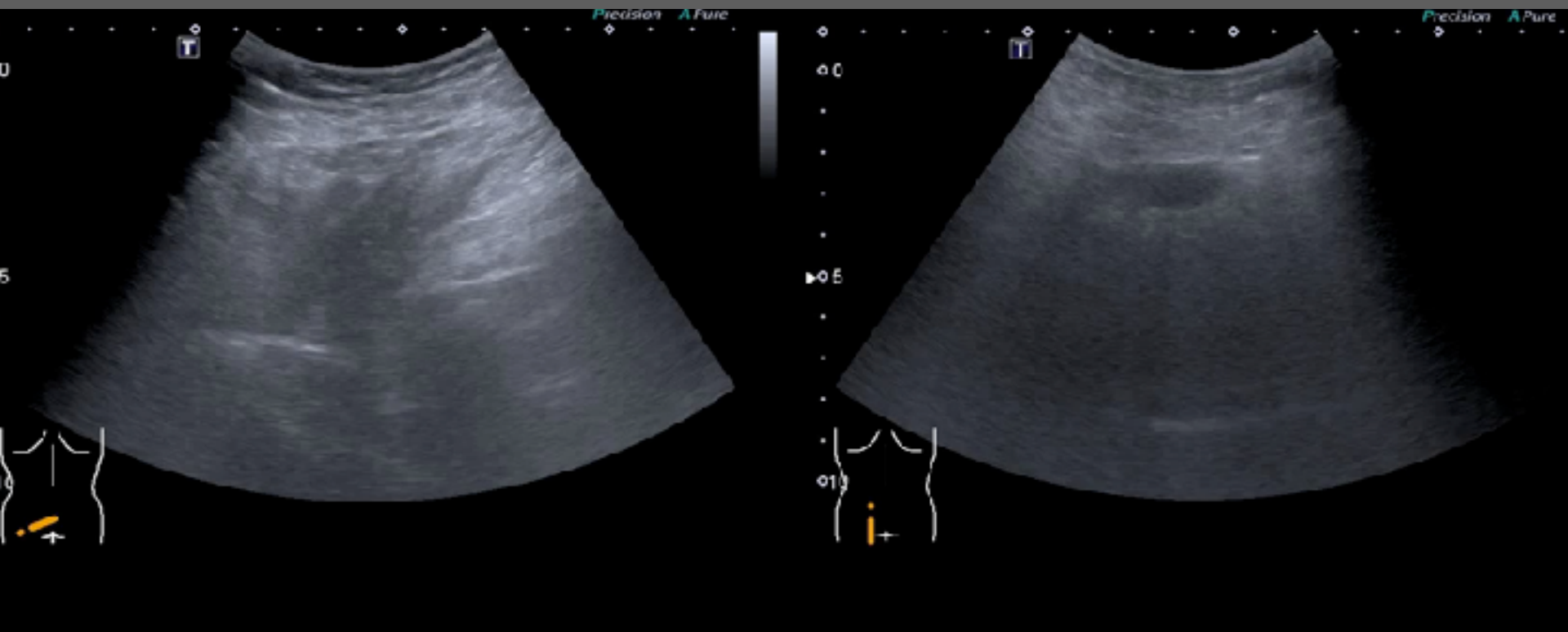
2

跌坐後左臀部痛，返家後腫起來

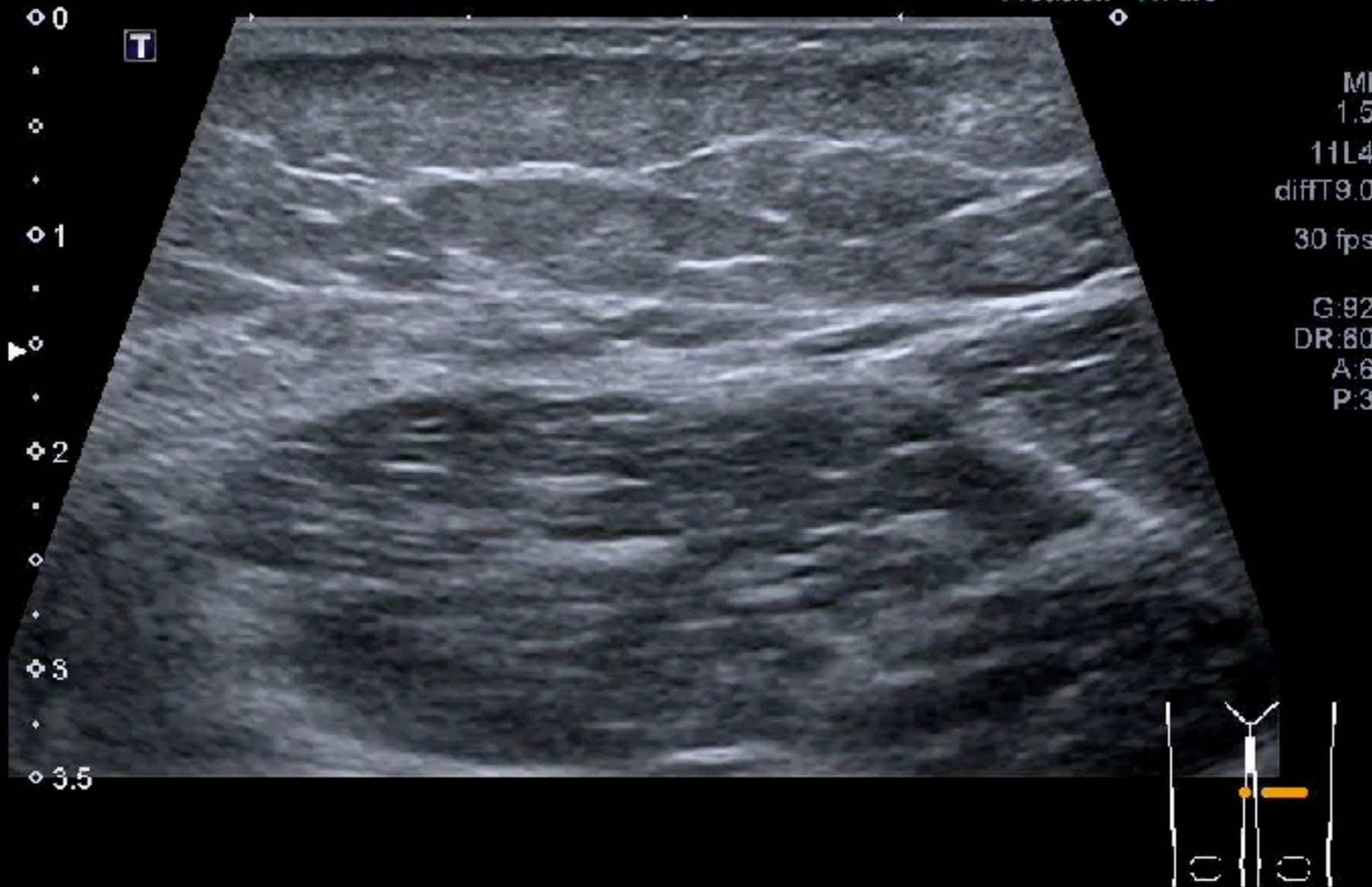


R

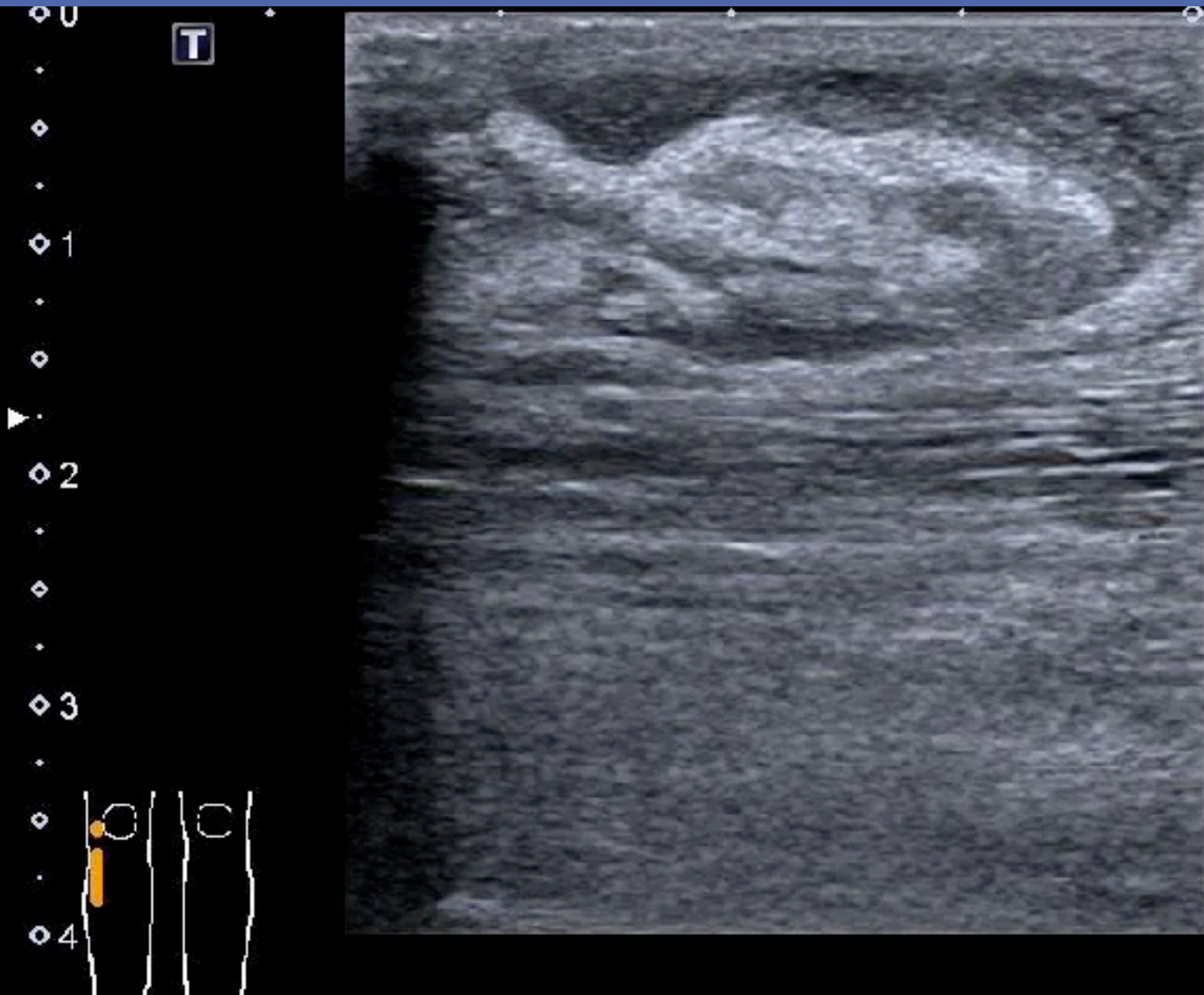
跌坐後左臀部痛，返家後腫起來



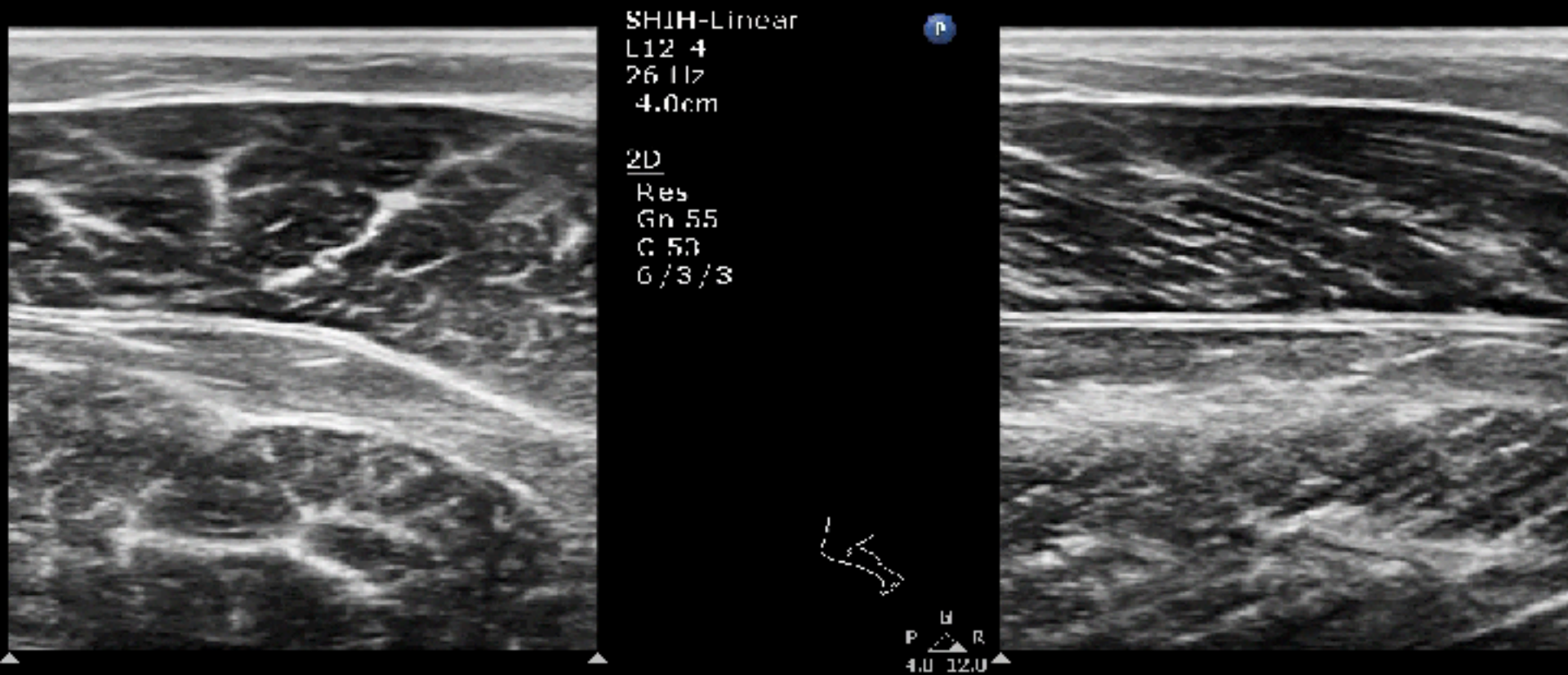
Left thigh contusion



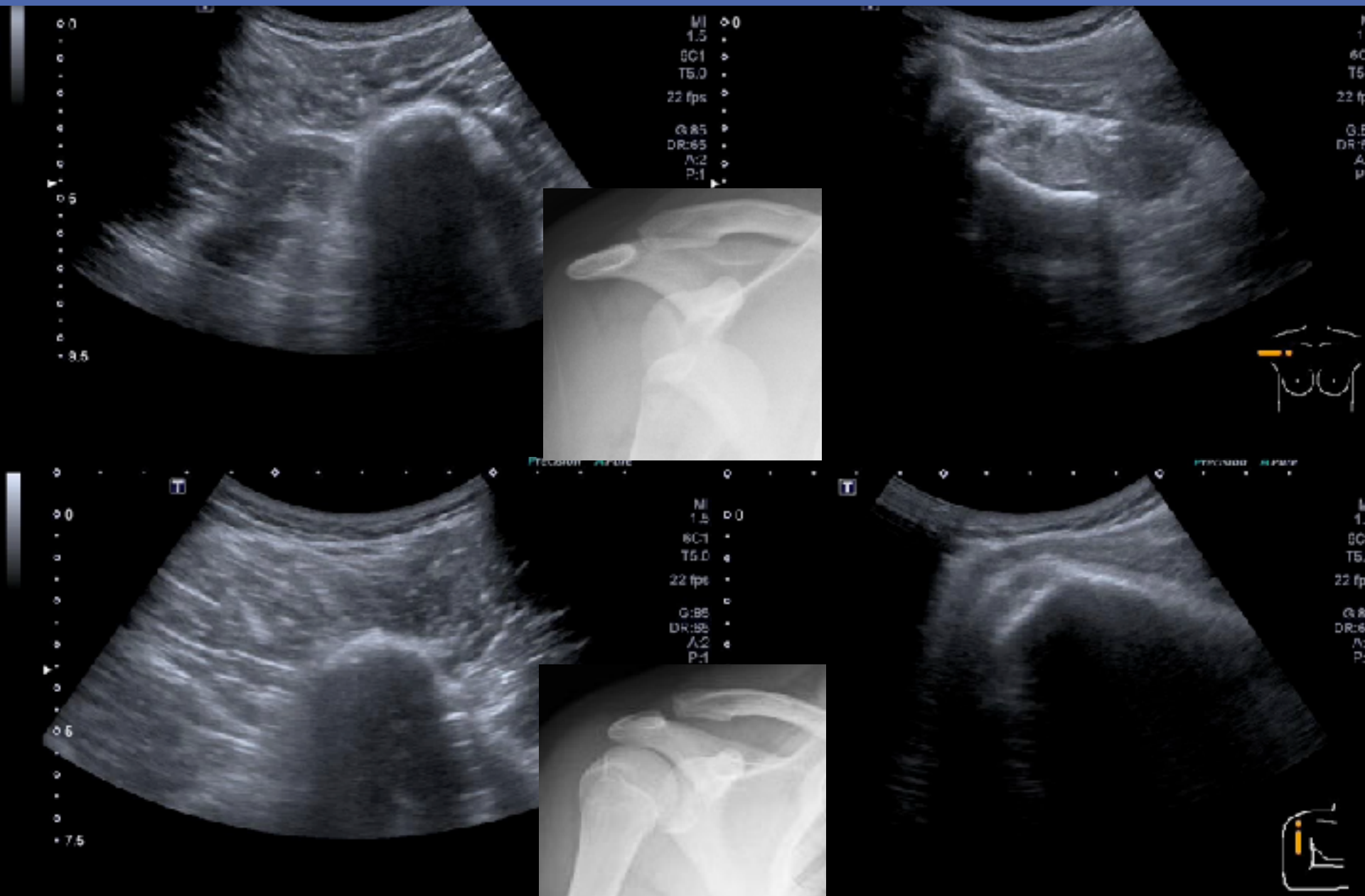
Knee contusion



26F with thigh contusion



Diagnosis & Confirmation



Point-of-care ultrasound for the diagnosis of shoulder dislocation: A systematic review and meta-analysis

Michael Gottlieb, MD*, Dallas Holladay, DO, Gary D. Peksa, PharmD

Department of Emergency Medicine, Rush University Medical Center, Chicago, IL, United States of America

Study 7 ; Assessment 739 ; Dislocation 306

Table 1
Characteristics of the included studies.

Study	Study population	Country	Study location	Mean patient age	Male patients (%)	Shoulder dislocations (%)	Ultrasound transducer	Ultrasound technique	Operator experience
Bianchi 1994	10	United States	ND	35.5 years	ND	2 (20%)	Linear	Posterior	ND
Abbasi 2013	142	Iran	ED	31.6 years	126 (91.3%)	71 (50%)	Linear	Anterior + lateral	Attending, resident
Ahmadi 2016	108	Iran	ED	30.1 years	91 (64.1%)	13 (12%)	Linear	Anterior + lateral	Attending
Akyol 2016	197	Turkey	ED	33.9 years	164 (80.6%)	99 (50%)	Linear	Posterior	Attending
Lahham 2016	84	United States	ED	45 years	52 (62%)	19 (22.6%)	Linear	Posterior	Student
Seyedhosseini 2017	163	Iran	ED	35.9 years	140 (83.3%)	79 (48.5%)	Curvilinear	Posterior	Attending, resident
Secko 2018	35	United States	ED	ND	ND	23 (66%)	Linear or curvilinear	Posterior	Attending

ND, not described; ED, emergency department.

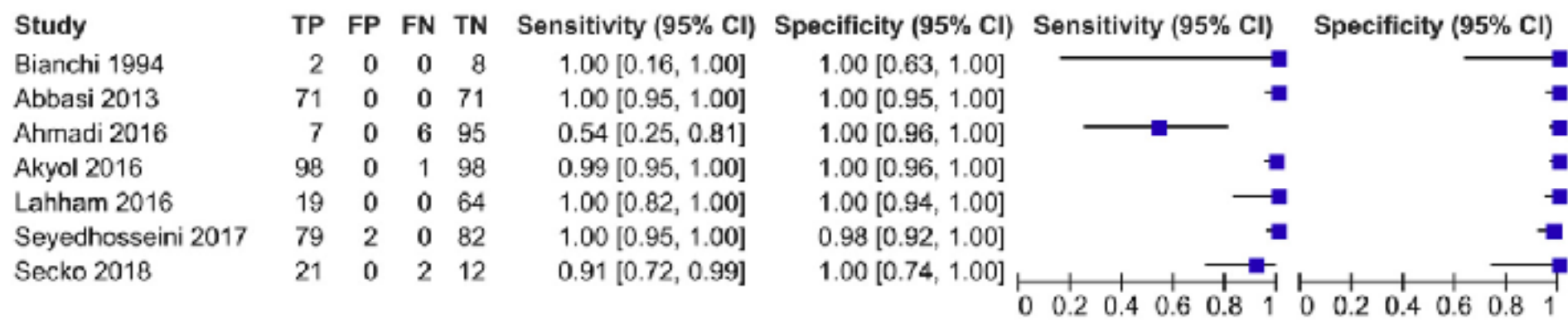


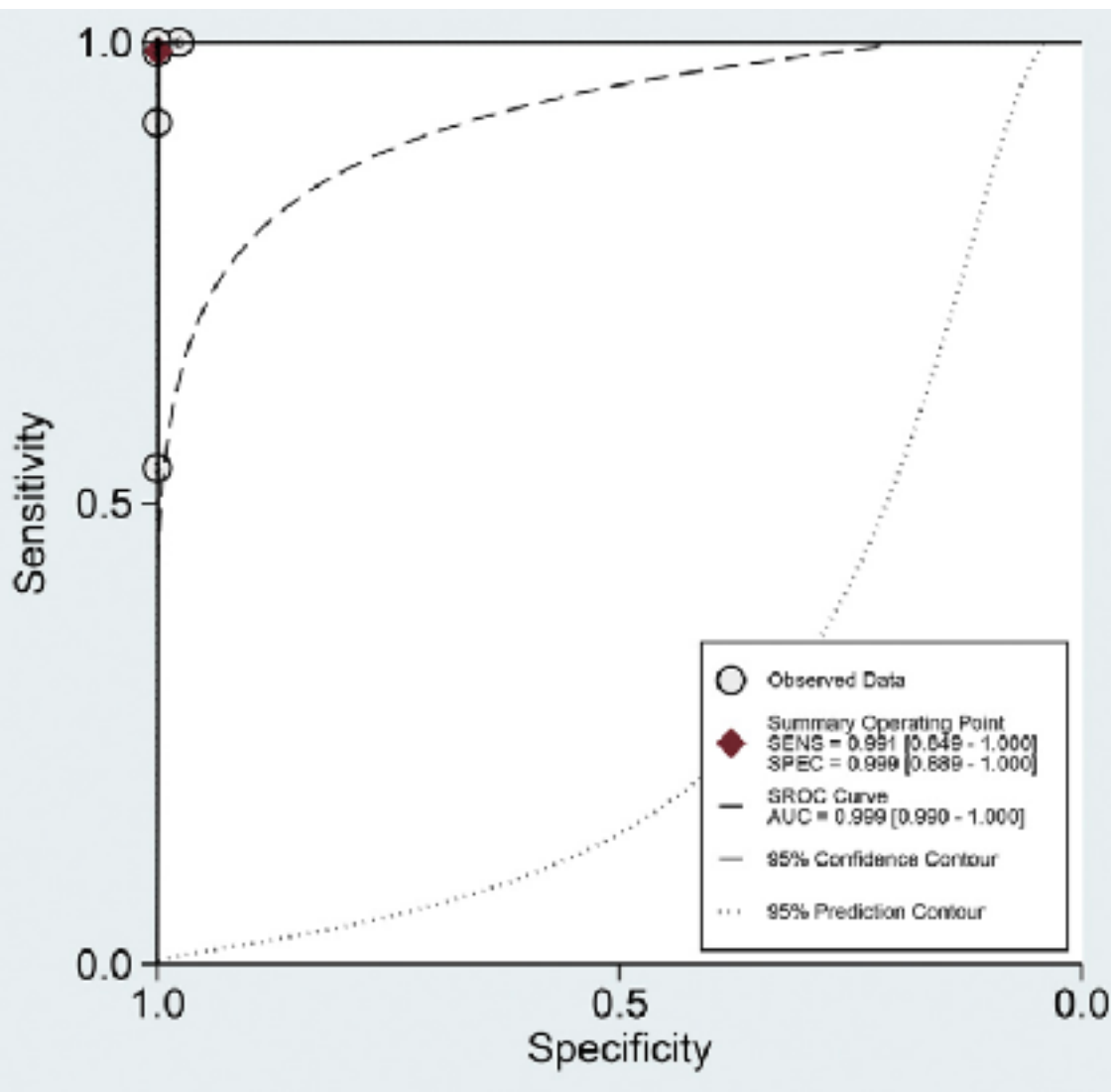
Fig. 2. Forest diagram of the overall sensitivity and specificity of ultrasound for identifying shoulder dislocations.



Point-of-care ultrasound for the diagnosis of shoulder dislocation: A systematic review and meta-analysis

Michael Gottlieb, MD*, Dallas Holladay, DO, Gary D. Peksa, PharmD

Department of Emergency Medicine, Rush University Medical Center, Chicago, IL, United States of America



Sensitivity 99.1%

Specificity 99.9%

LR+ 796.2

LR- 0.01

AJEM 2019;37:757-761

Point-of-care ultrasound for the diagnosis of shoulder dislocation: A systematic review and meta-analysis

Michael Gottlieb, MD*, Dallas Holladay, DO, Gary D. Peksa, PharmD

Department of Emergency Medicine, Rush University Medical Center, Chicago, IL, United States of America

Sensitivity 97.9% Specificity 99.8%

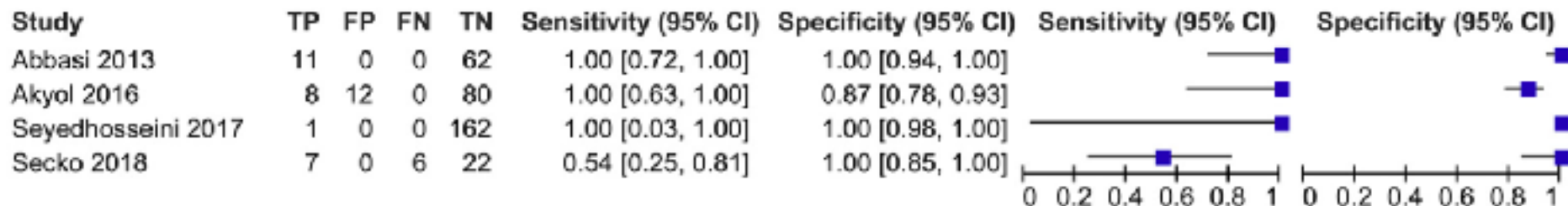


Fig. 5. Forest diagram of the overall sensitivity and specificity of ultrasound for identifying fractures.

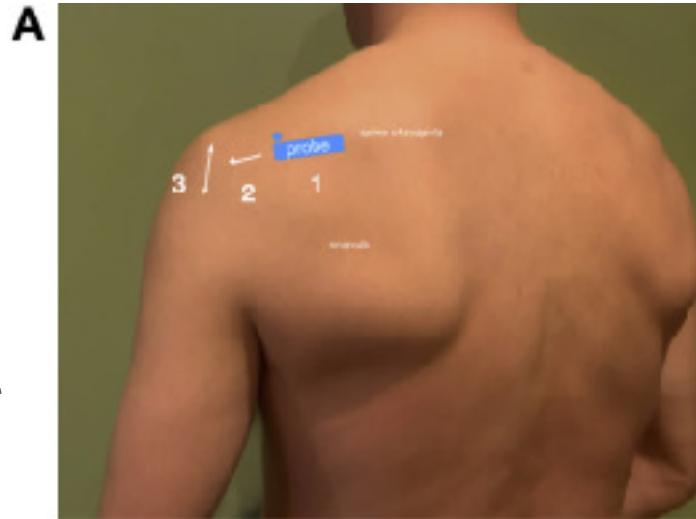


Musculoskeletal Ultrasonography to Diagnose Dislocated Shoulders: A Prospective Cohort

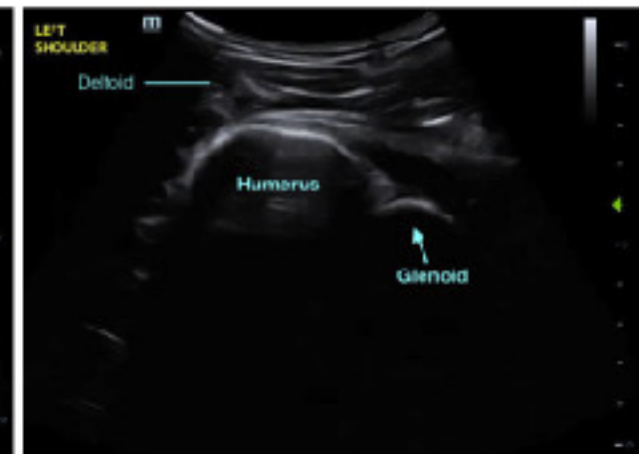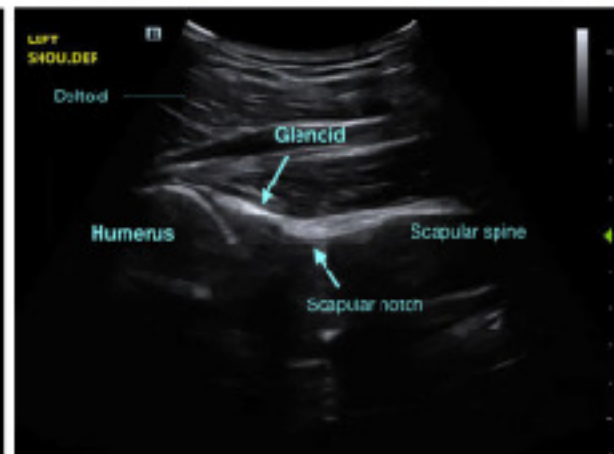
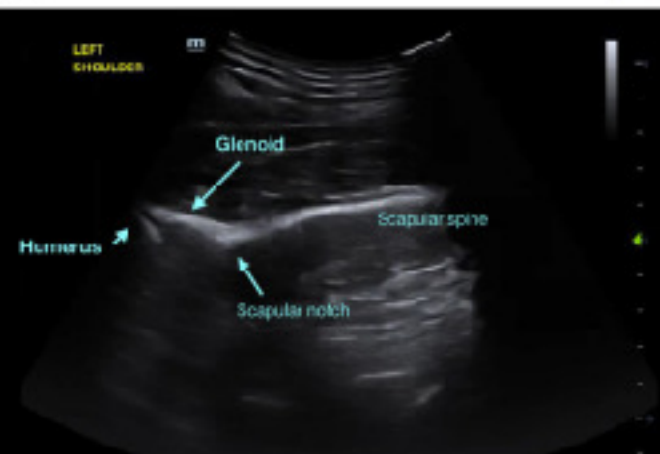Michael A. Secko, MD, RDMS*; Lindsay Reardon, MD; Michael Gottlieb, MD; Eric J. Morley, MD; Mathew R. Lohse, MD; Henry C. Thode, Jr, PhD; Adam J. Singer, MD

Multicenter
Prospective
Observational

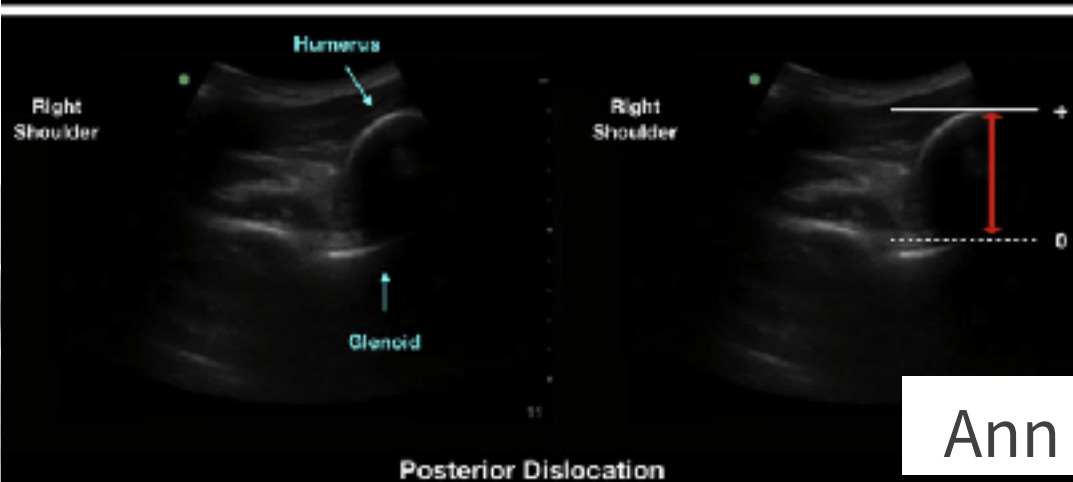
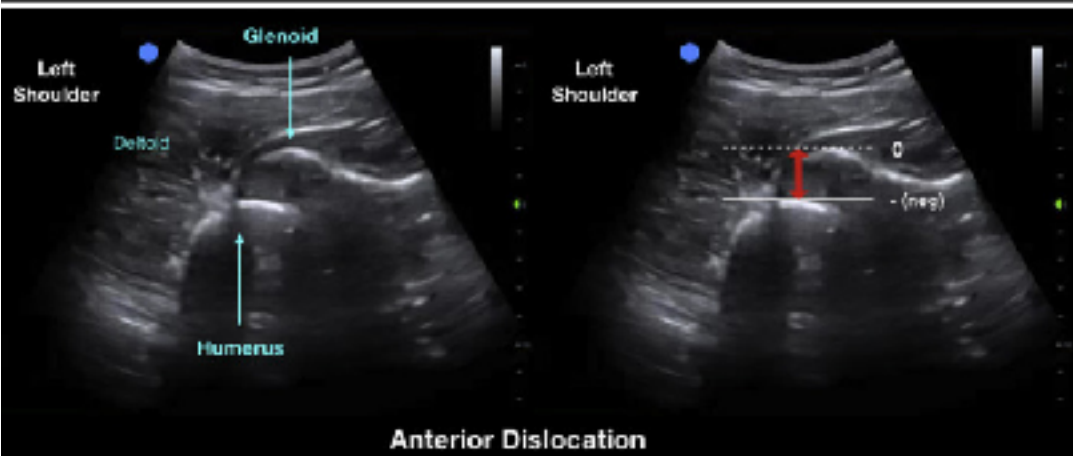
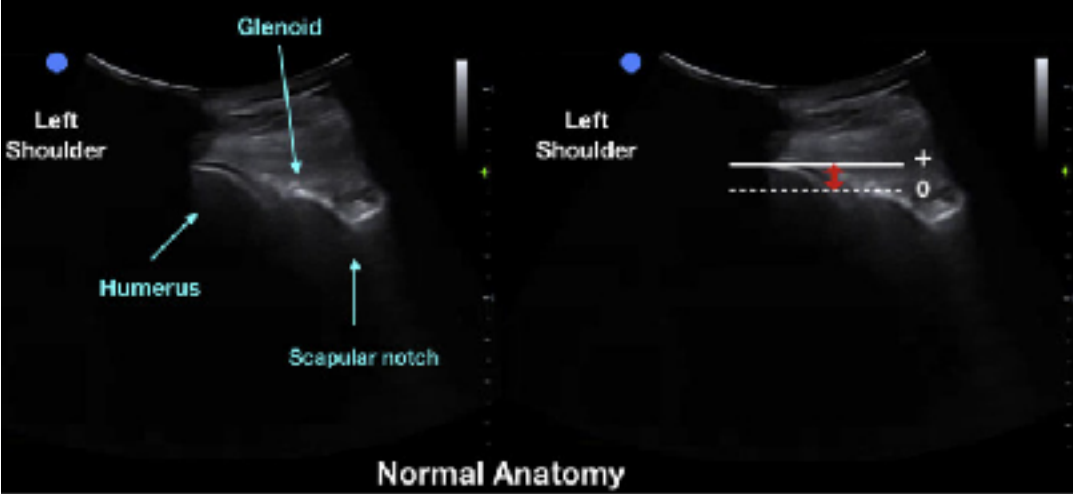
65 patients



B



1

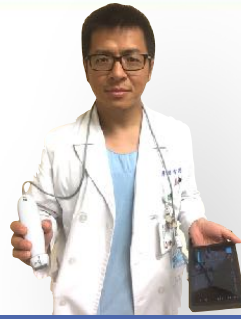

Sensitivity 100%
Specificity 100%

Sens (Fx) 92%
Spes (Fx) 100%

Median 19s

GH(d-A) -1.83cm
GH(d-N) 0.22cm
GH(d-P) 3.3cm



Abscess

Effusion

Occult Fx

Radiolucent FB

Tendon

Muscle



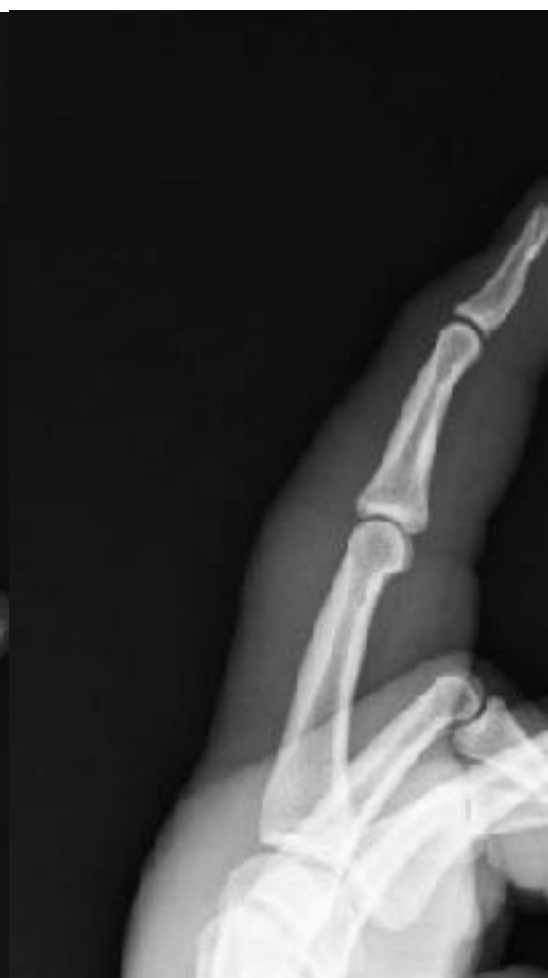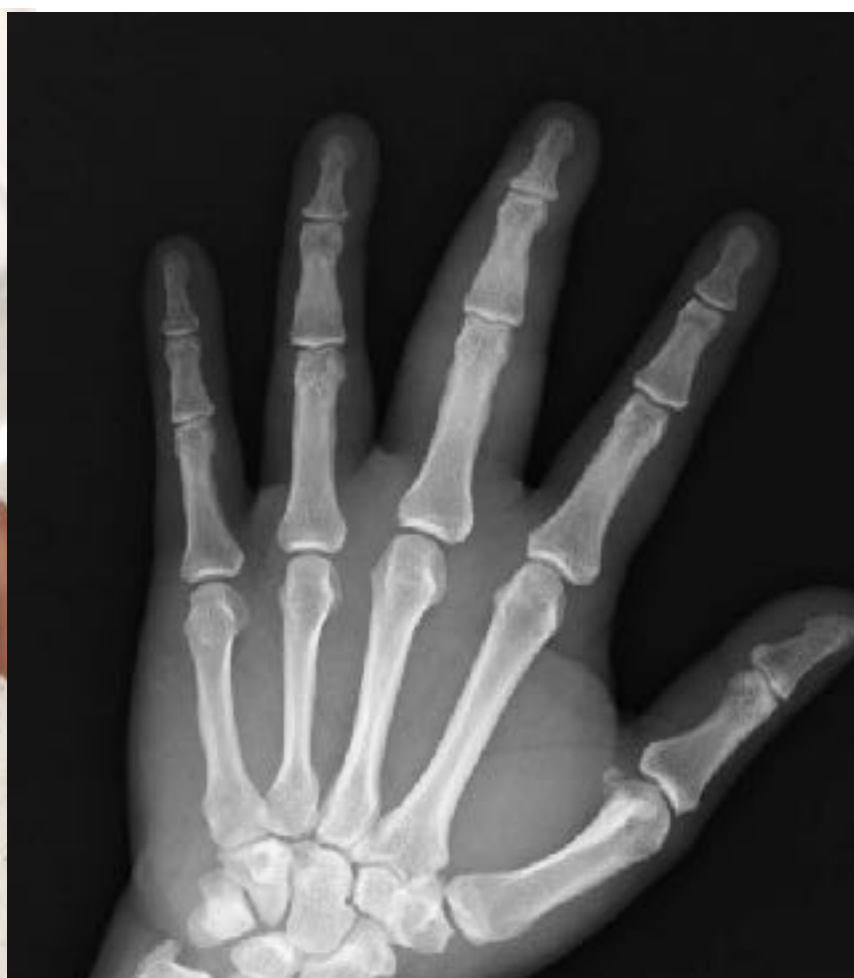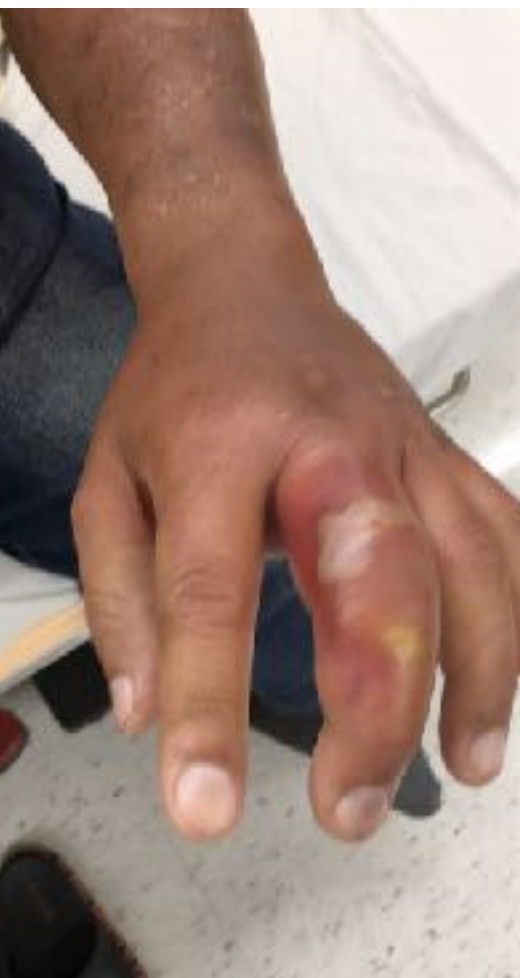juice119@gmail.com

POCUSAcademy.com

FB: Emergency Ultrasound Training Cen

Taipei Medical University Center for Education in Medical Simulation

左手中指腫痛

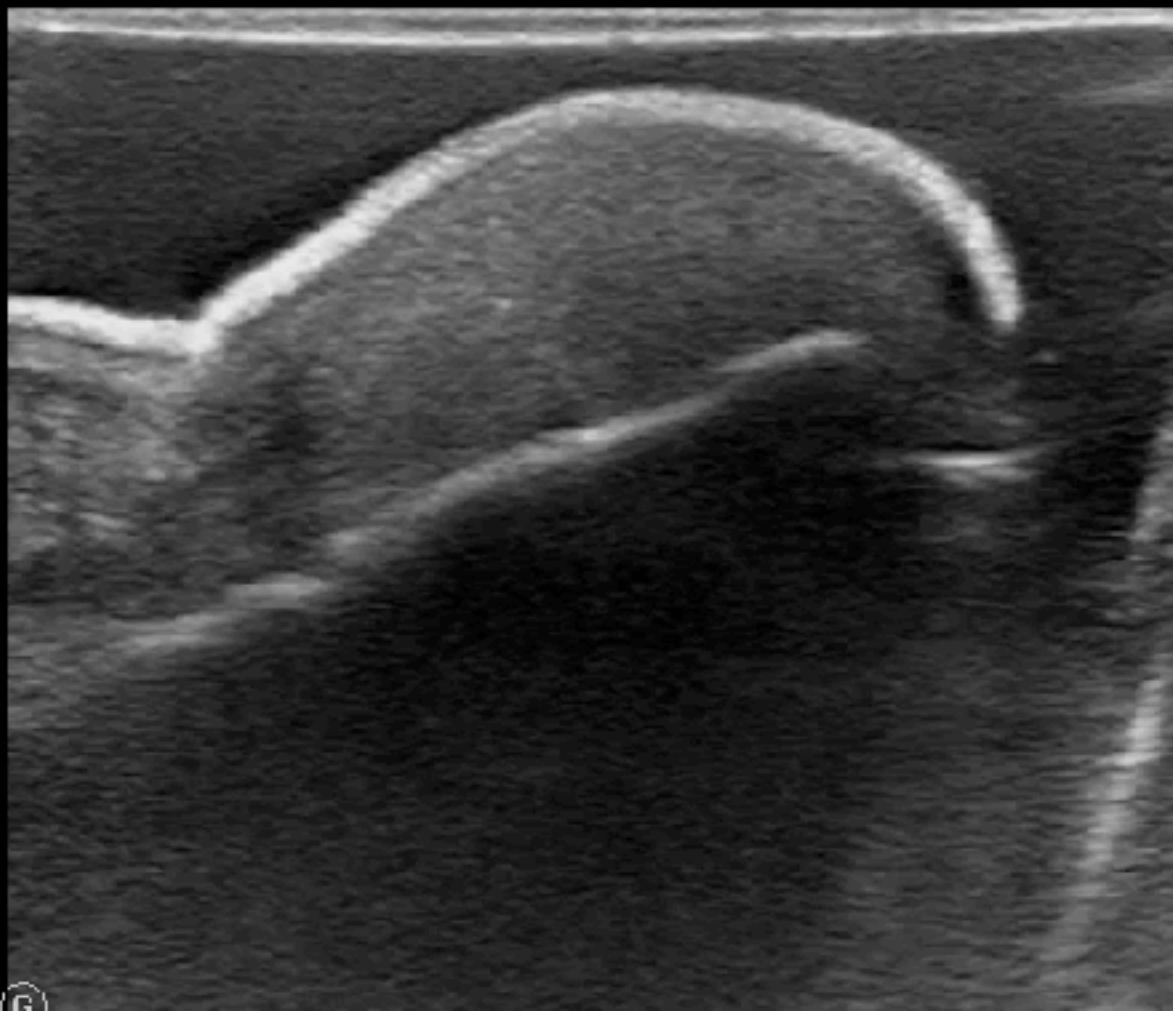

左手中指腫痛

Arterial
L12-3
42 Hz
3.5cm

2D
HGen
Gn 92
C. 41
3/3/2

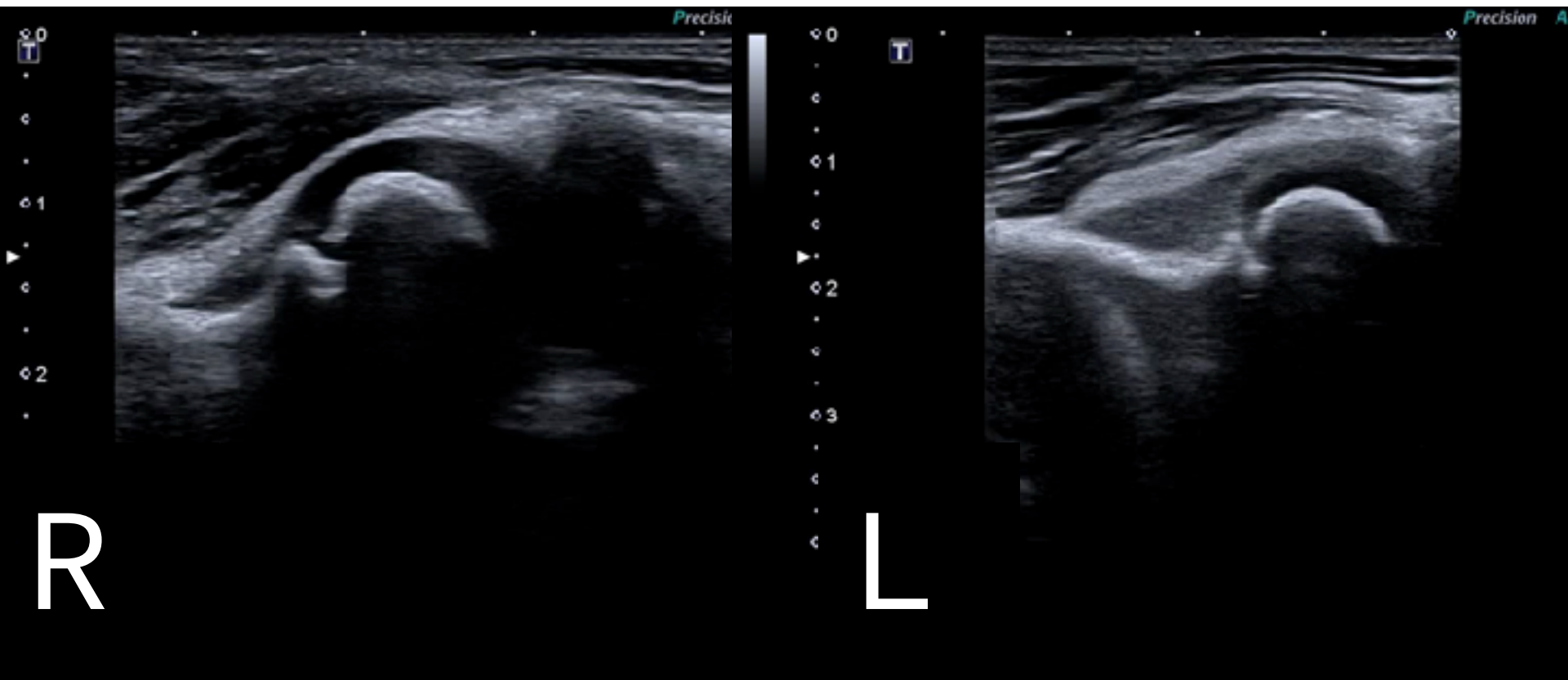
P



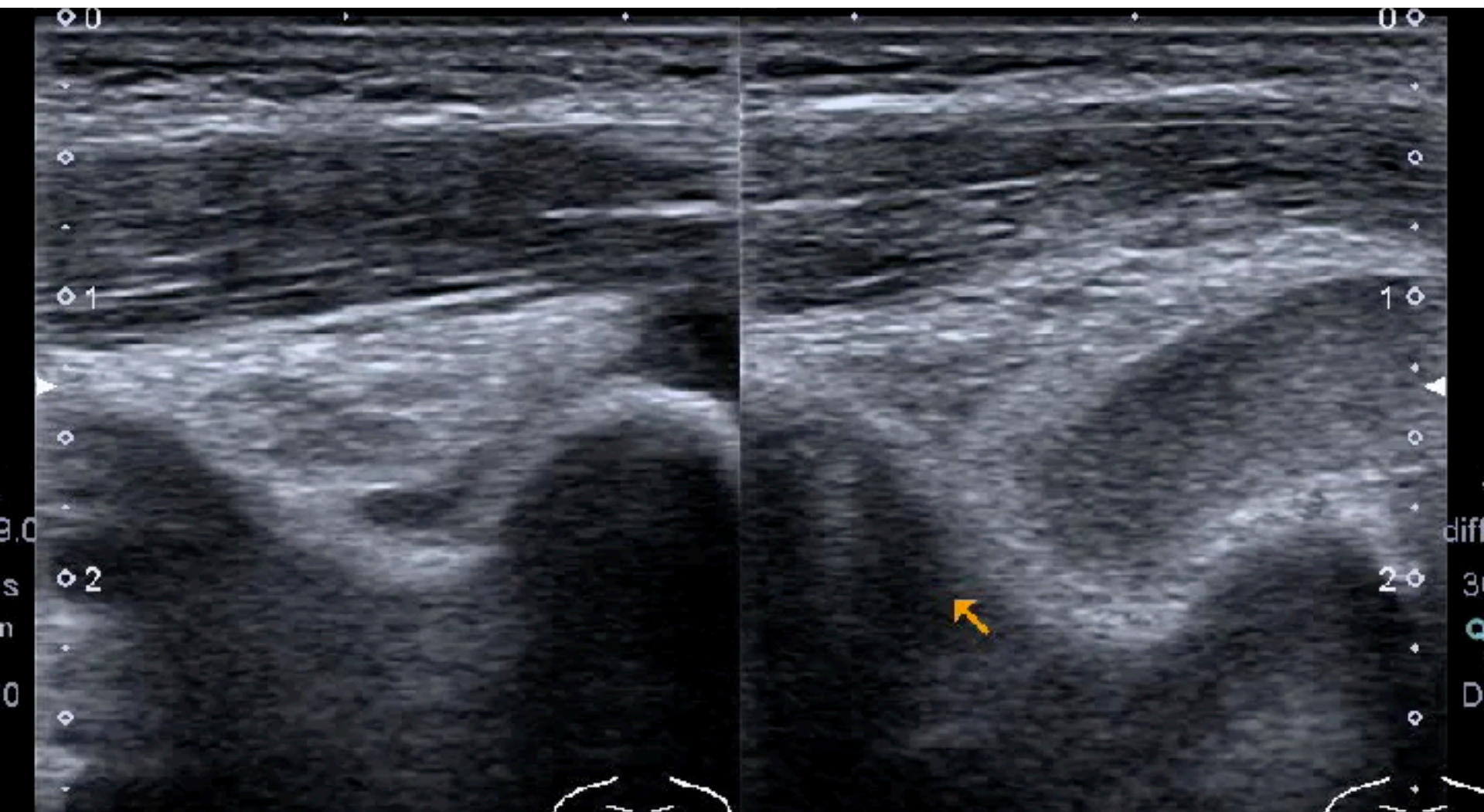
2



6歲男童，左肘受傷



6歲男童，左肘受傷



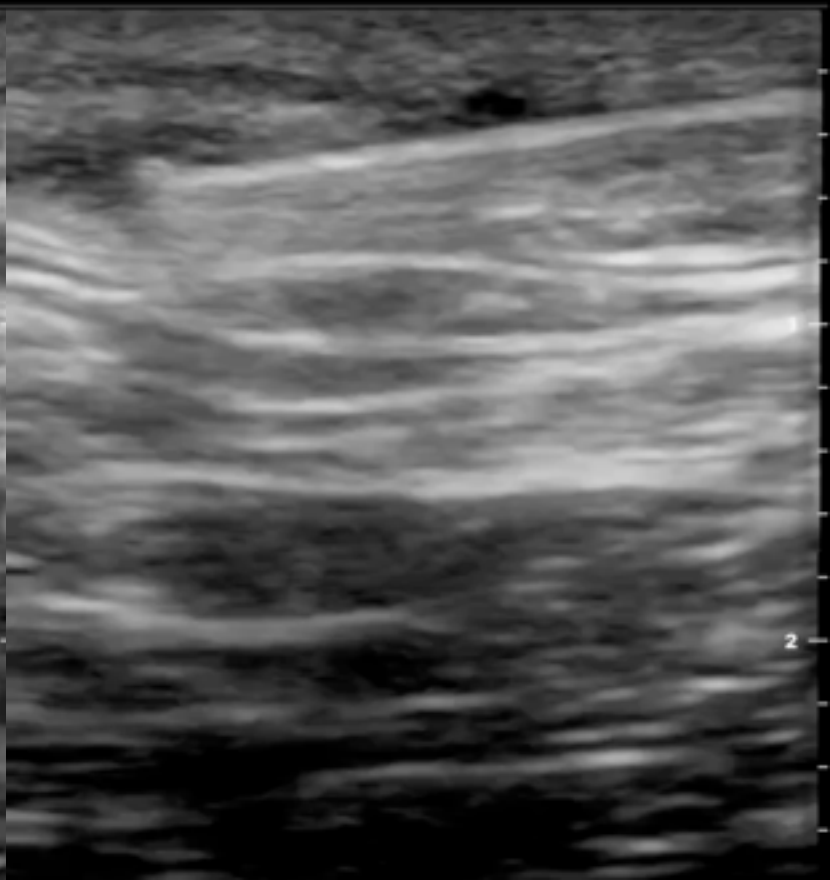
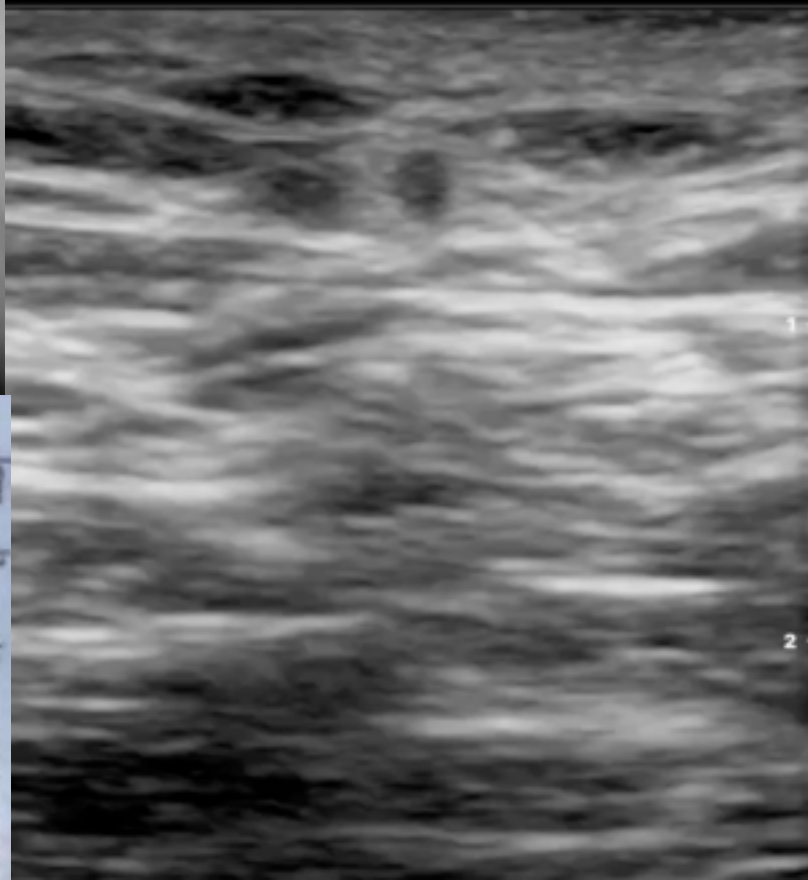
大腿 F B

TIS: 0.01, MI: 0.26, Small Organ

TIS: 0.01, MI: 0.26, Small Organ

B

B



54歲男，注射處腫痛

