



**臺中榮民總醫院**

**POCUS 訓練工作坊**

**急性腹痛超音波介紹**

# POCUS Academy

*Point-of-care ultrasound is the visual stethoscope in the 21st century*

# Password: 20200926



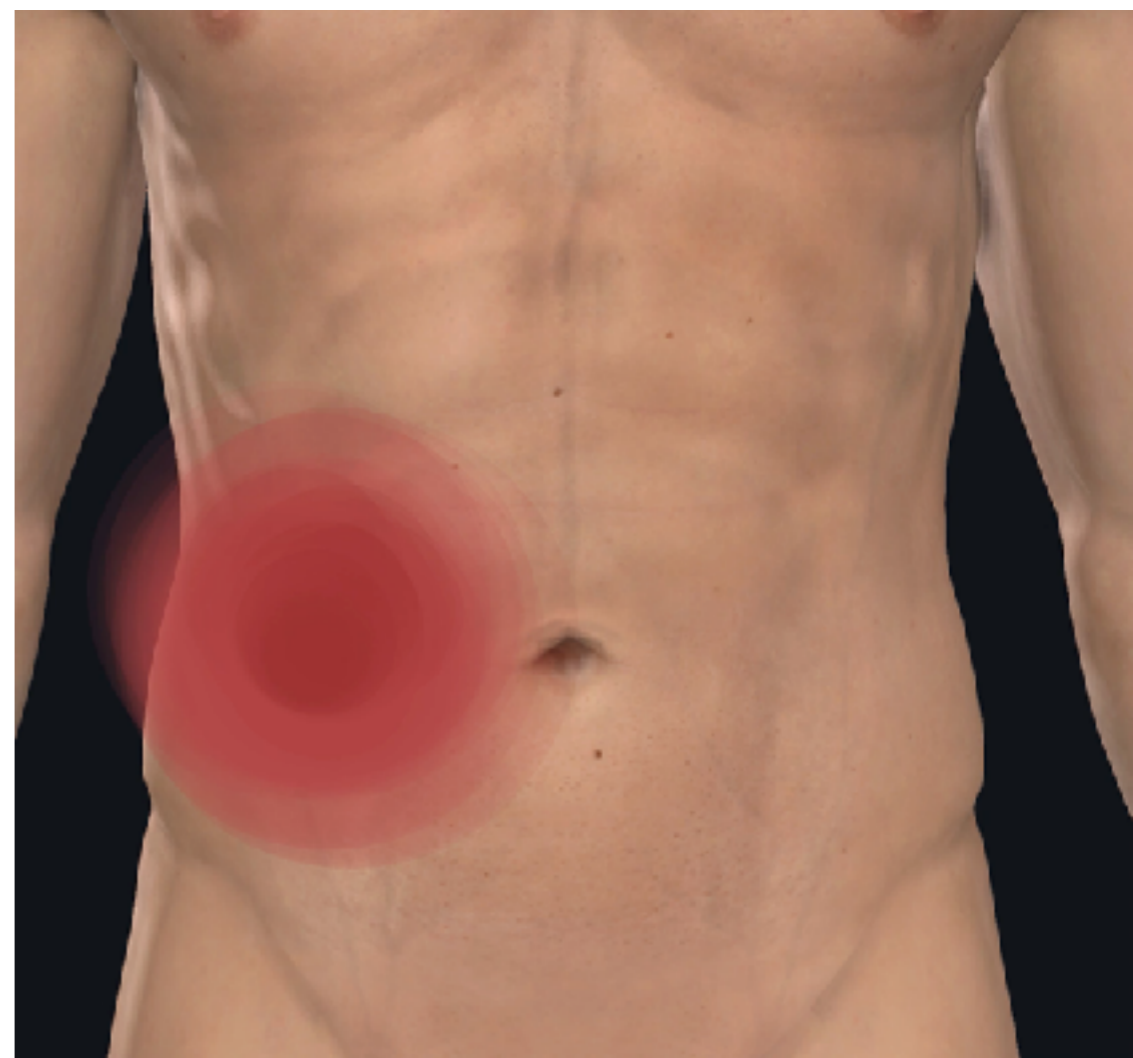
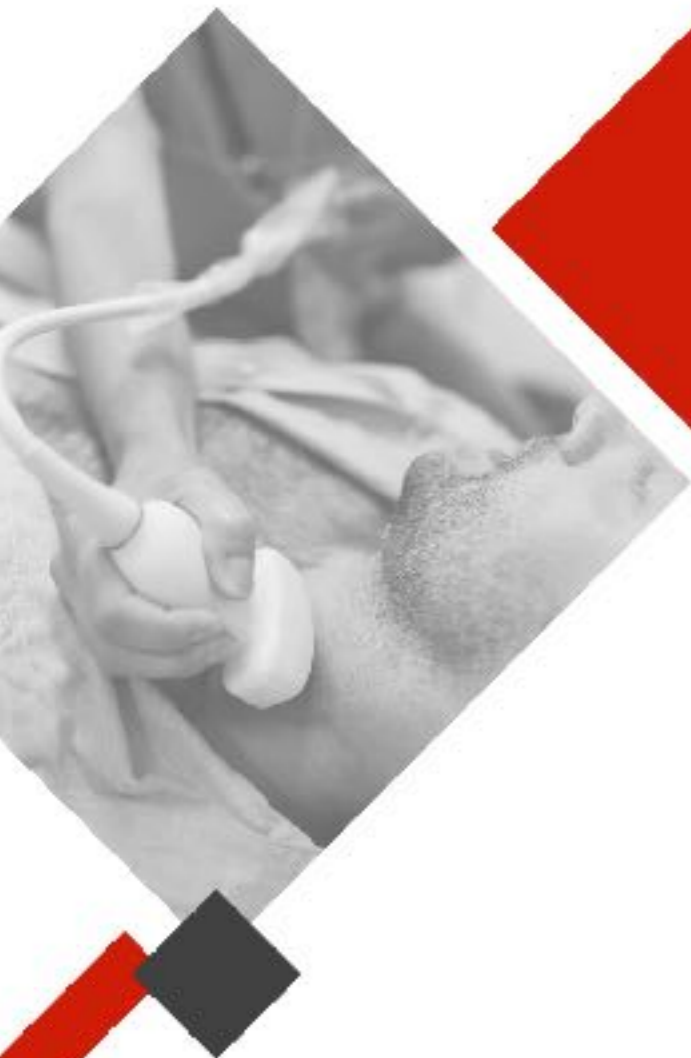[juice119@gmail.com](mailto:juice119@gmail.com)

**FB: Emergency Ultrasound Training Center**

Taipei Medical University Center for Education in Medical Simulation



ULTRASOUND  
PROGRAM



# POCUS 在急性腹痛的應用

陳國智醫師 西園醫院急診

# POCUS

## Point-of-Care Ultrasound

“ultrasonography brought to  
the patient and performed by  
the provider in real time”

---

Moore, C. L., & Copel, J. A. NEJM 2011

# POCUS-急診緣由

症狀  
問題

線索  
時間

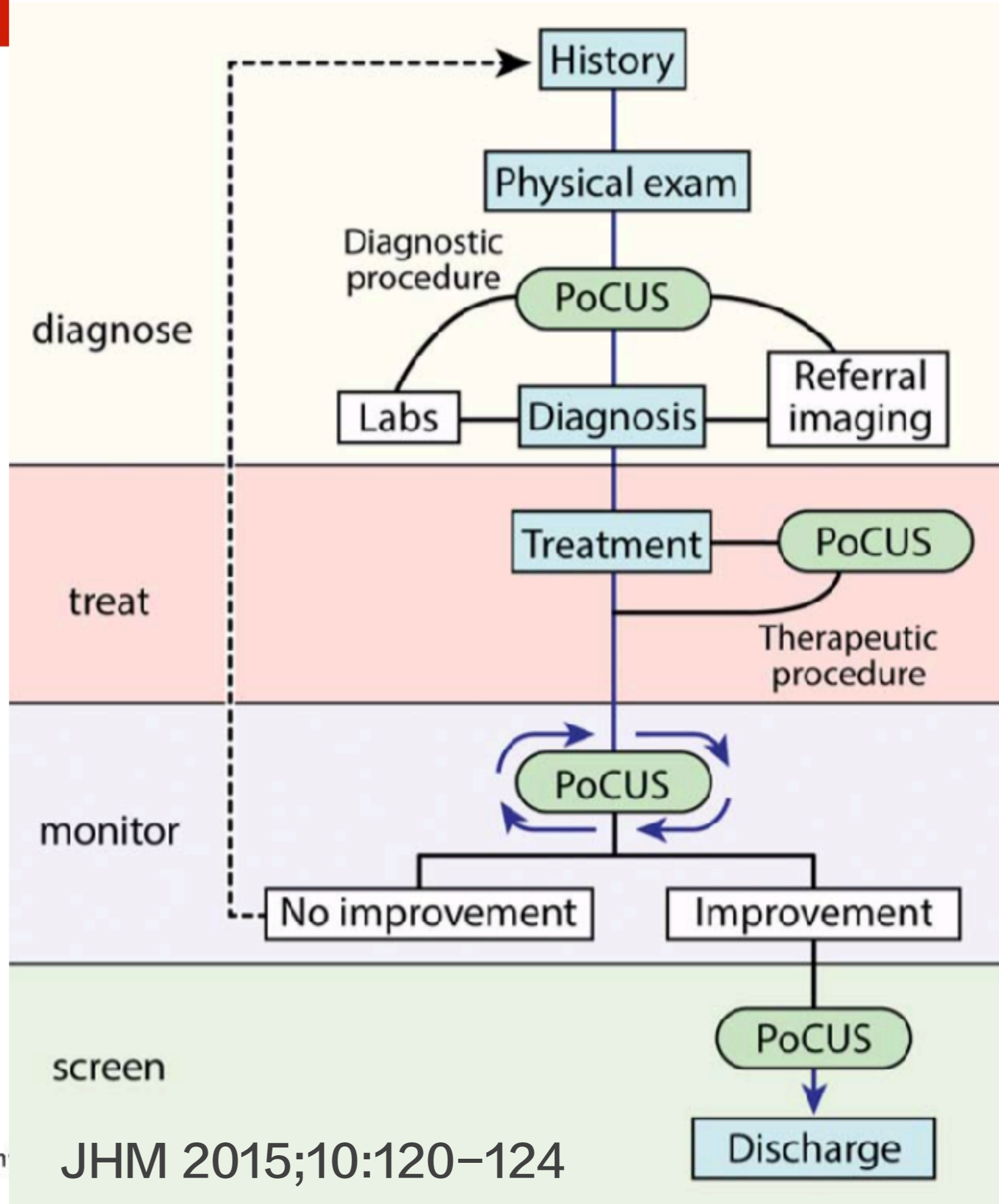
診斷  
治療

雜

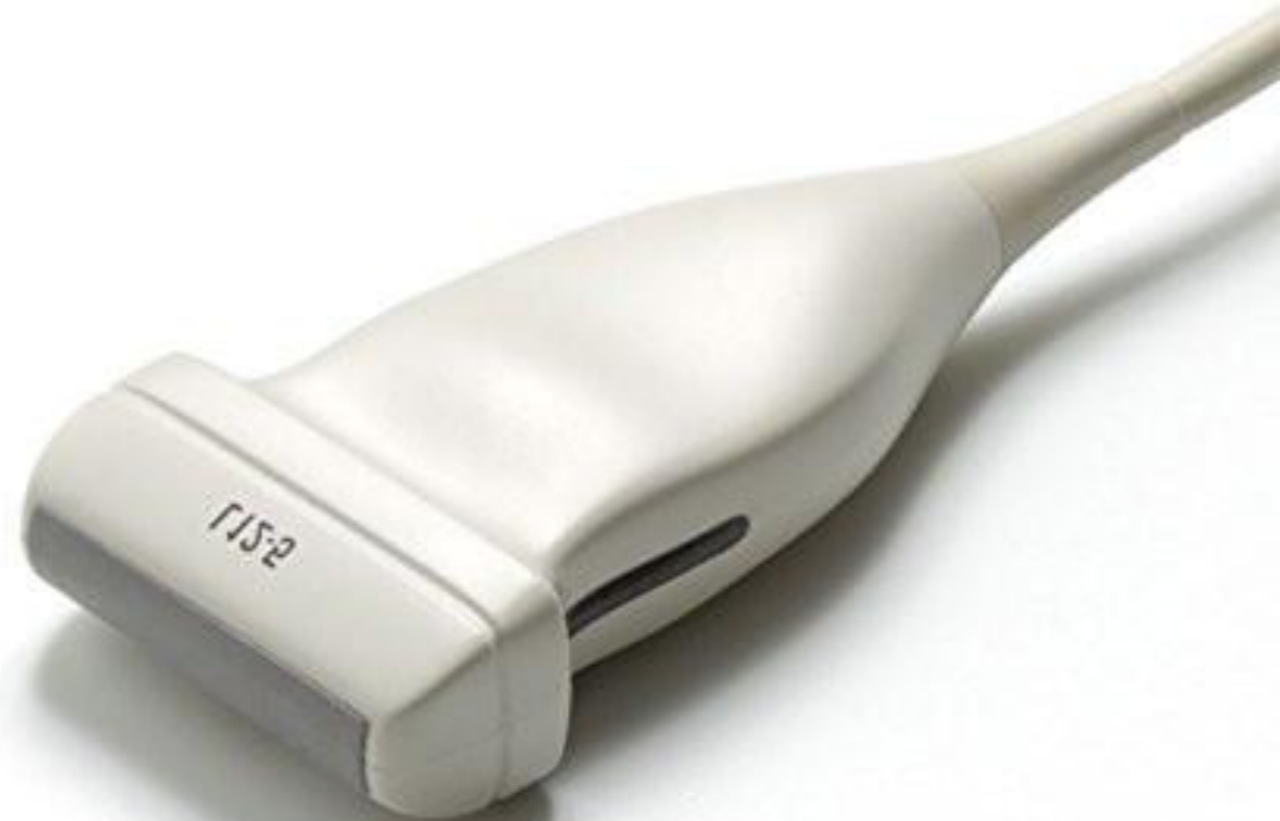少

快

# POCUS 住院病人



# 探頭選擇：腹為主／線為輔



急診POCUS不用NPO  
系統性掃描之後再聚焦





# 操控 6 大技巧

X 短軸

Y 長軸

Z 軸心

The diagram illustrates six ultrasound manipulation techniques:

- Sweep:** Shows a cross-sectional view of the aorta. A small diagram below indicates the probe's movement along the Z-axis.
- Slide:** Shows a longitudinal view of the aorta with the liver above it. Labels include "Cephalad" and "Caudal". A small diagram below shows the probe moving along the Y-axis. Text: "Slide to bifurcation".
- Rotation:** Shows a cross-sectional view of the aorta. A small diagram below indicates the probe's rotation around the Z-axis.
- Fan:** Shows a longitudinal view of the aorta with the liver above it. Labels include "Cephalad" and "Caudal". A small diagram below shows the probe's fan motion. Text: "keep probe at contact site".
- Rock:** Shows a longitudinal view of the aorta with the liver above it. A white arrow points along the "axis of aorta". A small diagram below shows the probe's rocking motion. Text: "keep probe at contact site".
- Compression:** Shows a cross-sectional view of the aorta. A small diagram below indicates the probe's compression motion.





# 操控 6 大技巧

**X** 短軸

**Sweep**  
掃

**Fan/Tilt**  
傾

**Y** 長軸

**Slide**  
滑

**Rock**  
搖

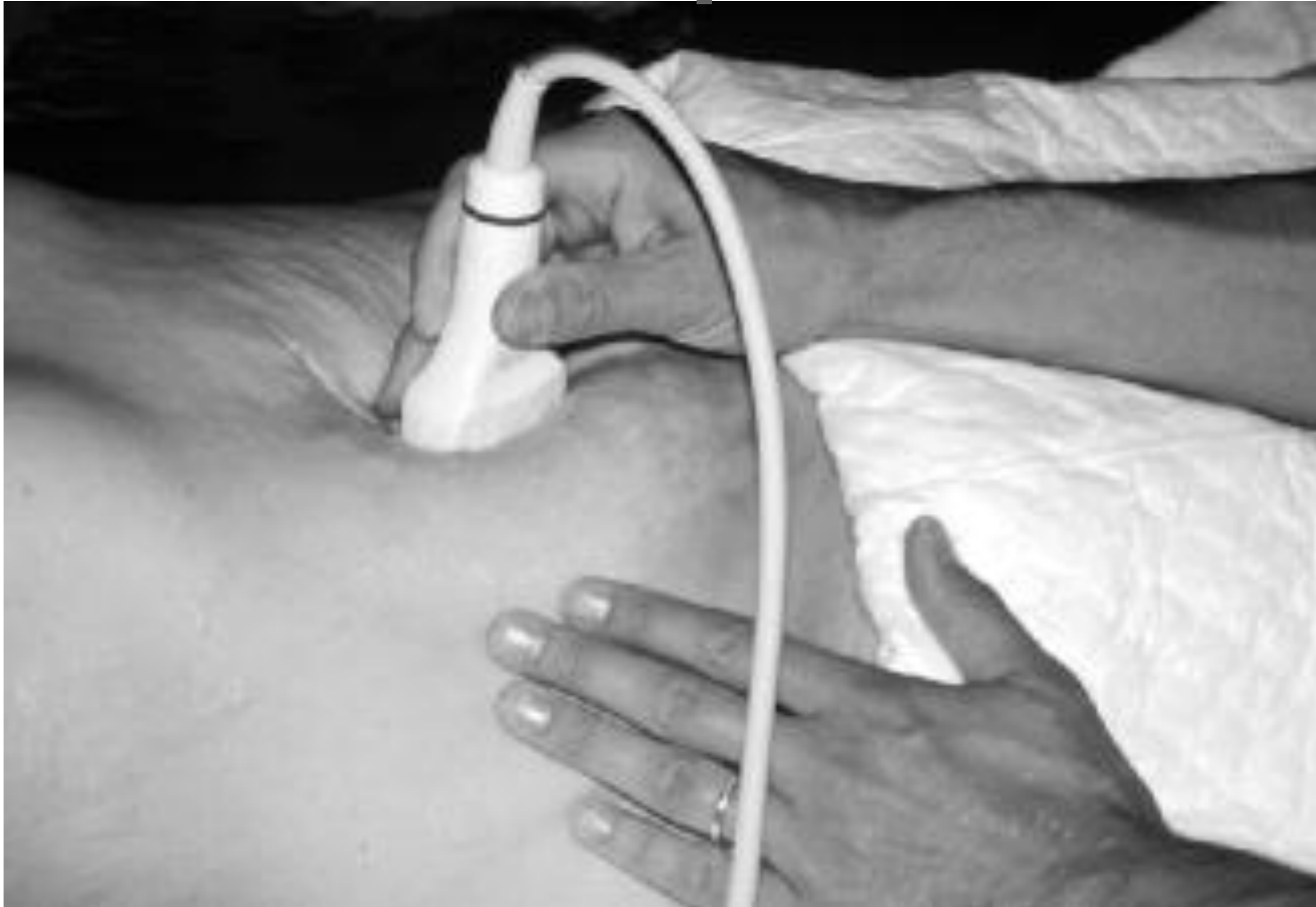**Z** 軸心

**Rotate**  
轉

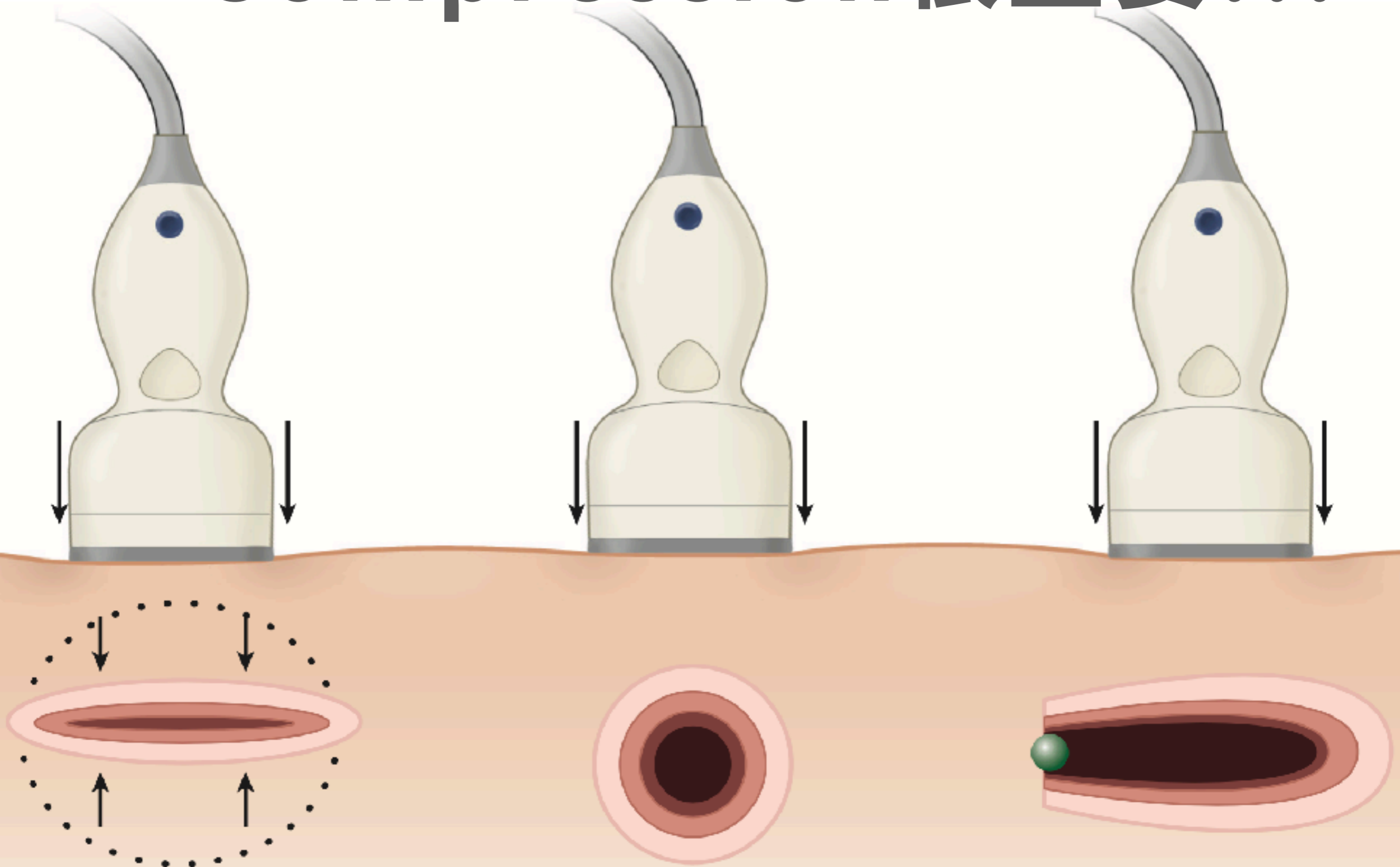
**Compress**  
壓

# Graded compression

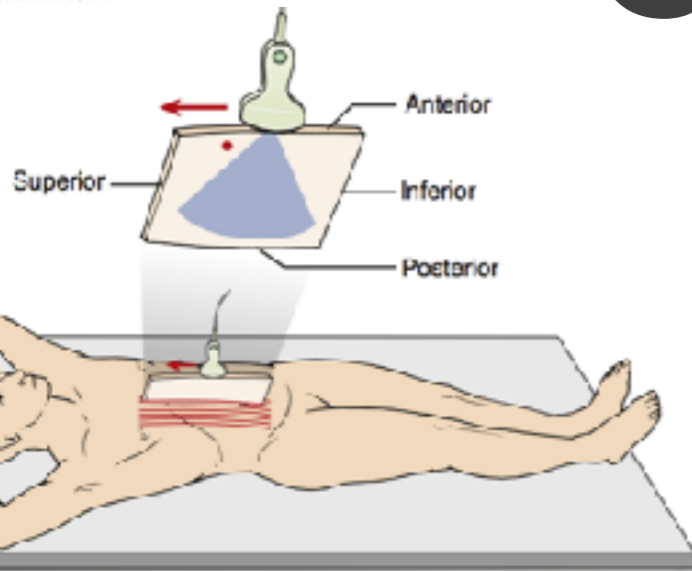
溫柔  
穩定  
施壓  
停留  
觀察



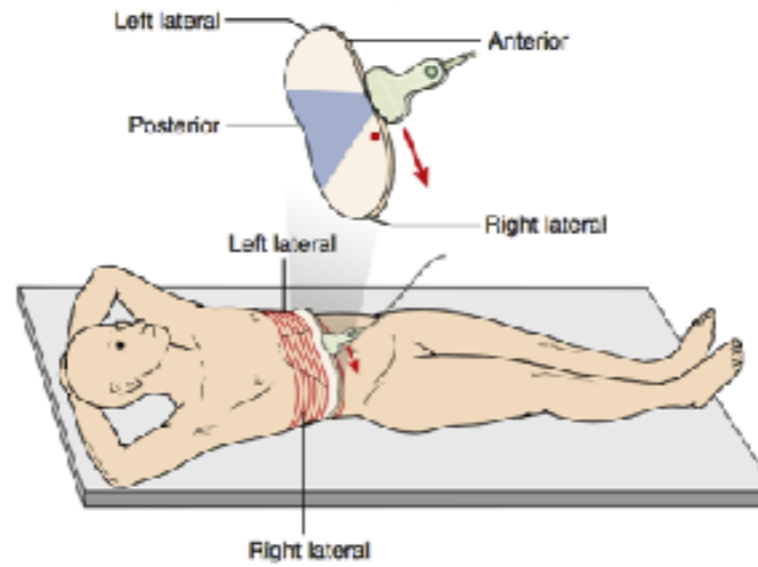
# Compression 很重要!!!



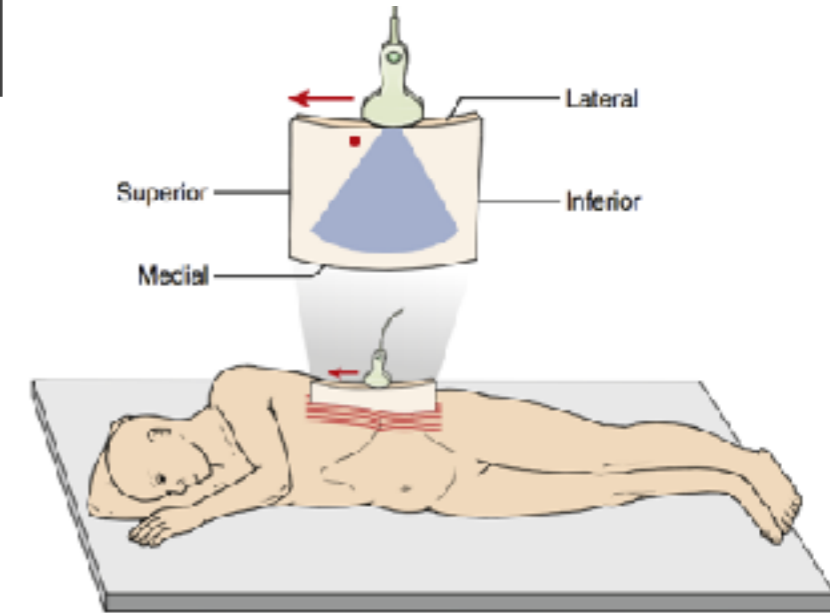
# 3D 立體掃描



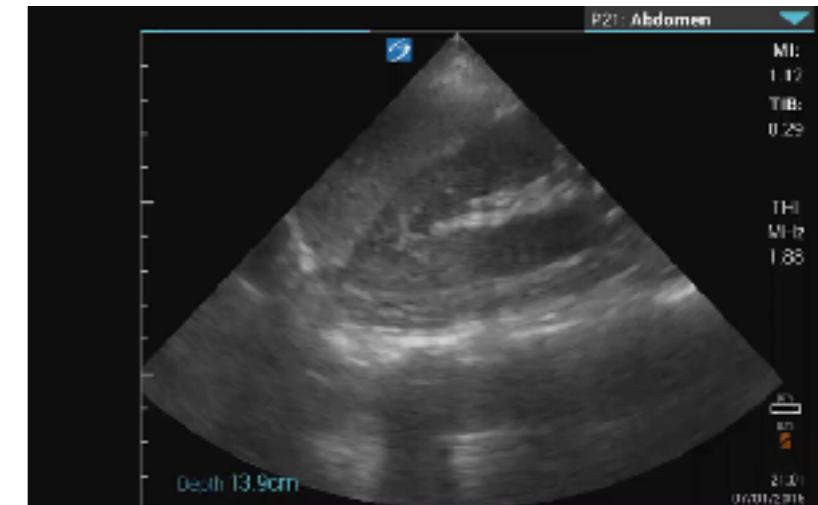
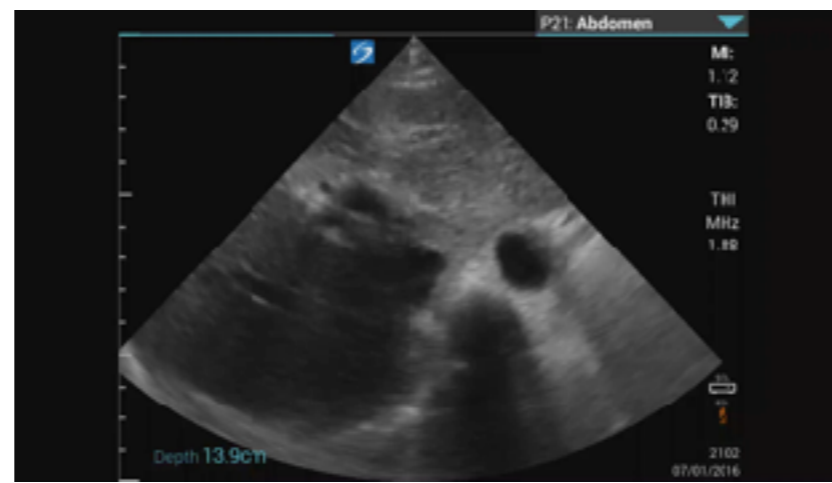
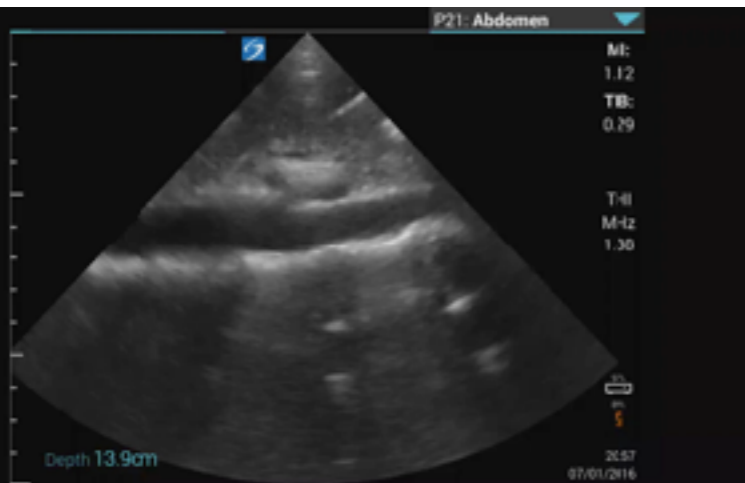Sagittal 縱



Transverse 橫



Coronal 側



# Approach to Abdominal Pain

**L**ocation

**O**nset

**T**ype

**S**everity

**O**ther locations (radiation)

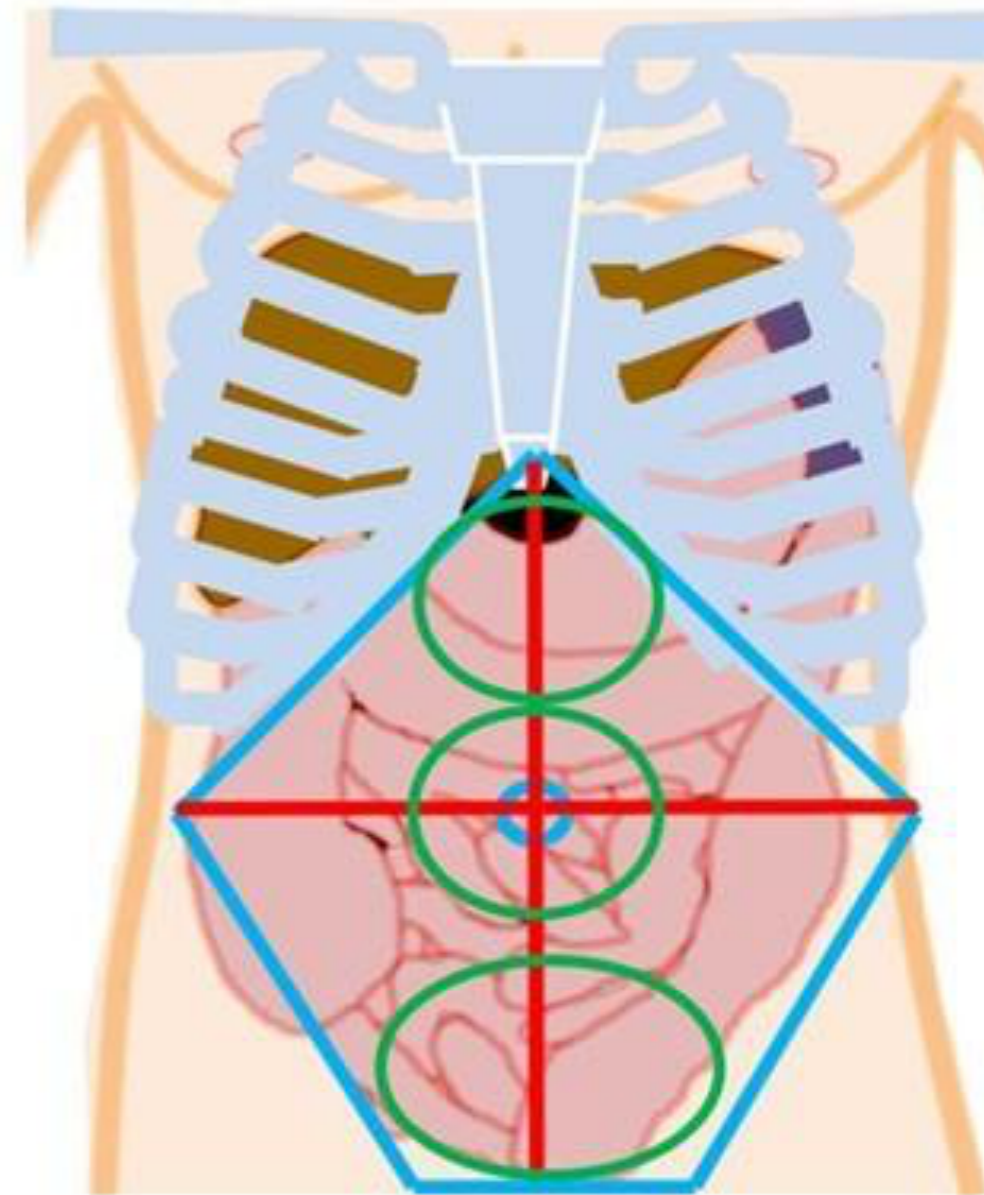
**F**actors (aggravating / alleviating)

**P**rogression

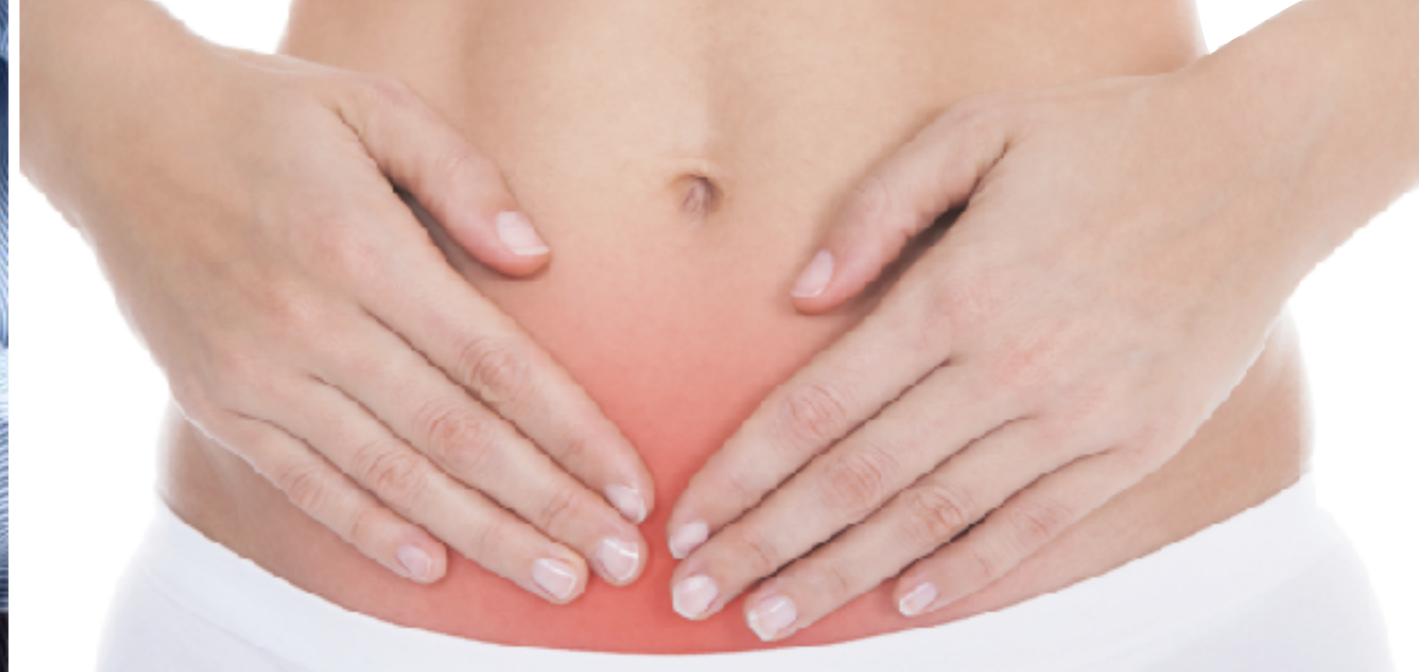**A**ssociated symptoms

**I**nsight (what do they think it is)

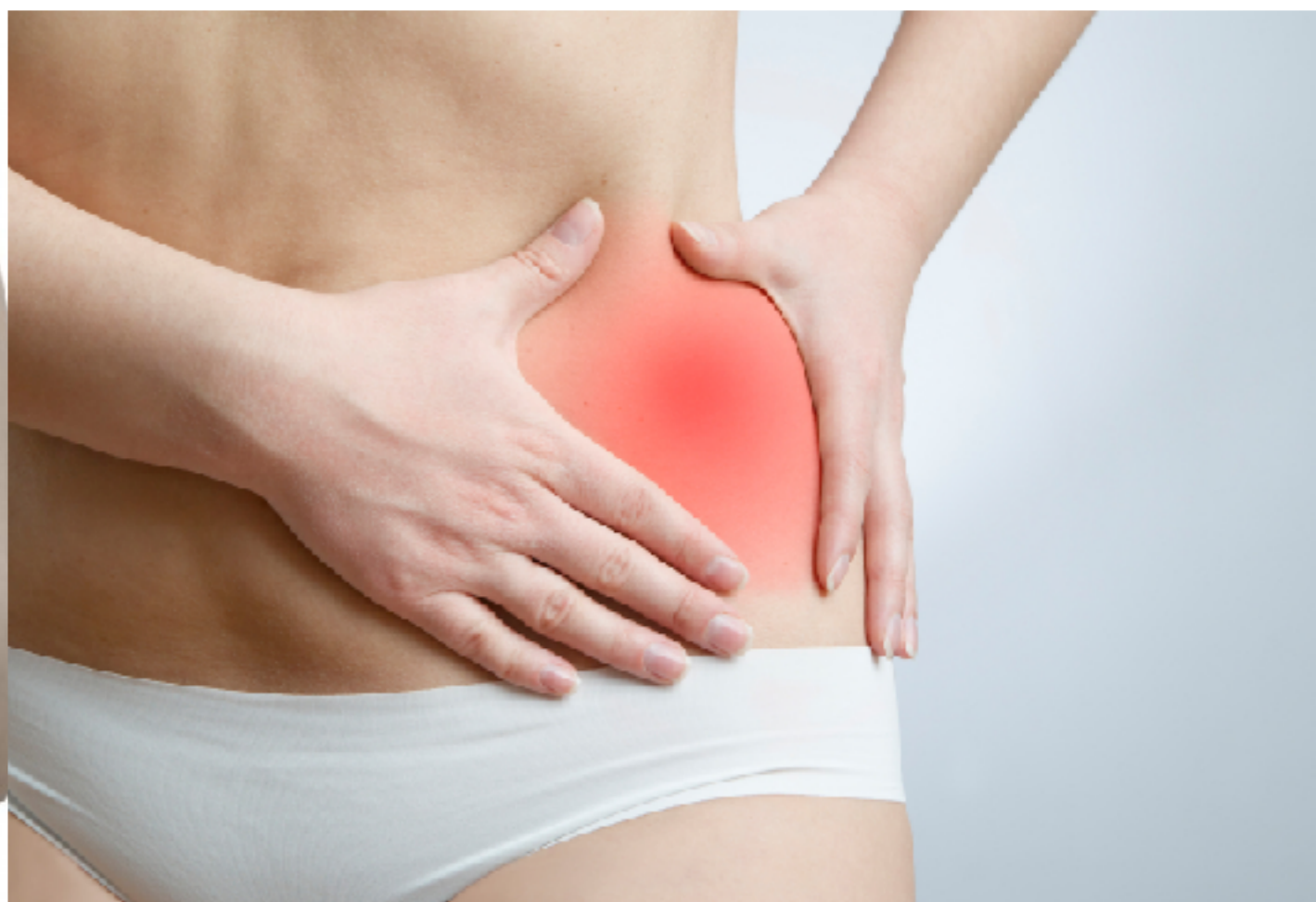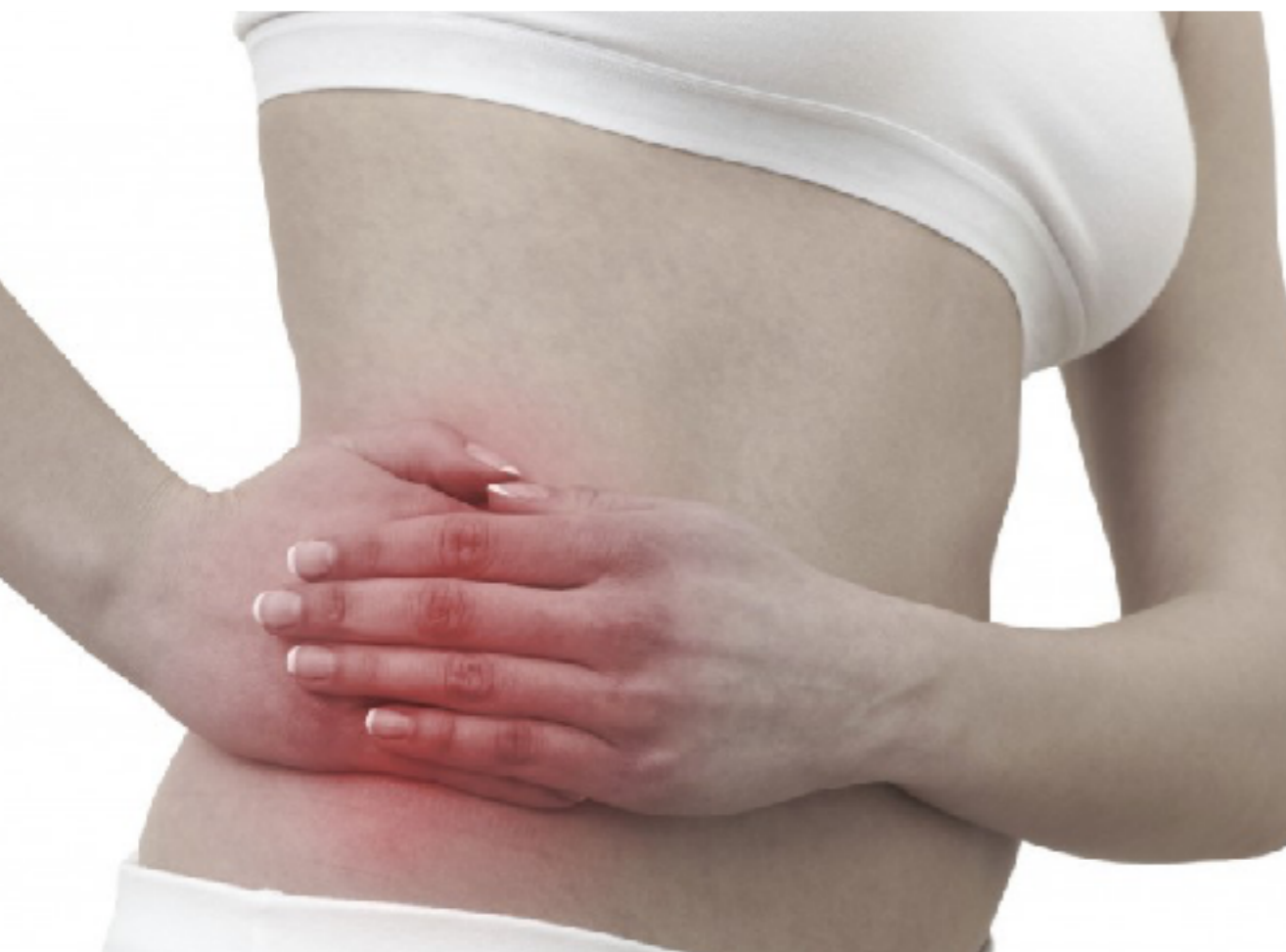**N**eed relief (what have they taken)



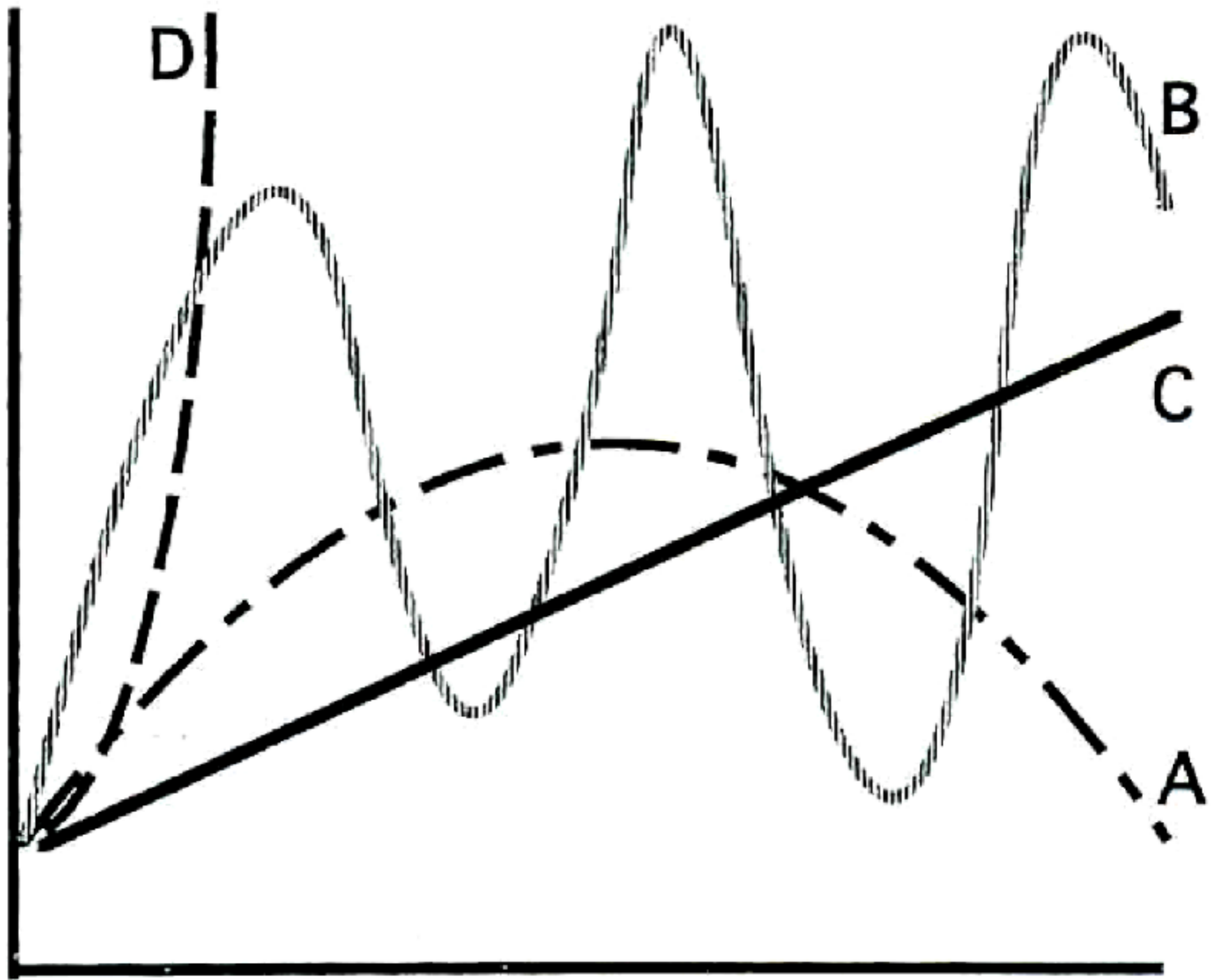
@kwburak



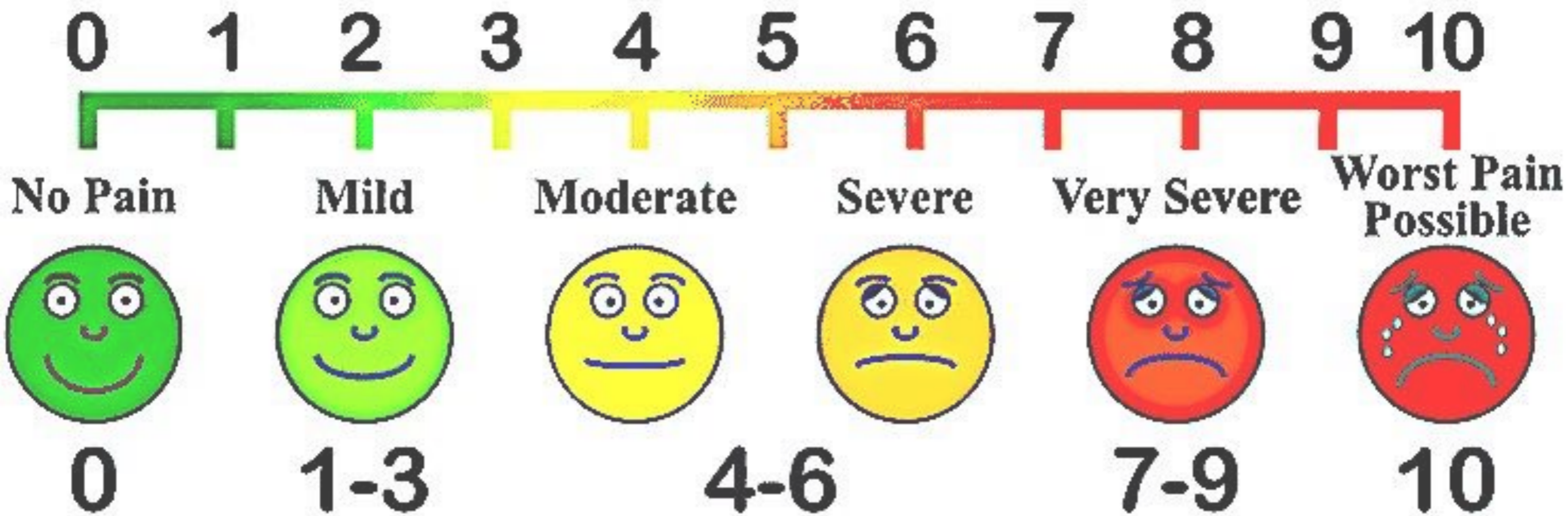
**該如何下手???**



Severity



Time







病史詢問



理學檢查



Y

POCUS

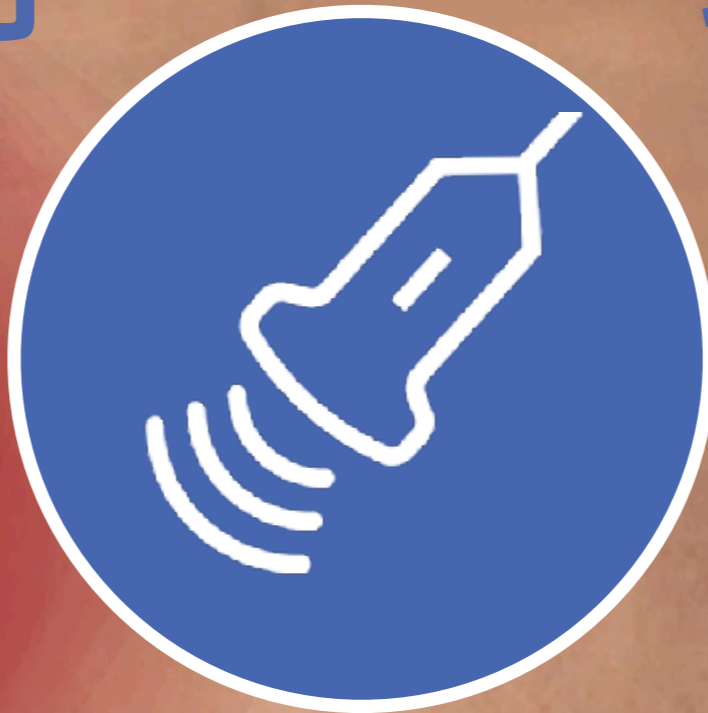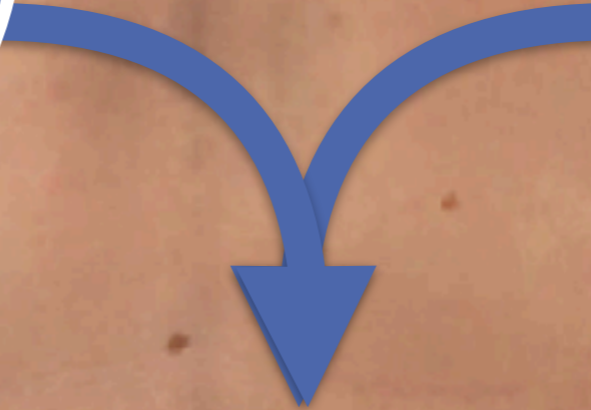N



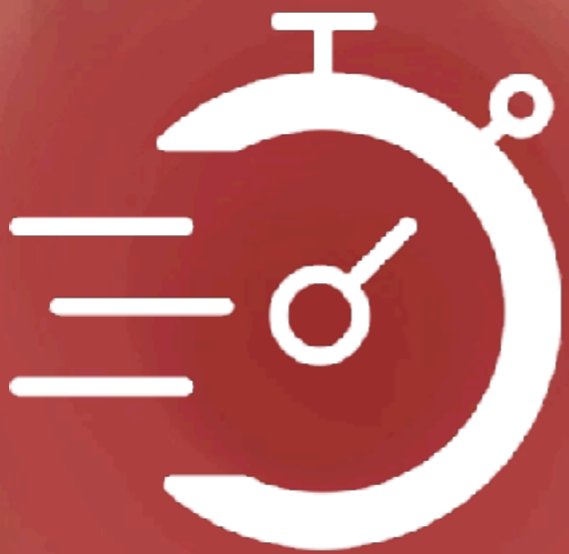病史詢問



理學檢查



POCUS



# I-AIM

## Indication



**Acquire**



**Interpret**



**Make  
decision**

**Bahner DP, et al. J Ultrasound Med 2012**



ULTRASOUND  
PROGRAM

# POCUS

for

Acute

**ABDOMEN**

**A** for aorta

**B** for biliary

**D** for diaphragm

**O** for obstruction

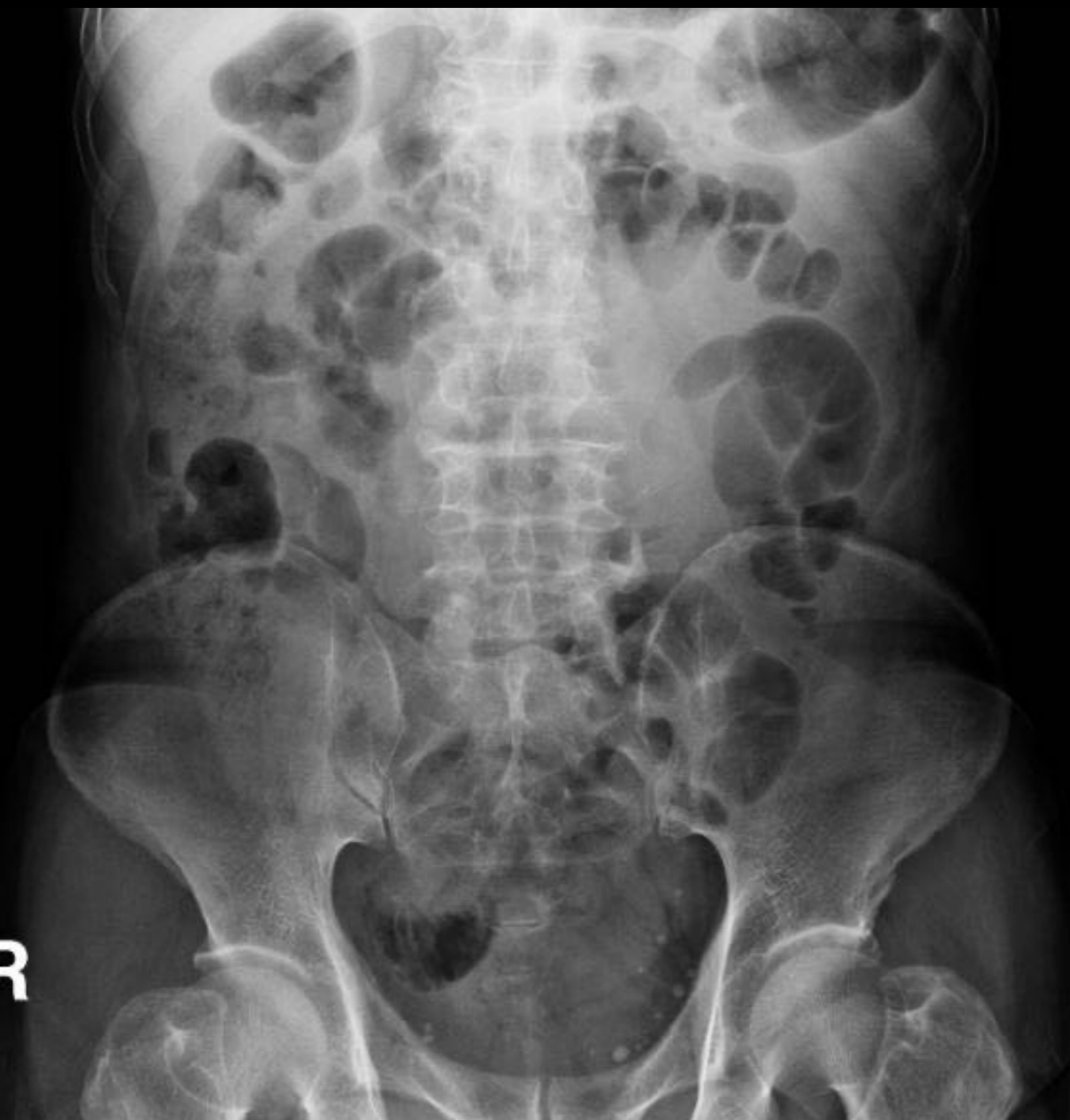**M** for moving fluid or gas

**E** for ectopic pregnancy

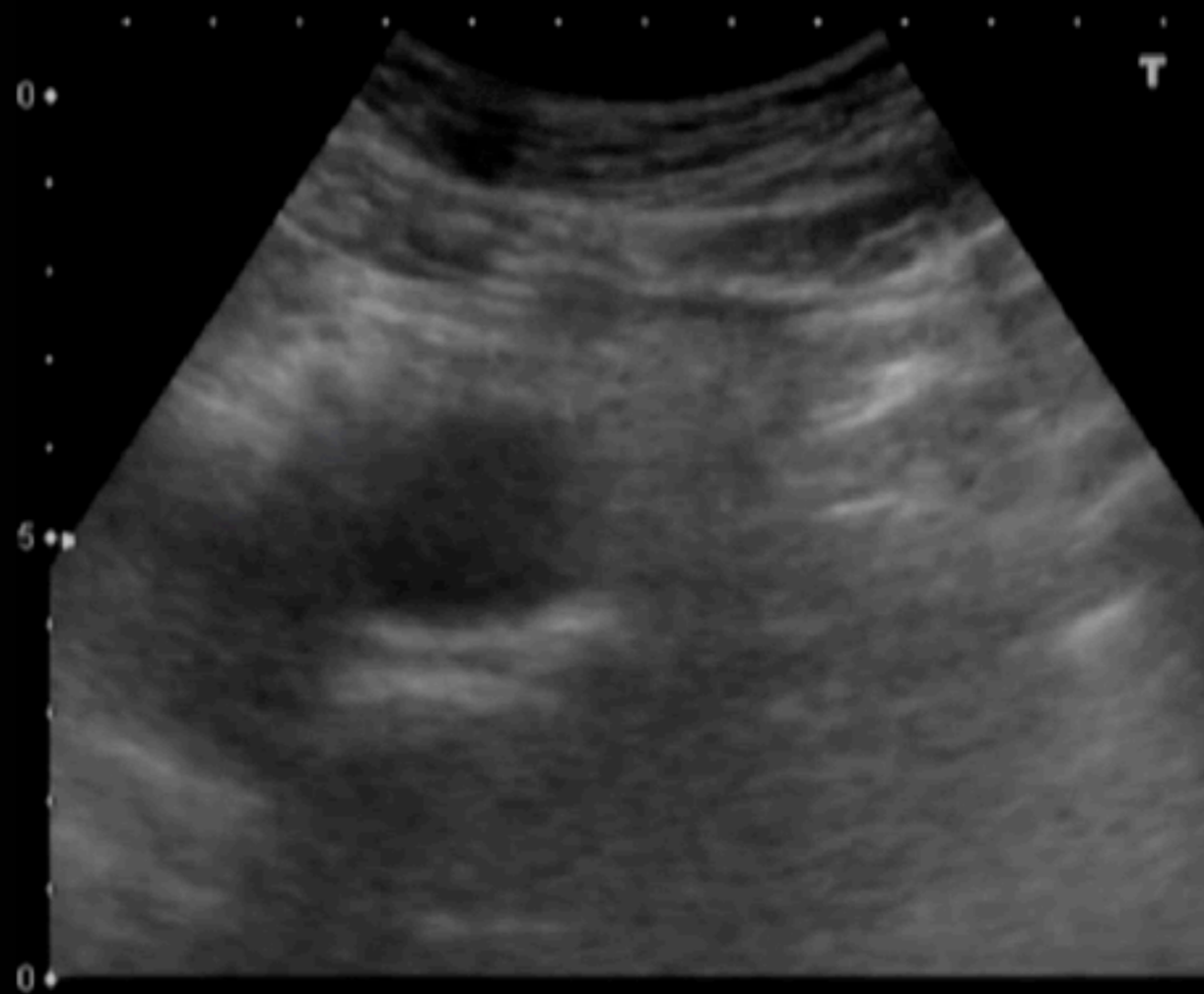
**N** for nephropathy



# 59M, Abd pain & hematuria



POCUS Academy©ChenK

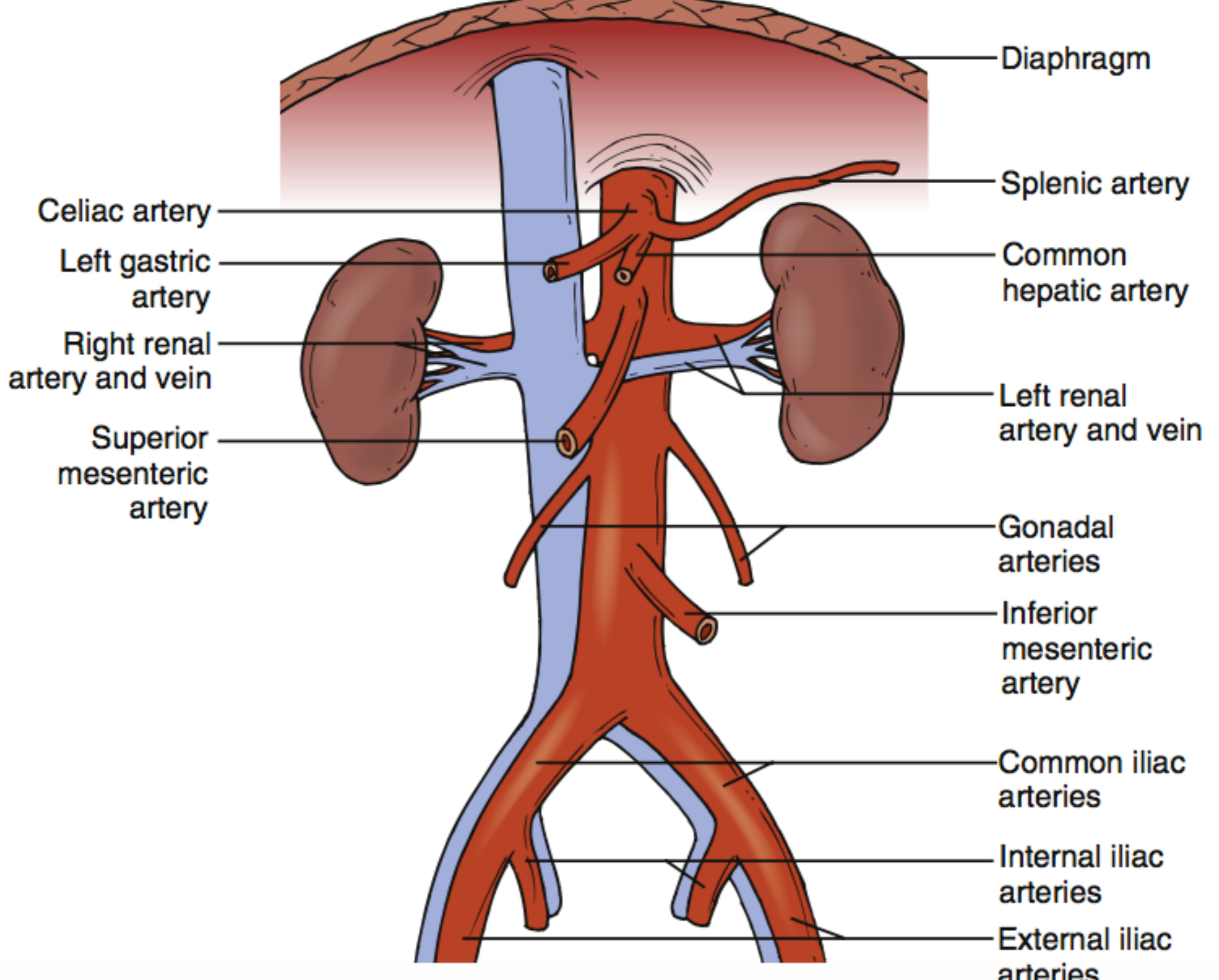


Free 8

# ABDOMEN

A for AAA & AD

3<sub>cm</sub>



# AAA



3<sub>cm</sub>

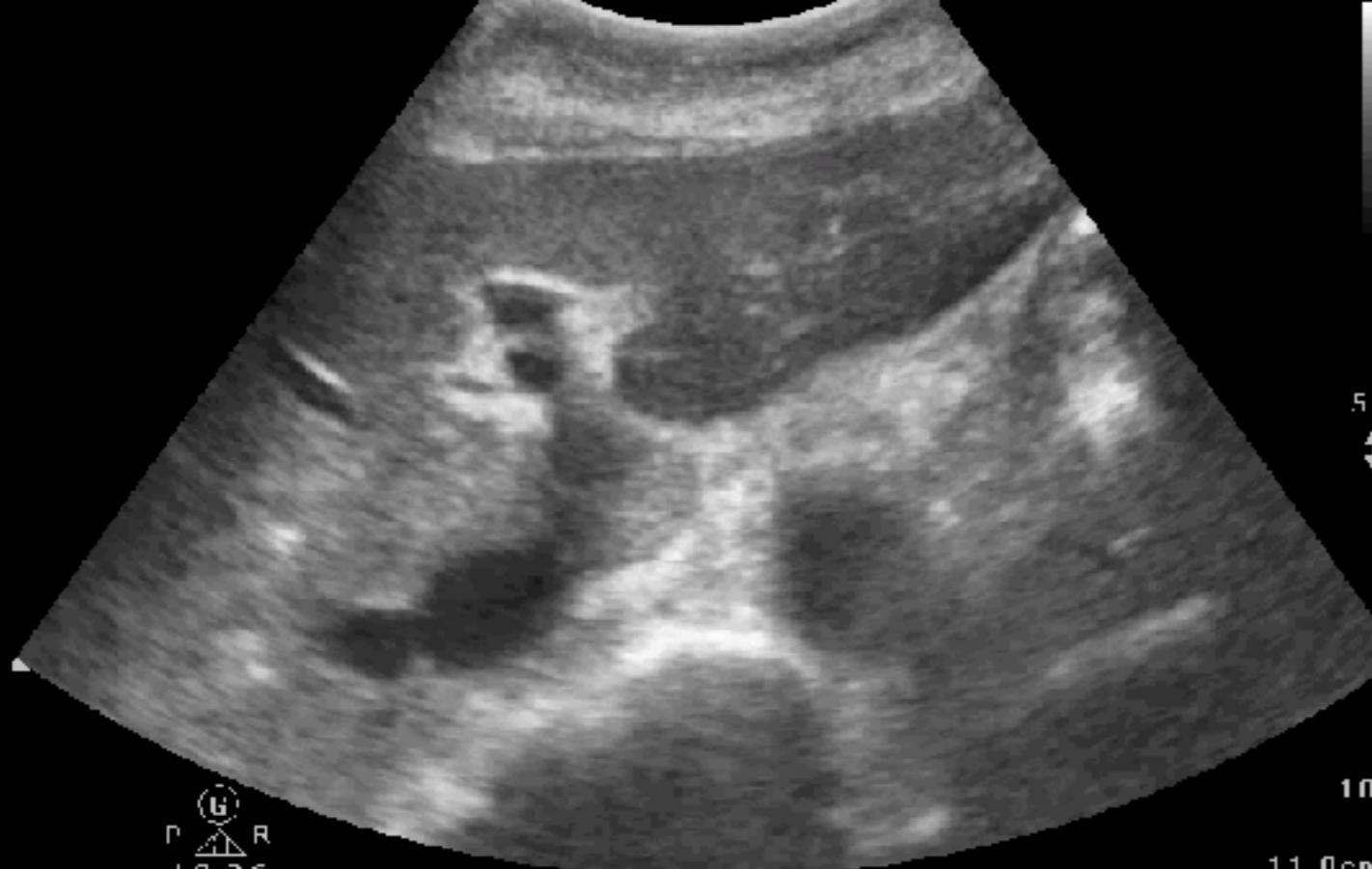The diagram illustrates a stylized human figure in red. A vertical white arrow on the left points downwards, indicating the location of the abdominal aorta. A horizontal white double-headed arrow indicates the diameter of the aneurysm, which is labeled as 3 cm. A red circle highlights the aneurysm area on the right side of the torso.

> 50 y/o  
Syncope  
Hypotension  
ABD/Flank/Back/Groin

Sensitivity **97.5-100%**  
Specificity **94.1-100%**



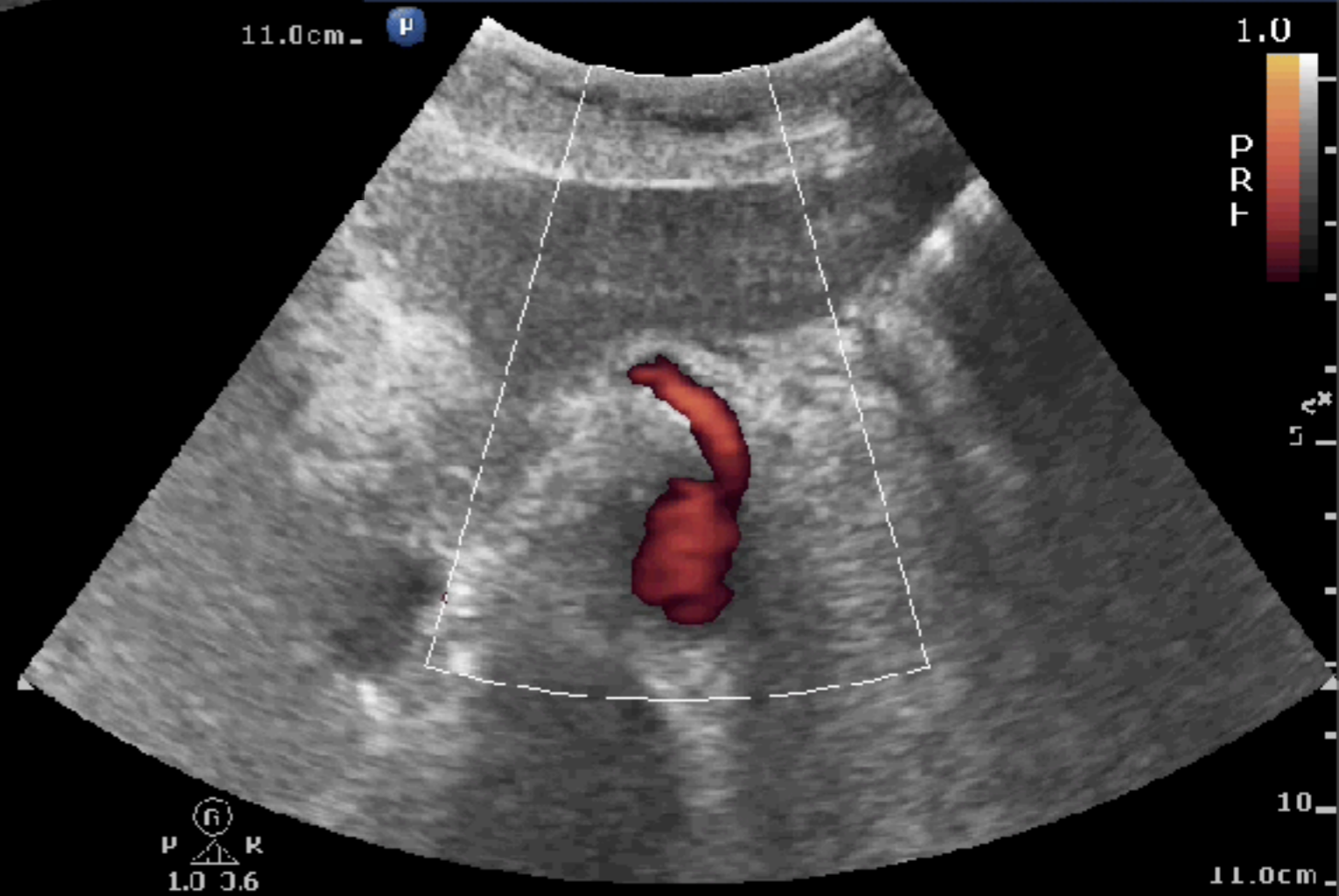
1  
Hz  
0cm  
  
en  
66  
56  
3/3

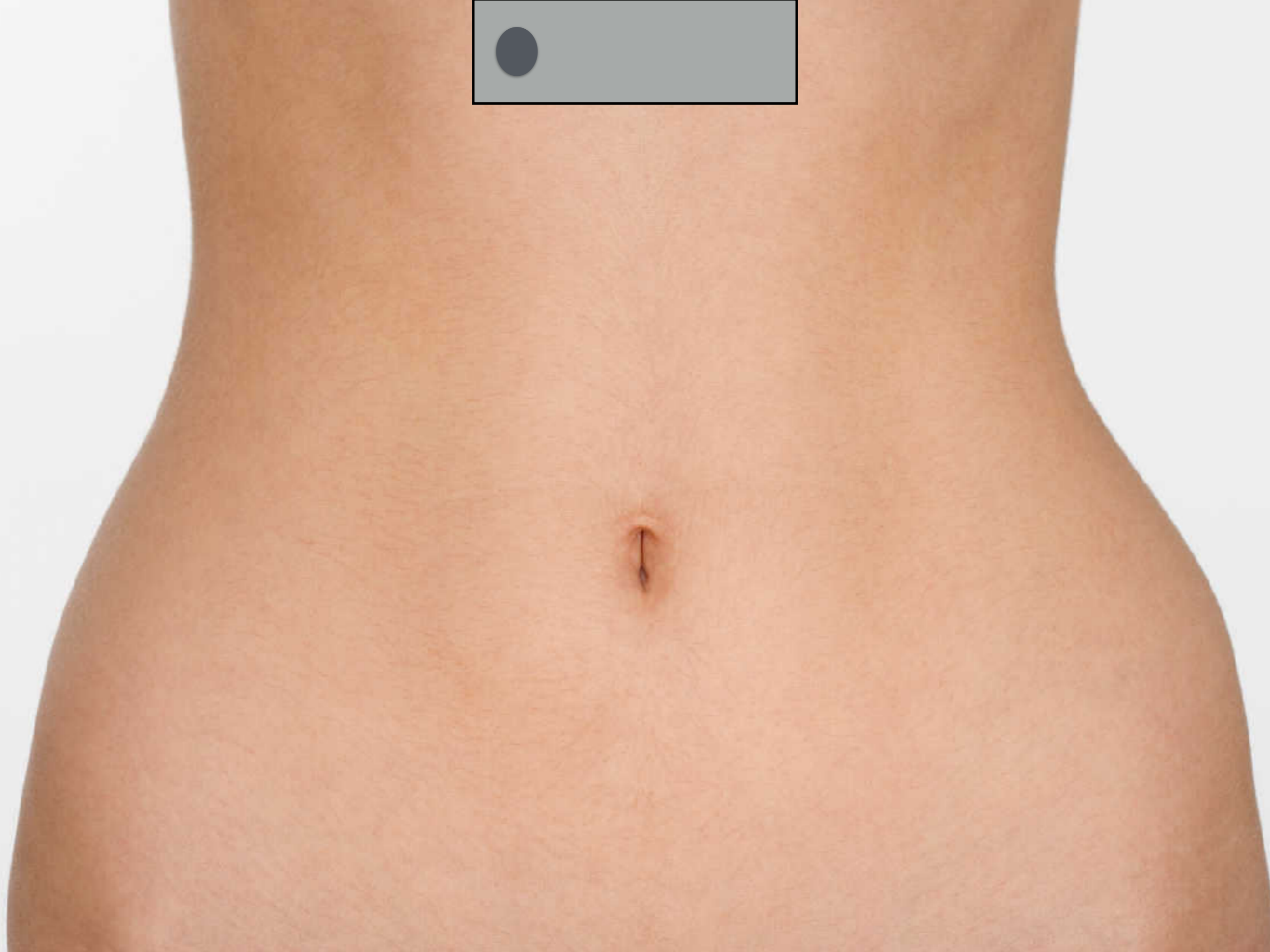


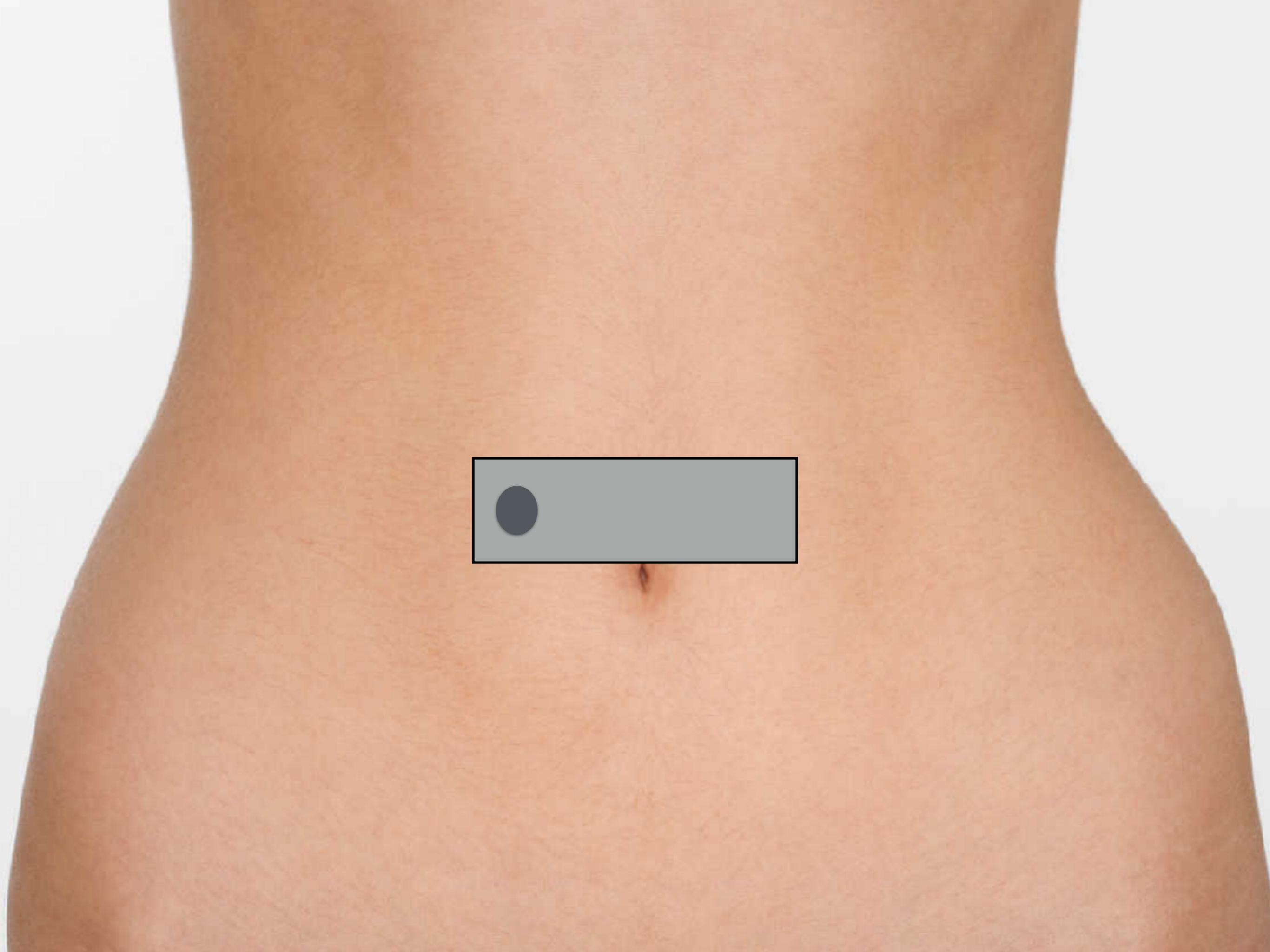
# Seagull Sign

# Celiac trunk

2D  
HGen  
Gn 56  
C 56  
3/3/3  
  
CPA  
2.5 MHz  
Gn 66  
1/8/4  
Ftr High  
Baseln 8





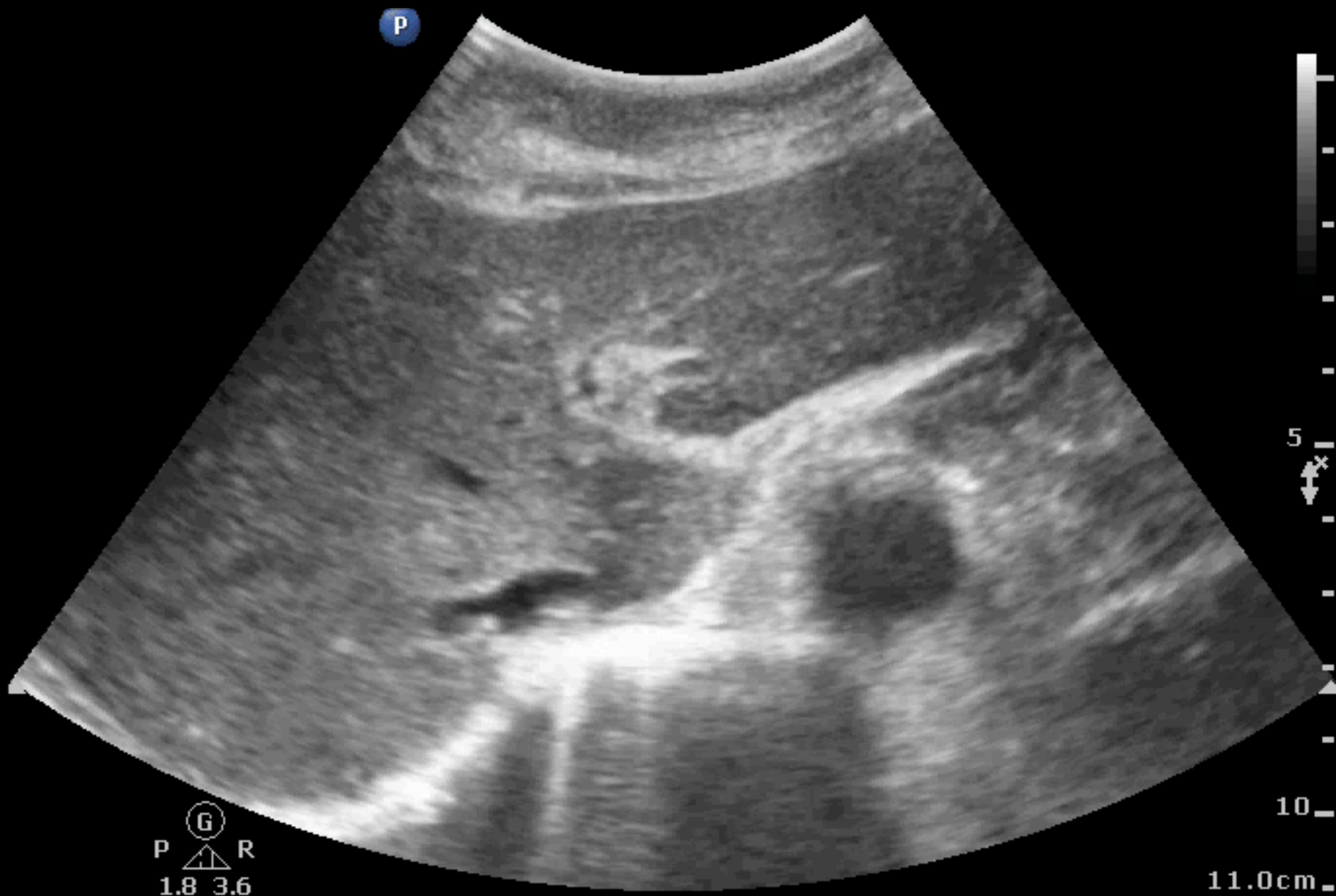

# ABDOMEN

Abd Gen  
C5-1  
42 Hz  
11.0cm

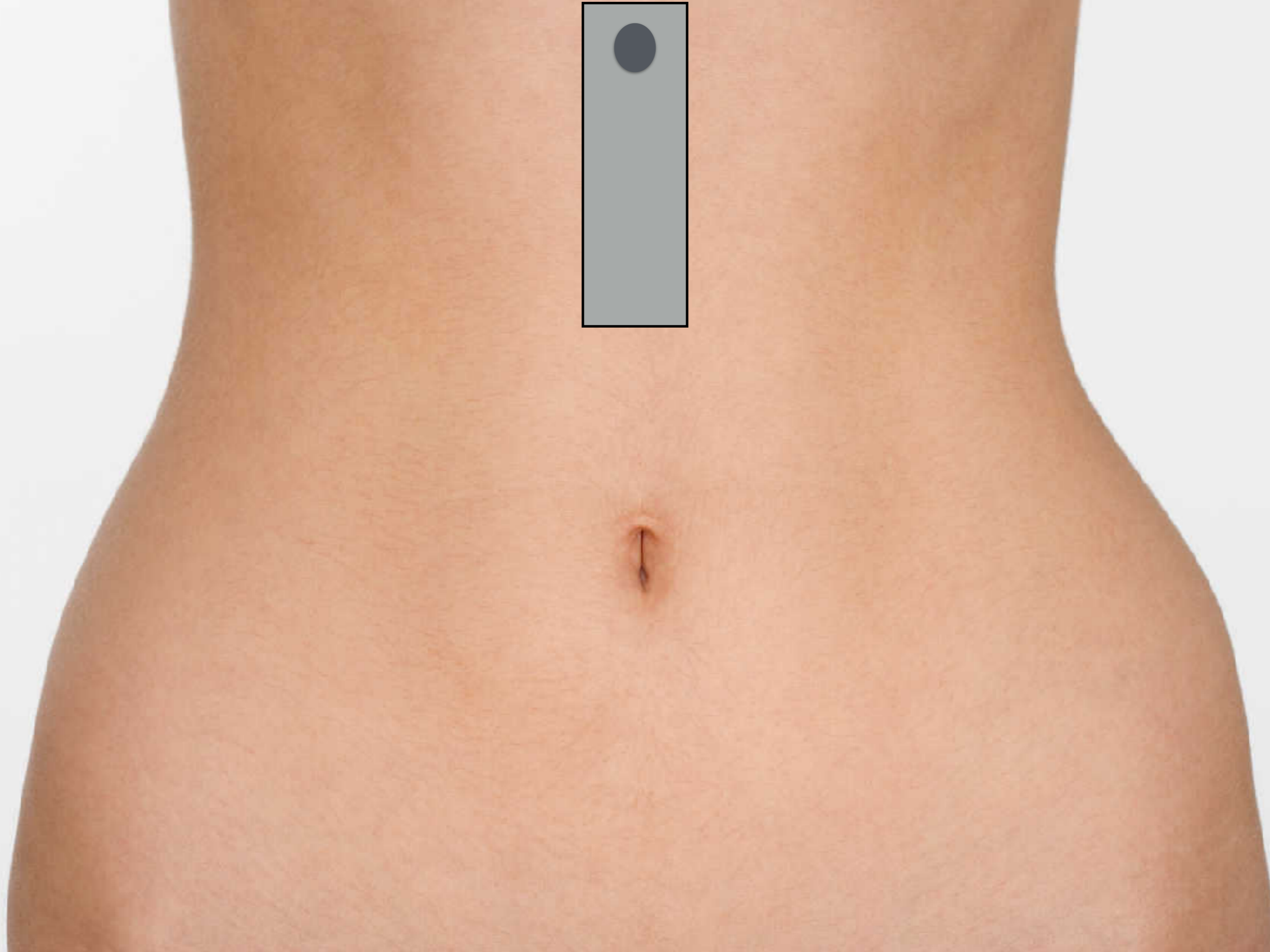
2D

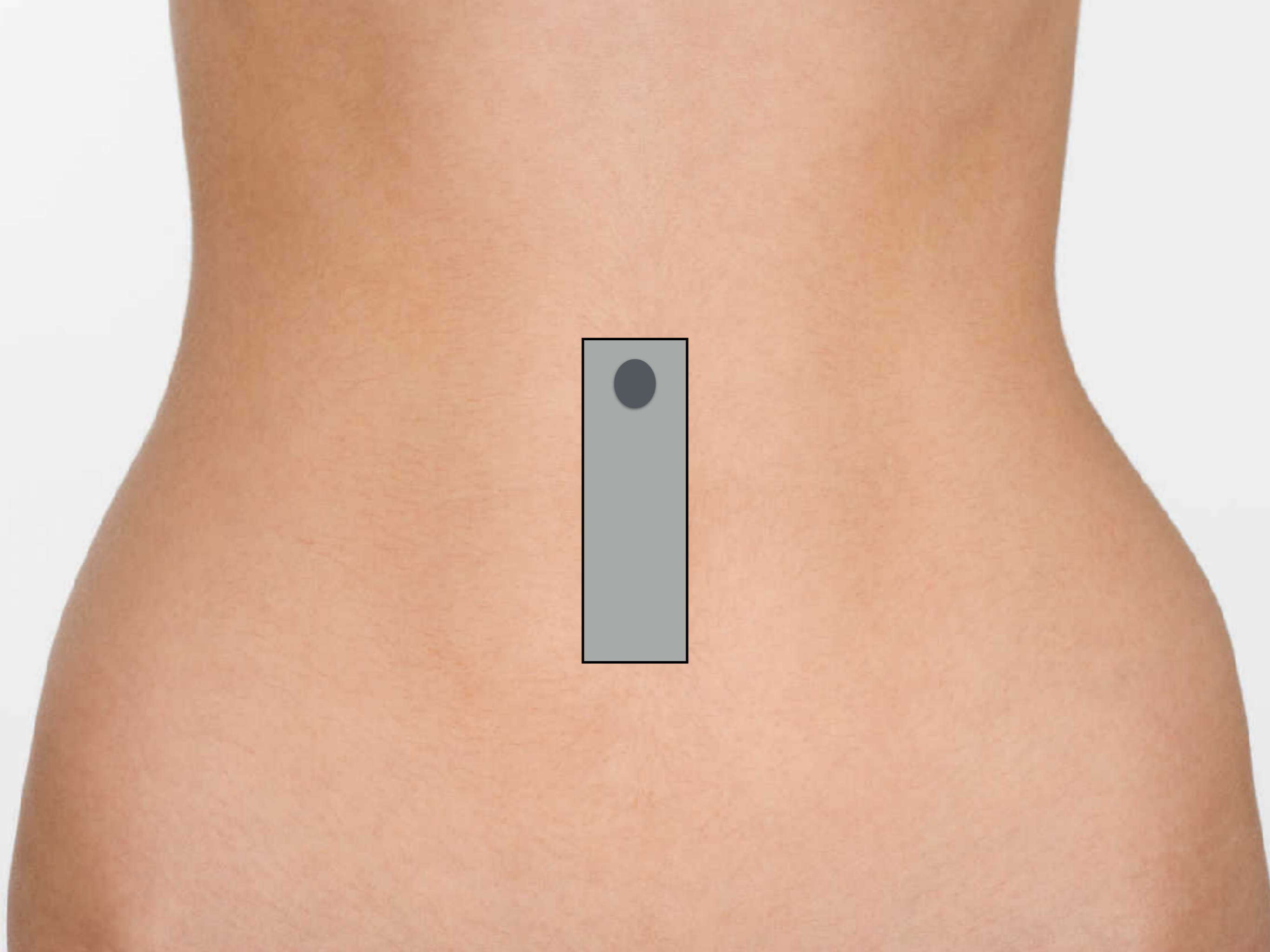
HGen  
Gn 66  
C 56  
3/3/3



G  
P R  
1.8 3.6

11.0cm



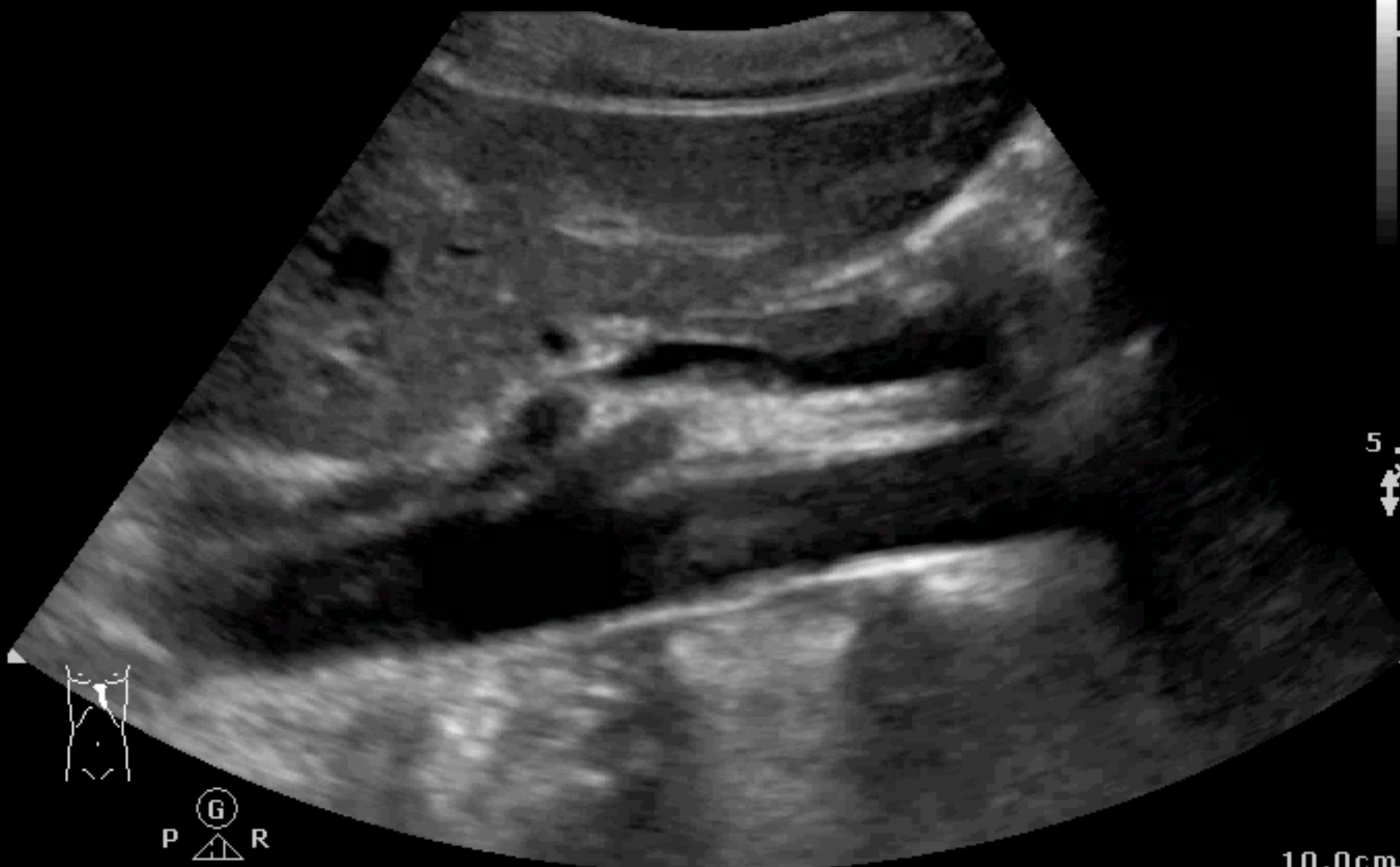

# ABDOMEN

Abd Gen  
C5-1  
45 Hz  
10.0cm

2D

HGen  
Gn 60  
C 56  
3/3/3



5

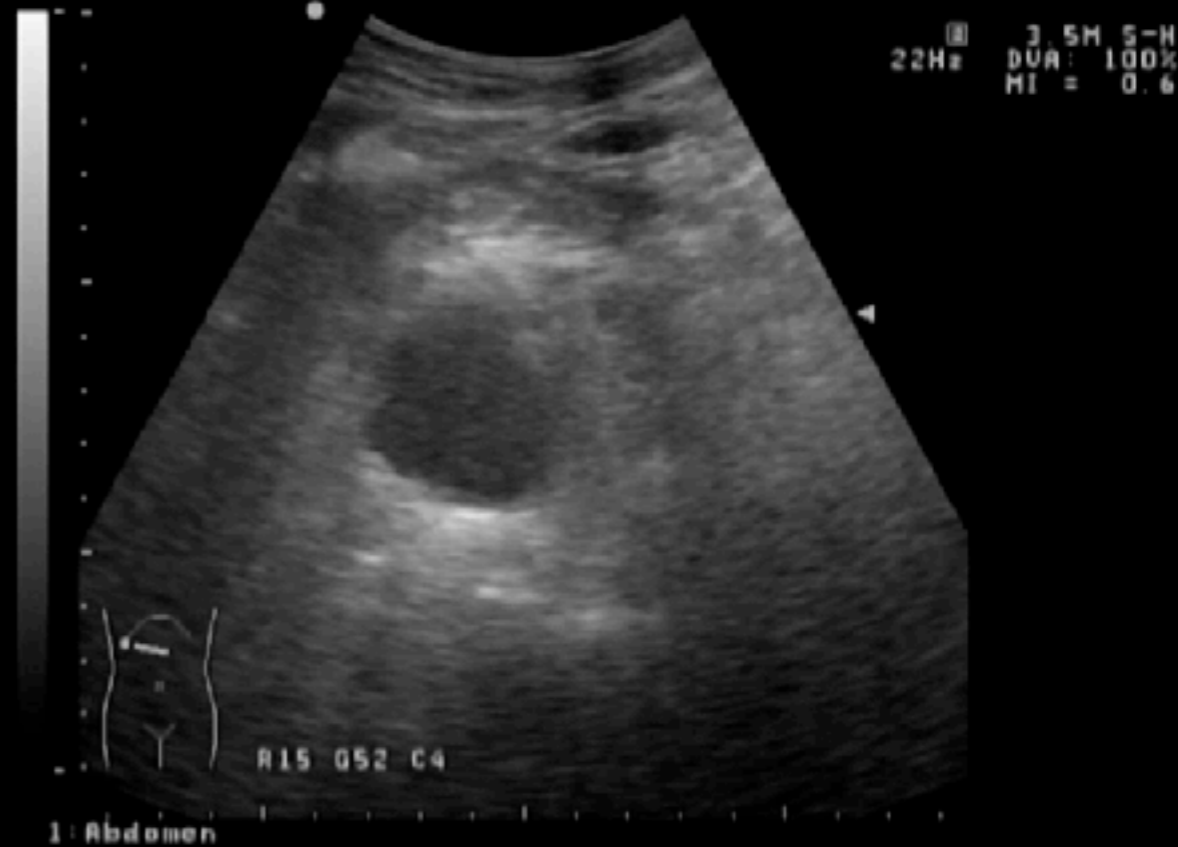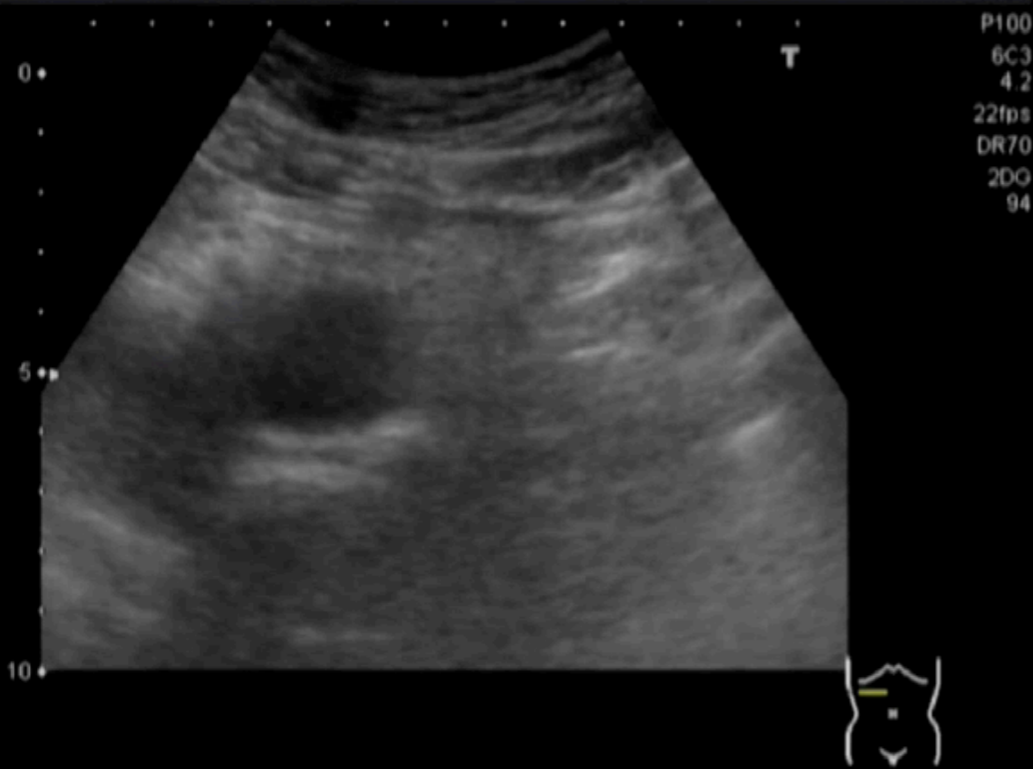
10.0cm

# ABDOMEN

A for AAA, not for rupture

POCUS Academy©ChenKC

POCUS Academy©ChenKC



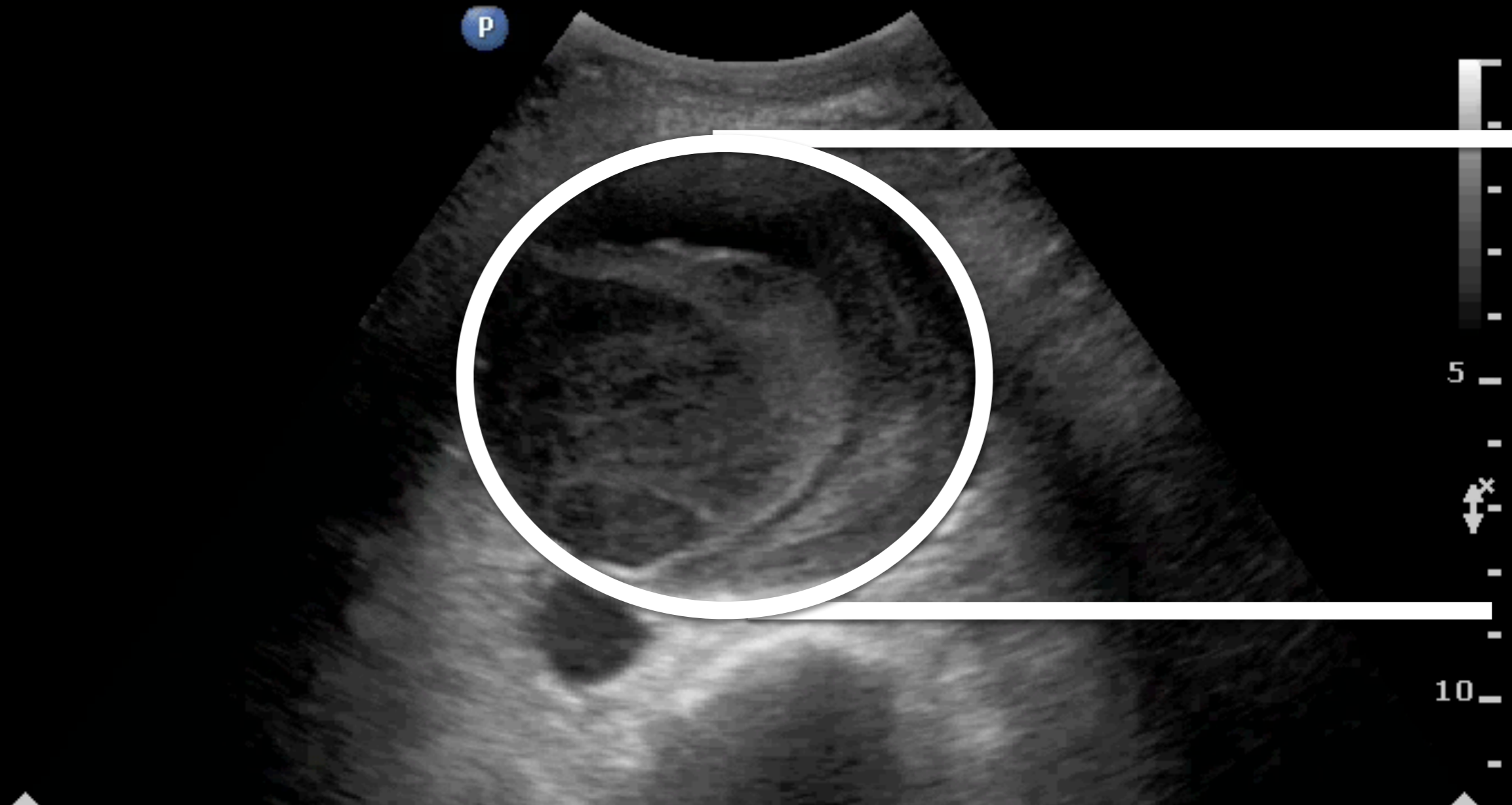


# ABDOMEN

Abd Gen  
C5-1  
34 Hz  
15.0cm

2D

HGen  
Gn 57  
C 56  
3/3/3



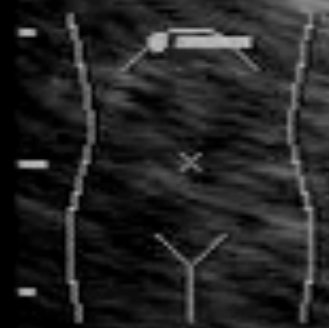
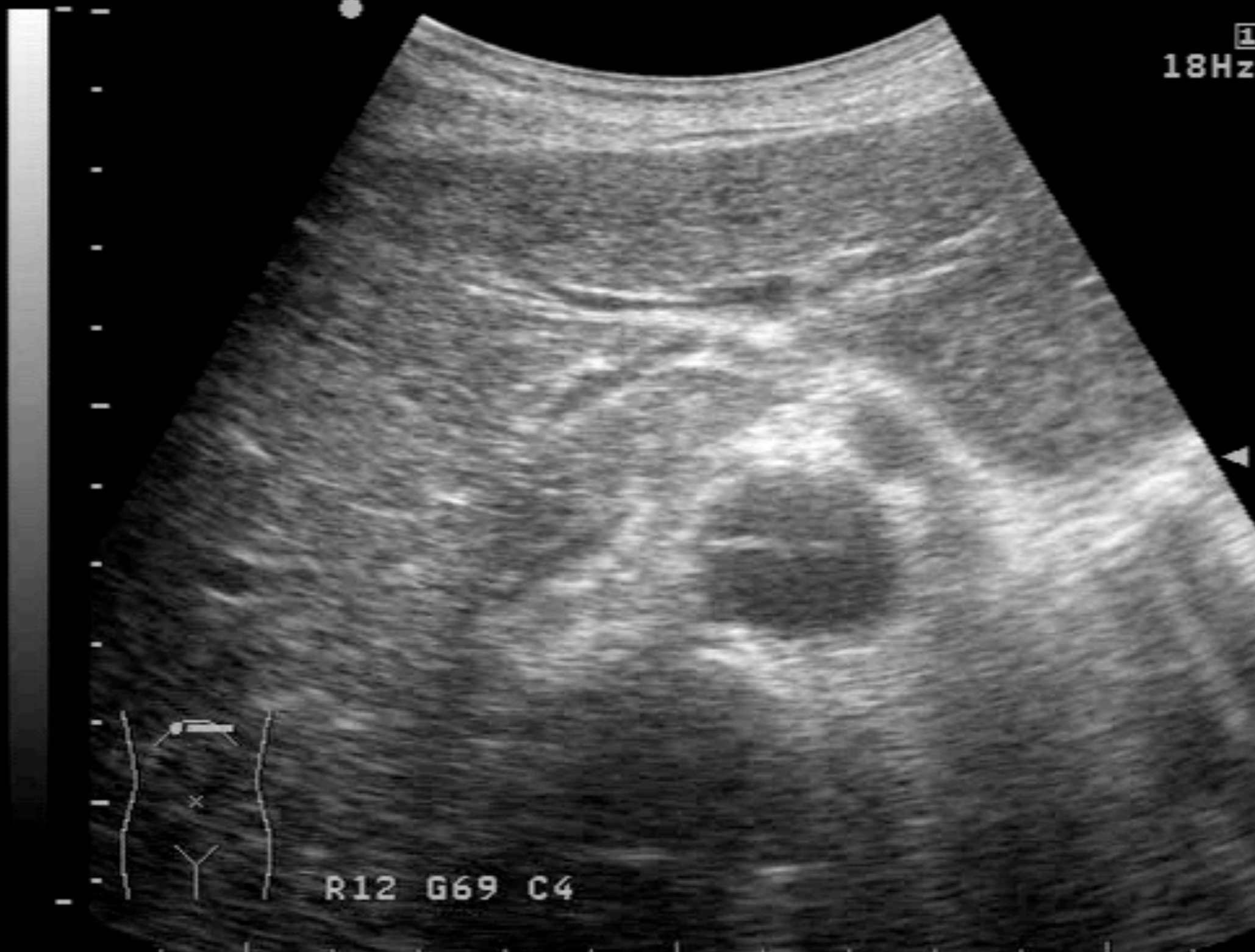**Eyeballing**

# 65M, epigastric pain after dinner

SHIN KONG HOSPITAL ER IDI  
[

: YJ : 11 OCT. 28, 10  
20:33:03

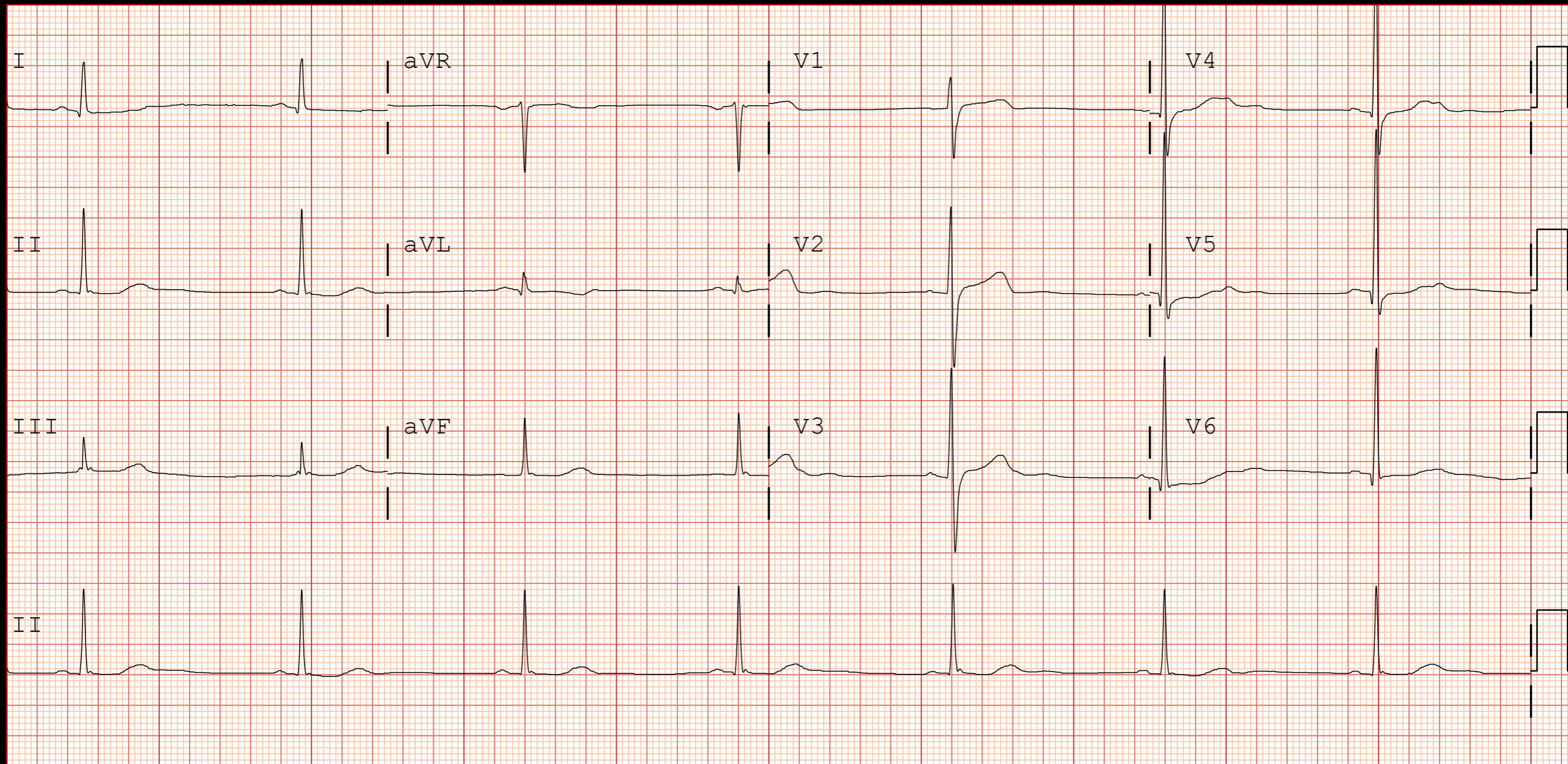
18Hz 3.5M S-H  
DVA: 100%  
MI = 0.6



R12 G69 C4

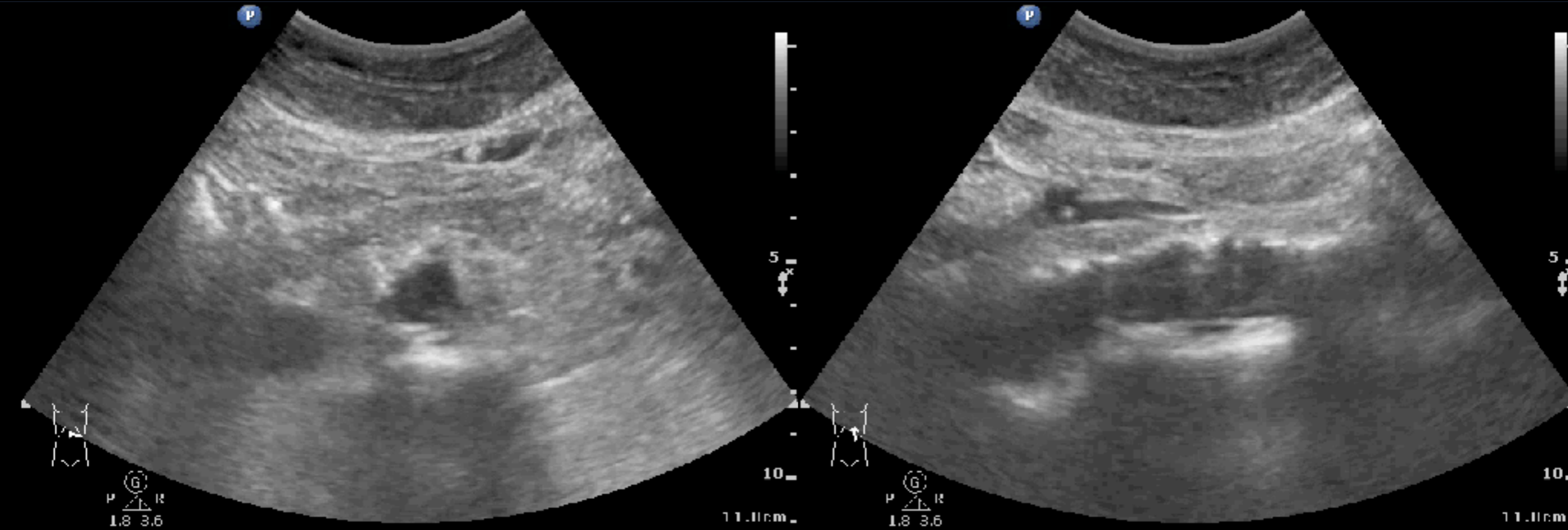
1: Abdomen

# 63M, chest/abd pain & low BP



# ABDOMEN

## Aortic dissection

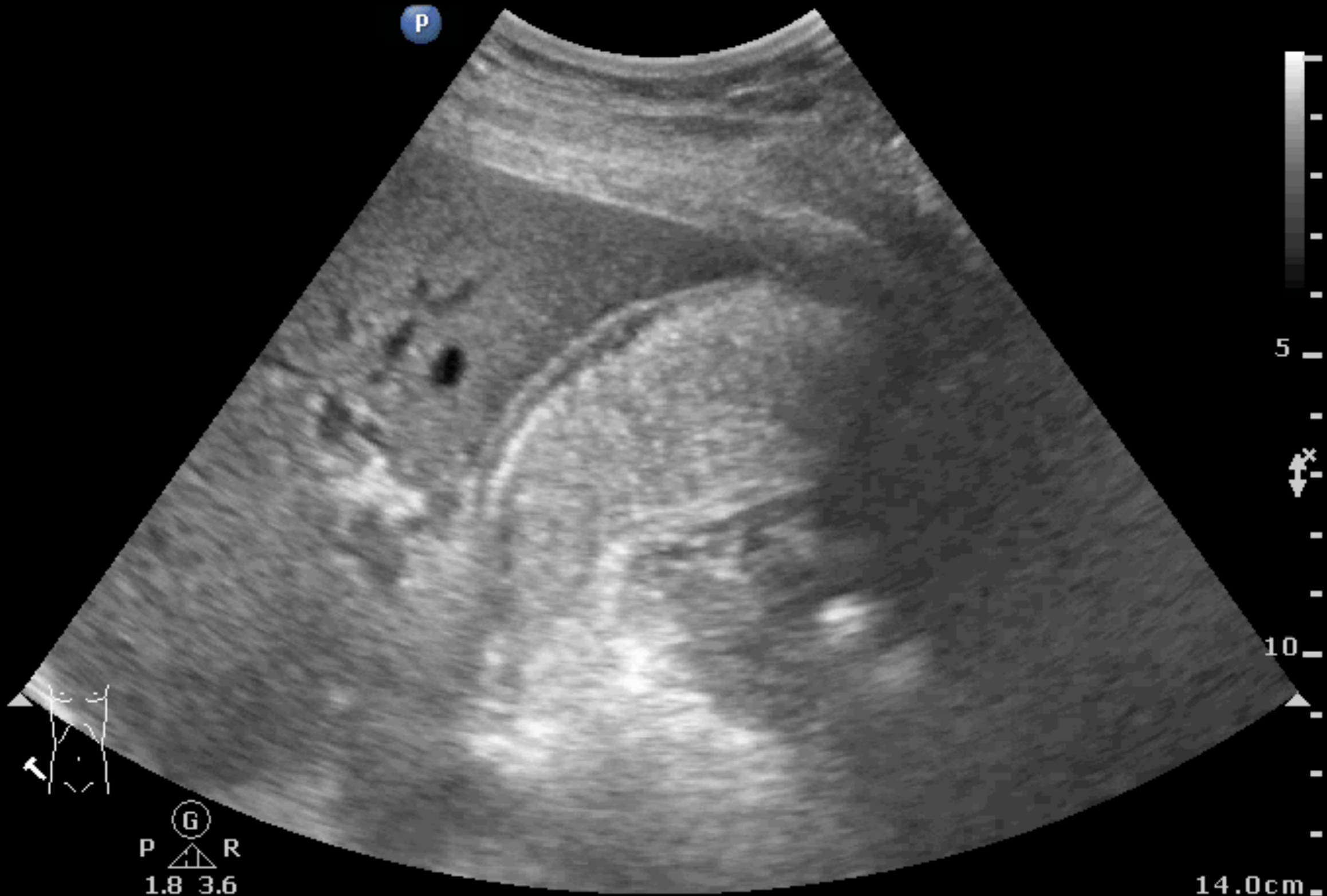


# 59M, epigastric pain at midnight

Abd Gen2  
C5-1  
36 Hz  
14.0cm

2D

HGen  
Gn 100  
C 56  
3 / 3 / 3

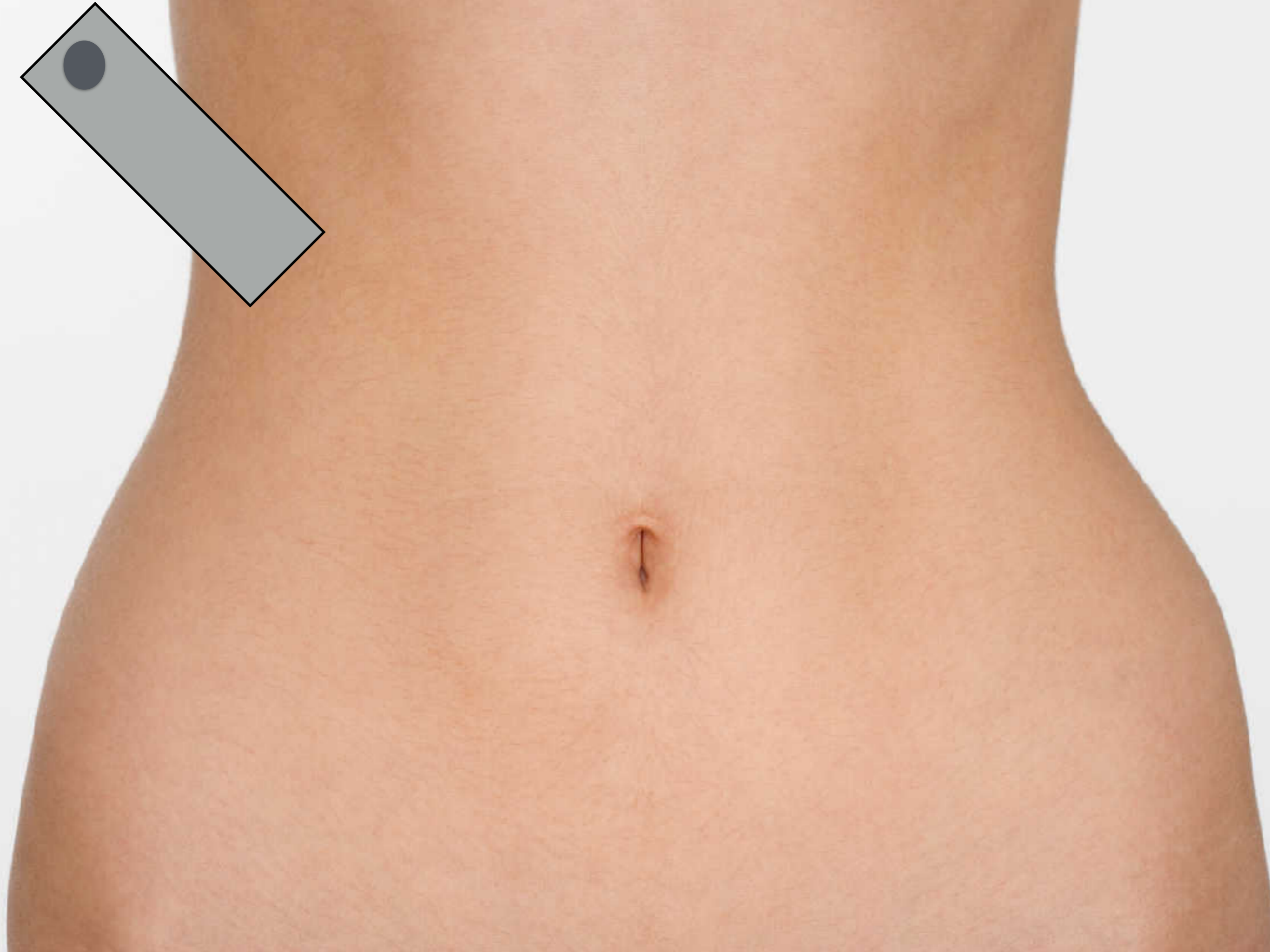

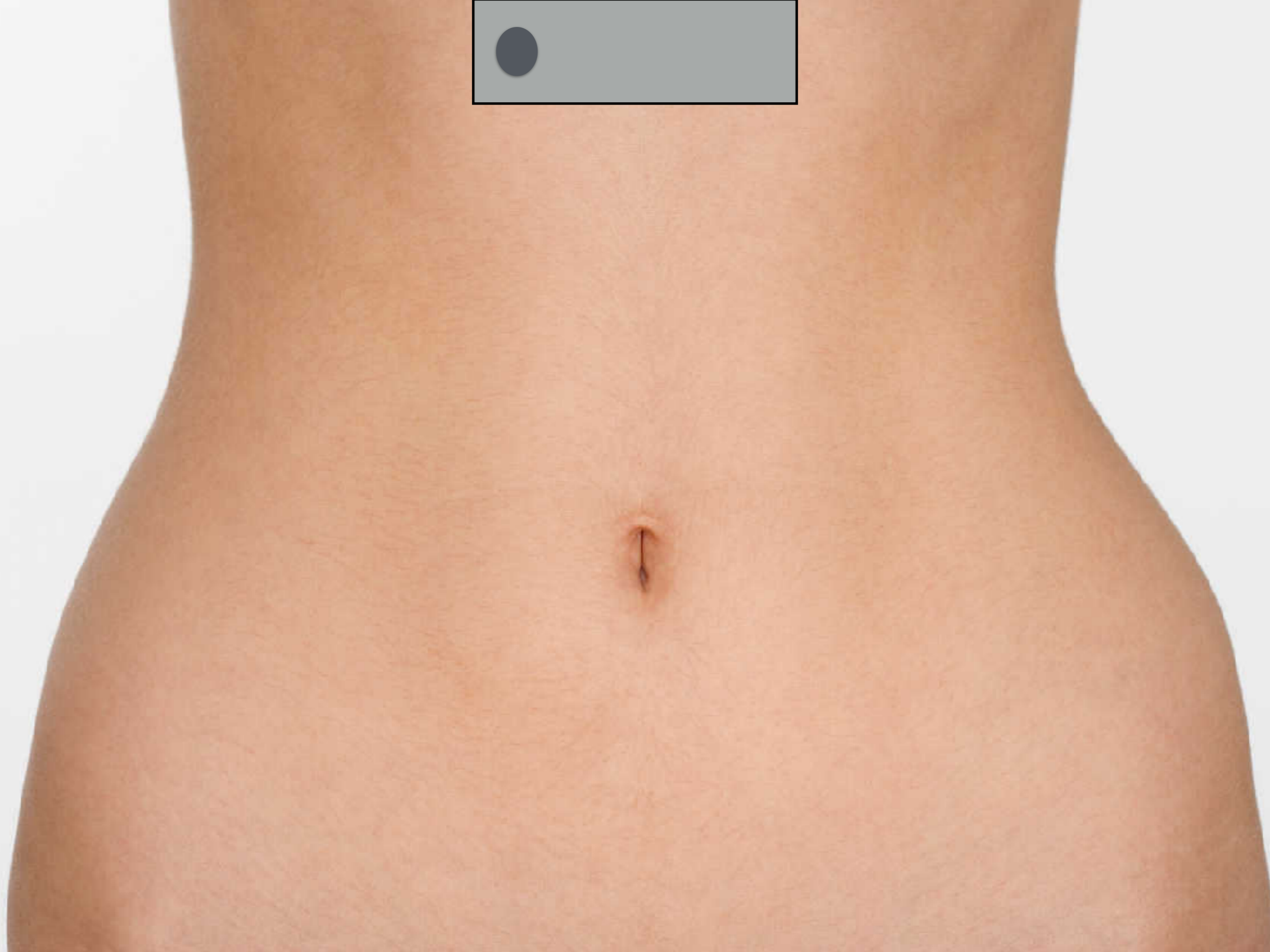
14.0cm

# ABDOMEN

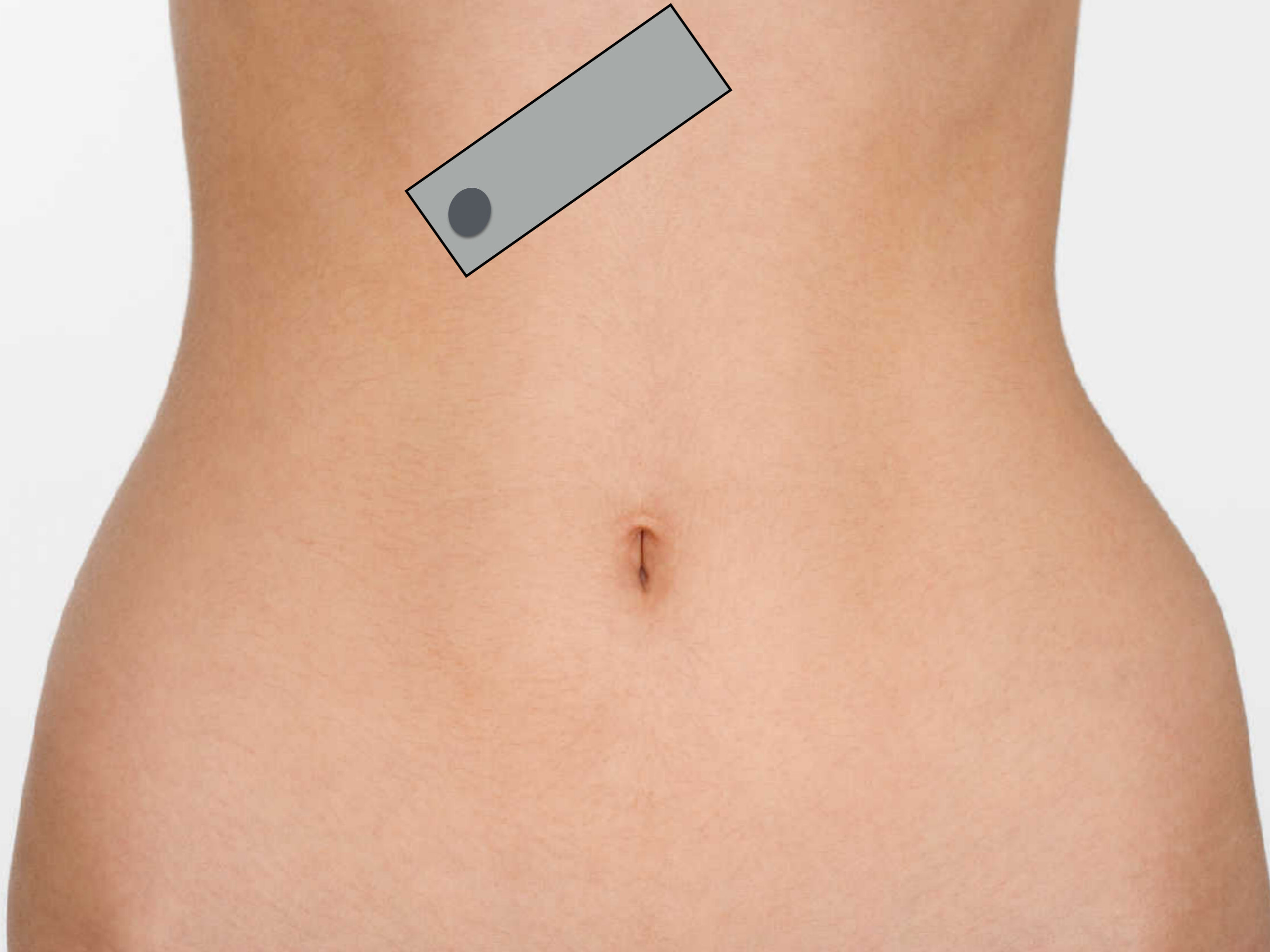
**B for GB stone & dilatation**


**3** mm      **7** mm      **11** mm



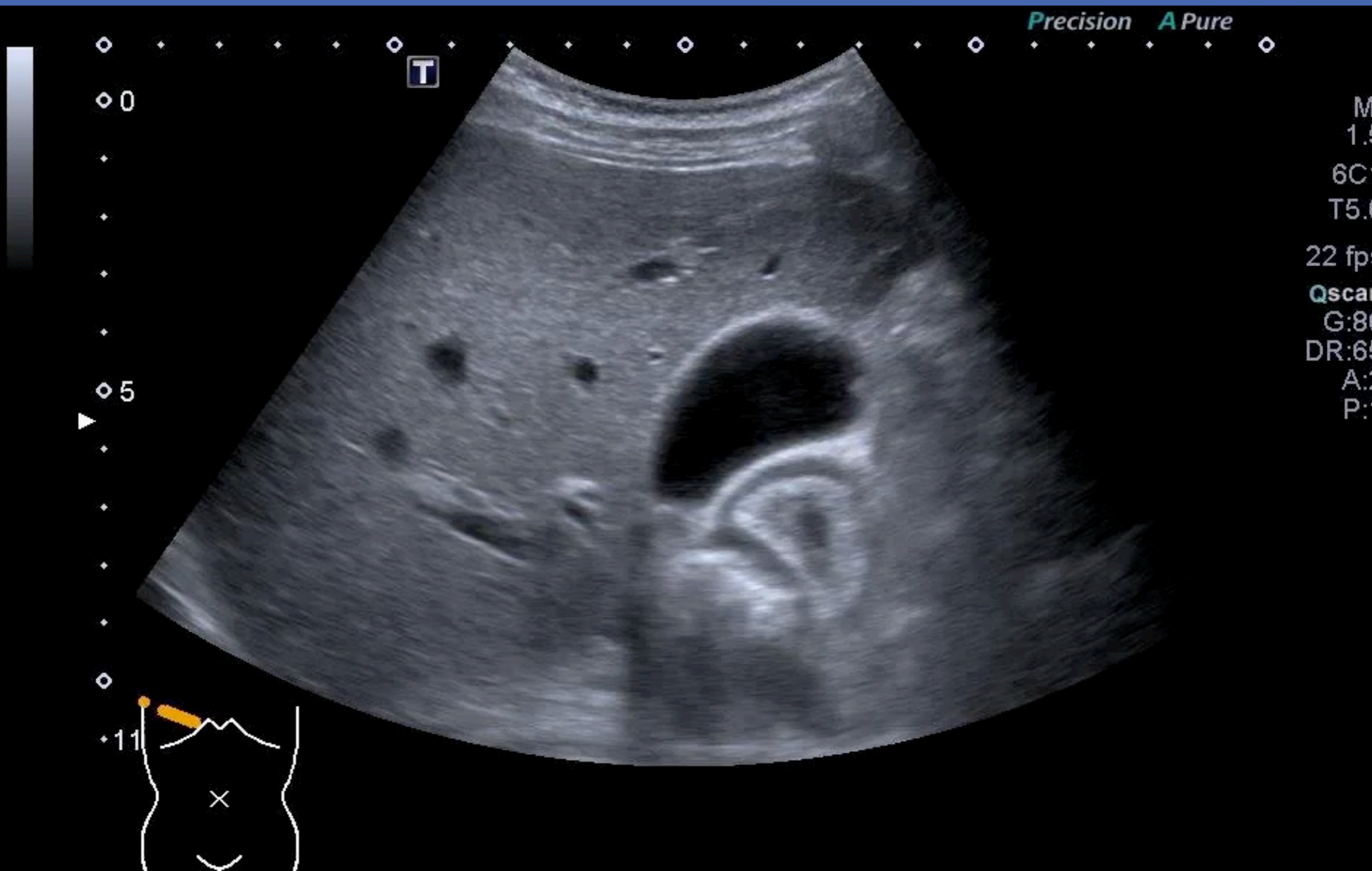







# 讀讀看，你看到了什麼？

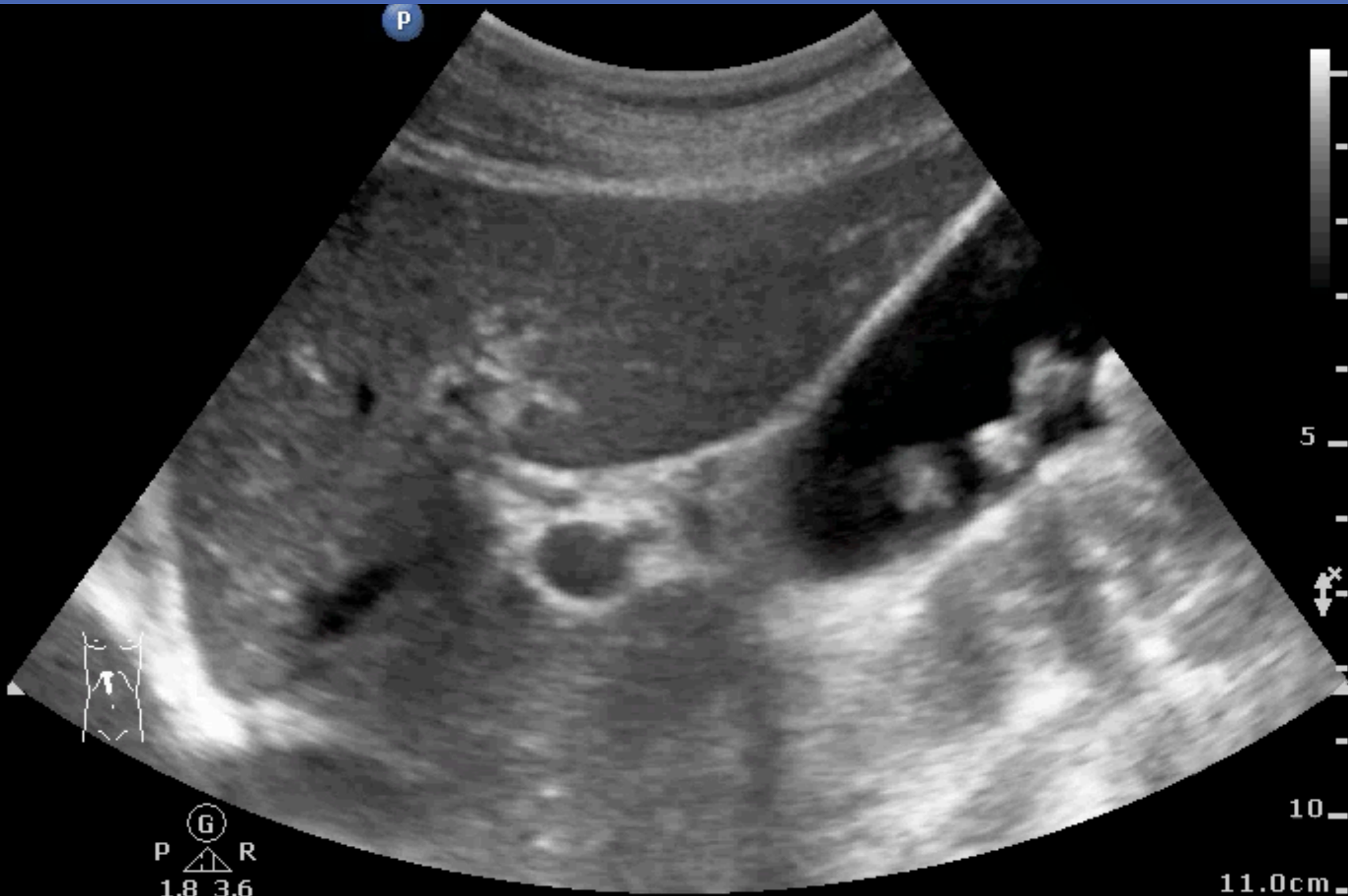


# 讀讀看，你看到了什麼？

Abd Gen  
C5-1  
42 Hz  
11.0cm

2D

HGen  
Gn 80  
C 56  
3 / 3 / 3



G  
P R  
1.8 3.6

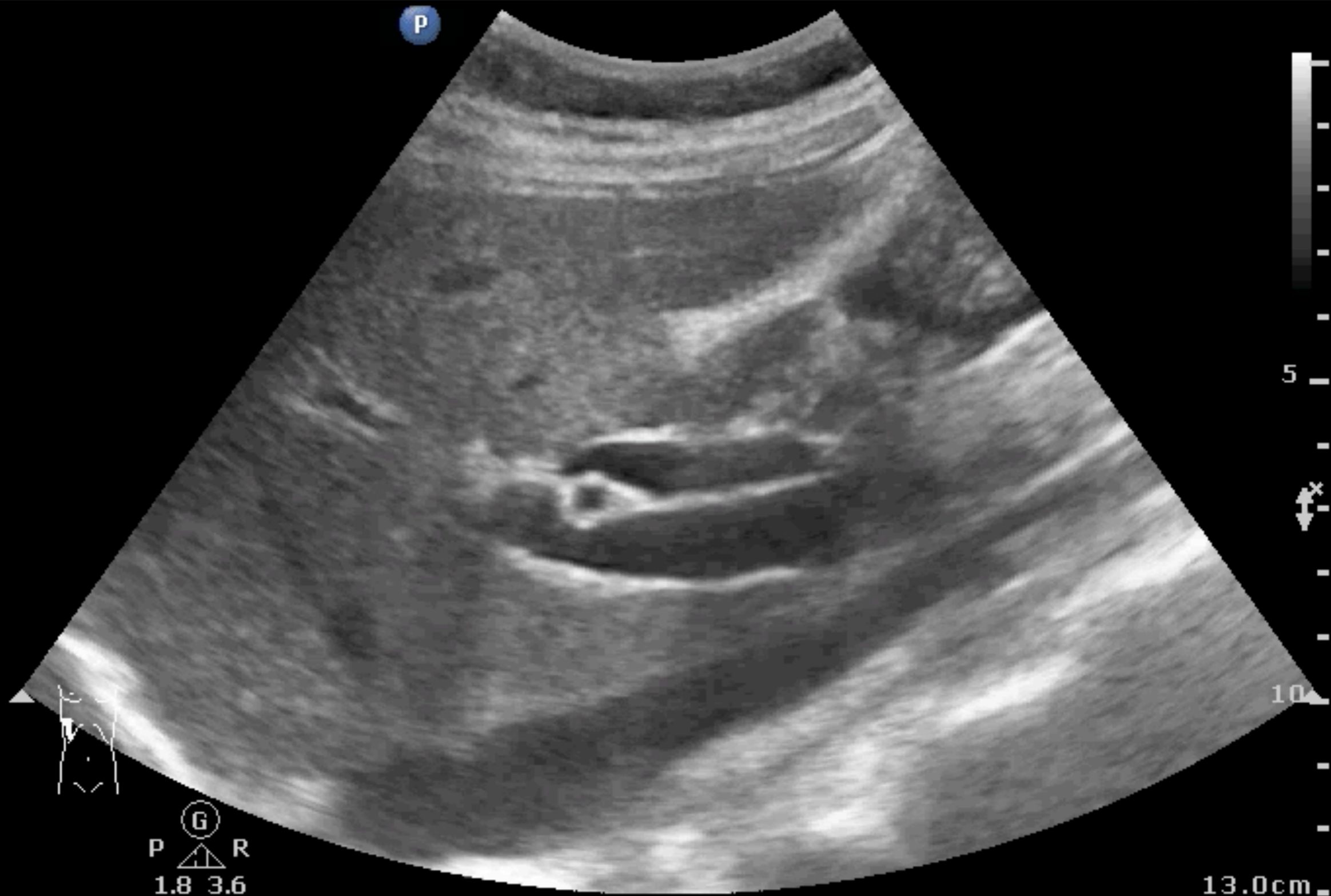11.0cm

# 讀讀看，你看到了什麼？

Abd Gen  
C5-1  
38 Hz  
13.0cm

2D

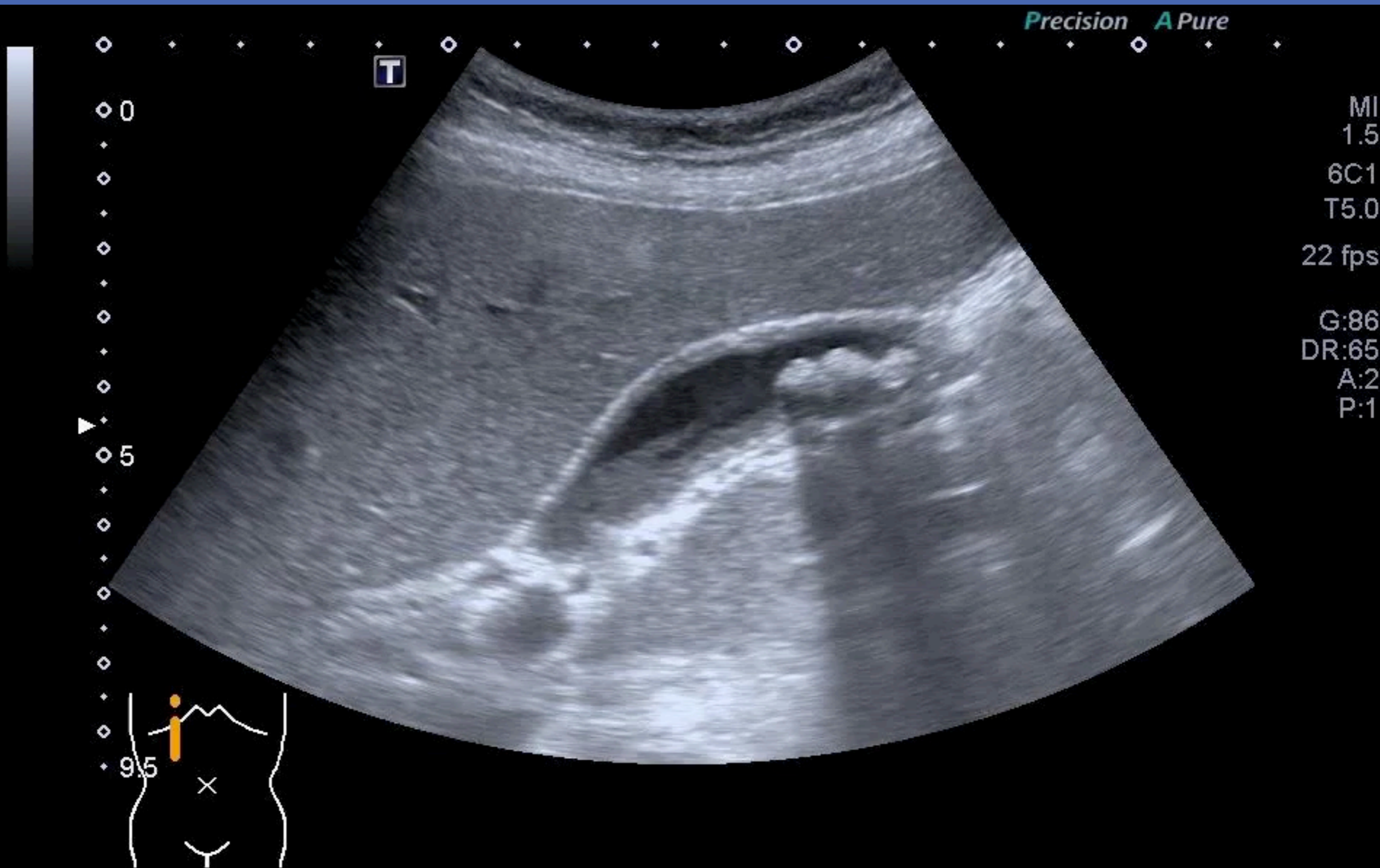
HGen  
Gn 82  
C 56  
3 / 3 / 3



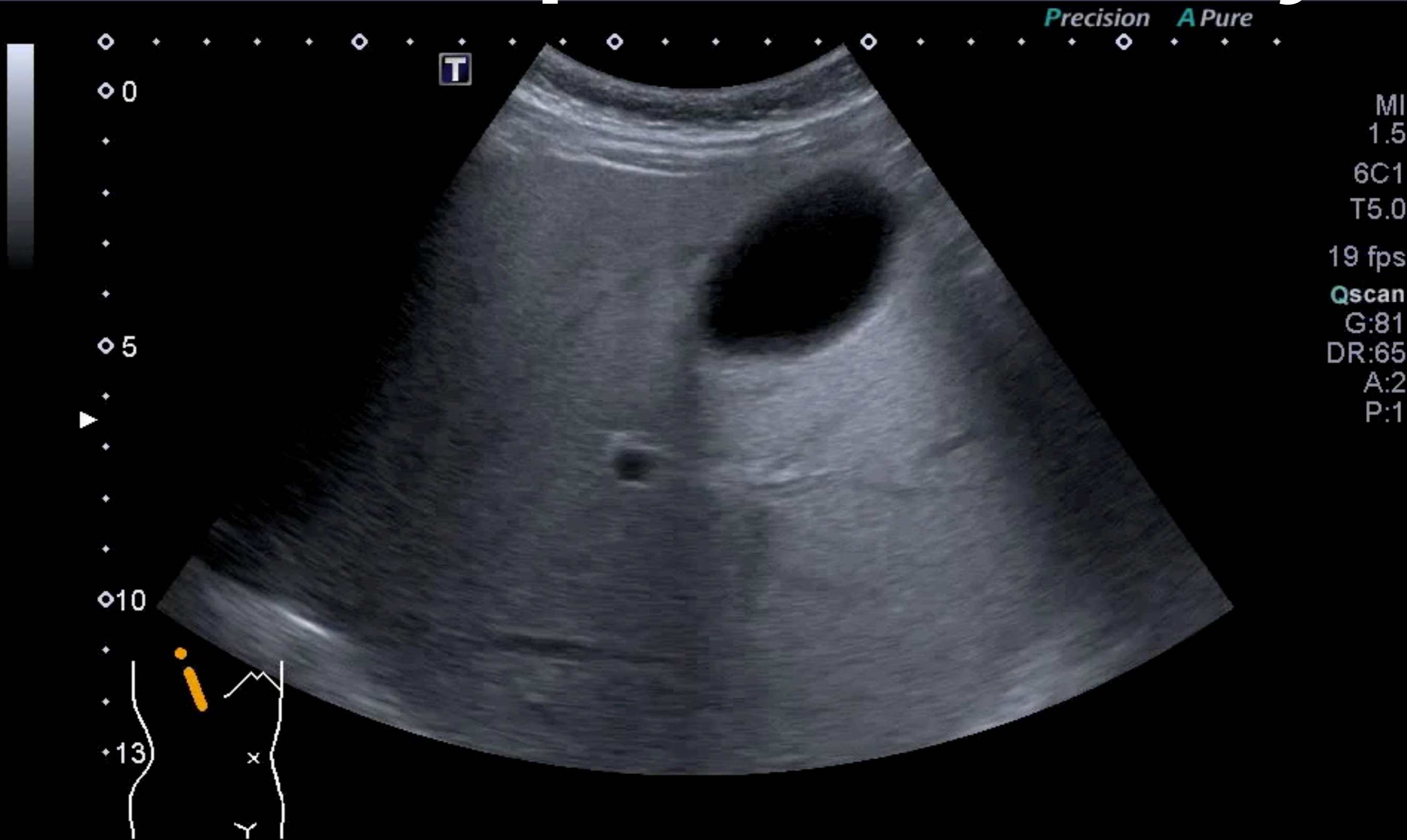
P  $\triangle$  R  
1.8 3.6

13.0cm

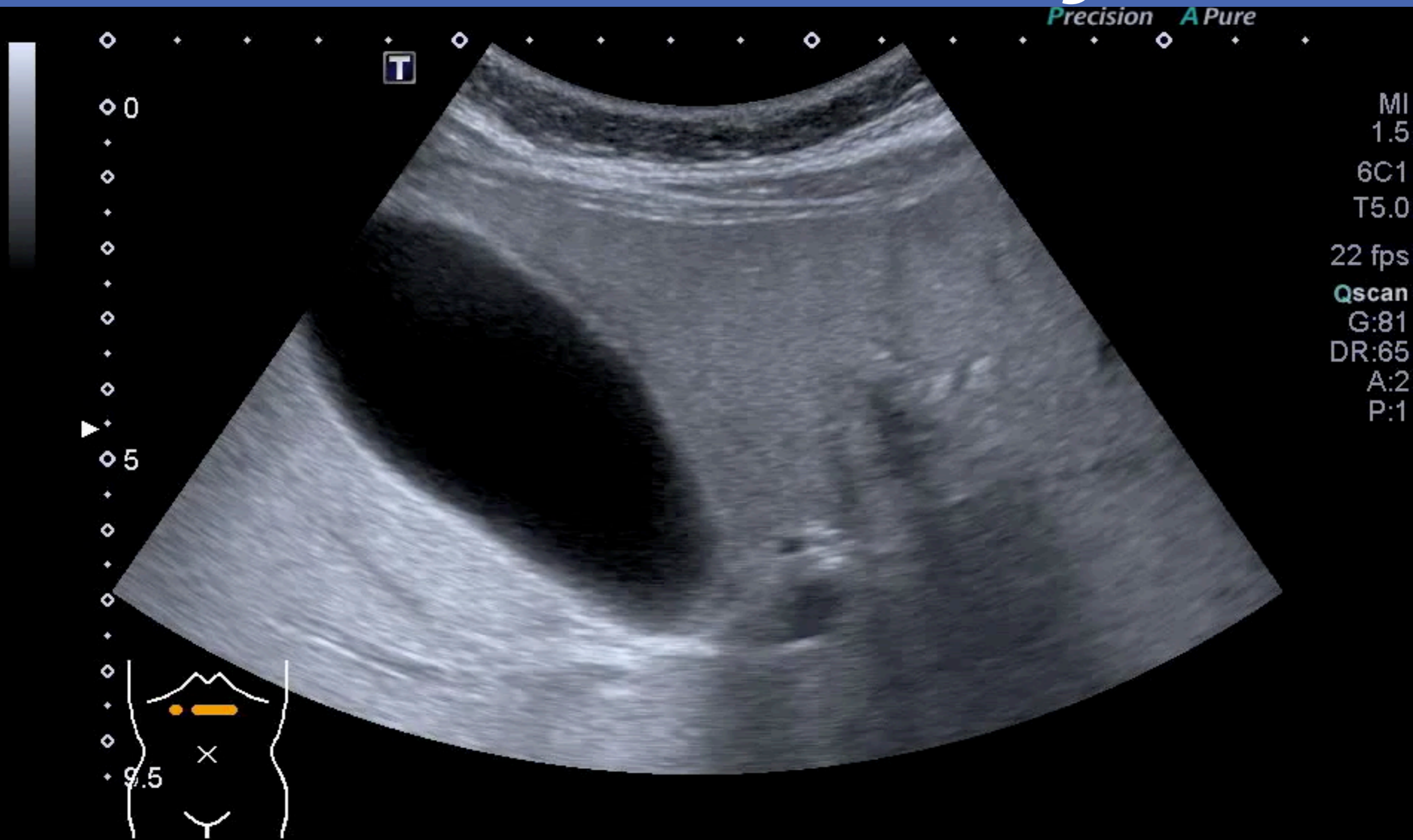
# 讀讀看，你看到了什麼？



# 61F , ABD pain for 3-4 days



# GB stones & Cholecystitis





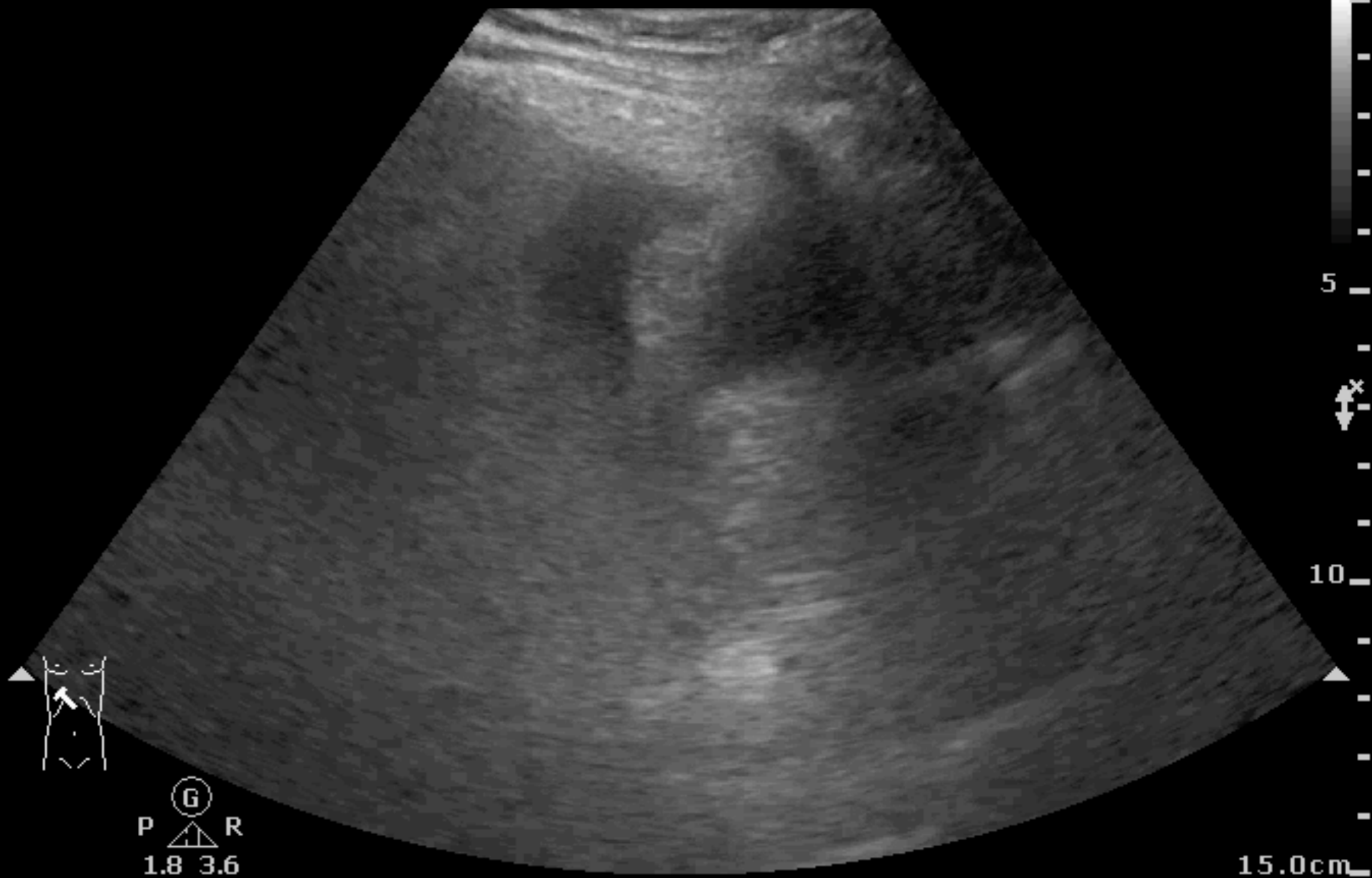
# ABDOMEN

## 45M, RUQ pain & fever

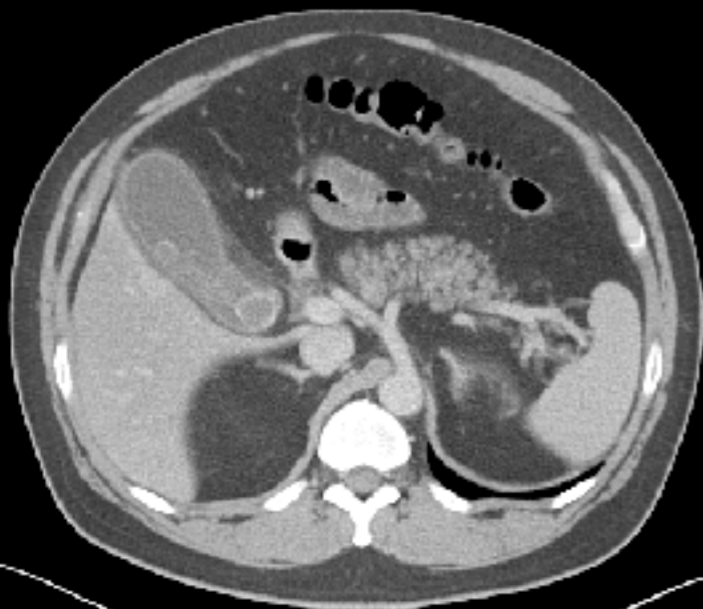
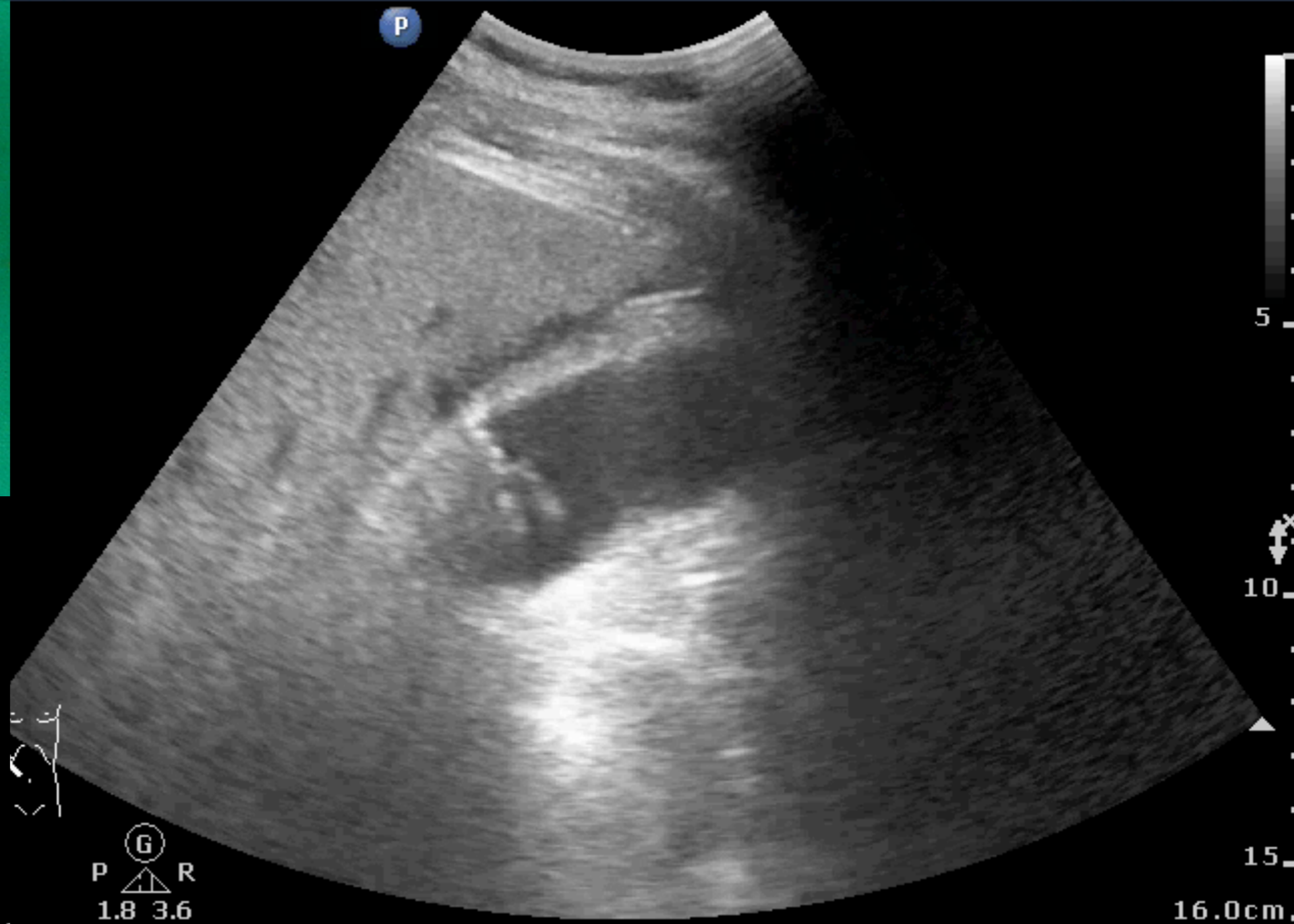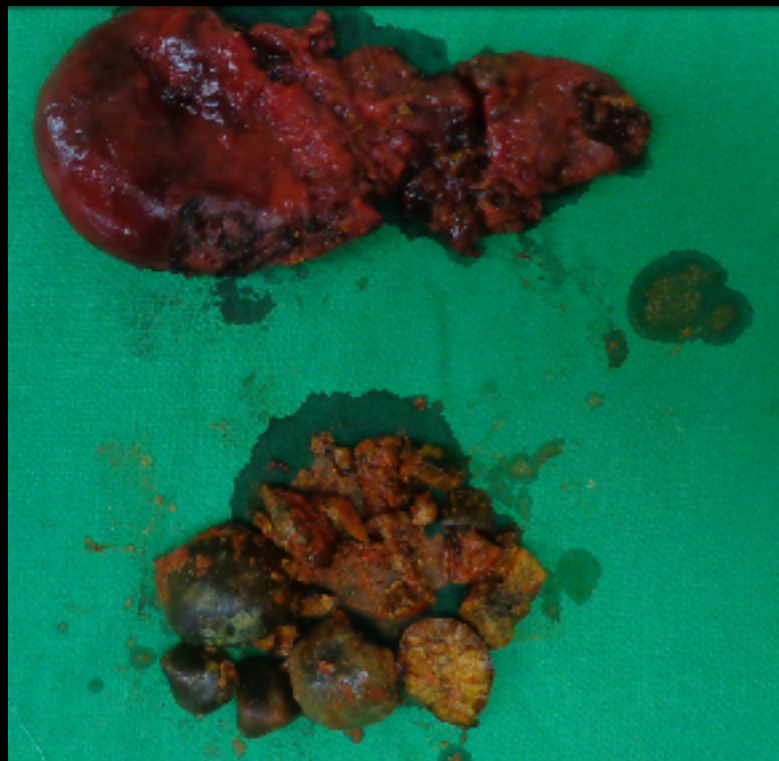
Abd Ge  
C5-1  
34 Hz  
15.0cm

2D

HGen  
Gn 100  
C 56  
3/3/3



# Acute calculous cholecystitis



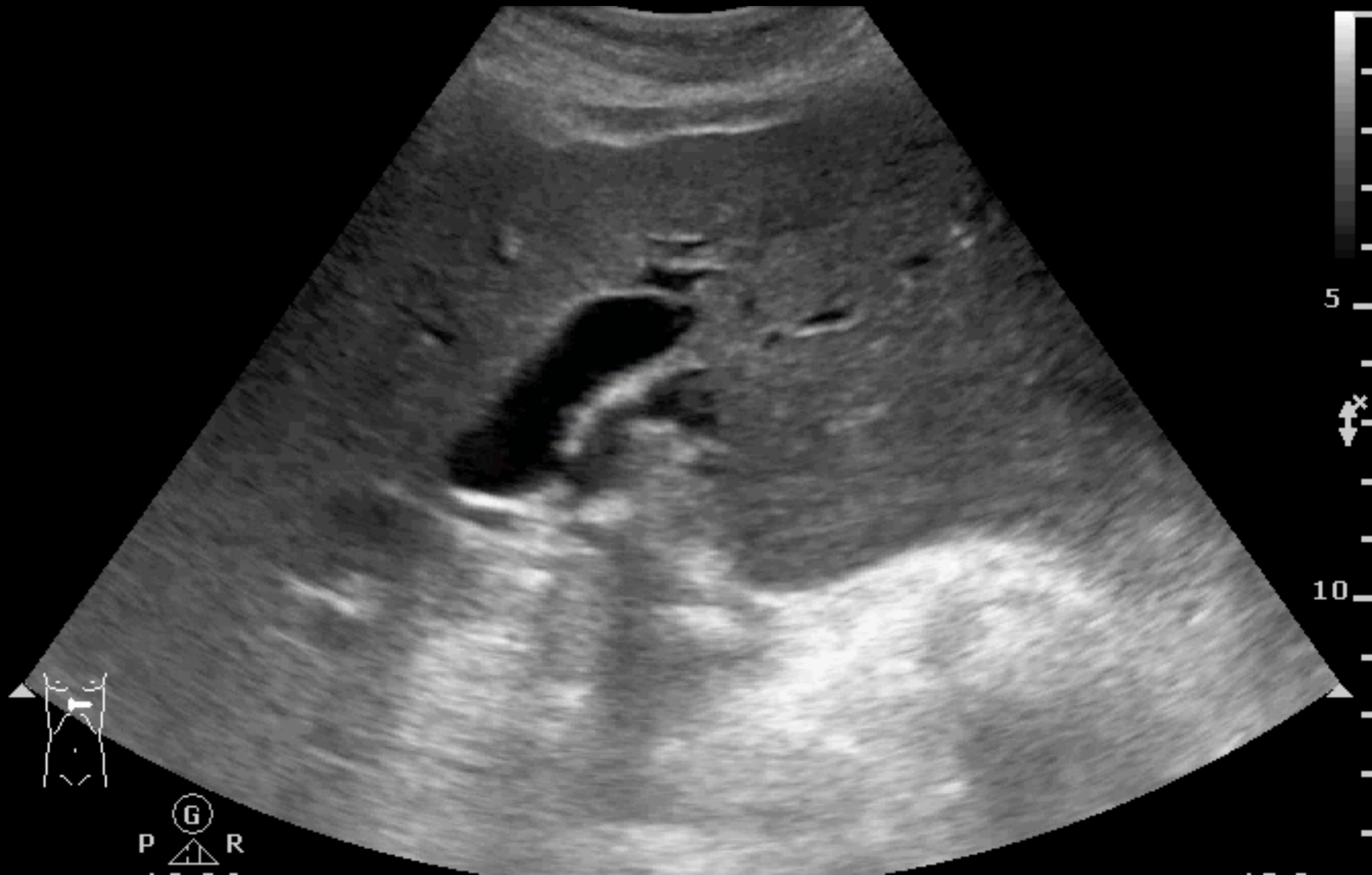# ABDOMEN

## 76F, Fever & Chills

Abd Ge  
C5-1  
34 Hz  
15.0cm

2D

HGen  
Gn 78  
C 56  
3/3/3



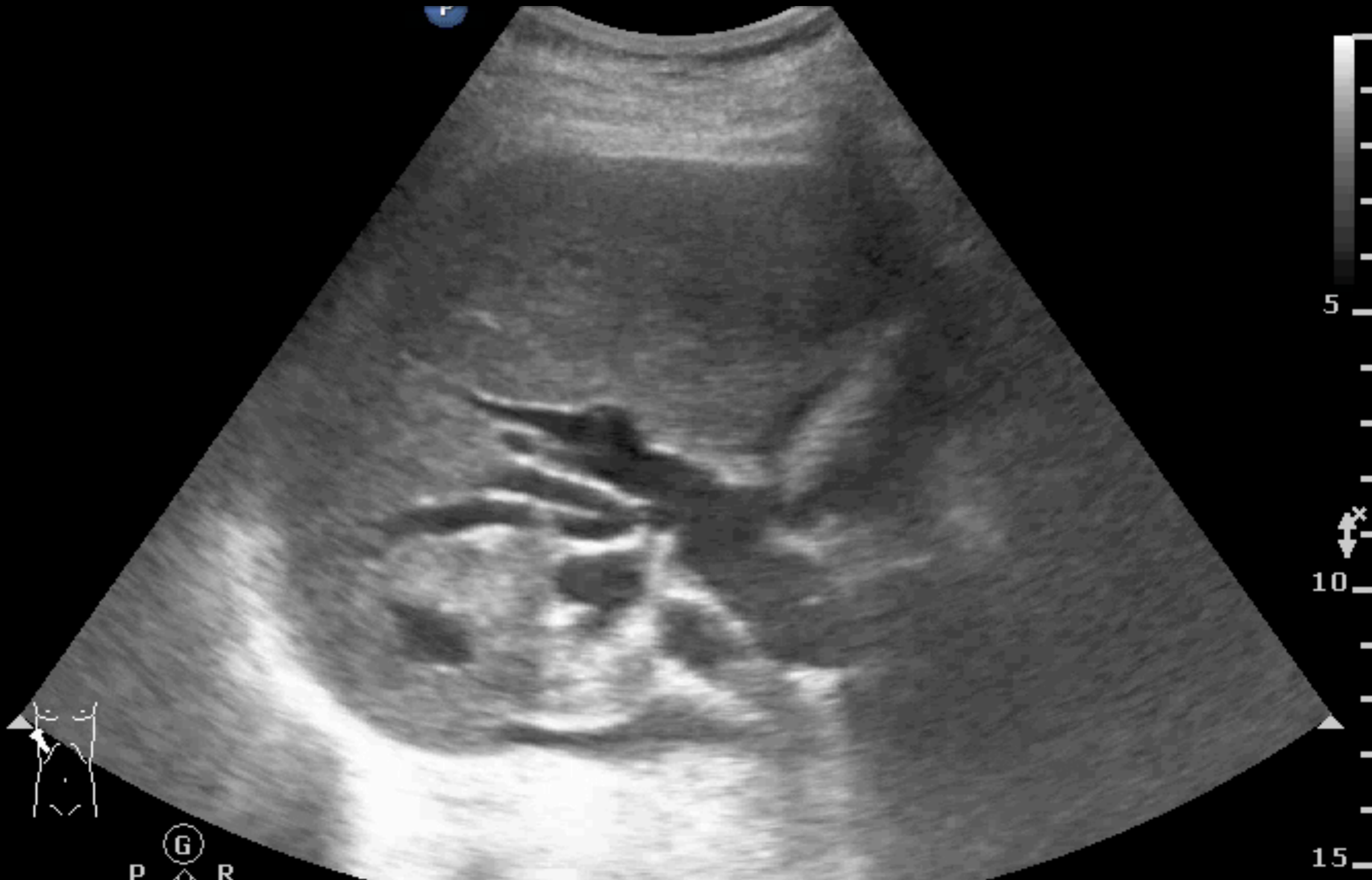# ABDOMEN

## 76F, Fever & Chills

Abd Gen2  
C5-1  
32 Hz  
16.0cm

2D

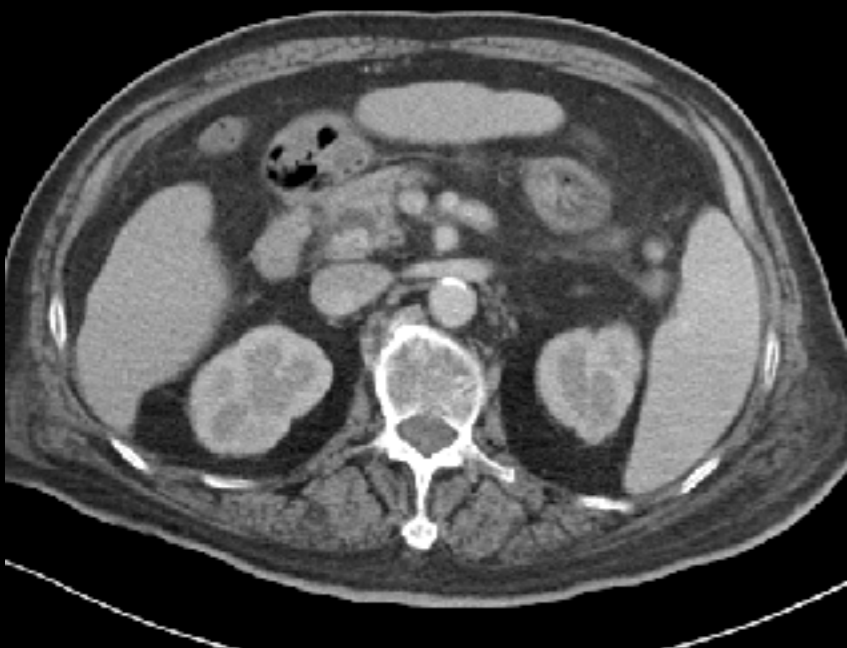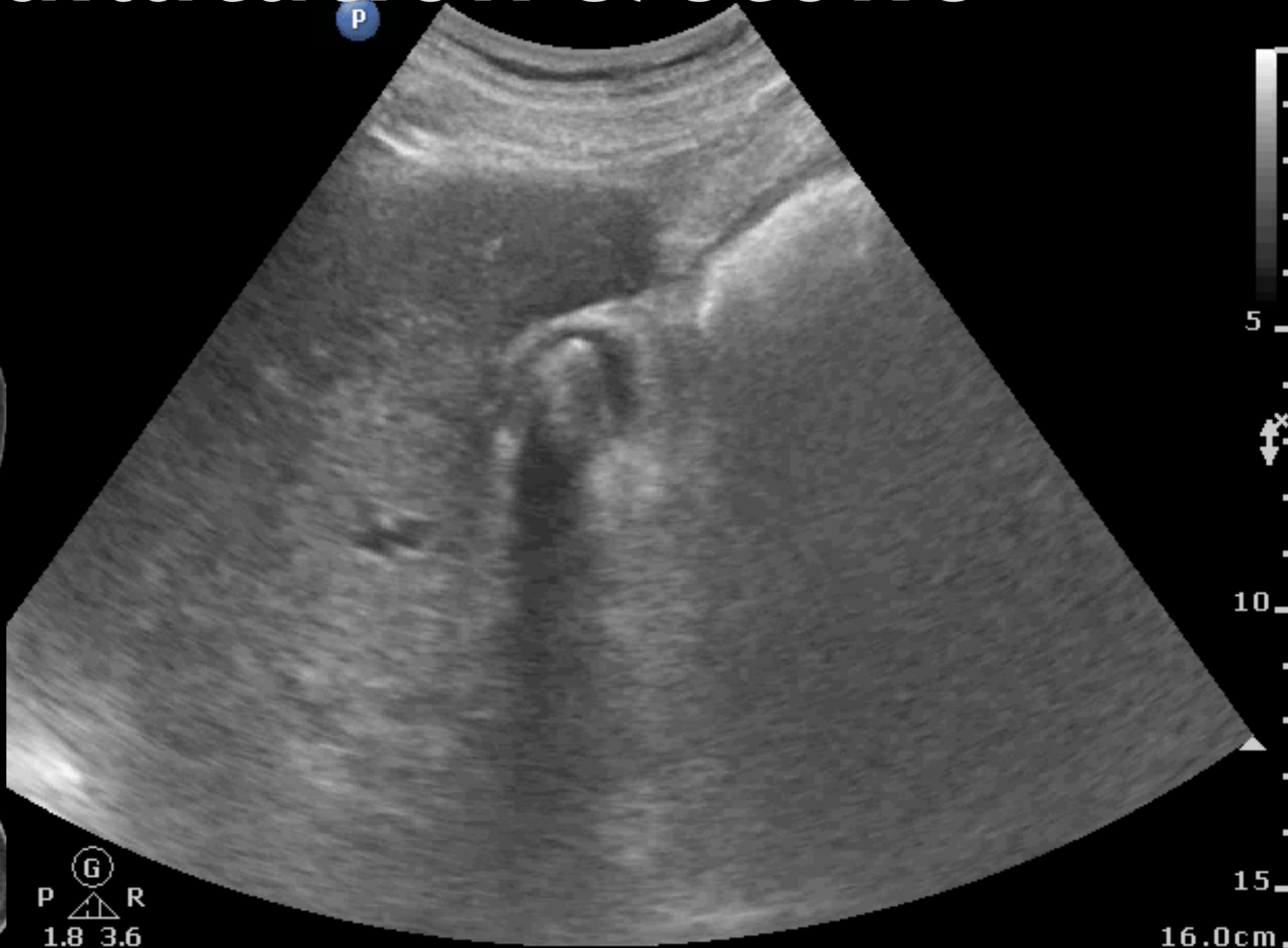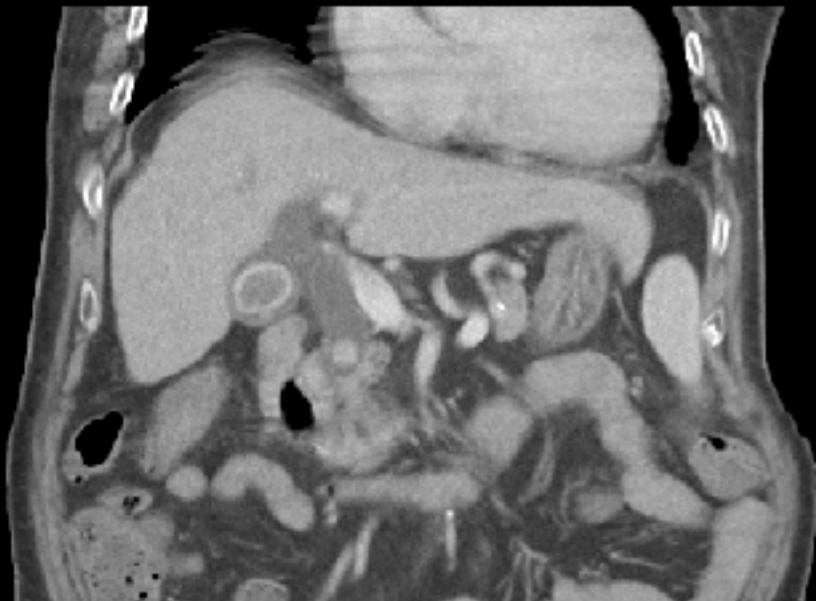
HGen  
Gn 100  
C 56  
3 / 3 / 3



# ABDOMEN

## CBD dilatation & stone

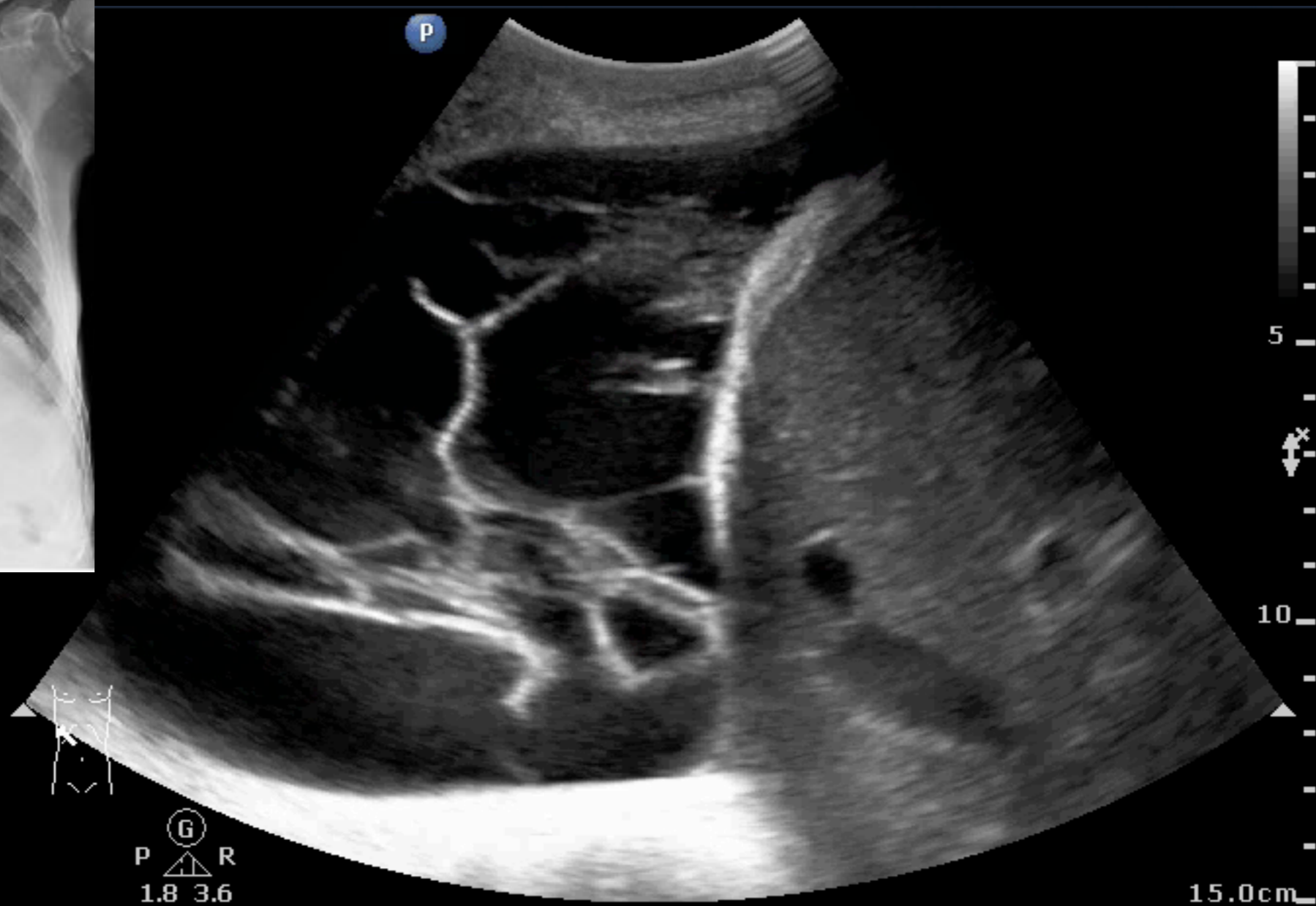
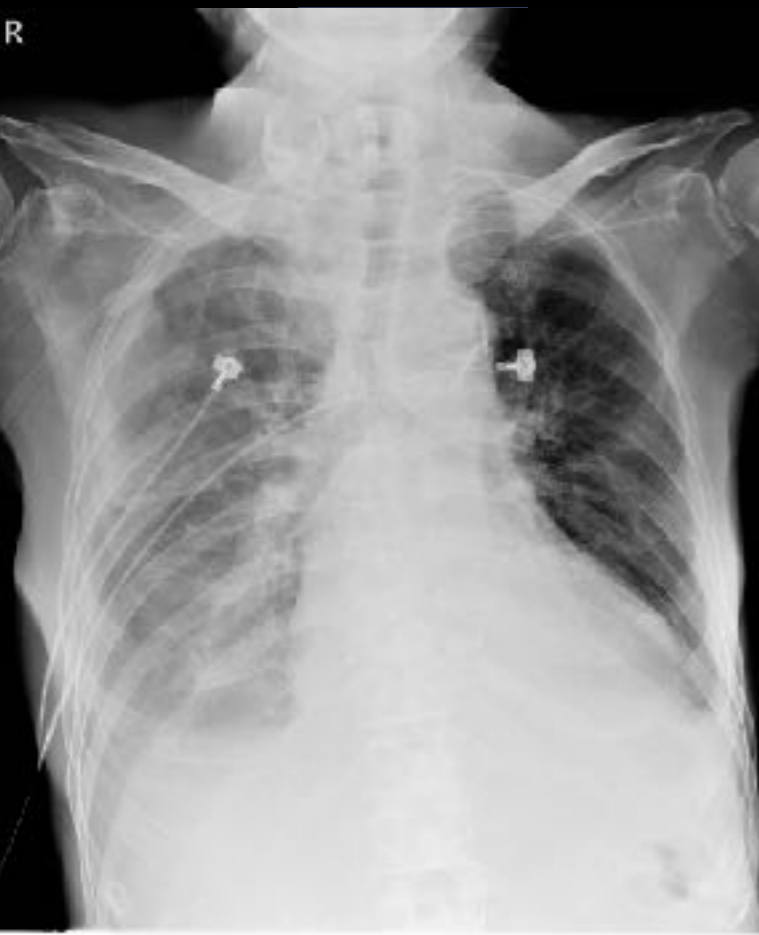Abd Gen2  
C5-1



P  R  
1.8 3.6

15  
16.0cm

# 73M, chest/abd pain & SOB



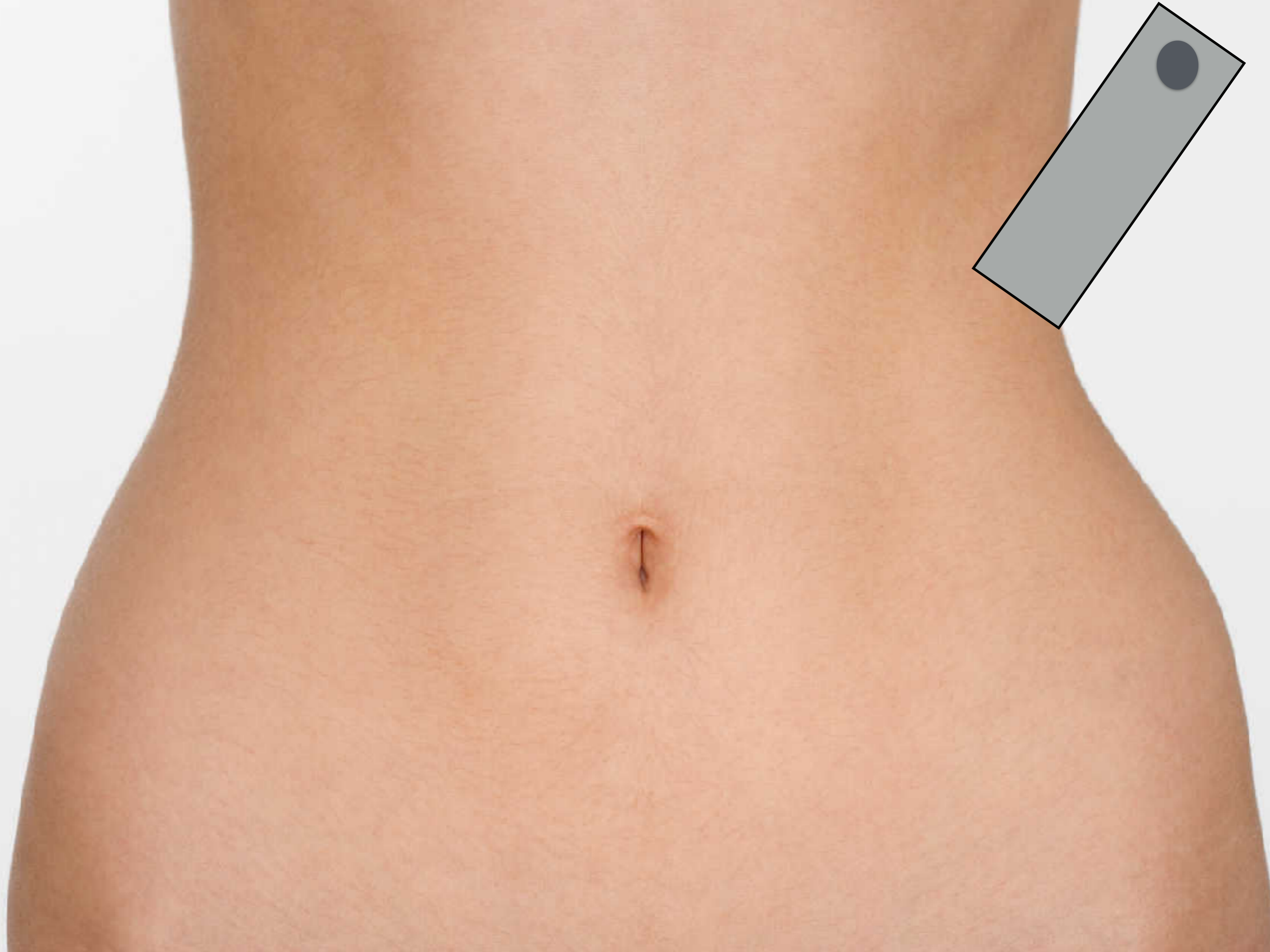# AB**D**DOMEN

D for diaphragm

# Outsider







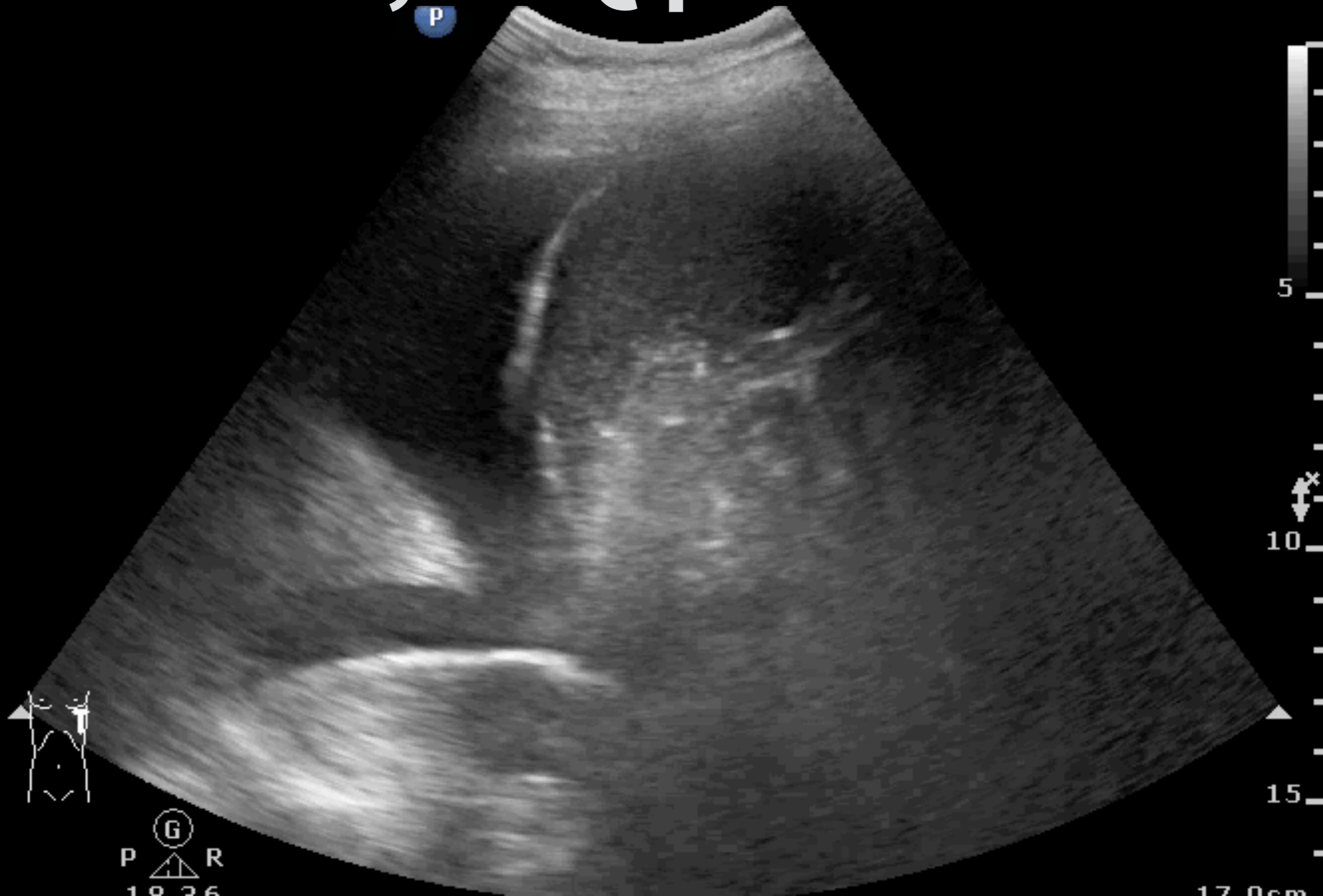
# ABDOMEN

45M, LUQ pain

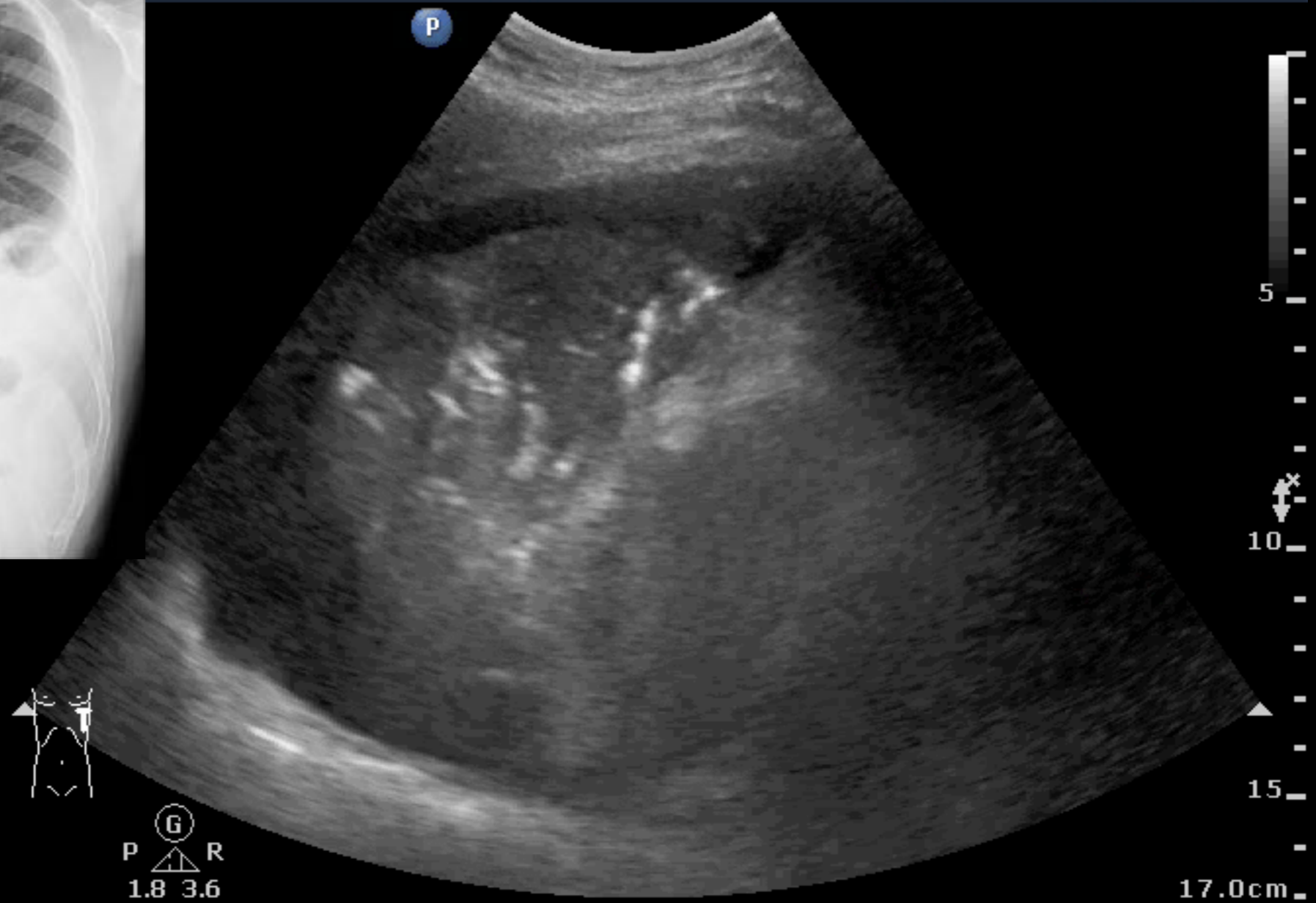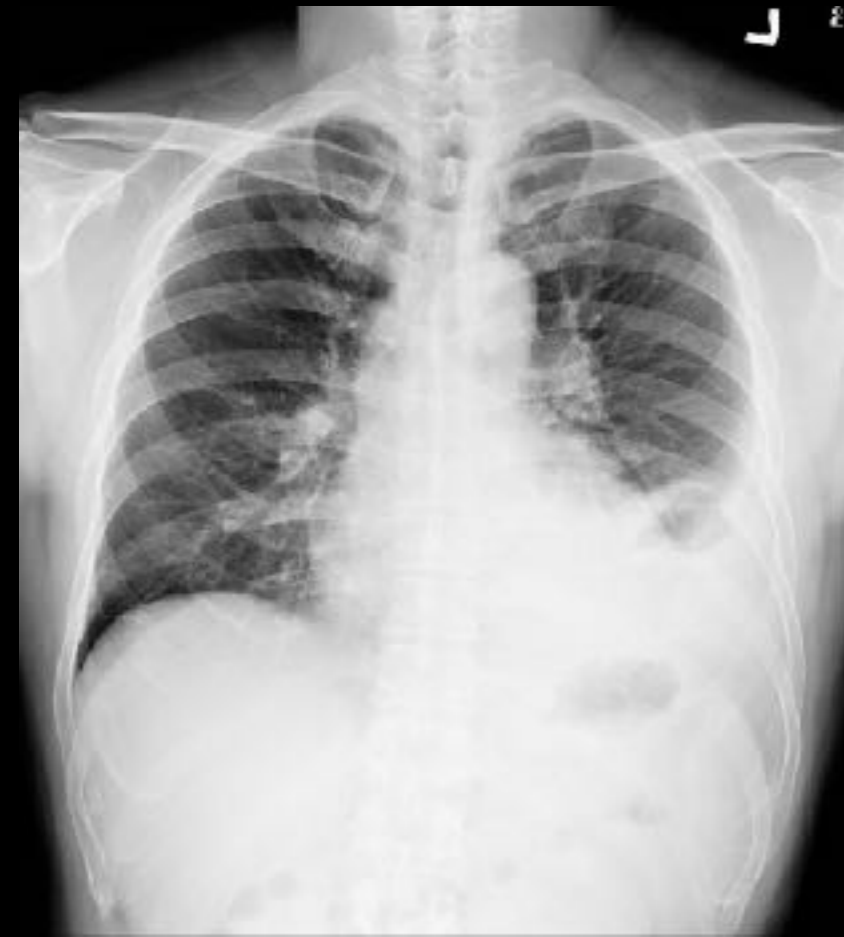Abd Gen  
C5-1  
31 Hz  
17.0cm

2D

HGen  
Gn 100  
C 56  
3/3/3

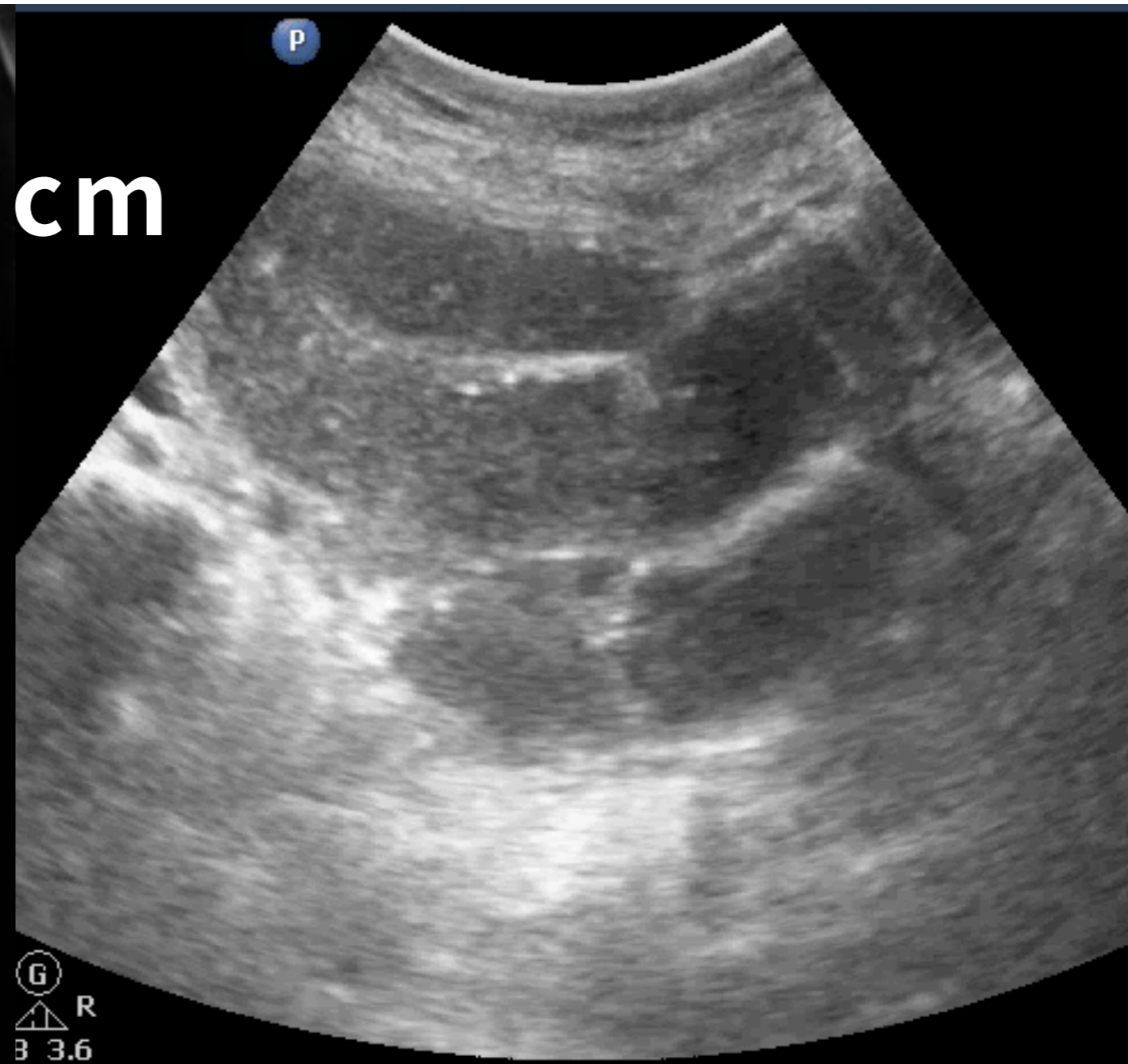
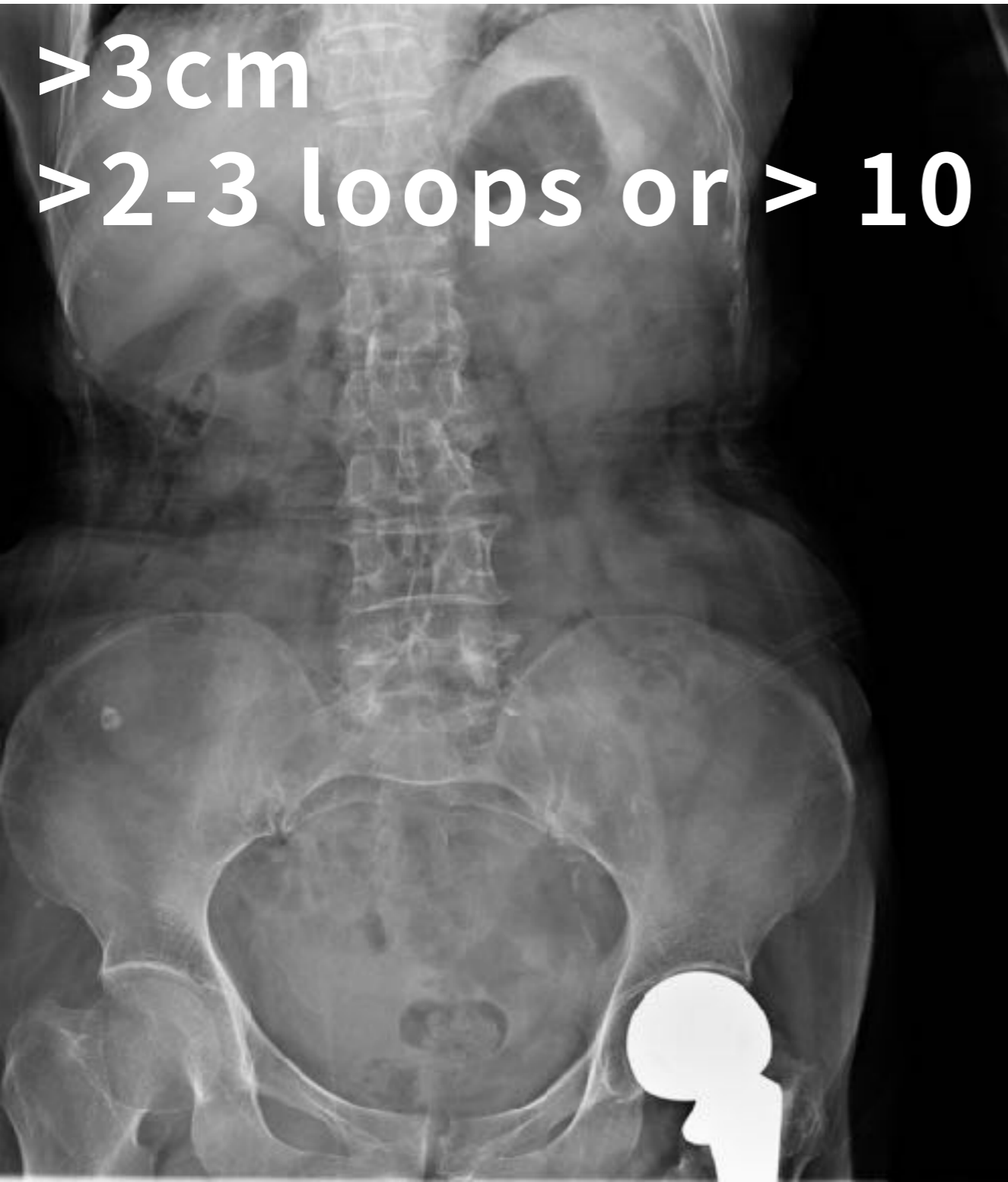


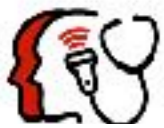# PN & parapneumonic effusion



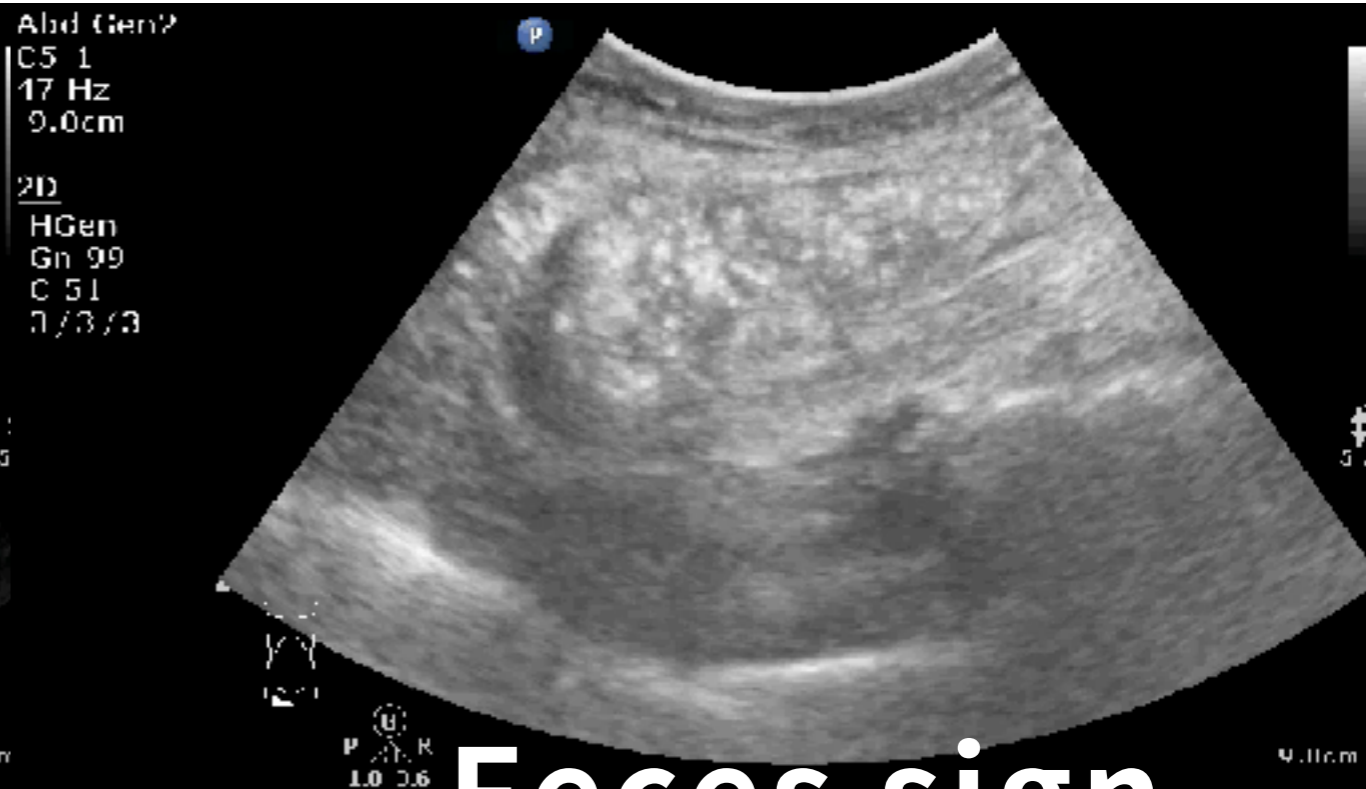
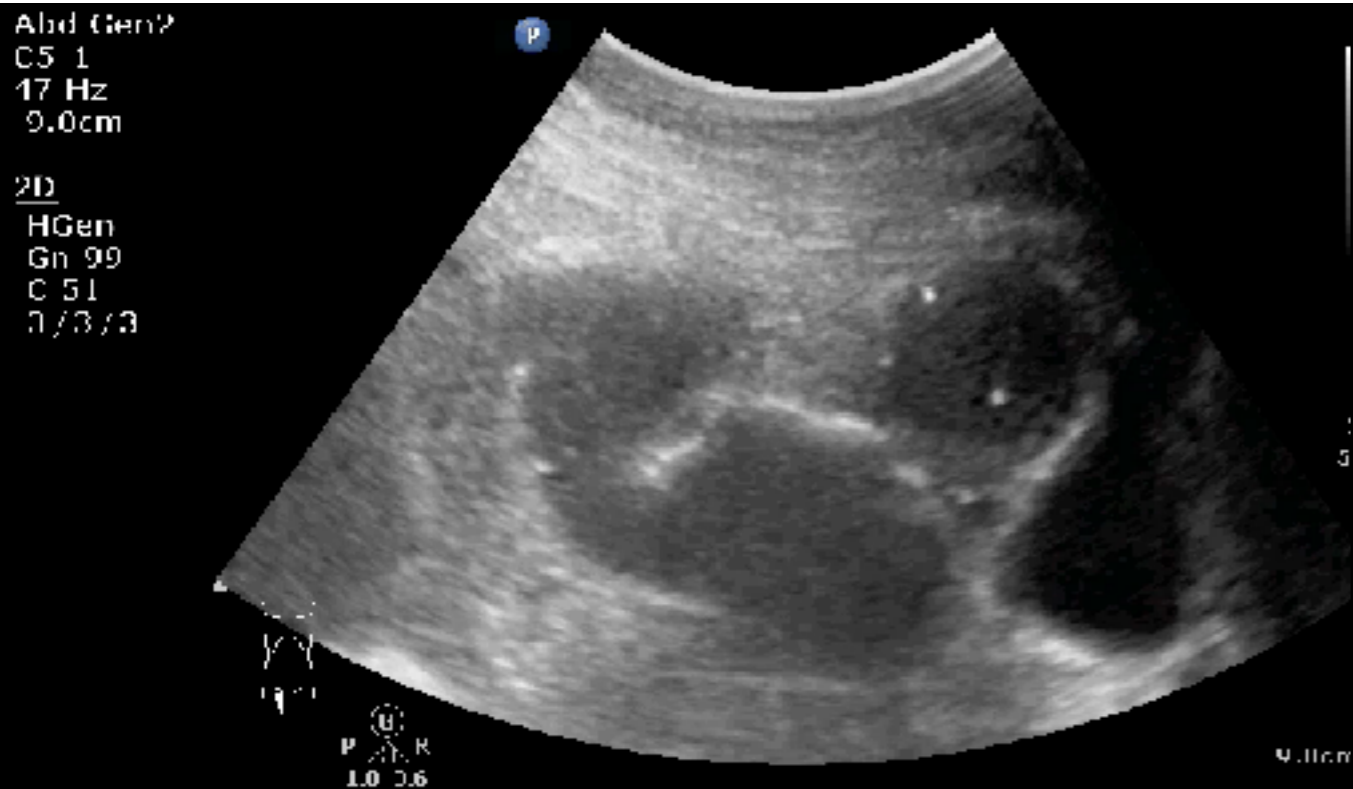# 88F, diffuse abdominal pain

**> 3 cm**  
**> 2-3 loops or > 10 cm**

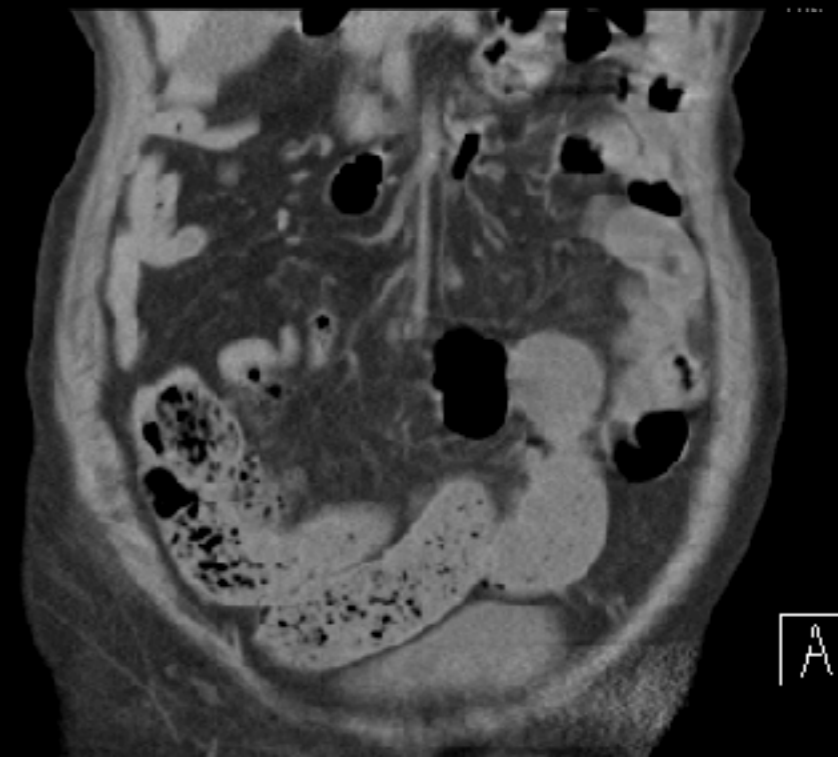
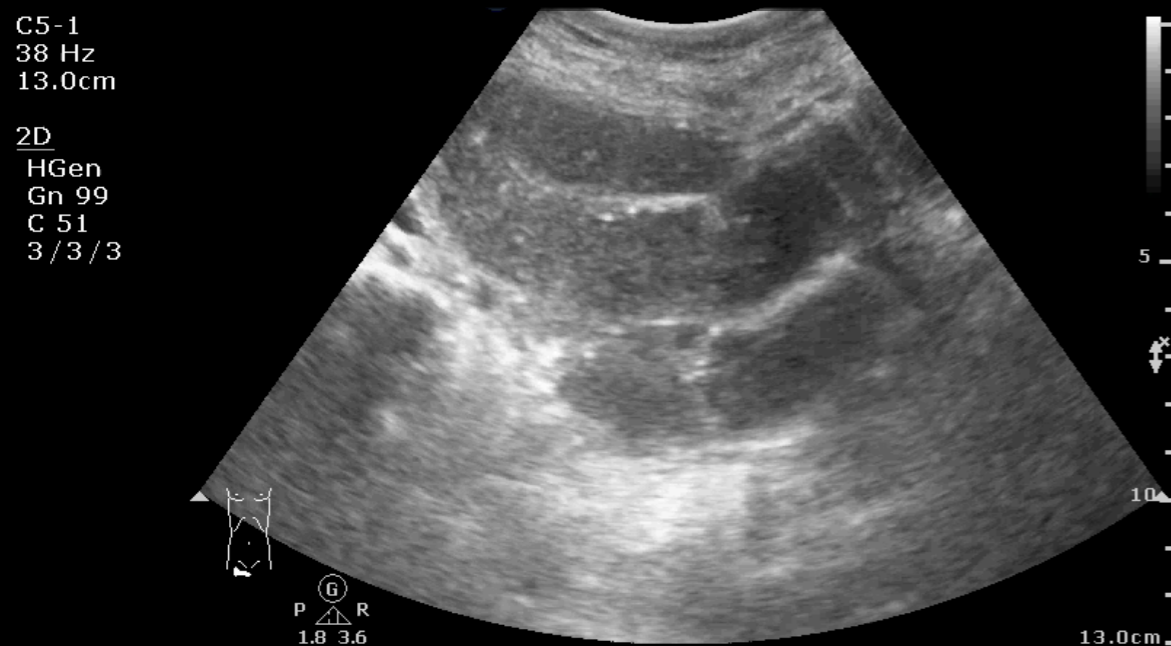




# 88F, diffuse abdominal pain



**Feces sign**

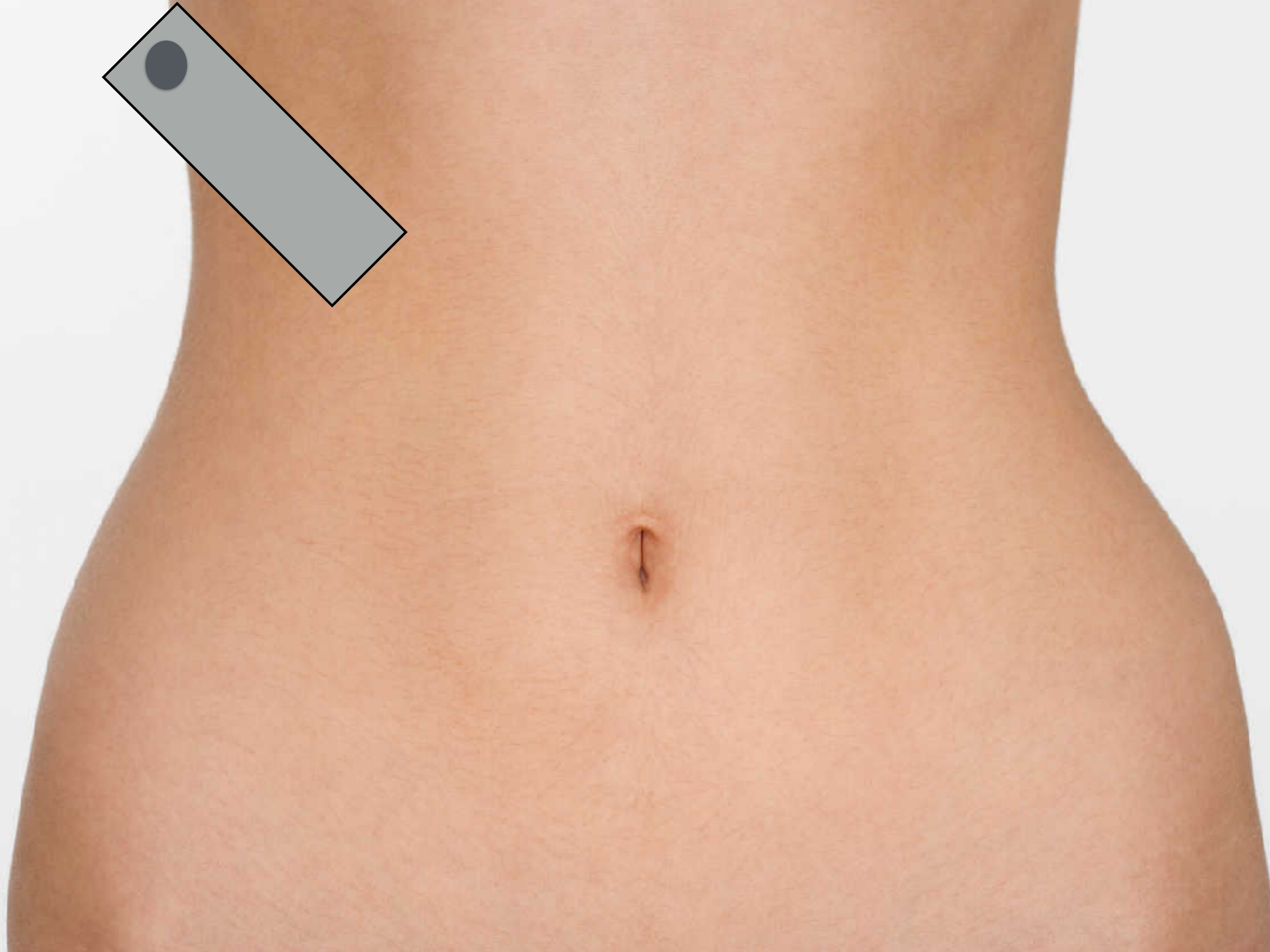

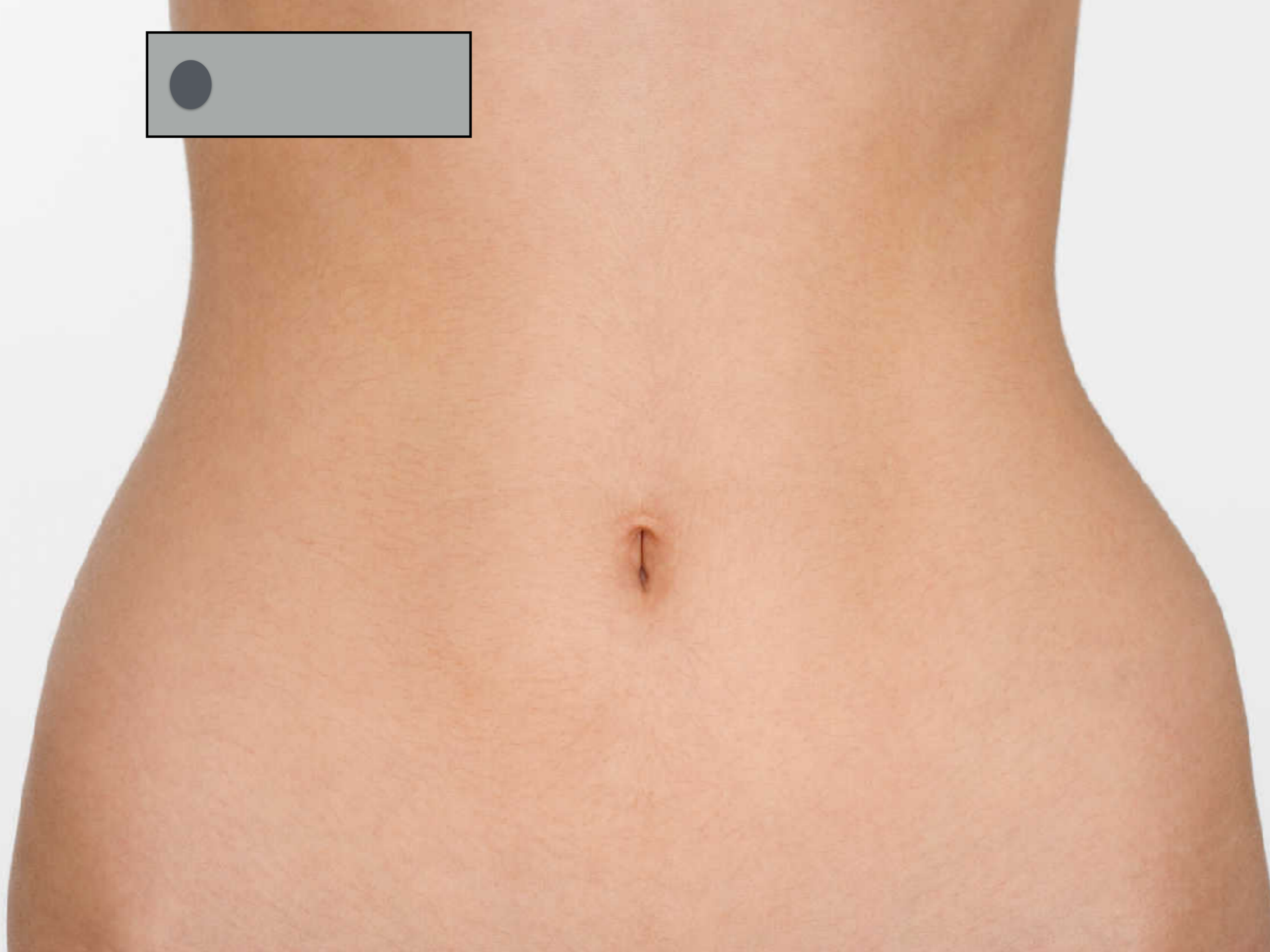# ABDOMEN

**O for obstruction  
(SBO & Intussusception)**

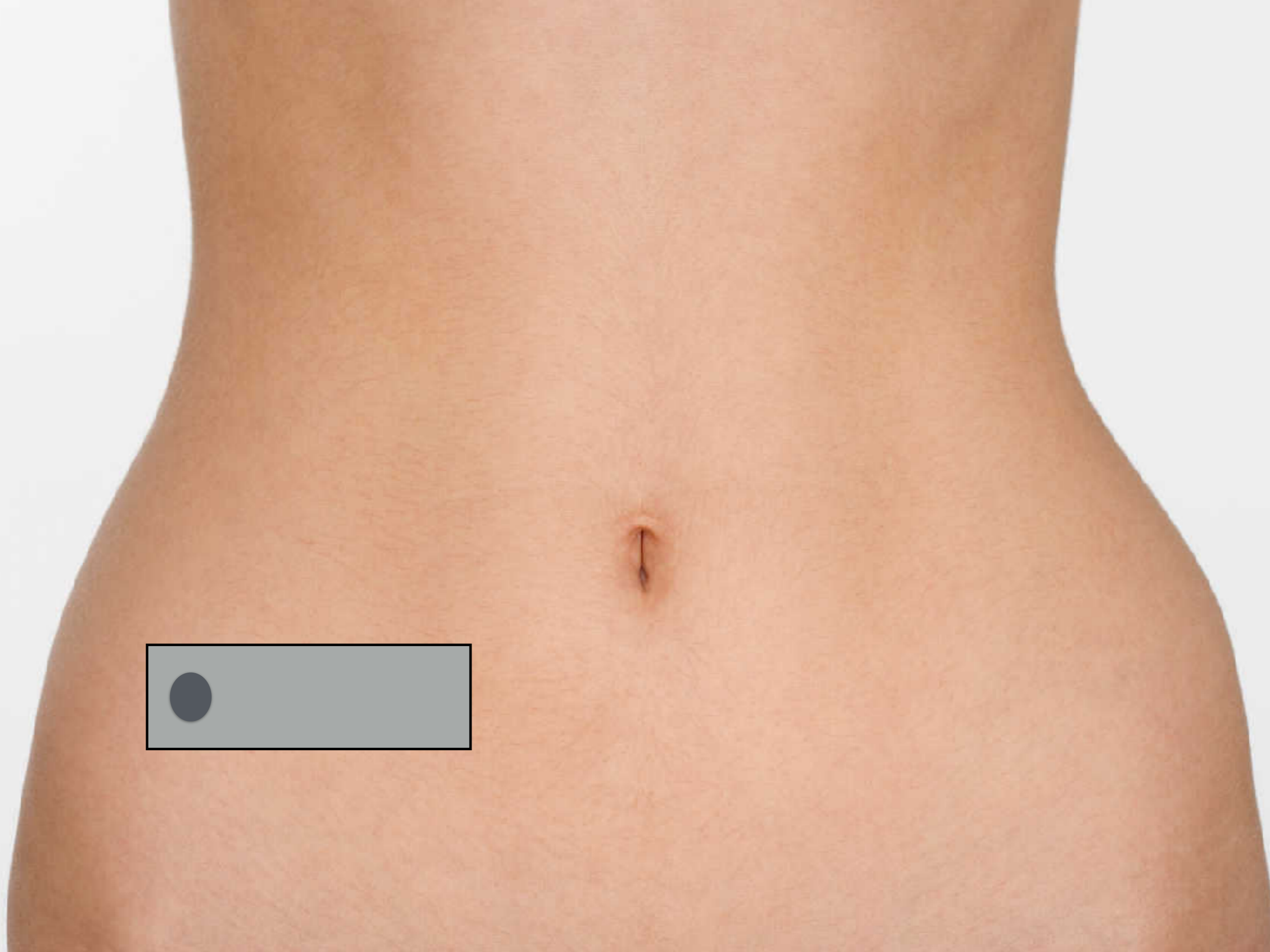
**3**  
cm

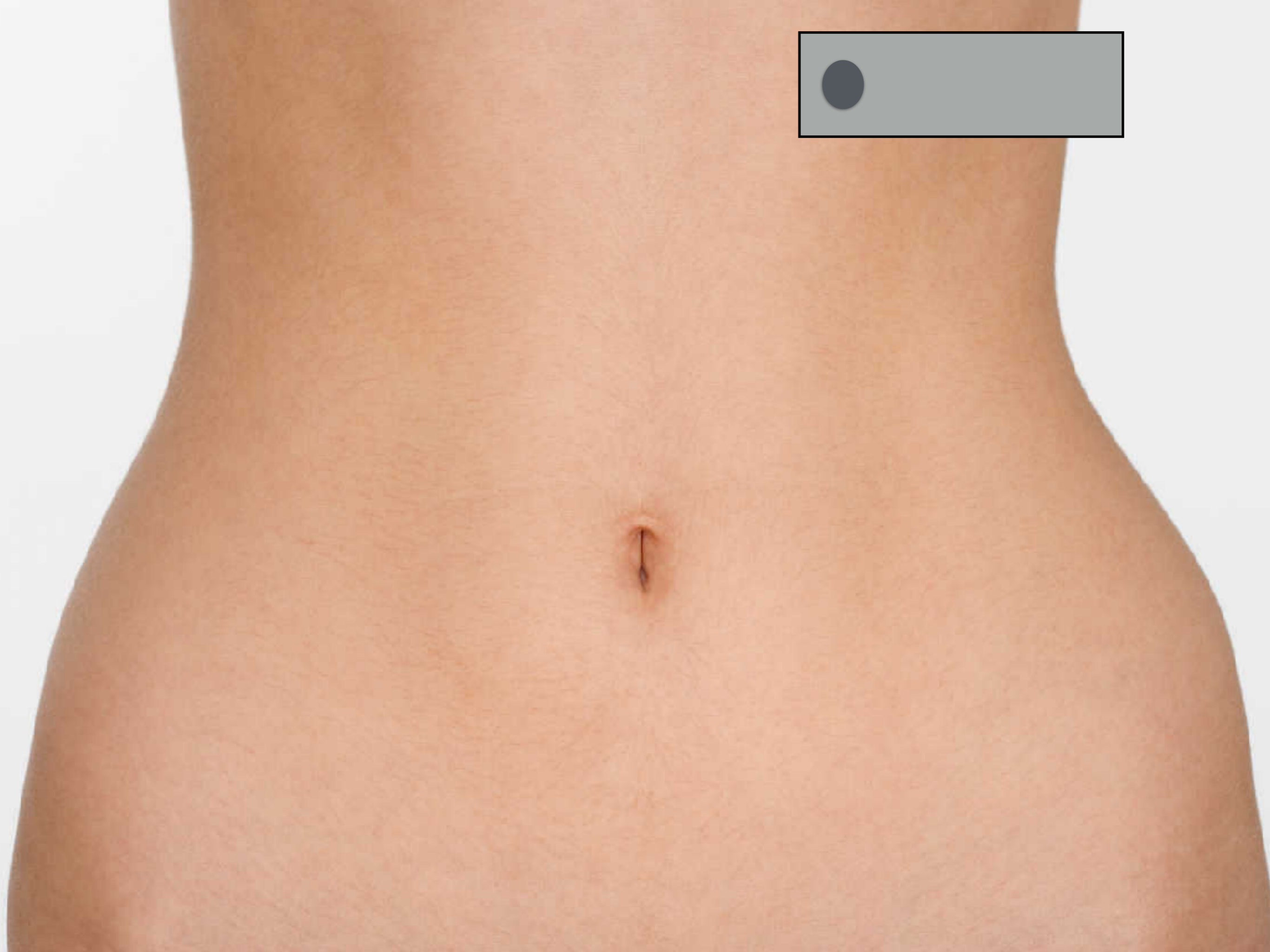**5**  
cm

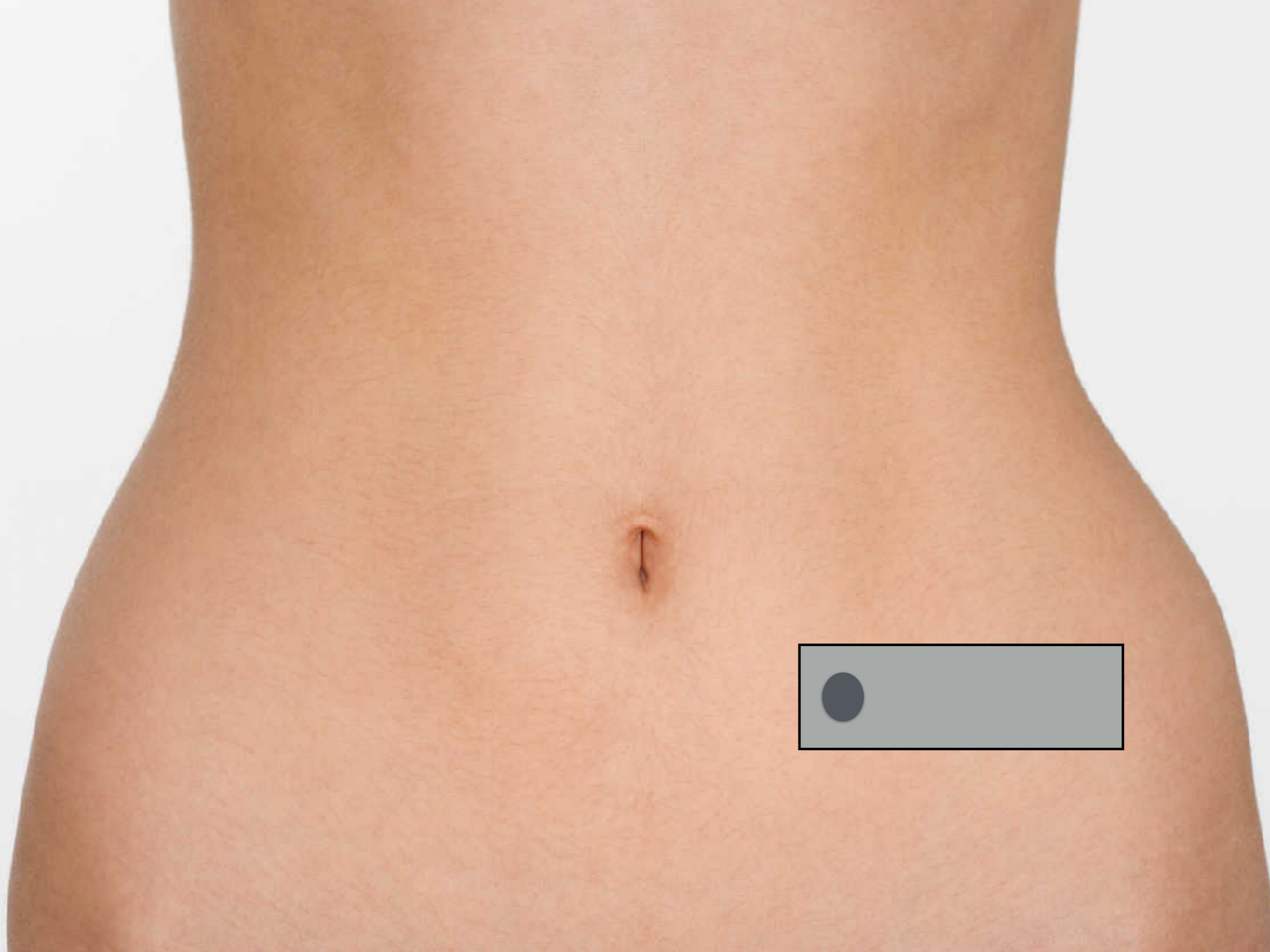


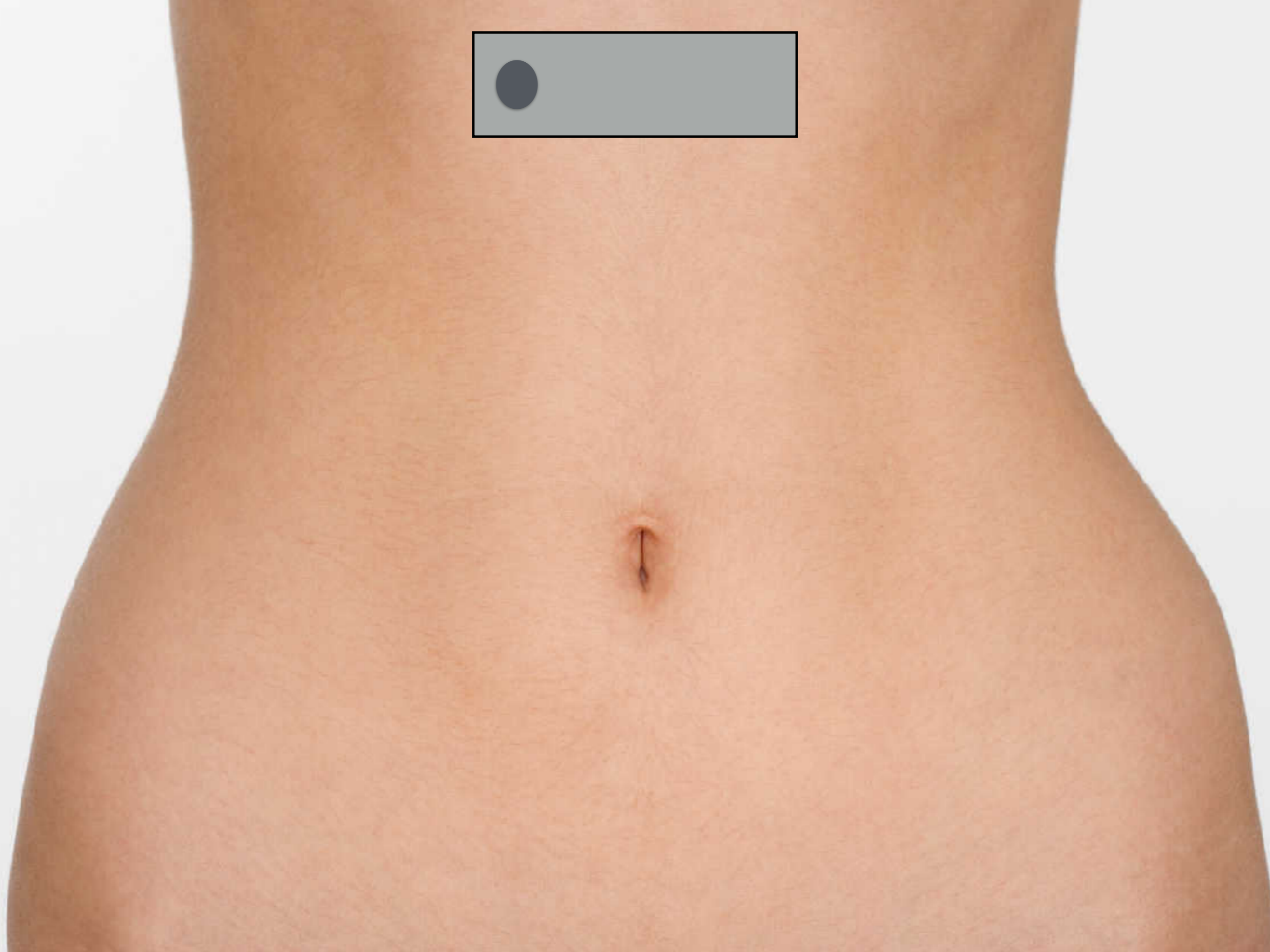


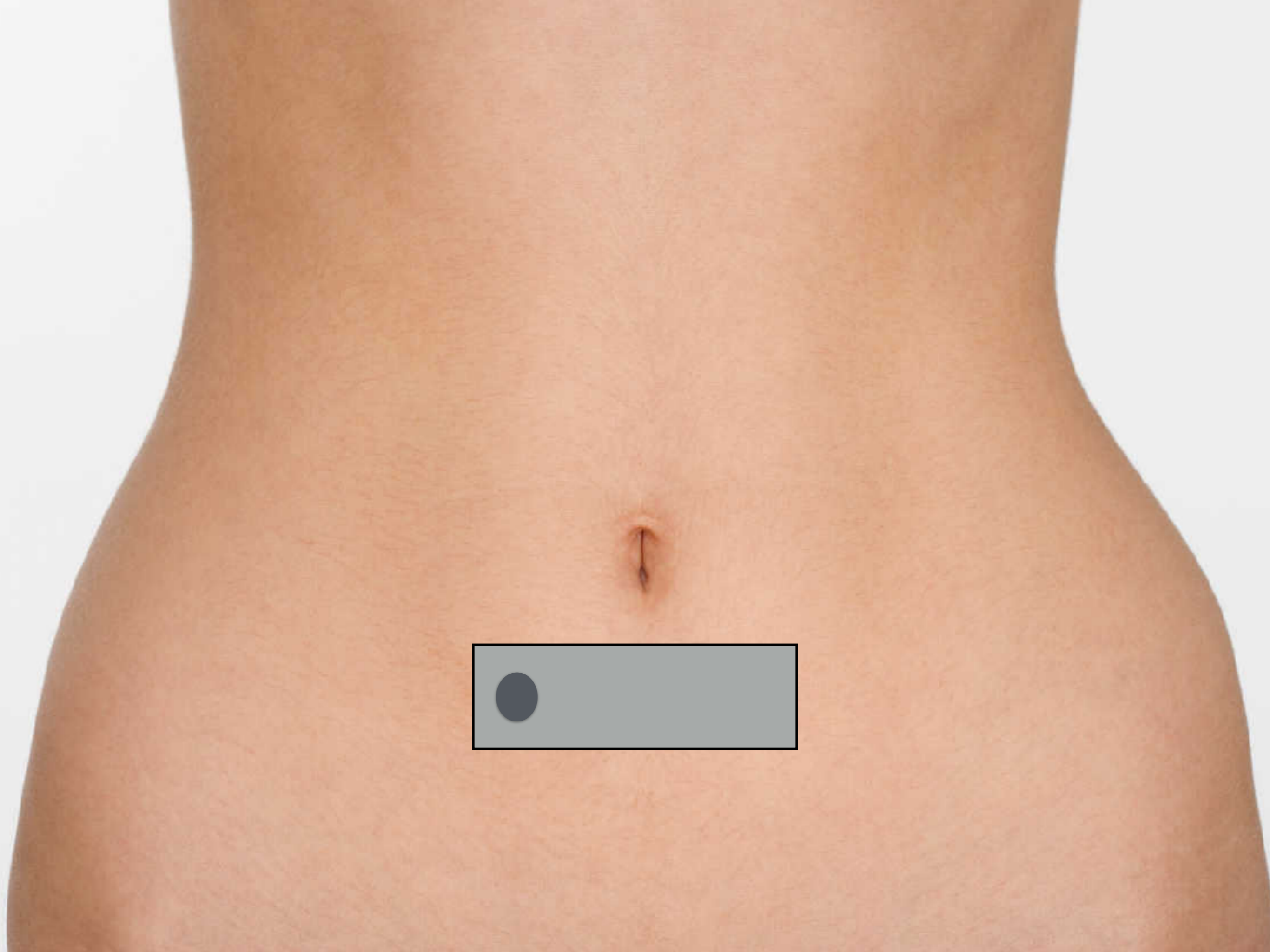








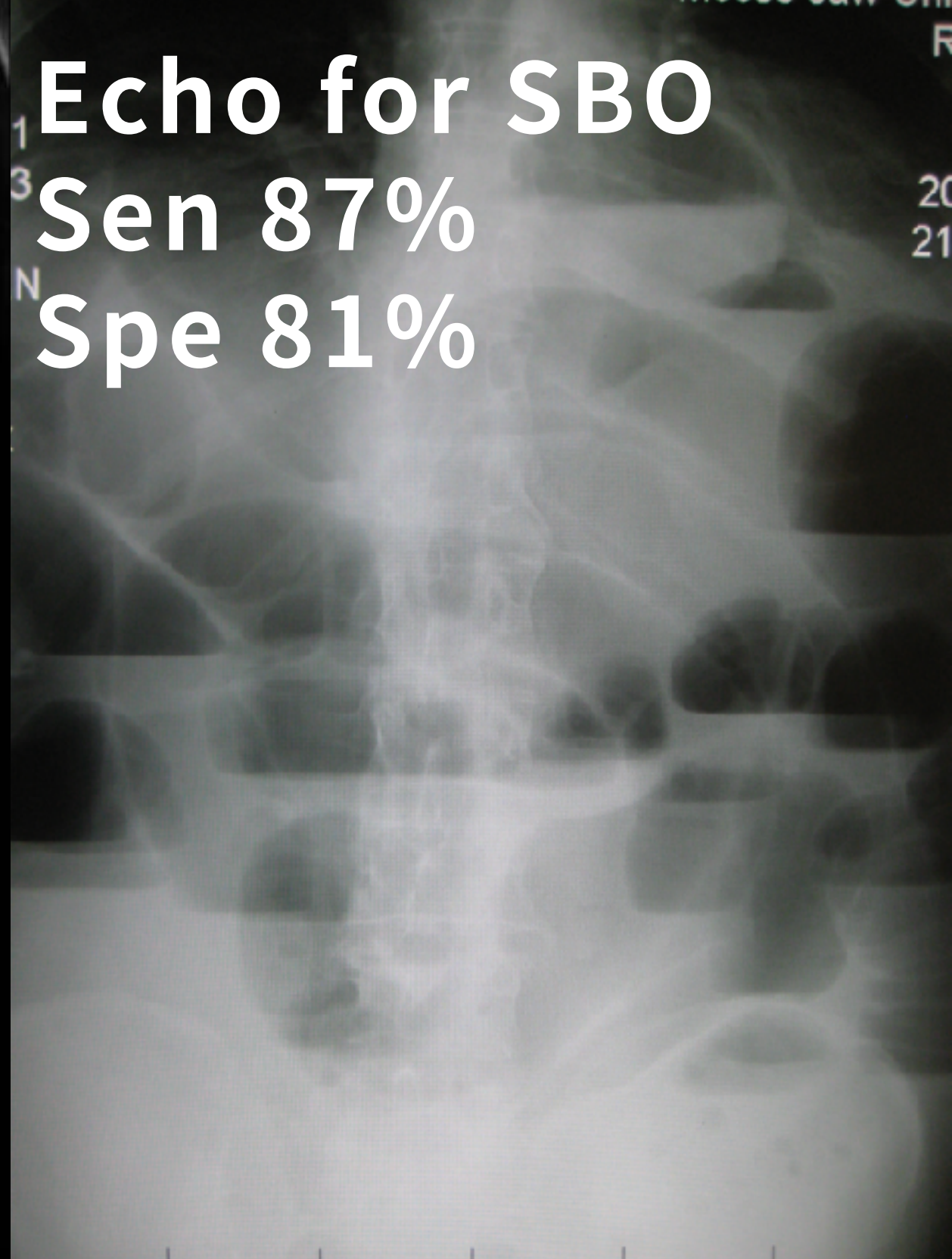




# X光要開【對】的條件才有用啊

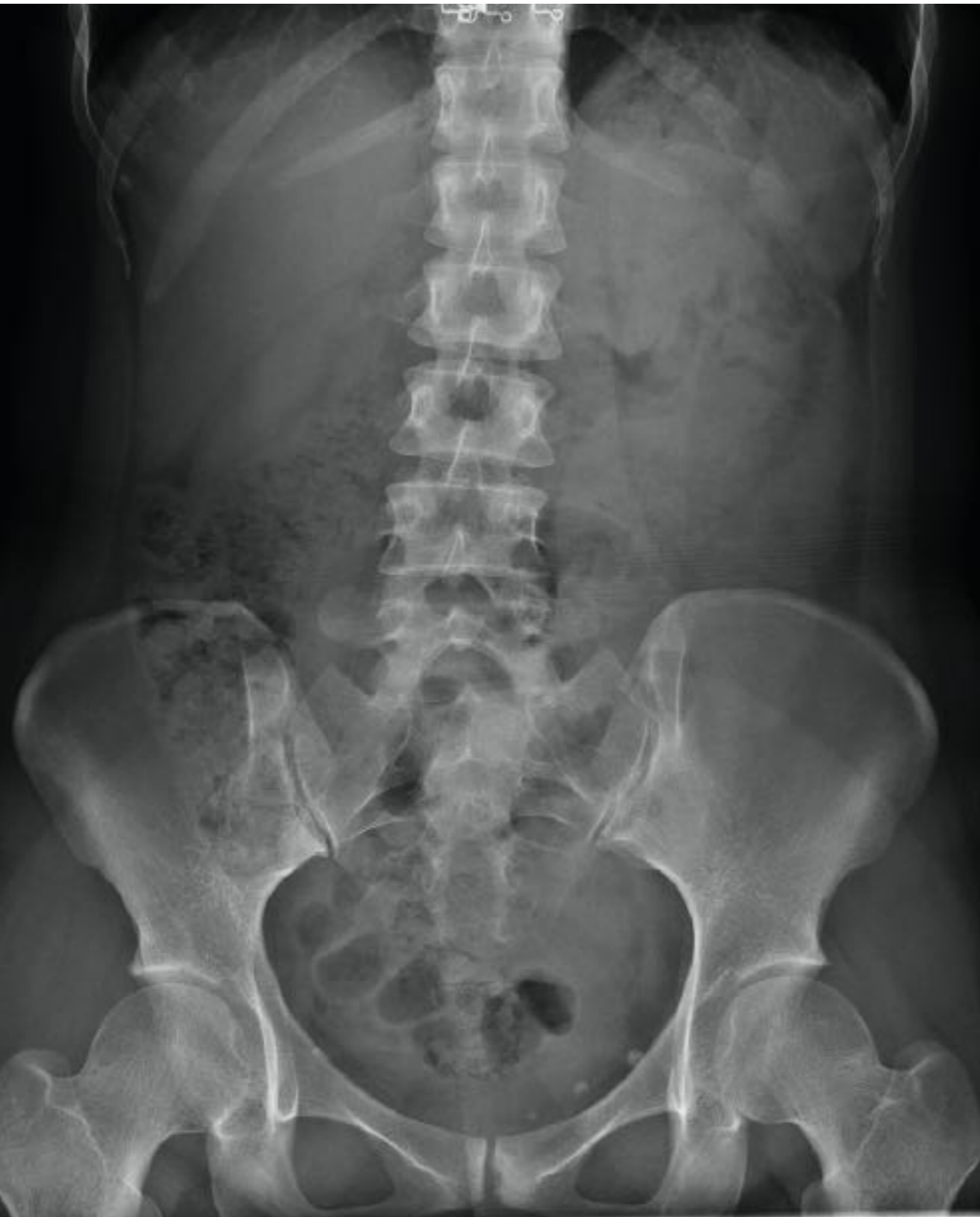

X-ray for SBO  
Sen 75%  
Spe 66%

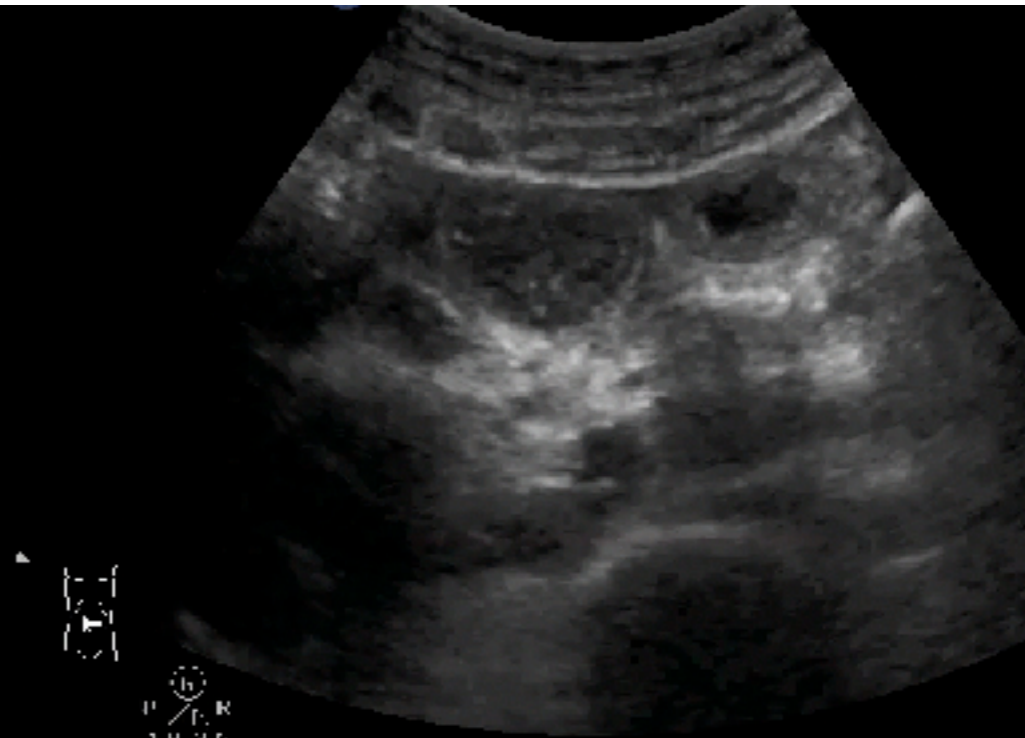


Echo for SBO  
Sen 87%  
Spe 81%

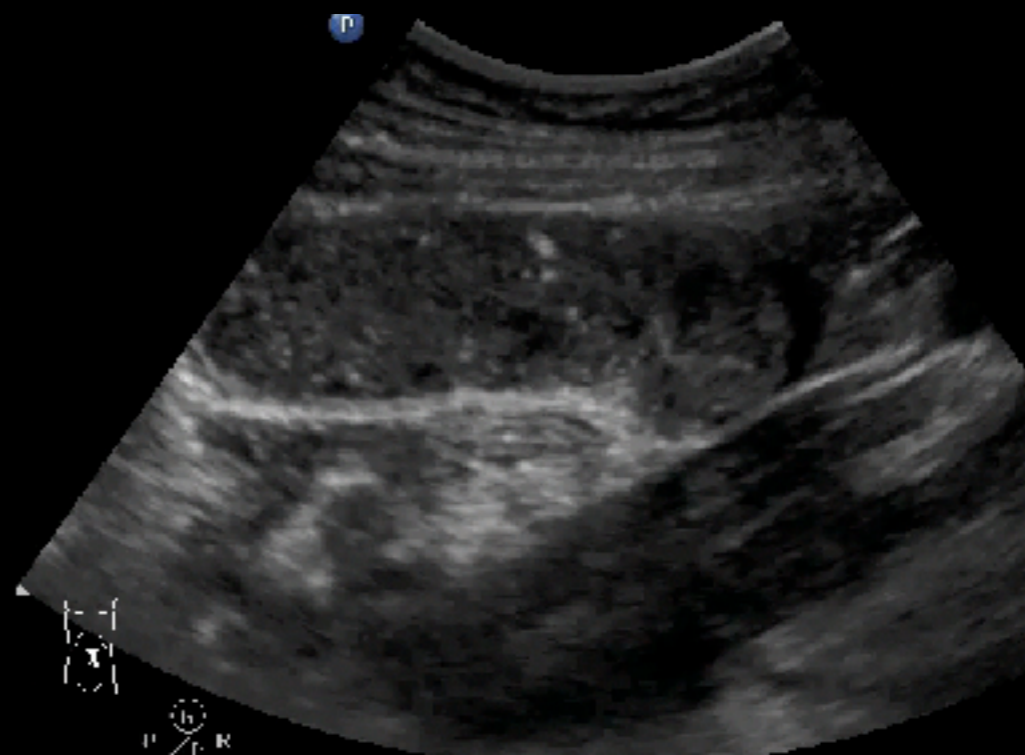
# F/31, ABD pain & vomiting for 2Ds



15 1  
15 Hz  
10.0cm  
ID  
II Gen  
Gn 51  
I: 56  
3/3/3

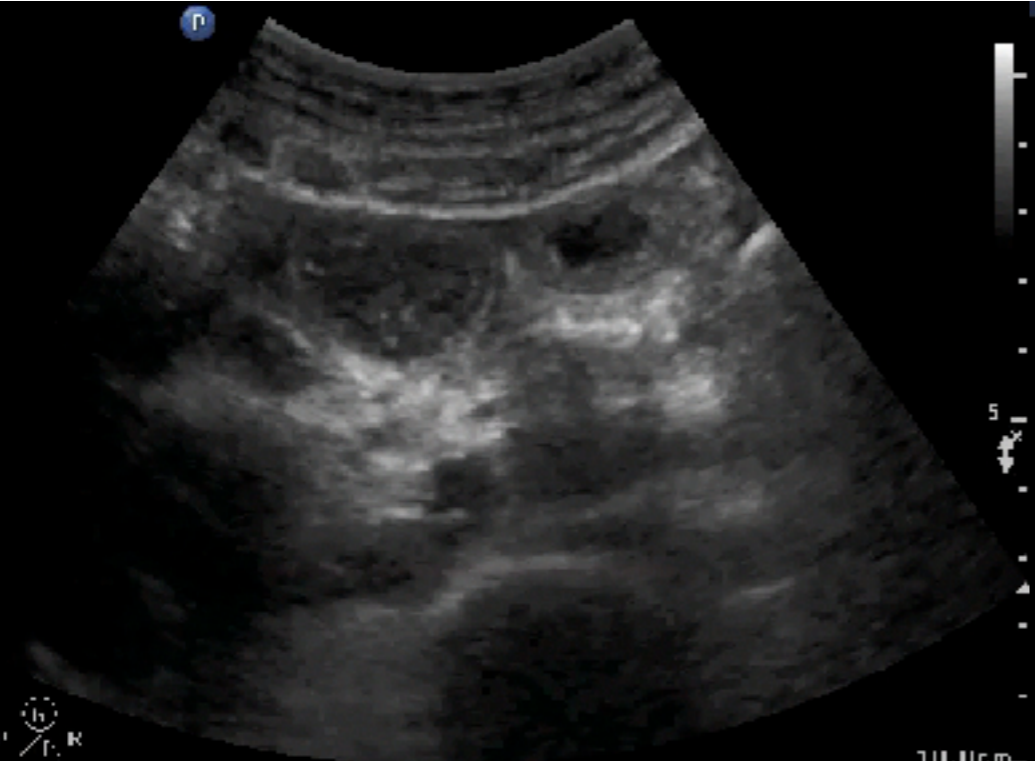


Abd Gen  
15 1  
15 Hz  
10.0cm  
ID  
II Gen  
Gn 45  
I: 56  
3/3/3



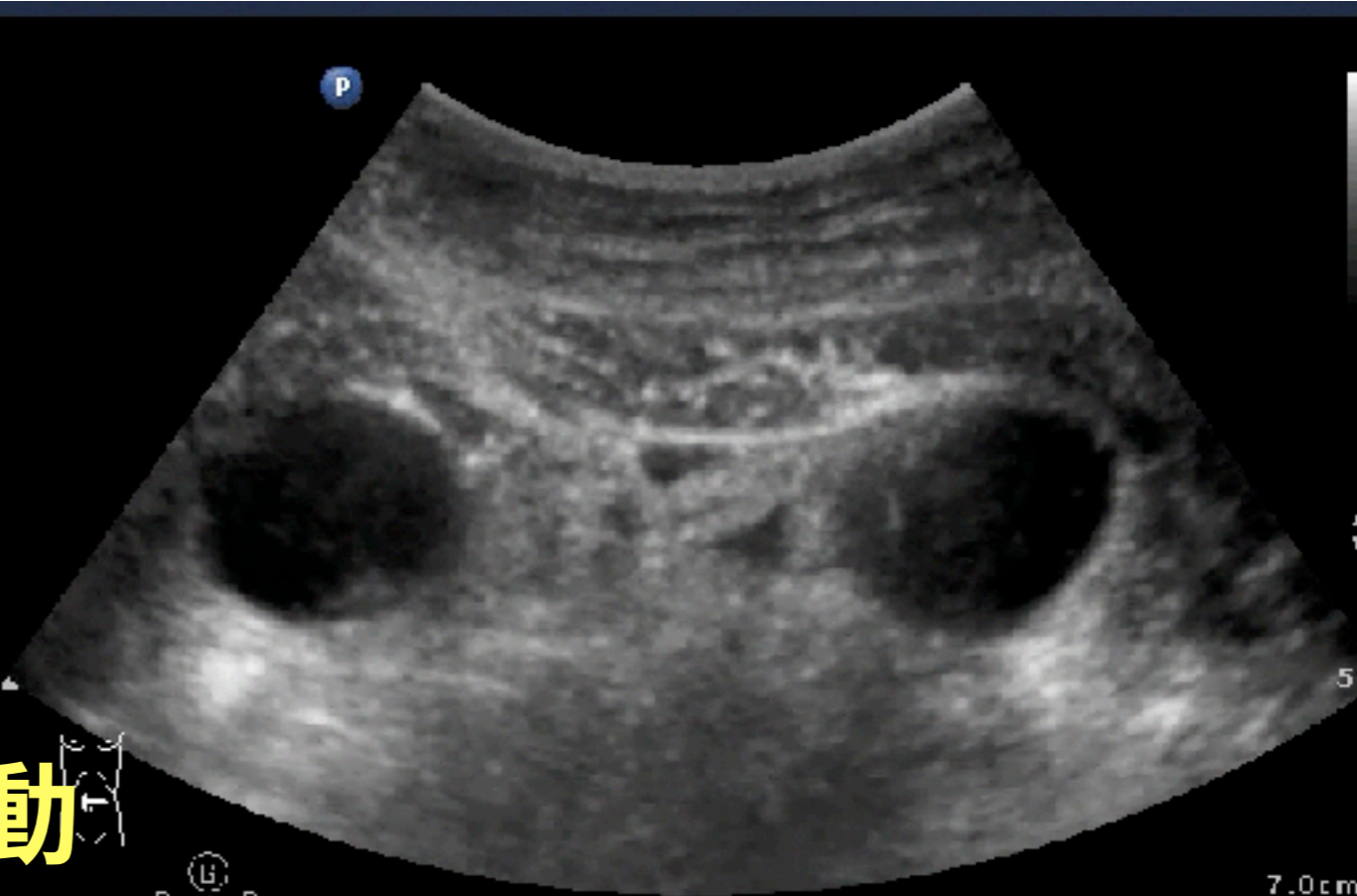
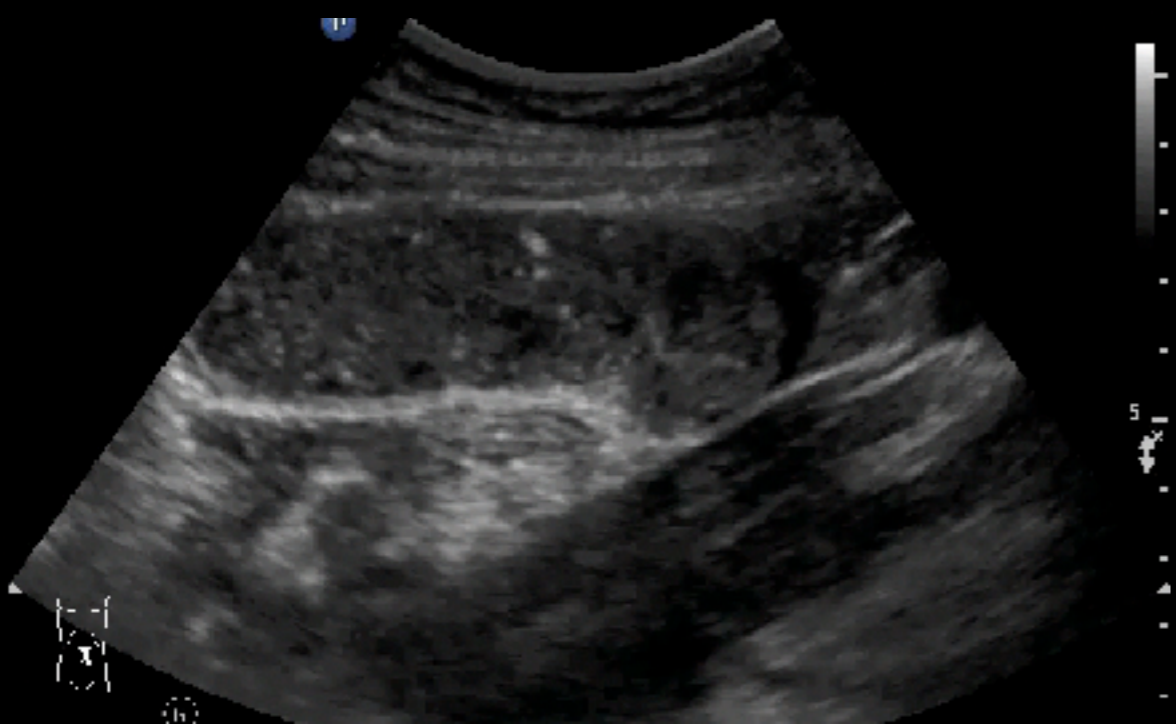
# Adhesion ileus

Abd Gen  
35 1  
35 Hz  
10.0cm  
2D  
11Gen  
Gn 51  
0:56  
3/3/3



沾黏的腸子不會隨呼吸滑動

Abd Gen  
35 1  
35 Hz  
10.0cm  
2D  
11Gen  
Gn 45  
0:56  
3/3/3

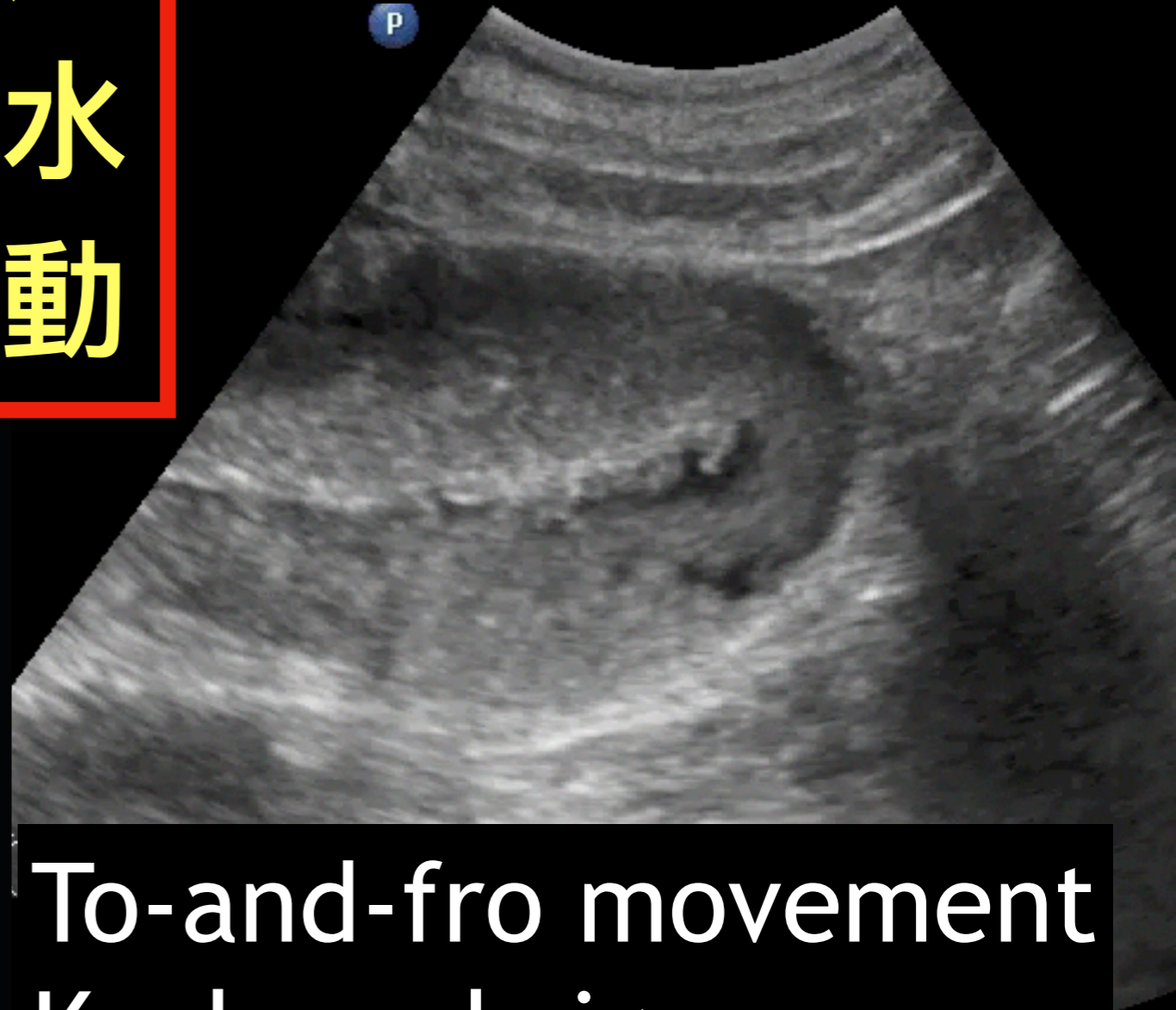
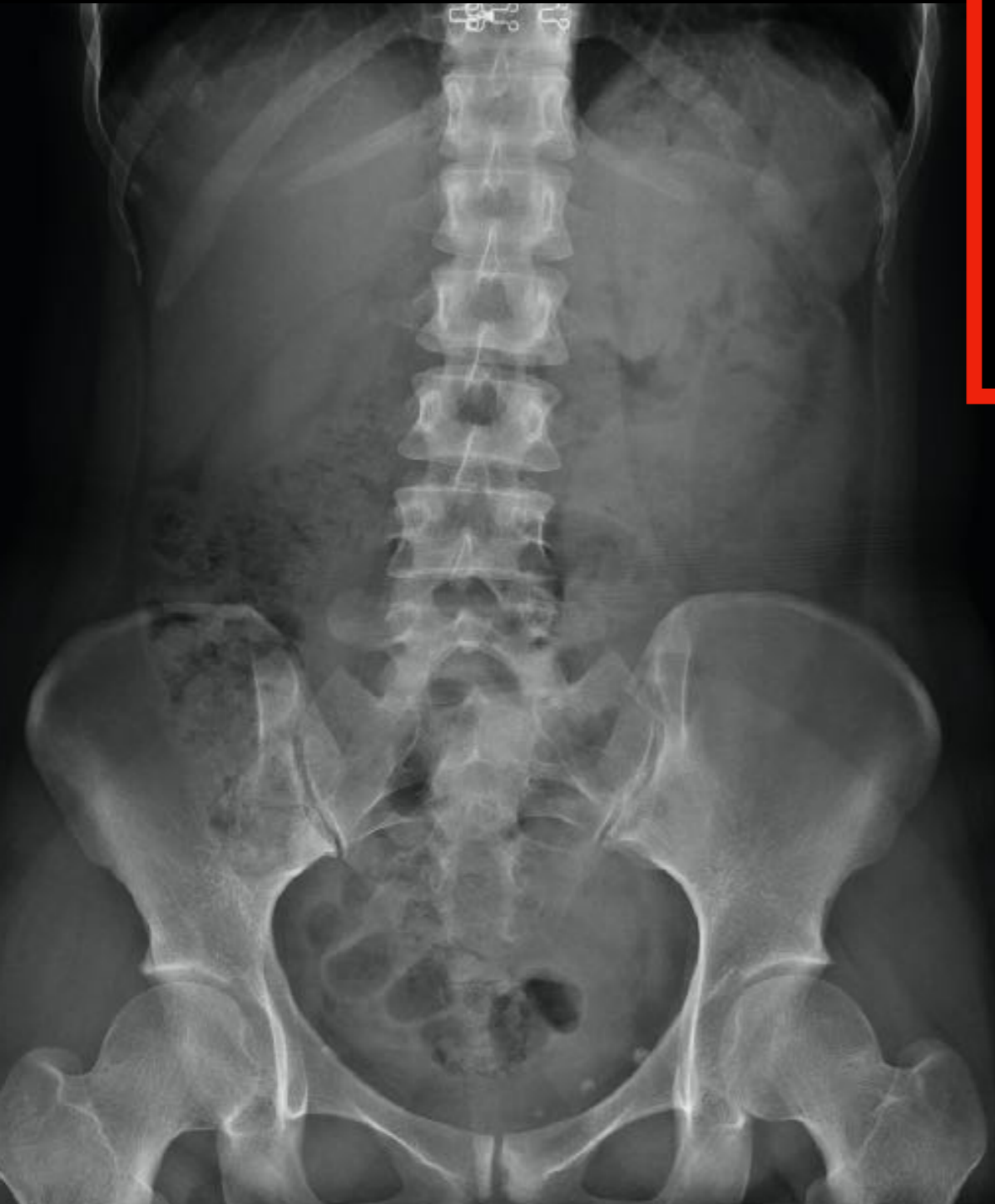

Keyboard sign  
Tanga sign 腸間液體  
Adhesion band



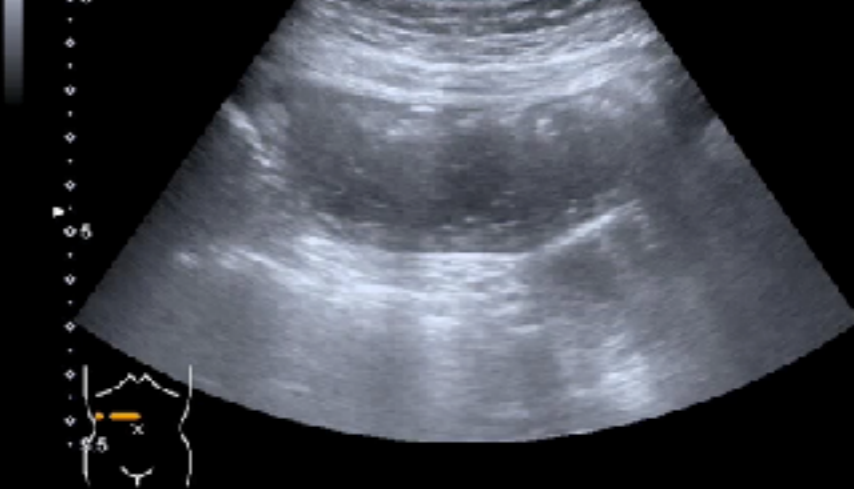
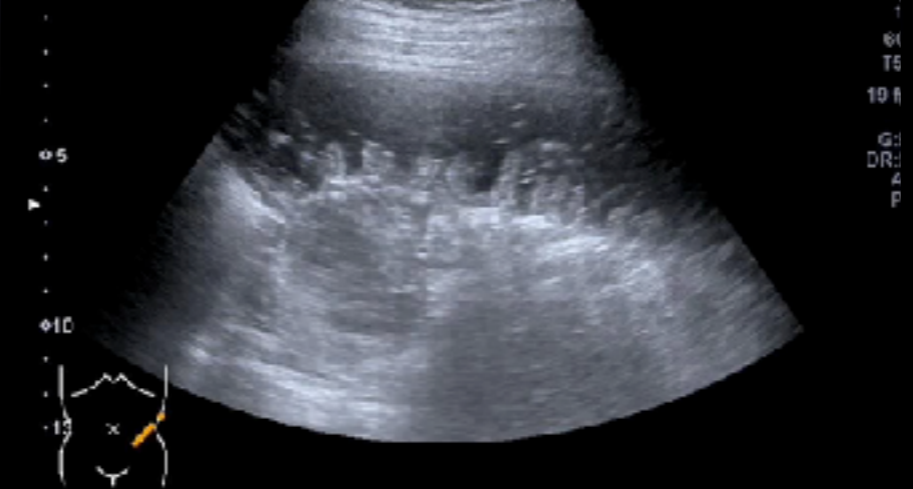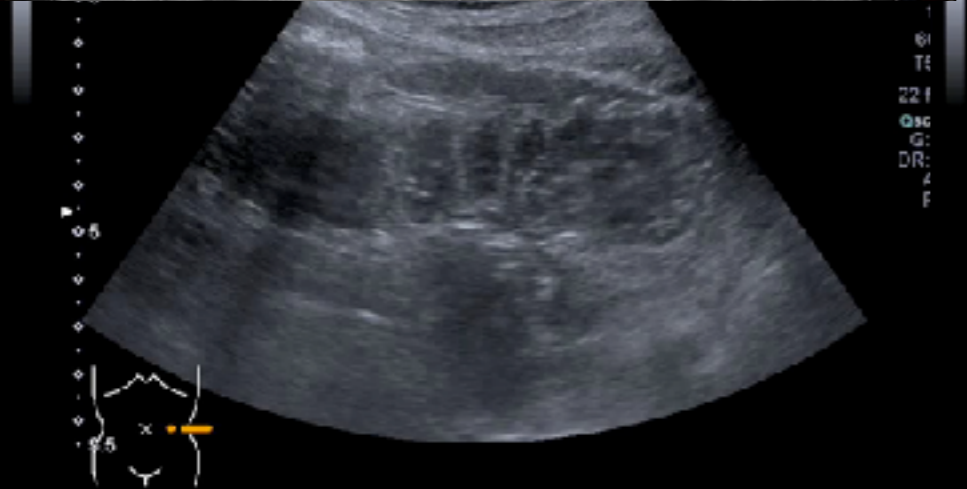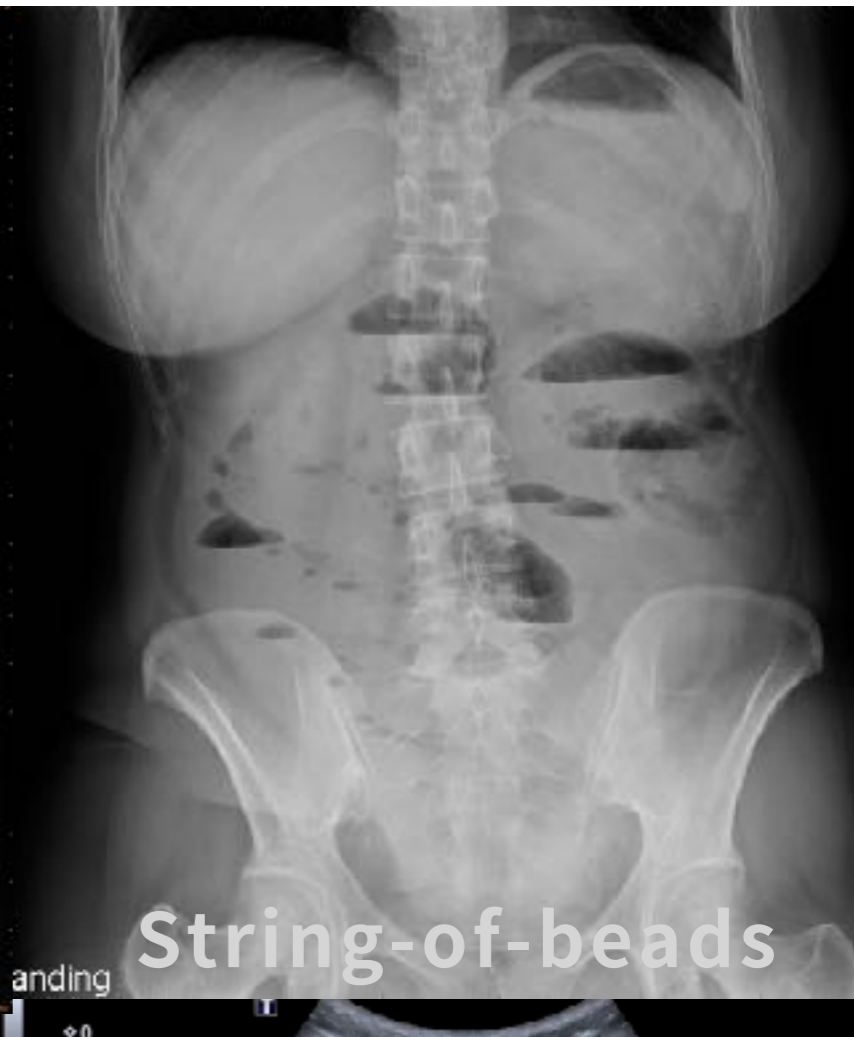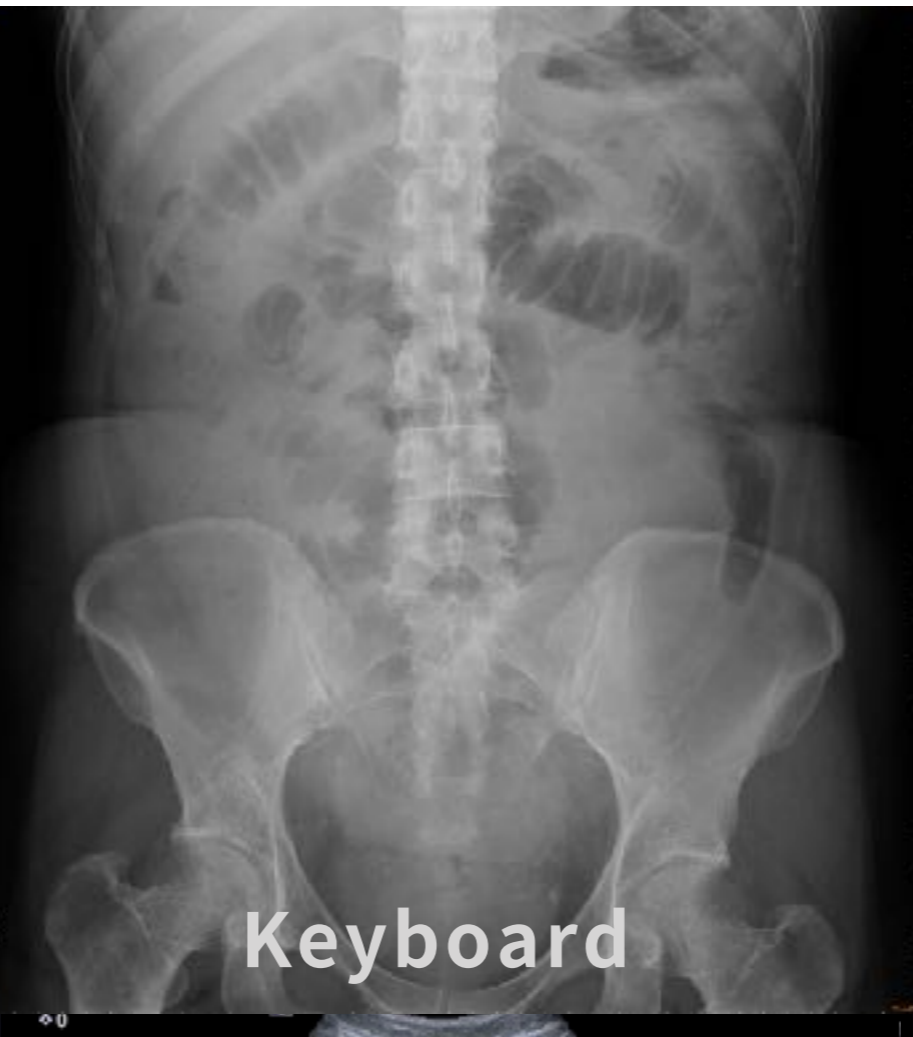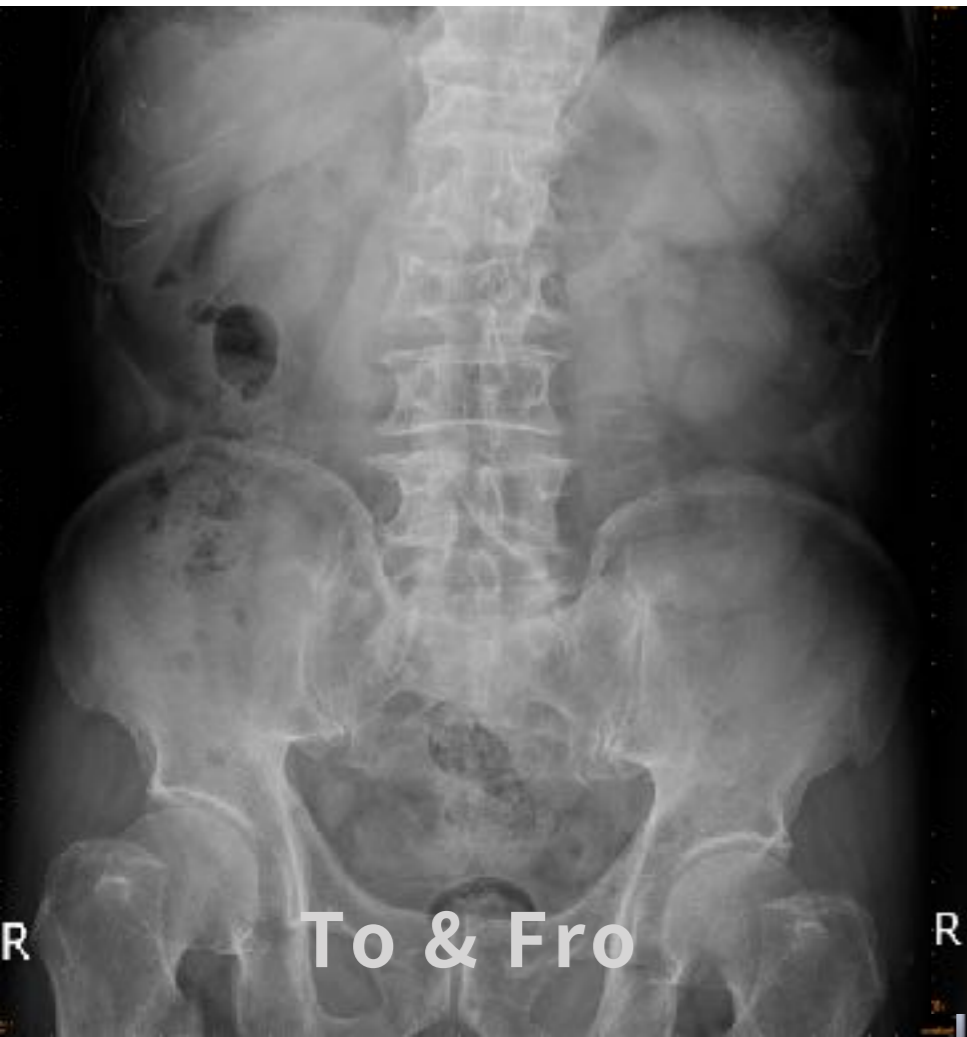# POCUS is useful for gasless ileus

壁厚  
腹水  
蠕動



To-and-fro movement  
Keyboard sign  
Tanga sign

# SBO



## TAKE-HOME MESSAGE

For trained operators, ultrasonography possesses sensitivity and specificity comparable to that of abdominal computed tomography (CT) for the diagnosis of small bowel obstruction.

### US for SBO diagnosis LR + >20起跳

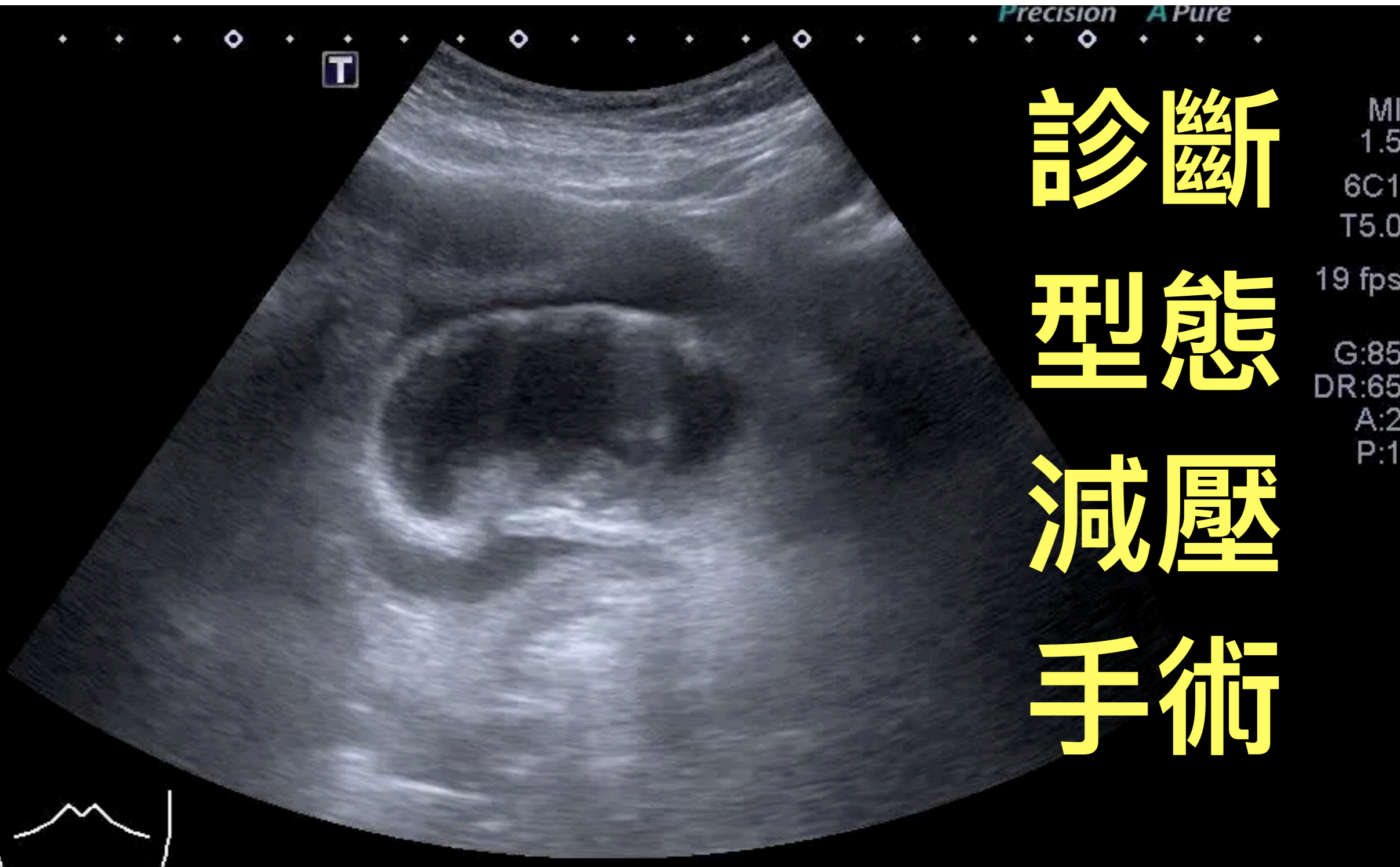
Ultrasonographic Diagnosis of SBO	Specificity (95% CI)	Sensitivity (95% CI)	+LR (95% CI)	-LR (95% CI)	SROC AUC (95% CI)
Overall	0.97 (0.88–0.99)	0.92 (0.89–0.95)	27.5 (7.7–98.4)	0.08 (0.06–0.11)	0.96 (0.94–0.97)
ED	0.96 (0.86–0.99)	0.93 (0.89–0.95)	21.1 (6.5–68.9)	0.08 (0.05–0.12)	0.96 (0.94–0.97)
Non-ED	0.99 (0.60–1.00)	0.92 (0.85–0.96)	70.8 (1.5–3279.7)	0.08 (0.05–0.15)	0.96 (0.94–0.98)

CI, Confidence interval; +LR, positive likelihood ratio; -LR, negative likelihood ratio; SBO, small bowel obstruction; SROC, summary receiver operating characteristic; AUC, area under the curve.

Cottlieb M, et al. AJEM 2017

# 超音波在SBO時的好處

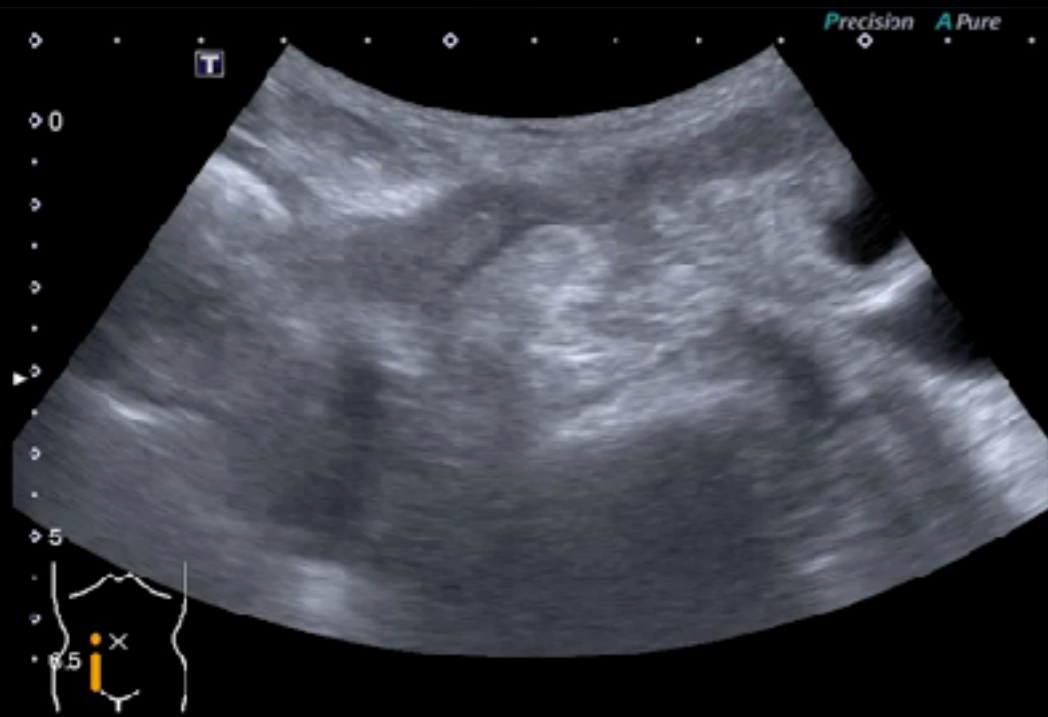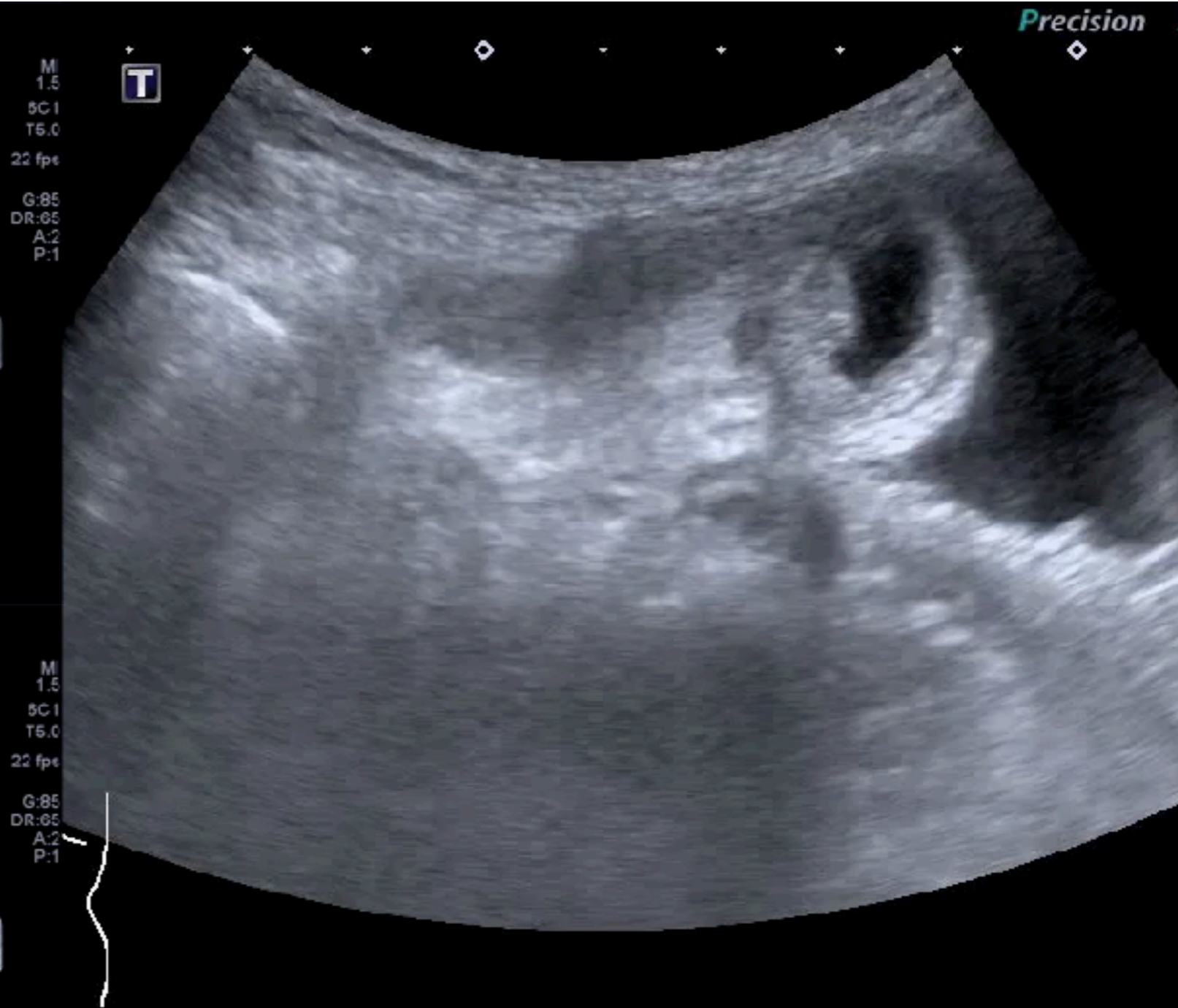
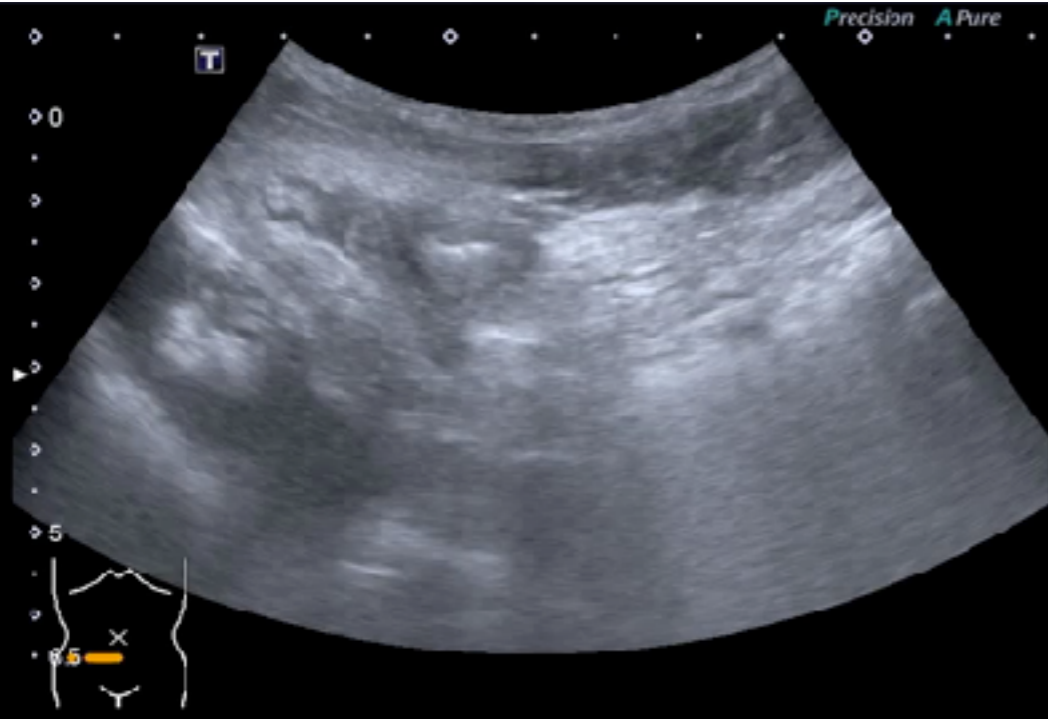
管徑  
壁厚  
腹水  
蠕動



診斷  
型態  
減壓  
手術

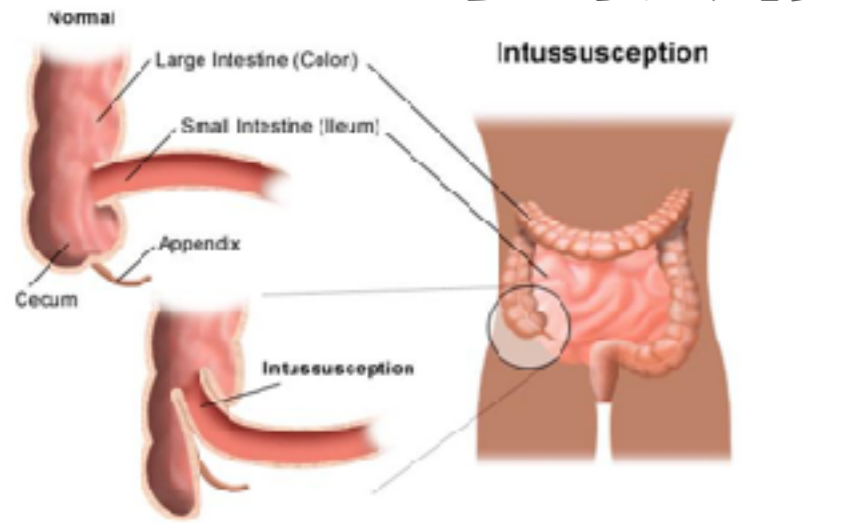
# 66M, right inguinal painful swelling

## 診斷 & 協助擬定復位路徑



# Intussusception

## 小孩優先找右上腹



Ileum "telescopes" inside ascending colon, obstructing passage of intestinal contents.

Bleeding → "Currant jelly stools"

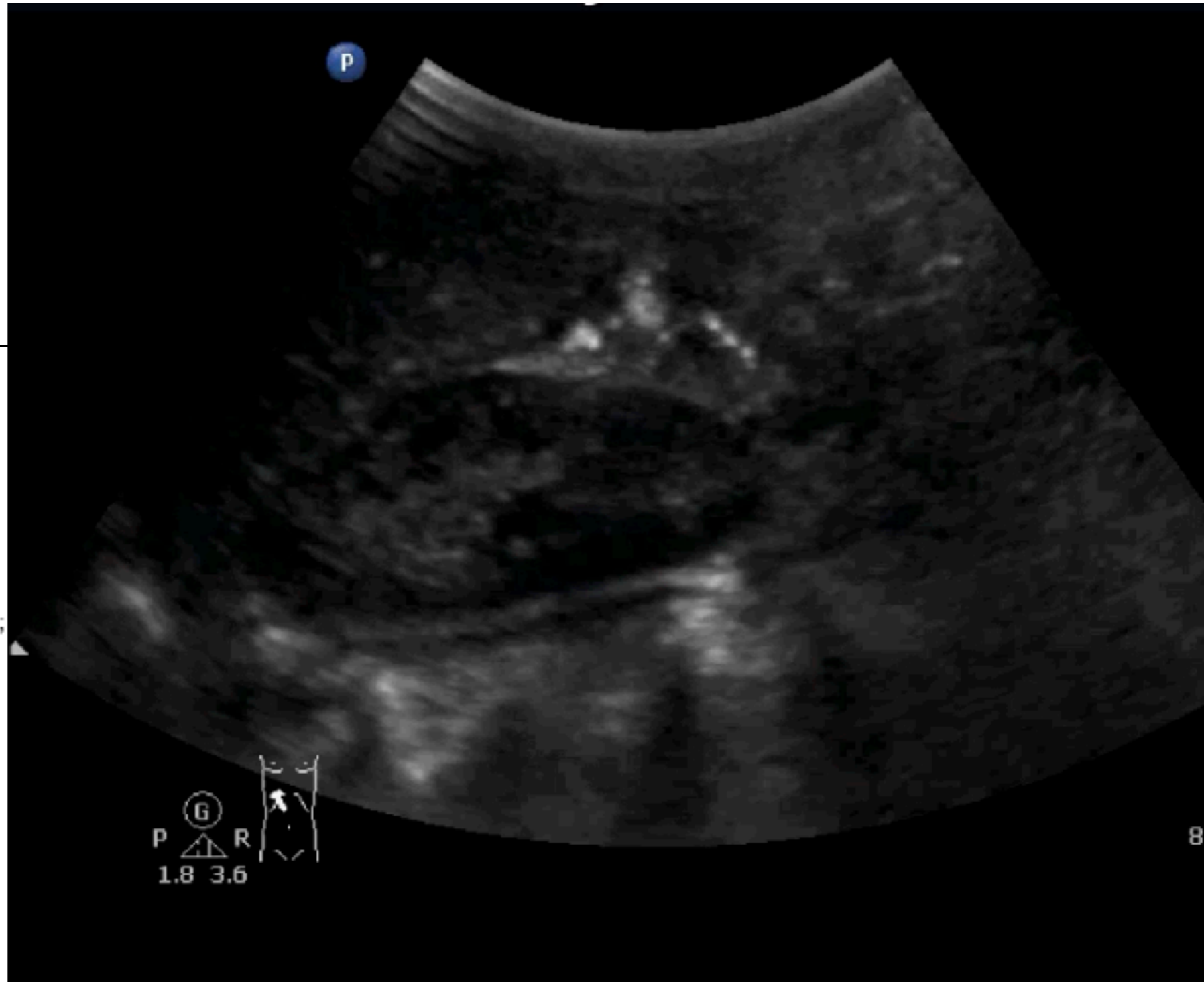
Blood vessels become trapped between layers; blood flow decreases.

Edema

Strangulation of bowel

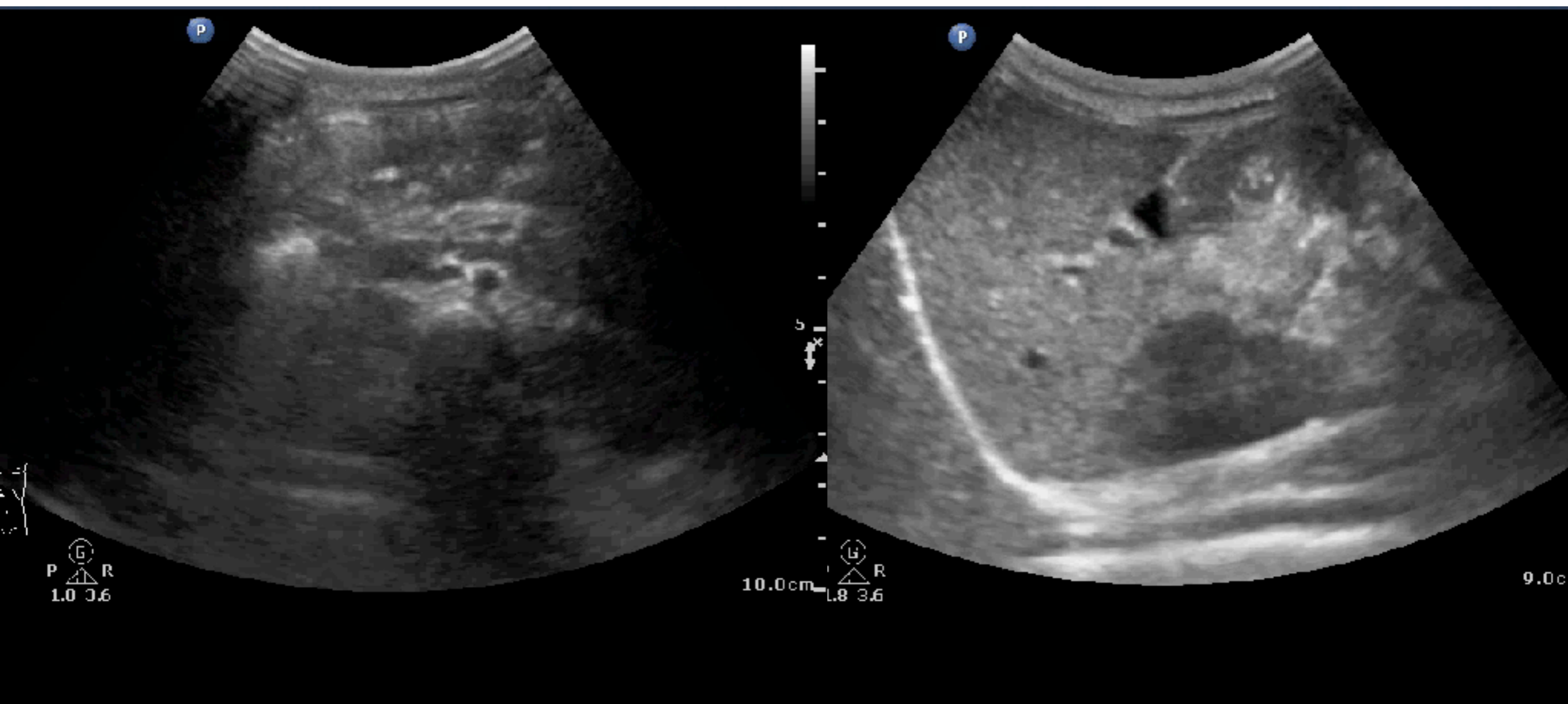
Gangrene, sepsis, shock

Death

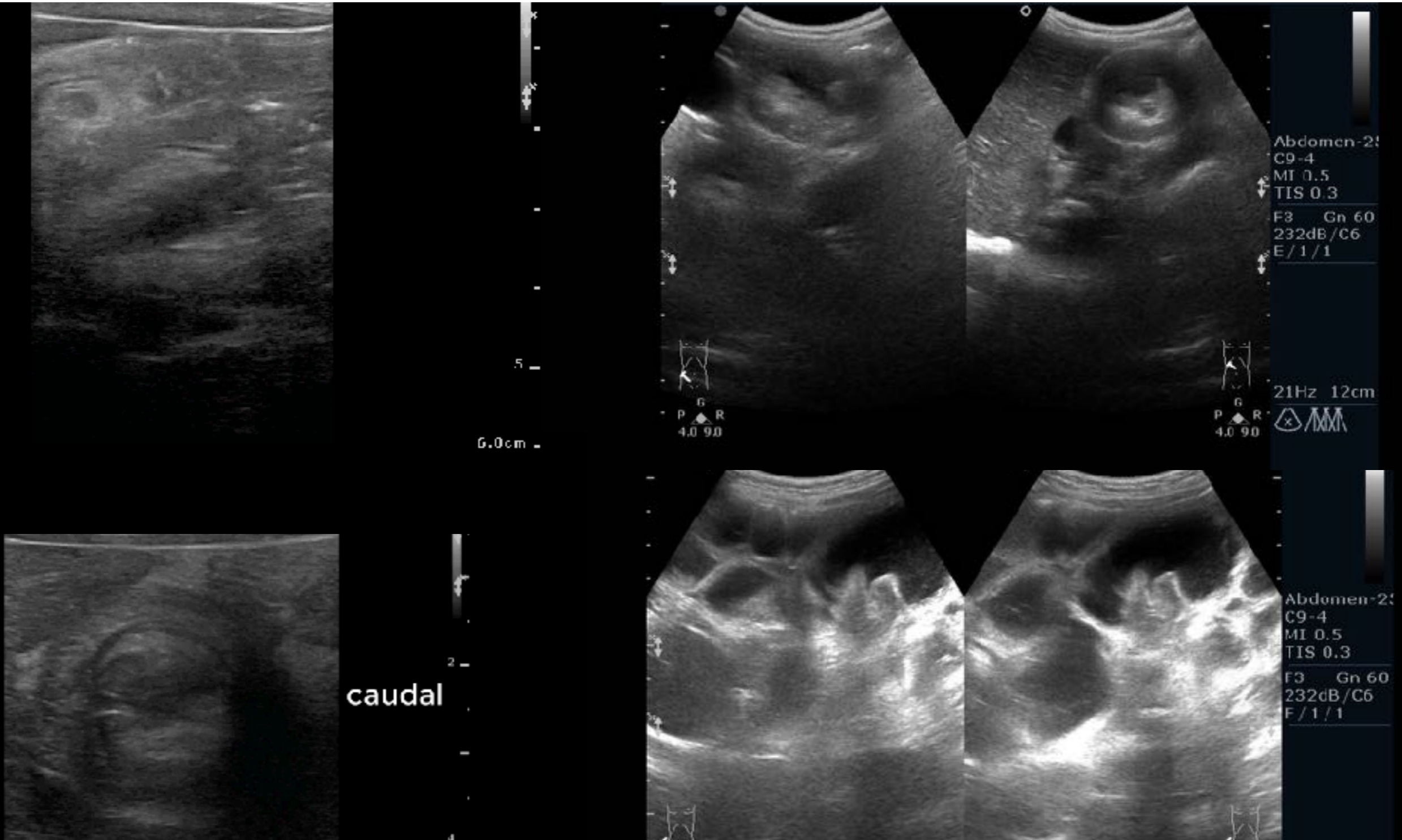


# 7個月大男童，間歇性溢奶

## 間歇性或周期性都要小心

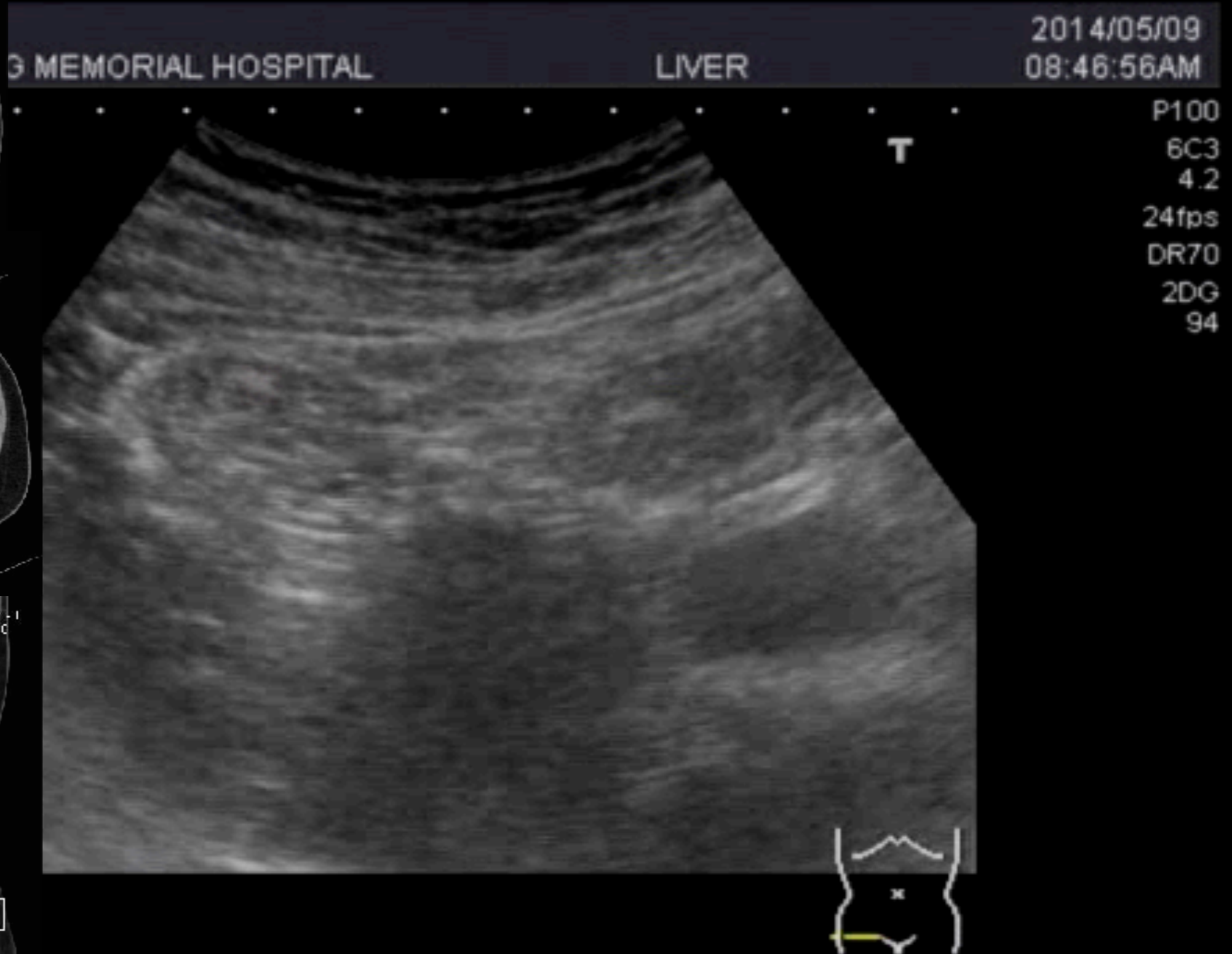
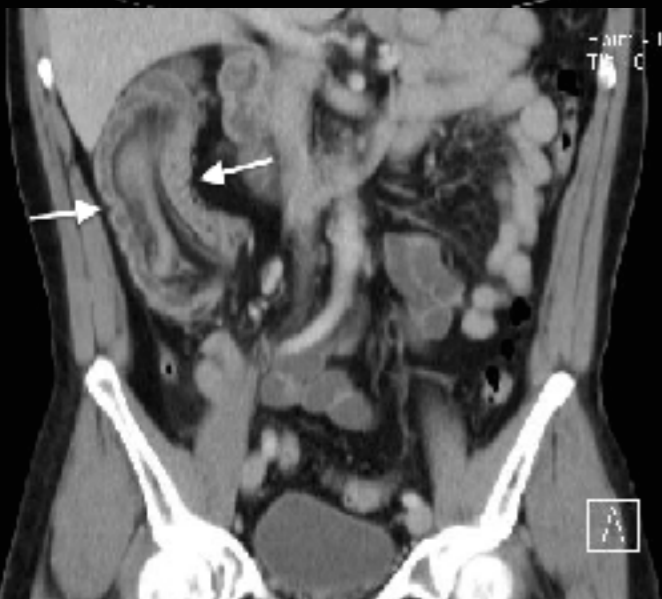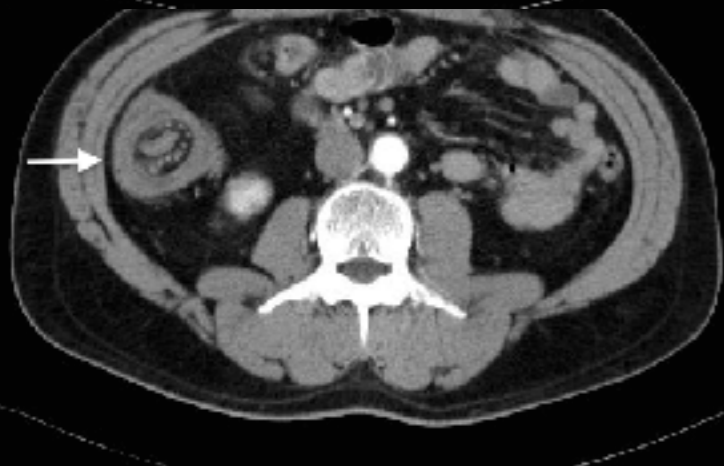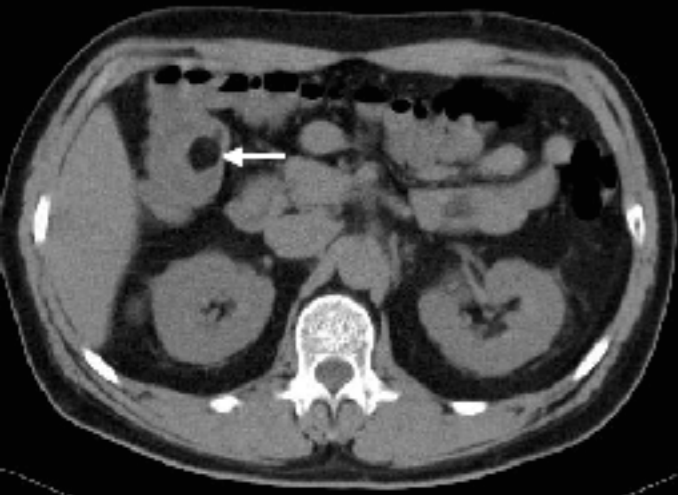


# Leading point Guide reduction

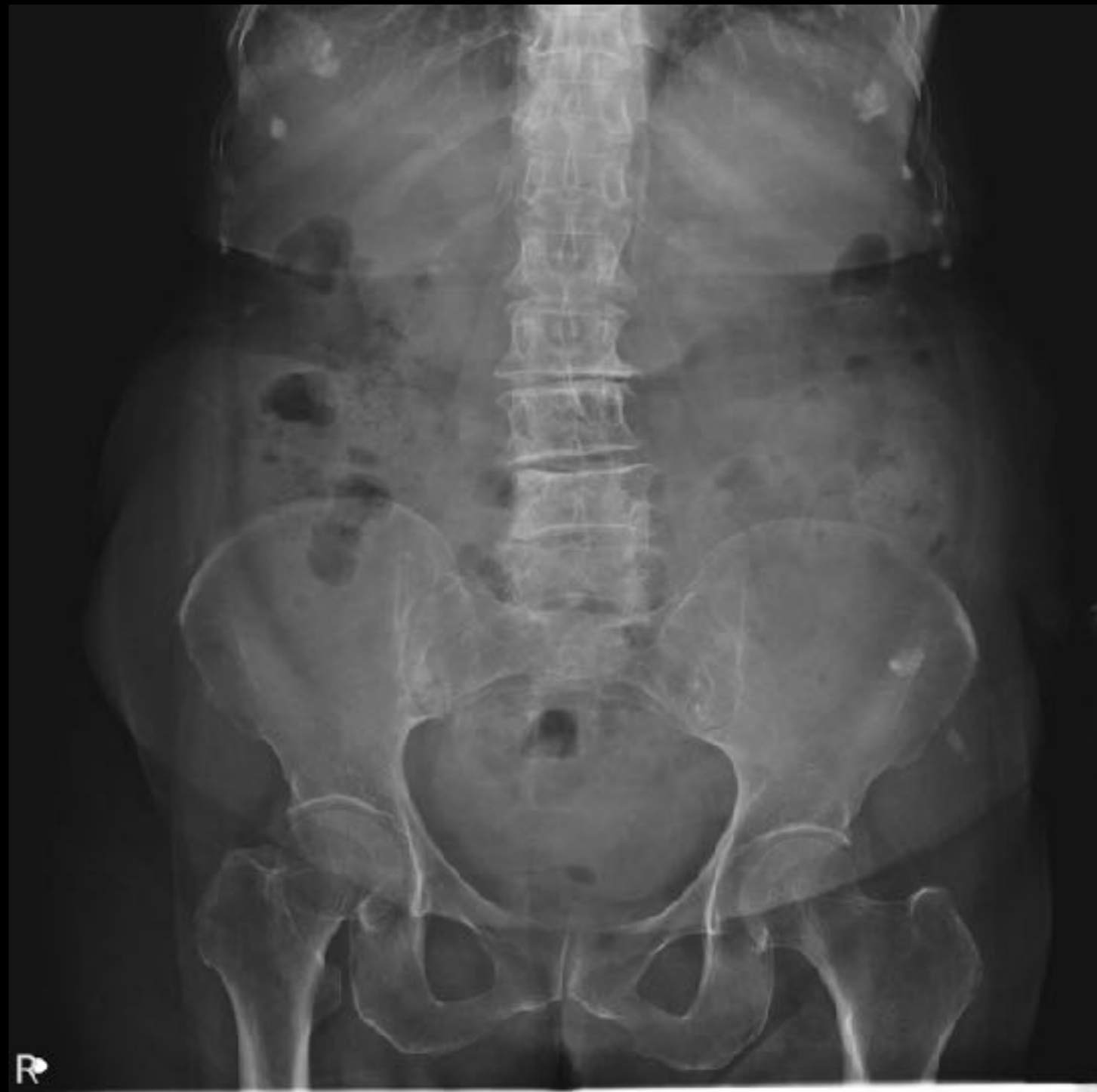
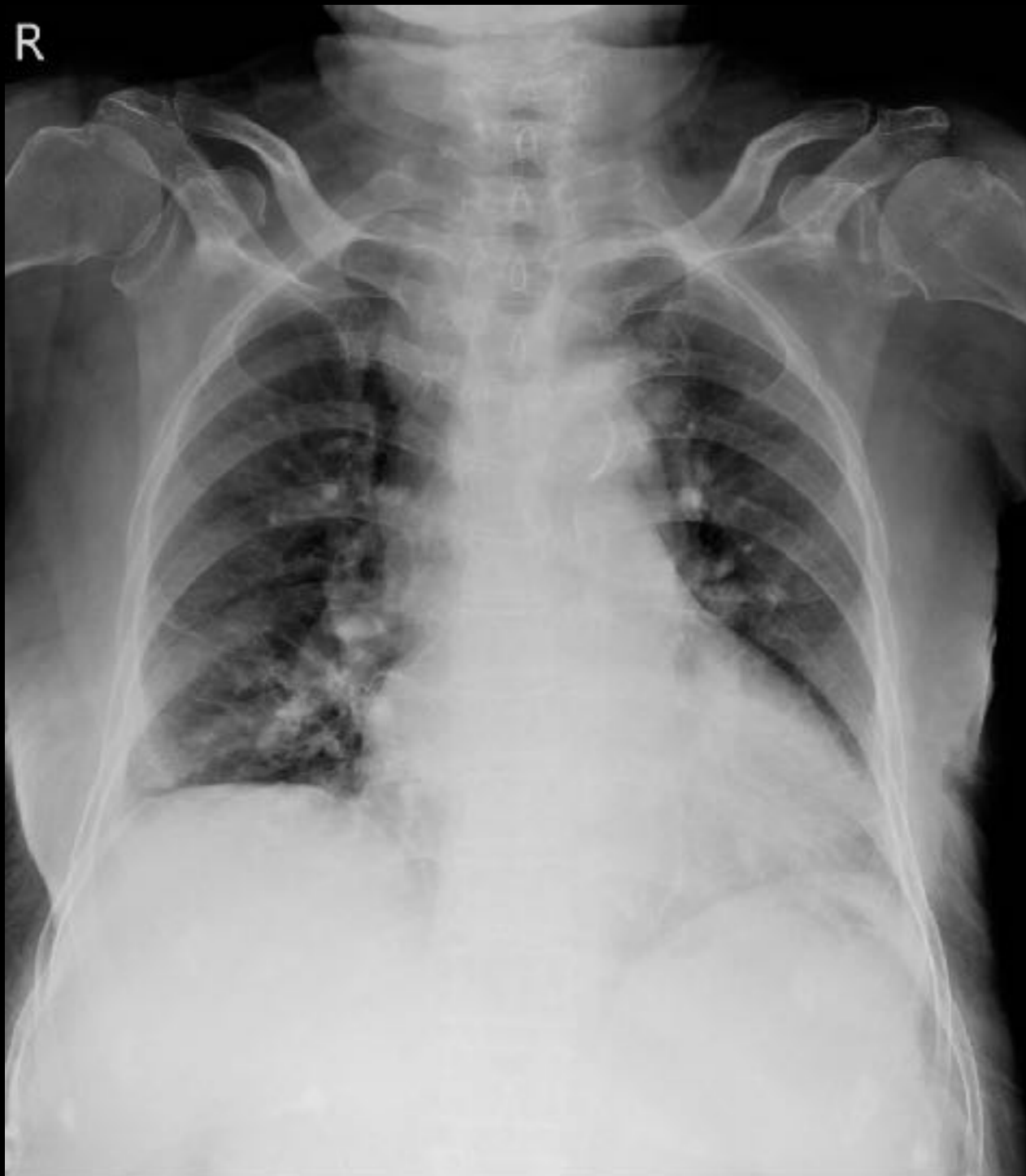


# 51M, ABD pain and tarry stool



# 80F, diffuse abdominal pain

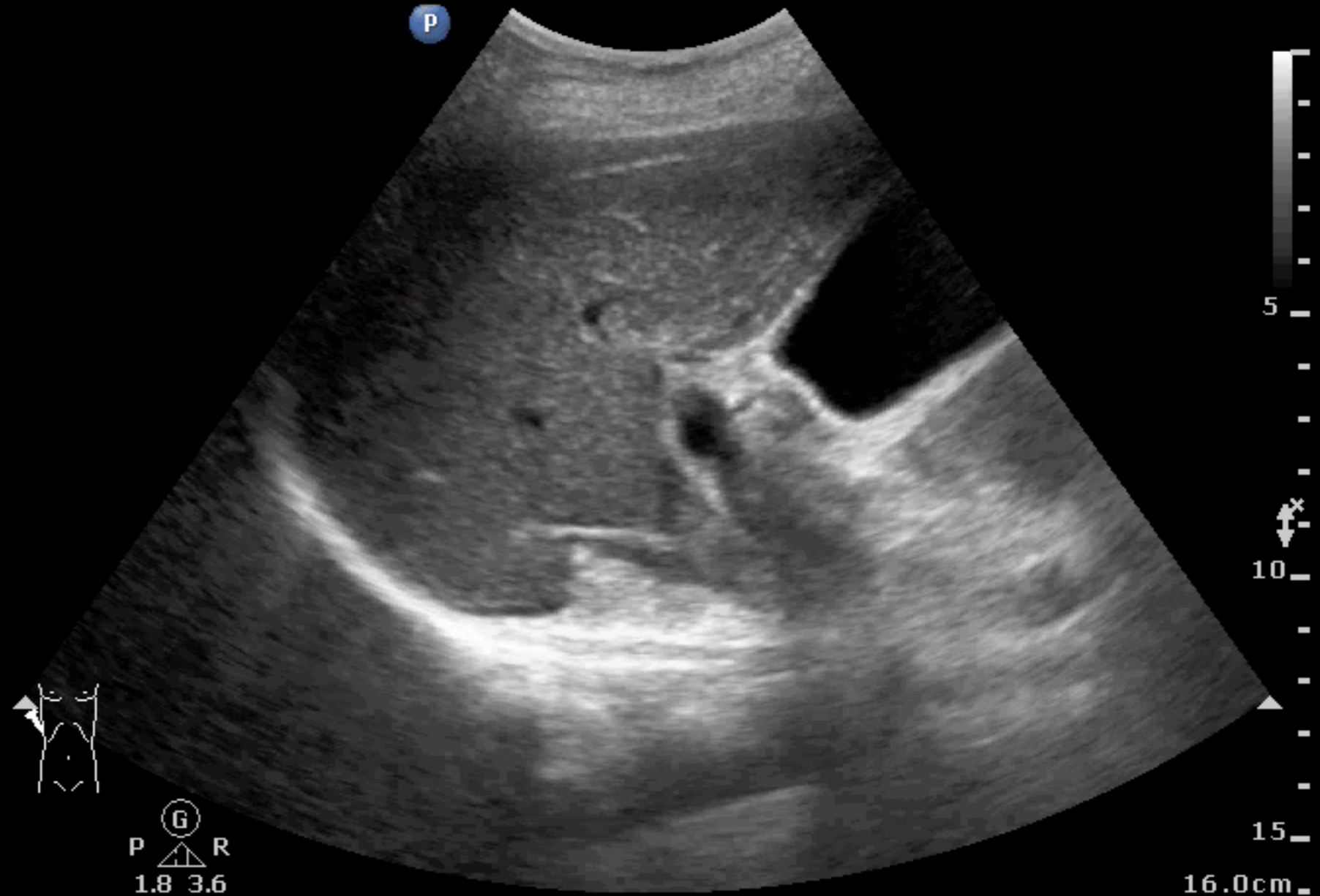

# 80F, diffuse abdominal pain

PHILIPS

Abd Gen2  
C5-1  
32 Hz  
16.0cm

2D  
HGen  
Gn 90  
C 56  
3/3/3



# ABDOMEN

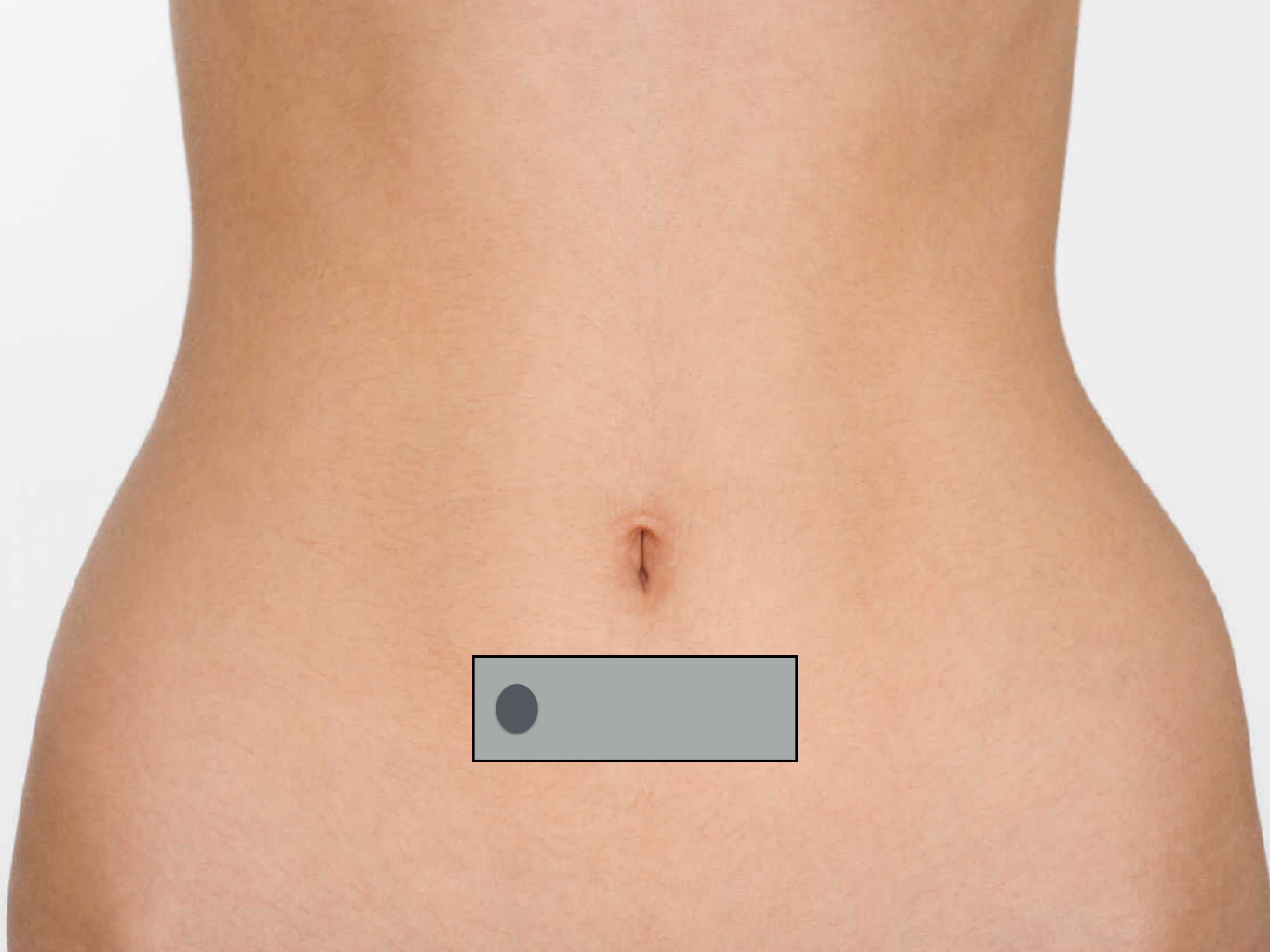
M for moving fluid or air

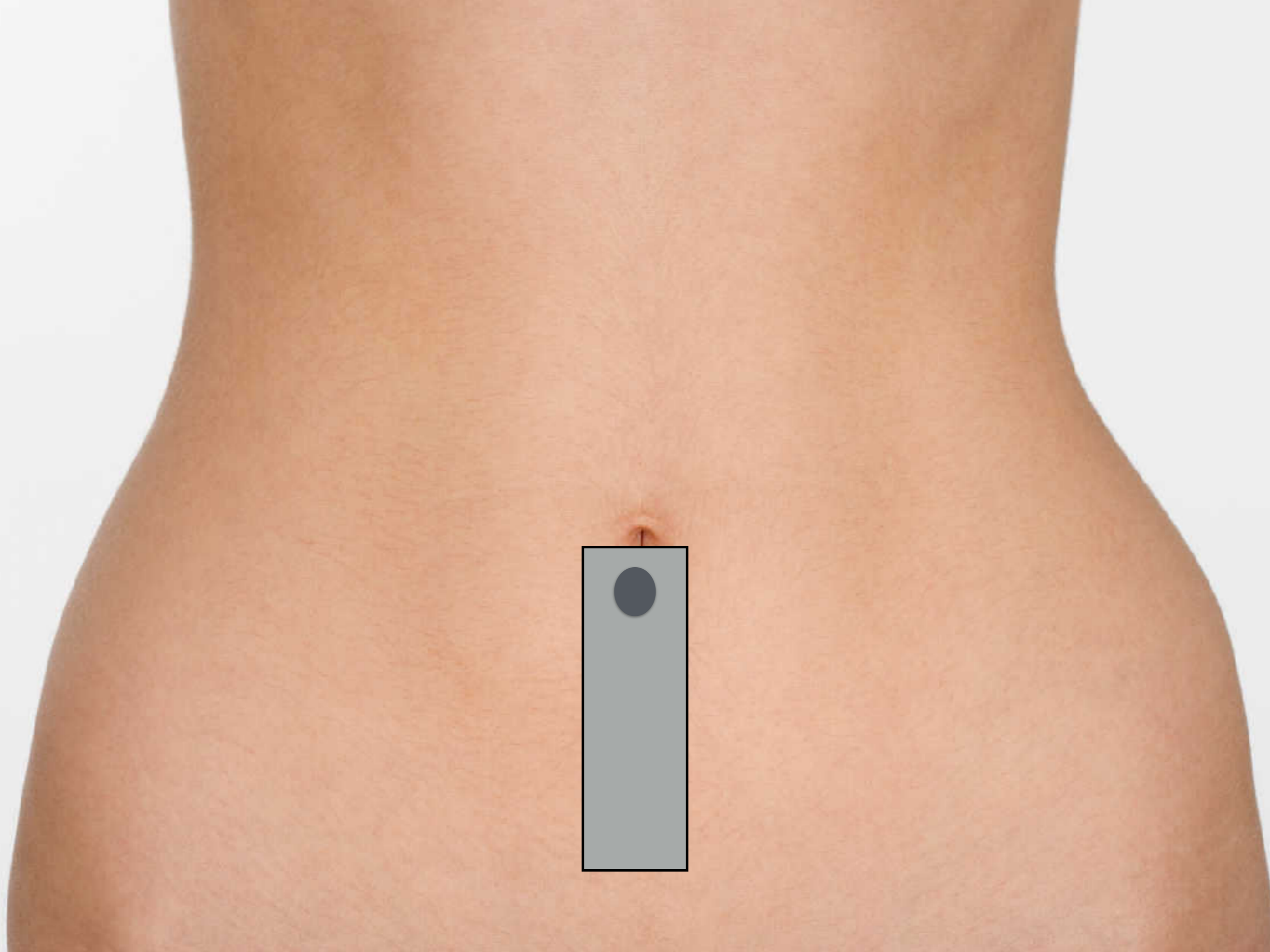
**FAST / Liver surface**



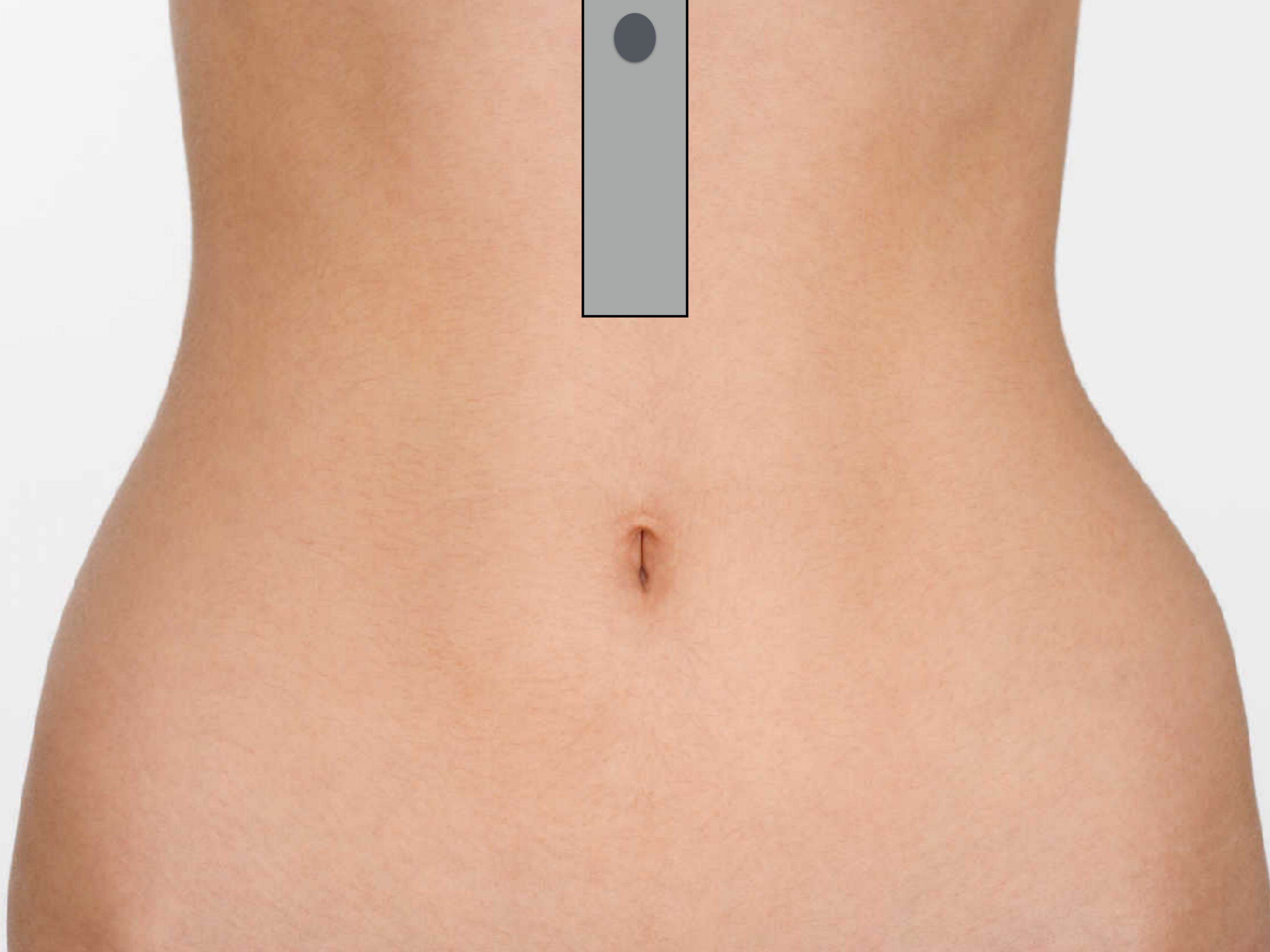


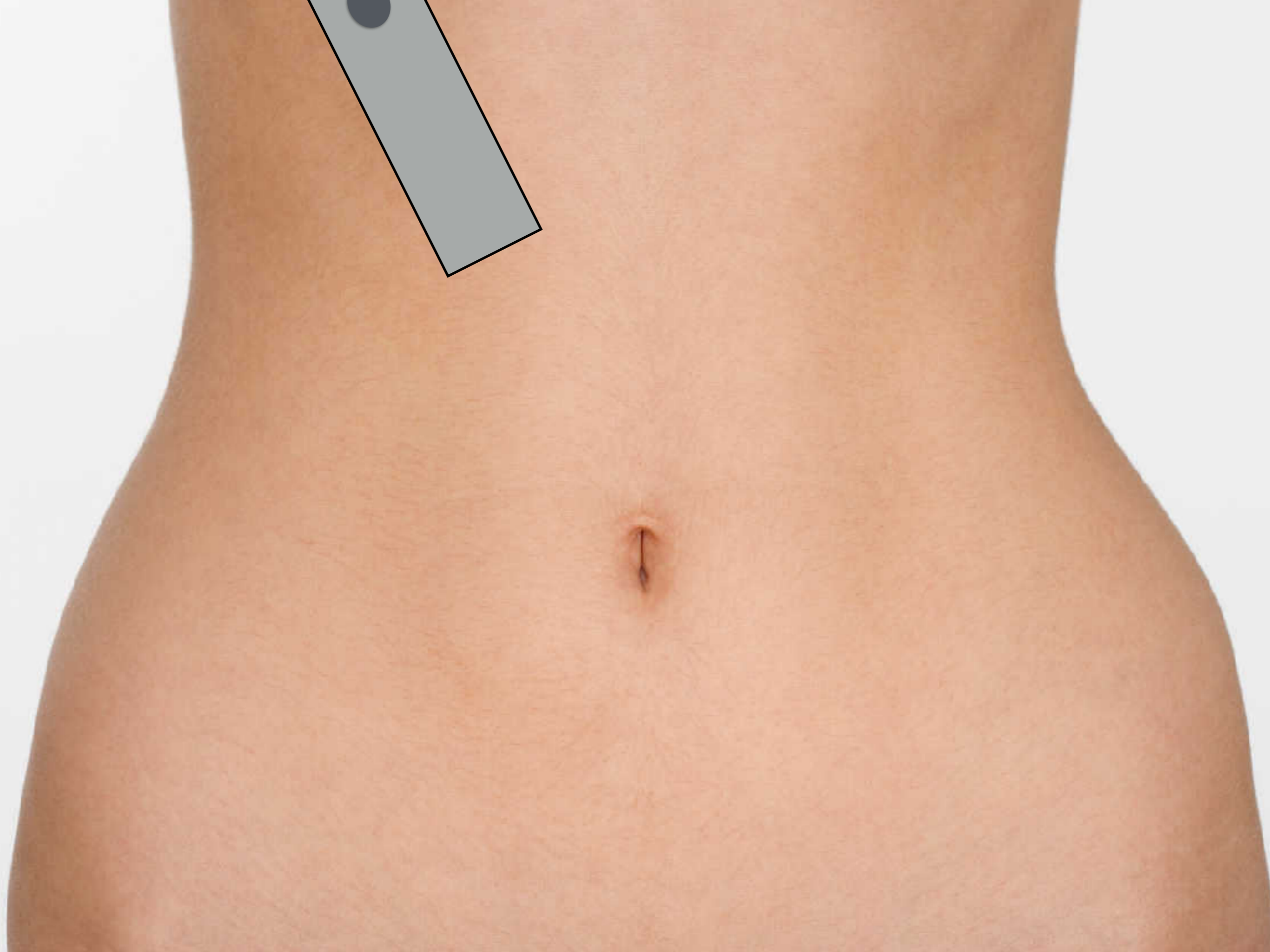








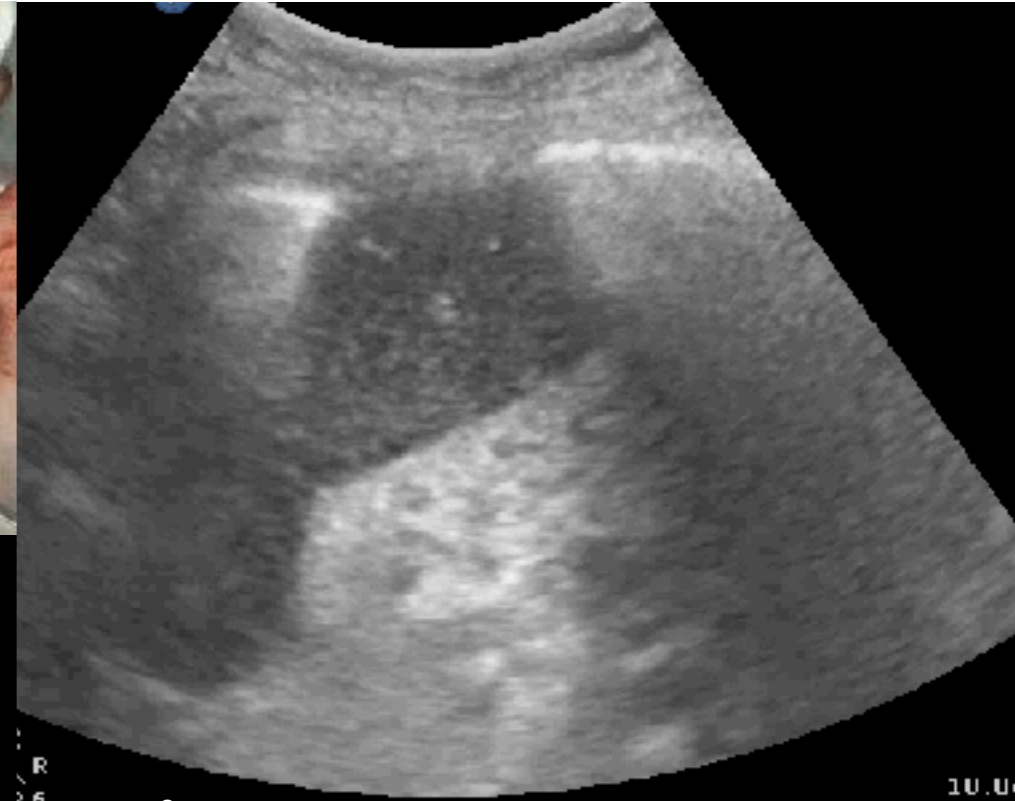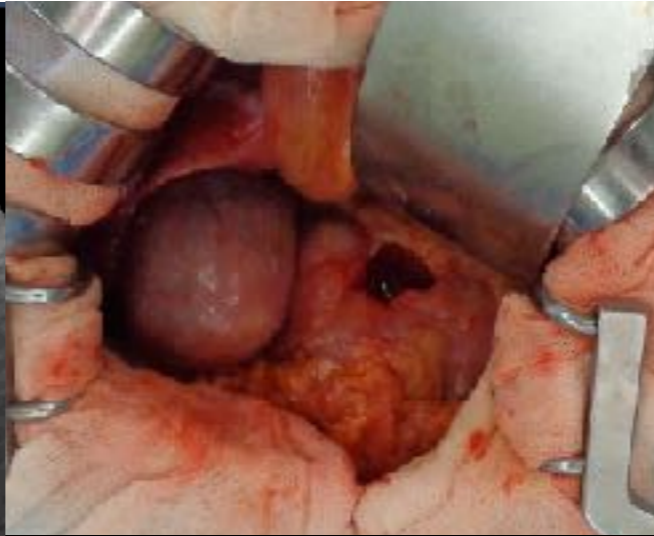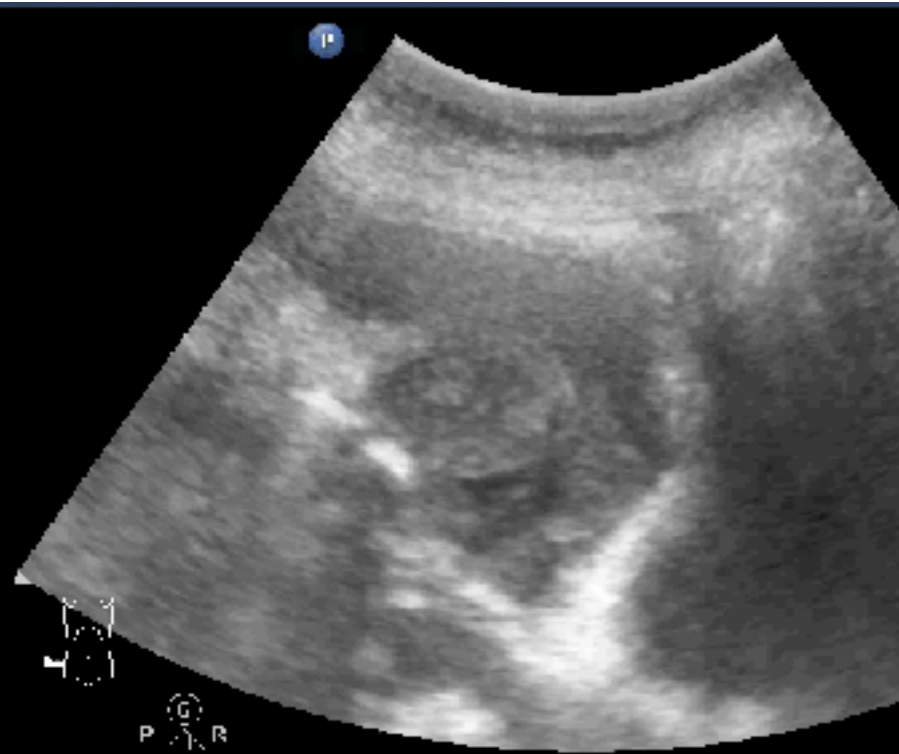






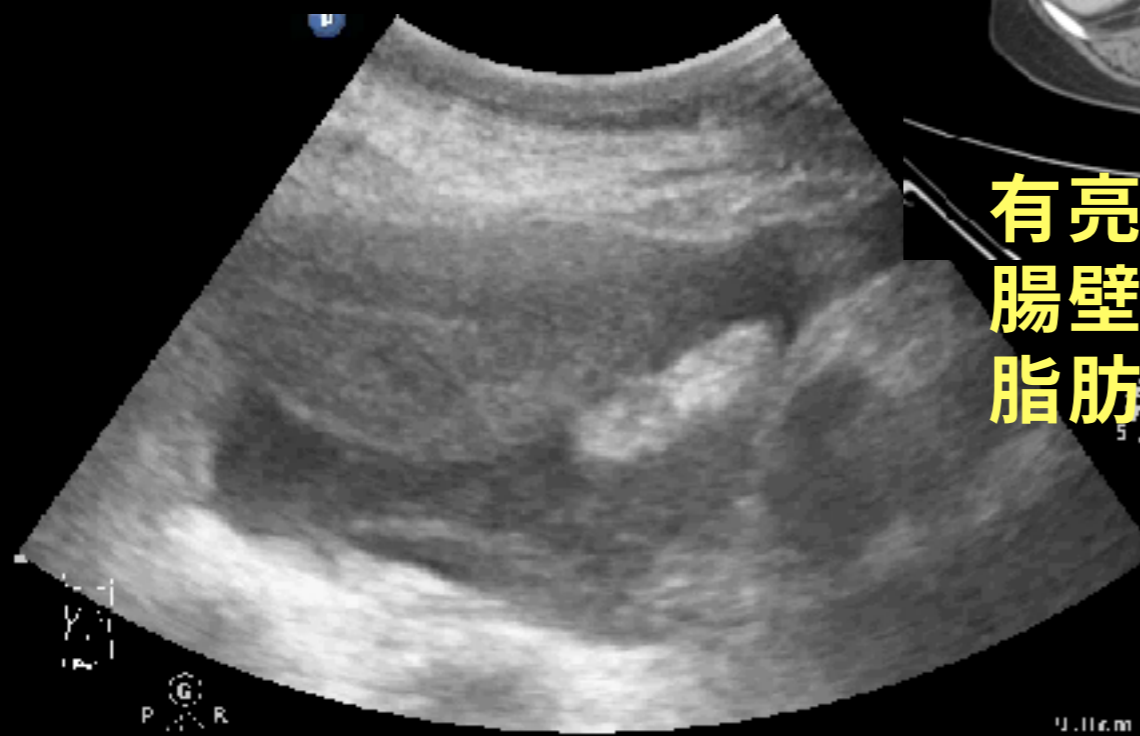# 80F, diffuse abdominal pain

Abd Gen2  
C5-1  
17 Hz  
9.0cm  
2D  
HGen  
Gn 100  
C 56  
3/3/3

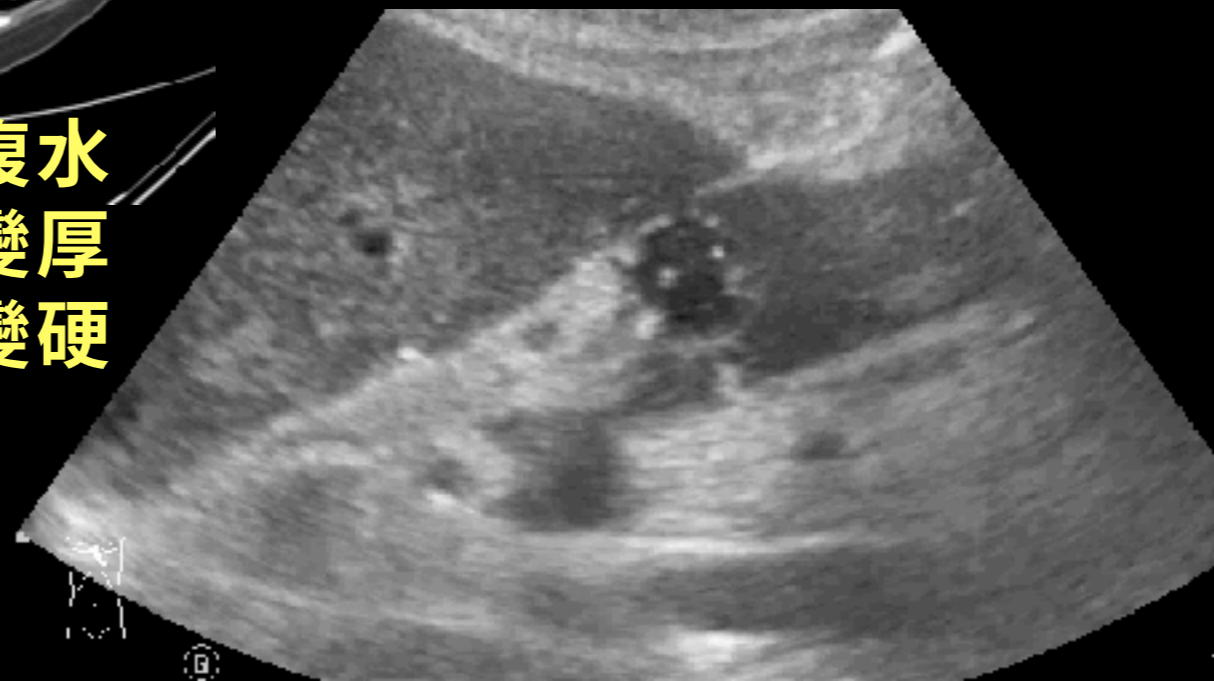


Scissors maneuver

Abd Gen2  
C5-1  
17 Hz  
9.0cm  
2D  
HGen  
Gn 100  
C 56  
3/3/3

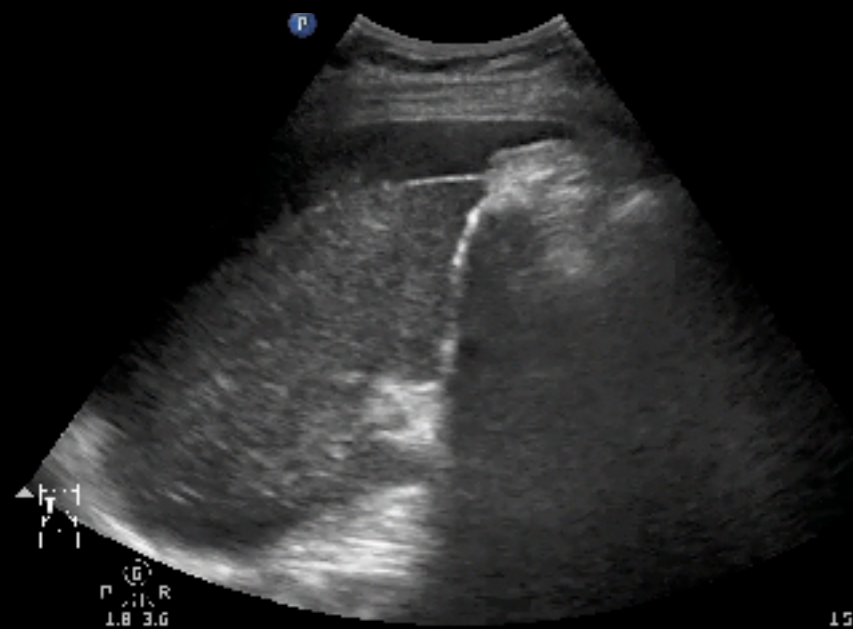


有亮度的腹水  
腸壁異常變厚  
脂肪變亮變硬

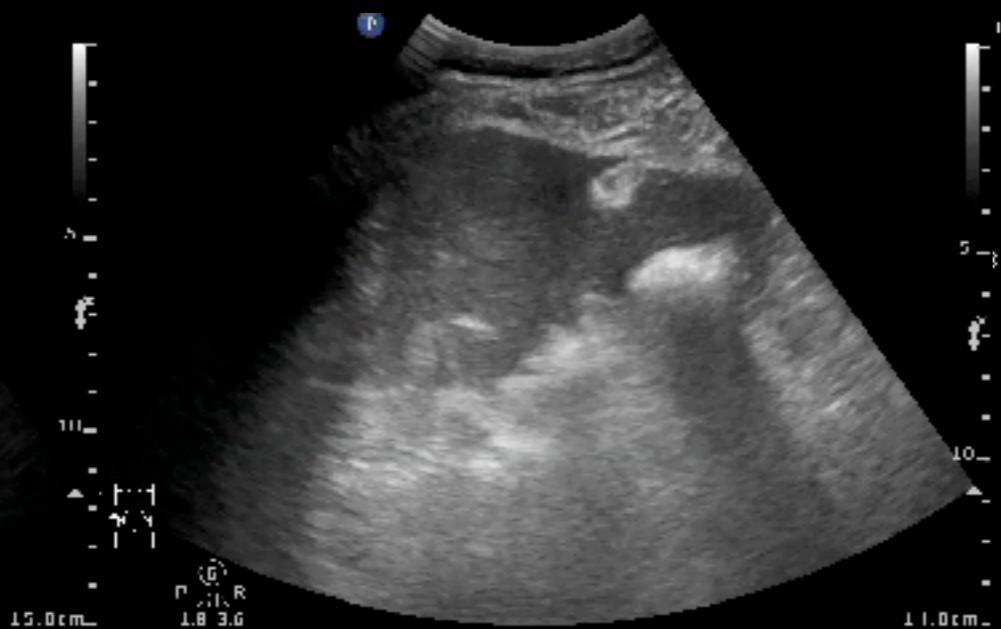

# Dirty ascites: 水往下流

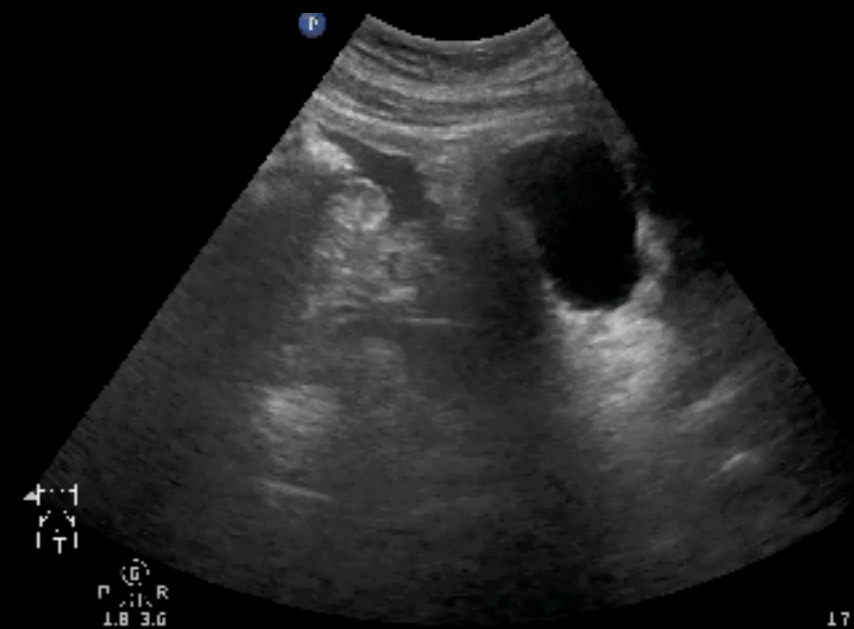
Around liver



Paracolic gutter



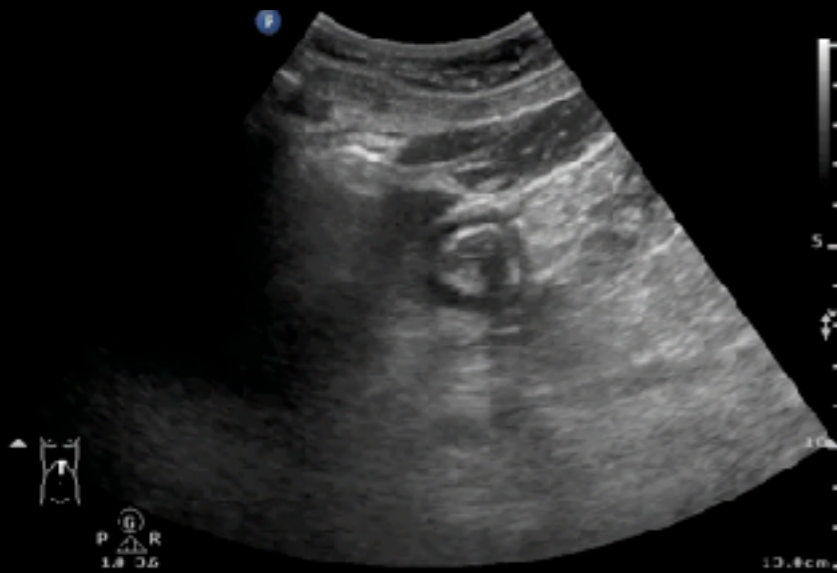Pelvis



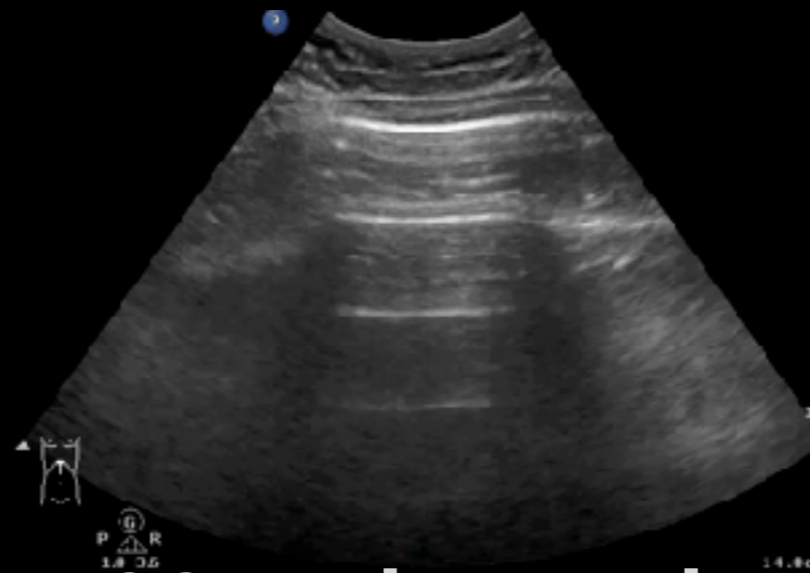
**FAST倒三角是最基本的**

# Free air: 往上找

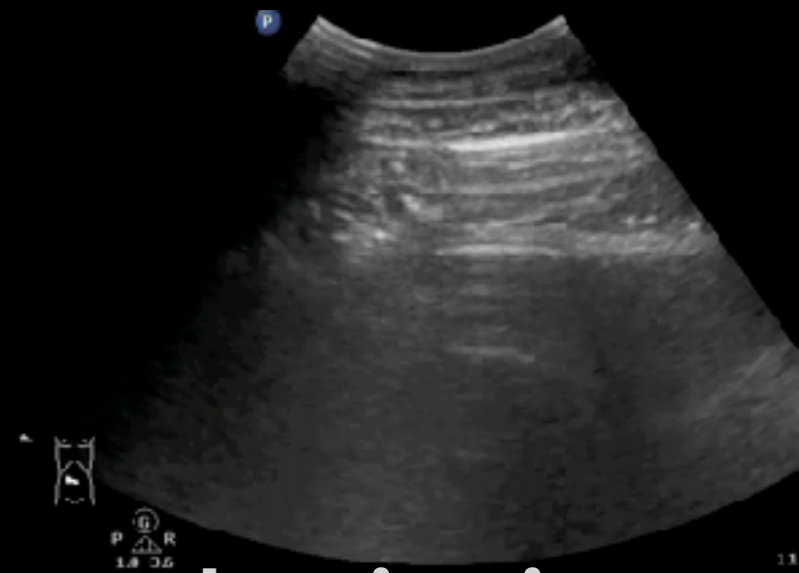Liver surface



Curtain sign



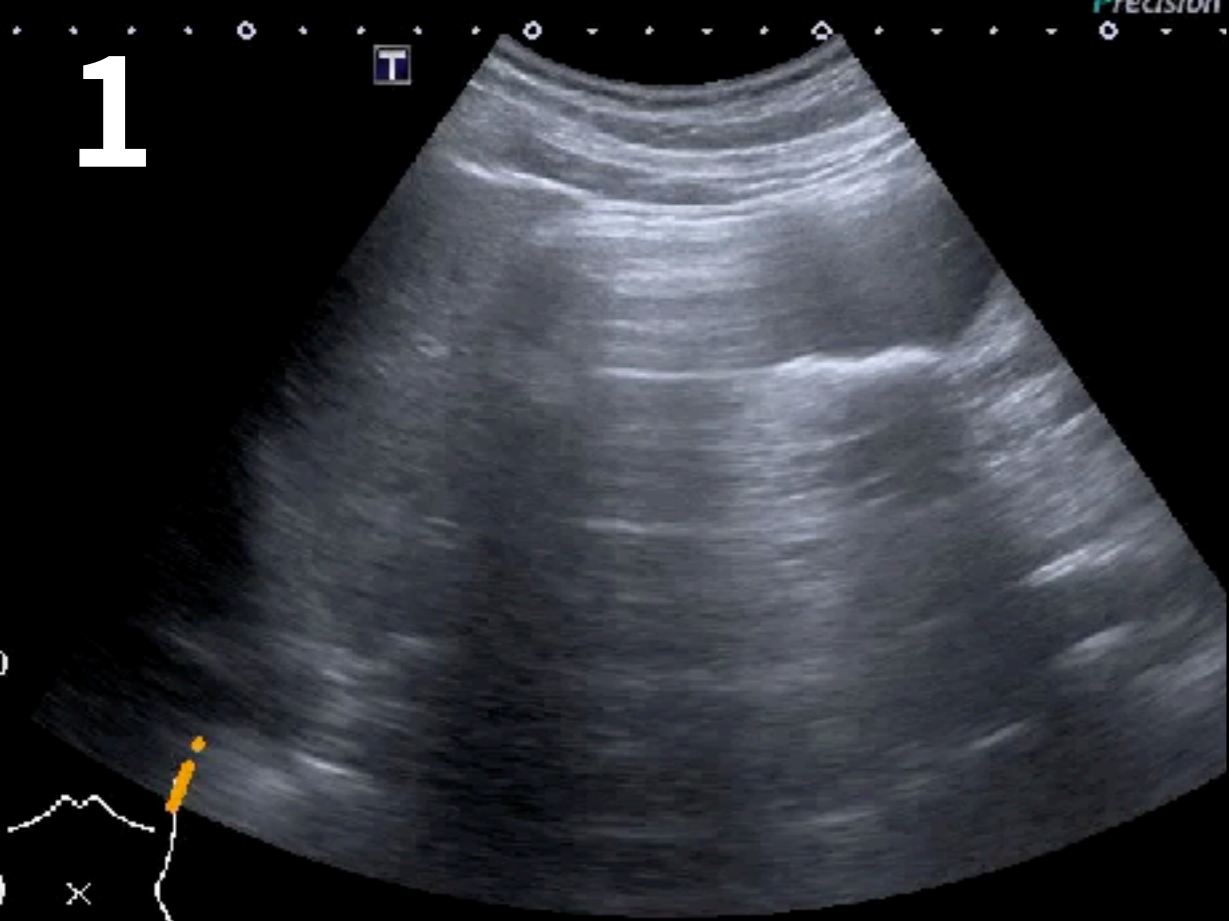
EPSS



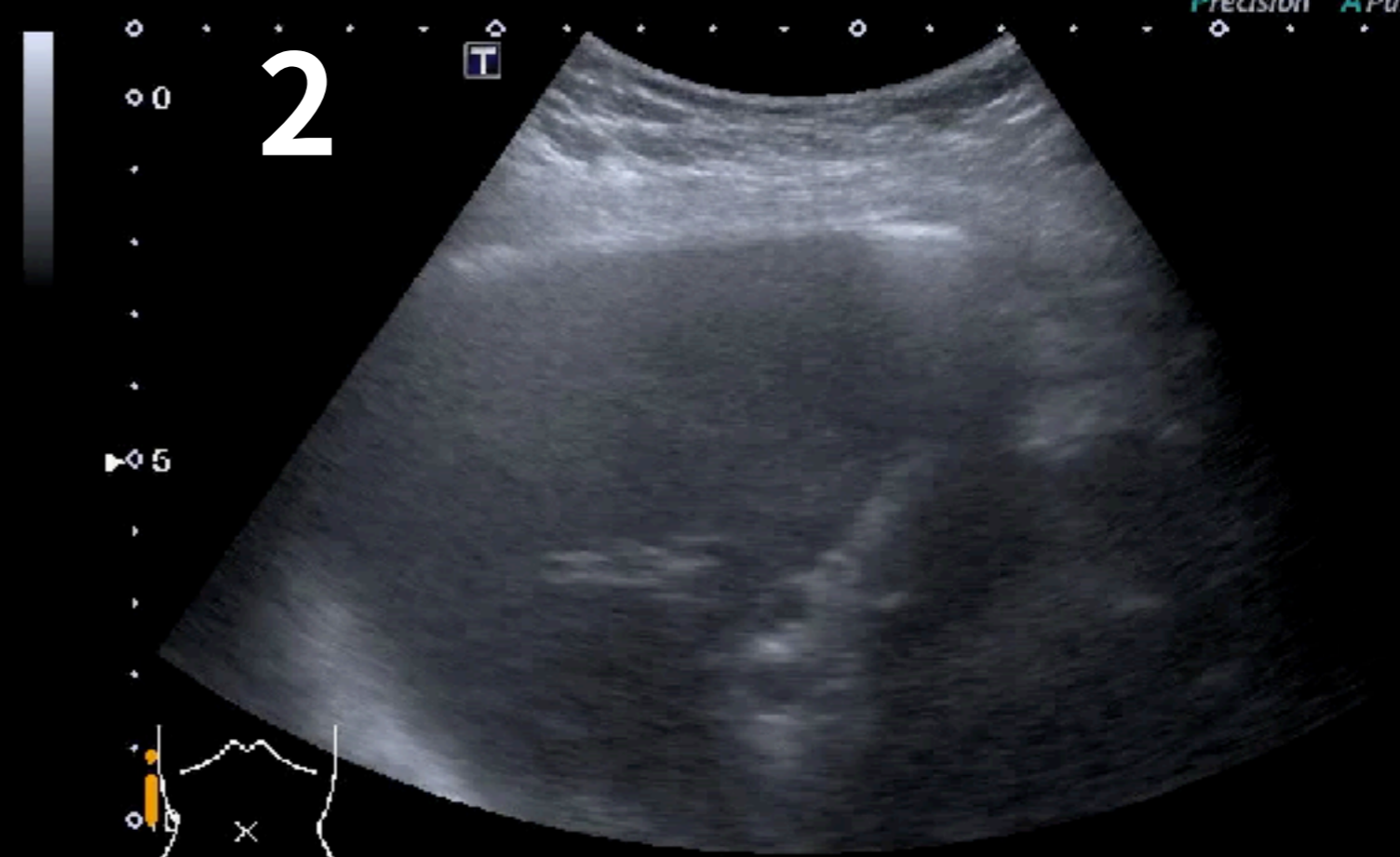
EPSS: Enhanced peritoneal strip sign

游離氣存在界面變亮  
跟肺部的氣胸一個樣  
不要忘了可以壓一壓

1

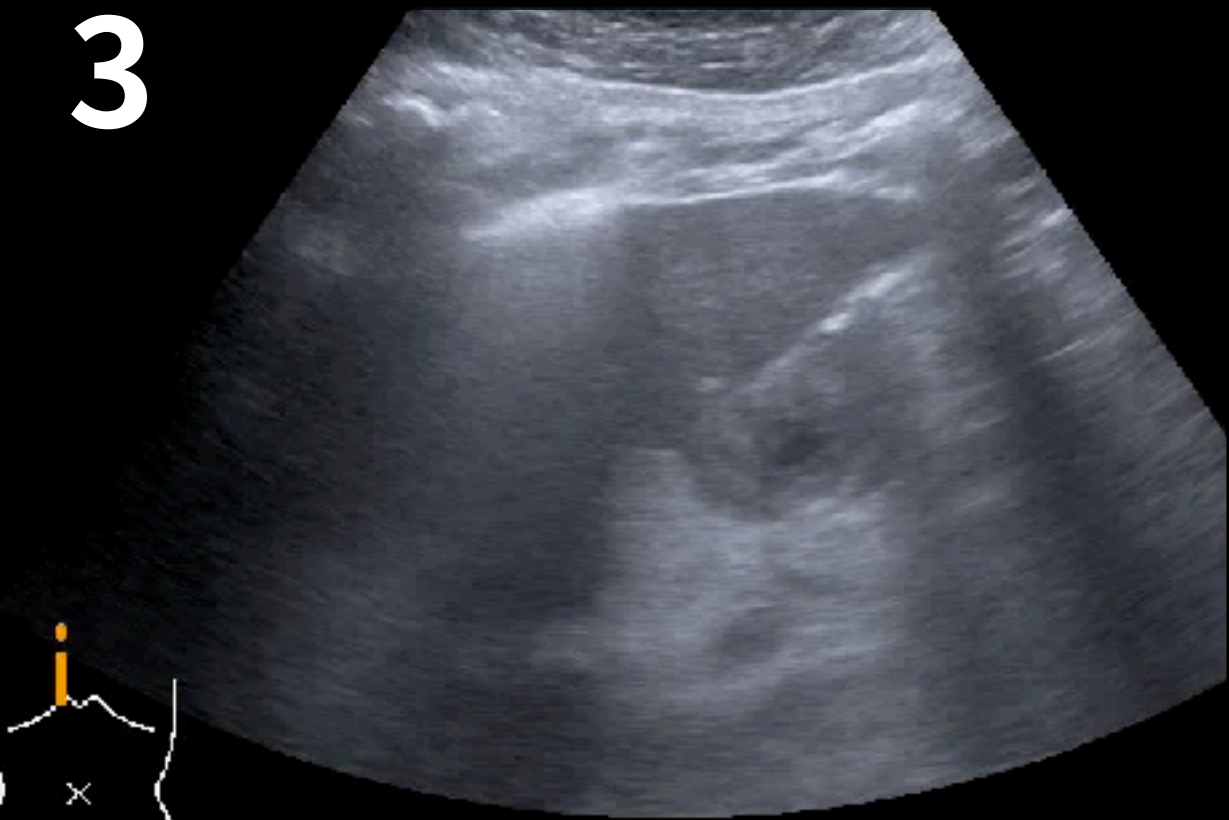


2

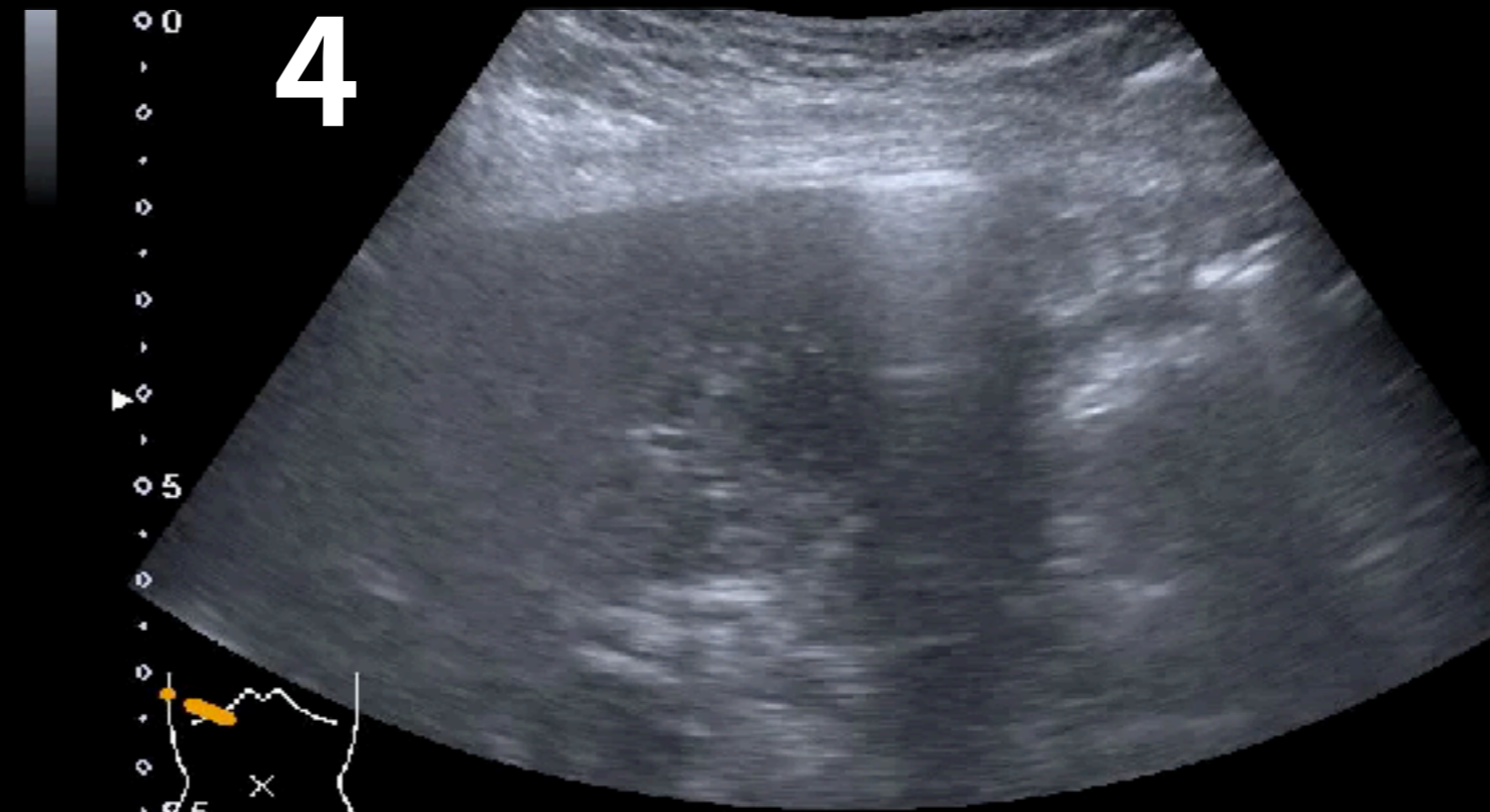


請問那一段影片不是Pneumoperitoneum？

3



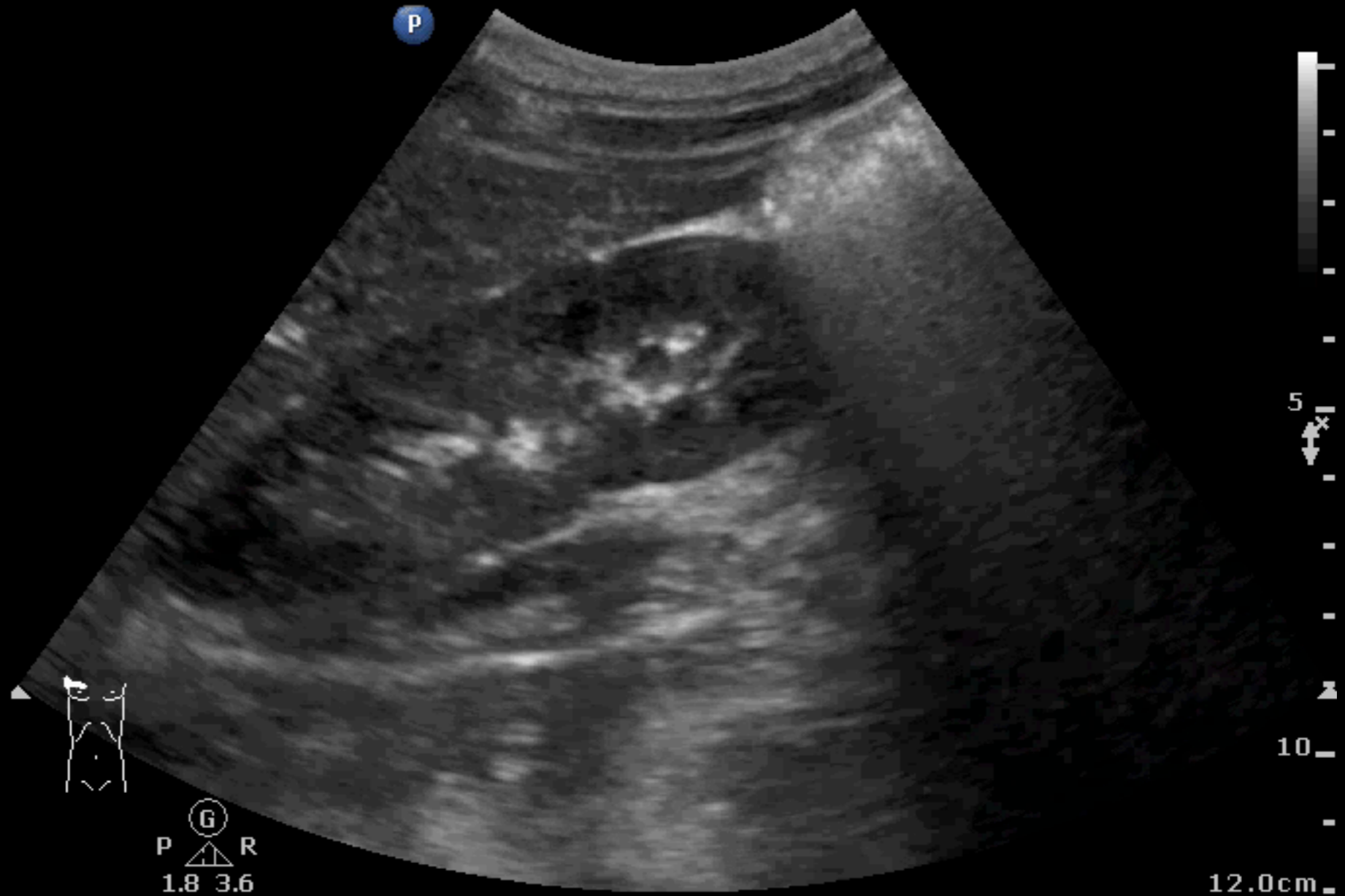
4



# 33F, low abdominal pain & shock

Abd Gen  
C5-1  
39 Hz  
12.0cm

2D  
HGen  
Gn 71  
C 56  
3 / 3 / 3



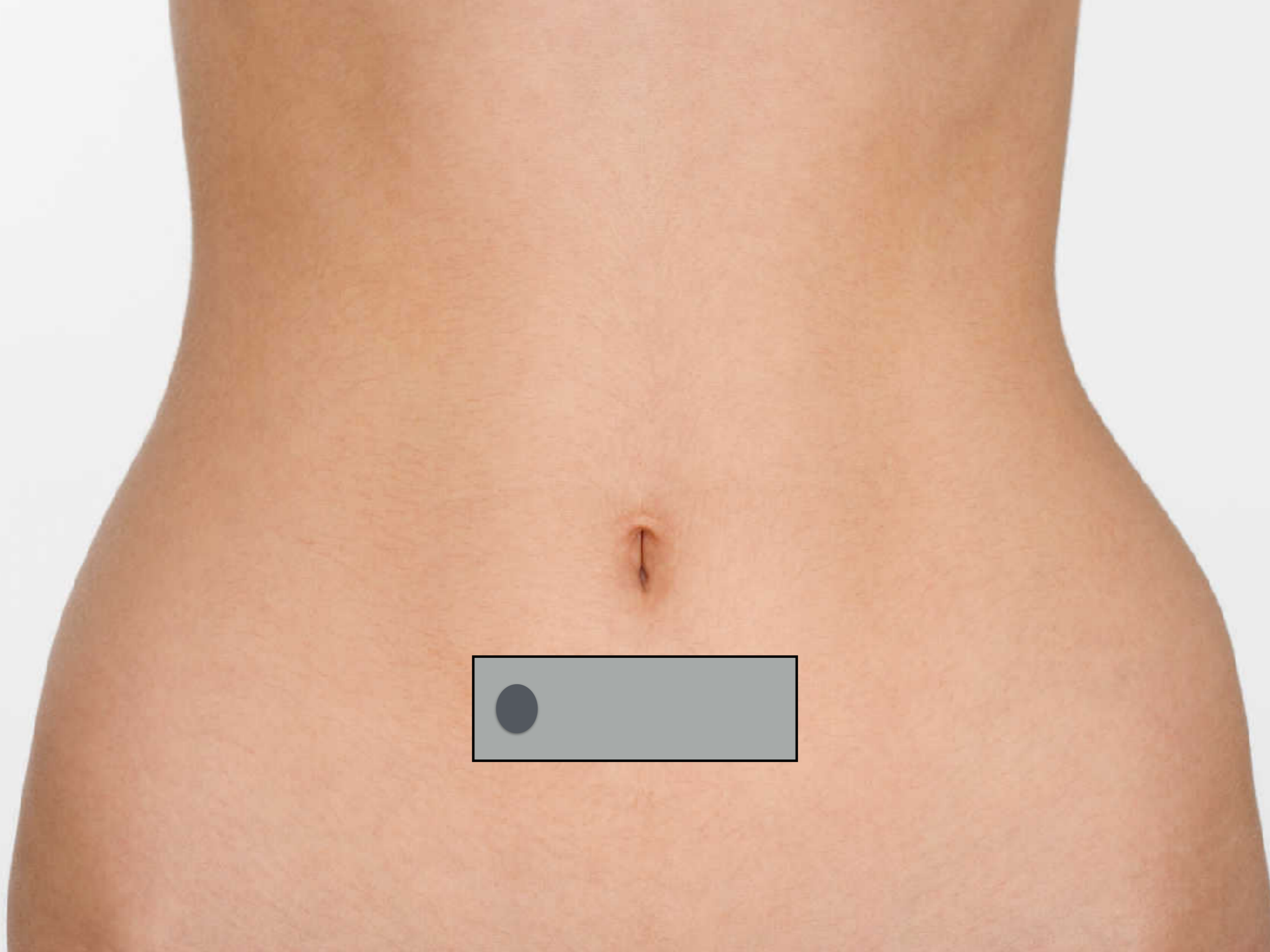
# ABDOMEN **E**

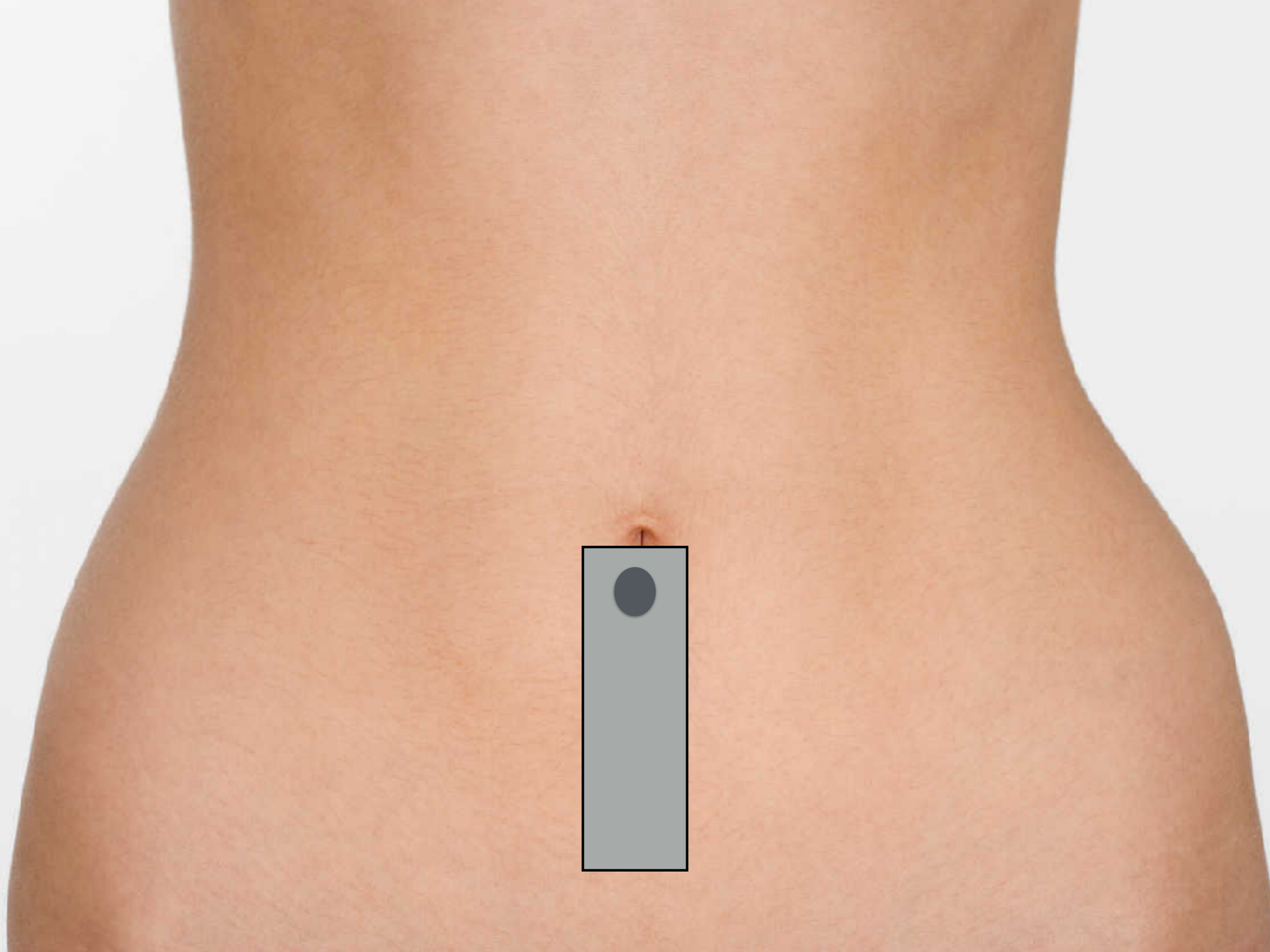
**E for ectopic pregnancy**

**Ascites & IUUP**



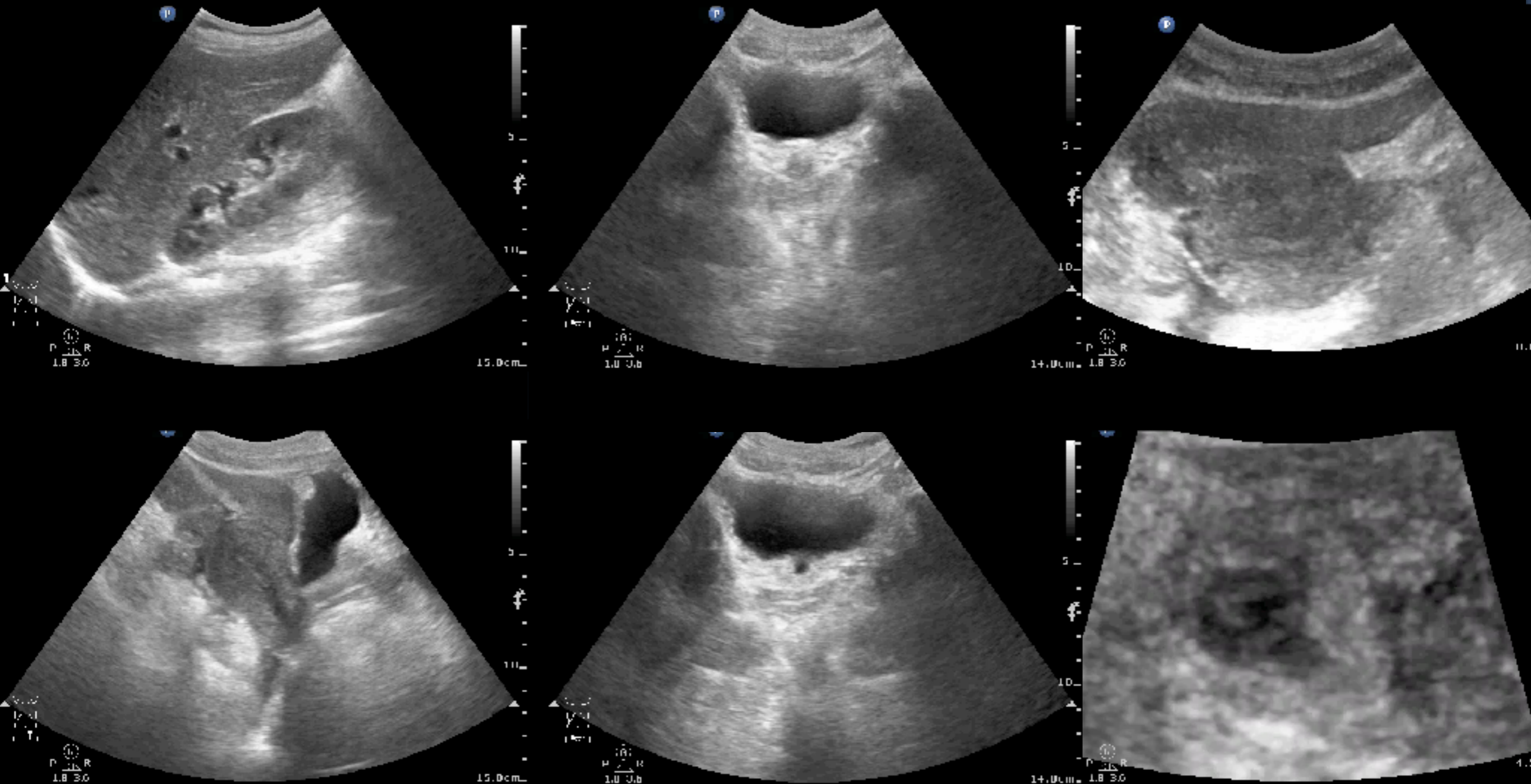






# ABDOMEN

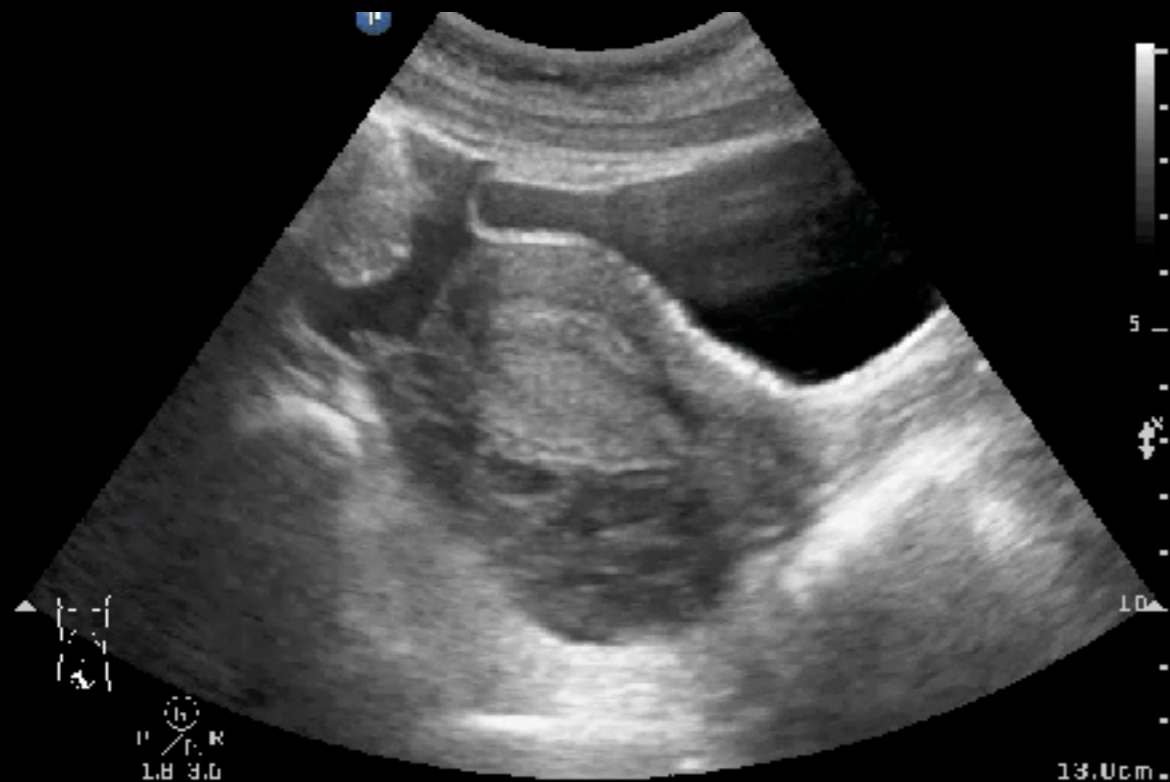
25F, abdominal pain



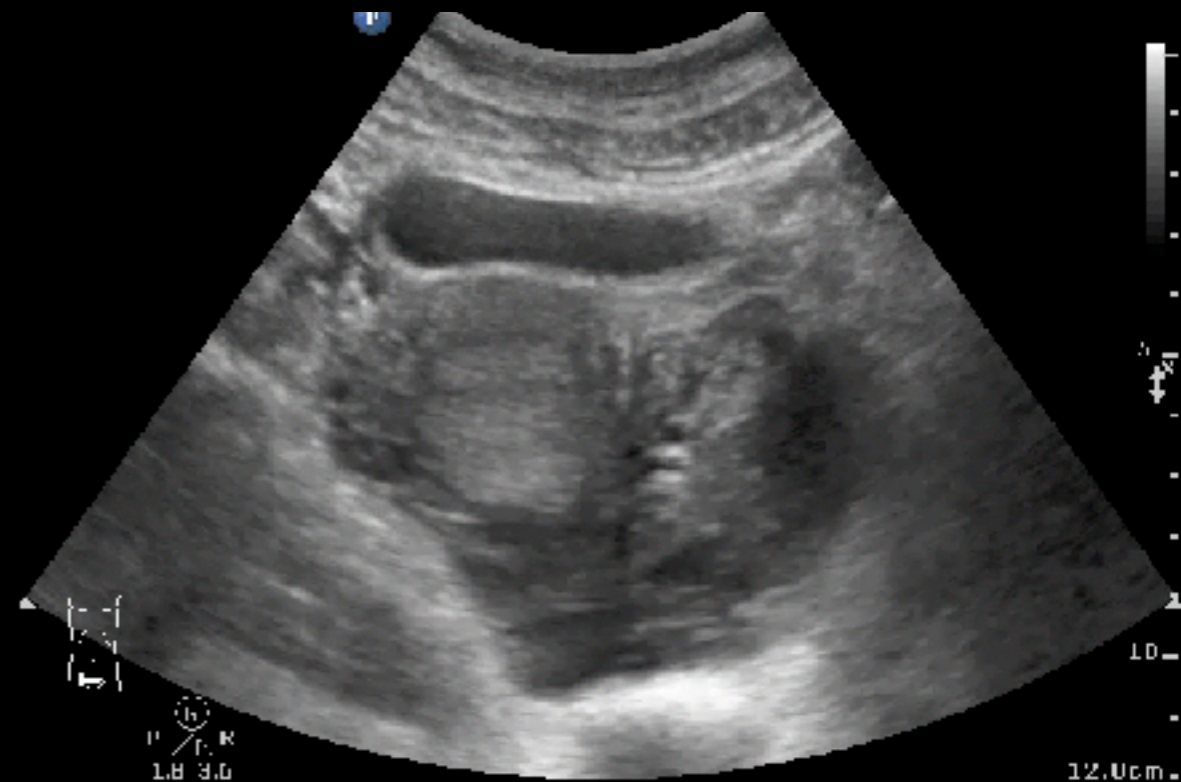
**14F, acute lower abdominal pain with cold sweating**

**Female acute abdomen or shock consider **ovarian cyst rupture****

Abd Gen  
[15 1  
38 Hz  
13.0cm  
2D  
11Gen  
[1n 7/8  
[1 56  
3/3/3



Abd Gen  
[15 1  
39 Hz  
12.0cm  
2D  
11Gen  
[1n 7/8  
[1 56  
3/3/3



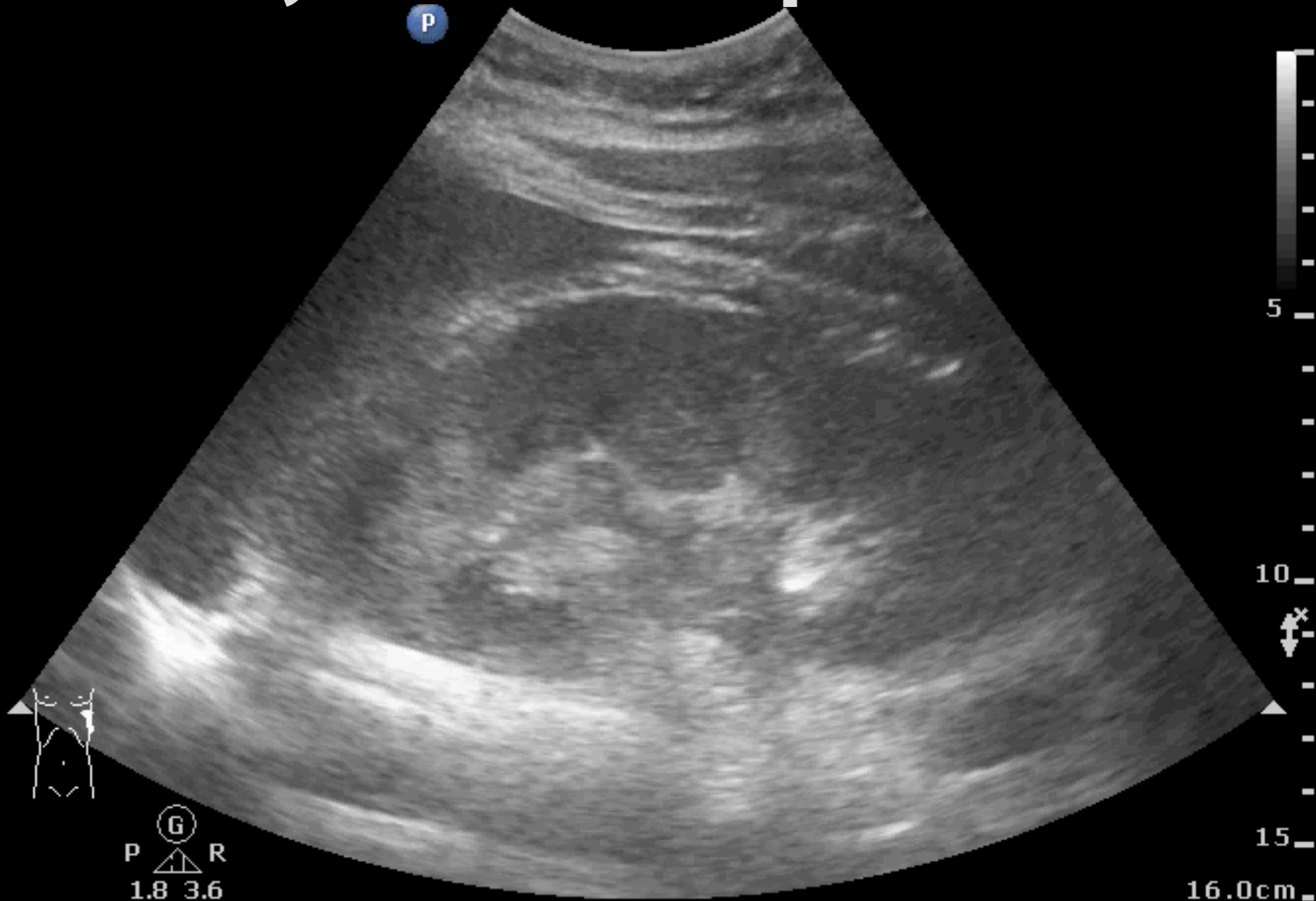
**Echo first** then Urine pregnancy test

# 25M, left flank pain

Abd Gen2  
C5-1  
32 Hz  
16.0cm

2D

HGen  
Gn 93  
C 56  
3/3/3



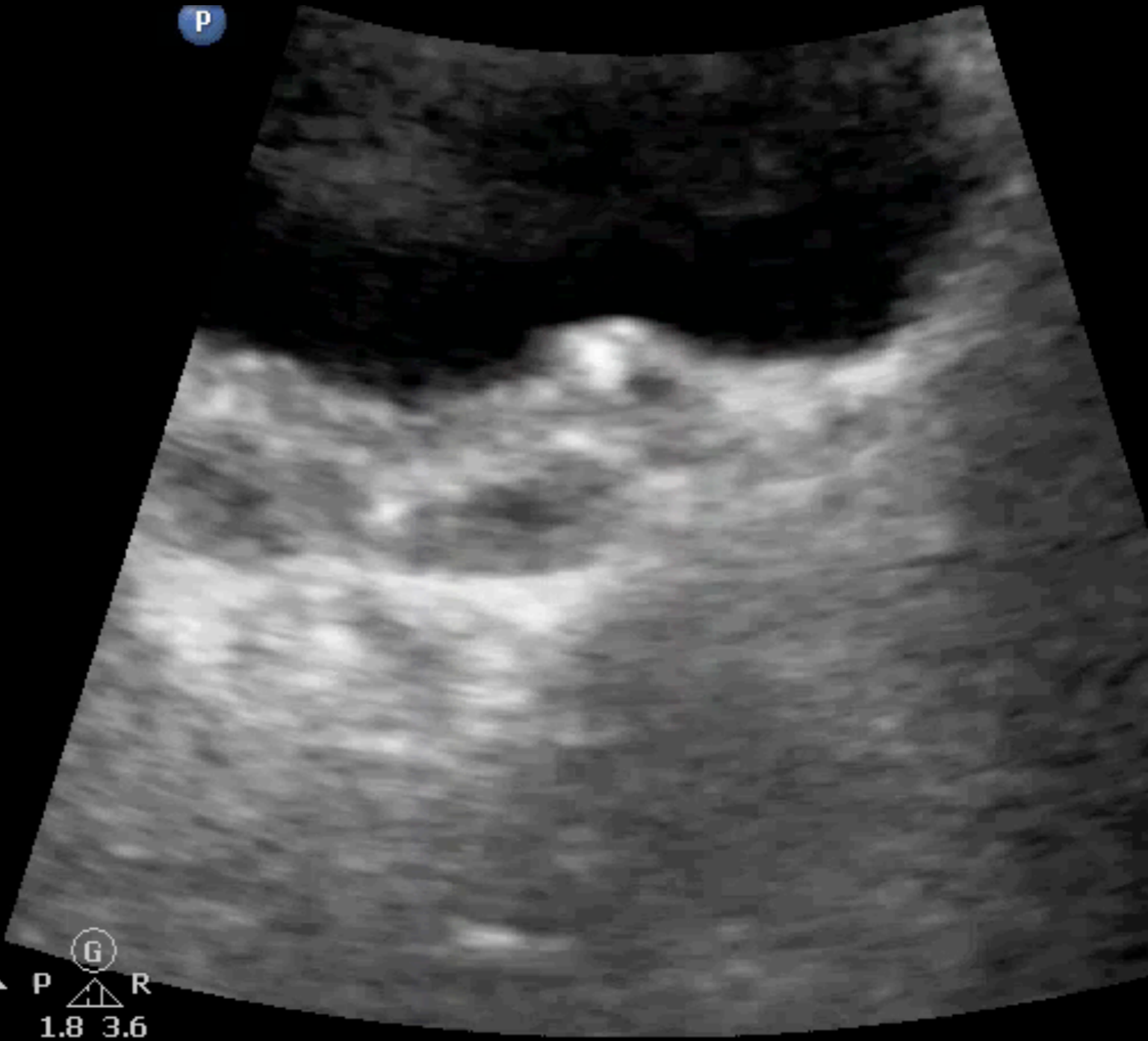
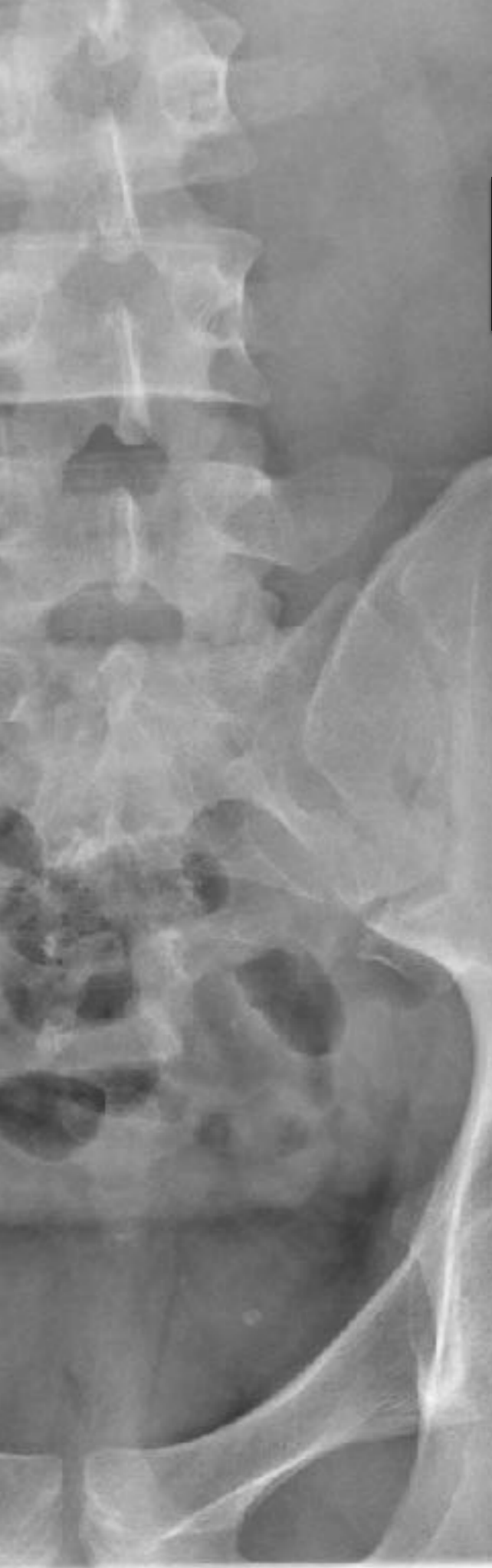
P (G) R  
1.8 3.6

16.0cm

# L UJV stone

Abd Gen2  
C5-1  
73 Hz  
HD Zoom

2D  
HGen  
Gn 58  
C 56  
3 / 3 / 3



▲ P R  
1.8 3.6

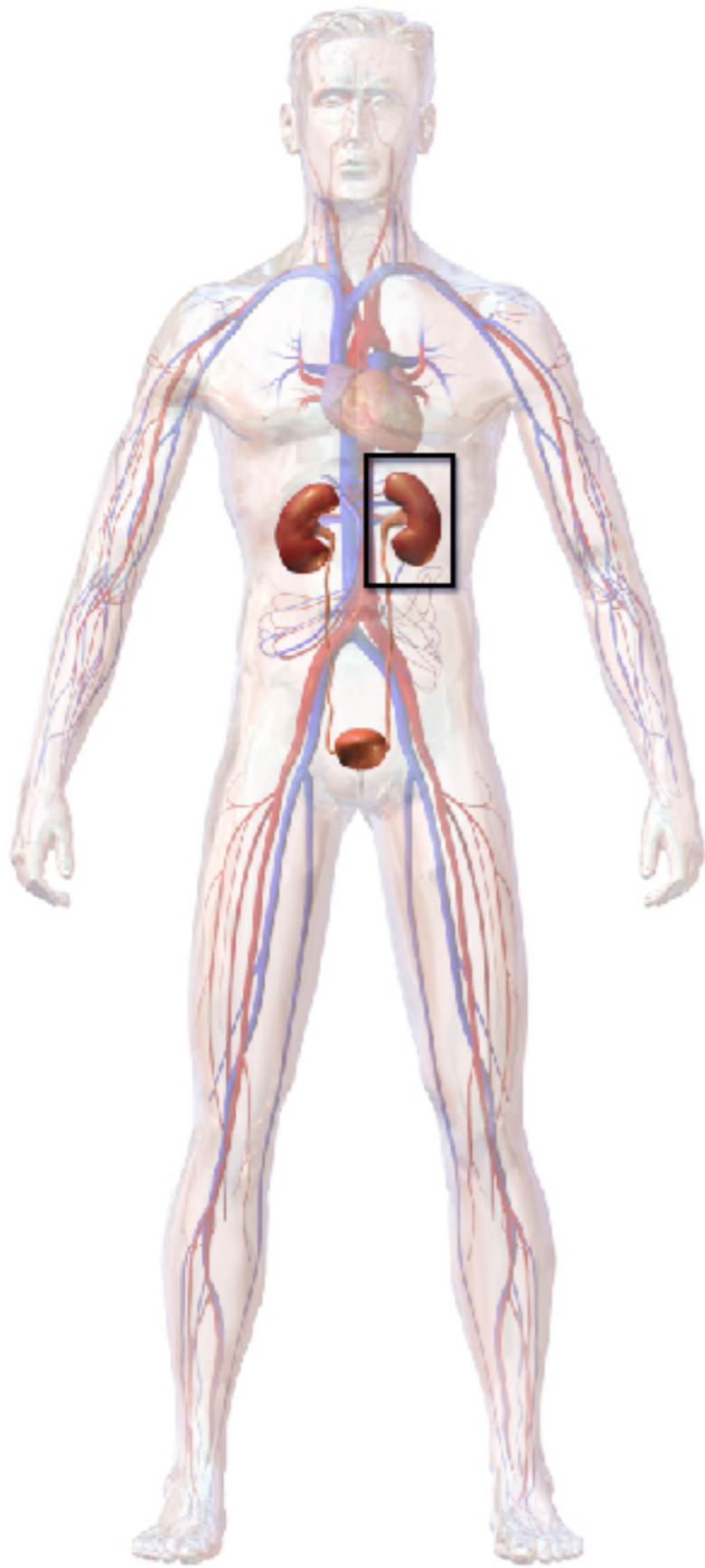
# ABDOMEN **N**

**N for nephropathy**

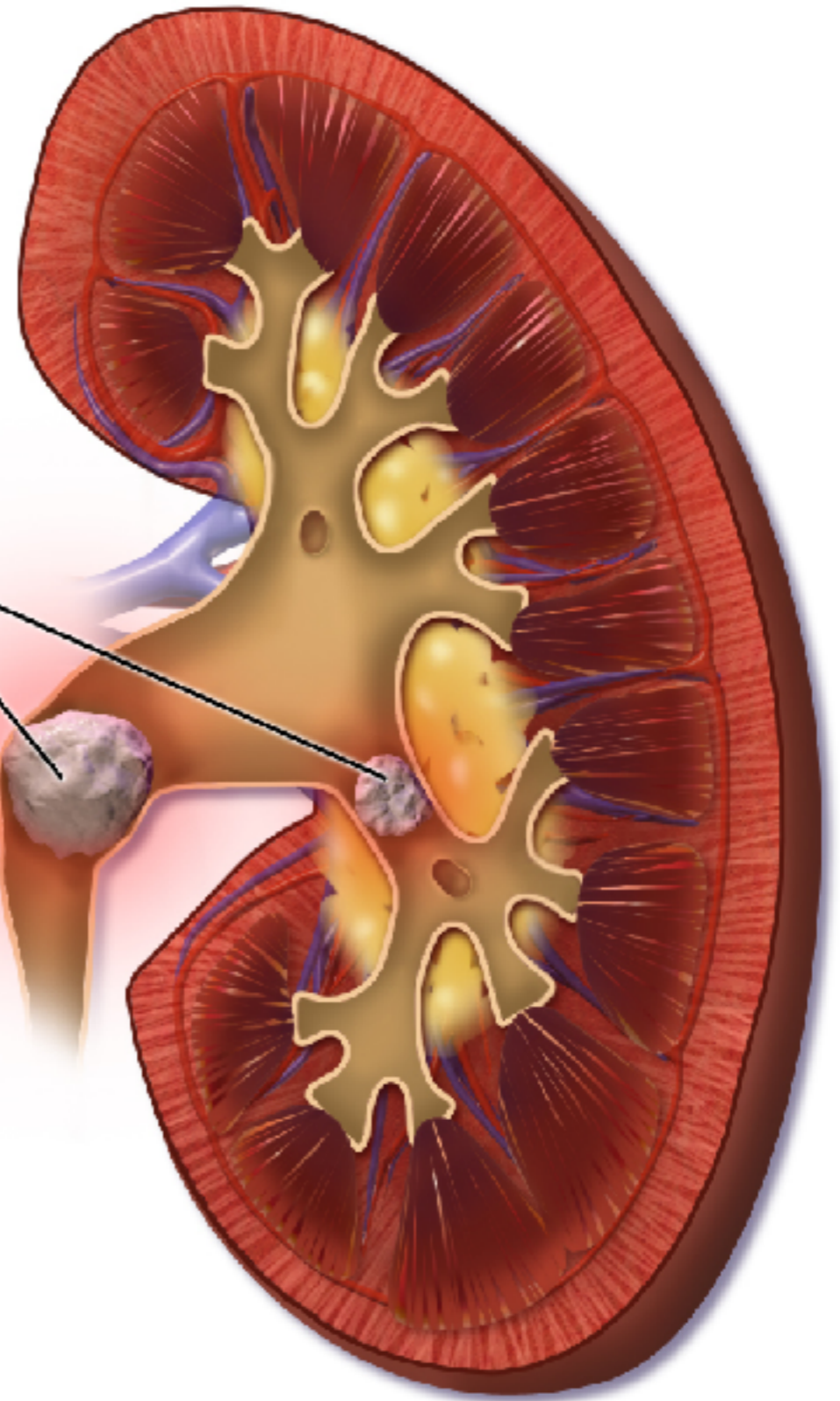
**Hydronephrosis & KuB**





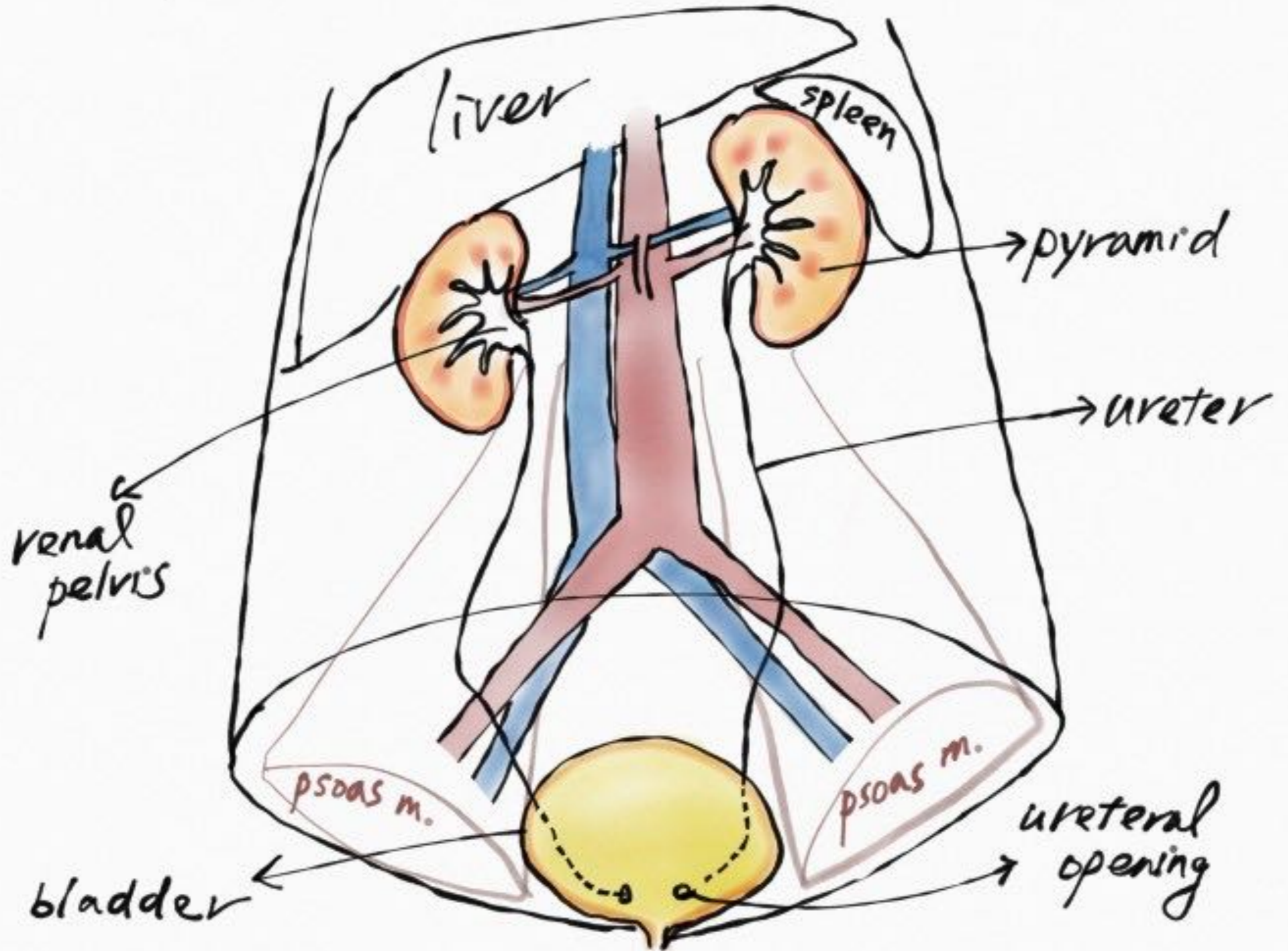



Kidney stones



# Kidney Stones

Copyright © 2016 HSU CHZ CHAN ET. All rights reserved





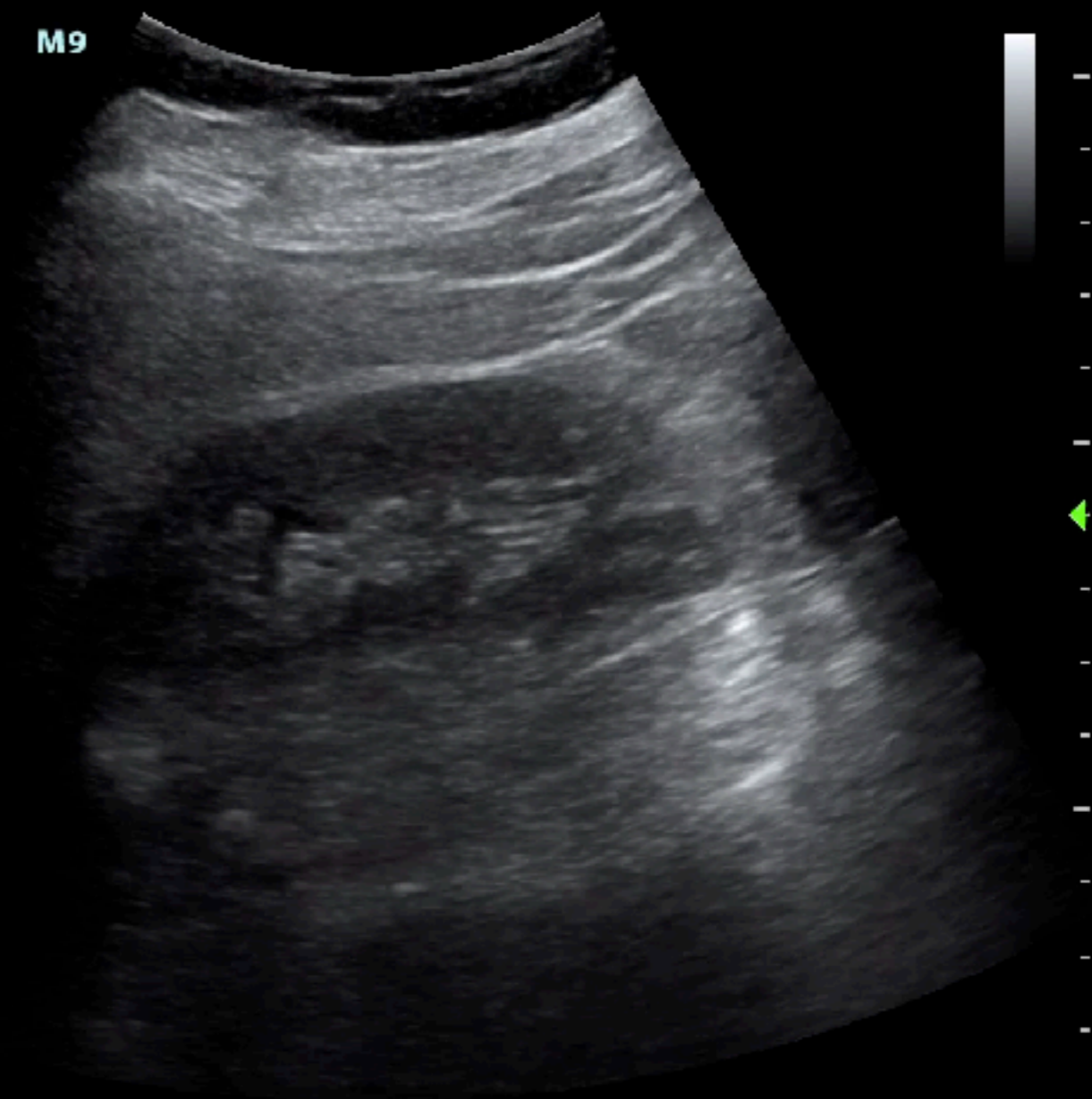
13-03-2016 16:07:02

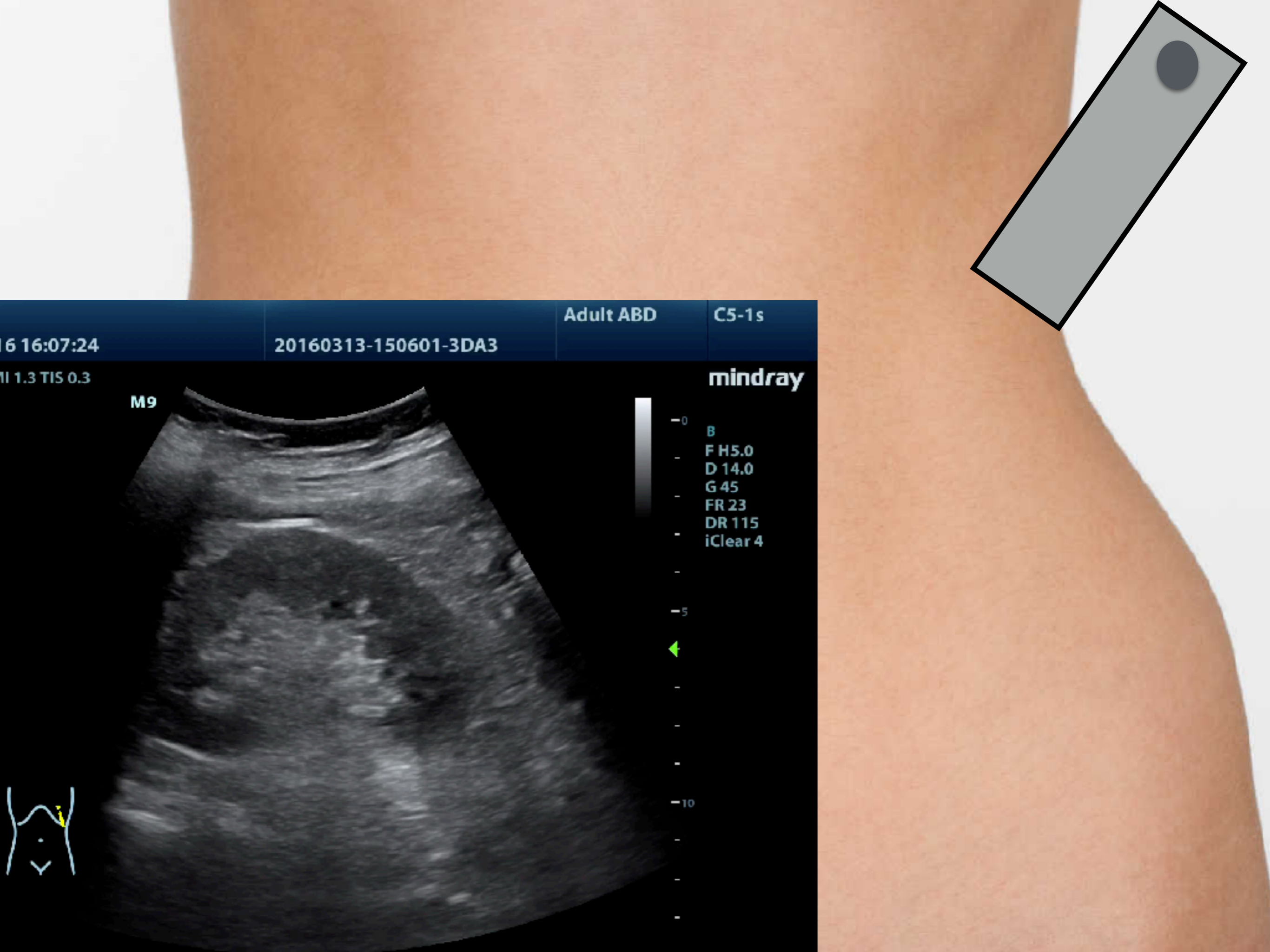
20160313-150601-3DA3

Adult ABD

AP 96.6% MI 1.3 TIS 0.3

M9





16 16:07:24      20160313-150601-3DA3      Adult ABD      C5-1s

MI 1.3 TIS 0.3      **mindray**

M9

-0  
B  
F H5.0  
D 14.0  
G 45  
FR 23  
DR 115  
iClear 4


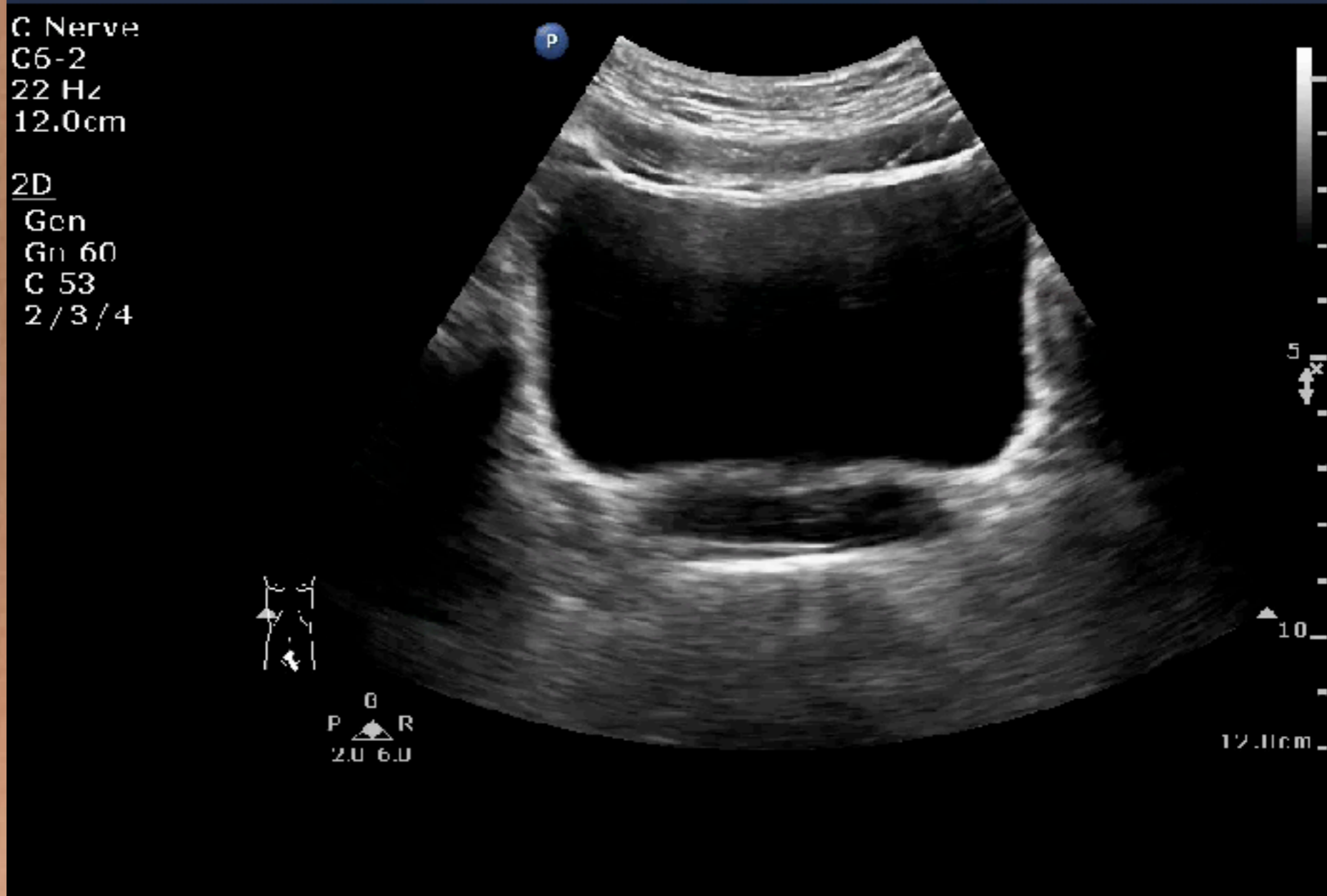
-5

-10



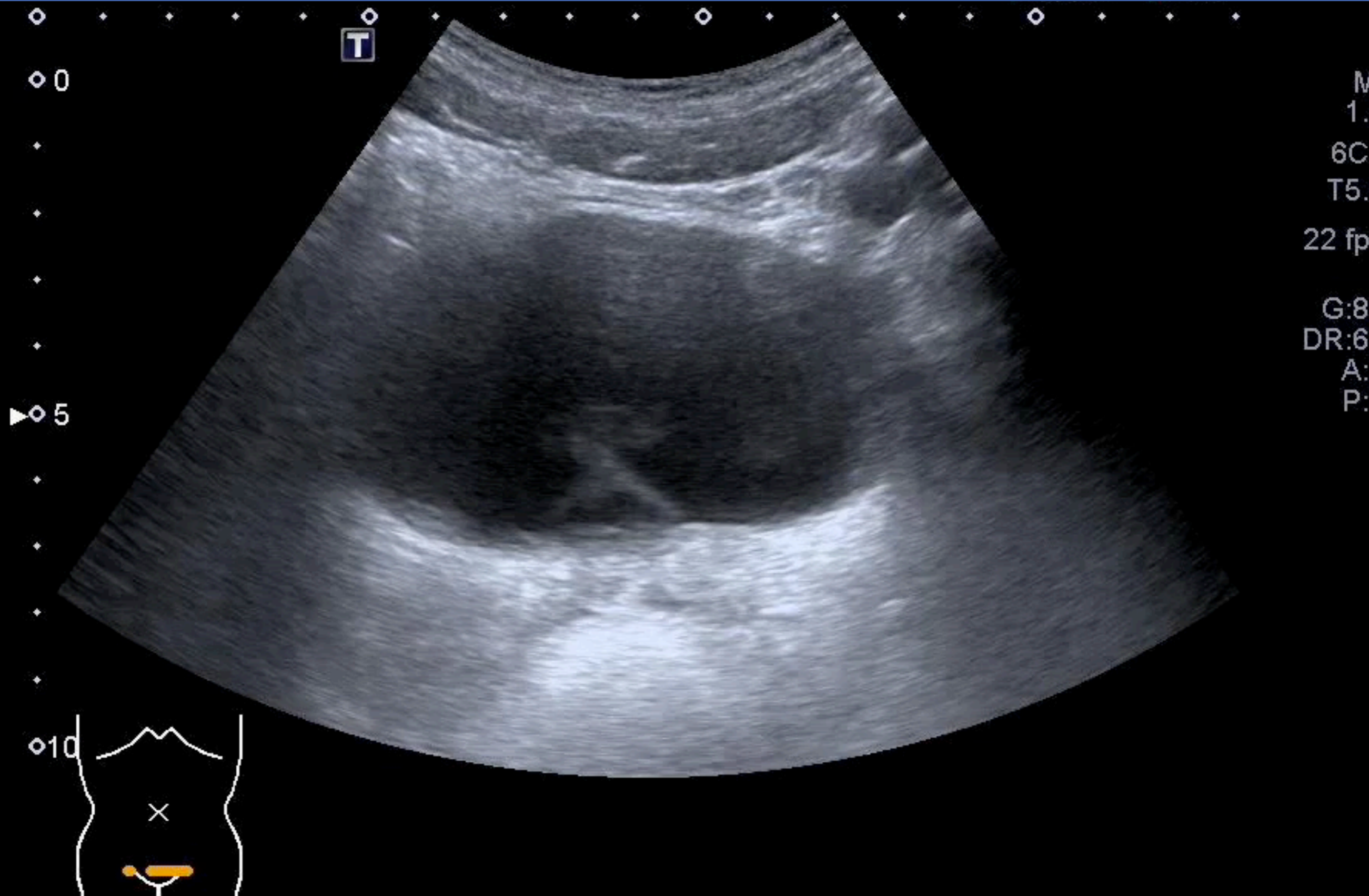
C. Nerve  
C6-2  
22 Hz  
12.0cm

2D  
Gen  
Gn 60  
C 53  
2/3/4

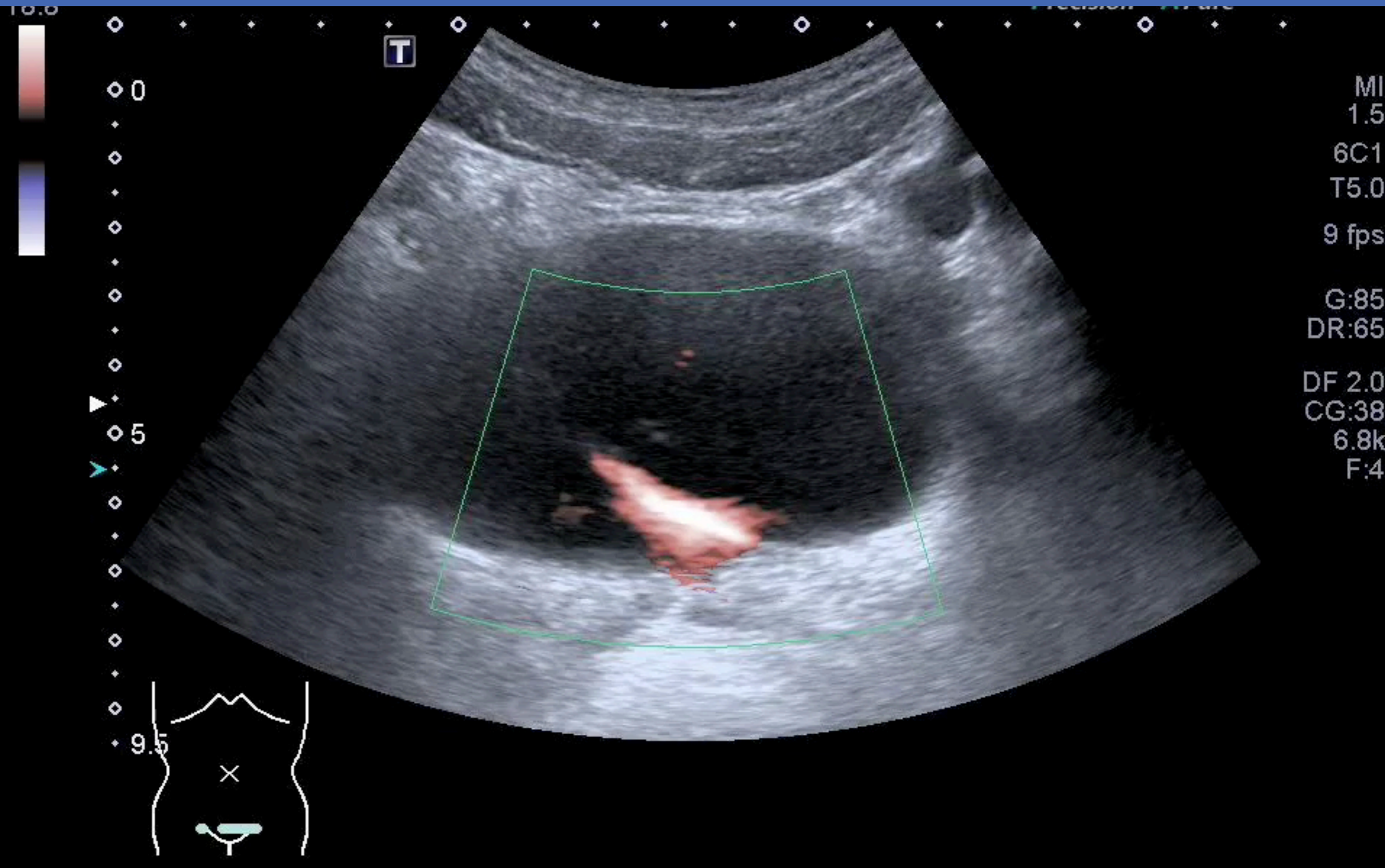




# Urinary jet



# Urinary jet





# When will you use US ?

Pain

Infection

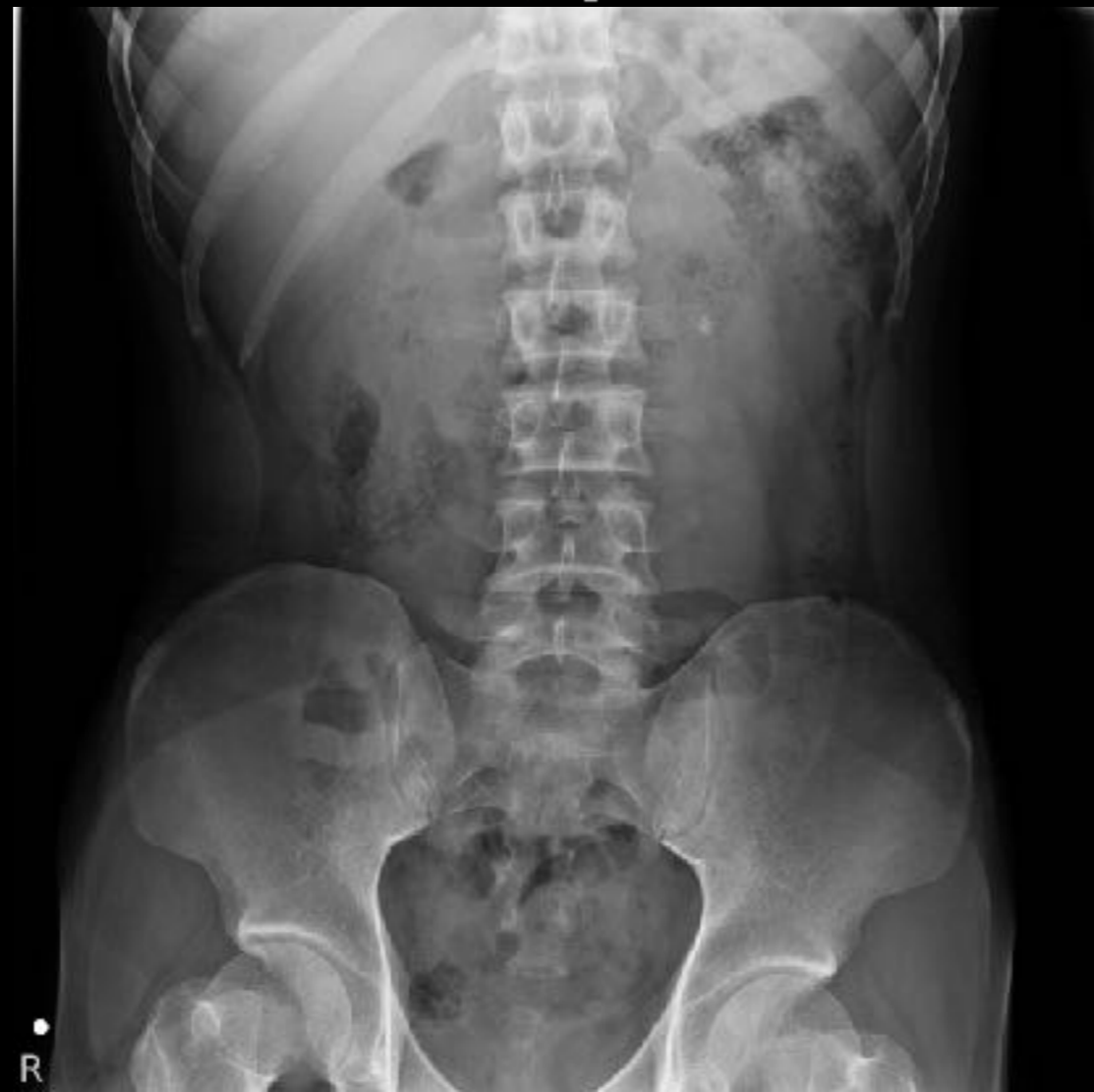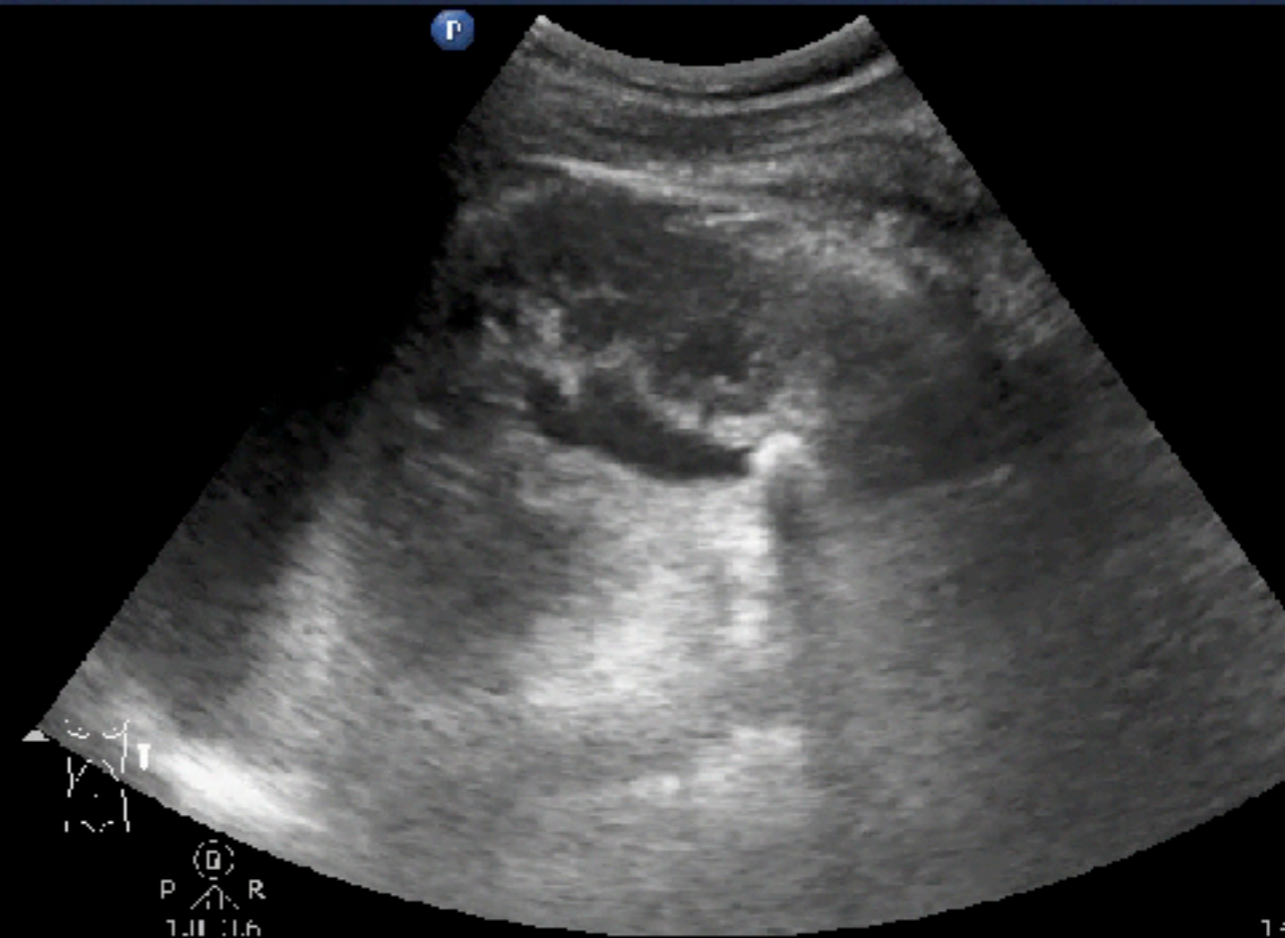
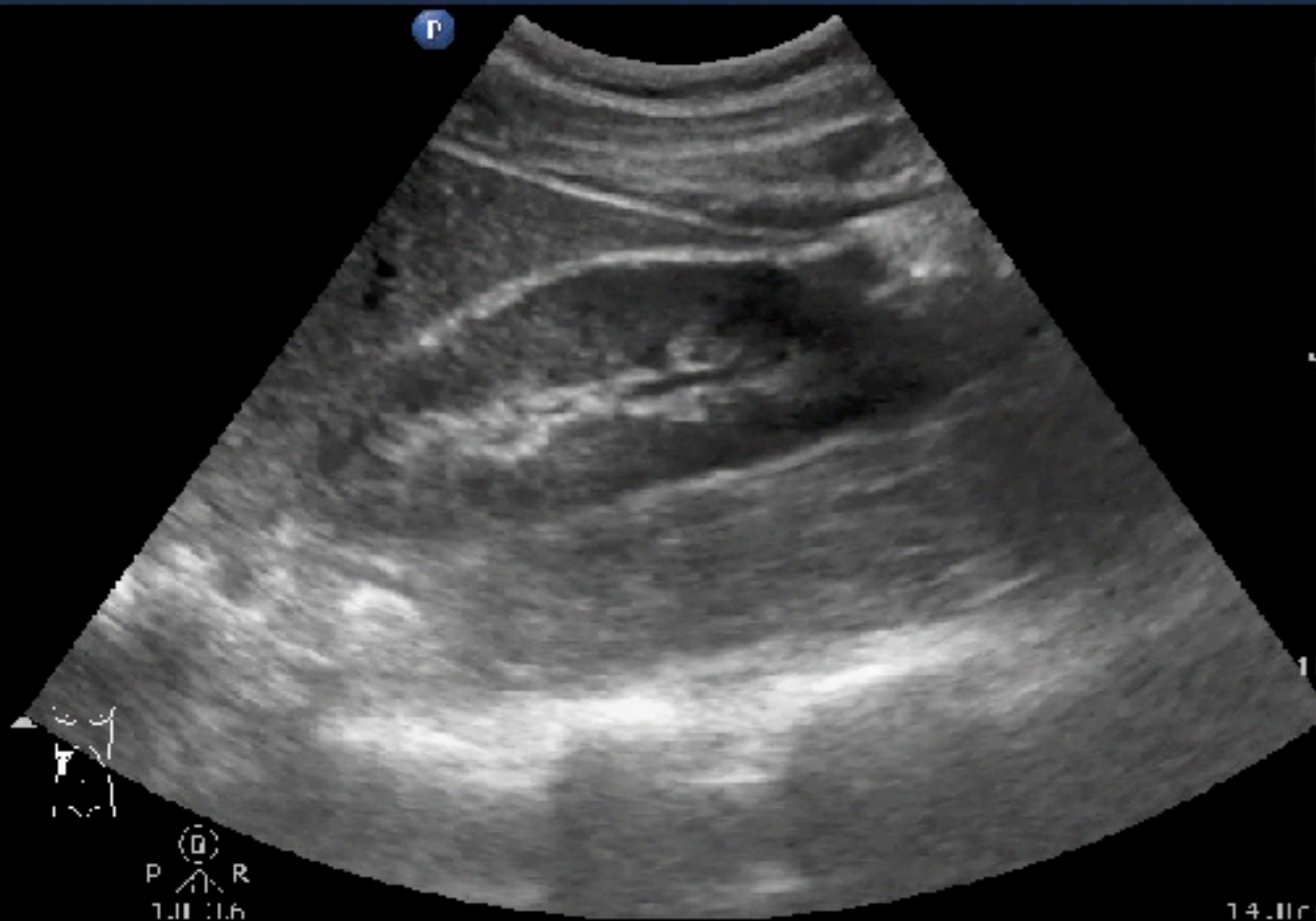
Failure

# GU emergency

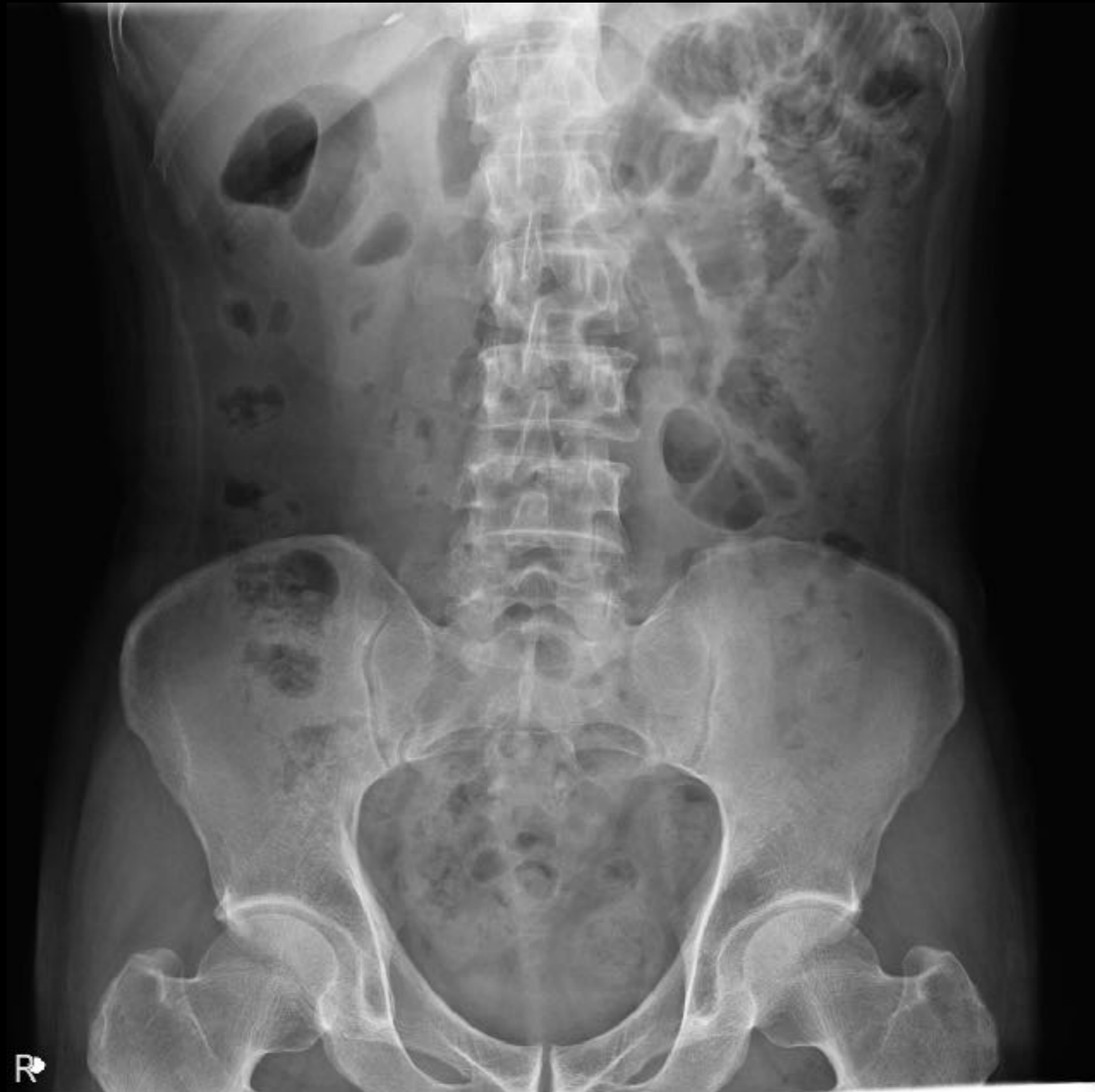**POCUS first**

or

**Urine first**



# 54M, right flank/abd pain

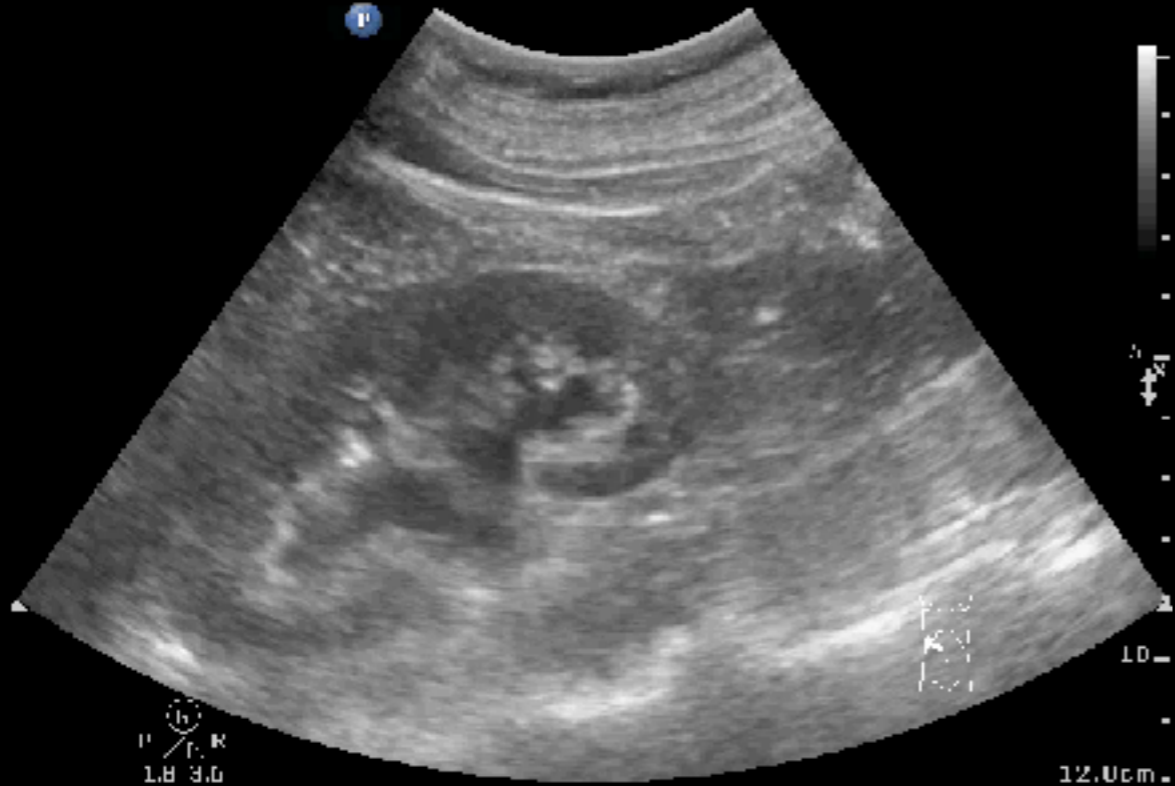


# ABDOMEN **N**

54M, right flank/abd pain

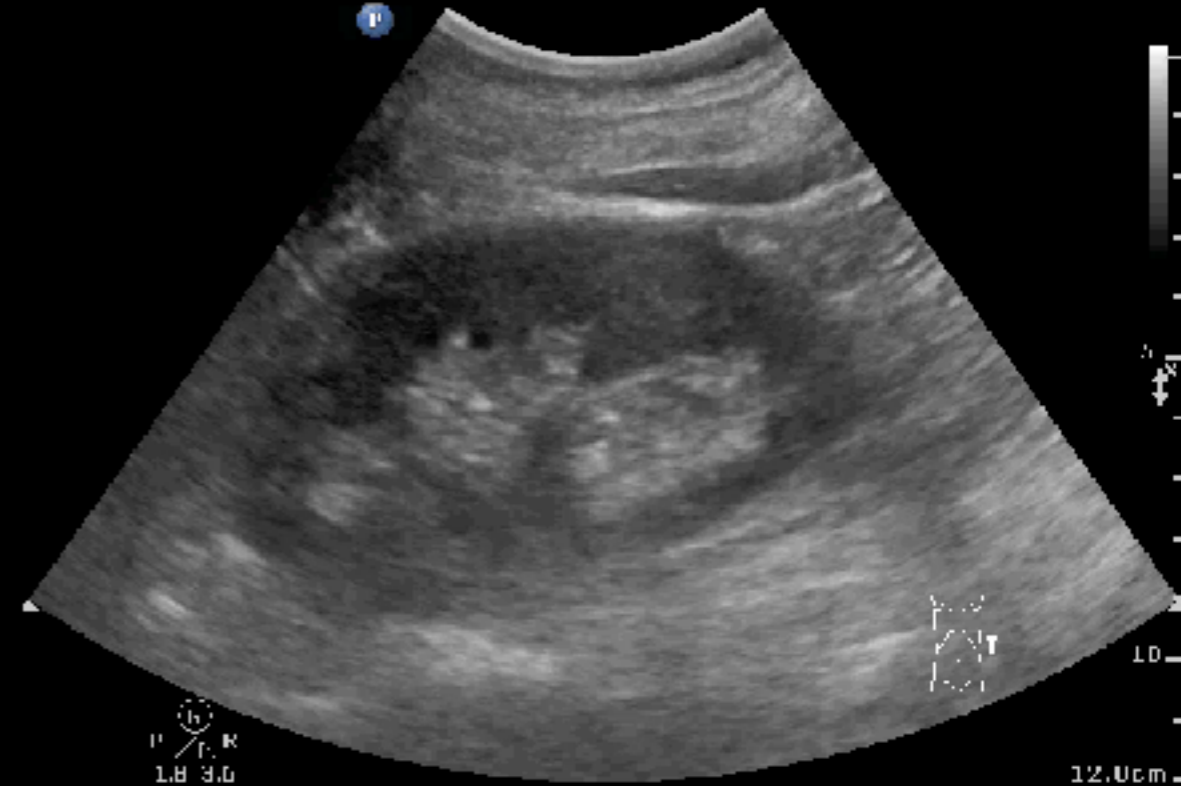Abd Gen2  
11.5 1  
39 Hz  
12.0cm

2D  
11Gen  
11.5 1  
11.55  
3/3/3



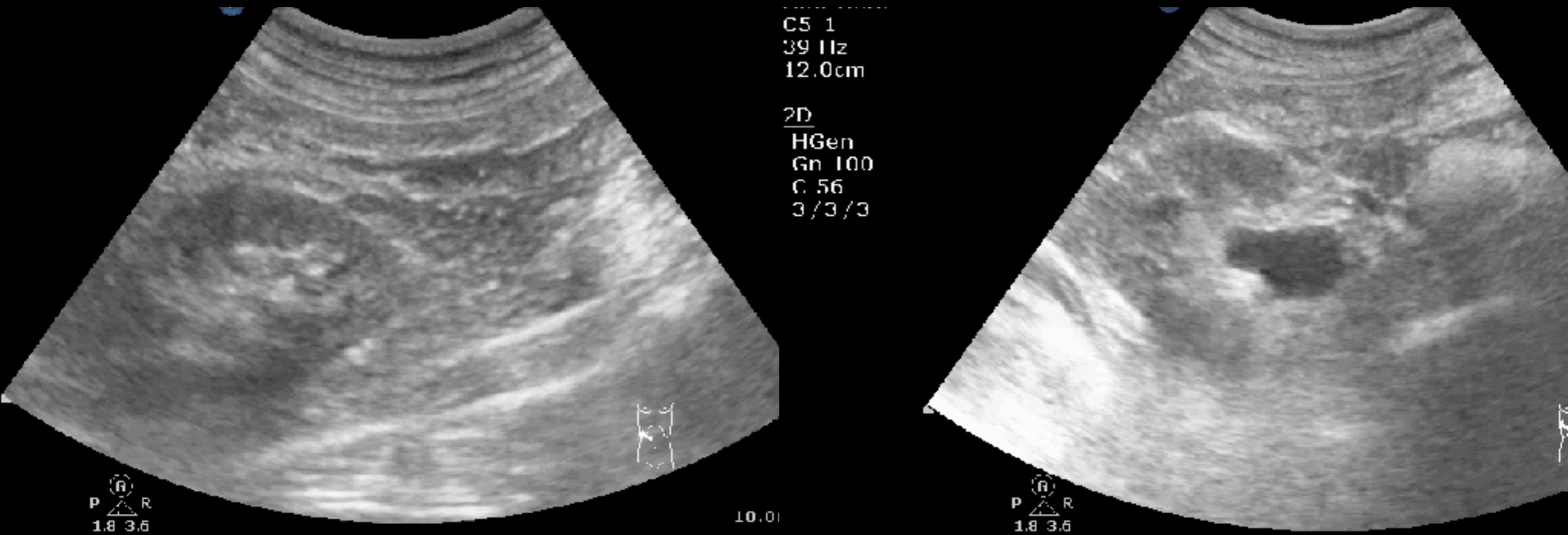
Abd Gen2  
11.5 1  
39 Hz  
12.0cm

2D  
11Gen  
11.5 1  
11.55  
3/3/3

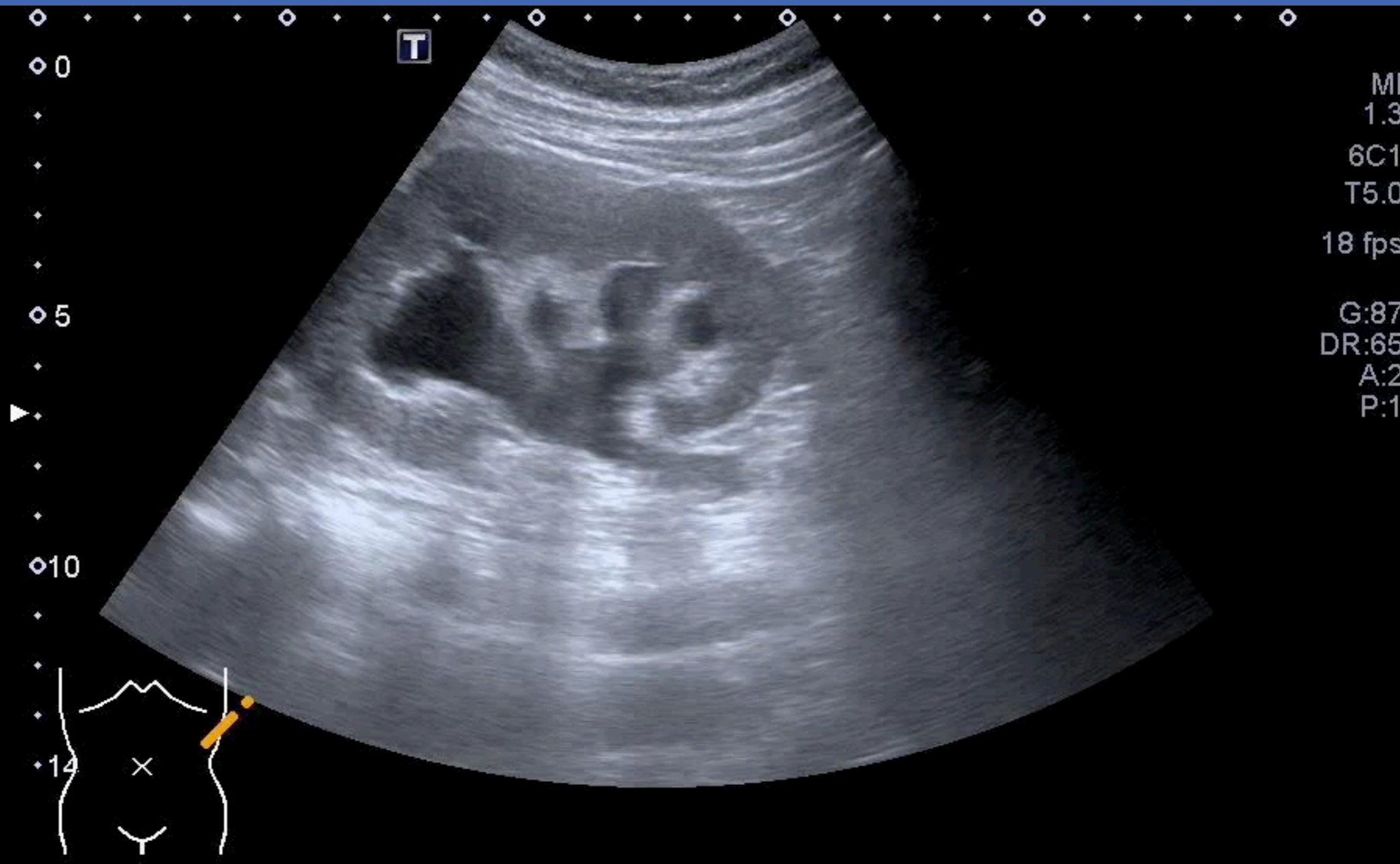

# ABDOMEN **N**

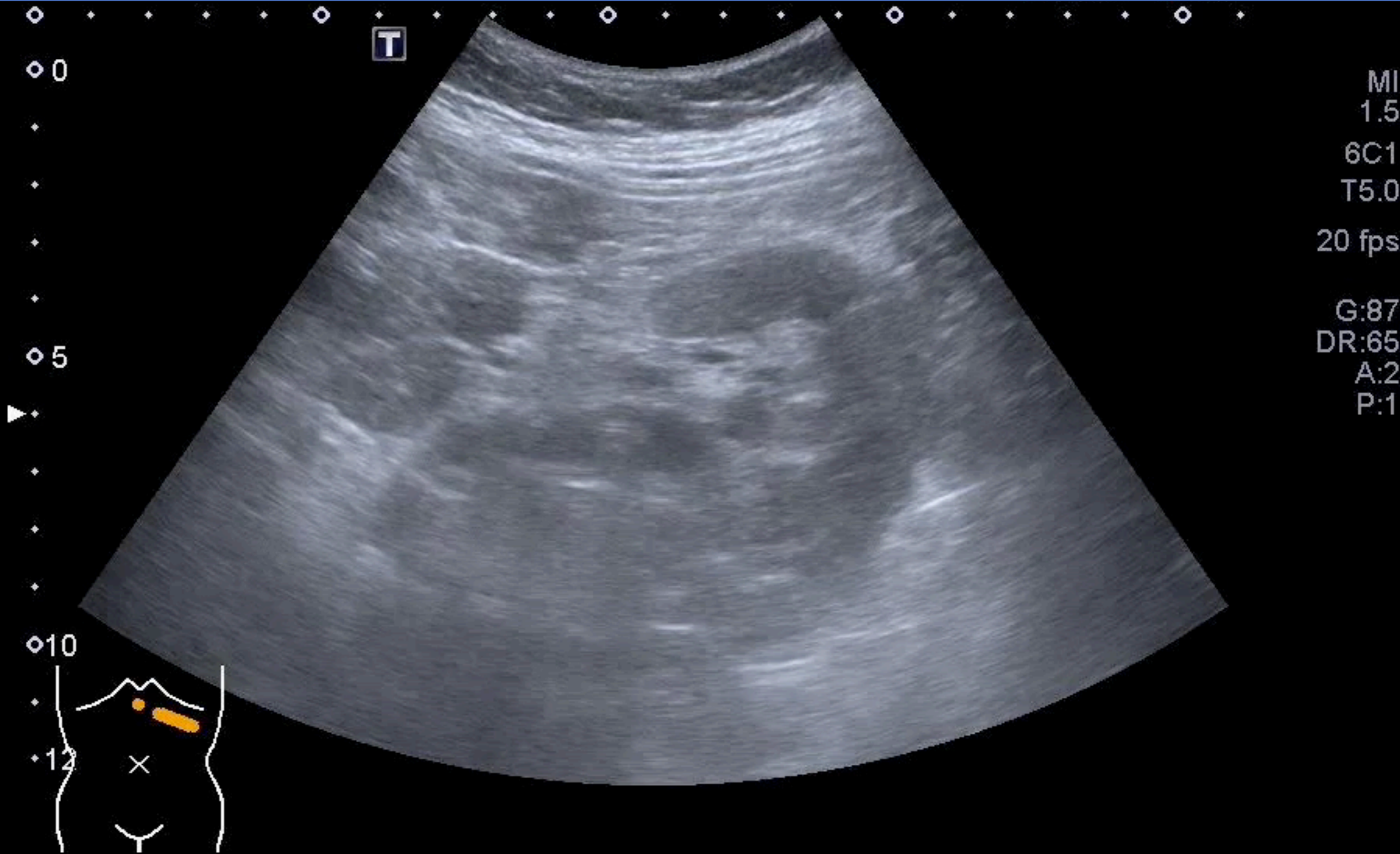
## Ureteral stone



# What do you see ?

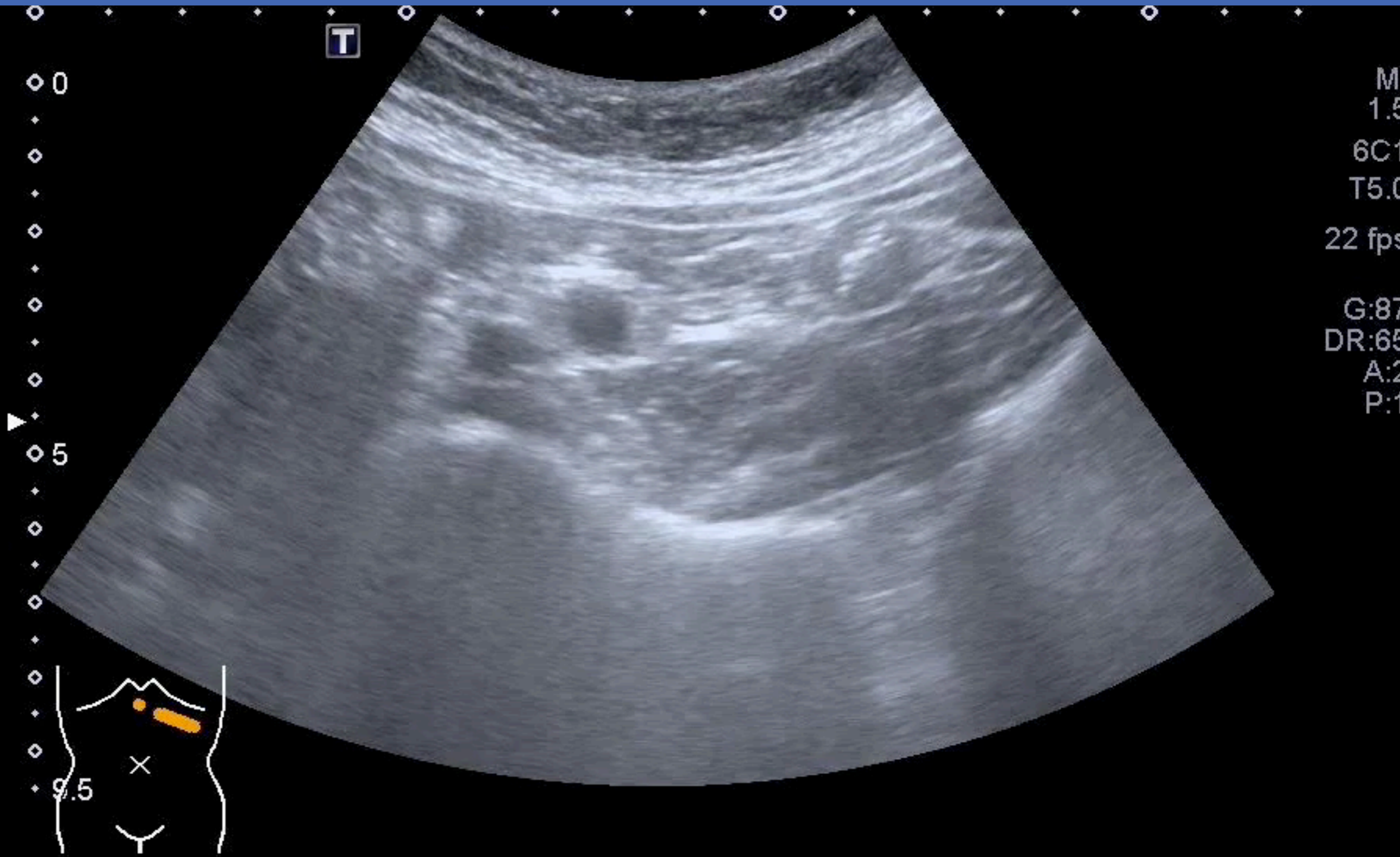


# How to move the probe ?

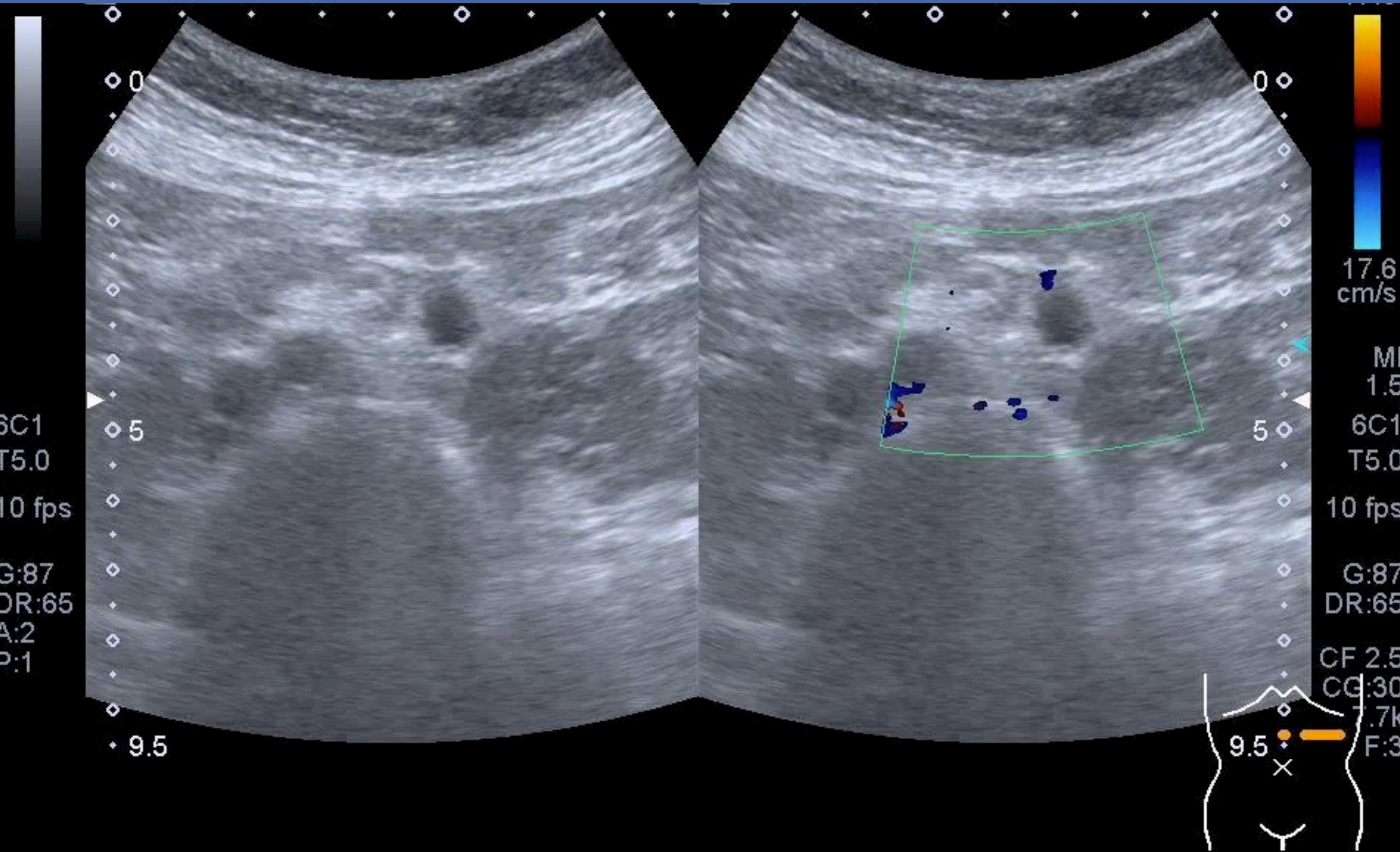





# What is the skill ?



# Twinkling artifact



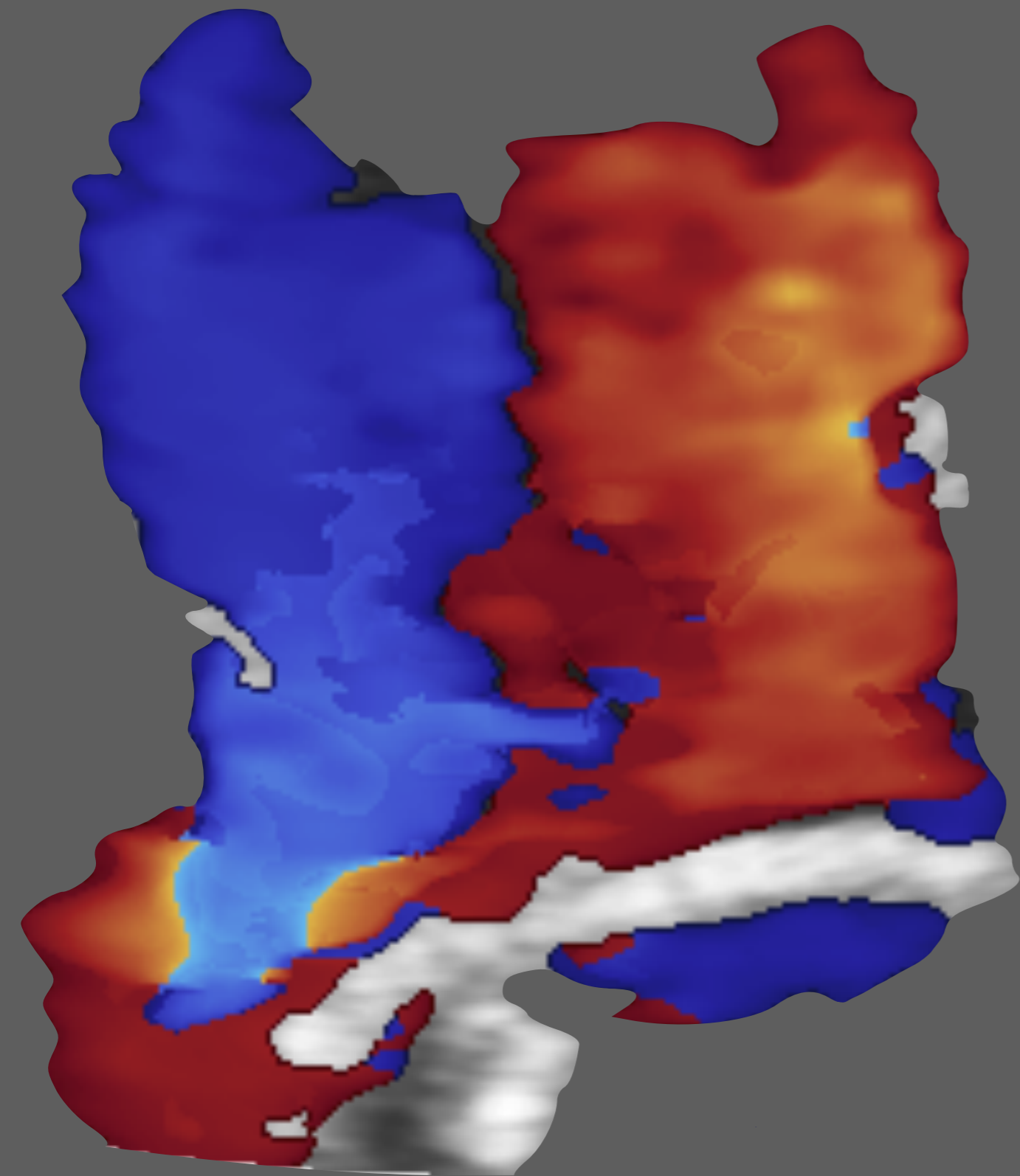


**64M,  
左下腹痛  
1小時  
冒冷汗  
結石病史**

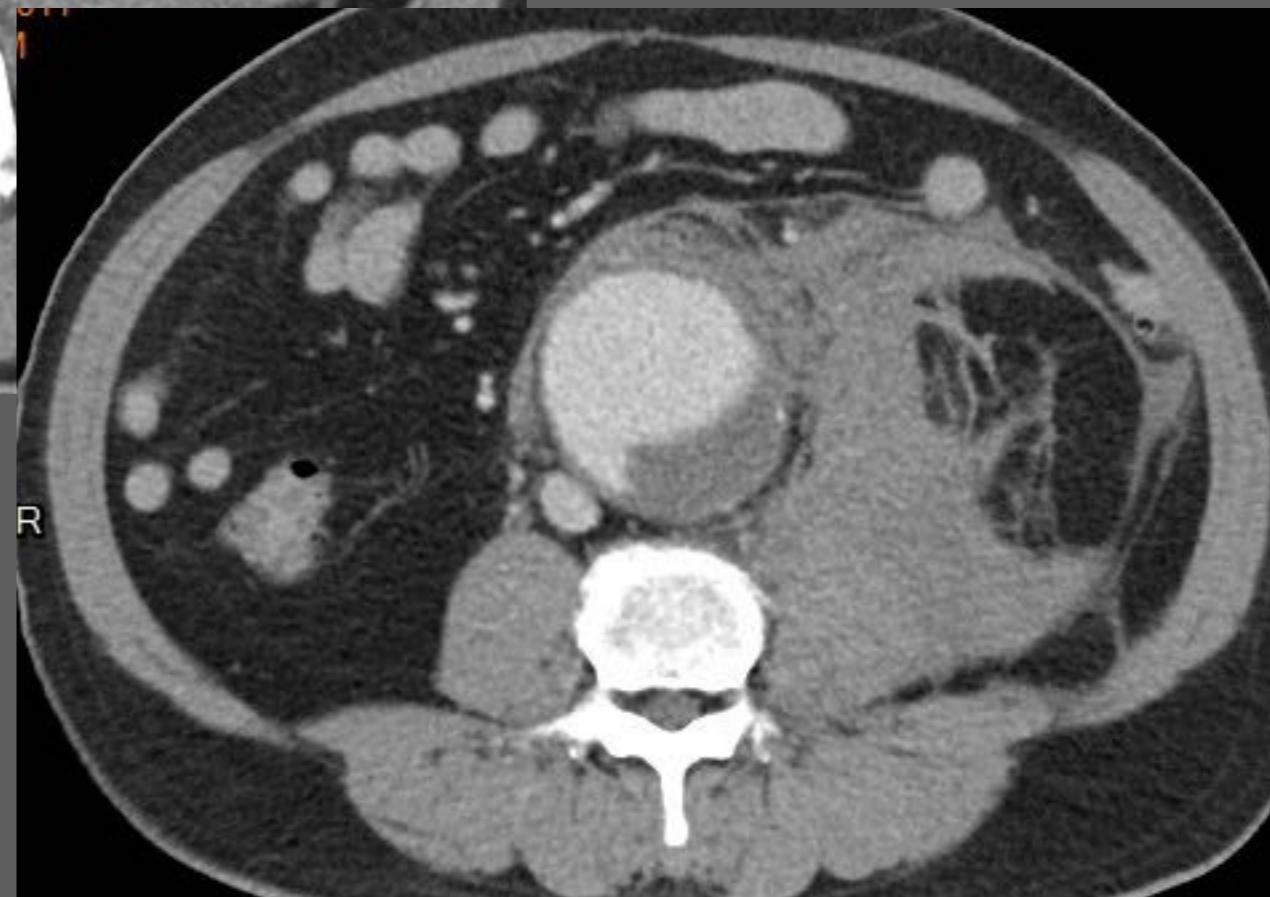
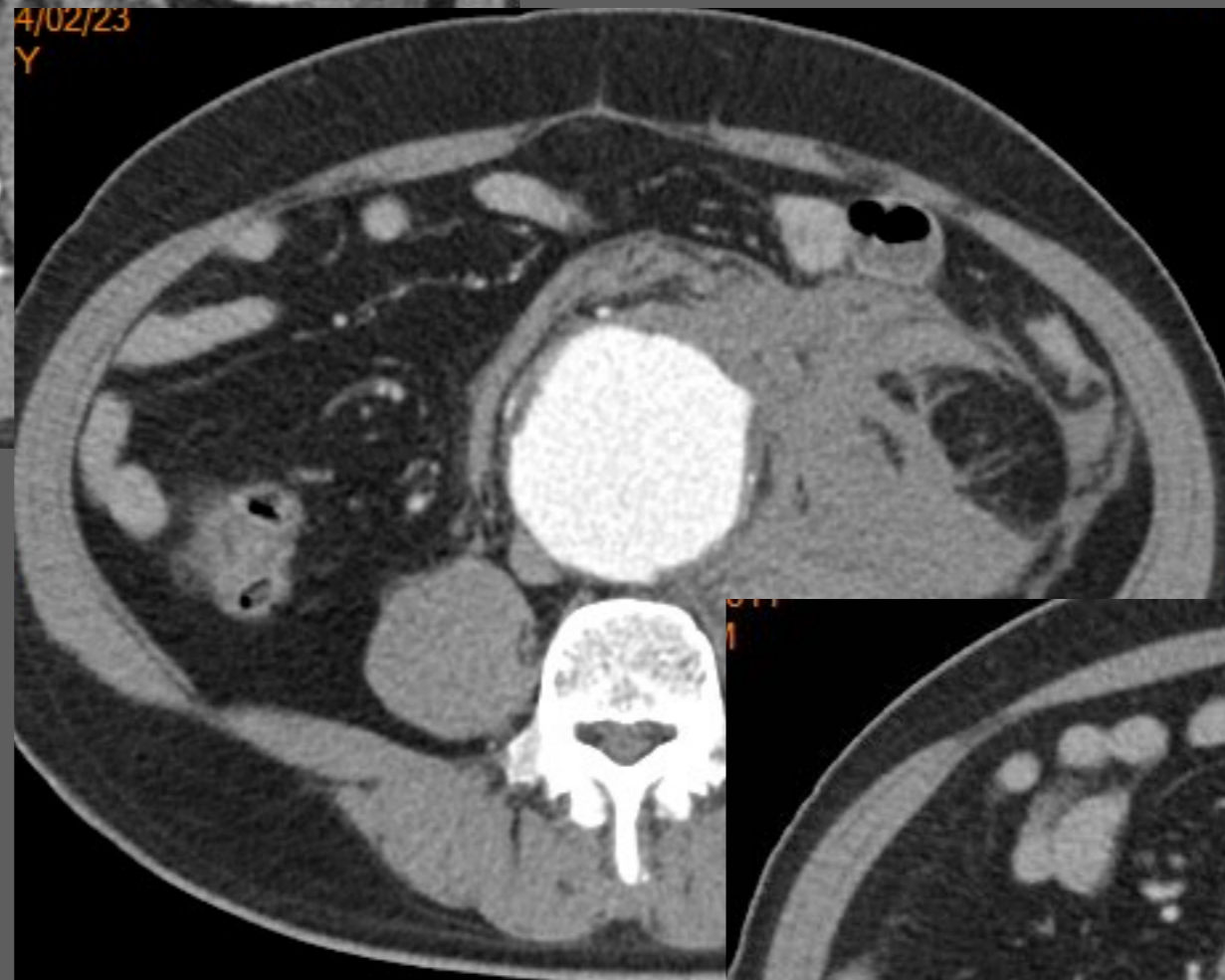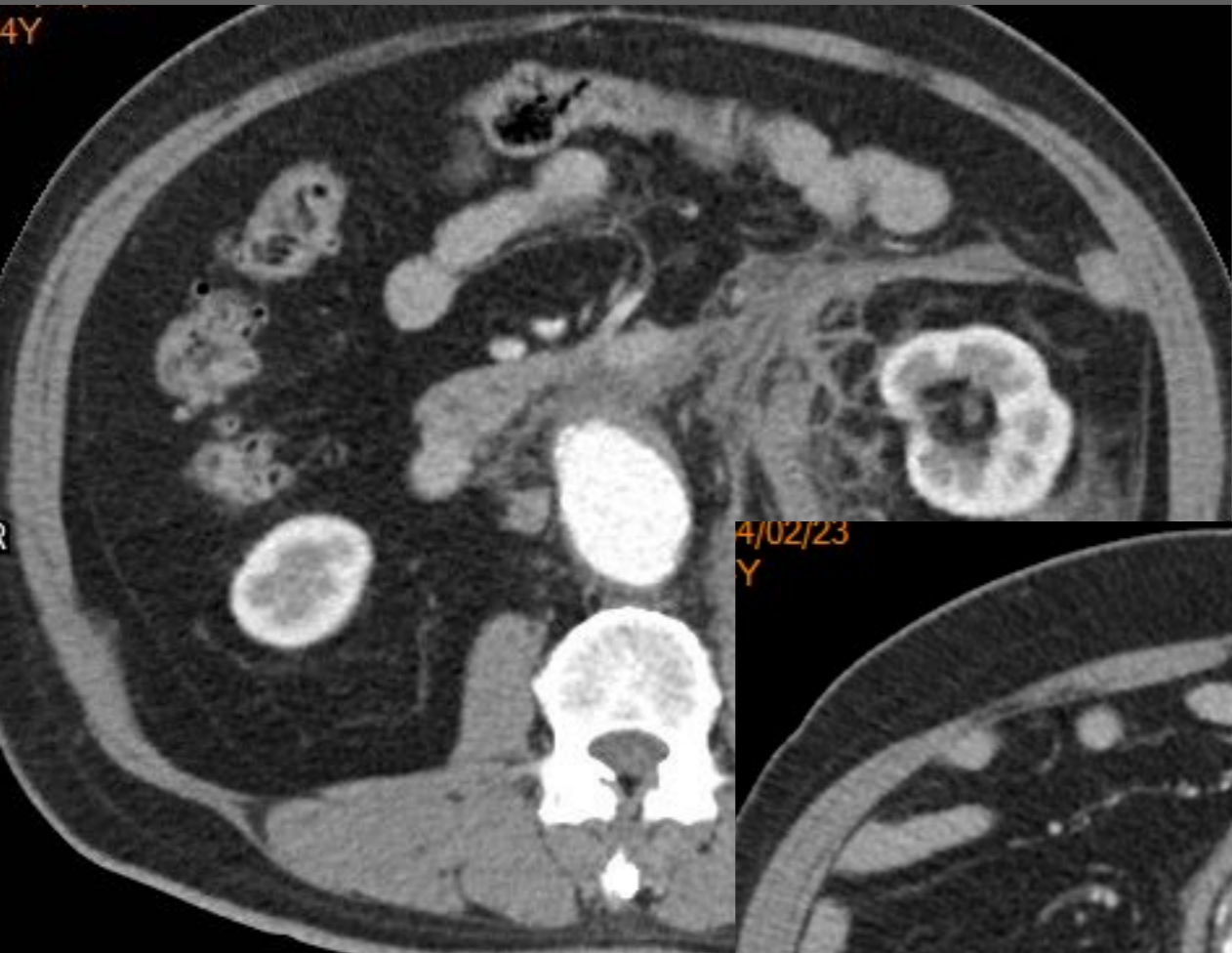**PR 117**

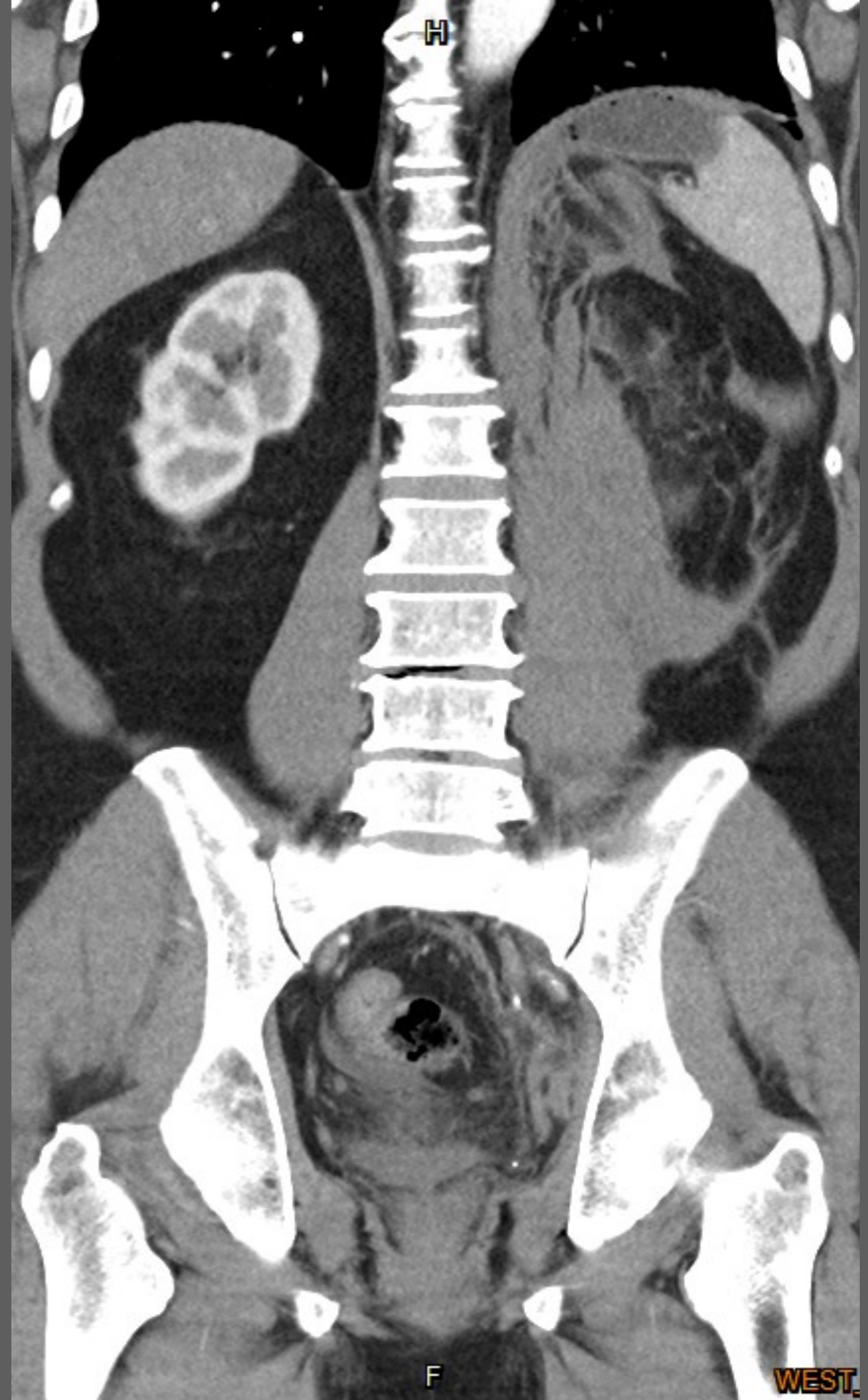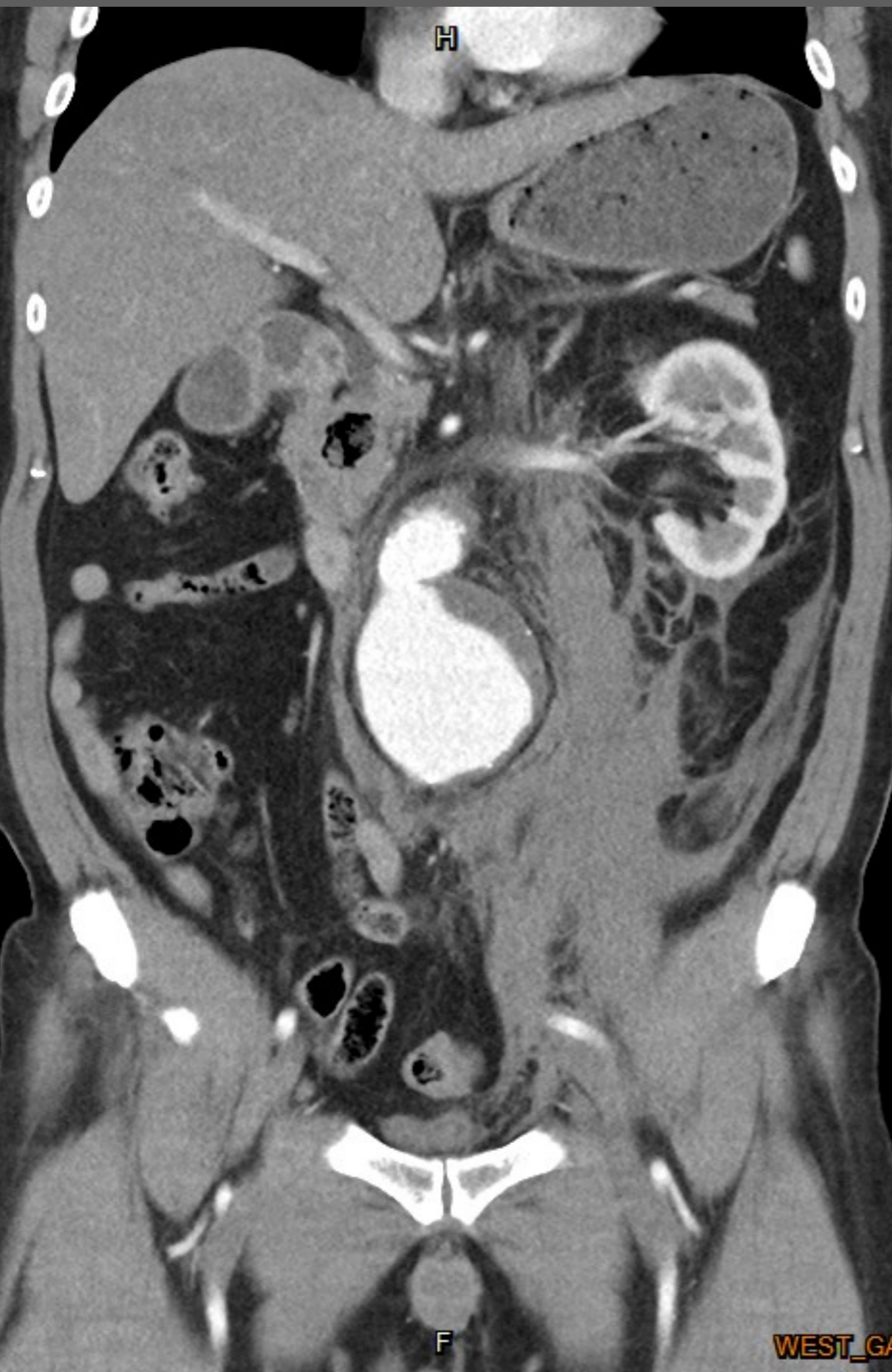**BP**

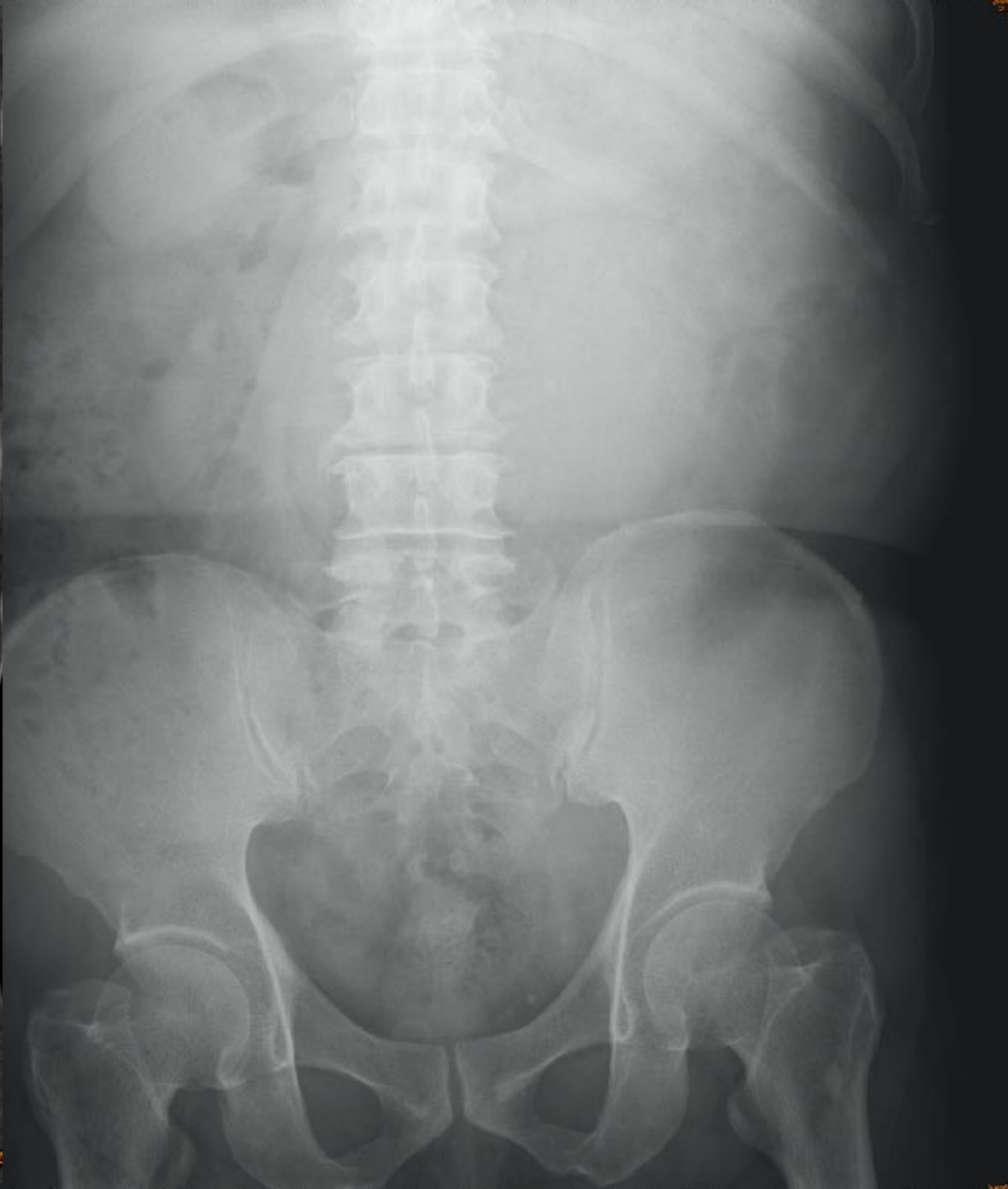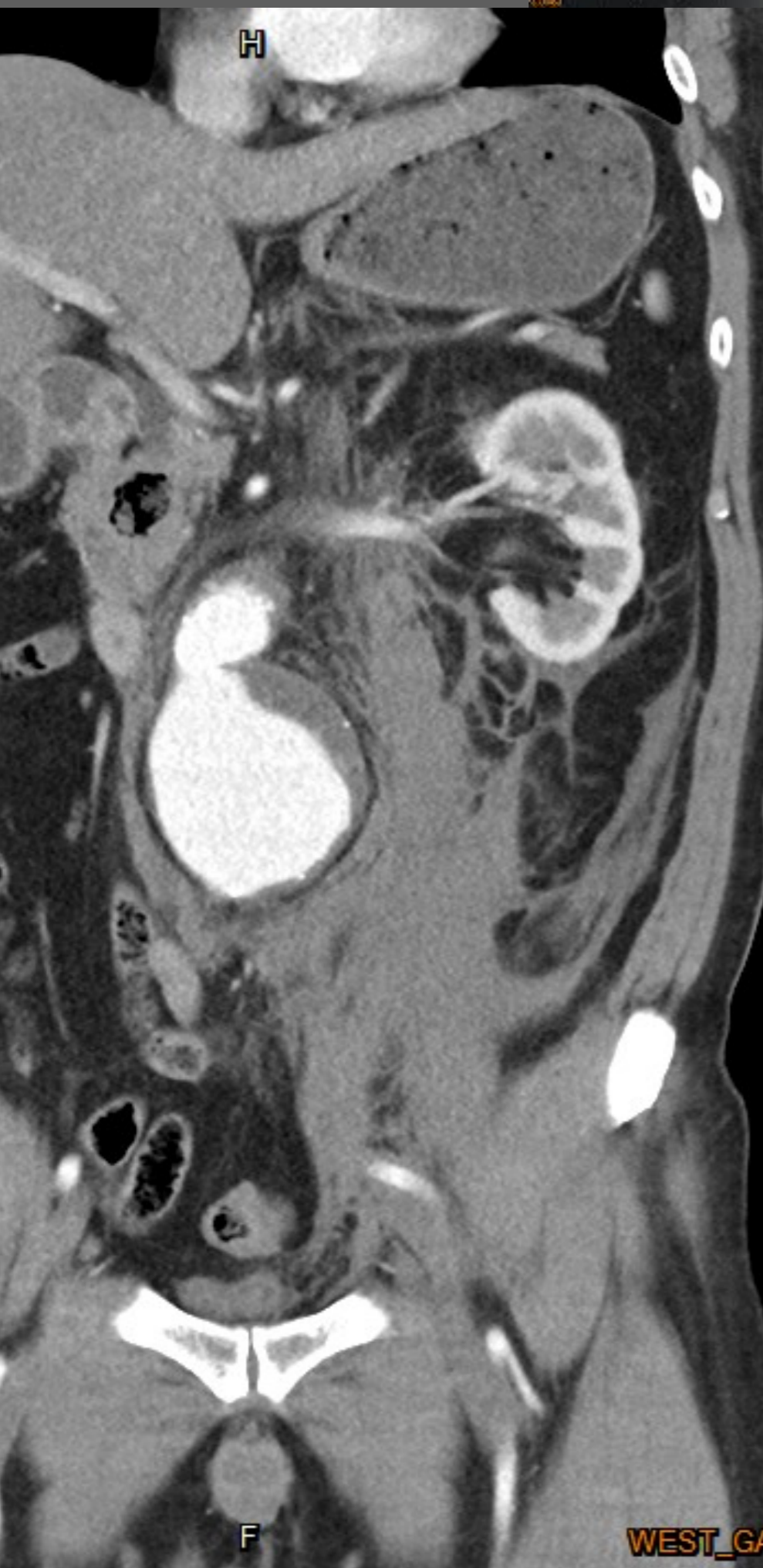
**88/62**



腰痛 + 冒冷汗，  
我的病人可能是  
主動脈瘤破裂？

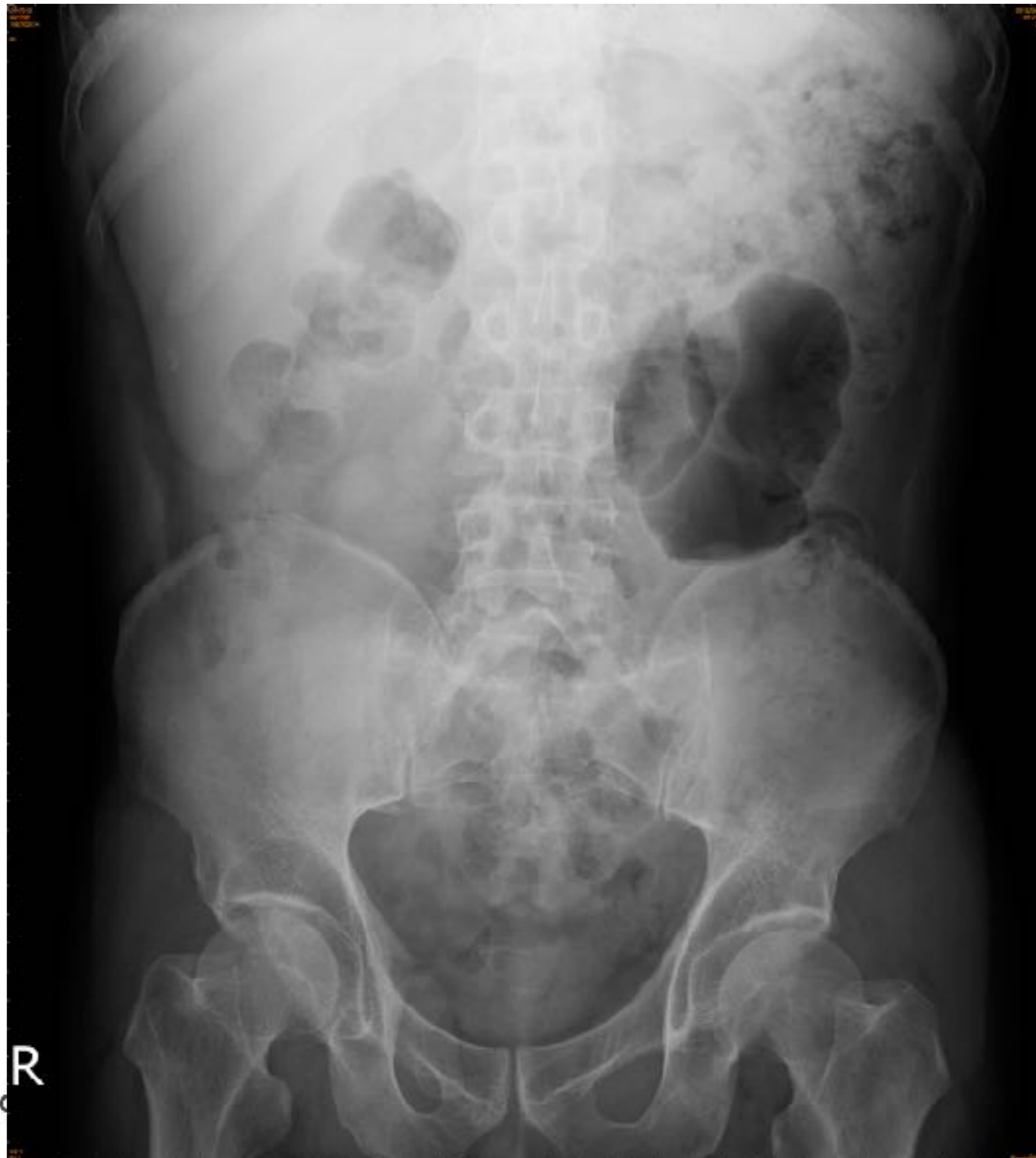




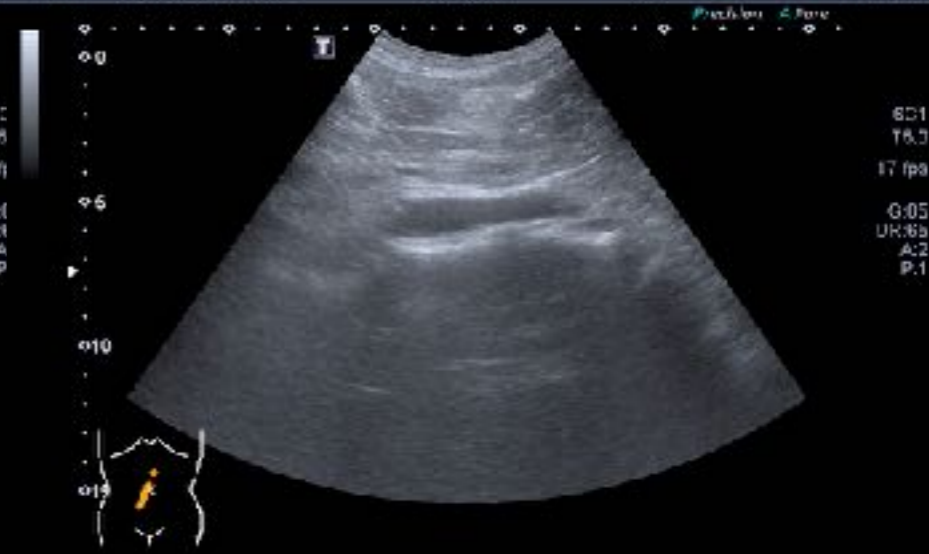
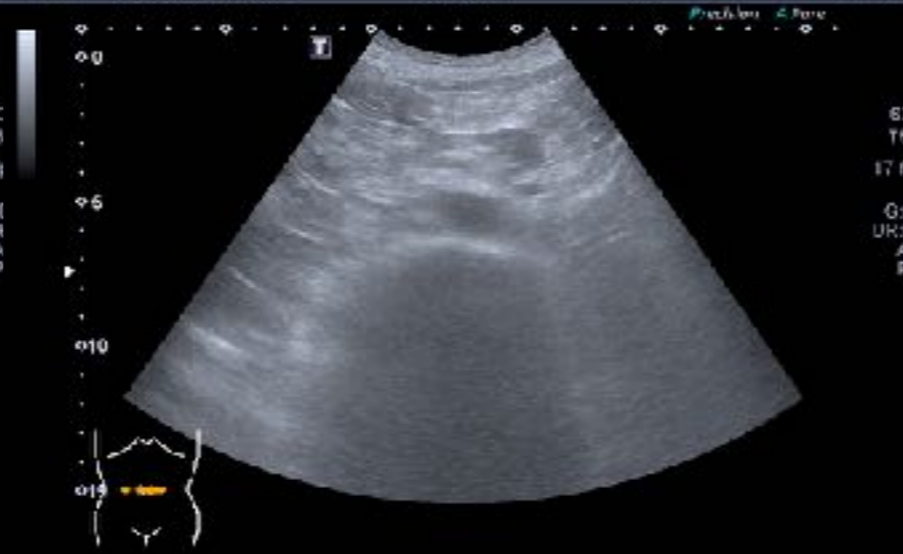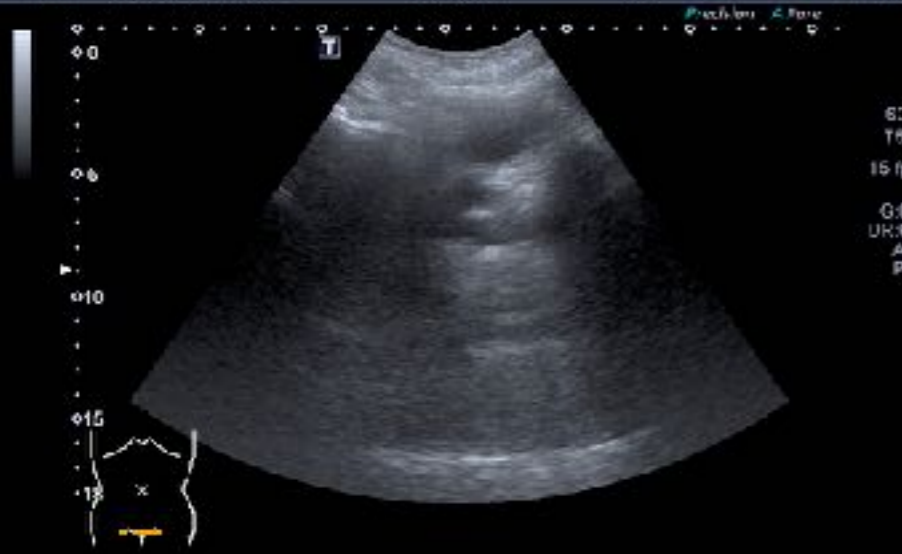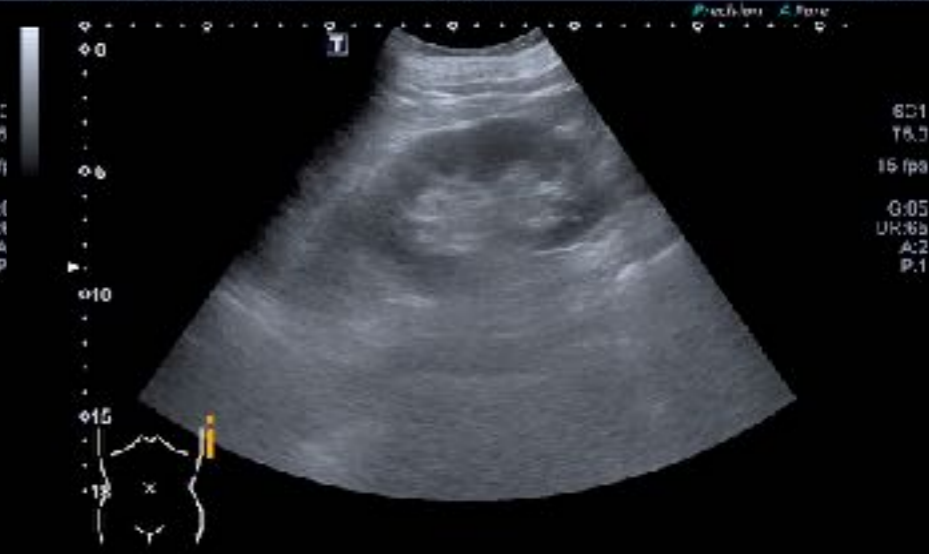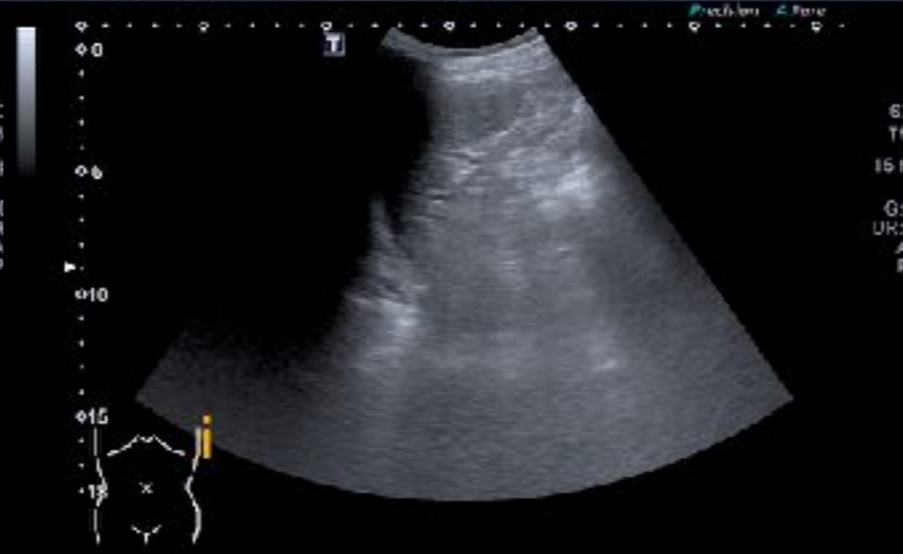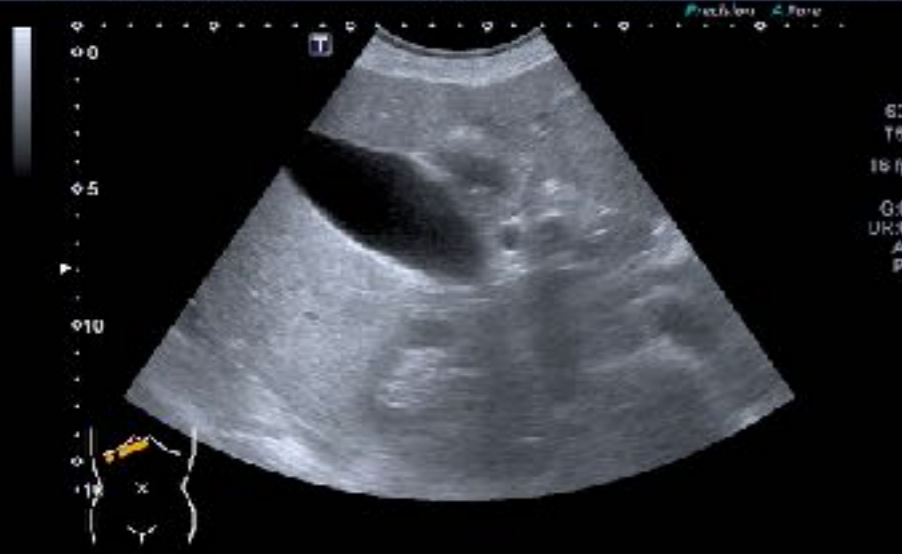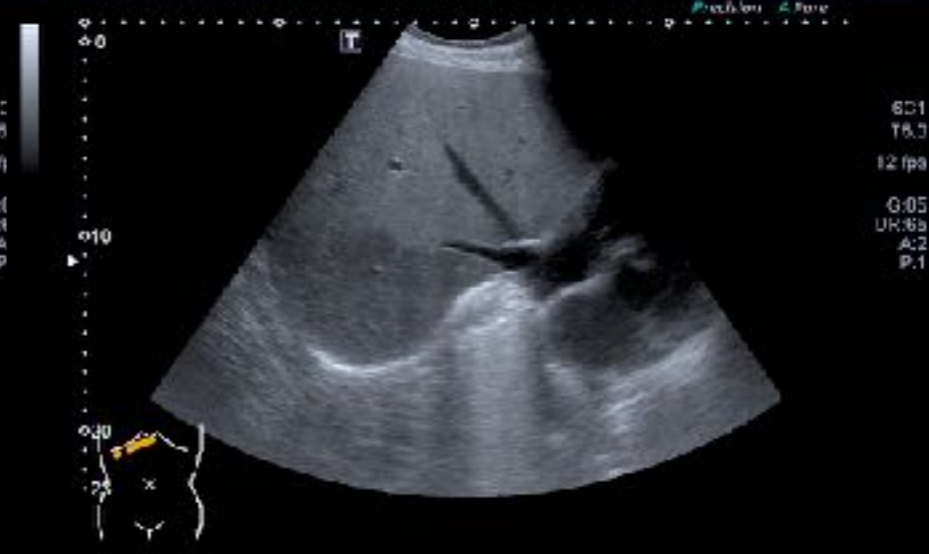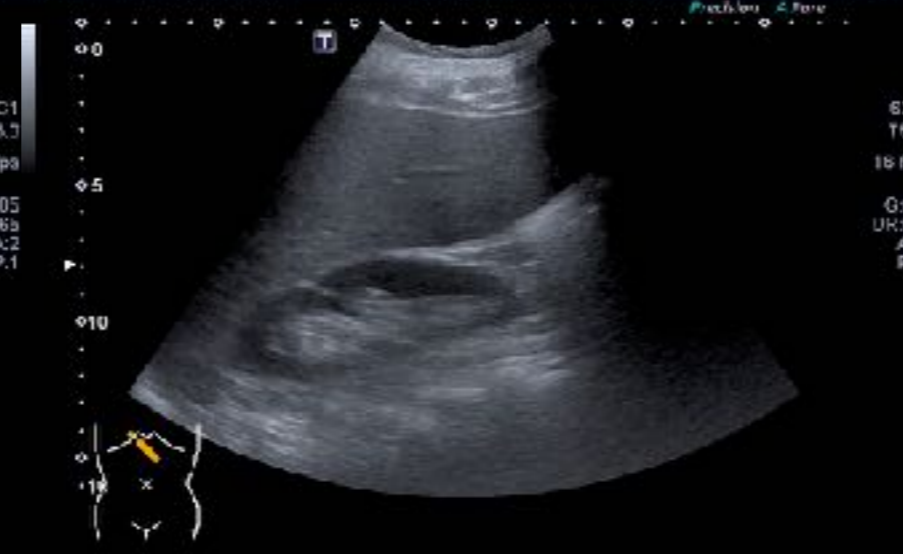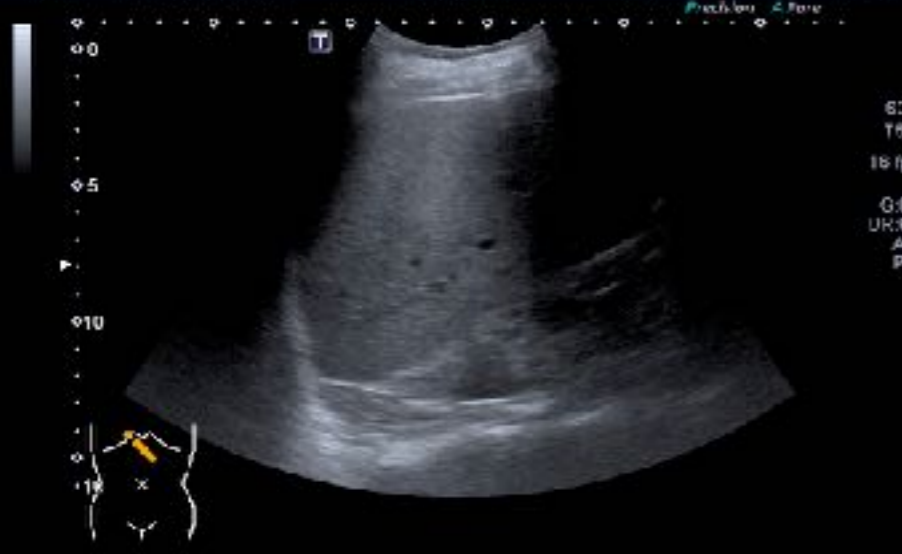# 51M, RUQ pain

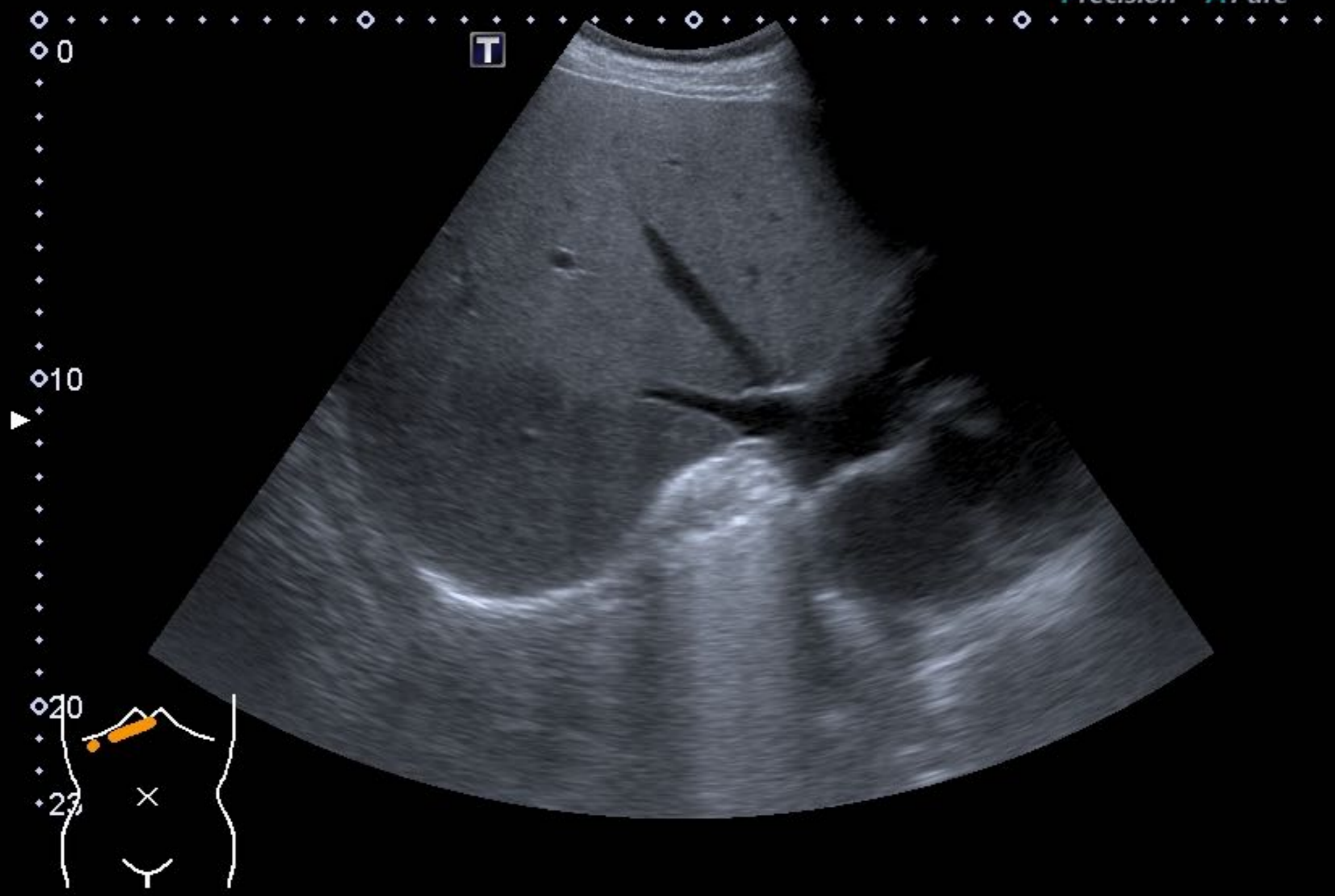
WBC 13000; CRP 8.5



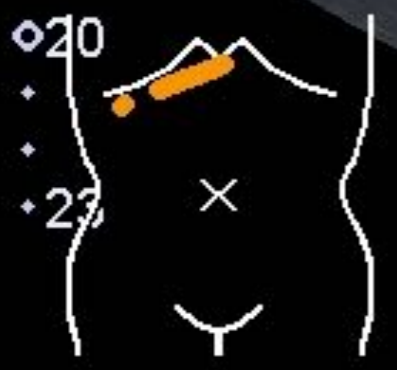



Precision A Pure



6C1  
 T5.0  
 12 fps  
 G:85  
 DR:65  
 A:2  
 P:1



T

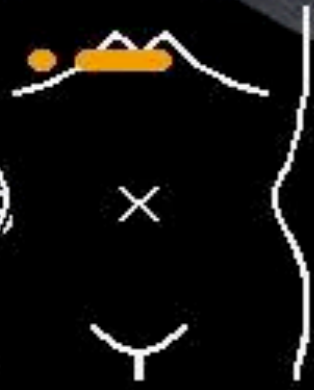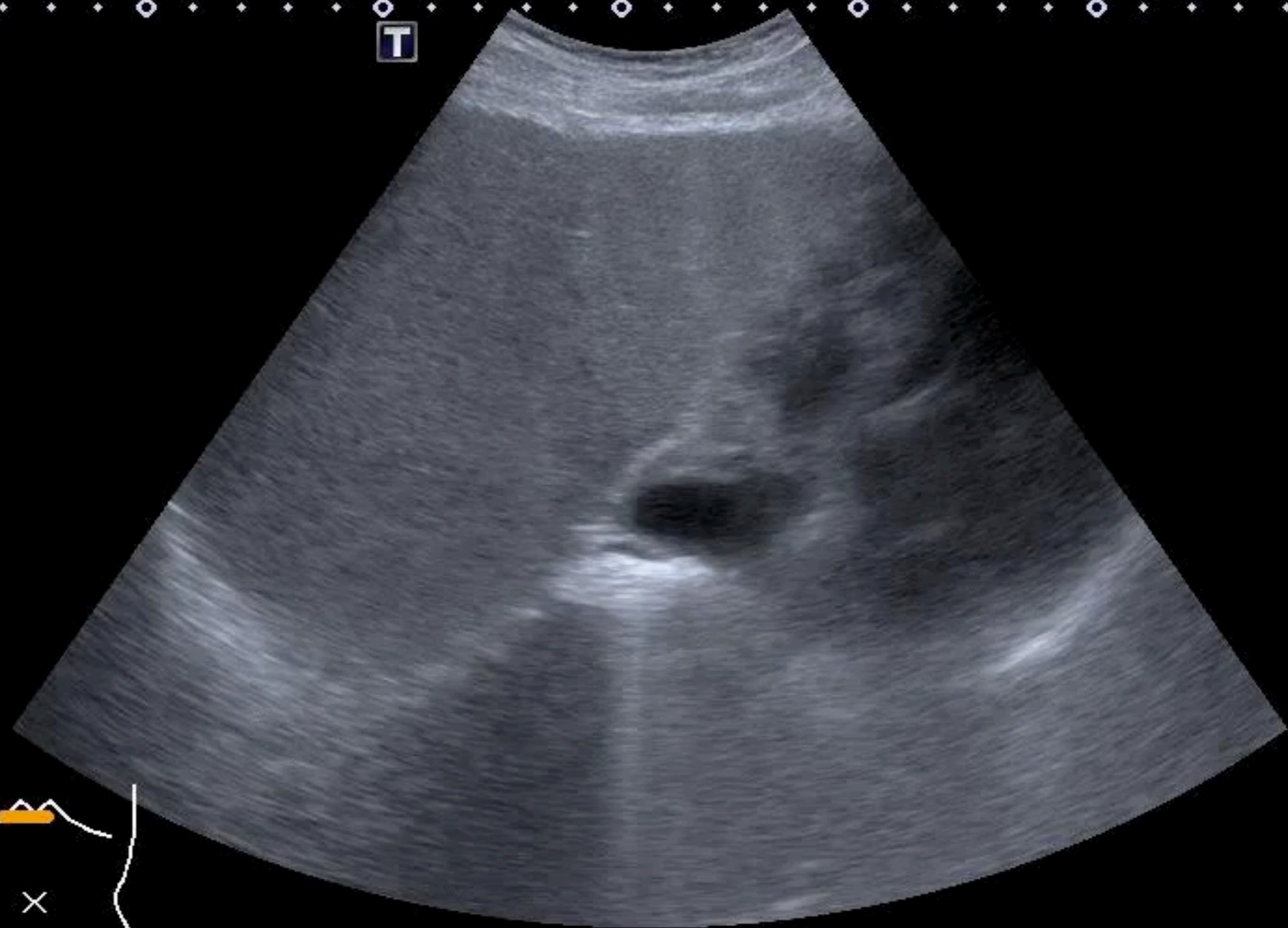
0

5

10

15

18

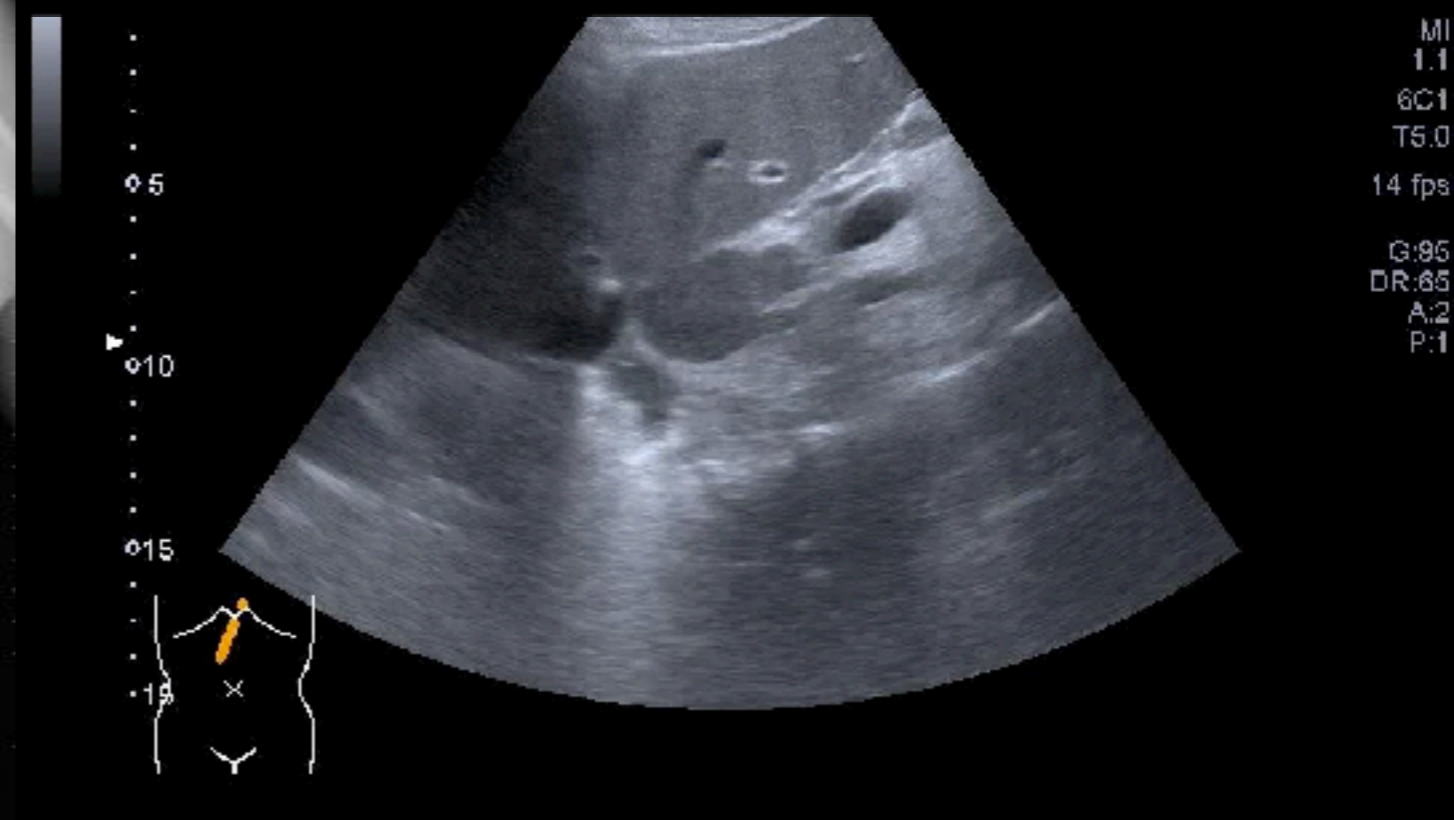
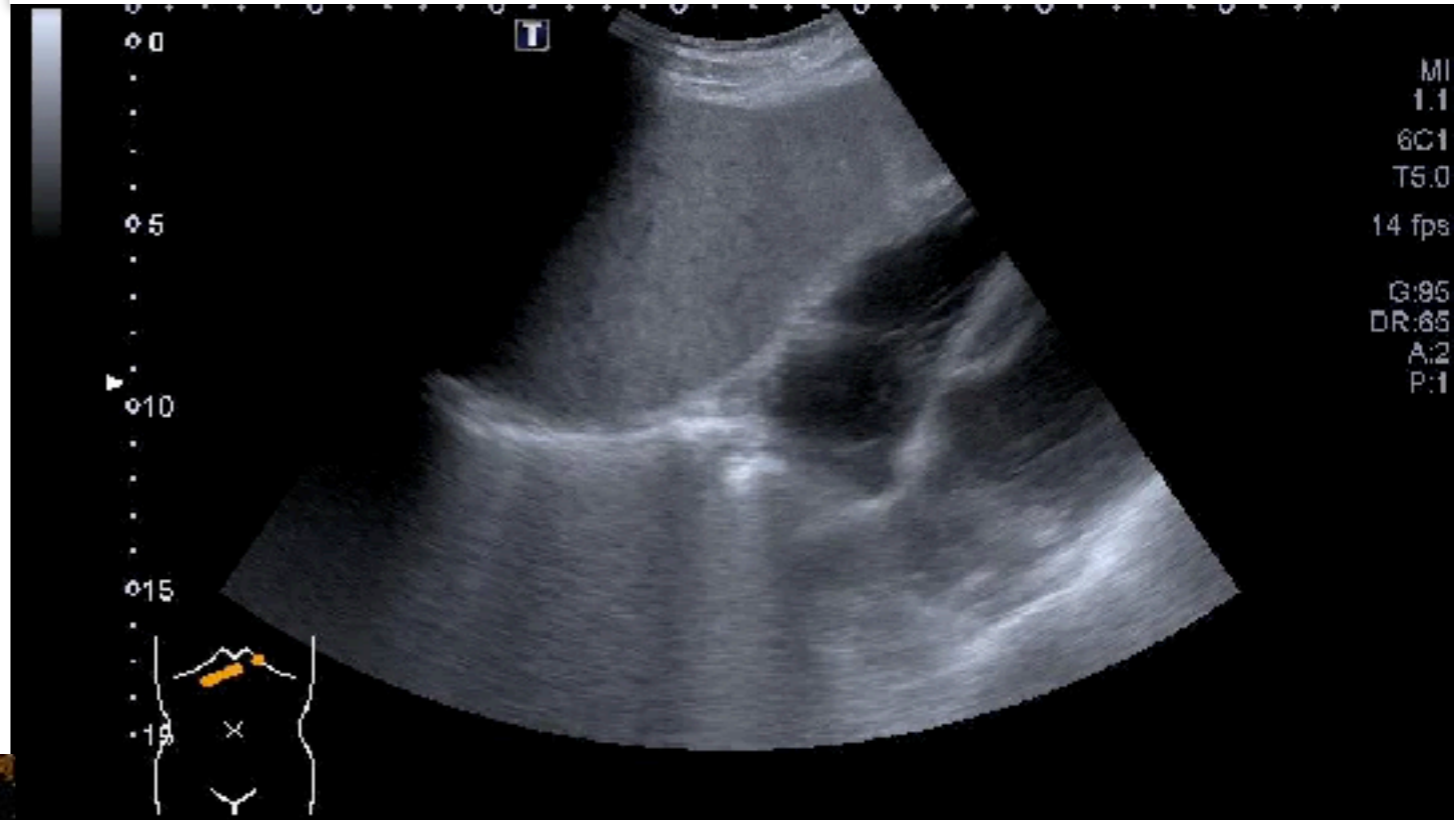
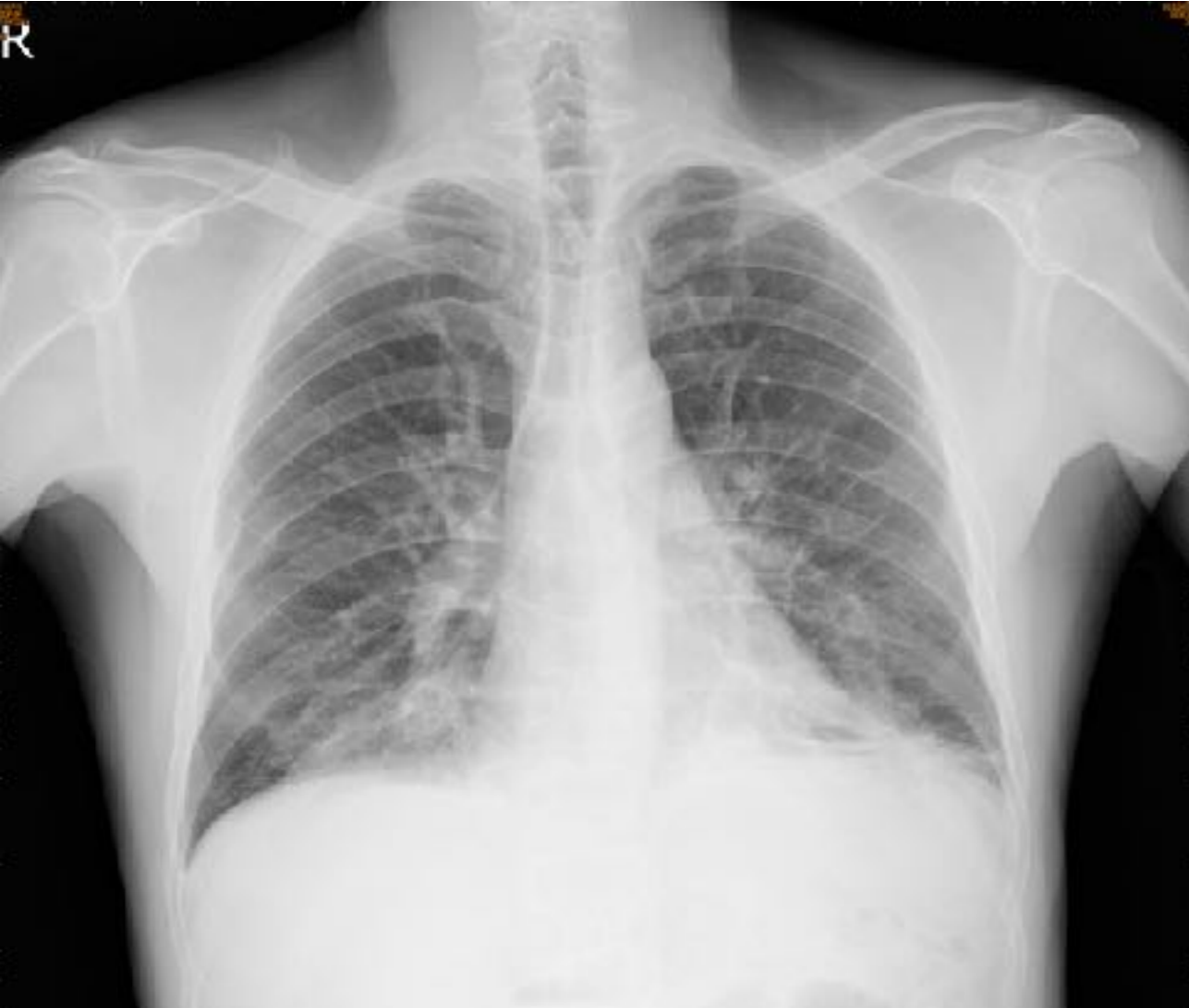



ULTRASOUND  
PROGRAM

# 2nd WINDOW

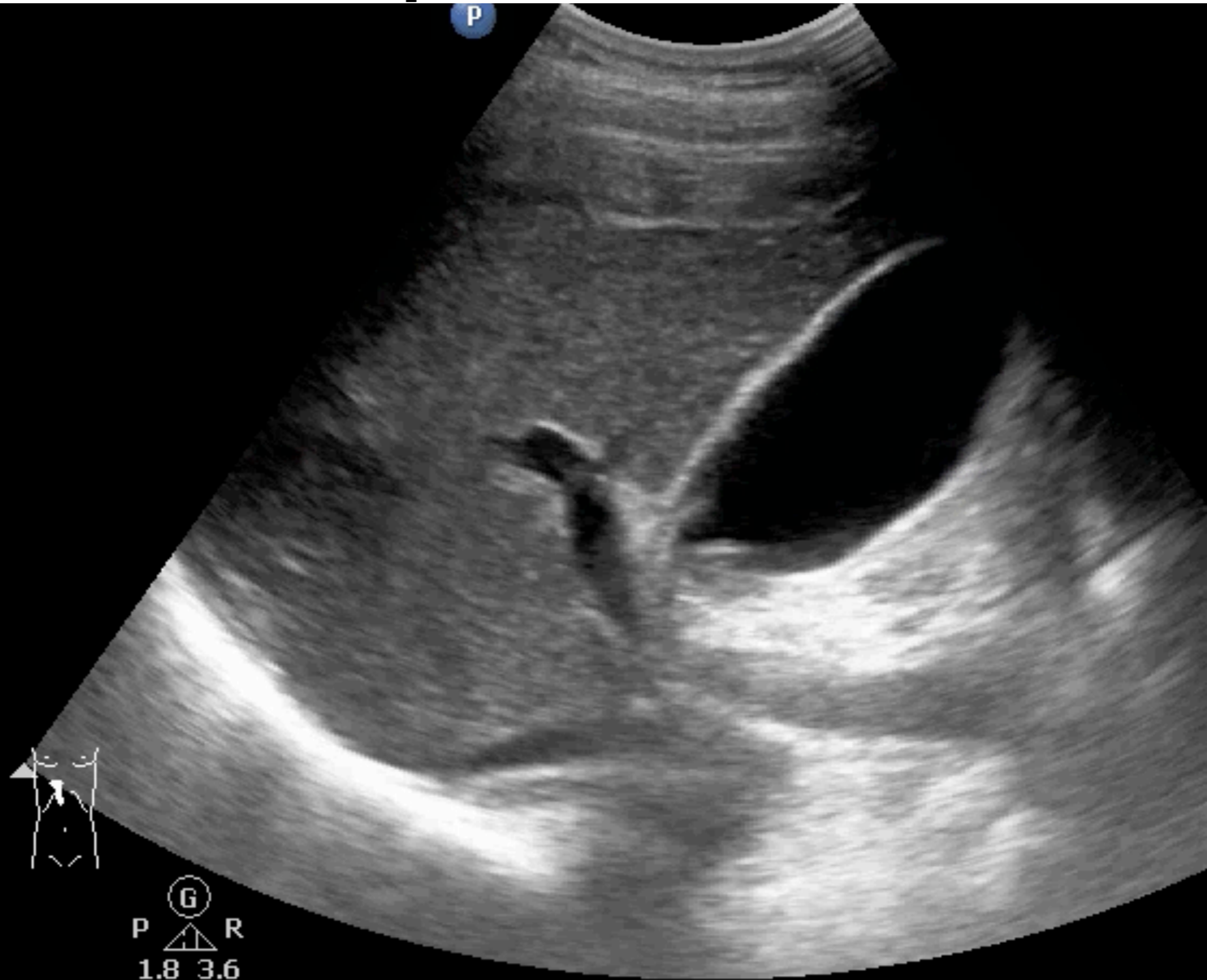## (肝 & 背)

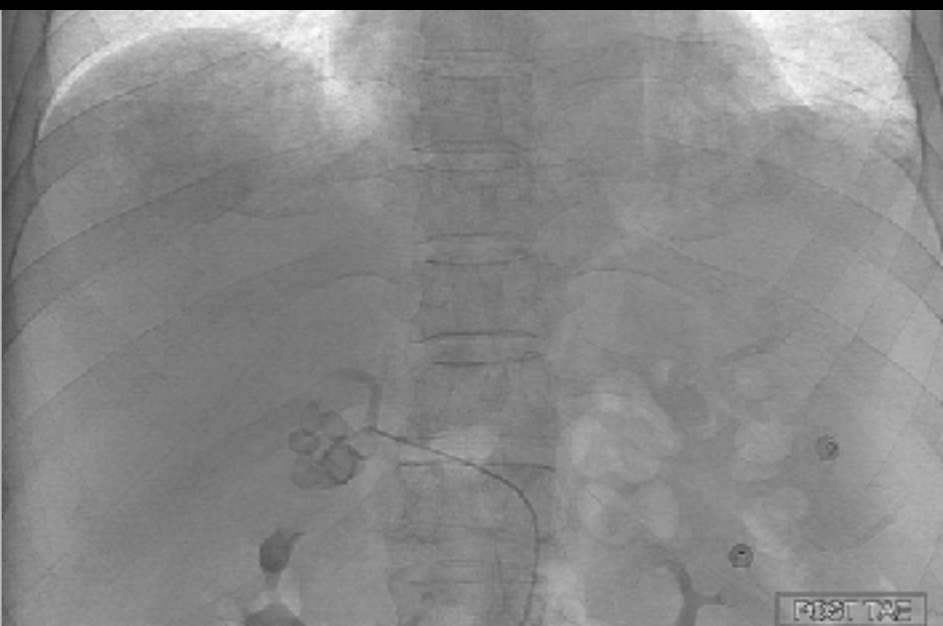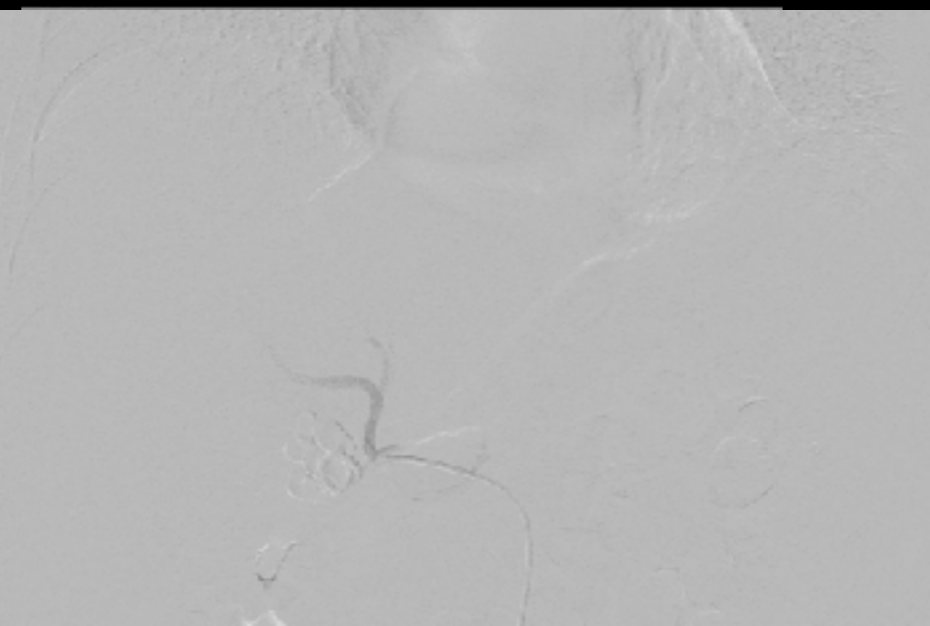
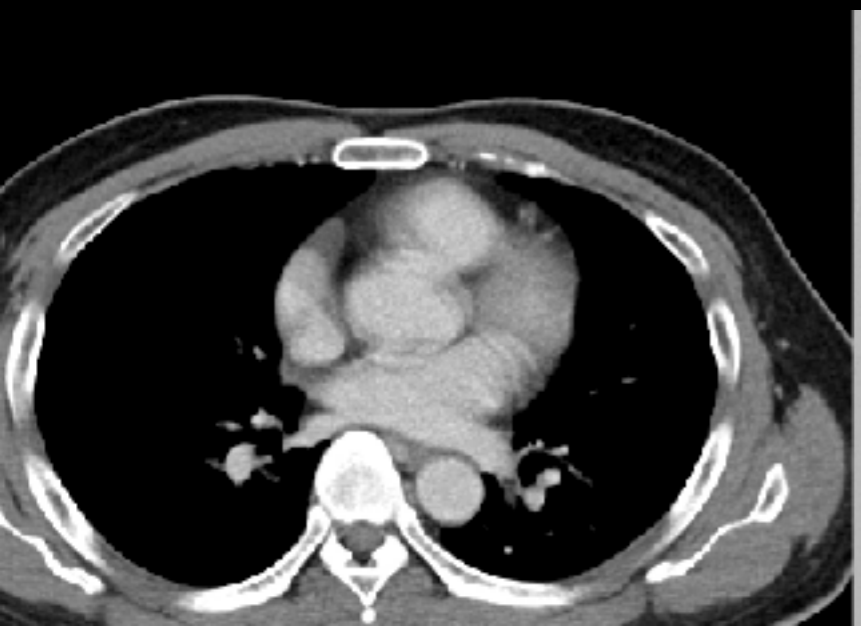
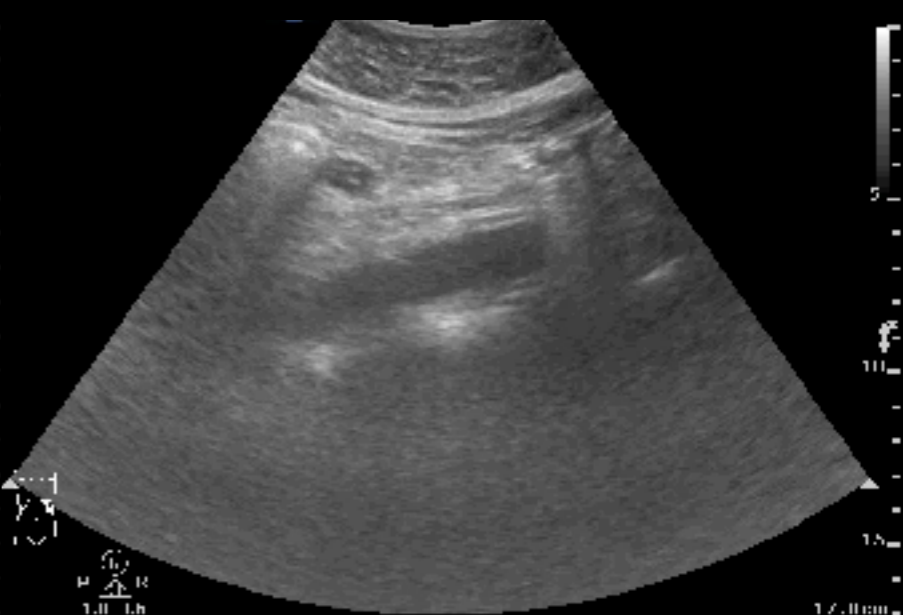

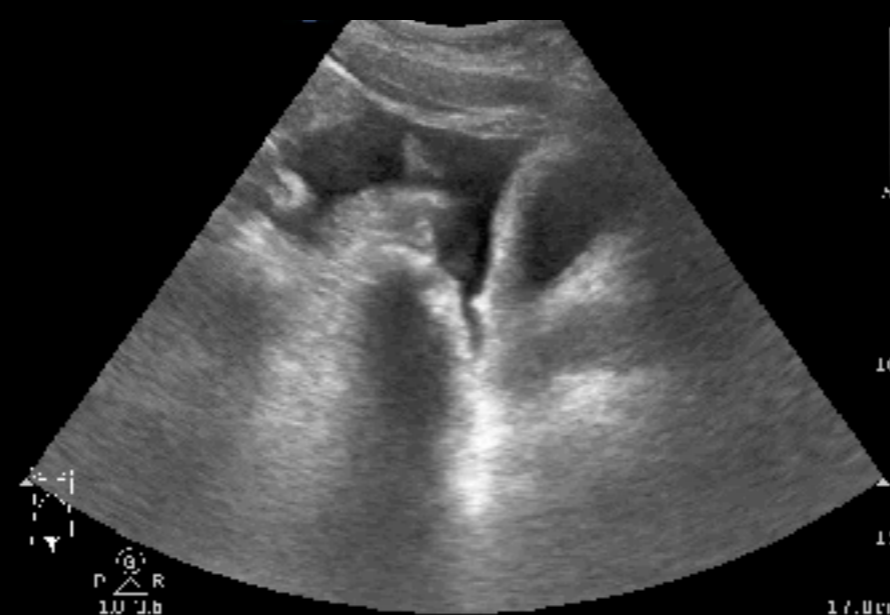
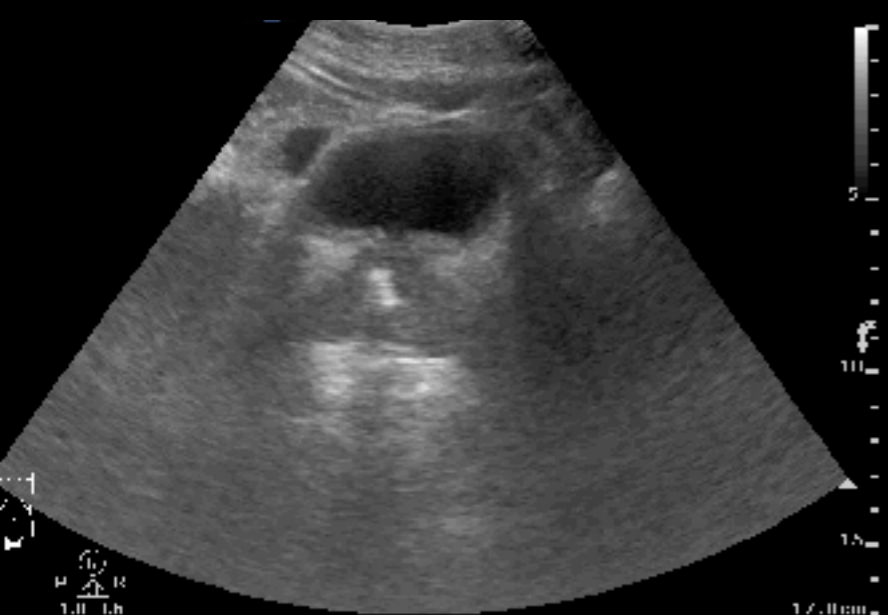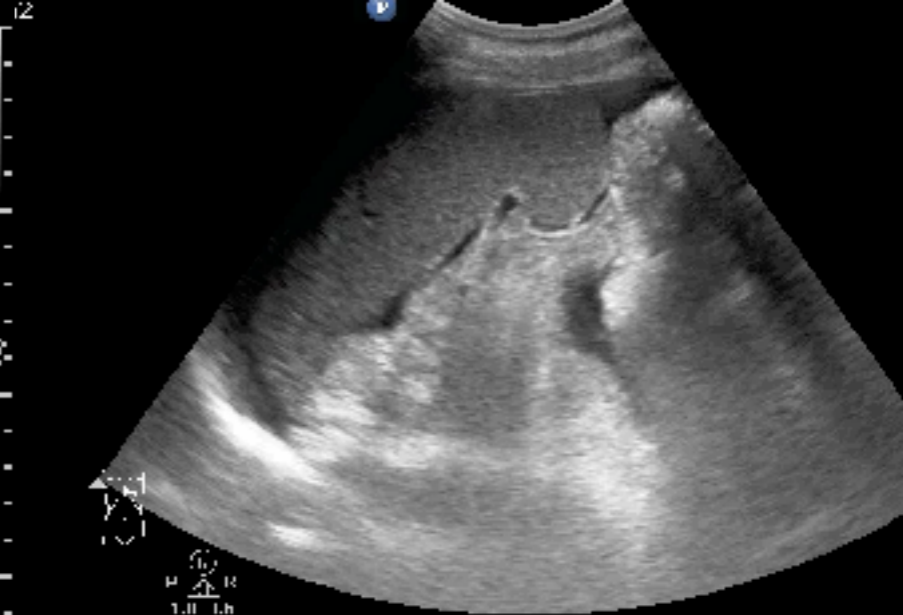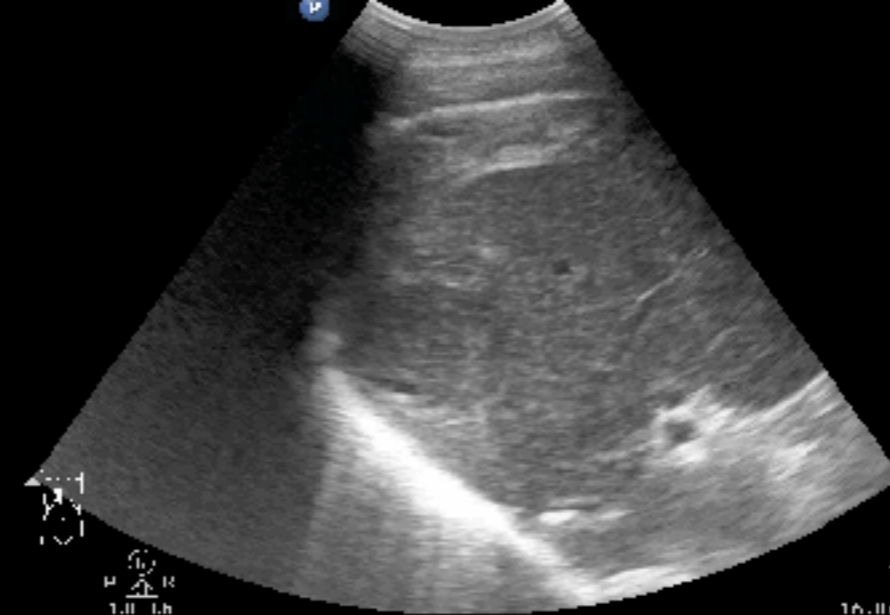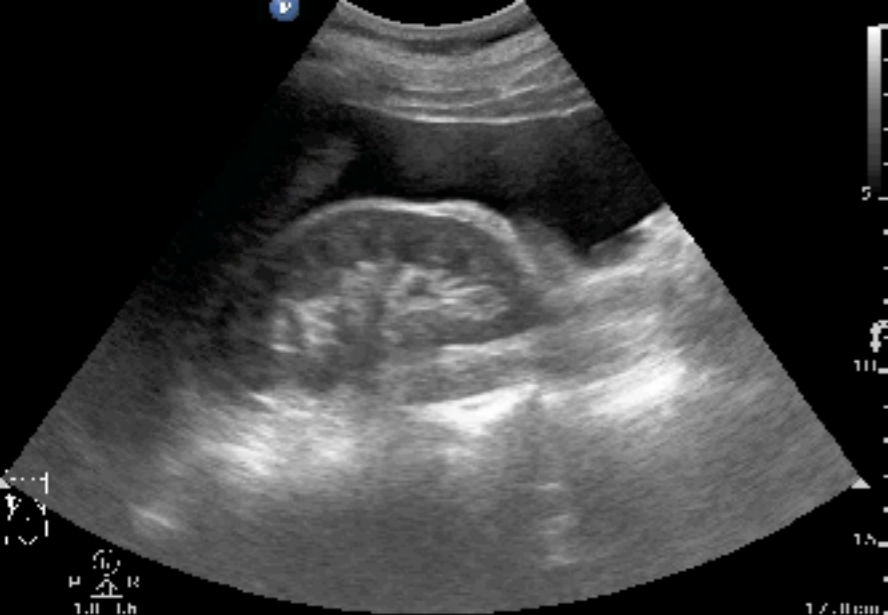# 52M, RUQ pain

Abd Gen2  
C5-1  
31 Hz  
17.0cm

2D  
HGen  
Gn 86  
C 56  
3 / 3 / 3



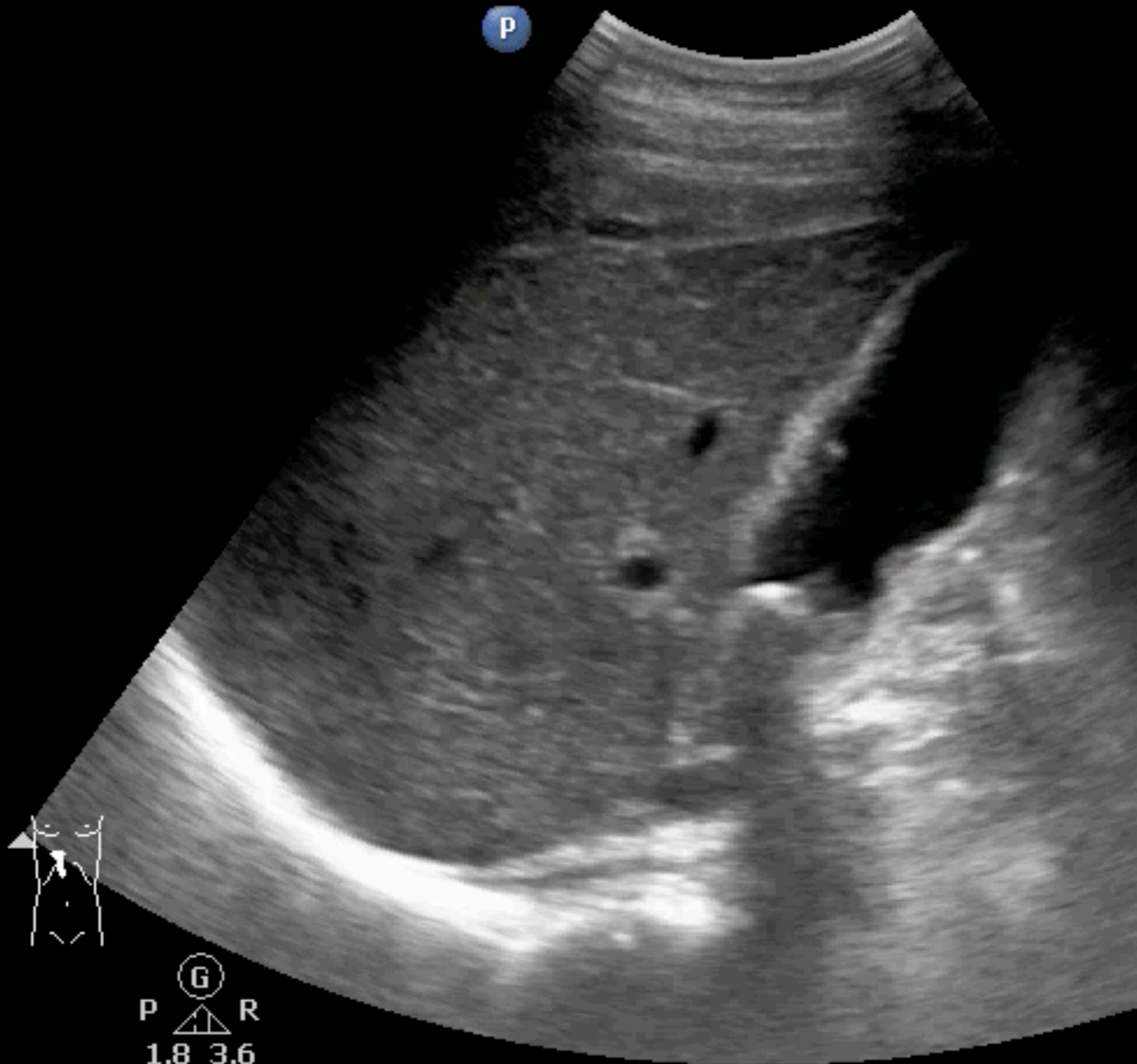

# What else ?

Abd Gen2  
C5-1  
31 Hz  
17.0cm

2D

HGen  
Gn 86  
C 56  
3 / 3 / 3





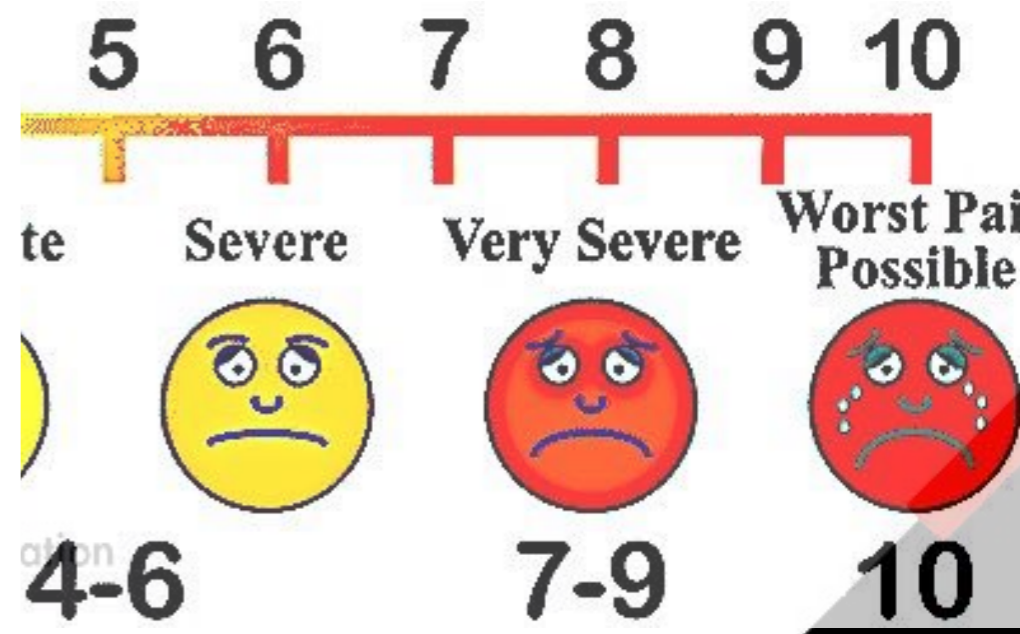
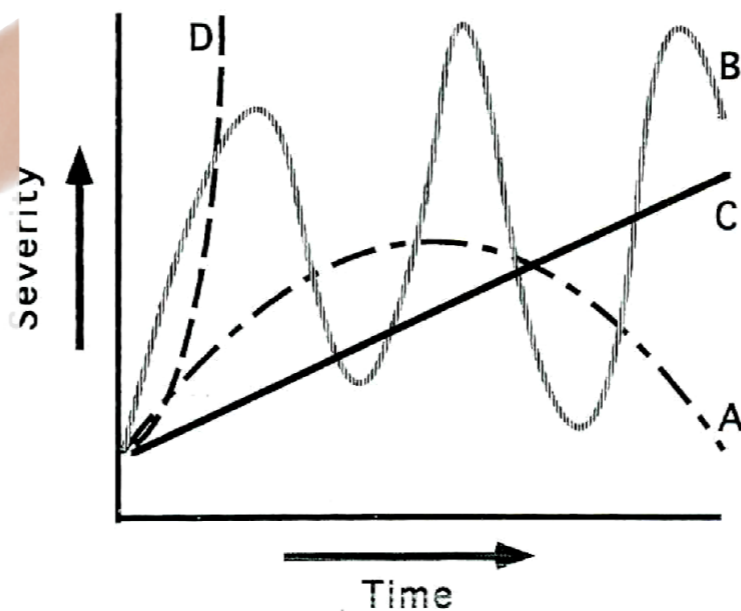
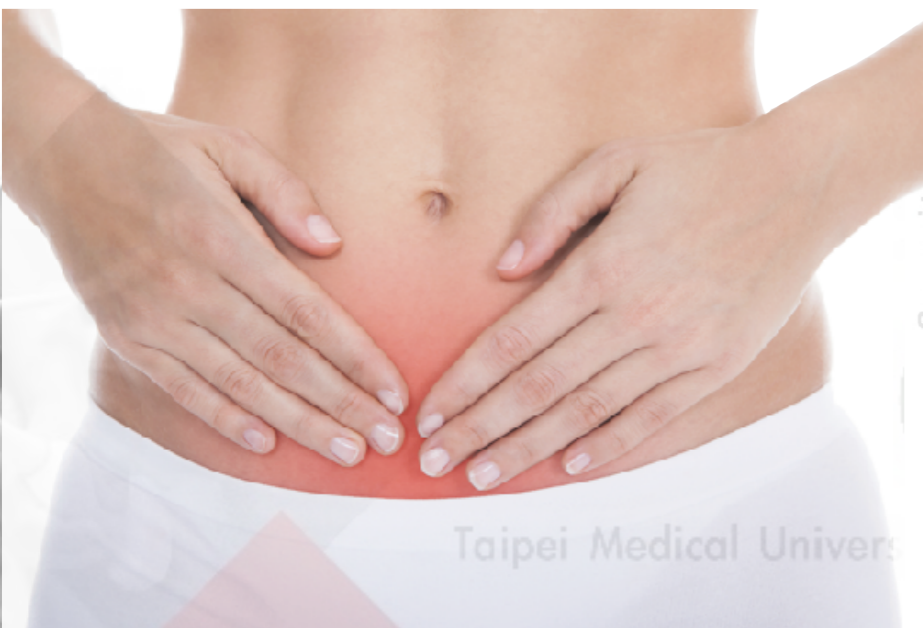病史詢問



POCUS



理學檢查







ULTRASOUND  
PROGRAM

# POCUS

## for

## Acute

# ABDOMEN

**A** for aorta

**B** for biliary

**D** for diaphragm

**O** for obstruction

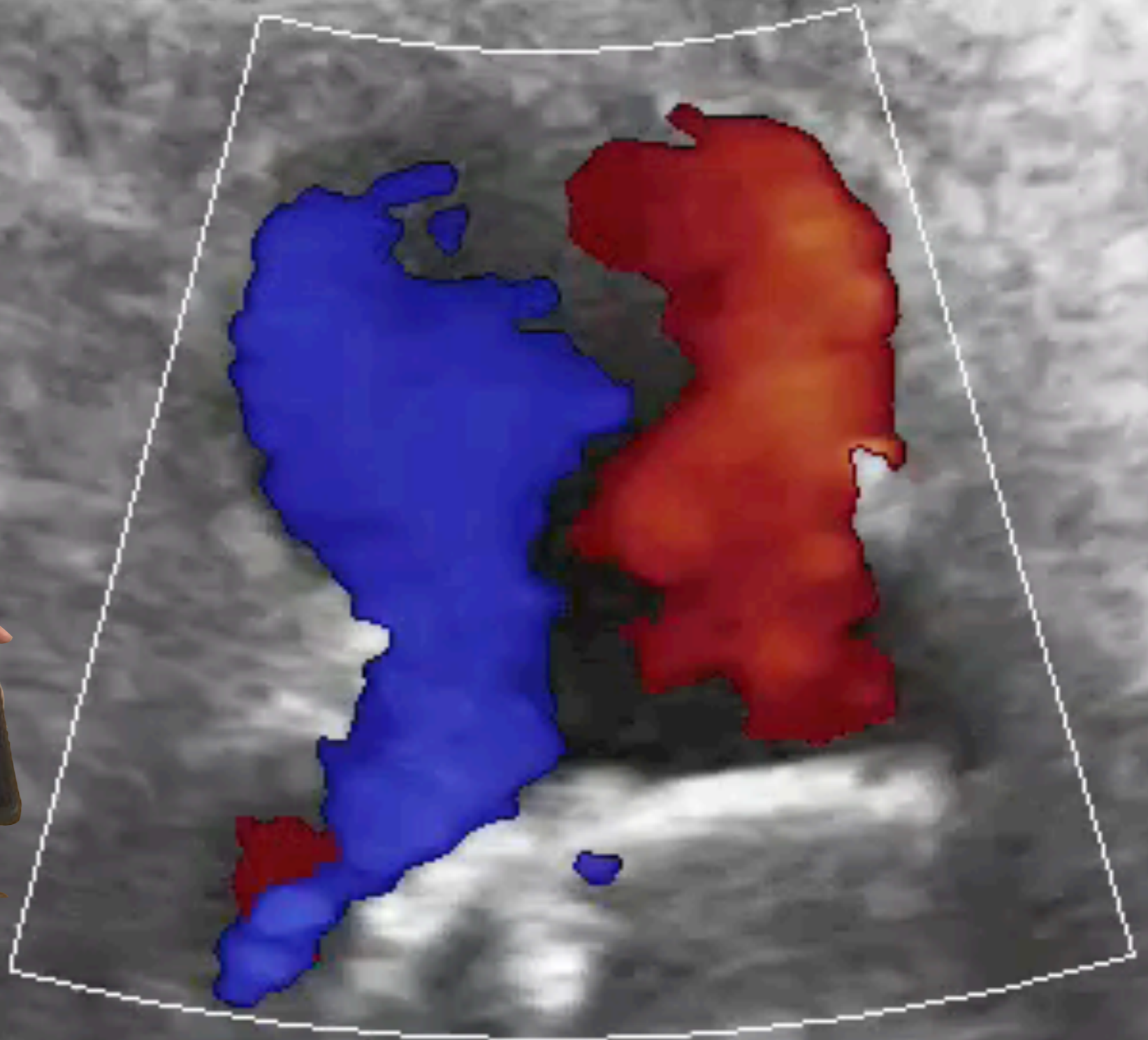
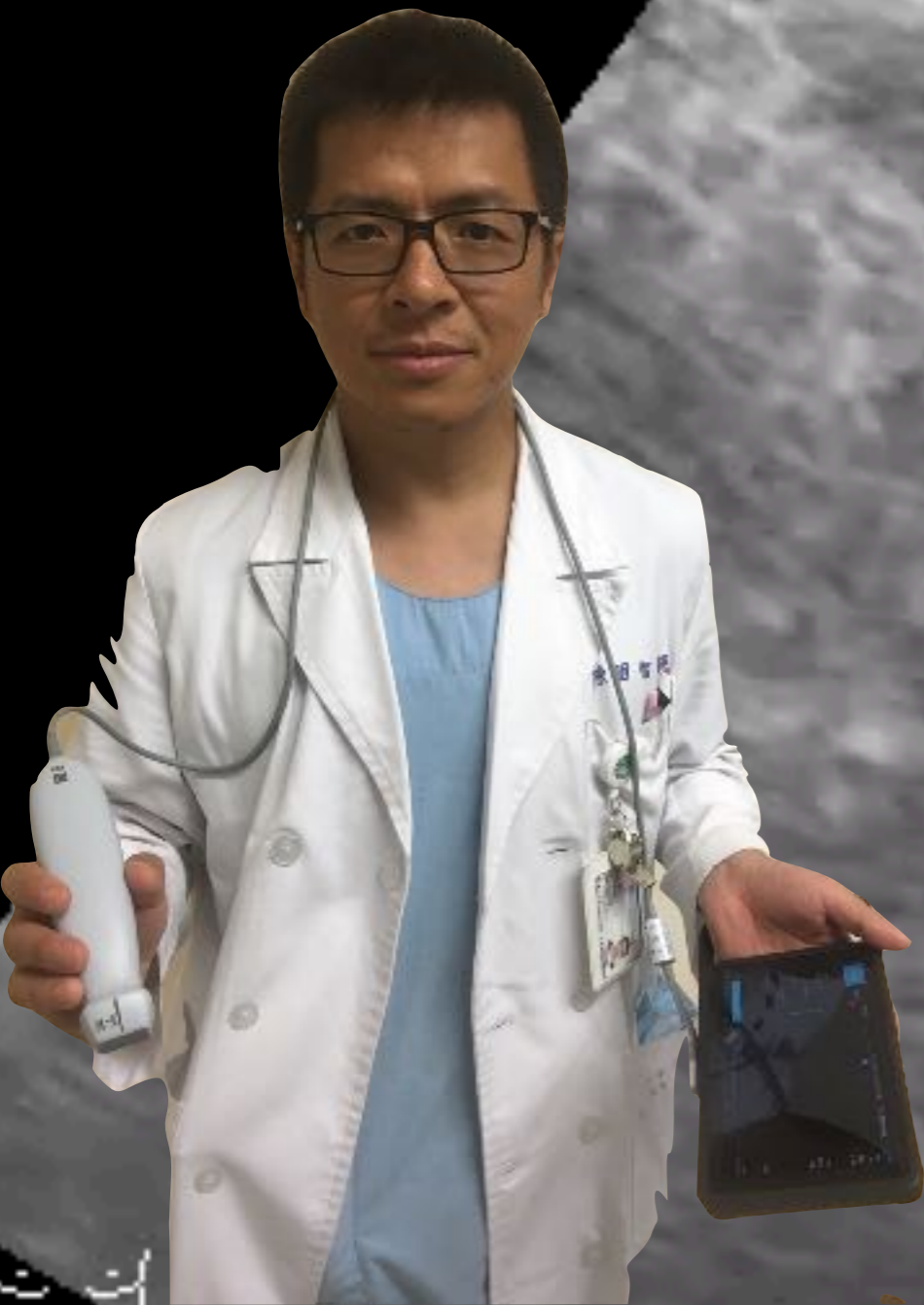**M** for moving fluid or gas

**E** for ectopic pregnancy

**N** for nephropathy



# POCUS幫你【透視】急性腹痛



# POCUS Academy

*Point-of-care ultrasound is the visual stethoscope in the 21st century*

**Password: 20200926**



[juice119@gmail.com](mailto:juice119@gmail.com)

**FB: Emergency Ultrasound Training Center**

Taipei Medical University Center for Education in Medical Simulation

## **EFSUMB Position Paper: Recommendations for Gastrointestinal Ultrasound (GIUS) in Acute Appendicitis and Diverticulitis**

**EFSUMB-Positionspapier: Empfehlungen für den gastrointestinalen Ultraschall (GIUS) bei akuter Appendizitis und Divertikulitis**

Prevalence of appendicitis in Western country: 7-8%

Useful technique: **Graded Compression**

**3** major goals of US

- 1. Exclusion of alternative disease**
- 2. Confirmation of typical appendicitis**
- 3. Ruling out by providing a normal appendix**

## **EFSUMB Position Paper: Recommendations for Gastrointestinal Ultrasound (GIUS) in Acute Appendicitis and Diverticulitis**

**EFSUMB-Positionspapier: Empfehlungen für den gastrointestinalen Ultraschall (GIUS) bei akuter Appendizitis und Divertikulitis**

3 most important criteria in the confirmation of acute appendicitis

1. Max. diameter of appendix > 6 mm
2. Maximal pain over the appendix
3. Hyperechoic periappendiceal tissue

# Acute Appendicitis: Sonographic Diagnosis

## IDENTIFY APPENDIX

Blind ended

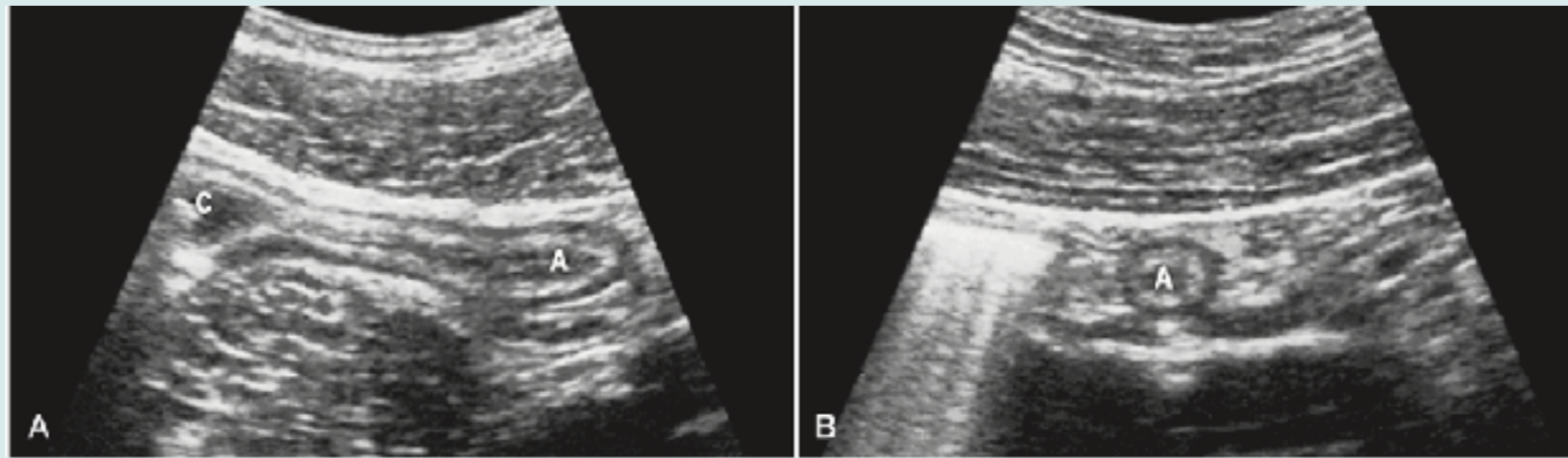
Noncompressible

Aperistaltic tube

Gut signature

Arising from base of cecum (typically appendix is caudal to the base of the cecum but it may also be retrocecal and retroileal)

Diameter greater than 6 mm (some use 7 mm for greater specificity)

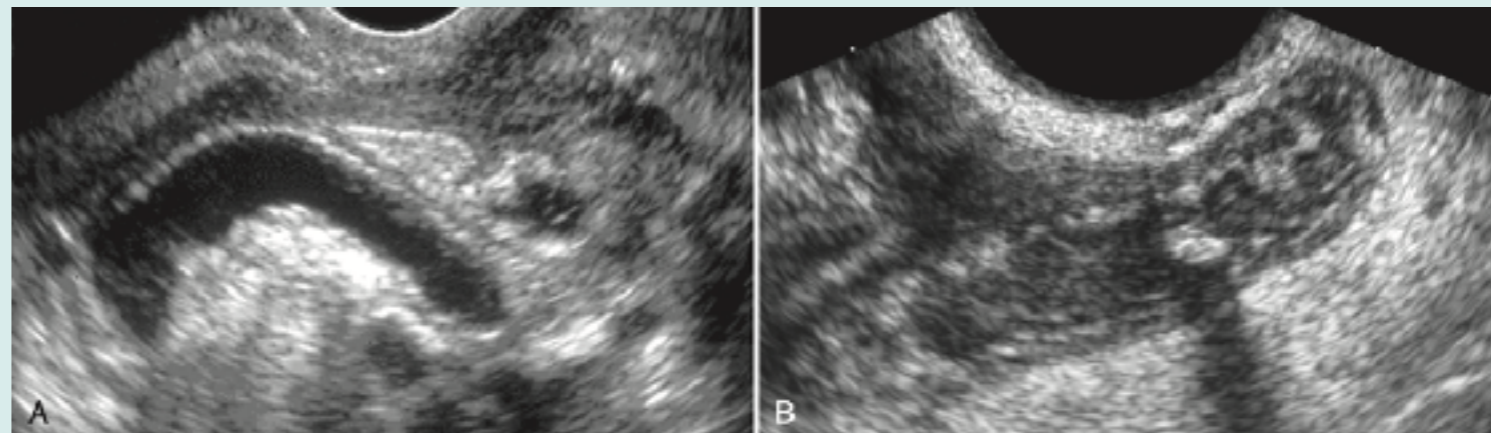


## SUPPORTIVE FEATURES

Inflamed perienteric fat

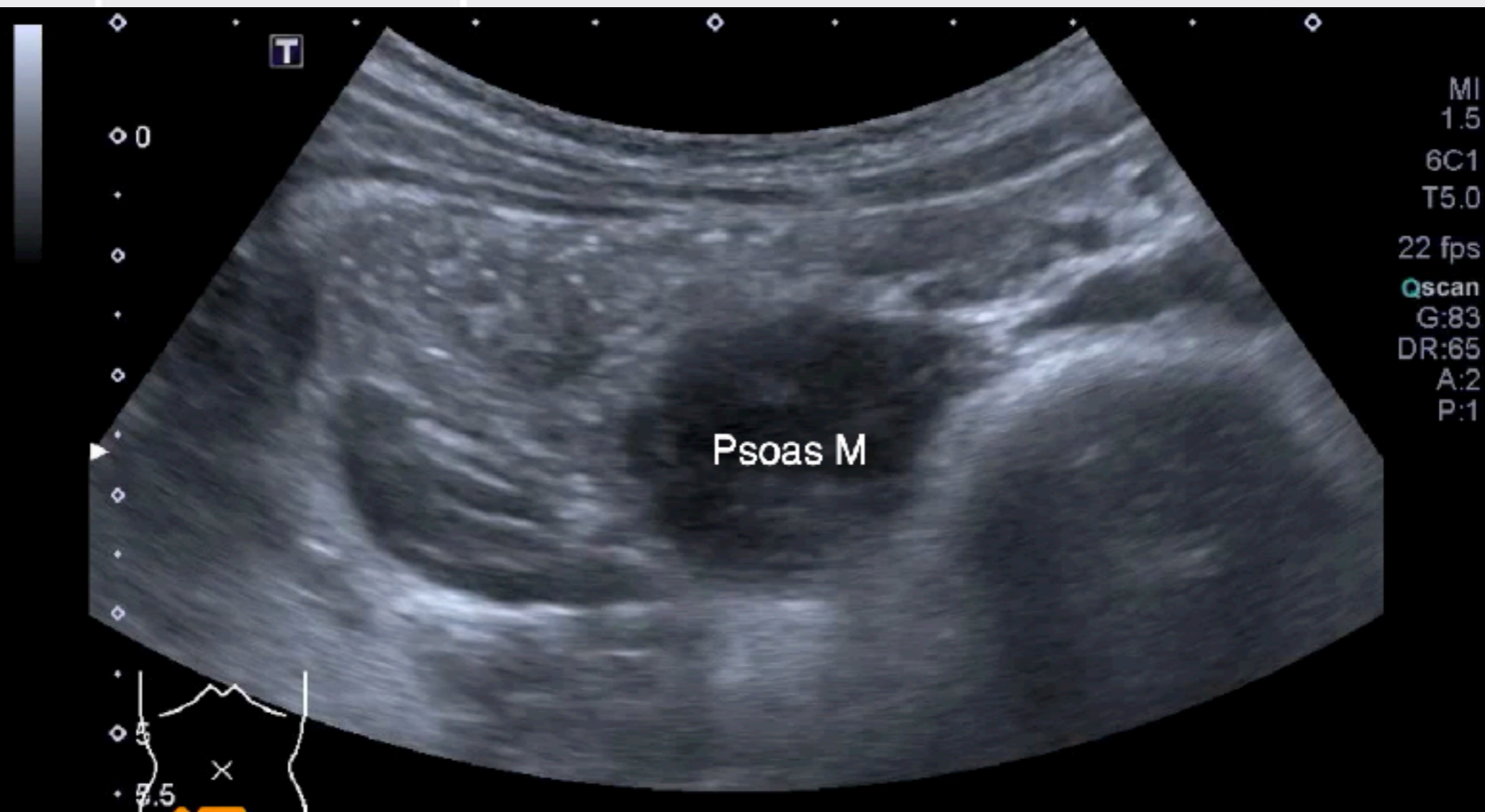
Pericecal collections

Appendicolith



► **Table 1** Based on clinical assessment, laboratory results, and possibly scoring results, three scenarios are common in the daily routine.

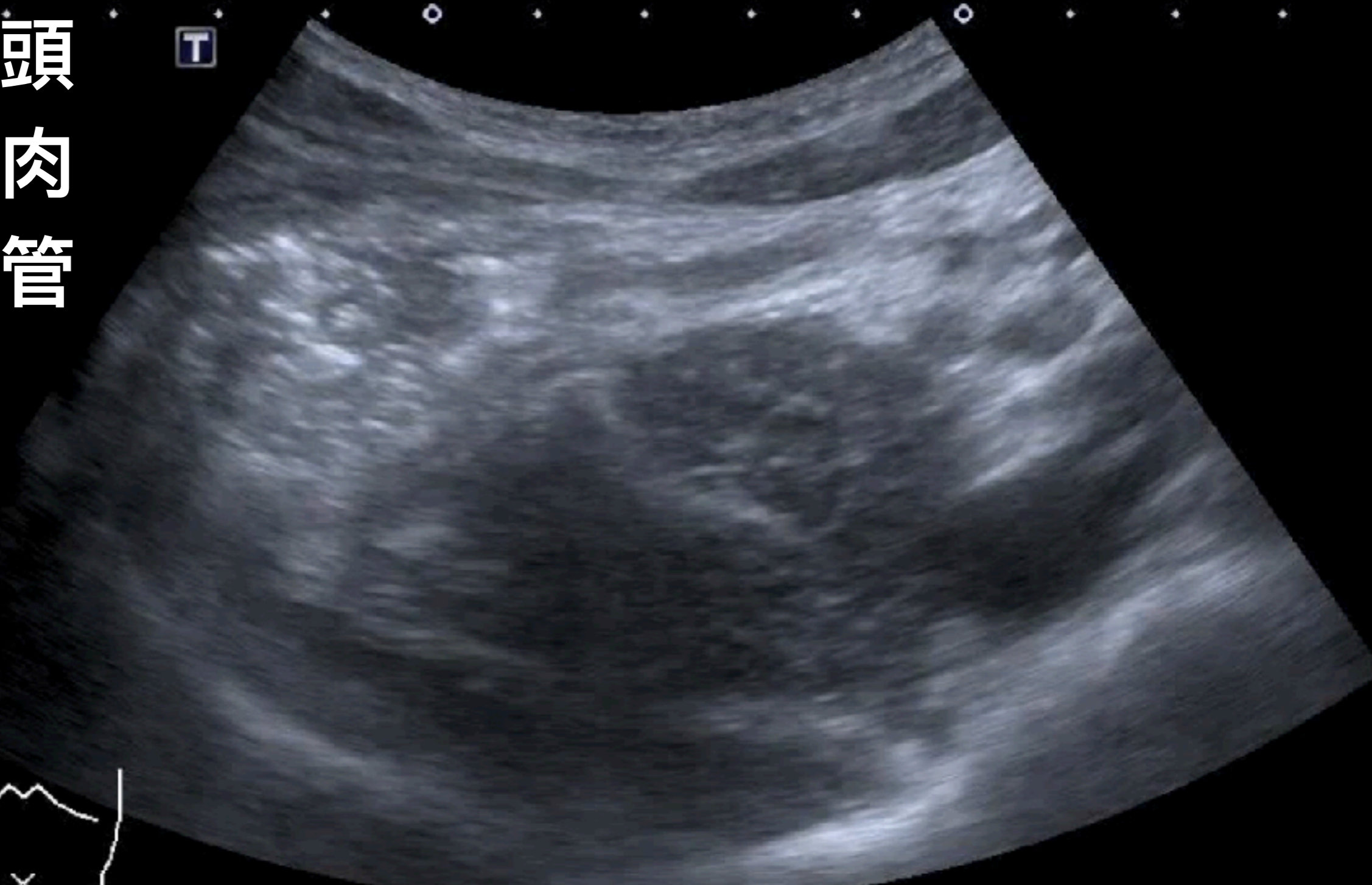
risk of appendicitis	Alvarado or AIR points	impact of sonography
low	0 – 4	visualization of the normal appendix in its full length definitively rules out appendicitis complete ultrasound is helpful in finding an alternative diagnosis
intermediate	5 – 8	validation of an inflamed appendix confirms the need for surgery if the diagnosis remains unclear, complementary CT, MRI or serial ultrasound performed by an experienced operator may be helpful
high	> 8	confirmation of acute appendicitis diagnosis of complications, e. g. abscess



# Landmarks first

POCUSAcademy©ChenKC

骨頭  
肌肉  
血管



1  
60  
T5  
22 f  
G:  
DR:  
A  
P





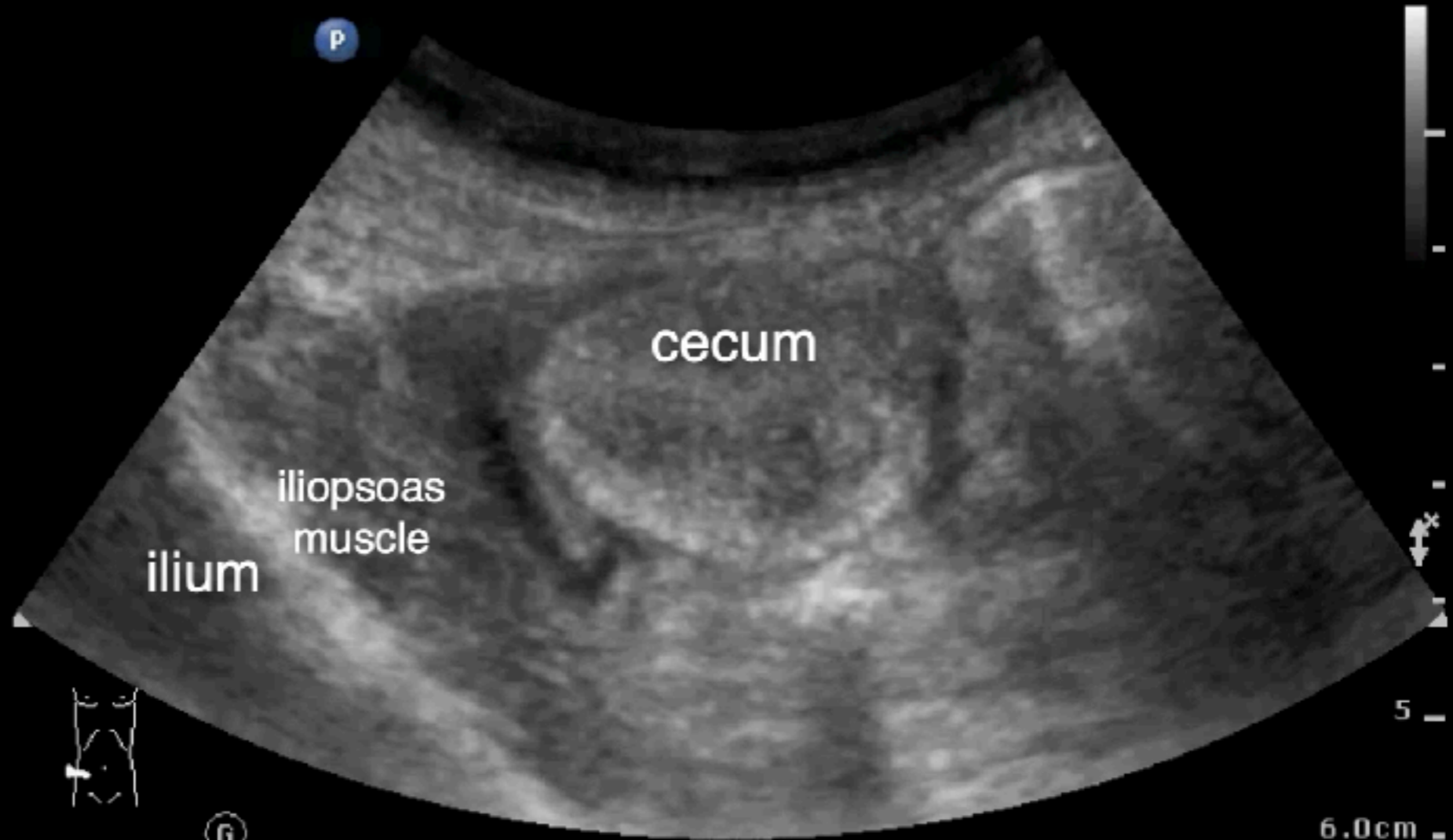# 這個Appendix會轉彎

CT怎麼看，探頭就怎麼動，最後才花式

PHILIPS LEE 20628754 POCUSAcademy©ChenKC MT 1.0 T15 0.1 11/7/2018 9:04:11 AM

Abd Gen2  
C5-1  
58 Hz  
6.0cm

2D  
HGen  
Gn 60  
C 56  
3 / 3 / 3



G  
P R  
1.8 3.6

Transverse scan over RLQ area