臺中榮民總醫院
Taichung Veterans General Hospital

臺中榮民總醫院

POCUS 訓練工作坊

呼吸急症超音波介紹

Lung ultrasound

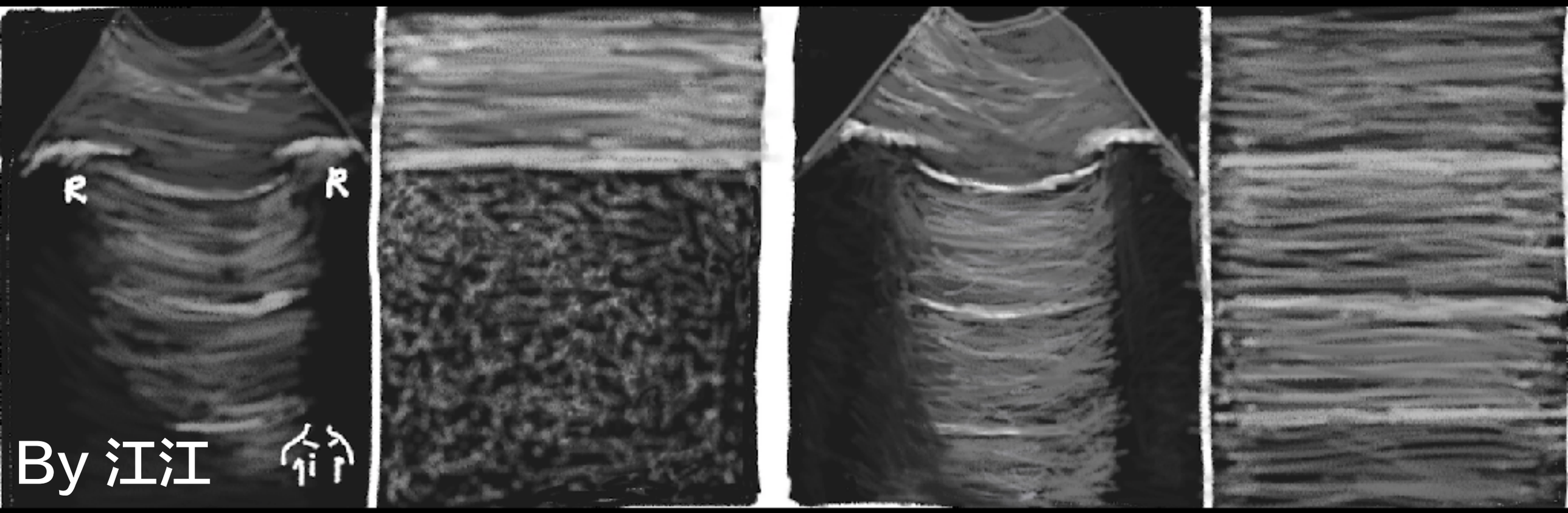

ChenKC@POCUSAcademy

ULTRASOUND
PROGRAM

POCUS Academy

Point-of-care ultrasound is the visual stethoscope in the 21st century

Password: 20200926



juice119@gmail.com

FB: Emergency Ultrasound Training Center

Taipei Medical University Center for Education in Medical Simulation

Resuscitative

Diagnostic

Procedural Guidance

Symptom– or Sign-Based

Therapeutic

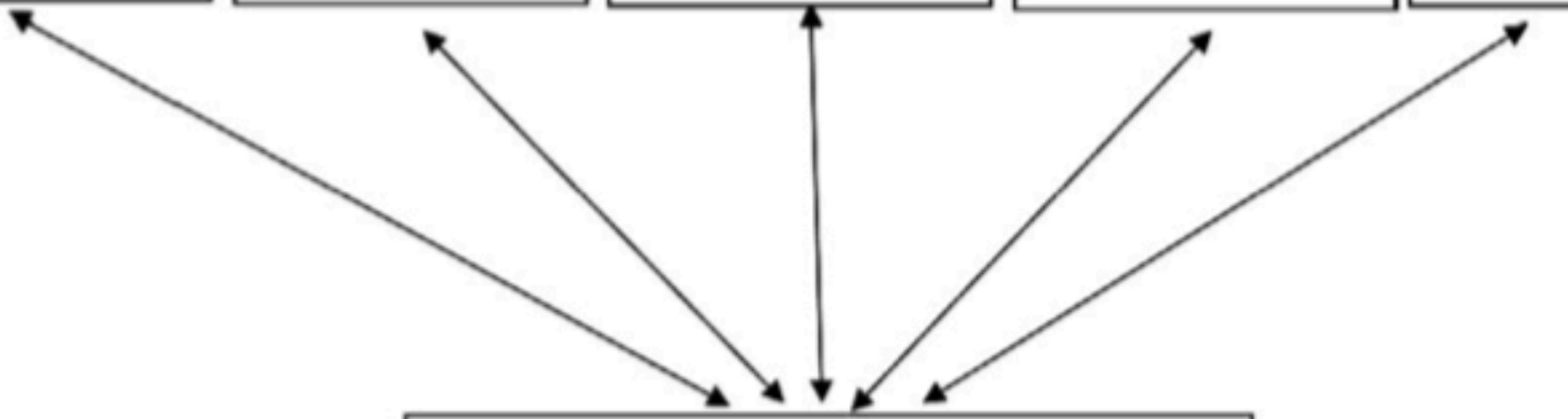

Core Applications

Trauma

Intrauterine Pregnancy

AAA

Cardiac/HD Assessment

Biliary

Urinary Tract

DVT

Soft-tissue/Musculoskeletal

Thoracic/Airway

Ocular

Bowel

Procedural Guidance

ACEP 2016

12

F.O.R.E.S.I.G.H.T. Comprehensive Perioperative Ultrasound Examination

Focused
Peri**O**perative
Risk
Evaluation
Sonography
Involving
Gastro-Abdominal
Hemodynamic, and
Trans-Thoracic Ultrasound

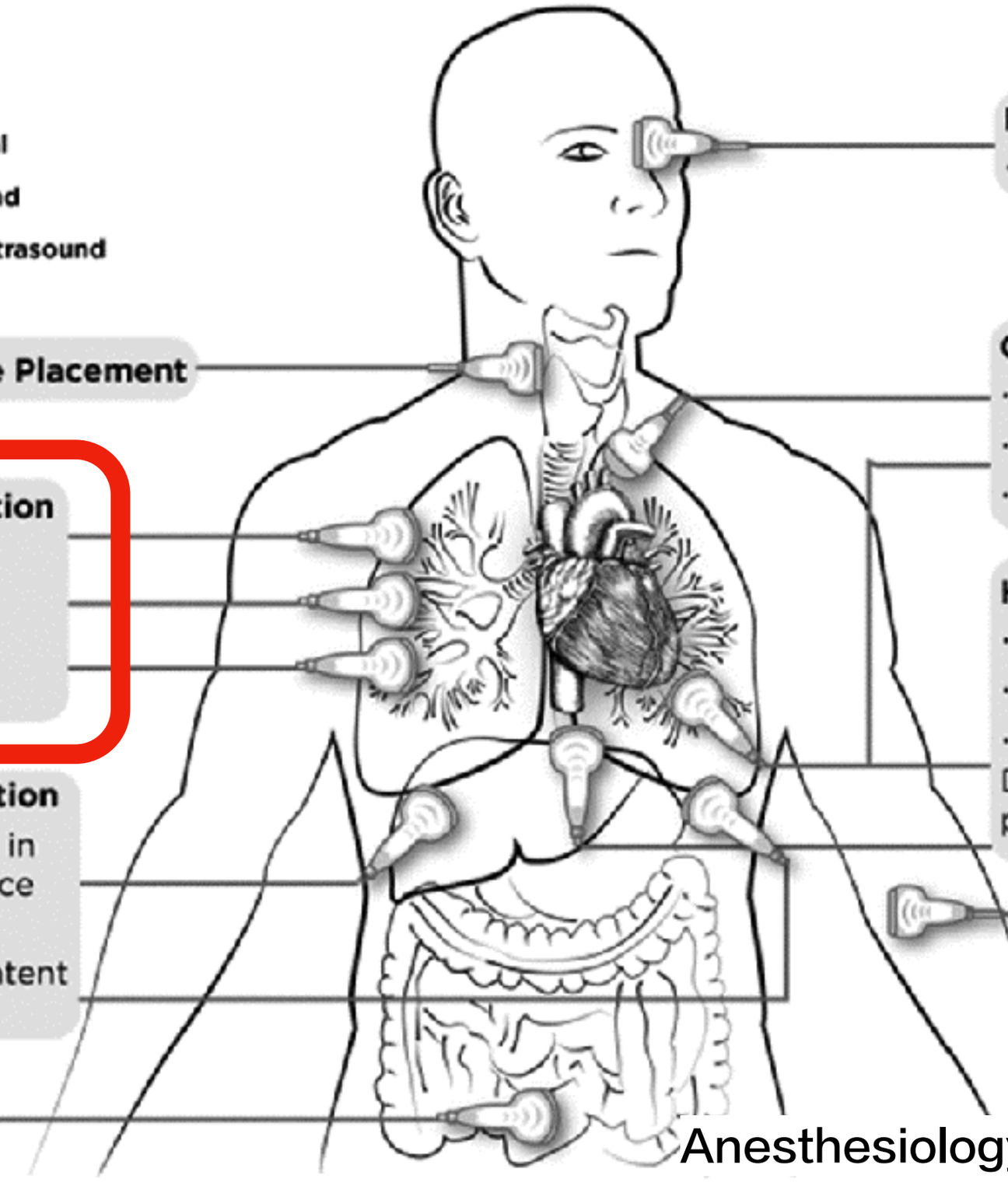

Endotracheal Tube Placement

Pulmonary Evaluation
- Pneumothorax
- Pleural effusion
- Severe alveolar interstitial disease

Abdominal Evaluation
- Evaluate free fluid in interperitoneal space via 3 windows
- Assess gastric content and volume

ICP Accessment
- Optic sheath diameter

Cardiac Evaluation
- R/L ventricular function
- Pericardial effusion
- Severe valvular abnormalities

Hemodynamics
- IVC collapsibility
- LV end diastolic area
- Respiratory variation on Doppler flow across LVOT/ peripheral arteries

Vascular Access
- Demonstrate image acquisition of peripheral veins/arteries

Anesthesiology. 2015 Sep;123(3):670–82

	IMAGE AREA	IMAGE ACQUISITION	PROBE
1	Heart	Parasternal Long Axis (PLAX)	Phased
2	Inferior Vena Cava	Subcostal	Phased
3	Lung	Anterior, Lateral, Posterior	Linear
4	Kidney	Longitudinal, Transverse	Curved
5	Bladder	Suprapubic	Curved
6	Dialysis Fistula	Longitudinal and Transverse	Linear

Johns Hopkins **Nephrology** fellowship

POCUS curriculum

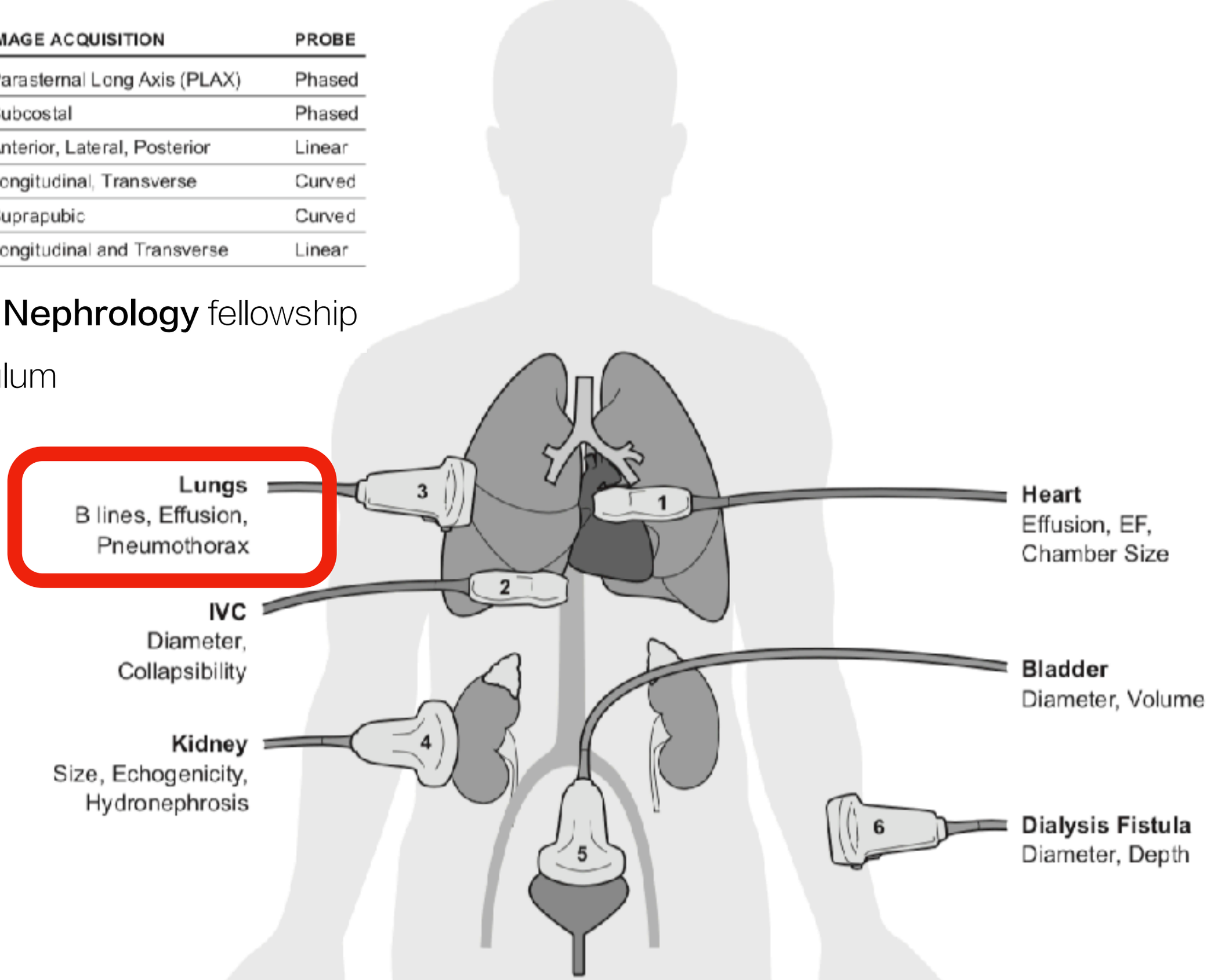

Semin Dial. 2018 Mar;31(2):154–162

Do you know all ?

Sign	Images	Description	Pathology
Sliding sign	Figure 2	Movement between the two layers of the pleura during normal respiration	Normal
A-lines	Figure 6	Hyperechoic horizontal lines parallel to pleural line occurring at regular intervals below the pleura Artefacts from reverberations between probe and pleura	Seen in normal lungs as well as pneumothorax and emphysematous lungs
B-lines	Figure 1	Hyperechoic artefacts that originate at the pleural line and extend from the probe to the edge of the screen, without fading and perpendicular to the pleural line Artefacts that occur when the interstitium and alveoli are thickened predominantly from becoming oedematous with fluid	Presence of three or more B-lines per intercostal space is evidence of interstitial fluid. If seen diffusely in two or more zones bilaterally is usually indicative of pulmonary oedema
Z-lines	-	Hyperechoic artefact that originates at and perpendicular to the pleural line but does not extend to the edge of the ultrasound window and are shorter, wider and less defined than B-lines	Normal or pneumothorax
V-lines (spine sign)	-	Fluid acts as an acoustic window to enable visualisation of the V-line of vertebral bodies and the posterior thoracic wall in a supine patient	Pleural fluid
E-lines	-	Comet tail artefacts that are superficial to the pleural line	Echogenic foreign bodies or subcutaneous emphysema
Stratosphere sign	Figure 2	The loss of lung sliding beneath the pleura	Pneumothorax
Liver sign (mirror sign)	Figure 4	Tissue similar in consistency to liver tissue seen on US	Lung consolidation absent in pleural effusion
Sea shore sign (M mode)	Figure 2	Pleura appears as horizontal lines and the underlying lung as grainy, making up the sea and sandy shore, respectively	Normal M mode appearance of lung
Bar code sign (M mode)	Figure 3	Bar code-like appearance throughout M mode	Pneumothorax

Wimalasena Y, et al. EMJ 2107

I-AIM

Indication

Acquisition

Interpretation

Making decision

ChenKC@POCUSAcademy

I-AIM

Indication

Acquisition

ChenKC@POCUSAcademy

Transducers

Linear

Curve

Sector

Best for PTX ?

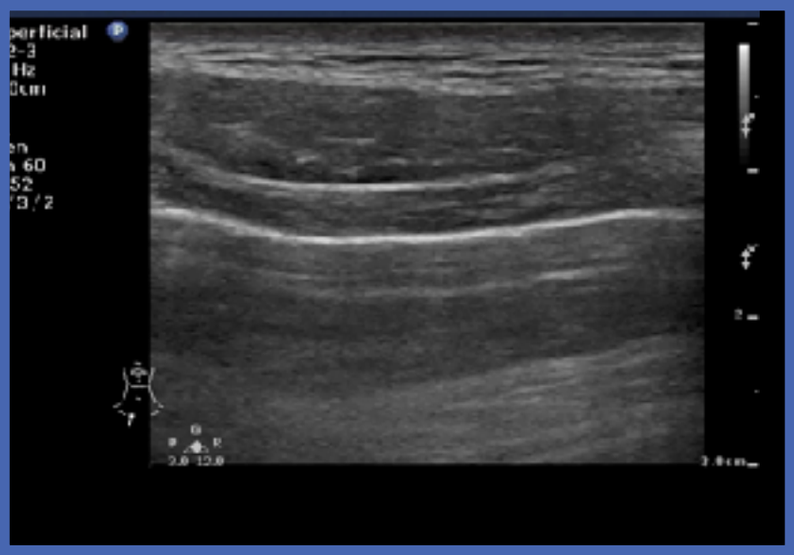

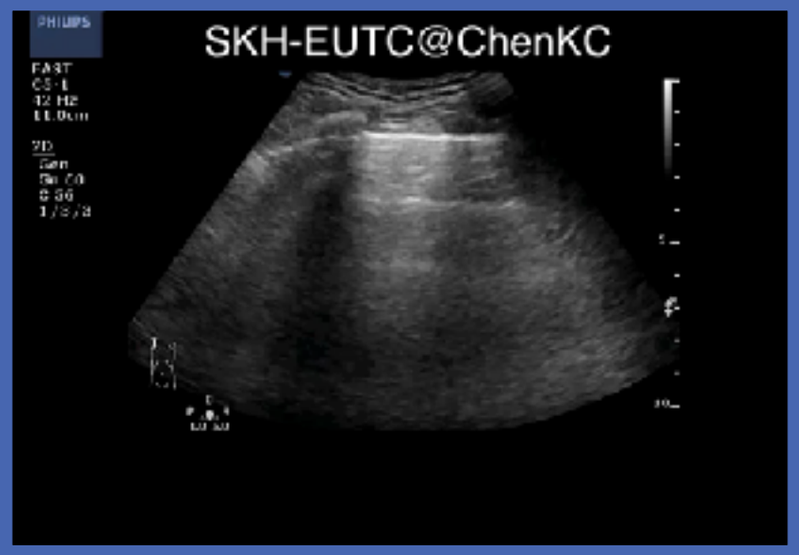

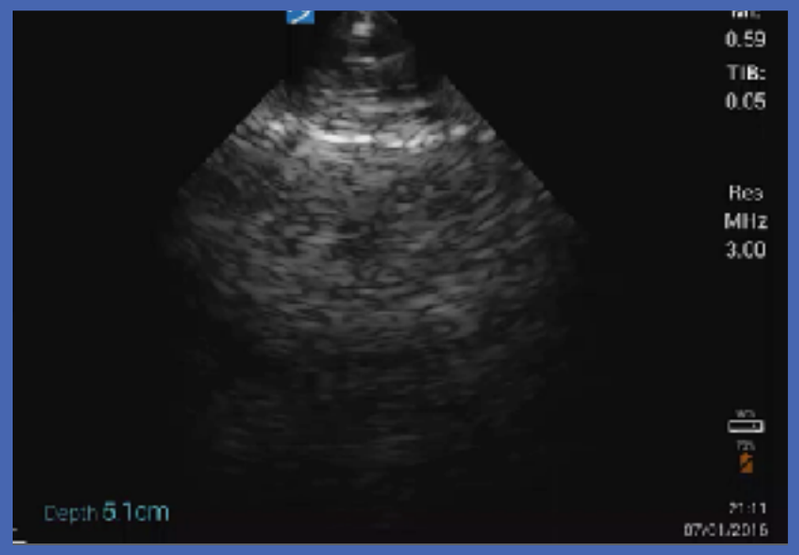

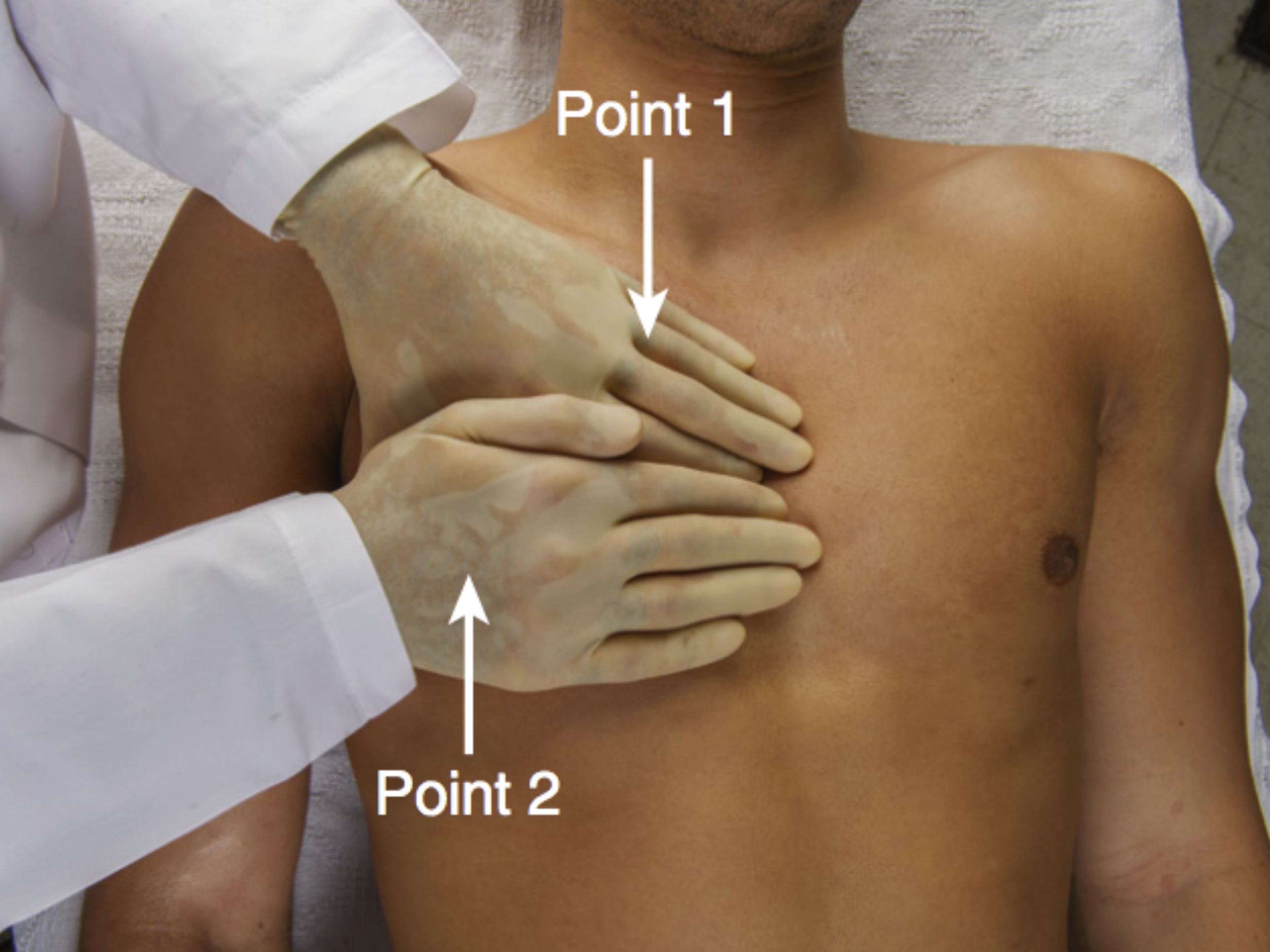
Point 1
Point 2

Essential Anatomy 5

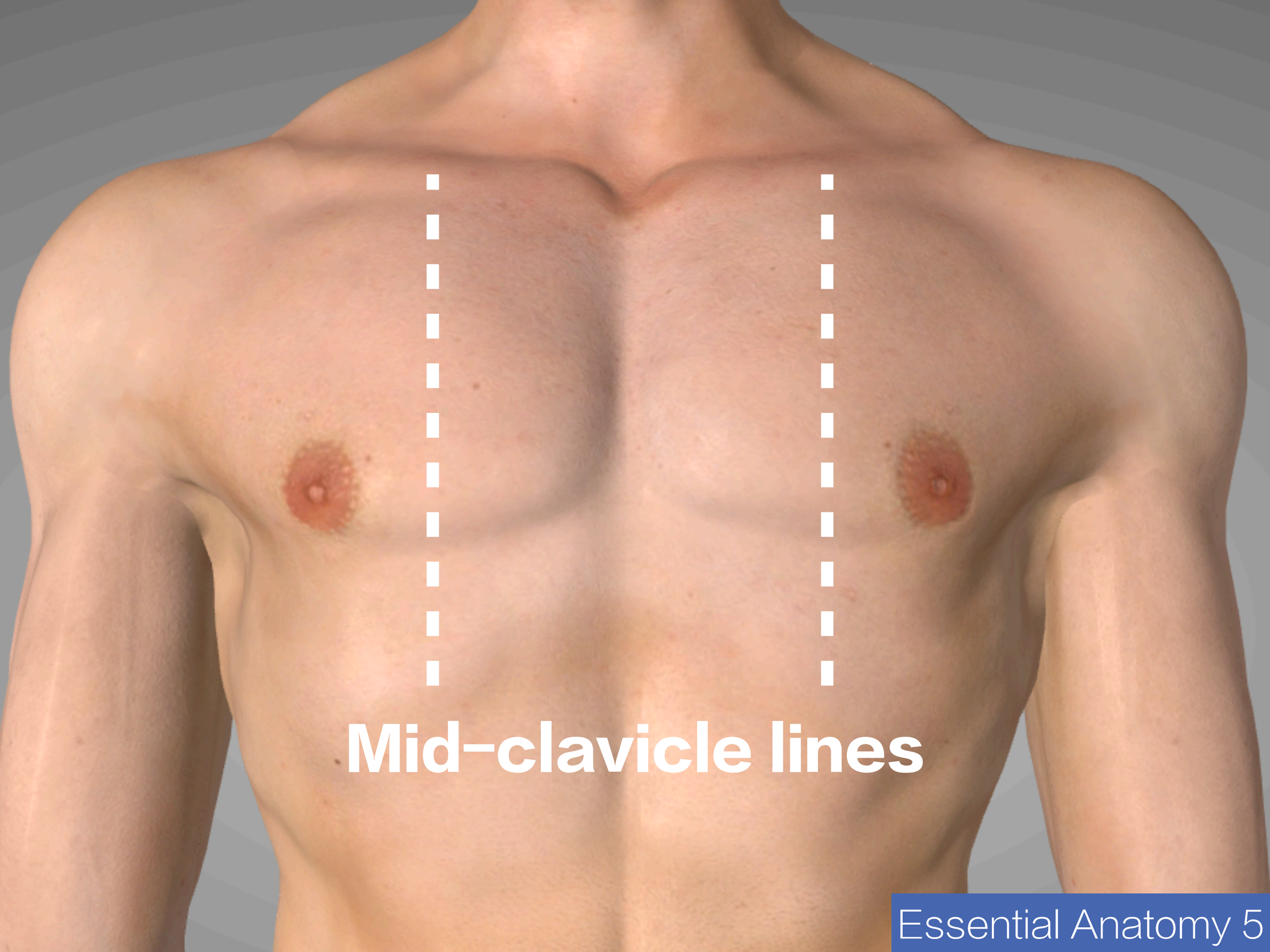
Mid-clavicle lines

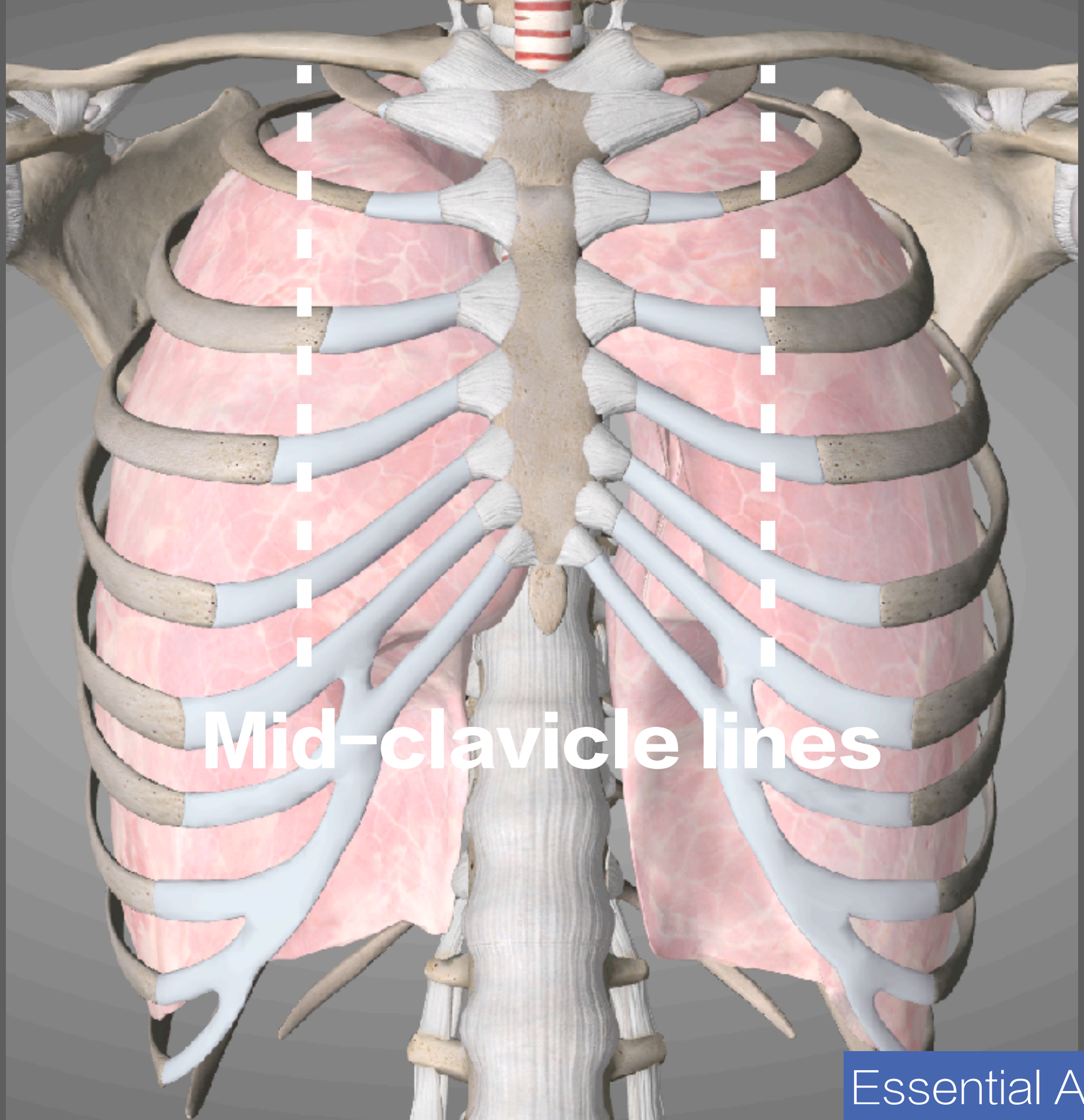
Mid-clavicle lines

Mid-clavicle lines

Mid-clavicle lines

Mid-clavicle lines

Essential Anatomy 5

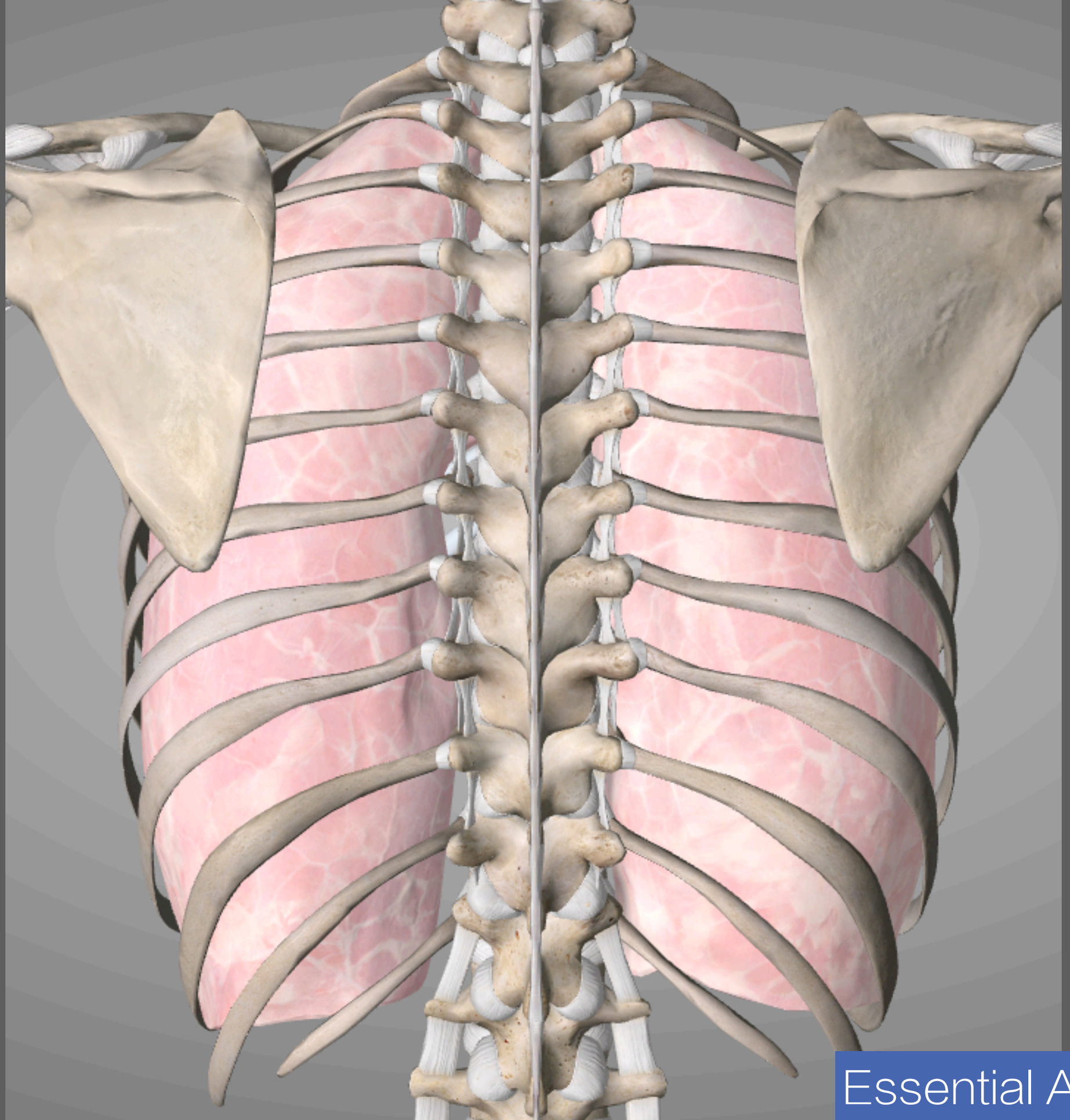

Essential Anatomy 5

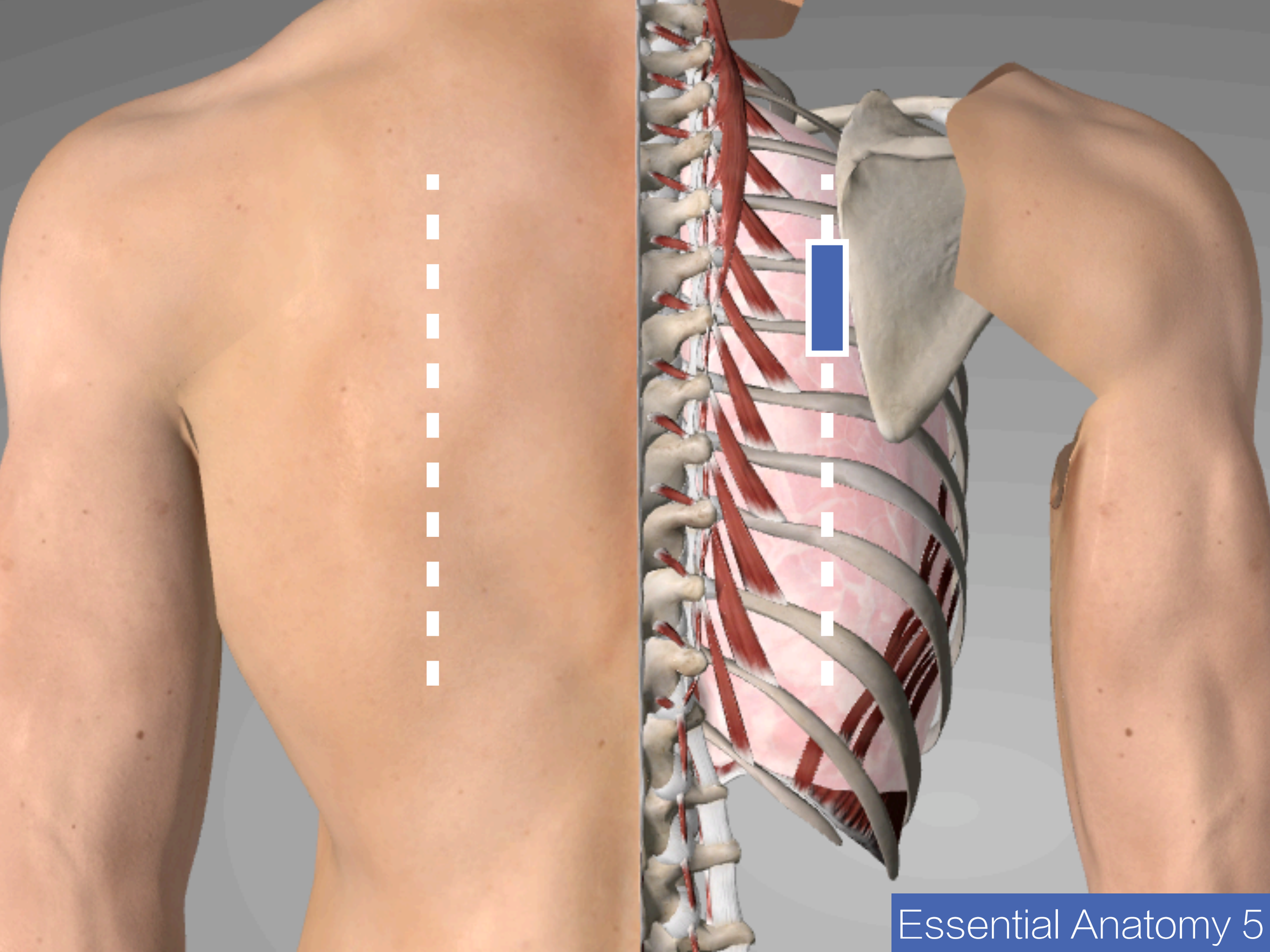

Essential Anatomy 5

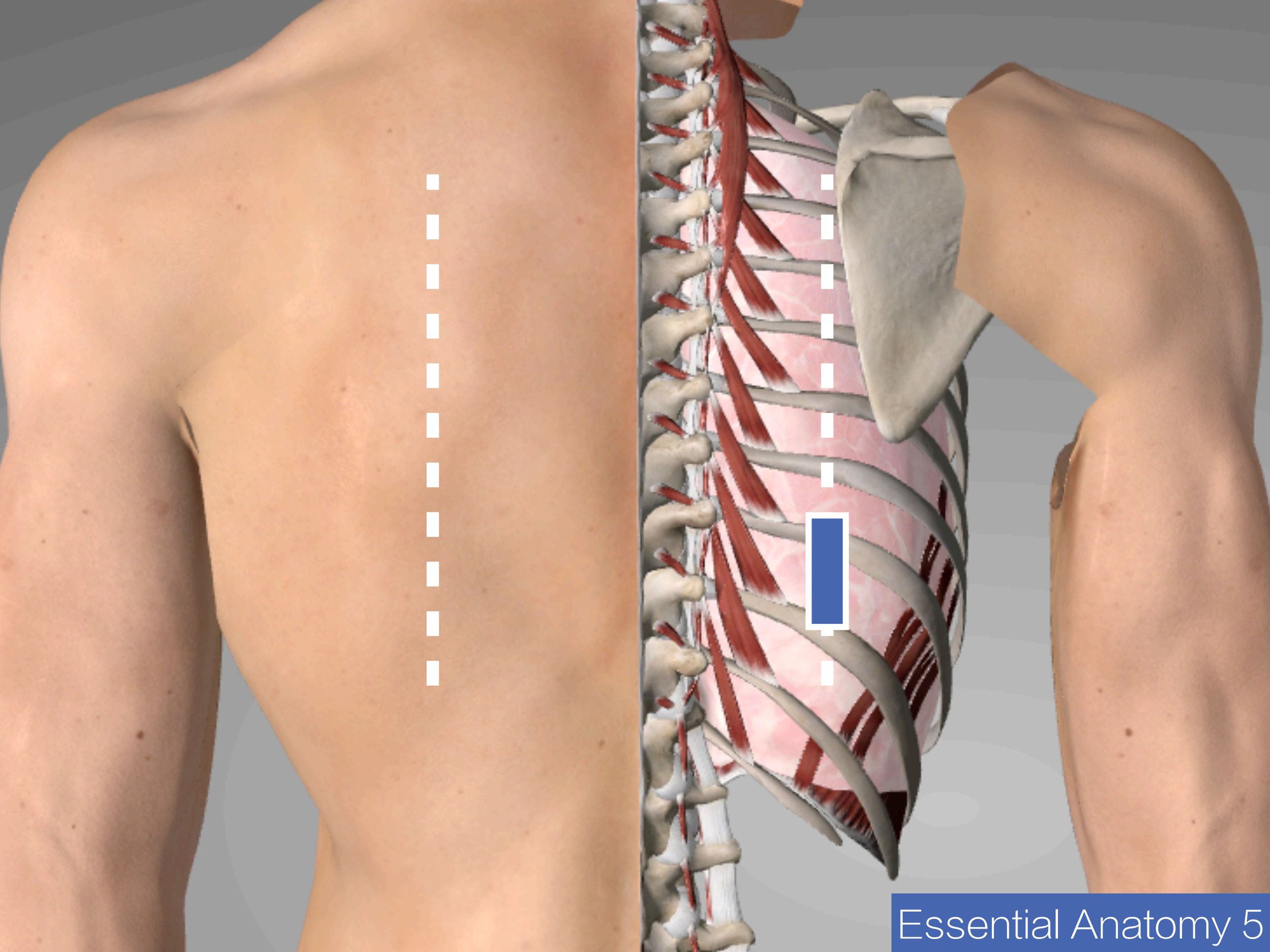

Essential Anatomy 5

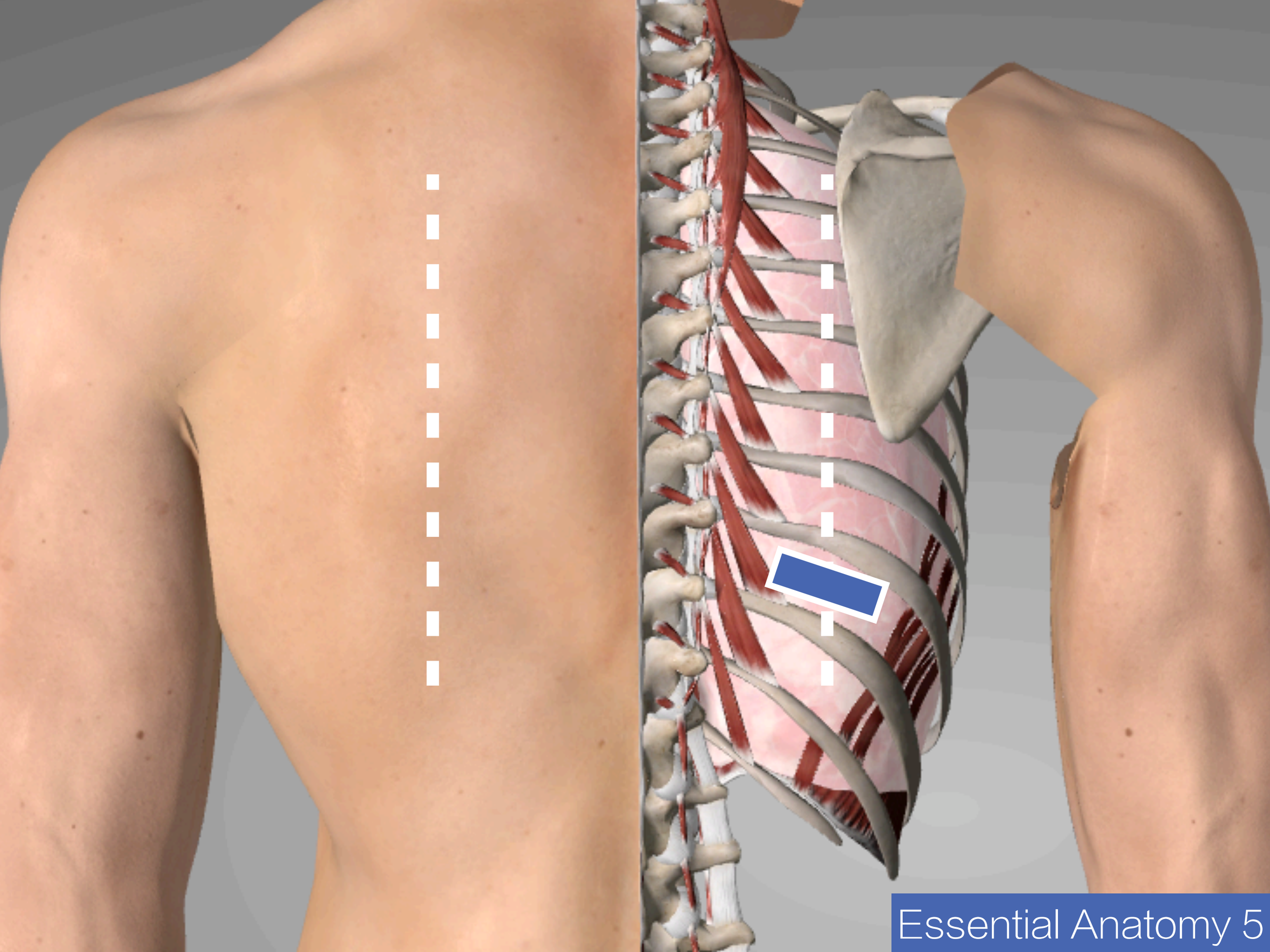
Essential Anatomy 5

Highest point

Highest point

Highest point

Highest point

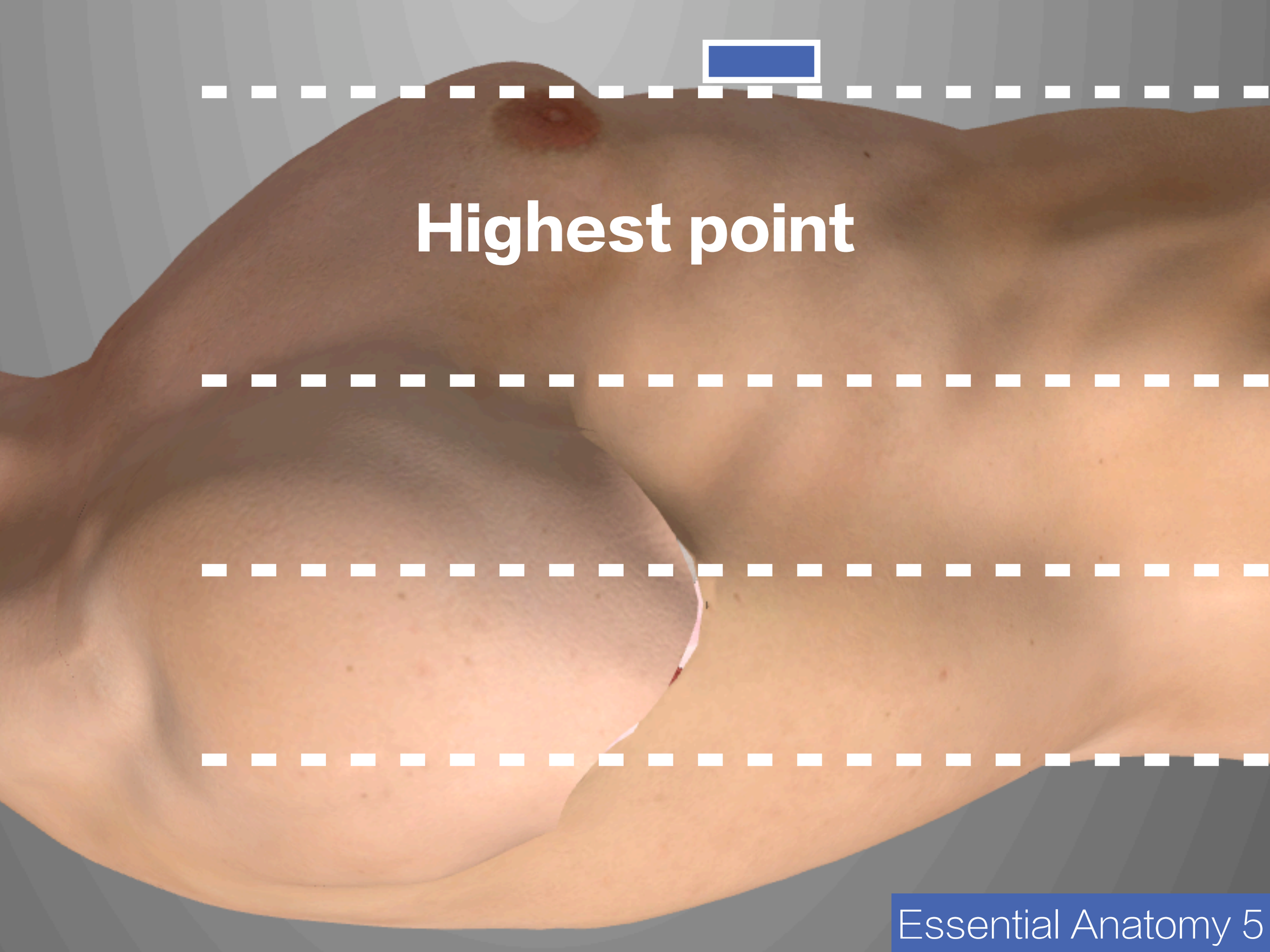
Highest point

Highest point

Highest point

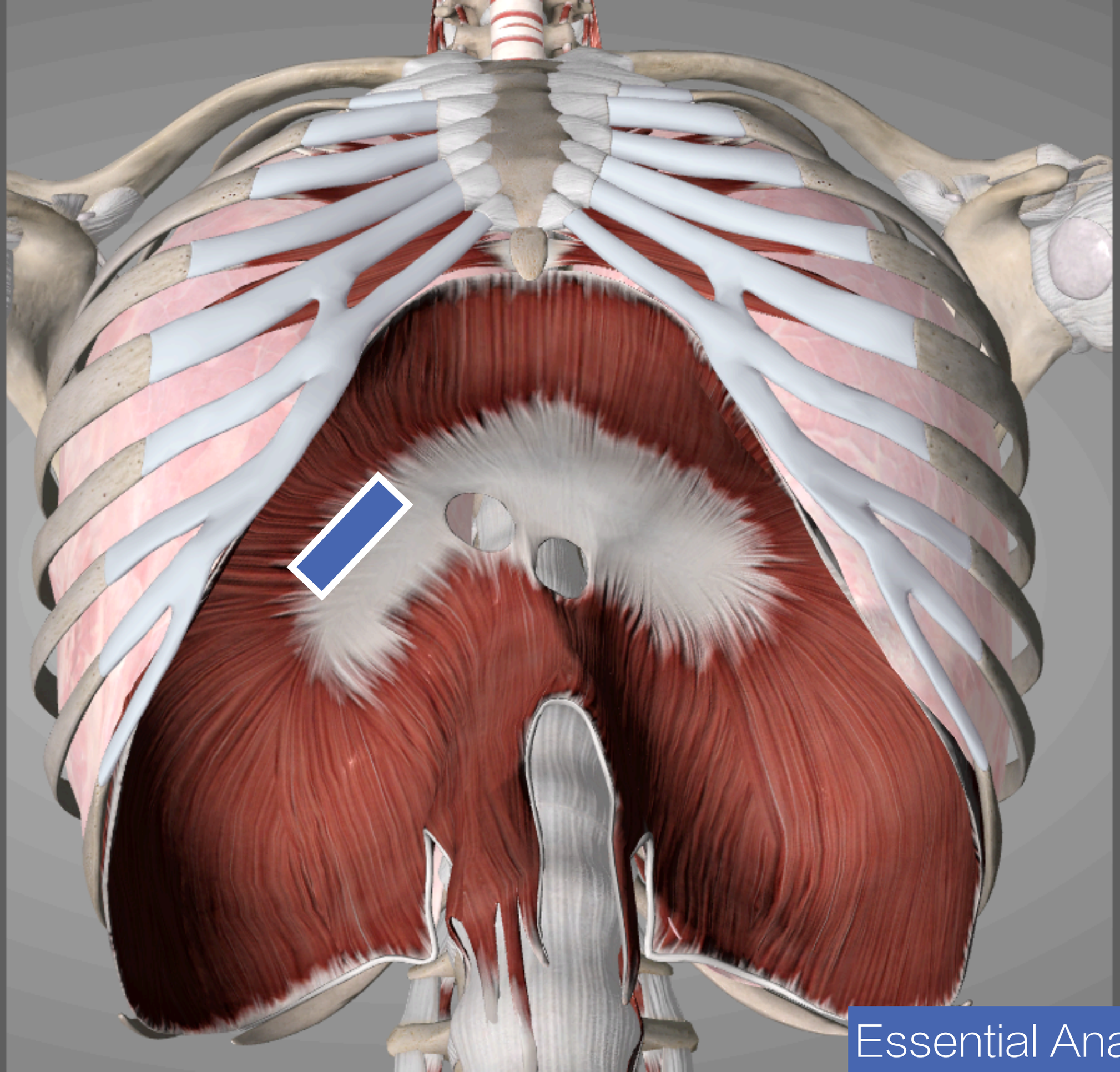

Essential Anatomy 5

51M, Epigastric pain & CPR 8.5

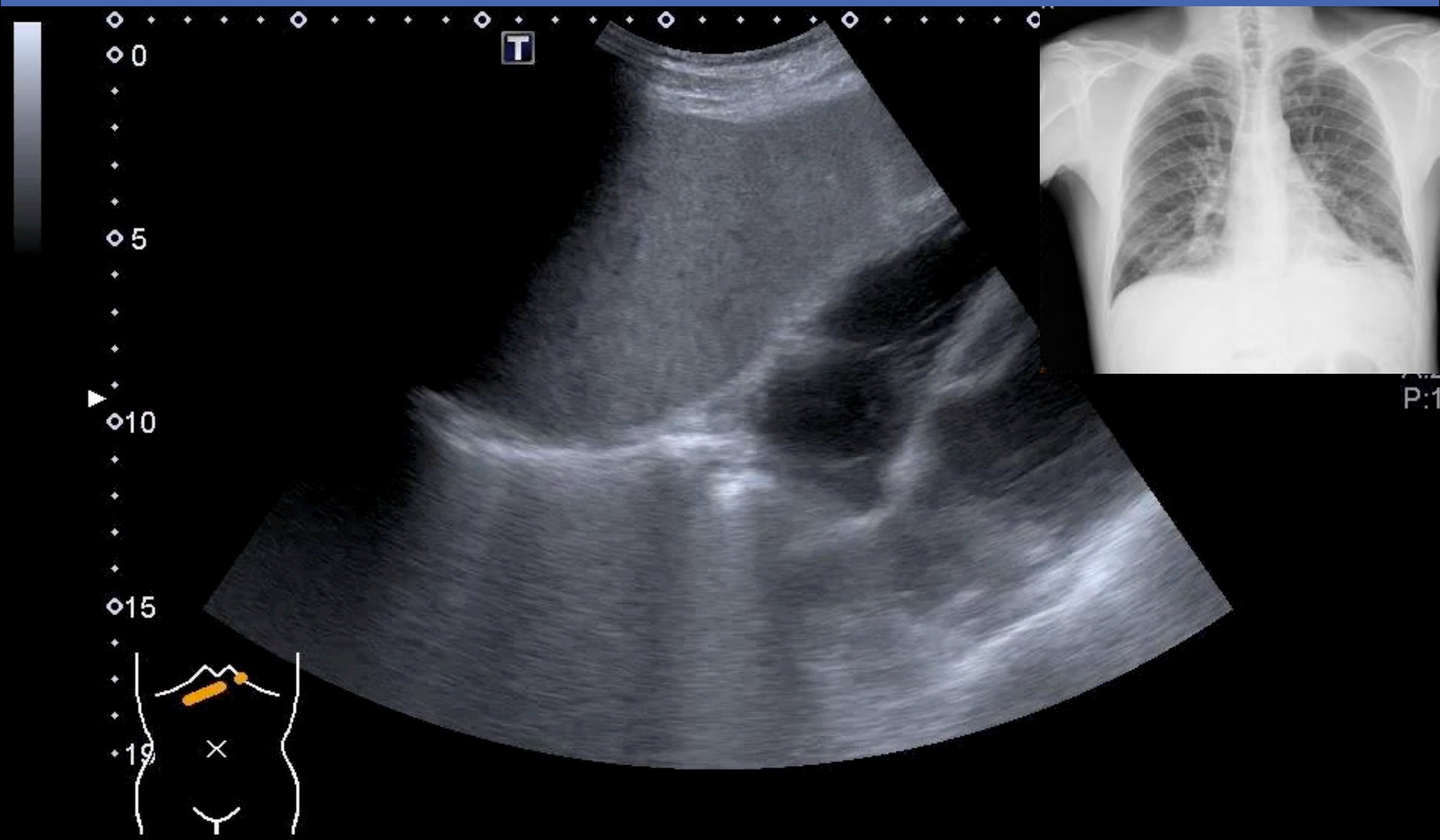

I-AIM

Indication

Acquisition

Interpretation

ChenKC@POCUSAcademy

基本原則：垂直

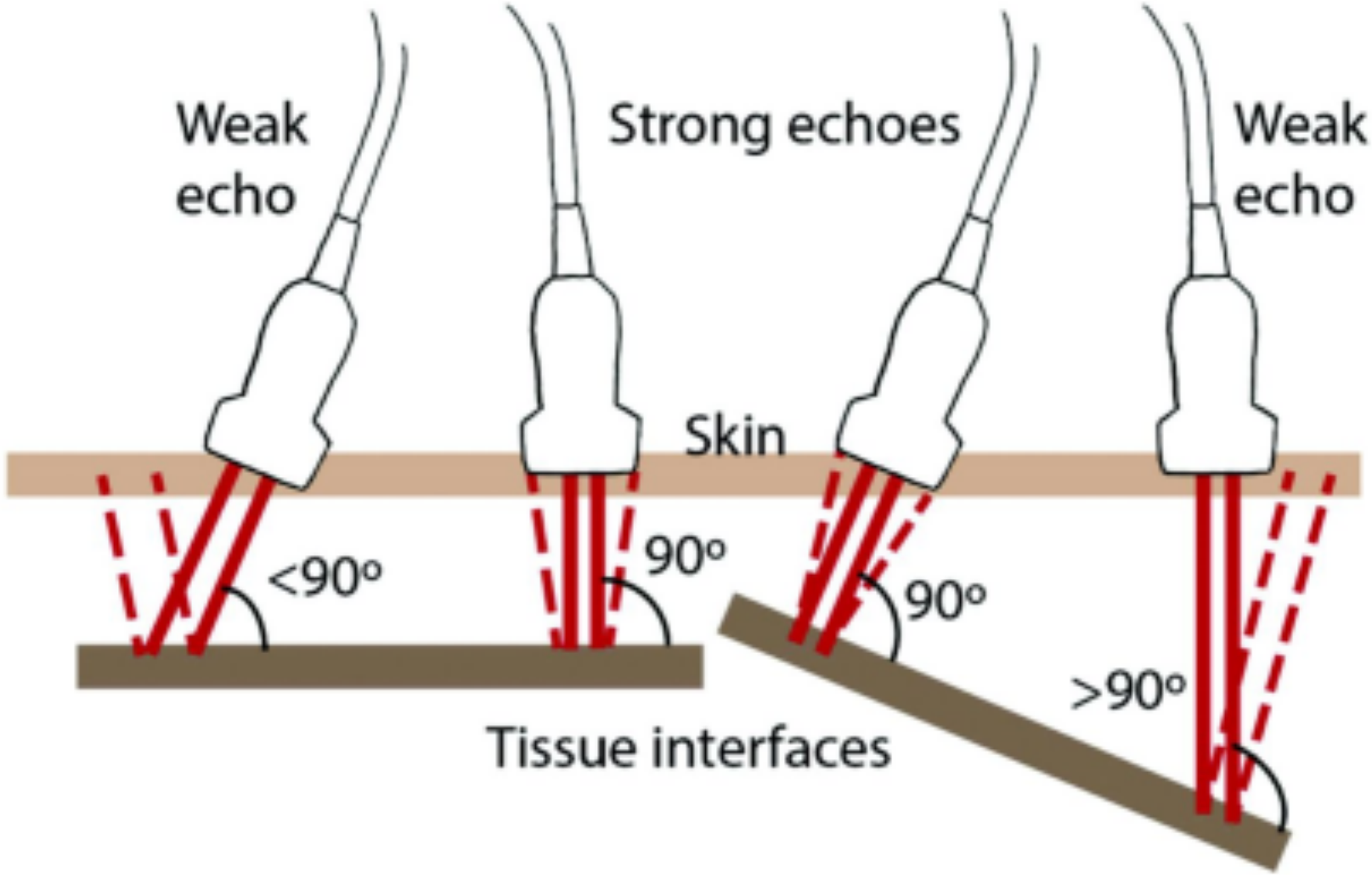
Weak
echo
Strong echoes
Weak
echo
Skin
<90°
90°
90°
>90°
Tissue interfaces

基本原則：　氣／水

Air　　Fluid

基本原則：　氣／水

Air

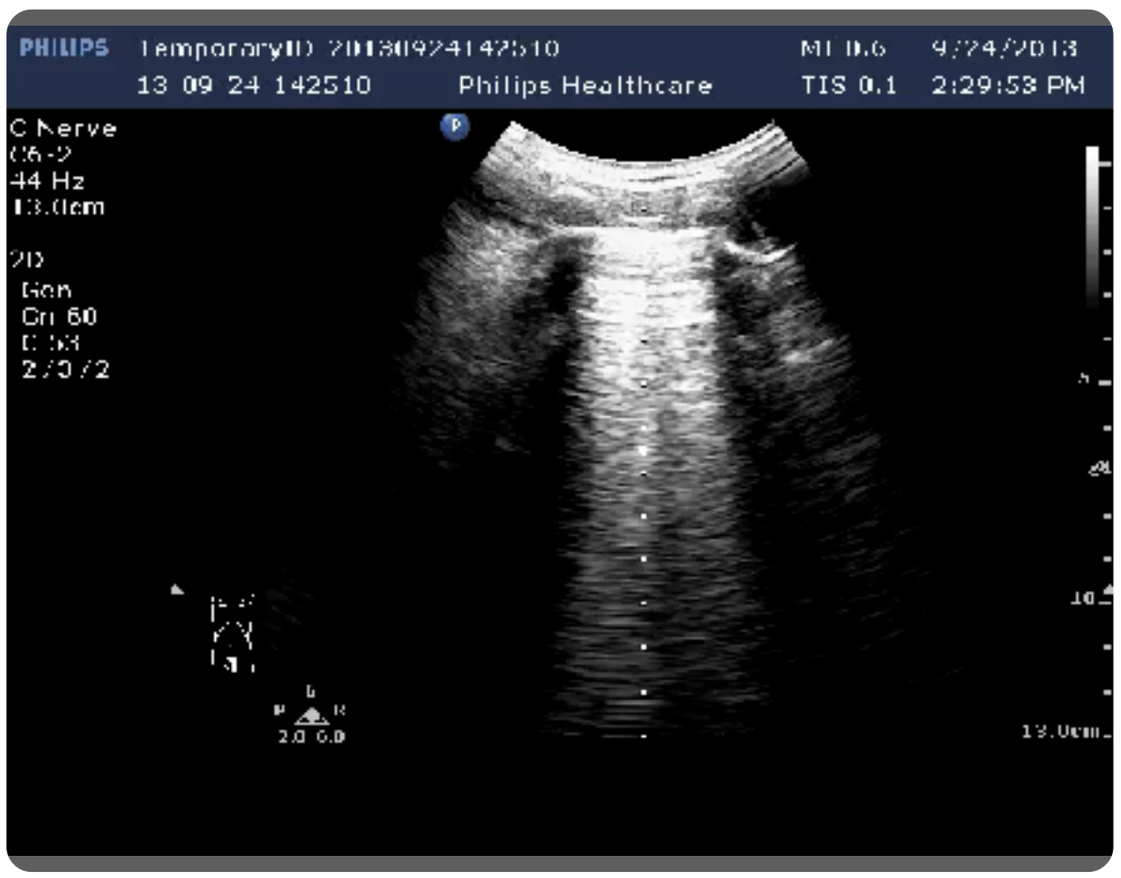

Fluid

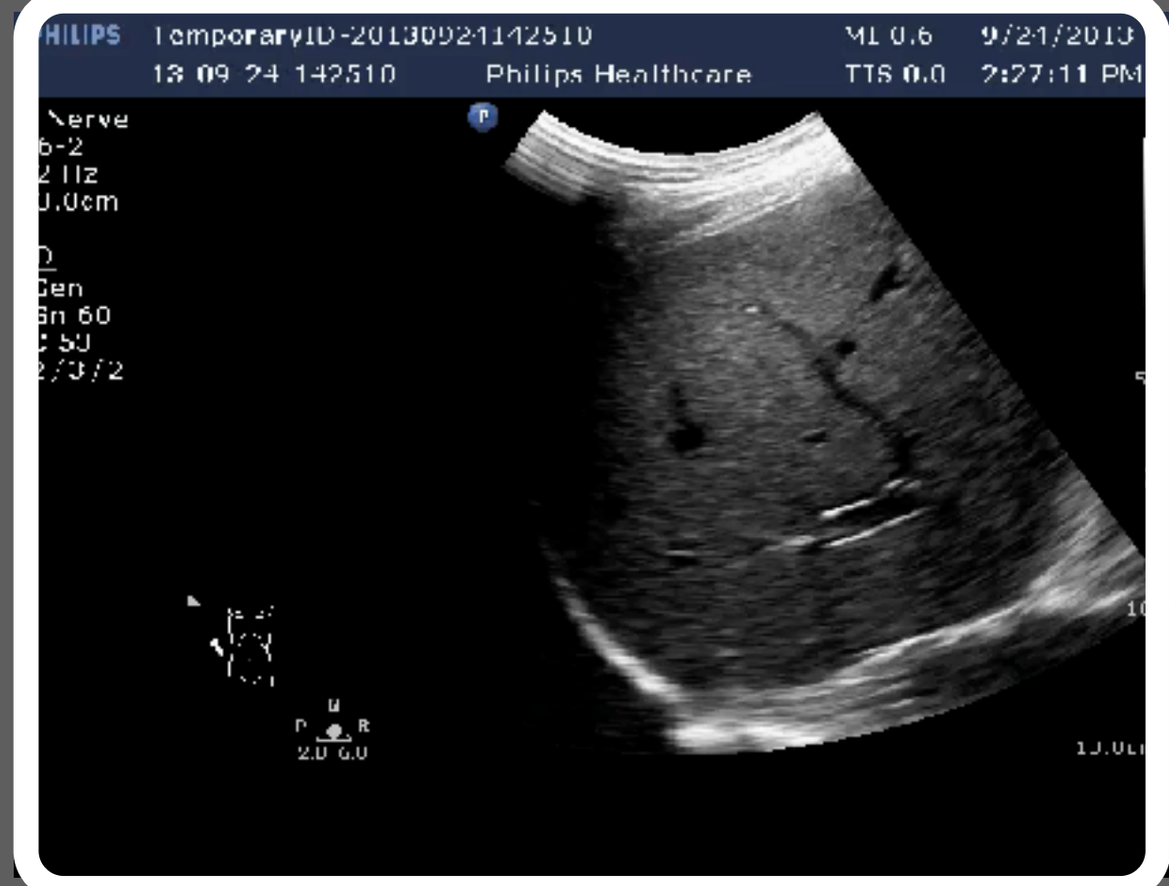

基本原則：　氣／水

Air 100%

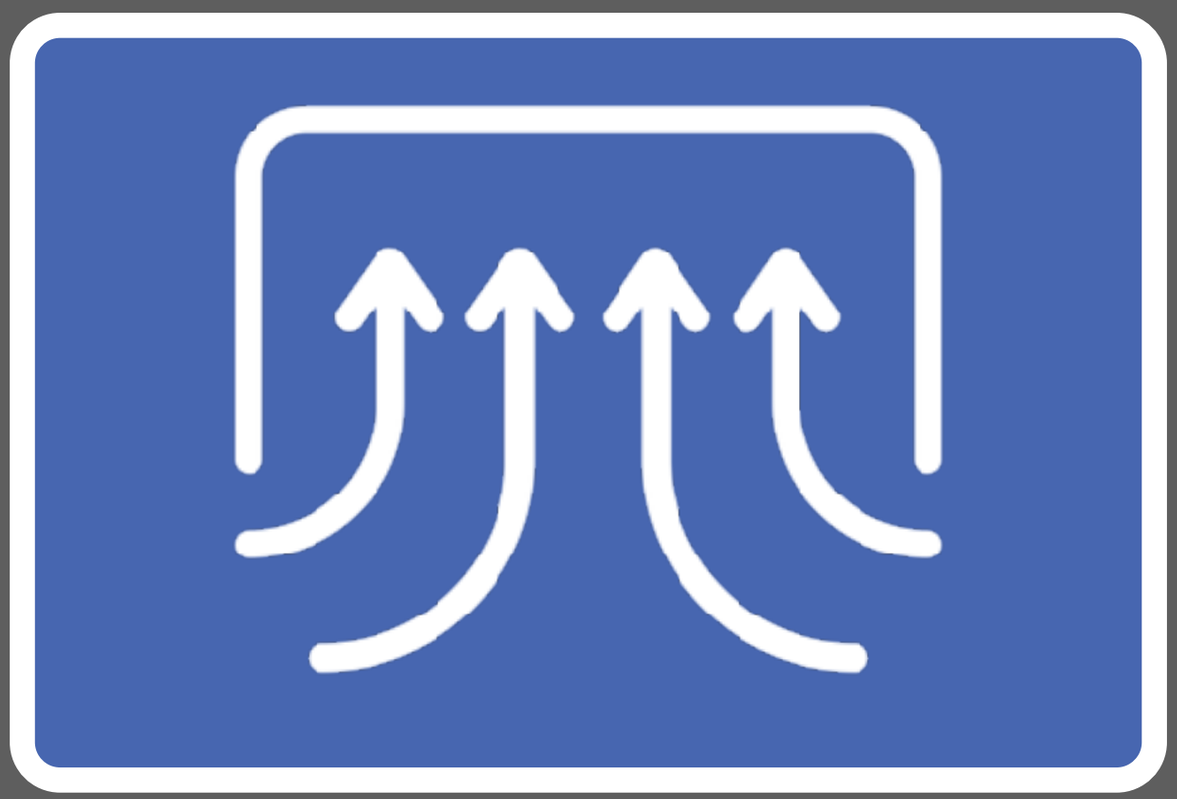

基本原則：　氣／水

Air 100%

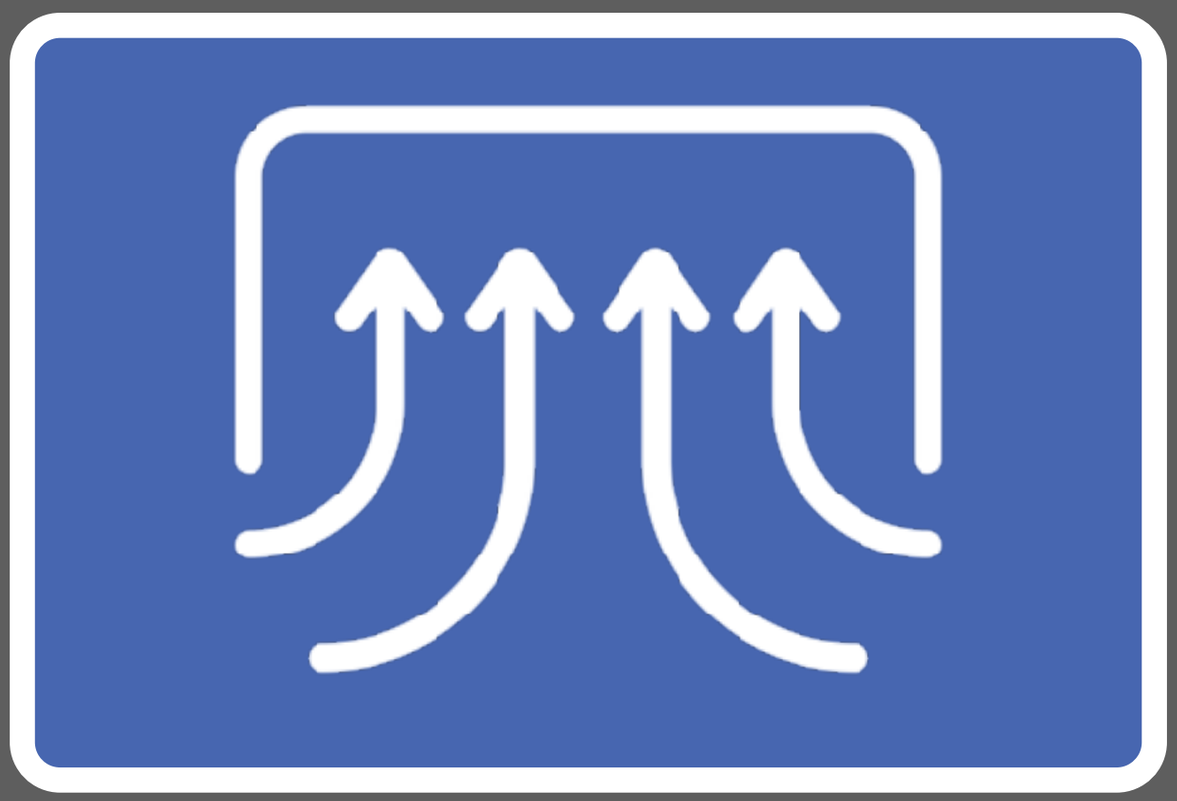

Pneumothorax

ChenKC@POCUSAcademy

基本原則：　氣／水

Air 100%

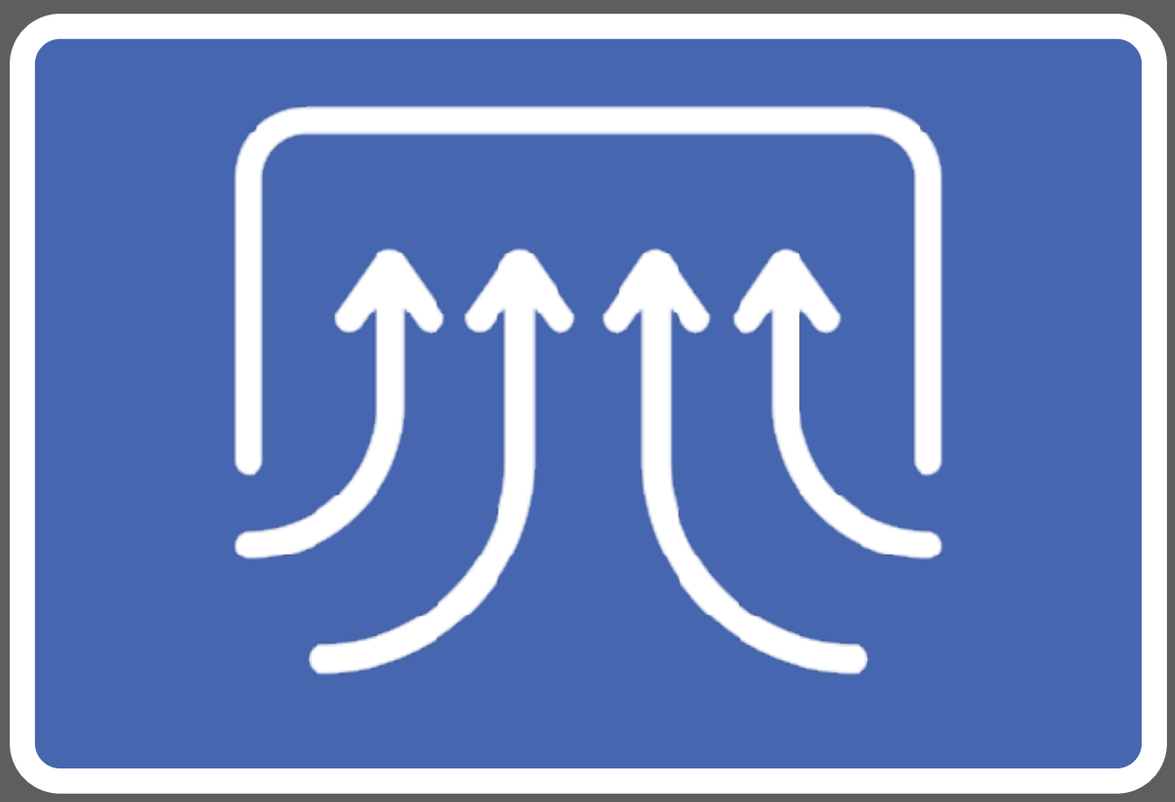

Fluid 100%



Pneumothorax

ChenKC@POCUSAcademy

基本原則：　氣／水

Air 100%

Fluid 100%

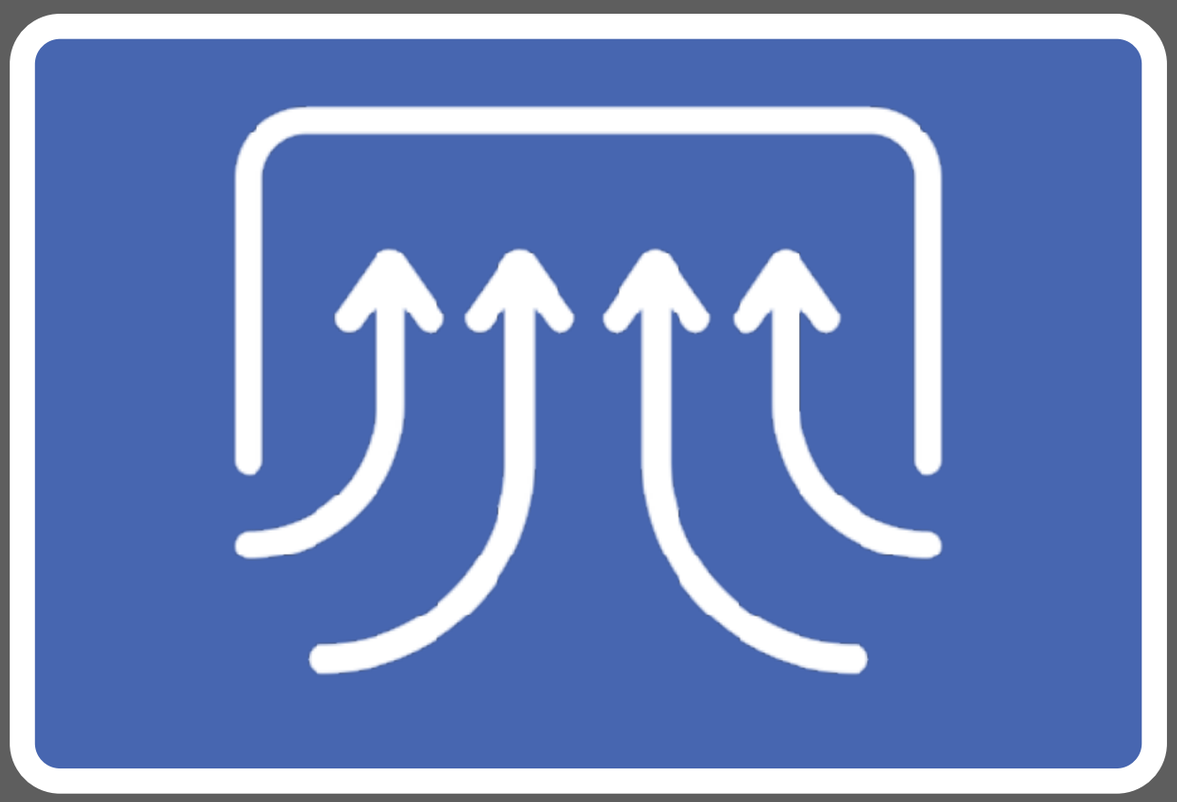



Pneumothorax

Pleural effusion

ChenKC@POCUSAcademy

基本原則：　真/假

True　　Artifact

基本原則：　真/假

True

Pneumonia
Pleural effusion
Pleural mass

Artifact

基本原則：　真/假

True	Artifact
Pneumonia Pleural effusion Pleural mass	Normal lung Pneumothorax AIS

基本原則：　真／假

True

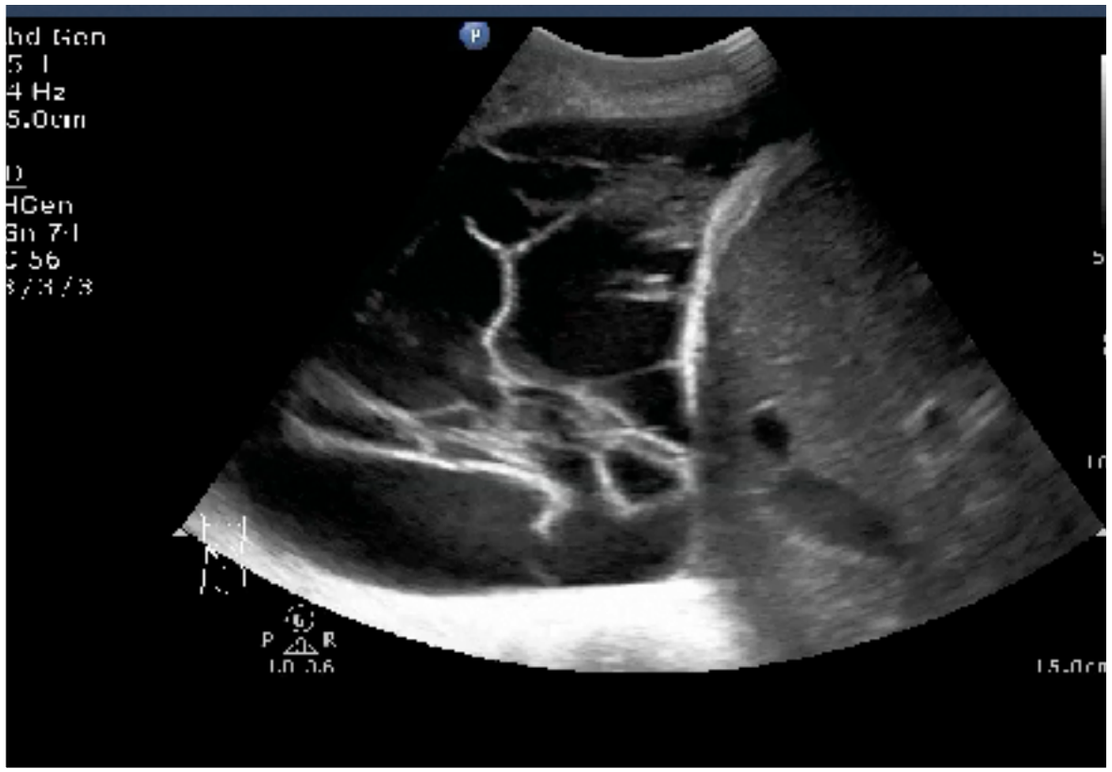

基本原則：　真／假

True

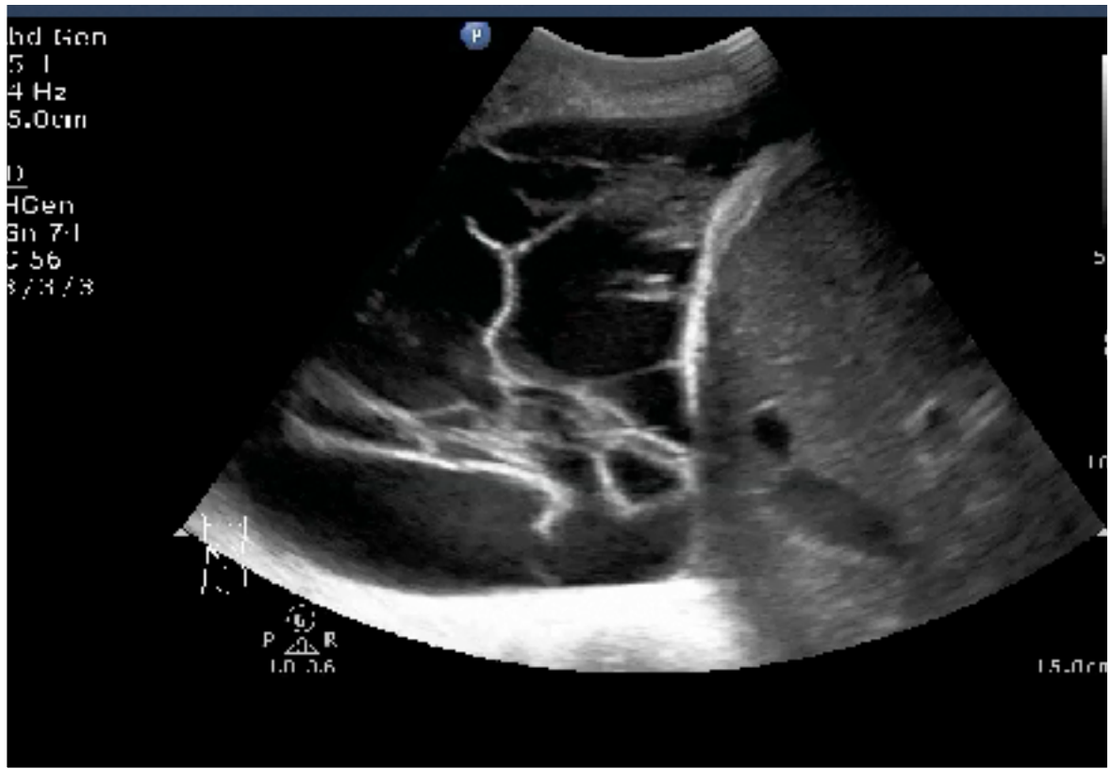

Artifact

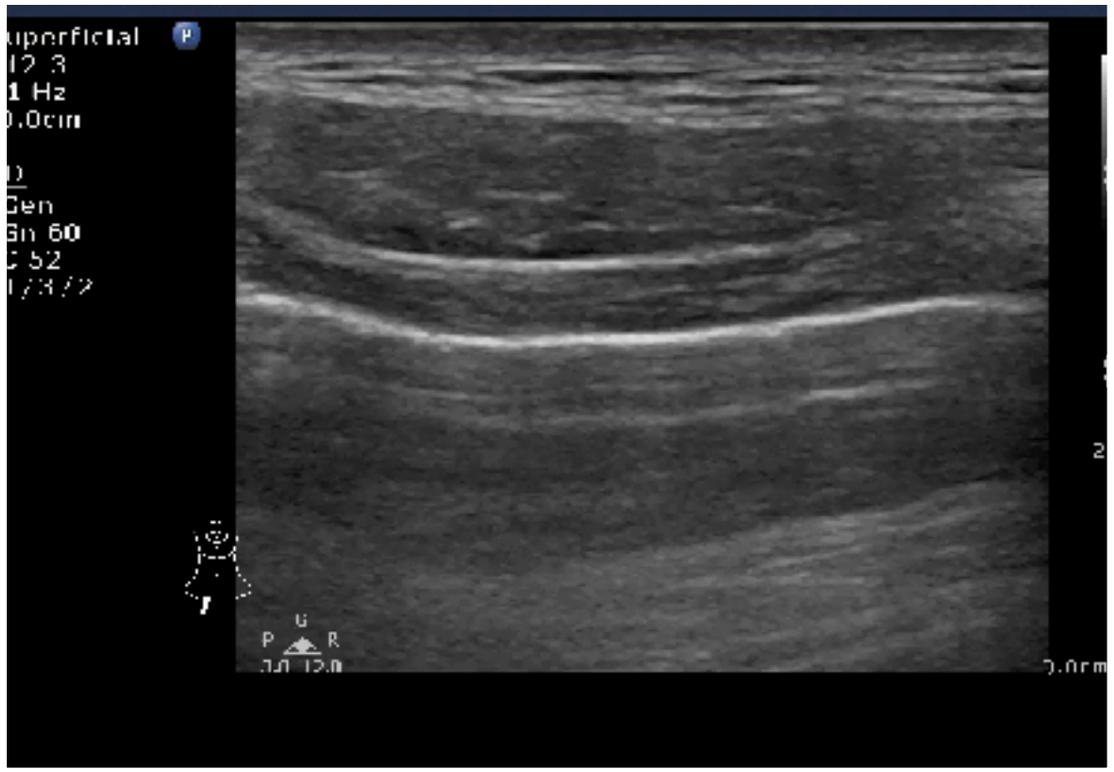

基本假影：A lines

A lines

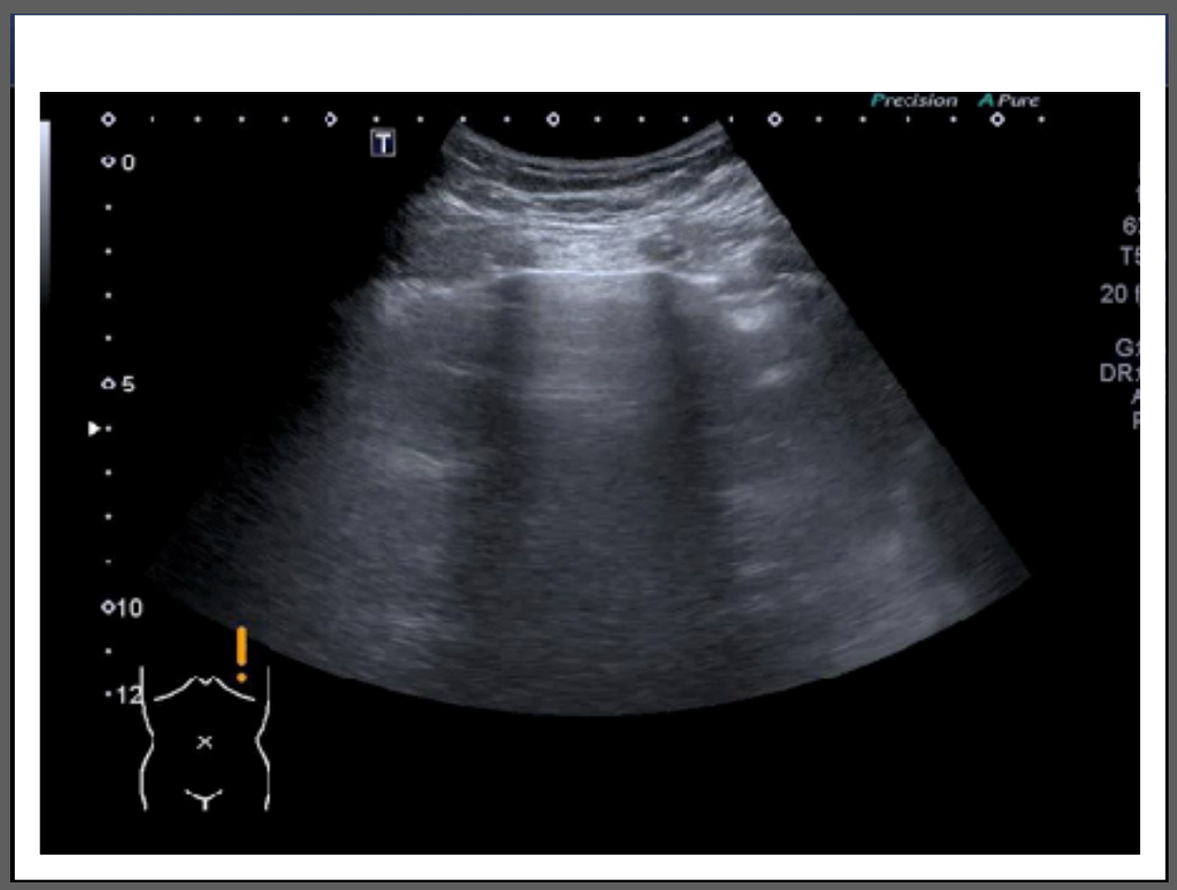

Pleural

Equal

Horizontal

ChenKC@POCUSAcademy

基本假影：B lines

B lines

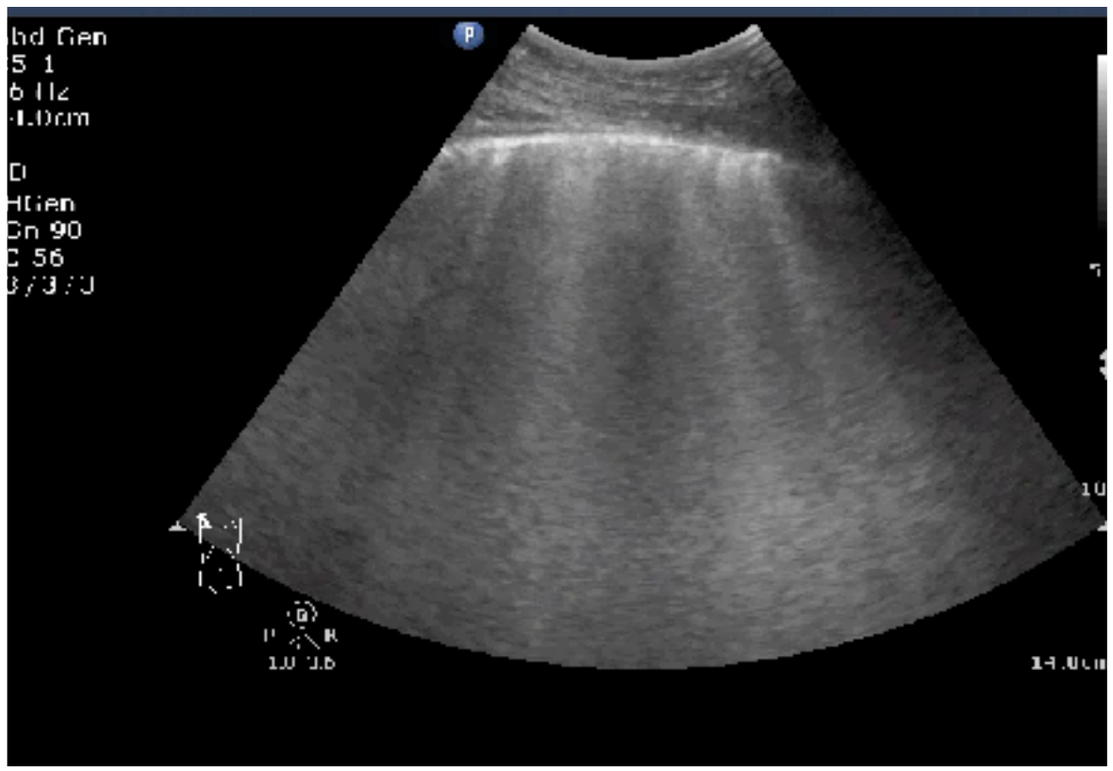

Pleural

Vertical

> 3 in ICS

Intensive Care Med (1999) 25: 383–388
© Springer-Verlag 1999

ORIGINAL

D. Lichtenstein
G. Mezière
P. Biderman
A. Gepner

The comet-tail artifact: an ultrasound sign ruling out pneumothorax

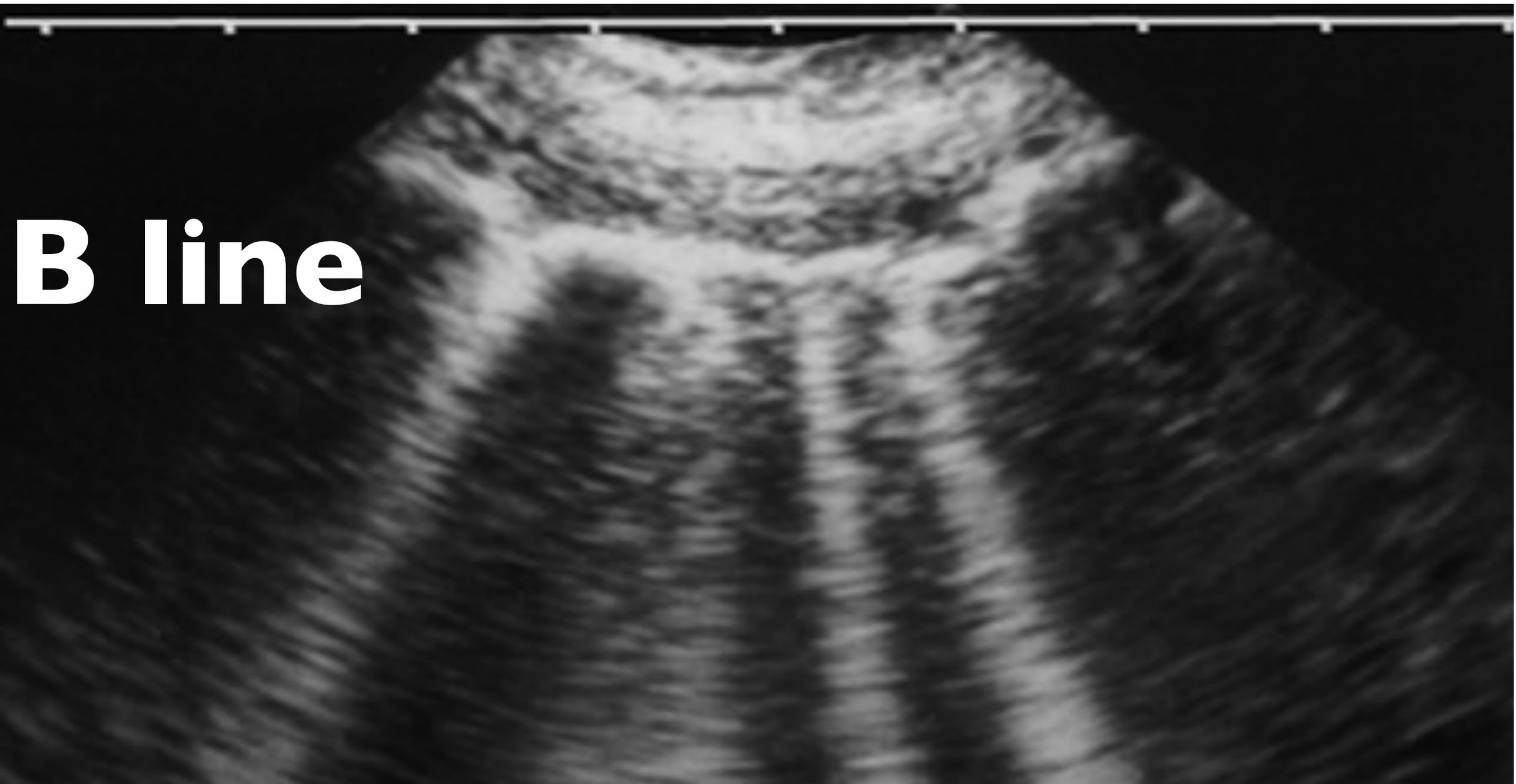

基本假影： A / B

US B lines ~ Kerley B lines

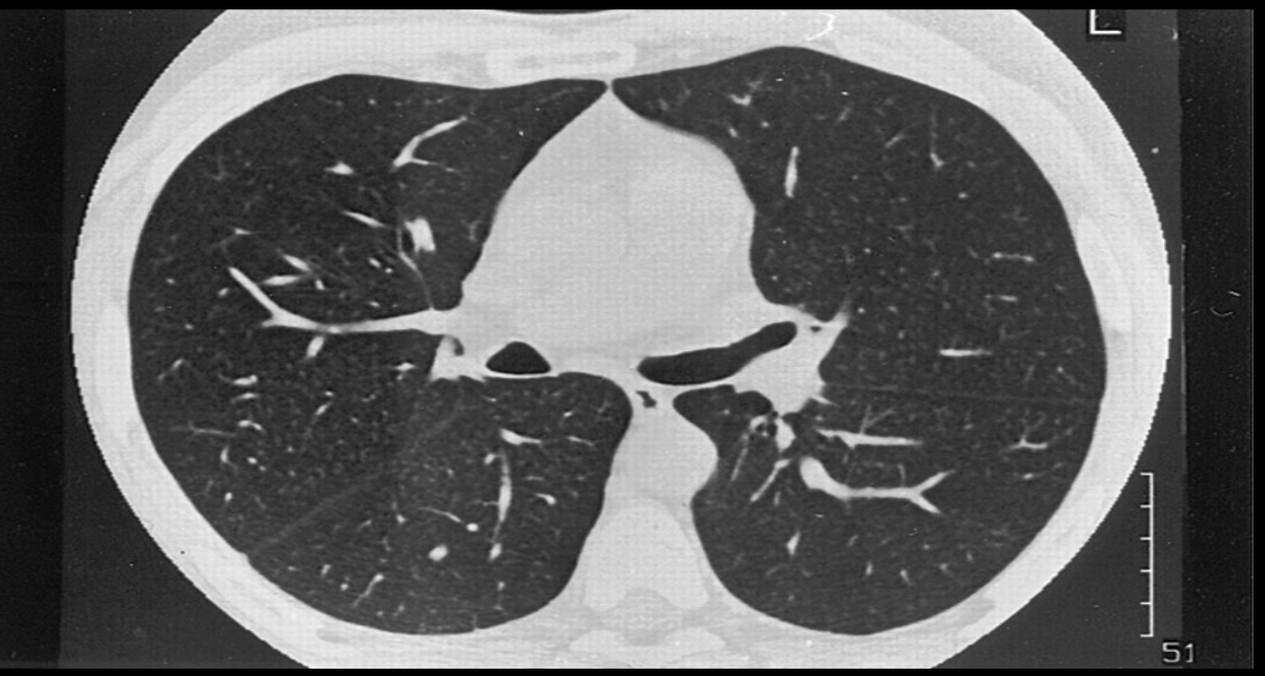

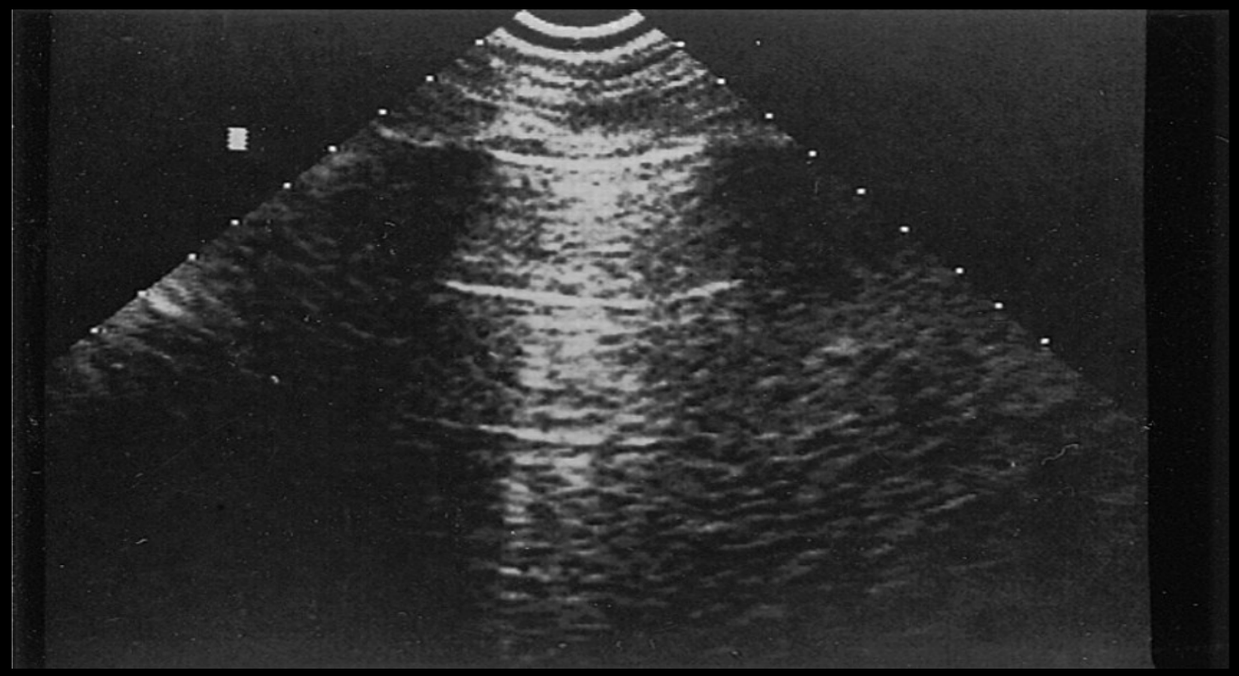

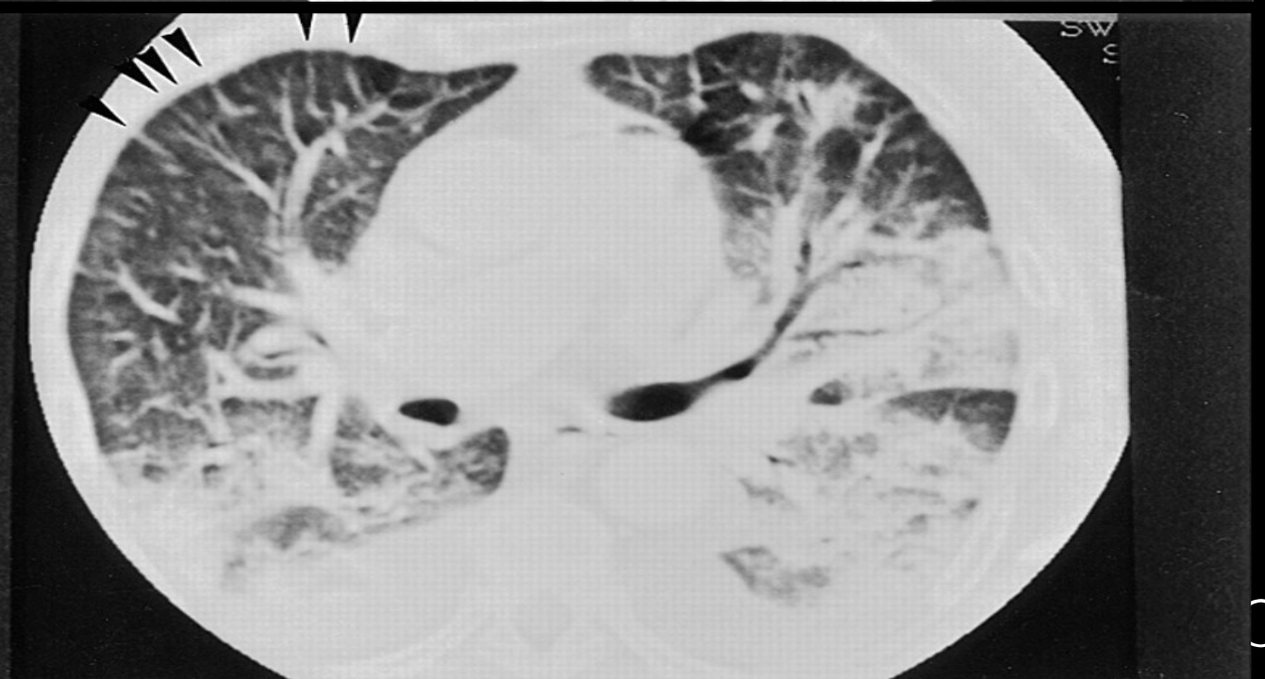

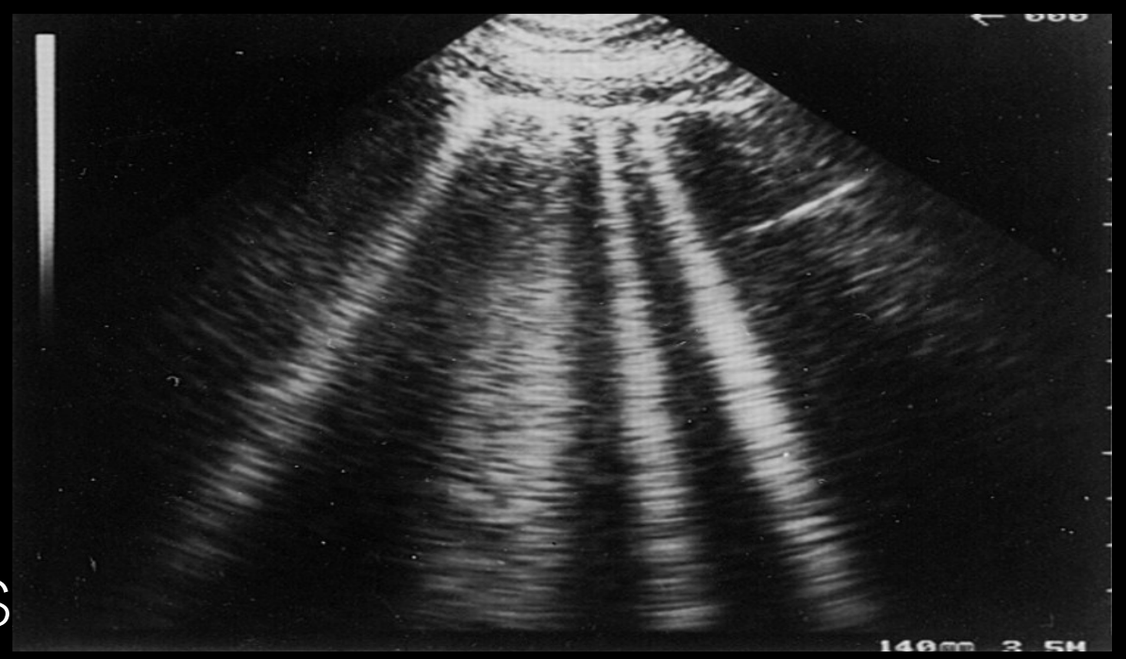

OCUS

基本假影： A / B

A

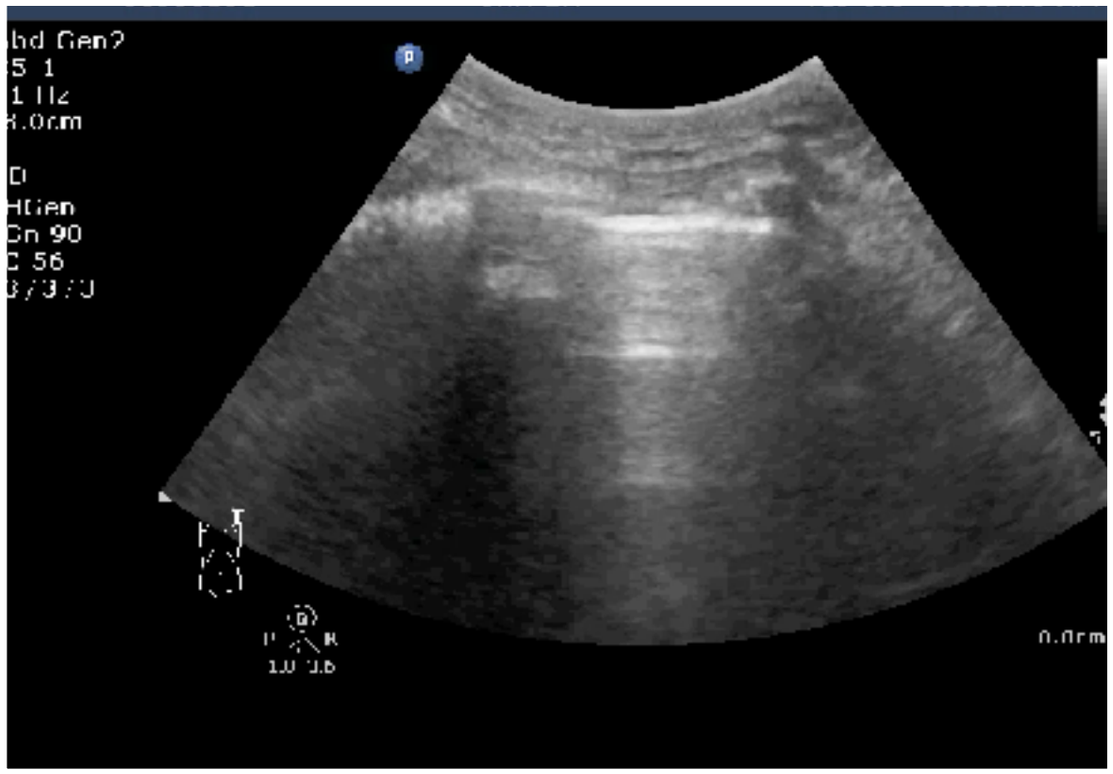

B

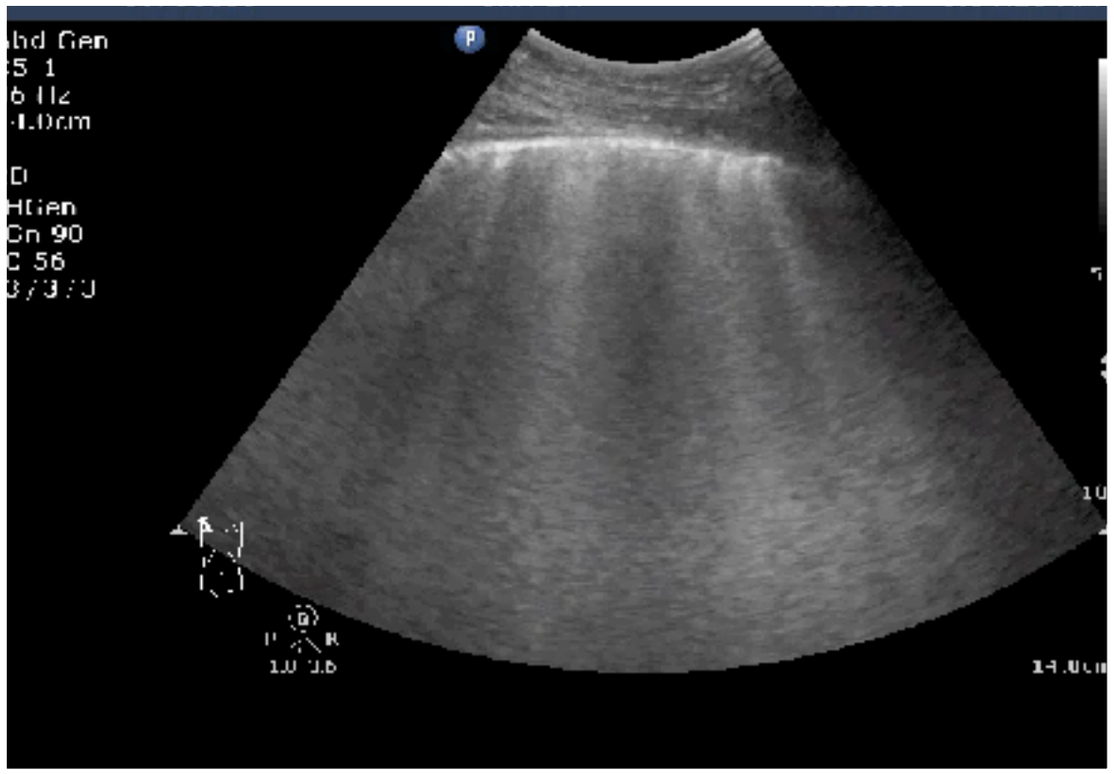

那一個影片有問題 ??

ChenKC@POCUSAcademy

基本分析：　動／靜

Static　　Dynamic

ChenKC@POCUSAcademy

基本分析：　動／靜

Static

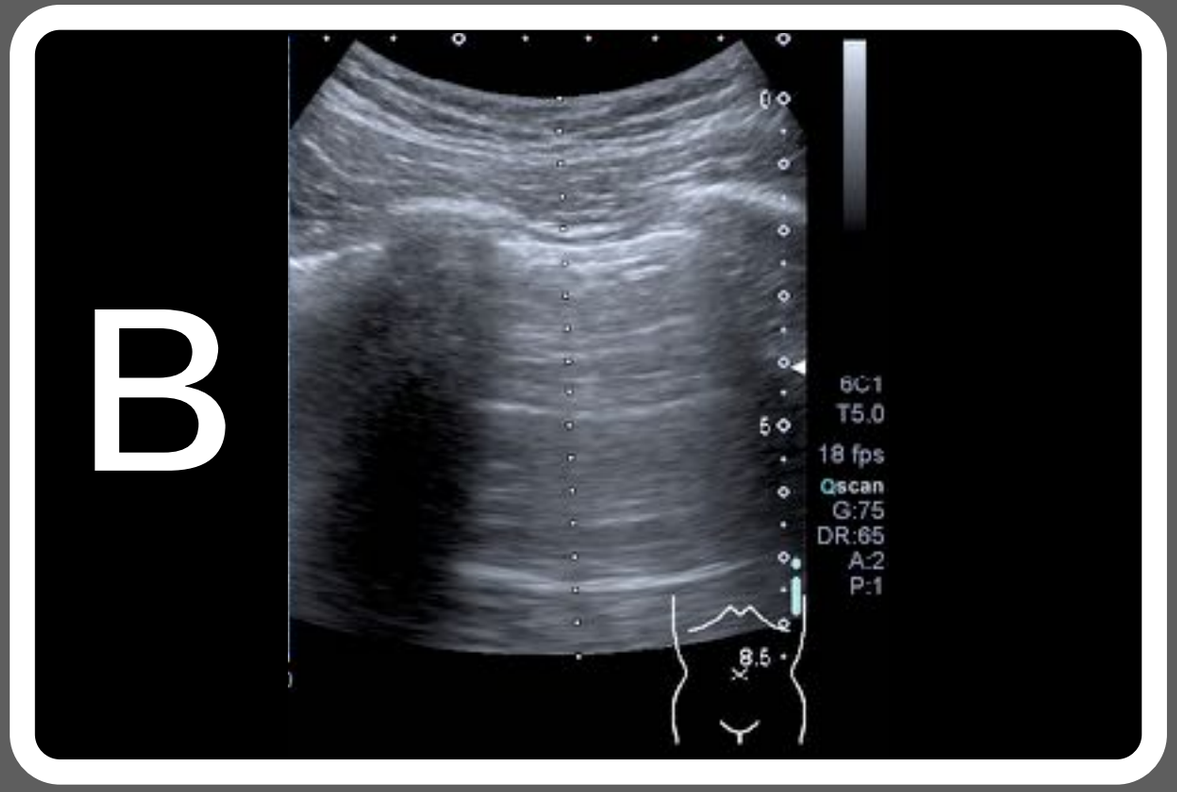

基本分析：　動／靜

Static　　Dynamic

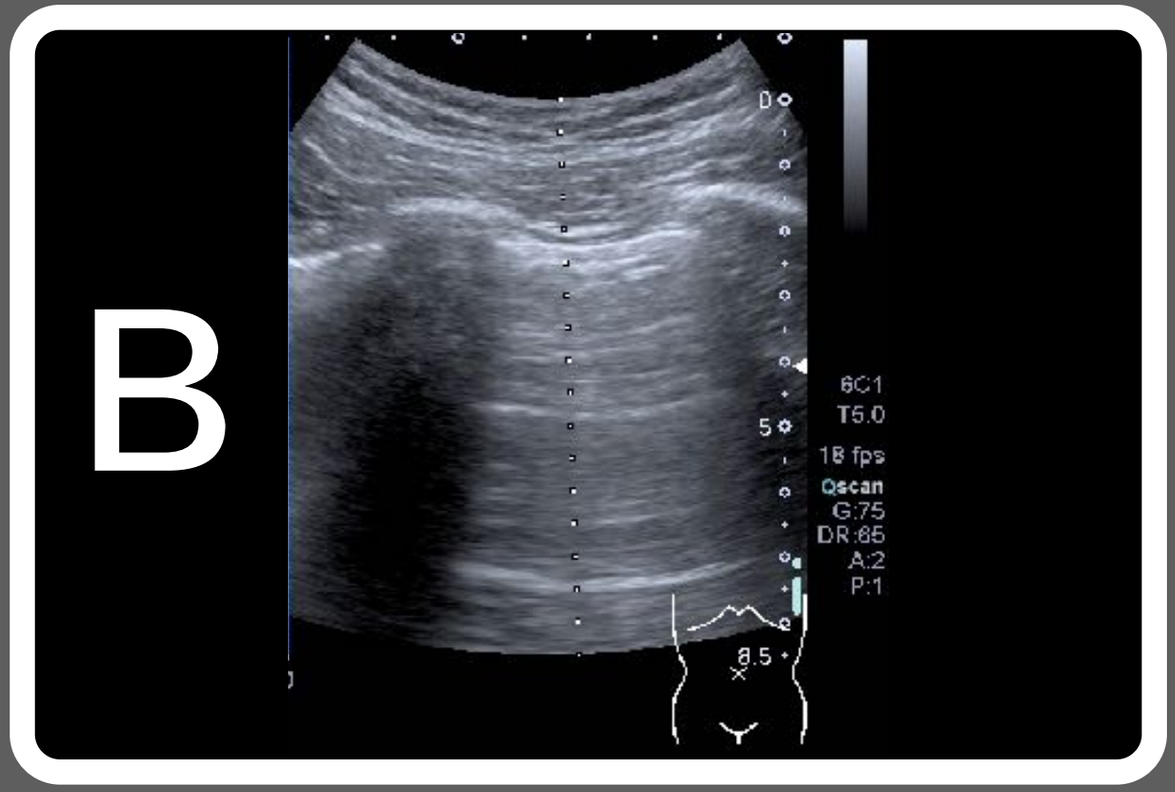



正常肺部的動與靜


0
5
8.5
-3.0
-2.0
-1.0
0
Qscan:70 / MDR:55 / T5.0

T
Precision A Pure
Bat sign
0
5
8.5
MI
1.5
6C1
T5.0
18 fps
Qscan
G:75
DR:65
A:2
P:1

Bat sign & Pleura

Superficial
L12-3
46 Hz
3.5cm

2D
Res
Gn 60
C 56
3/2/1



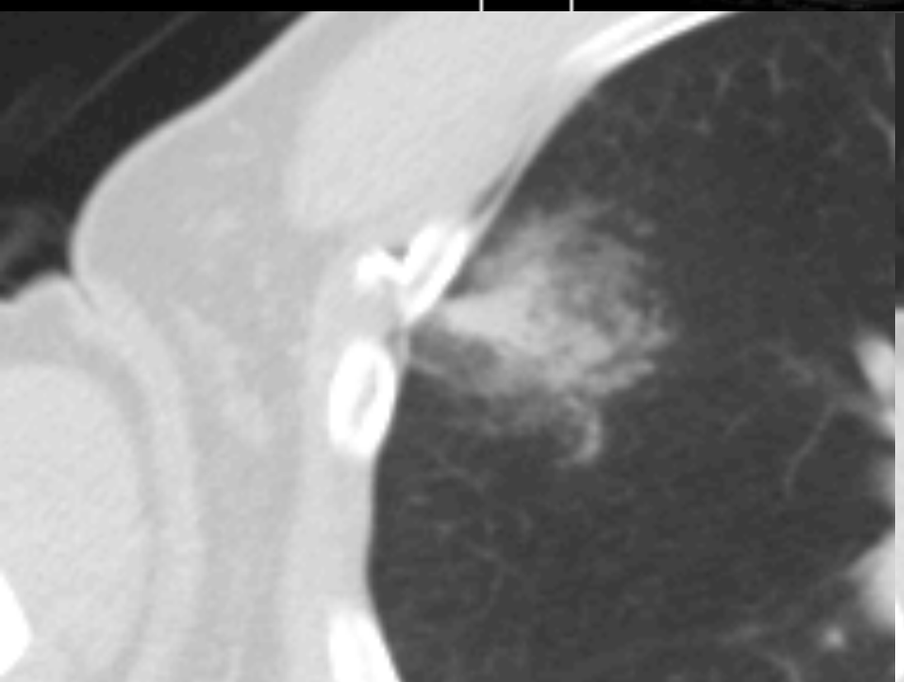

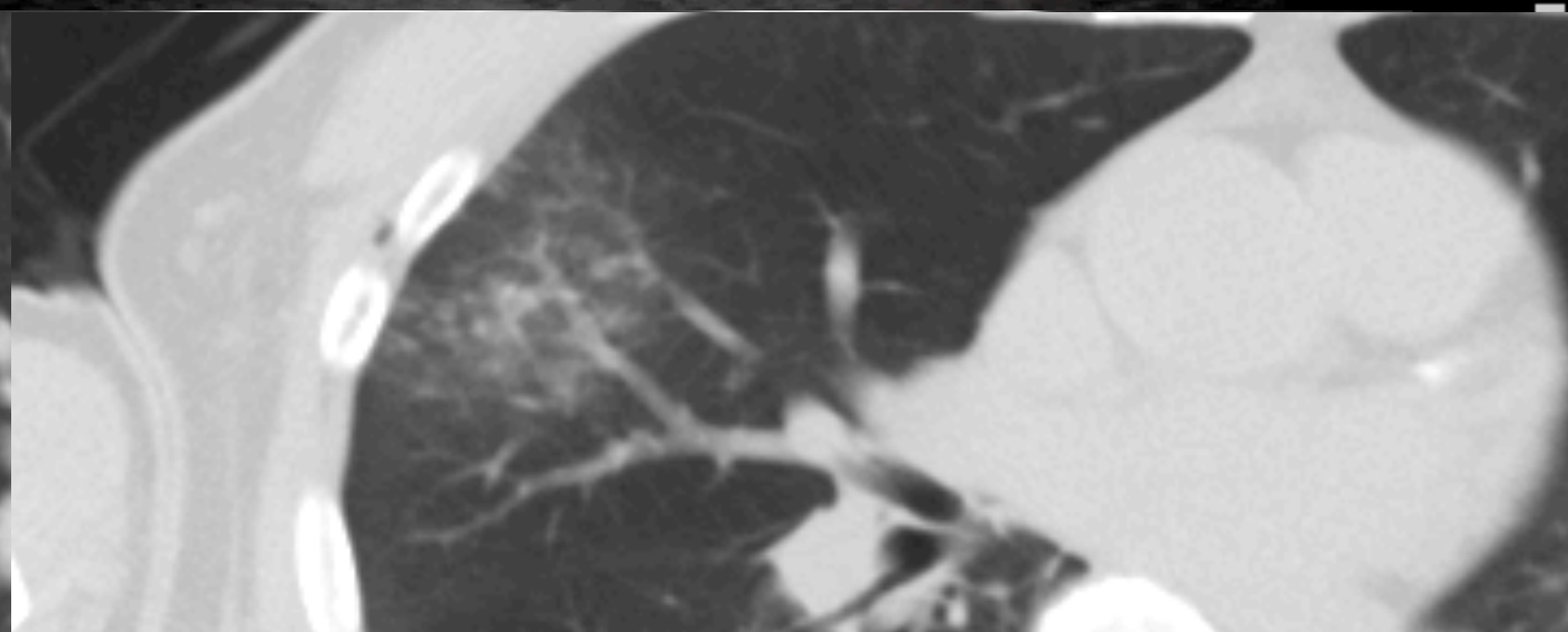

正常肺部的動與靜

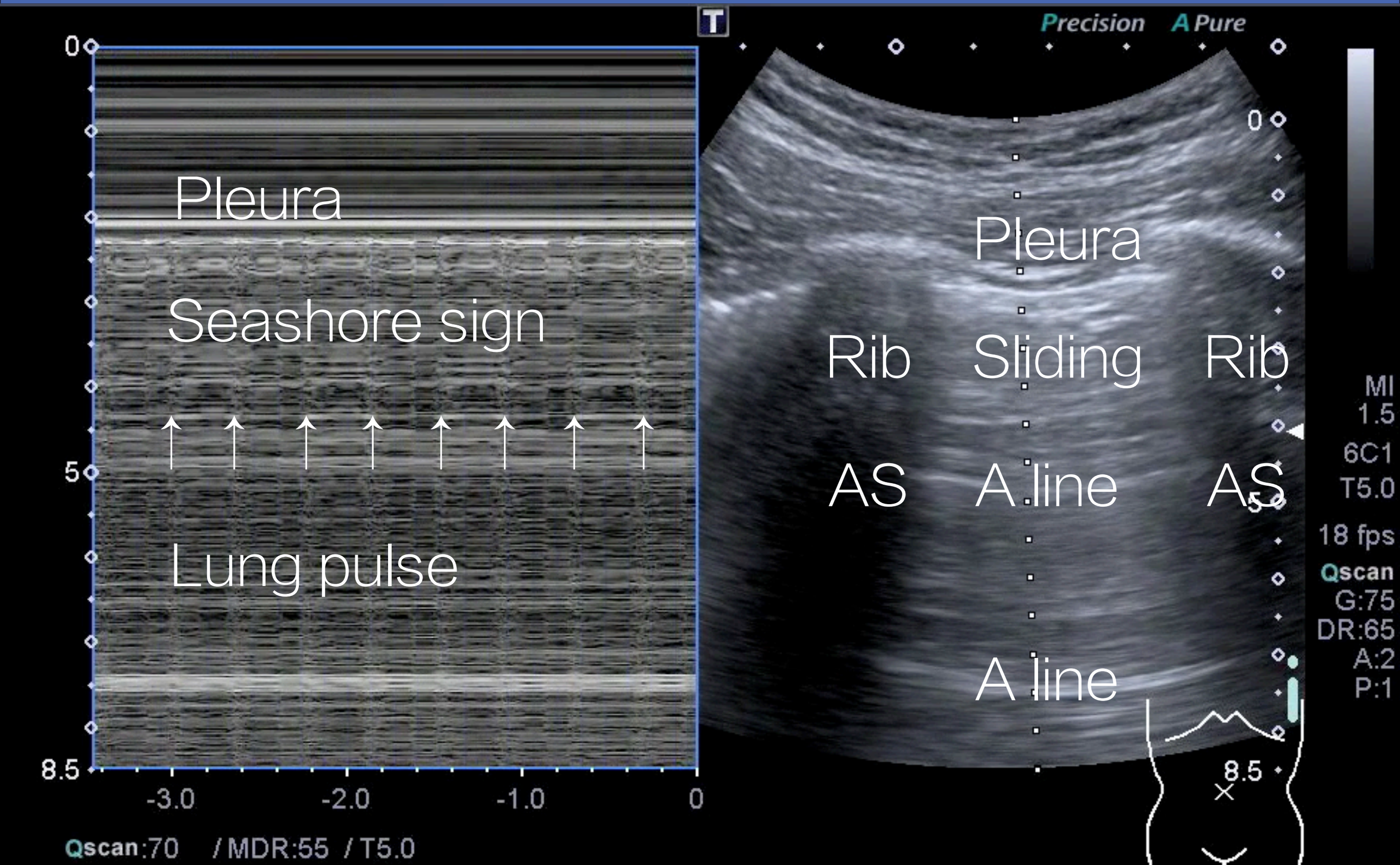
Pleura
Seashore sign
Lung pulse
-3.0
-2.0
-1.0
0
8.5
Qscan:70 / MDR:55 / T5.0
Precision A Pure
Pleura
Rib
Sliding
Rib
AS
A line
AS
A line
MI
1.5
6C1
T5.0
18 fps
Qscan
G:75
DR:65
A:2
P:1

Intensive Care Med (2003) 29:2187–2192
DOI 10.1007/s00134-003-1930-9

ORIGINAL

Daniel A. Lichtenstein
Nathalie Lascols
Sébastien Prin
Gilbert Mezière

The "lung pulse": an early ultrasound sign of complete atelectasis

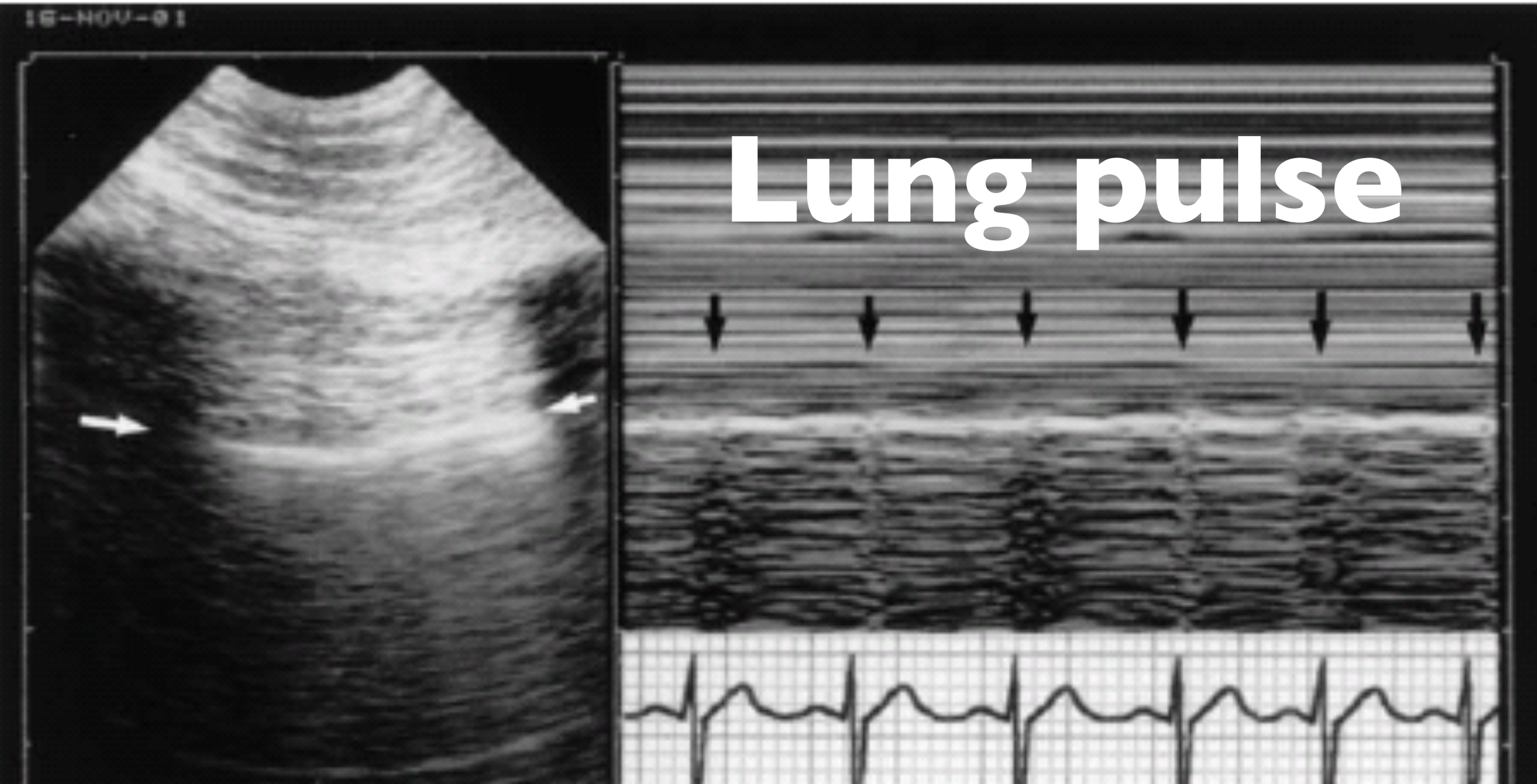

LUS的建議：四原則

氣水

真假

AB

動靜

LUS 醫療決策

Snot: 安心地排除吧

Spin: 有看到很可信

ChenKC@POCUSAcademy

好用的Rule out

Sliding
B lines
Lung pulse

ChenKC@POCUSAcademy

LUS for SABE

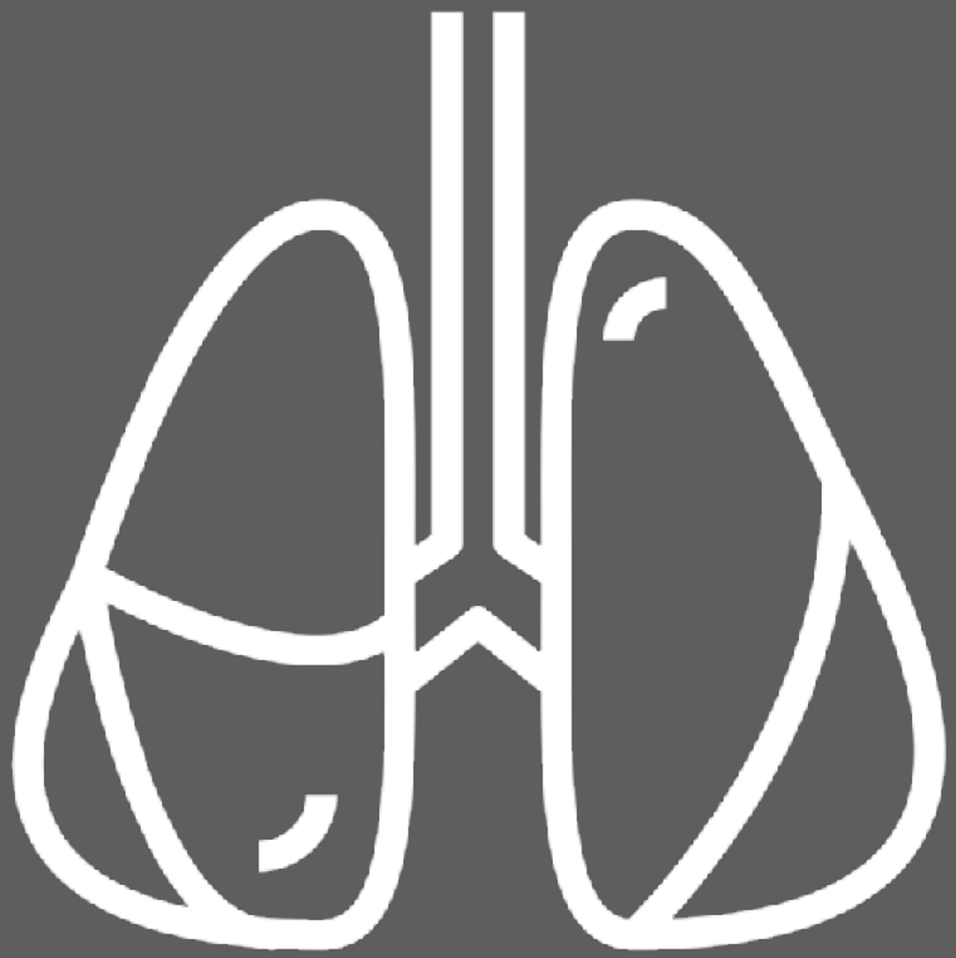

Sliding

A line

B line

Effusion

ChenKC@POCUSAcademy

BLUE Protocol

(Bedside Lung Ultrasound in Emergency Protocol)



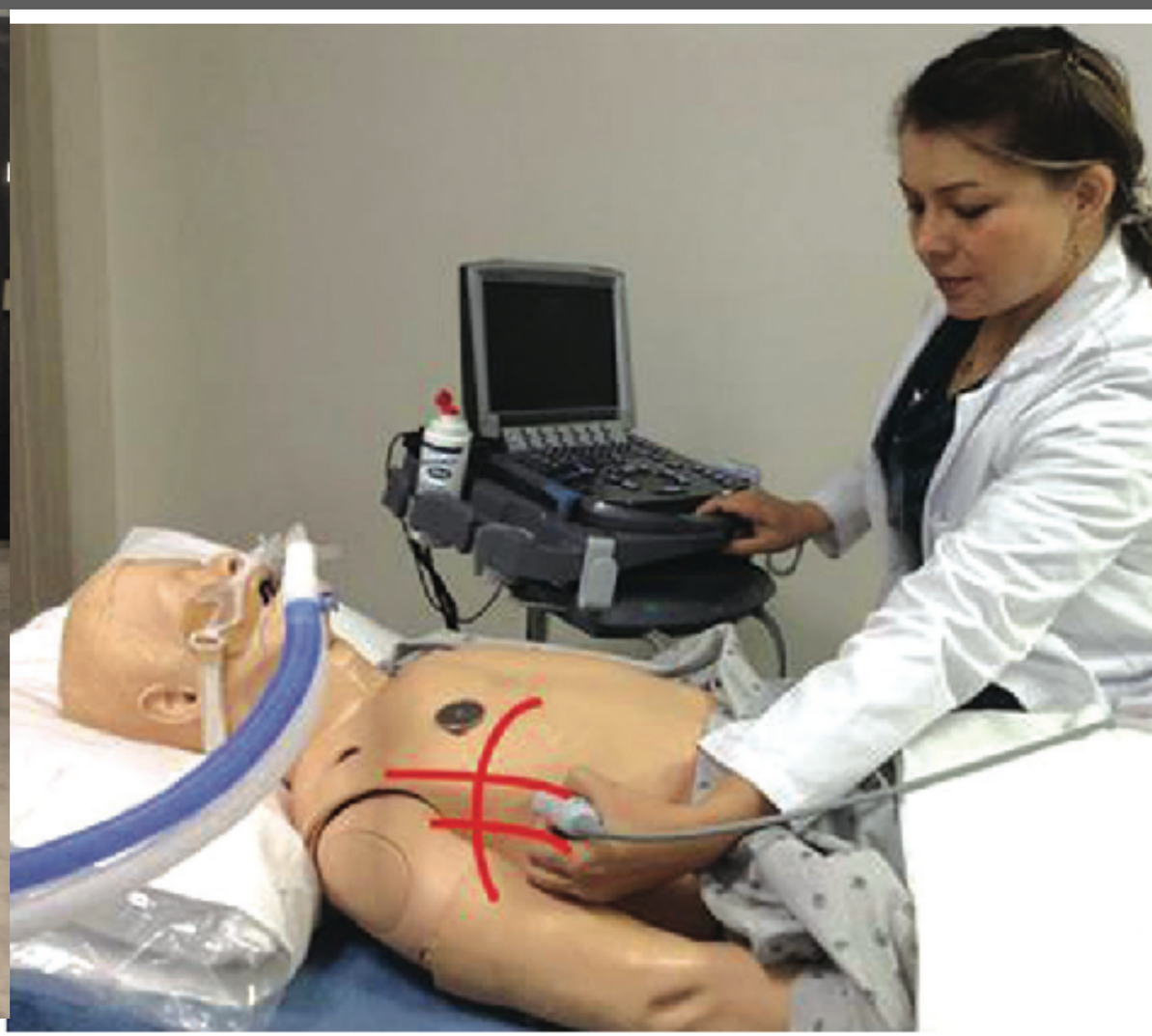

Daniel Lichtenstein

Is there lung sliding?

No

Absent lung pulse?
Stratosphere sign?

No

CXR or CT chest to rule out PTX

Yes

Lung Point?

No

Yes

Pneumothorax

Yes

What is the underlying pattern?

A-line pattern

Perform DVT study

Negative

COPD/asthma most likely; consider metabolic or neurologic causes; pulmonary embolism still possible

Positive

Pulmonary embolism

Is effusion clinically significant

Effusion

B-line pattern

Characterize

Bilateral, uniform with smooth, thin pleura

Pulmonary edema

Unilateral, patchy with irregular pleura

Early or atypical pneumonia

Bilateral with areas of sparing and irregular pleura

ARDS

Consolidation

Characterize

Atelectasis

Volume loss with static or no air bronchograms

No volume loss with dynamic air bronchograms

Pneumonia

Is there lung sliding?

No

Absent lung pulse?
Stratosphere sign?

No

CXR or CT chest to rule out PTX

Yes

Lung Point?

No

Yes

Pneumothorax

Yes

Is effusion clinically significant

Effusion

Atelectasis

Volume loss with static or no air bronchograms

What is the underlying pattern?

Consolidation

Characterize

No volume loss with dynamic air bronchograms

Pneumonia

A-line pattern

Perform DVT study

Negative

COPD/asthma most likely; consider metabolic or neurologic causes; pulmonary embolism still possible

Positive

Pulmonary embolism

B-line pattern

Characterize

Bilateral, uniform with smooth, thin pleura

Pulmonary edema

Unilateral, patchy with irregular pleura

Early or atypical pneumonia

Bilateral with areas of sparing and irregular pleura

ARDS

Is there lung sliding?

No

Absent lung pulse?
Stratosphere sign?

No

CXR or CT chest to rule out PTX

Yes

Lung Point?

No

Yes

Pneumothorax

Yes

Is effusion clinically significant

Effusion

Atelectasis

Volume loss with static or no air bronchograms

What is the underlying pattern?

Consolidation

Characterize

No volume loss with dynamic air bronchograms

Pneumonia

A-line pattern

Perform DVT study

Negative

COPD/asthma most likely; consider metabolic or neurologic causes; pulmonary embolism still possible

Positive

Pulmonary embolism

B-line pattern

Characterize

Bilateral, uniform with smooth, thin pleura

Pulmonary edema

Unilateral, patchy with irregular pleura

Early or atypical pneumonia

Bilateral with areas of sparing and irregular pleura

ARDS

Sliding

BLUE Exam Points

Point 1

Point 2

Point 3

Point 4

A profiles

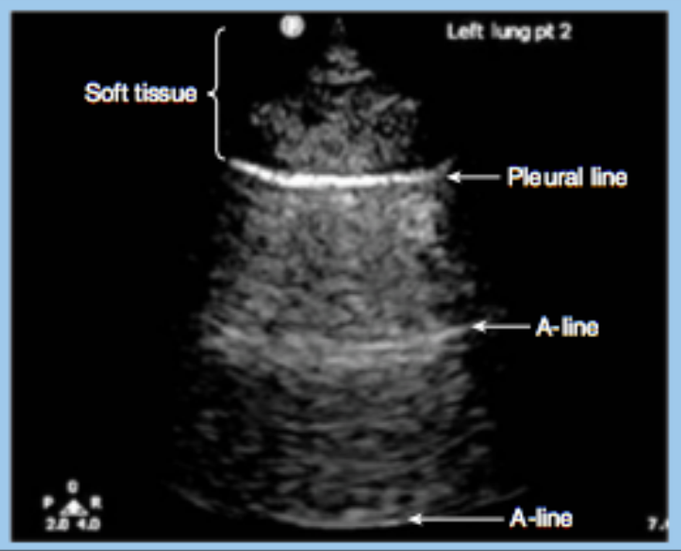

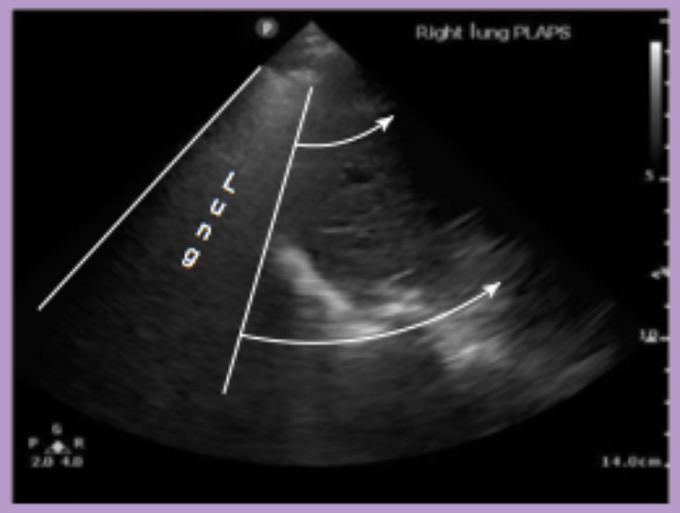

A profile = A-lines + sliding
- **Normal**
- If symptomatic, consider:
  - Pulmonry embolism
  - COPD, asthma
  - Nonpulmonary conditions

A' profile = A-lines + no sliding
- **Pneumothorax**
- Pleurodesis (*chemical, infection/inflammatory, fibrosis*)
- Lung volume loss (*complete atelectasis, mainstem intubation, mucous plug, pneumonectomy*)

B profiles

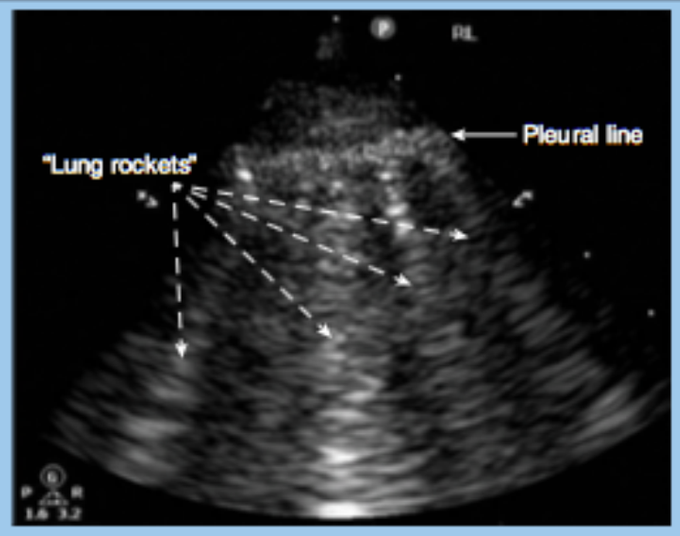

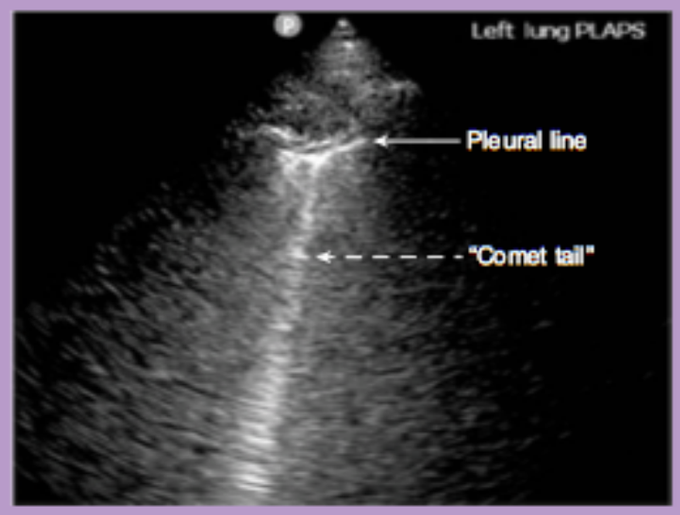

B profile = Bilateral B-lines + sliding
- **Pulmonary edema**
- ARDS (*diffuse*)

A/B profile = Unilateral B-lines + sliding
- Pneumonia (*mild*)
- ARDS (*focal*)
- Scarring

B' profile = Bilateral B-lines + no sliding
- Pneumonia (*severe*)

C profile

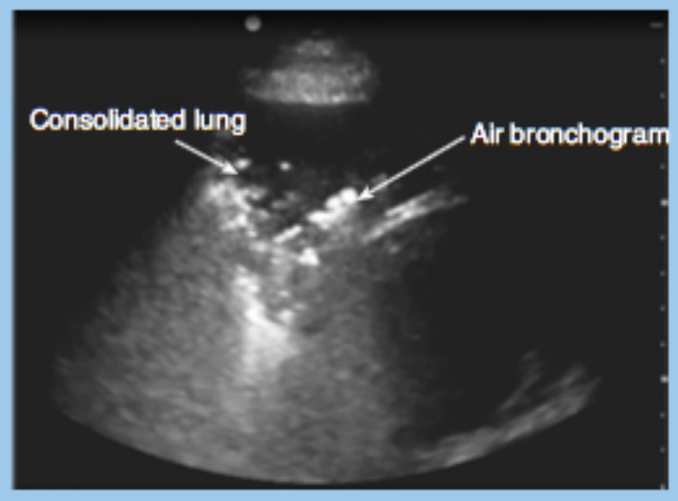

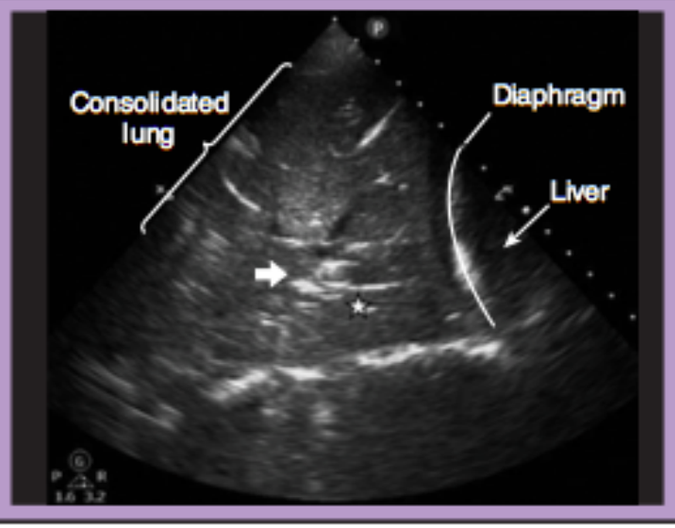

C profile = Consolidation pattern
- **Pneumonia**
- Atelectasis
  - Resorptive
  - Compressive

BLUE 4 points

Point 1

Point 2

Head <<<<< Sagittal view >>>>> Toe

Point 3

Point 4

LUS for PAP

PTX

AIS

PLE

ChenKC@POCUSAcademy

LUS for PAP

PTX

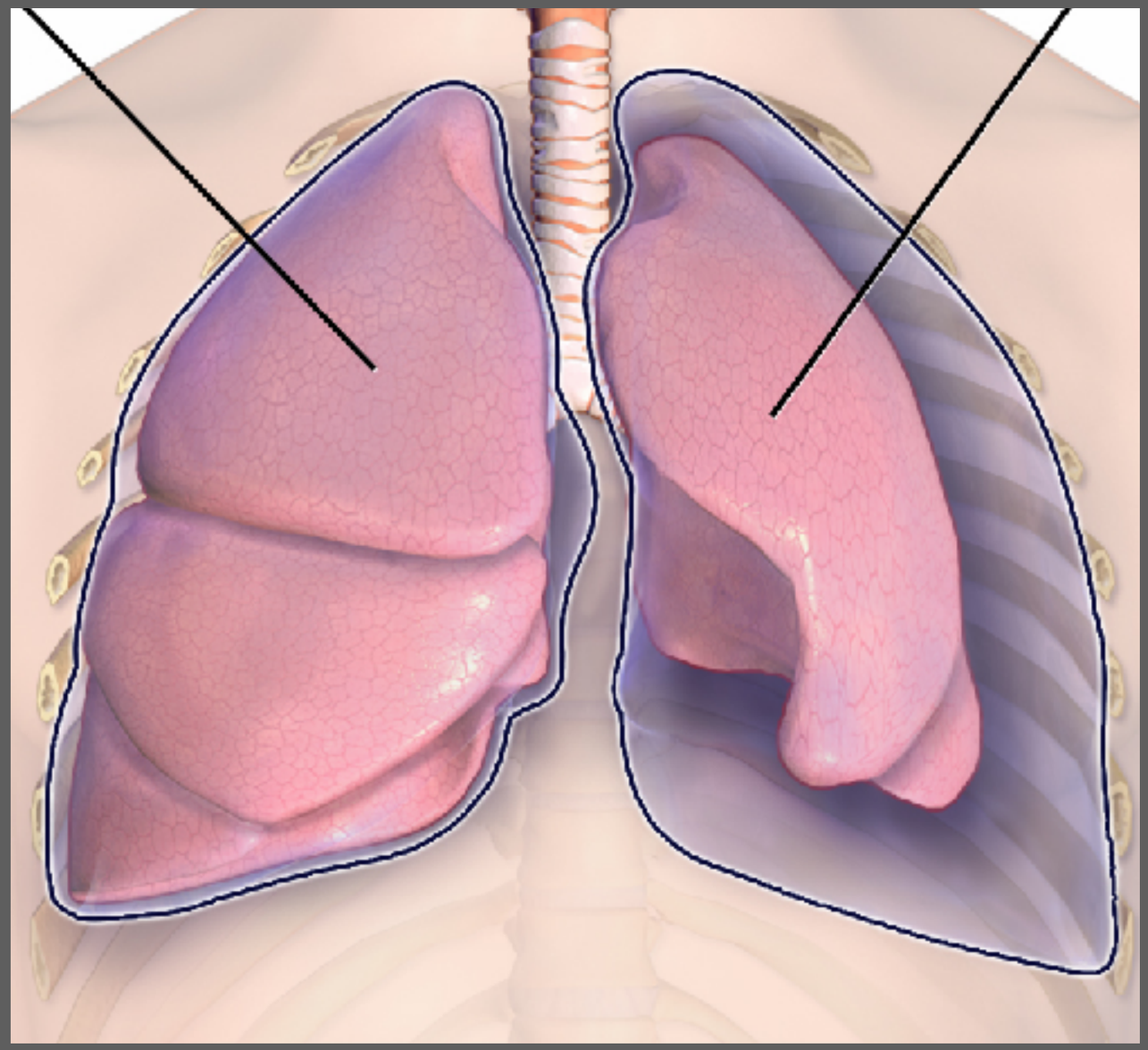

ChenKC@POCUSAcademy

LUS for PTX

Table 2 Lung ultrasound in the diagnosis of pneumothorax

Study (first author)	n	Sensitivity (%)	Specificity (%)	Ultrasound LR+/LR−	Gold standard	Sonographer type
Kirkpatrick[54]	225	US 49 CXR 21	US 100 CXR 99	Undefined/0.51	CT	Novice trauma surgeons
Knudtson[65]	328	US 92	US 99	92/0.081	CXR	Trauma surgeons
Chung[33]	97	US 80 CXR 47	US 94 CXR 94	13/0.21	CT	Experienced radiologists
Lichtenstein[66]	200	US 95	US 94	16/0.053	CT	Intensivists
Zhang[10]	135	US 86 CXR 27	US 97 CXR 100	29/0.14	CT and chest drain	EP
Sartori[67]	285	US 100 CXR 87	US 100 CXR 100	Undefined/0	CT	Experienced physicians not otherwise specified
Lichtenstein[6]	260	US 81	US 100	Undefined/0.19	Final clinical diagnosis	Experienced intensivists
Nagarsheth[34]	79	US 81 CXR 31	US 100 CXR 100	Undefined/0.19	CT	Novice surgeon
Ding[68]	7569	US 88 CR 52	US 99 CR 100	88/0.12	CT or air escape (meta-analysis)	Meta-analysis varied
Alrajhi[69]	1048	US 91 CXR 50	US 98 CXR 99	46/0.092	CT or air escape (meta-analysis)	Meta-analysis varied
Xirouchaki[22]	84	US 75 CXR 0	US 93 CXR 99	11/0.27	CT	Experienced intensivist





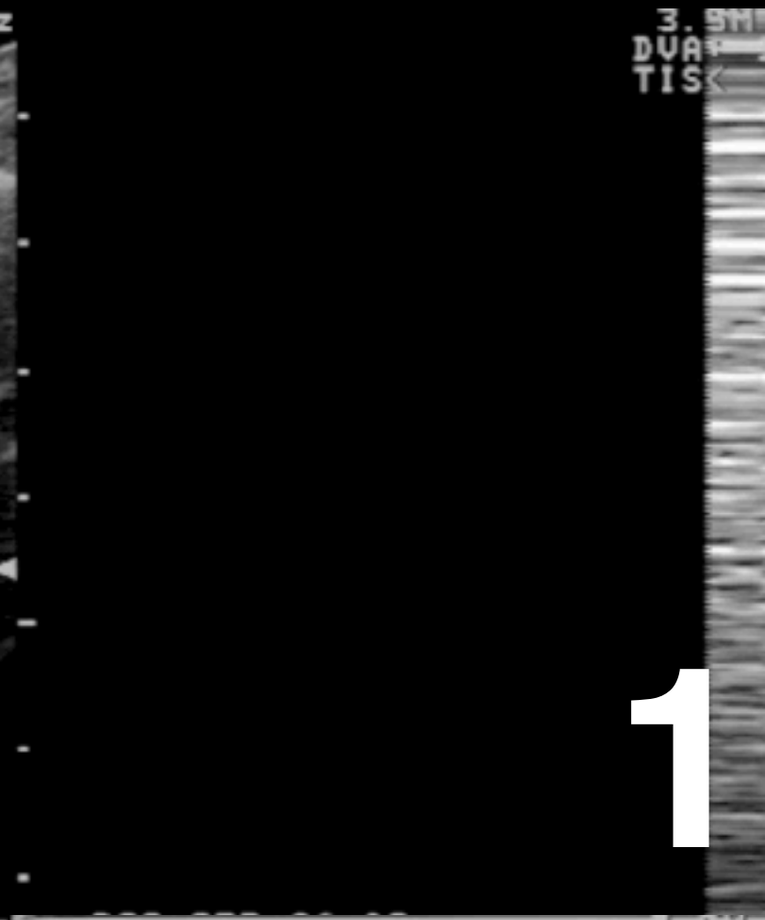

1

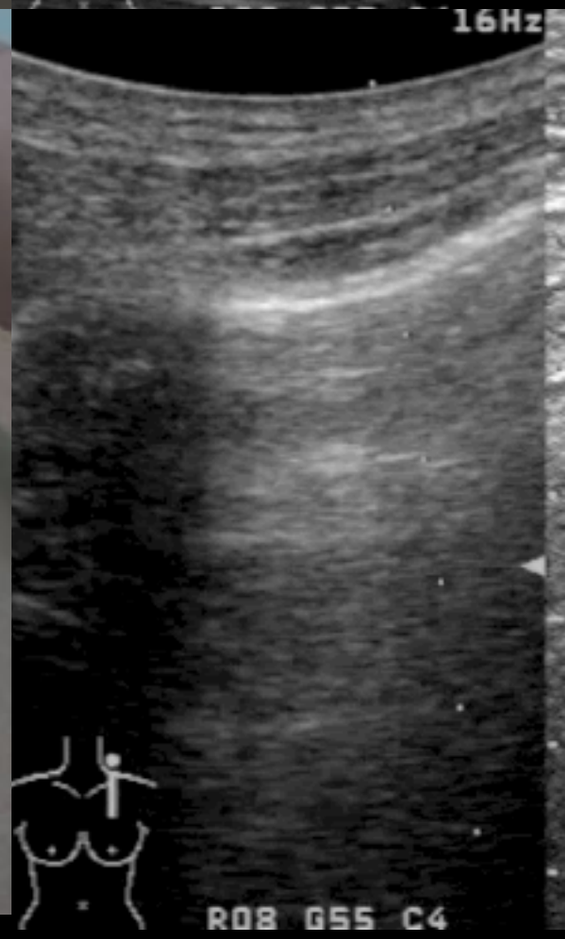

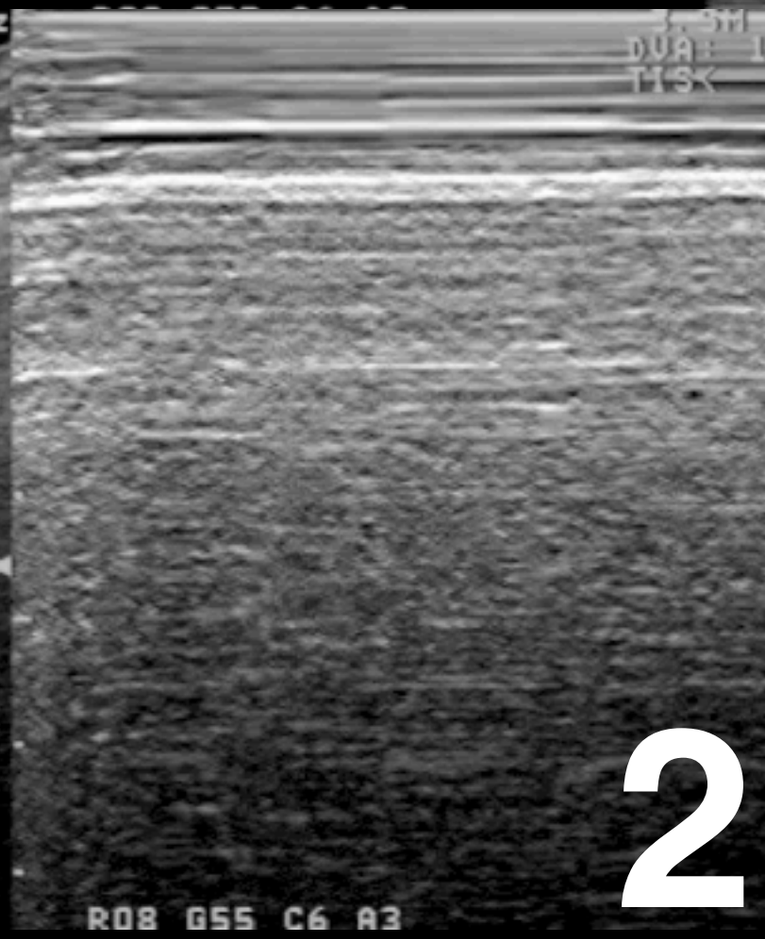

2

LUS for PTX: **When** ?

- **When suspect pneumothorax**

- Cardiac arrest/ unstable patient
- **Radio-occult pneumothorax**
- **Limited-resource areas**

- More accurately rules in PTX than supine CXR

Normal ??

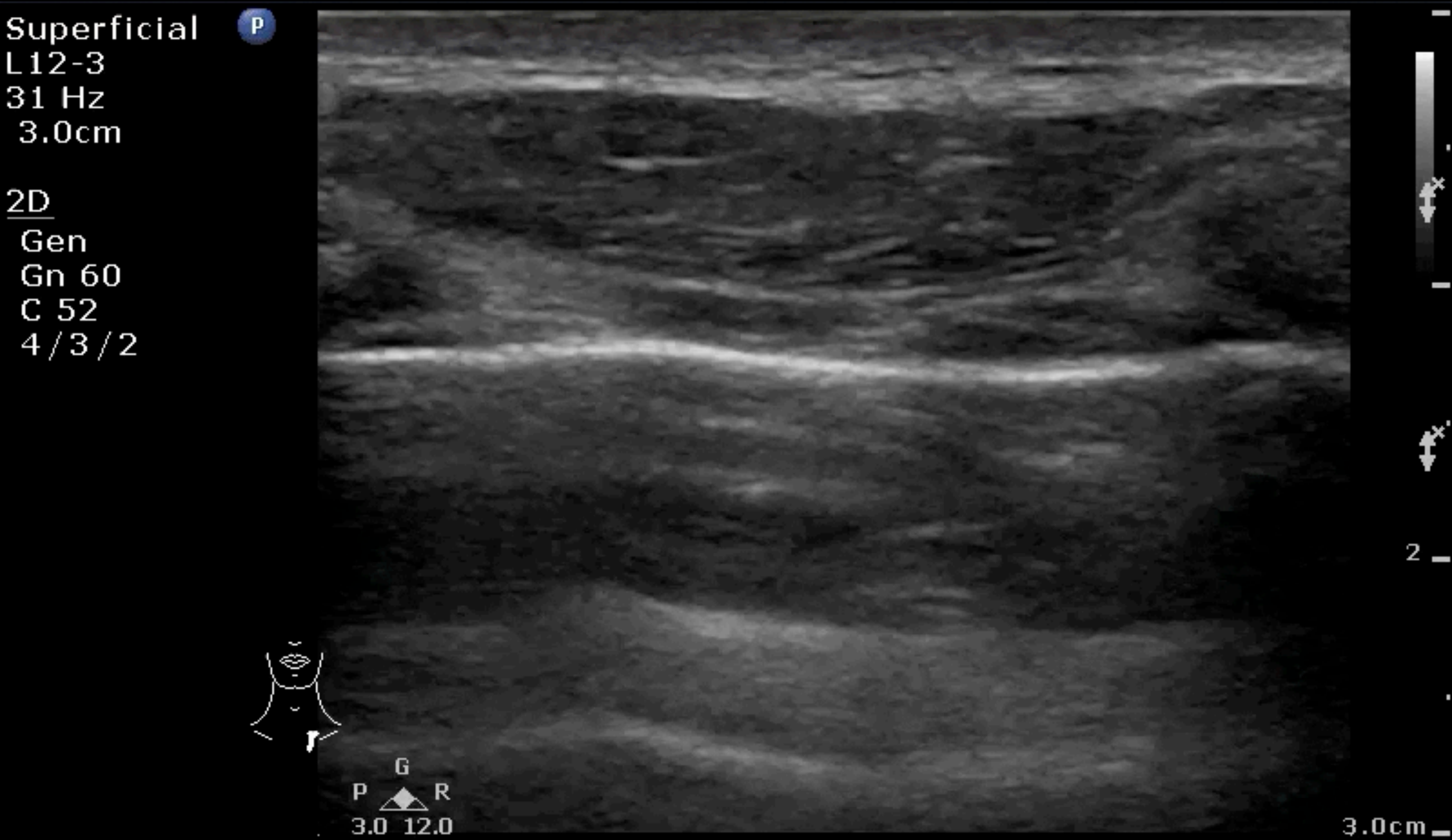
Superficial
P
L12-3
31 Hz
3.0cm
2D
Gen
Gn 60
C 52
4/3/2
G
P
R
3.0 12.0
2
3.0cm

Normal ??

Superficial
P
L12-3
31 Hz
3.0cm
2D
Gen
Gn 60
C 52
4/3/2
G
P
R
3.0 12.0
2
3.0cm

Pneumothorax

Normal

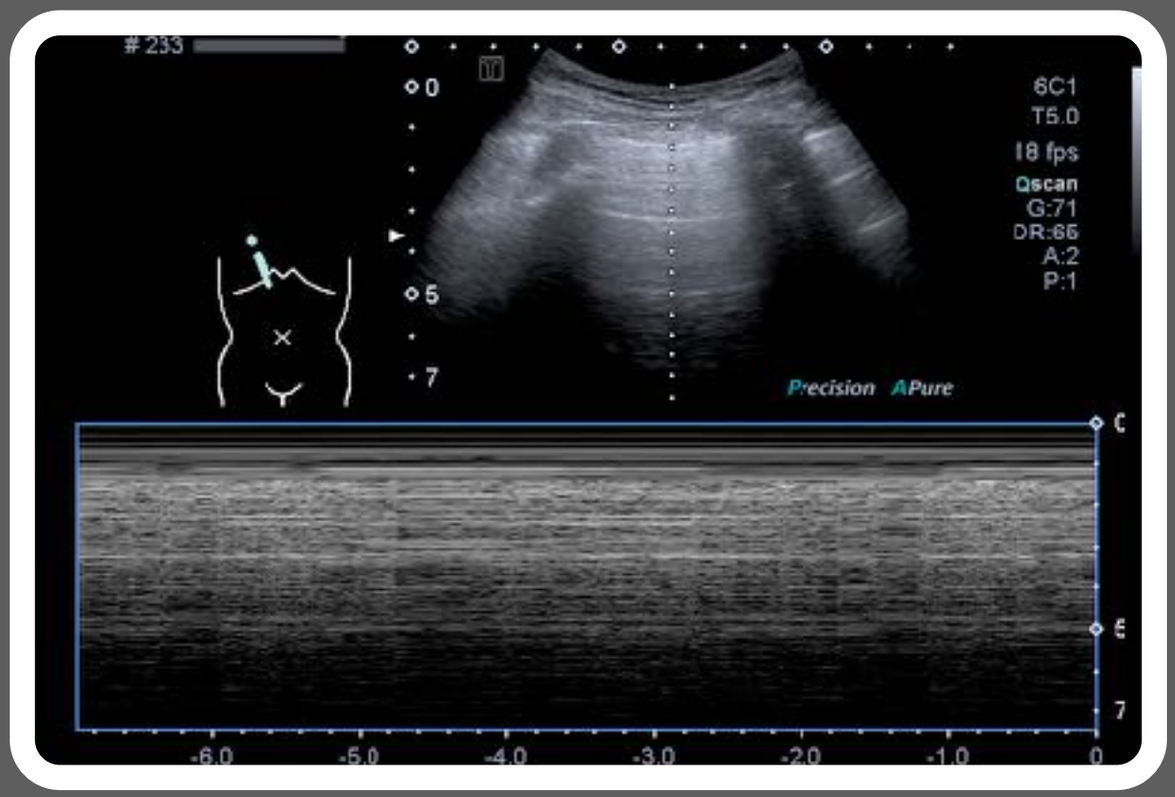

Seashore sign

Pneumothorax

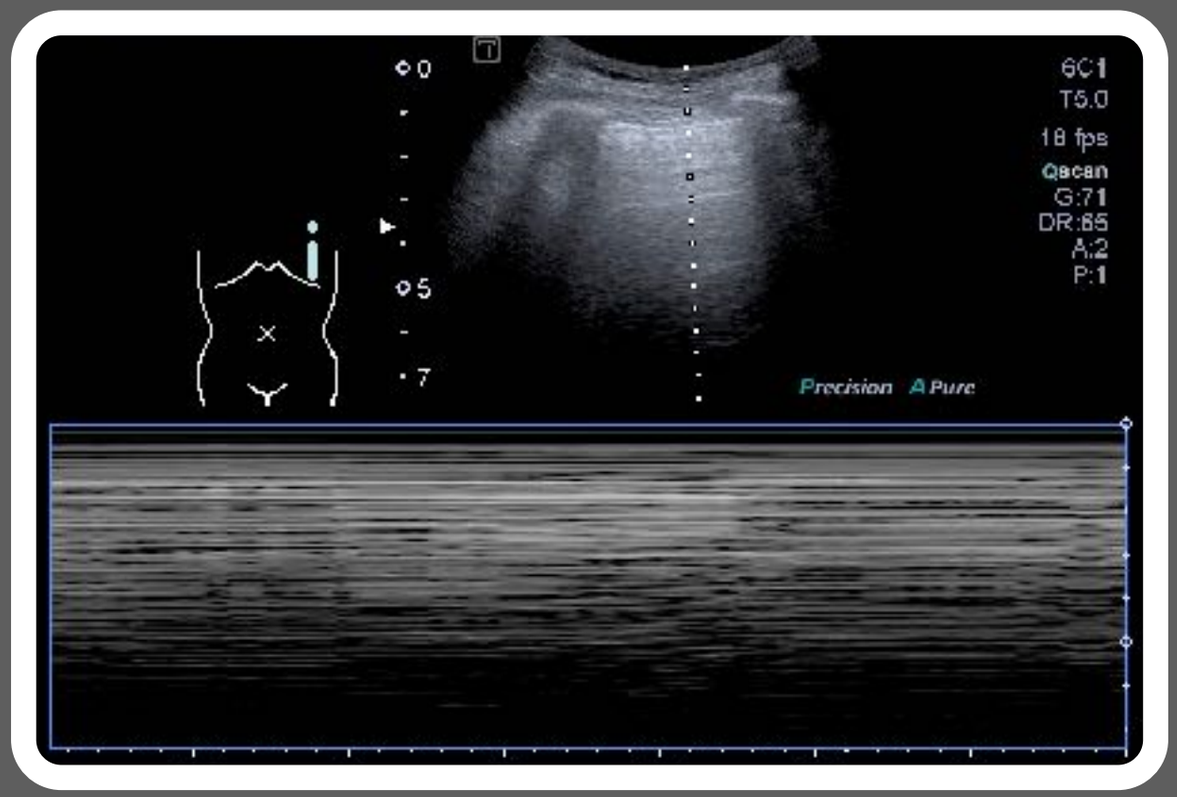

Stratosphere sign

ChenKC@POCUSAcademy

Pneumothorax

Normal Pneumothorax

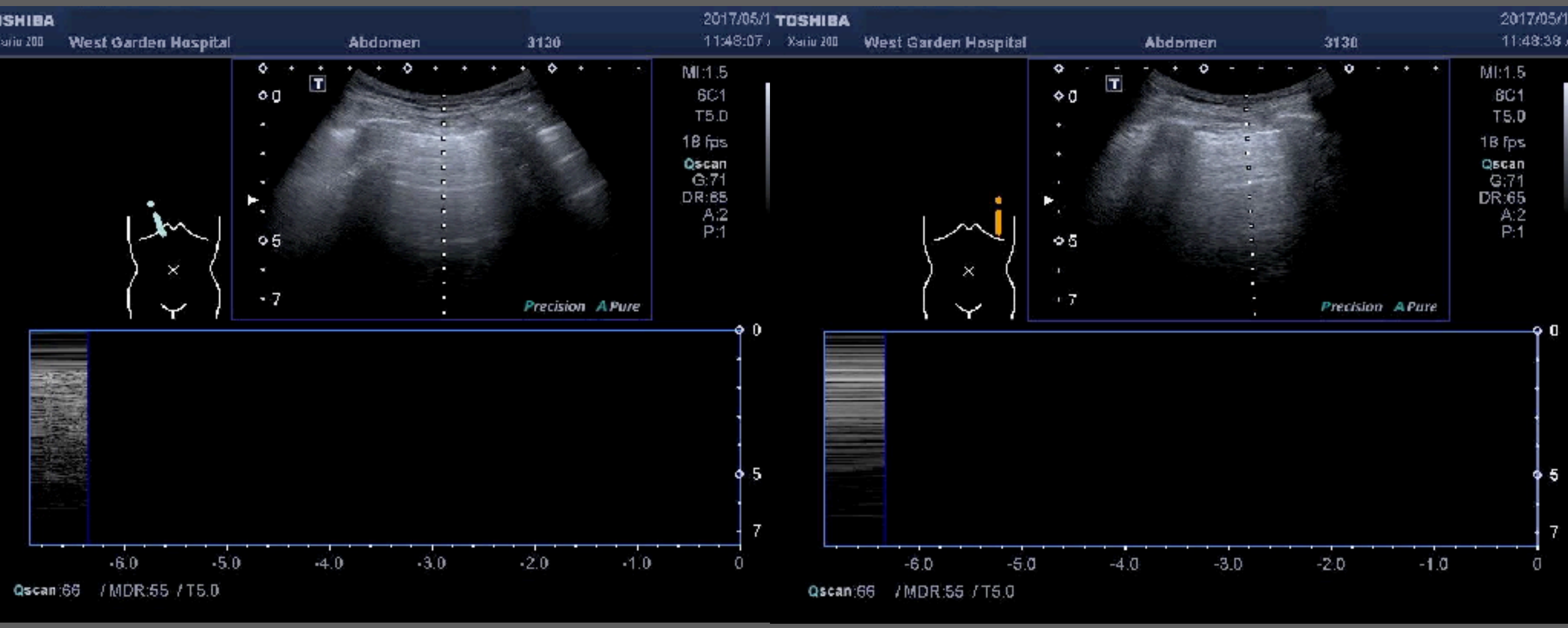

Specificity 100%

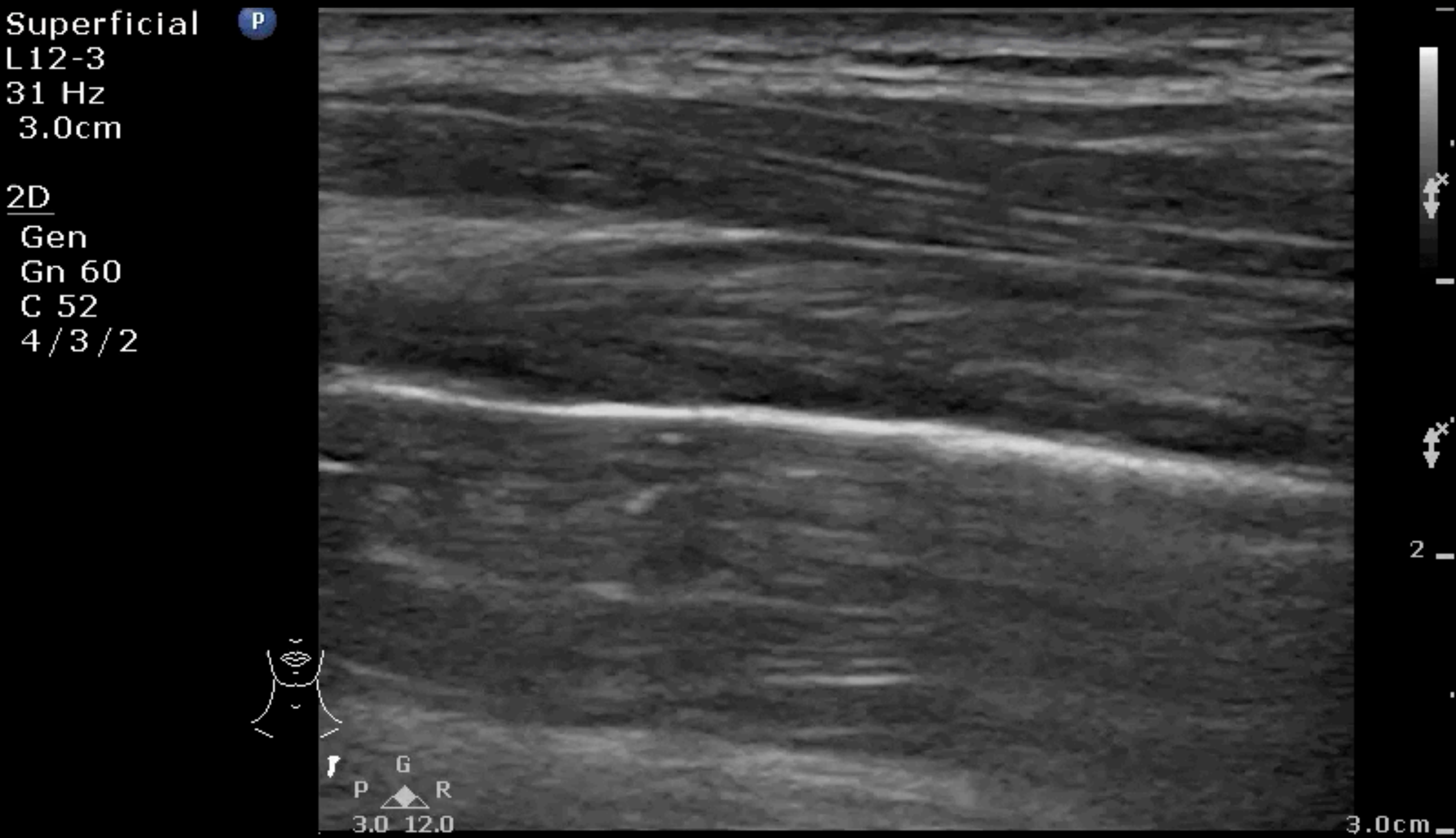

Summary

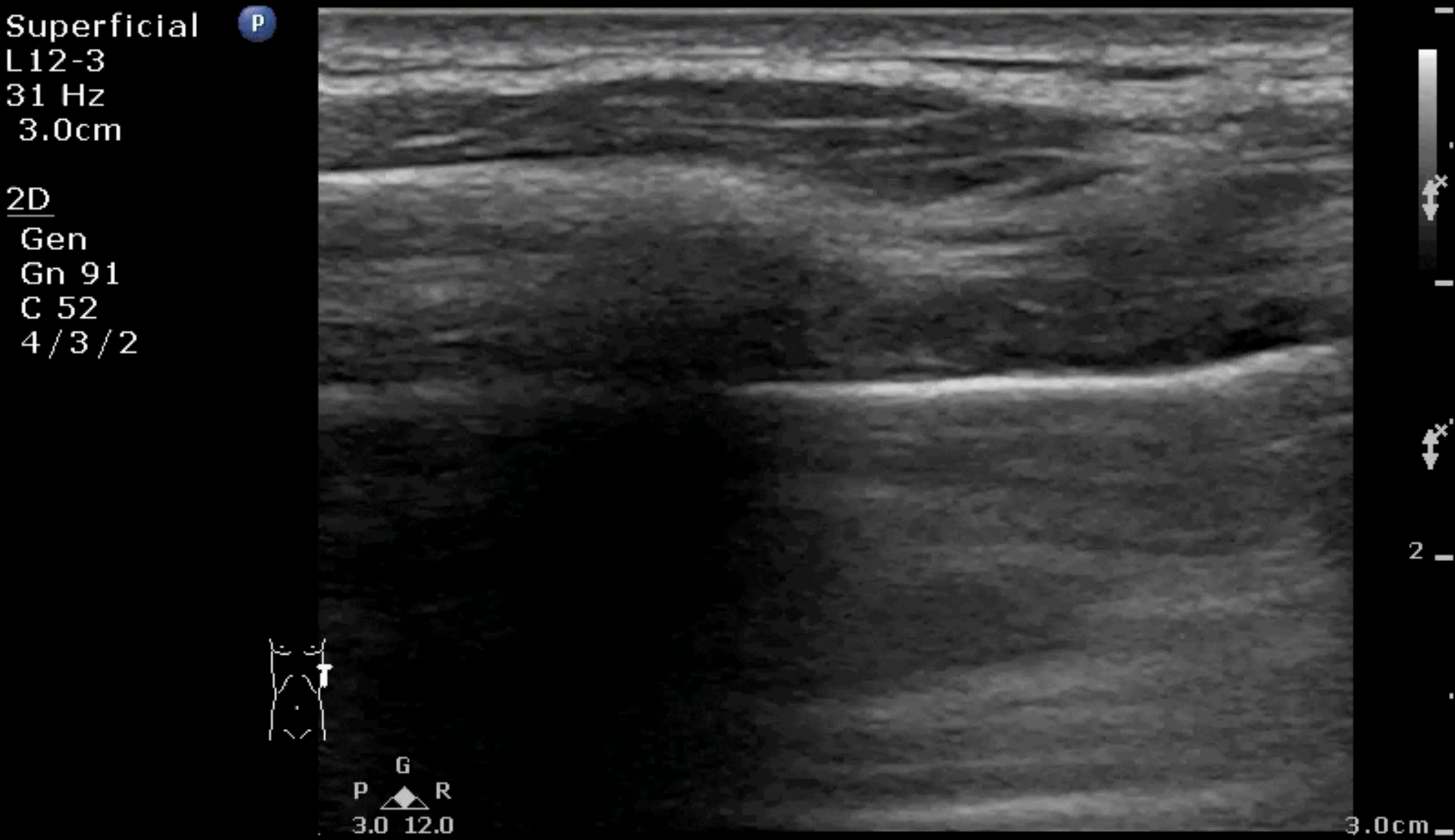
Superficial
L12-3
31 Hz
3.0cm
2D
Gen
Gn 91
C 52
4/3/2
G
P
R
3.0 12.0
2
3.0cm

Lung point

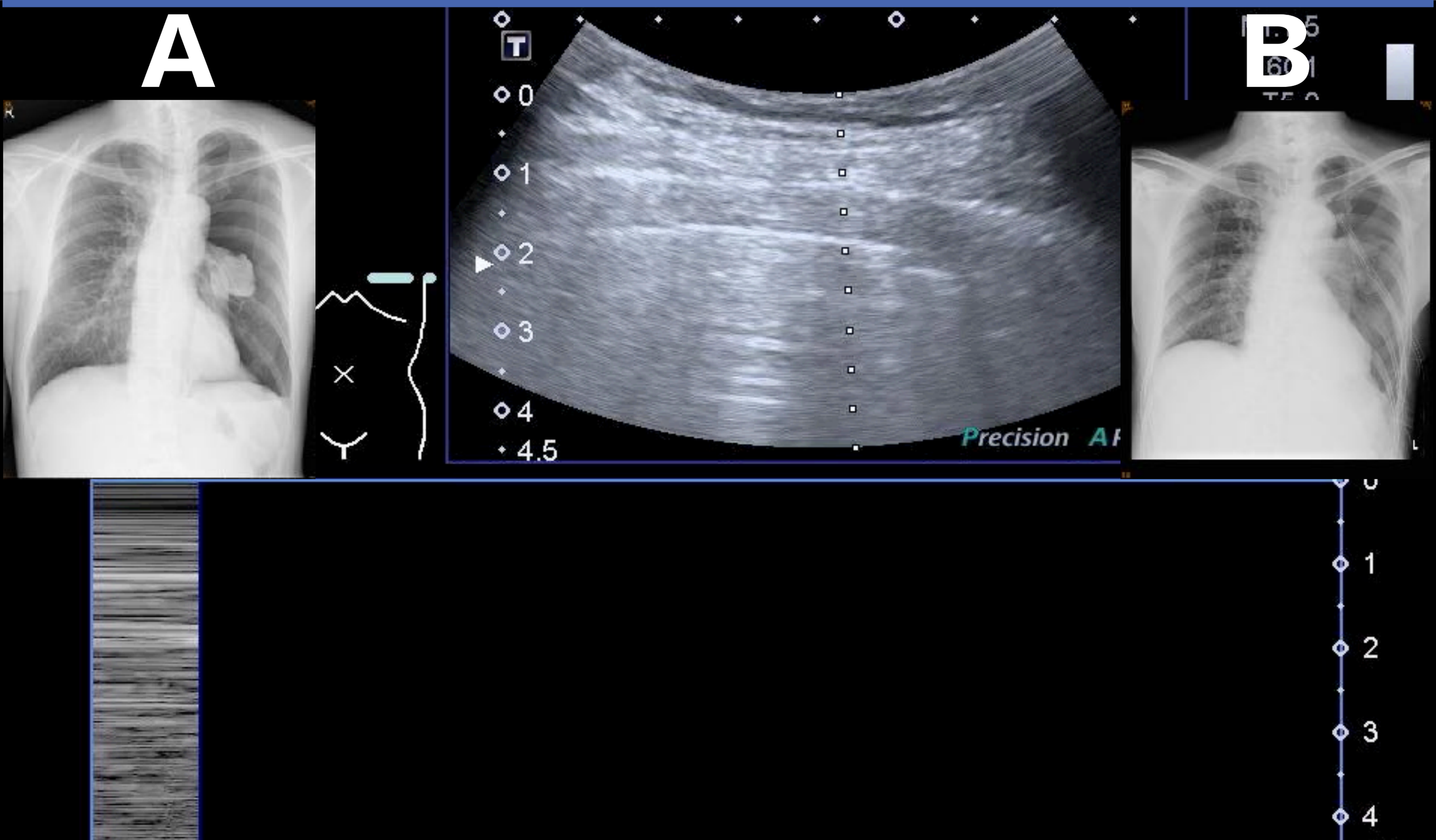

Point 1

PTX

BLUE 4 points

Point 2

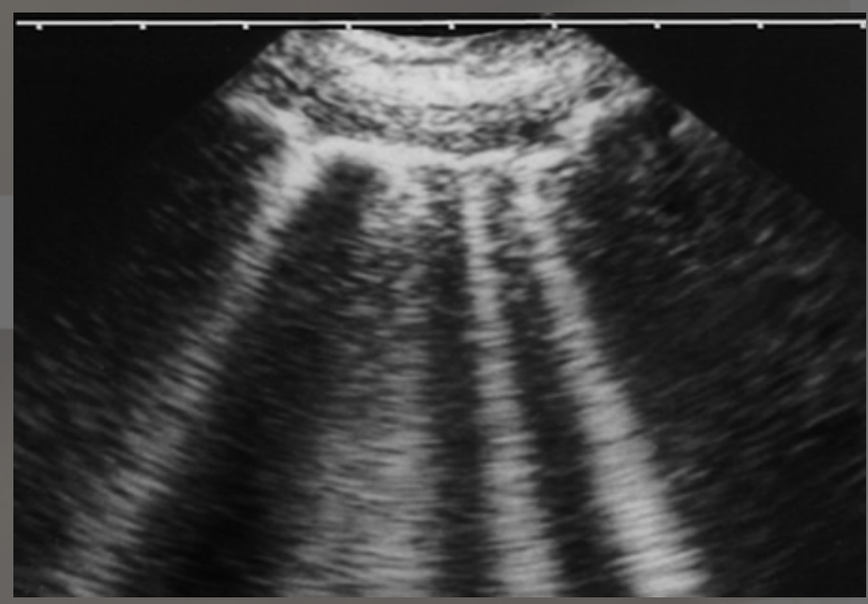

Highest

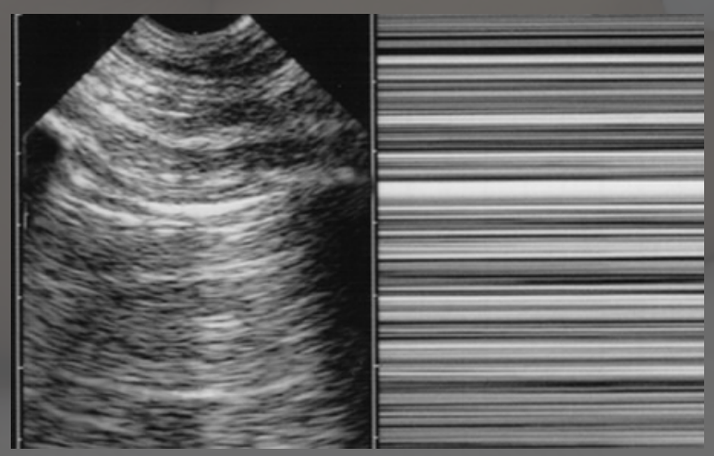

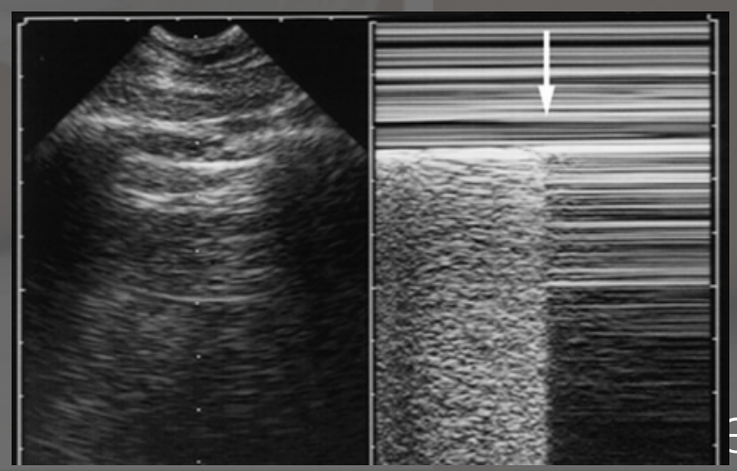

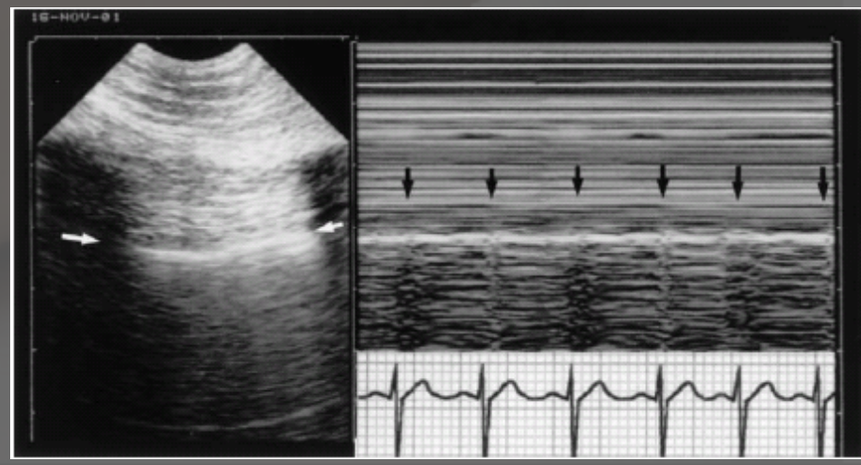

emy

PTX

4

SBP Point

No sliding

No B lines

No pulse

Lung point

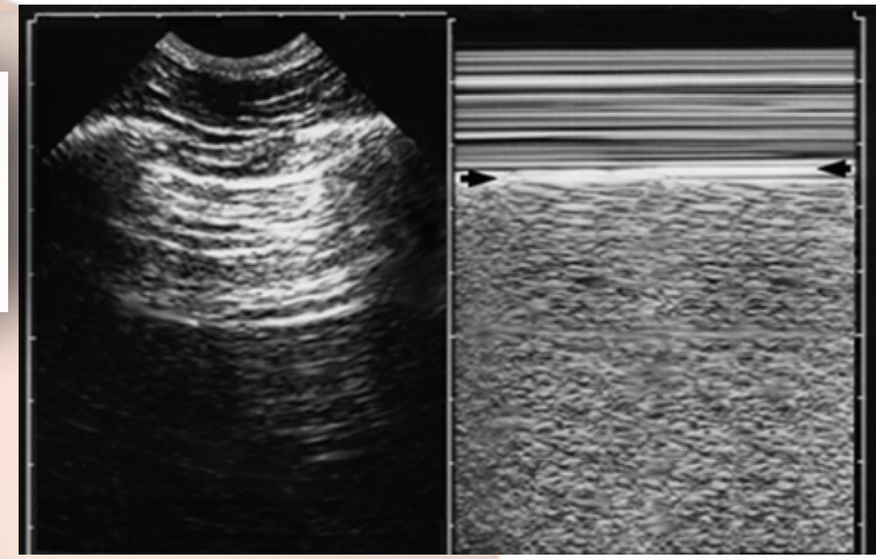

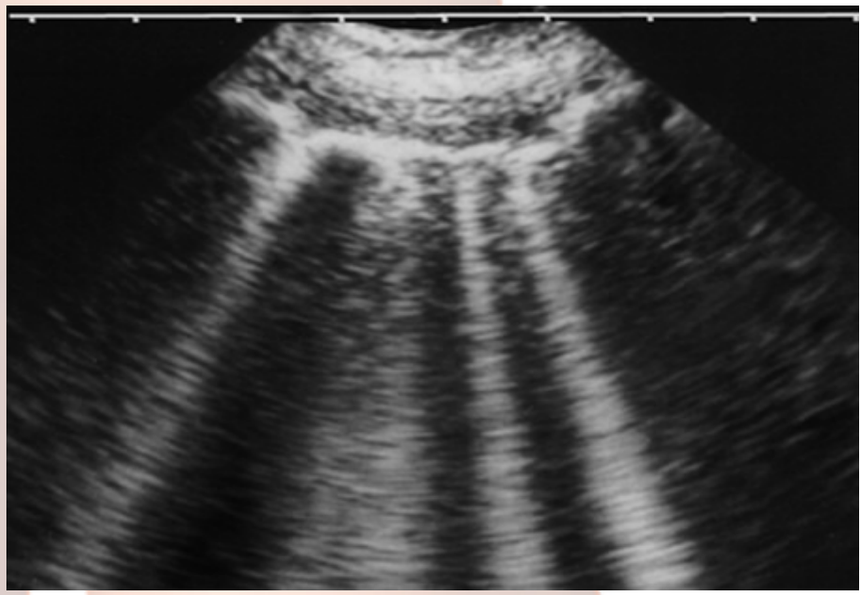

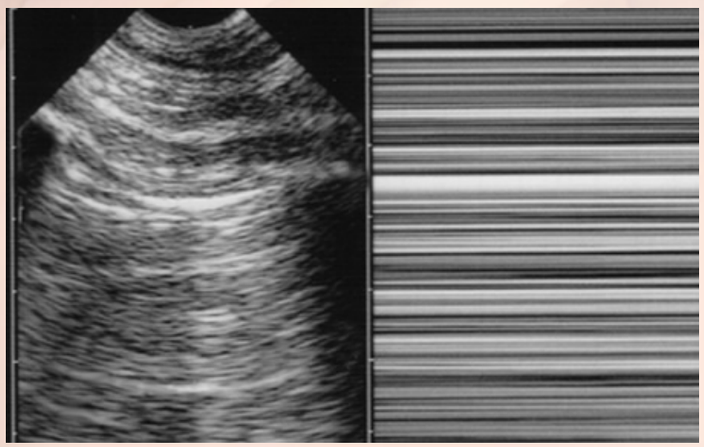

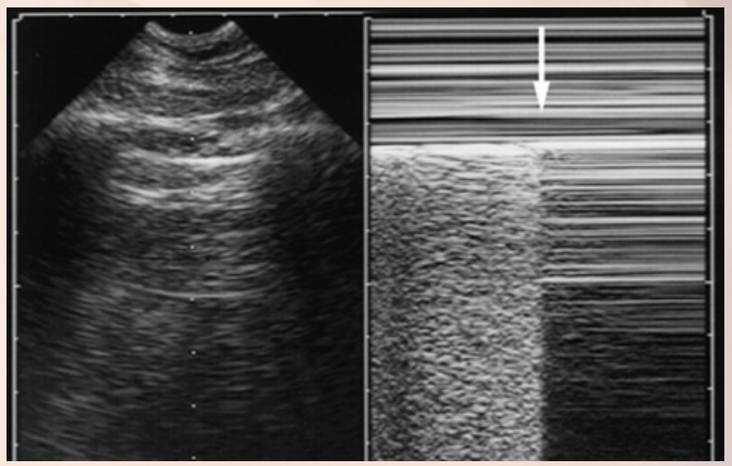

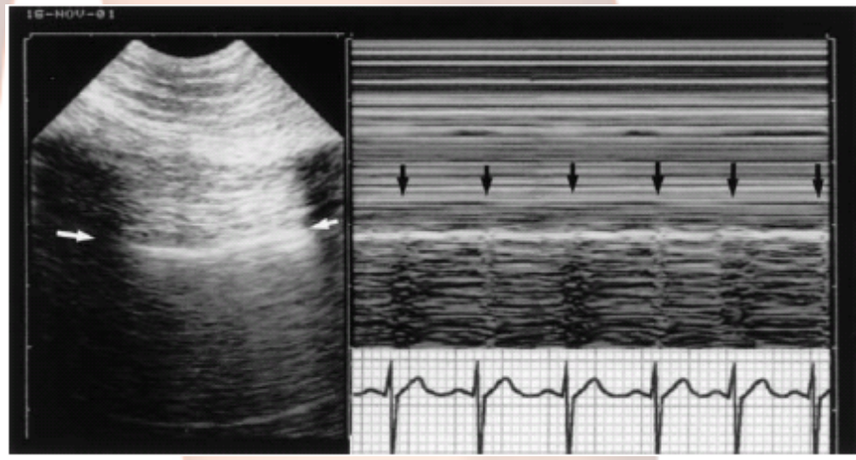

PLUS for PAP

PTX

AIS

3

2

3

ChenKC@POCUSAcademy

AIS

BLUE 4 points

Point 1

Point 2

Point 3

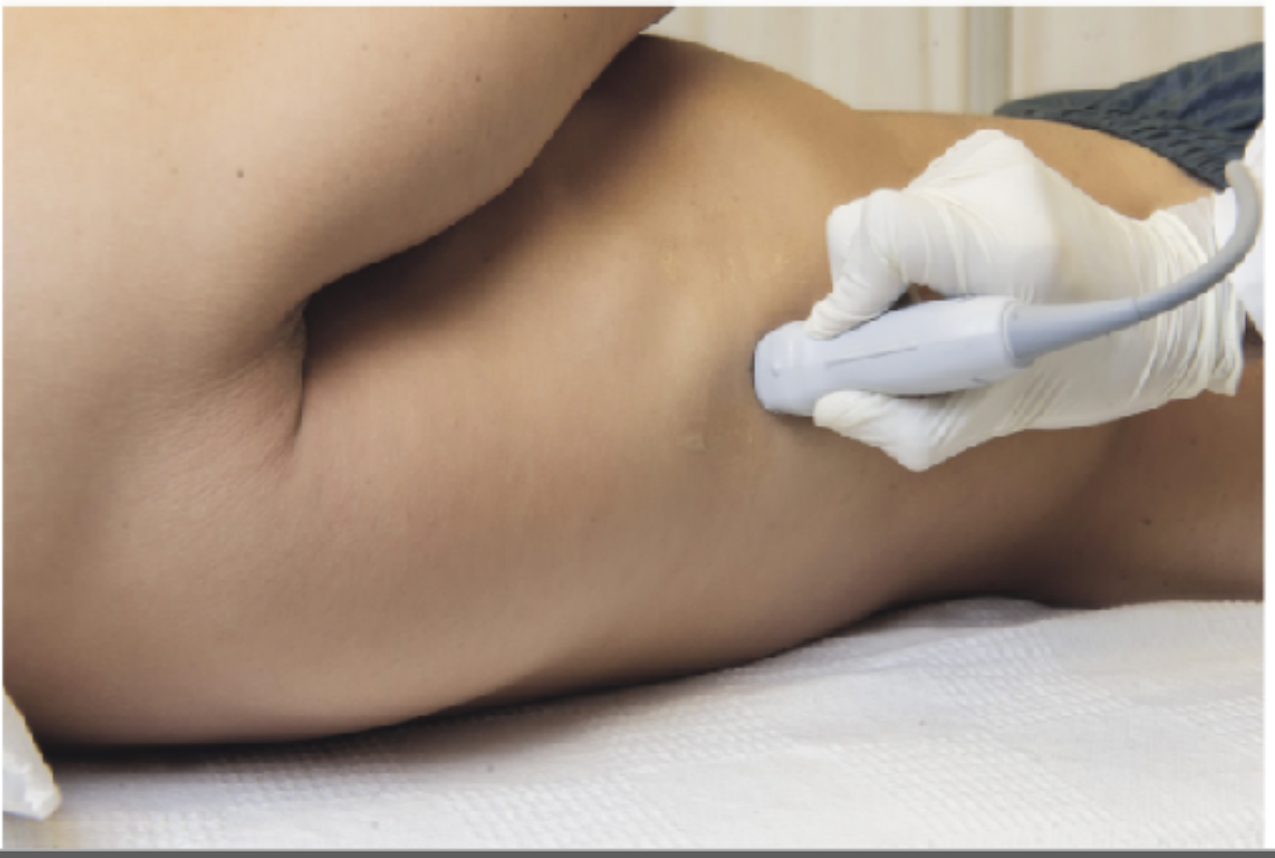

Point 4

3x2

CUSAcademy

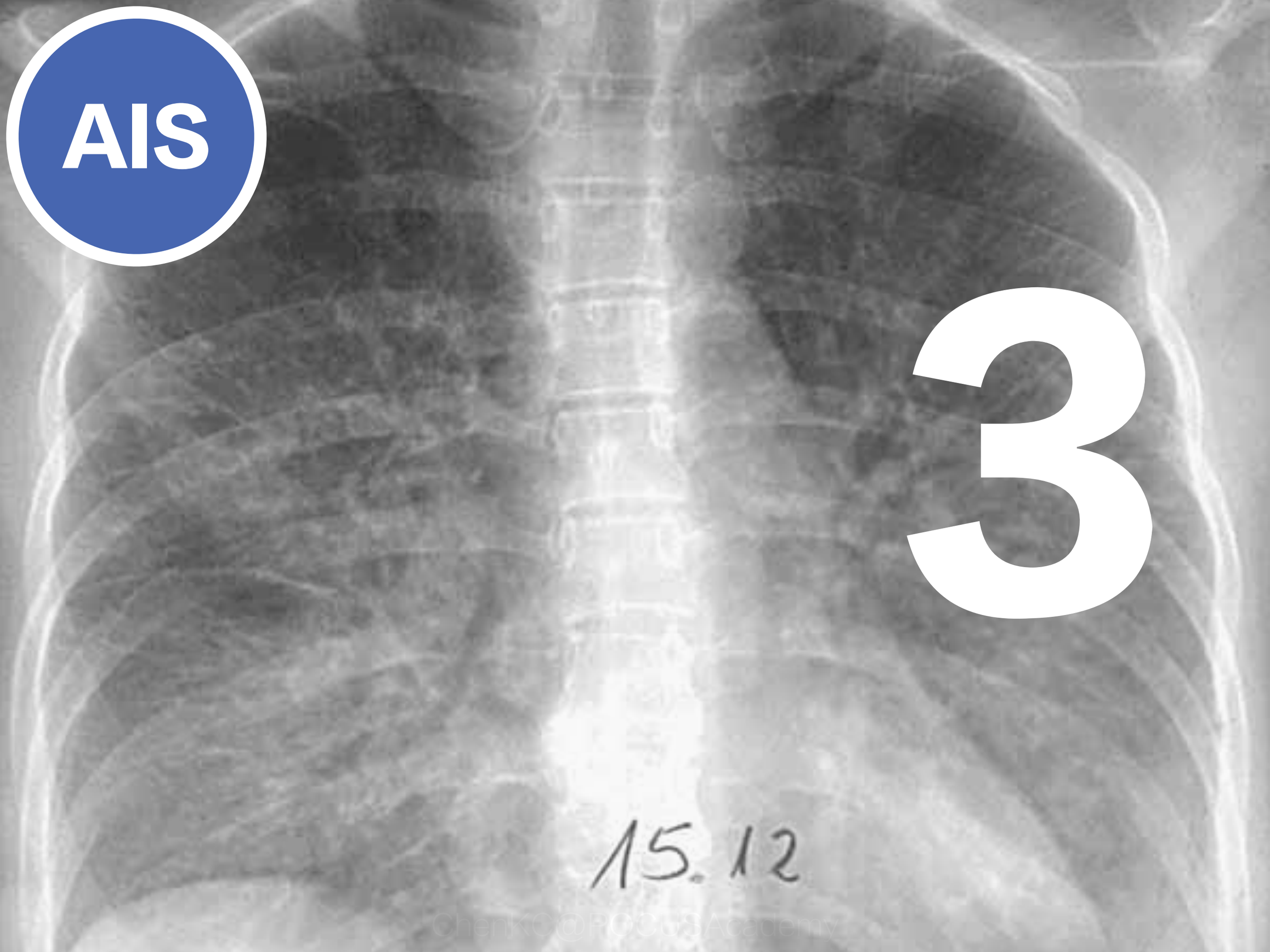

ChenKC@POCUSAcademy

LUS for lung

Table 1 Lung ultrasound in the diagnosis of cardiogenic pulmonary oedema

Study (first author)	n	US sensitivity/specificity	US LR+/LR−	Gold standard	Sonographer type
Lichtenstein[5]	250	93.4/93	13/0.071	CXR	Experienced intensivist
Lichtenstein[15]	146	100/92	13/0	CXR	Experienced intensivist
Agricola[16]	20	90/86	6.4/0.12	CXR/PiCCO/Echo	Cardiologist
Volpicelli[20]	300	85/98	43/0.15	CXR/CT/Final diagnosis	EP or radiologist
Gargani[24]	149	81/85	5.4/0.22	NT-proBNP	Sonographer not otherwise specified
Lichtenstein[6]	301	97/95	19/0.032	Final clinical diagnosis	Experienced intensivists
Liteplo[2]	100	58/85	3.9/0.49	Final clinical diagnosis	EP or LU- trained student
Maines[19]	23	83/91	9.2/0.19	ICD measure	Experienced physicians not otherwise specified
Vitturi[61]	152	97/79	4.6/0.038	Final clinical diagnosis	Not specified
Prosen[62]	248	100/95	20/0	Final clinical diagnosis	EP
Xirouchaki[22]	42	46/80	2.3/0.68	CT	Experienced intensivist
Cibinel[63]	56	93.6/84	5.9/0.076	Final clinical diagnosis	EP
Al Deeb[23]	1075	94.1/92.4	12/0.064	Meta-analysis	Meta-analysis- physicians or medical students
Chiem[27]	380	87/49 (one positive lung zone)	1.7/0.3	Final clinical diagnosis	Novice EP
Pivetta[64]	1005	97/97.4	37/0.031	Final clinical diagnosis	EP

ChenKC@POCUSAcademy Wimalasena Y, et al. EMJ 2107













B lines/ Lung rockets

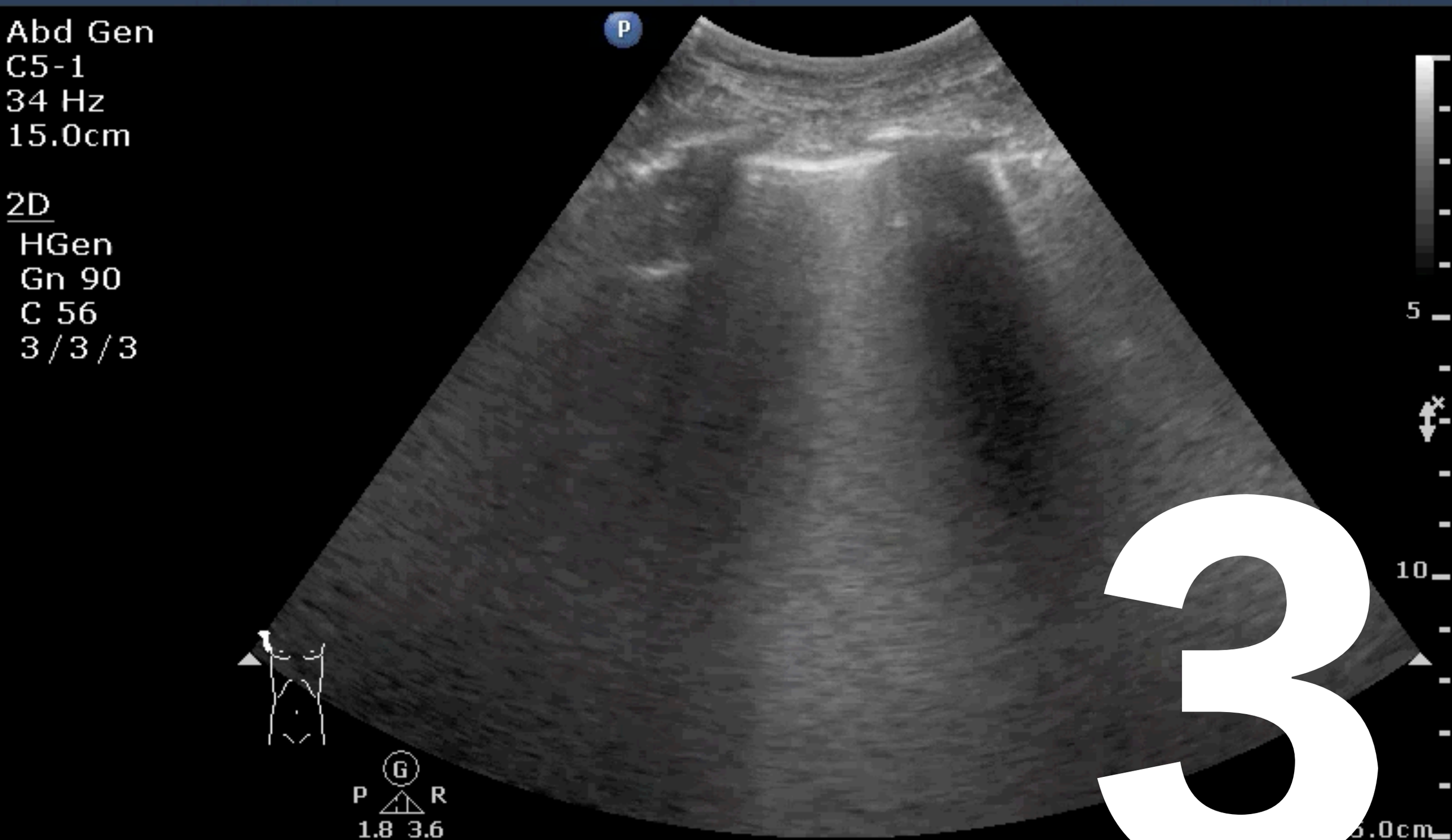

sit

AIS

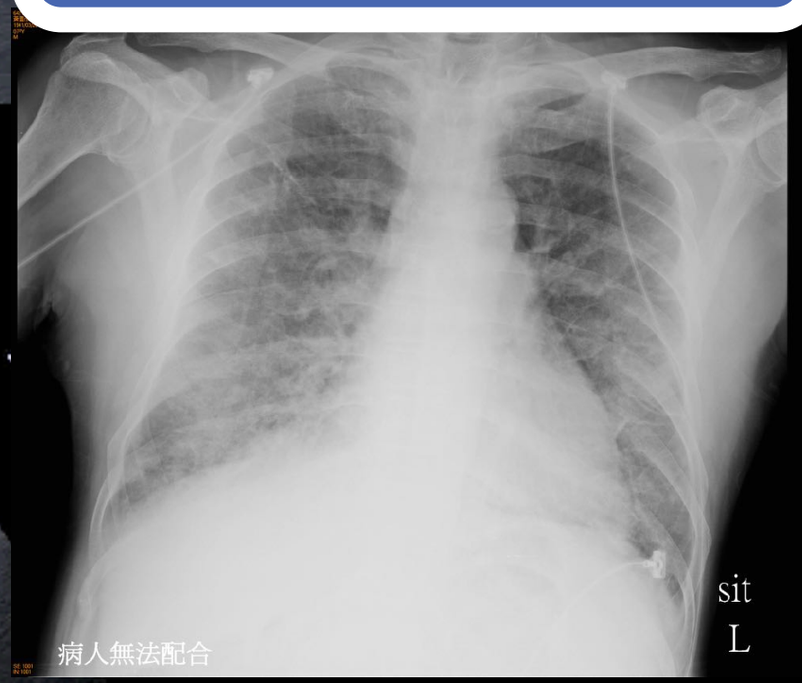

sit

L

AIS: Bilateral & Diffuse

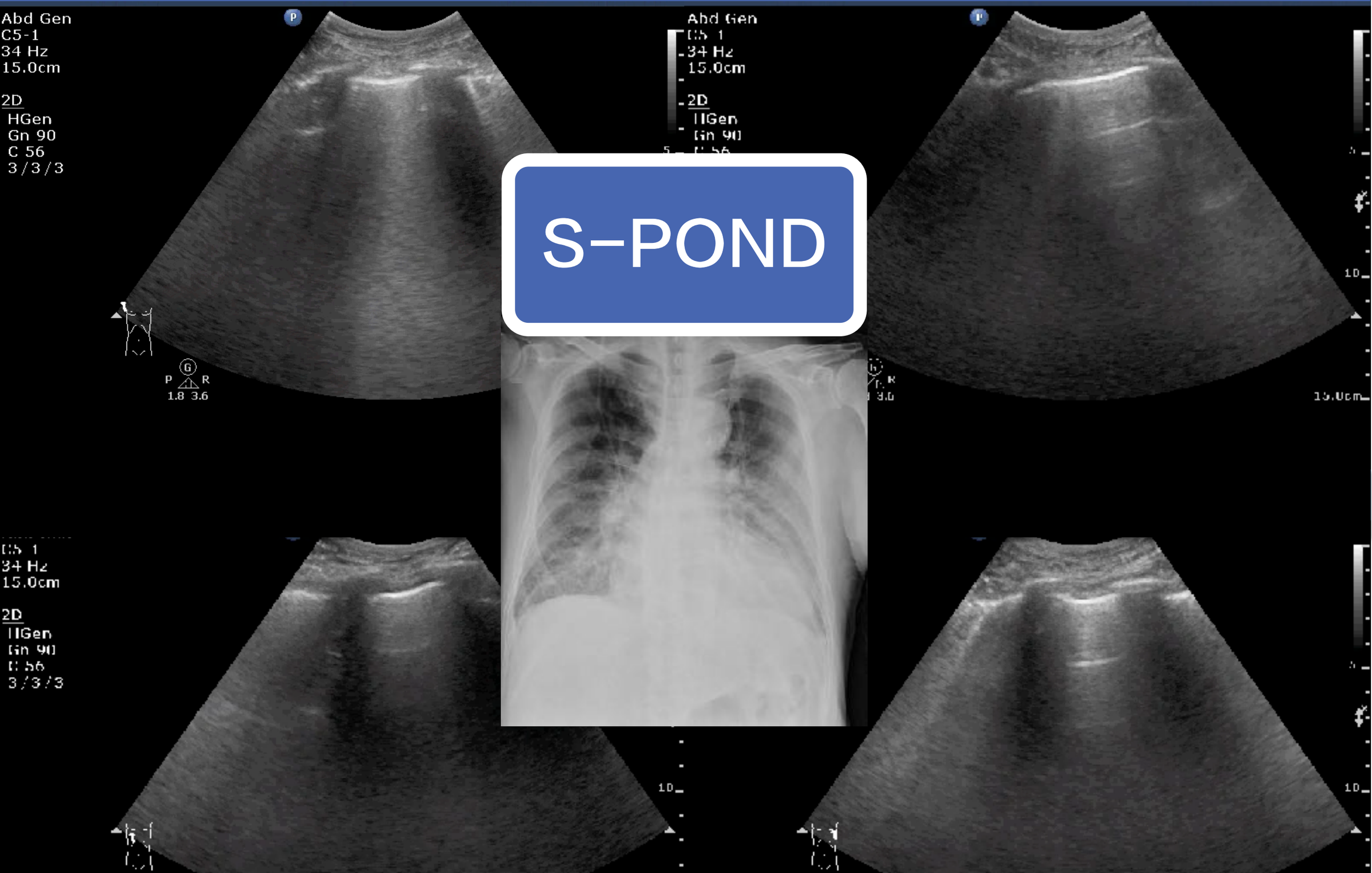

AIS: Localized

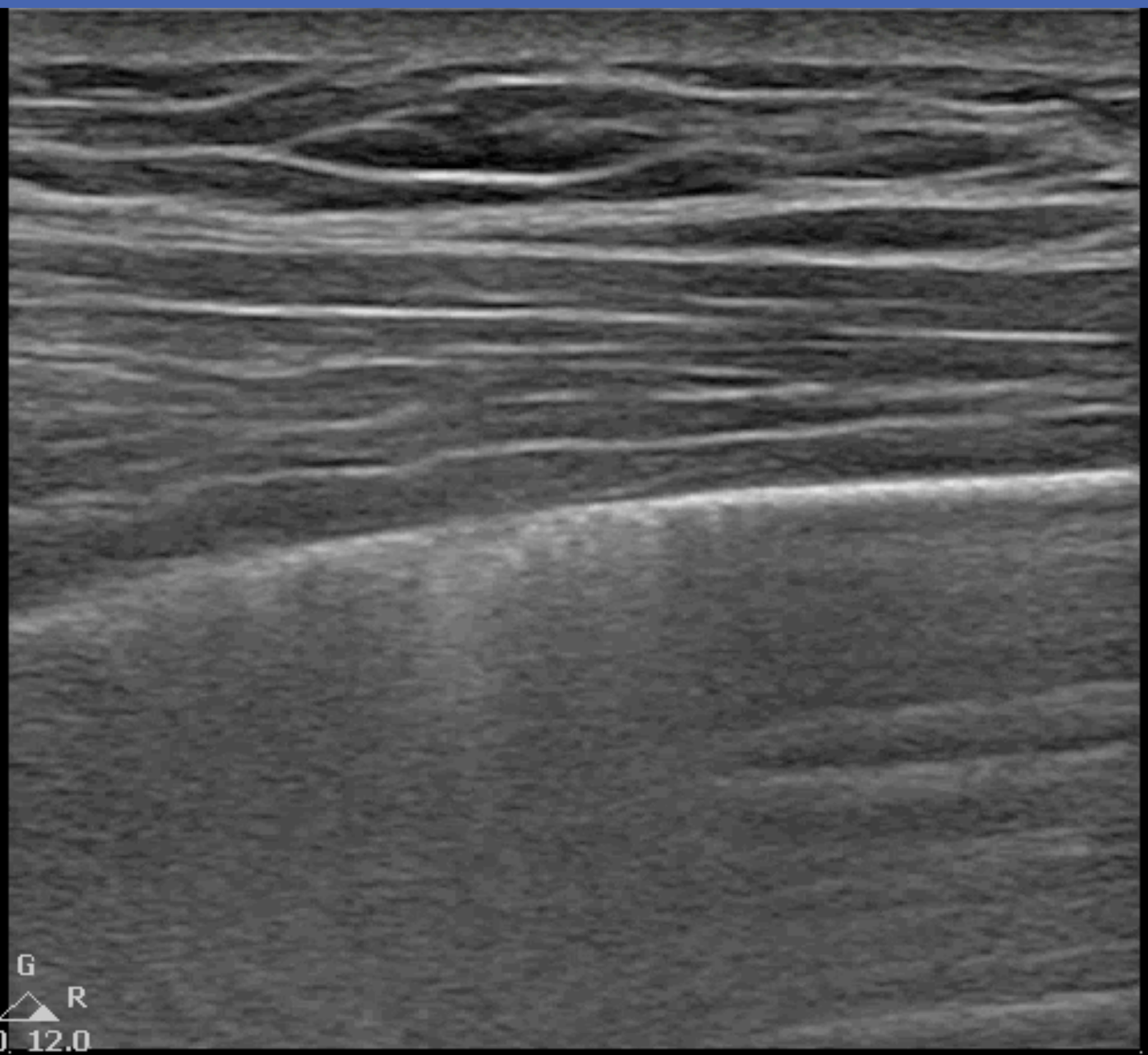

Pneumonia

Pneumonitis

Atelectasis

Contusion

Infarction

Pleural disease

Neoplasia

Normal lung

L

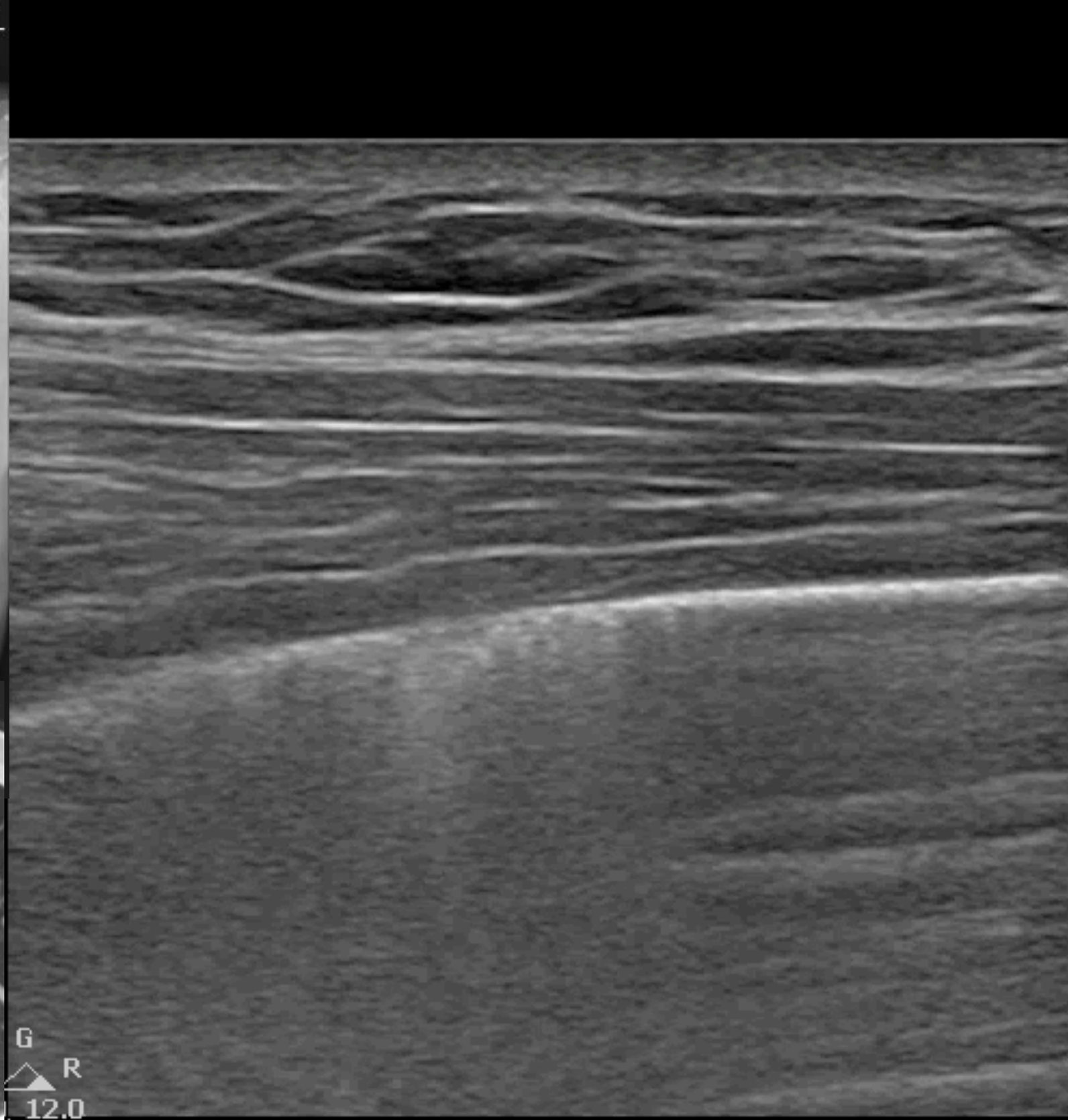
G
R
12.0

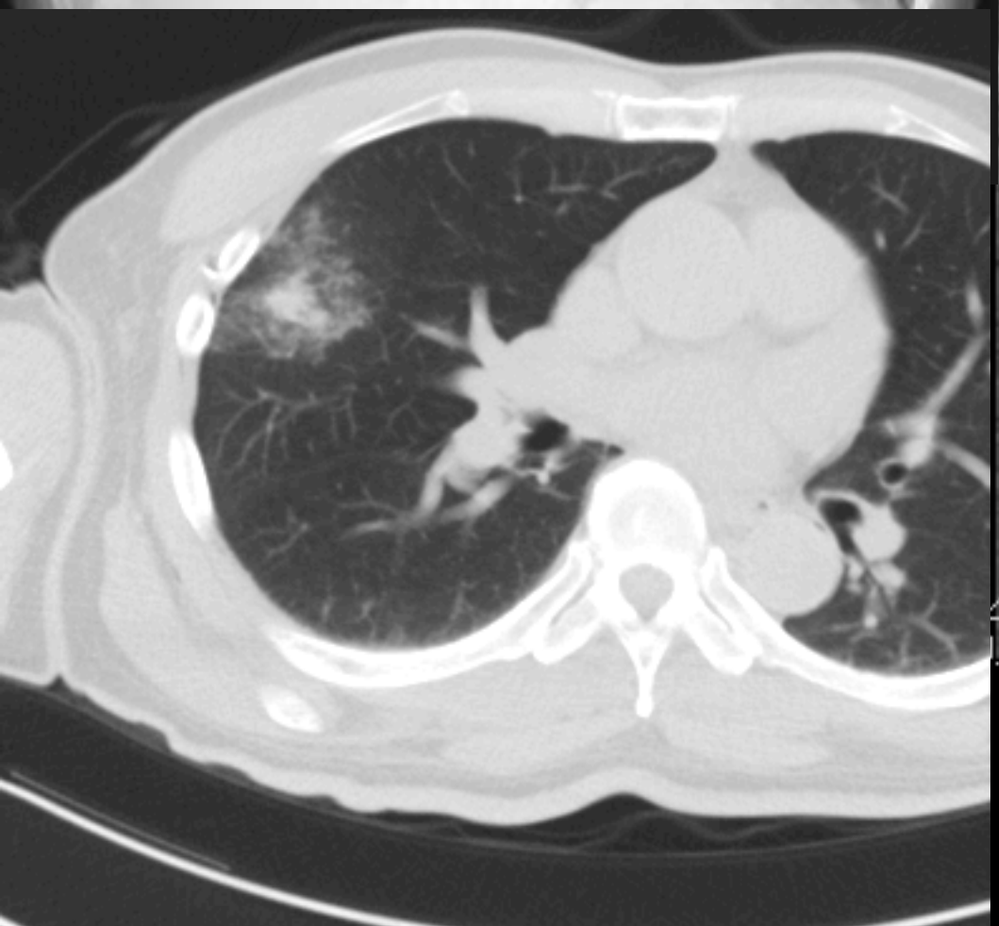

Better one ?

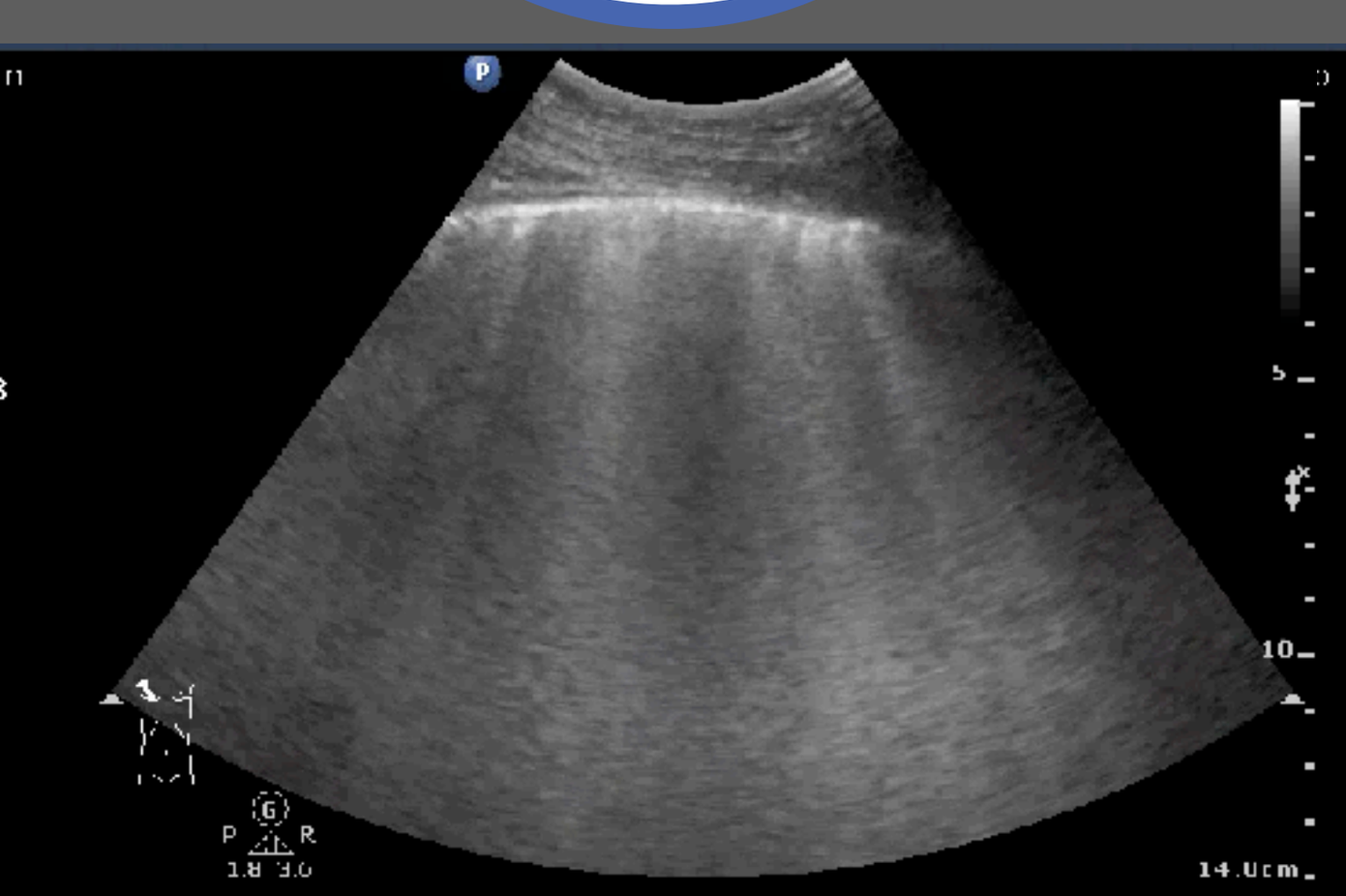

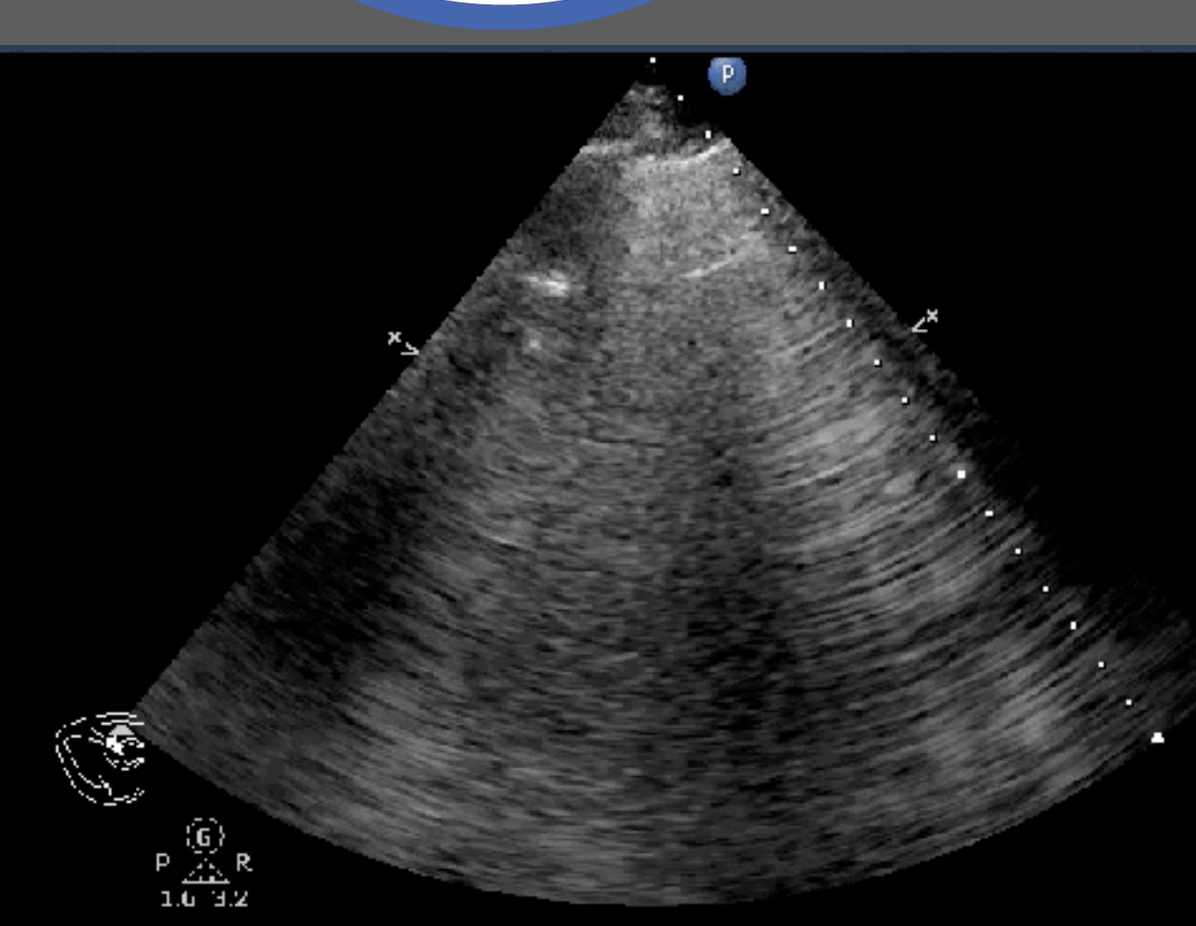

LUS for PAP

PTX

AIS

PLE

ChenKC@POCUSAcademy

PLE

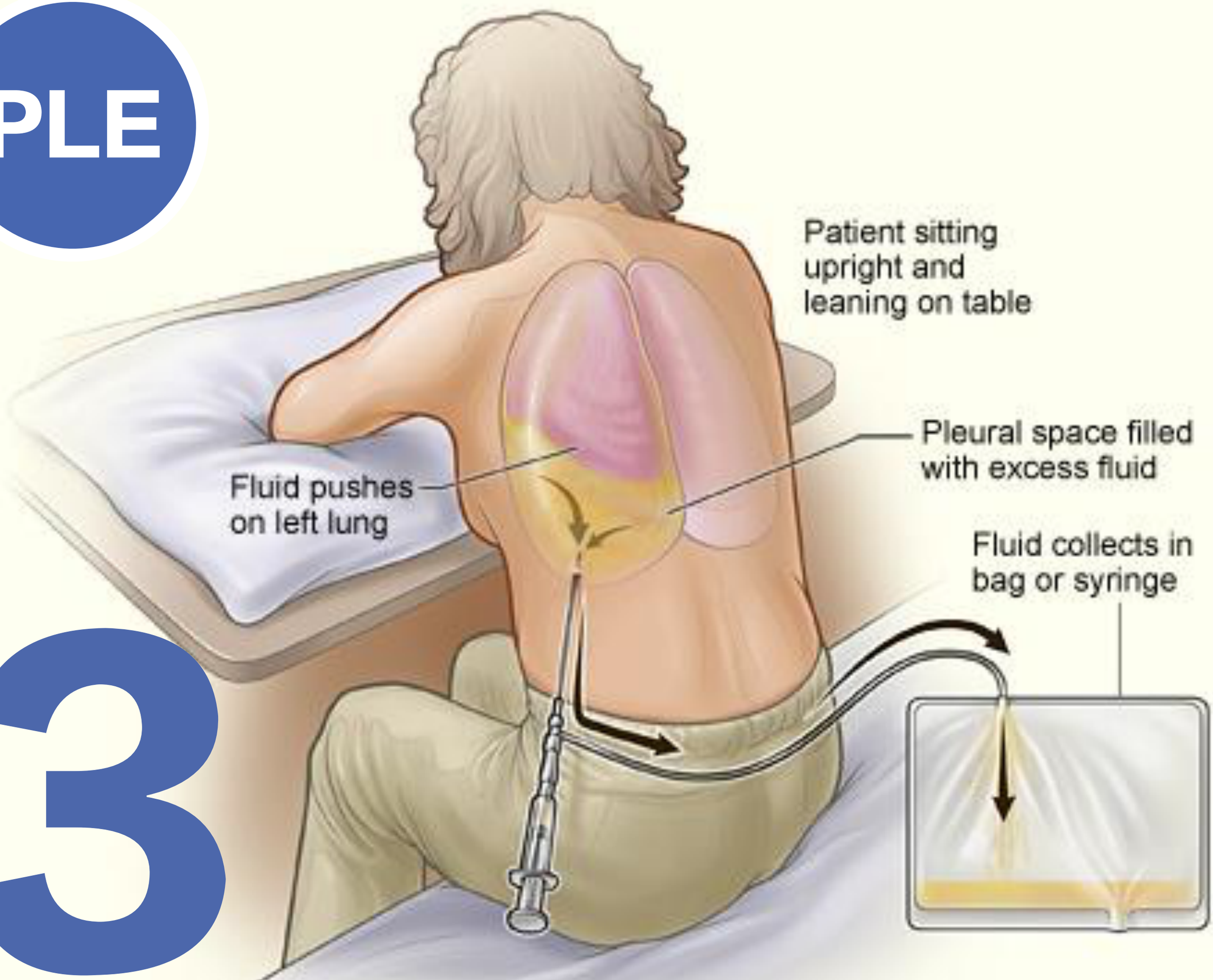
Patient sitting upright and leaning on table
Pleural space filled with excess fluid
Fluid pushes on left lung
Fluid collects in bag or syringe

3

PLE

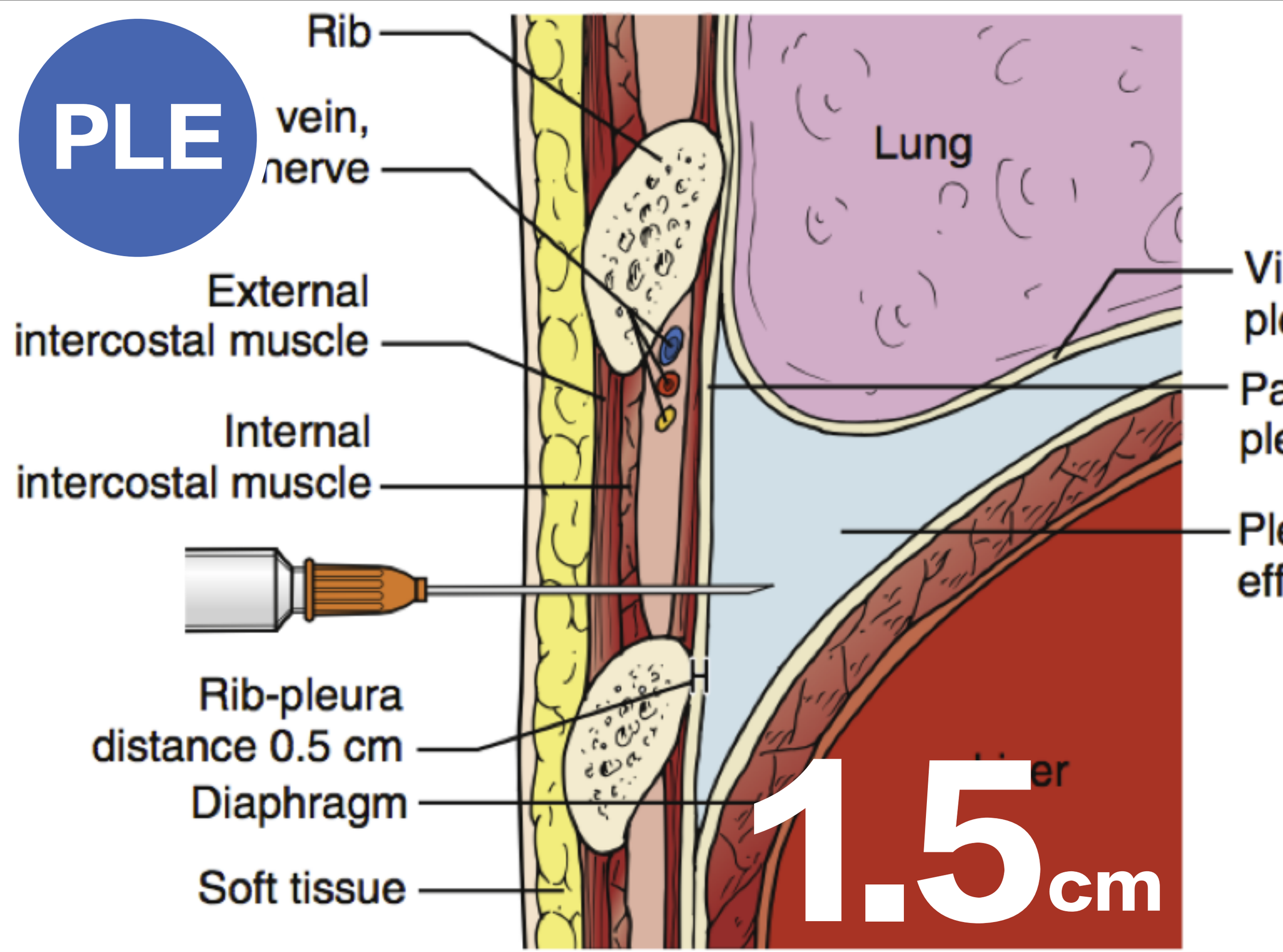
Rib
vein,
nerve
External
intercostal muscle
Internal
intercostal muscle
Rib-pleura
distance 0.5 cm
Diaphragm
Soft tissue
Lung
Vi
pl
Pa
pl
Pl
eff
er
1.5cm

LUS for PLE

Table 4 Lung ultrasound in the diagnosis of pleural effusion

Study (first author)	n	Sensitivity (%)	Specificity (%)	Ultrasound LR+/LR−	Gold standard	Sonographer type
Ma[72]	240	US 96	US 100	Undefined/0.04	CT	EP
Rozycki[73]	47	US 84	US 100	Undefined/0.16	CT	Surgeons
Abboud[74]	142	US 12	US 98	6/0.9	CT	Experienced EP
Lichenstein[3]	32	US 92	US 93	13/0.086	CT	Experienced intensivist
Brooks[75]	61	US 92	US 100	Undefined/0.08	Composite gold standard	Experienced EP or surgeon
Xirouchaki[77]	42	US 100 CXR 65	US 100 CXR 81	Undefined/0	CT	Experienced intensivist
Schleder[76]	24	Hand US 91 CXR 74	Hand US 100 CXR 31	Undefined/0.09	High-end US	Intensivist

ChenKC@POCUSAcademy Wimalasena Y, et al. EMJ 2107

Point 1

PLE

BLUE points

Point 2

Anechoic
Sharp sign
Sinusoid sign

Point 3

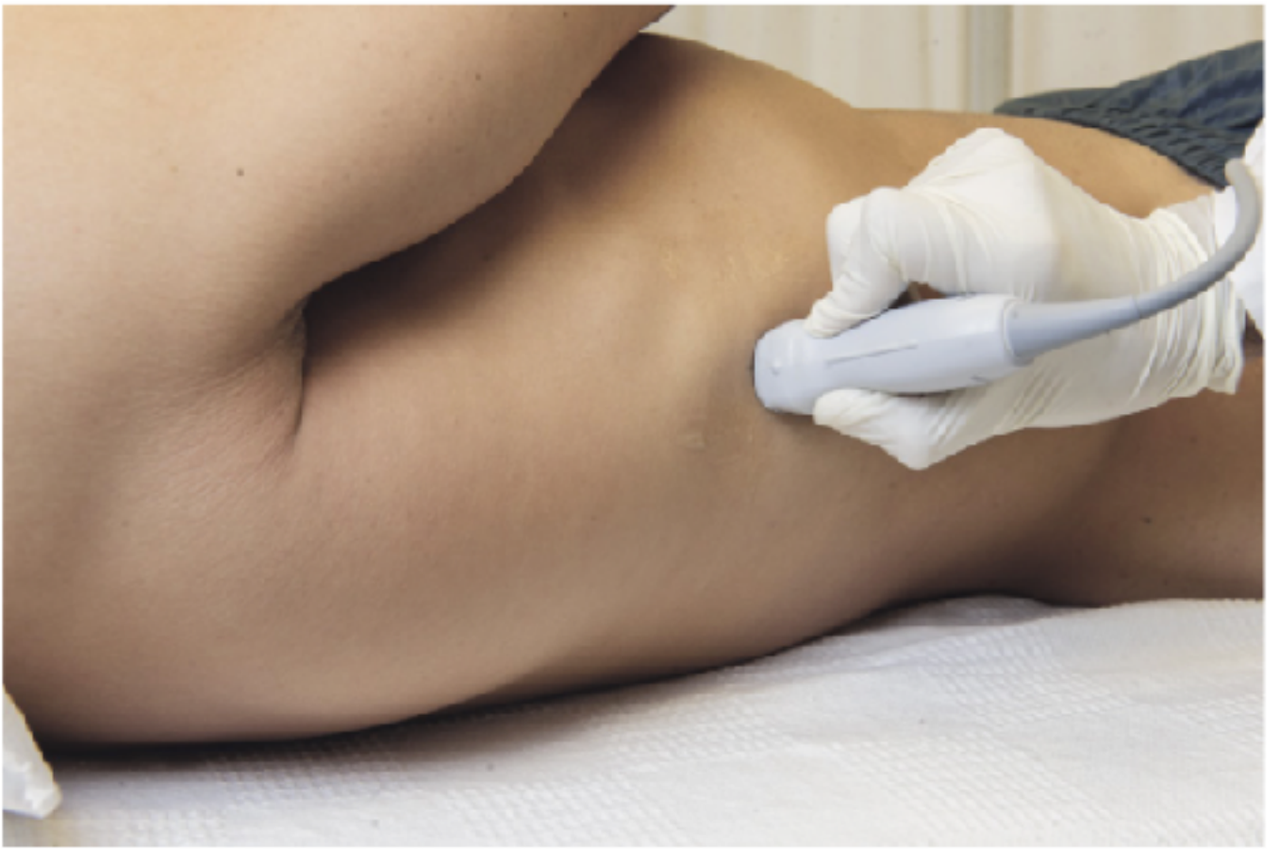

Point 4

Diaphragm





Diaphragm

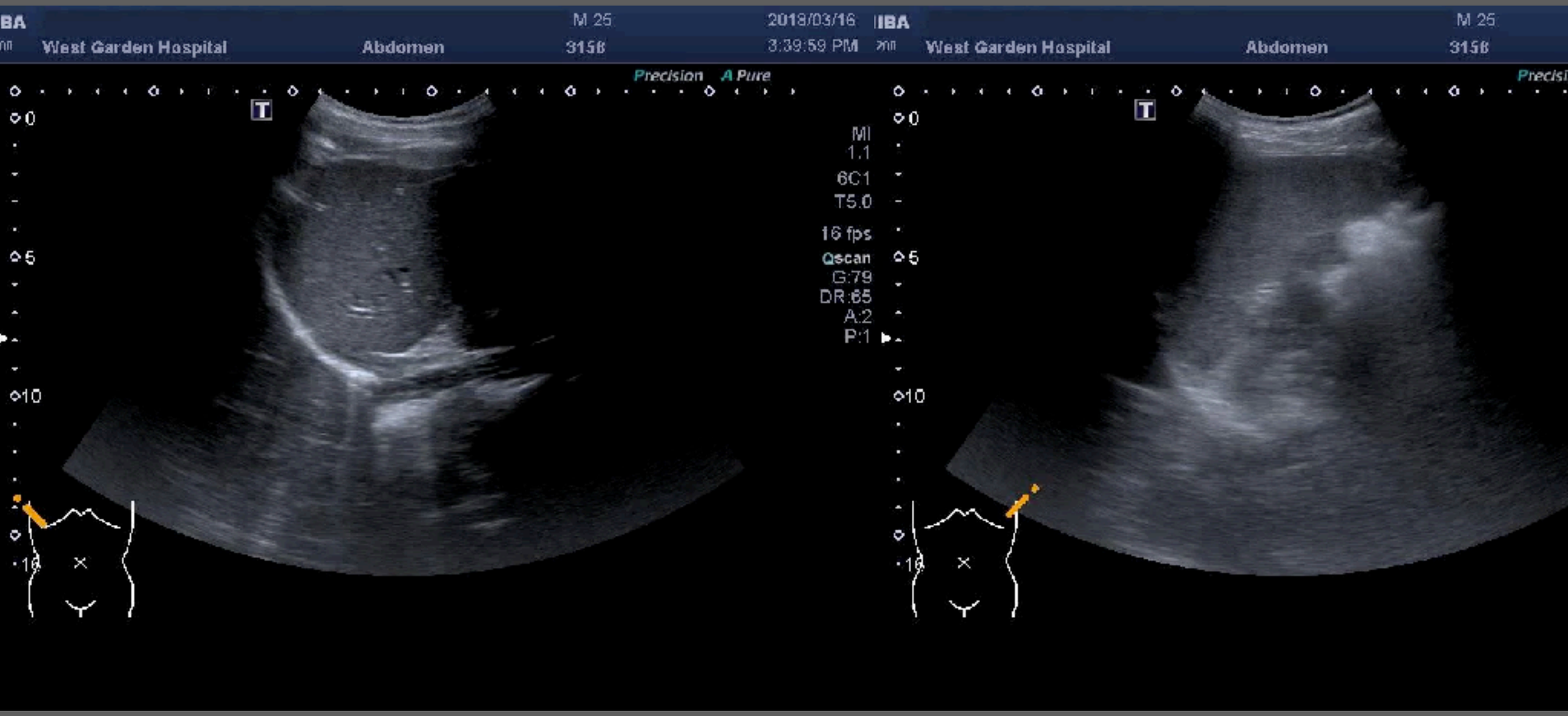
BA
M 25
2018/03/16
3:39:59 PM
West Garden Hospital
Abdomen
315ß
Precision
A Pure
MI
1.1
6C1
T5.0
16 fps
Qscan
G:79
DR:65
A:2
P:1
IBA
M 25
West Garden Hospital
Abdomen
315ß

Diaphragm

Sharp sign

Sinusoid sign

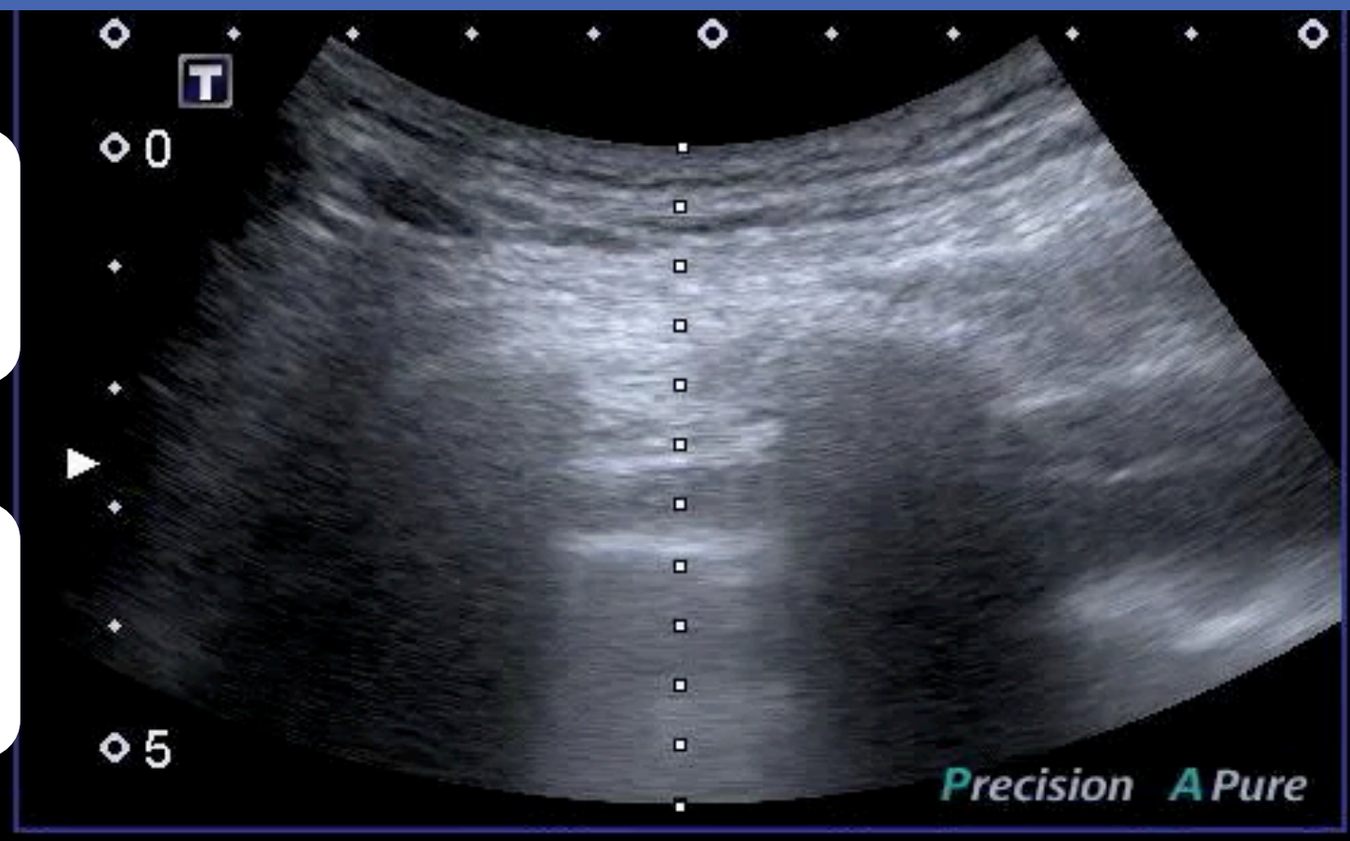

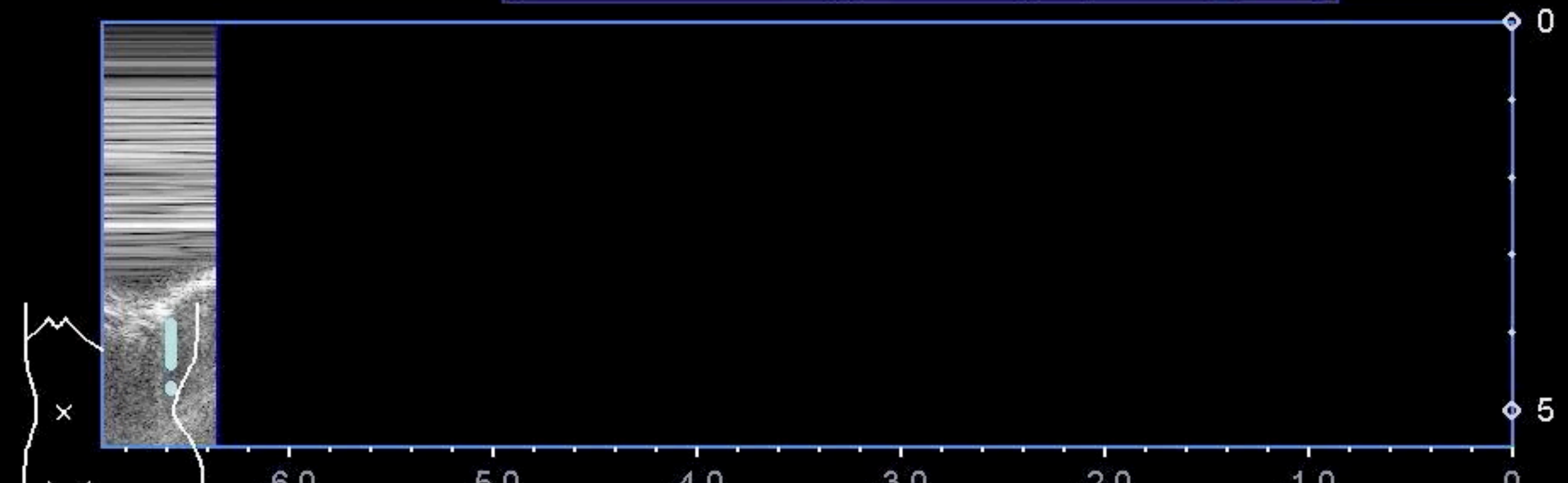

SKH-EUTC©ChenKC

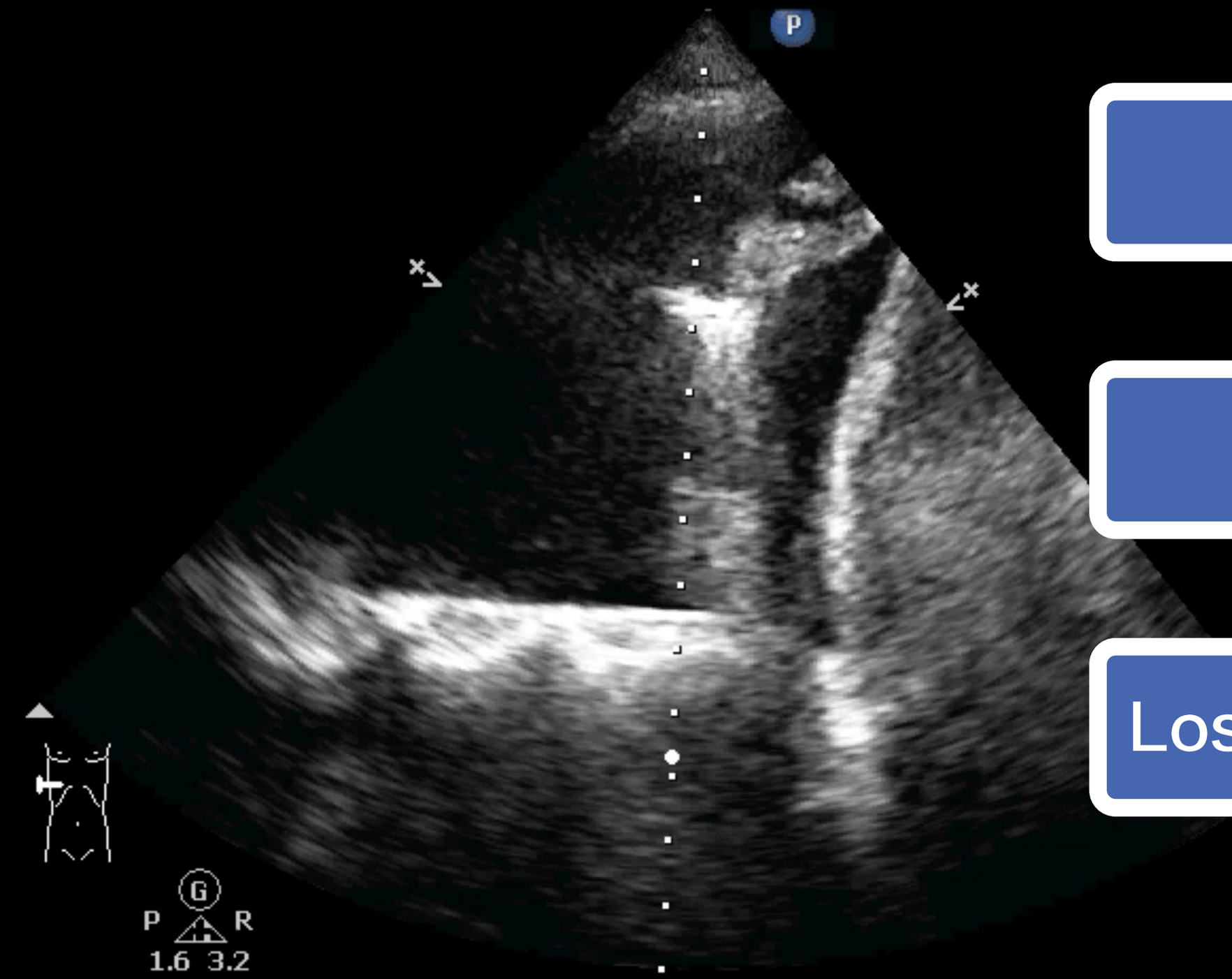

Jellyfish sign

Spine sign

Loss of curtain sign

Plankton sign

P
P
R
1.6 3.2

P
P
R
1.6 3.2

D aorta

Pericardial

vs

Pleural

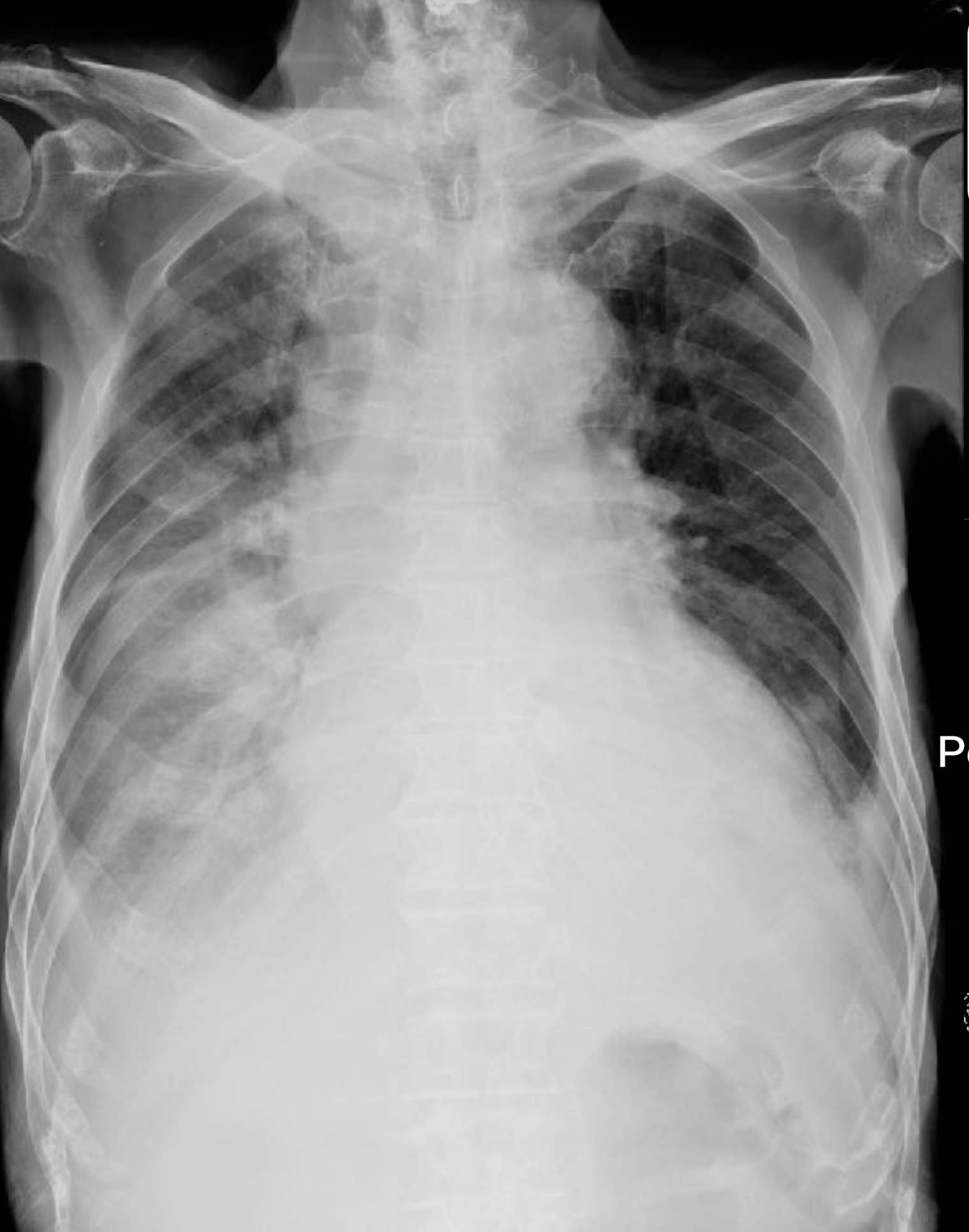

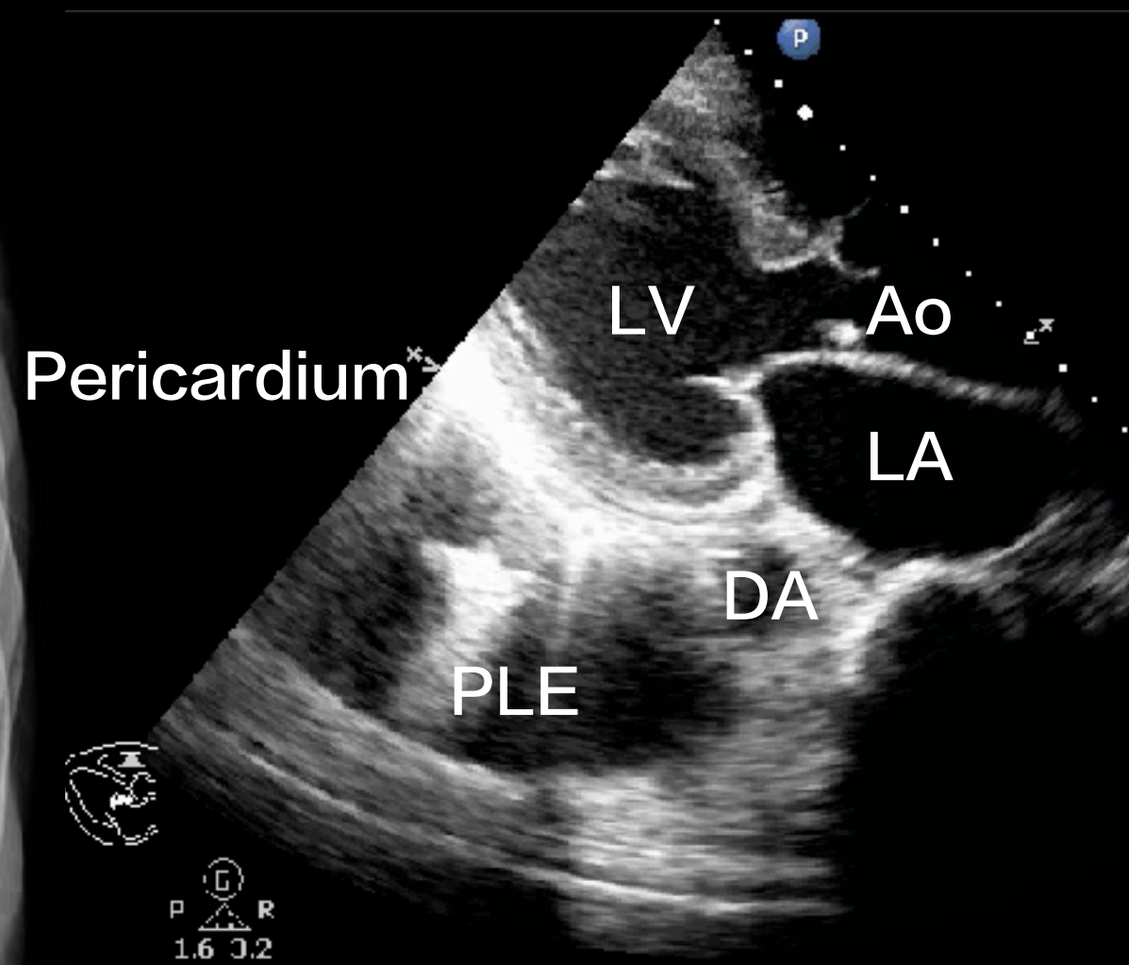

50M, F & Cough

Parapneumonic Effusion

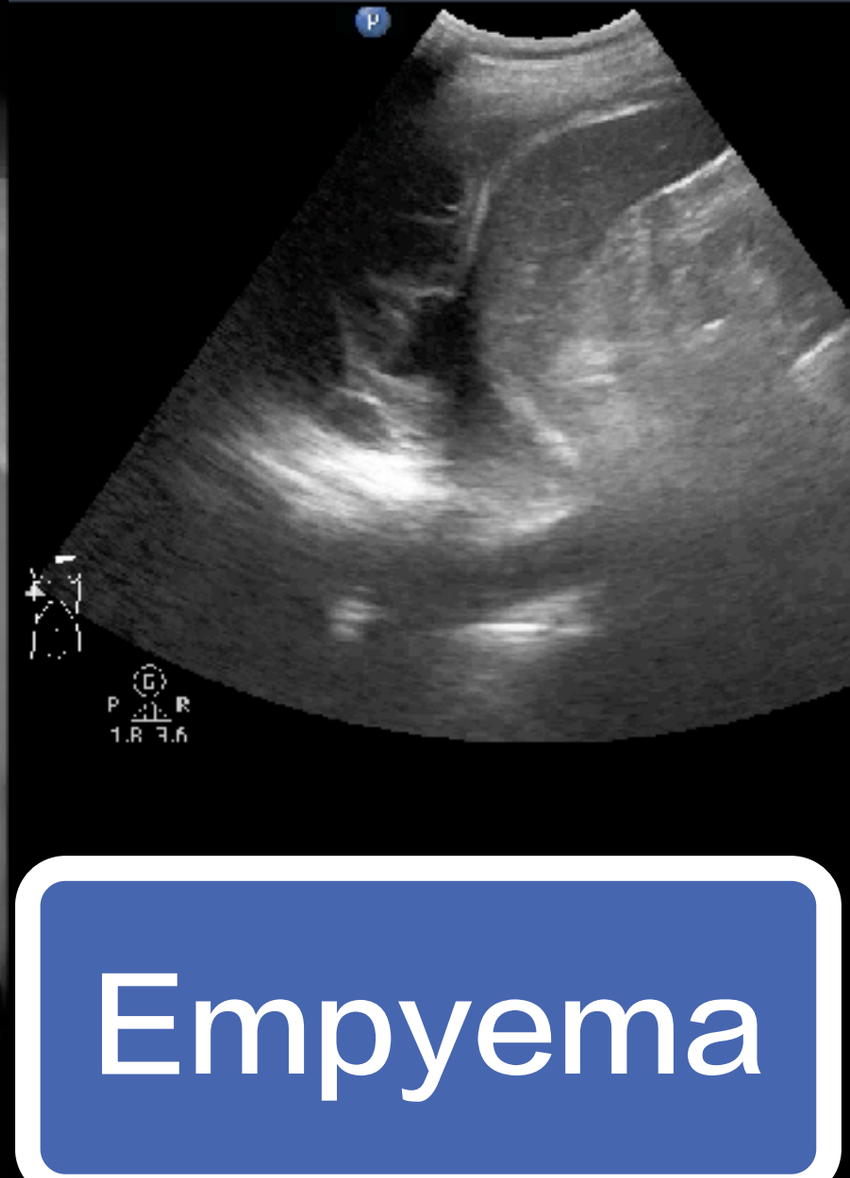

Empyema

Septation
Fibrin
Particles

73M, F & Dyspnea

Empyema

What do you see ?

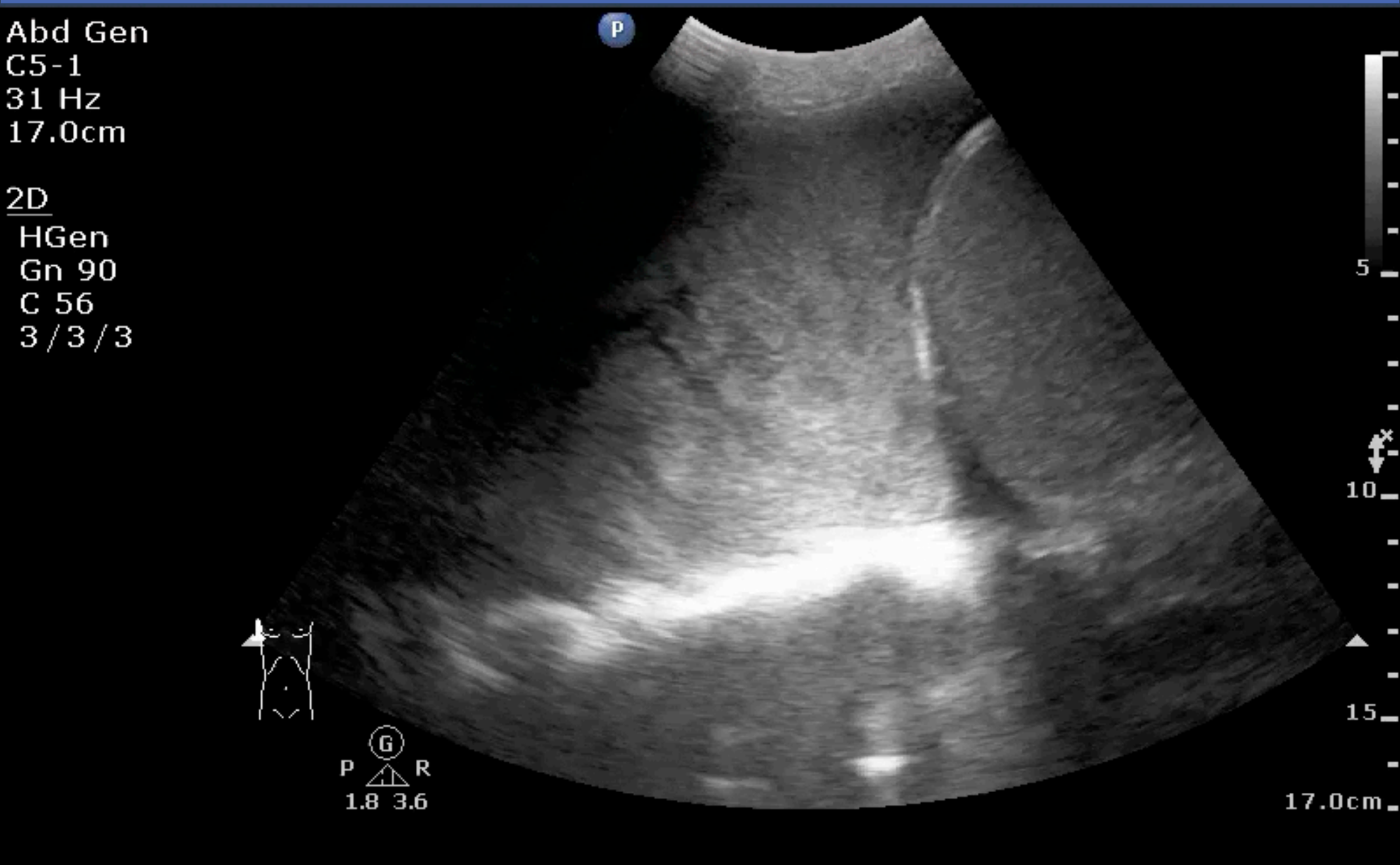

R

P

R

P

US for PLE

Detection

Volume

Nature

Safety

Drainage

Improve ventilatory mechanics & Assist weaning

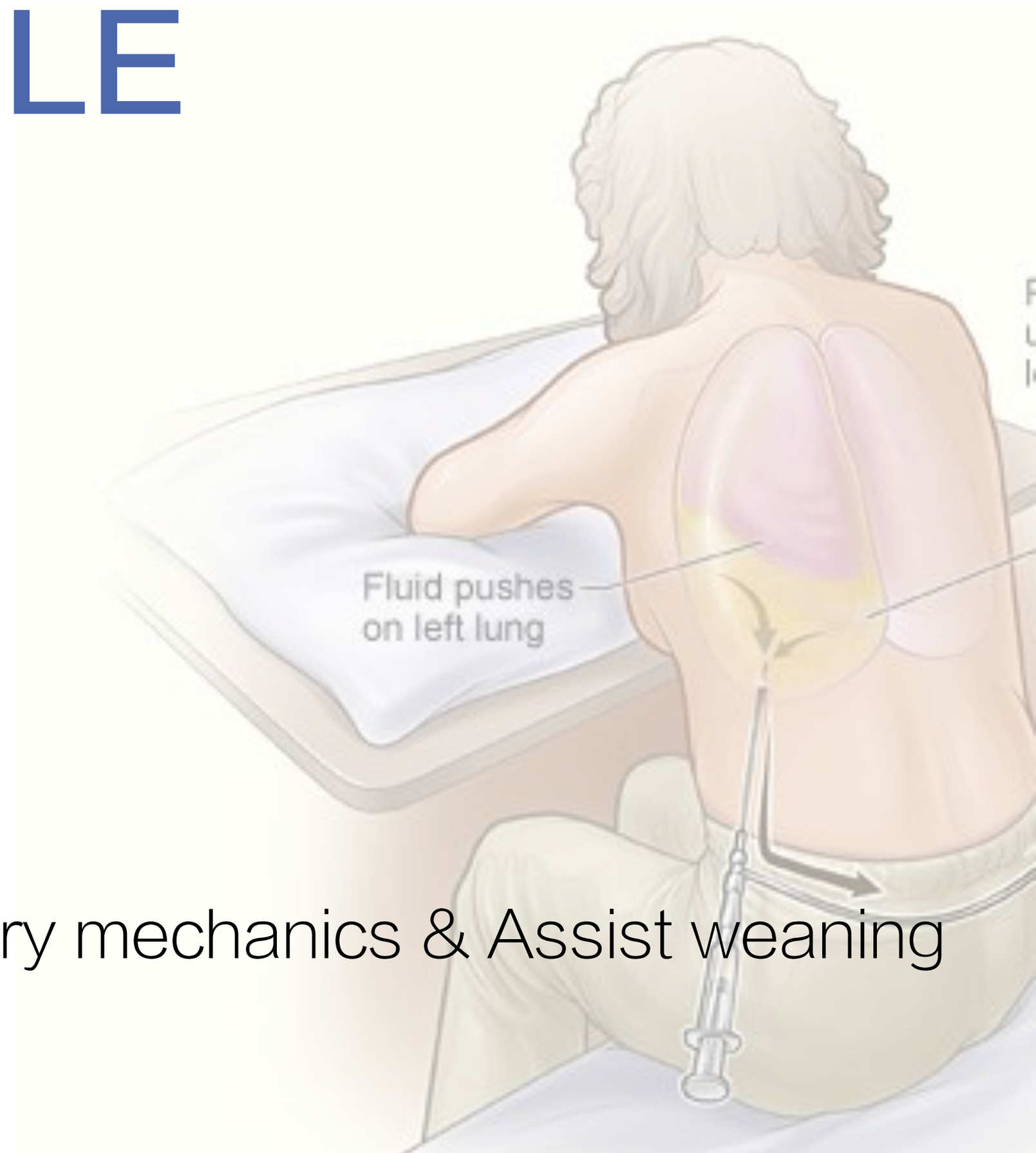

28F, 來抽肋膜積液吧 !?

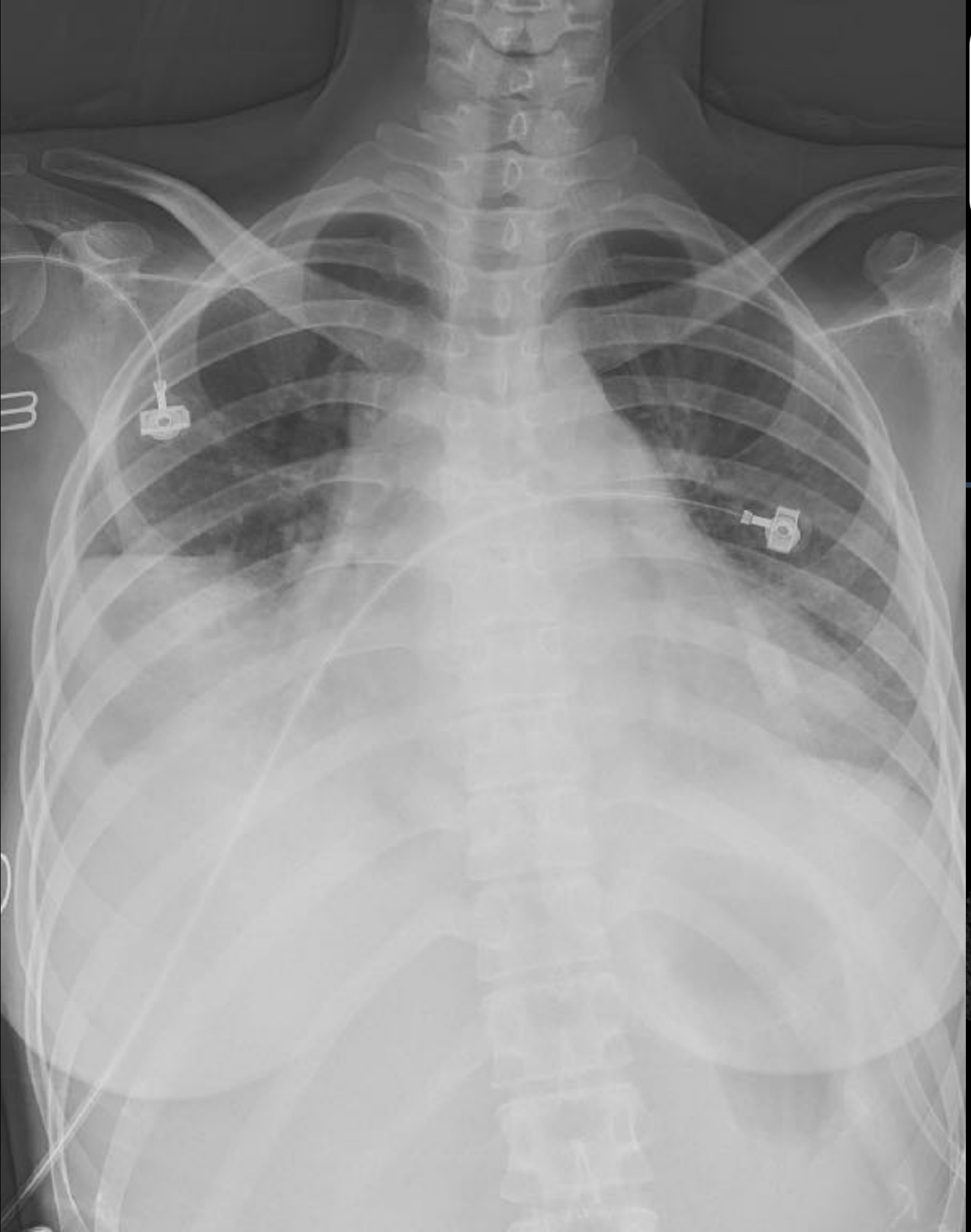

Pneumonia

Consolidation
Air-bronchogram

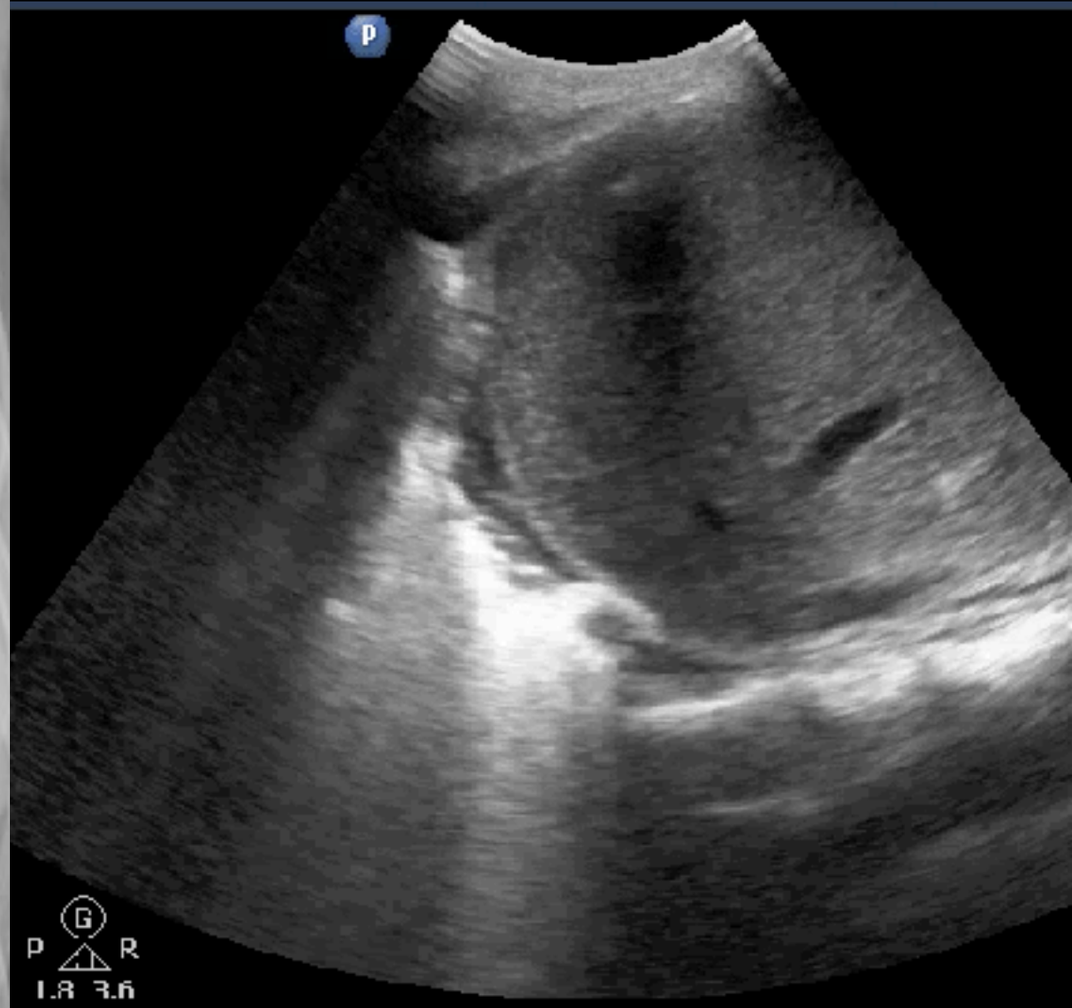

Consolidation

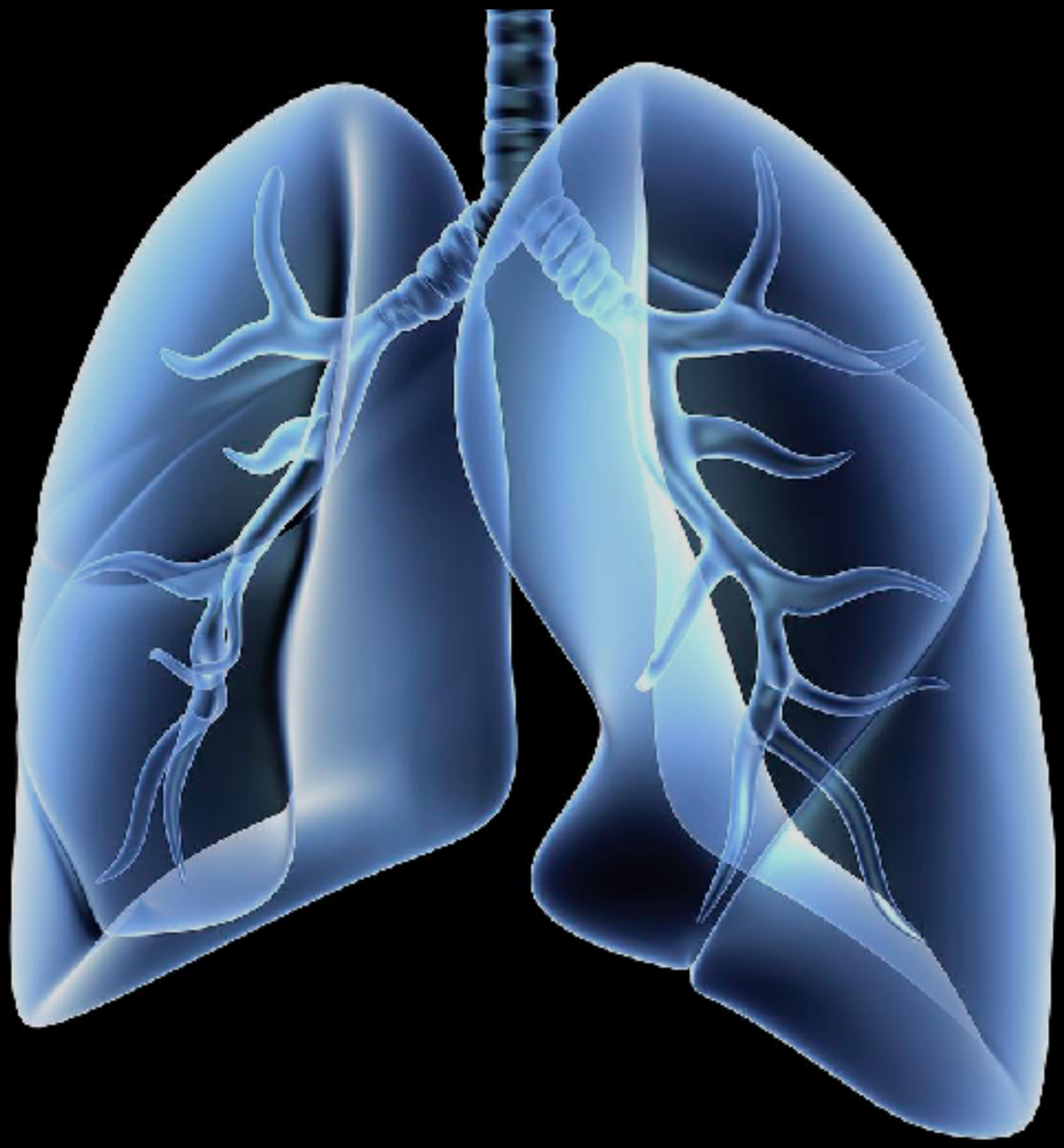

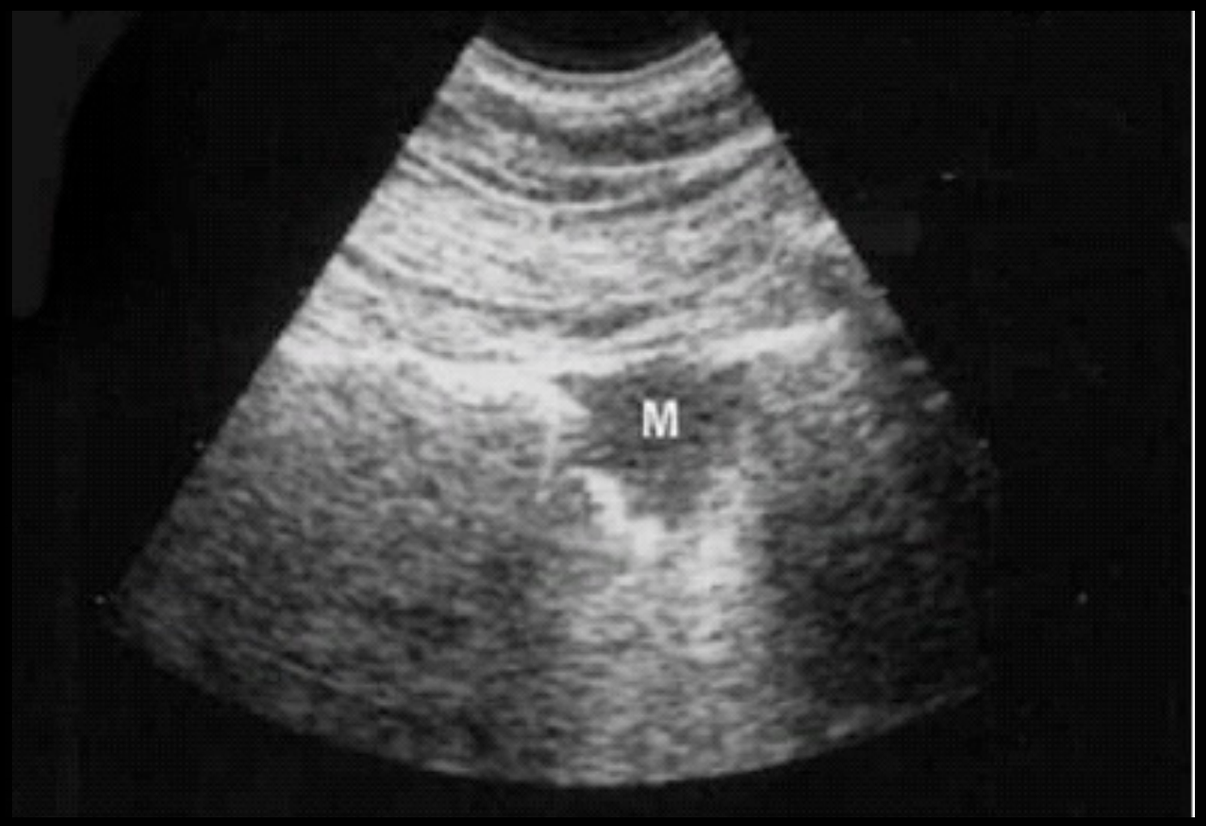

98.5% abut the pleura
Sensitivity 90%
Specificity 98%

LUS for Consolidation

Table 3 Lung ultrasound in the diagnosis of lung consolidation

Study (first author)	n	US sensitivity/specificity (%)	Ultrasound LR+/LR−	Gold standard	Sonographer type
Lichtenstein[3]	32	93/100	Undefined/0.07	CT	Experienced intensivist
Lichtenstein[7]	118	90/98	45/0.1	CT	Experienced intensivists
Lichtenstein[6]	260	89/94	15/0.12	Final clinical diagnosis	Experienced intensivists
Xirouchaki[22]	42	100/78	4.5/0	CT	Experienced intensivist
Corterello[4]	81 (pneumonia)	98/95	20/0.021	Final clinical diagnosis	Experienced EP
Chavez[70]	1172 (pneumonia)	94/96	24/0.063	CXR, CT or clinical criteria (meta-analysis)	Meta-analysis varied
Nazerian[71]	285	83/96	21/0.18	CT	Experienced EP or internist
Llamas-Álvarez[41]	2359	80–90/70–90	Not calculated	Meta-analysis	Meta-analysis varied

ChenKC@POCUSAcademy Wimalasena Y, et al. EMJ 2107

















C profile

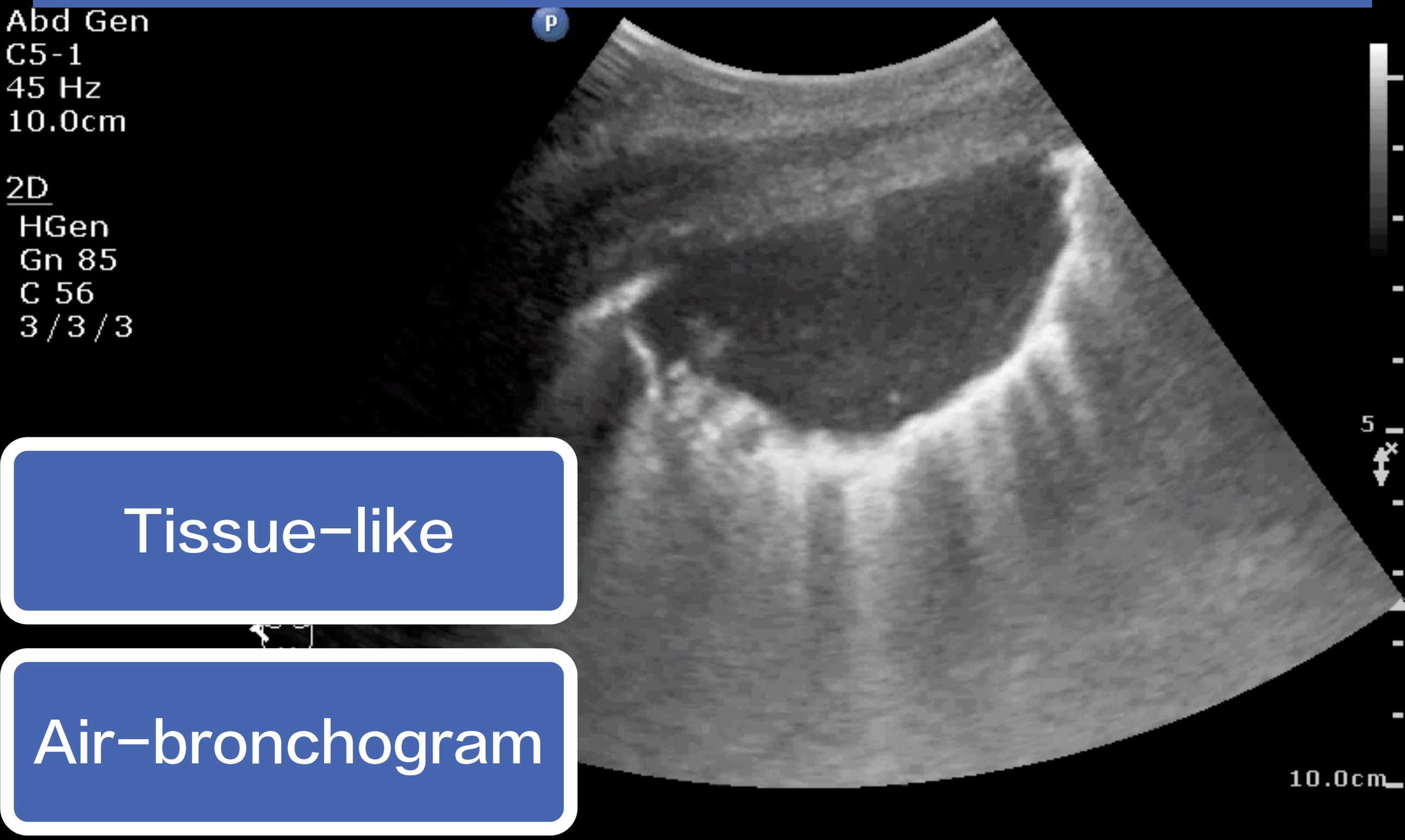

Tissue-like

Air-bronchogram

Dynamic air-bronchogram

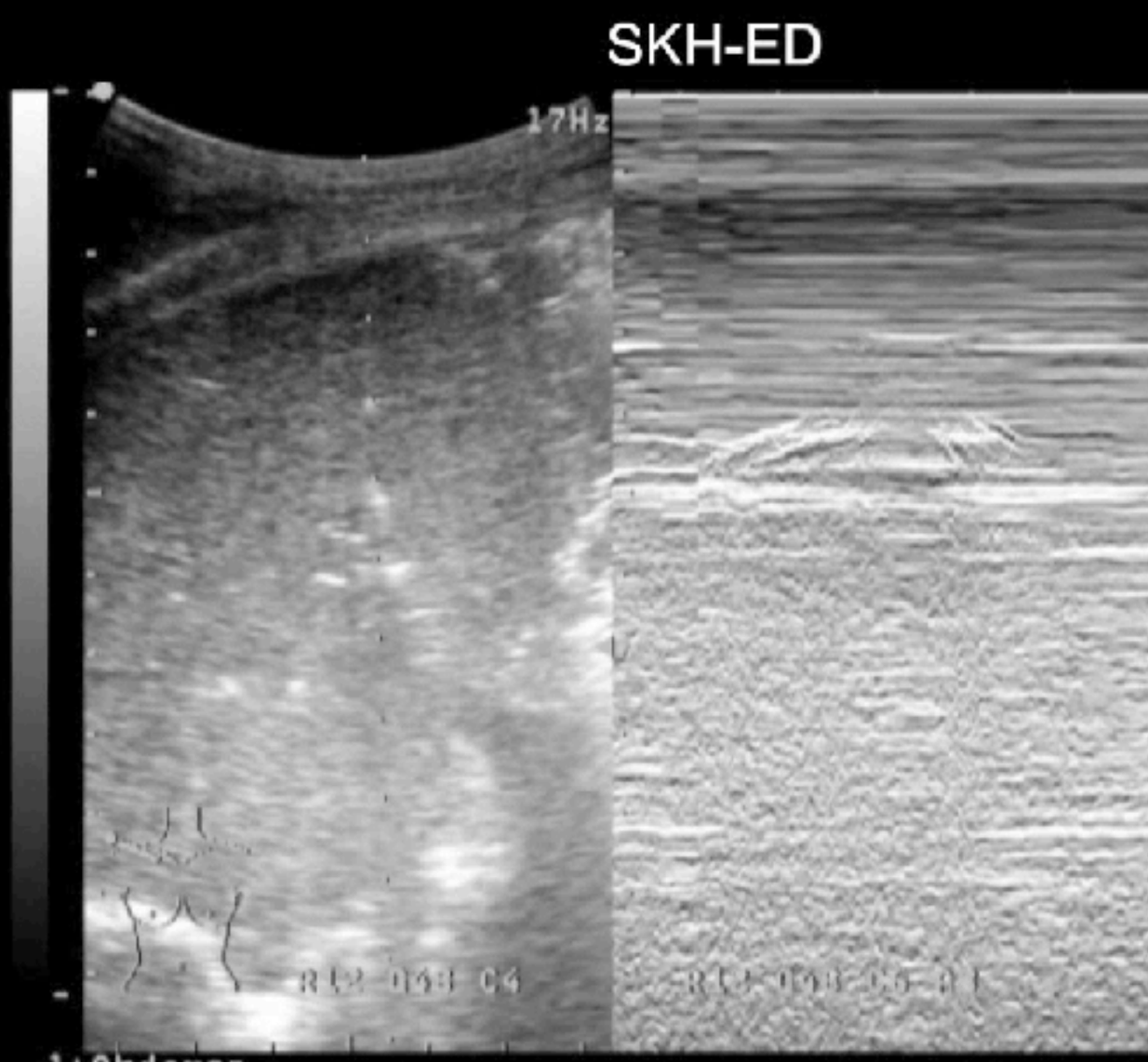

ABCD

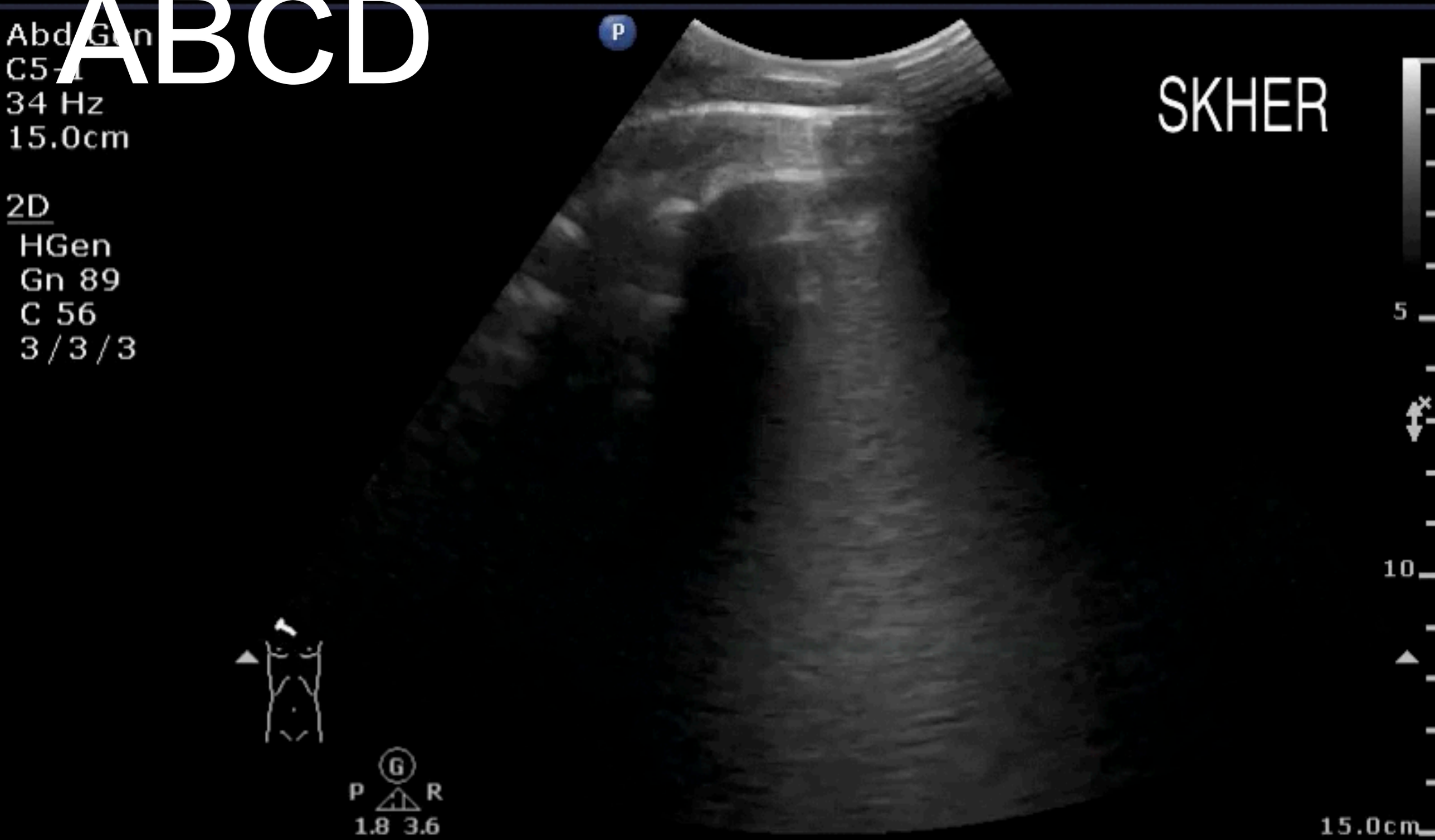
Abd HGen
C5-1
34 Hz
15.0cm
2D
HGen
Gn 89
C 56
3/3/3
P
SKHER
5
10
15.0cm
G
P
R
1.8 3.6

L

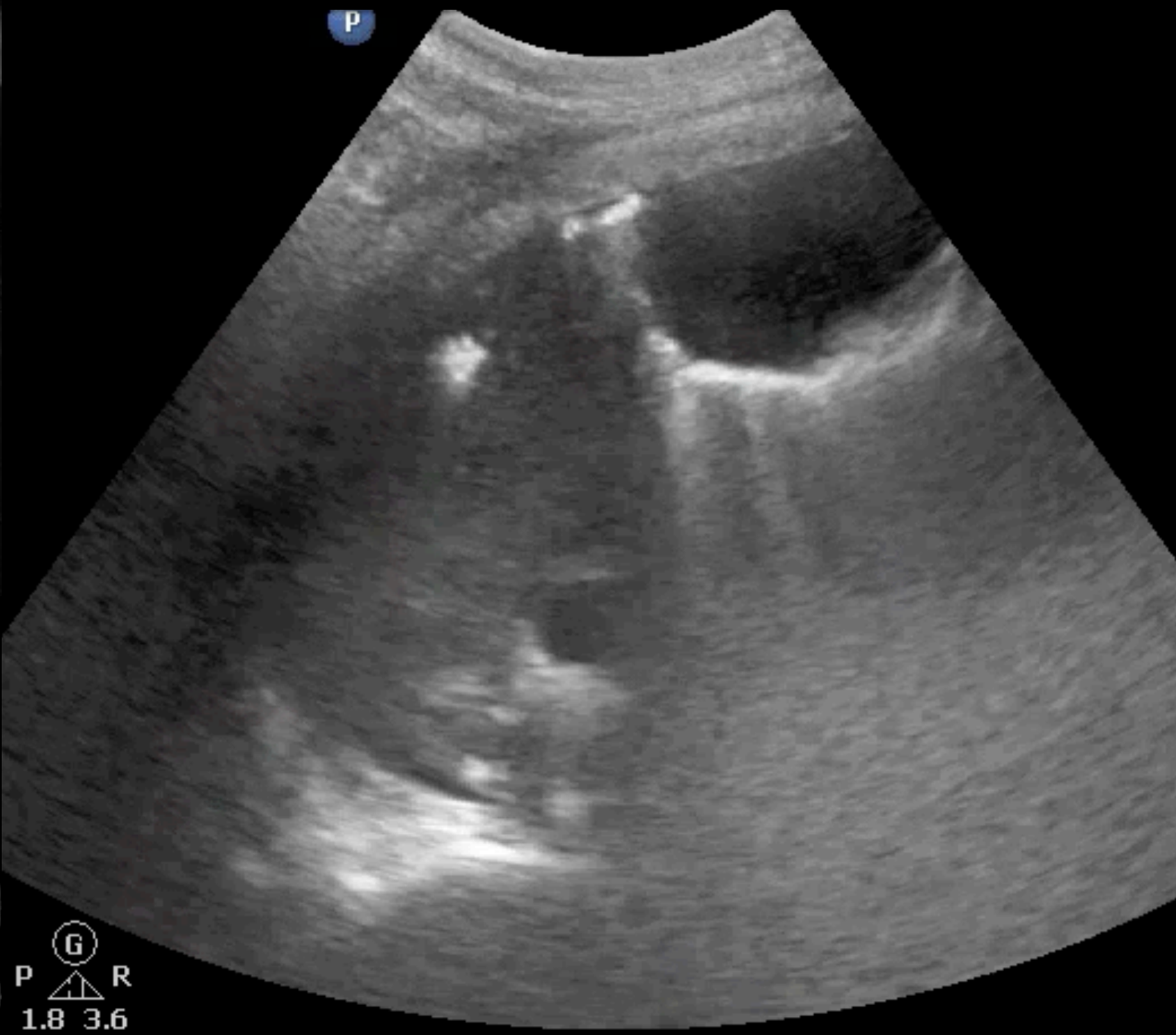
P

G
P
R
1.8 3.6

Superficial
L12-3
41 Hz
5.0cm

2D
Res
Gn 100
C 56
3/2/1



G
P R
3.0 12.0

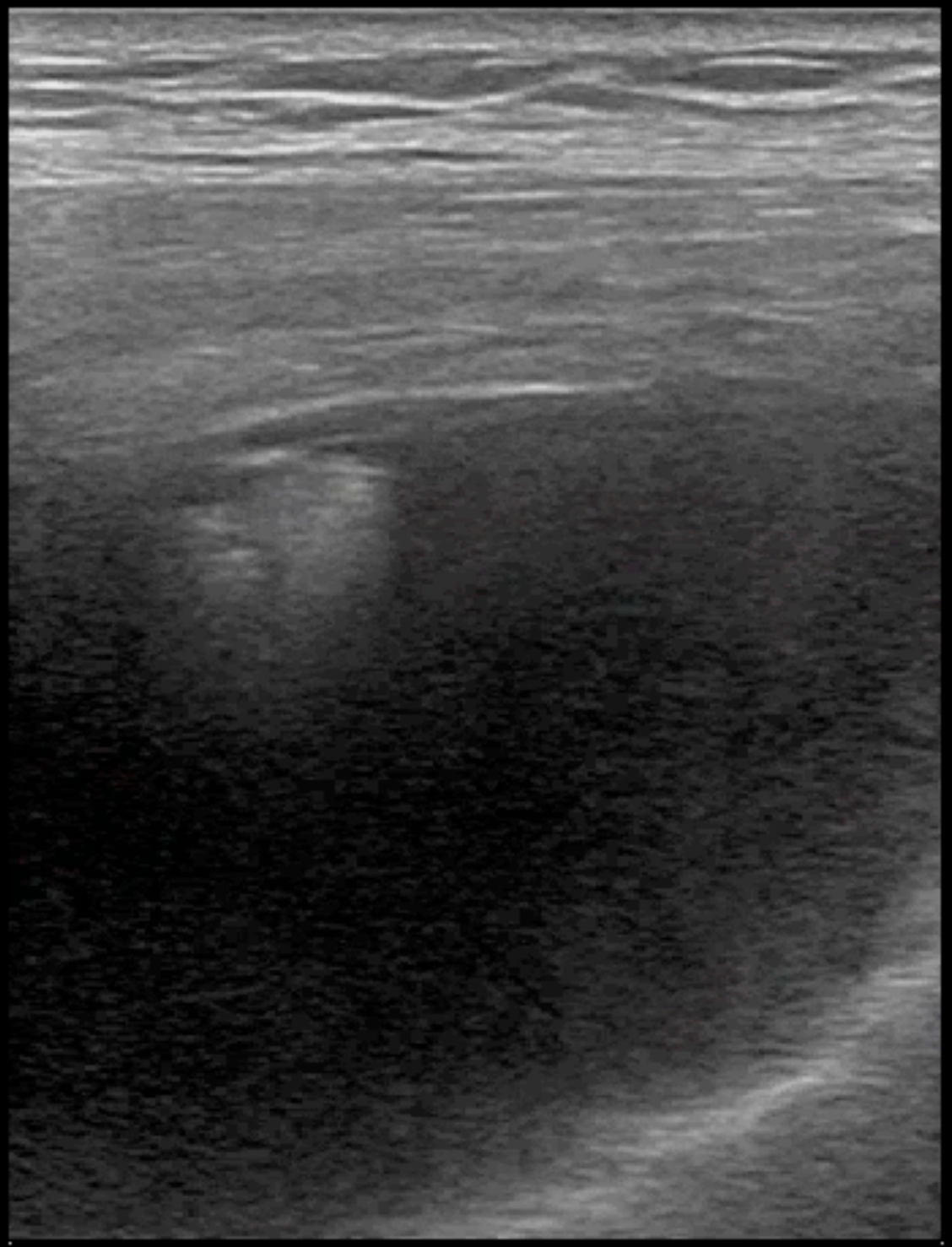

2

4

5.0cm

76M, Dyspnea & desaturation

76M, Dyspnea & desaturation

Sex	M		Prolonged QT.
Study Date	2017/10/15 22:12:14	P-R-T axes	19 ,93 ,51
			Abnormal ECG.

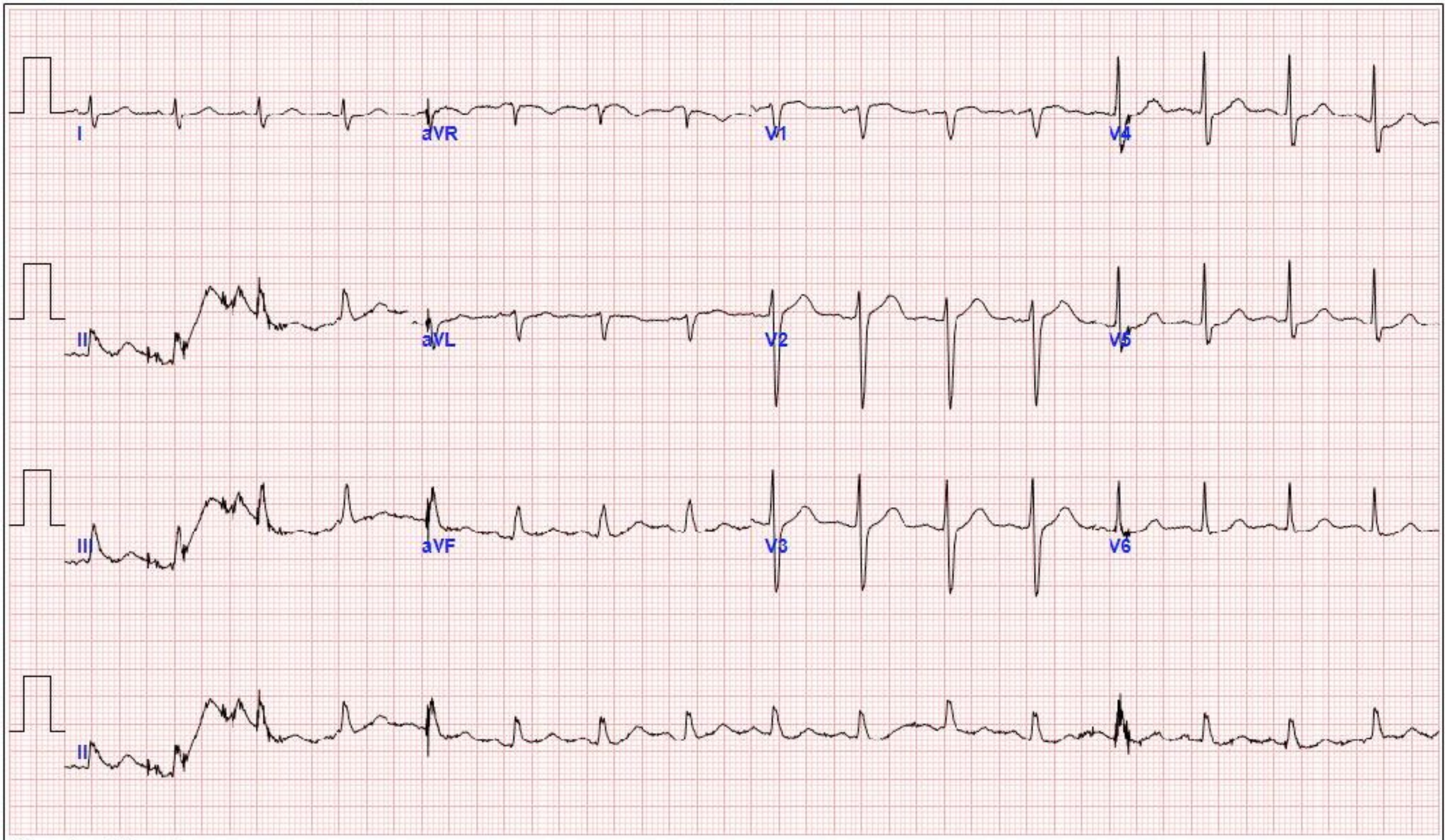

25 mm/sec 10 mm/mv

76M, Dyspnea & desaturation

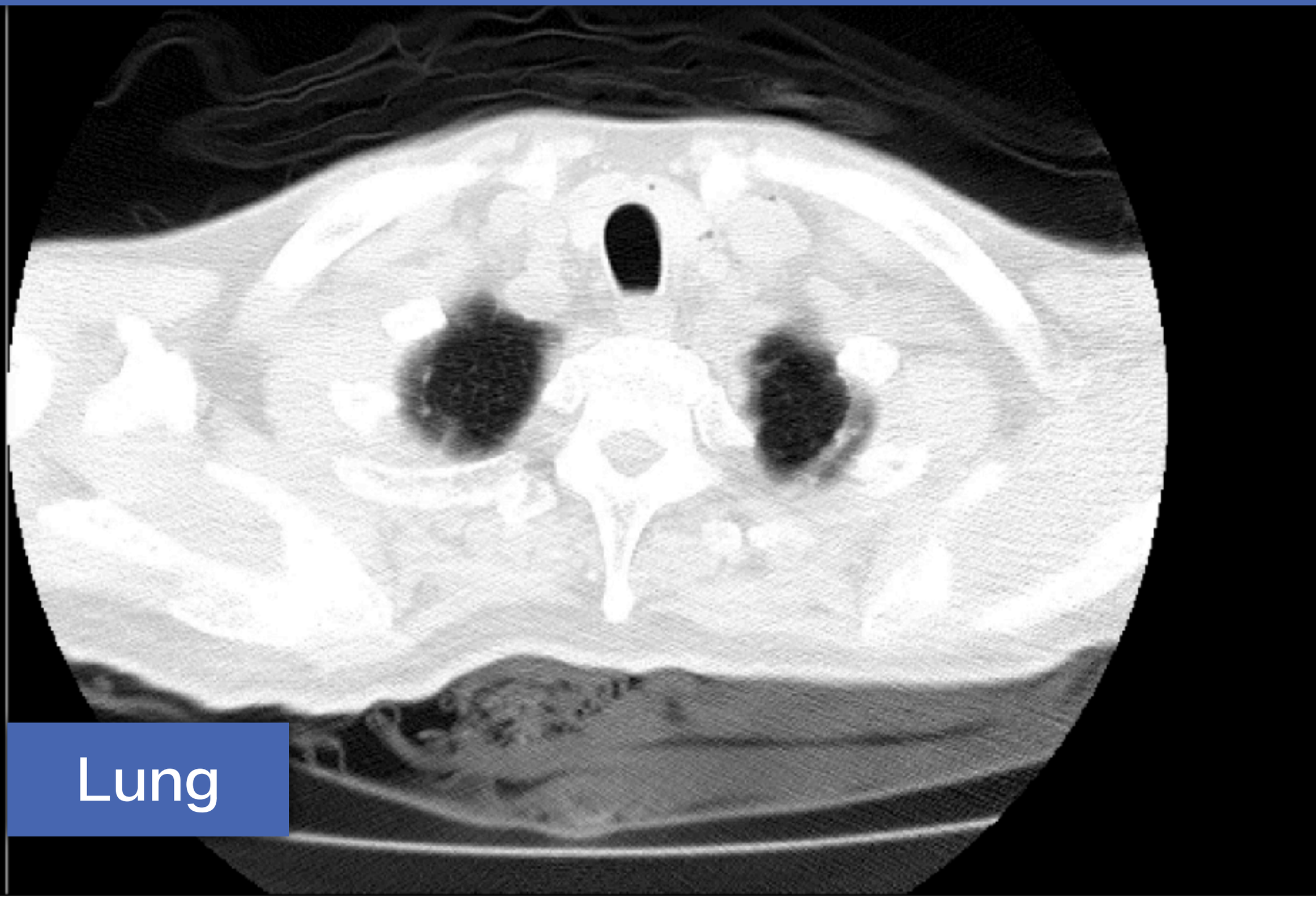

Lung

76M, Dyspnea & desaturation

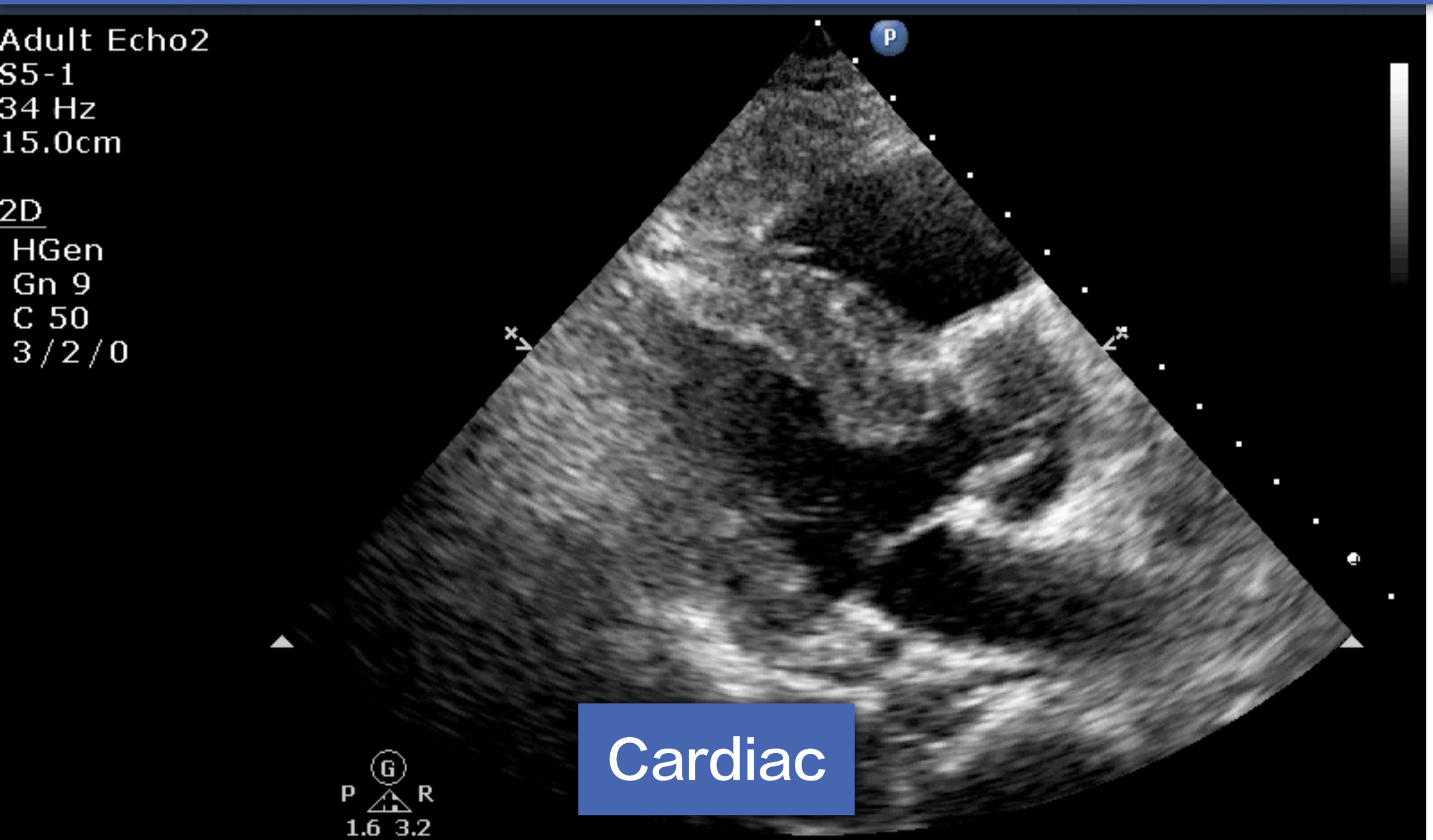

76M, Dyspnea & desaturation

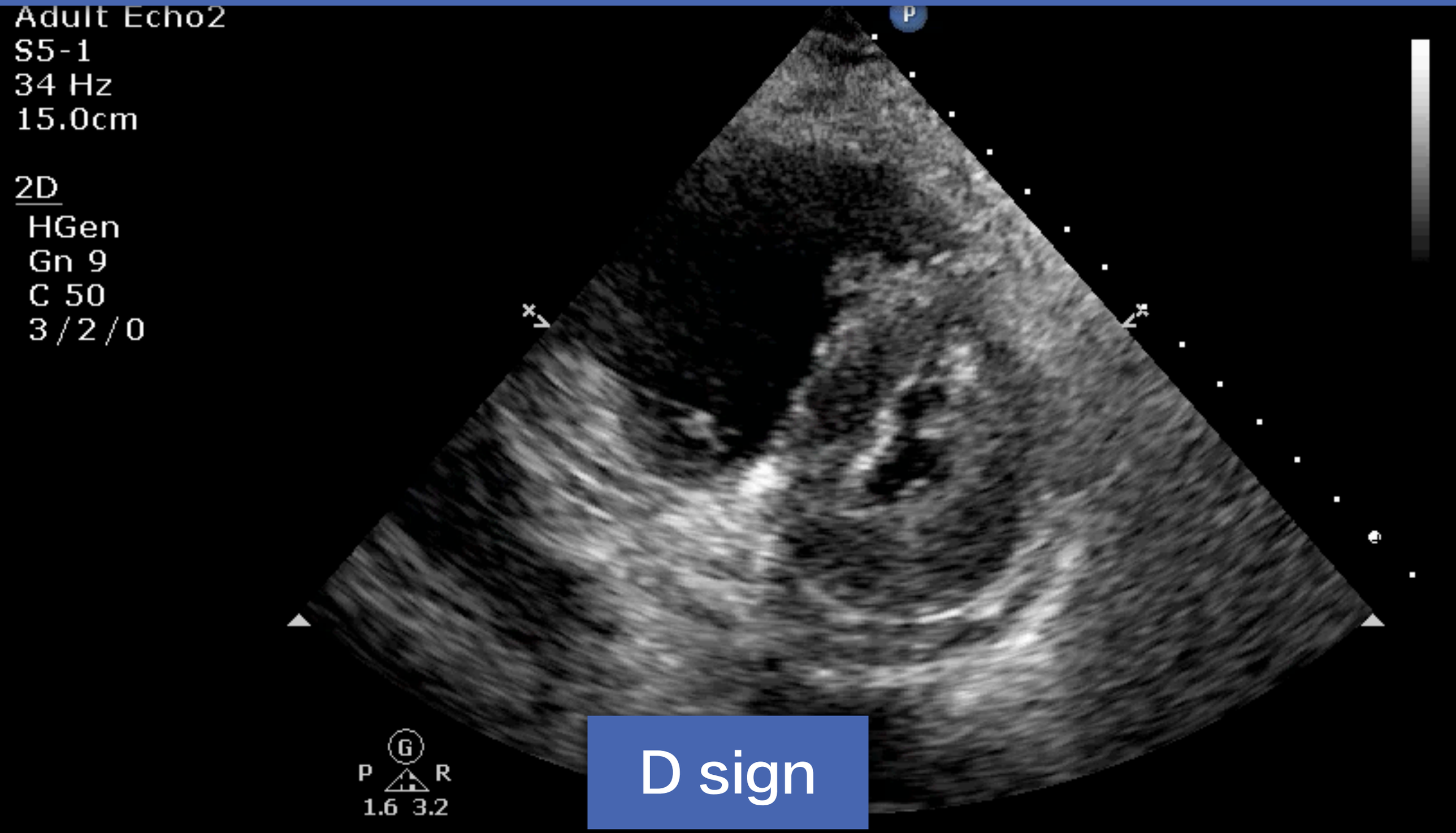

Pulmonary embolism

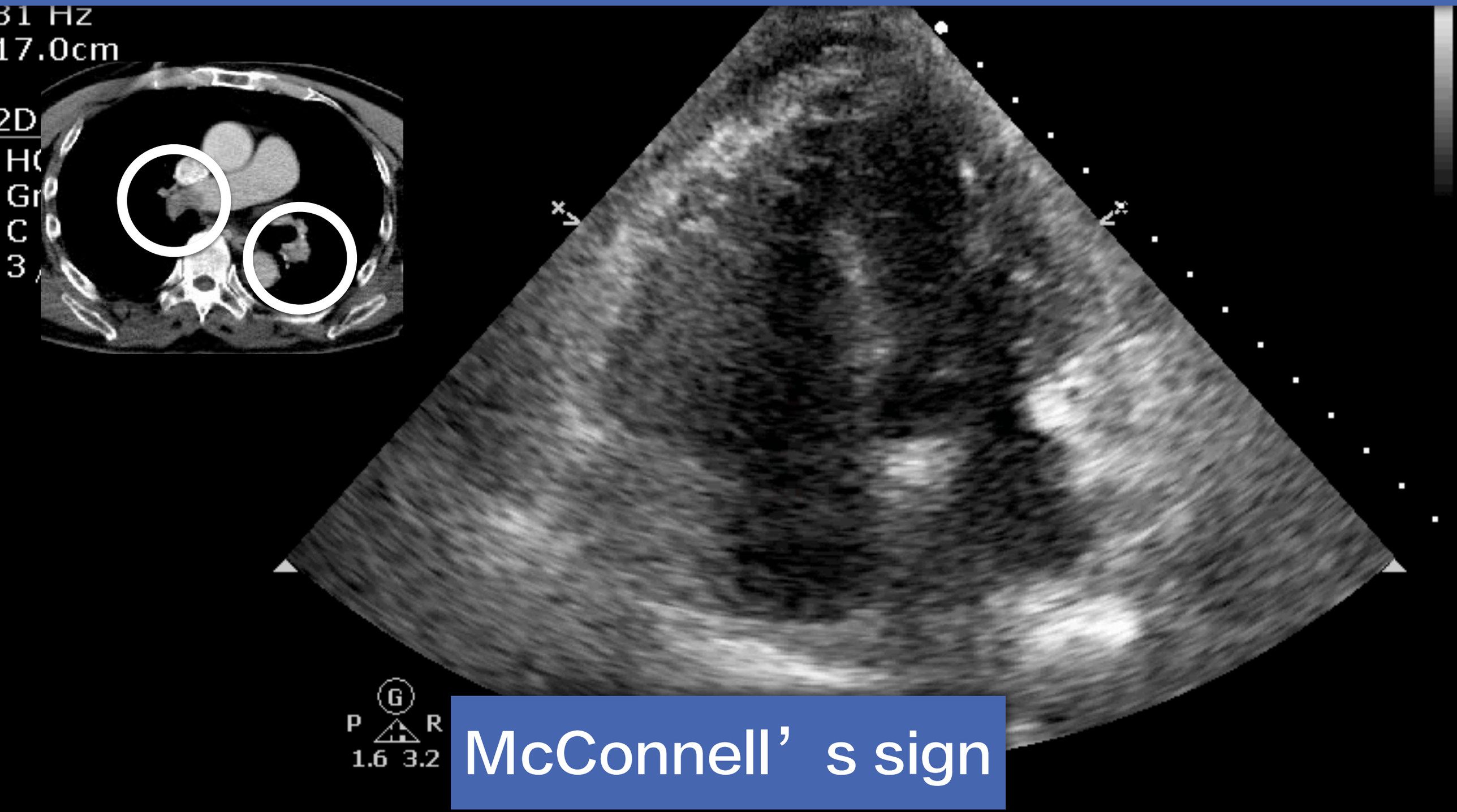

McConnell’s sign

Pulmonary embolism

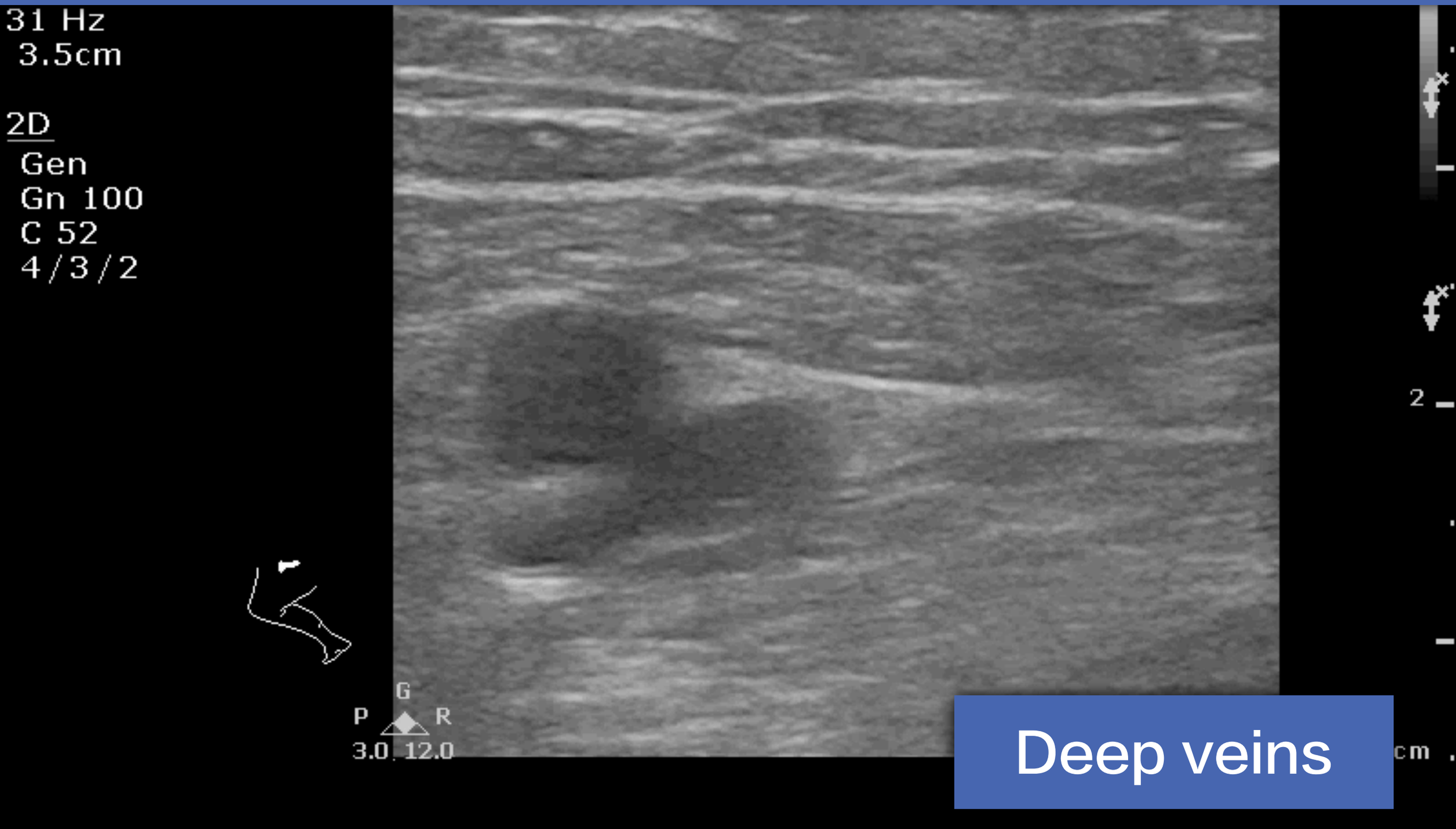

Deep veins

Pulmonary embolism

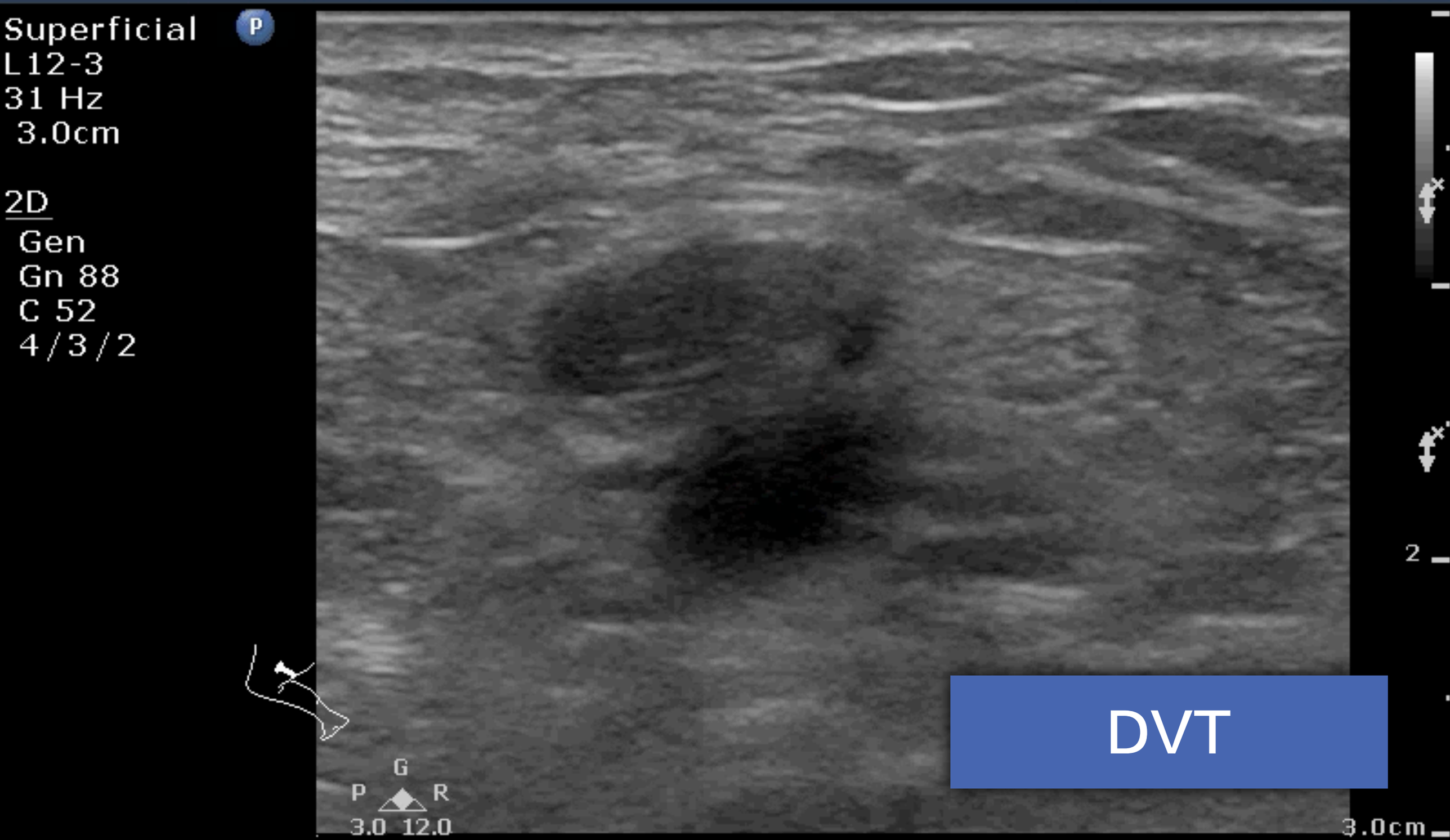

Pulmonary infarction

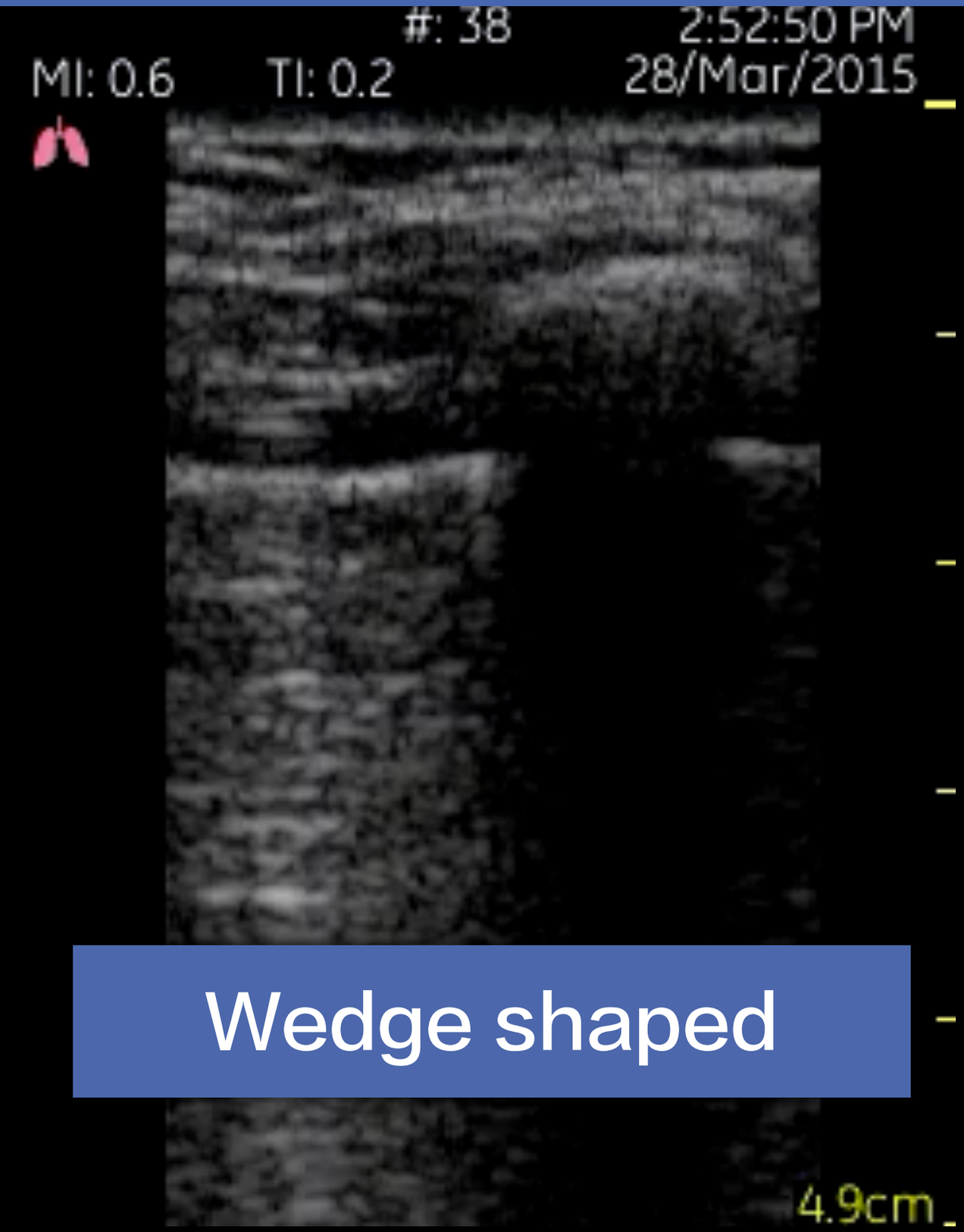

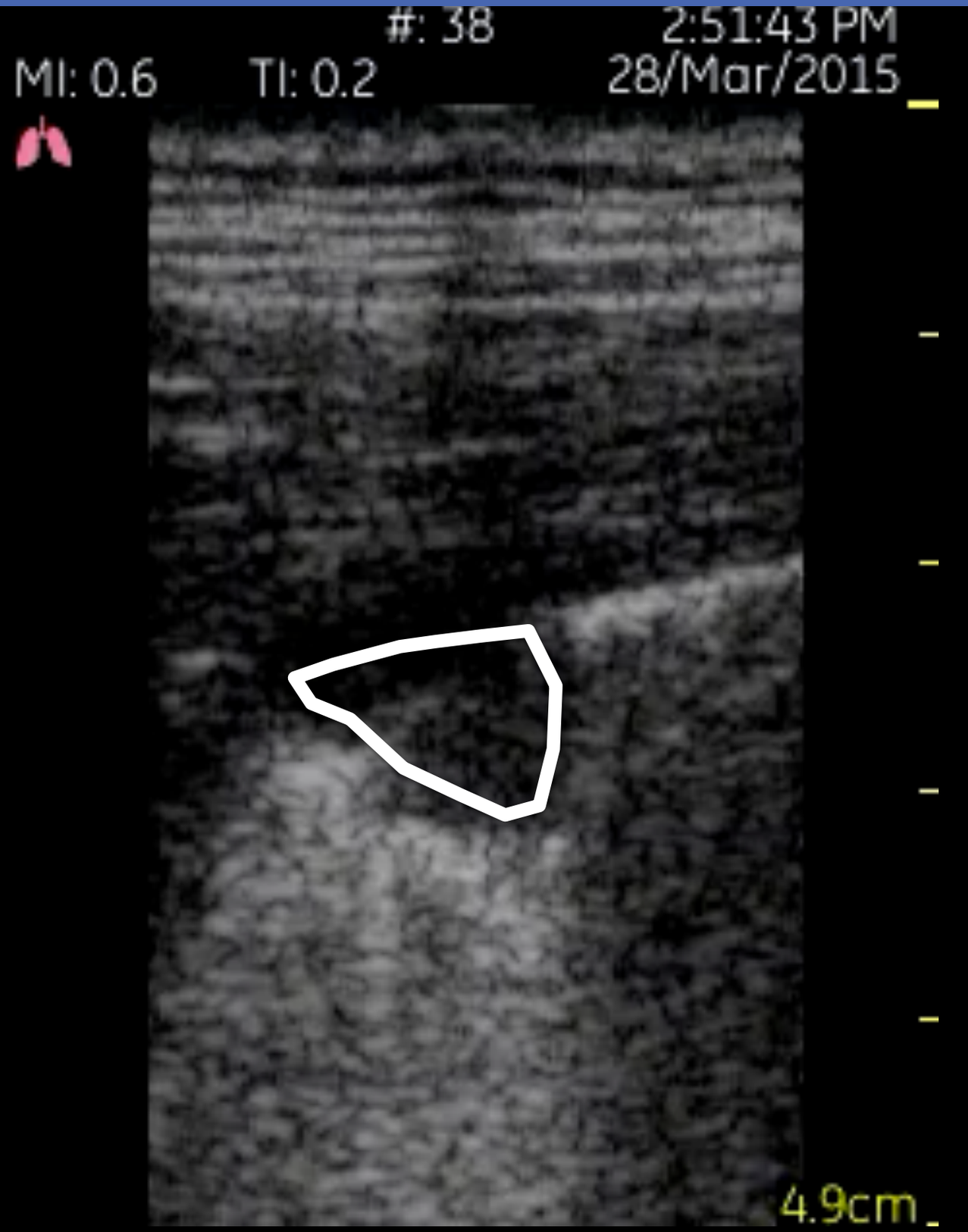

Wedge shaped

過來人的建議

呼吸喘看肺－心－靜

肺栓塞看靜－心－肺

ChenKC@POCUSAcademy

18M, MBA Victim

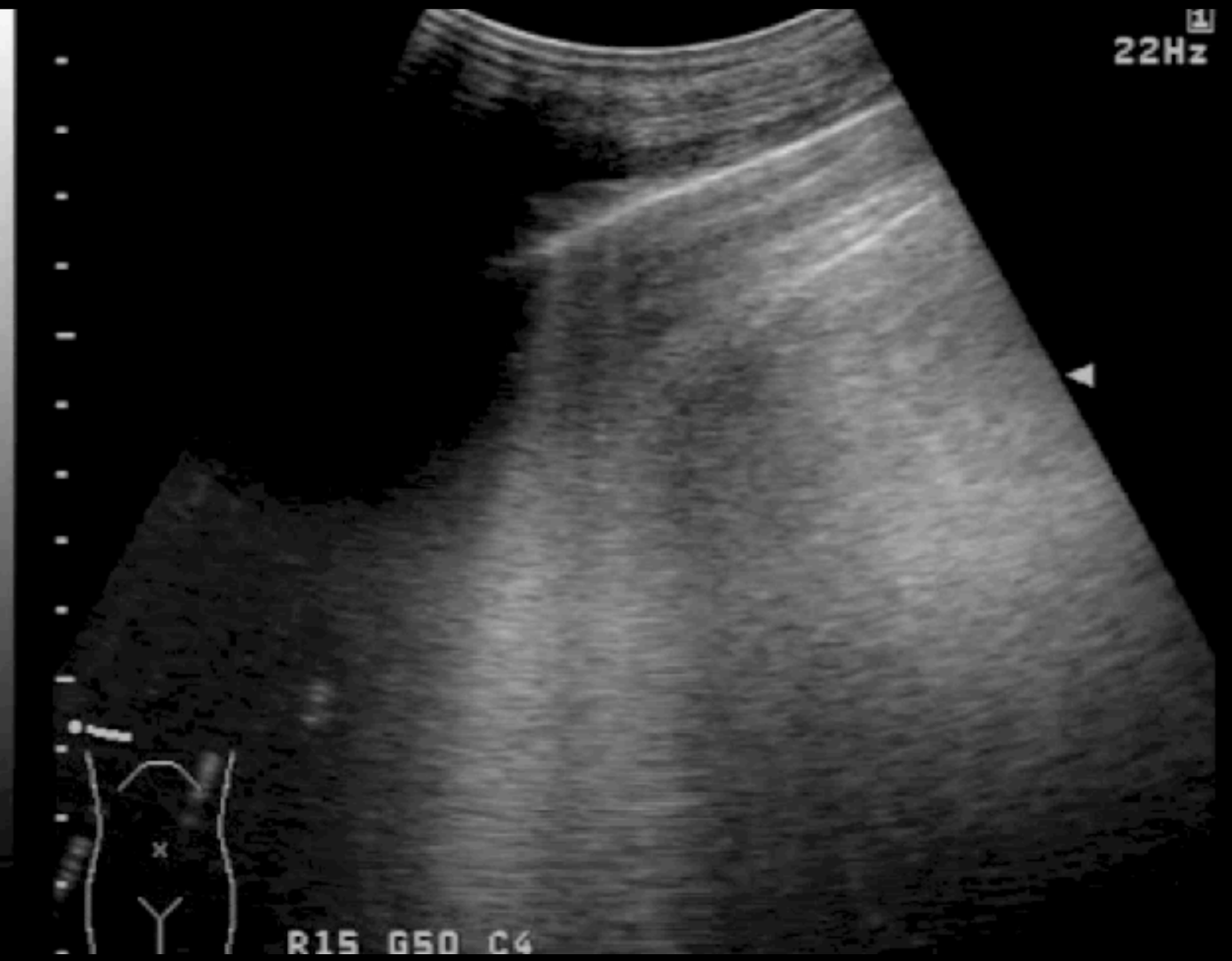

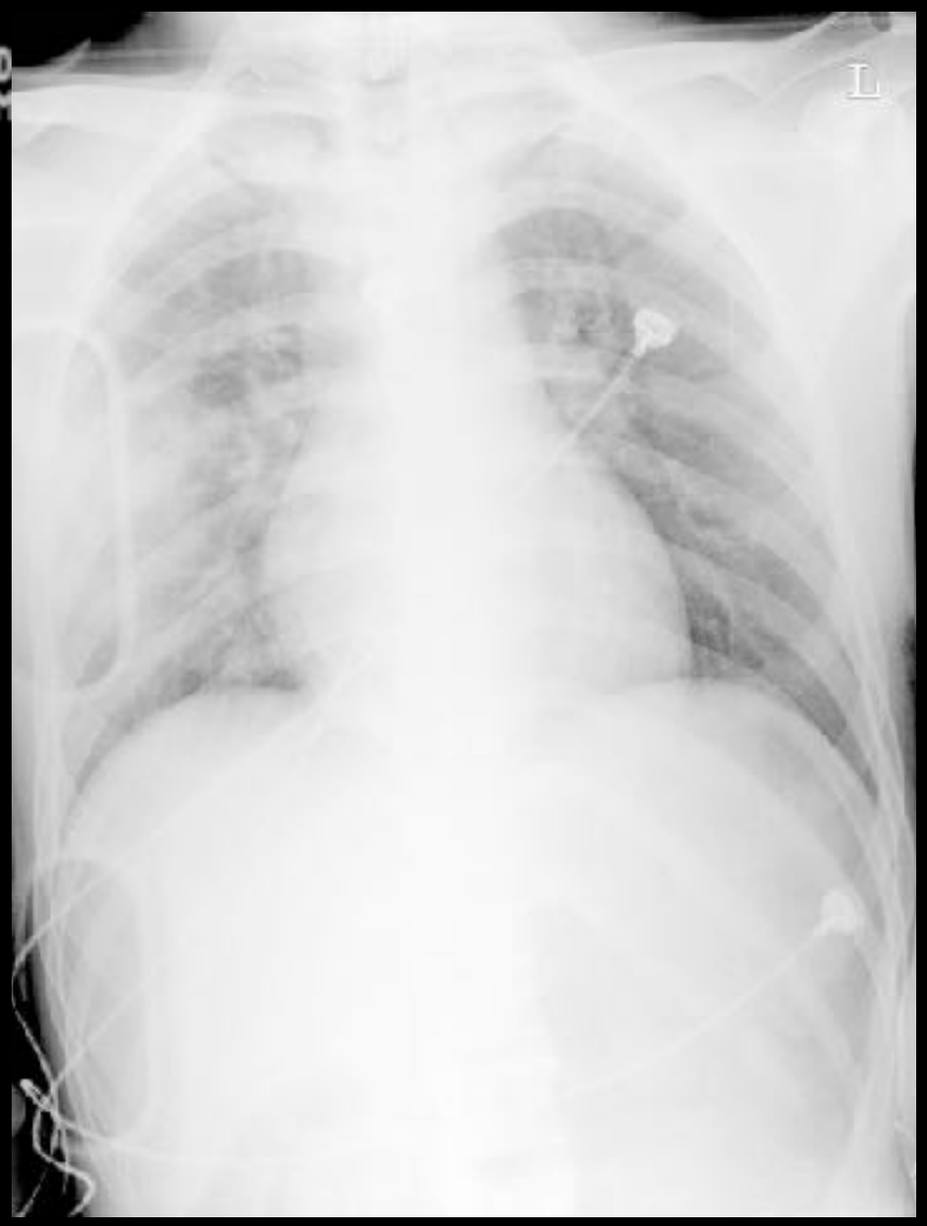

Back !!!

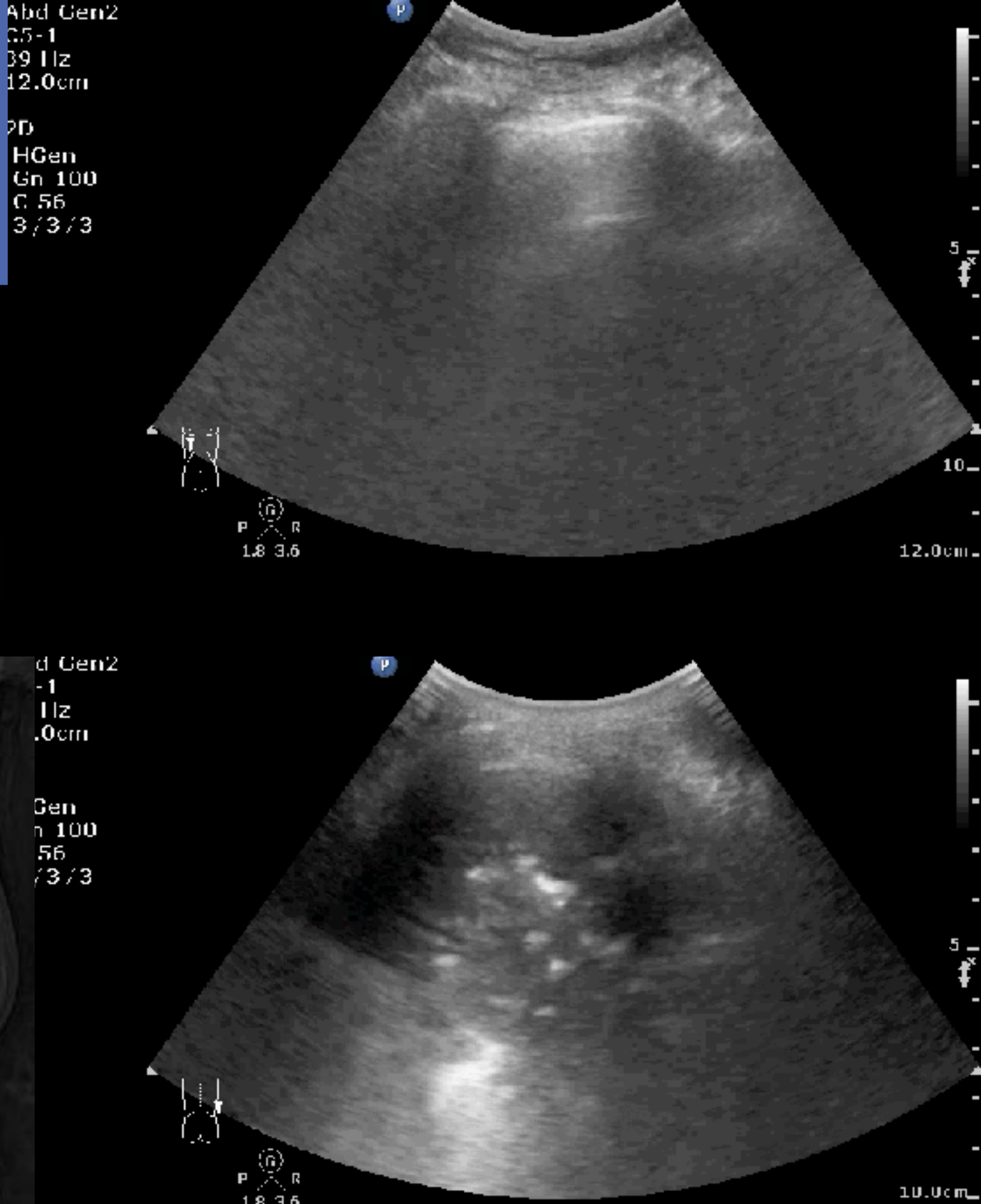
Abd Gen2
C5-1
39 Hz
12.0cm
9D
HGen
Gn 100
C 56
3/3/3
P
P R
1.8 3.6
5
10
12.0cm

d Gen2
-1
Hz
.0cm
Gen
n 100
56
/3/3
P
P R
1.8 3.6
5
10.0cm

30F, CS referred for pigtail

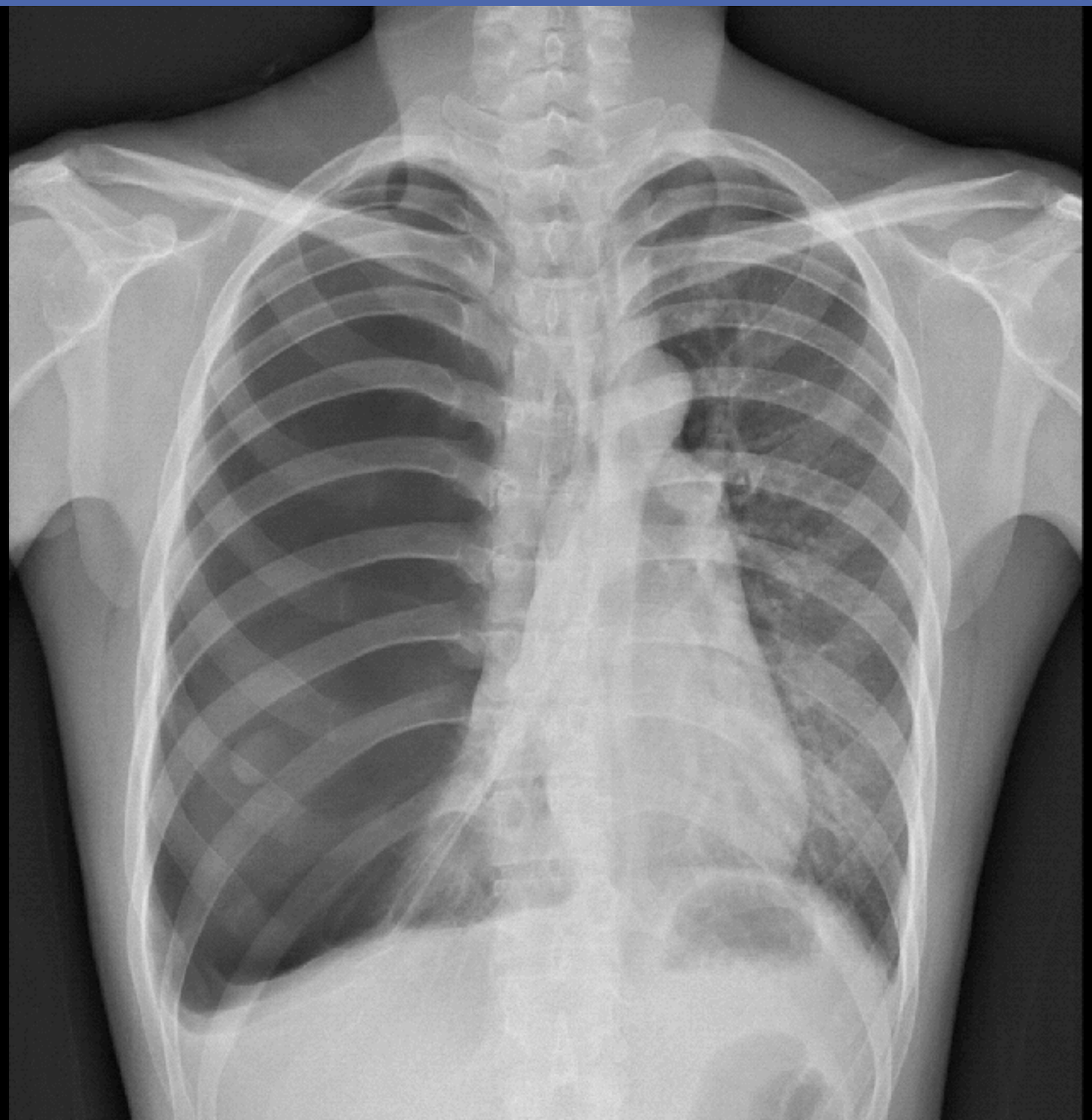

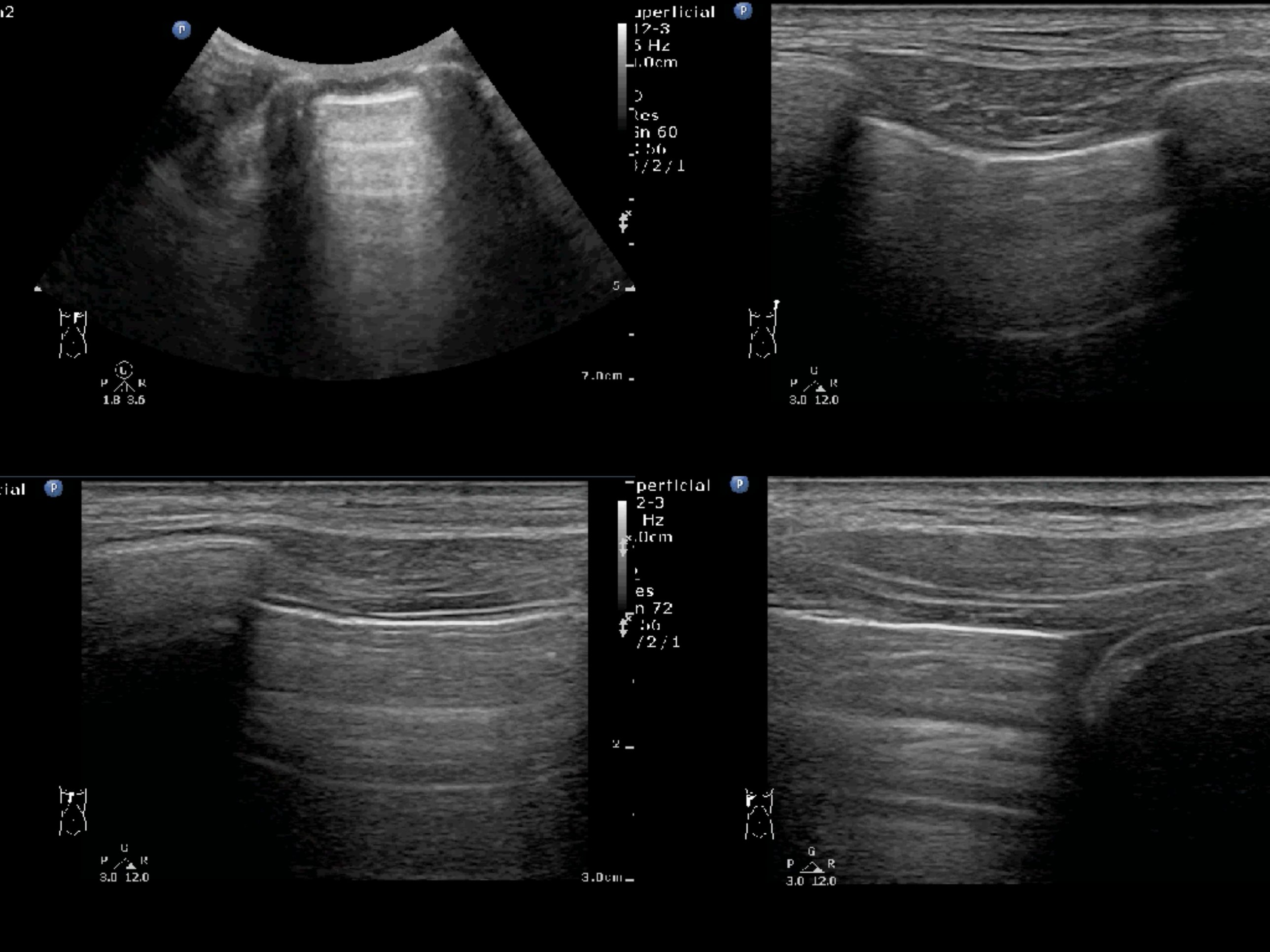

perficial
12-3
5 Hz
Res
Gn 60
/2/1
7.0cm
1.8 3.6
3.0 12.0
perficial
2-3
Hz
es
n 72
/2/1
3.0cm
3.0 12.0
3.0 12.0

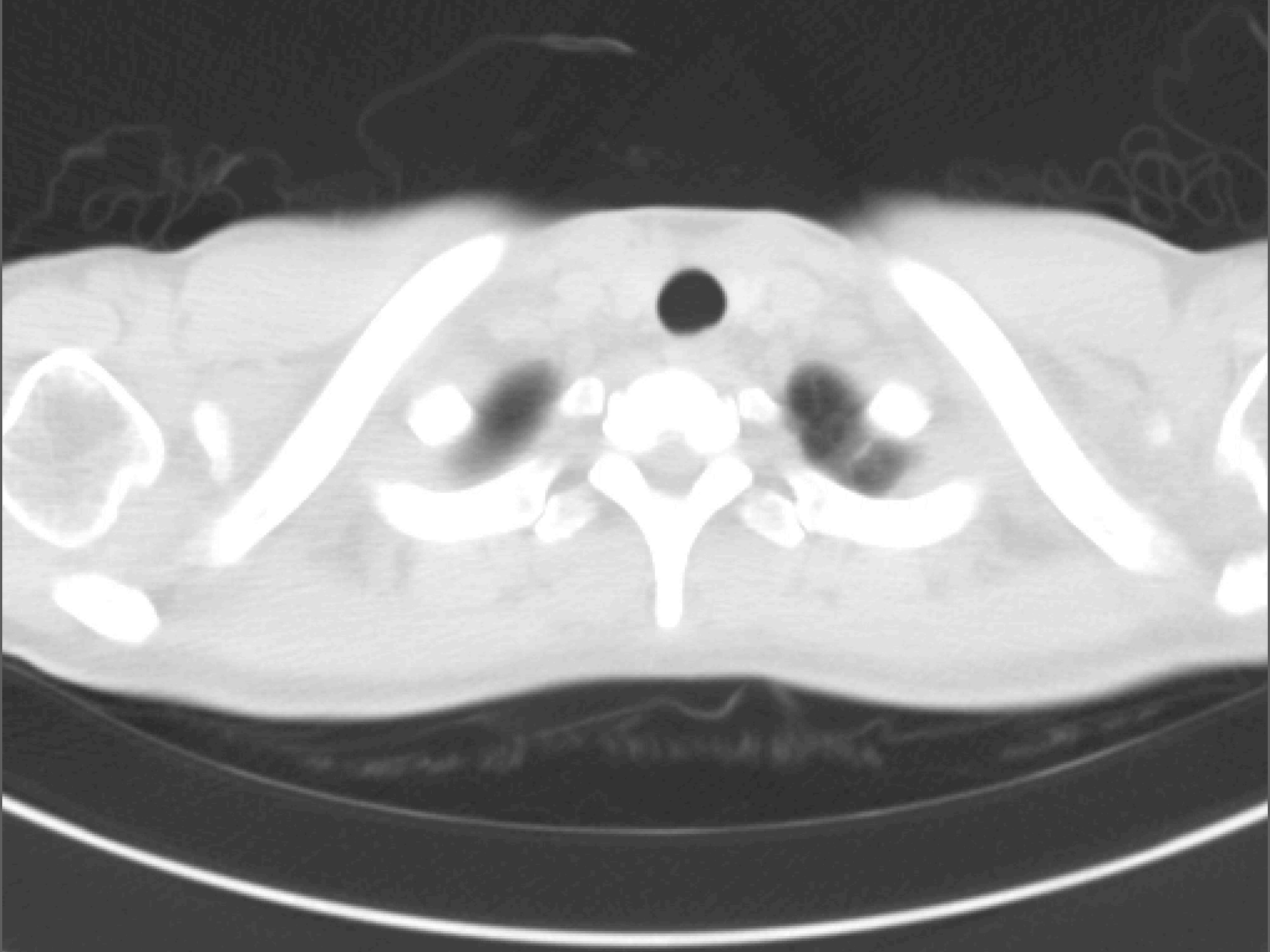

67M, left upper chest pain

ChenKC@POCUSAcademy

54M, COPD & CHF, Dyspnea

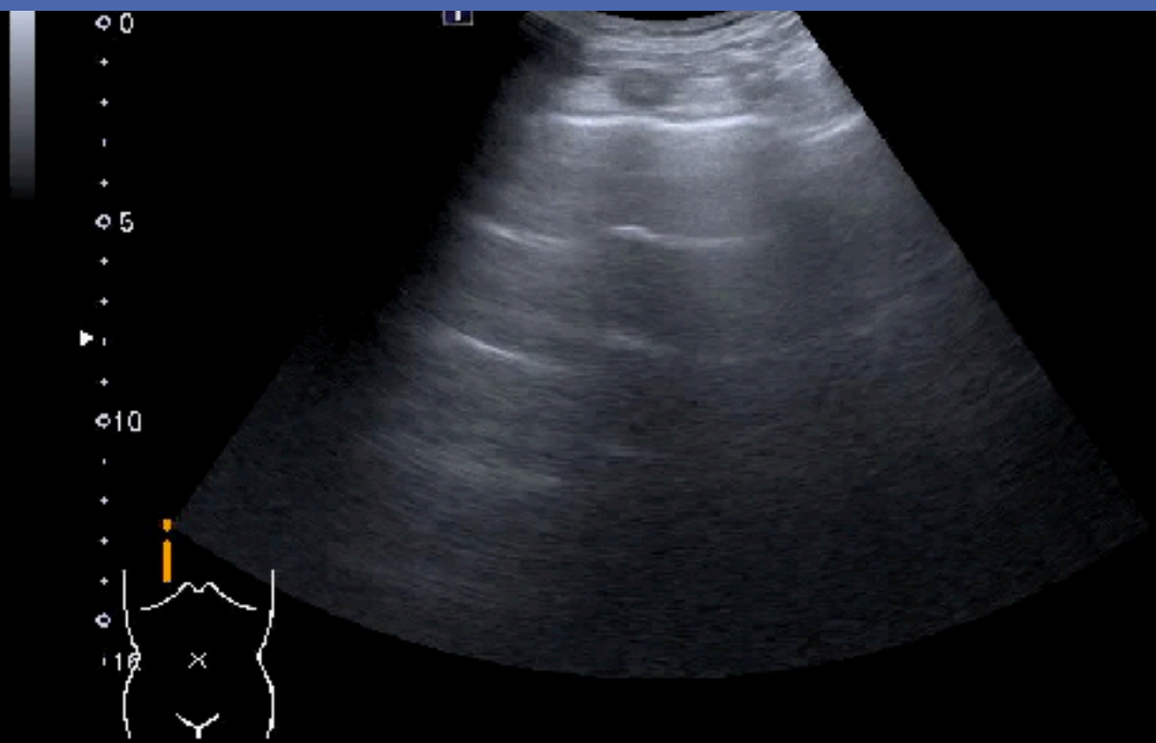

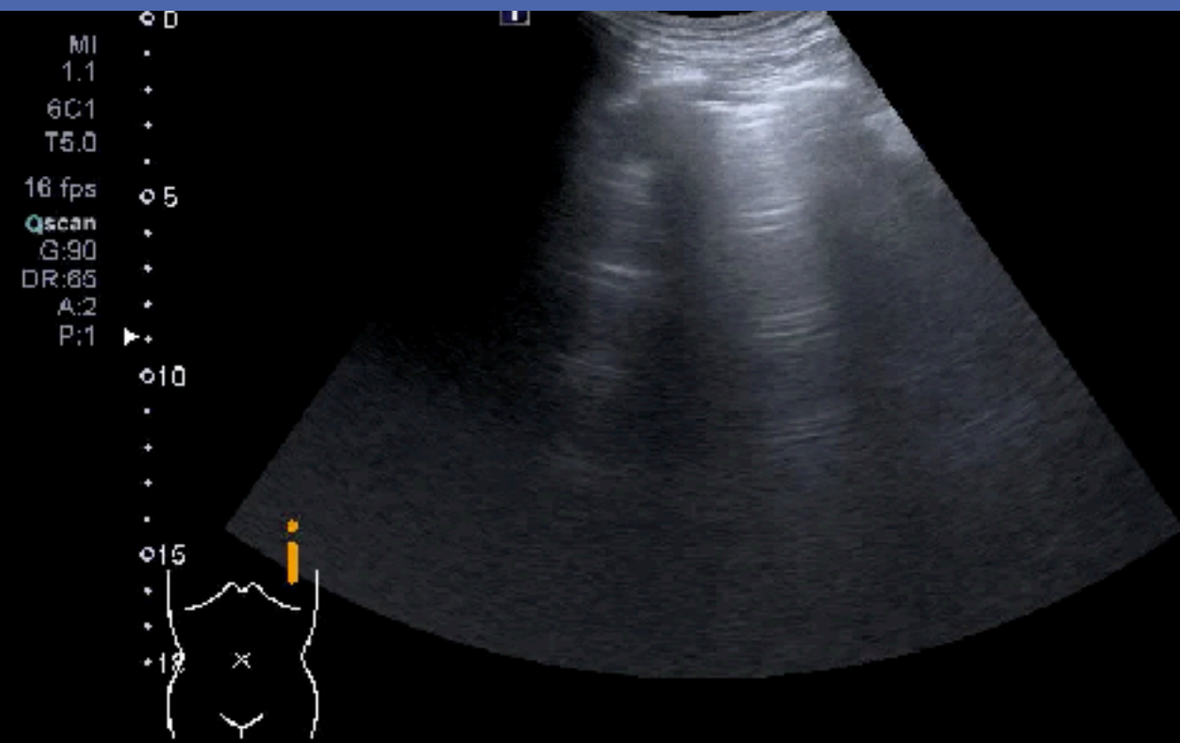

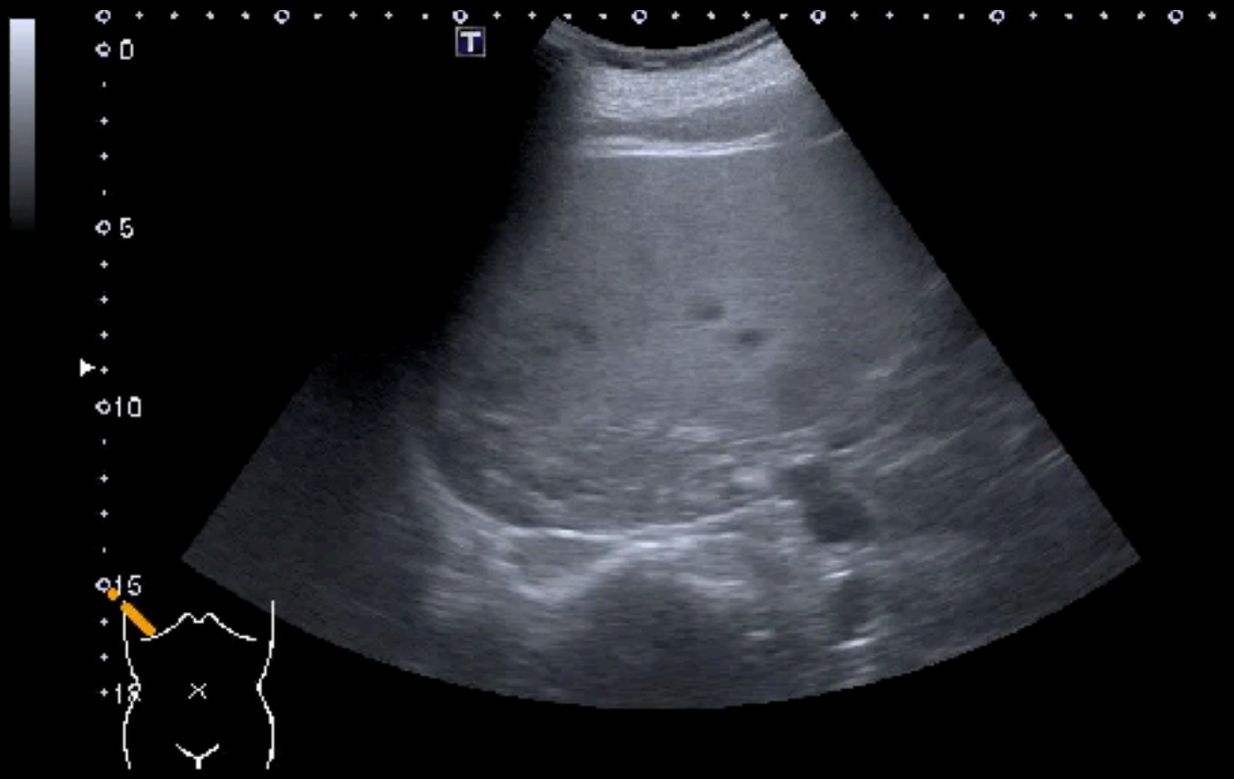

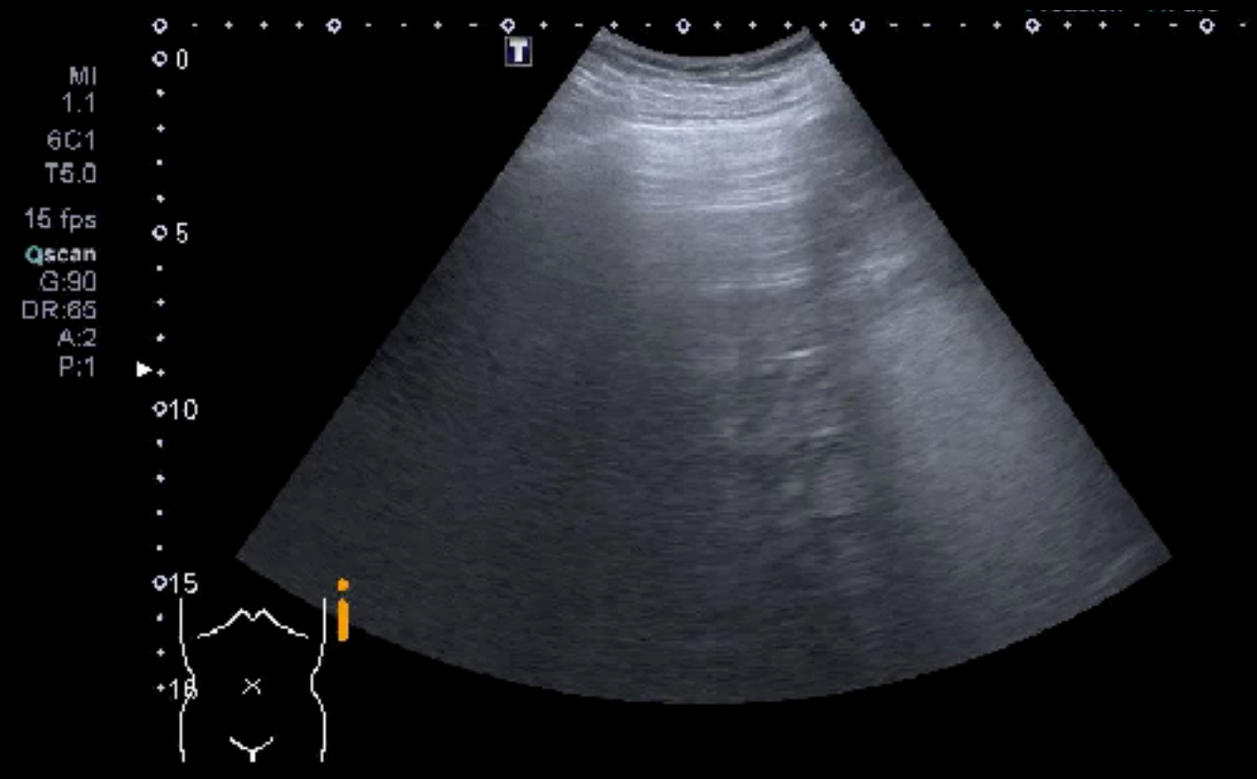

Indication

- Respiratory symptoms and/or signs
- Unclear chest radiograph findings
- Monitoring and prognosis

Pretest probability ←
- History
- Physical examination
- ABG
- ECG

Acquisition

	DIAGNOSTIC HYPOTHESIS		
	Pleural effusion suspected	PTX suspected	Increased lung density suspected
Patient position Probe selection & orientation Protocol selection Picture optimization	• Semisitting (or supine) • Low-frequency probe • Maintain postprocessing artifacts reduction algorithms • Start examination from lung bases; identify diaphragm and spine	• Ideally supine • If possible, high-frequency probe • Consider M-mode and Power Doppler • Identify least dependent zone	• Semisitting or supine • Low-frequency and high-frequency probes • If B-line pattern analysis, deactivate post-processing artifacts reduction algorithms • Complete lung examination (anterior, lateral, and posterior surfaces, bilaterally)

Interpretation

PLEURAL LINE INTERFACE

Fluid

Pleural effusion/ Hemothorax

- Size
- Fluid characteristics

A-line Pattern

Lung sliding? YES / NO
Lung pulse? YES / NO
Vertical artifact? YES / NO

PTX likely
Lung point? YES
PTX highly likely

Normal lung density at pleural line

Consider:
- PEEP effect/lung overinflation
- Lung pathology not reaching pleural line
- Early stages of lung pathology
- Performance of further tests

Diagnostic / Nondiagnostic

Increased Lung Density

- ***Increased lung weight*** (water, cells, pus, blood, proteins, connective tissue, lipids) ***and/or***
- ***Lung deflation***

B-line Pattern

Diffuse	Focal

Sonographic findings that may help in differential diagnosis
- B-lines distribution (homogeneous/nonhomogeneous distribution)
- B-lines "density" (B1 pattern; B2 pattern)
- Decreased lung sliding
- Decreased/increased lung pulse
- Gravity-dependent or -independent pattern
- Presence/absence of pleural line abnormalities
- Presence/absence of subpleural abnormalities (e.g., focal consolidations)

Solid

Large area of lung consolidation	Small subpleural consolidation

Sonographic findings that may help in differential diagnosis
- Distribution
- Detection of air bronchogram(s)
- Detection of fluid bronchogram(s)
- Vascular pattern within the consolidation

Anesthesiology 9 2017, Vol.127, 568–582

Interpretation

PLEURAL LINE INTERFACE

Fluid

Pleural effusion/ Hemothorax

- Size
- Fluid characteristics

A-line Pattern

Lung sliding? YES / NO

Lung pulse? YES / NO

Vertical artifact? YES / NO

PTX likely

Lung point? YES

PTX highly likely

Normal lung density at pleural line

Consider:

- PEEP effect/lung overinflation
- Lung pathology not reaching pleural line
- Early stages of lung pathology
- Performance of further tests

Increased Lung Density

- ***Increased lung weight*** (water, cells, pus, blood, proteins, connective tissue, lipids) ***and/or***
- ***Lung deflation***

B-line Pattern

Diffuse | **Focal**

Sonographic findings that may help in differential diagnosis

- B-lines distribution (homogeneous/nonhomogeneous distribution)
- B-lines "density" (B1 pattern; B2 pattern)
- Decreased lung sliding
- Decreased/increased lung pulse
- Gravity-dependent or -independent pattern
- Presence/absence of pleural line abnormalities
- Presence/absence of subpleural abnormalities (e.g., focal consolidations)

Solid

Large area of lung consolidation | **Small subpleural consolidation**

Sonographic findings that may help in differential diagnosis

- Distribution
- Detection of air bronchogram(s)
- Detection of fluid bronchogram(s)
- Vascular pattern within the consolidation

Diagnostic | **Nondiagnostic**

Differential diagnosis

Fluid	A-line Pattern	Normal lung density at pleural line	B-line Pattern	Solid
• Transudate • Exudate • Hemothorax • Empyema	• PTX • Bullous disease • Lung overinflation (e.g., COPD, mechanical ventilation) • Pleural adhesions • Bronchial obstruction			

AIR CONTENT ↑

- Asthma exacerbation
- COPD exacerbation
- Pulmonary embolism
- Infectious/neoplastic process without pleural line involvement
- Lung overinflation (e.g., COPD, mechanical ventilation)
- Bronchial obstruction (early)
- Metabolic or neurologic causes

- Cardiogenic (hydrostatic) pulmonary edema
- Nonhydrostatic pulmonary edema (e.g., ARDS)
- Infection
- Pneumonitis
- Idiopathic interstitial pneumonias and other ILDs
- Alveolar hemorrhage
- Alveolar proteinosis
- Normal pattern (if isolated at lung bases)

- Lung consolidation
- Pulmonary infarct
- Pulmonary contusion
- Atelectasis (compression or obstruction)
- Primary lung cancer/tumor or metastasis

LUNG DENSITY →

Medical Decision-making

- Integration with clinical context (pretest probability)
- Consistency or inconsistency of findings with pretest diagnostic hypothesis
- LUS diagnostic or nondiagnostic
- Changes in diagnostic and therapeutic approach

Anesthesiology 9 2017, Vol.127, 568–582

LUS for critically ill patients

ARJCCM 2018

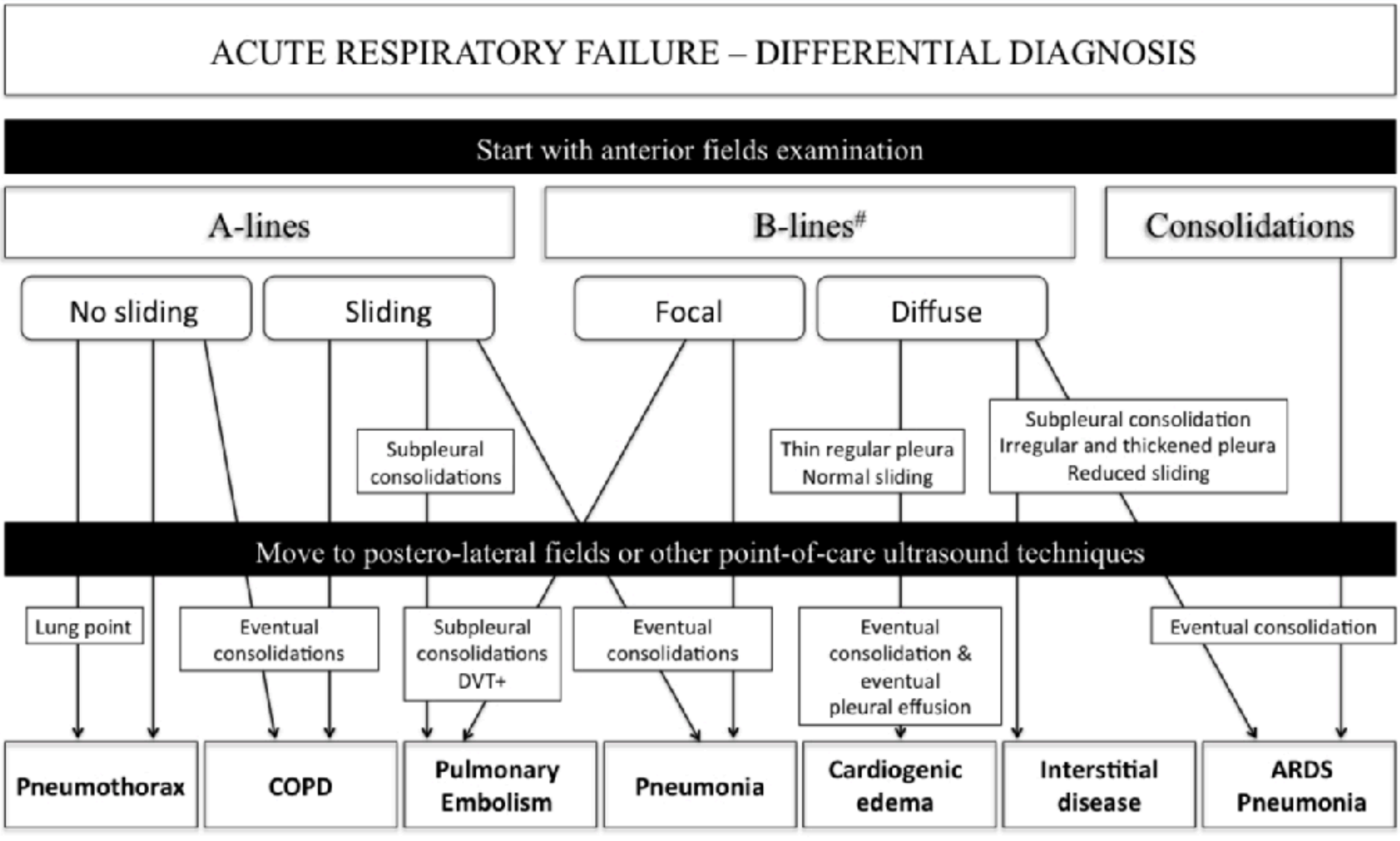

Lung Aeration Score

12 regions: 0 ~ 36

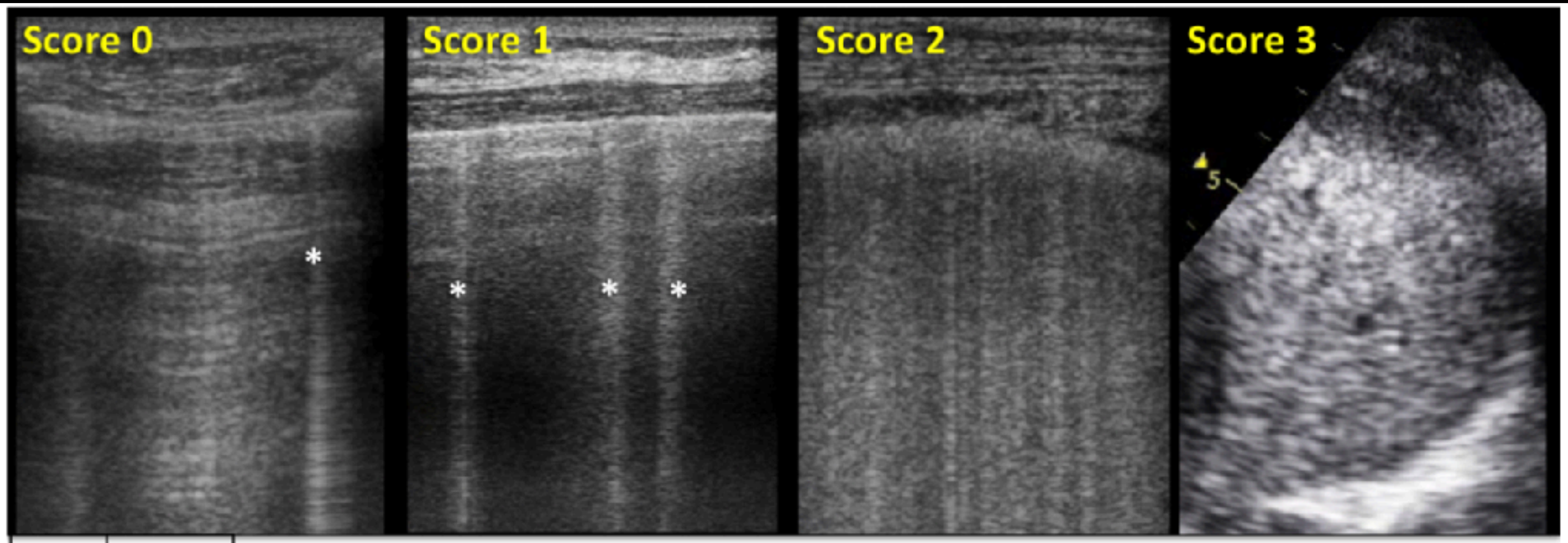

Take Home Message

氣
水

真
假

A
B

動
靜

PTX

AIS

PLE

ChenKC@POCUSAcademy

Sliding

A-B-C-D-E

ChenKC@POCUSAcademy