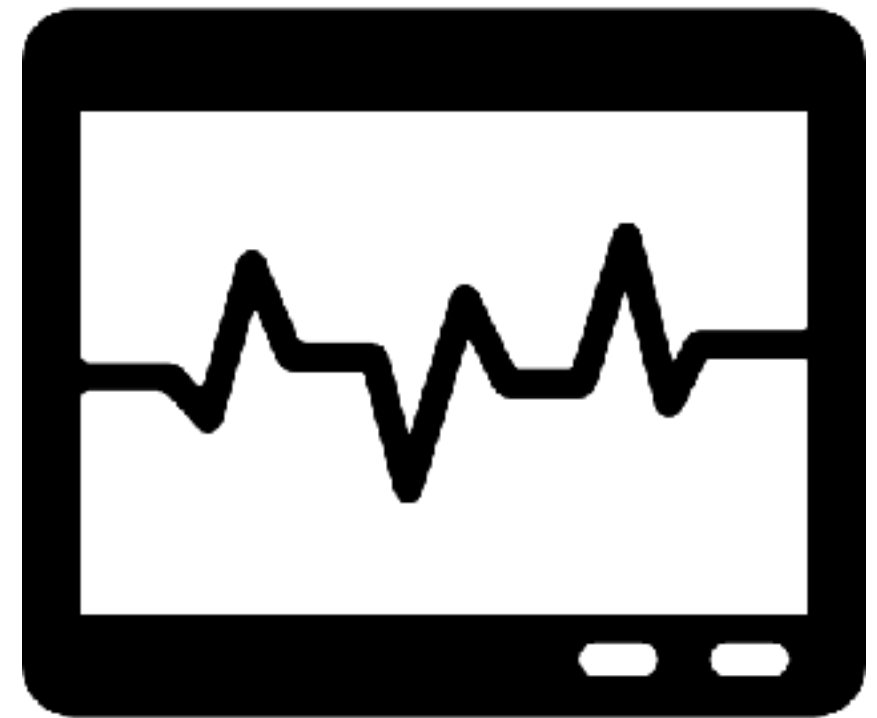
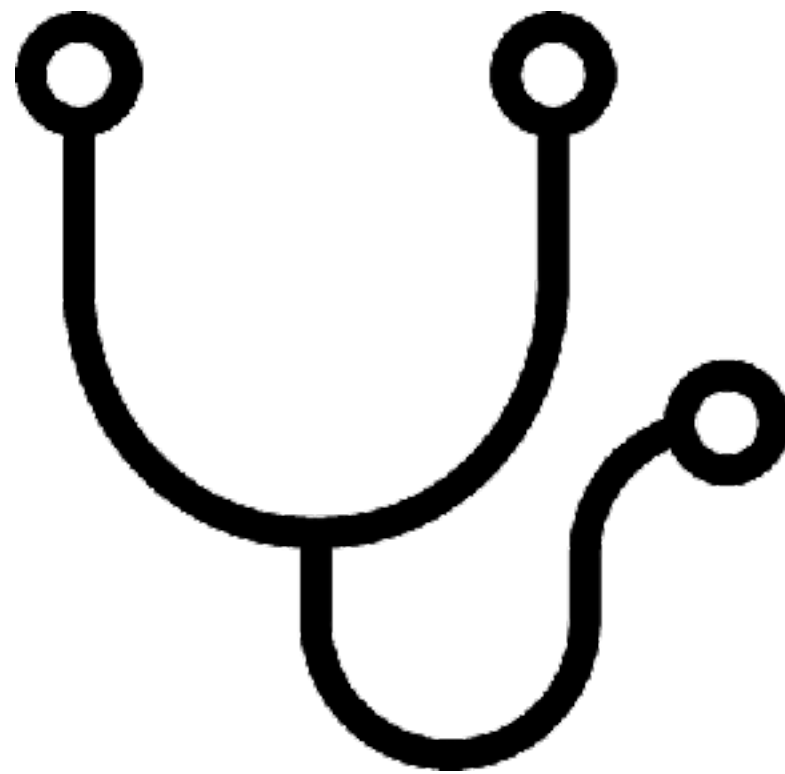
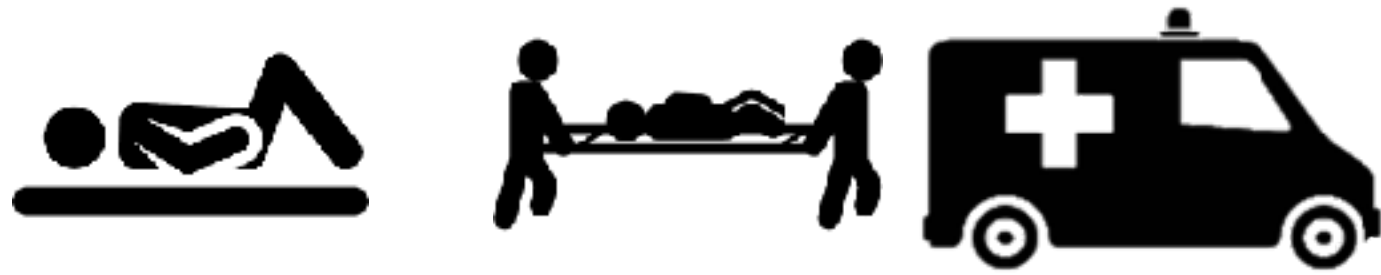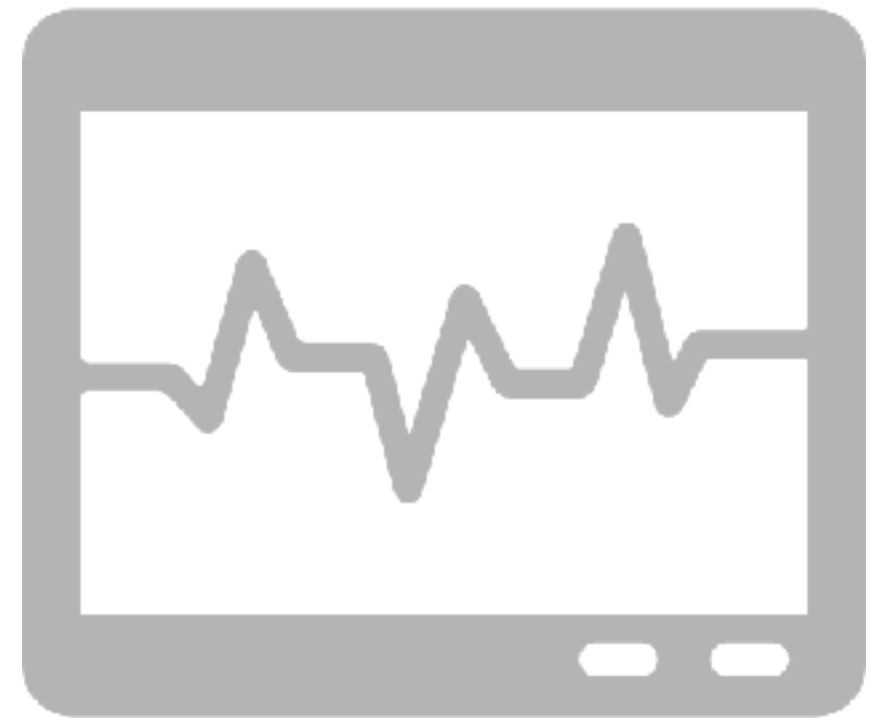
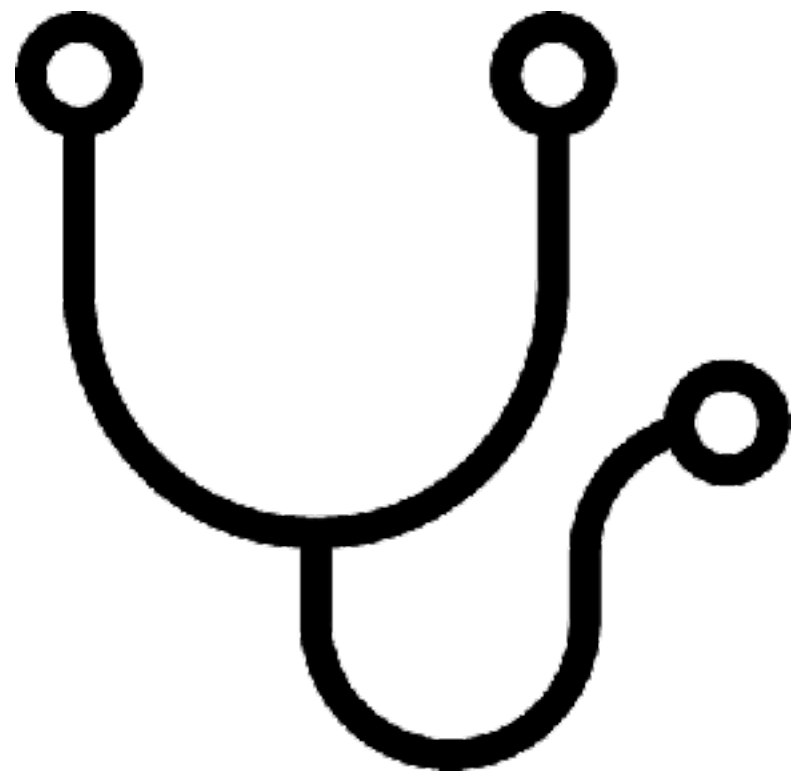




Prehospital POCUS

Jen-Tang, Sun MD MSc
Department of emergency medicine,
Far East Memorial Hospital







**Shortness of
Breath**



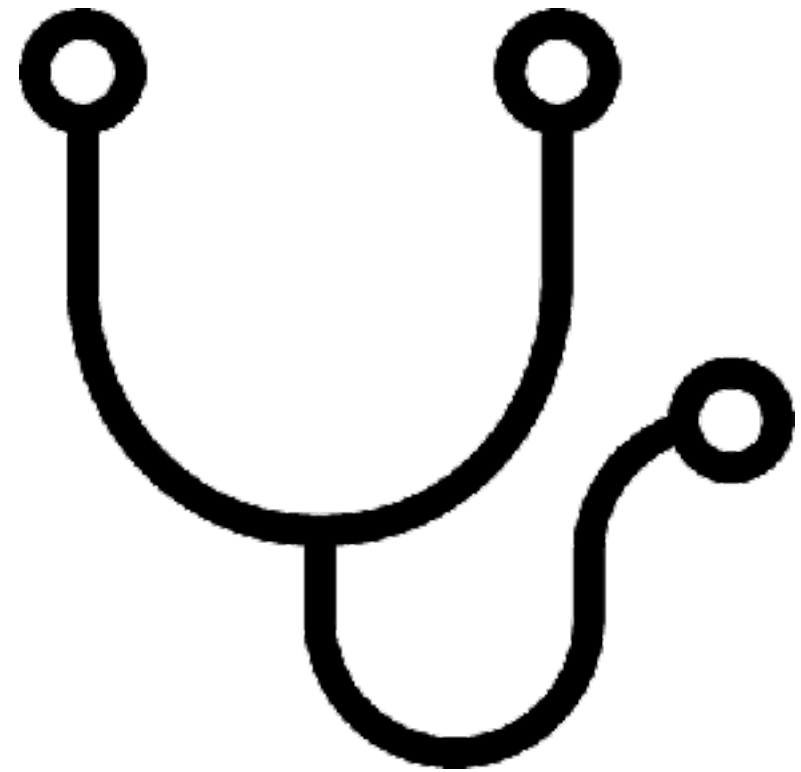
60 y/o

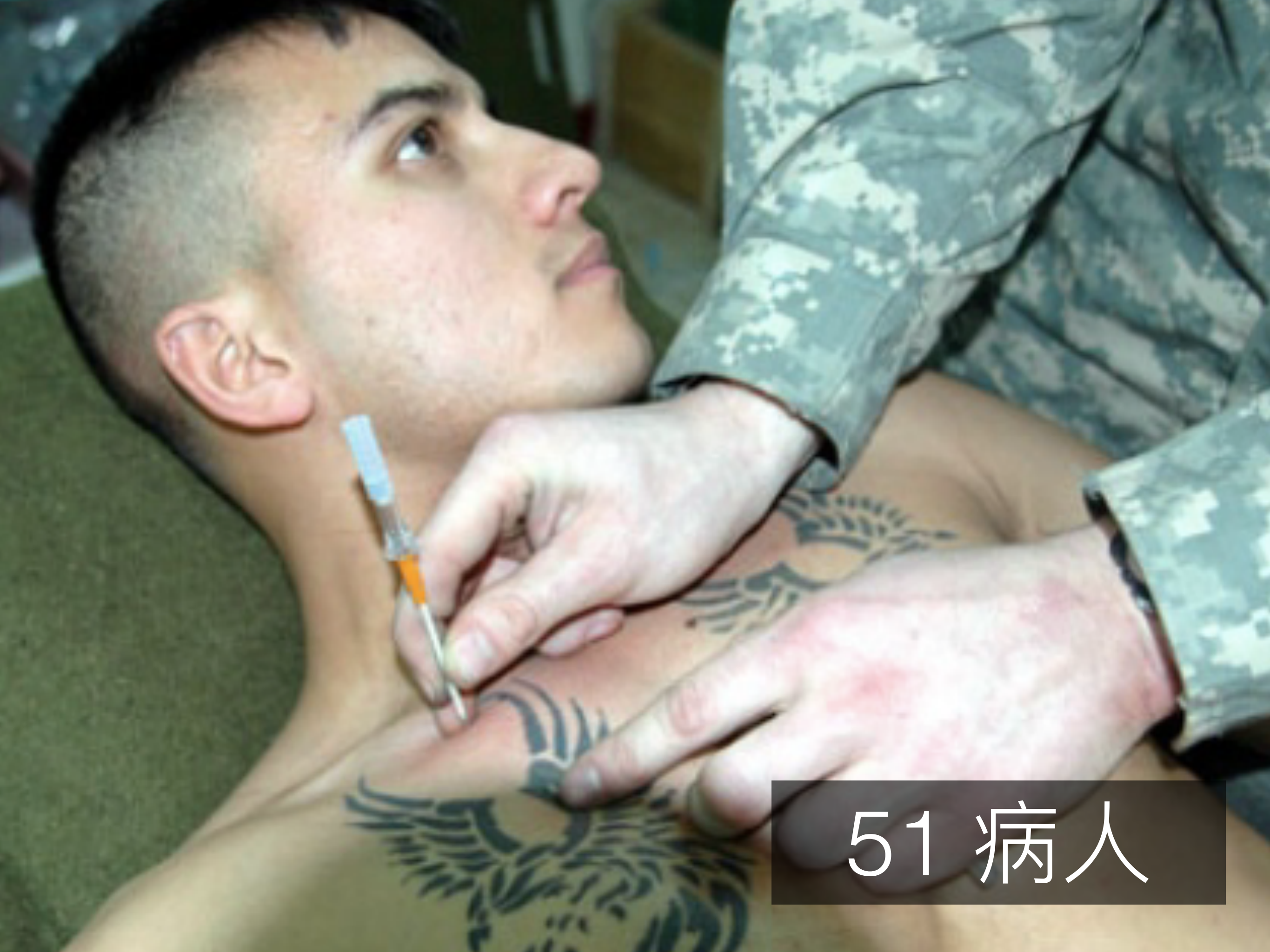心衰竭病史

車禍後喘

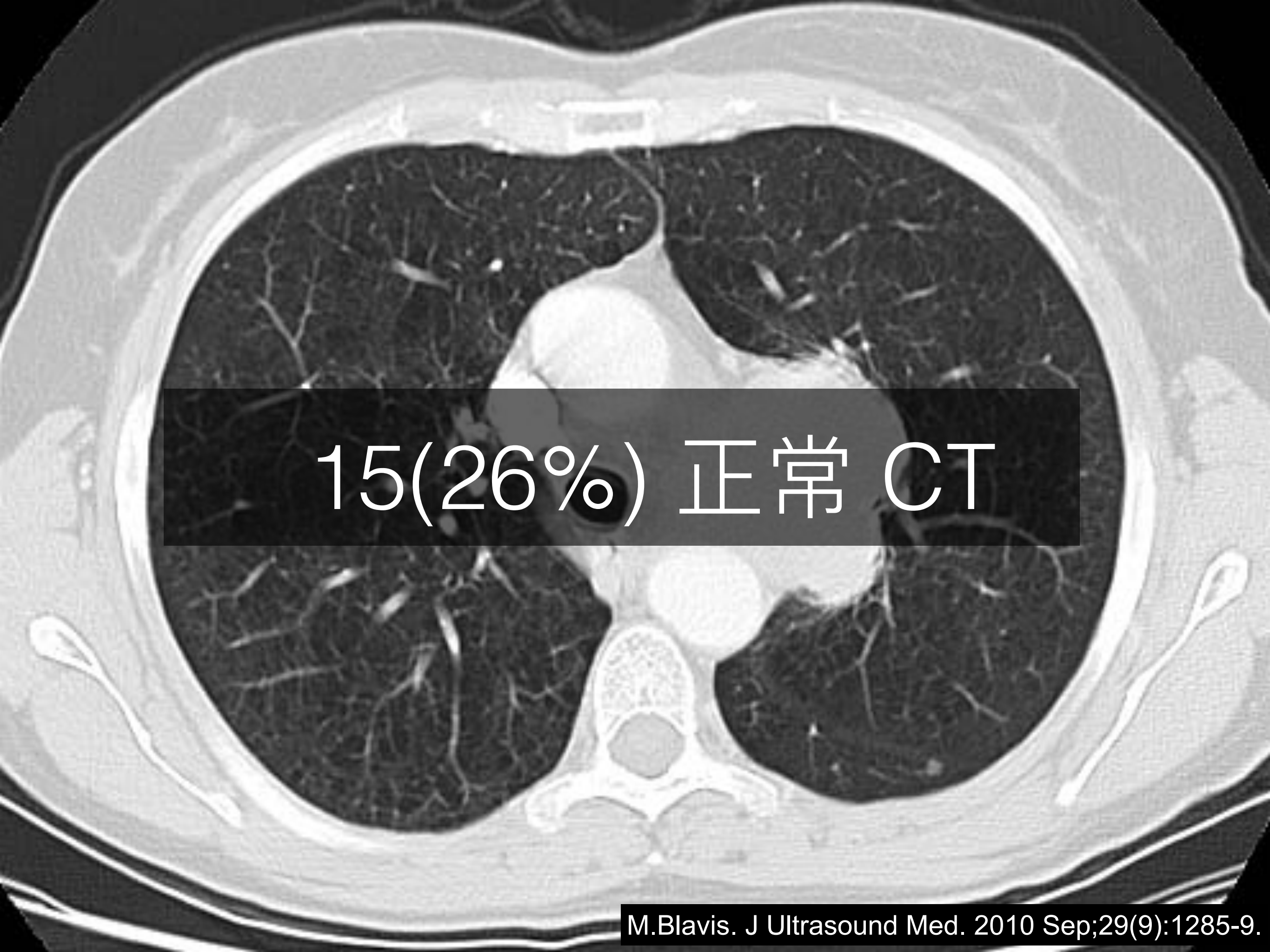
SpO₂:85% RR:40

JVE:(+)





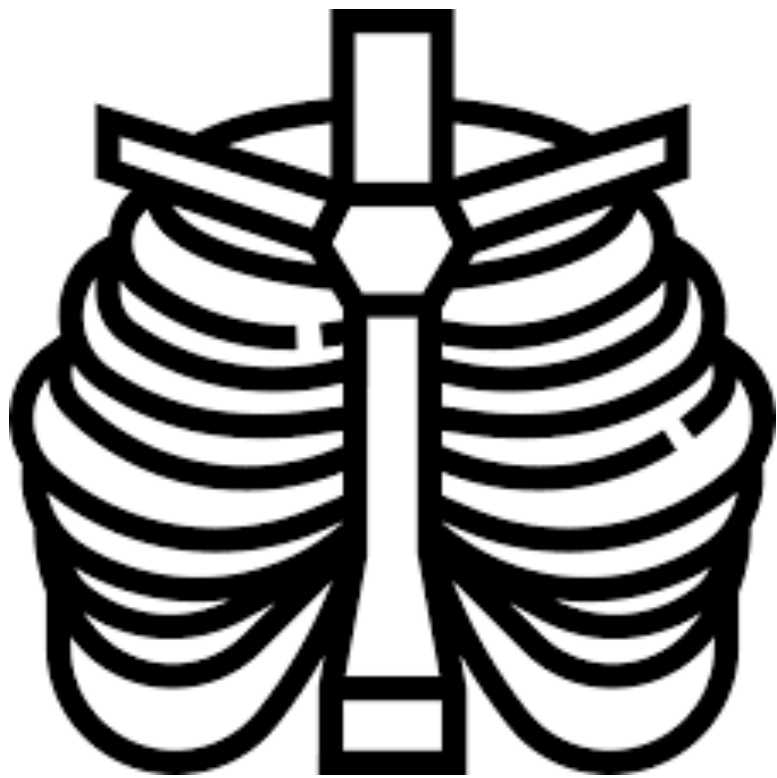
51 病人



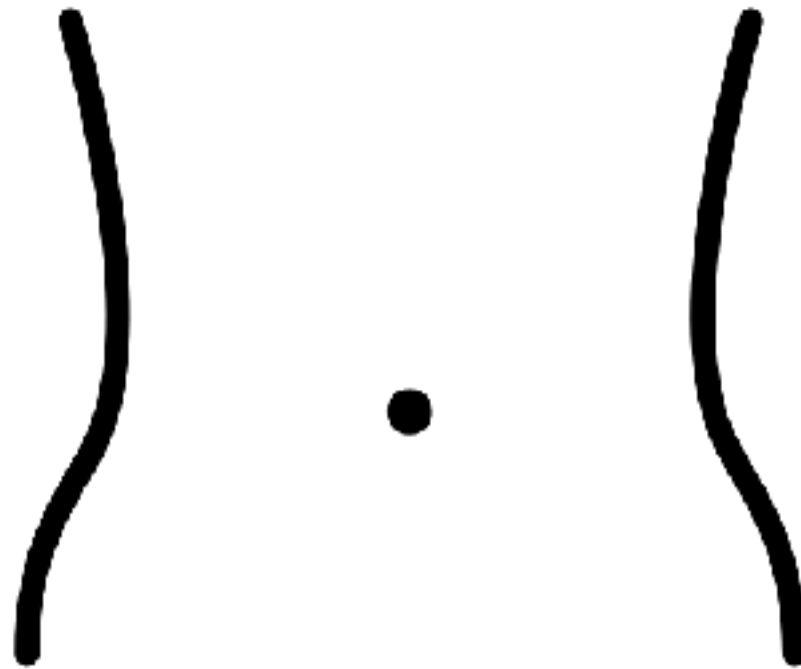
15(26%) 正常 CT

到院前 vs ED 診斷


AIS>2
誤診率



31.2%



51.8%



56.1%



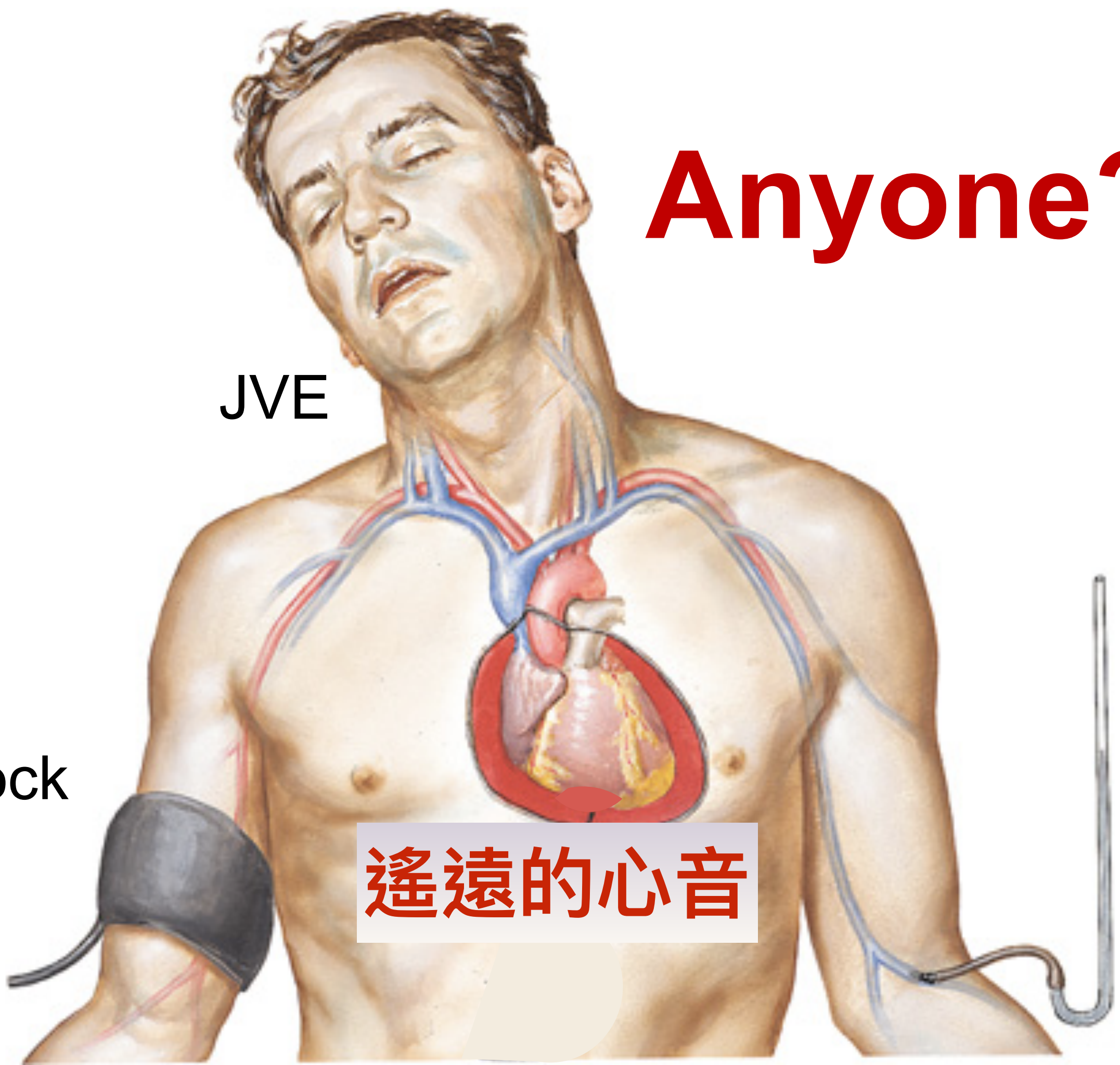
Crackles

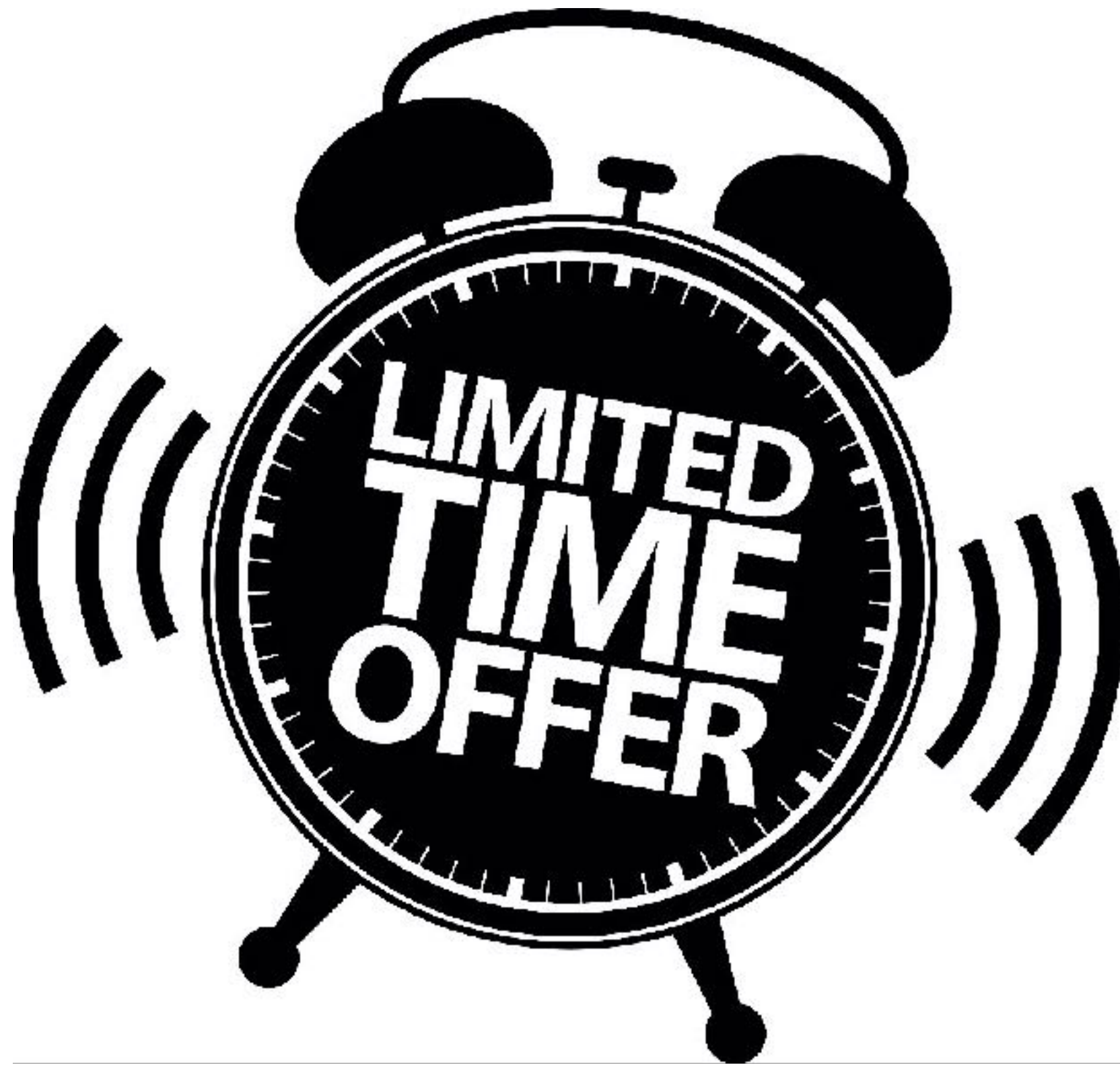Anyone??



JVE

Shock

遙遠的心音







Time to Add a Fifth Pillar to Bedside Physical Examination


Inspection, Palpation, Percussion, Auscultation, and Insonation

Jagat Narula, MD, PhD; Y. Chandrashekar, MD; Eugene Braunwald, MD

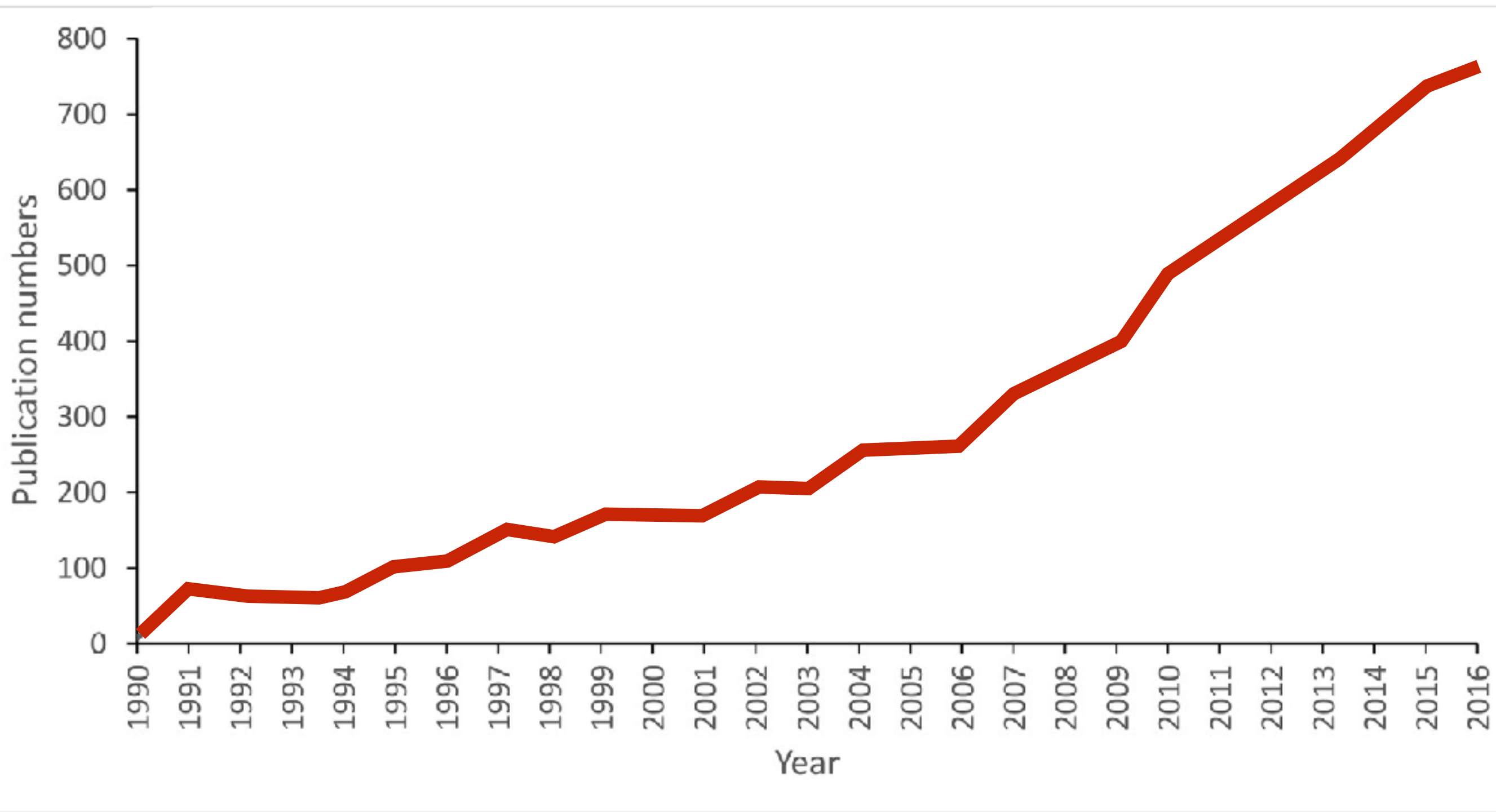


Insonation
超音波化

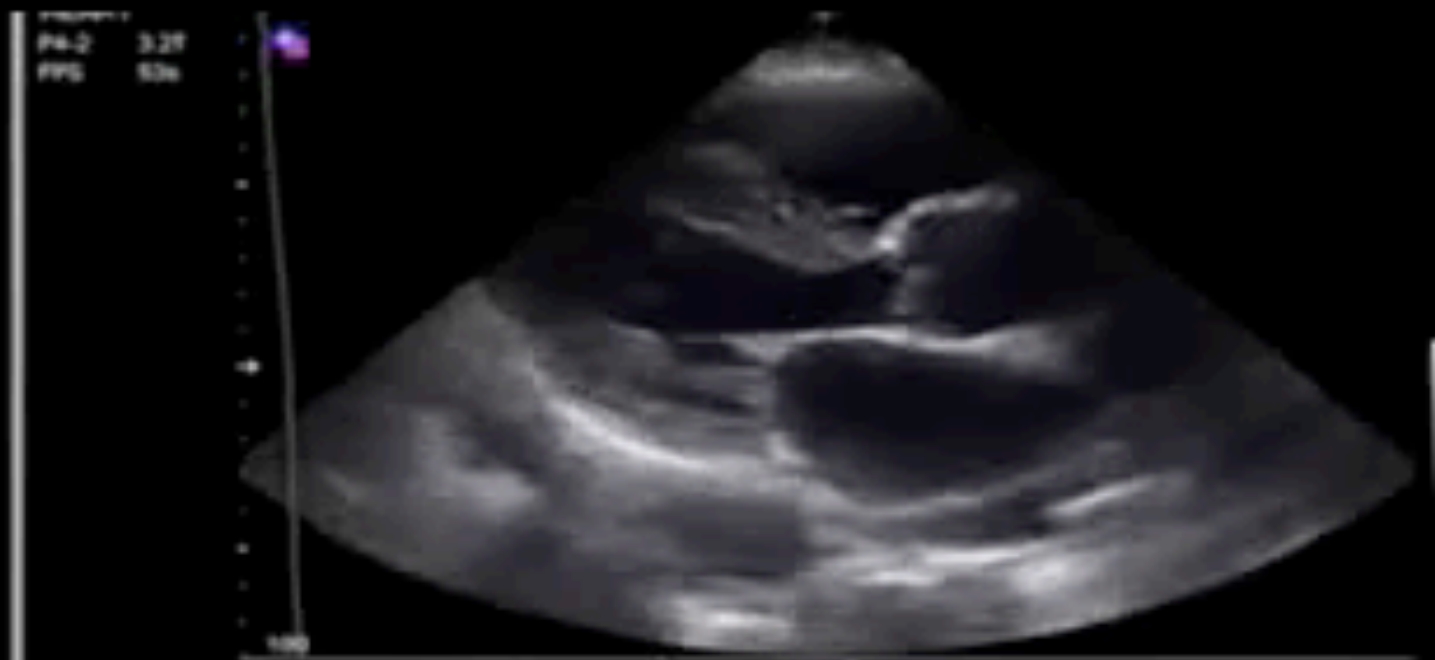
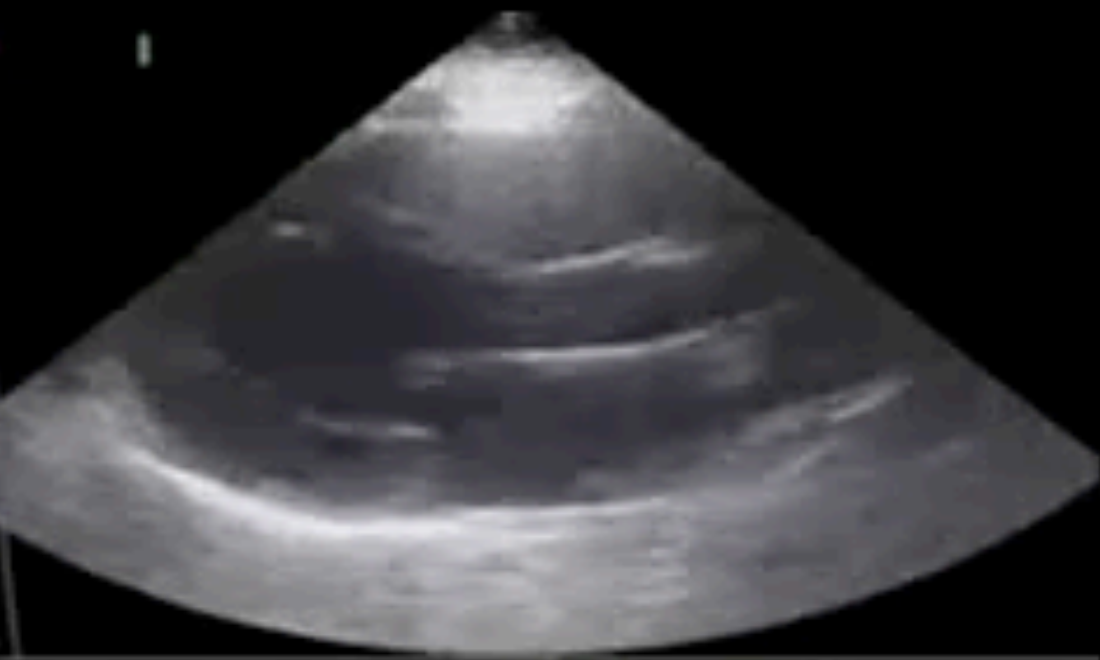




“由照顧者把超音波帶到病患身邊實
時間執行超音波”





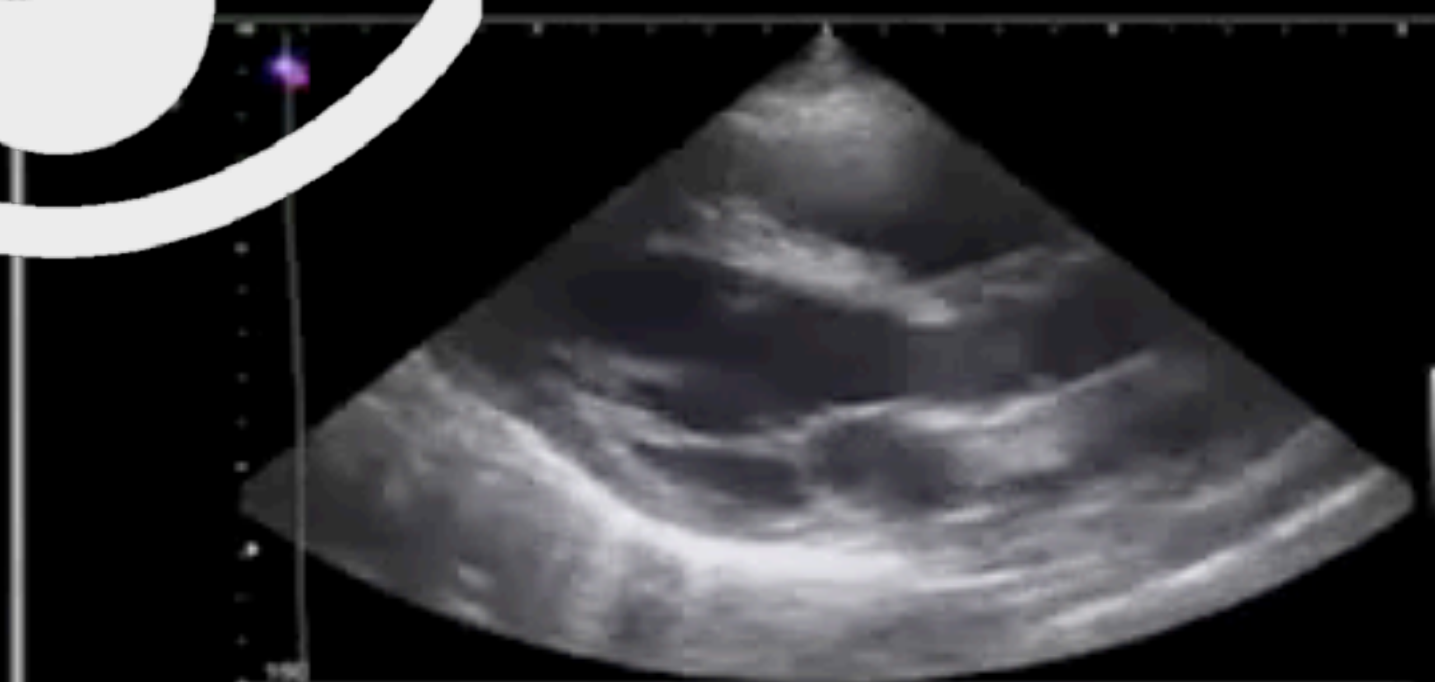
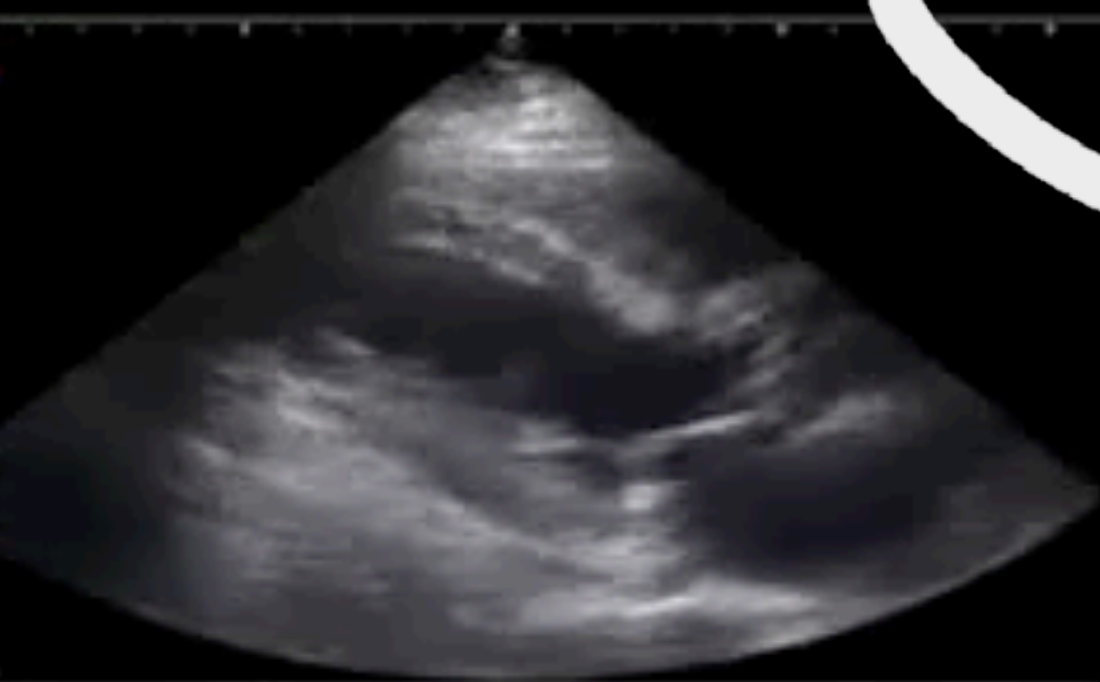


1.0 Tx 100%



2016/10/04
14:03 10:00

1.0 Tx 100%




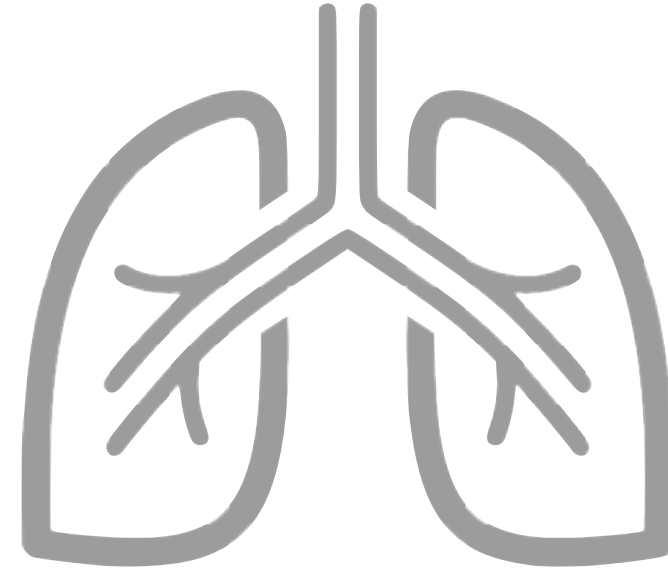
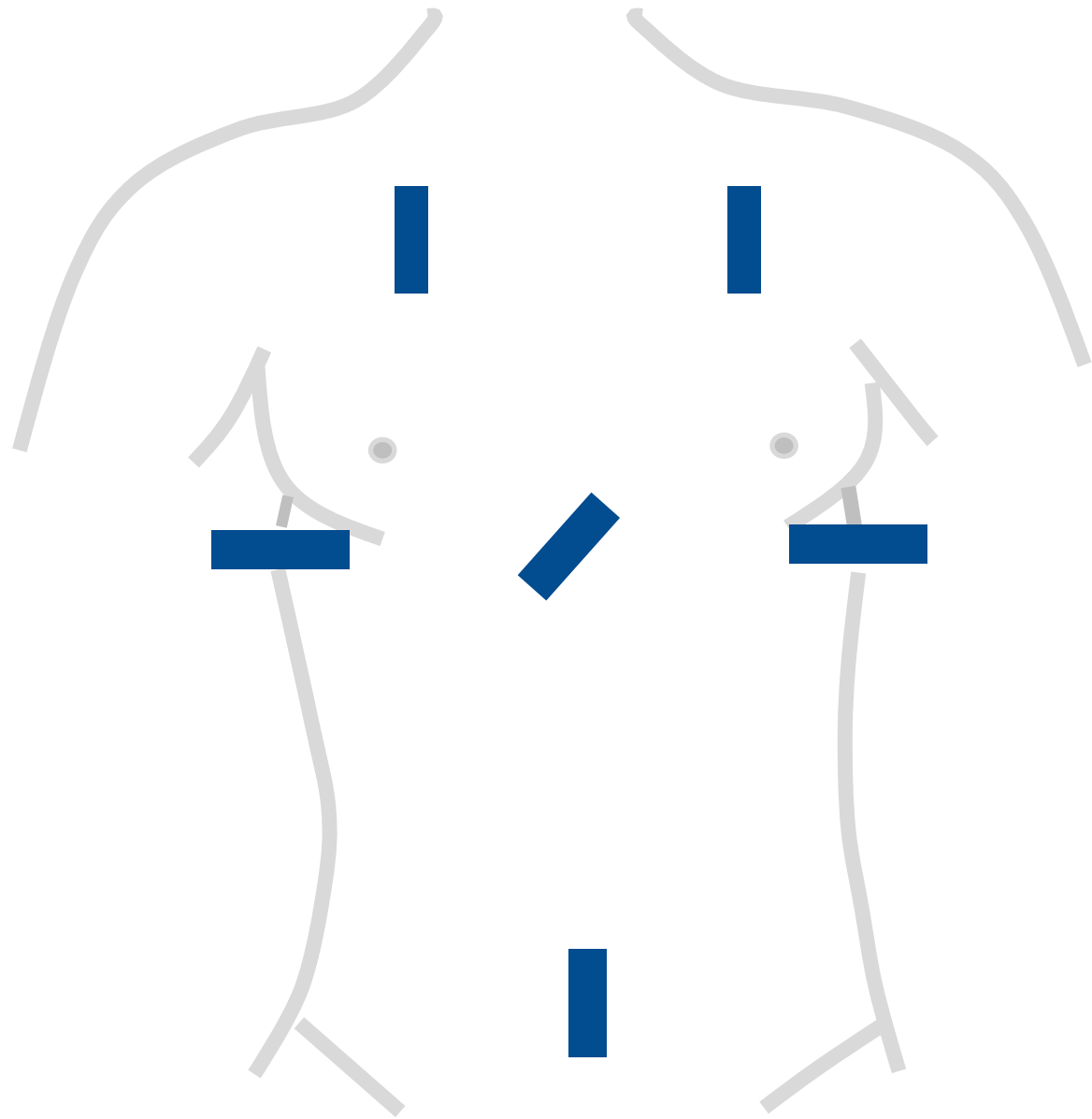
1.0 Tx 100%



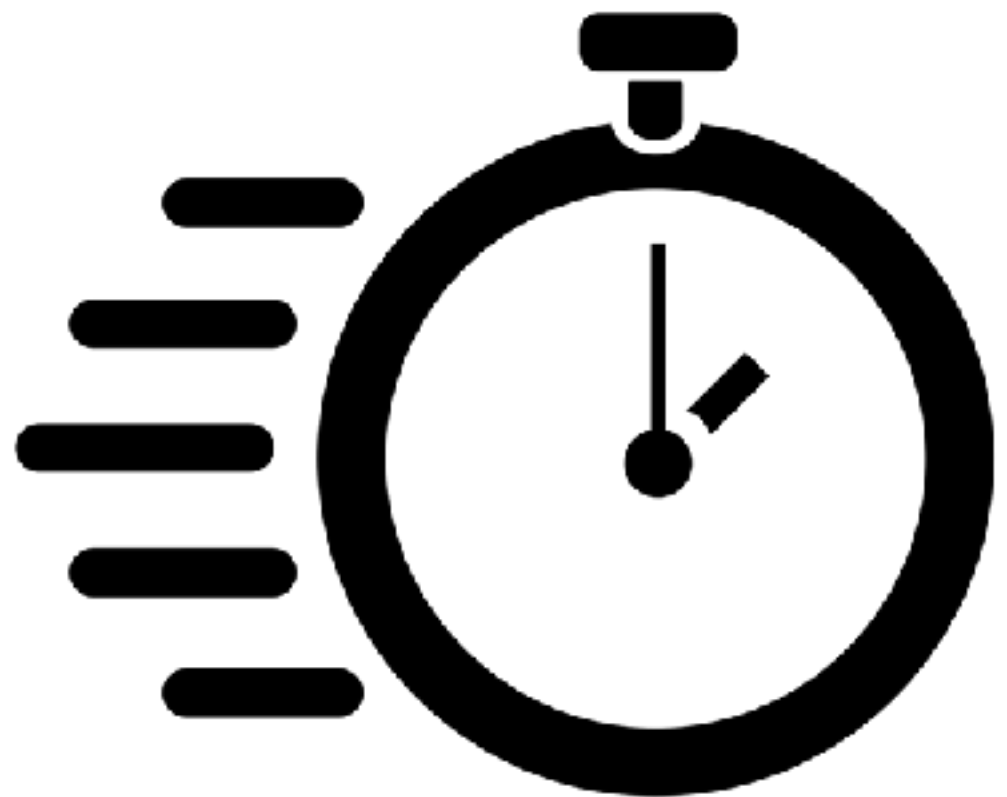

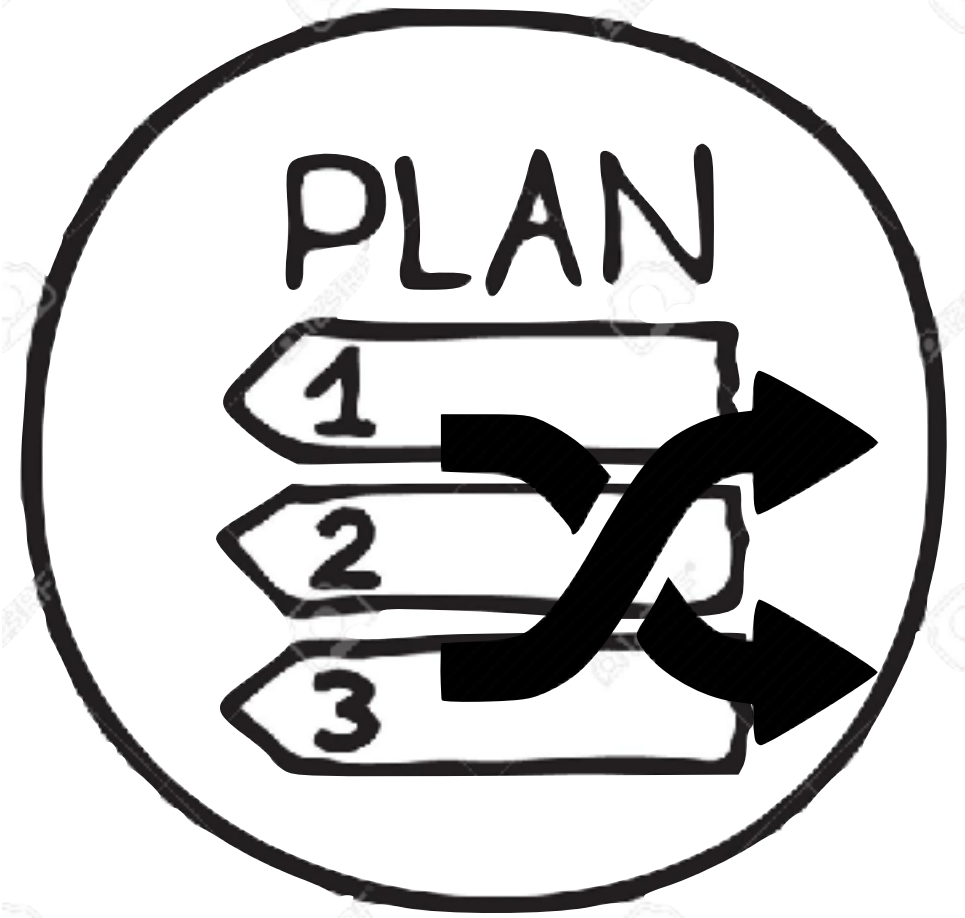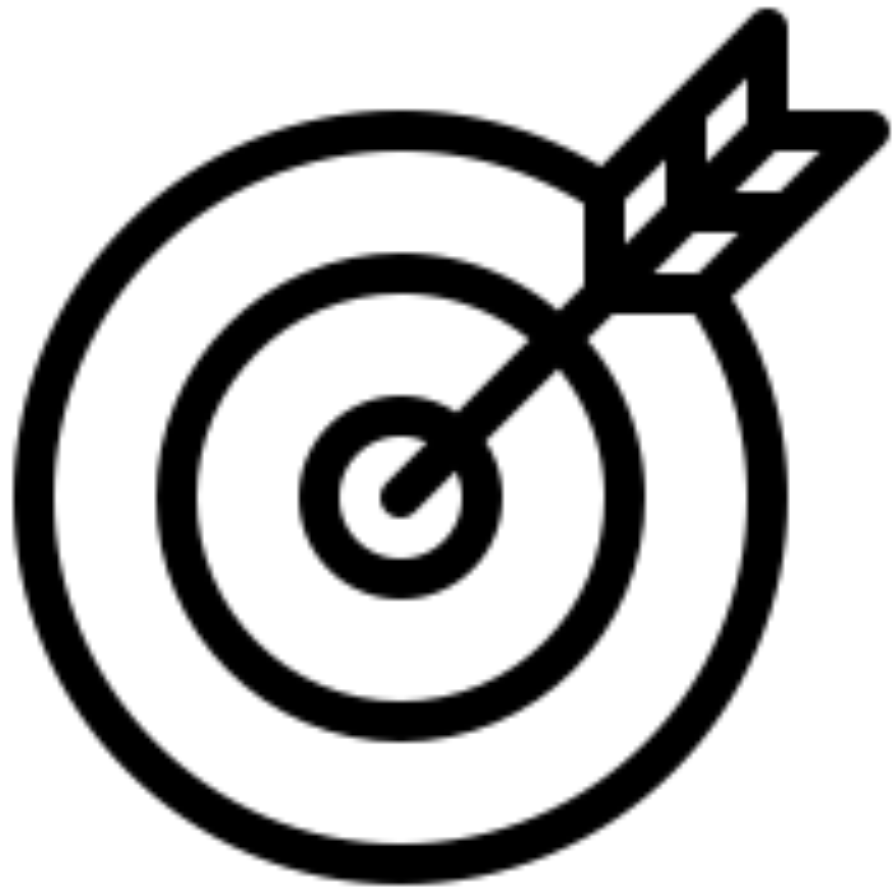
2016/10/04
14:03 10:04 10:04 Tx 100%



臨床用途



E-FAST




Sen 85% Spe 86%



Sen 100% Spe 95%



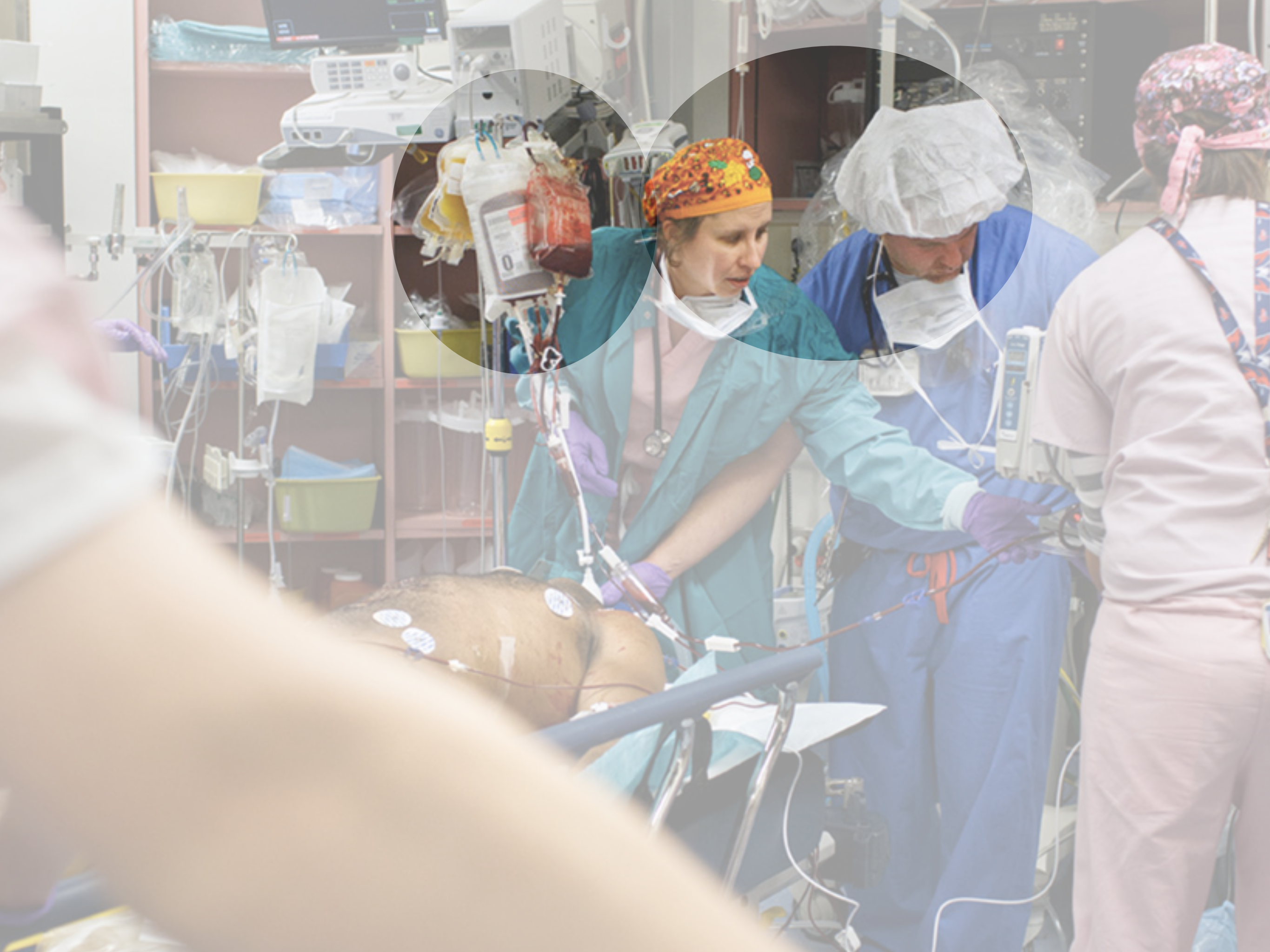
45%

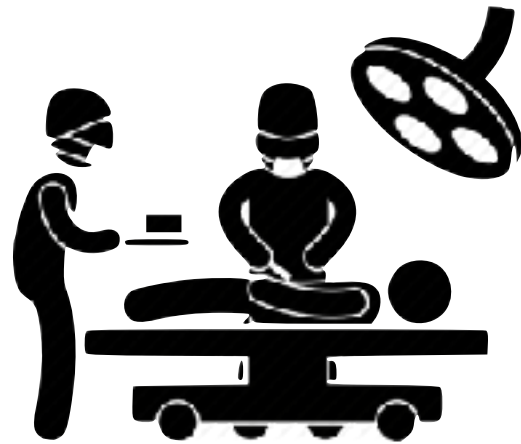



MAJOR INJURIES:			
HOSPITAL DESTINATION: <input type="text"/>			
ORIENTED <input checked="" type="checkbox"/>		DISORIENTED <input type="checkbox"/>	
		UNCONSCIOUS <input type="checkbox"/>	
TIME	PULSE	B/P	RESPIRATION
DECEASED			
IMMEDIATE NO. 100867			
DELAYED NO. 100867			
MINOR NO. 100867			

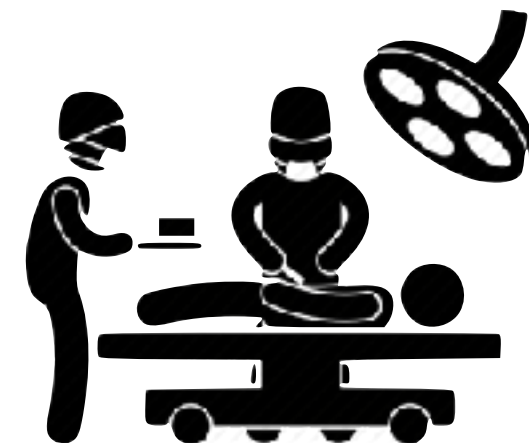

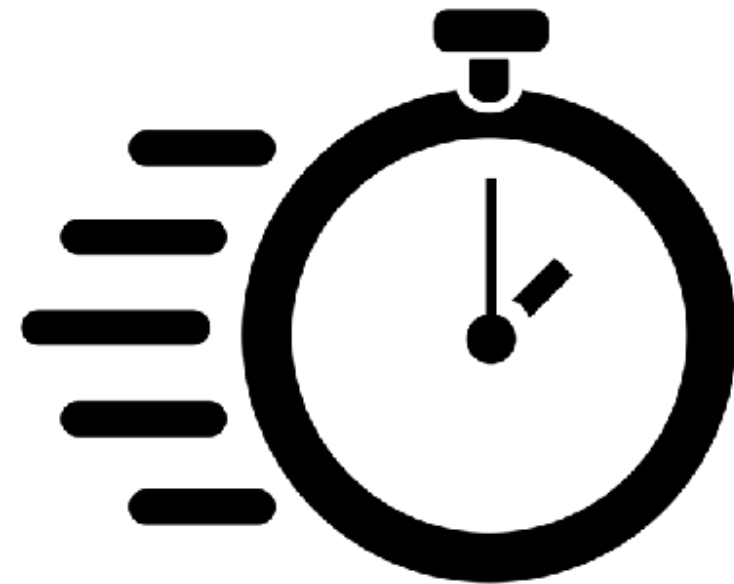
Br J Surg. 2006
 JEM. 2013
 Injury 2015





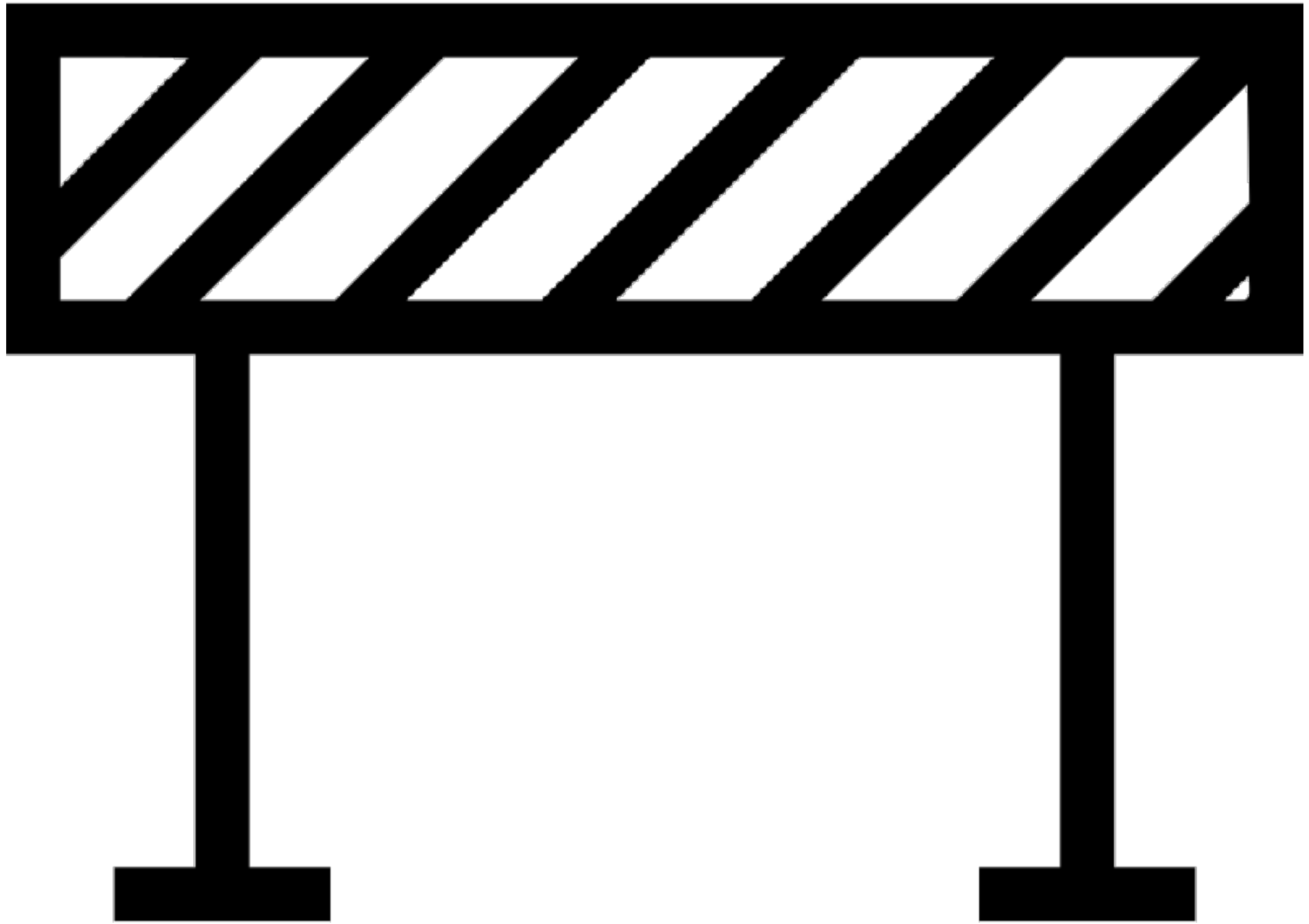


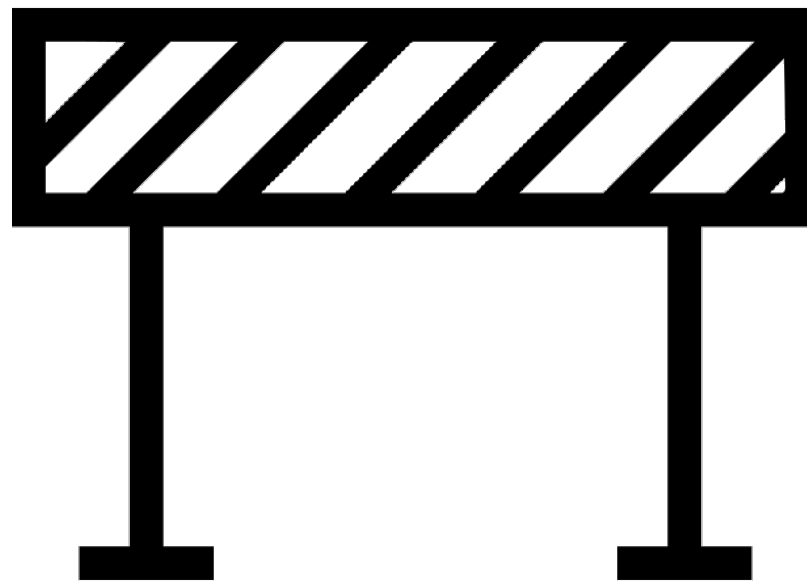
20min



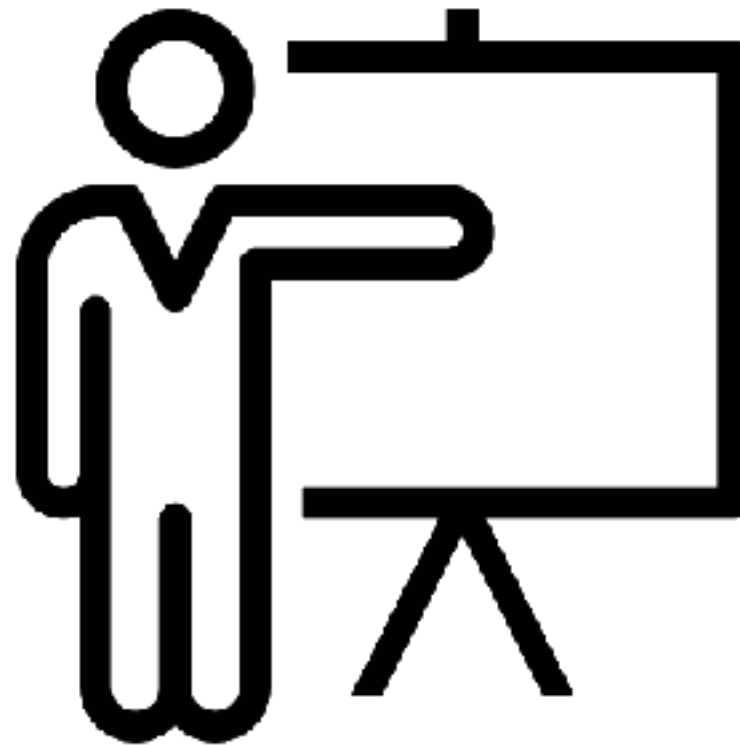
138min

EMJ 2014

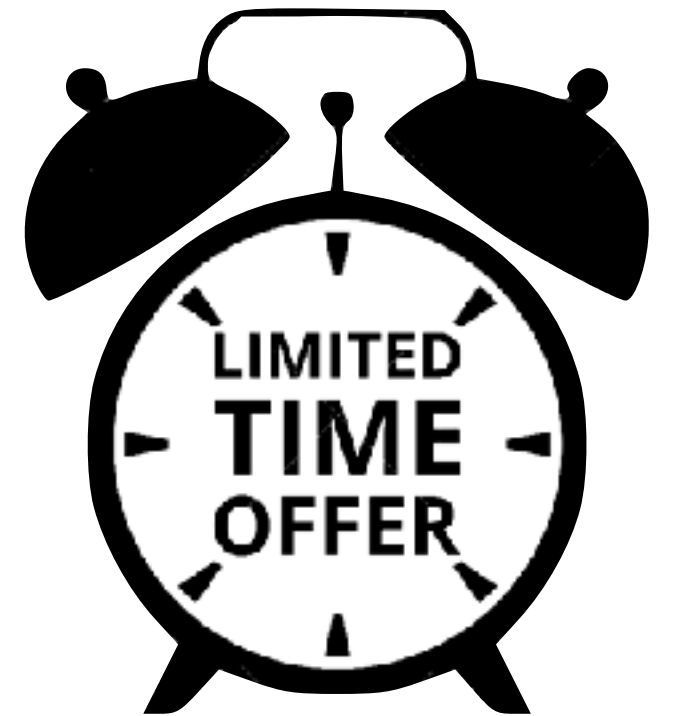



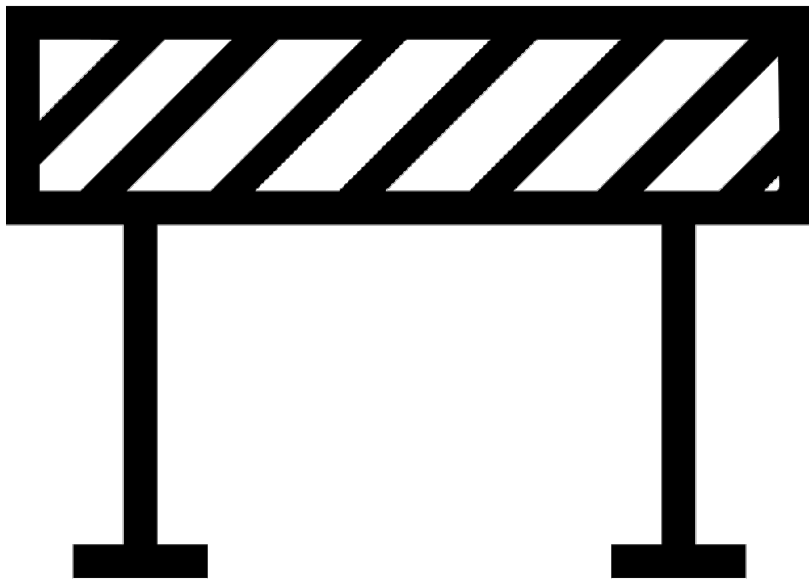
89%



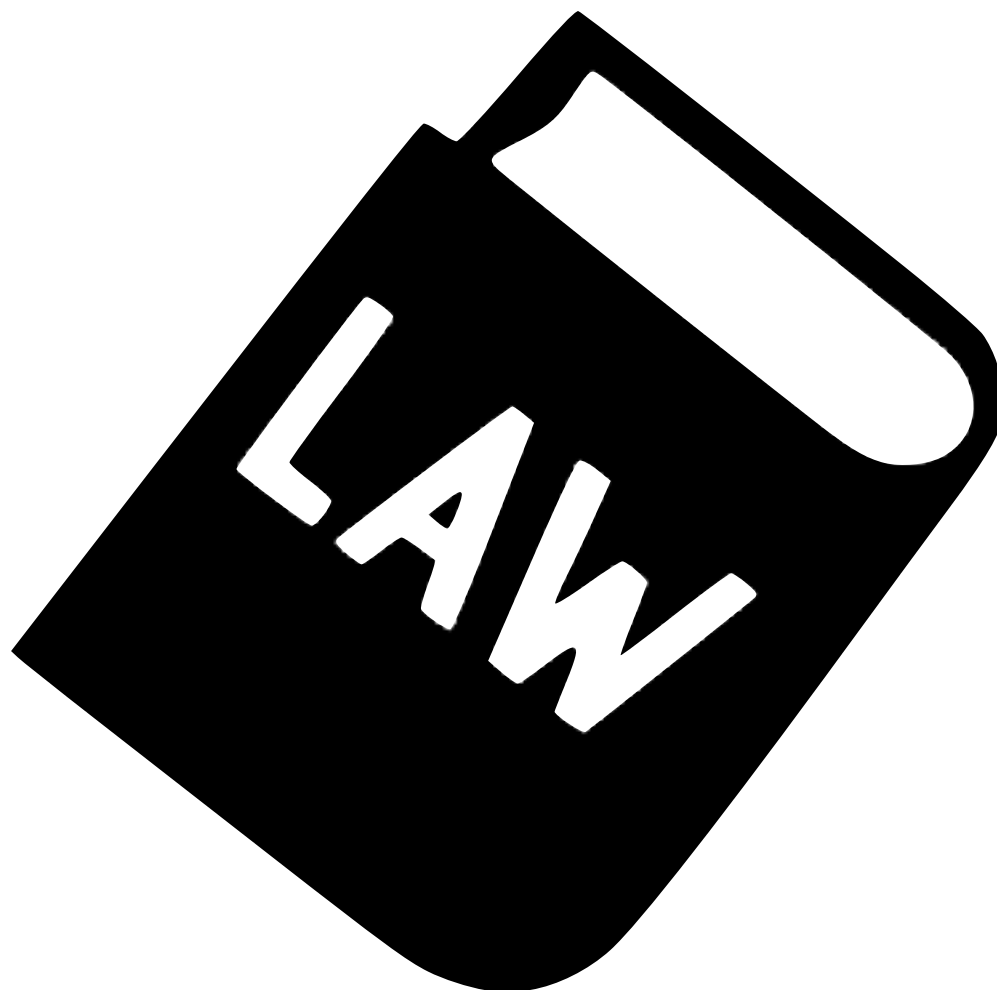54%



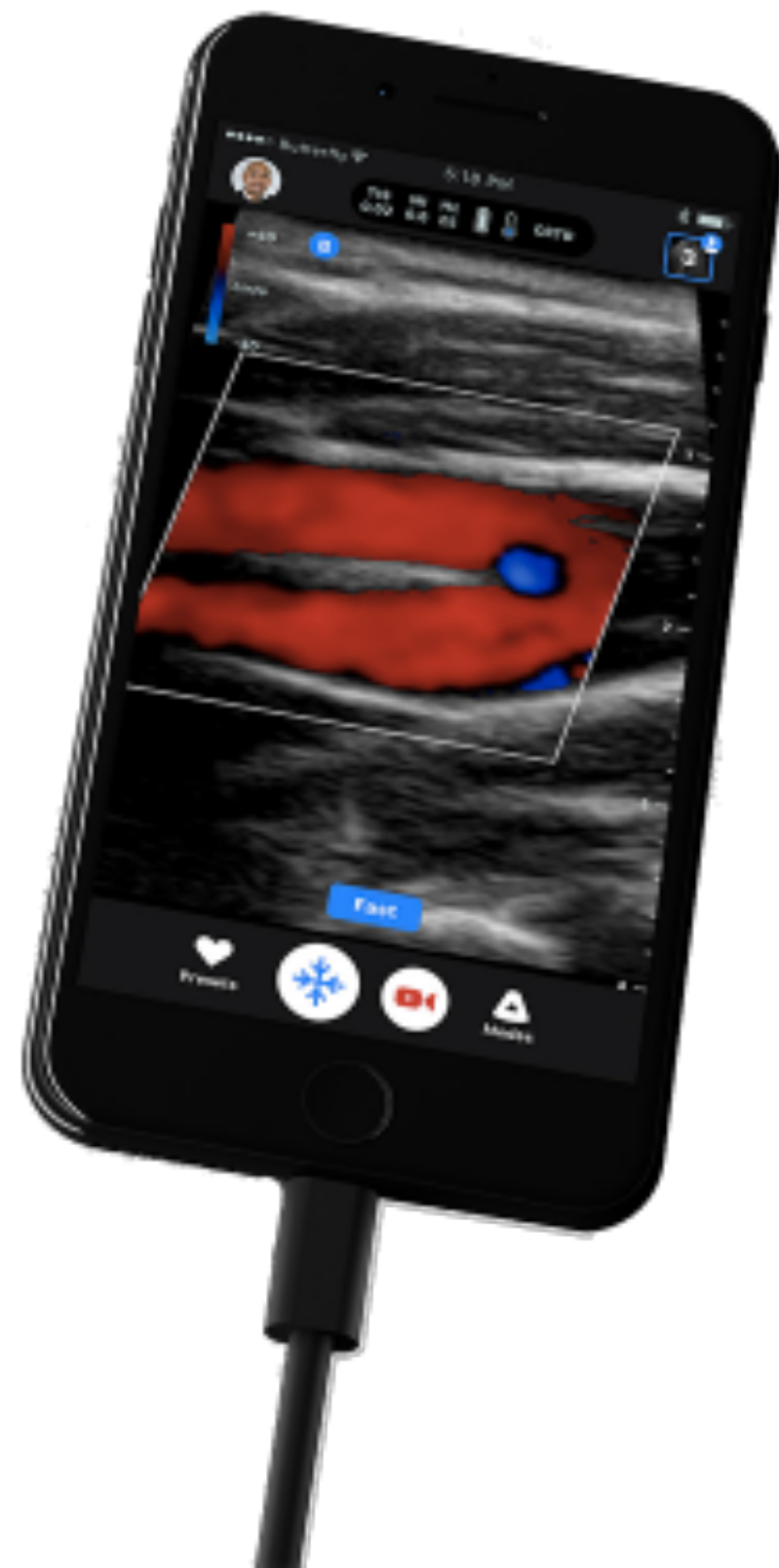48%



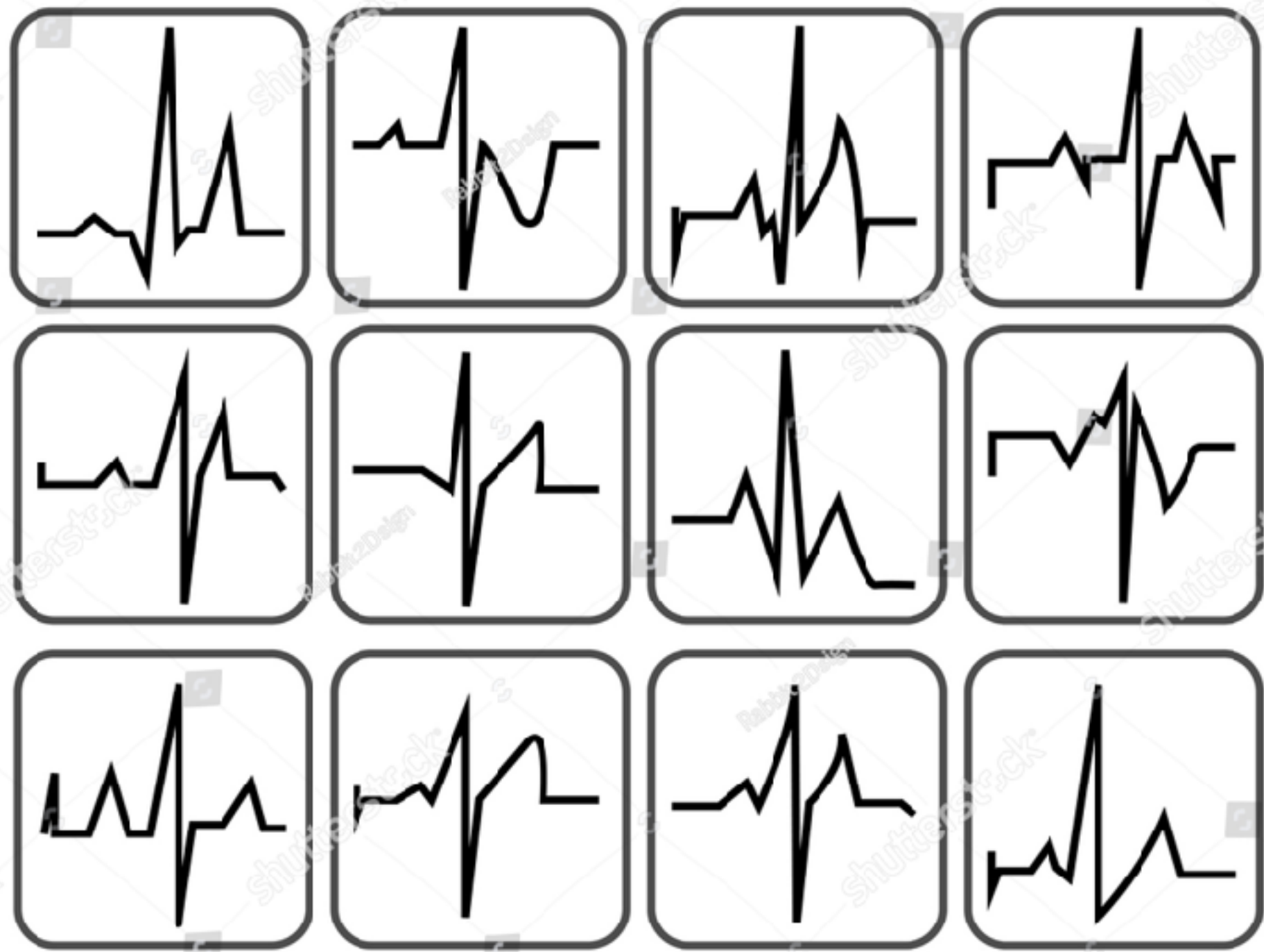

38%

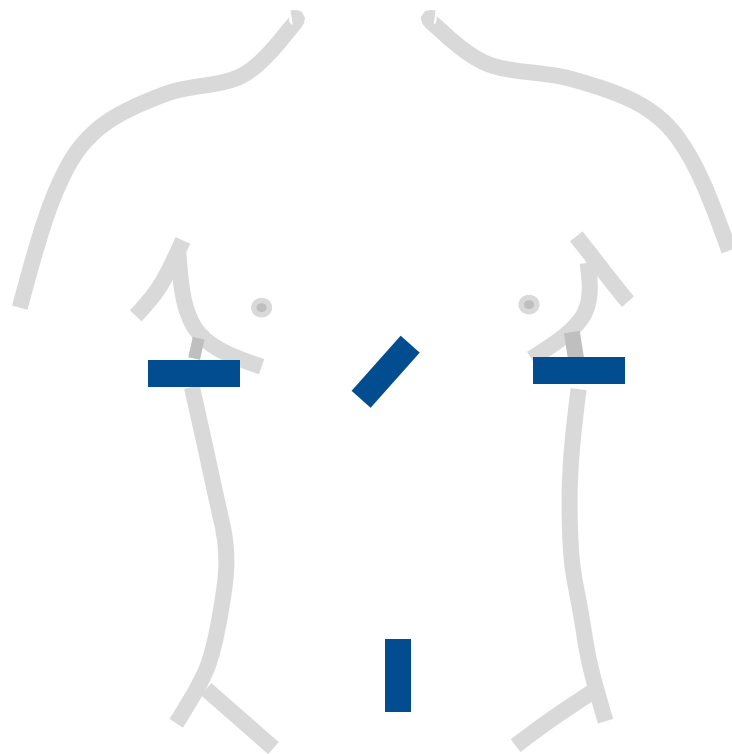


38%



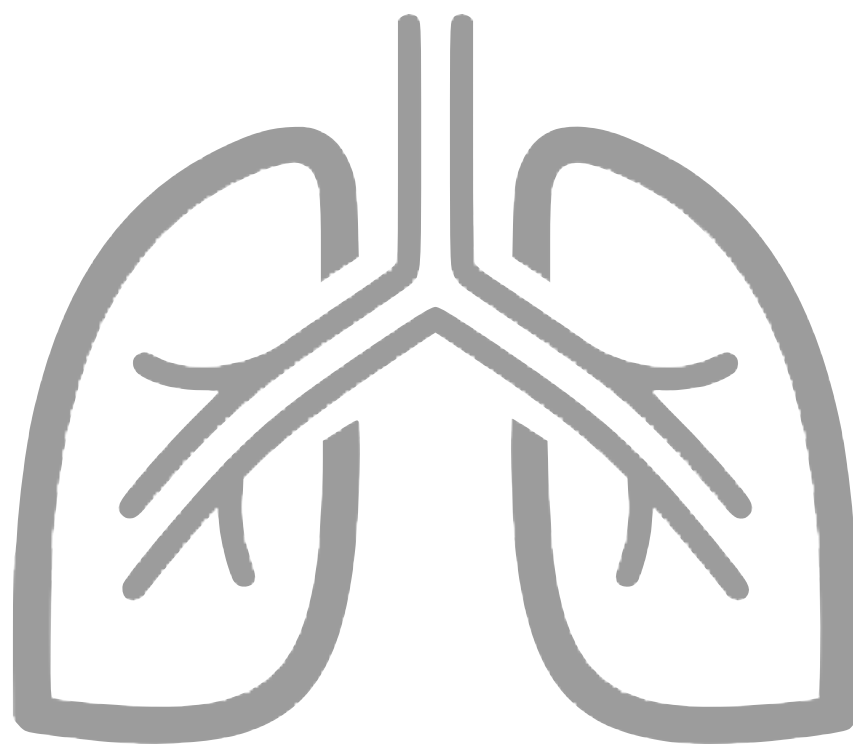
2,000
USD!!





FAST

**6-8
hrs**



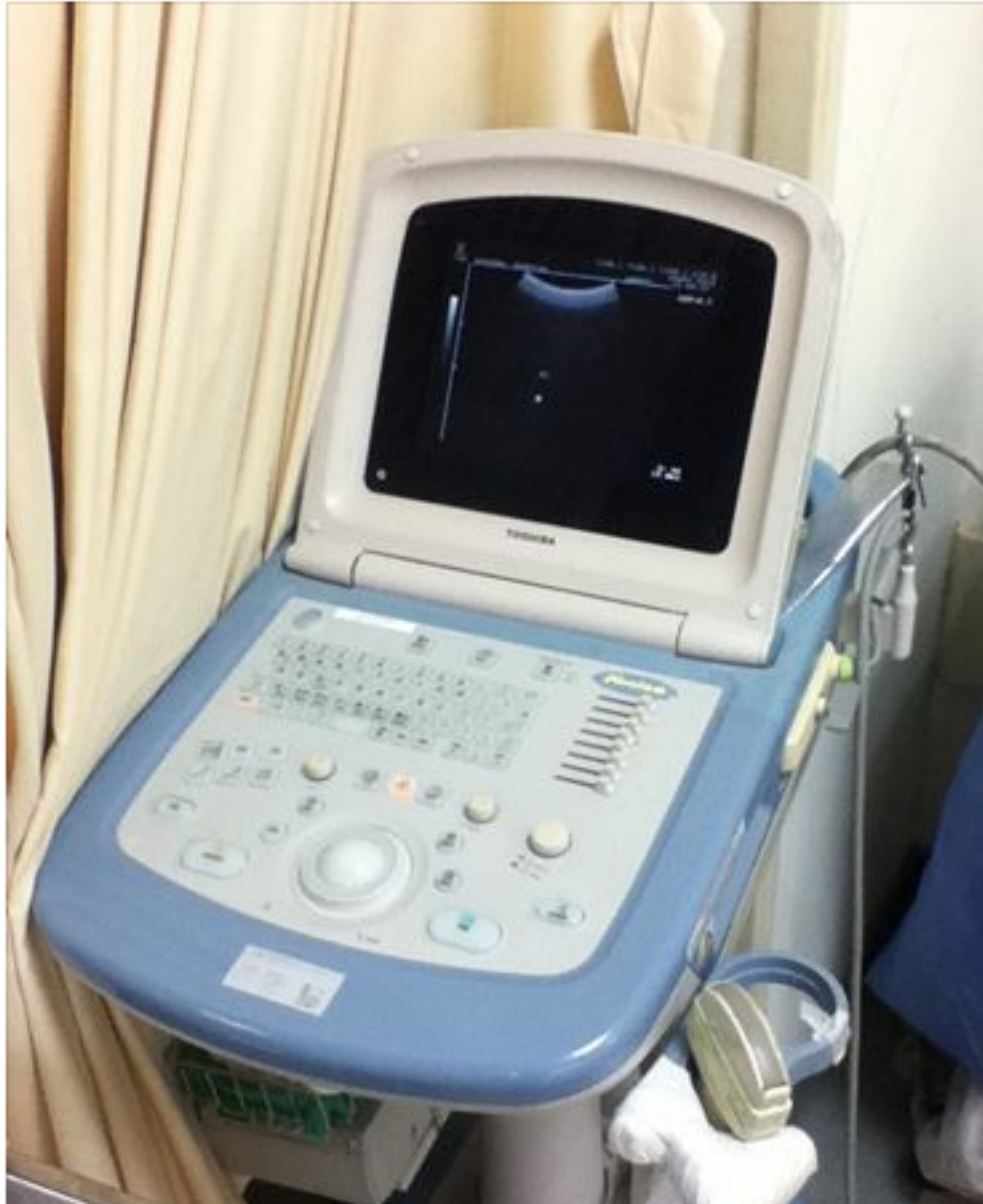**25
mins**



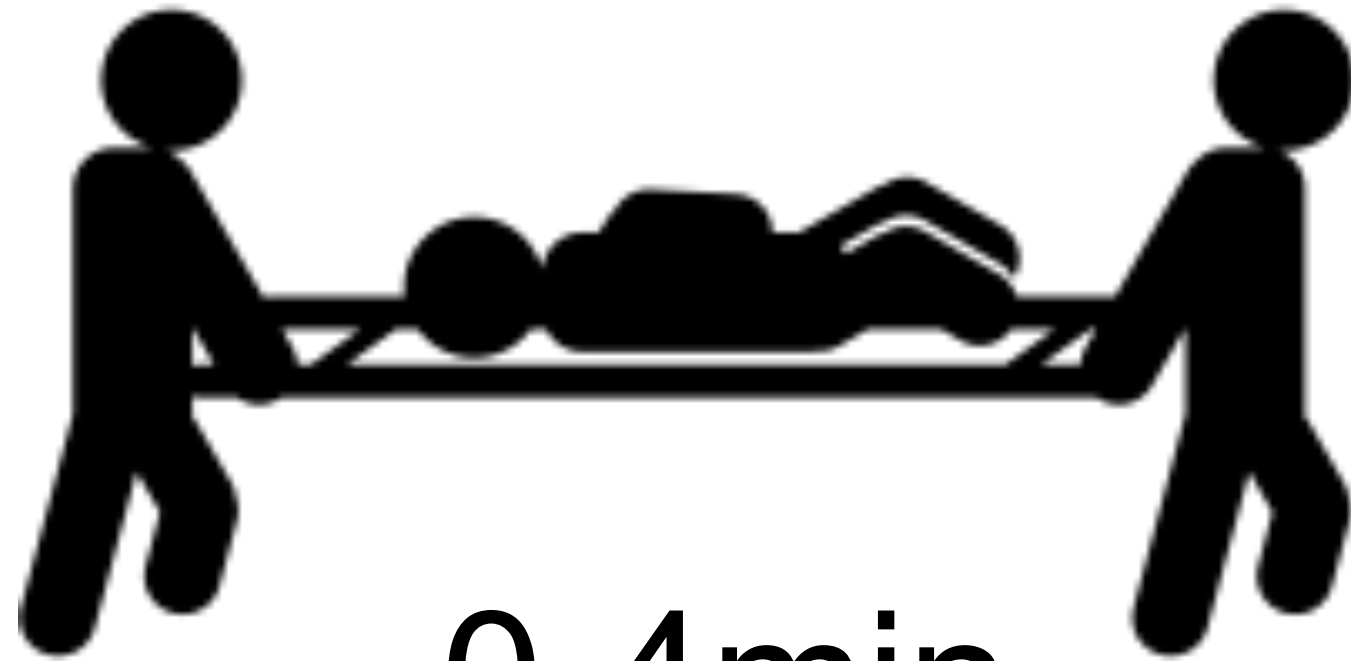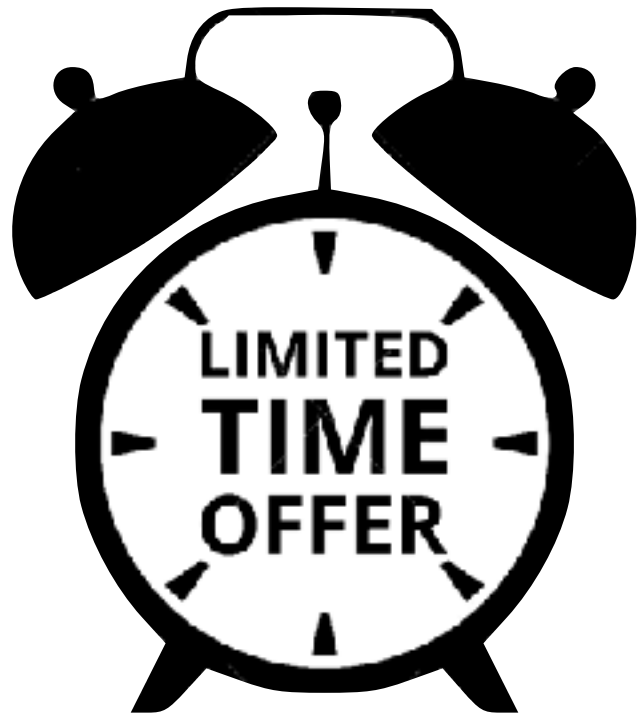Mink Tsai

2013年10月3日 · 人

有緣再見了，我在亞東最好的朋友~ — 在亞東醫院急診室。



Goodbye~
My Best friend
in FEMH



0-4min



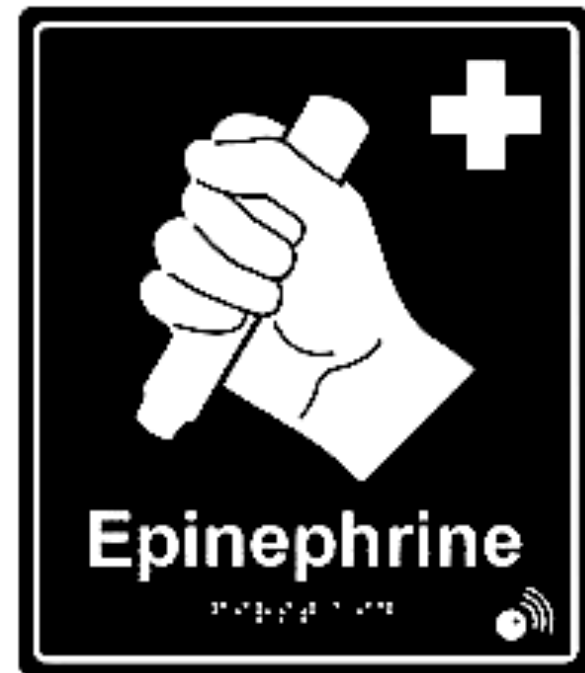3.5min

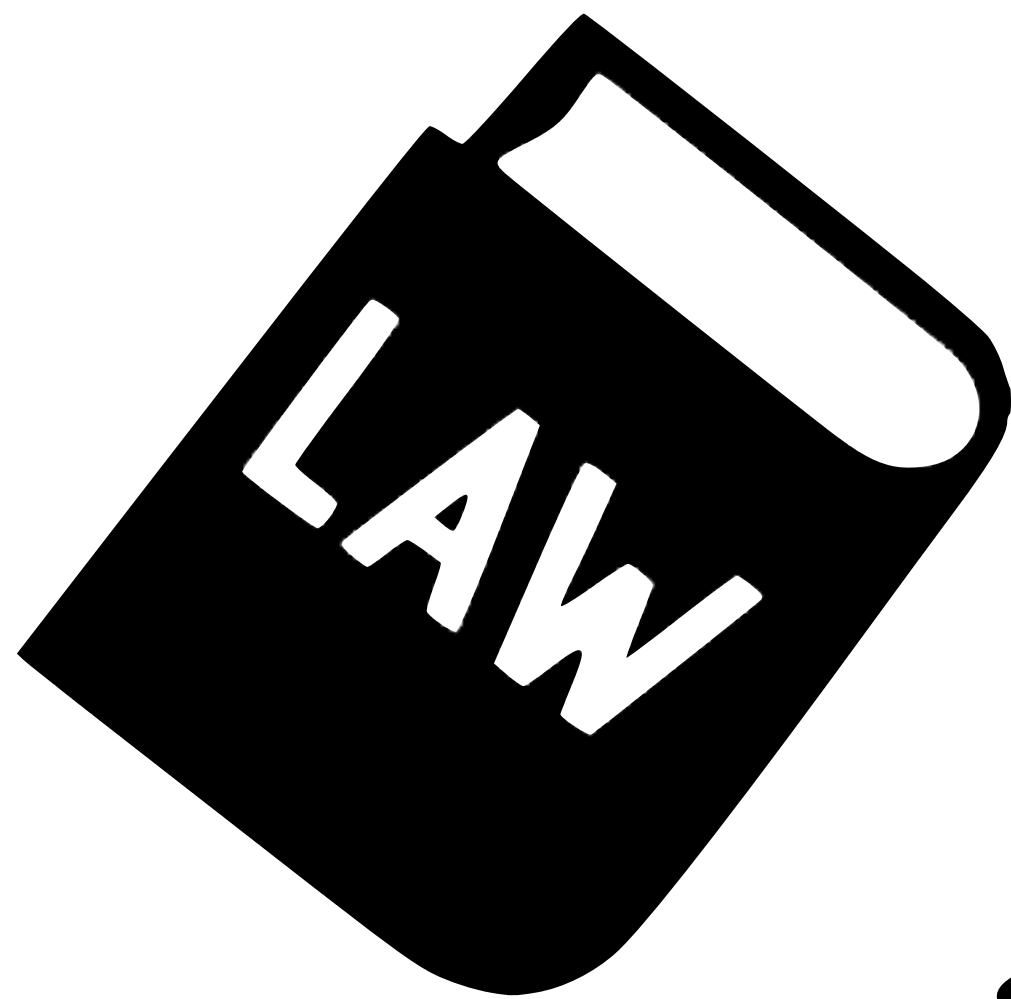


< 1min



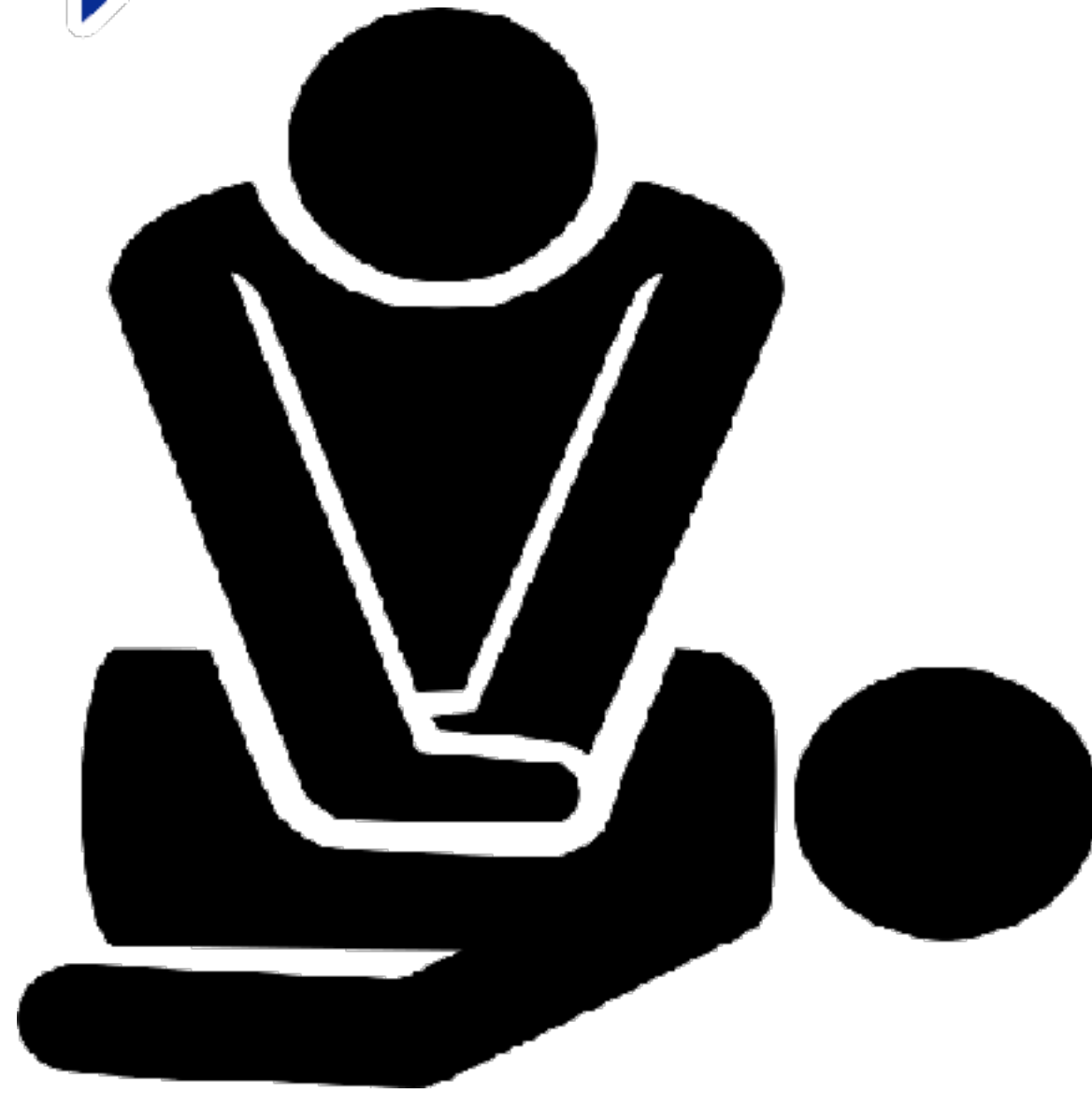3.9min










To Be or

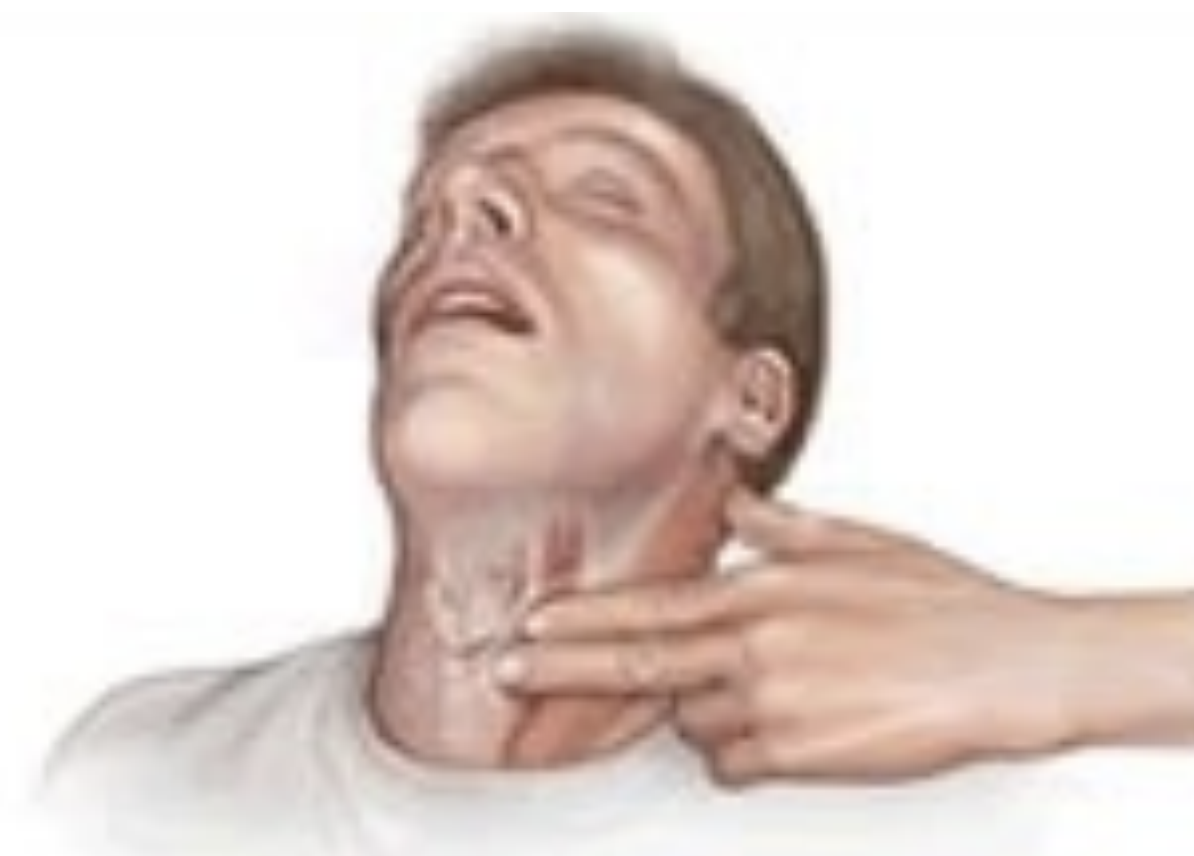

Not To Be

沒脈搏

有脈搏





52% within 5 sec

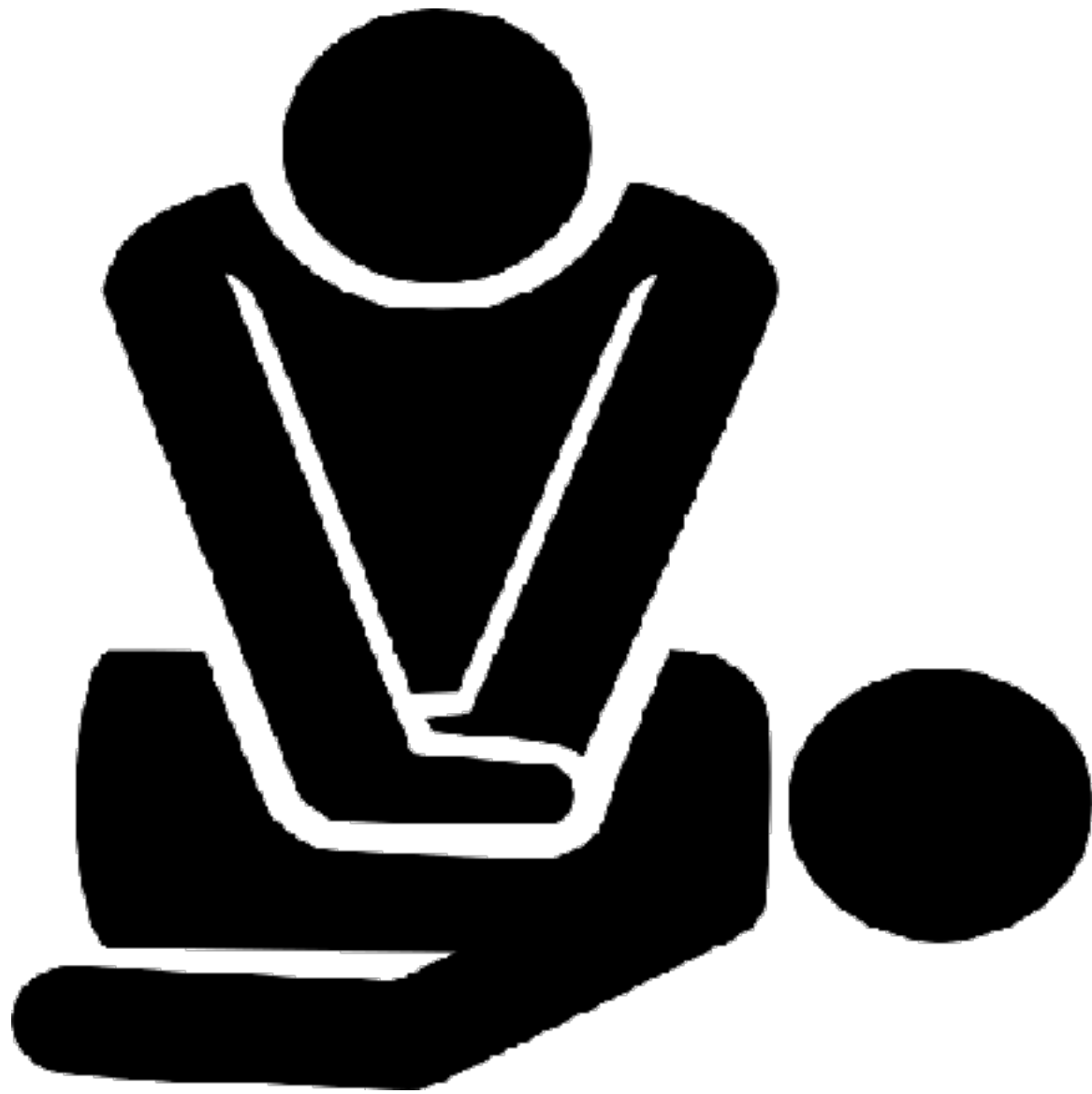Resuscitation 1998



3hrs training

**100% Accuracy of
Cardiac activity**

To Be or



15分後

Monitor: Asystole

Not To Be

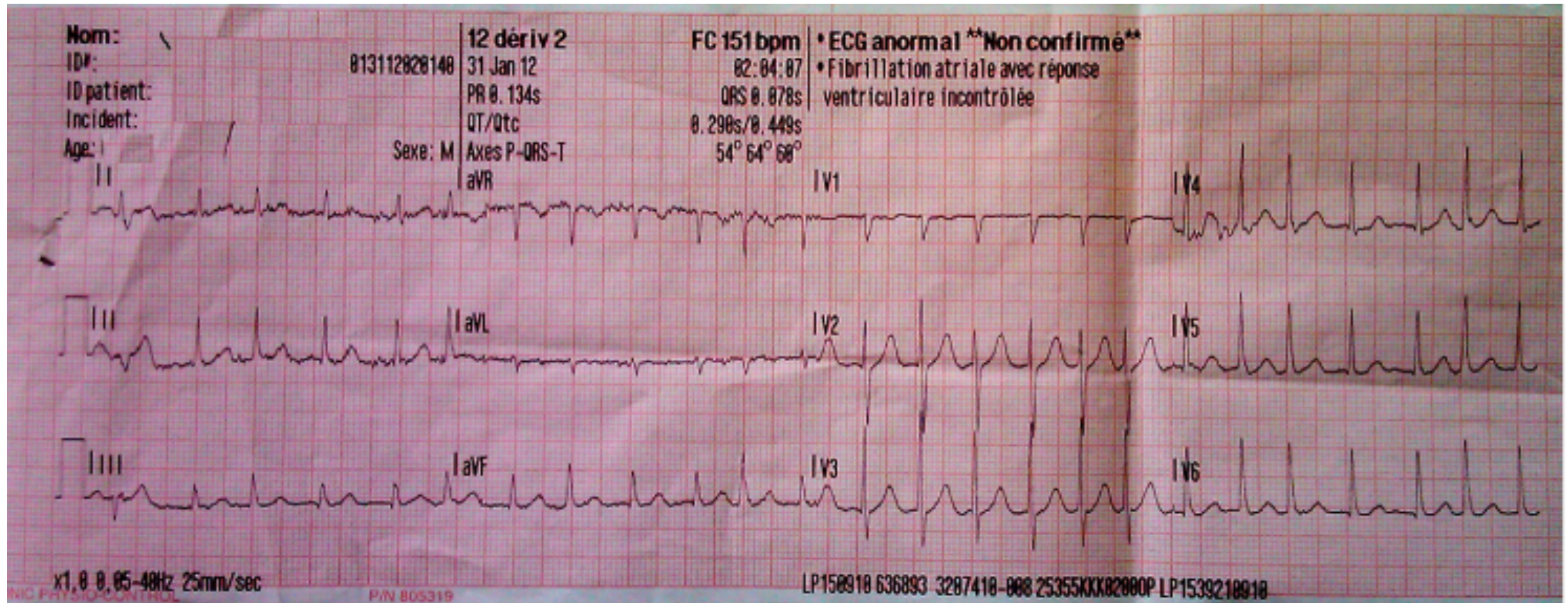


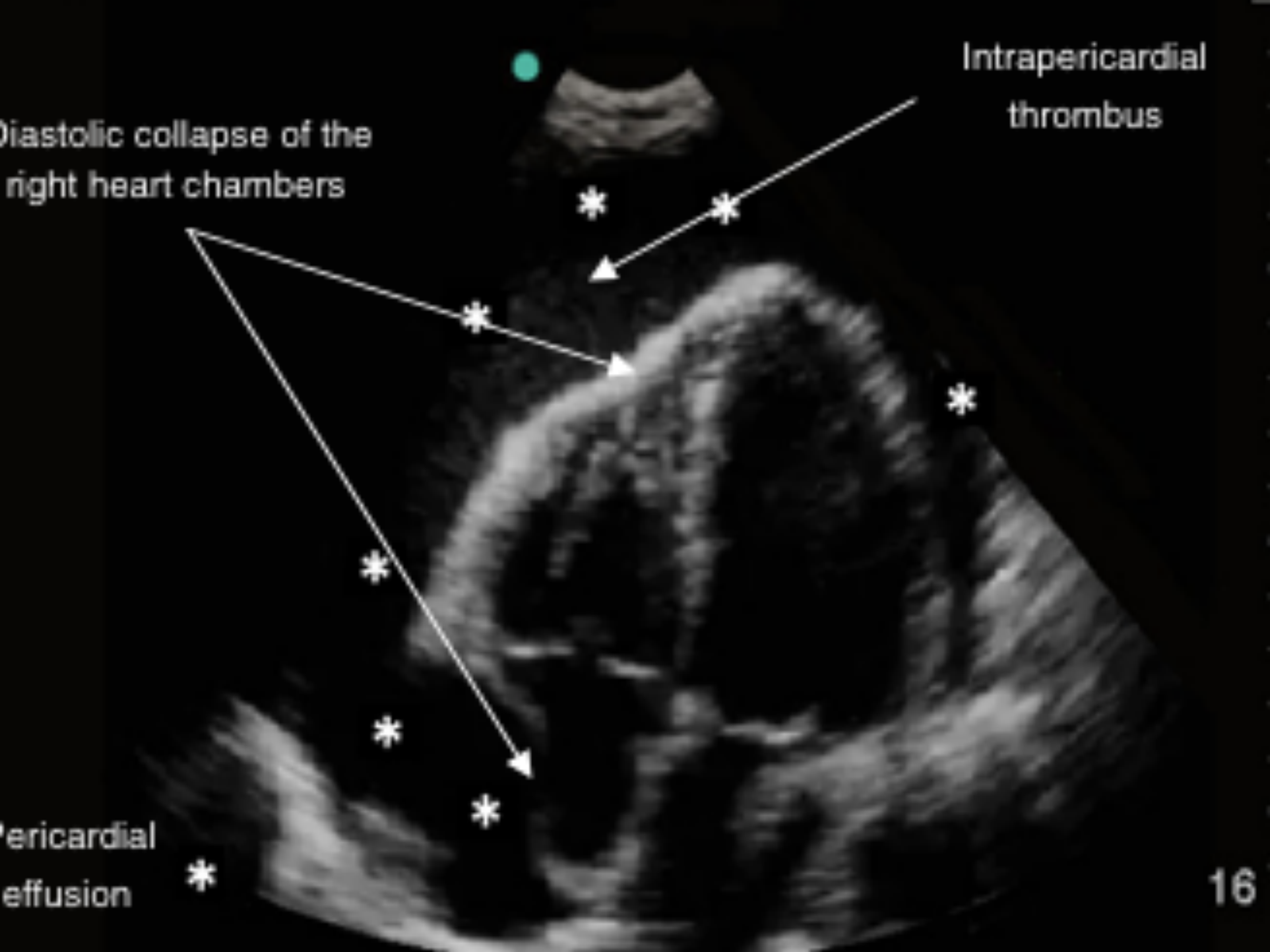
Sen 90%
PPV:99%
For non-survival



Shortness of Breath

57 y/o 男性 喘
4年前開過心臟
BP:79/64
SpO2:82% RR:40
JVE:(+)





Intrapericardial
thrombus

Diastolic collapse of the
right heart chambers

Pericardial
effusion



ELSEVIER

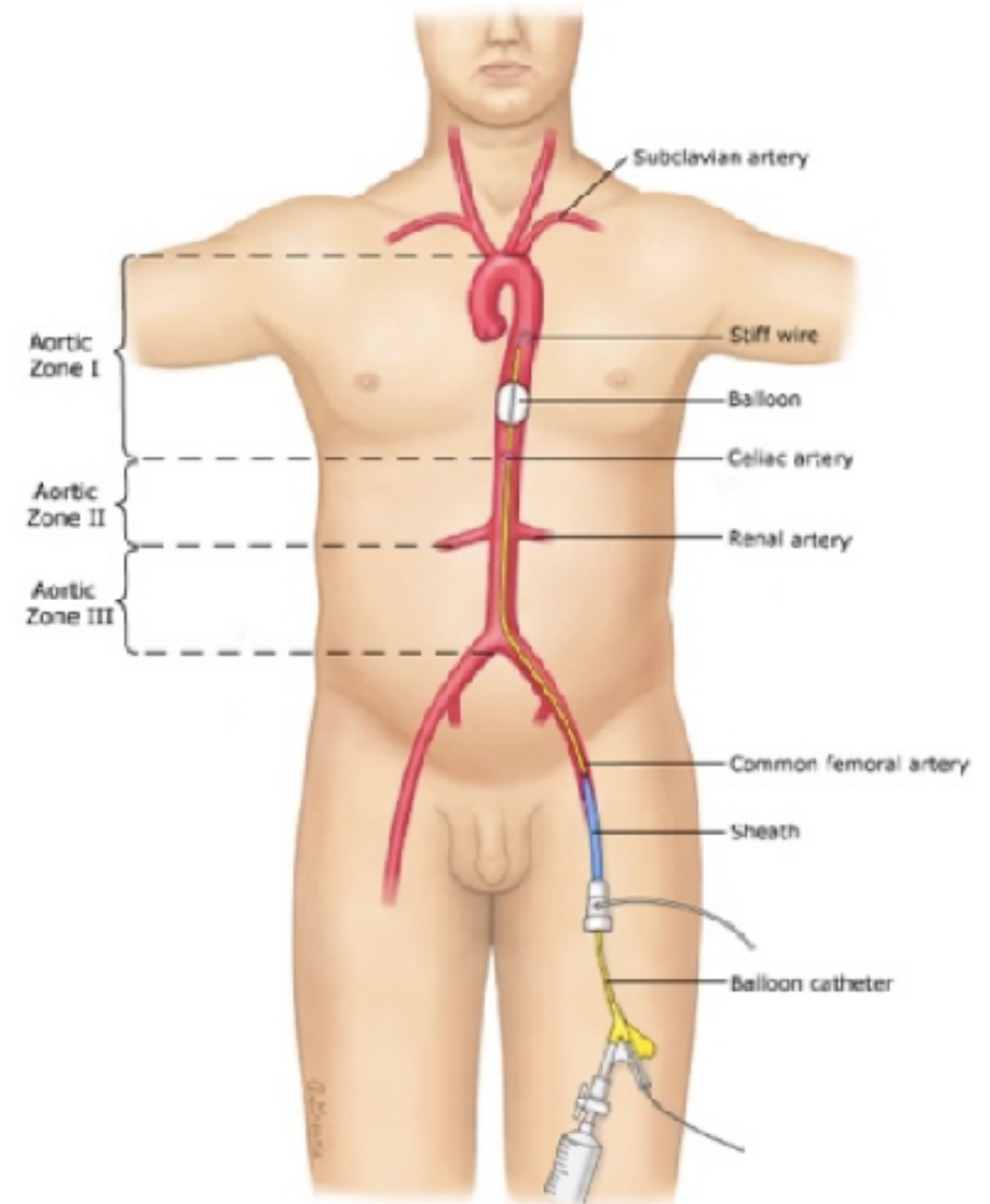

Resuscitation

journal homepage: www.elsevier.com/locate/resuscitation

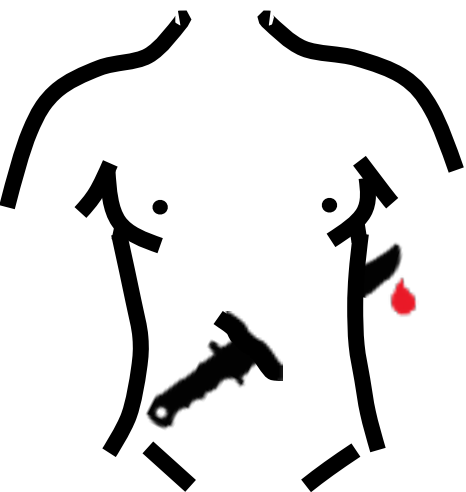


Clinical paper


Pre-hospital Resuscitative Endovascular Balloon Occlusion of the Aorta (REBOA) for exsanguinating pelvic haemorrhage




ABC score




Penetrating
(1分)



$HR > 120$
(1分)

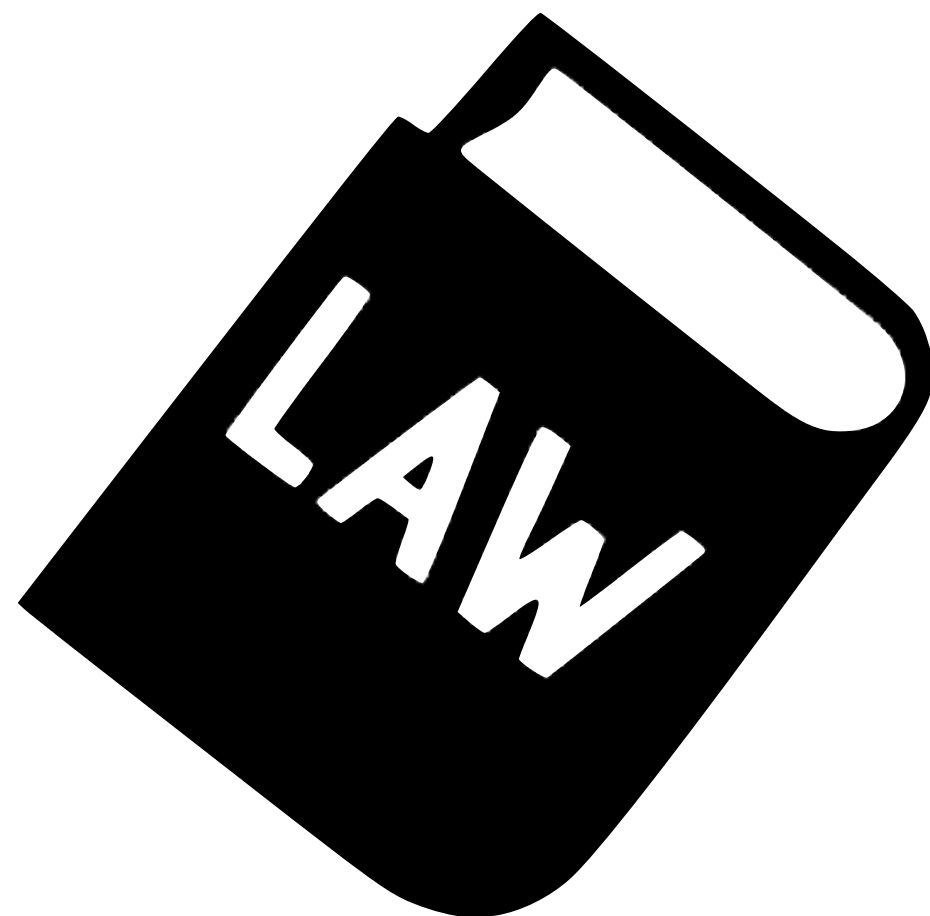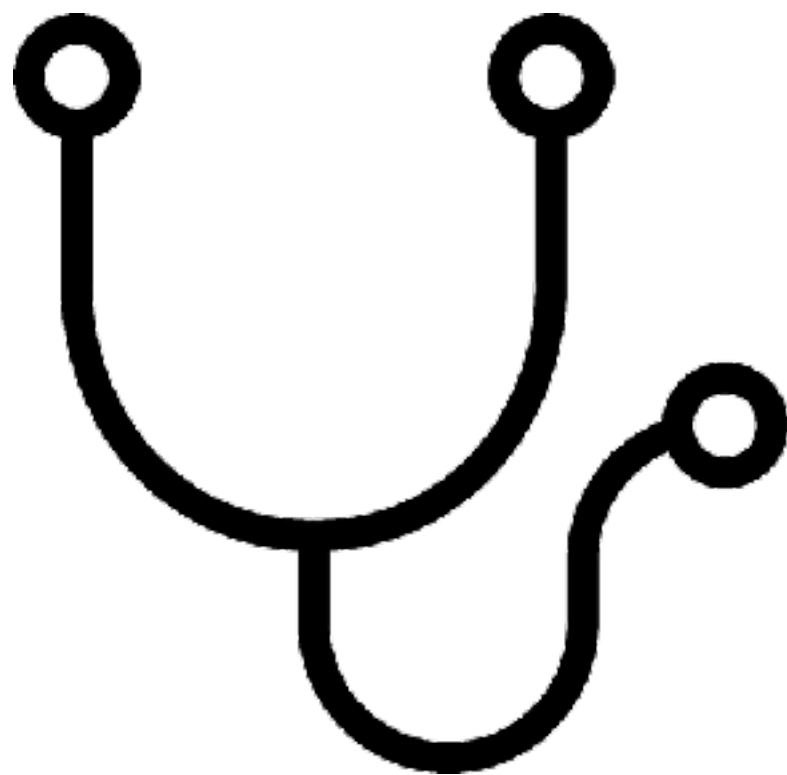

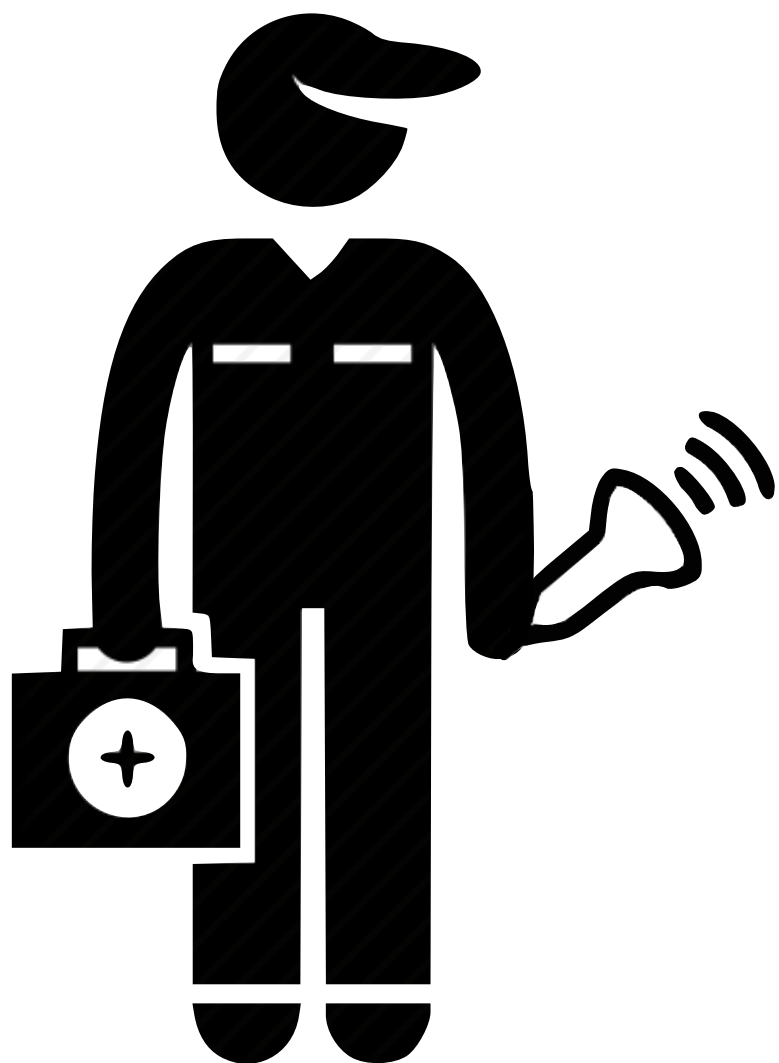
$SBP < 90$
(1分)



FAST(+)
(1分)

MTP if ABC score ≥ 2





Sun Jen-Tang M.D MSc.
tangtang05231980@hotmail.com



tangtang05321980@hotmail.com