A surgeon in a blue scrubs and mask is pointing upwards with his right hand. He is wearing a blue surgical cap and glasses. The background shows other surgeons in a sterile operating room environment.

# 超音波在急診 骨骼肌肉系統應用

陳國智 西園急診醫學科

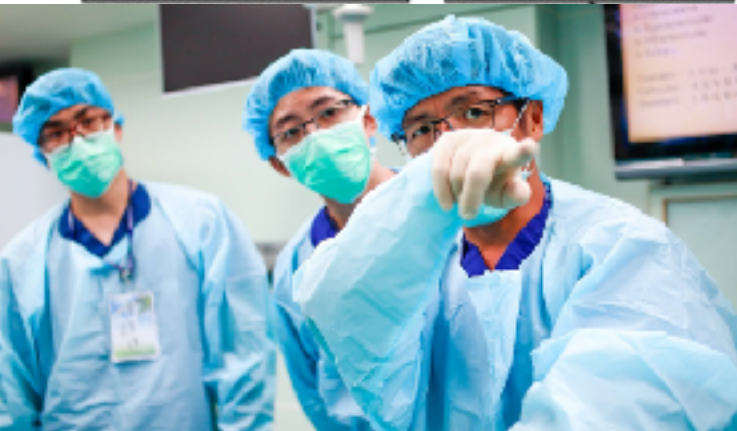Resuscitative

Diagnostic

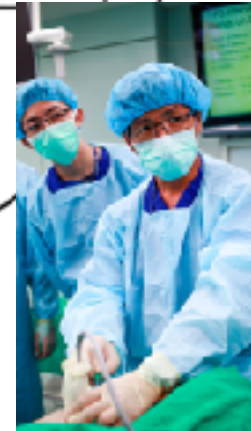Procedural  
Guidance

Symptom- or  
Sign-Based

Therapeutic



Diagnostician



Interventionist

Core Applications

- Trauma
- Intrauterine Pregnancy
- AAA
- Cardiac/HD Assessment
- Biliary
- Urinary Tract
- DVT
- Soft-tissue/Musculoskeletal
- Thoracic/Airway
- Ocular
- Bowel
- Procedural Guidance

ACEP

2016

12 核心

5大應用

REVIEW

Open Access



# An overview of point-of-care ultrasound for soft tissue and musculoskeletal applications in the emergency department

Kuo-Chih Chen<sup>1,2</sup>, Aning Chor-Ming Lin<sup>3,4</sup>, Chee-Fah Chong<sup>1,2</sup> and Tzong-Luen Wang<sup>1,2</sup>

## Musculoskeletal Ultrasound in the Emergency Department

Vito Chianca, MD<sup>1</sup> Francesco Di Pietto, MD, PhD<sup>2</sup> Marcello Zappia, MD, PhD<sup>3</sup>  
Domenico Albano, MD<sup>1,4</sup> Carmelo Messina, MD<sup>1,5</sup> Luca Maria Sconfienza, MD, PhD<sup>1,5</sup>

<sup>1</sup>IRCCS Istituto Ortopedico Galeazzi, Milano, Italy

<sup>2</sup>Dipartimento di Diagnostica per immagini, Pineta Grande Hospital, Castel Volturno (CE), Italy

<sup>3</sup>Department of Medicine and Health Sciences, Università del Molise, Campobasso, Italy

<sup>4</sup>Section of Radiological Sciences, Department of Biomedicine, Neurosciences and Advanced Diagnostics, University of Palermo, Palermo, Italy

<sup>5</sup>Dipartimento di Scienze Biomediche per la Salute, Università degli Studi di Milano, Milano, Italy

Semin Musculoskelet Radiol 2020;24:167–174.



Address for correspondence Vito Chianca, MD, IRCCS Istituto Ortopedico Galeazzi, via Riccardo Galeazzi 4, 20161 Milano, Italy (e-mail: vitochianca@gmail.com).

Soft tissue infection  
Joint effusion  
Foreign body  
Long bone fracture  
Muscle & Tendon injury  
Vascular occlusion  
Procedures

---

---

*Seminars in*

ROENTGENOLOGY

---

---

# Musculoskeletal Ultrasound in the Emergency Department: Is There a Role?

Michael V. Perone, MD, and Corrie M. Yablon, MD <https://doi.org/10.1053/j.ro.2020.09.004>

# Limitations of US

In the hands of highly skilled practitioners, the performance of MSK US in the assessment of superficial soft tissue and tendon injury is equal to MRI. A barrier to the performance of MSK US in the ED is the high degree of training that is required of personnel, both to scan and to interpret the images. Sonographers must be able to recognize the artifacts inherent to MSK US and must be able to manipulate the various parameters in order to optimize image quality. It is vital to have a sophisticated understanding of MSK anatomy and the varied sonographic appearances of tissues such as skin, subcutaneous fat, muscle, tendon, ligament, and synovium, both when normal and abnormal. Without this high level of understanding, the resulting images can be confusing at best, and cause missed diagnoses at worst. <https://doi.org/10.1053/j.ro.2020.09.004>

# I-AIM

## Indication



**Acquire**



**Interpret**

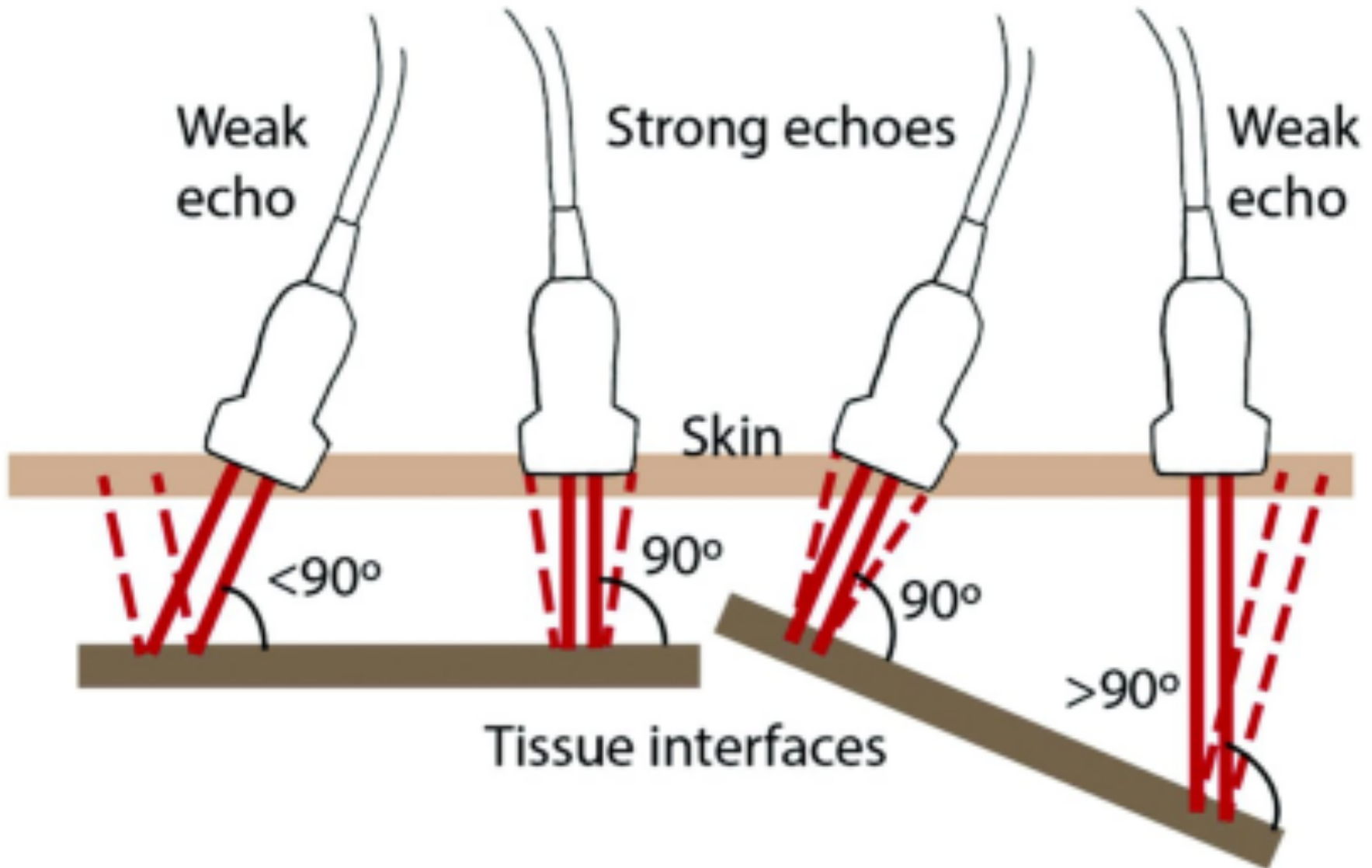


**Make  
decision**

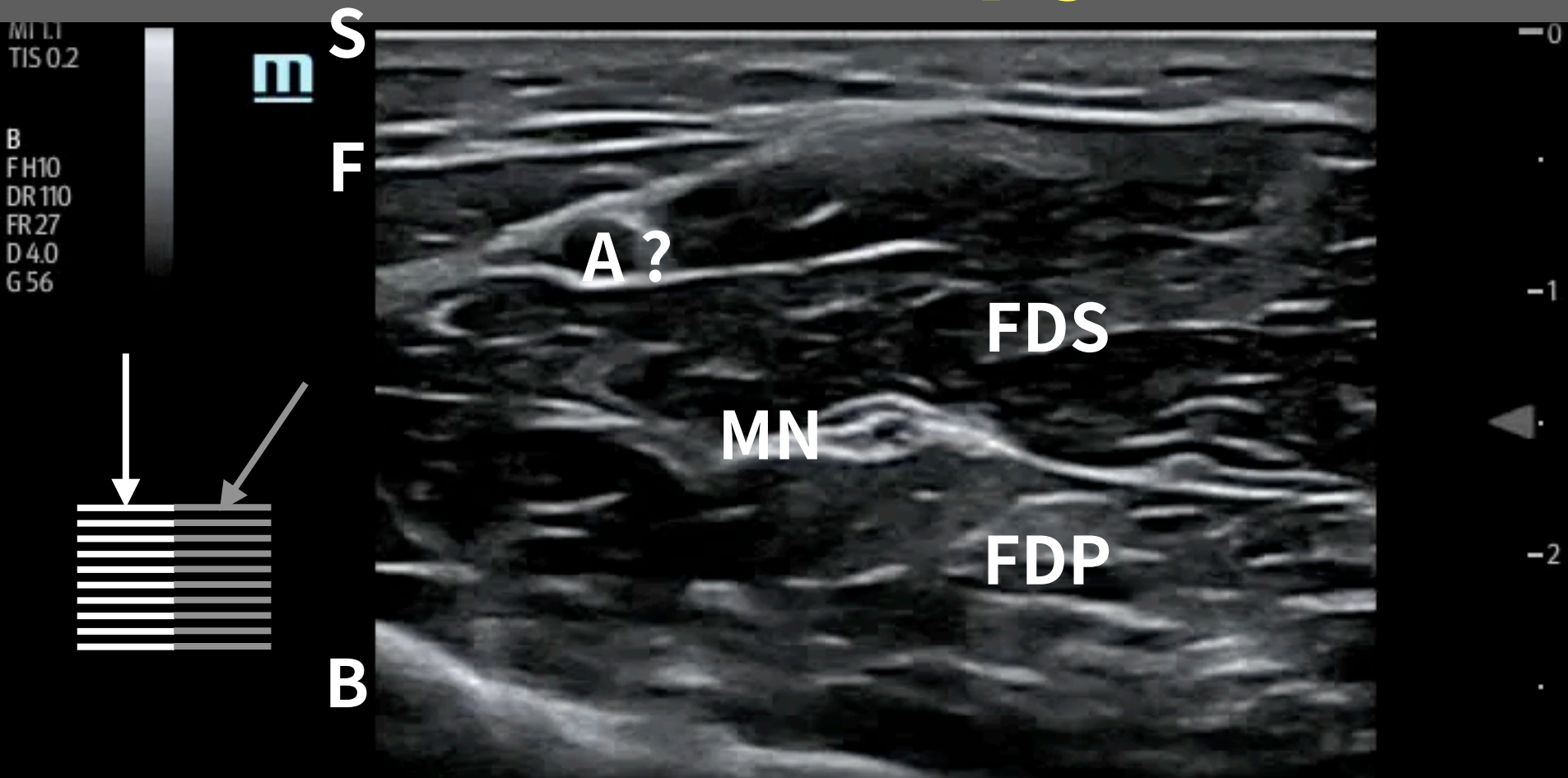
# Probe



# Perpendicular to **Target**



# Anisotropy



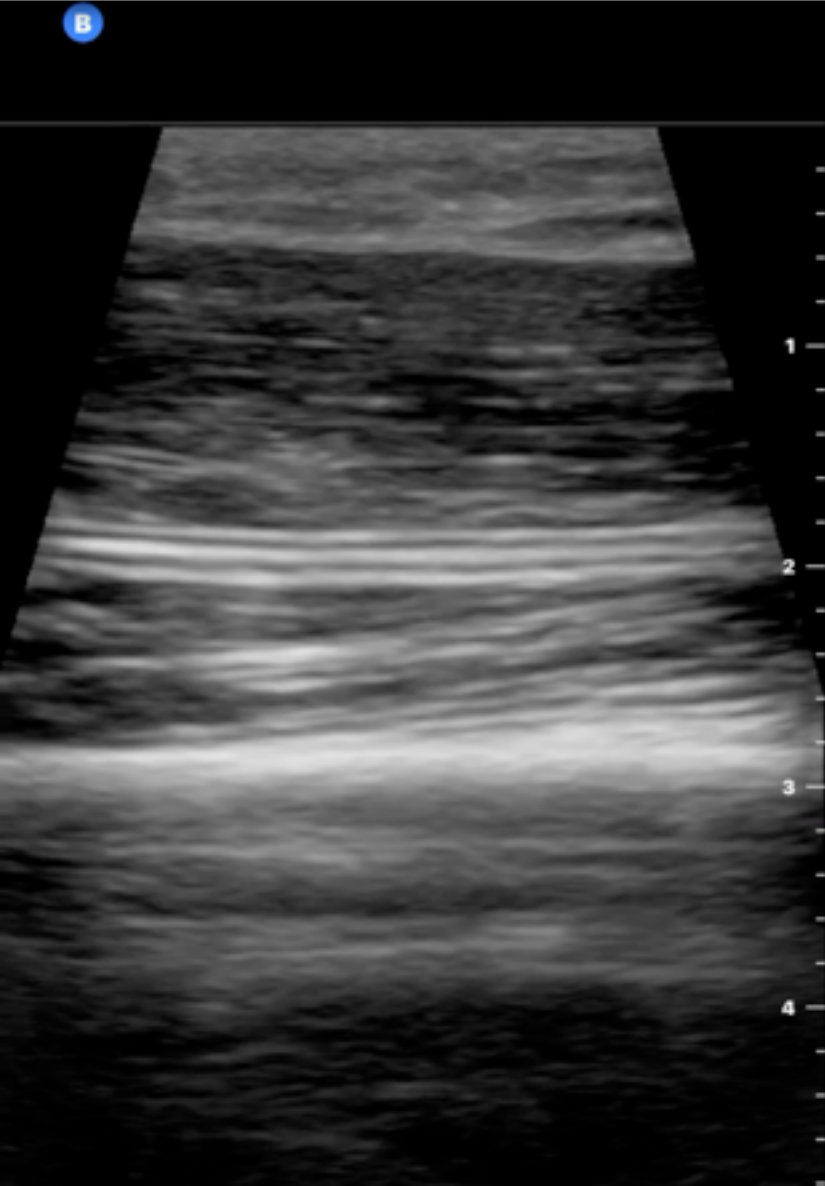
**Tendon**

**Nerve**

**Muscle**

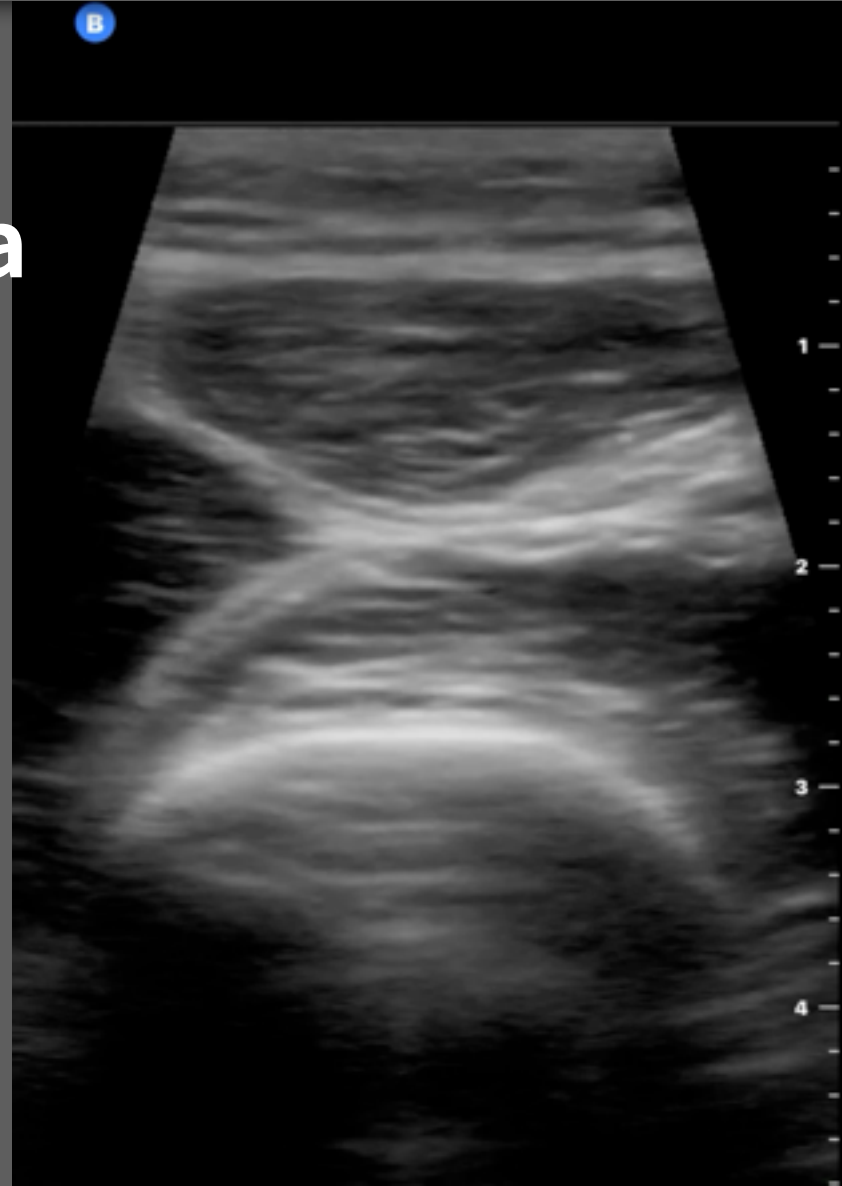

# Define 3 layers



Skin  
Fascia

Bone

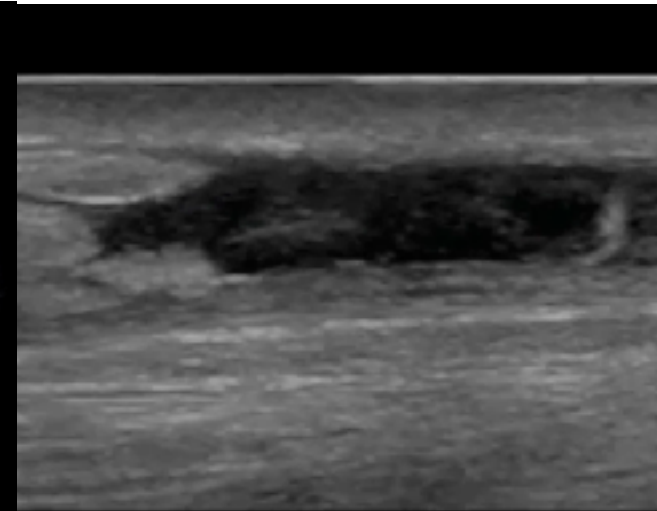
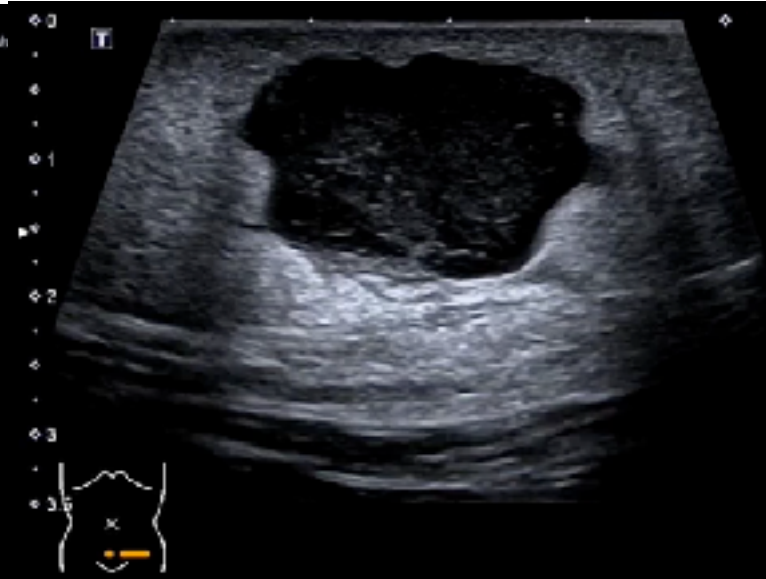
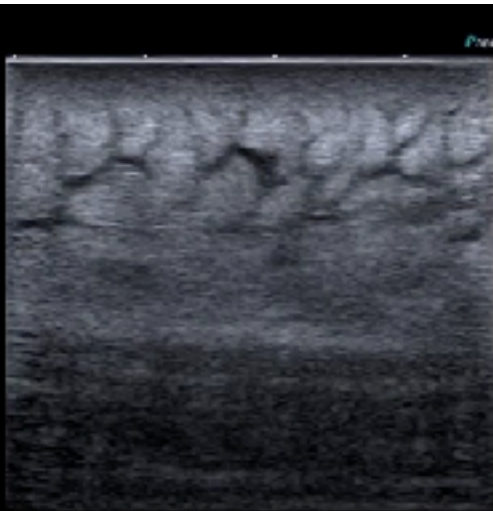


# Soft tissue infection

**Cellulitis**

**Abscess**

**NF**



**Cobblestone**

**Collection**

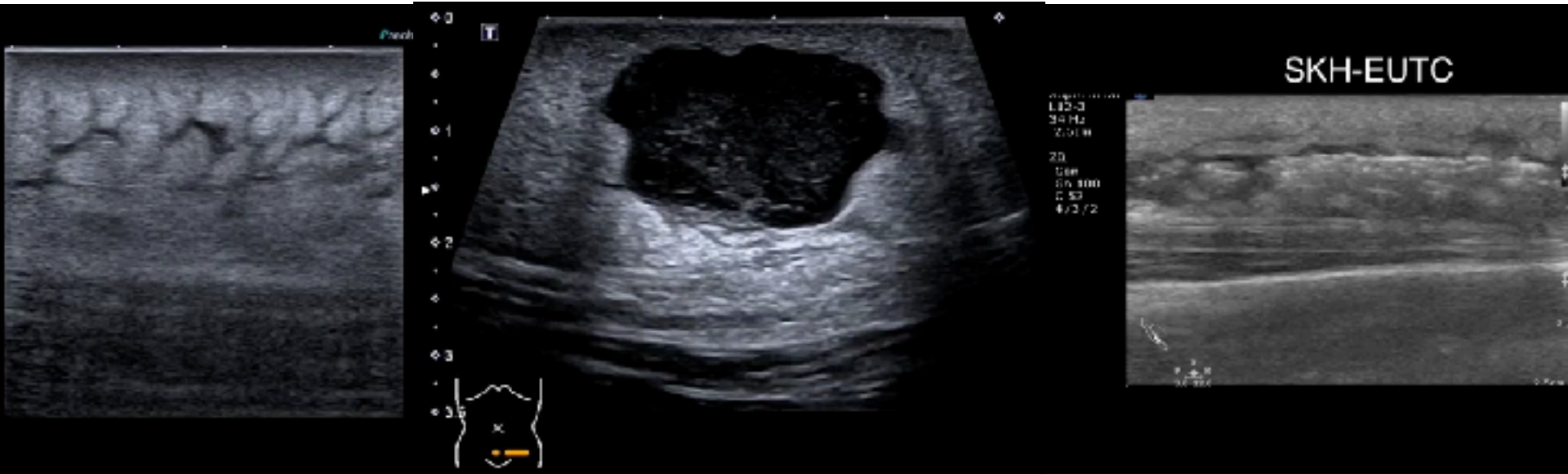**Fascial fluid >4mm**

# Soft tissue infection

**Cellulitis**

**Abscess**

**NF**



**Cobblestone**

**Collection**

**STAFF**

# Point-of-Care Ultrasonography for the Diagnosis of Skin and Soft Tissue Abscesses: A Systematic Review and Meta-analysis

Michael Gottlieb, MD\*; Jacob Avila, MD; Mark Chottiner, MD; Gary Peksa, PharmD

## Study 14 ; Patients 2656

Study	Study Population	Country	Study Location	Study Population	Mean Age, Years	Female Patients, %	Abscesses, %	Sonographer Specialty	Sonographer Experience	Criterion Standard
Dunham, 1987	25	India	ID	Paediatrics	2	54.5	74	MD	MD	Presence on initial US or recurrent abscesses at 72 h
Hugh-Williams, 2000	55	United States	ID	NO	40	73	70	Emergency medicine	MD	Presence on US
Squires, 2005	109	United States	ID	Adult	39	51	60	Emergency medicine	A, R	Presence on US if drainage attempted or resolution of symptoms if no drainage attempted
Royal, 2006	128	United States	ID	Adult	42	41	43	Emergency medicine	A	Presence on US at initial visit or 32 h follow-up
EMF2, 2010	87	United States	UP	EMERGENCY	3.2	42	44	Emergency medicine	A, F	Presence on US if drainage attempted or resolution of symptoms if no drainage attempted
Dingus, 2012	47	United States	ID	Adult	40	73	85	Emergency medicine	A, F	Presence on US
Harari, 2012	45	United States	ID	Paediatrics	5.2	65	72	Pediatric emergency medicine	A, F	Presence on US
Moran, 2014	262	United States	ID	Paediatric	7	64	64	Paediatric emergency medicine	A, F	Presence on US at initial visit or 2 day follow-up. All other cases were designated as no abscess.
Adams, 2016	114	United States	UP	Paediatric	7	54	64	Paediatric emergency medicine	A, F	Presence on US at initial visit or 4-10 day follow-up. All other cases were designated as no abscess.
Hawkins, 2017	38	United States	ID/IC	NO	40	73	70	EM/FP	MD	US
Lee, 2018	305	United States	ID	Paediatrics	7.7	54	41	Emergency medicine	A, F, R	Presence on US at initial visit or 7- to 10-day follow-up. All other cases were designated as no abscess.
Desmet, 2018	109	United States	ID	Adults	52.5	45	70	Emergency medicine	A, F	Repeated US with purulent drainage within 10 days
Levine, 2019	27	United States	ID	Paediatrics	5.2	35	31	Pediatric emergency medicine	A	OT or otology ultrasonography
Moran, 2019	1,215	United States	ID	Adults and paediatrics	50	52	60	Emergency medicine	A, F, R	Presence on US at initial visit or 7-day follow-up. All other cases were designated as no abscess.

Sensitivity 94.6%

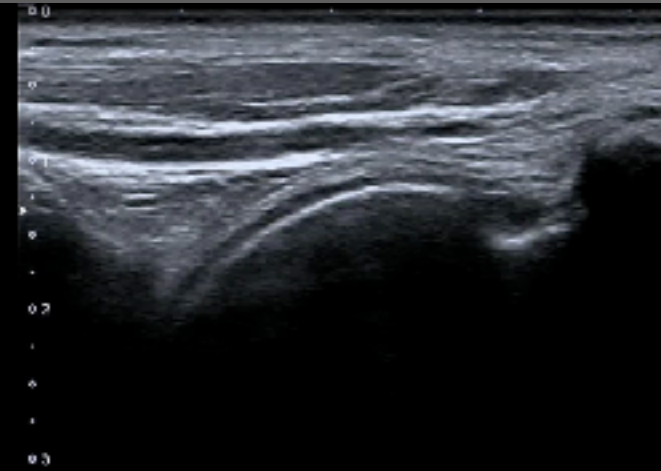
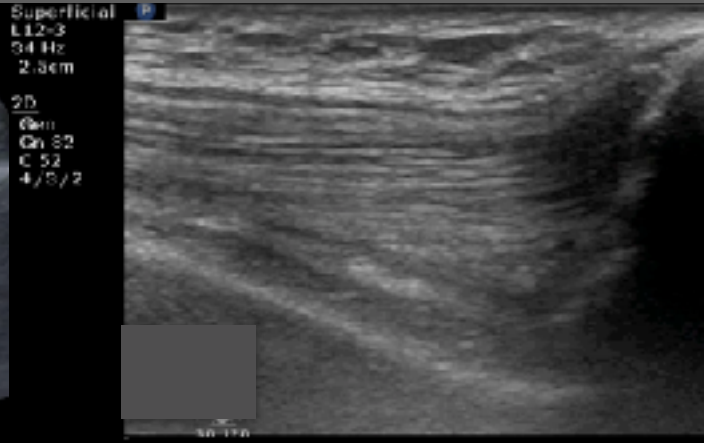
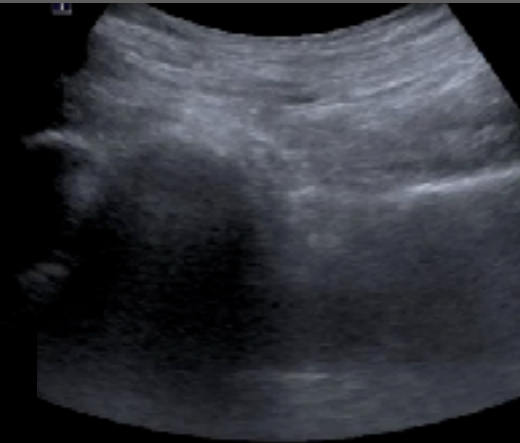Specificity 85.4%

LR+ 6.5

LR- 0.06

NO, Not described; ID, inpatient and drainage; A, attending physician; R, resident; physician; EM, emergency medicine; FP, family practice; F, fellow physician; CT, computed tomography

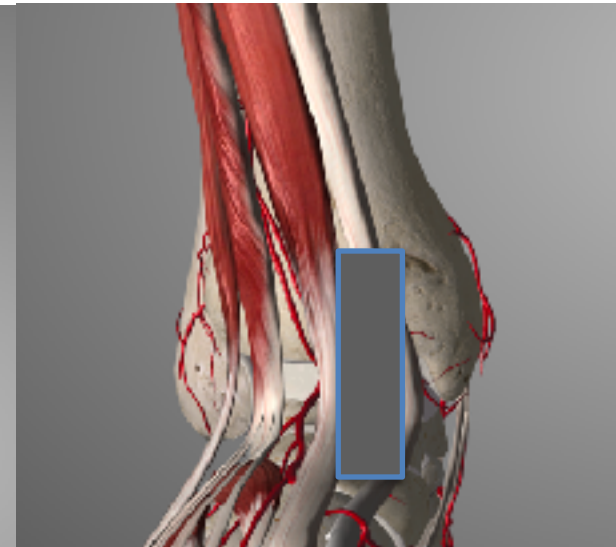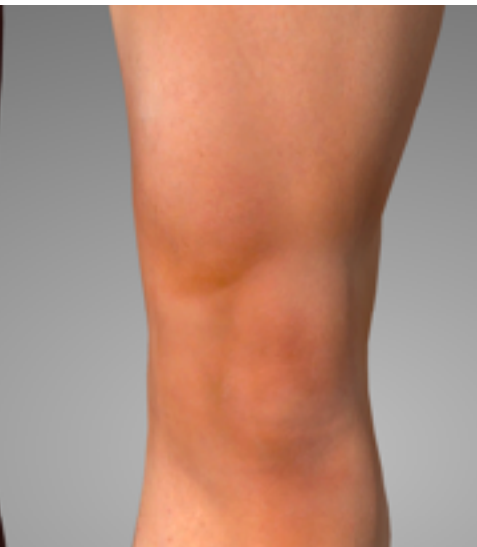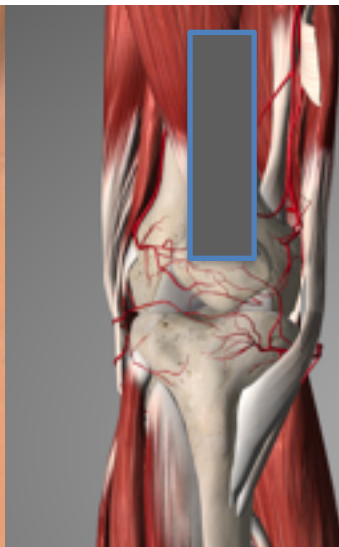
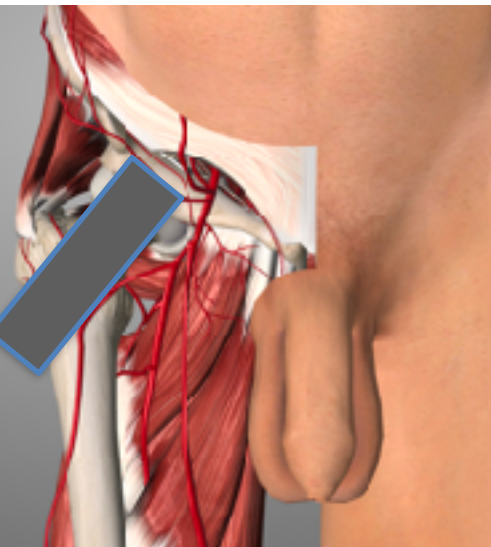
# Lower extremity joints



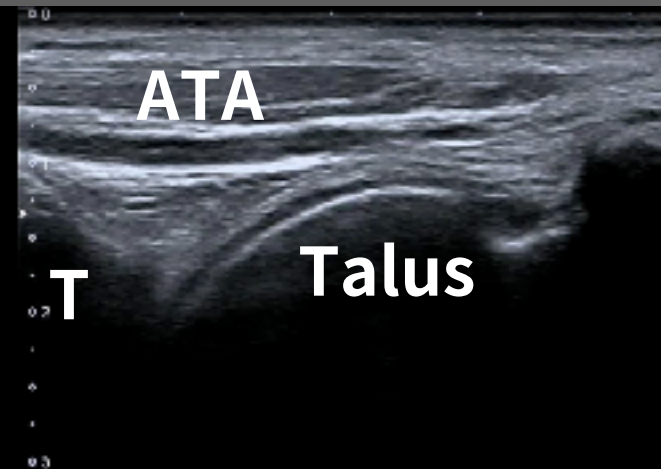
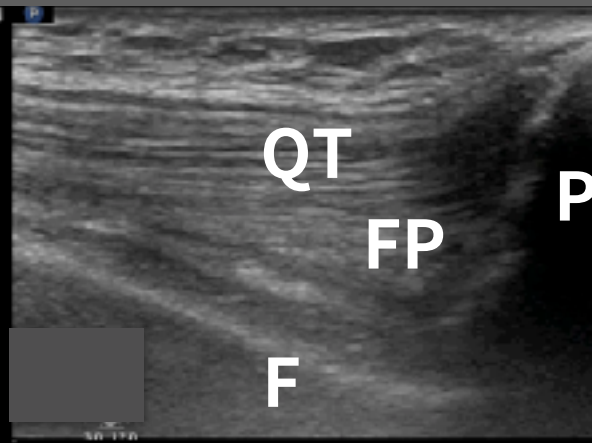
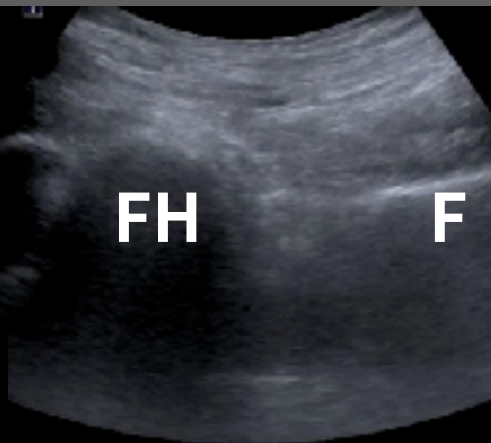
Hip

Knee

Ankle



# LE Joint effusion

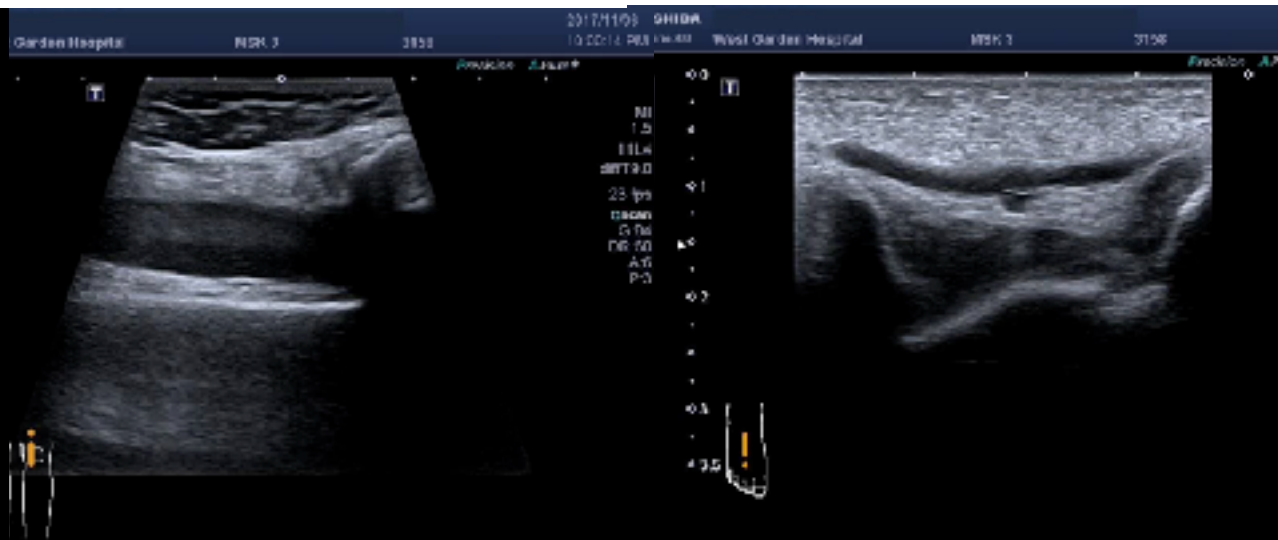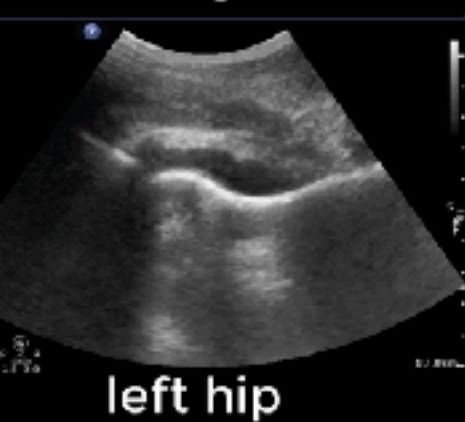


Hip

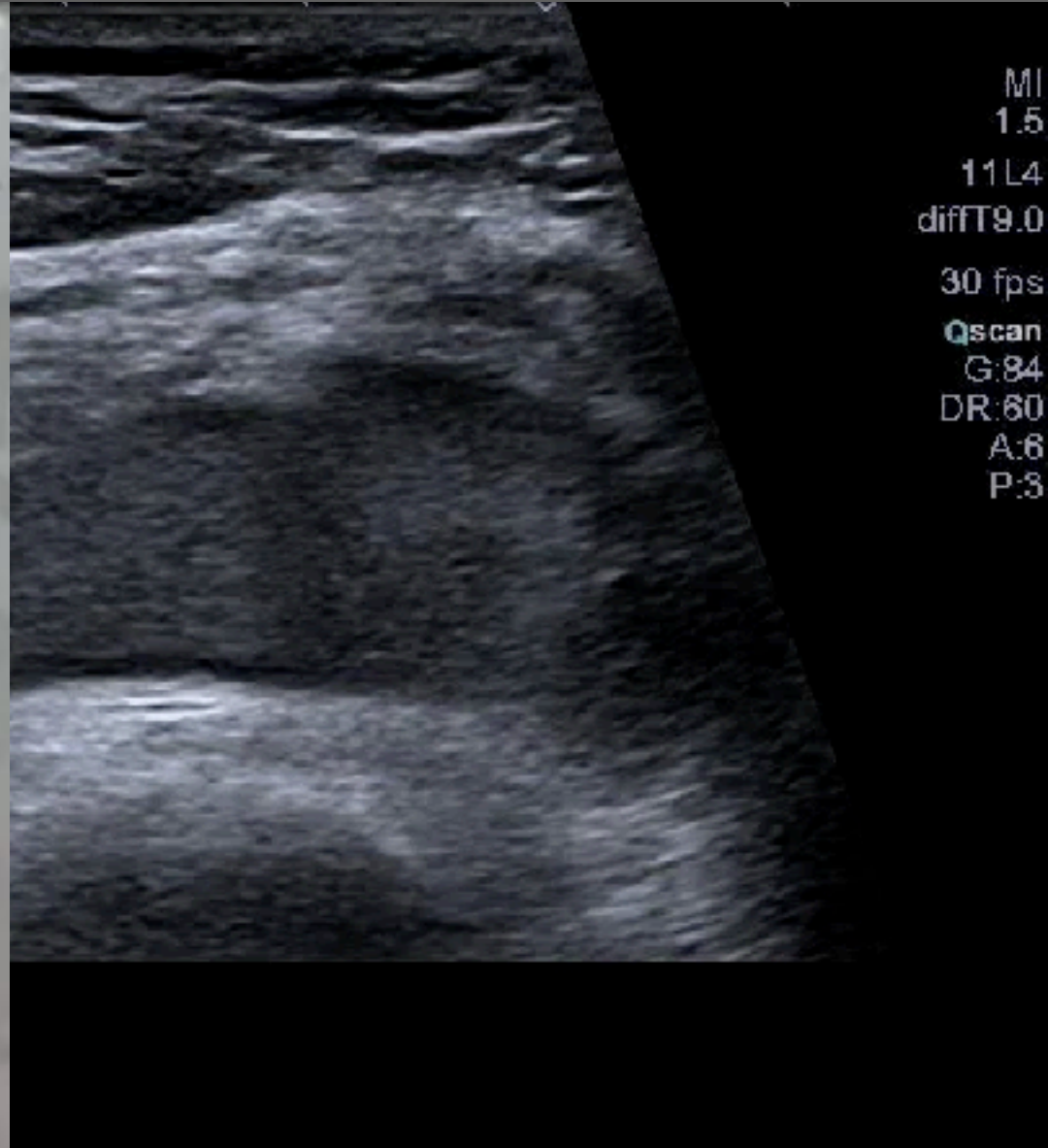
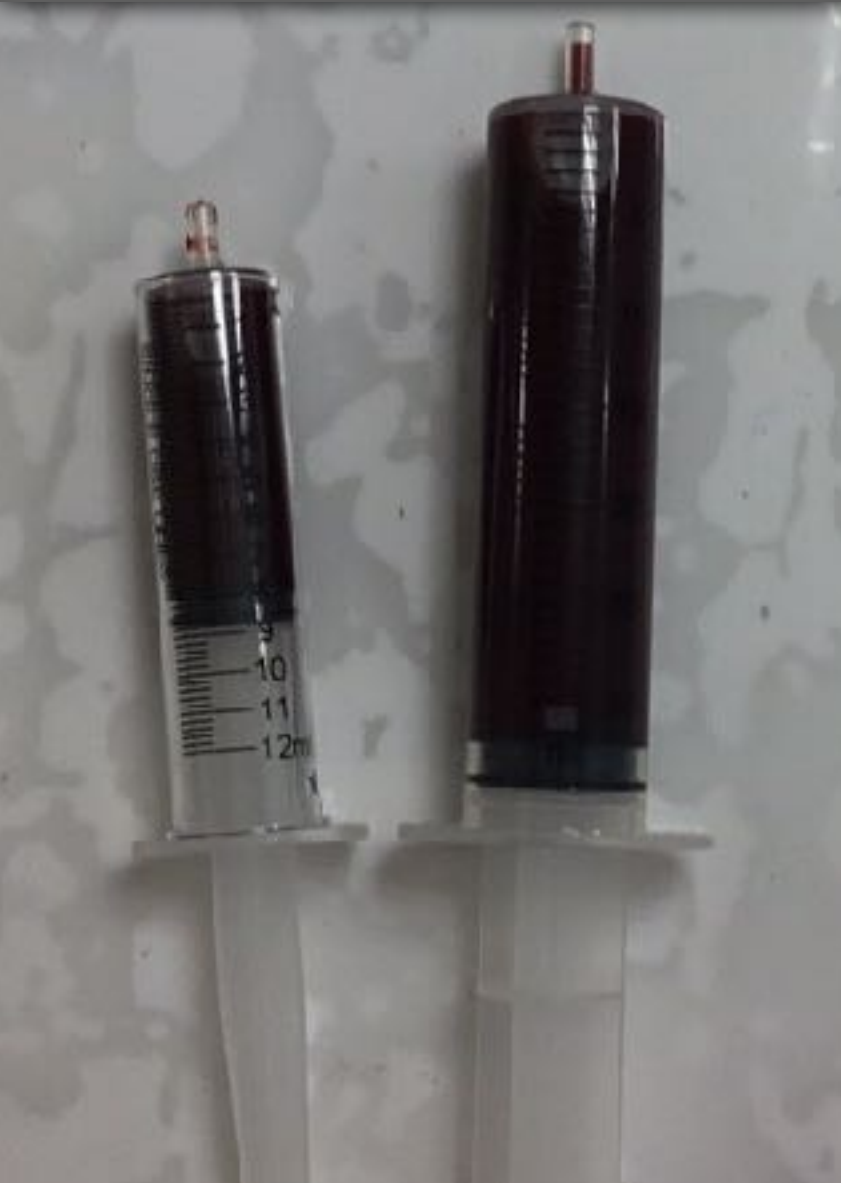Knee

Ankle

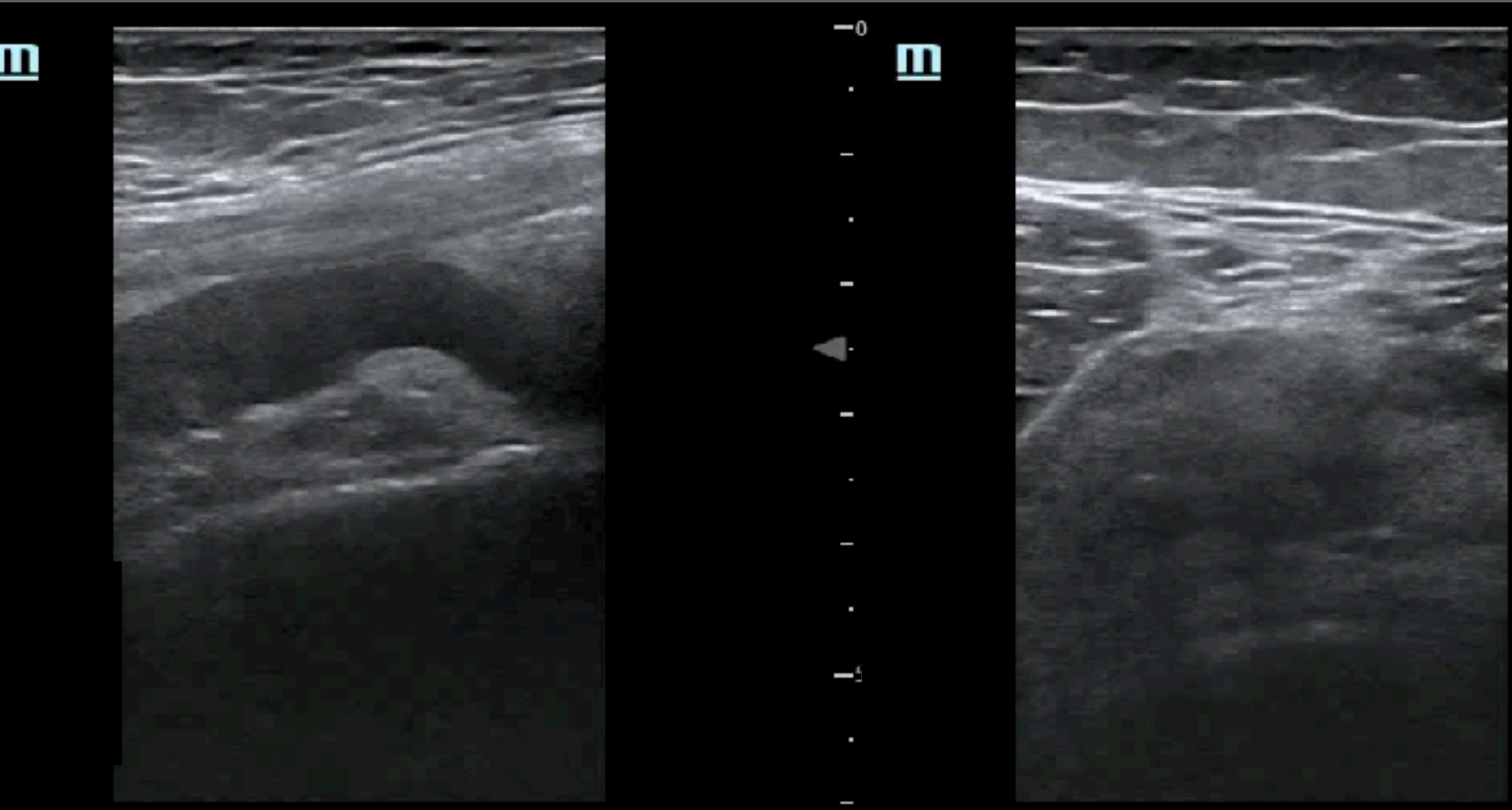
SKH-EUTC©ChenKC



# Needling for hemarthrosis



# Lipohemarthrosis

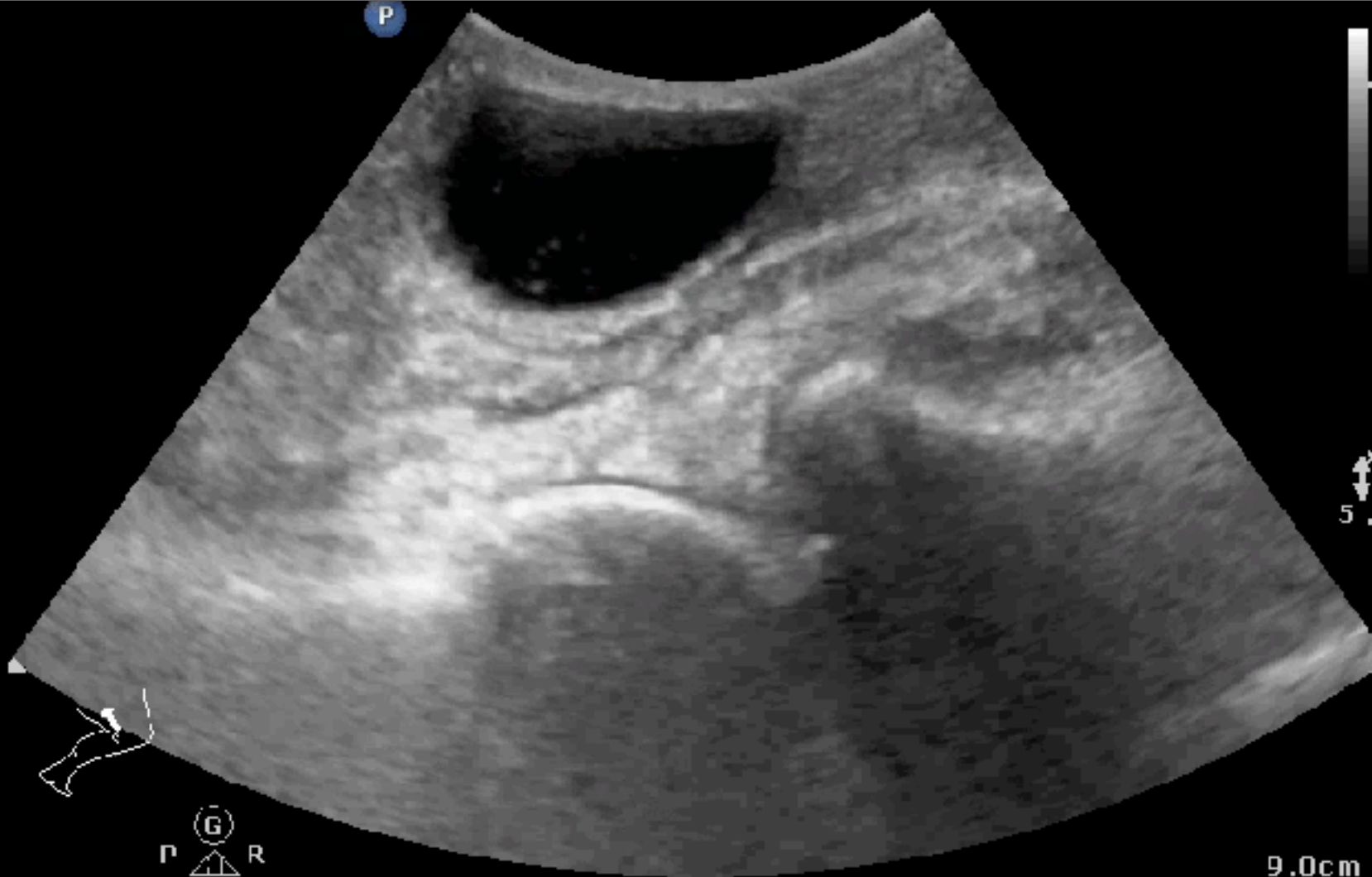



# Baker's cyst

ADU Gen7  
C5-1  
47 Hz  
9.0cm

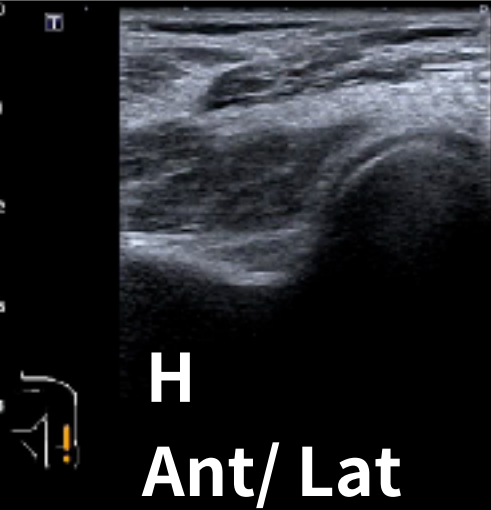
2D  
HGen  
Gn 85  
C 56  
3 / 3 / 3



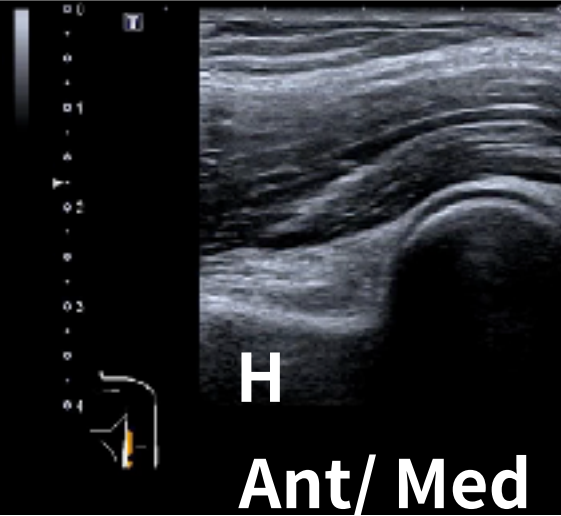
Ⓞ  
P R  
1.8 3.6

9.0cm

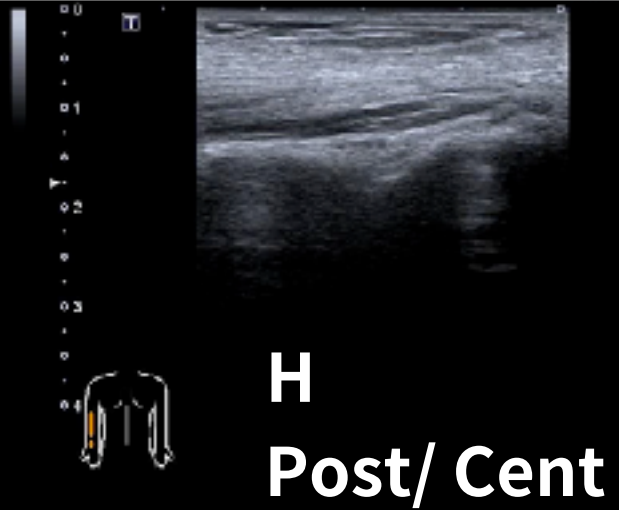
# Elbow fossa



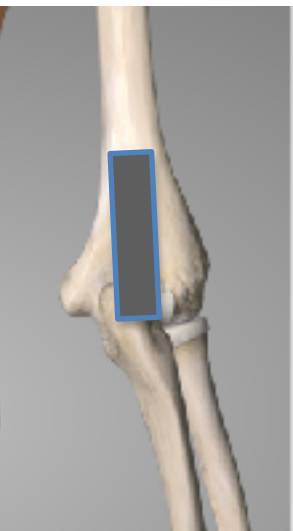
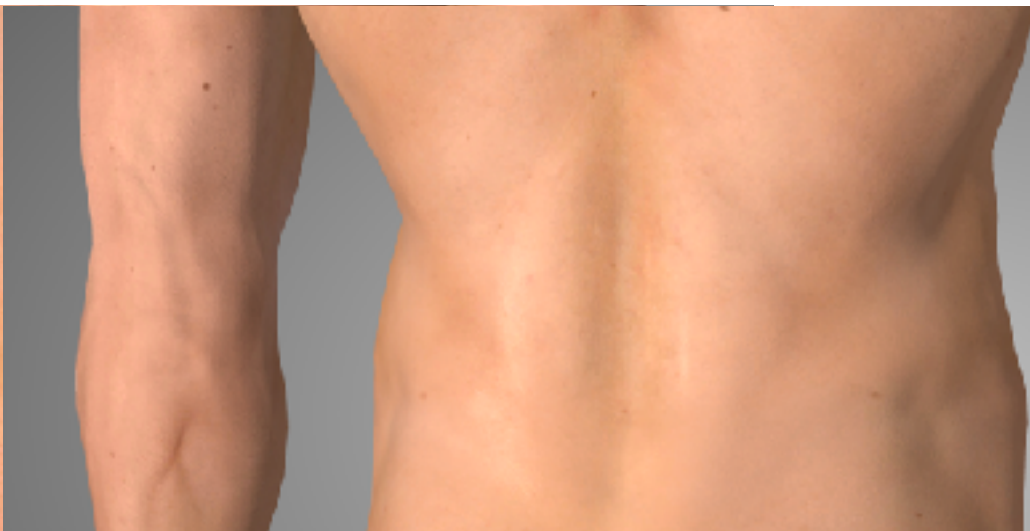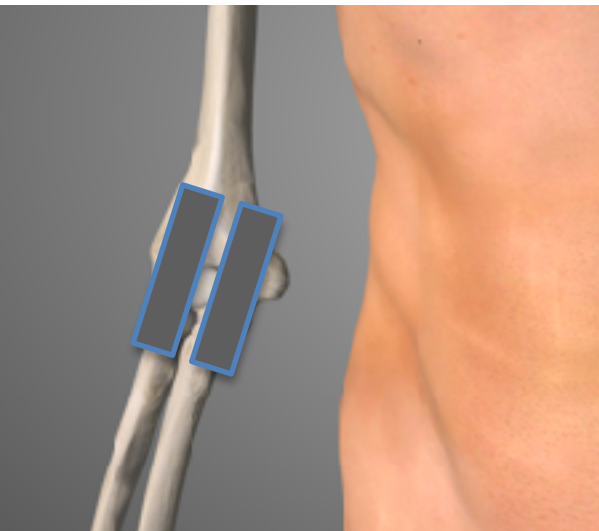
**Radial fossa**



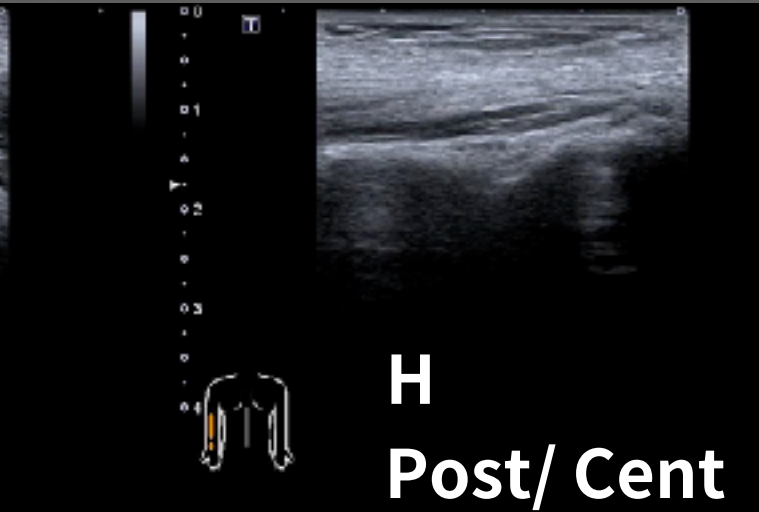
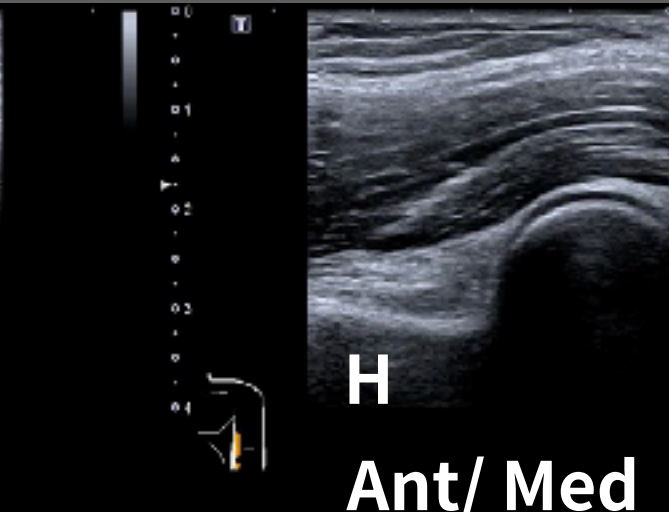
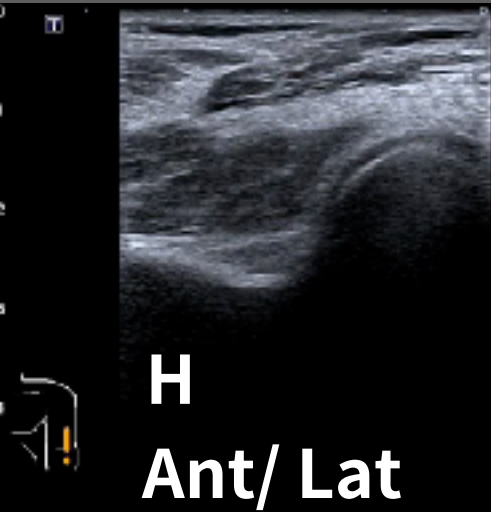
**Coronoid fossa**



**Olecranon fossa**



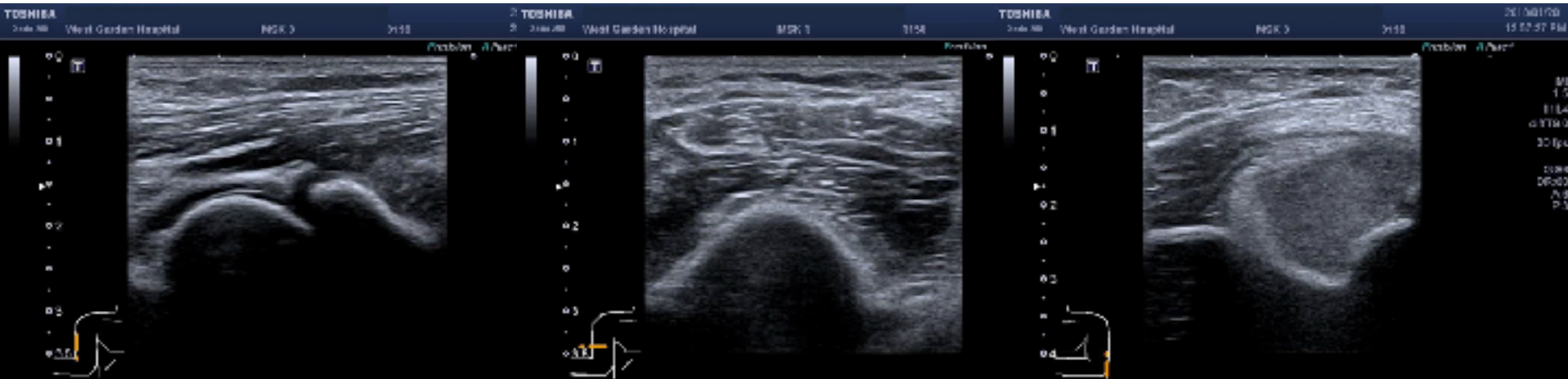# Elbow effusion



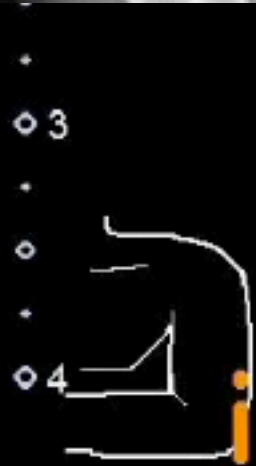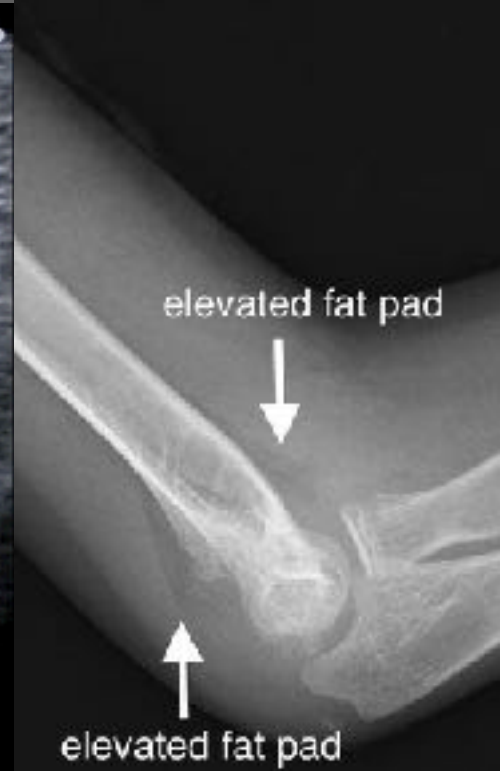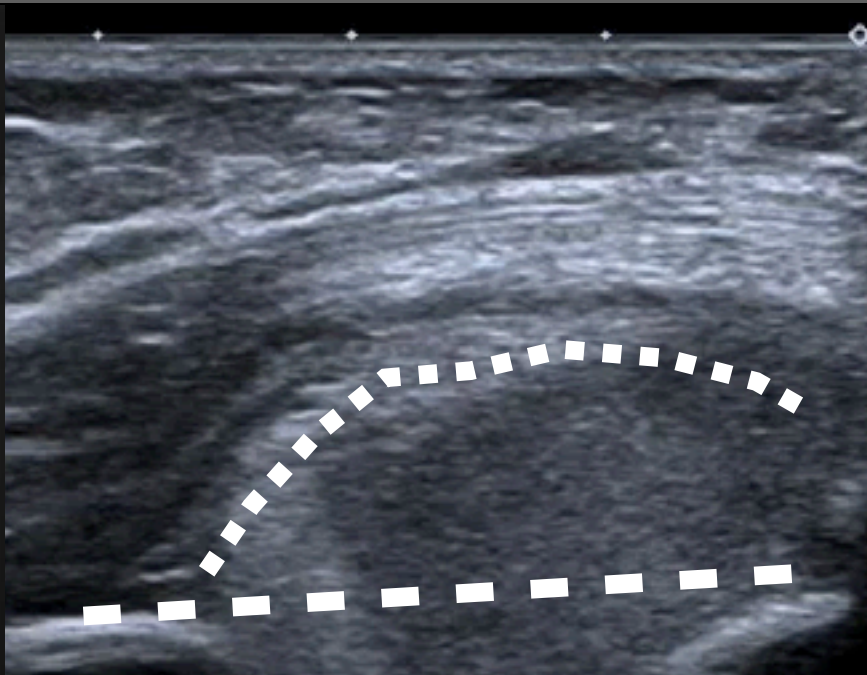
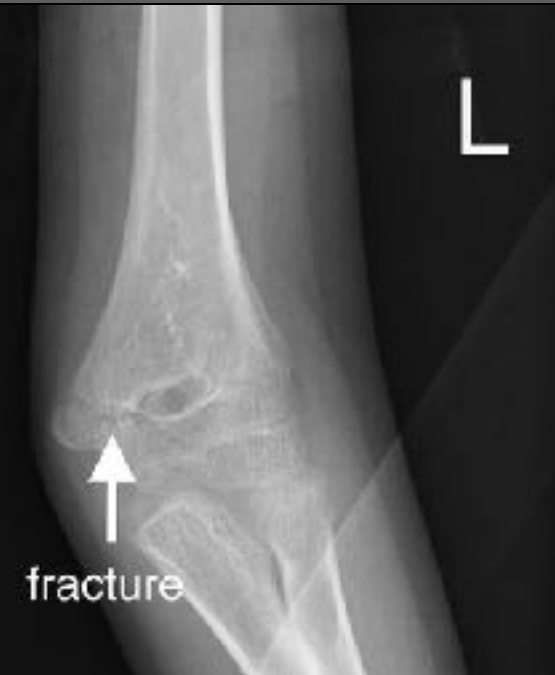**Radial fossa**

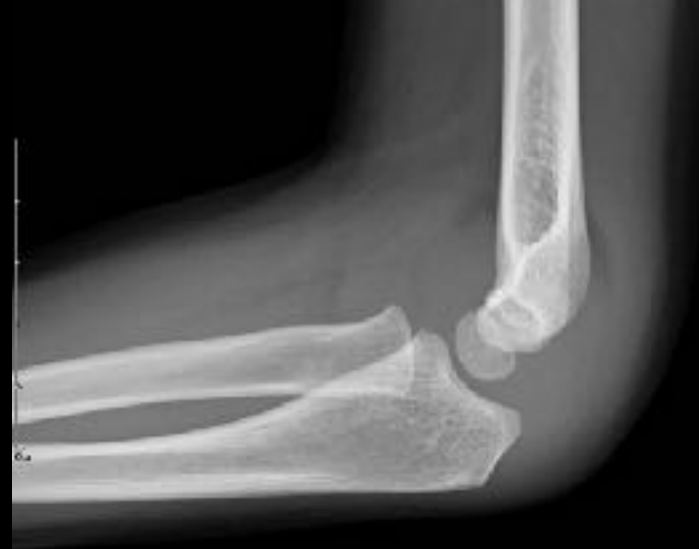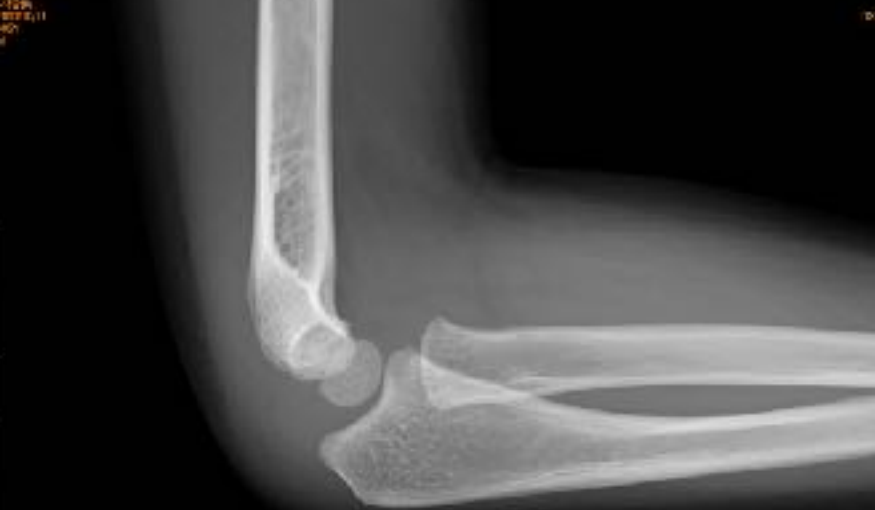**Coronoid fossa**

**Olecranon fossa**



# Elevated fat pad sign

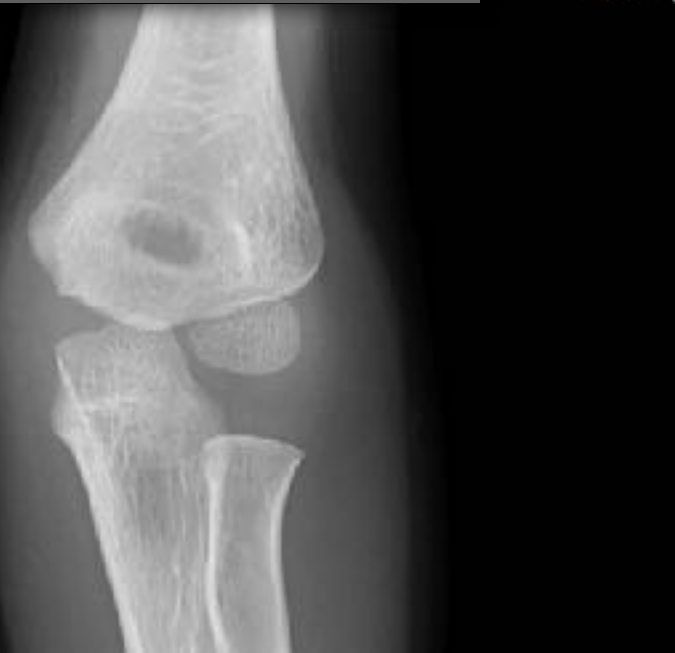
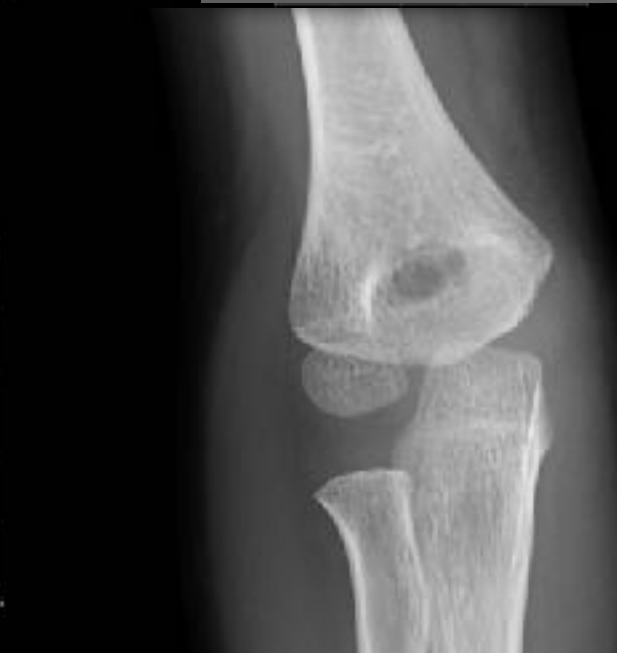


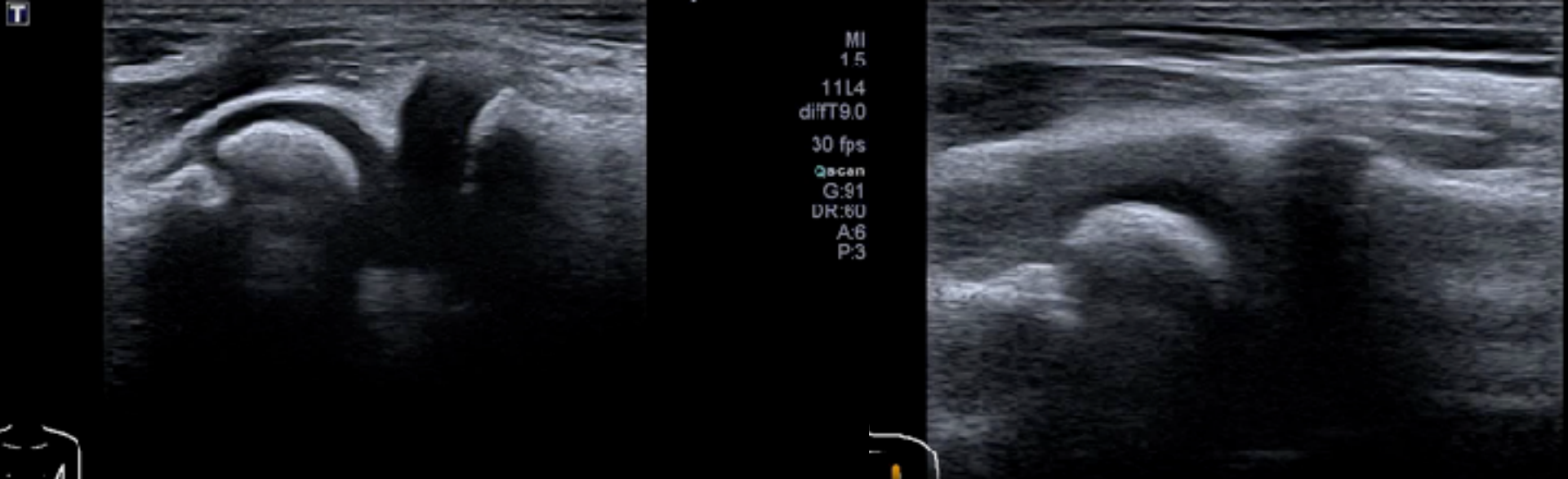
R

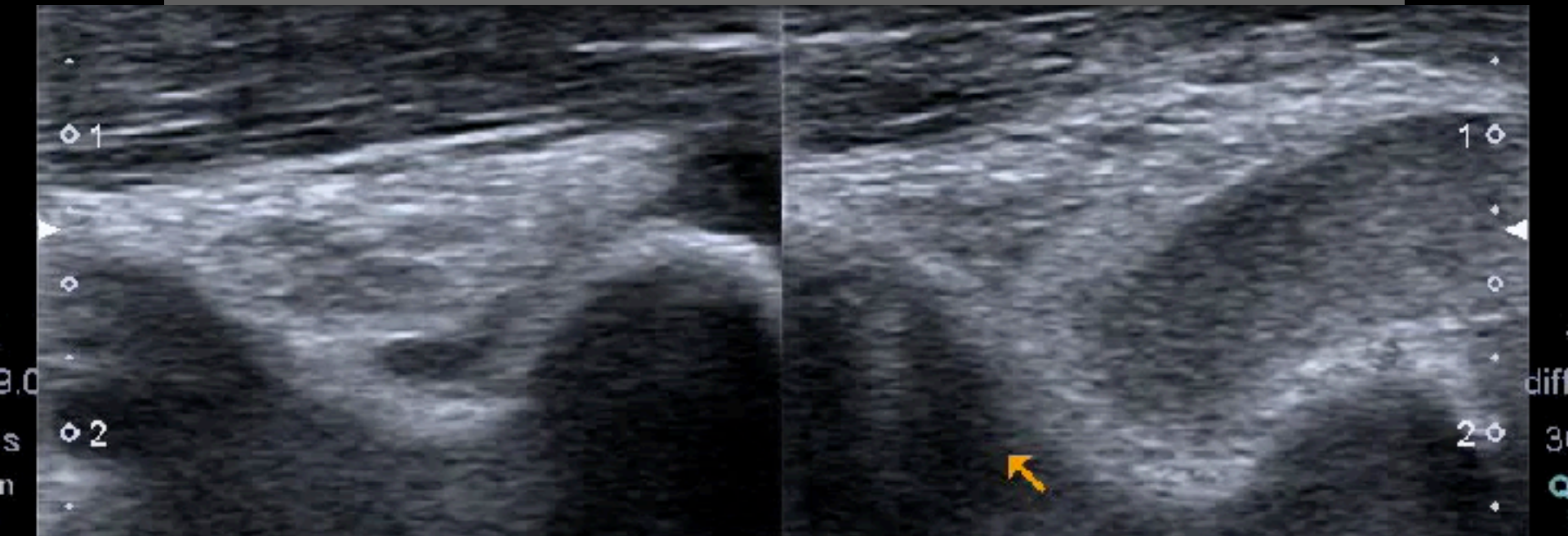
6歲男童，左肘受傷

L

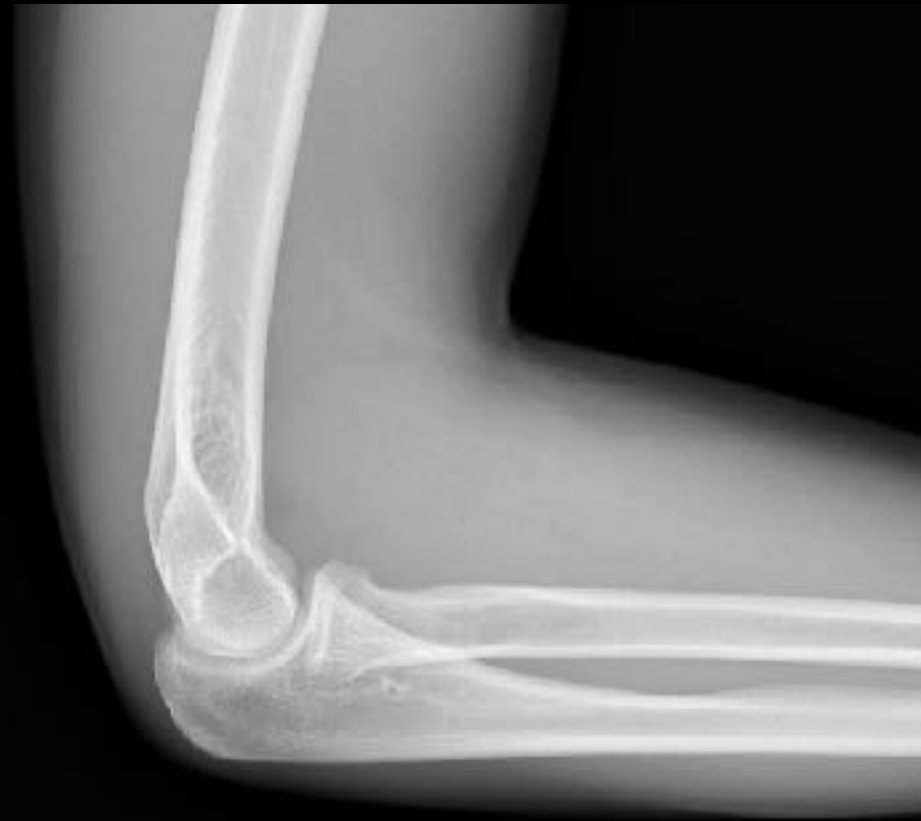
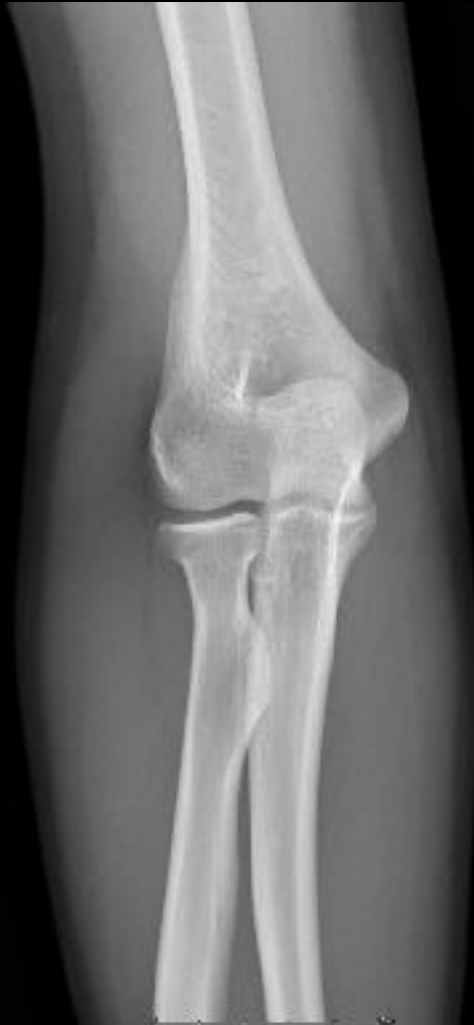


# Hemarthrosis



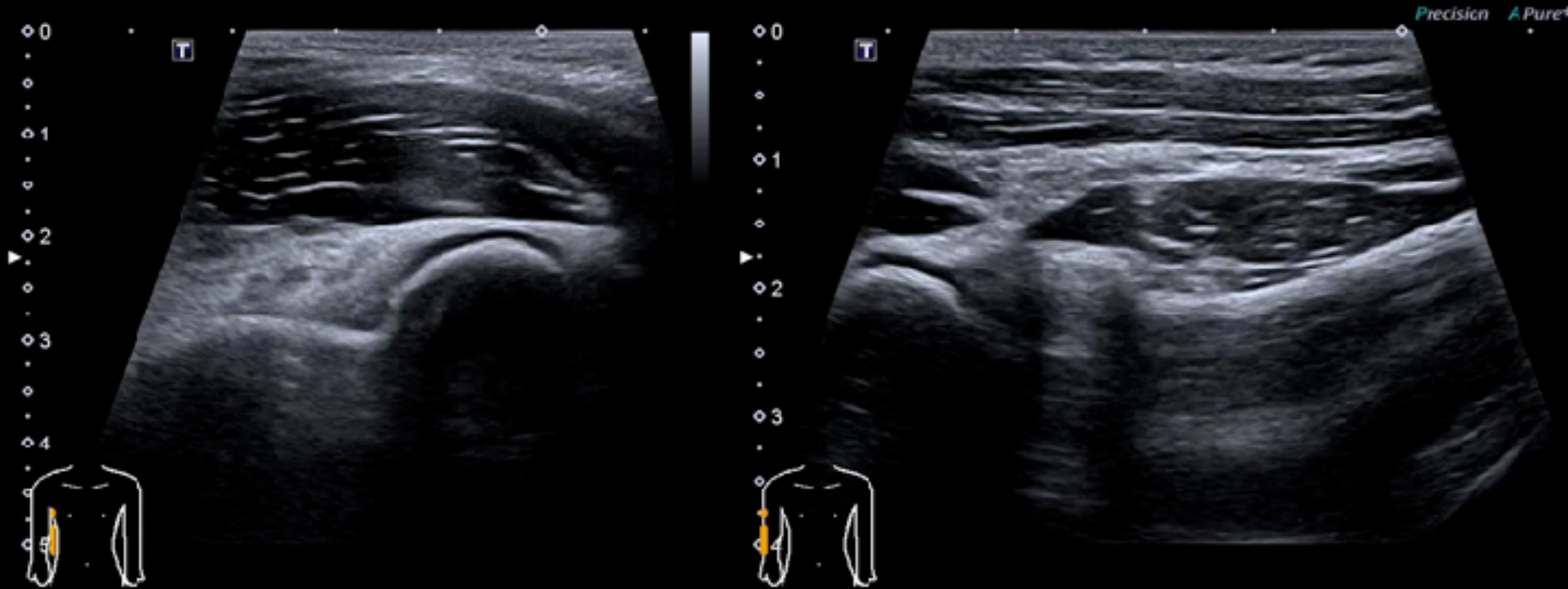
# M/18, 機車車禍，致右手肘疼痛



R

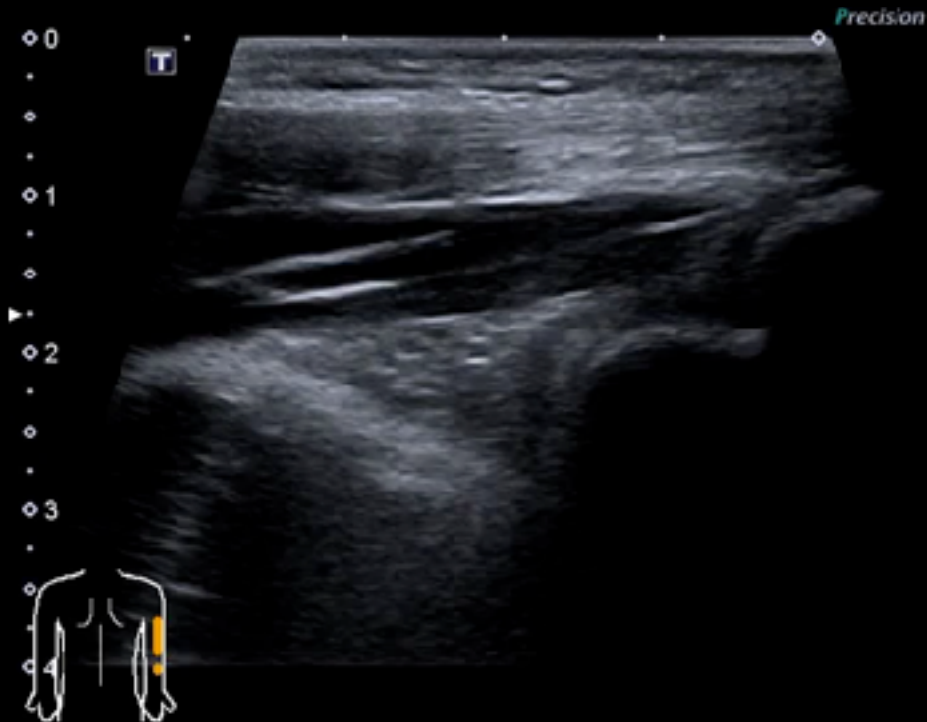
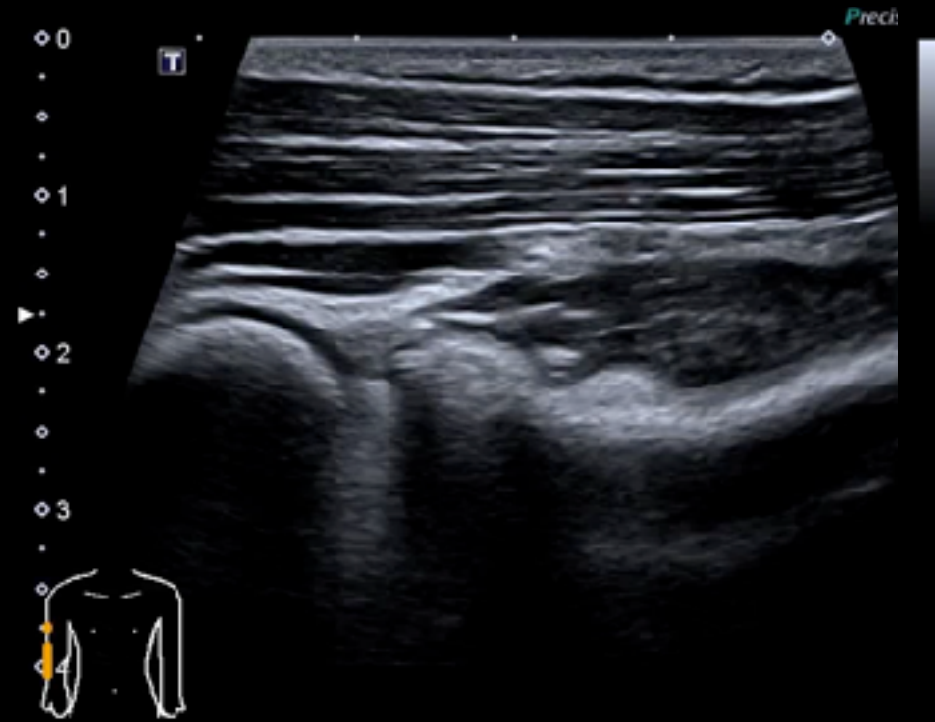
R

# M/18, 機車車禍，致右手肘疼痛

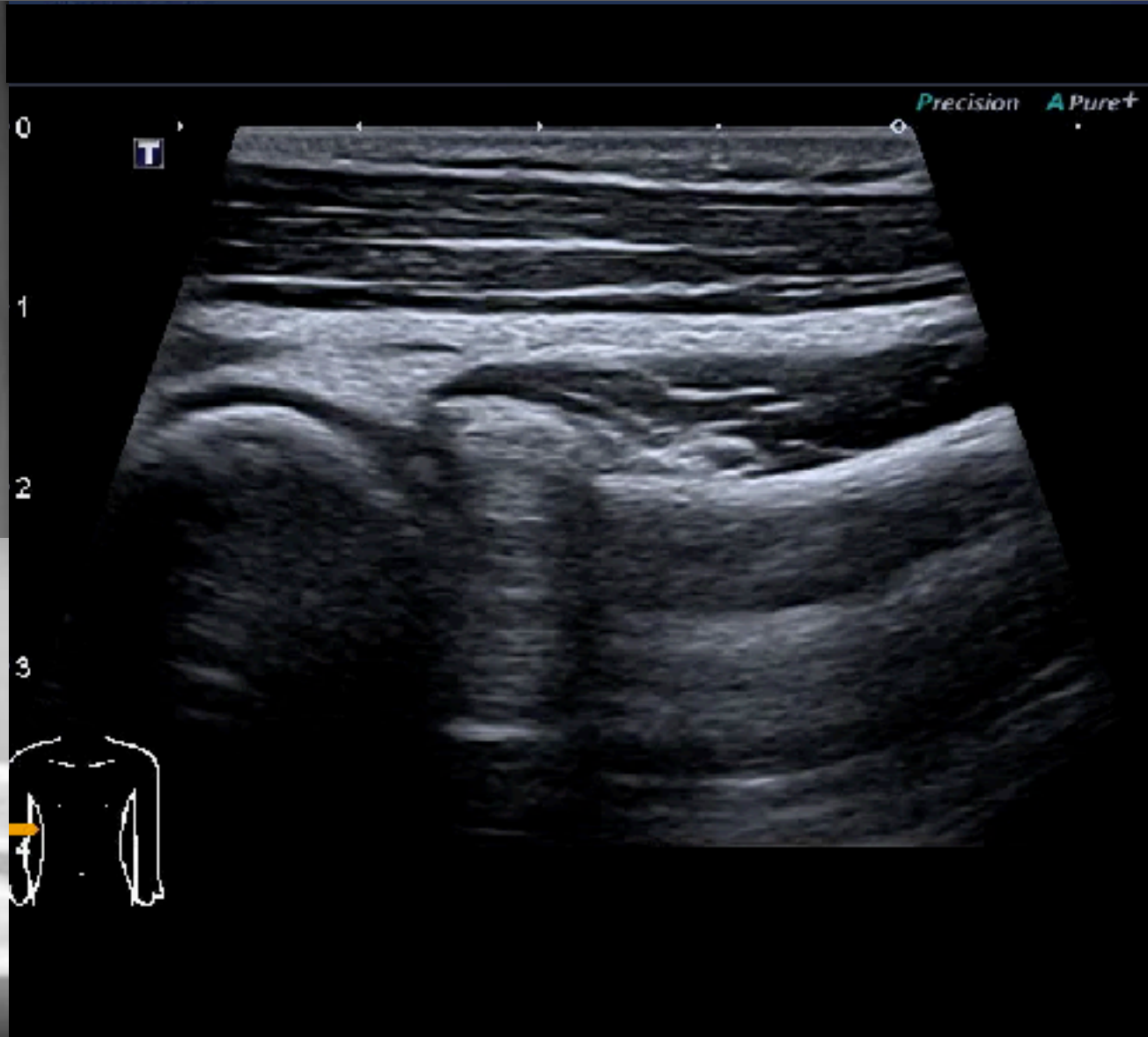
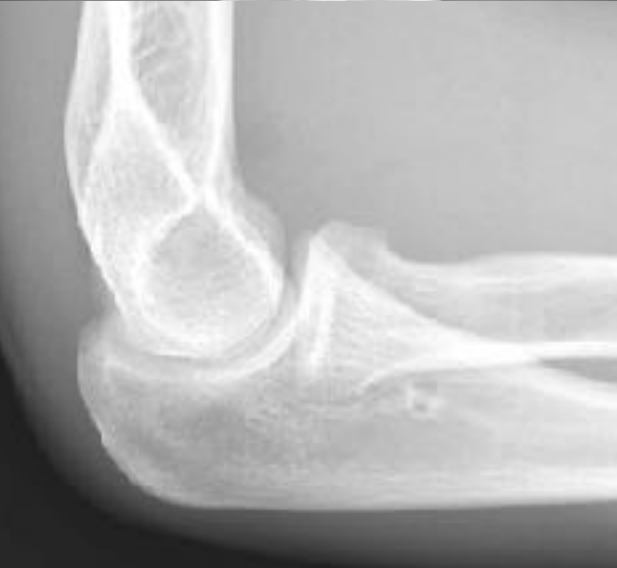
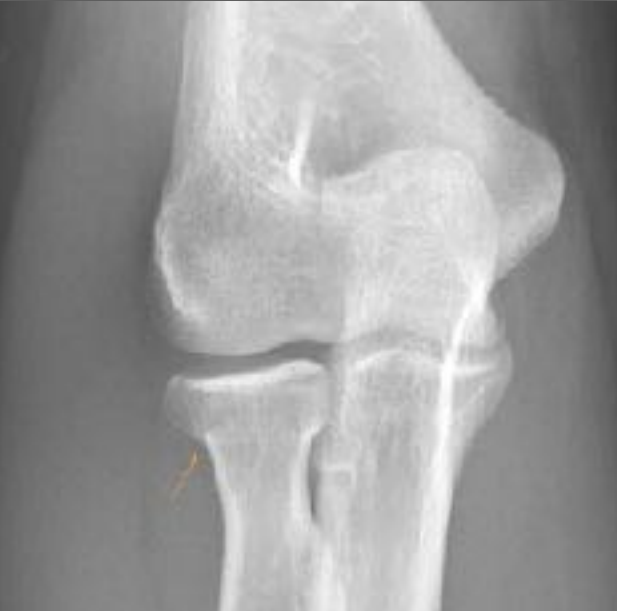


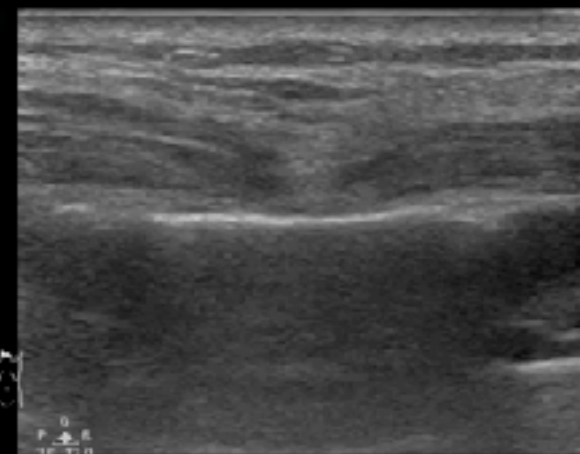
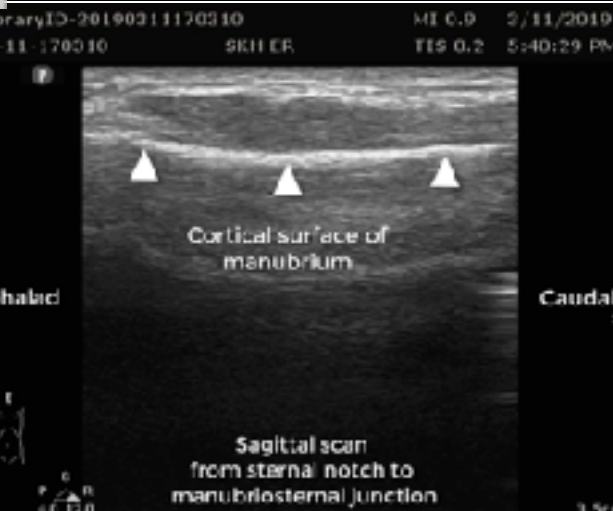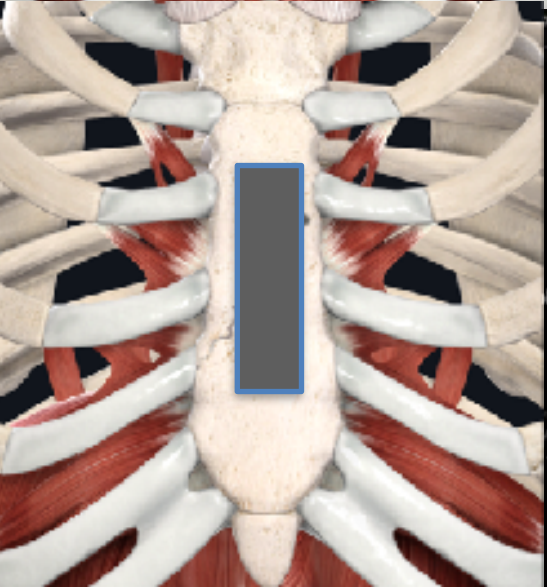
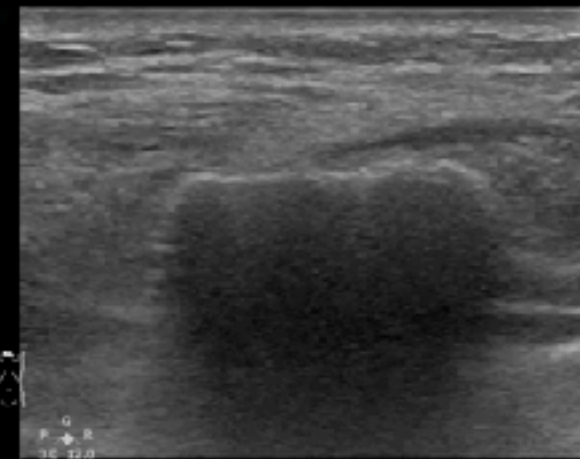
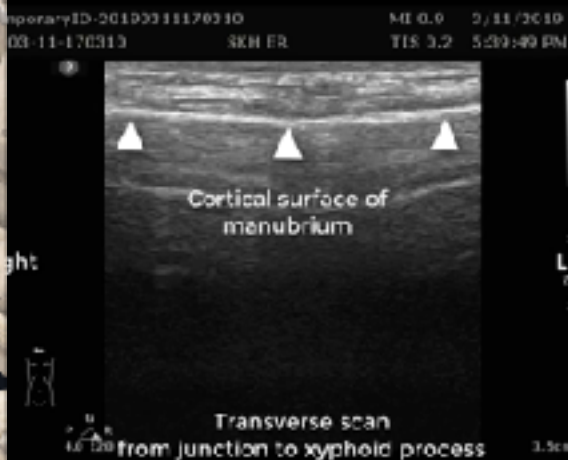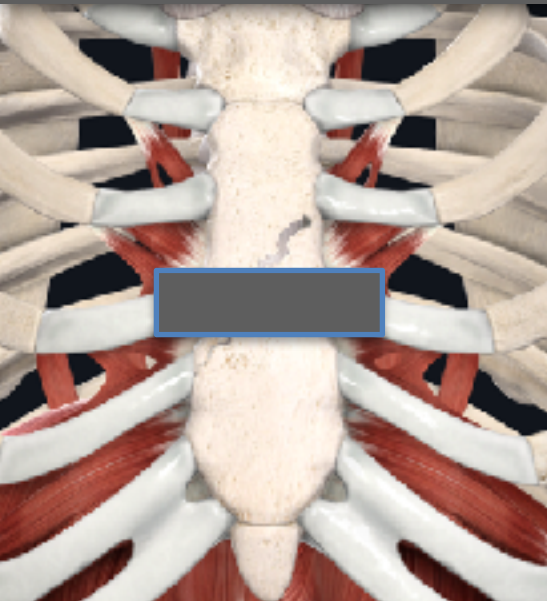
# M/18, 機車車禍，致右手肘疼痛



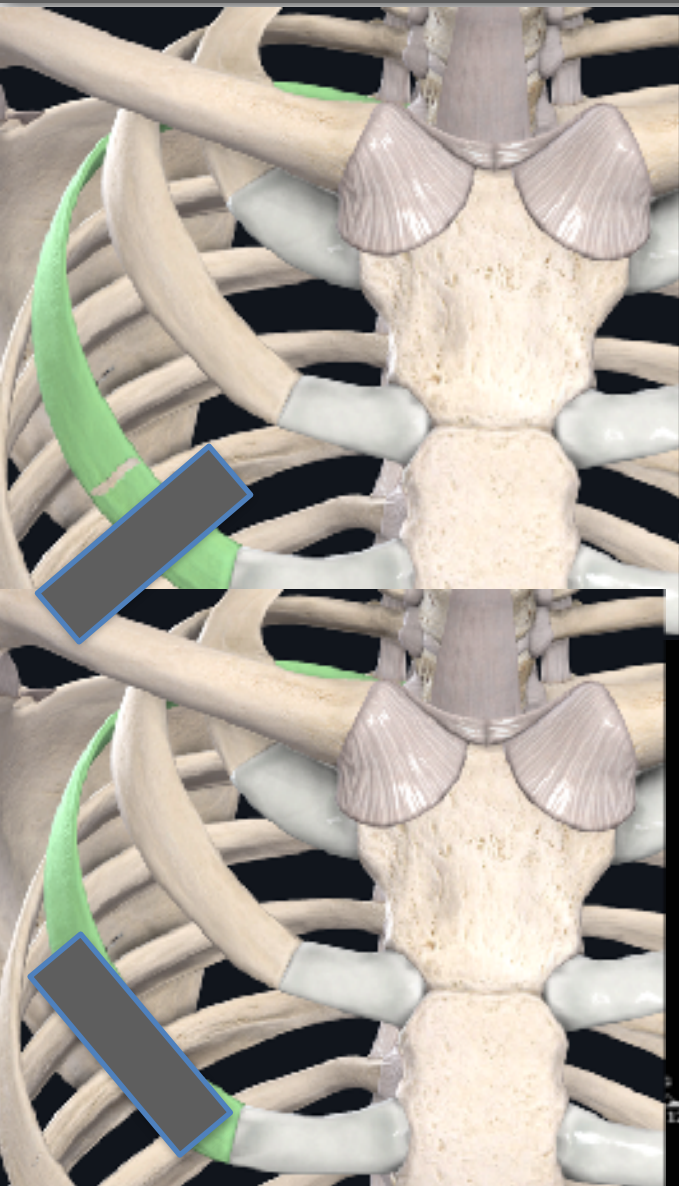
# Radial head fracture & Hemarthrosis



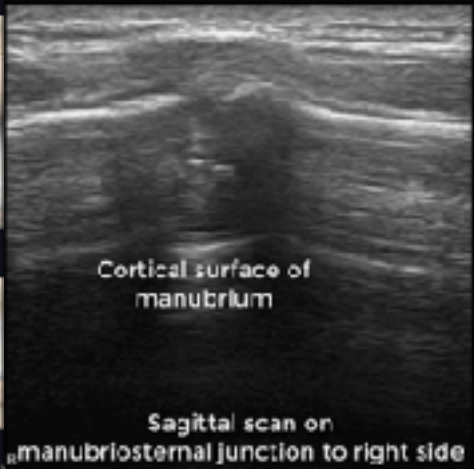# Sternal fracture



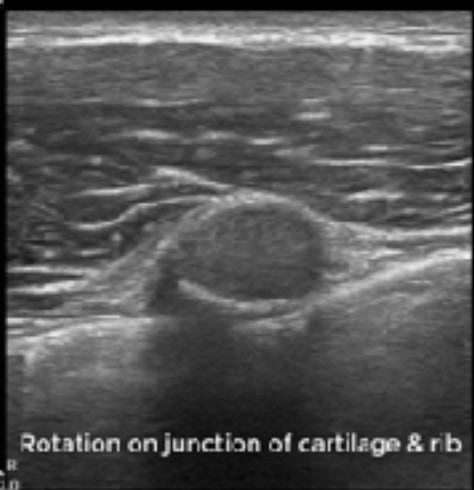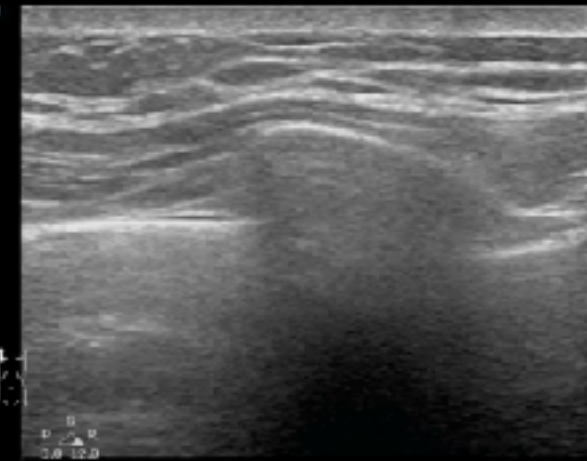
# Rib fracture



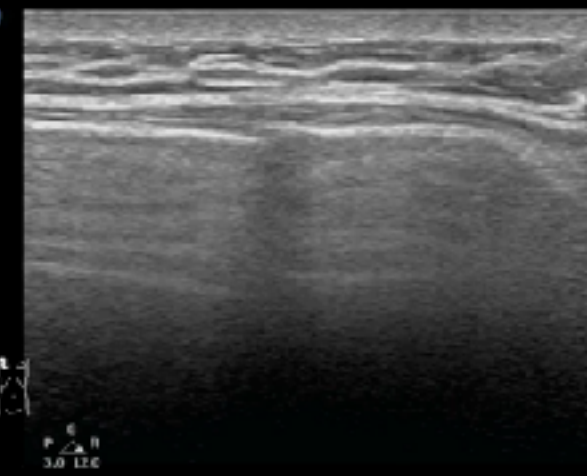
20190311170310 MI 0.9 3/11  
SKH-ER TIS 0.2 5:40



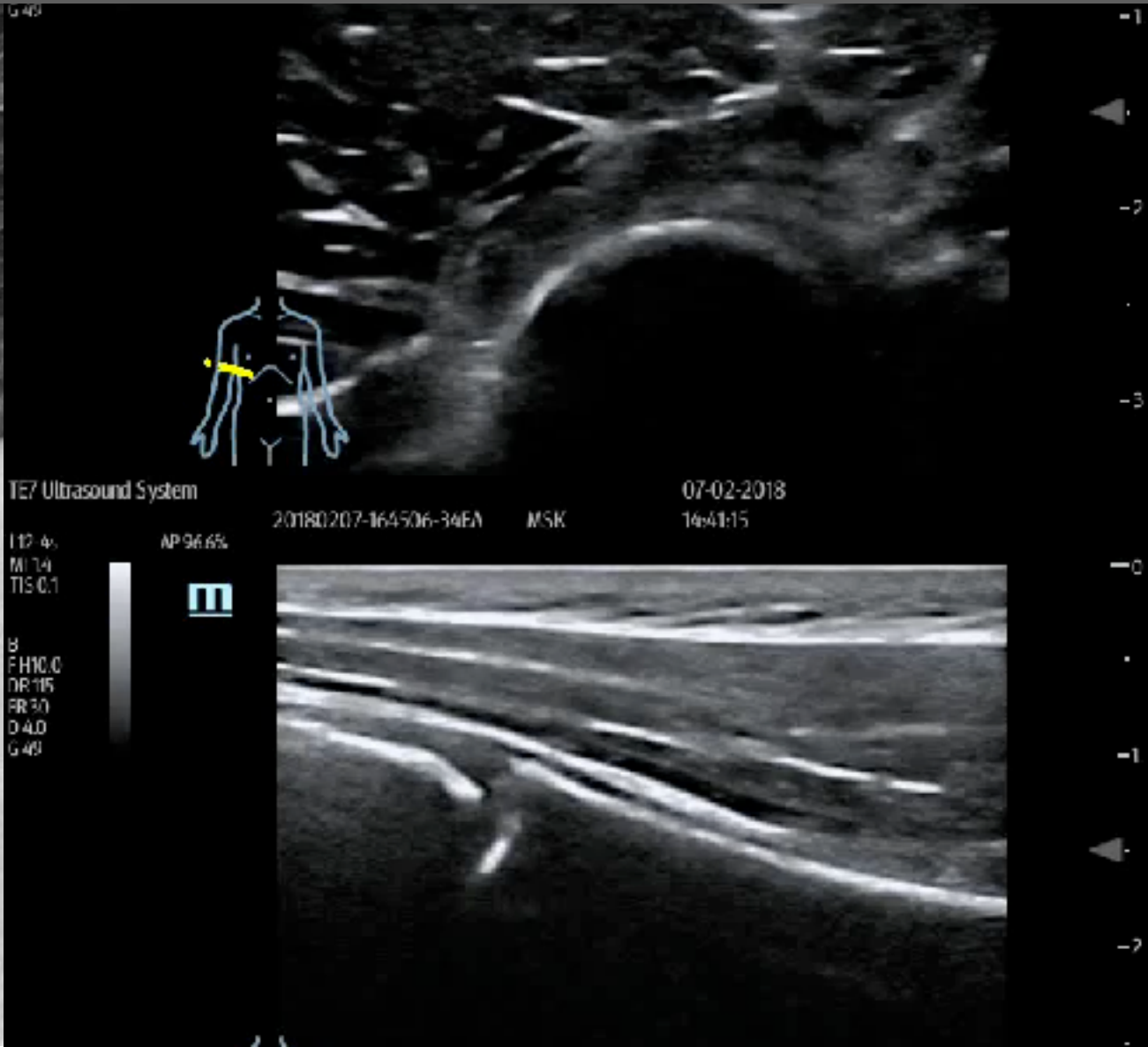
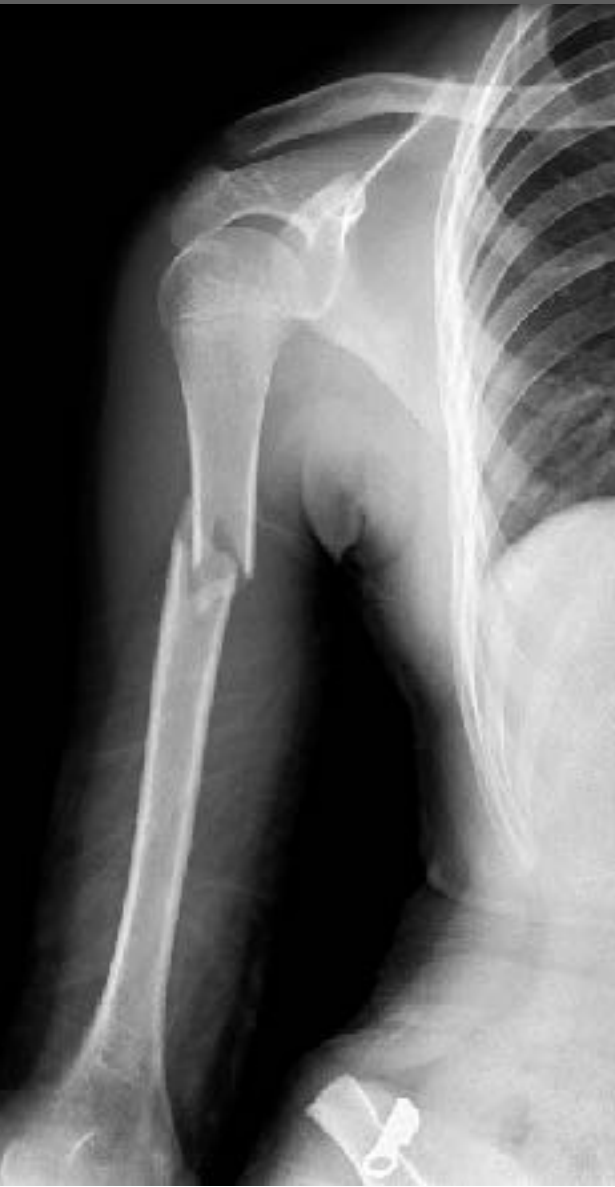Superficial  
L12-3  
46 Hz  
3.0cm  
2D  
Res  
Gm 96  
C 56  
3/2 / 1



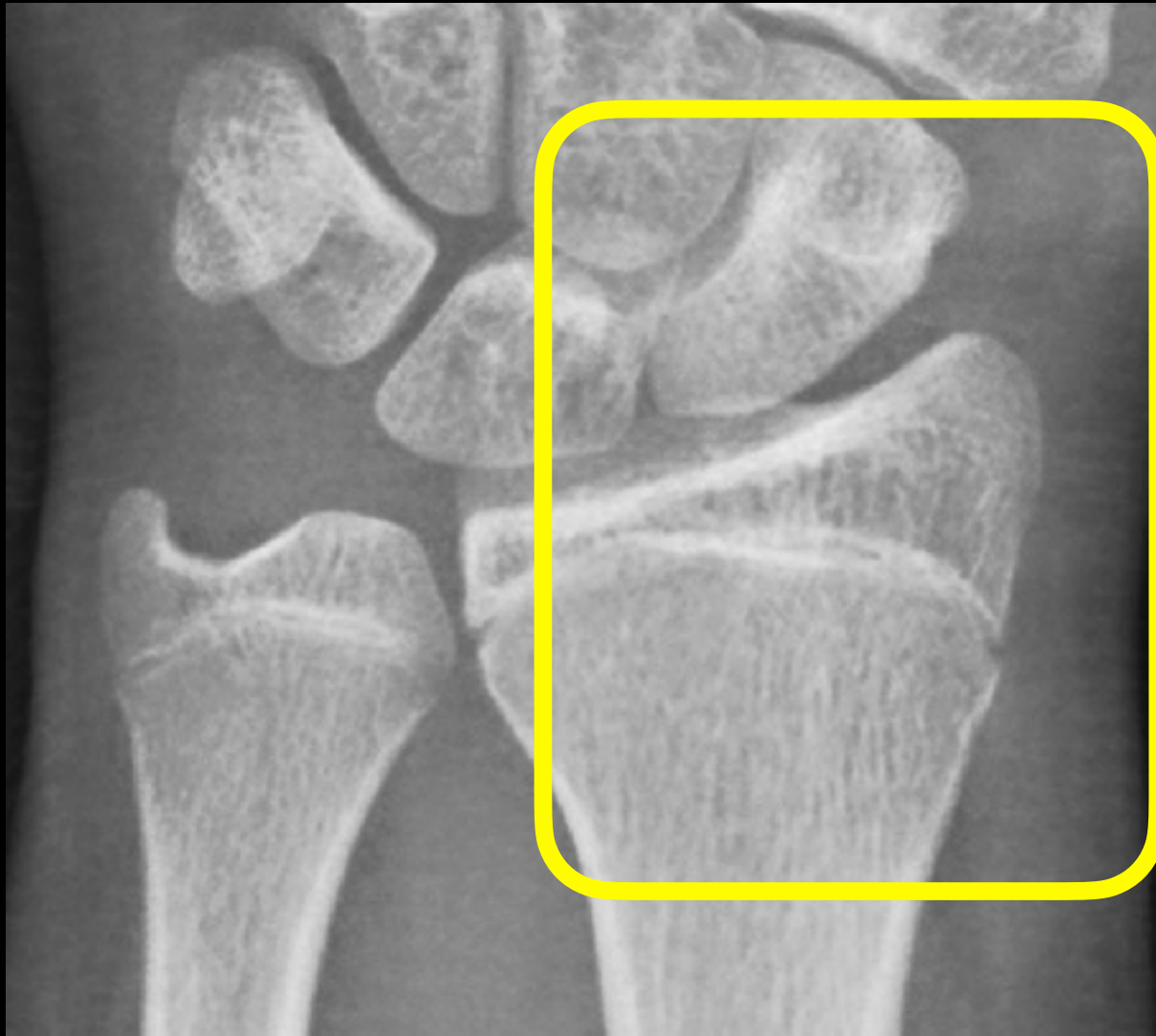
Superficial  
L12-3  
46 Hz  
3.0cm  
2D  
Res  
Gm 96  
C 56  
3/2 / 1



# Humeral fracture

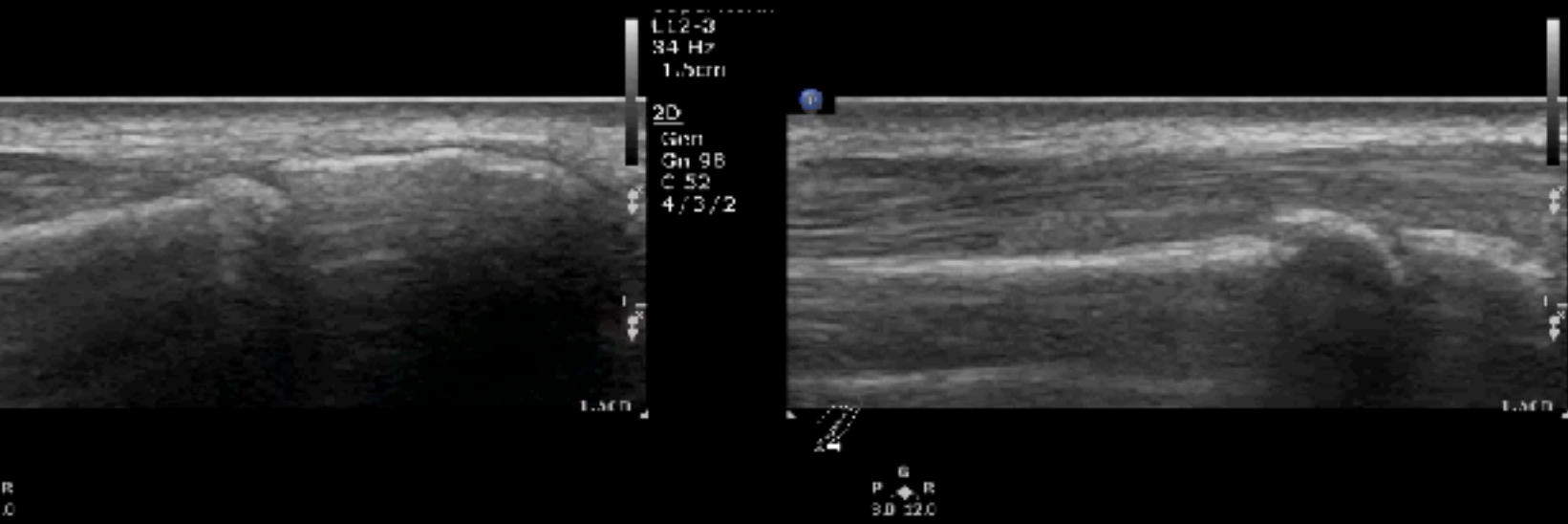


# 15M with left wrist pain



Right radius

Left radius

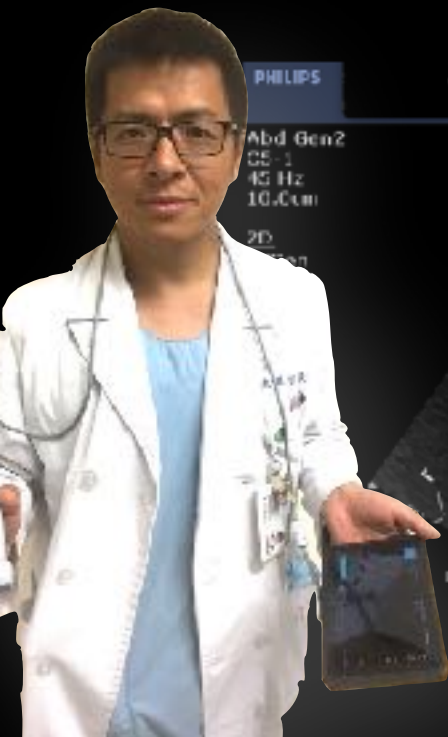


# How to interpret ?

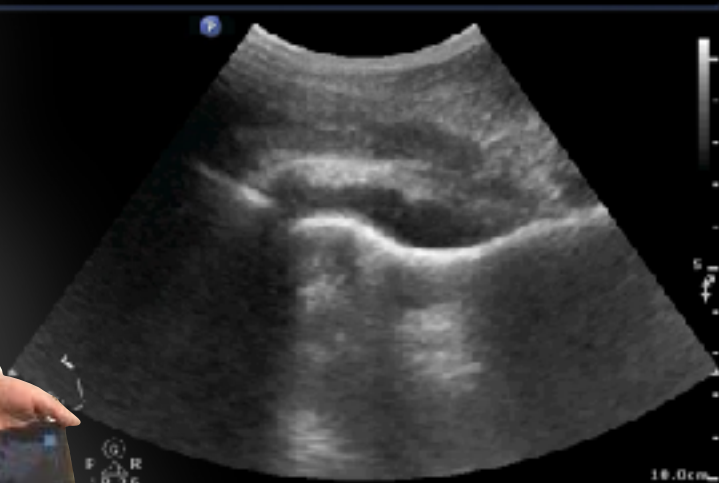Consult

Capture

Compare

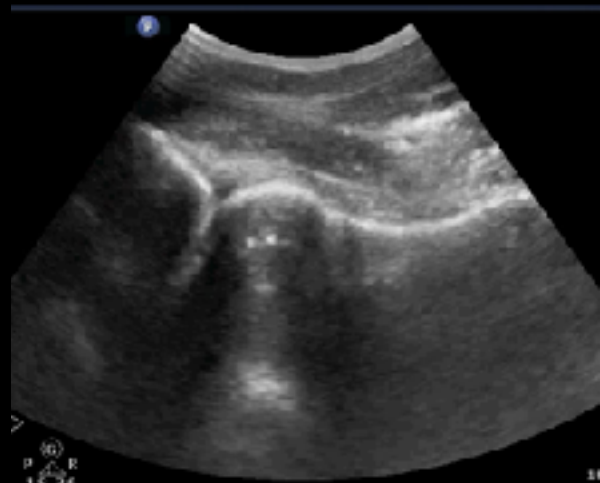

SKH-EUTCC©ChenKC



left hip

SKH-EUTCC©ChenKC



right hip

Sono-Anatomy Sono-Pattern Sono-Diagnosis

看不懂時就橫縱都錄一段影片事後看或問專家

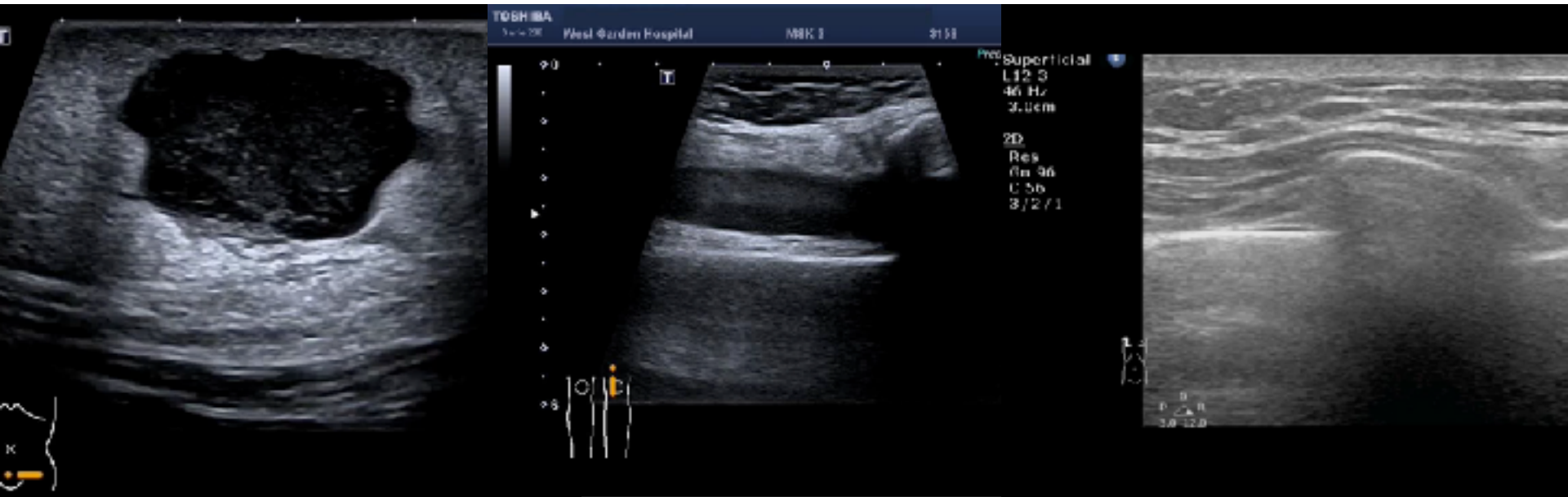


# Essential ER MSK POCUS

Soft tissue

Joint

Bone

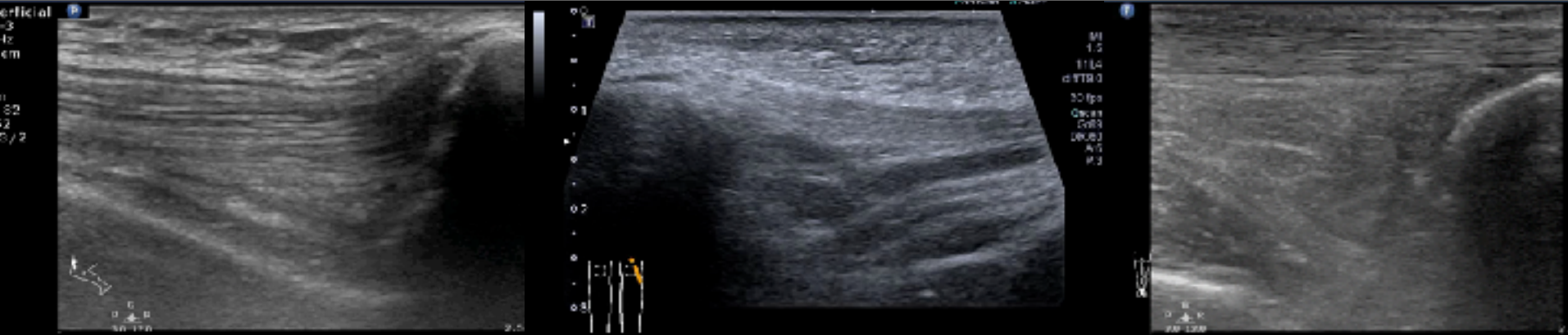


Abscess

Effusion

Occult

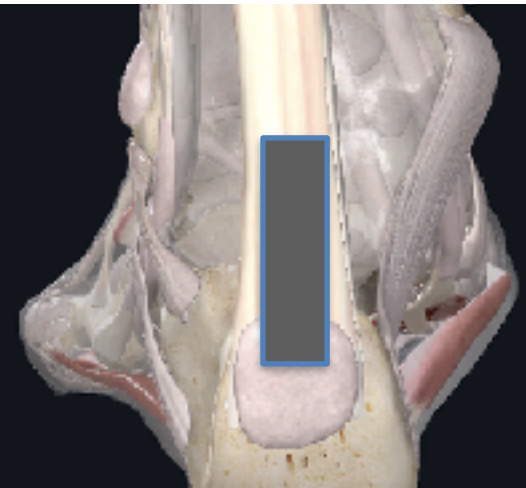
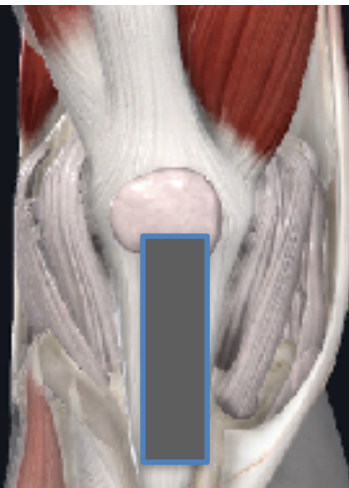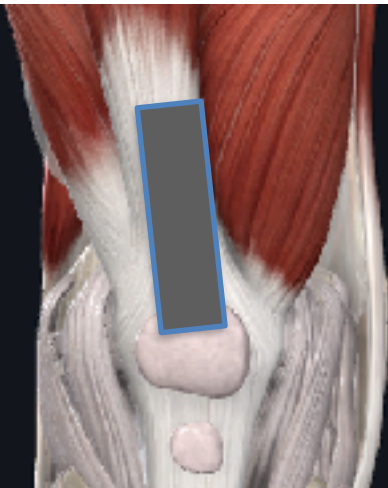# Tendon



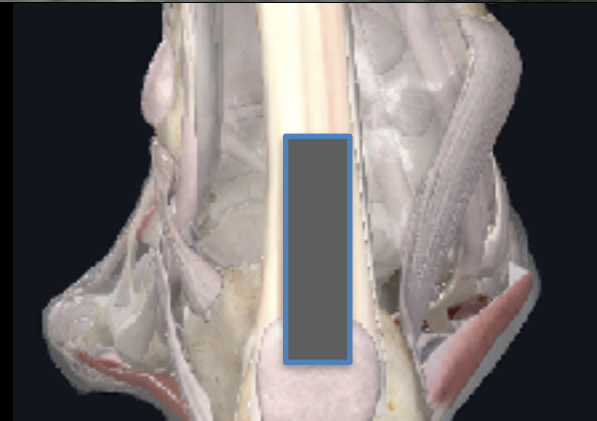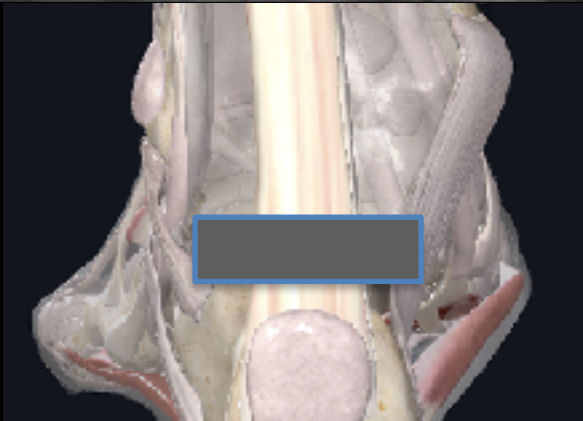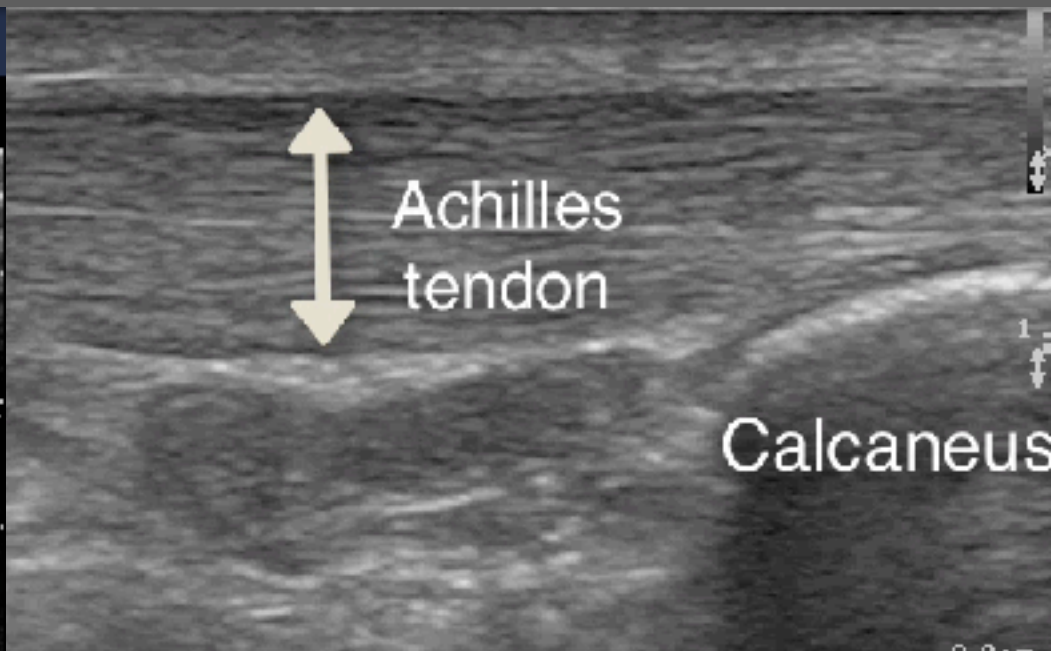
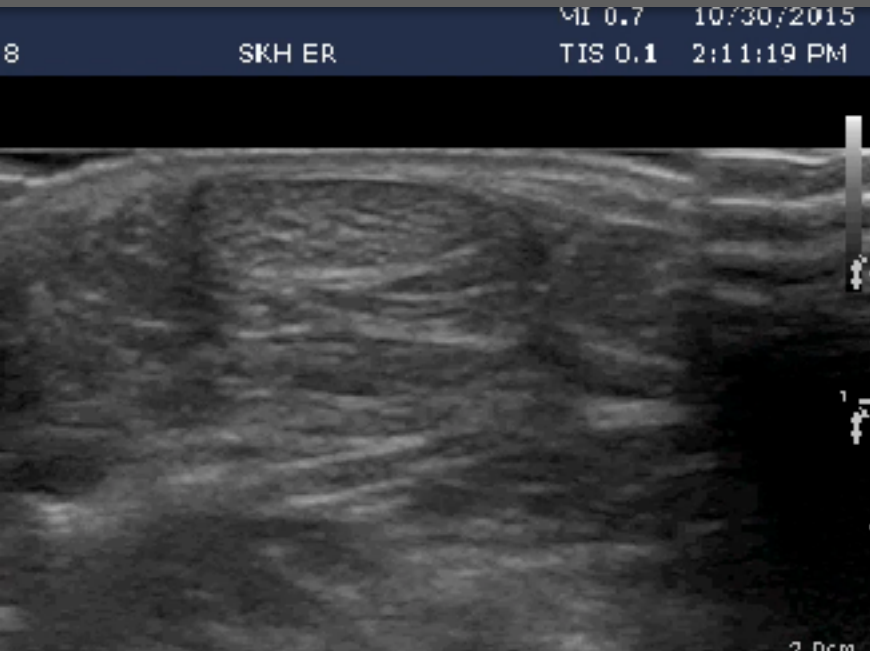
**Quadriceps  
Tendon**

**Patellar  
Tendon**

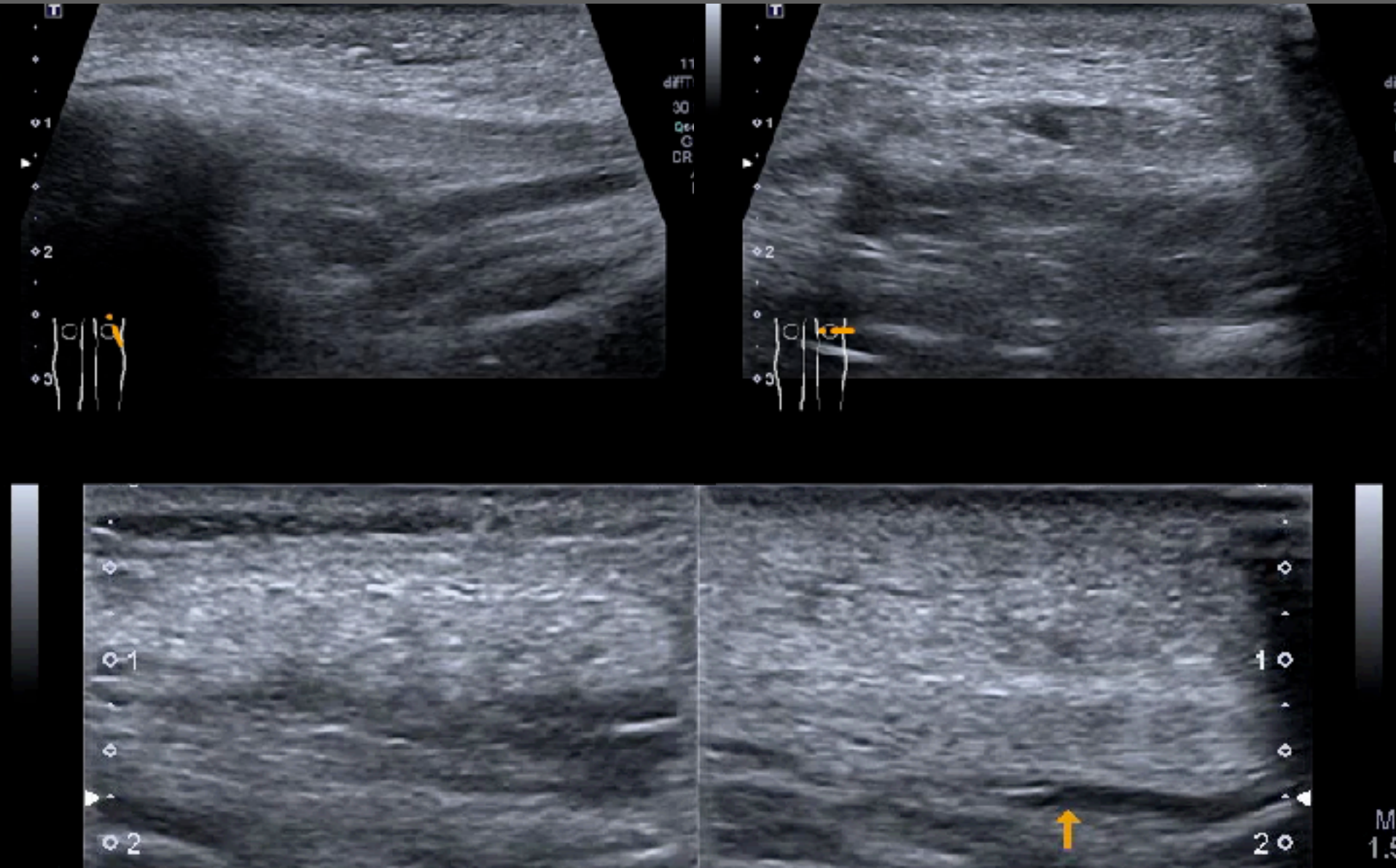
**Achilles  
Tendon**



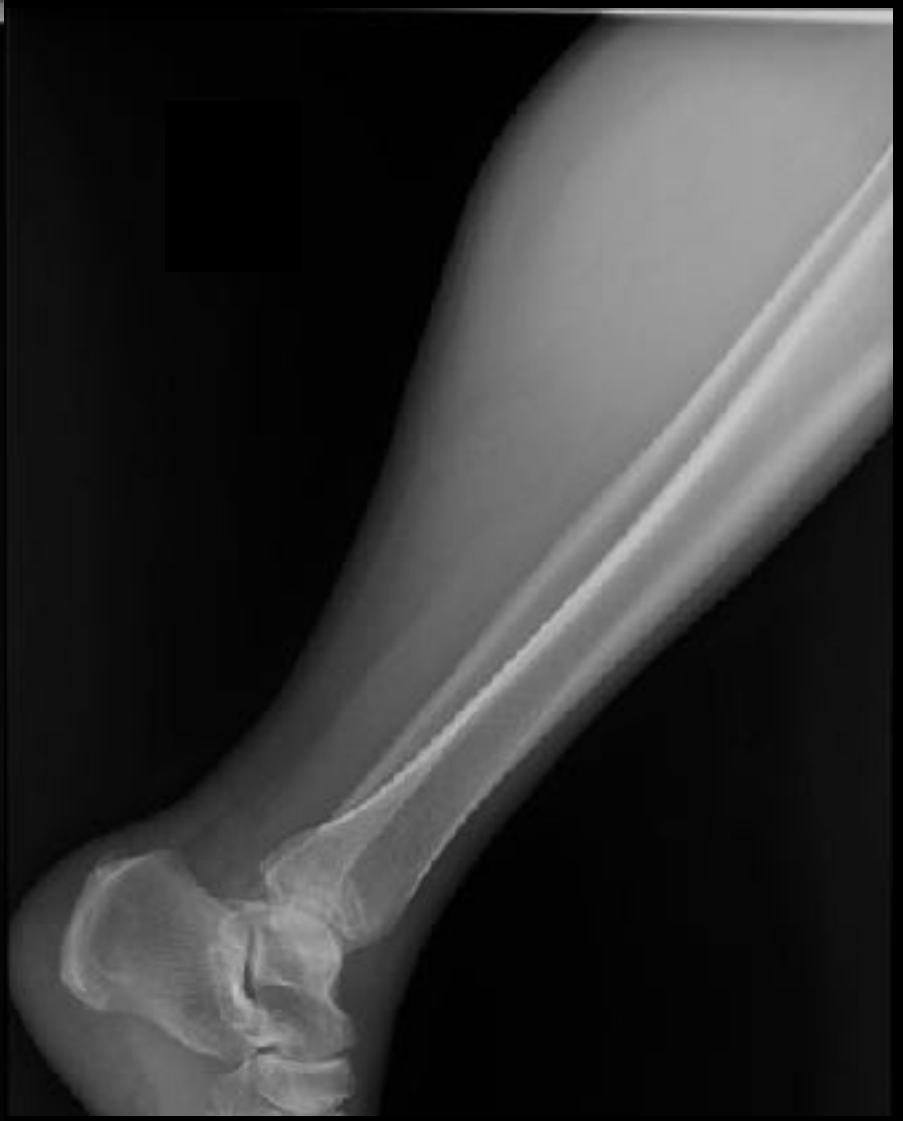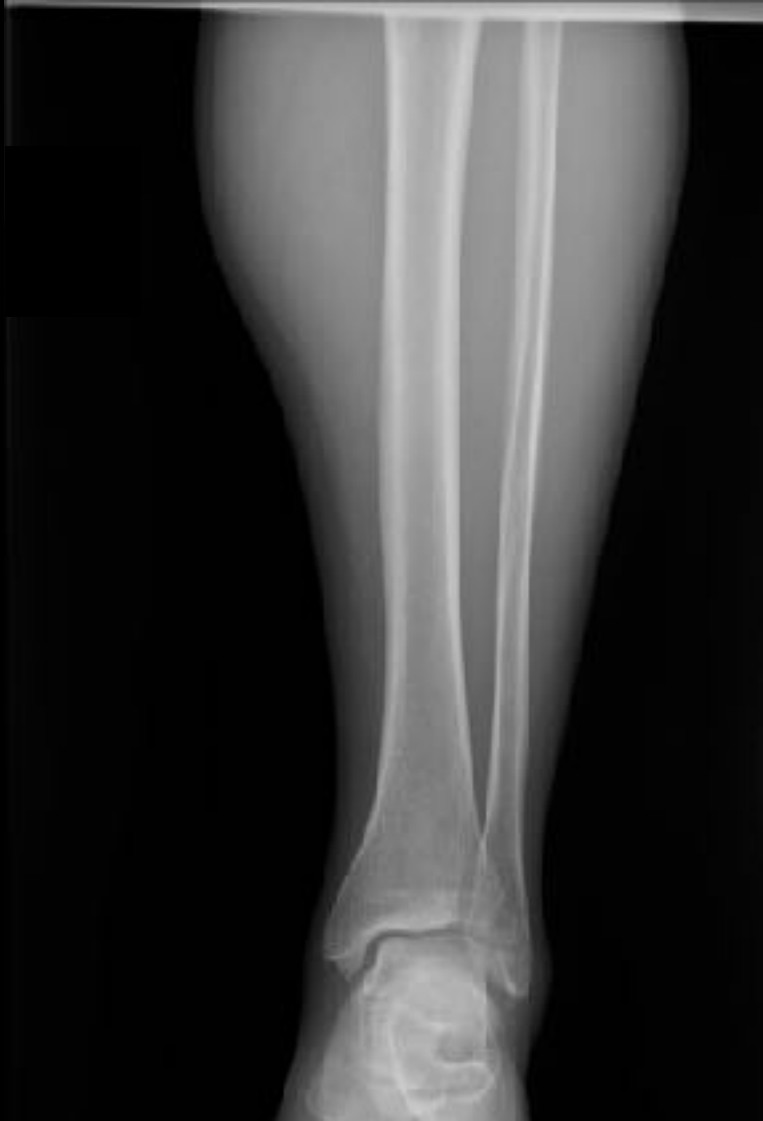# Achilles tendon rupture



# Patellar tendon injury

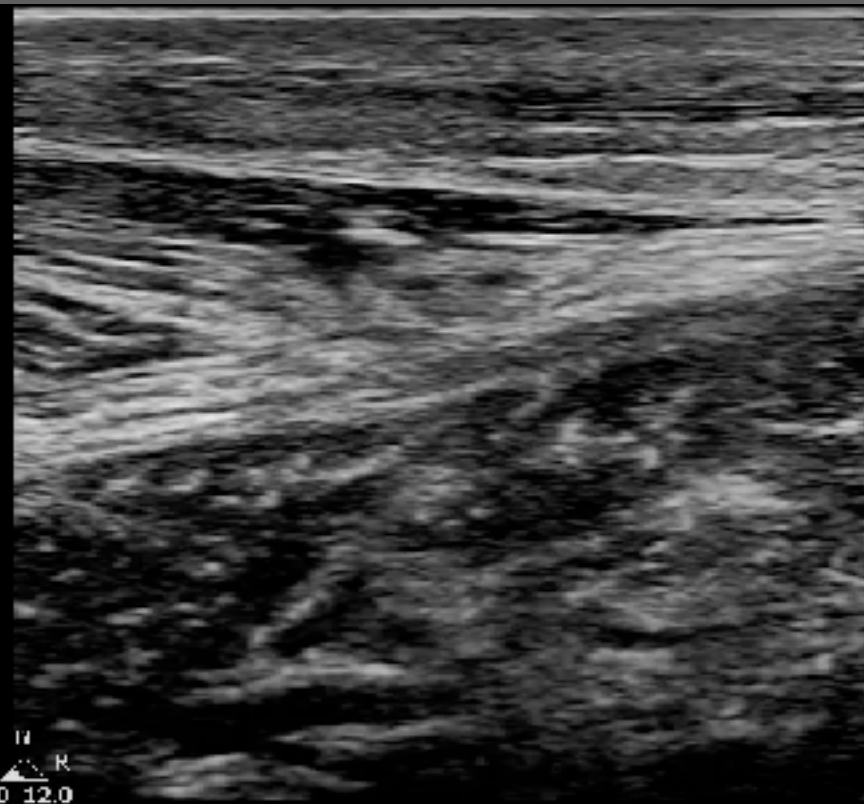


# 58M, right leg pain while running

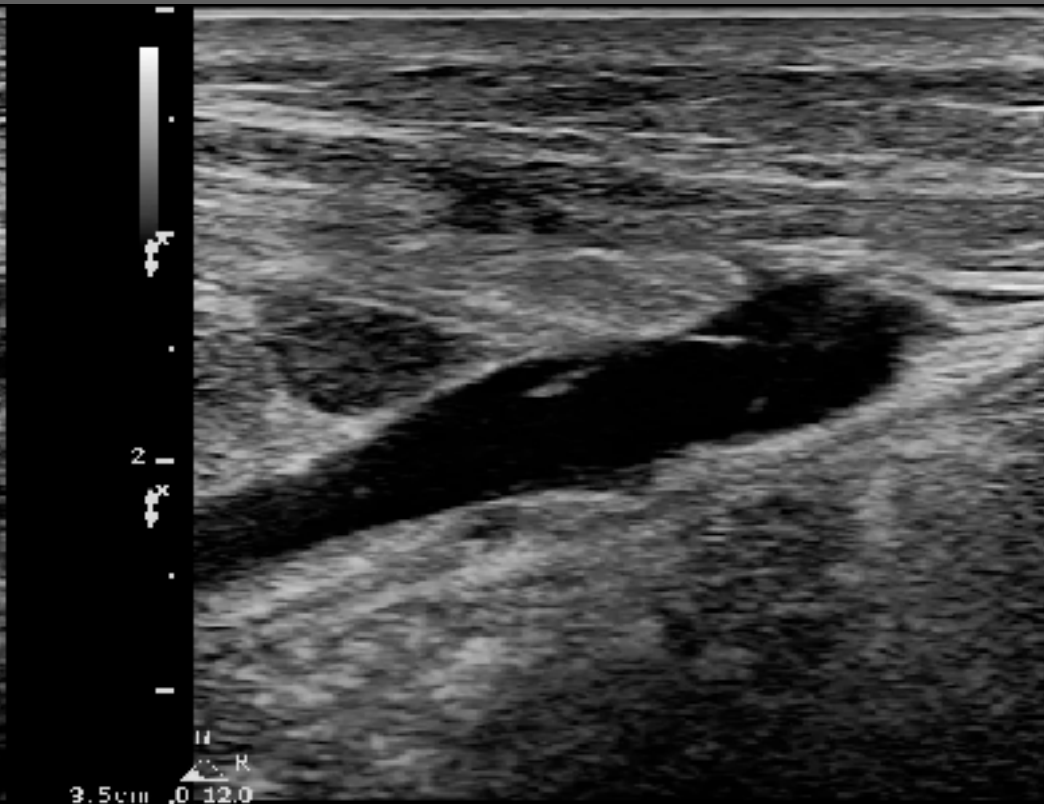

# Calf muscle tear

Left calf



Right calf



# Point-of-care ultrasound for the diagnosis of shoulder dislocation: A systematic review and meta-analysis

Michael Gottlieb, MD\*, Dallas Holladay, DO, Gary D. Peksa, PharmD

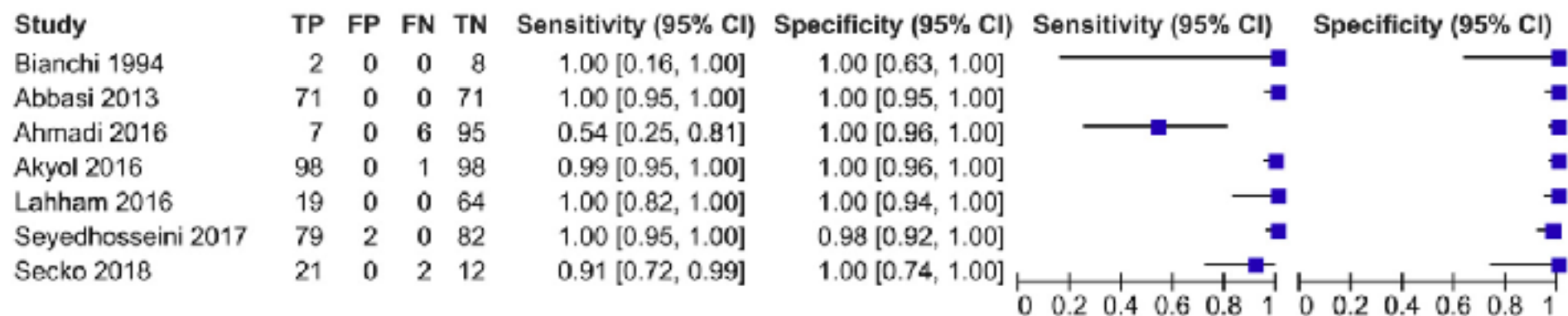
Department of Emergency Medicine, Rush University Medical Center, Chicago, IL, United States of America

## Study 7 ; Assessment 739 ; Dislocation 306

**Table 1**  
Characteristics of the included studies.

Study	Study population	Country	Study location	Mean patient age	Male patients (%)	Shoulder dislocations (%)	Ultrasound transducer	Ultrasound technique	Operator experience
Bianchi 1994	10	United States	ND	35.5 years	ND	2 (20%)	Linear	Posterior	ND
Abbasi 2013	142	Iran	ED	31.6 years	126 (91.3%)	71 (50%)	Linear	Anterior + lateral	Attending, resident
Ahmadi 2016	108	Iran	ED	30.1 years	91 (64.1%)	13 (12%)	Linear	Anterior + lateral	Attending
Akyol 2016	197	Turkey	ED	33.9 years	164 (80.6%)	99 (50%)	Linear	Posterior	Attending
Lahham 2016	84	United States	ED	45 years	52 (62%)	19 (22.6%)	Linear	Posterior	Student
Seyedhosseini 2017	163	Iran	ED	35.9 years	140 (83.3%)	79 (48.5%)	Curvilinear	Posterior	Attending, resident
Secko 2018	35	United States	ED	ND	ND	23 (66%)	Linear or curvilinear	Posterior	Attending

ND, not described; ED, emergency department.

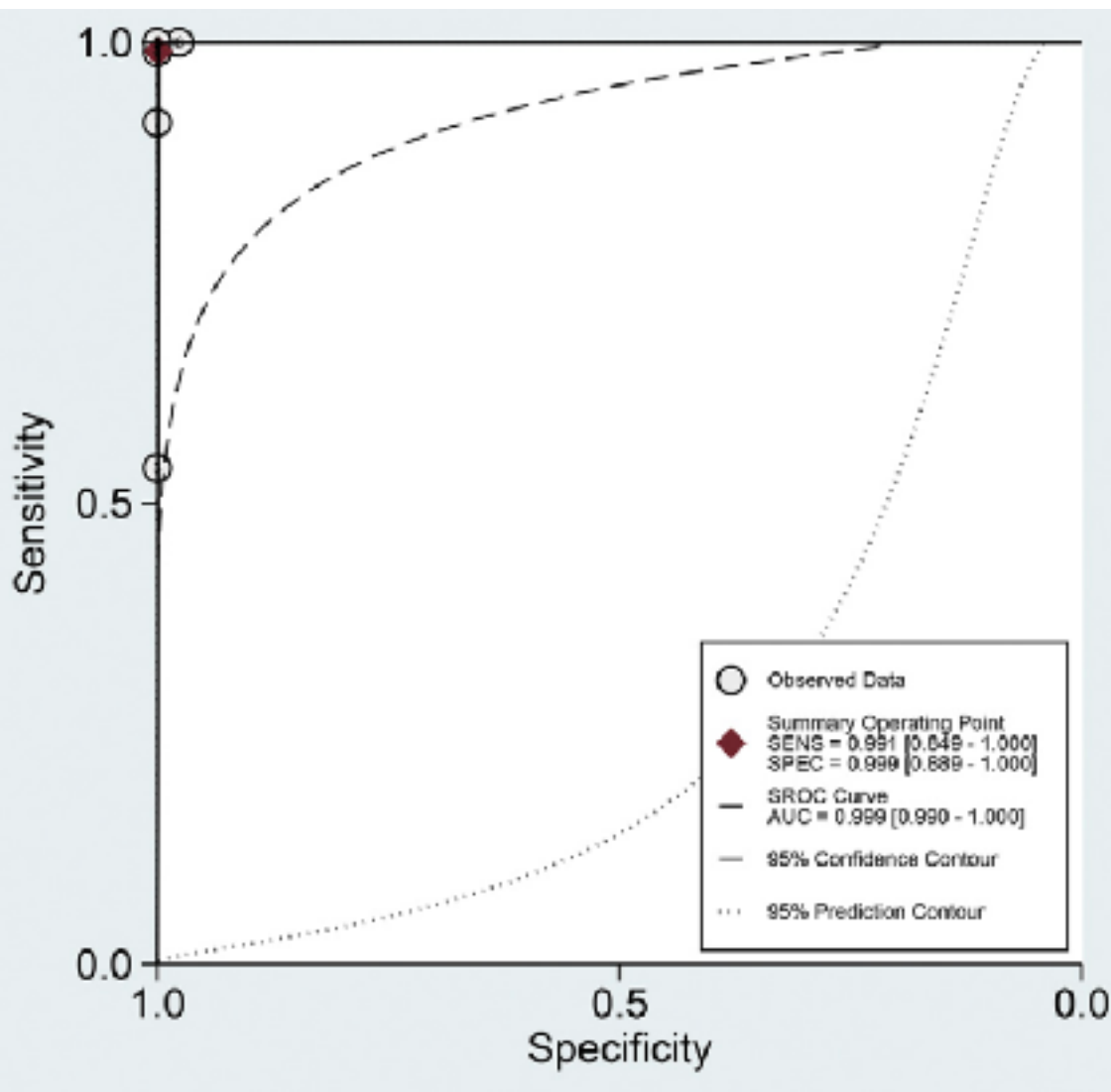


**Fig. 2.** Forest diagram of the overall sensitivity and specificity of ultrasound for identifying shoulder dislocations.

# Point-of-care ultrasound for the diagnosis of shoulder dislocation: A systematic review and meta-analysis

Michael Gottlieb, MD\*, Dallas Holladay, DO, Gary D. Peksa, PharmD

Department of Emergency Medicine, Rush University Medical Center, Chicago, IL, United States of America



Sensitivity 99.1%

Specificity 99.9%

LR+ 796.2

LR- 0.01

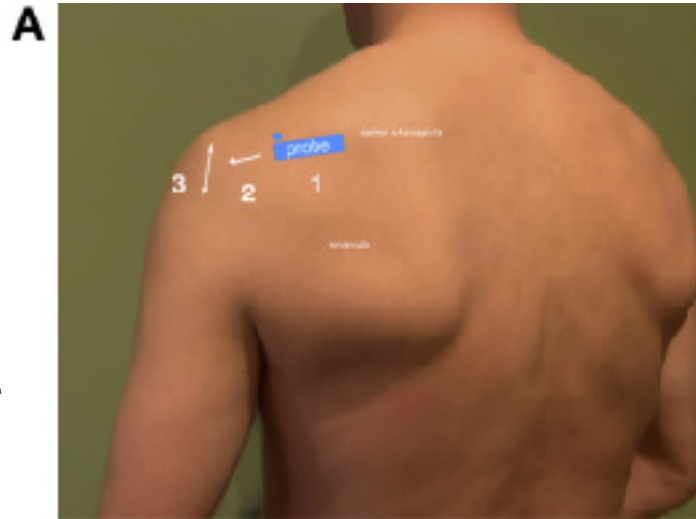
AJEM 2019;37:757-761



# Musculoskeletal Ultrasonography to Diagnose Dislocated Shoulders: A Prospective Cohort

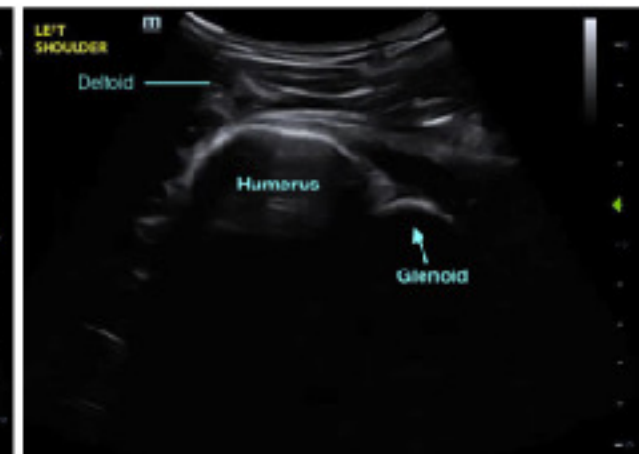
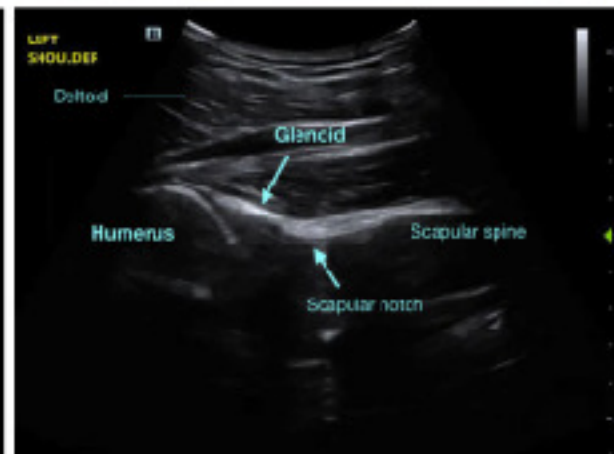
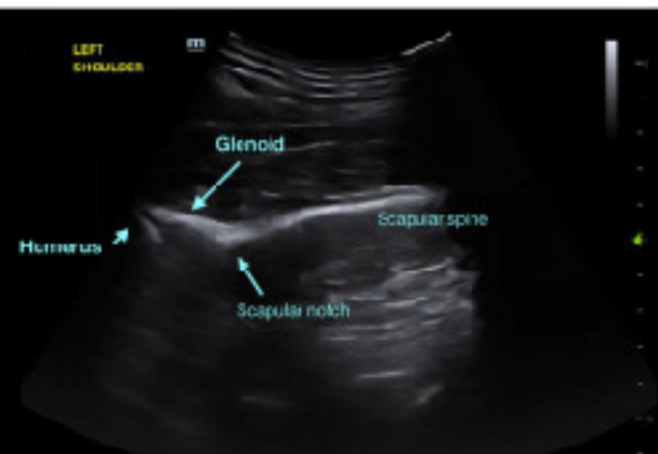Michael A. Secko, MD, RDMS\*; Lindsay Reardon, MD; Michael Gottlieb, MD; Eric J. Morley, MD; Mathew R. Lohse, MD; Henry C. Thode, Jr, PhD; Adam J. Singer, MD

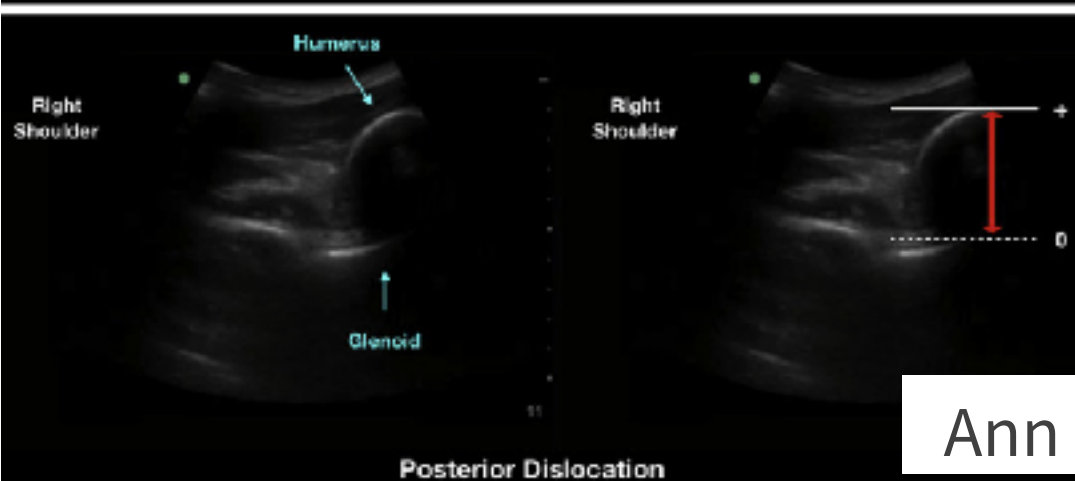
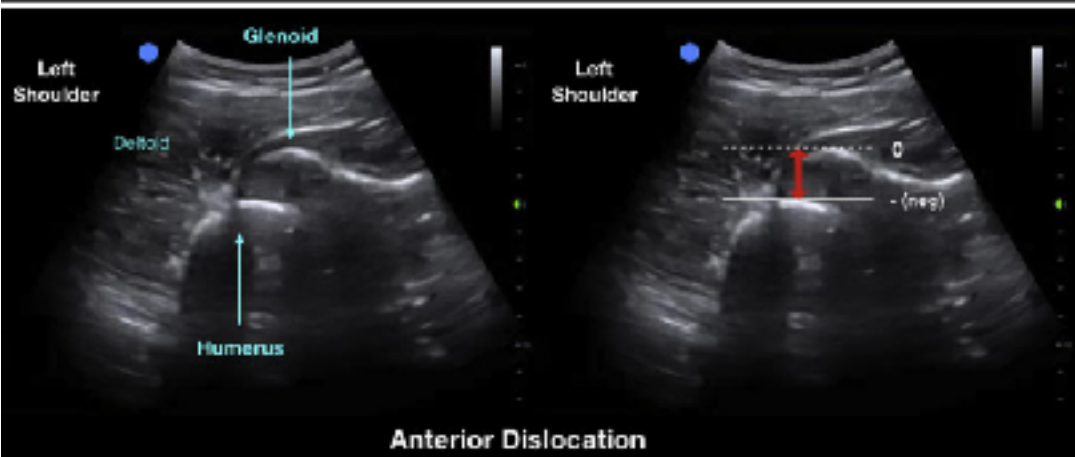
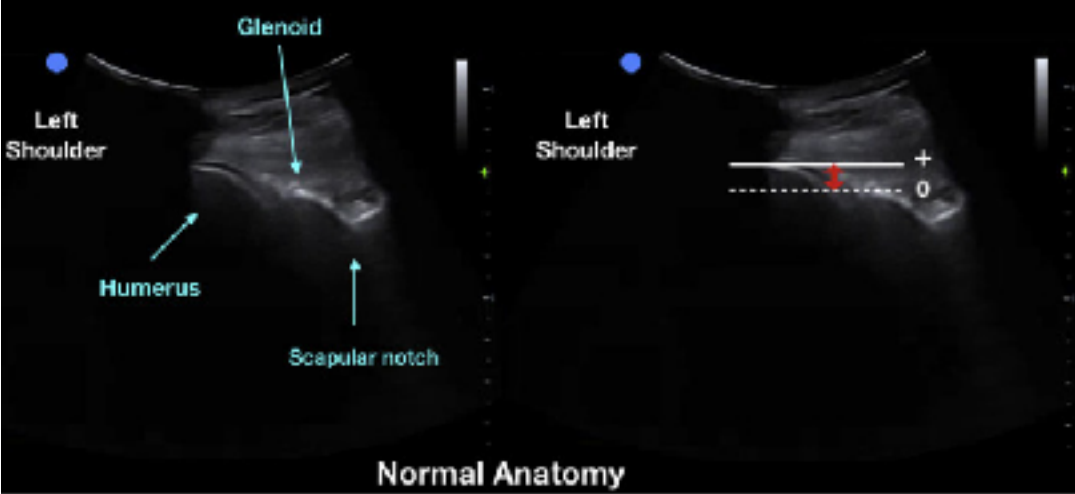
Multicenter  
Prospective  
Observational



65 patients

**B**





Sensitivity 100%  
 Specificity 100%

Sens (Fx) 92%  
 Spes (Fx) 100%

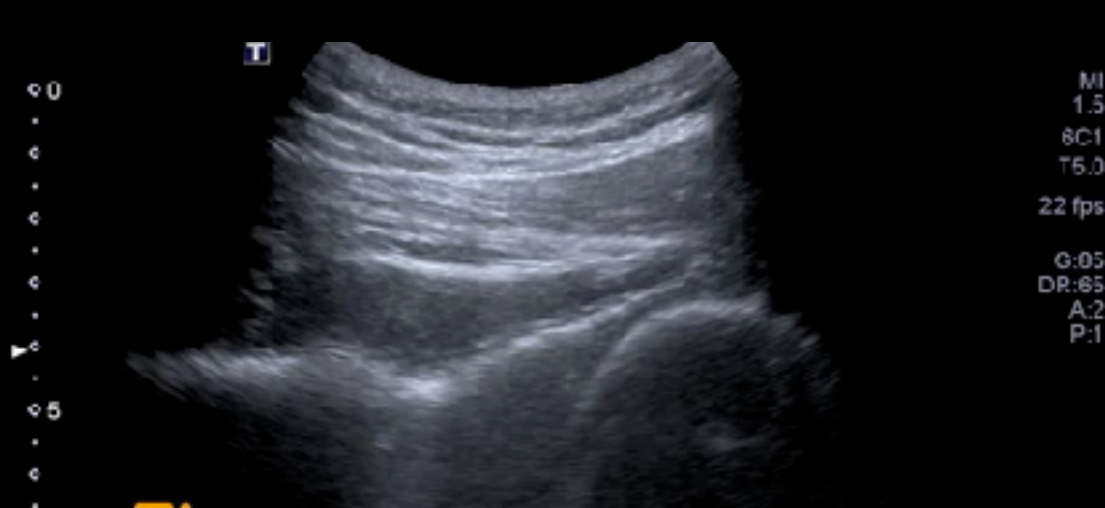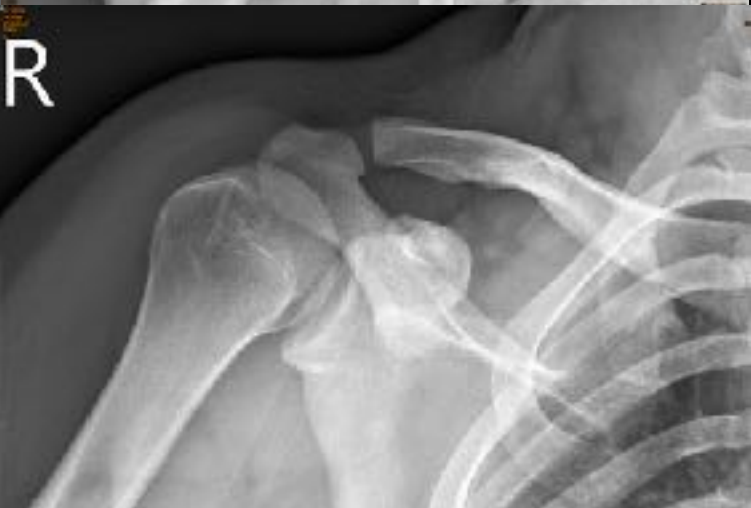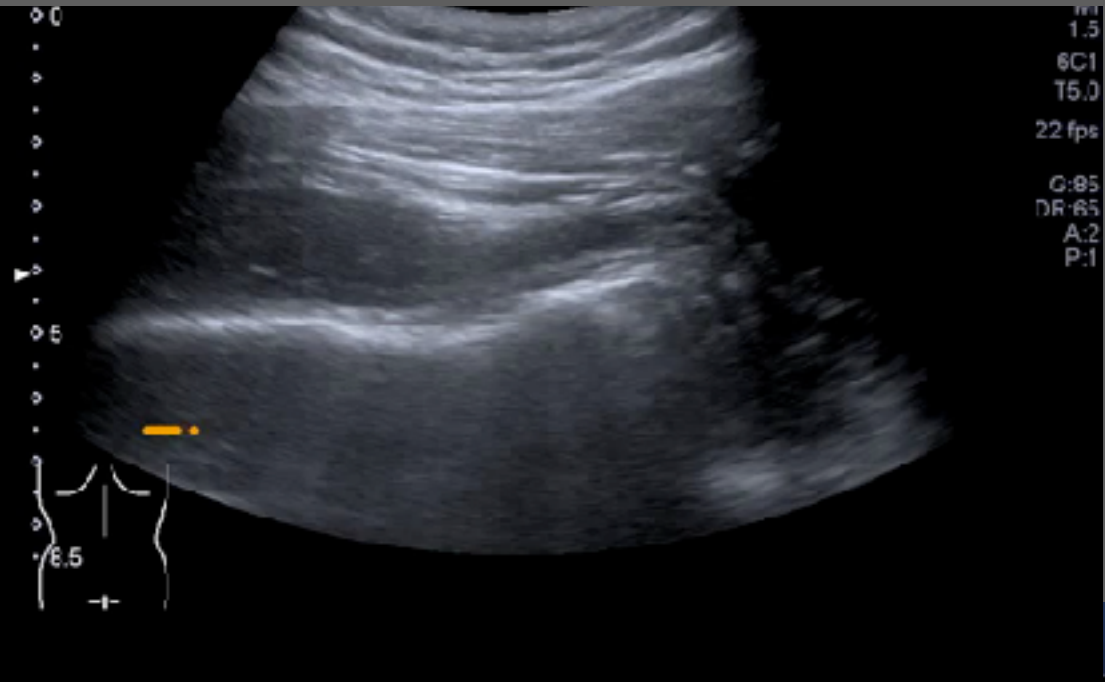
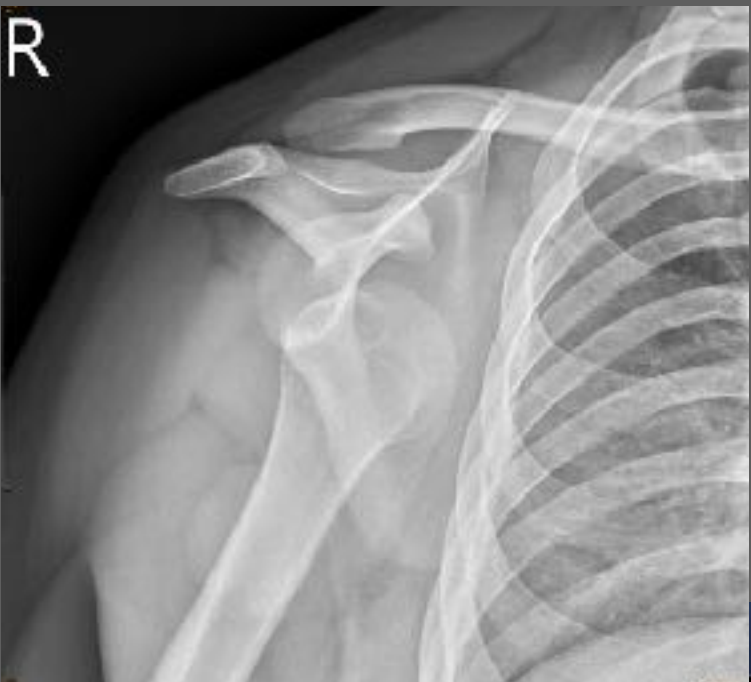Median 19s

GH(d-A) -1.83cm

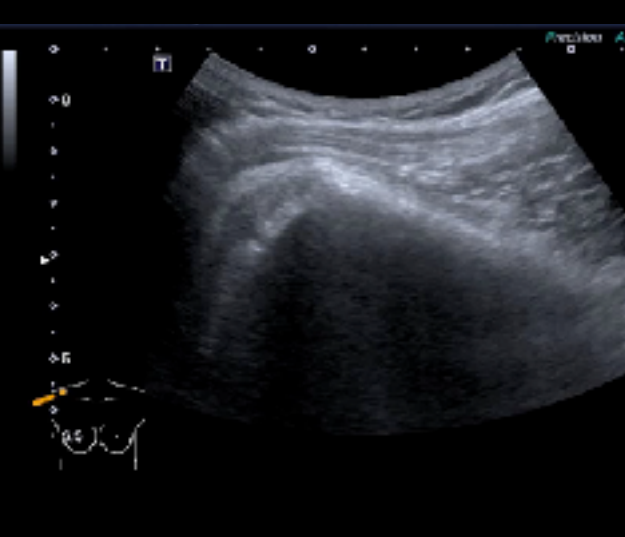
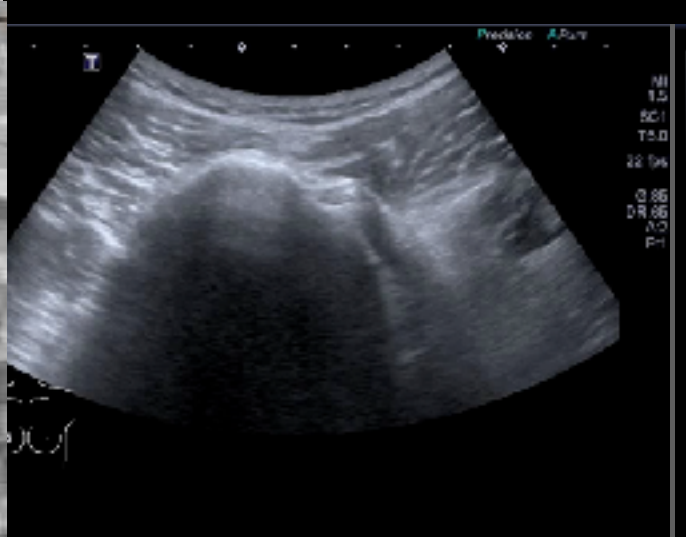
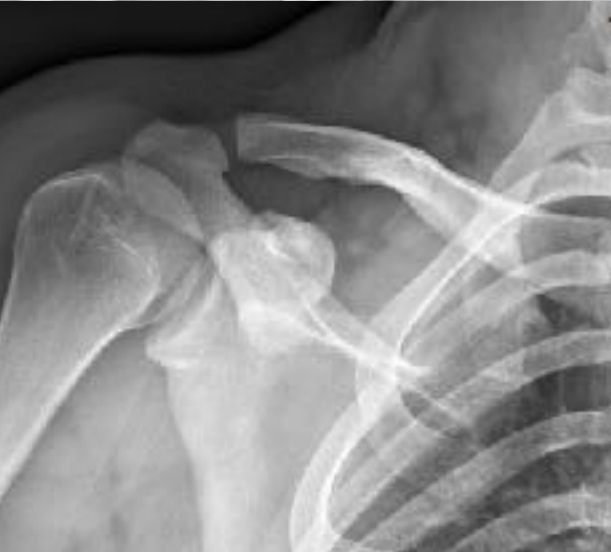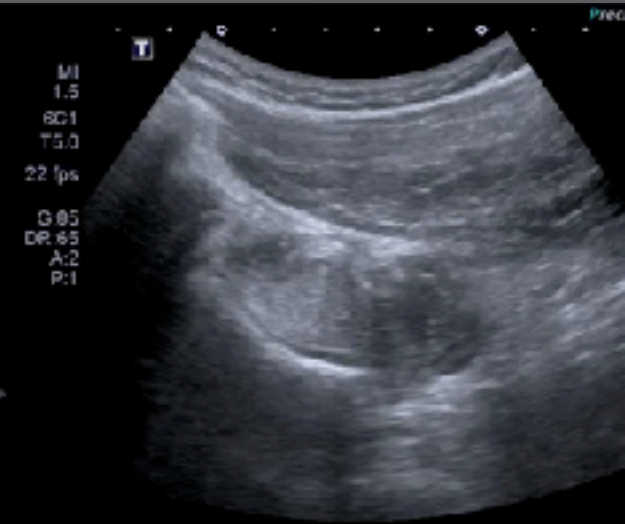
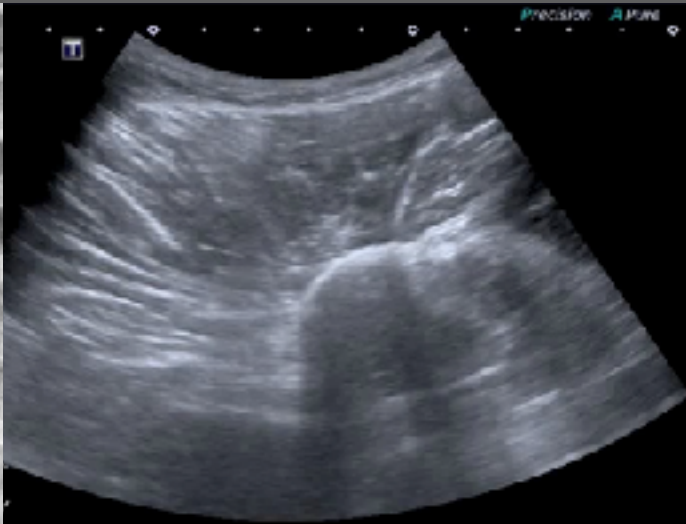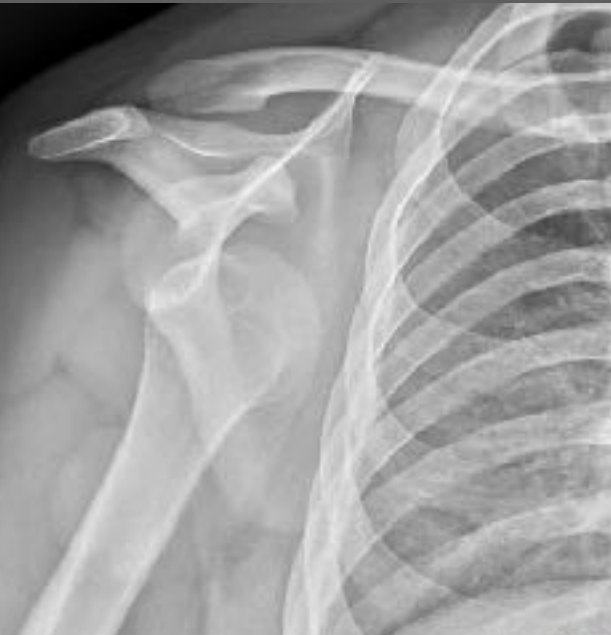GH(d-N) 0.22cm

GH(d-P) 3.3cm

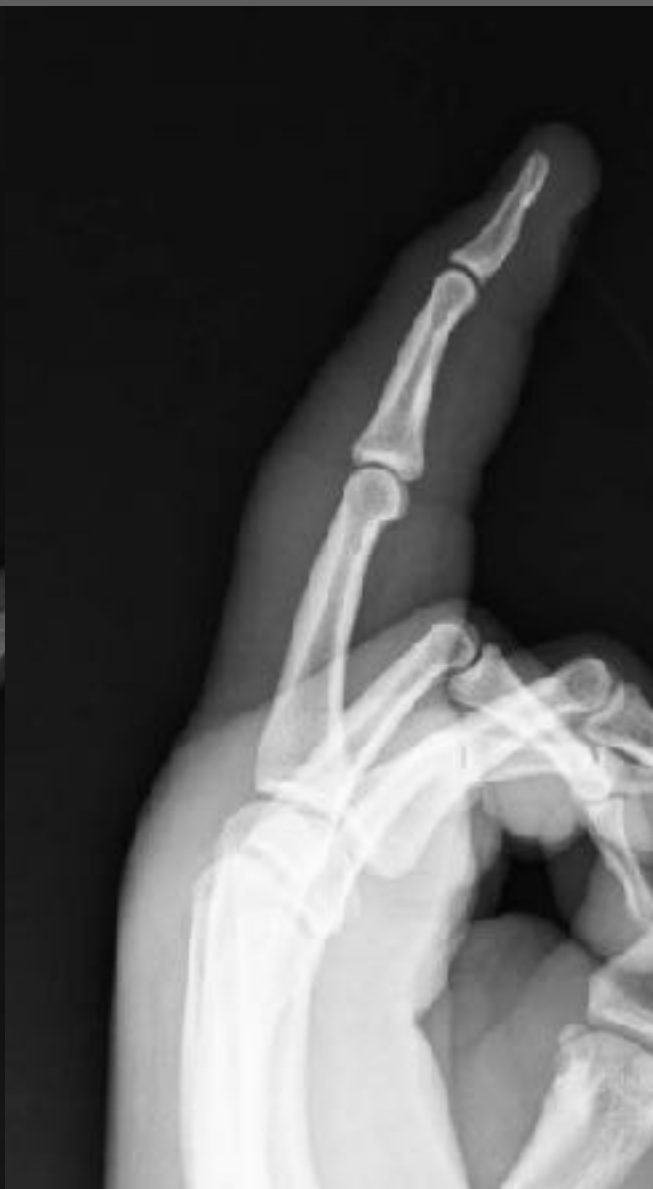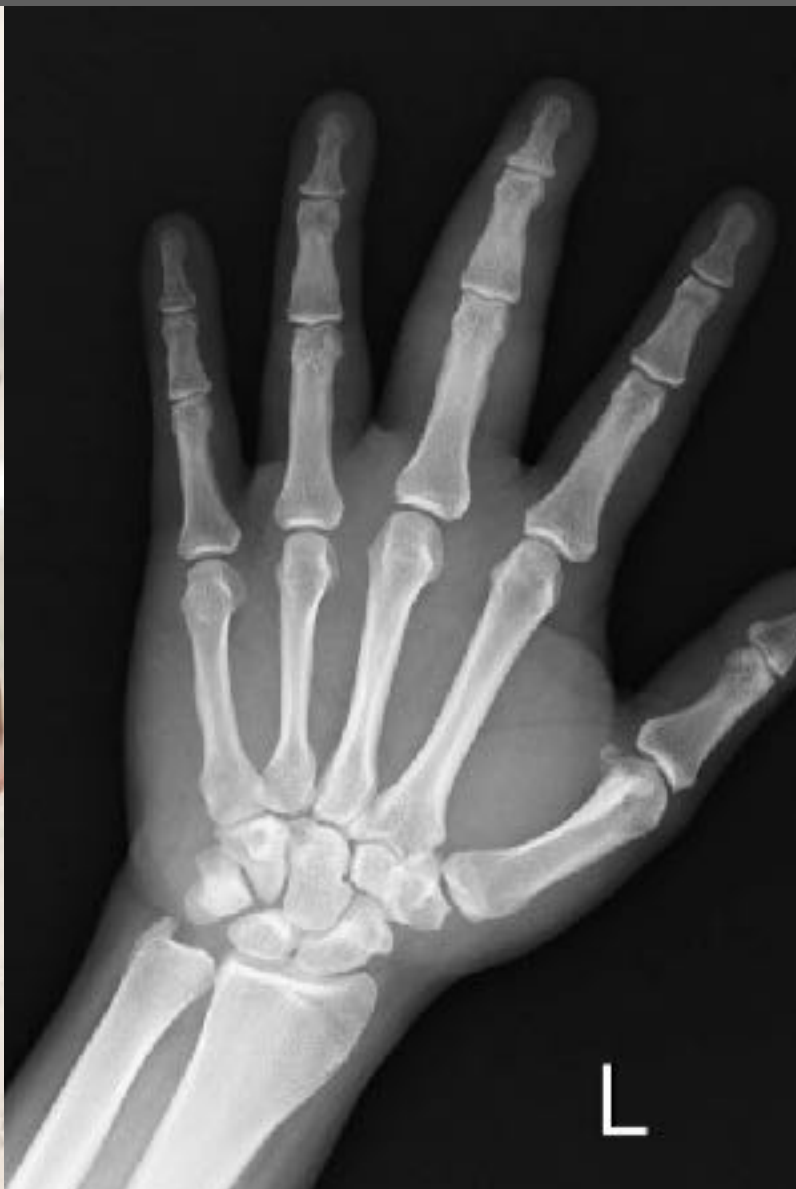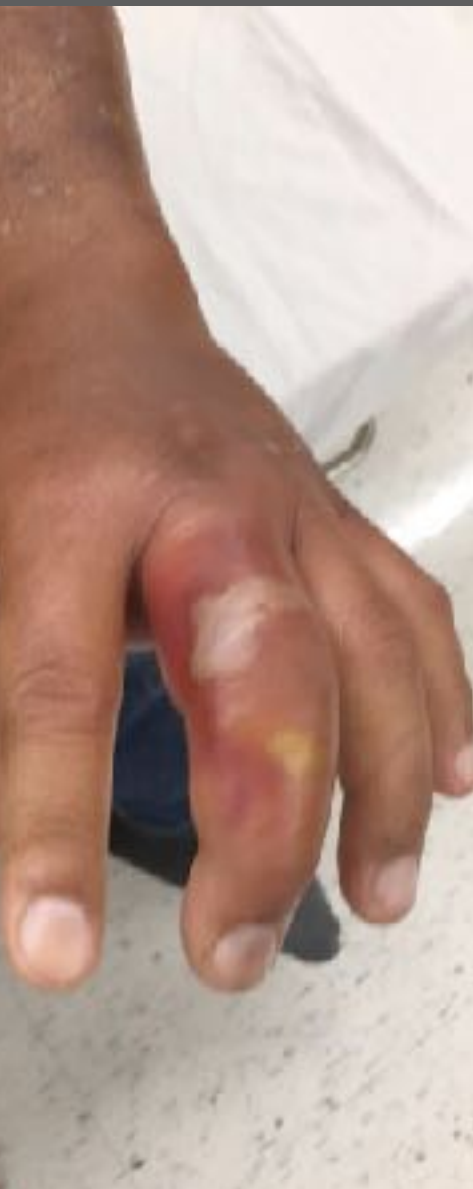# M/20, 工作時從階梯滑下用手去抓致右肩脫位



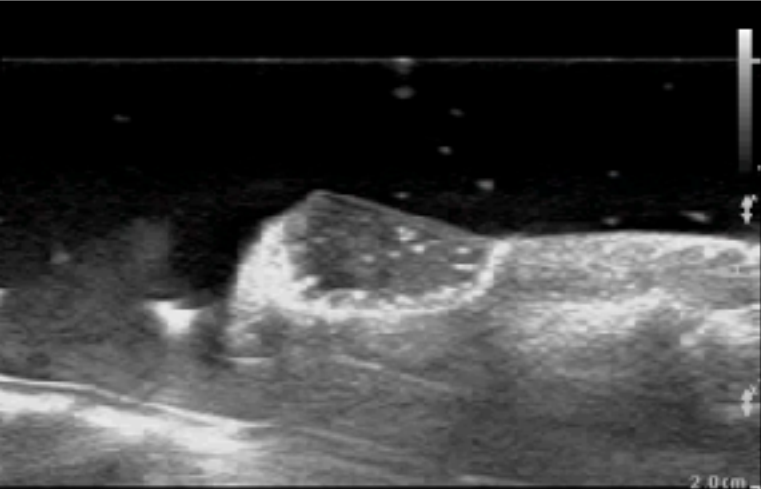
# Anterior approach for diagnosis, block & reduction



# 左手中指腫痛

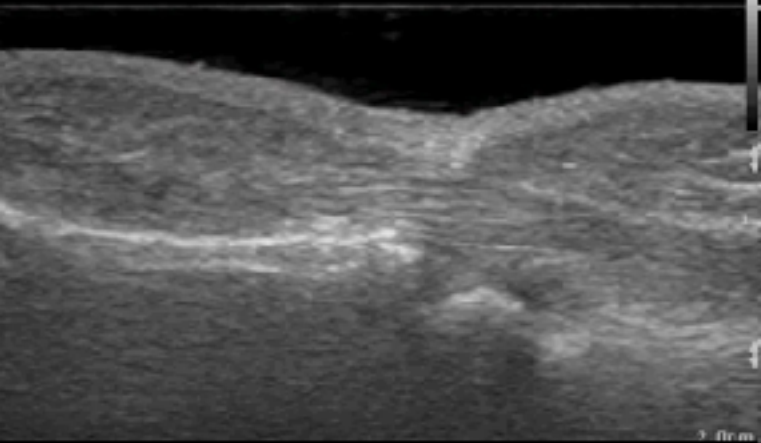


# Water bath method



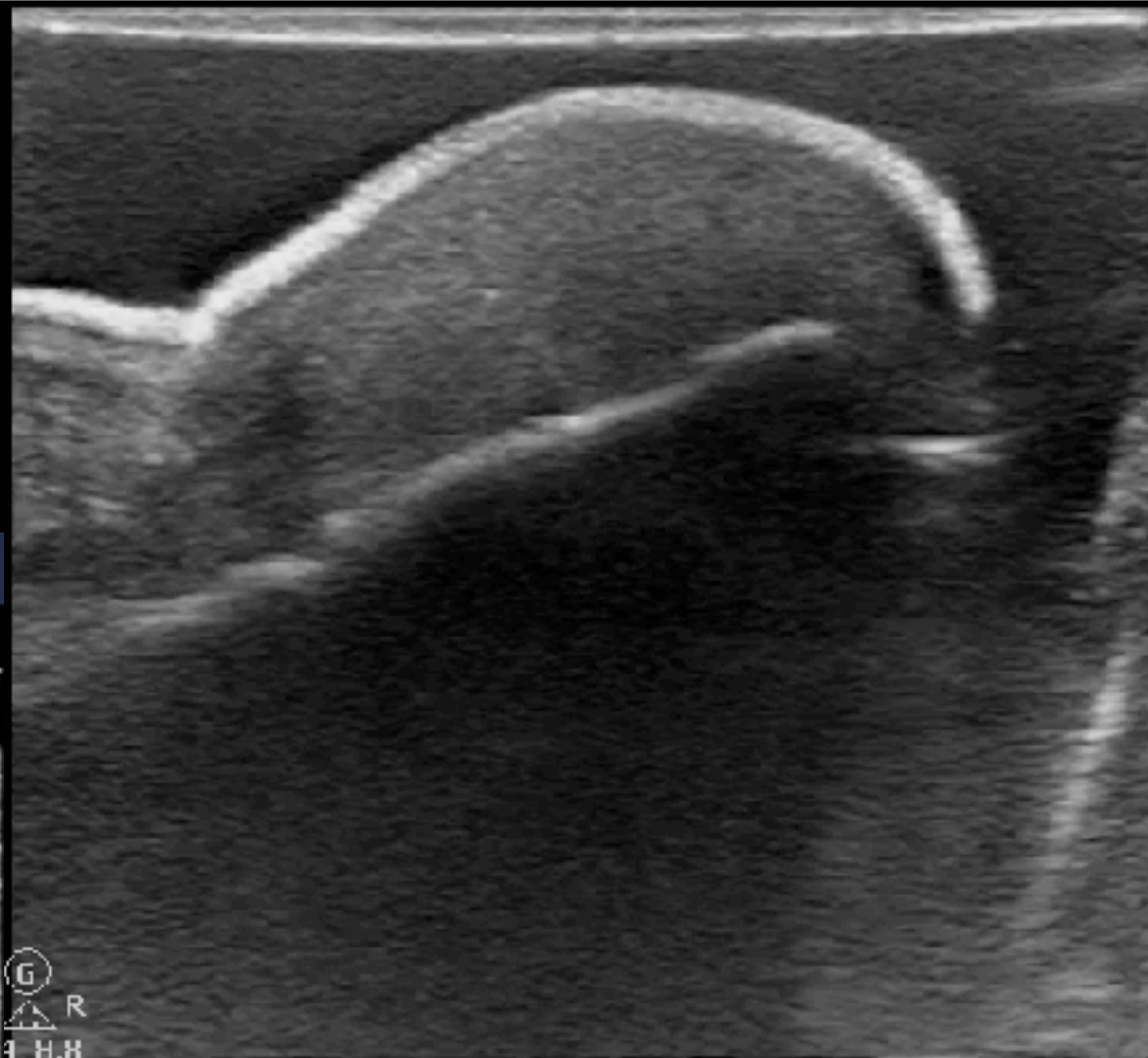G  
D R  
3.0 12.3

2.0cm



G  
P R  
2.0 12.0

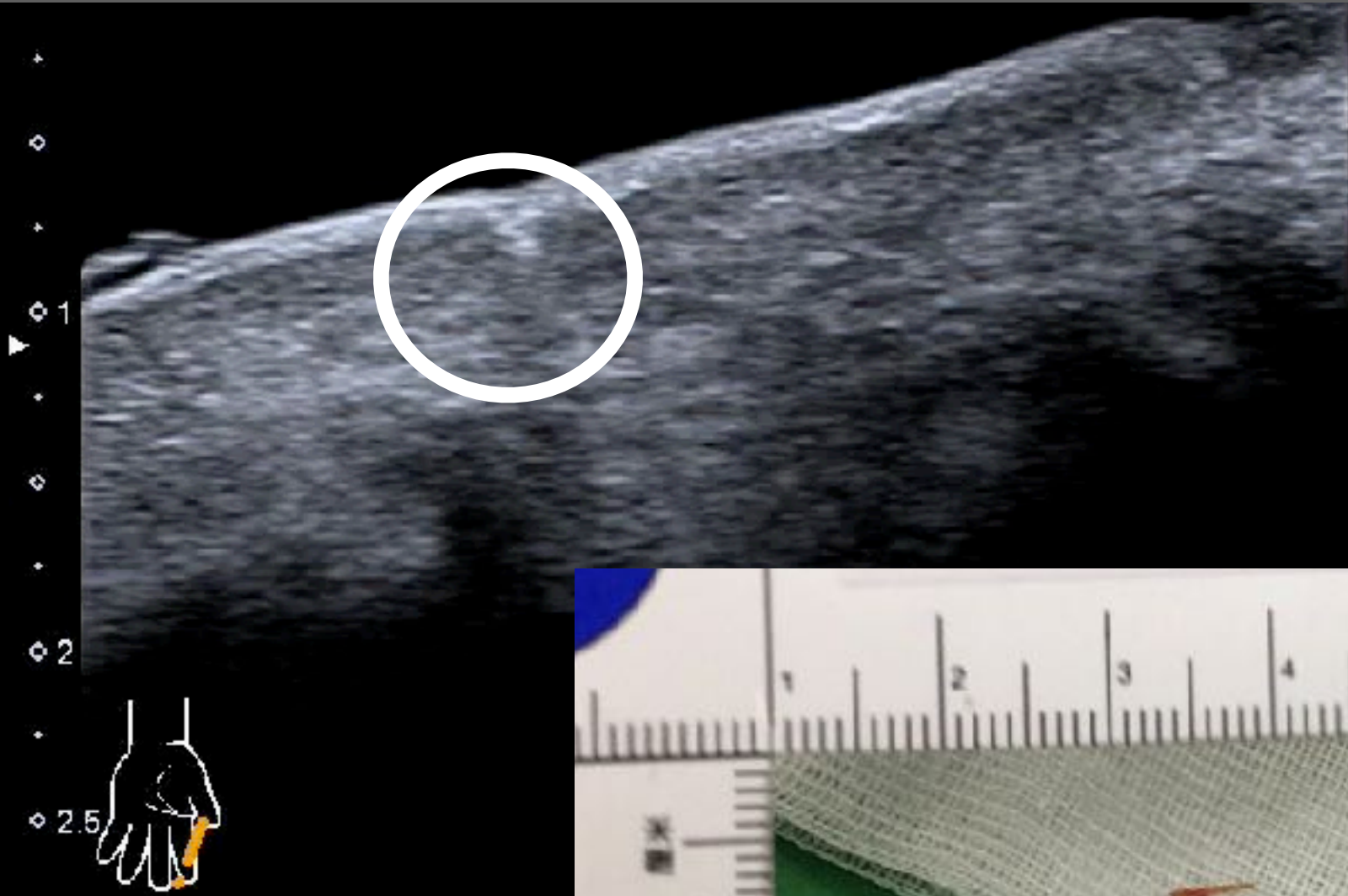
2.0cm




G  
R  
4 H.H

2.0cm

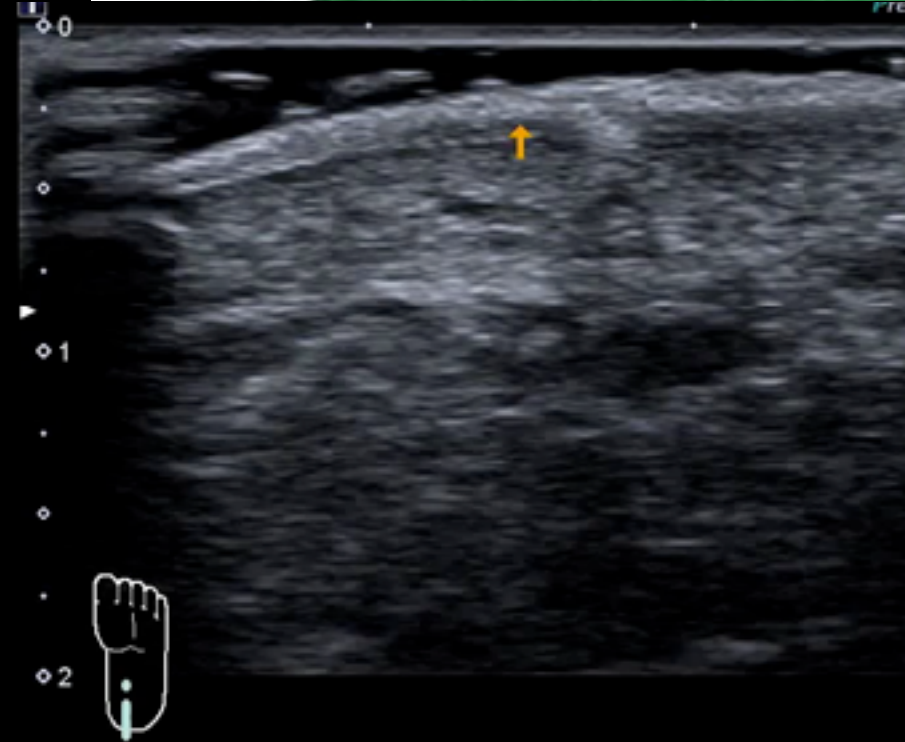
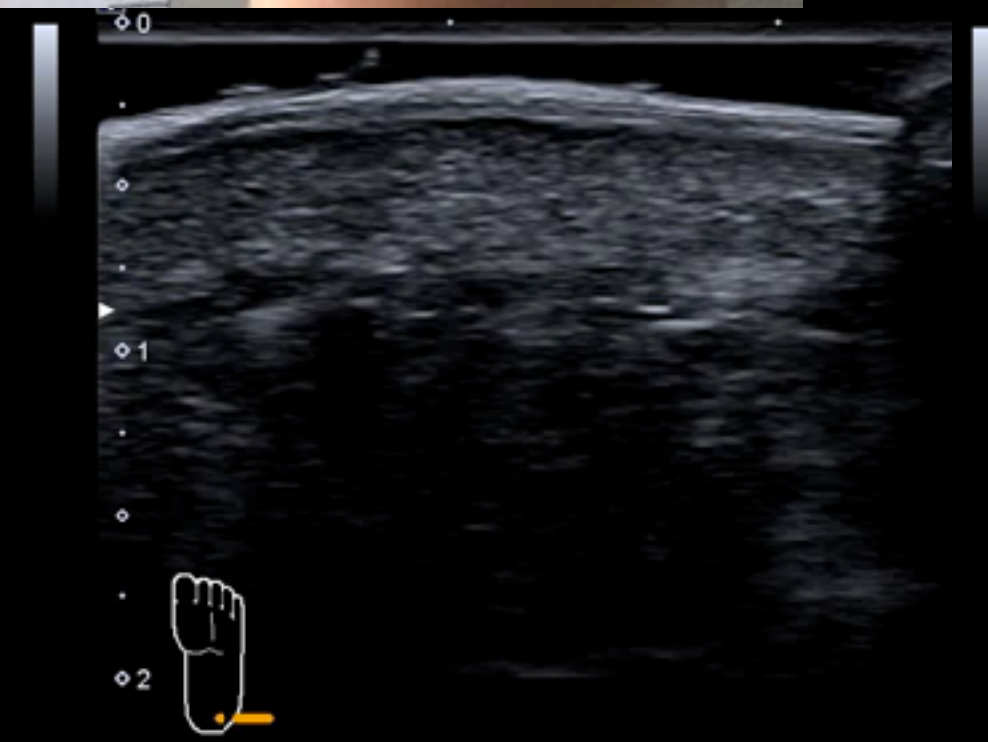
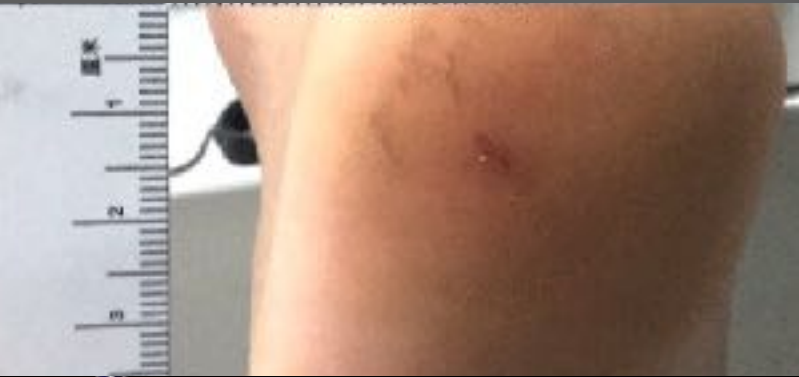# Water bath



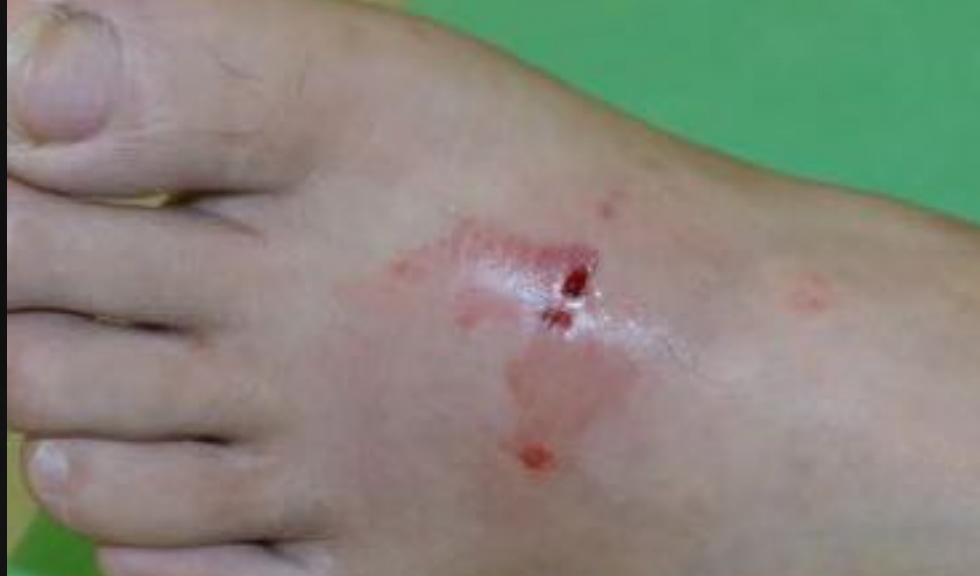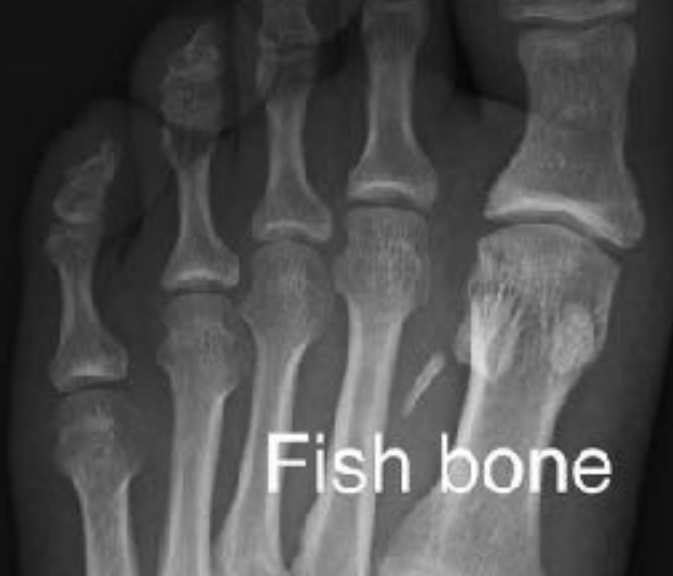M  
1.5  
11L4  
diffT9.0  
30 fps  
G:86  
DR:60  
A:6  
P:3



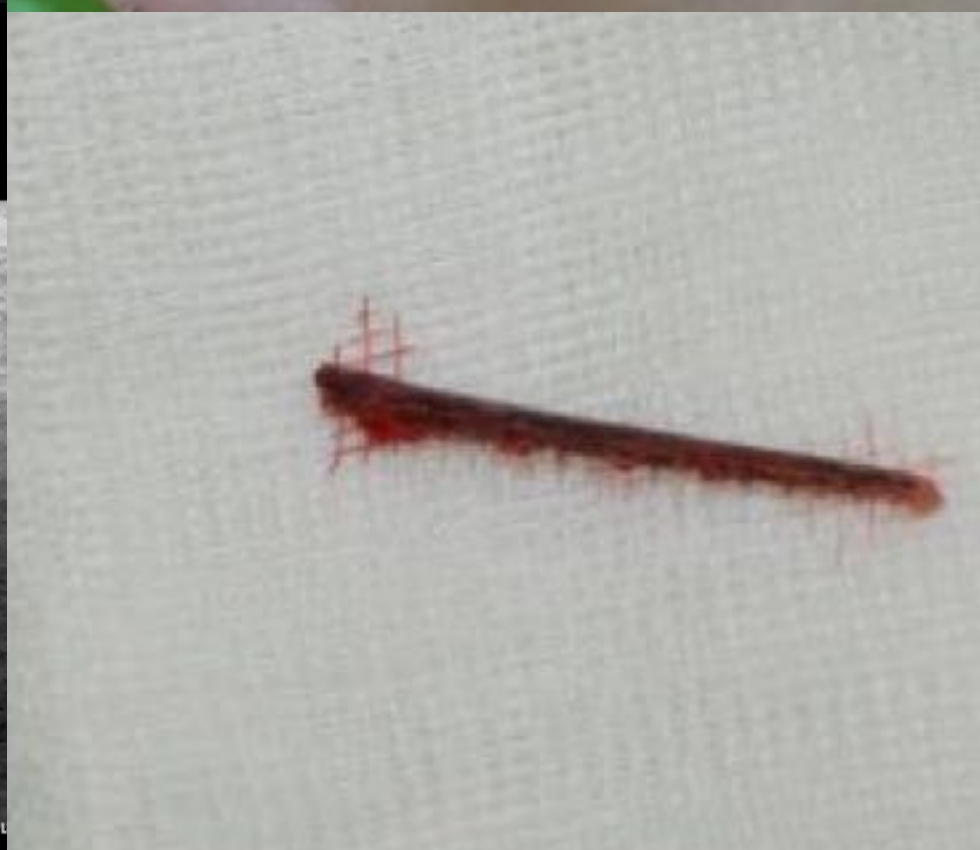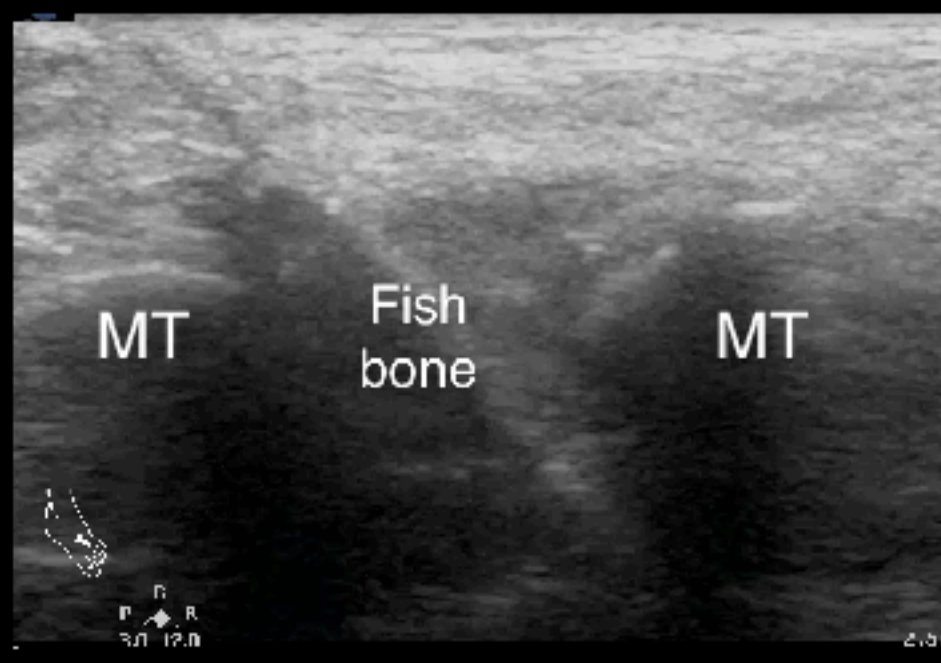
# 踩到碎玻璃，覺得有異物

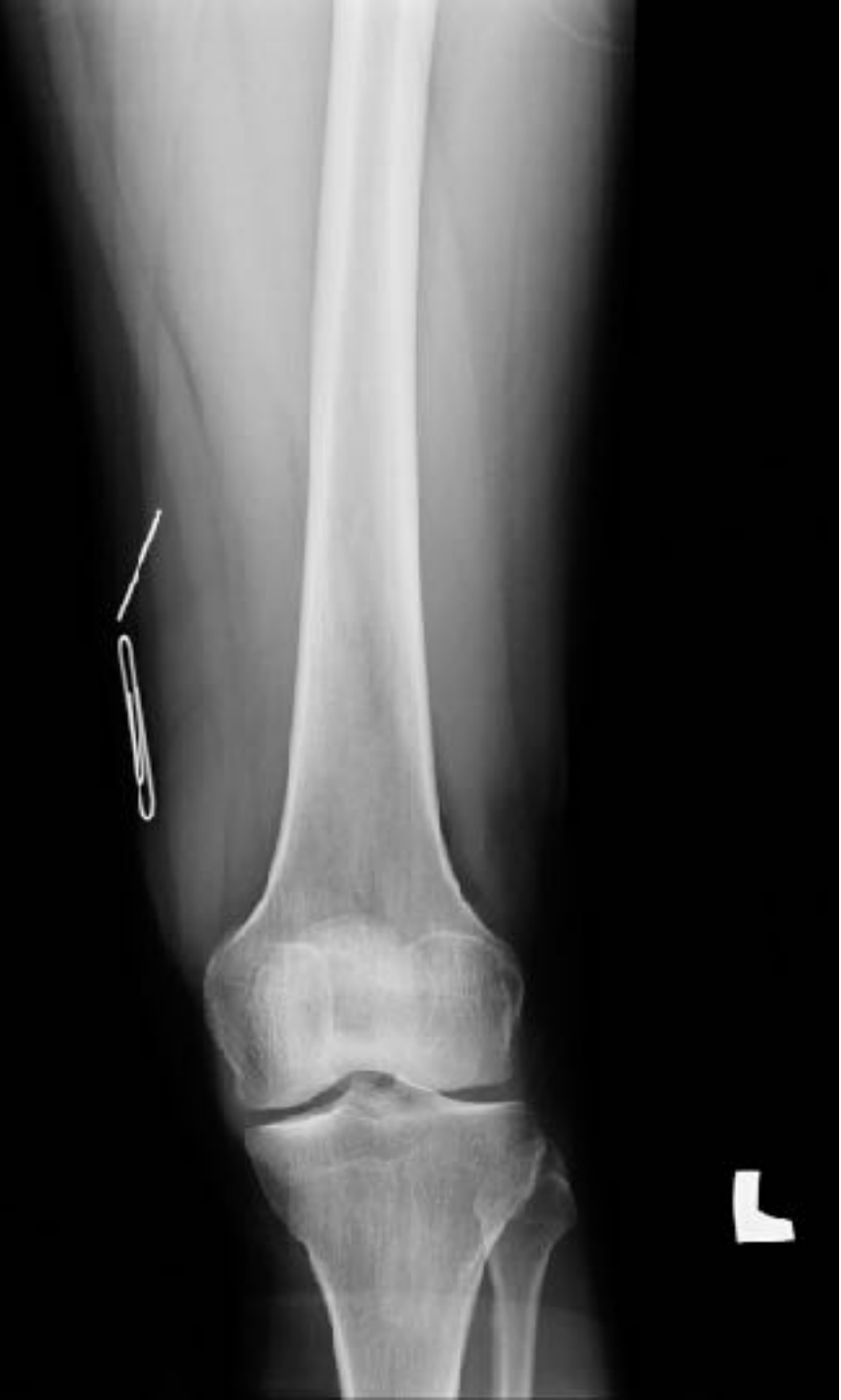
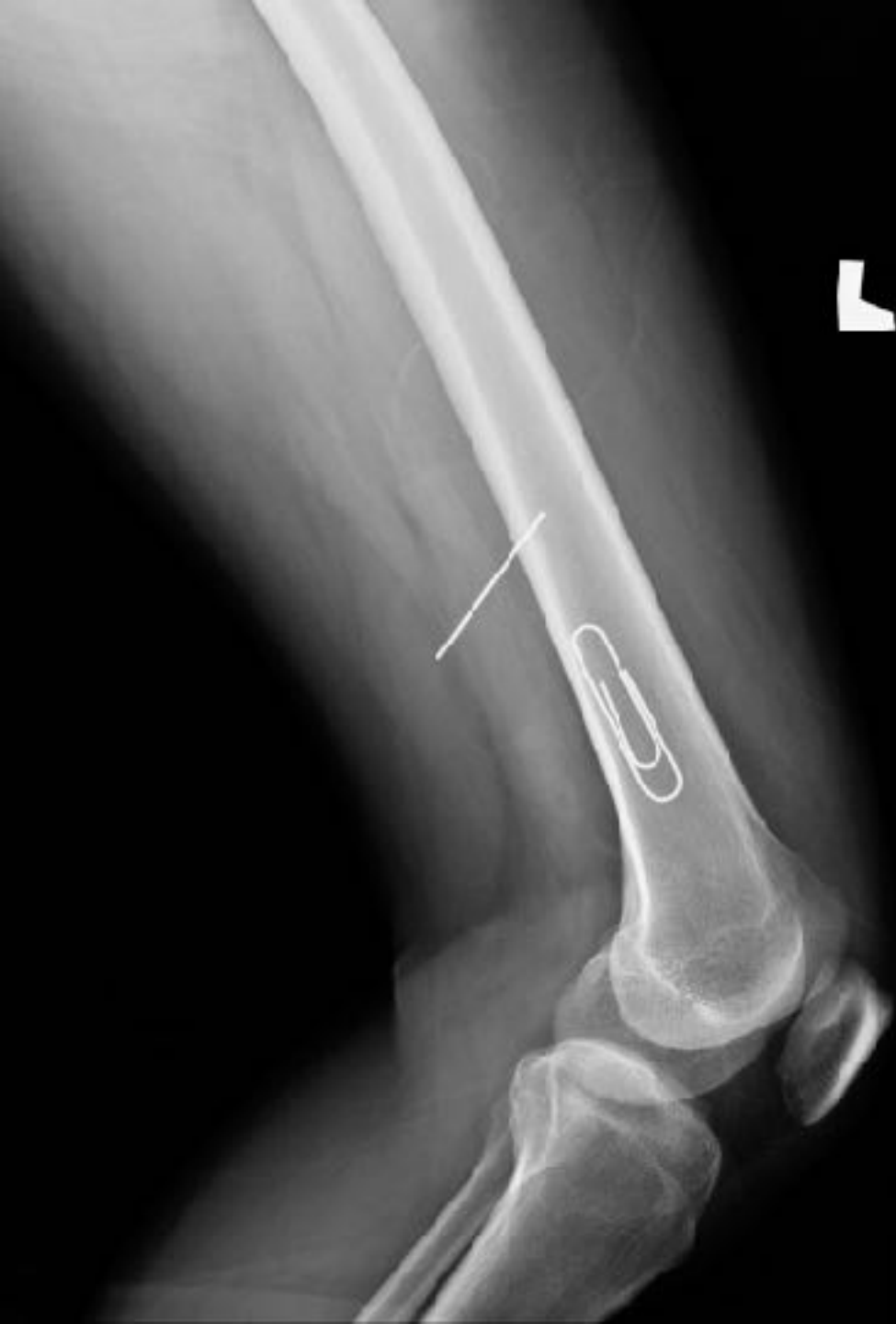




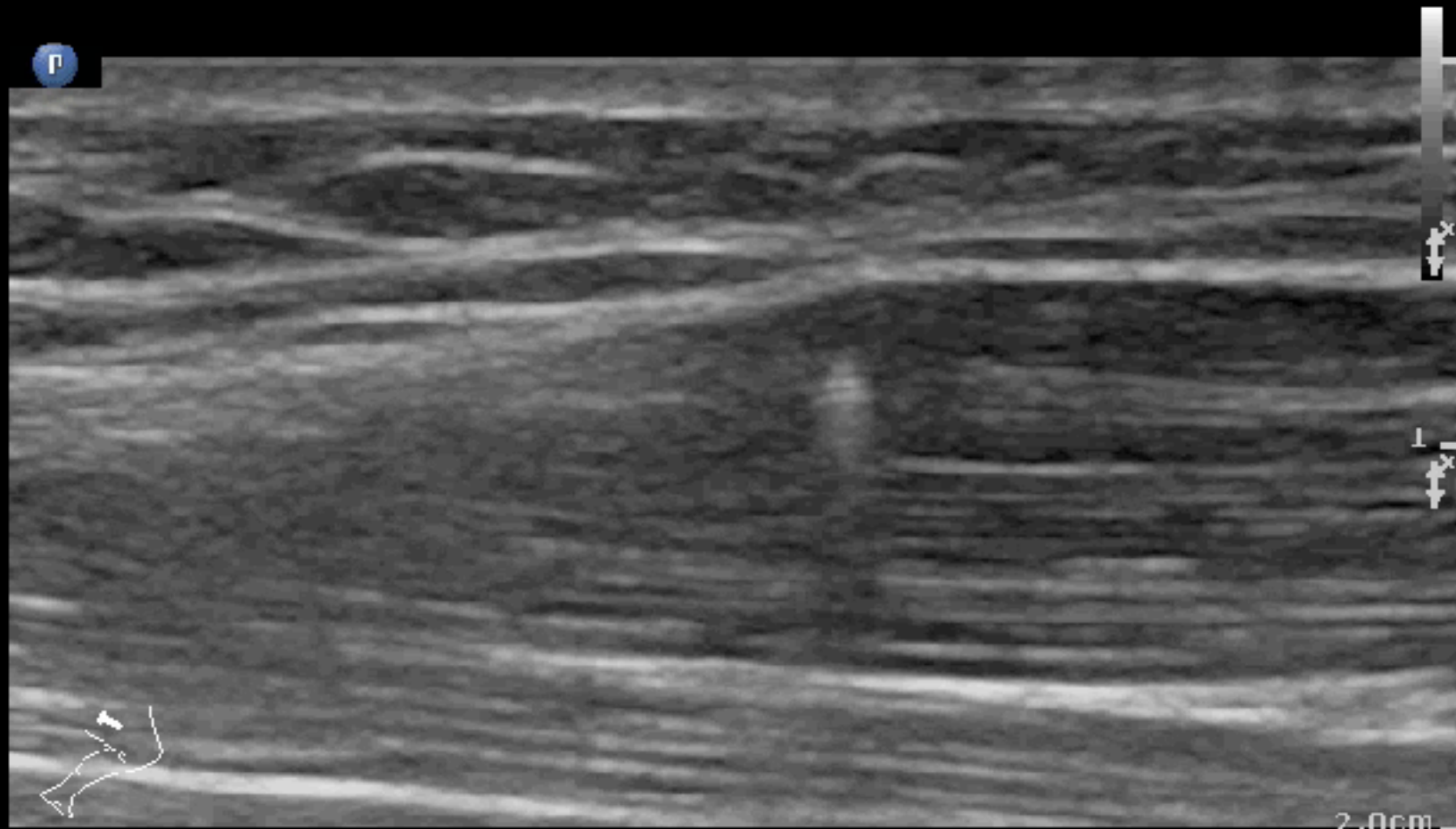
# SKH-EUTC





superficial  
L12-3  
34 Hz  
2.0cm

2D  
Gen  
Gn 60  
C. 57  
4/3/2



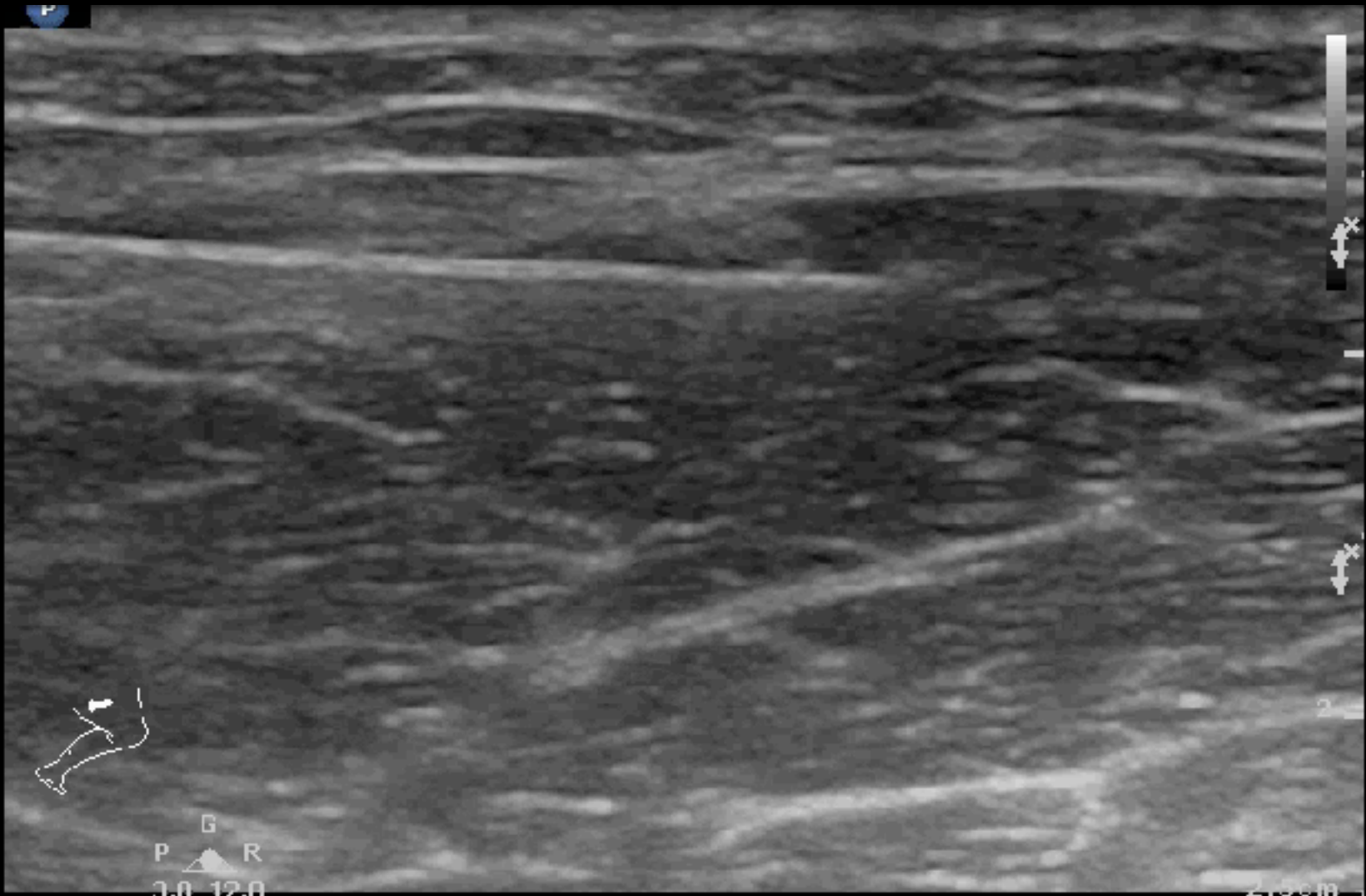
2.0cm

P R  
3.0 12.0

Superficial  
L12-3  
34 Hz  
2.5cm

2D

Gen  
Gn 60  
C 52  
1/3/2

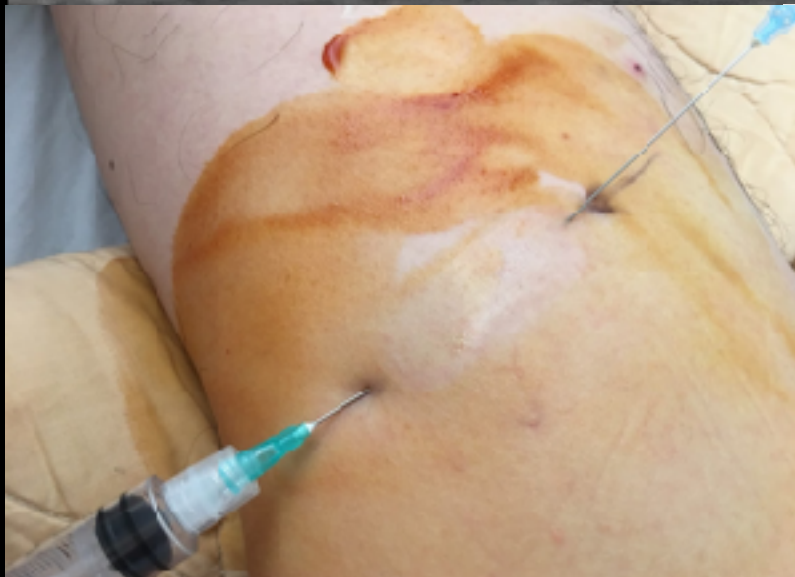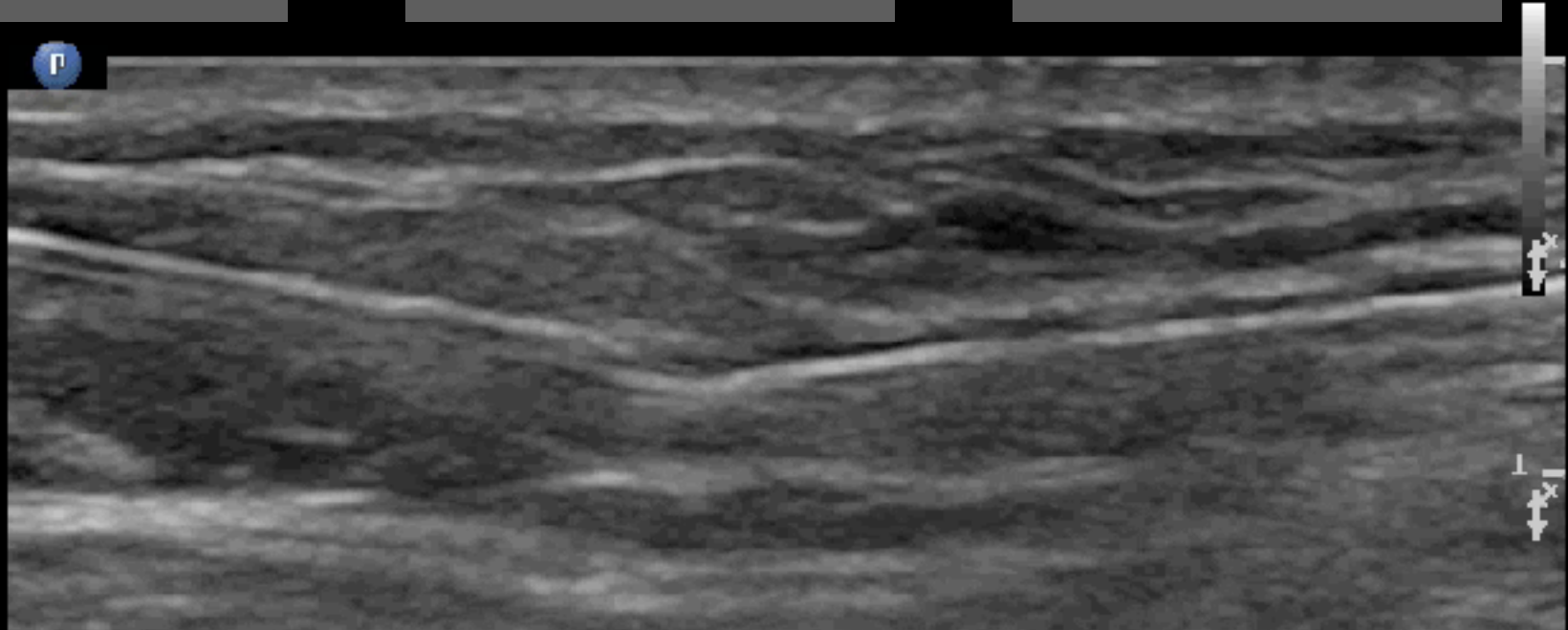


# Localization

# 2 needle

# Removal

L12  
34 Hz  
2.0cm  
7D  
Gen  
Gn 60  
C. 57  
4/3/2



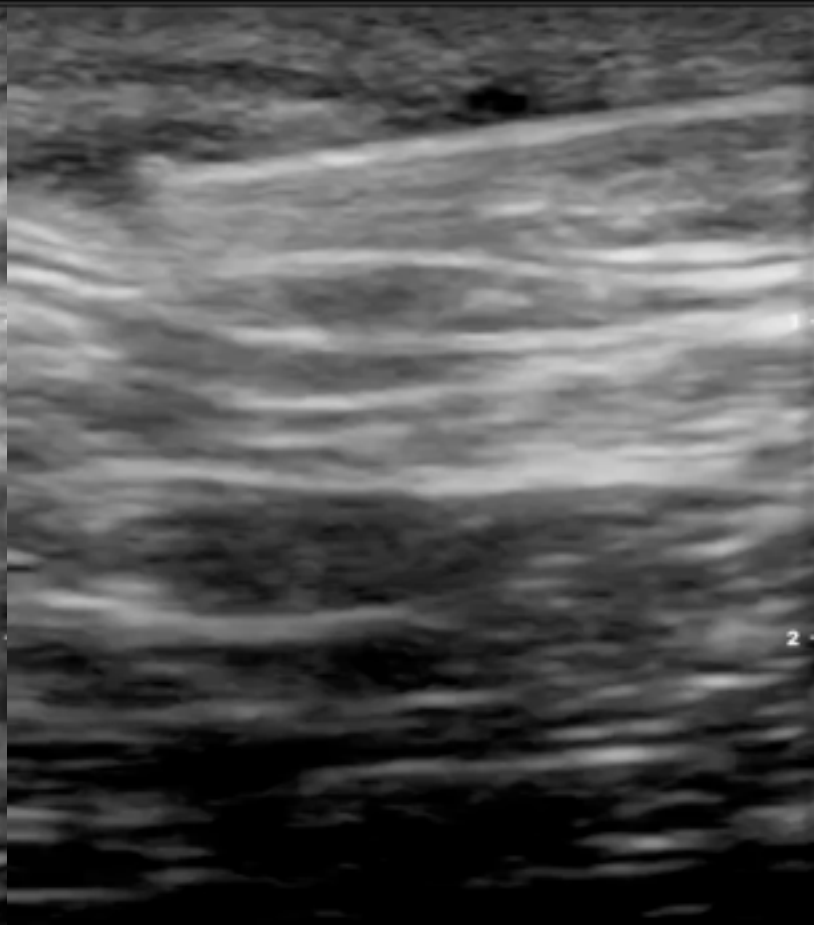
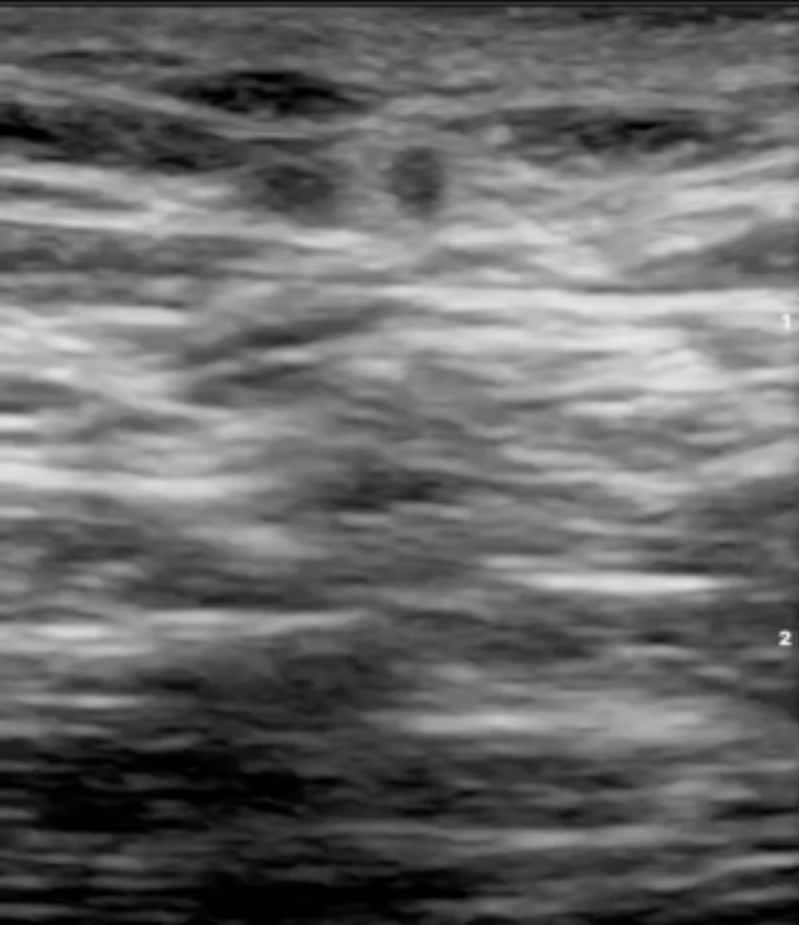
# 大腿痛和異物感

TIS: 0.01, MI: 0.26, Small Organ

TIS: 0.01, MI: 0.26, Small Organ

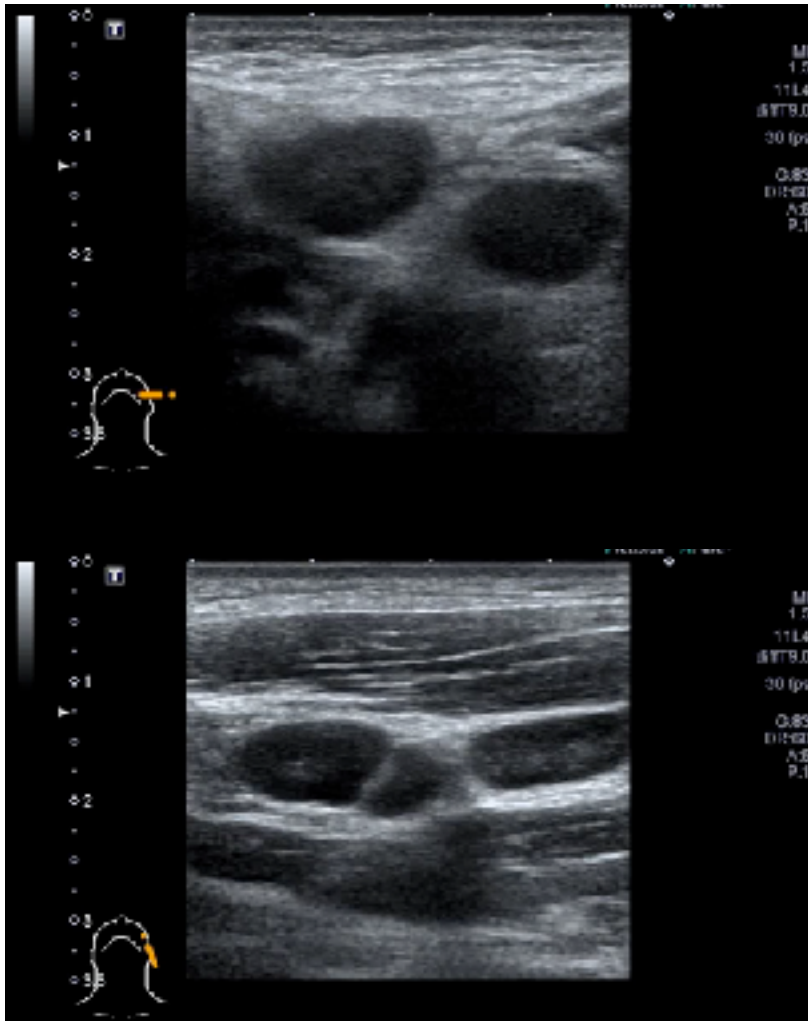
B

B

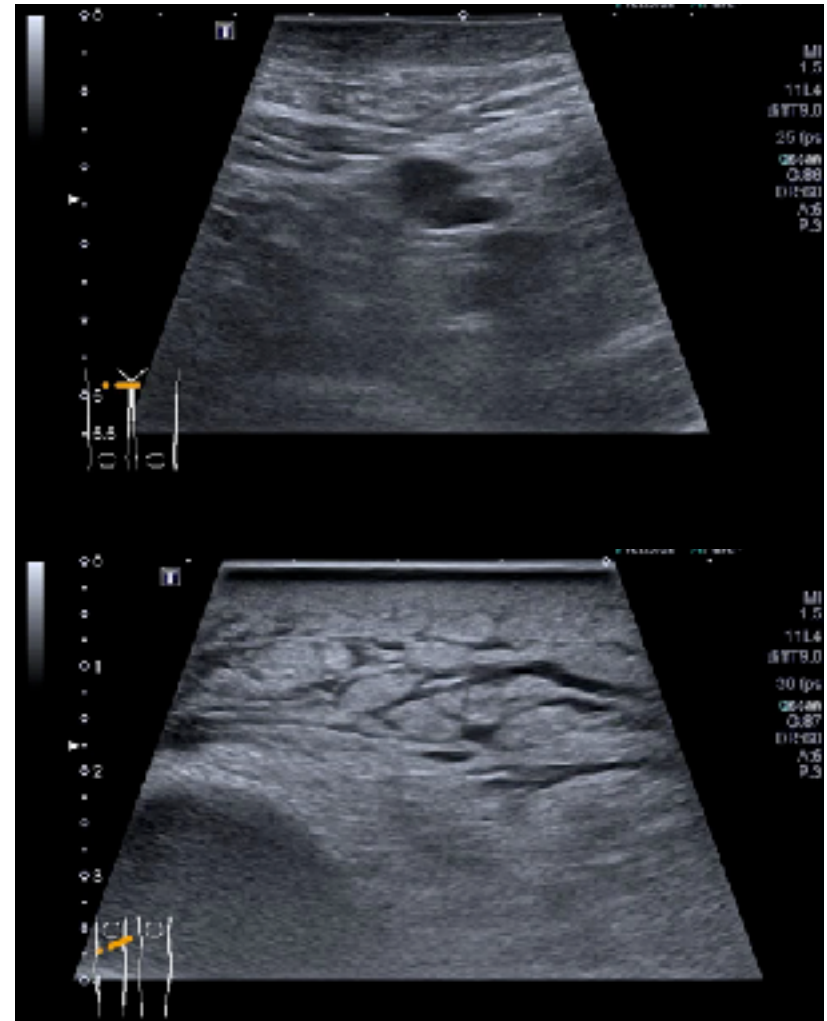


# Lymphadenopathy

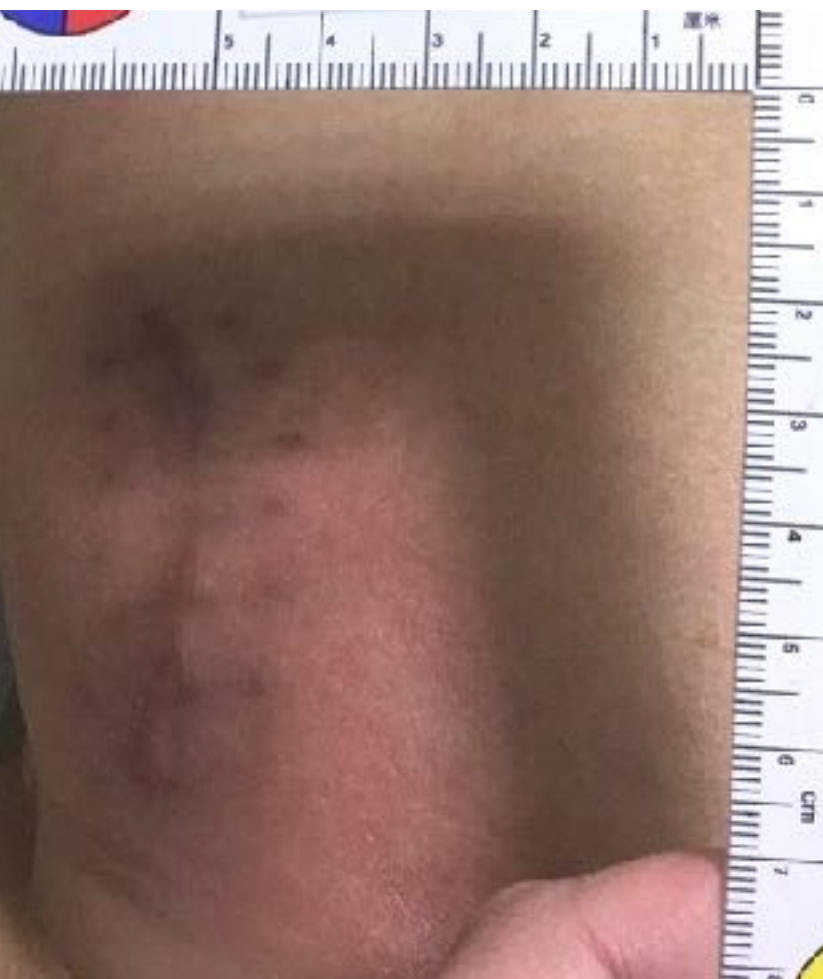39M, fever & neck pain



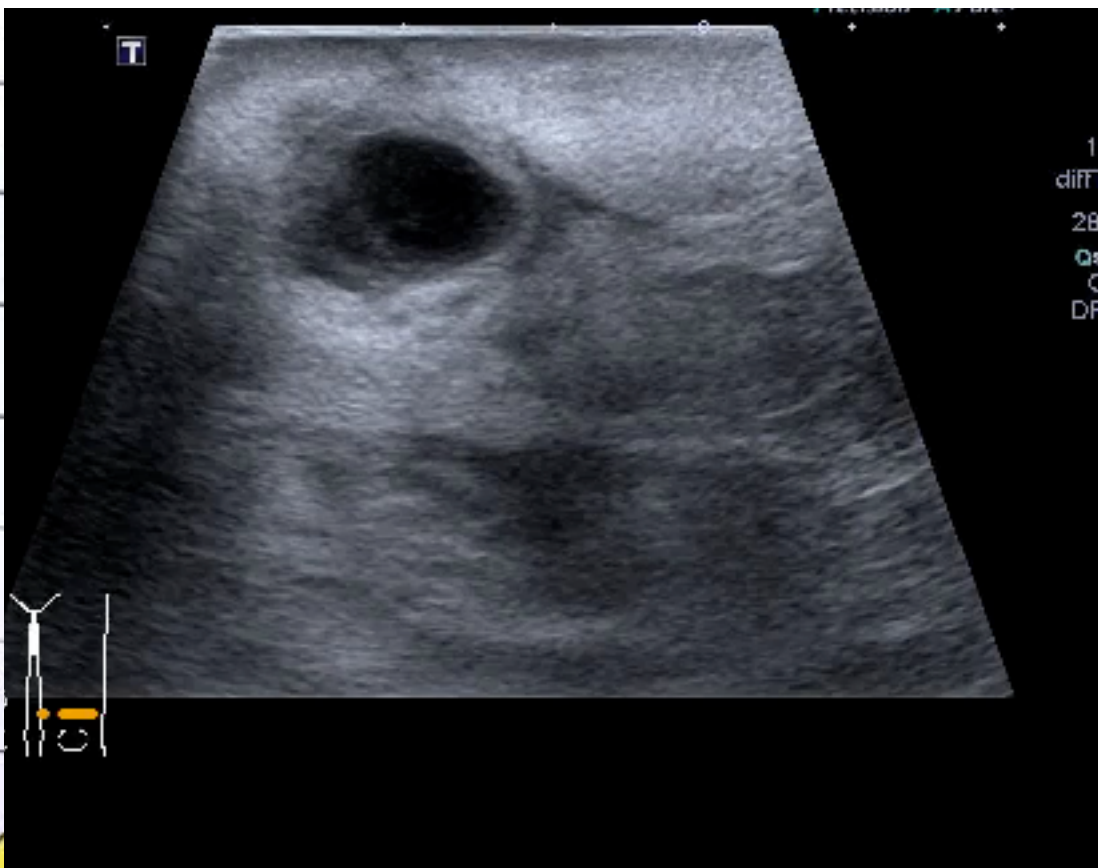
86M, F & R leg redness



# 71M, 2個月前CABG，近一週左大腿紅腫



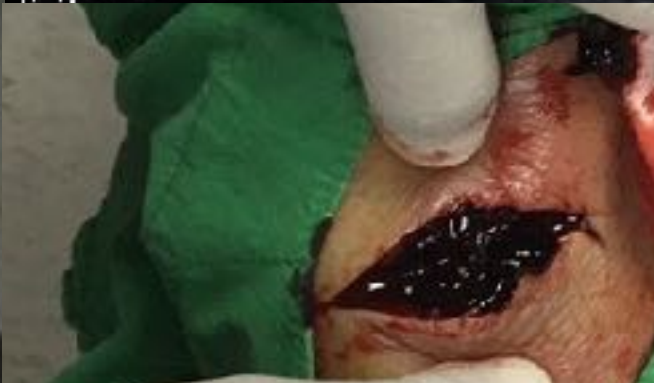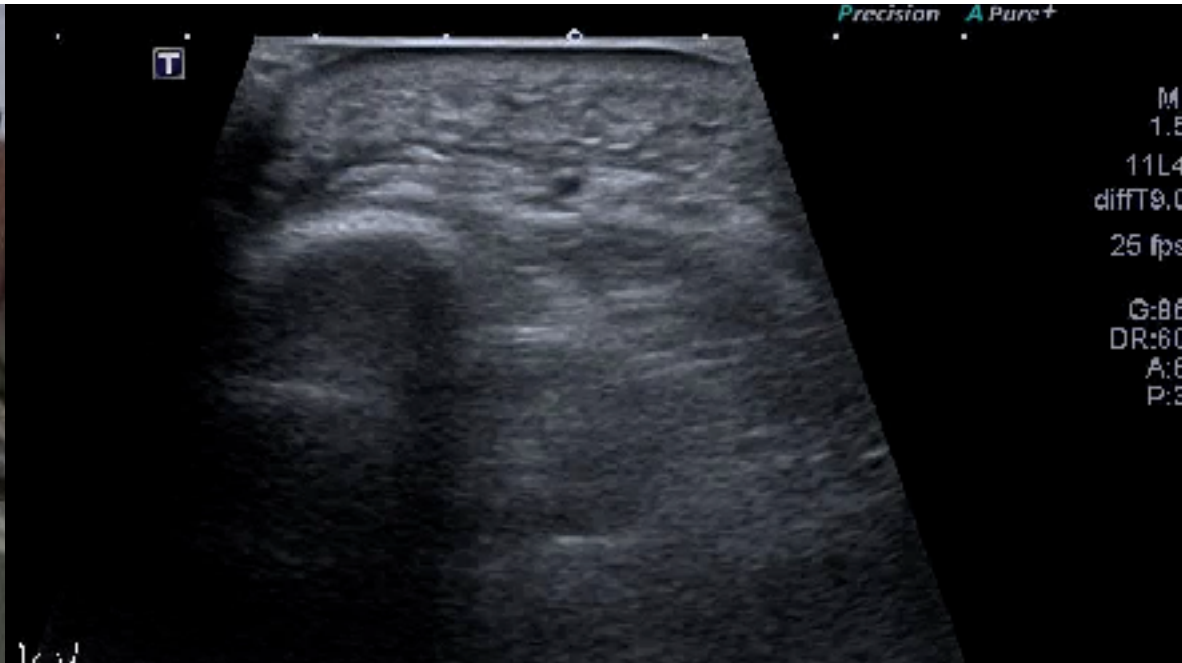
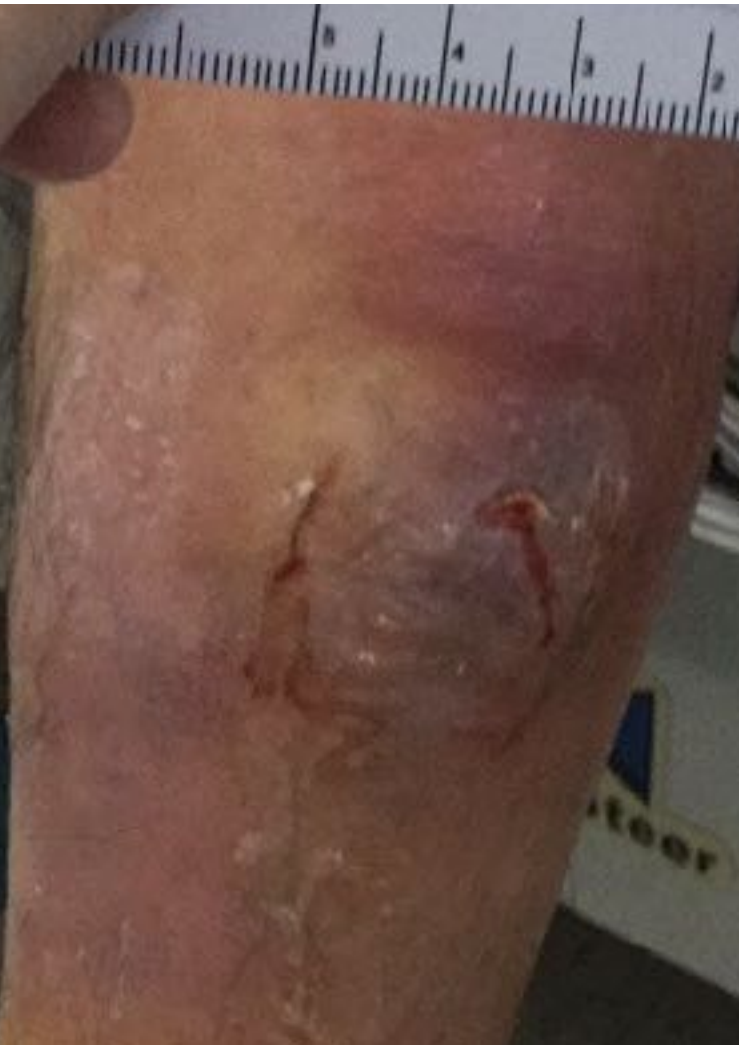Abscess (S. aureus)



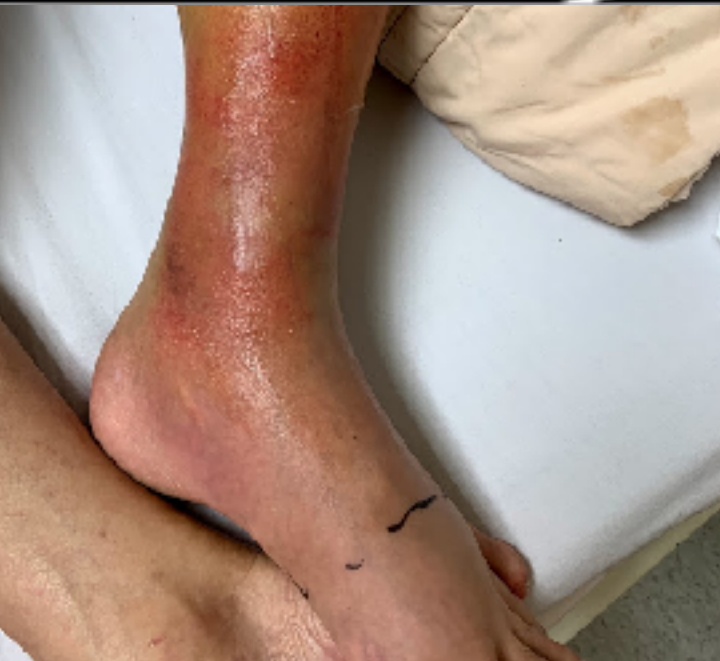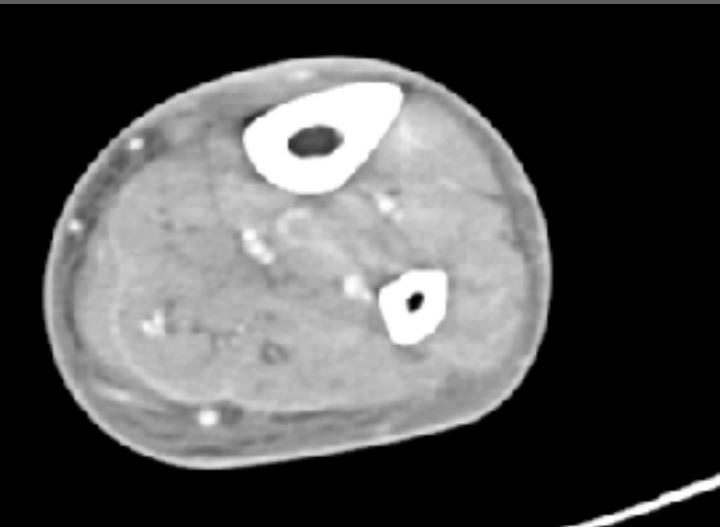


# 60M, Right leg contusion & swelling 1wk

Diagnosis → Adductor canal block → I & D

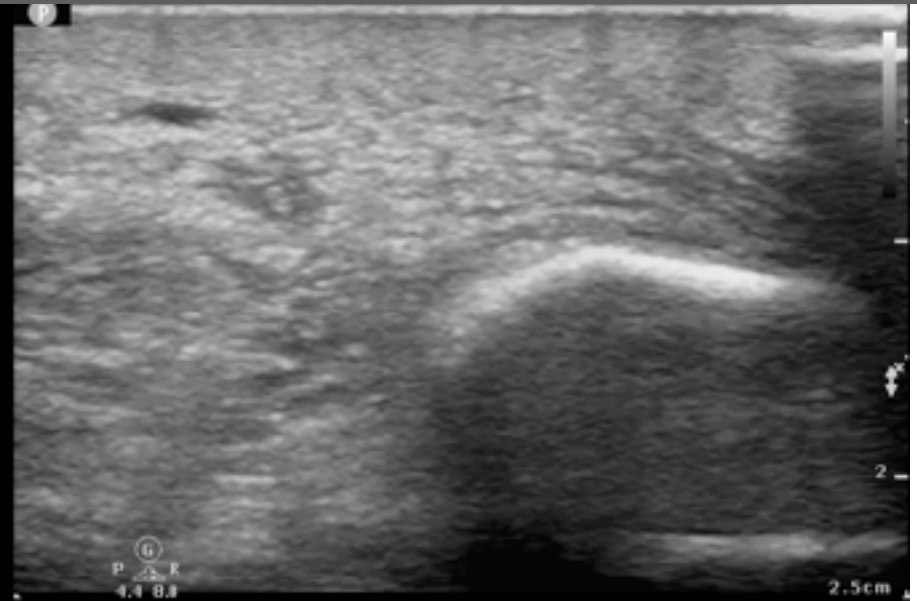


# 60M, L leg swelling & redness for 2 weeks



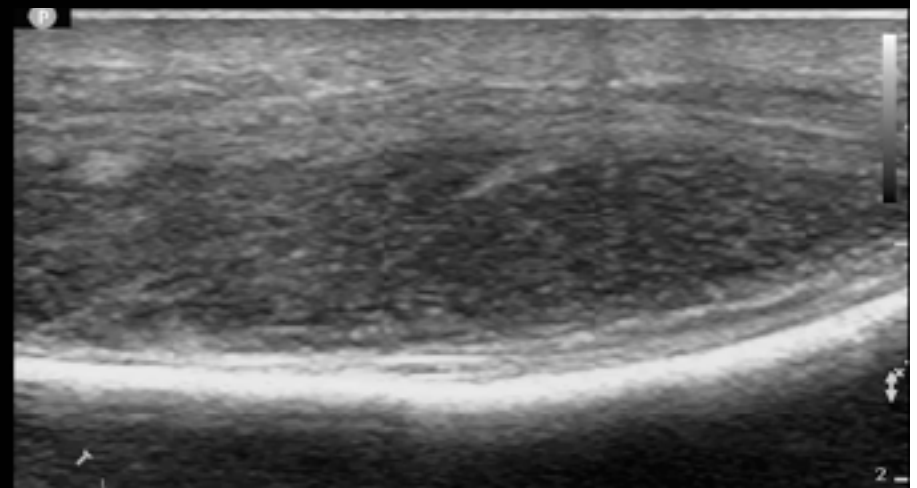
Arterial  
L12-3  
49 Hz  
2.5cm

2D  
HGen  
Gn 78  
C 41  
3/3/2

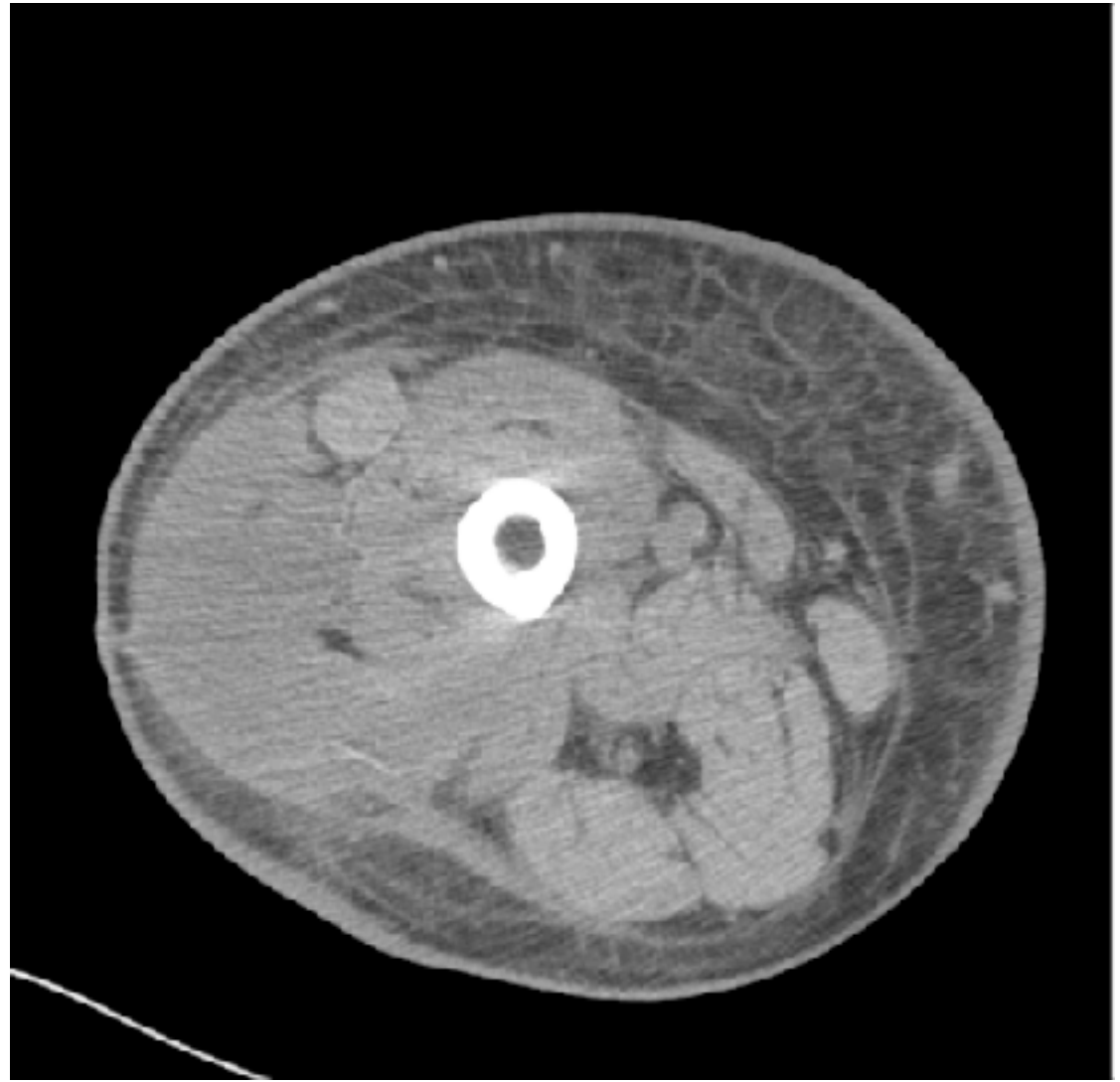
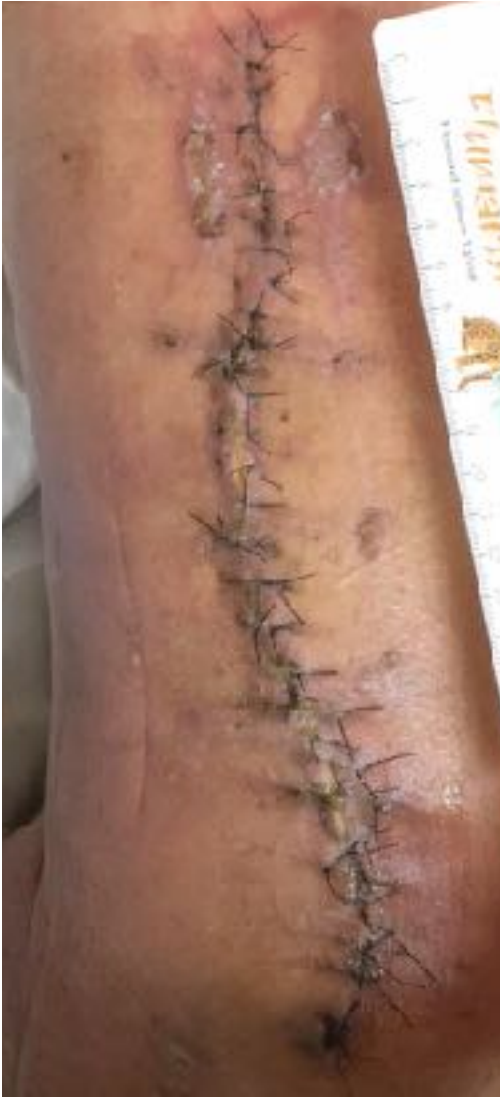
Arterial  
L12-3  
49 Hz  
2.5cm

2D  
HGen  
Gn 76  
C 41  
3/3/2



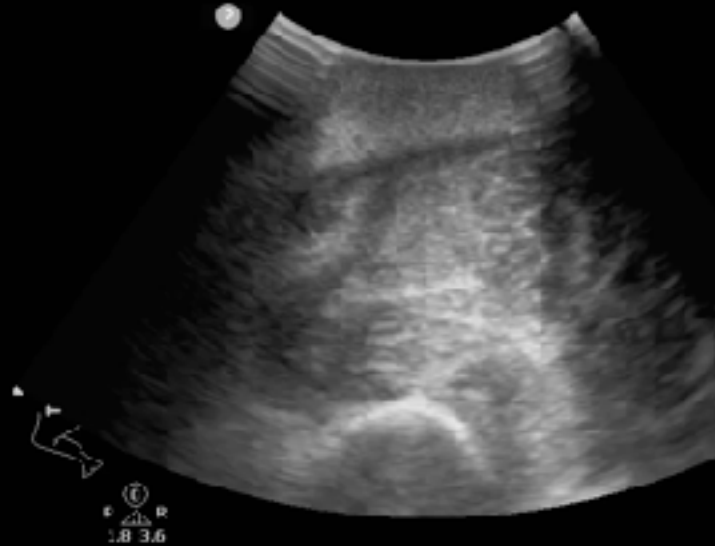# 38M, recurrent thigh painful swelling



# Necrotizing fasciitis

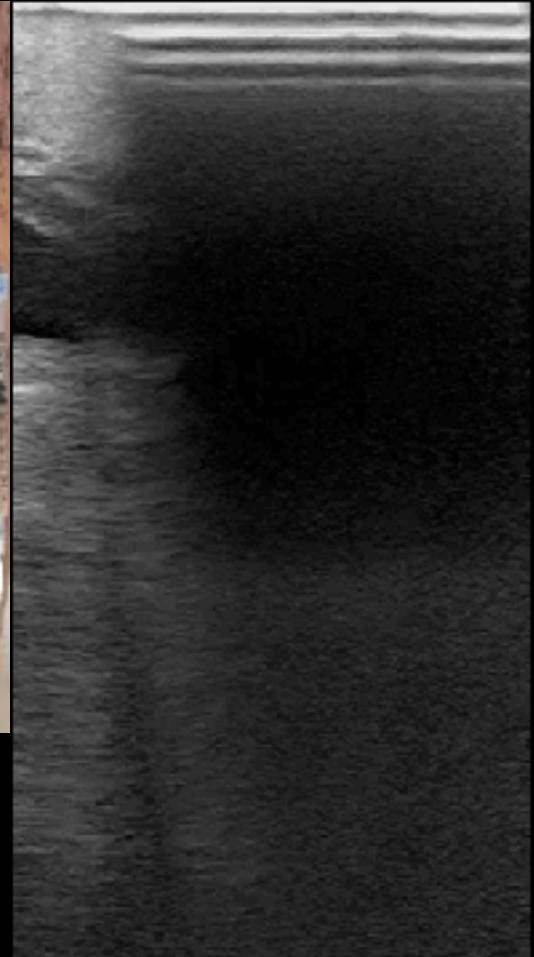
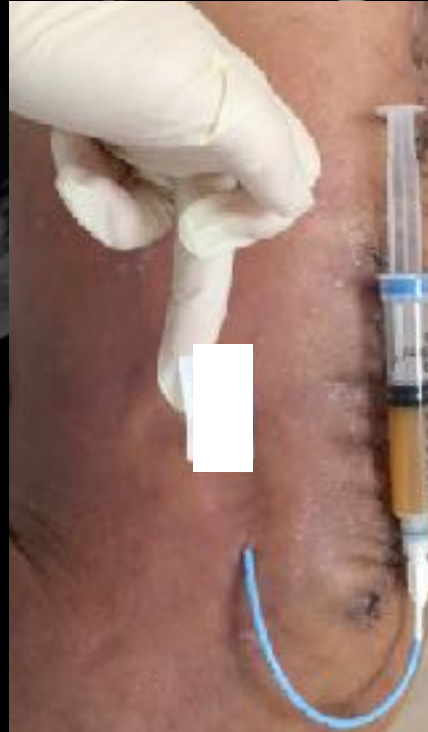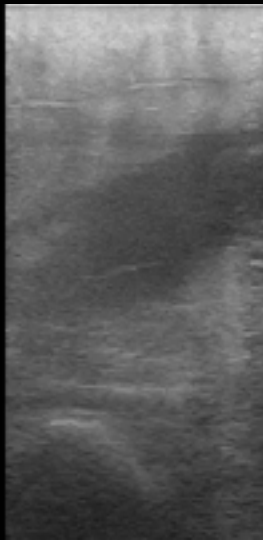
Abd Gen  
C5-1  
51 Hz  
8.0cm

2D  
HGen  
Gn 65  
C 56  
3/3/3



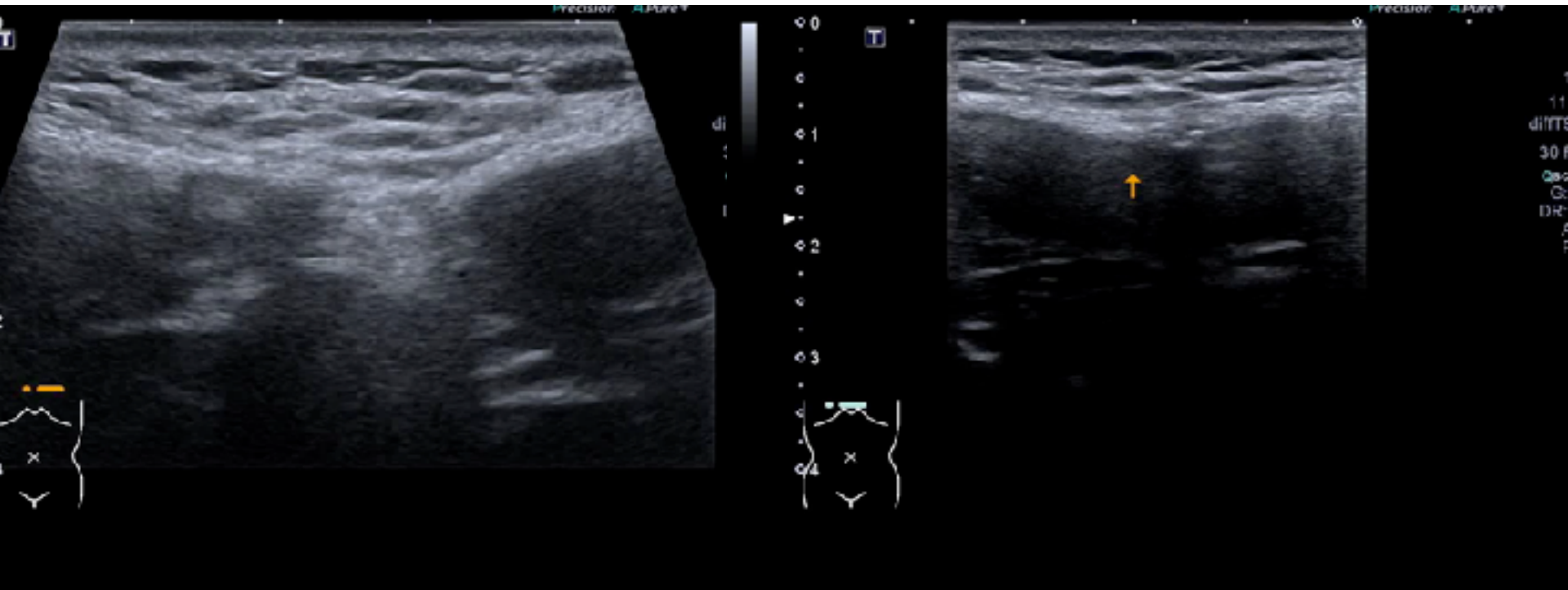
Arterial  
L12-3  
26 Hz  
8.0cm

2D  
HGen  
Gn 100  
C 41  
3/3/2



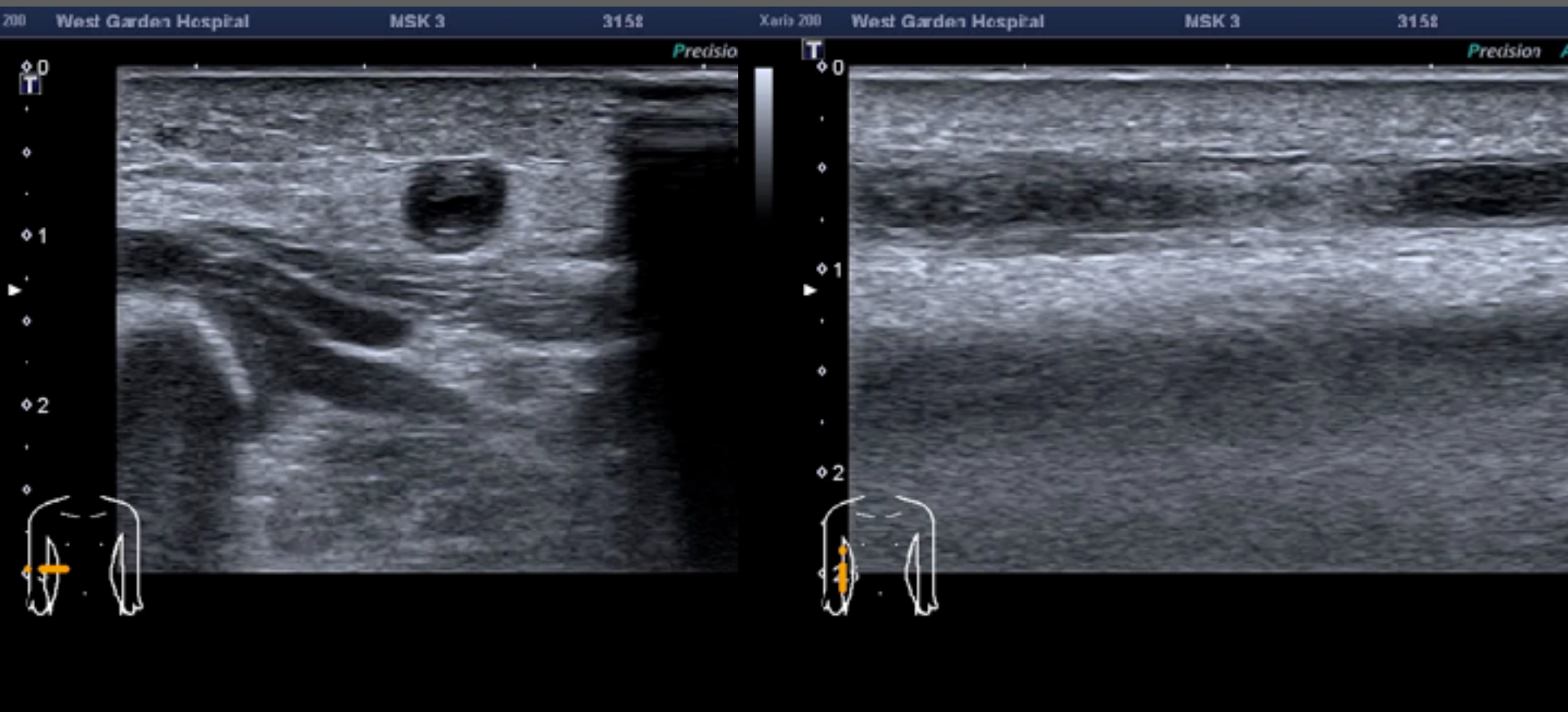
# 28M, 劍突處突起會痛，約2週

Prominent xiphoid process ==> Xiphodynia



# 54歲男，注射處腫痛

## Superficial thrombophlebitis



# Pattern recognition

Axillary pain

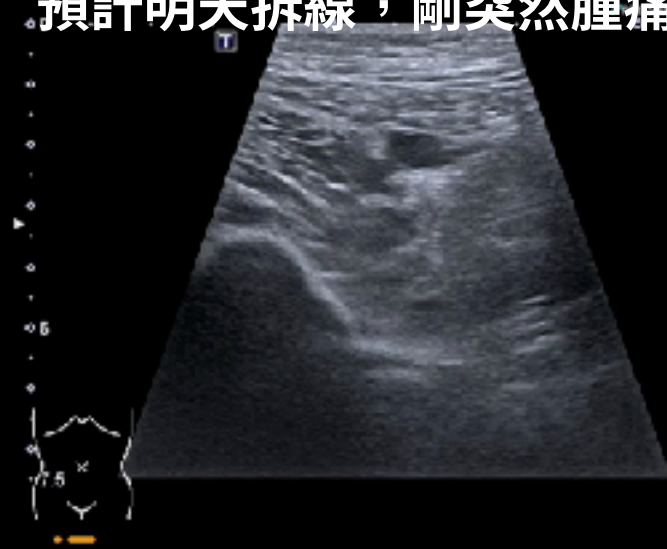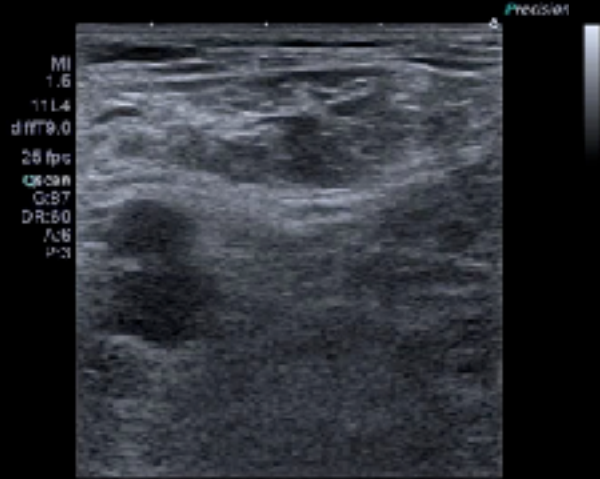
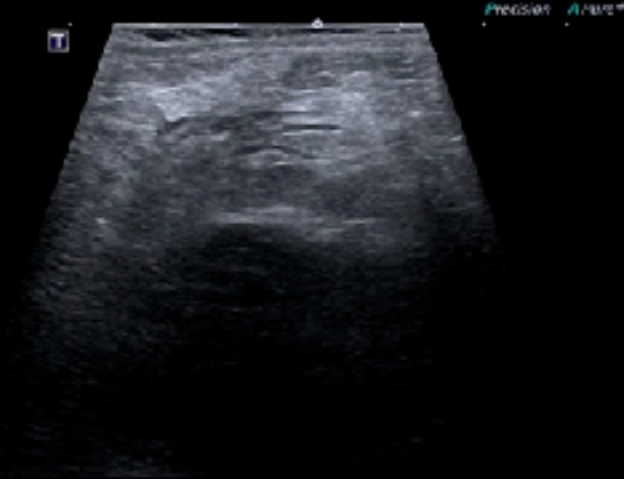Inguinal pain

Thigh pain

前幾天腋下長一顆東西

右腳和鼠蹊痛1天

上個月拔右髌釘子，  
預計明天拆線，剛突然腫痛



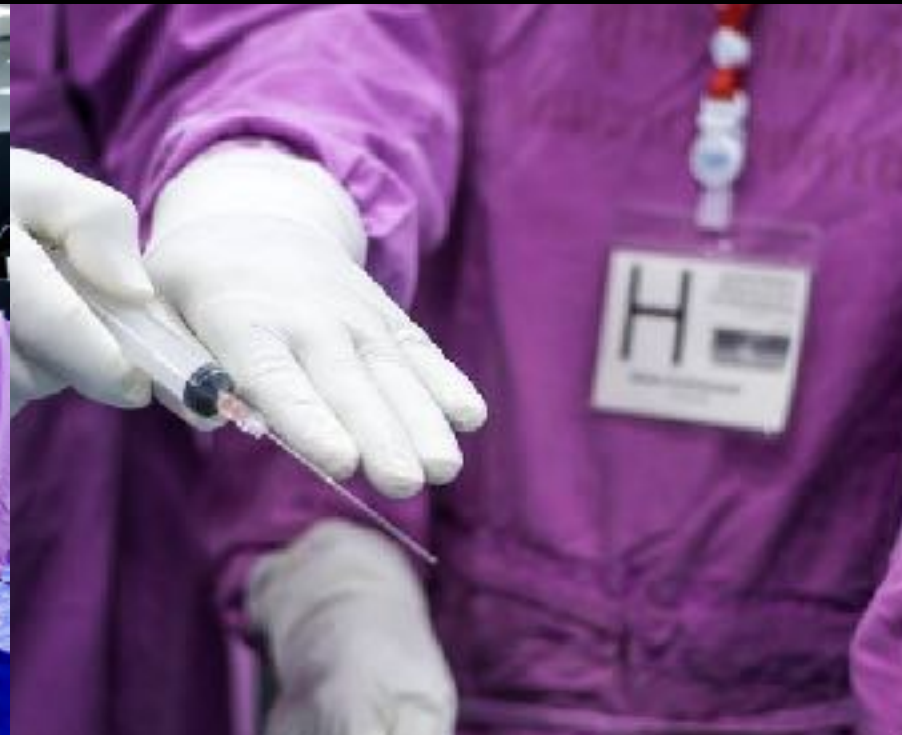Abscess

Lymphadenitis

Hematoma

# Diagnostician

沒被骨頭空氣擋到的都看得到



# Interventionist

只要找到縫隙針就送得到