



衛生福利部雙和醫院  
(委託臺北醫學大學興建經營)  
Taipei Medical University · Shuang Ho Hospital,  
Ministry of Health and Welfare



# Holistic Ultrasound in ER

Vscan Air Sharing Session 2022/02/27

陳國智醫師  
雙和醫院 急診醫學科

# 陳國智 醫師



醫用超音波學會指導醫師  
WINFOCUS director / instructor  
急救加護醫學會重症超音波負責人

急診 / 重症 / 介入 / 急性疼痛

## 經歷

新光急診超音波訓練中心主任

西園醫院急診醫學科主任

急診醫學會超音波委員會主委

台灣疼痛醫學會大體模擬手術講師

診  
斷

監  
測

介  
入

POINT OF CARE ULTRASOUND

~ 存在於臨床需求之所在 ~

解剖

Anatomy

形態

Pattern

診斷

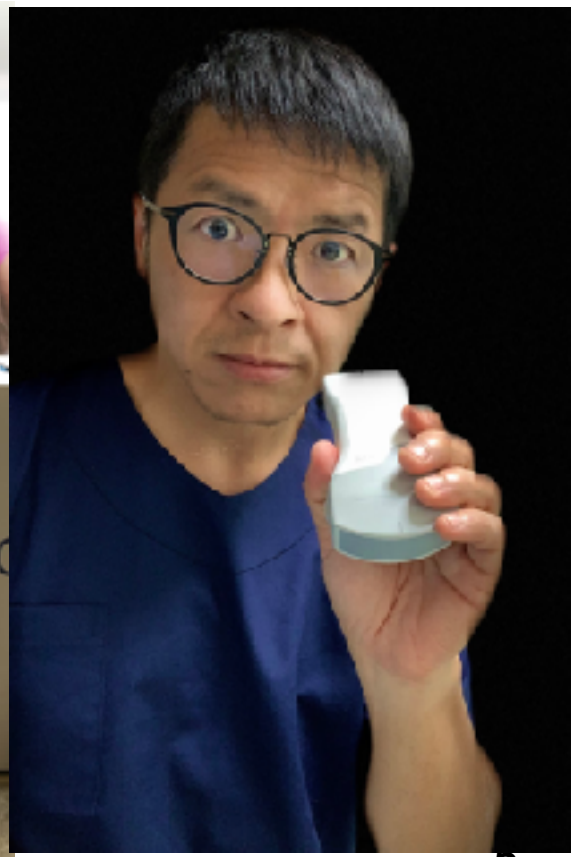
Diagnosis

# HOLISTIC ULTRASOUND

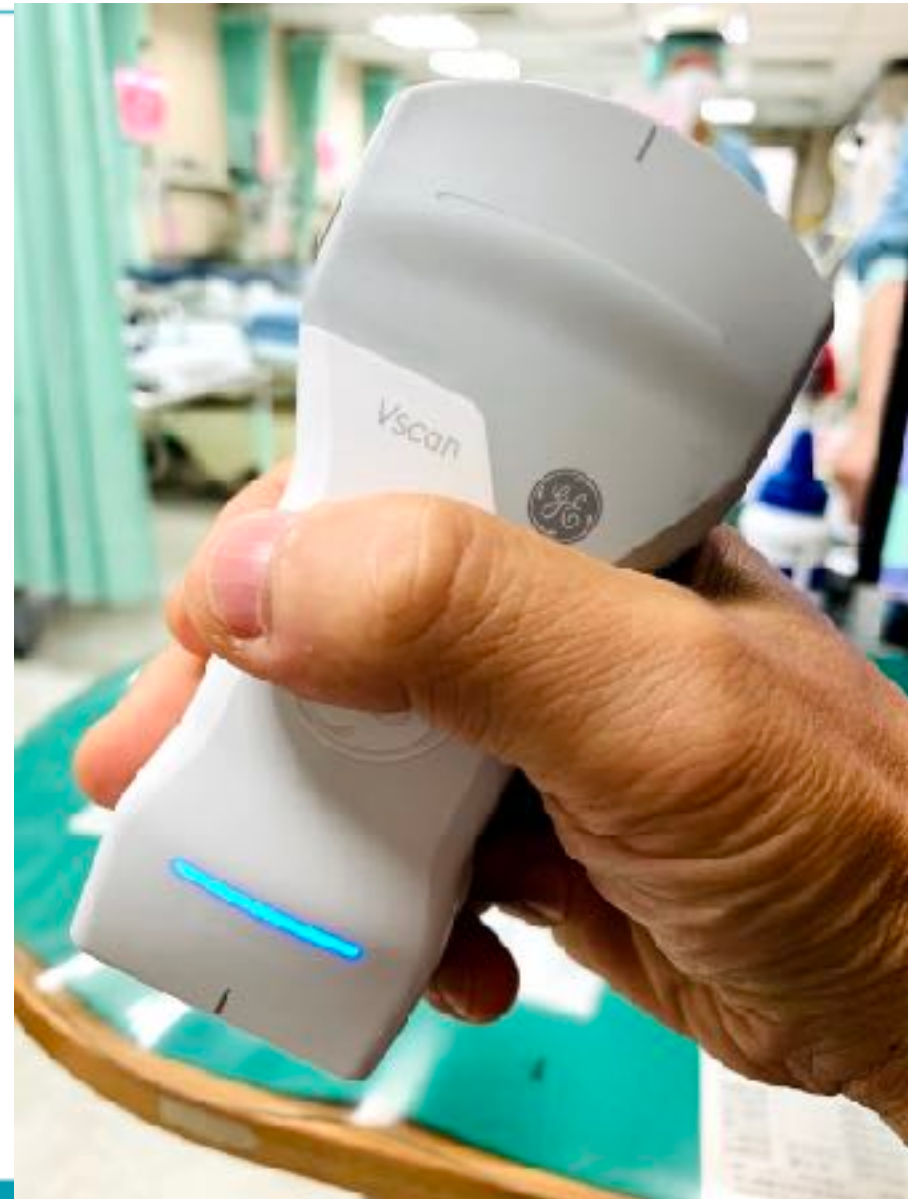## Holistic medicine

Treatment that deal with the whole person,  
not just the injury or disease

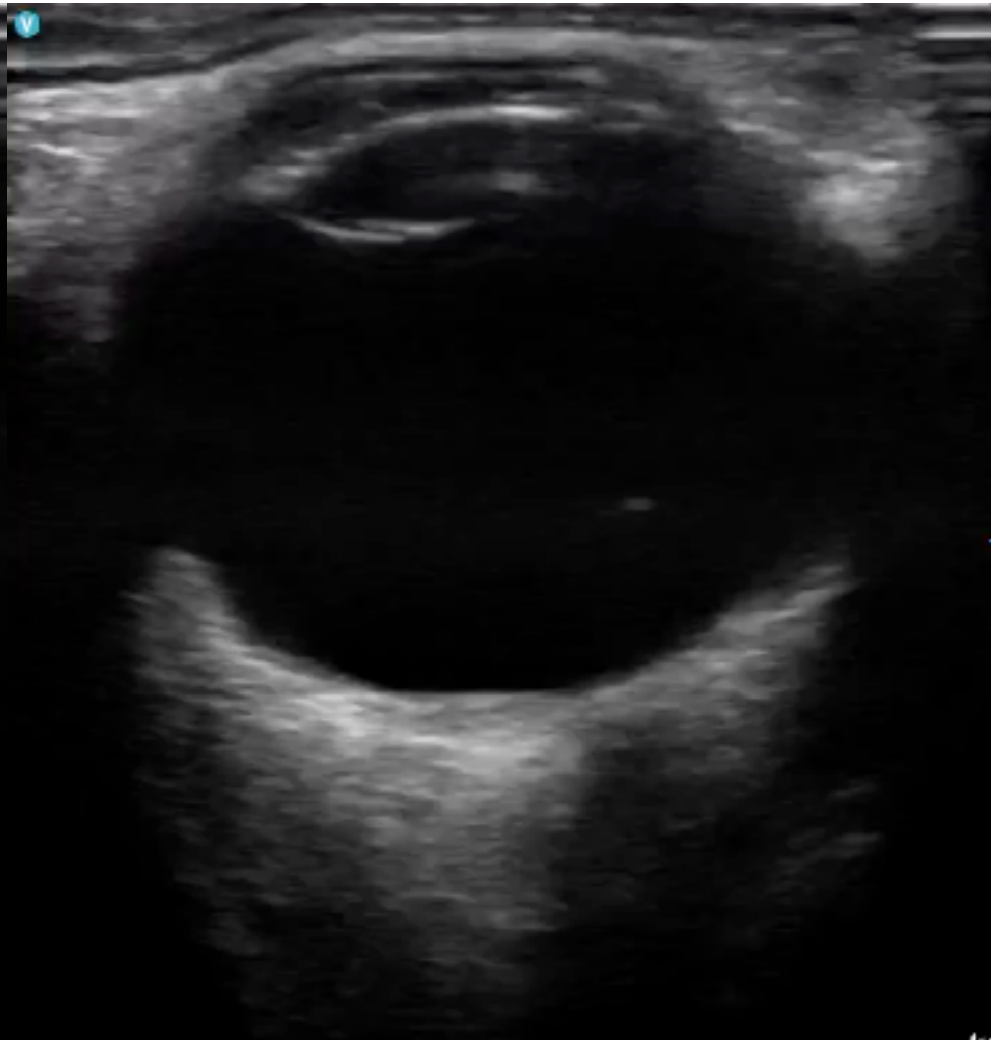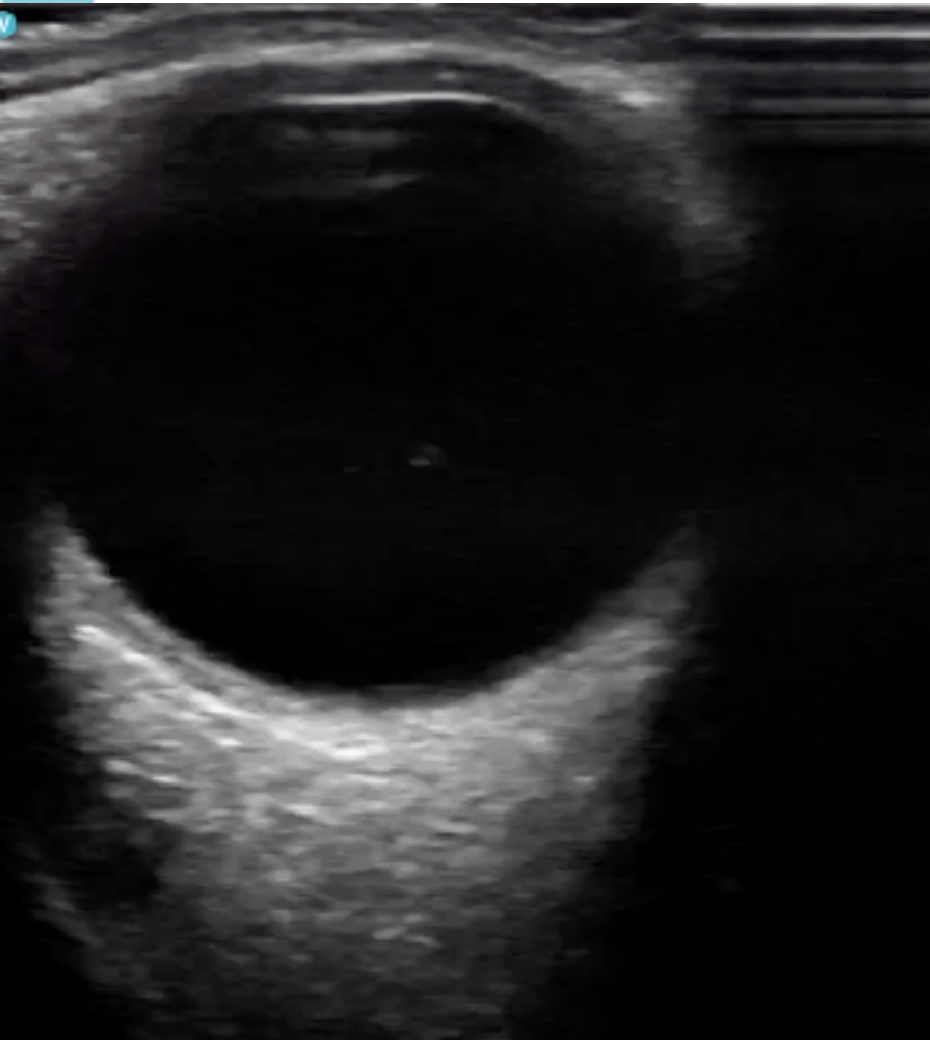
# GE Vscan generation



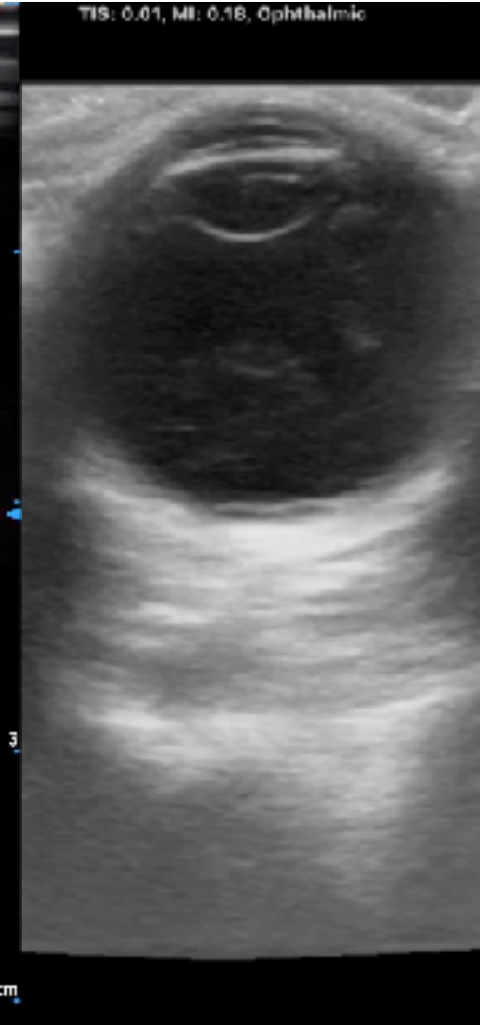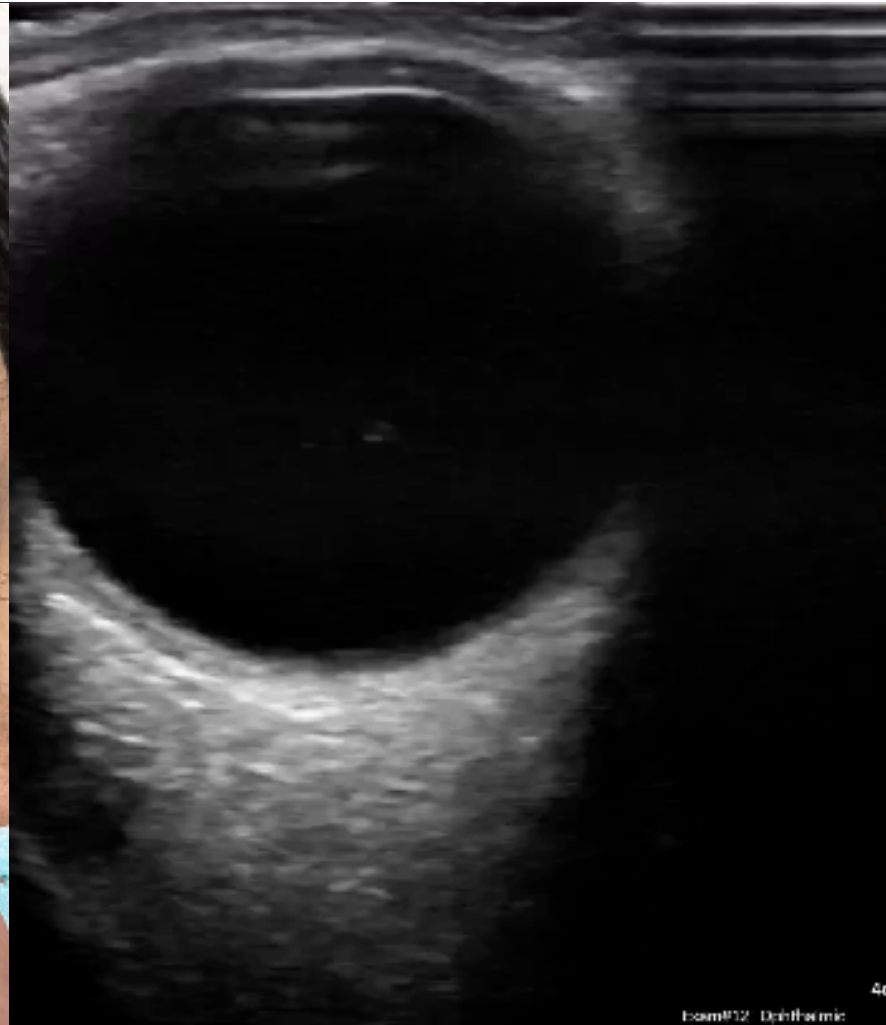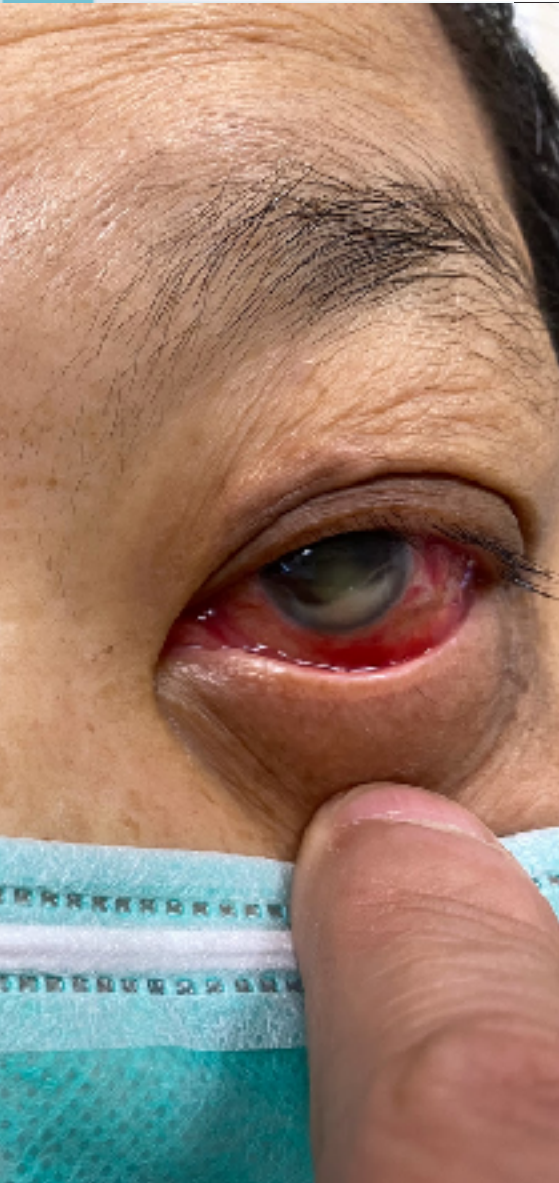
# 雙槍俠 (腹/深 & 線/淺)



# EYE (ONSD, RD, VD, VH)

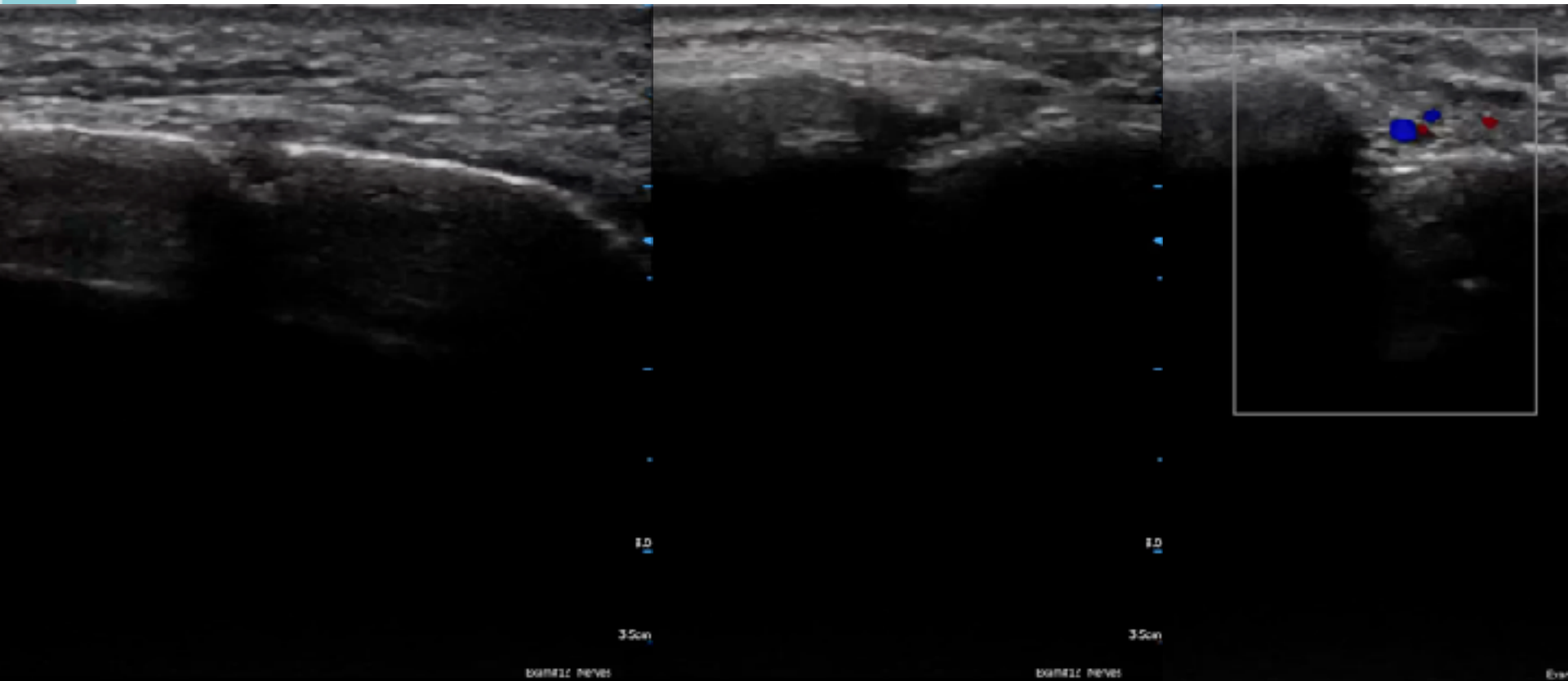


# Liver abscess / Endophthalmitis

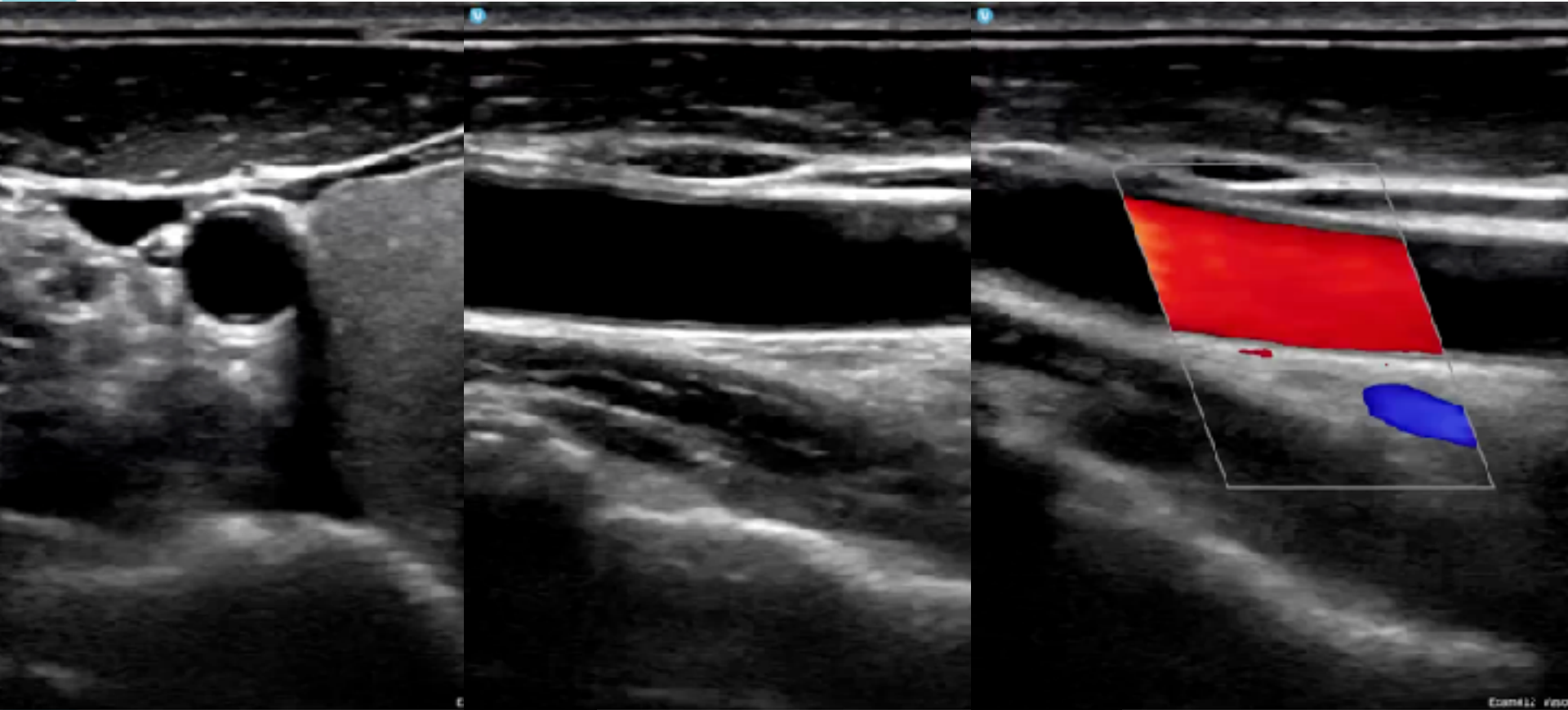




# Mandible & maxillary nerve



# Common carotid artery



Exam12 Vaso

# 52M, Chest pain



ACE

2022-01-28

2022-01-28

Tracheal

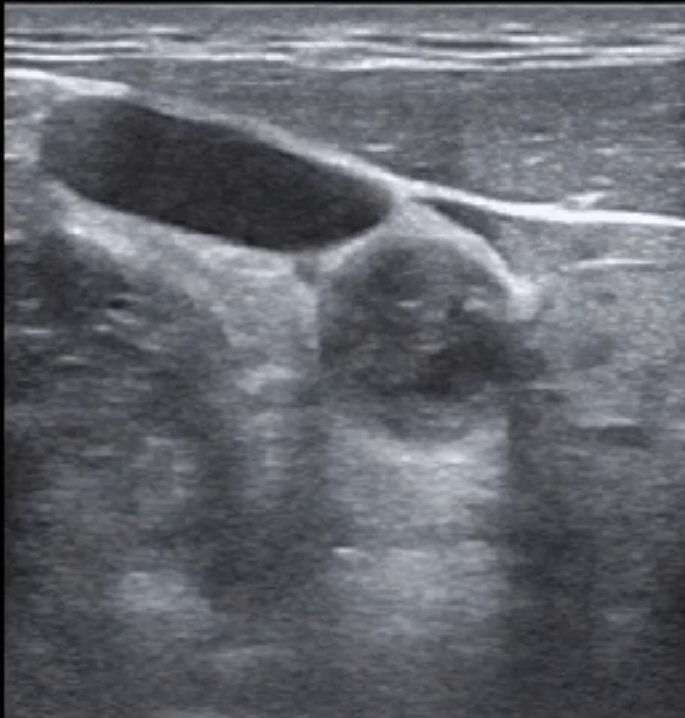
15:34:01

Tracheal

15:33:21

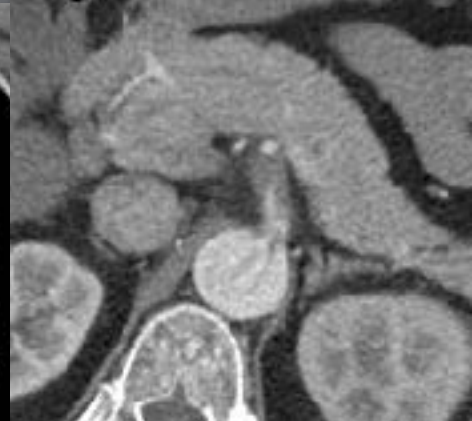
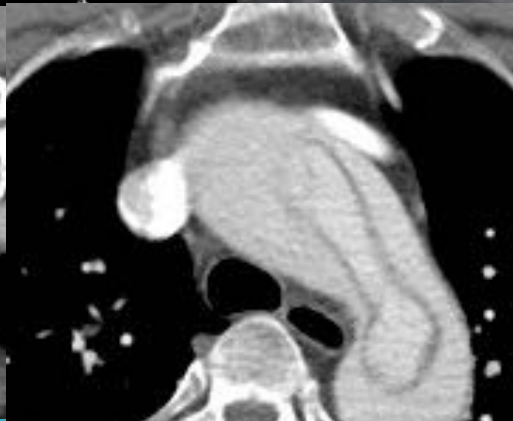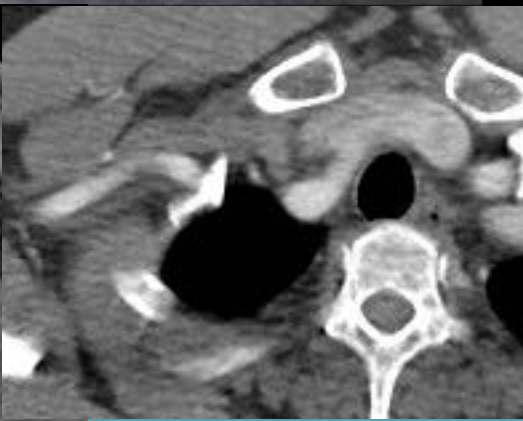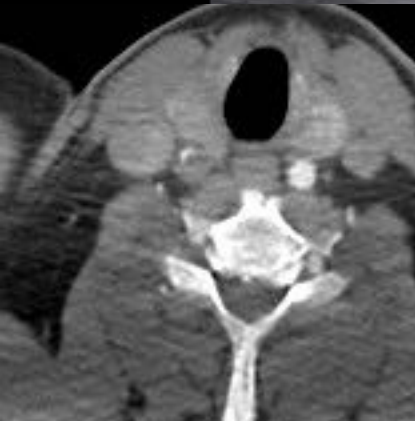
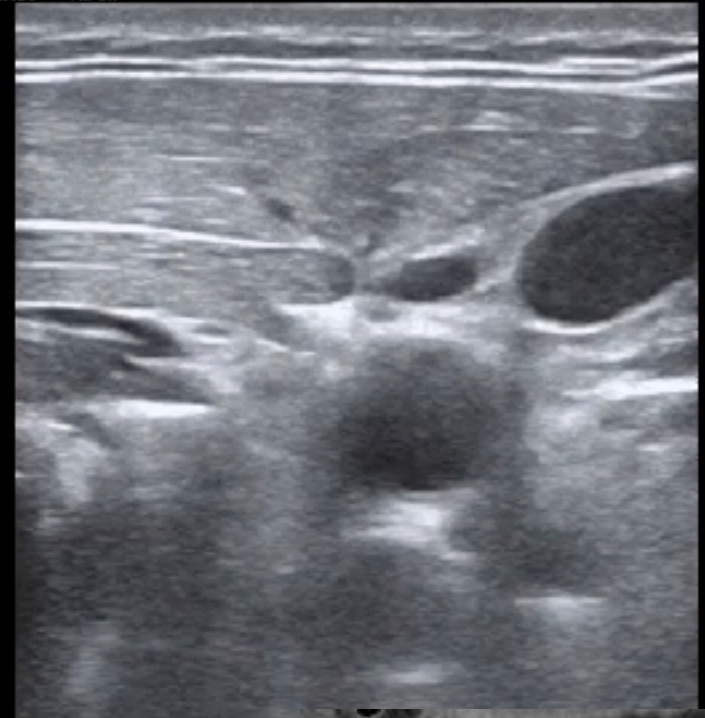
L12 4s

m

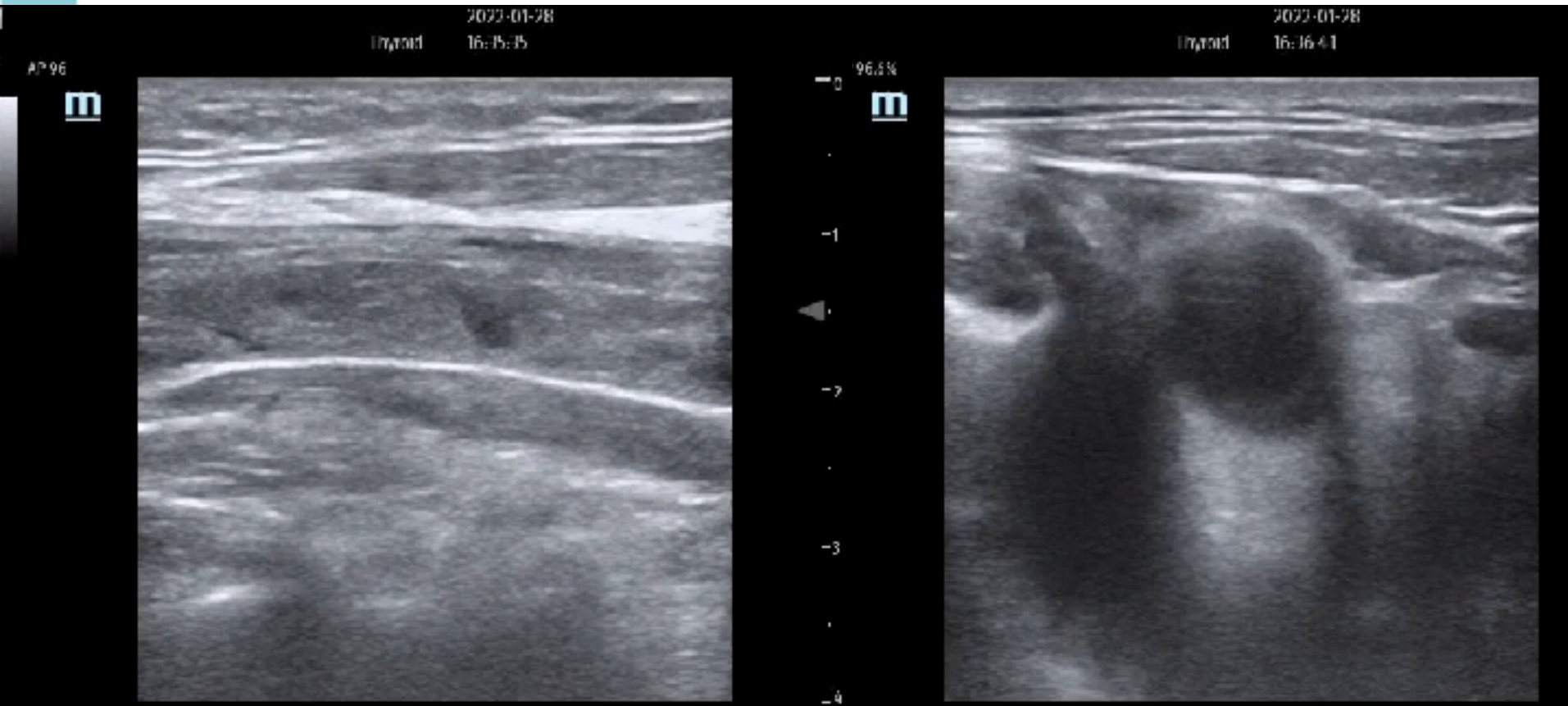


RI: 96.6%

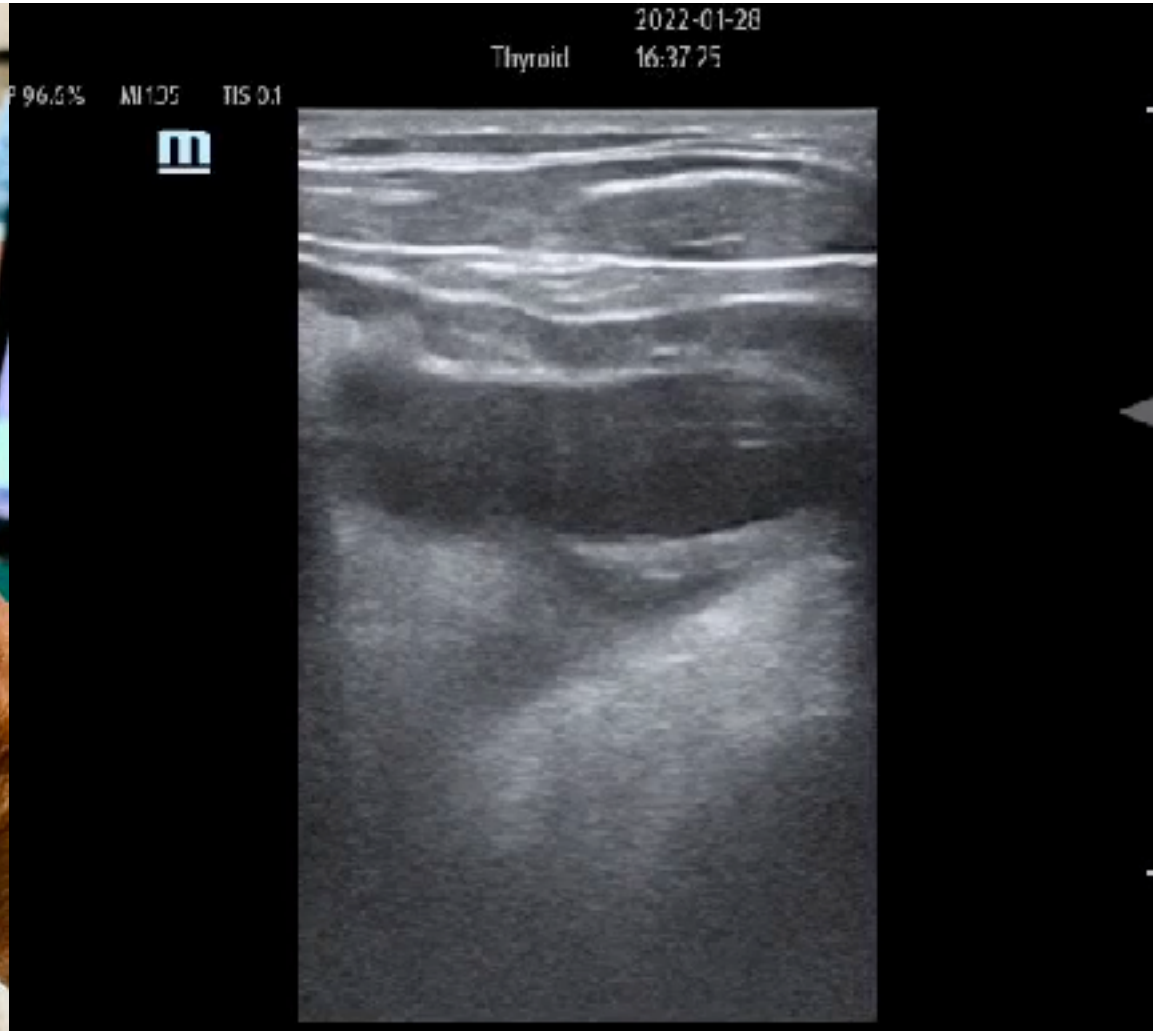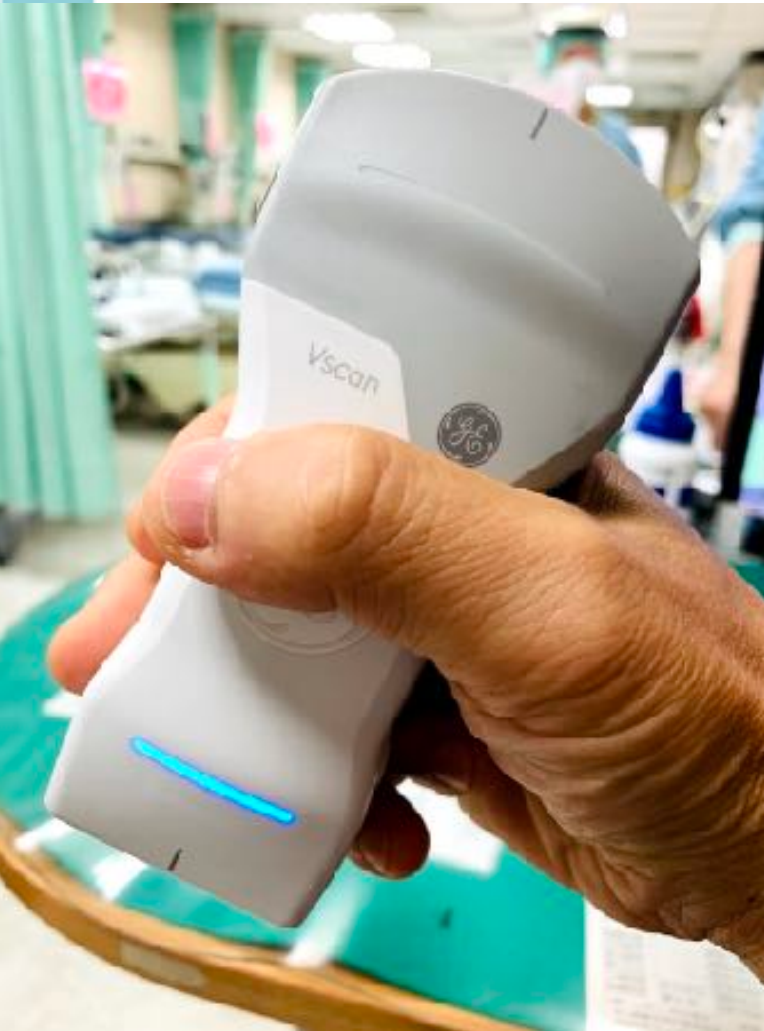m



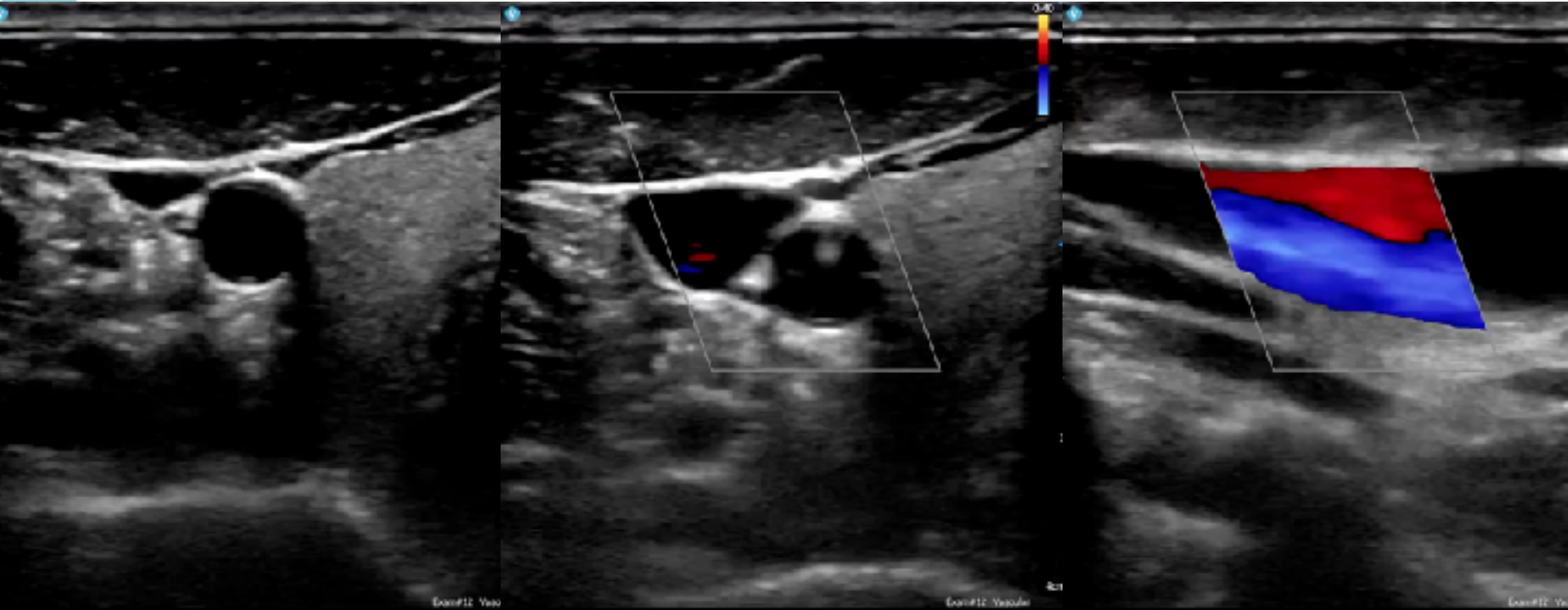
# Aortic dissection



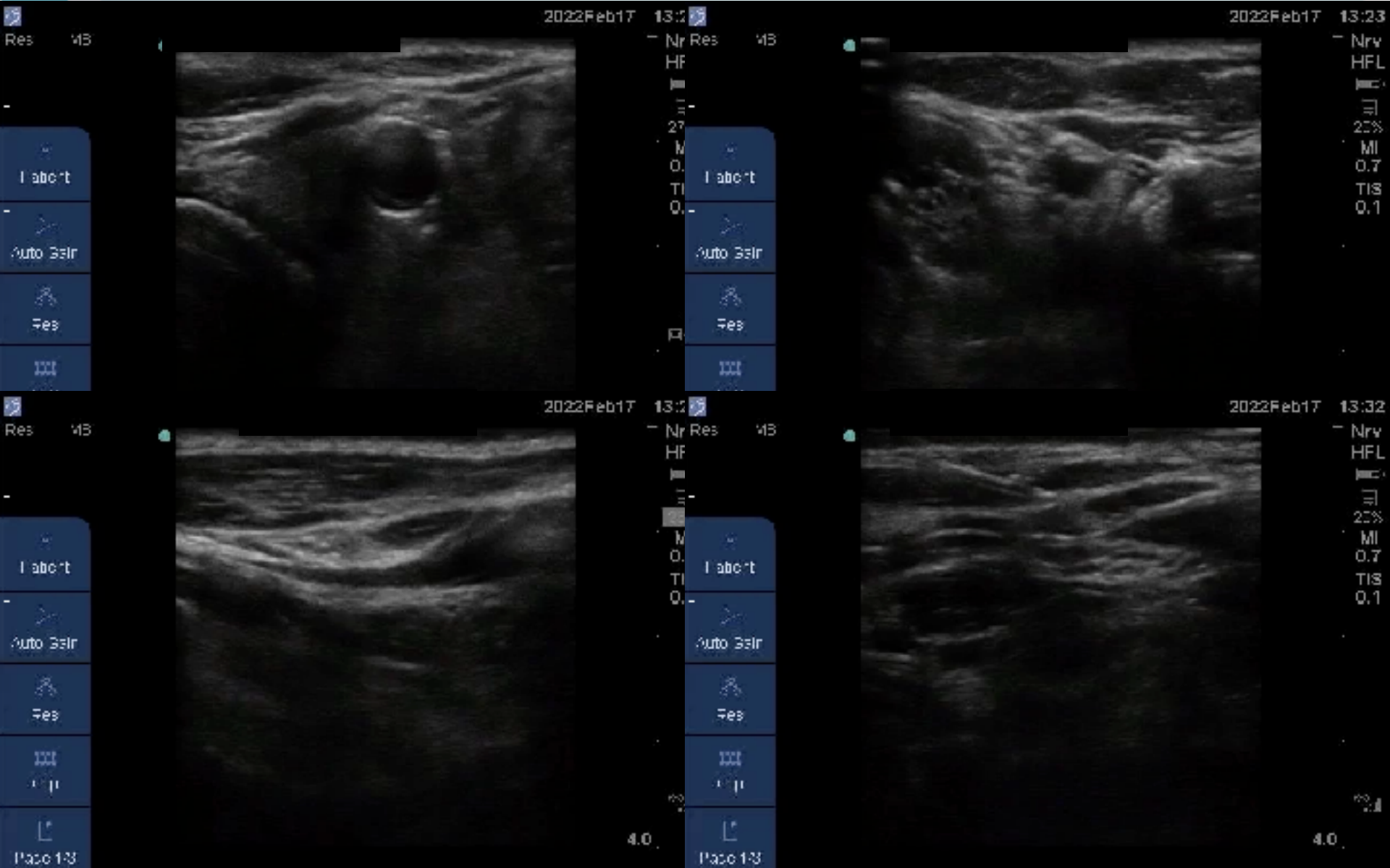
# AD (CCA-Pericardium-ABD Ao)



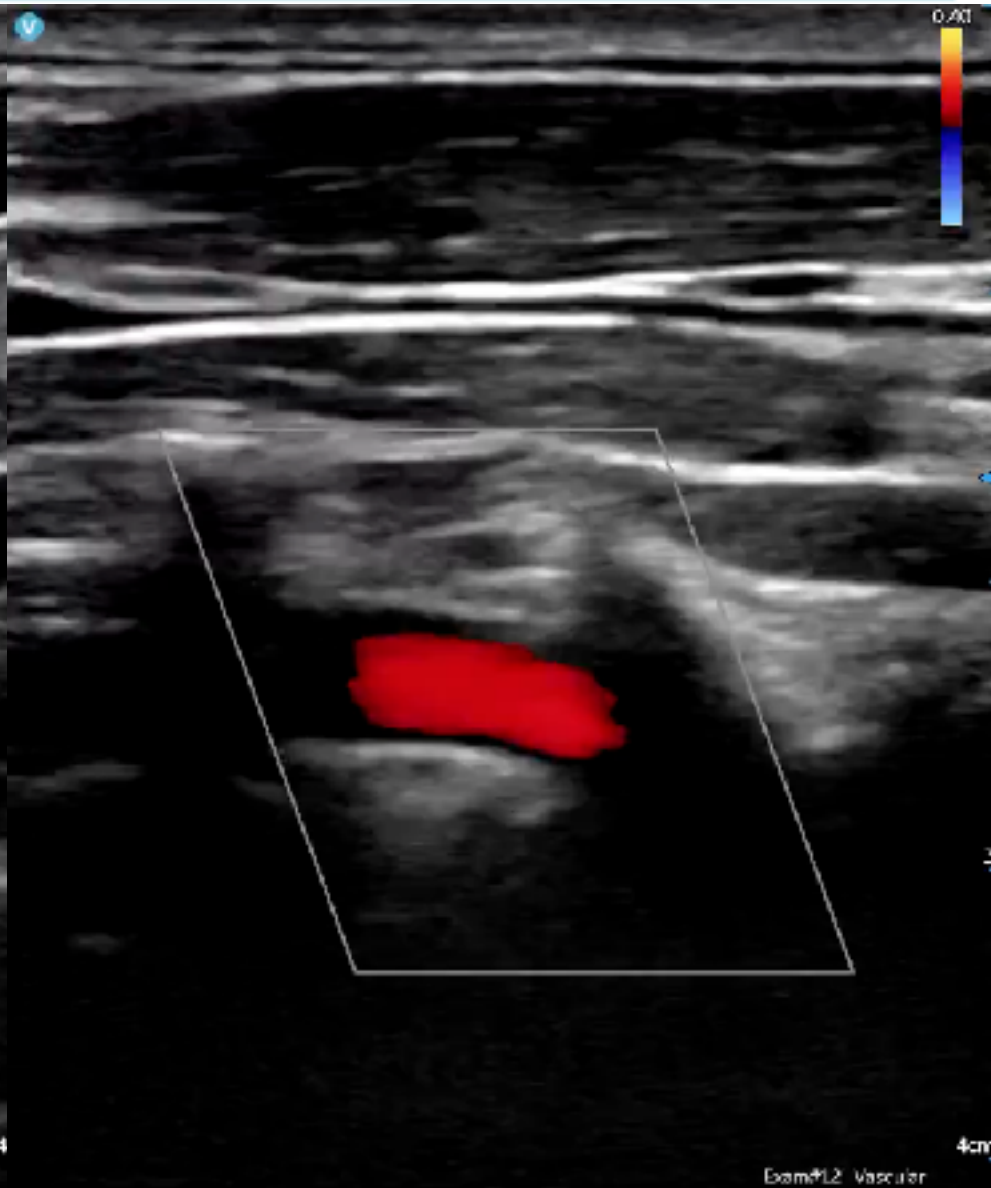
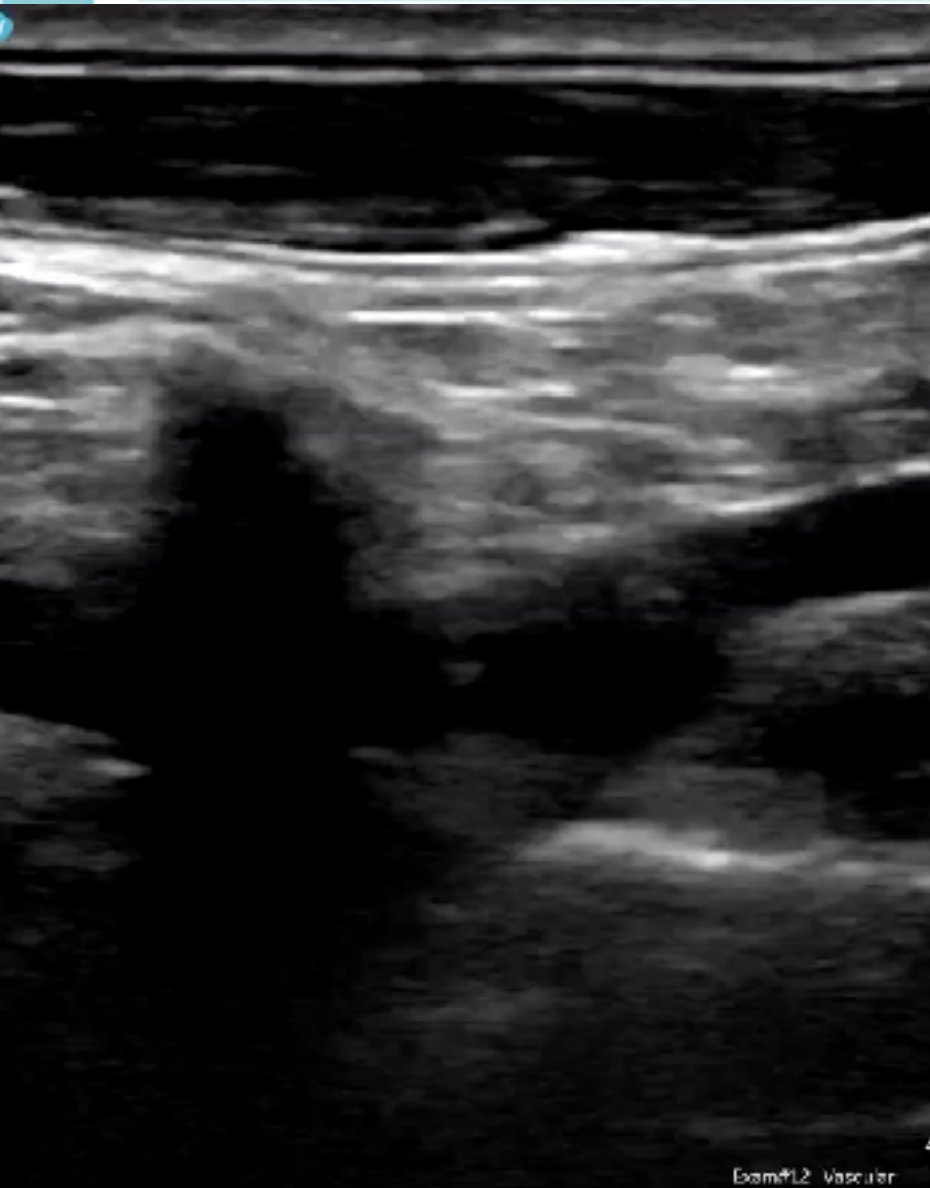
# Internal jugular vein / CVC



# Echo guided CVC on left IJV

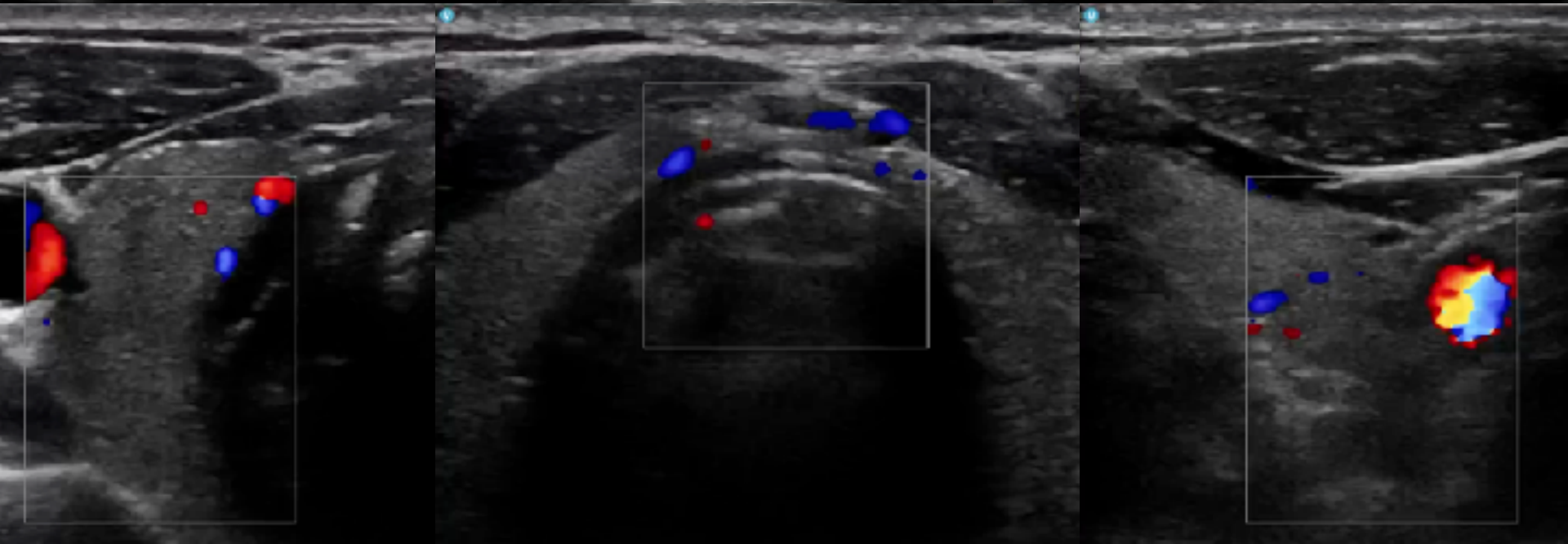
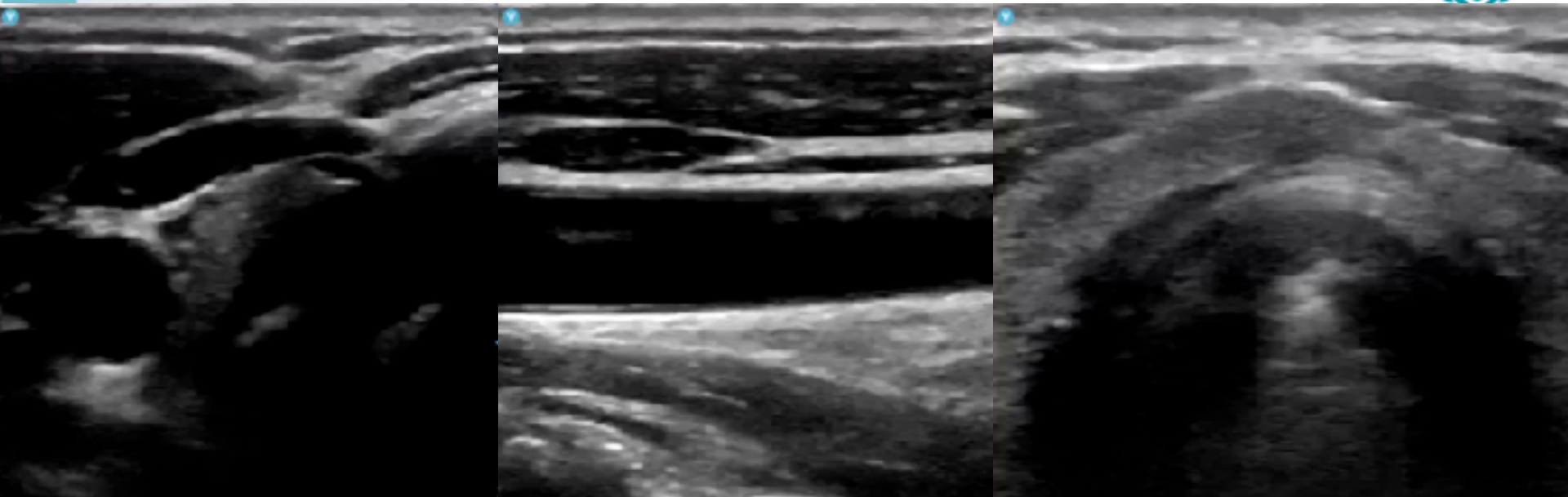


# Vertebral artery

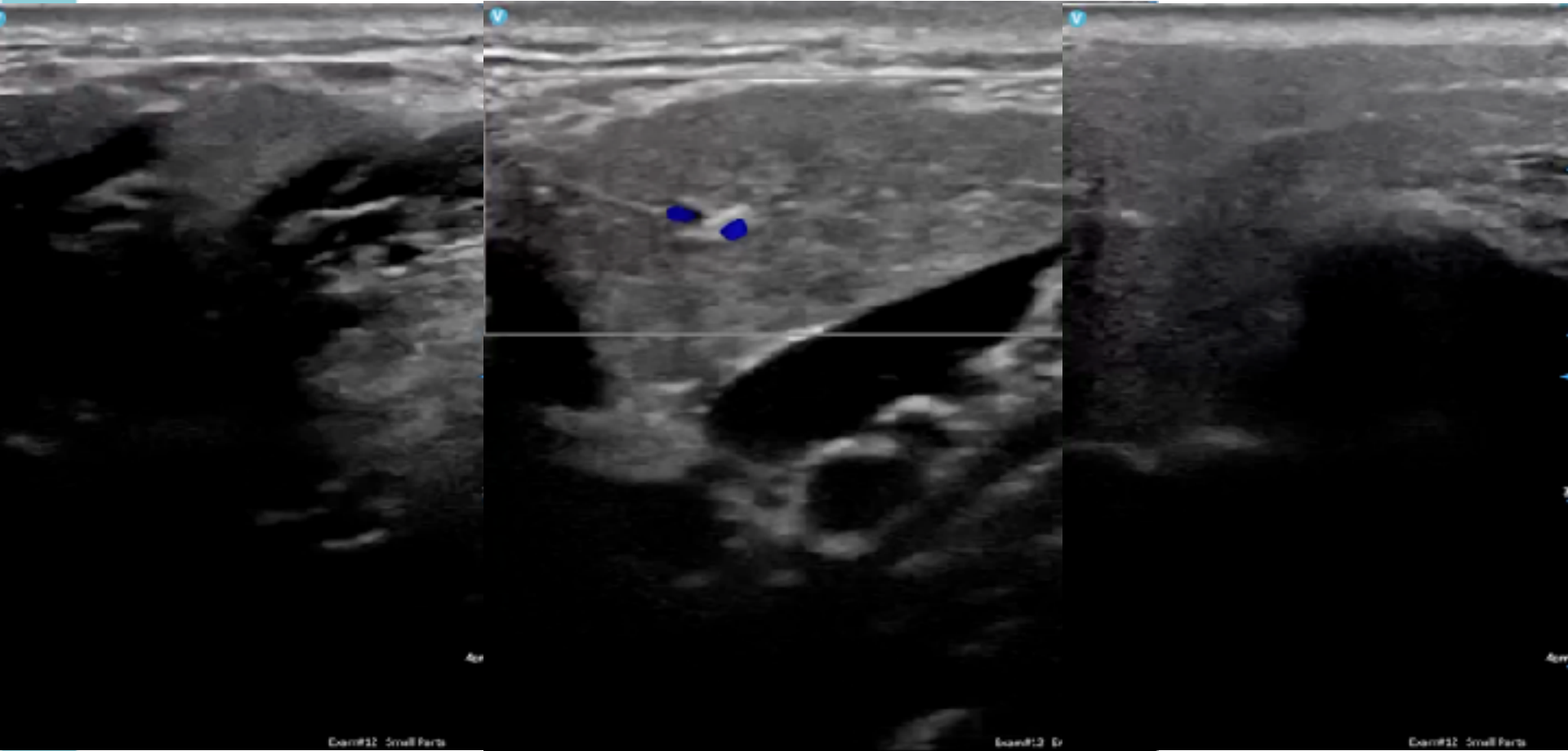




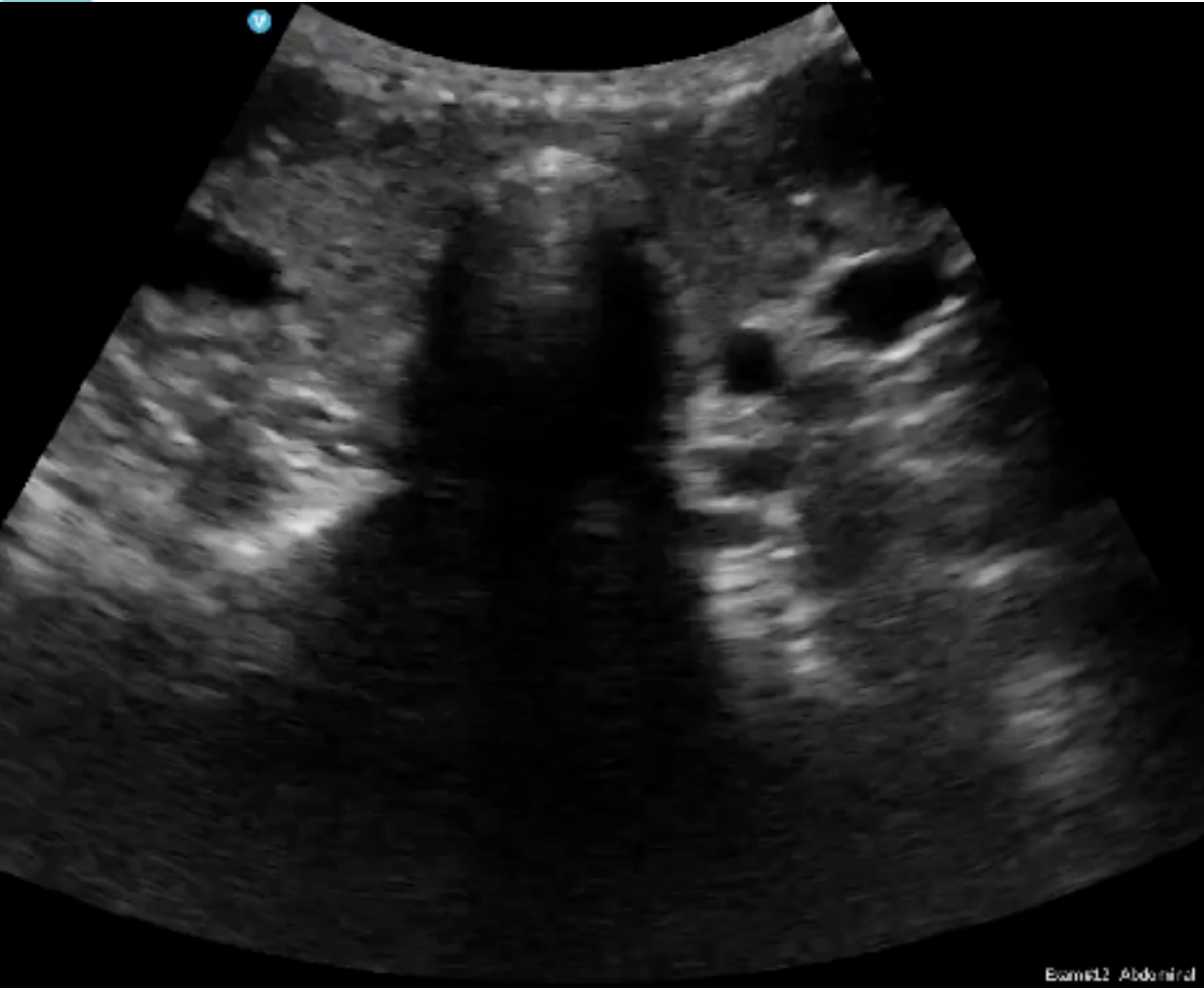# Thyroid gland



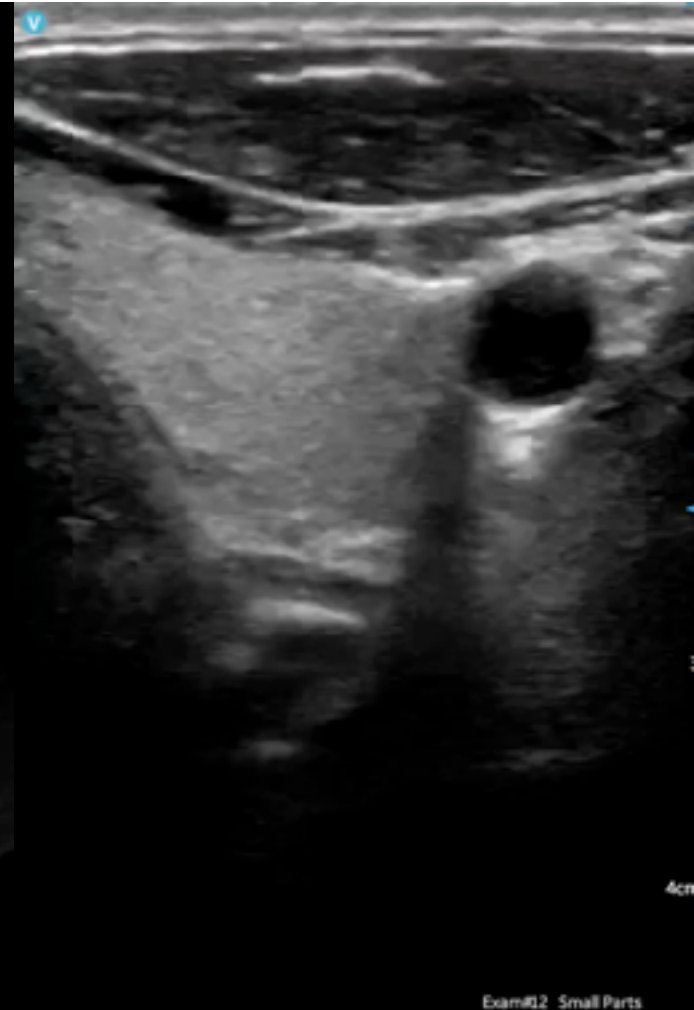
# Submandibular & Parotid glands



# Trachea & Eso for intubation



Exam#12 - Abdominal



Exam#12 - Small Parts

# 75F, shock & resuscitation



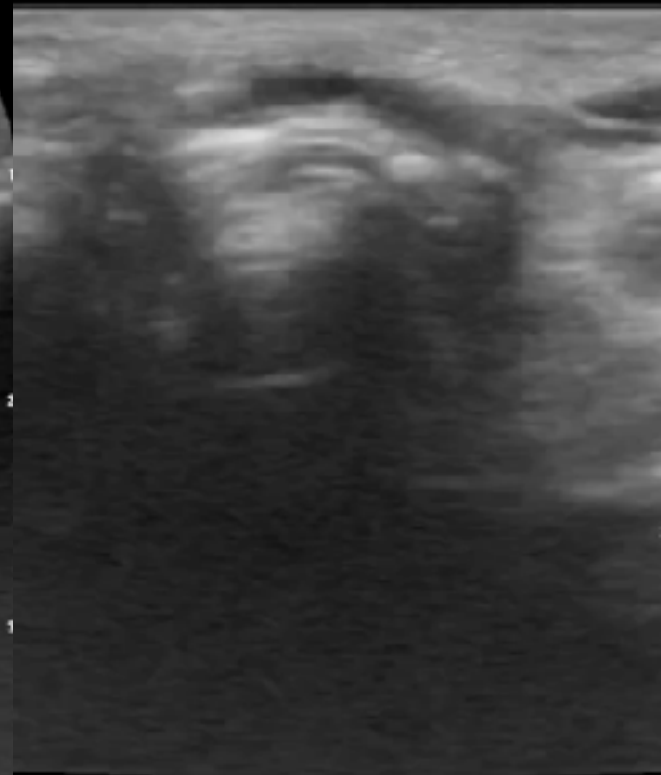
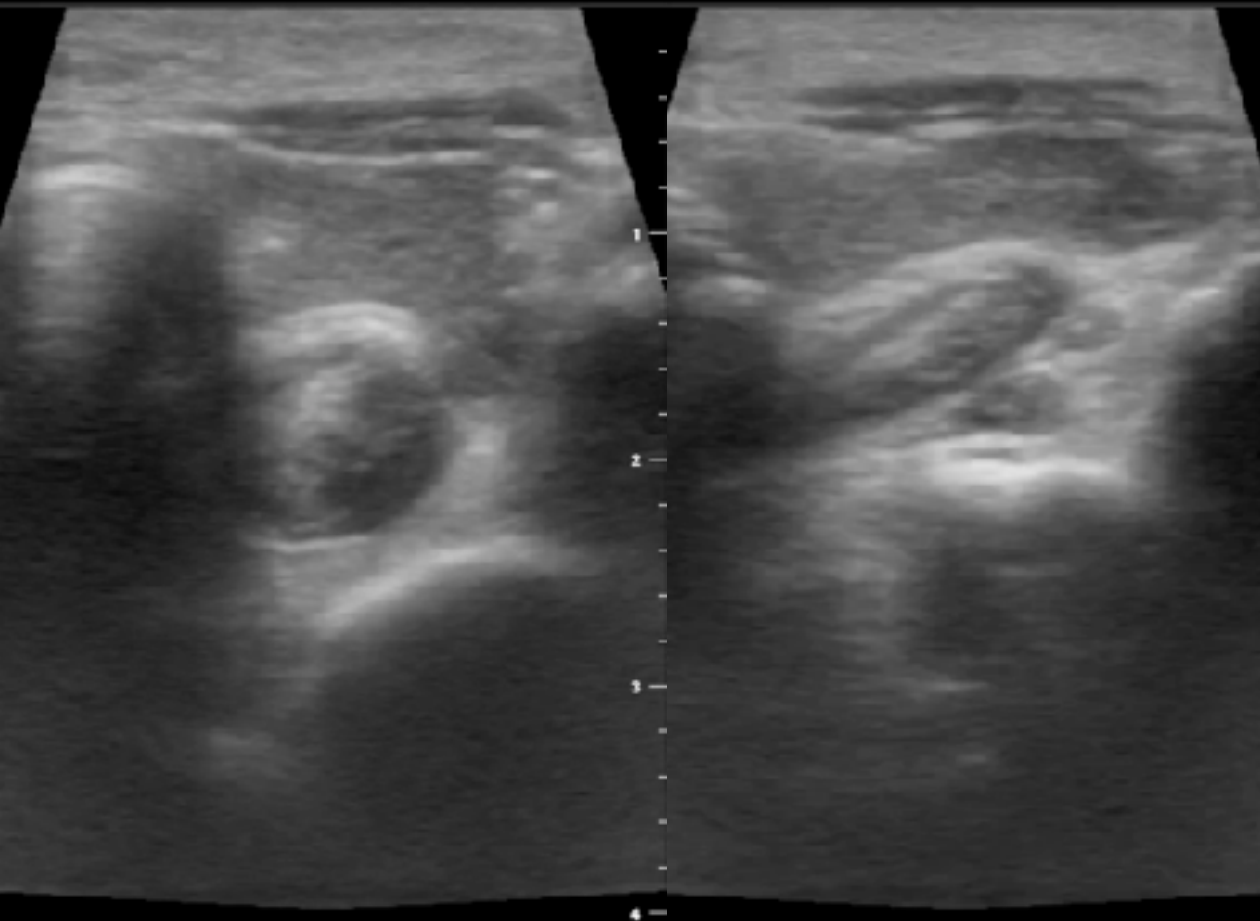
TIS: 0.01, MI: 0.35, MSK-Soft Tissue

TIS: 0.01, MI: 0.35, MSK-Soft Tissue

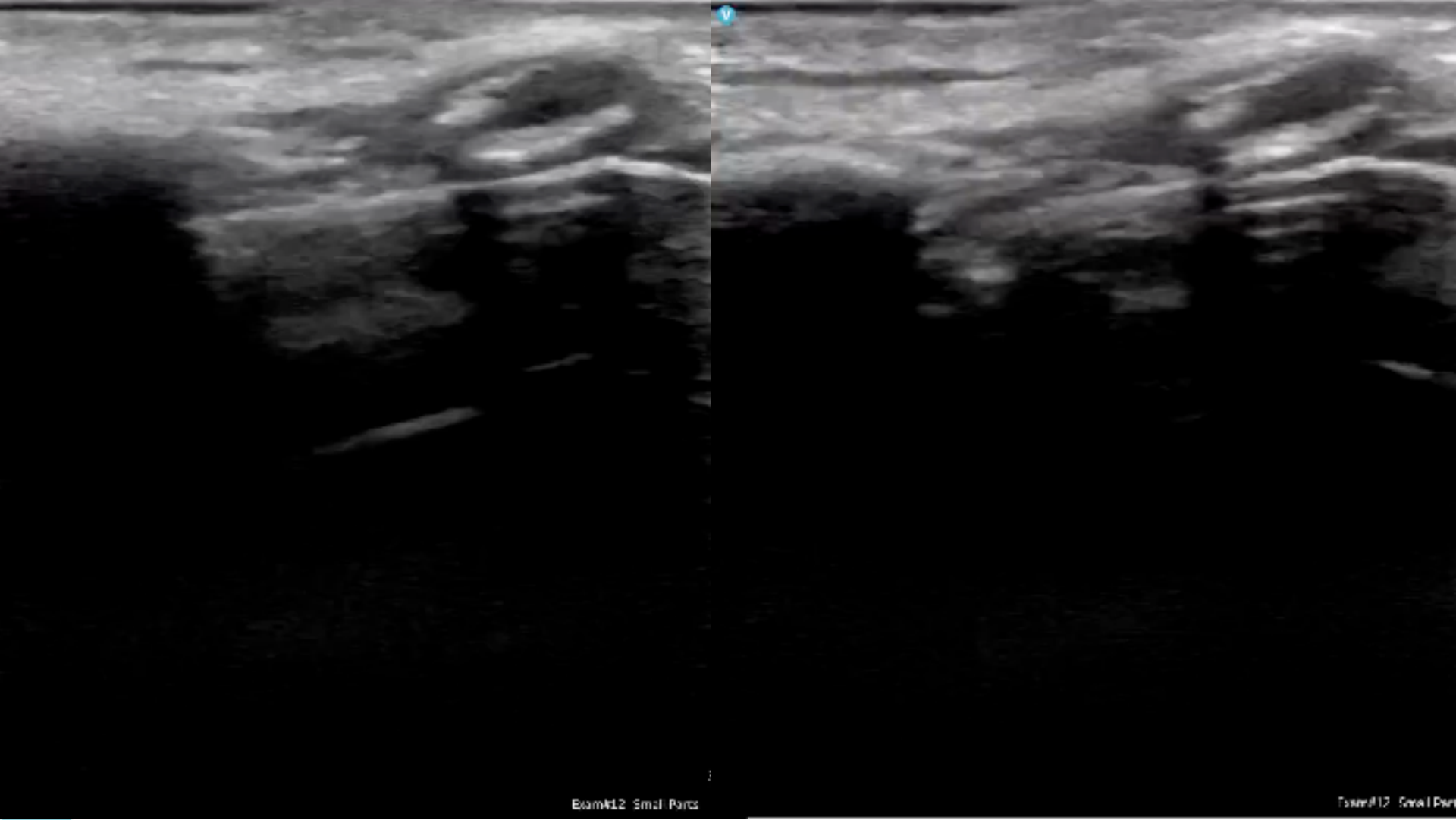
TIS: 0.01, MI: 0.26, MSK-Soft Tissue

B

B



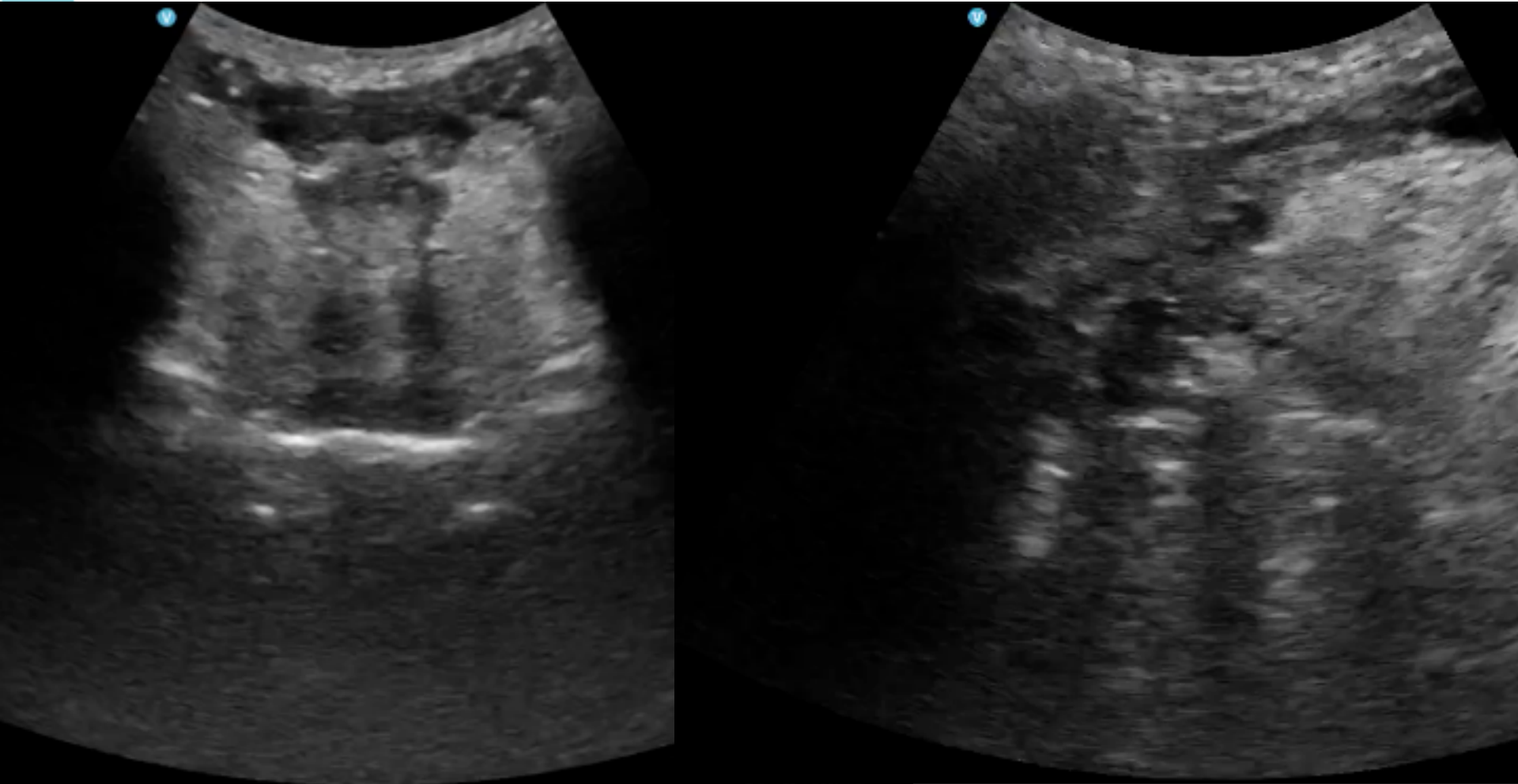
# Surgical airway: CTM & PDT



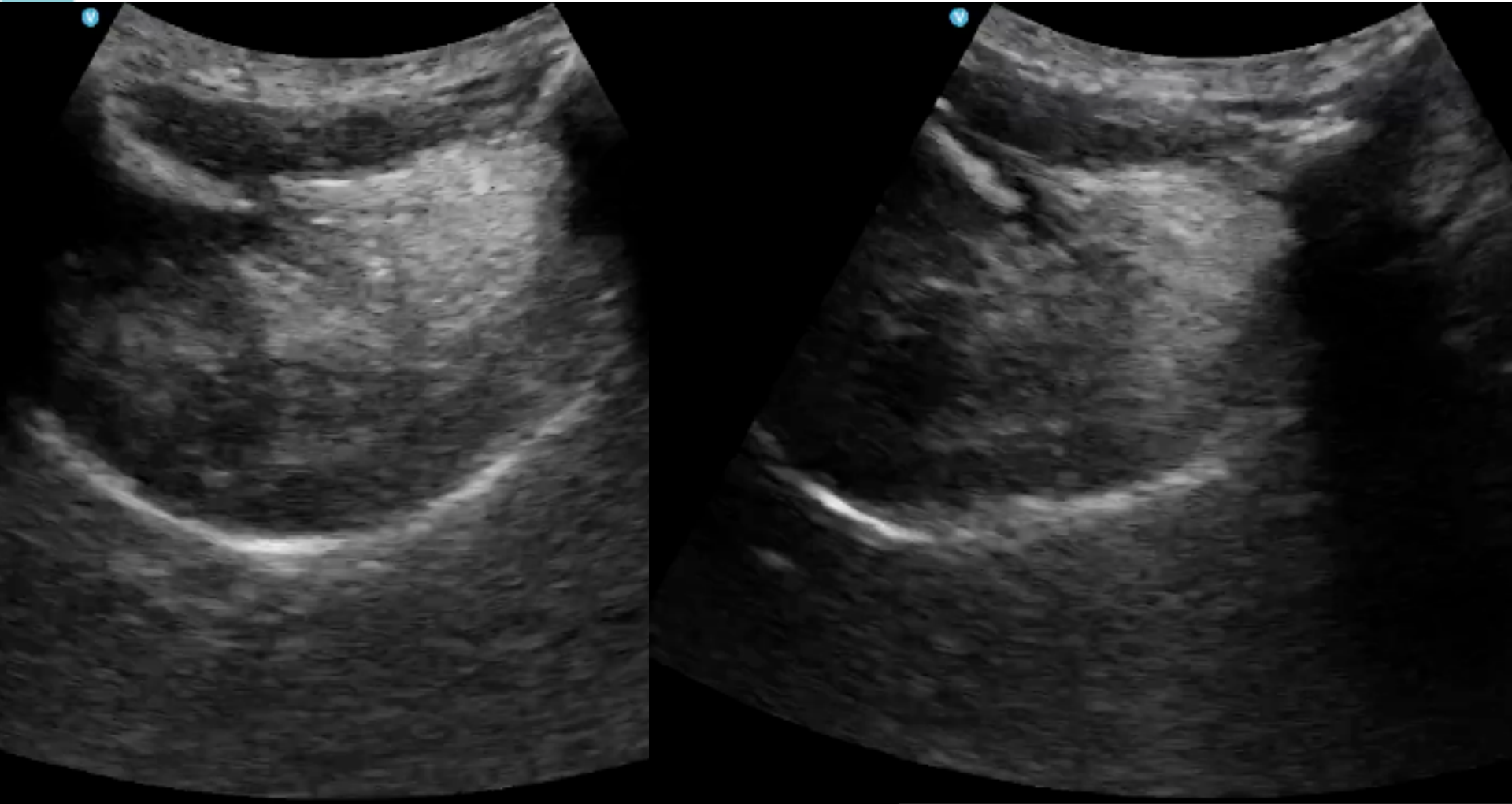
Exam#12 - Small Parts

Exam#12 - Small Parts

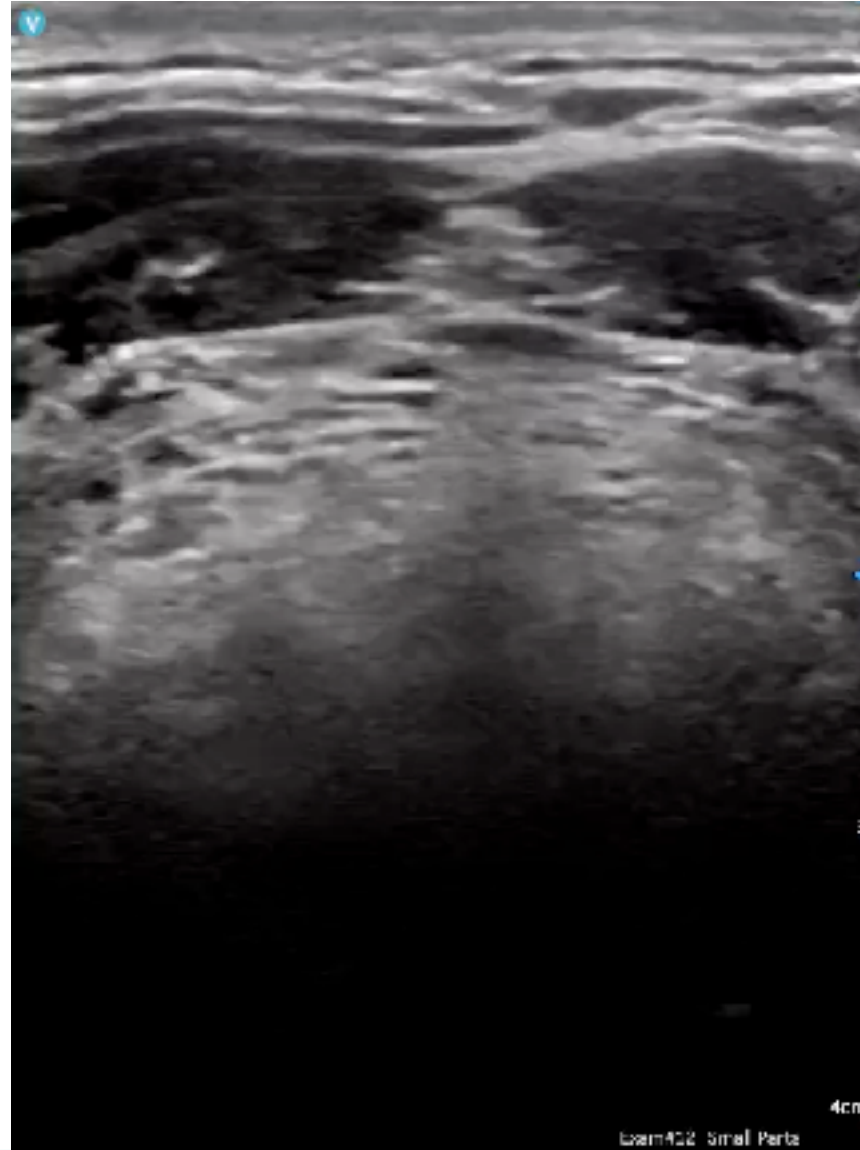
# Tongue & Tonsil



# Tongue, hyoid bone & epiglottis



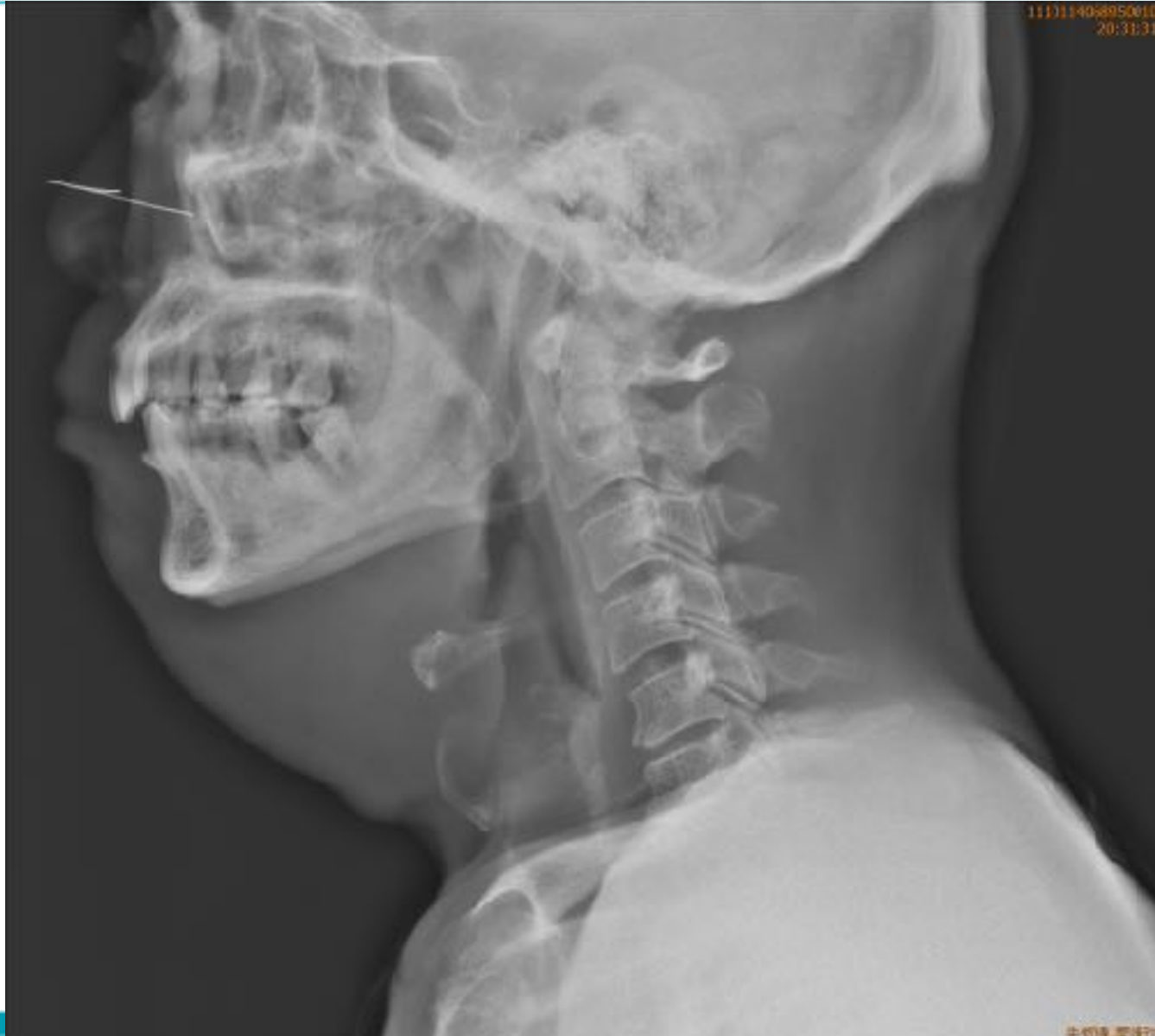# Epiglottitis





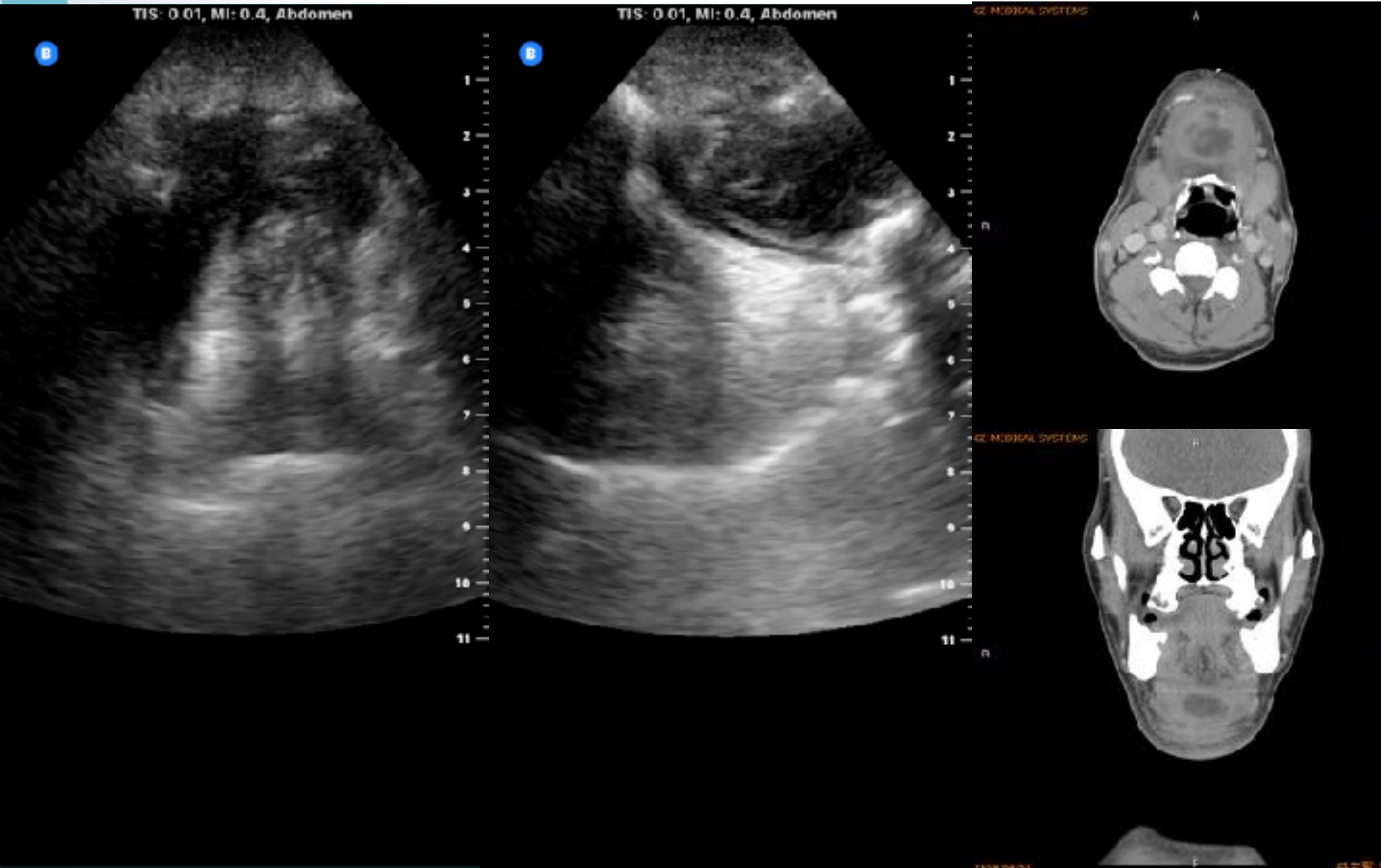


# 62M, neck swelling for 4-5 days

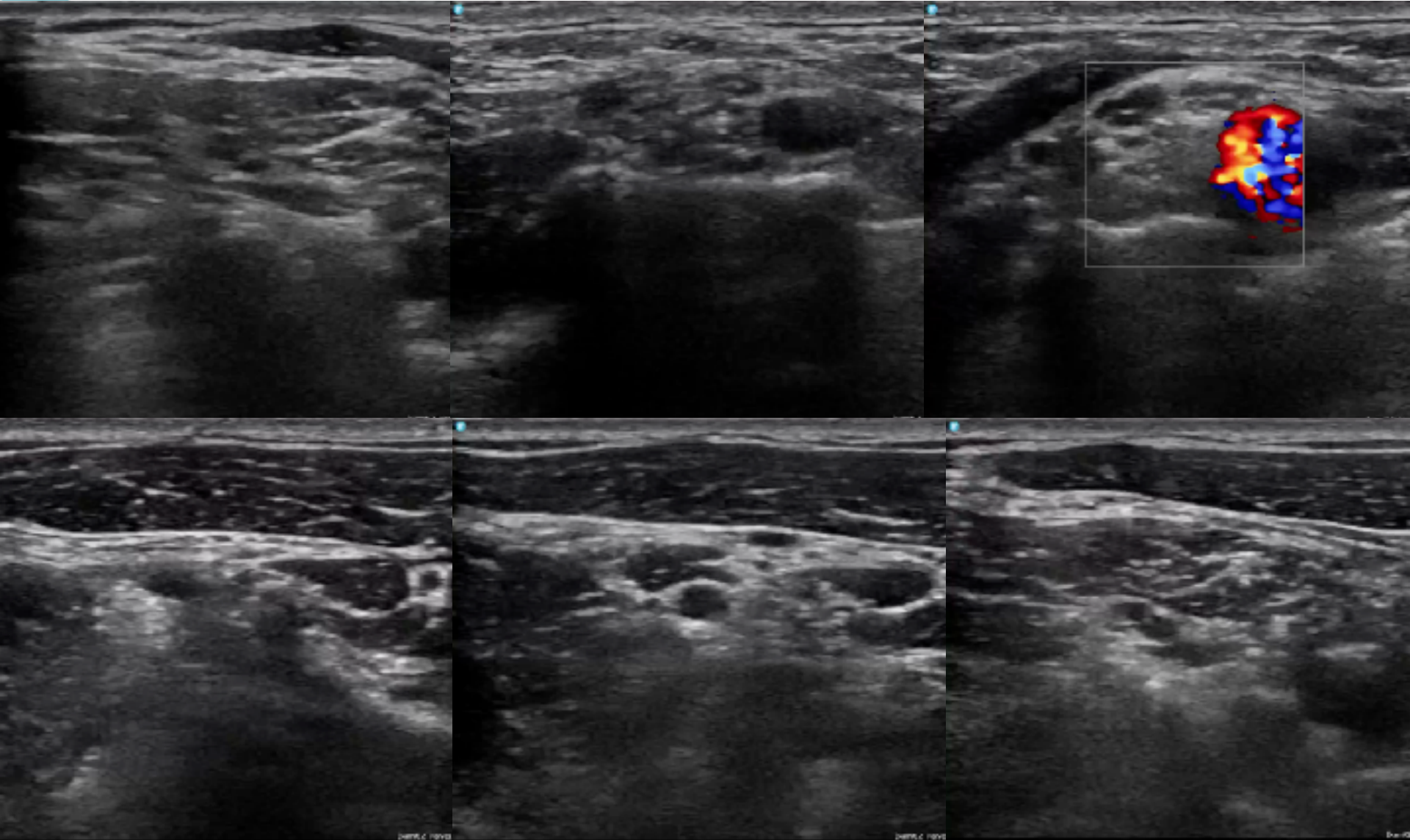




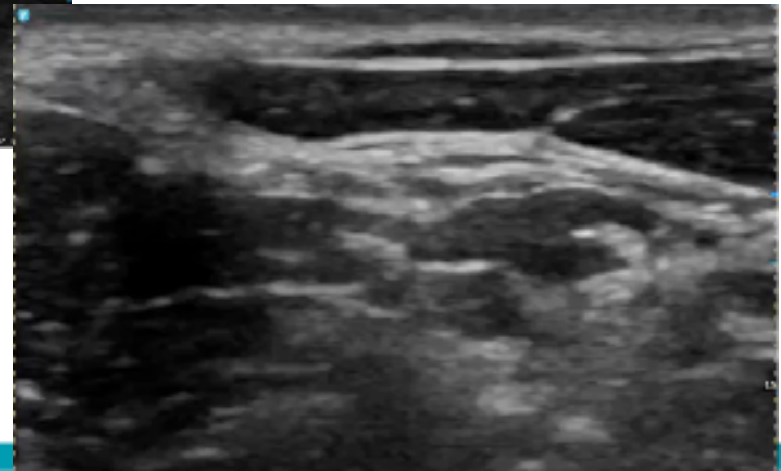
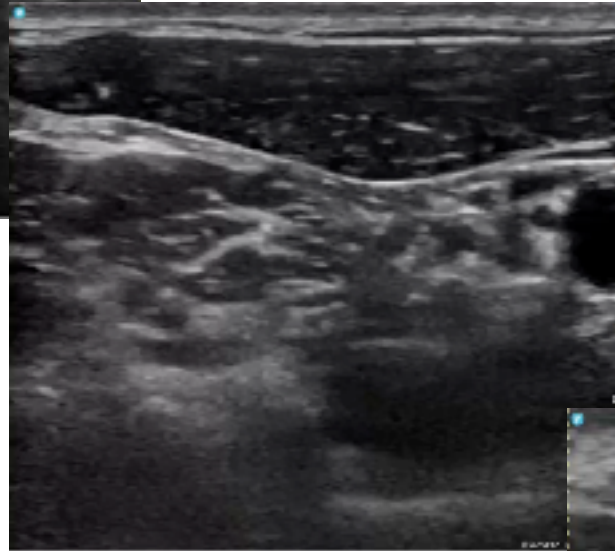
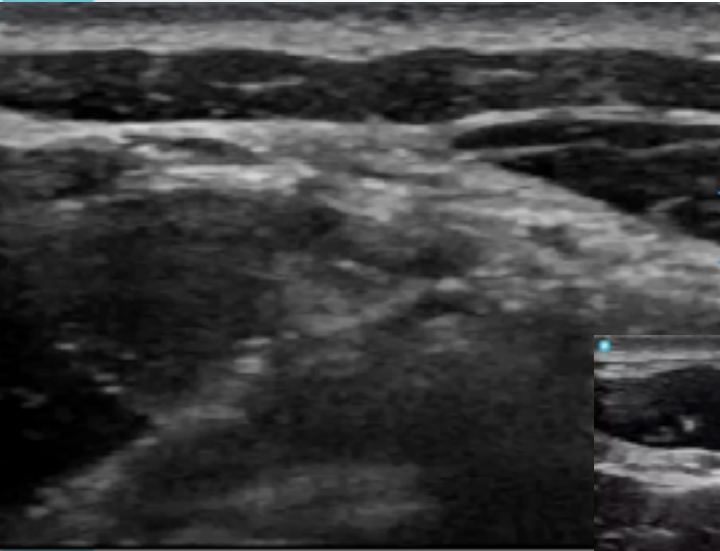
# 62M, neck swelling for 4-5 days



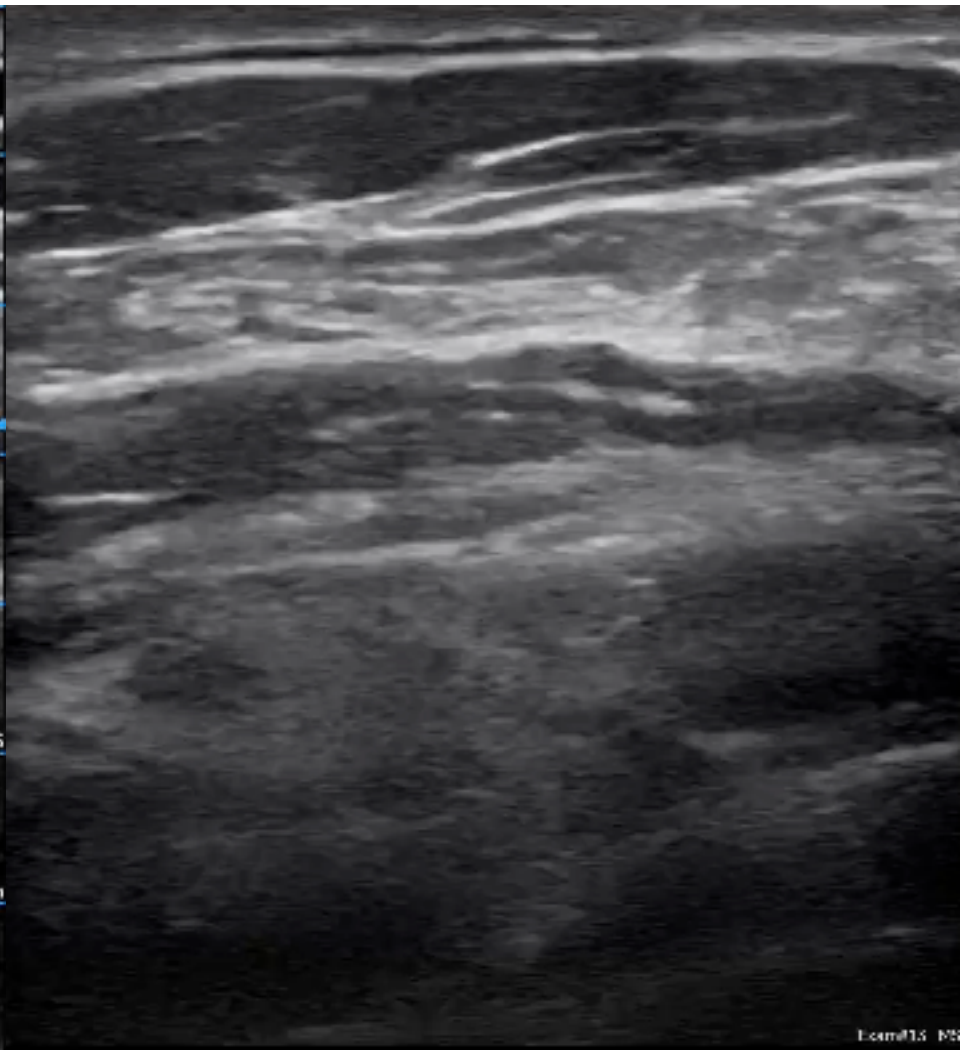
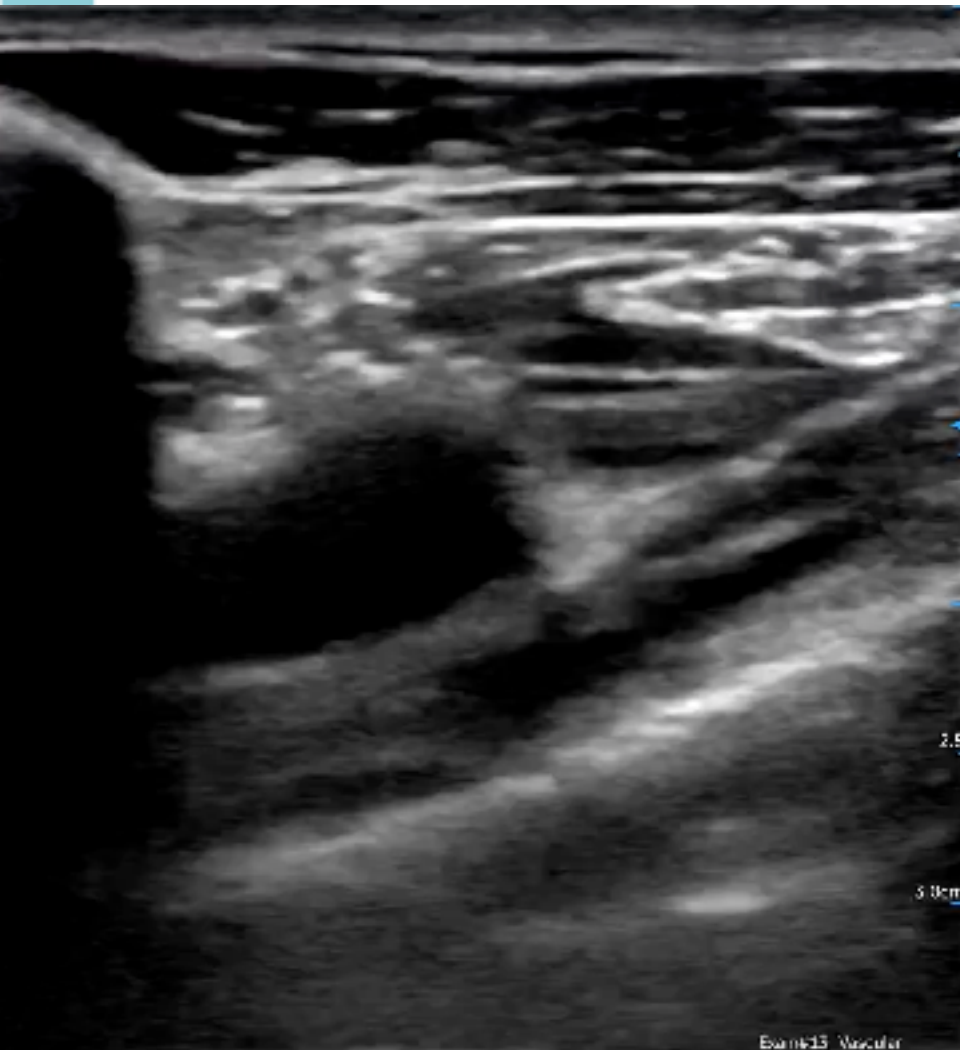# Brachial plexus



# Superficial cervical plexus



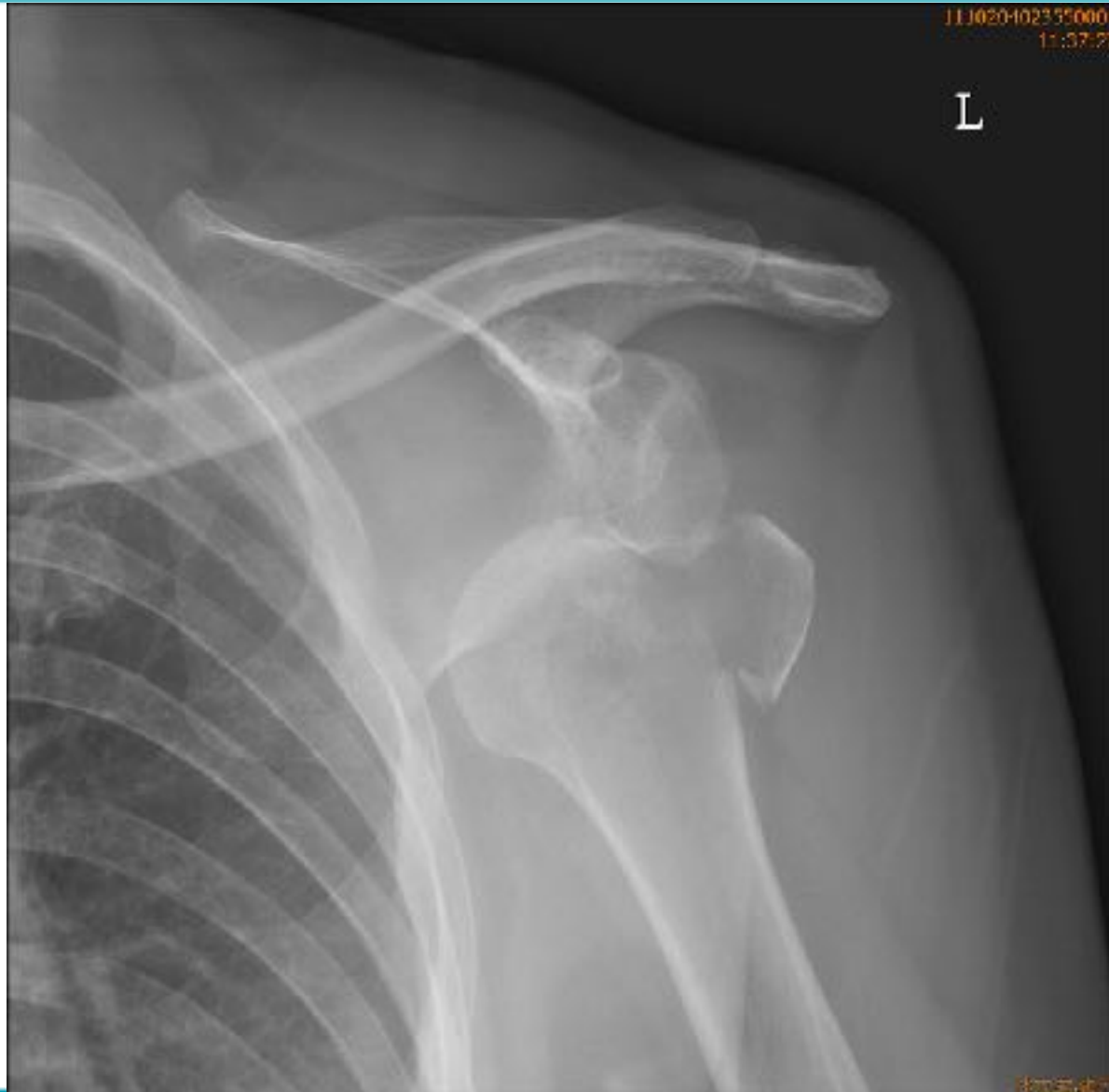# Infraclavicular vessels & nerves



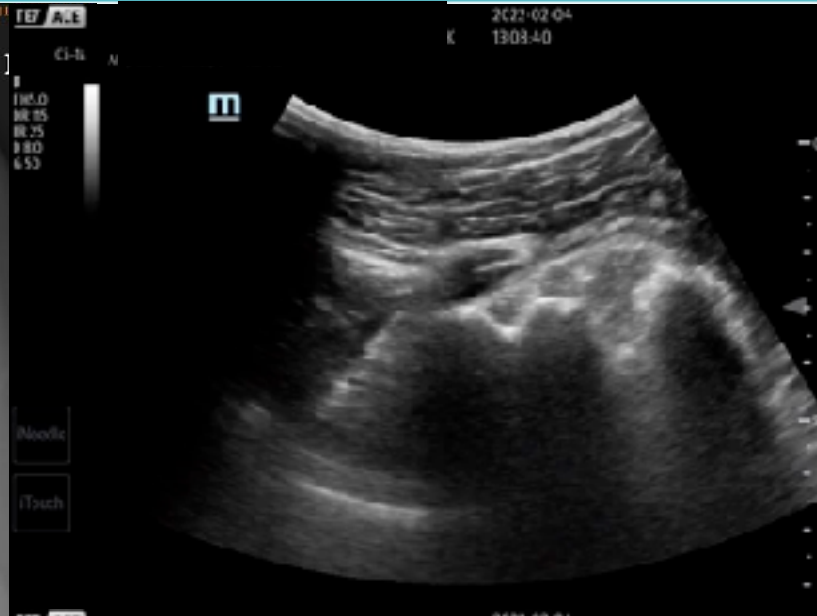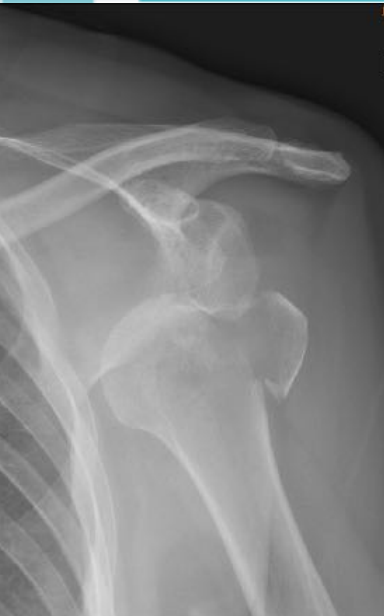Exam13 Vascular

Exam13 MS

# 56M, left shoulder fracture / dislocation



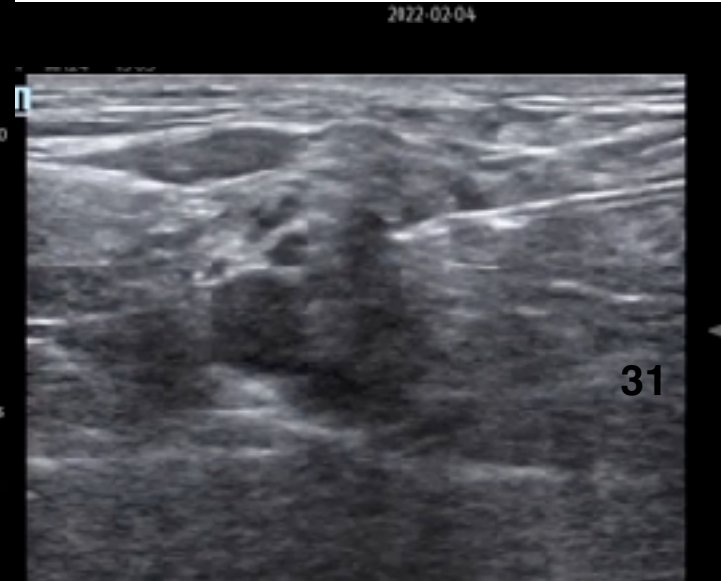
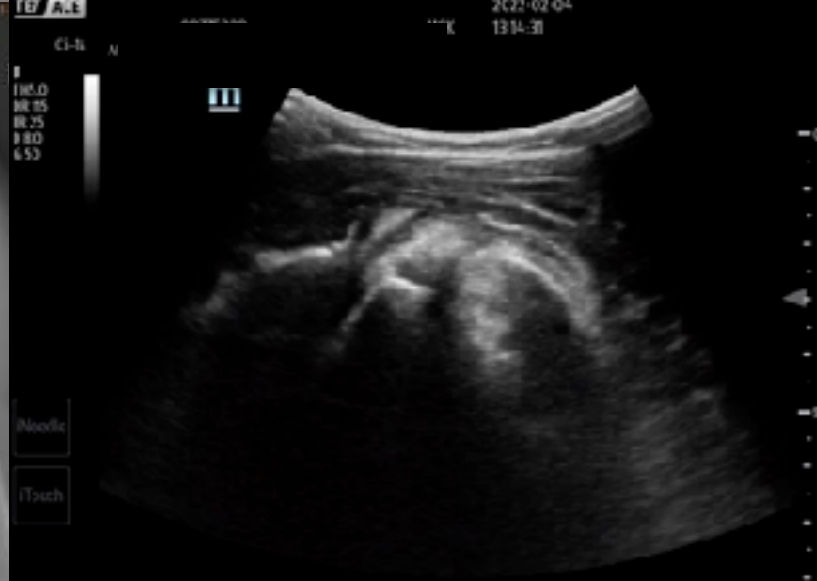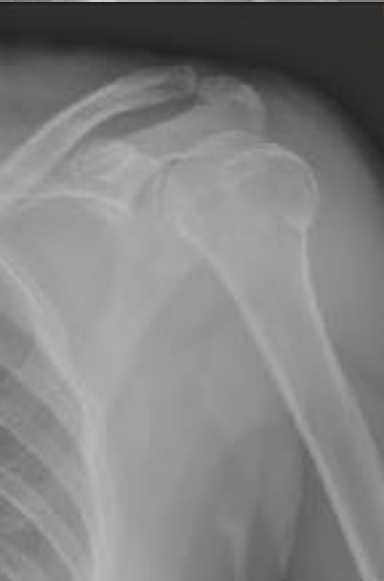# Role of POCUS



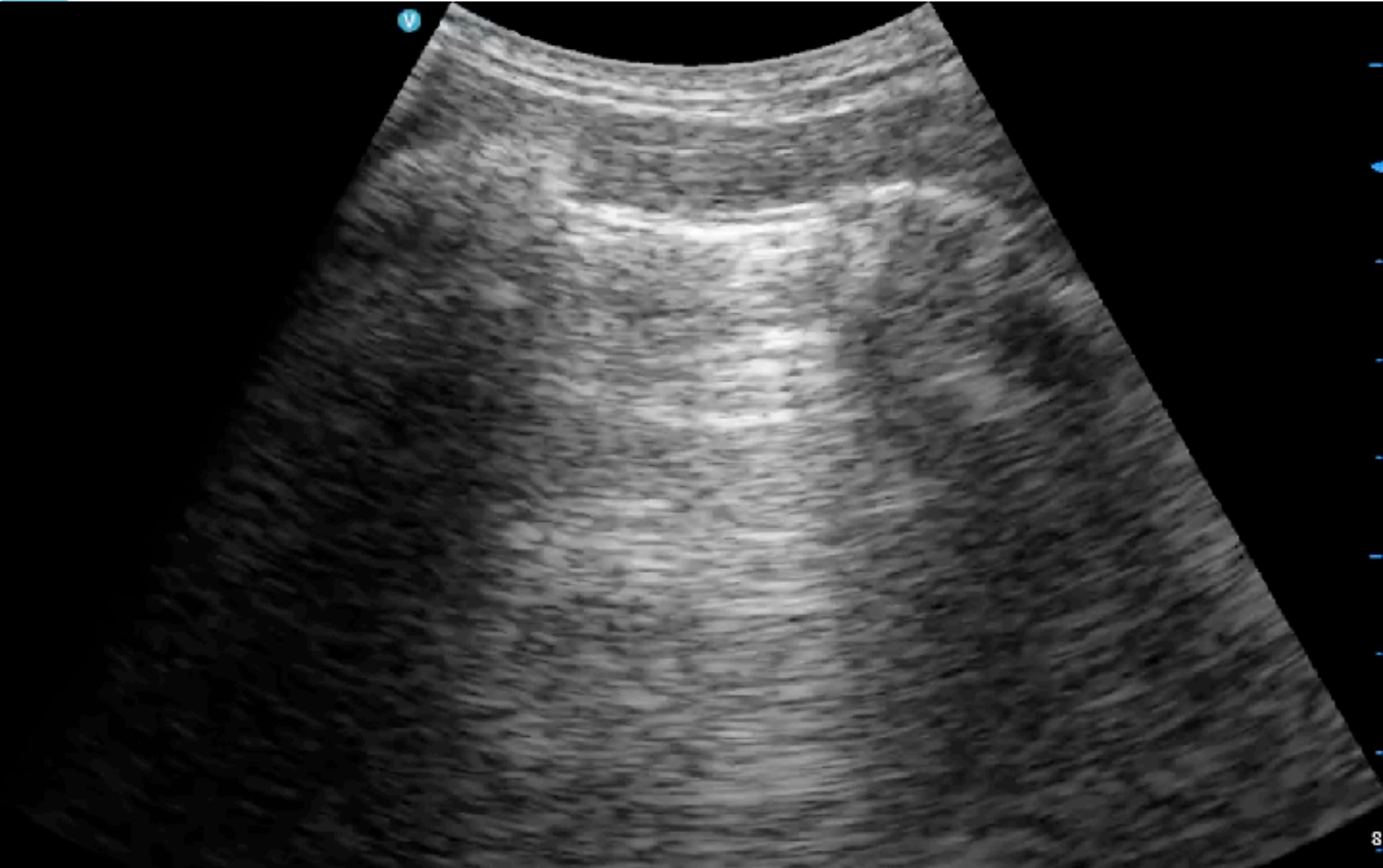**Dislocation**

**Pain control**

**Reduction**

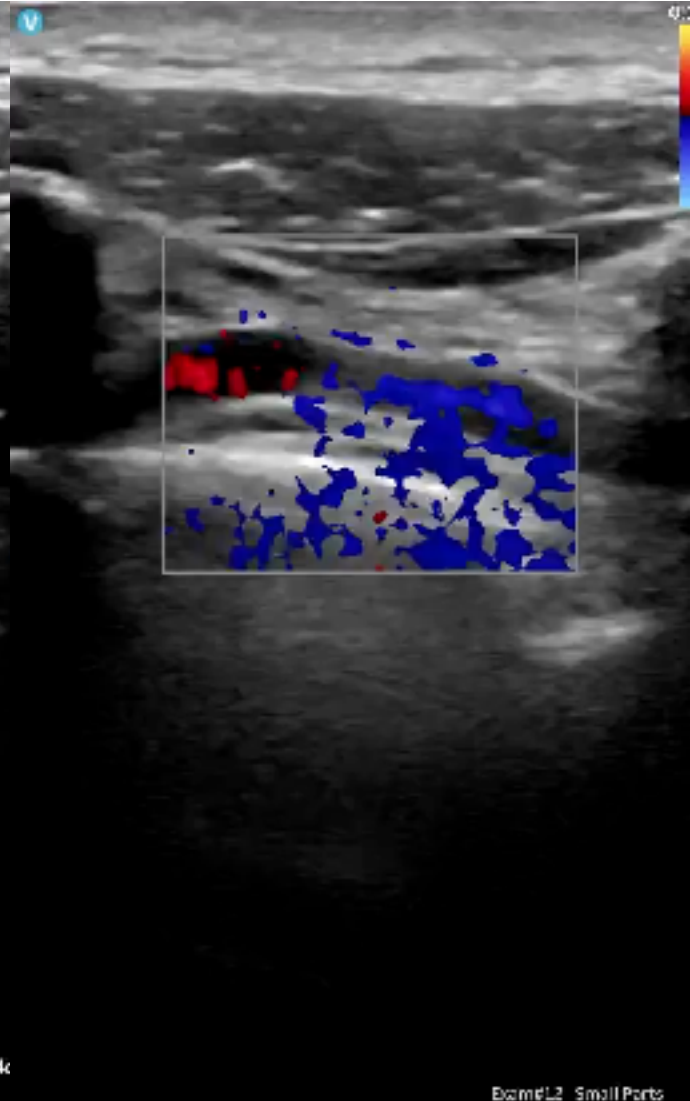
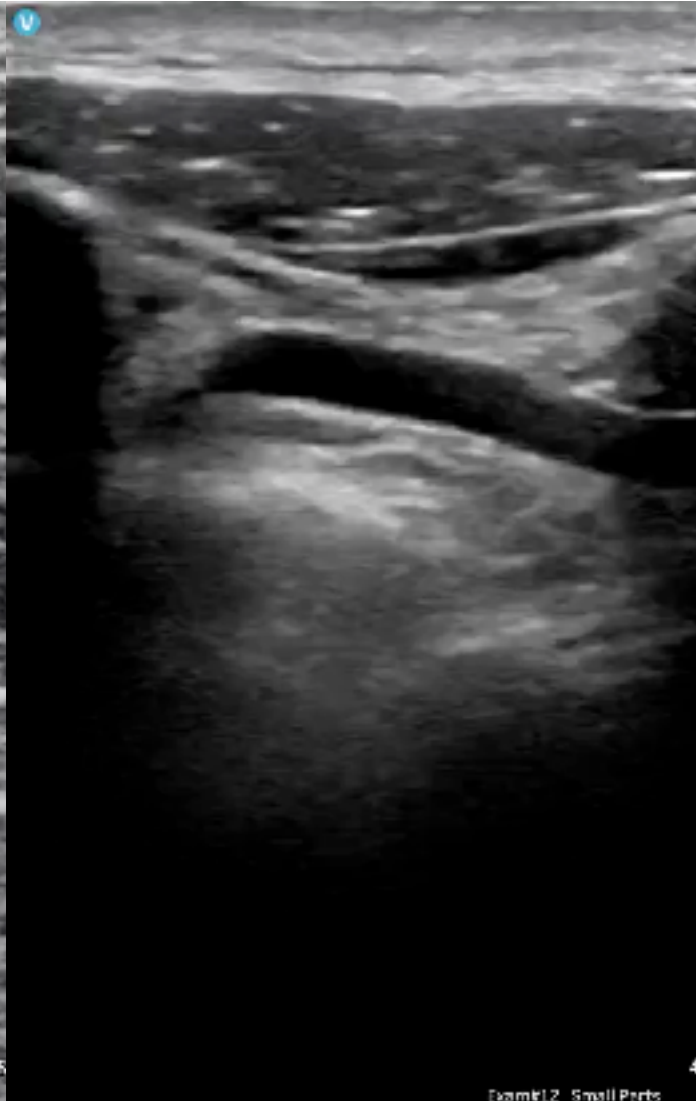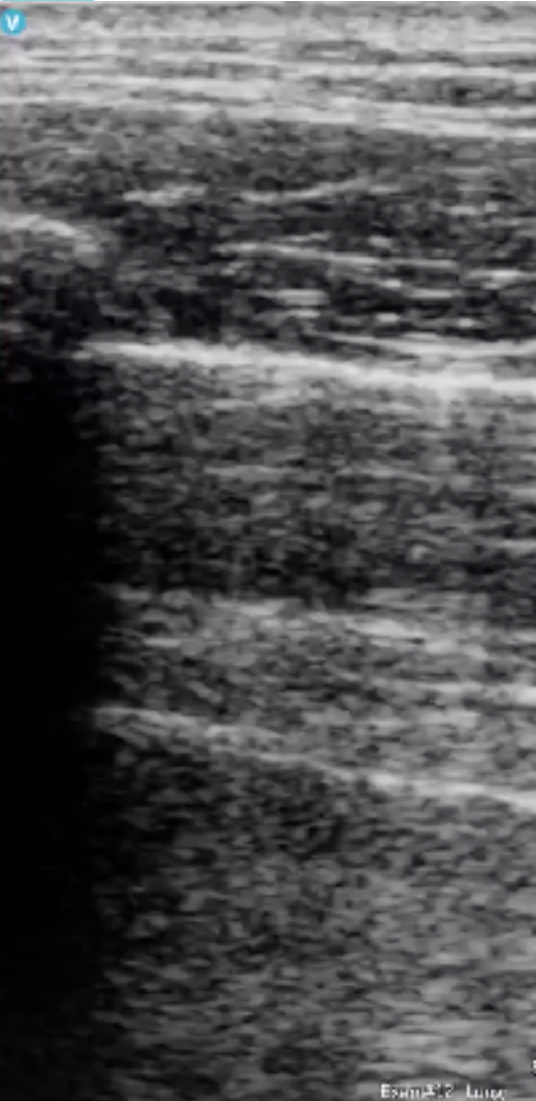


# Bat sign, sliding & A lines

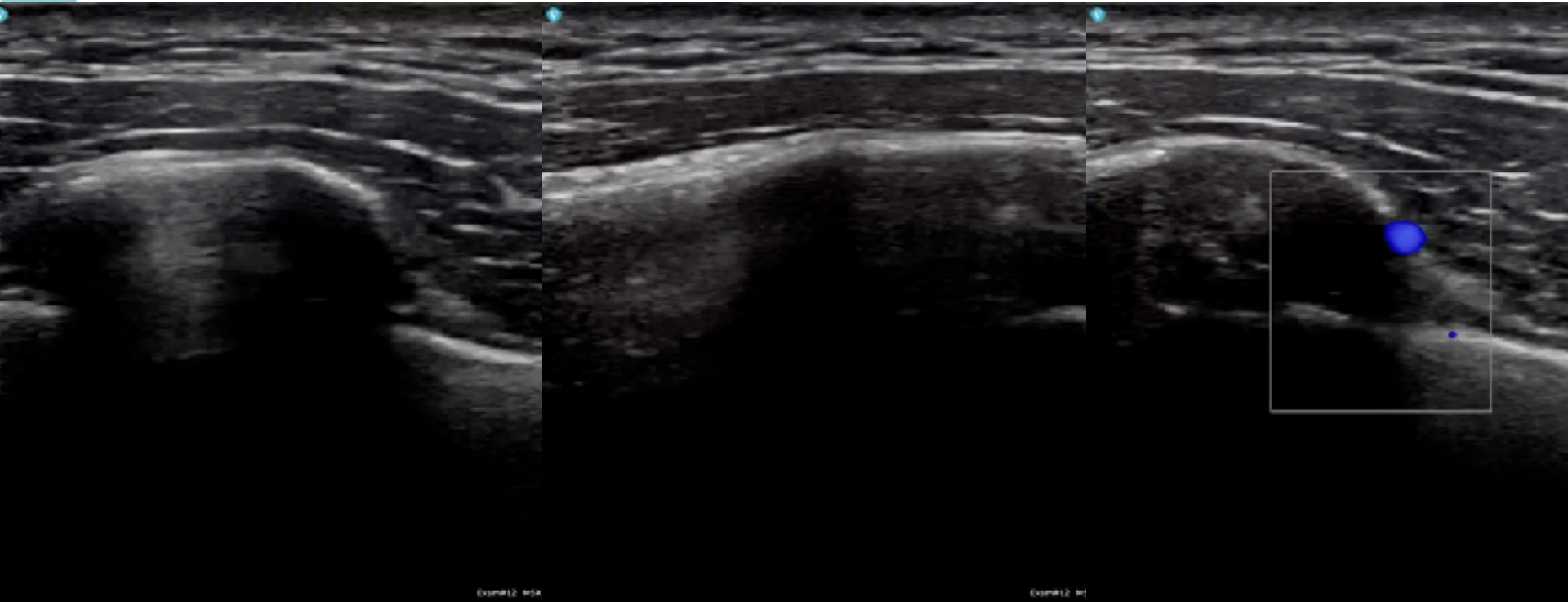




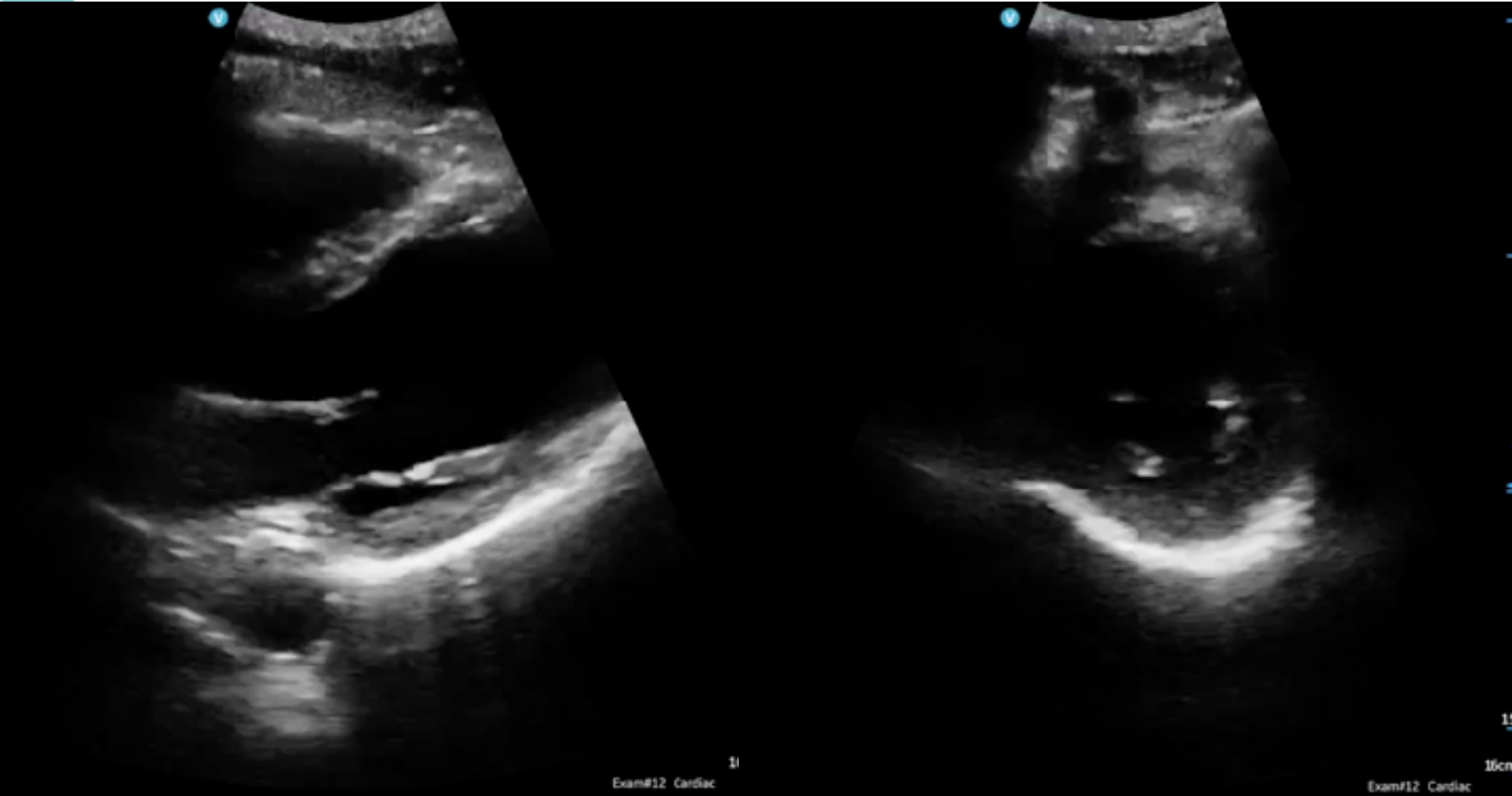
# Sliding & Internal thoracic artery



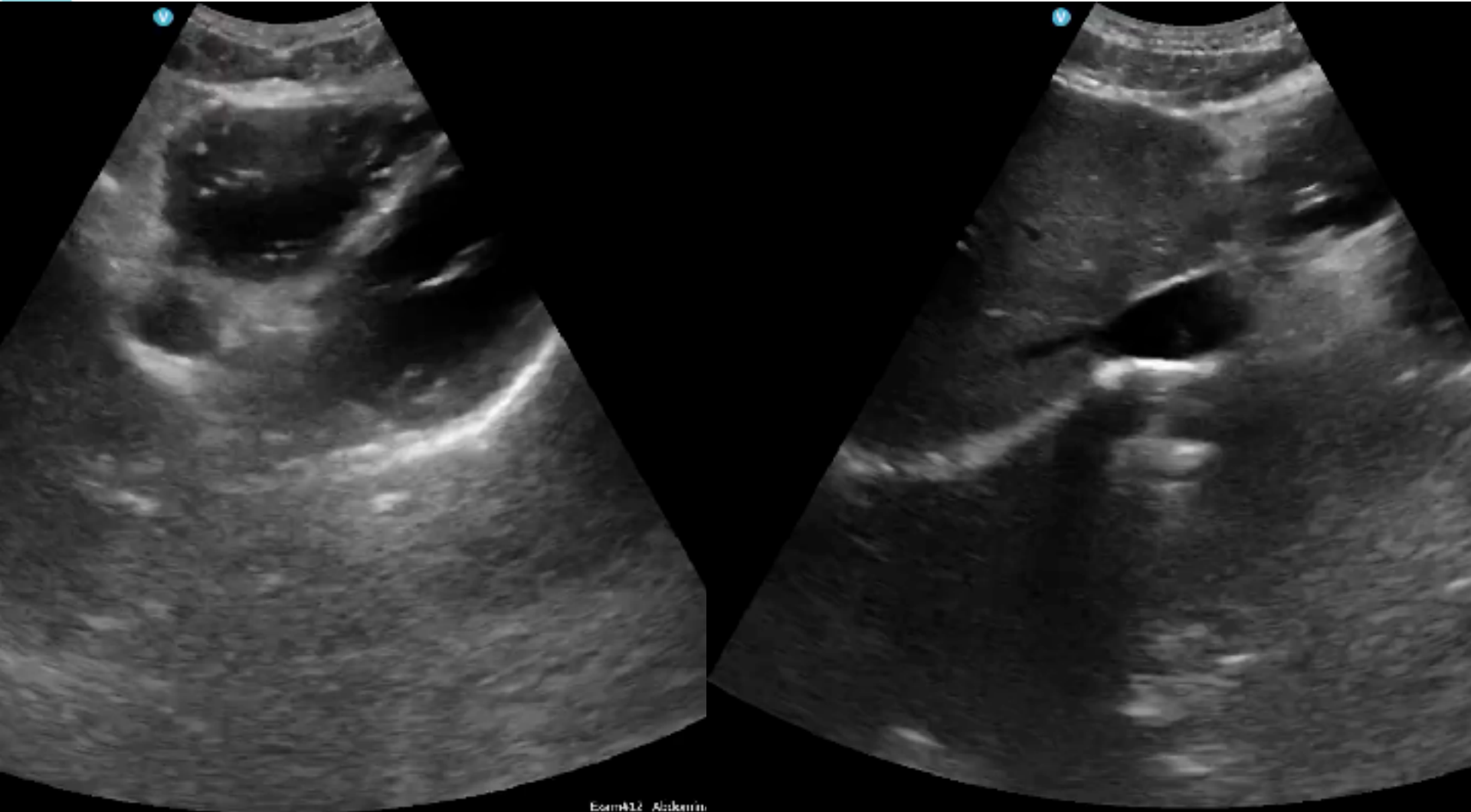
# Rib



# Parasternal heart

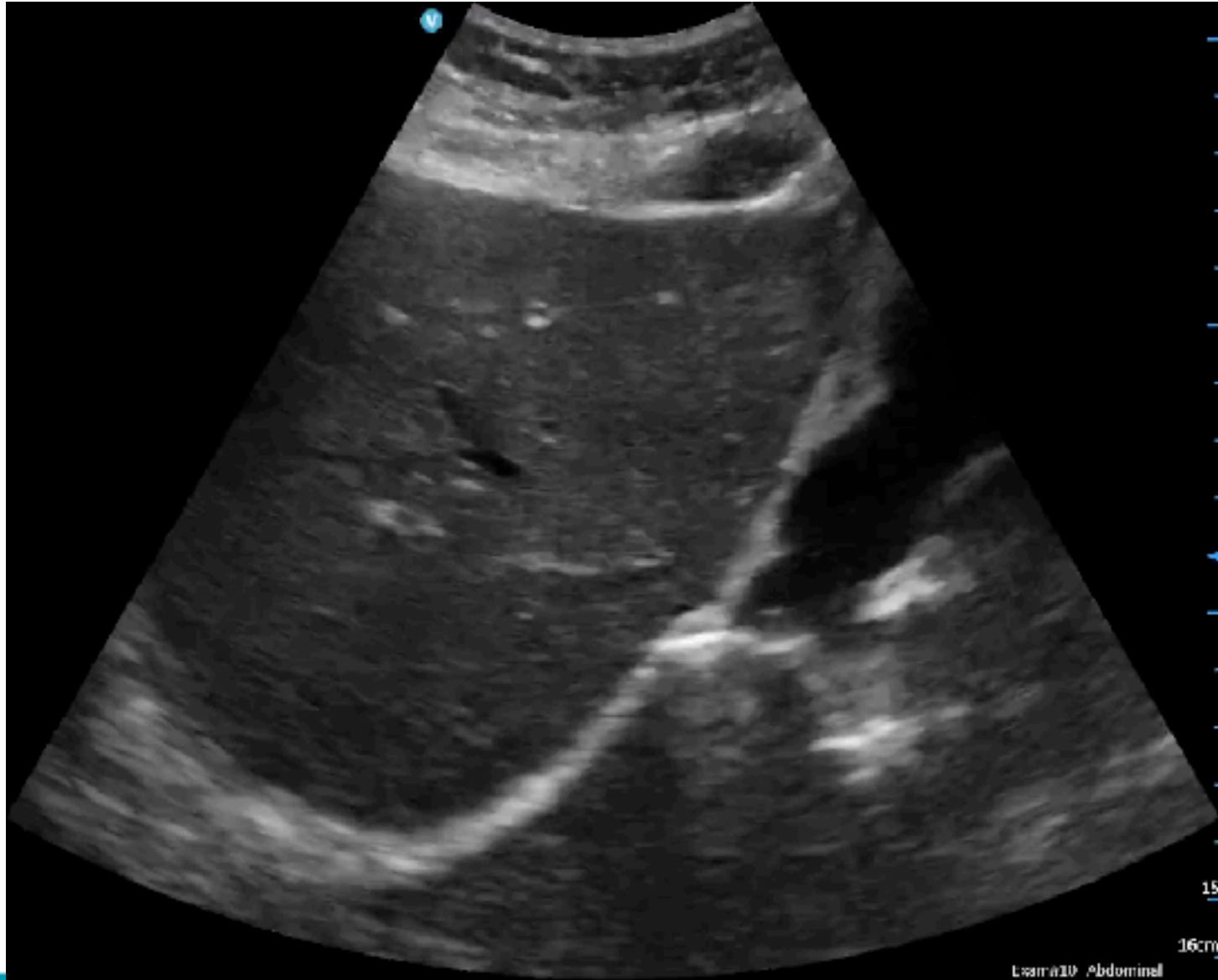

# Subcostal view

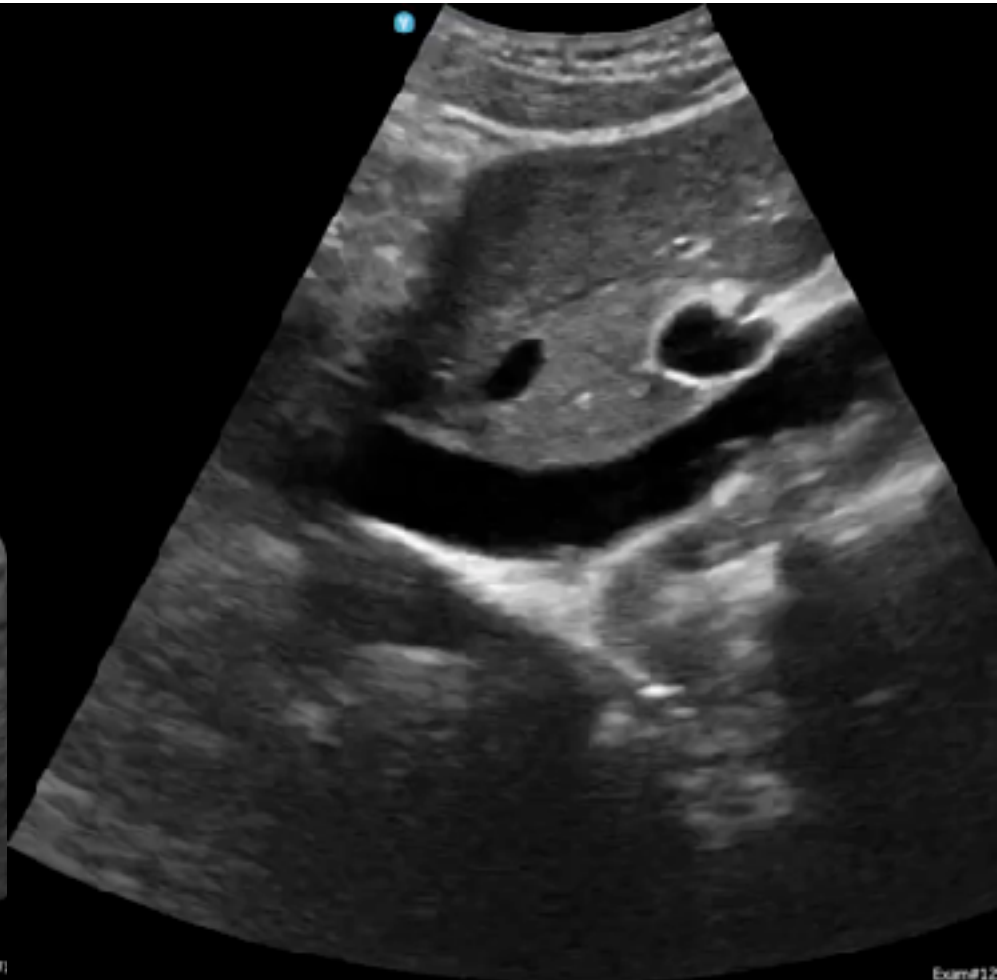
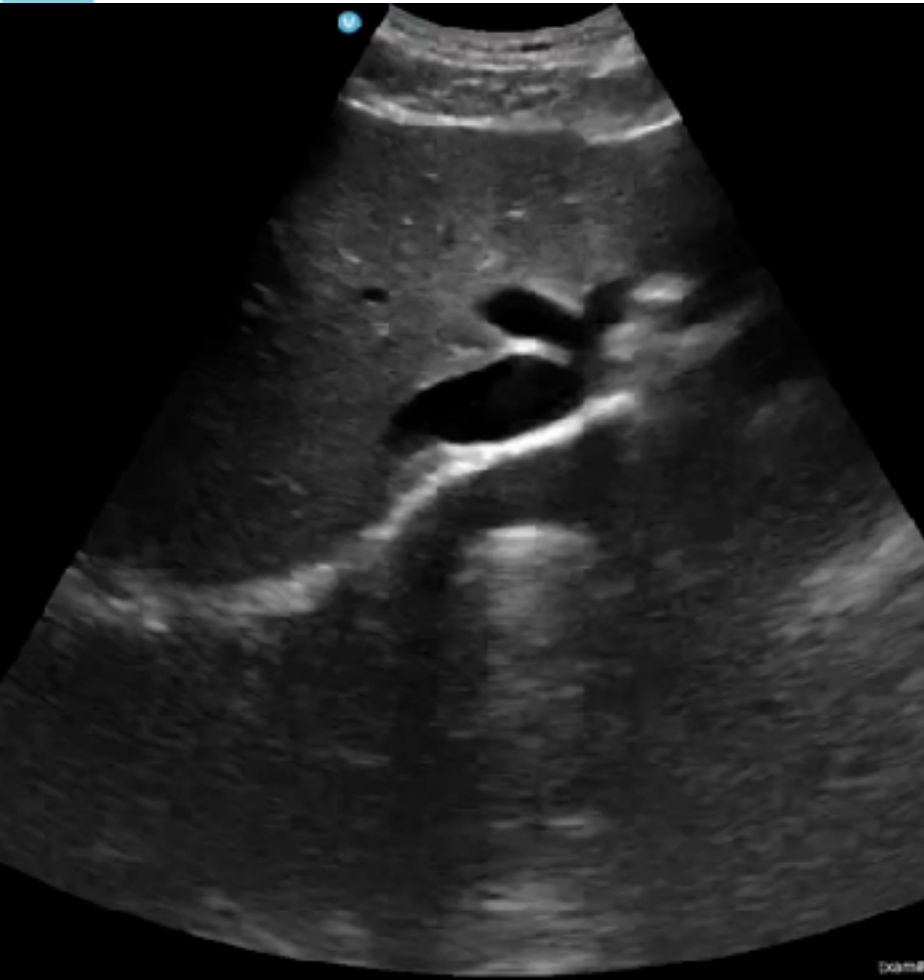

Exam412 - Abdomin

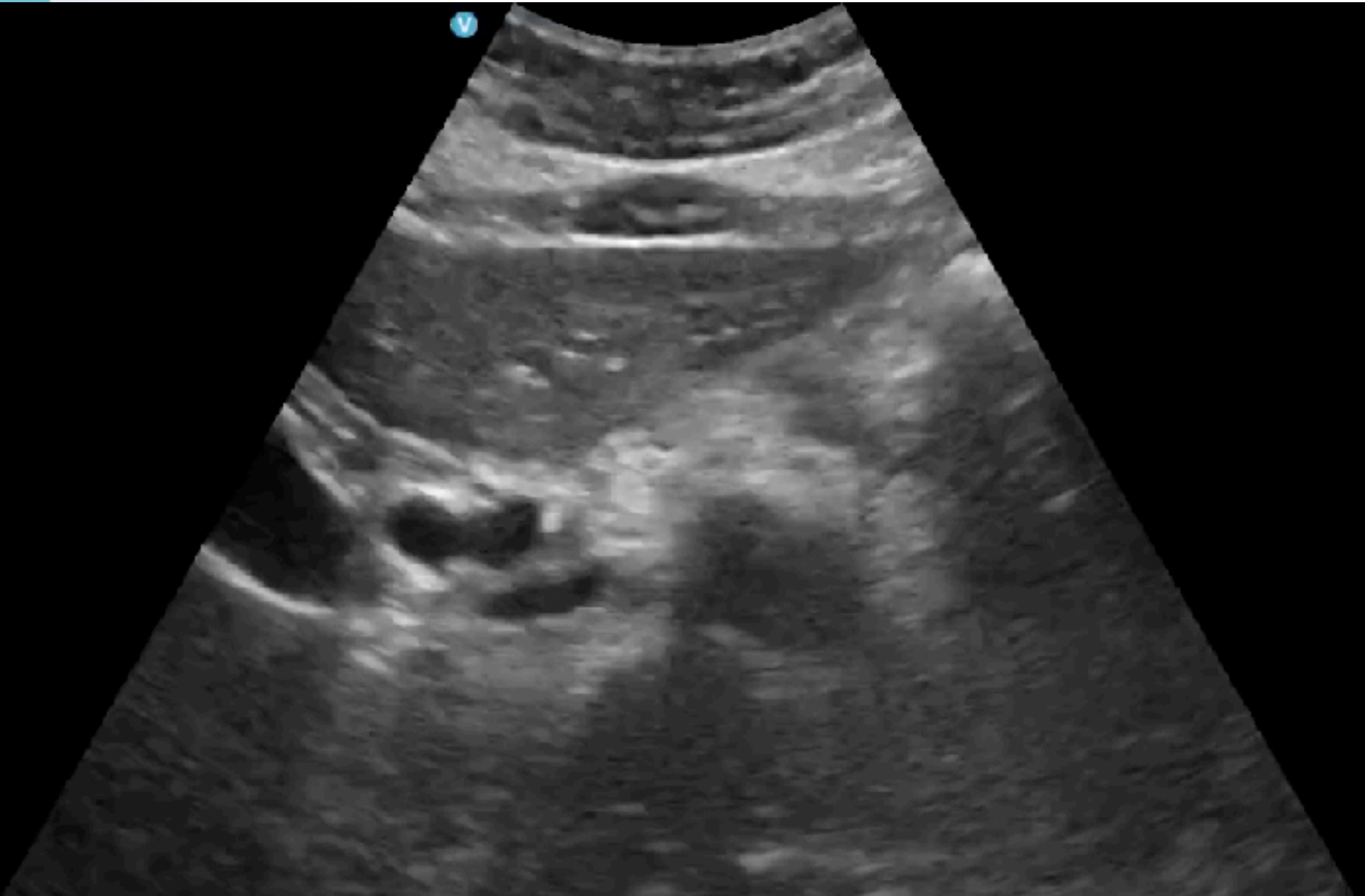
# Subcostal view



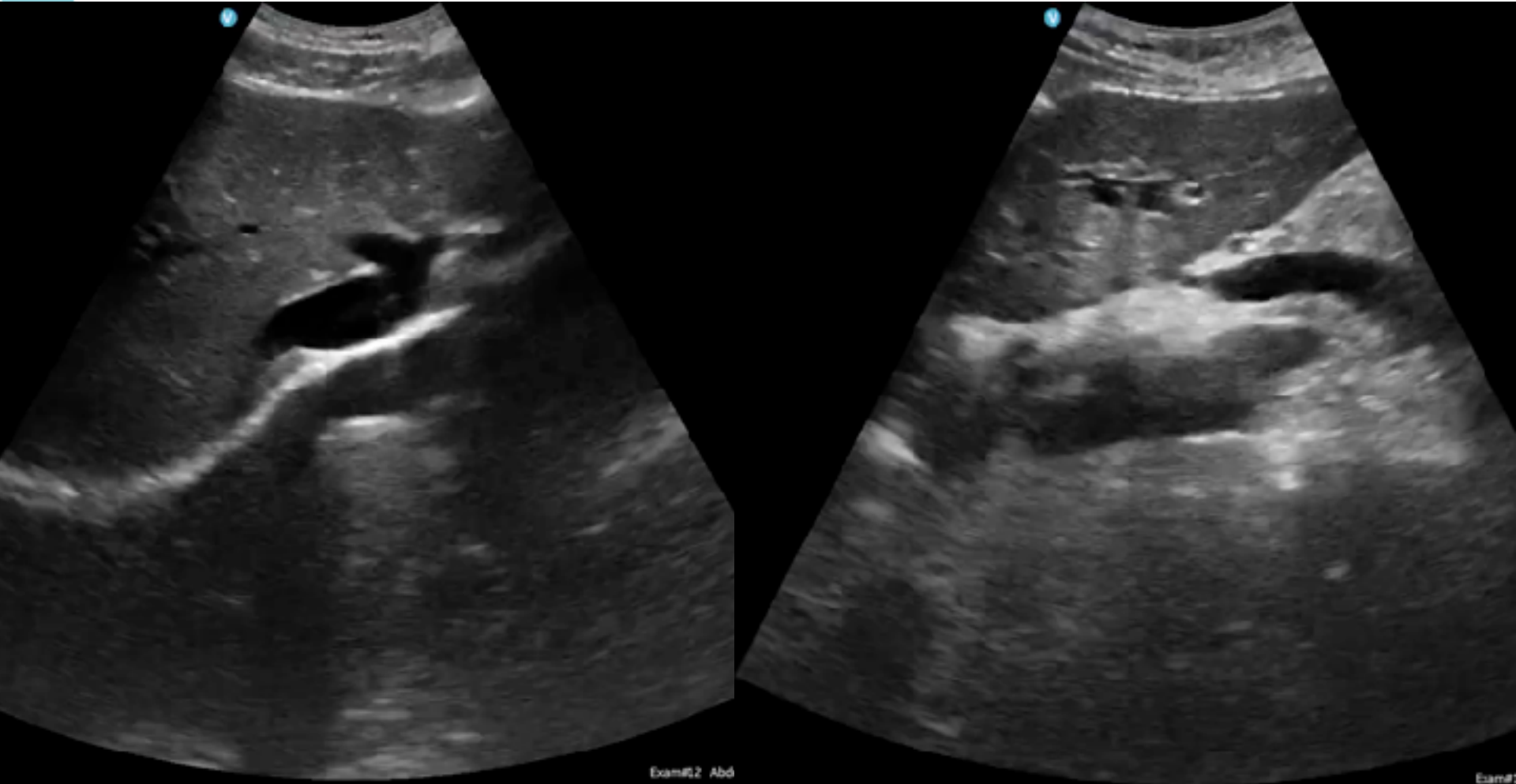
# IVC & hepatic veins



# Liver surface & EC junction



# Subcostal evaluation for aorta

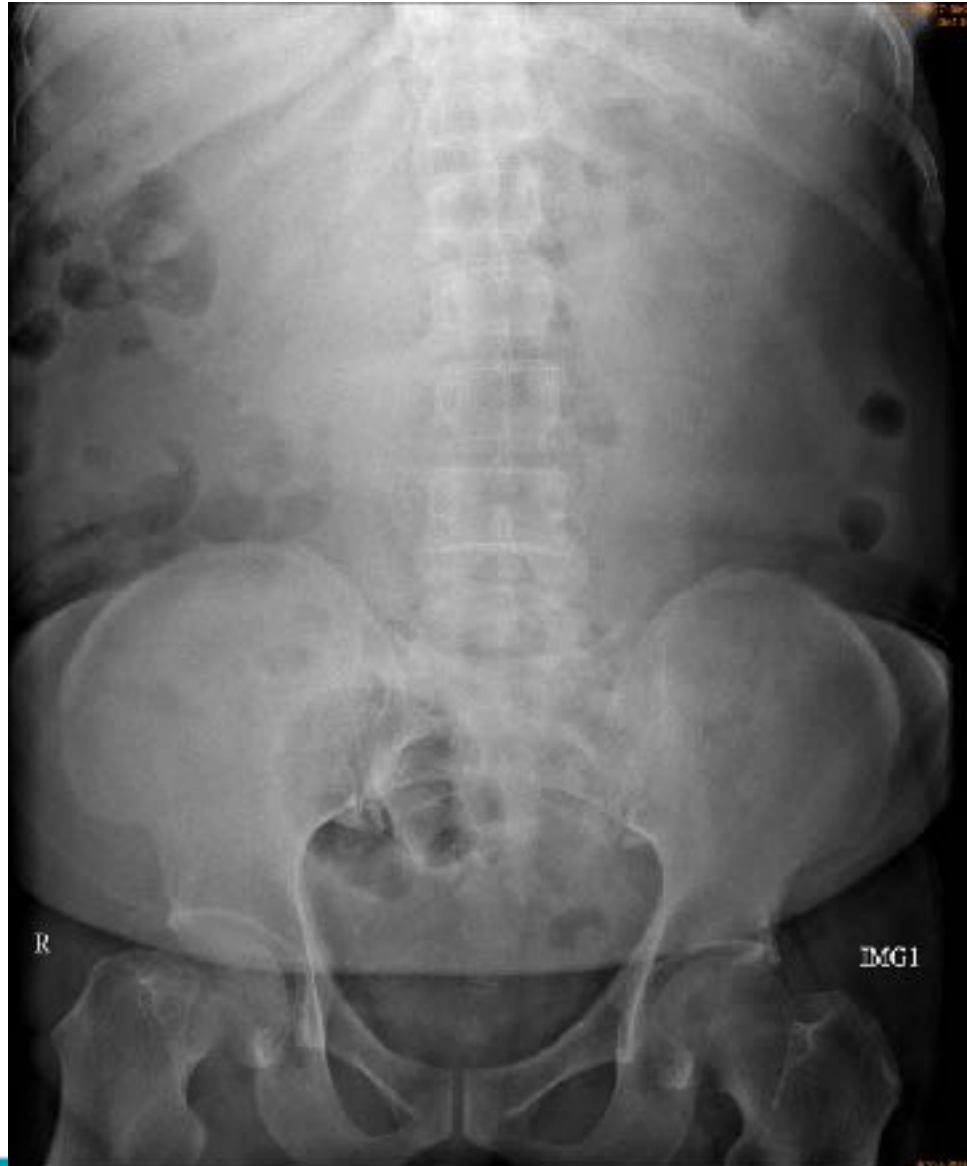

Exam#2 Abd

Exam#2

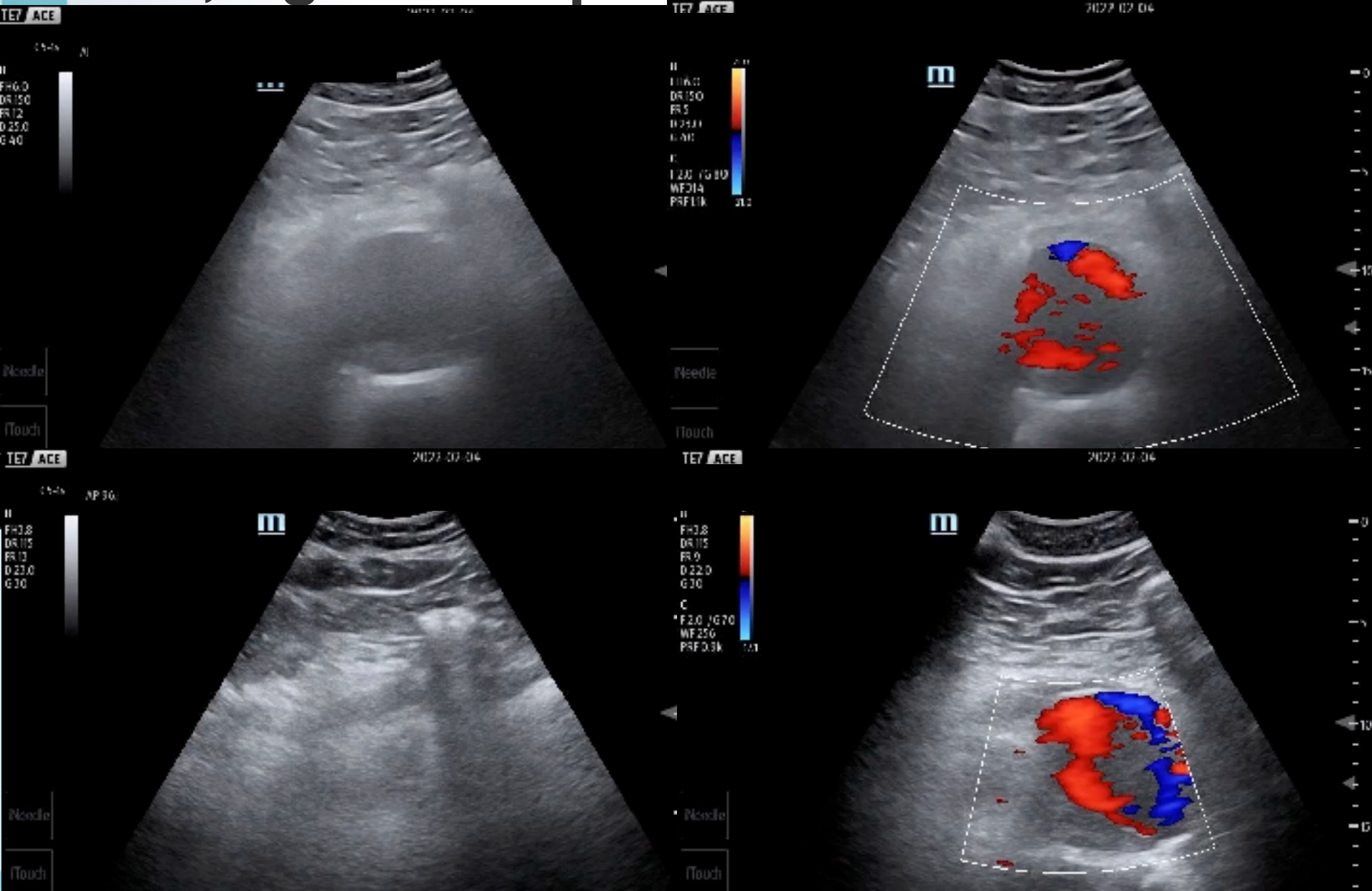


# 74M, right flank pain & cold sweating

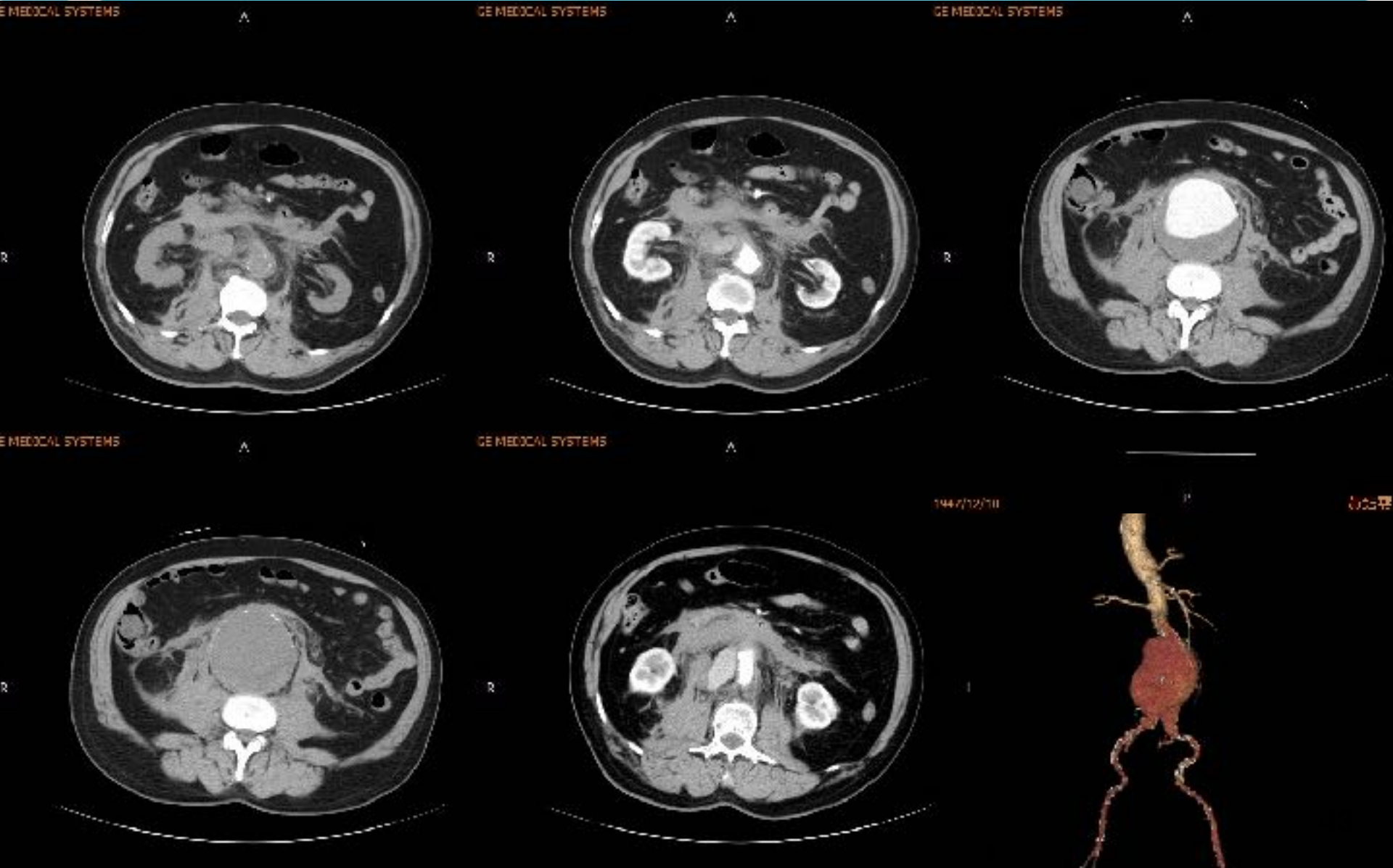




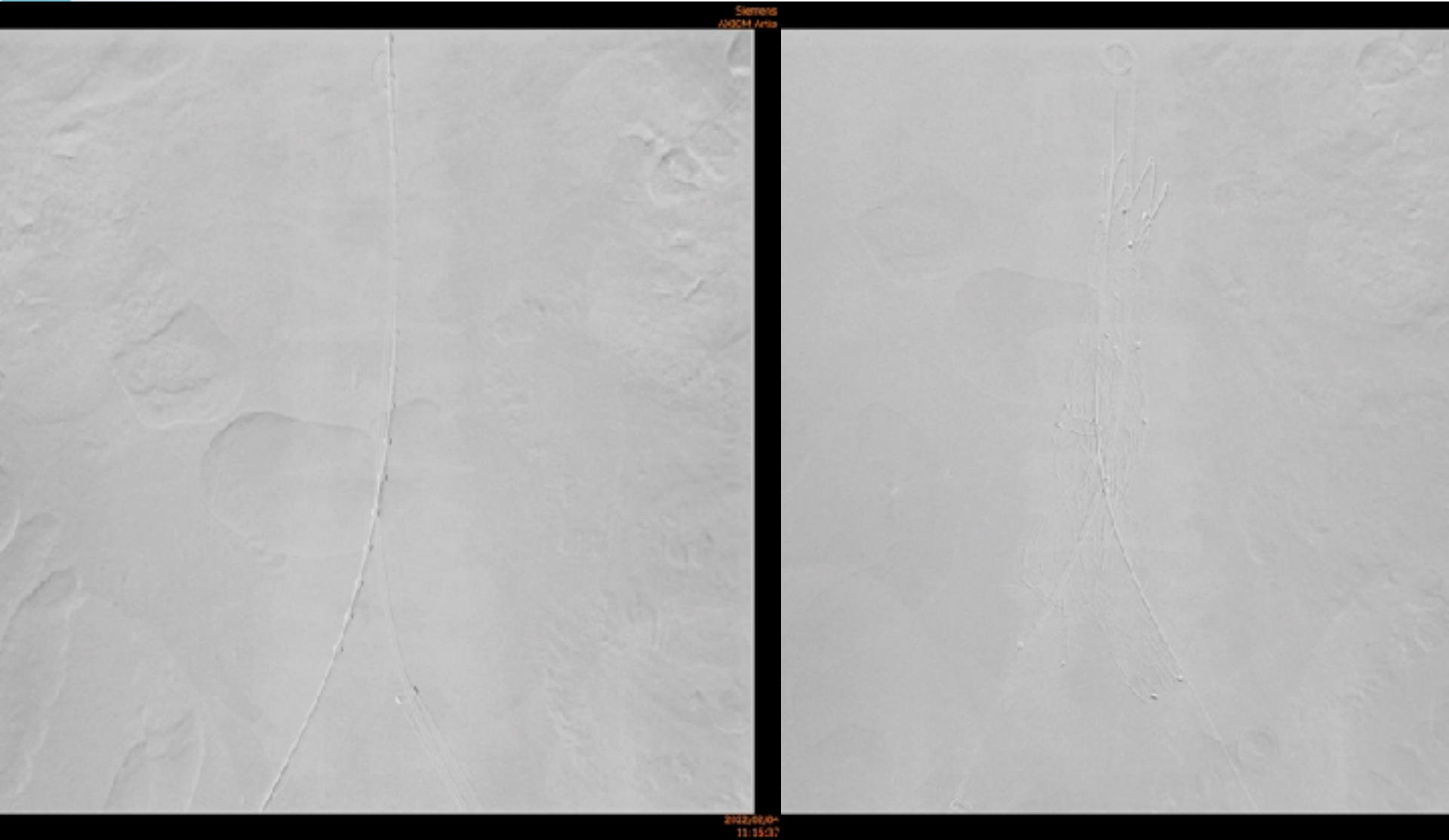
# 74M, right flank pain & cold sweating



# 74M, right flank pain & cold sweating



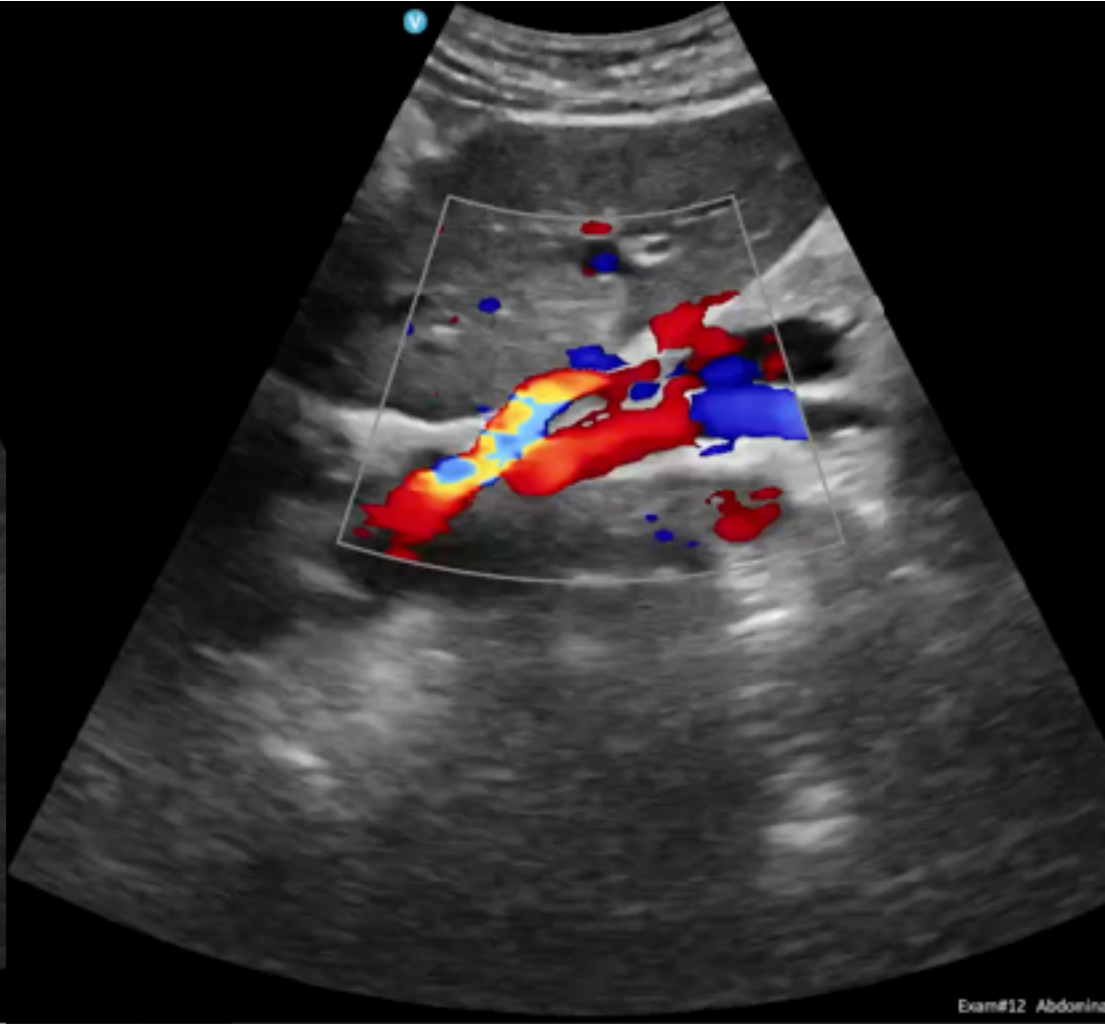
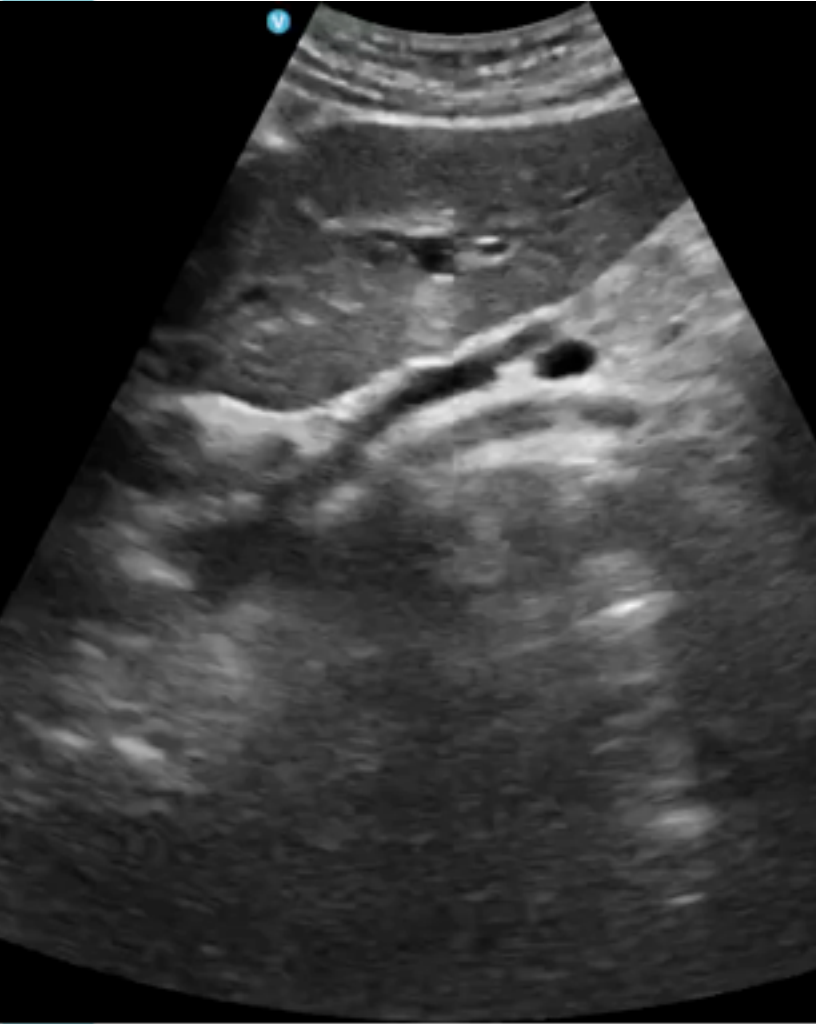
# Emergent surgery



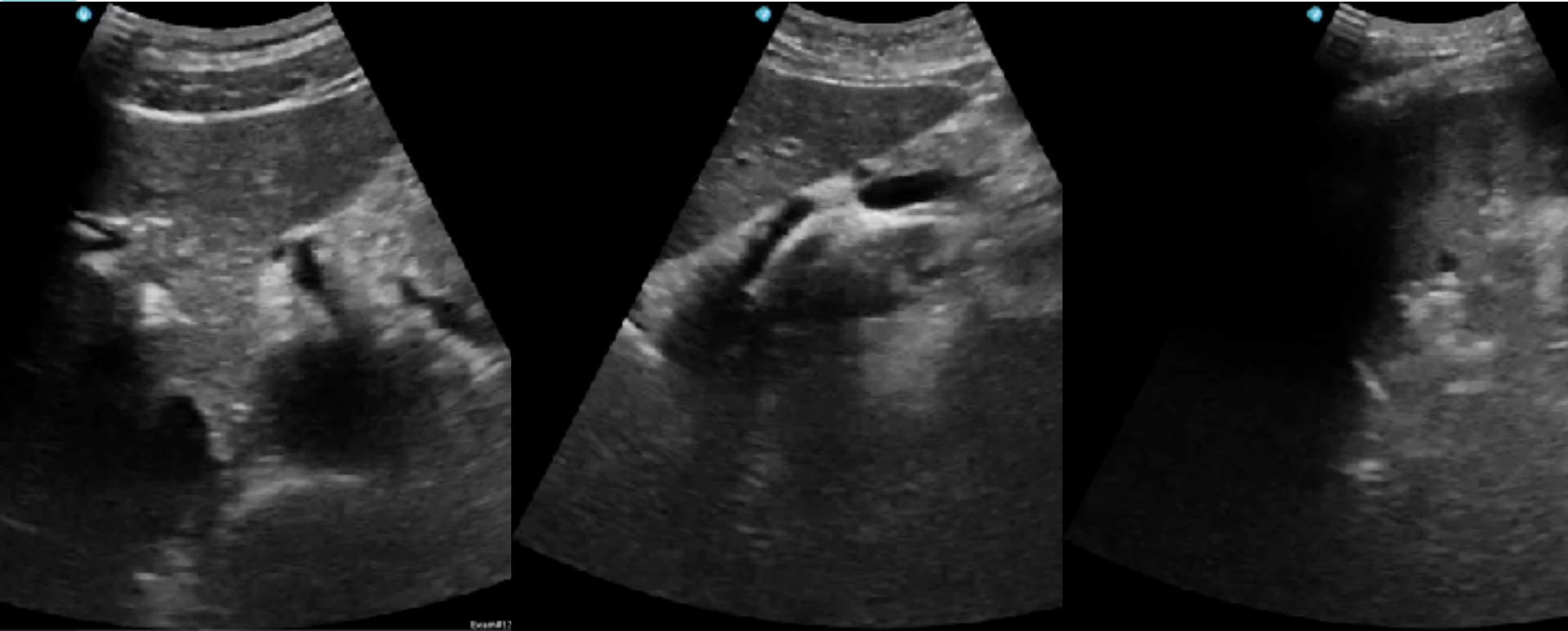
Siemens  
AOCM Arise

2022/06/04  
11:15:07

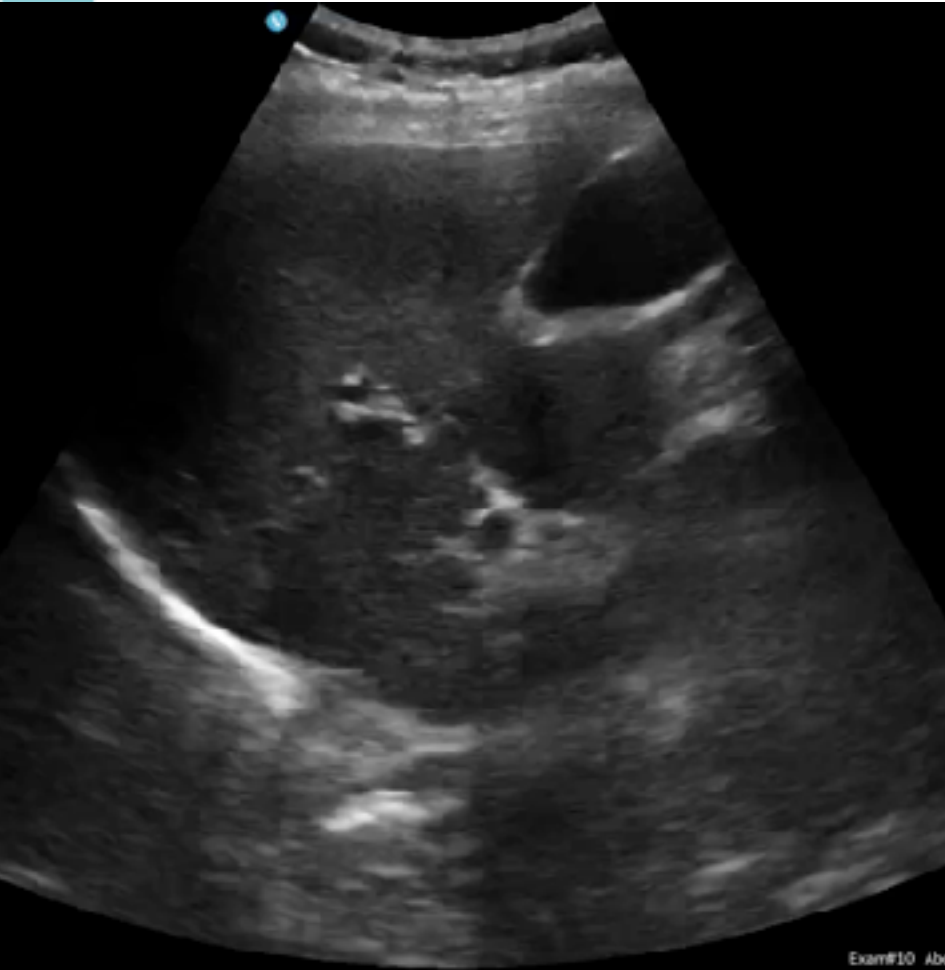# Celiac trunk & SMA



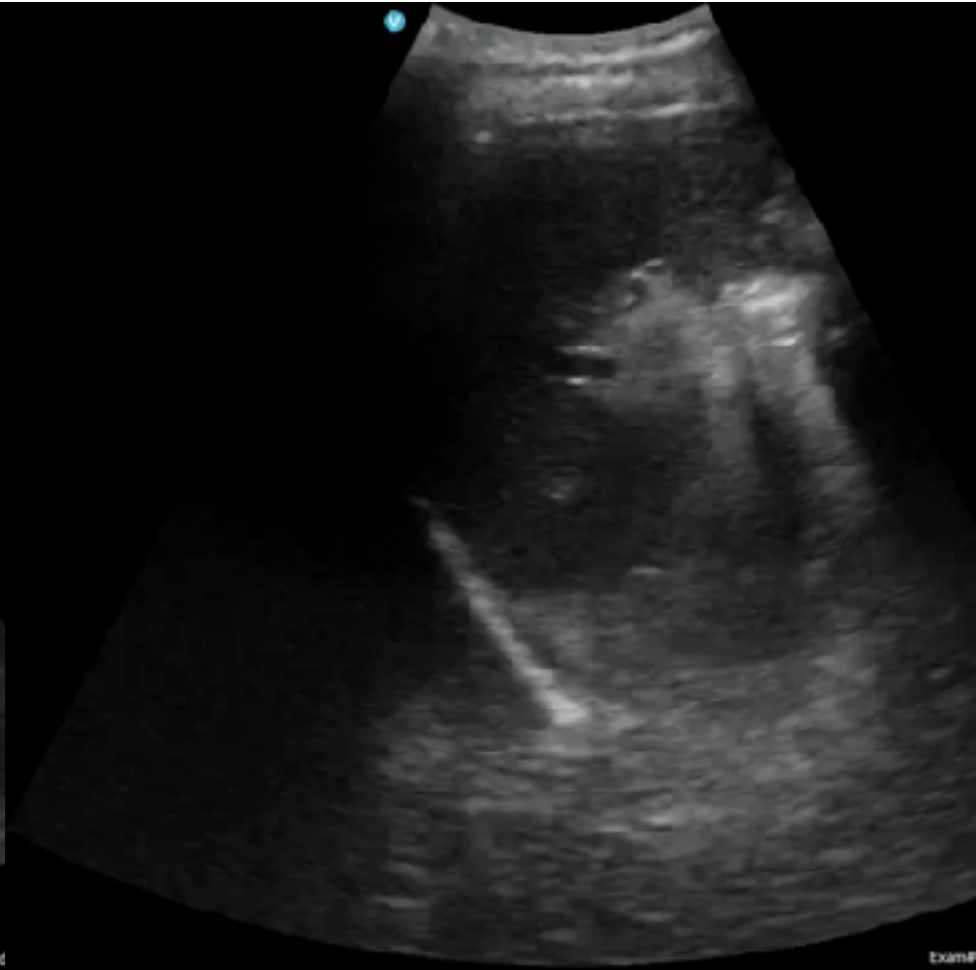# Pancreas



# RUQ & LUQ views

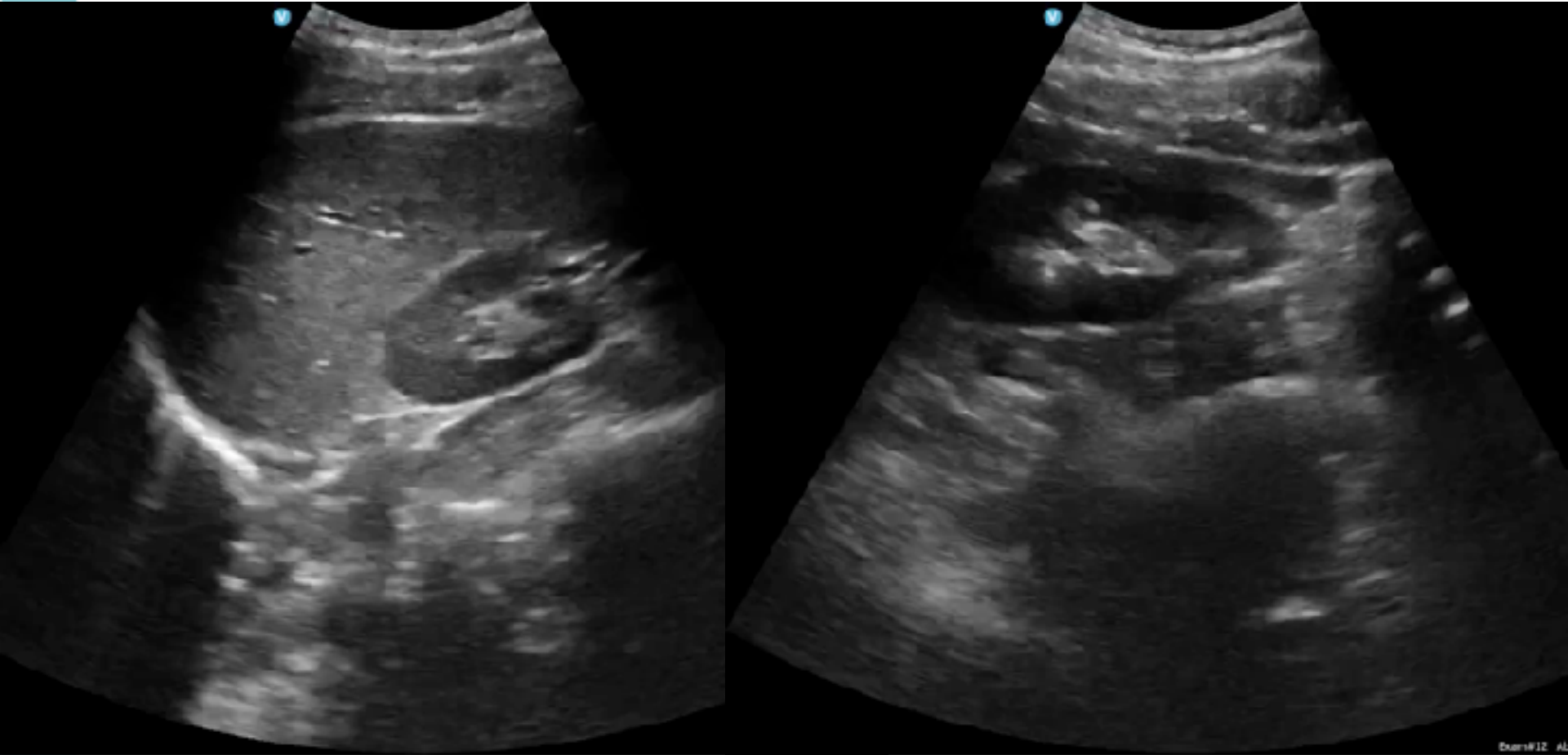


Exam#10 Abd



Exam#

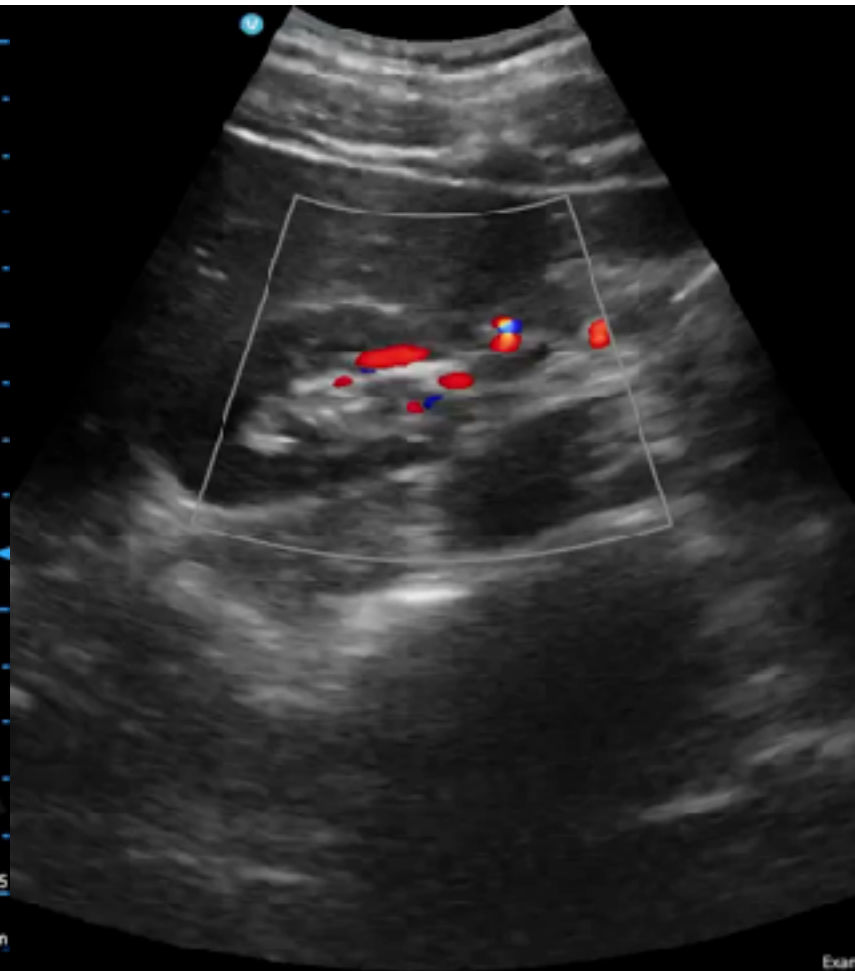
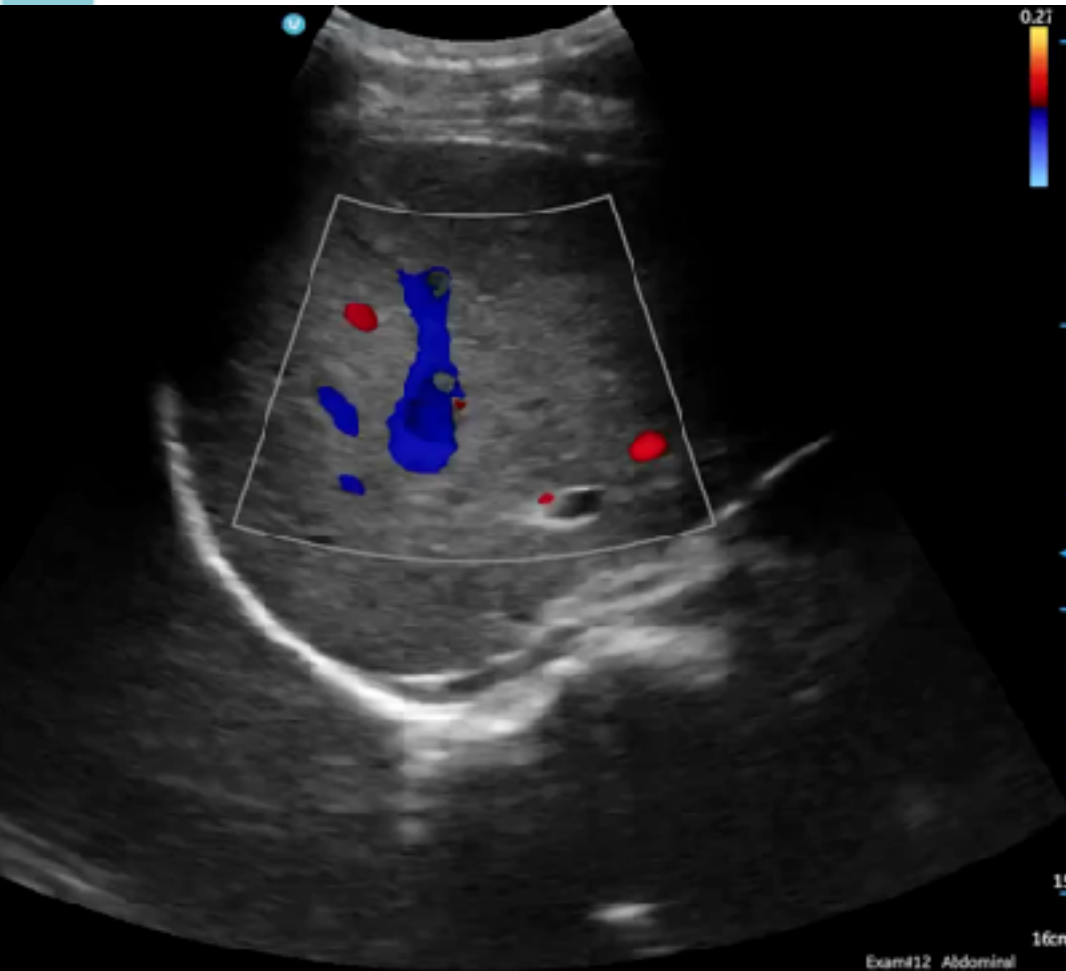
# Both kidneys & psoas muscles



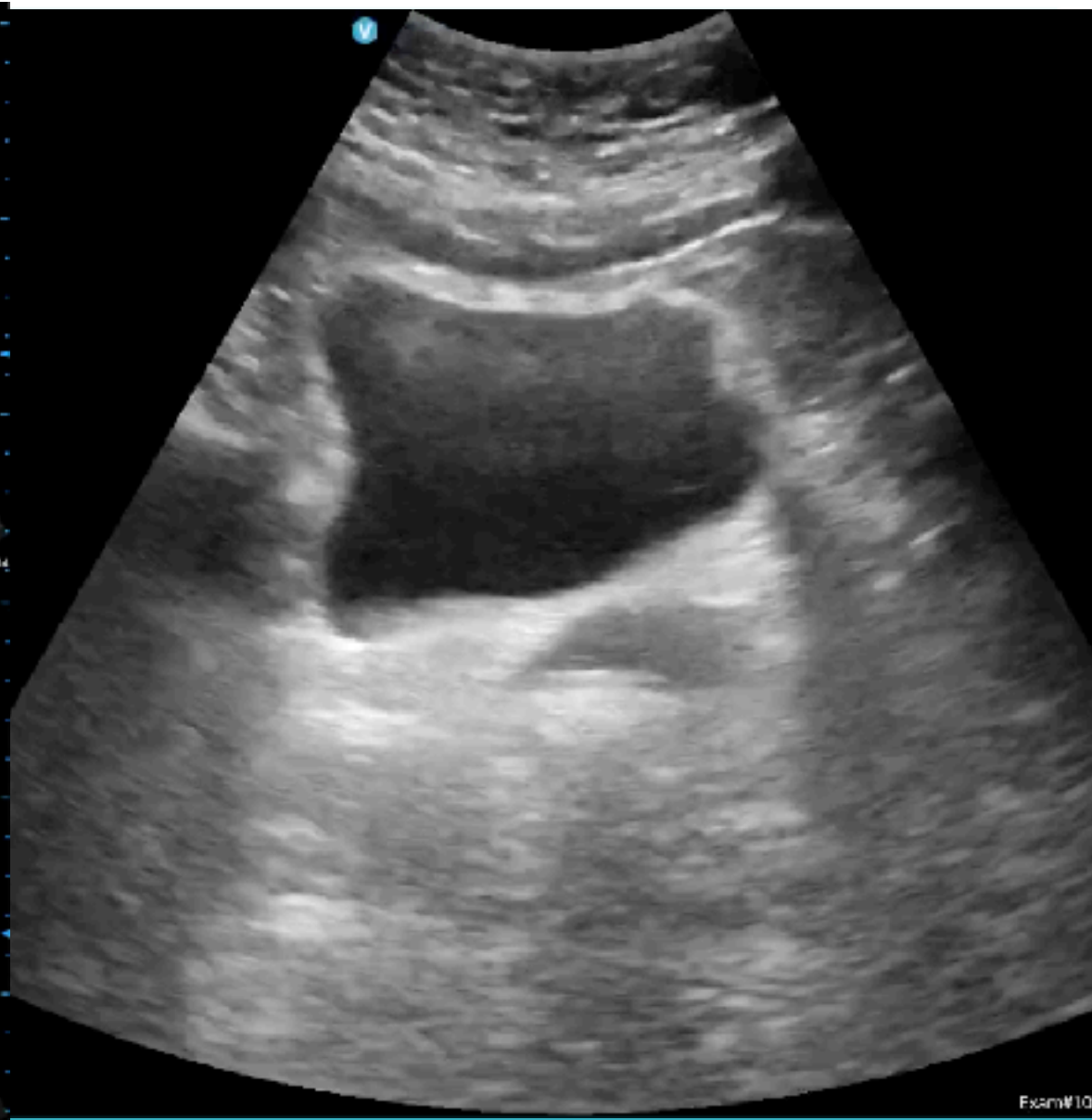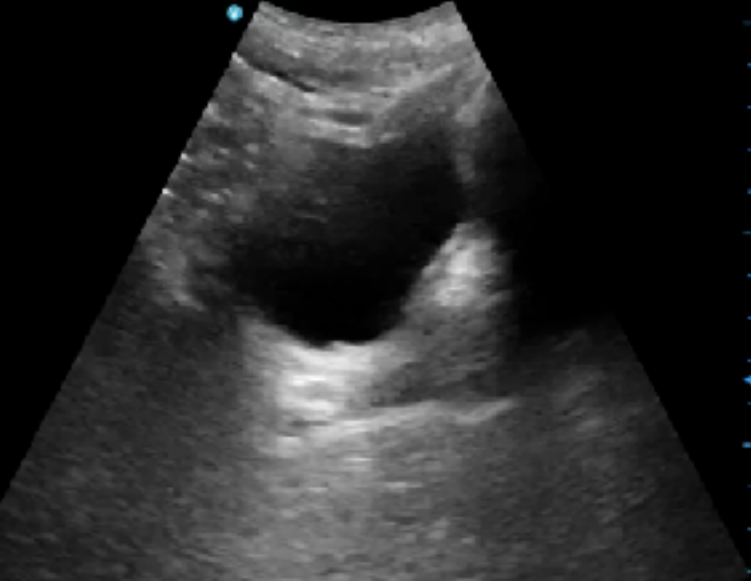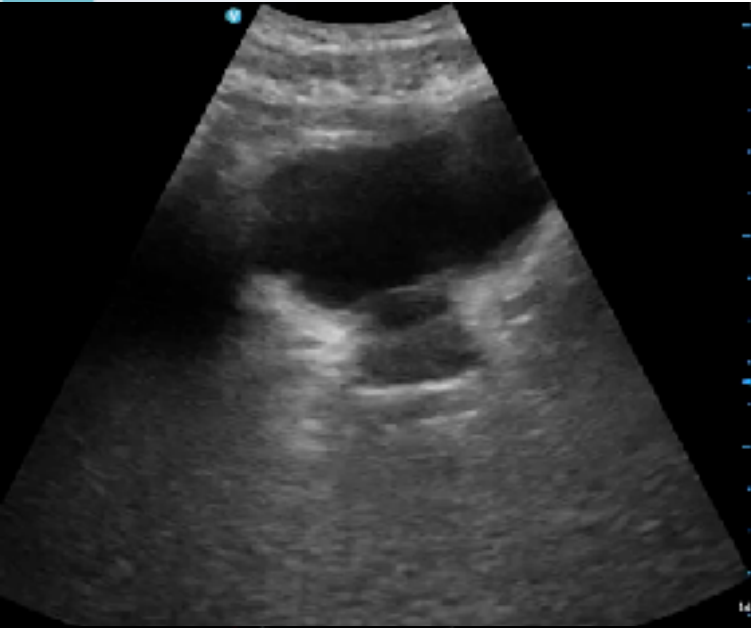
Exam 112, Al.



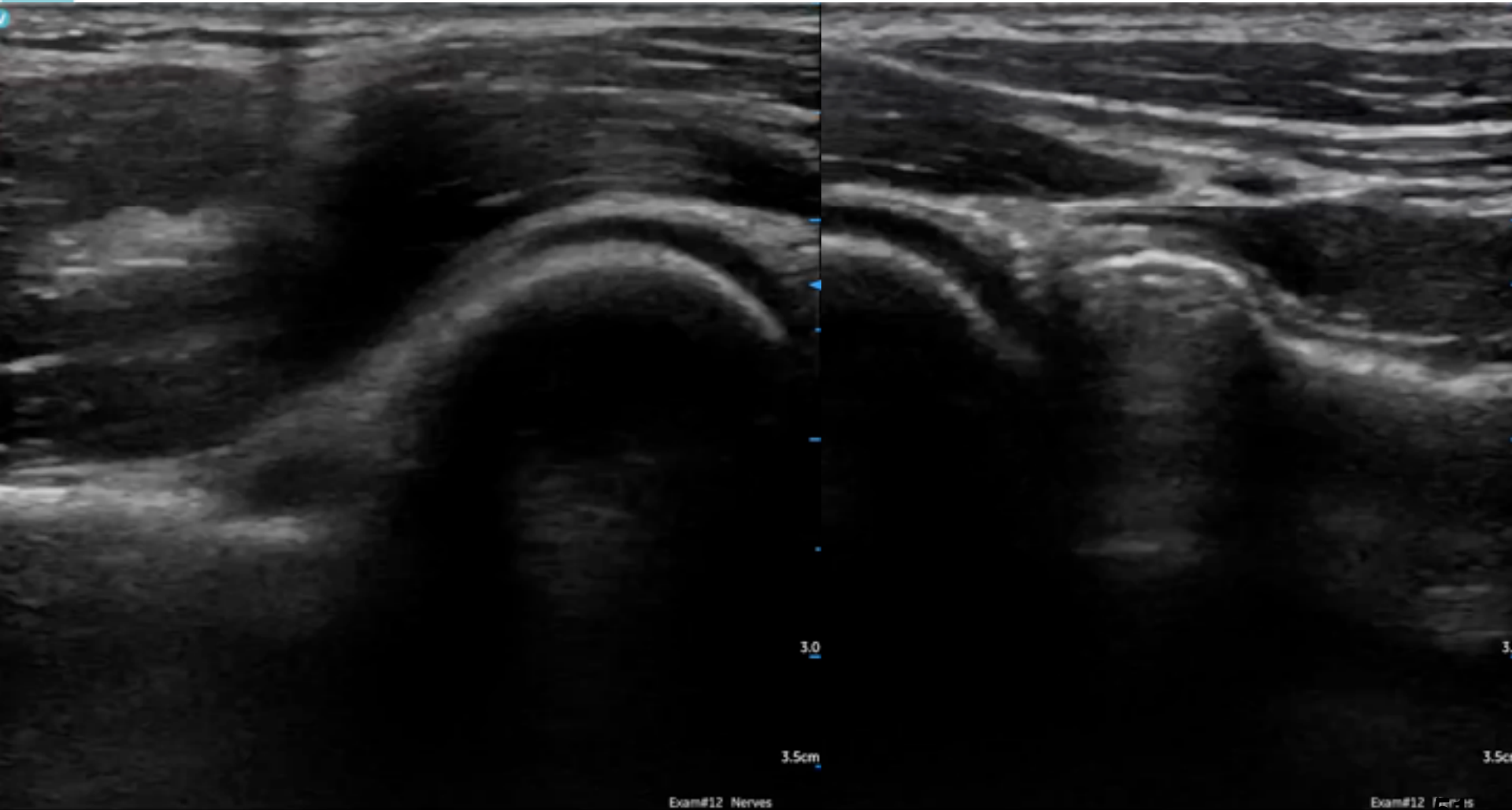
# Solid organ vessels



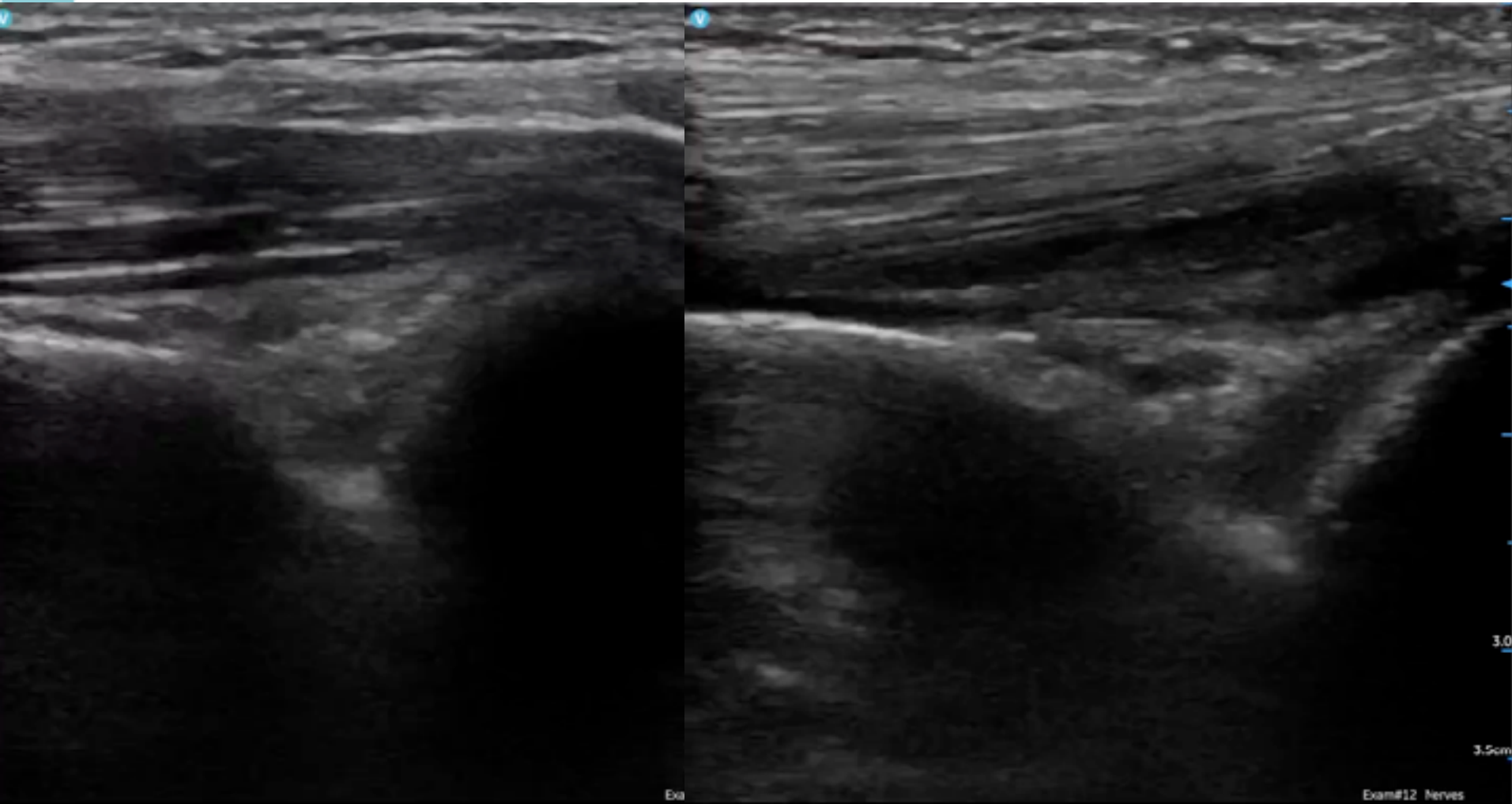
# Urinary bladder & Pelvis



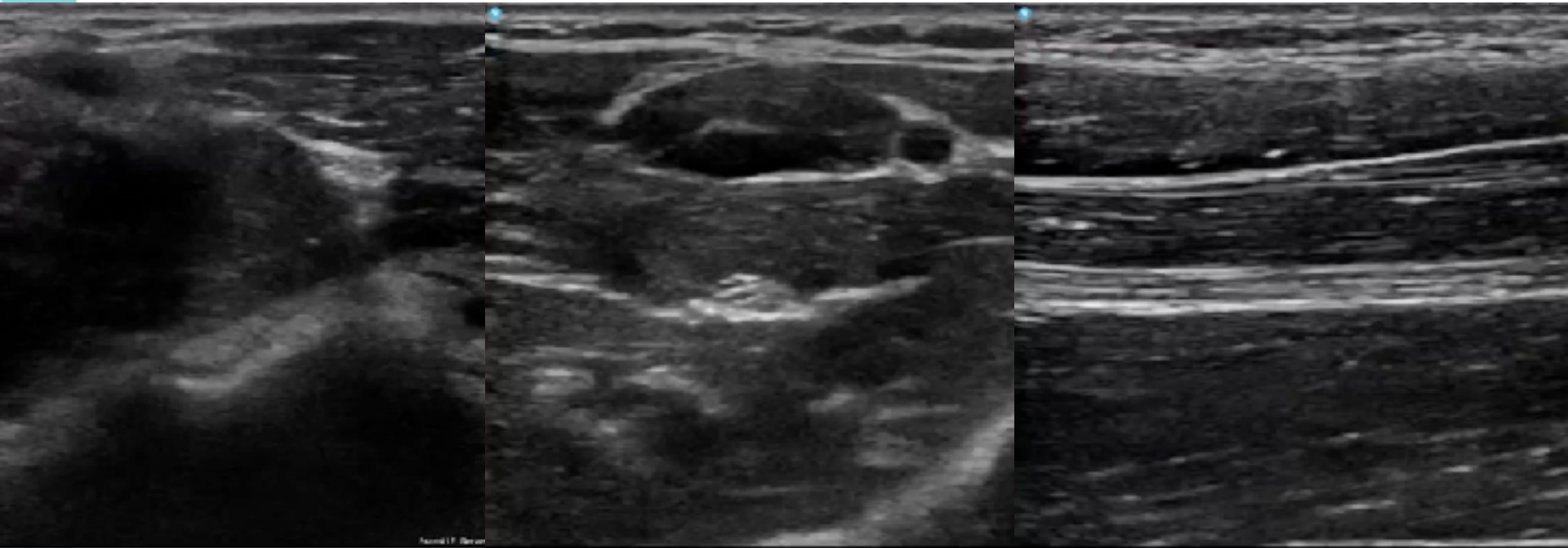
# Radial fossa & Radial head



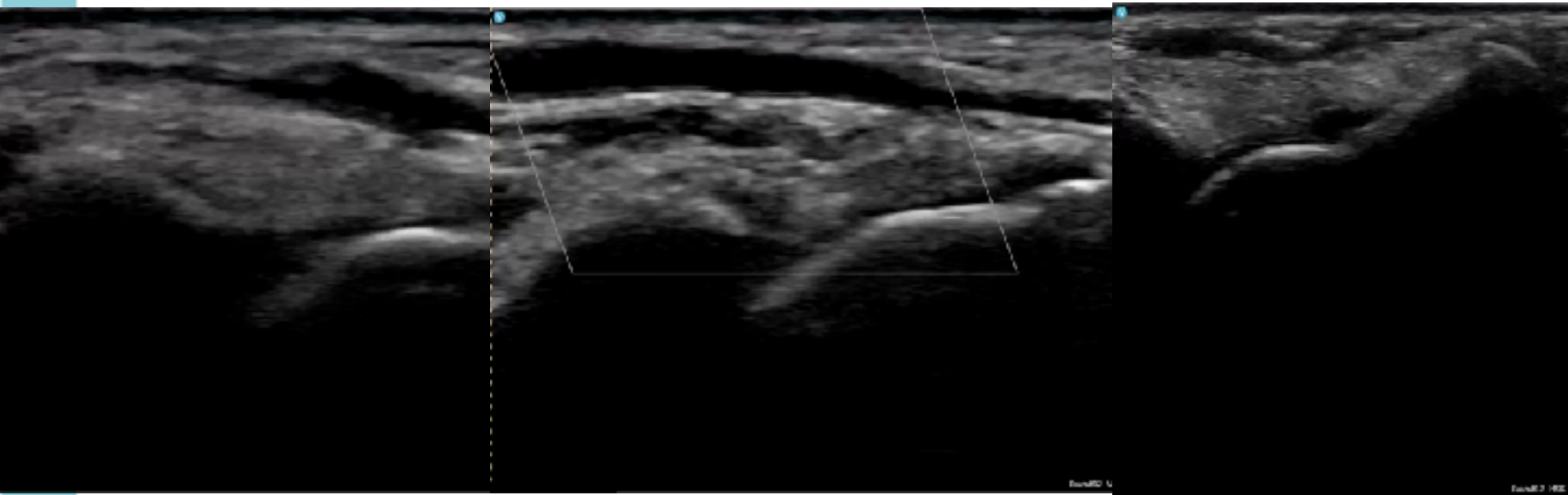
# Coronoid & Olecranon fossa



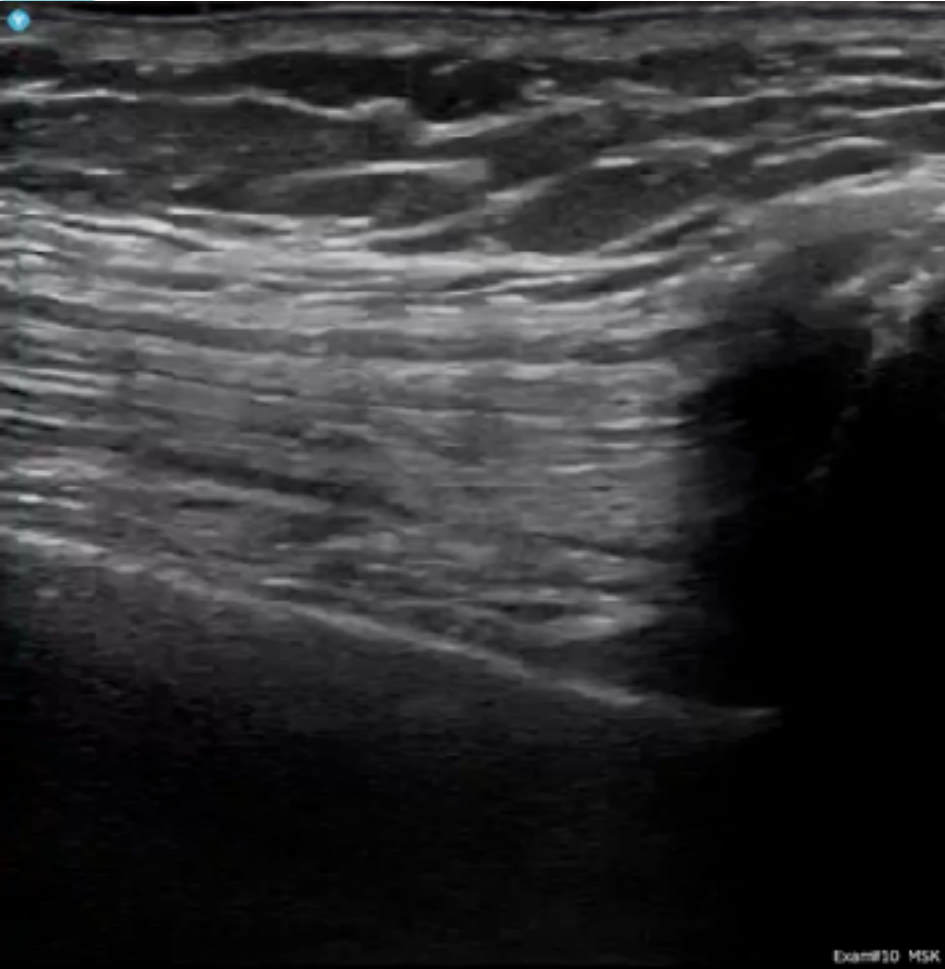# Forearm nerves



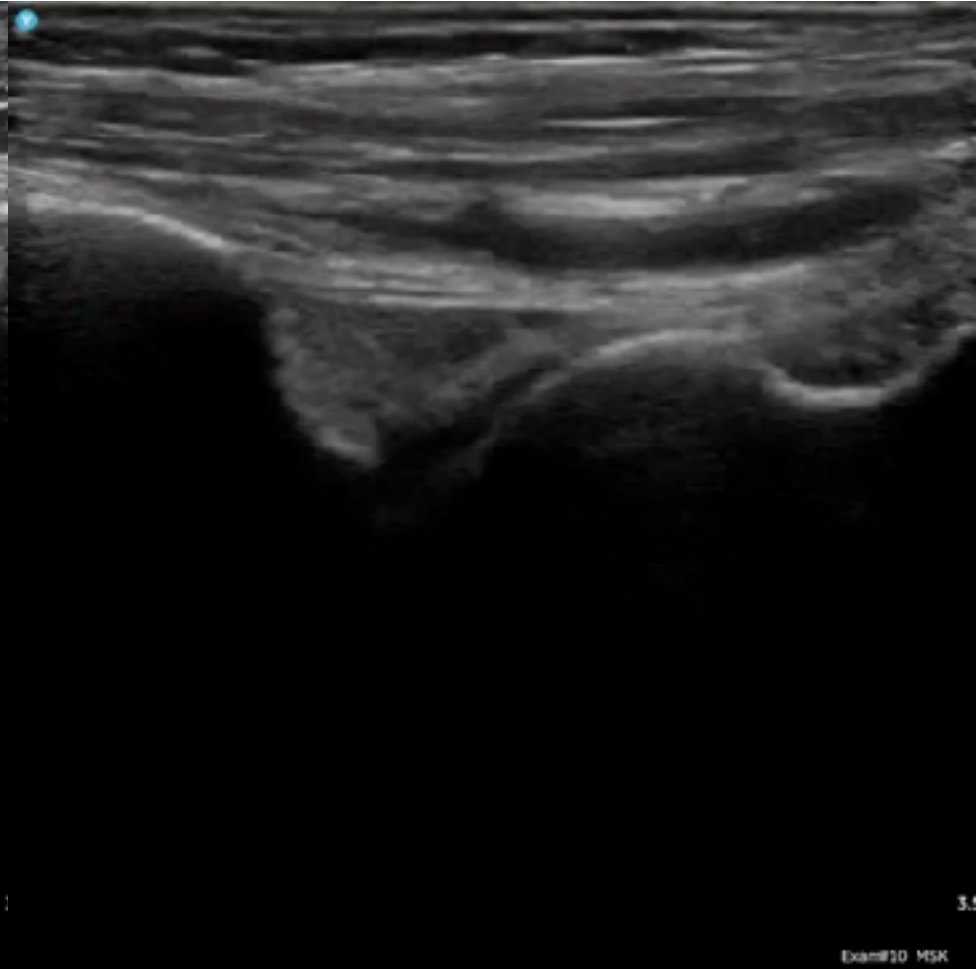# Radial artery & Scaphoid



# Joint effusion



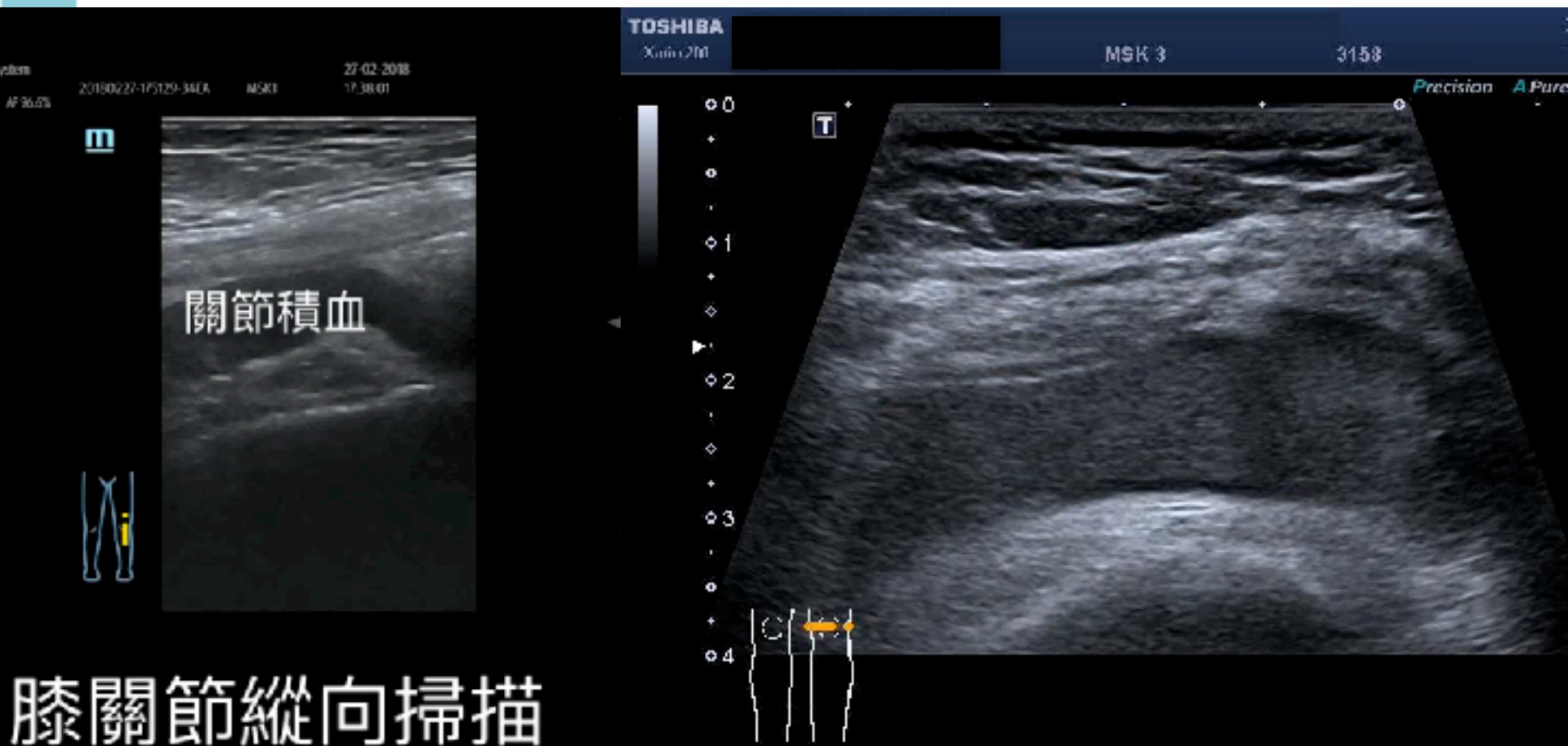
Exam#10 MSK



Exam#10 MSK

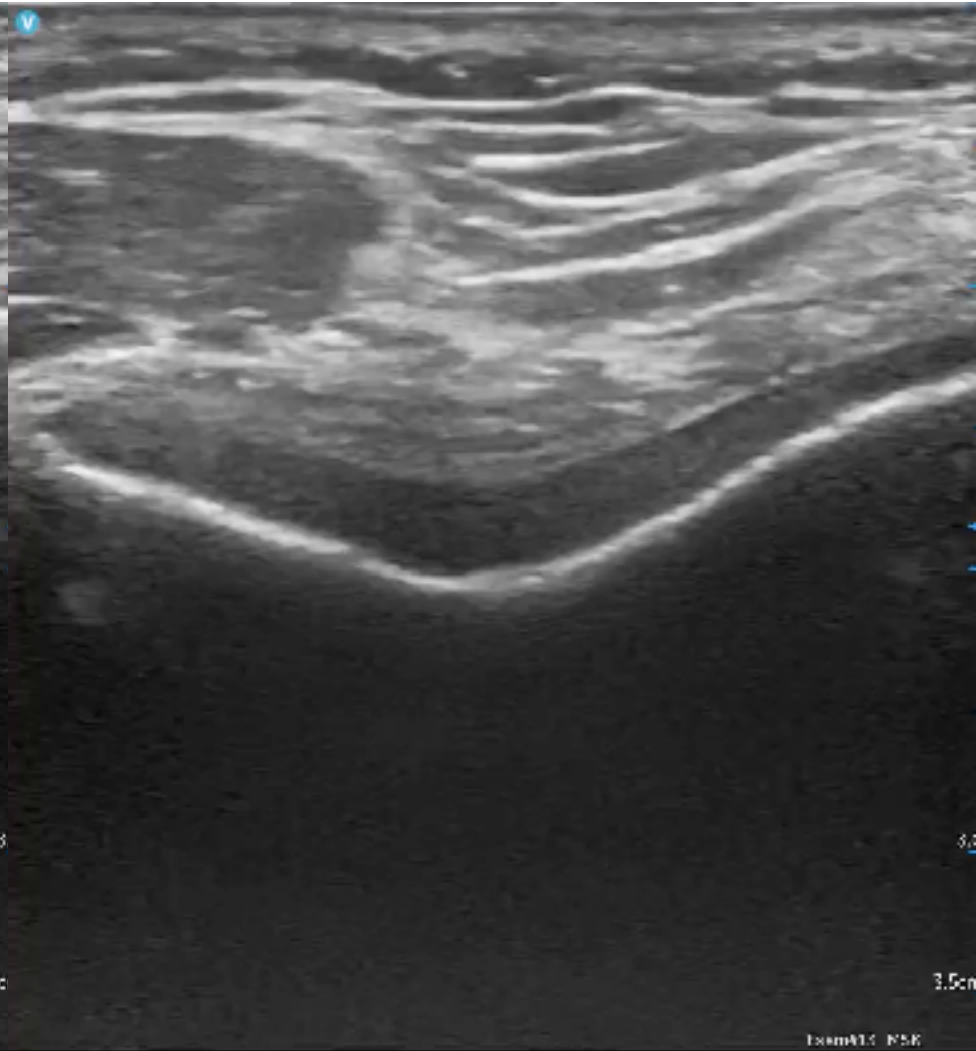
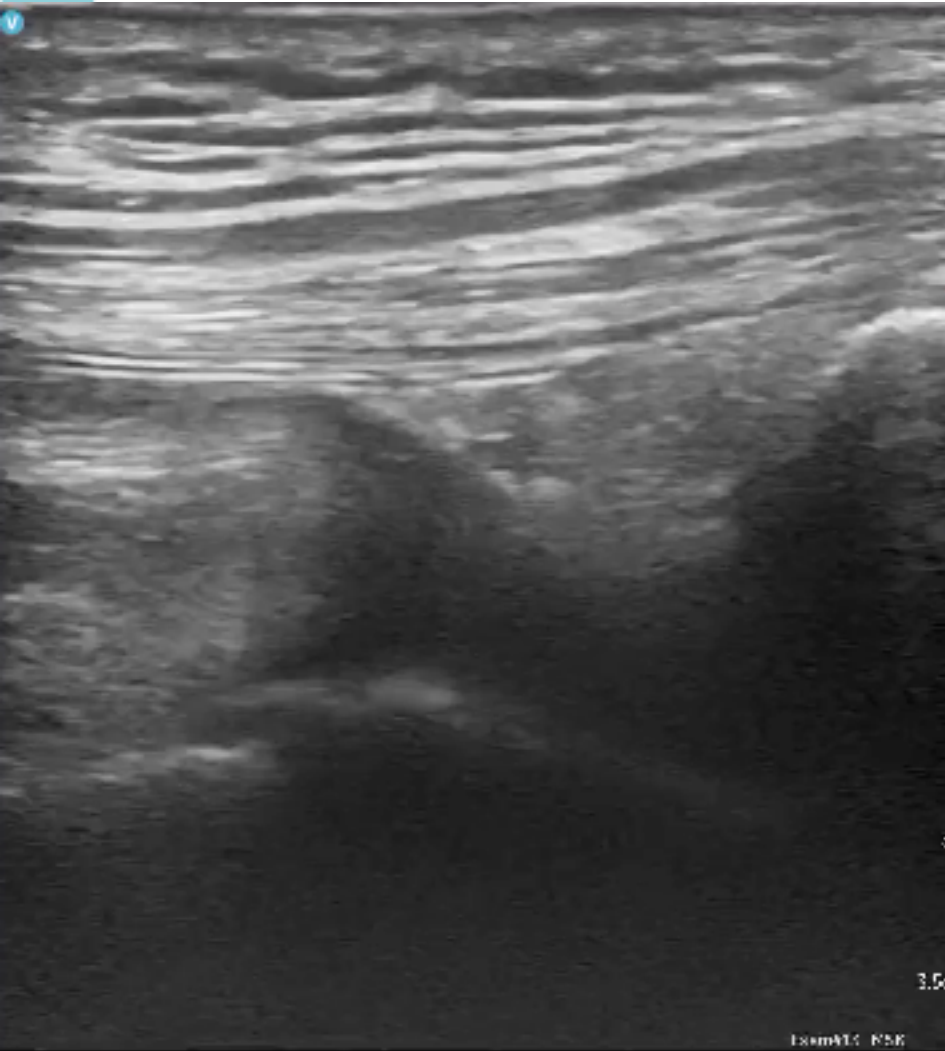


# Joint effusion & aspiration





# Dynamic evaluation



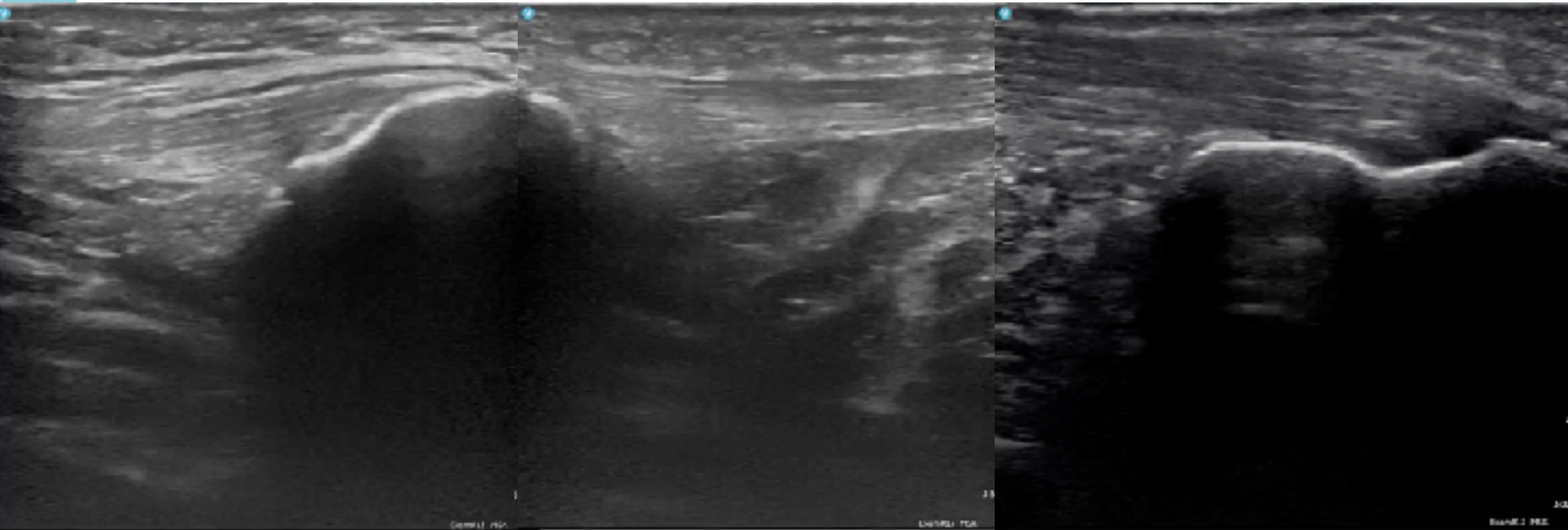
# Major tendons



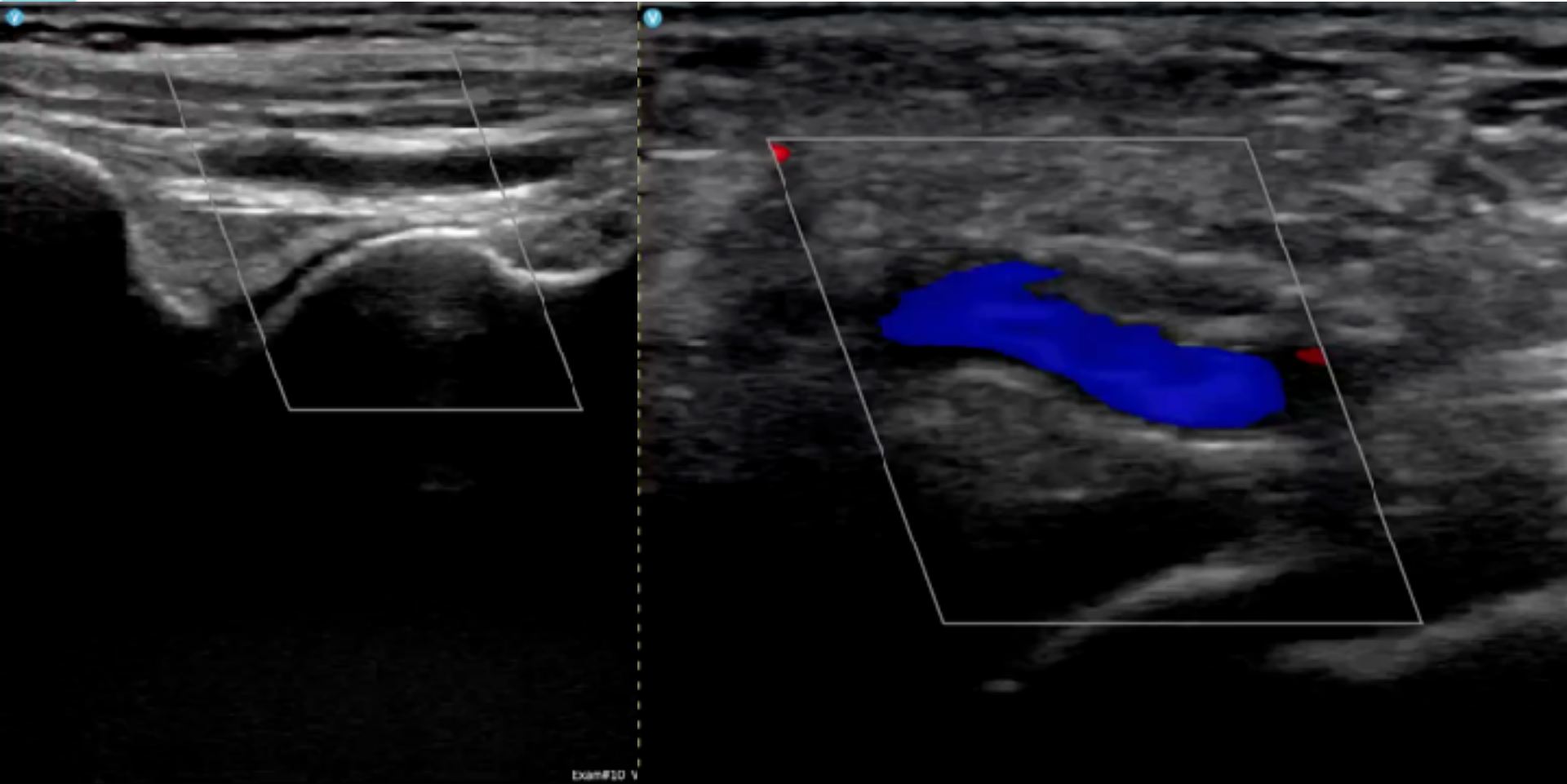
**Quadriceps**

**Patellar**

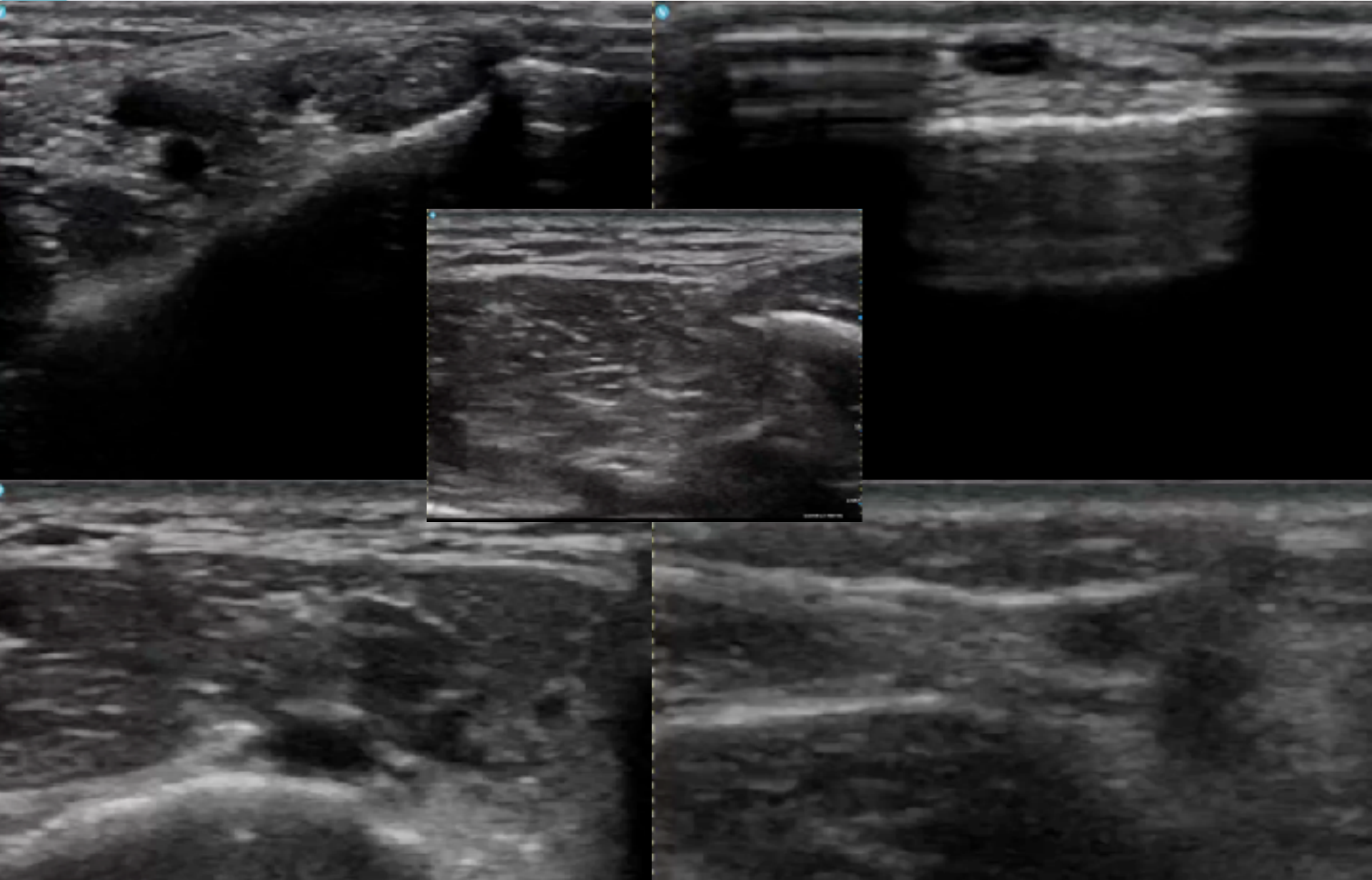
**Achilles**



# Tibia artery (anterior & posterior)

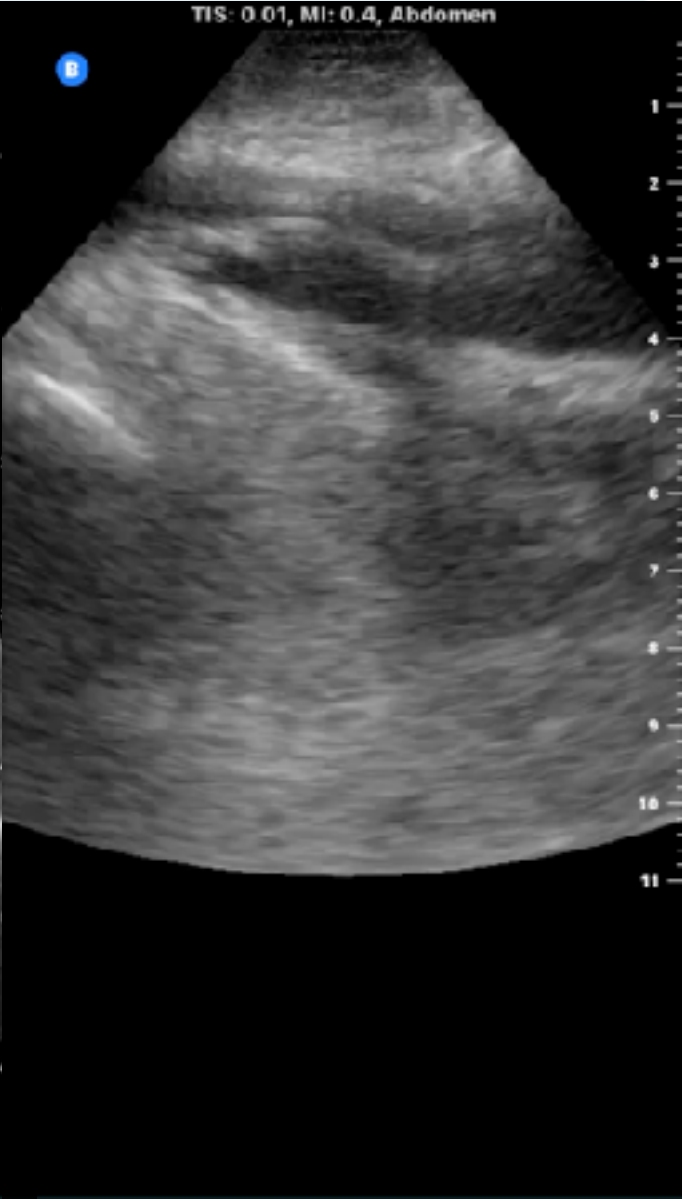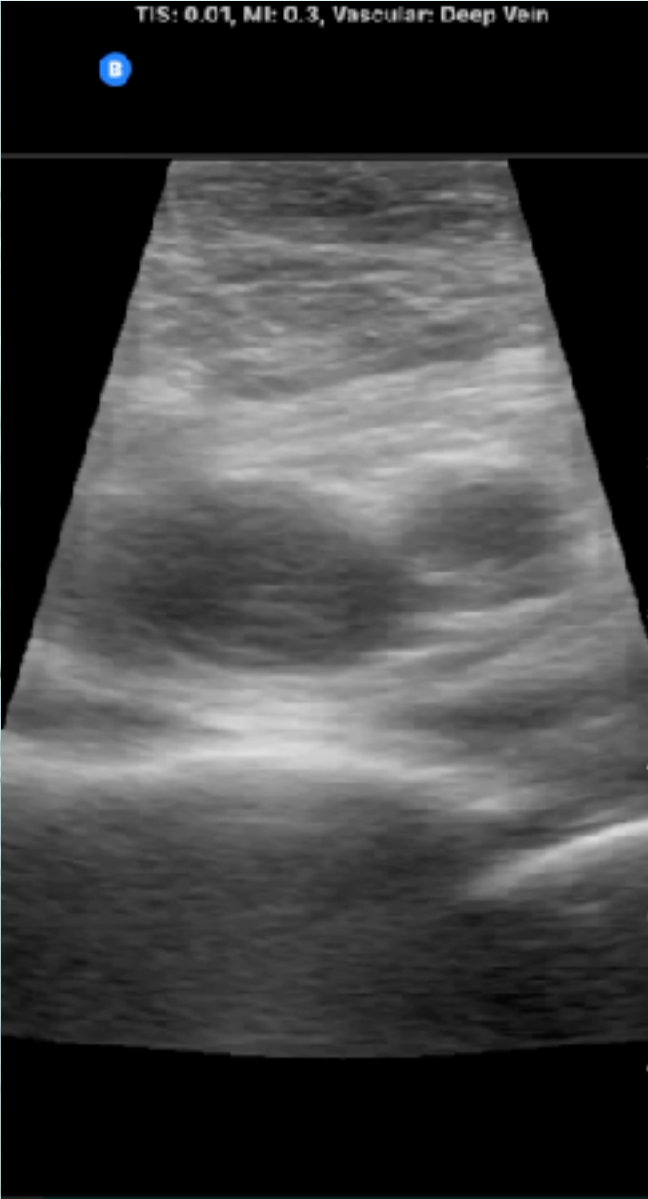
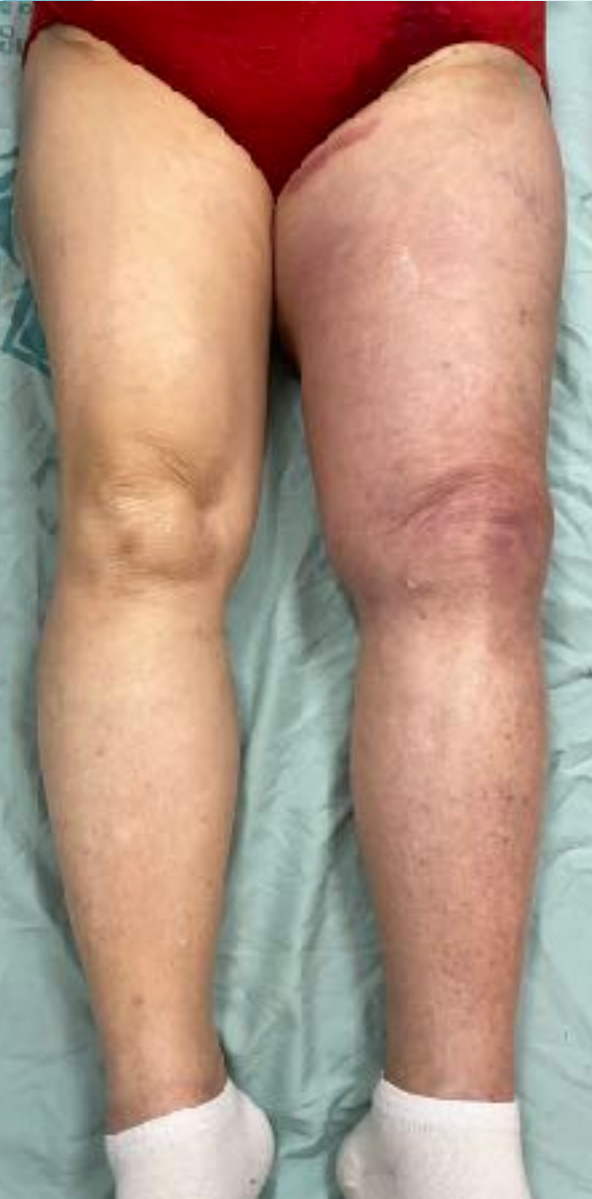


# Ankle block





# 83, left leg swelling for 3 days



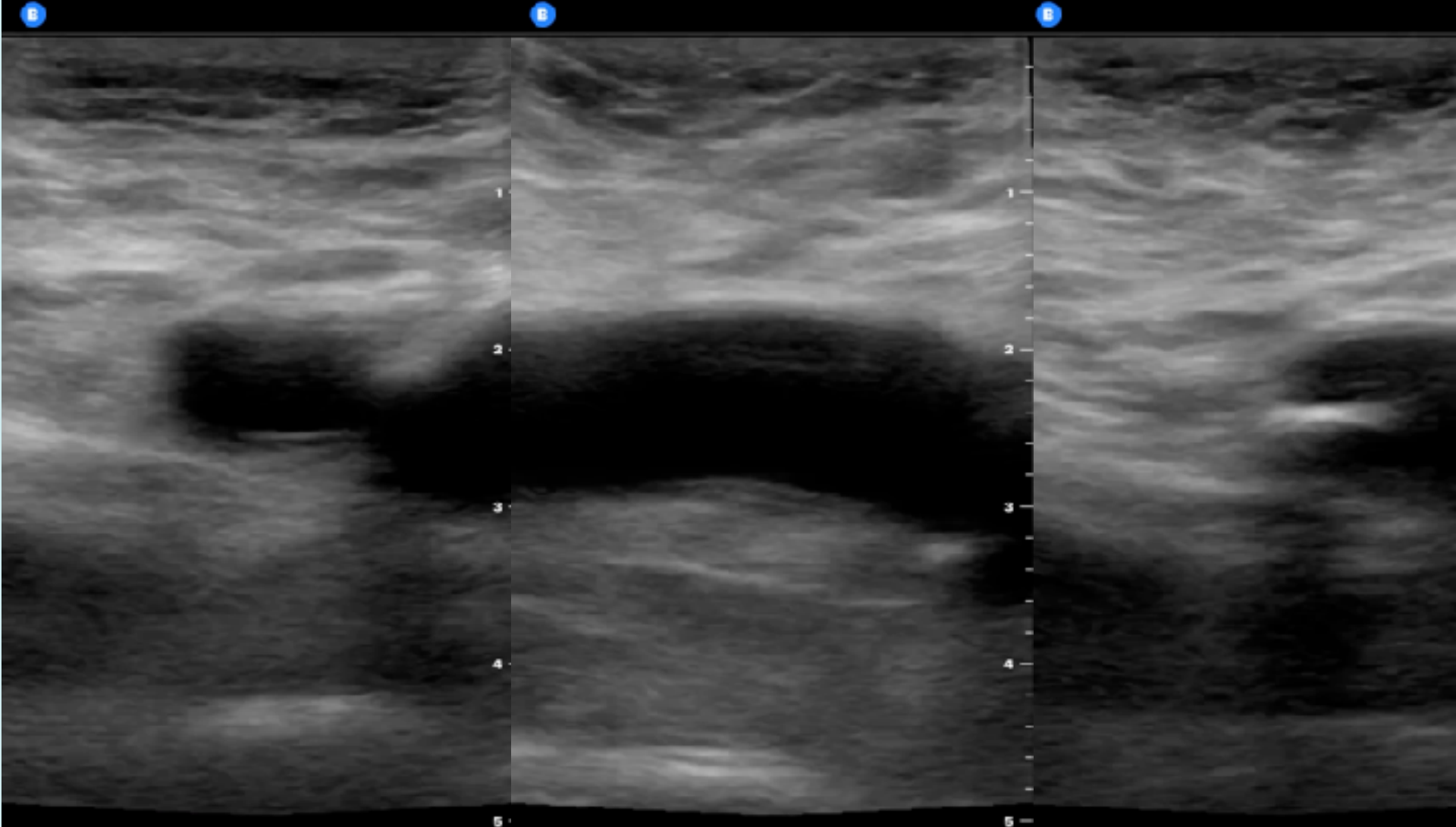
# 99M, IHCA, A line insertion



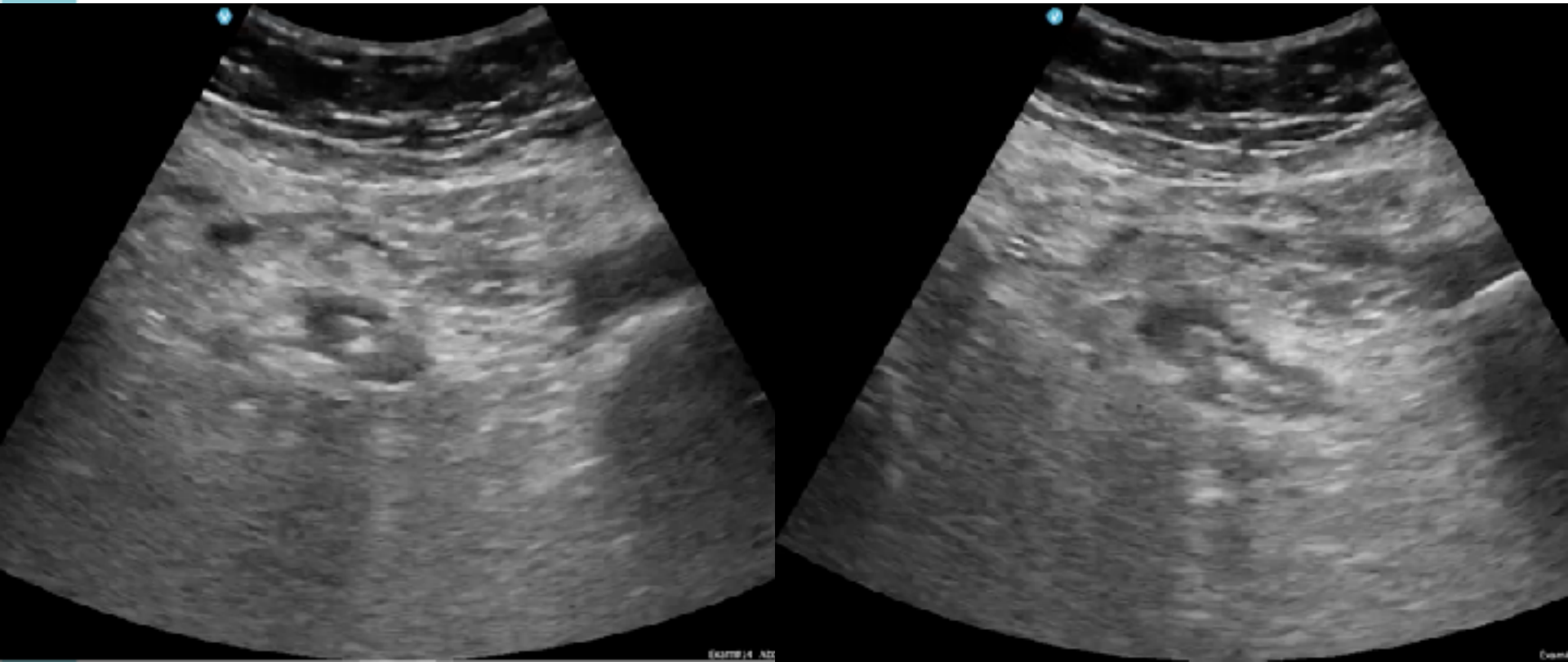
TIS: 0.01, MI: 0.45, Vascular: Access

TIS: 0.01, MI: 0.45, Vascular: Access

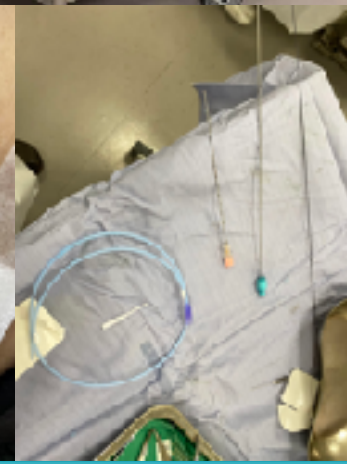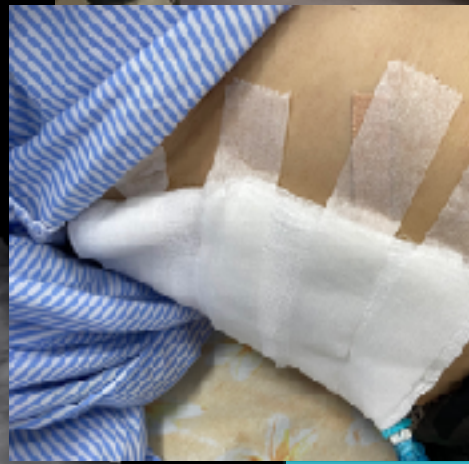
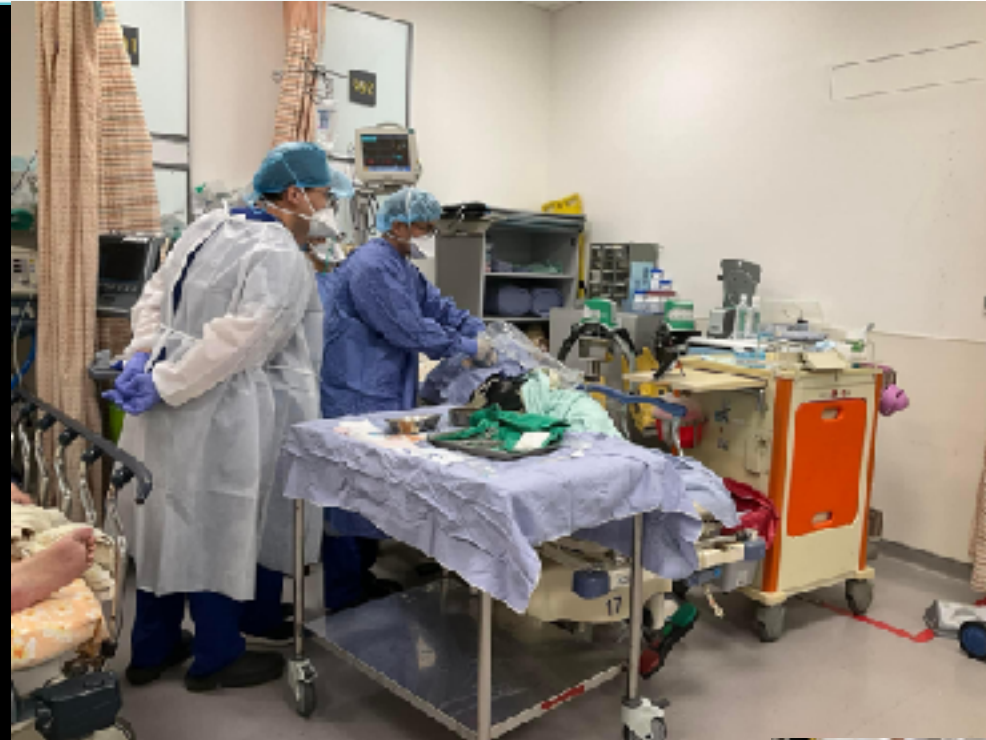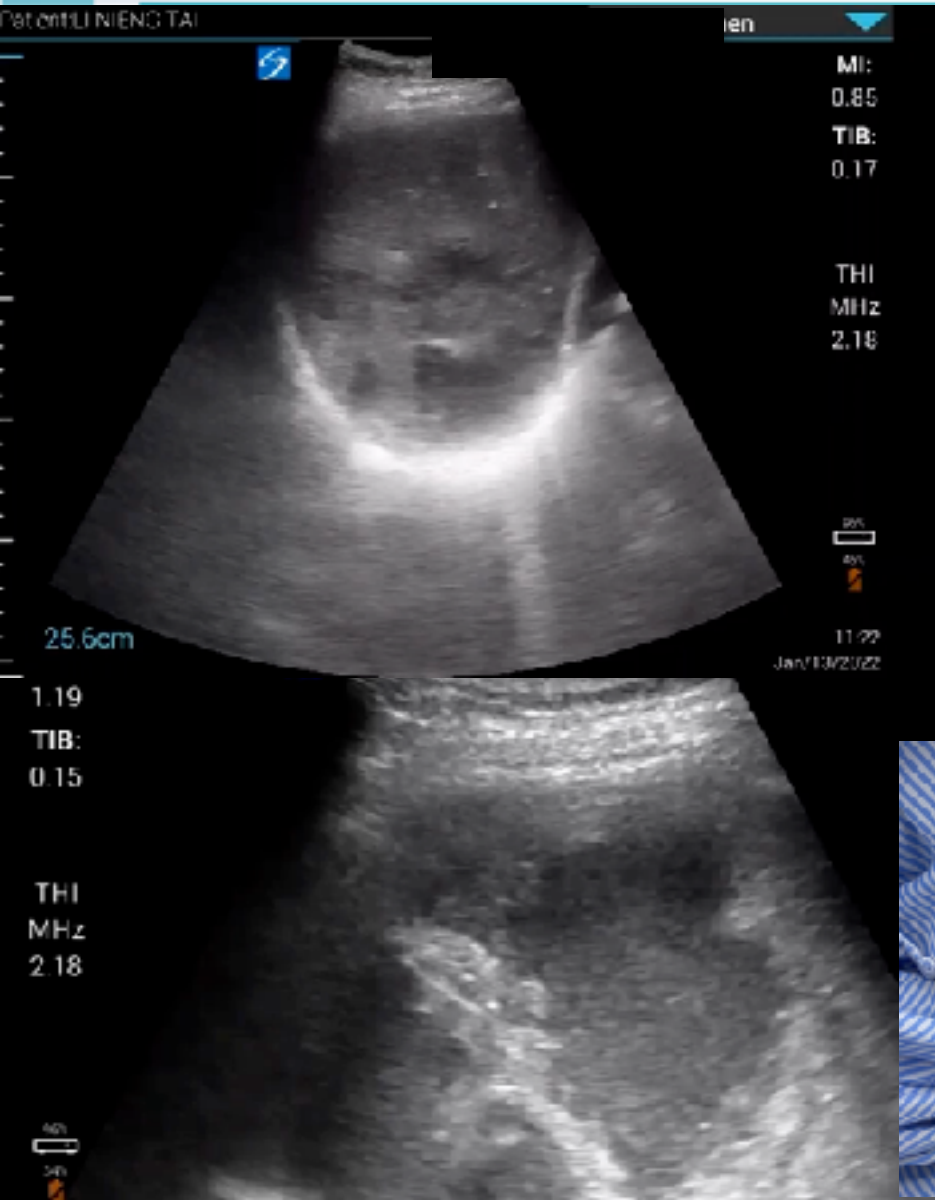
TIS: 0.01, MI: 0.45, Vascular: Access



# Cecal Diverticulitis

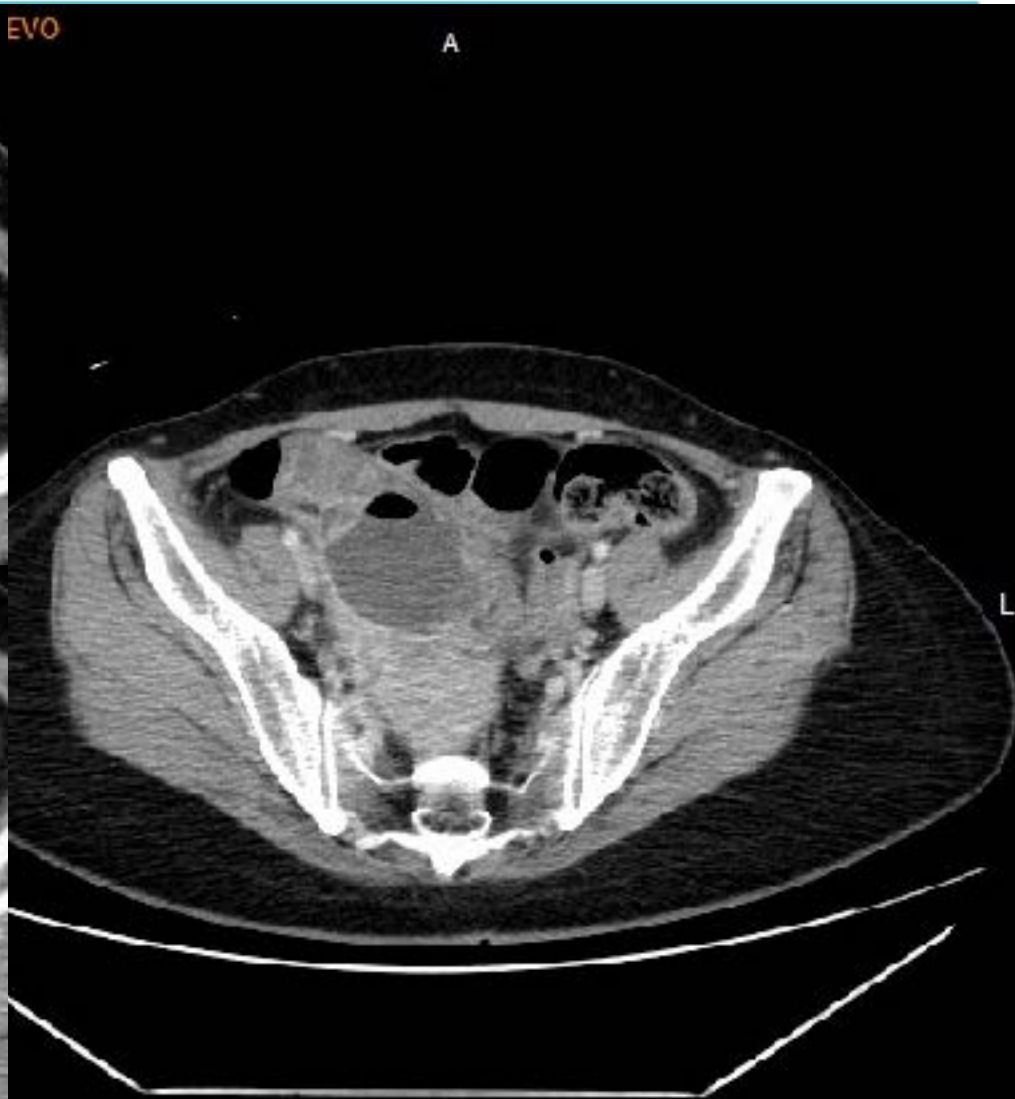
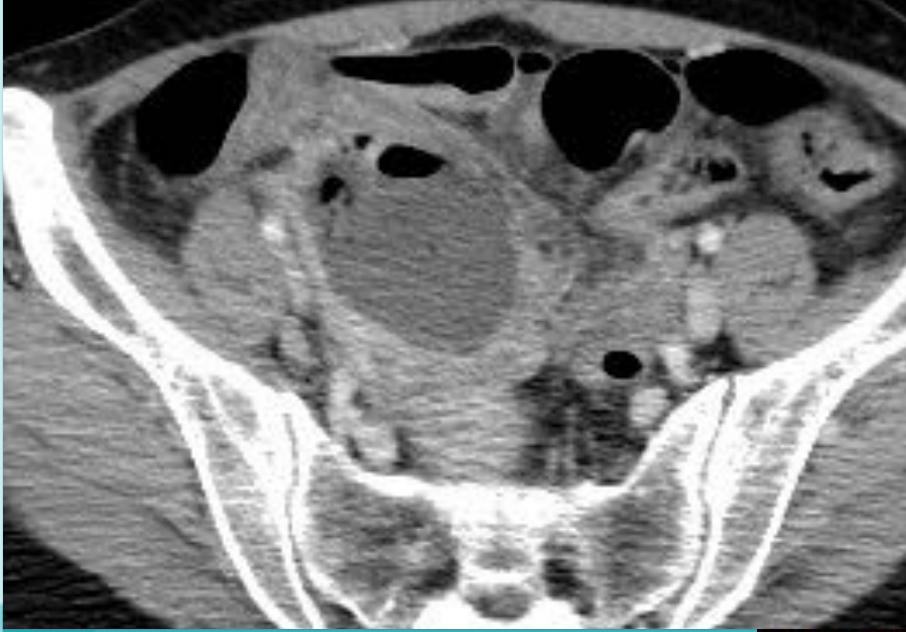
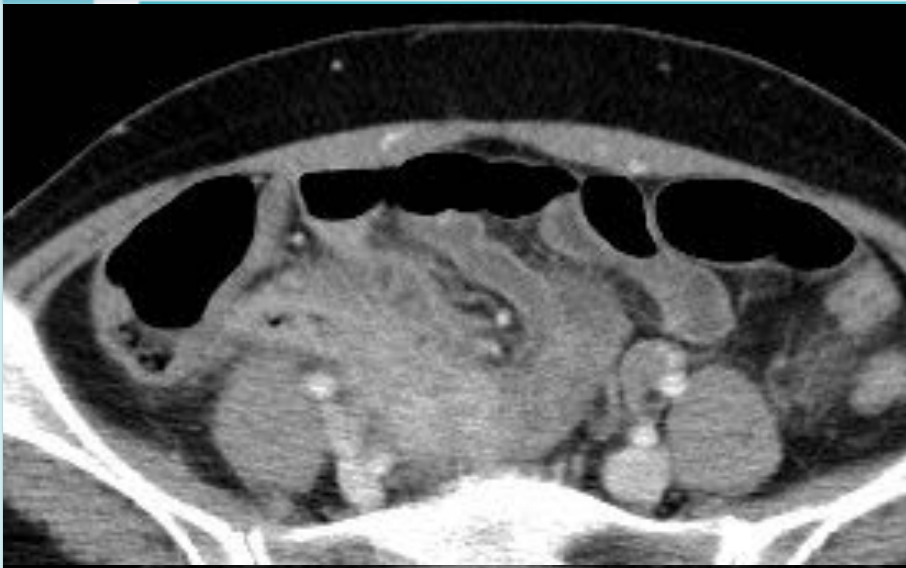# Liver abscess



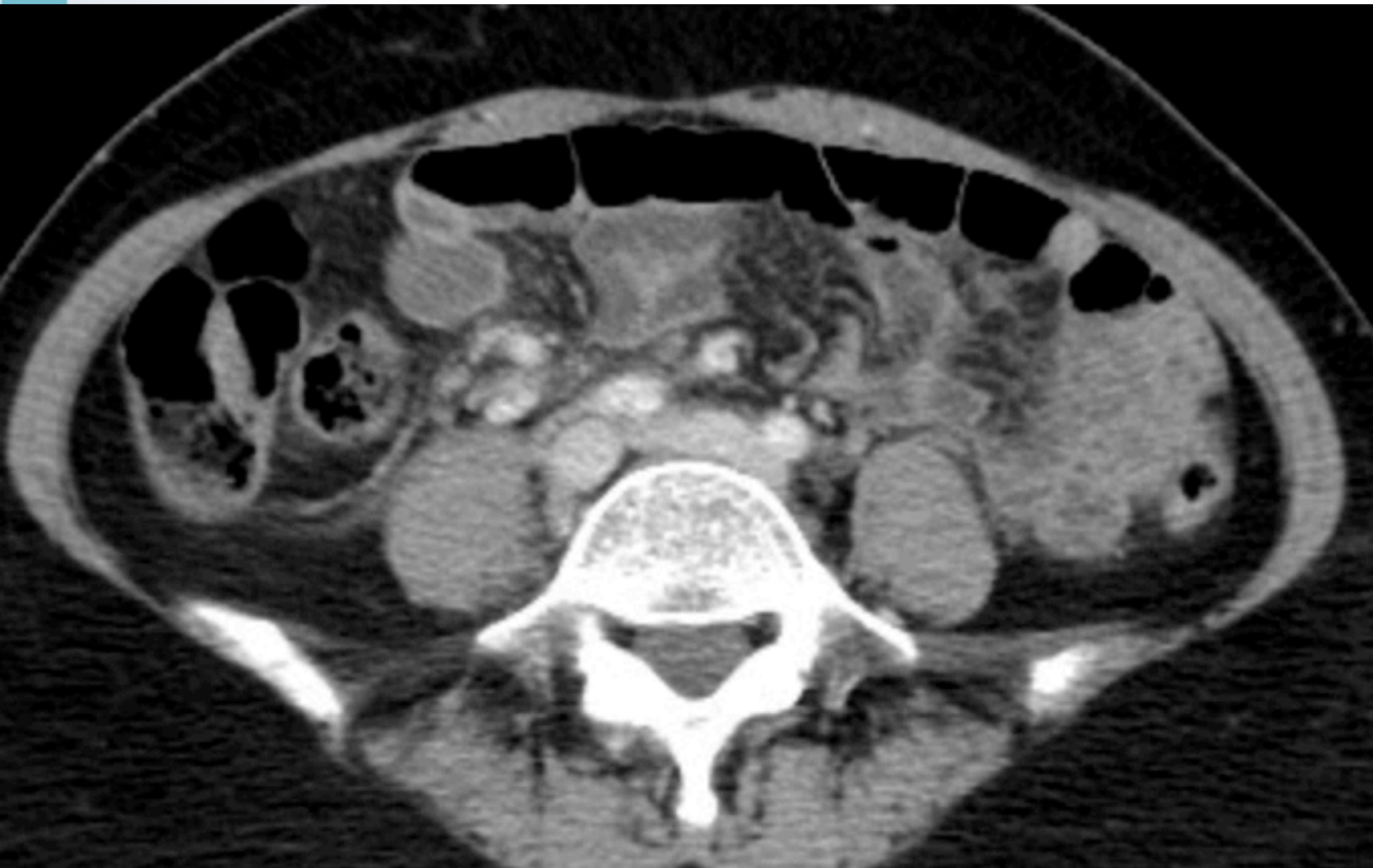

# 50F, RLQ pain for one week

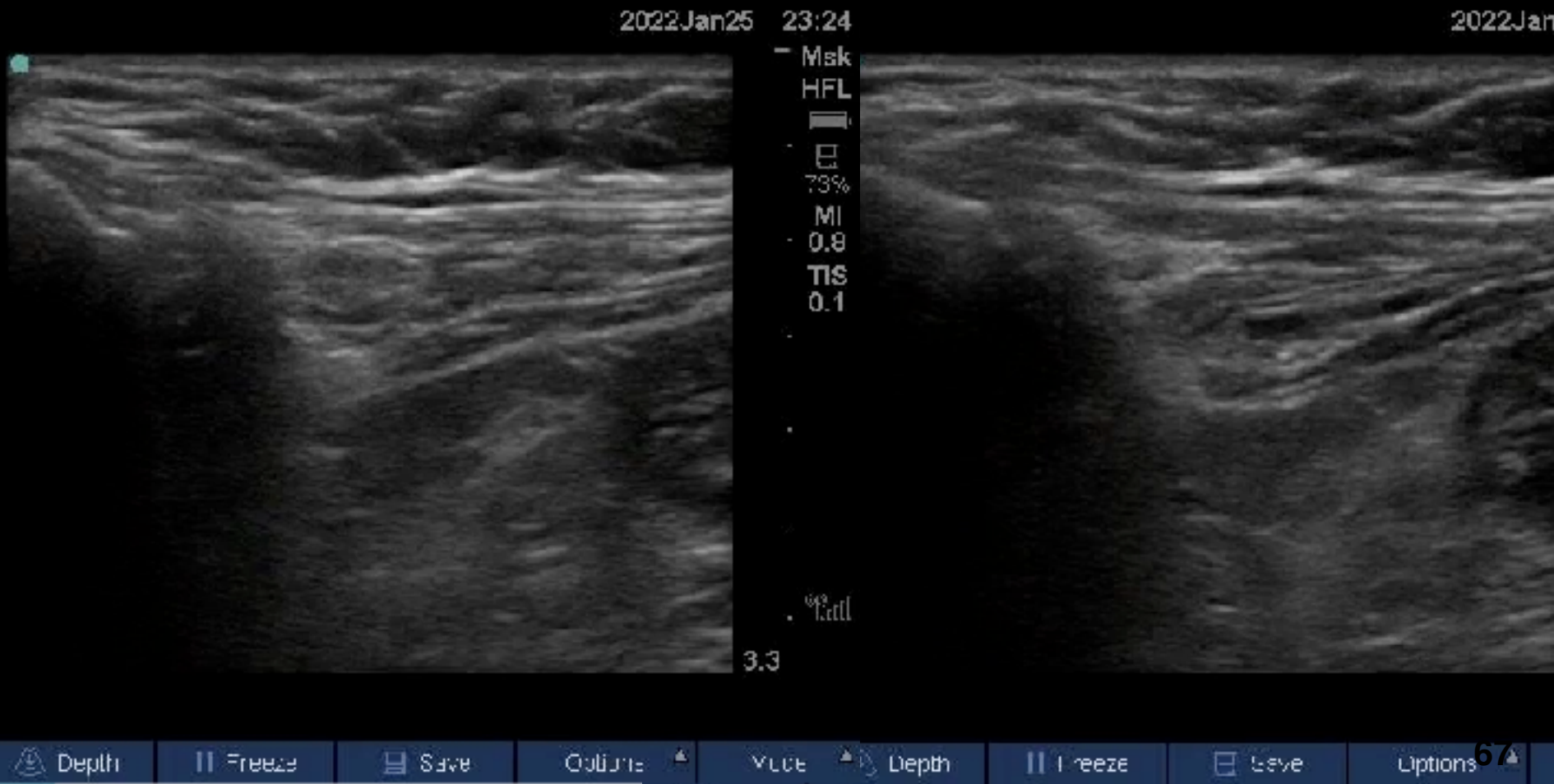

23:30:  
15:37:

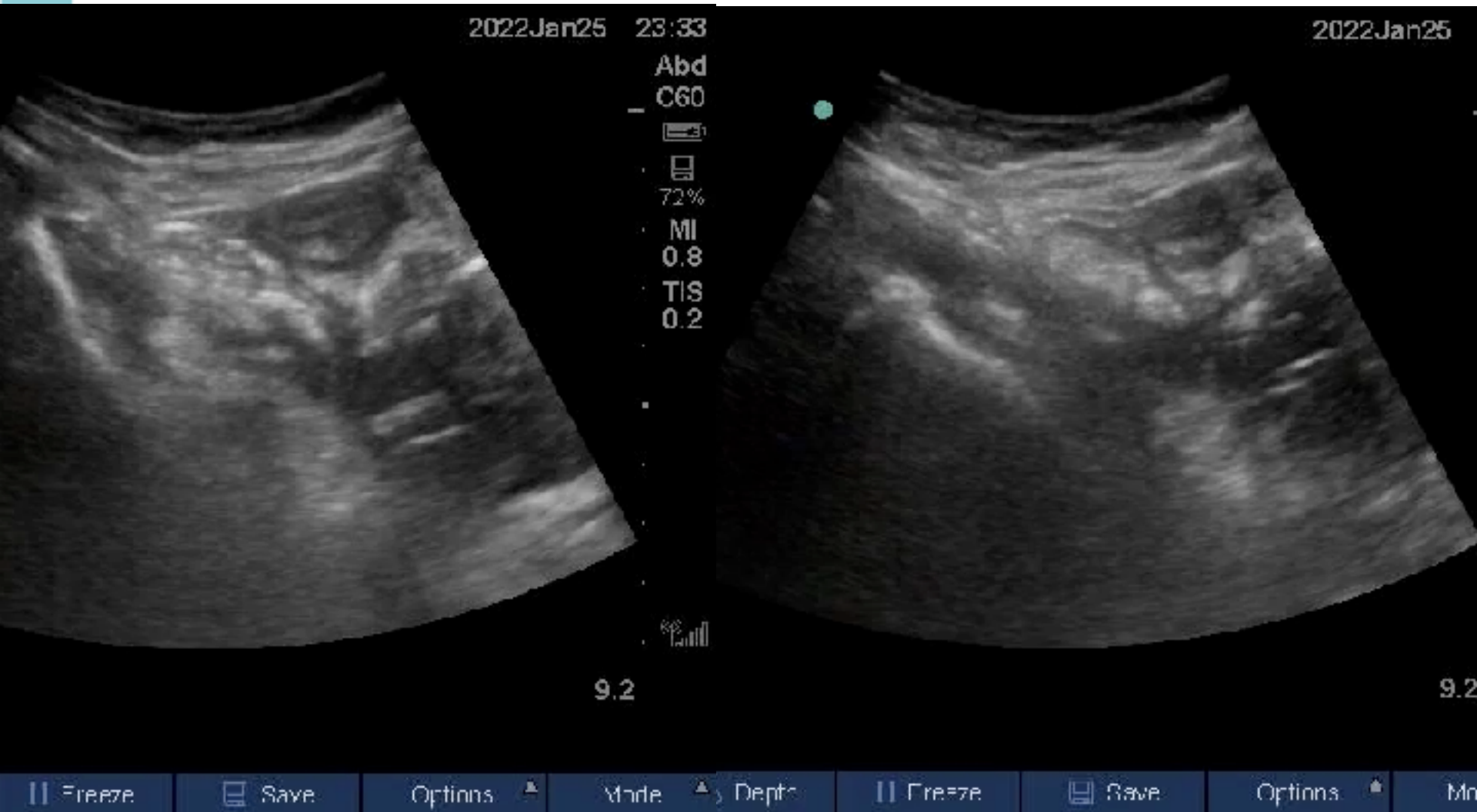# Radiology: no safe route for drainage



# Ilioinguinal & iliohypogastric nerve block



# Rupture appendix & potential route





# Pigtail drainage - guidewire

CHANG  
GenTHI MB

2022Jan25 23:49

Abd  
C60

70%

MI  
0.8

TIS  
0.2

9.2

69

Patient

Auto Gain

Gen

Clip

Page 1/3

# Pigtail drainage - pigtail through guidewire



CHANG  
GenTHI MB

2022Jan25 23:52

Abd  
\_ C60  
70%  
MI 0.8  
TIS 0.2

Patient

Auto Gain

Gen

Clip

Page 1/3

9.2

70

# Pigtail drainage - pigtail through guidewire



CHANG  
GenTHI MB

2022Jan25 23:54

Abd  
C60  
69%  
MI  
0.8  
TIS  
0.2

Patient

Auto Gain

Gen

Clip

Page 1/3

9.2

71



# Pigtail drainage - pigtail

CHANG 2022Jan25 23:54  
GenTHI MB

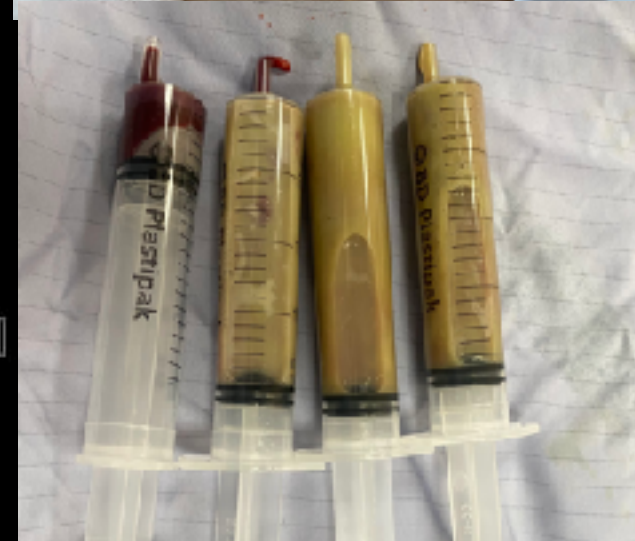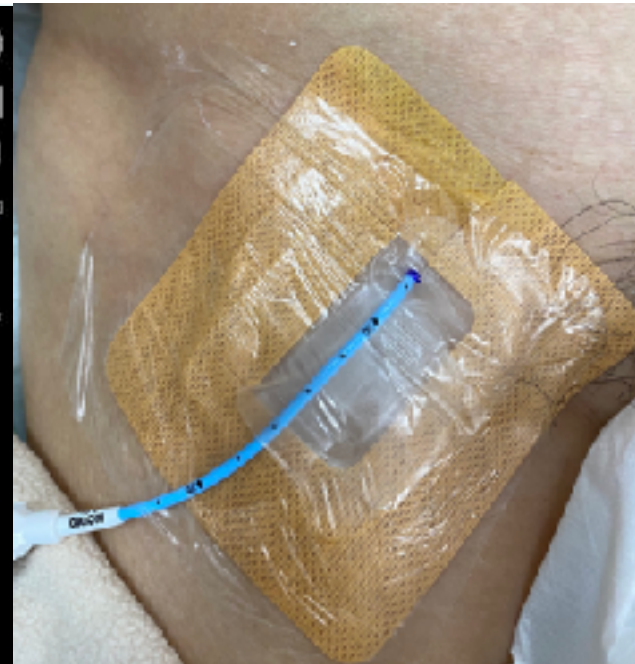
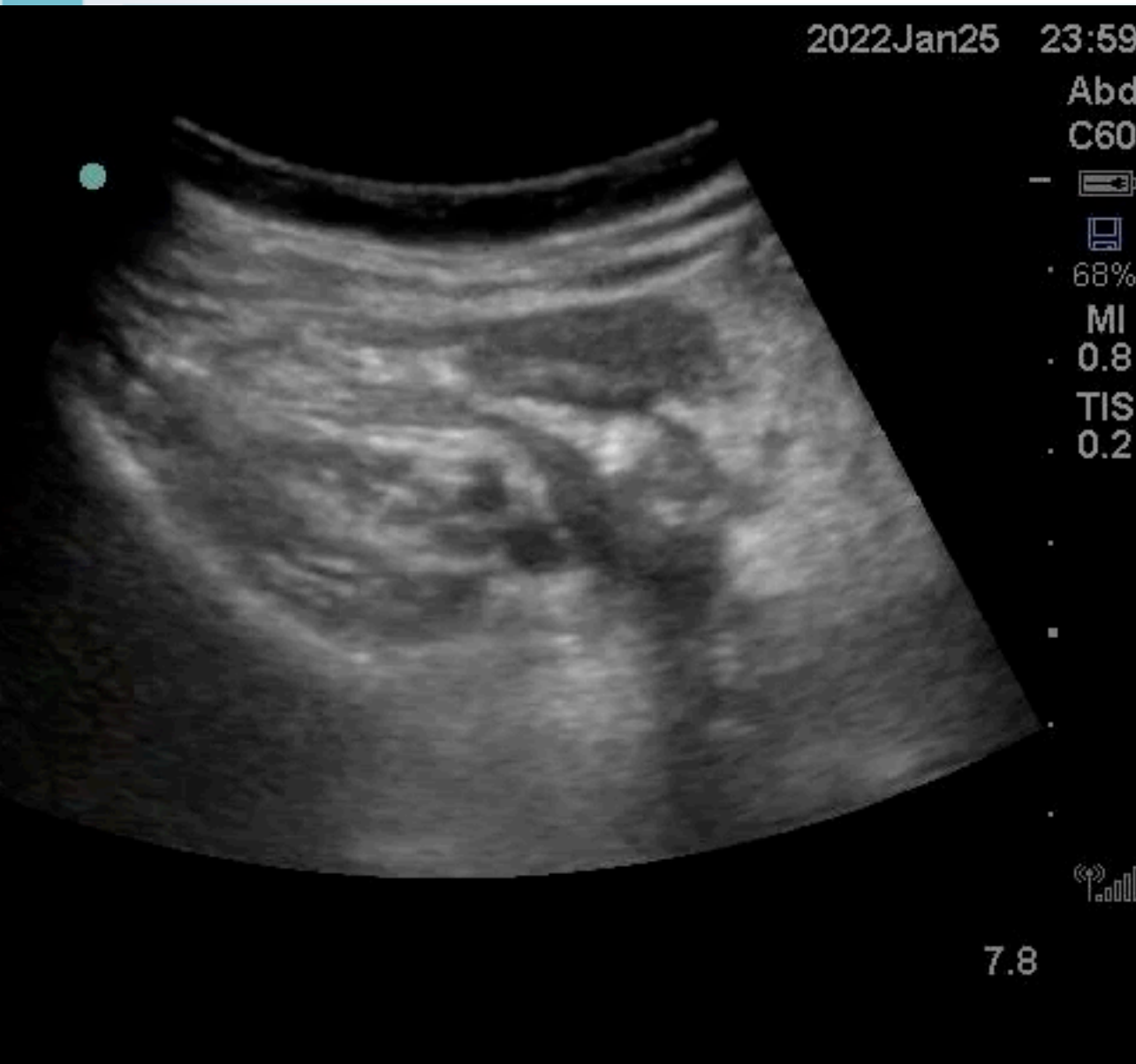
Abd  
C60  
69%  
MI 0.8  
TIS 0.2

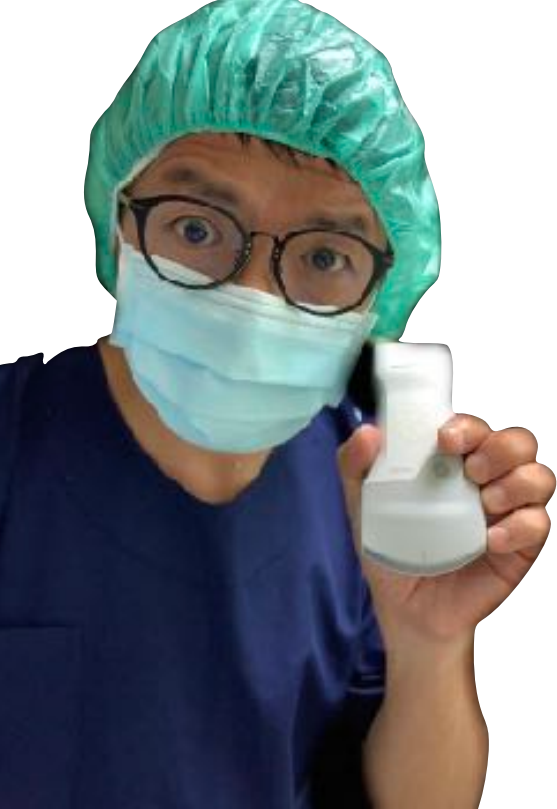Patient  
Auto Gain  
Gen  
Clip  
Page 1/3

9.2 72



# Advanced POCUS in ER





努力可能會說謊，  
但努力不會白費。

羽生結弦

**HOLISTIC ULTRASOUND**

[juice119@gmail.com](mailto:juice119@gmail.com) / [POCUSacademy.com](http://POCUSacademy.com)