



# POCUS

## 急性腹痛的應用

陳國智雙和急診醫學科

# 陳國智 醫師



醫用超音波學會指導醫師

WINFOCUS director / instructor

**急診 / 重症 / 介入 / 急性疼痛**

經歷

新光急診超音波訓練中心主任

西園醫院急診醫學科主任

急診醫學會超音波委員會主委

台灣疼痛醫學會大體模擬手術講師

急救加護醫學會重症超音波負責人

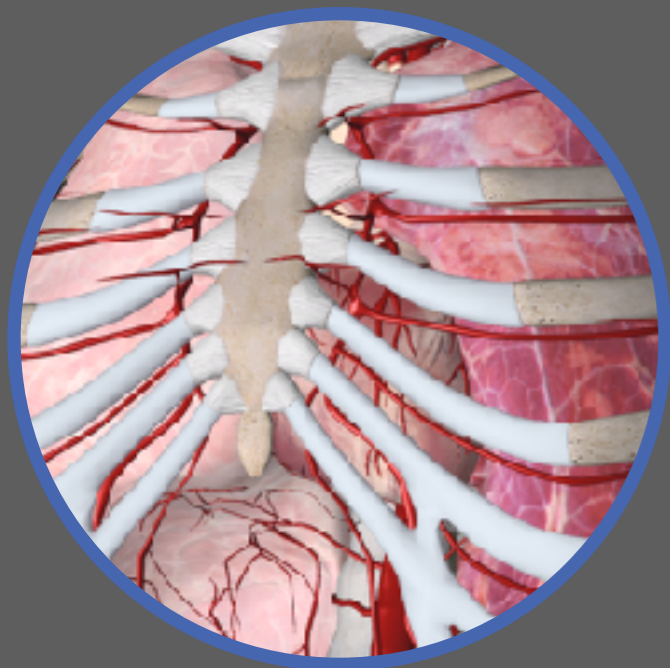
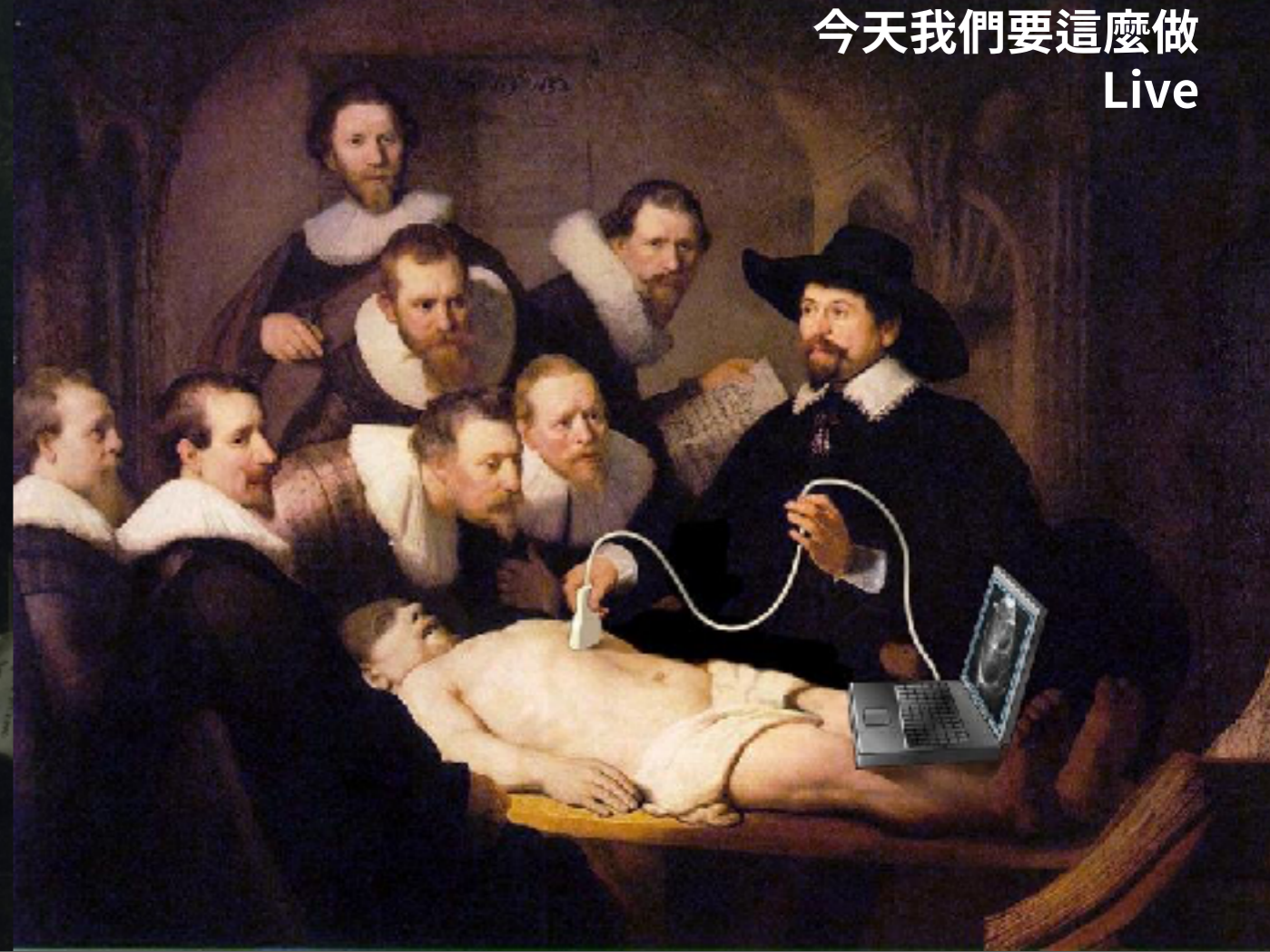
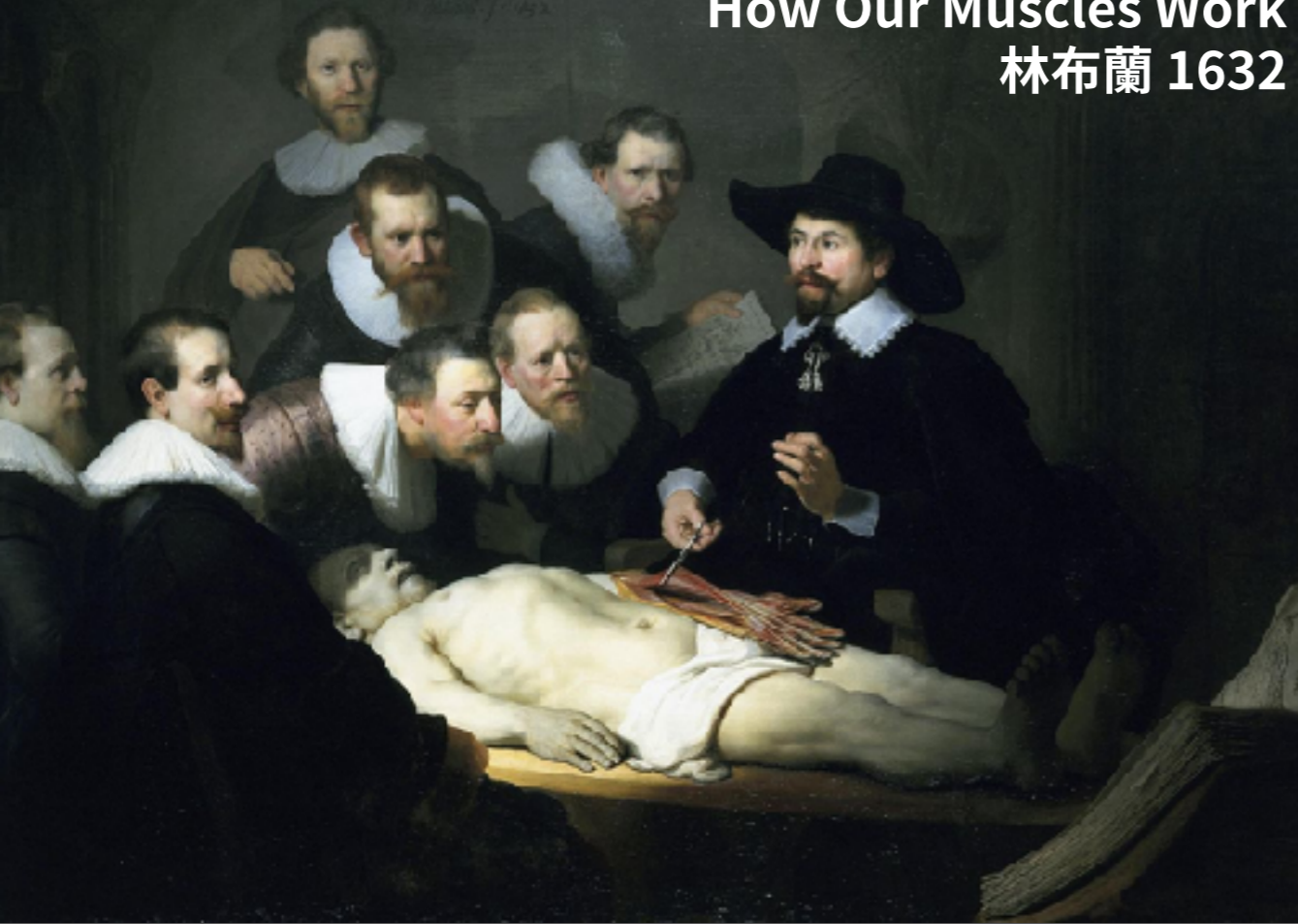[juice119@gmail.com](mailto:juice119@gmail.com)





The Anatomy Lesson of Dr. Nicolaes Tulp  
How Our Muscles Work  
林布蘭 1632

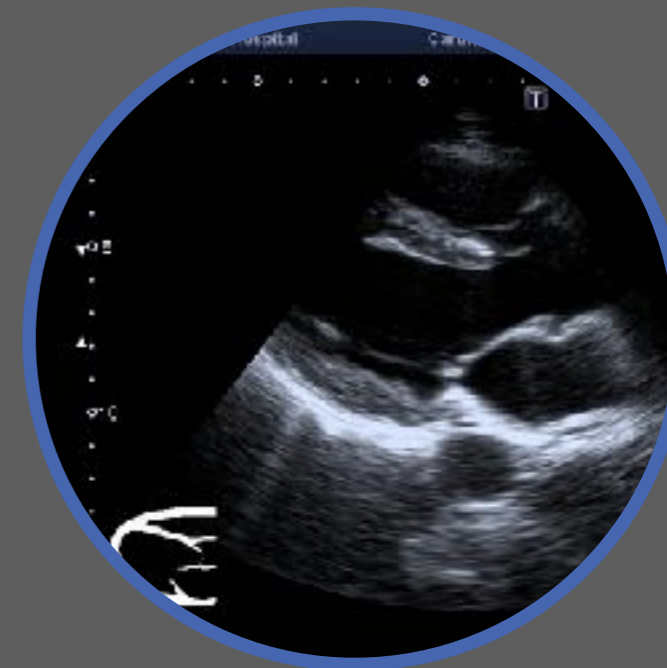
今天我們要這麼做  
Live



Anatomy



Probe



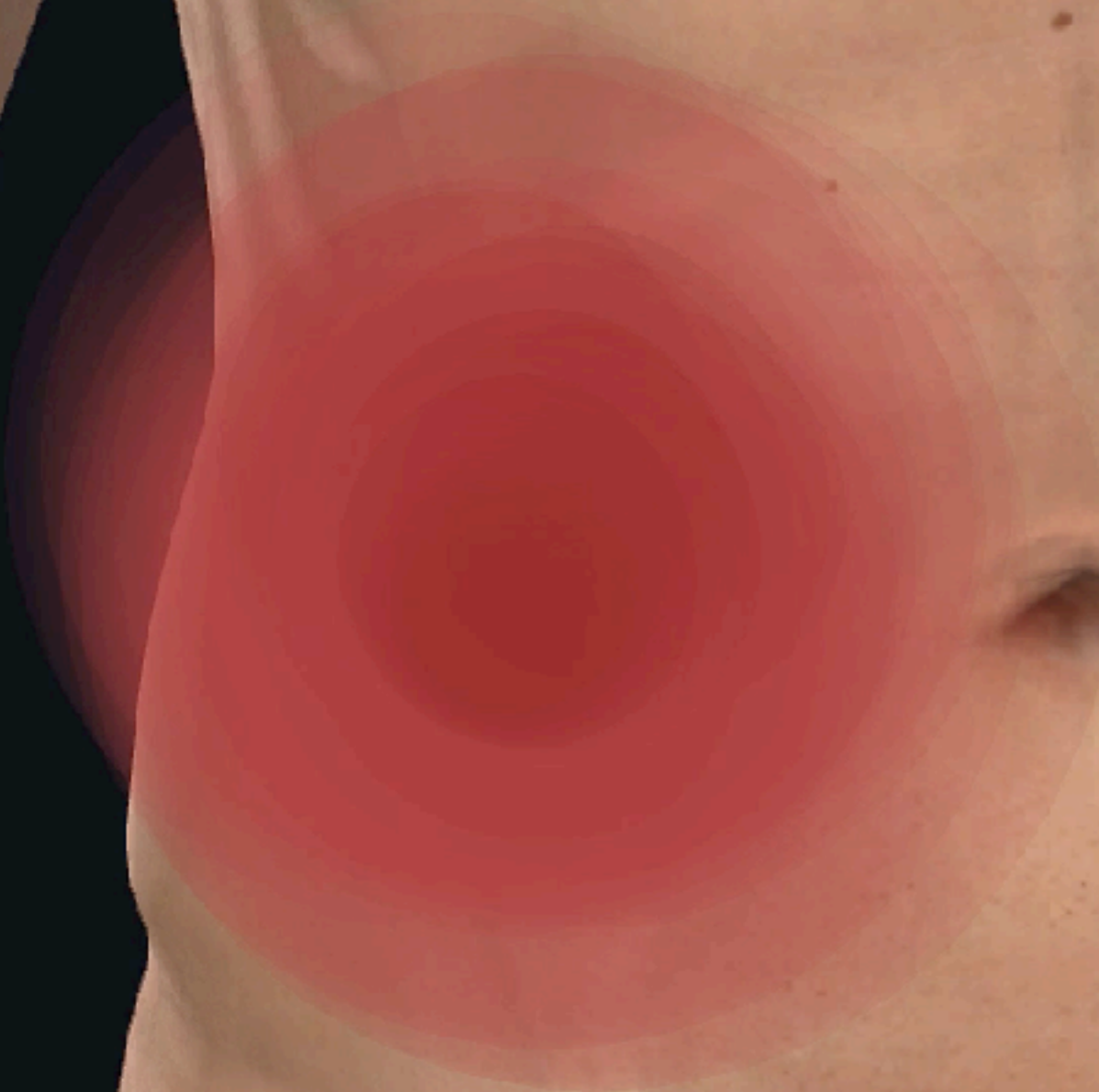
Echo



病史  
詢問

理學  
檢查

ECHO  
評估







可以  
同步  
病史詢問

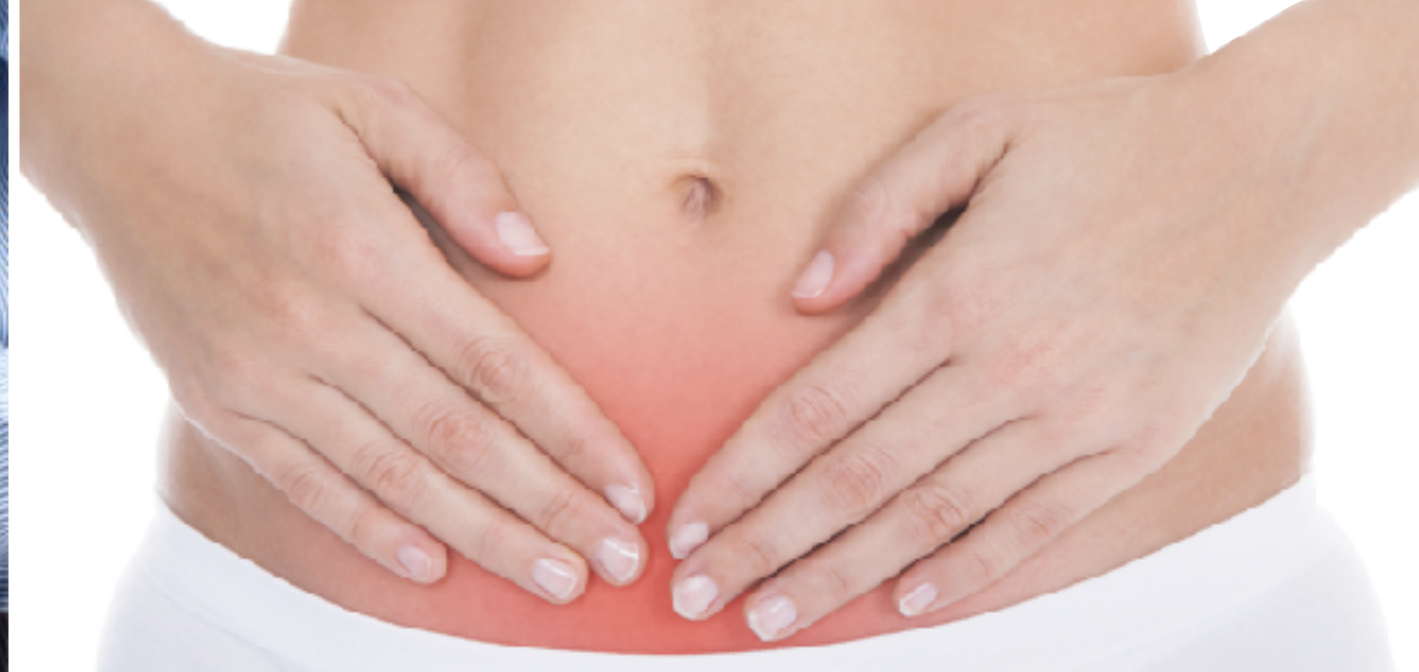理學檢查  
不可  
省略



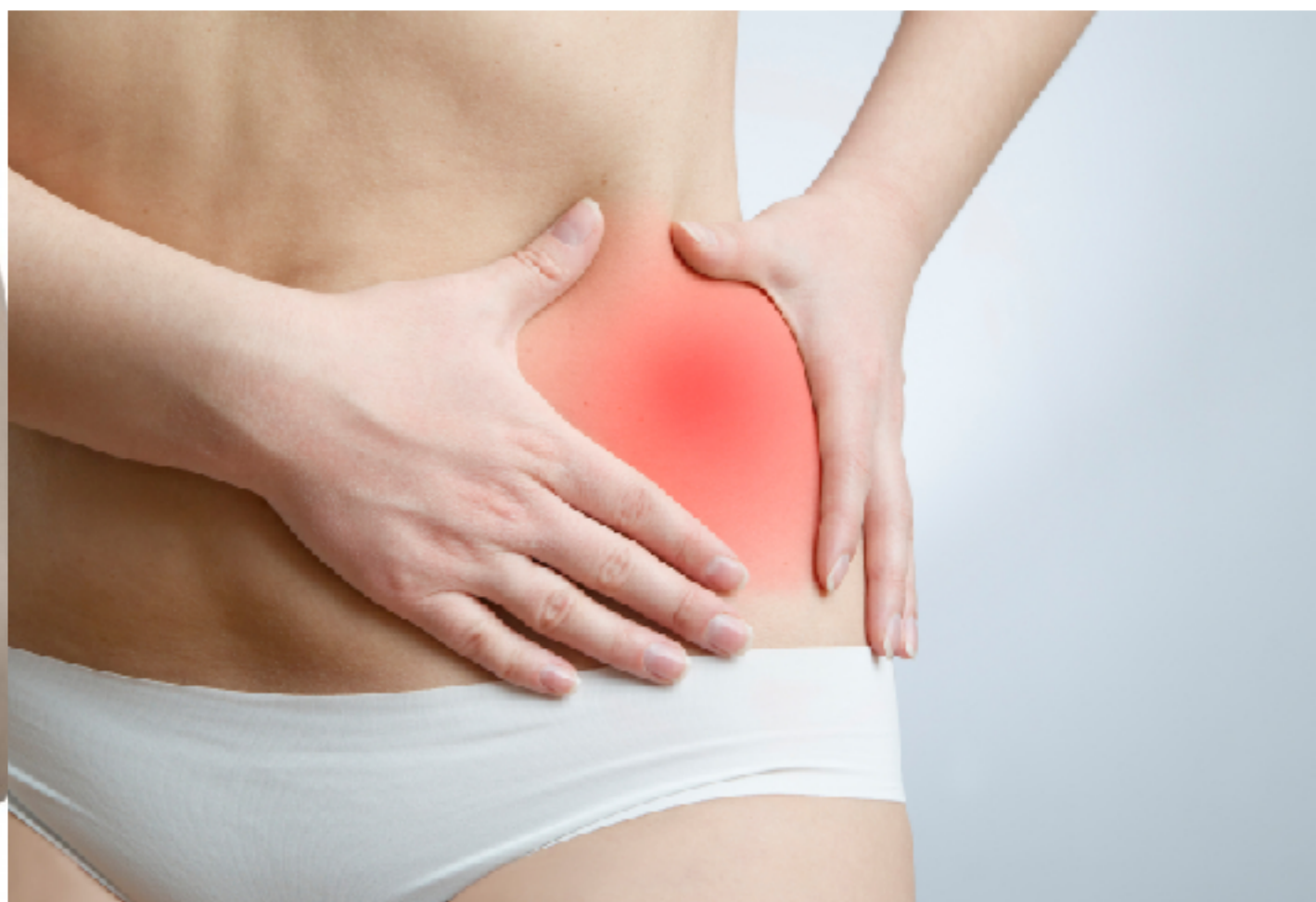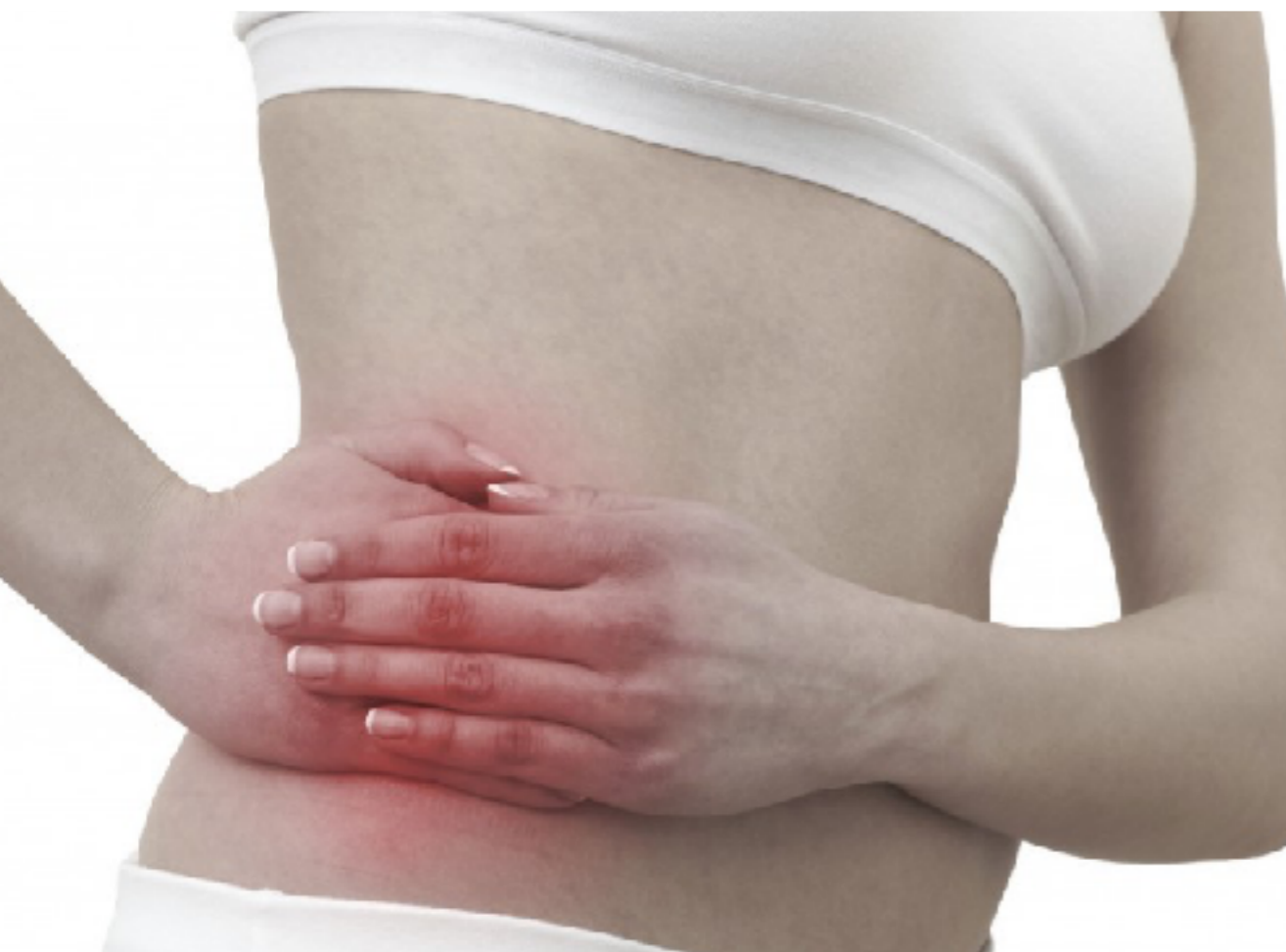Y

POCUS

N



該如何下手??





# Approach to Abdominal Pain

**L**ocation

**O**nset

**T**ype

**S**everity

**O**ther locations (radiation)

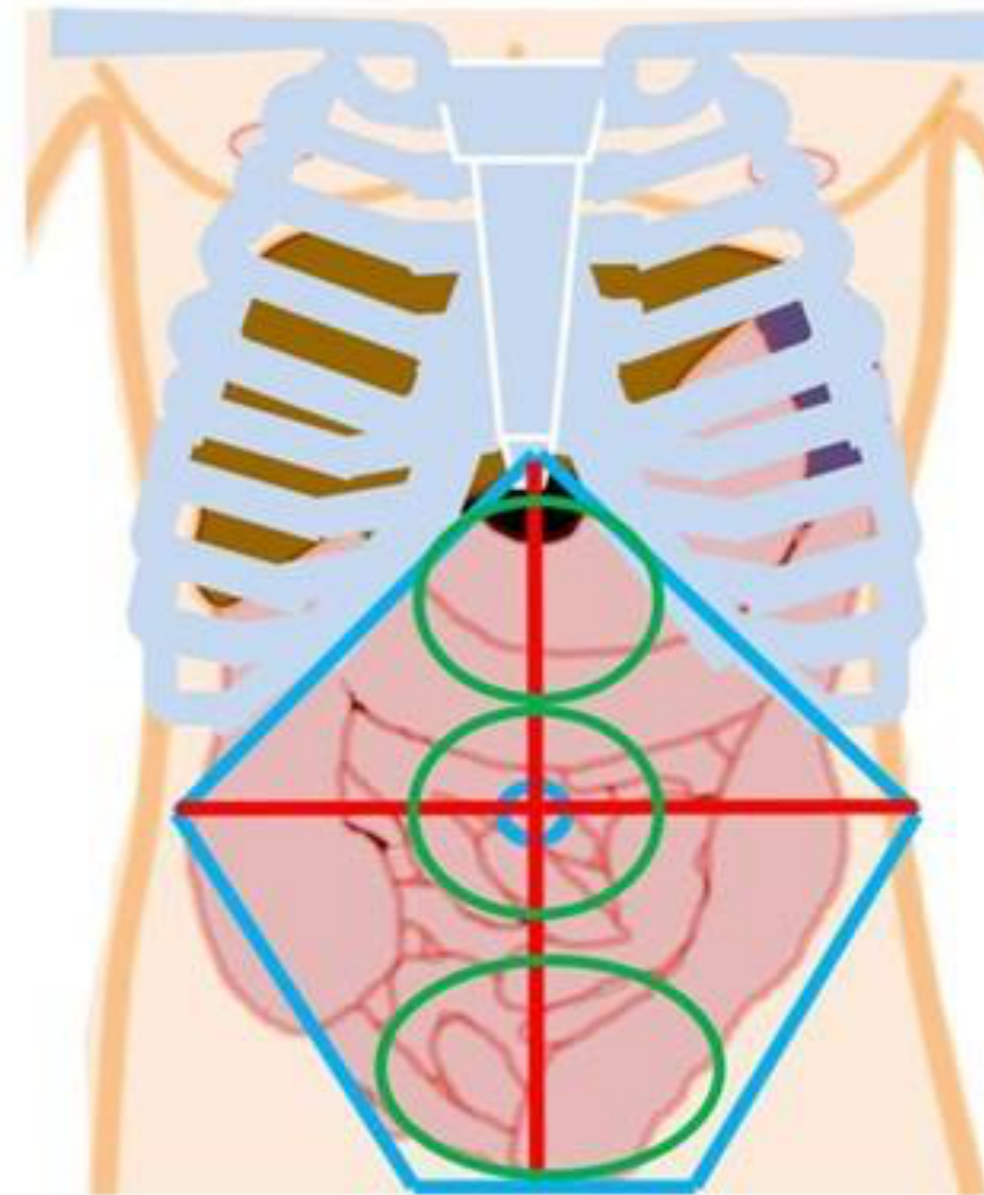
**F**actors (aggravating / alleviating)

**P**rogression

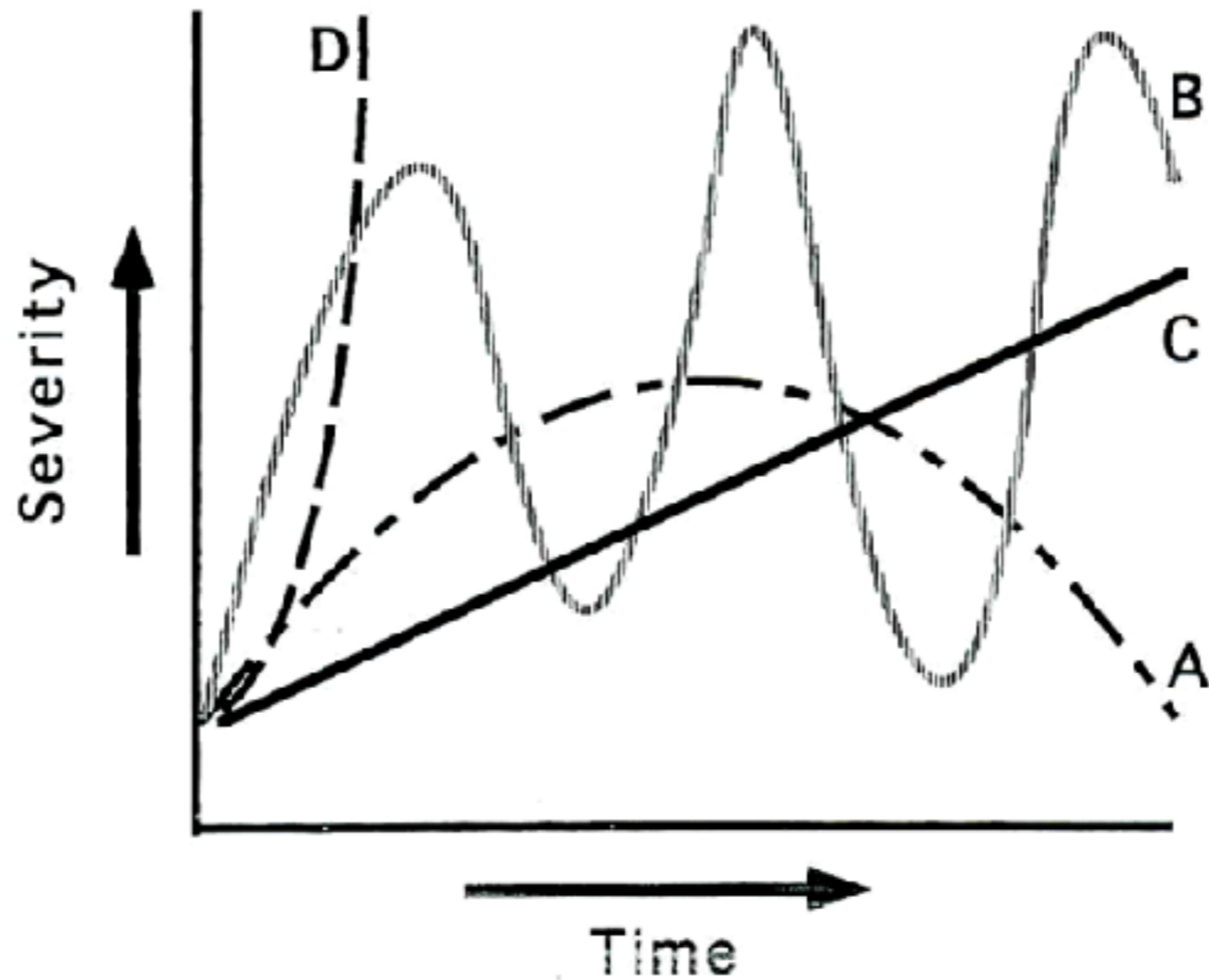
**A**ssociated symptoms

**I**nsight (what do they think it is)

**N**eed relief (what have they taken)



@kwburak



No Pain

Mild

Moderate

Severe

Very Severe

Worst Pain Possible



0

1-3

4-6

7-9

10



# I-AIM

## POINT



**Acquire**



**Interpret**



**Make  
decision**

# Acute Abdomen

## Internal bleeding ?



**FAST**



**Free Fluid**



**CT/TAE/OP**

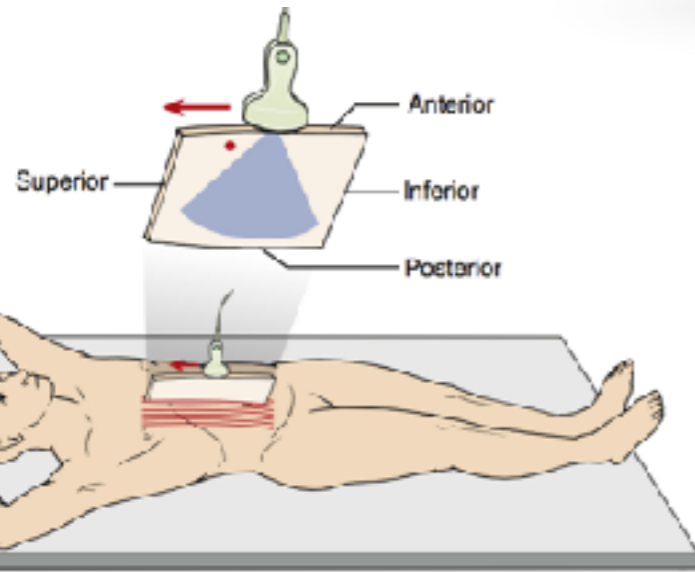


# 探頭選擇：腹為主／線為輔

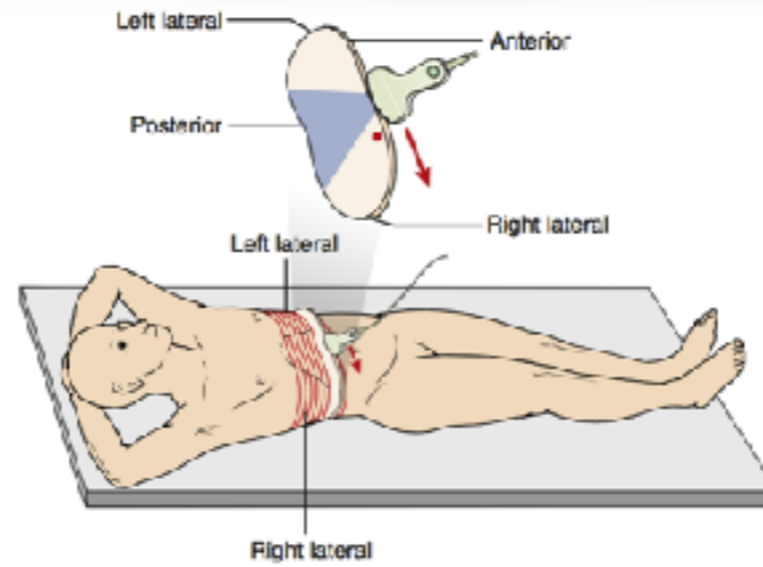


**急診POCUS不用NP0**  
**系統性掃描之後再聚焦**

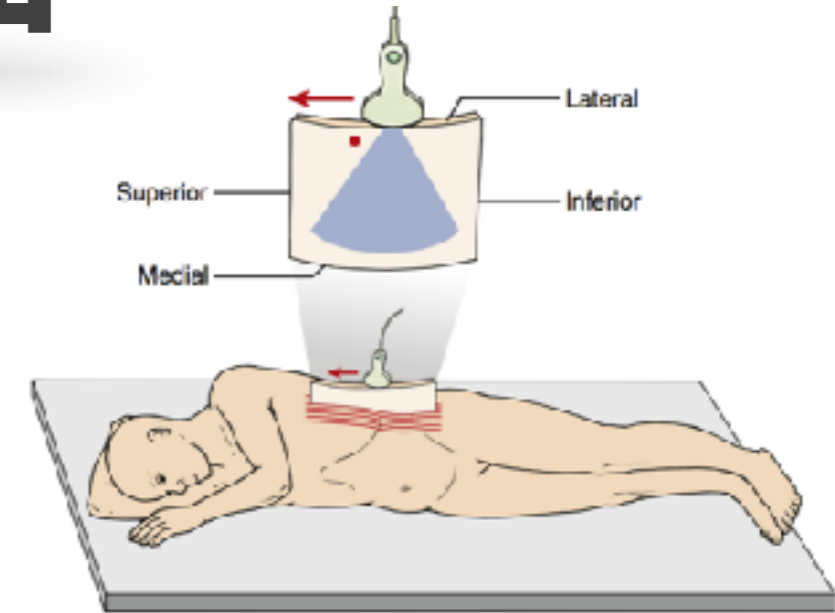
# 3D 立體掃描



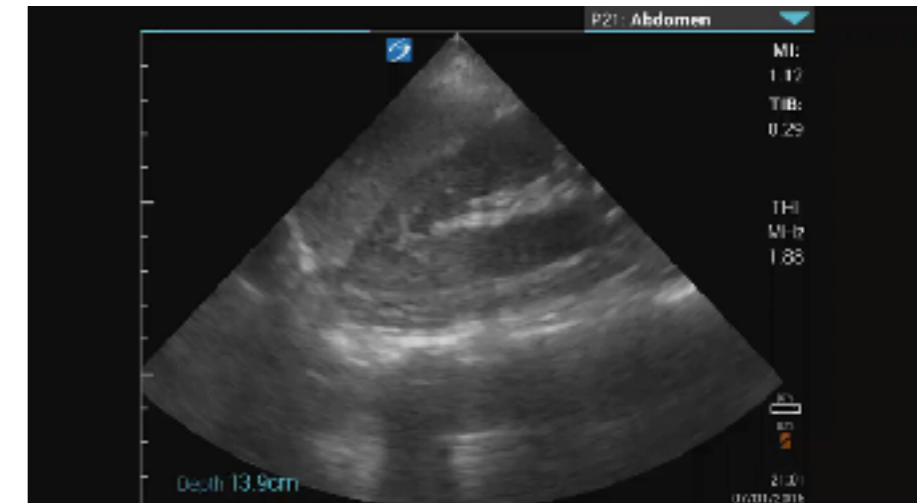
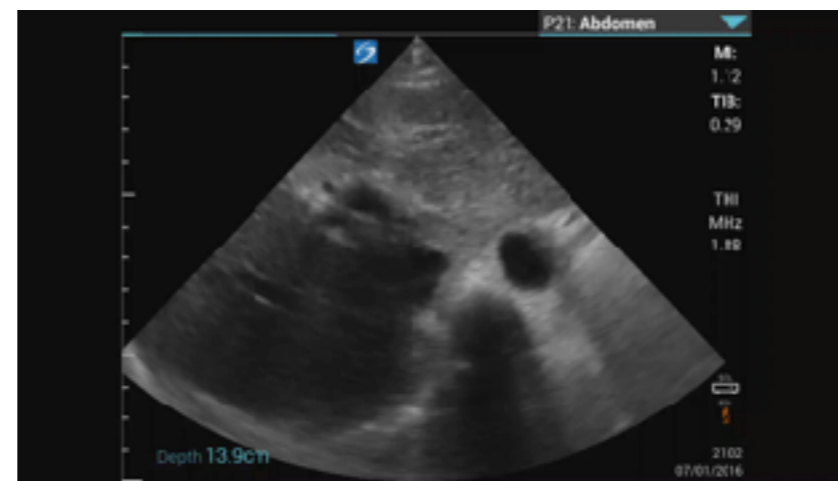
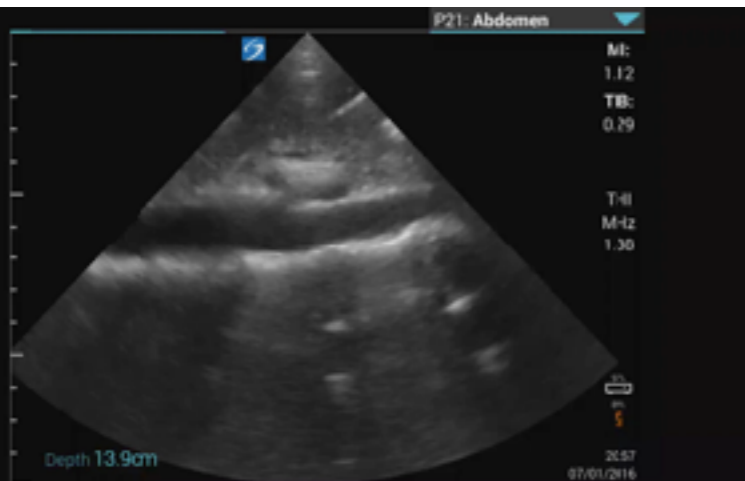Sagittal 縱



Transverse 橫



Coronal 側

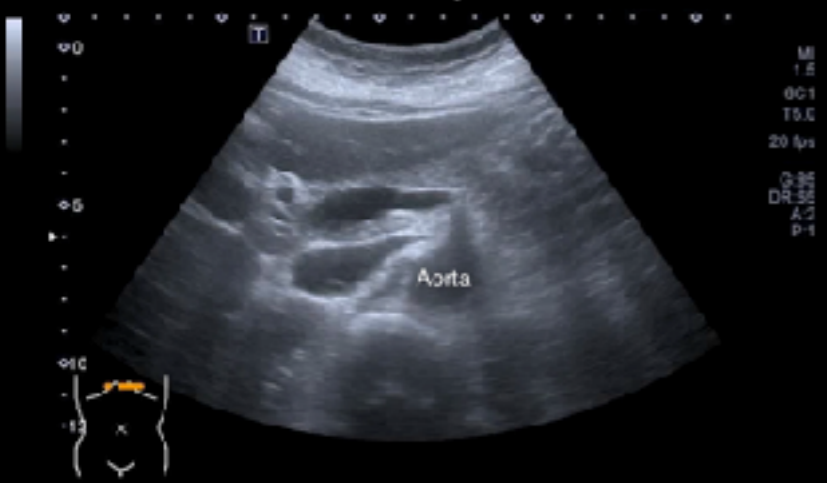



# 熟悉操控 6 大技巧

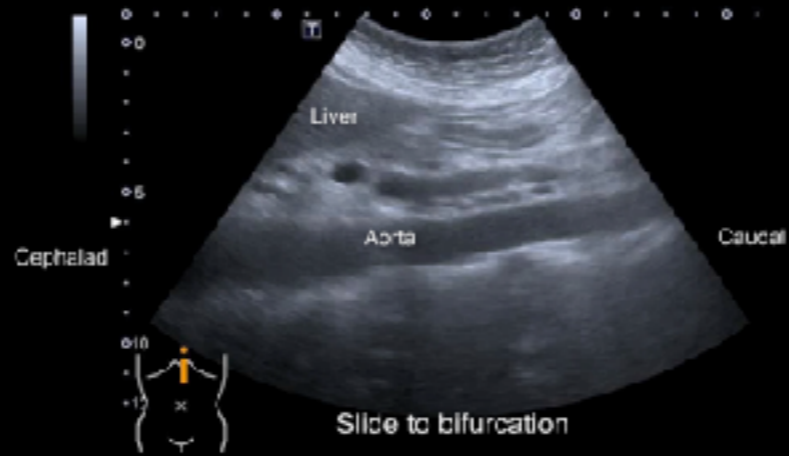
## X

### Sweep



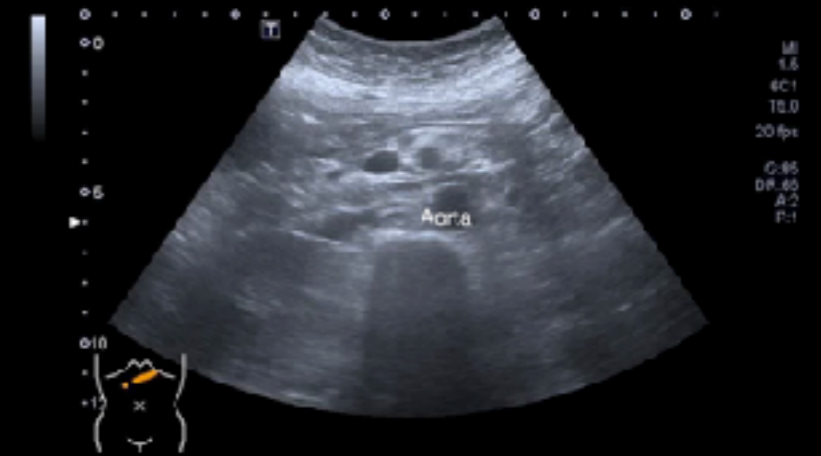## Y

### Slide

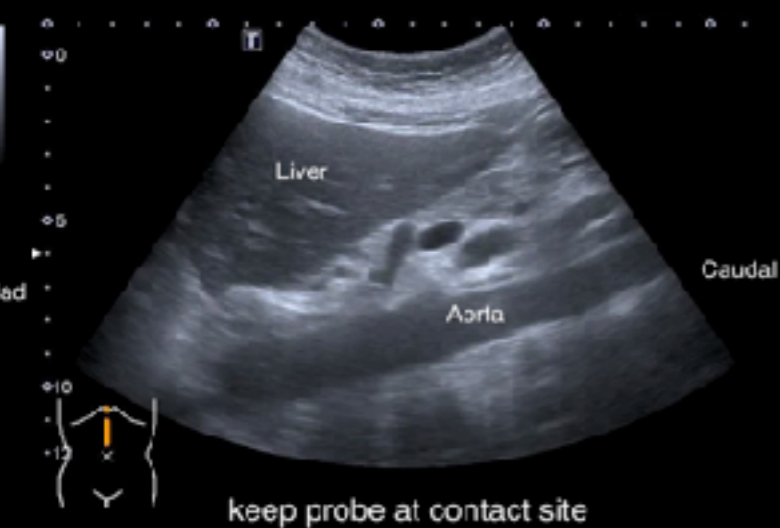

## Z

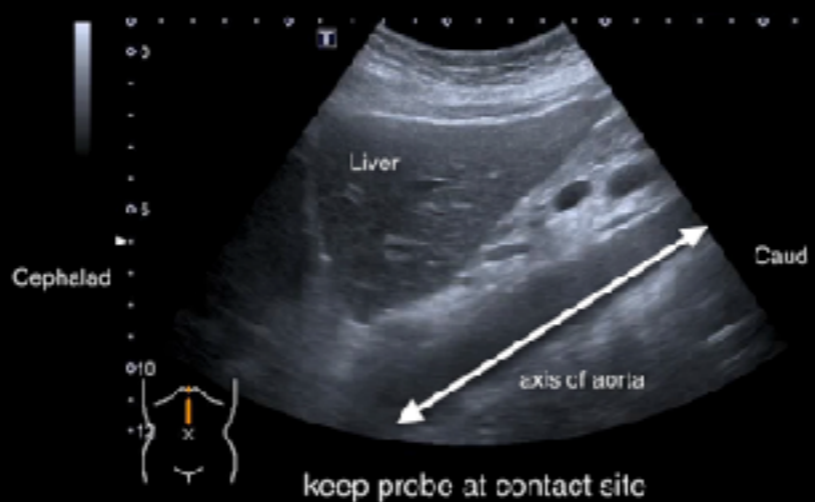
### Rotation



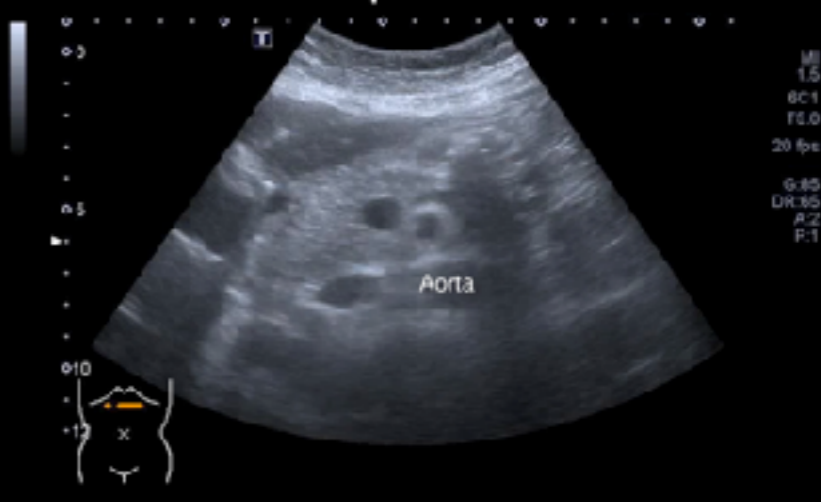### Fan



### Rock

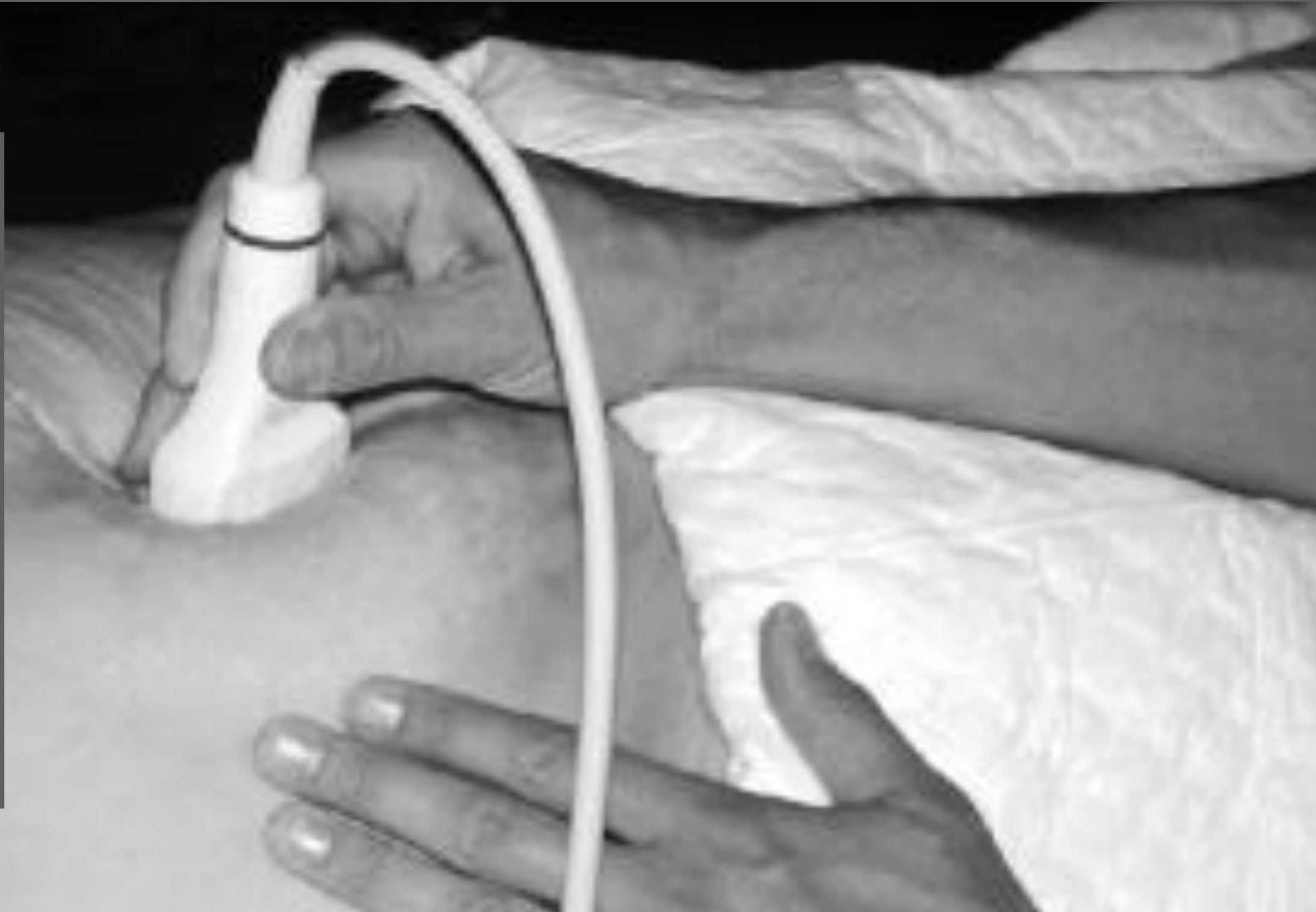

### Compression



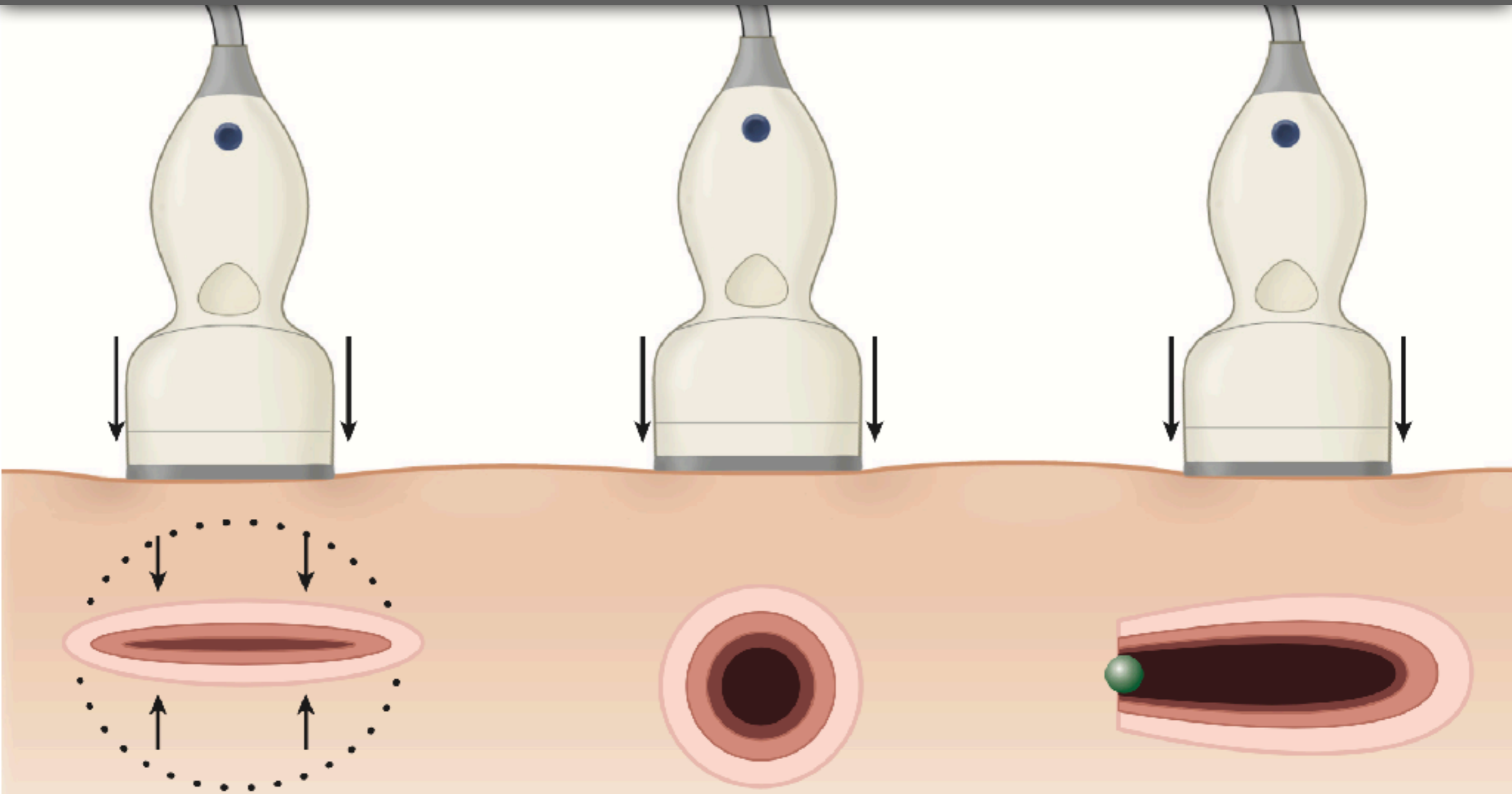
# Graded compression

溫柔  
穩定  
施壓  
停留  
觀察





# Compression很重要!!!



# POCUS

for

# Acute

# ABDOMEN

**A** for aorta

**B** for biliary

**D** for diaphragm

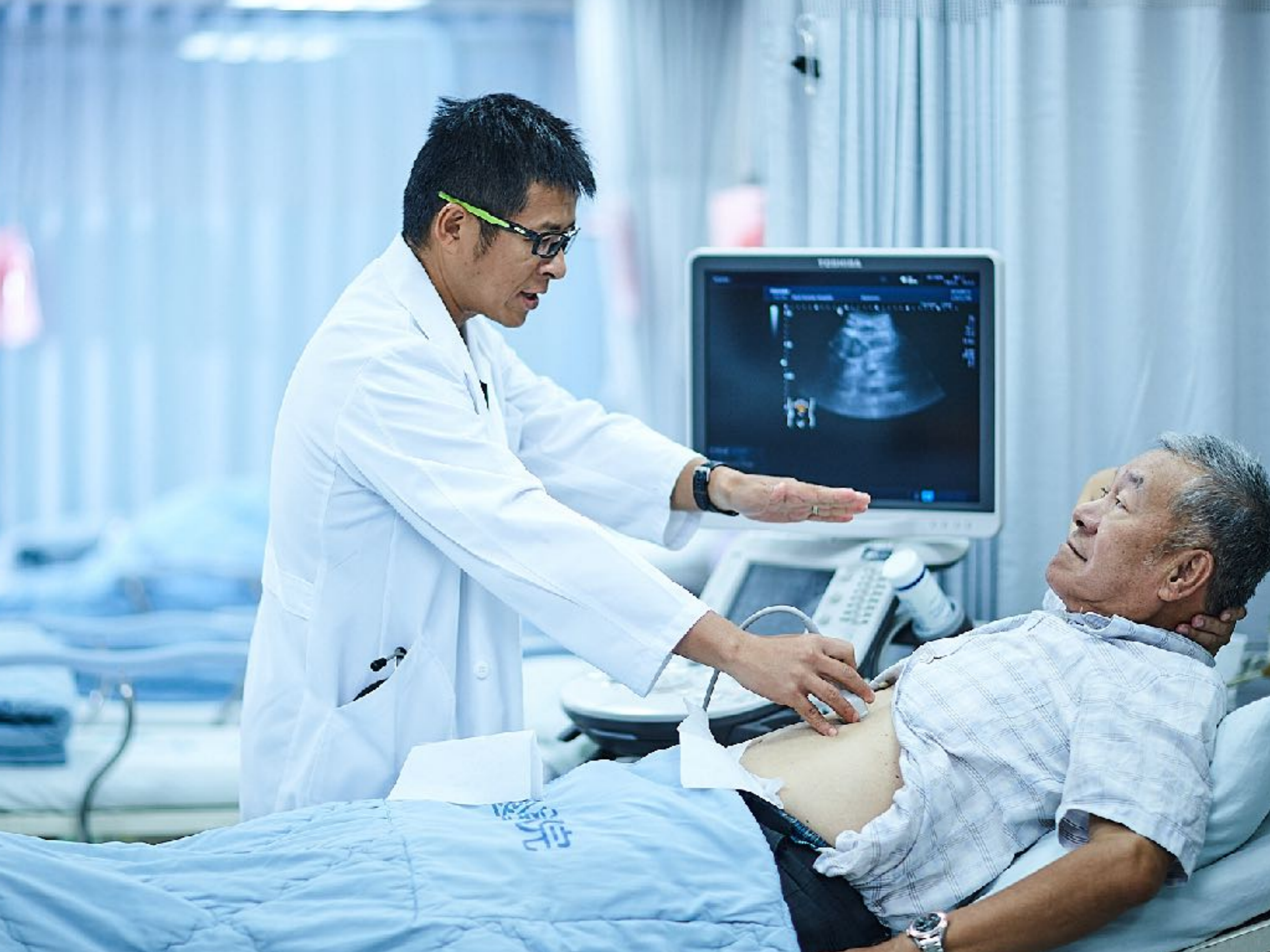**O** for bowel obstruction

**M** for moving fluid & air

**E** for ectopic pregnancy

**N** for nephropathy





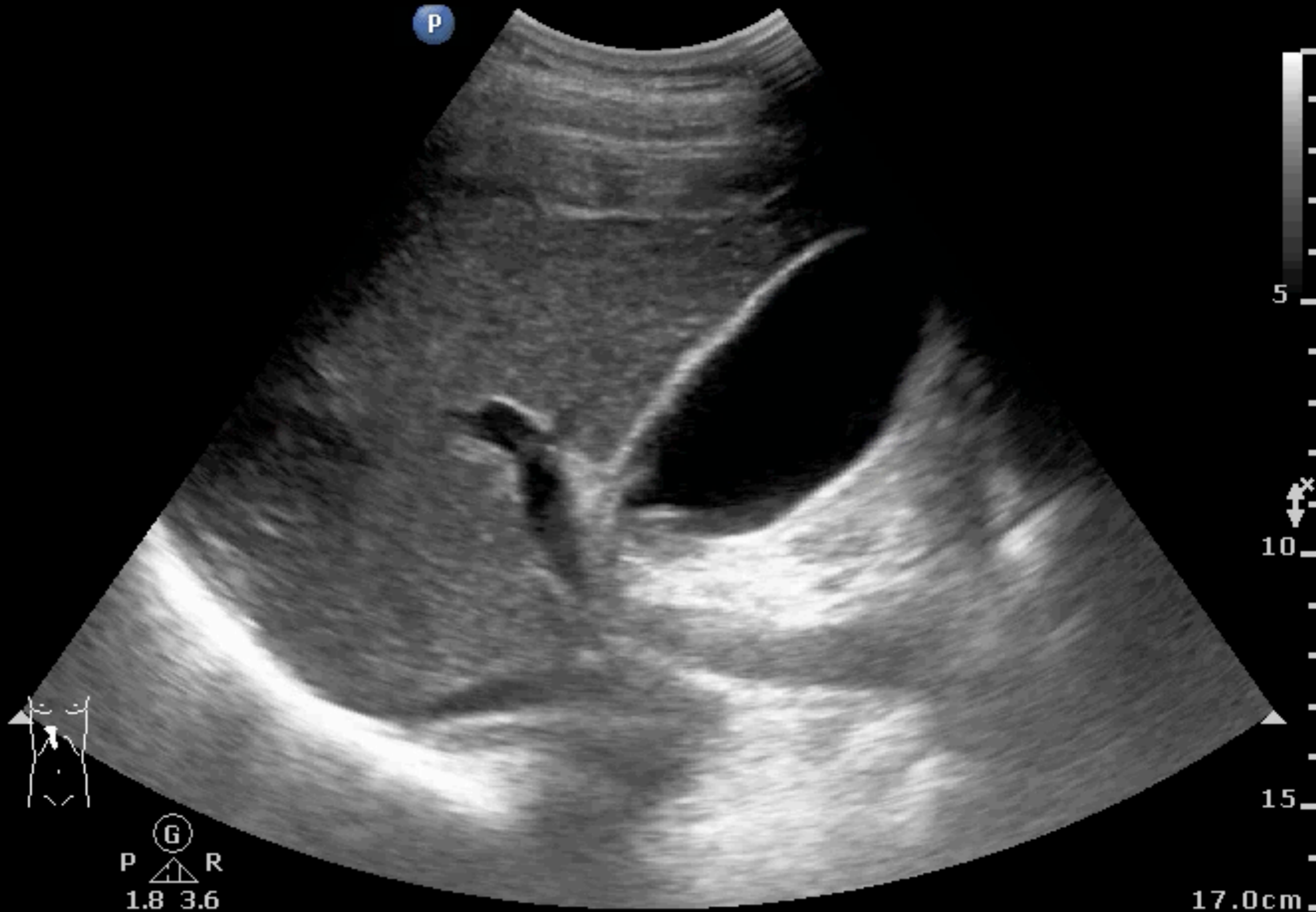

# 52M, RUQ pain, your diagnosis ?

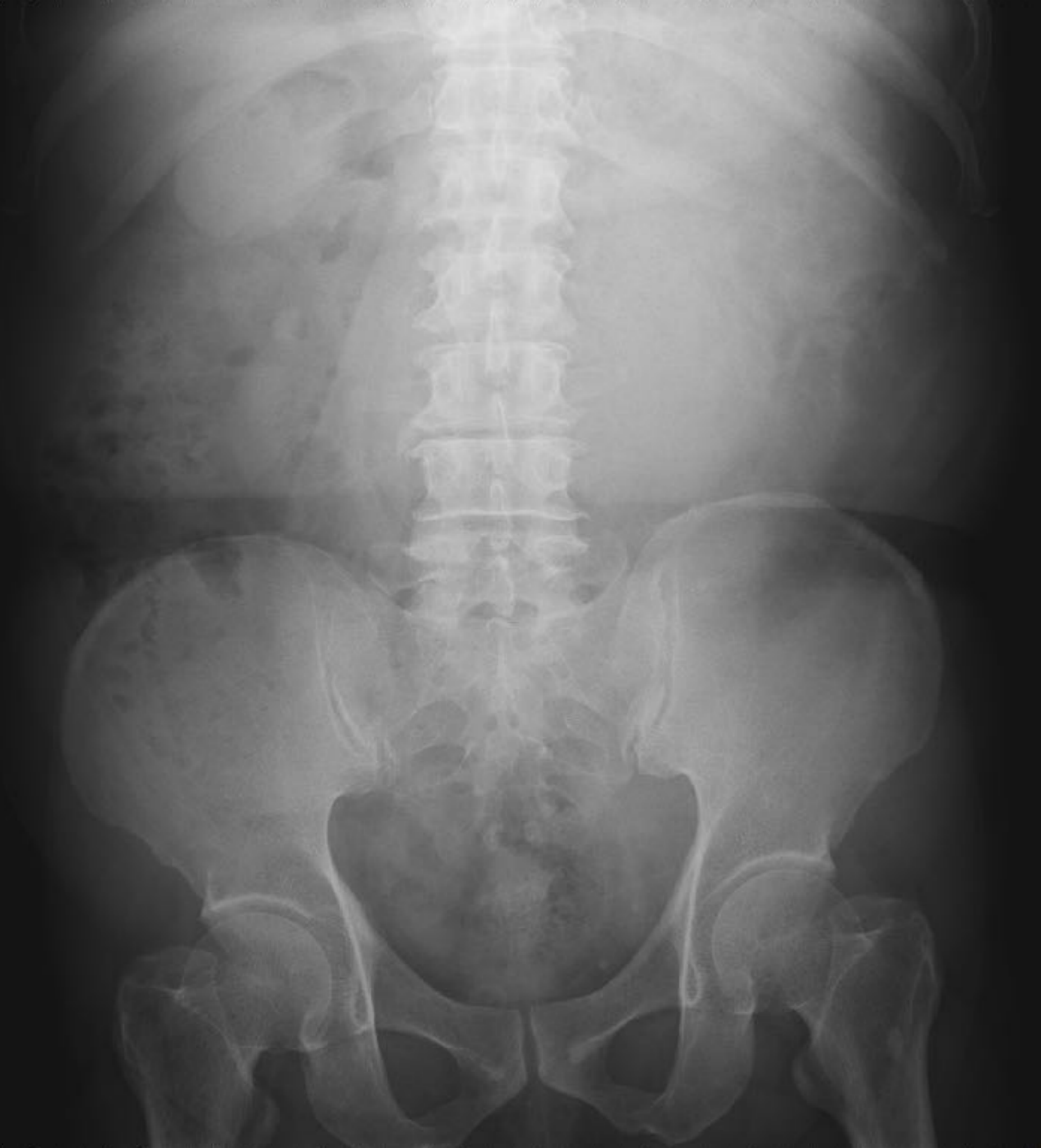
Abd Gen2  
C5-1  
31 Hz  
17.0cm

2D

HGen  
Gn 86  
C 56  
3 / 3 / 3





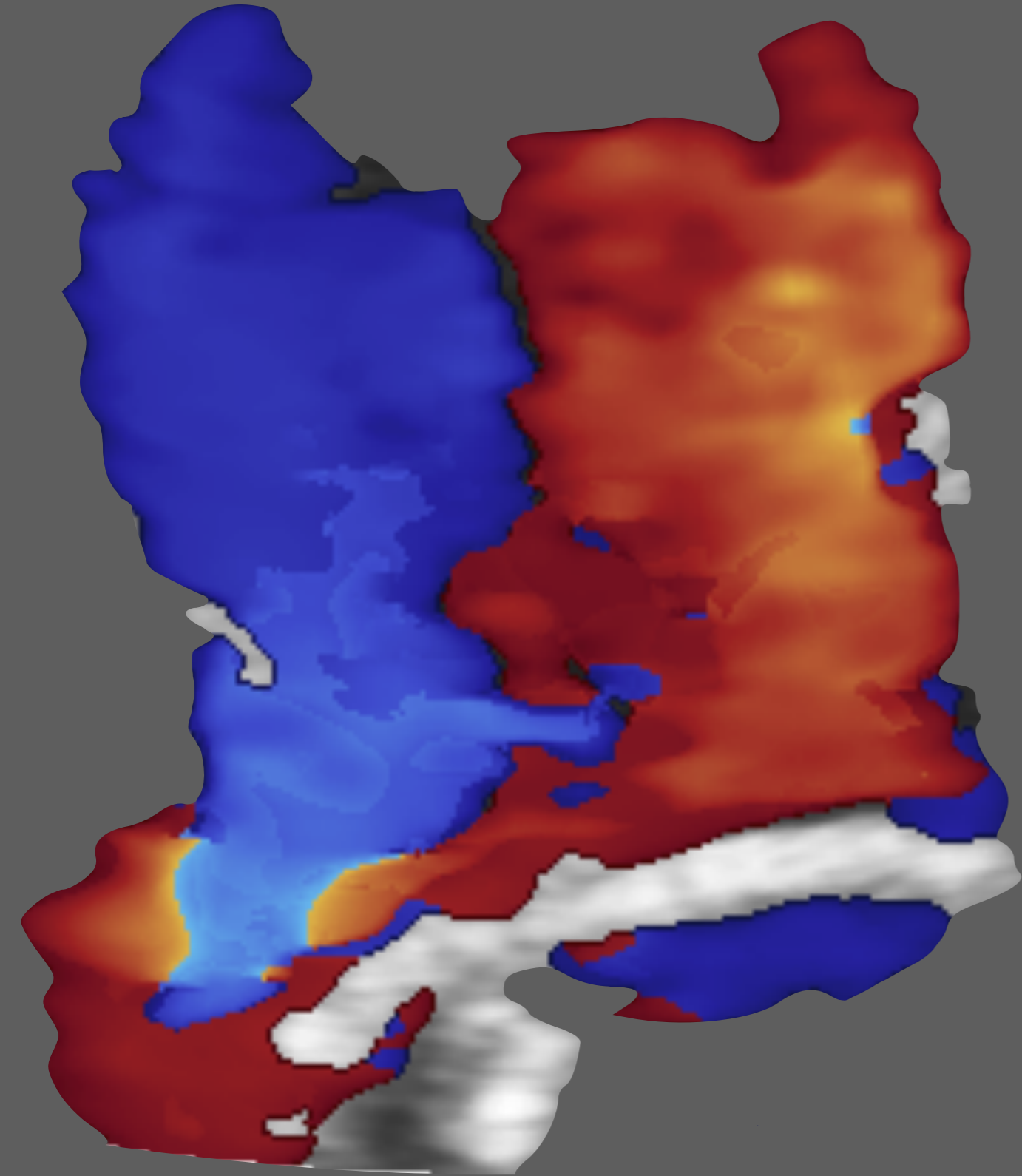


**64M,  
左下腹痛  
1小時  
冒冷汗  
結石病史**

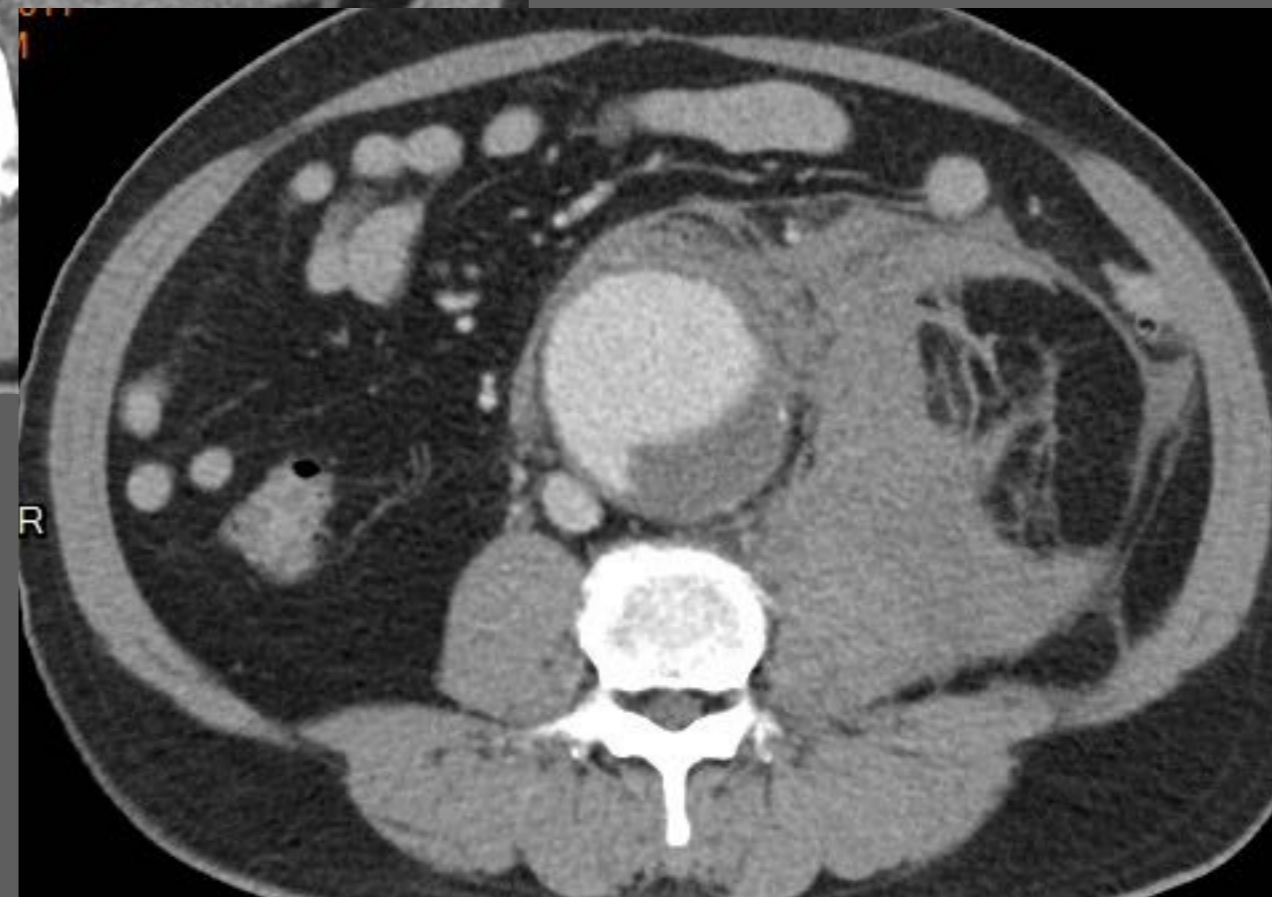
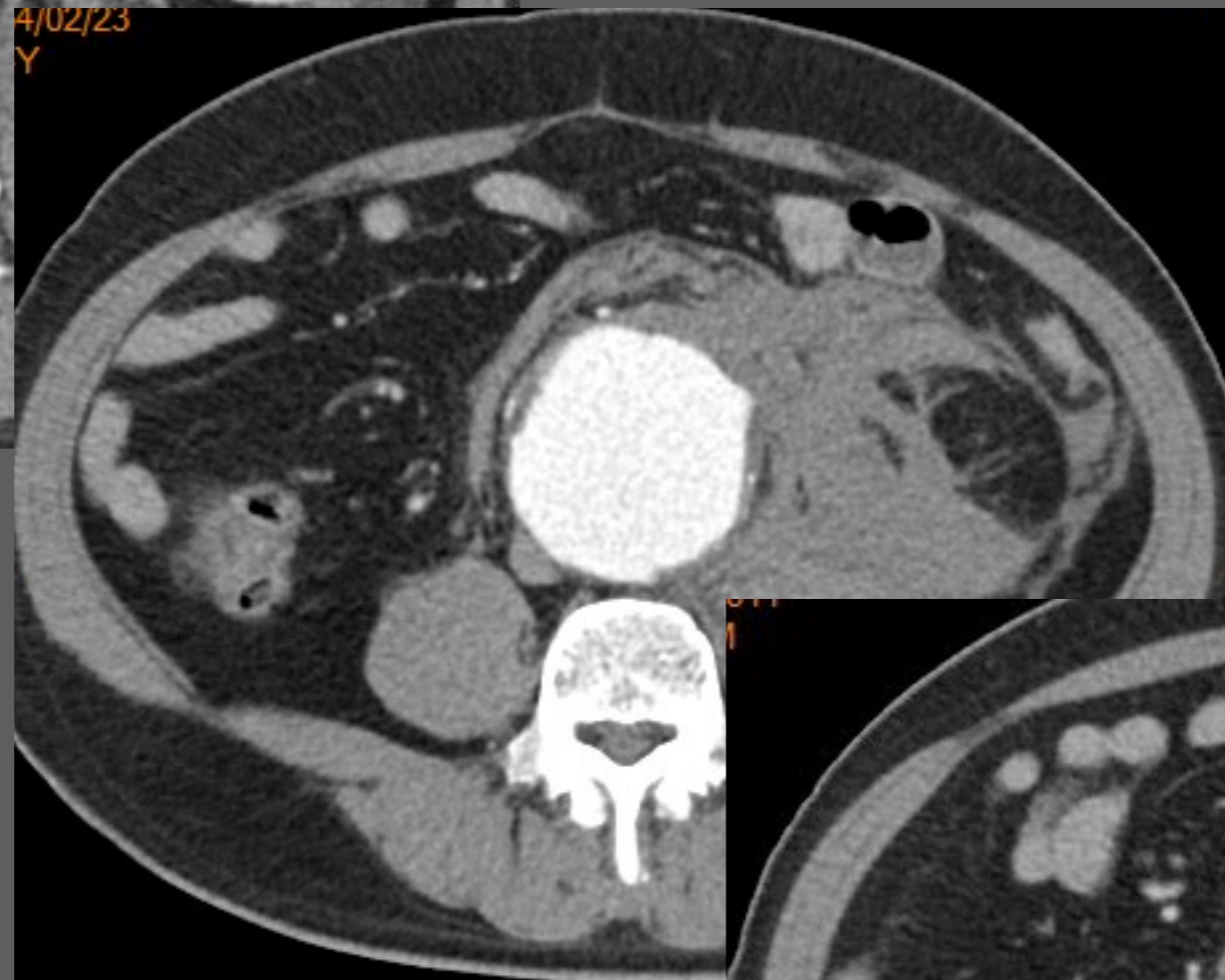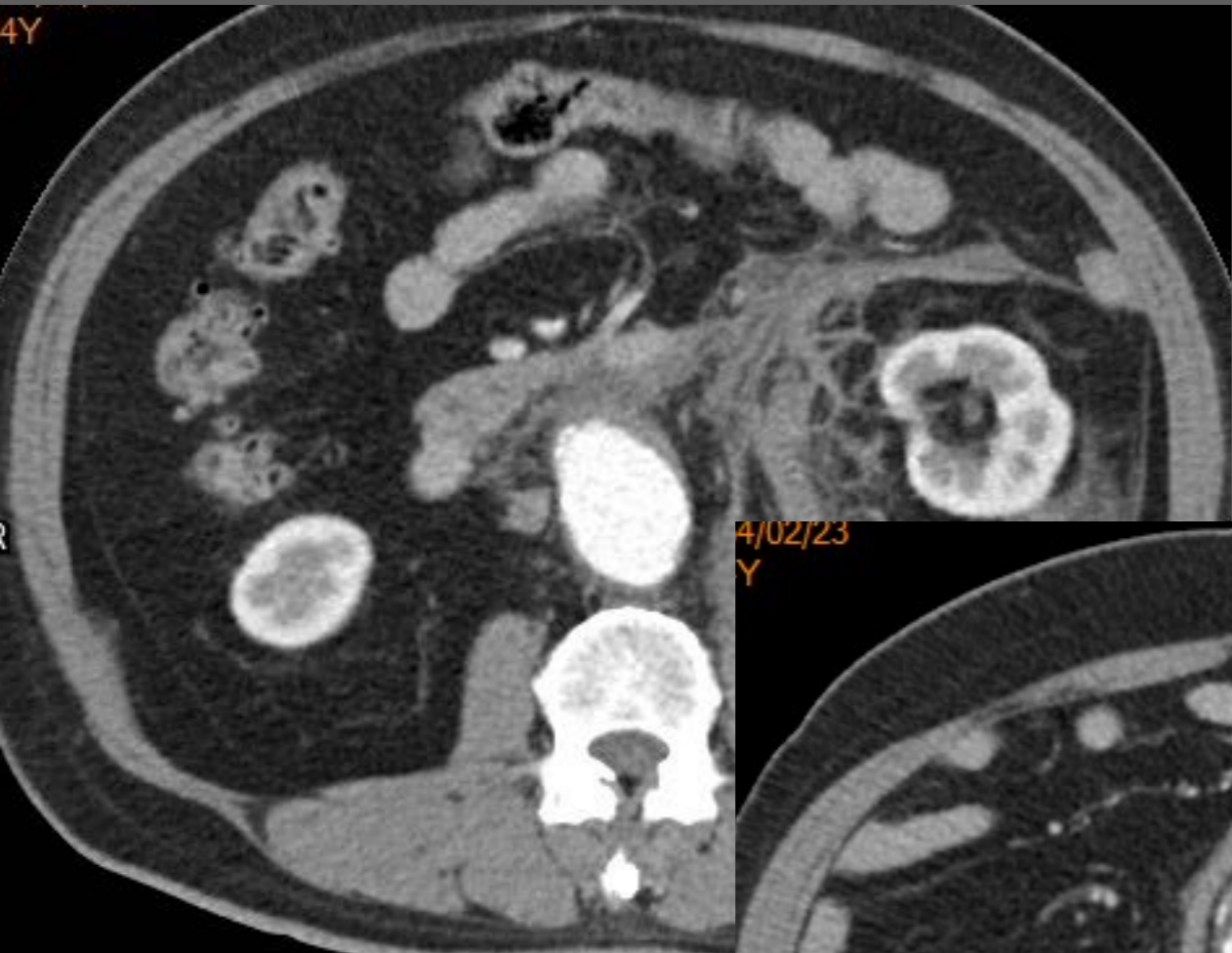**PR 117**

**BP**

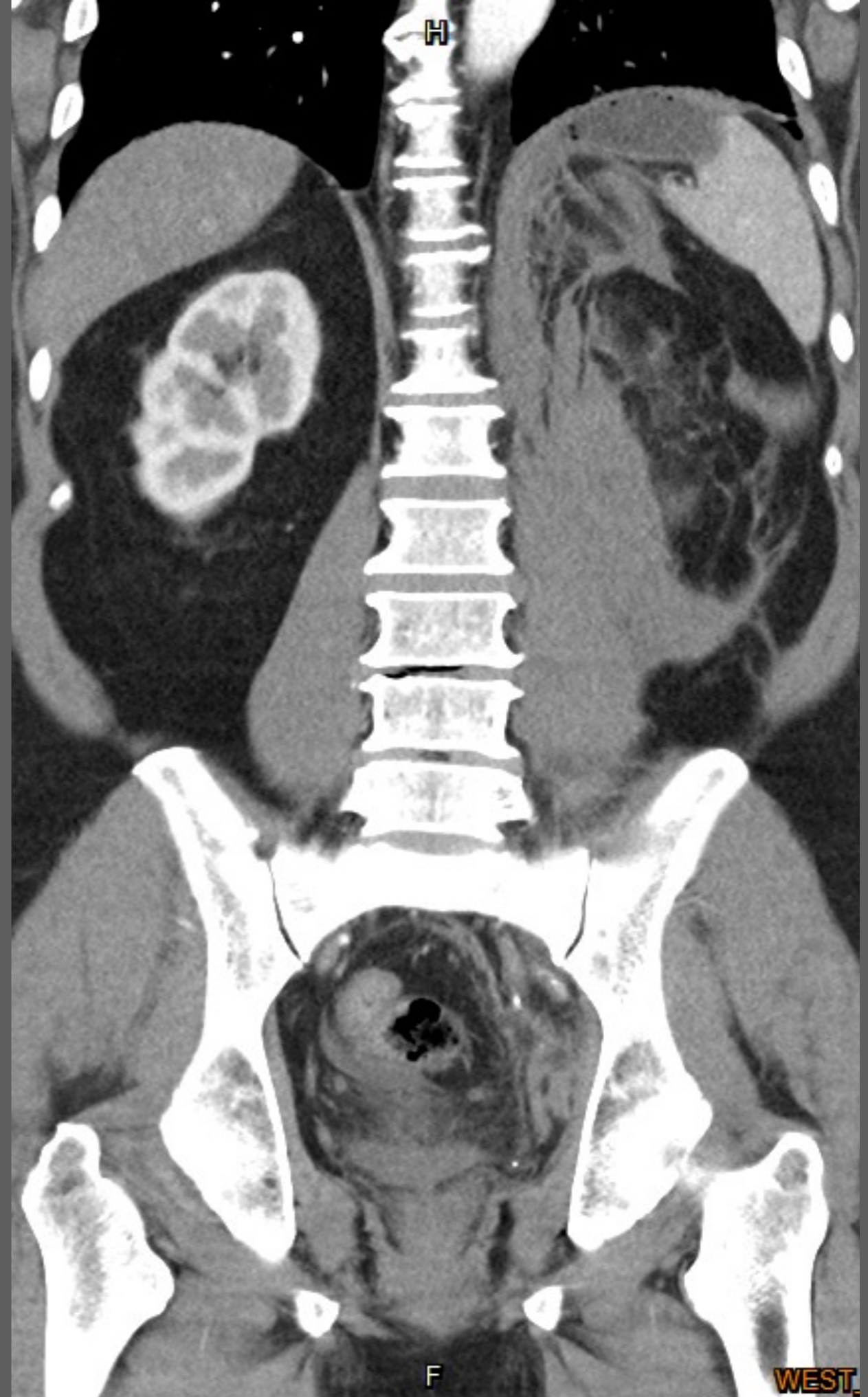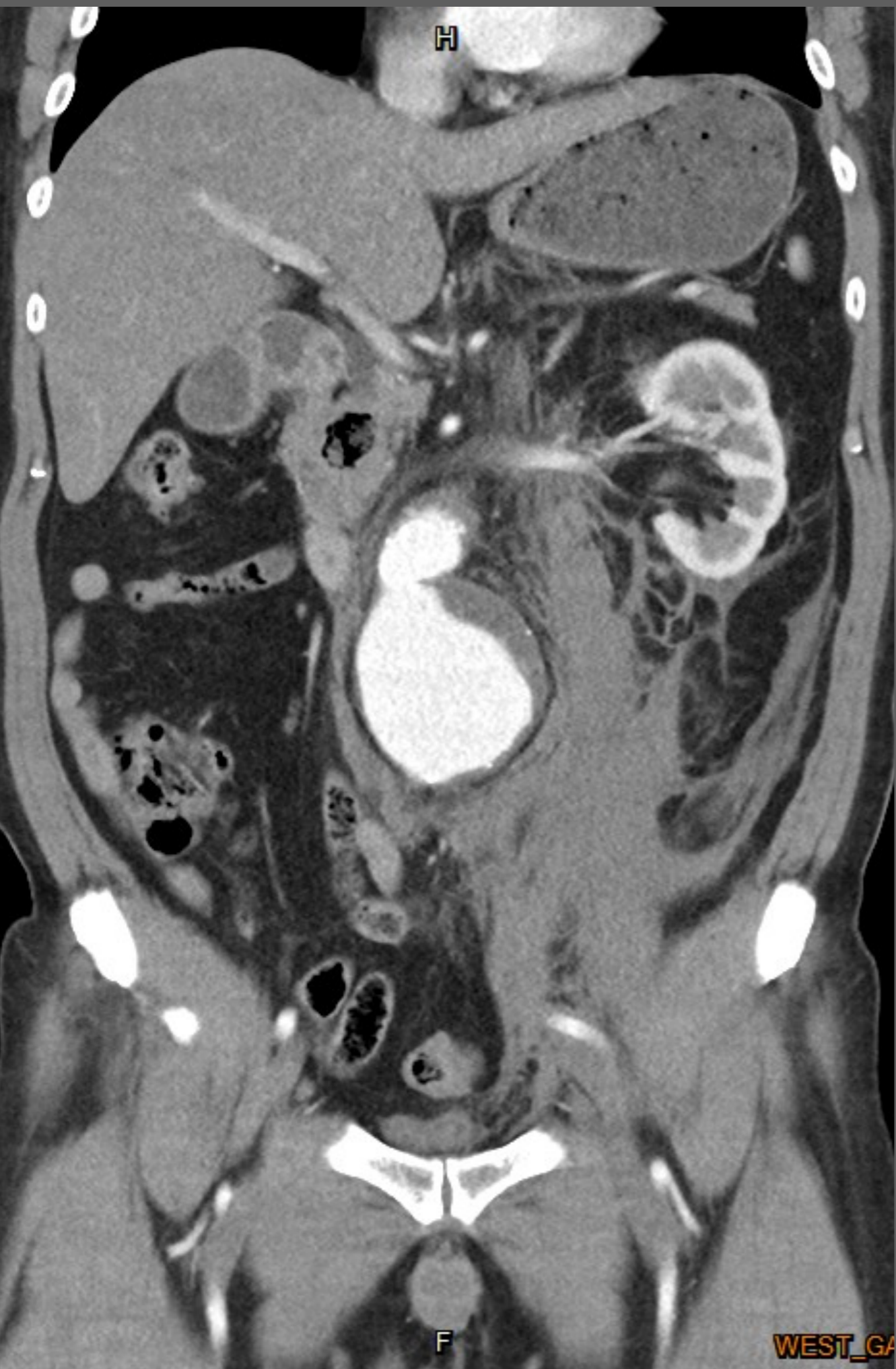**88/62**



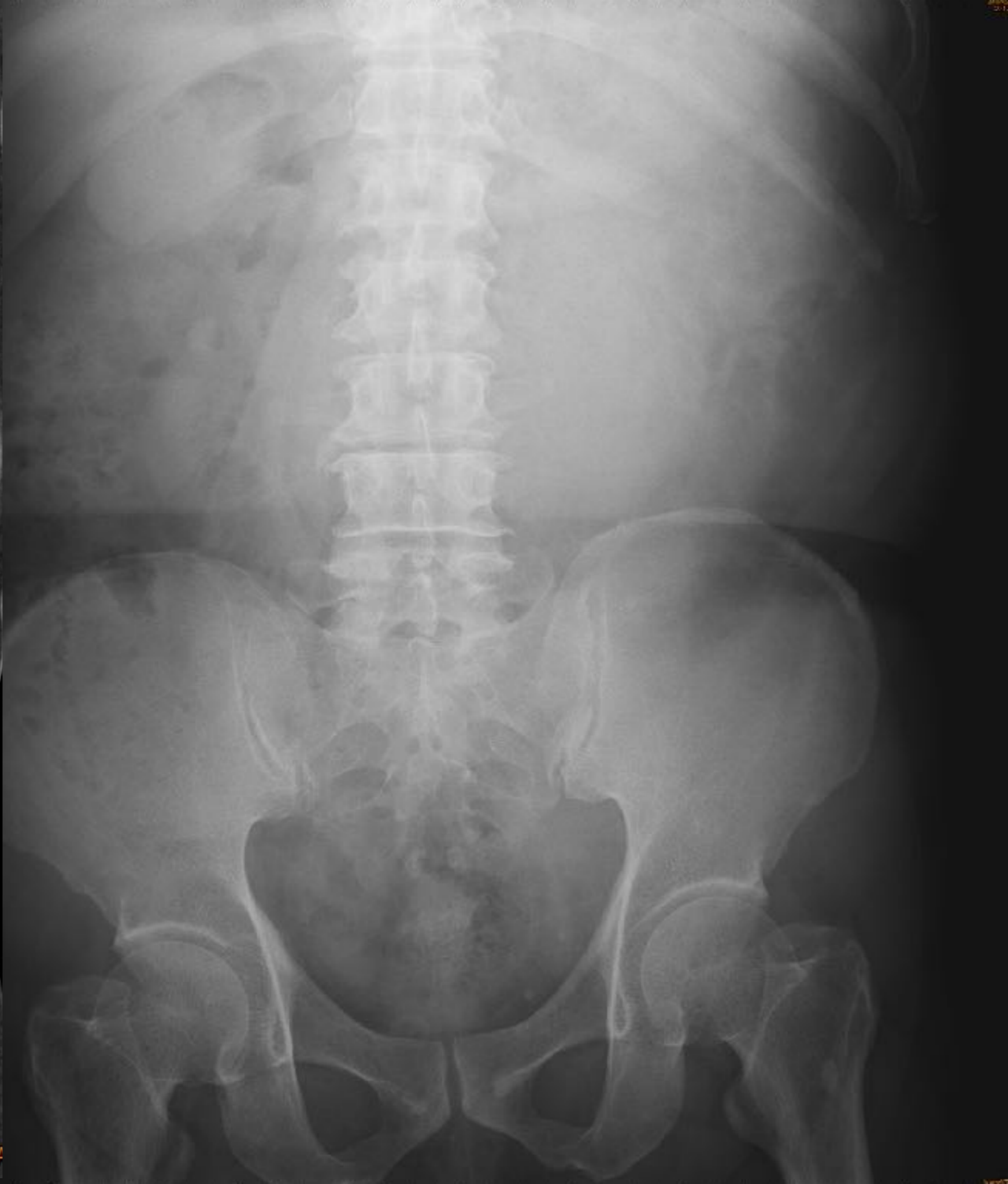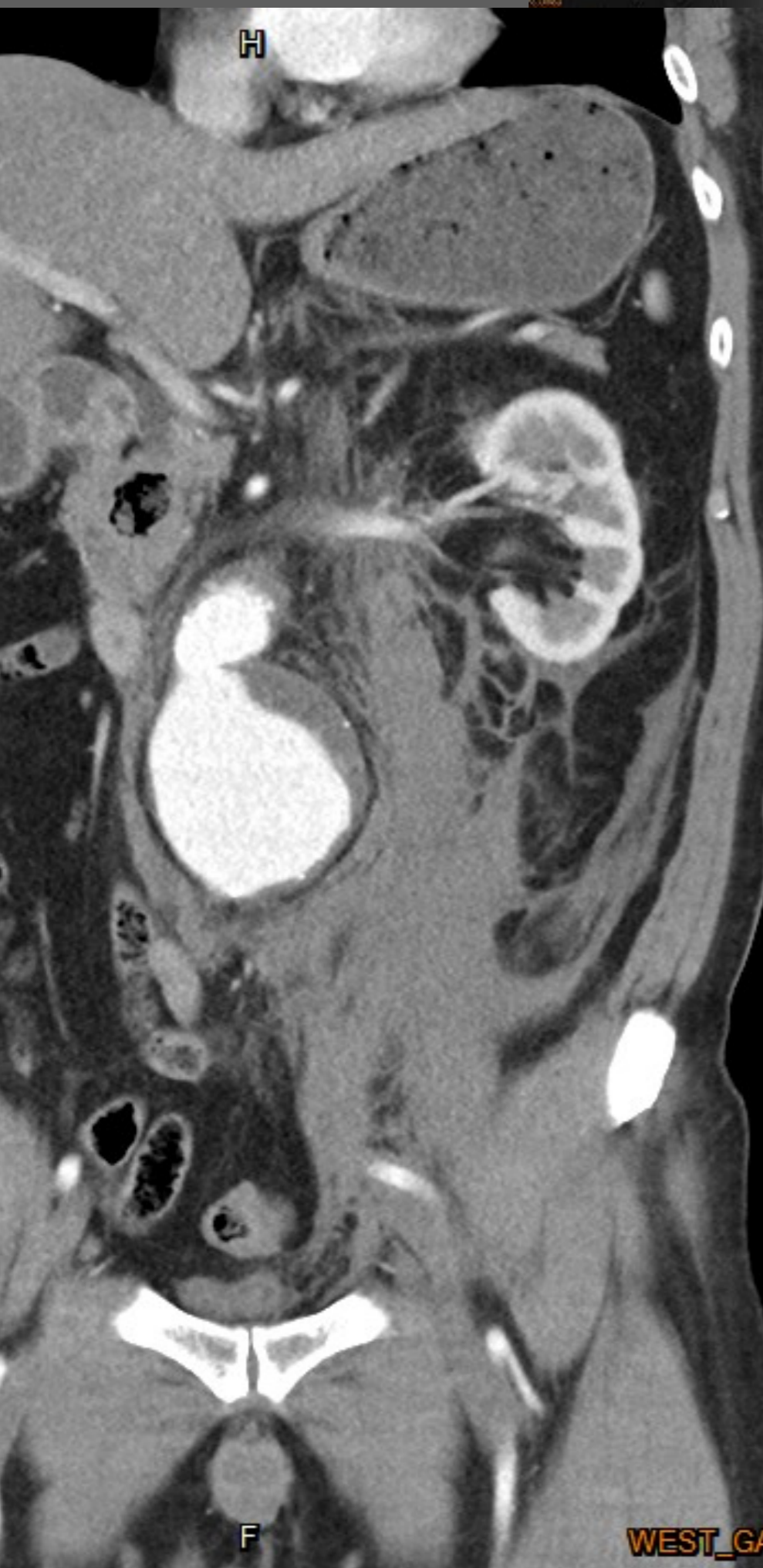
腰痛 + 冒冷汗，  
我的病人可能是  
主動脈瘤破裂？









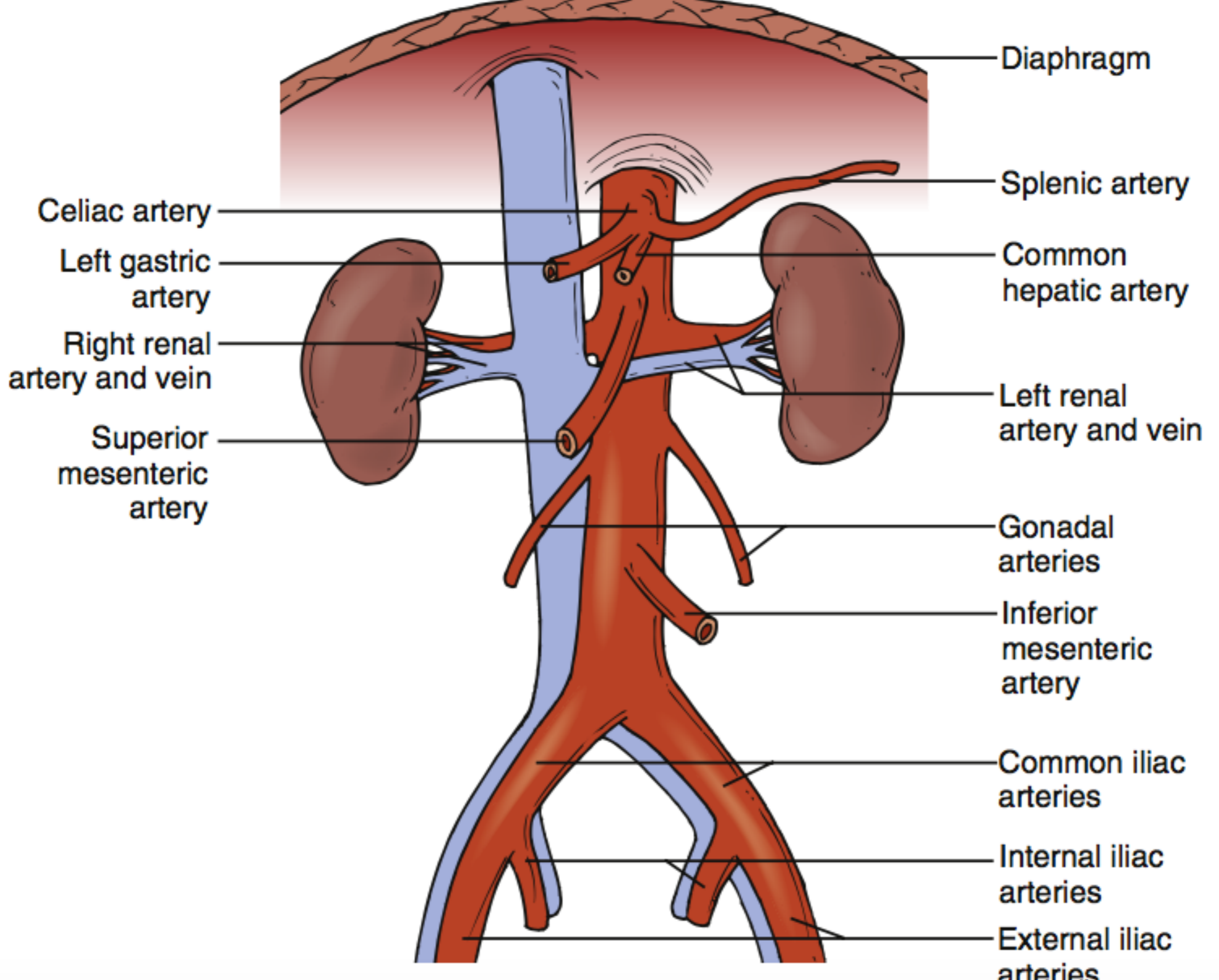


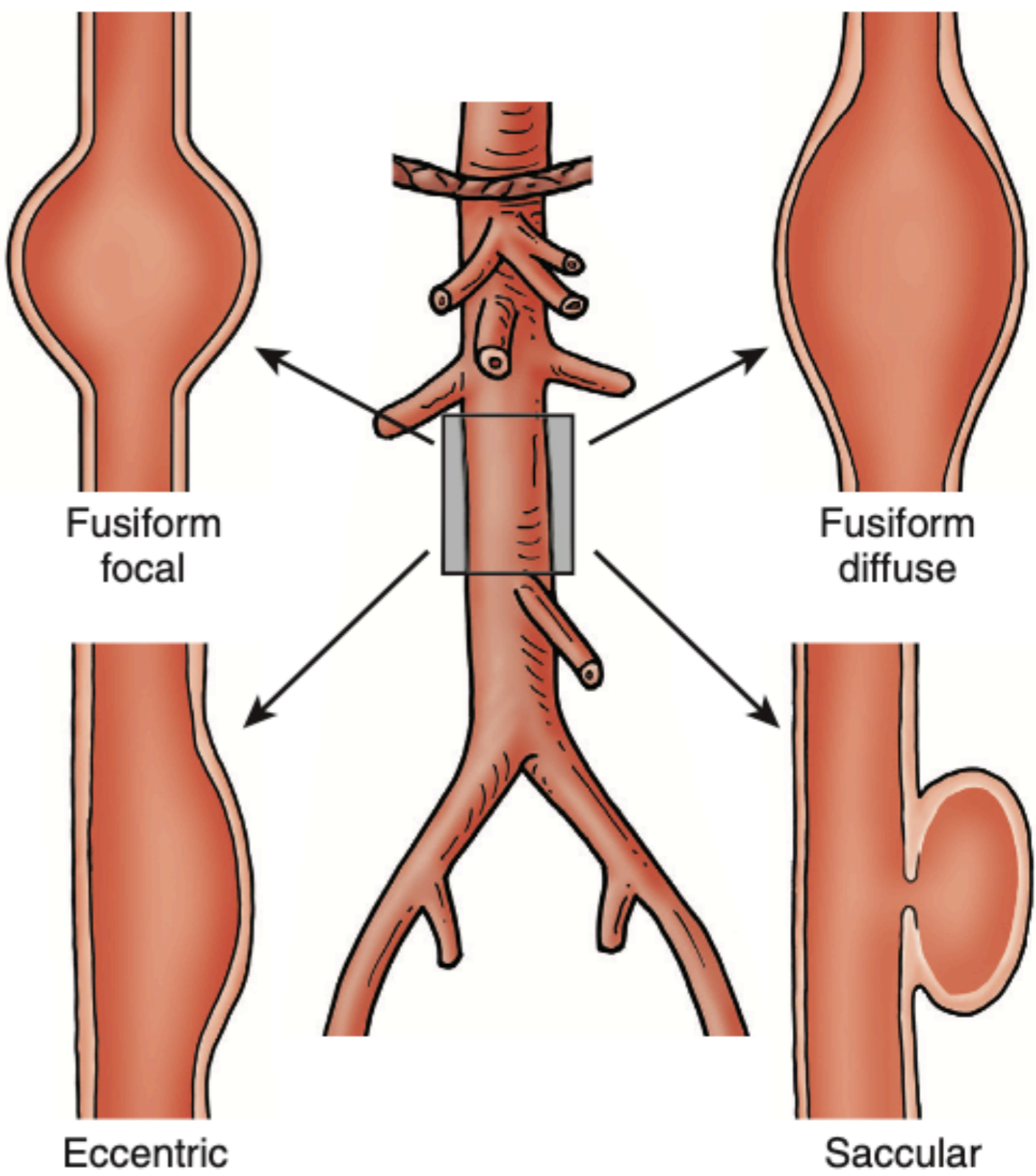
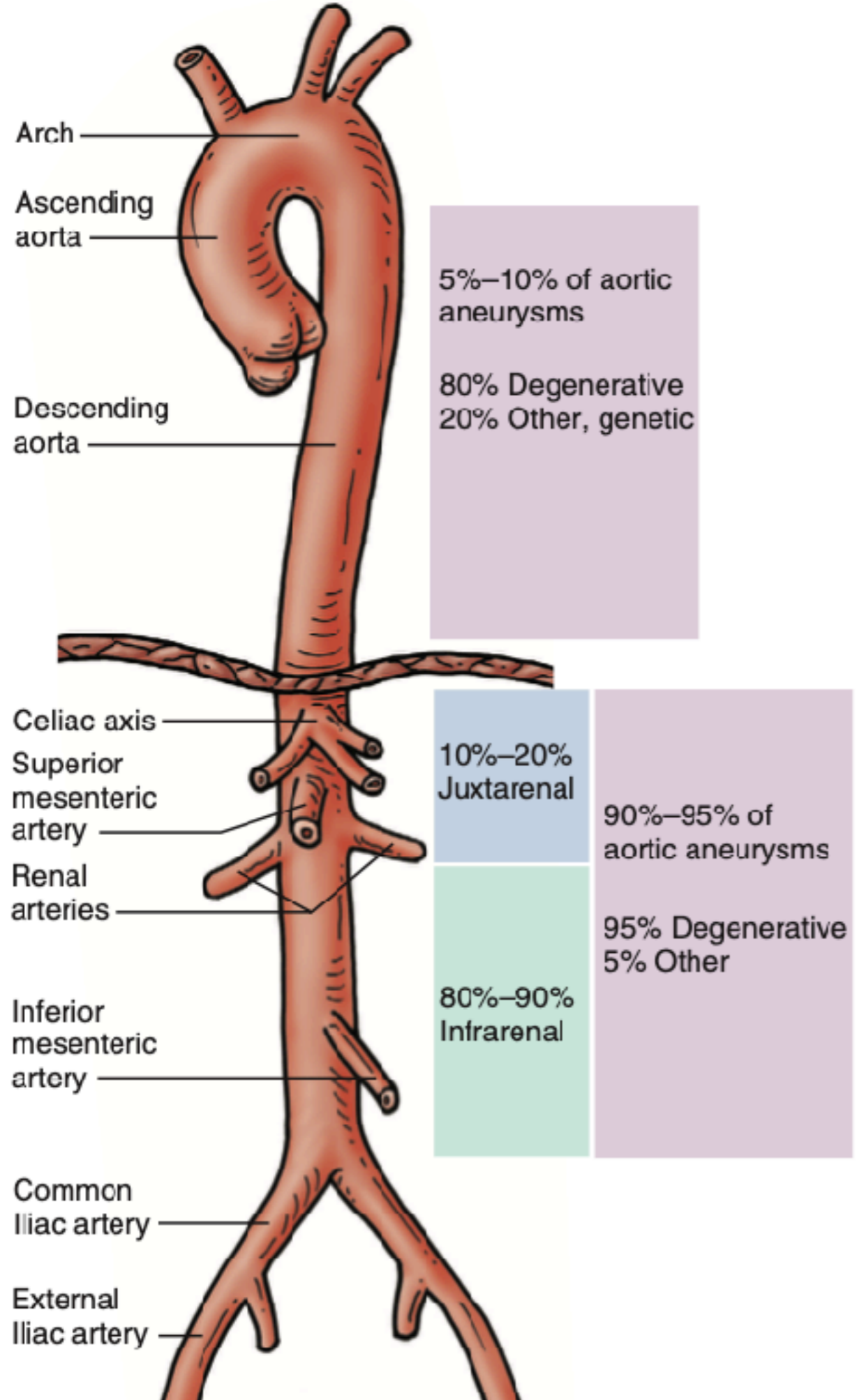
**A**BDOMEN

A for AAA

**3**cm



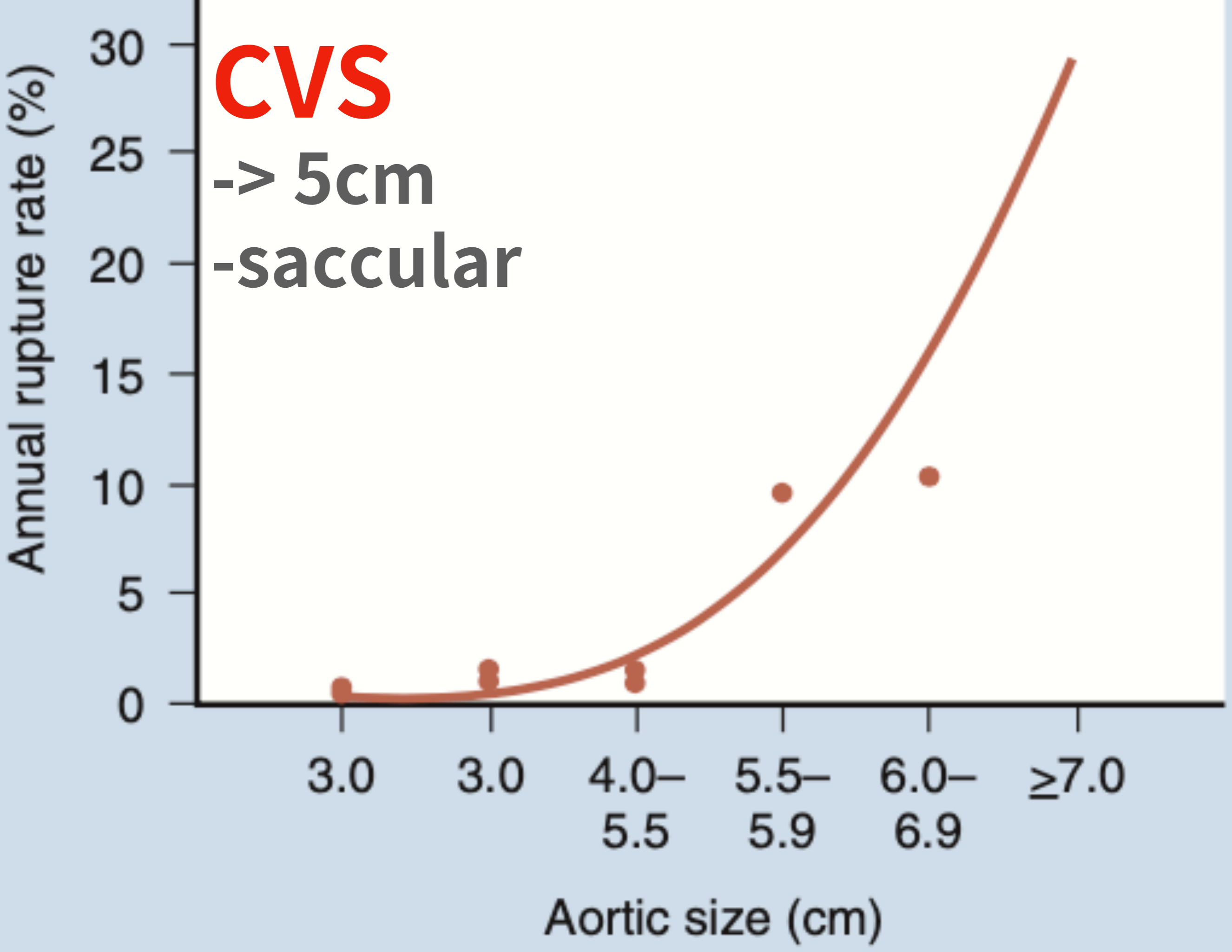




**CVS**

**-> 5cm**

**-saccular**





# AAA

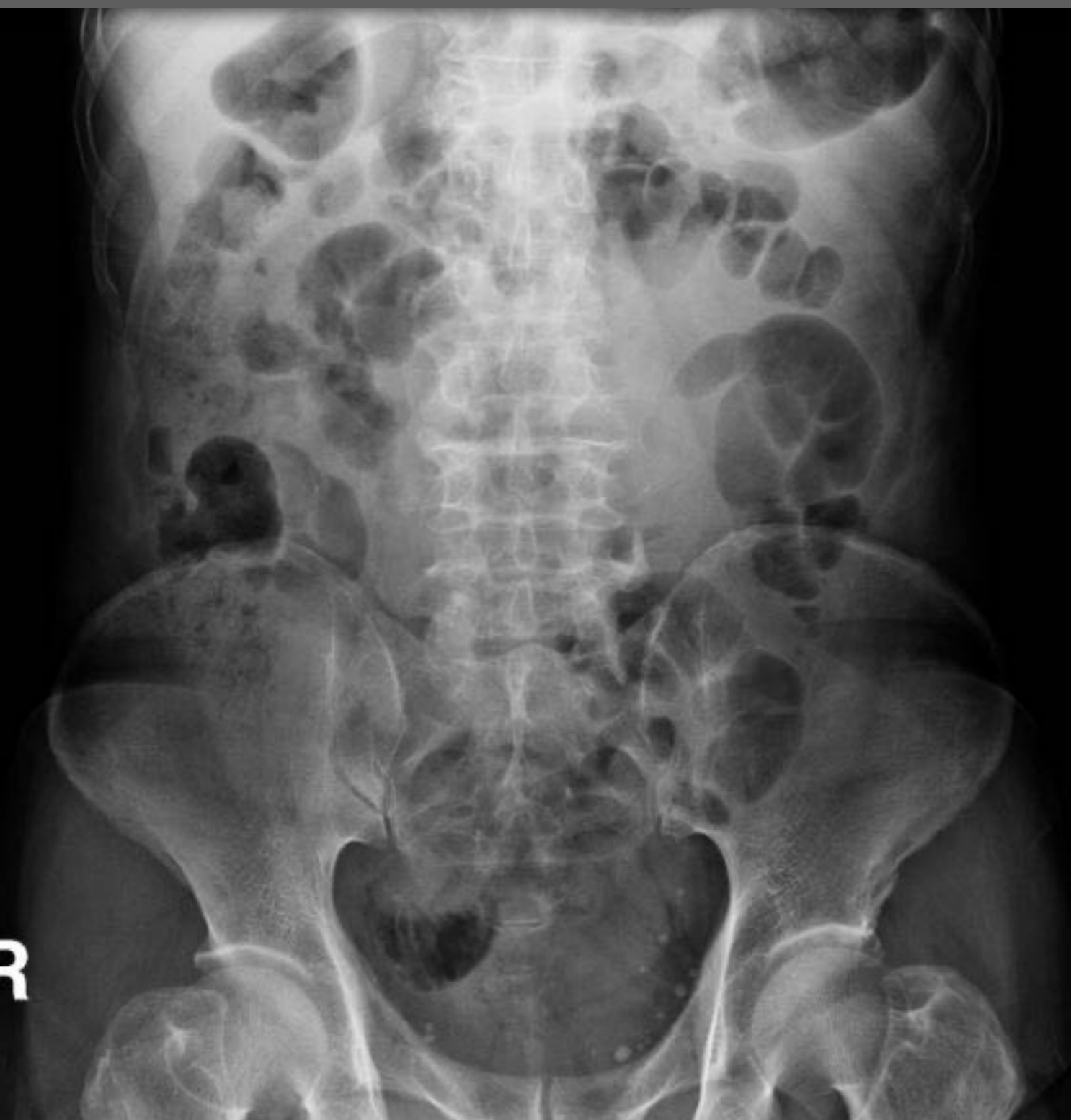

**3** cm

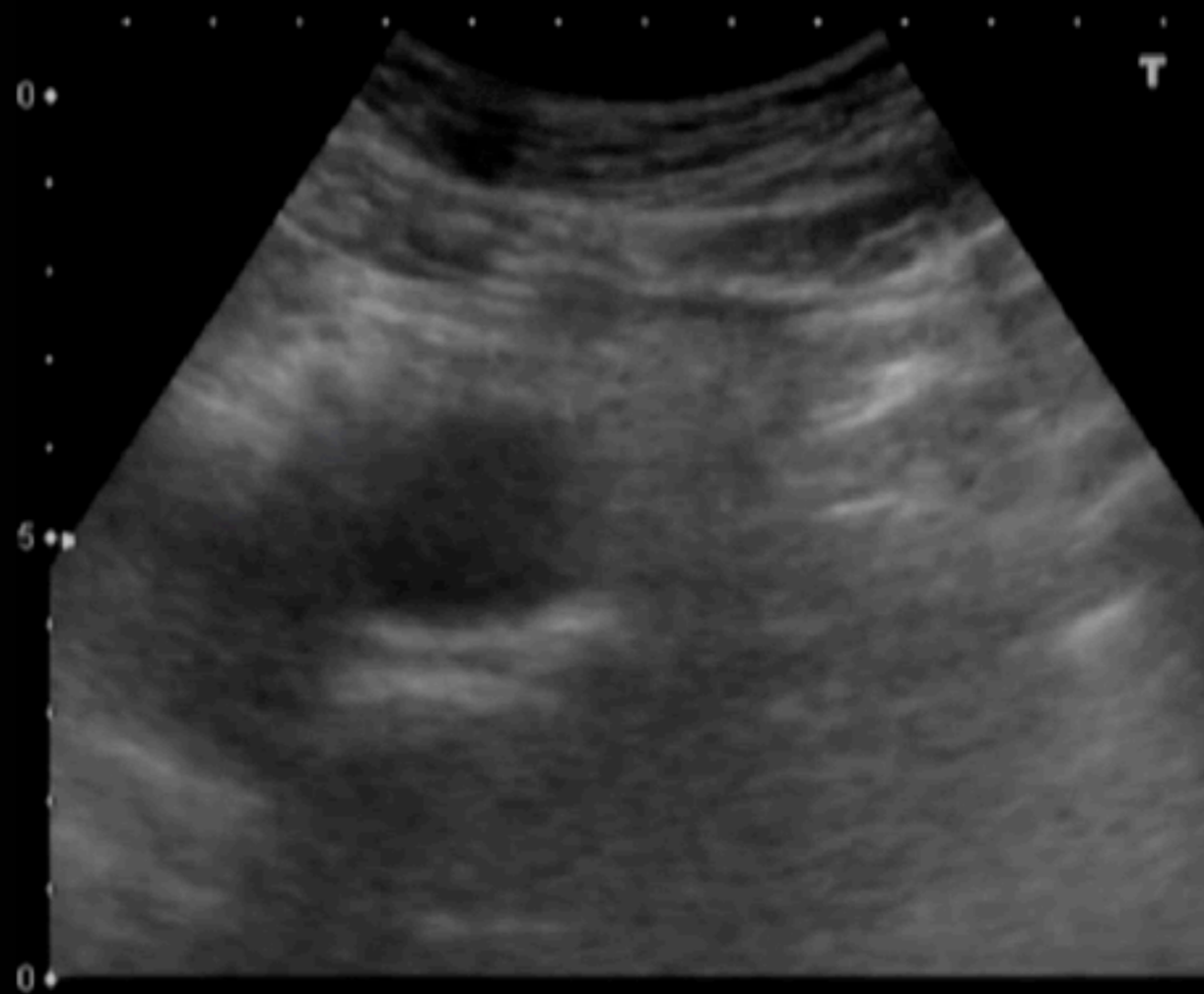**> 50 y/o**  
**Syncope**  
**Hypotension**  
**ABD/Flank/Back/Groin**

Sensitivity **97.5-100%**  
Specificity **94.1-100%**

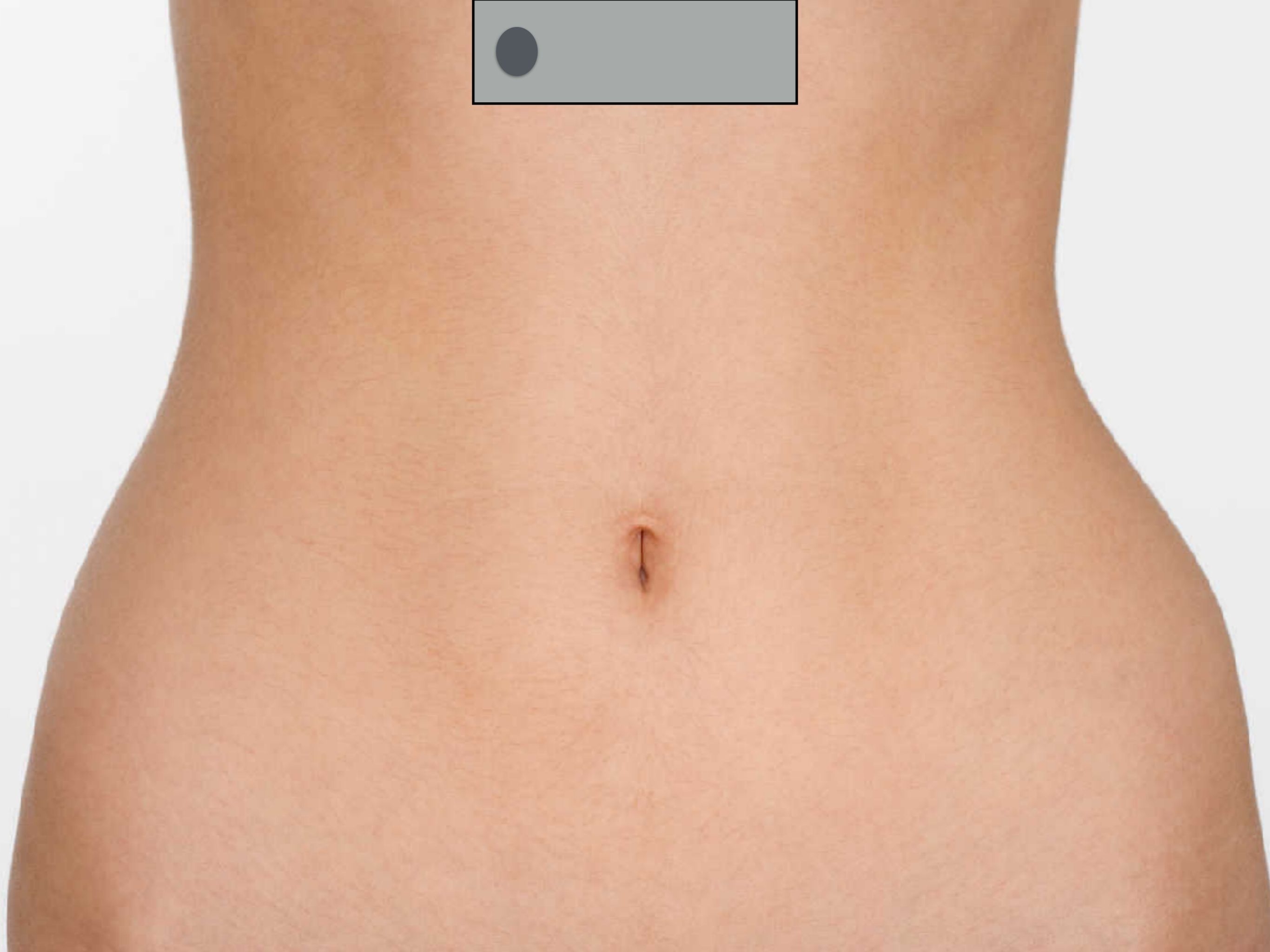
# 59M, Abd pain & hematuria



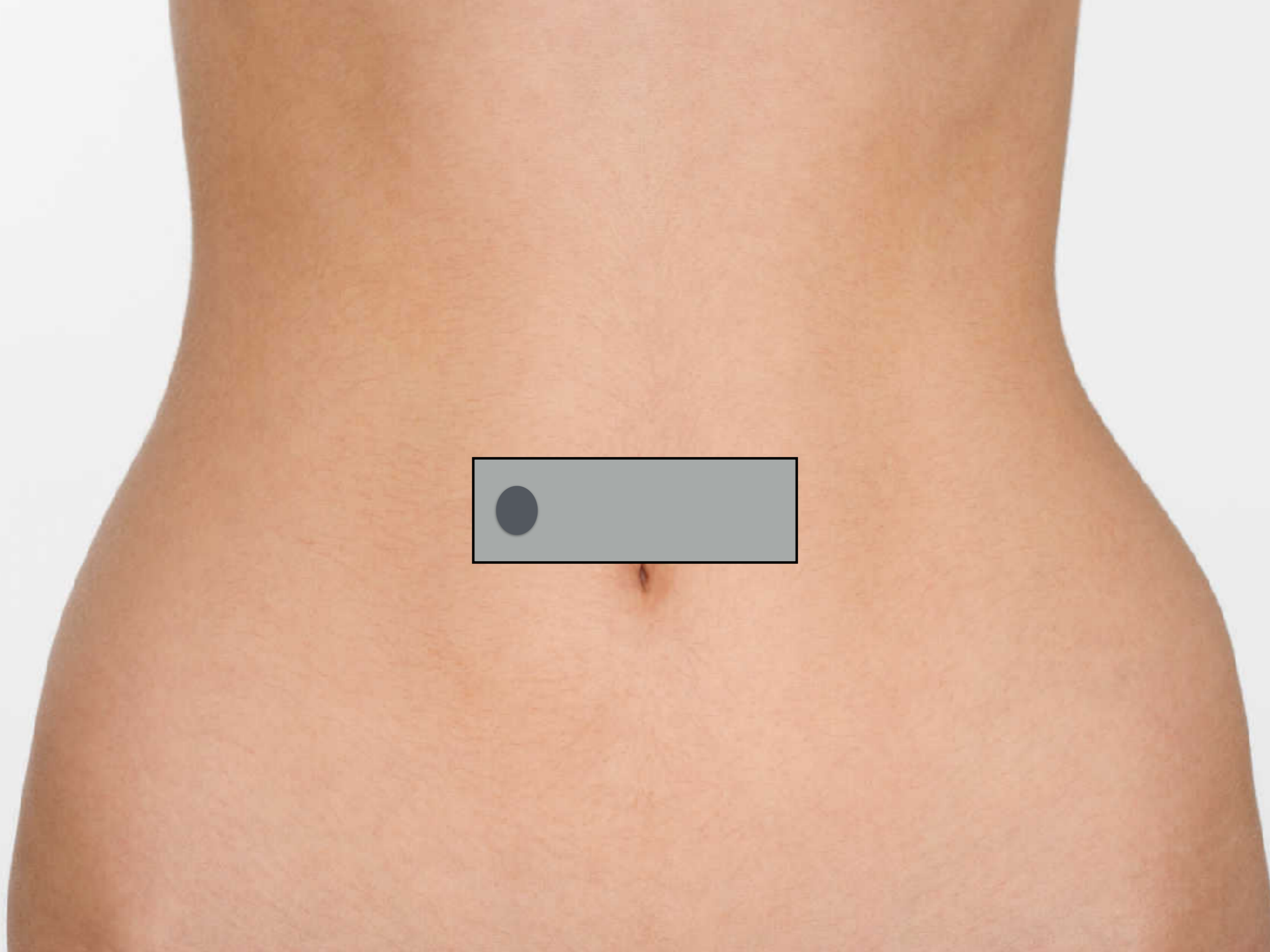
POCUS Academy©ChenK



Free 8





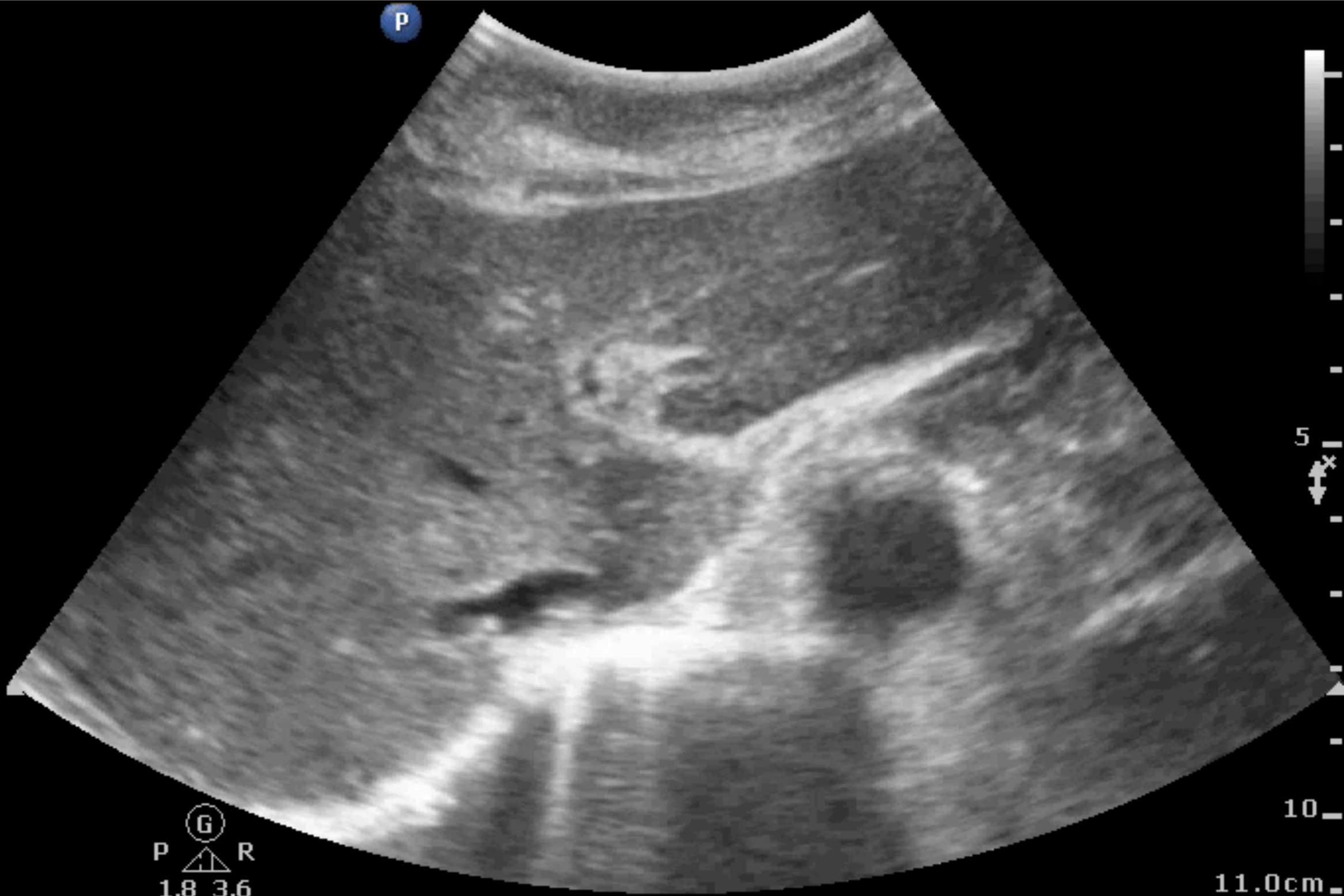

# Abdominal aorta

Abd Gen  
C5-1  
42 Hz  
11.0cm

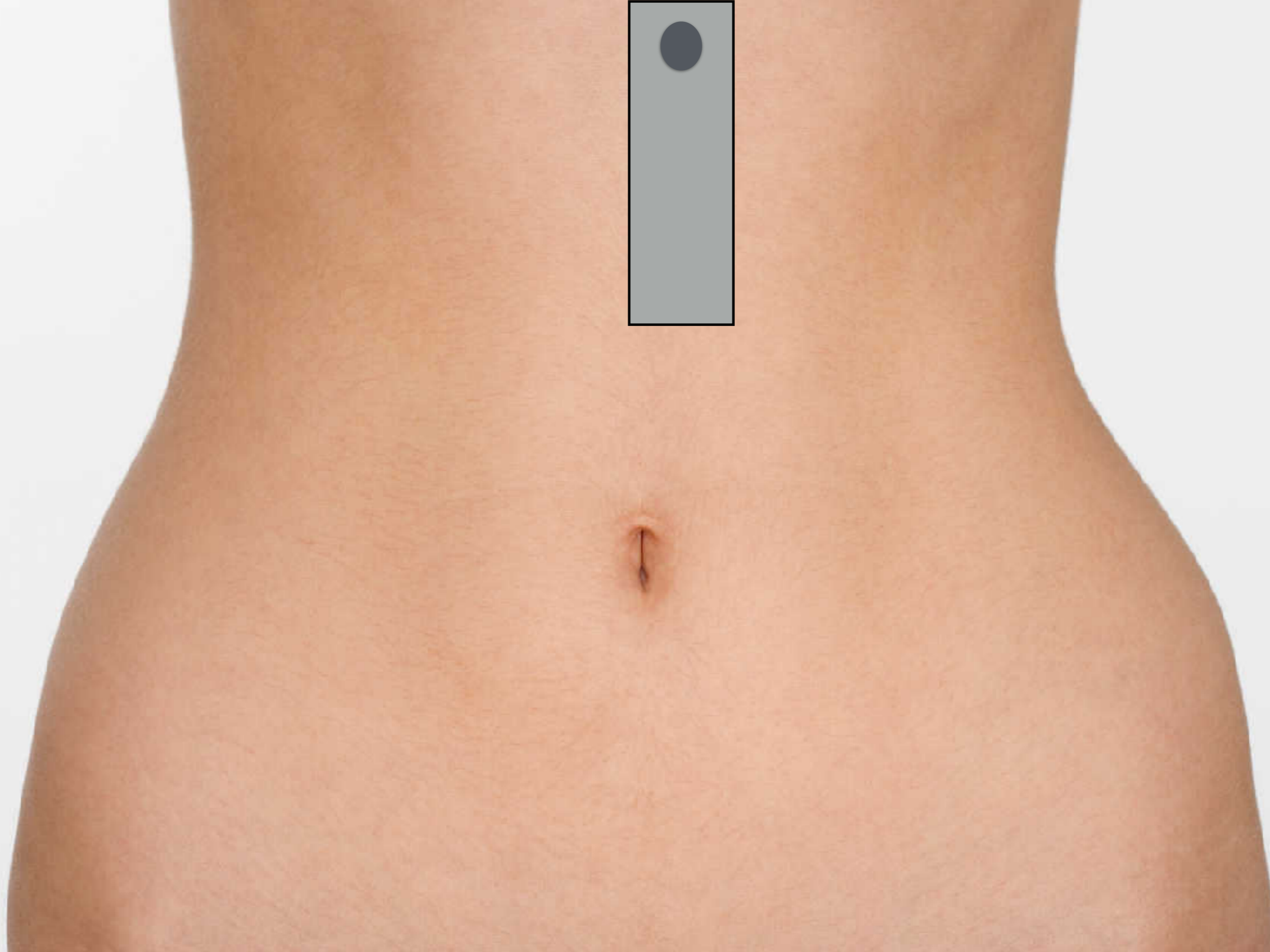
2D

HGen  
Gn 66  
C 56  
3 / 3 / 3

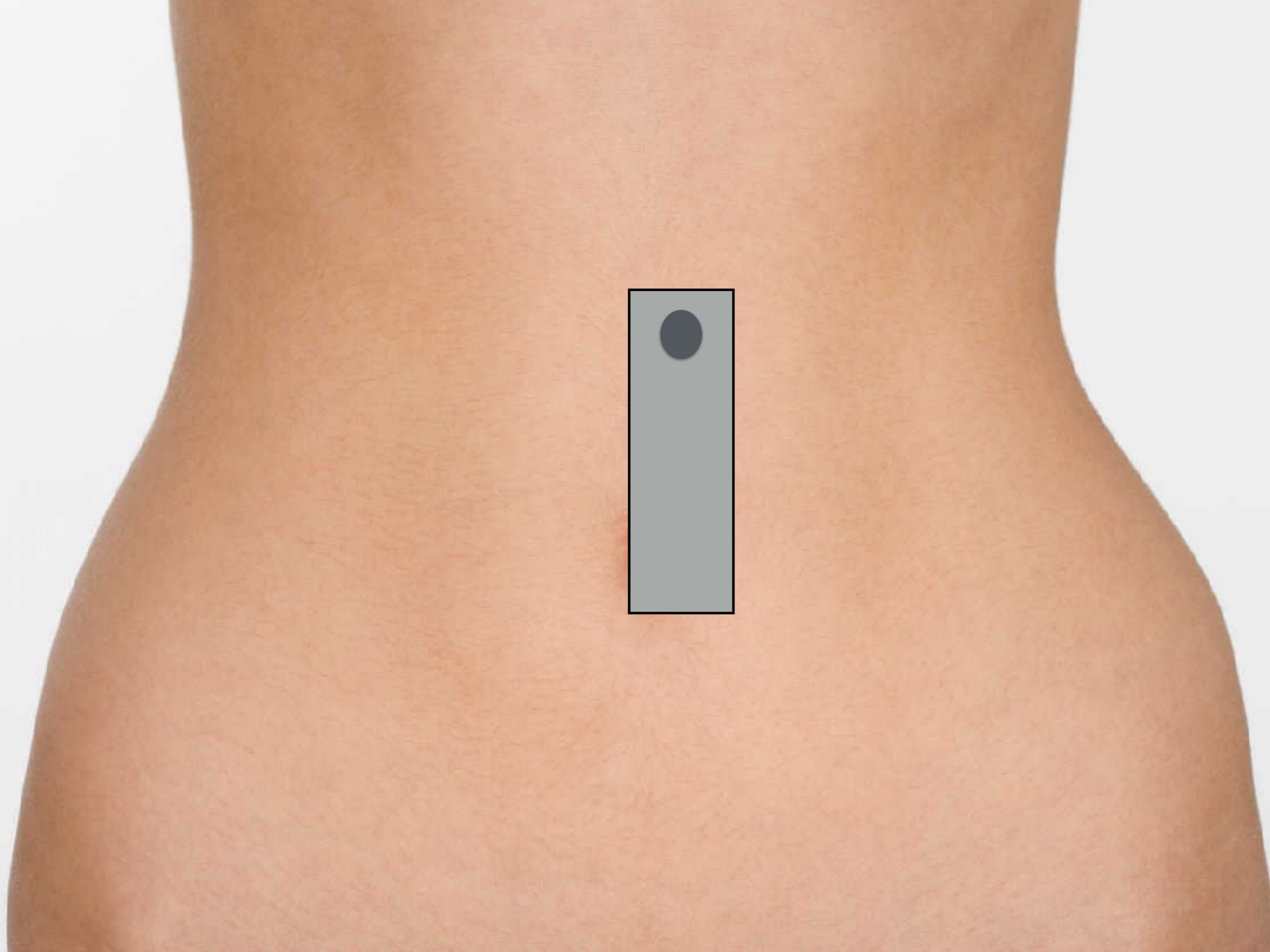


P  $\text{\textcircled{G}}$  R  
1.8 3.6

11.0cm





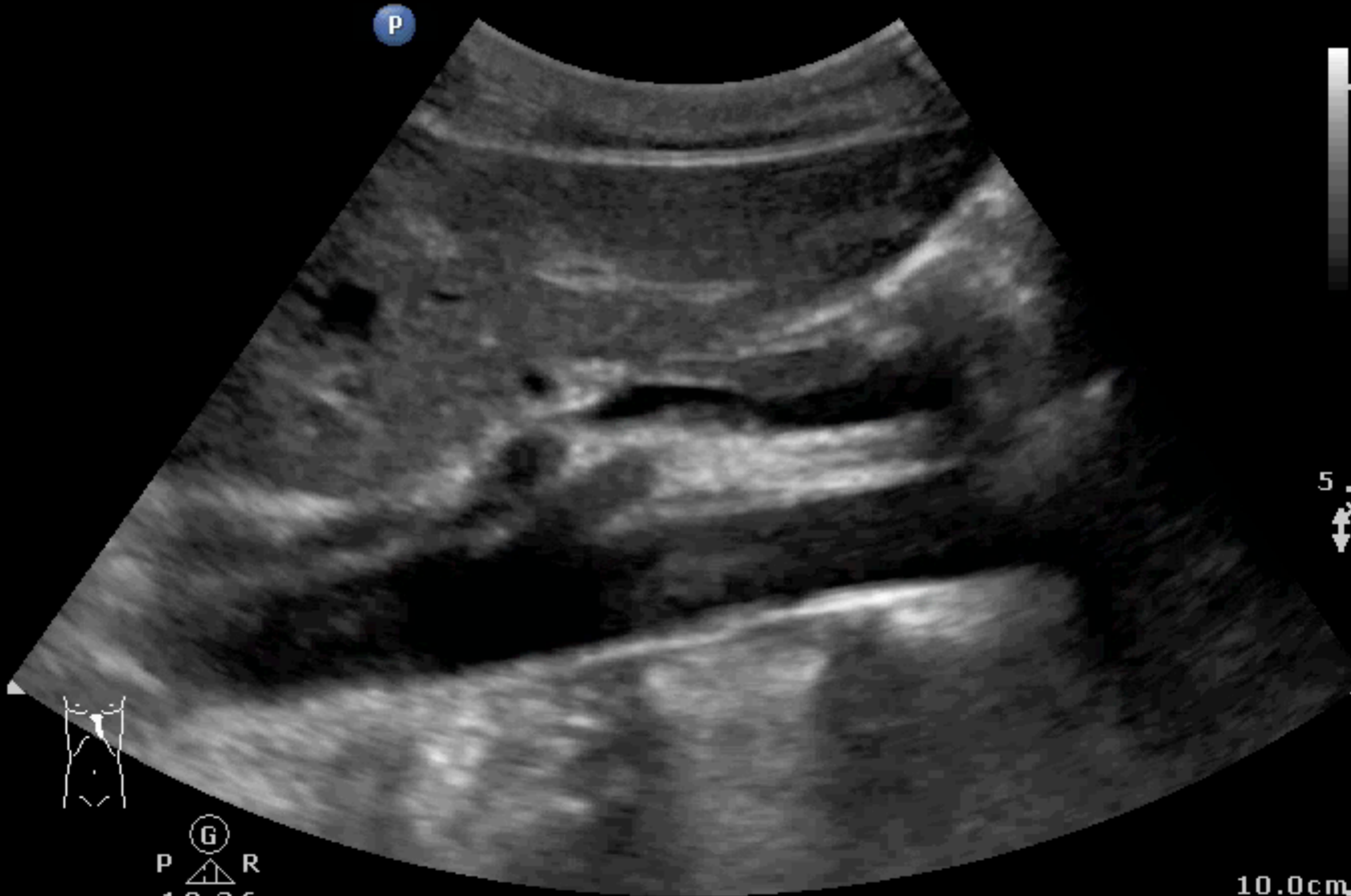

# Abdominal aorta

Abd Gen  
C5-1  
45 Hz  
10.0cm

2D

HGen  
Gn 60  
C 56  
3/3/3

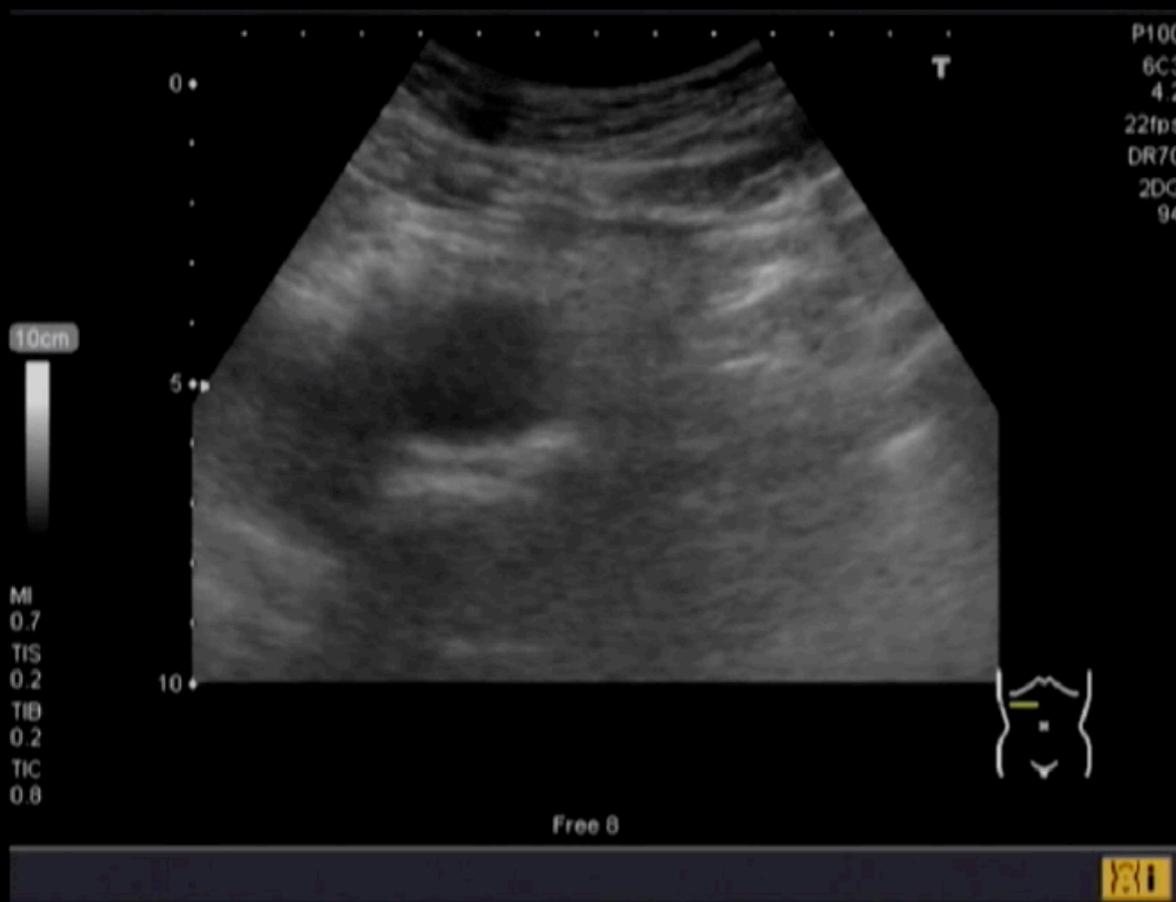

G  
P R  
1.8 3.6

10.0cm

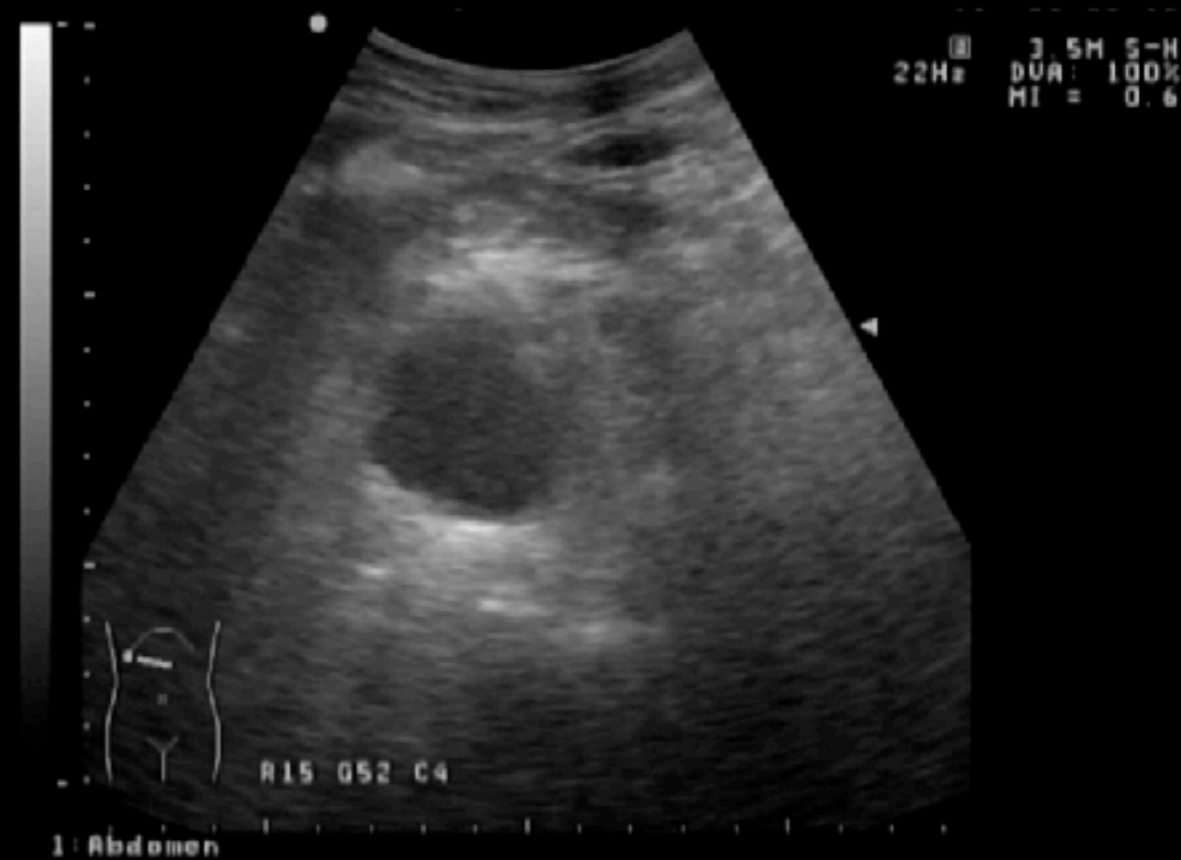# A for AAA, not for rupture

POCUS Academy©ChenKC



A

POCUS Academy©ChenKC

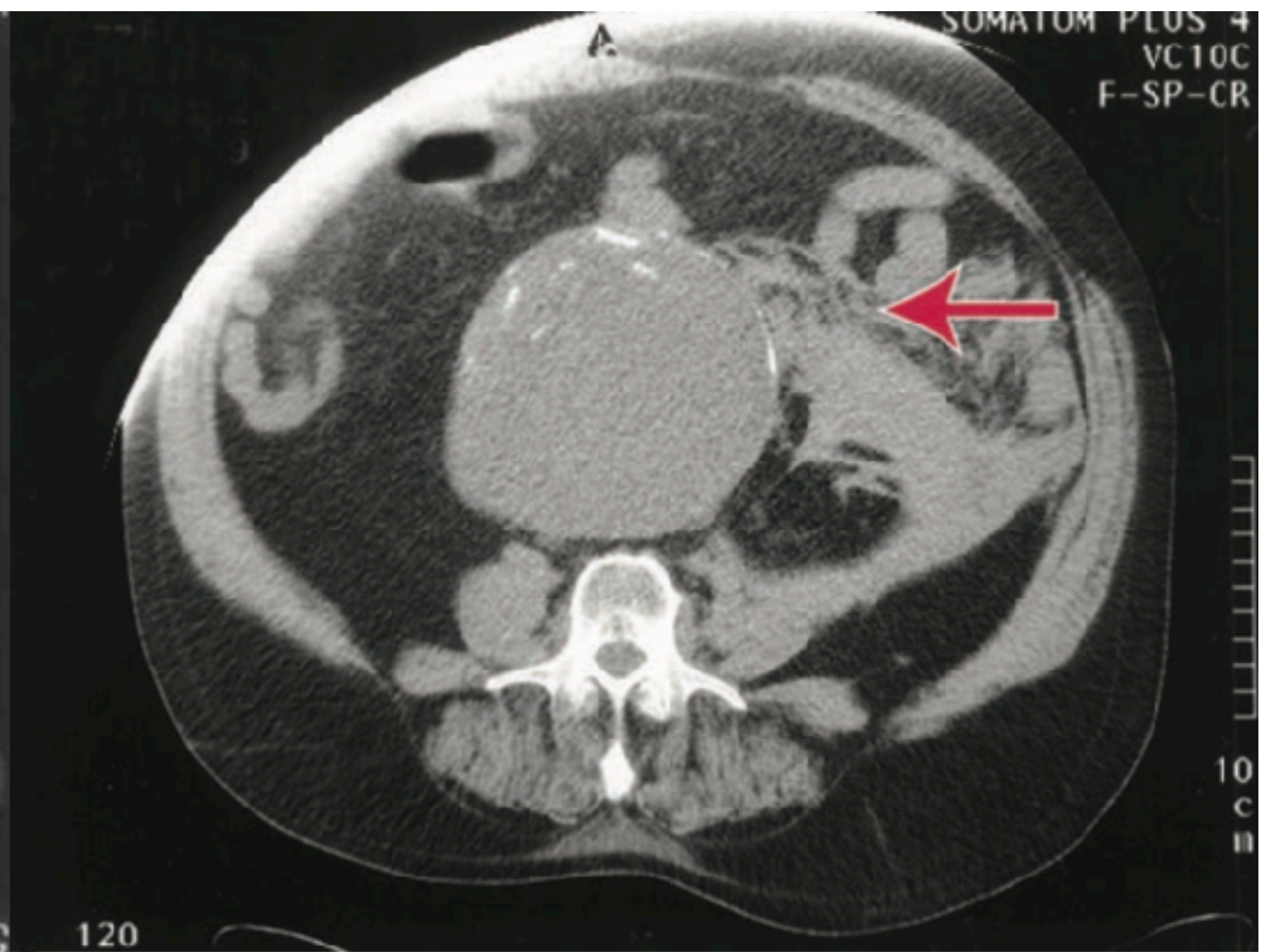
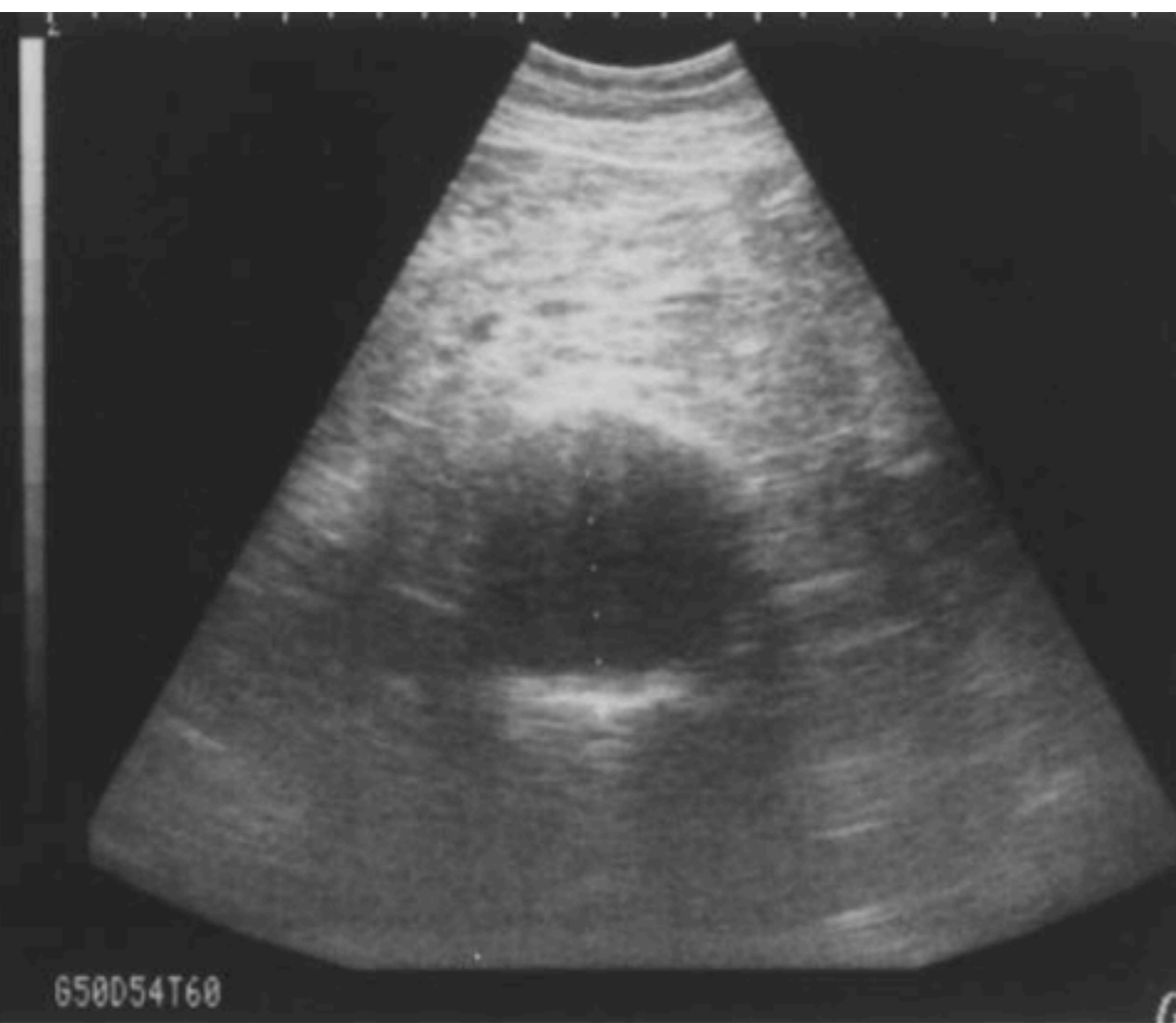


B



# Echo for AAA ( 3~5cm)

## Not for rupture



# Eyeballing

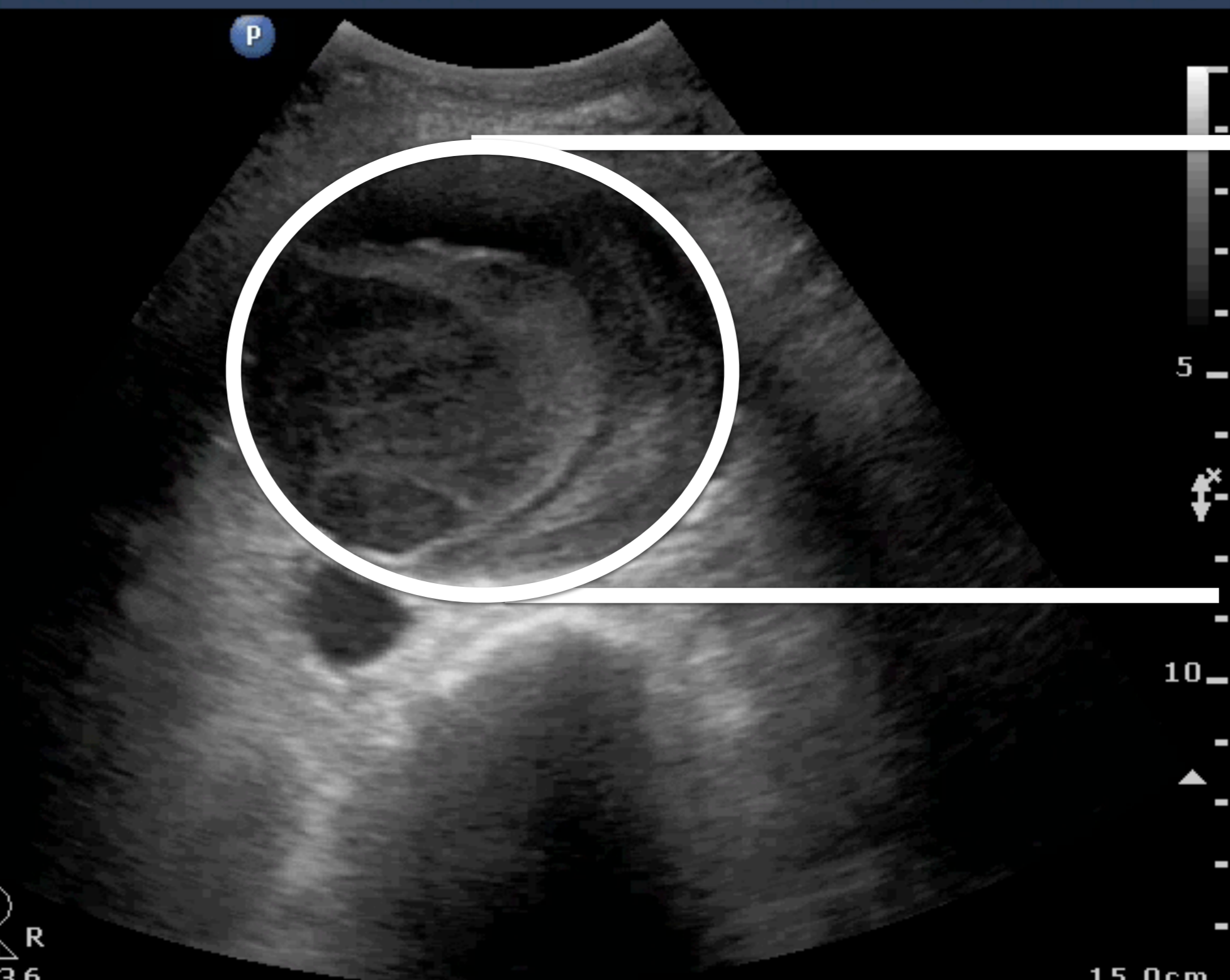
Abd Gen  
C5-1  
34 Hz  
15.0cm

2D

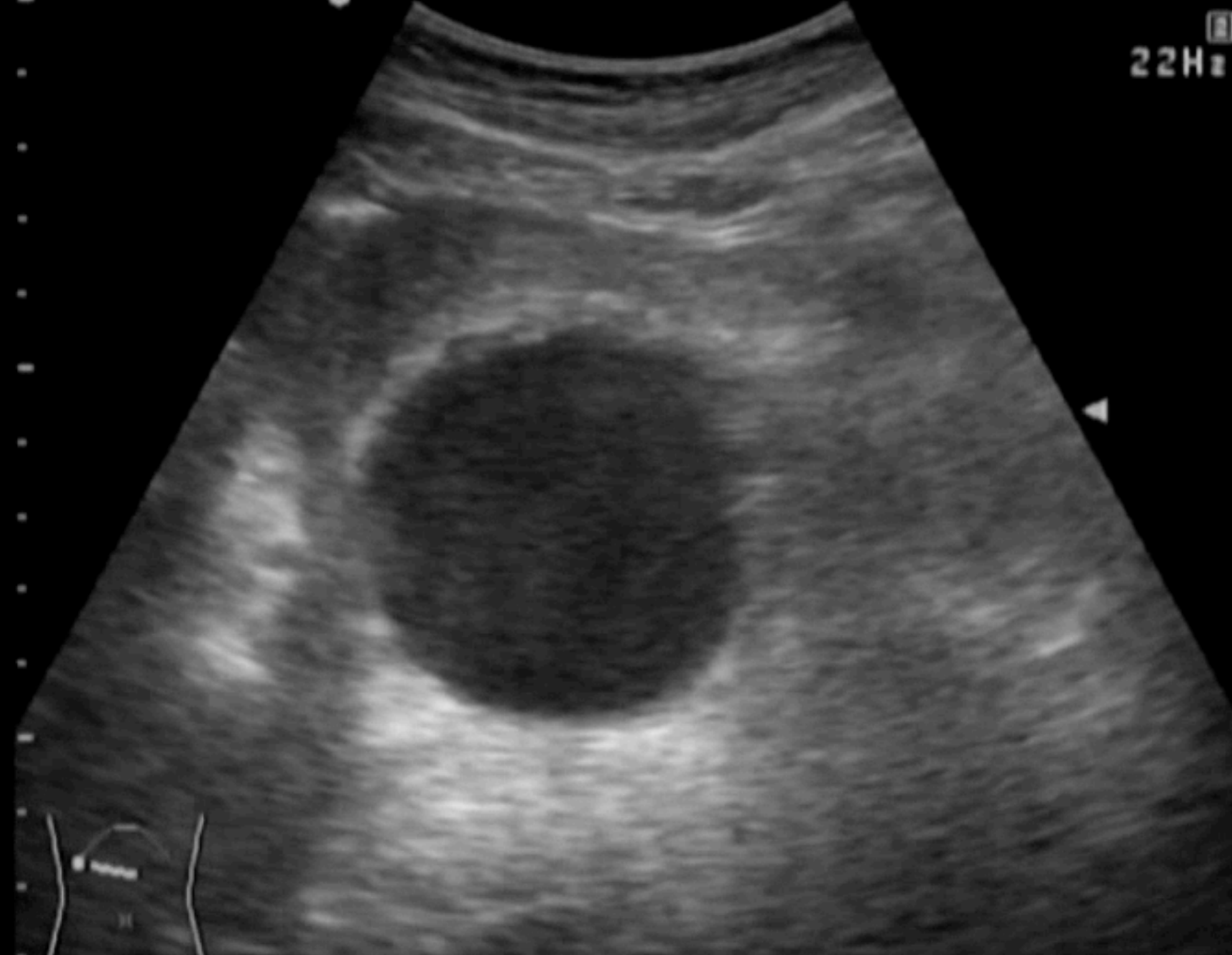
HGen  
Gn 57  
C 56  
3 / 3 / 3

P  R  
1.8 3.6

15.0cm



22Hz 3.5M S-H  
DUA: 100%  
MI = 0.6



AAA protocol

3<sub>cm</sub>

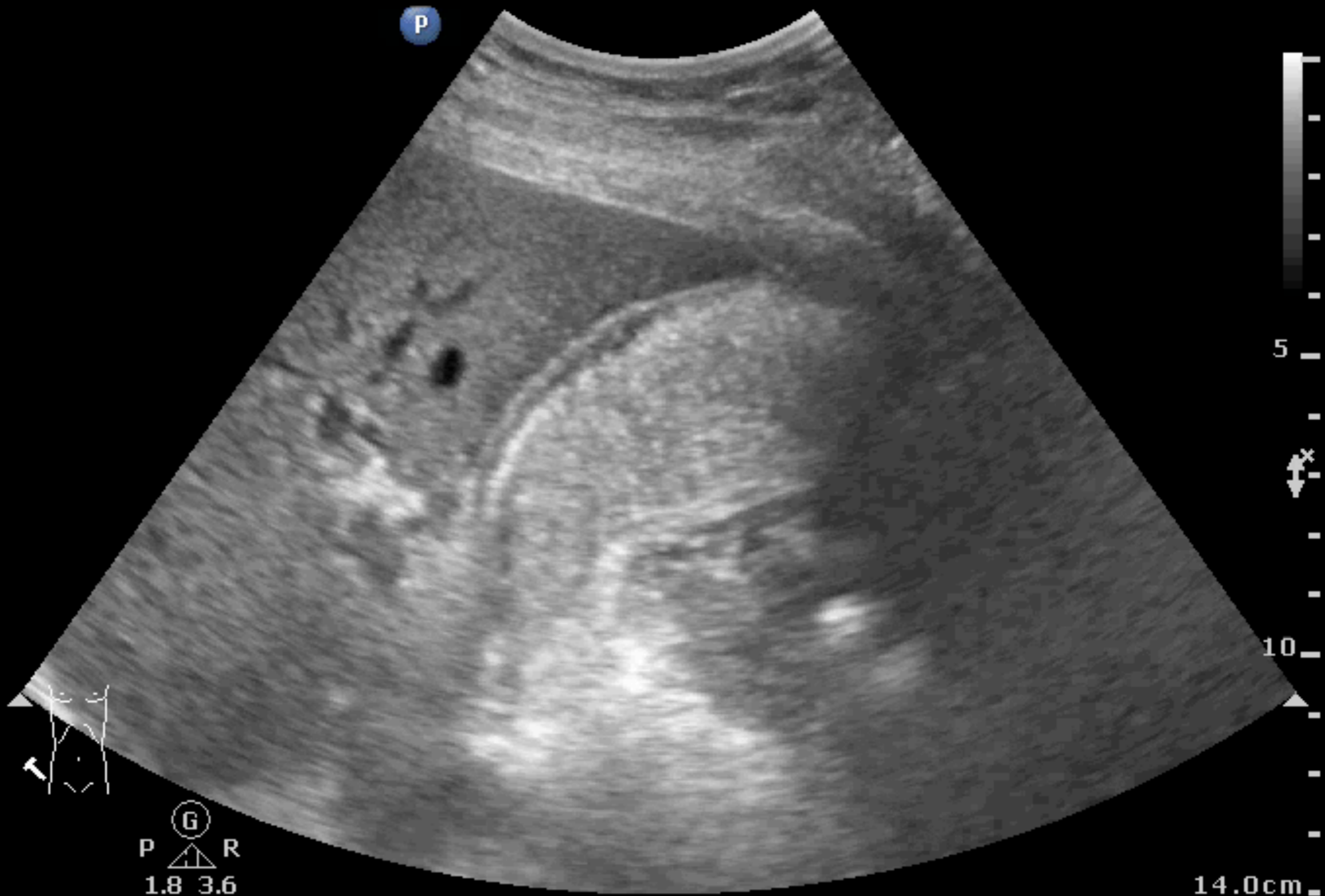
Not for rupture



# 59M, epigastric pain at midnight

Abd Gen2  
C5-1  
36 Hz  
14.0cm

2D  
HGen  
Gn 100  
C 56  
3 / 3 / 3



# ABDOMEN

B for GB stone & dilatation

3

mm

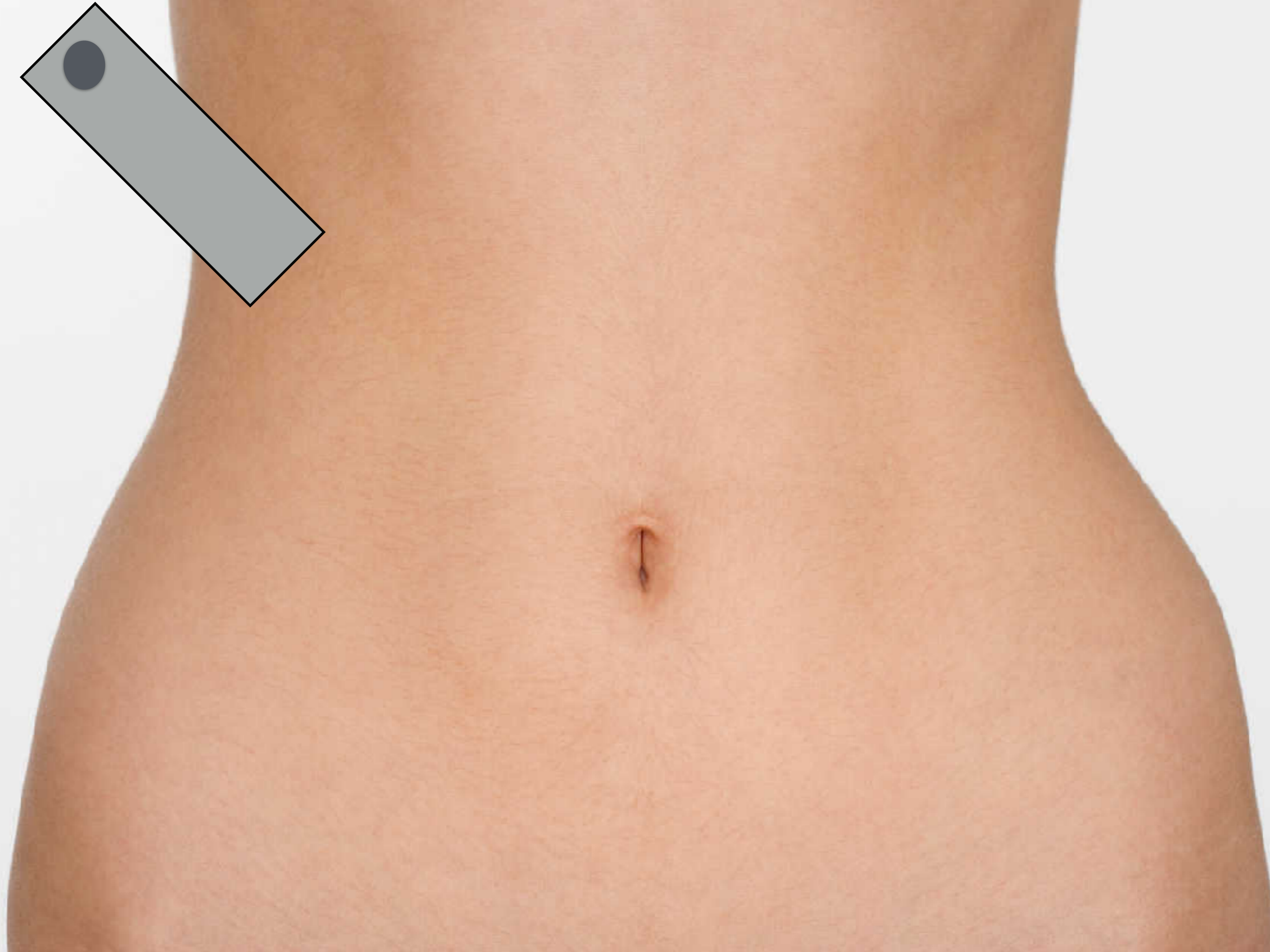7

mm

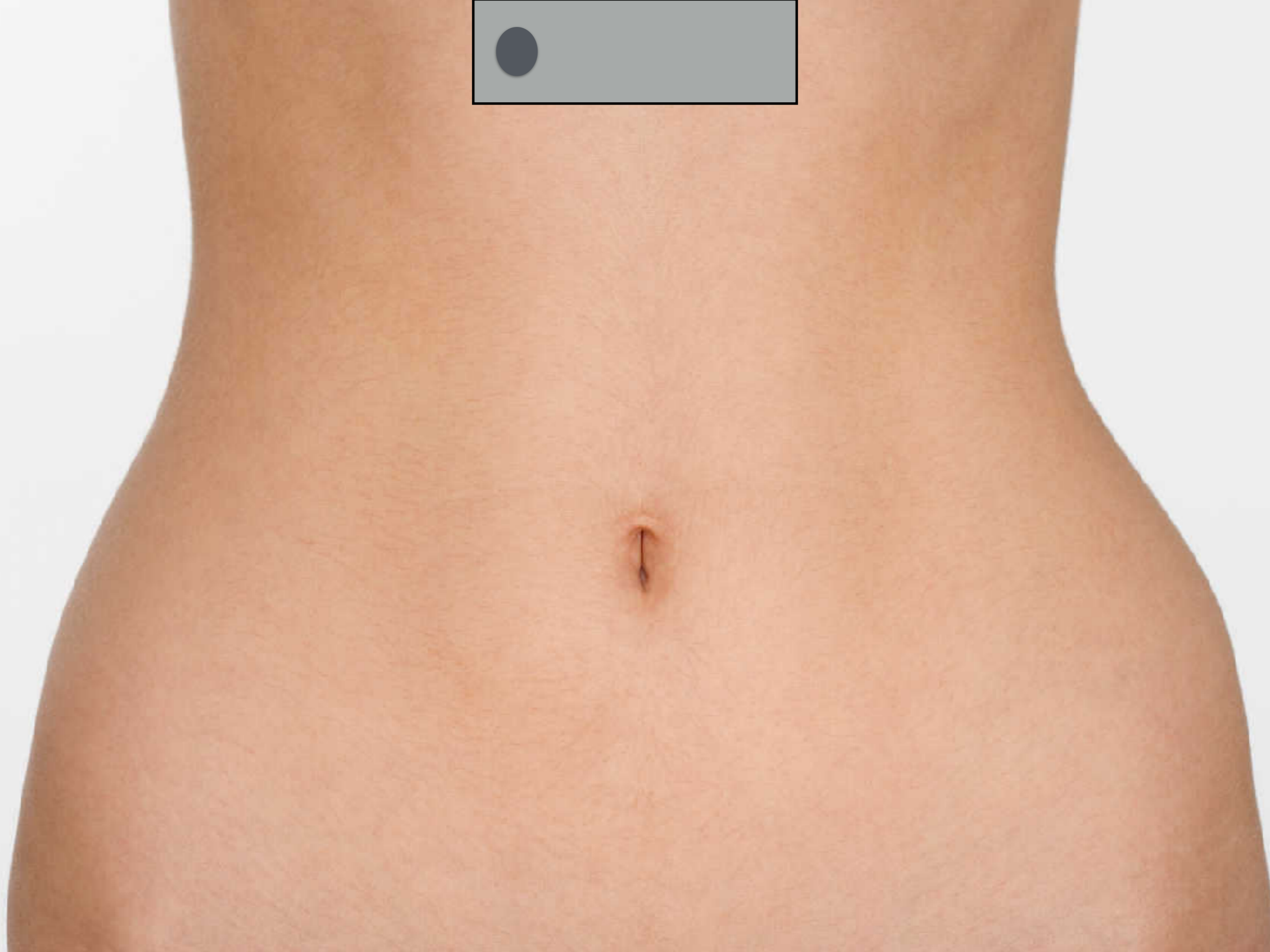
11

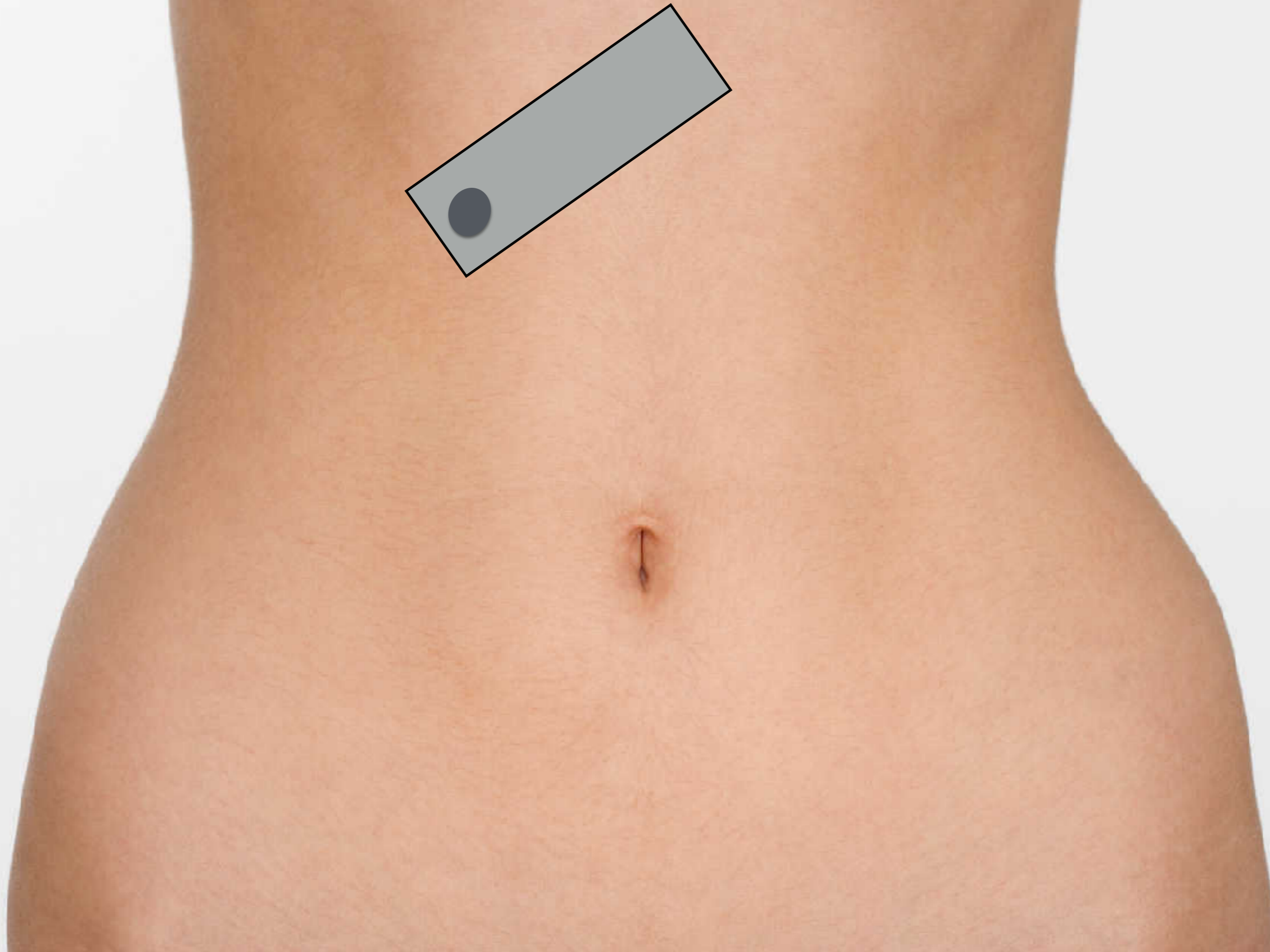
1

mm











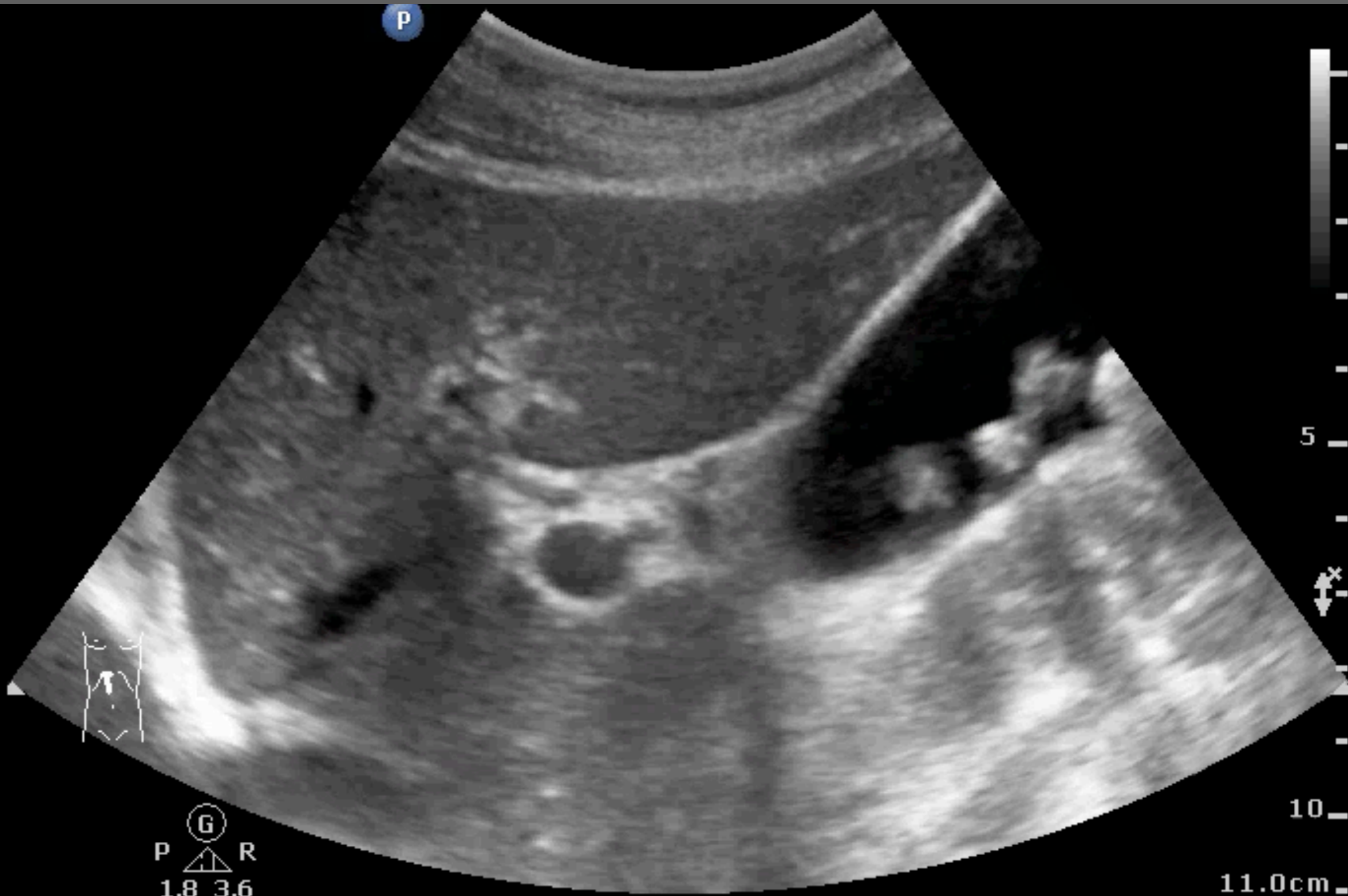


# 讀讀看，你看到了什麼？

Abd Gen  
C5-1  
42 Hz  
11.0cm

2D

HGen  
Gn 80  
C 56  
3 / 3 / 3



G  
P R  
1.8 3.6

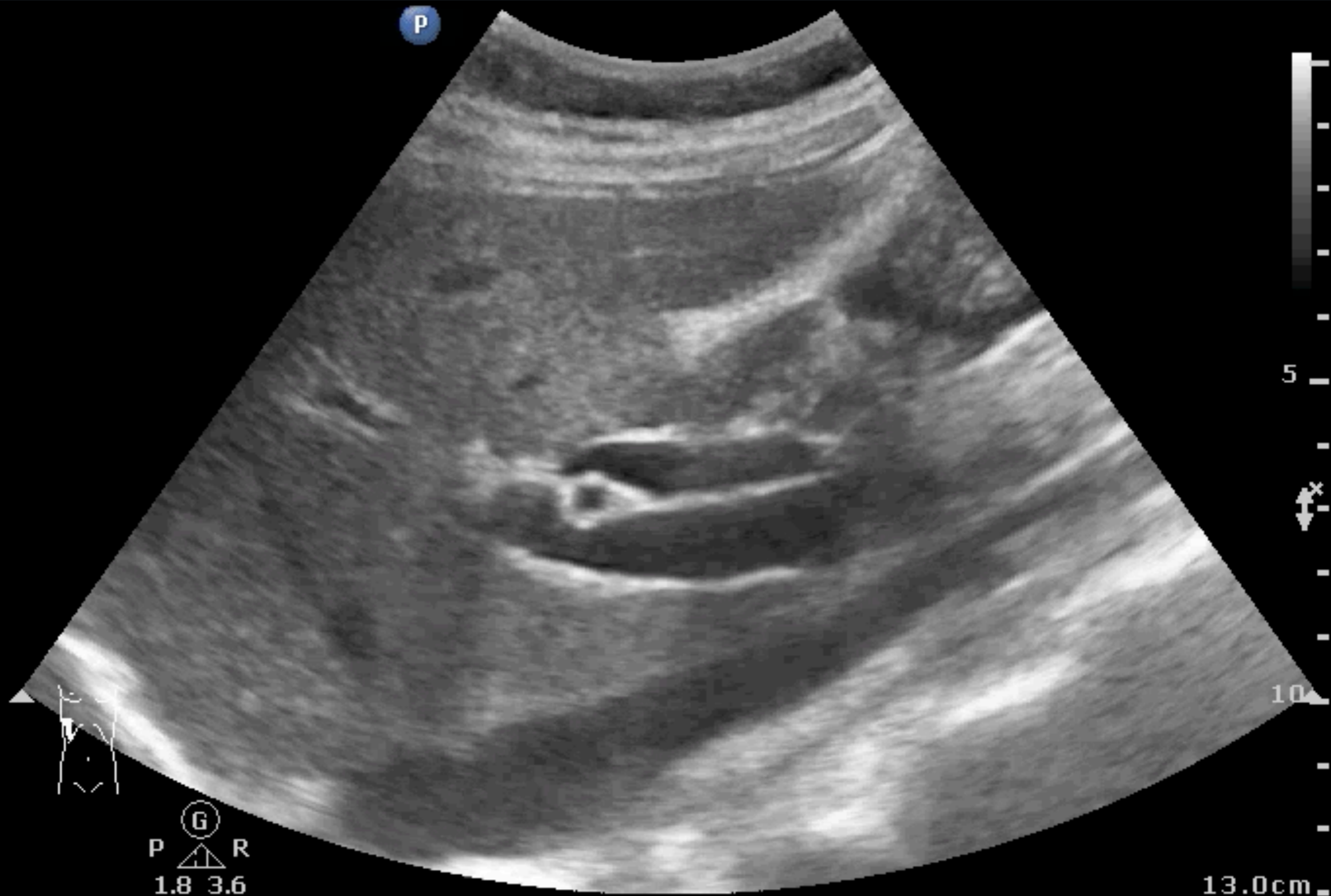11.0cm

# 讀讀看，你看到了什麼？

Abd Gen  
C5-1  
38 Hz  
13.0cm

2D

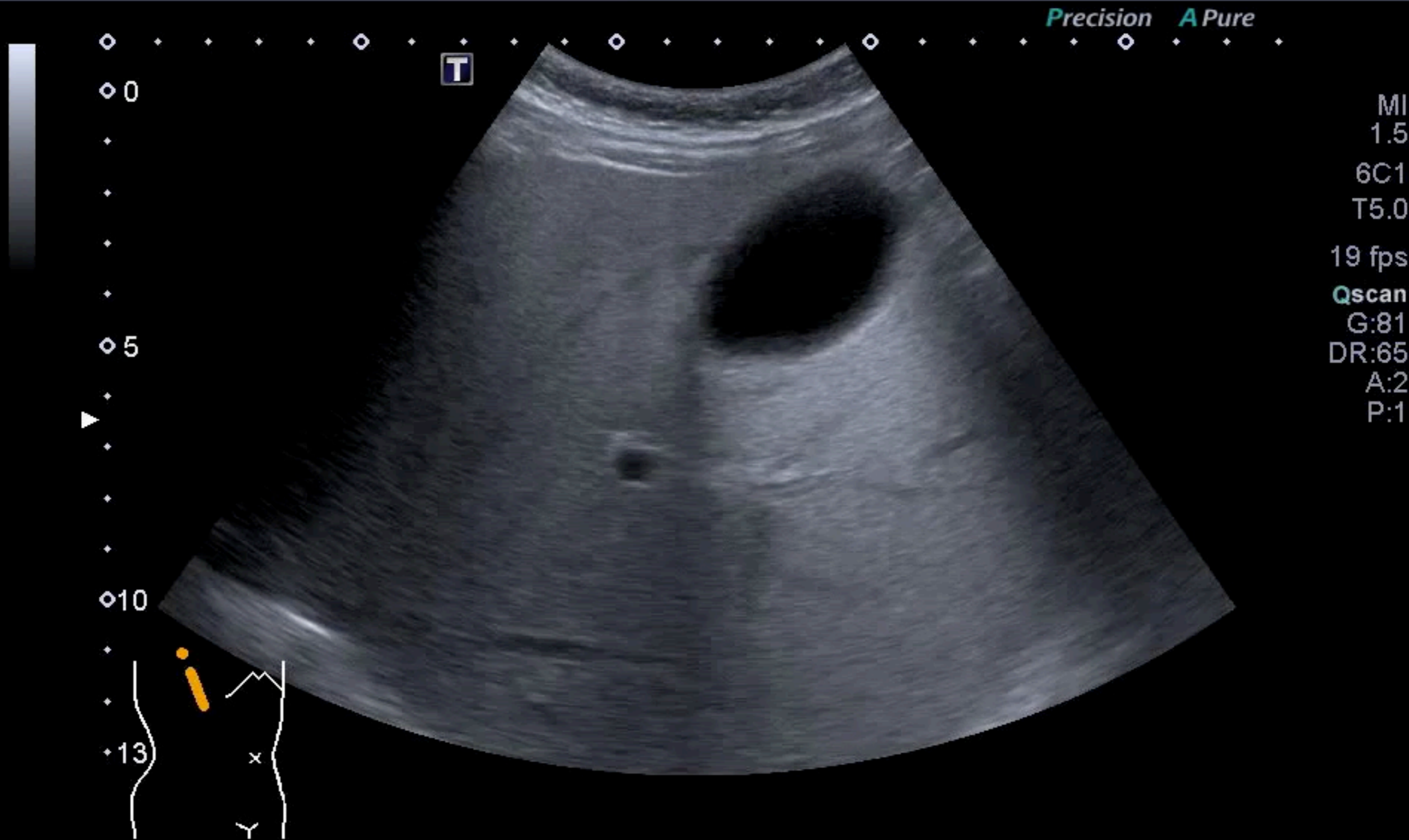
HGen  
Gn 82  
C 56  
3 / 3 / 3



⊙ G  
P △ R  
1.8 3.6

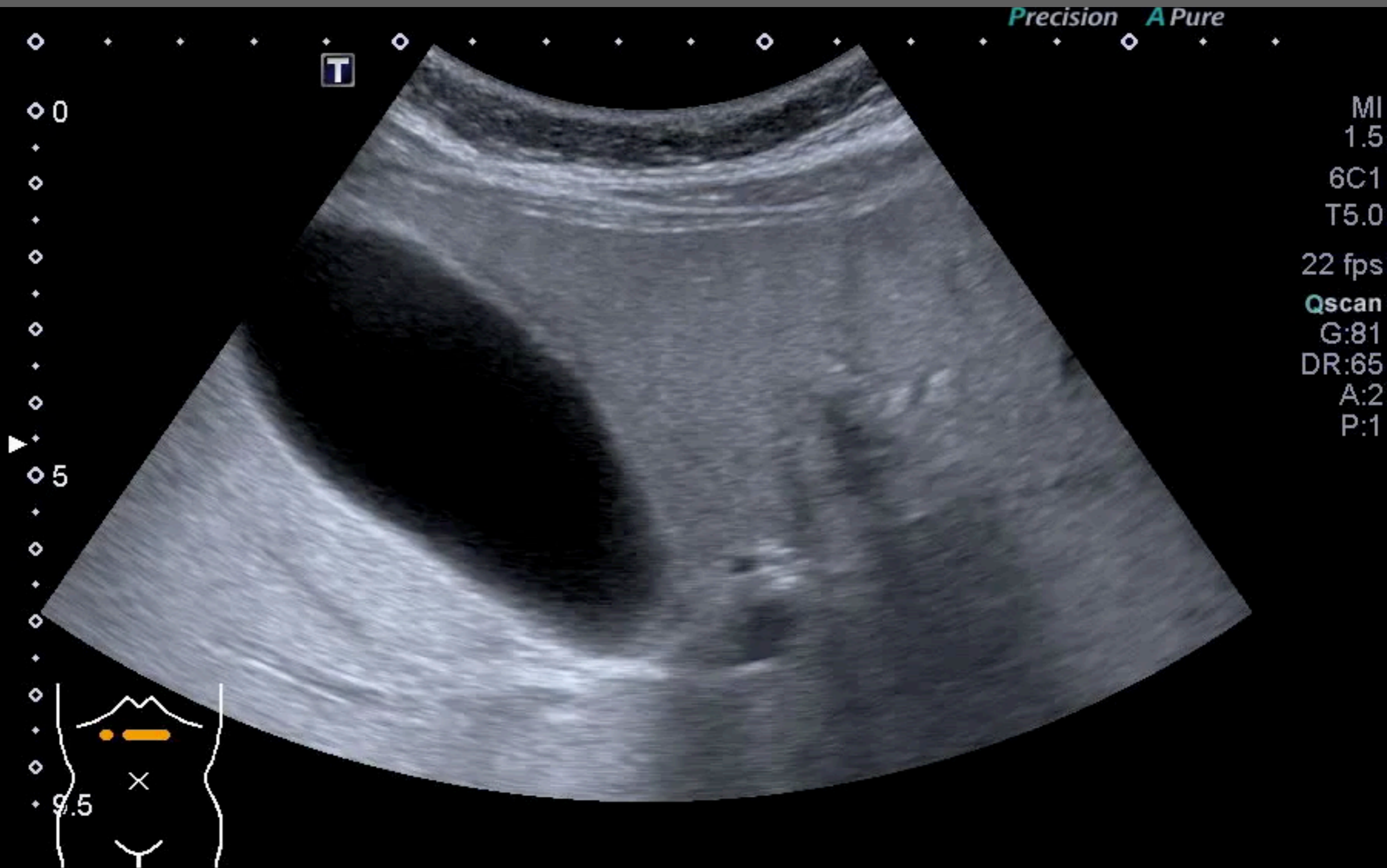
13.0cm

# 61F , ABD pain for 3-4 days





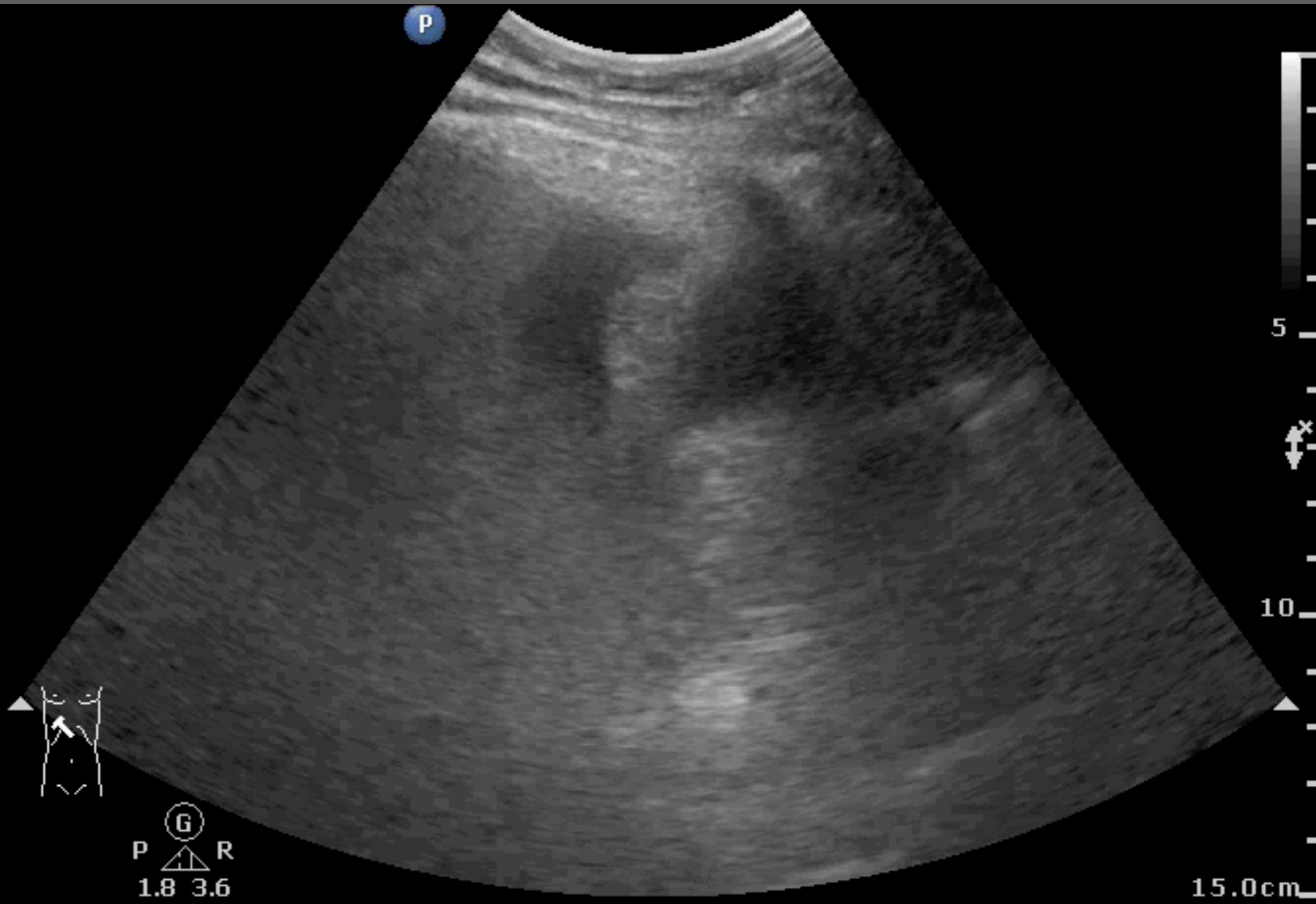# GB stones & Cholecystitis



# 45M, RUQ pain & fever

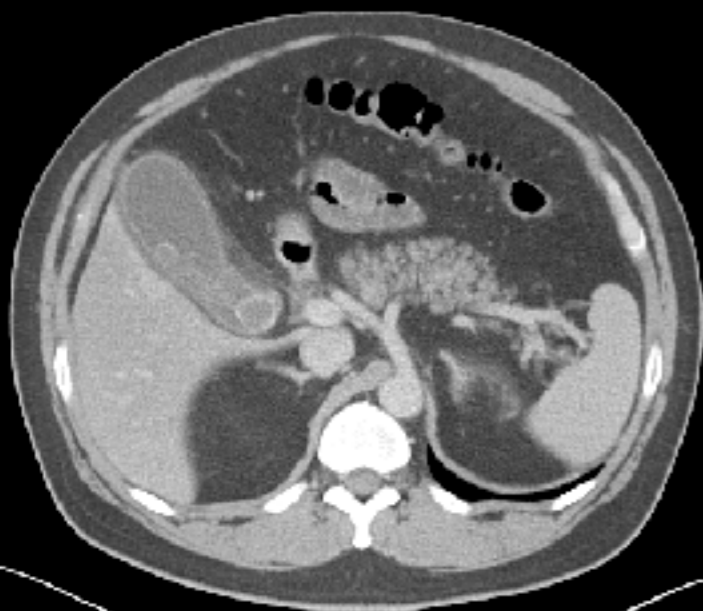
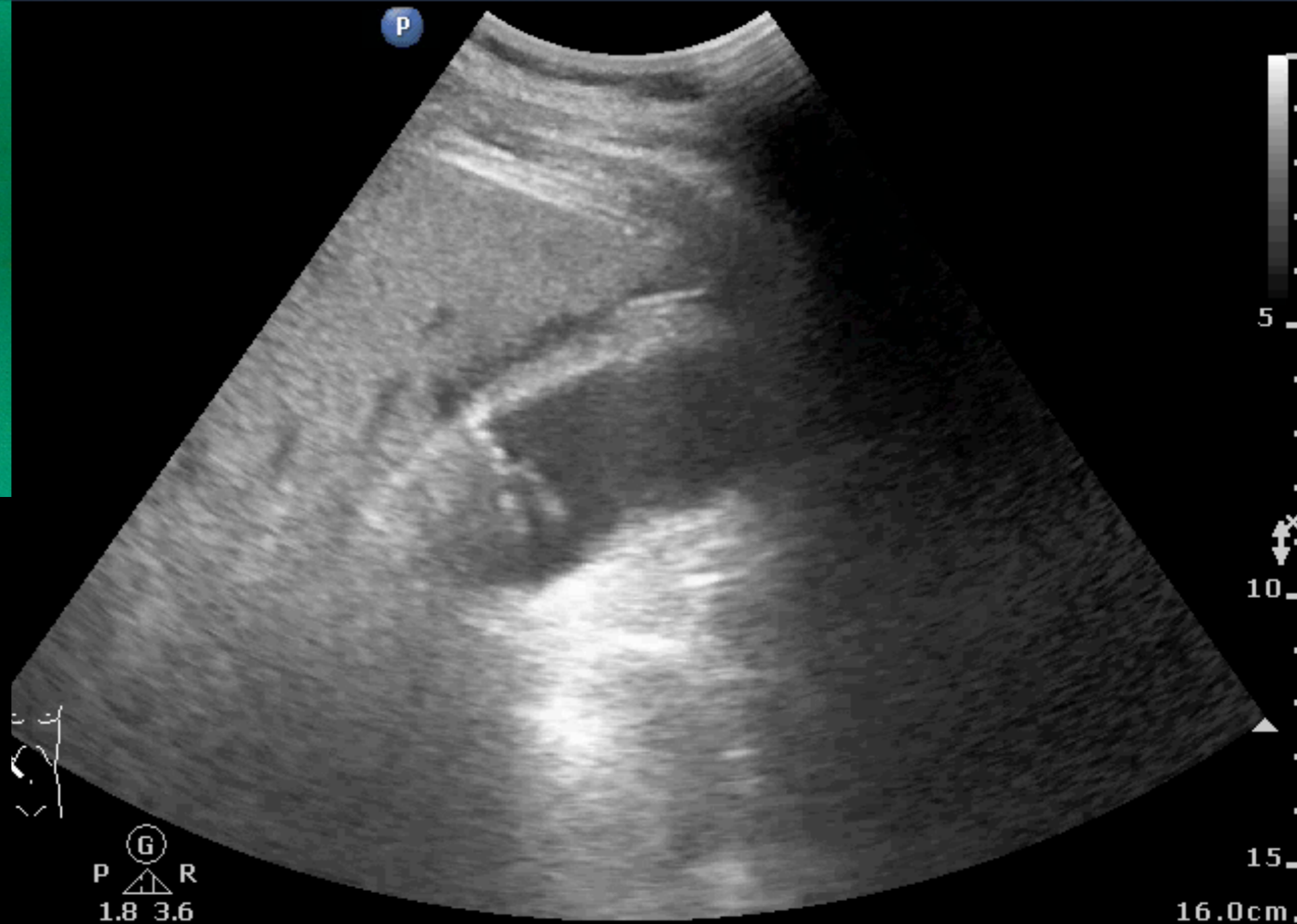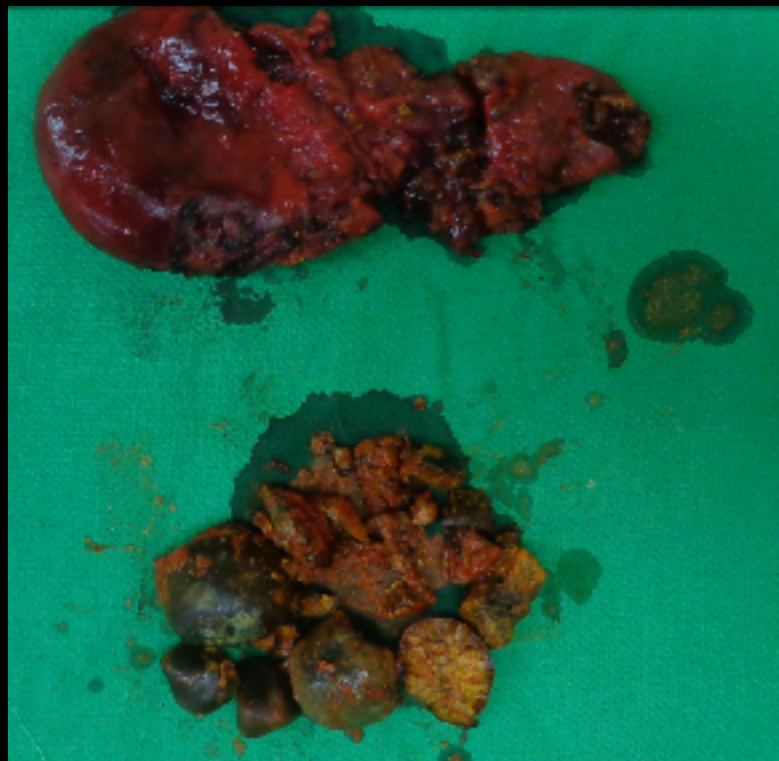
Abd Gen2  
C5-1  
34 Hz  
15.0cm

2D  
HGen  
Gn 100  
C 56  
3 / 3 / 3





# Acute calculous cholecystitis



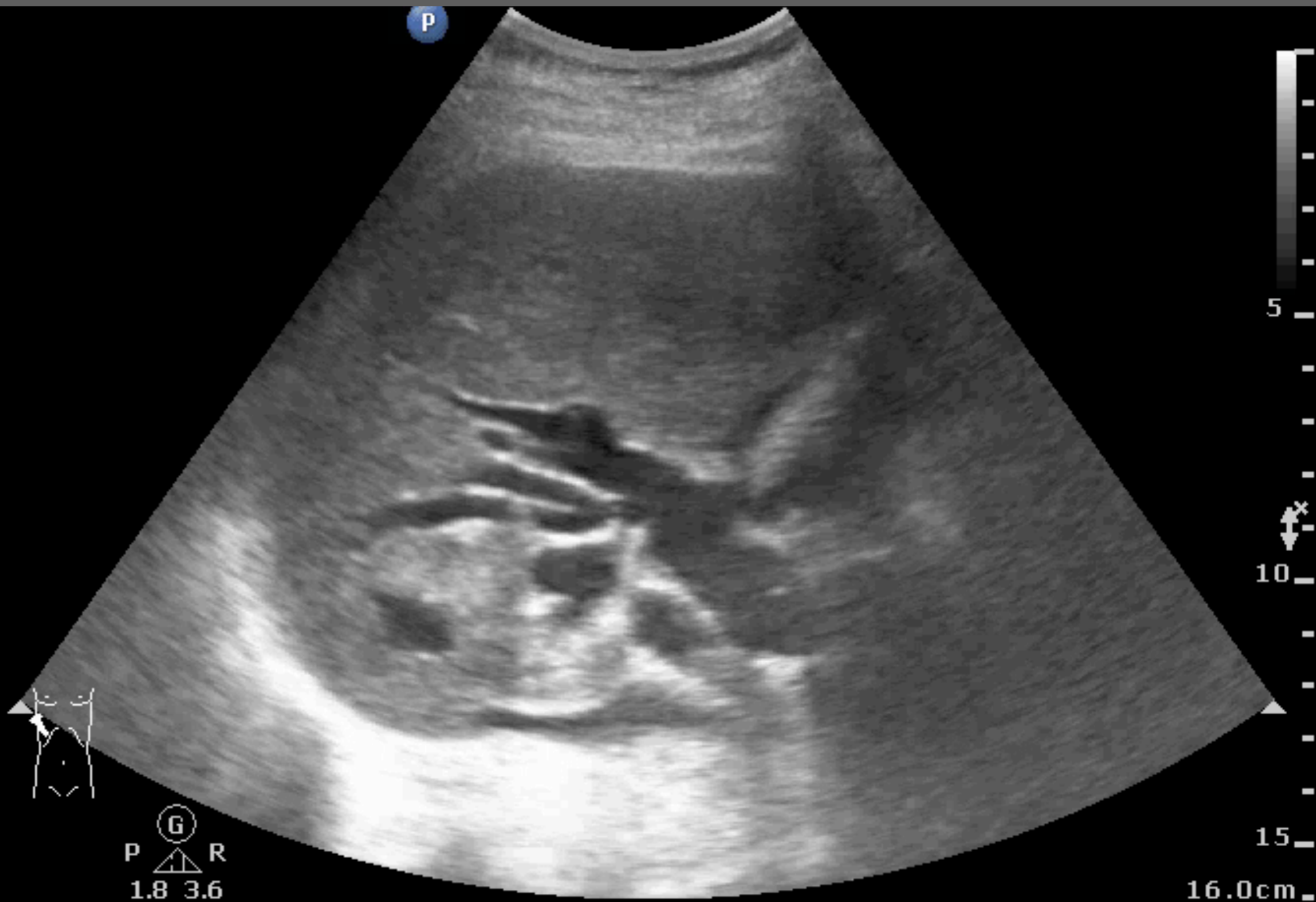

# 76F, Fever & Chills

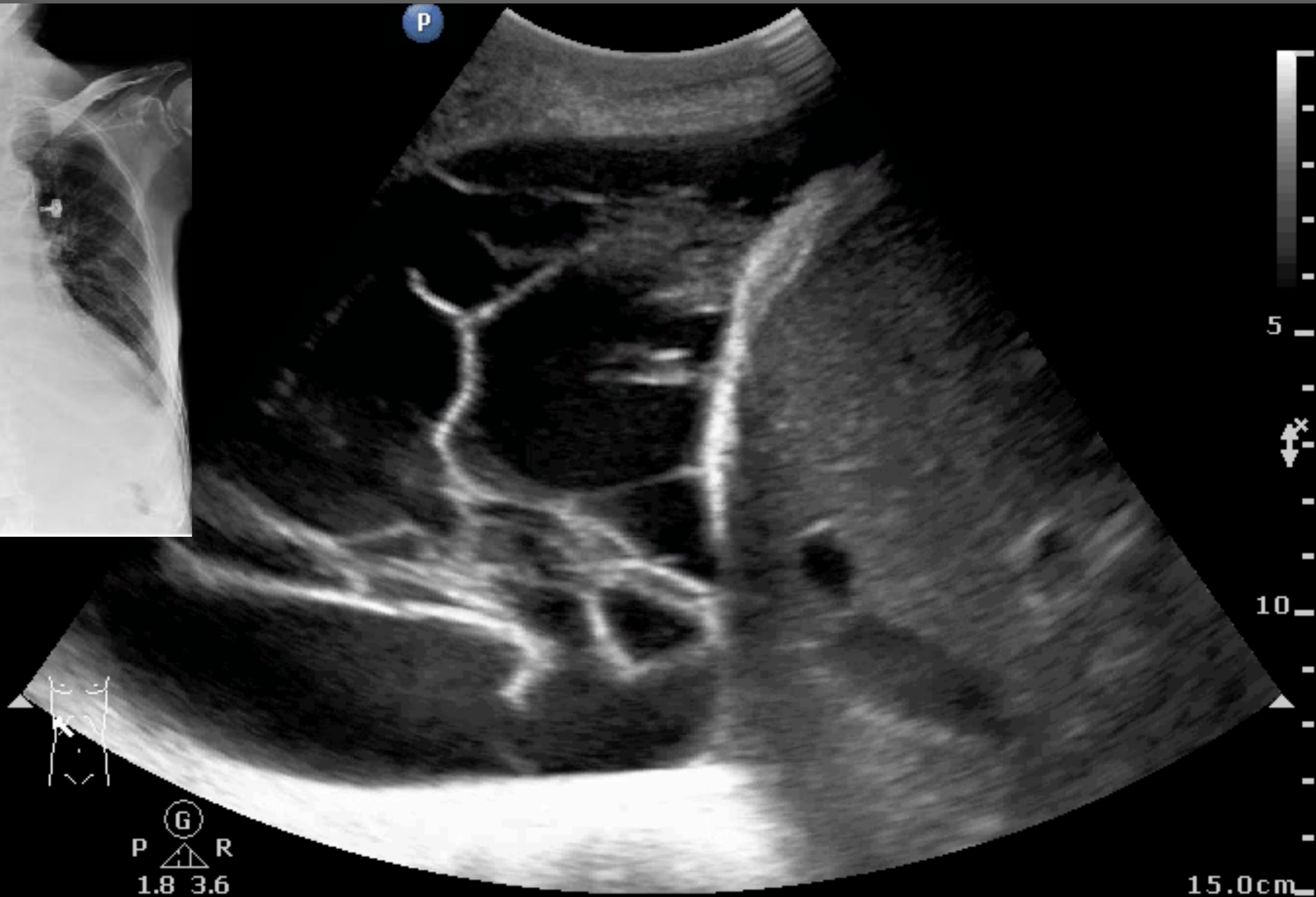
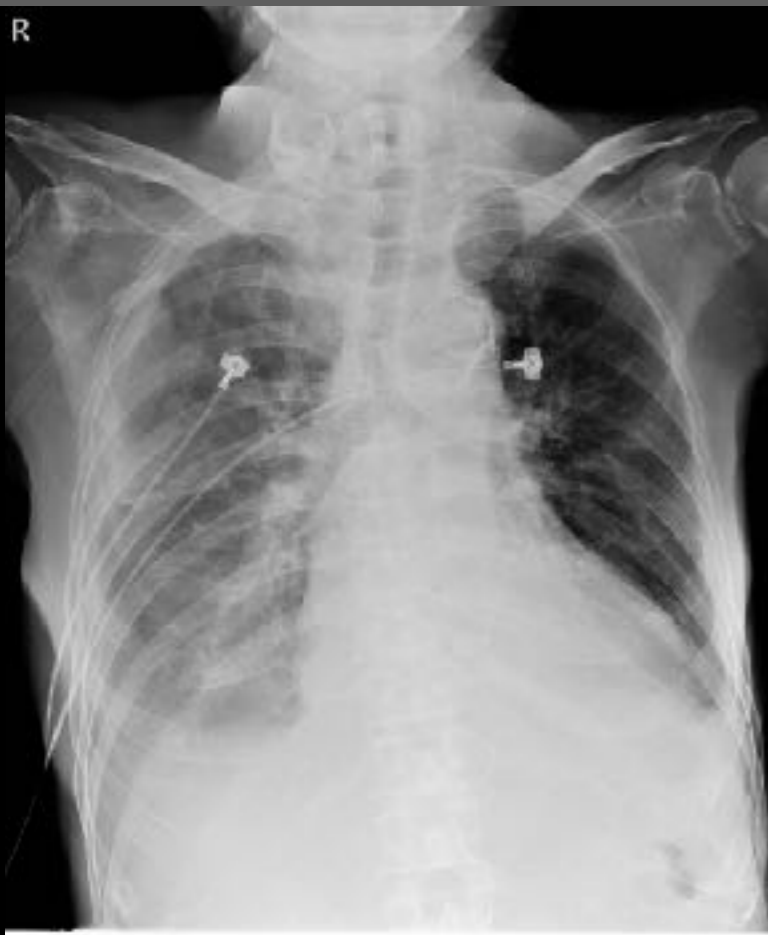Abd Gen2  
C5-1  
32 Hz  
16.0cm

2D

HGen  
Gn 100  
C 56  
3 / 3 / 3



# 73M, chest/abd pain & SOB



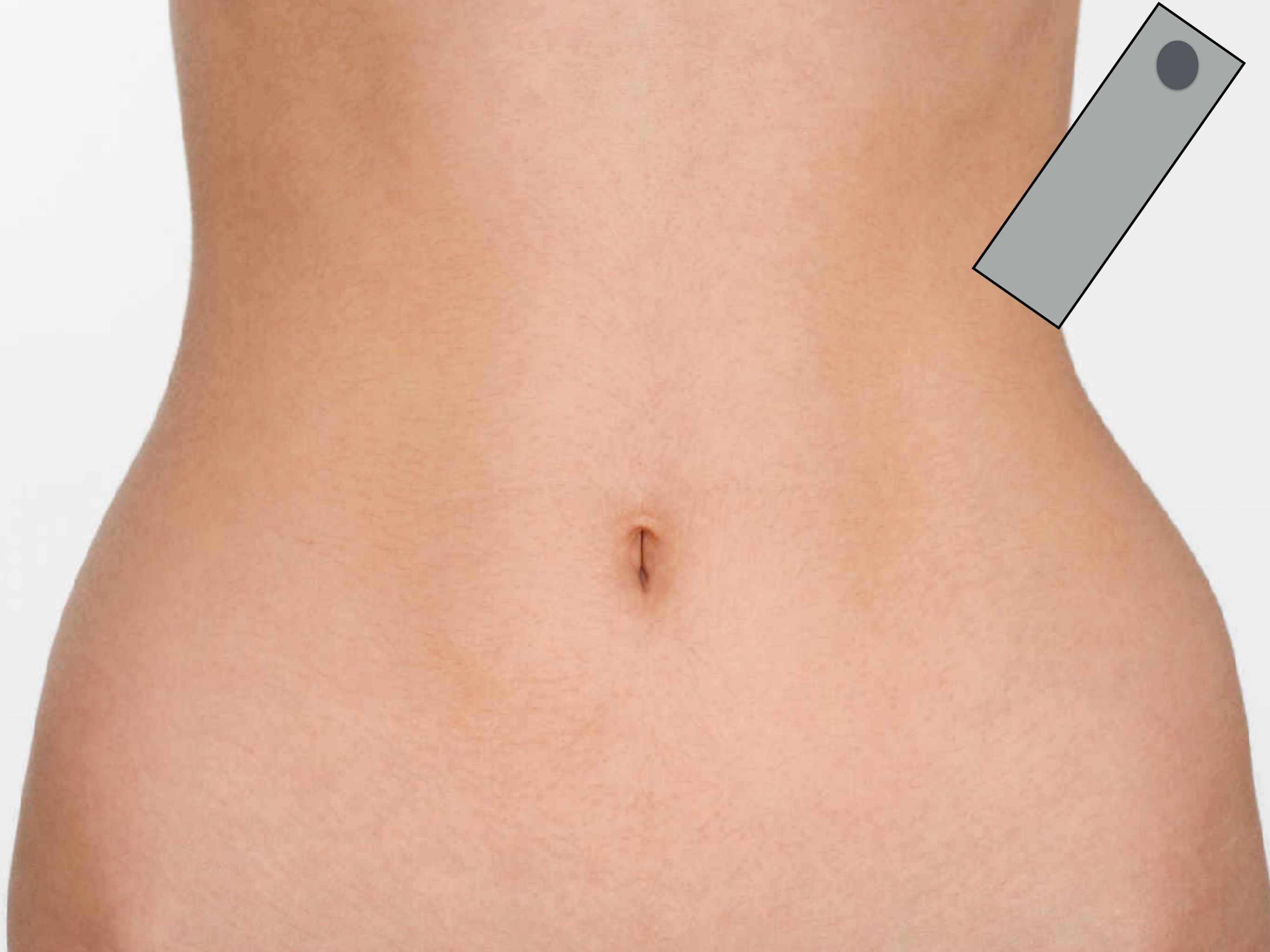**ABDOMEN**

**D for diaphragm**

**Outsider**



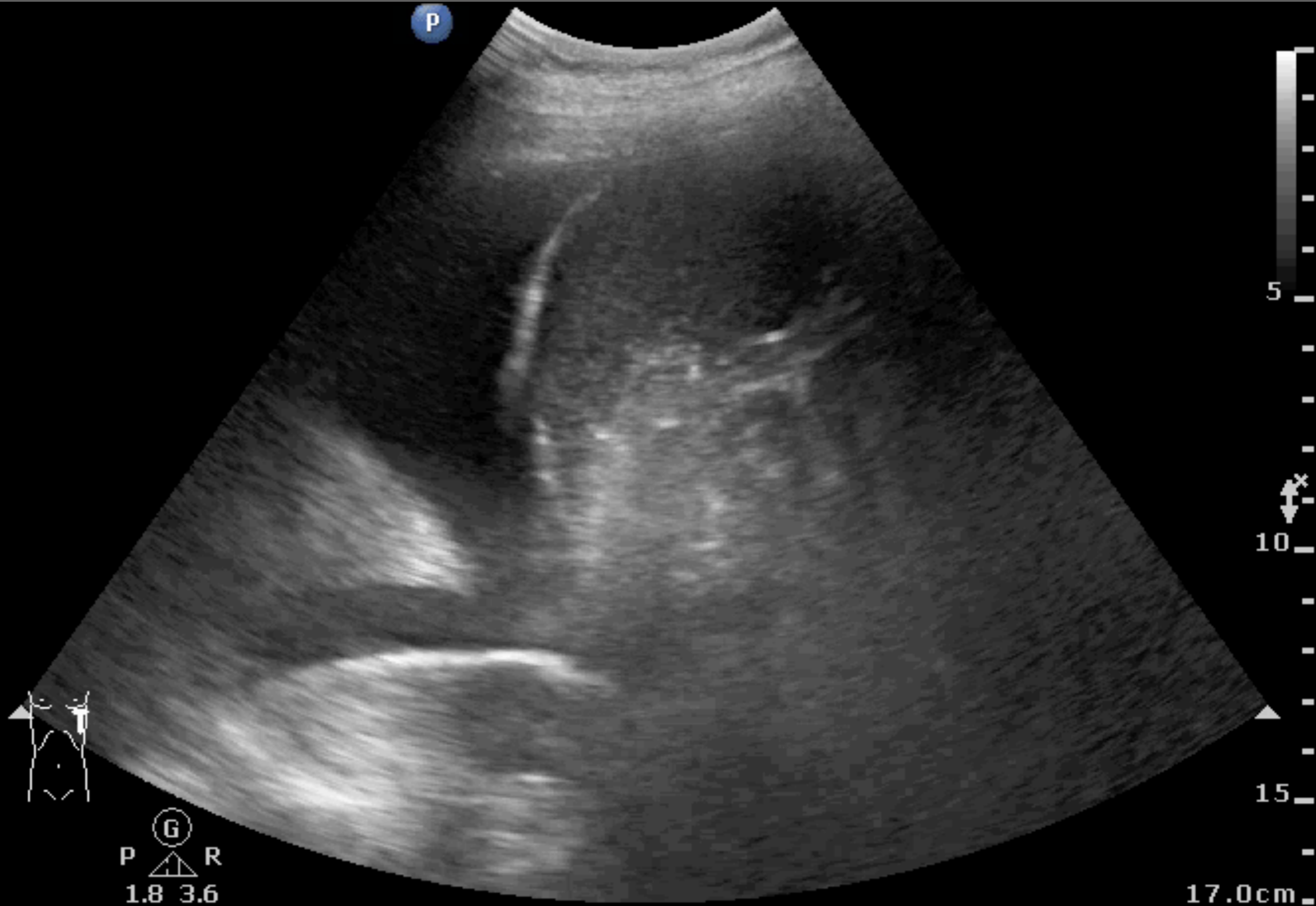



# 45M, LUQ pain

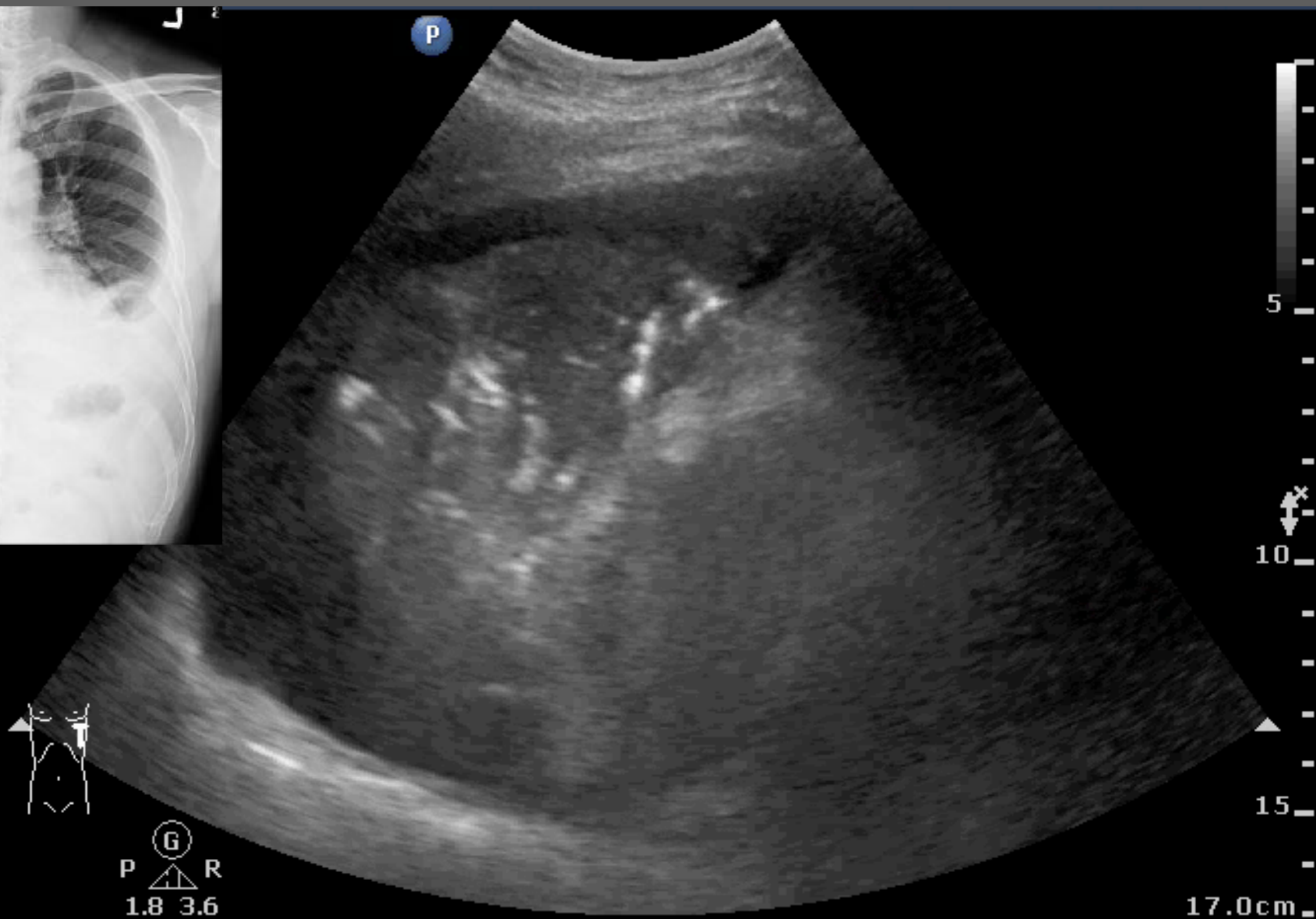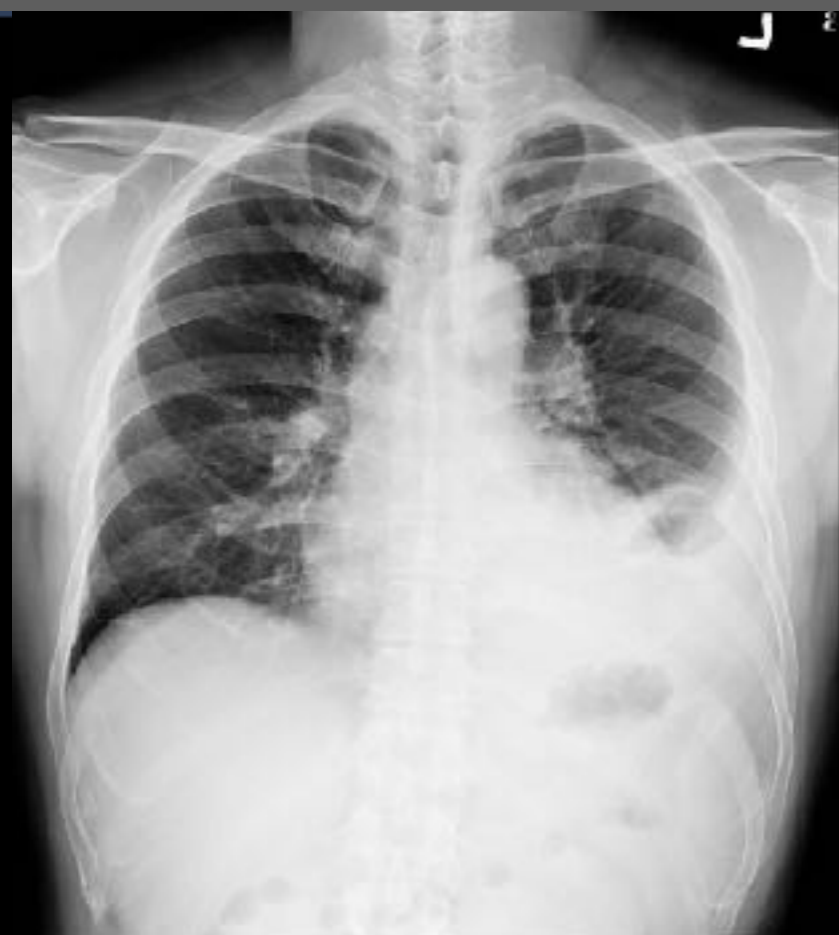Abd Gen  
C5-1  
31 Hz  
17.0cm

2D  
HGen  
Gn 100  
C 56  
3/3/3





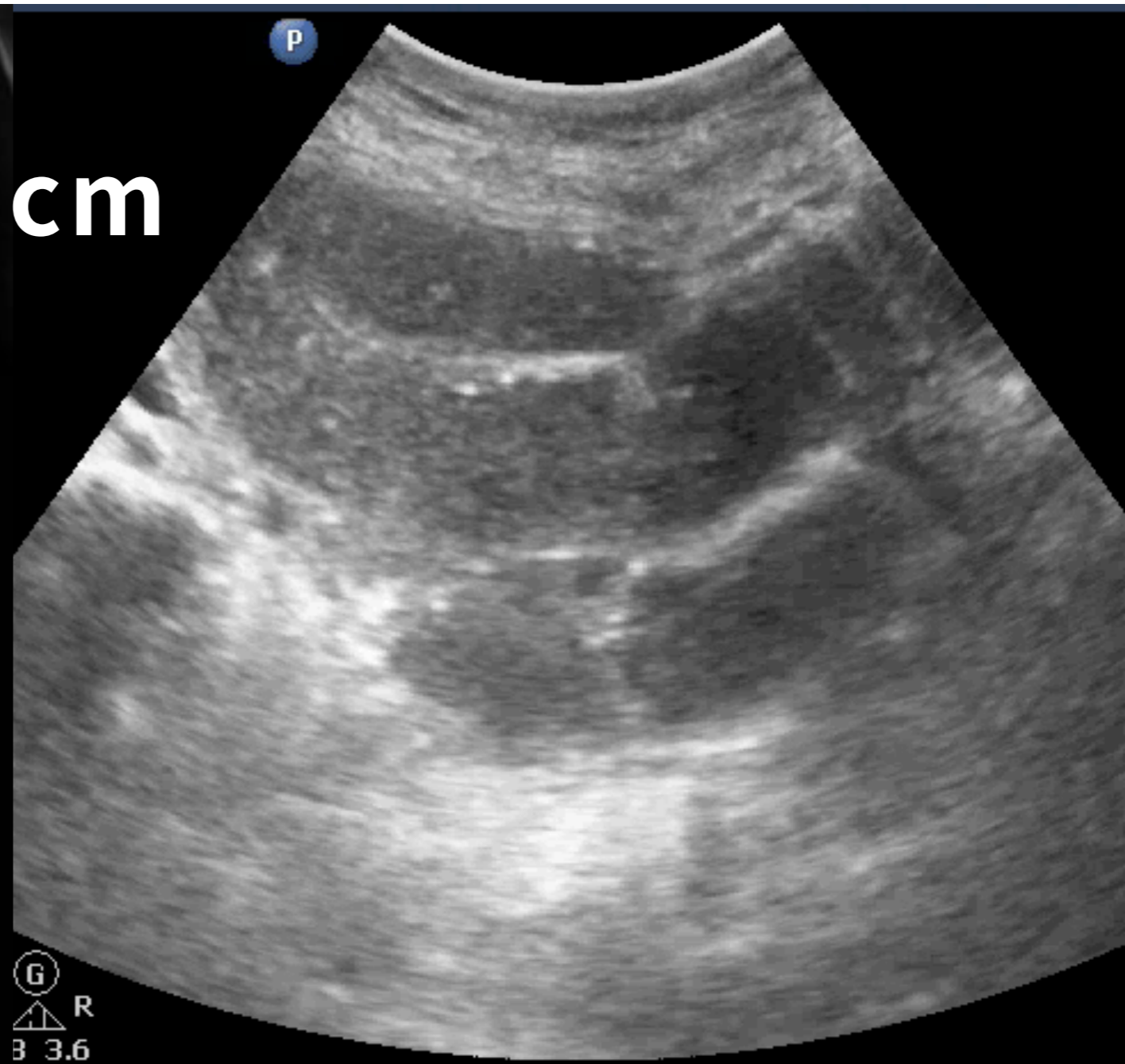
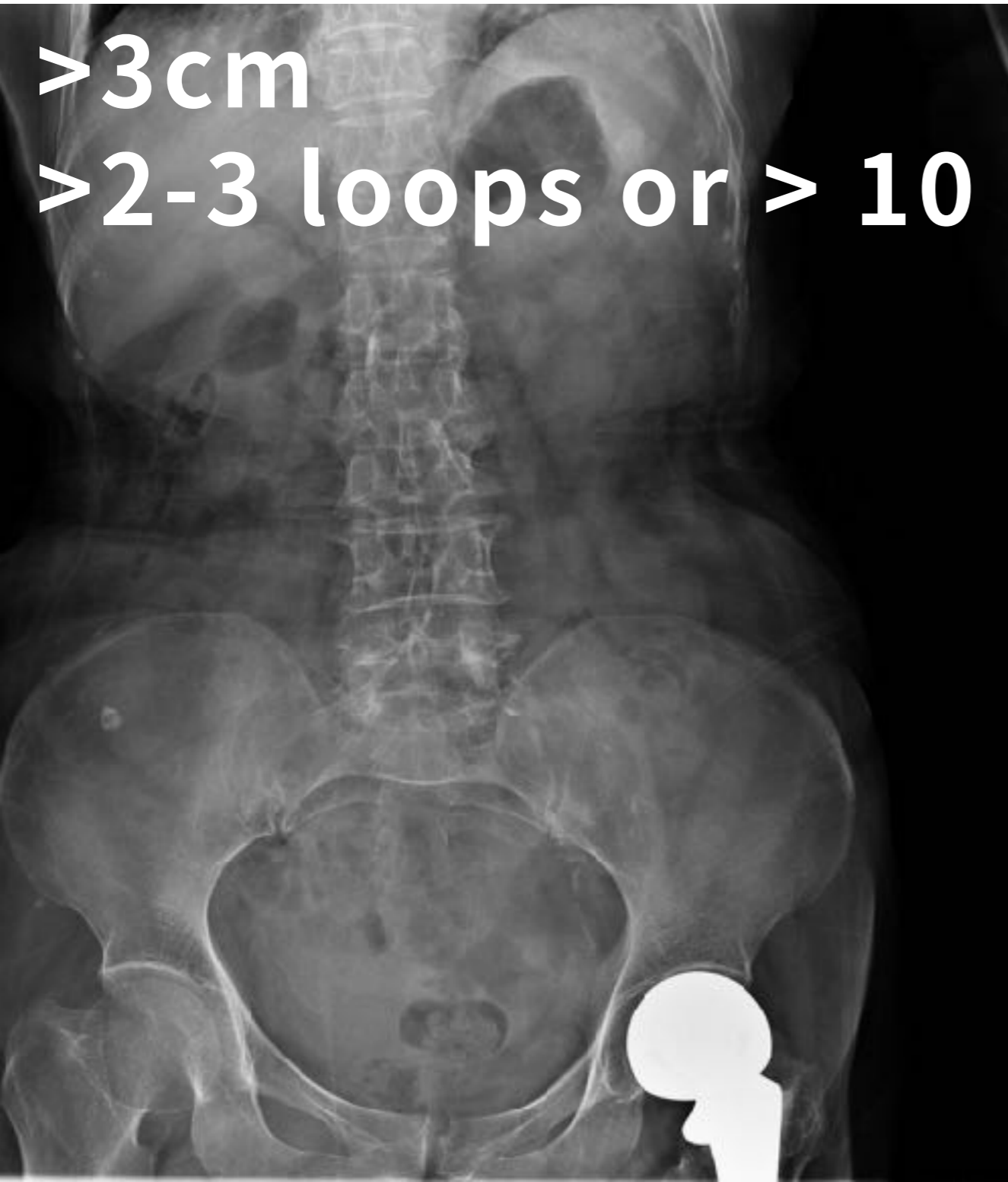
# PN & parapneumonic effusion



# 88F, diffuse abdominal pain

> 3 cm

> 2-3 loops or > 10 cm



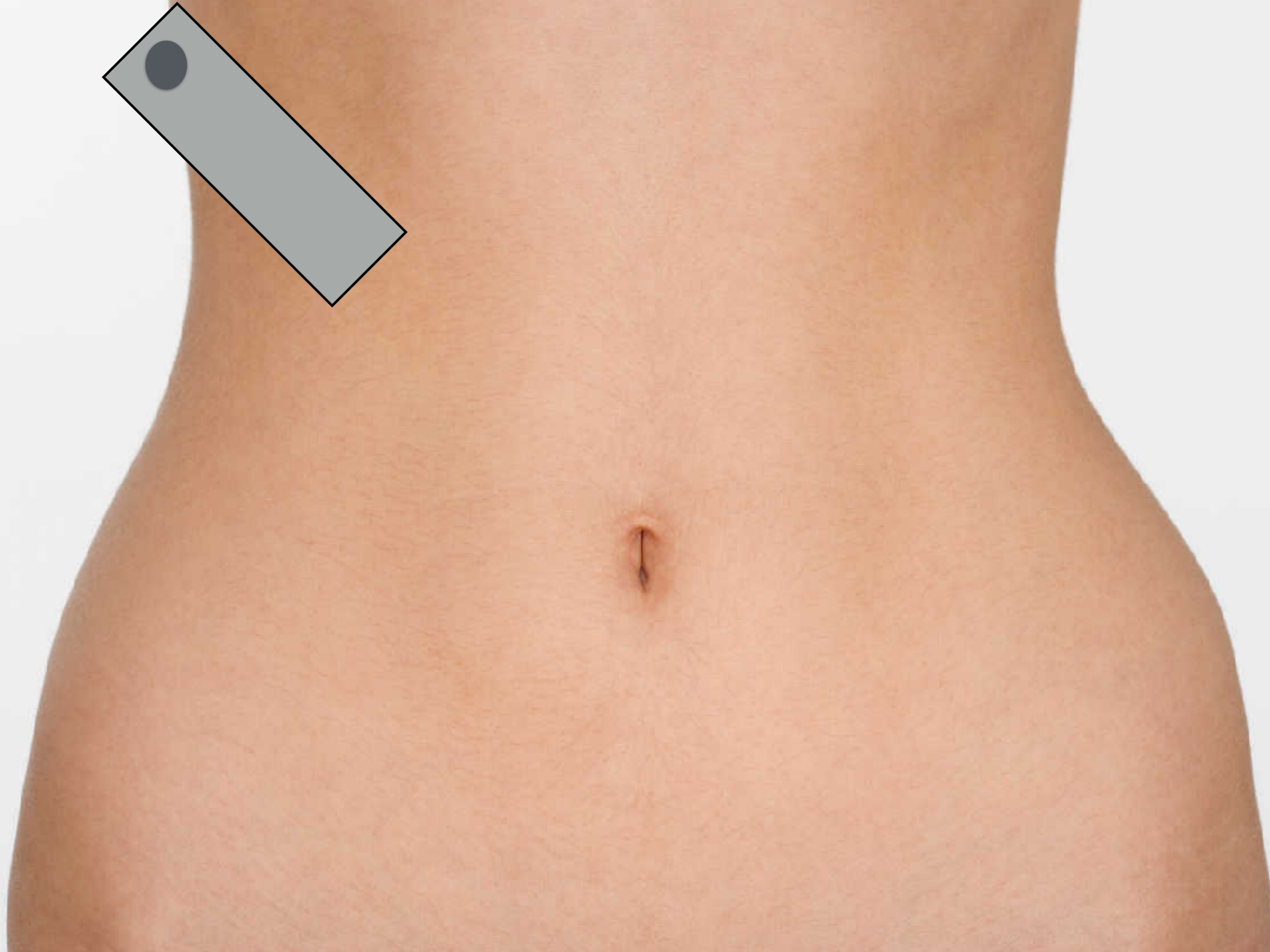# ABDOMEN

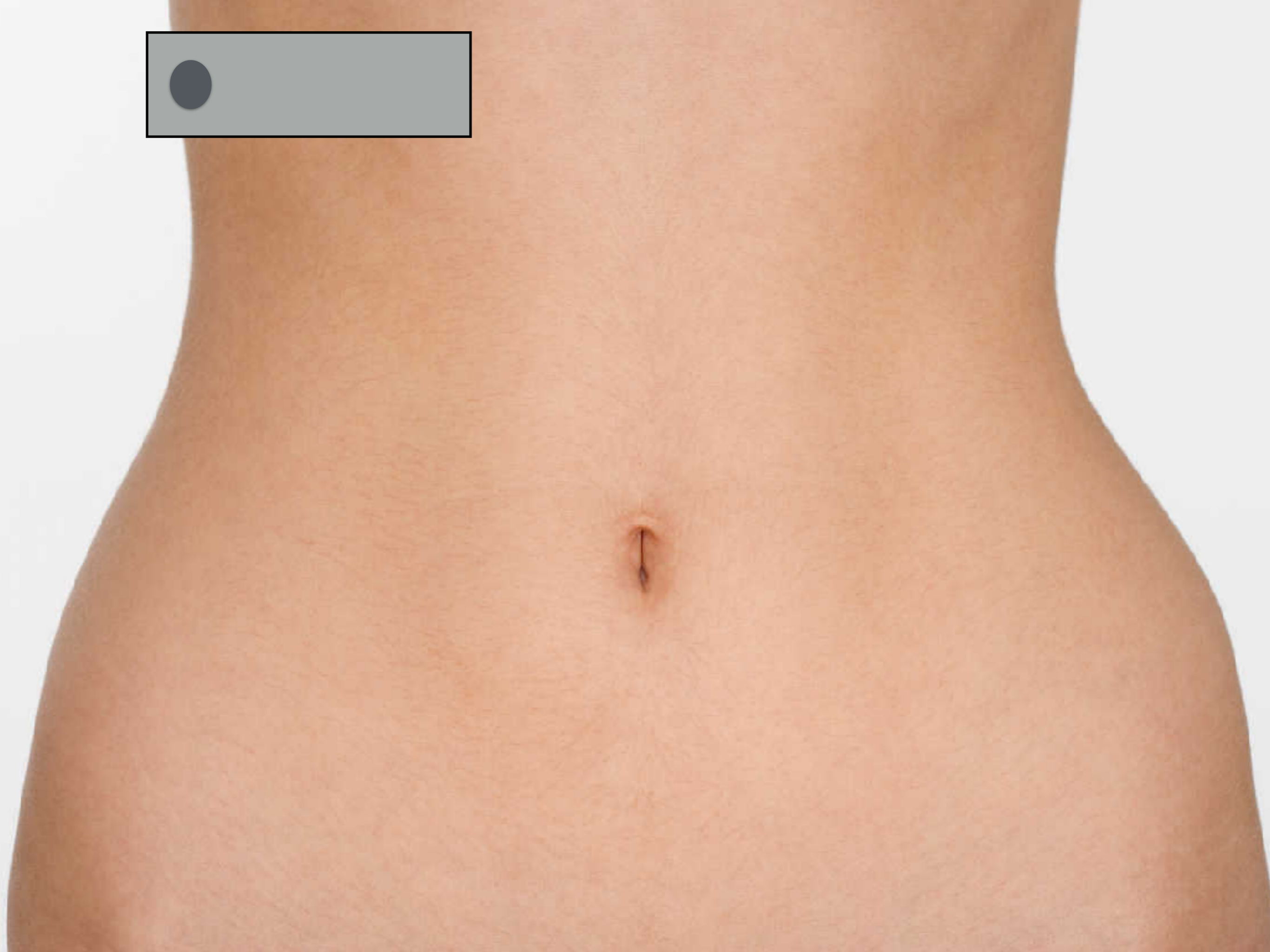**O for obstruction**  
**(SBO & Intussusception)**

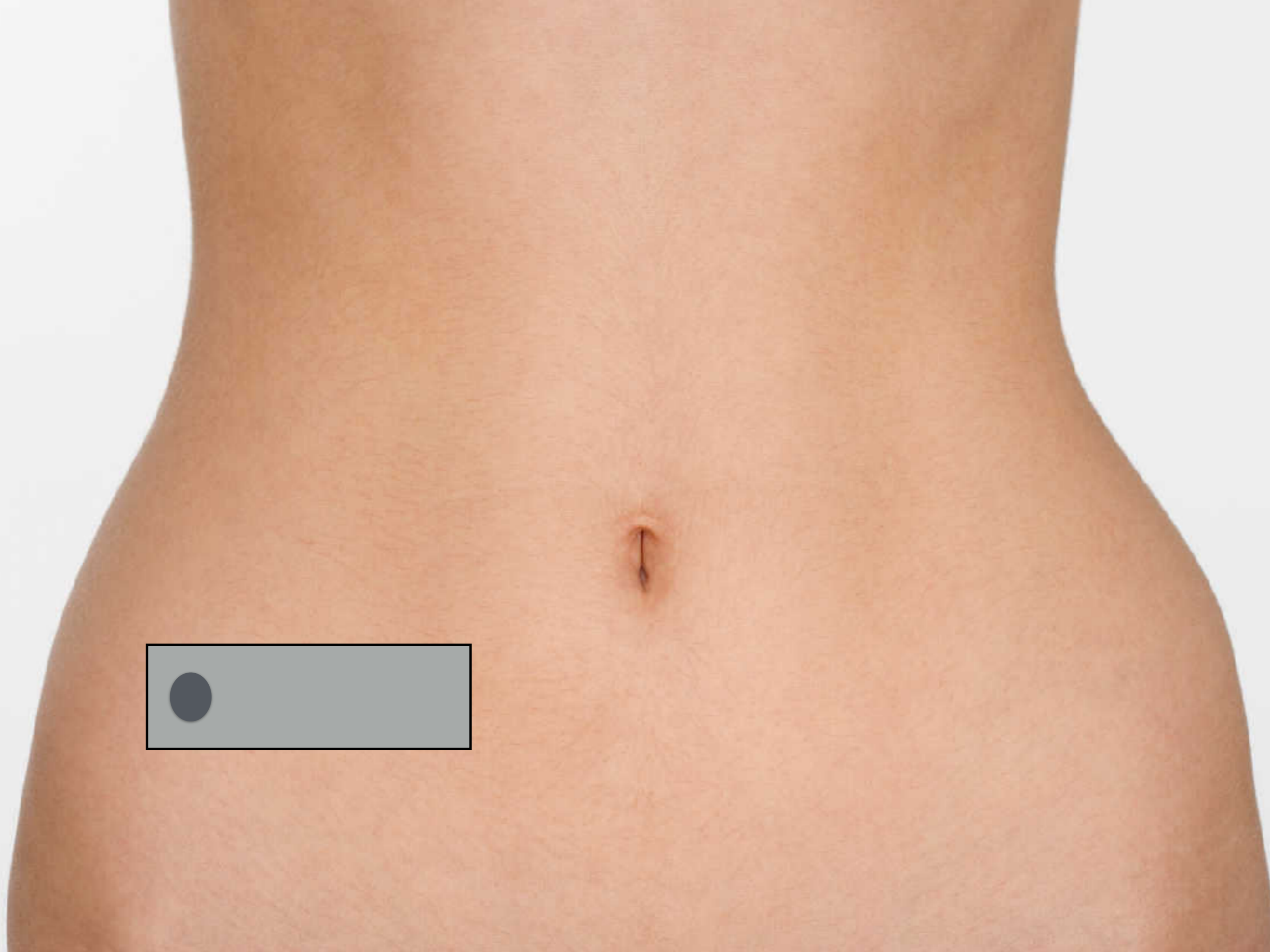
**3**  
cm

**5**  
cm

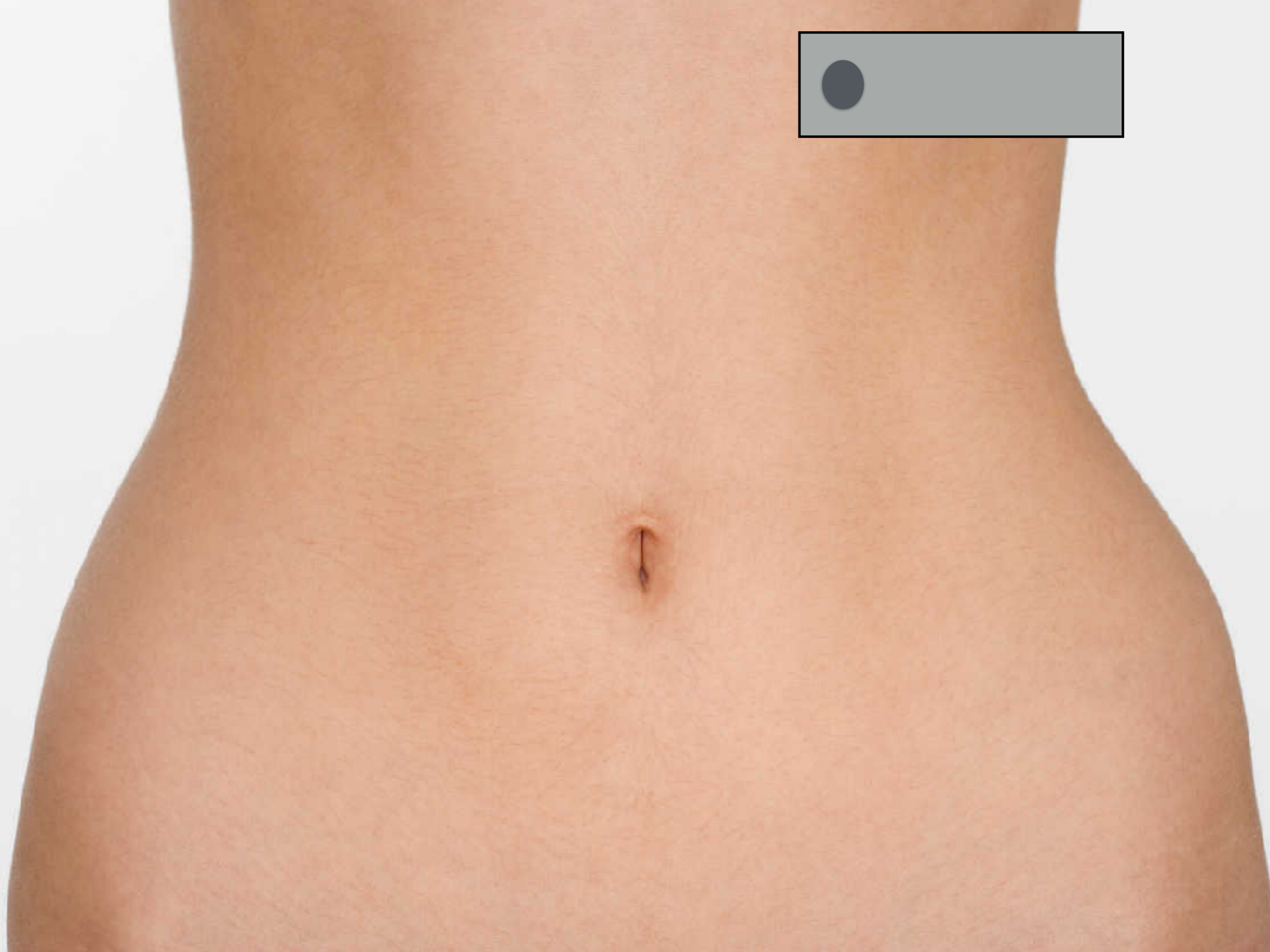

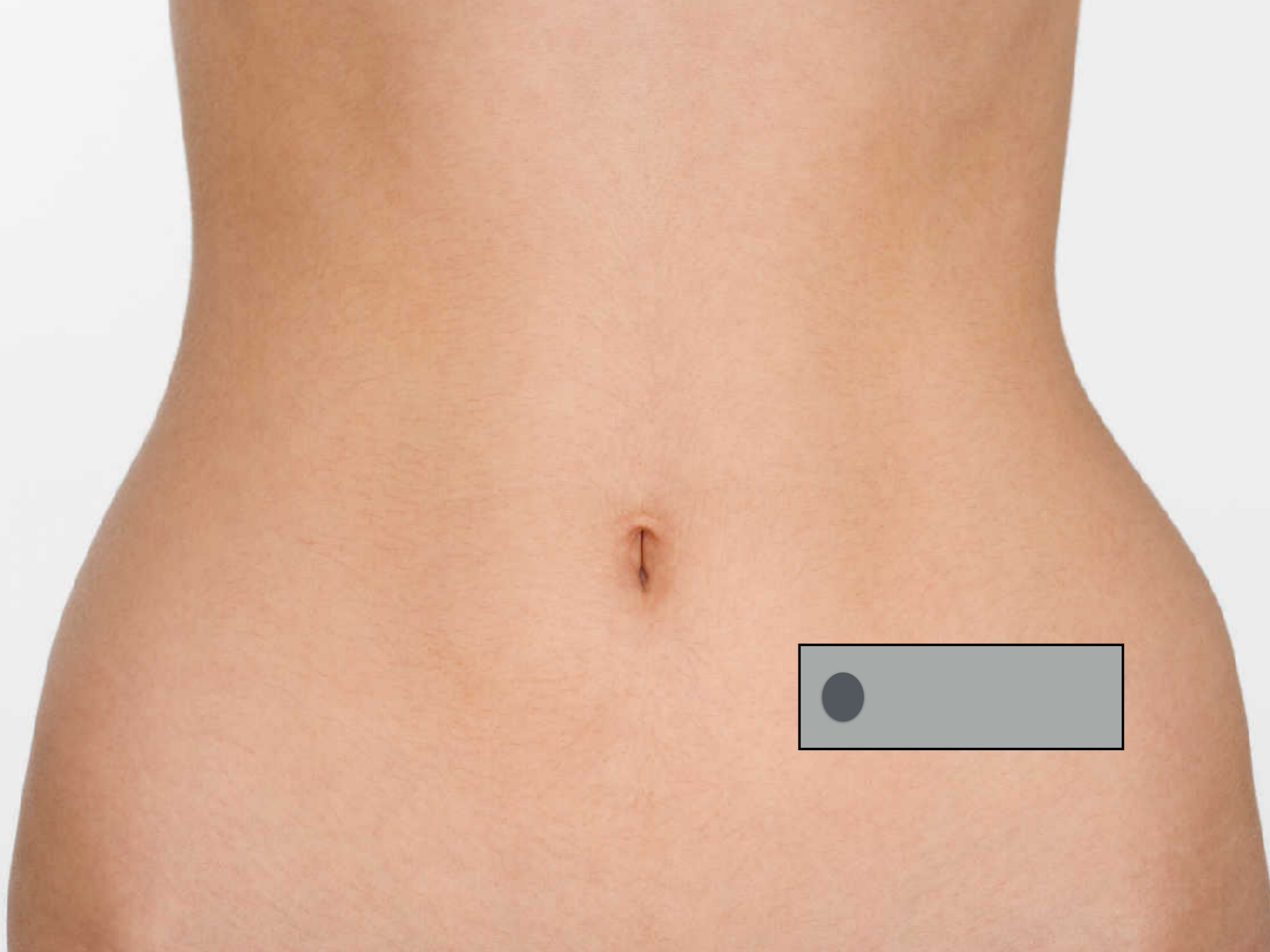



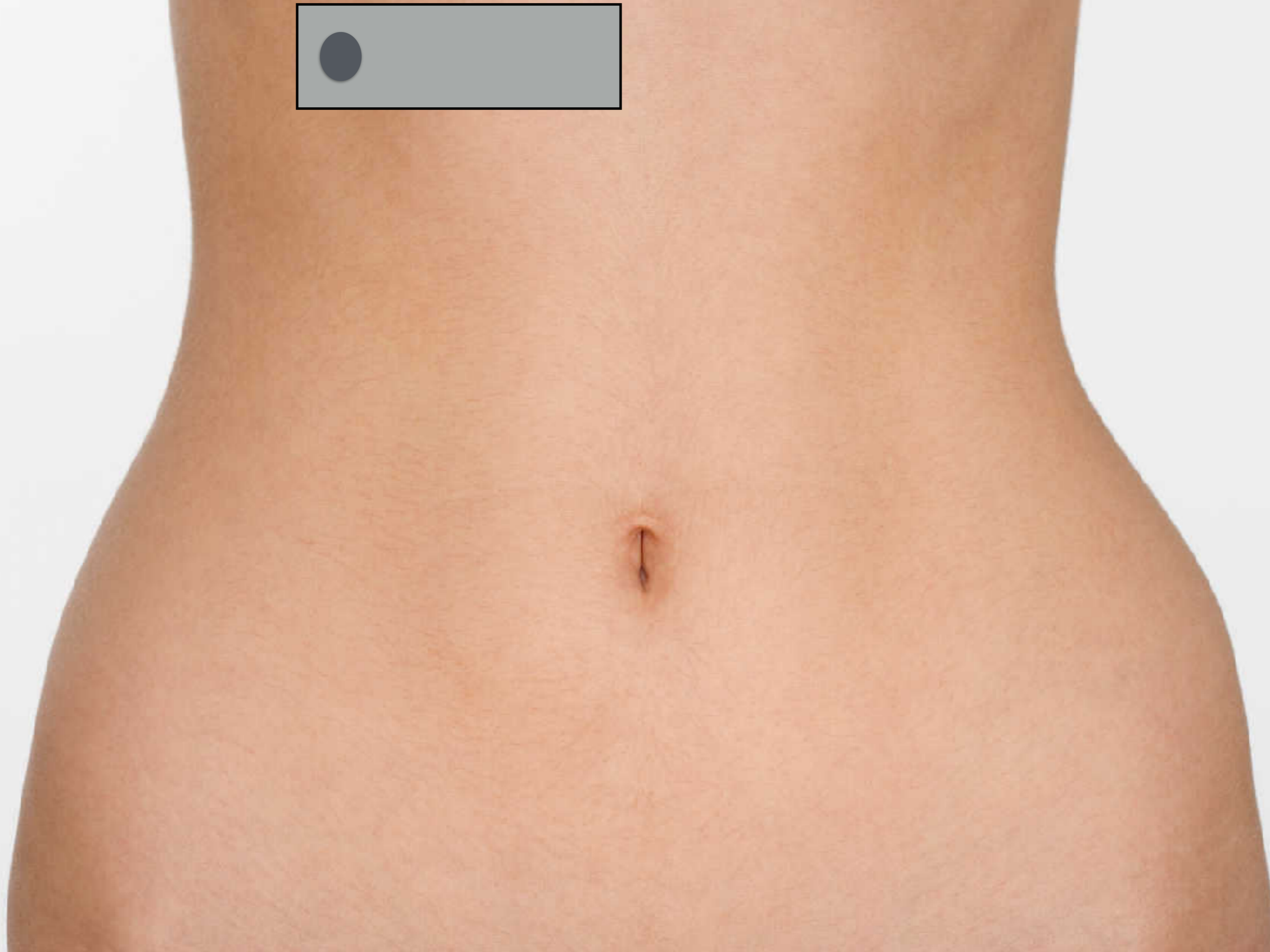


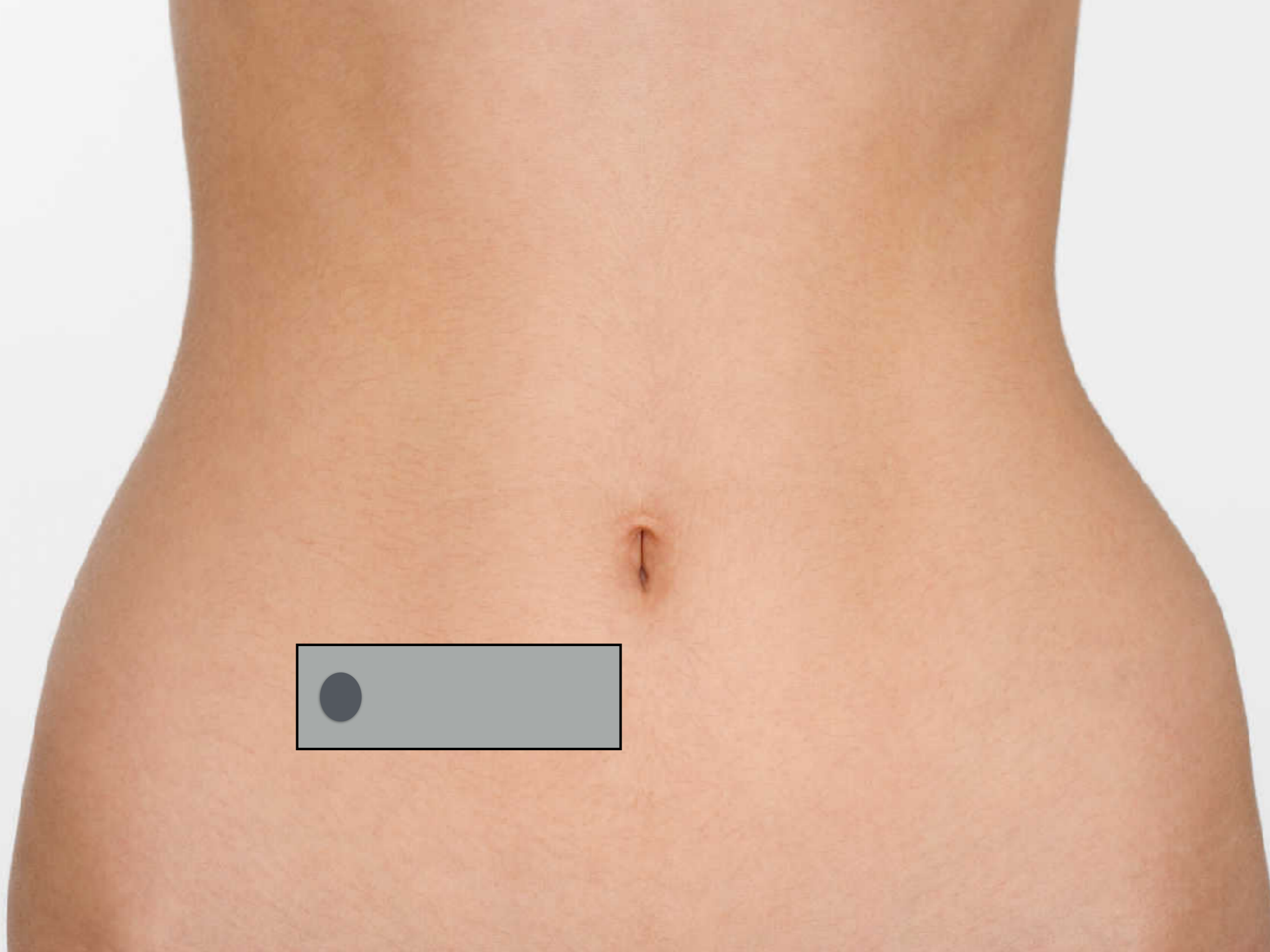


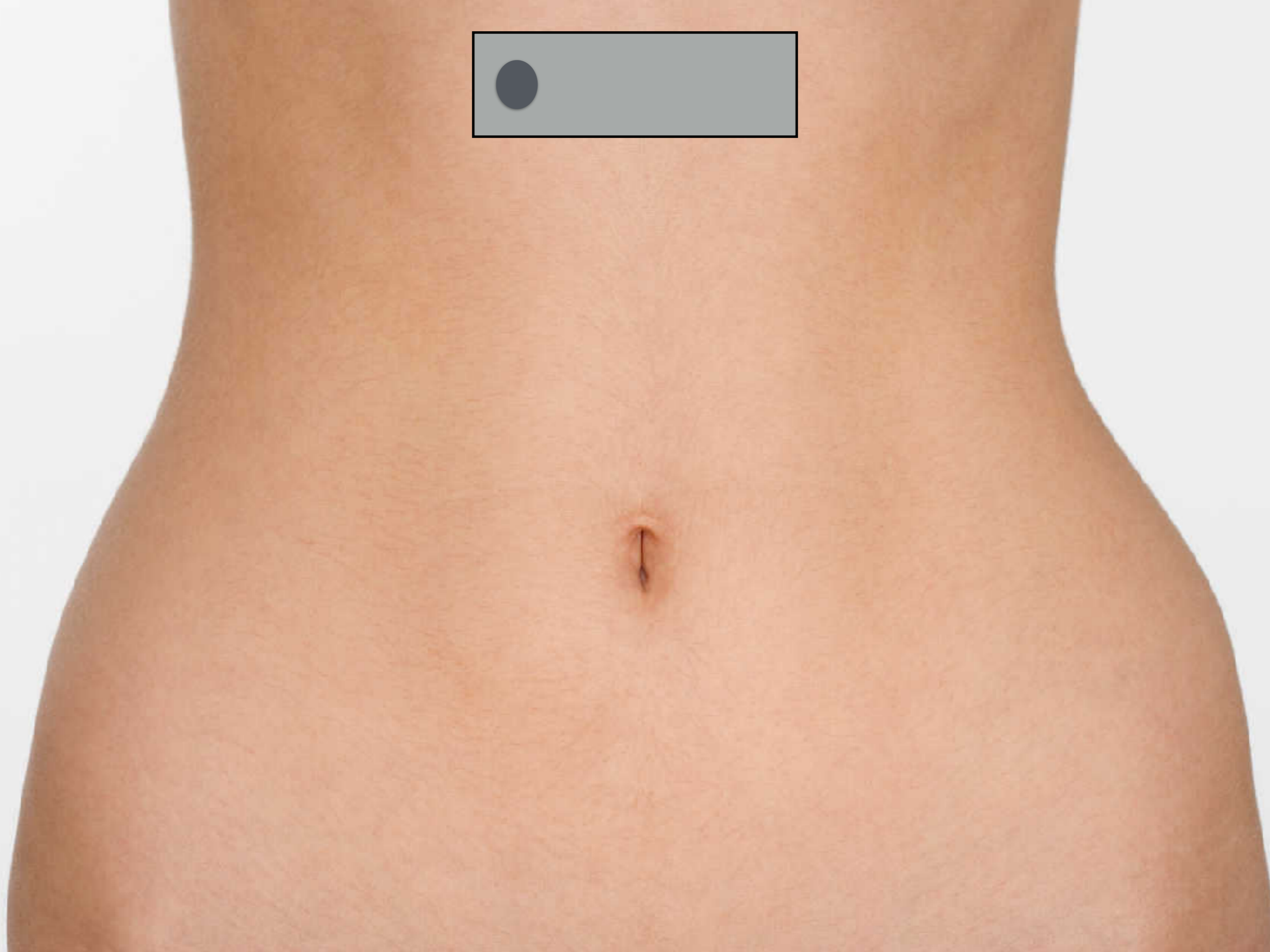


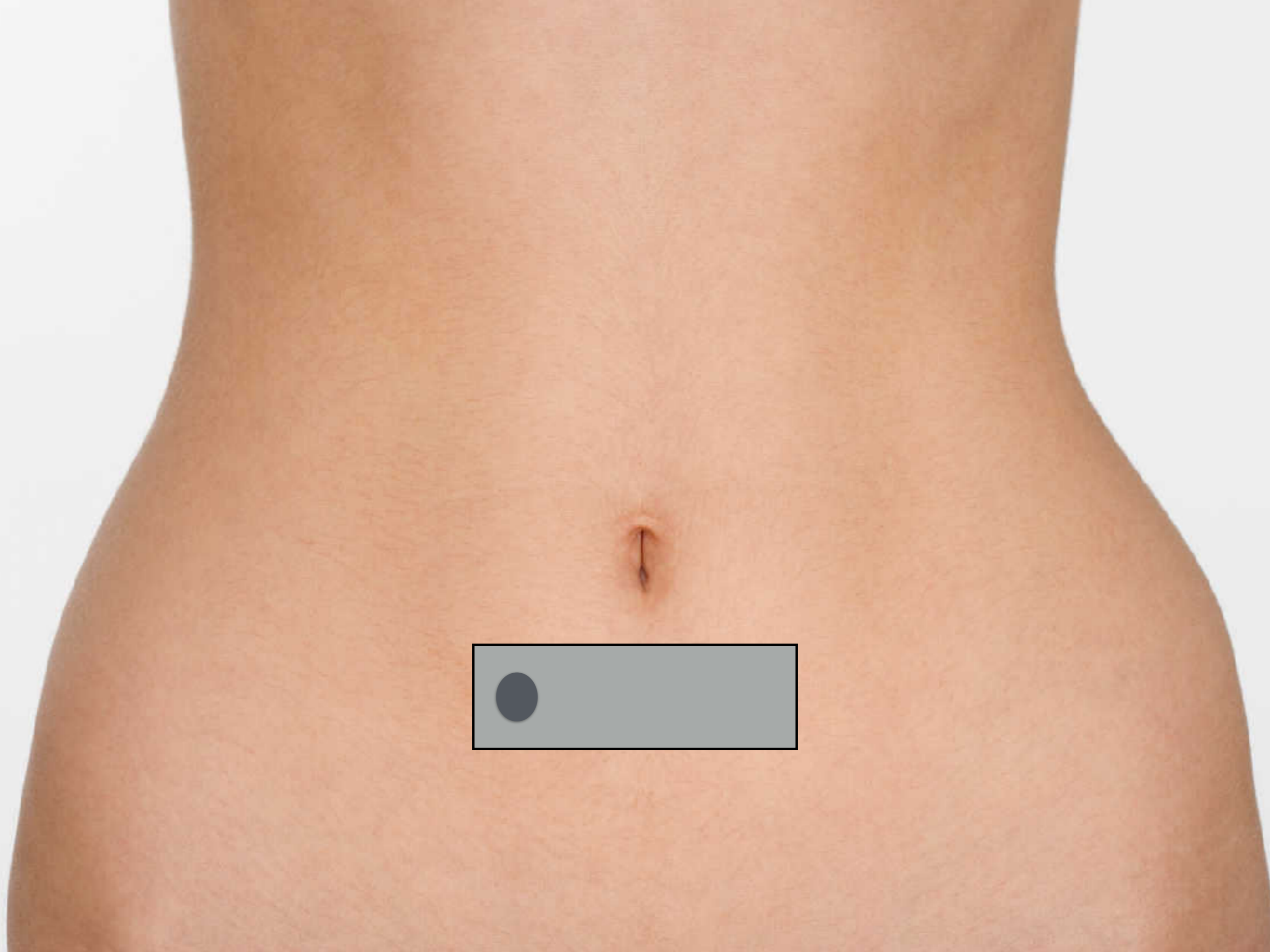




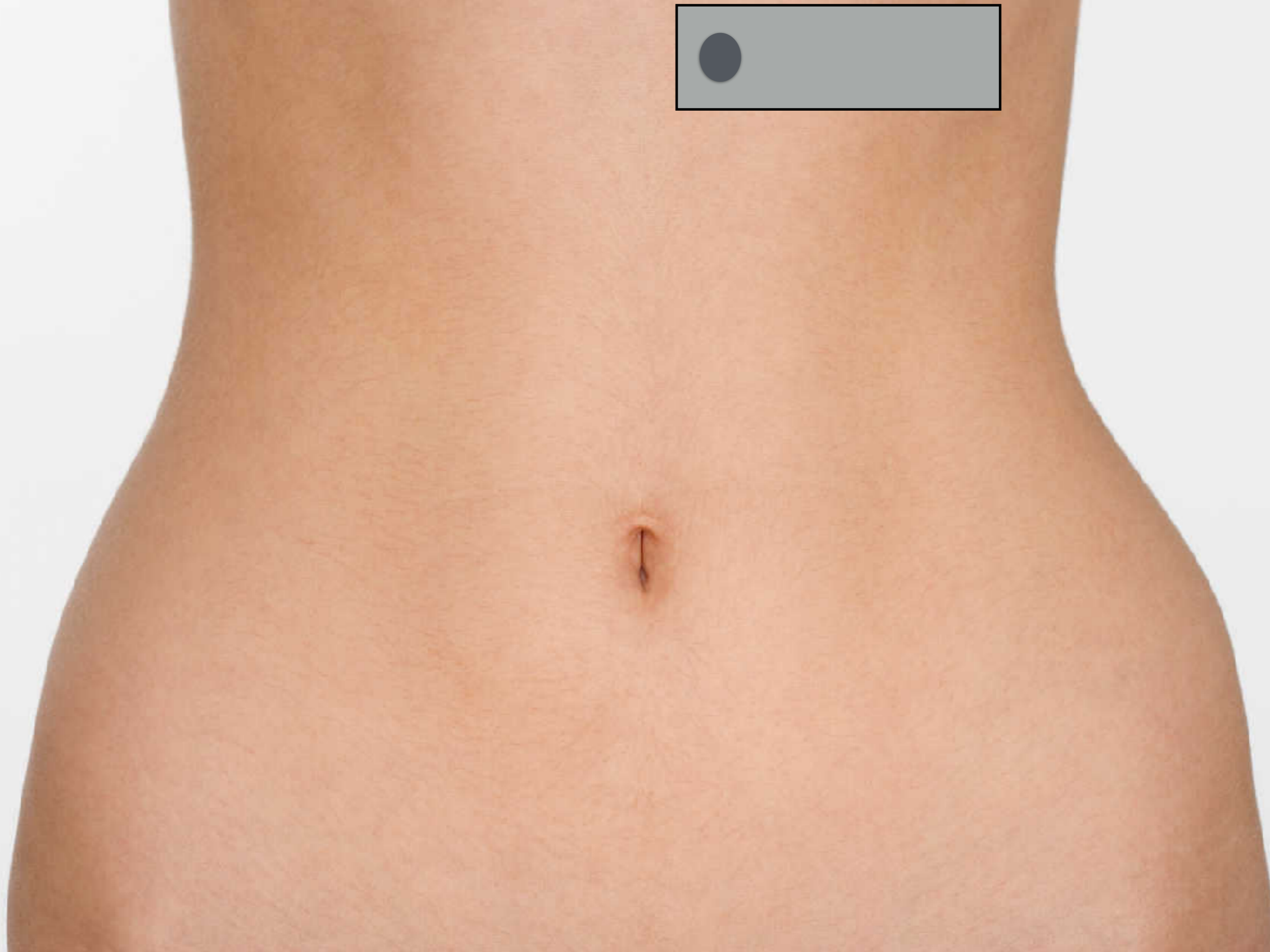


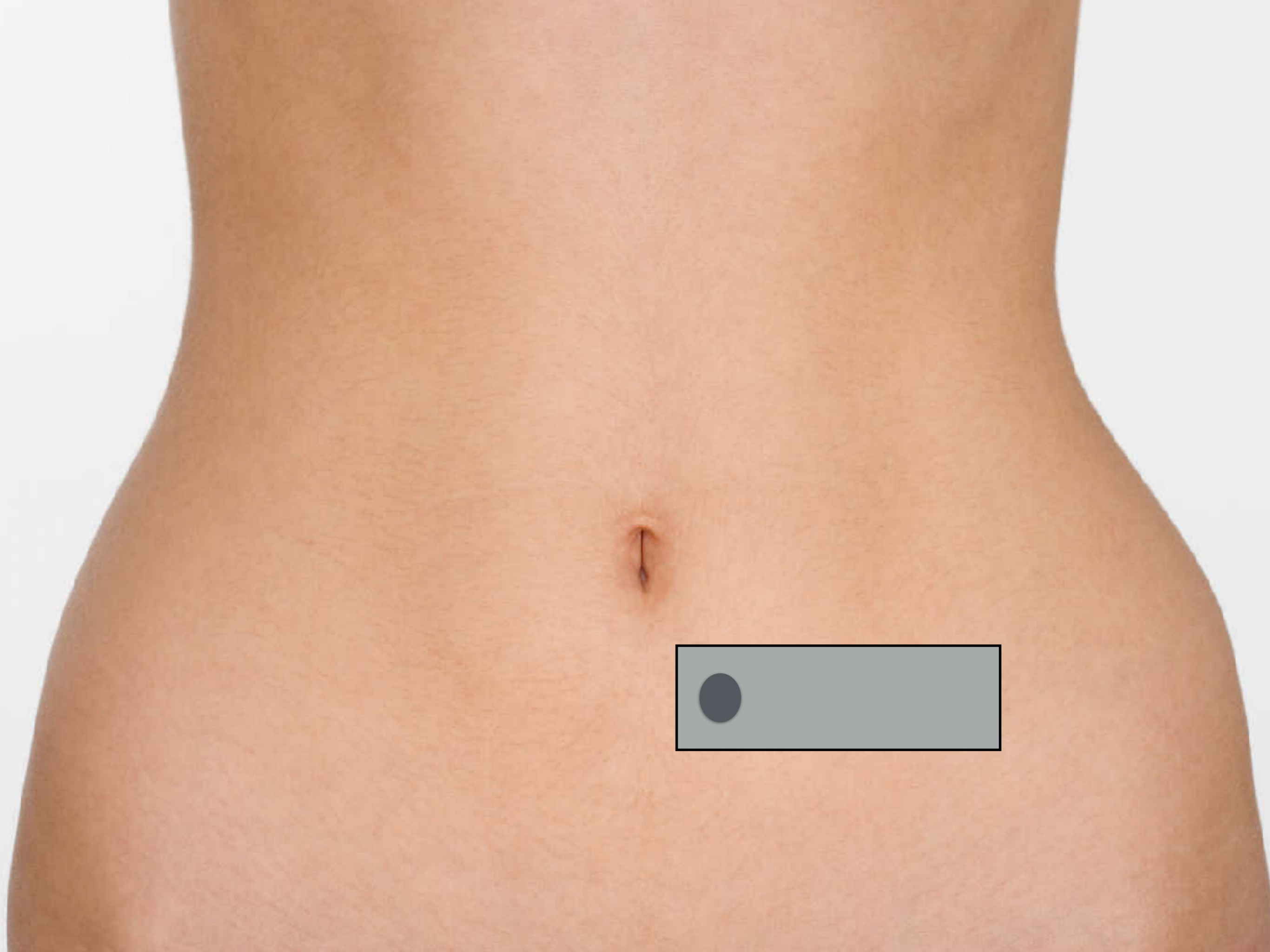










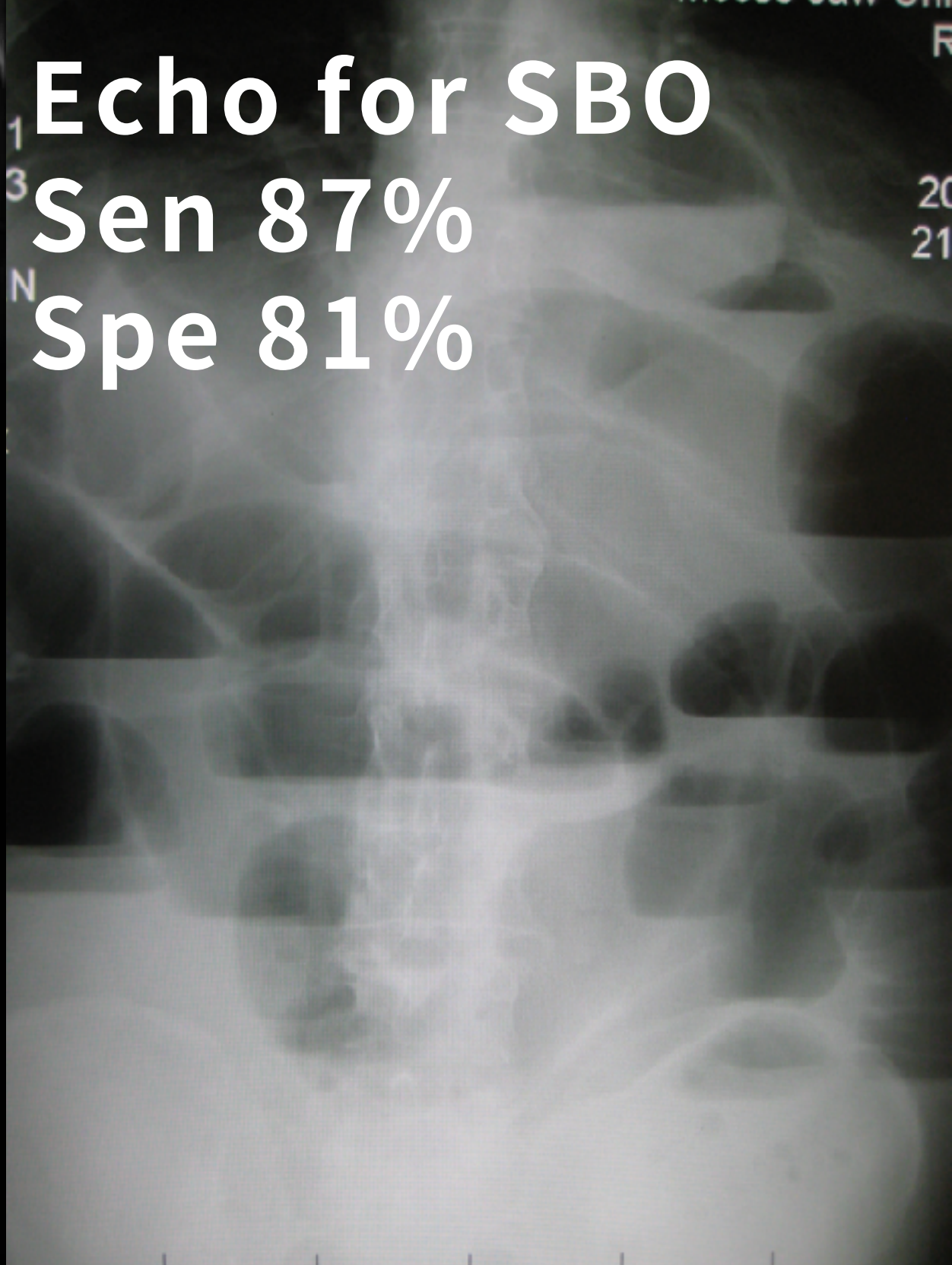




# X光要開【對】的條件才有用啊



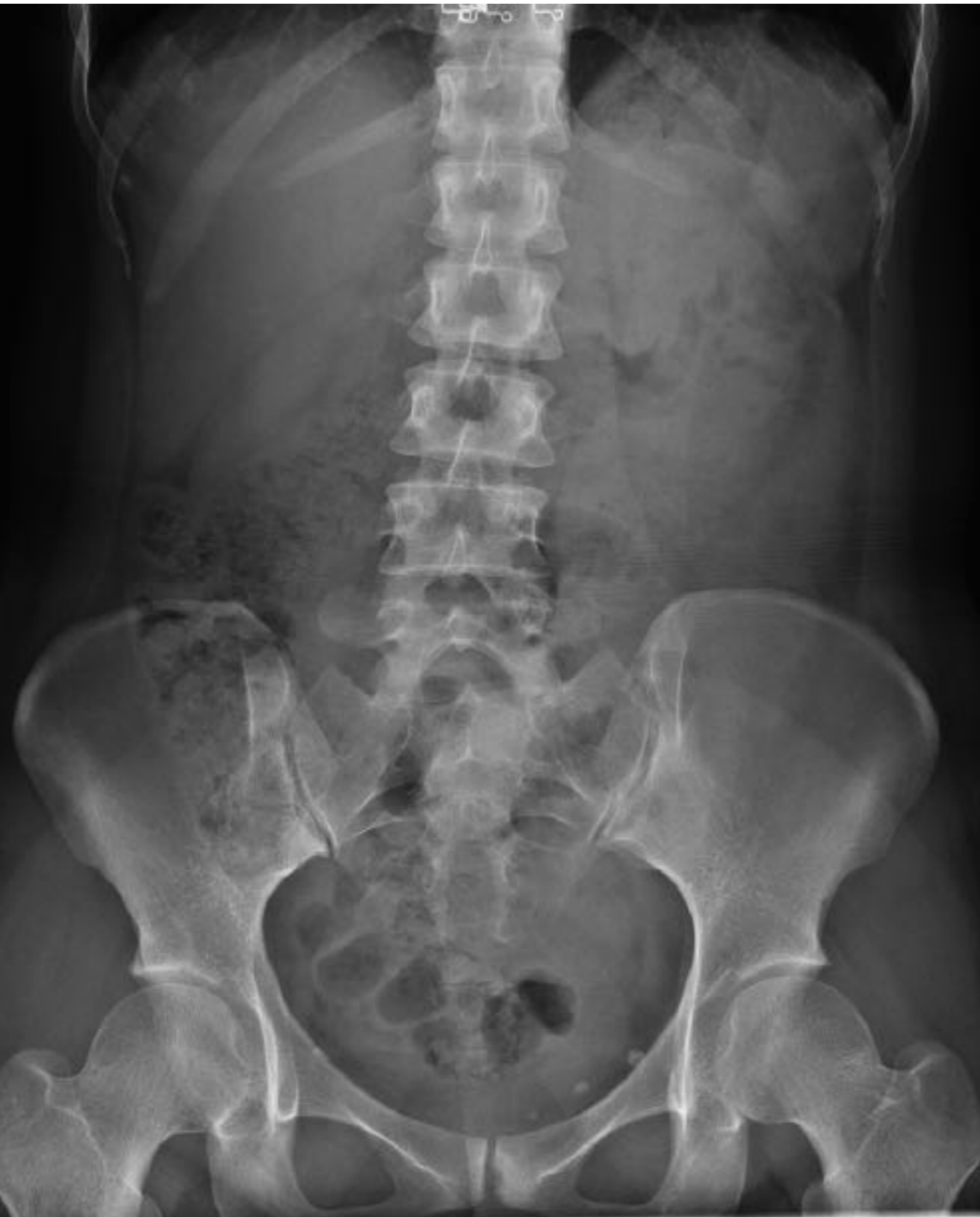**X-ray for SBO**  
**Sen 75%**  
**Spe 66%**



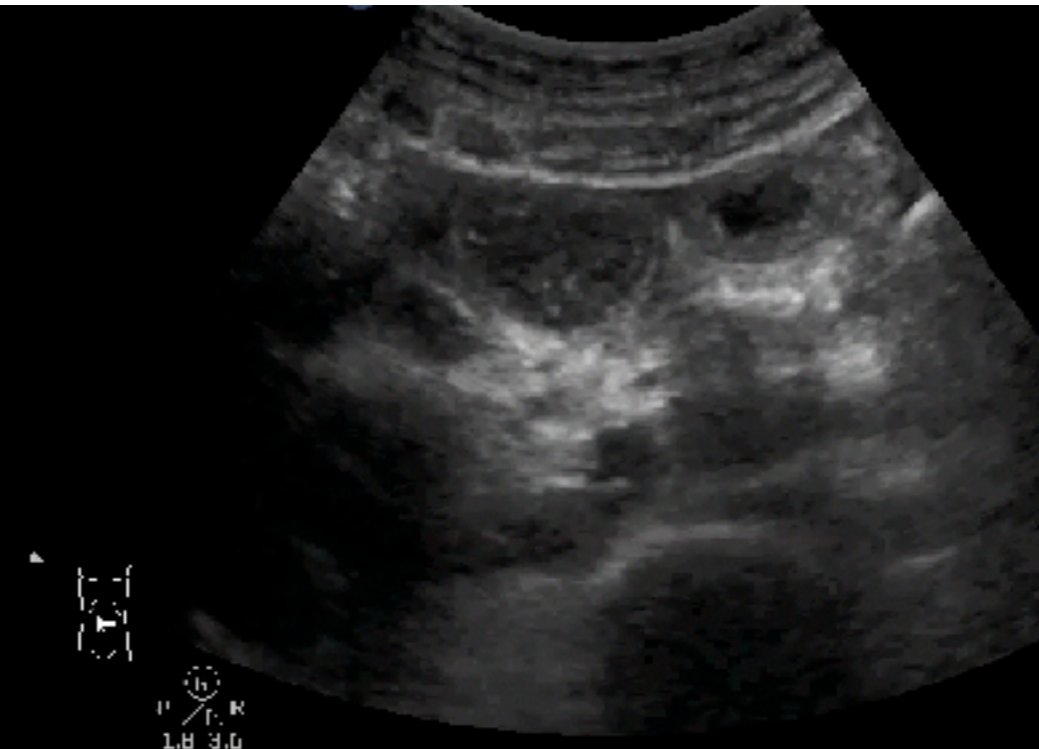
**Echo for SBO**  
**Sen 87%**  
**Spe 81%**



# F/31, ABD pain & vomiting for 2Ds

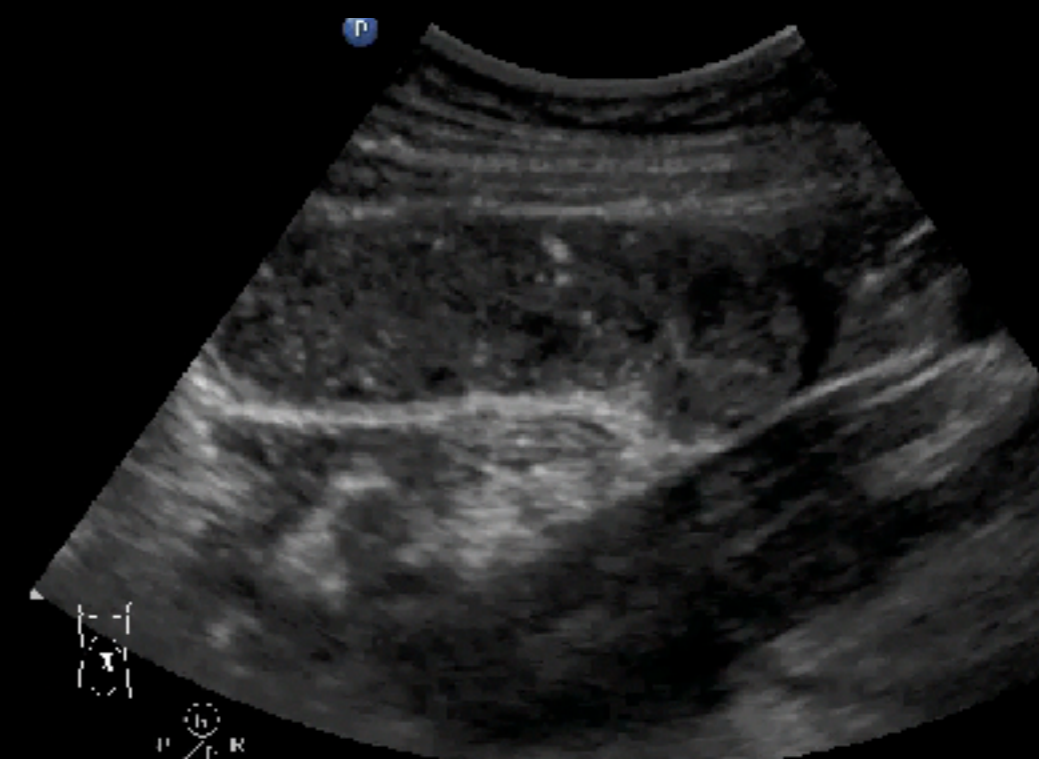


5 1  
15 Hz  
10.0cm  
ID  
II Gen  
Gn 51  
I: 56  
3/3/3



15  
P  
1.8 3.0

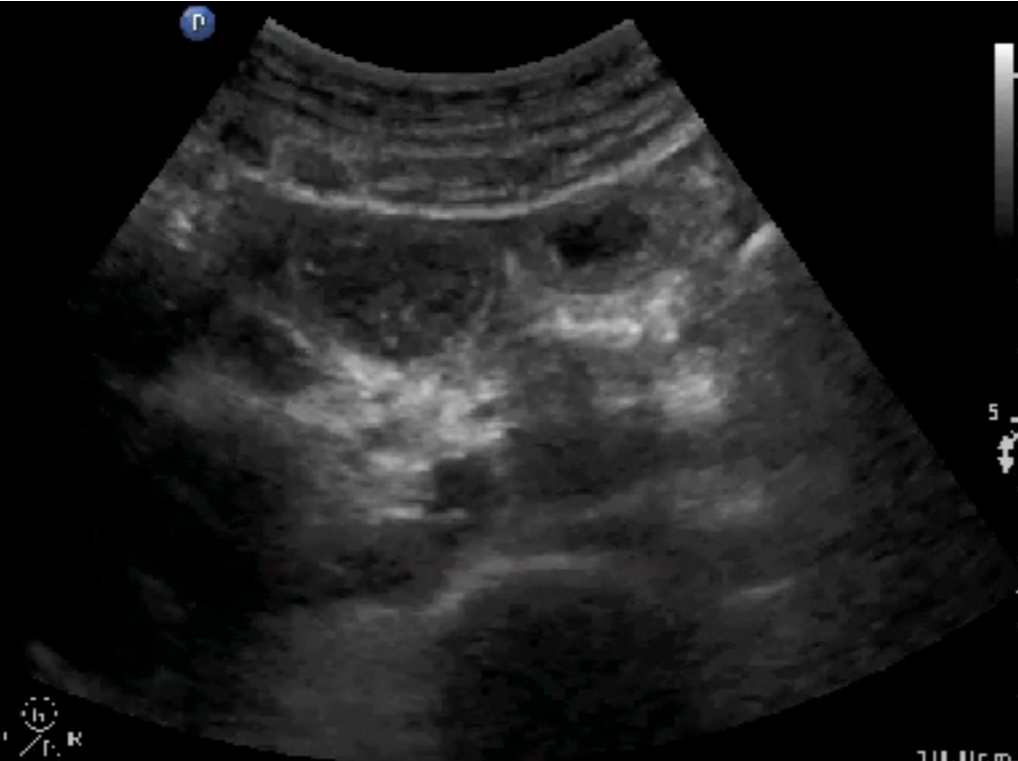
Abd Gen  
5 1  
15 Hz  
10.0cm  
ID  
II Gen  
Gn 45  
I: 56  
3/3/3



15  
P  
1.8 3.0

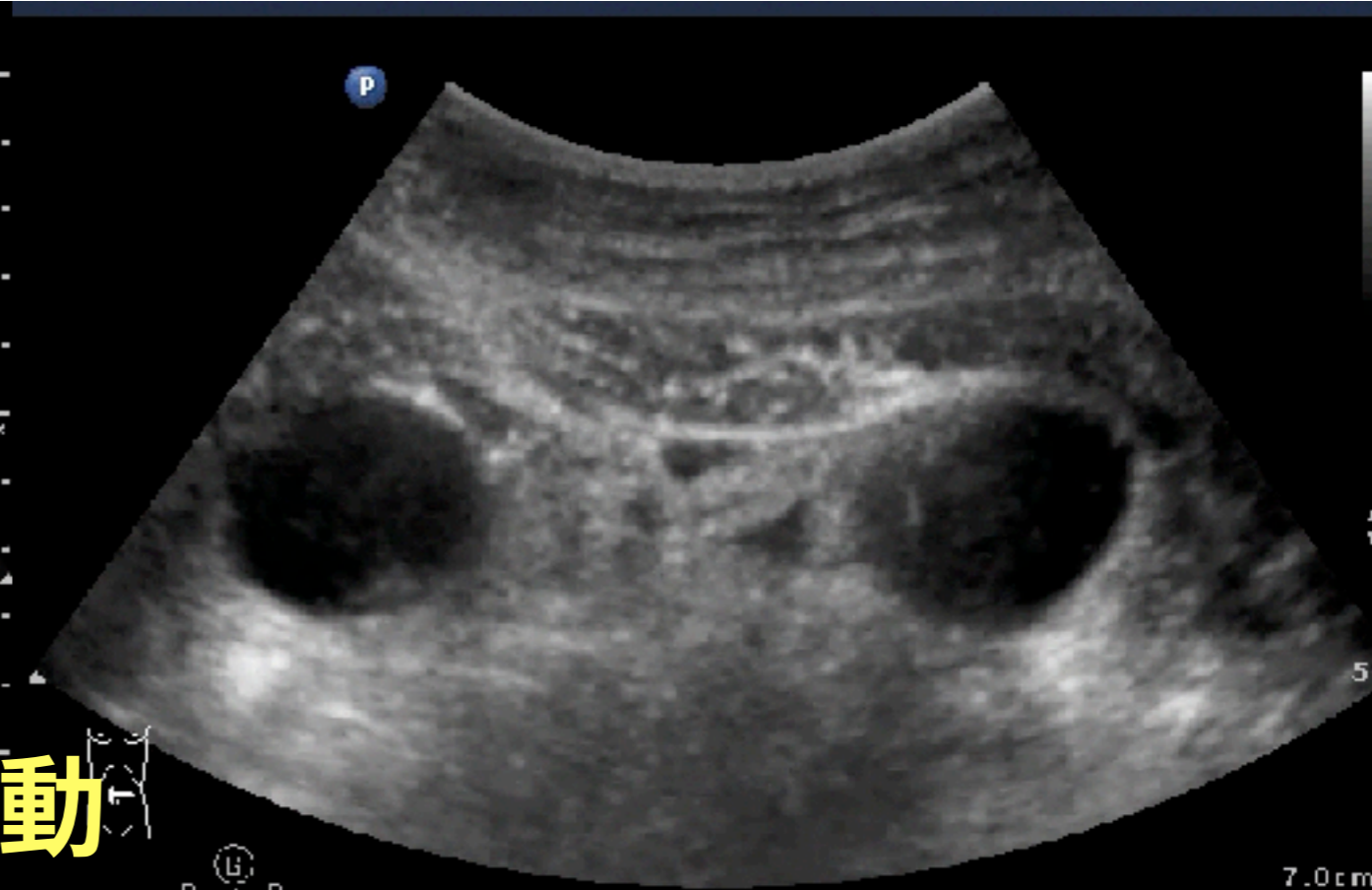
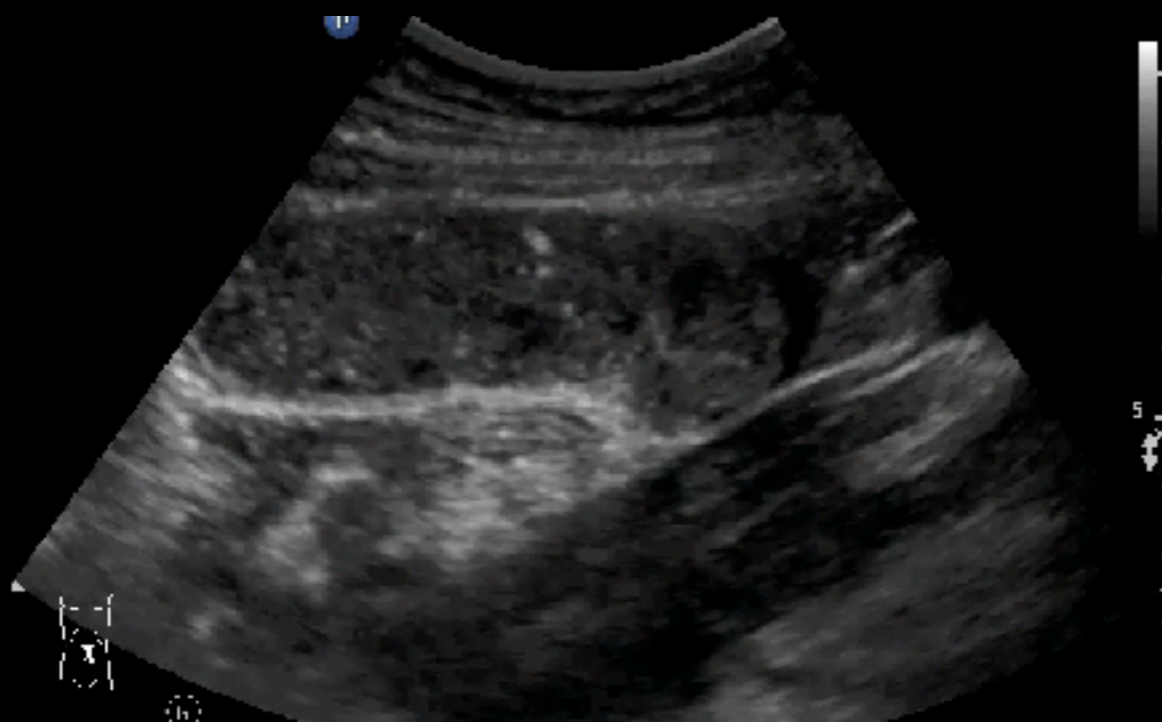
# Adhesion ileus

Abd Gen  
35 1  
35 Hz  
10.0cm  
2D  
11Gen  
Gn 51  
1:56  
3/3/3



沾黏的腸子不會隨呼吸滑動

Abd Gen  
35 1  
35 Hz  
10.0cm  
2D  
11Gen  
Gn 45  
1:56  
3/3/3

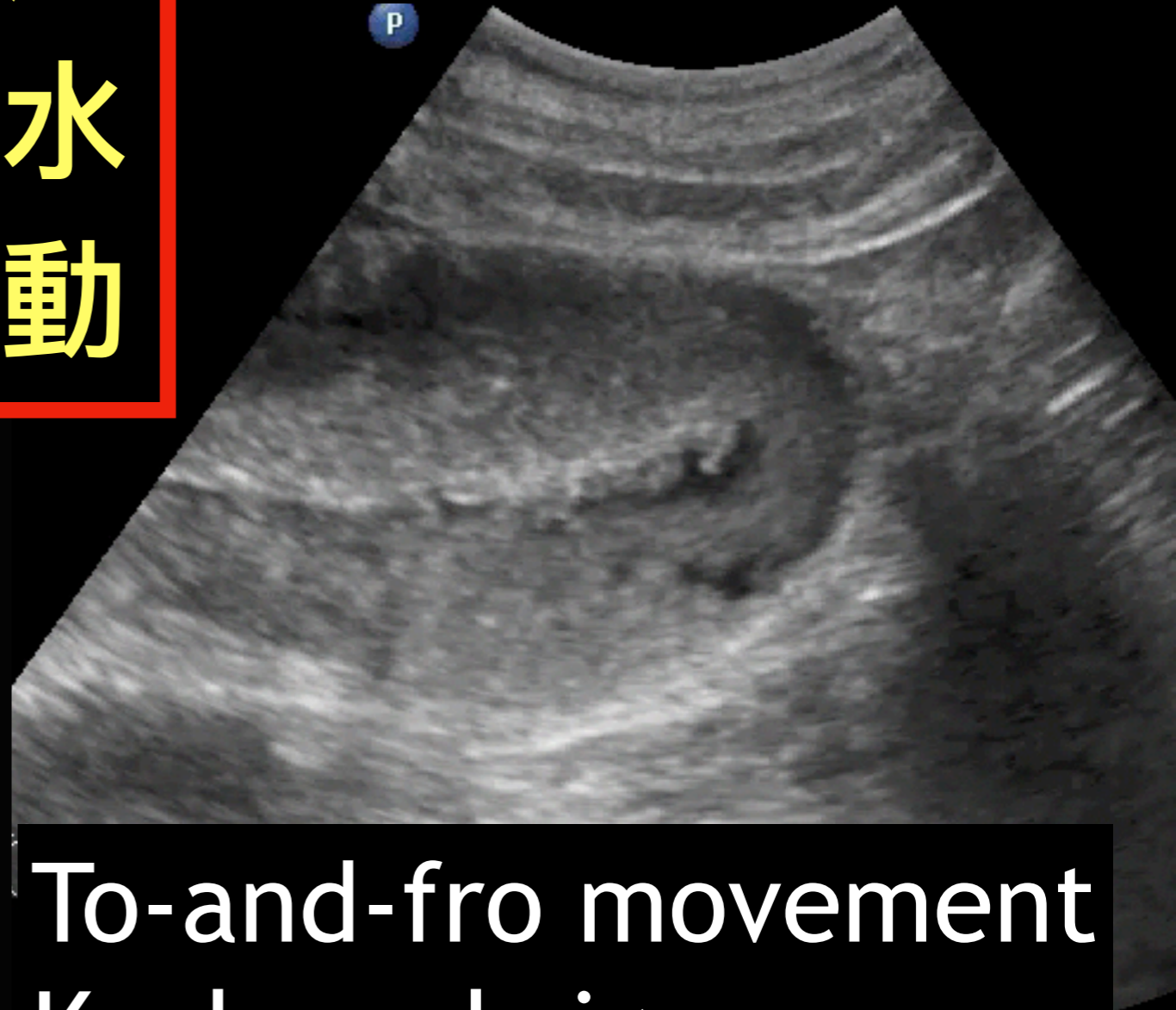
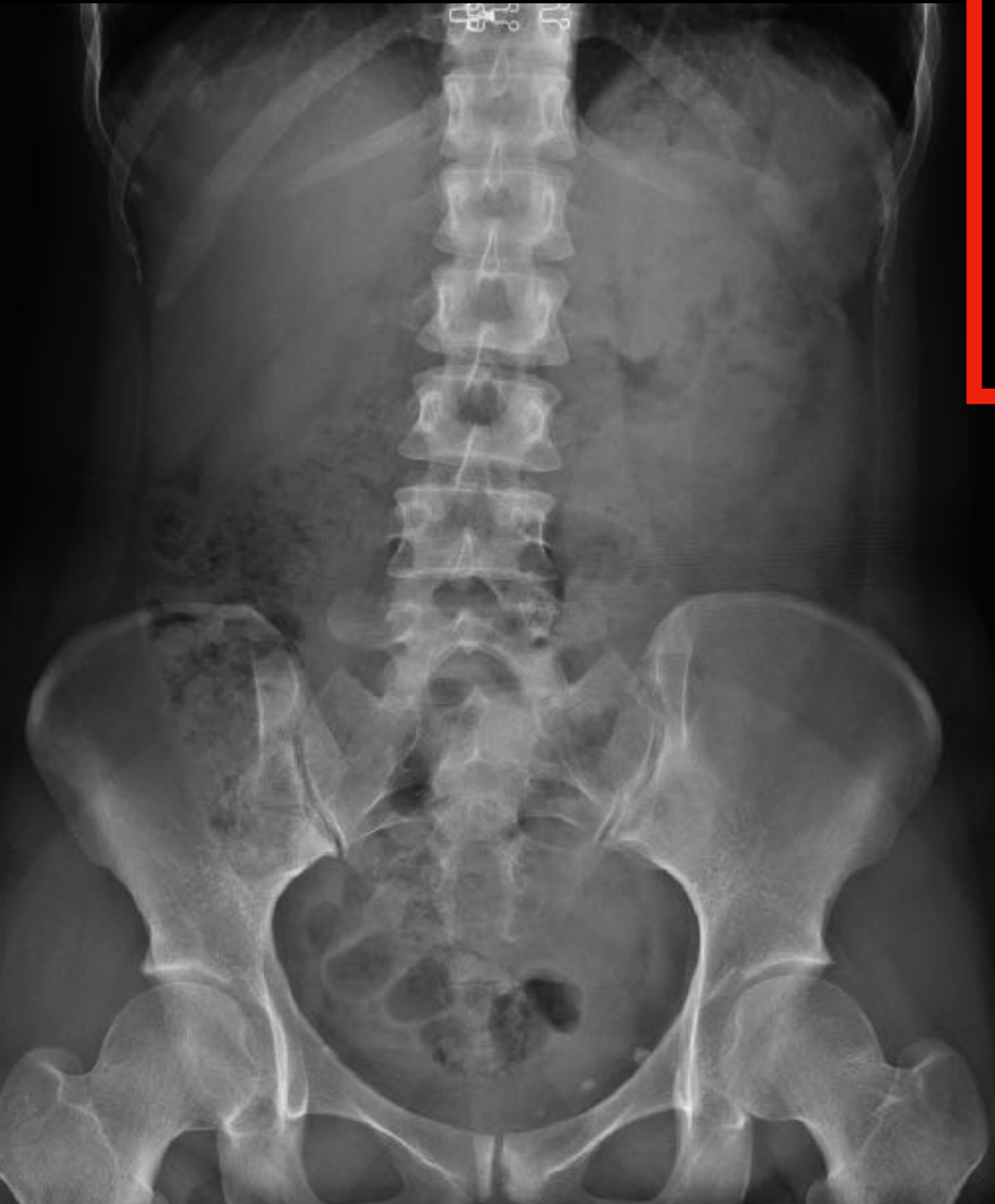

Keyboard sign  
Tanga sign 腸間液體  
Adhesion band



# POCUS is useful for gasless ileus

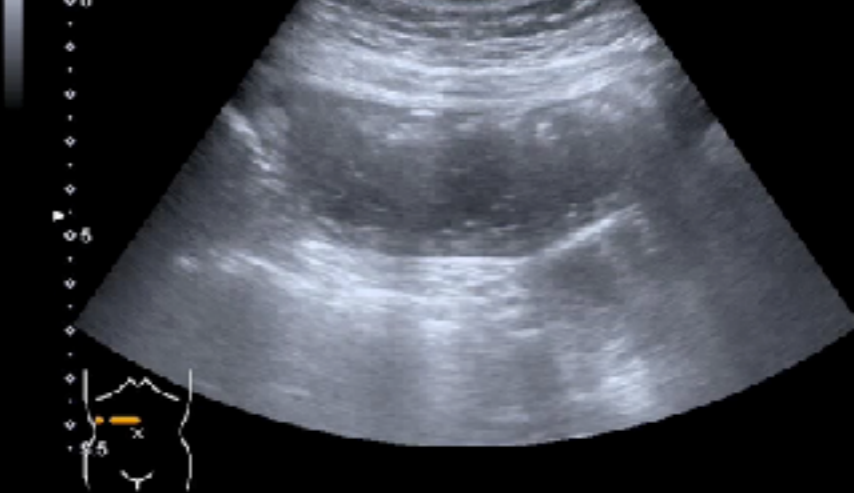
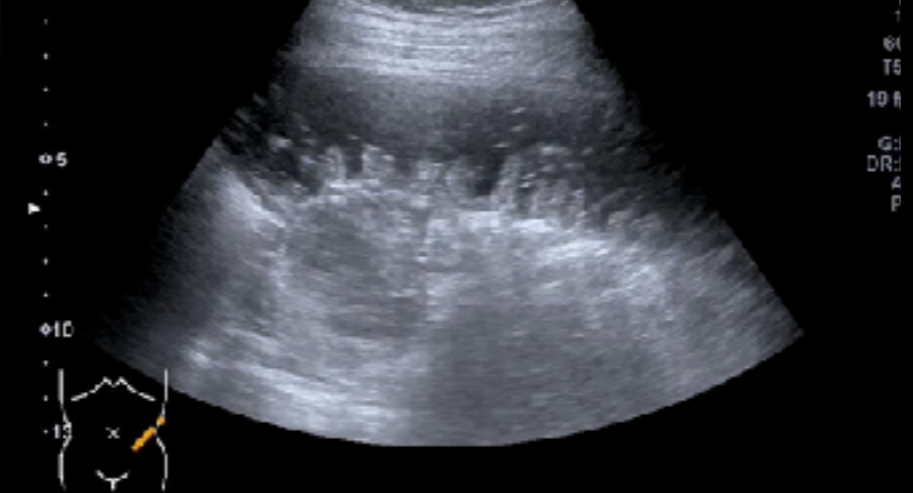
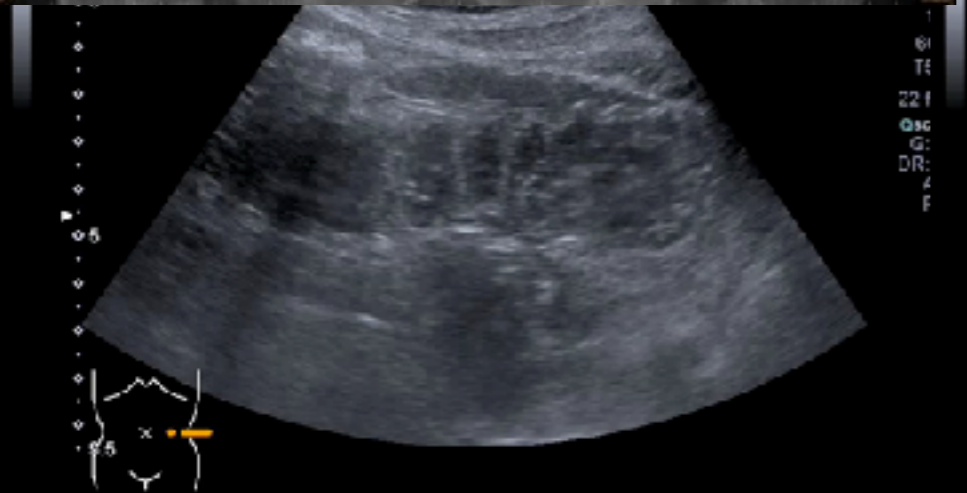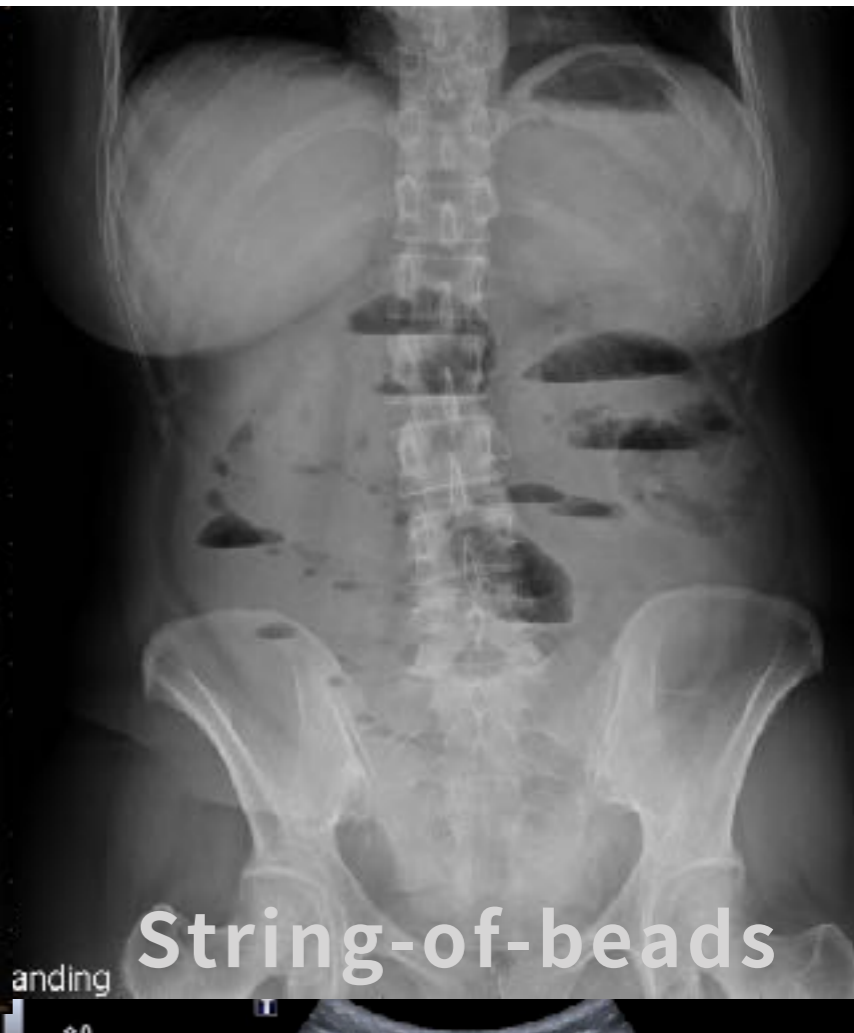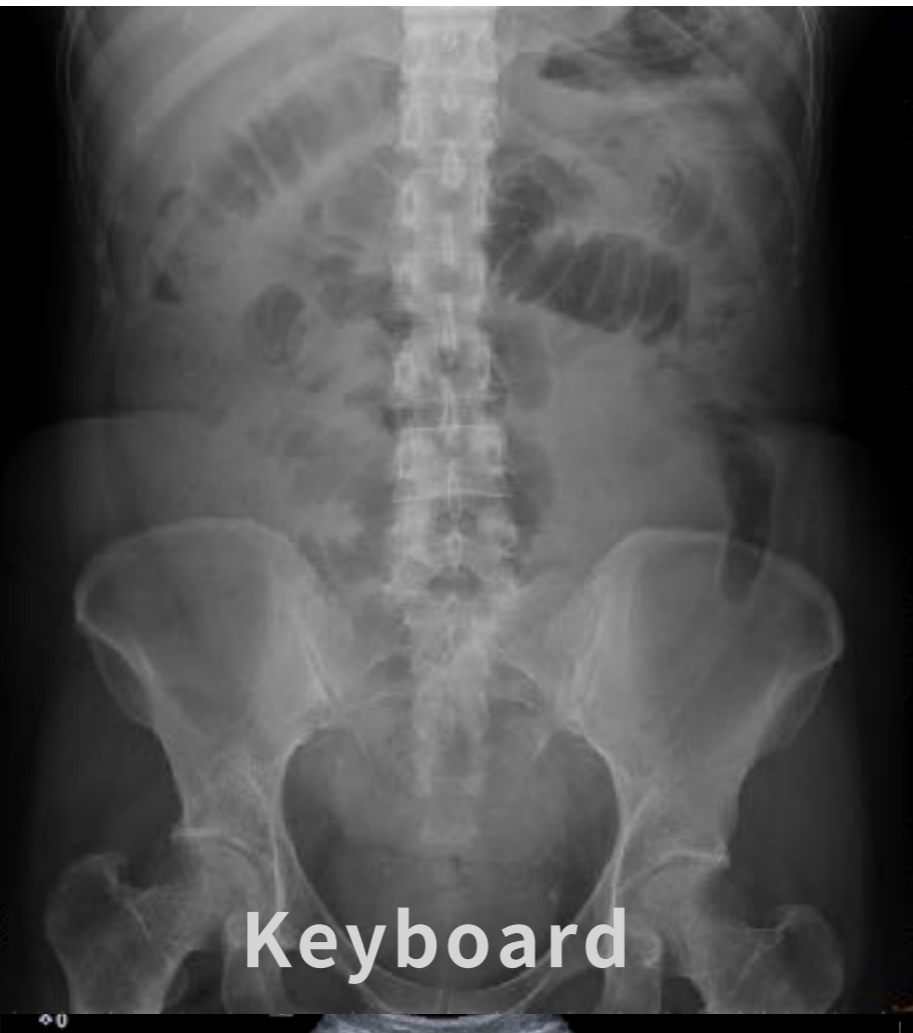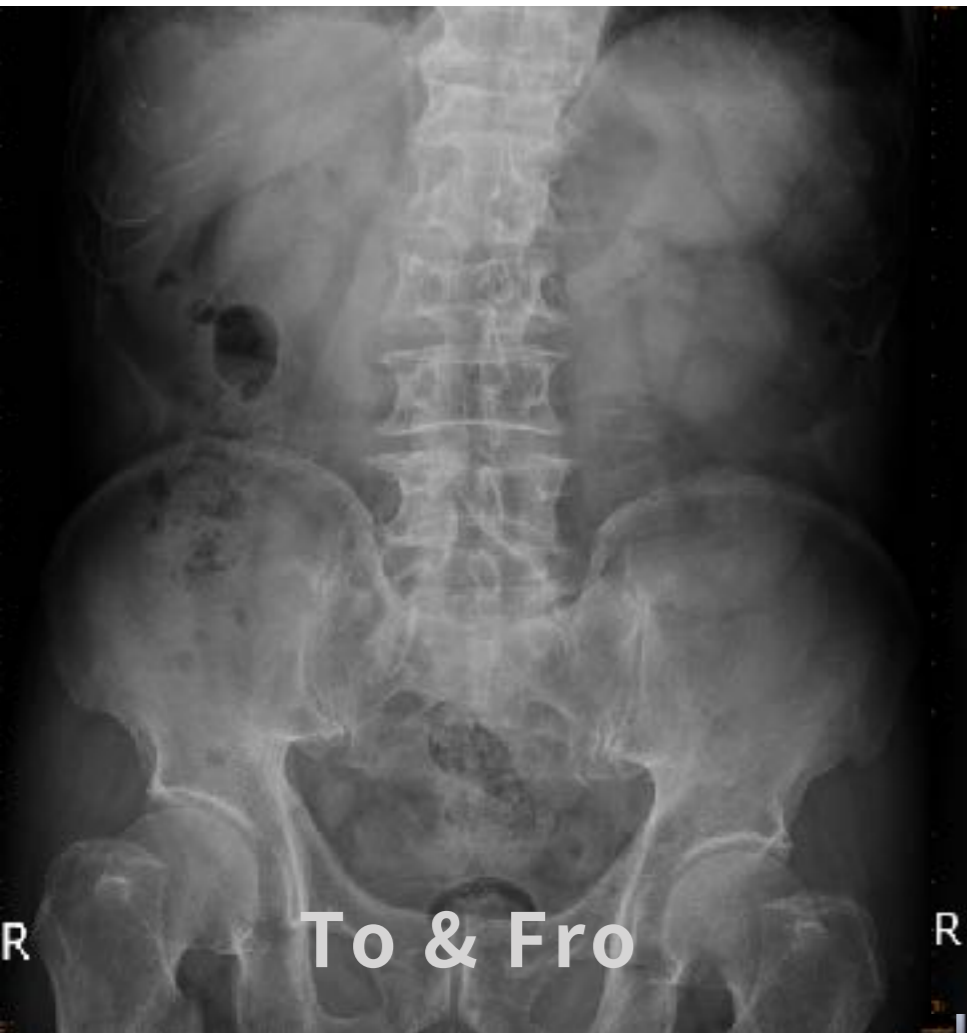壁厚  
腹水  
蠕動



To-and-fro movement  
Keyboard sign  
Tanga sign



# Small Bowel Obstruction



## TAKE-HOME MESSAGE

For trained operators, ultrasonography possesses sensitivity and specificity comparable to that of abdominal computed tomography (CT) for the diagnosis of small bowel obstruction.

**US for SBO diagnosis LR + >20起跳**

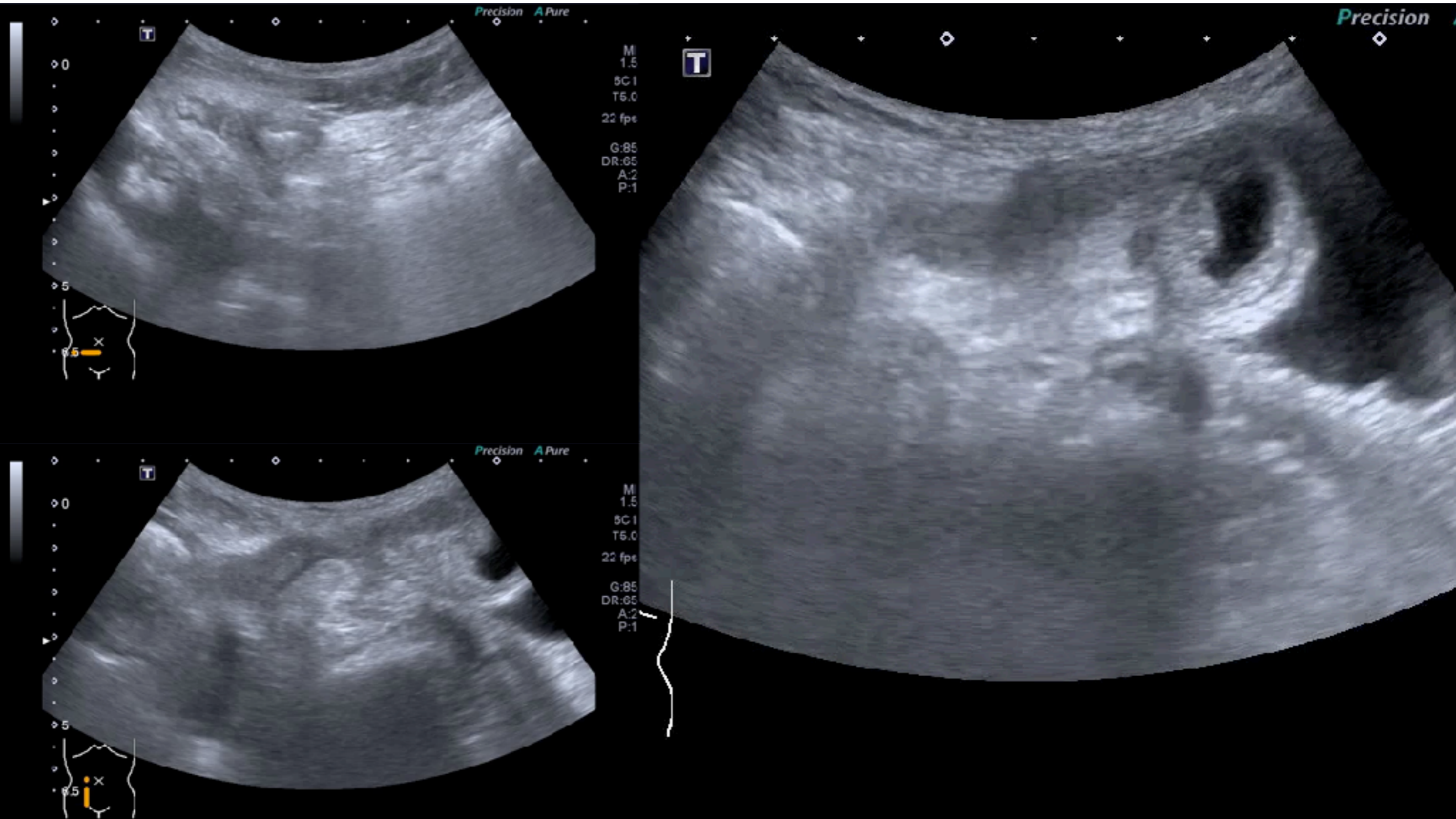
<b>Ultrasonographic Diagnosis of SBO</b>	<b>Specificity (95% CI)</b>	<b>Sensitivity (95% CI)</b>	<b>+LR (95% CI)</b>	<b>-LR (95% CI)</b>	<b>SROC AUC (95% CI)</b>
Overall	0.97 (0.88–0.99)	0.92 (0.89–0.95)	27.5 (7.7–98.4)	0.08 (0.06–0.11)	0.96 (0.94–0.97)
ED	0.96 (0.86–0.99)	0.93 (0.89–0.95)	21.1 (6.5–68.9)	0.08 (0.05–0.12)	0.96 (0.94–0.97)
Non-ED	0.99 (0.60–1.00)	0.92 (0.85–0.96)	70.8 (1.5–3279.7)	0.08 (0.05–0.15)	0.96 (0.94–0.98)

*CI*, Confidence interval; *+LR*, positive likelihood ratio; *-LR*, negative likelihood ratio; *SBO*, small bowel obstruction; *SROC*, summary receiver operating characteristic; *AUC*, area under the curve.



# 66M, right inguinal painful swelling

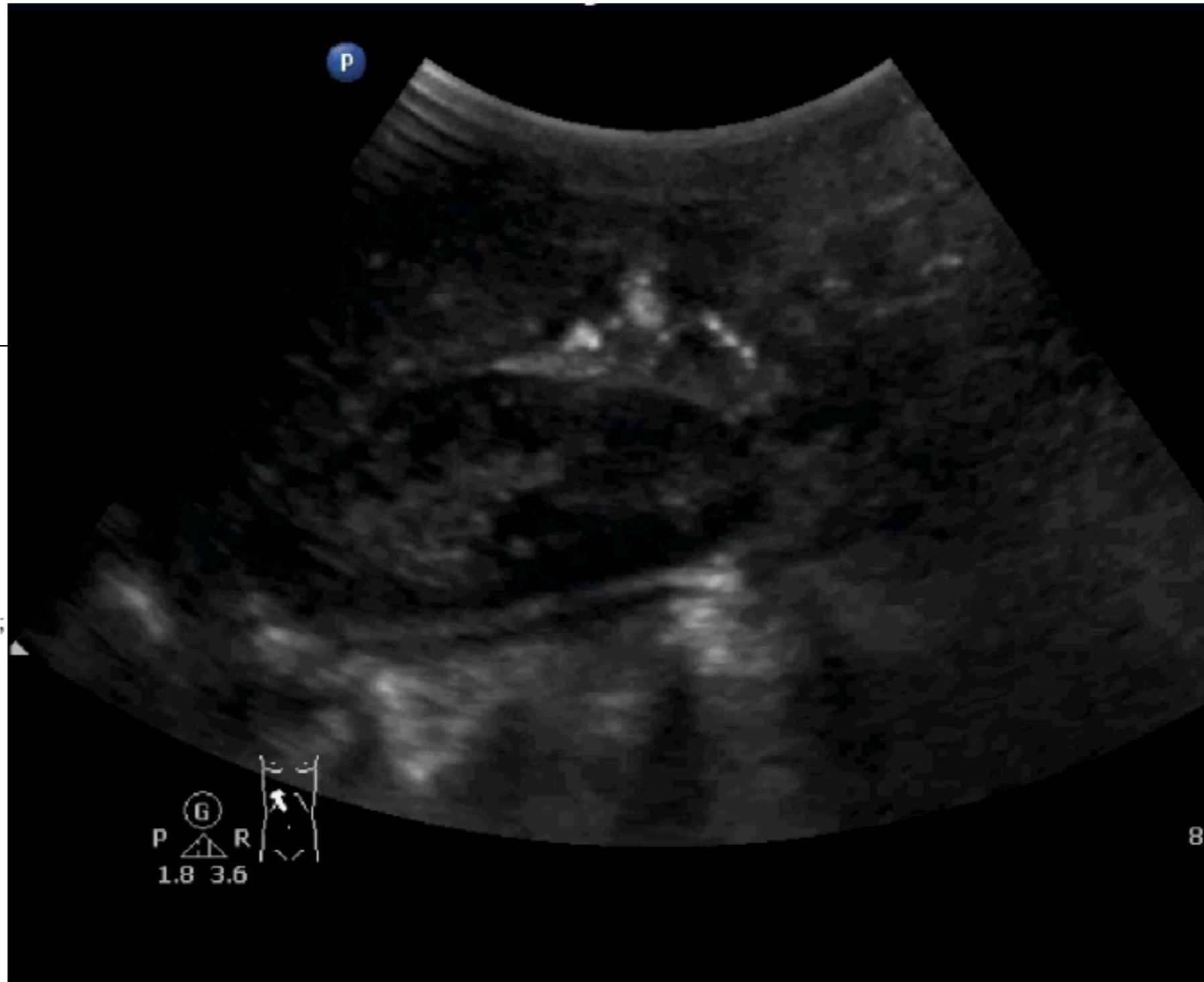
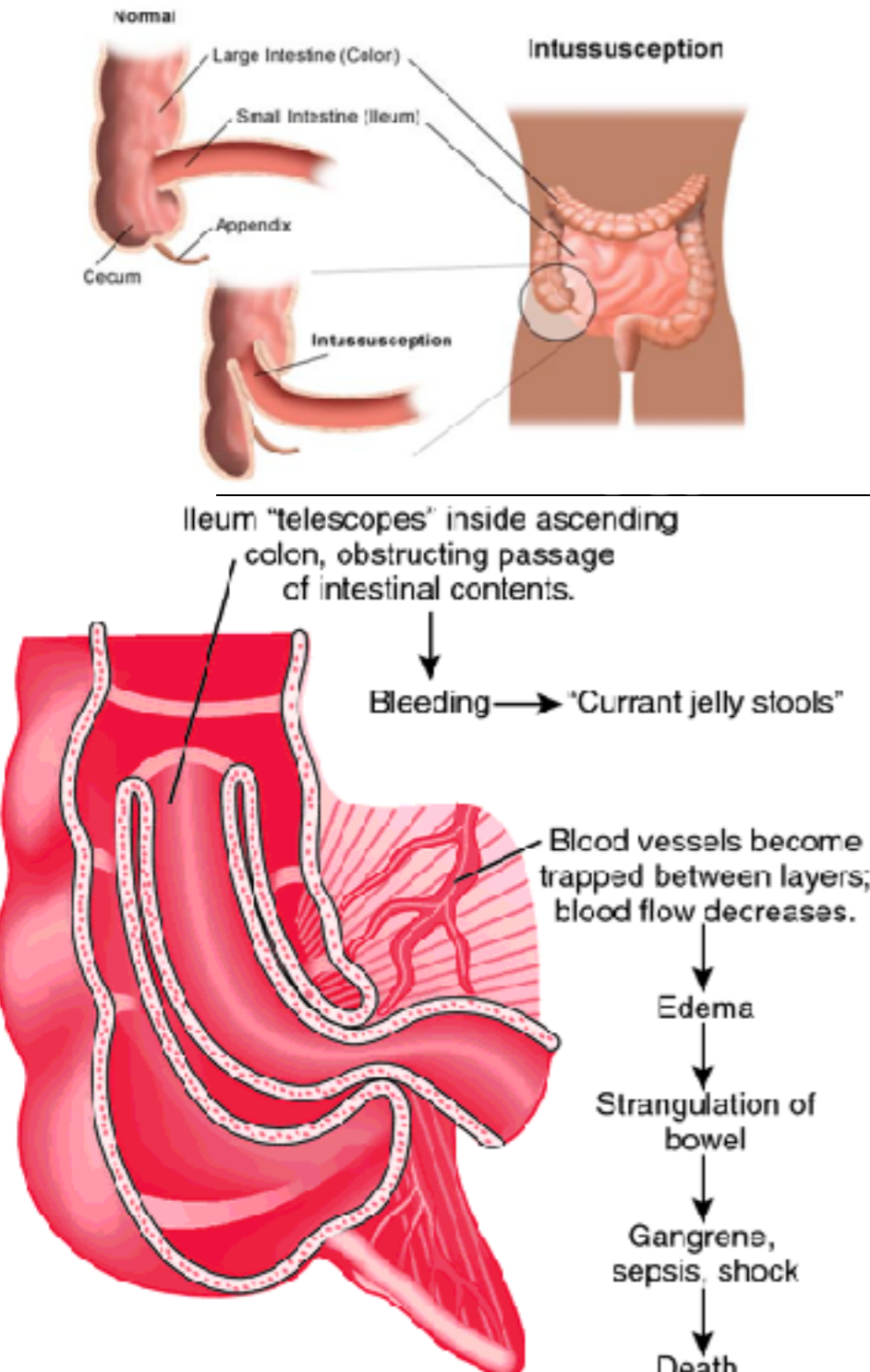
## 診斷 & 協助擬定復位路徑





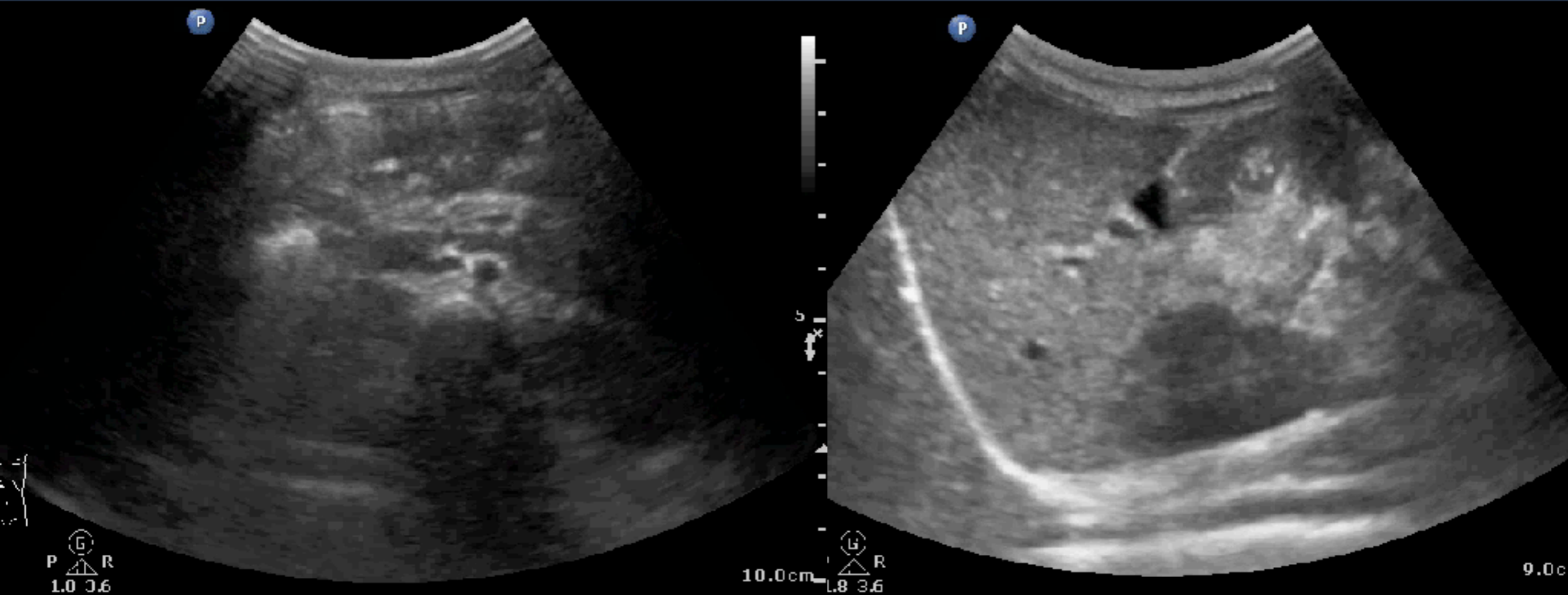
# Intussusception

## 小孩優先找右上腹

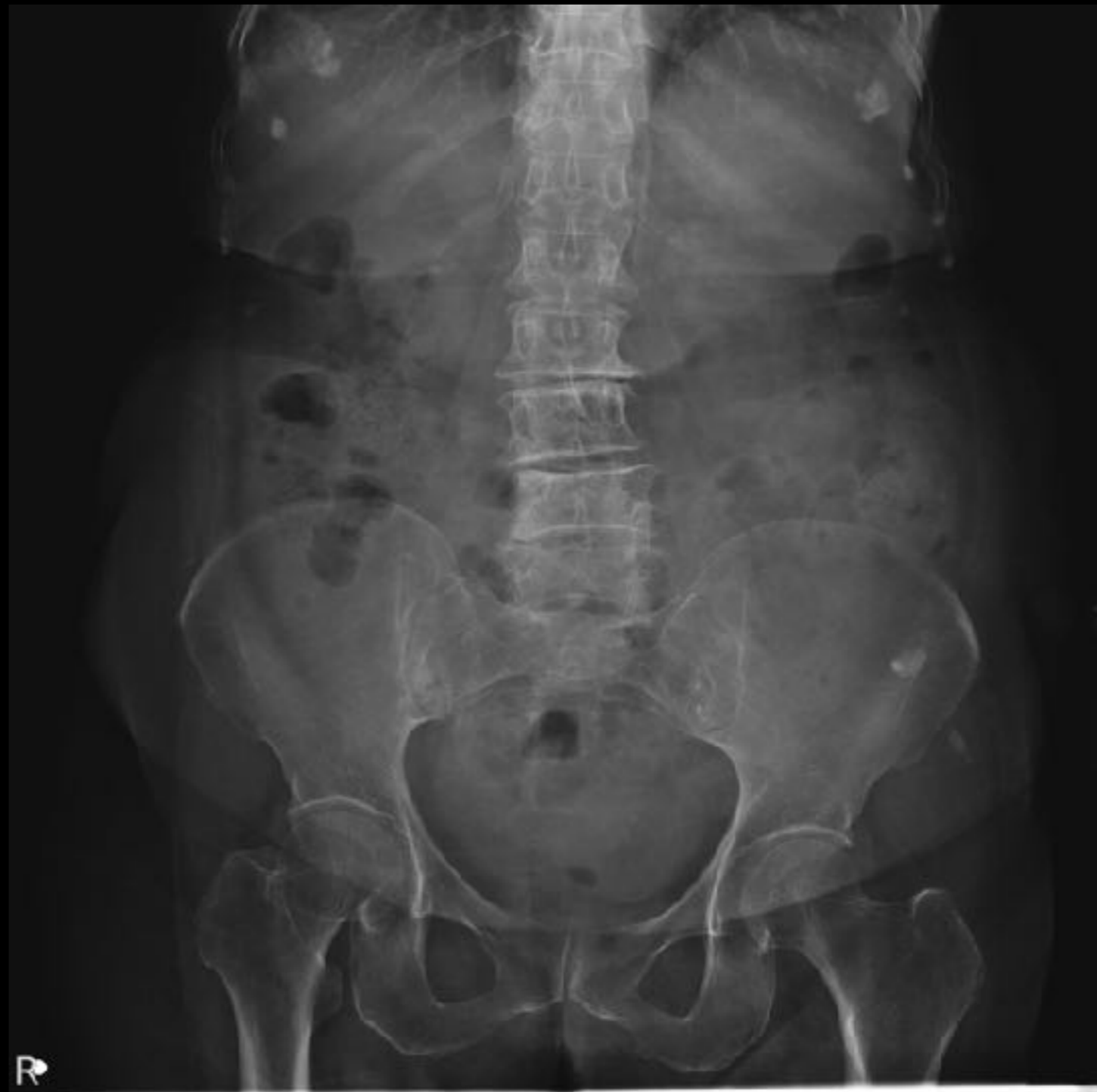
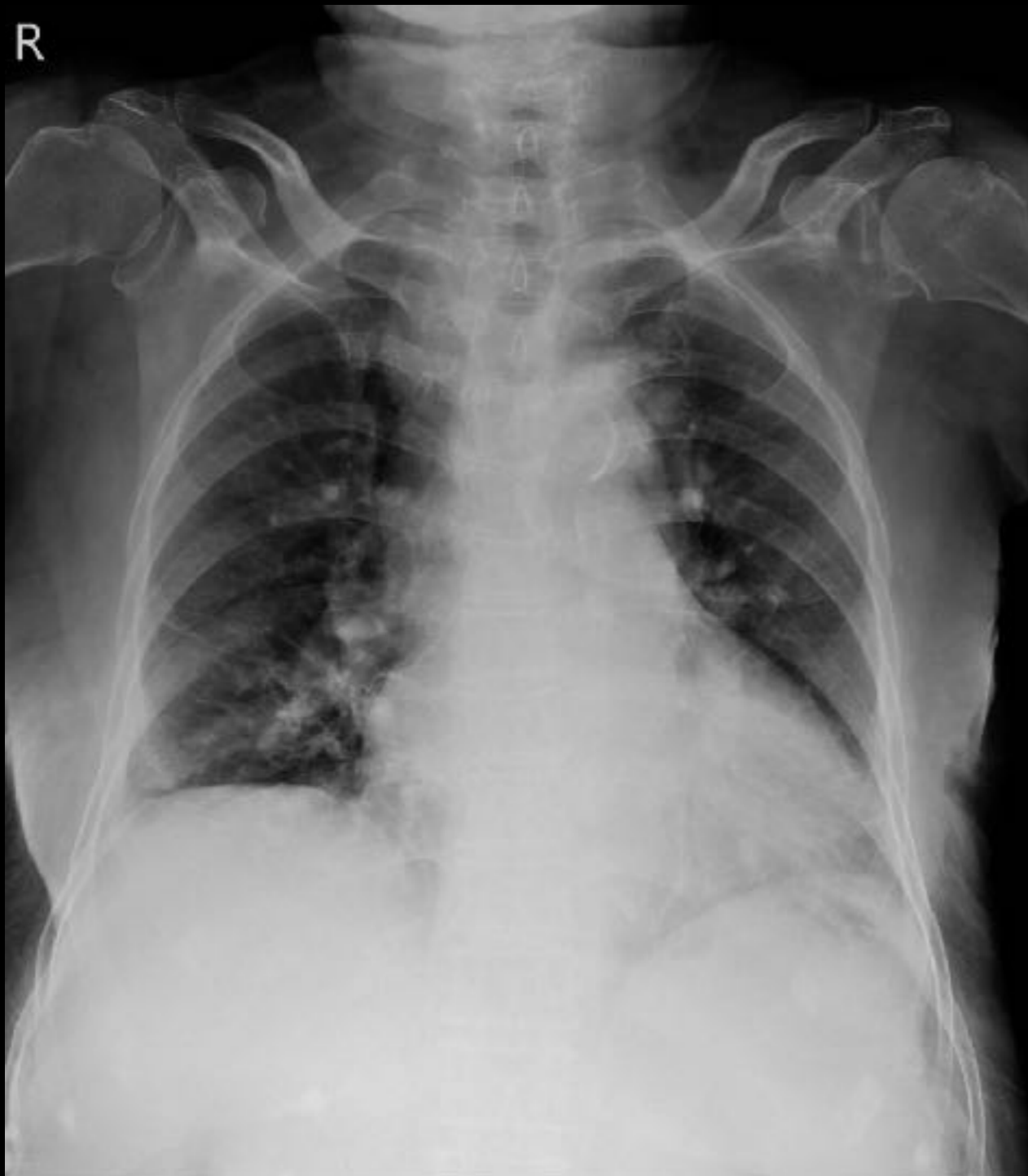
# 7個月大男童，間歇性溢奶

間歇性或周期性都要小心



# 80F, diffuse abdominal pain

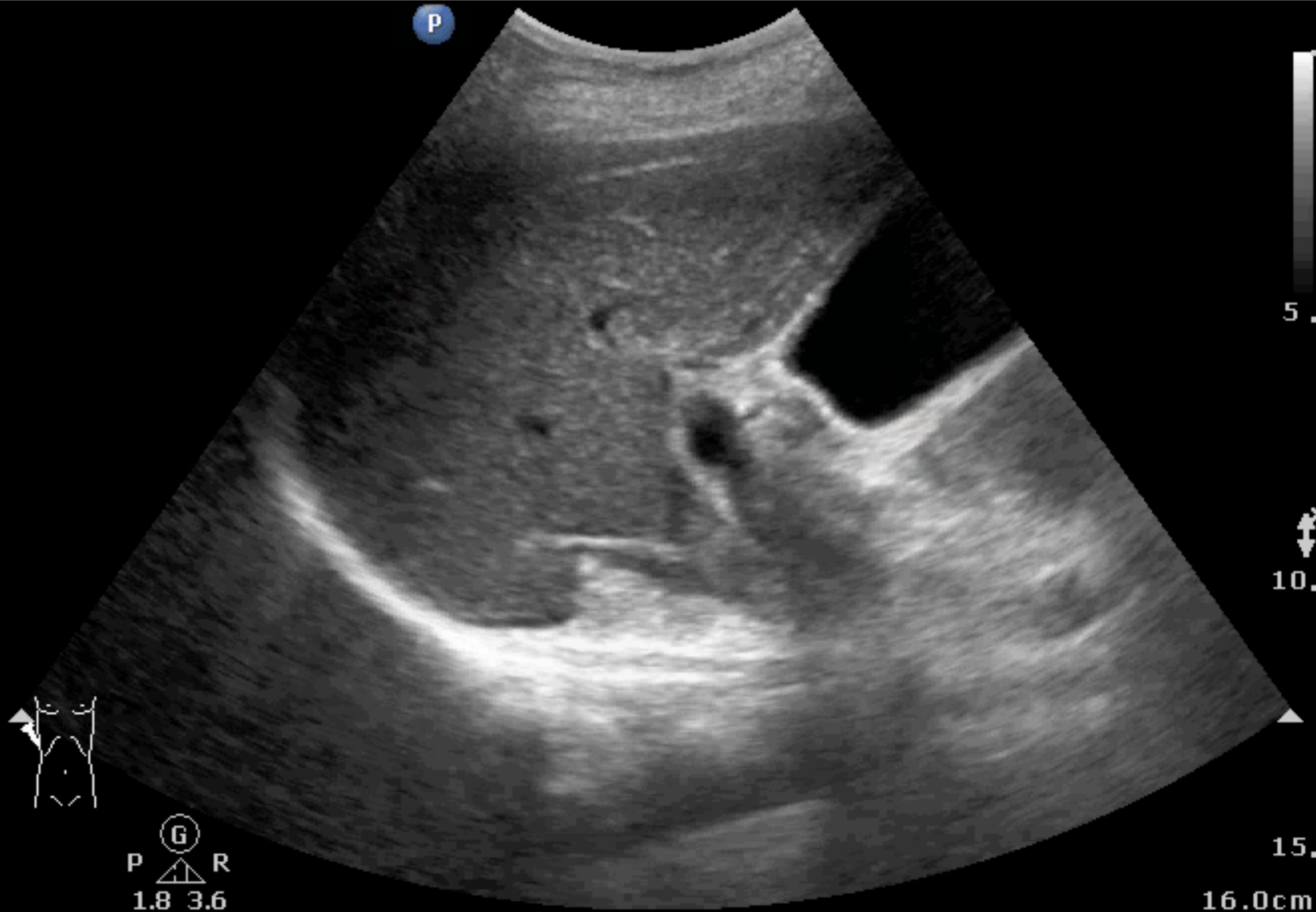



# 80F, diffuse abdominal pain

Abd Gen2  
C5-1  
3.2 Hz  
16.0cm

2D  
HGen  
Gn 90  
C 56  
3/3/3



15.  
16.0cm

# ABDOMEN

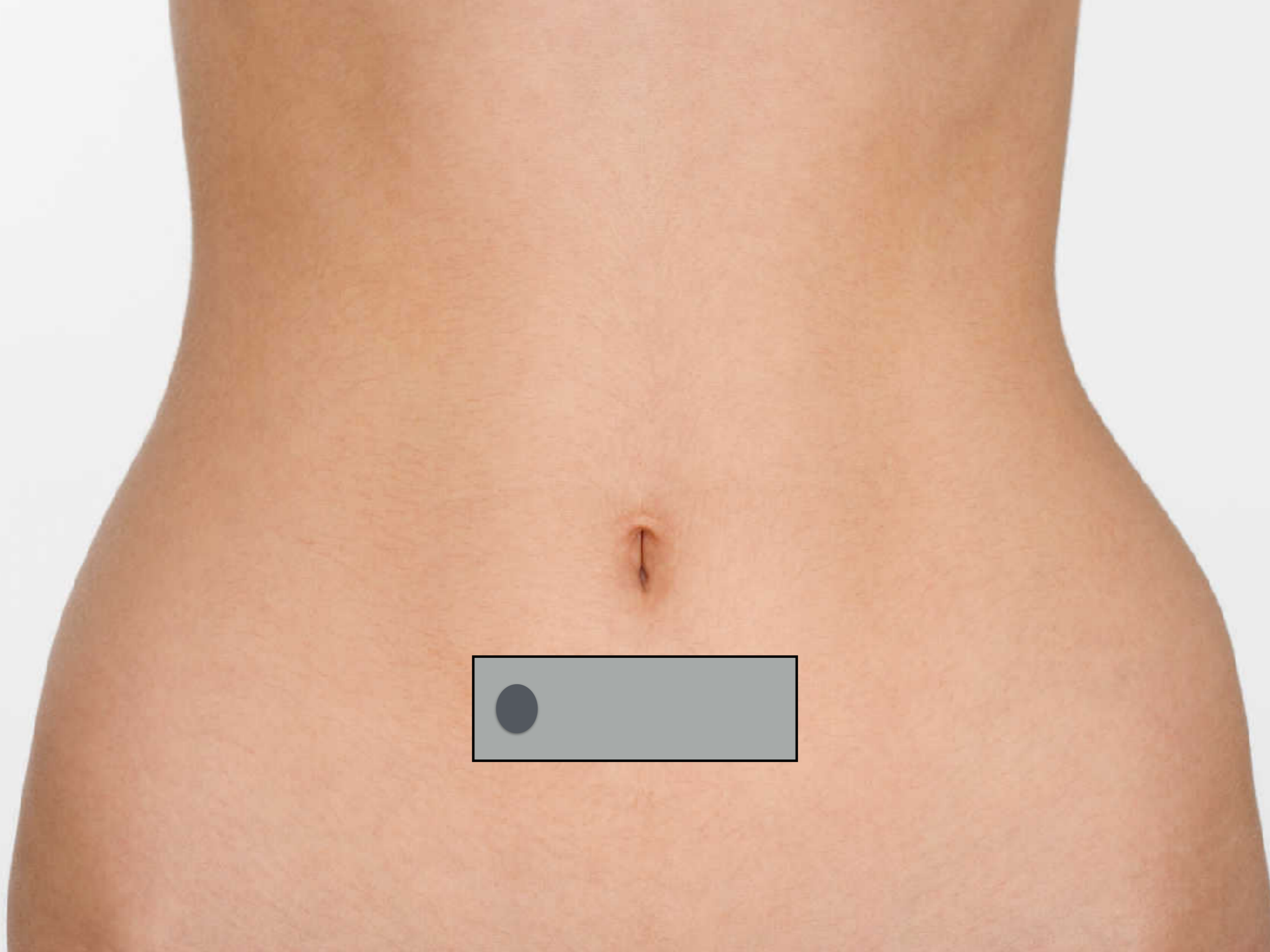
M for moving fluid or air

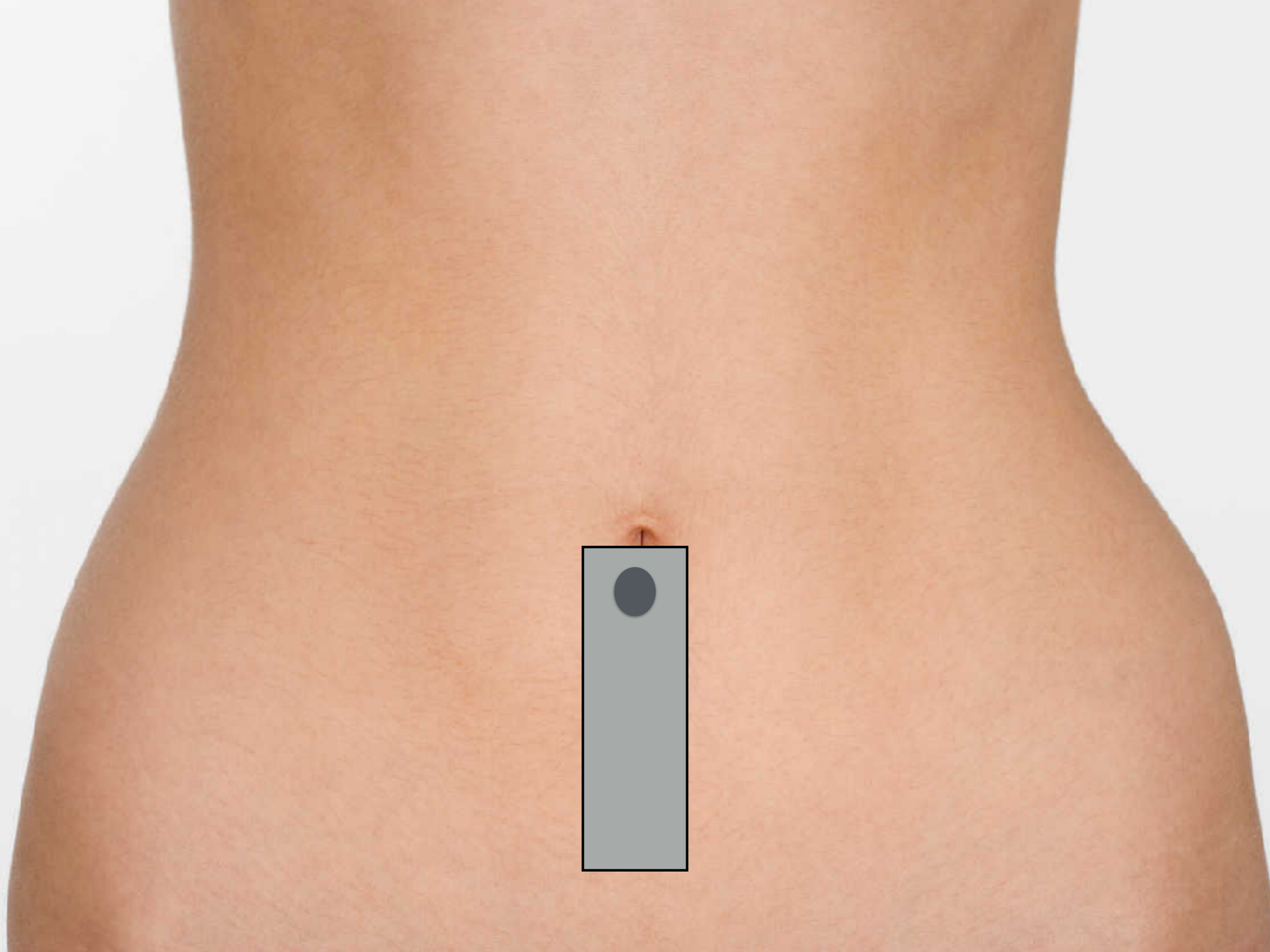
**FAST / Liver surface**



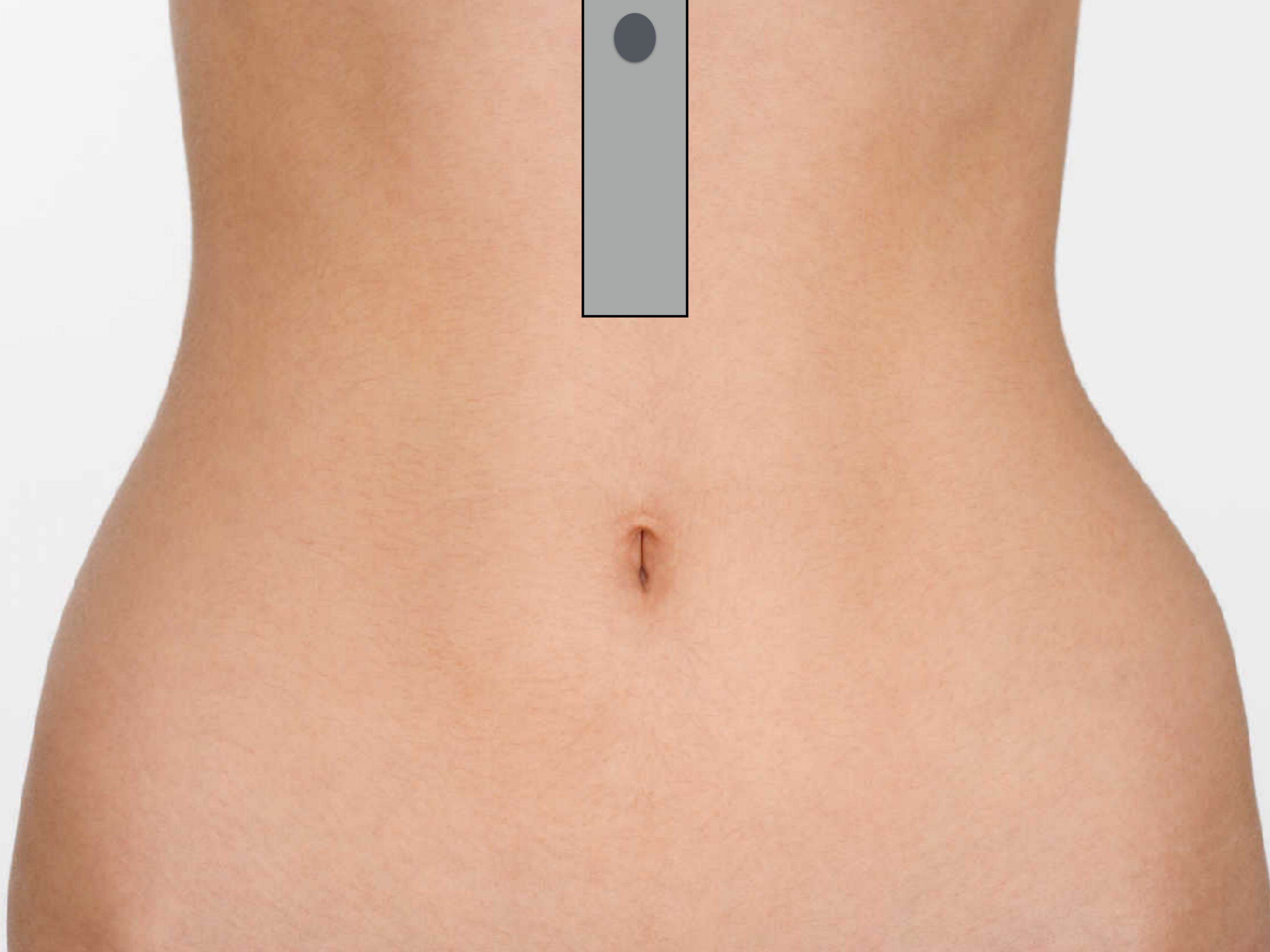


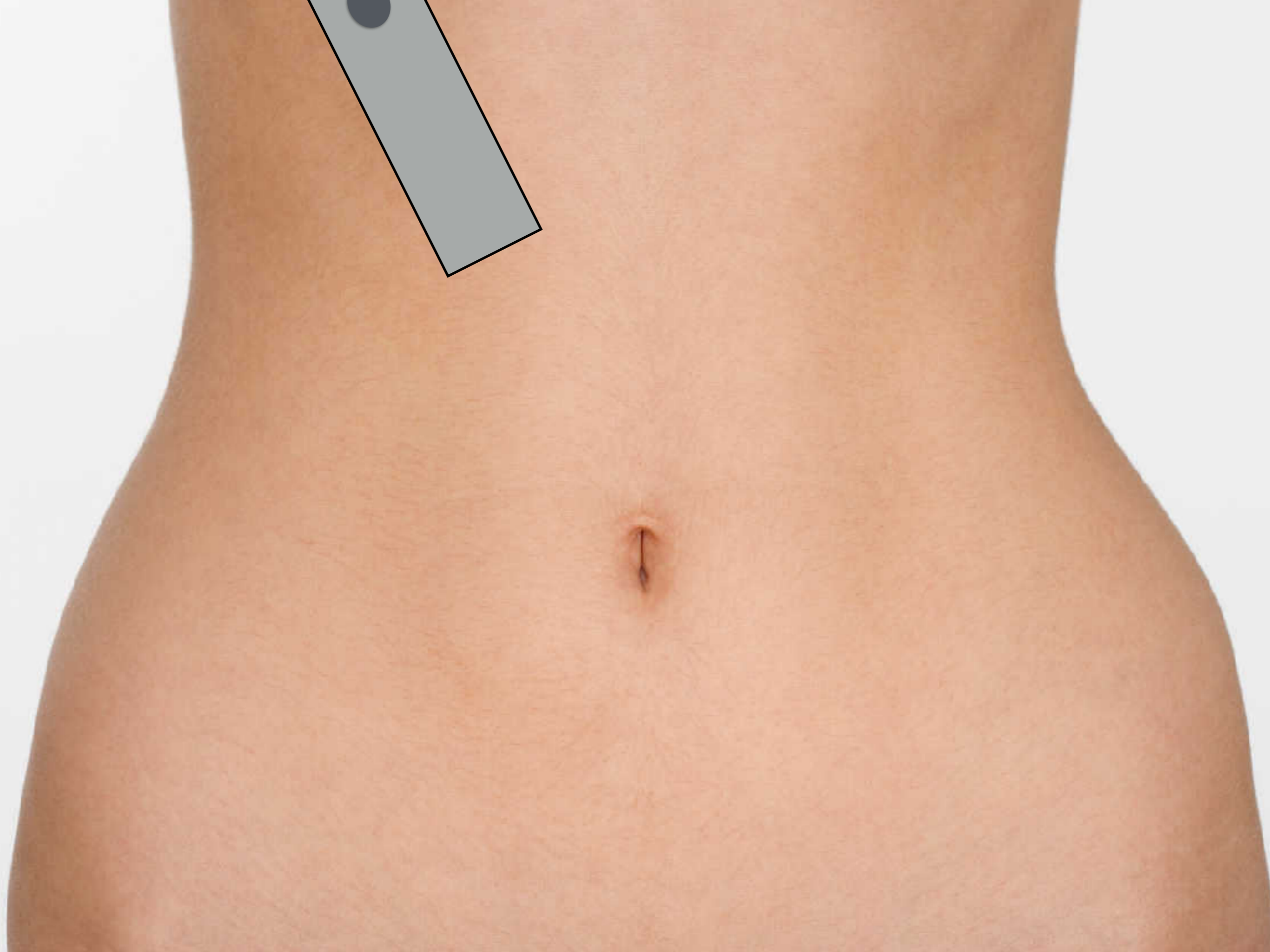






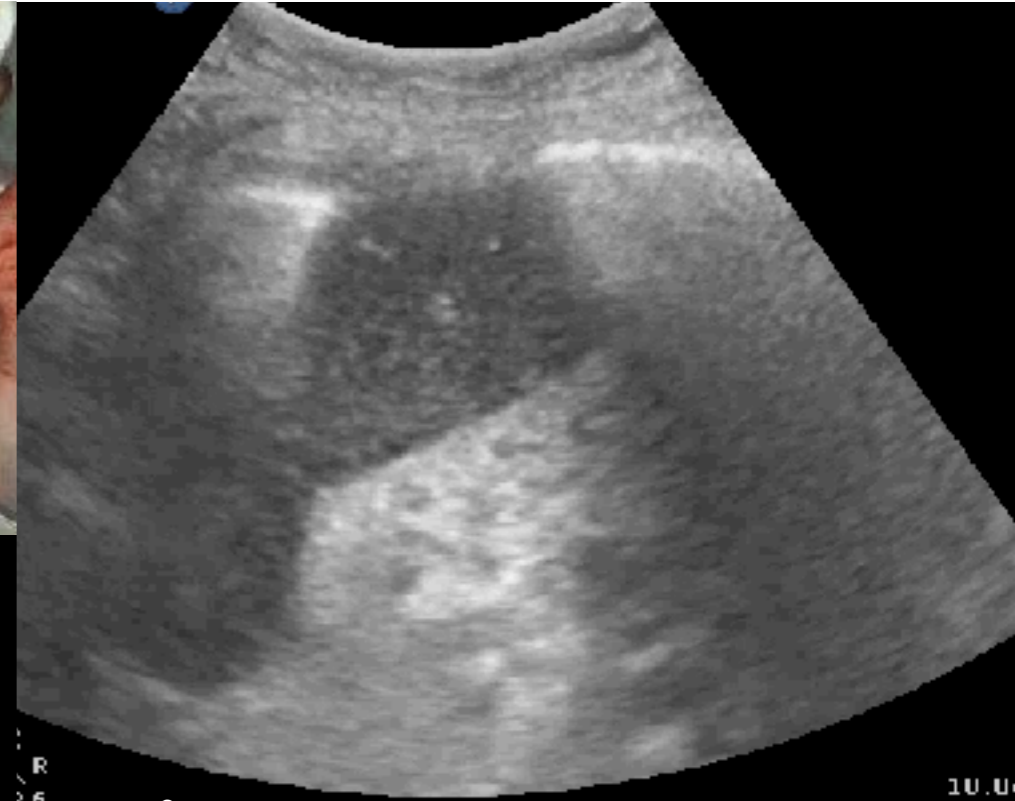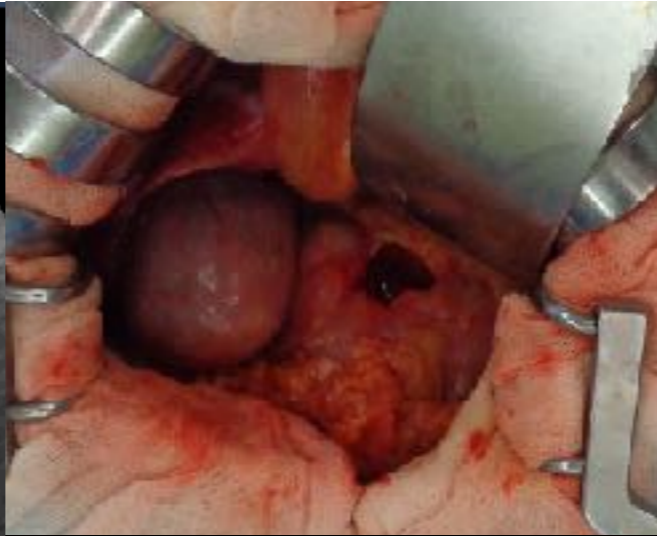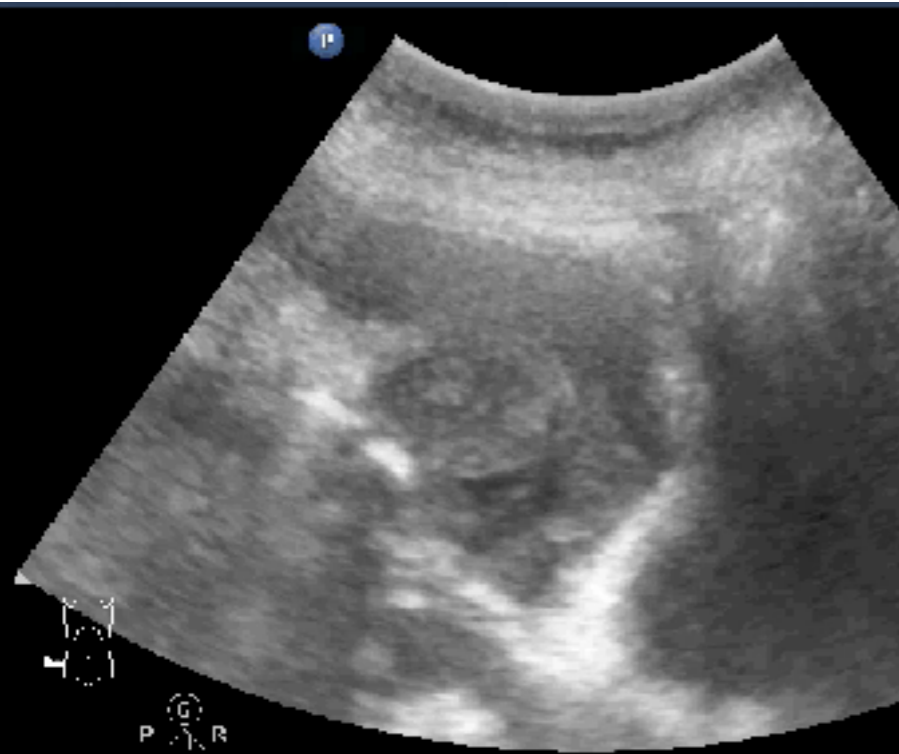






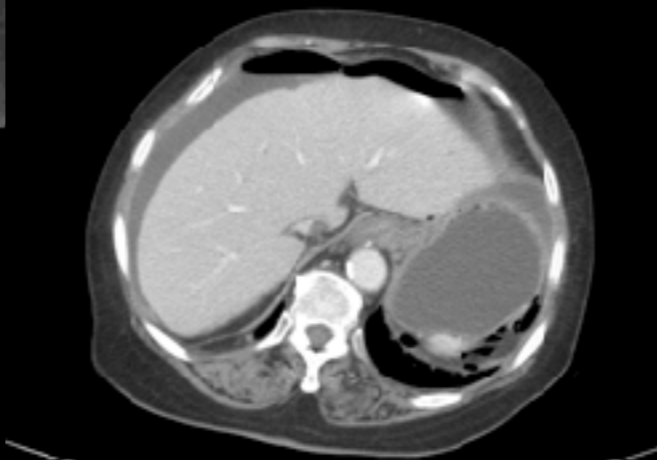
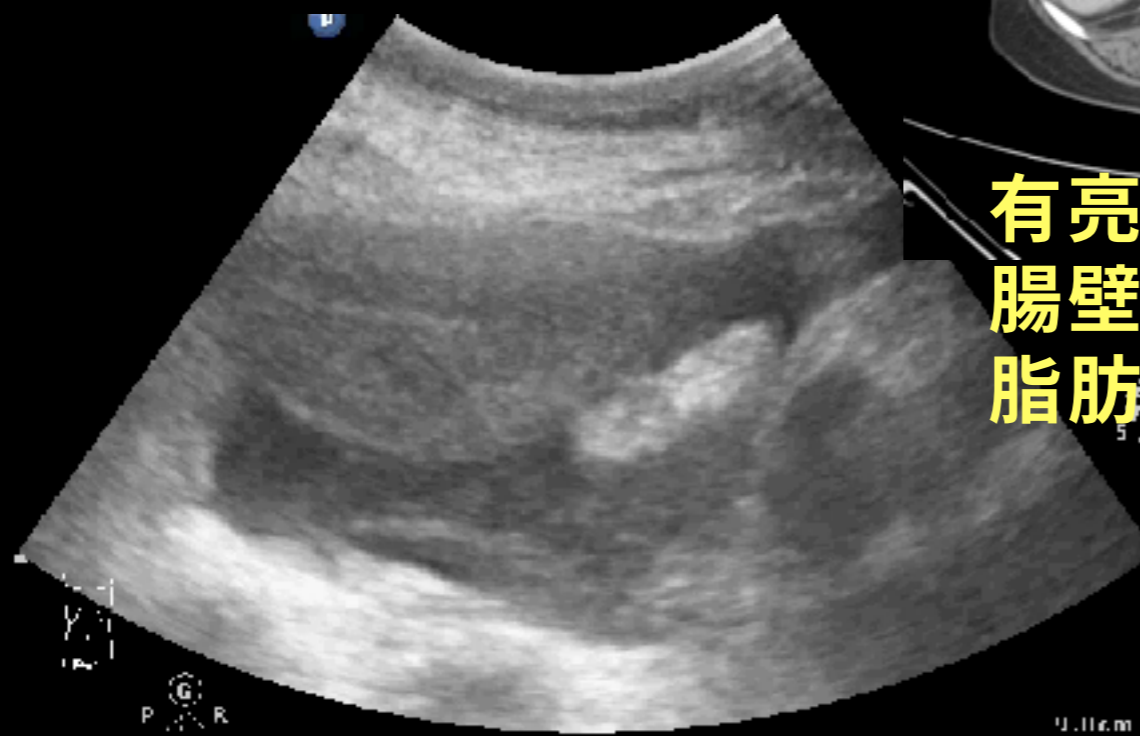# 80F, diffuse abdominal pain

Abd Gen2  
C5-1  
17 Hz  
9.0cm  
2D  
HGen  
Gn 100  
C 56  
3/3/3

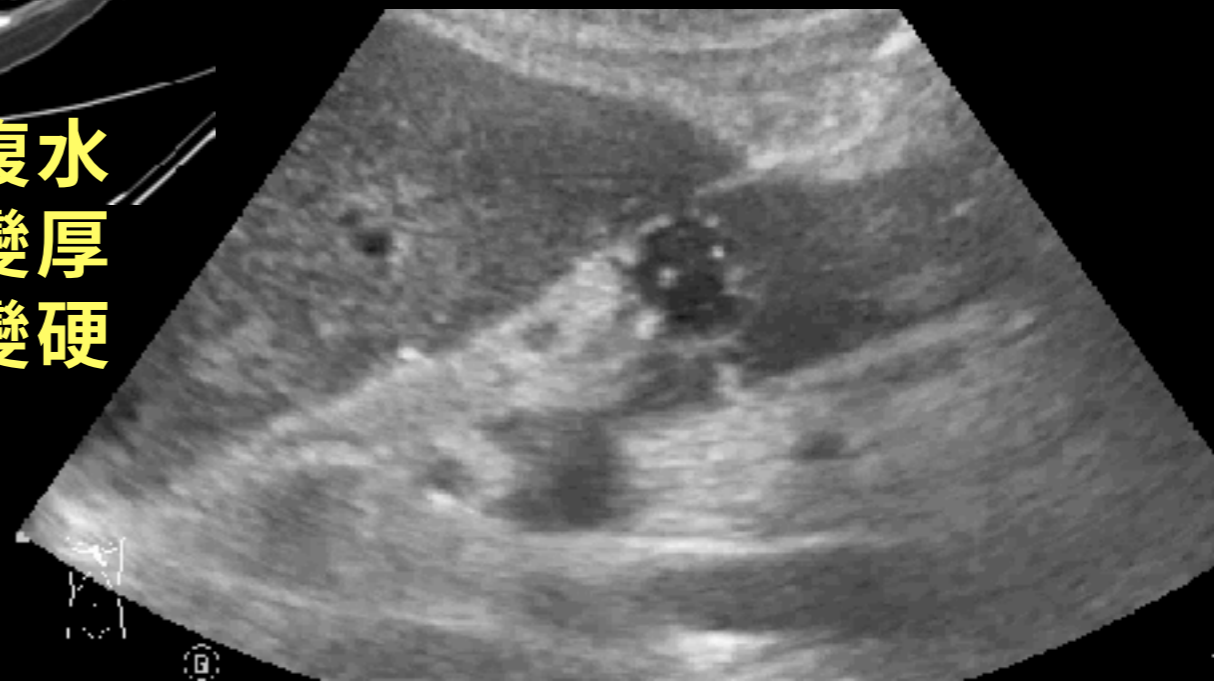


Scissors maneuver

Abd Gen2  
C5-1  
17 Hz  
9.0cm  
2D  
HGen  
Gn 100  
C 56  
3/3/3



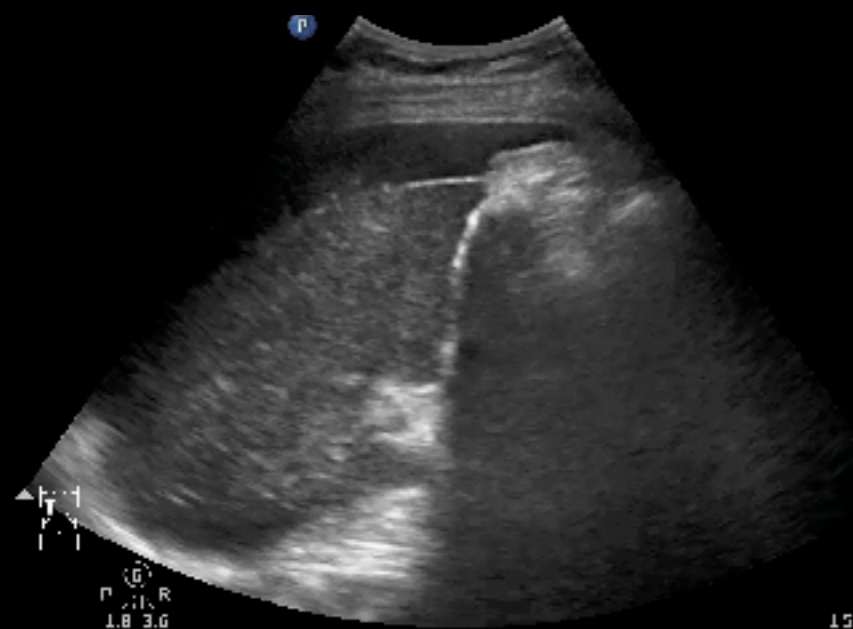
有亮度的腹水  
腸壁異常變厚  
脂肪變亮變硬



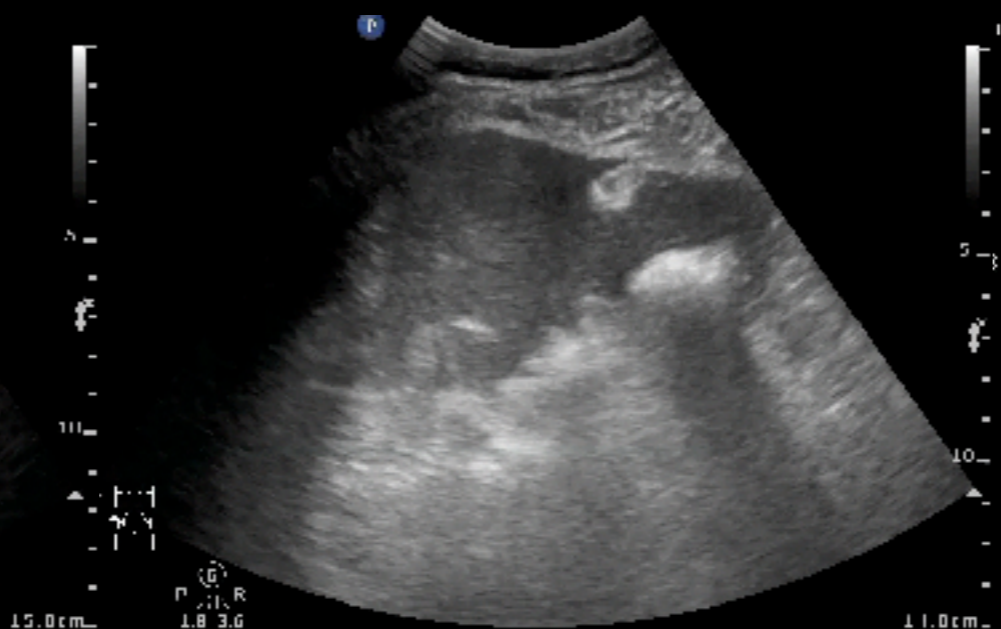

# Dirty ascites: 水往下流

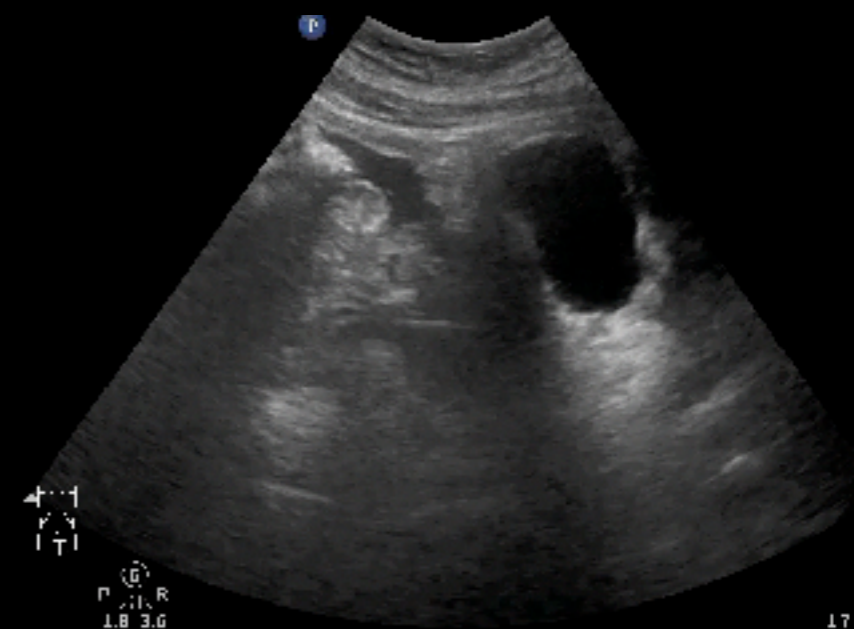
Around liver



Paracolic gutter



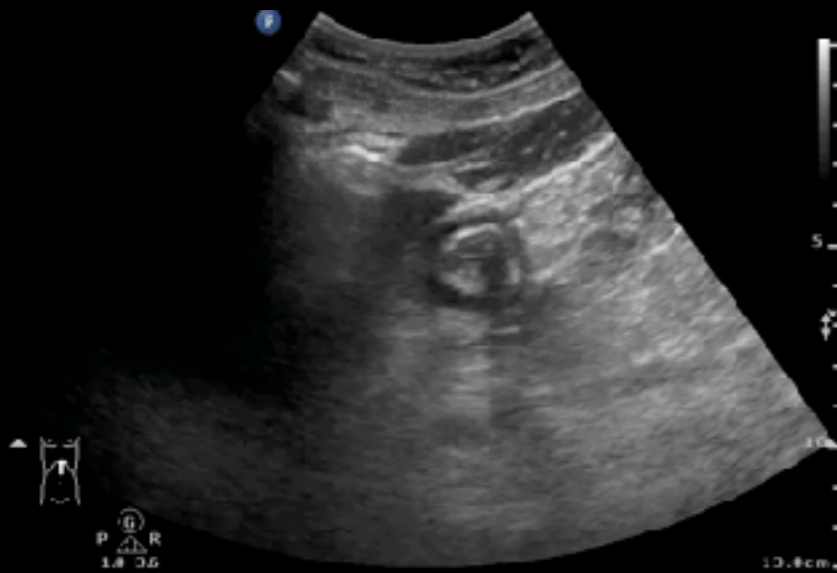Pelvis



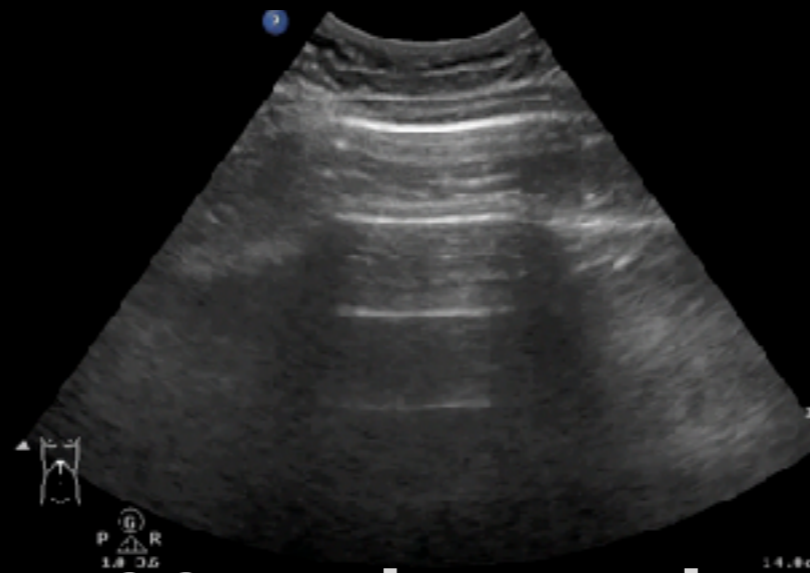
**FAST倒三角是最基本的**

# Free air: 往上找

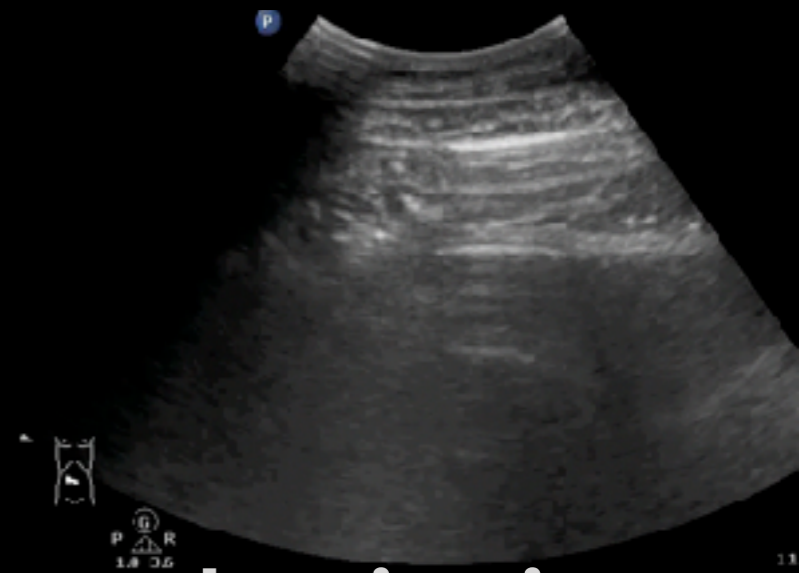Liver surface



Curtain sign



EPSS

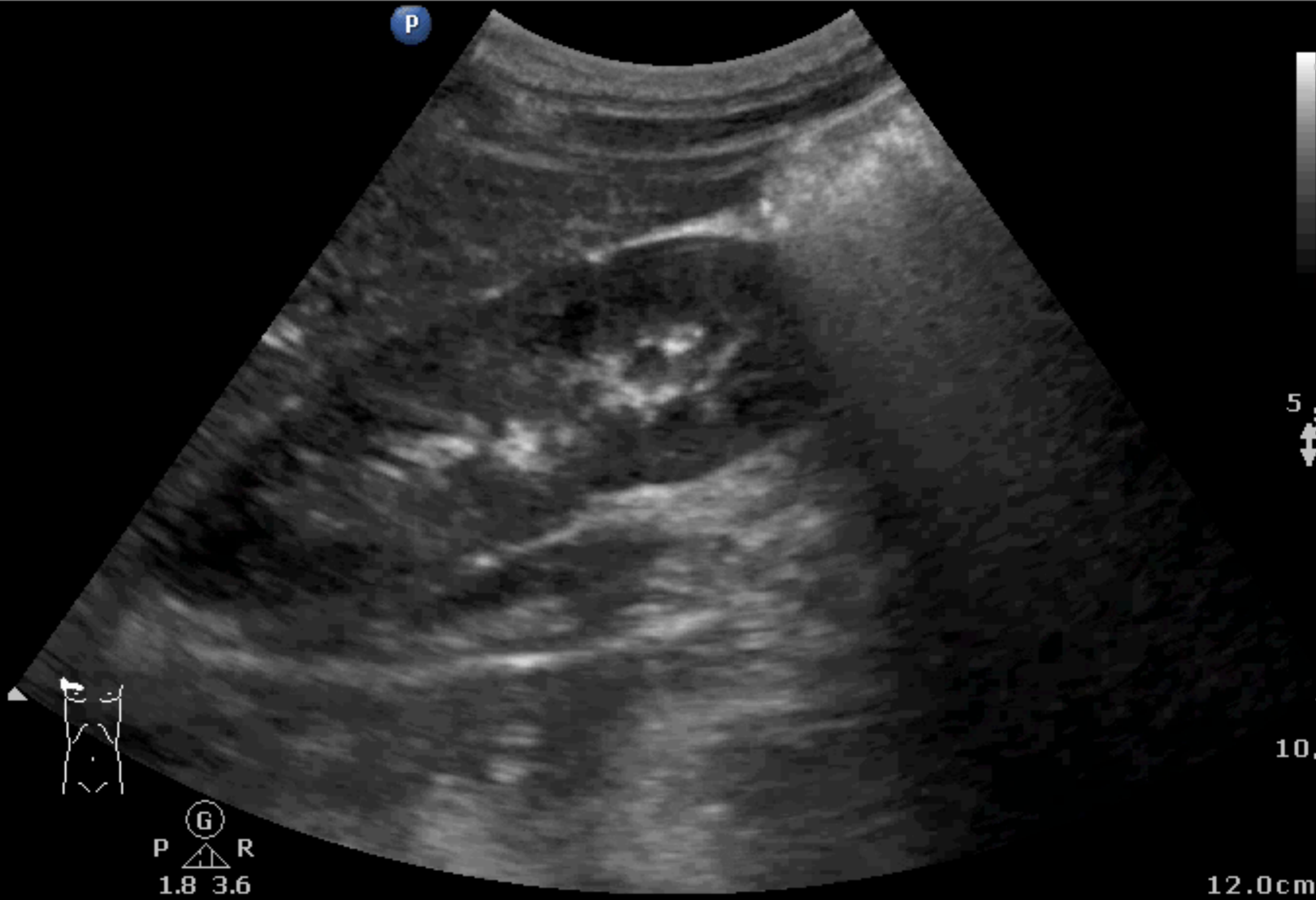


EPSS: Enhanced peritoneal strip sign

游離氣存在界面變亮  
跟肺部的氣胸一個樣  
不要忘了可以壓一壓

# 33F, low abdominal pain & shock

Abd Gen  
C5-1  
39 Hz  
12.0cm  
2D  
HGen  
Gn 71  
C 56  
3/3/3



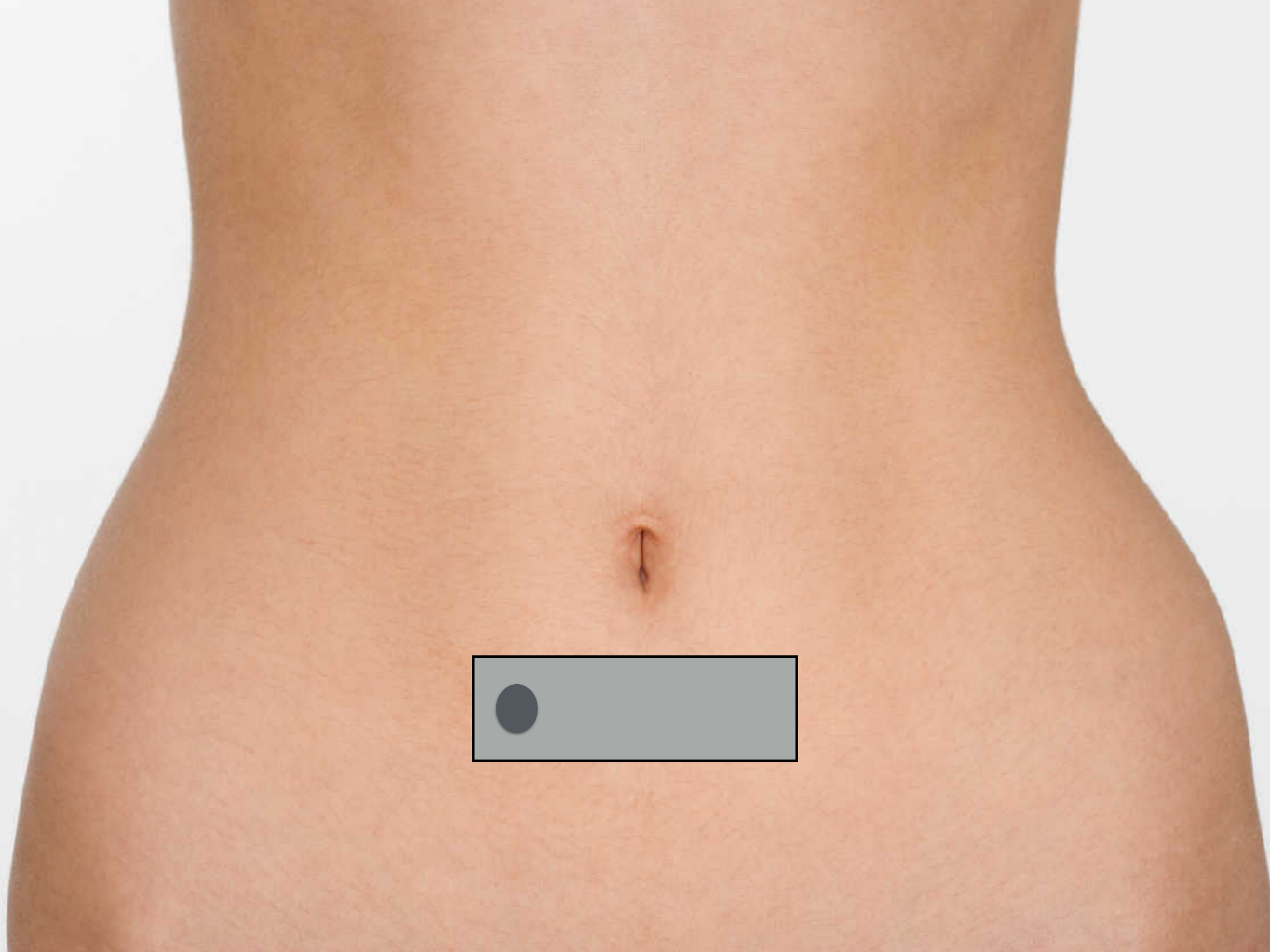


# ABDOMEN

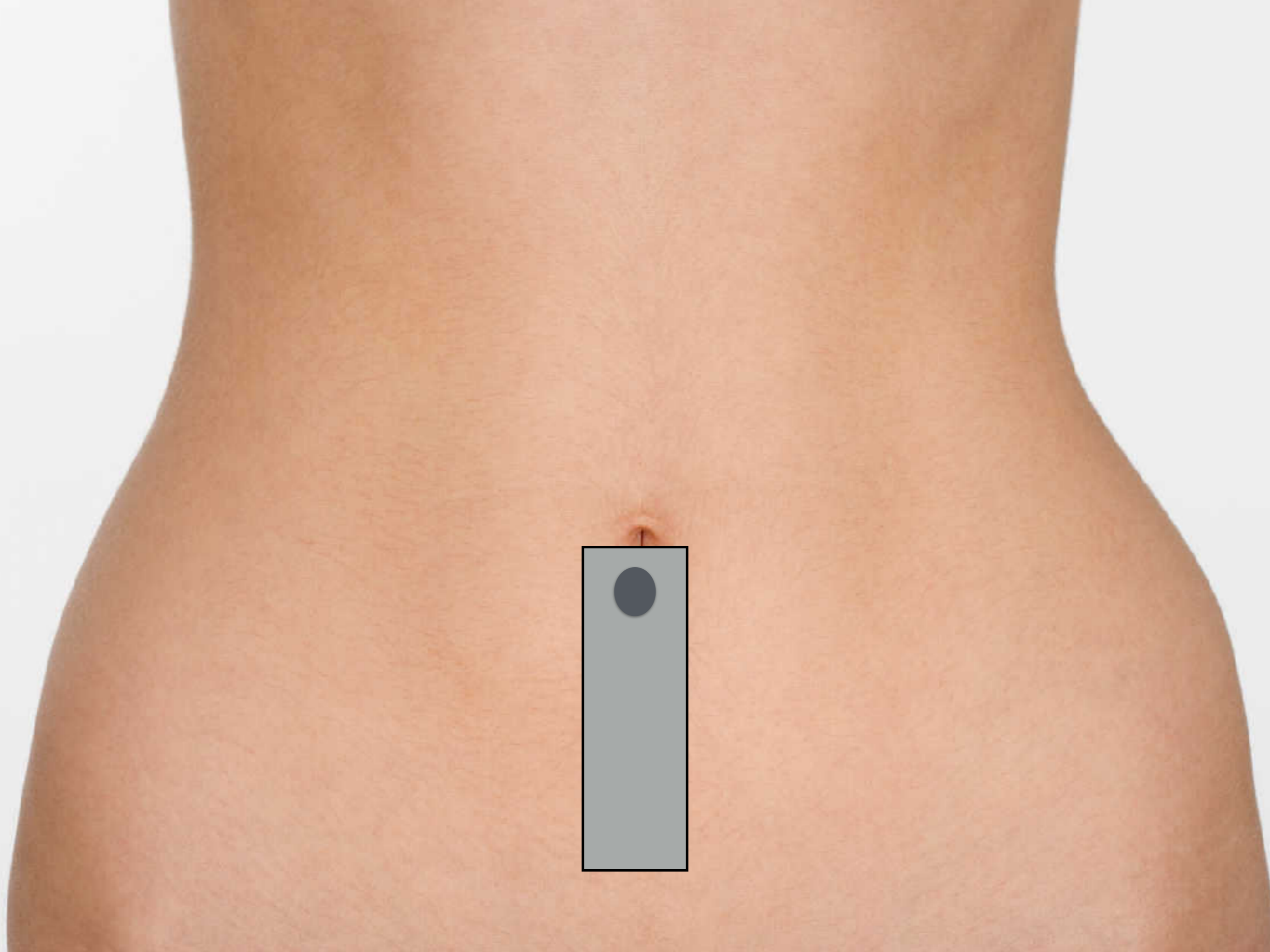
E for ectopic pregnancy

**Ascites & IUUP**

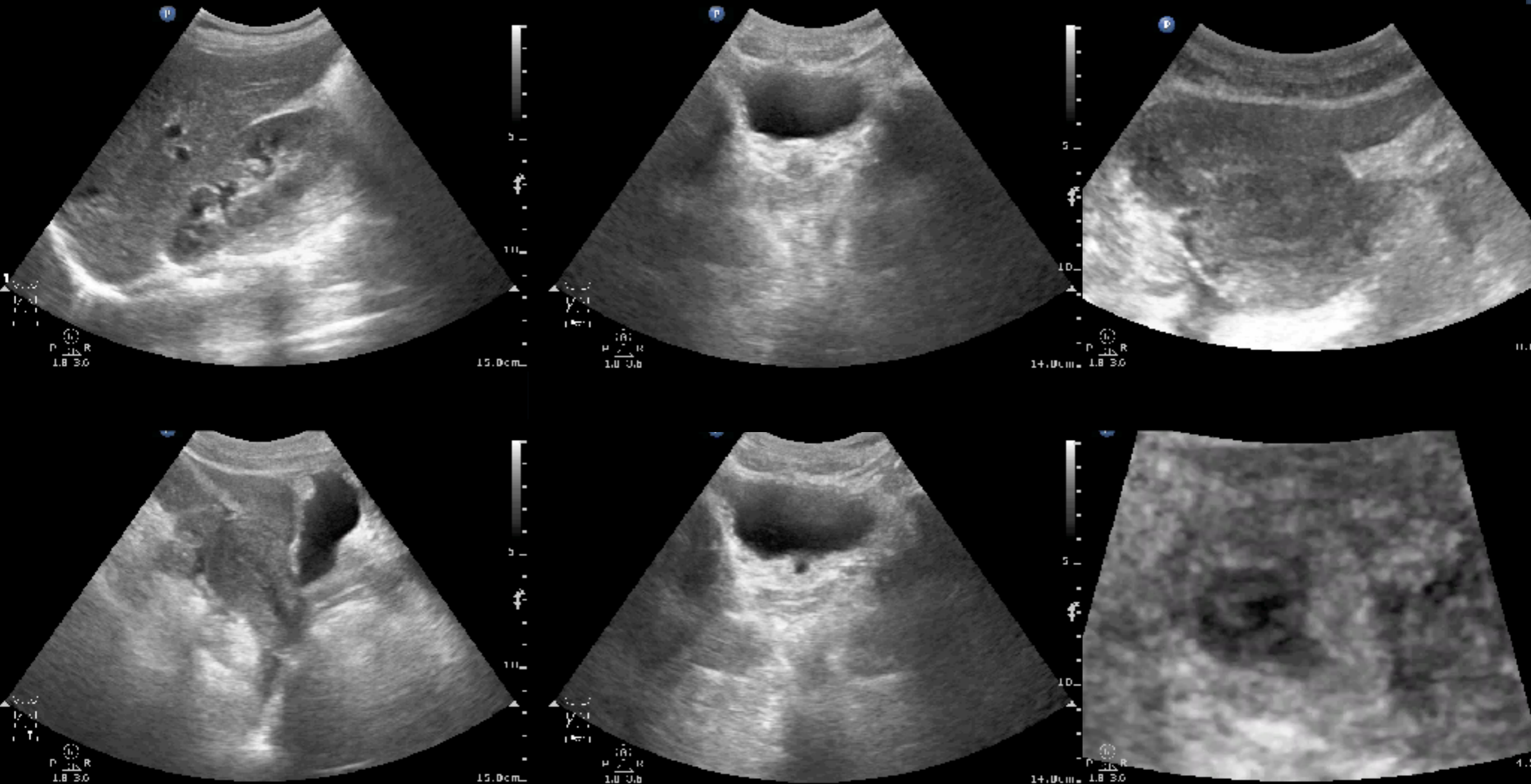








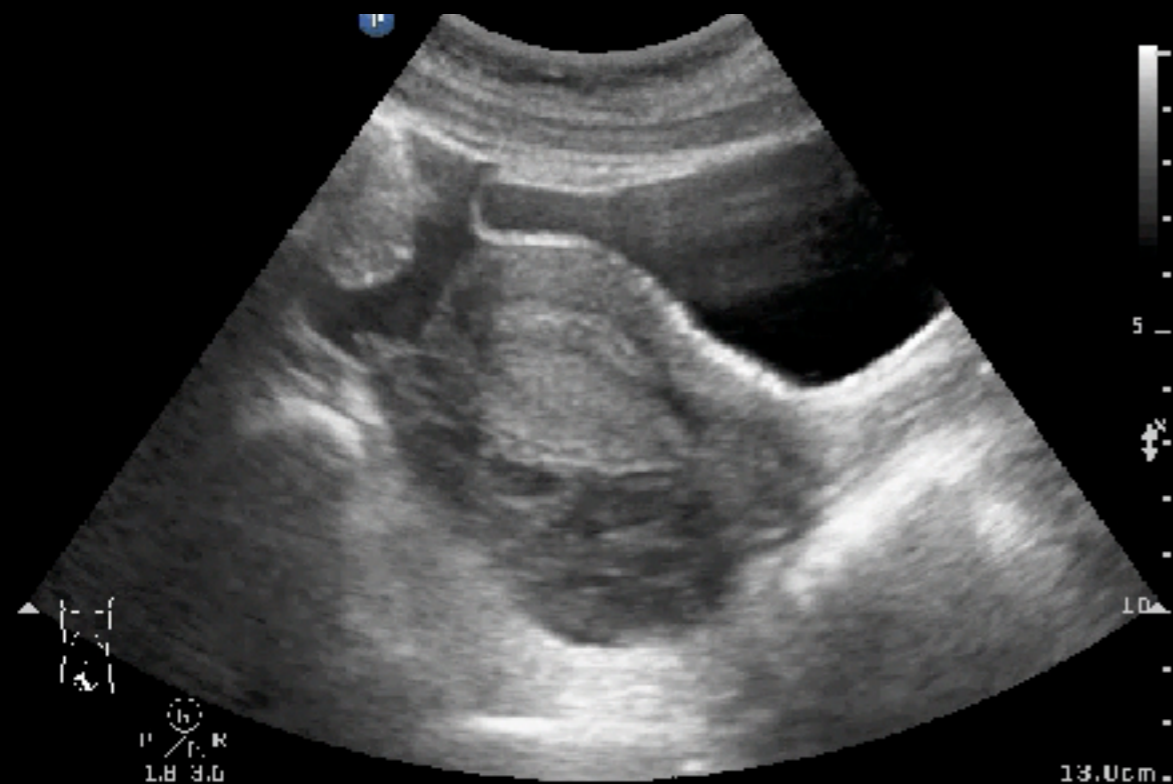
# 25F, abdominal pain



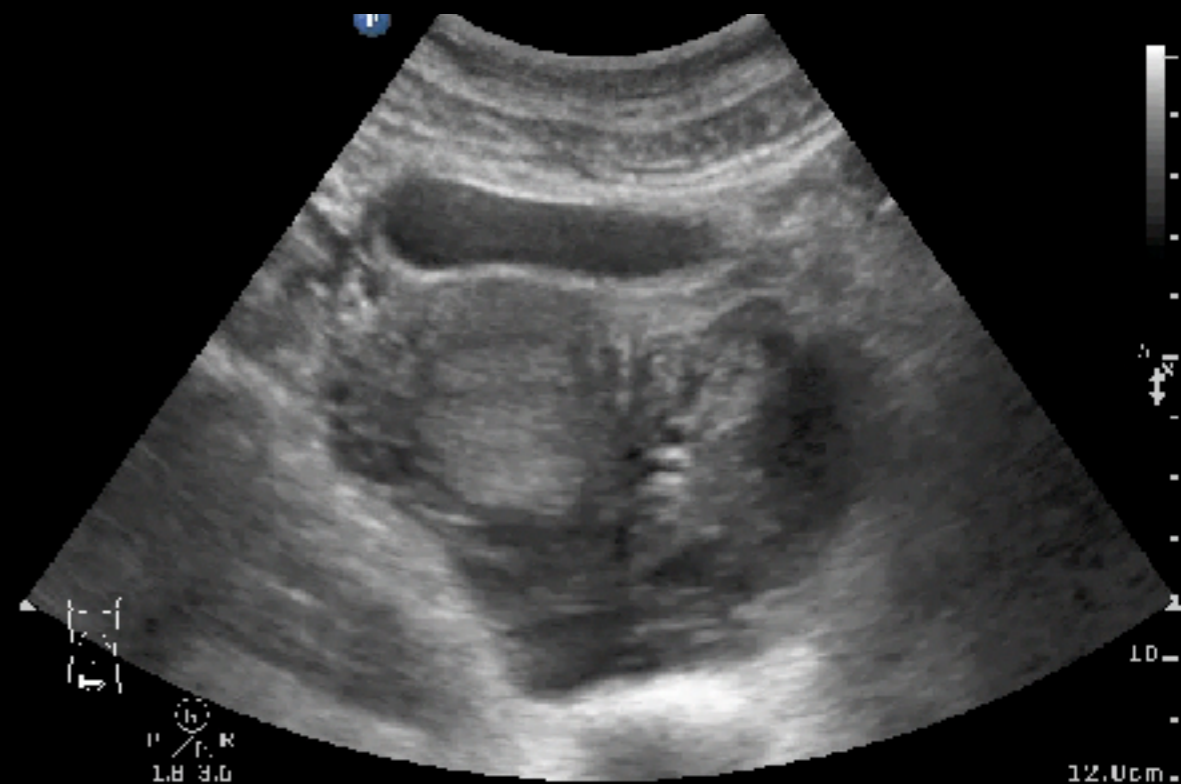
**14F, acute lower abdominal pain with cold sweating**

**Female acute abdomen or shock consider **ovarian cyst rupture****

Abd Gen  
[15 1  
38 Hz  
13.0cm  
2D  
11Gen  
[in 7/8  
[1 56  
3/3/3



Abd Gen  
[15 1  
39 Hz  
12.0cm  
2D  
11Gen  
[in 7/8  
[1 56  
3/3/3



**Echo first** then Urine pregnancy test

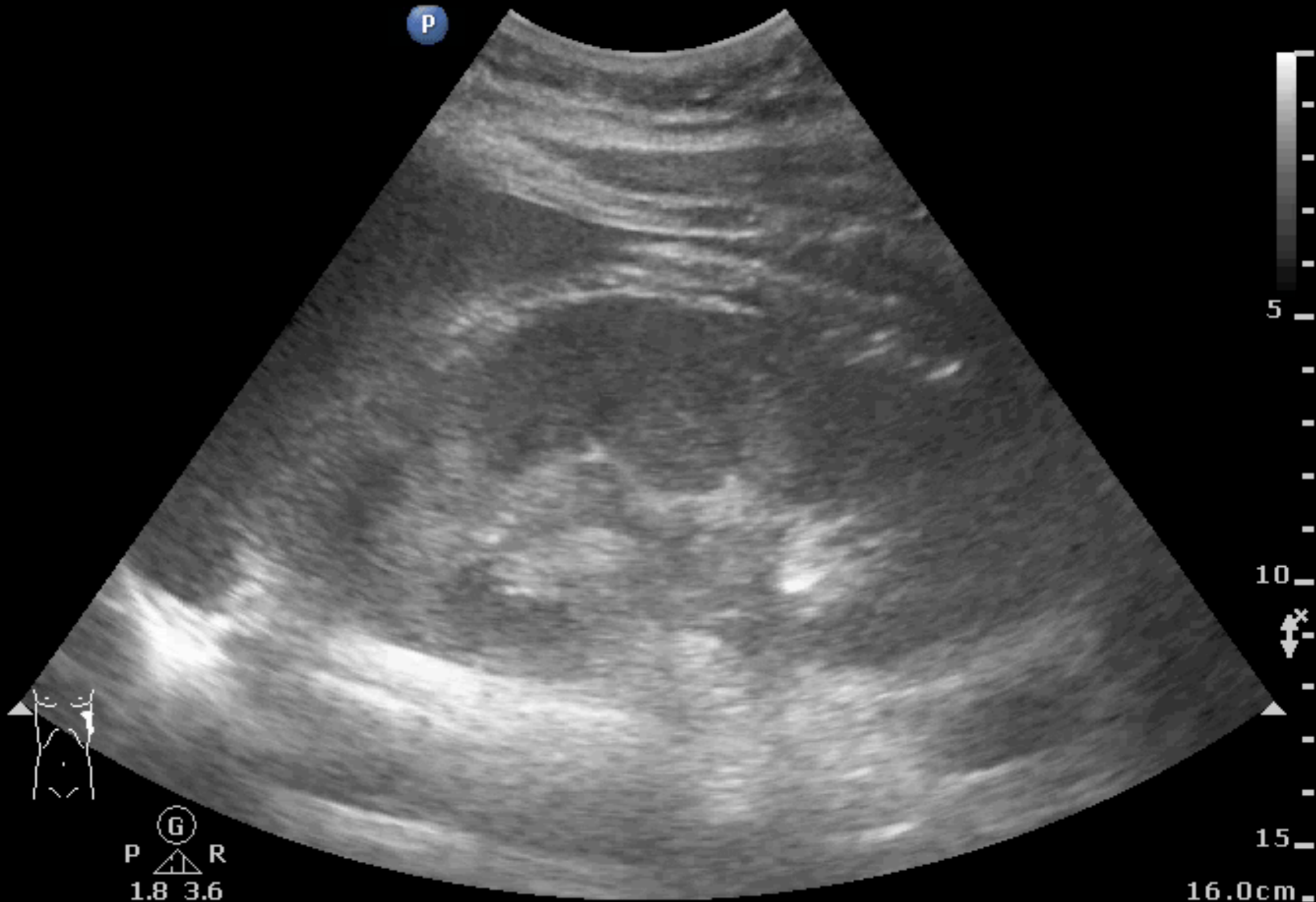

# 25M, left flank pain

Abd Gen2  
C5-1  
32 Hz  
16.0cm

2D

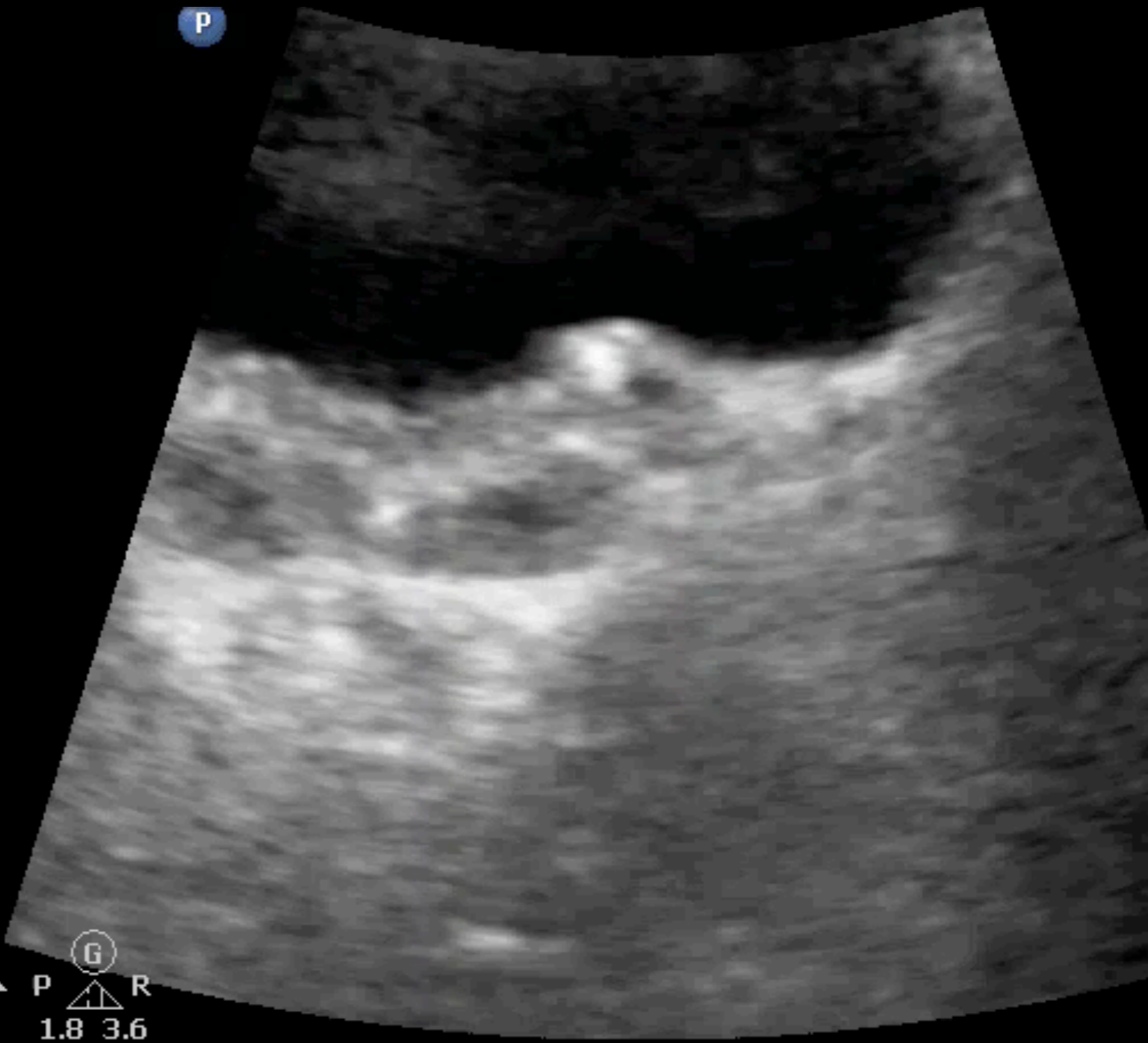
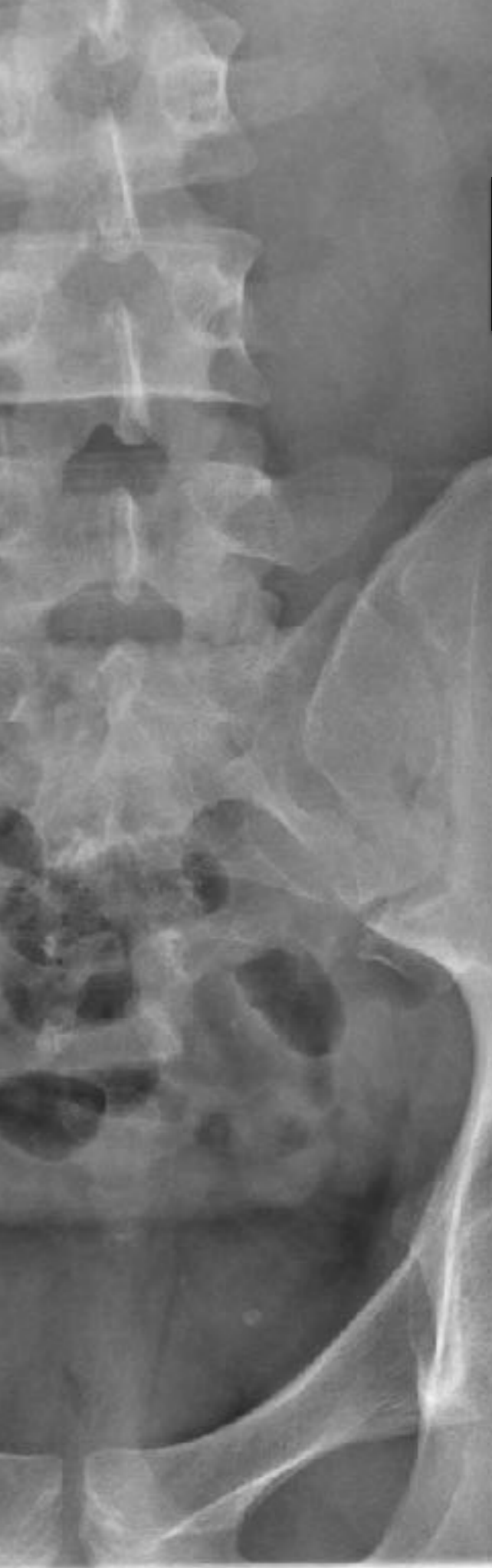
HGen  
Gn 93  
C 56  
3/3/3



# L UJV stone

Abd Gen2  
C5-1  
73 Hz  
HD Zoom

2D  
HGen  
Gn 58  
C 56  
3 / 3 / 3



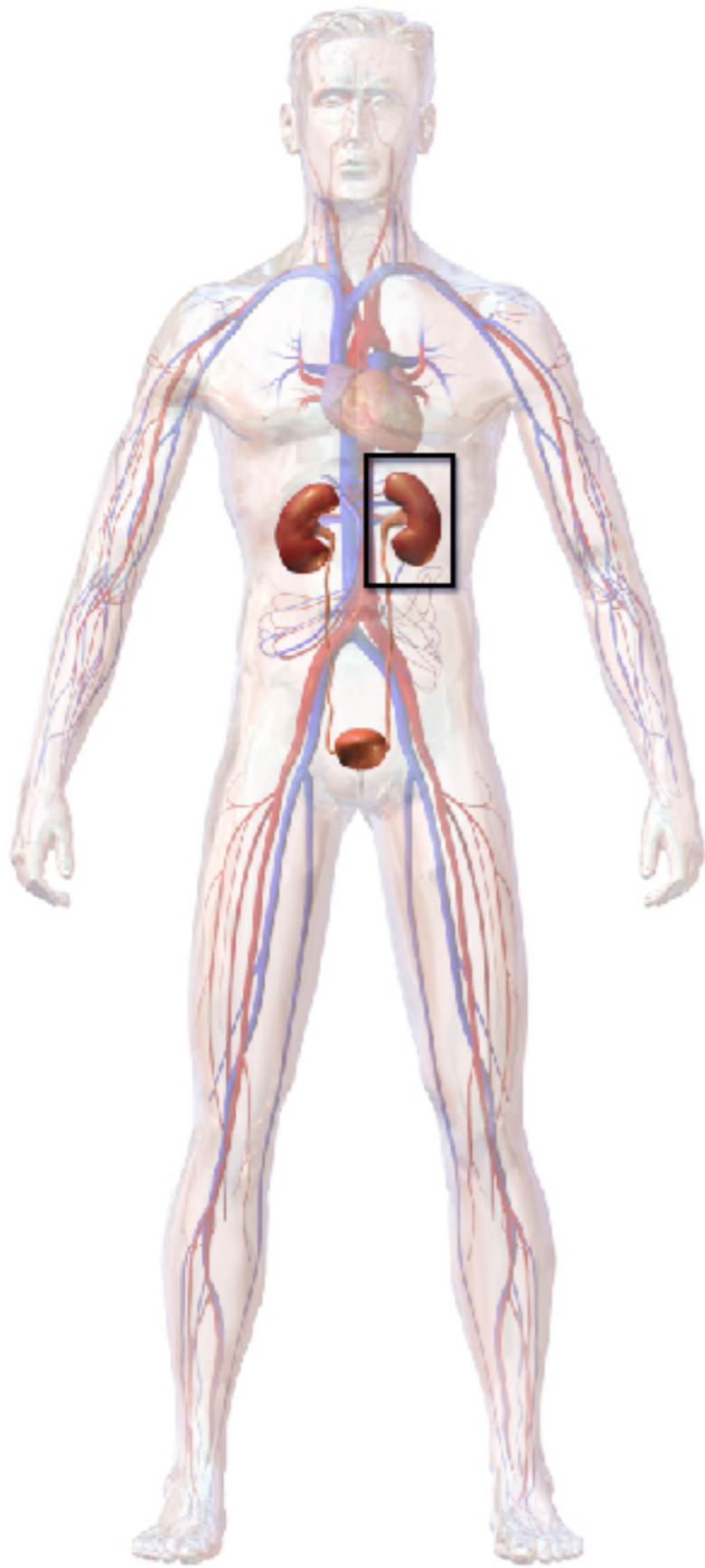
▲ P R  
1.8 3.6

**ABDOMEN**

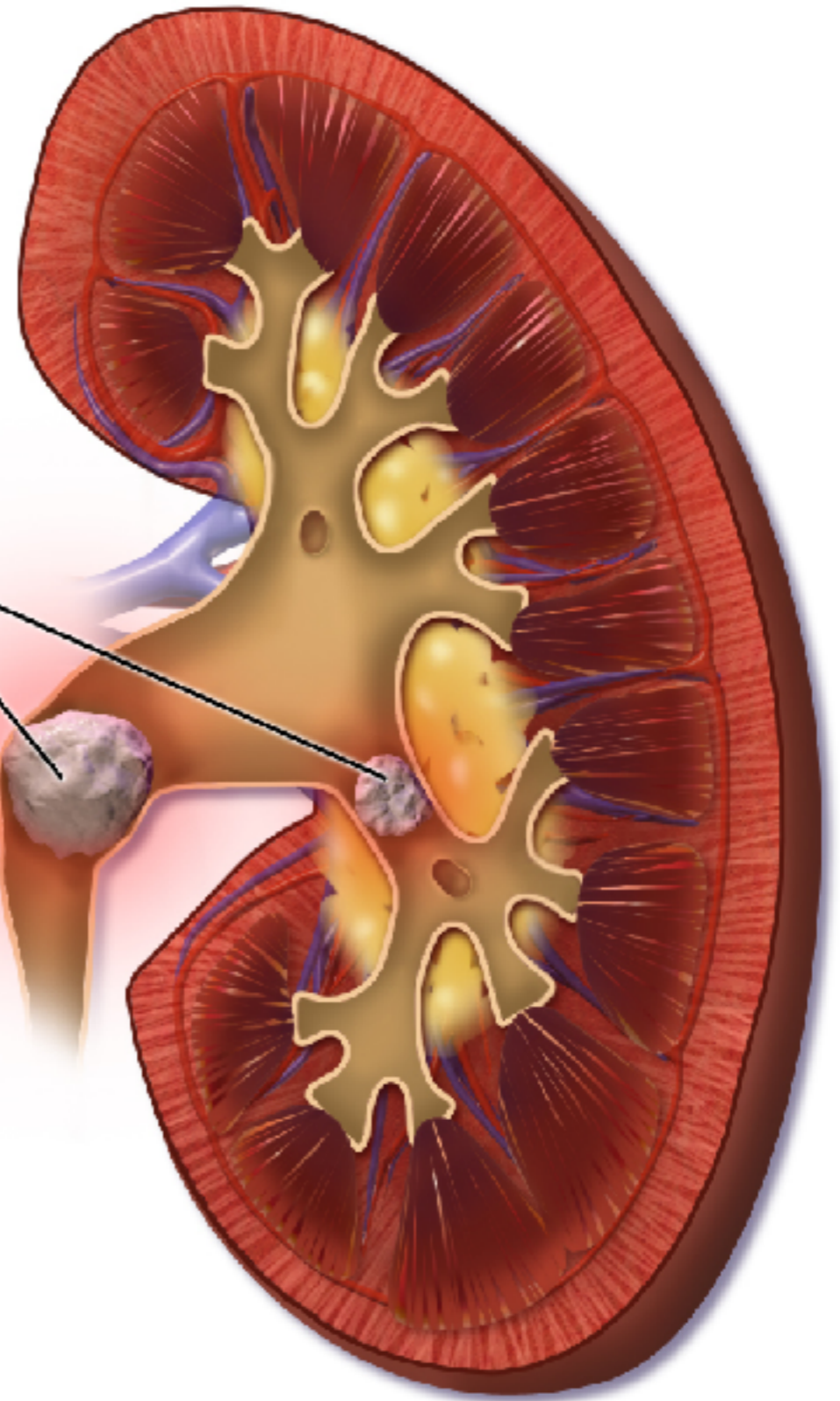
**N for nephropathy**

**Hydronephrosis & KuB**



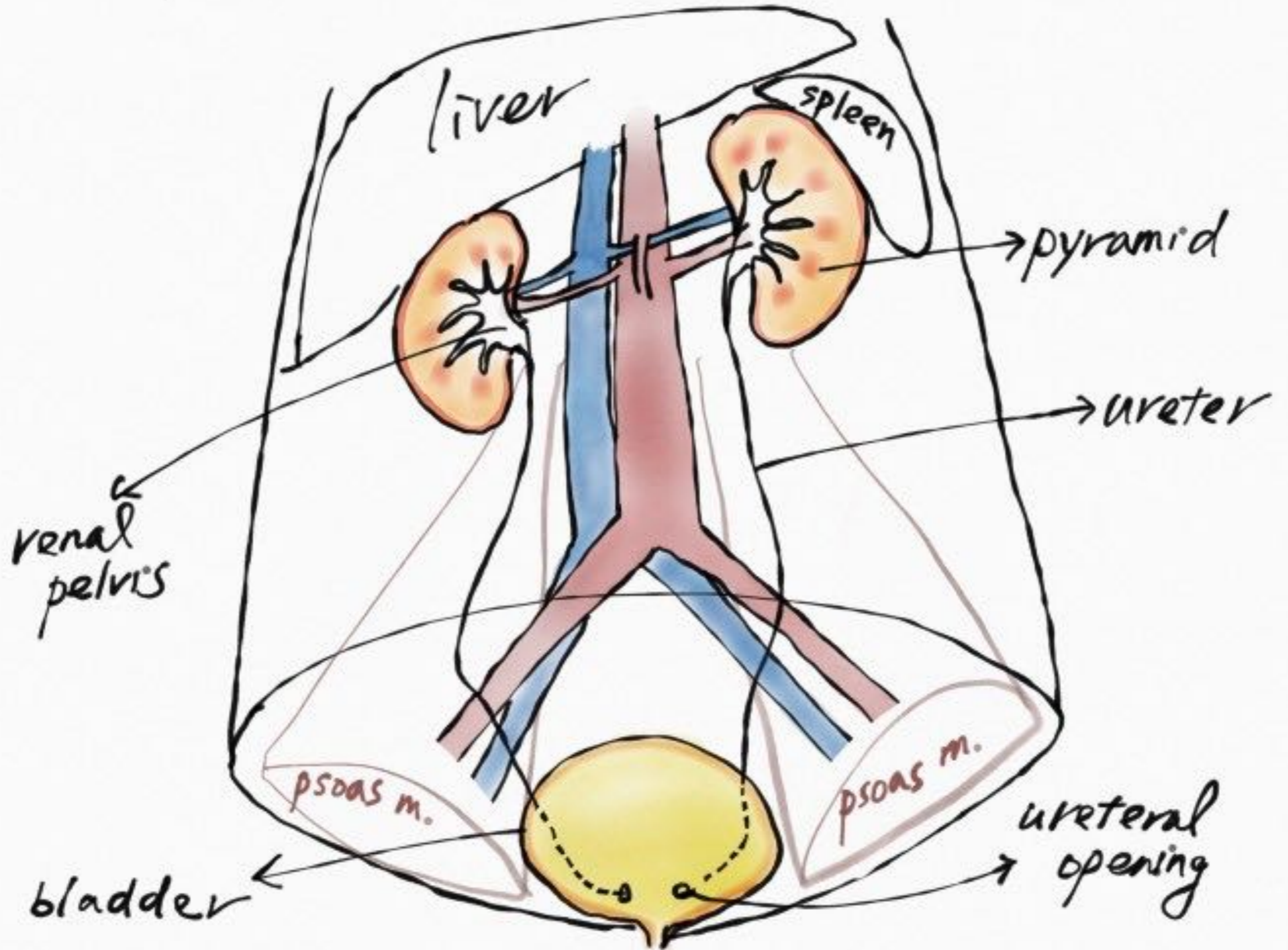


Kidney stones




# Kidney Stones

Copyright © 2016 HSU CHZ CHAN ET. All rights reserved







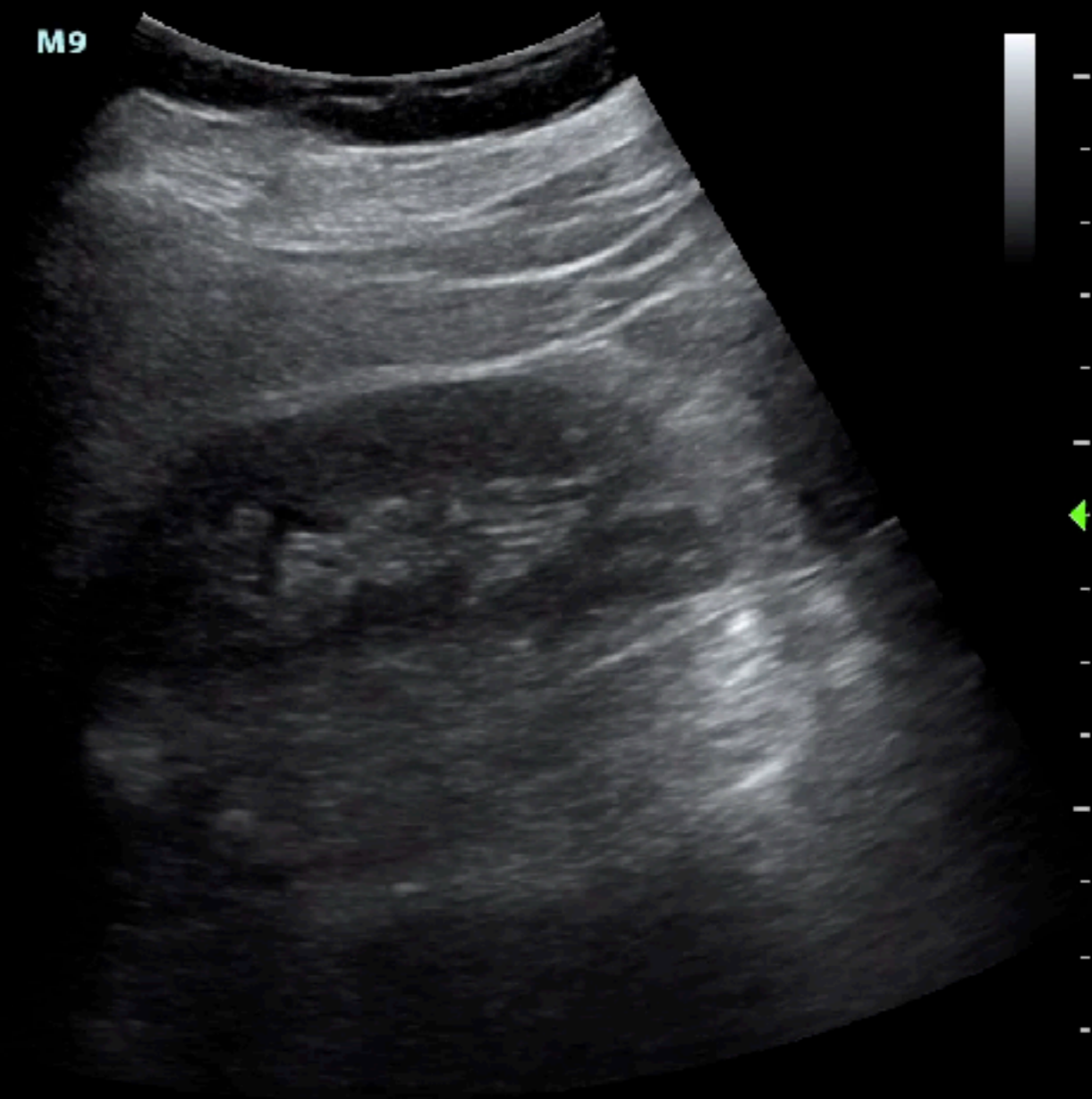
13-03-2016 16:07:02

20160313-150601-3DA3

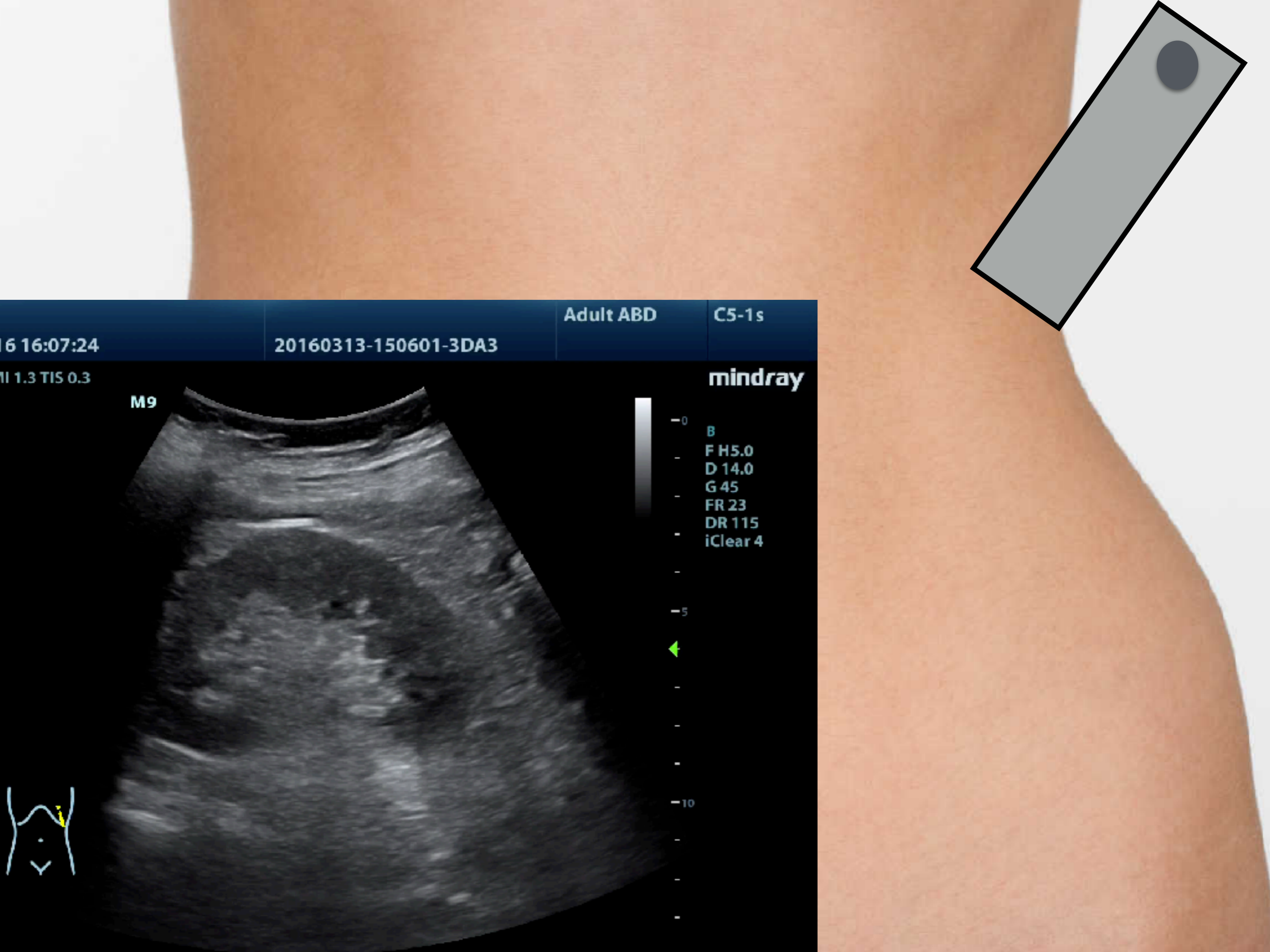
Adult ABD

AP 96.6% MI 1.3 TIS 0.3

M9







16 16:07:24      20160313-150601-3DA3      Adult ABD      C5-1s

MI 1.3 TIS 0.3      **mindray**

M9

-0  
B  
F H5.0  
D 14.0  
G 45  
FR 23  
DR 115  
iClear 4

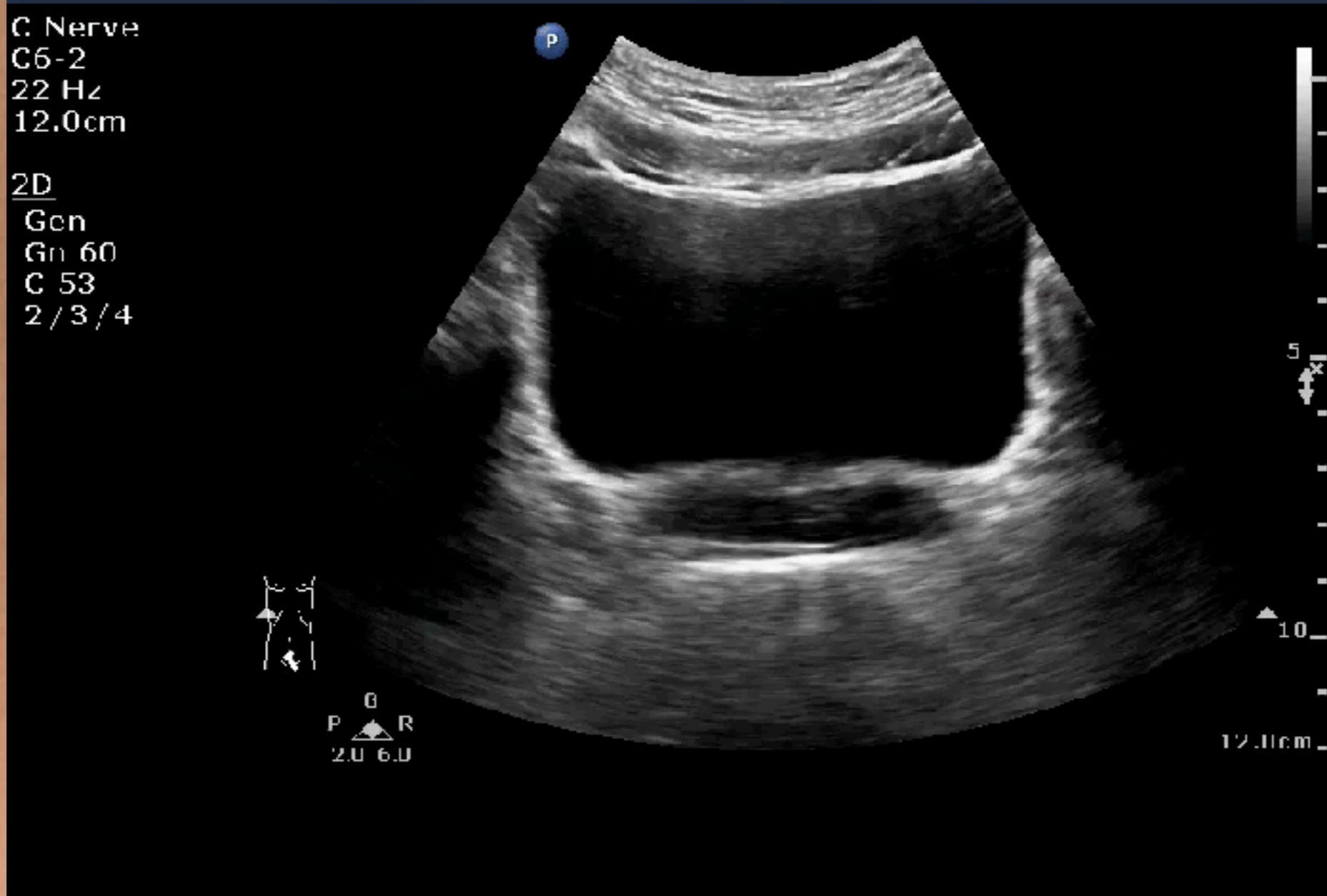
-5

-10




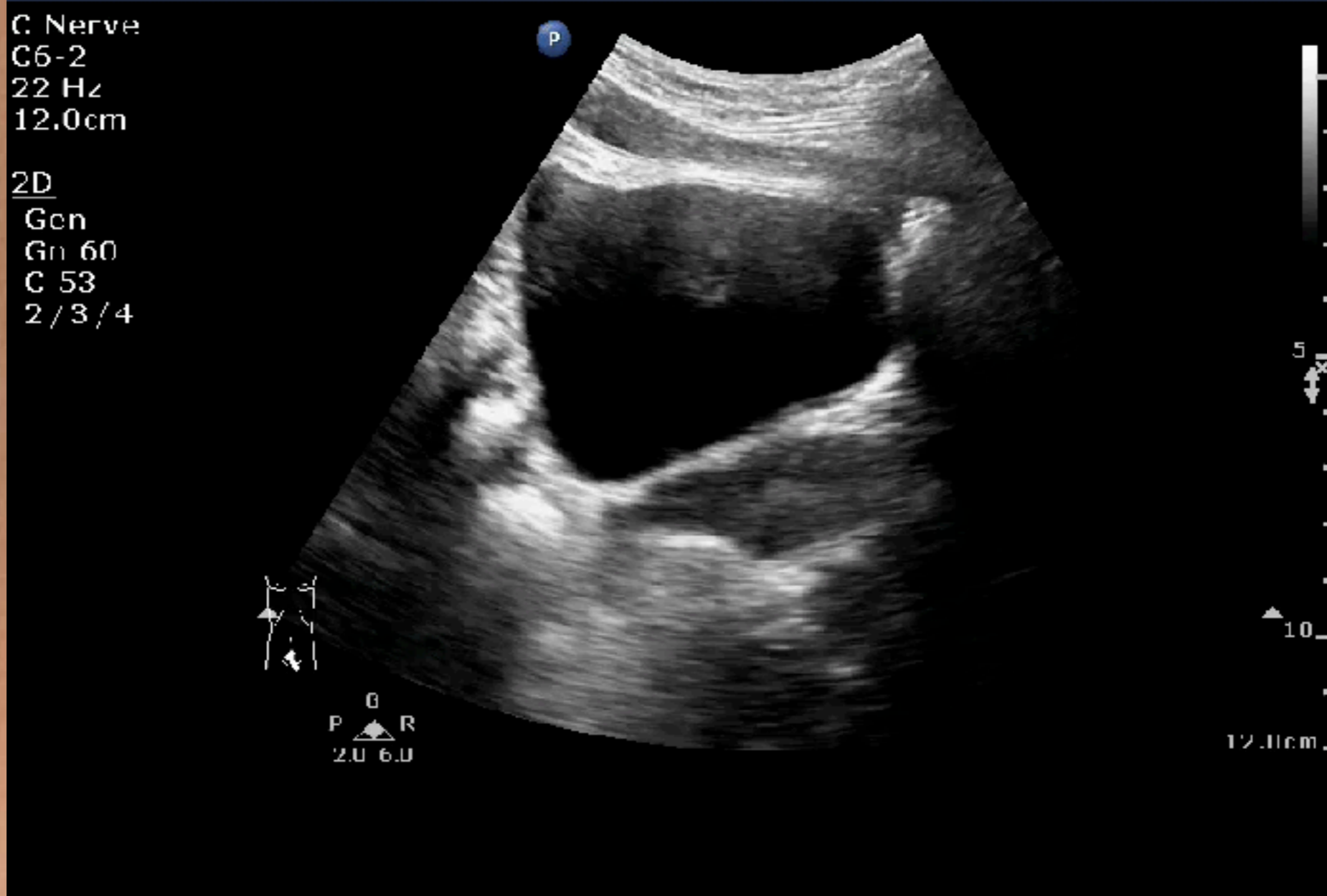
C. Nerve  
C6-2  
22 Hz  
12.0cm

2D  
Gen  
Gn 60  
C 53  
2/3/4



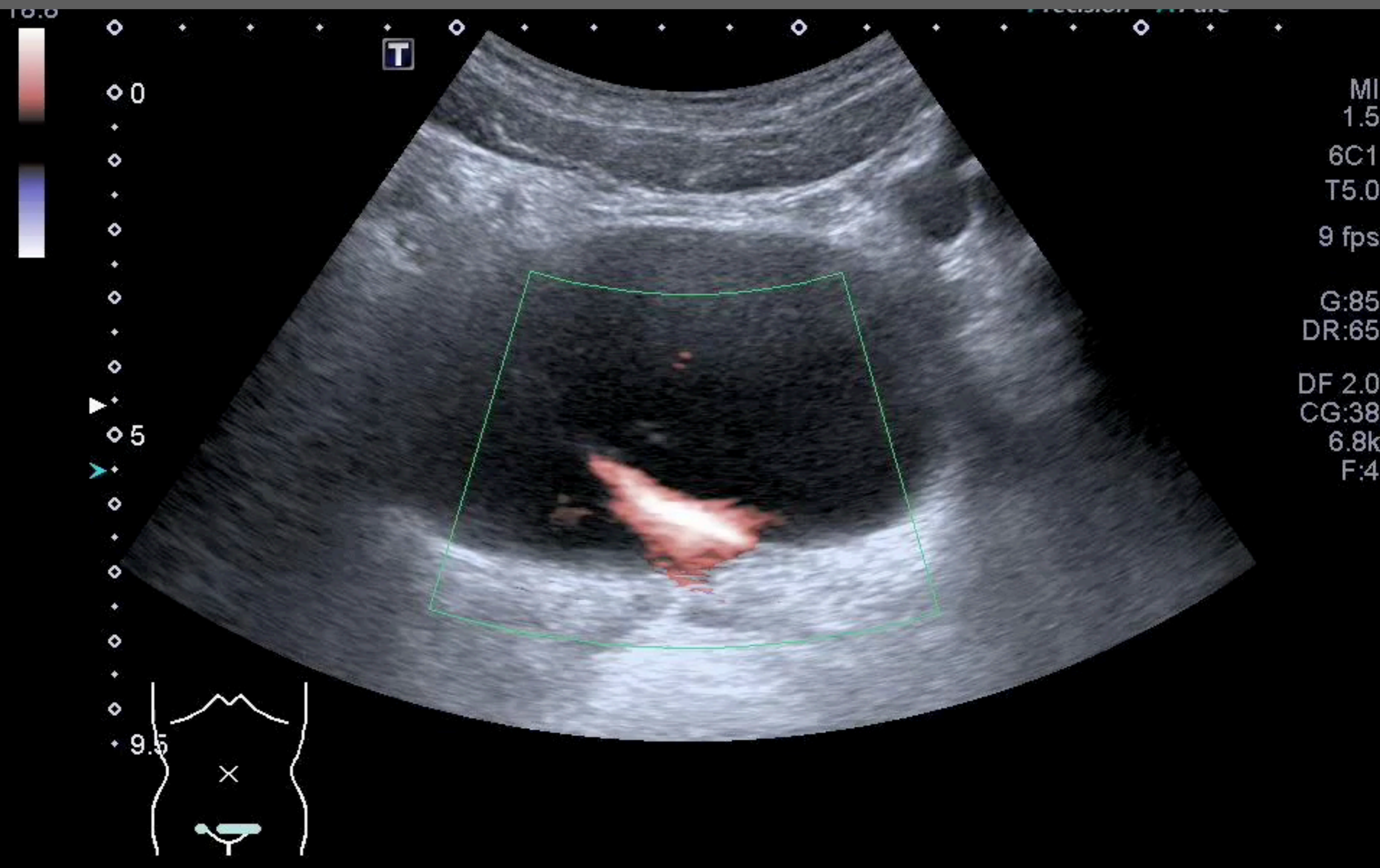
C. Nerve  
C6-2  
22 Hz  
12.0cm

2D  
Gen  
Gn 60  
C 53  
2 / 3 / 4



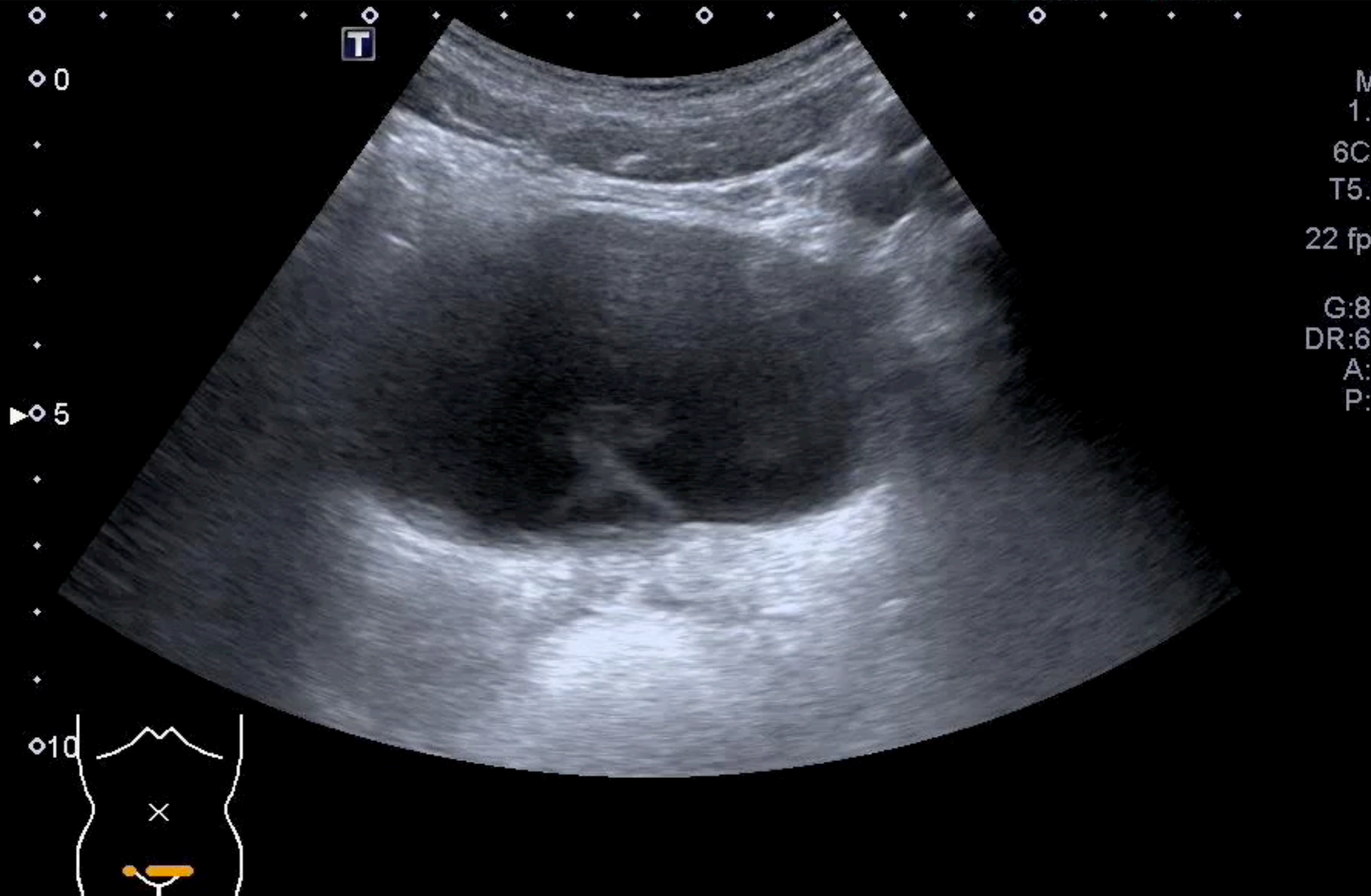


# Urinary jet





# Urinary jet



# When will you use US for GU emergency?

**Pain**

**Infection**

**Failure**

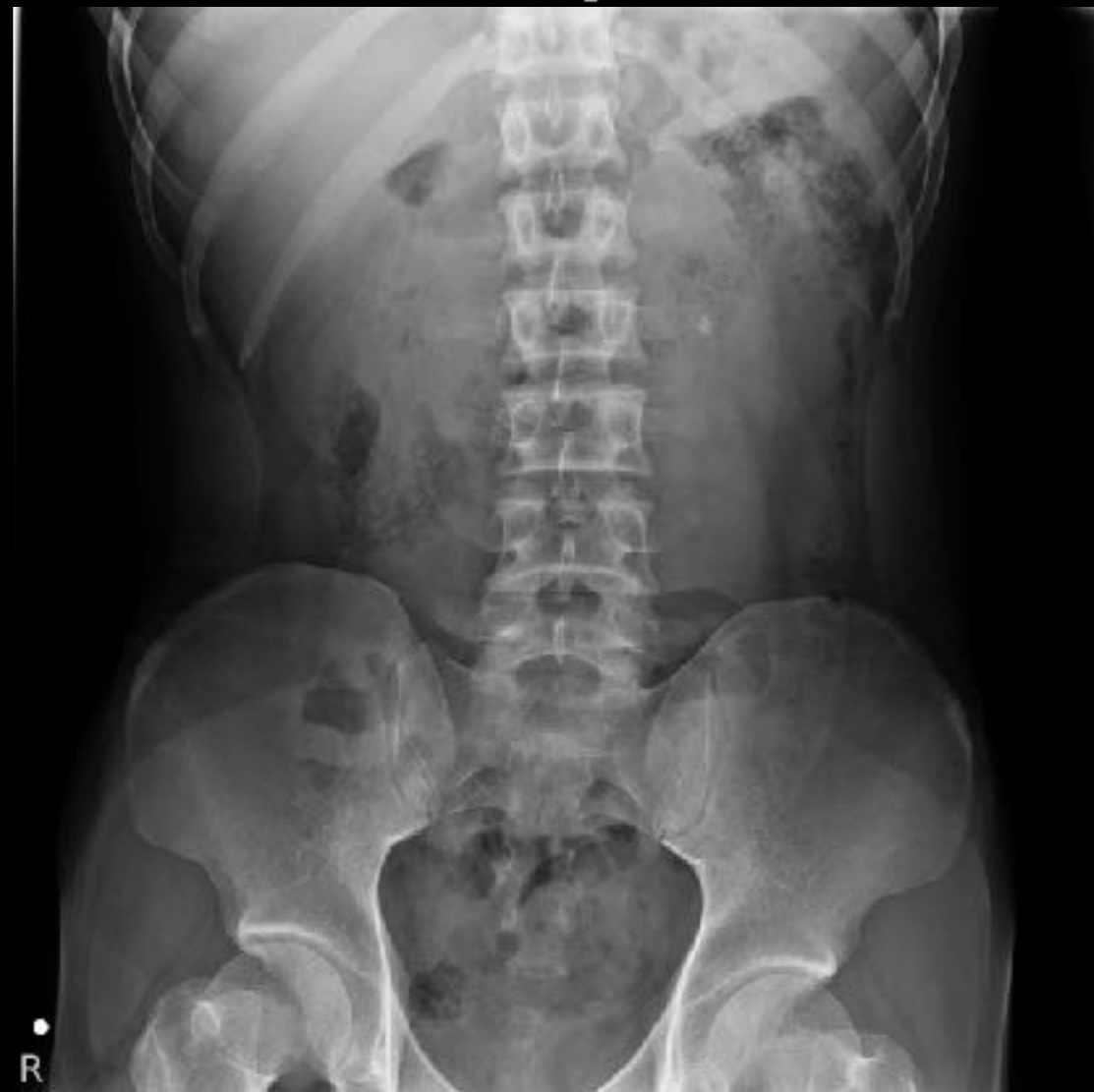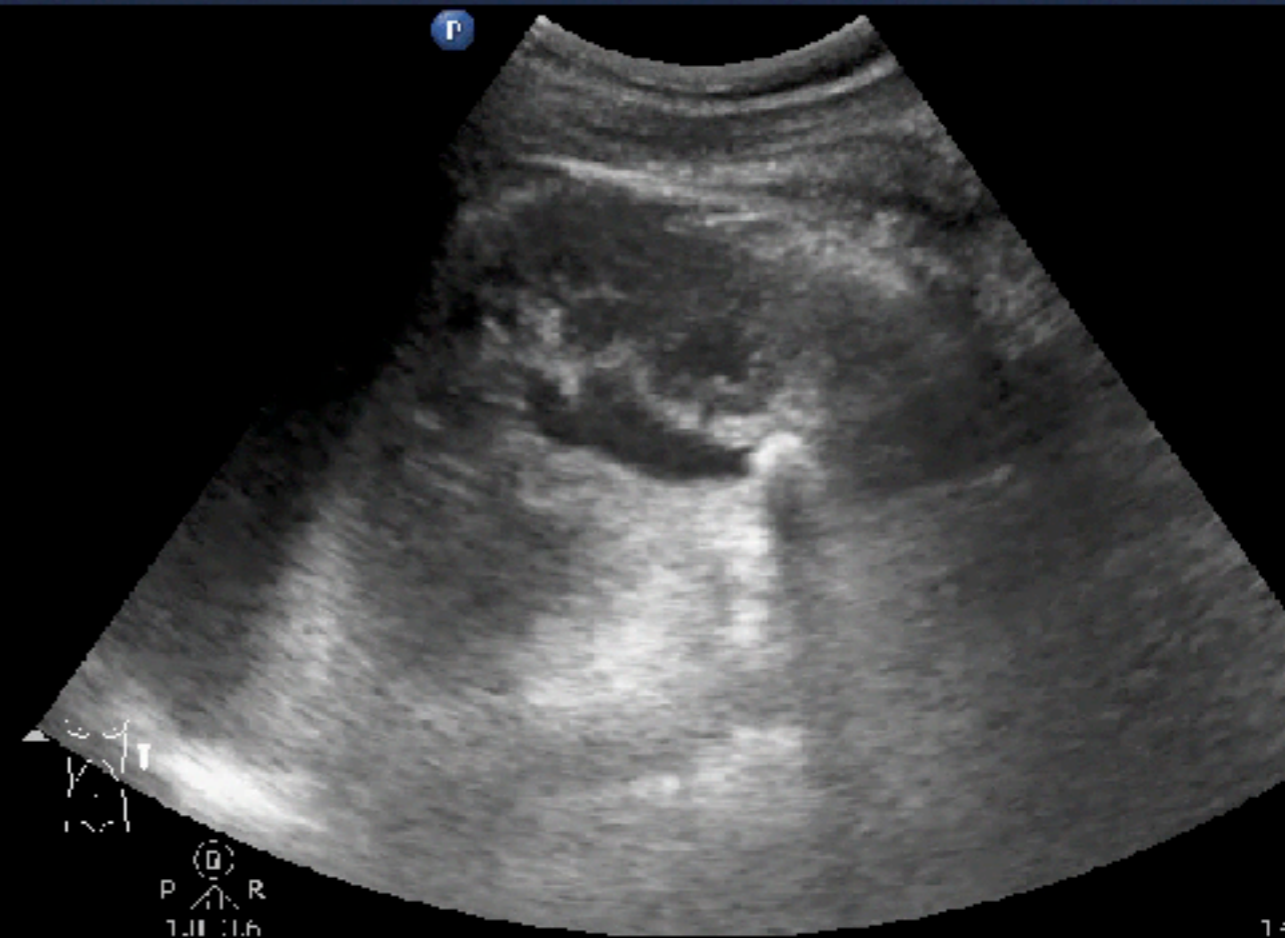
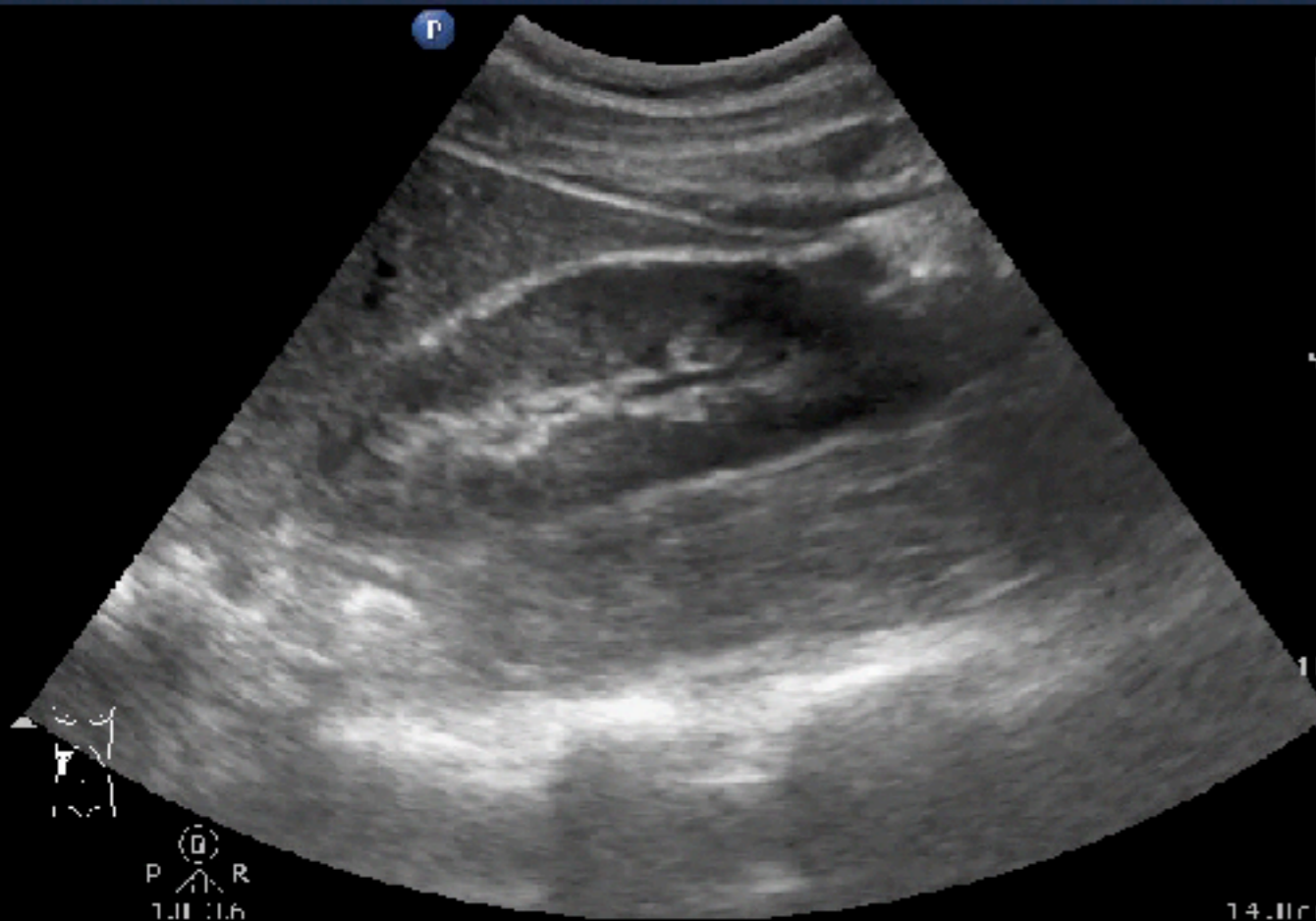


# GU emergency

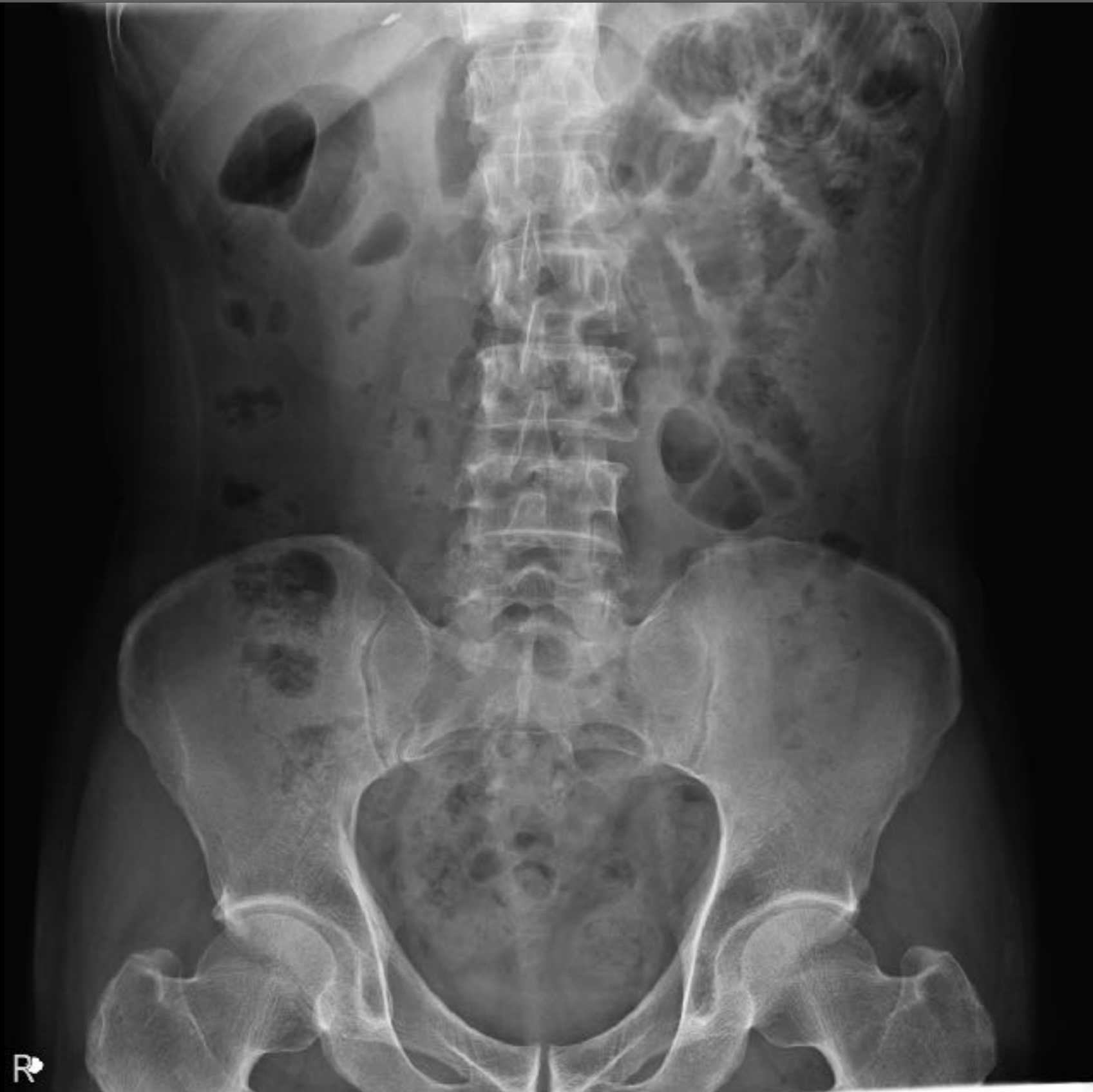**POCUS first**

or

**Urine first**



# 54M, right flank/abd pain

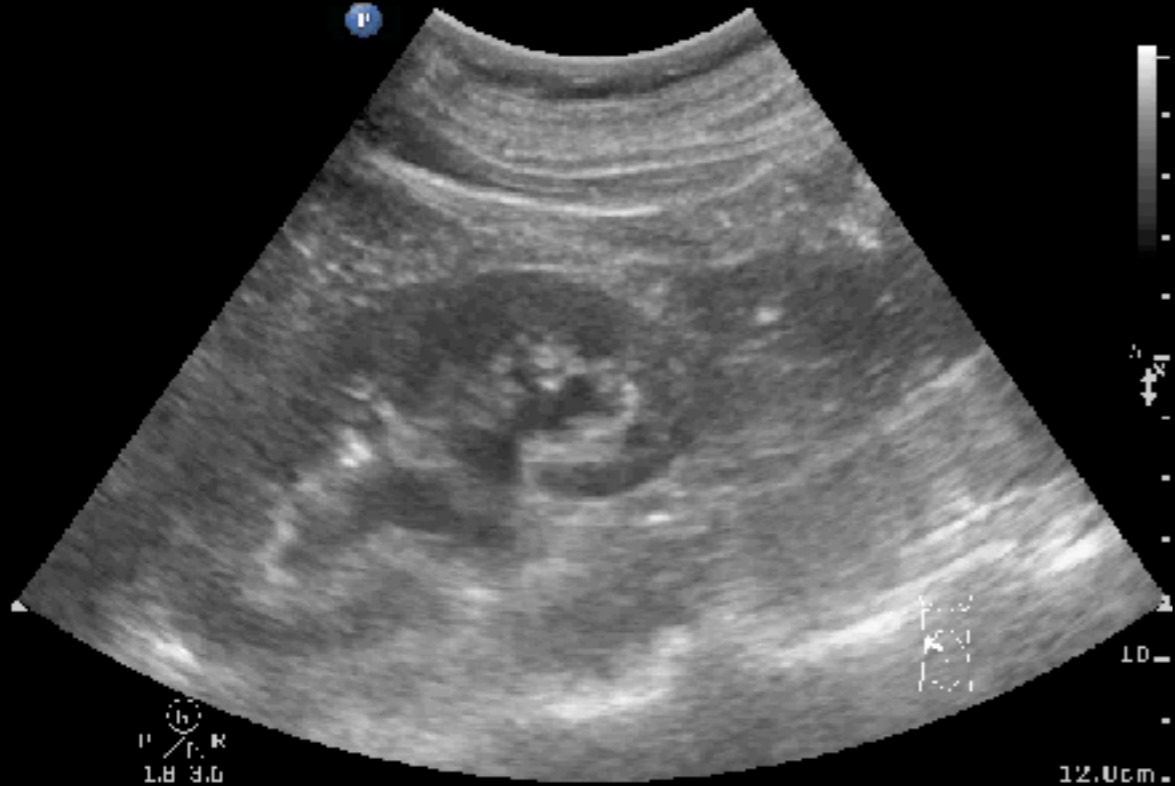




# 54M, right flank/abd pain

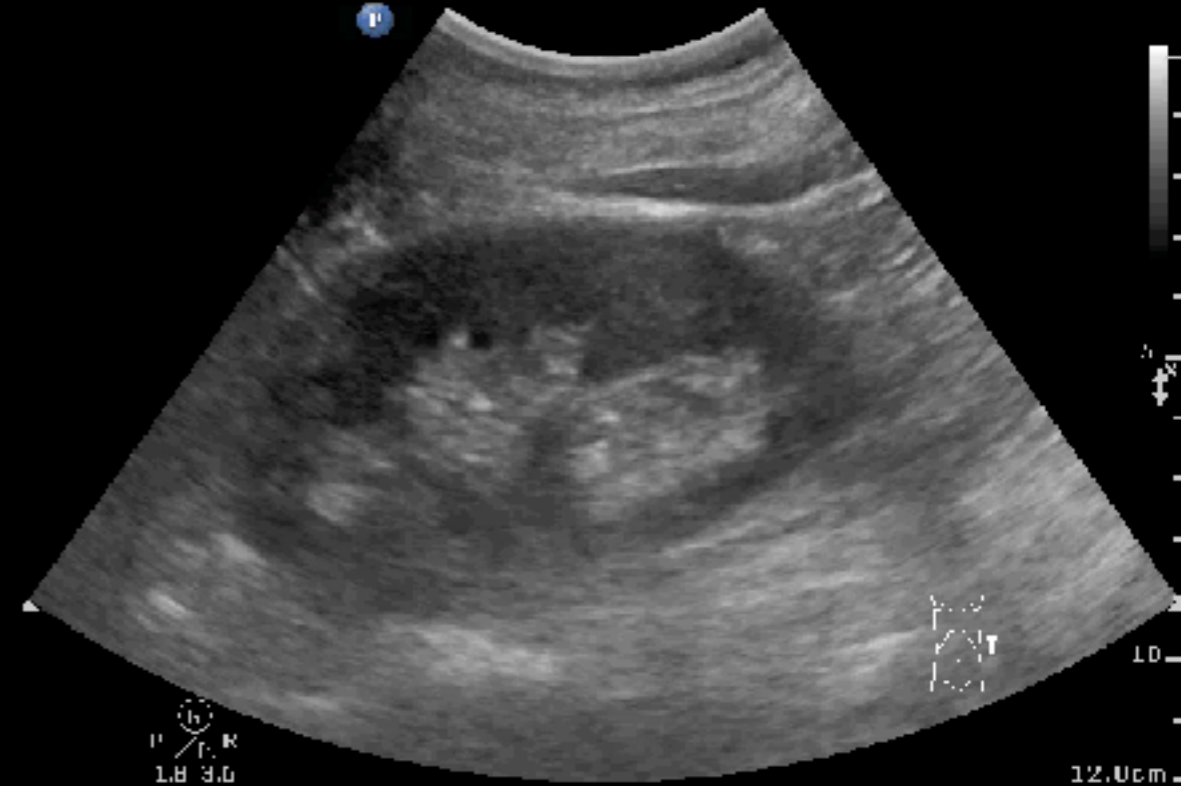Abd Gen2  
11.5 1  
39 Hz  
12.0cm

2D  
11Gen  
11.5 1  
11.55  
3/3/3

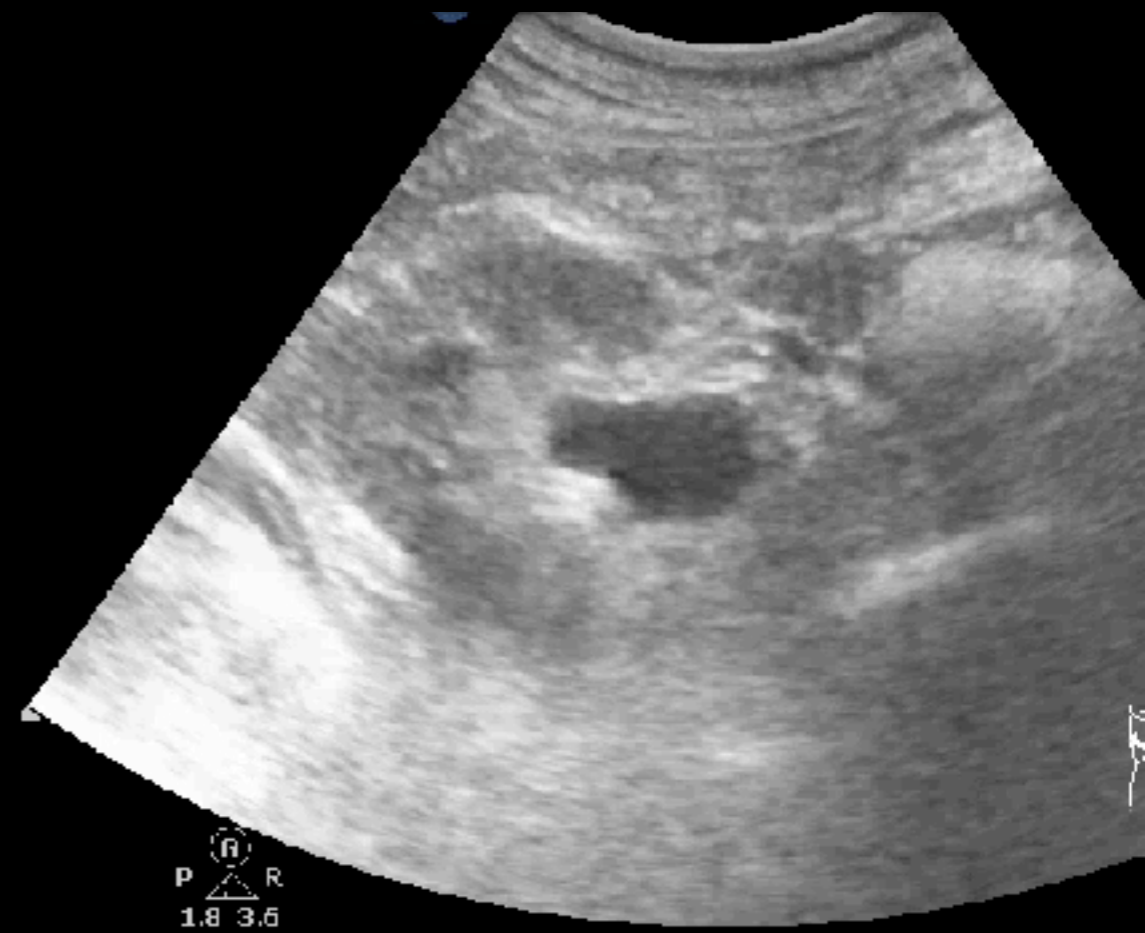
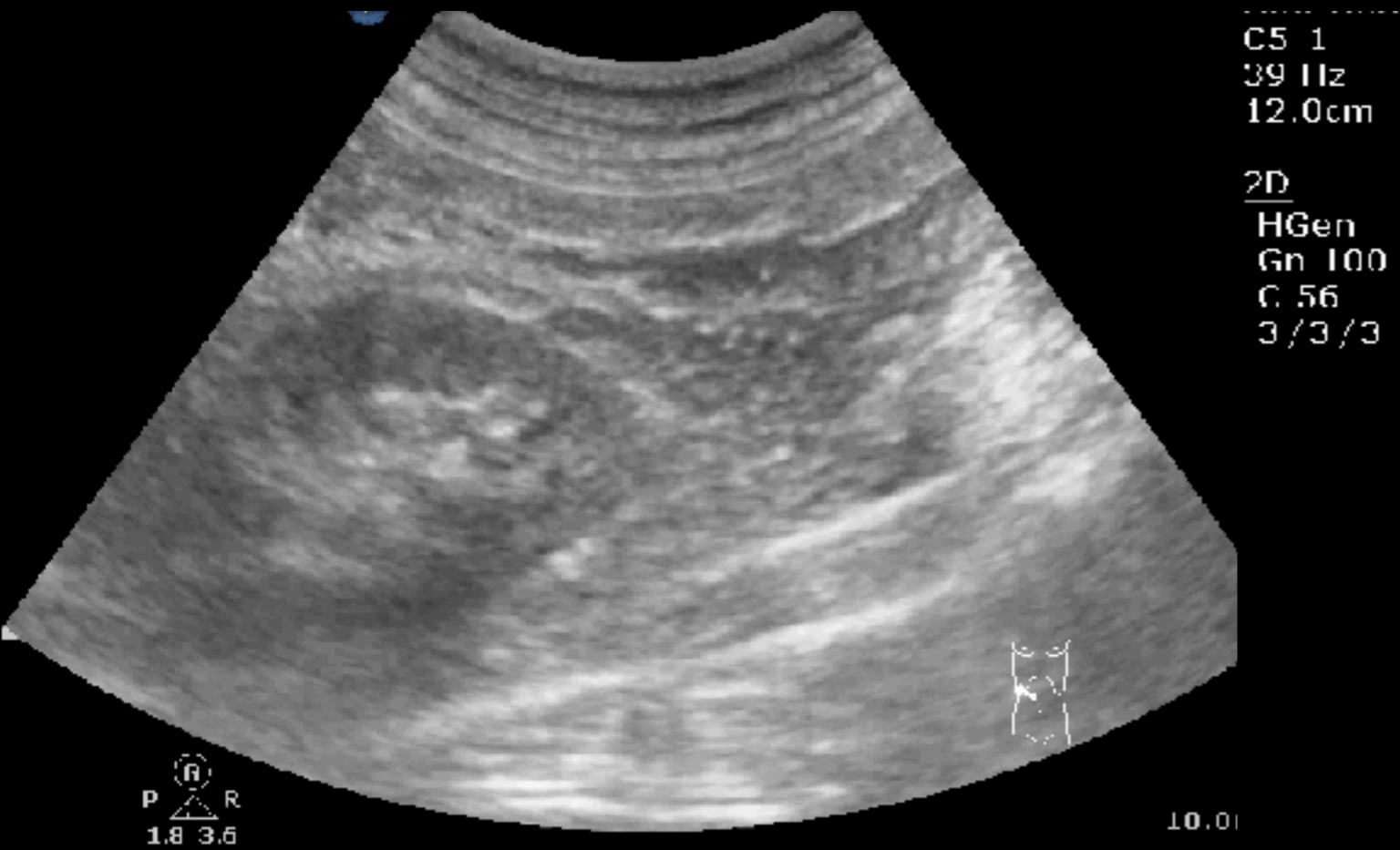


Abd Gen2  
11.5 1  
39 Hz  
12.0cm

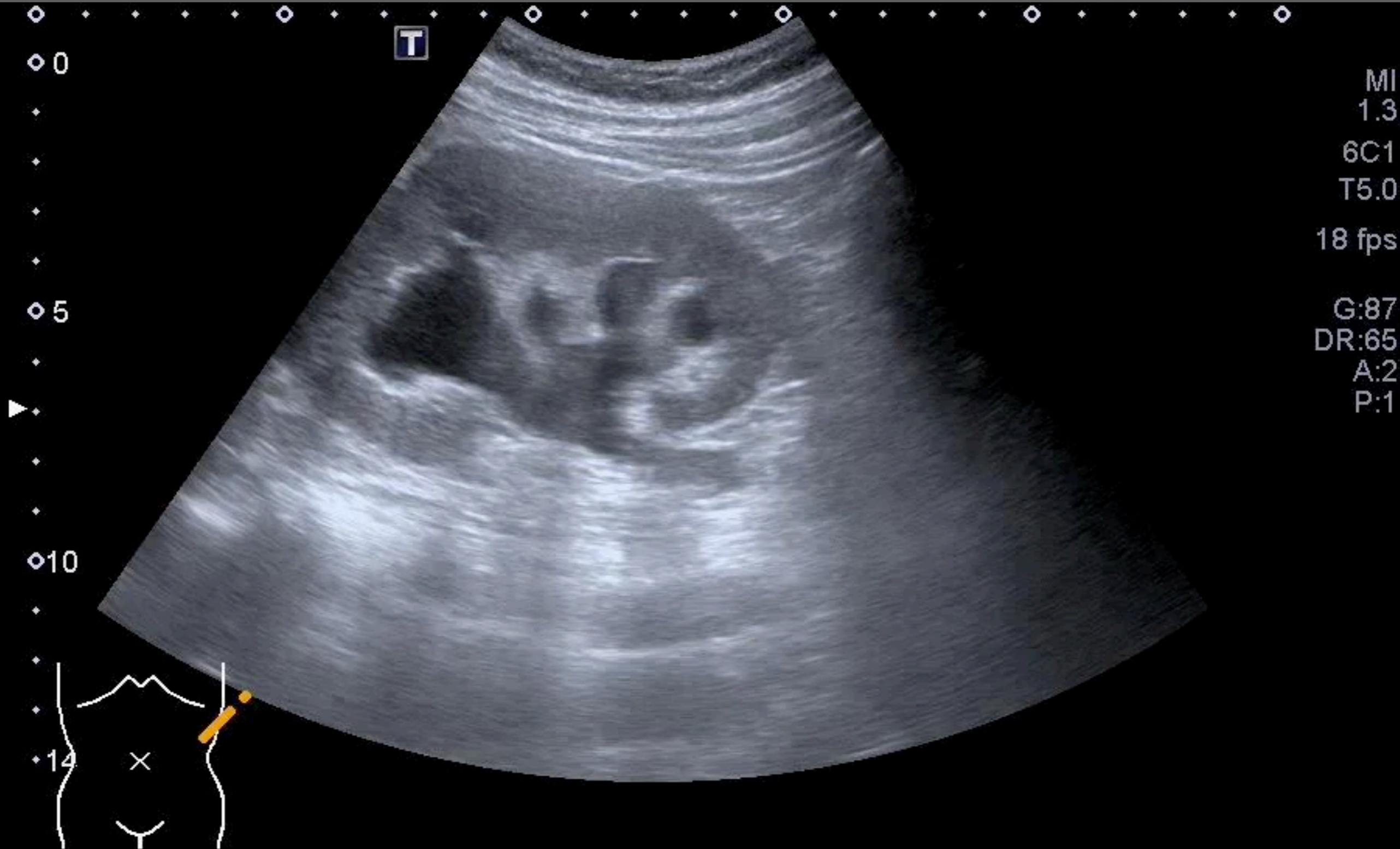2D  
11Gen  
11.5 1  
11.55  
3/3/3



# Ureteral stone

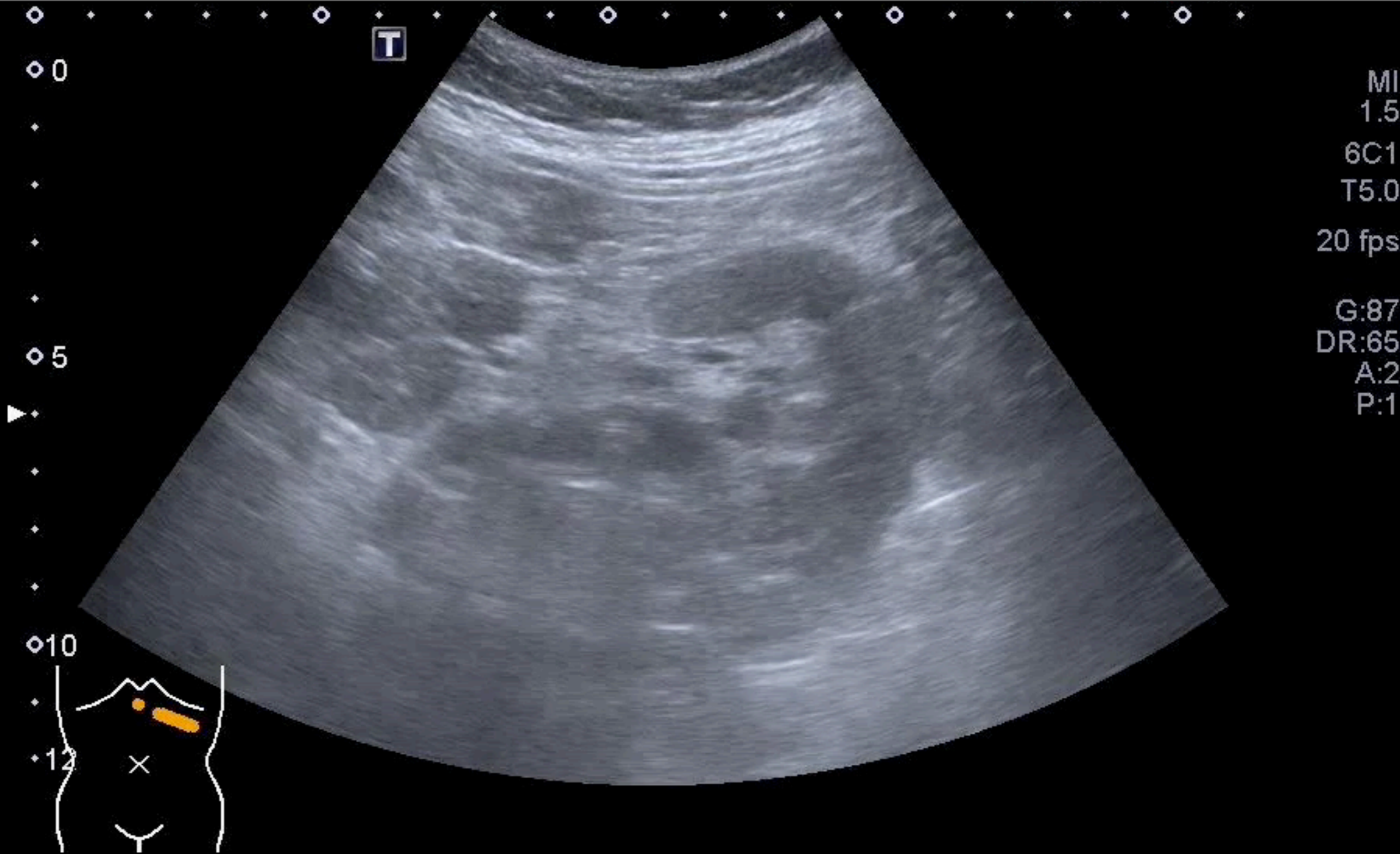


# Hydronephrosis (Coronal)

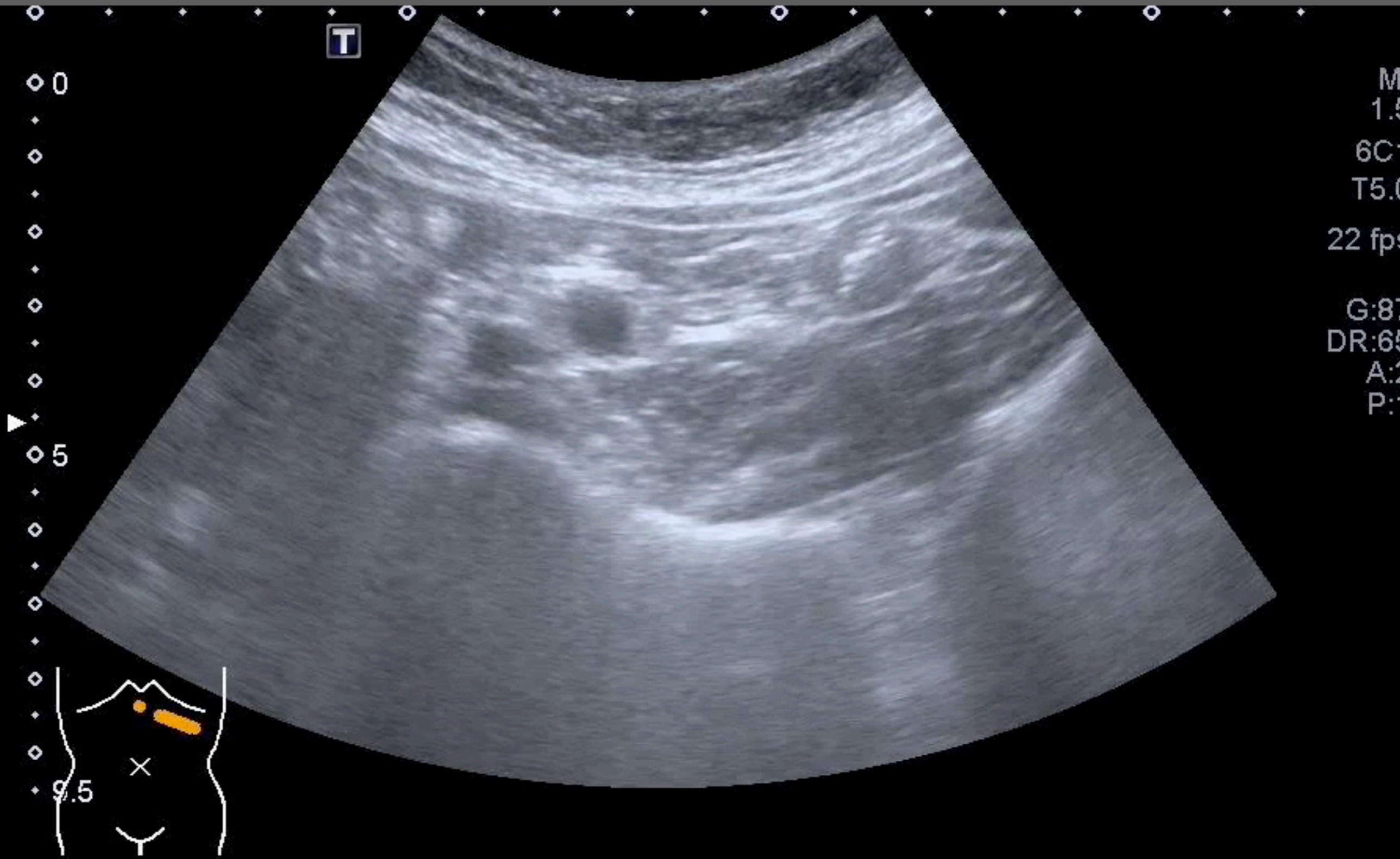



# Transverse (medial to colon)

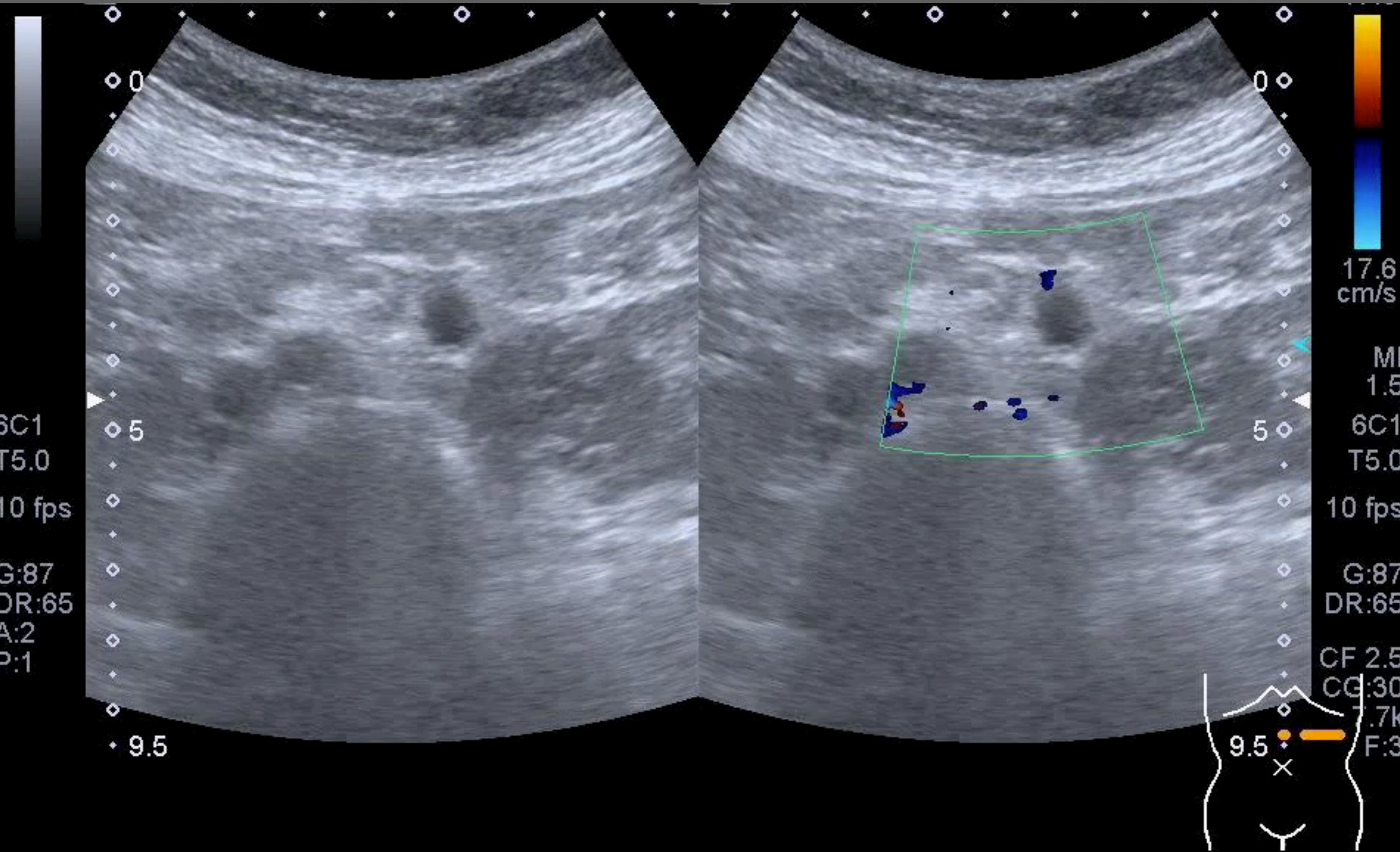


# Rotation





# Twinkling artifact





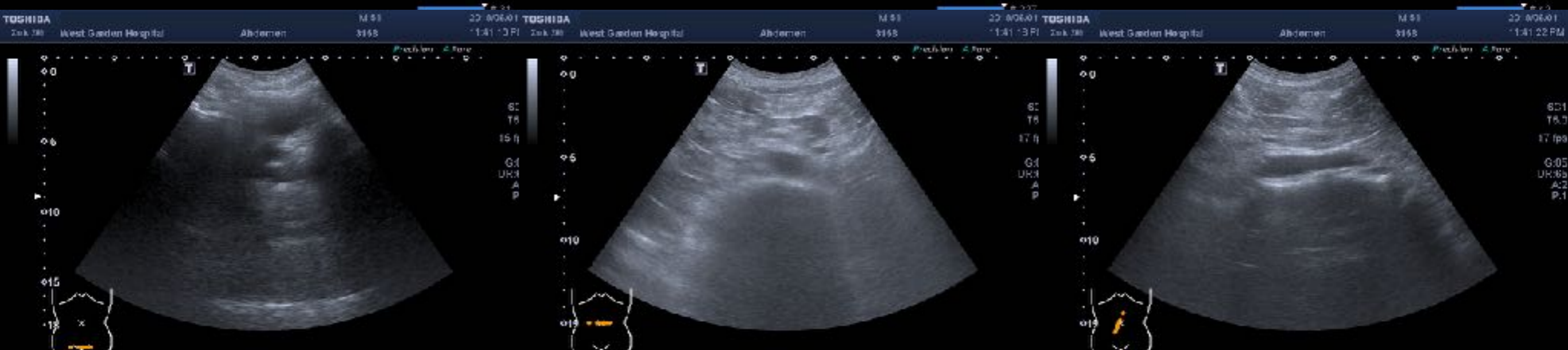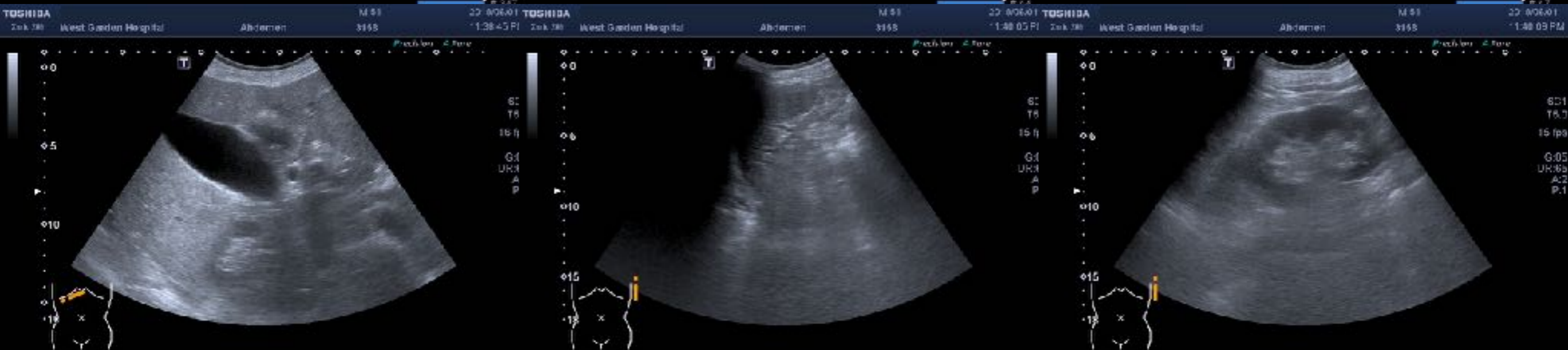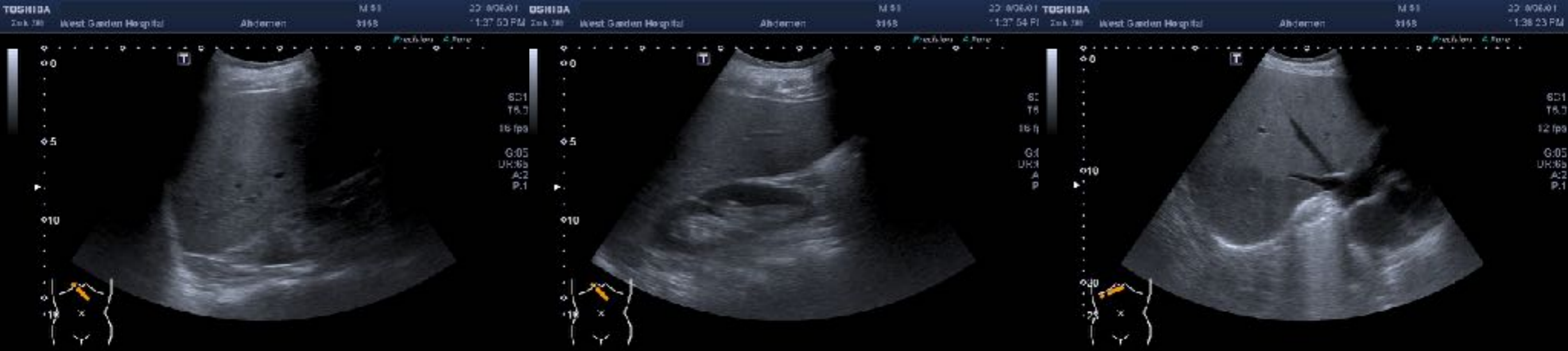51M,  
RUQ pain

WBC 13000;

CRP 8.5

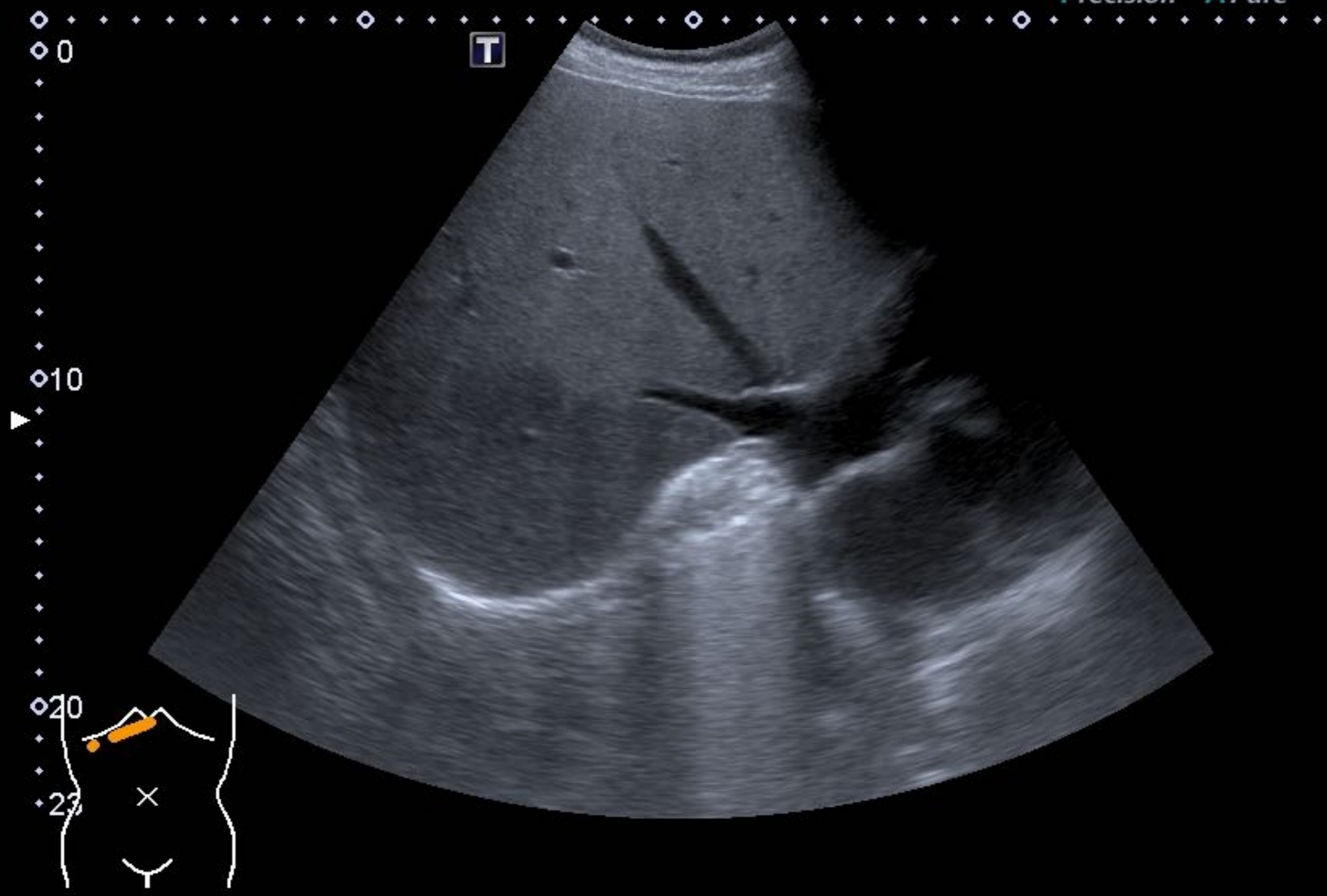
R







Precision A Pure



6C1  
T5.0  
12 fps  
G:85  
DR:65  
A:2  
P:1



T

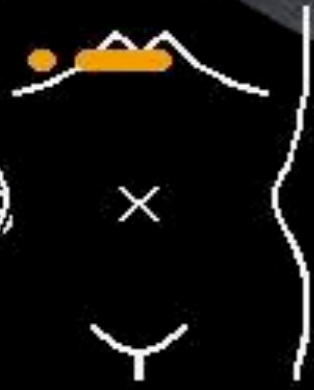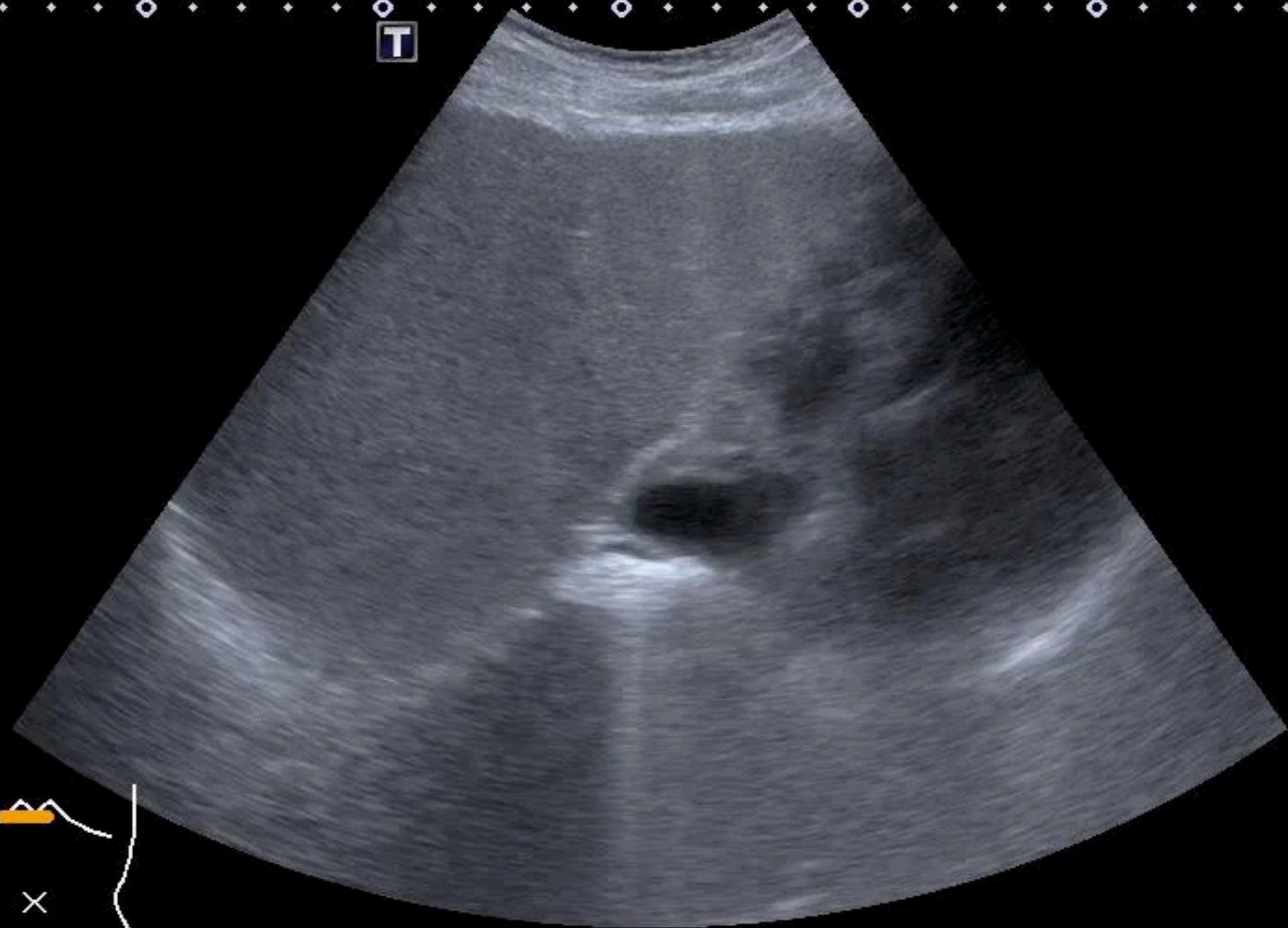
0

5

10

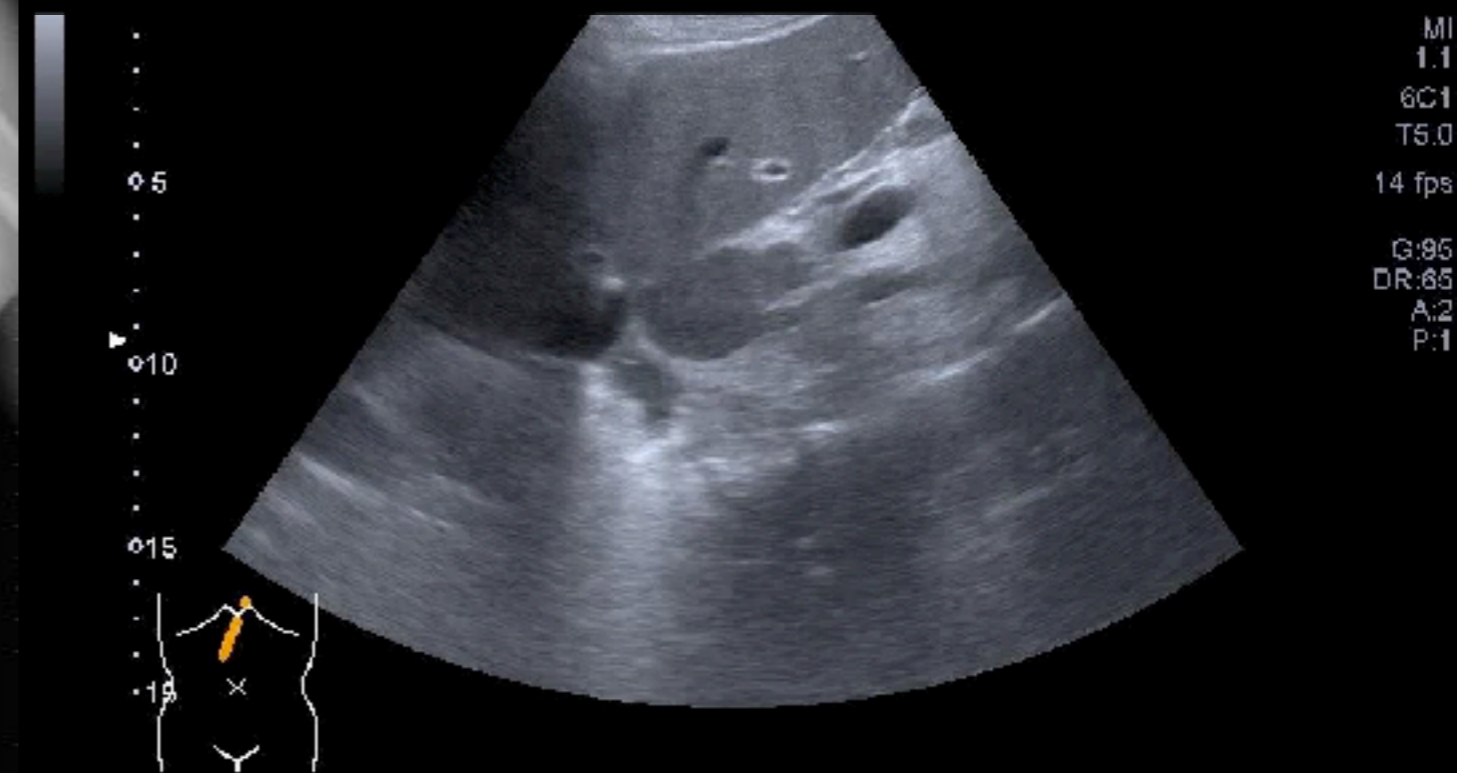
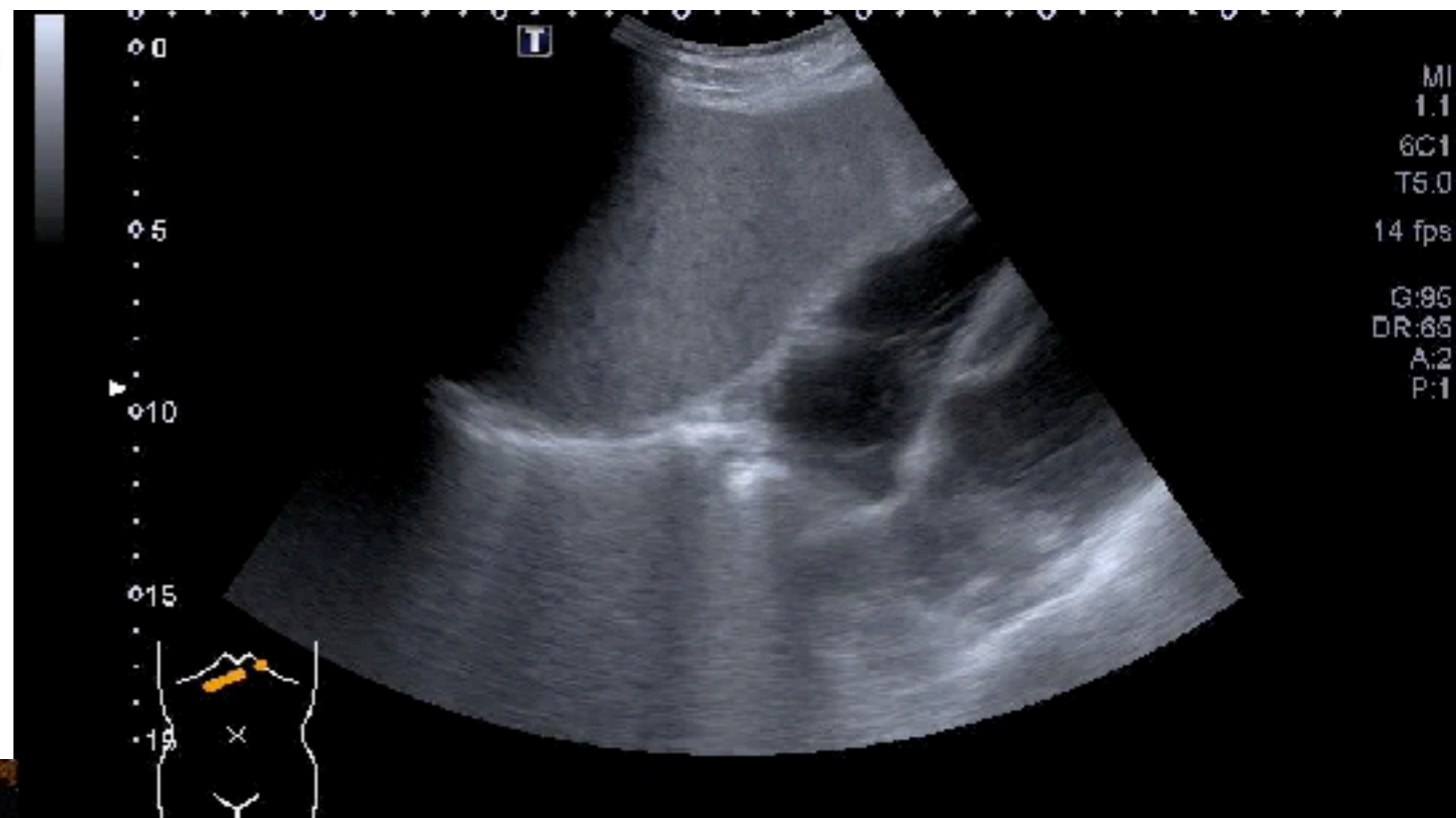
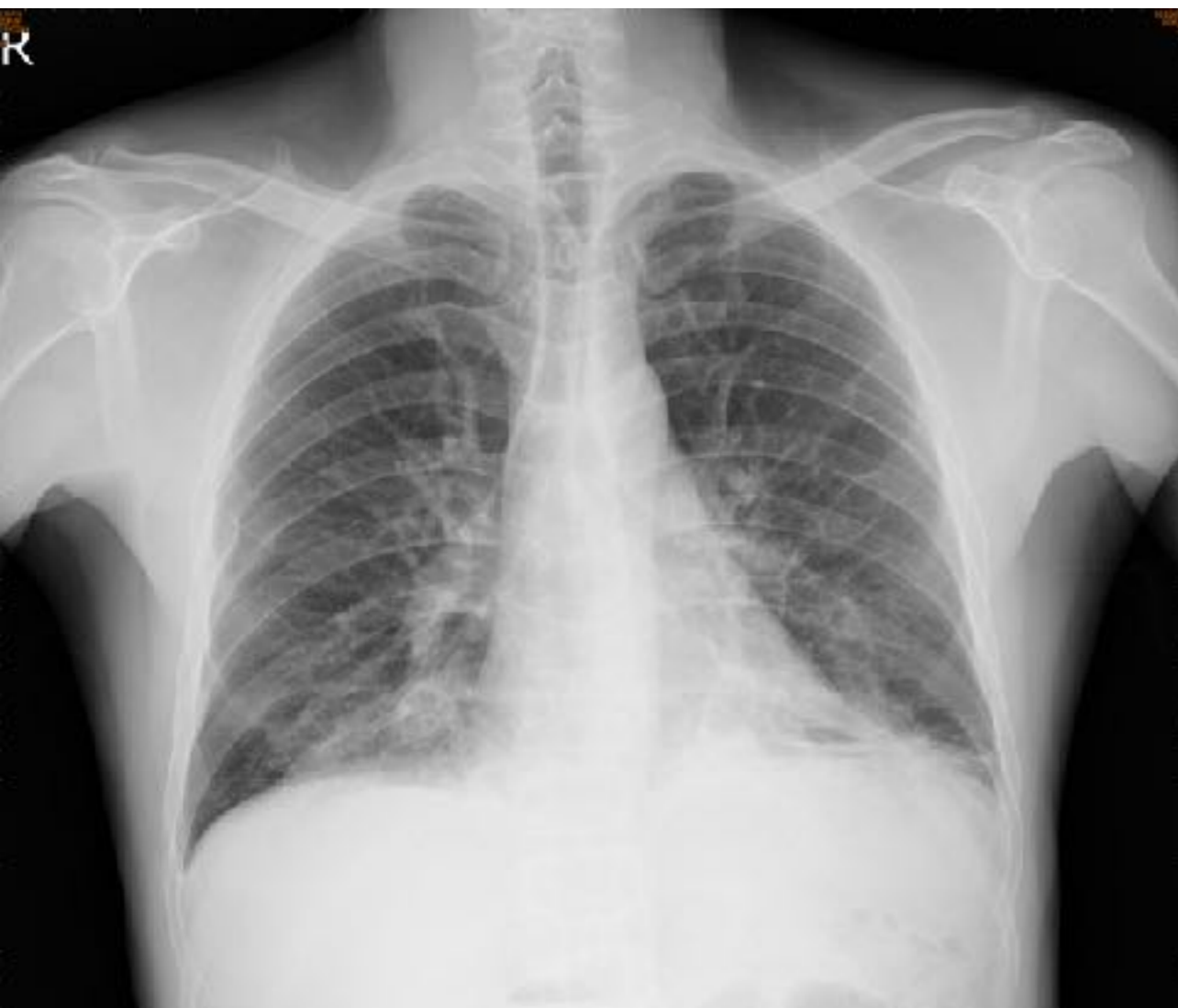15

18



15  
D

# 2nd WINDOW (肝 & 背)



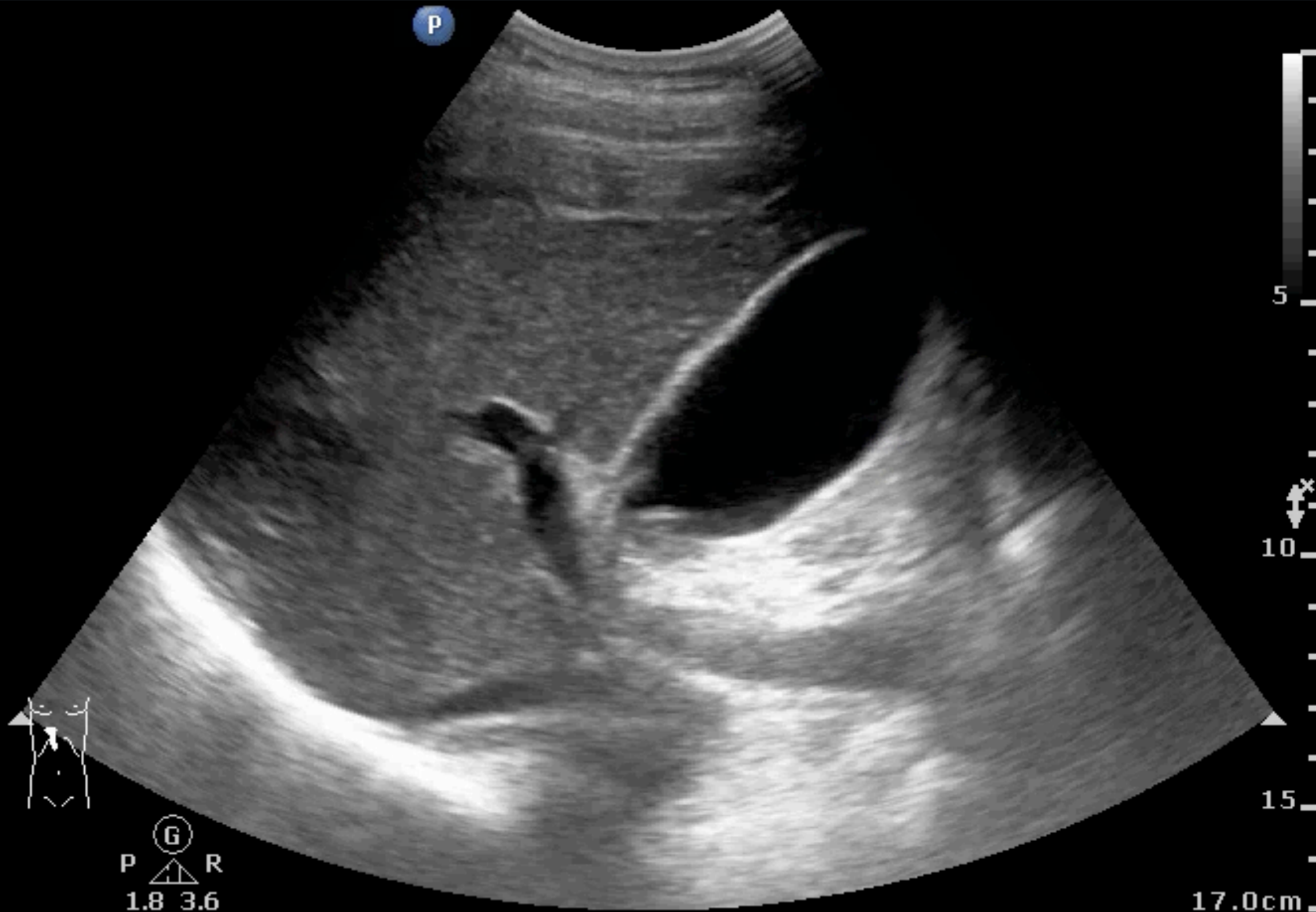

# 52M, RUQ pain

Abd Gen2  
C5-1  
31 Hz  
17.0cm

2D

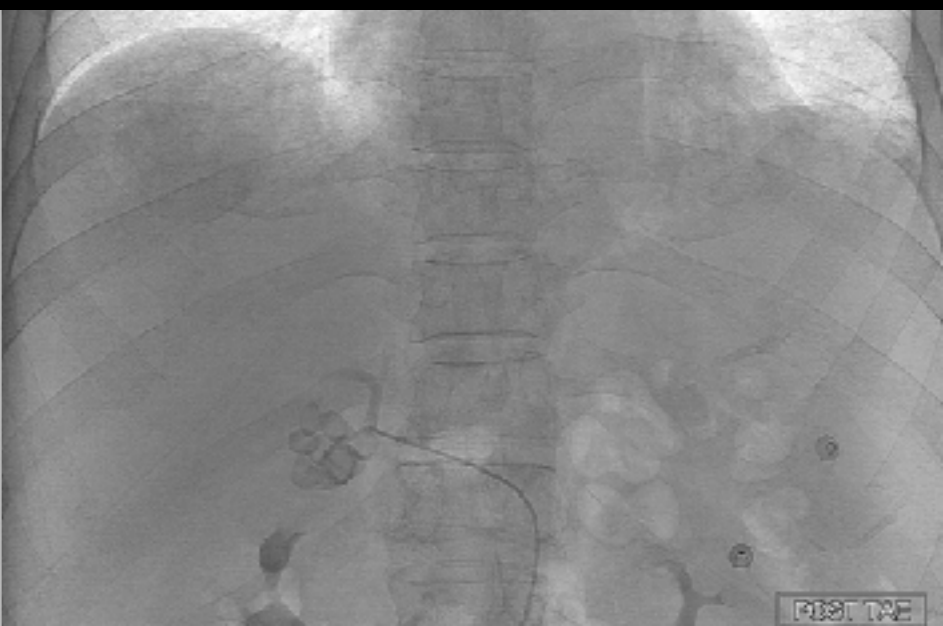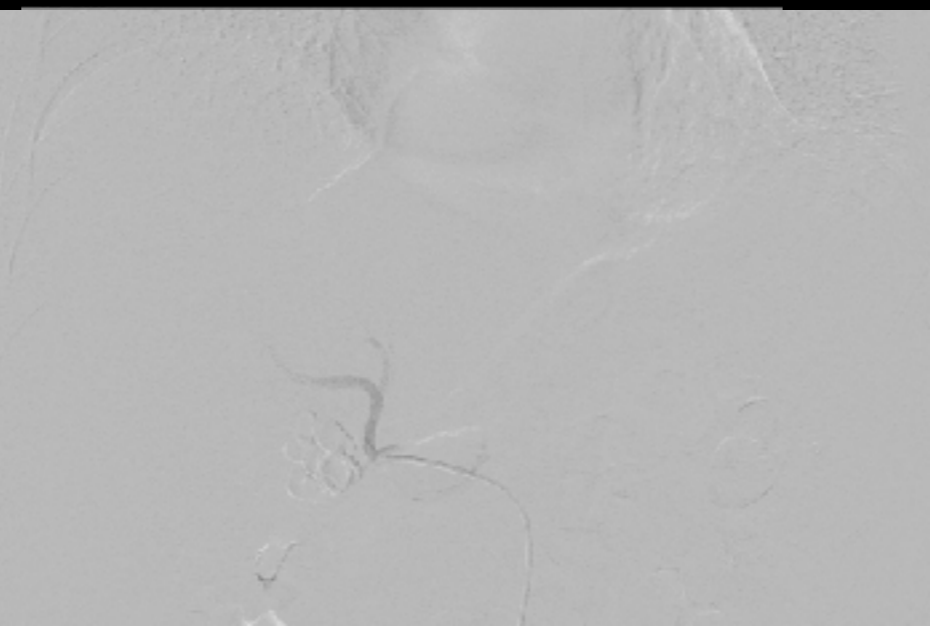
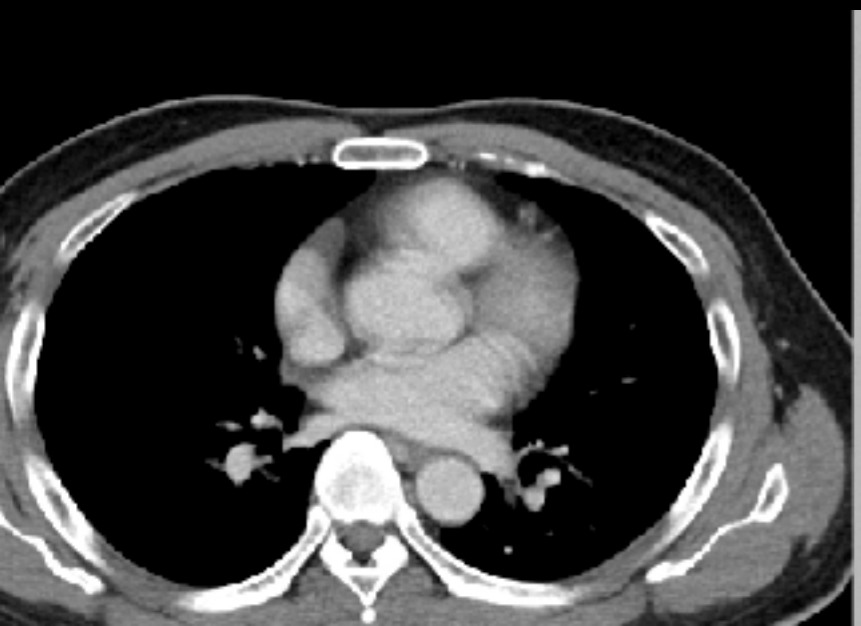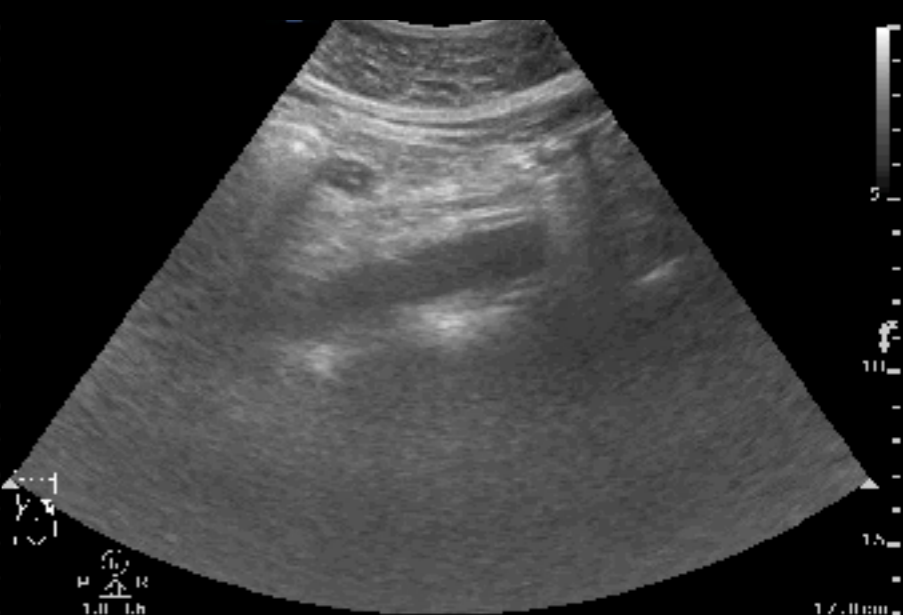
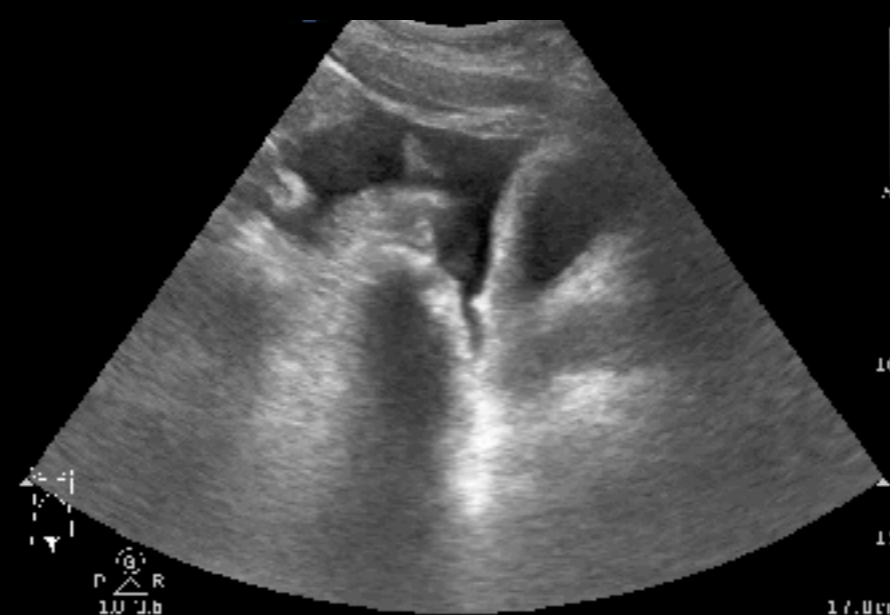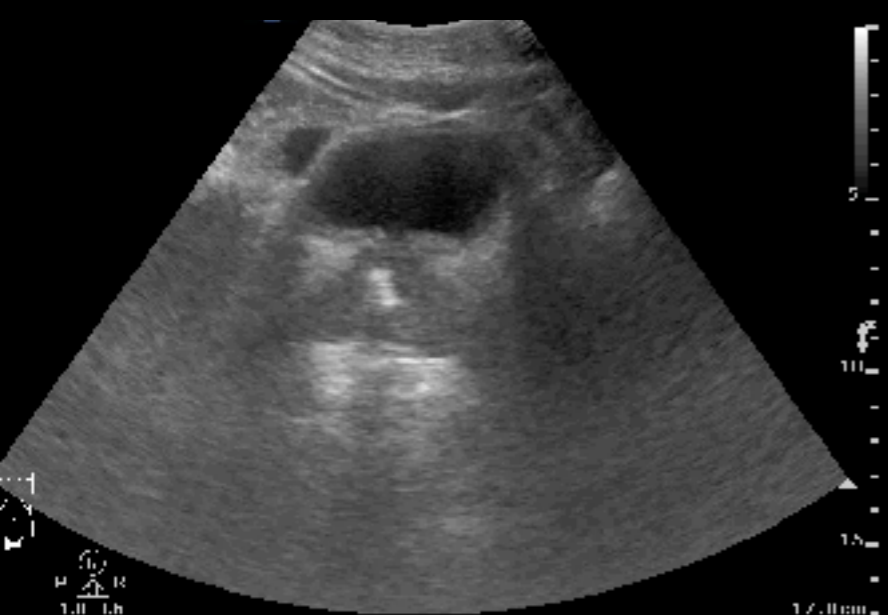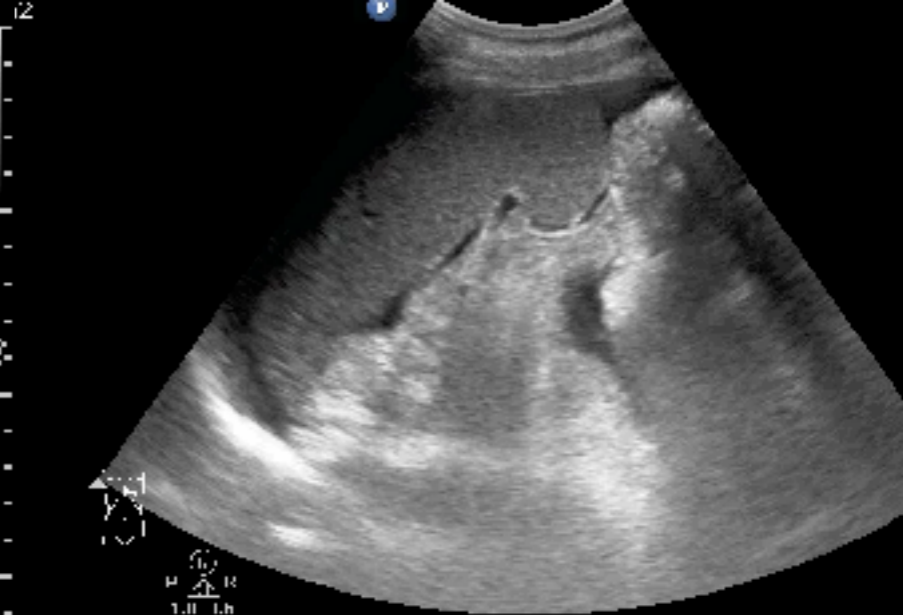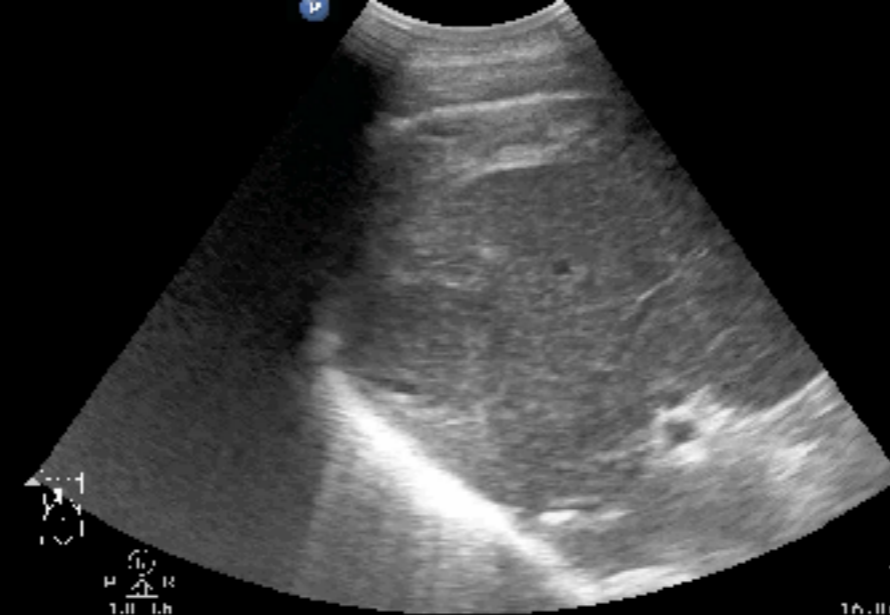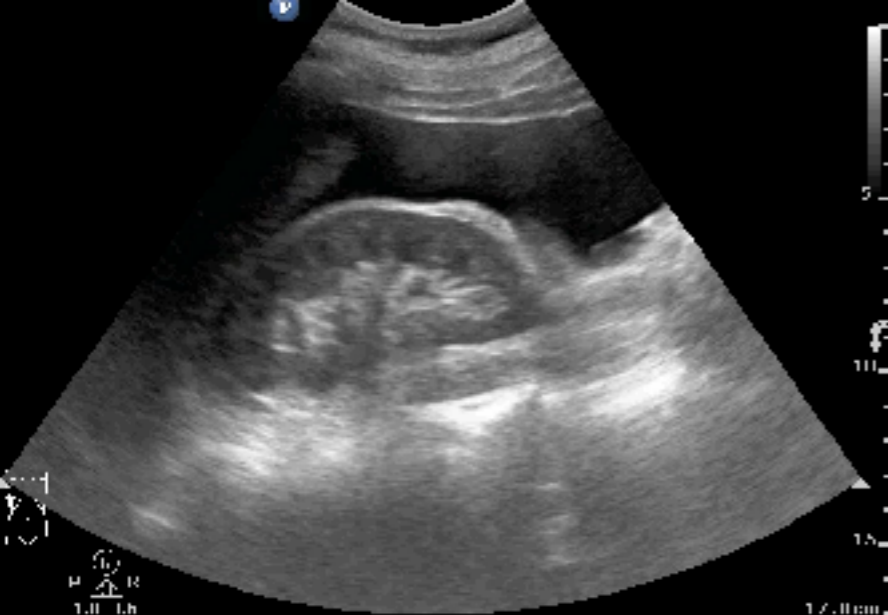HGen  
Gn 86  
C 56  
3/3/3



G  
P R  
1.8 3.6

17.0cm



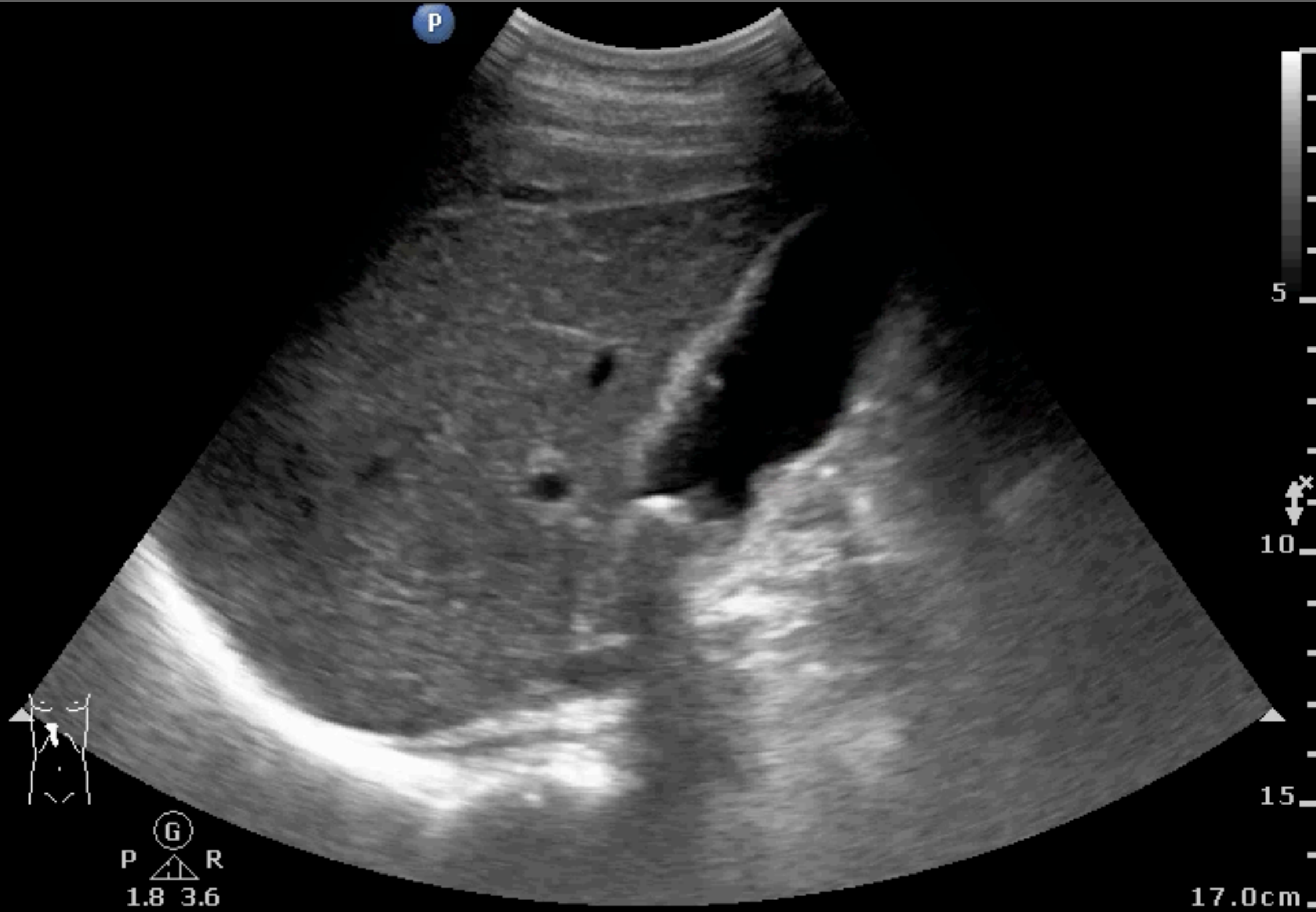

# Premature closure

Abd Gen2  
C5-1  
31 Hz  
17.0cm

2D

HGen  
Gn 86  
C 56  
3/3/3



17.0cm



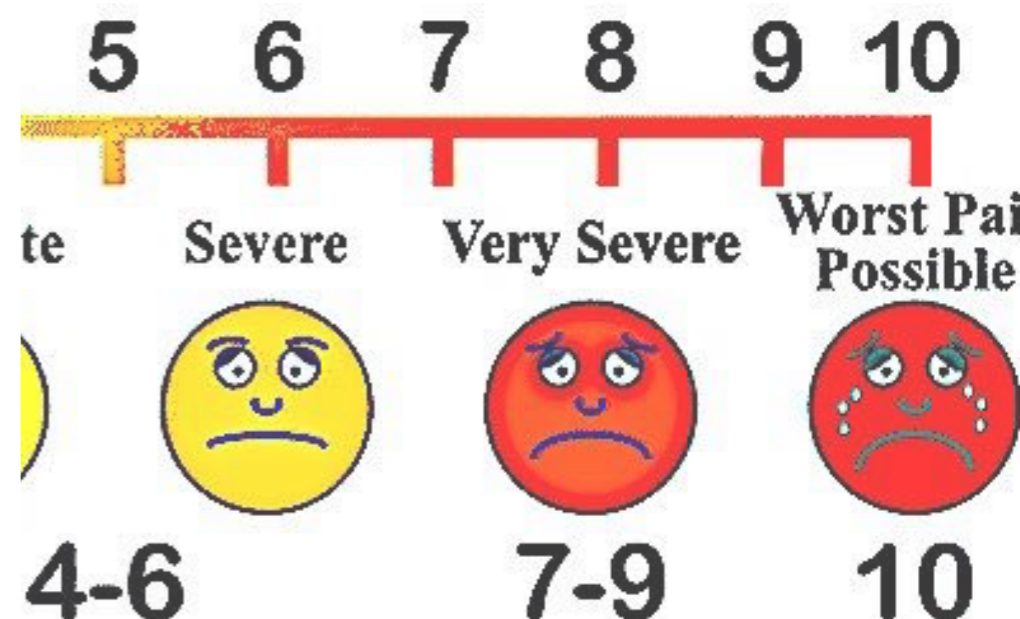
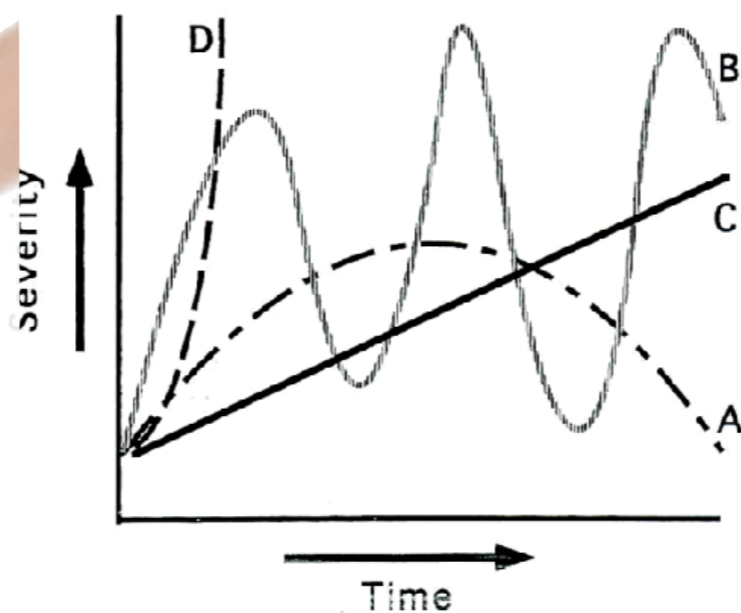
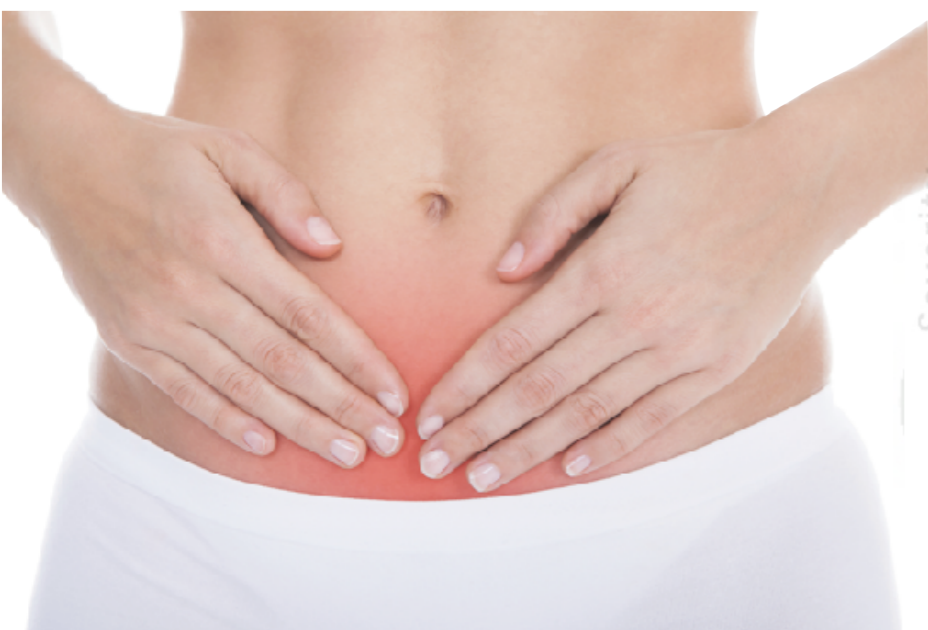

病史詢問



理學檢查

# POCUS





# POCUS

for

# Acute

# ABDOMEN

**A** for aorta

**B** for biliary

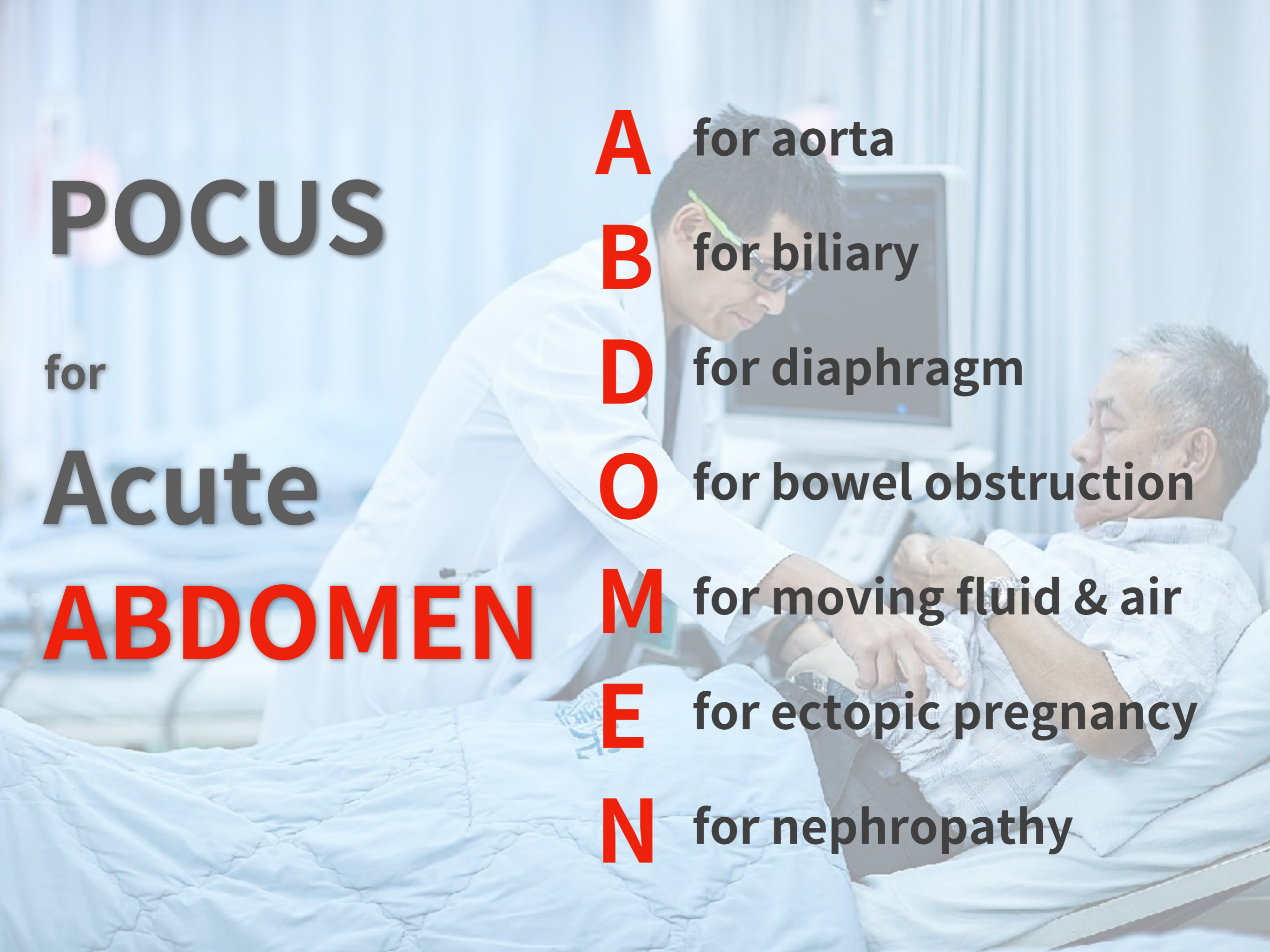**D** for diaphragm

**O** for bowel obstruction

**M** for moving fluid & air

**E** for ectopic pregnancy

**N** for nephropathy





# POCUS幫你【透視】急性腹痛

