



衛生福利部雙和醫院  
(委託臺北醫學大學興建經營)  
Taipei Medical University · Shuang Ho Hospital,  
Ministry of Health and Welfare



# 雙和急診超音波教學

## 8 Essential POCUS skills for PGY

---

陳國智醫師 急診醫學科

# 陳國智 醫師

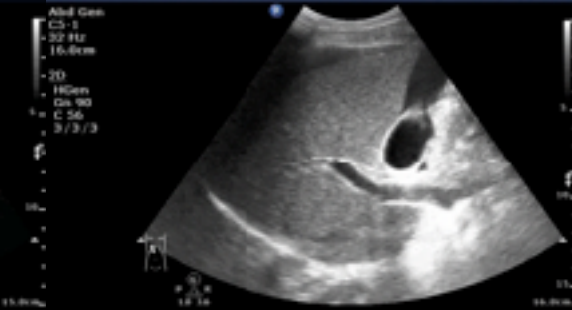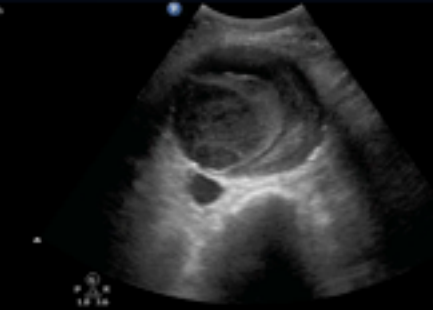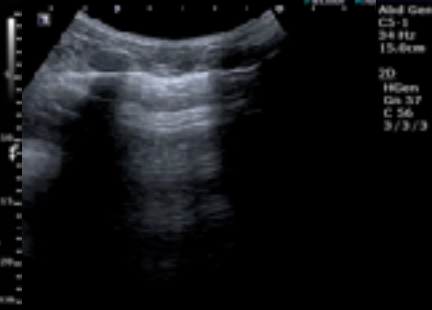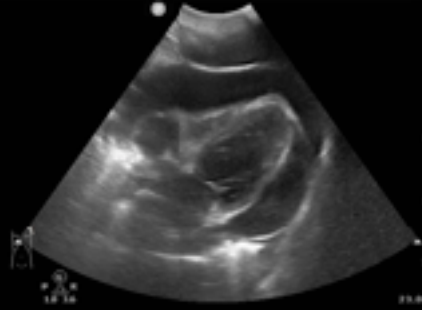


急診超音波臨床評核醫師  
醫用超音波學會指導醫師  
WINFOCUS director / instructor

**急診 / 重症 / 介入 / 急性疼痛**

經歷

新光急診超音波訓練中心主任  
西園醫院急診醫學科主任  
急診醫學會超音波委員會主委  
台灣疼痛醫學會大體模擬手術講師  
急救加護醫學會重症超音波負責人



**HEART**

**LUNG**

**AORTA**

**FAST**

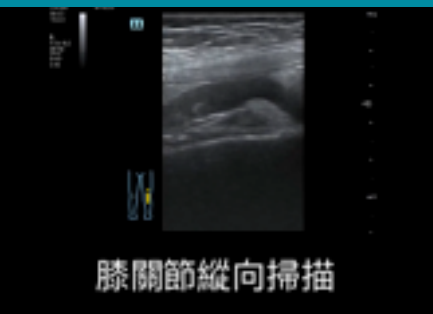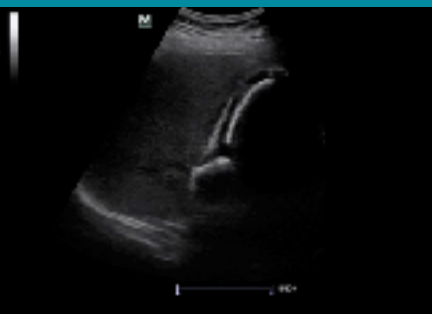
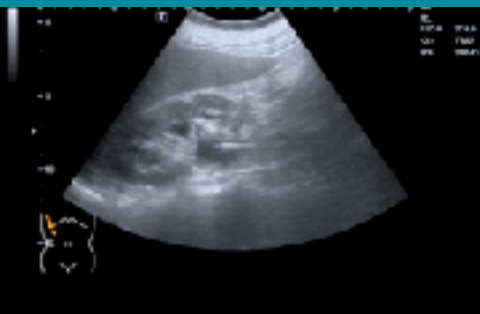**KIDNEY**

**BILIARY**

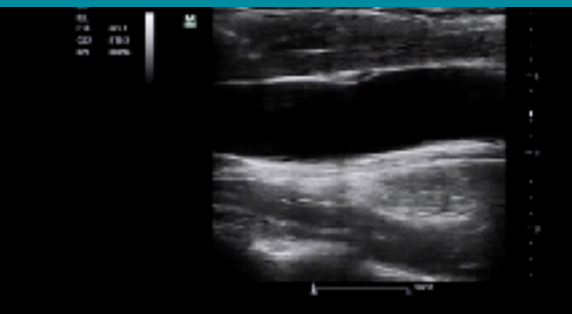
**KNEE**

**CVC**

# 8 ESSENTIAL SKILLS



膝關節縱向掃描



# I-AIM

## POINT



**Acquire**



**Interpret**



**Make  
decision**

# I-AIM (Acute abdomen)

## Free fluid ?



探頭/FAST介面



有無游離液體



臨床決策

# Point-of-Care UltraSound

## POCUS的核心在協助臨床決策

**YES**



**NO**

有無游離液體

# POCUS 常用探頭



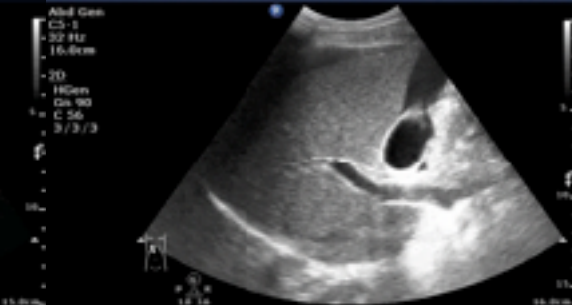
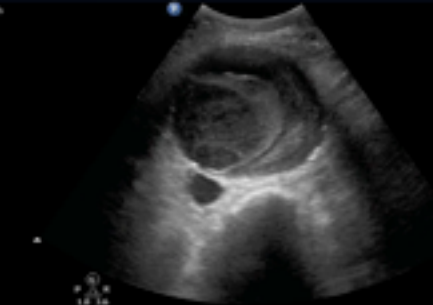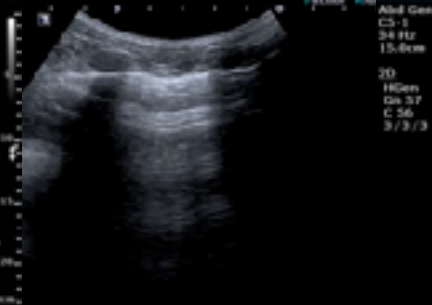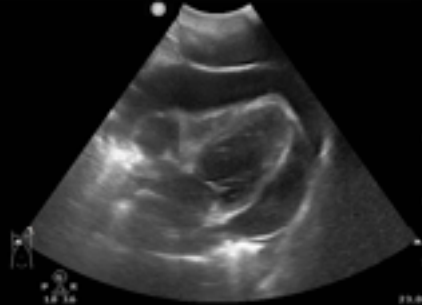
弧



線



扇



**HEART**

**LUNG**

**AORTA**

**FAST**

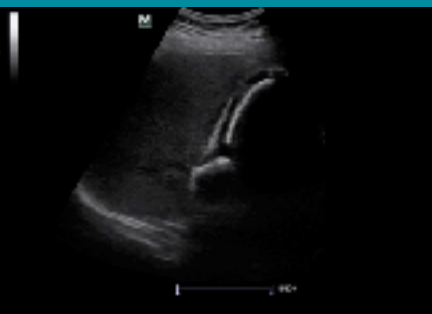
**KIDNEY**

**BILIARY**

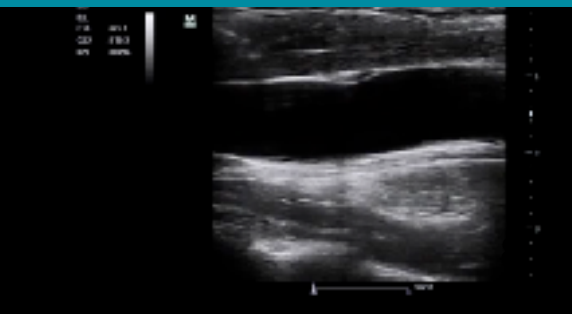
**KNEE**

**CVC**

# 8 ESSENTIAL SKILLS



膝關節縱向掃描





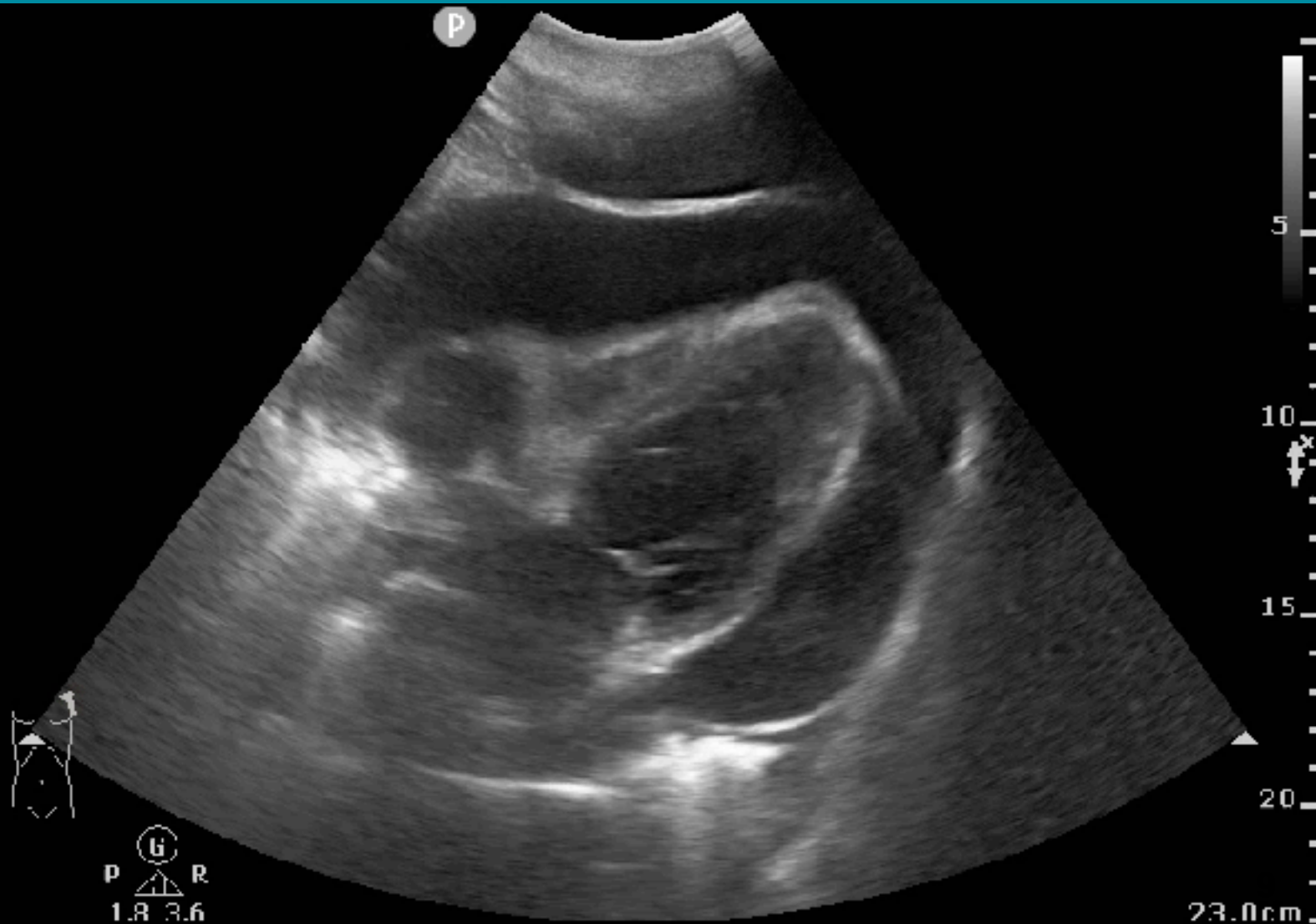


# HEART

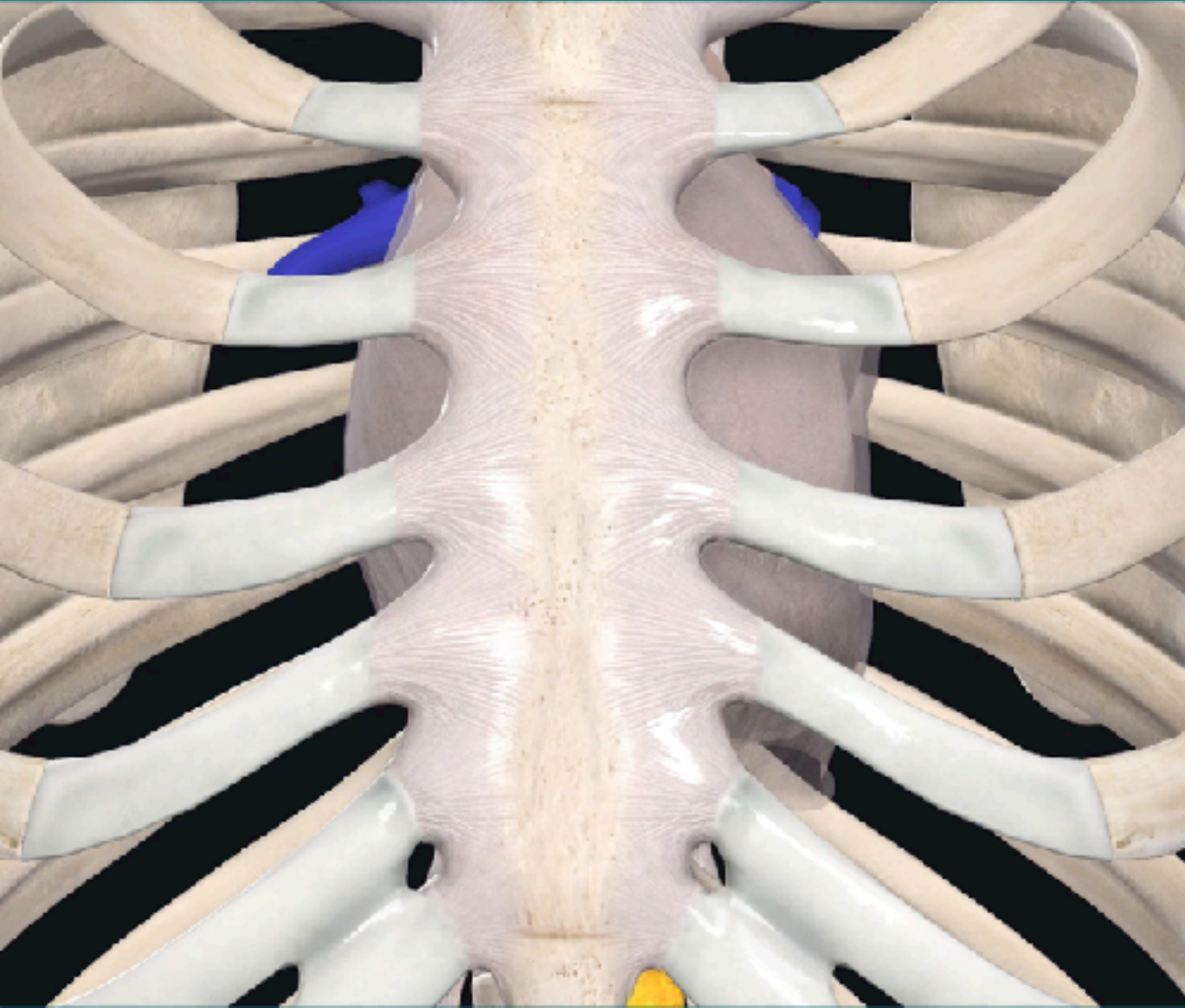
Abd Gen  
C5-1  
75 H7  
23.0cm

2D

HGen  
Gn 100  
C 56  
3 / 3 / 3

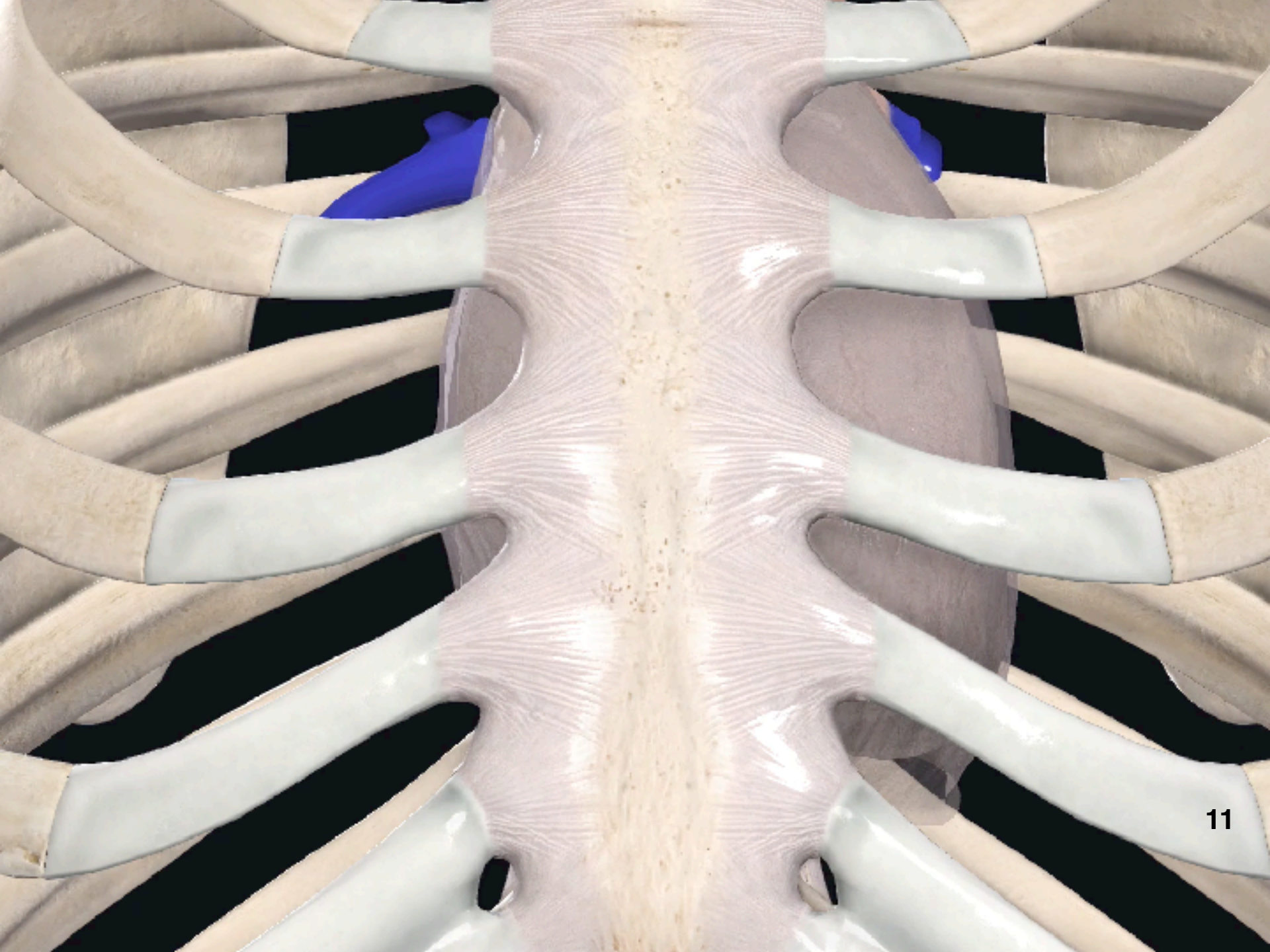


# HEART



Arrest  
**Activity**

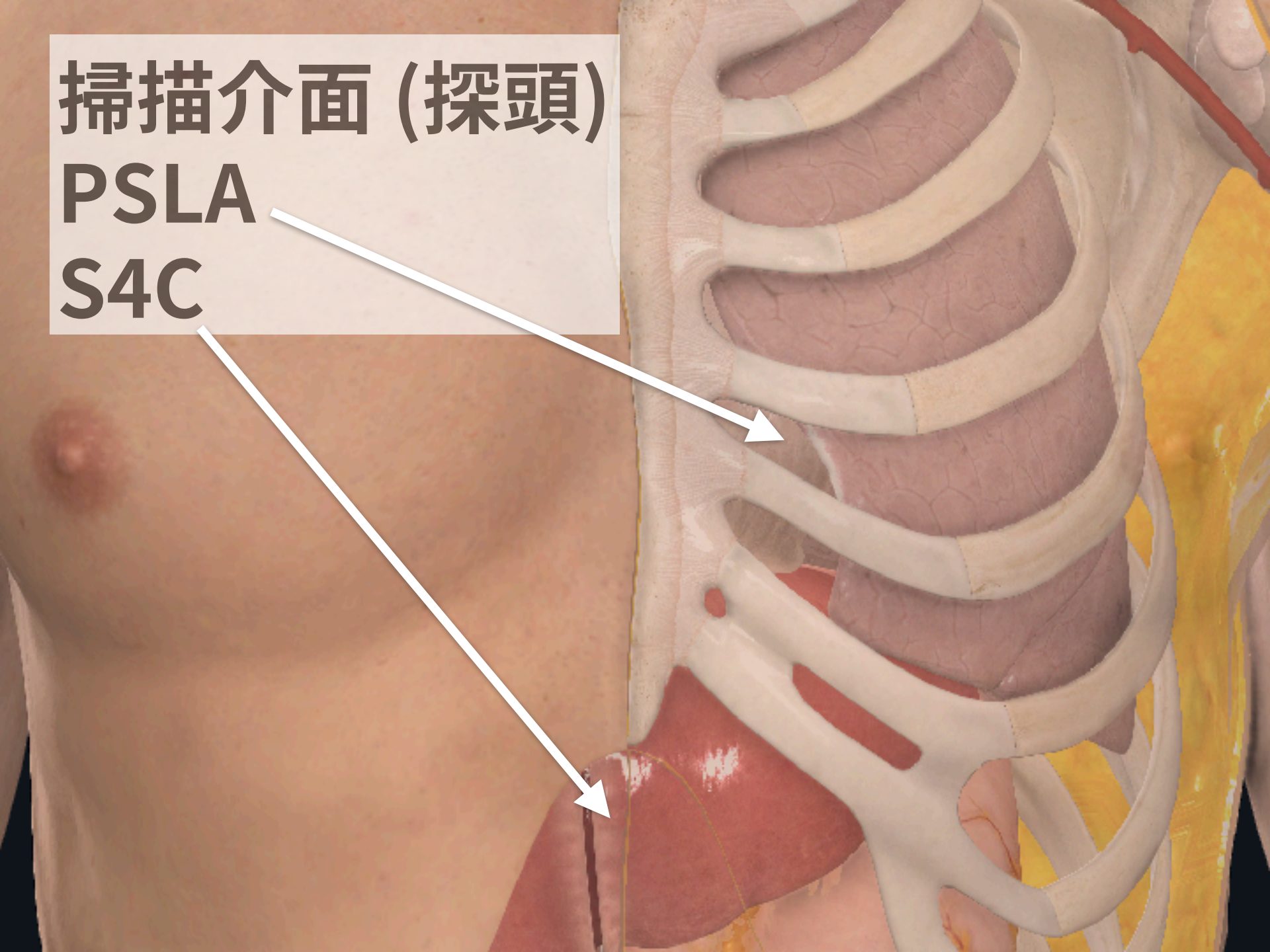
Shock  
**Effusion**



掃描介面 (探頭)

PSLA

S4C

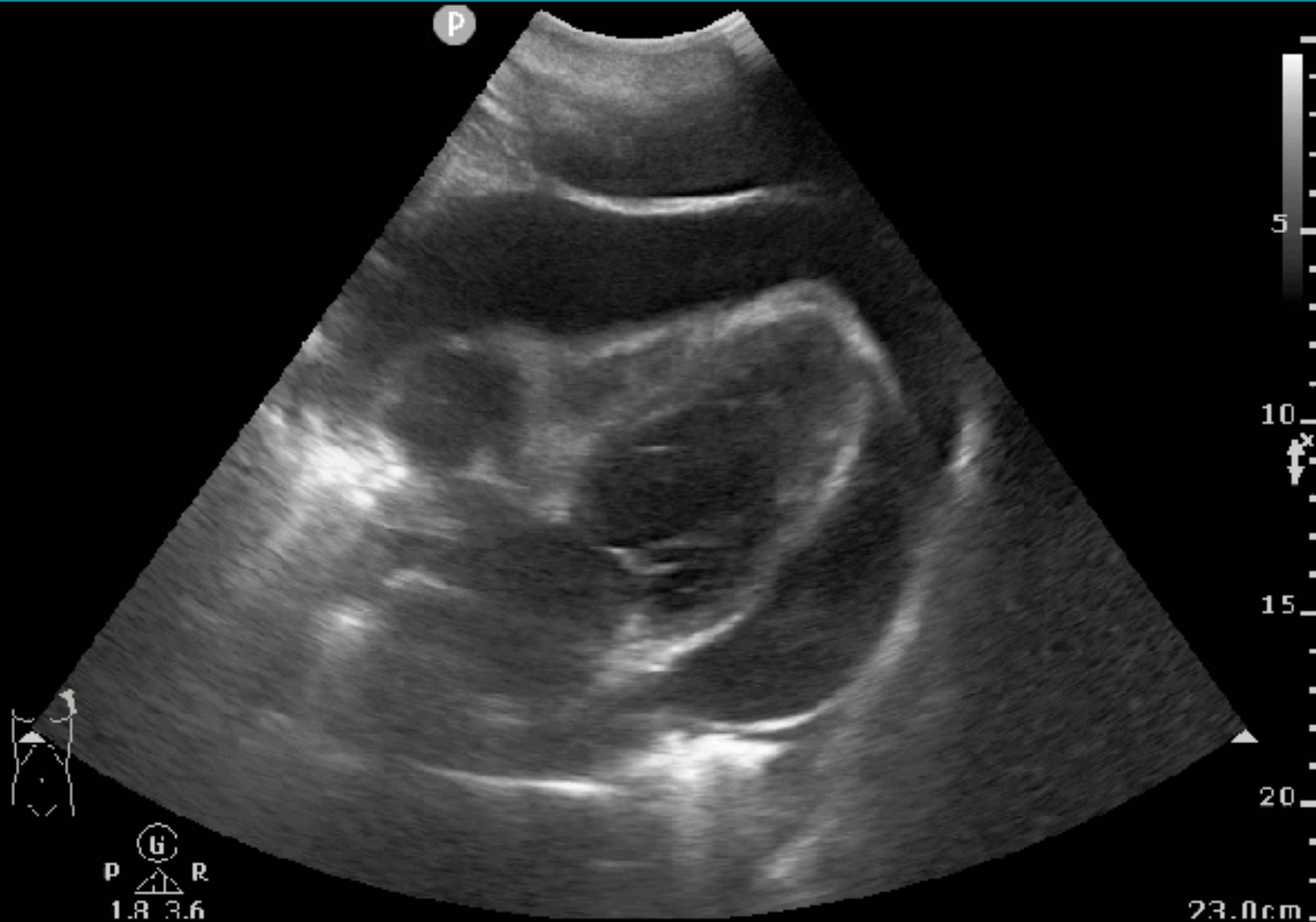


# PSLA OR S4C ?

Abd Gen  
C5-1  
75 H7  
23.0cm

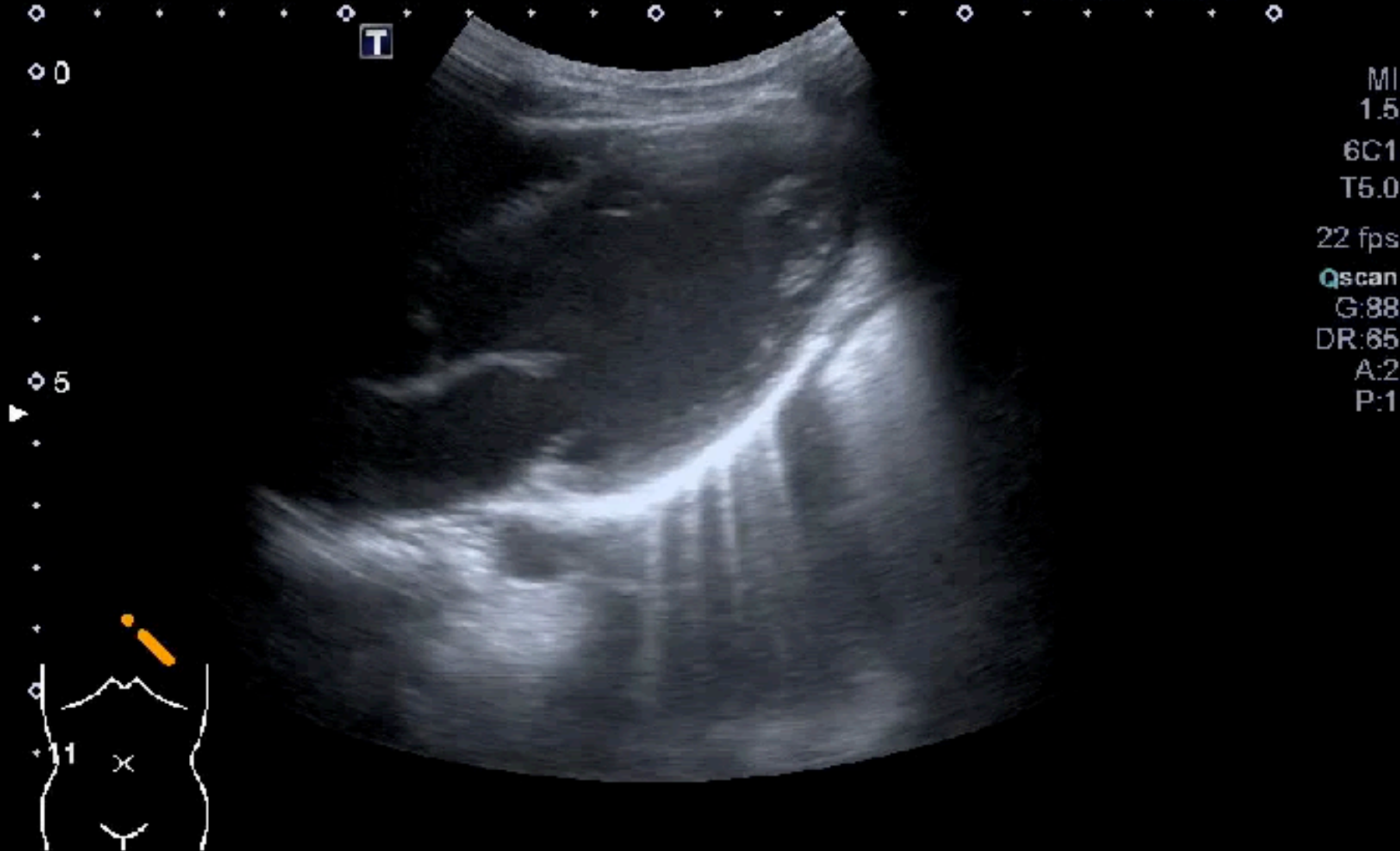
2D

HGen  
Gn 100  
C 56  
3 / 3 / 3



23.0cm

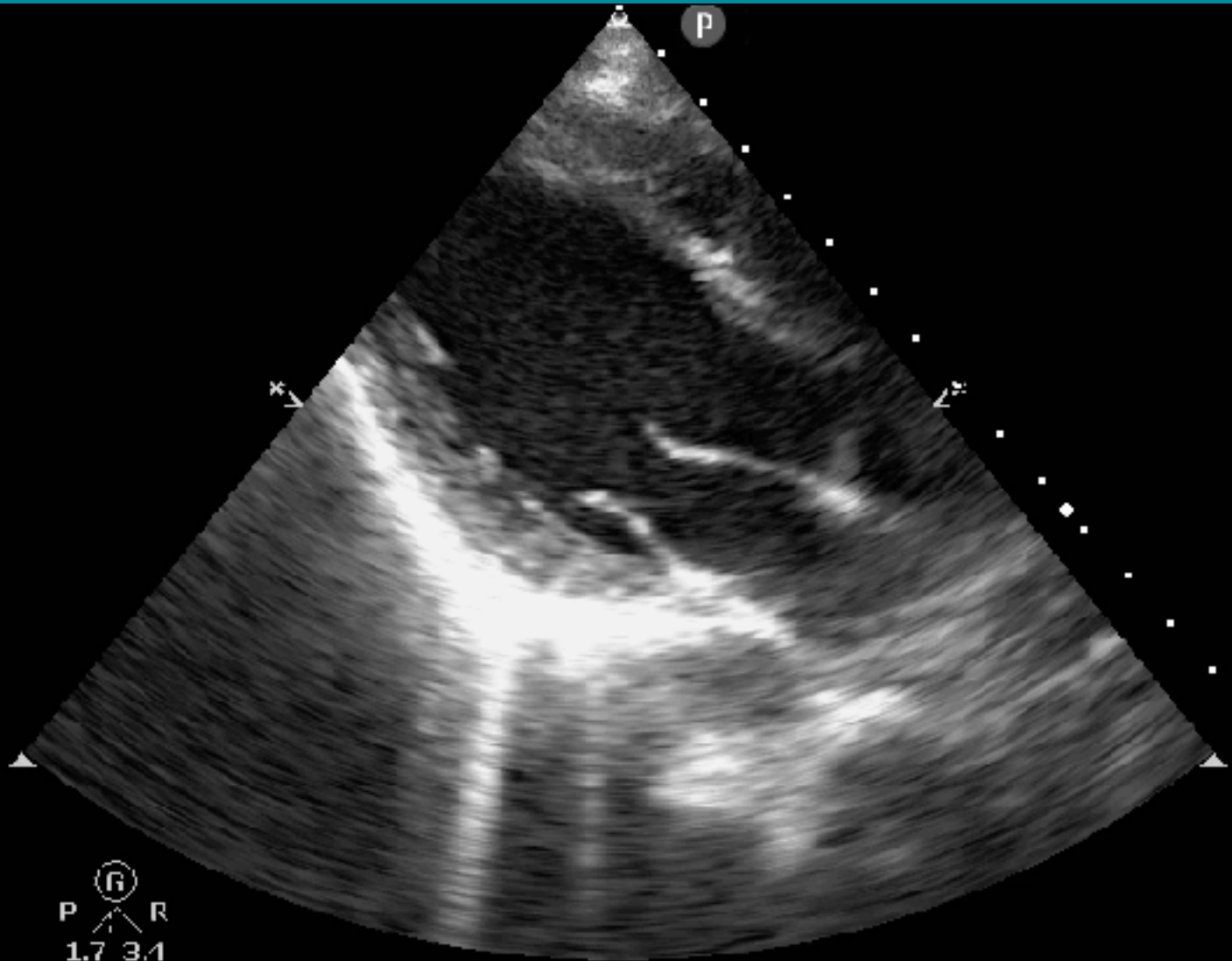
# PARASTERNAL LONG AXIS



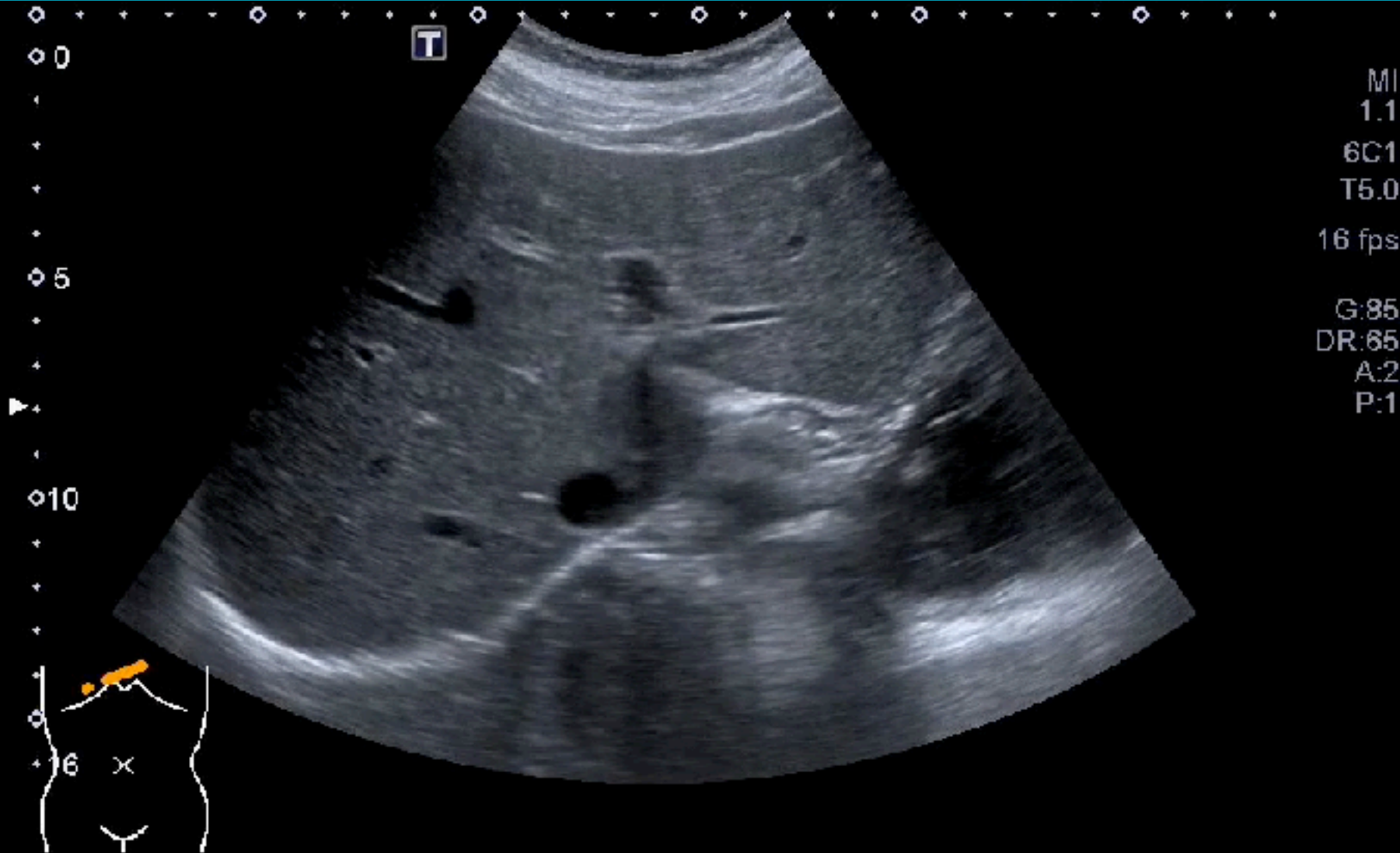
# PARASTERNAL LONG AXIS

Adult Echo  
S1-1  
77 Hz  
15.0cm

2D  
HGen  
Gn 100  
55  
3/2/0  
50 mm/s

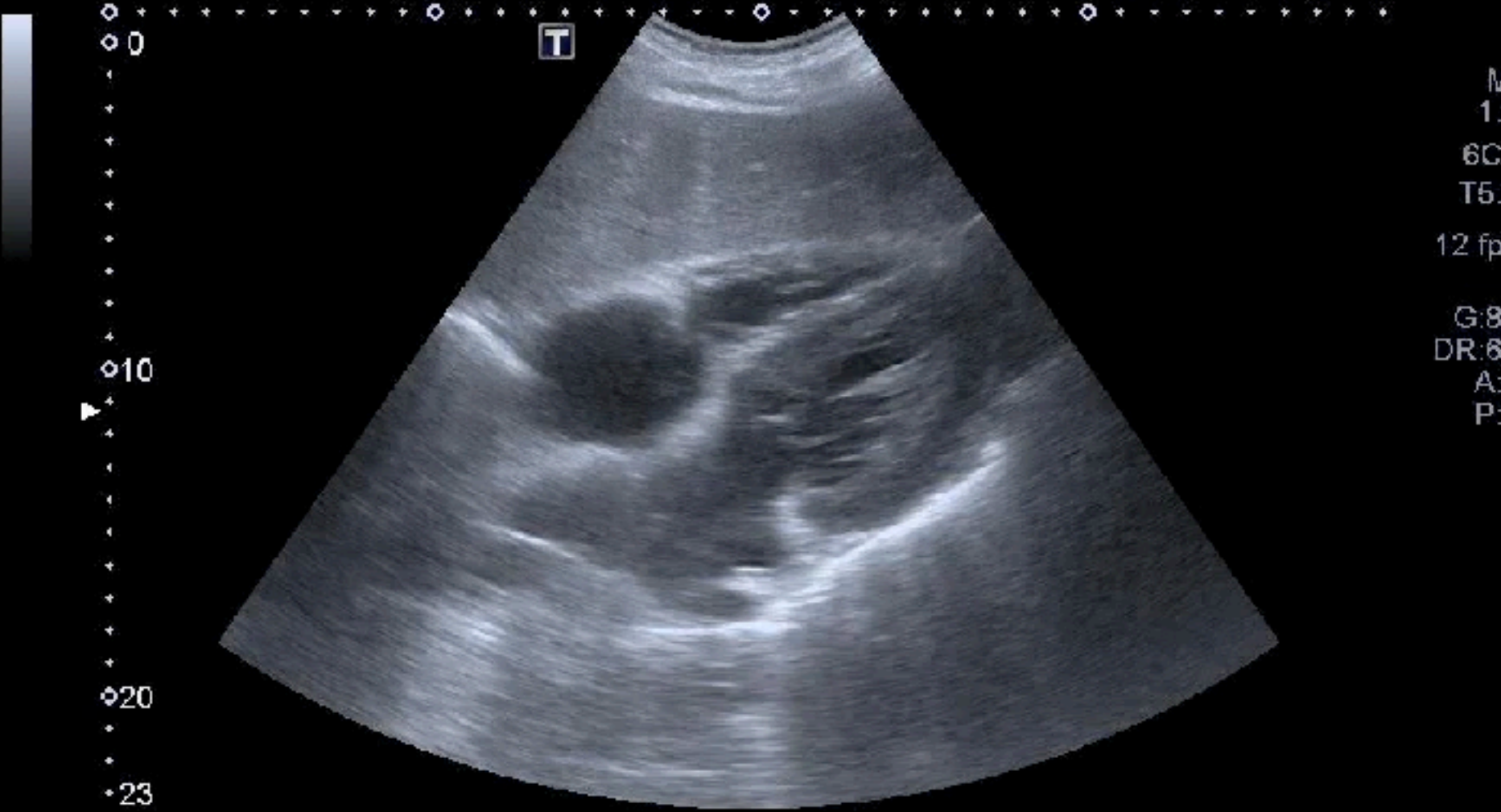

# SUBCOSTAL 4 CHAMBER





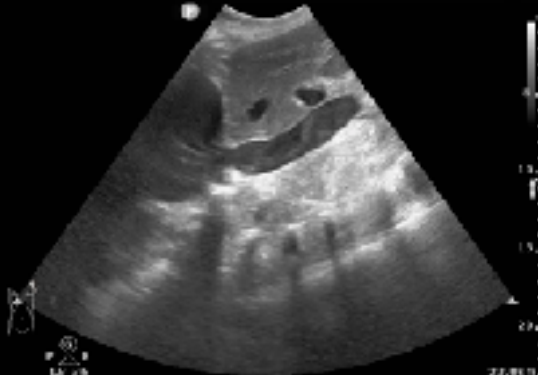# CARDIAC ARREST



# CARDIAC TAMPONADE

1.5d Con  
3-1  
3.8Hz  
7.0cm

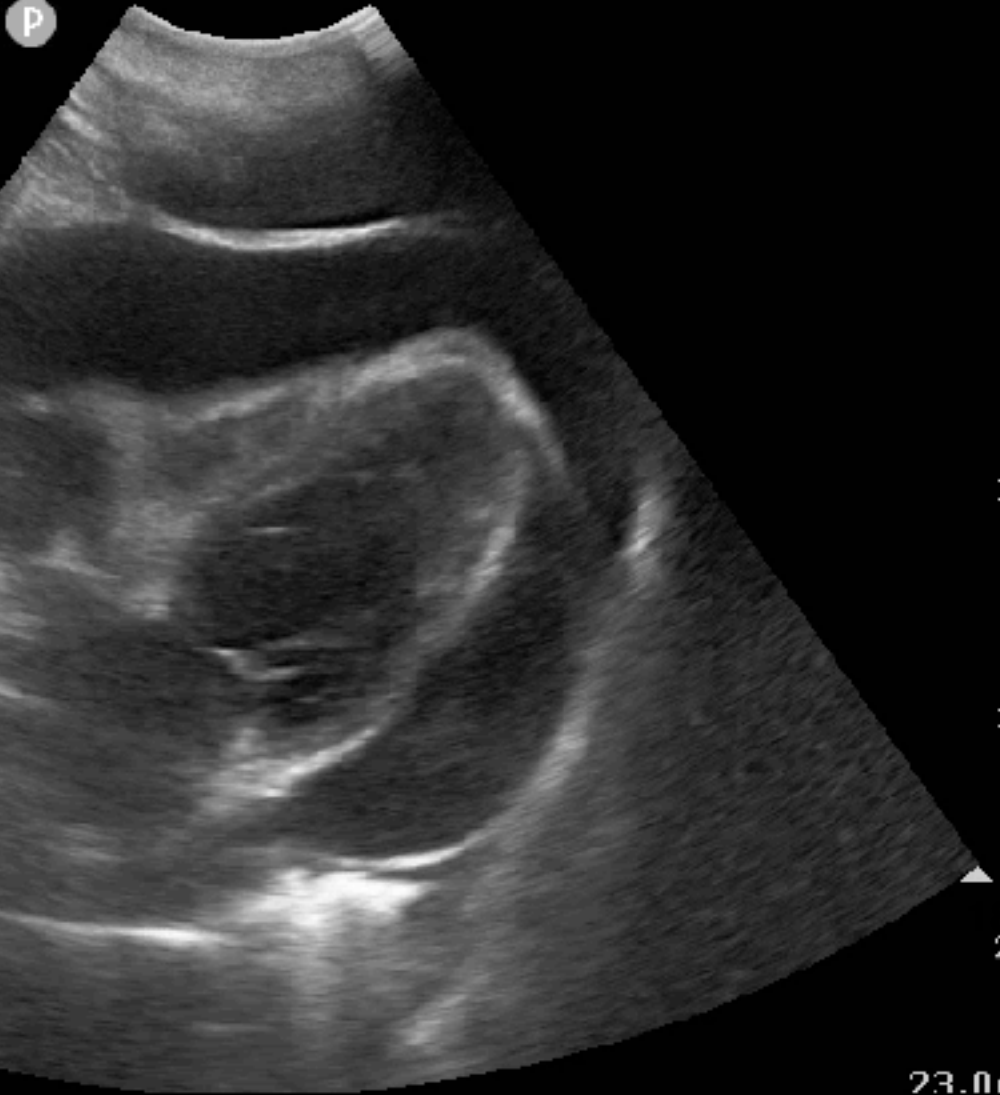
HD  
H0cm  
10.0cm  
0.56  
3/3/3



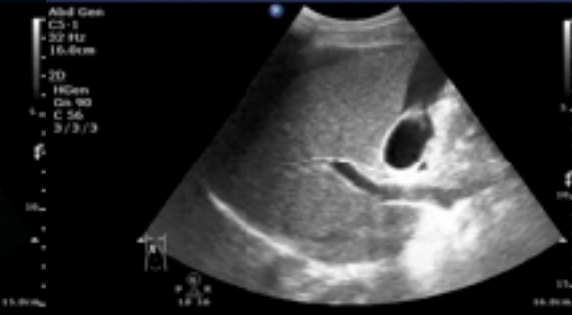
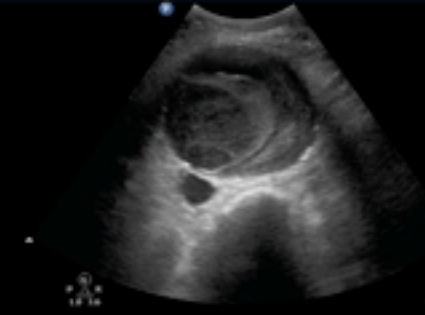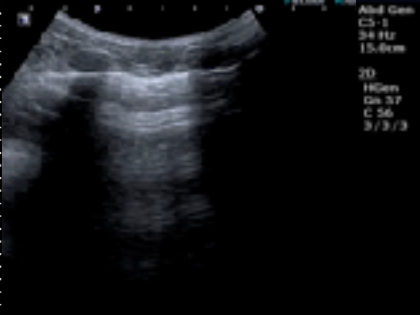
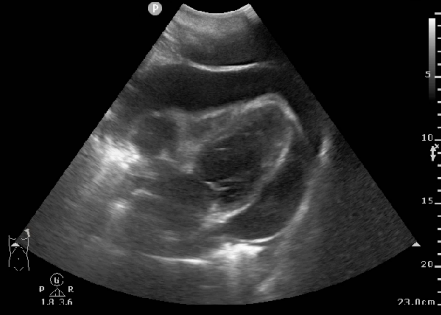
3/3/3



G  
P R  
1.8 3.6



5  
10  
15  
20  
23.0cm



HEART

LUNG

AORTA

FAST

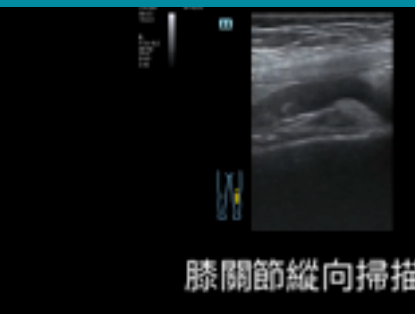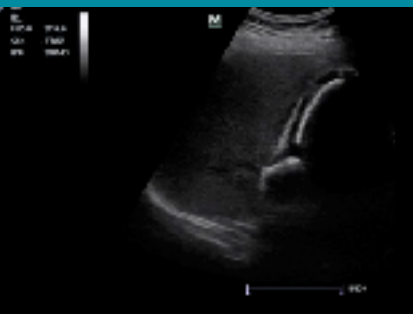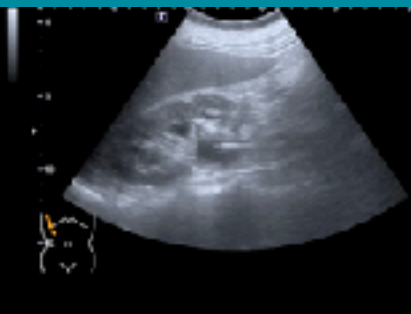KIDNEY

BILIARY

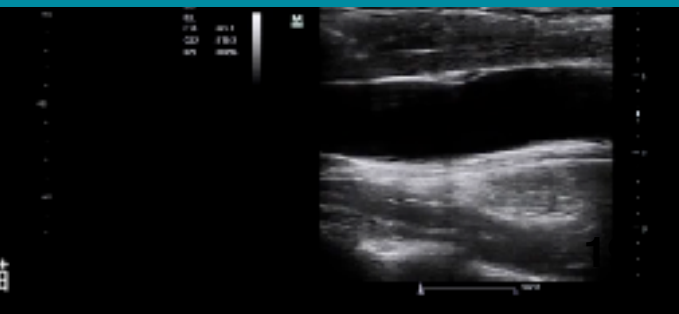KNEE

CVC

# 8 ESSENTIAL SKILLS

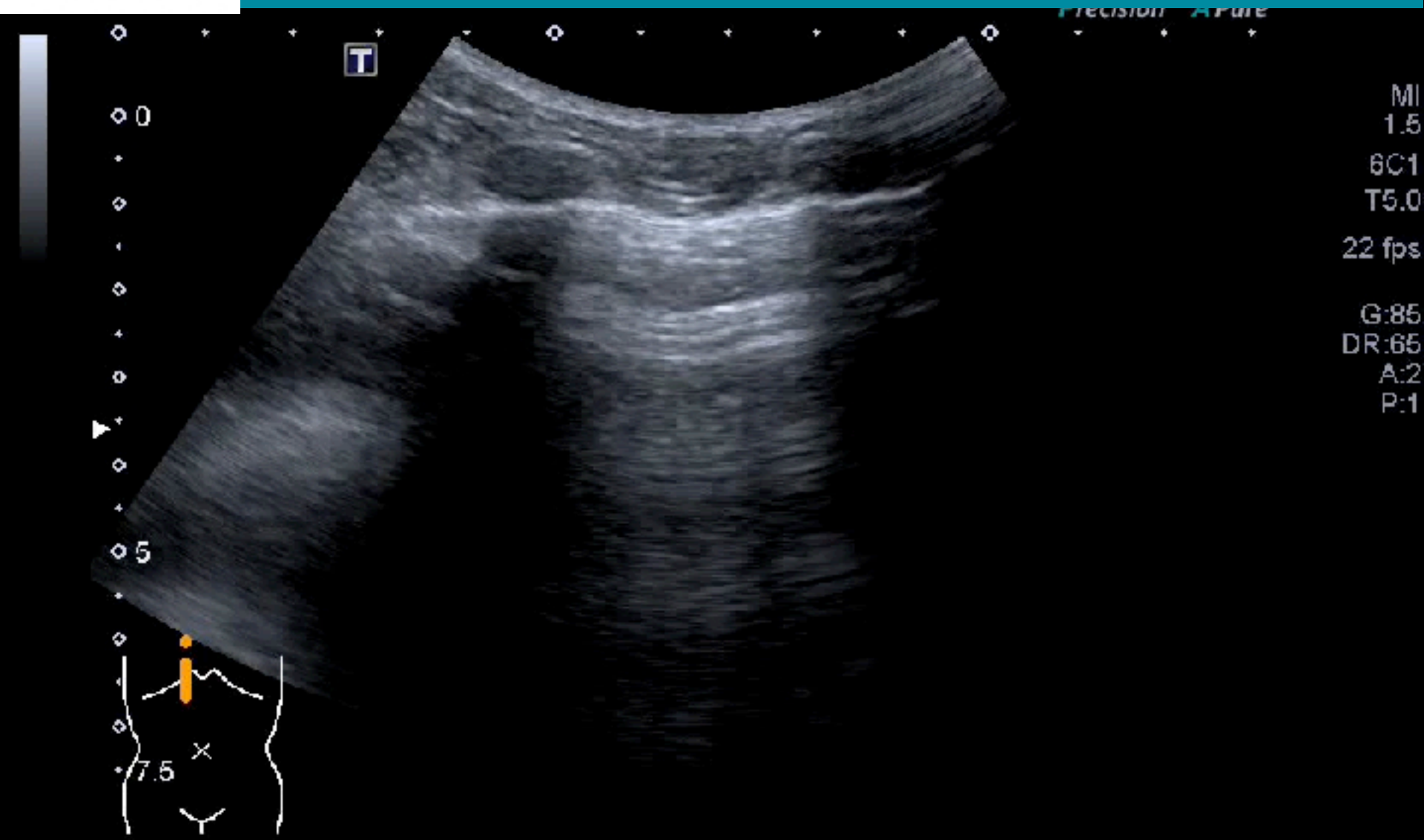


膝關節縱向掃描

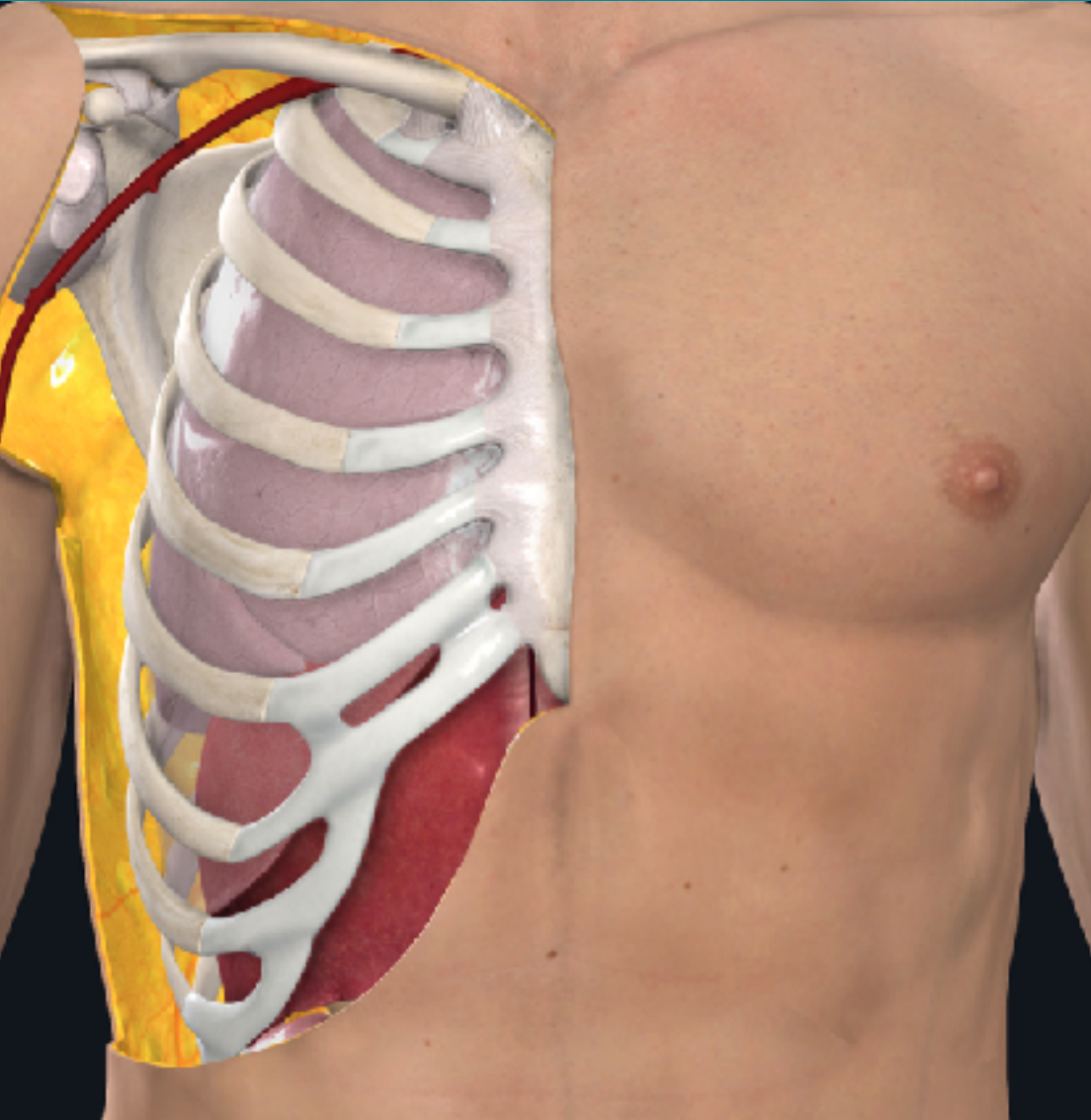




# LUNG

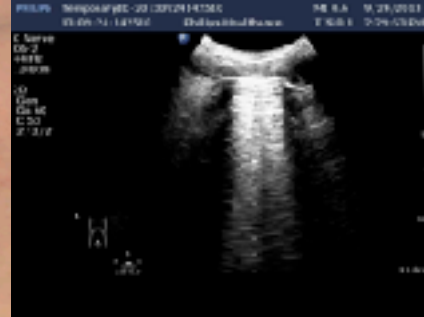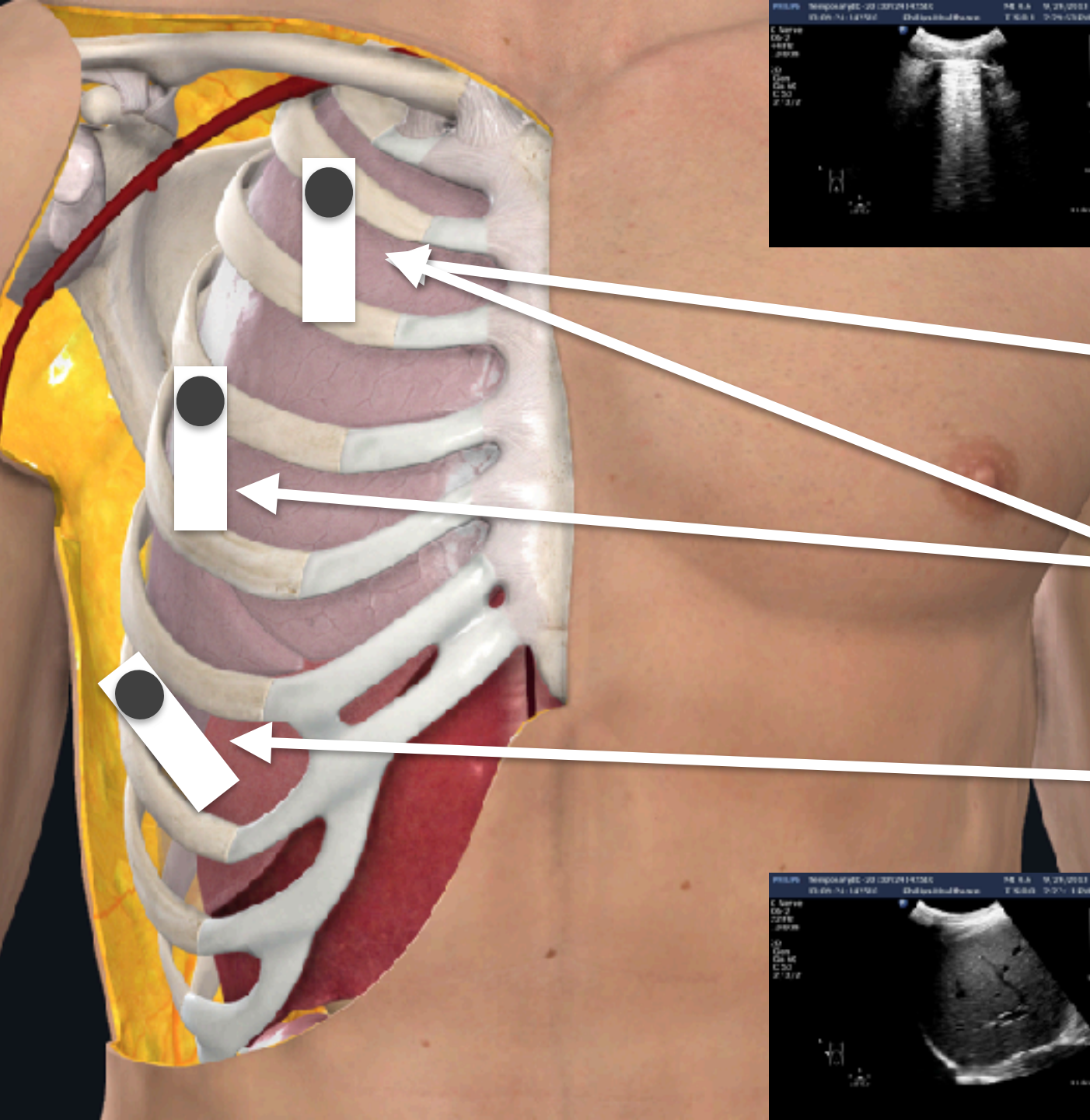


# LUNG



Dyspnea  
Chest pain

**PTX**  
**AIS**  
**PLE**

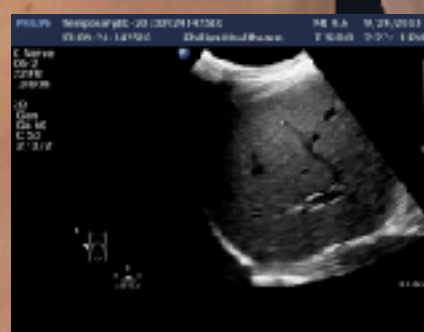


**AIR**

**PTX**

**AIS**

**PLE**



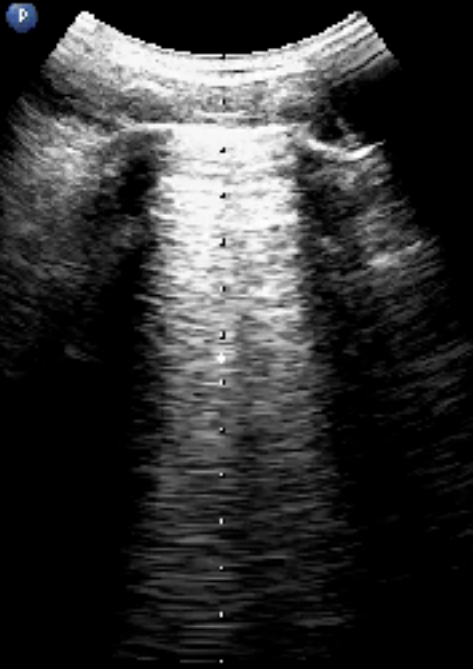
**FLUID**

# NORMAL LUNG

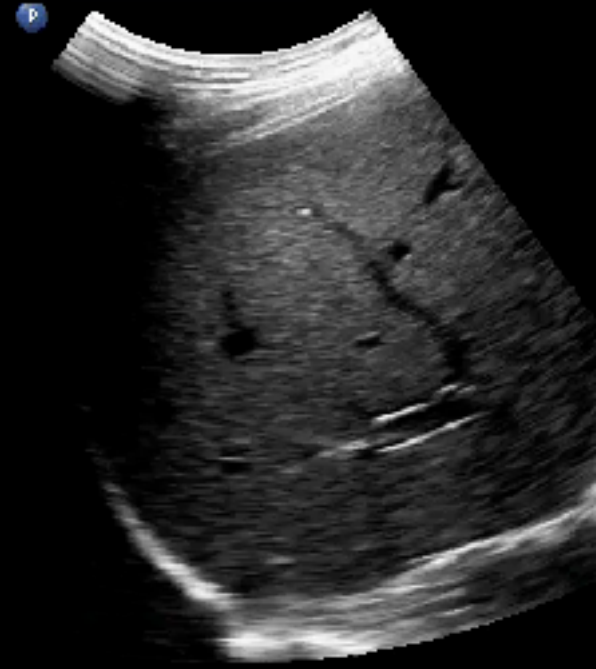
## 肋膜/滑動

## 橫膈膜/移動

TemporaryID 20130924142510 MT 0.6 9: PHILIPS TemporaryID 20130924142510 MT 0.6 9:24  
13 09 24 142510 Philips Healthcare TIS 0.1 2: 13 09 24 142510 Philips Healthcare TIS 0.0 2:27



C Nerve  
CG-2  
22 Hz  
13.0cm  
  
2D  
Gen  
Gr 60  
C 53  
2/3/2

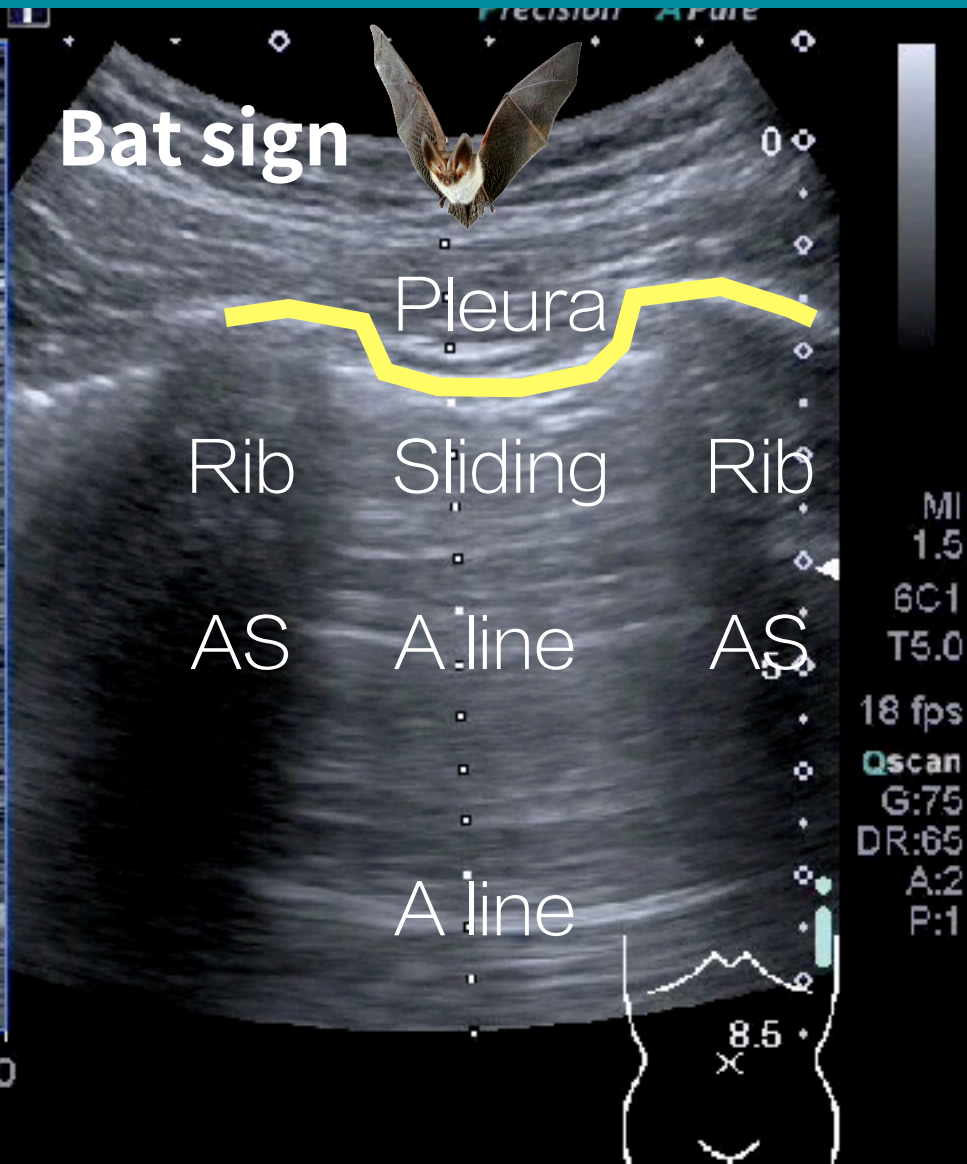
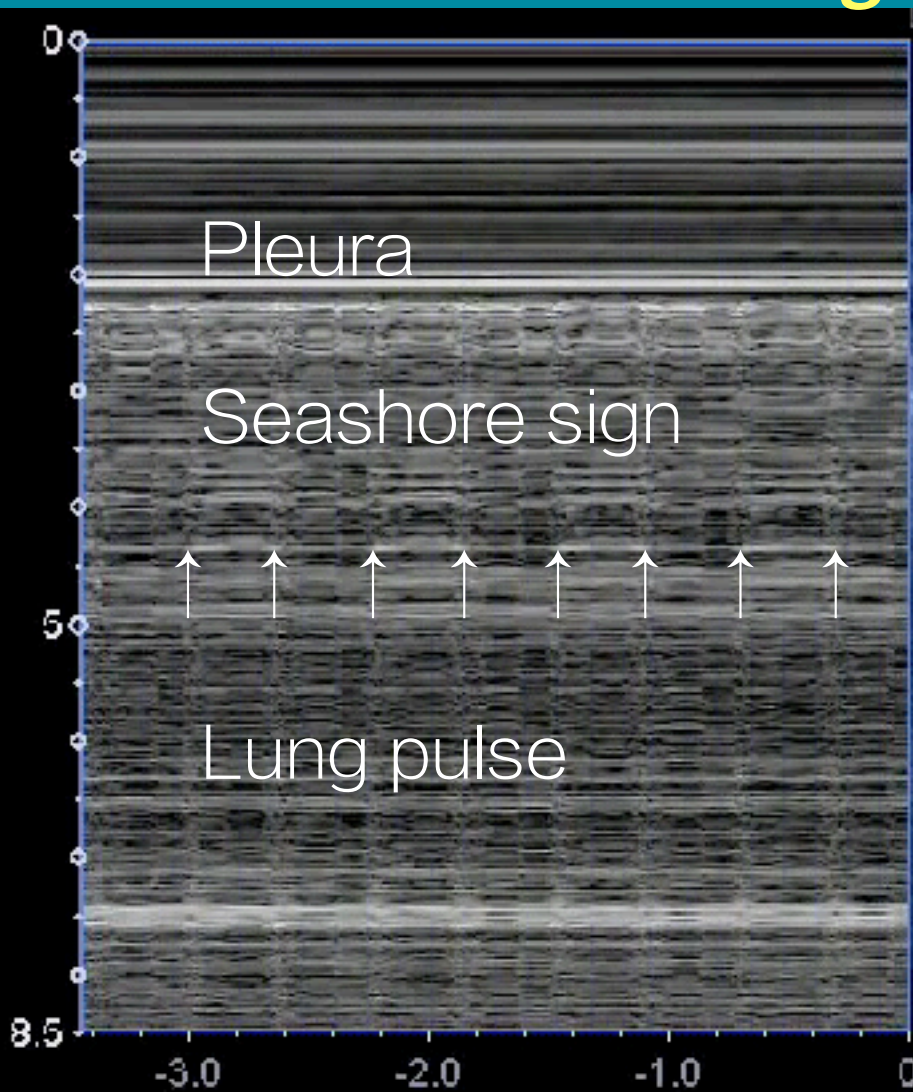


G  
P ▲ K  
2.0 G.0

G  
P ▲ K  
2.0 G.0

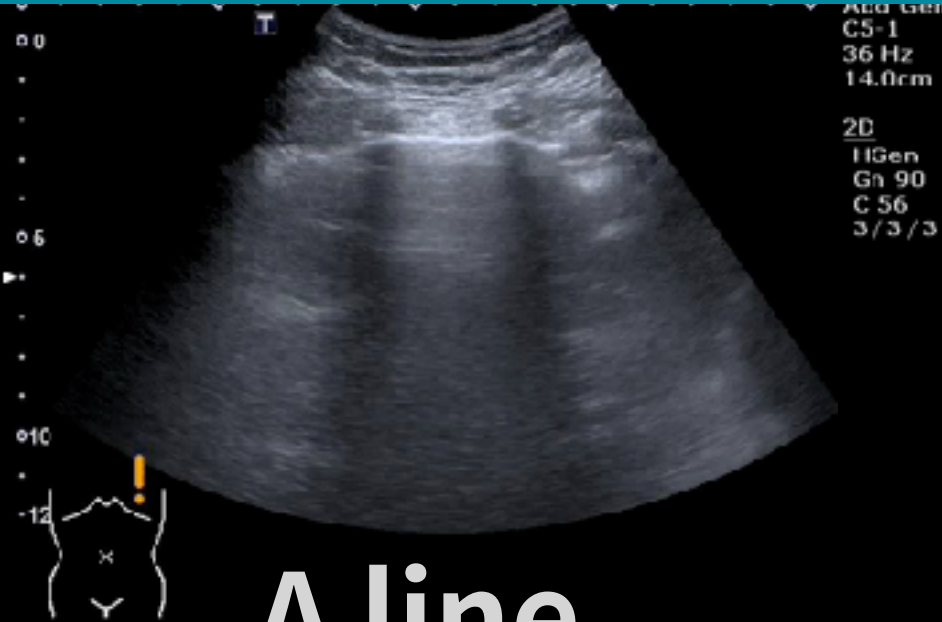# NORMAL LUNG

## Sliding + A lines



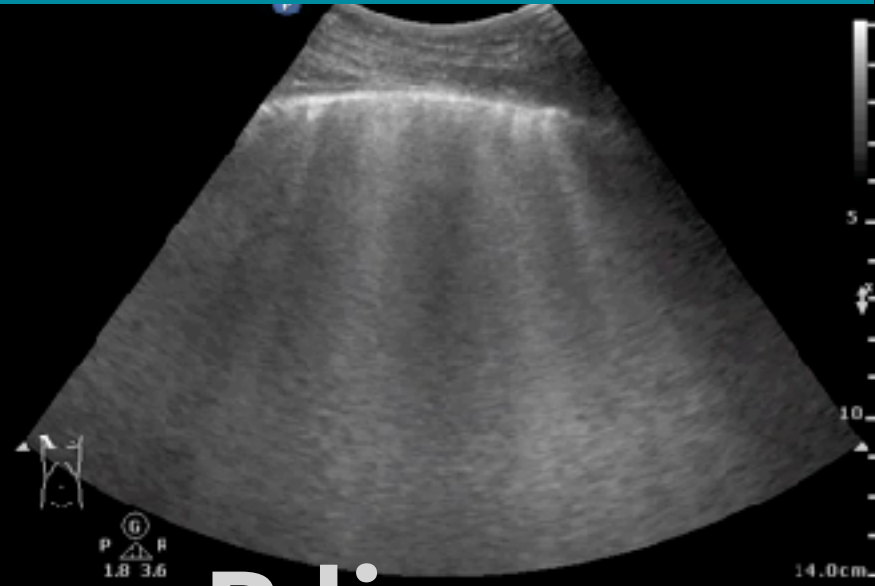

# SLIDING FIRST



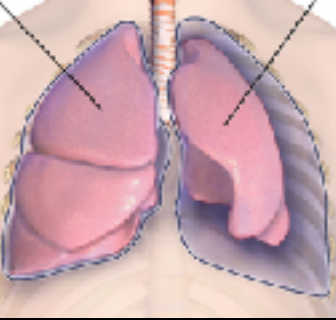
A line

肋膜下  
水平線  
等距離



B line

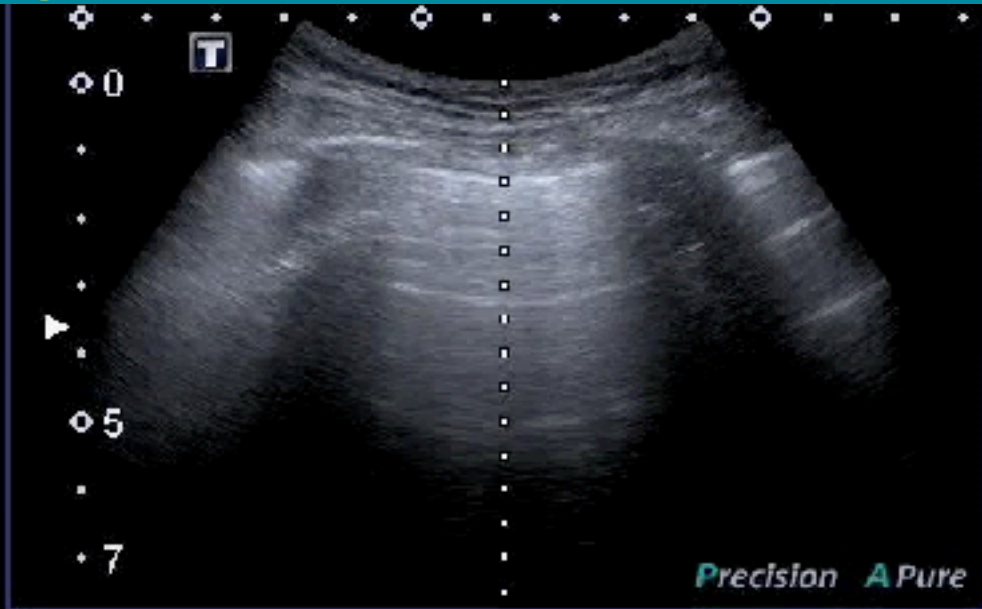
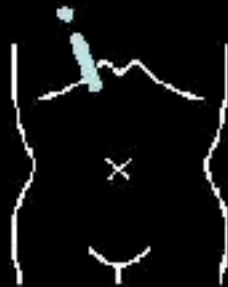肋膜下  
垂直線  
大於三




# PNEUMOTHORAX ?

Sliding + A lines = Normal pleura

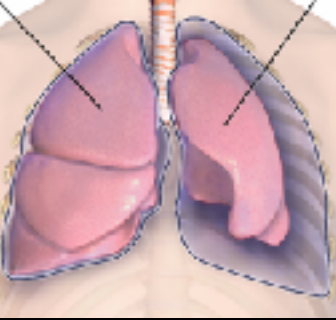
Seashore sign



MI:1.5  
6C1  
T5.0  
18 fps  
Qscan  
G:71  
DR:65  
A:2  
P:1



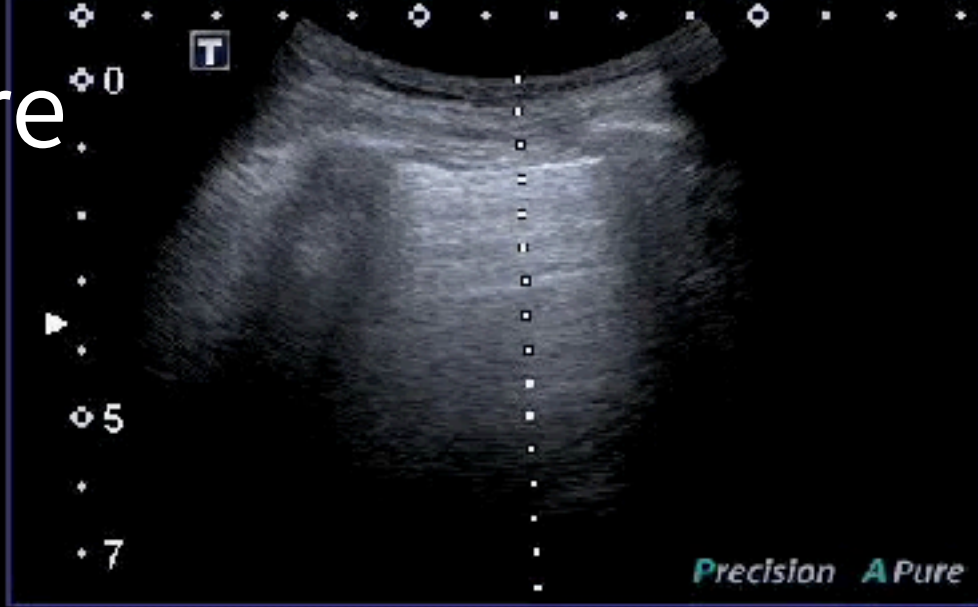
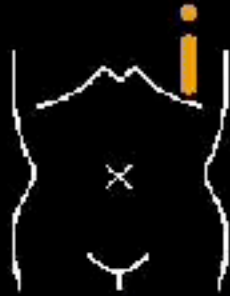0  
5  
7



# PNEUMOTHORAX ?


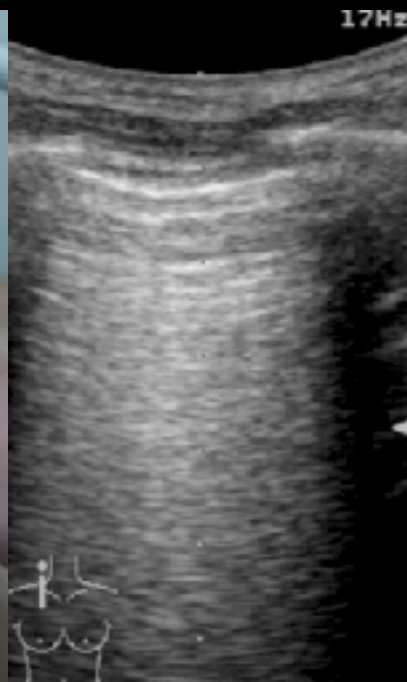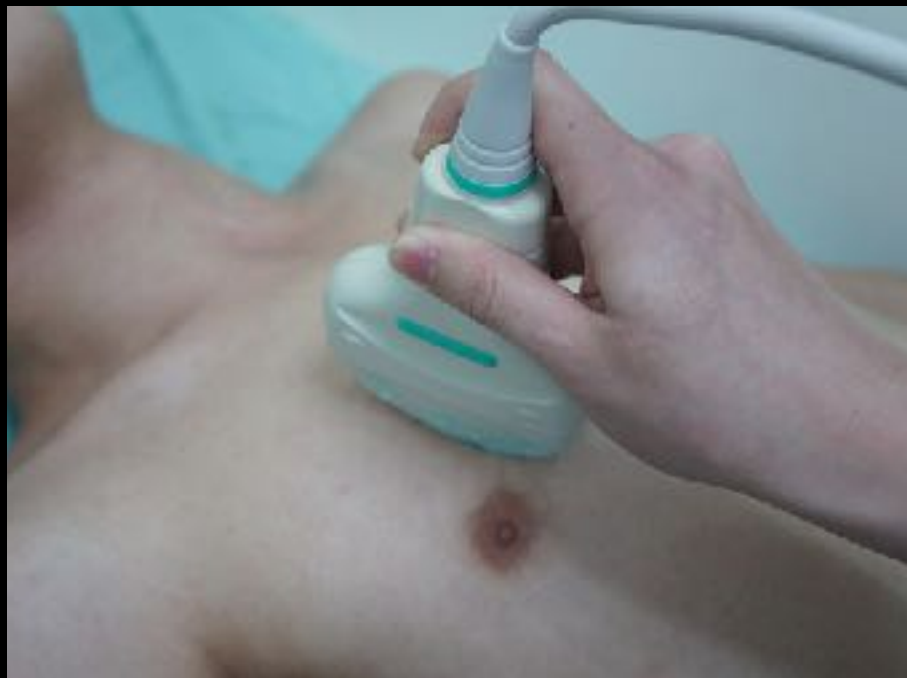
No Sliding + A lines >> Consider PTX

Stratosphere  
sign

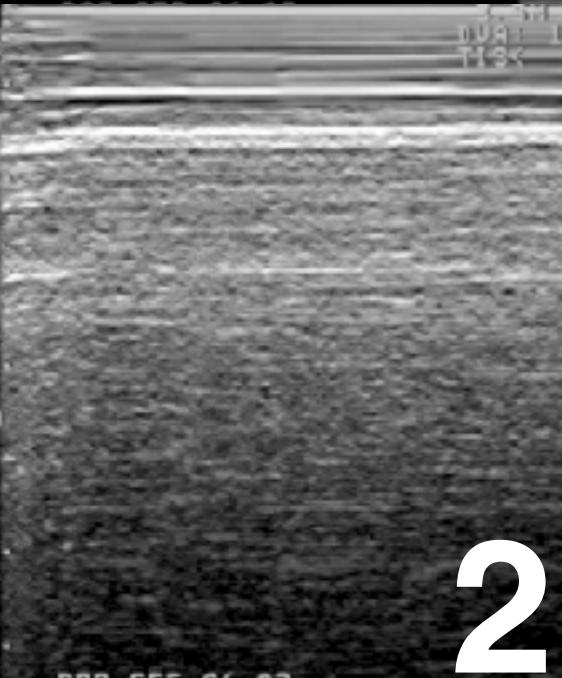
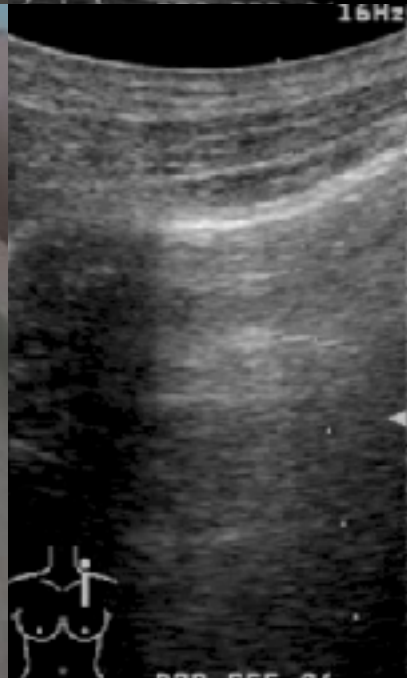
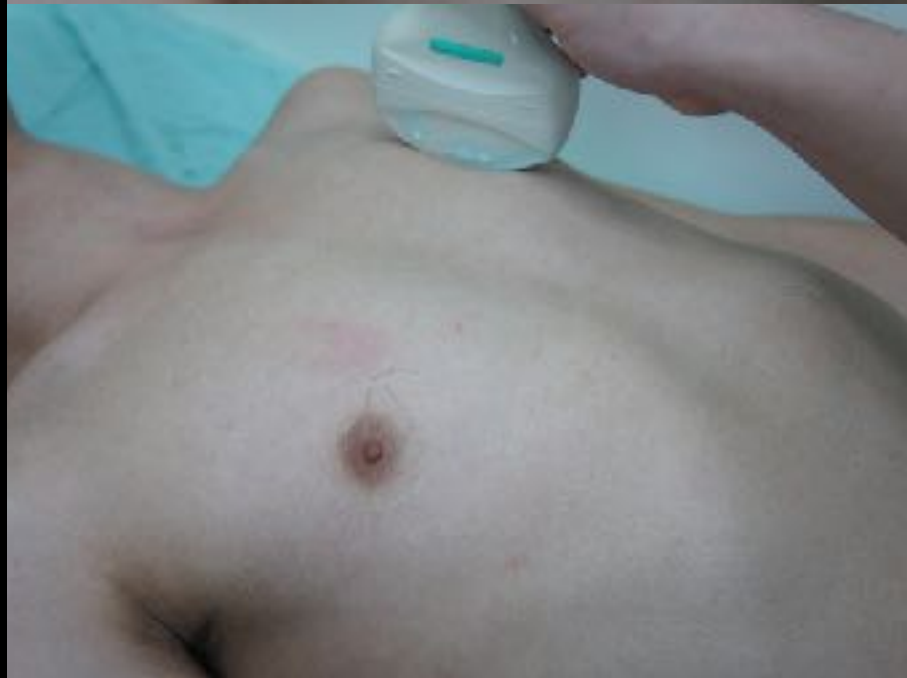
MI:1.5  
6C1  
T5.0  
18 fps  
Qscan  
G:71  
DR:65  
A:2  
P:1





1



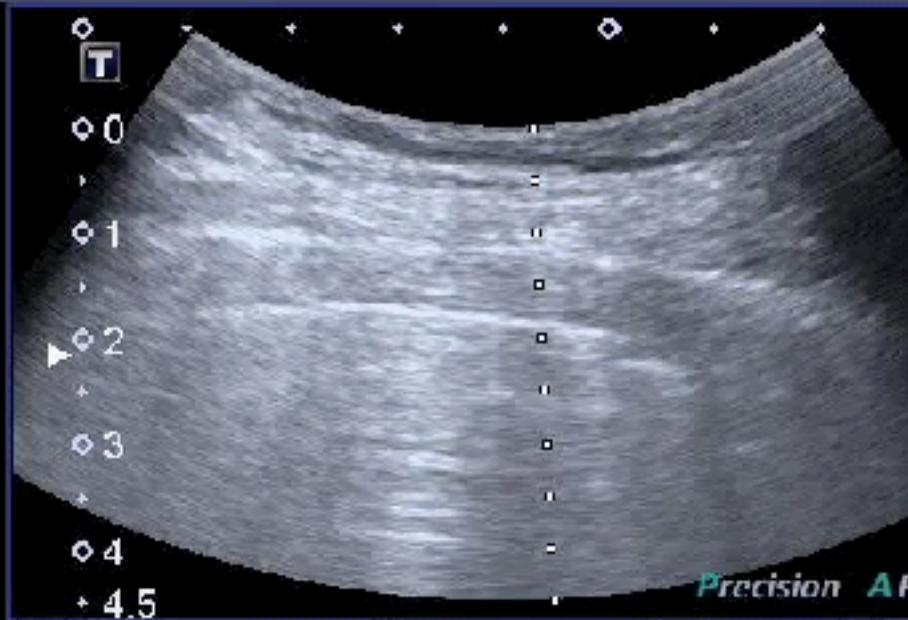
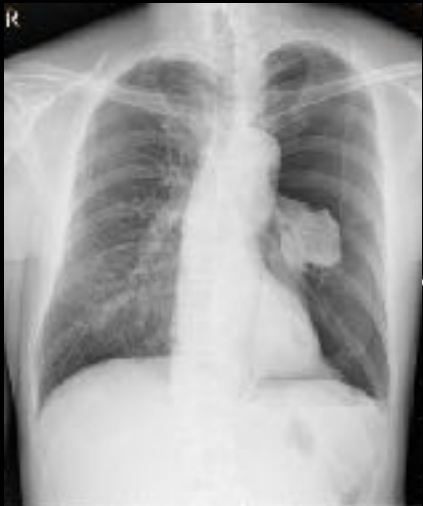2

R08 055 C4

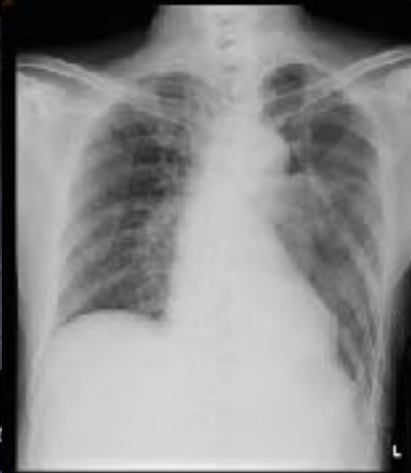
R08 055 C6 A3

# Lung Point

**A**



**B**



**PTX**

**SBP Point**

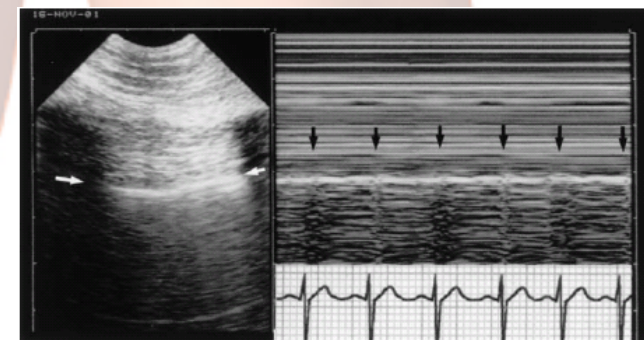
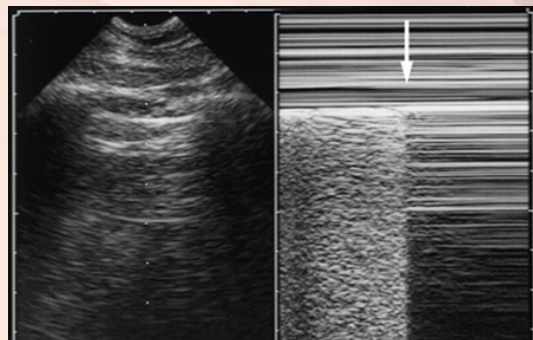
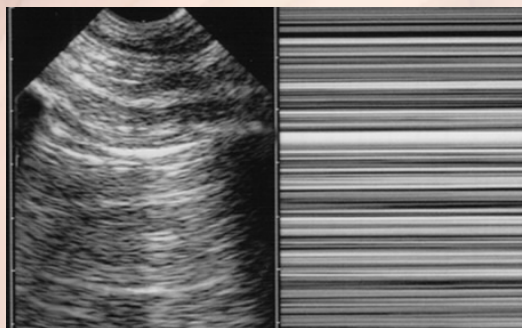
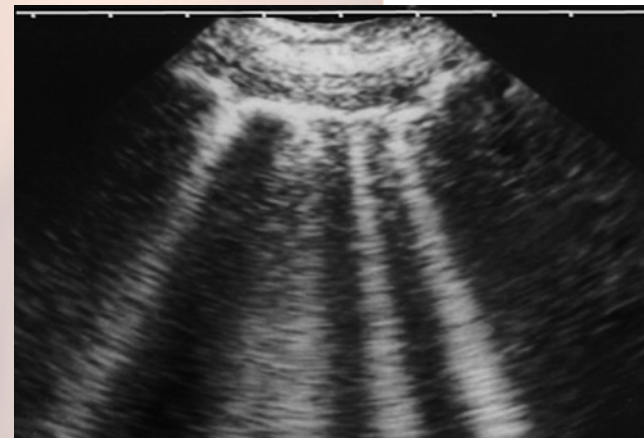
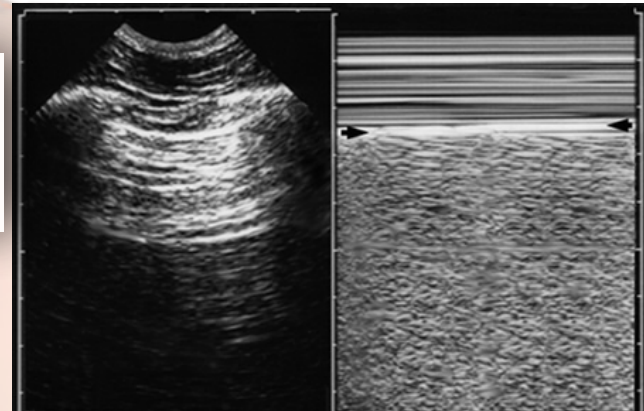
**4**

No sliding

No B lines

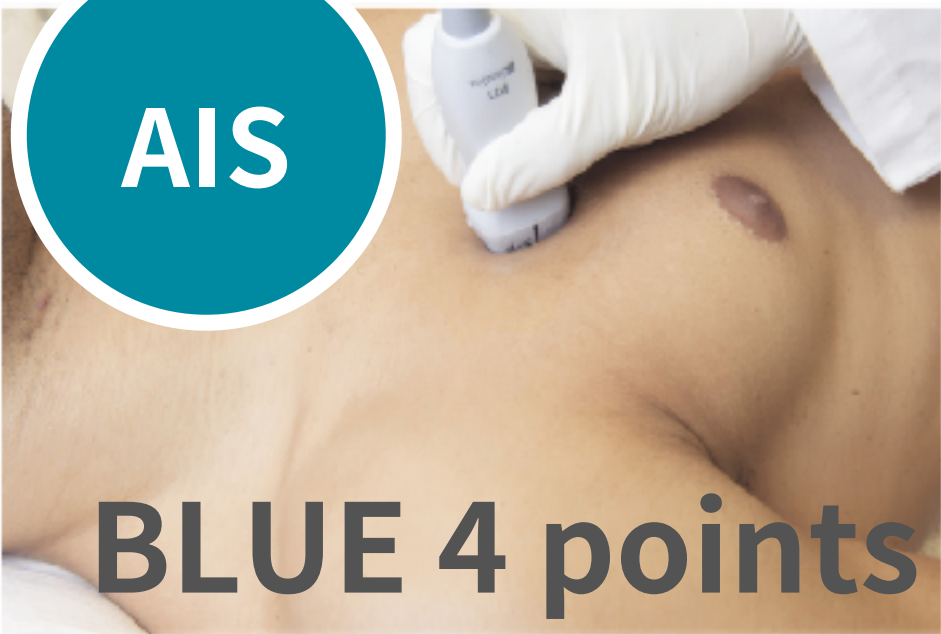No pulse

Lung point



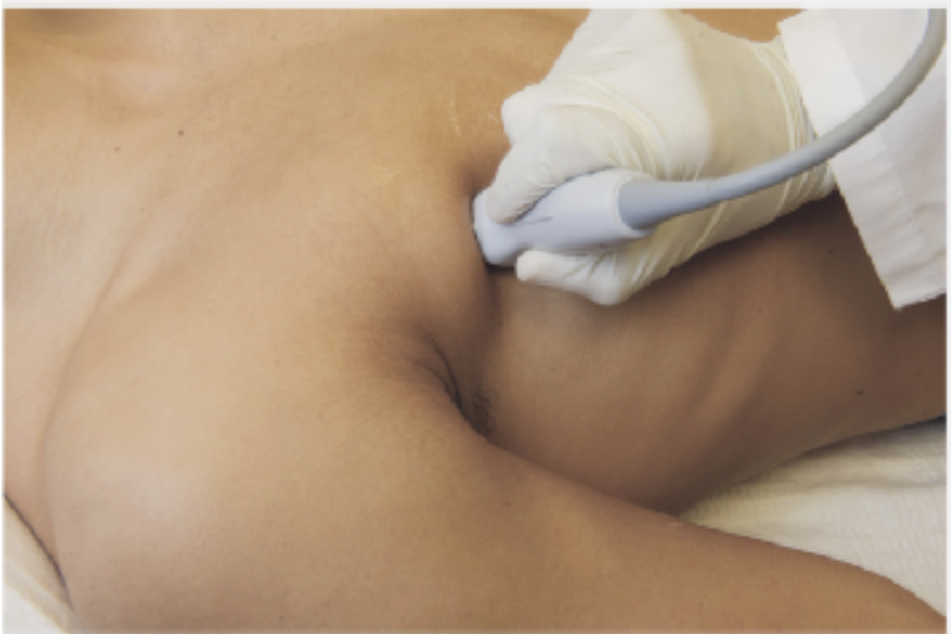**AIS**

Point 1

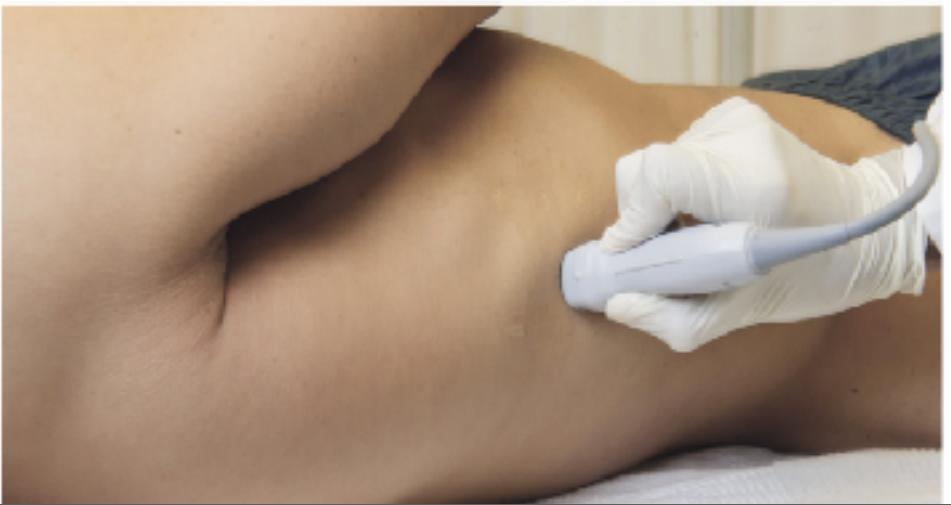

**BLUE 4 points**

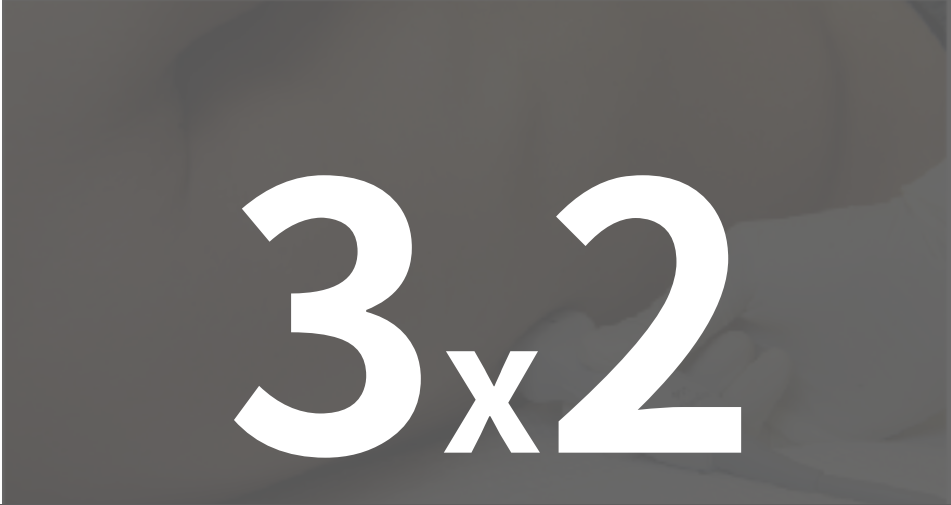Point 2



Point 3



Point 4

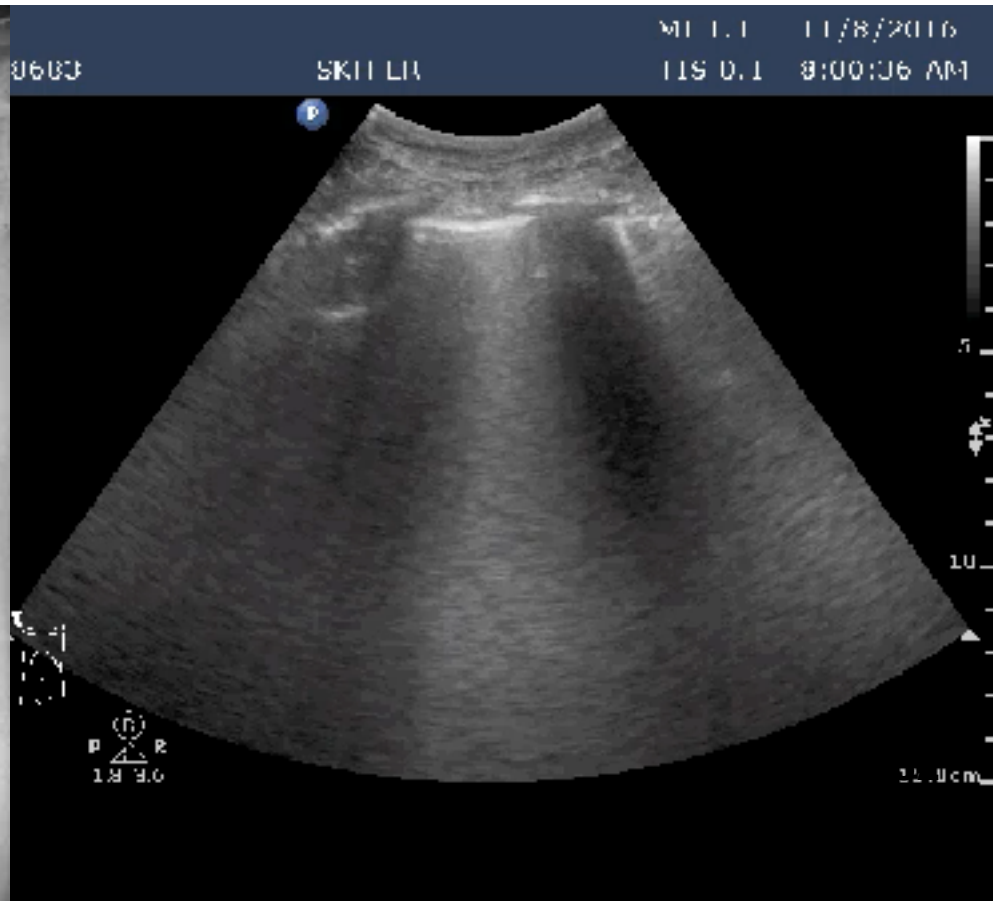
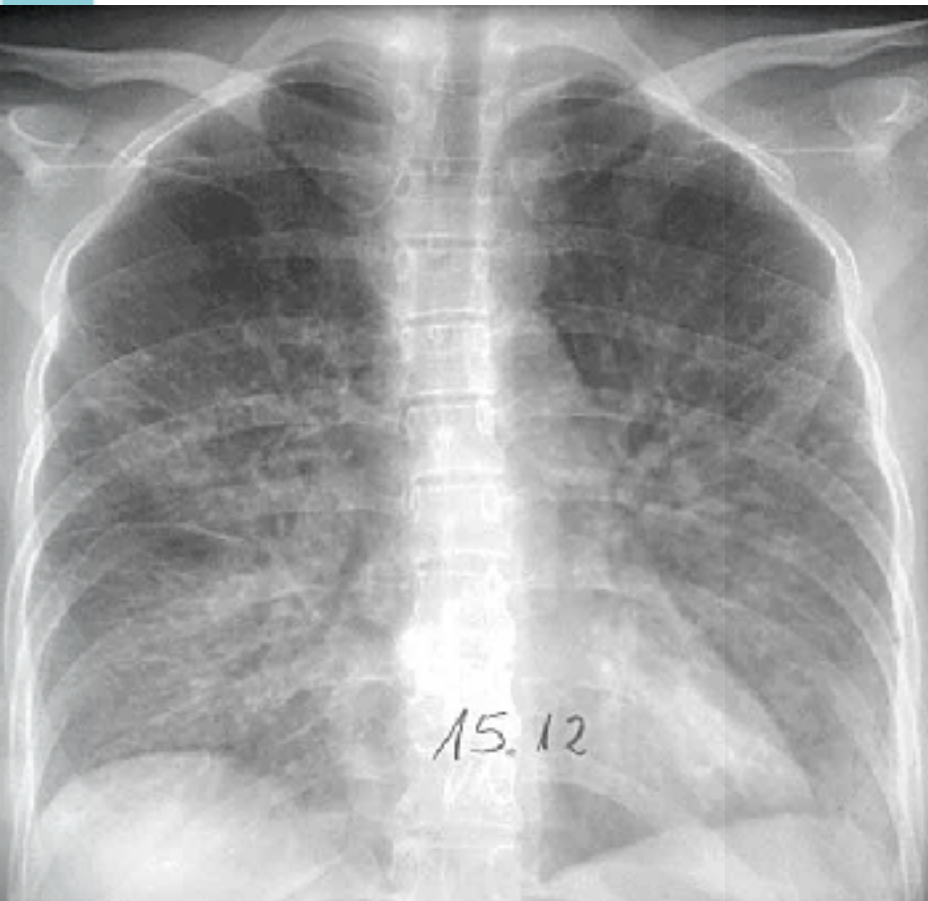


**3x2**

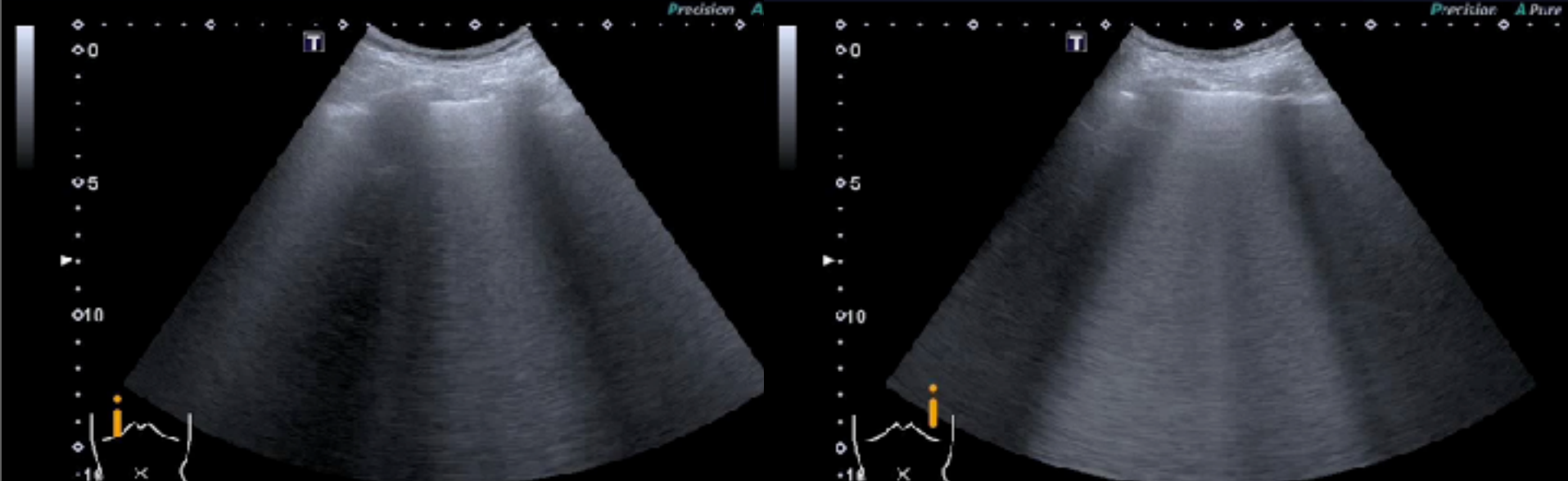
**Alveolar Interstitial Syndrome**

# LUNG ROCKETS

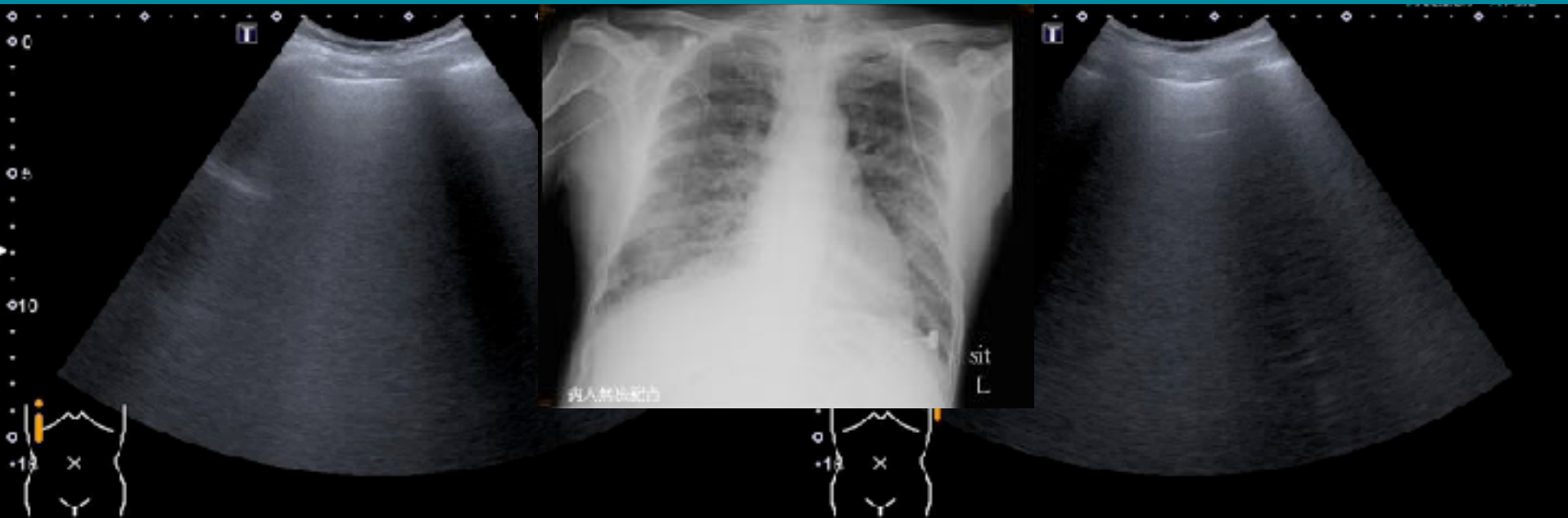
ICS > 3 B lines



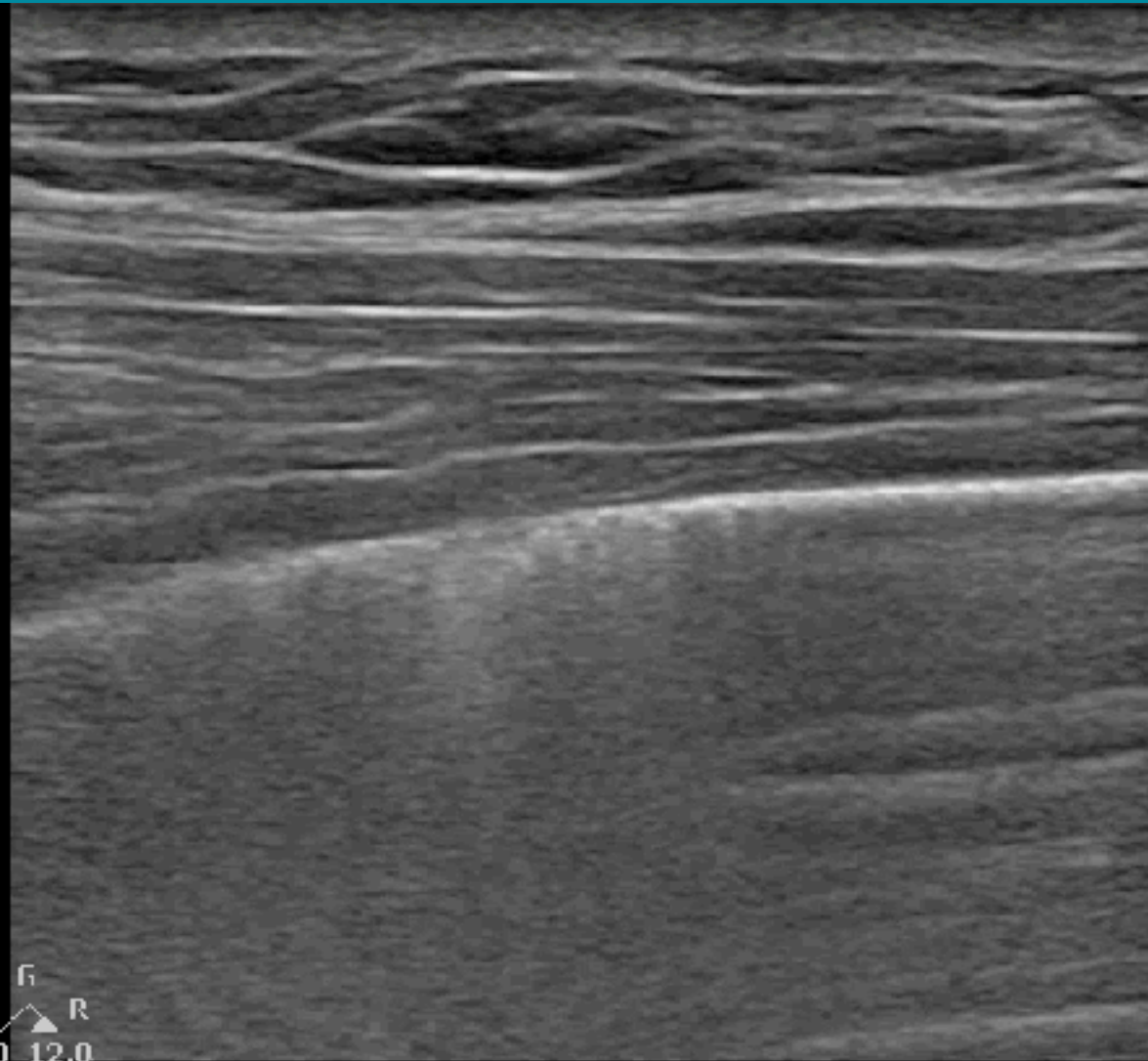




# ALEVOLAR INTERSTITIAL SYNDROME



# AIS: Localized



**Pneumonia**

**Pneumonitis**

**Atelectasis**

**Contusion**

**Infarction**

**Pleural disease**

**Neoplasia**

**Normal lung**

# PLEURAL EFFUSION

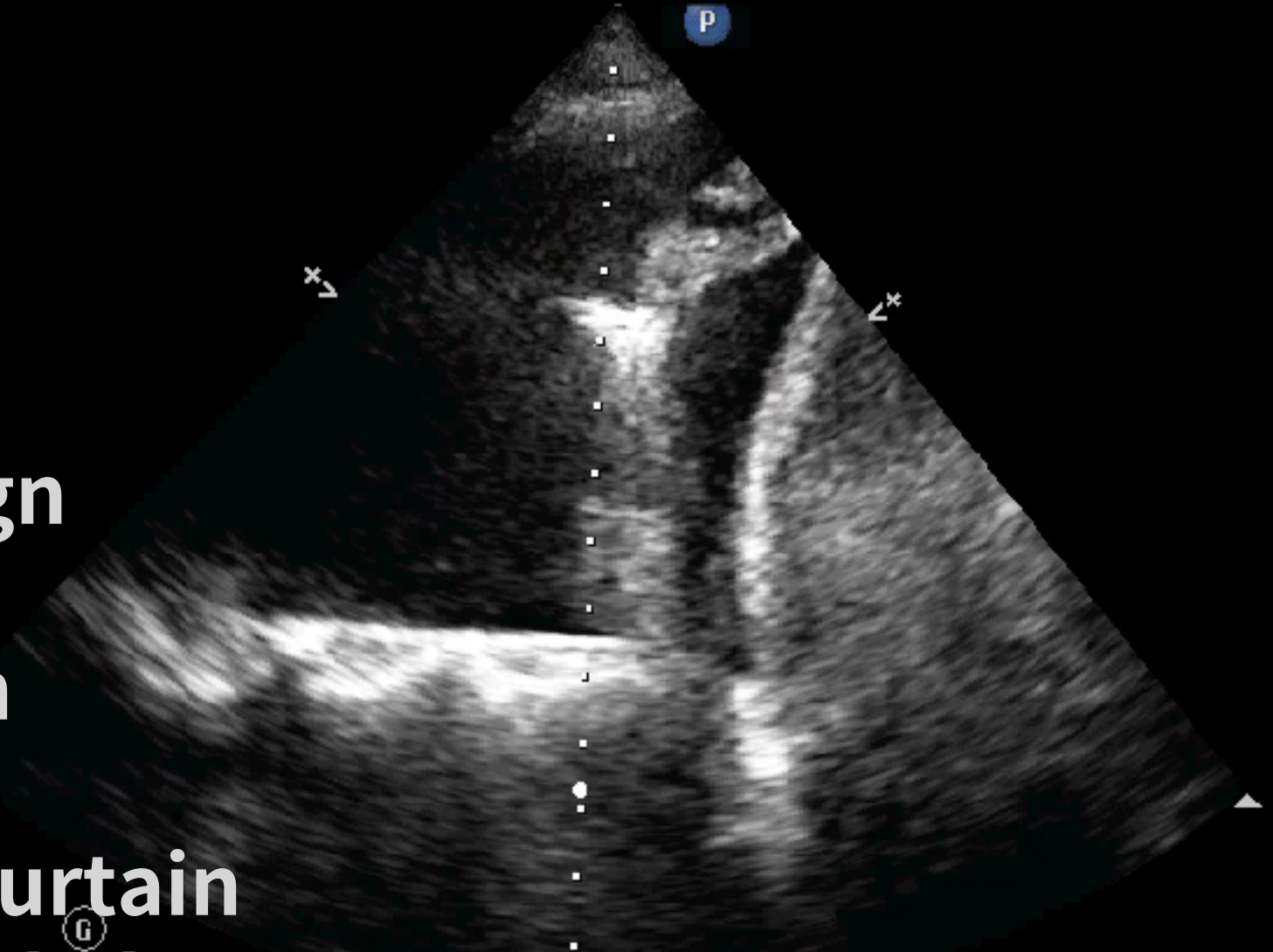
Adult Echo2  
G-1  
: Hz  
5.0cm

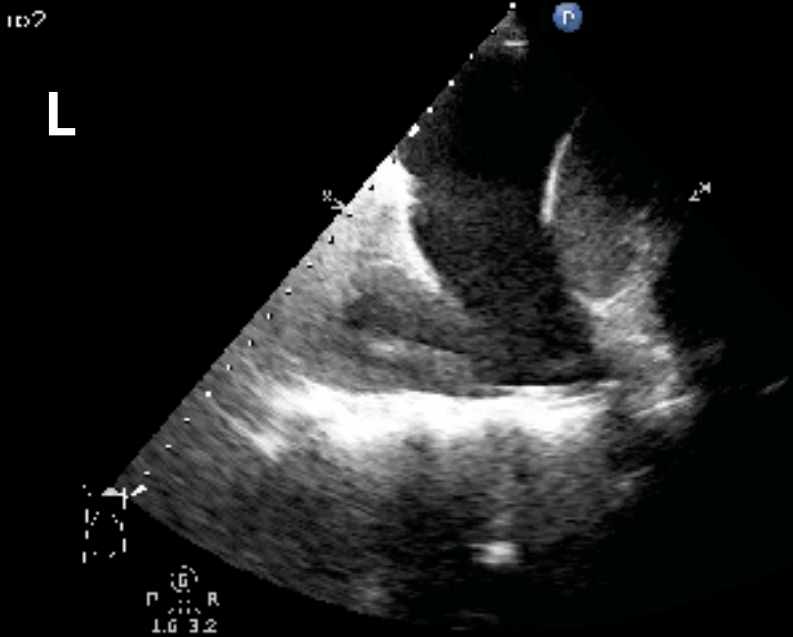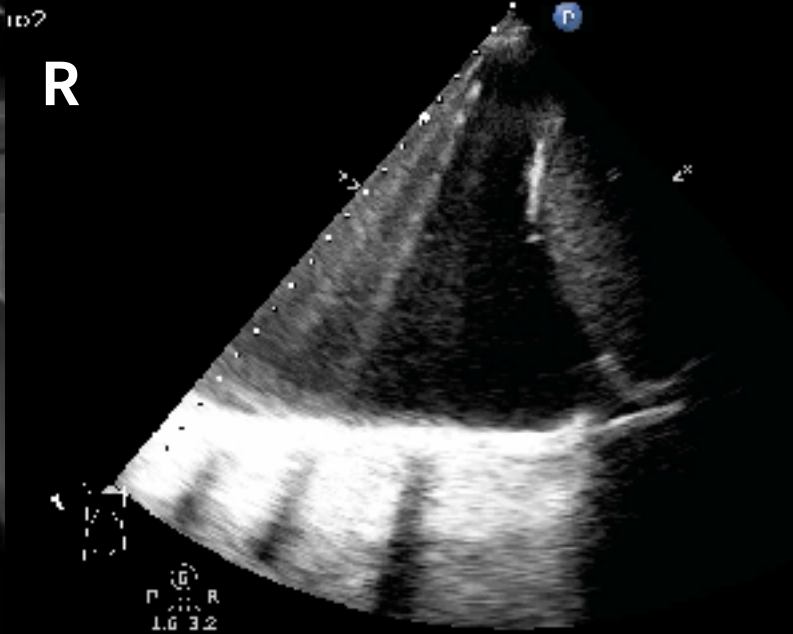
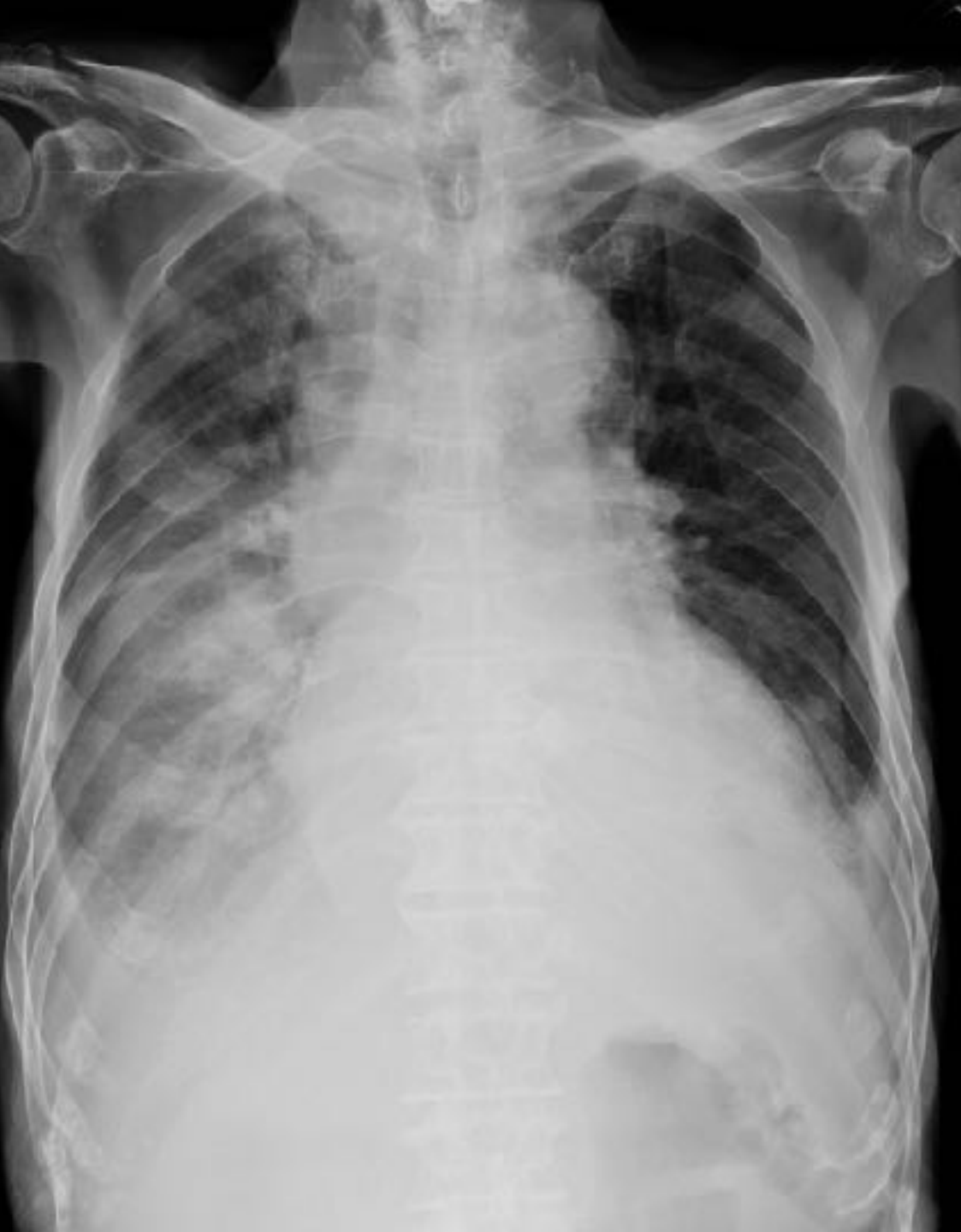Gen  
n 30  
50  
/ 2 / 0

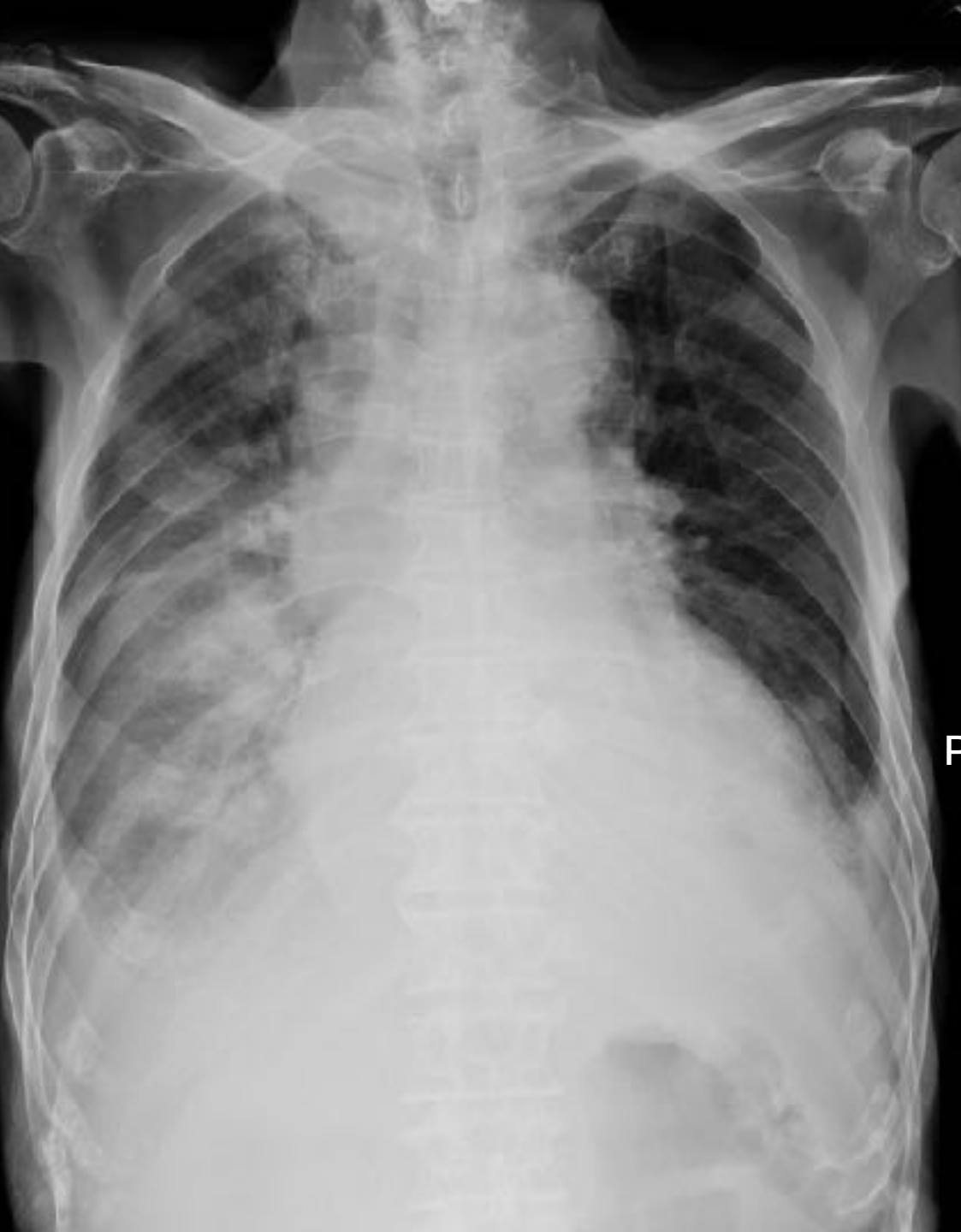**Spine sign**

**Jelly fish**

**Loss of curtain**



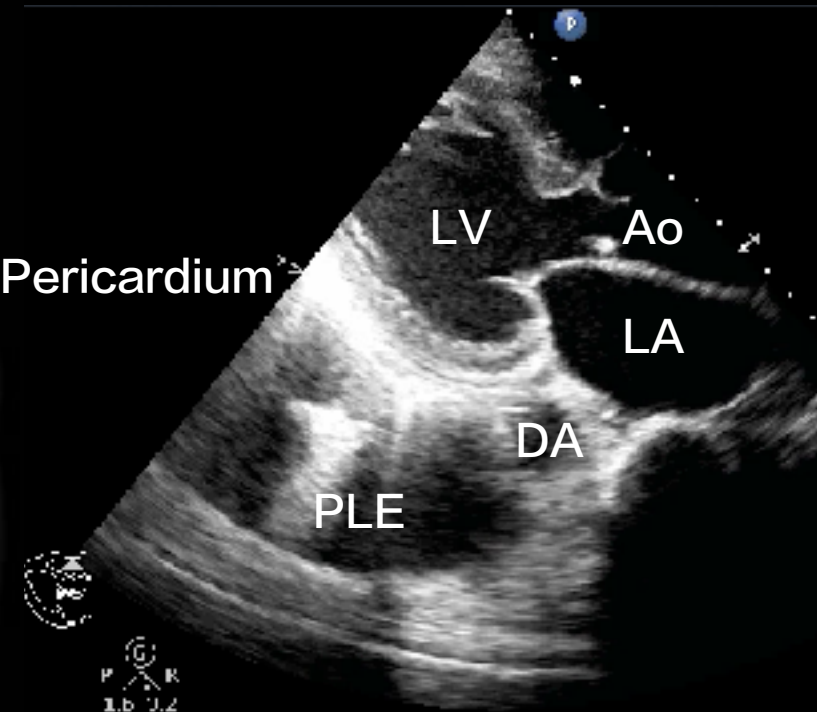




# D aorta

## Pericardial vs Pleural

Pericardium



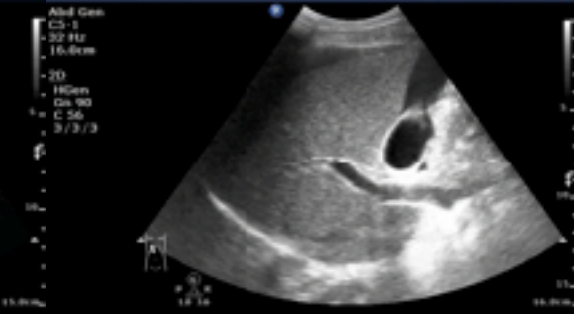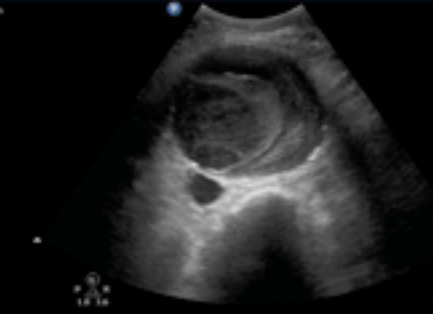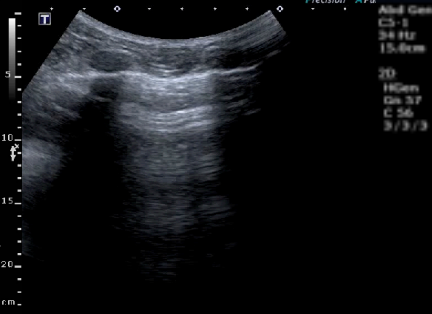
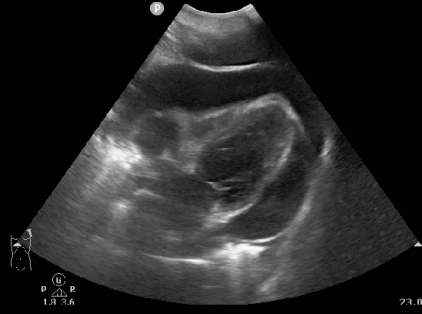LV

Ao

LA

DA

PLE



HEART

LUNG

AORTA

FAST

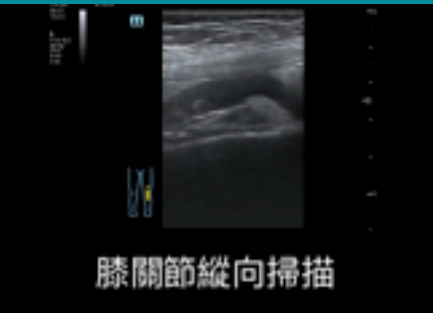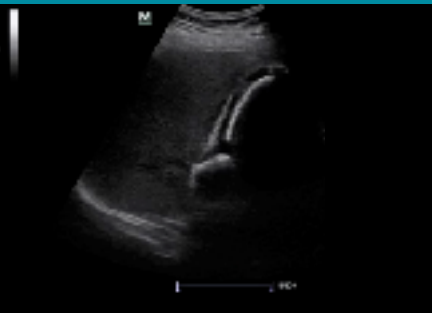
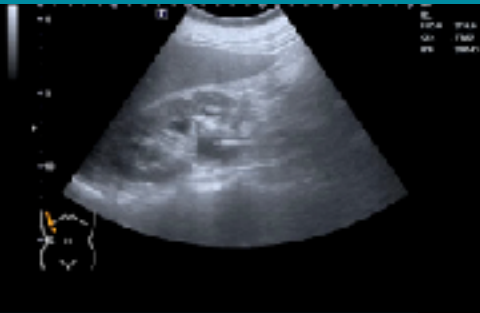KIDNEY

BILIARY

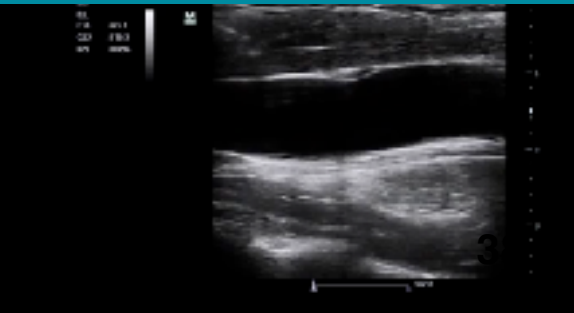
KNEE

CVC

# 8 ESSENTIAL SKILLS



膝關節縱向掃描



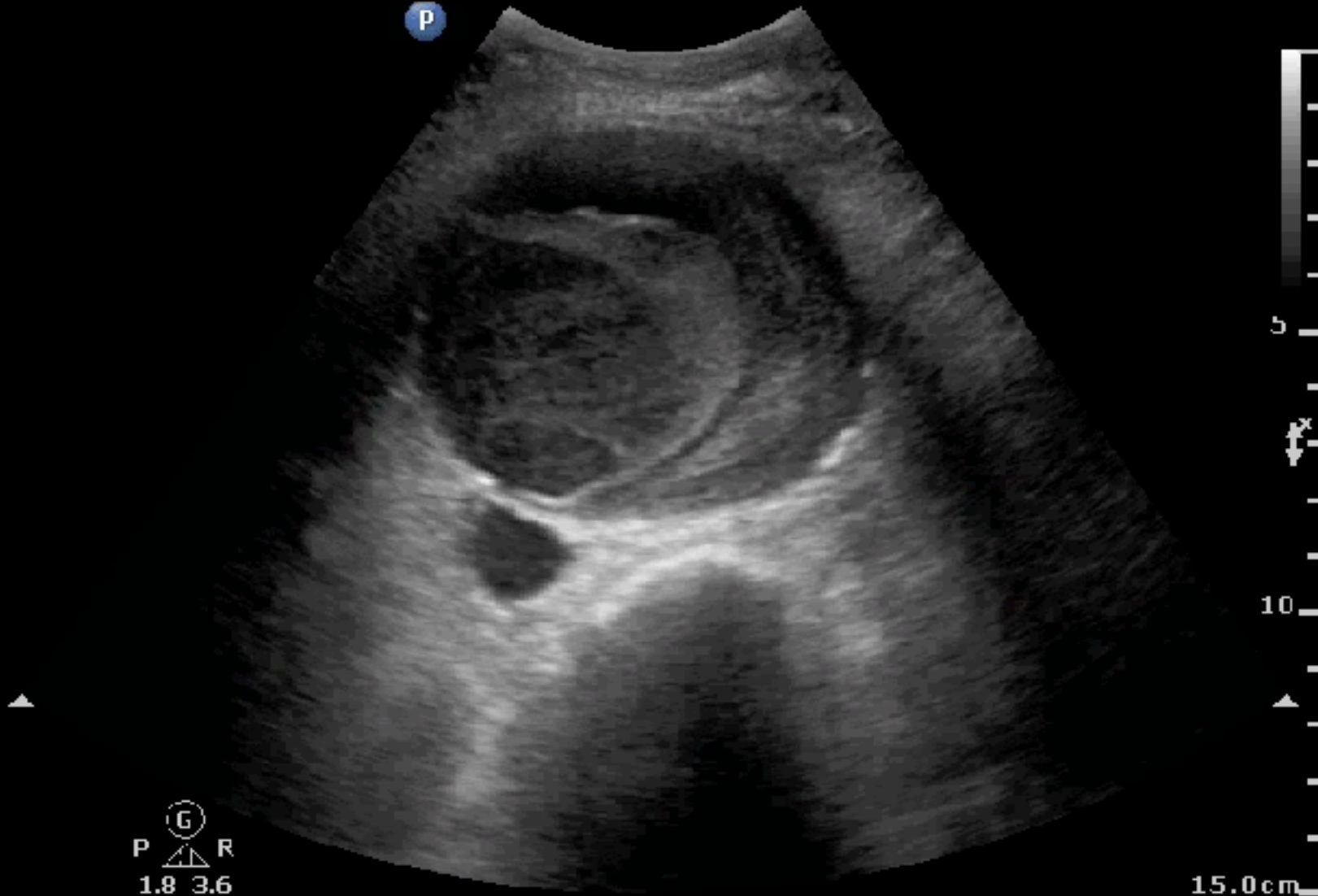


# AORTA

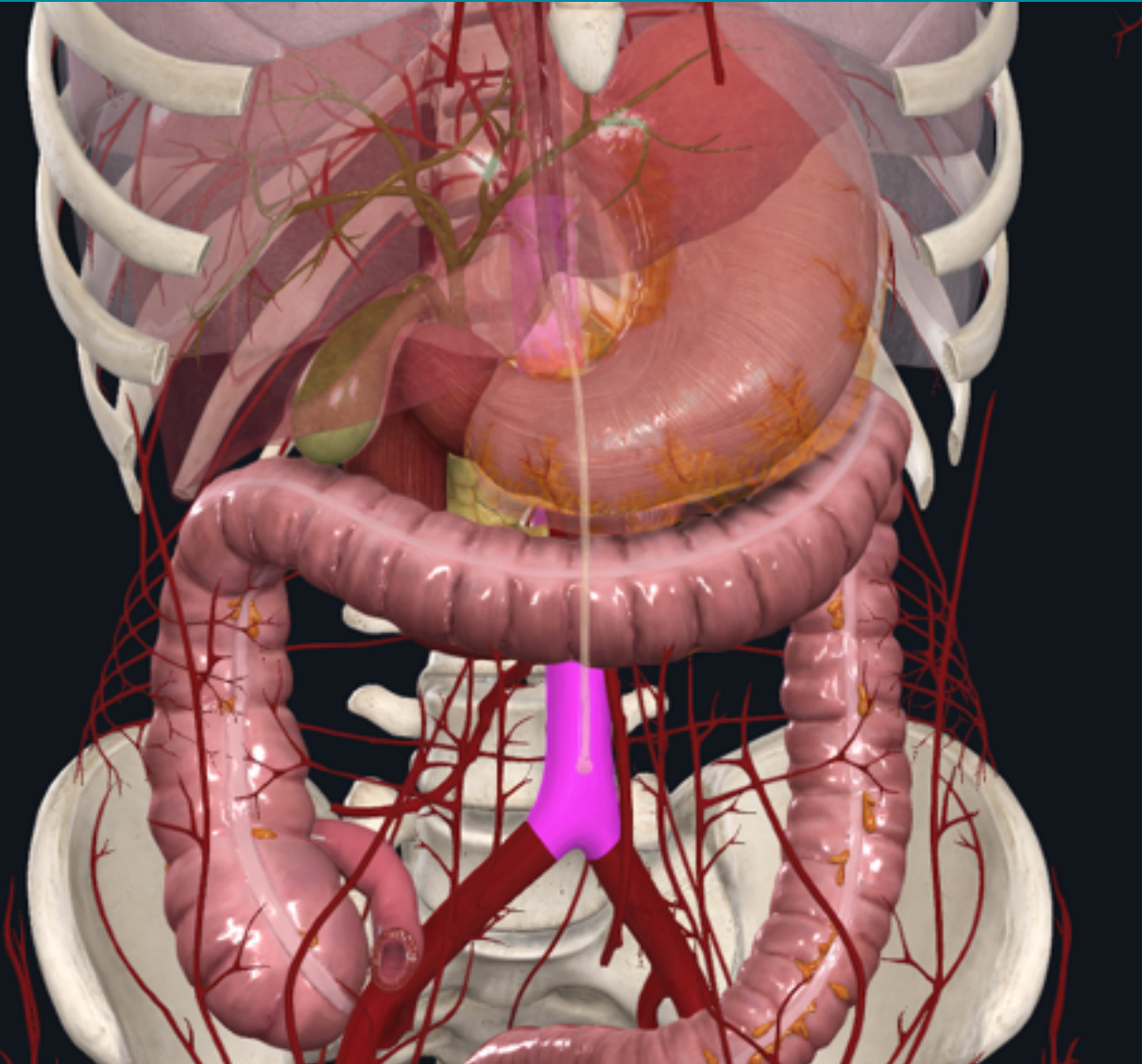
Abd Gen  
C.5-1  
34 Hz  
15.0cm

2D

HGen  
Gn 57  
C 56  
3 / 3 / 3



# AORTA

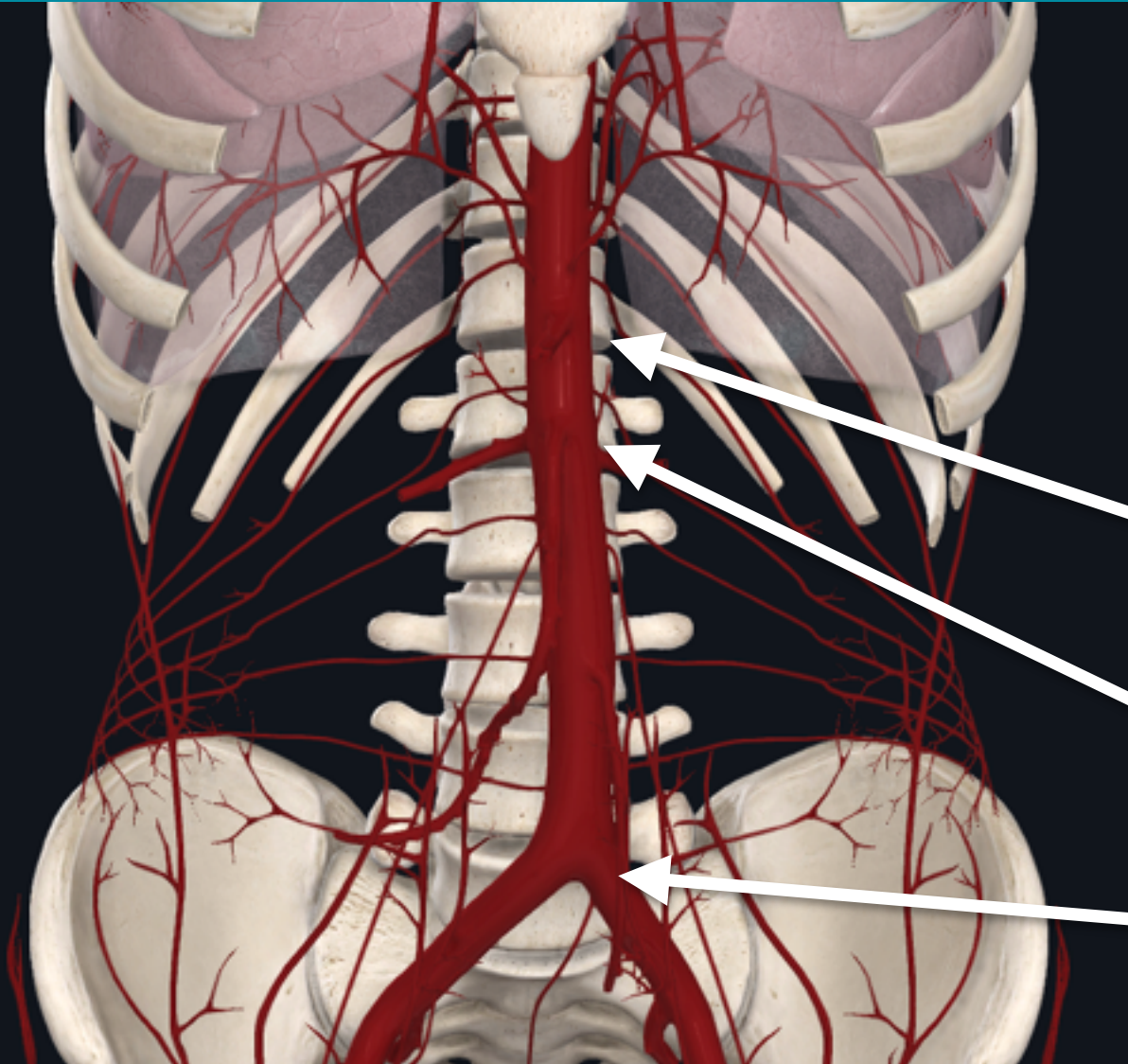


Pain  
Shock

**AAA**



# AORTA



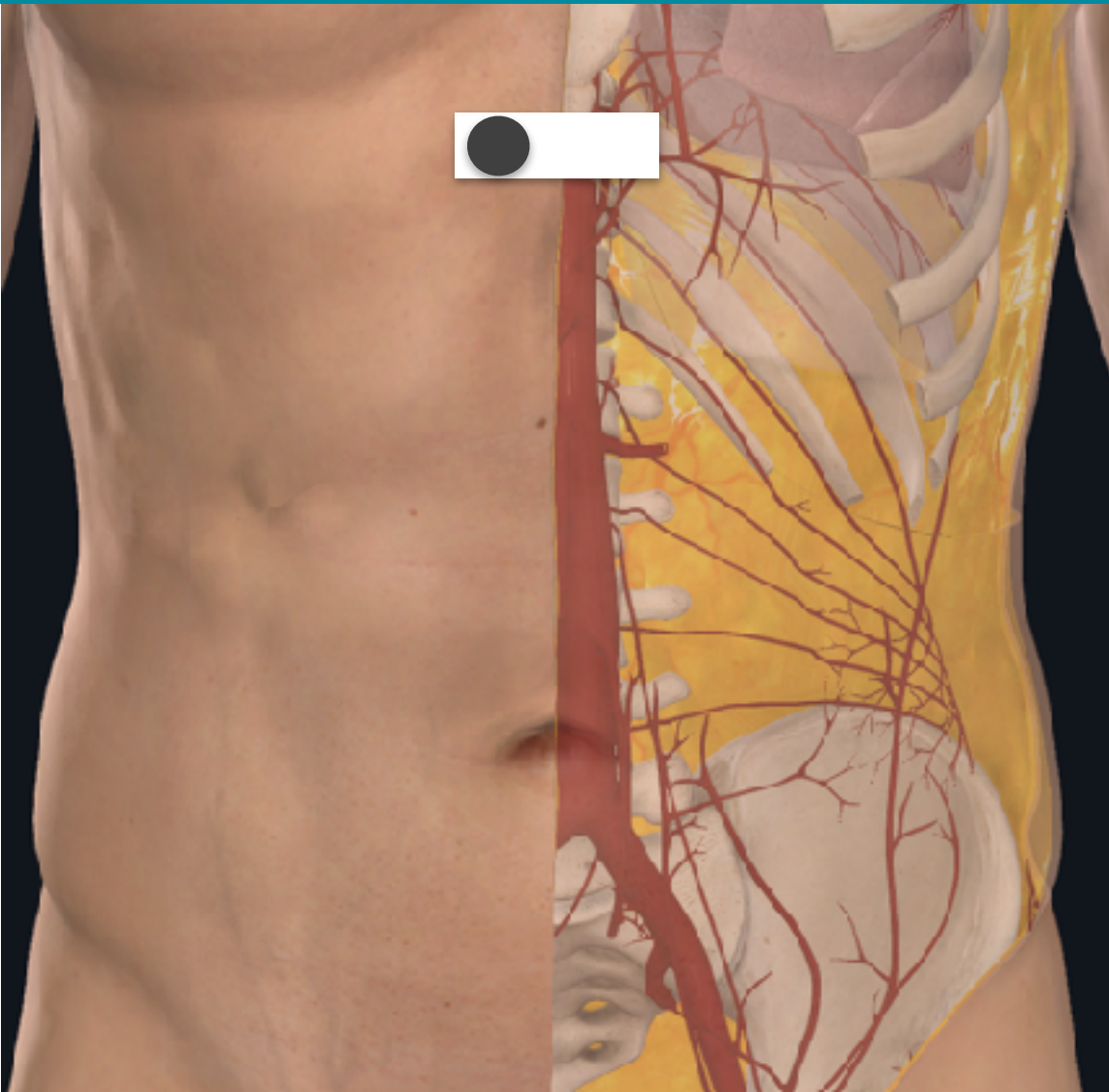
**Abdominal  
Aorta (3cm)**

**Celiac trunk**

**SMA**

**Bifurcation**

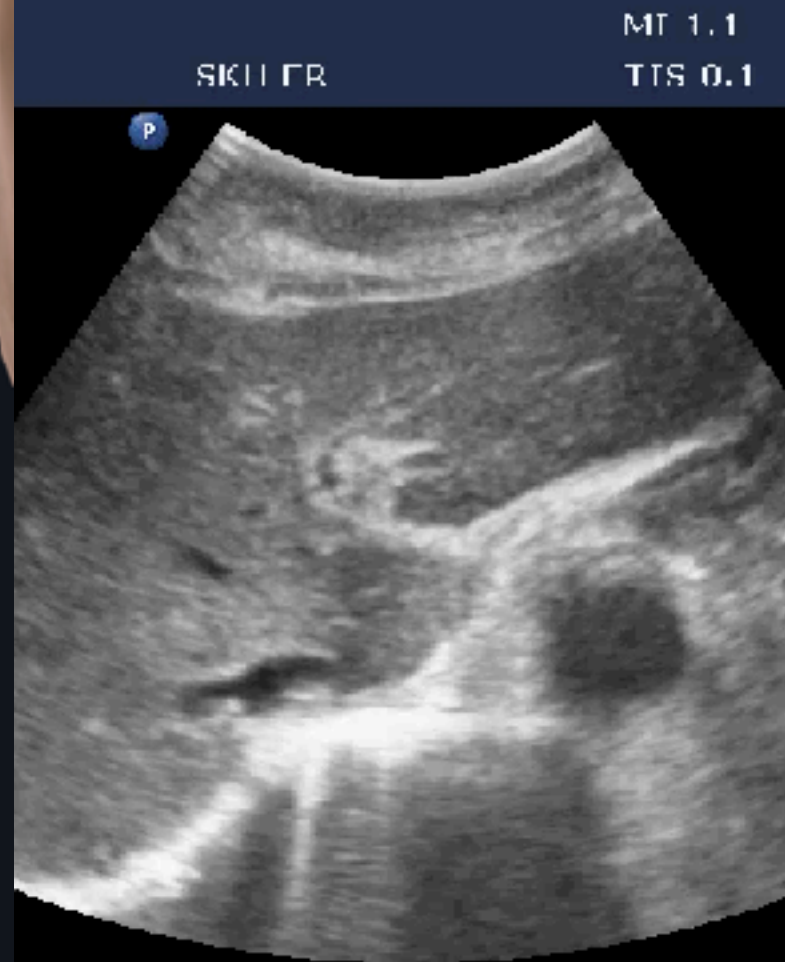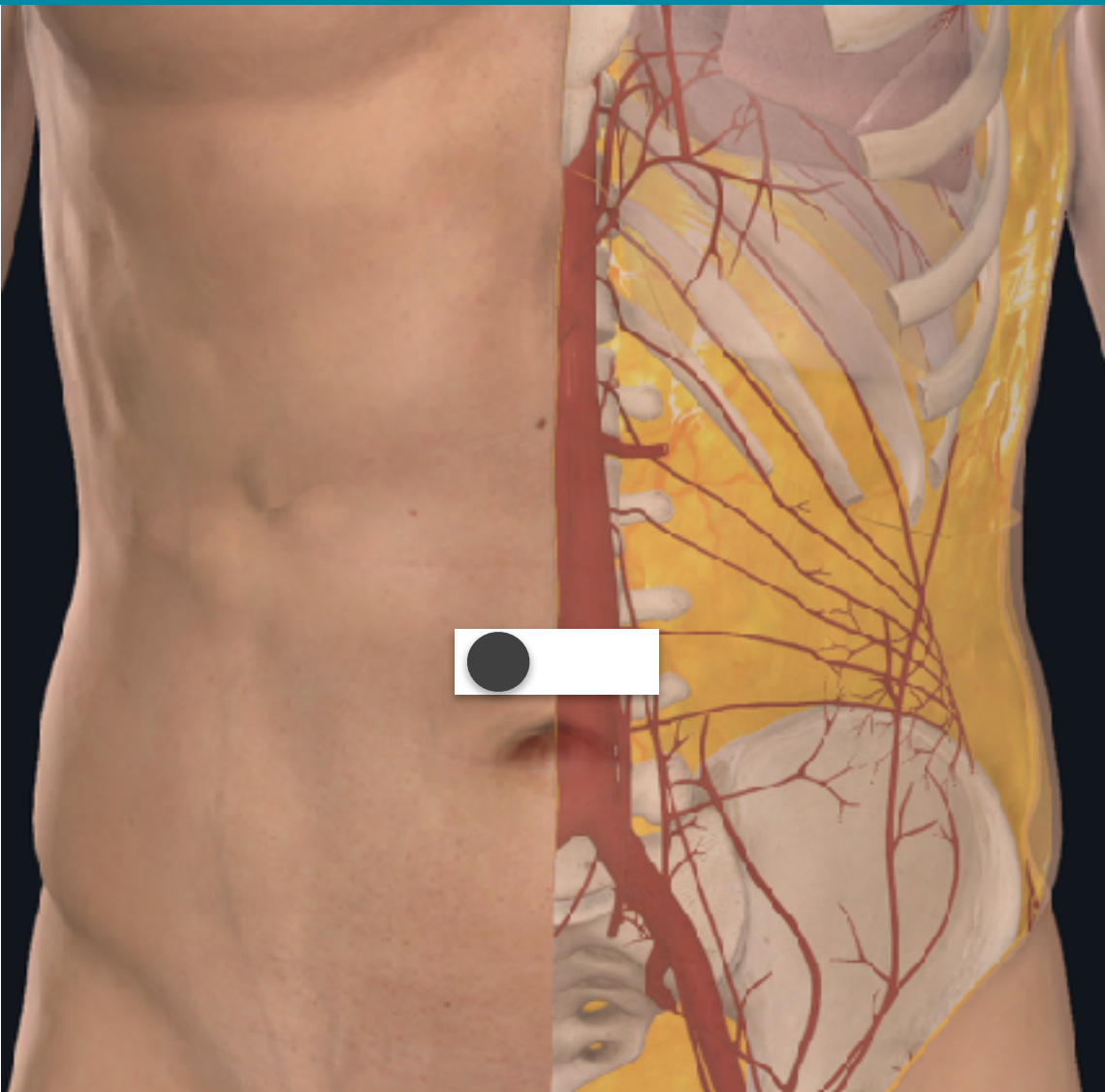
# AORTA



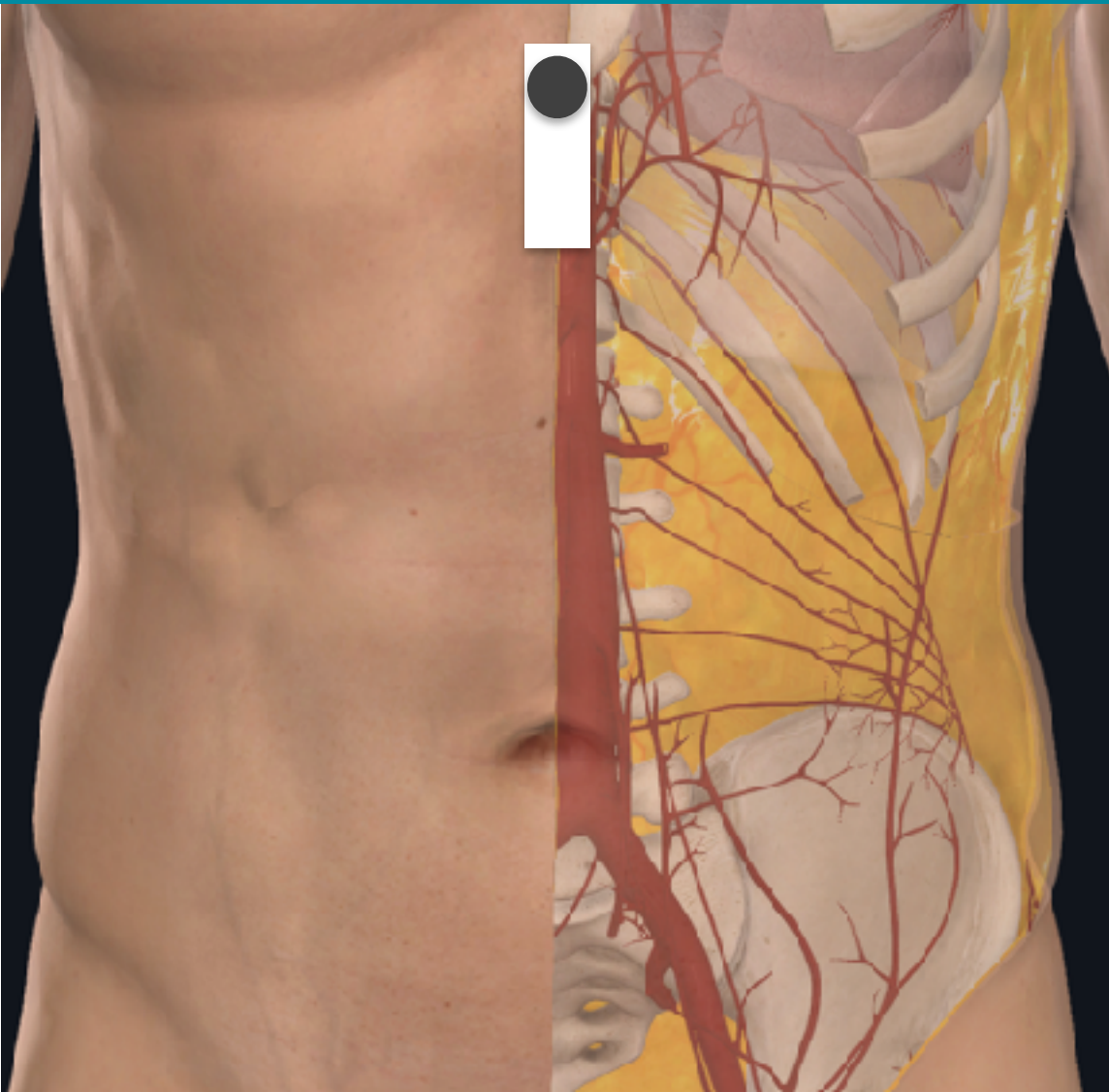
**探頭: 弧形**

**位置: 劍突下**

# AORTA



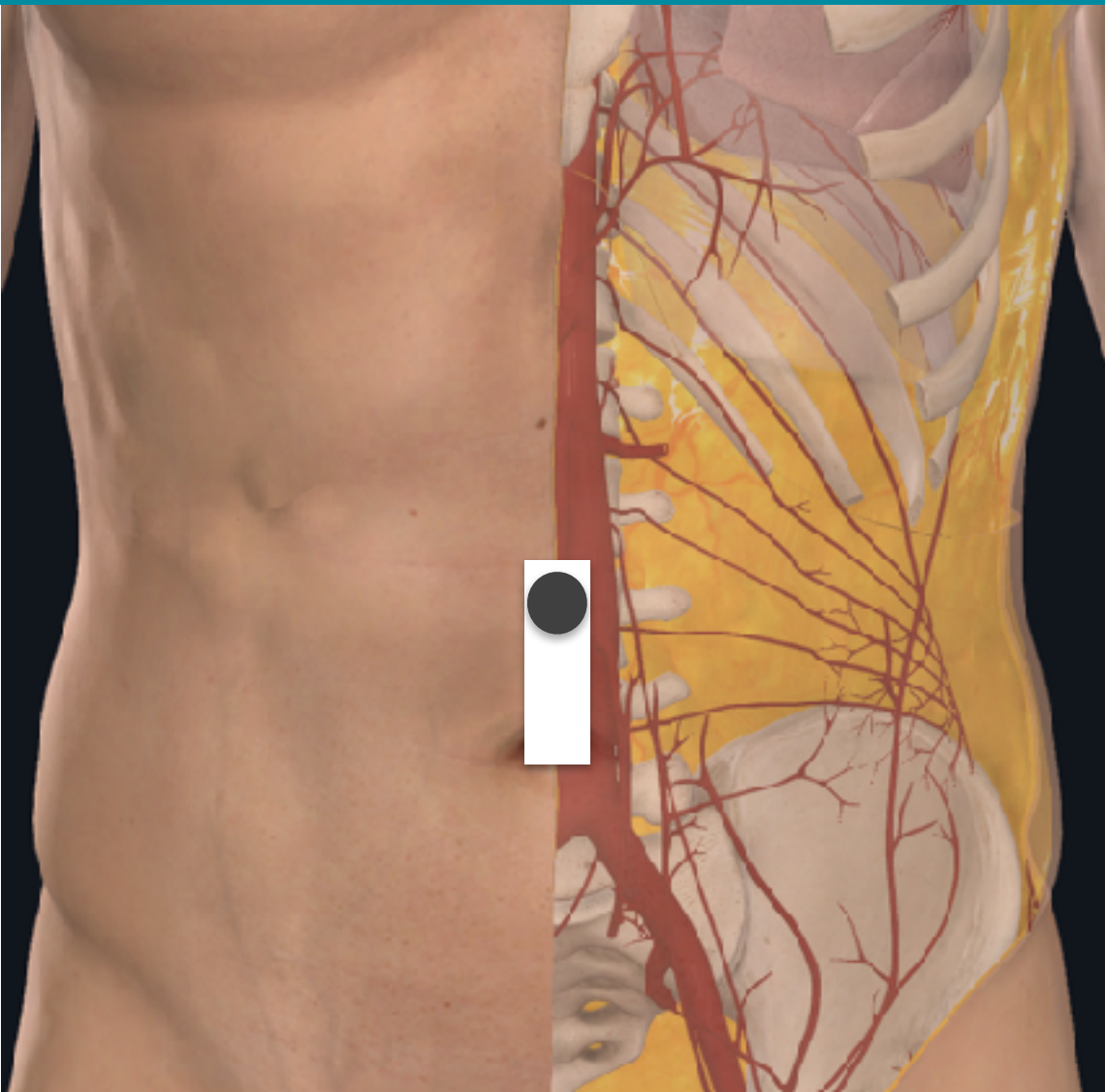
# AORTA



**探頭: 弧形**

**位置: 劍突下**

# AORTA

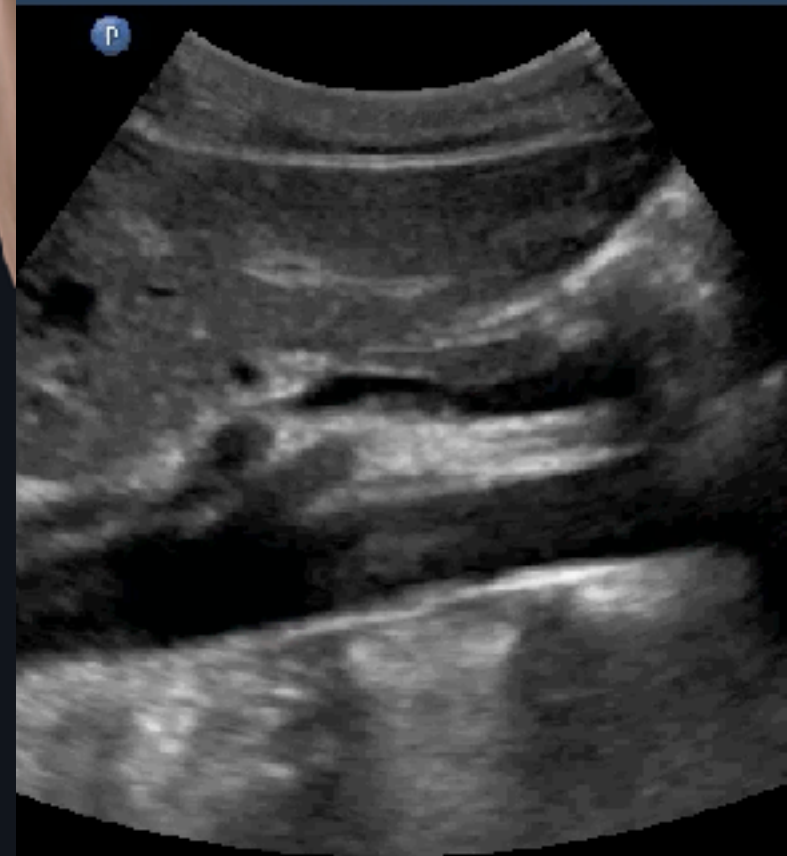

160331172347

SKII ER

MI 1.1

TIS 0.1

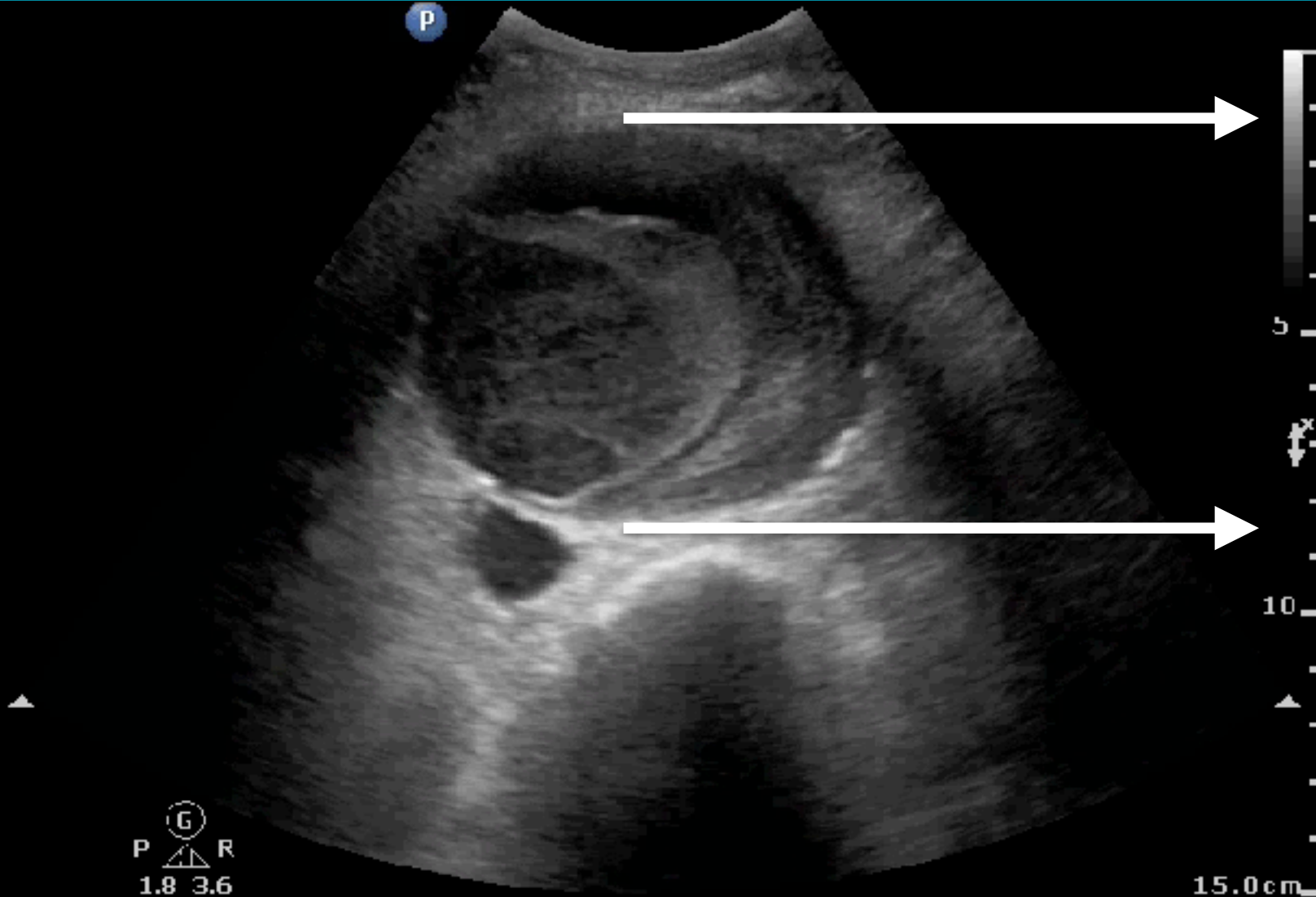


# AAA: EYEBALLING

Abd Gen  
C.5-1  
34 Hz  
15.0cm

2D

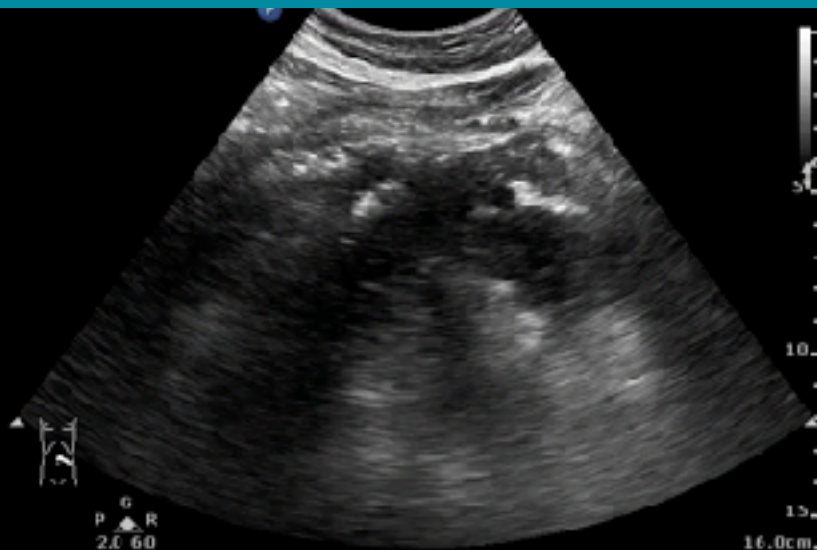
HGen  
Gn 57  
C 56  
3/3/3



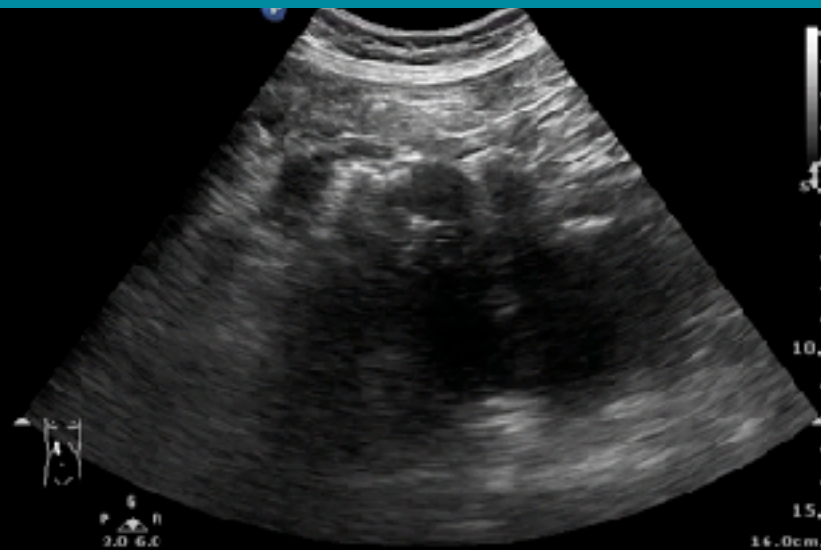
15.0cm

# AAA ?

C Nerve  
C6-2  
22 Hz  
16.0cm

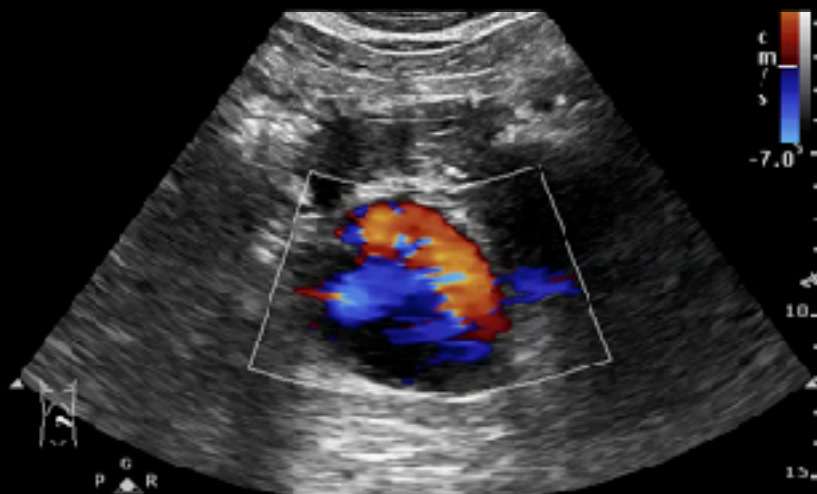


C Nerve  
C6-2  
22 Hz  
16.0cm



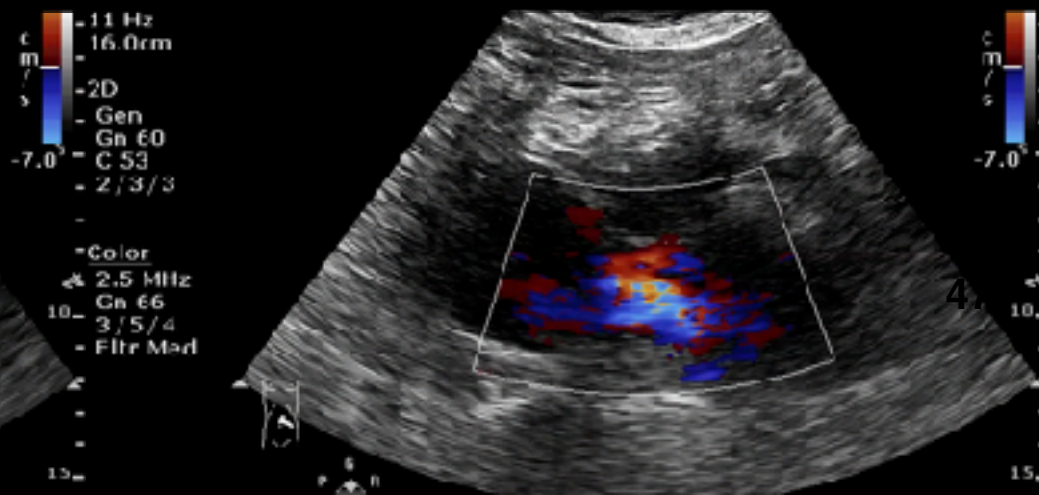
11 Hz  
16.0cm

2D  
Gen  
Gh 60  
C 53  
2/3/3

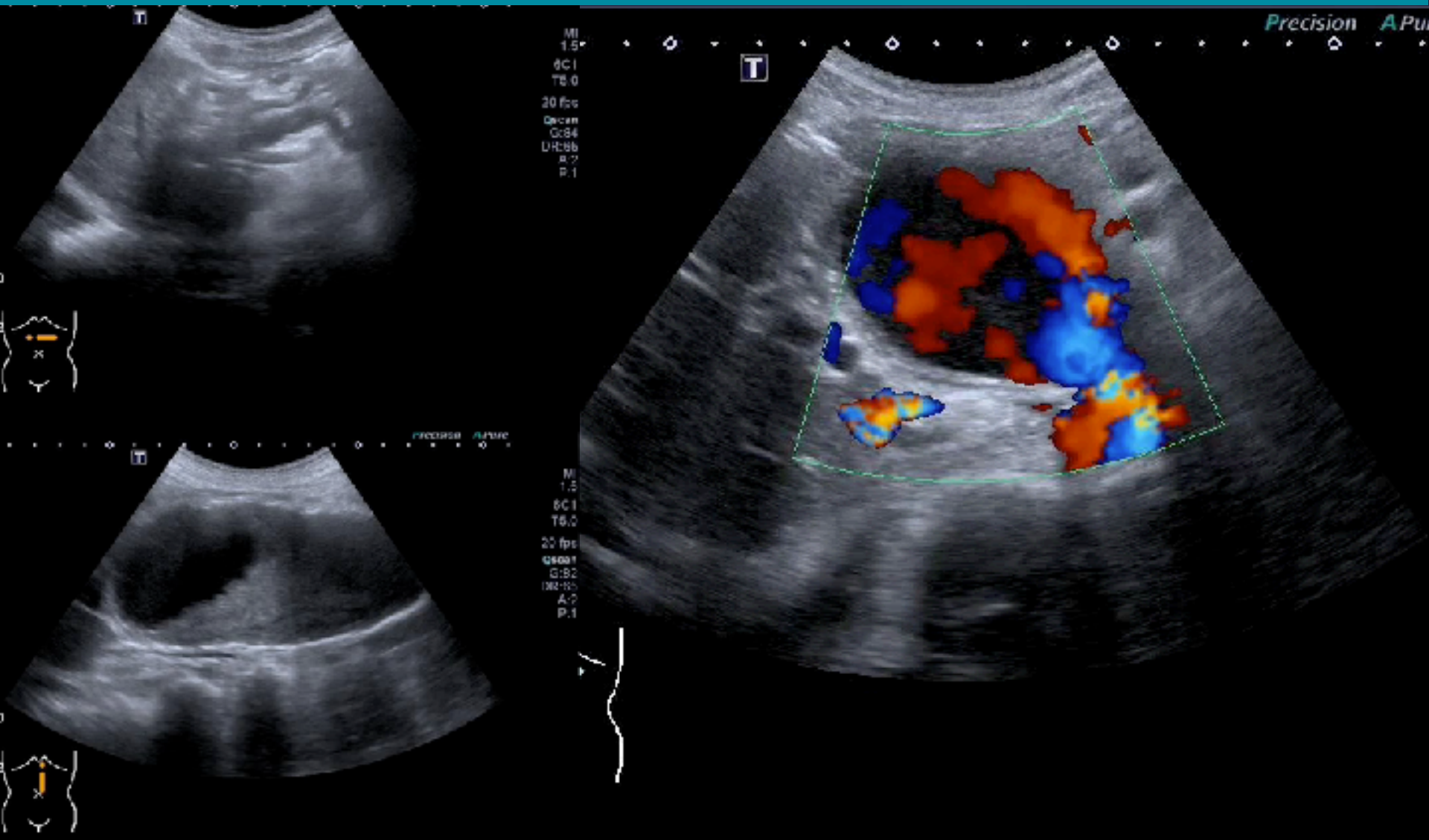


11 Hz  
16.0cm

2D  
Gen  
Gh 60  
C 53  
2/3/3

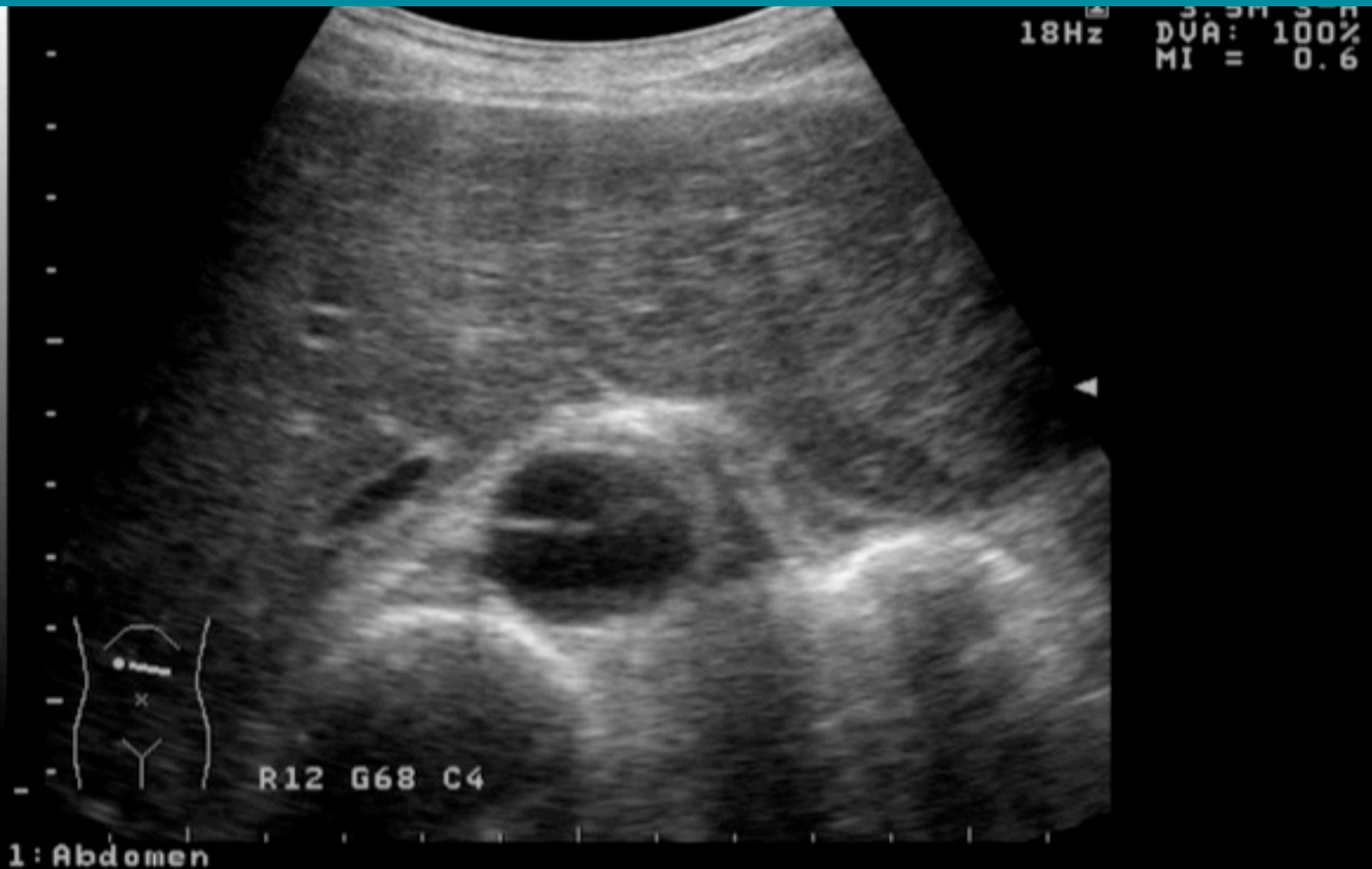


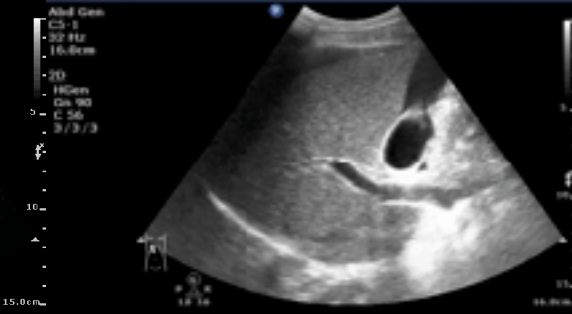
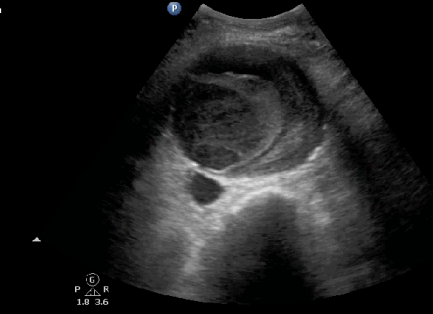
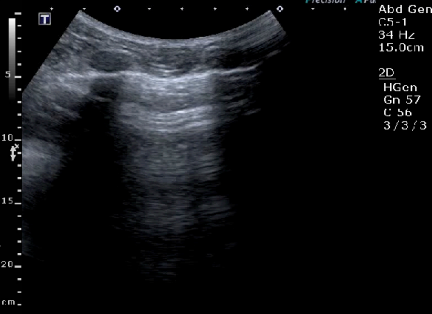
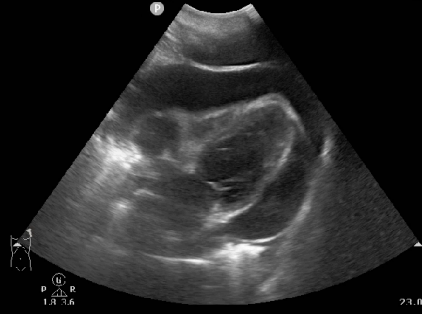
# AAA ?





# AAA ?





HEART

LUNG

AORTA

FAST

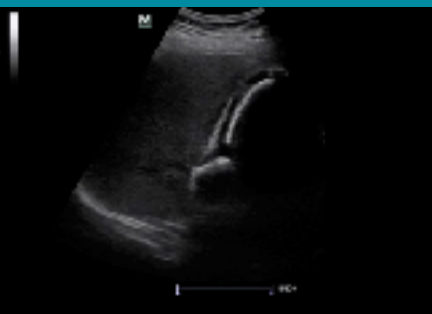
KIDNEY

BILIARY

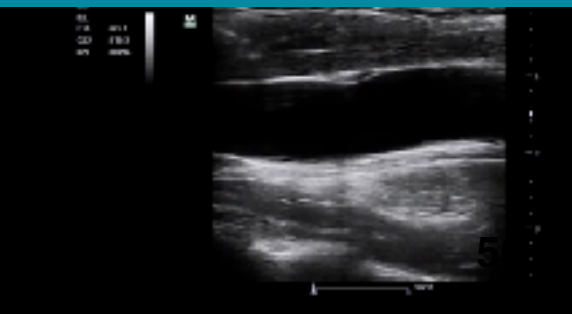
KNEE

CVC

# 8 ESSENTIAL SKILLS



膝關節縱向掃描

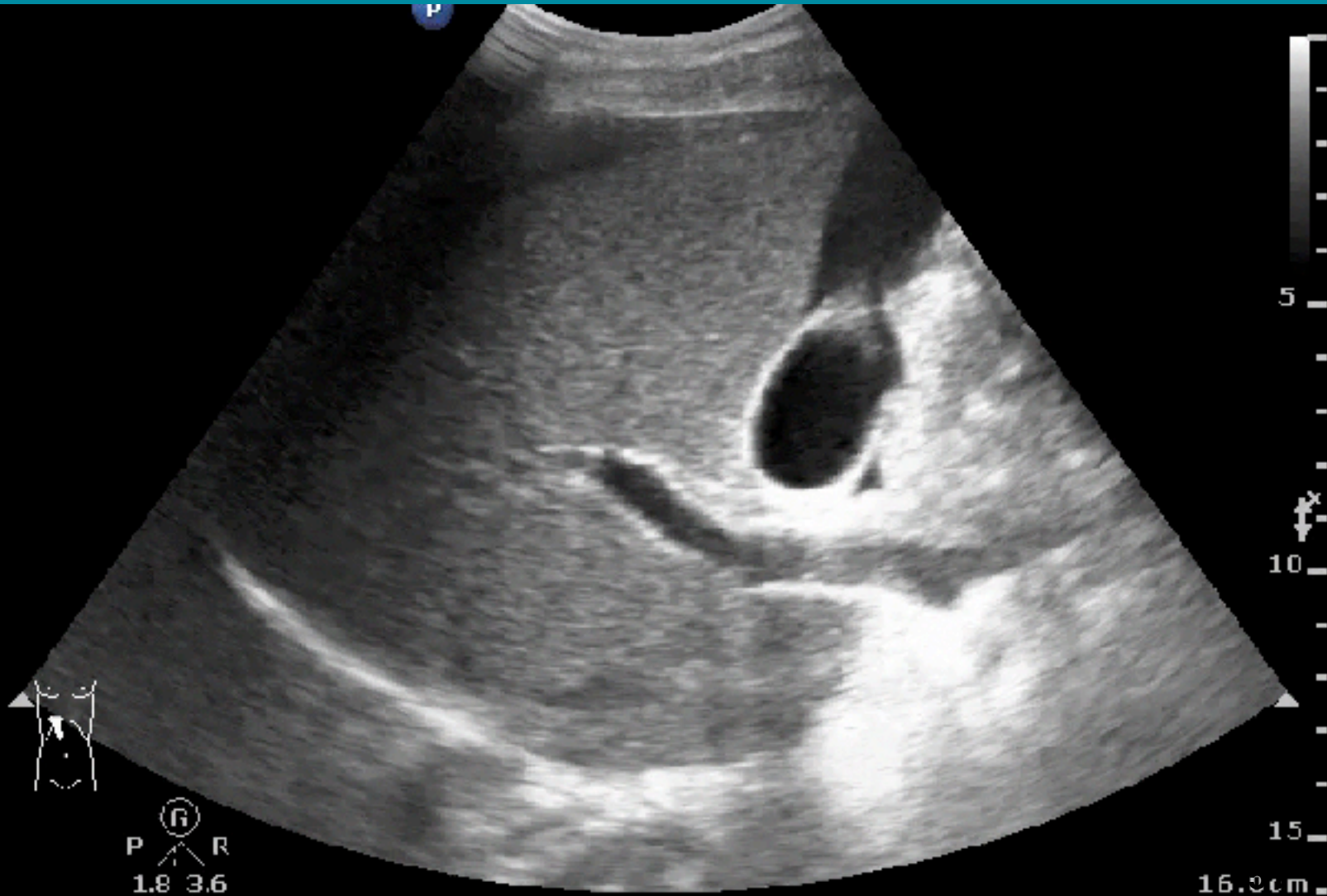


# FAST

## FOCUSED ASSESSMENT WITH SONOGRAPHY FOR TRAUMA

Abd Gen  
C5-1  
32 Hz  
16.0cm

2D  
HGen  
Gn 90  
C. 56  
3/3/3



P R  
1.8 3.6

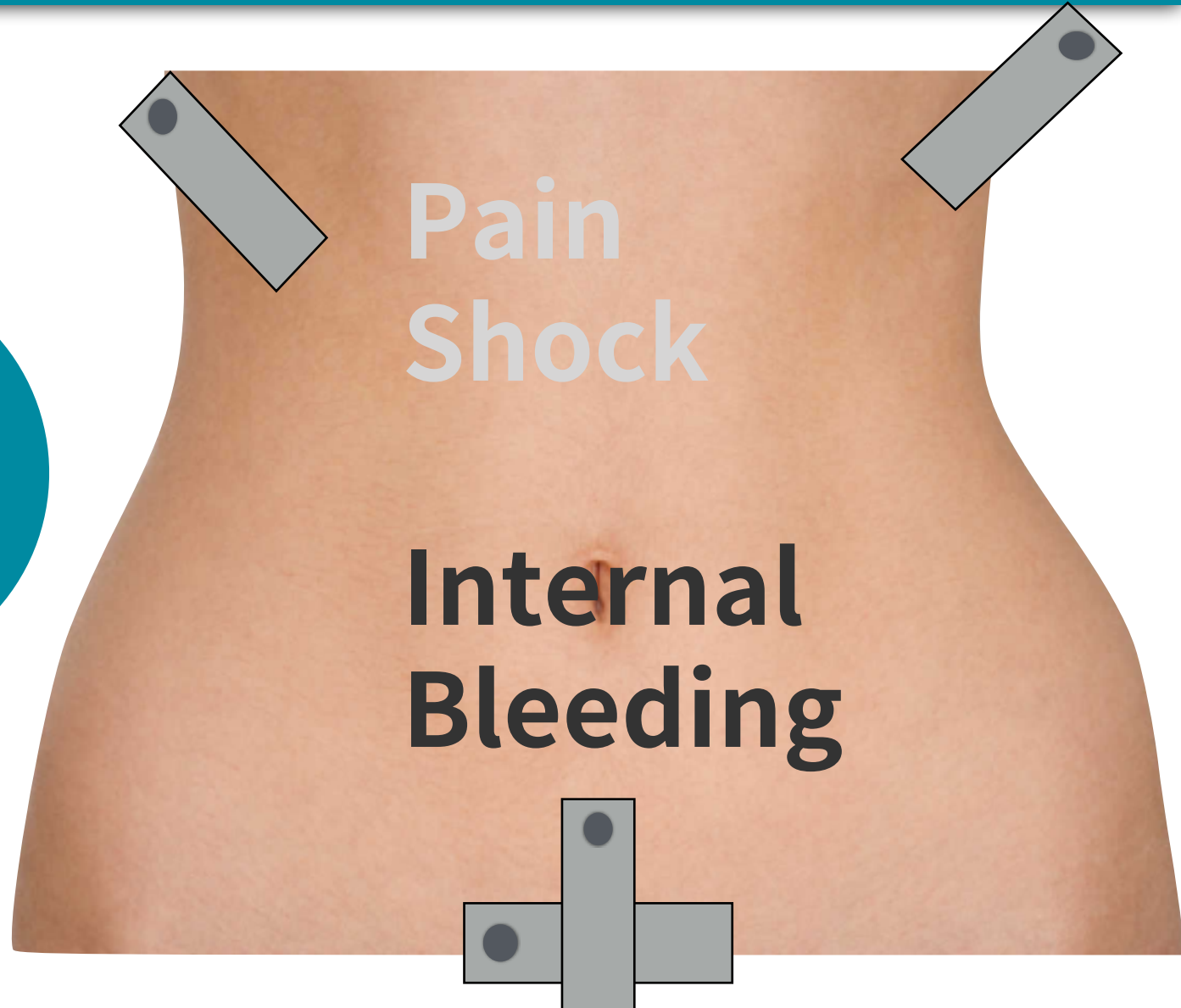
16.2cm



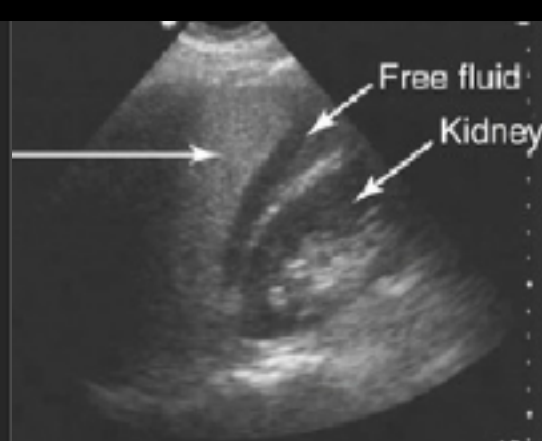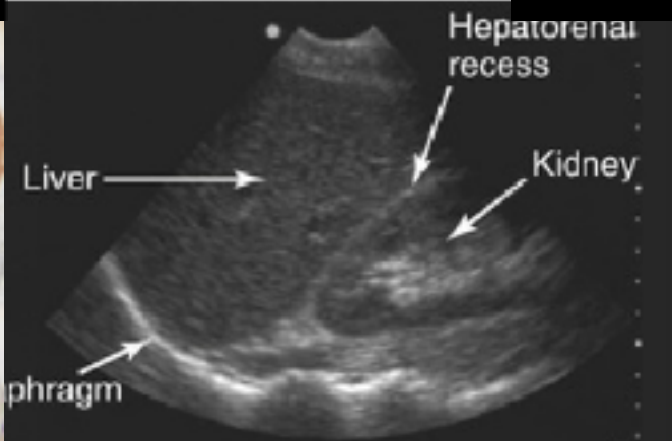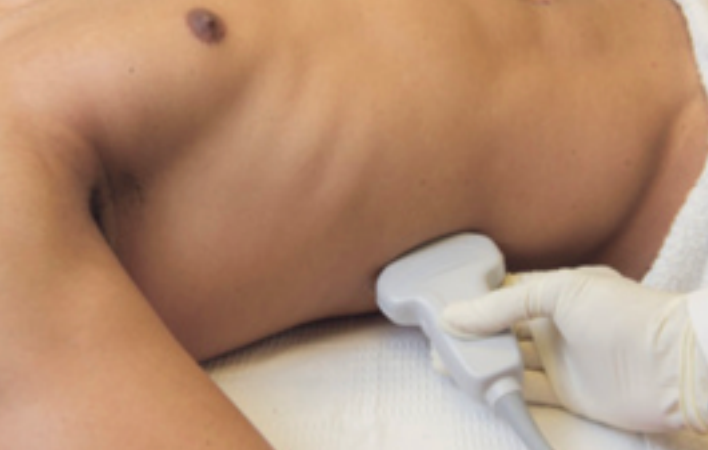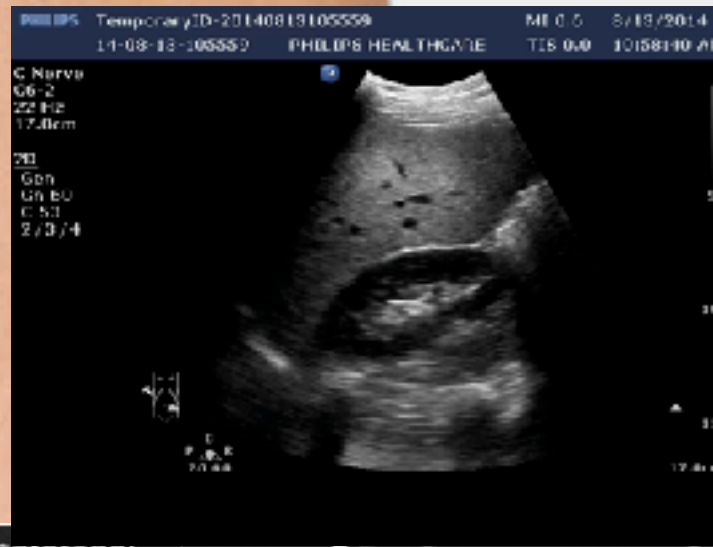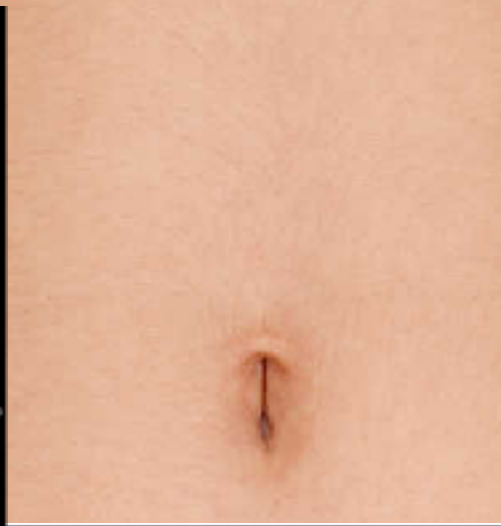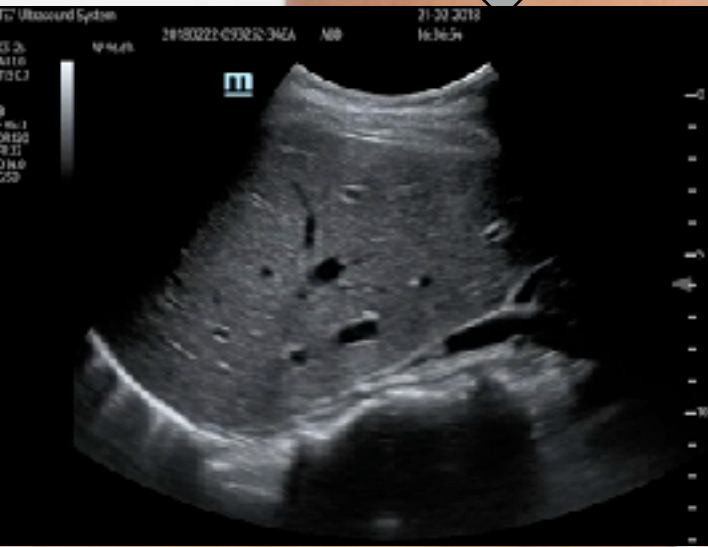# Free fluid



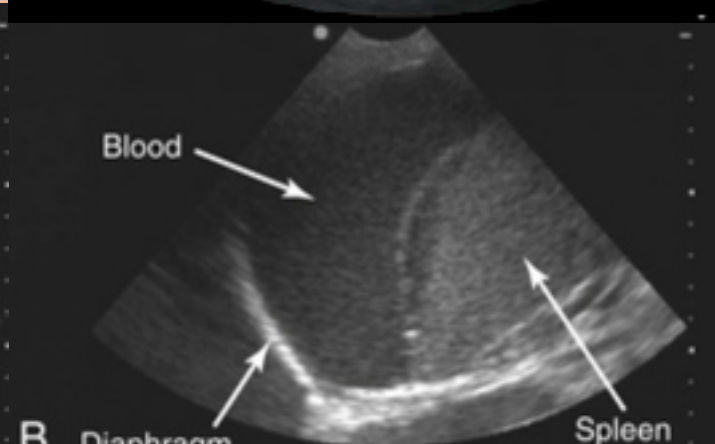
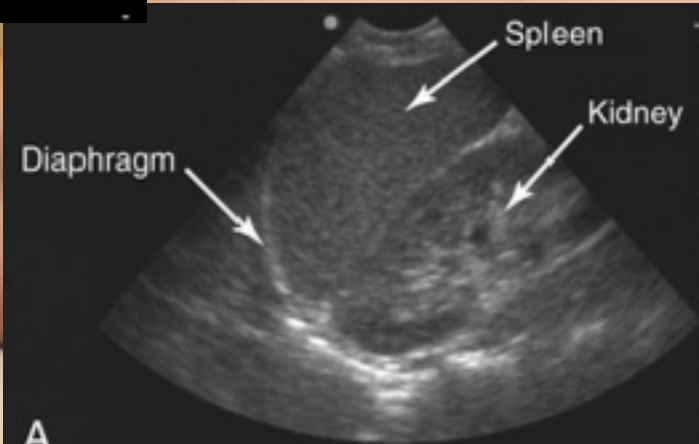
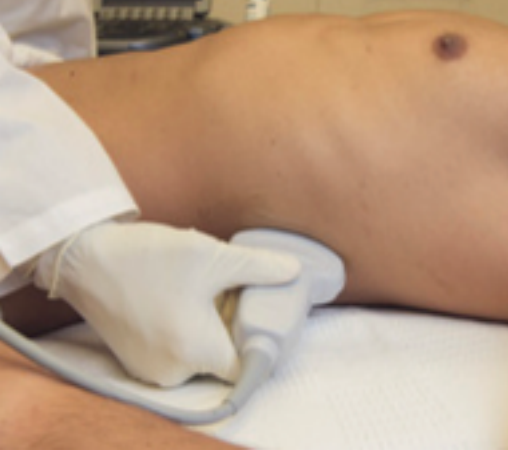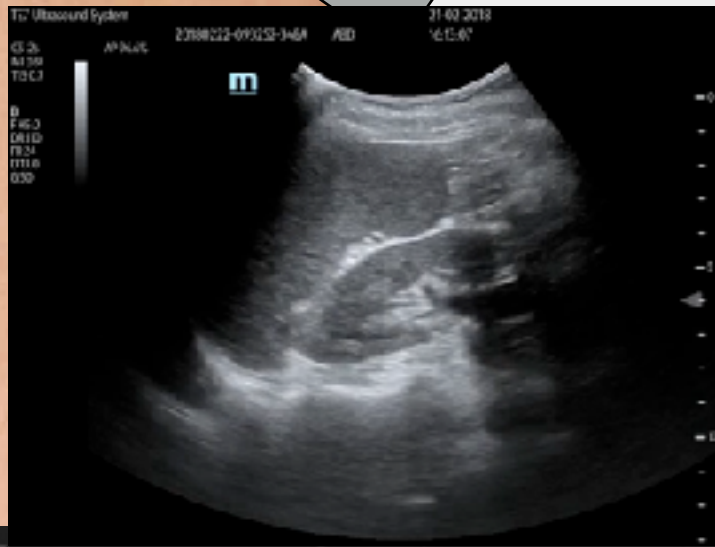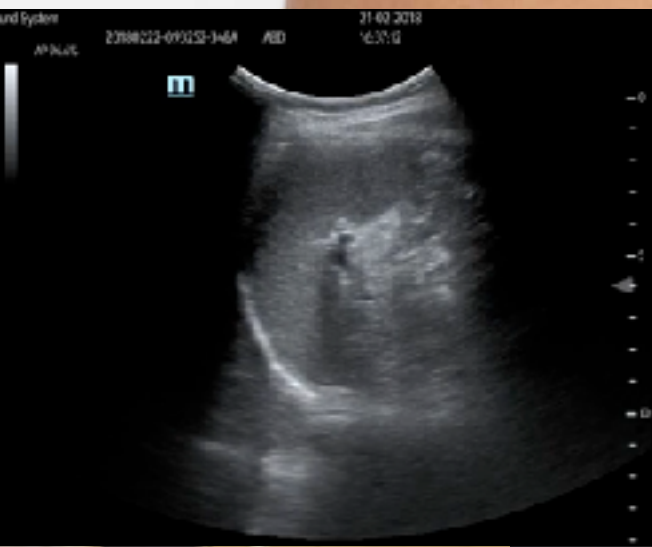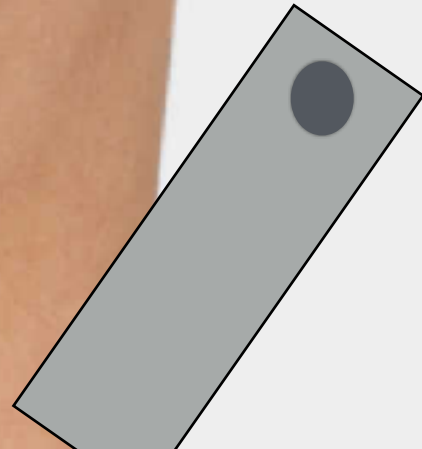
倒三角  
掃描介面

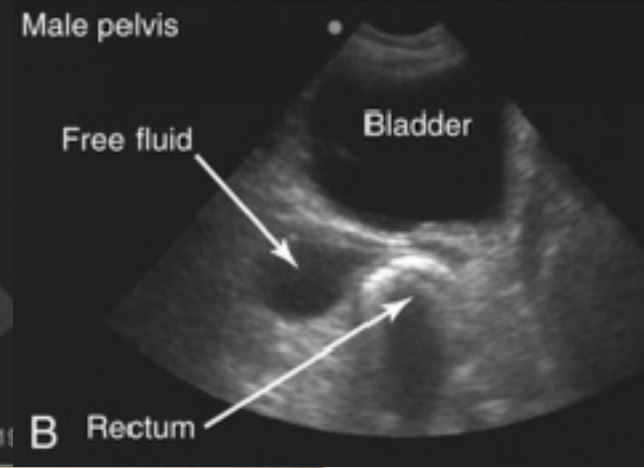
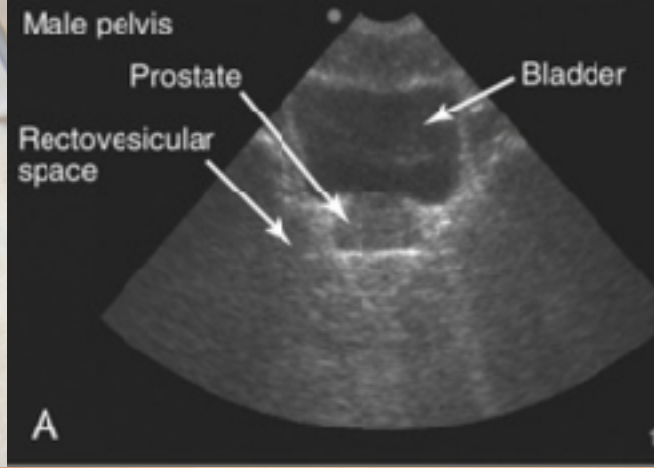
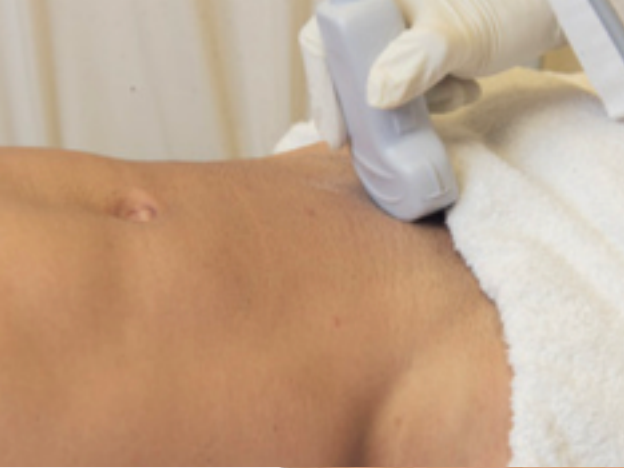

劍突-腋前線交界點  
平行肋間掃描以避開肋骨  
第一目標:肝腎介面(Morrison's pouch)  
第二目標:橫膈膜

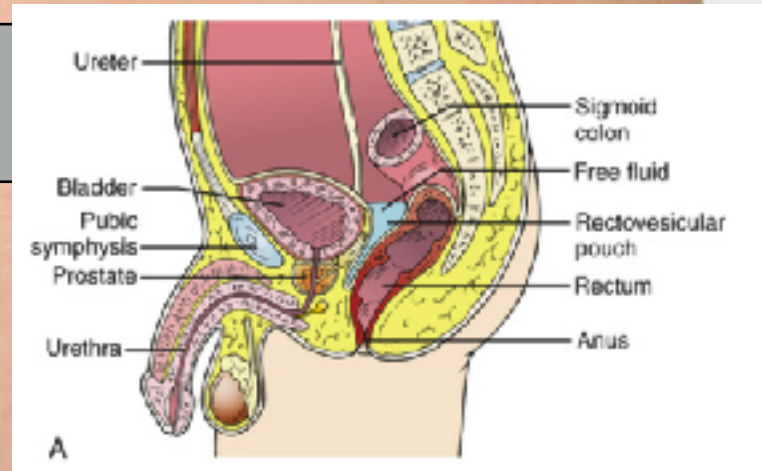
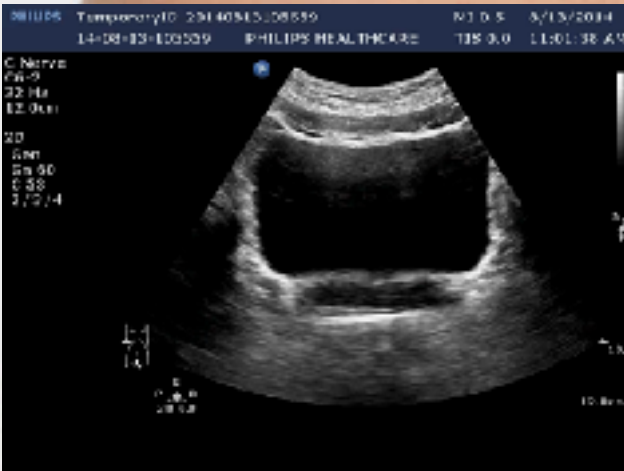

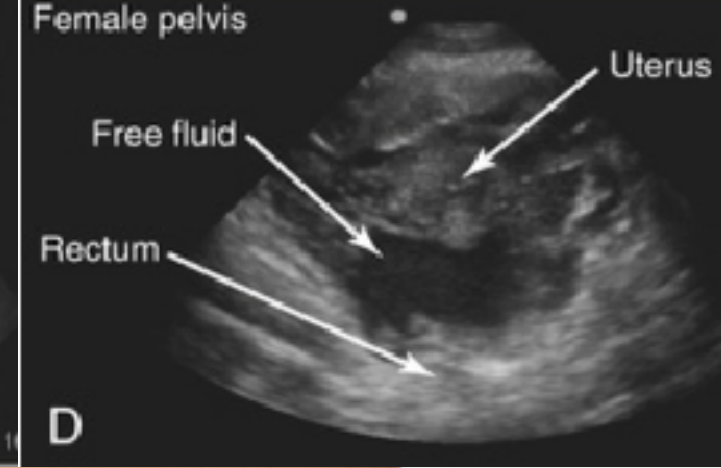
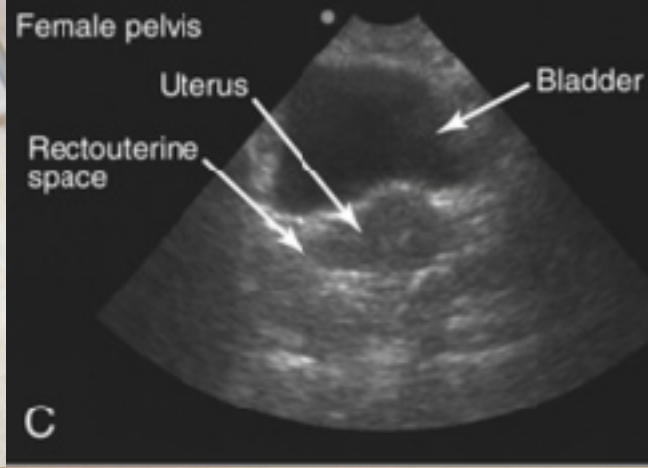
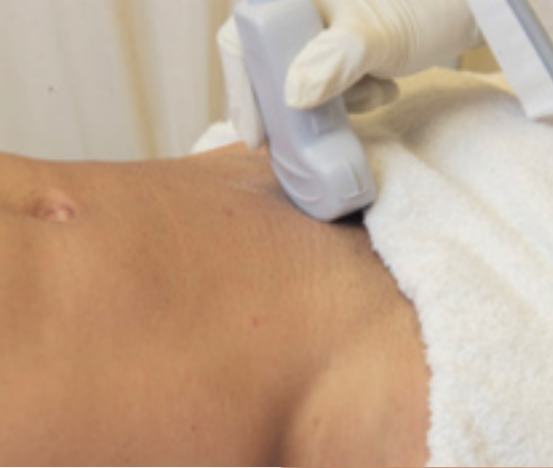劍突-腋後線交界點  
平行肋間掃描以避開肋骨  
第一目標:橫膈膜下  
第二目標:脾腎交界



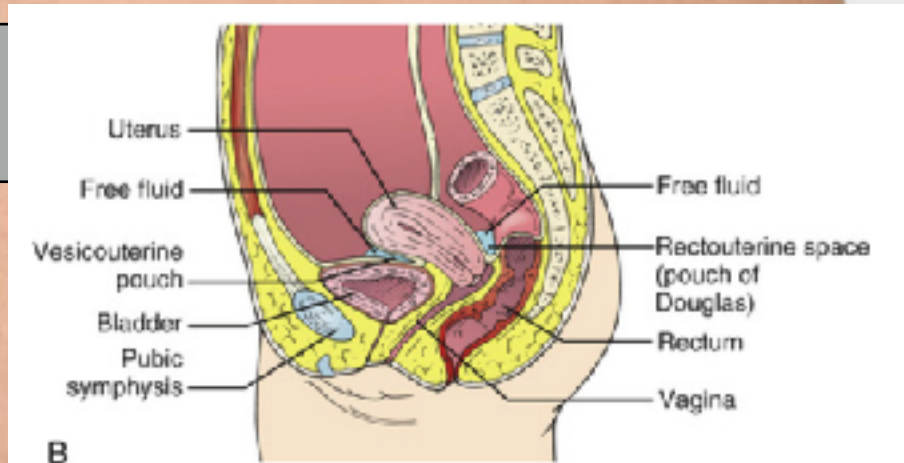
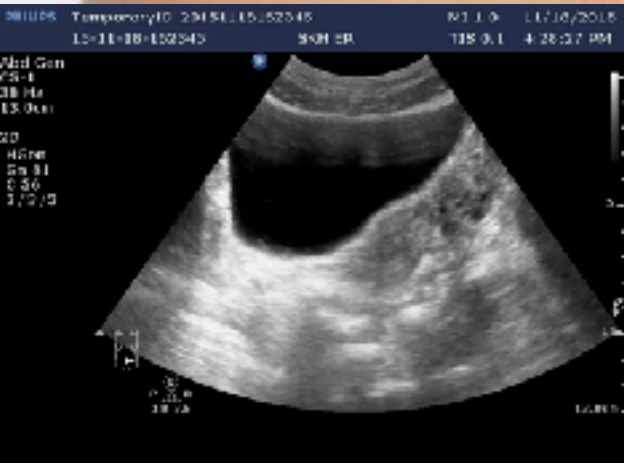


恥骨聯合上方  
Tilt探頭進行掃描  
要有好的視窗(尿液)  
主要目標: 膀胱下方





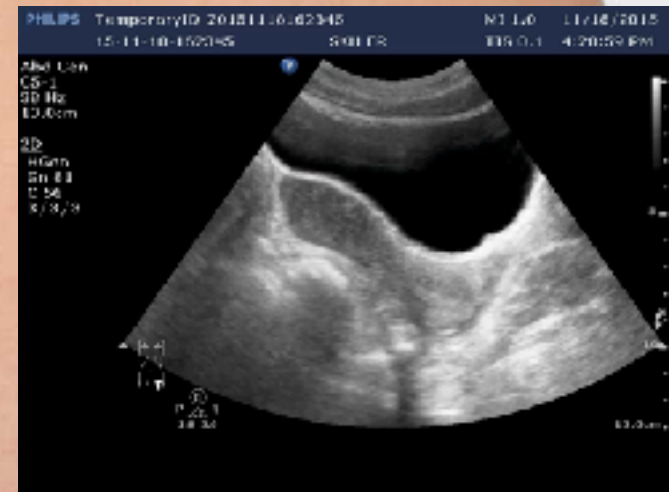
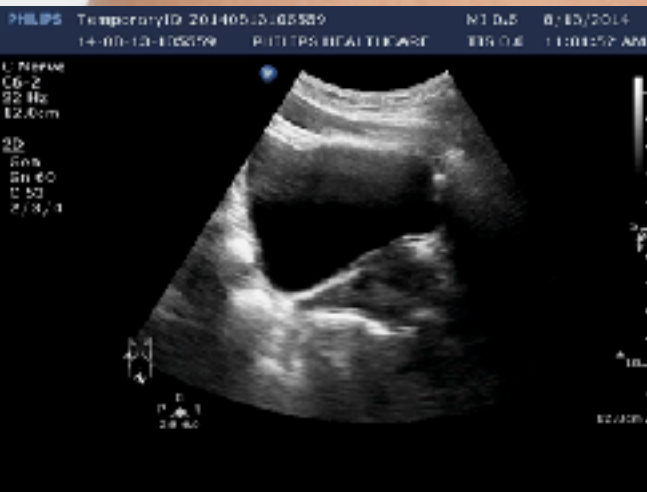恥骨聯合上方  
Tilt探頭進行掃描(頭腳)  
要有好的視窗(尿液)  
第一目標:子宮下方  
第二目標:膀胱子宮間





# 為什麼一定要有這個介面呢？

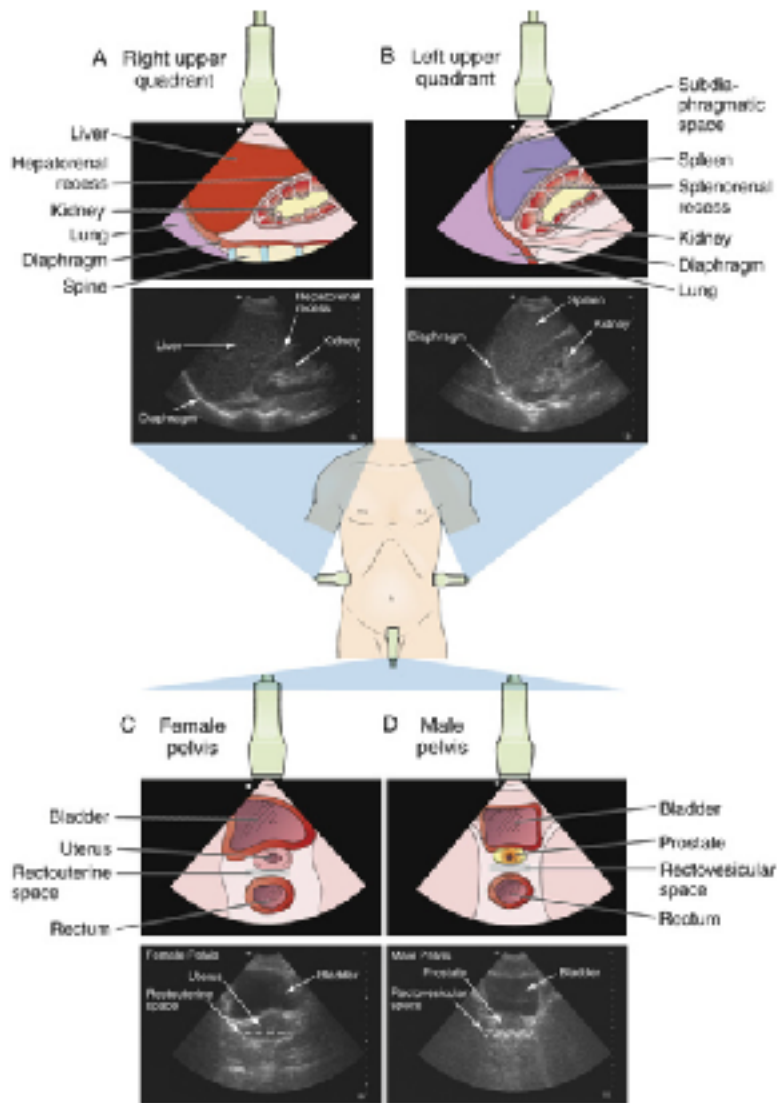
恥骨聯合上方  
Tilt探頭進行掃描(左右)  
要有好的介面(尿液)  
第一目標:子宮下方  
第二目標:膀胱子宮間  
男:膀胱下方



# 腹腔積液 Free fluid



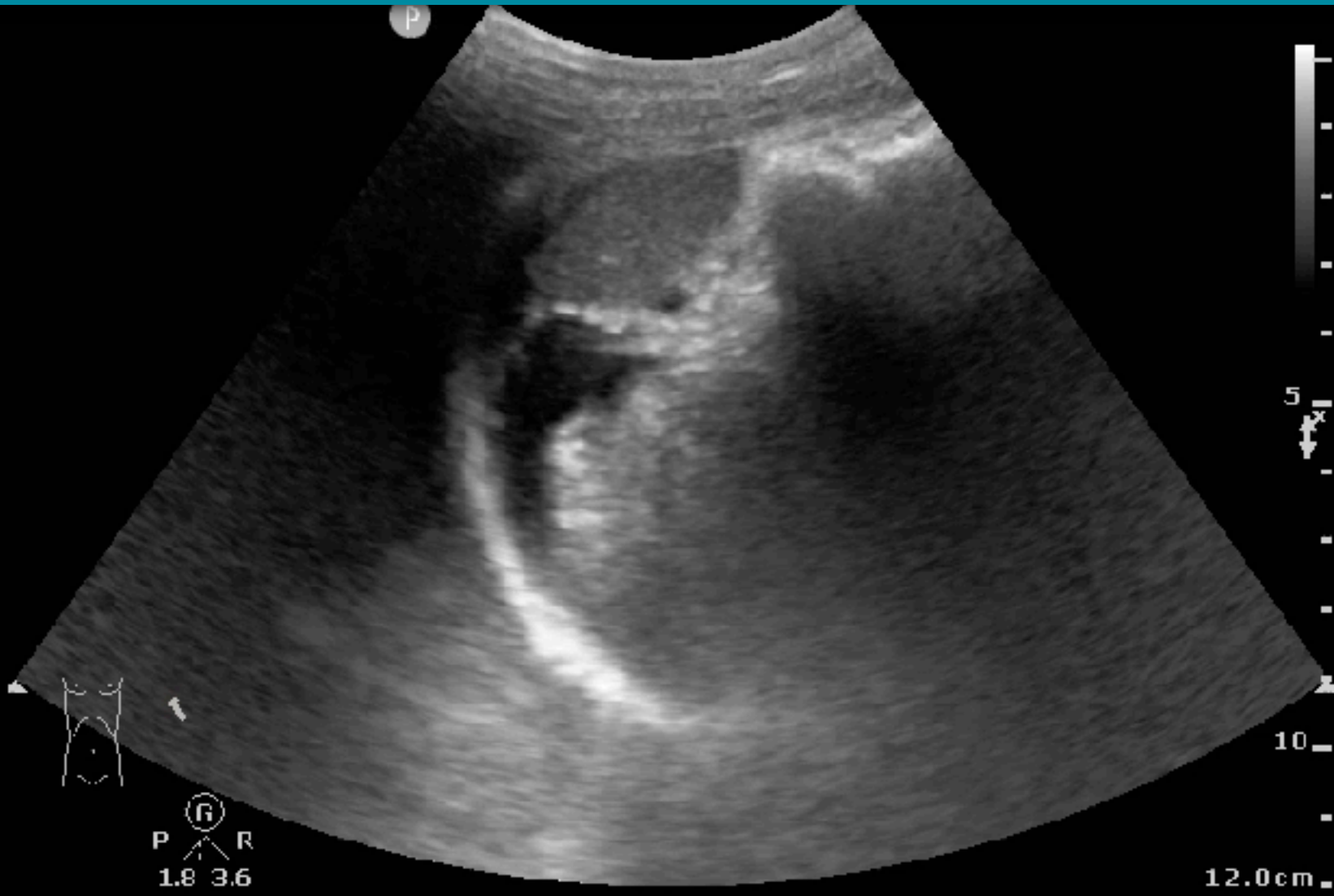
倒三角  
掃描介面



# Free fluid ?

Abd Gen  
C5-1  
39 Hz  
12.0cm

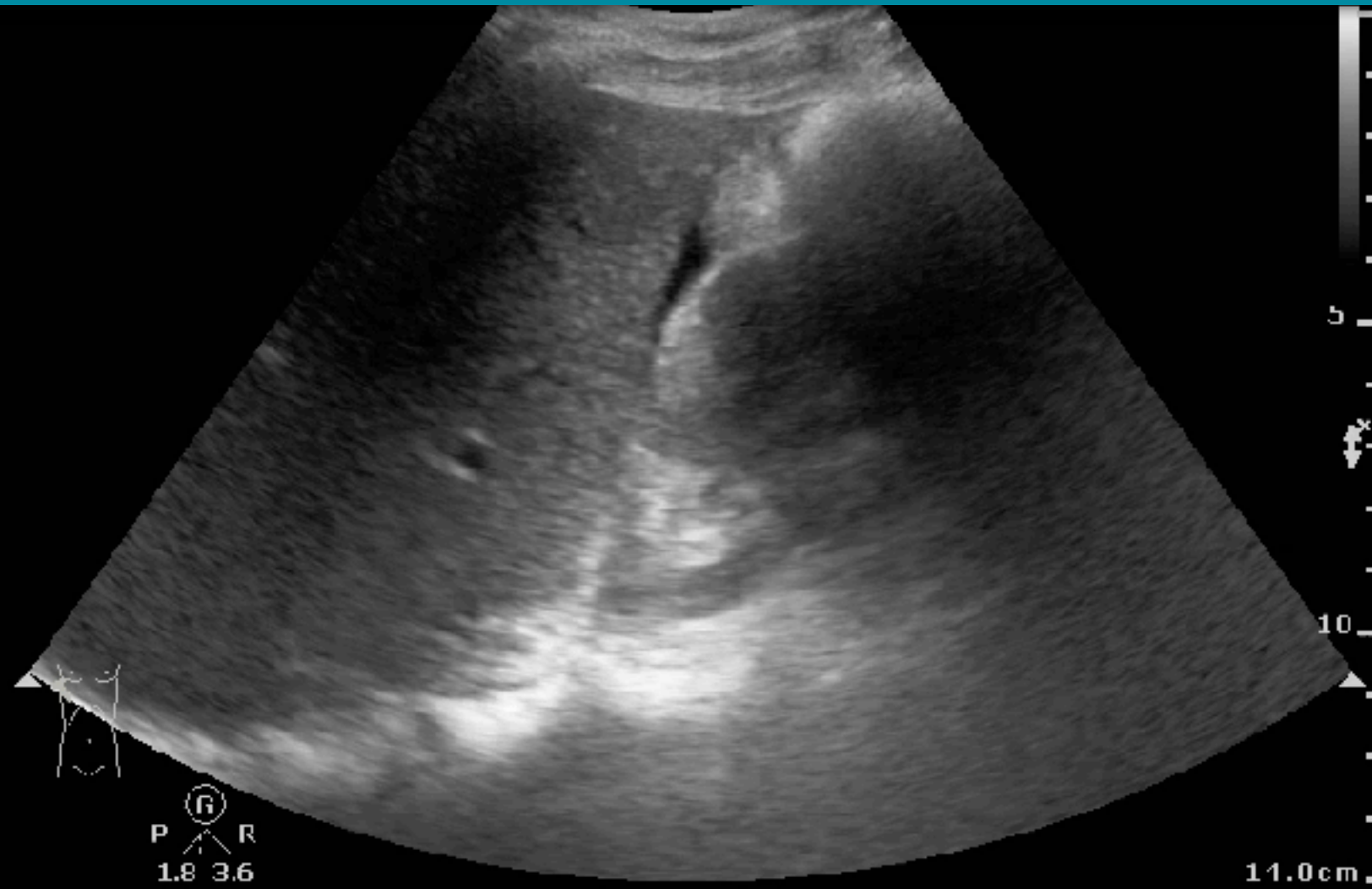
2D  
HGen  
Gn 100  
C. 56  
3/3/3



# Free fluid ?

C5-1  
36 Hz  
14.0cm

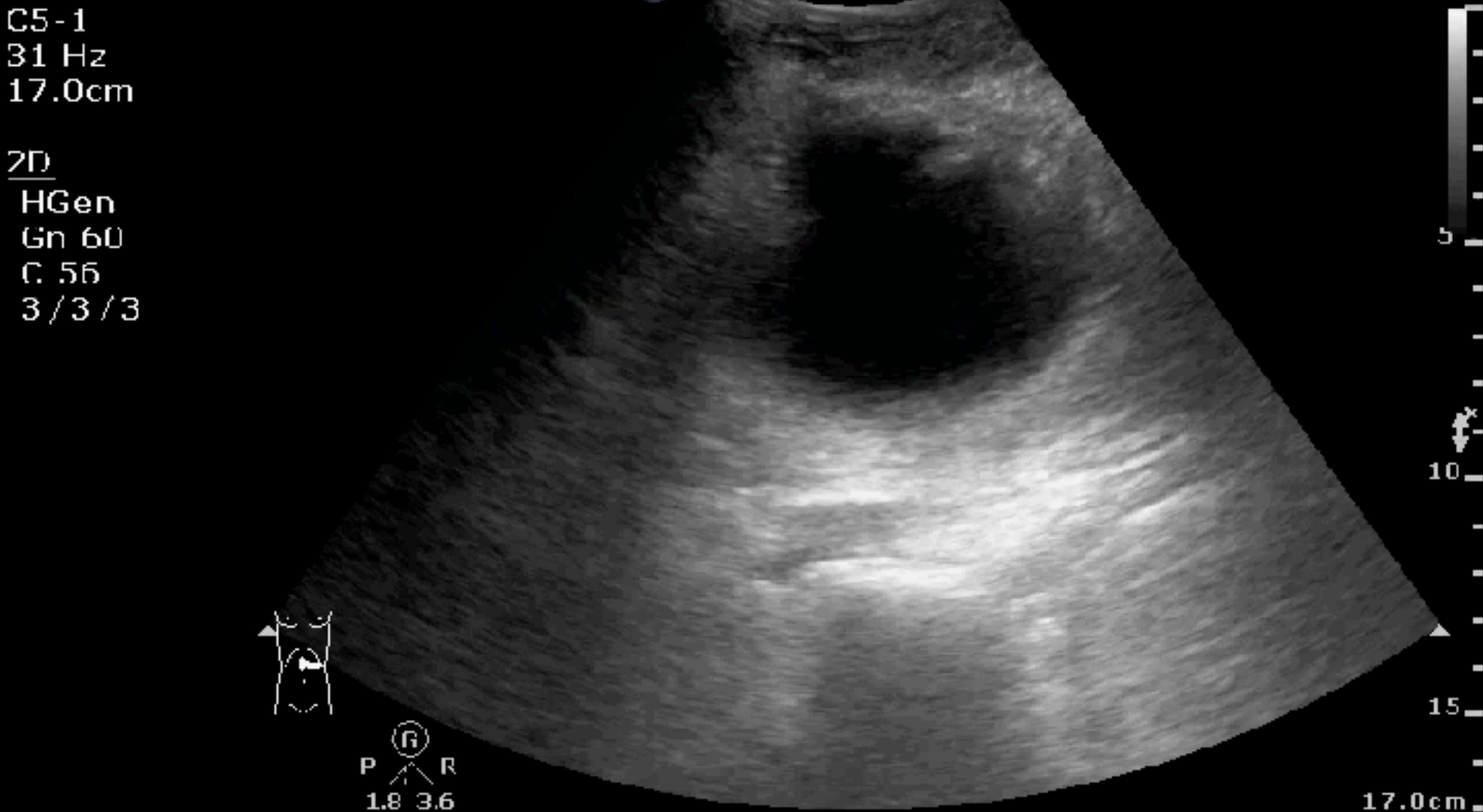2D  
HGen  
Gn 100  
C. 56  
3/3/3



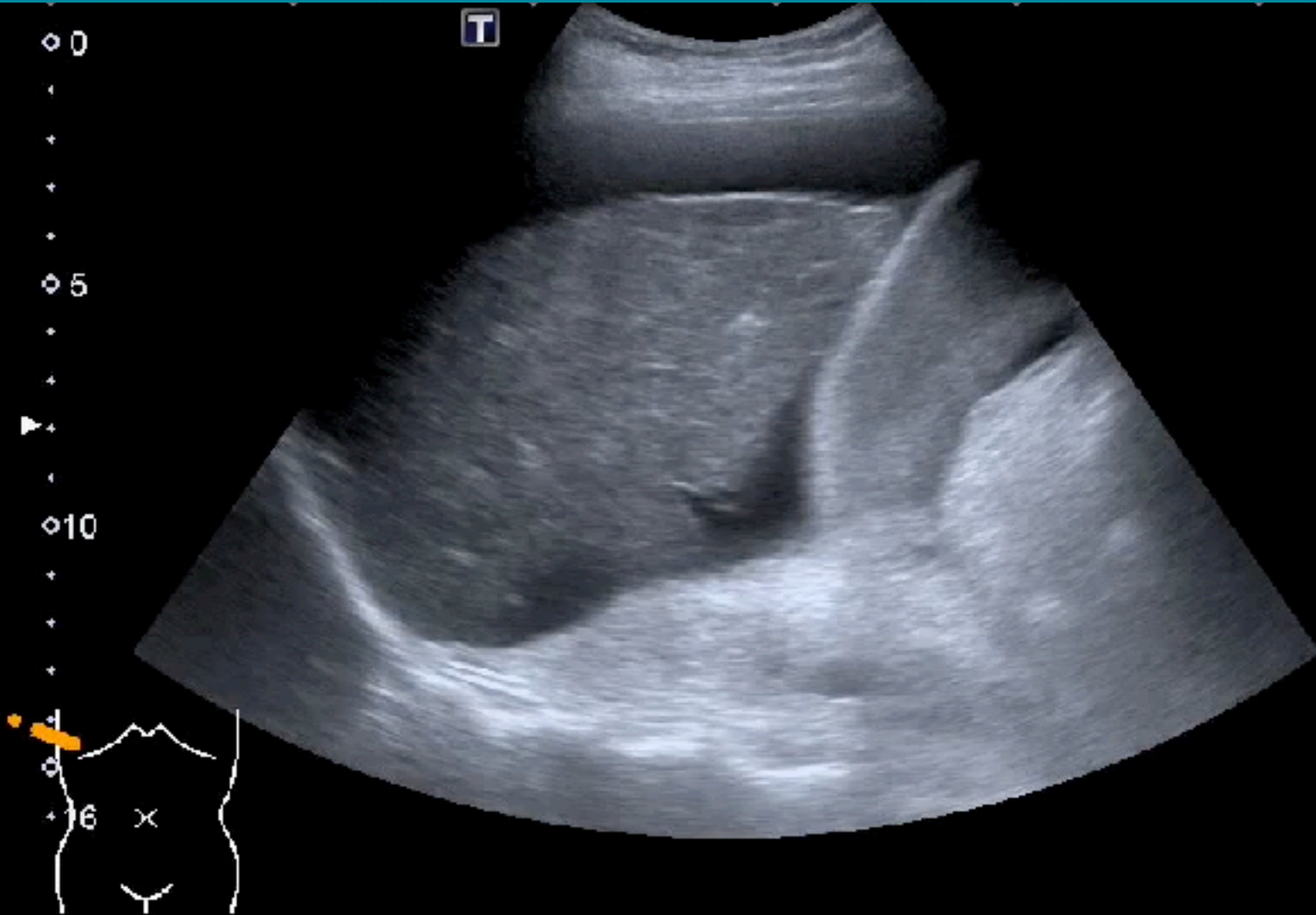14.0cm

P R  
1.8 3.6

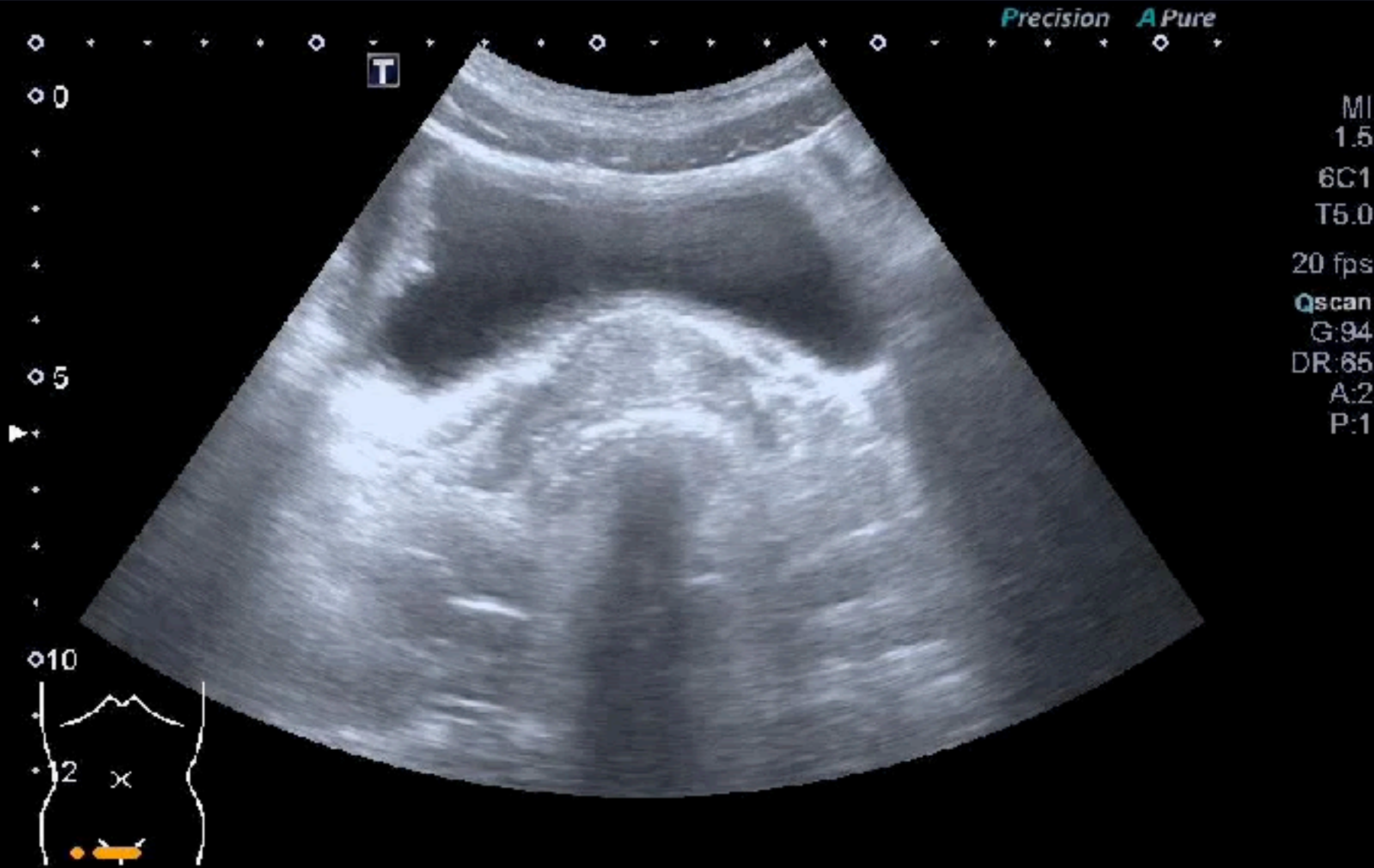
# Free fluid ?



# Free fluid ?



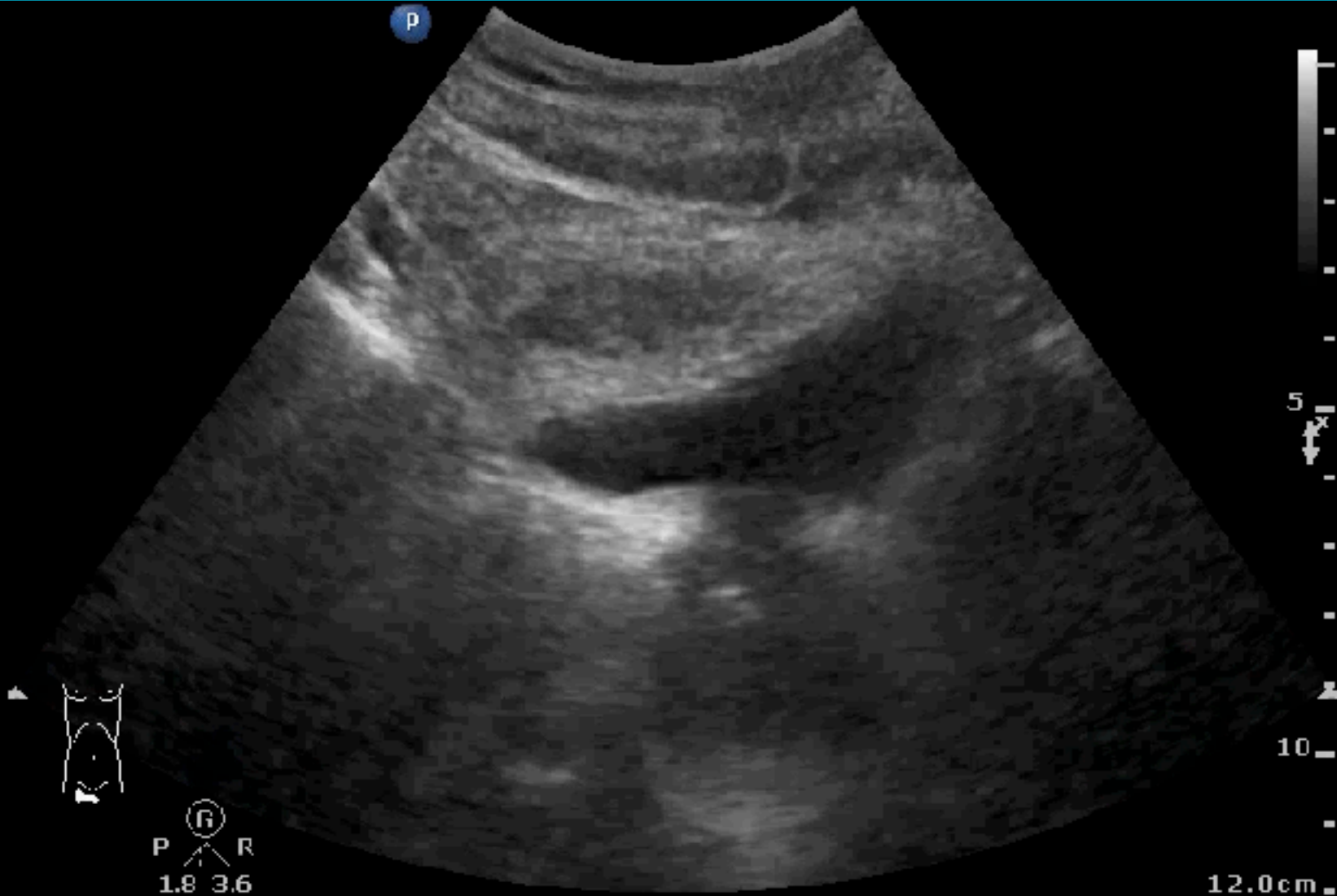# Free fluid ?



# Free fluid ?

Abd Gen  
C5-1  
39 Hz  
12.0cm

2D  
HGen  
Gn 66  
C. 58  
3 / 3 / 3

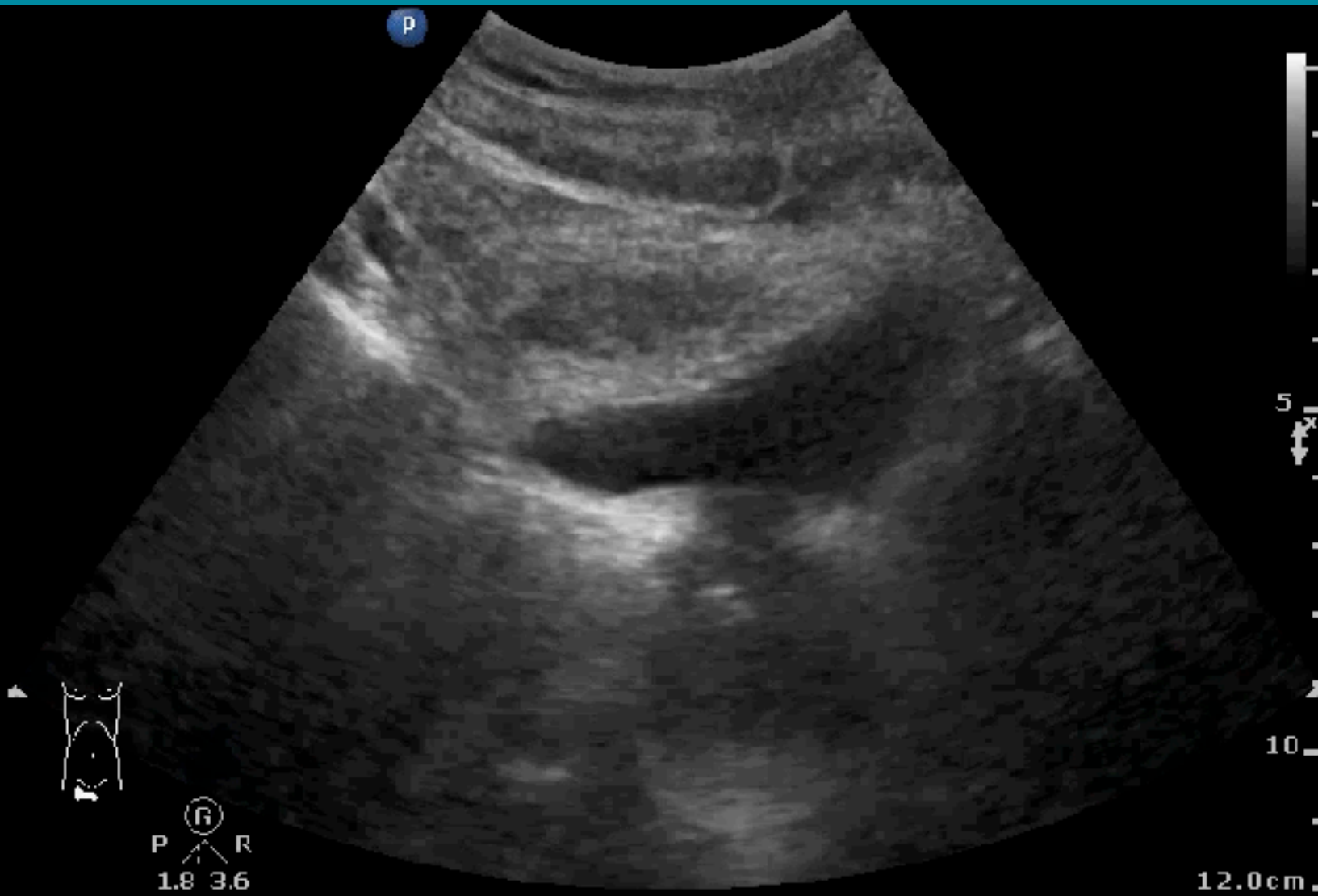



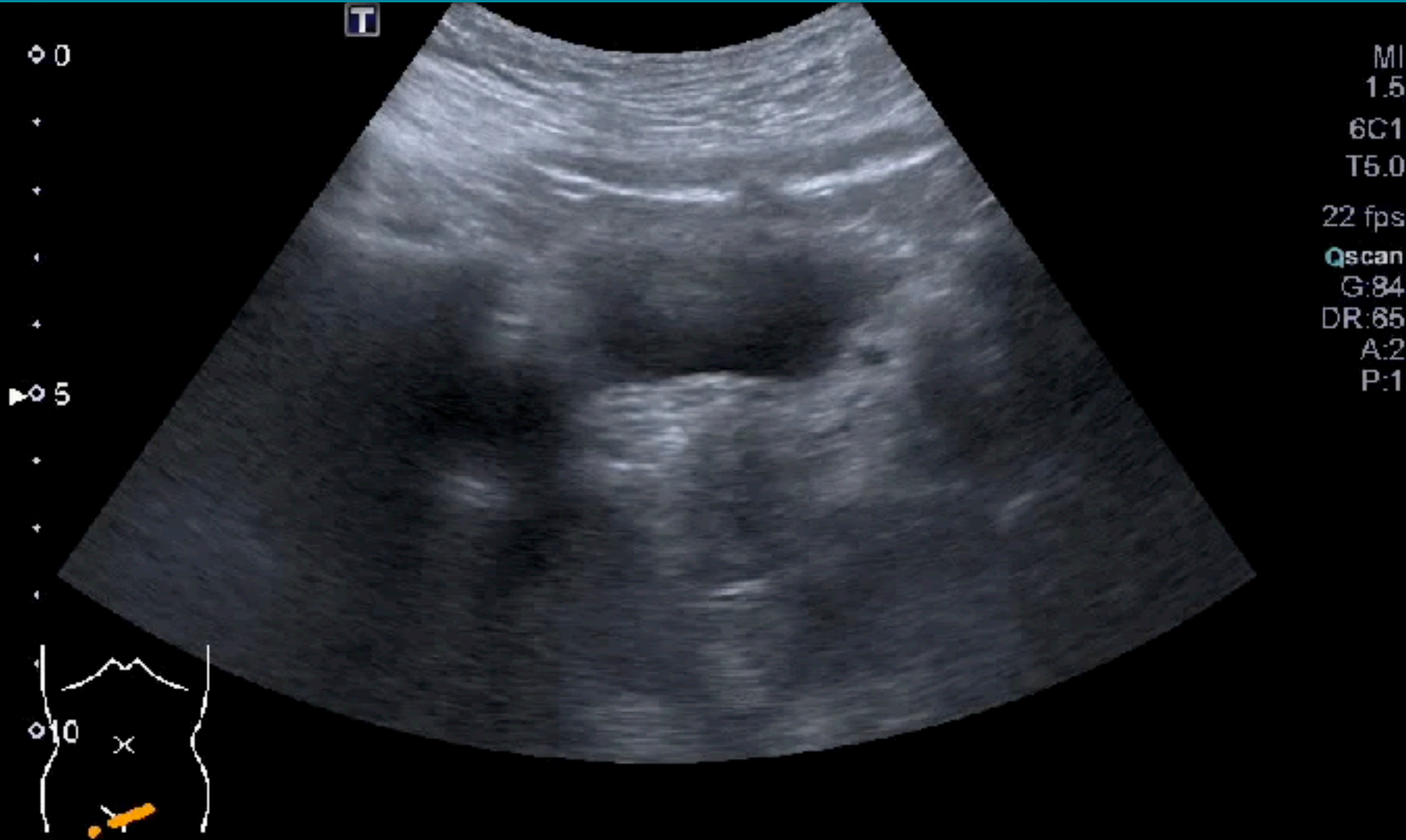
# Free fluid ?

Abd Gen  
C5-1  
39 Hz  
12.0cm

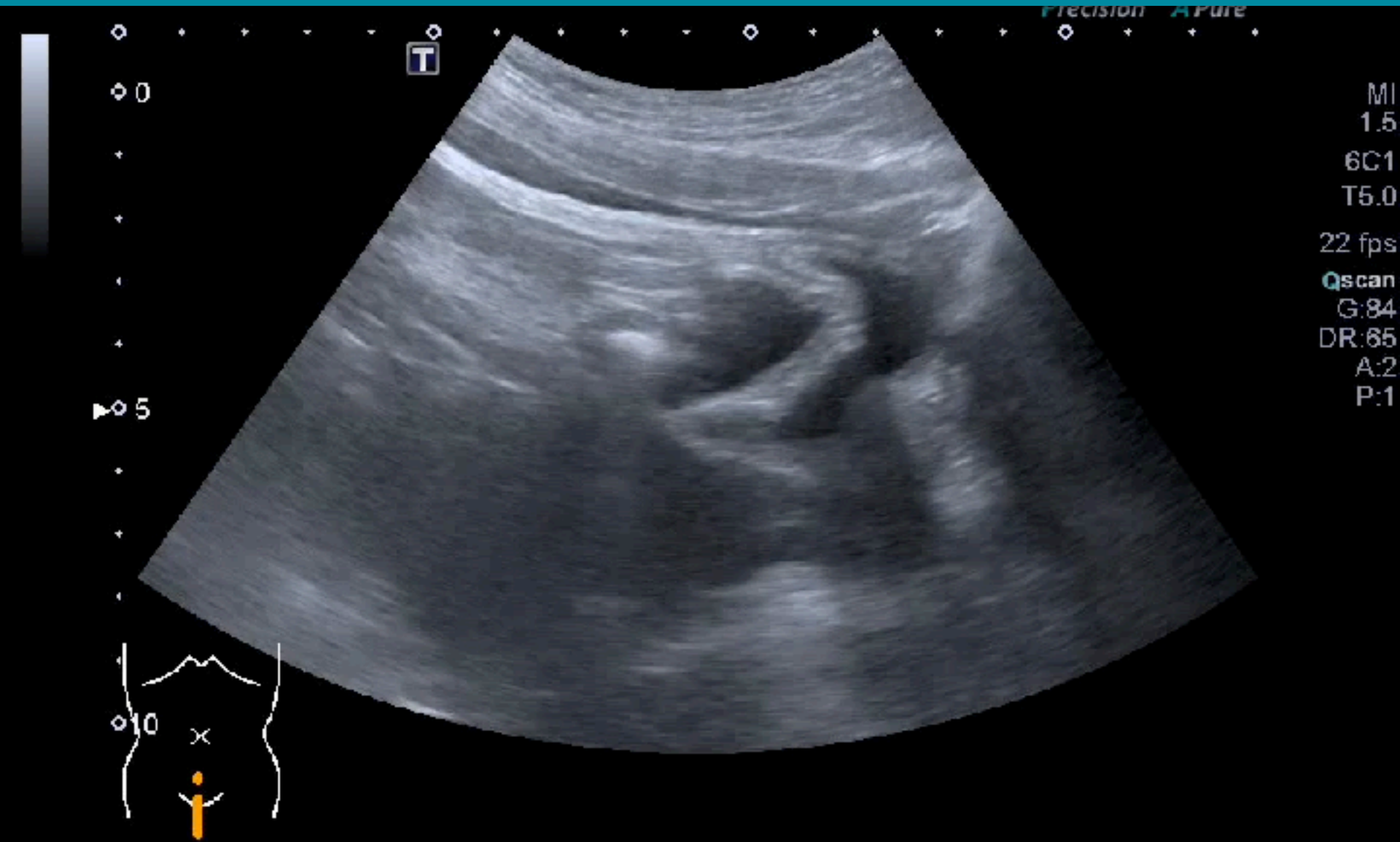2D  
HGen  
Gn 66  
C. 58  
3 / 3 / 3



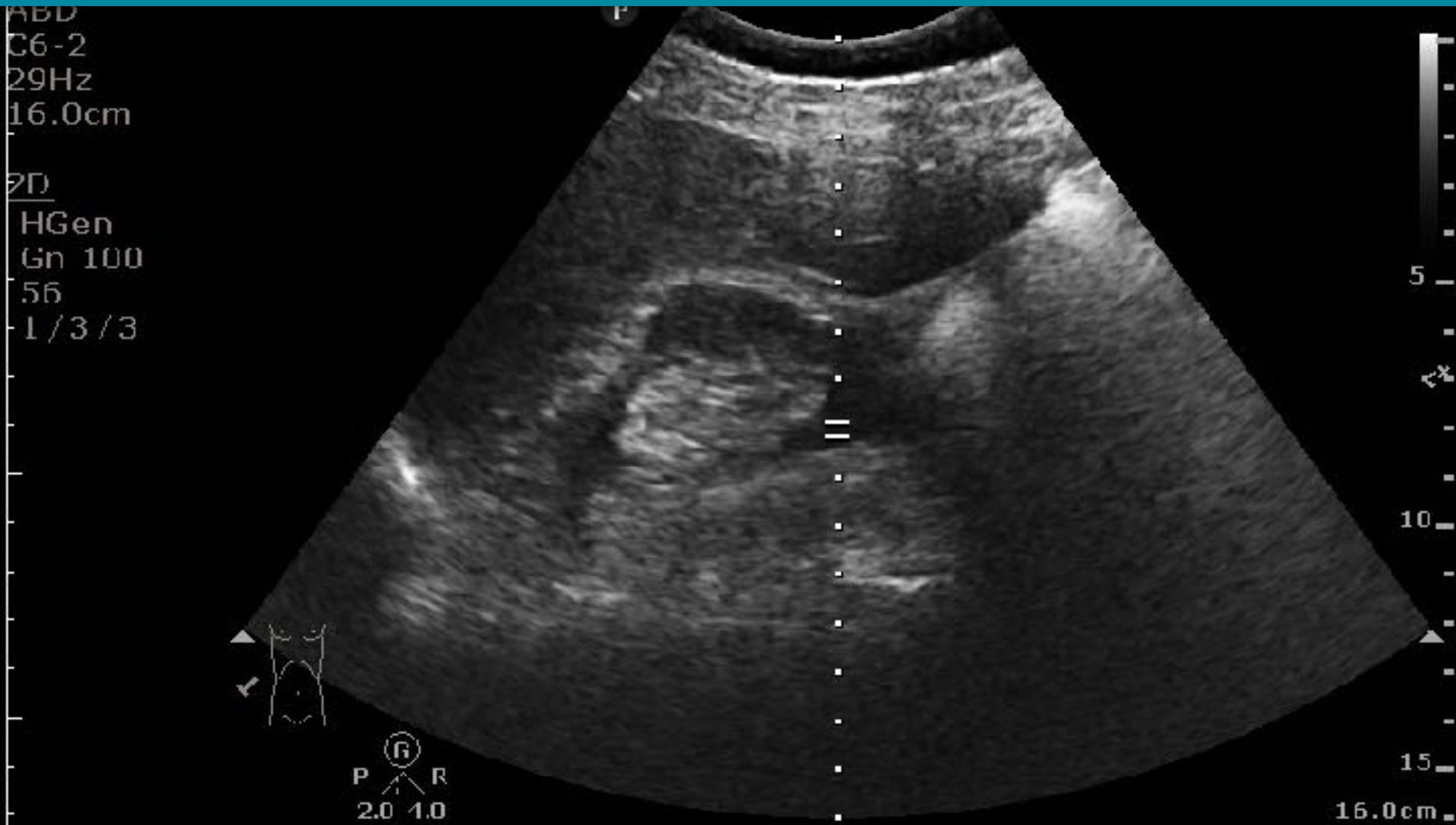
# Free fluid ?



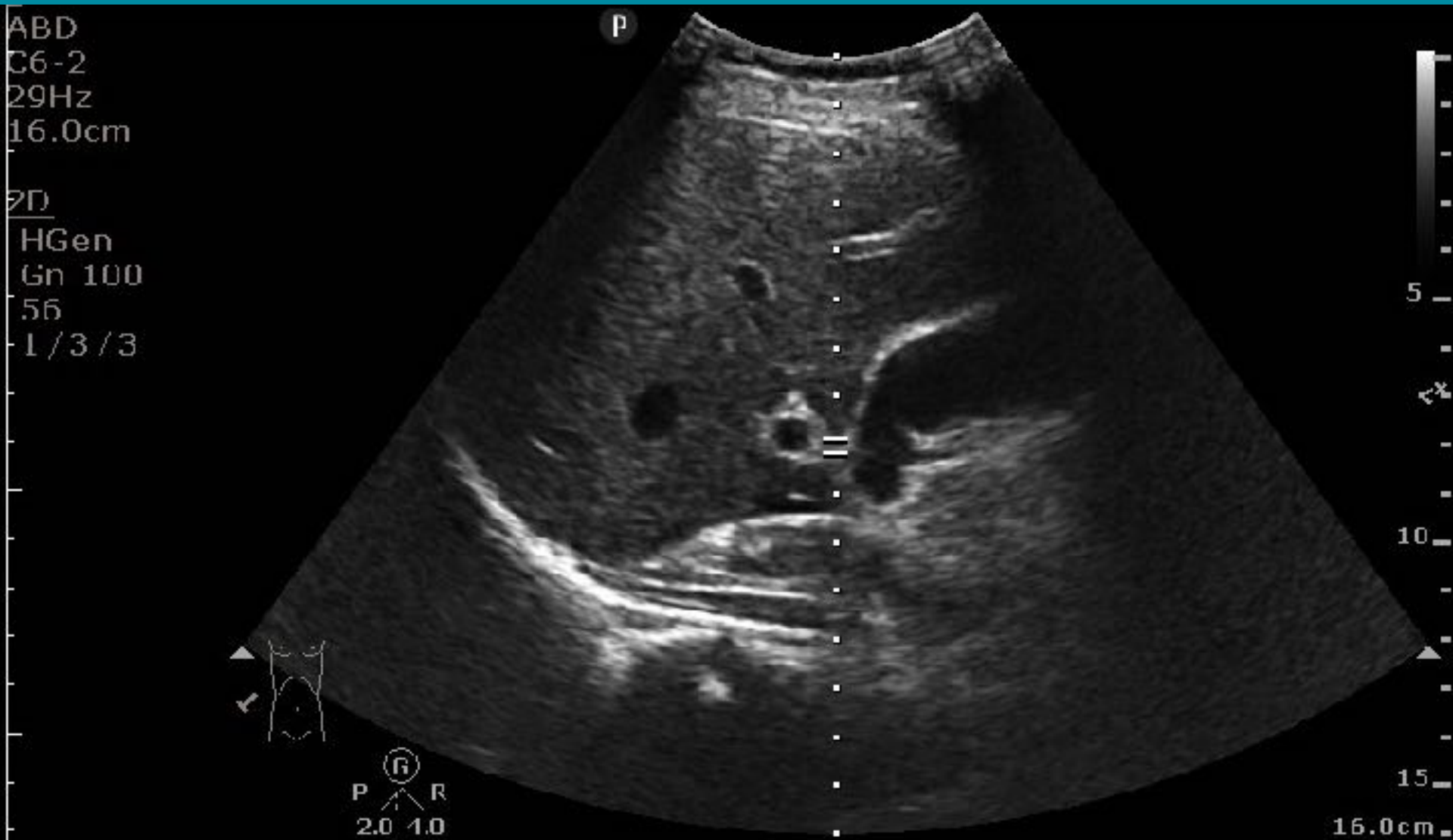# Free fluid ?



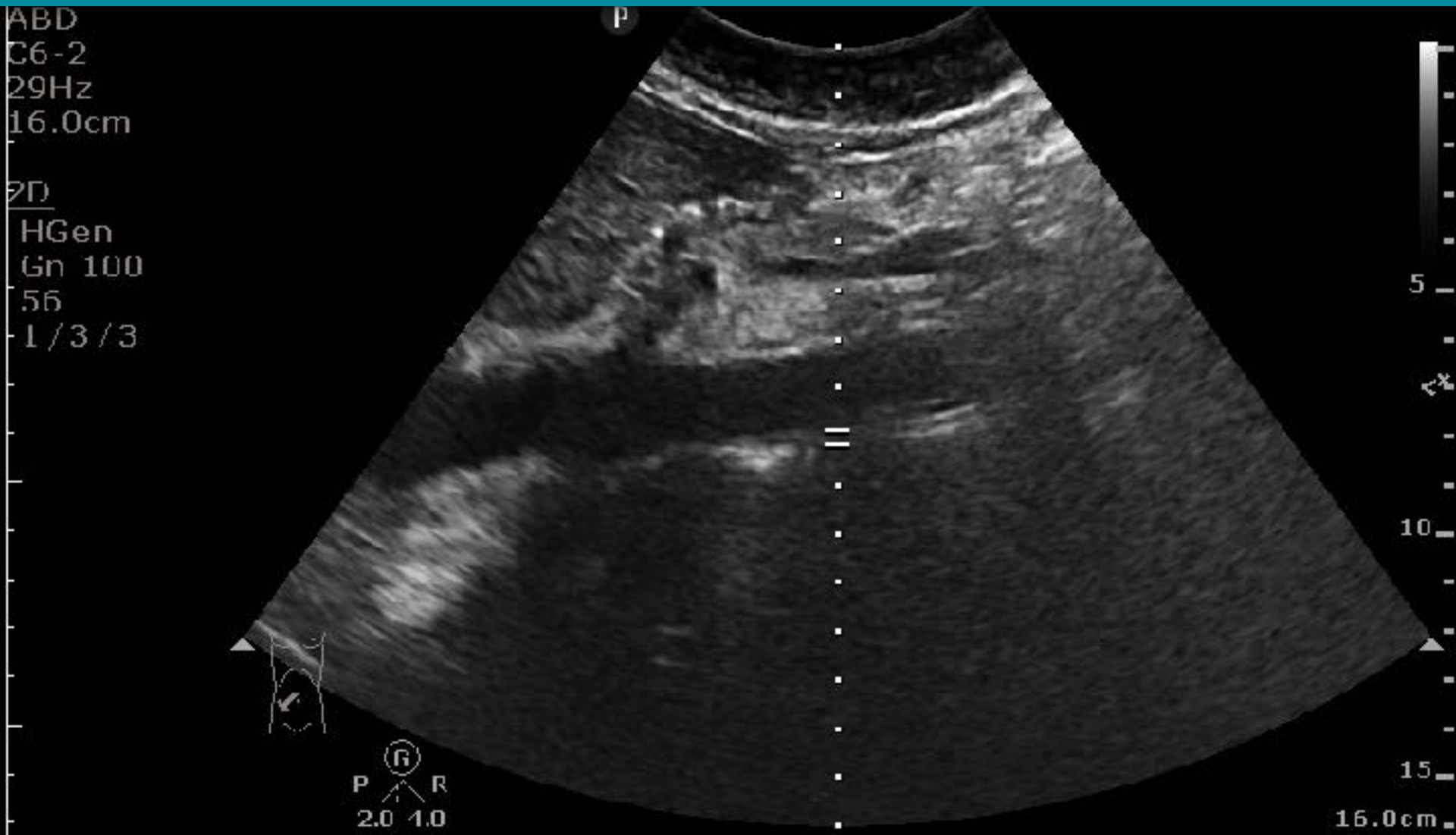# 45M , abdominal pain



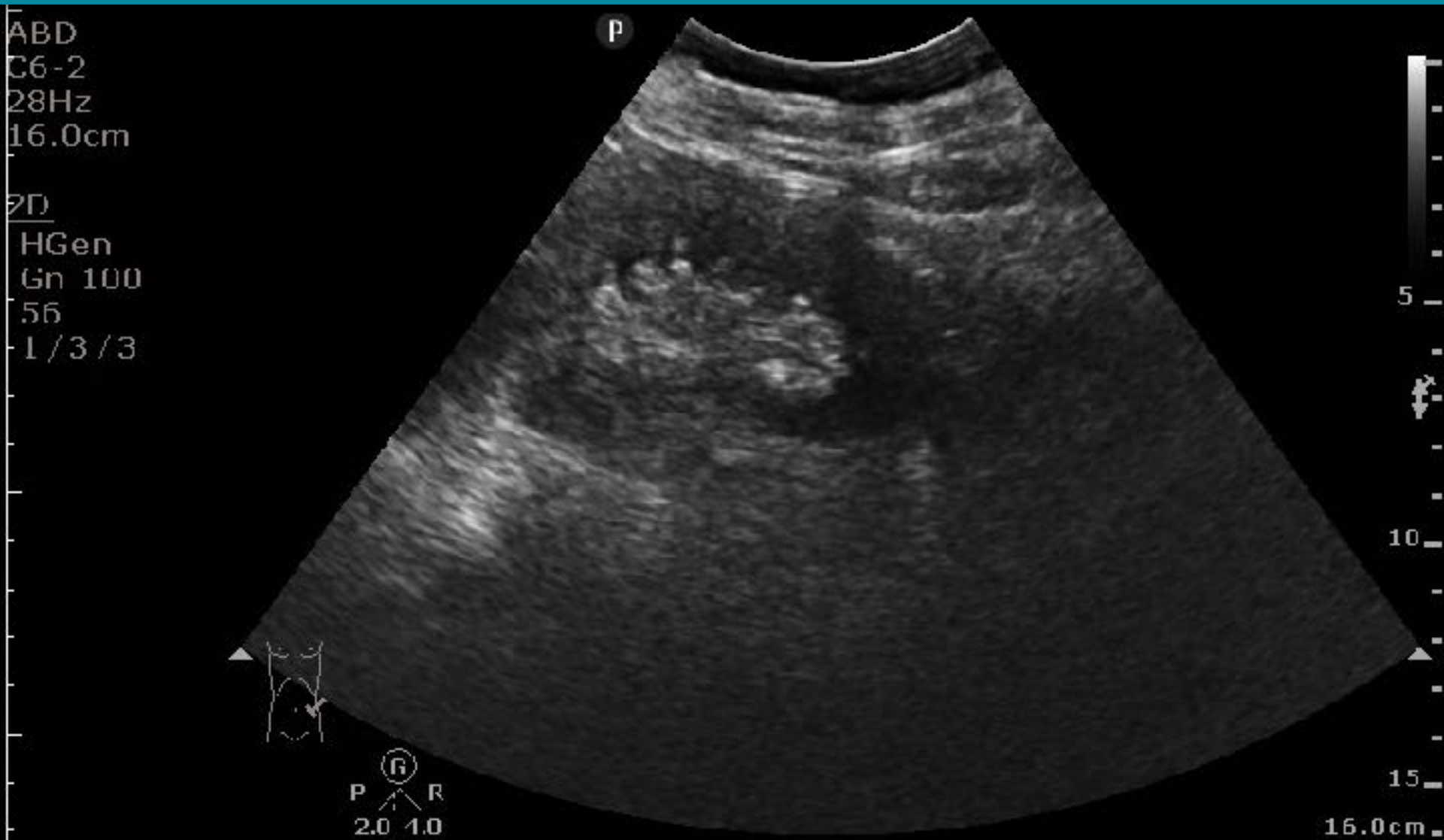
# 45M , abdominal pain



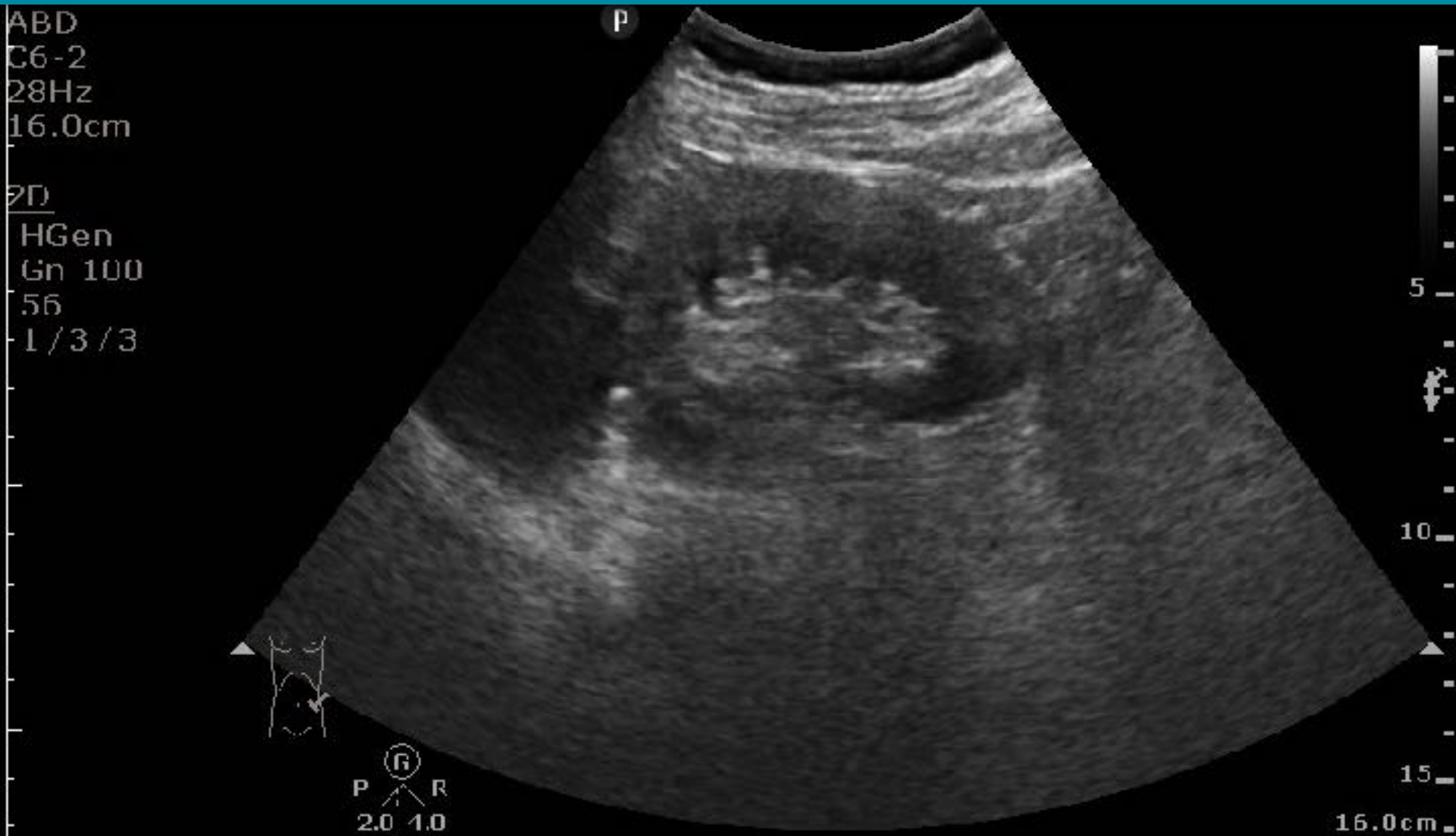# 45M , abdominal pain



# 45M , abdominal pain

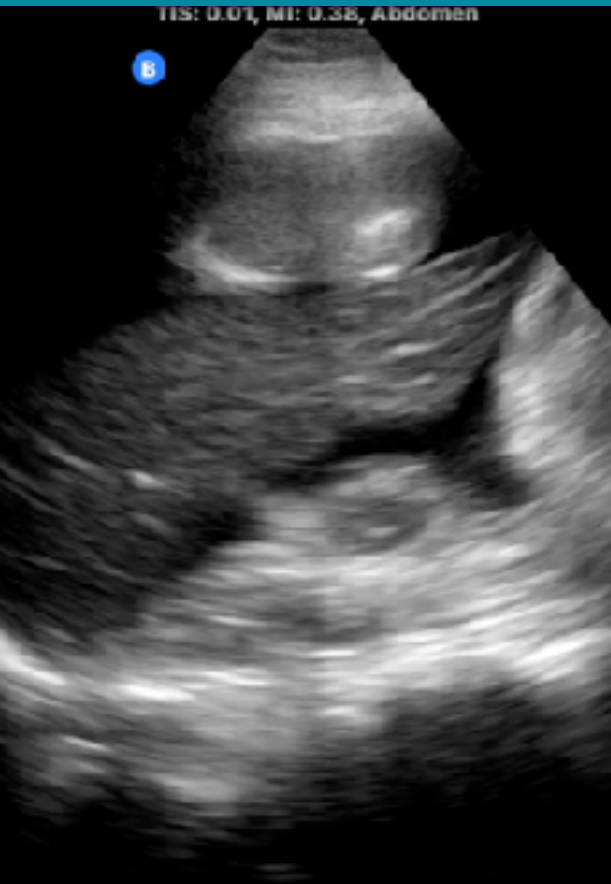

# 45M , abdominal pain

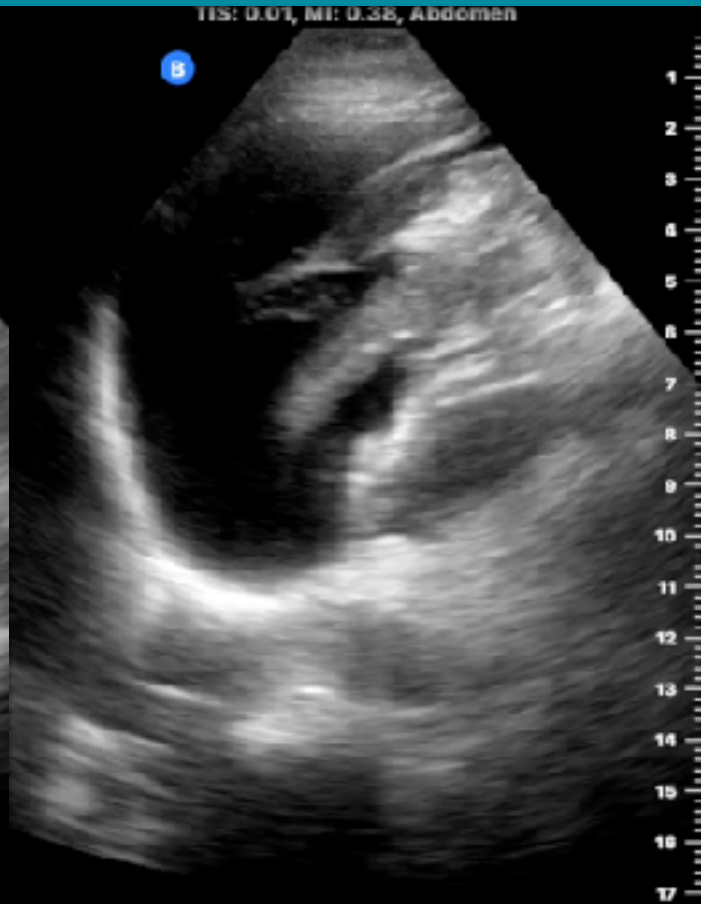



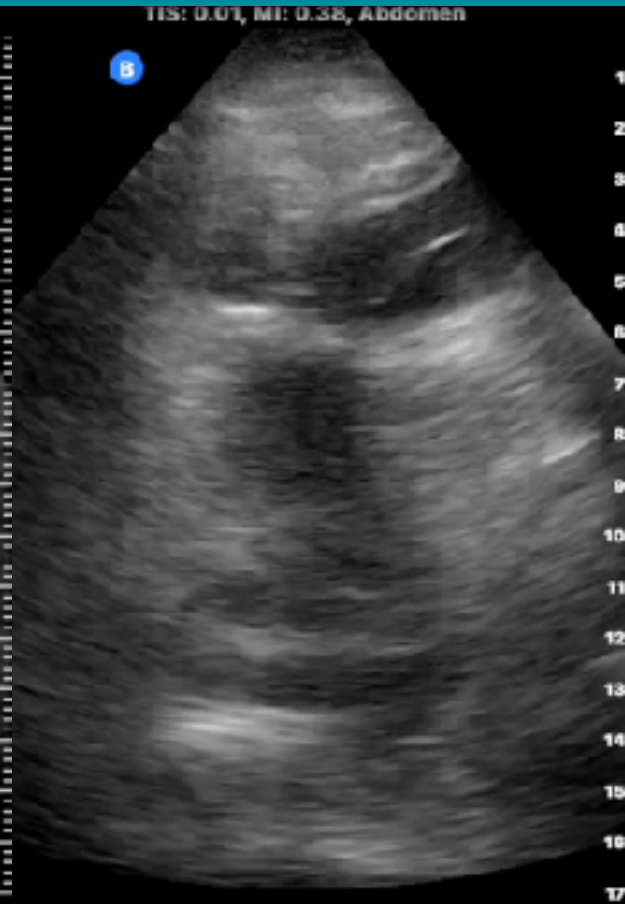# Free fluid ?



右上腹



左上腹



骨盆横

# 腹腔積液Free fluid



有無游離液體

患者姿勢  
患者體形  
積液來源  
經過時間  
影像品質  
掃描技術

增加介面

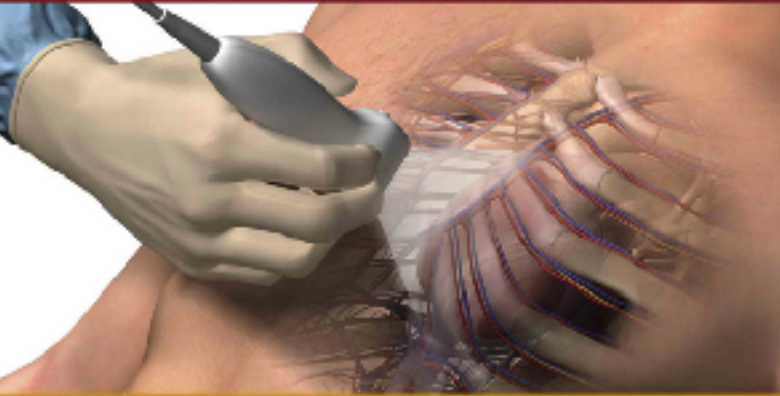
增加頻次

替代影像

# 腹腔積液 Free fluid

Second Edition

## Point-of-Care ULTRASOUND



Nilam J. Soni  
Robert Arntfield  
Pierre Kory

**主要目標: 腹腔內游離積液**

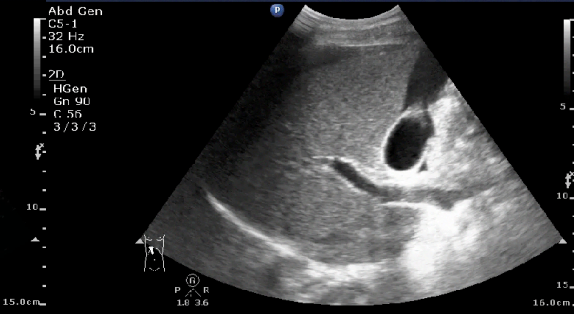
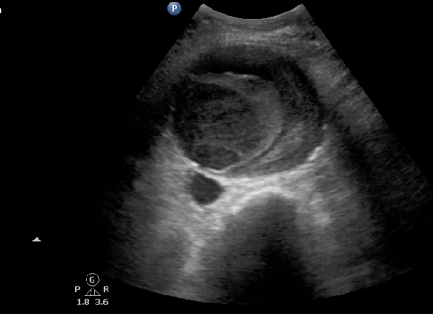
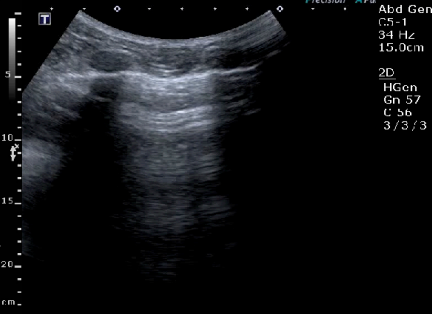
**善用視窗: 肝 / 脾 / 膀胱**

**水往低處流，愈遠愈游離愈黑**

**不易辨別來源和積液成份**

**胃部液體別誤判為游離液**

**游離液體不會有完整邊界**



HEART

LUNG

AORTA

FAST

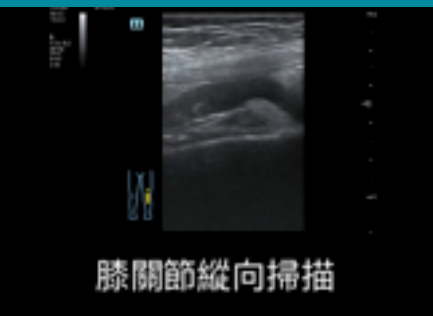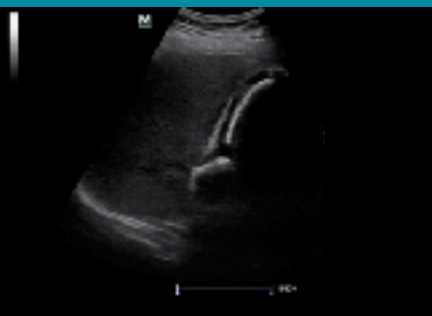
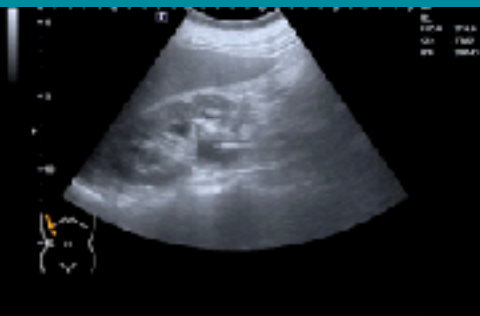KIDNEY

BILIARY

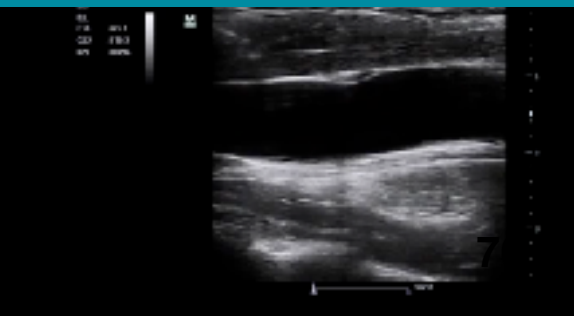
KNEE

CVC

# 8 ESSENTIAL SKILLS

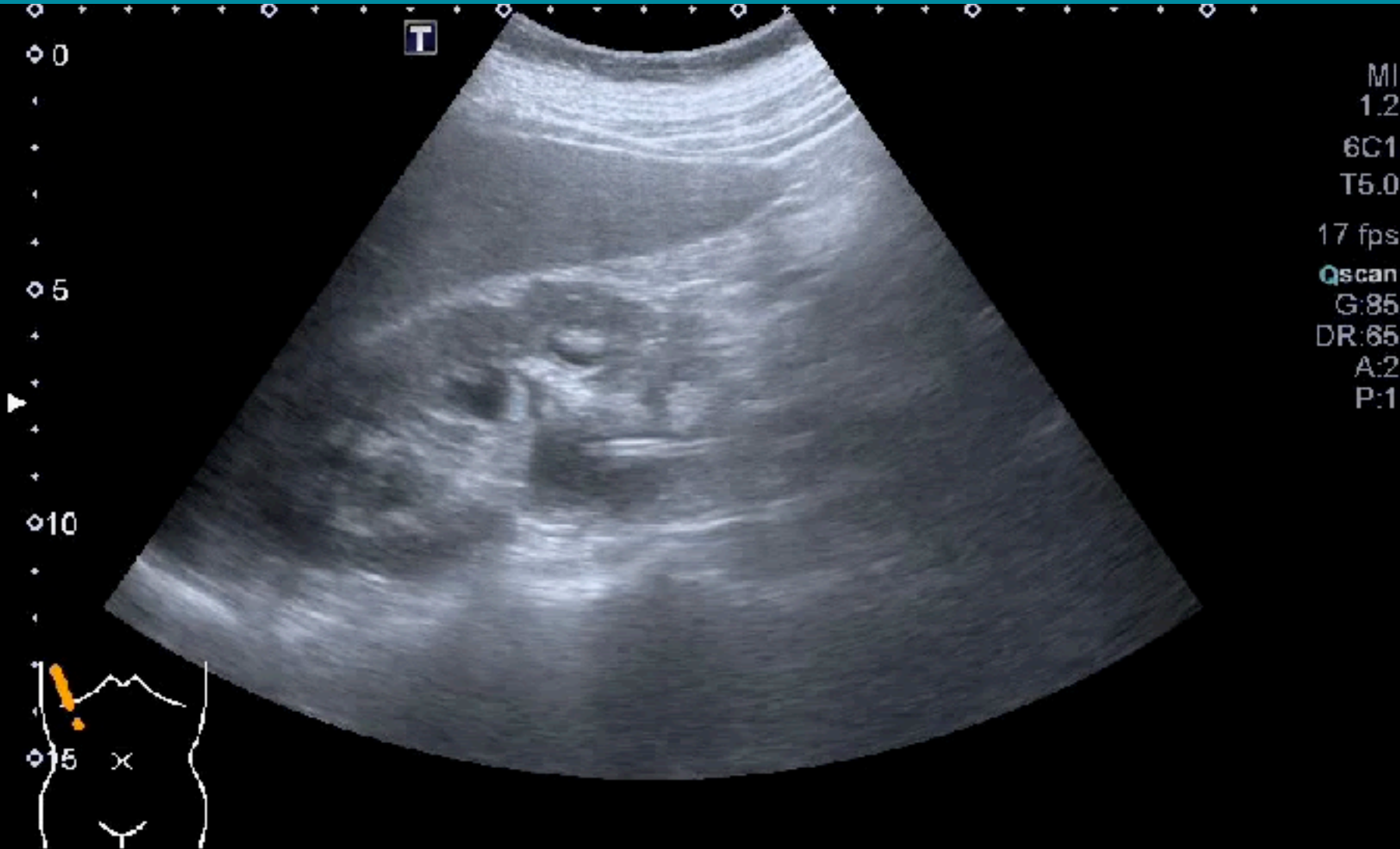


膝關節縱向掃描

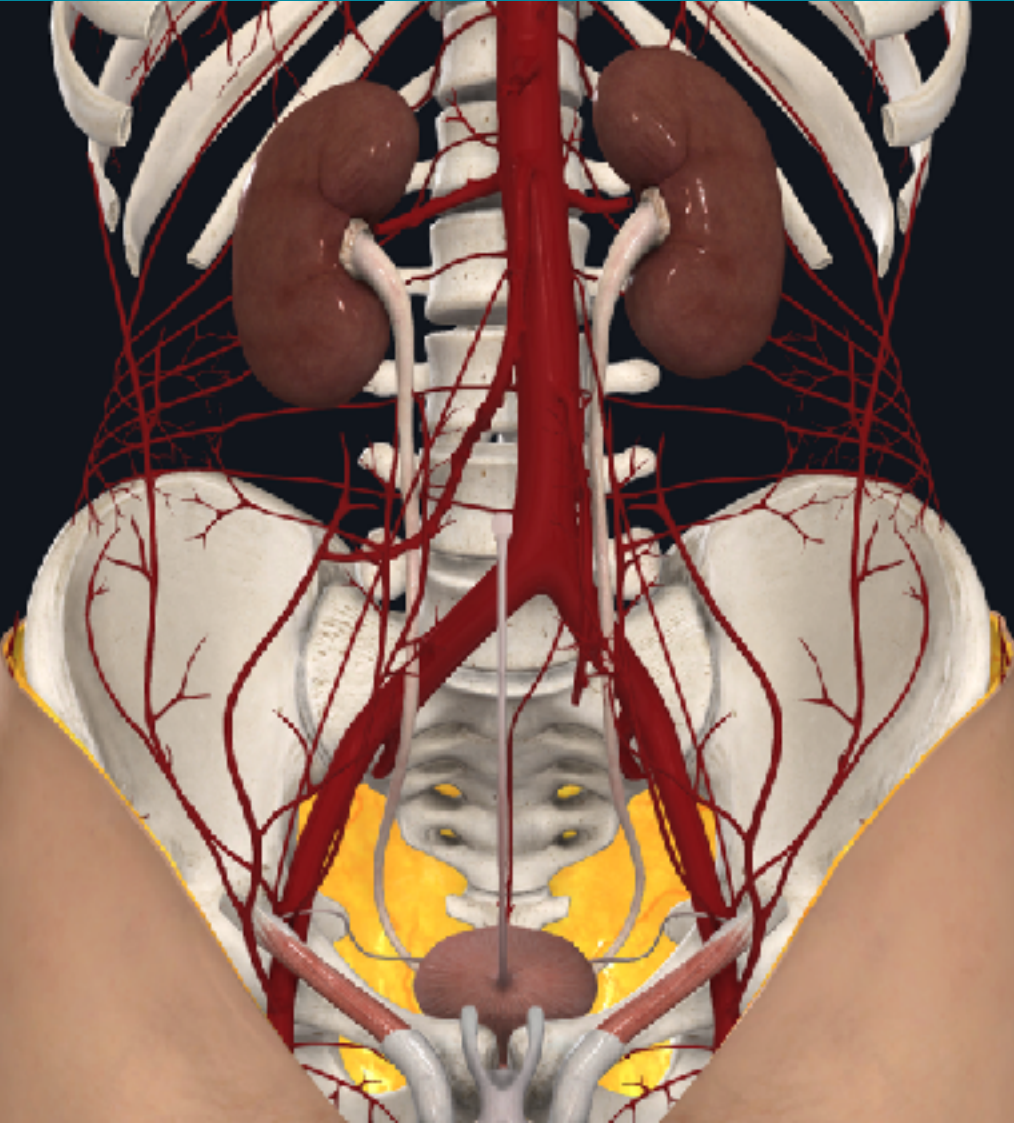



# KIDNEY



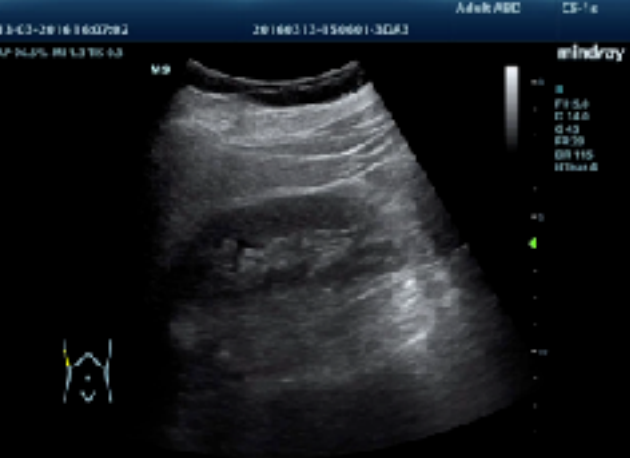# KIDNEY & UB



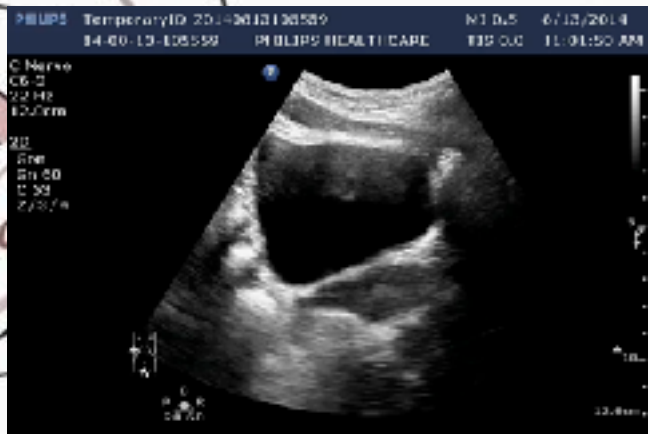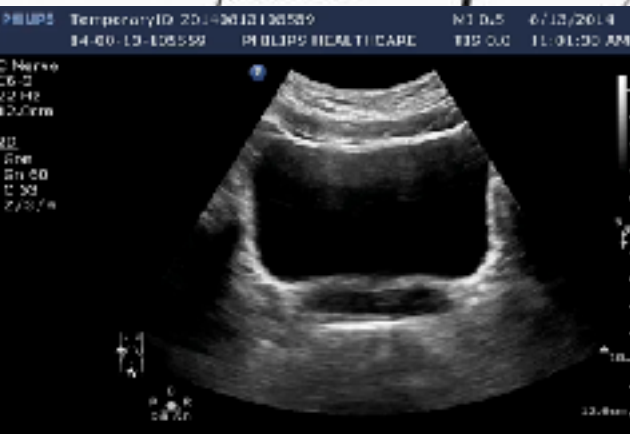
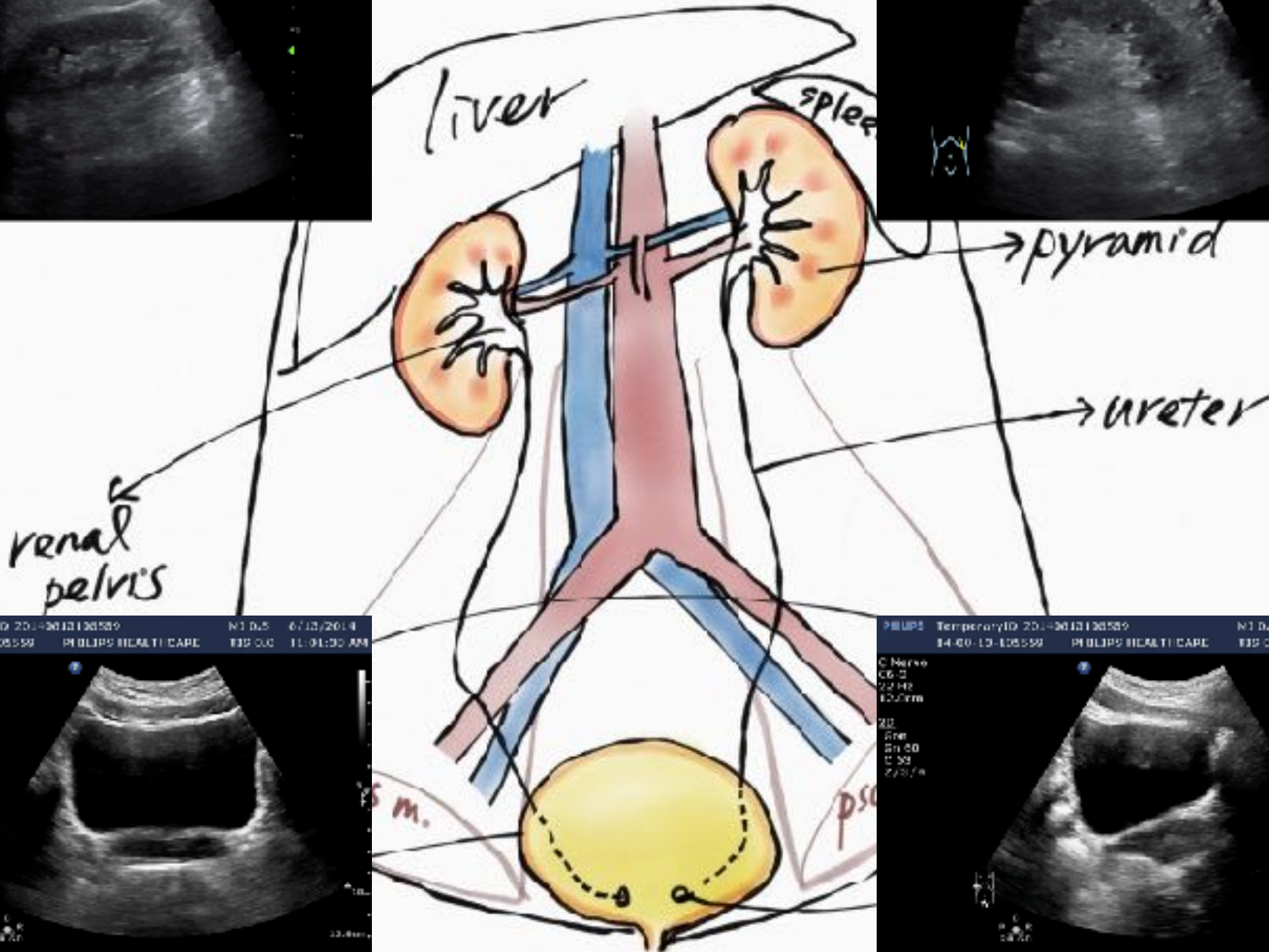
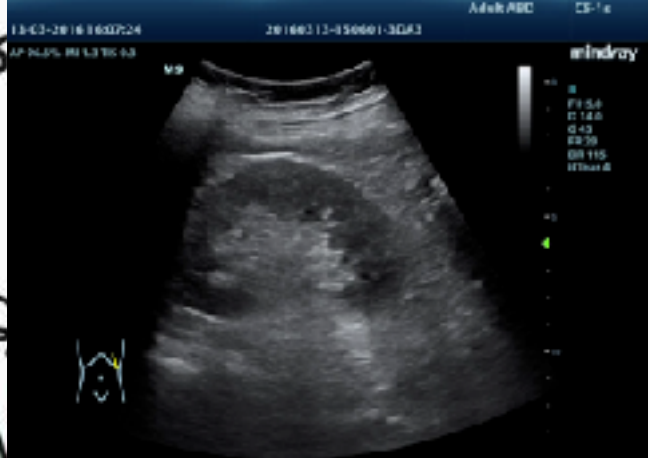Pain  
Infection  
Renal failure

**Obstruction**

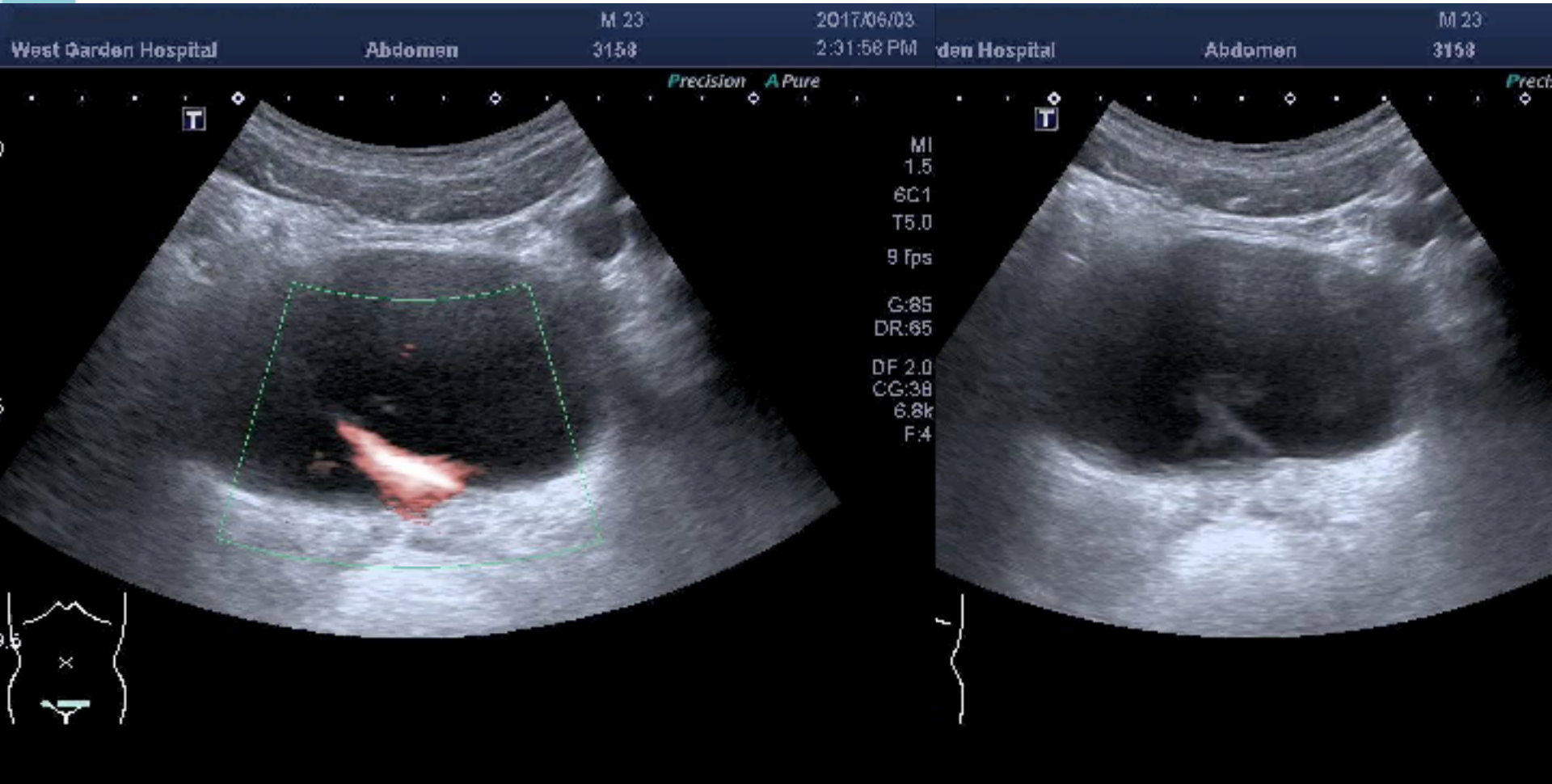
**永遠要想到AAA**



SIZE CHANGE. All rights reserved

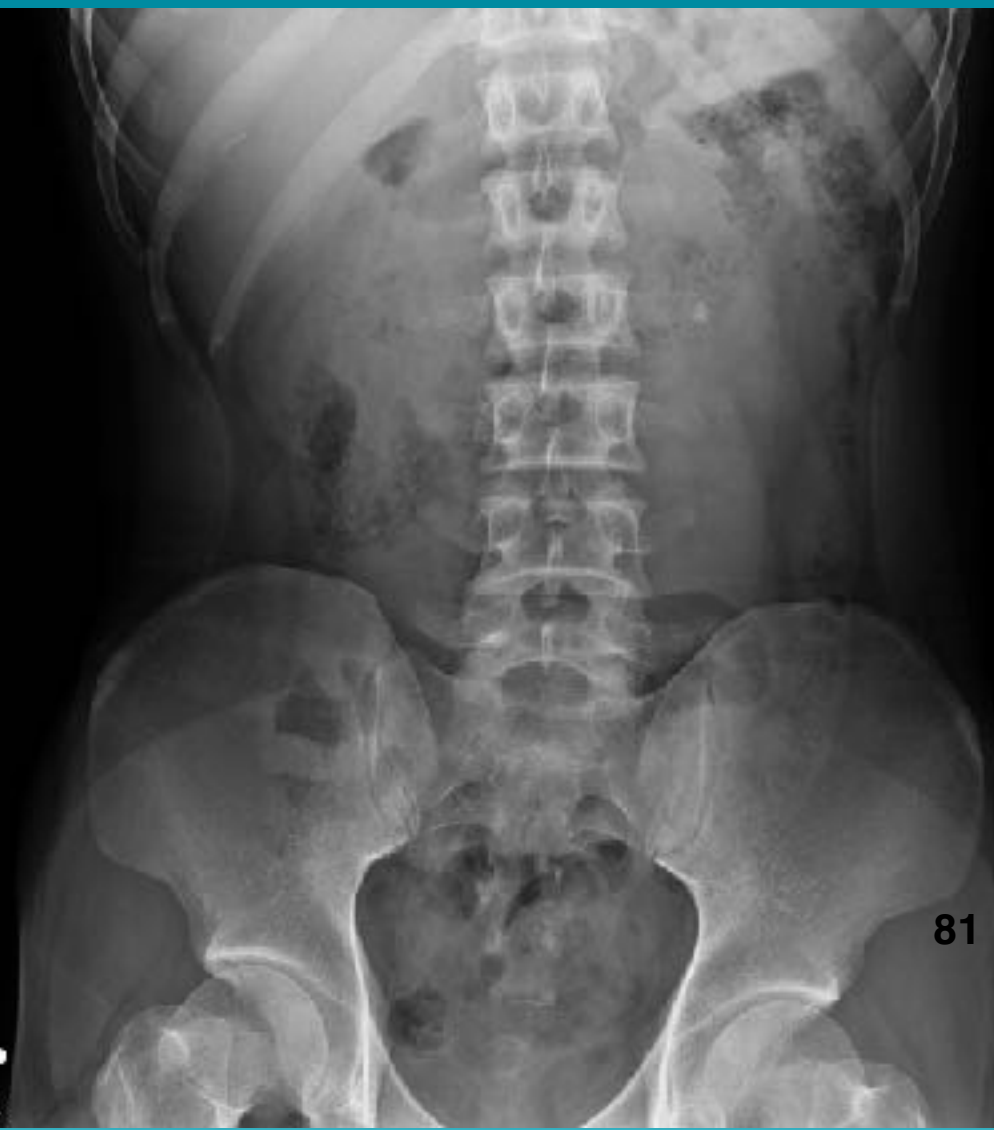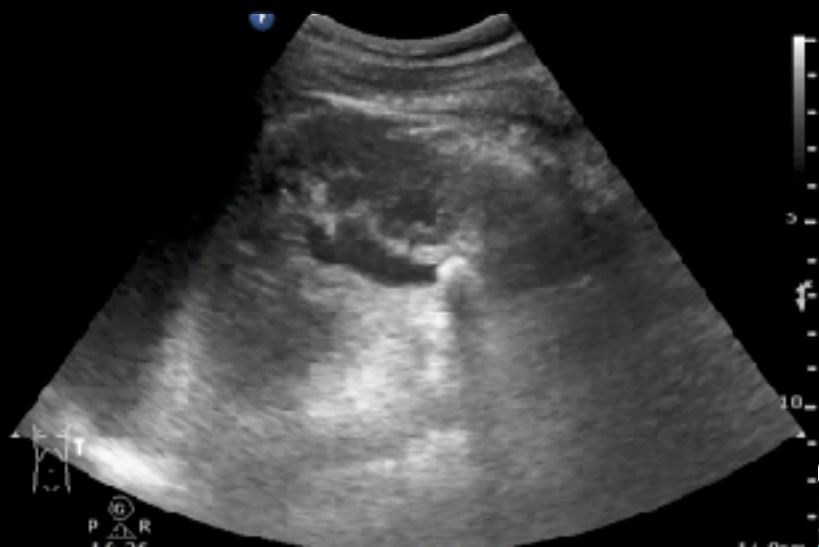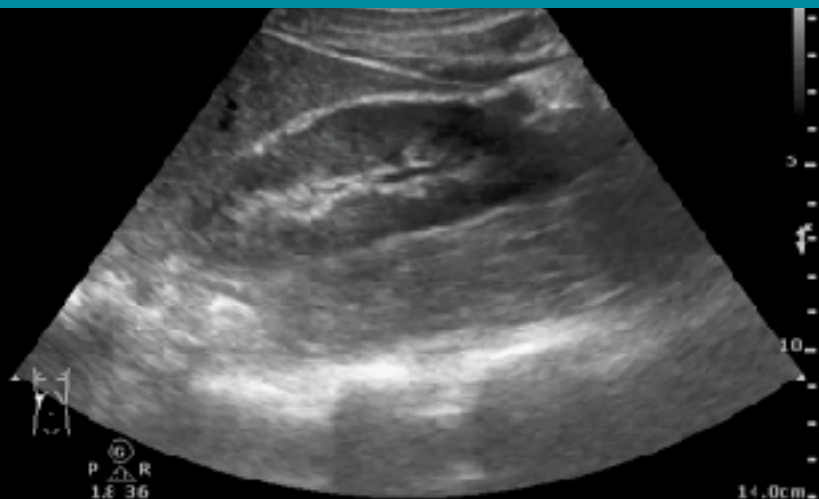


# URINARY JET





# LEFT FLANK PAIN

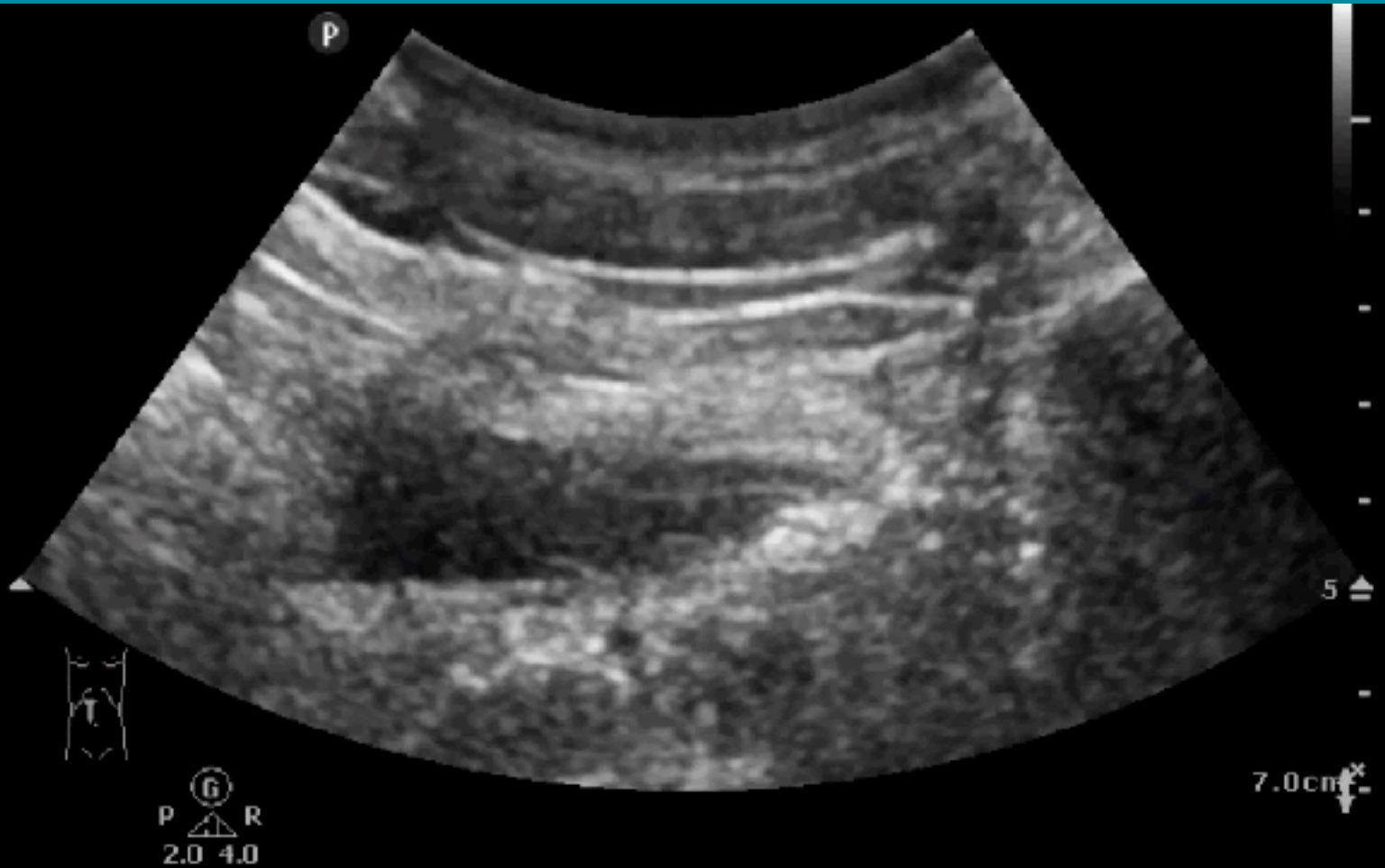

# L UVJ STONE

## TWINKLING ARTIFACT

C6-2  
47Hz  
7.0cm

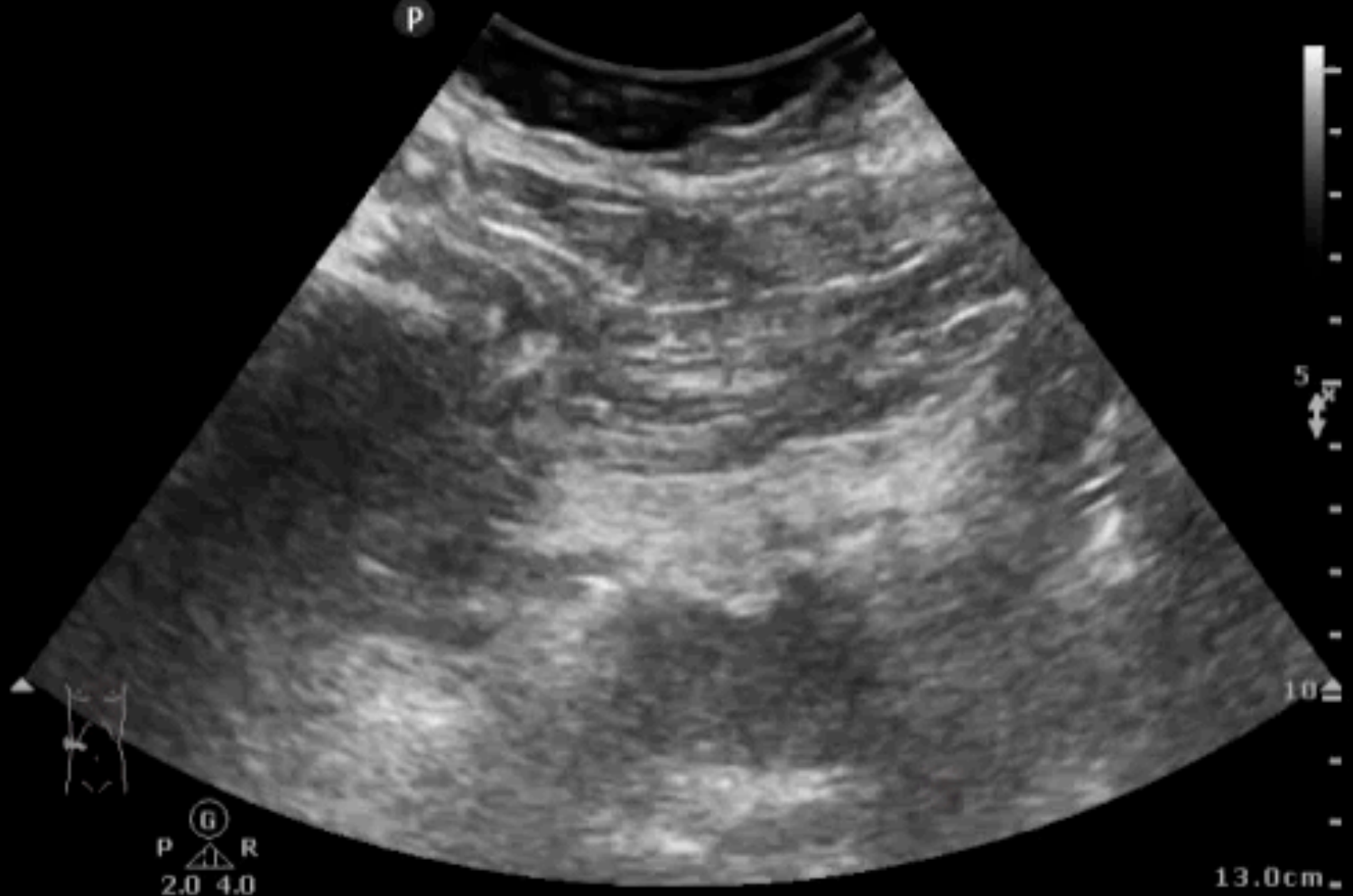2D  
HGen  
Gn 100  
56  
1/3/3



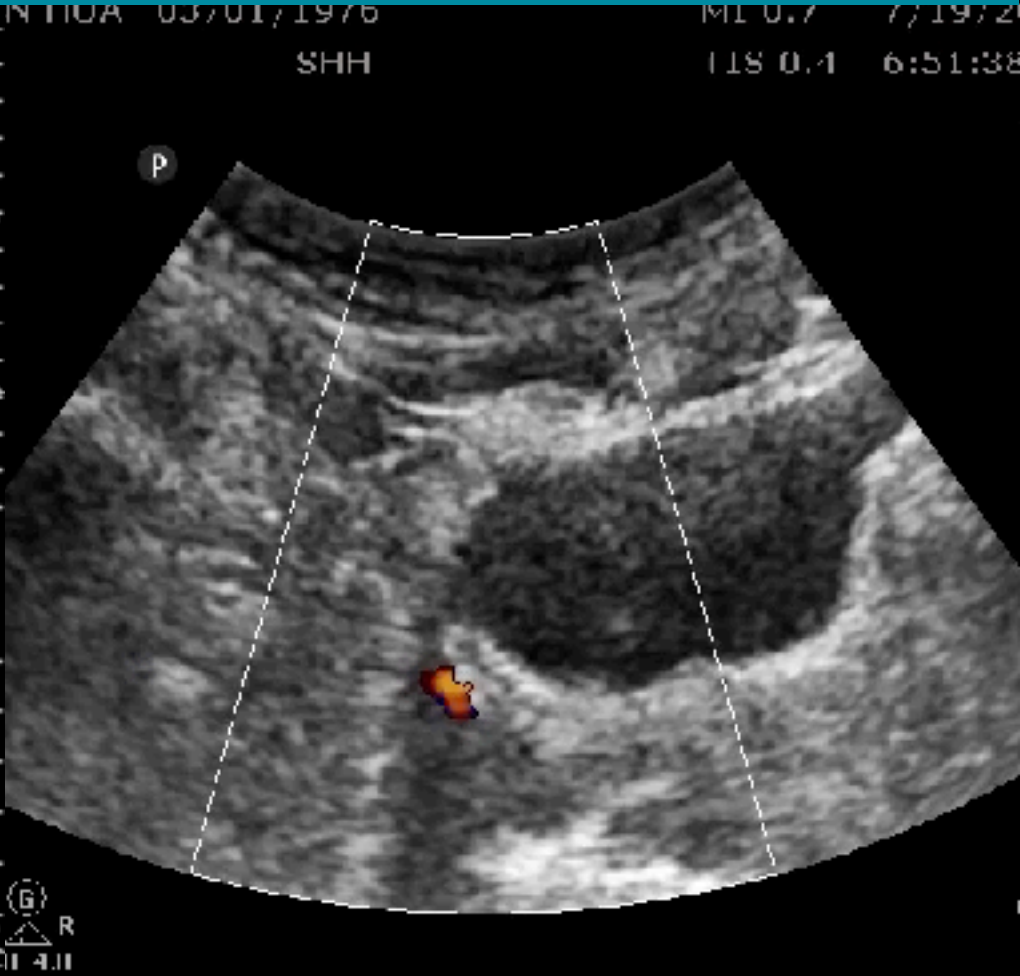
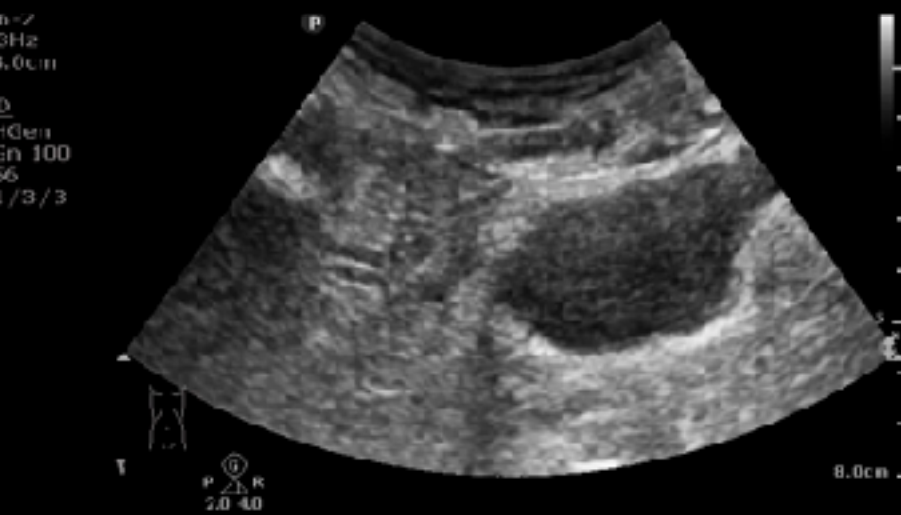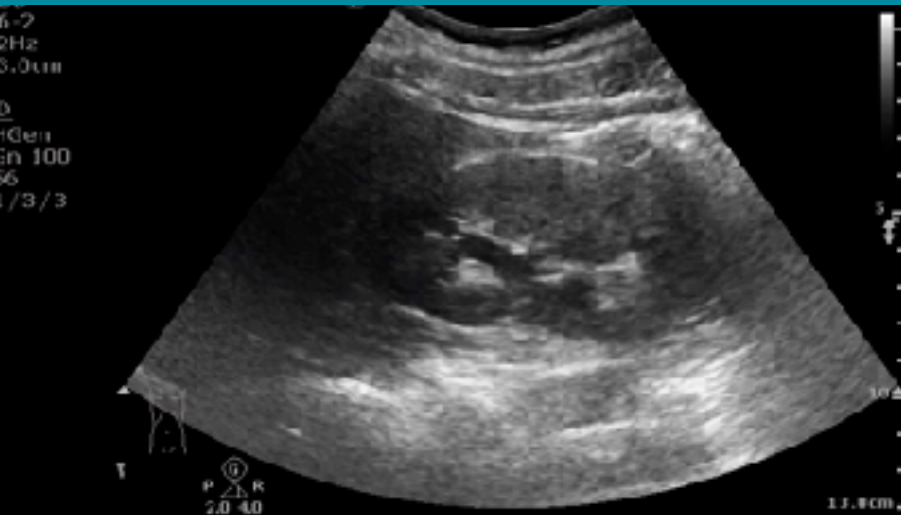# UVJ STONE

ABD  
C6-2  
32Hz  
13.0cm

2D  
HGen  
Gn 100  
56  
1/3/3



# R ABDOMINAL PAIN

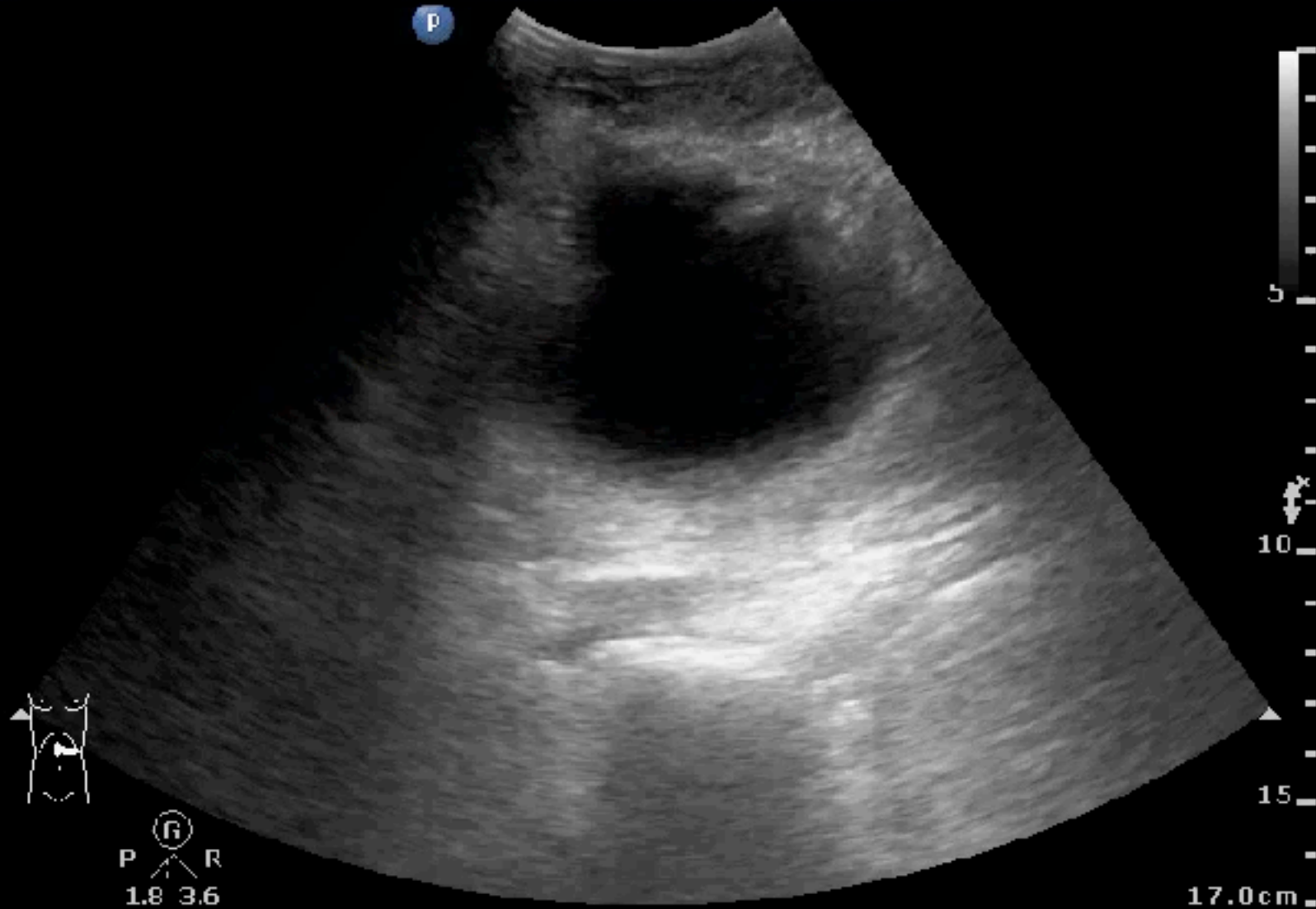


# AUR

Abd Gen  
C5-1  
31 Hz  
17.0cm

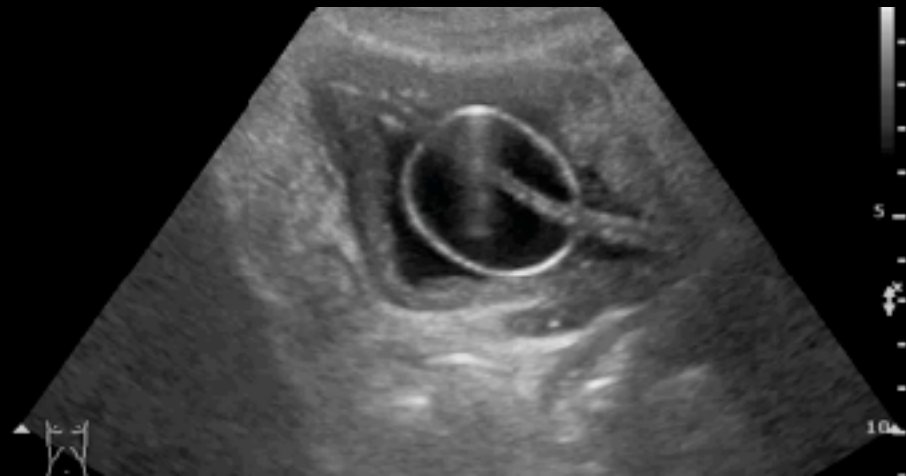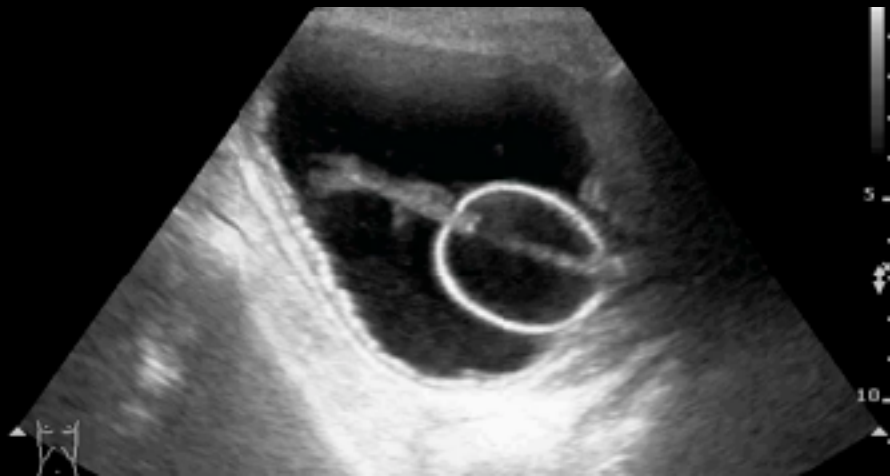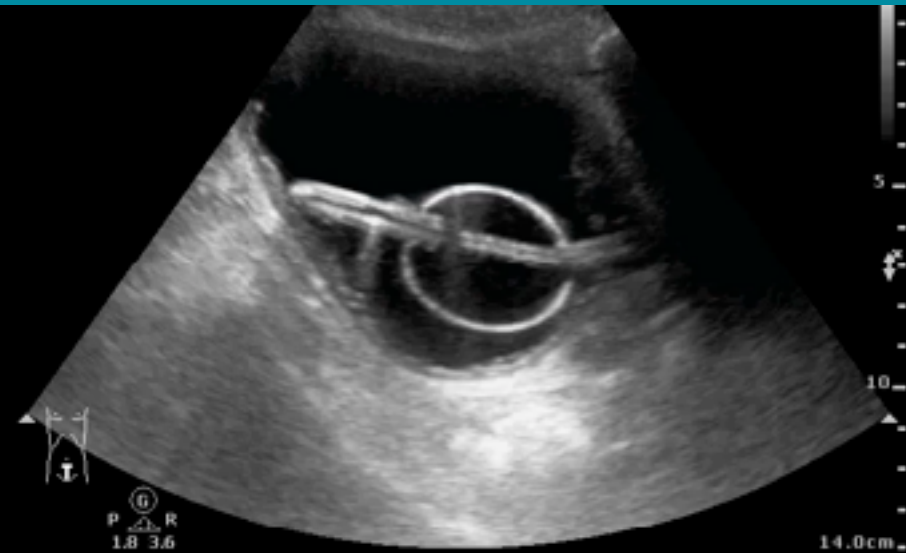
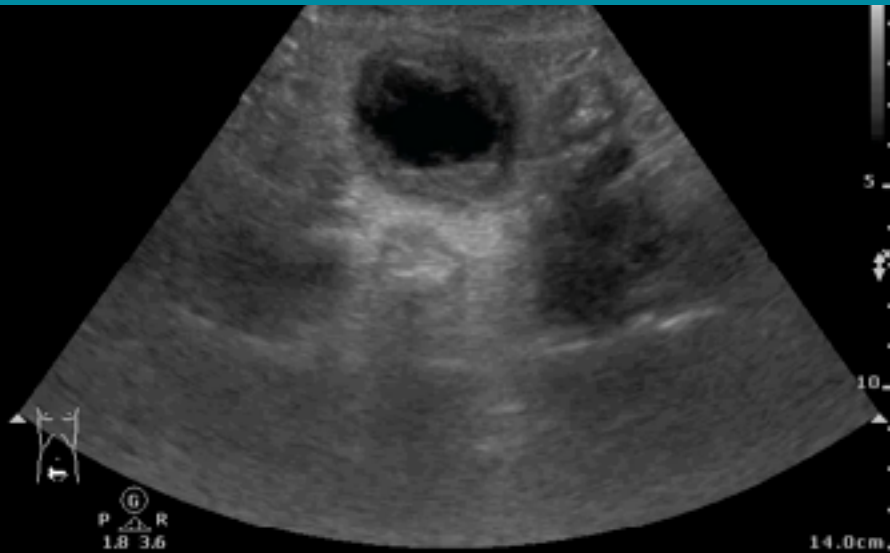
2D

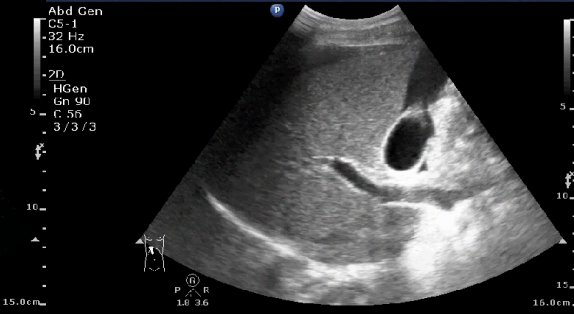
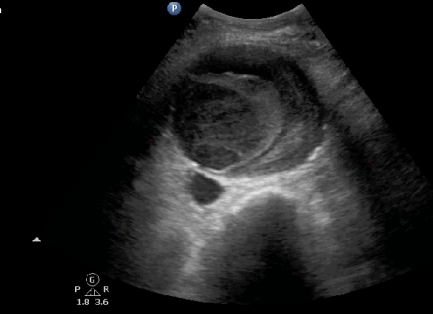
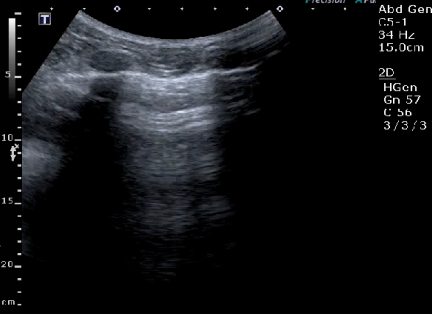
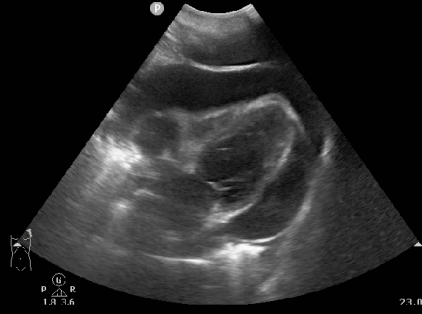
HGen  
Gn 60  
C. 56  
3 / 3 / 3



17.0cm

# NO URINE FROM FOLEY





HEART

LUNG

AORTA

FAST

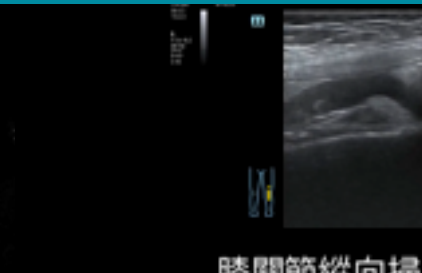
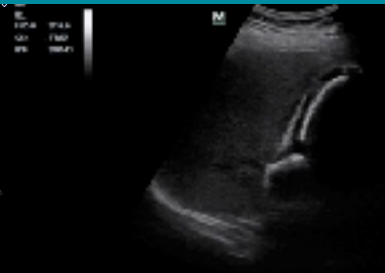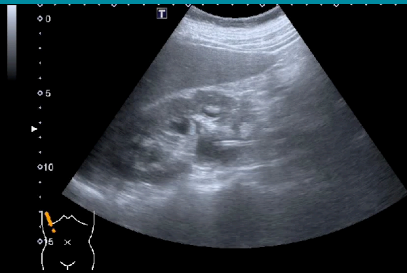
KIDNEY

**BILIARY**

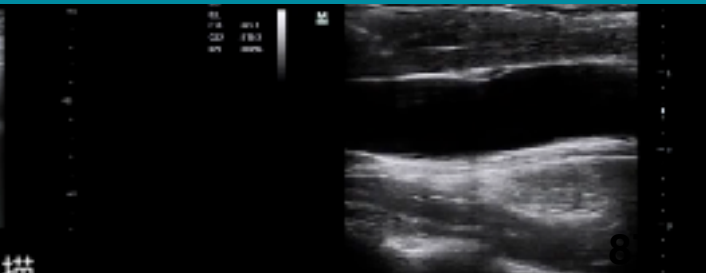**KNEE**

**CVC**

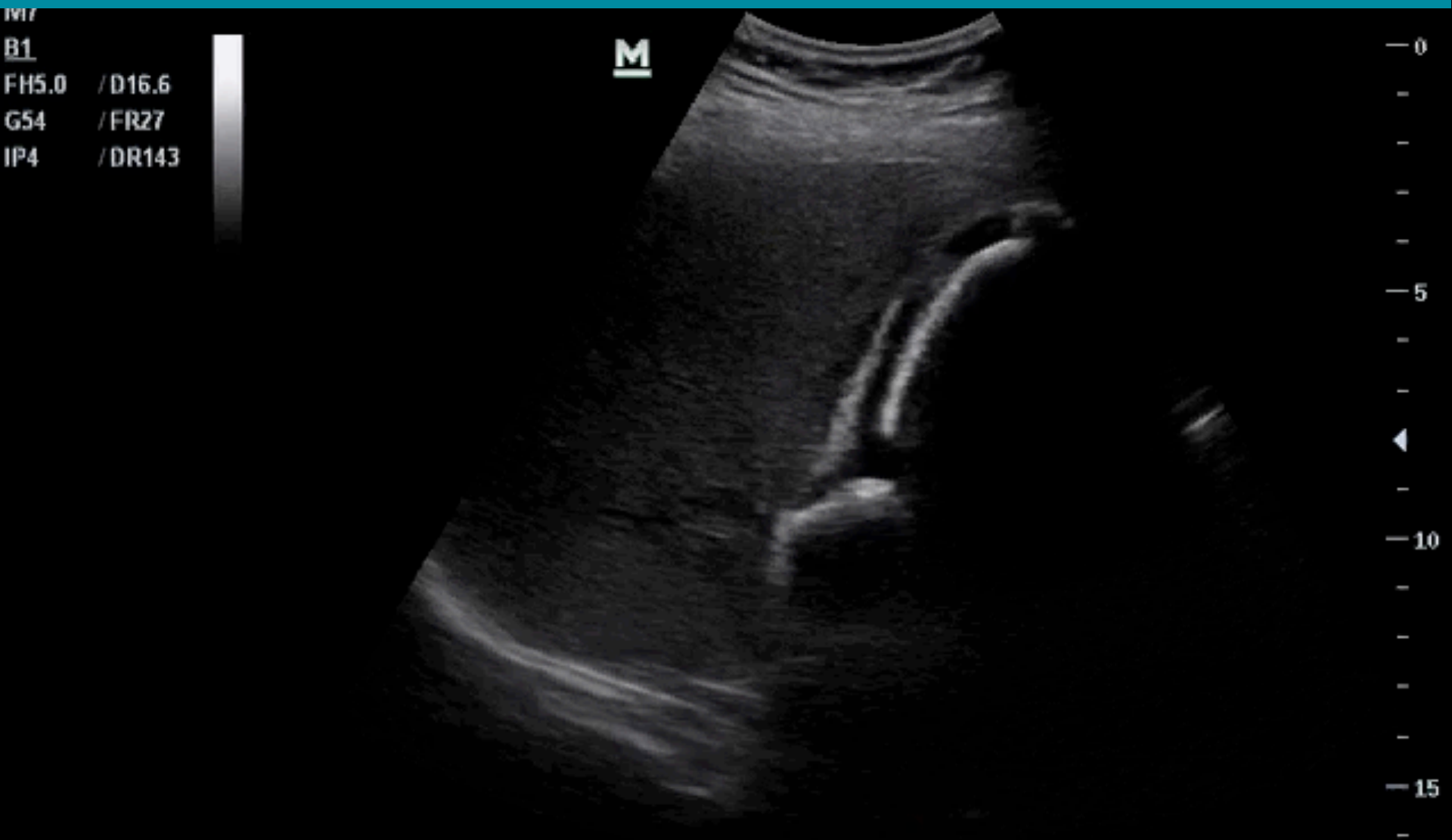# 8 ESSENTIAL SKILLS



膝關節縱向掃描



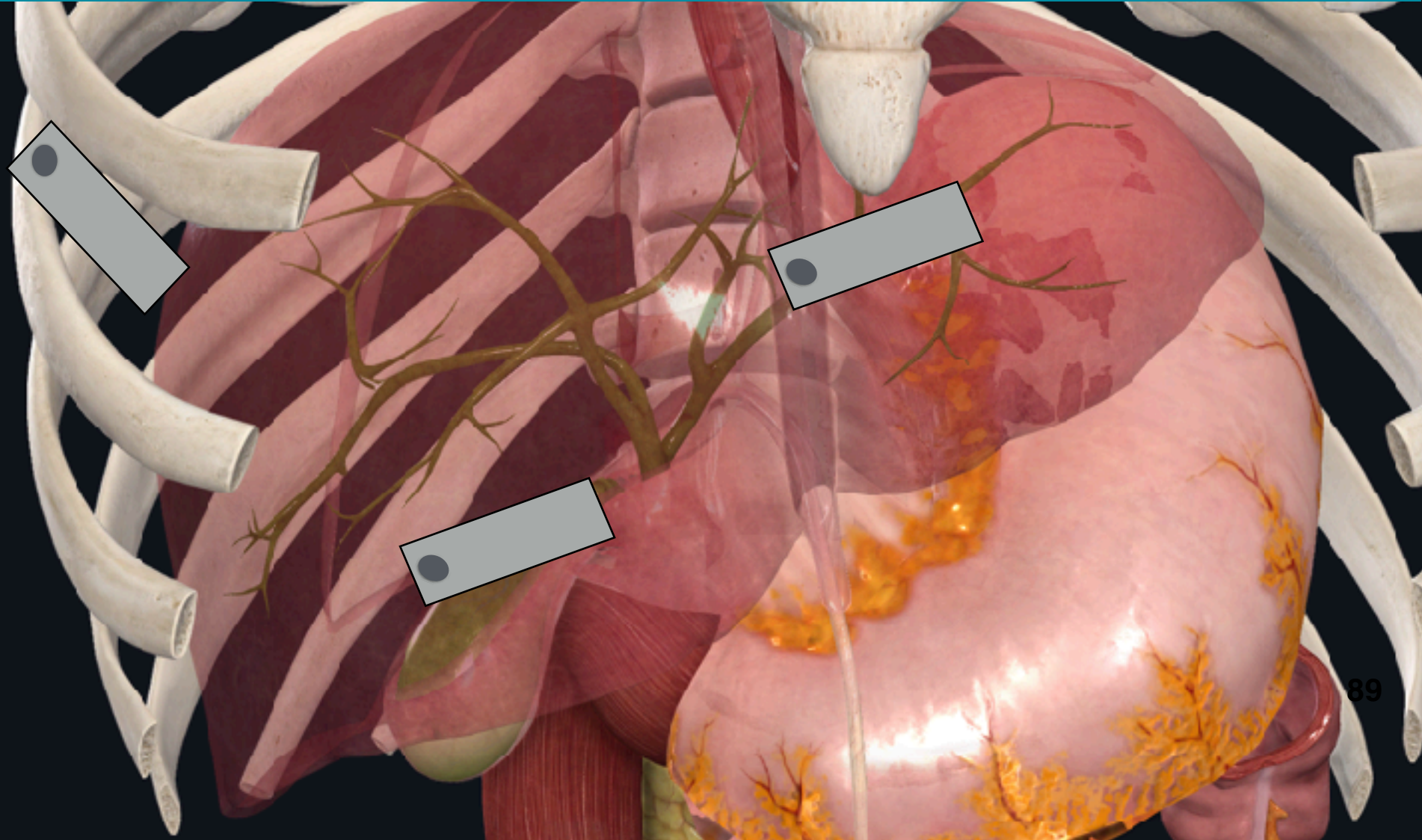
# BILIARY





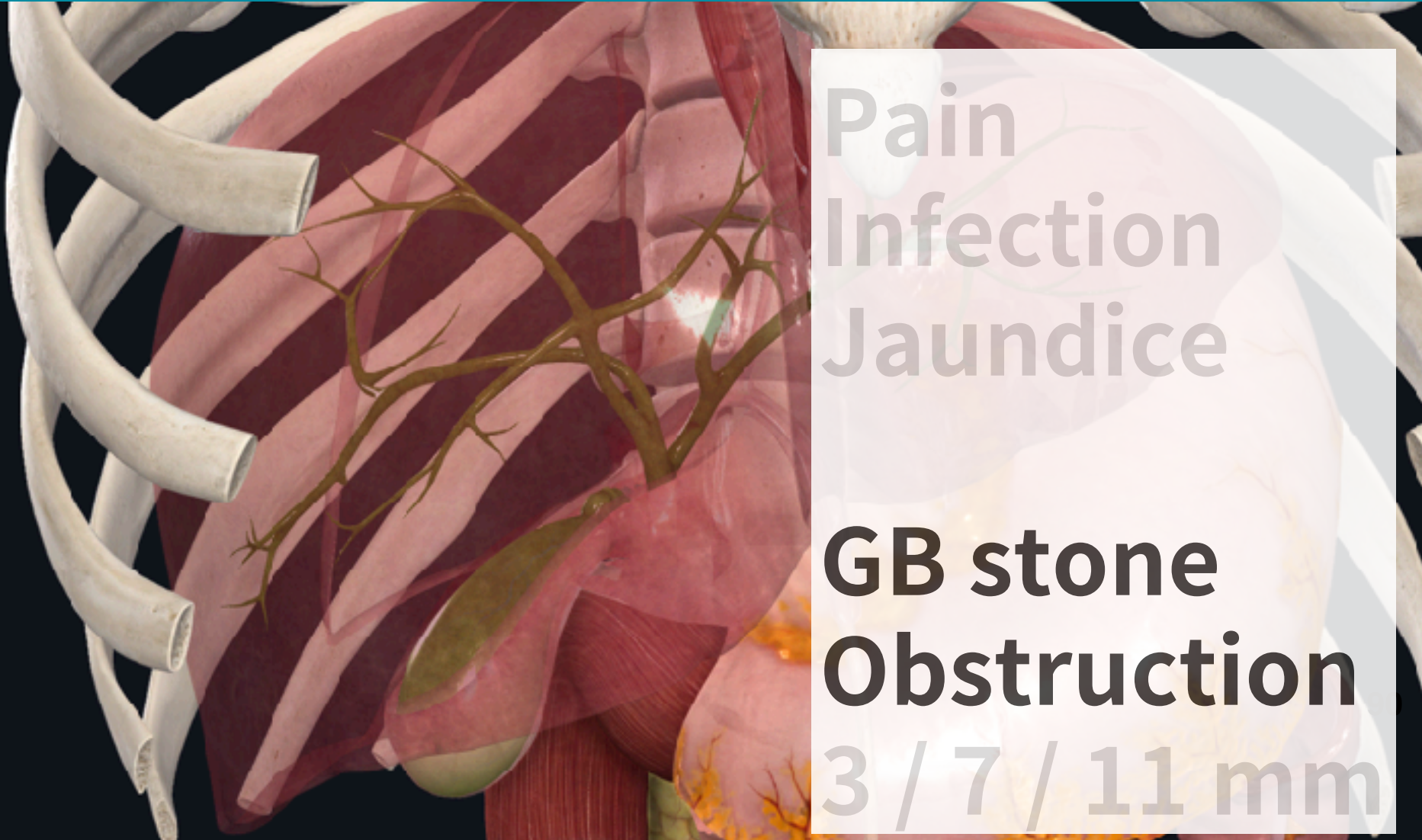


# BILIARY





# BILIARY



Pain  
Infection  
Jaundice

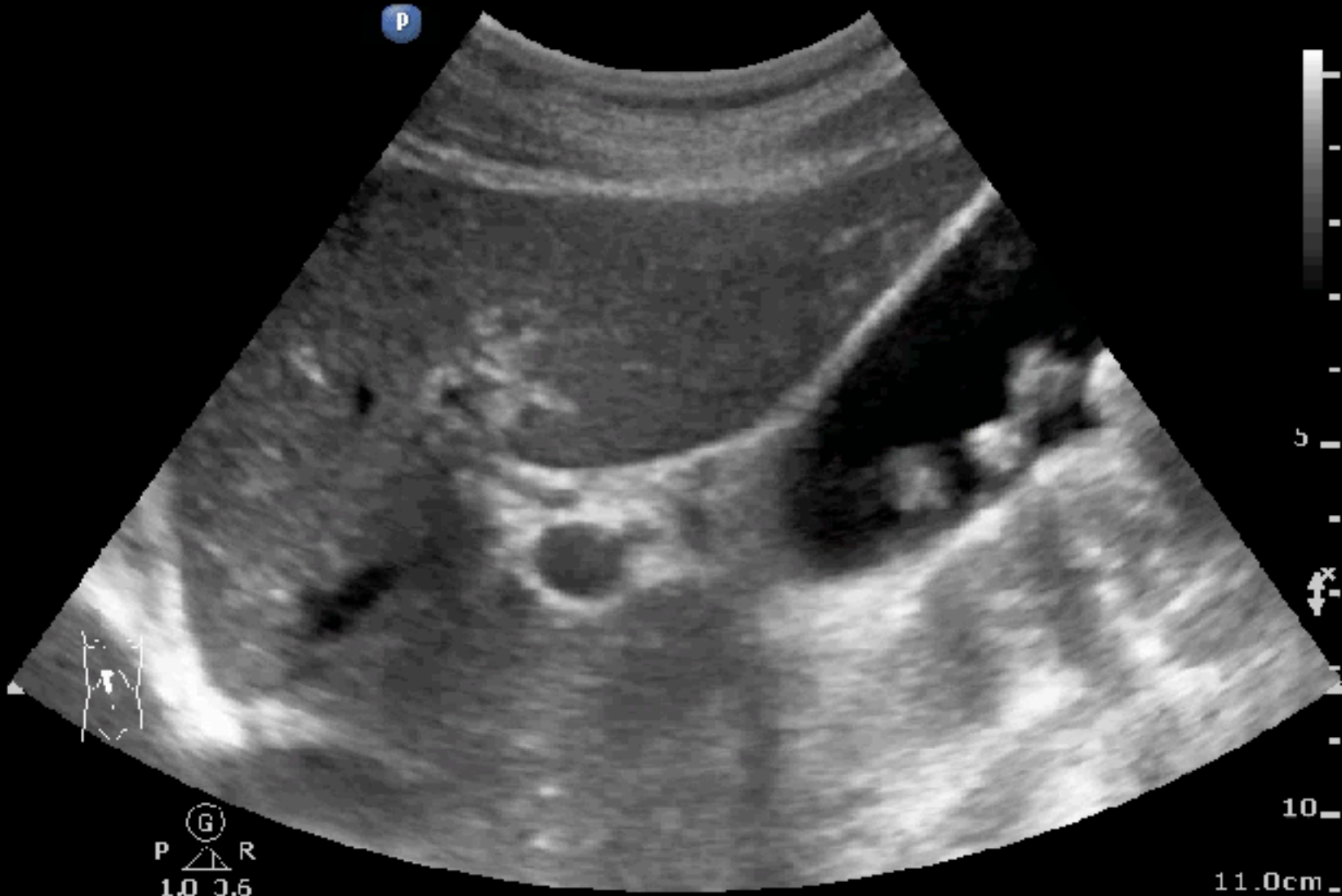**GB stone**  
**Obstruction**  
**3 / 7 / 11 mm**

# Mickey Mouse sign

Abd Gen  
C5-1  
42 Hz  
11.0cm

2D

HGen  
Gn 80  
C 56  
3 / 3 / 3

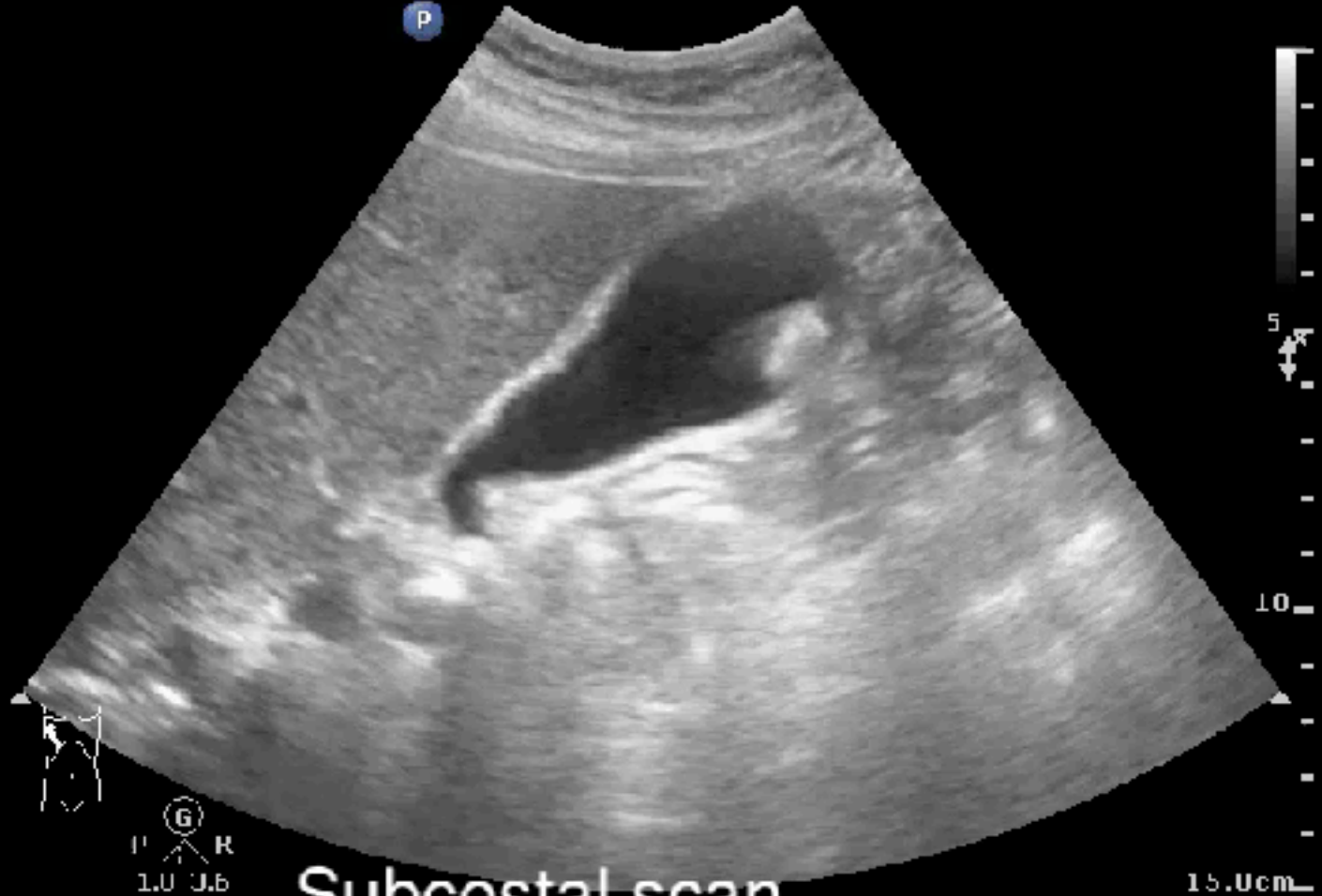

11.0cm

# GB stone ?

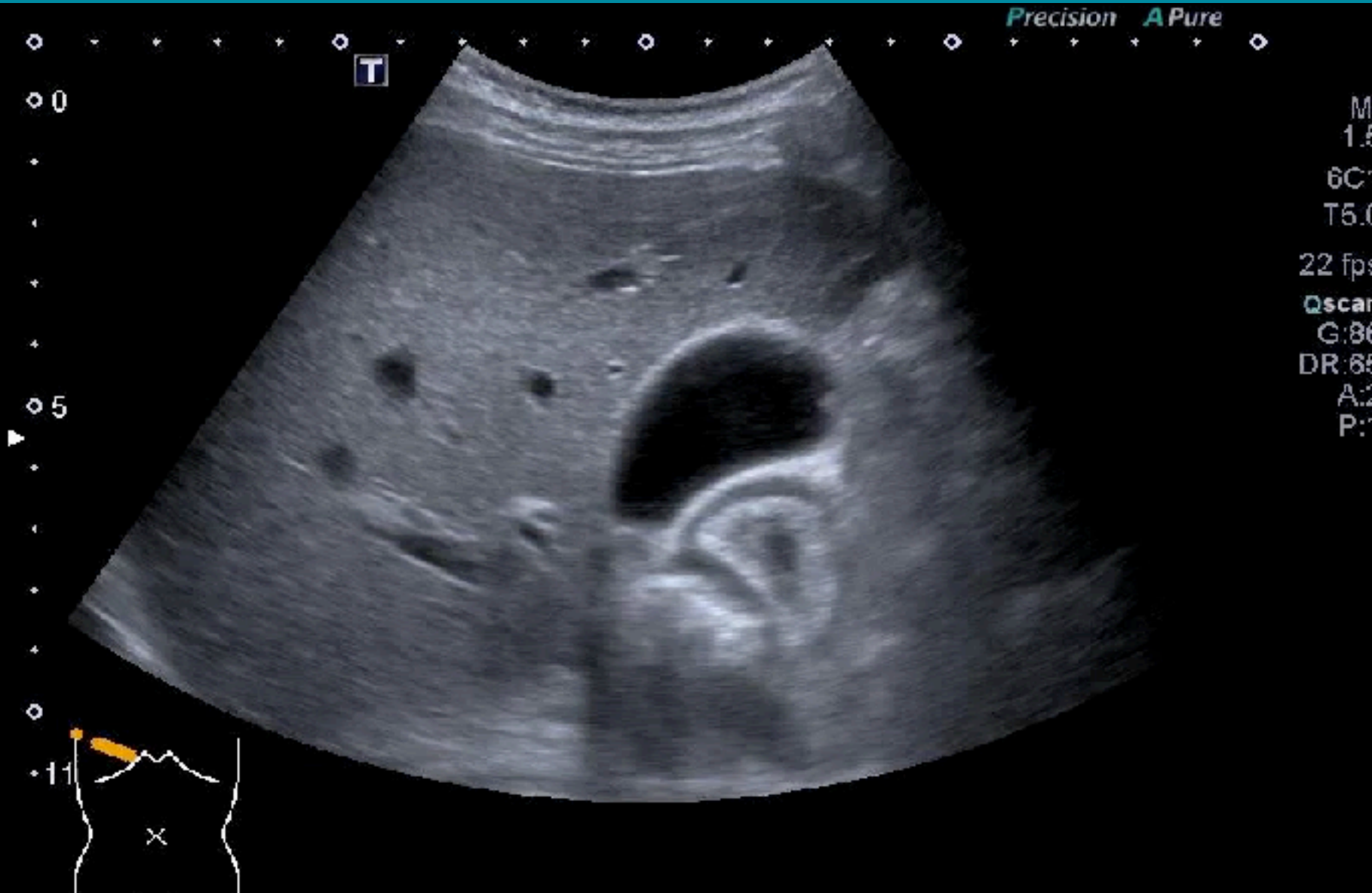Abd Gen  
C5 1  
34 Hz  
15.0cm

2D  
HGen  
Gr 100  
C 63  
3 / 3 / 3

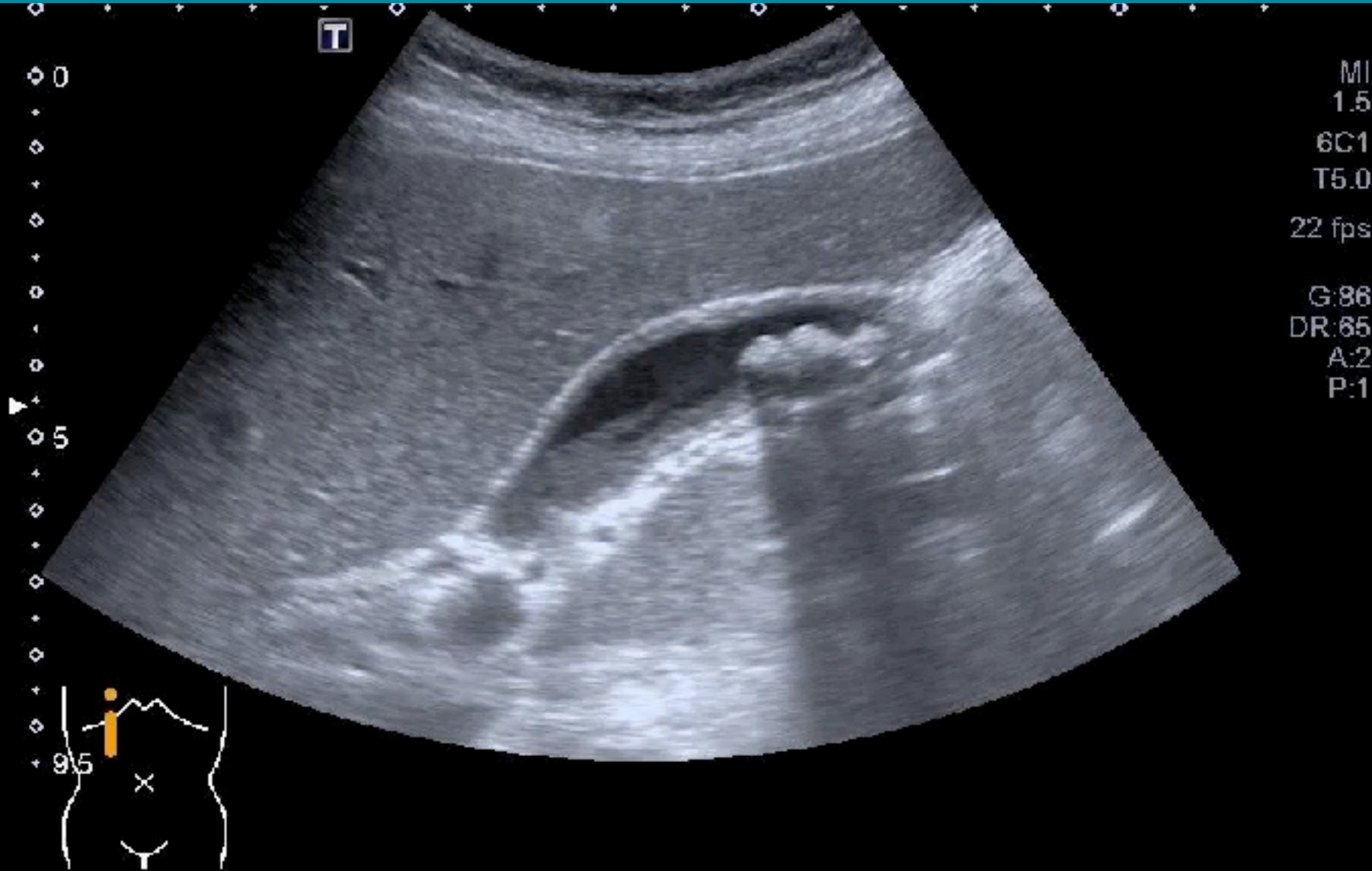

Subcostal scan  
L decubitus position

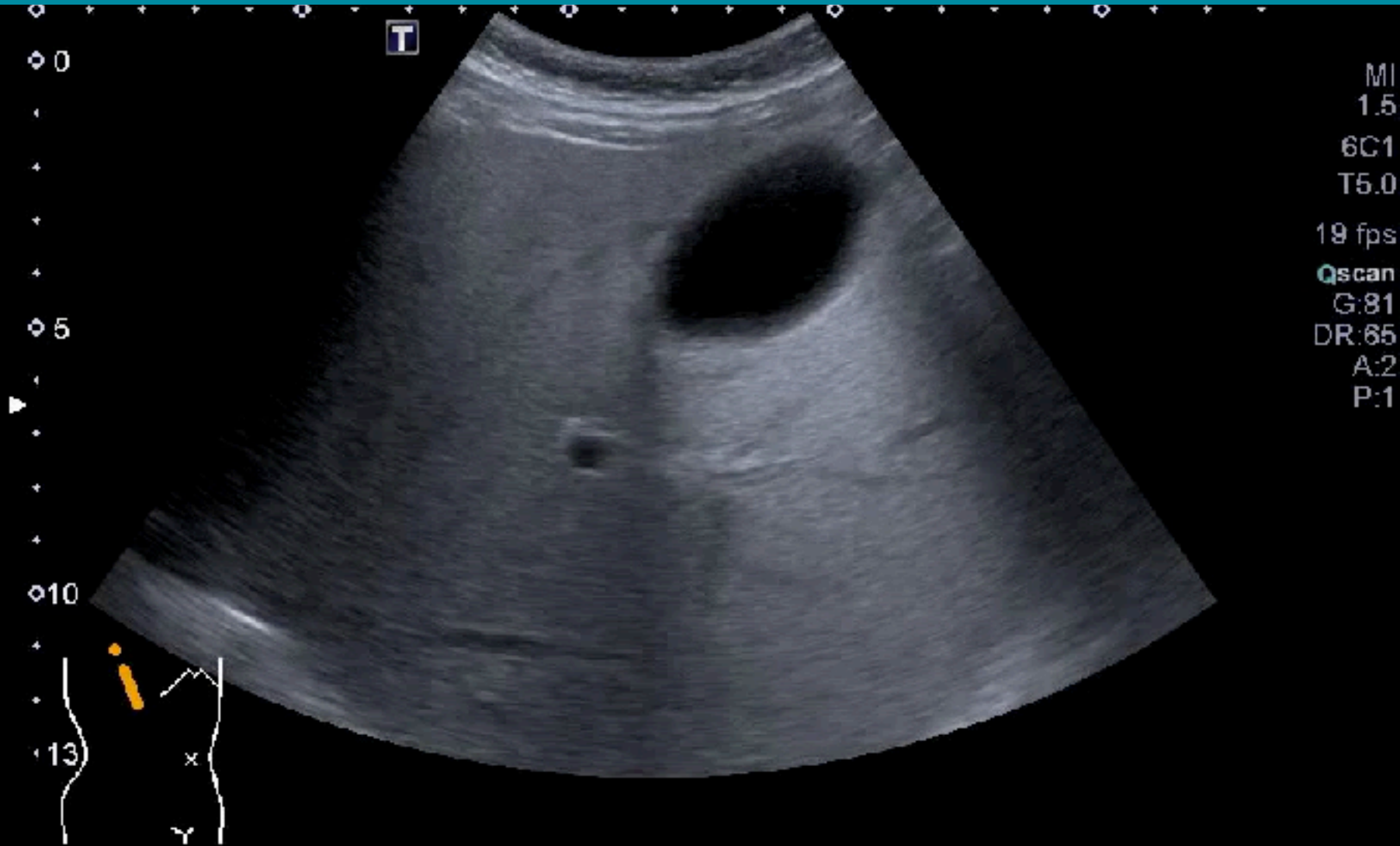# GB stone ?



# GB stone ?



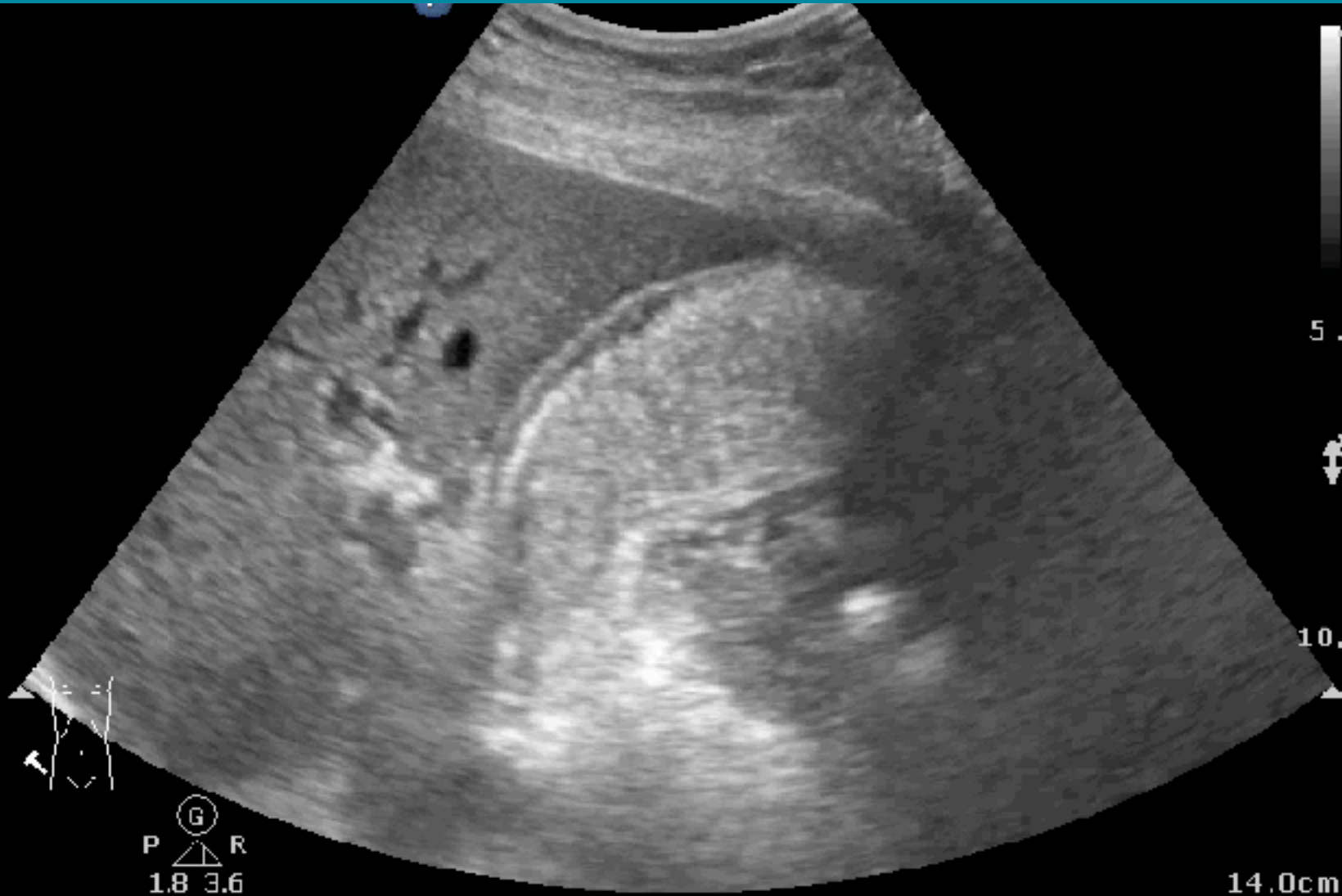
# GB stone ?



# GB stone ?

100.0cm  
25 1  
36 Hz  
14.0cm

2D  
HGen  
Gn 100  
C 56  
3 / 3 / 3

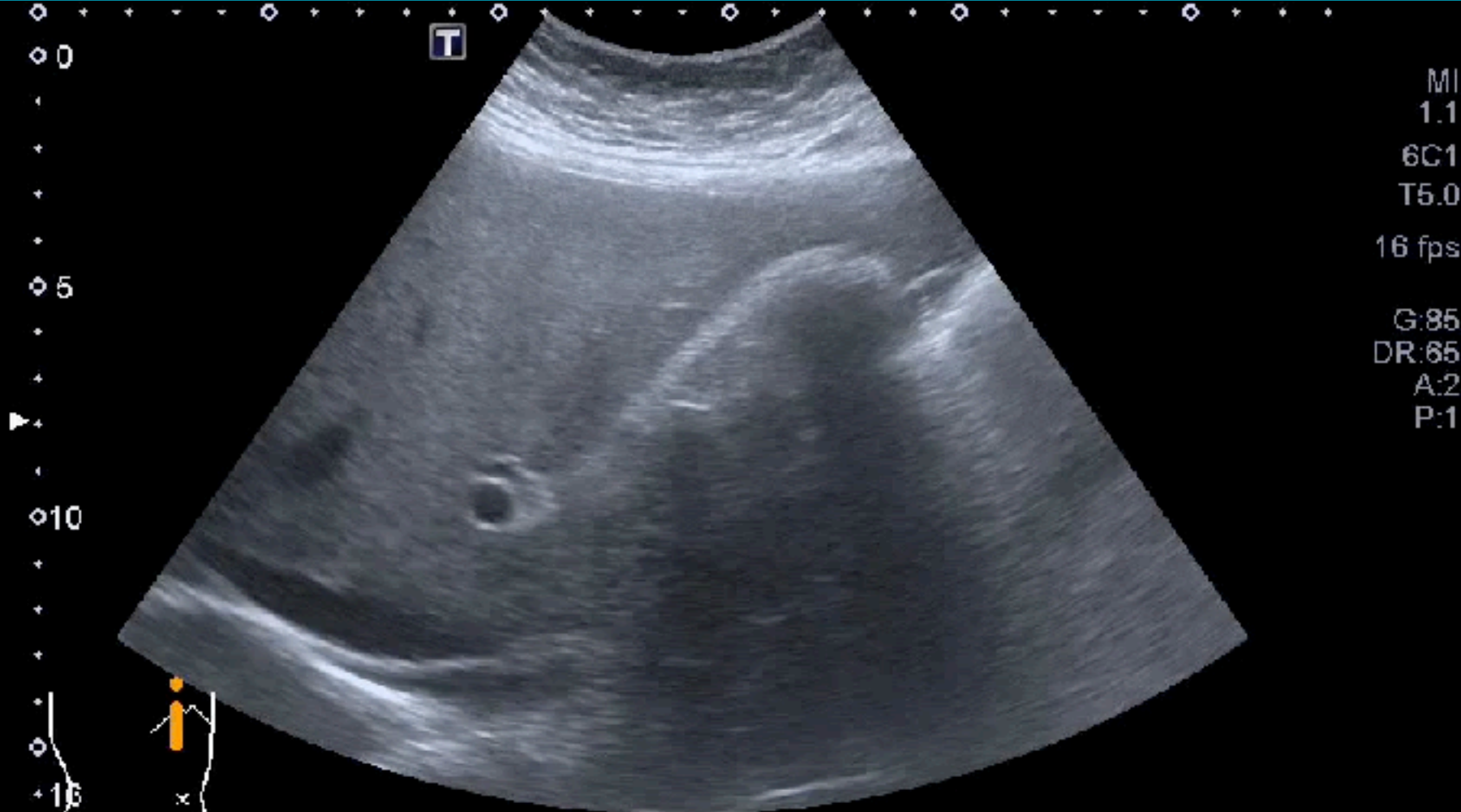

G  
P R  
1.8 3.6

14.0cm

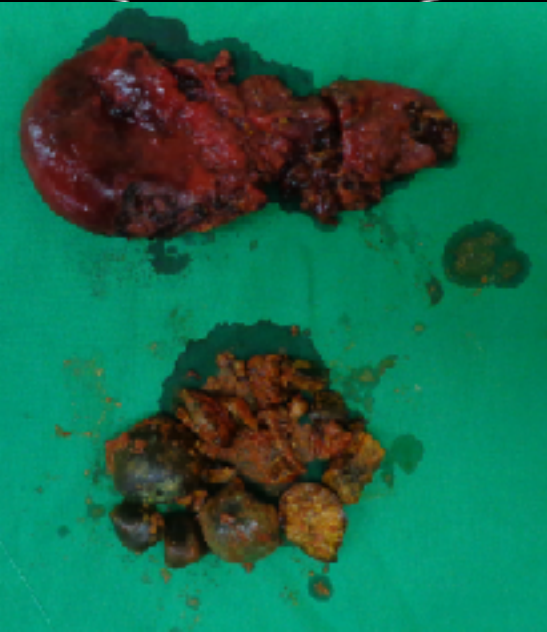
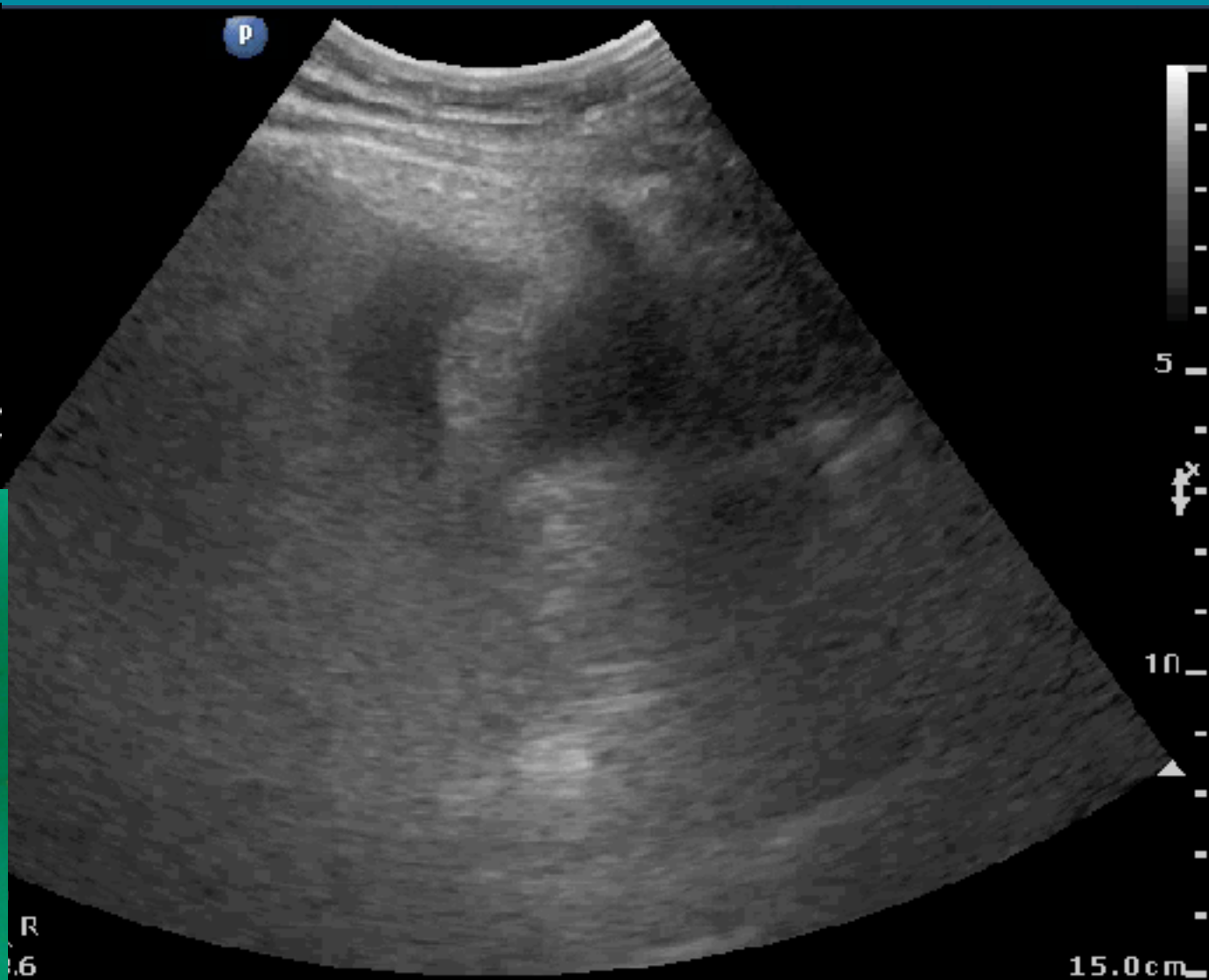
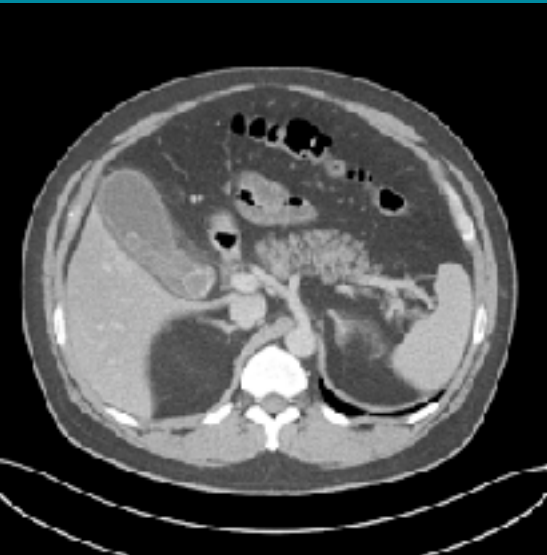


# GB stone ?



**Wall Echo Shadow (WES) sign**

# 45M, RUQ pain & fever



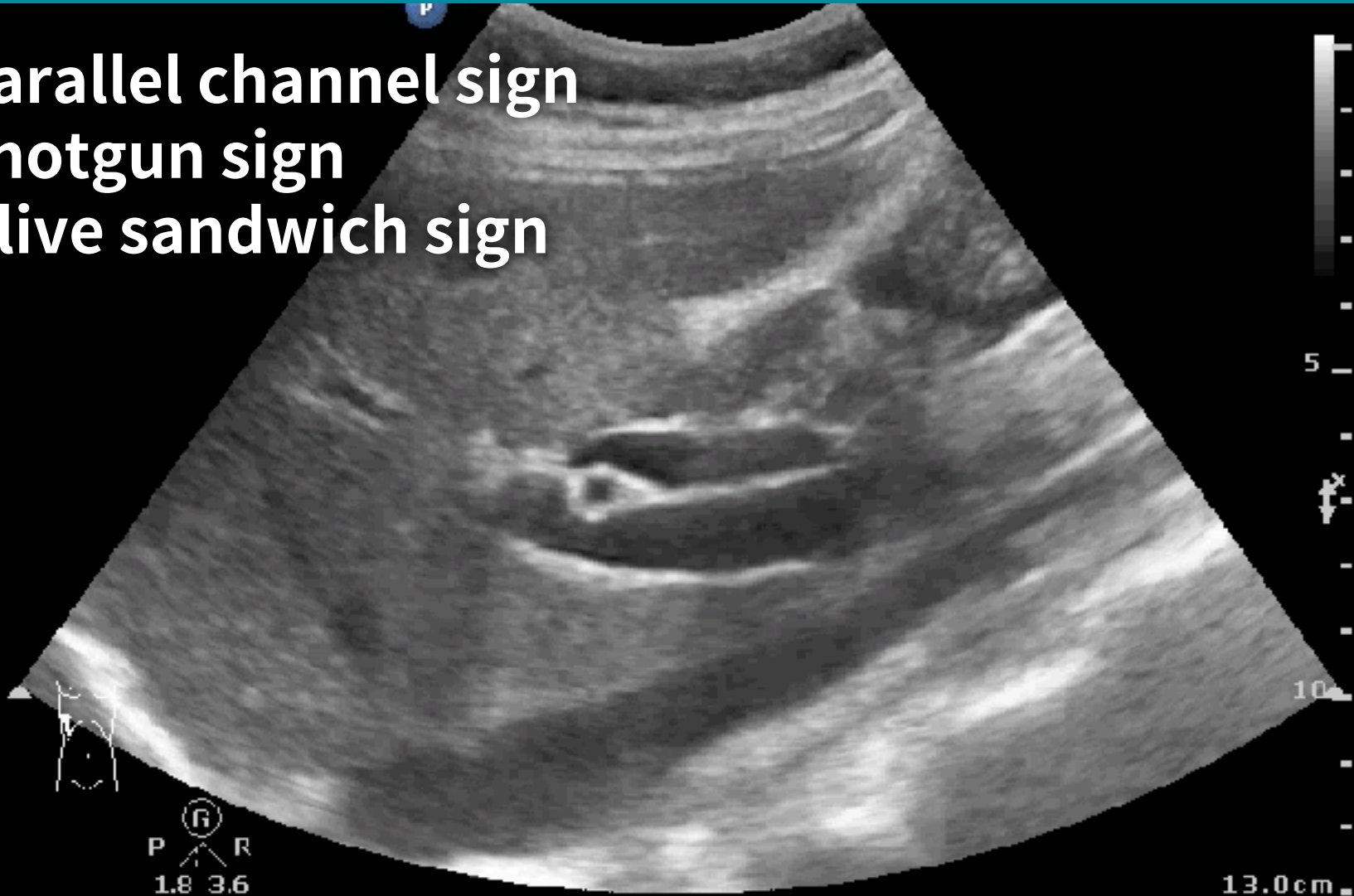
R  
6

15.0 cm

# Biliary dilatation ?

Abd Gen  
C5-1  
38 Hz  
13.0cm  
  
2D  
HGen  
Gn 82  
C. 56  
3/3/3

**Parallel channel sign**  
**Shotgun sign**  
**Olive sandwich sign**



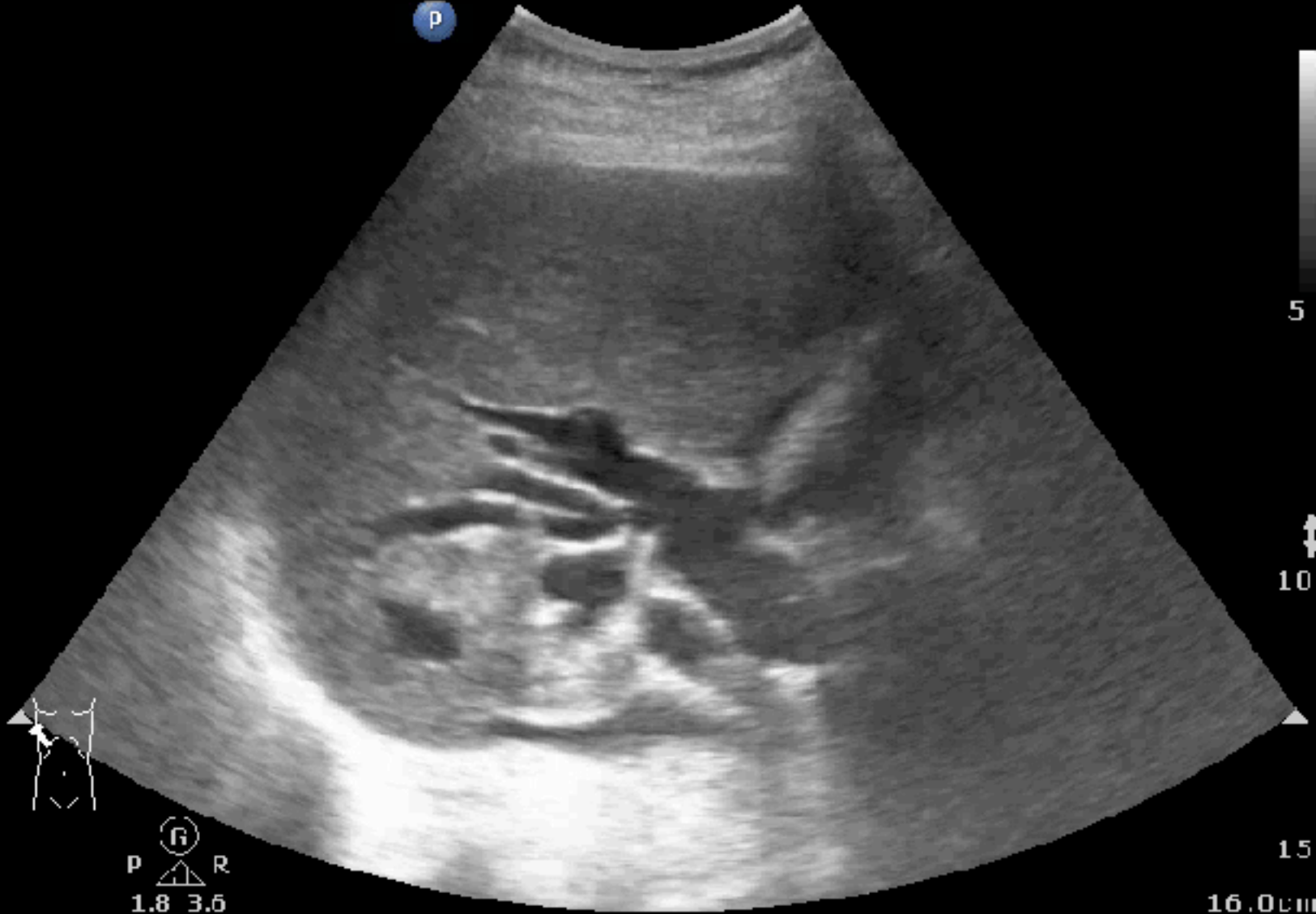P  
R  
1.8 3.6

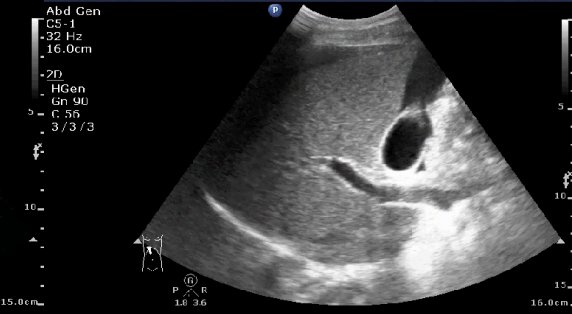
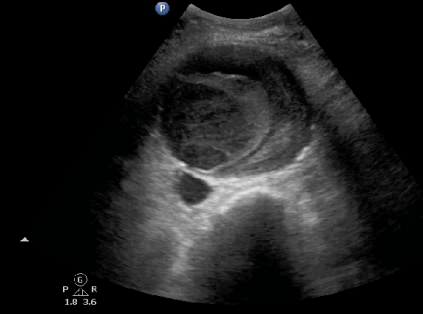
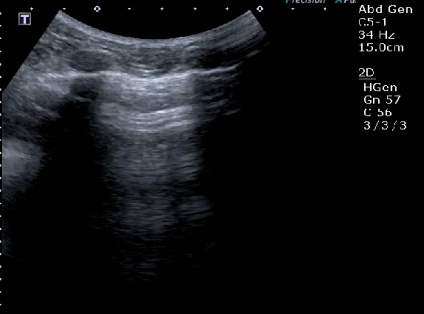
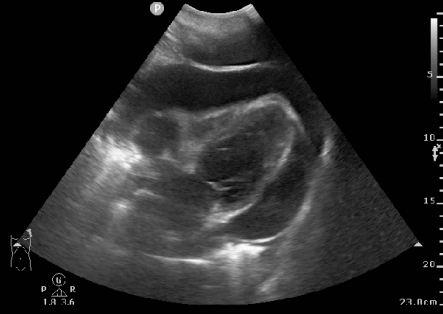
13.0cm

# 76F, Fever & Chills Biliary dilatation ?

Abd Gen2  
C5-1  
2 Hz  
6.0cm

D  
HGen  
Gn 100  
C 56  
3/3/3





HEART

LUNG

AORTA

FAST

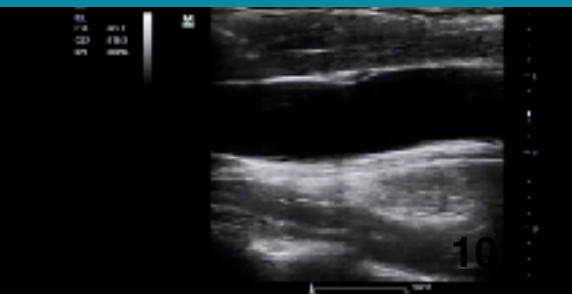
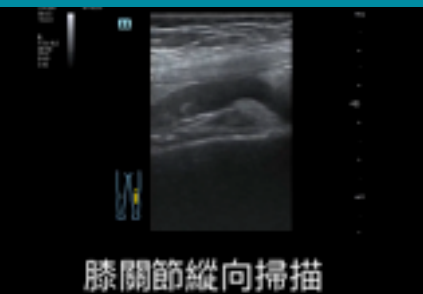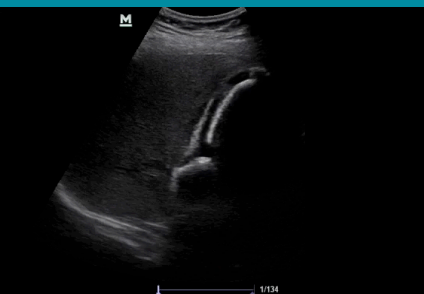
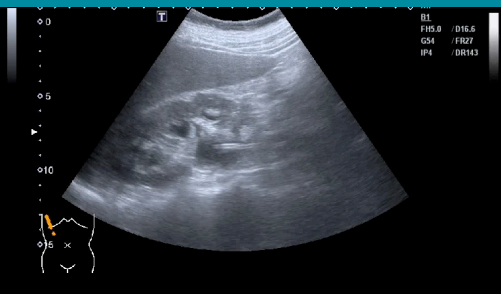
KIDNEY

BILIARY

KNEE

CVC

# 8 ESSENTIAL SKILLS



膝關節縱向掃描

# KNEE

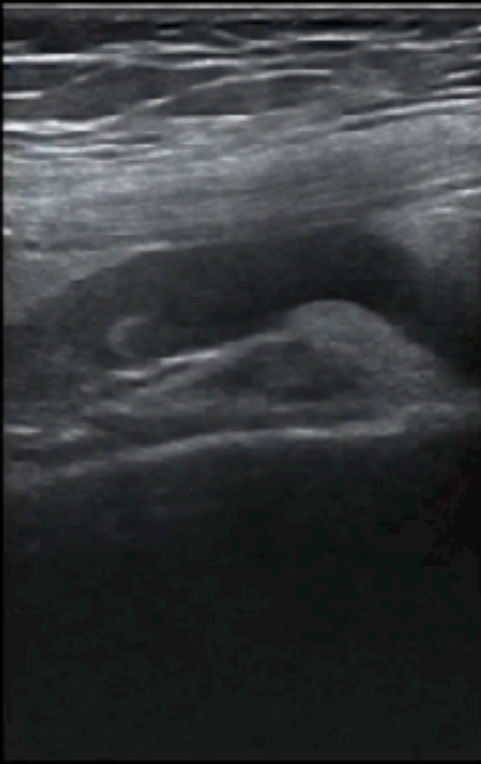20180227-175129-34EA MSK1 17:38:01

L14-GMs  
MI 0.5  
TIS 0.1

RF 96.6%

B  
F T.0-16.2  
DR 110  
FR 61  
D 5.9  
G 46

m



Pain  
Swelling

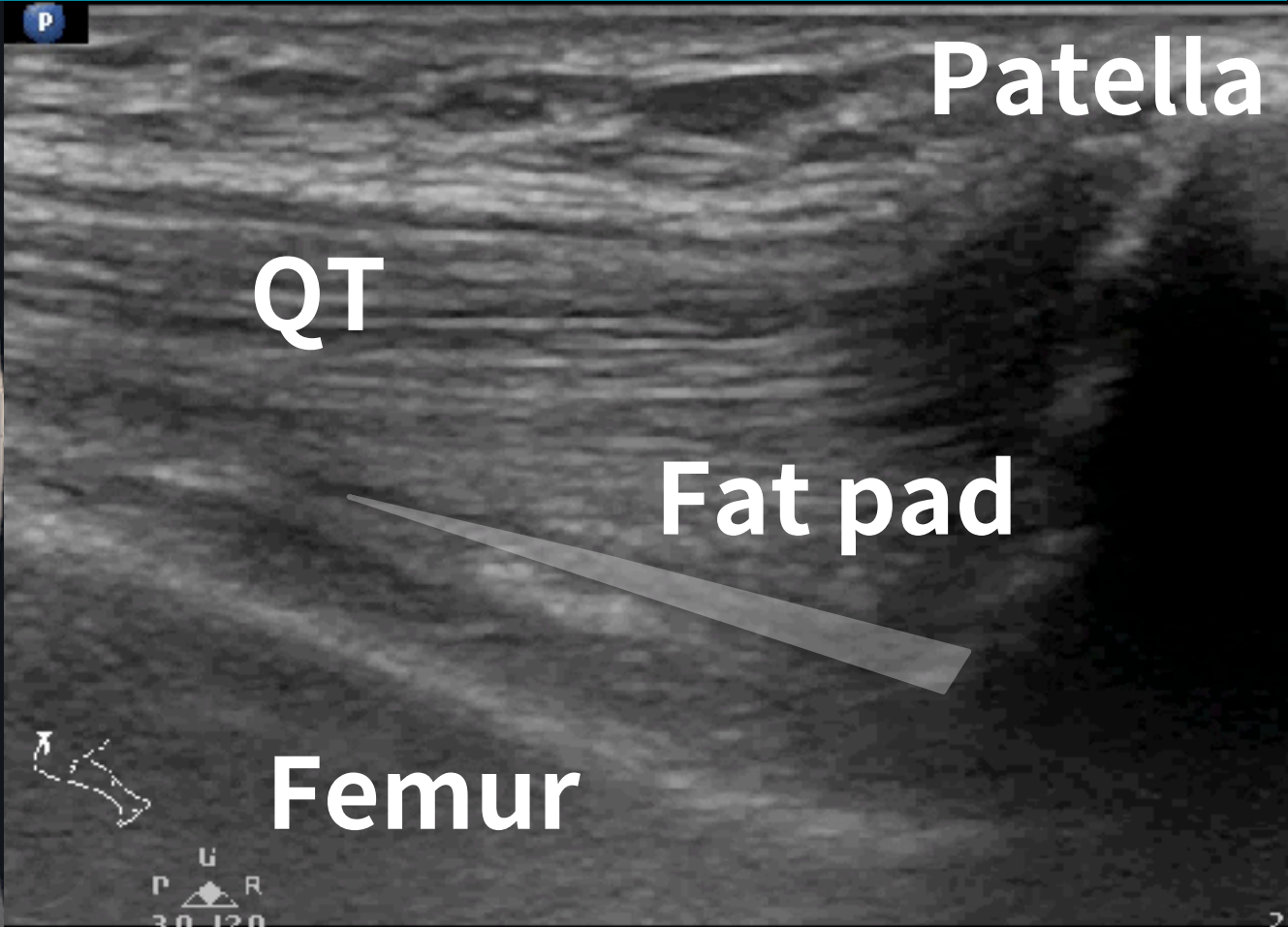
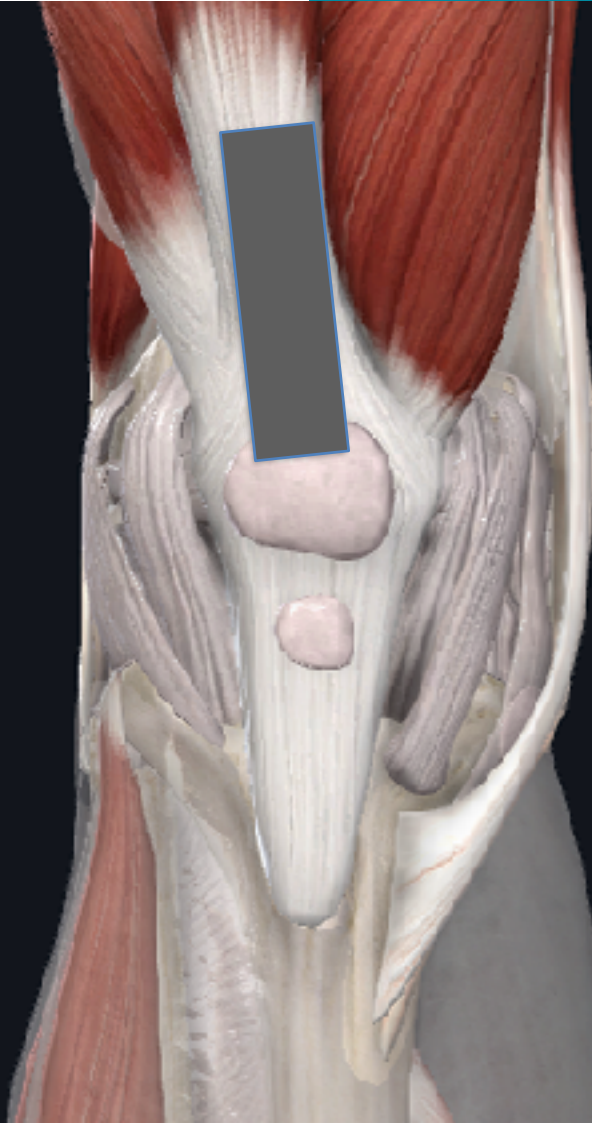Effusion

膝關節縱向掃描



# KNEE EFFUSION

Suprapatellar bursa



Patella

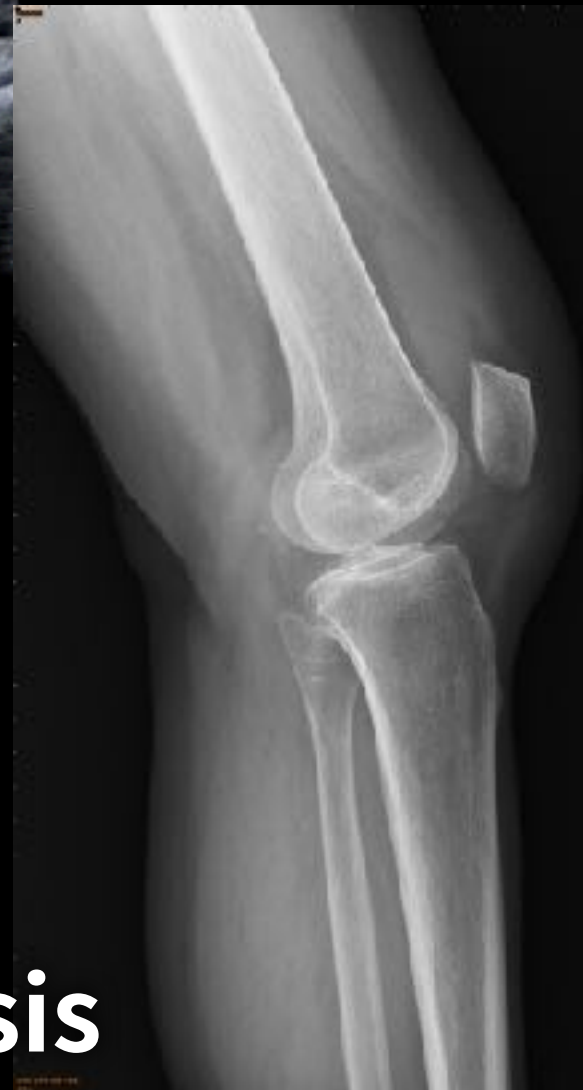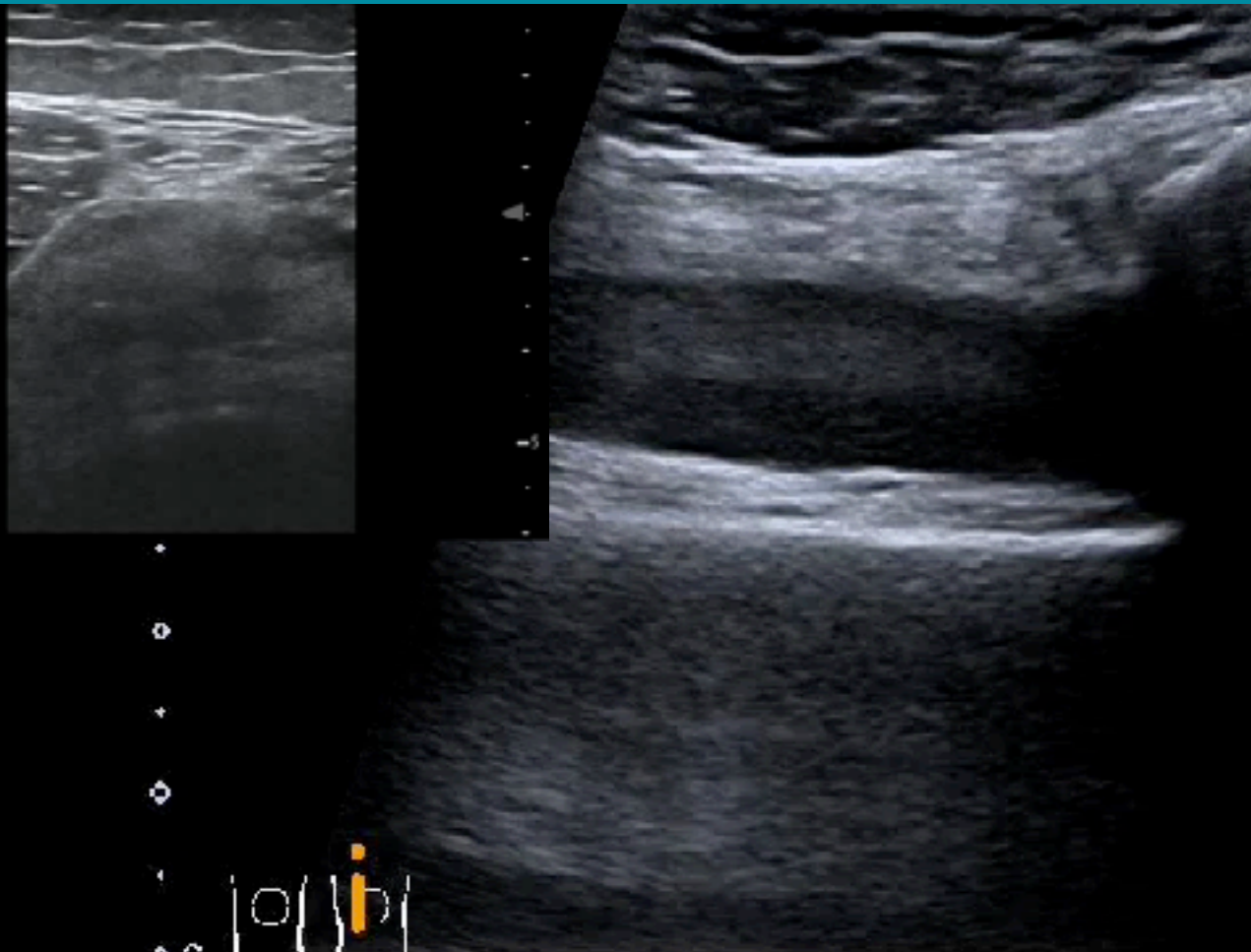
QT

Fat pad

Femur

U  
P R  
3.0 12.0

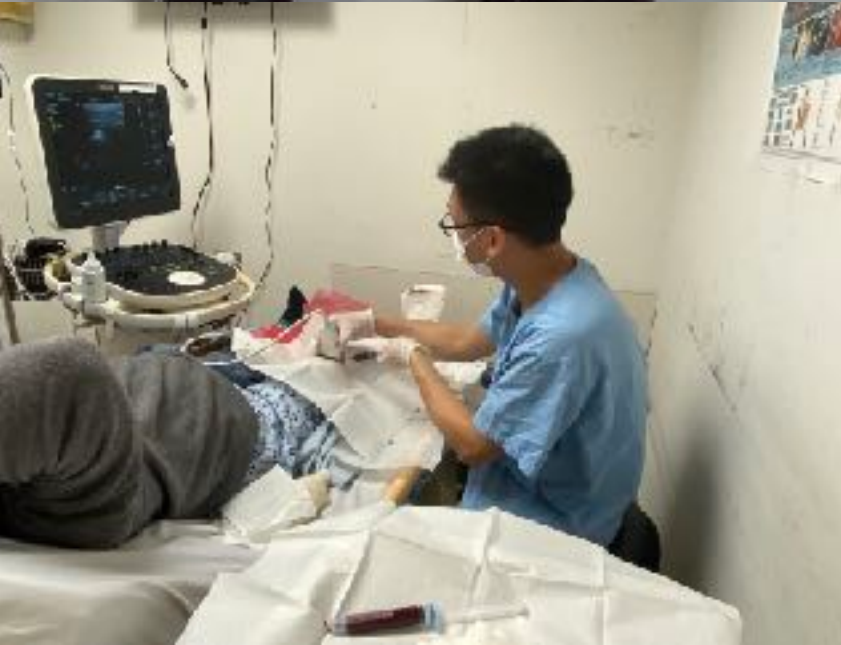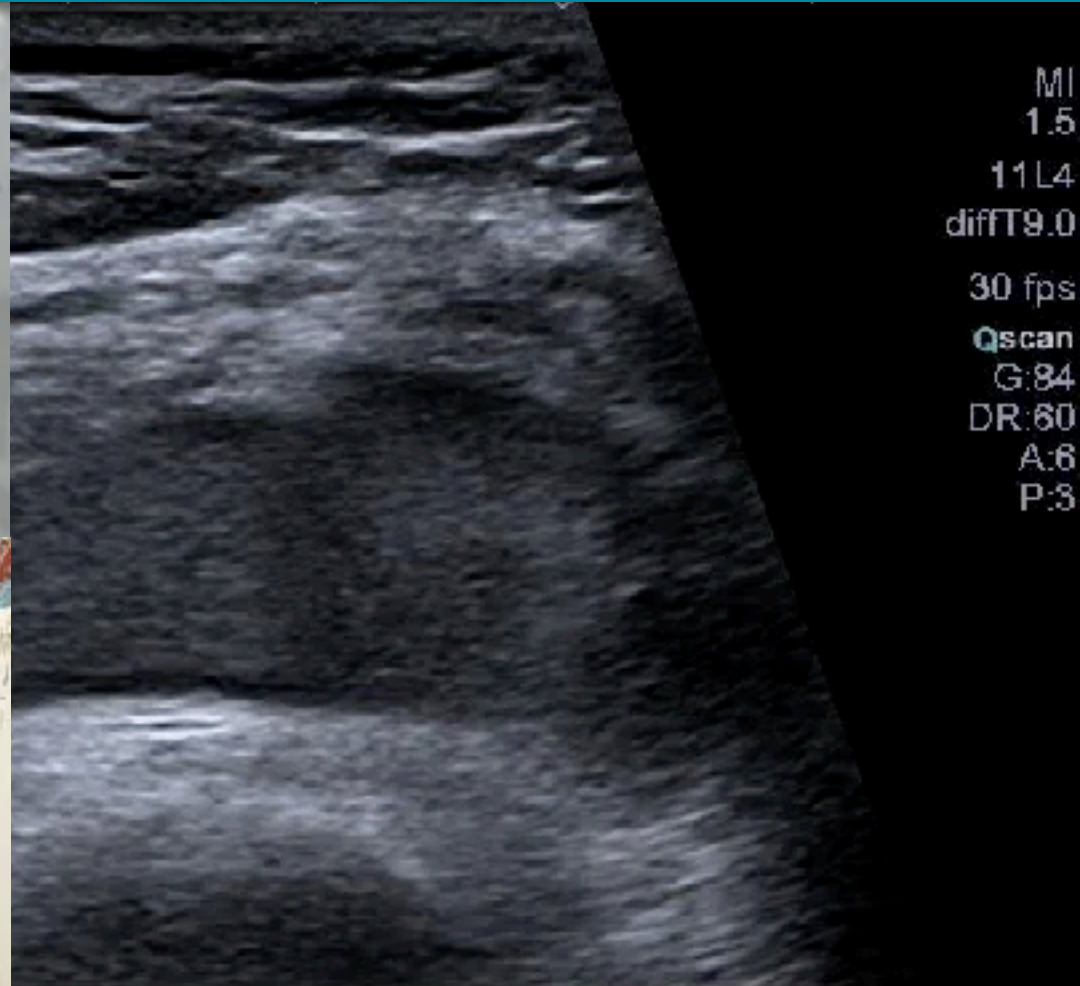
# KNEE INJURY

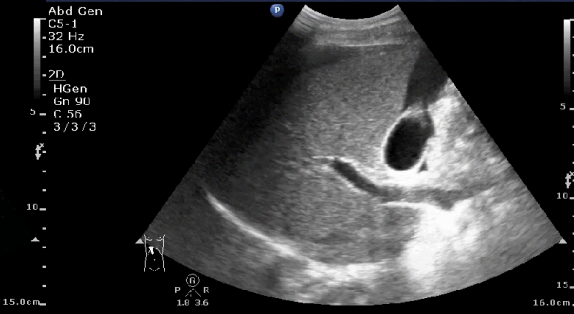
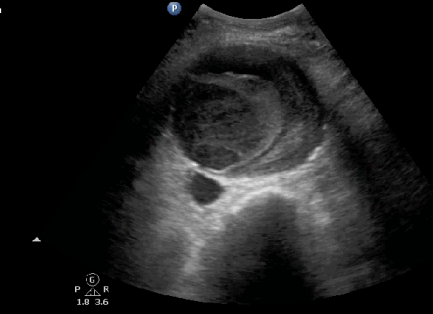
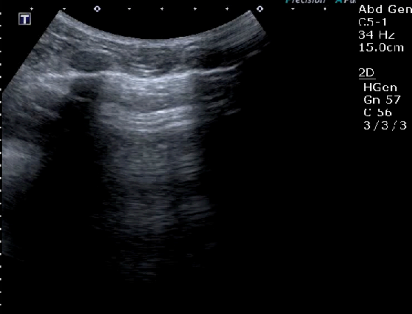


**Lipohemarthrosis**



# Joint effusion & aspiration





HEART

LUNG

AORTA

FAST

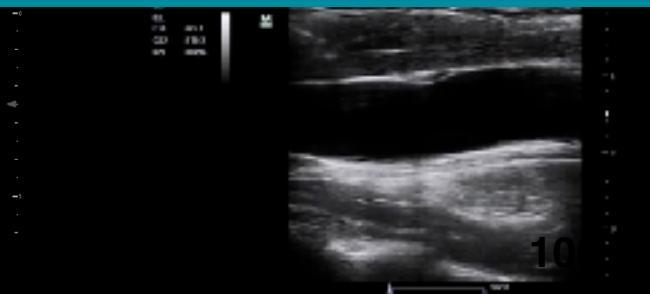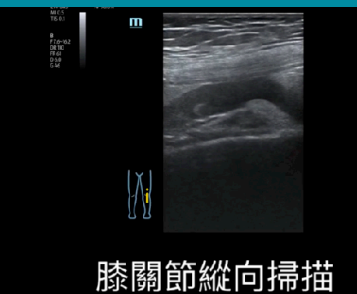
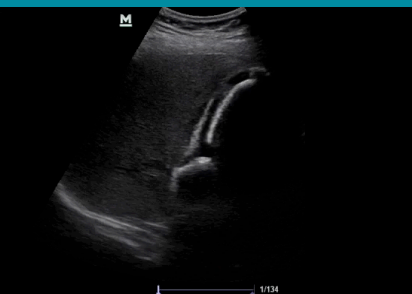
KIDNEY

BILIARY

KNEE

CVC

# 8 ESSENTIAL SKILLS



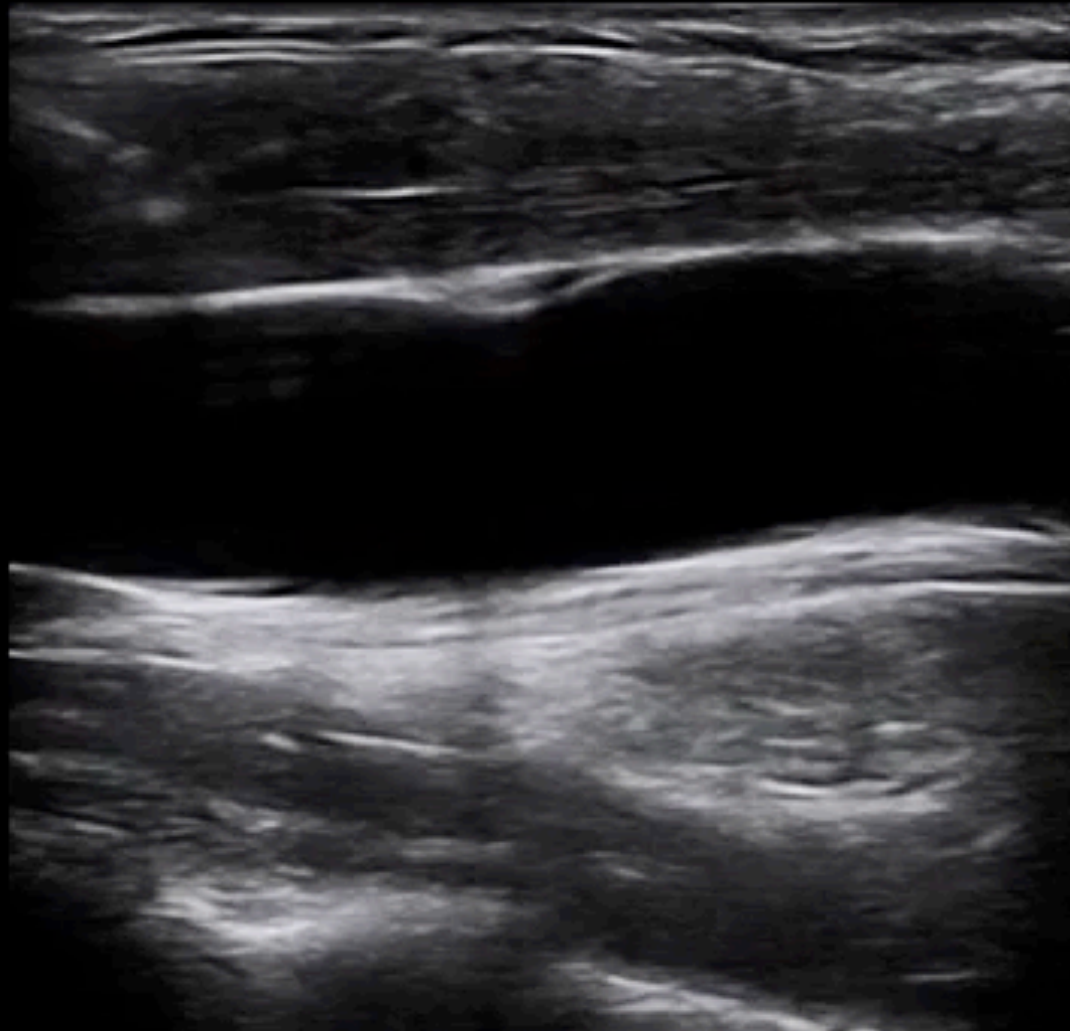
膝關節縱向掃描

# CVC

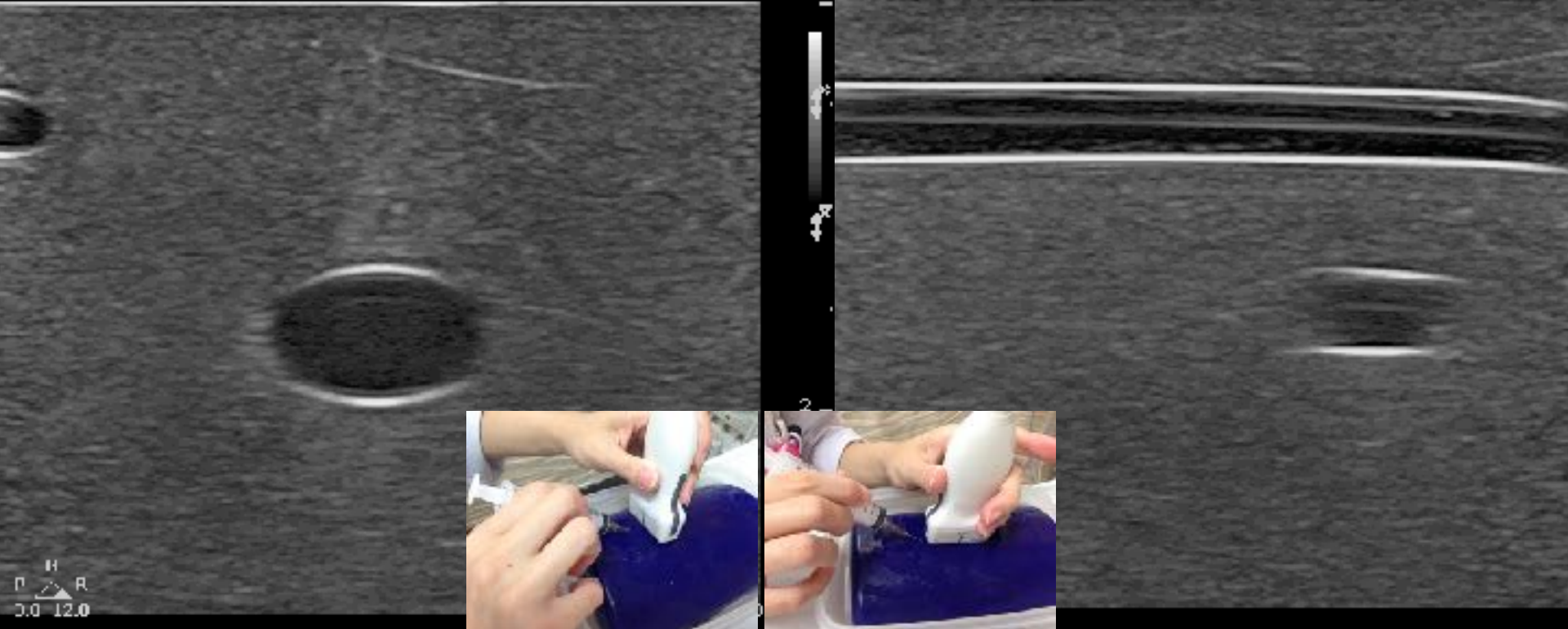
M7  
B1  
F10 /D3.7  
G52 /FR43  
IP5 /DR95



**M**



1/639



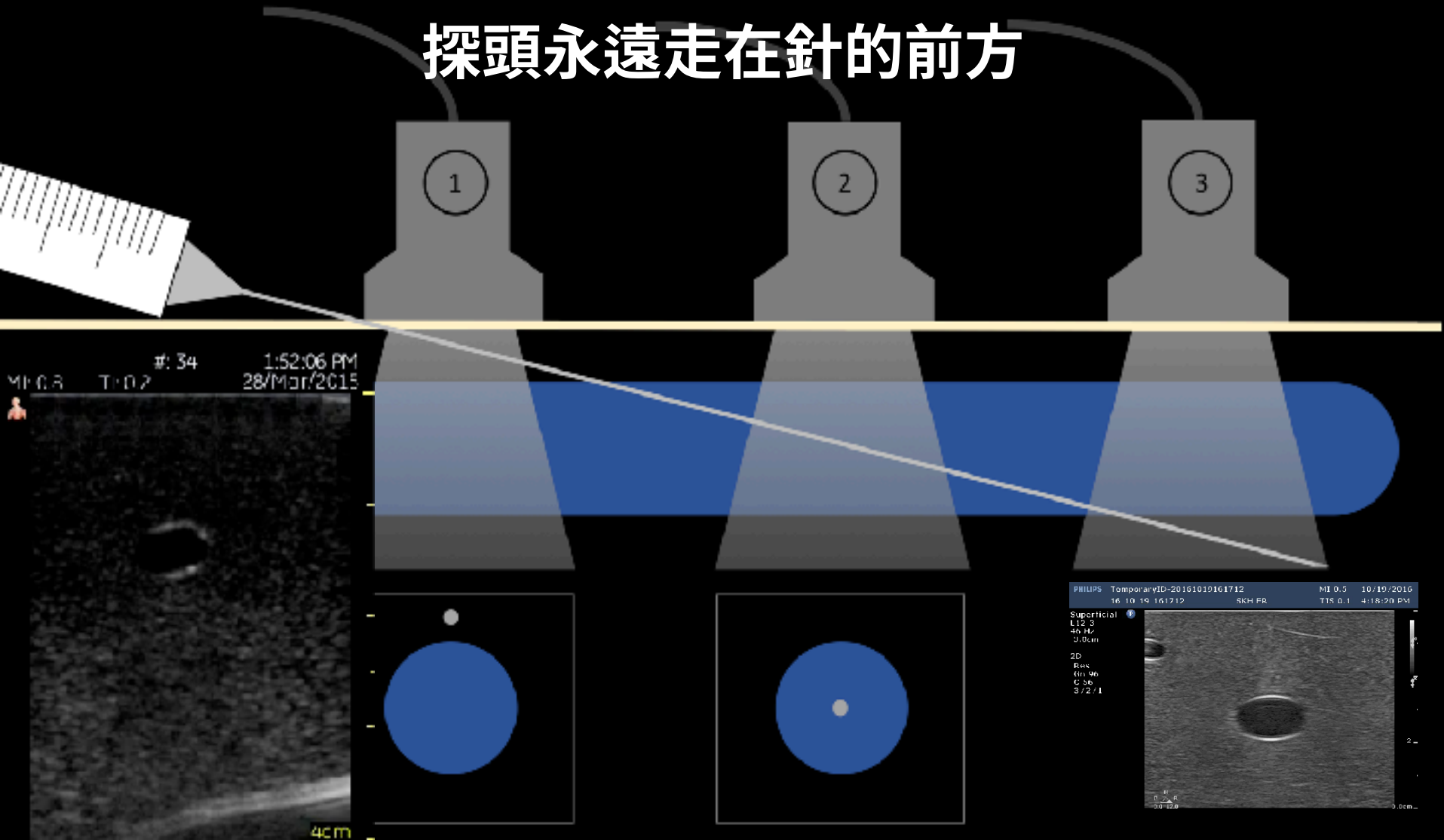
# MASTER NEEDLING

**Off-plane**  
追針尖

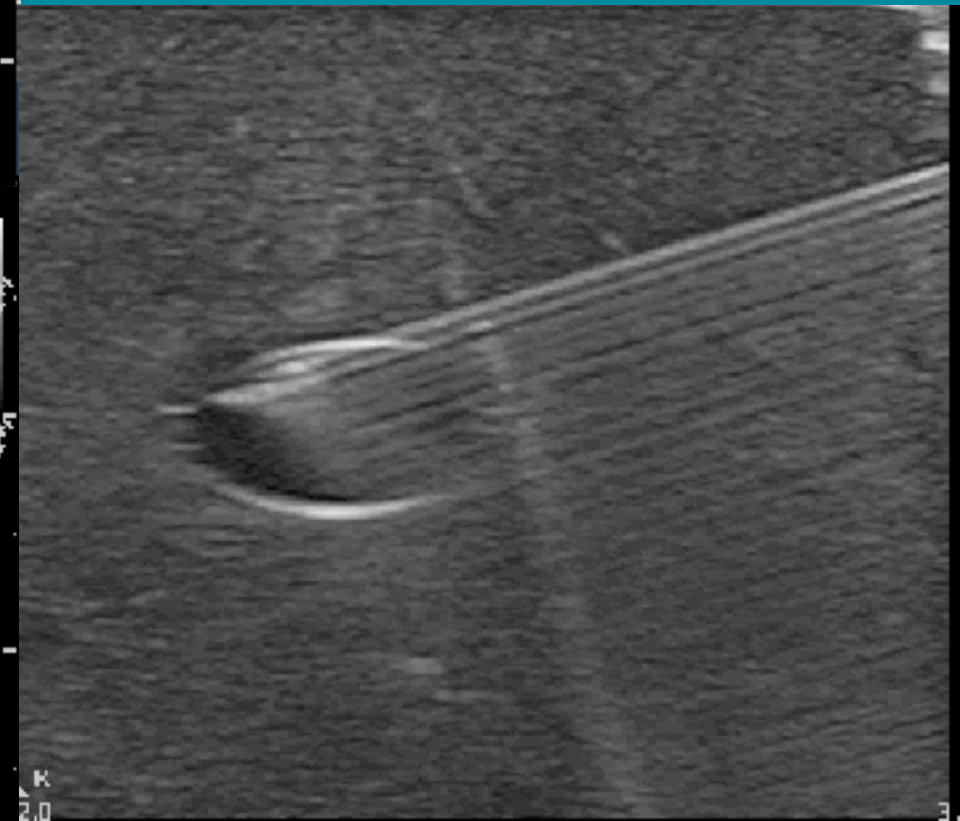
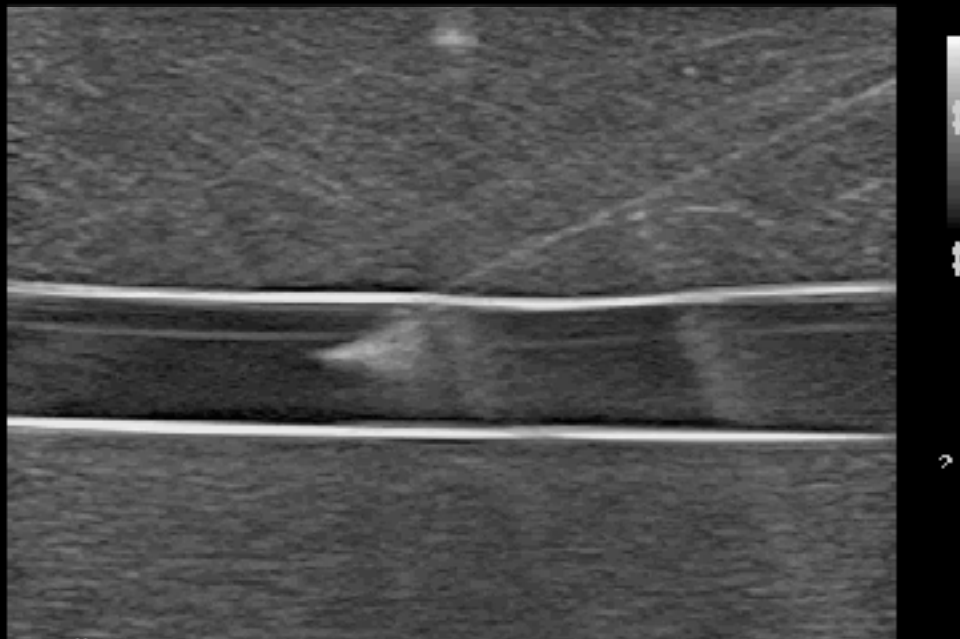
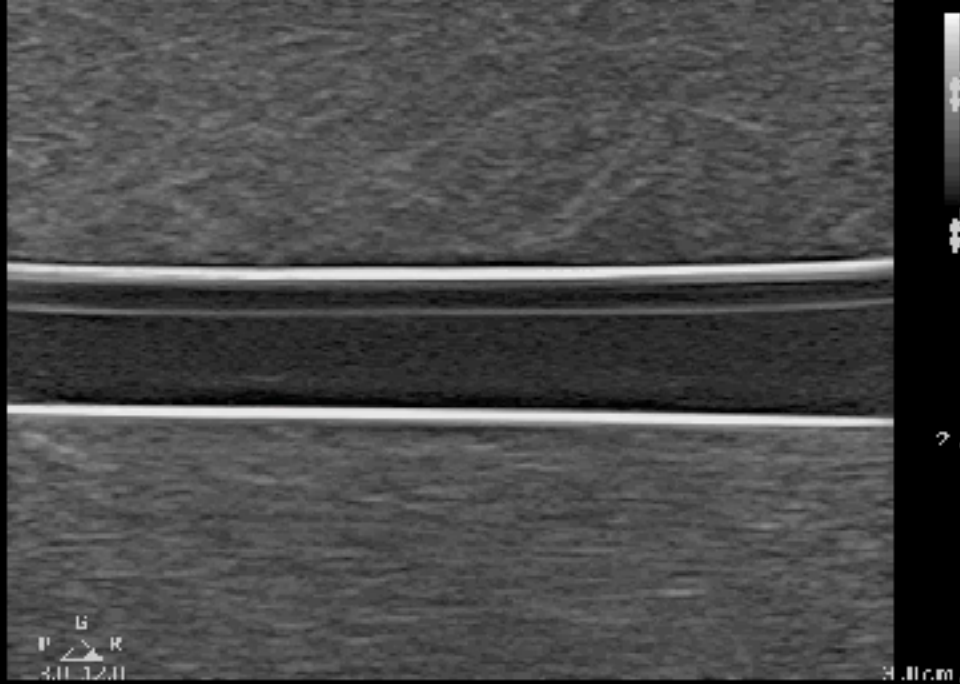
**In-plane**  
看針身

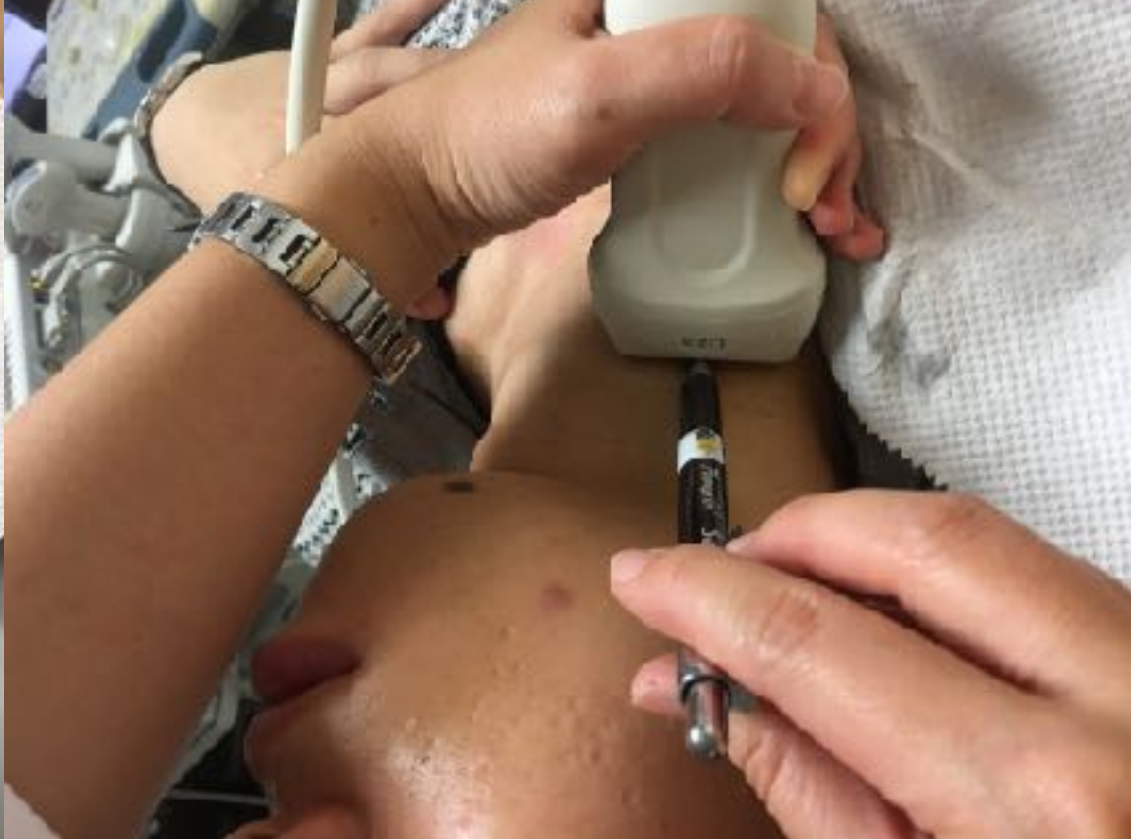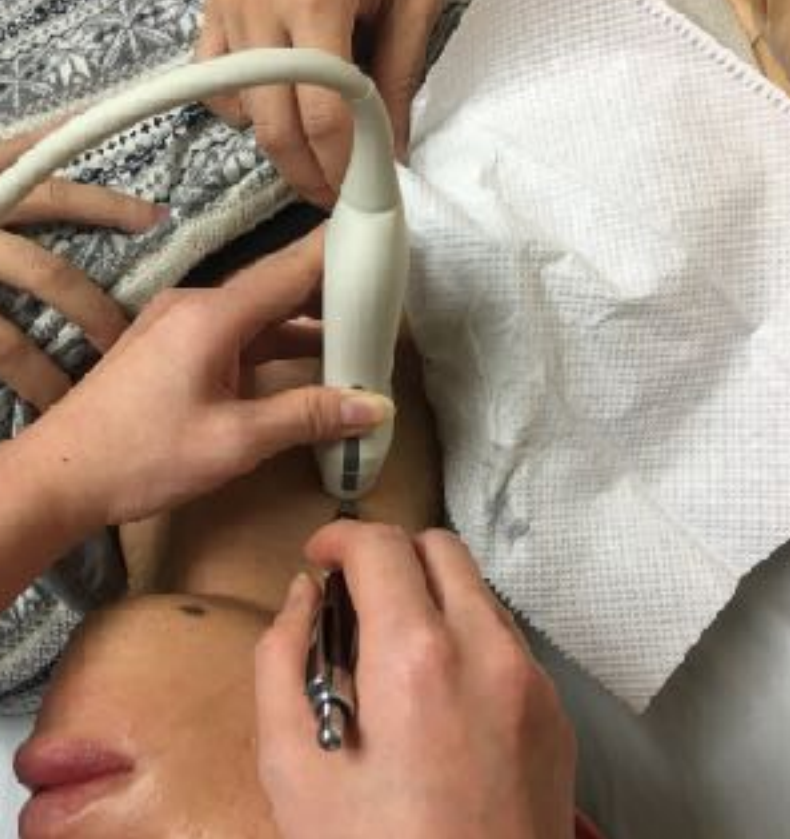# OFF-PLANE首重針尖

探頭永遠走在針的前方

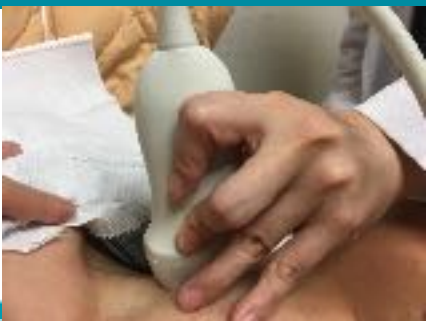

# NEEDLE OPTIMIZATION 探頭要垂直針身



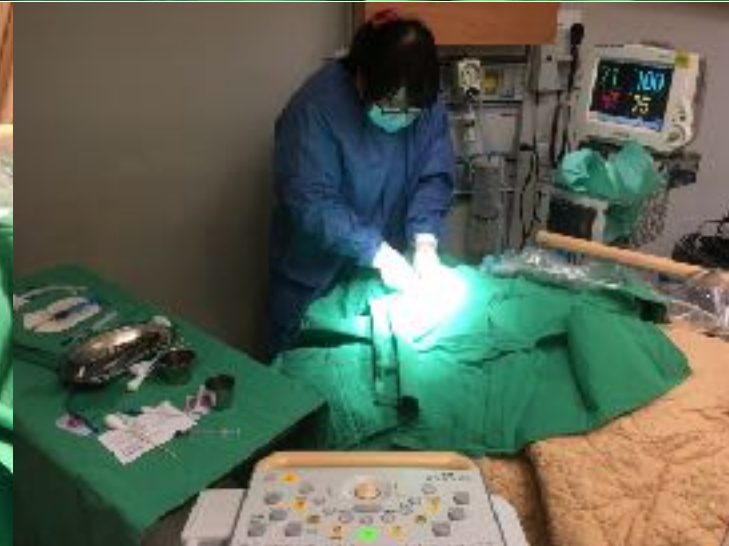
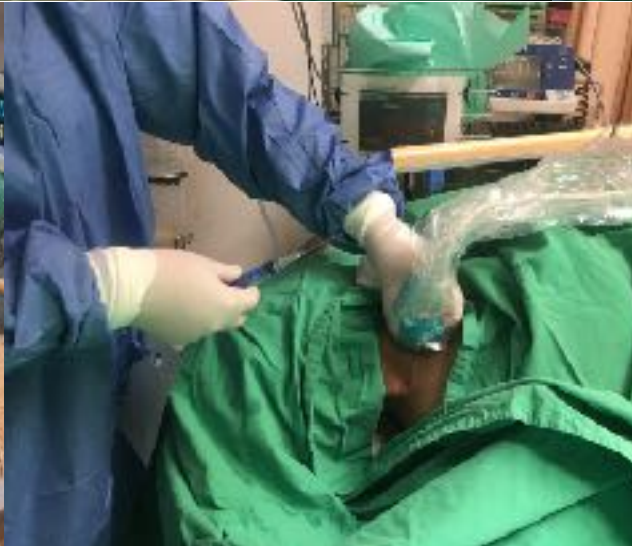
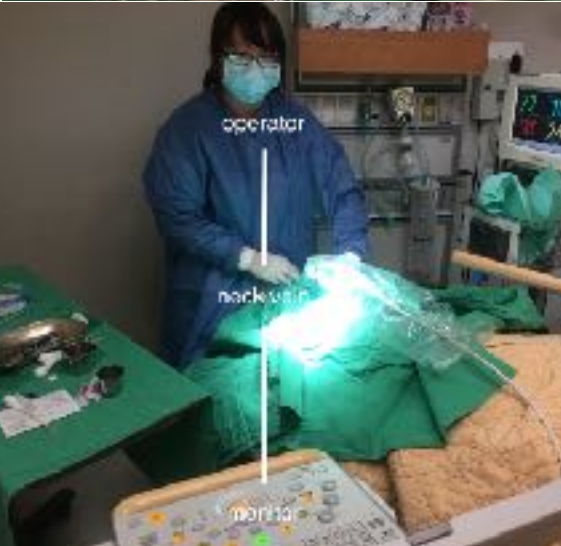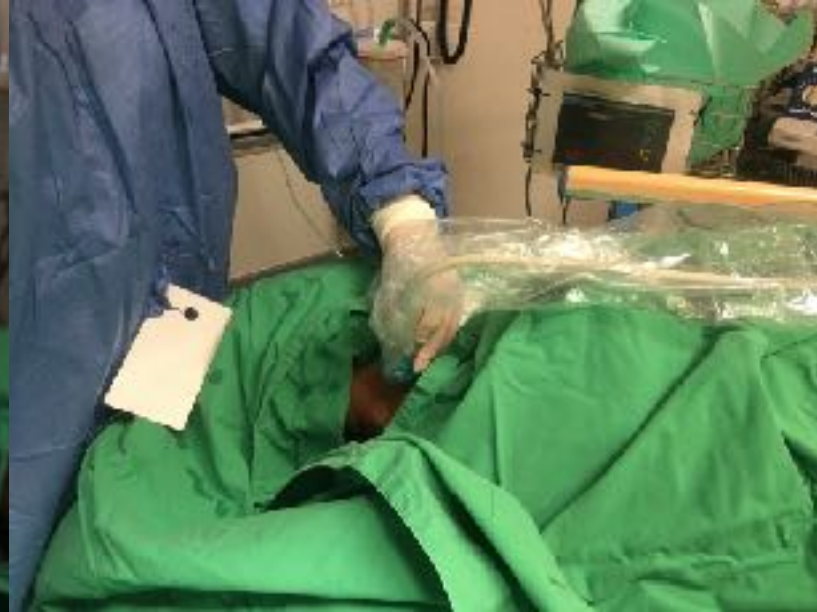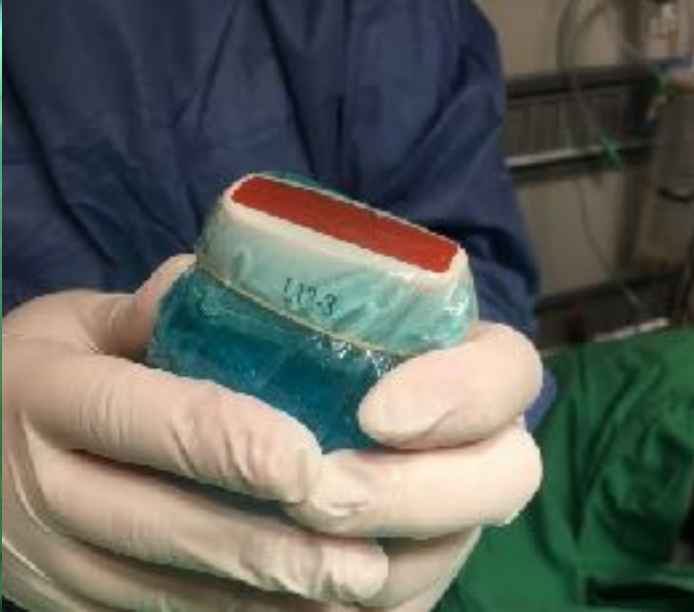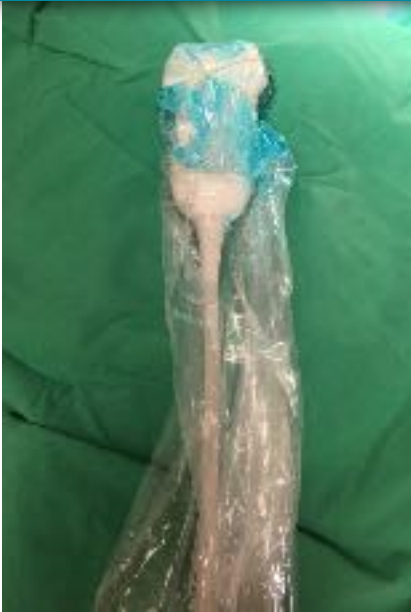## 練習定位和入針

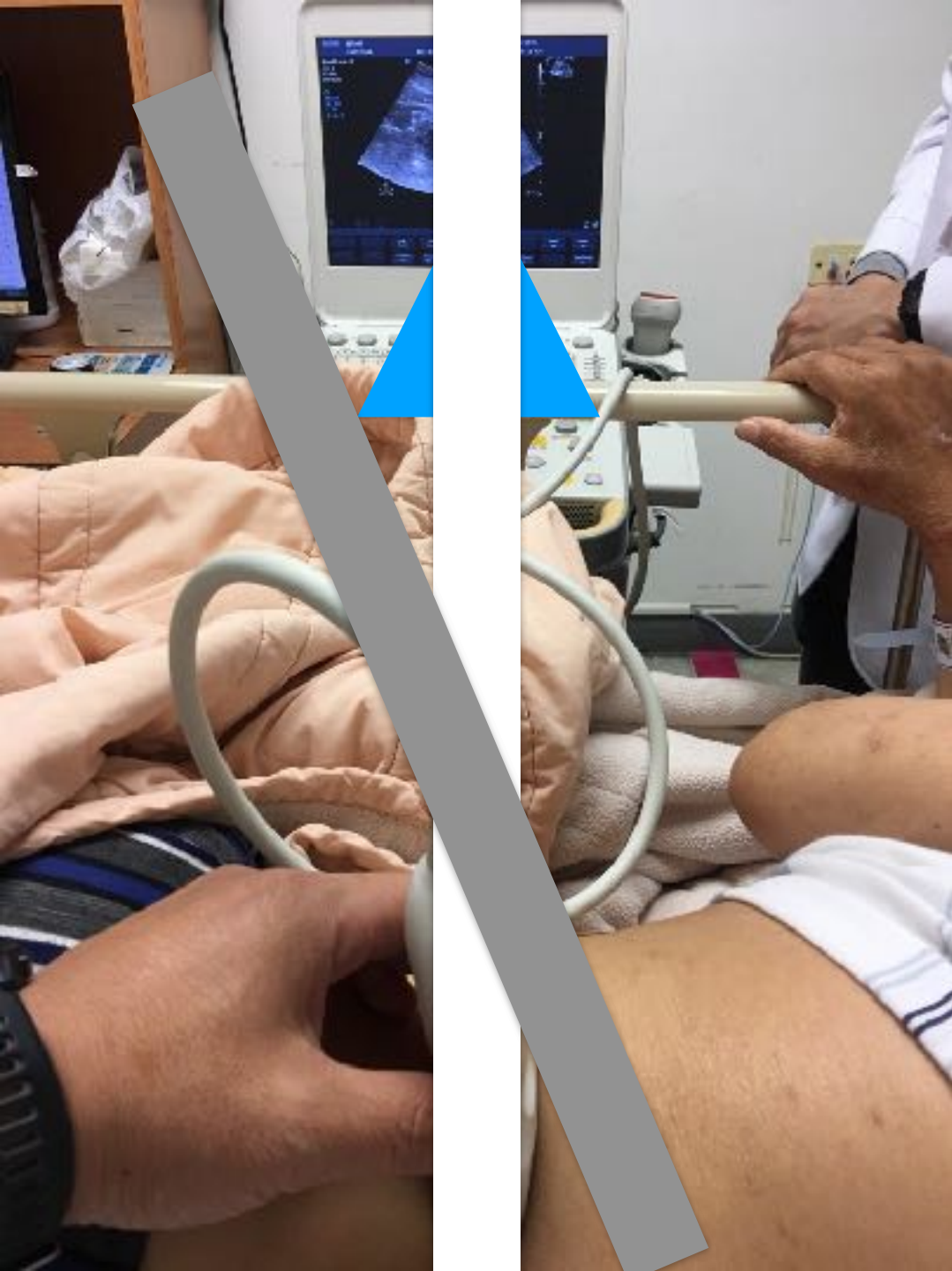

穩定的手要有良好的支撐<sup>111</sup>

# Sterile procedure





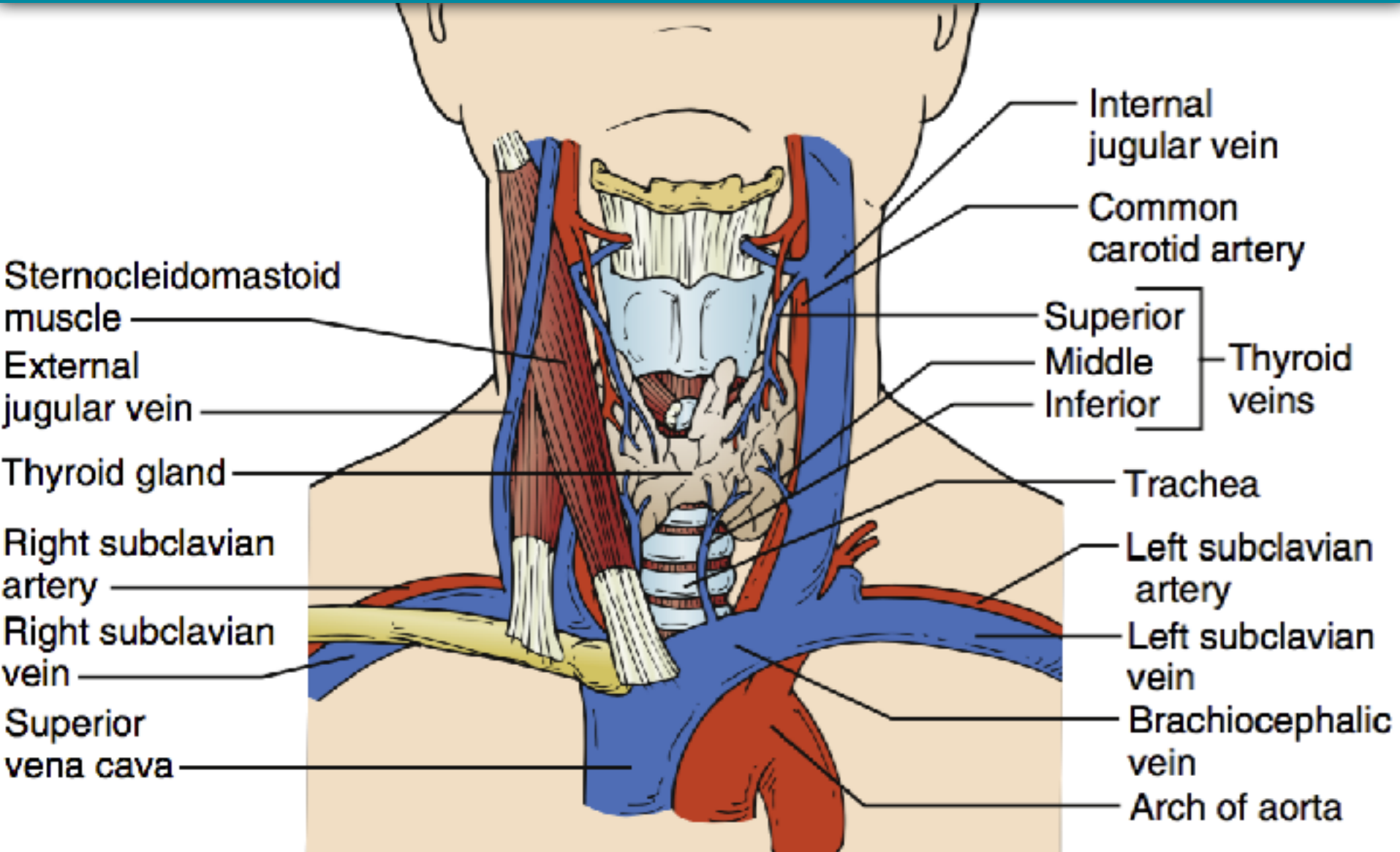


保持軸線

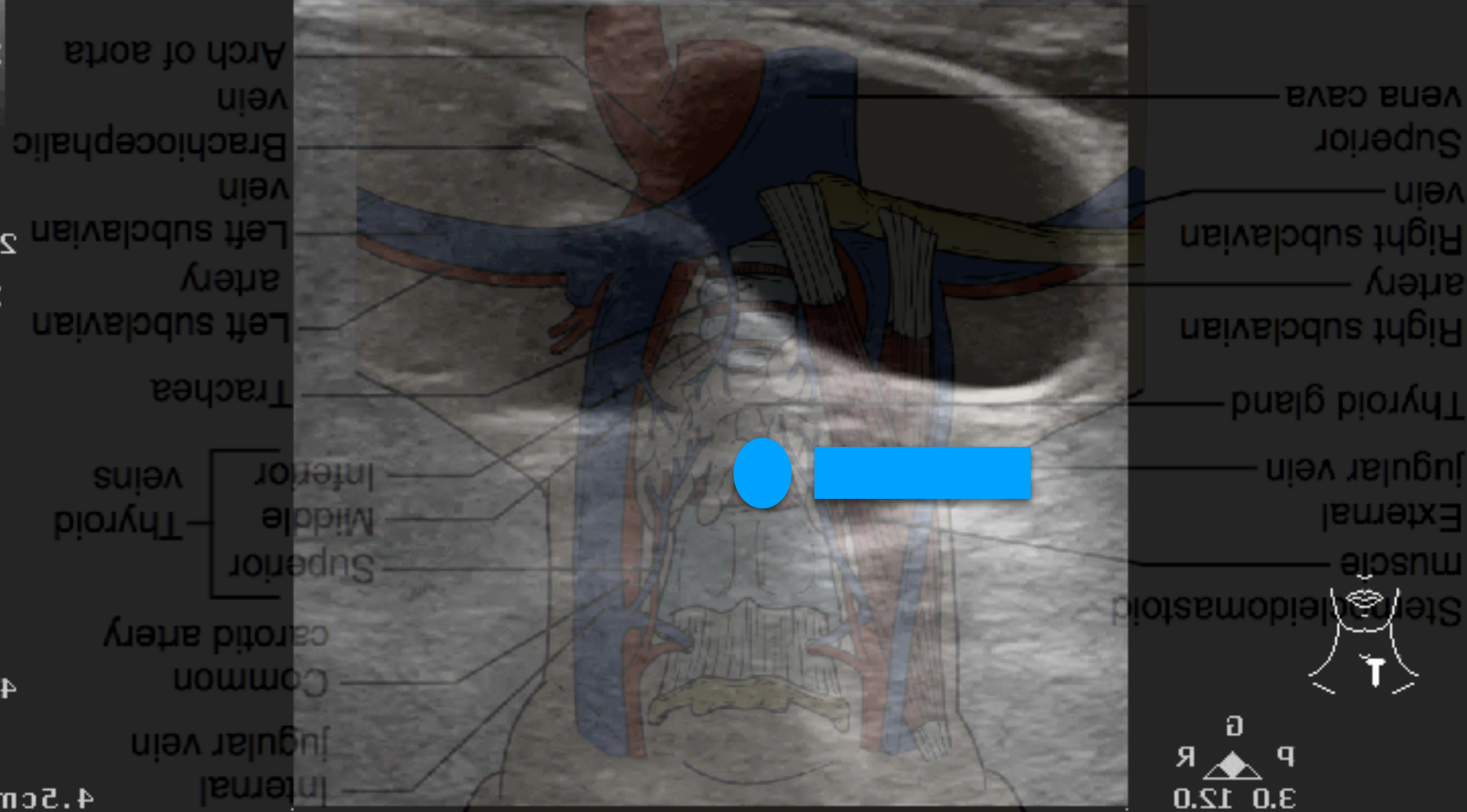堅守切面

擬定路徑

# Neck Vascular Structure



# 探頭的參考點和螢幕同方向

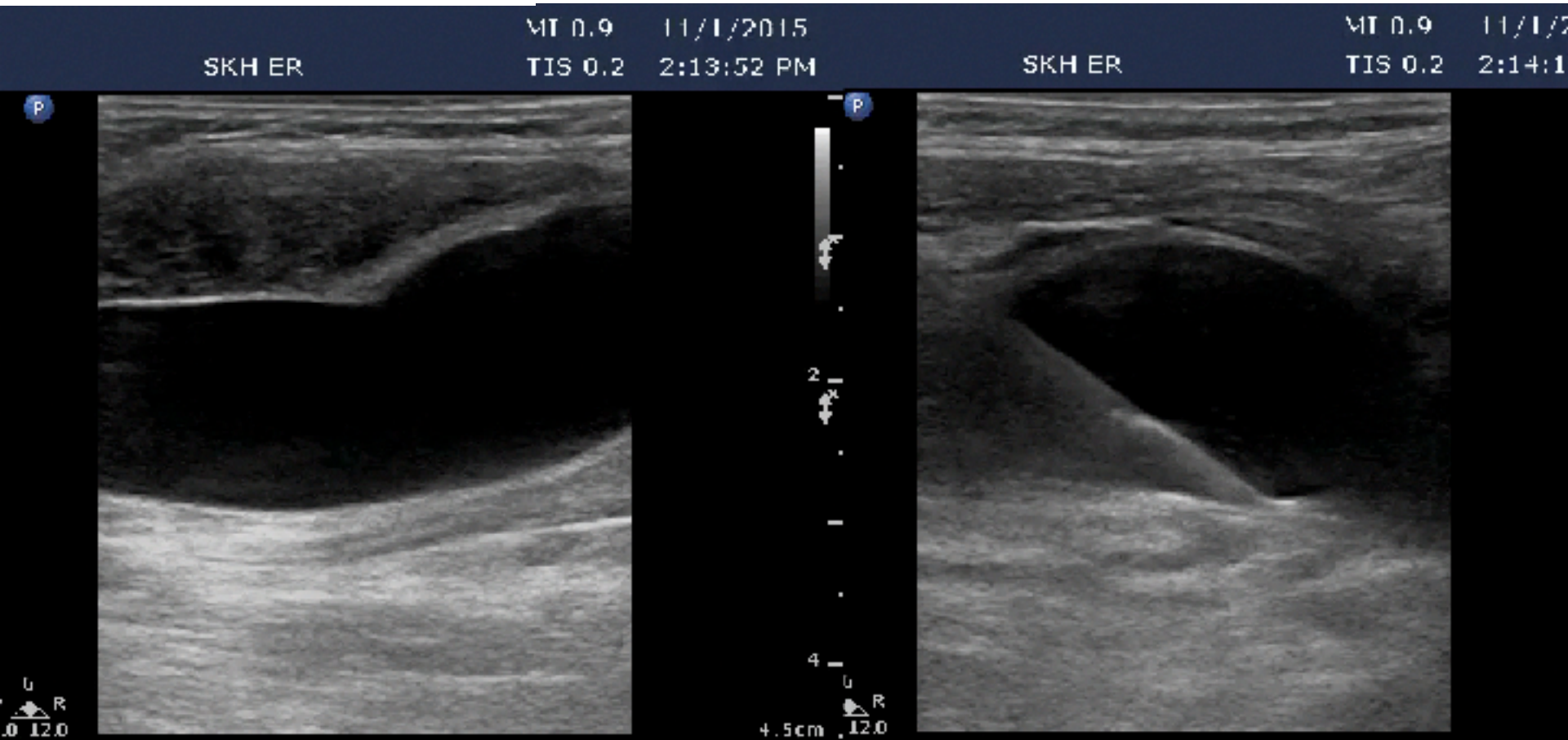


掃描者站頭側

# In plane IJV CVC

## Guiding needle

## Send guidewire

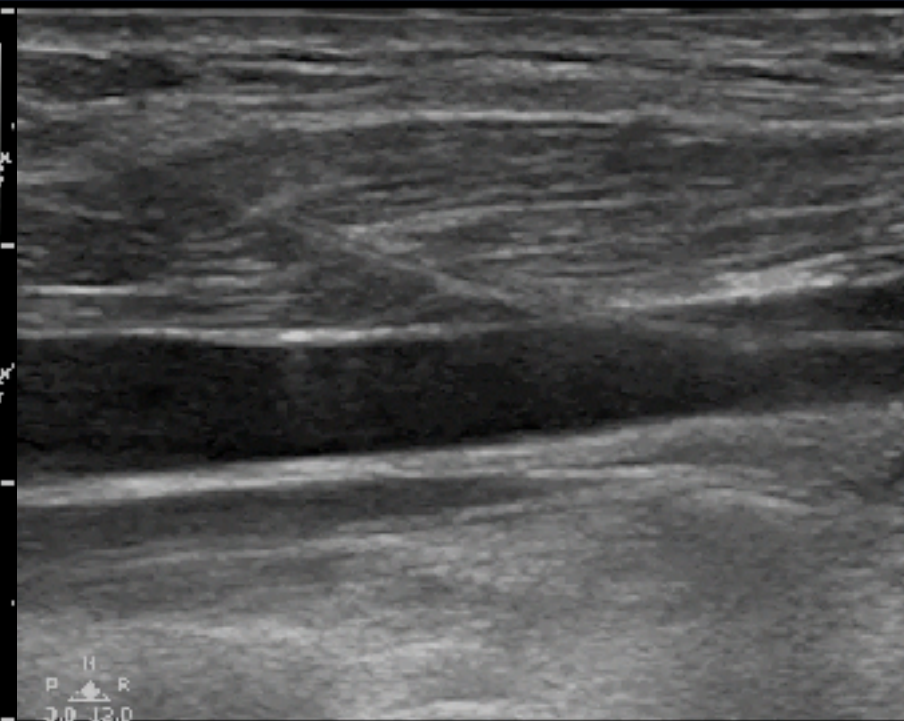
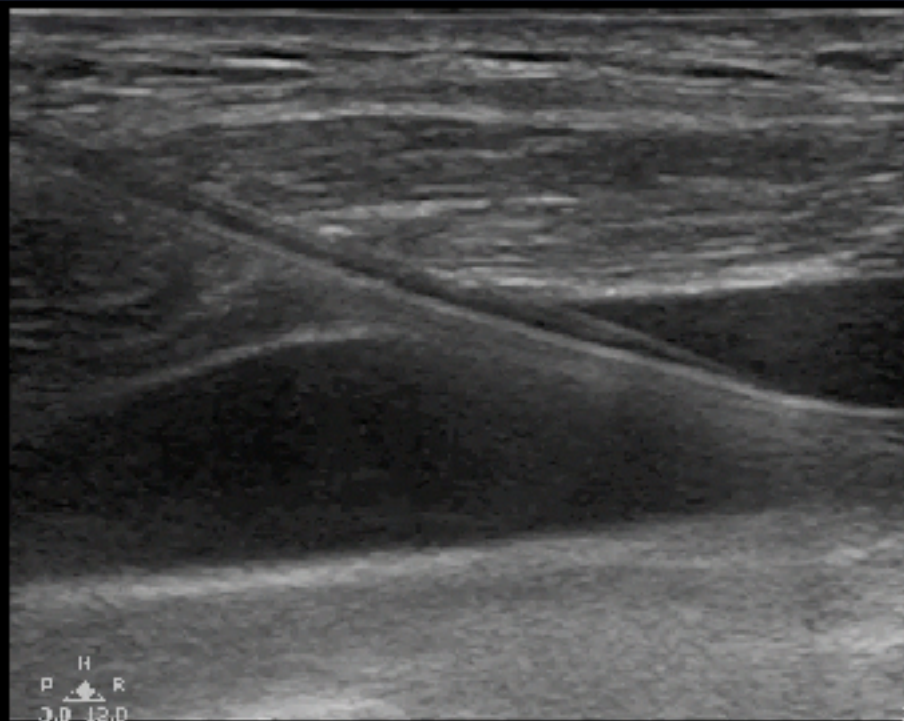


# In plane IJV CVC

Remove needle

Send catheter

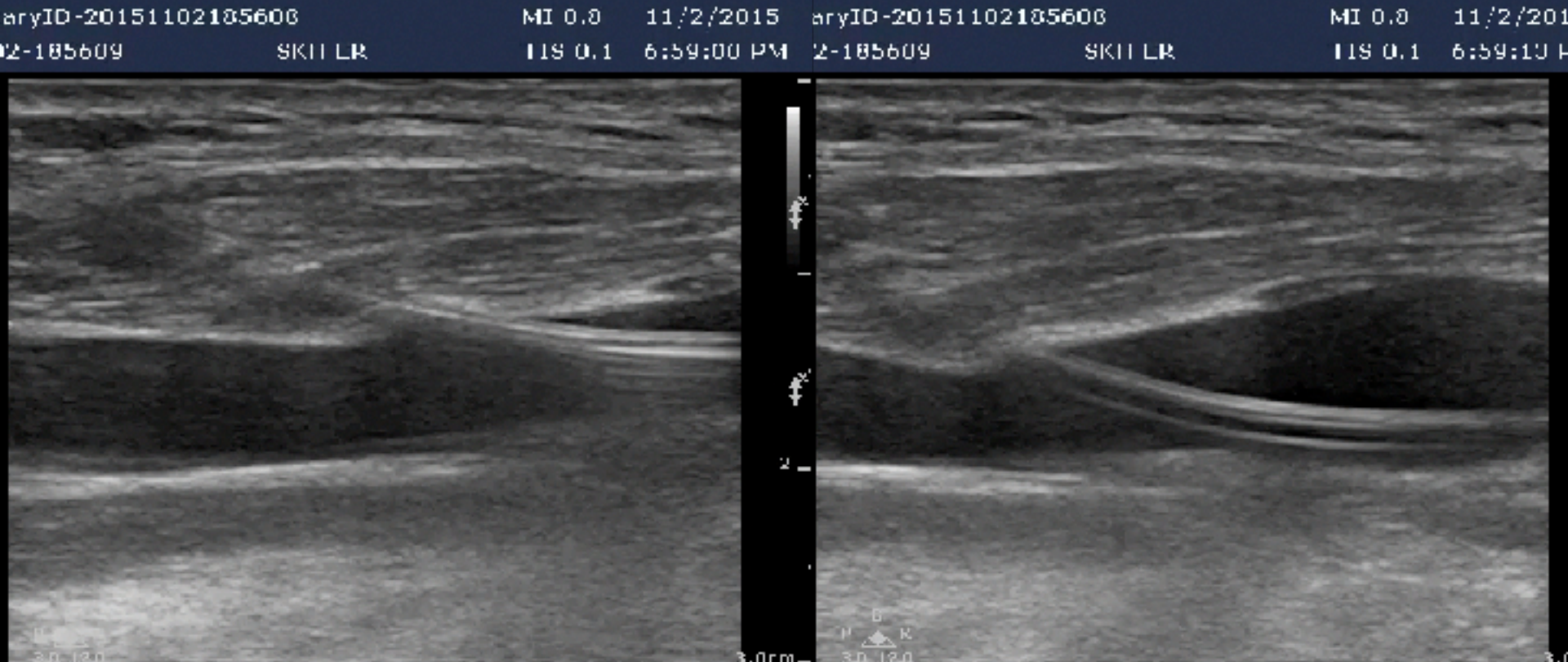
StudyID-20151102185608 MI 0.8 11/2/2015 StudyID-20151102185608 MI 0.8 11/2/2015  
02-185609 SKI LR FIS 0.1 6:58:10 PM 2-185609 SKI LR FIS 0.1 6:58:40



# In plane IJV CVC

Remove guidewire

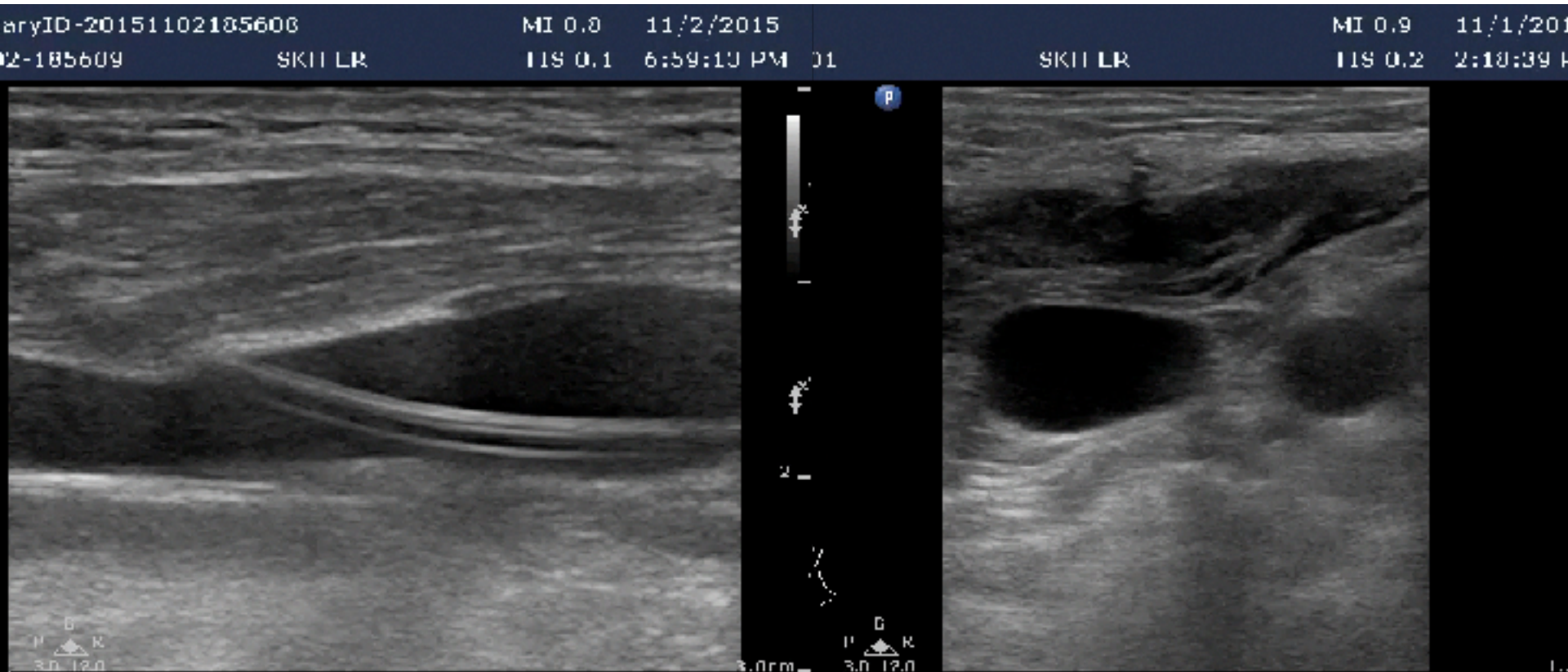
CVC catheter



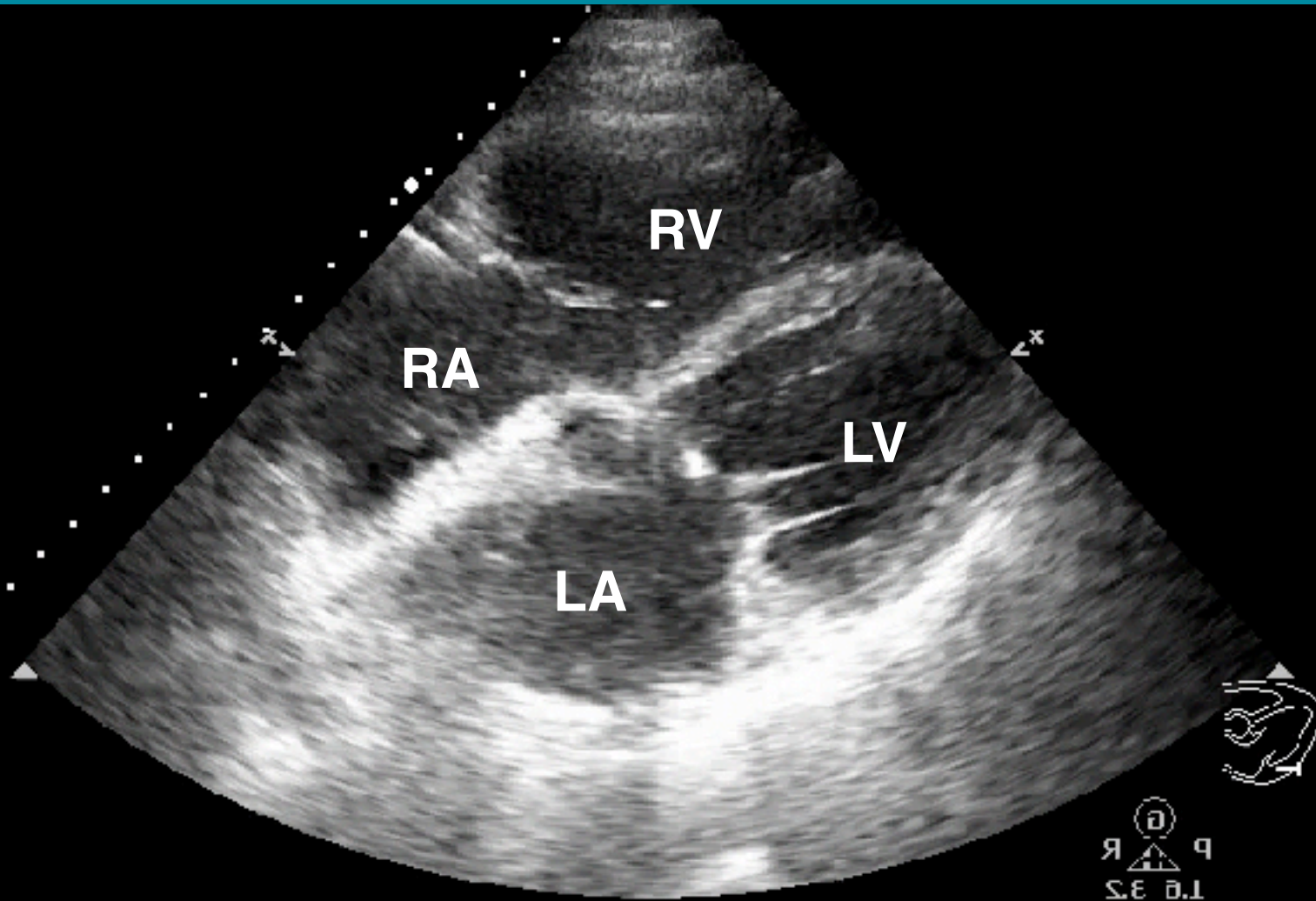
# CVC confirmation

CVC (sagittal)

CVC (transverse)



# Bubble test / Subcostal 4



3 / 2 / 0  
C 20  
An 20  
HGen  
2D  
21.0cm  
20 Hz  
1-0-1

1.0 3.2  
R  
L

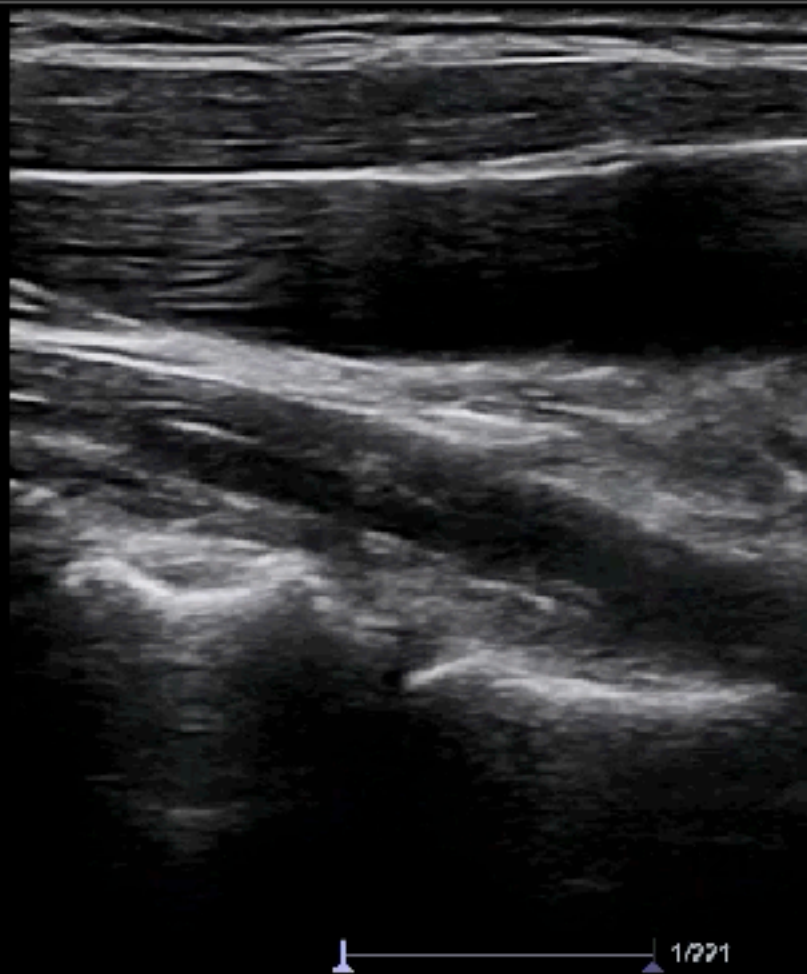
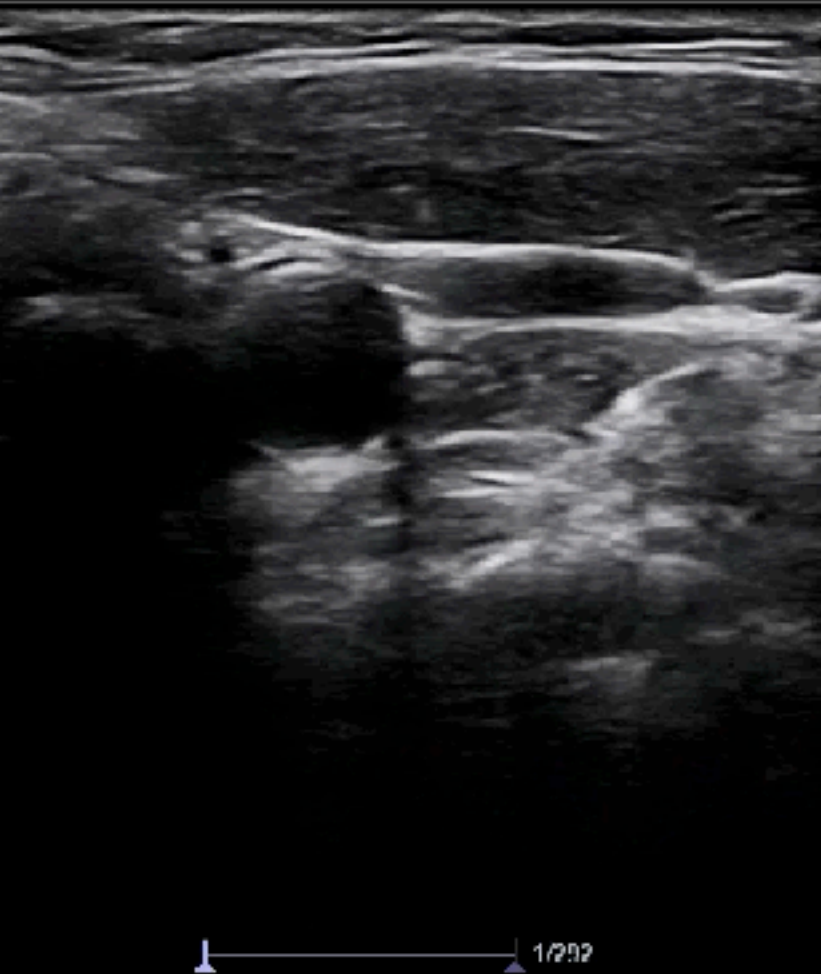


# CVC for septic shock

09/08/2022 08:27:15 AP 91.2% MI 1.0 TIS 0.1  
L12 4s CVC

09/08/2022 08:27:55 AP 91.2% MI 1.0 TIS 0.1  
L12 4s CVC

SHU CHLN 14951190



# CVC for septic shock

**mindray**

YIAN SHU CHEN 14951190

09/08/2022

08:36:30

AP 91.2% MI 1.0 TIS 0.1

L12.4s

CVC

M7

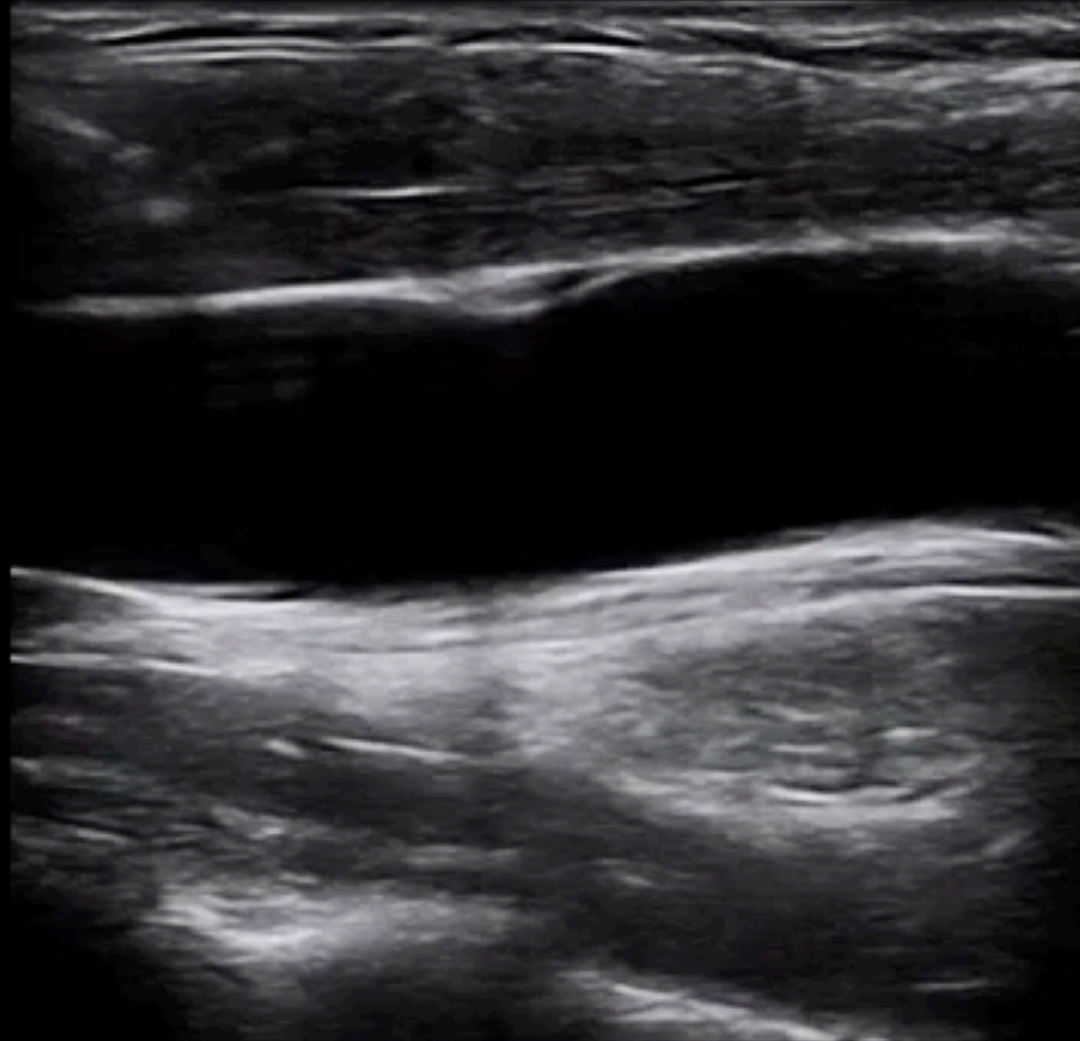
B1

F10 /D3.7

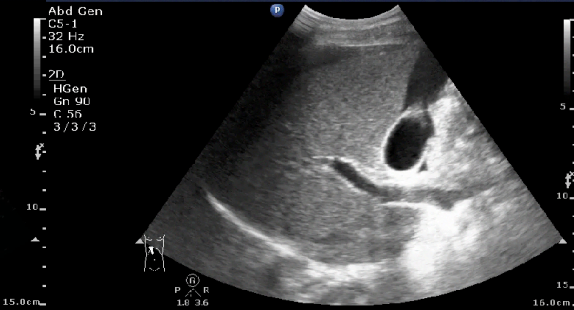
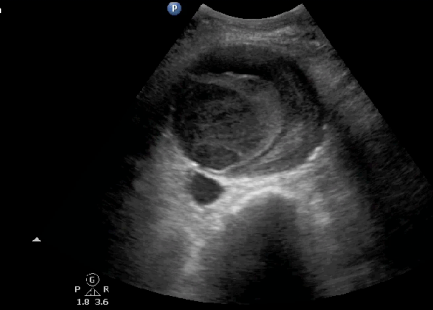
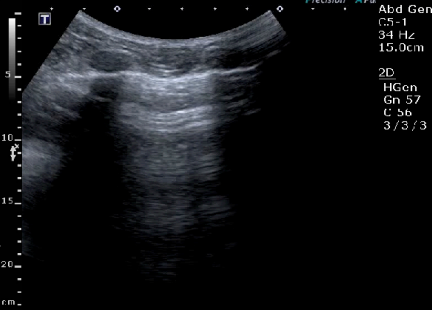
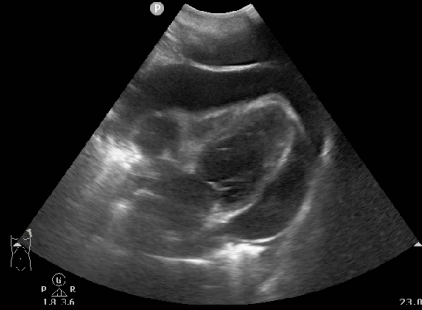
G52 /FR43

IP5 /DR95

**M**



1  
2  
3



目的明確

選對工具

標準掃描

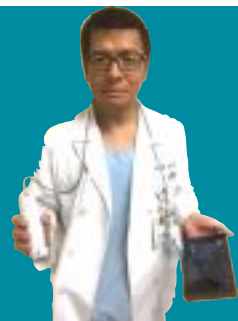辨識結構

正確判讀

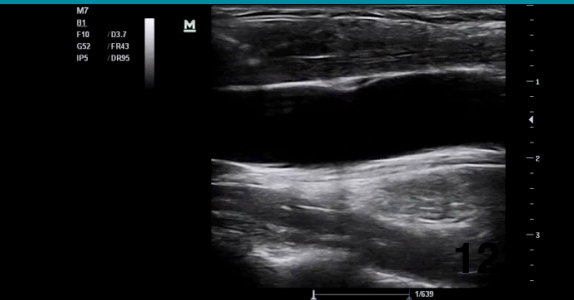
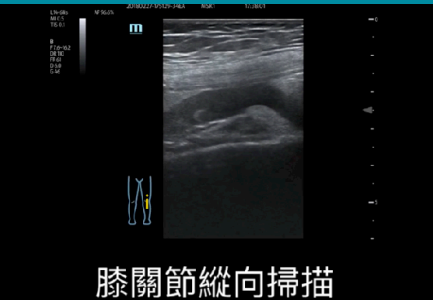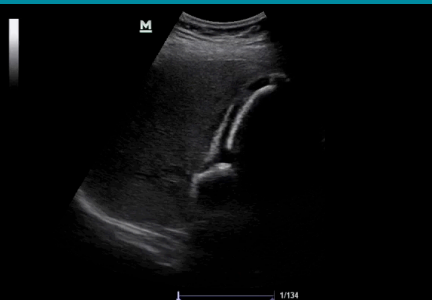
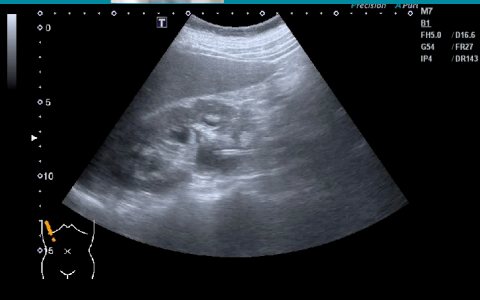了解限制

適時求助

記錄回顧



動得愈慢、看的愈快



膝關節縱向掃描