




衛生福利部雙和醫院  
(委託臺北醫學大學興建經營)  
Taipei Medical University · Shuang Ho Hospital,  
Ministry of Health and Welfare



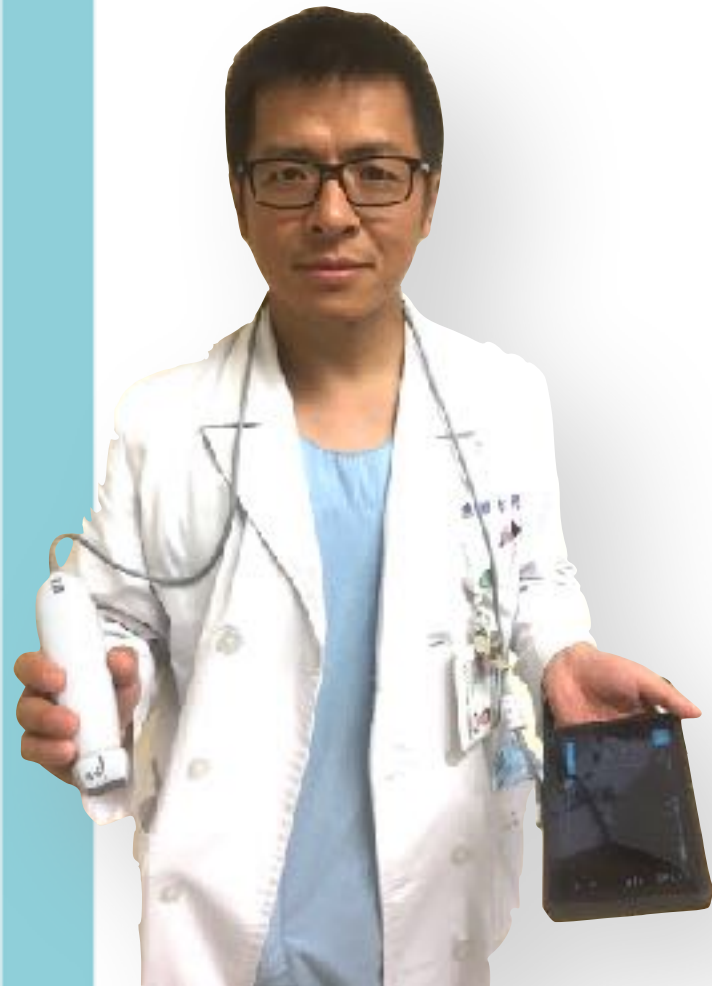# POCUS Training Program



陳國智醫師

雙和醫院 急診醫學科

# POCUS Academy



急救加護重症超音波工作坊  
PAIN - Module (1) 工作坊  
AEACUS Network President  
(前)急診超音波委員會主委  
(前)新光超音波訓練中心主任  
(前)西園醫院急診醫學科主任

Faculty

-WINFOCUS, PERCUSS, WFPICC  
-台灣疼痛醫學會

POCUS Academy

FB: Emergency Ultrasound Training Center



# POCUS

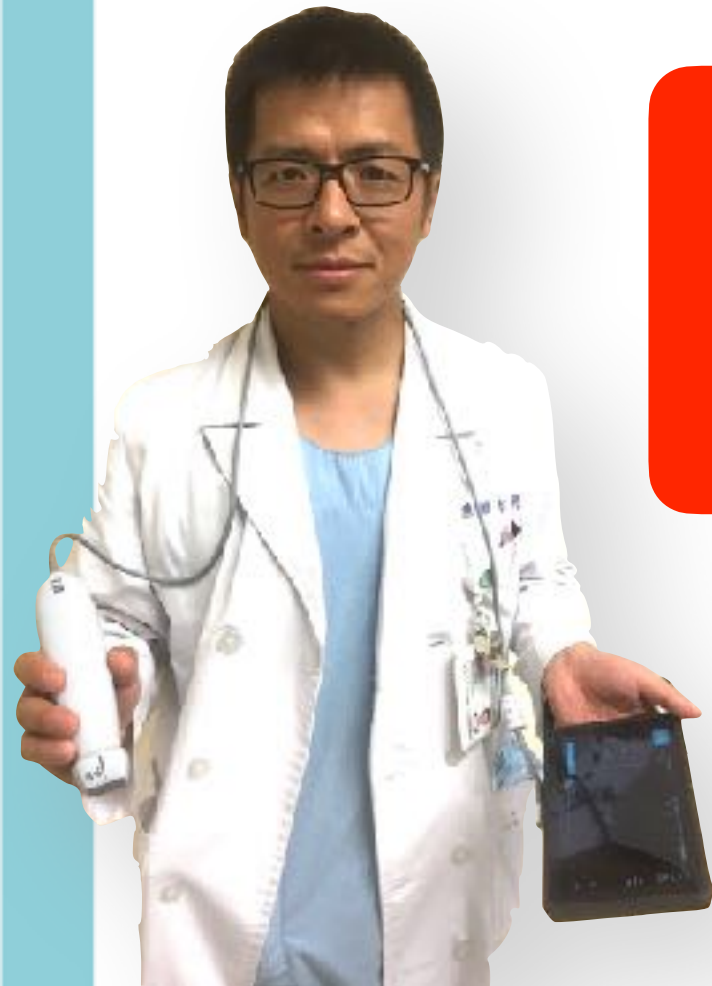Point-of-Care Ultrasound

“**ultrasonography** brought to the **patient** and performed by the **provider** in **real time**”

Moore, C. L., & Copel, J. A. NEJM 2011



# POCUS for Me



診  
斷

Diagnosis

監  
測

Monitoring

介  
入

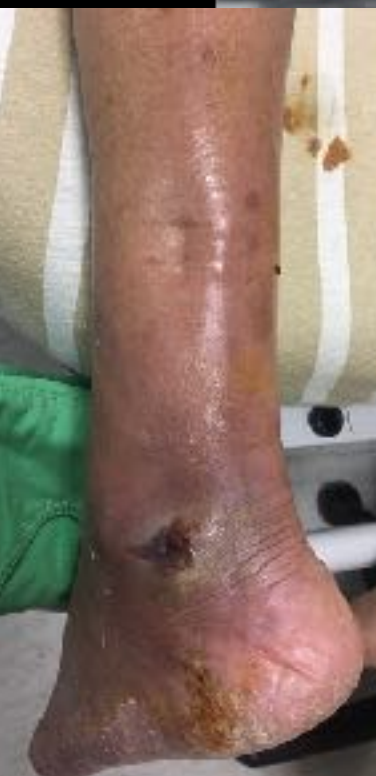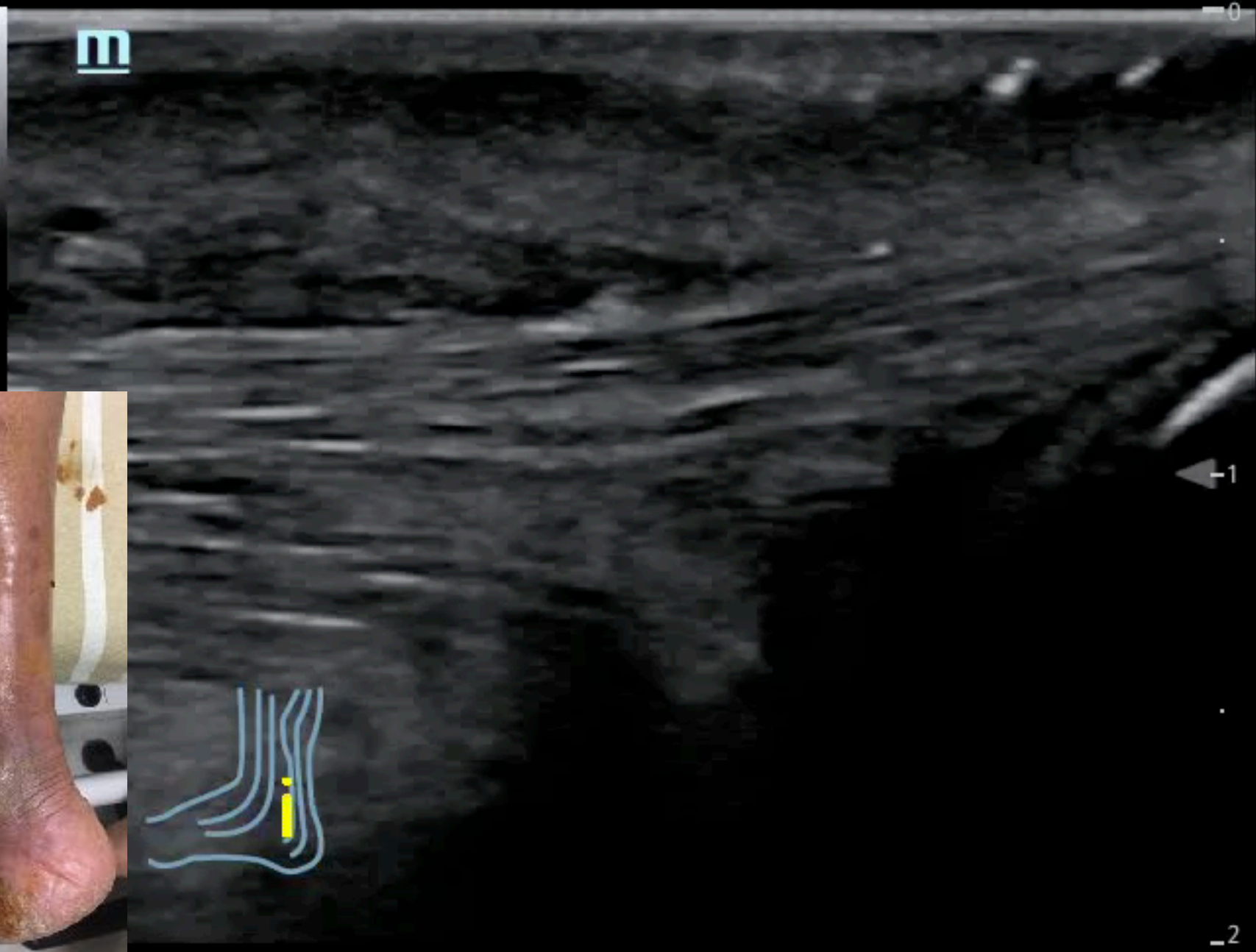
Intervention

L14-6Ns  
MI 13  
TIS 0.1

AP 96.6%



B  
FH10  
DR 110  
FR 27  
D 2.0  
G 46



-1

-2

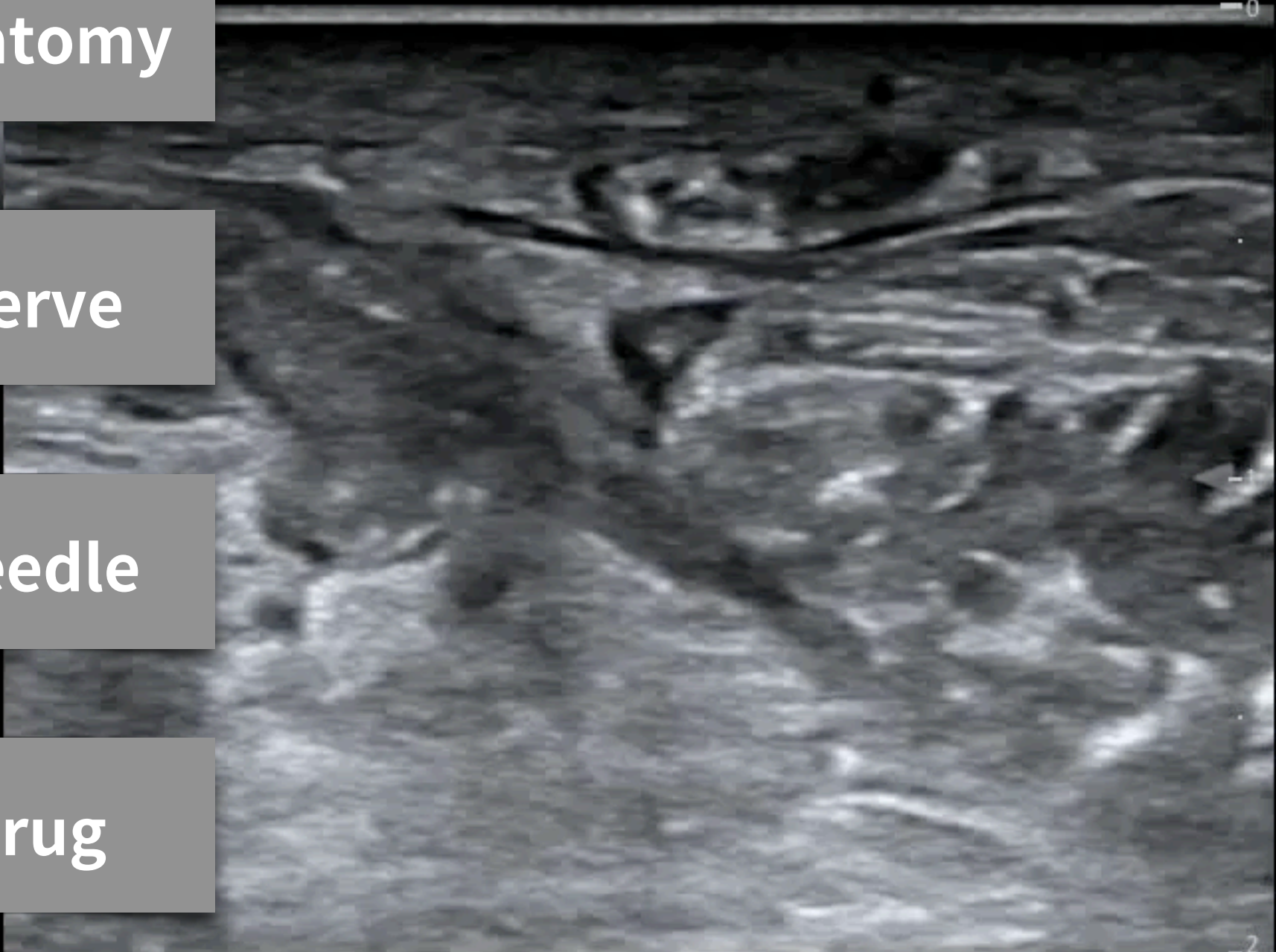
**Anatomy**

F 6.0~12.6  
DR 100  
FR 82  
D 2.0

**Nerve**

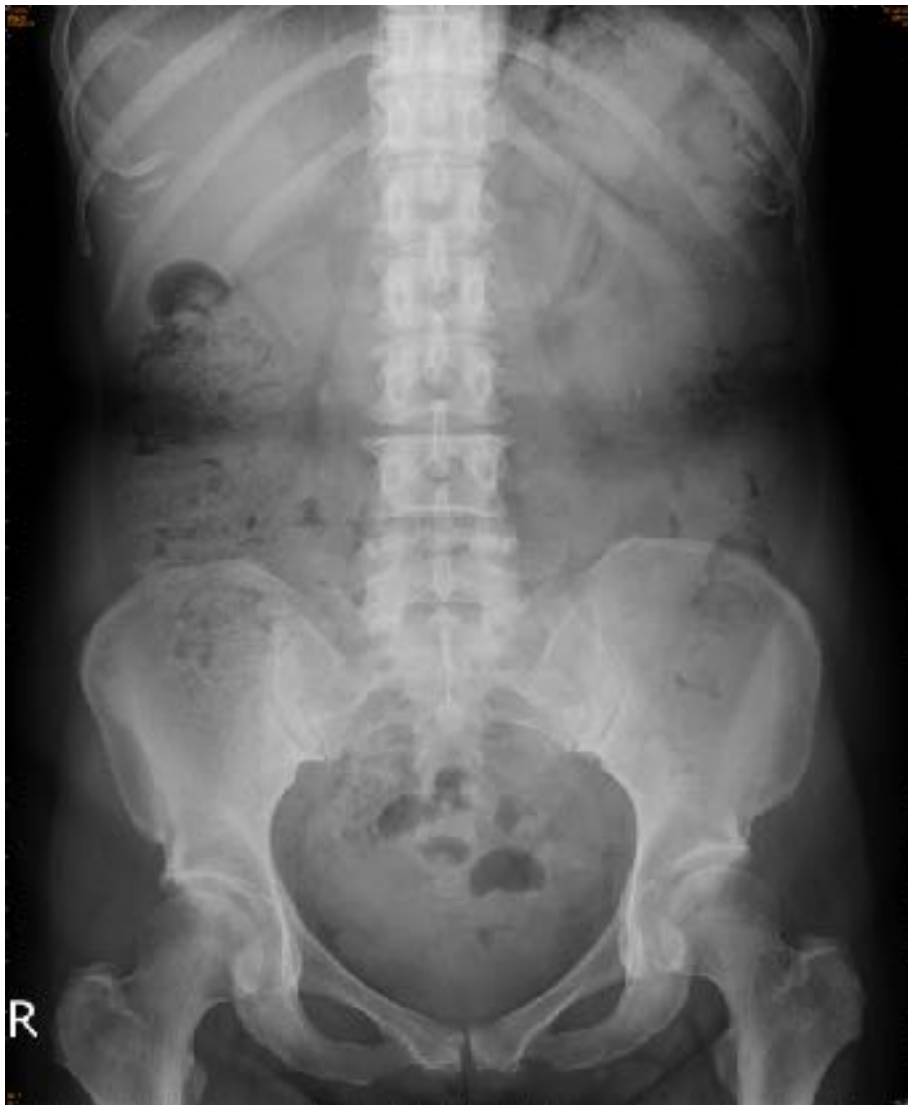**Needle**

**Drug**

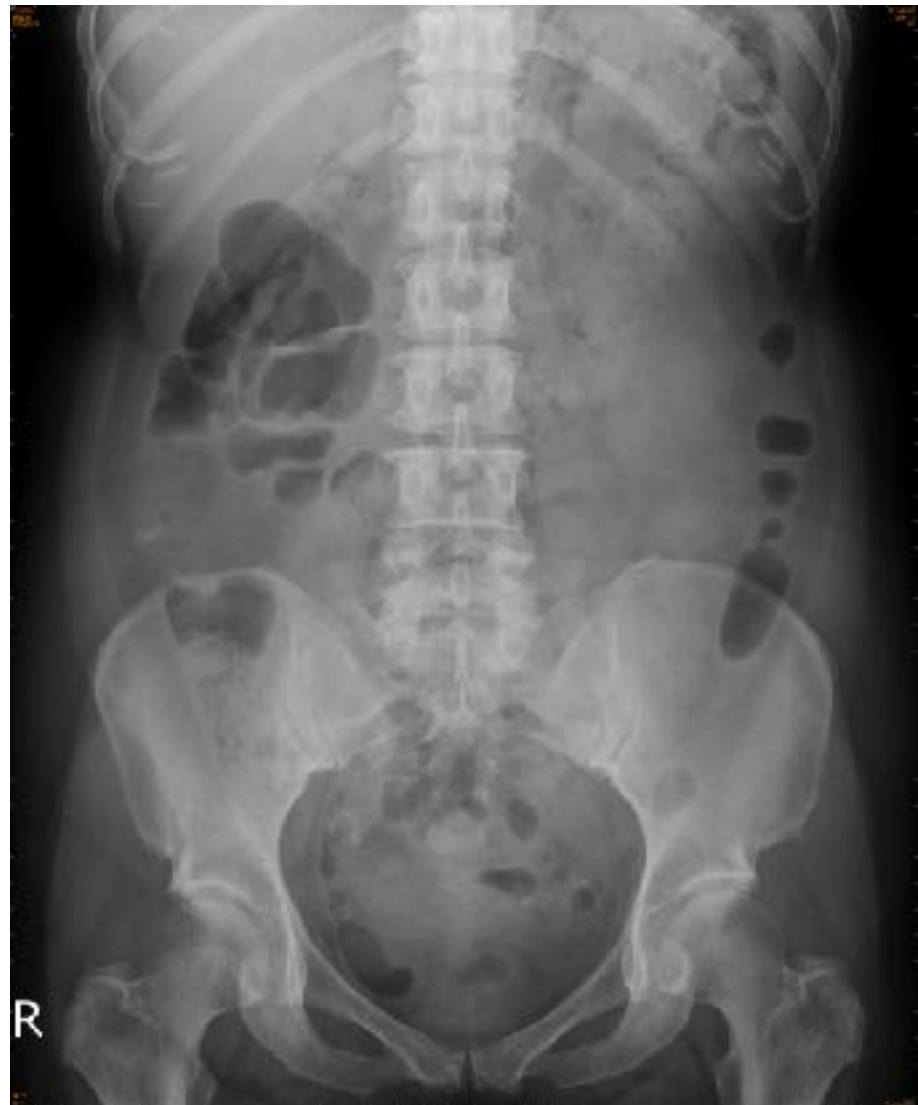

# 58F, 左腰腹痛併發燒2天

20160726

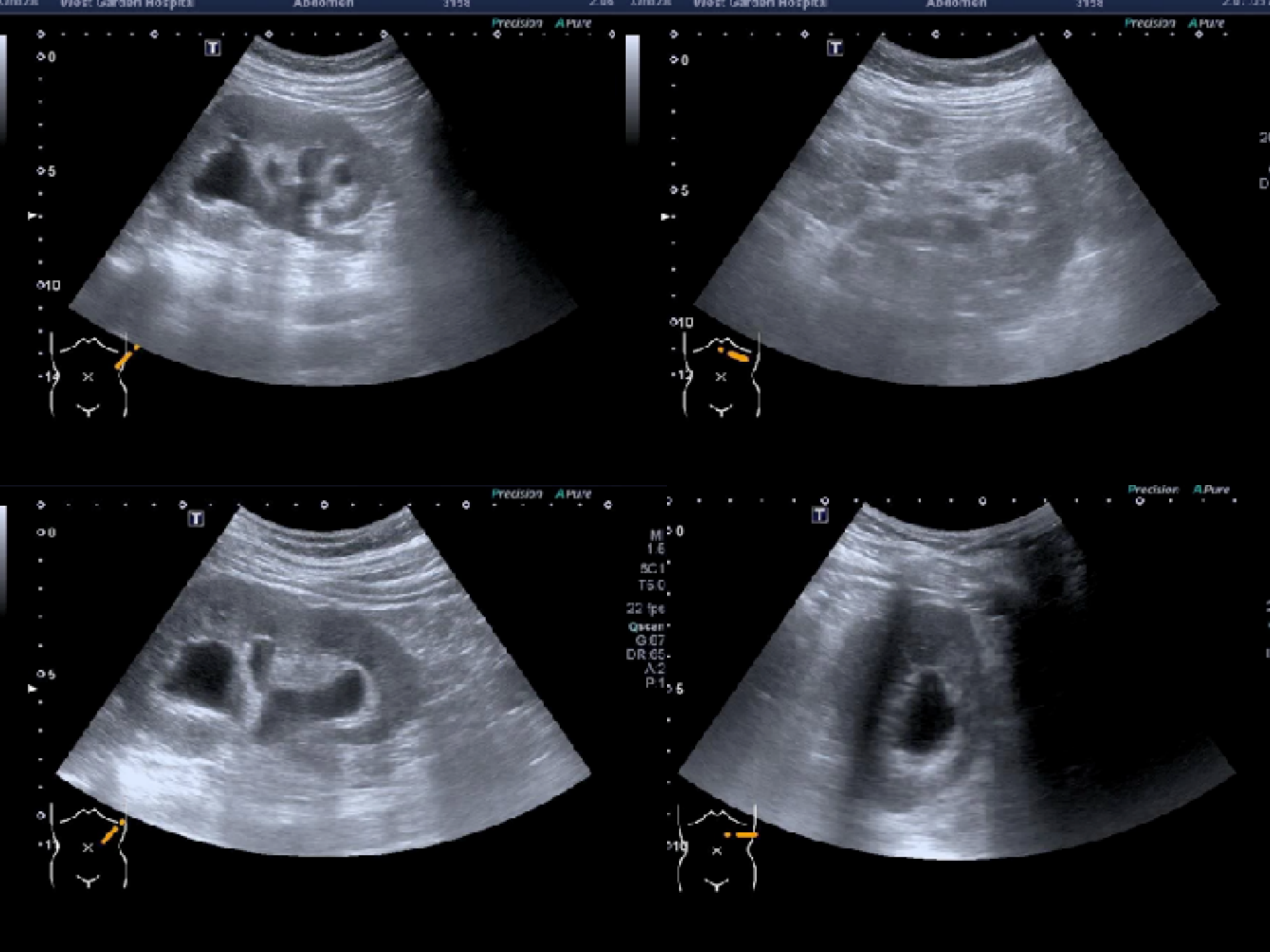


20180603











# 自我介紹 & 超音波實力自評

A photograph of medical professionals in a clinical setting. In the foreground, a person wearing a blue surgical cap, glasses, and a green surgical mask is looking towards the right. In the background, another person wearing a blue surgical cap and a blue surgical mask is visible. The background is slightly blurred, showing what appears to be a hospital or clinic environment.

個案影像討論 1H

期刊文獻分享 1H

掃描技巧指導 1H

臨床個案掃描 2H

## 雙和急診POCUS訓練規劃



**LE joint effusion**

01/07

**Airway**

01/14

**Needling**

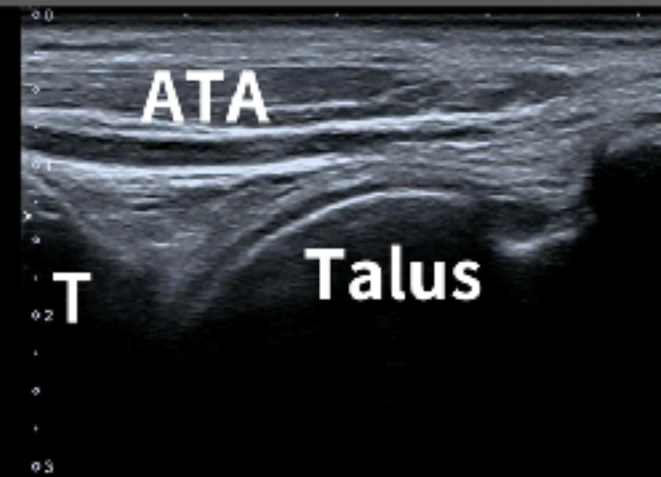
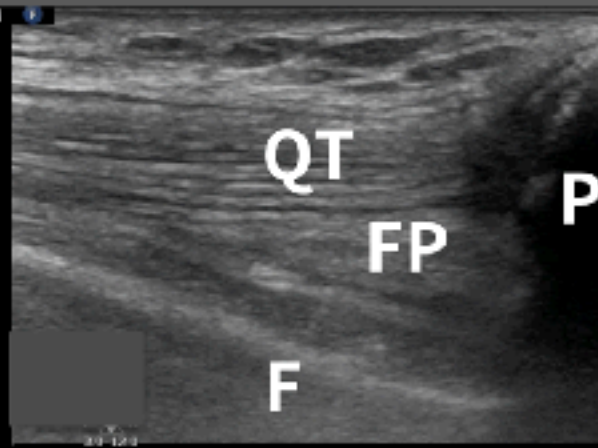
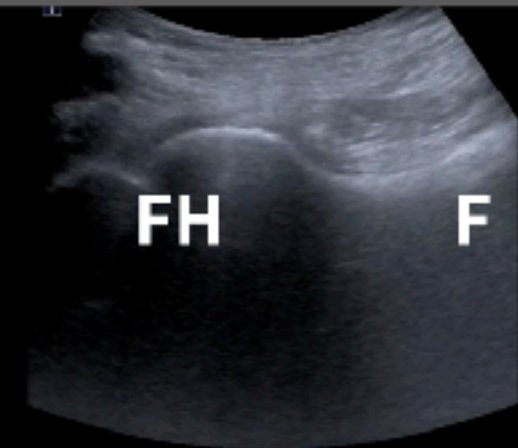
01/21

**VExUS protocol**

01/28

# 雙和急診POCUS訓練規劃

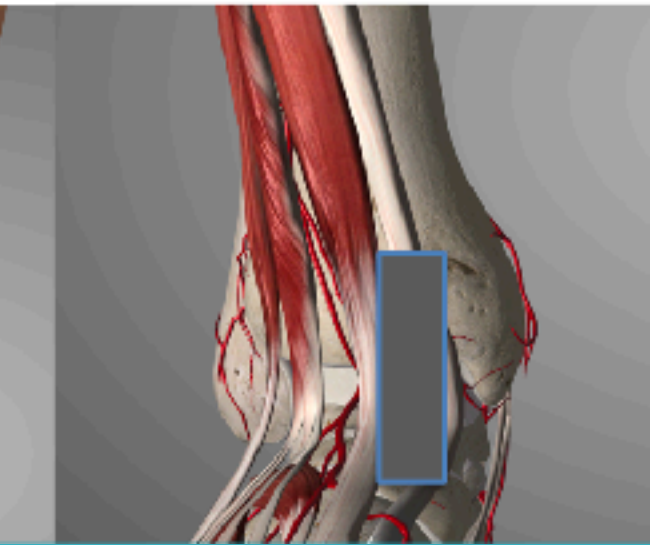
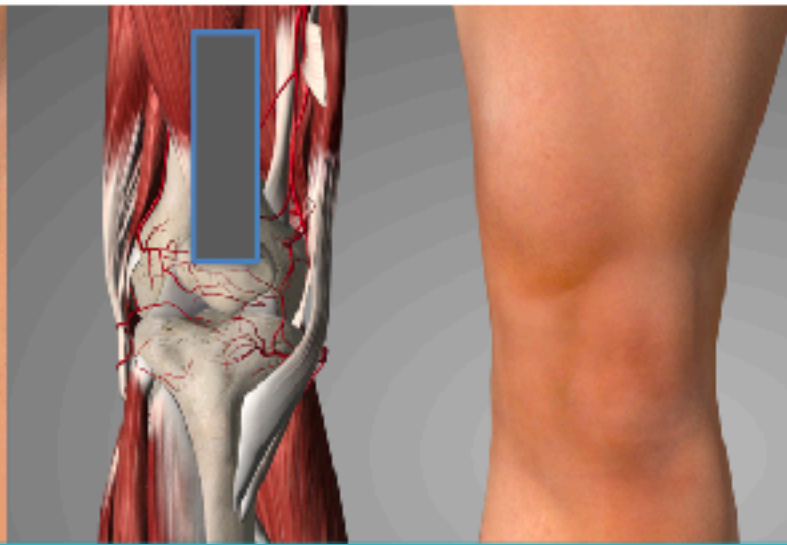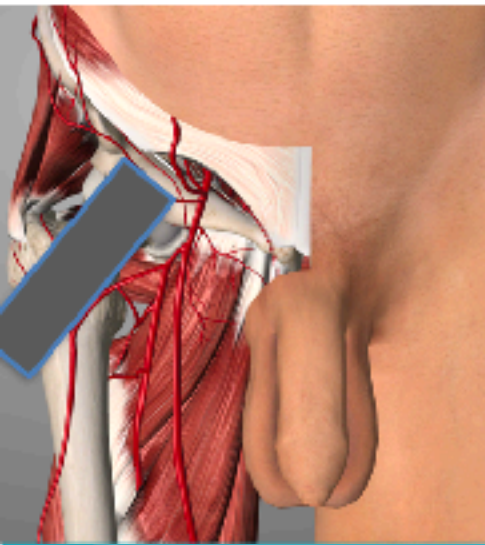
# LE Joint effusion

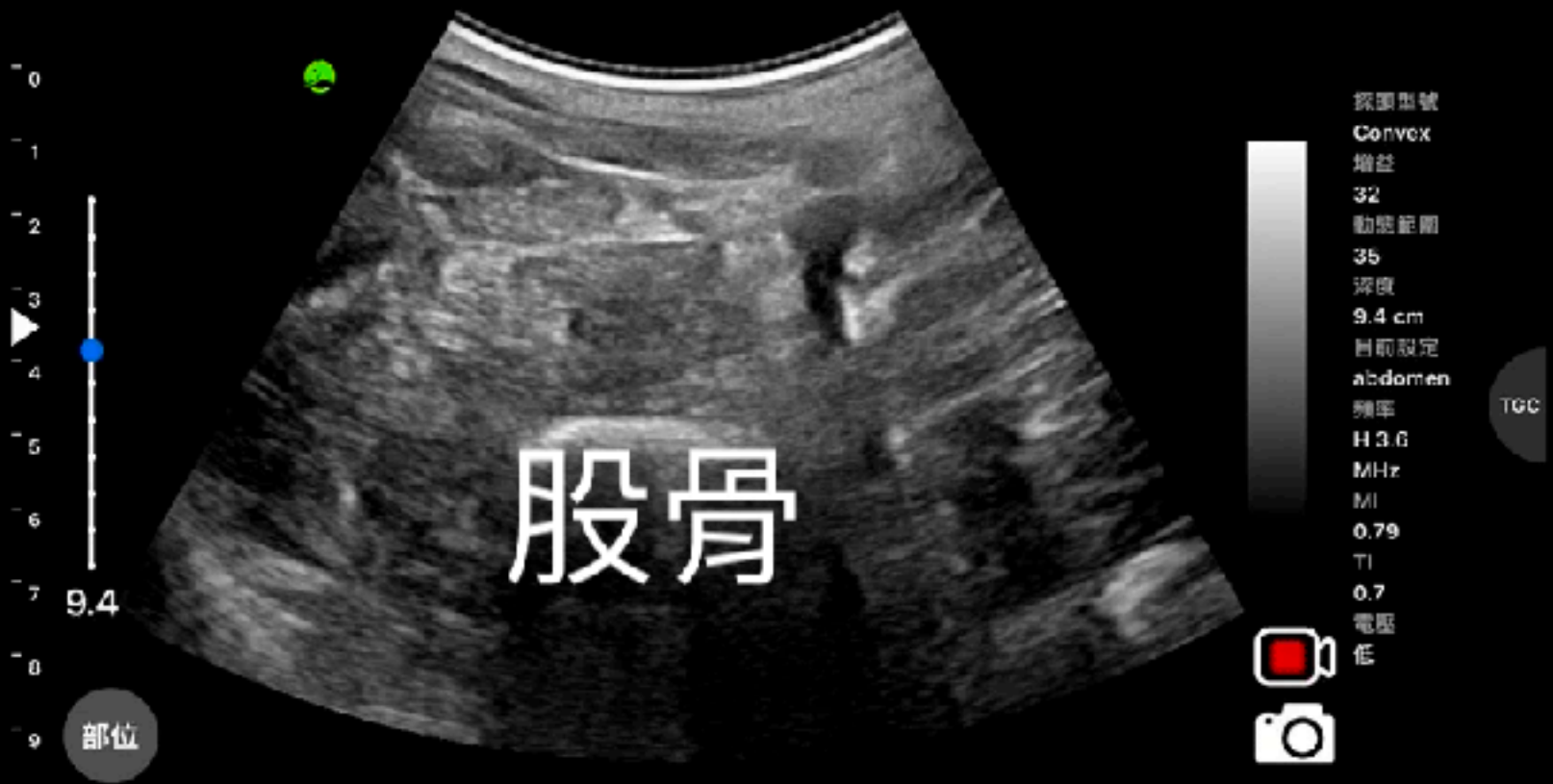

Hip

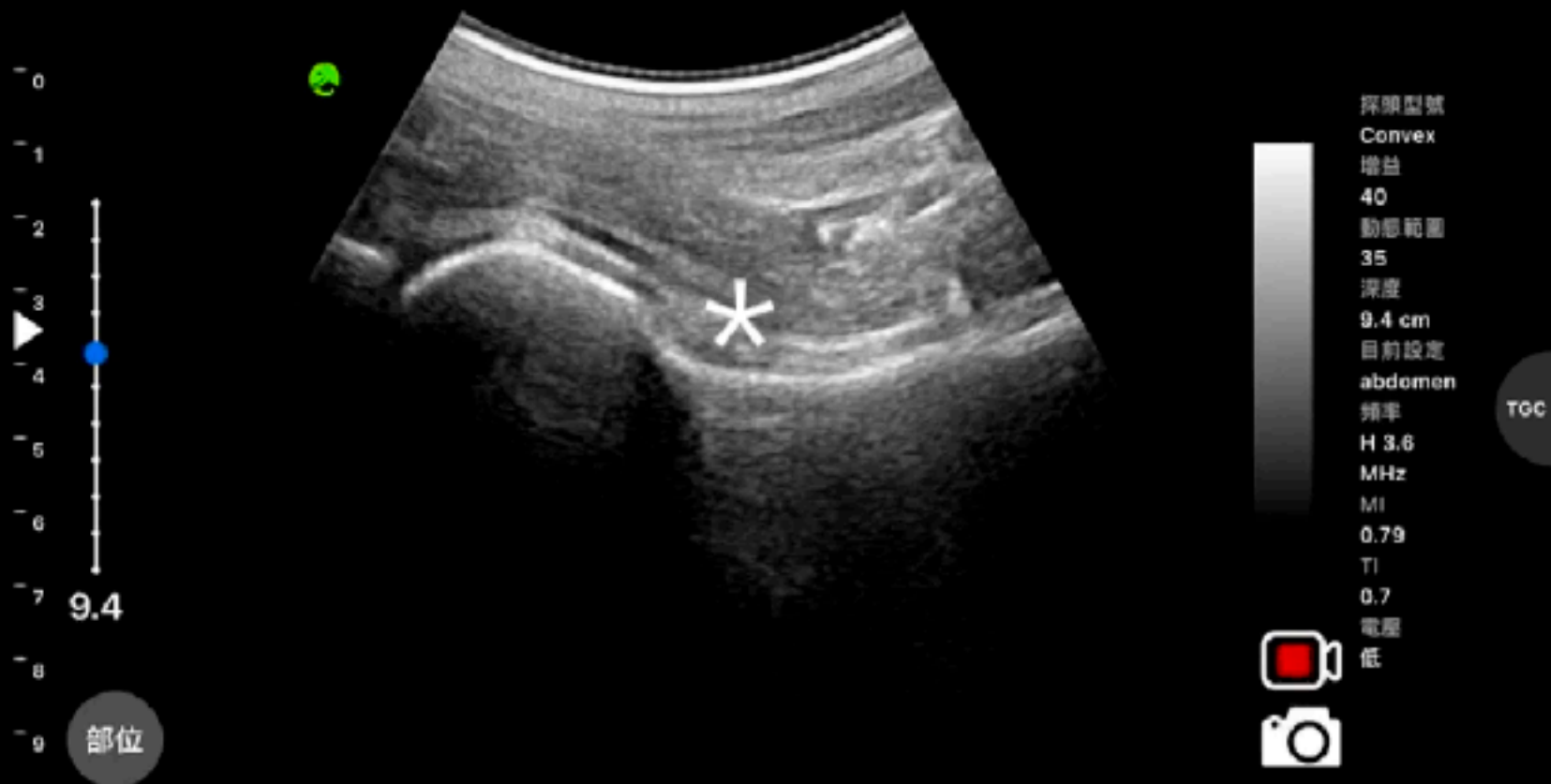Knee

Ankle

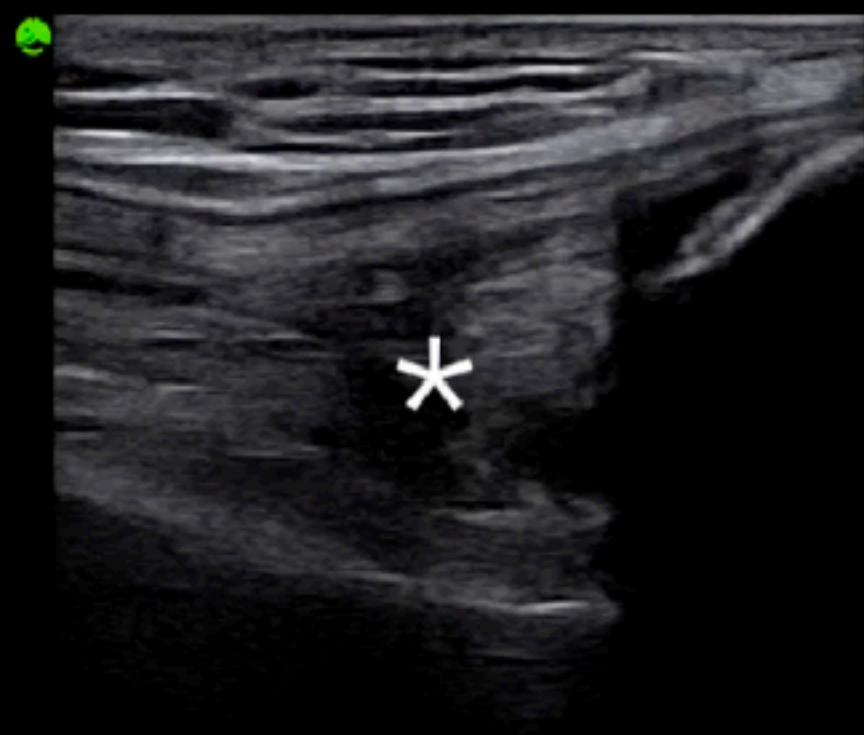




# 右大腿橫向掃描





\*關節積液觀察部位  
髁關節縱向掃描



探頭型號  
Linear  
增益  
52  
動態範圍  
37  
深度  
3.9 cm  
目前設定  
carotid  
頻率  
10.0  
MHz  
MI  
0.54  
TI  
0.56  
電壓  
高

TCC

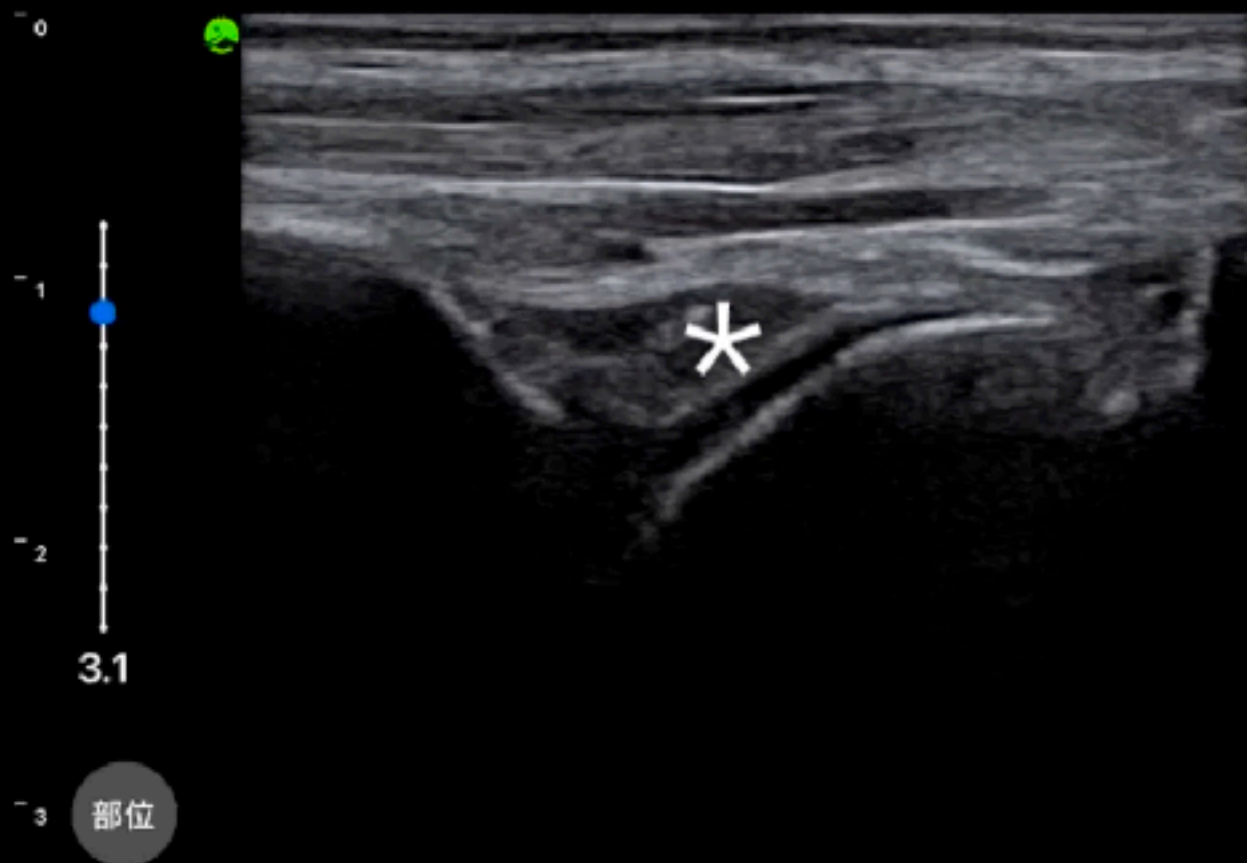


部位

# \*關節積液觀察部位

## 膝關節縱向掃描





探頭型號  
Linear  
增益  
52  
動態範圍  
37  
深度  
3.1 cm  
目前設定  
carotid  
頻率  
10.0  
MHz  
MI  
0.54  
TI  
0.56  
電壓  
高

TGC



\*關節積液觀察部位

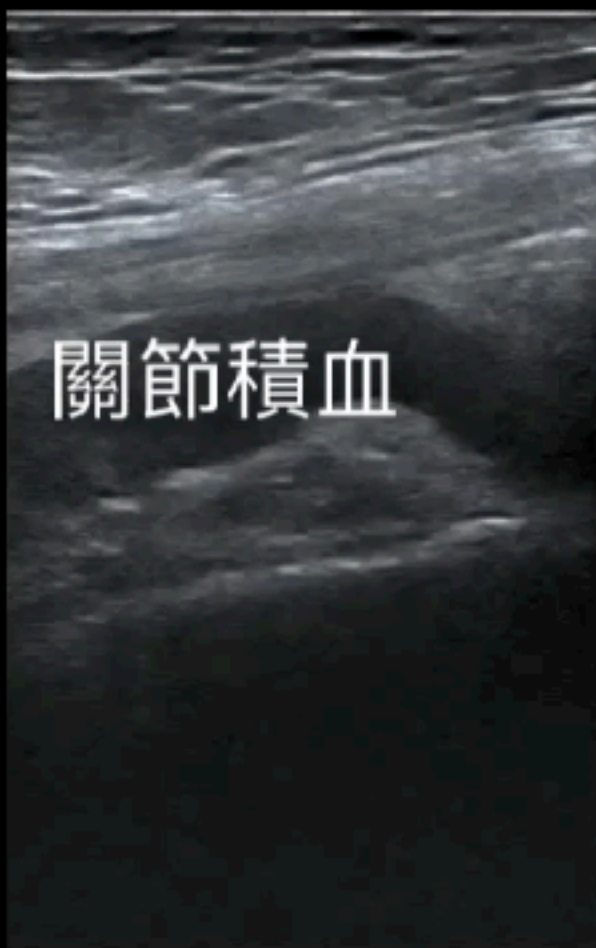踝關節縱向掃描

L14-6Ns  
MI 0.5  
TIS 0.1

AP 96.6%



B  
F 7.6-16.2  
DR 110  
FR 61  
D 6.0  
G 46



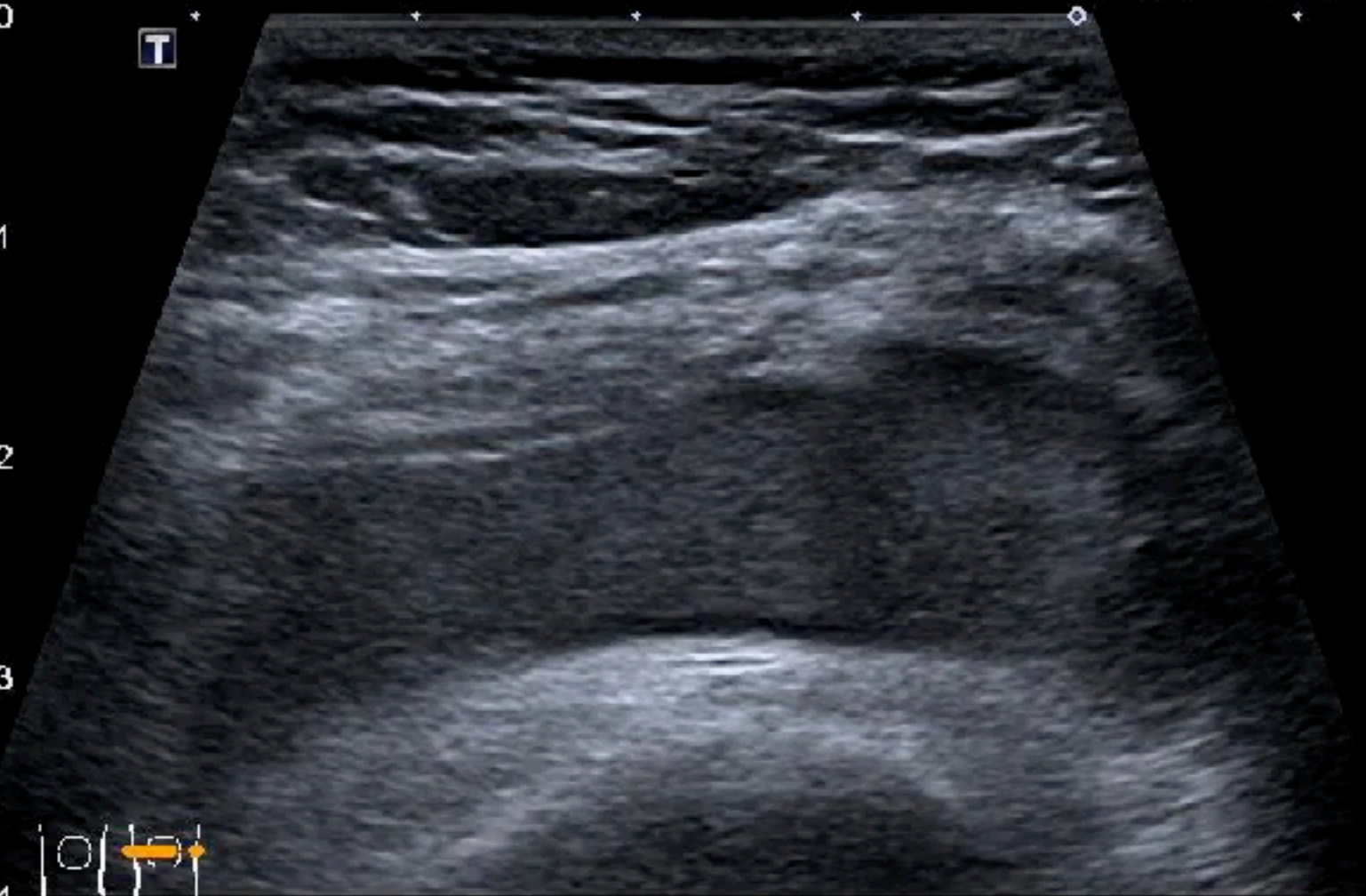關節積血

# 膝關節縱向掃描

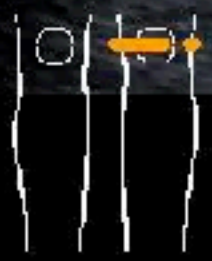Precision APure+

- 0
- 1
- 2
- 3
- 4

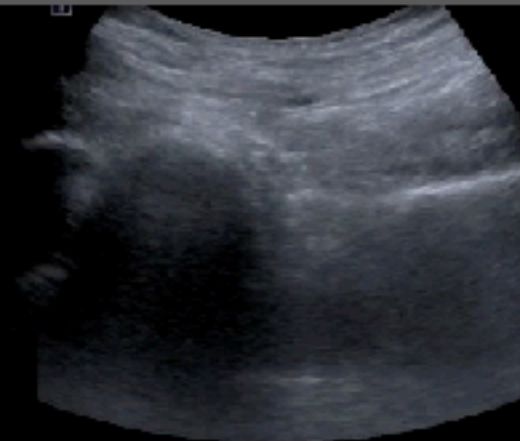T



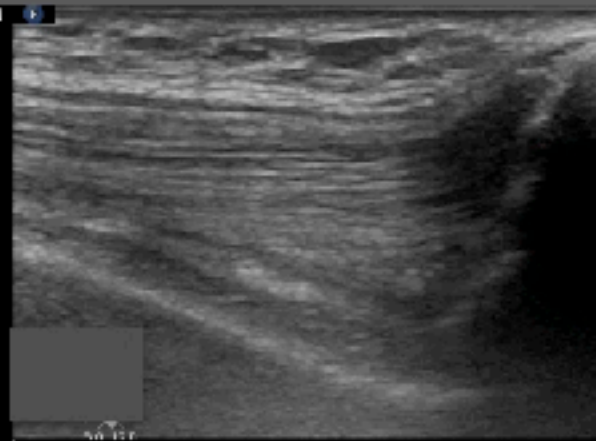
MI 1.5  
11L4  
diffT9.0  
30 fps  
Qscan  
G:84  
DR:60  
A:6  
P:3



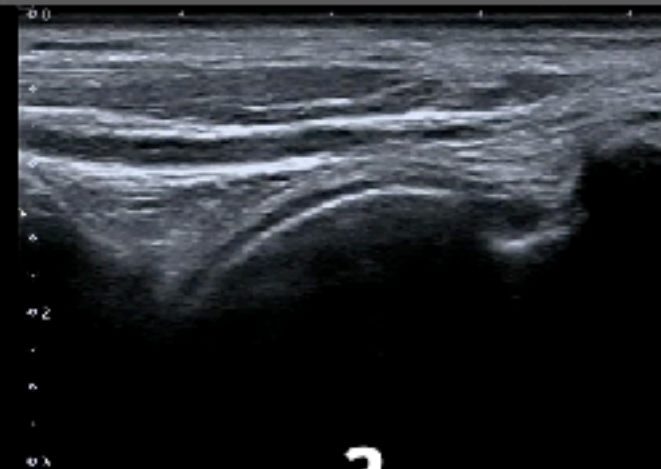
# Lower extremity joints



1

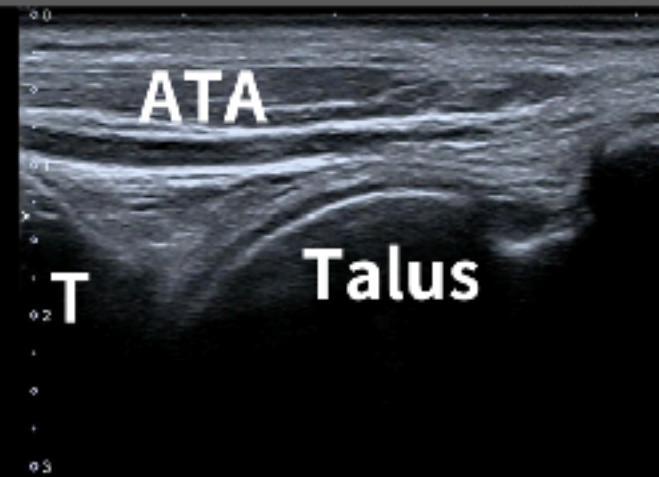
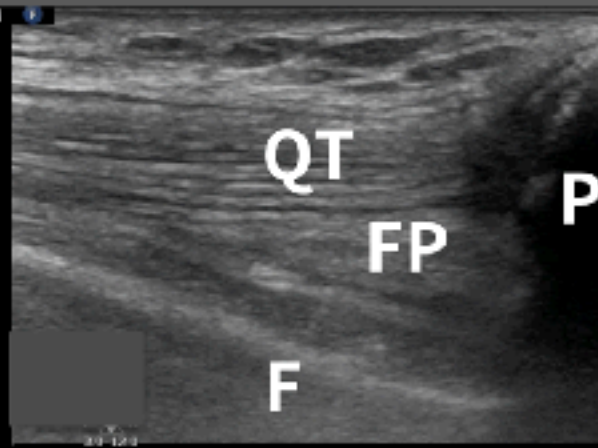
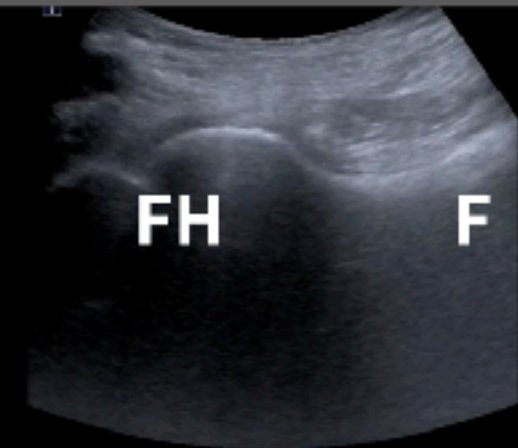


2



3

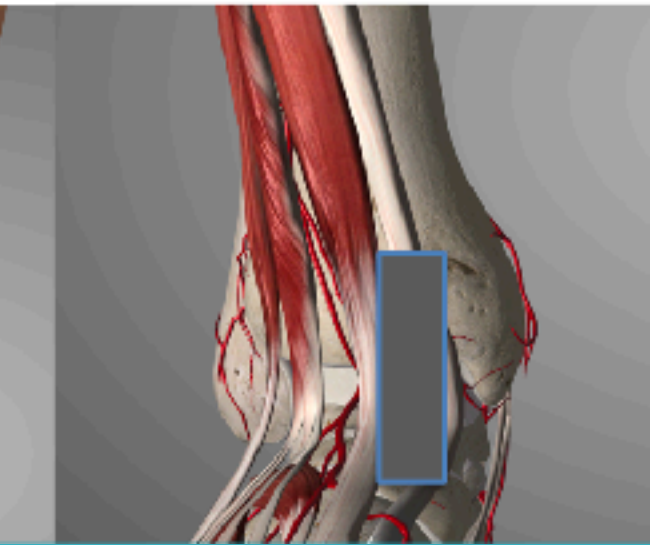
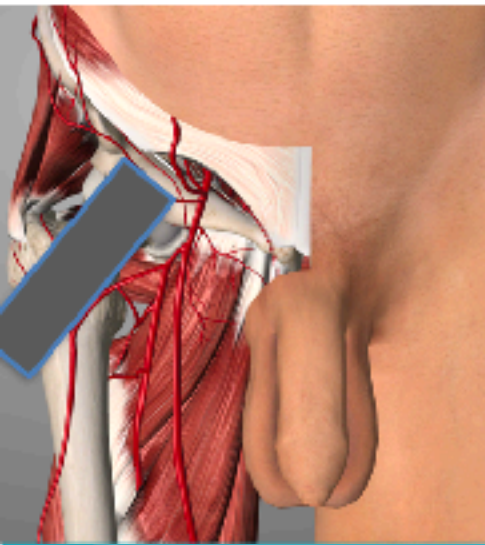
# LE Joint effusion



Hip

Knee

Ankle






衛生福利部雙和醫院  
(委託臺北醫學大學興建經營)  
Taipei Medical University · Shuang Ho Hospital,  
Ministry of Health and Welfare



# POCUS Imaging Reading



陳國智醫師

雙和醫院 急診醫學科

# 59M, falling down & L elbow injury



TIS: 0.01, MI: 0.28, MSK-Soft Tissue

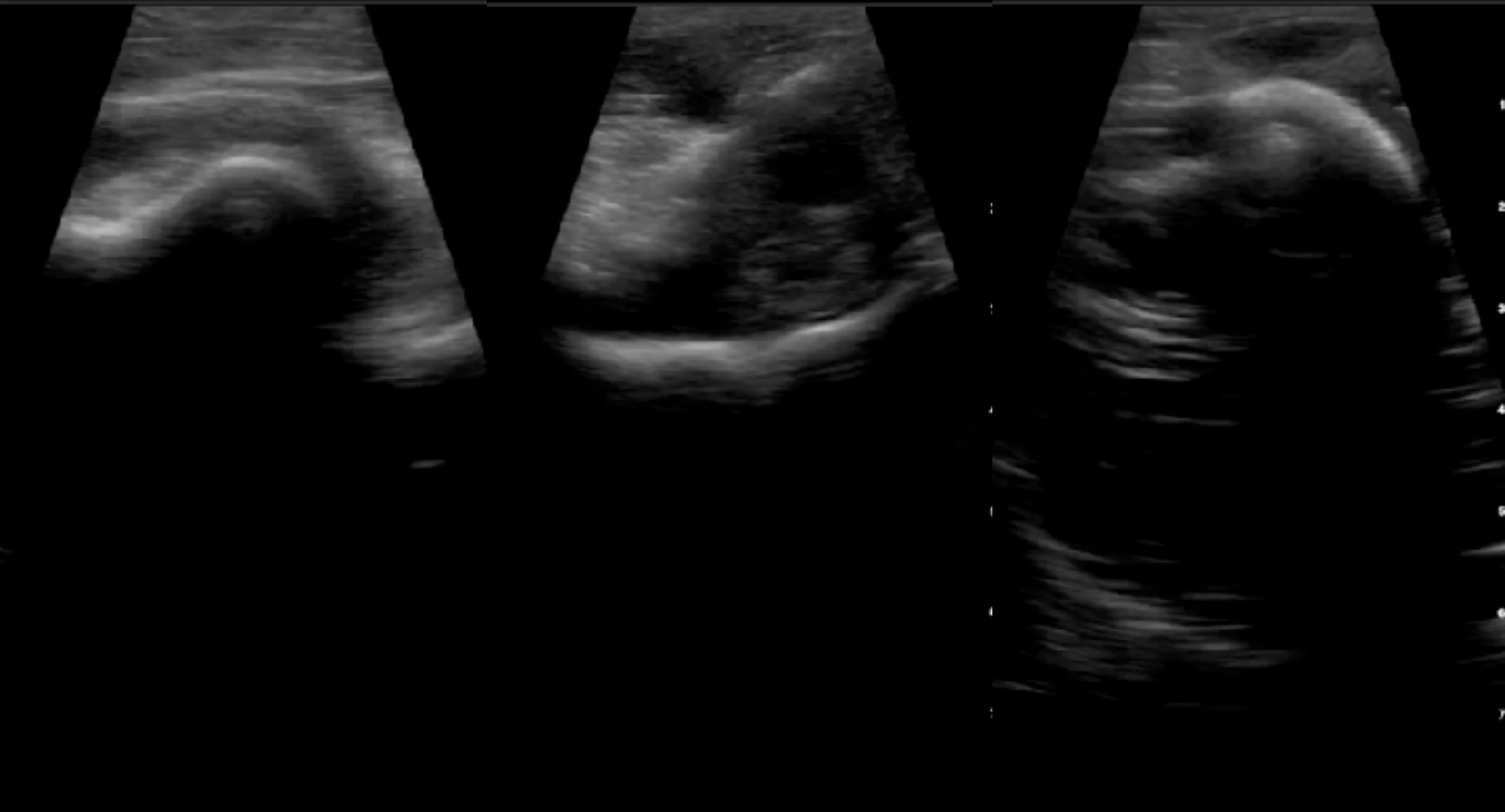B

TIS: 0.01, MI: 0.28, MSK-Soft Tissue

B

TIS: 0.01, MI: 0.28, MSK-Soft Tissue

B



# 59M, falling down & L elbow injury



TIS: 0.01, MI: 0.28, MSK-Soft Tissue

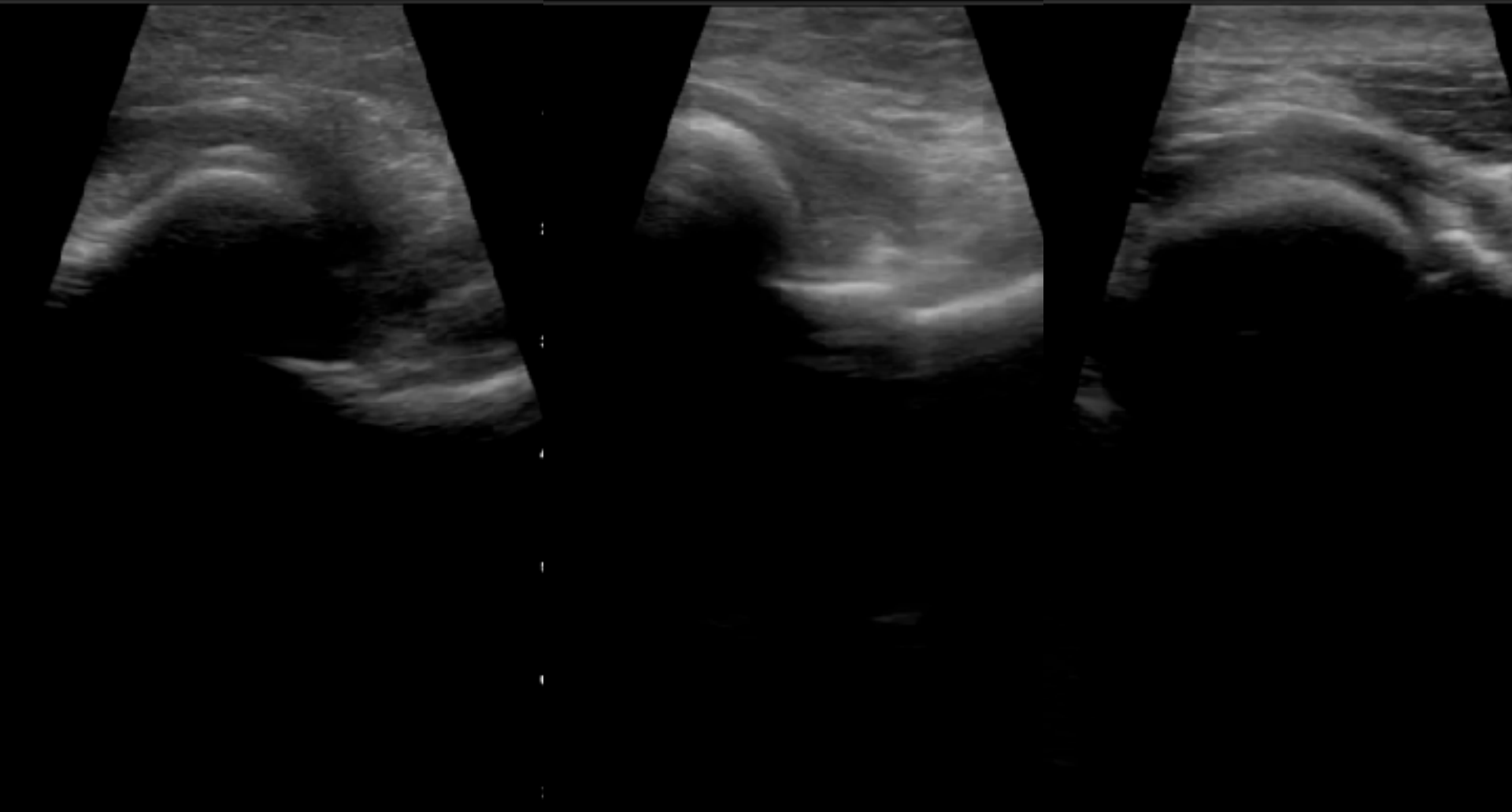
B

TIS: 0.01, MI: 0.28, MSK-Soft Tissue

B

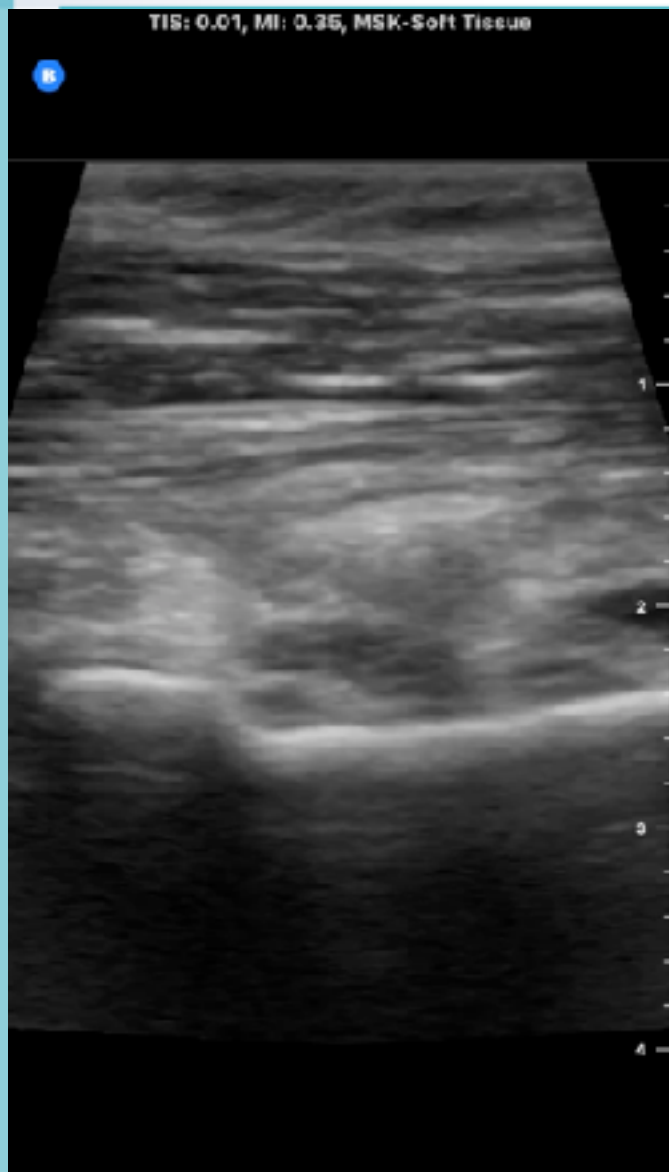
TIS: 0.01, MI: 0.47, MSK-Soft Tissue

B





# 59M, falling down & L elbow injury



脫位及復位的確認

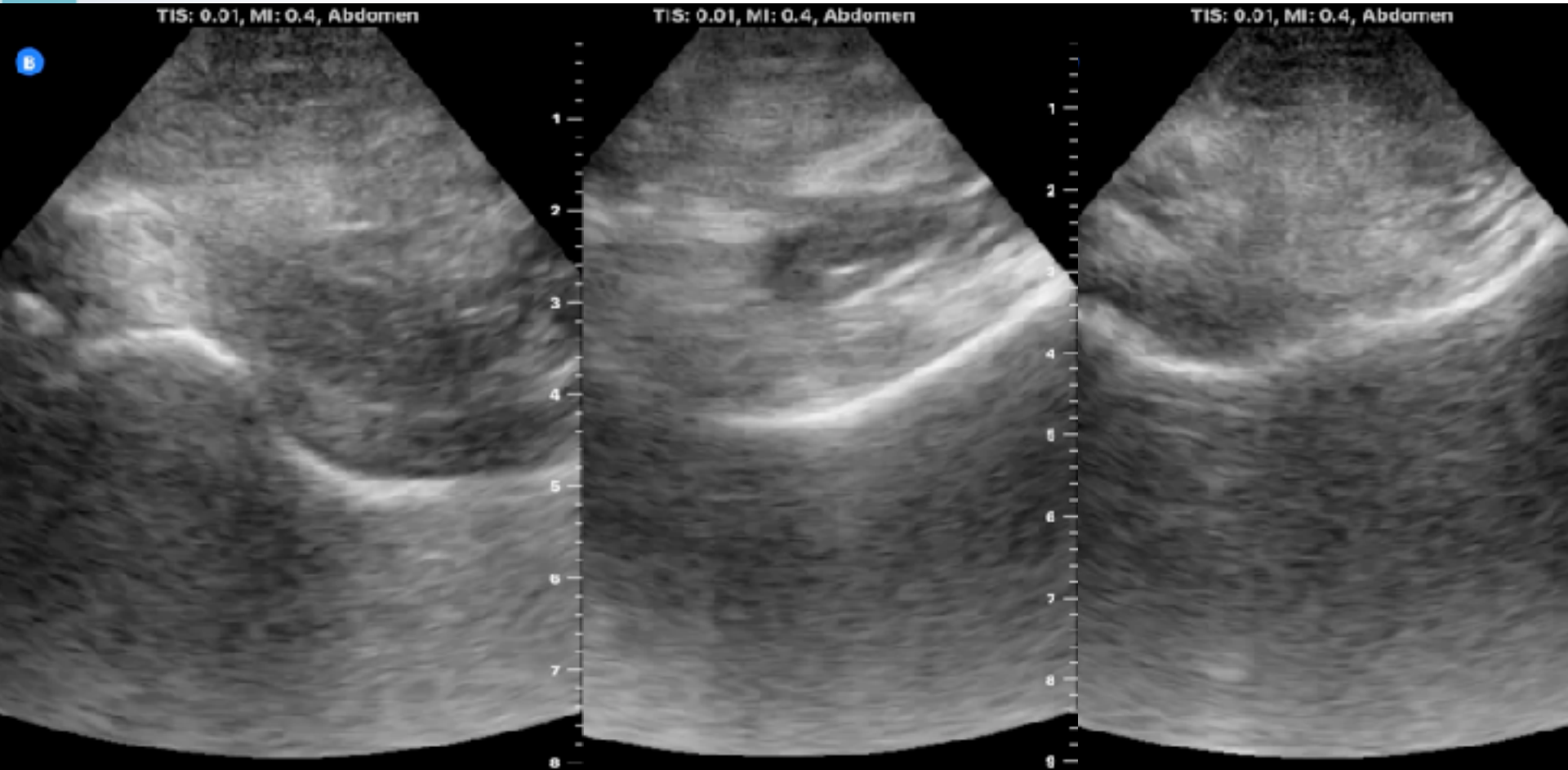
長骨和平骨骨折較易確認

復位後記得固定和提醒

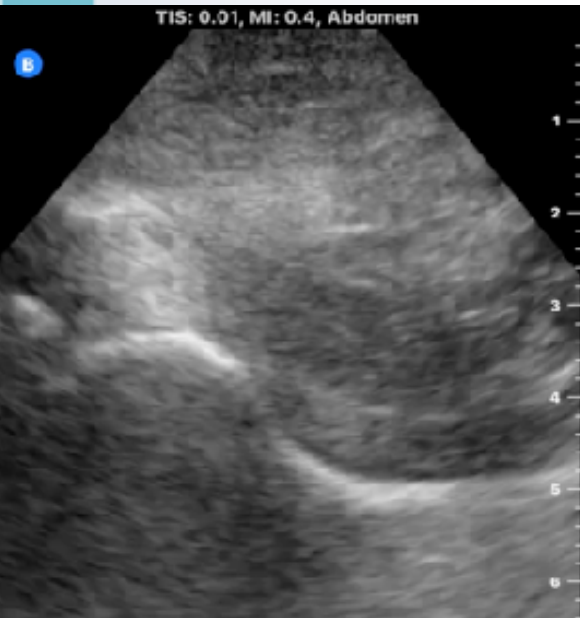小心追蹤X光時造成再脫位

復位前後檢查CSM

# Old man, DVT hx, Left hip pain



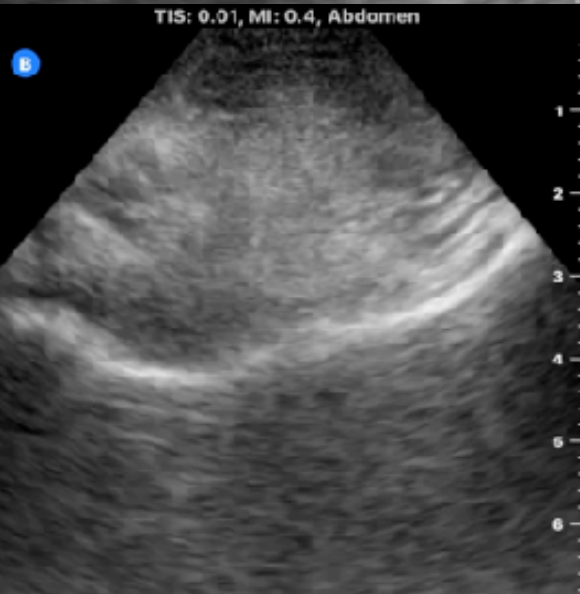# Old man, DVT hx, Left hip pain



不明顯病灶記得對比對側

注意有無關節積血或積液

DVT assessment



小心先入為主的誤認

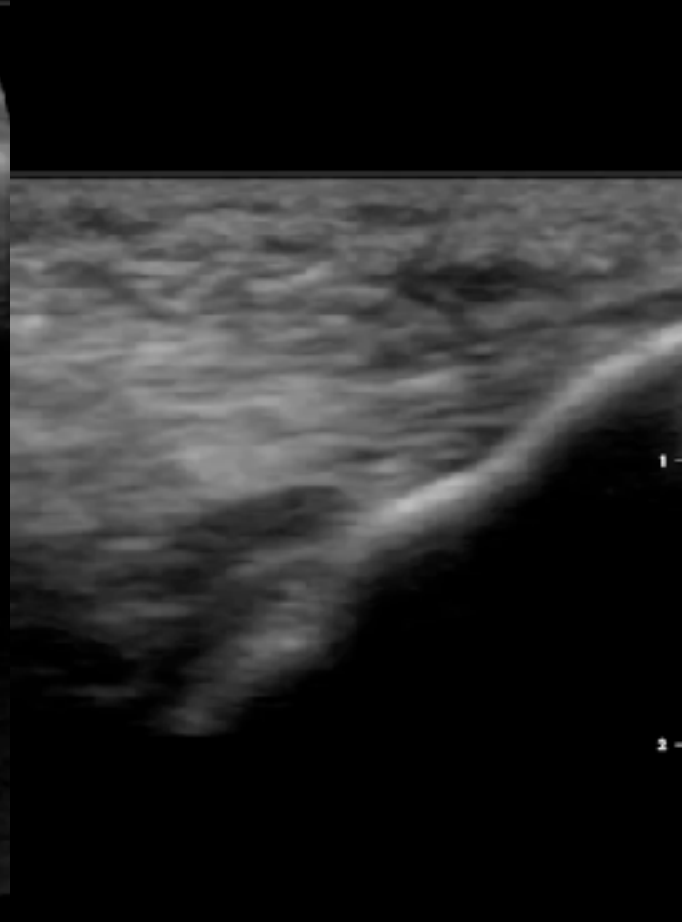
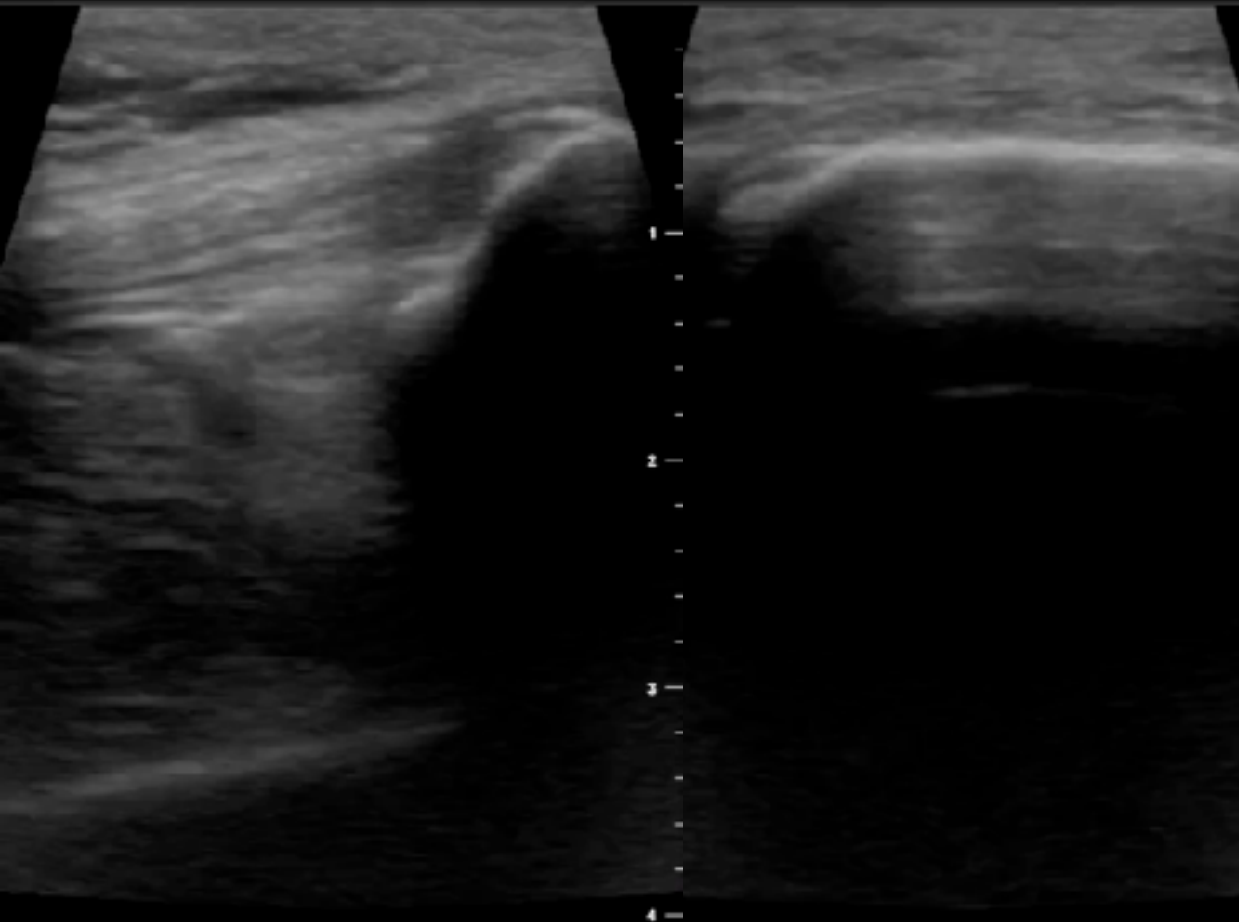
# 49F, TA, RK injury



TIS: 0.01, MI: 0.35, MSK-Soft Tissue

TIS: 0.01, MI: 0.35, MSK-Soft Tissue

TIS: 0.01, MI: 0.22, MSK-Soft Tissue



# 49F, TA, RK injury



TIS: 0.01, MI: 0.22, MSK-Soft Tissue

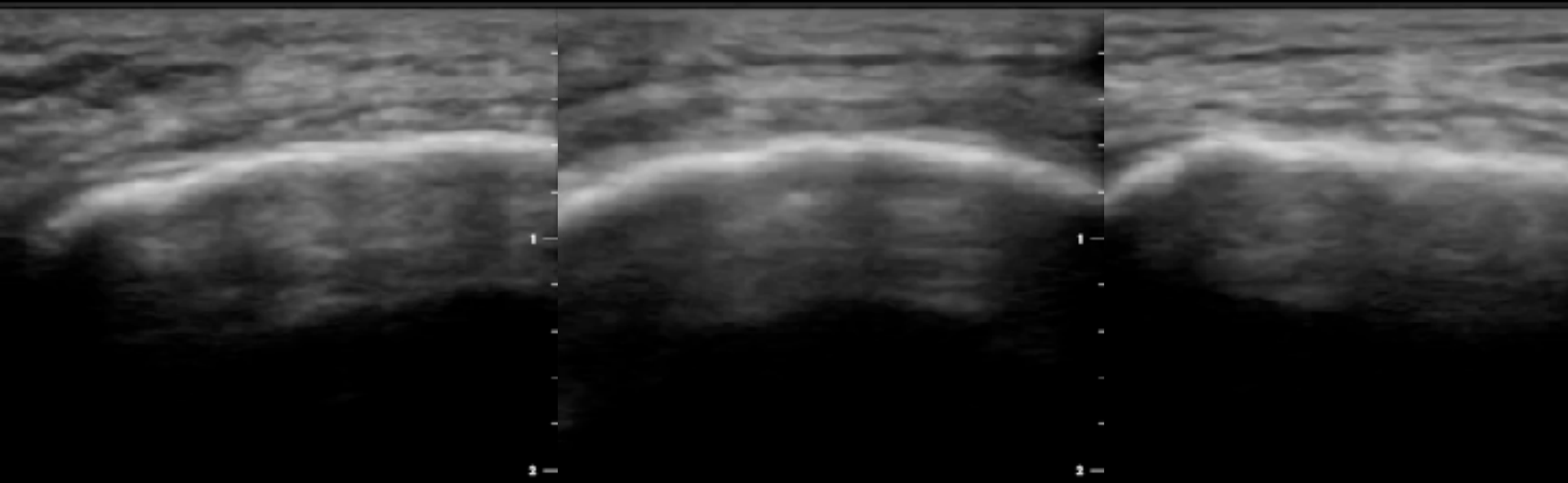
TIS: 0.01, MI: 0.22, MSK-Soft Tissue

TIS: 0.01, MI: 0.22, MSK-Soft Tissue

B

B

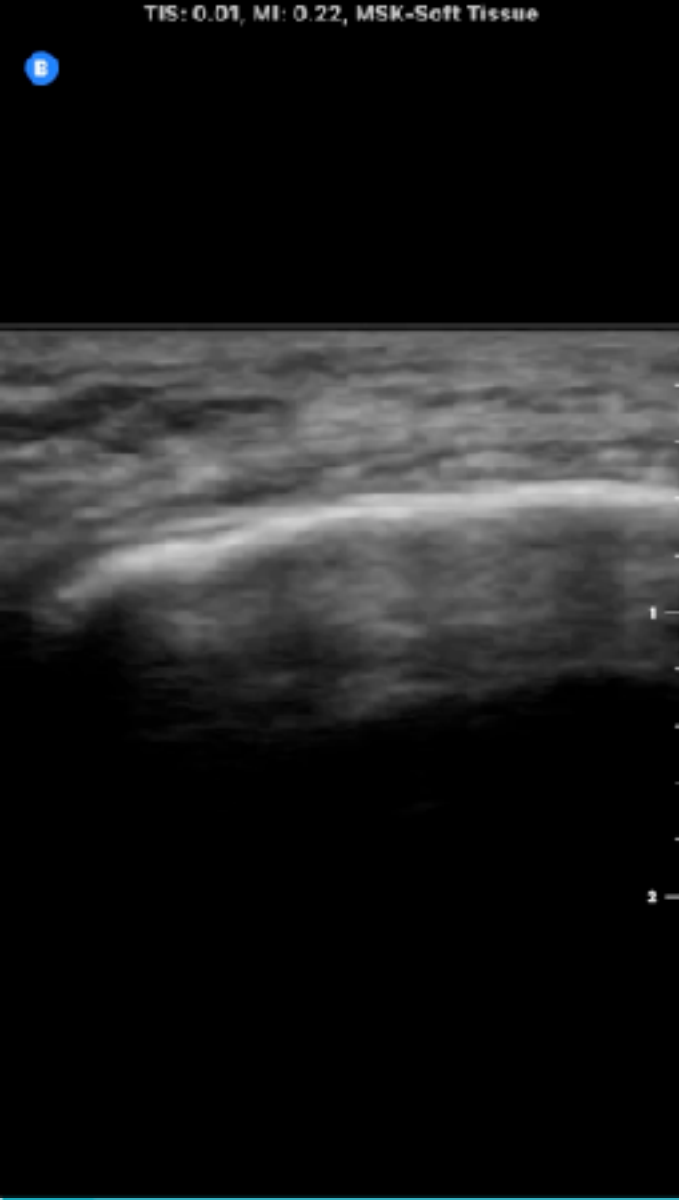
B





# 49F, TA, RK injury

TIS: 0.01, MI: 0.22, MSK-Soft Tissue



優先評估是否有關節積血

QT & PT 也要記得評估

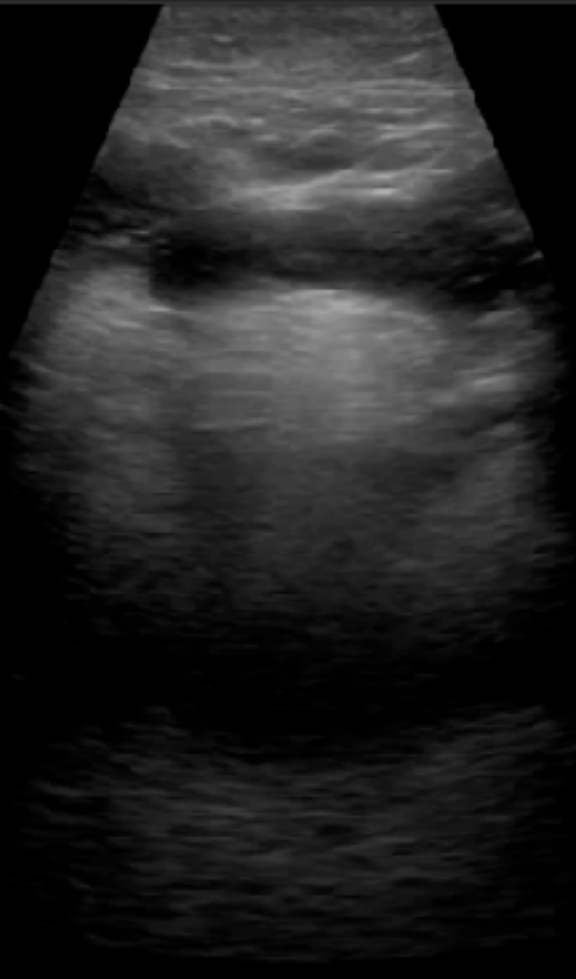Patella fracture (橫縱軸)

# 47M, Epiglottitis



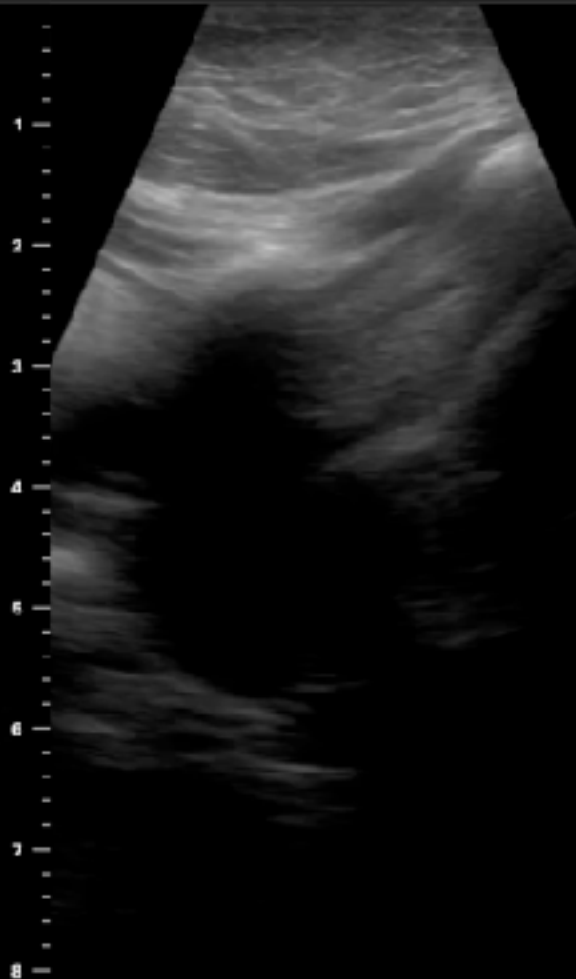
TIS: 0.01, MI: 0.25, MSK-Soft Tissue

B



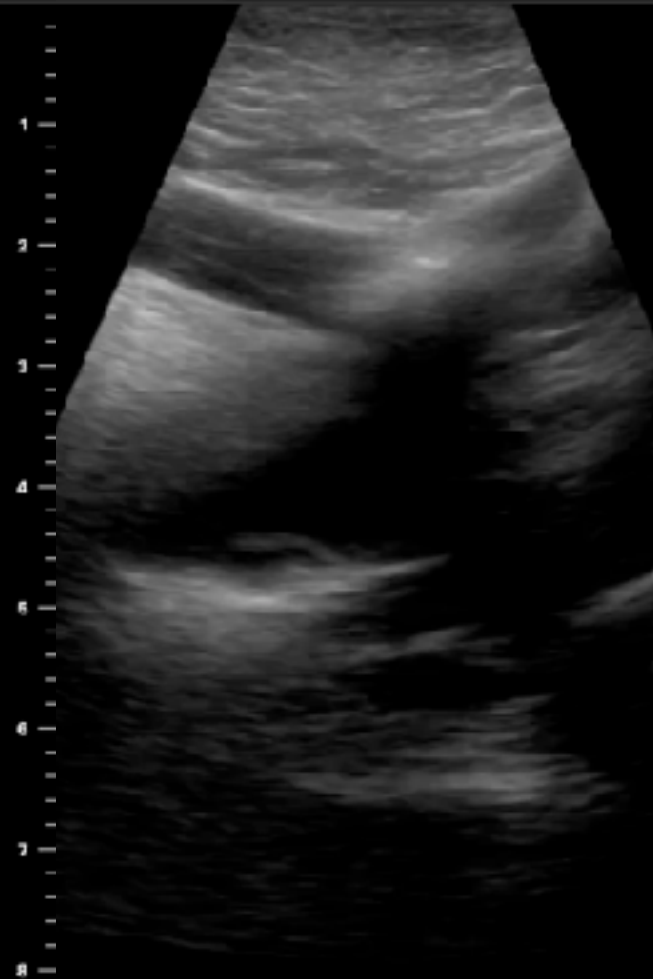
TIS: 0.01, MI: 0.25, MSK-Soft Tissue

B



TIS: 0.01, MI: 0.25, MSK-Soft Tissue

B



# 47M, Epiglottitis



TIS: 0.01, MI: 0.28, MSK-Soft Tissue

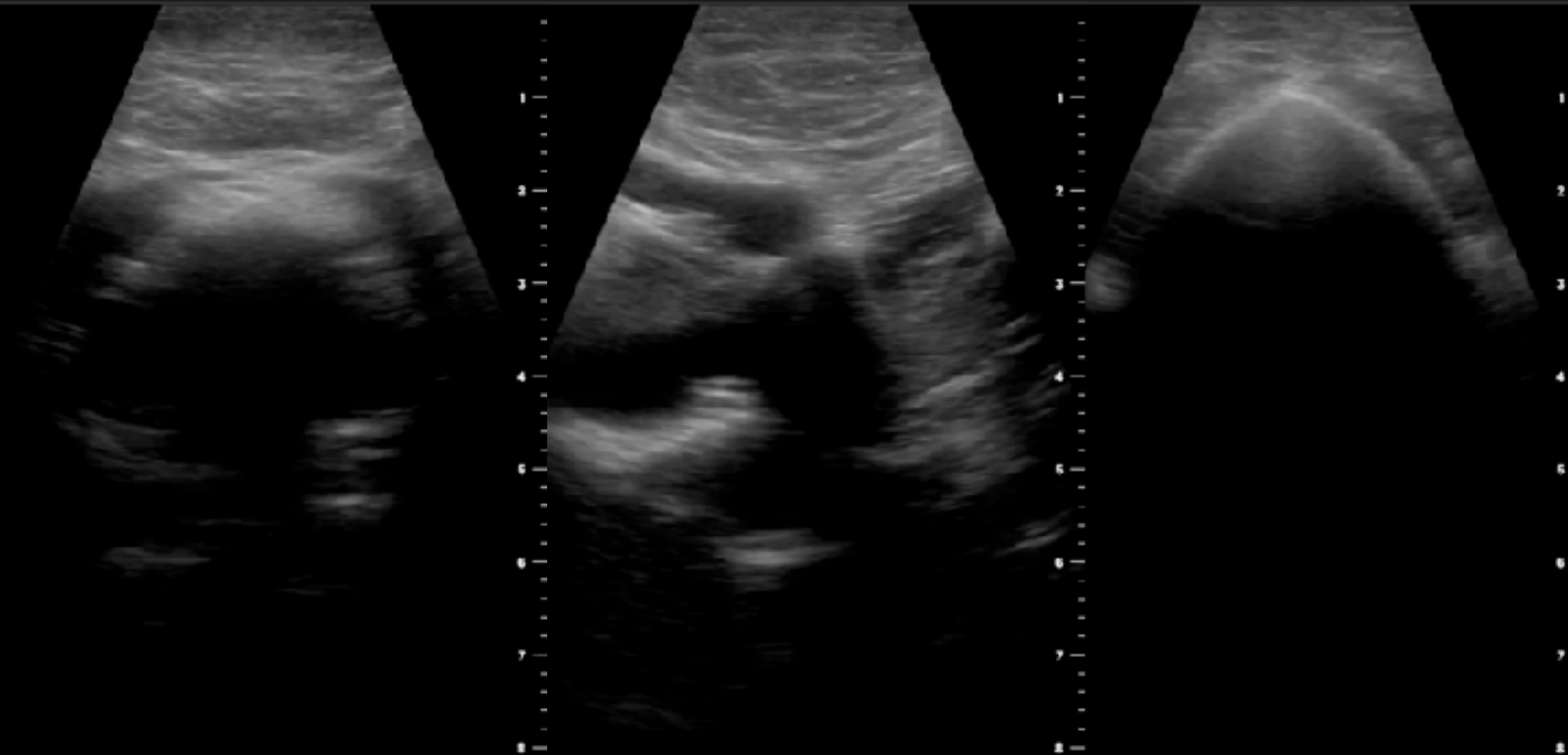
B

TIS: 0.01, MI: 0.28, MSK-Soft Tissue

B

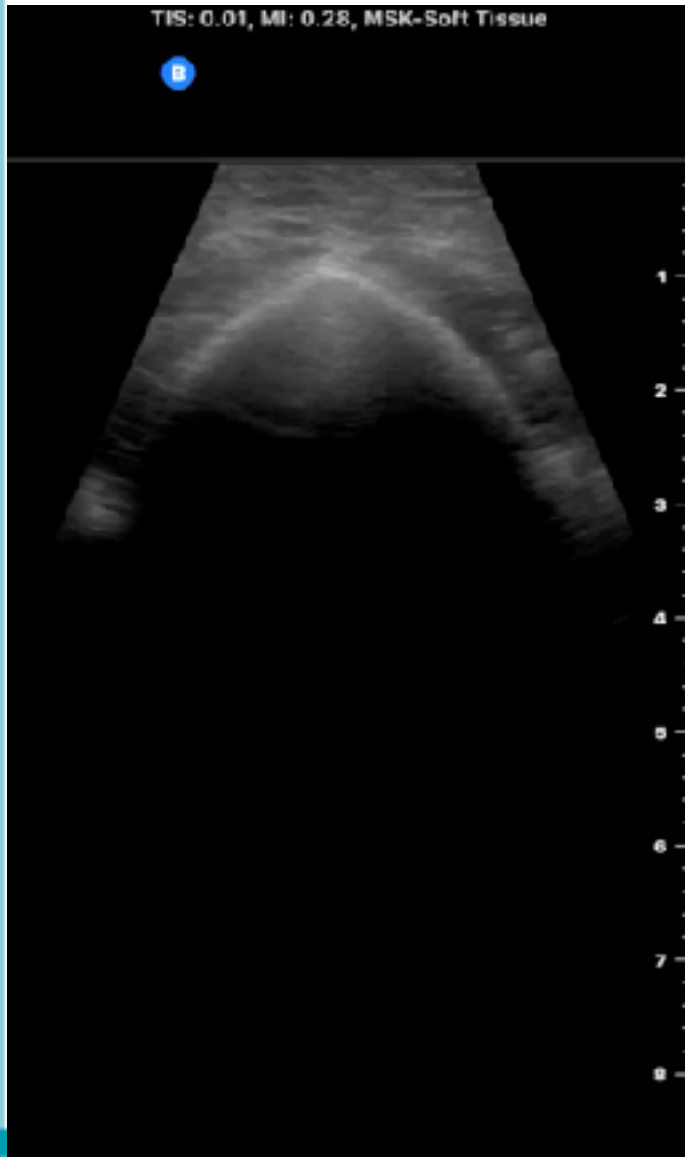TIS: 0.01, MI: 0.28, MSK-Soft Tissue

B





# 47M, Epiglottitis



Airway超音波的定位點

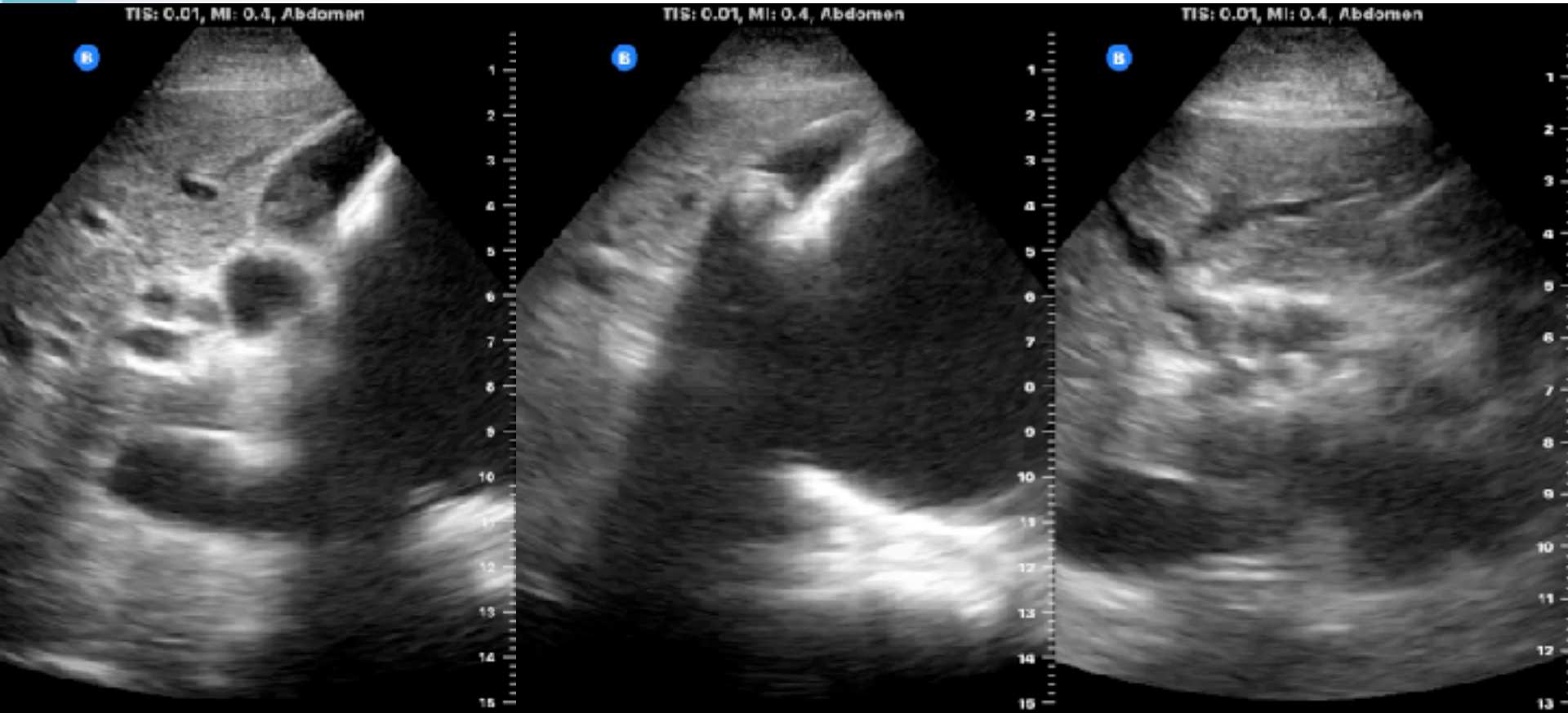
會厭掃描以橫向上往下定位

優先確認舌骨位置

前後徑  $> 3.2$  mm為腫大

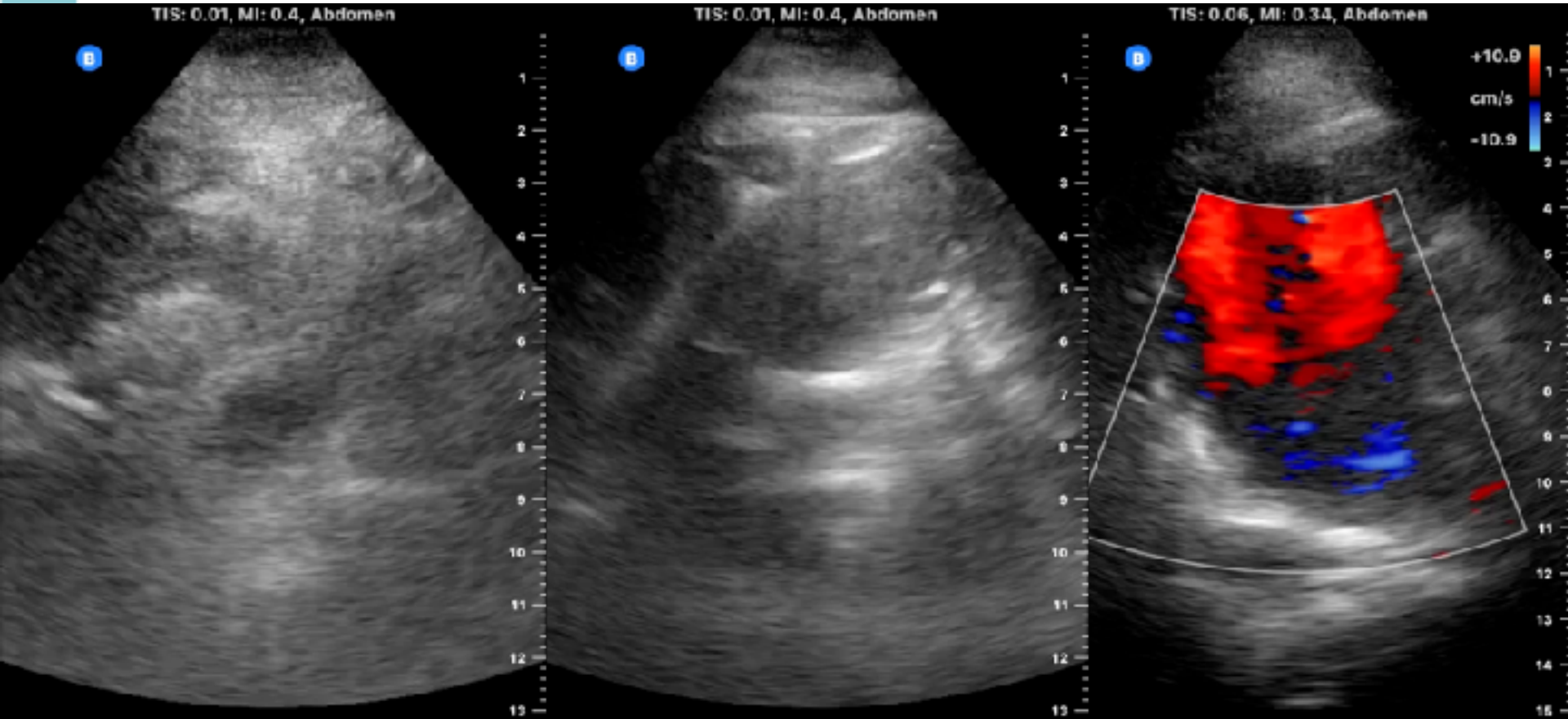


# 94M, epigastric pain & anemia



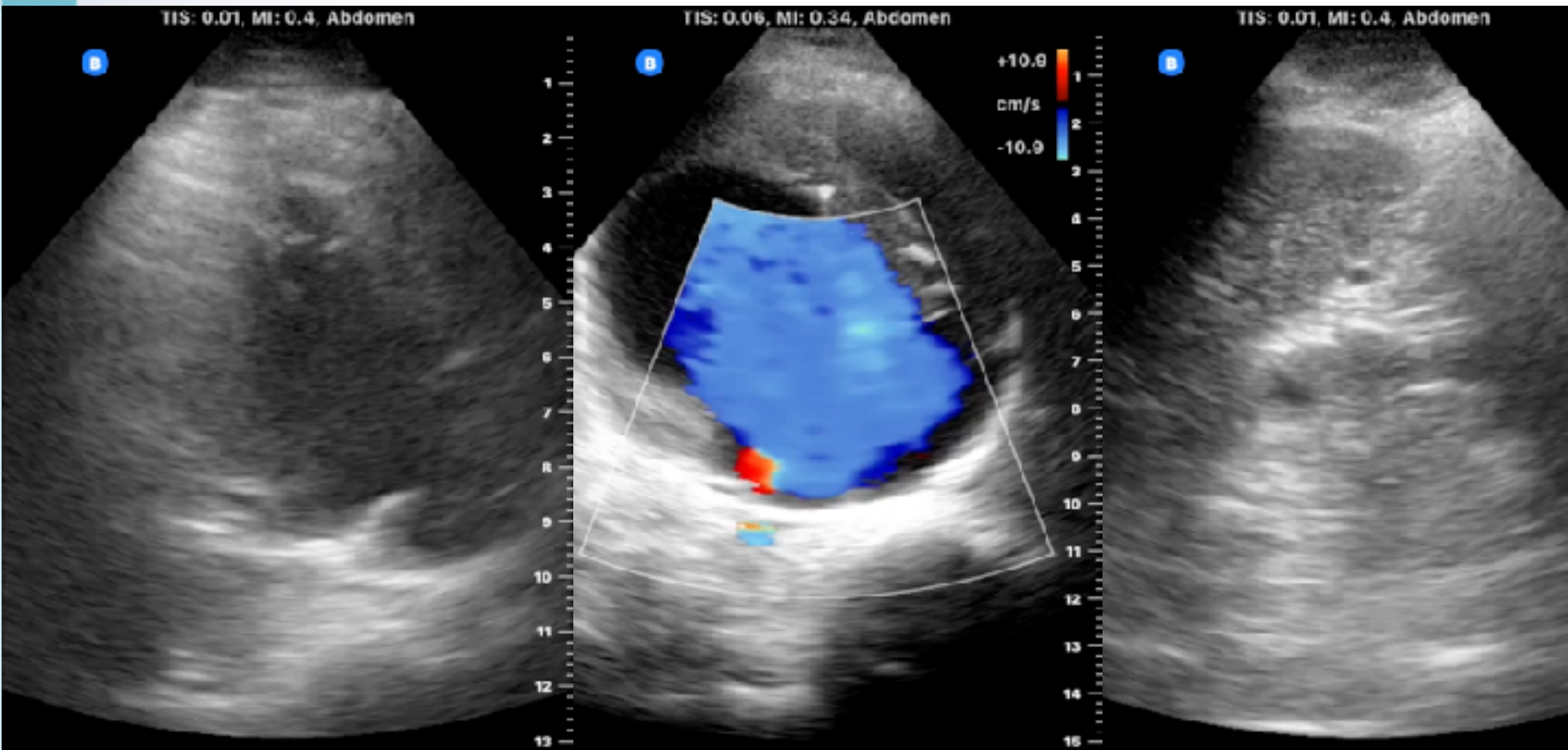


# 94M, epigastric pain & anemia

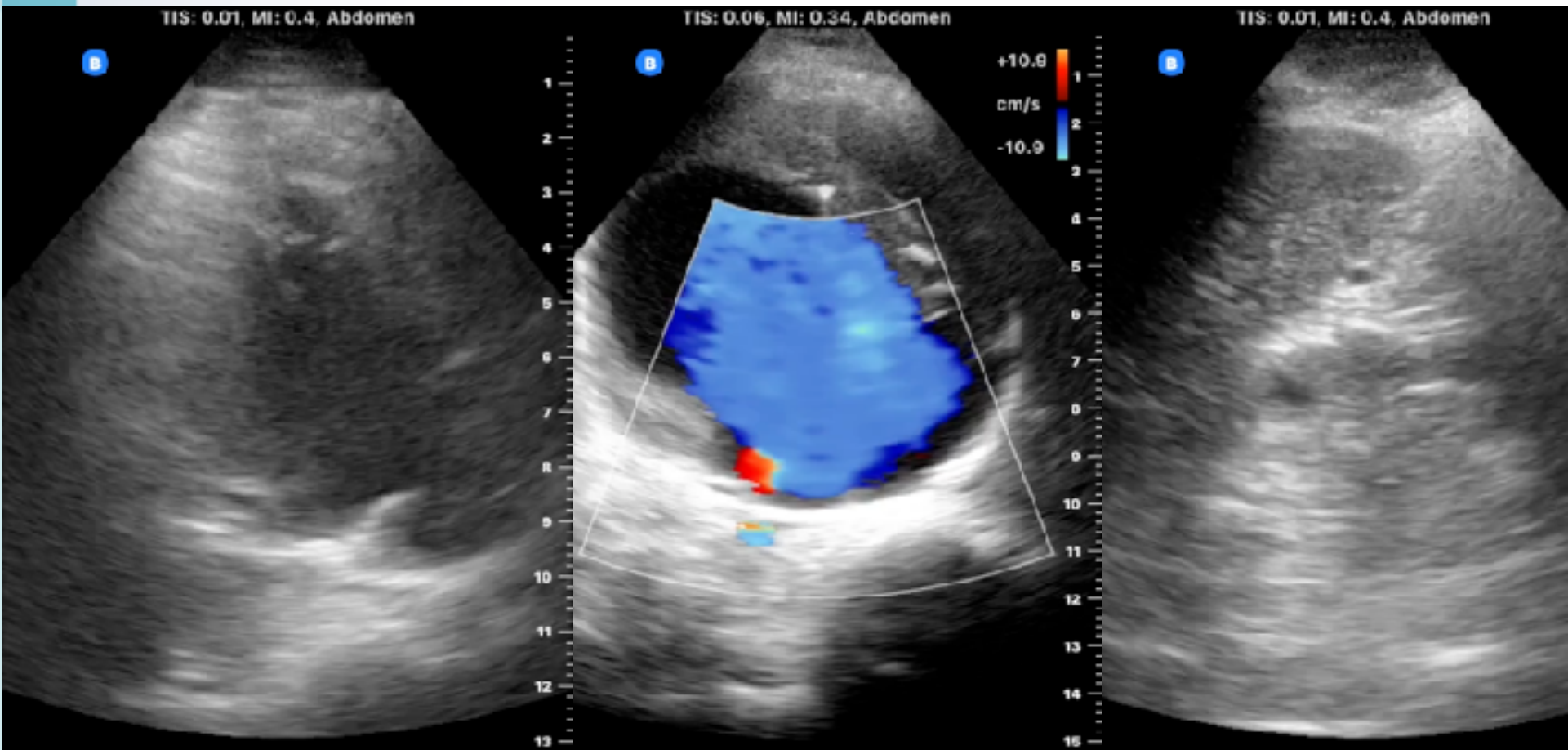




# 94M, epigastric pain & anemia

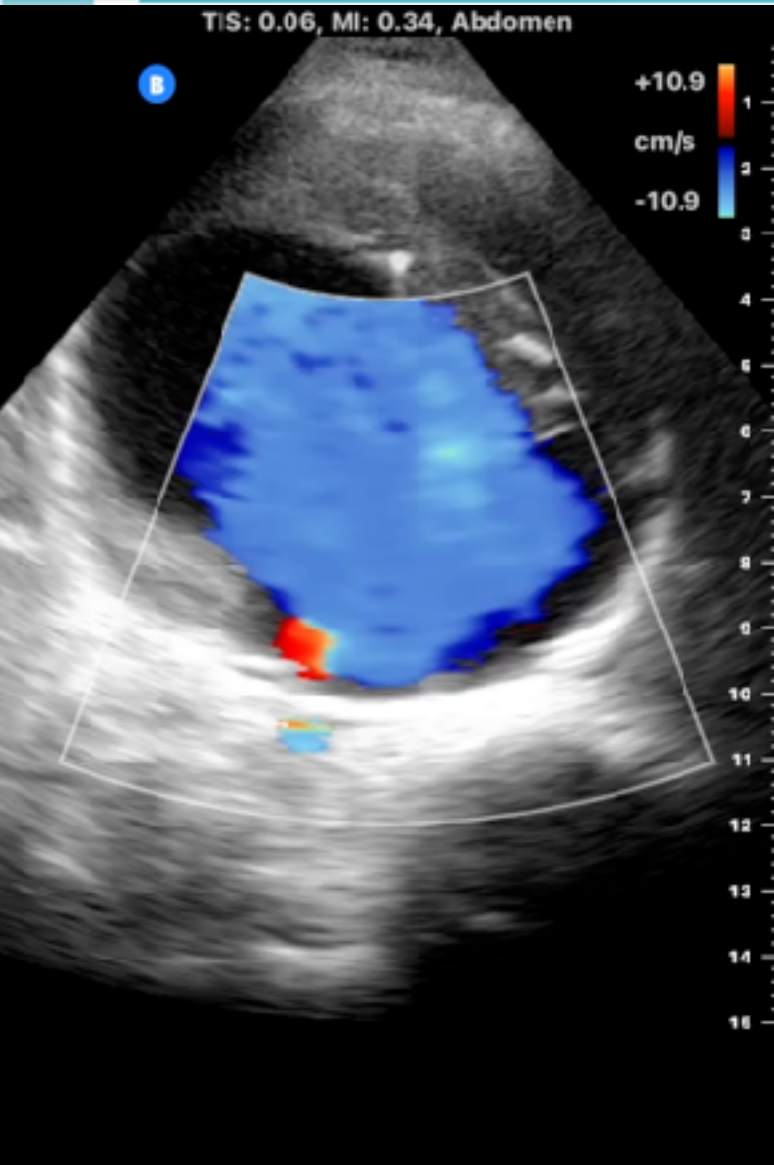


# 94M, epigastric pain & anemia





# 94M, epigastric pain & anemia



> 50 的腹/背/腰痛

不明Syncope

不明休克

重點病史和PE還是要確實

一定要掃描腹主動脈到分岔

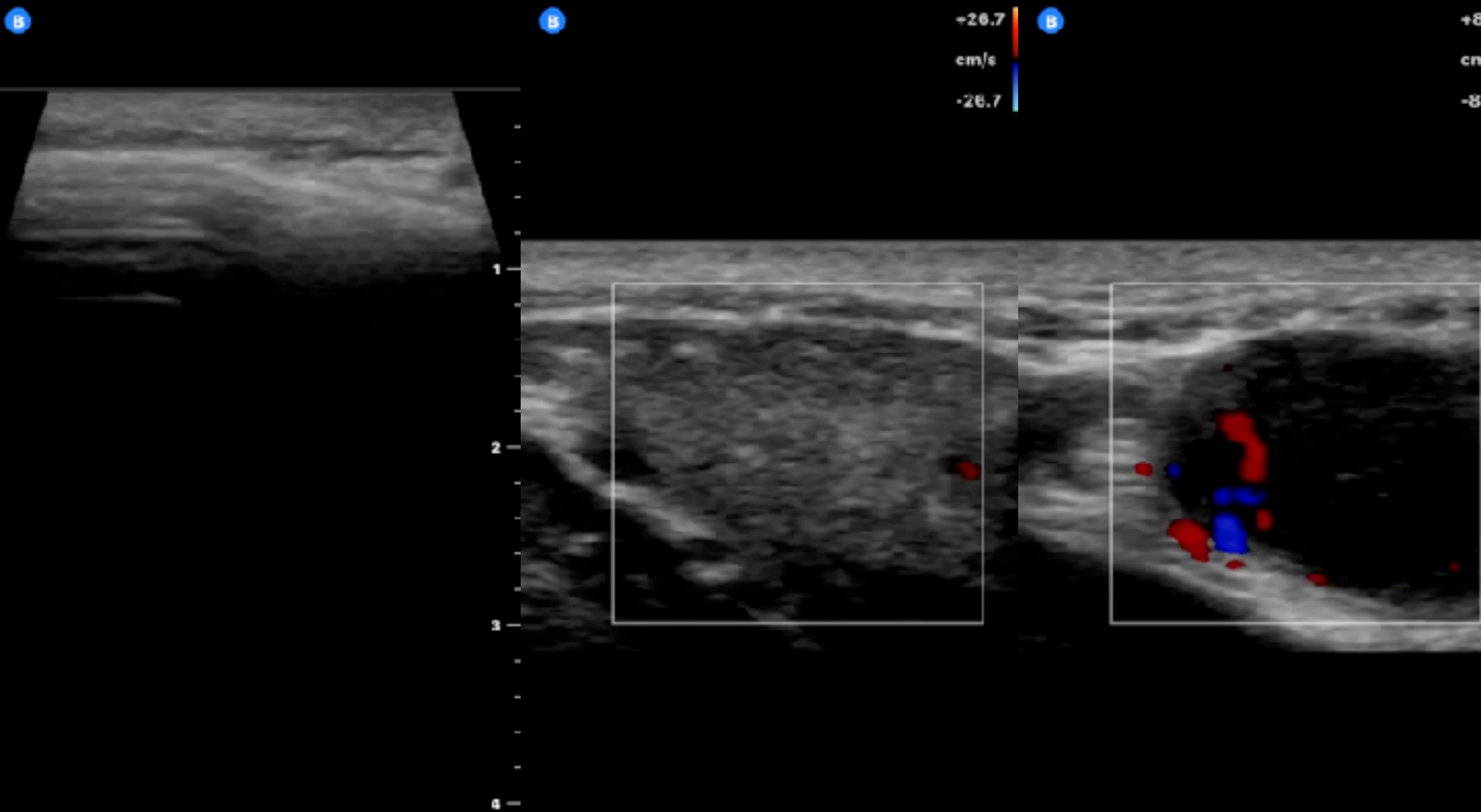
# 20M, Vietnam, L neck mass 1mo



TIS: 0.01, MI: 0.35, Small Organ

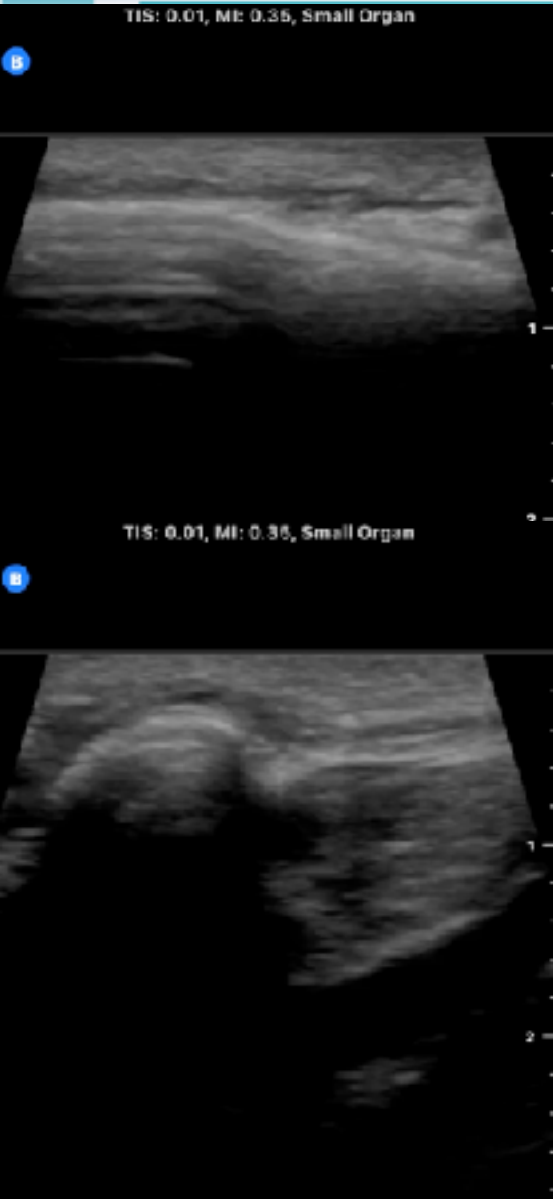TIS: 0.01, MI: 0.26, Small Organ

TIS: 0.01, MI: 0.26, Small Organ





# 20M, Vietnam, L neck mass 1mo



線形探頭

要有內在定位點 (如骨頭)

記得開彩色都卜勒評估

要想到Sialolithiasis & LN

頸部三腺要評估



# 78M, OHCA, A line access



TIS: 0.01, MI: 0.35, Vascular: Access

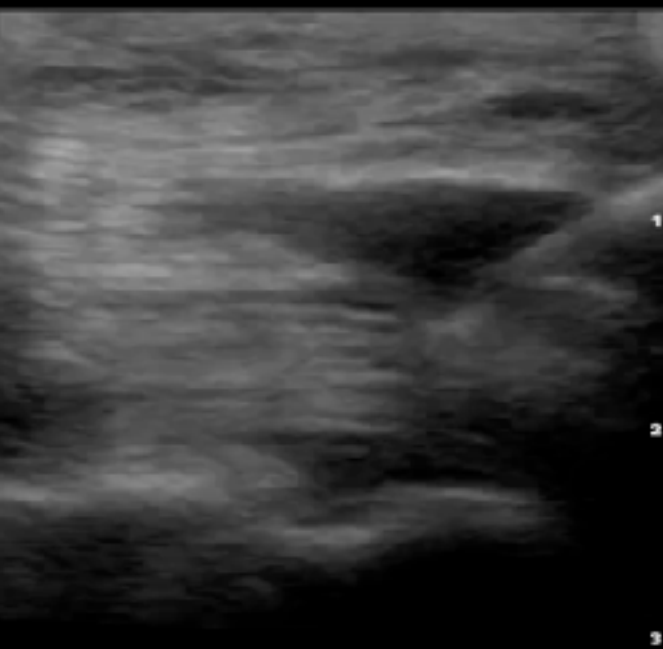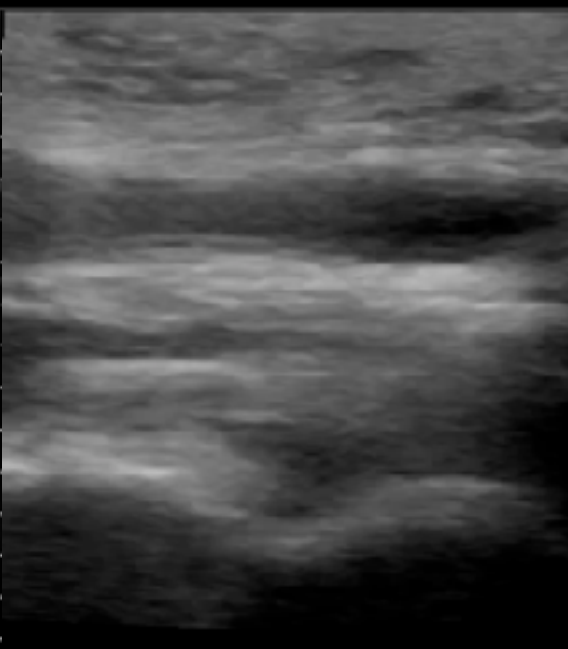
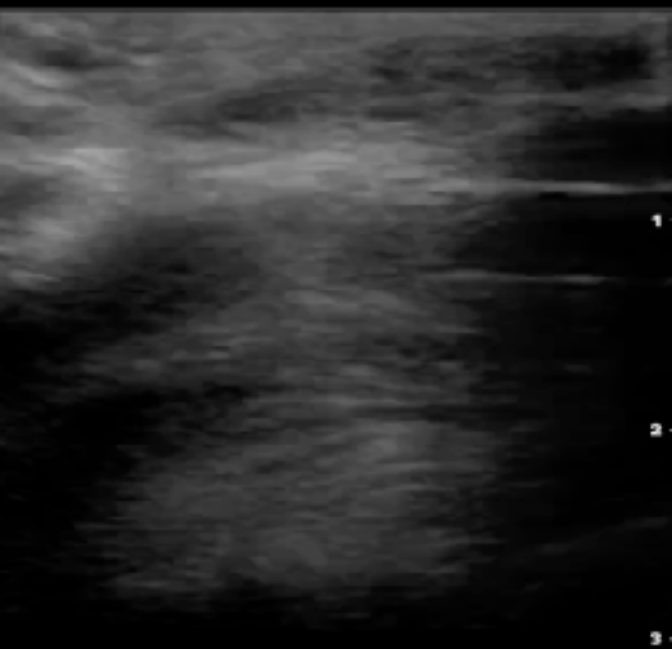
TIS: 0.01, MI: 0.35, Vascular: Access

TIS: 0.01, MI: 0.35, Vascular: Access

B

B

B



# 78M, OHCA, A line access



TIS: 0.01, MI: 0.35, Vascular: Access

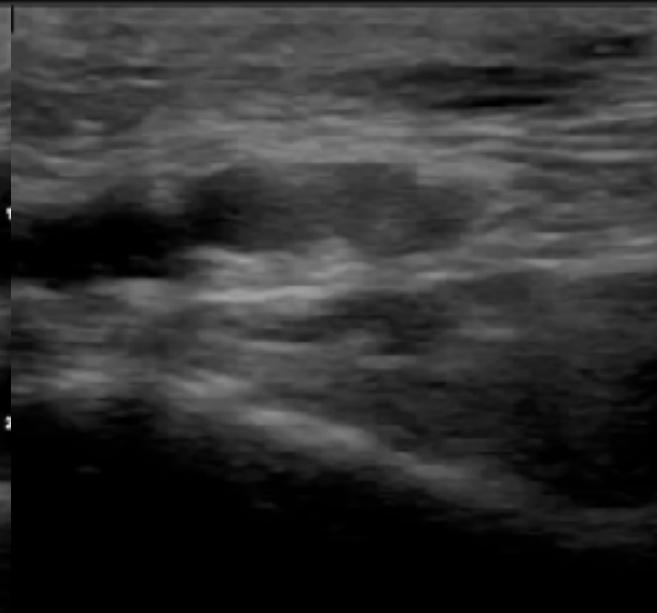
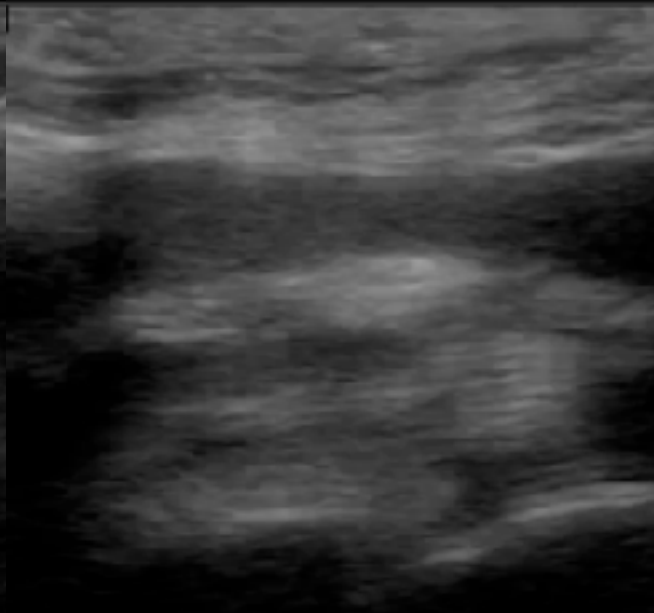
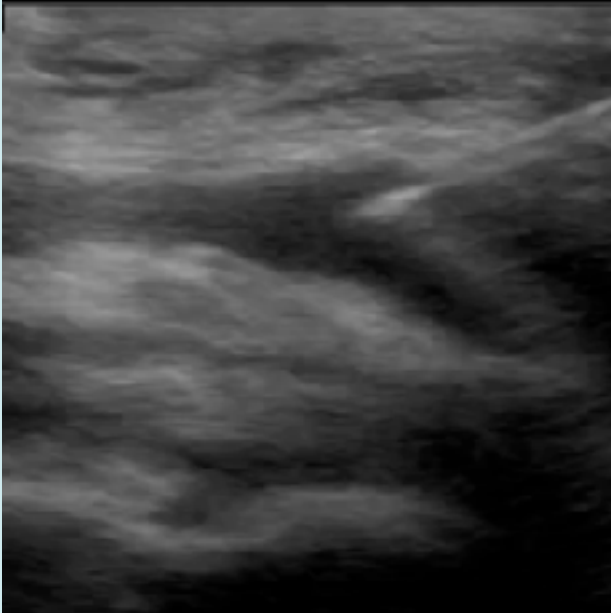
TIS: 0.01, MI: 0.35, Vascular: Access

TIS: 0.01, MI: 0.35, Vascular: Access

B

B

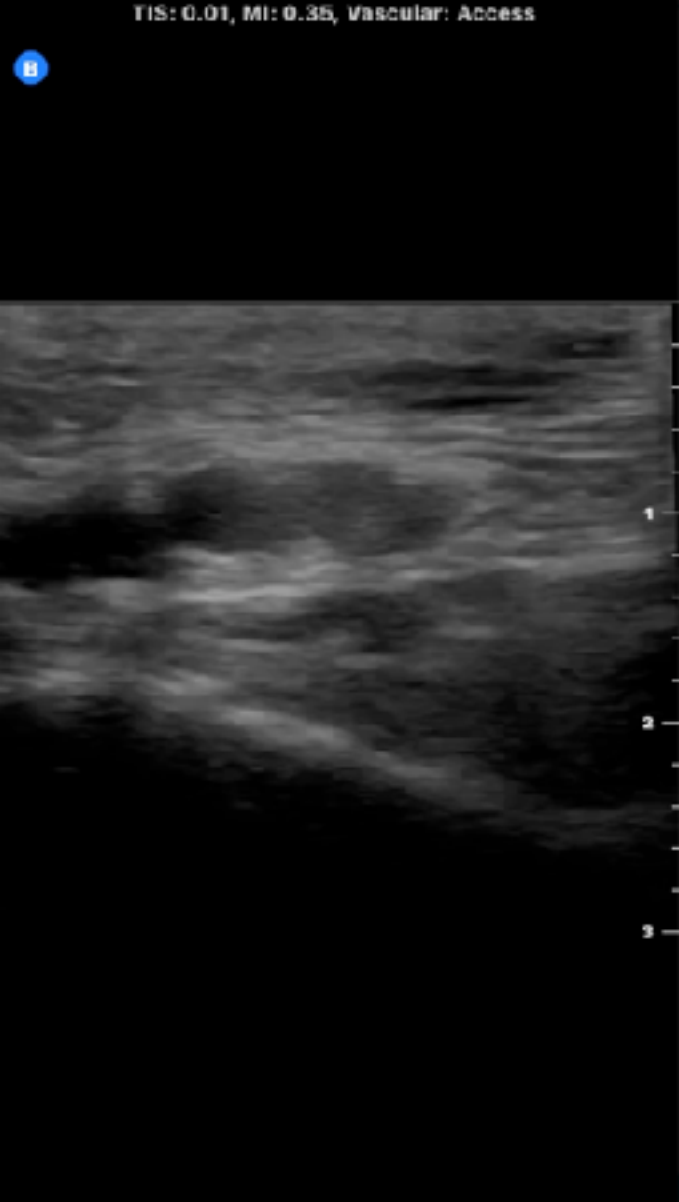
B





# 78M, OHCA, A line access

TIS: 0.01, MI: 0.35, Vascular: Access



要能熟練不同方向進針

最好能無菌同步下進行

單人操作定位優於雙人操作

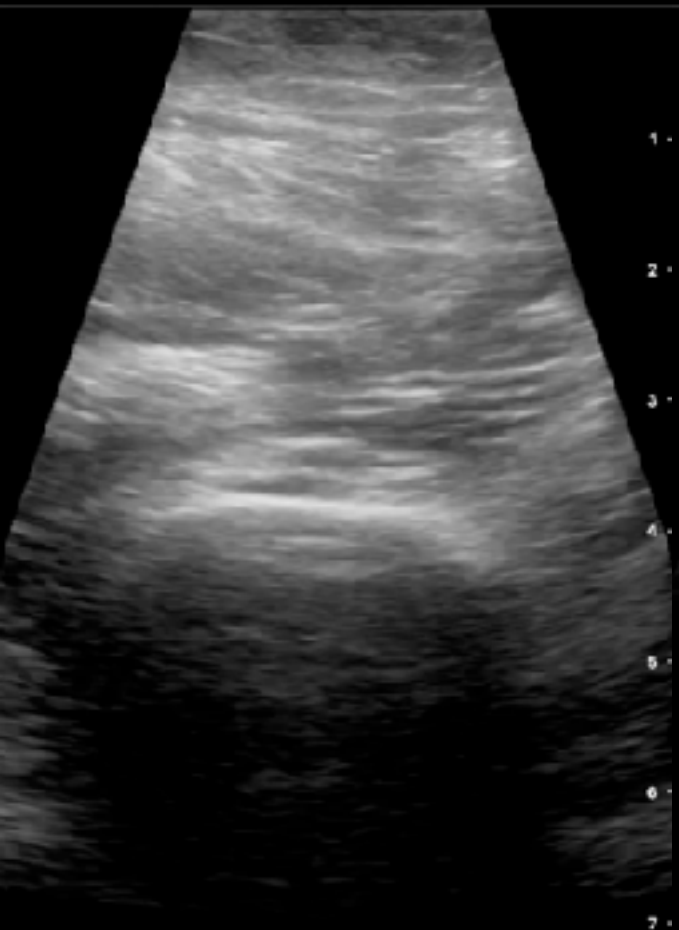確認入針介面位於探頭軸線

# 72F, R hip pain



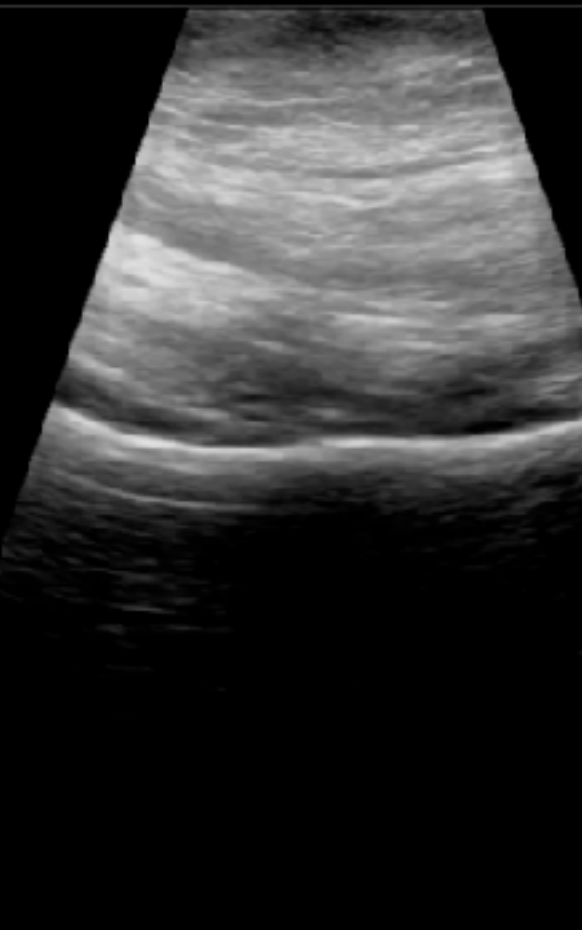
TIS: 0.01, MI: 0.28, Musculoskeletal

R



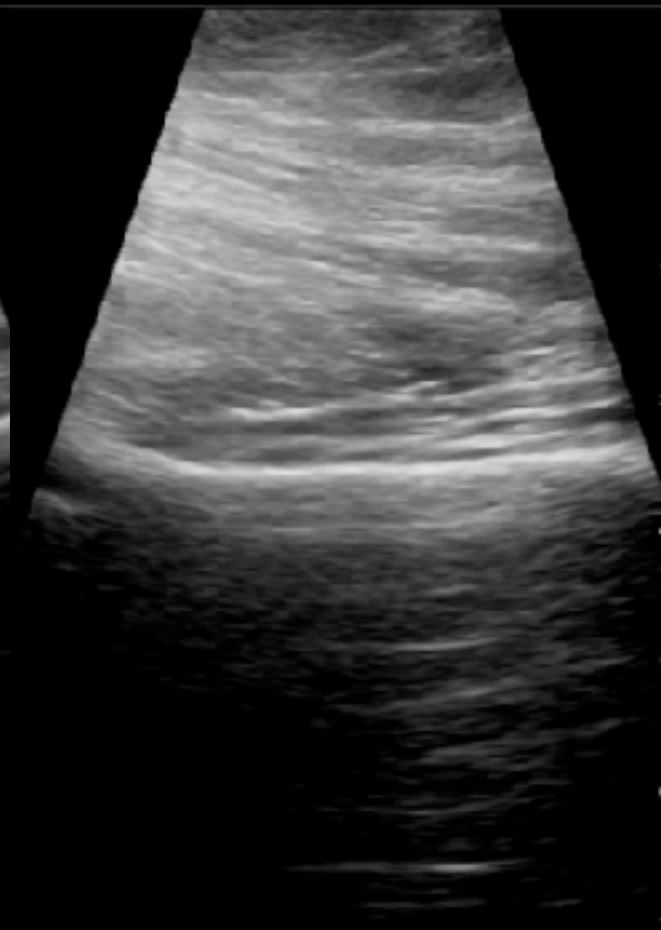TIS: 0.01, MI: 0.28, Musculoskeletal

R



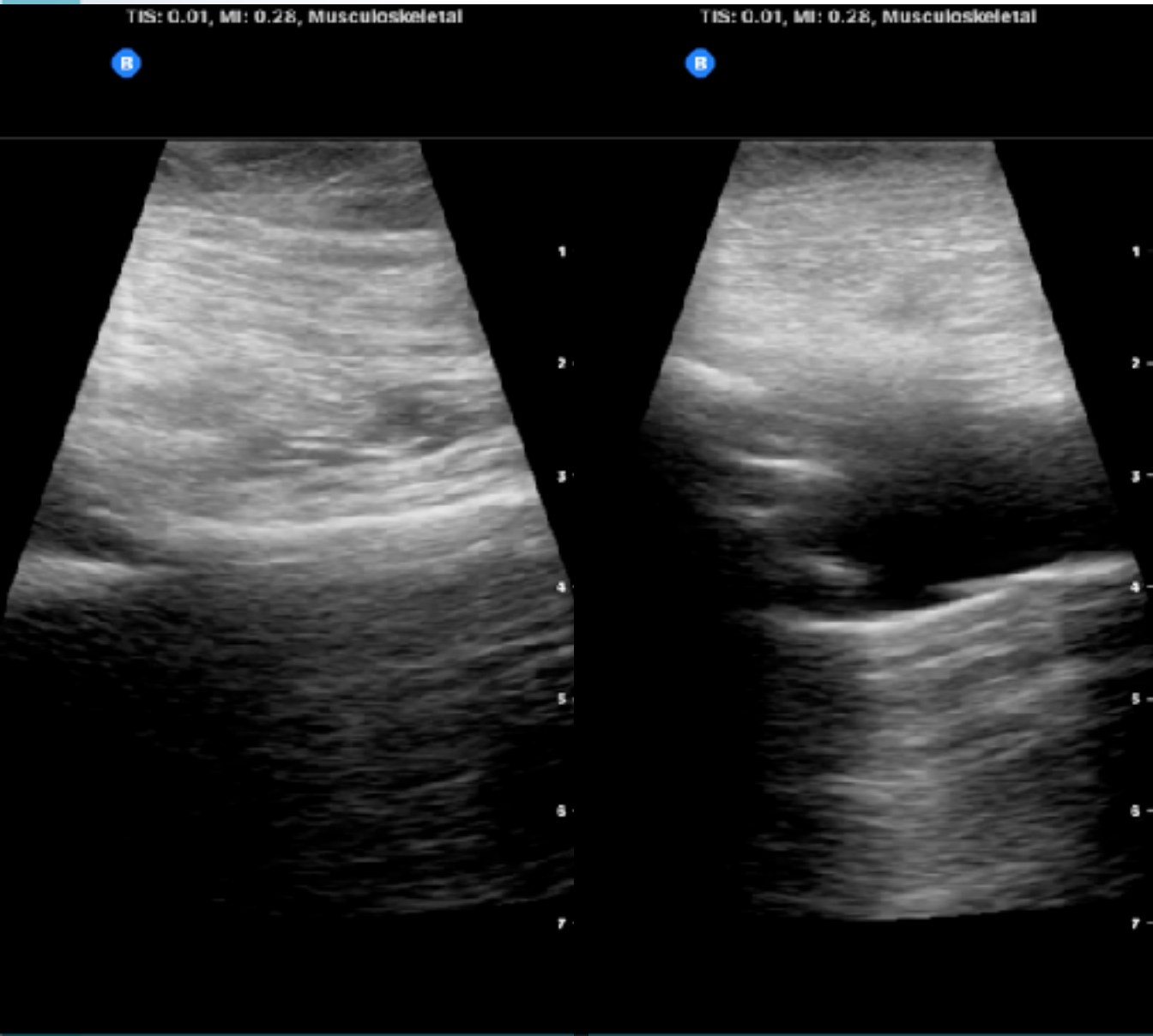
TIS: 0.01, MI: 0.28, Musculoskeletal

R





# 72F, R hip pain



對比

骨頭

植入物

臨床整合

# 43F, painful anal lesion



TIS: 0.01, MI: 0.28, MSK-Soft Tissue

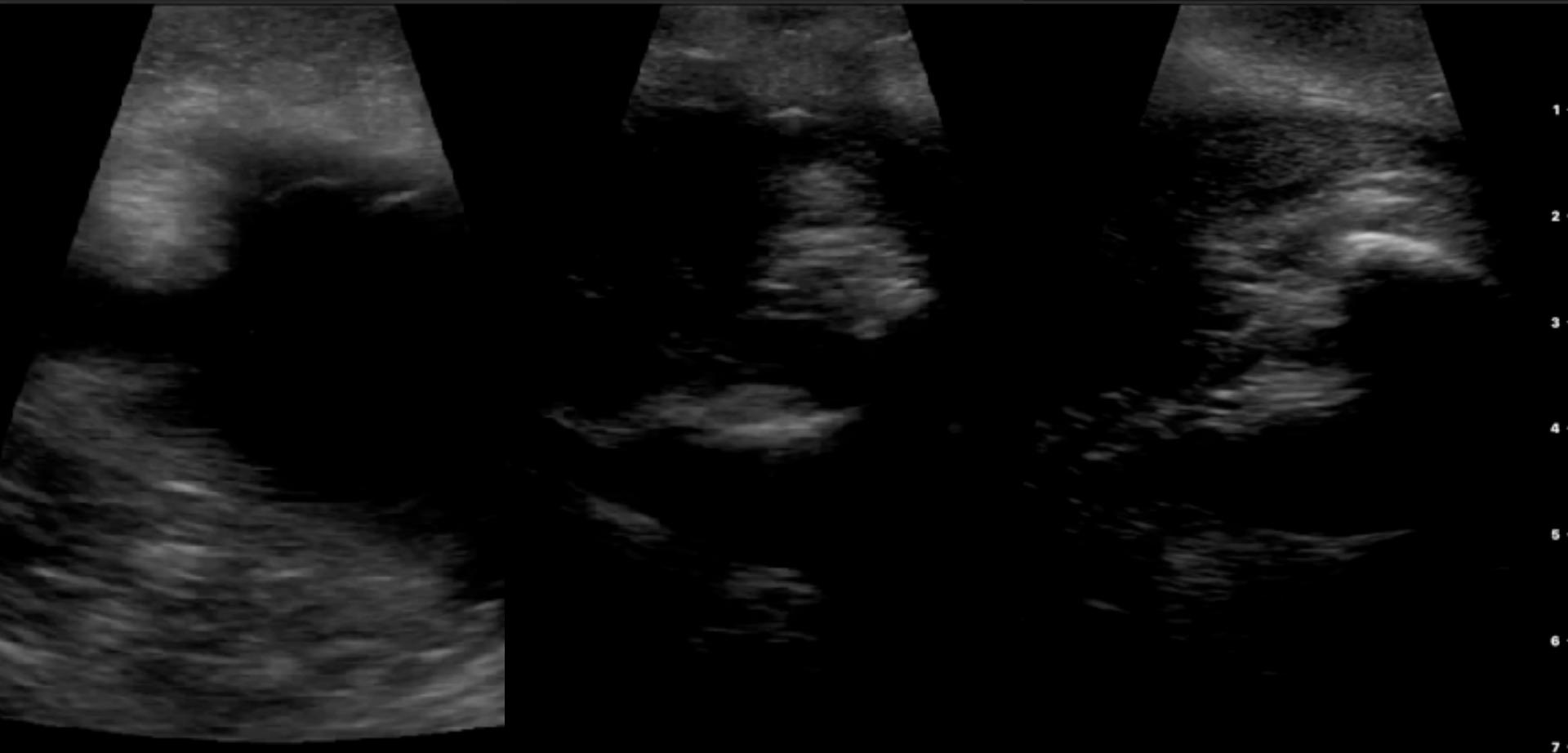
B

TIS: 0.01, MI: 0.28, MSK-Soft Tissue

B

TIS: 0.01, MI: 0.28, MSK-Soft Tissue

B



1

2

3

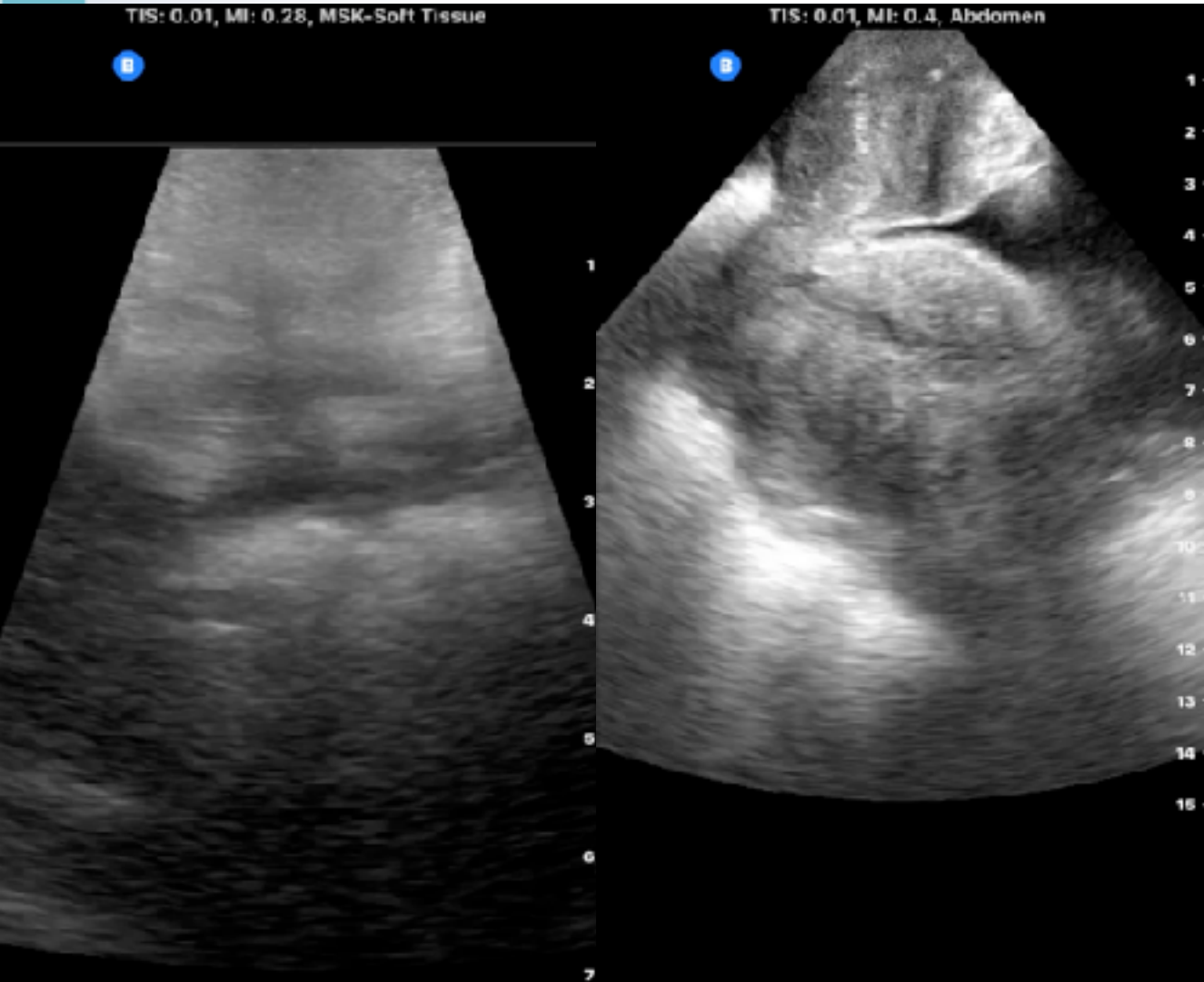
4

5

6

7

# 43F, painful anal lesion



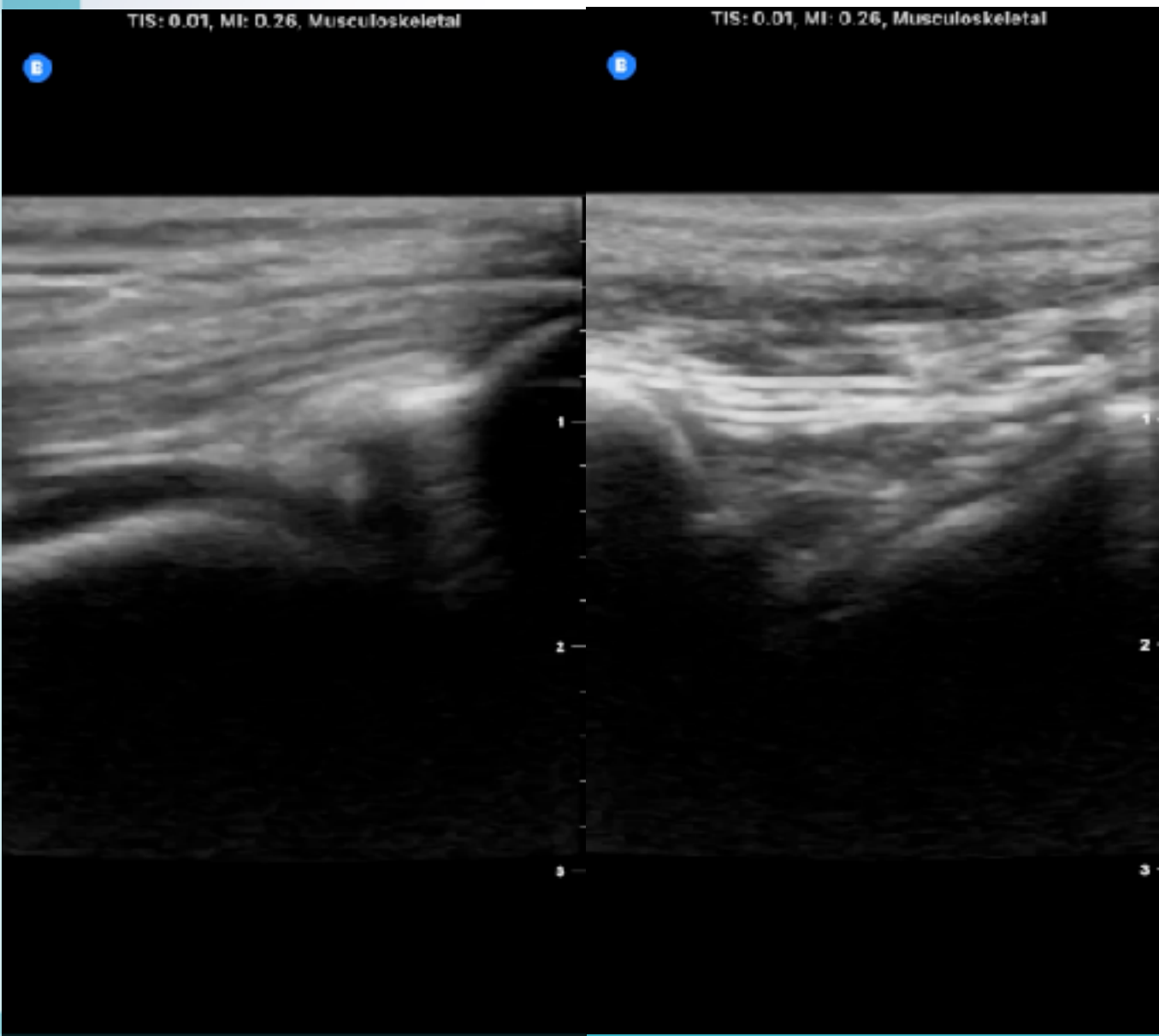
型態辨識

構造確認

切開引流

CT ??

# 21F, TA with knee injury



關節積血

QT

PT

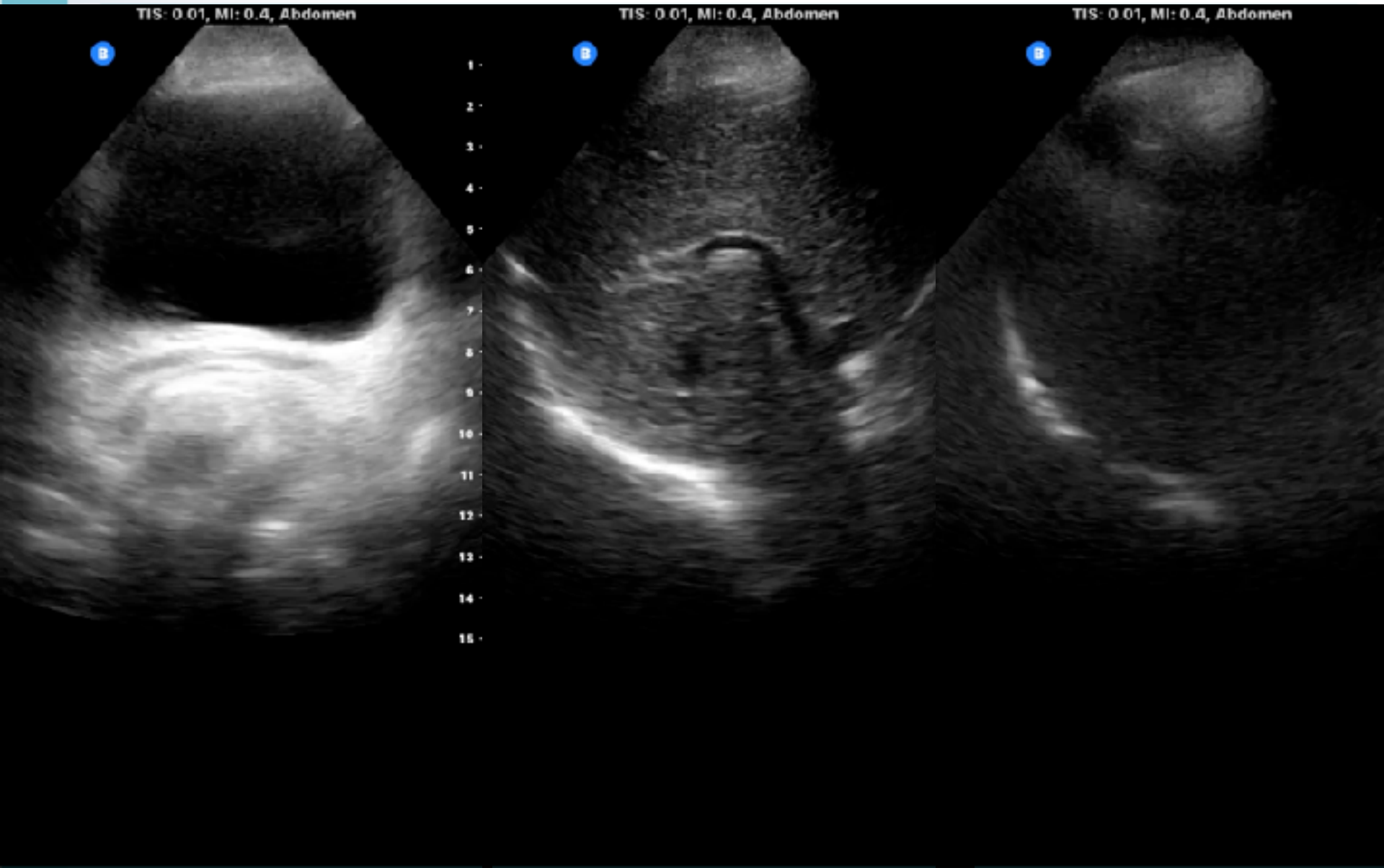
Patella

安心感確認

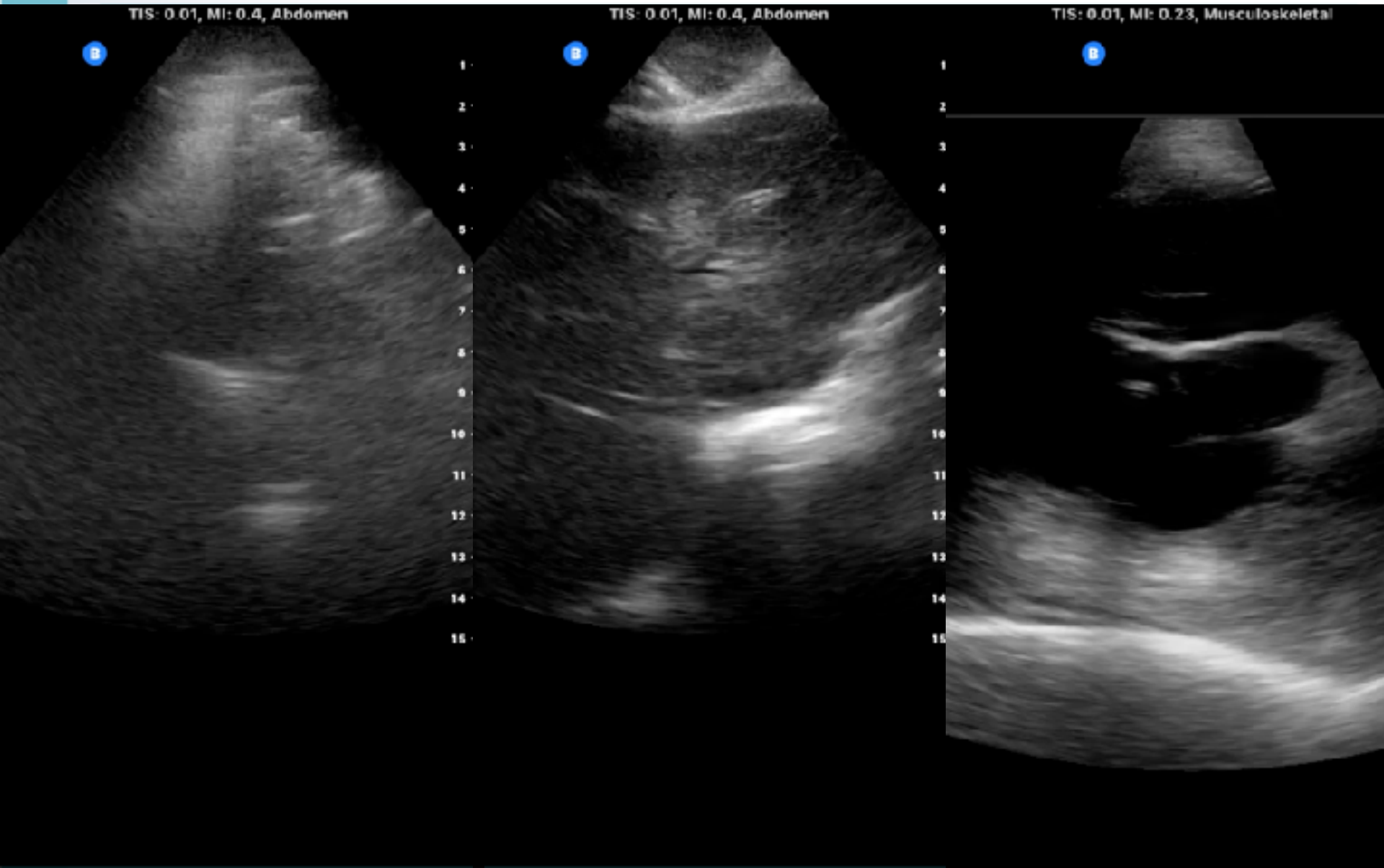
醫病關係提升



# 80F, leiomyosarcoma, no urine

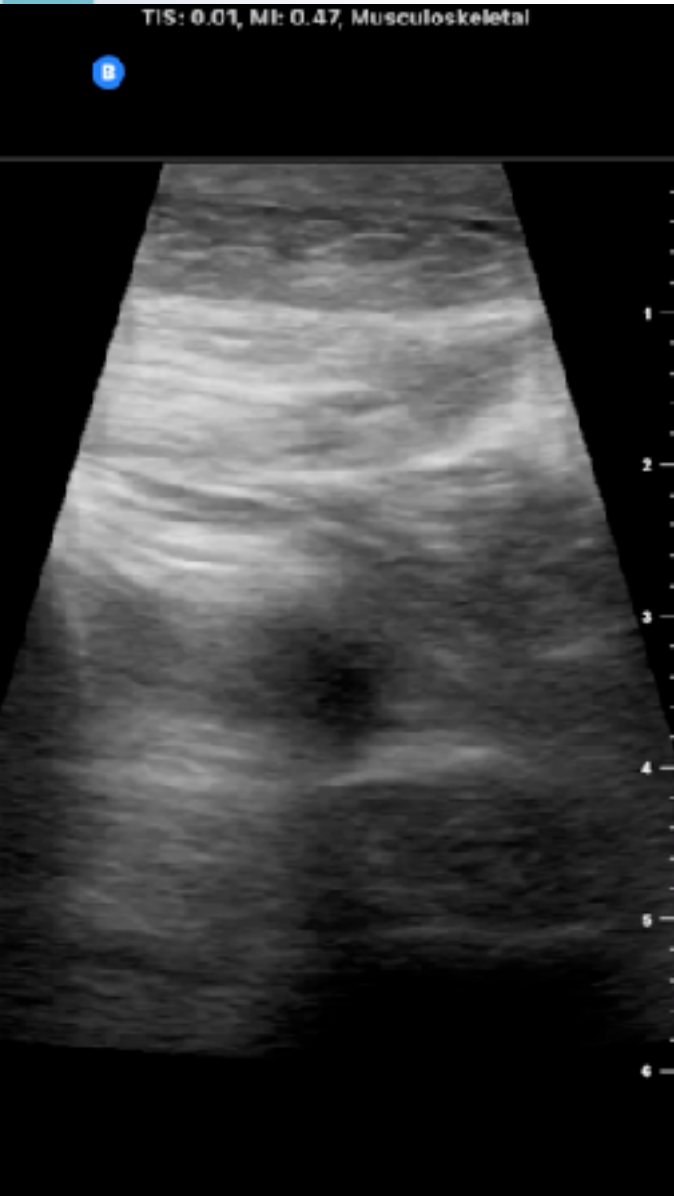

# 80F, leiomyosarcoma, no urine





# 80F, leiomyosarcoma, no urine



確認主要問題

評估會的部位

軟組織腫瘤型態

# 54M, oral cancer, LN meta / redness



TIS: 0.01, MI: 0.47, MSK-Soft Tissue

TIS: 0.01, MI: 0.47, MSK-Soft Tissue

TIS: 0.04, MI: 0.46, MSK-Soft Tissue

B

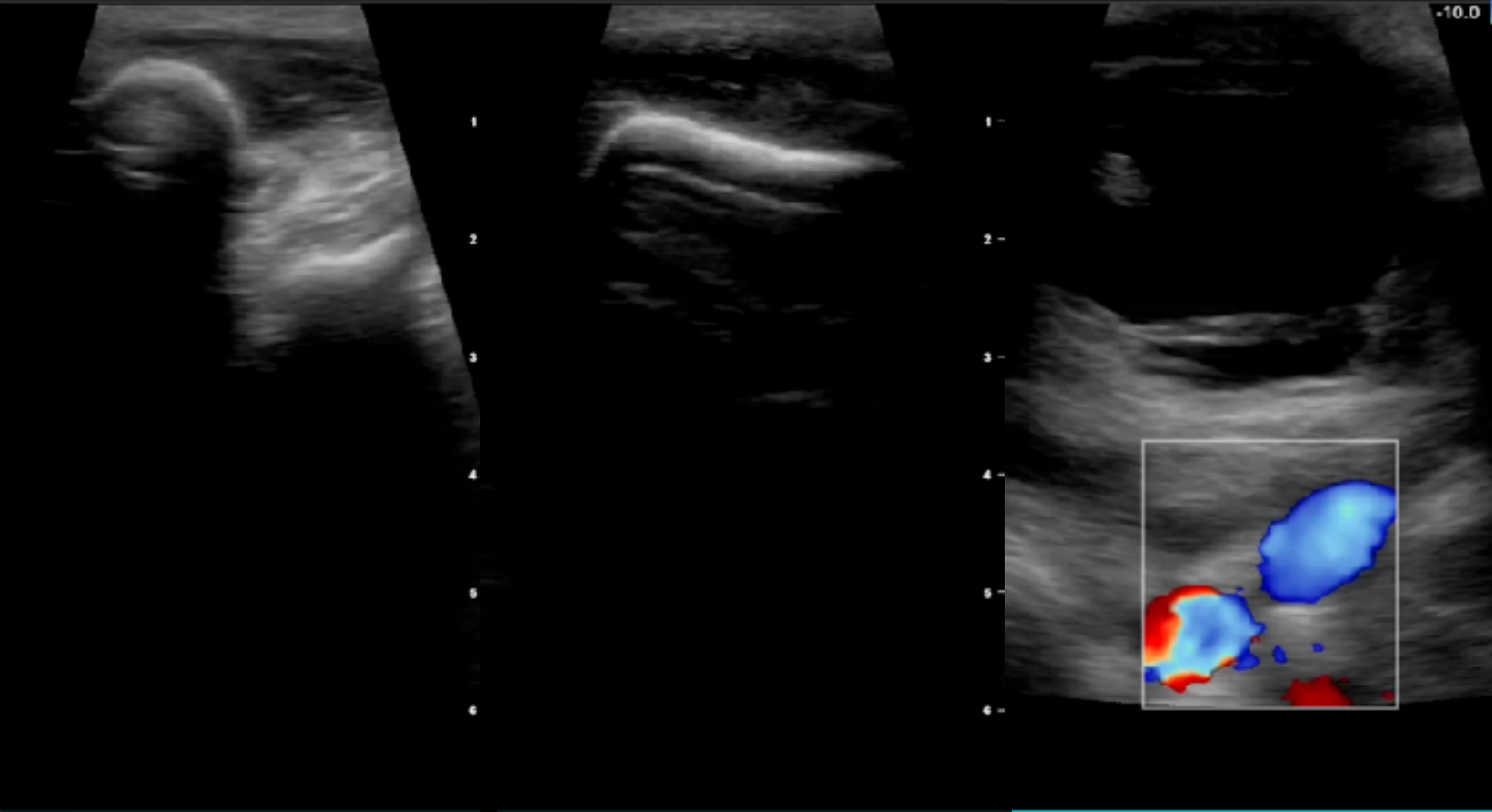
B

B

+10.0

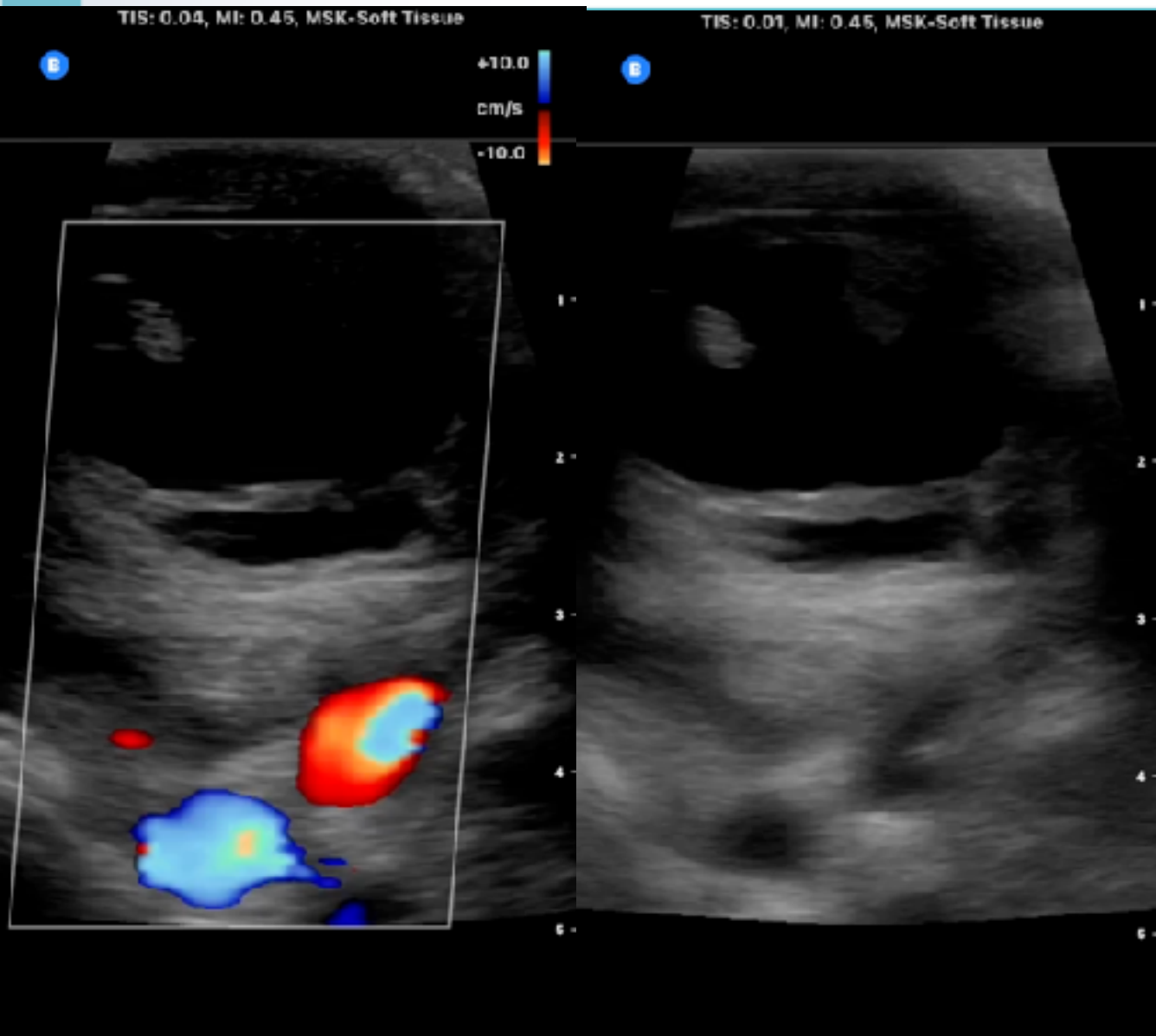
cm/s

-10.0





# 54M, oral cancer, LN meta / redness



內位定位

型態辨識

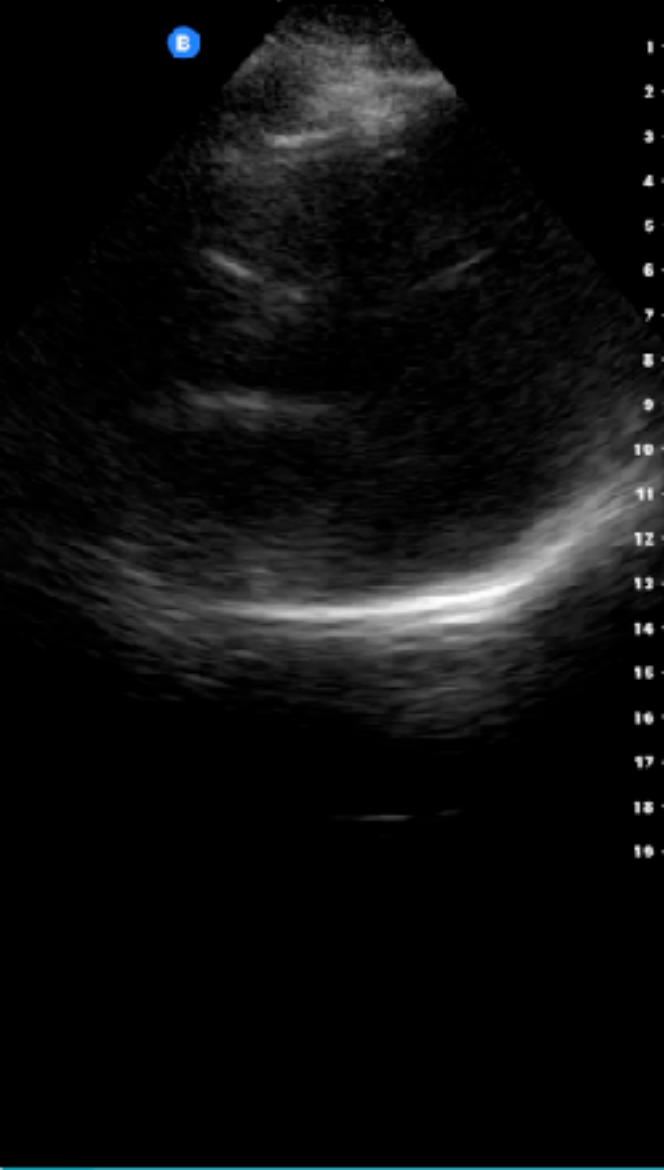
Red flag辨識

# 99M, IHCA



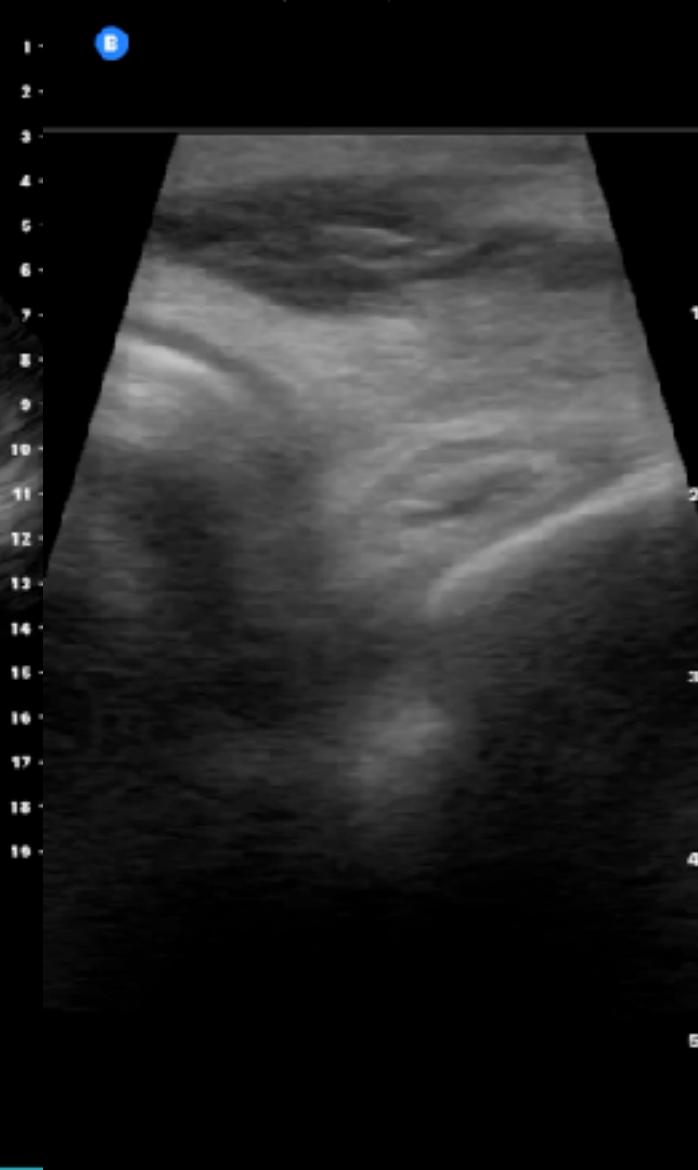TIS: 0.01, MI: 0.38, Abdomen

B



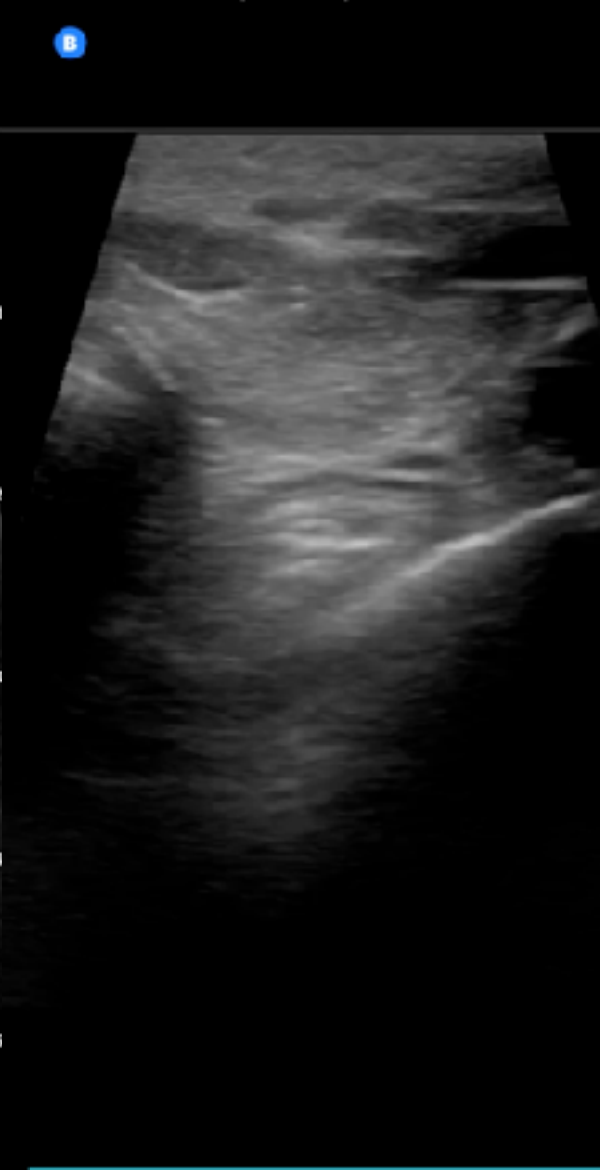TIS: 0.01, MI: 0.45, MSK-Soft Tissue

B



TIS: 0.01, MI: 0.45, MSK-Soft Tissue

B



# 99M, IHCA



TIS: 0.01, MI: 0.4, Abdomen

B

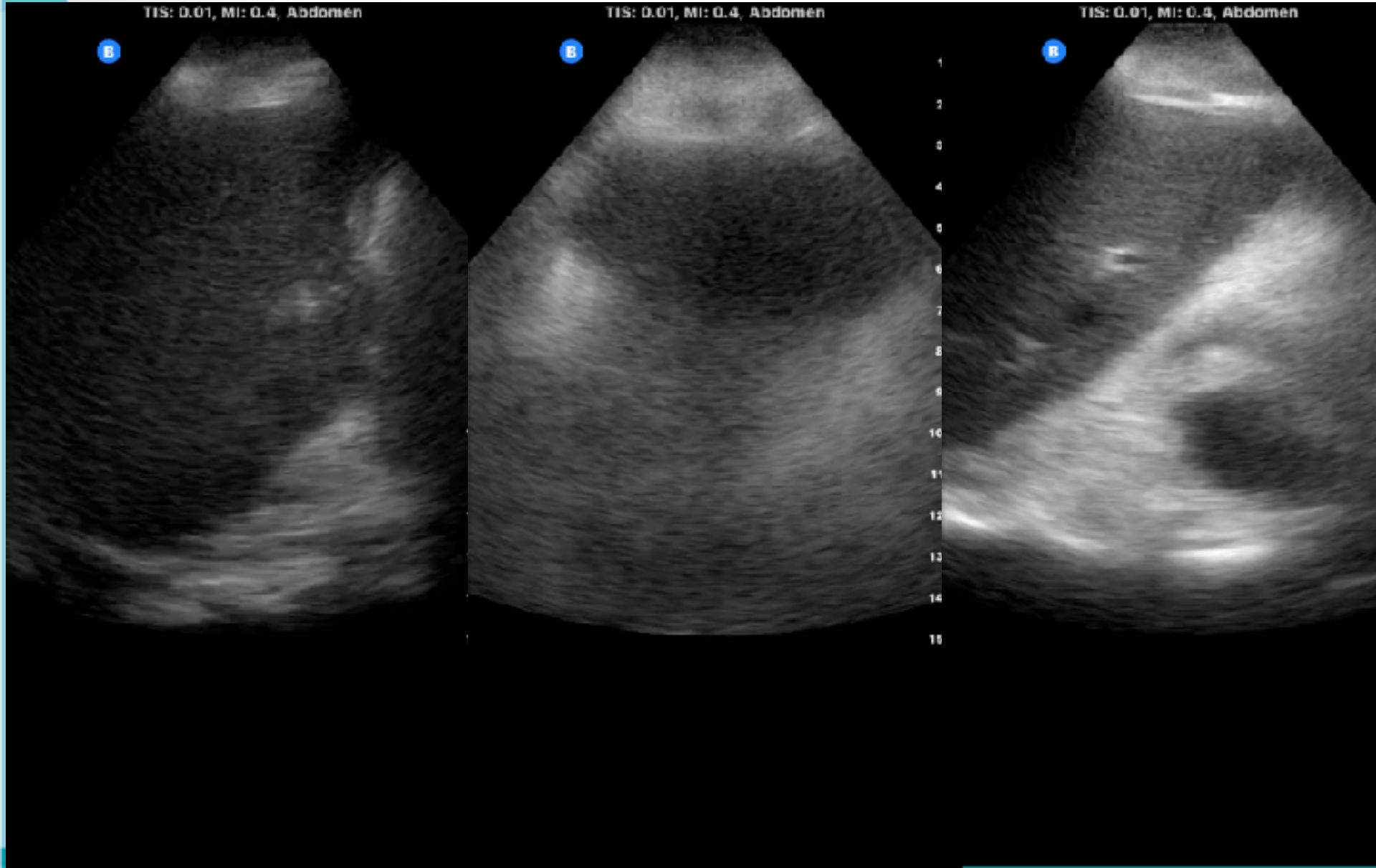
TIS: 0.01, MI: 0.4, Abdomen

B

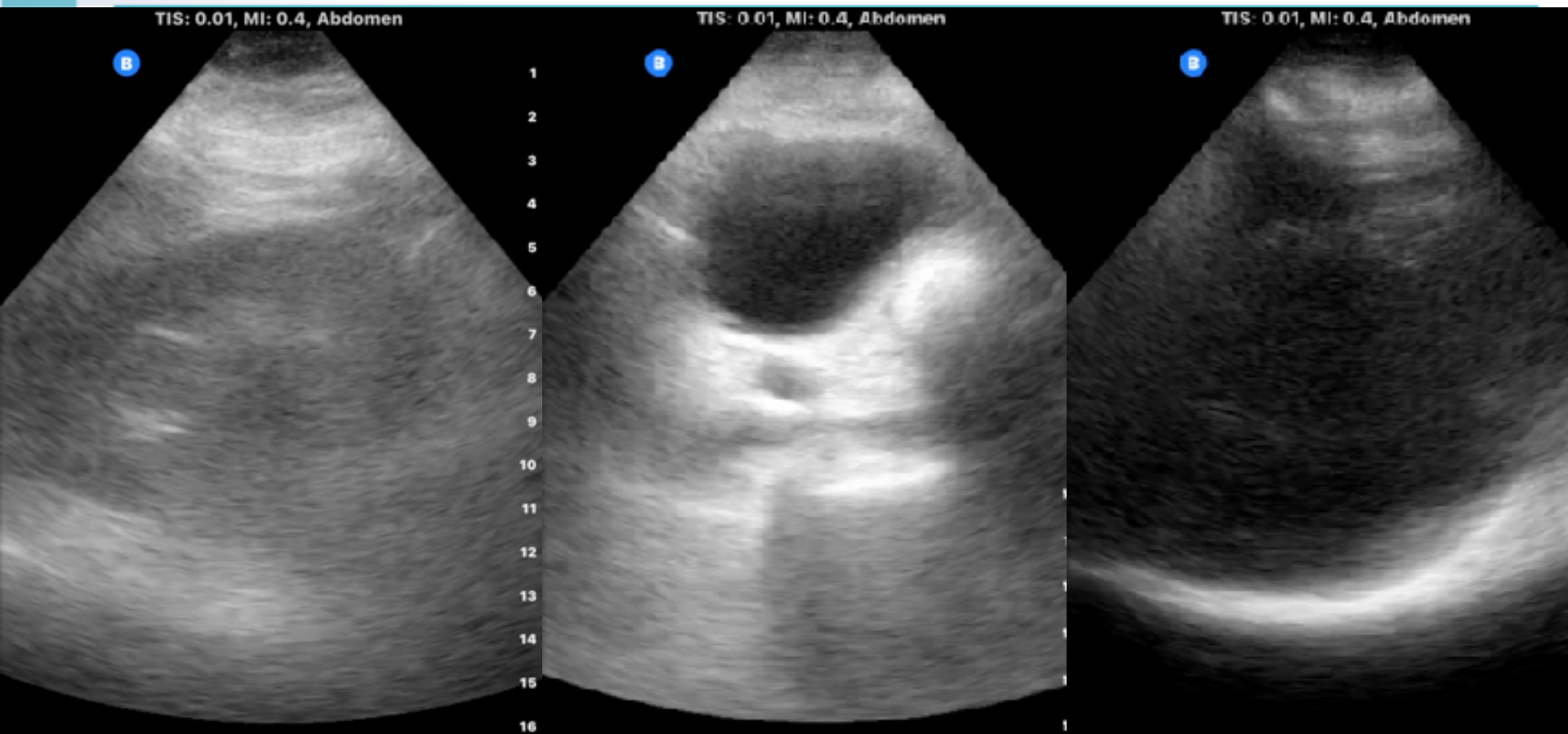
TIS: 0.01, MI: 0.4, Abdomen

R

1  
2  
3  
4  
5  
6  
7  
8  
9  
10  
11  
12  
13  
14  
15



# 99M, IHCA





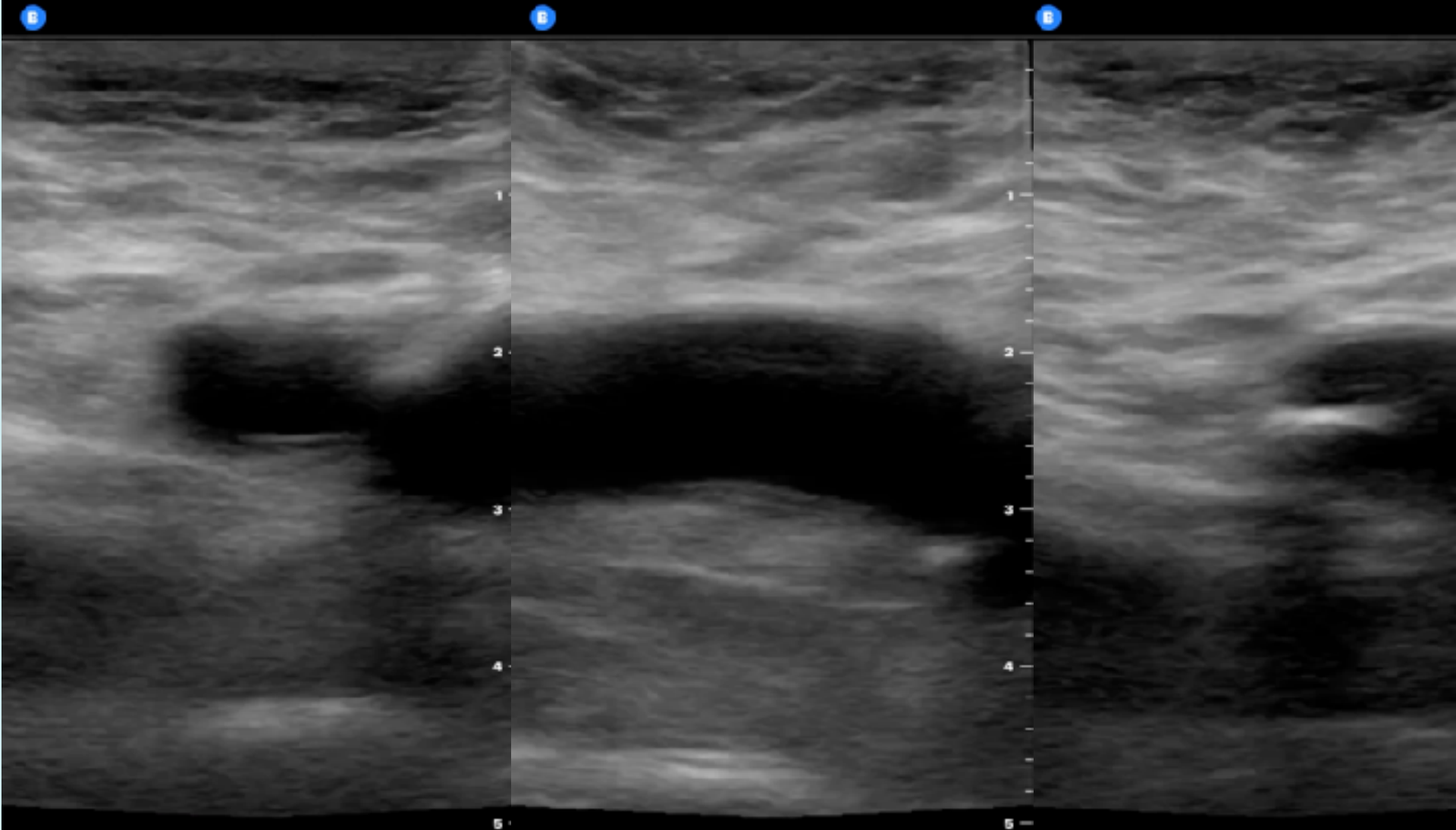
# 99M, IHCA



TIS: 0.01, MI: 0.45, Vascular: Access

TIS: 0.01, MI: 0.45, Vascular: Access

TIS: 0.01, MI: 0.45, Vascular: Access

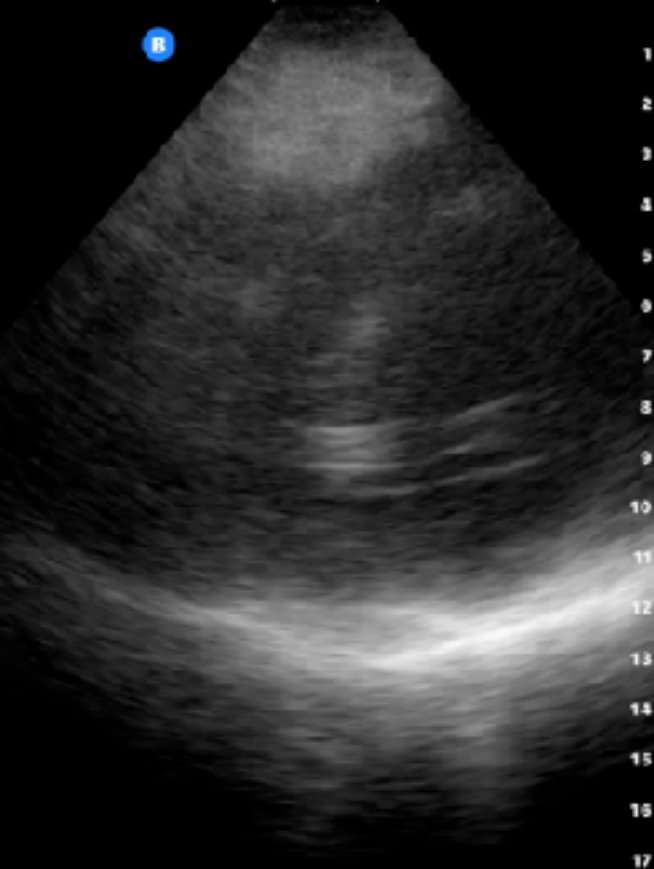

# 99M, IHCA



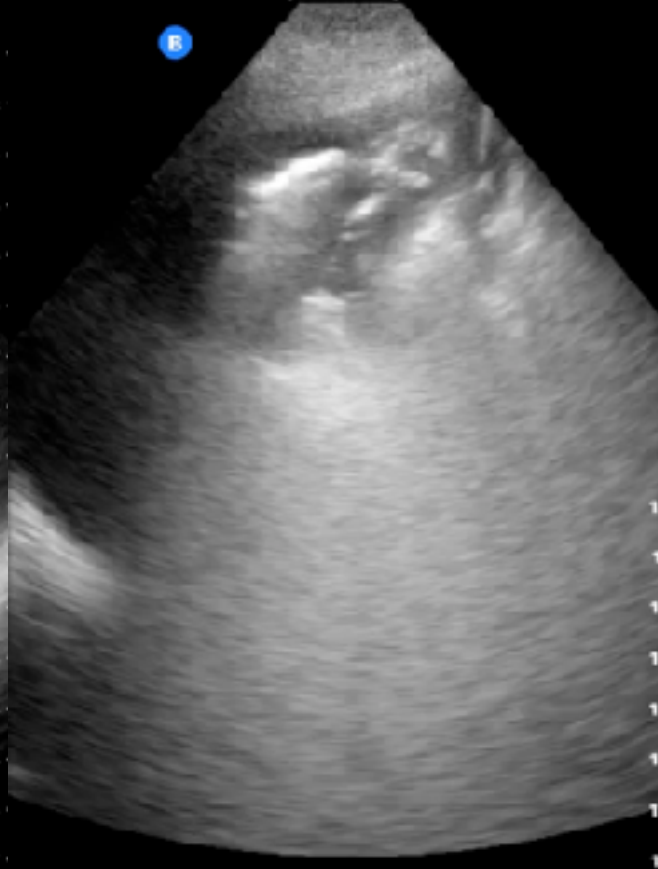TIS: 0.01, MI: 0.38, Abdomen

R



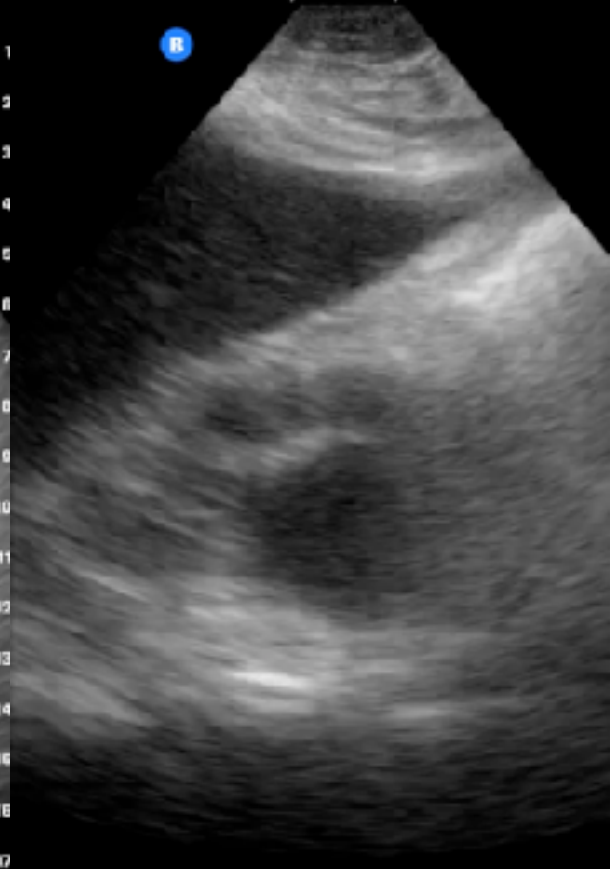TIS: 0.01, MI: 0.38, Abdomen

R

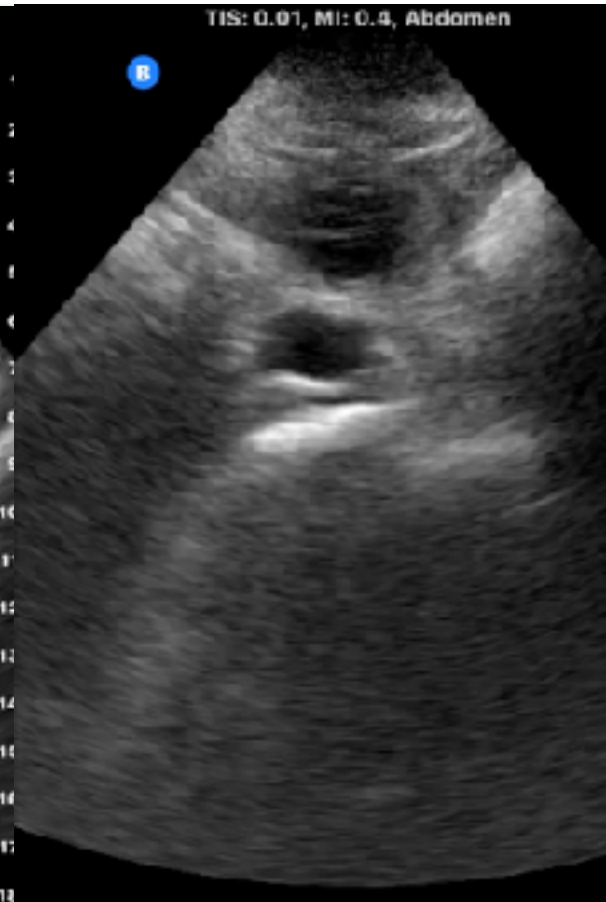
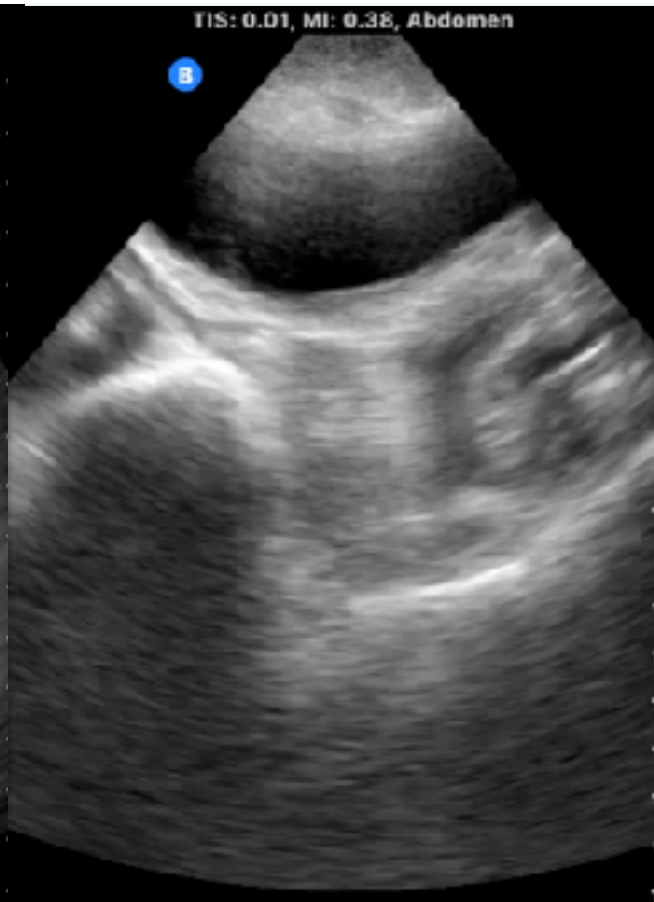
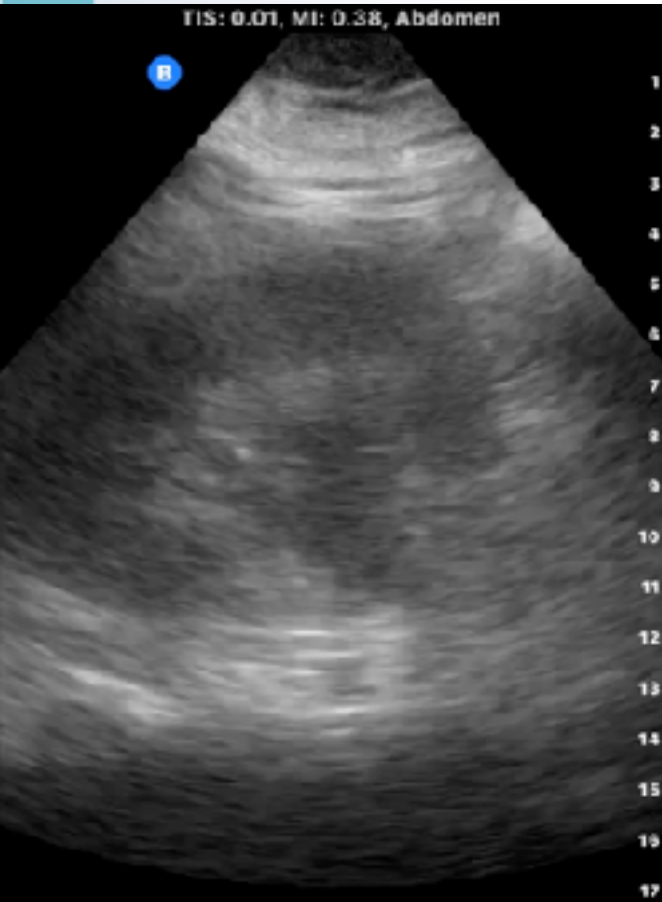TIS: 0.01, MI: 0.38, Abdomen

R



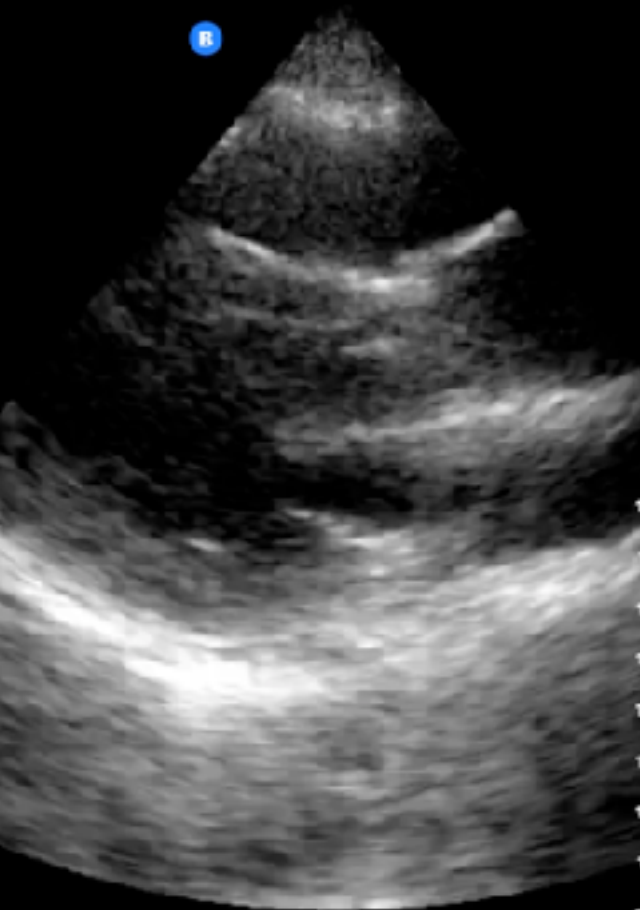# 99M, IHCA



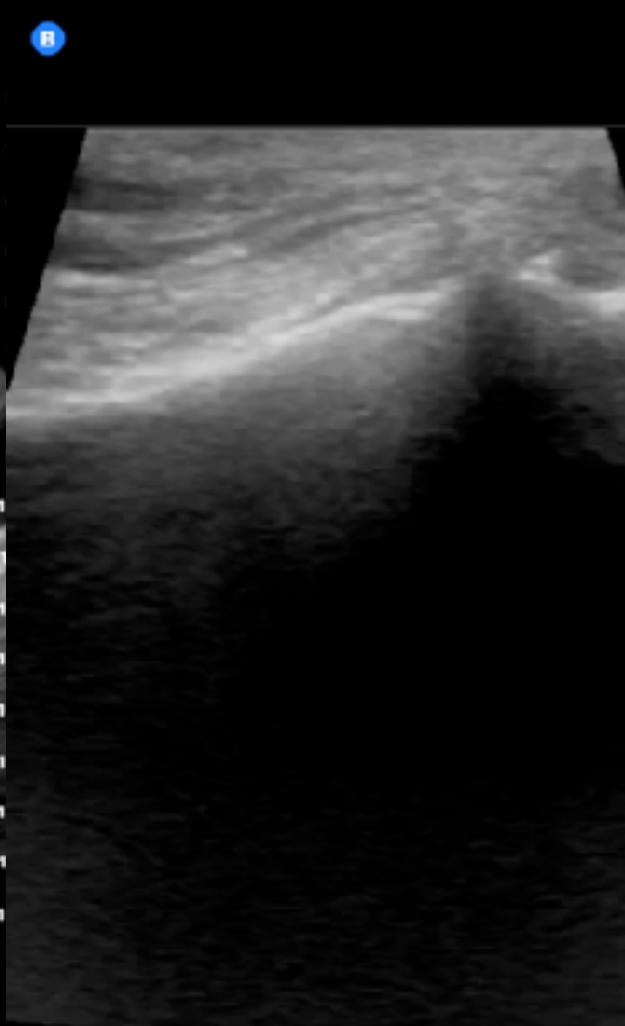
# 99M, IHCA



TIS: 0.02, MI: 0.48, Cardiac



TIS: 0.01, MI: 0.35, Musculoskeletal



TIS: 0.01, MI: 0.4, Abdomen

