



**Central access**

02/11

**Peripheral access**

02/18

**EFAST**

02/25

# 雙和急診POCUS訓練規劃

診  
斷

監  
測

介  
入

## POINT OF CARE ULTRASOUND

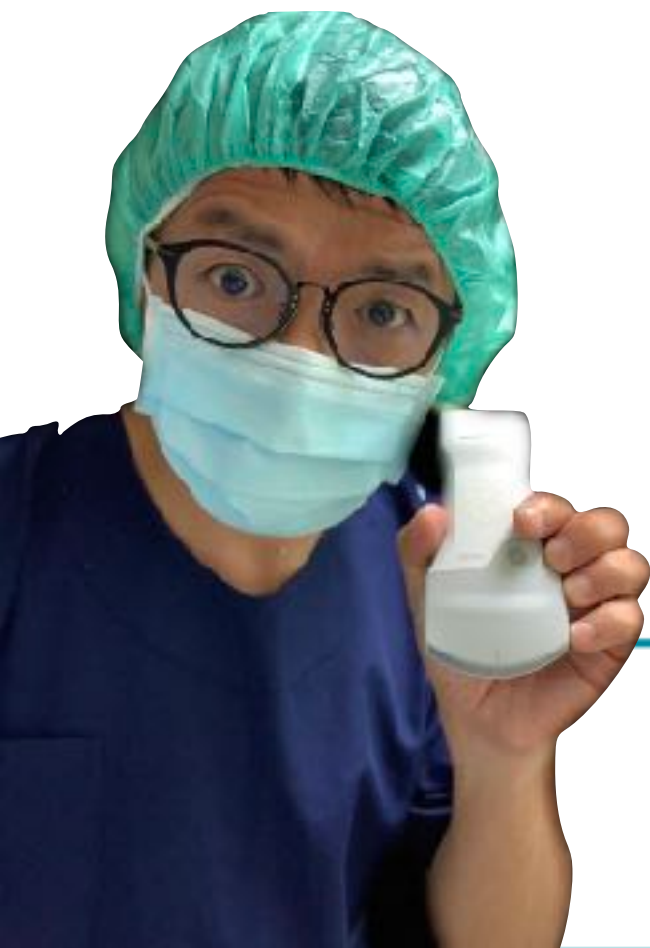POCUS ~ 存在於臨床需求之所在



衛生福利部雙和醫院  
(委託臺北醫學大學興建經營)  
Taipei Medical University · Shuang Ho Hospital,  
Ministry of Health and Welfare



# POCUS Imaging Reading



陳國智醫師

雙和醫院 急診醫學科

# 陳國智 醫師



醫用超音波學會指導醫師  
WINFOCUS director / instructor  
急救加護醫學會重症超音波負責人

急診 / 重症 / 介入 / 急性疼痛

## 經歷

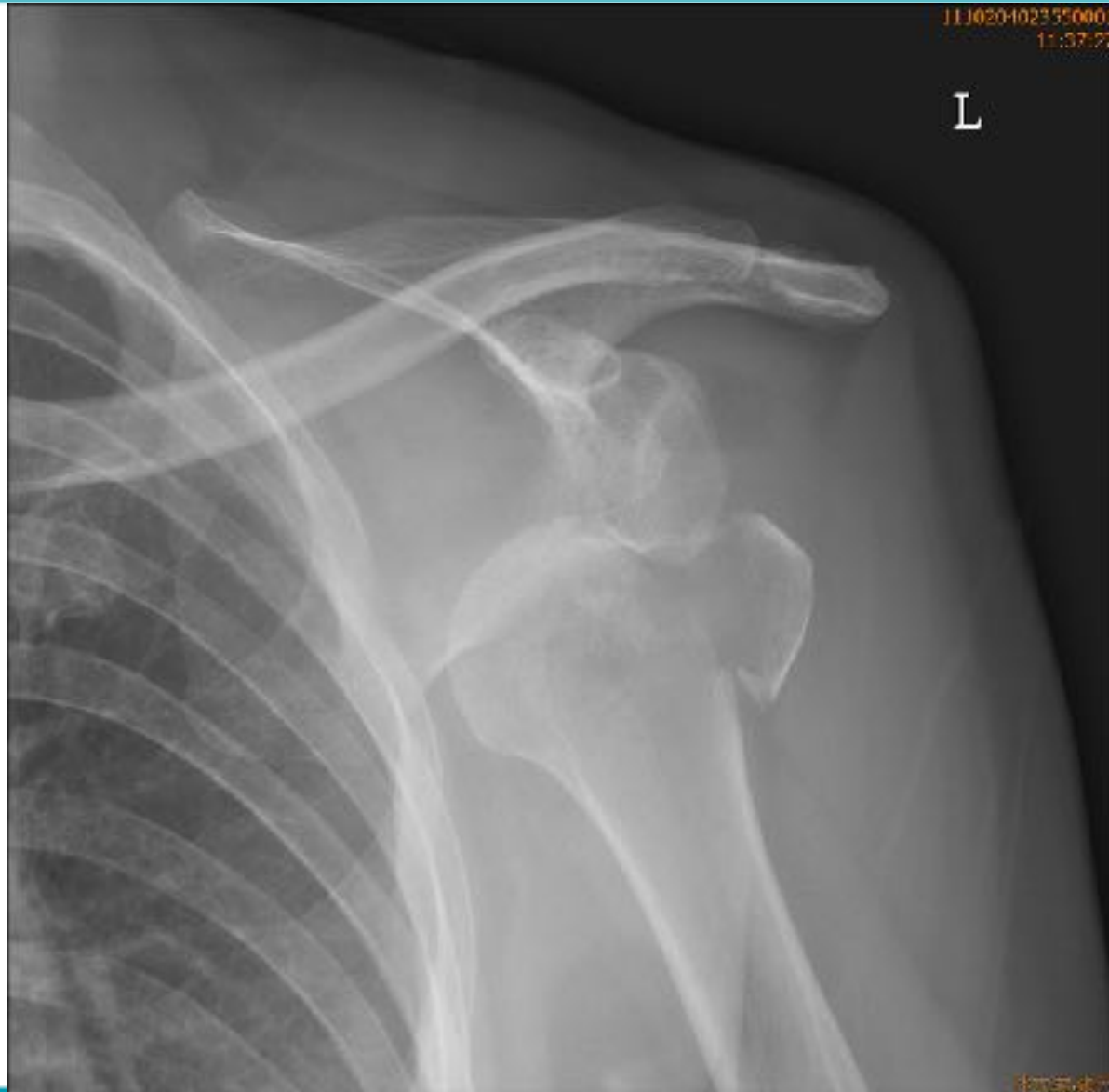
新光急診超音波訓練中心主任

西園醫院急診醫學科主任

急診醫學會超音波委員會主委

台灣疼痛醫學會大體模擬手術講師

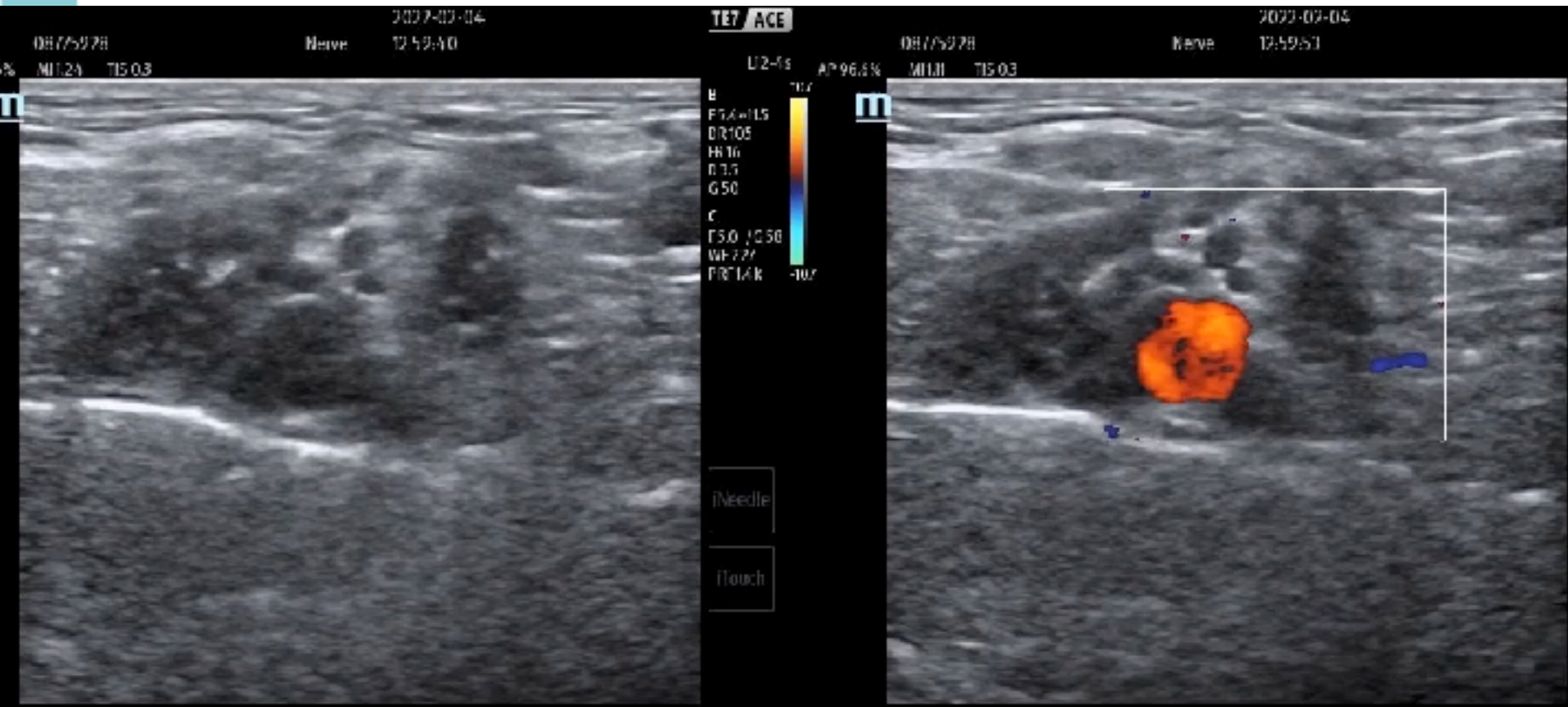
# 56M, left shoulder fracture / dislocation



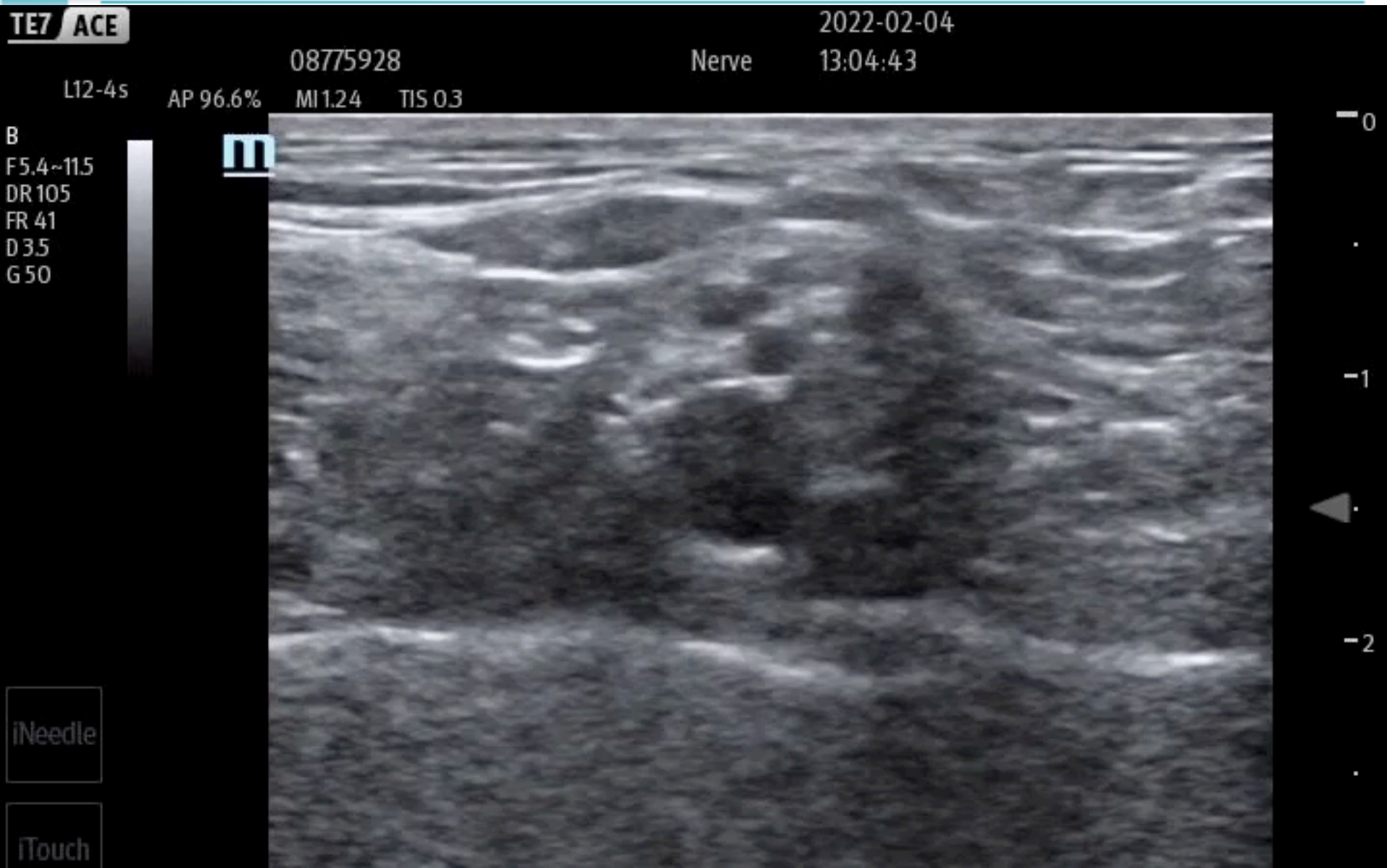# 56M, left shoulder fracture / dislocation



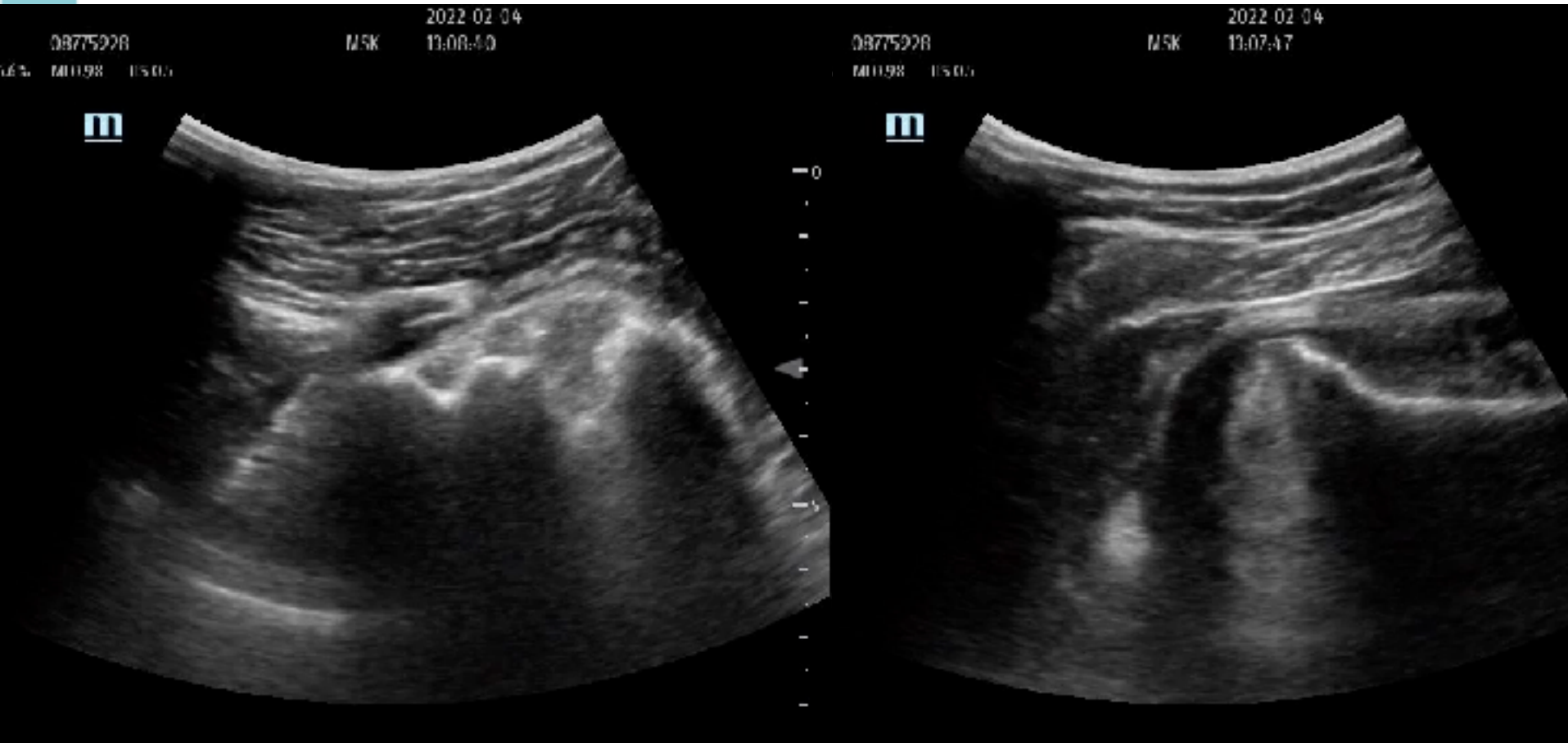
## Brachial plexus



# Supraclavicular brachial plexus block

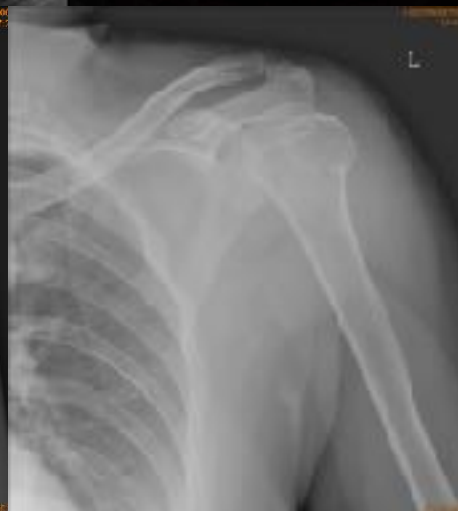
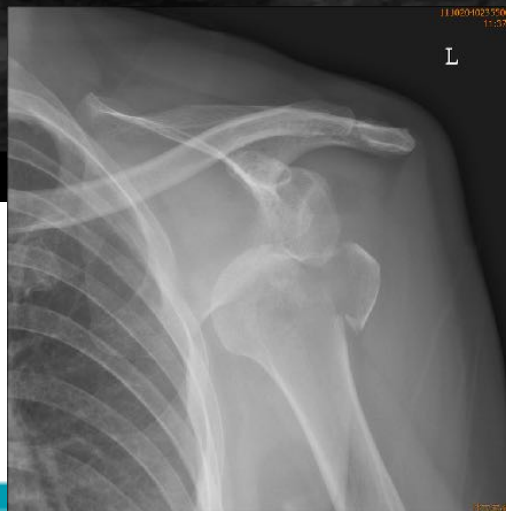
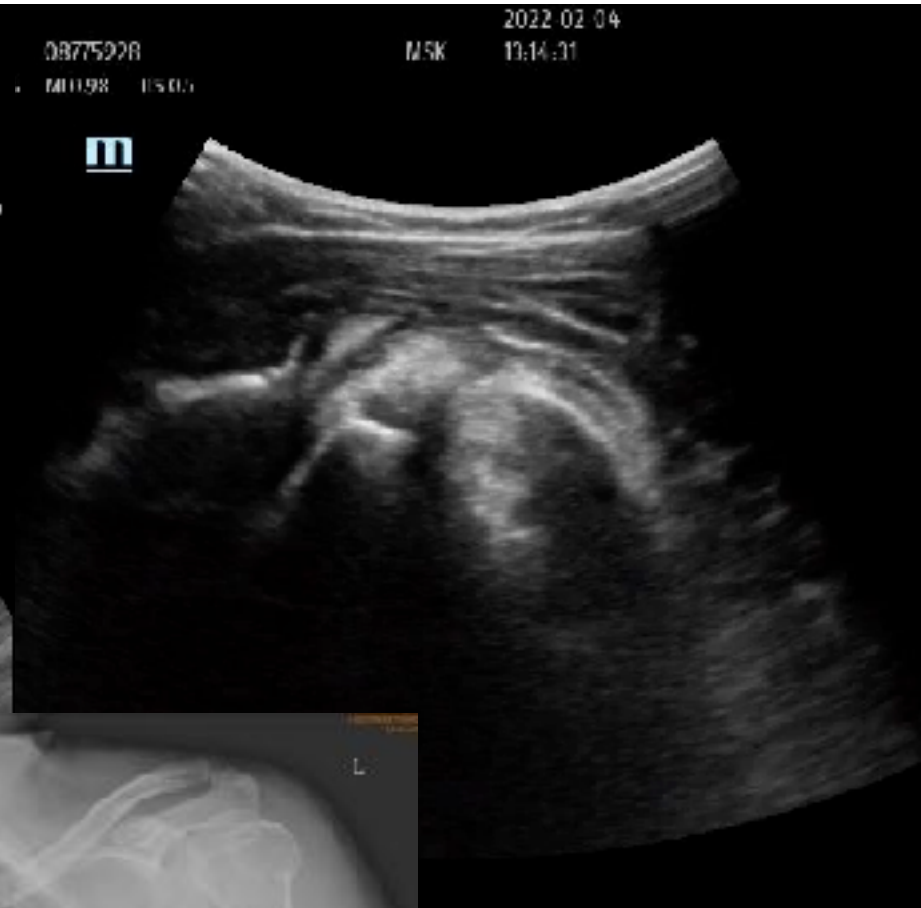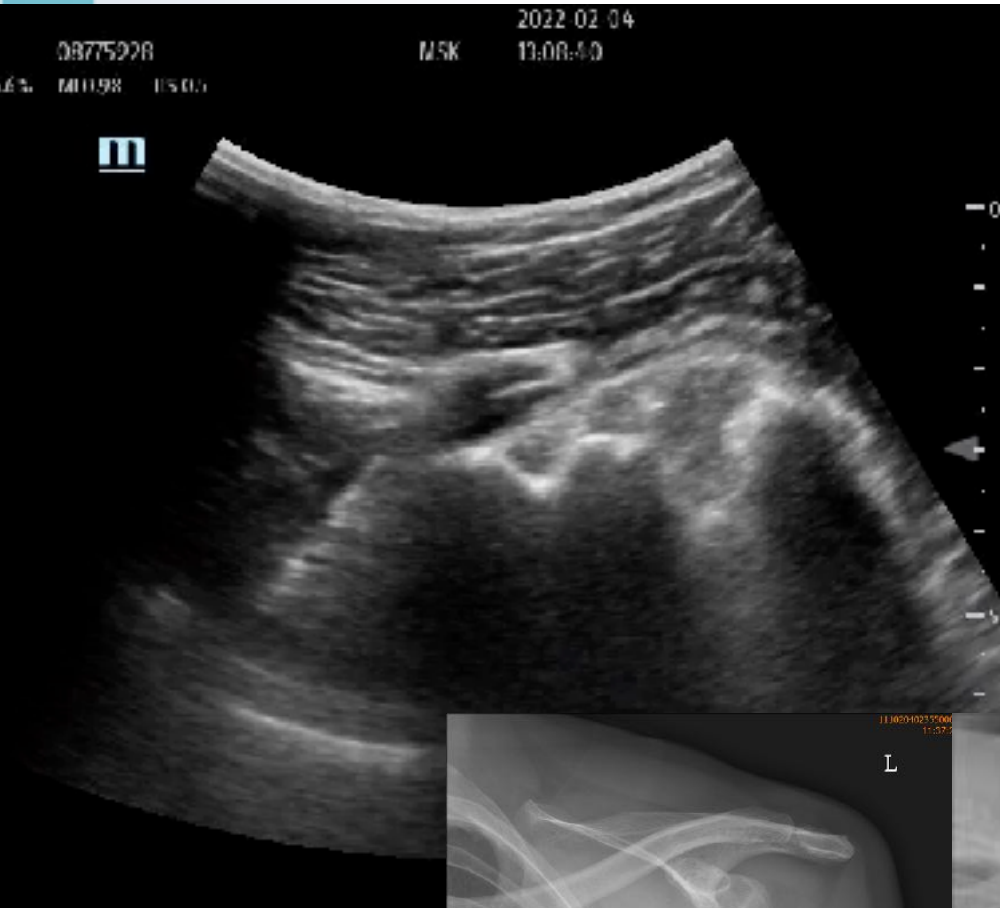# Anterior dislocation

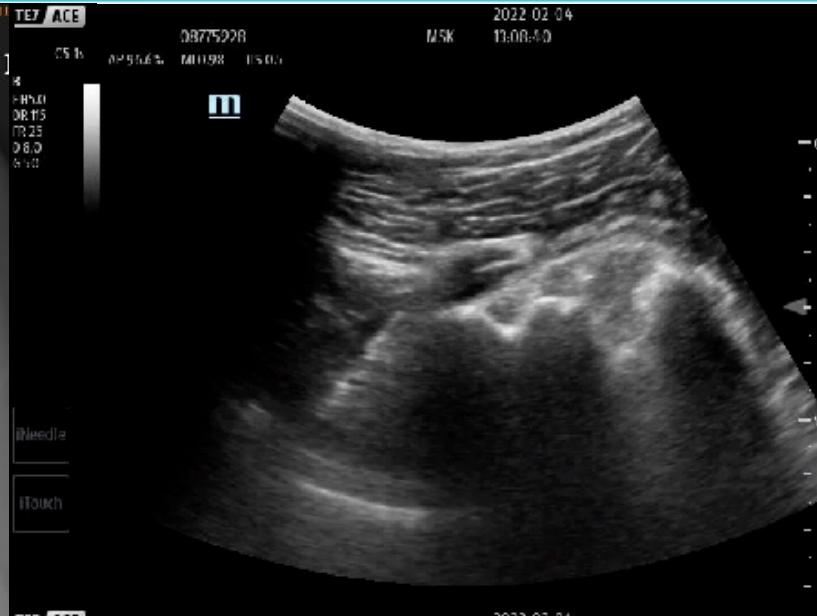
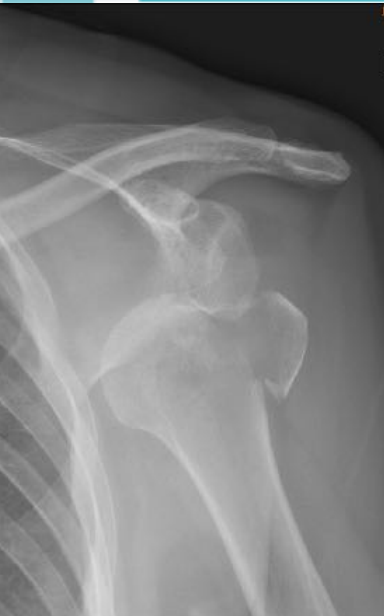


# Dislocation & Reduction



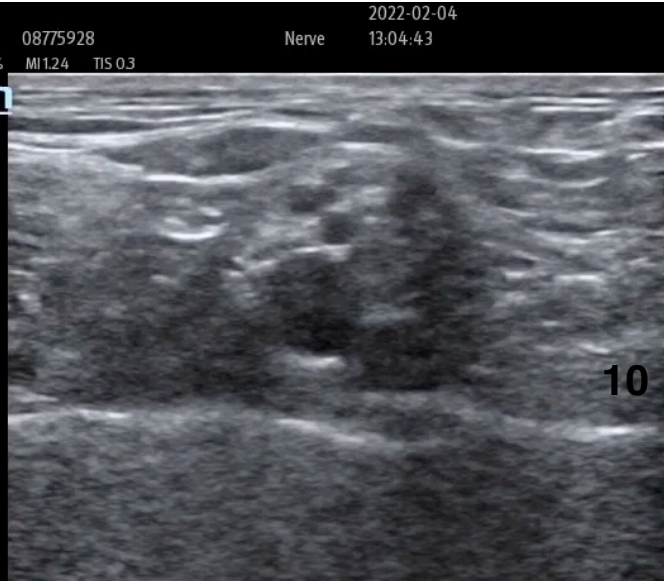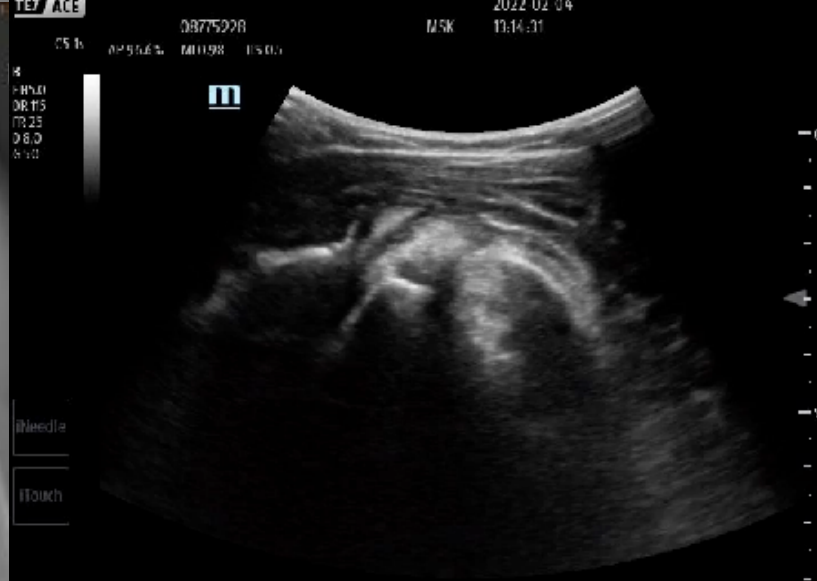
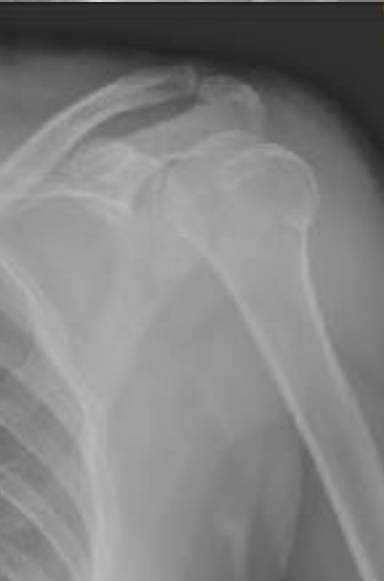# Role of POCUS



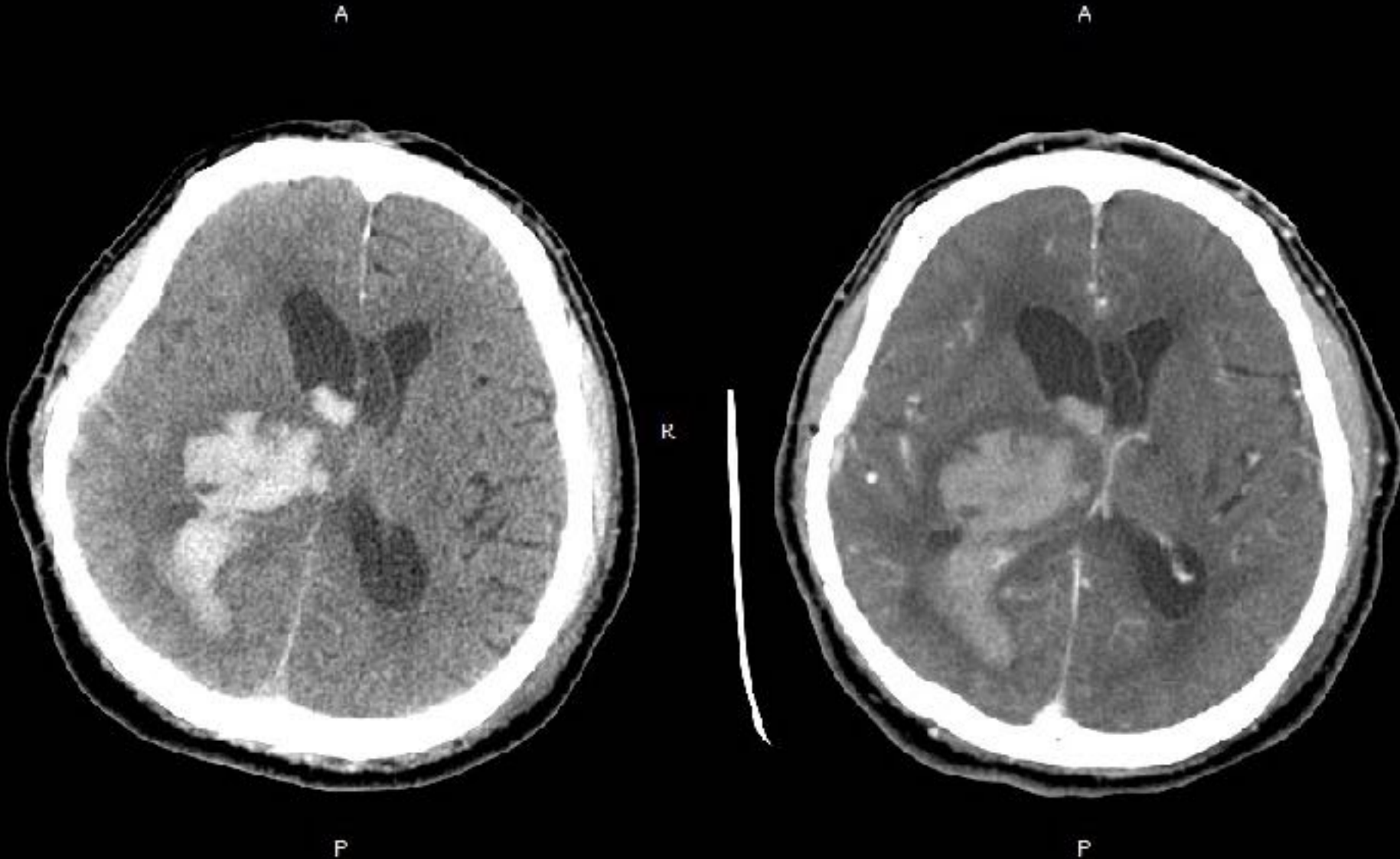
**Dislocation**

**Pain control**

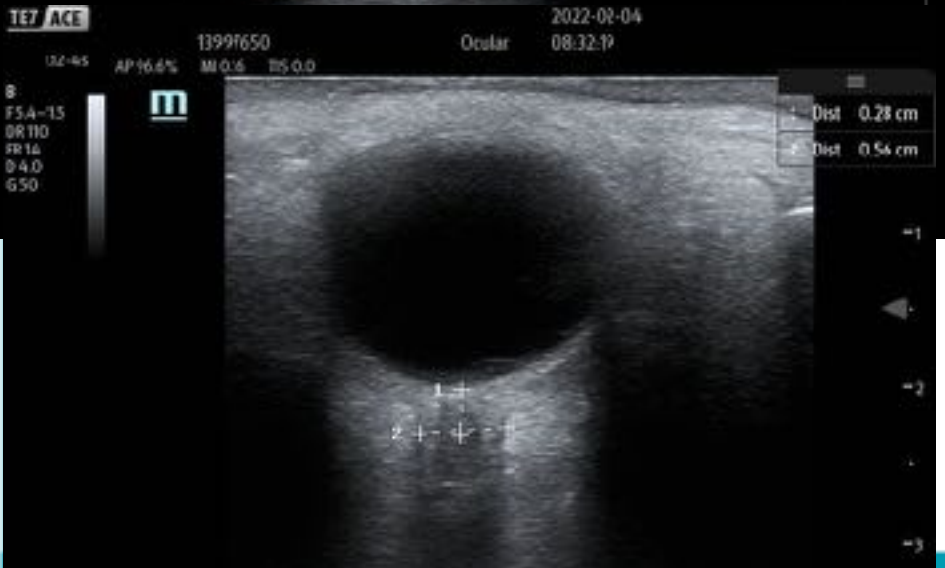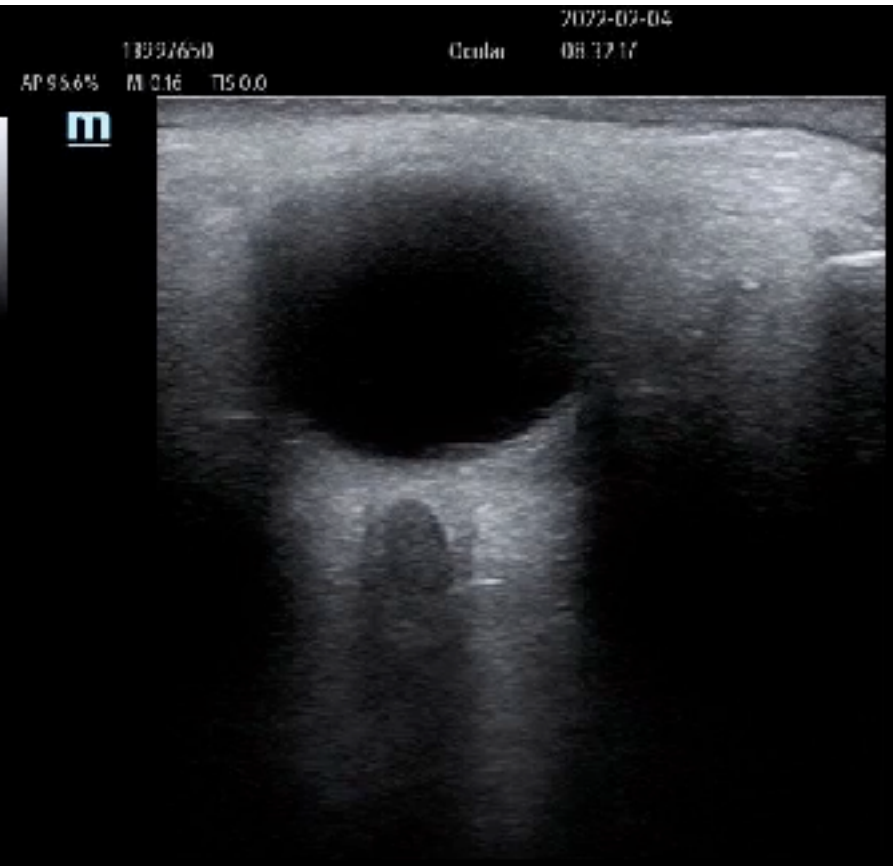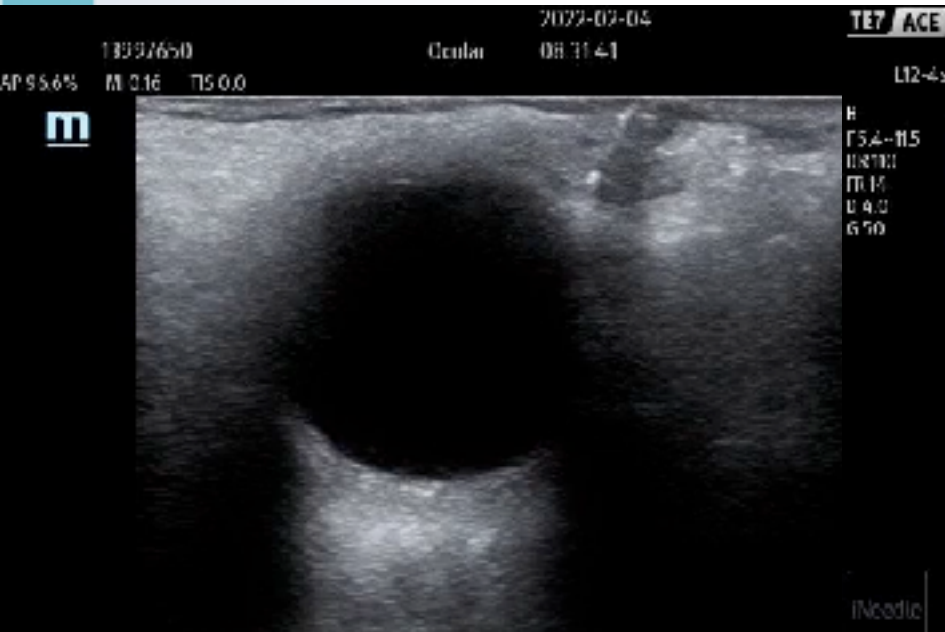**Reduction**



# 67M, AMS with left side weakness

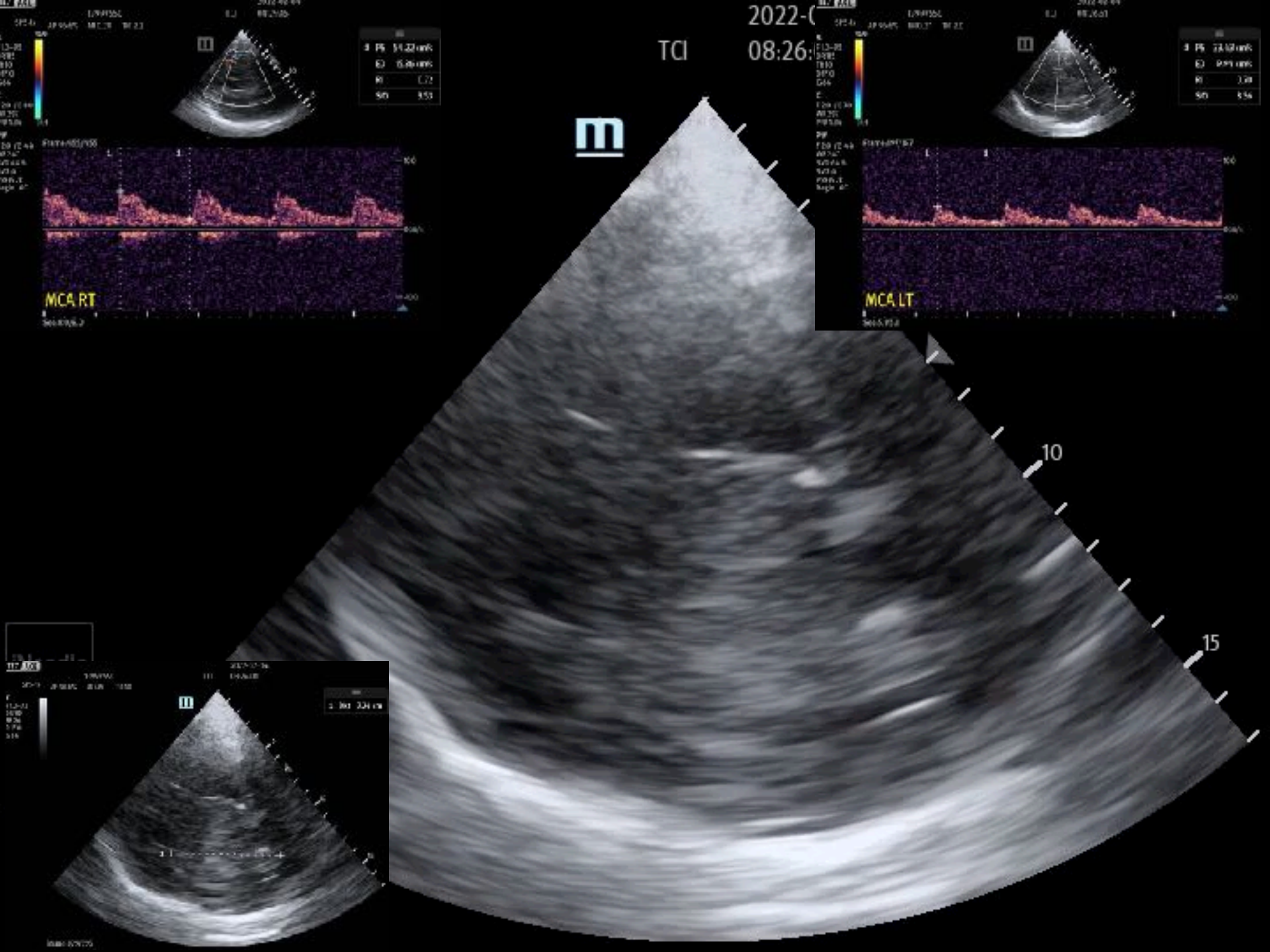


# Optic nerve sheath diameter (ONSD)

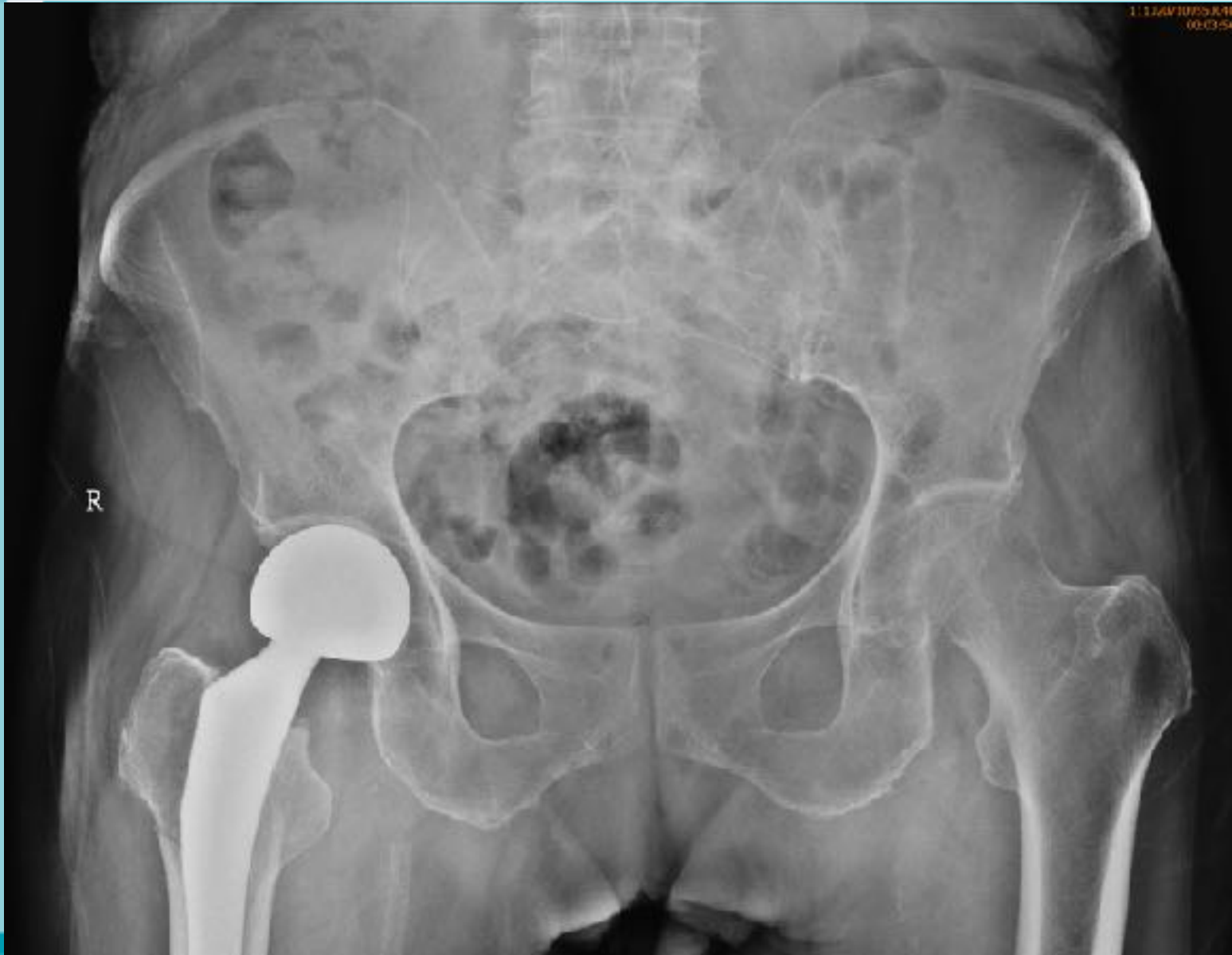

3mm  
>5mm

>>>> IICP

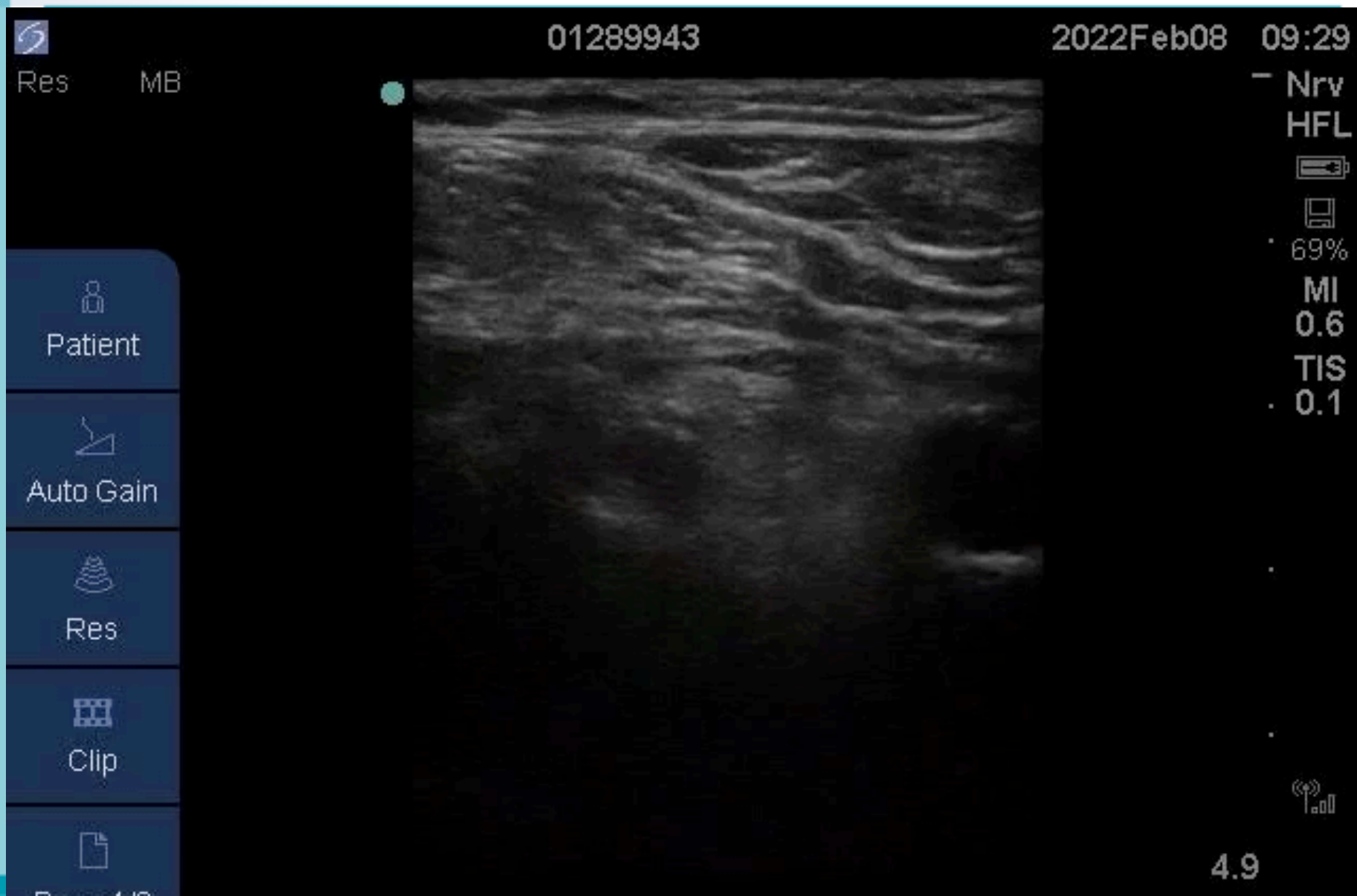

# 94F, right hip pain





# Femoral nerve block (佑達)





# Femoral nerve block (佑達)

01289943 2022Feb08 09:31

Res MB

— Nrv  
HFL  
69%  
MI  
0.6  
TIS  
0.1

Patient

Auto Gain

Res

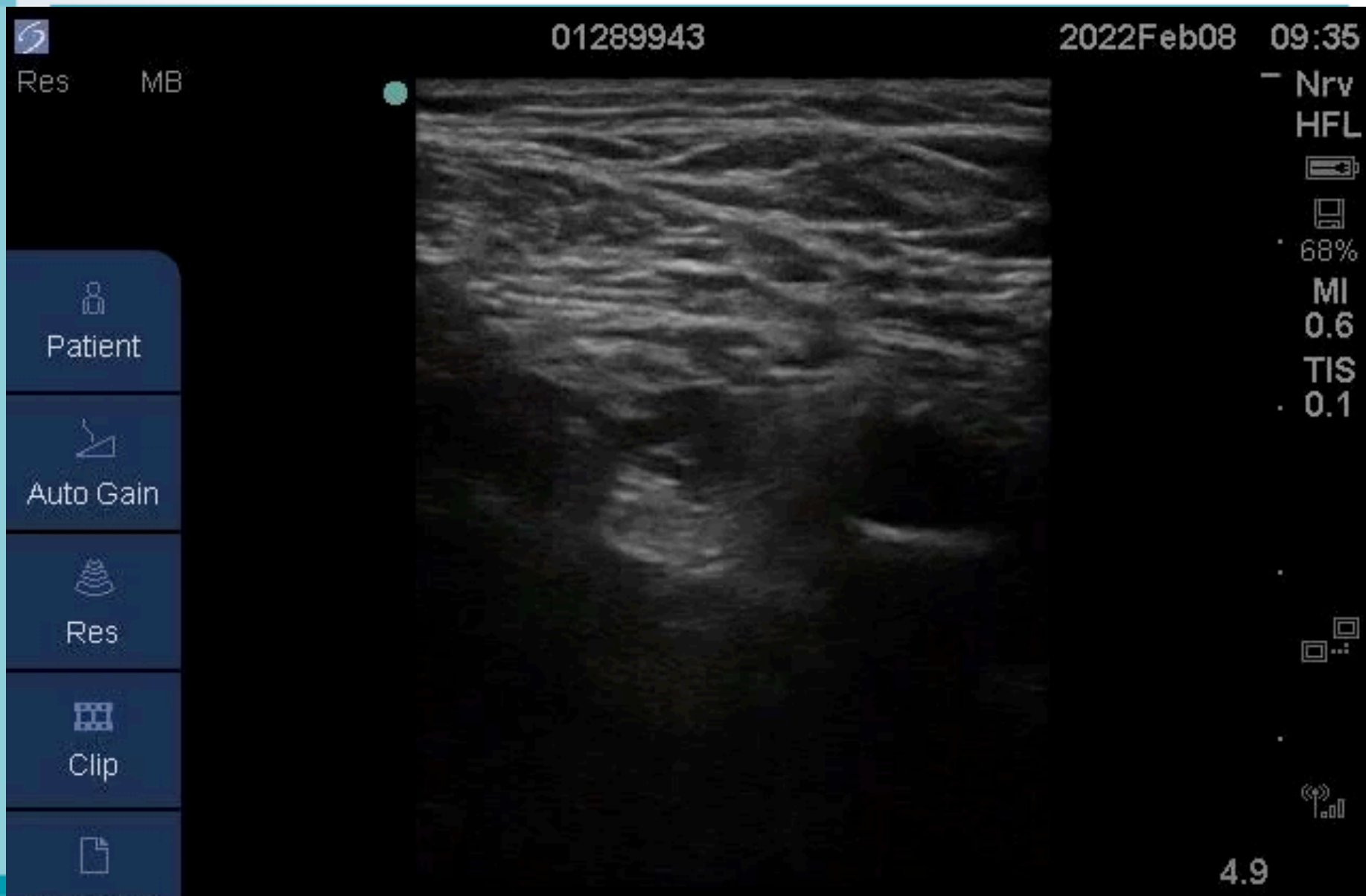Clip

4.9

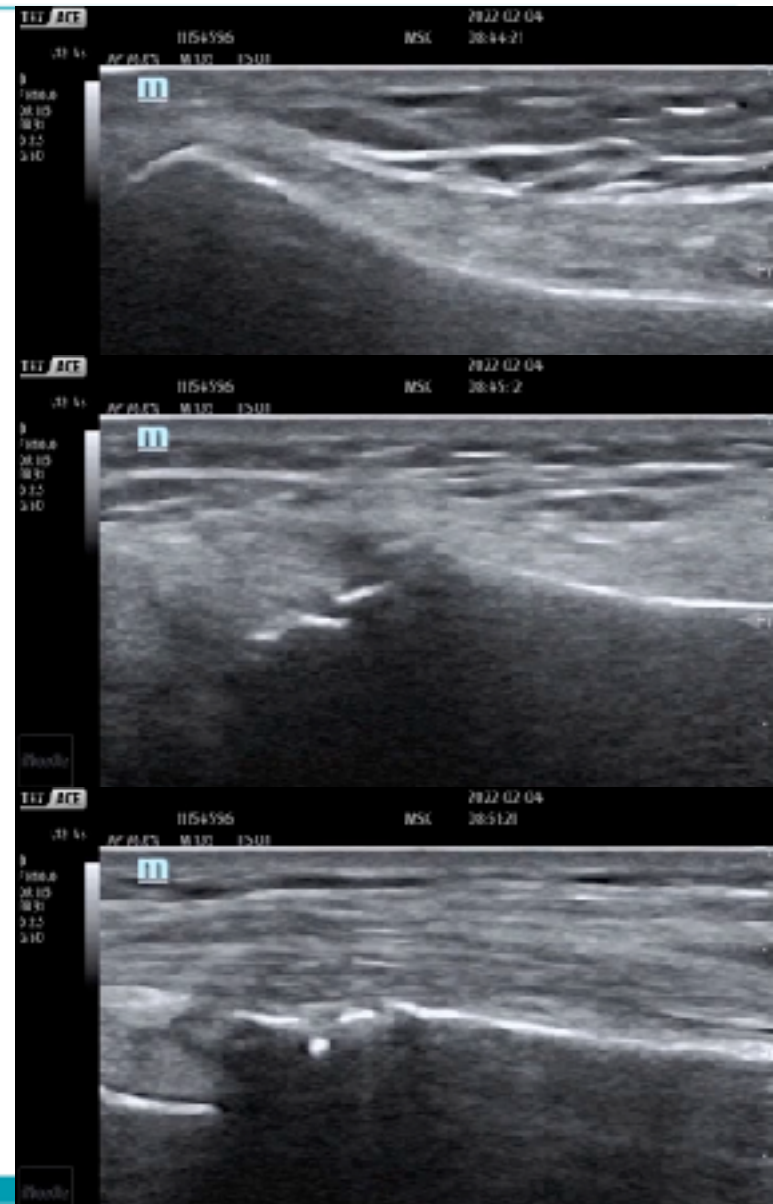
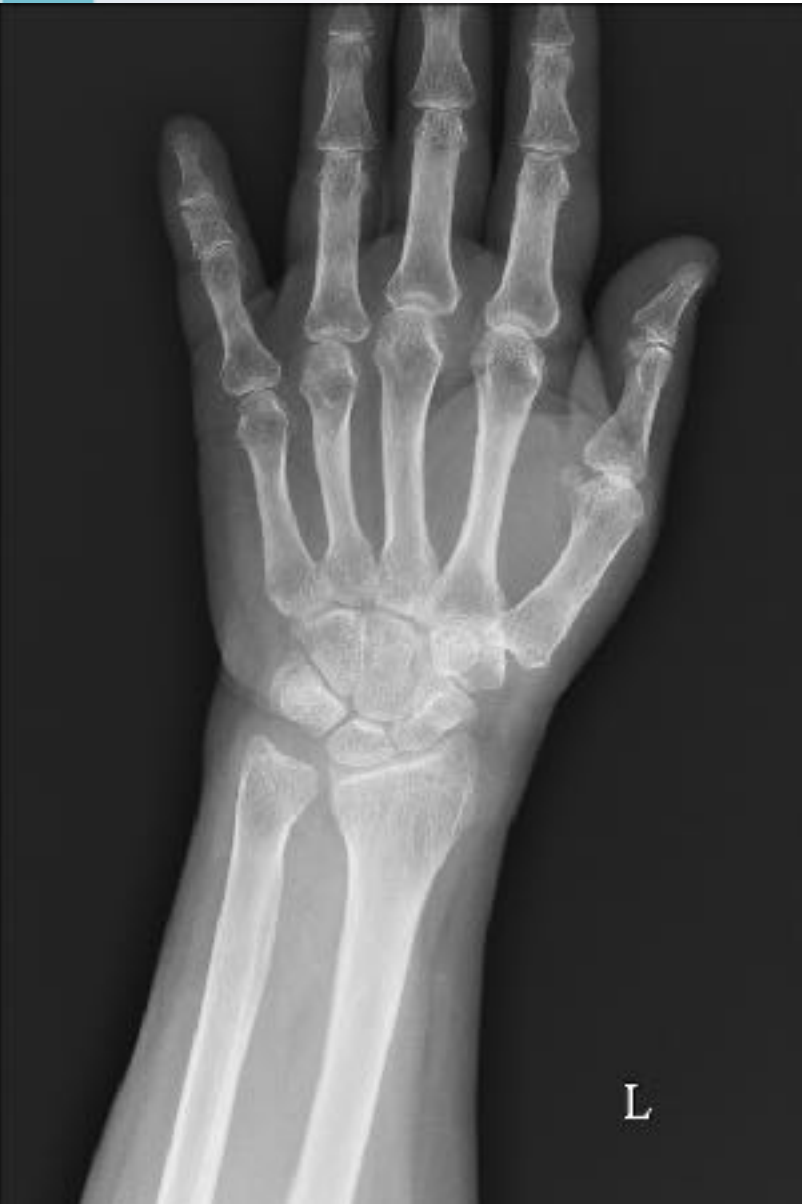


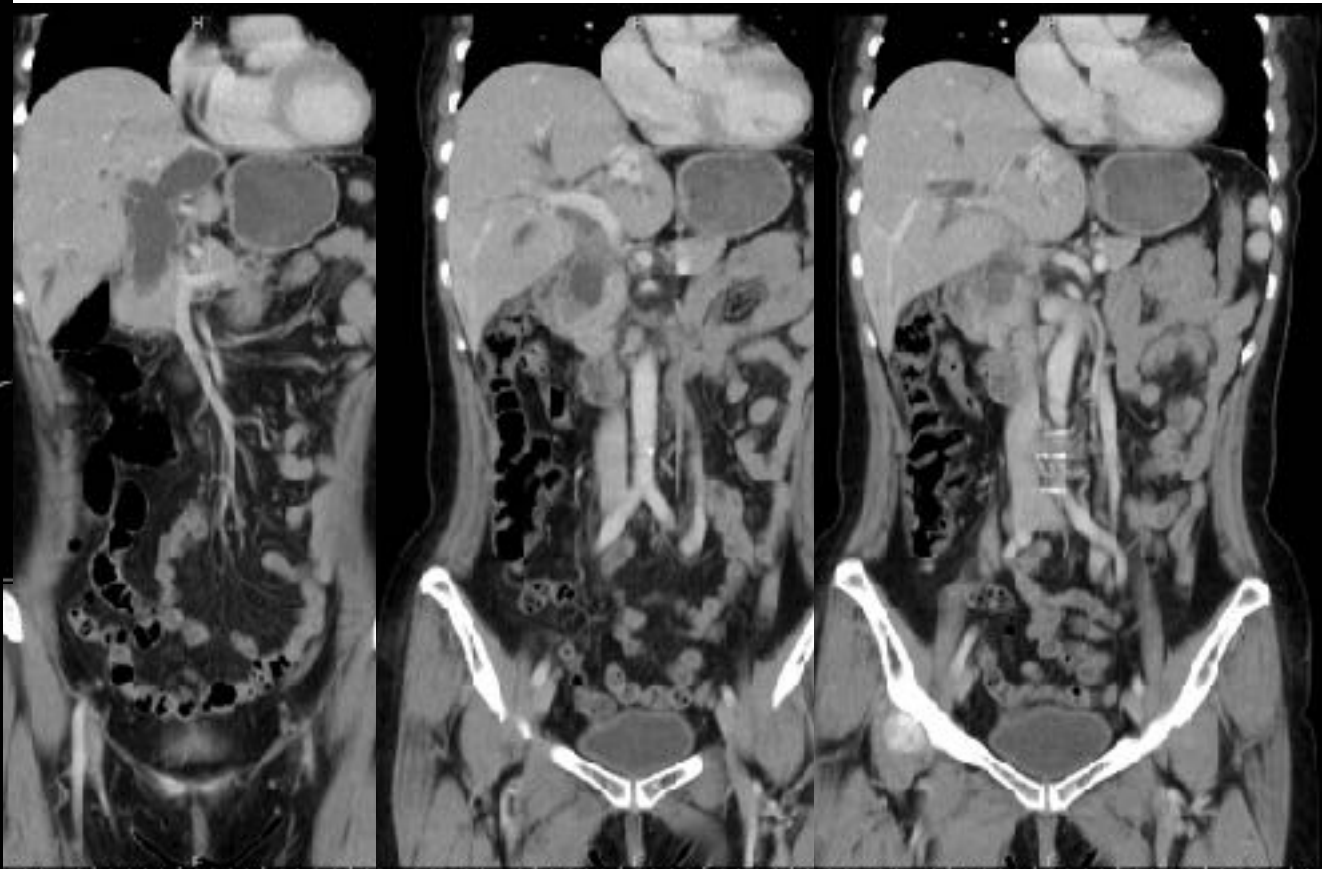
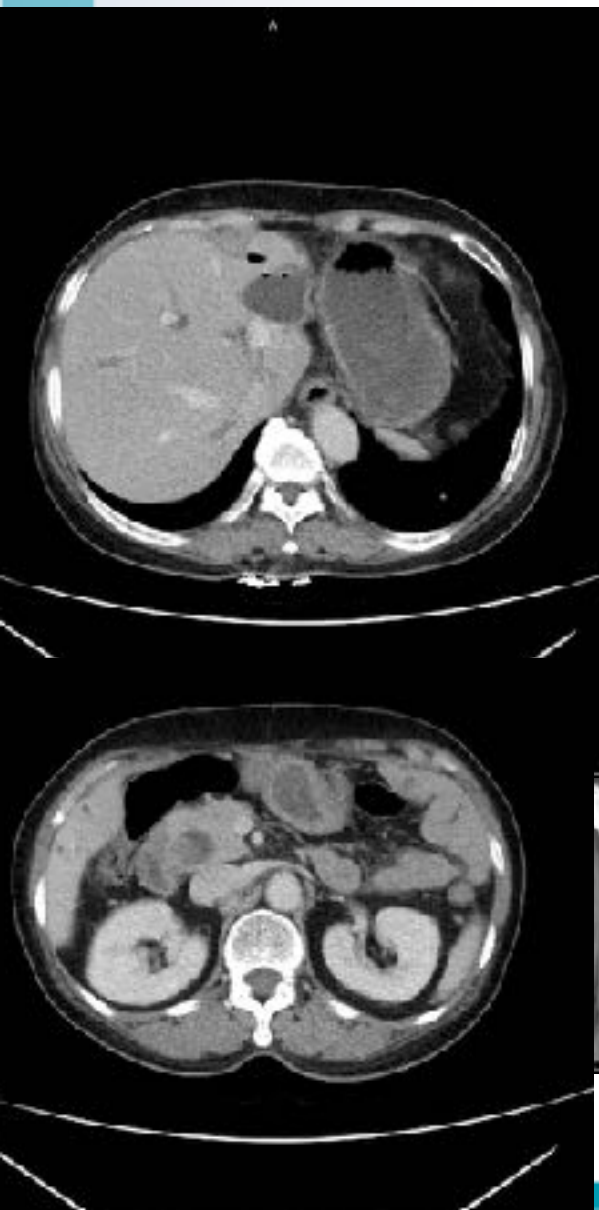# Femoral nerve block (佑達)



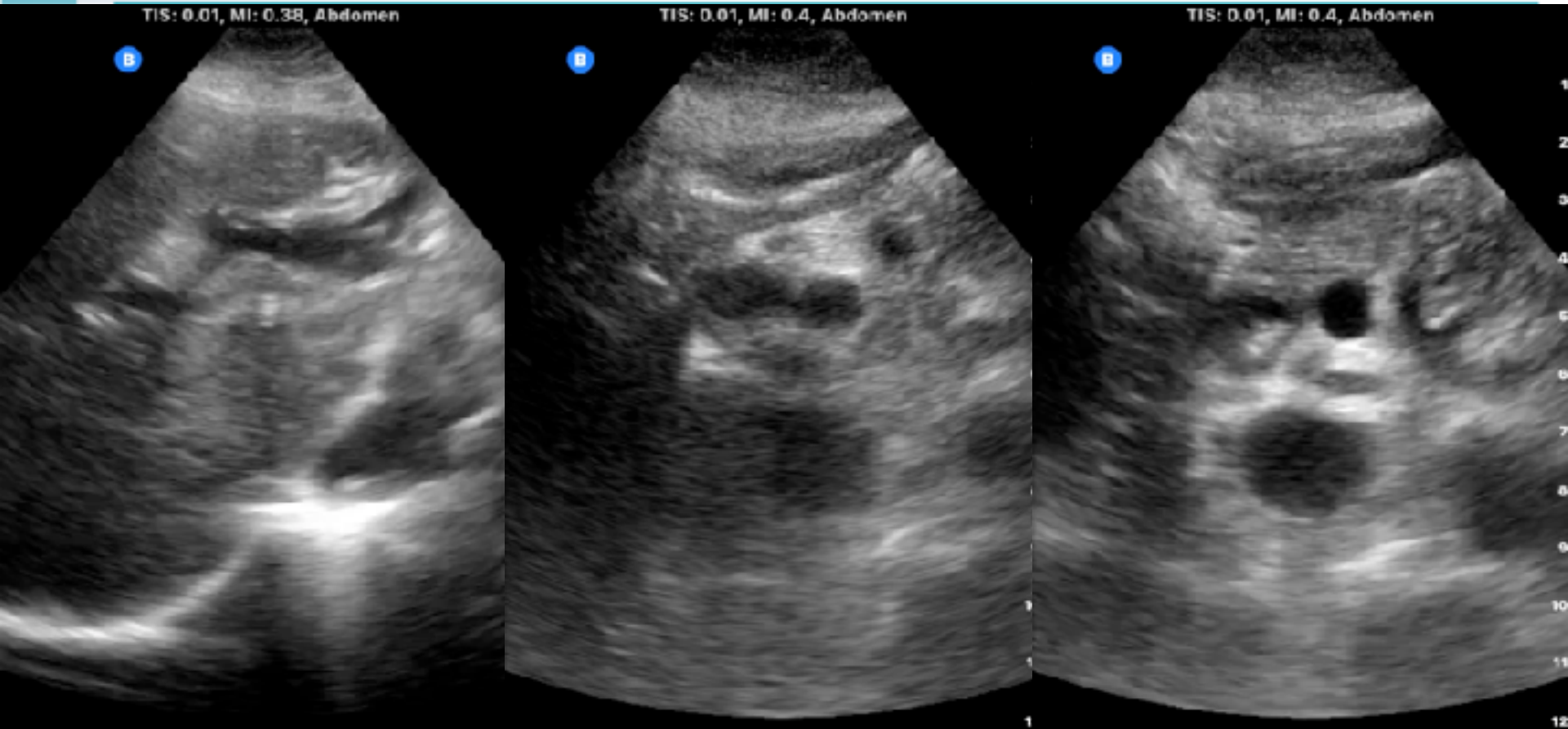
# 53F, left distal radial fracture



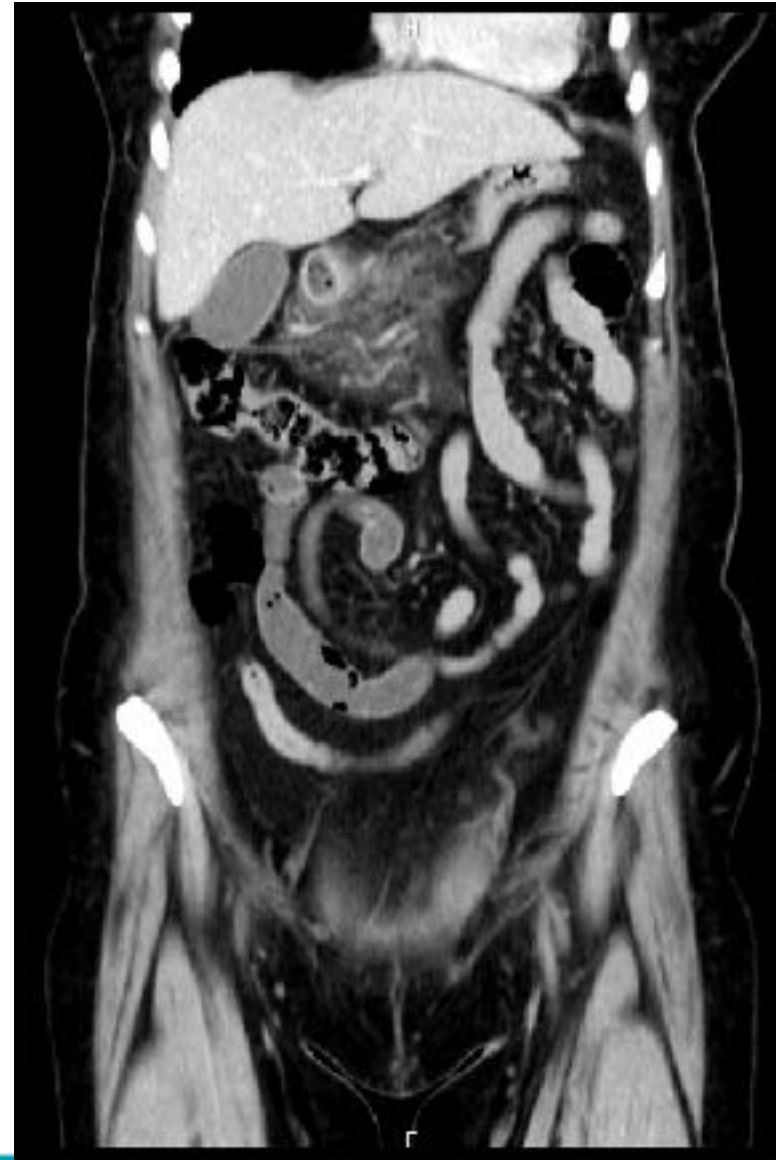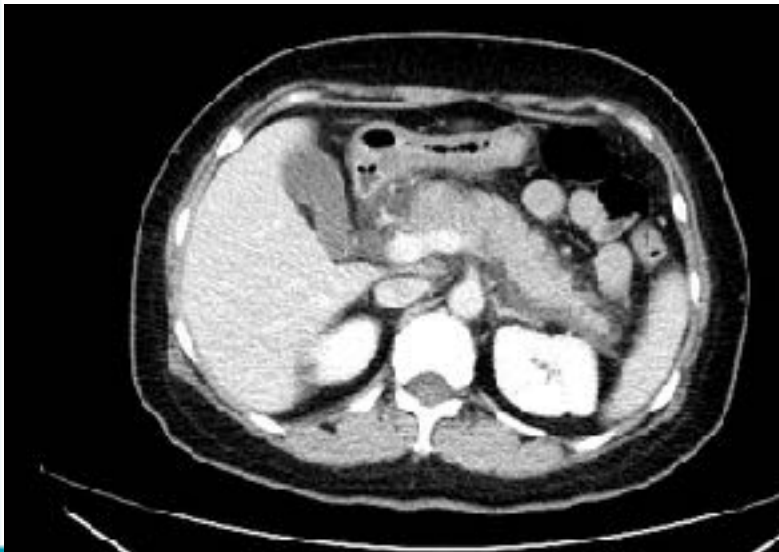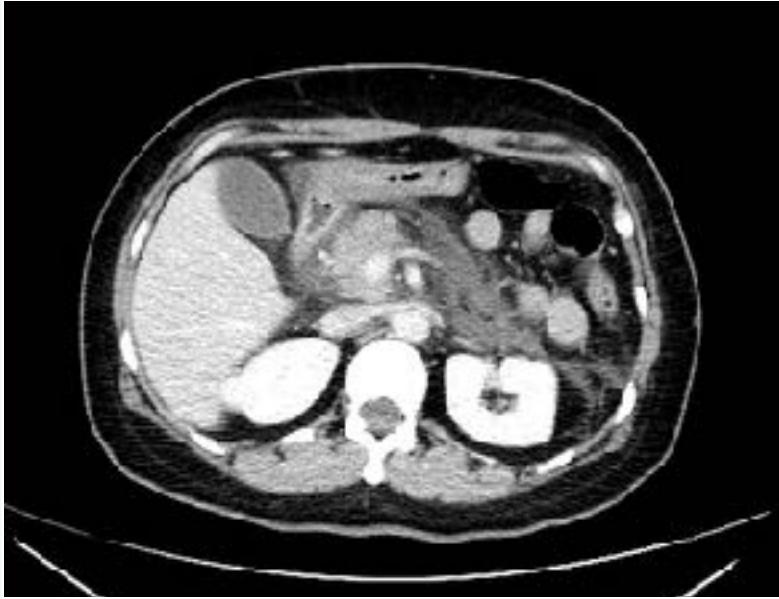# 68F, epigastric pain



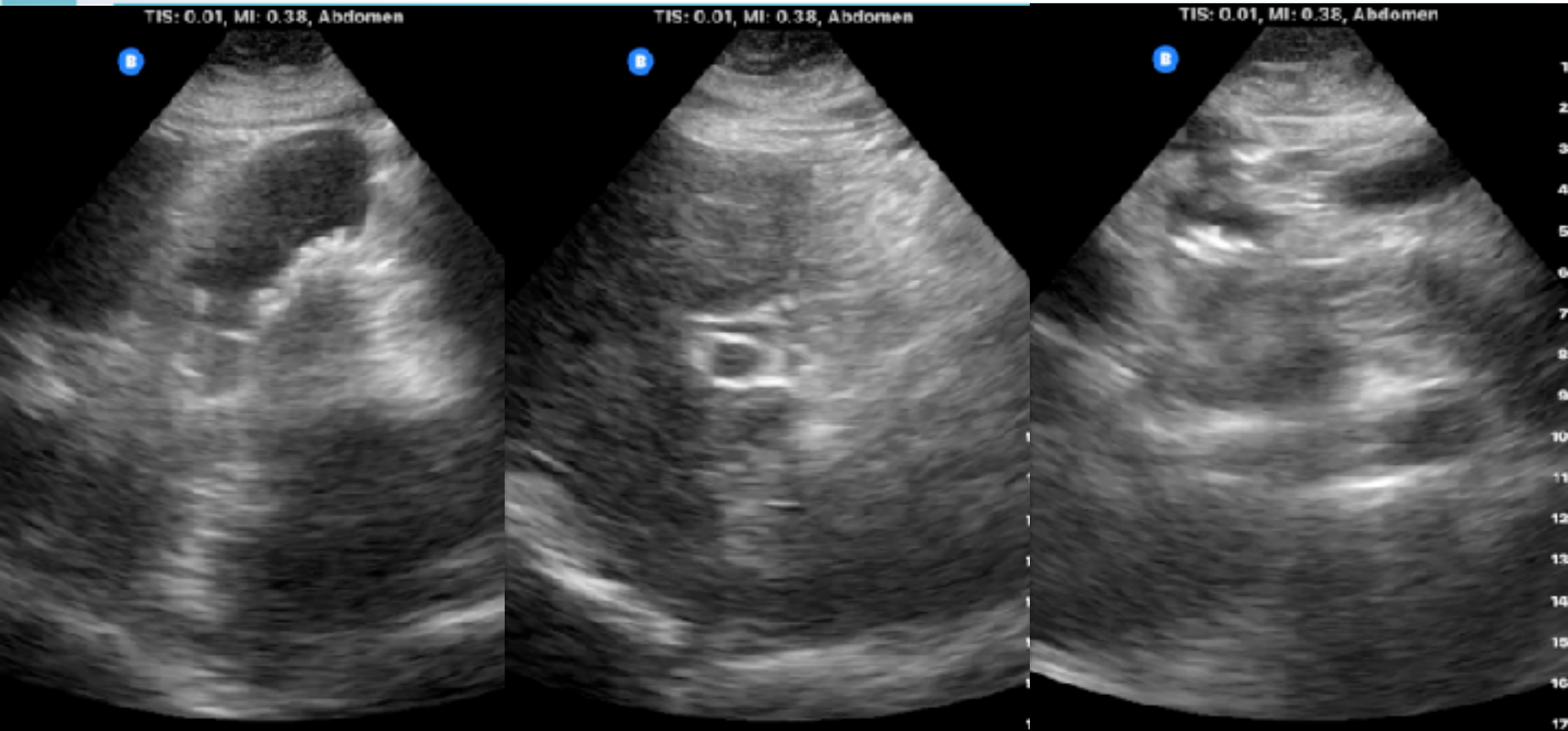
# CBD stones with obstruction



# 46F, pancreatitis



# 46F, pancreatitis

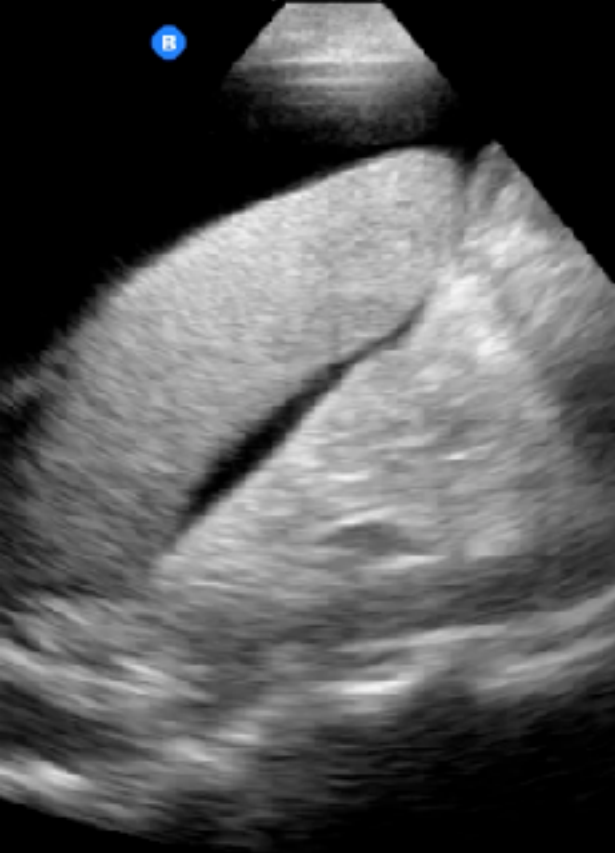

# 54M, Cirrhosis



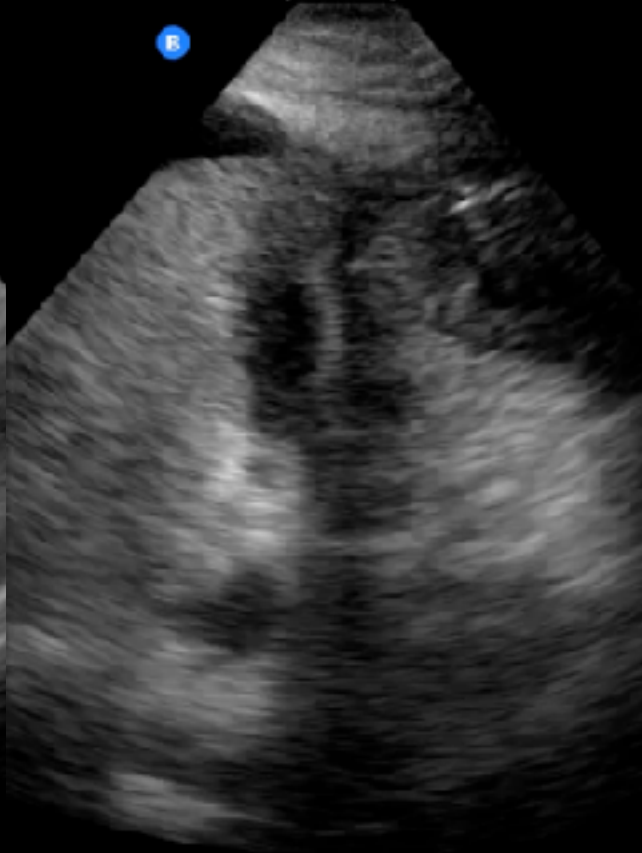TIS: 0.01, MI: 0.38, Abdomen

R



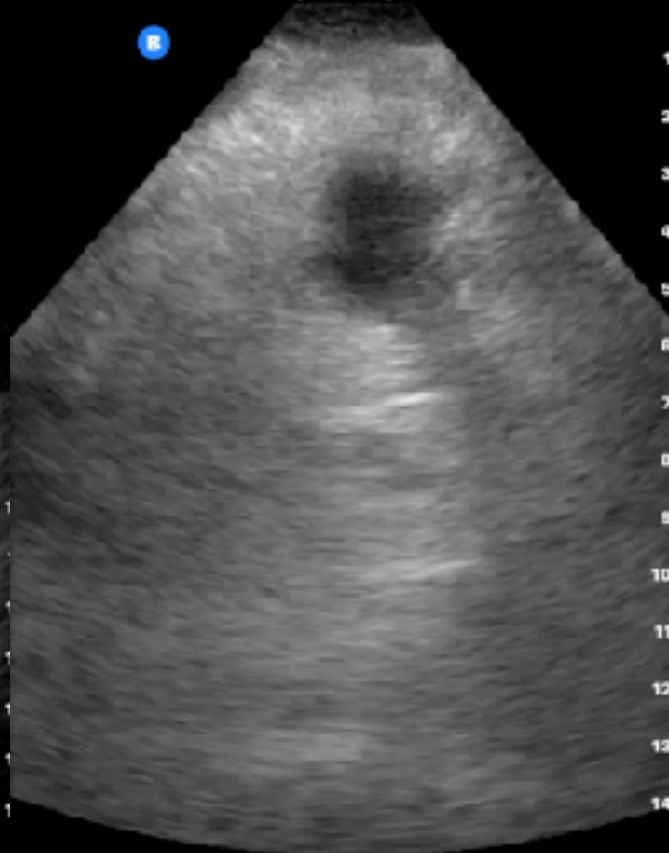TIS: 0.01, MI: 0.38, Abdomen

R

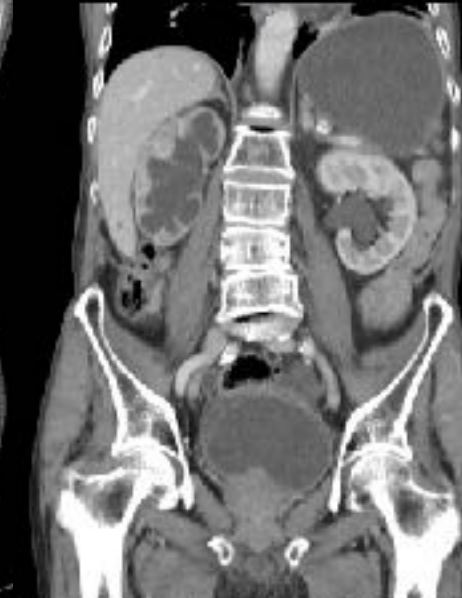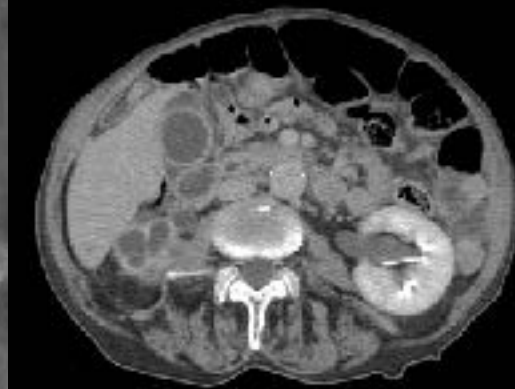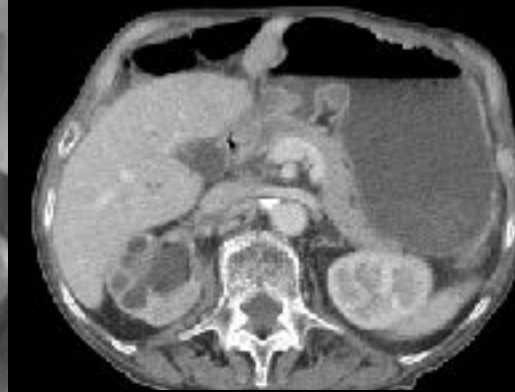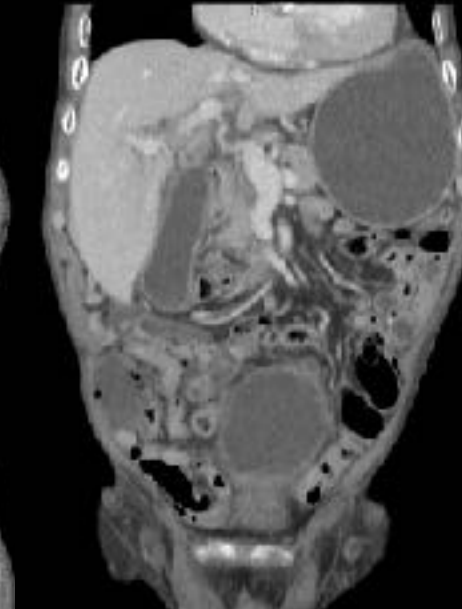


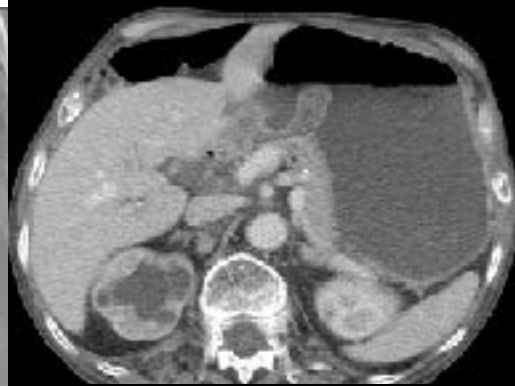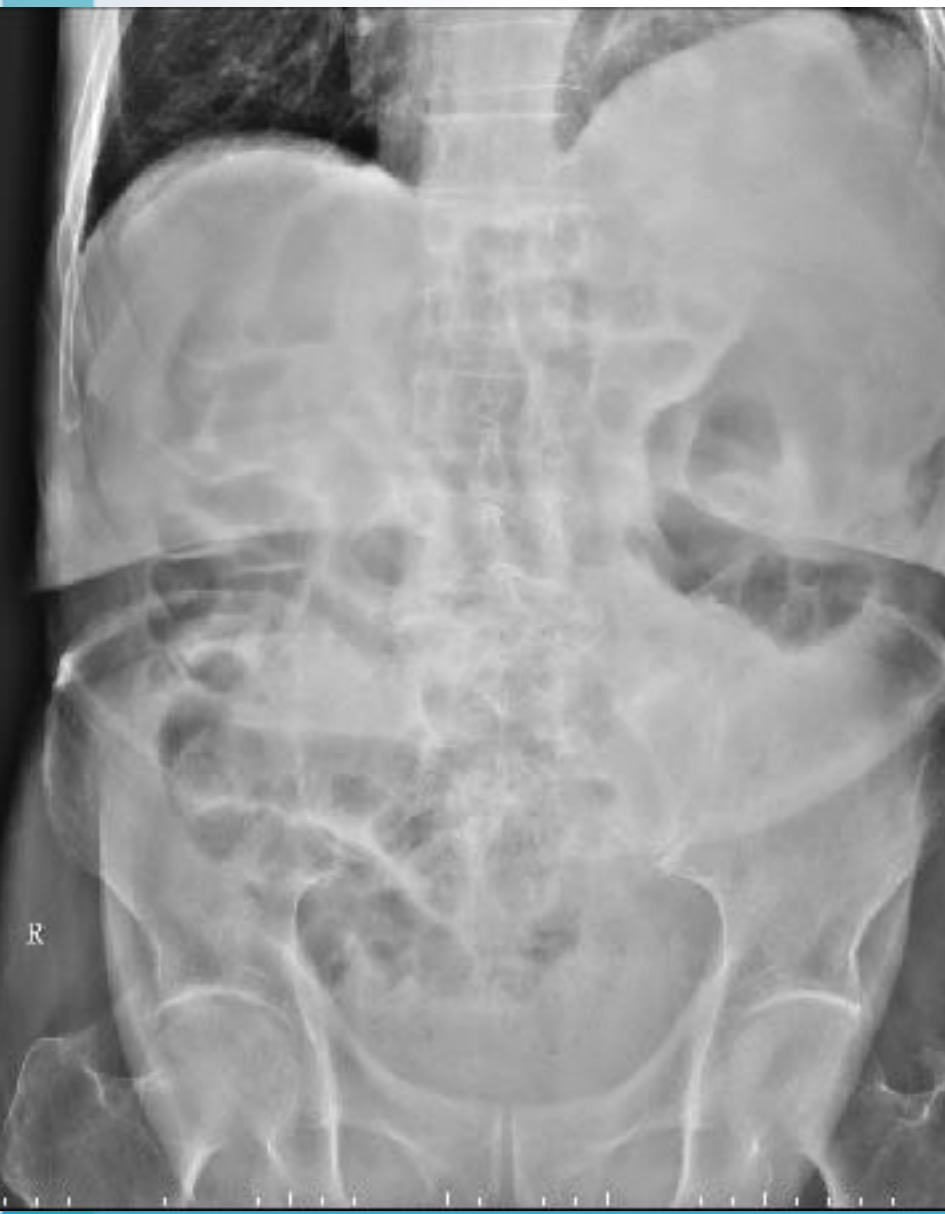TIS: 0.01, MI: 0.4, Abdomen

R



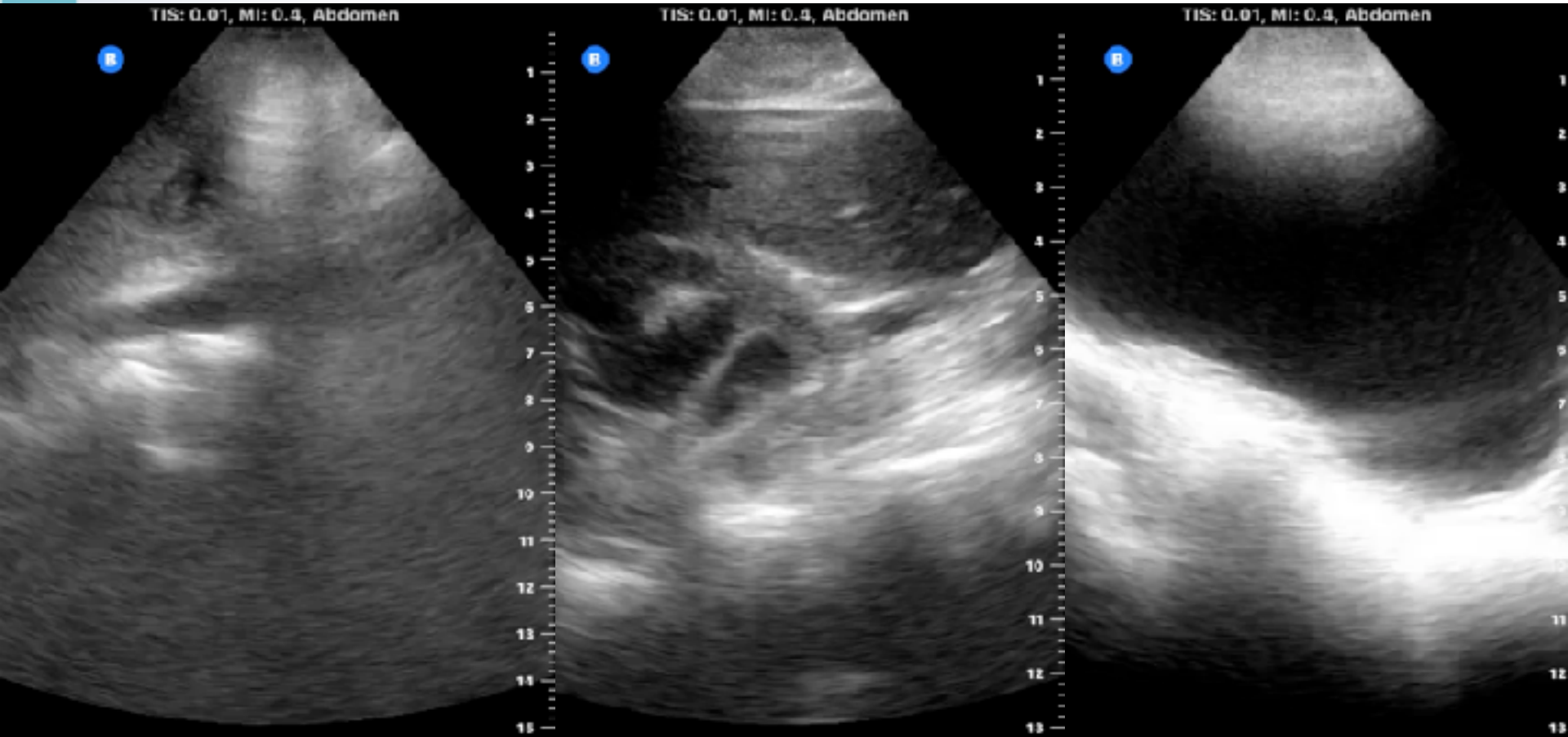
# 90M, GOO, AUR, Chr cholecystitis



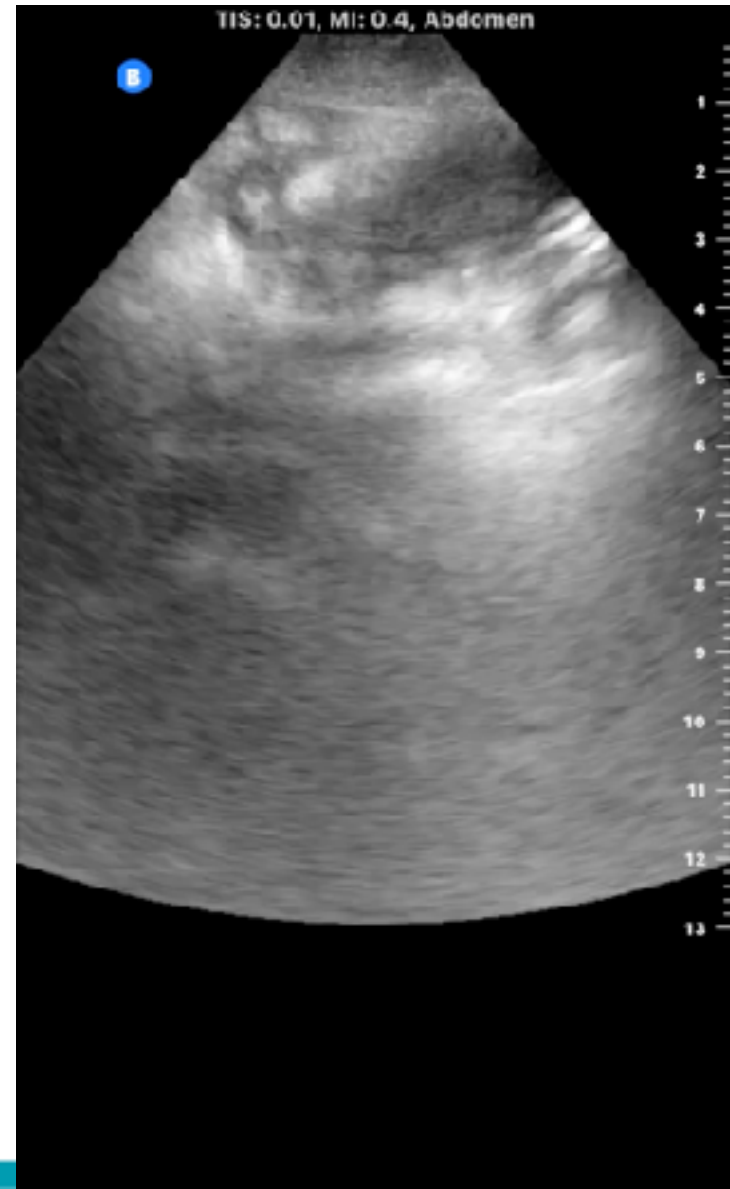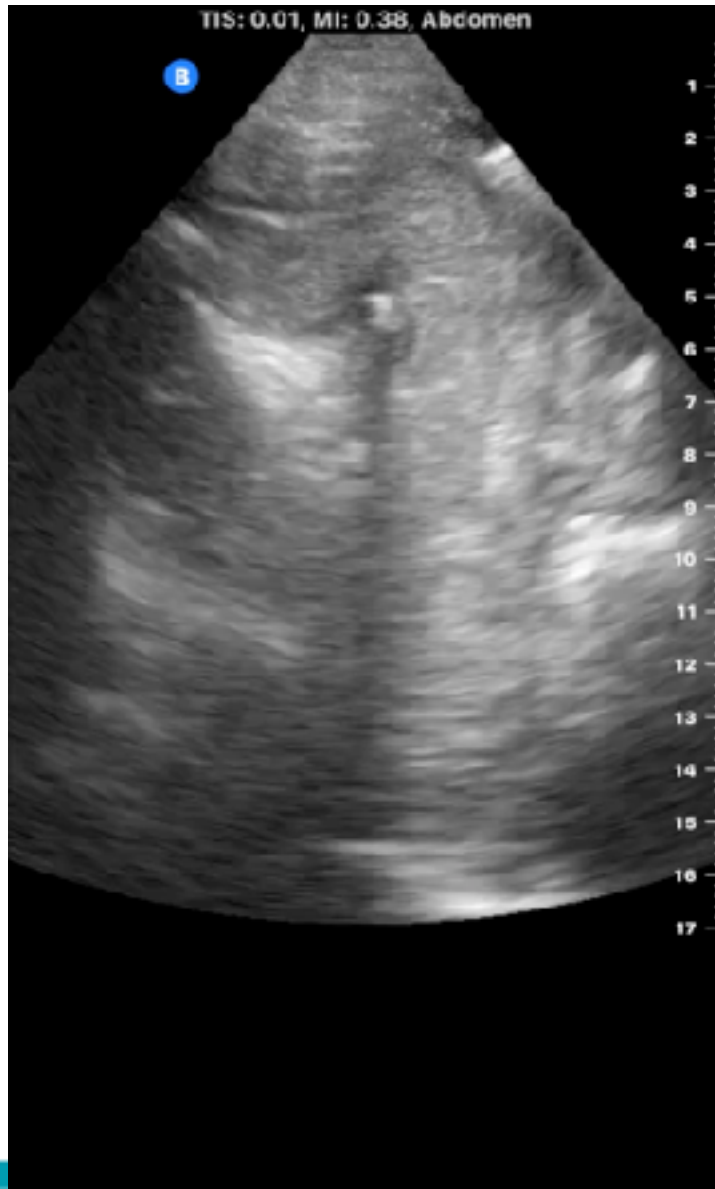R



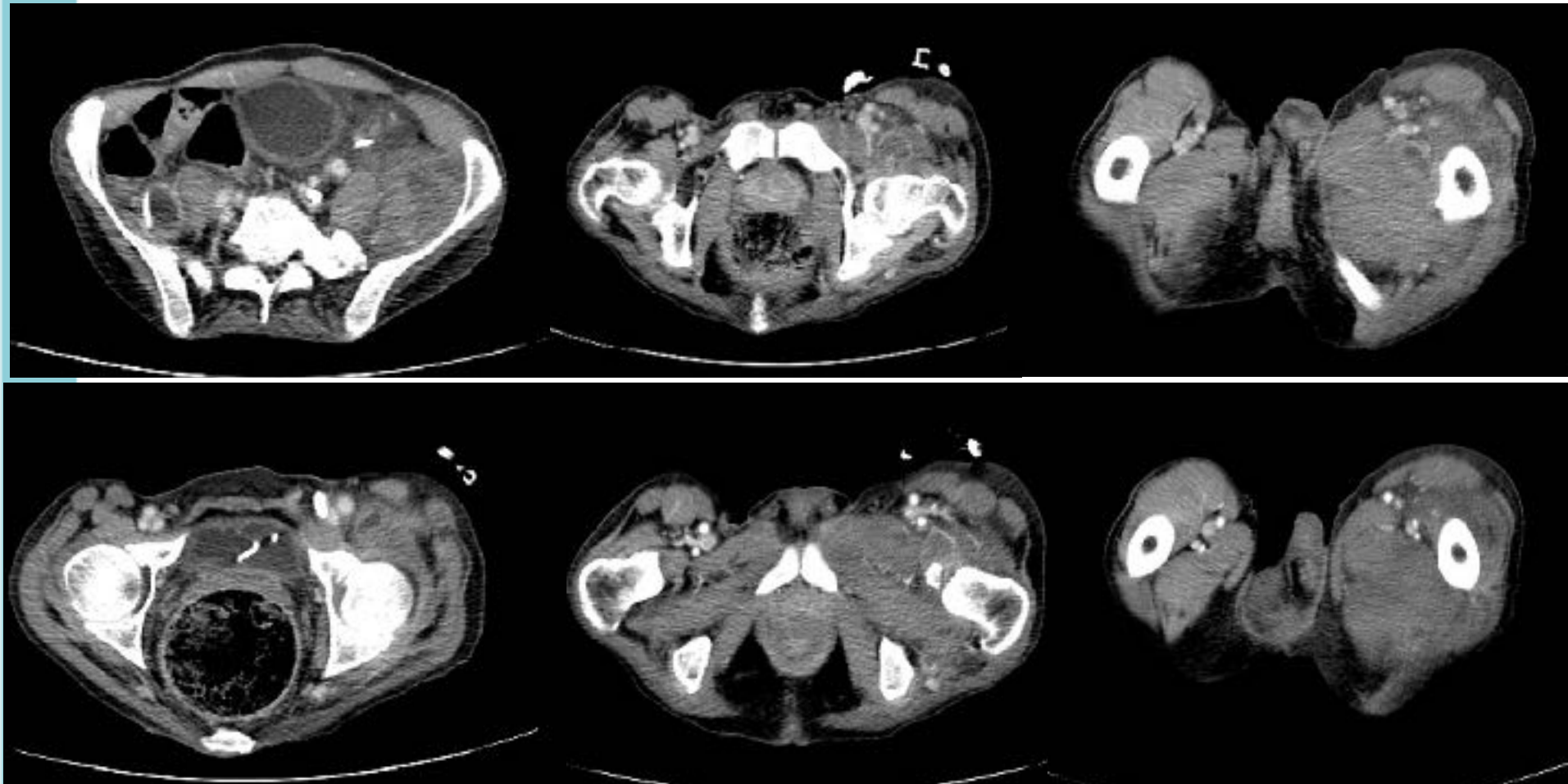
# 90M, GOO, AUR, Chr cholecystitis



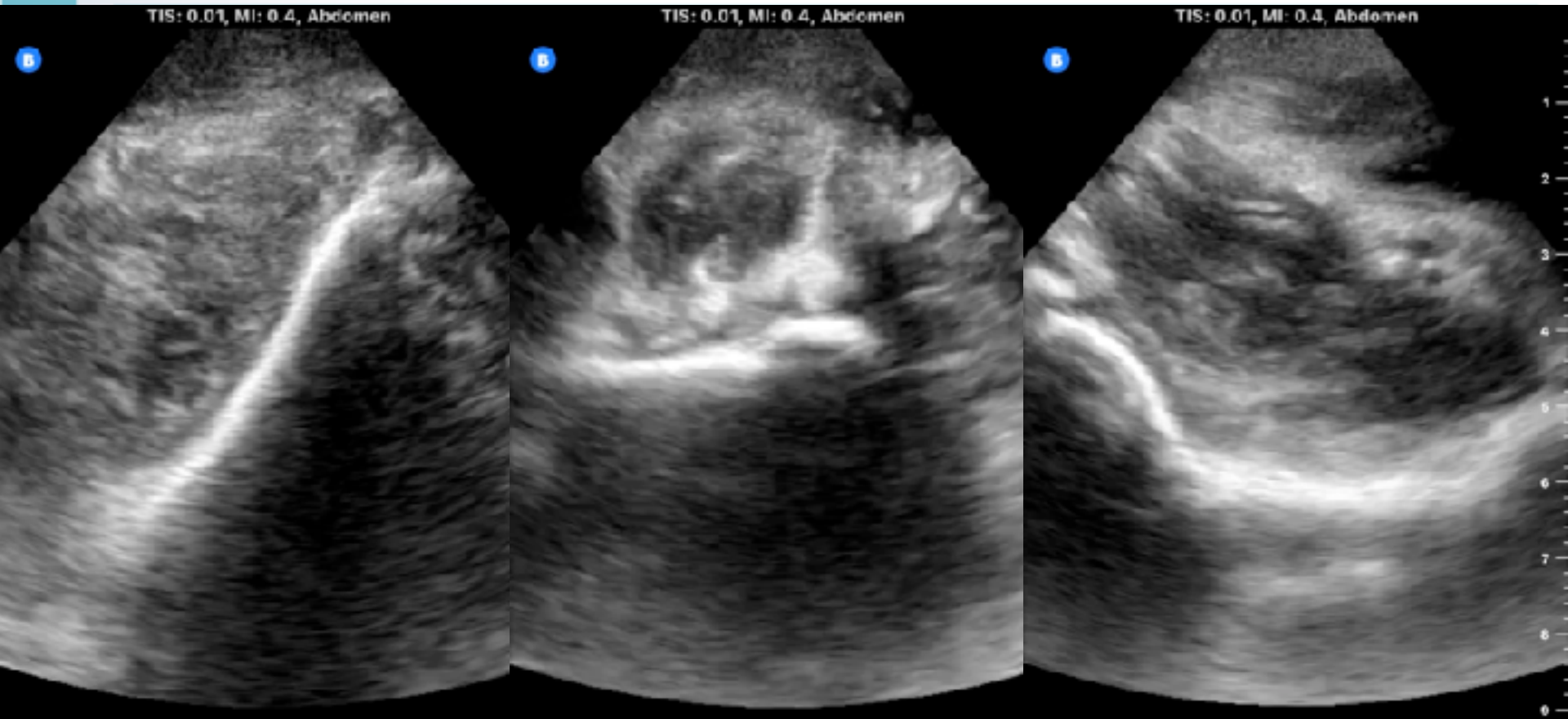
# 90M, GOO, AUR, Chr cholecystitis



# 47M, Iliacus muscle abscess

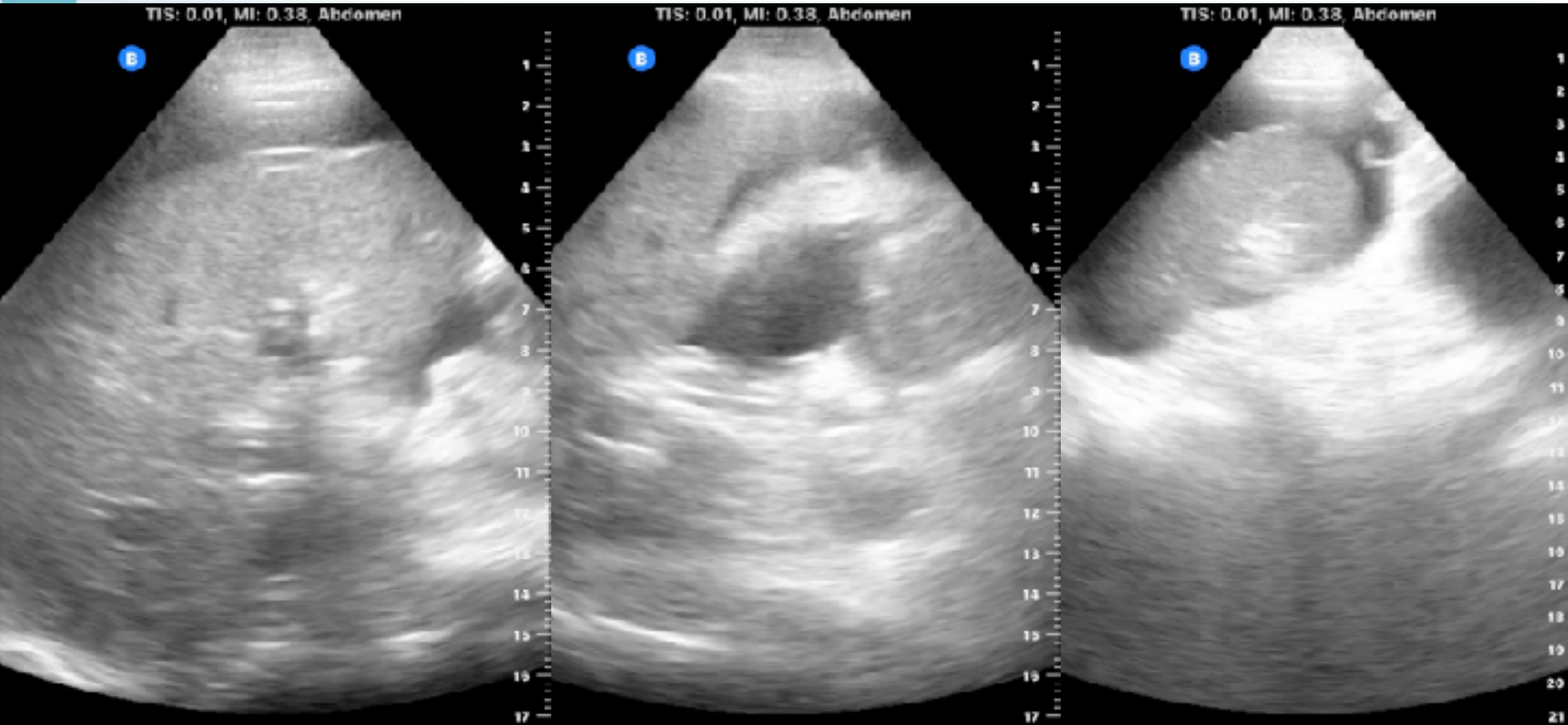


# 47M, Iliacus muscle abscess

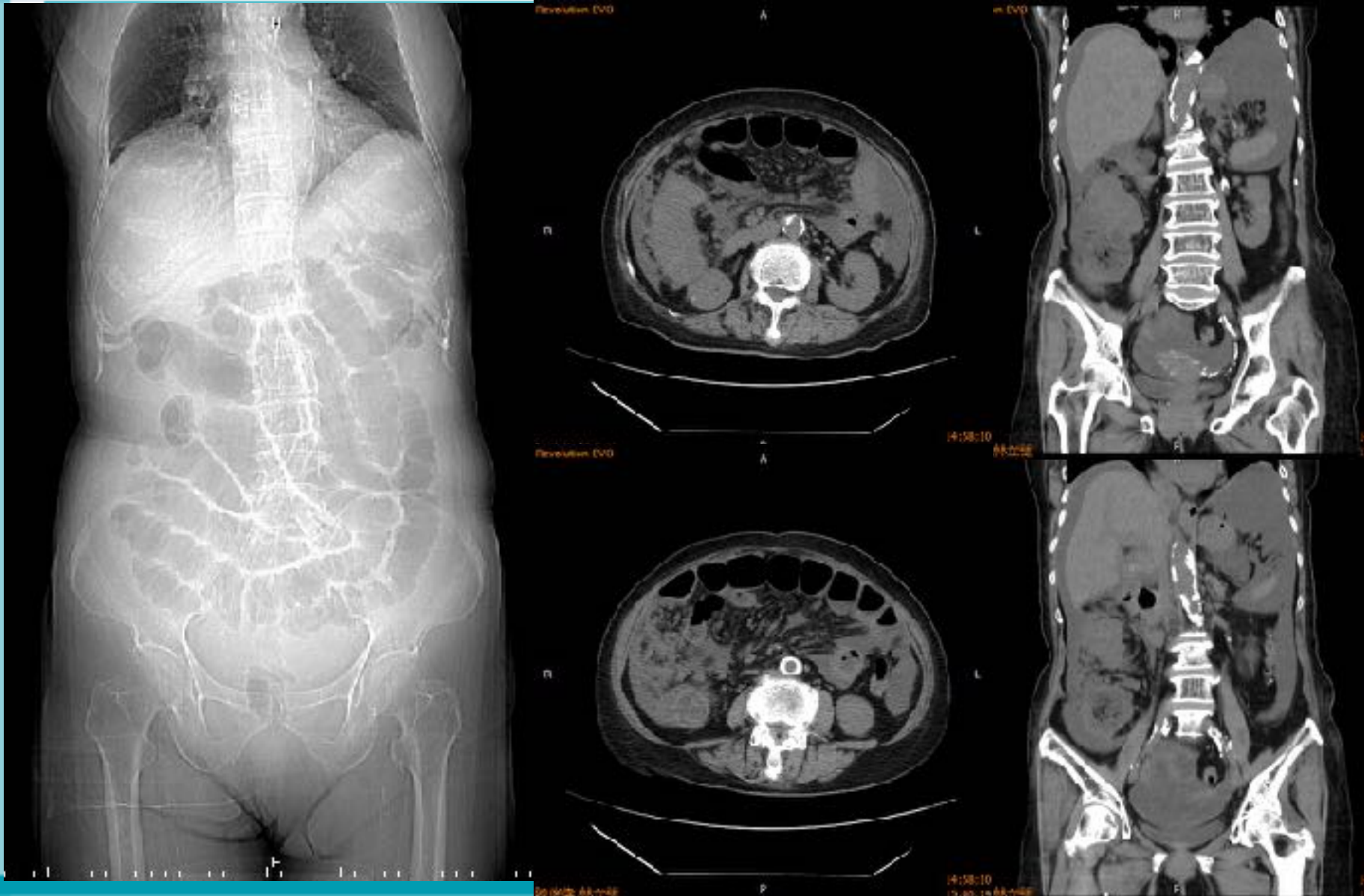




# 79F, Anemia, left side stroke / 做完胃鏡腹部漲痛



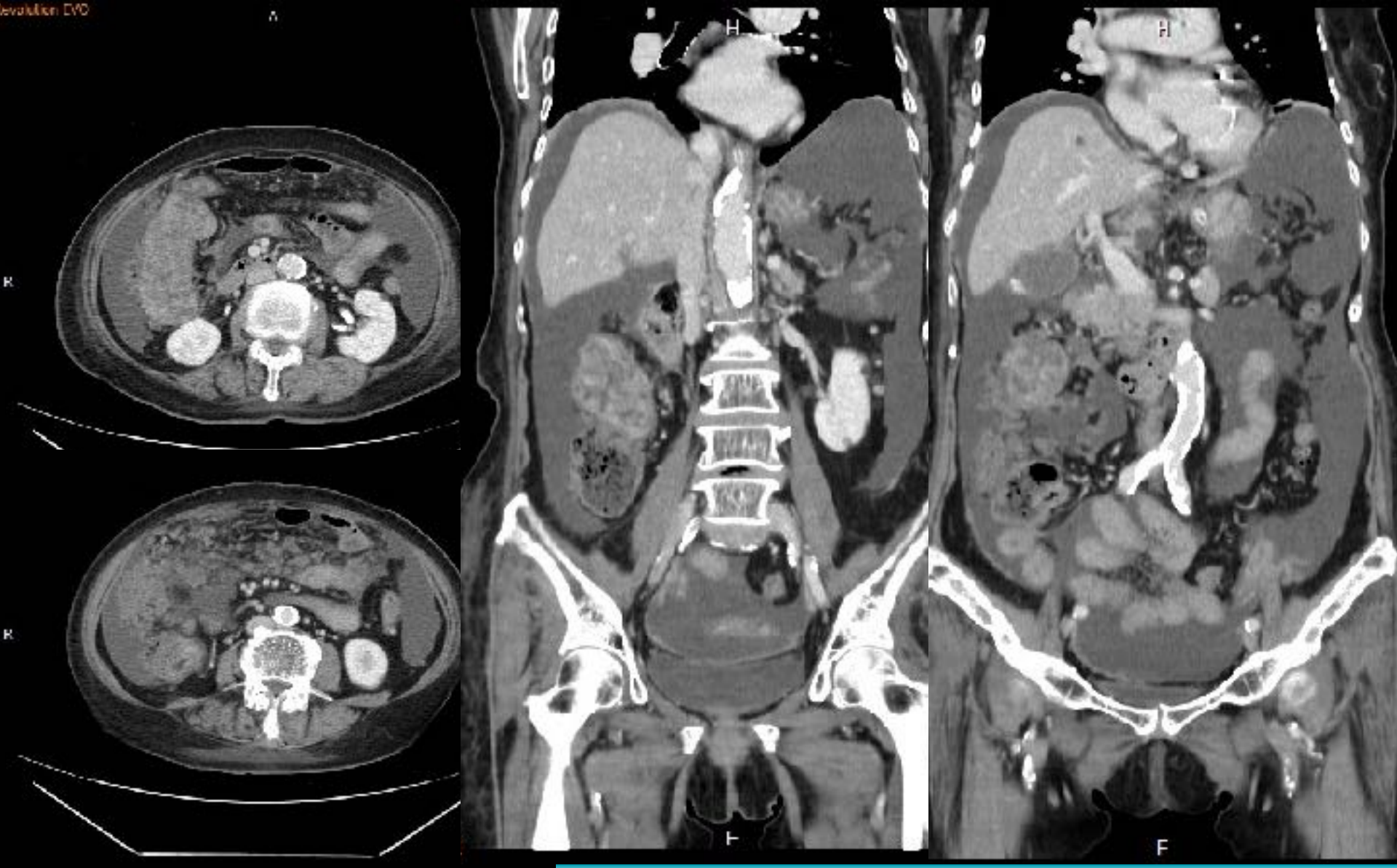# 79F, Anemia, left side stroke



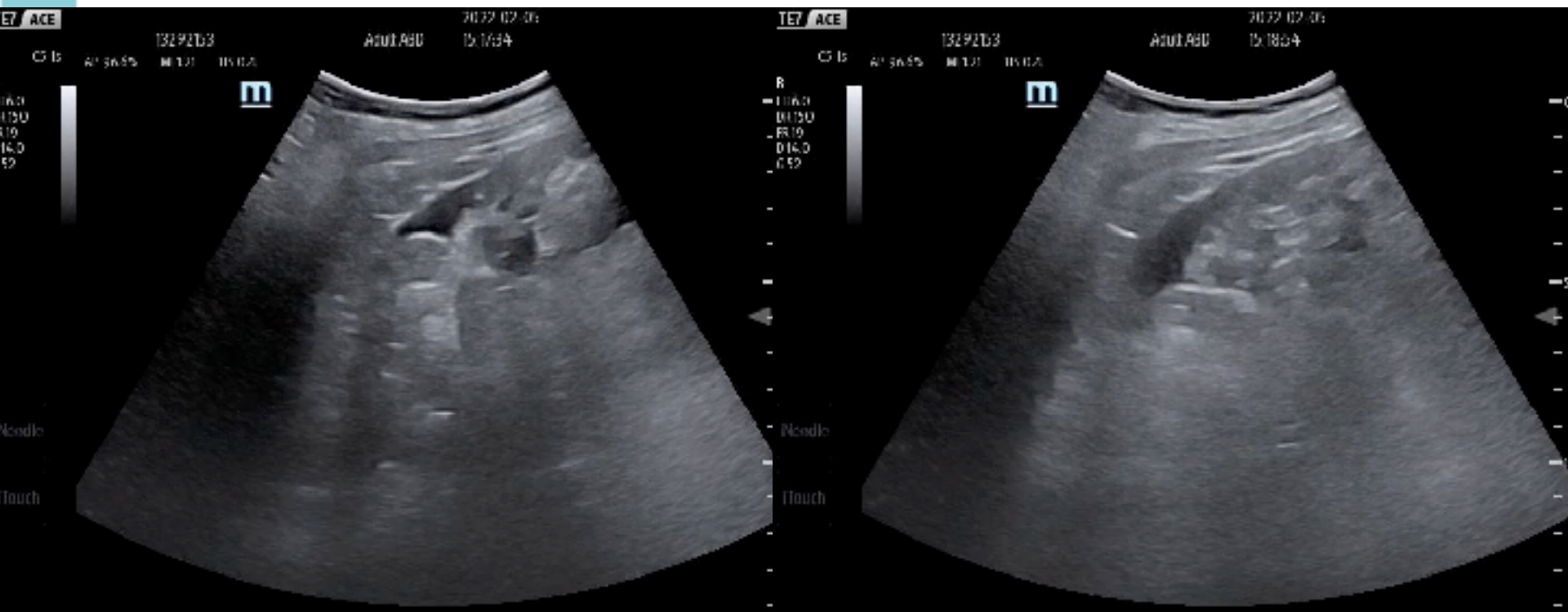
# 79F, Anemia, left side stroke



Revolution DVD

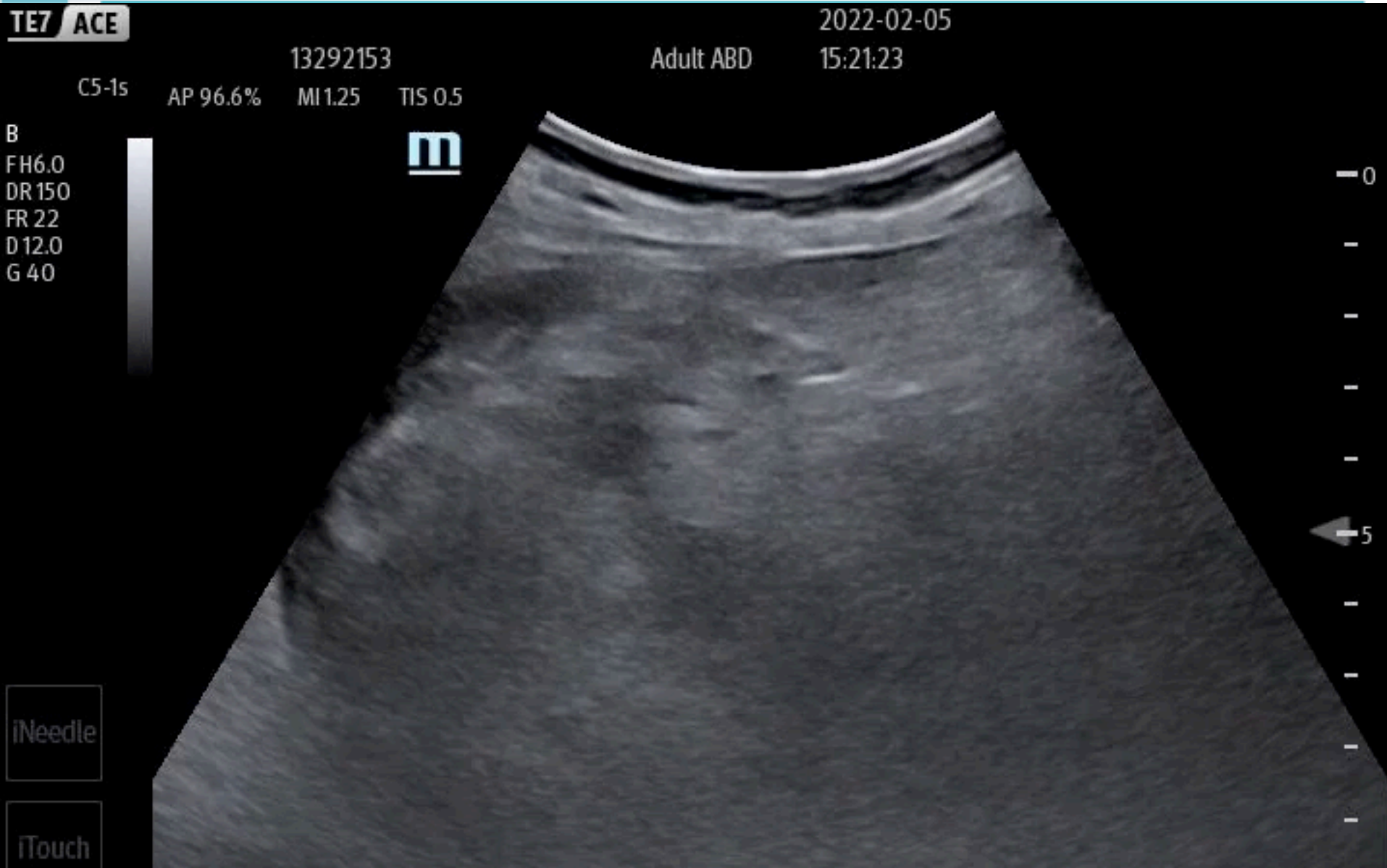


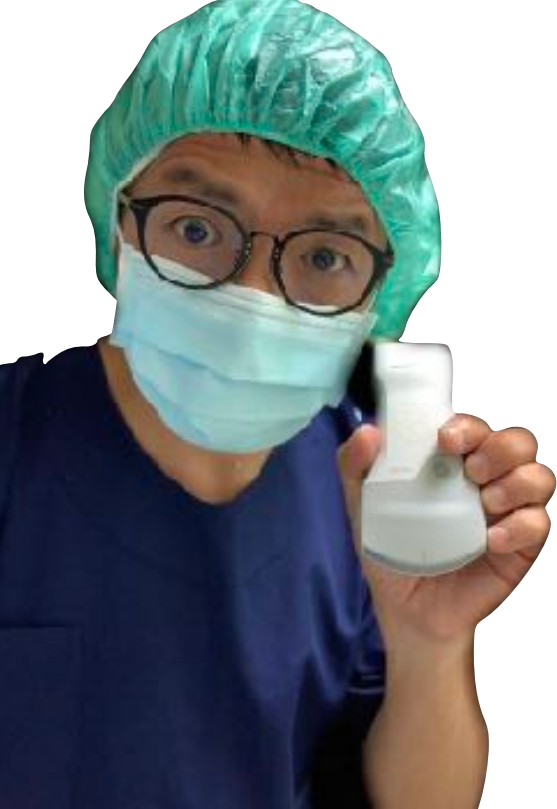# Colon cancer with carcinomatosis





# Colon cancer with carcinomatosis





努力可能會說謊，  
但努力不會白費。

羽生結弦

**HOLISTIC ULTRASOUND**

[juice119@gmail.com](mailto:juice119@gmail.com) / [POCUSacademy.com](http://POCUSacademy.com)