

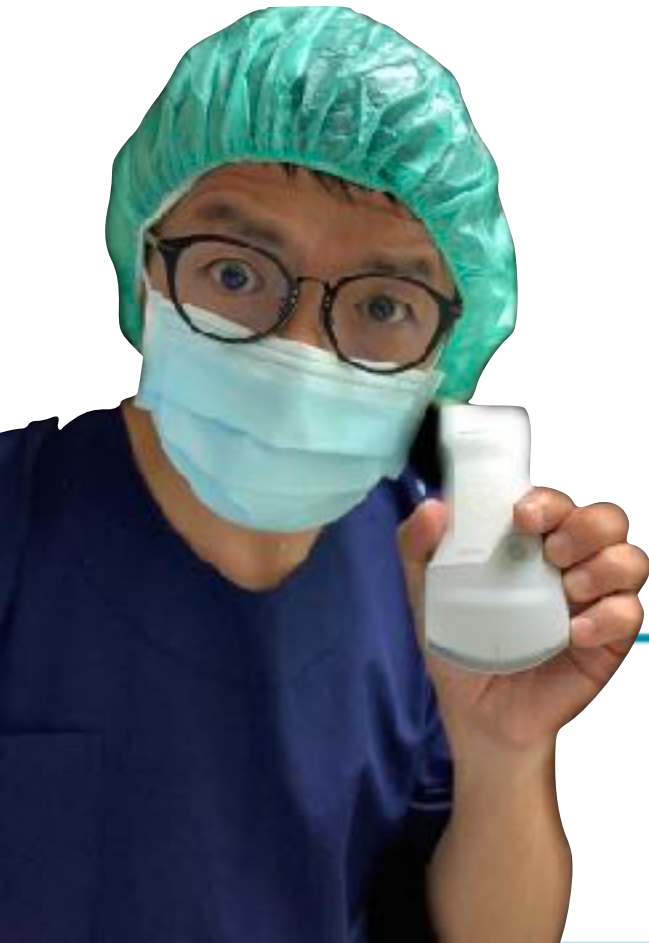

衛生福利部雙和醫院
(委託臺北醫學大學興建經營)
Taipei Medical University · Shuang Ho Hospital,
Ministry of Health and Welfare



Holistic Ultrasound in ER

Vscan Air Sharing Session 2022/02/27



陳國智醫師
雙和醫院 急診醫學科

陳國智 醫師



醫用超音波學會指導醫師
WINFOCUS director / instructor
急救加護醫學會重症超音波負責人

急診 / 重症 / 介入 / 急性疼痛

經歷

新光急診超音波訓練中心主任

西園醫院急診醫學科主任

急診醫學會超音波委員會主委

台灣疼痛醫學會大體模擬手術講師

診
斷

監
測

介
入

POINT OF CARE ULTRASOUND

~ 存在於臨床需求之所在 ~

解剖

Anatomy

形態

Pattern

診斷

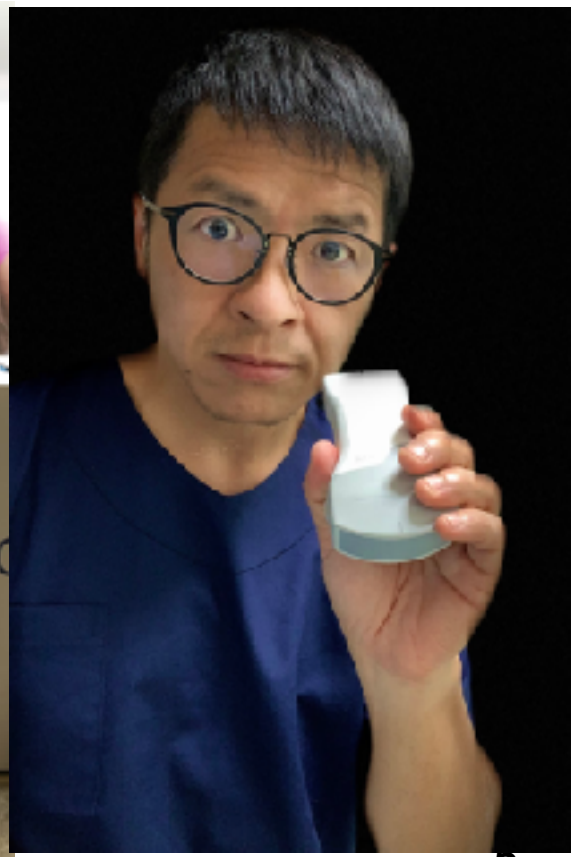
Diagnosis

HOLISTIC ULTRASOUND

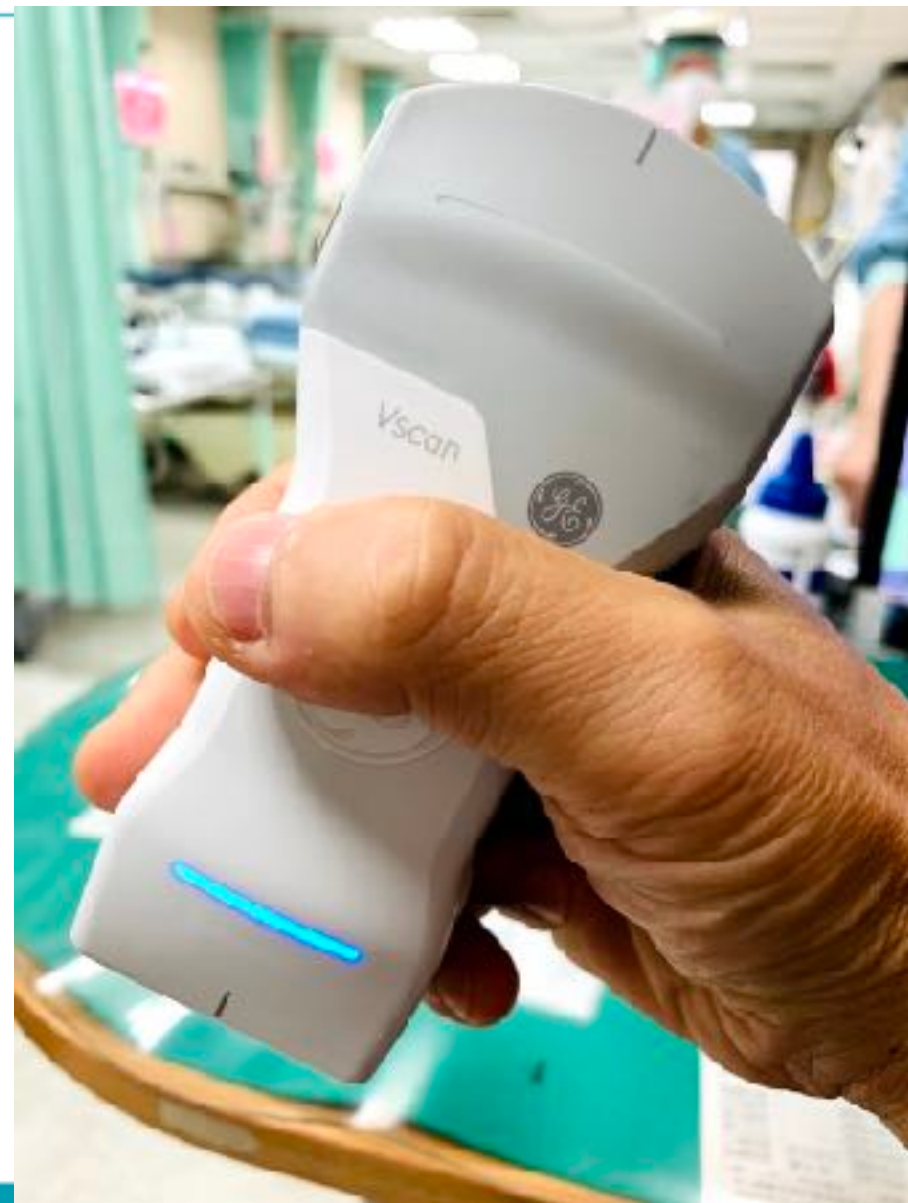Holistic medicine

Treatment that deal with the whole person,
not just the injury or disease

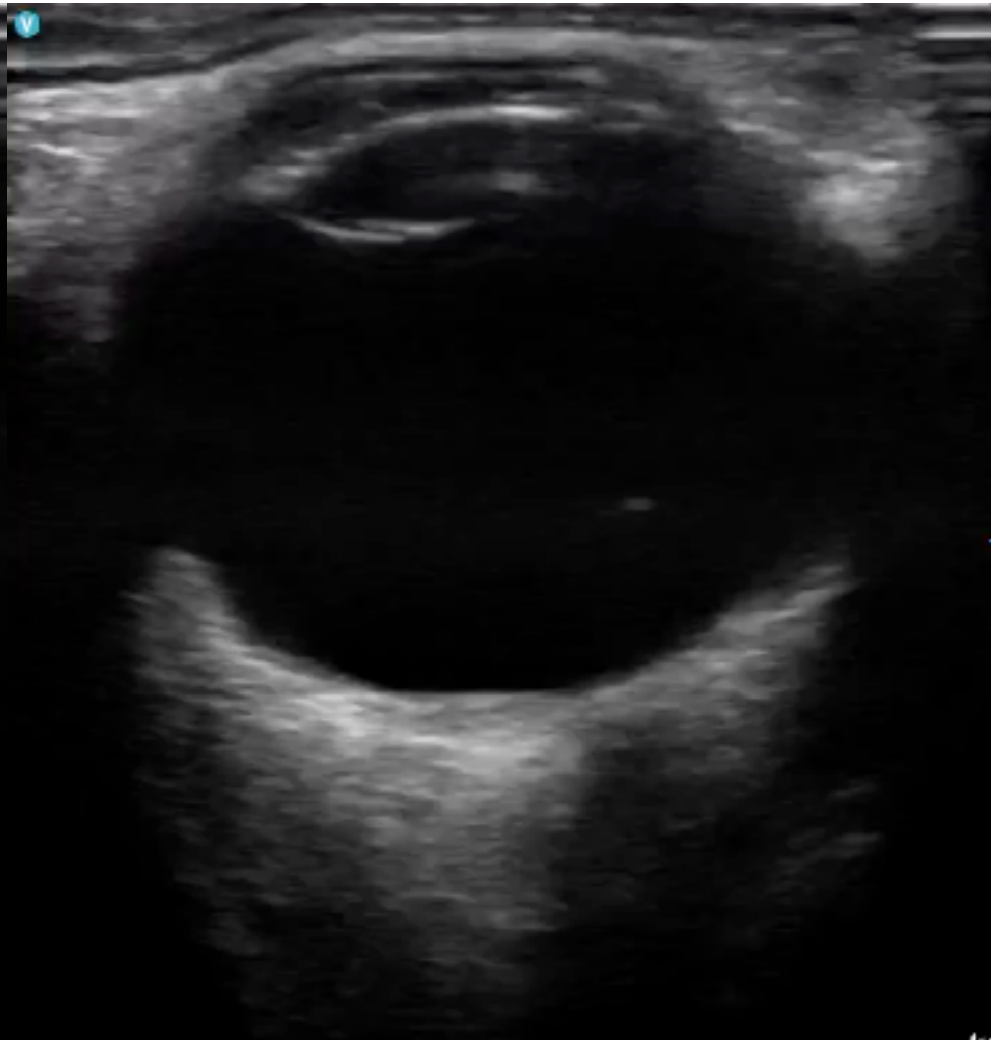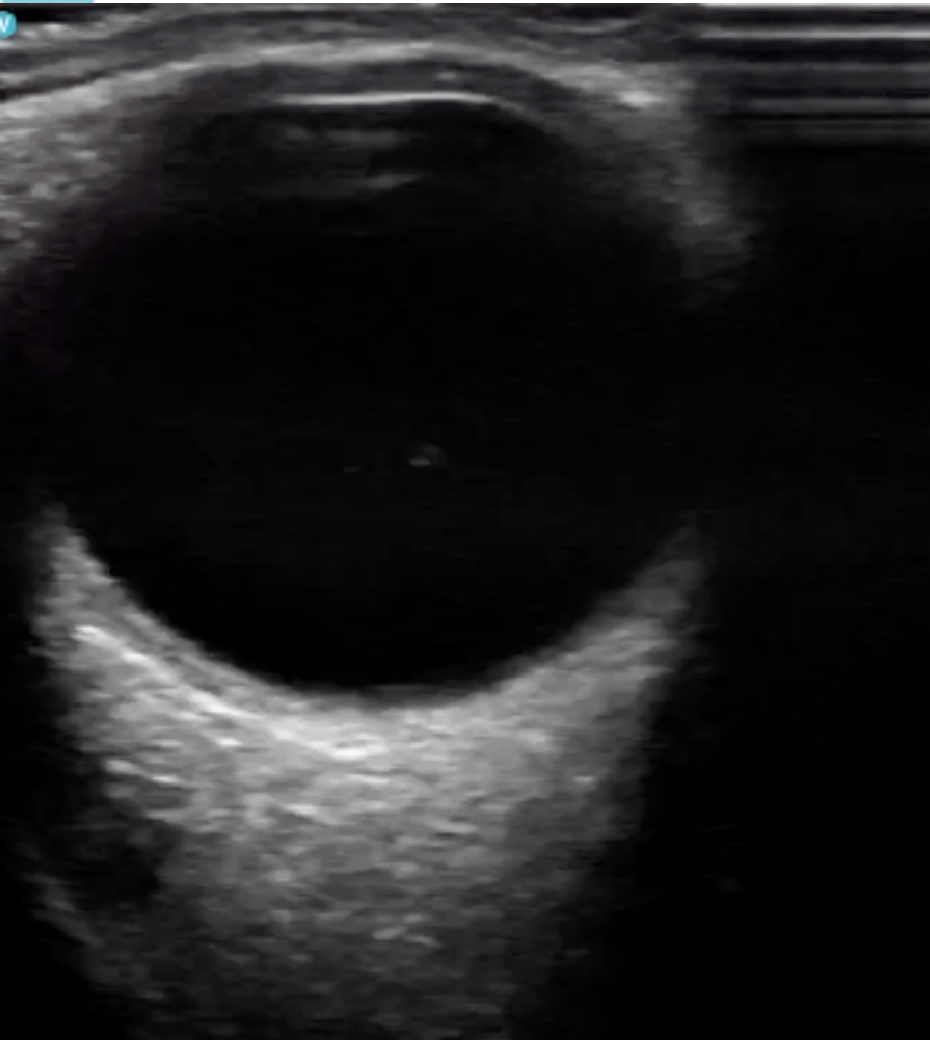
GE Vscan generation



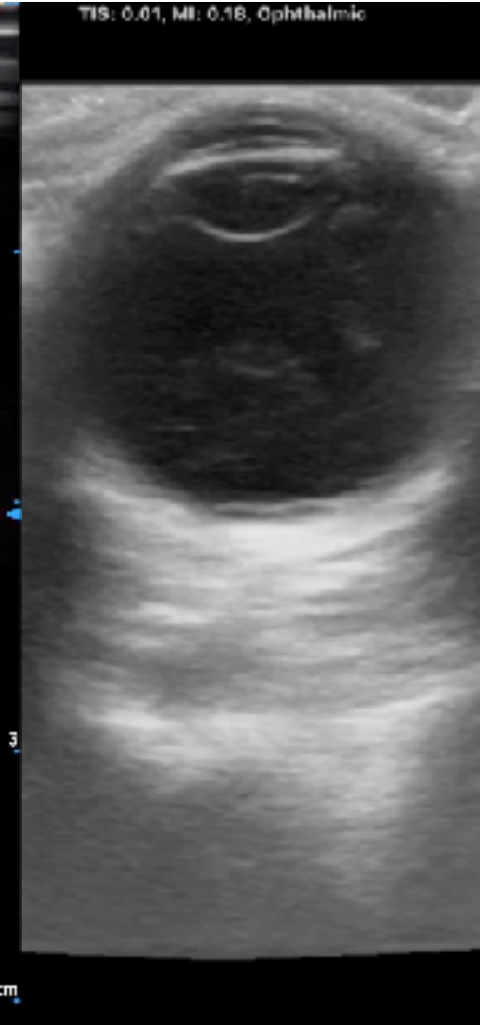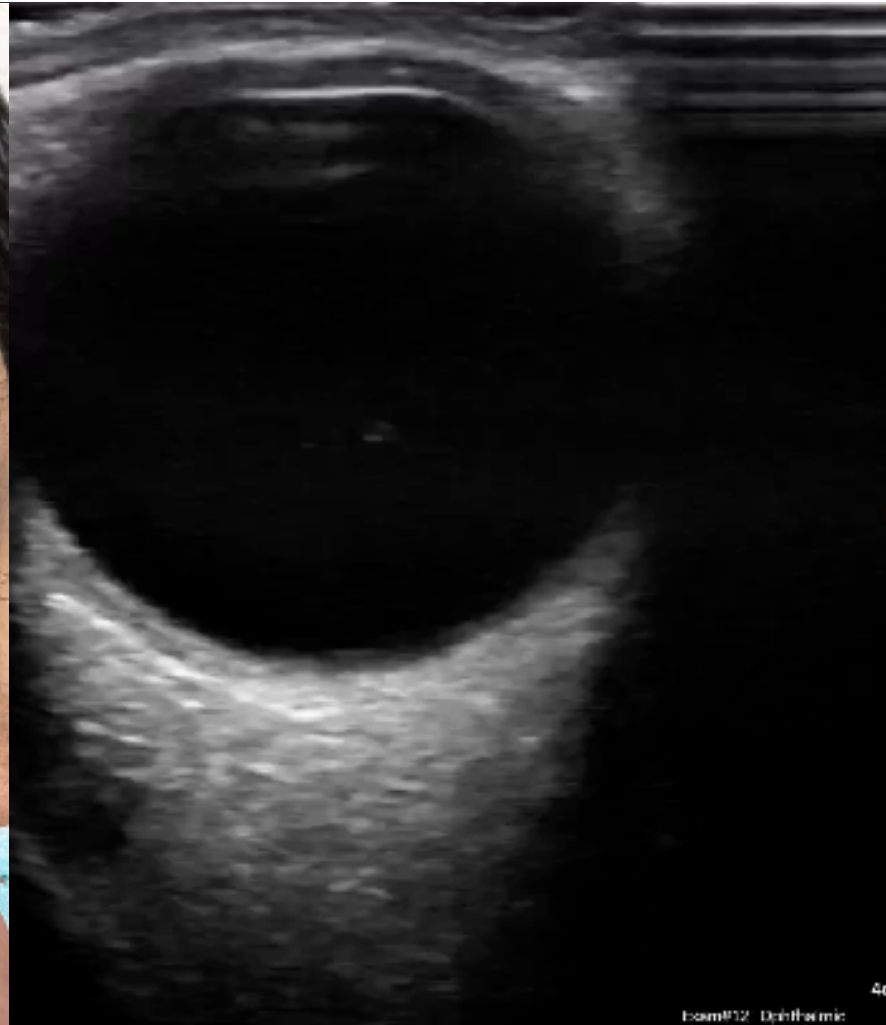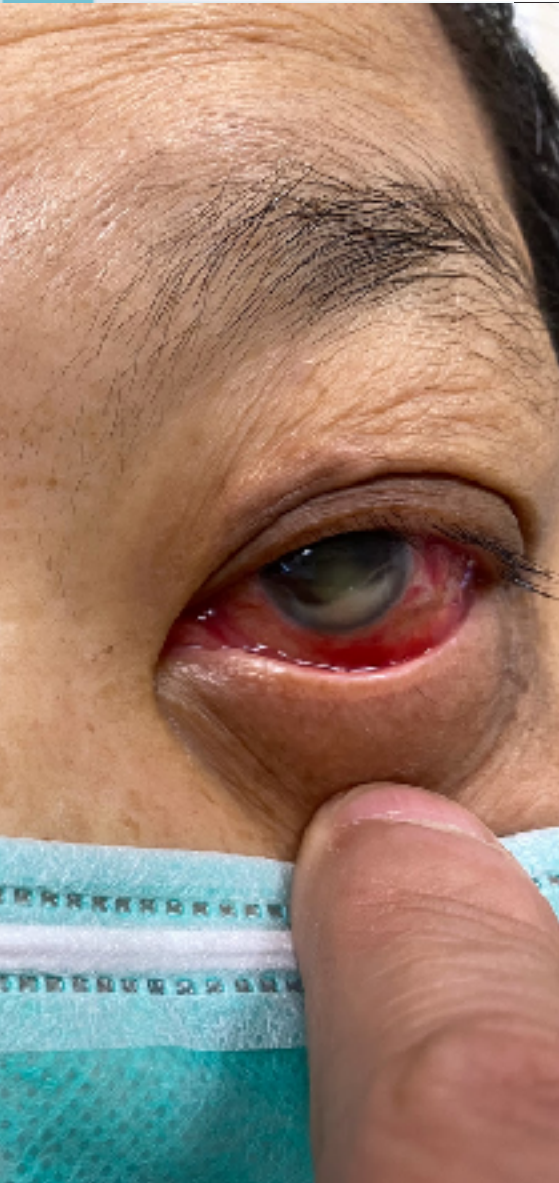
雙槍俠 (腹/深 & 線/淺)



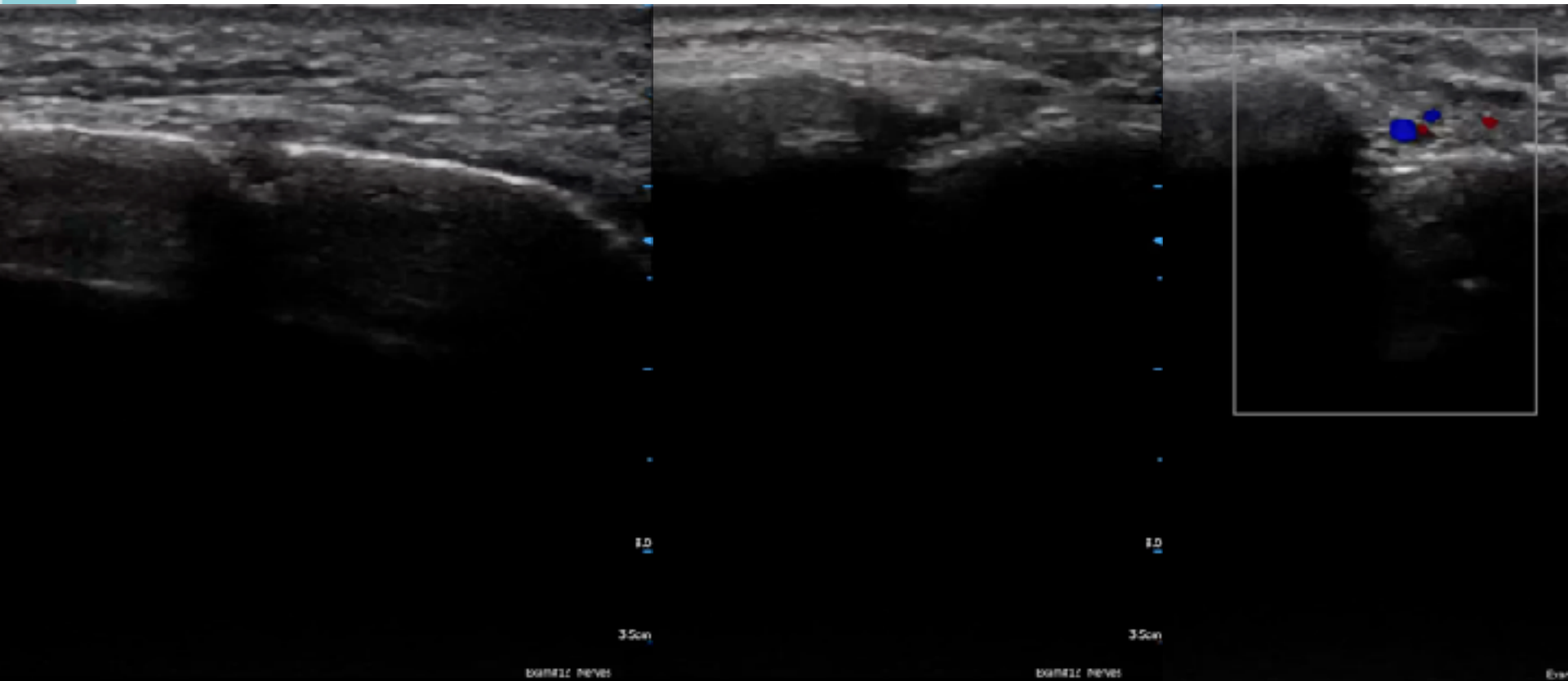
EYE (ONSD, RD, VD, VH)



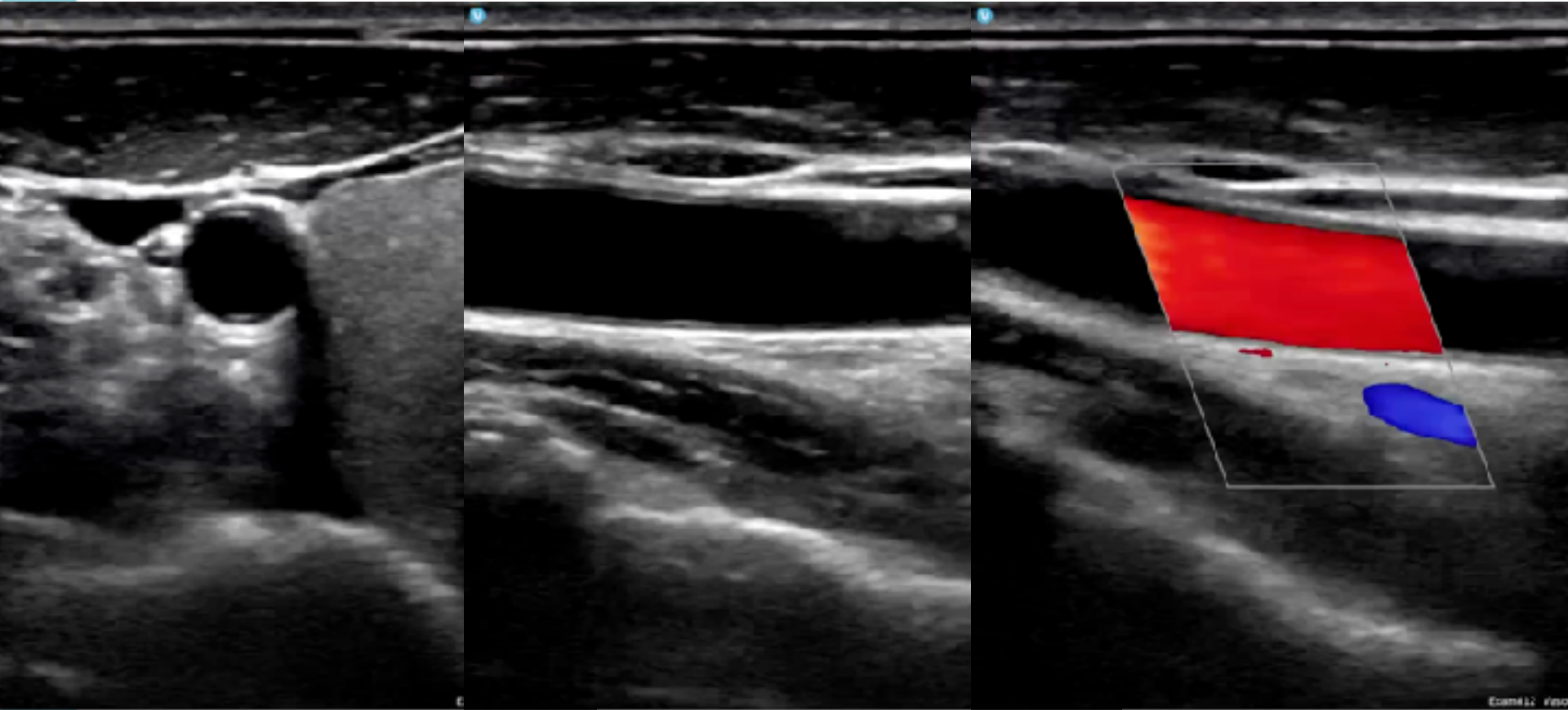
Liver abscess / Endophthalmitis



Mandible & maxillary nerve



Common carotid artery



52M, Chest pain



ACE

2022-01-28

2022-01-28

Tracheal

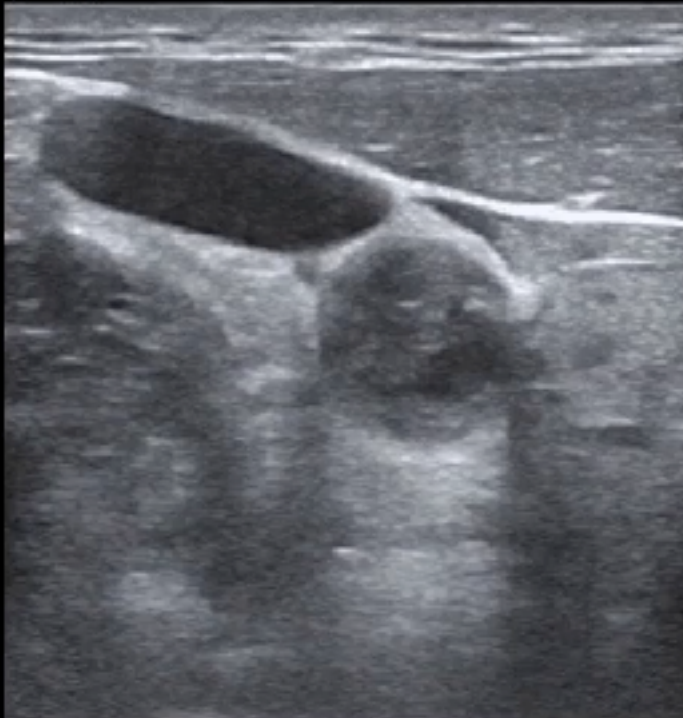15:34:01

Tracheal

15:33:21

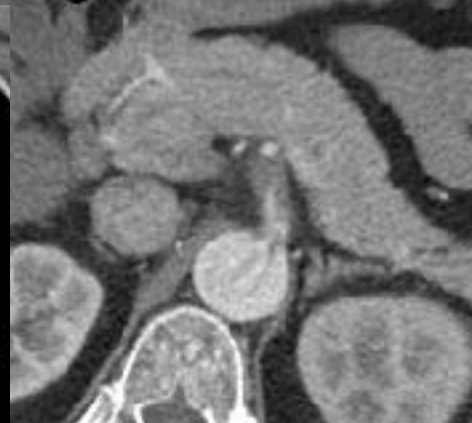
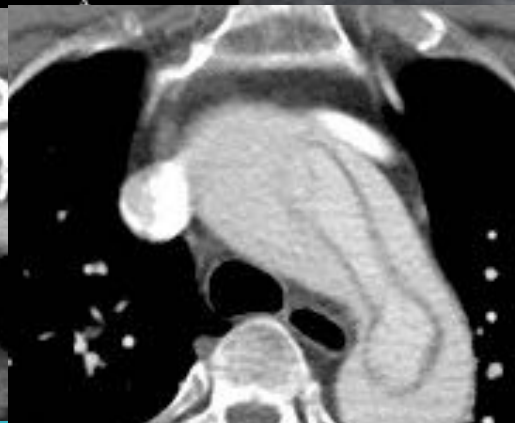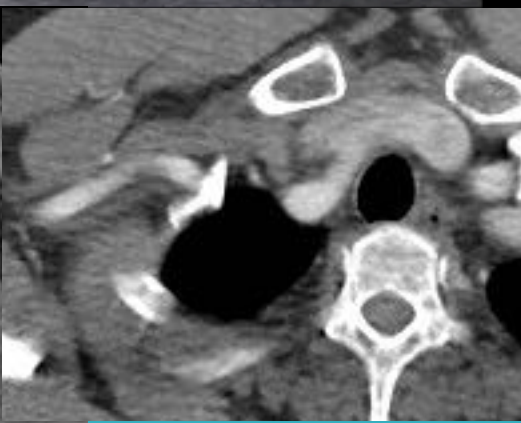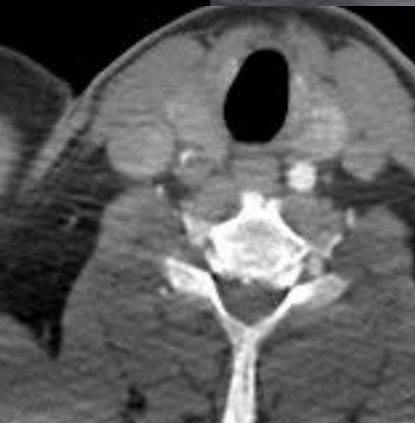
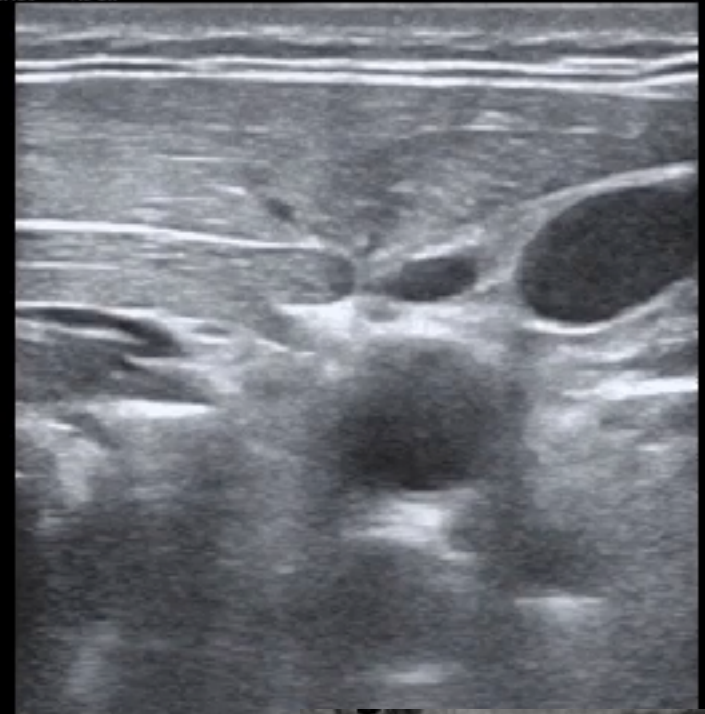
L12 4s

m

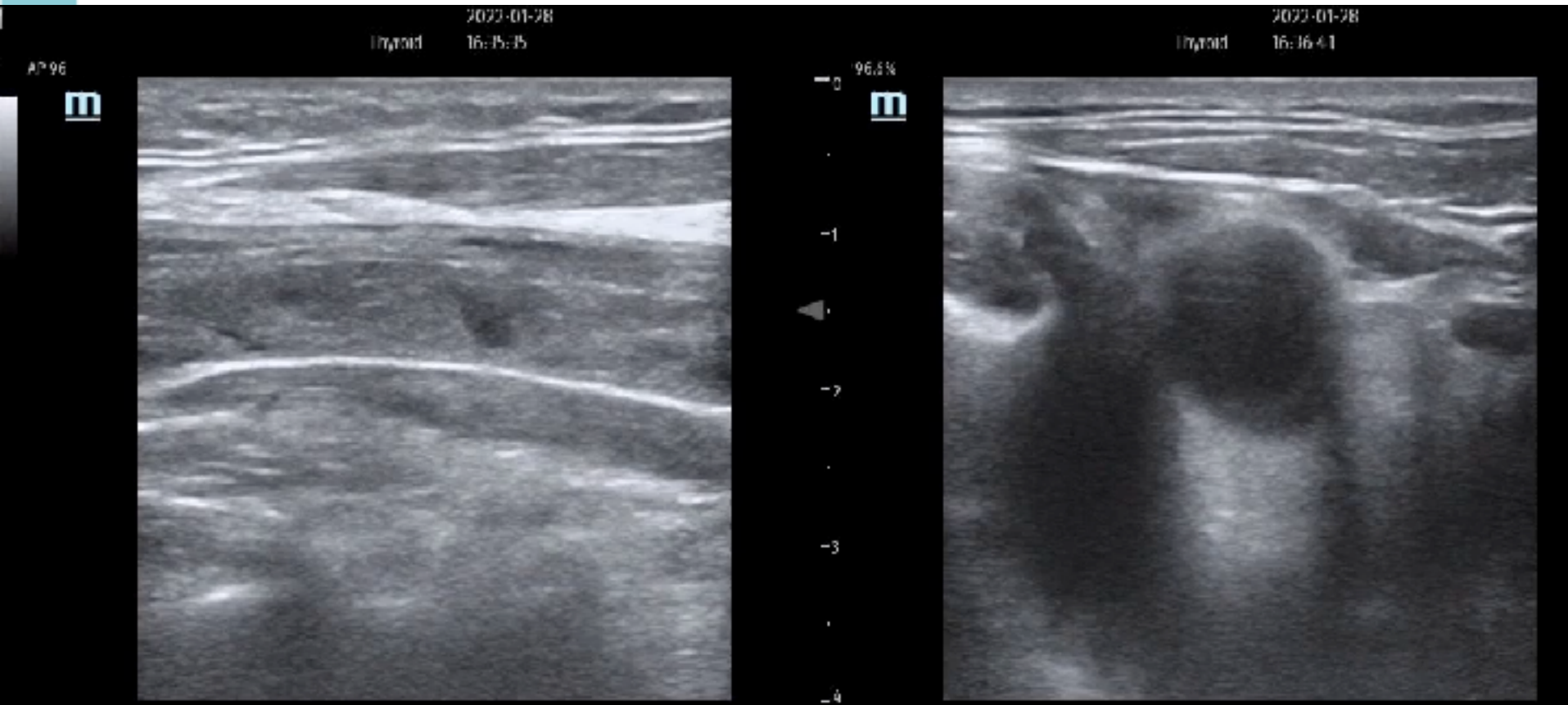


AI 96.6%

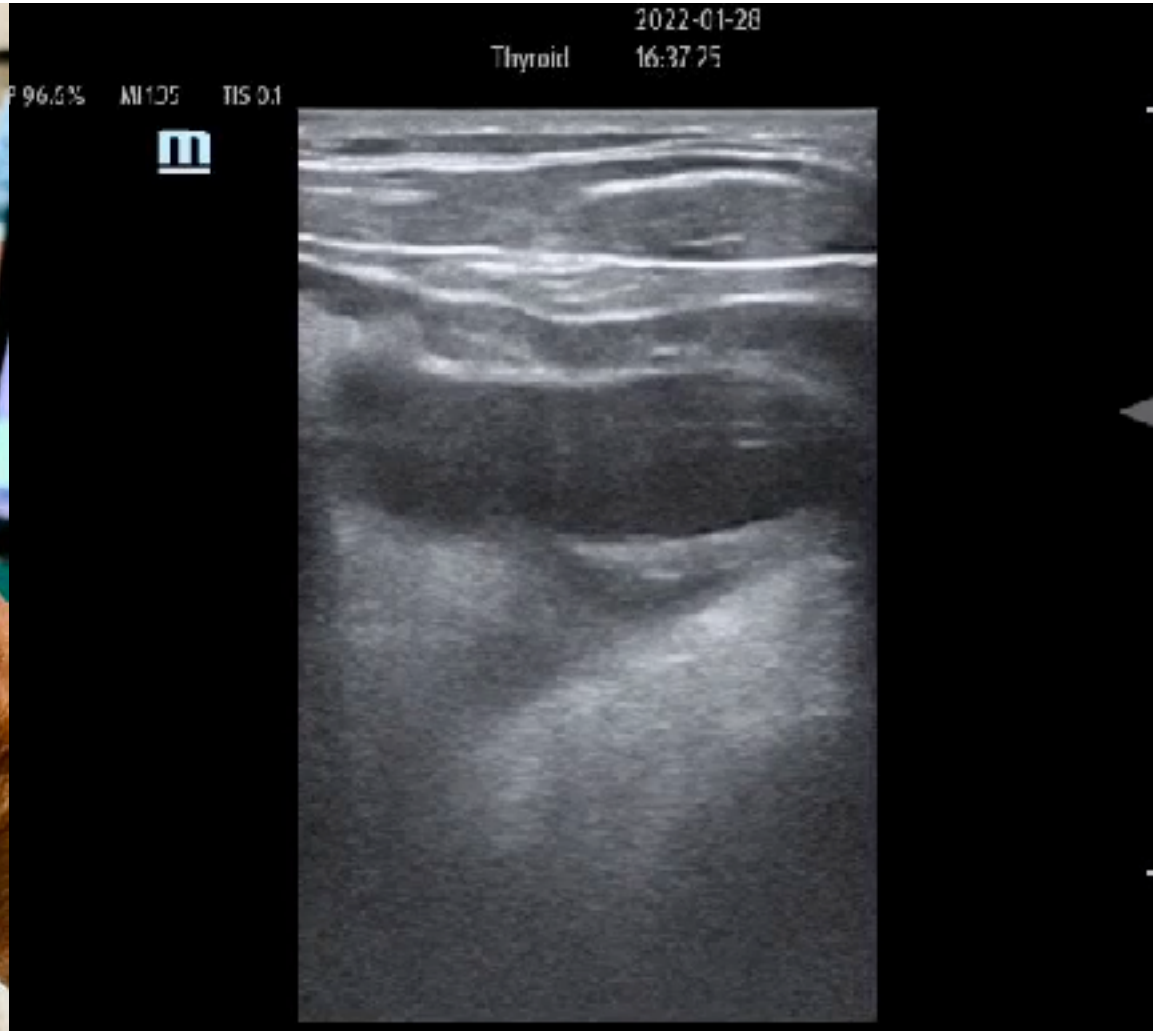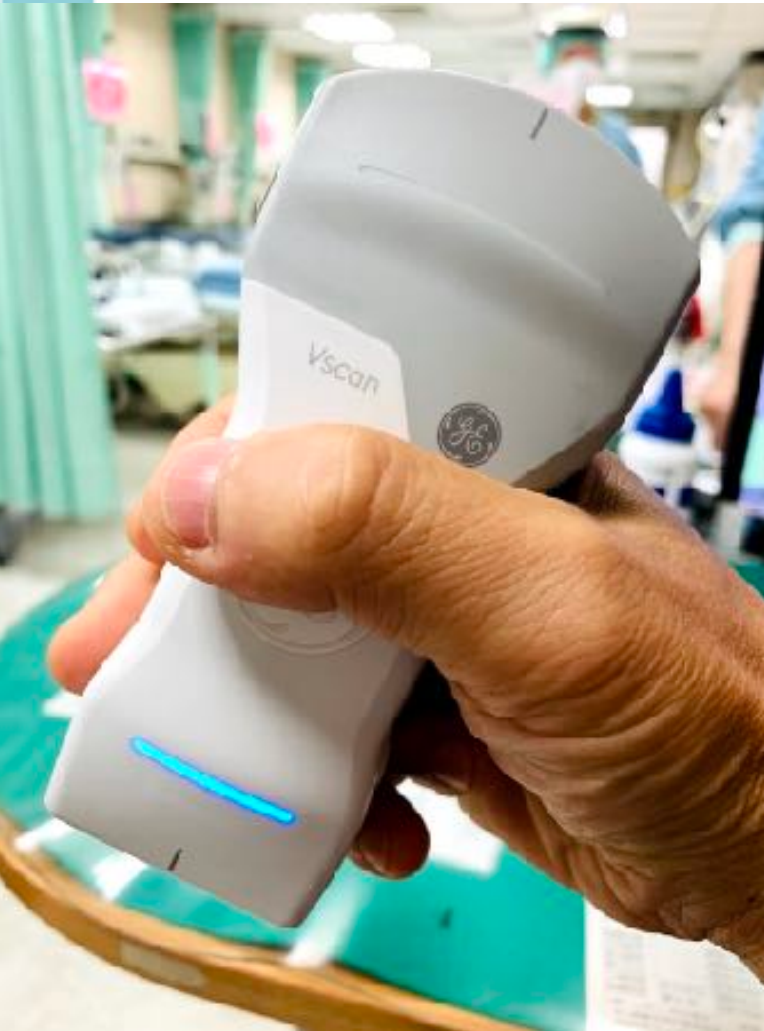m



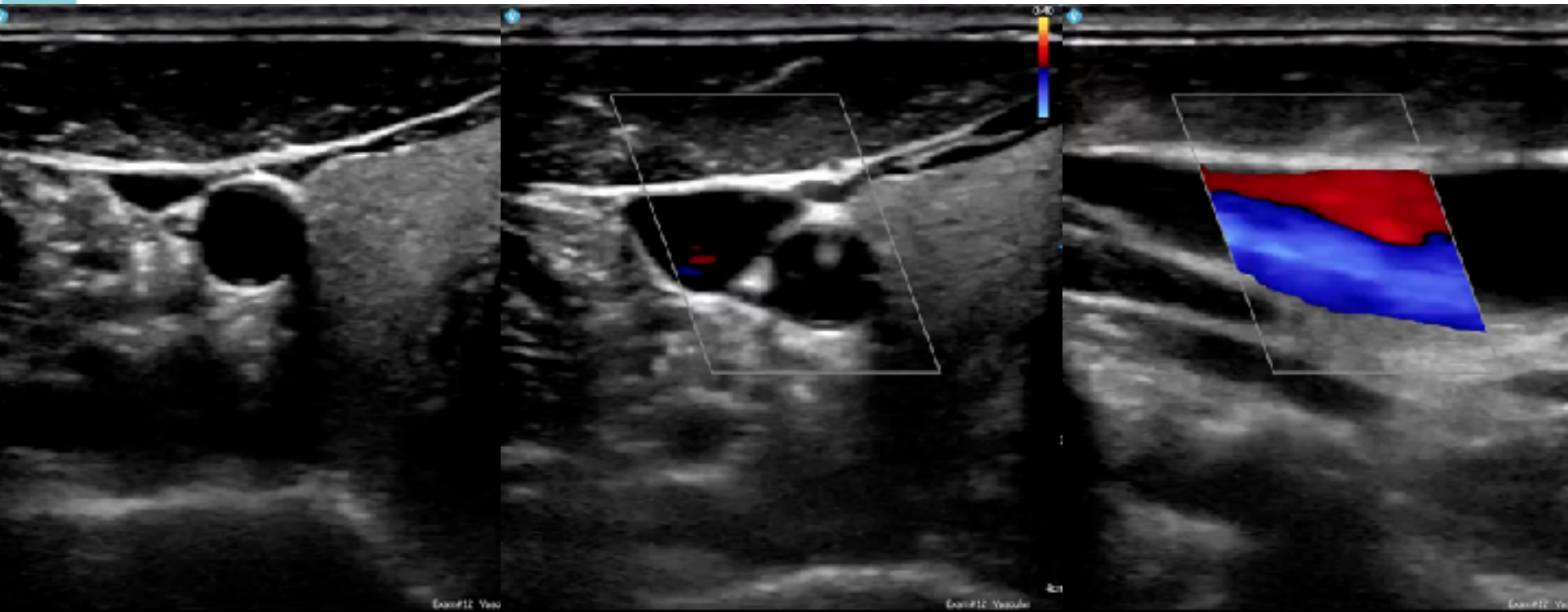
Aortic dissection



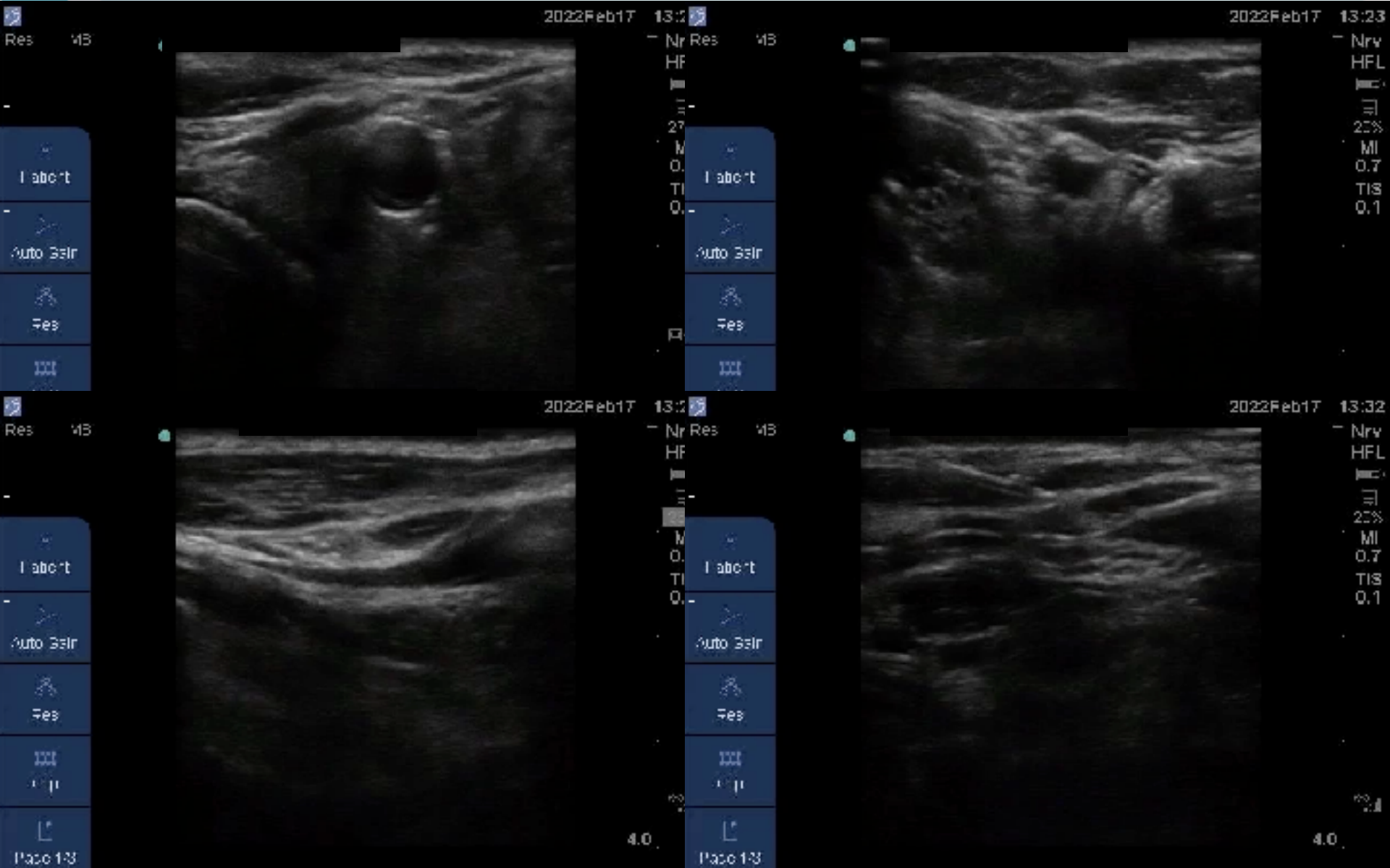
AD (CCA-Pericardium-ABD Ao)



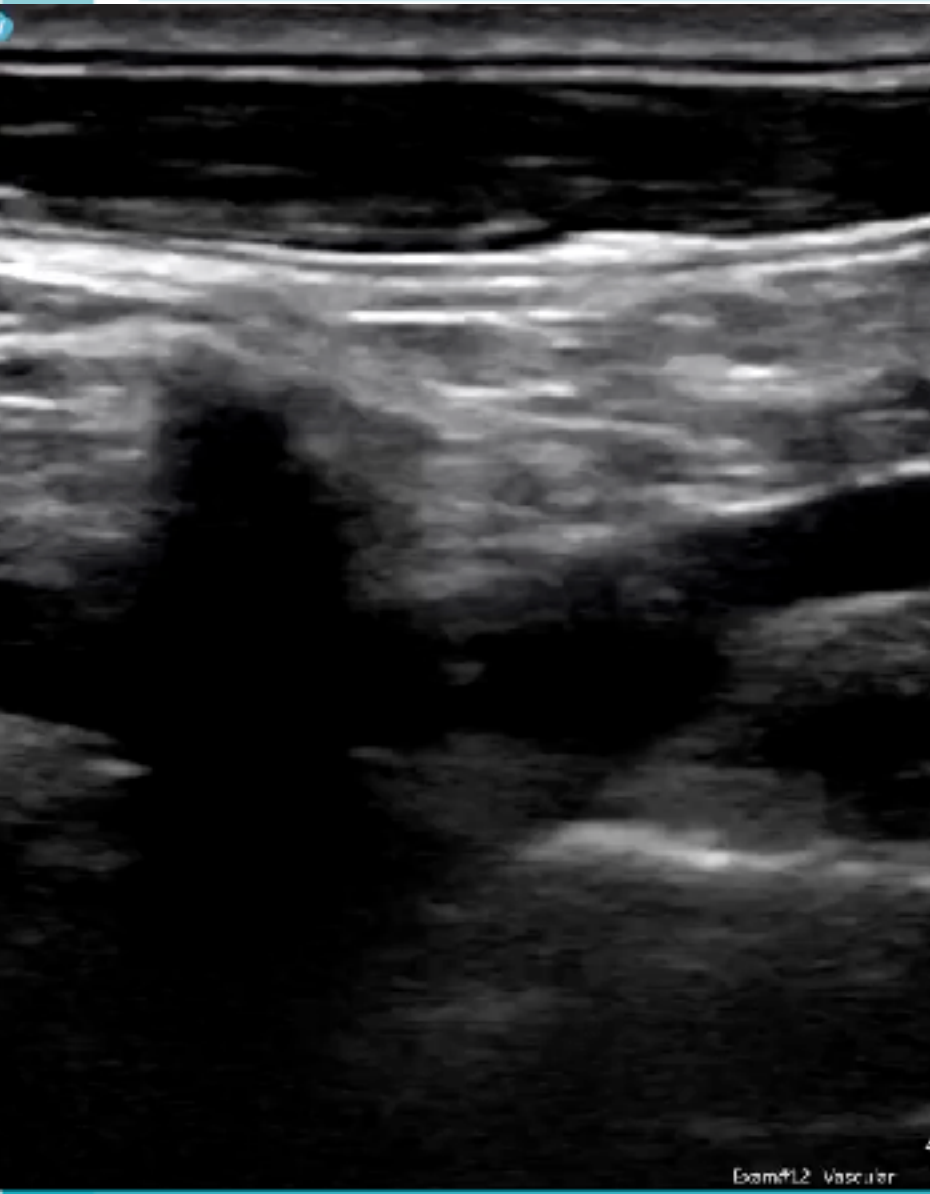Internal jugular vein / CVC



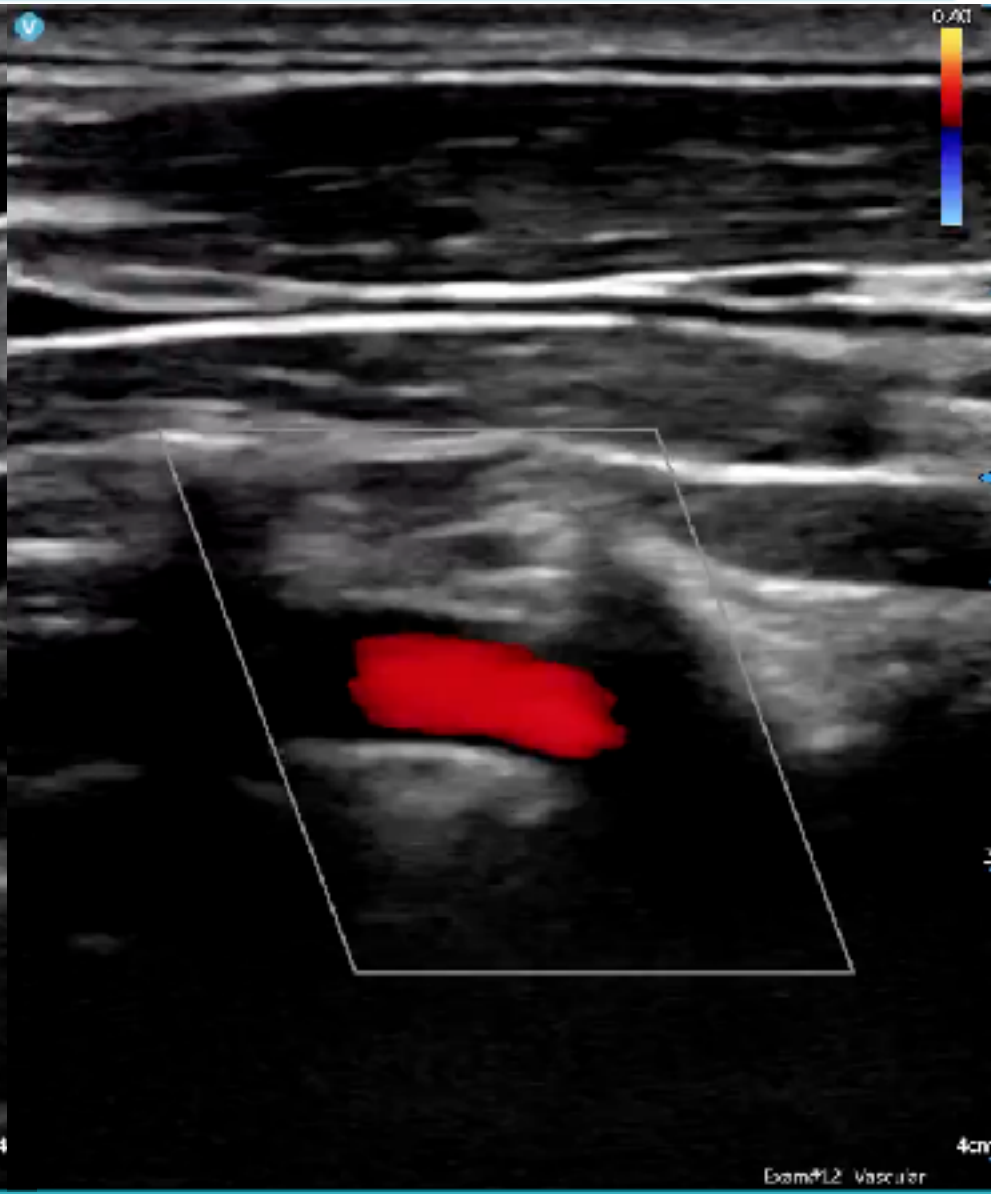
Echo guided CVC on left IJV



Vertebral artery

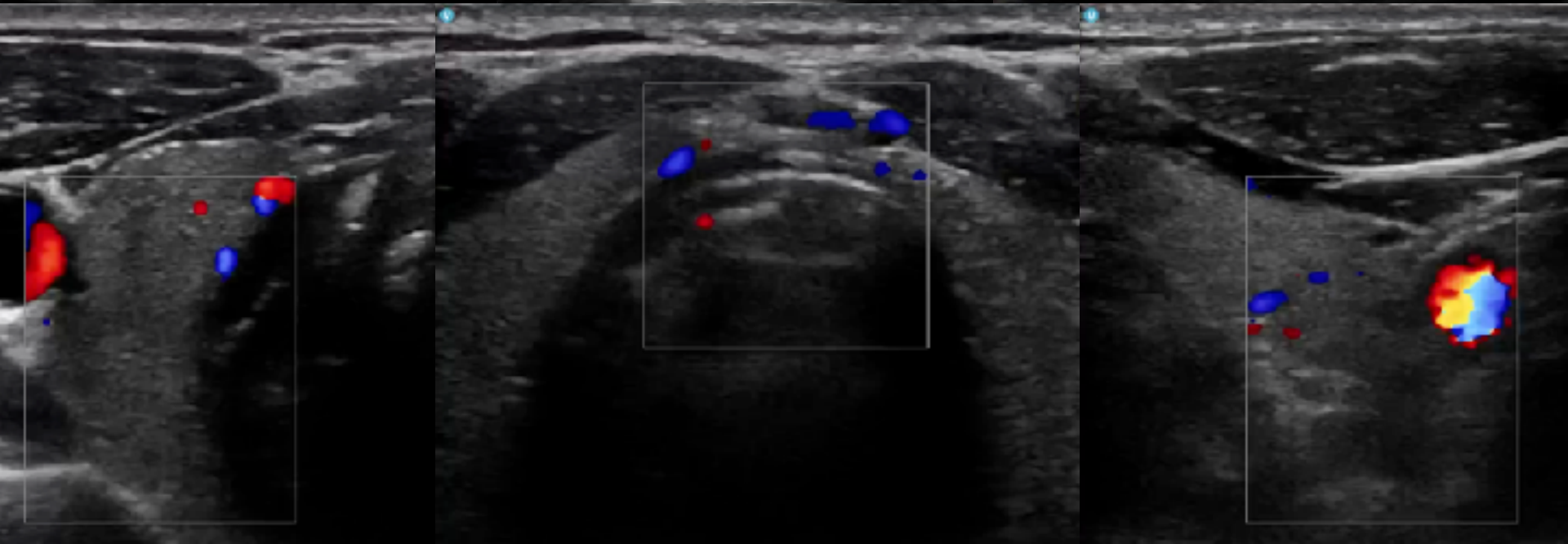
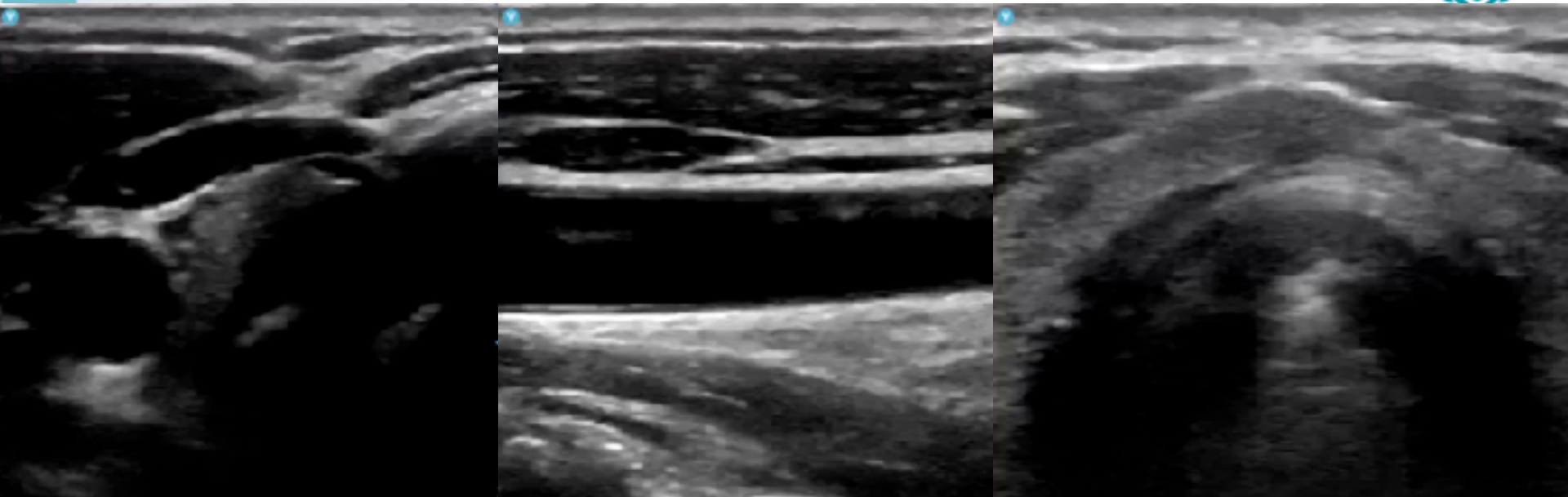


Exam#12 Vascular

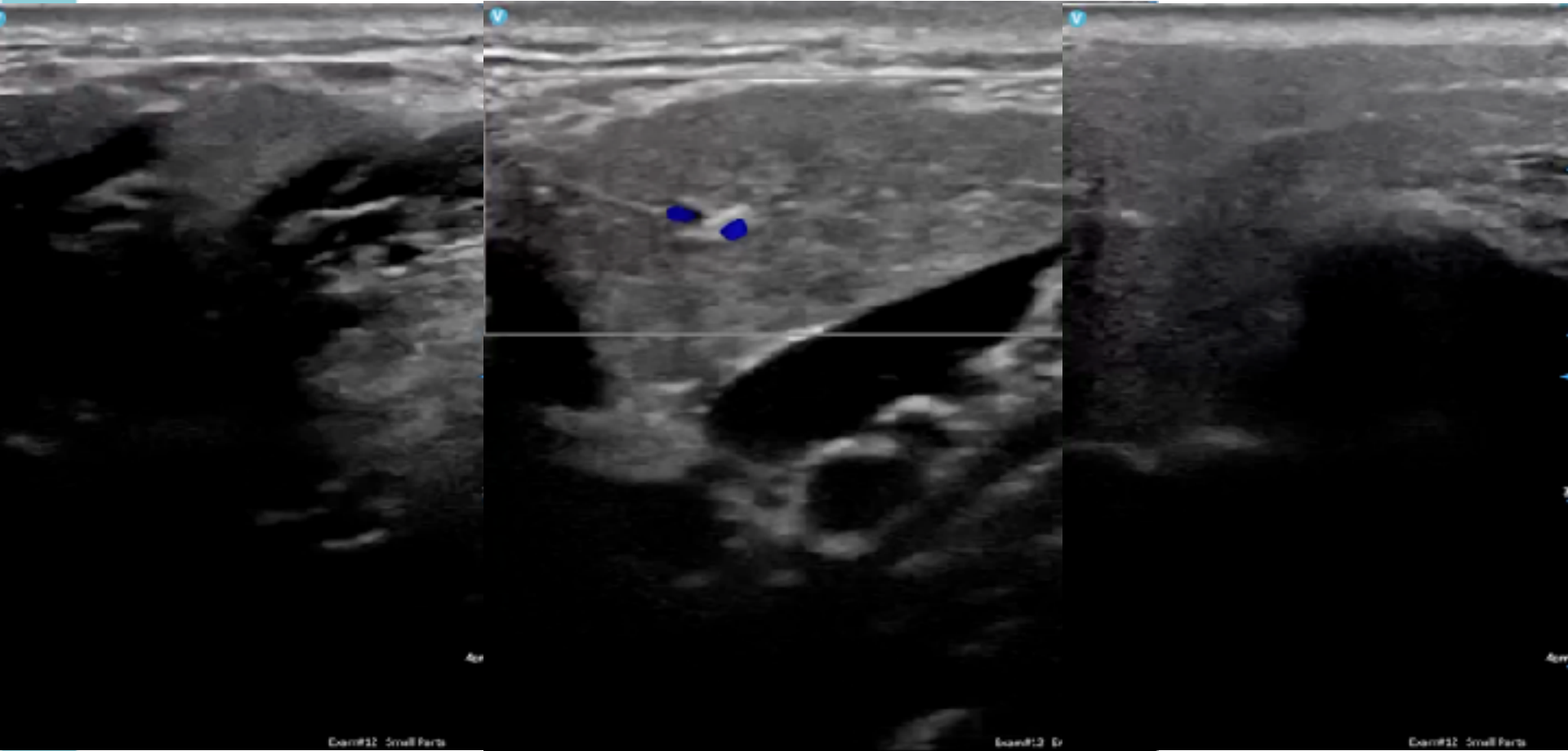


Exam#12 Vascular

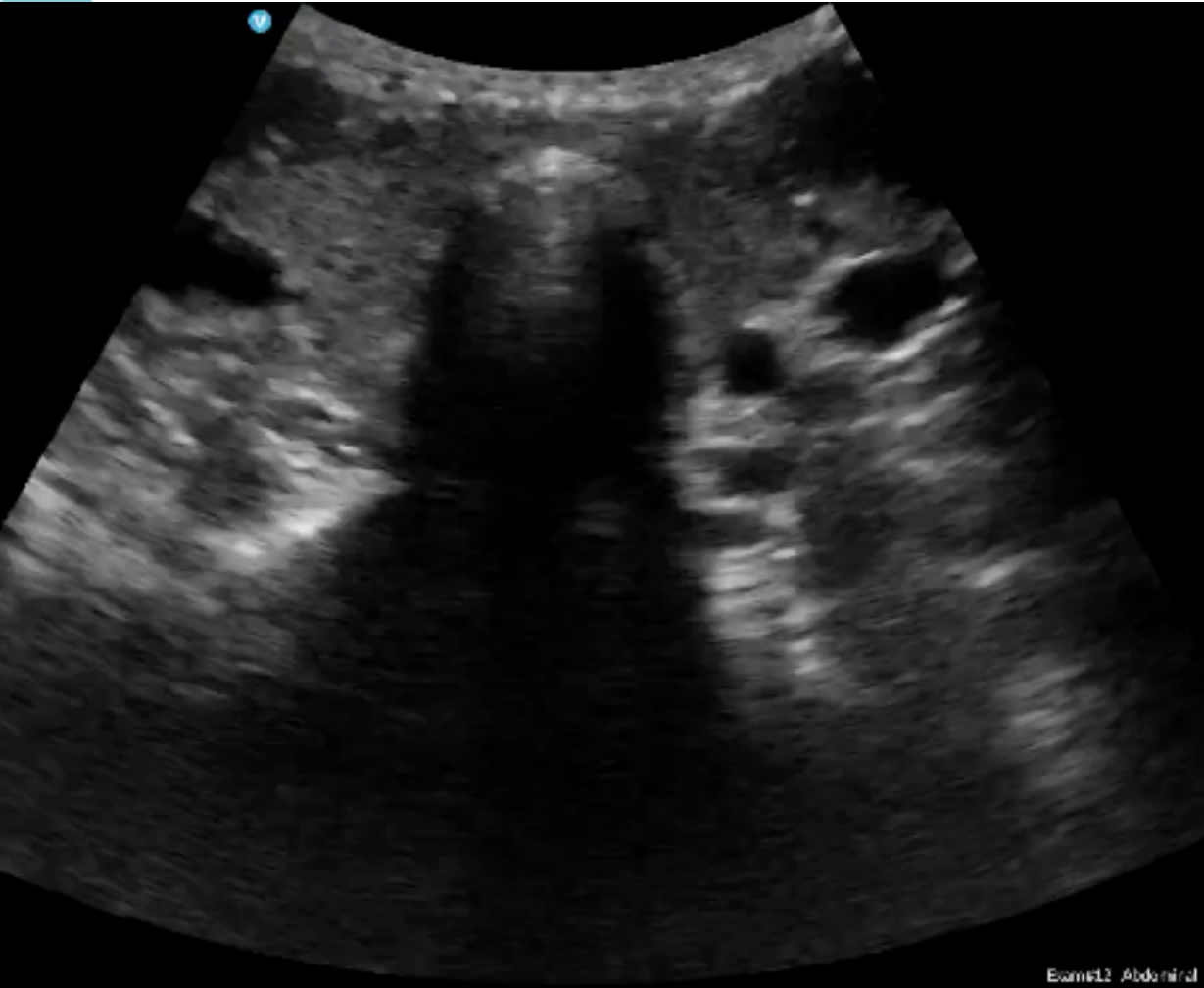Thyroid gland



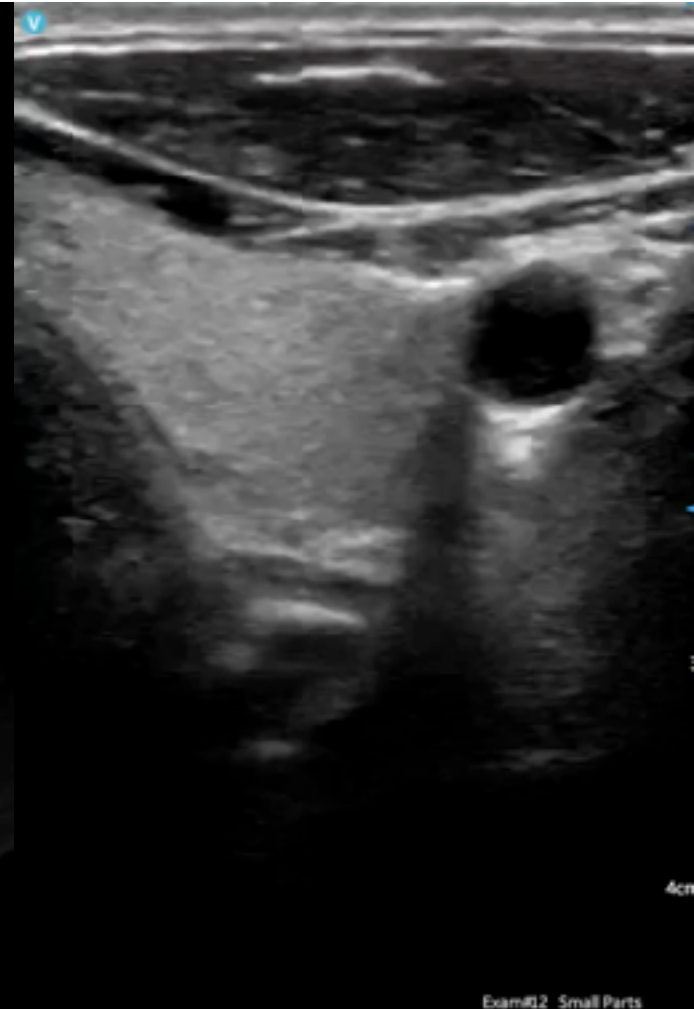
Submandibular & Parotid glands



Trachea & Eso for intubation



Exam#12 - Abdominal



Exam#12 - Small Parts

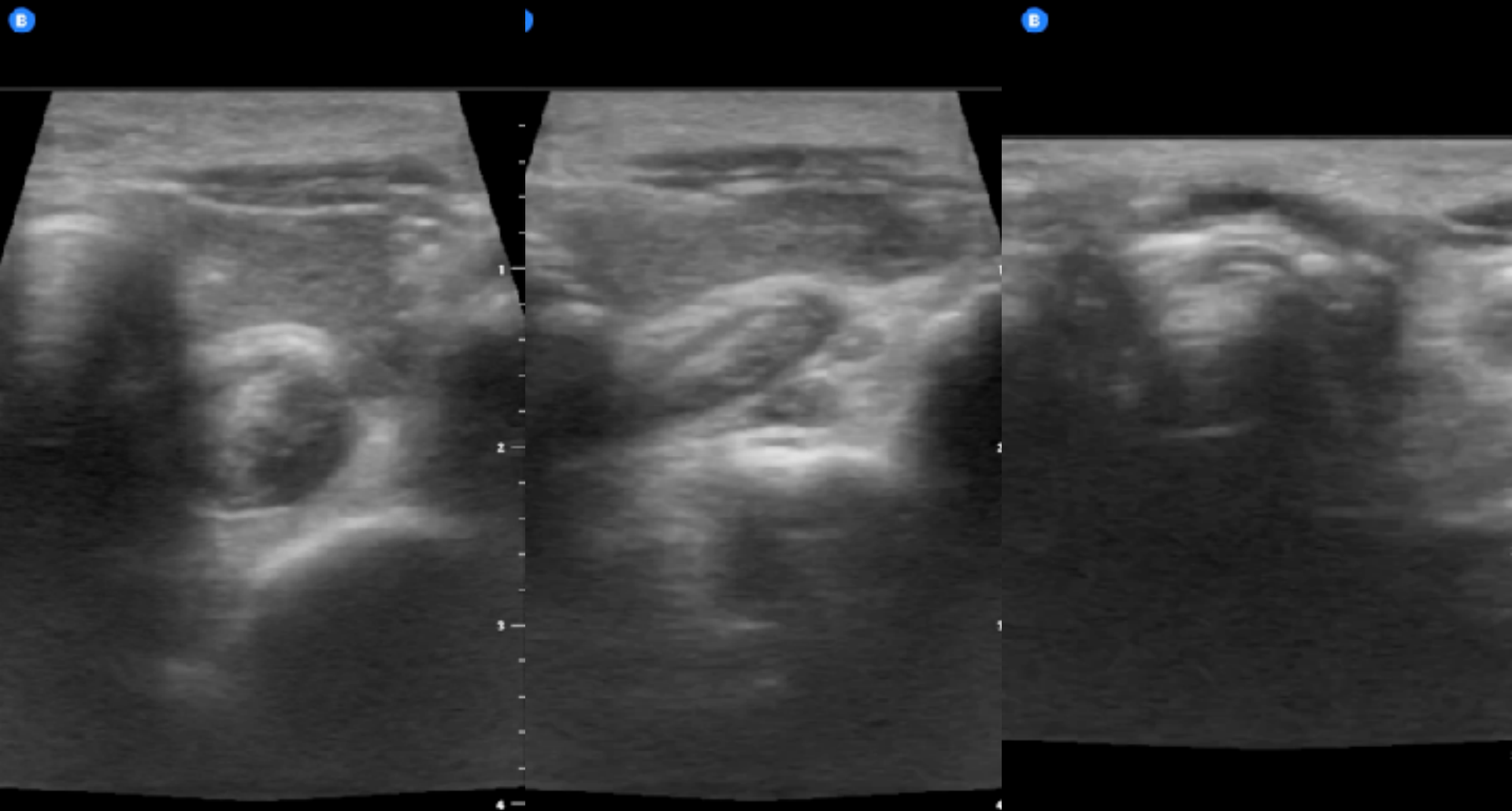
75F, shock & resuscitation



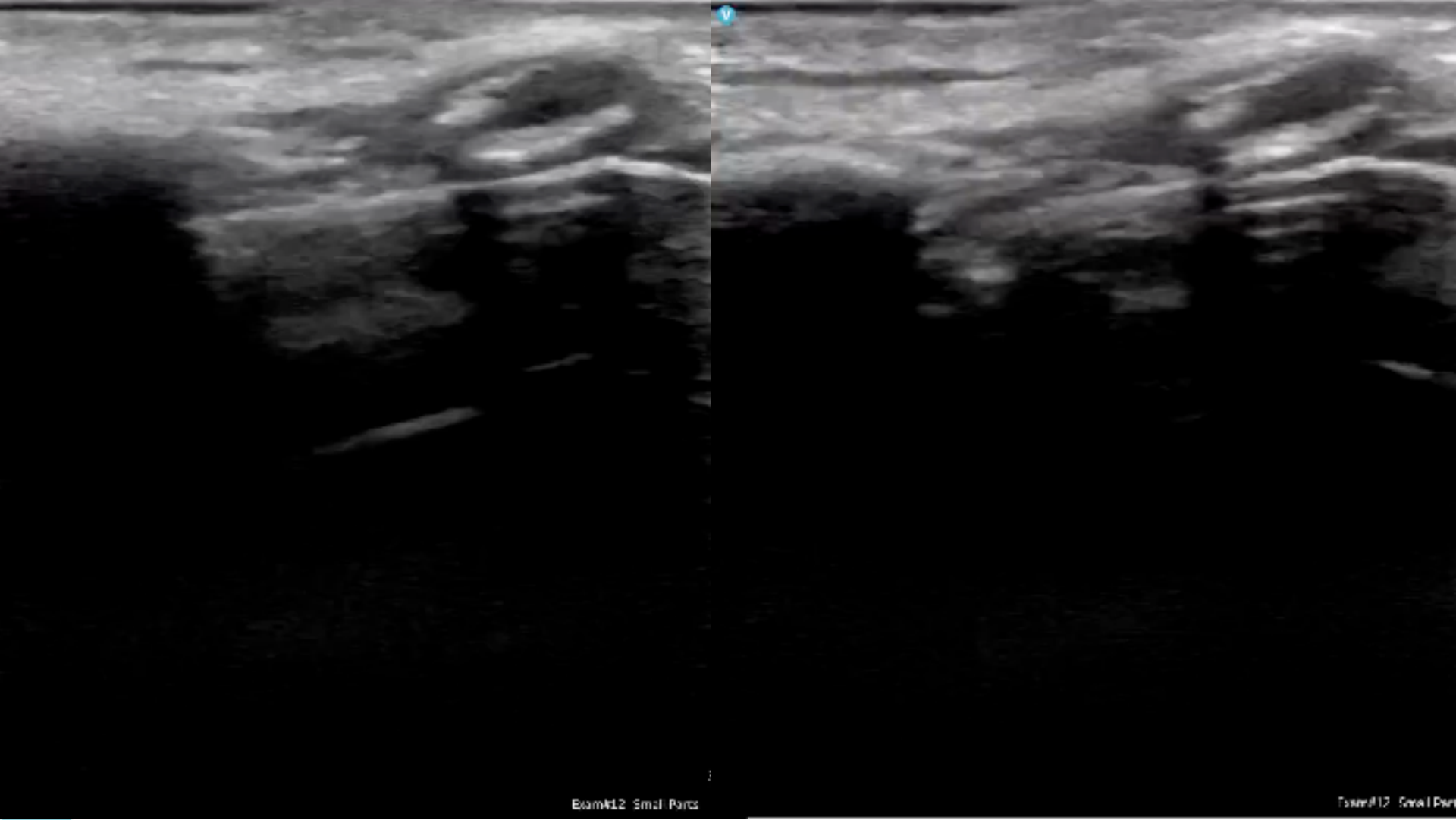
TIS: 0.01, MI: 0.35, MSK-Soft Tissue

TIS: 0.01, MI: 0.35, MSK-Soft Tissue

TIS: 0.01, MI: 0.26, MSK-Soft Tissue



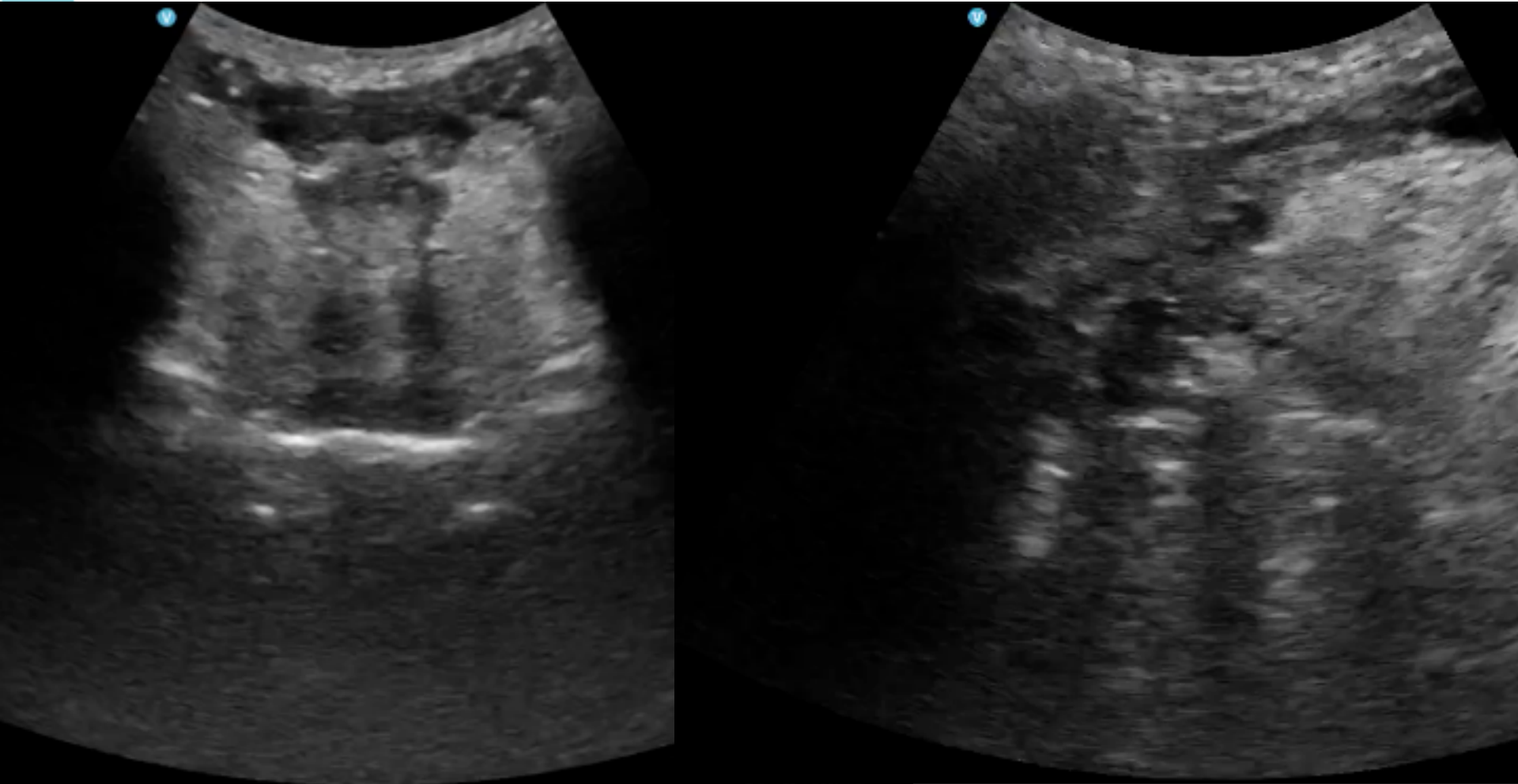
Surgical airway: CTM & PDT



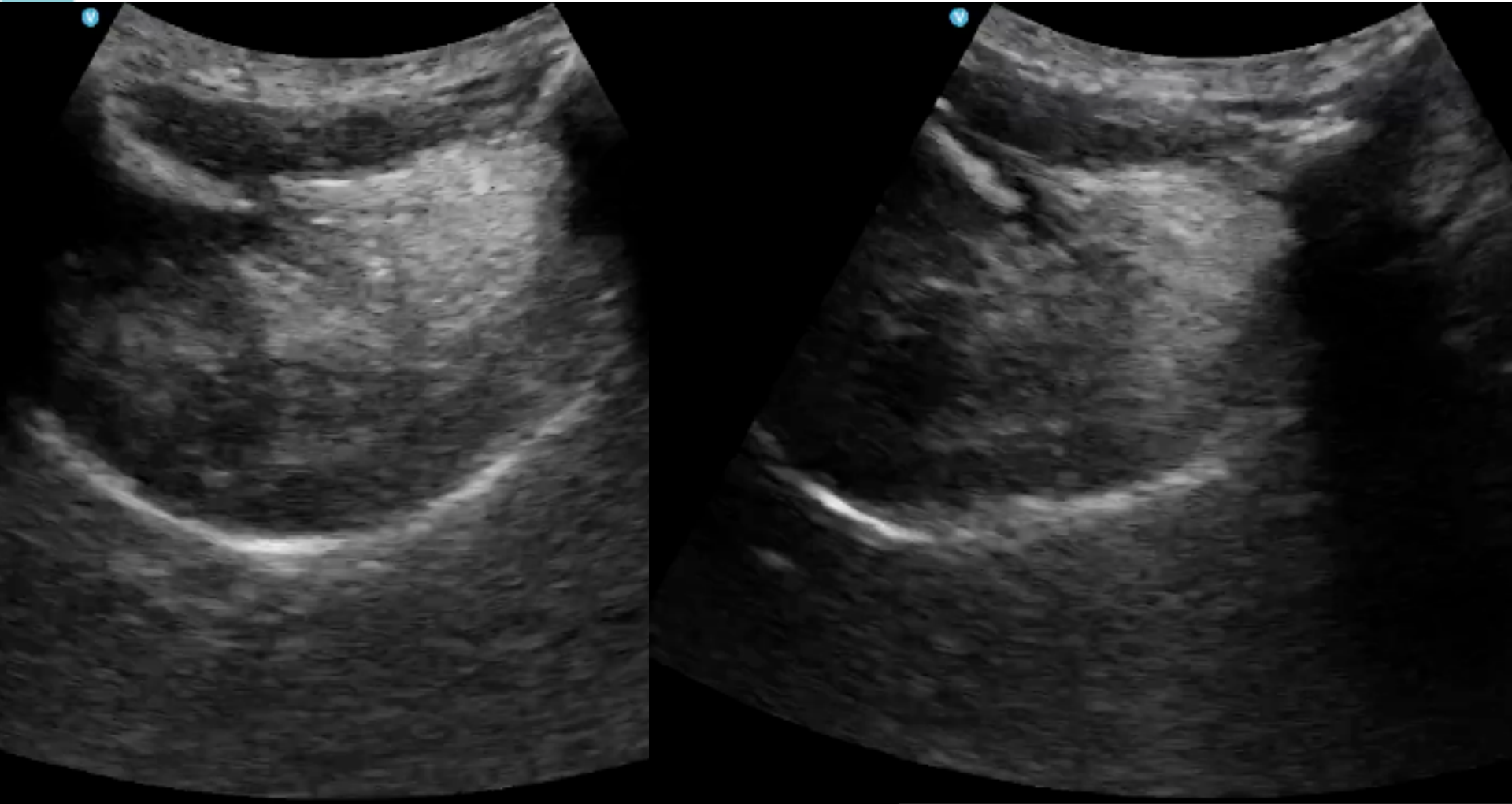
Exam#12 - Small Parts

Exam#12 - Small Parts

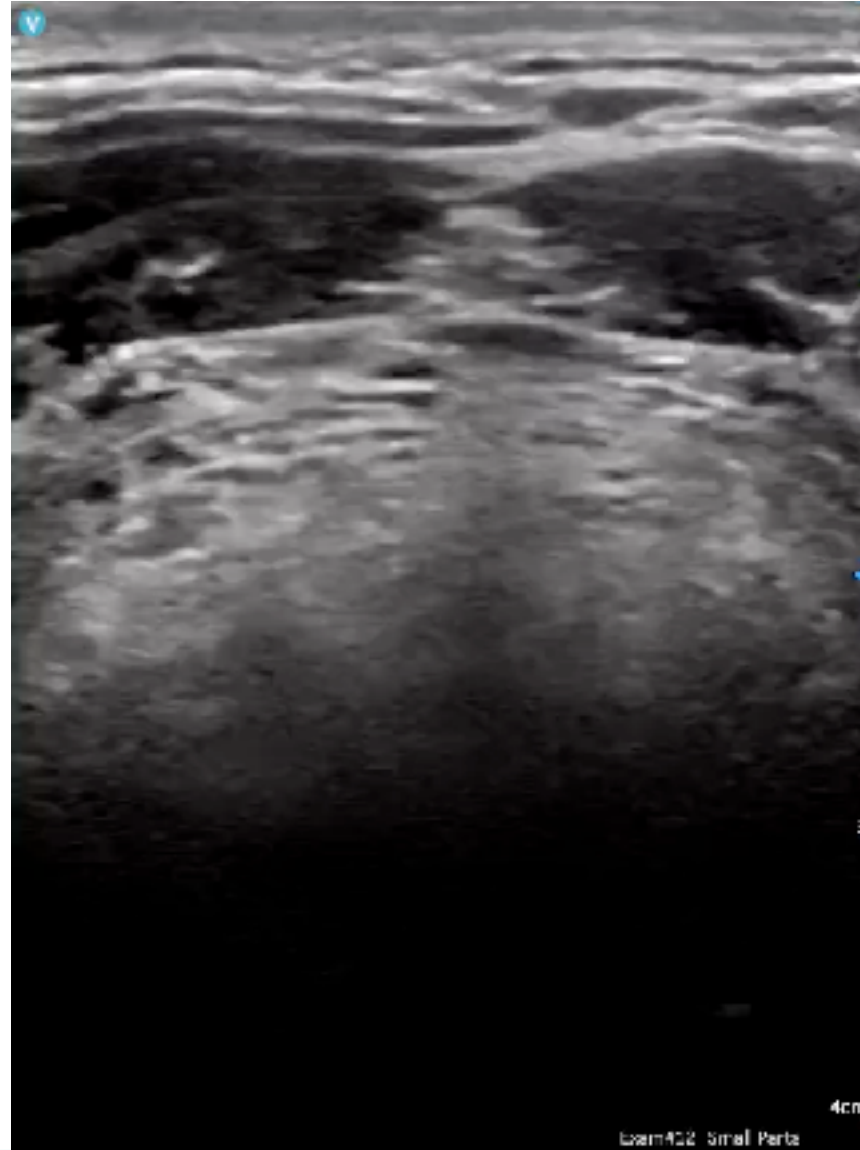
Tongue & Tonsil



Tongue, hyoid bone & epiglottis

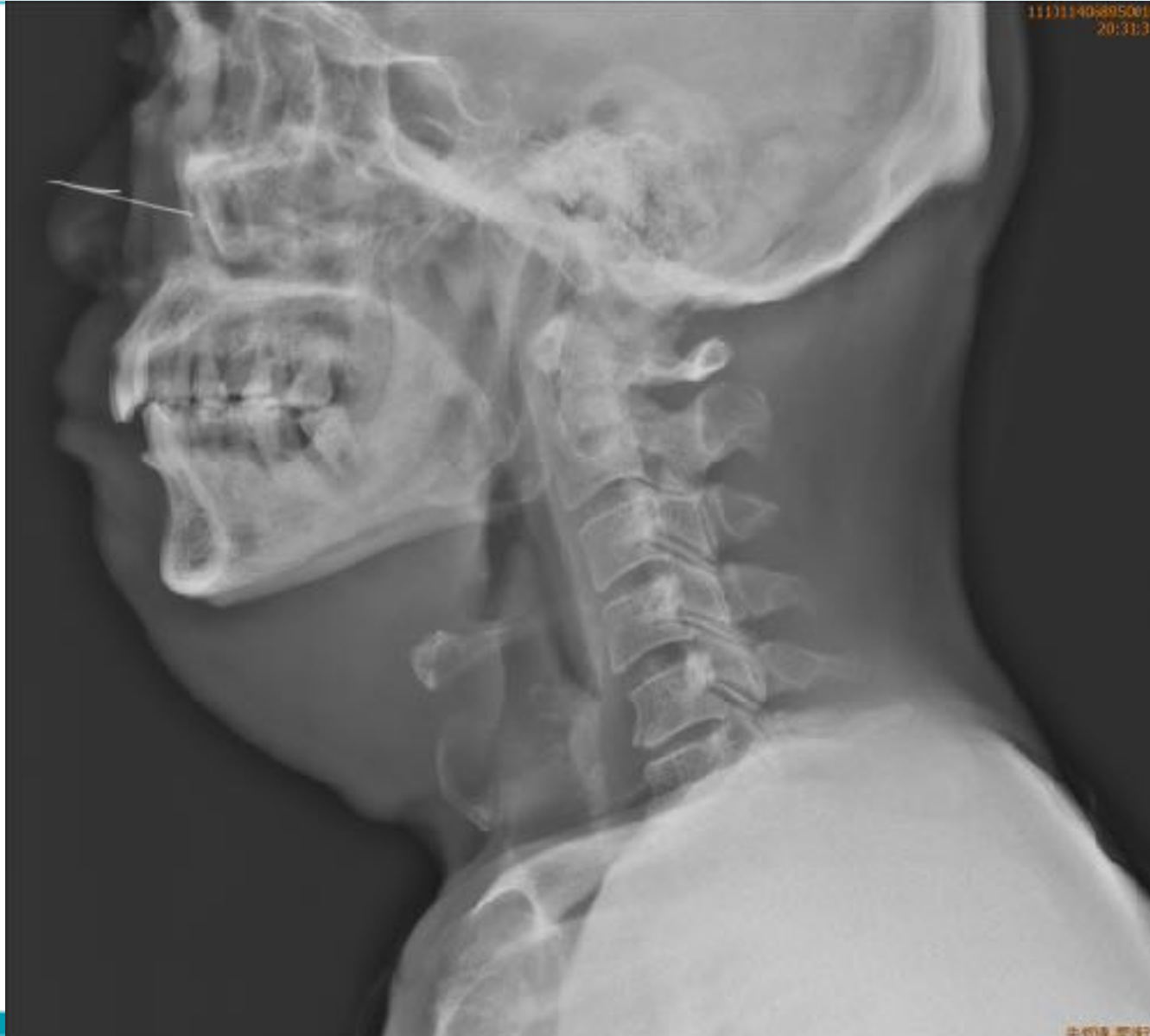

Epiglottitis



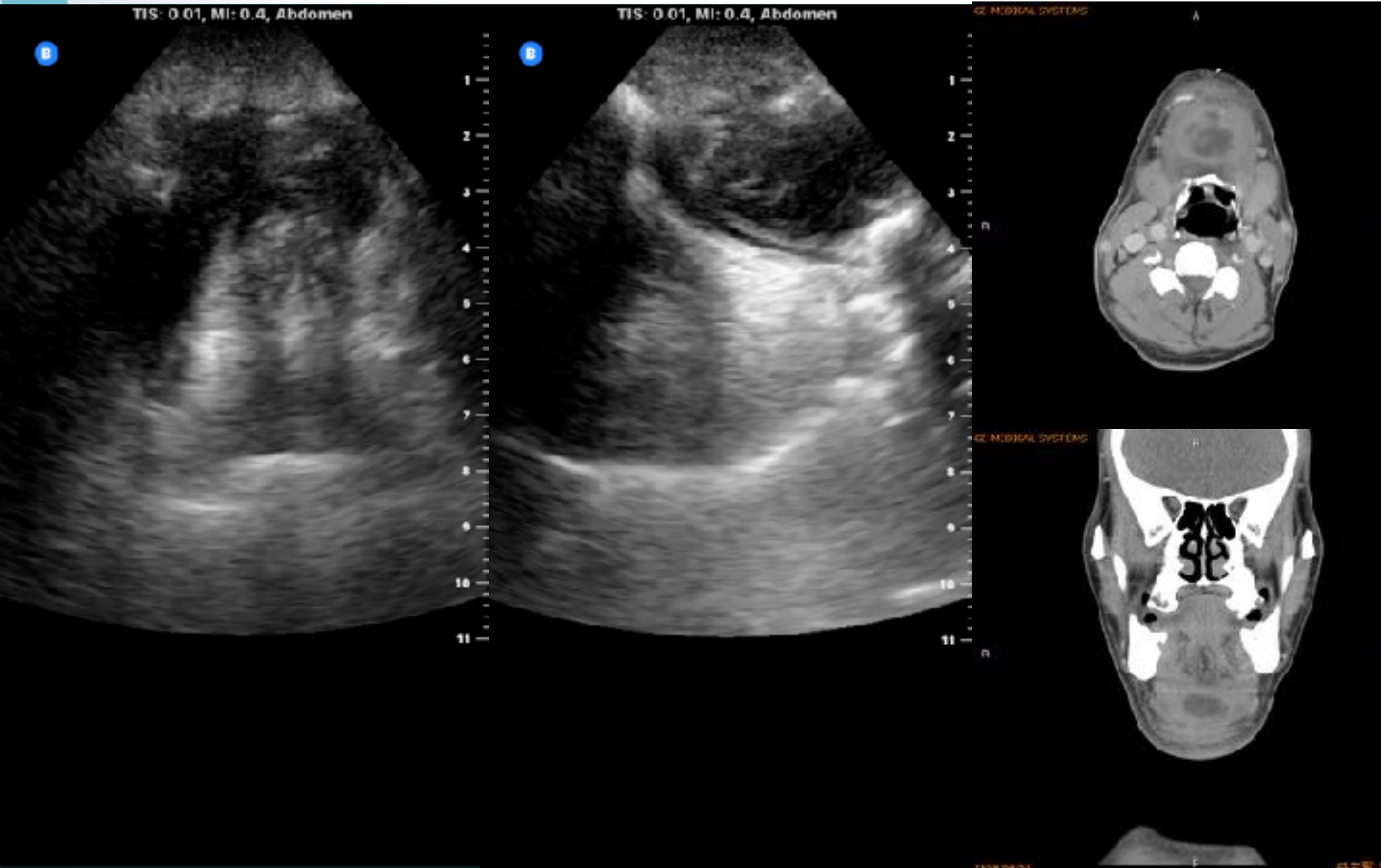


62M, neck swelling for 4-5 days

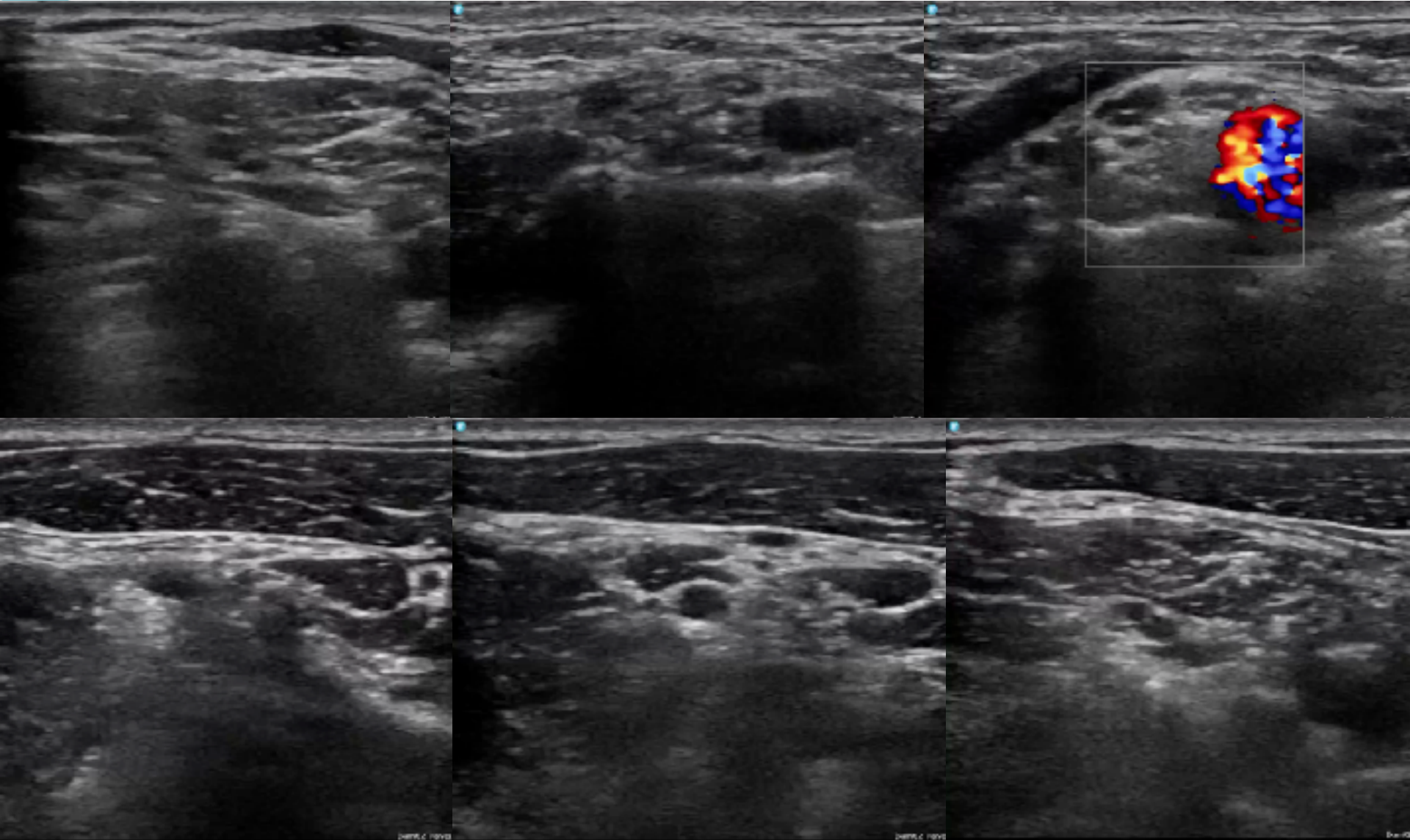




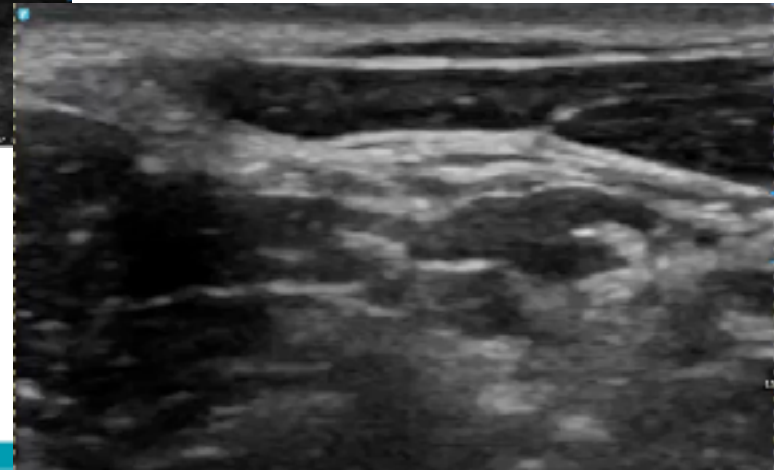
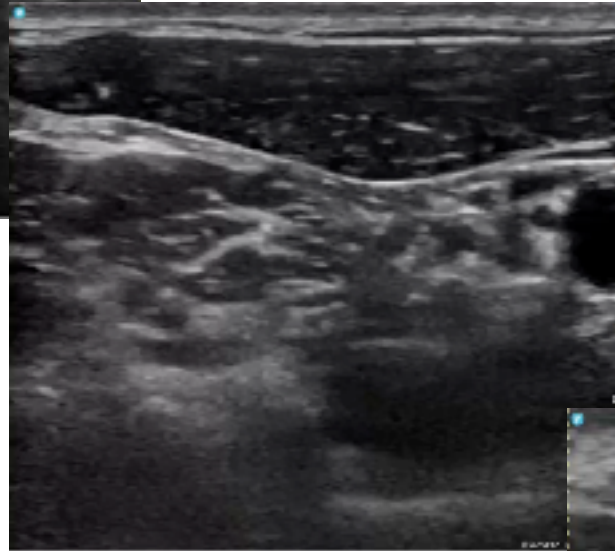
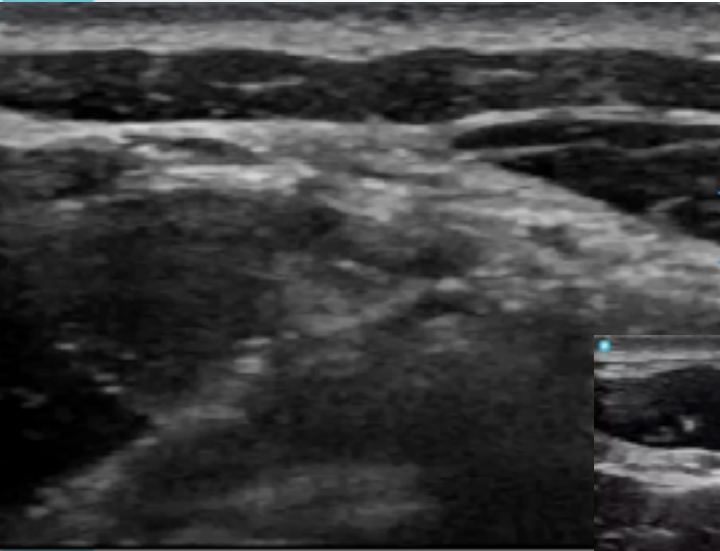
62M, neck swelling for 4-5 days



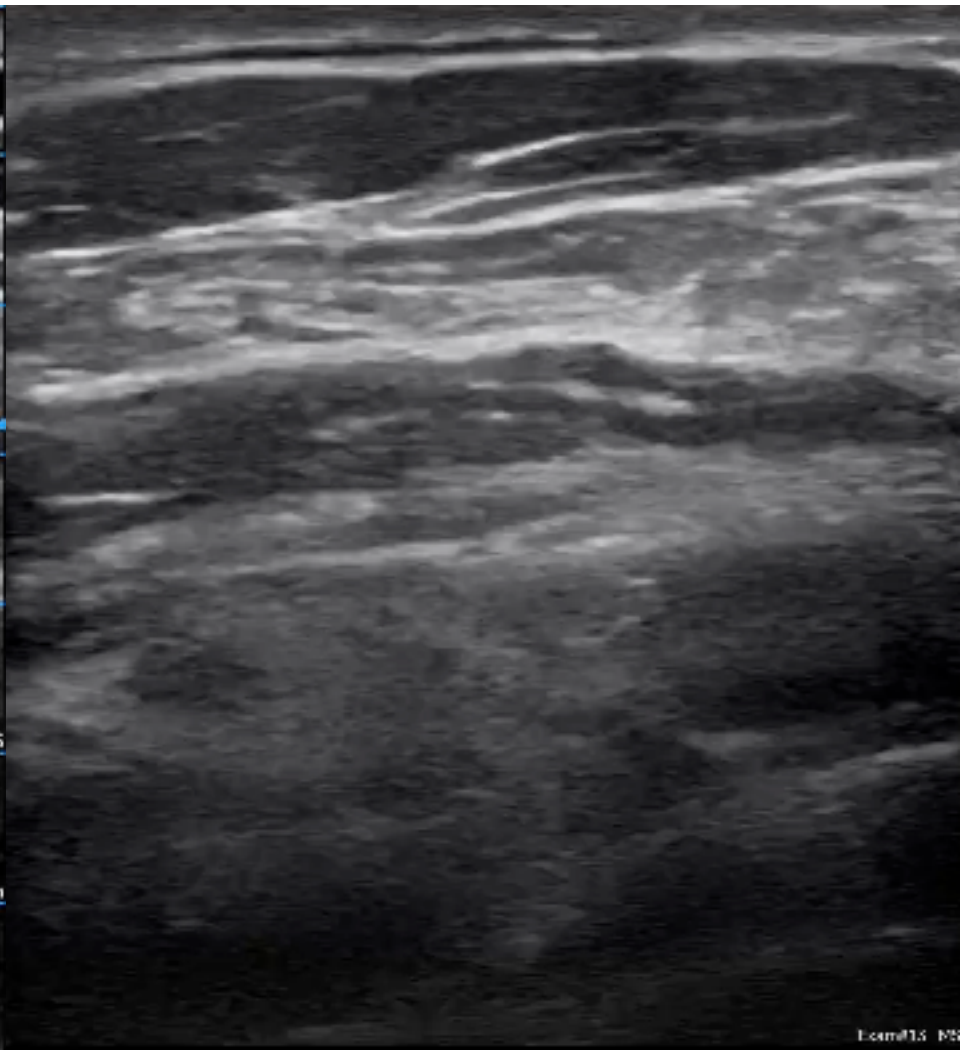
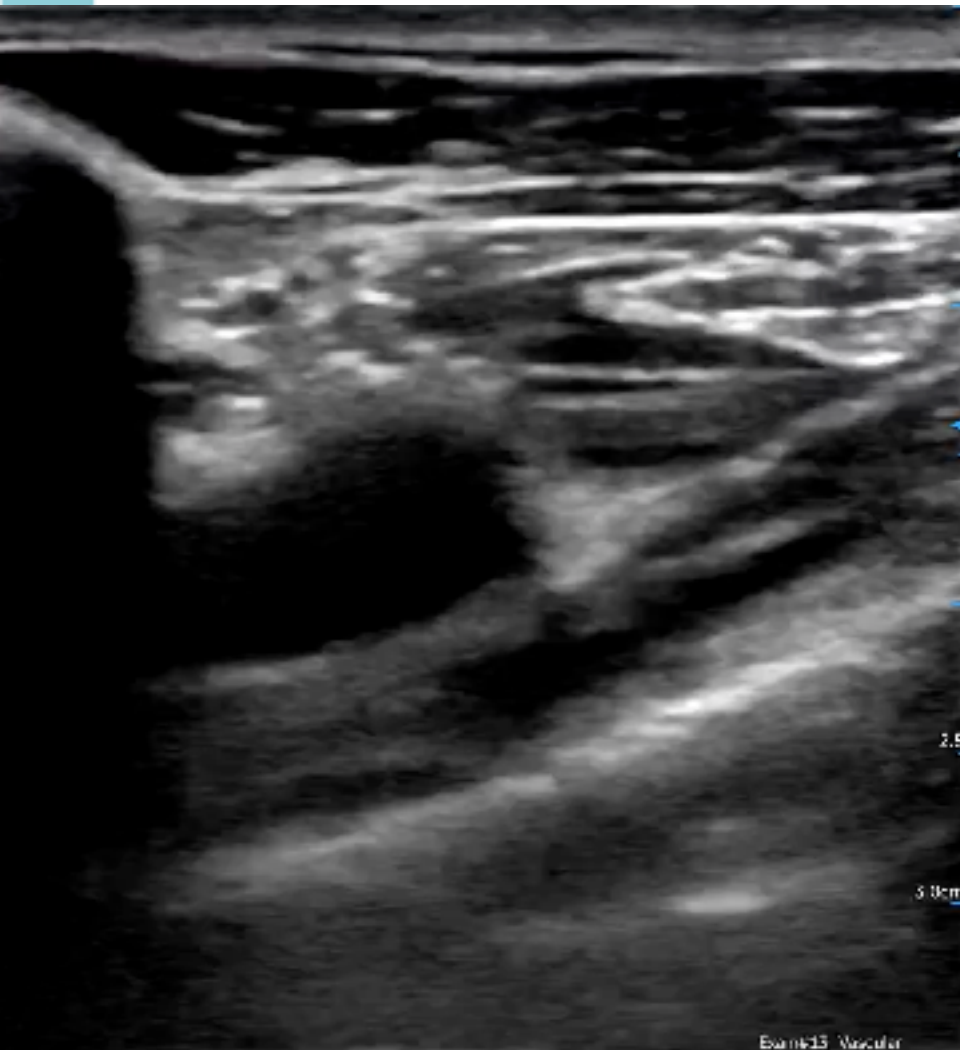Brachial plexus



Superficial cervical plexus



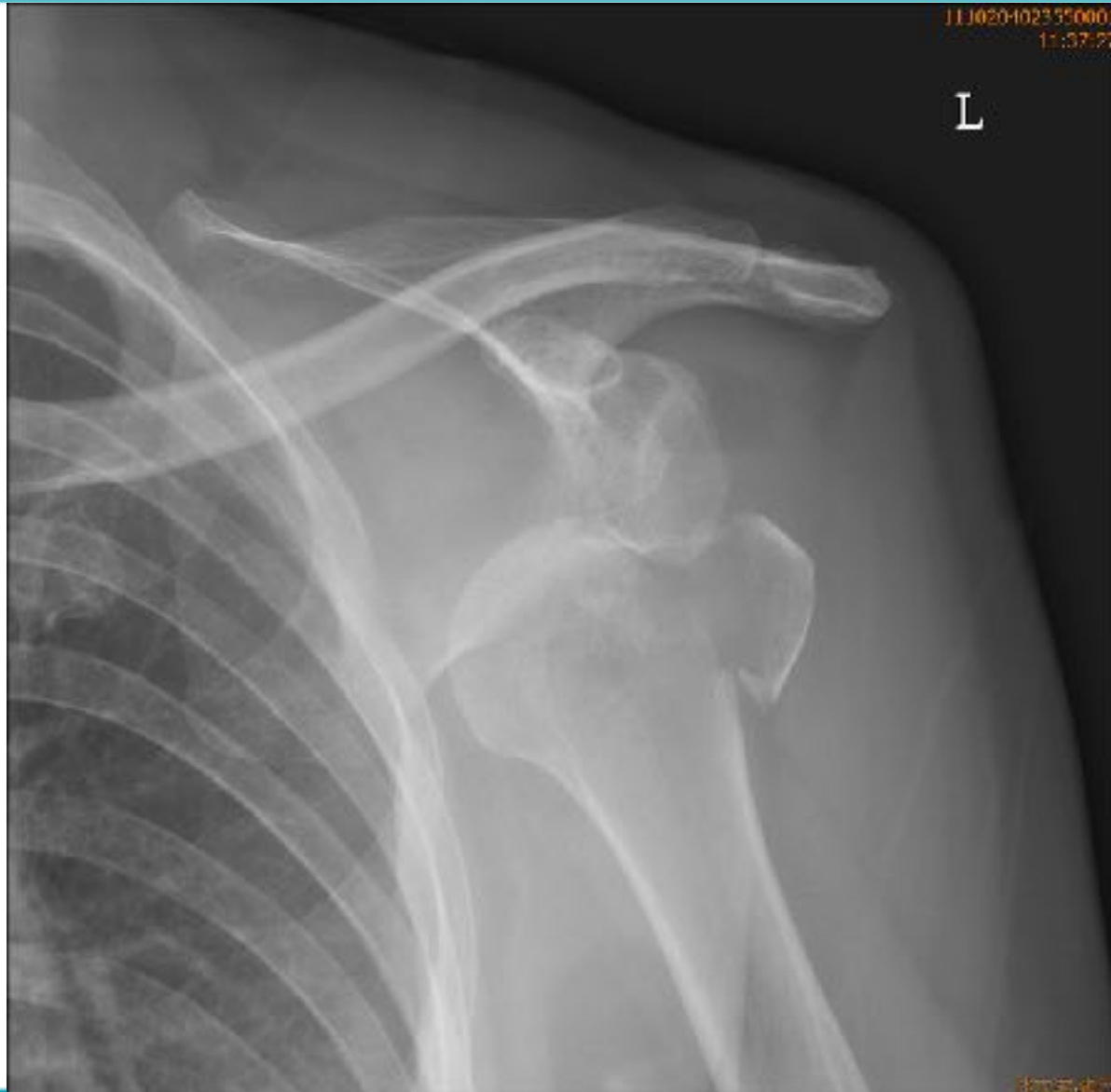Infraclavicular vessels & nerves



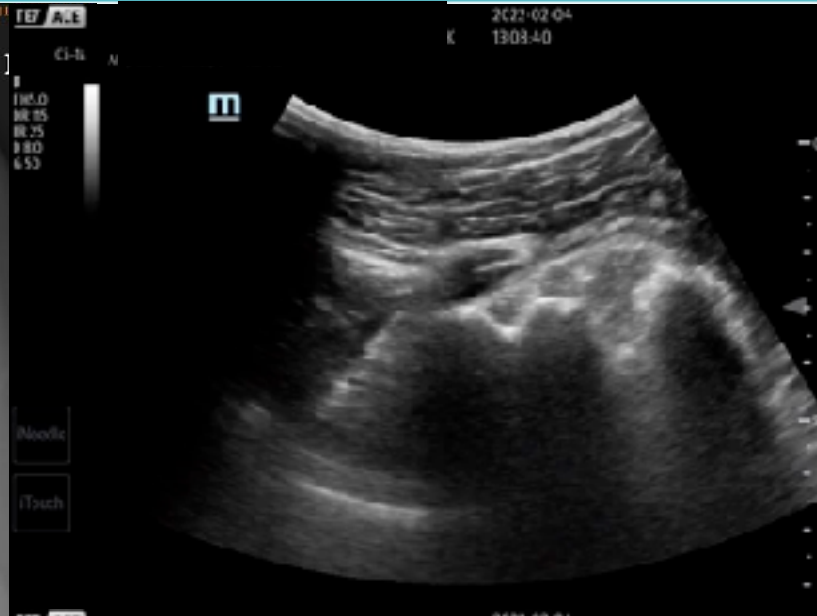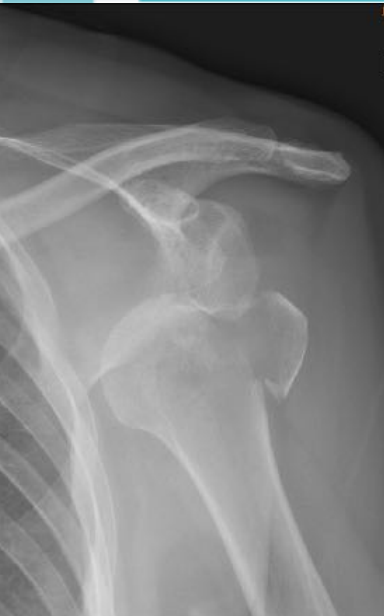Exam115 Vascular

Exam115 MS

56M, left shoulder fracture / dislocation



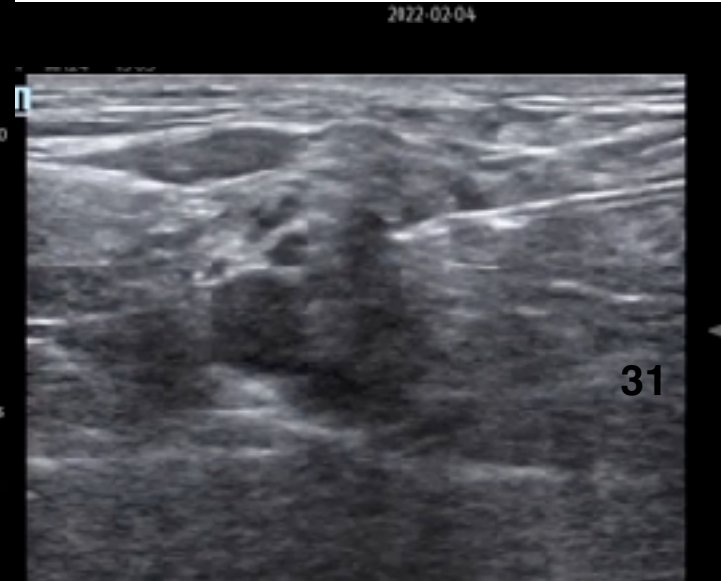
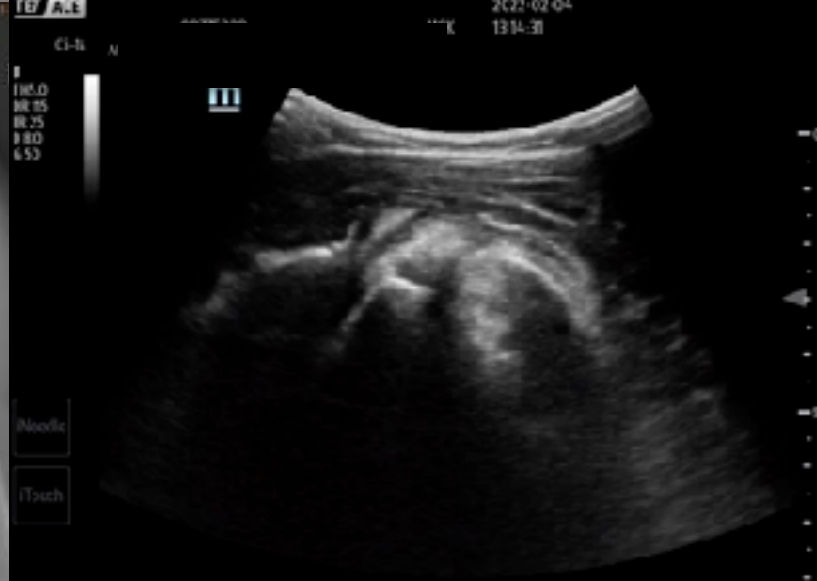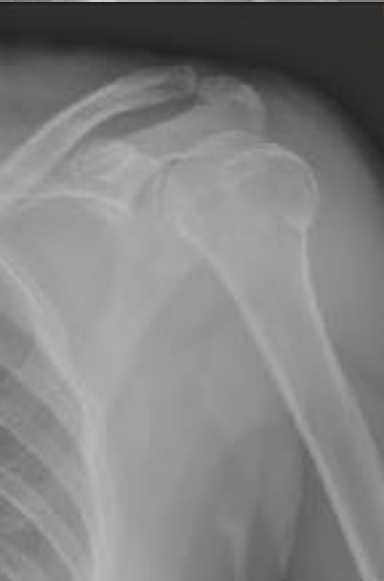Role of POCUS



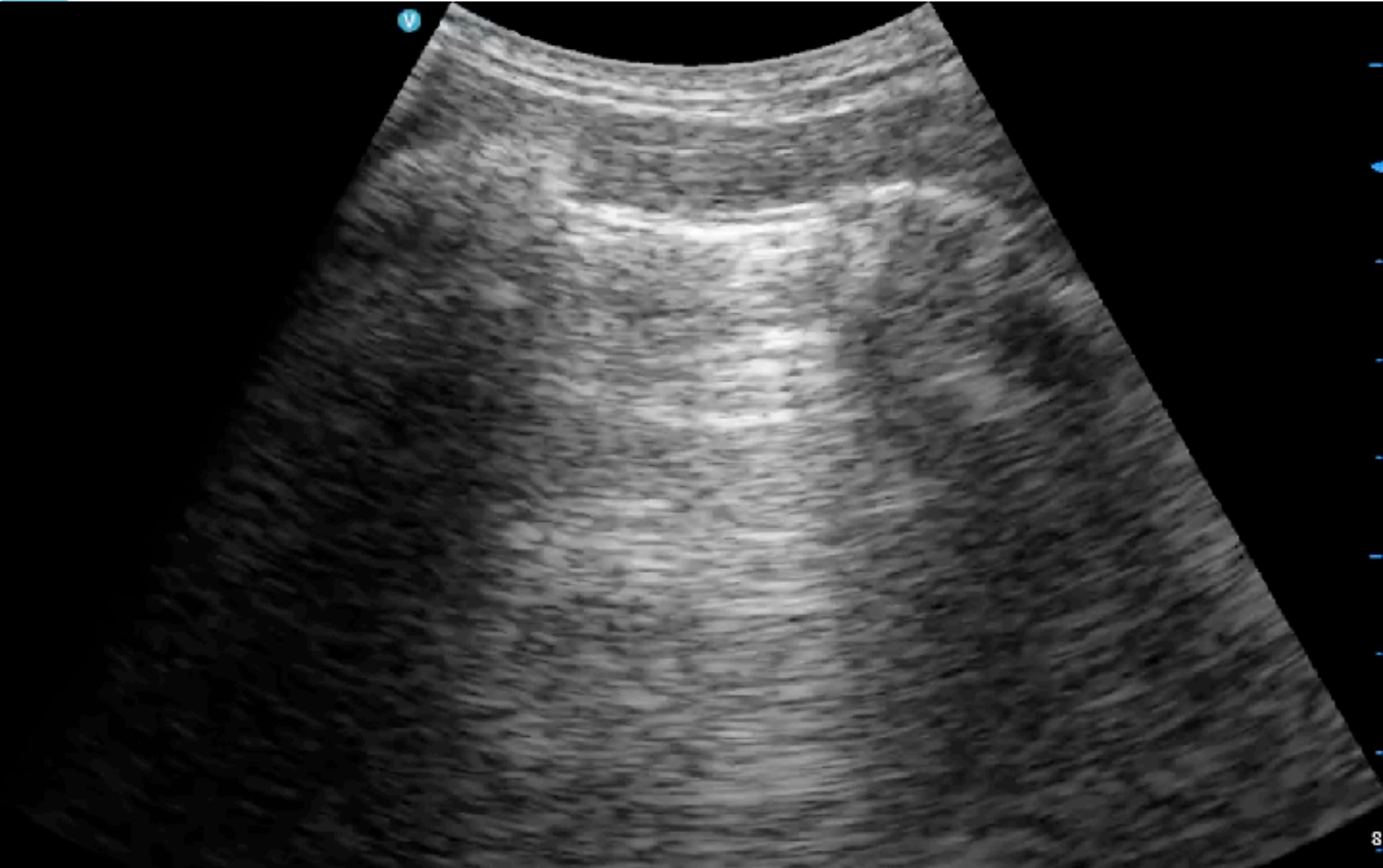Dislocation

Pain control

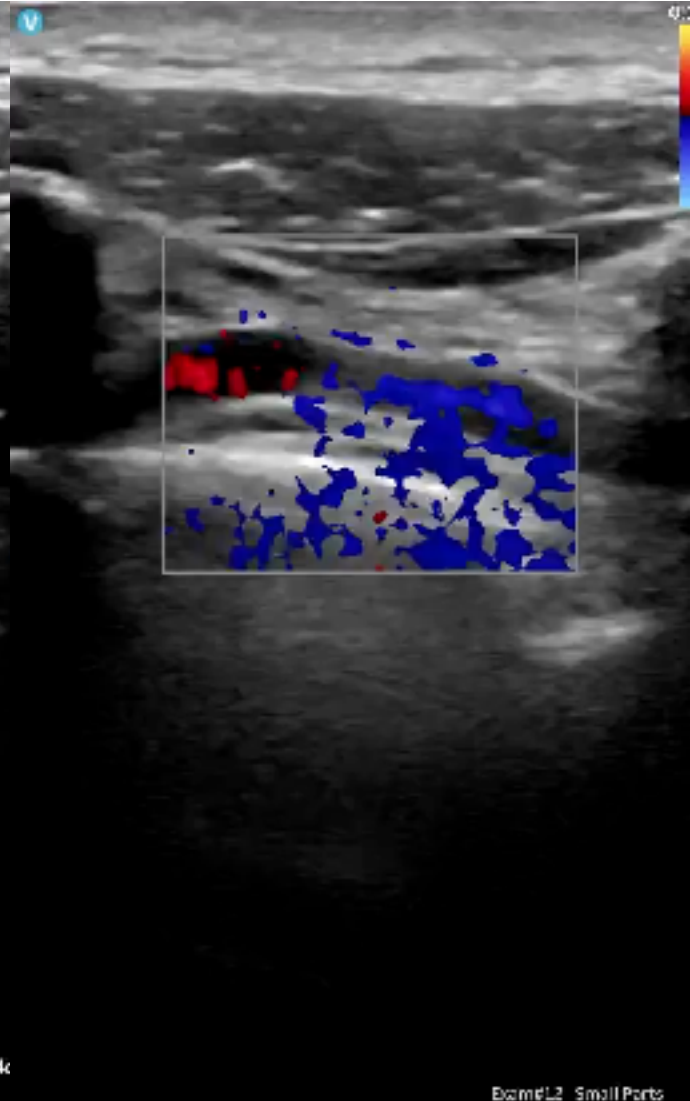
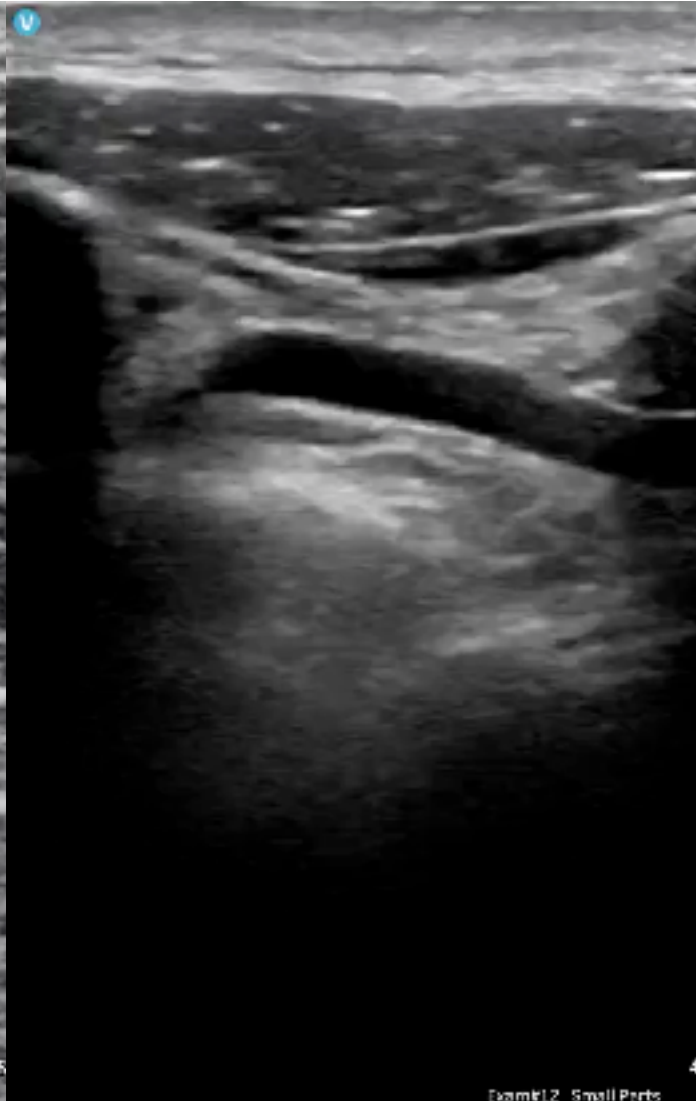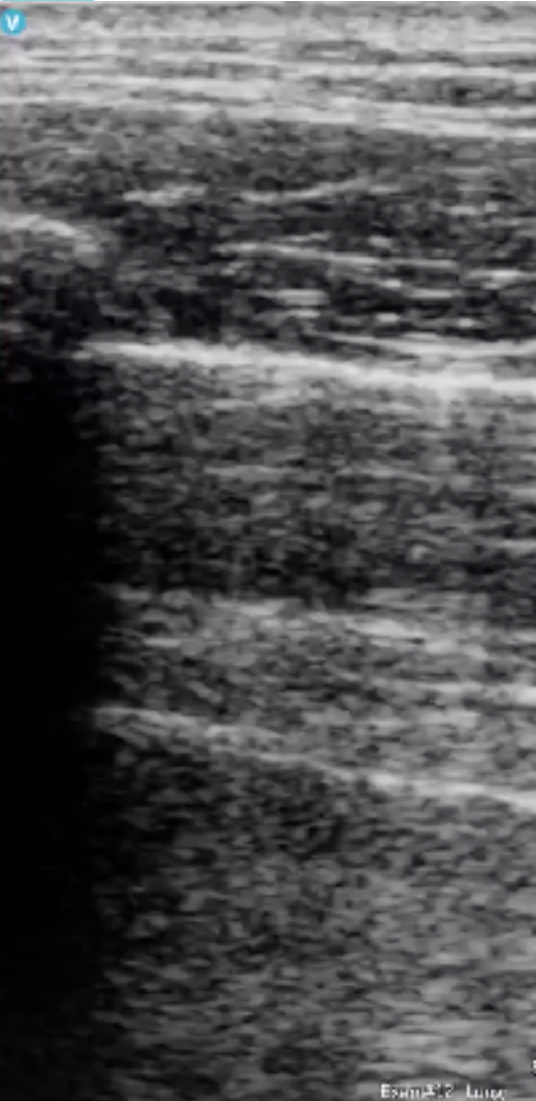
Reduction



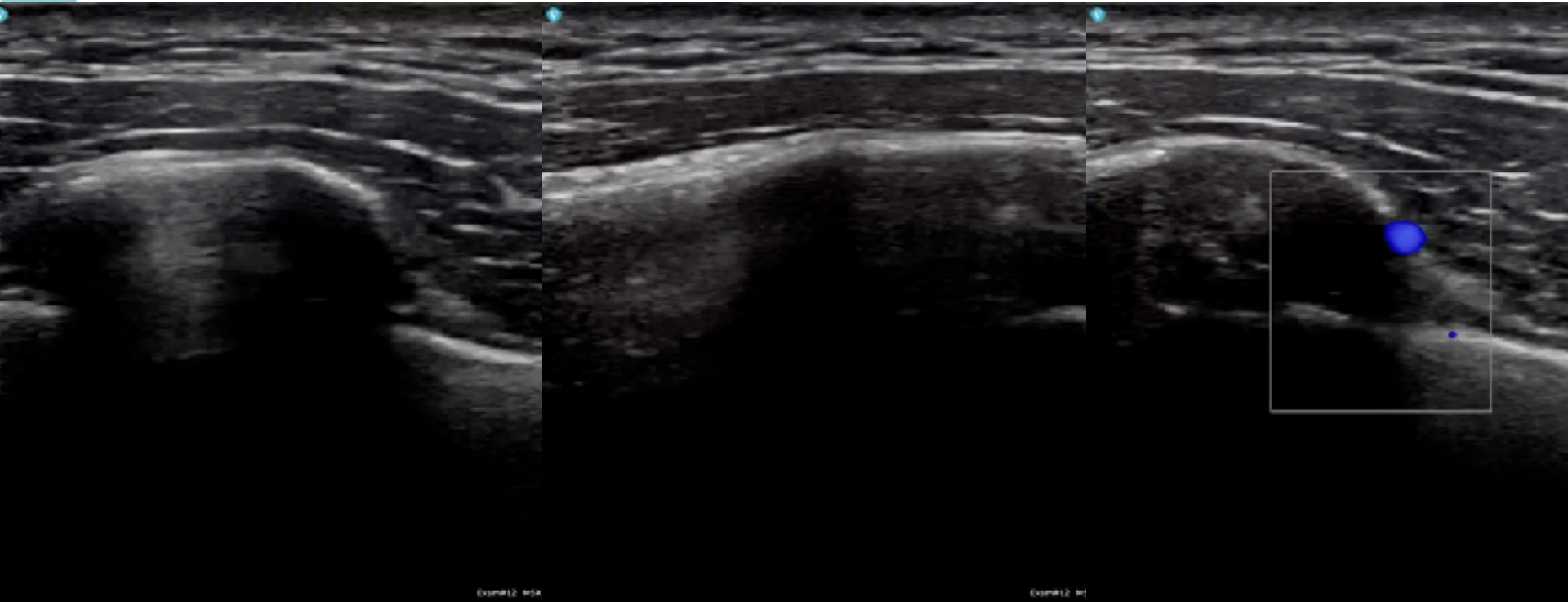
Bat sign, sliding & A lines



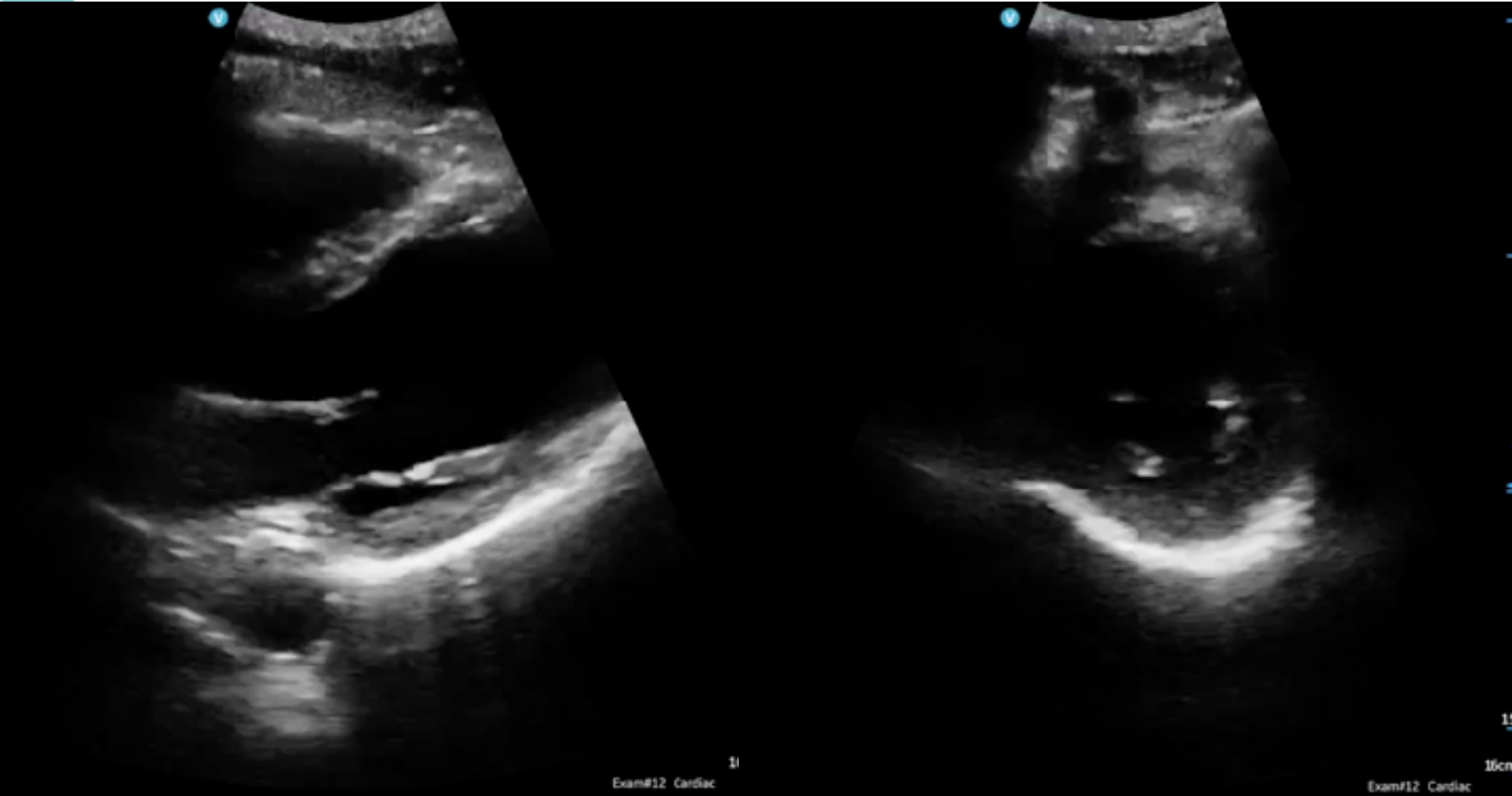
Sliding & Internal thoracic artery



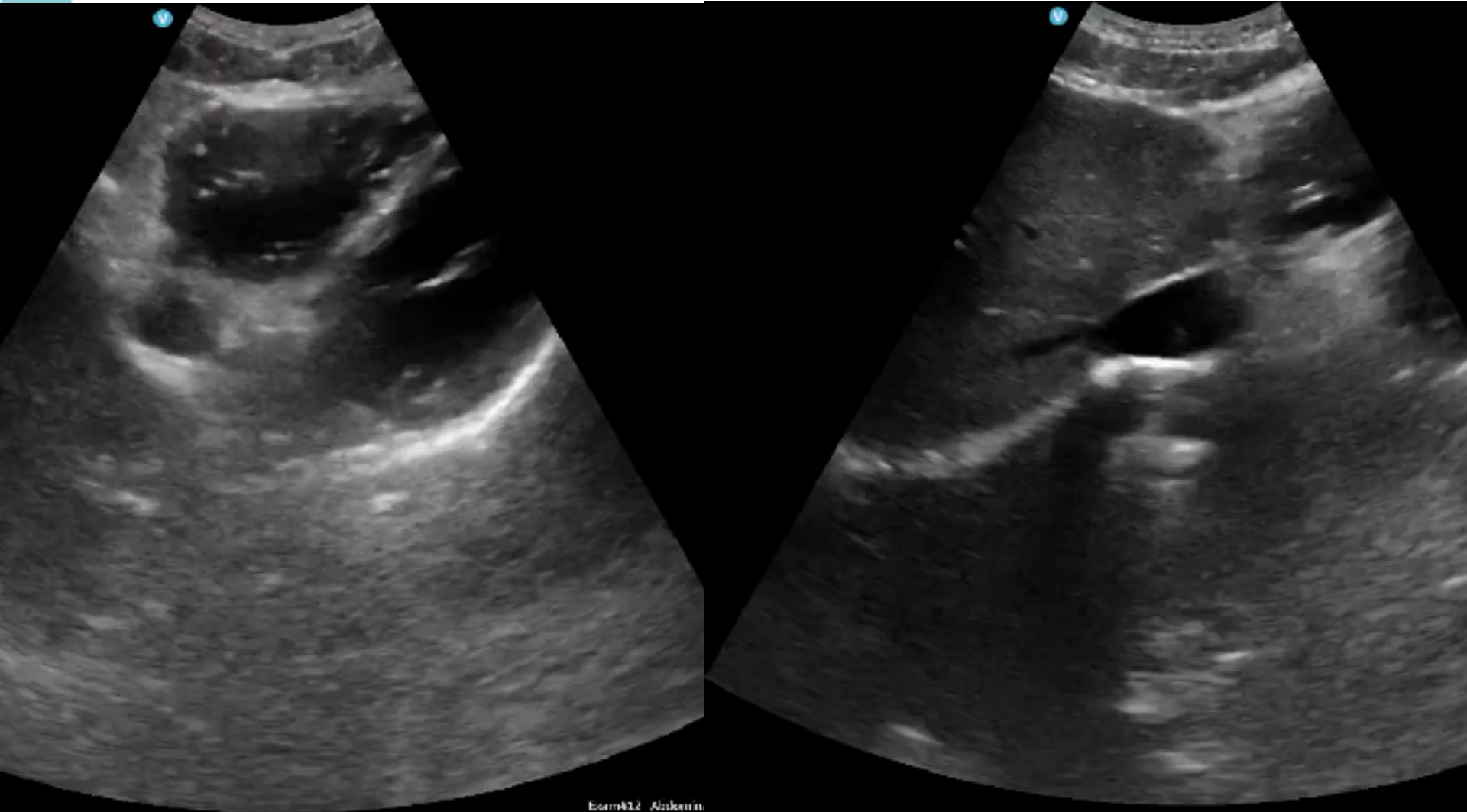
Rib



Parasternal heart

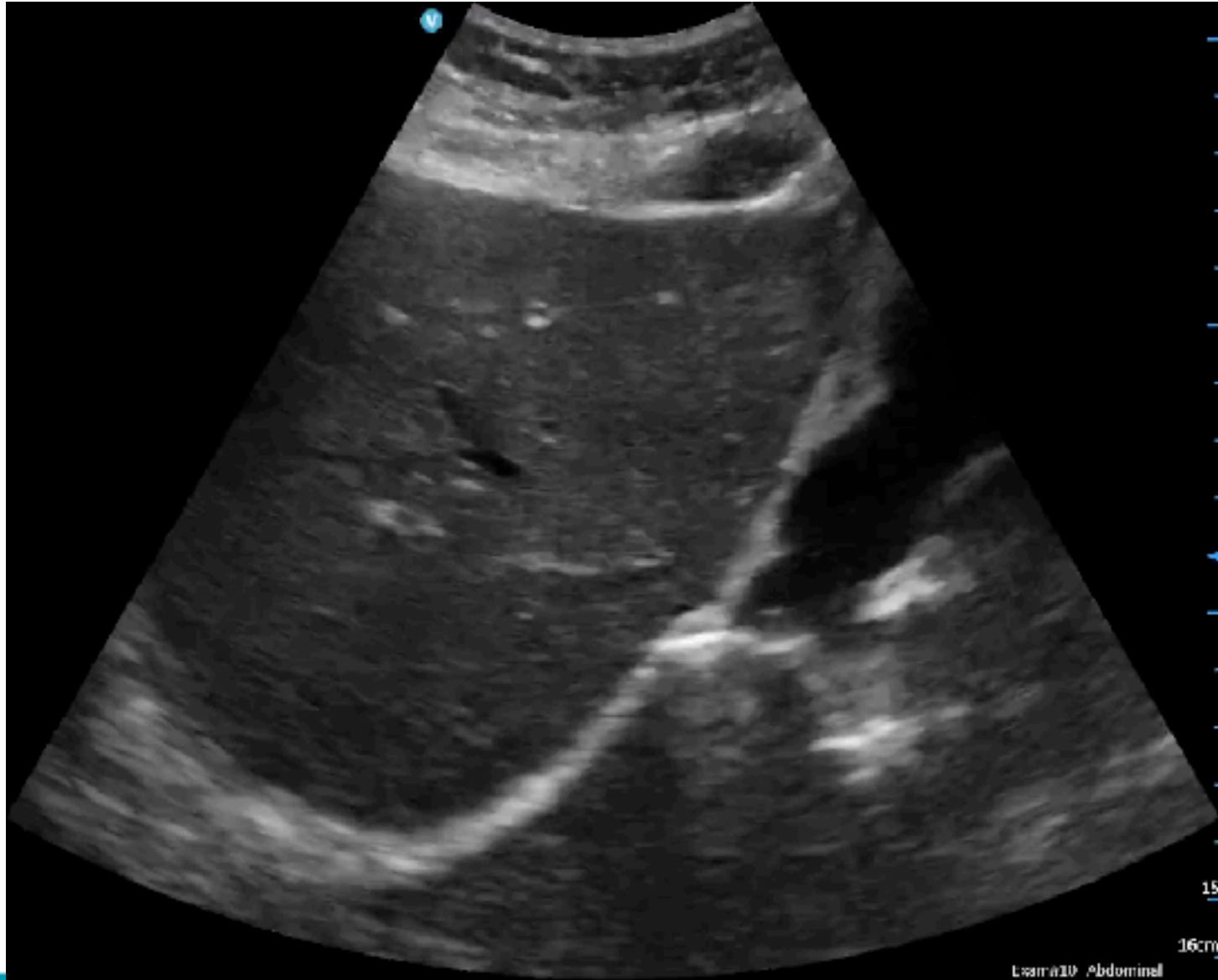

Subcostal view

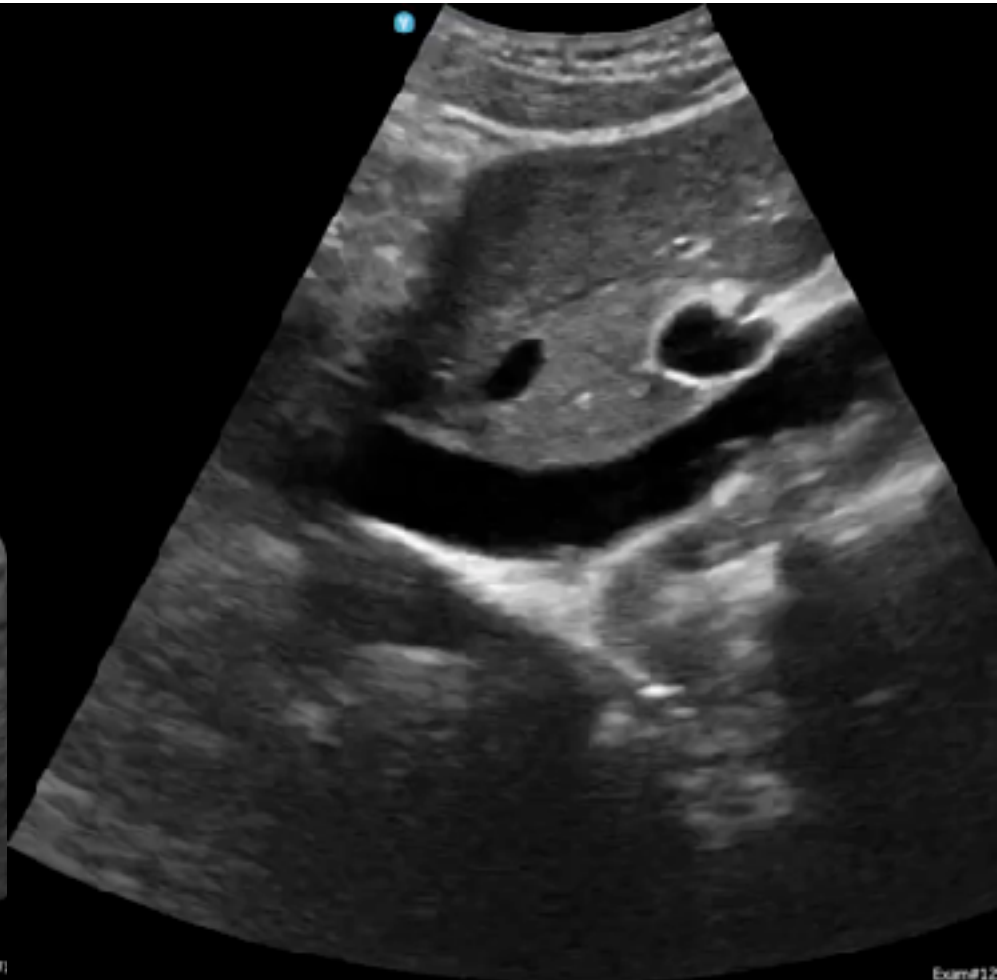
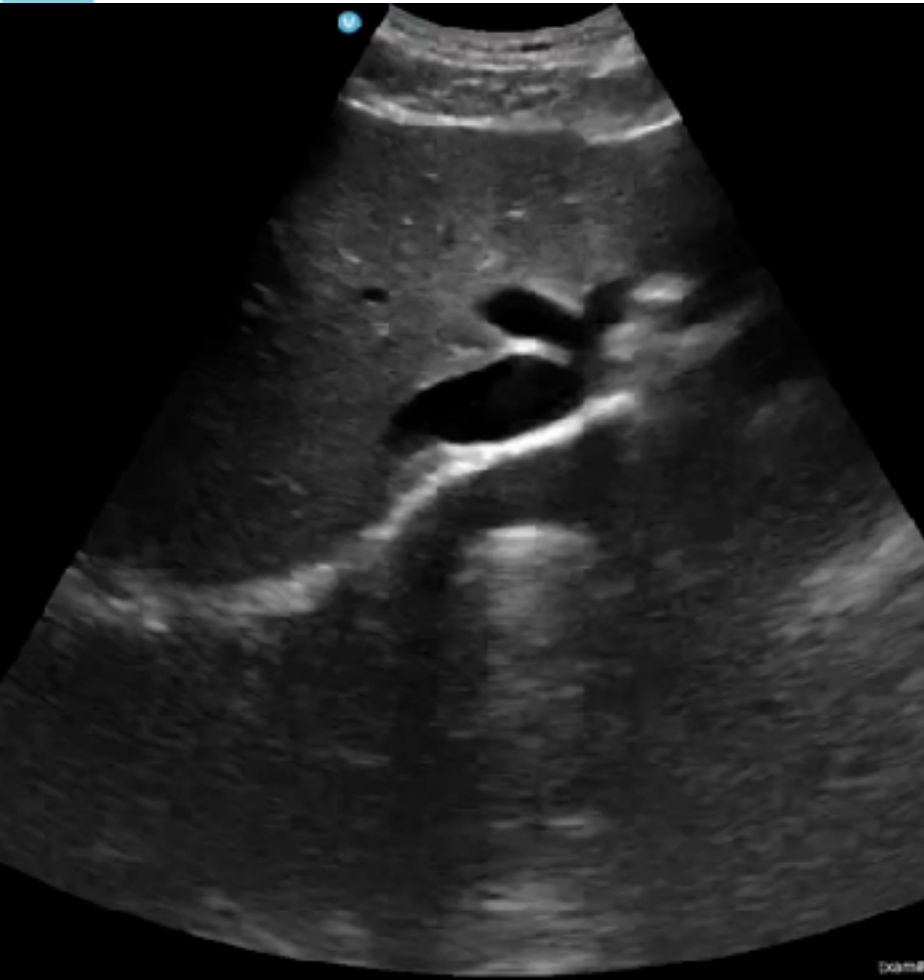

Exam12_Abdom01

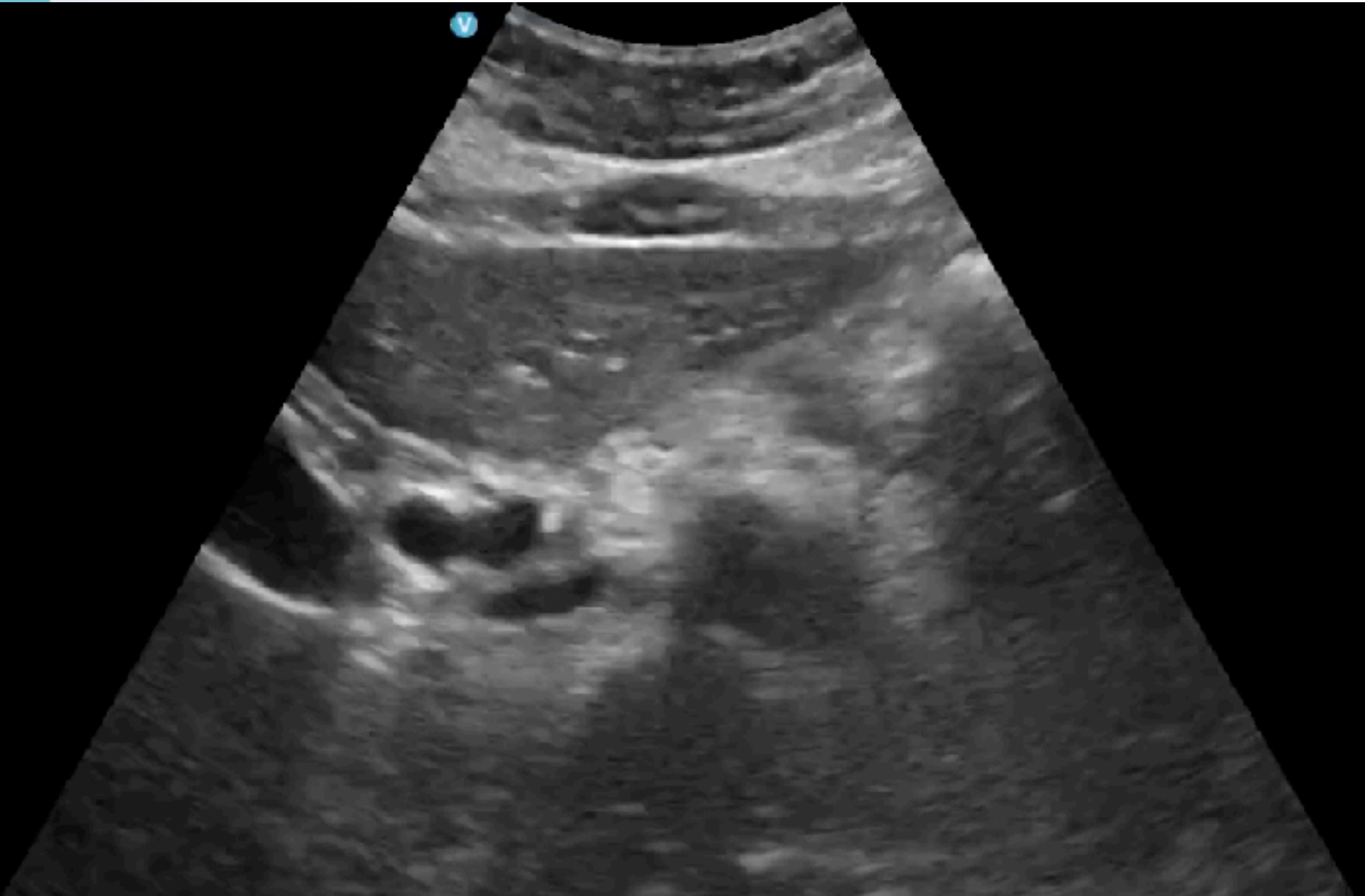
Subcostal view



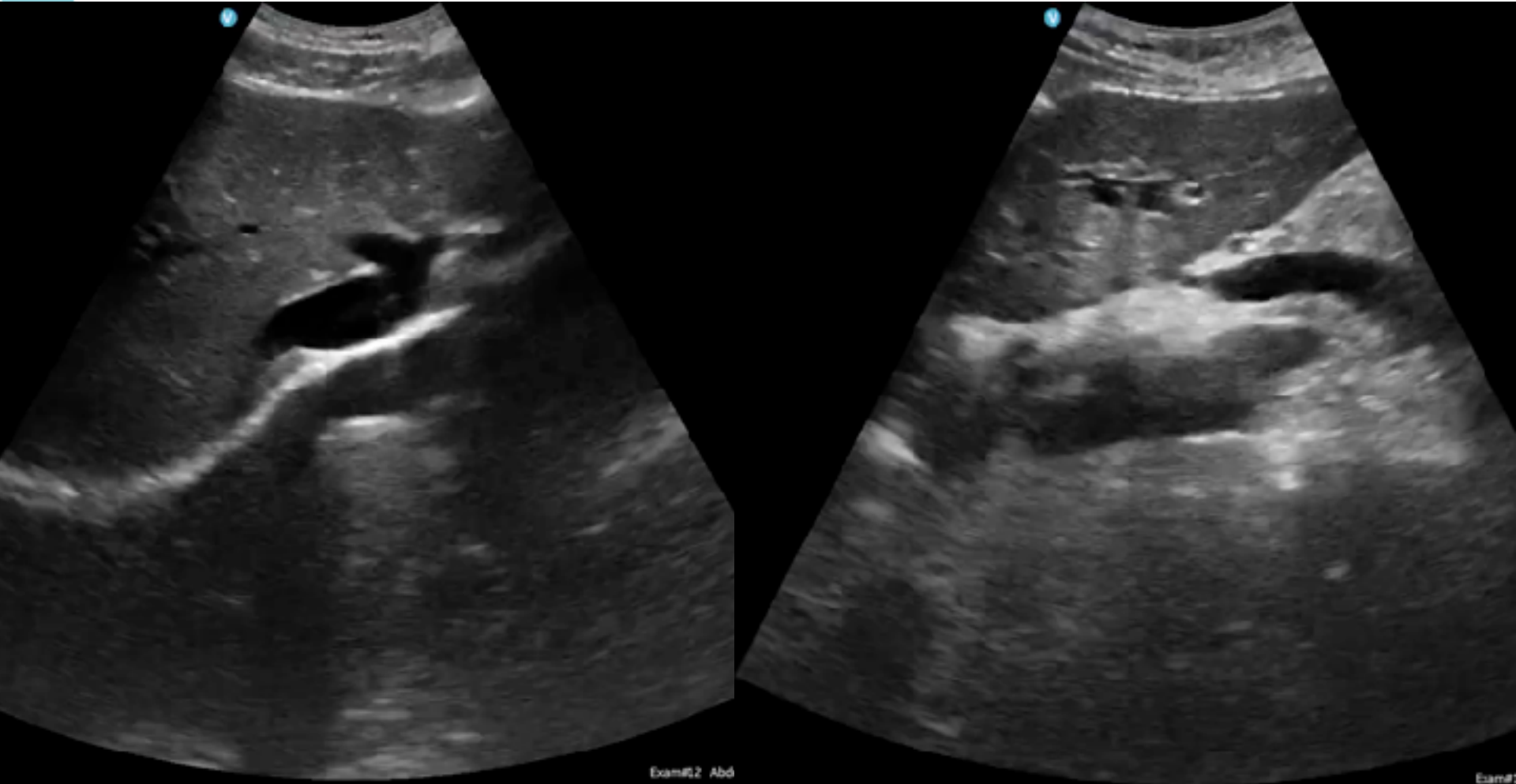
IVC & hepatic veins



Liver surface & EC junction



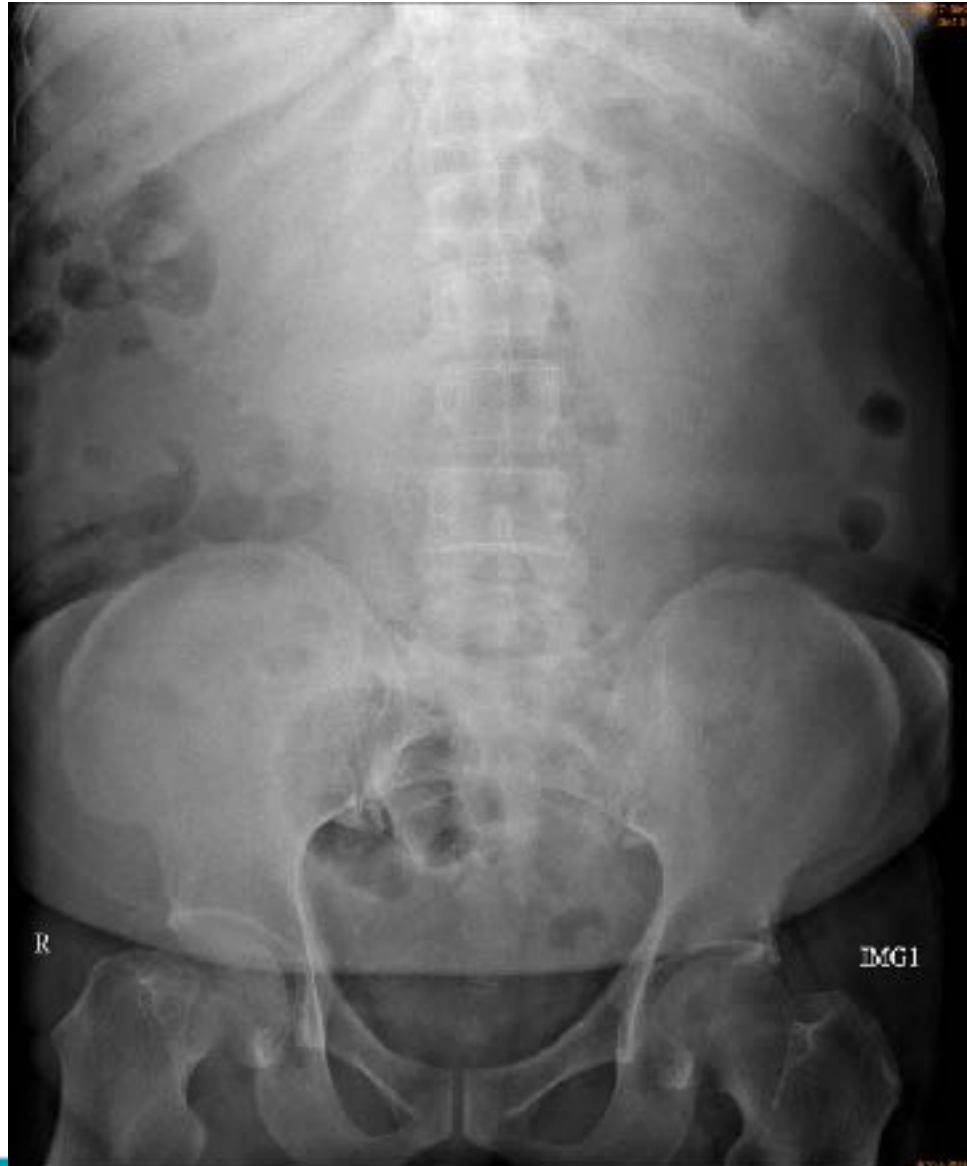Subcostal evaluation for aorta



Exam#2 Abd

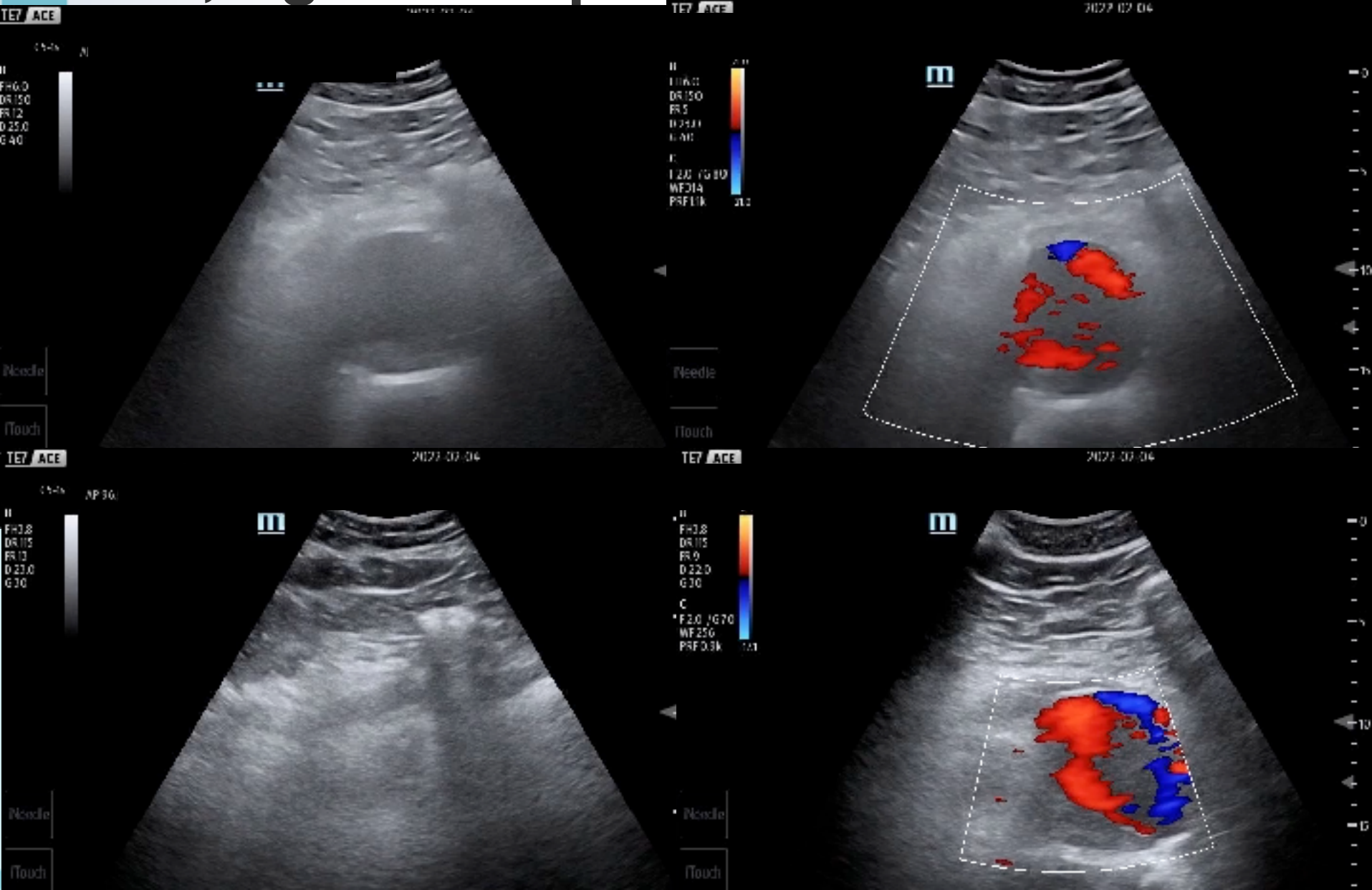
Exam#2

74M, right flank pain & cold sweating

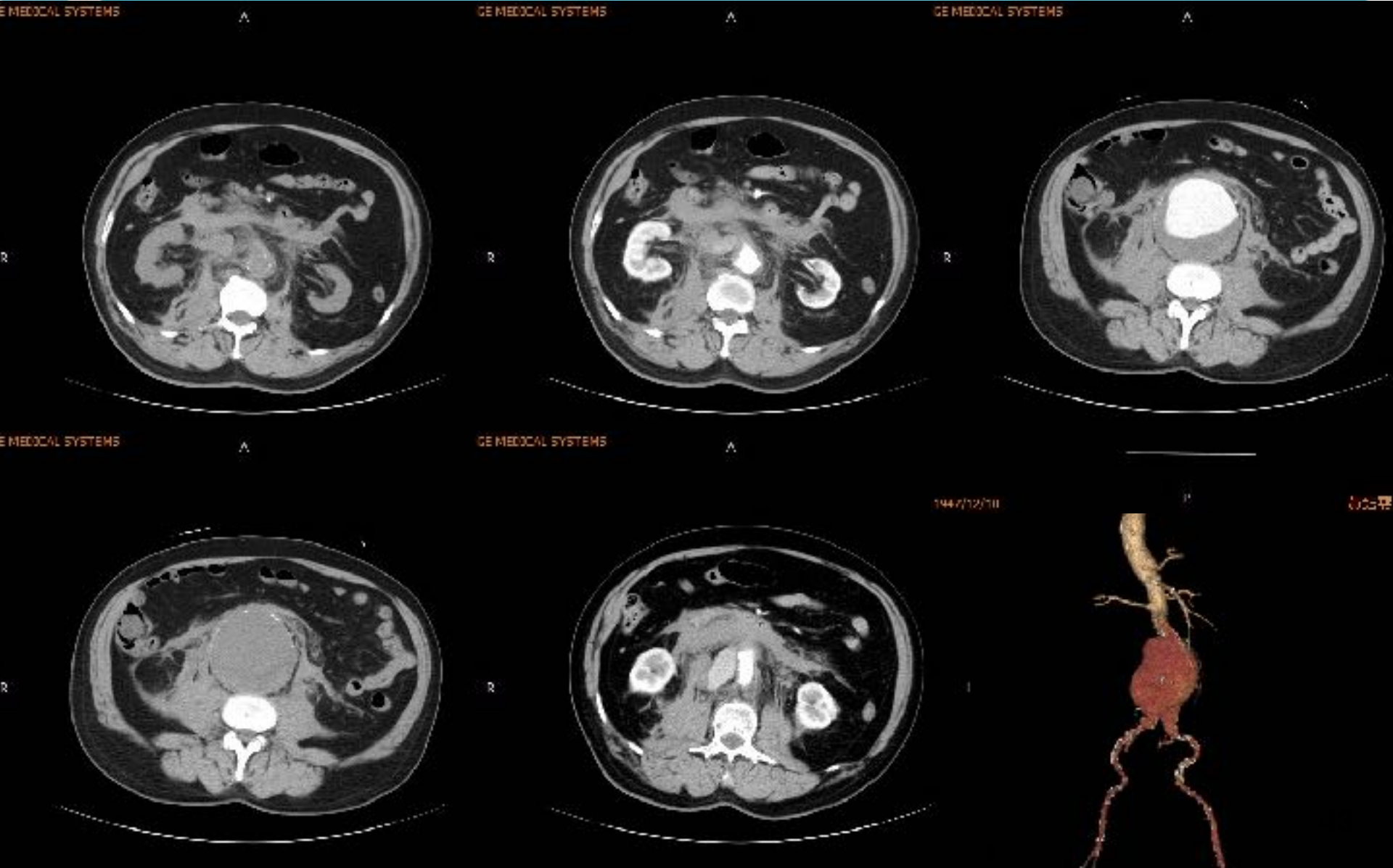




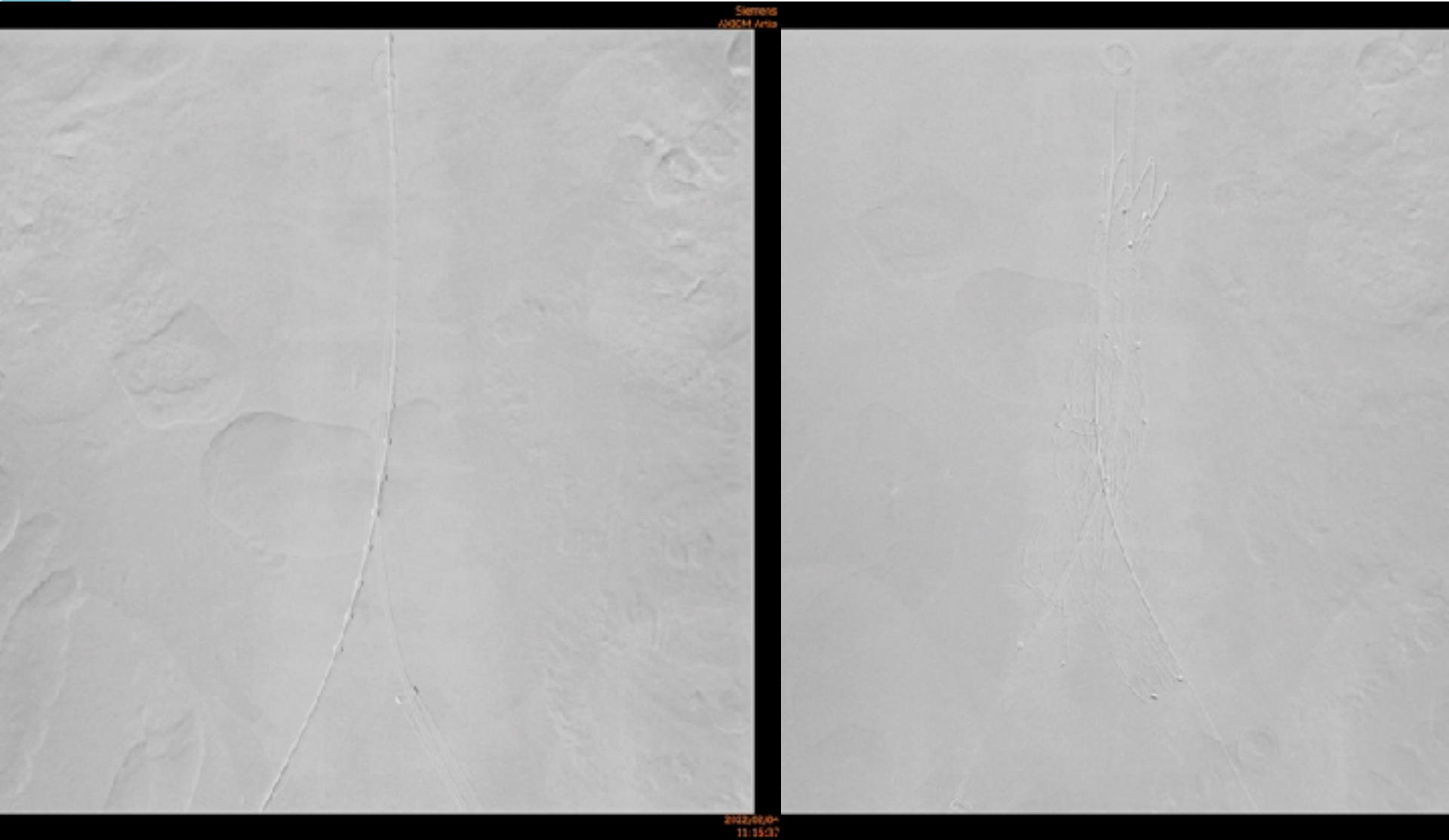
74M, right flank pain & cold sweating



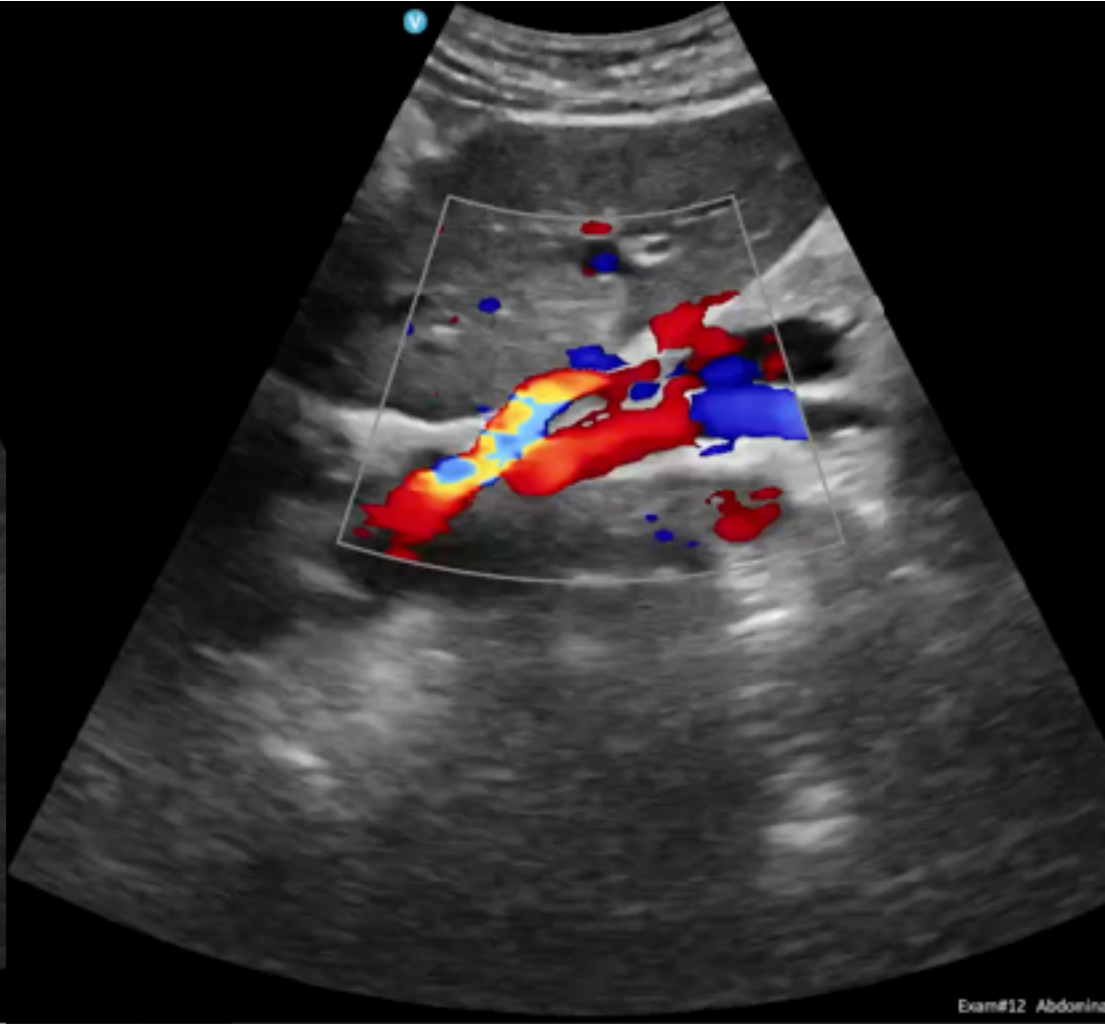
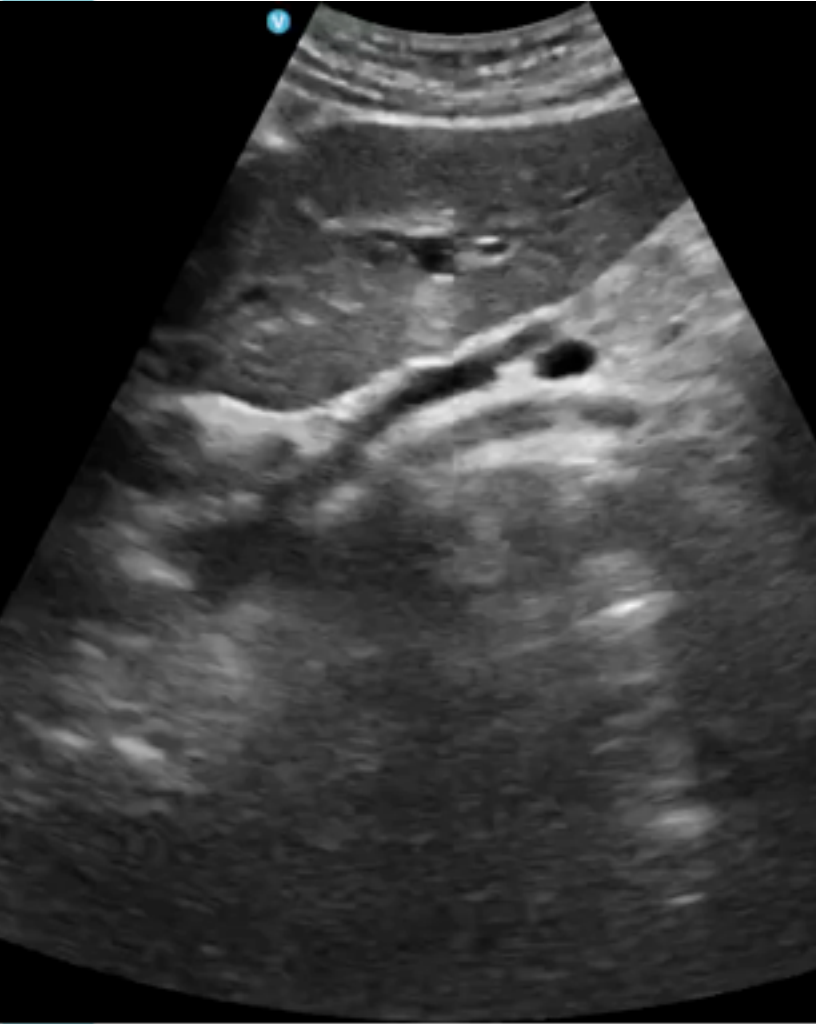
74M, right flank pain & cold sweating



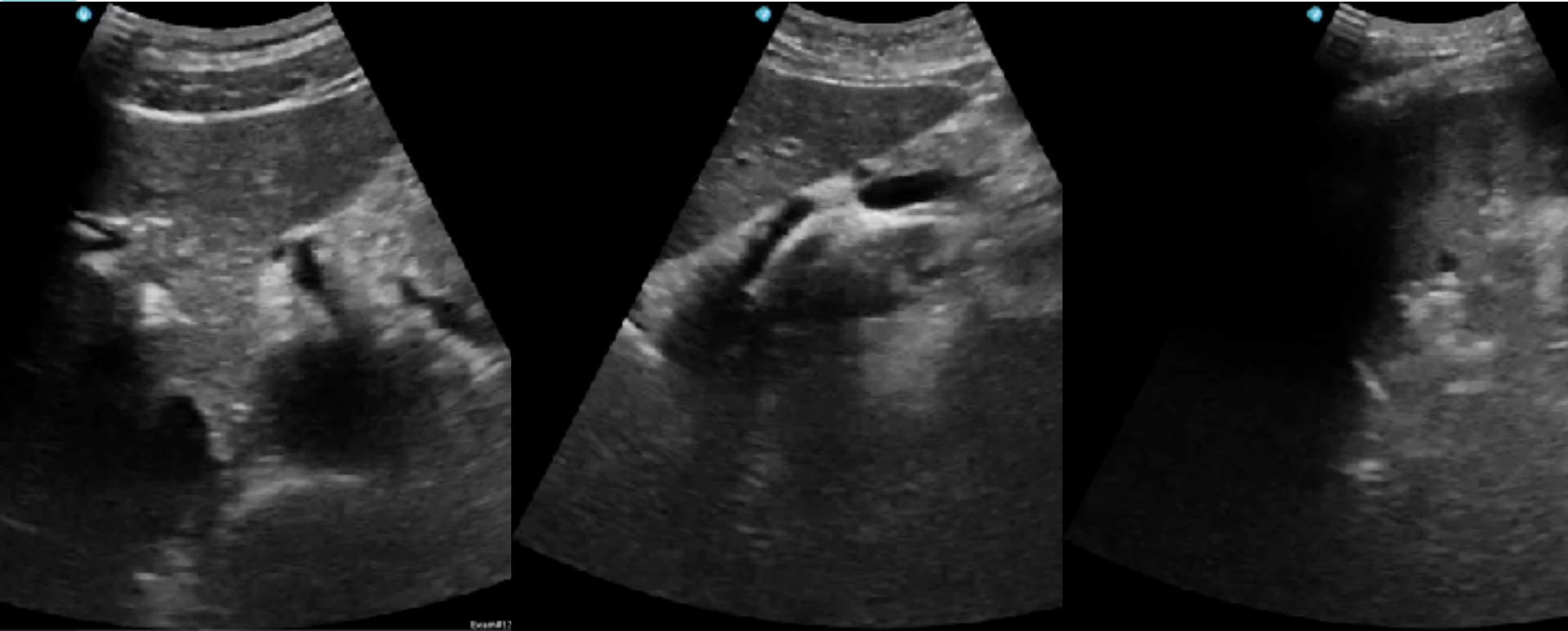
Emergent surgery



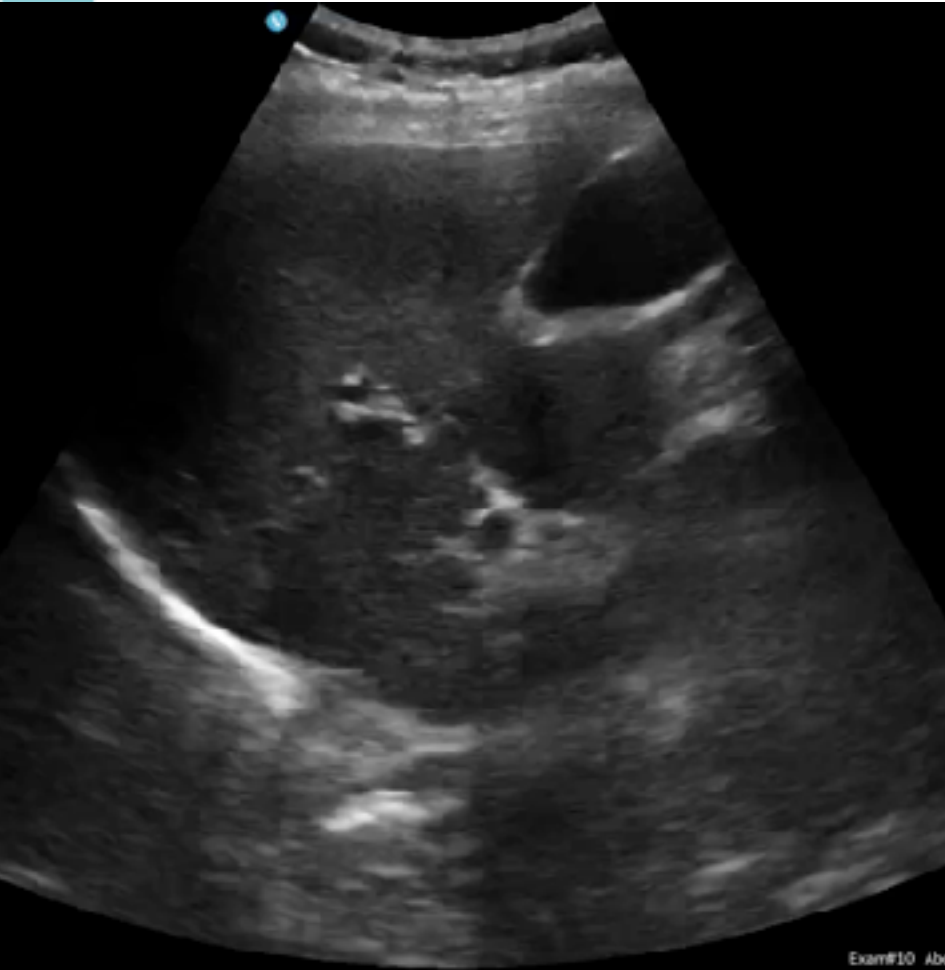Celiac trunk & SMA



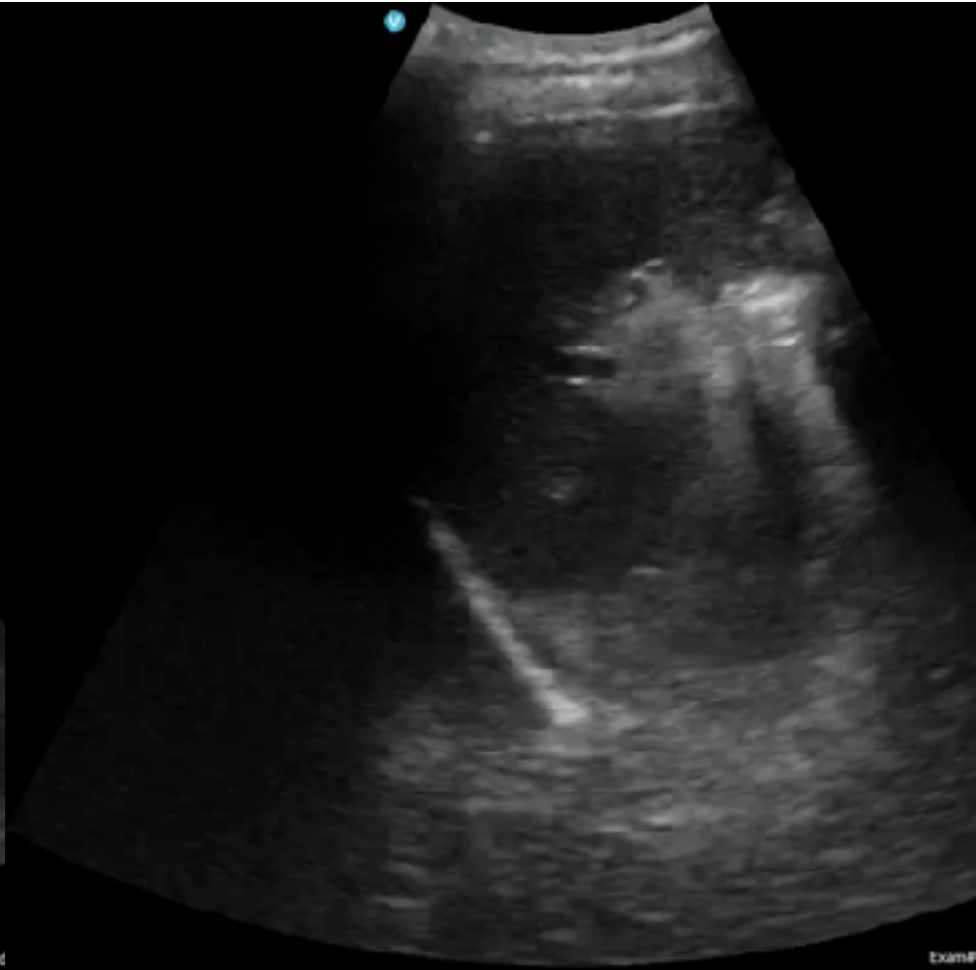Pancreas



RUQ & LUQ views

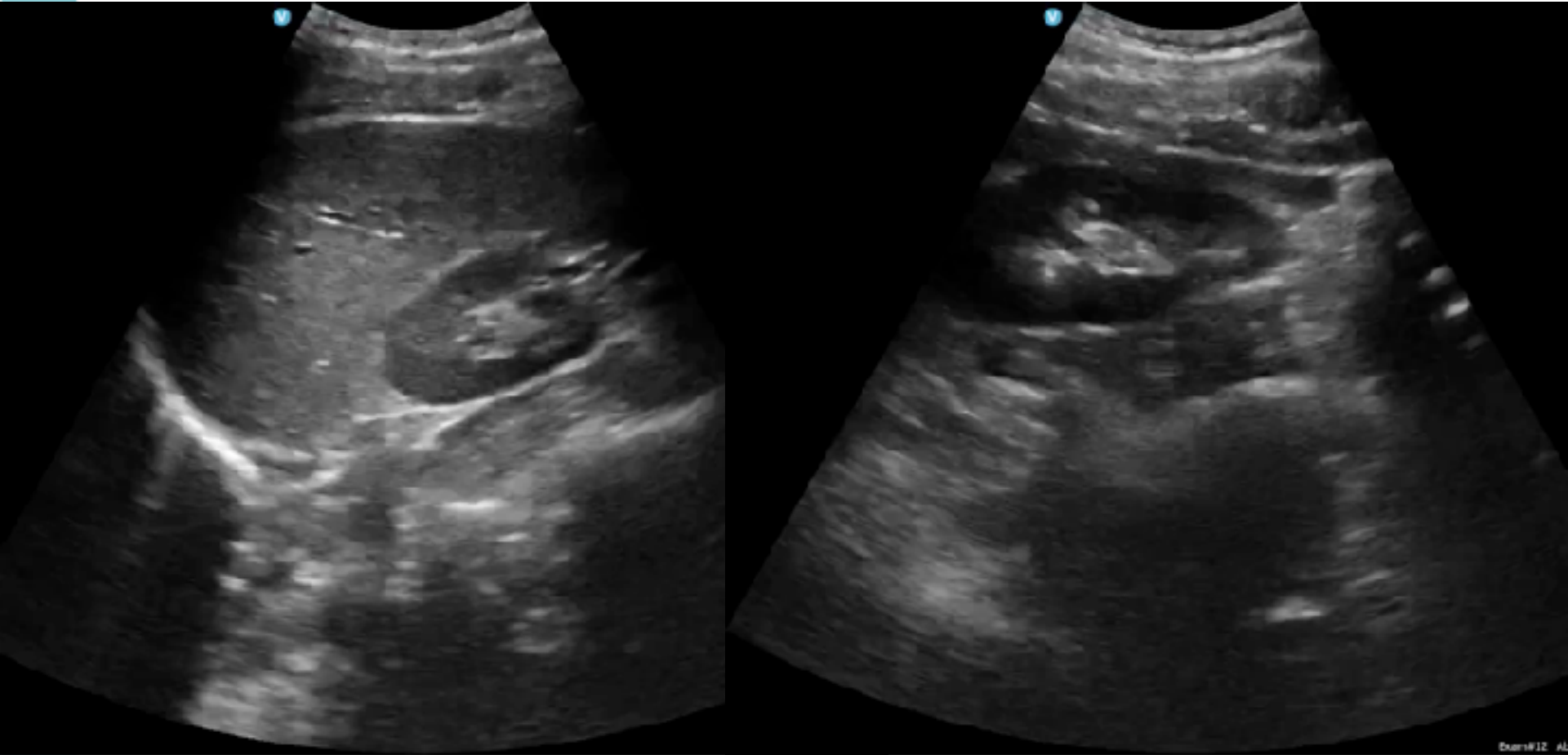


Exam#10 Abd



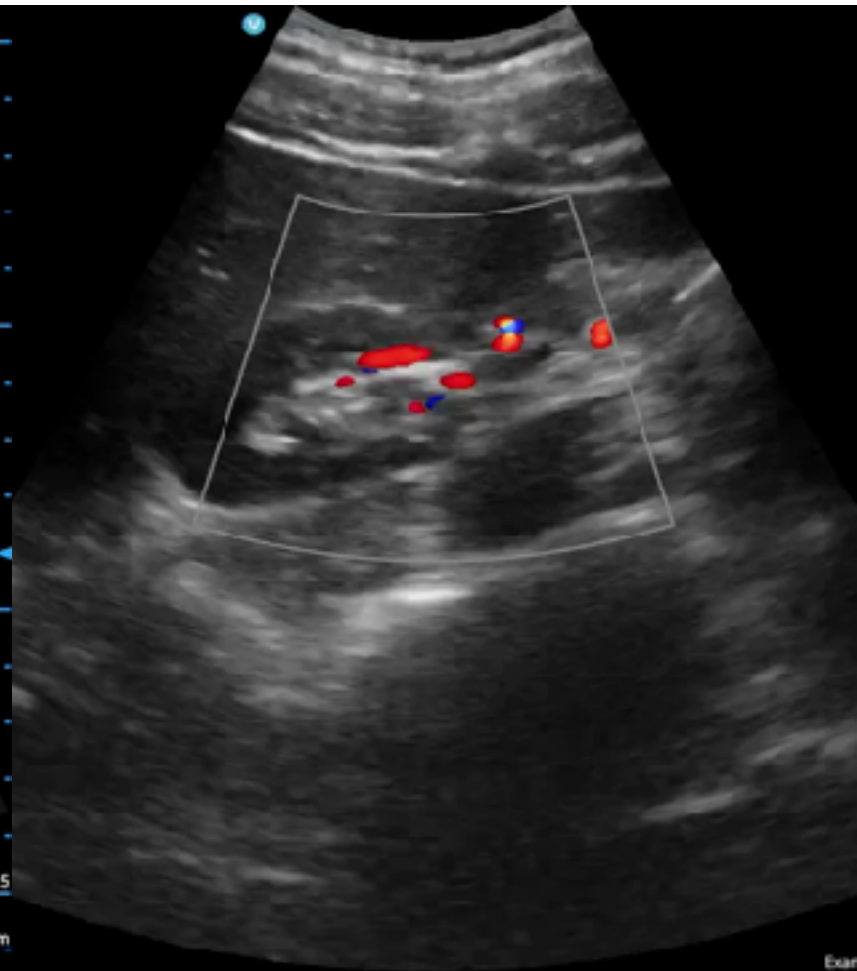
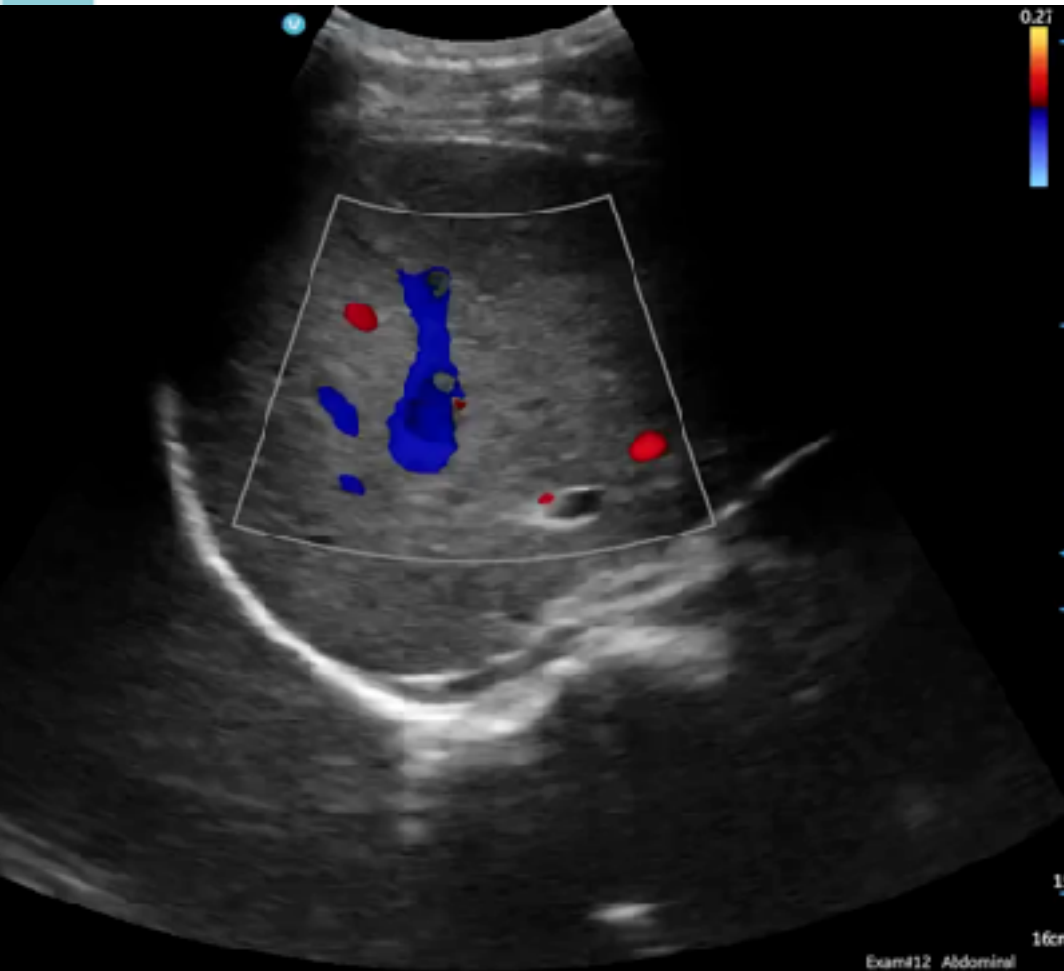
Exam#

Both kidneys & psoas muscles

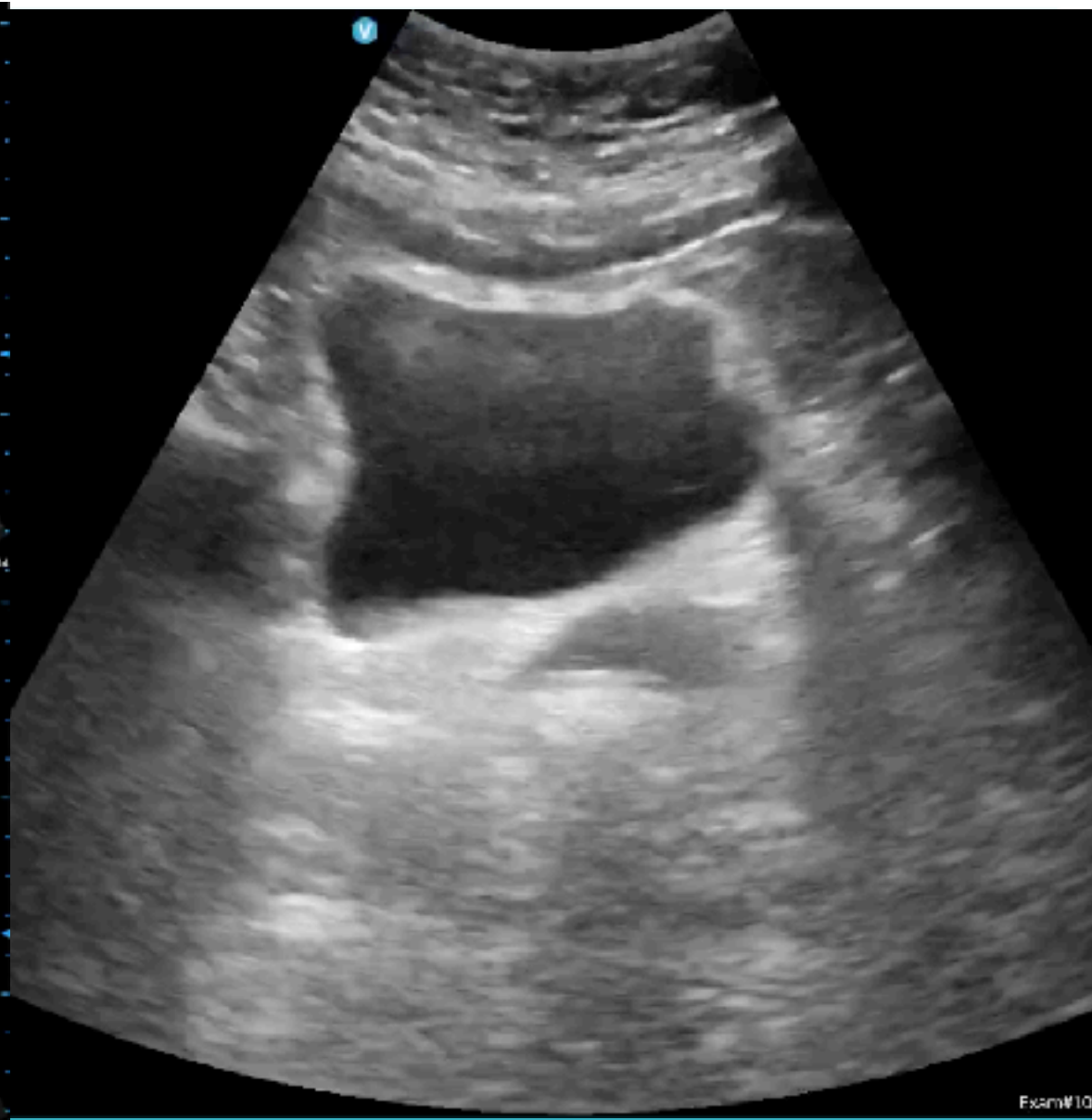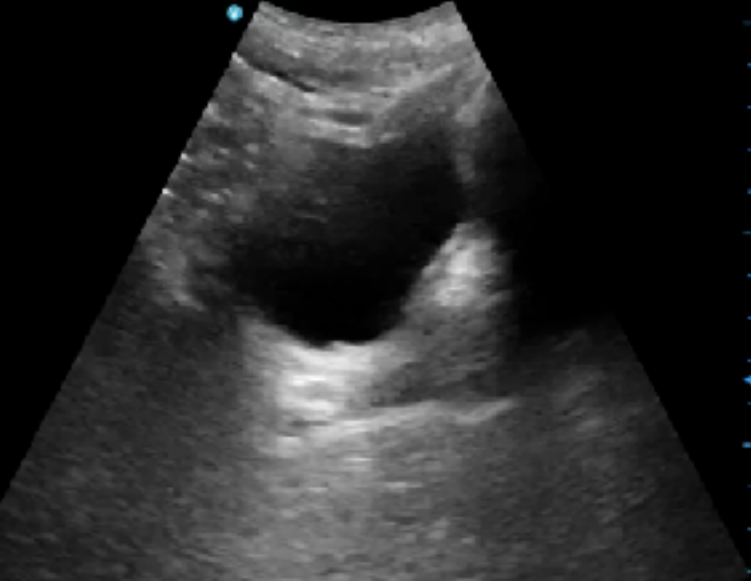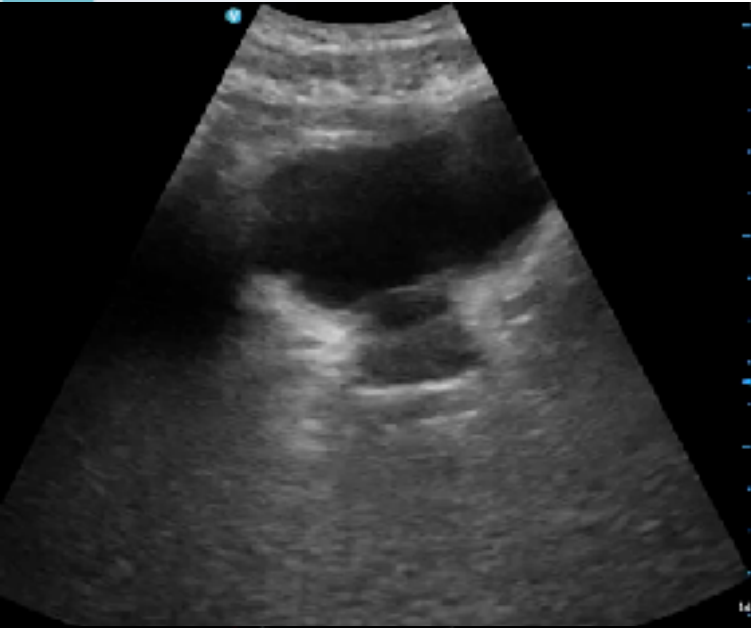


Exam 12, Al.

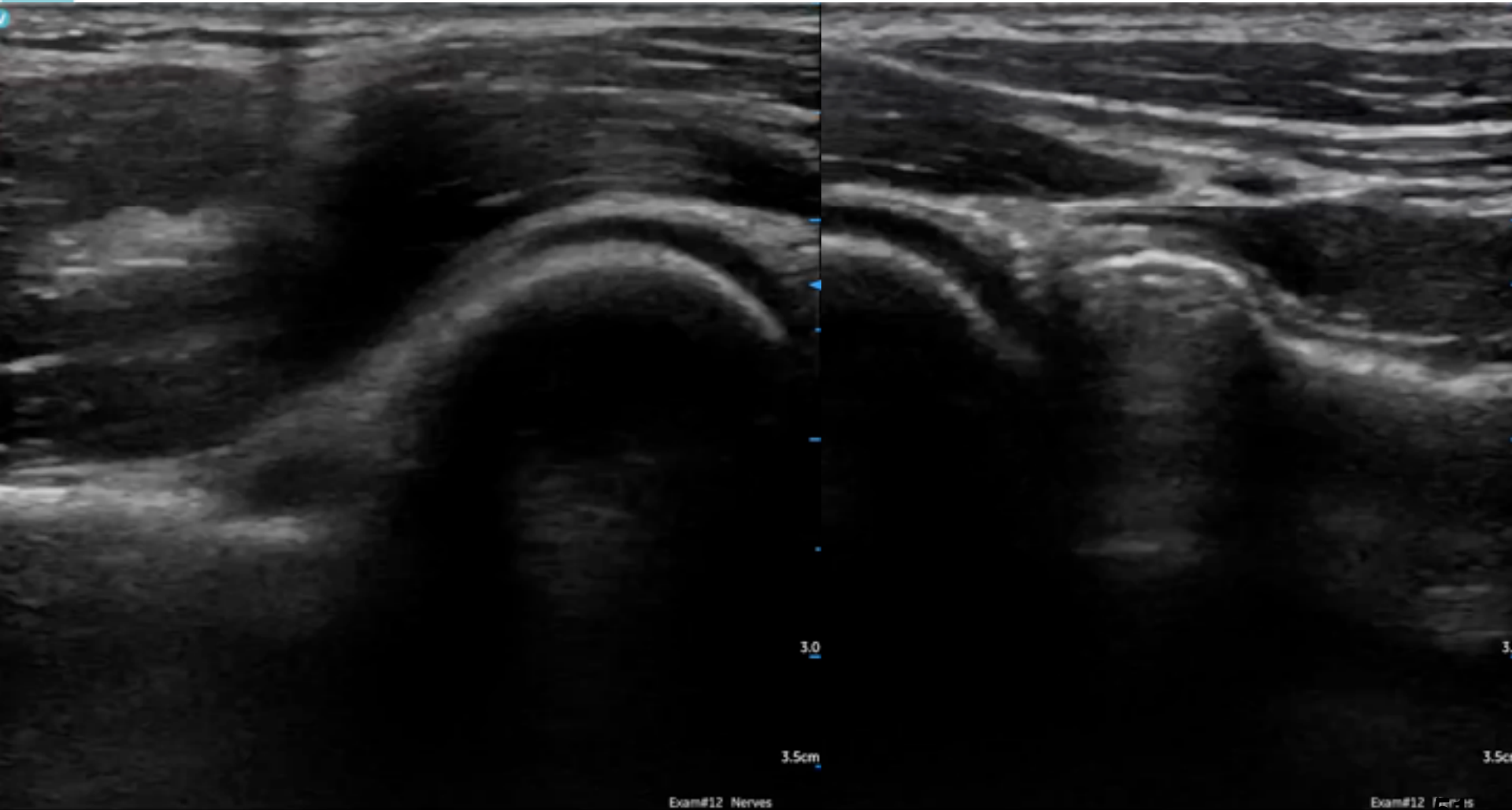
Solid organ vessels



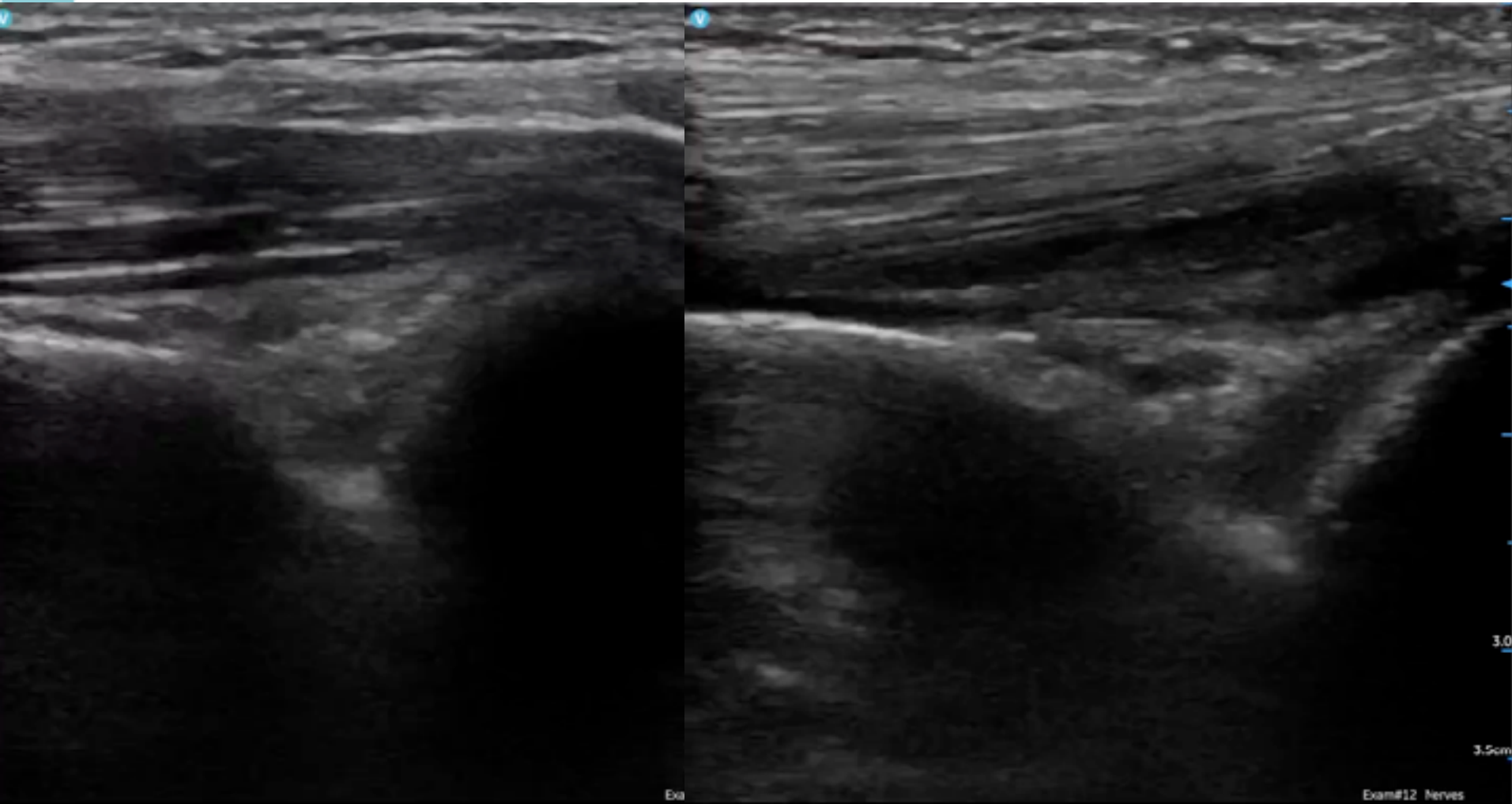
Urinary bladder & Pelvis



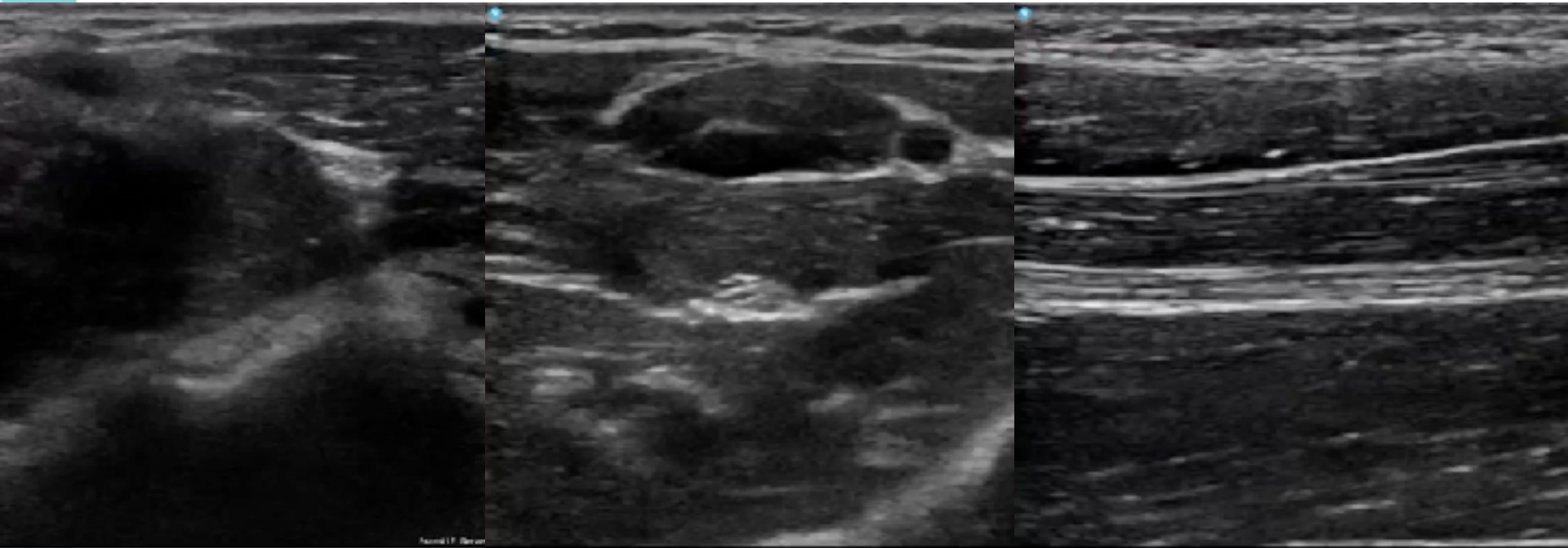
Radial fossa & Radial head



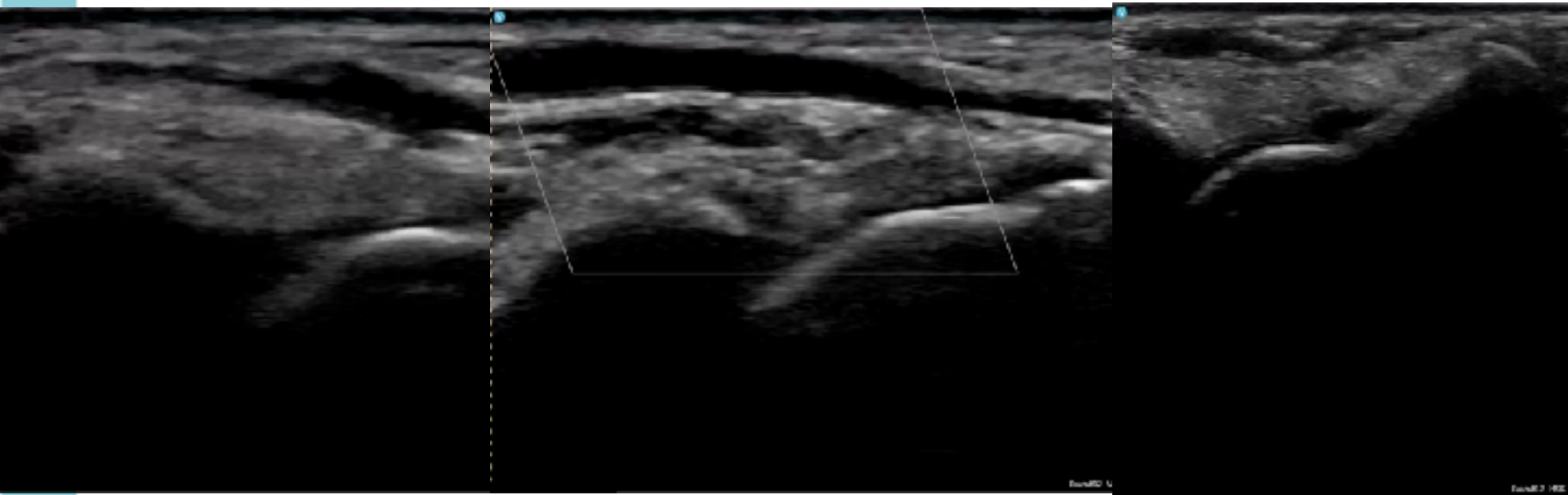
Coronoid & Olecranon fossa



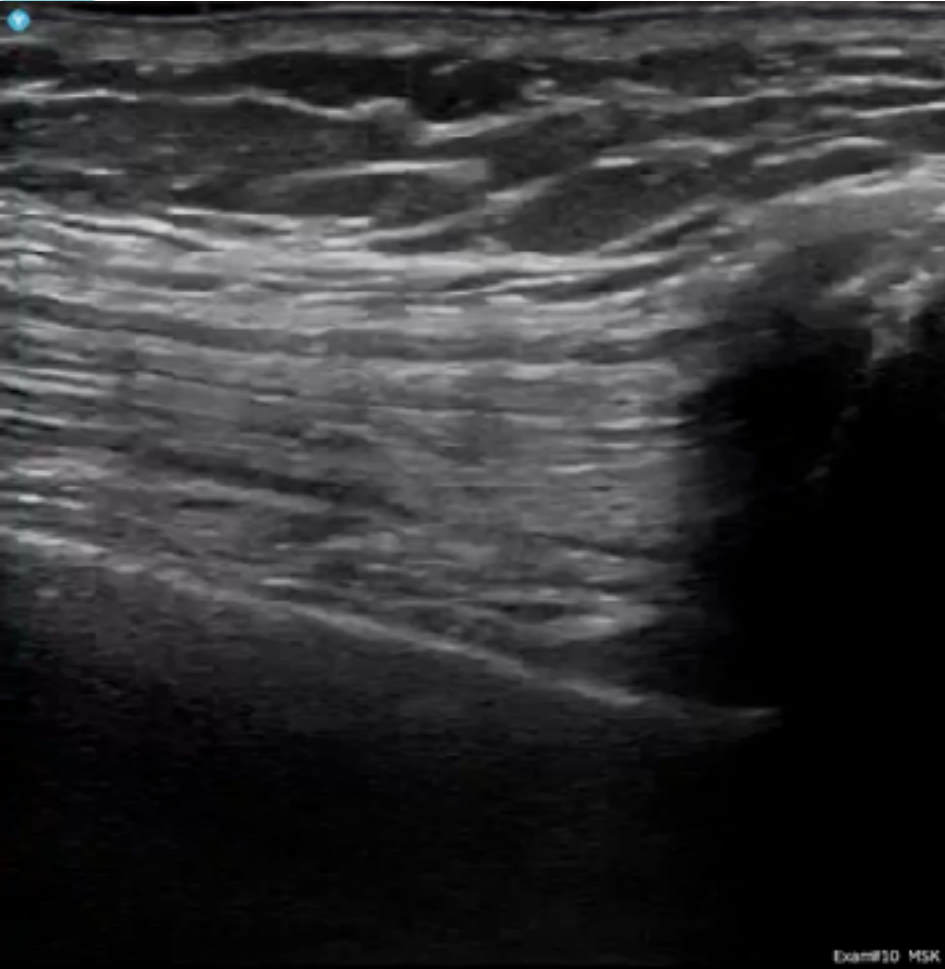Forearm nerves



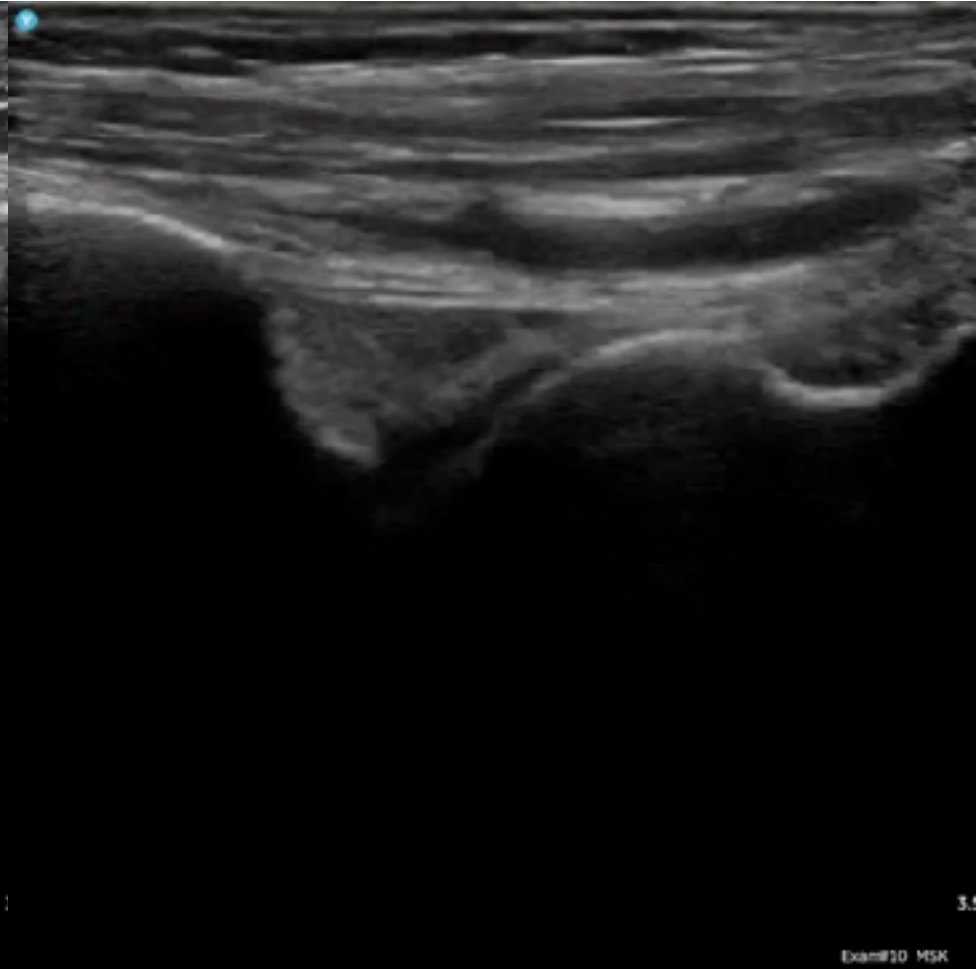Radial artery & Scaphoid



Joint effusion



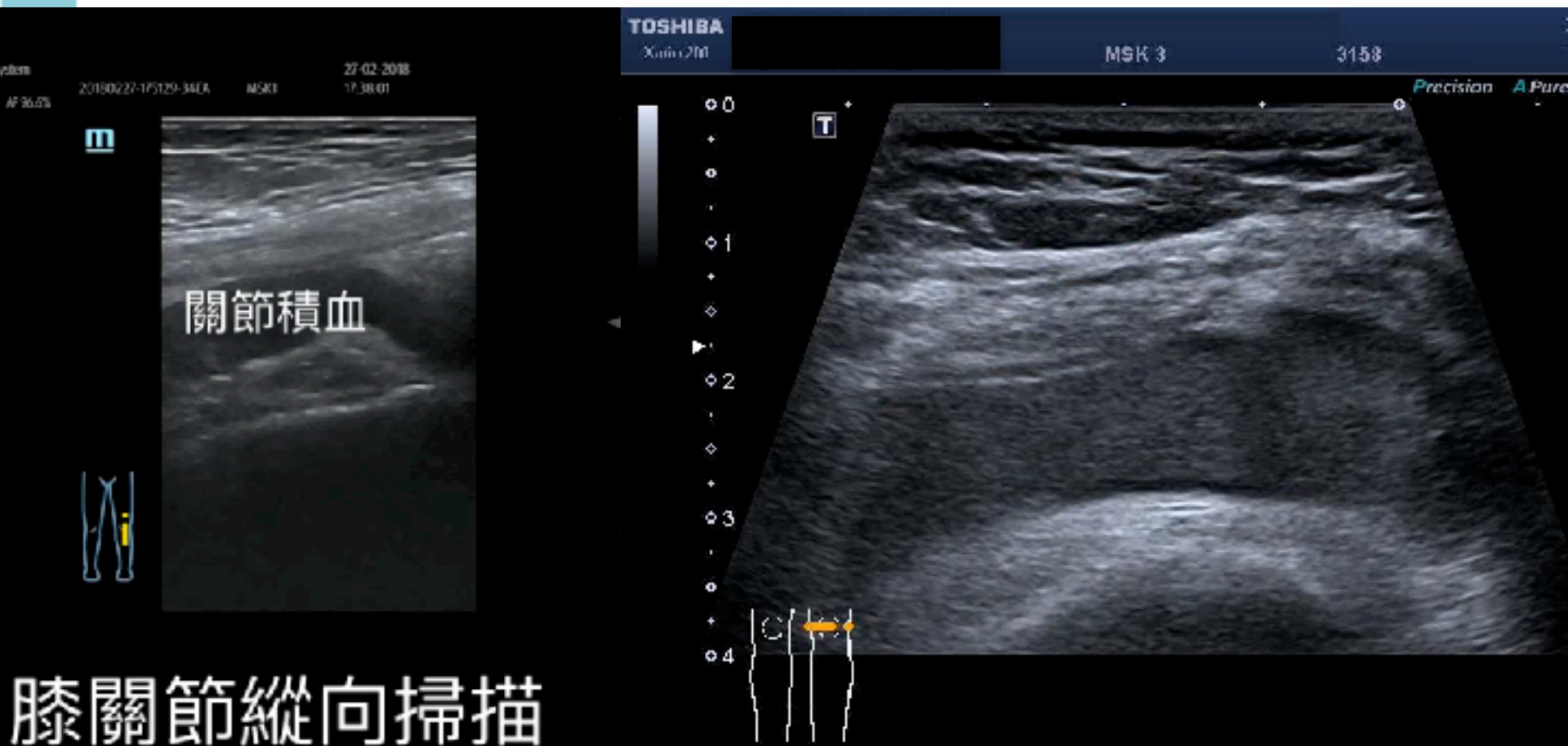
Exam#10 MSK



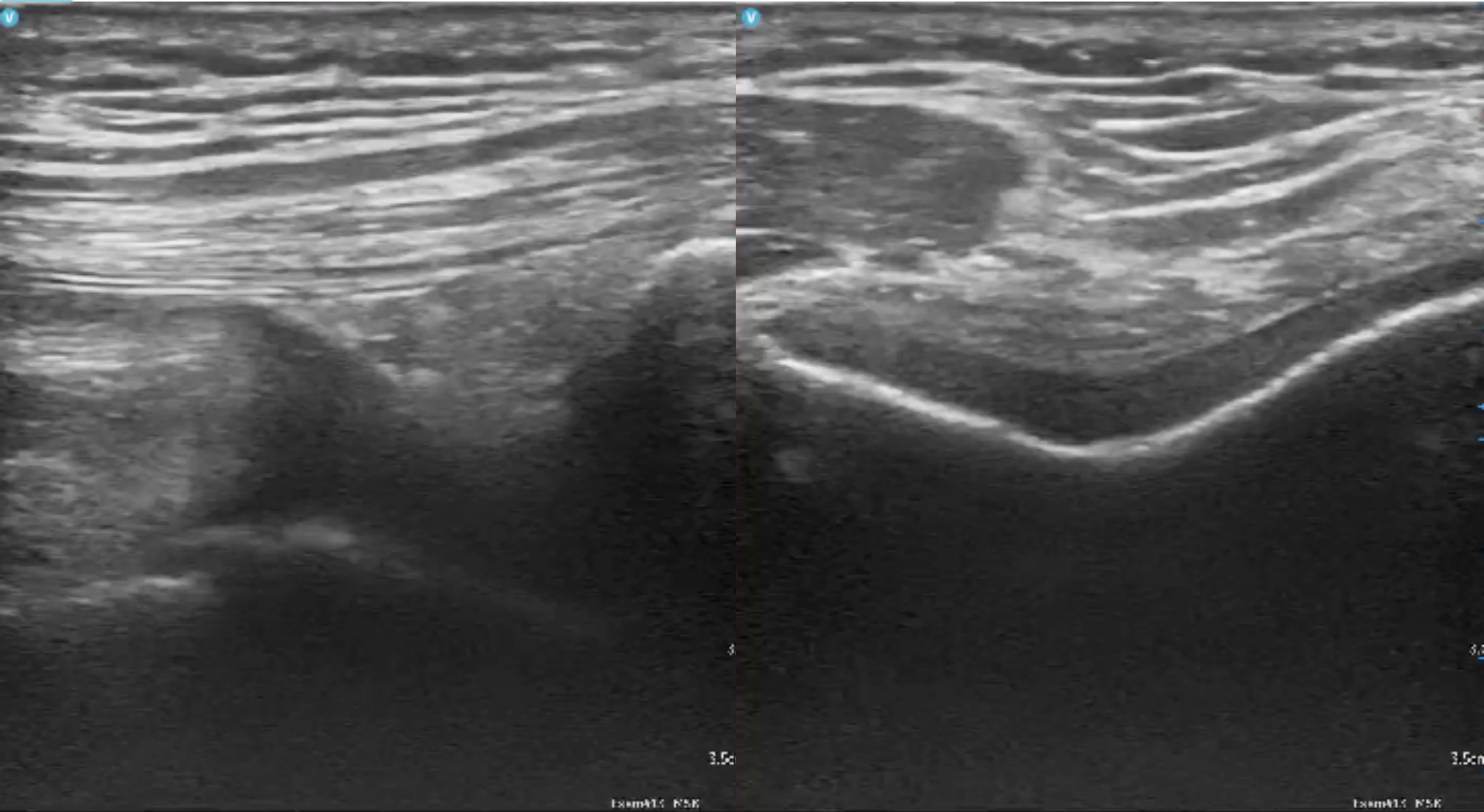
Exam#10 MSK



Joint effusion & aspiration



Dynamic evaluation



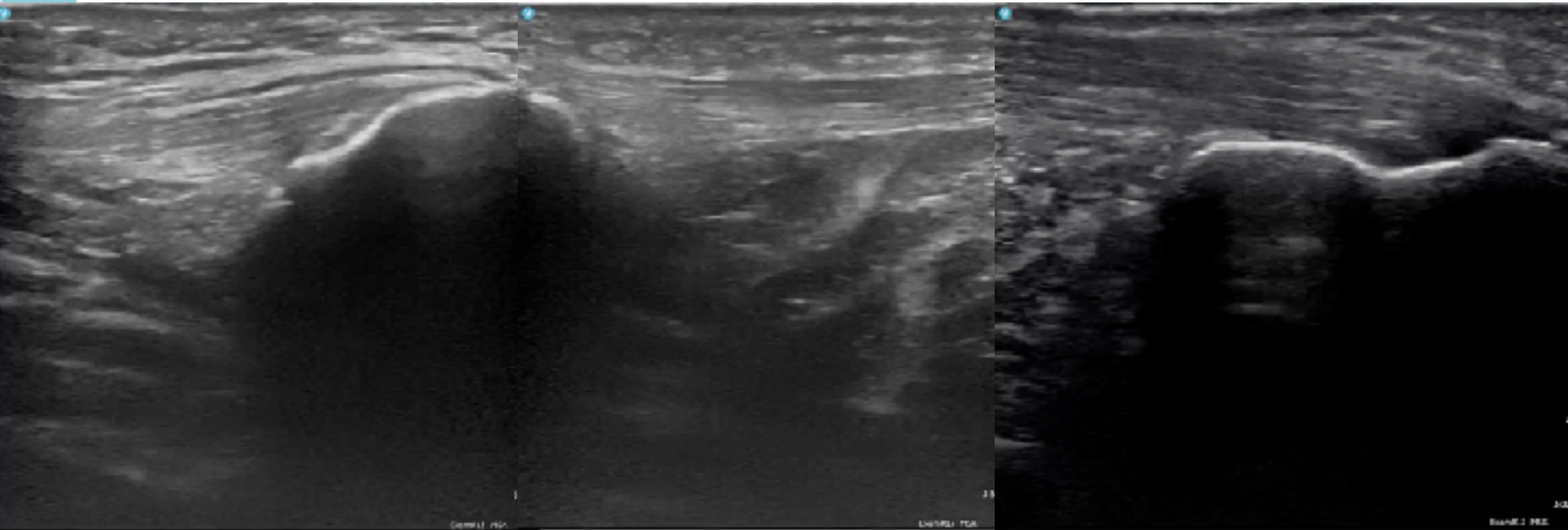
Major tendons



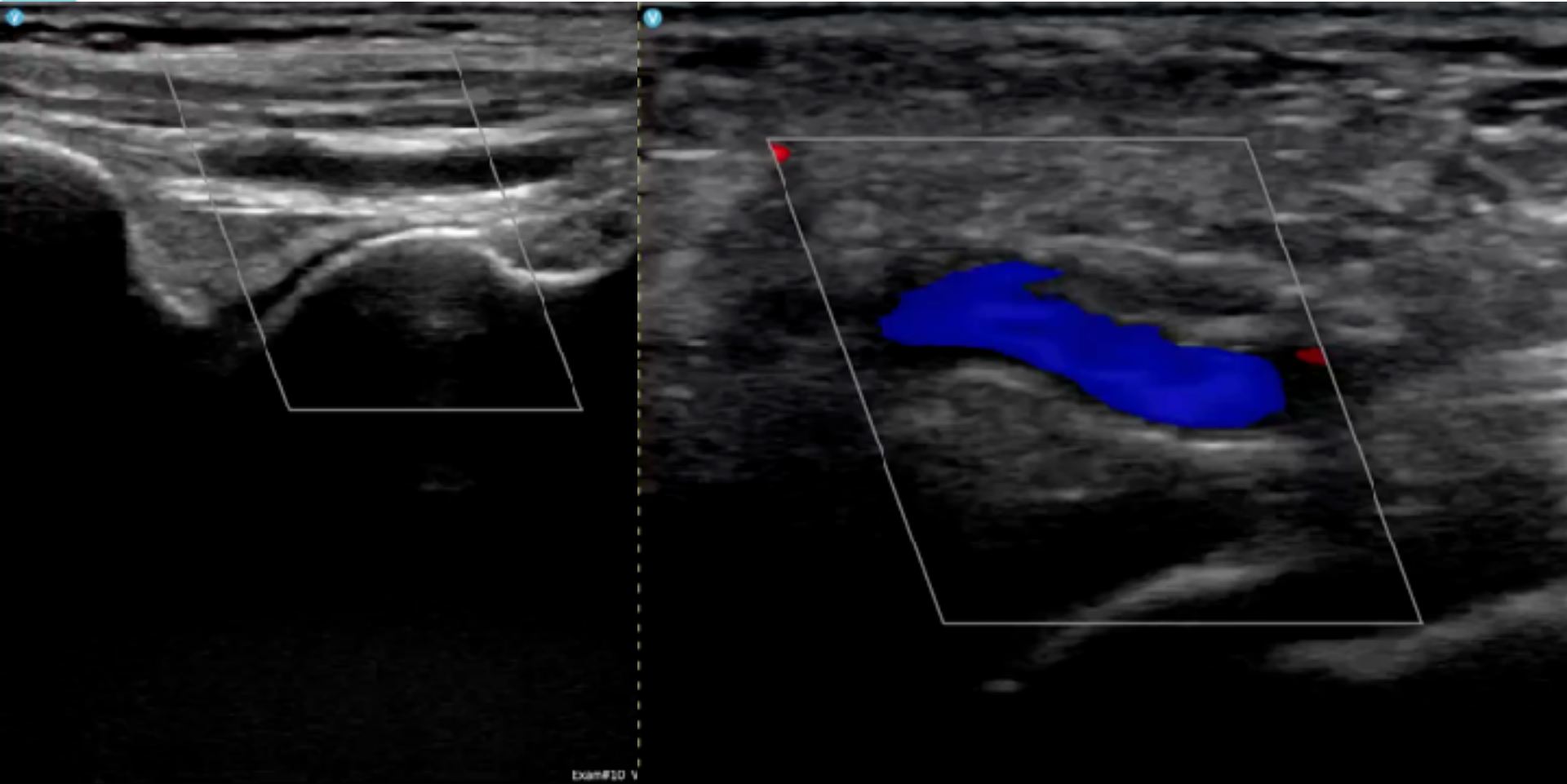
Quadriceps

Patellar

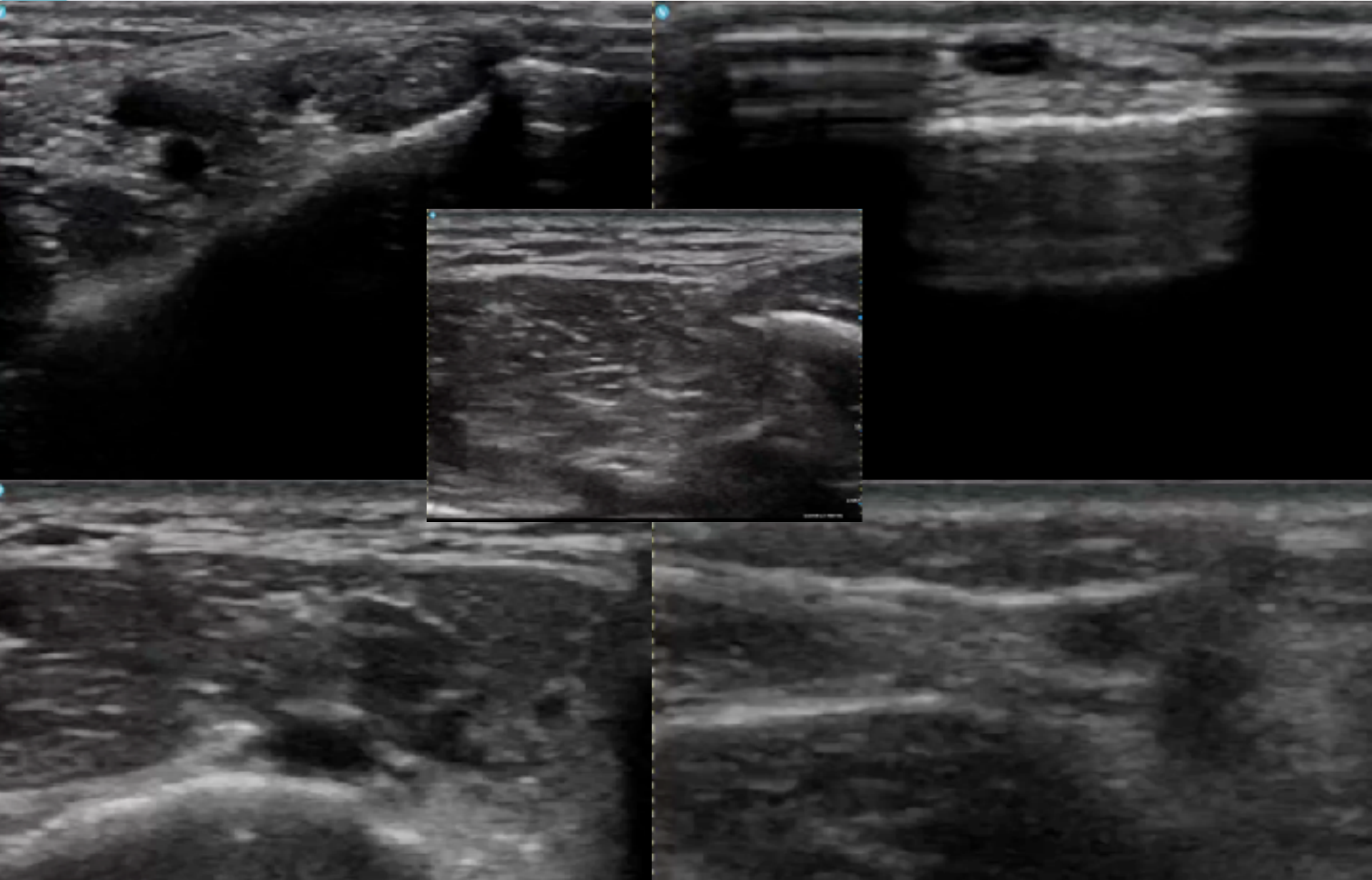
Achilles



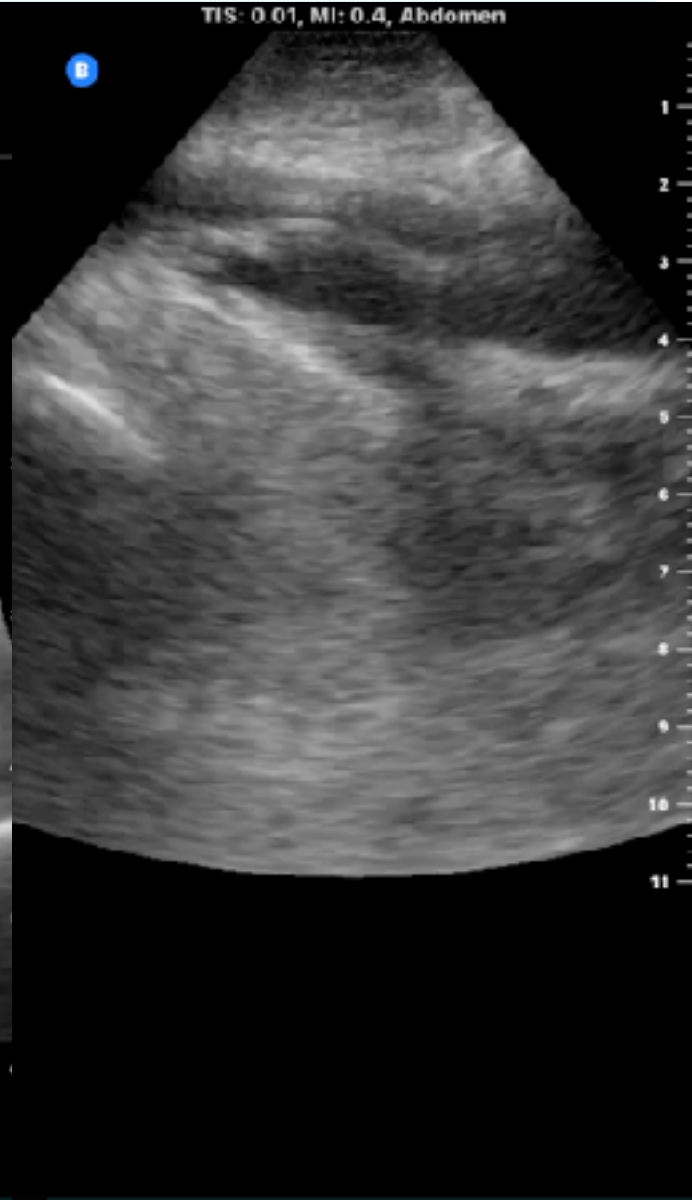
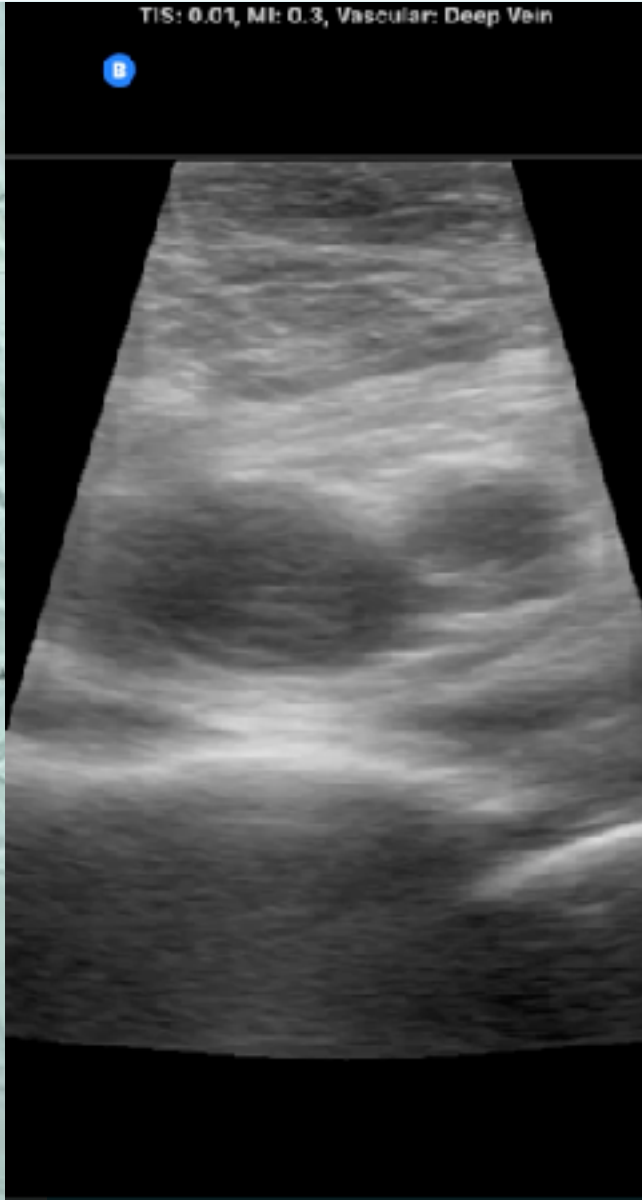
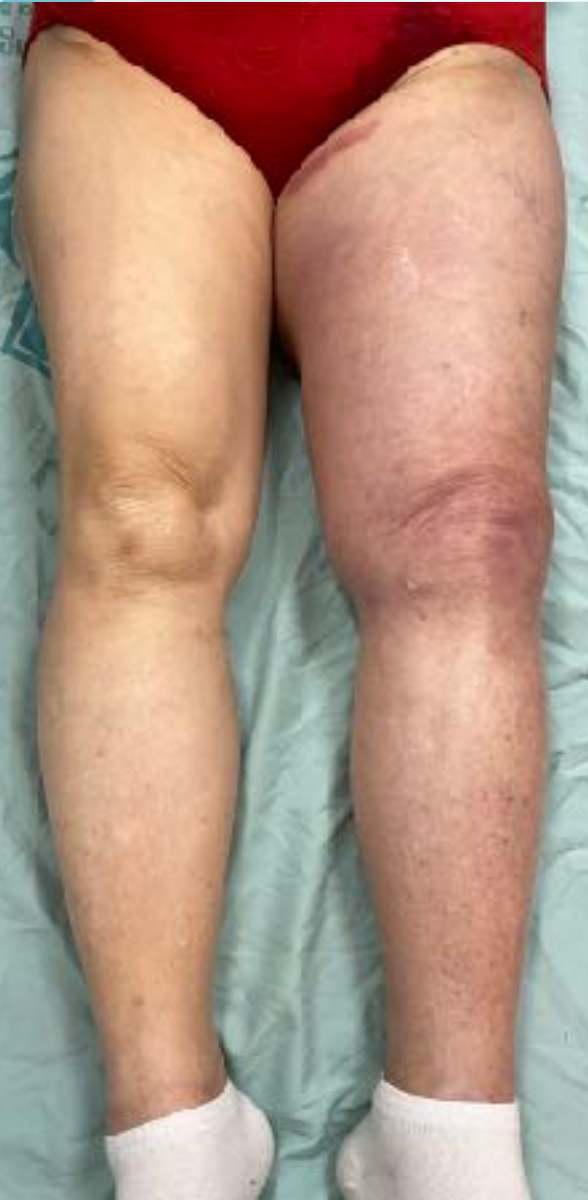
Tibia artery (anterior & posterior)



Ankle block



83, left leg swelling for 3 days



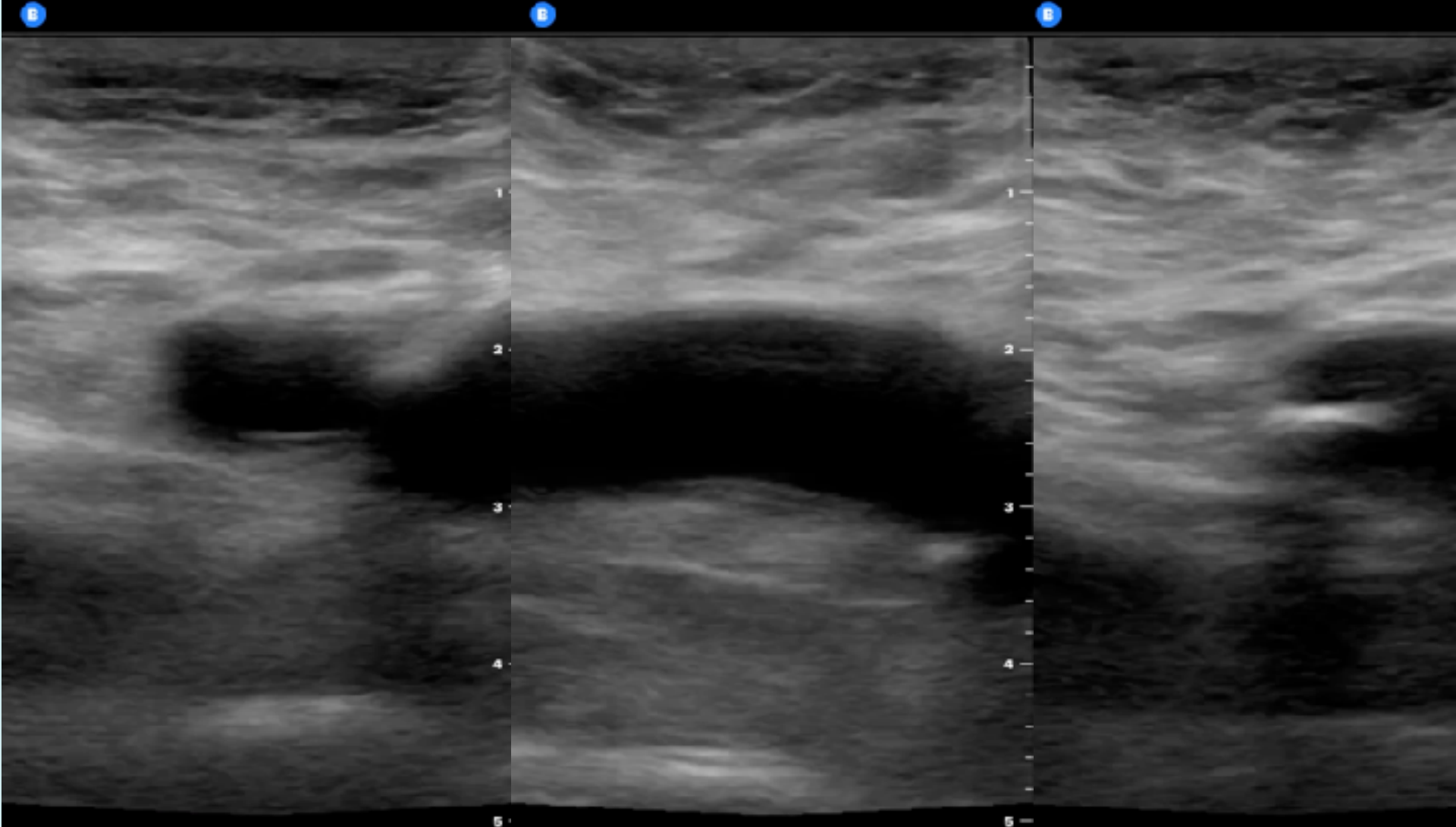
99M, IHCA, A line insertion



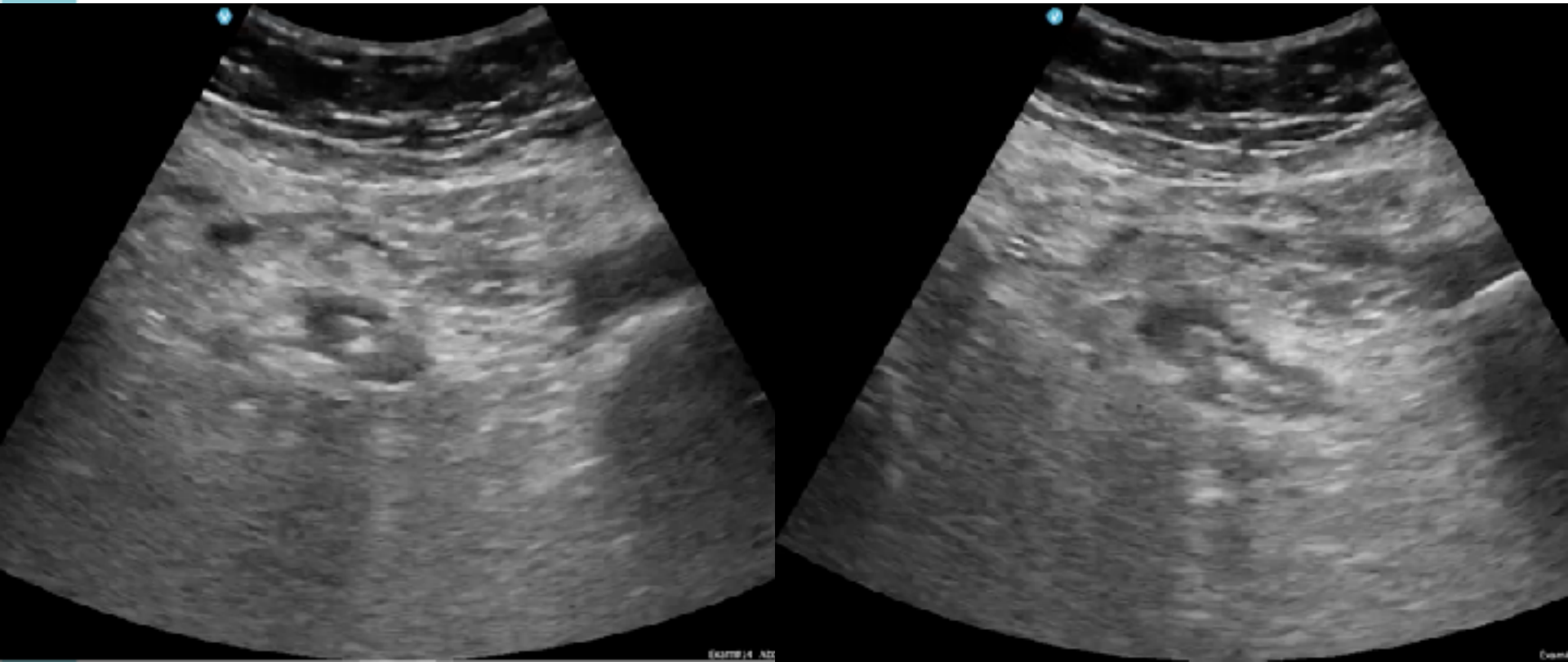
TIS: 0.01, MI: 0.45, Vascular: Access

TIS: 0.01, MI: 0.45, Vascular: Access

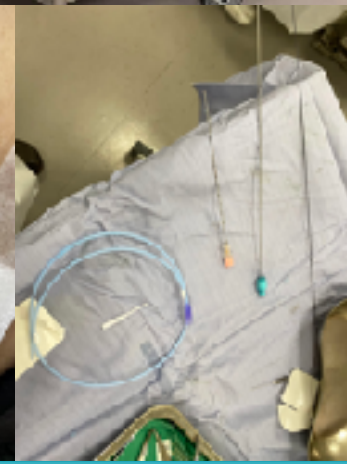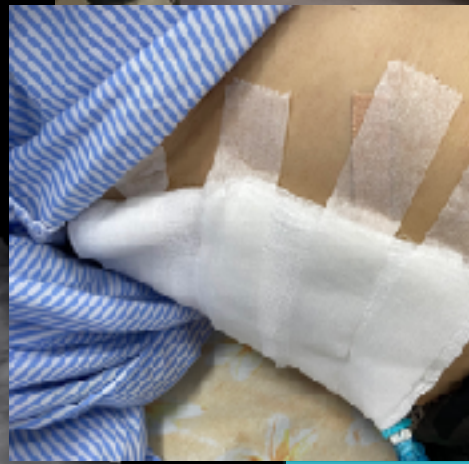
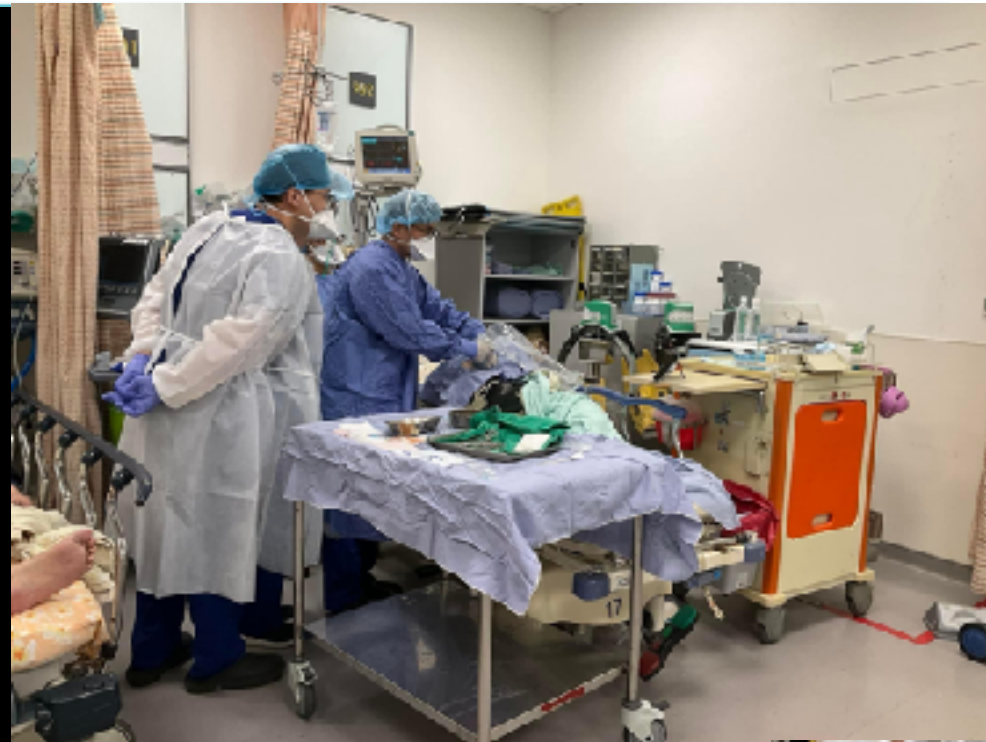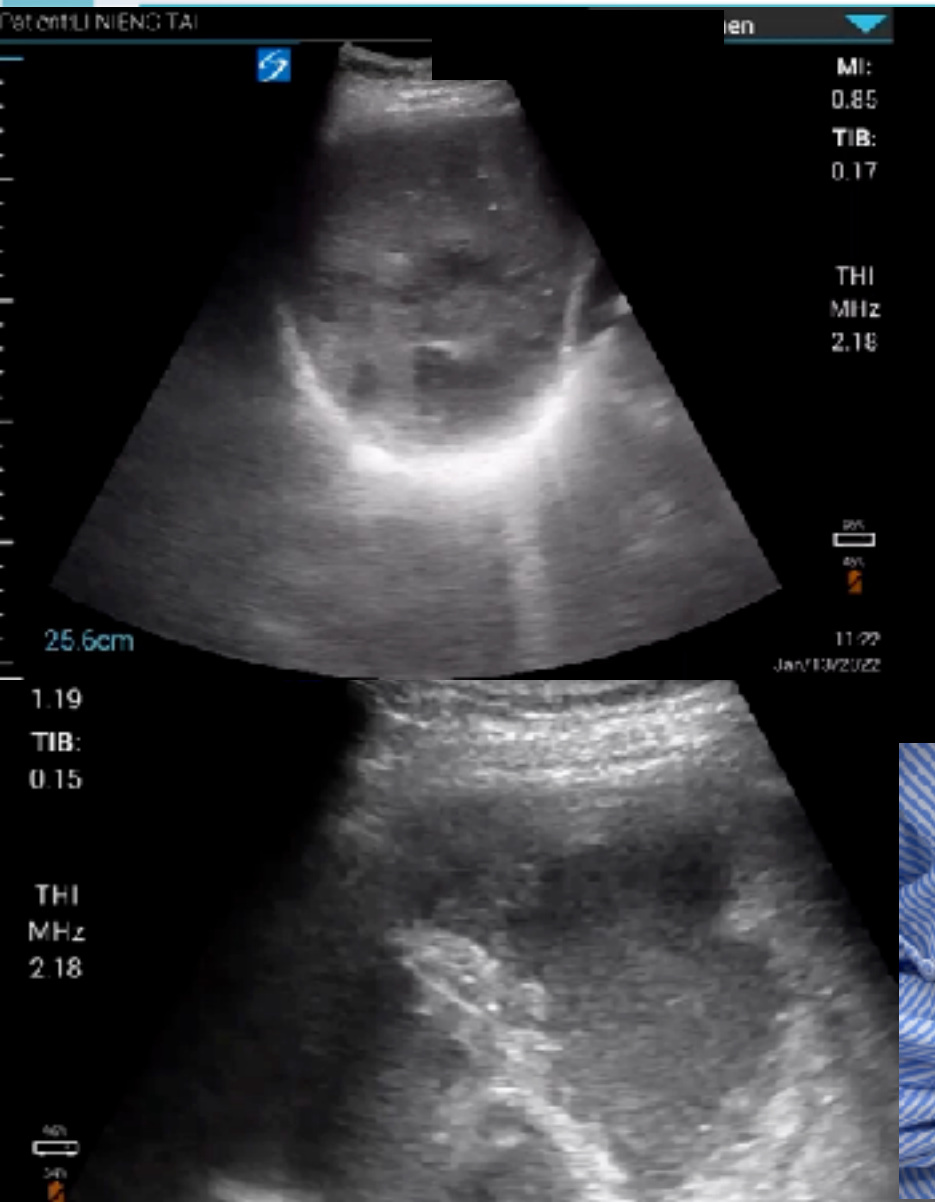
TIS: 0.01, MI: 0.45, Vascular: Access



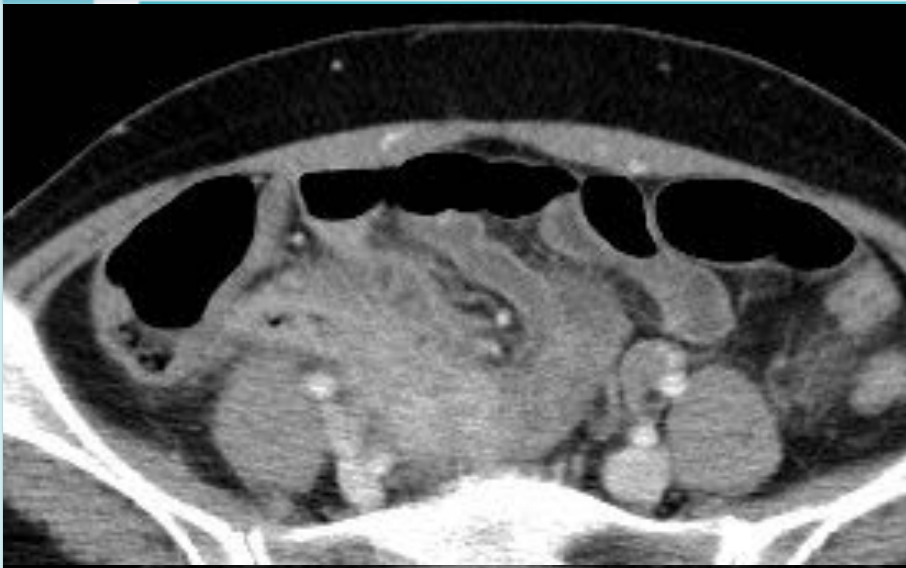Cecal Diverticulitis



Liver abscess

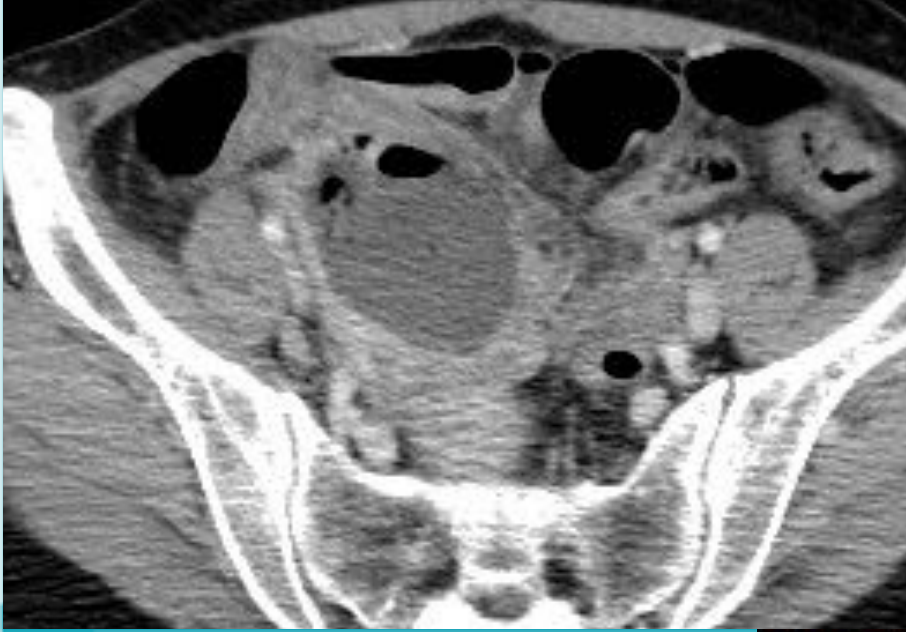

50F, RLQ pain for one week

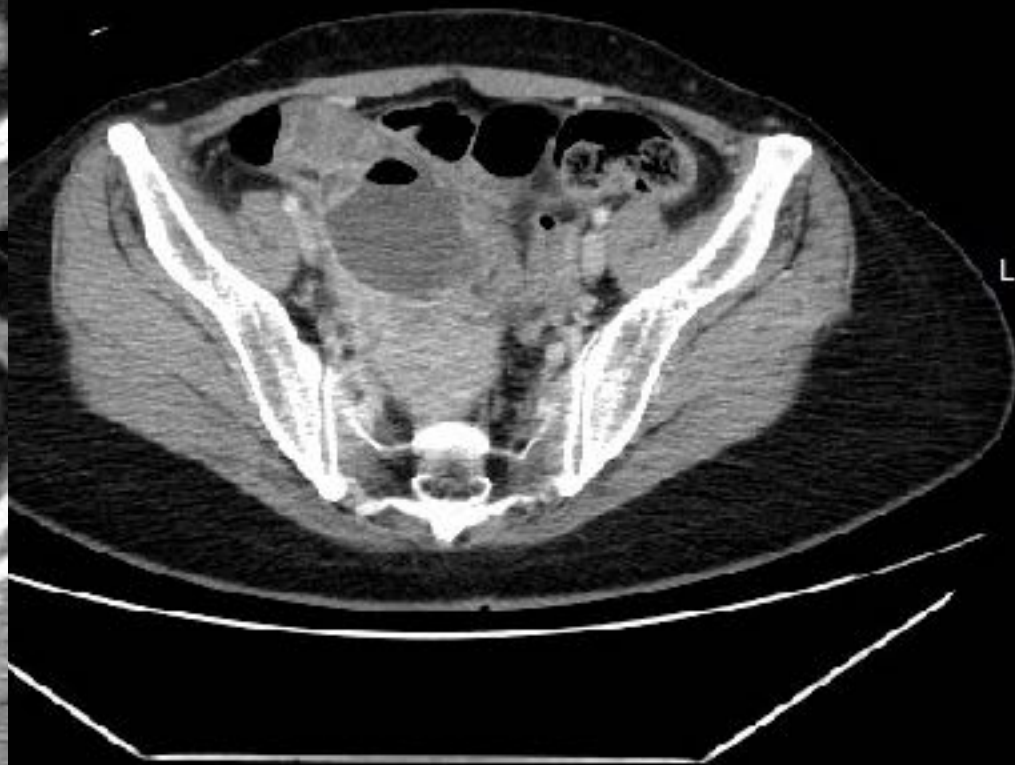

EVO

A



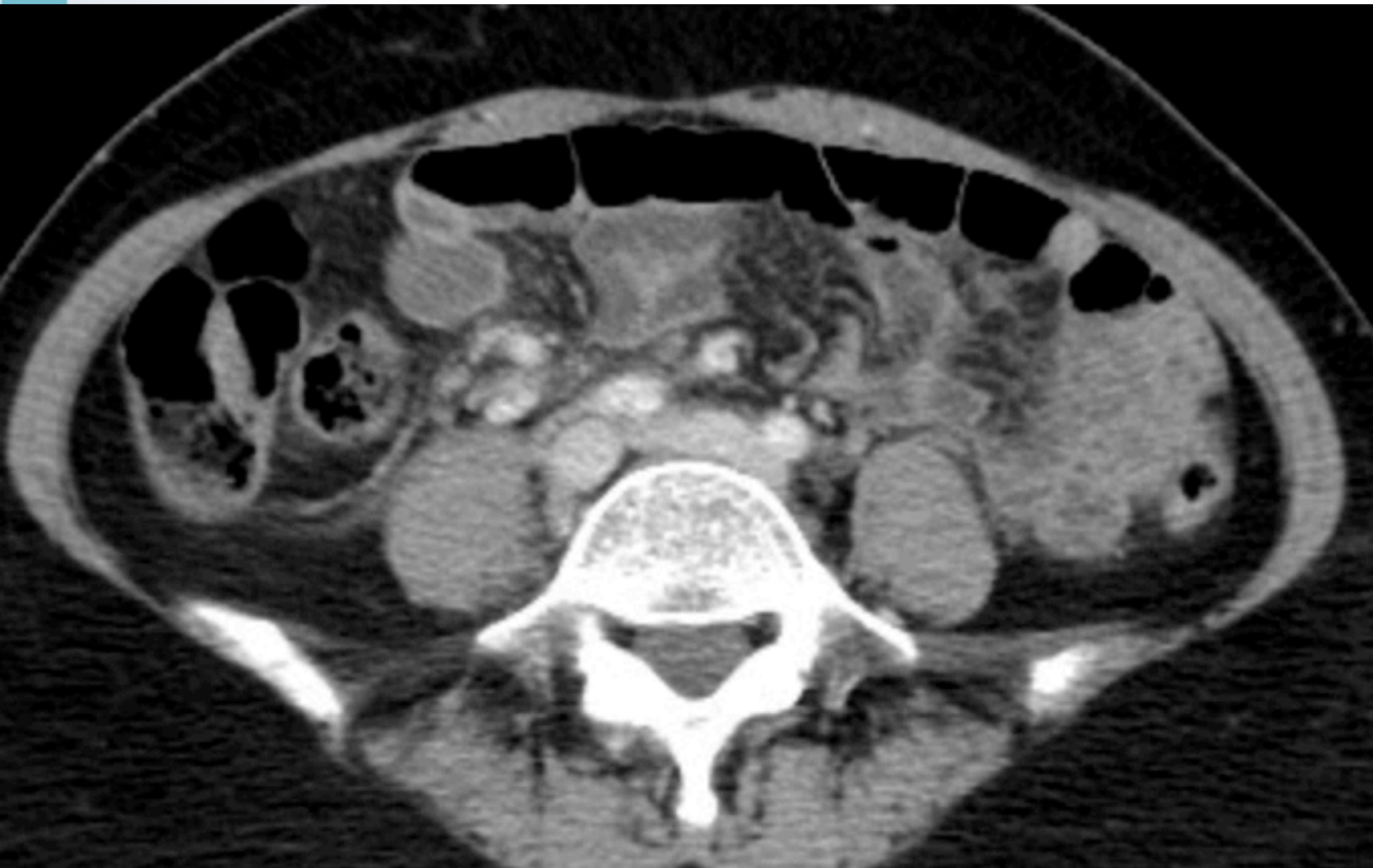名傑



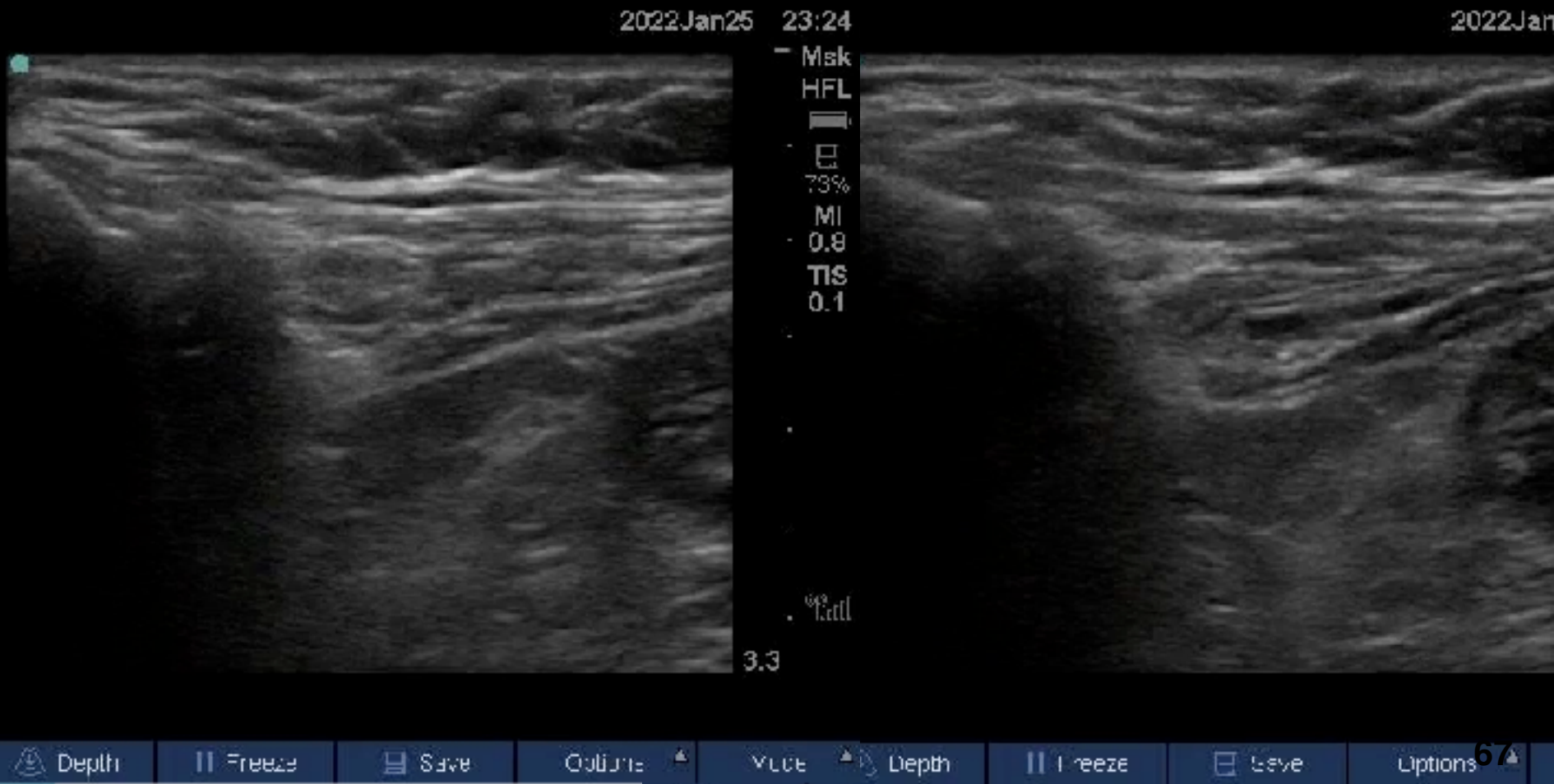P

23:30:
15:37:

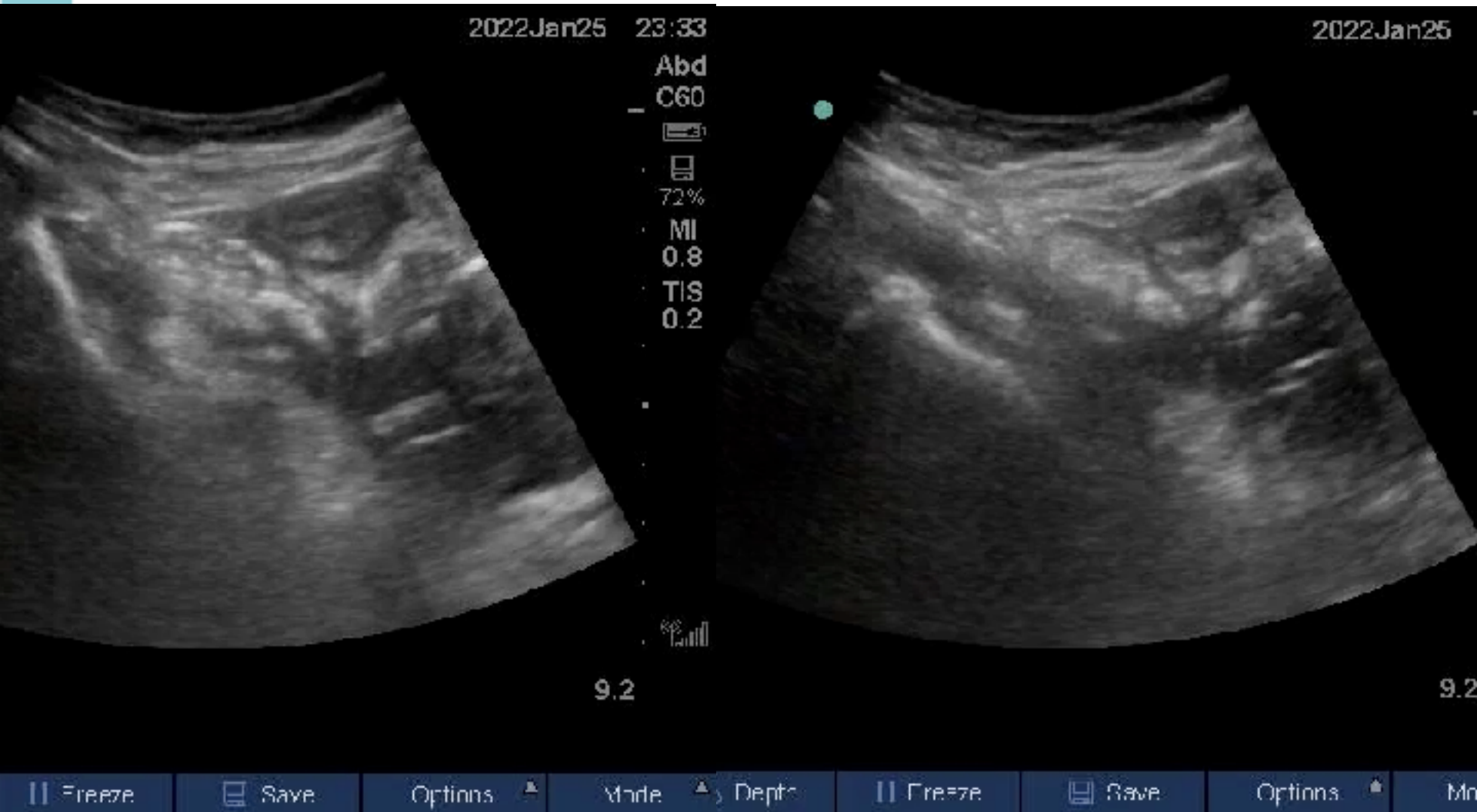Radiology: no safe route for drainage



Ilioinguinal & iliohypogastric nerve block



Rupture appendix & potential route





Pigtail drainage - guidewire

CHANG
GenTHI MB

2022Jan25 23:49

Abd
C60

70%

MI
0.8

TIS
0.2

Patient

Auto Gain

Gen

Clip

Page 1/3

9.2

69

Pigtail drainage - pigtail through guidewire



CHANG
GenTHI MB

2022Jan25 23:52

Abd
_ C60
70%
MI 0.8
TIS 0.2

Patient

Auto Gain

Gen

Clip

Page 1/3

9.2

70

Pigtail drainage - pigtail through guidewire



CHANG
GenTHI MB

2022Jan25 23:54

Abd
C60
69%
MI
0.8
TIS
0.2

Patient

Auto Gain

Gen

Clip

Page 1/3

9.2

71



Pigtail drainage - pigtail

CHANG
GenTHI MB

2022Jan25 23:54

Abd

C60



69%

MI

0.8

TIS

0.2



Patient



Auto Gain



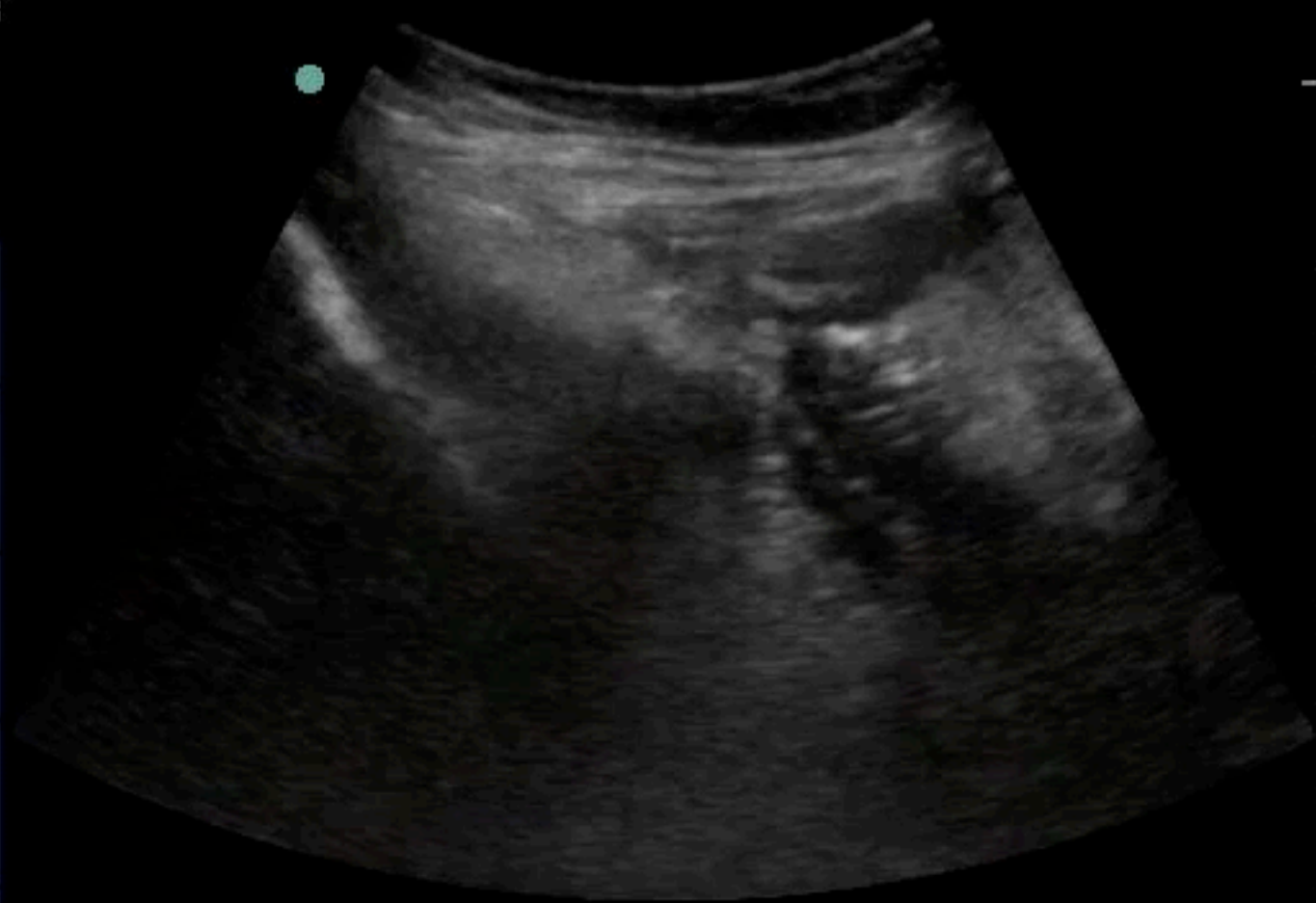
Gen



Clip



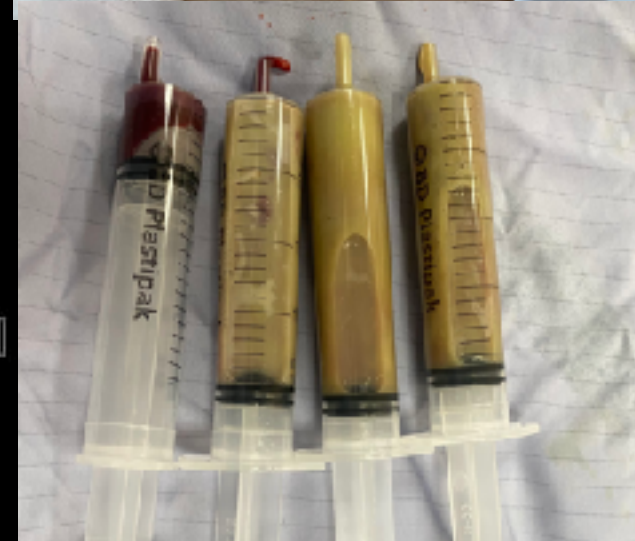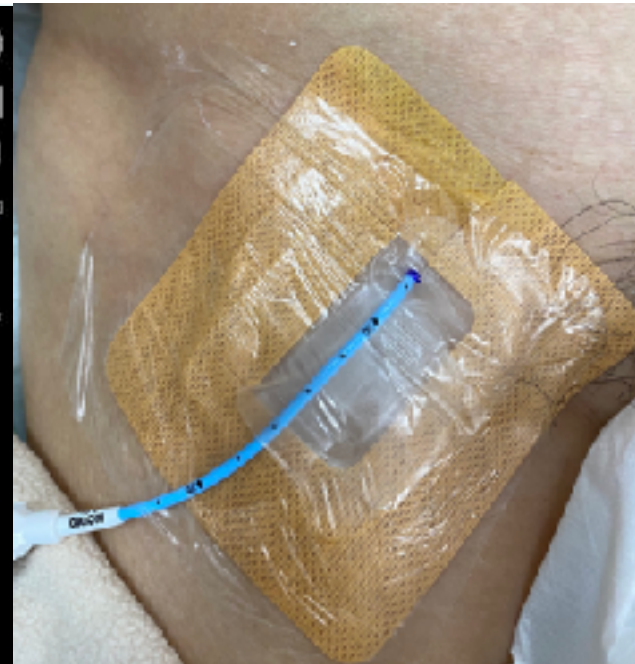
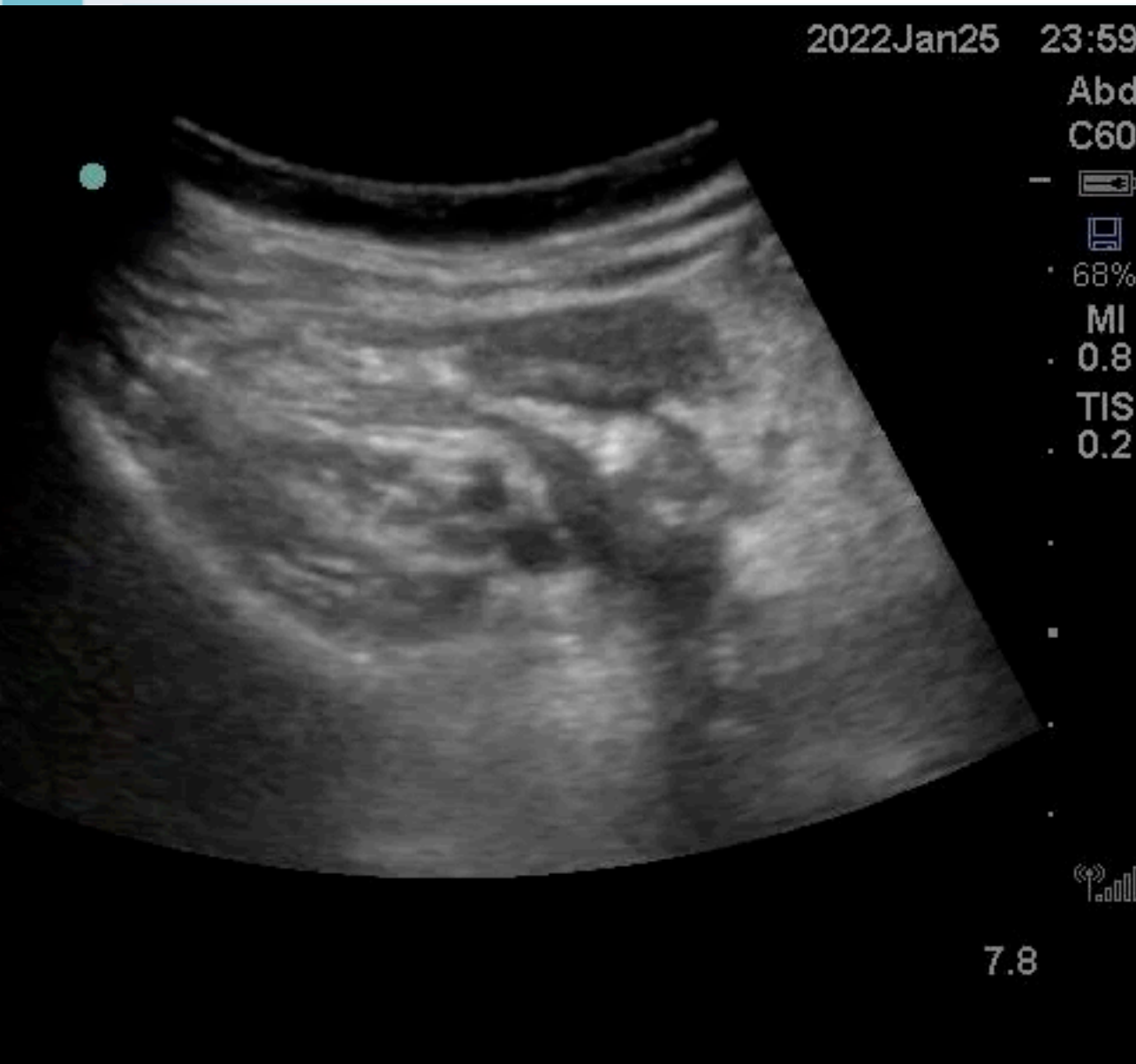
Page 1/3

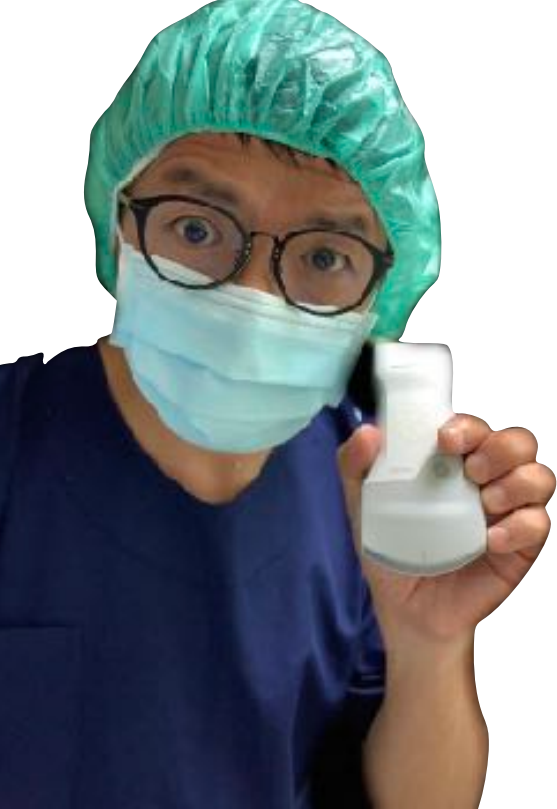

72

9.2

Advanced POCUS in ER





努力可能會說謊，
但努力不會白費。

羽生結弦

HOLISTIC ULTRASOUND

juice119@gmail.com / POCUSacademy.com