



雙和急診POCUS訓練

陳國智 醫師



醫用超音波學會指導醫師
WINFOCUS director / instructor
急救加護醫學會重症超音波負責人

急診 / 重症 / 介入 / 急性疼痛

經歷

新光急診超音波訓練中心主任

西園醫院急診醫學科主任

急診醫學會超音波委員會主委

台灣疼痛醫學會大體模擬手術講師



LE joint effusion

01/07

Airway

01/14

Needling

01/21

VExUS protocol

01/28

雙和急診POCUS訓練



Central access

02/11

Peripheral access

02/18

EFAST

02/25

雙和急診POCUS訓練



Basic ECHO

03/04

Nerve block-UE(1)

03/11

Nerve block-LE(1)

03/25

雙和急診POCUS訓練

診
斷

監
測

介
入

POINT OF CARE ULTRASOUND

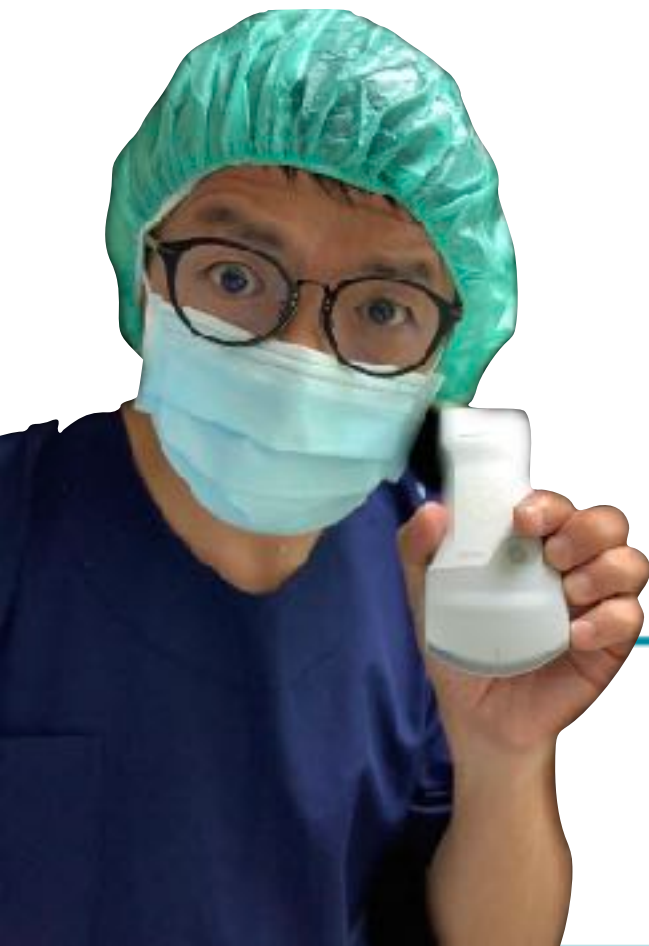~ 存在於臨床需求之所在 ~



衛生福利部雙和醫院
(委託臺北醫學大學興建經營)
Taipei Medical University · Shuang Ho Hospital,
Ministry of Health and Welfare



POCUS Imaging Reading



陳國智醫師

雙和醫院 急診醫學科

40F, ABD pain for 3 days



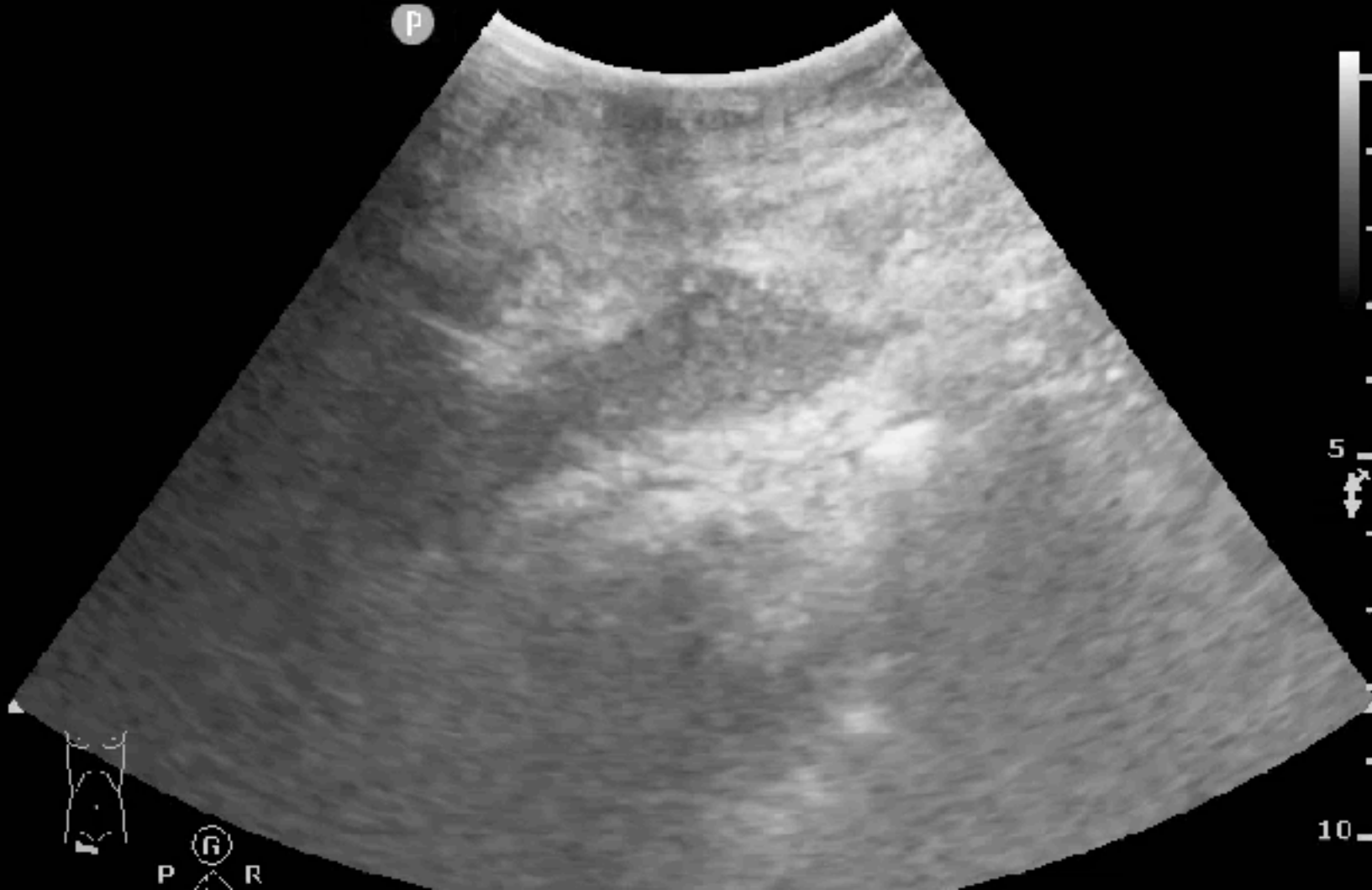
PHILIPS HAUNG
18642757

SKH ER

MI 1.1 2/21/2022
TIS 0.1 2:25:37 PM

Abd Gen
C5-1
42 Hz
11.0cm

2D
HGen
Gn 60
C. 56
3/3/3



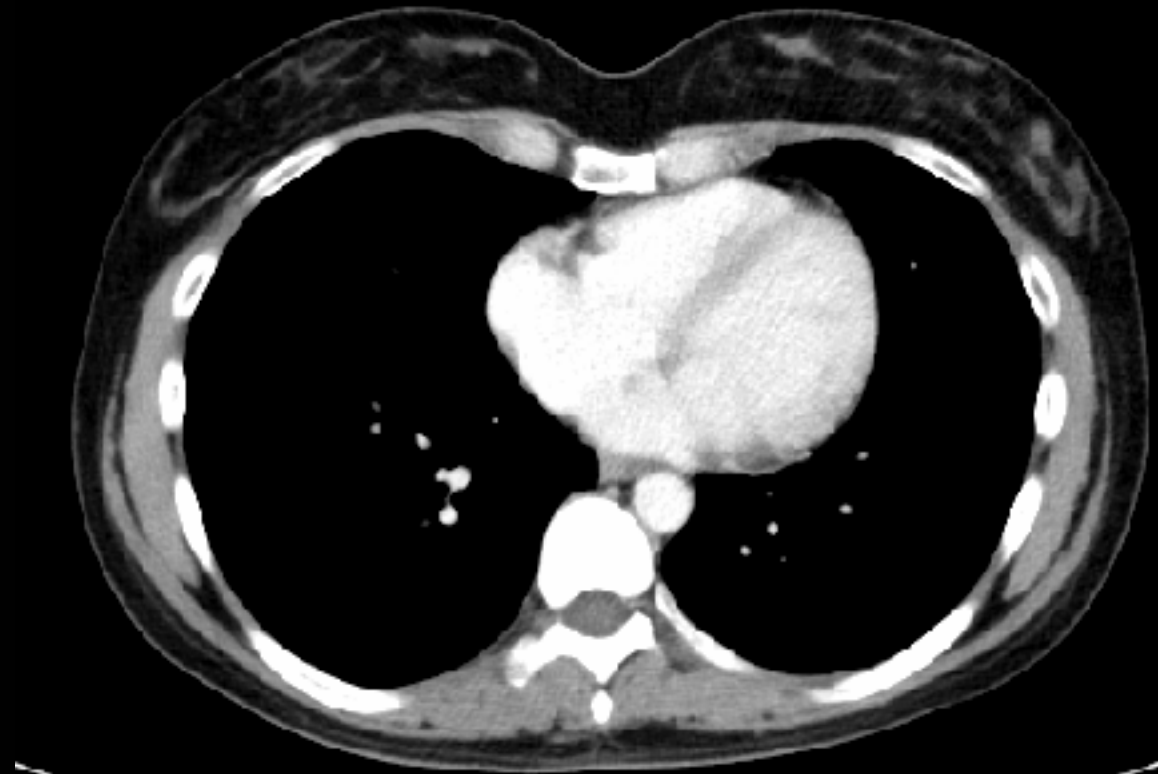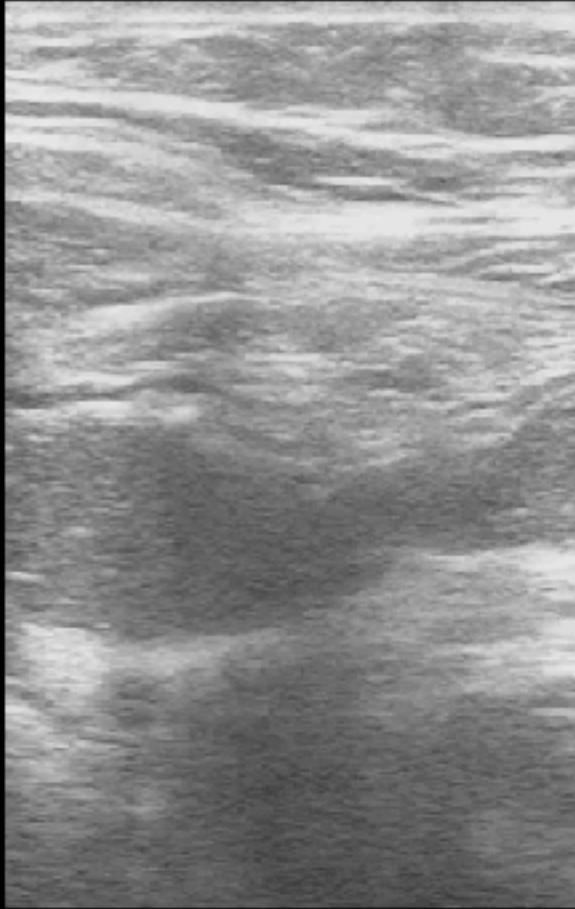
Appendicitis



SK11 ER

MI 1.1

TIS 0.1



61M, Ascites , UB history



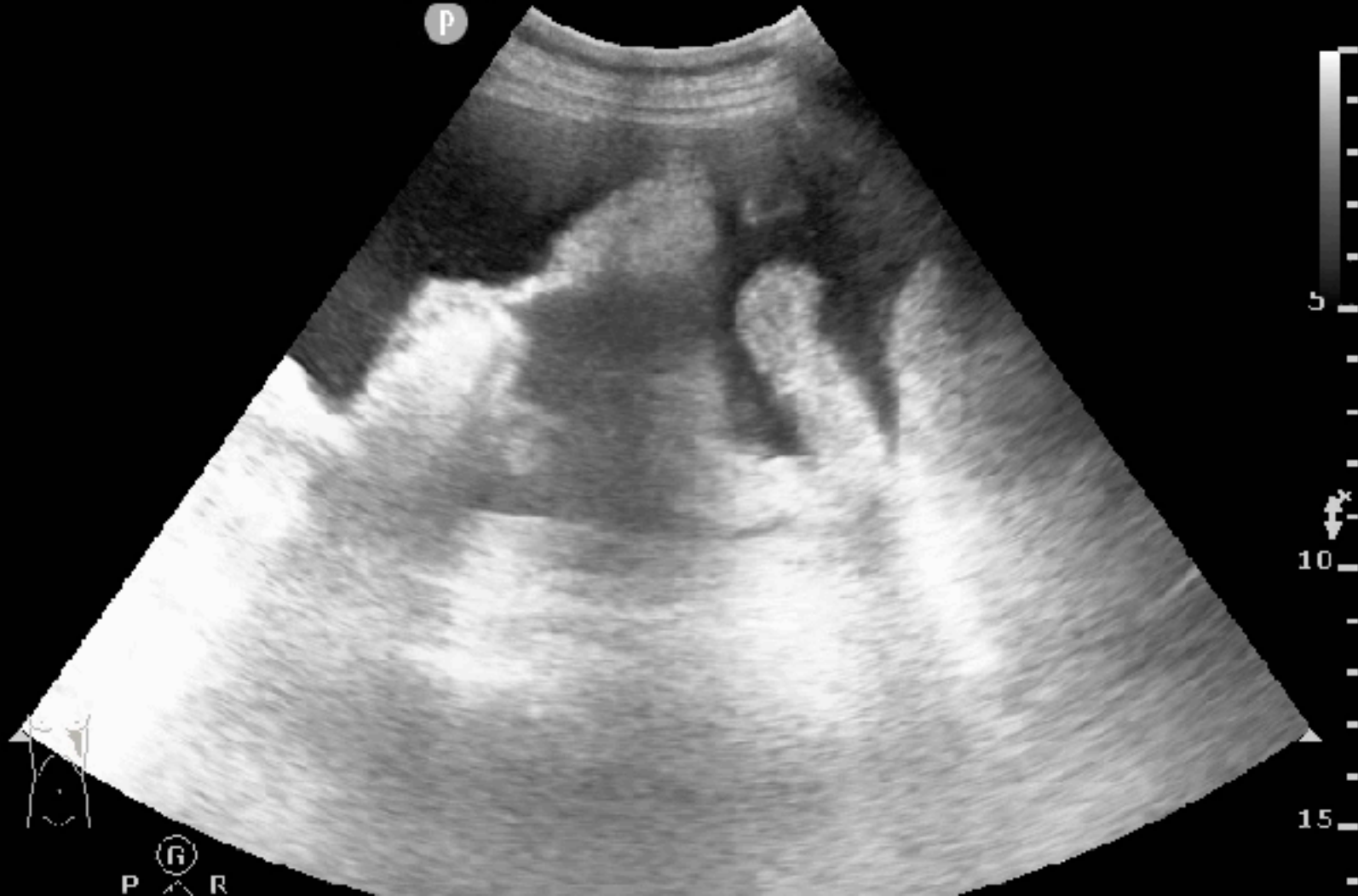PHILIPS HSU
09885976

SKH ER

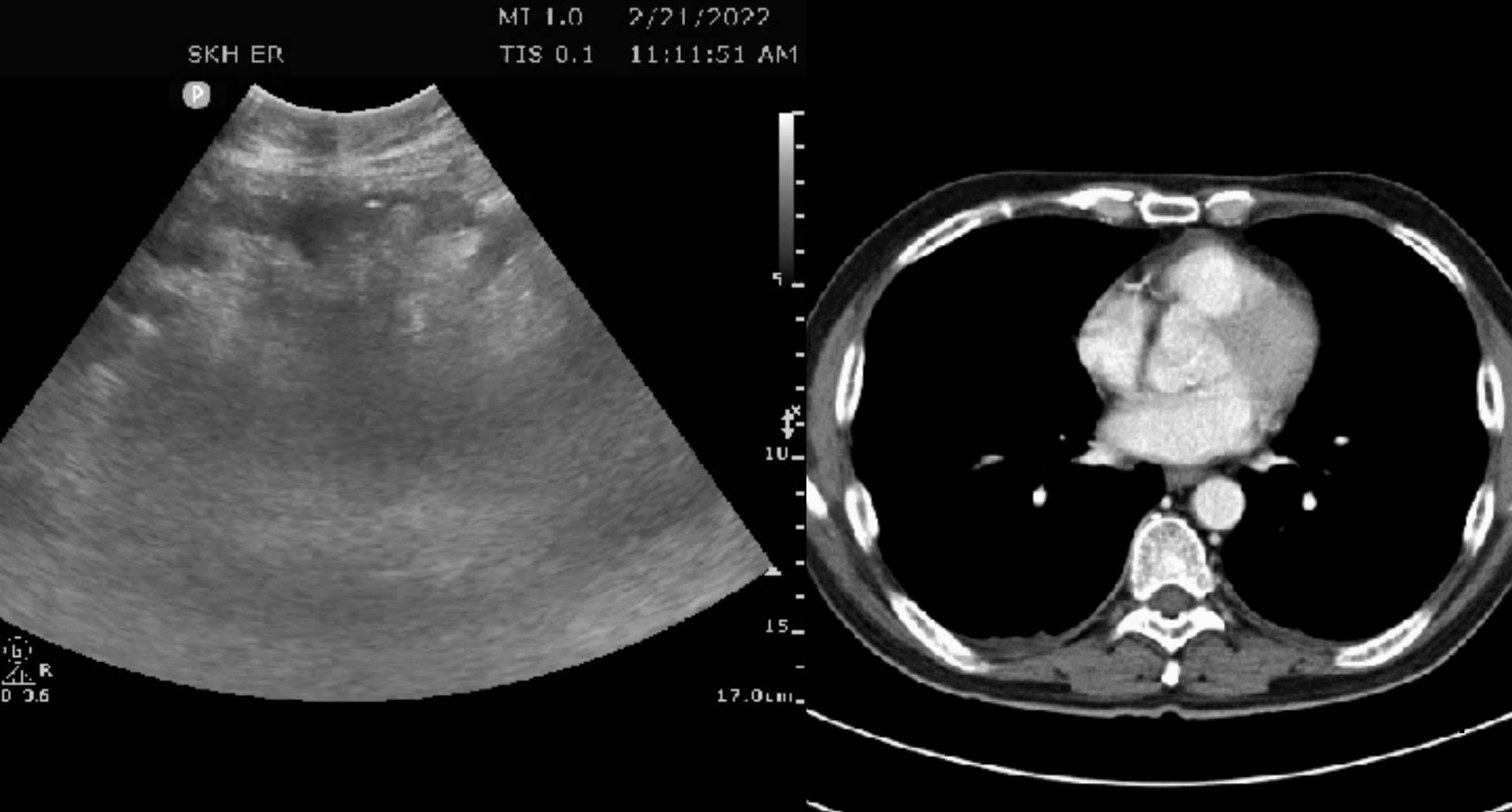MI 1.0 2/21/2022
TIS 0.1 11:13:33 AM

Abd Gen
C5-1
31 Hz
17.0cm

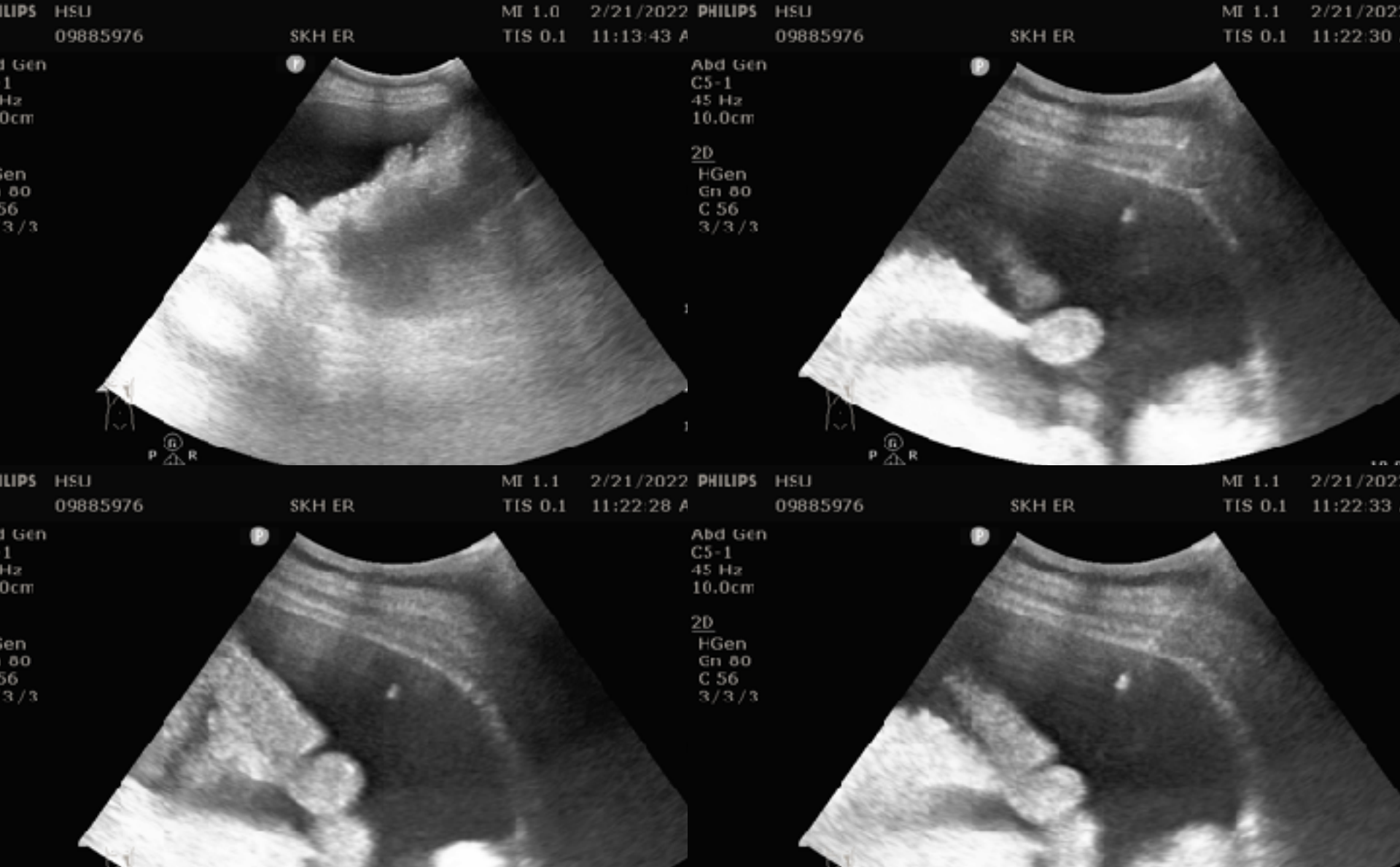
2D
HGen
Gn 80
C. 56
3/3/3



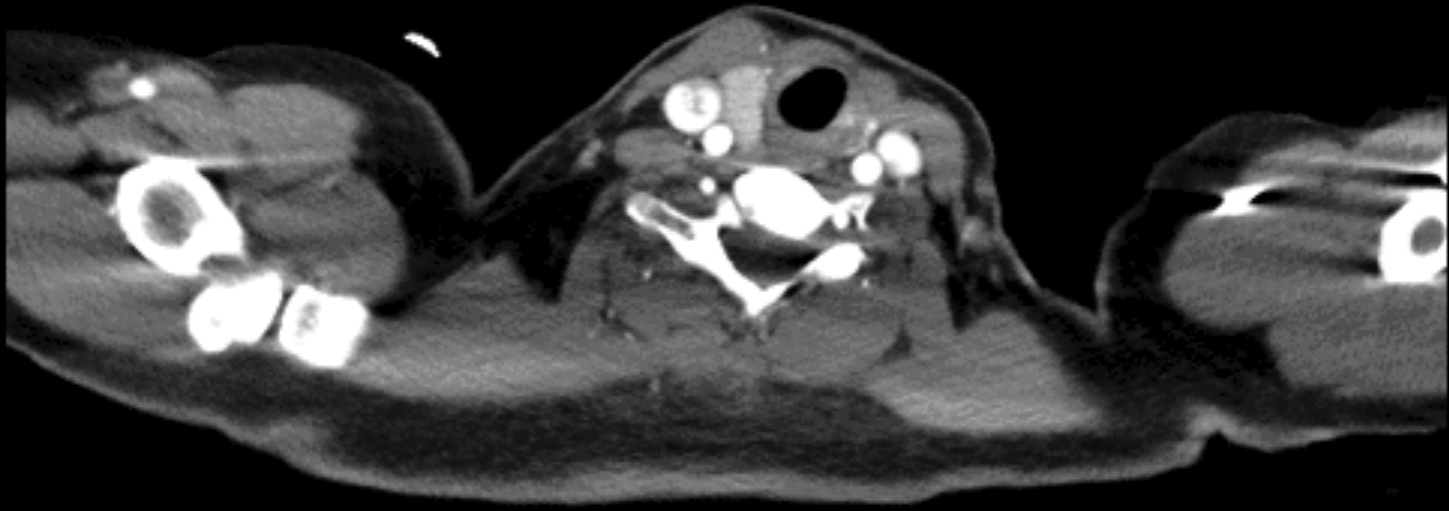
61M, Ascites , UB history



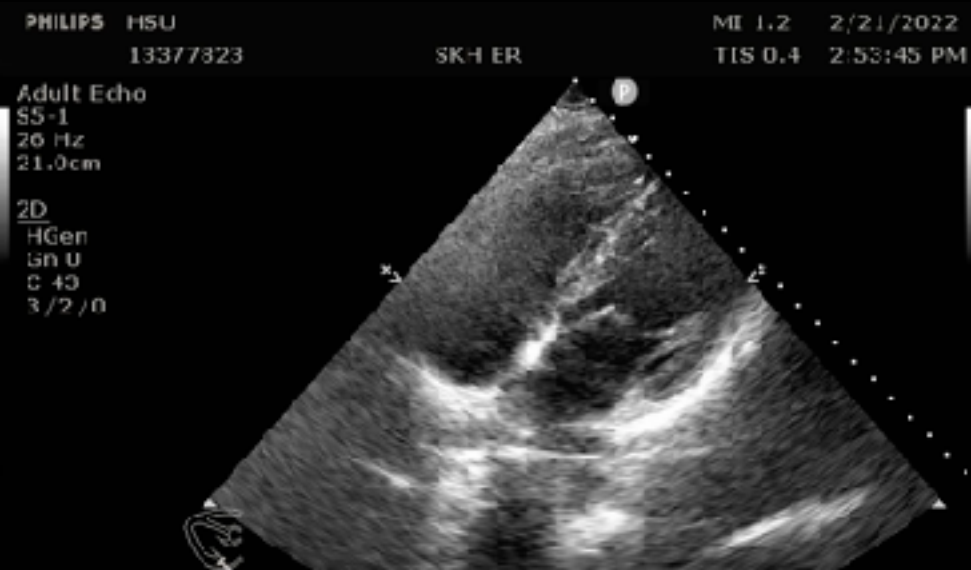
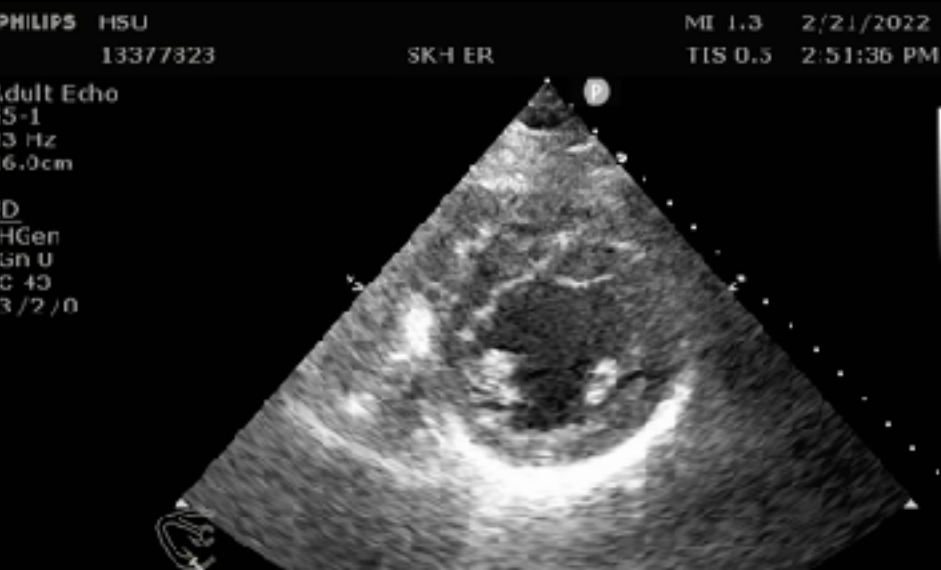
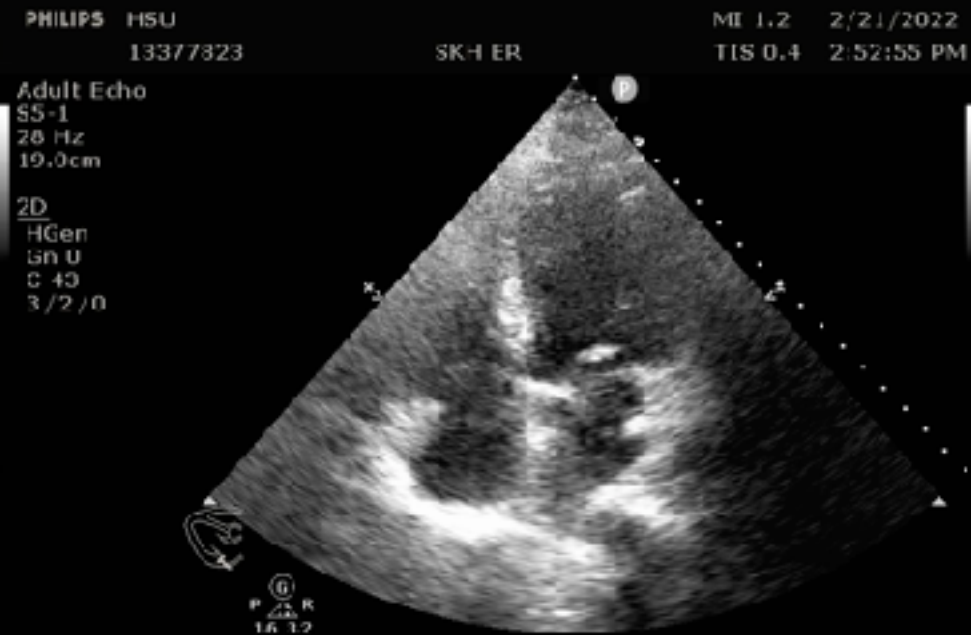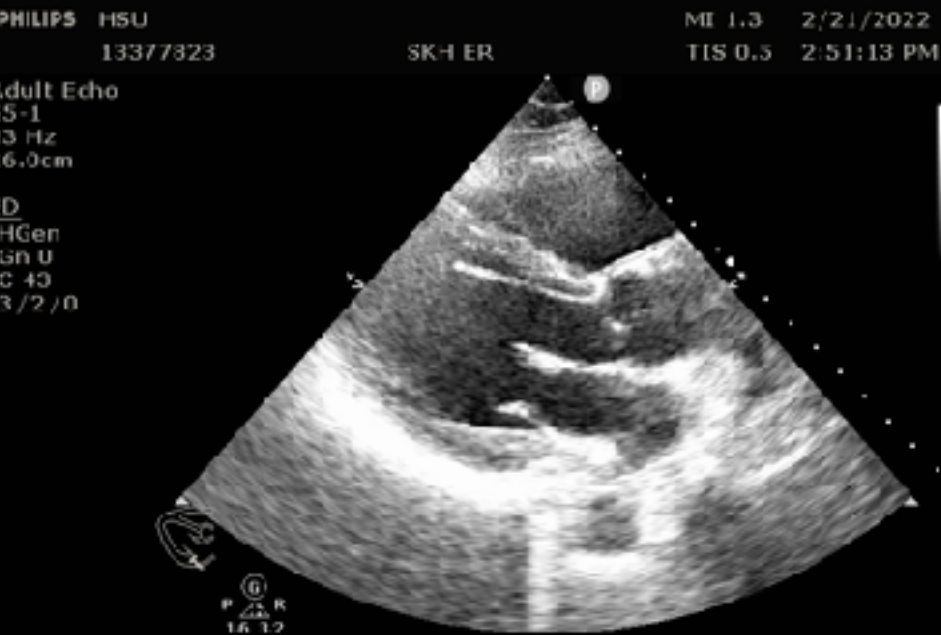Carcinomatosis / Needling



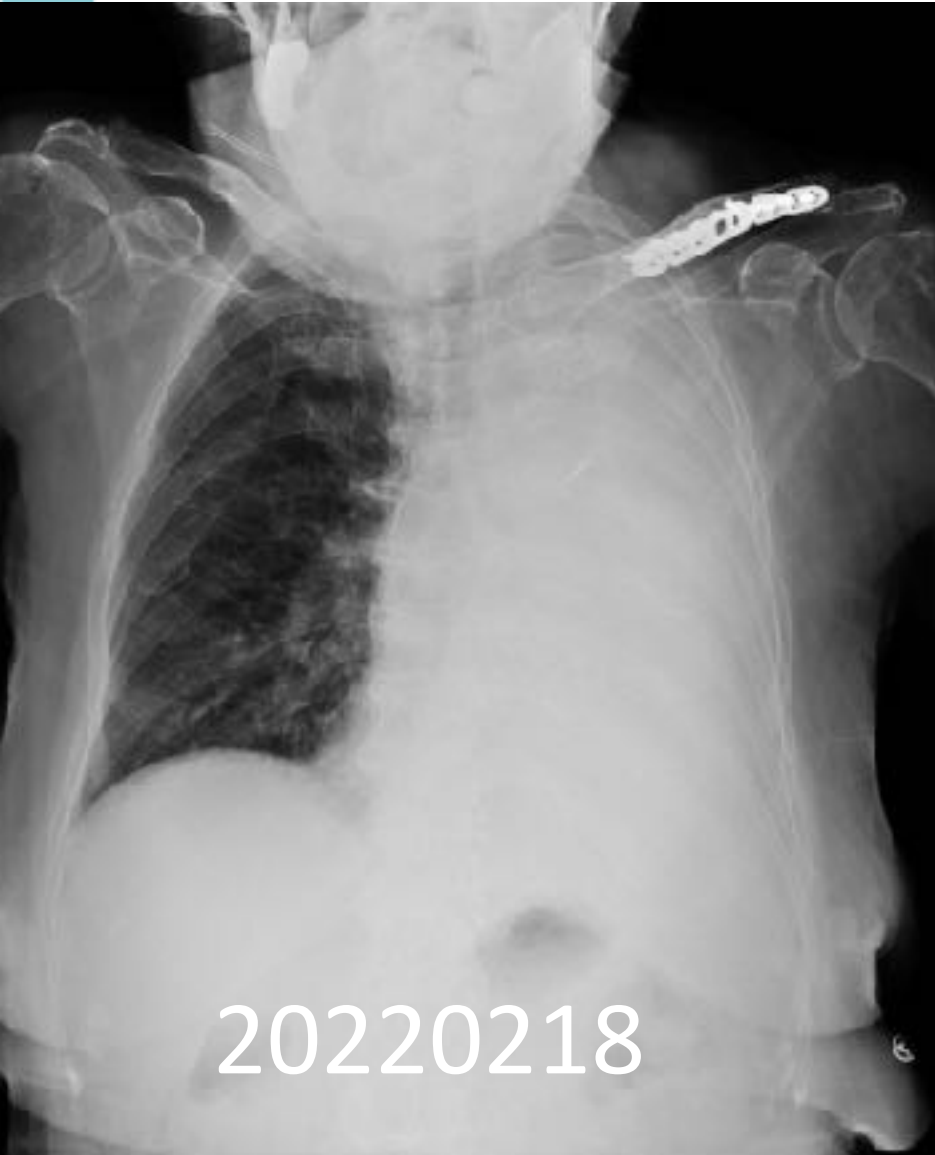41F, Suspect intracardiac thrombus



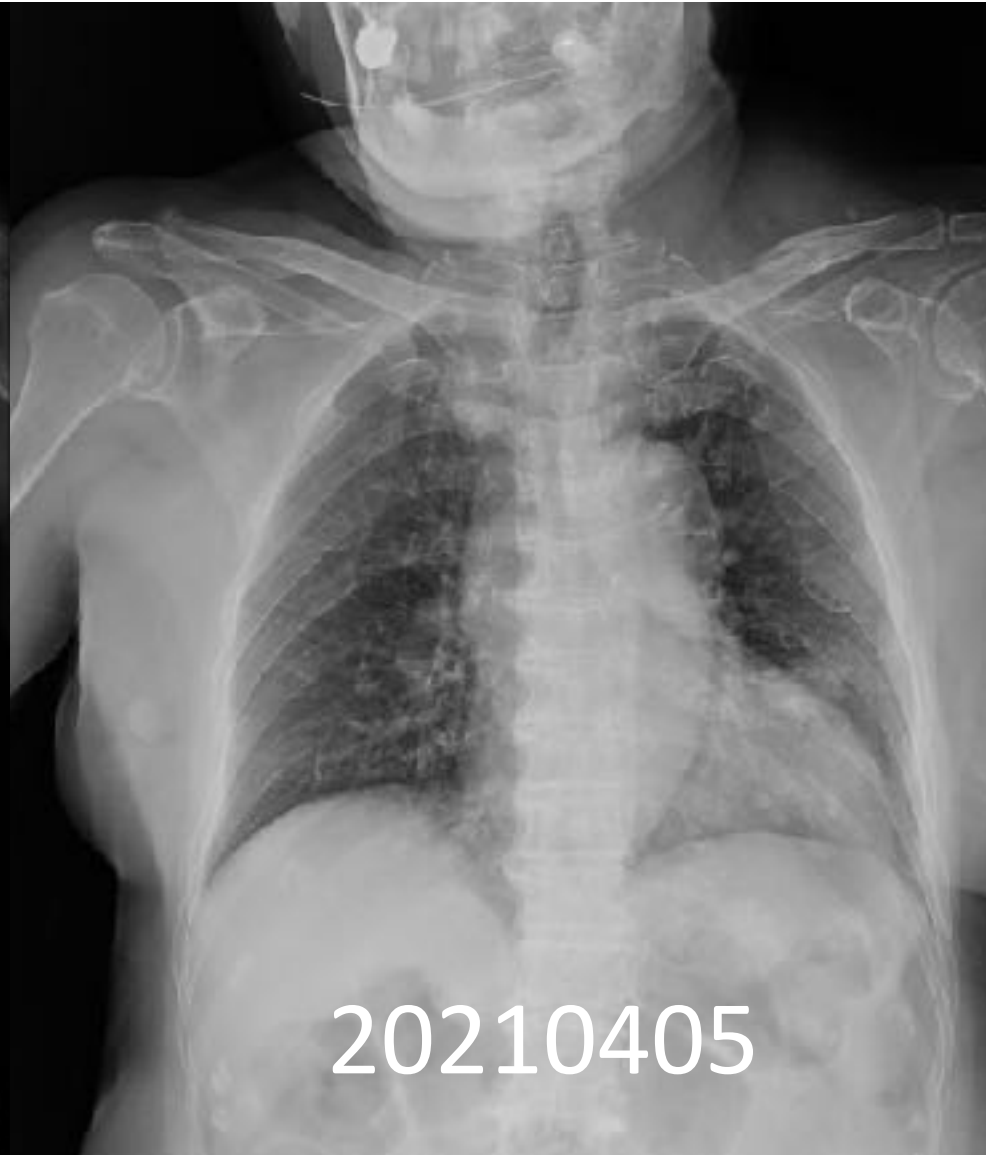No intracardiac thrombus



86F, for thoracentesis

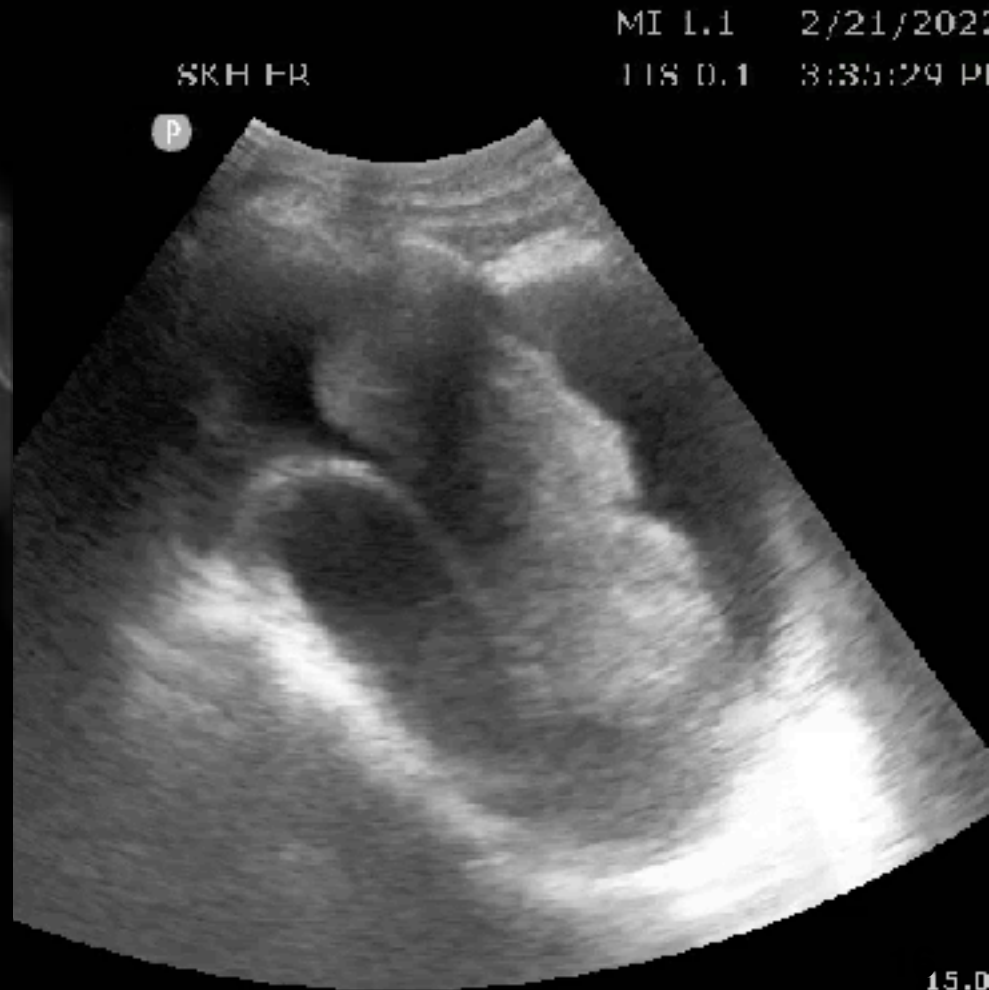
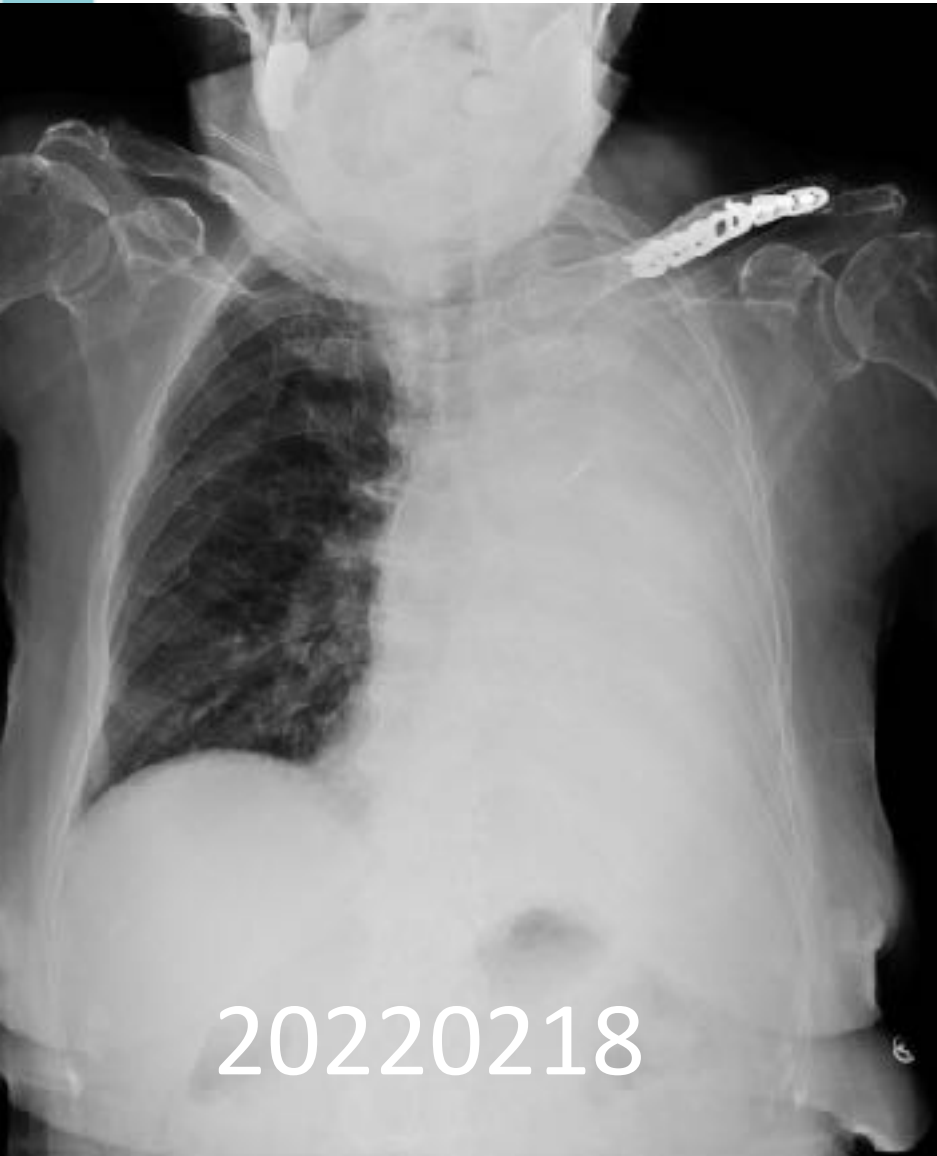
20220218



202110405

86F, for thoracentesis

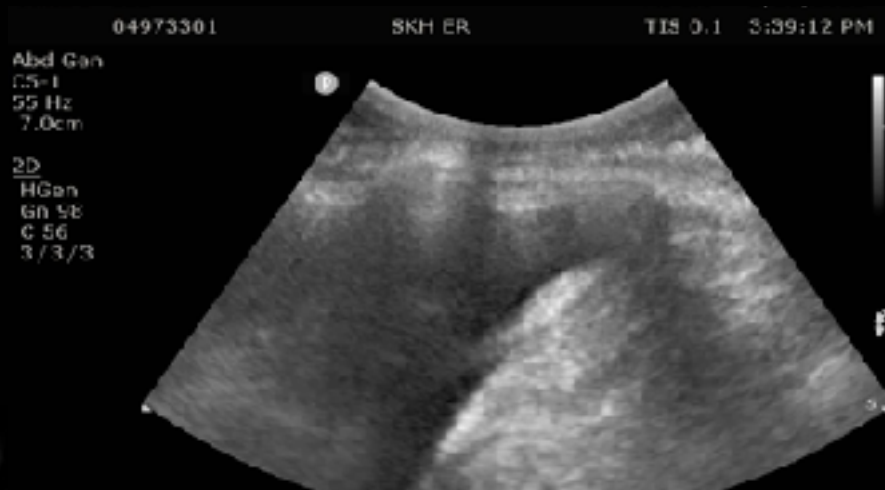
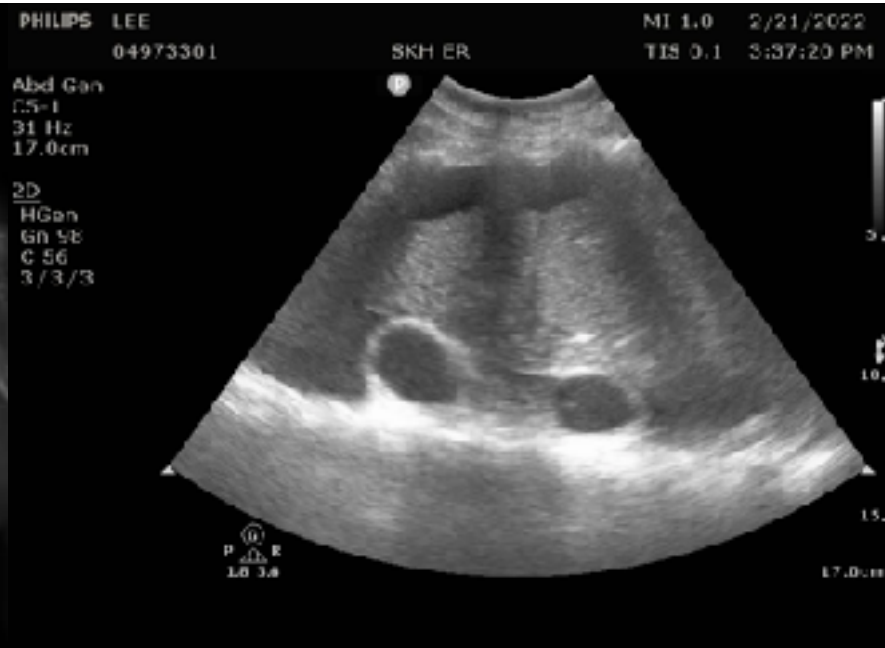
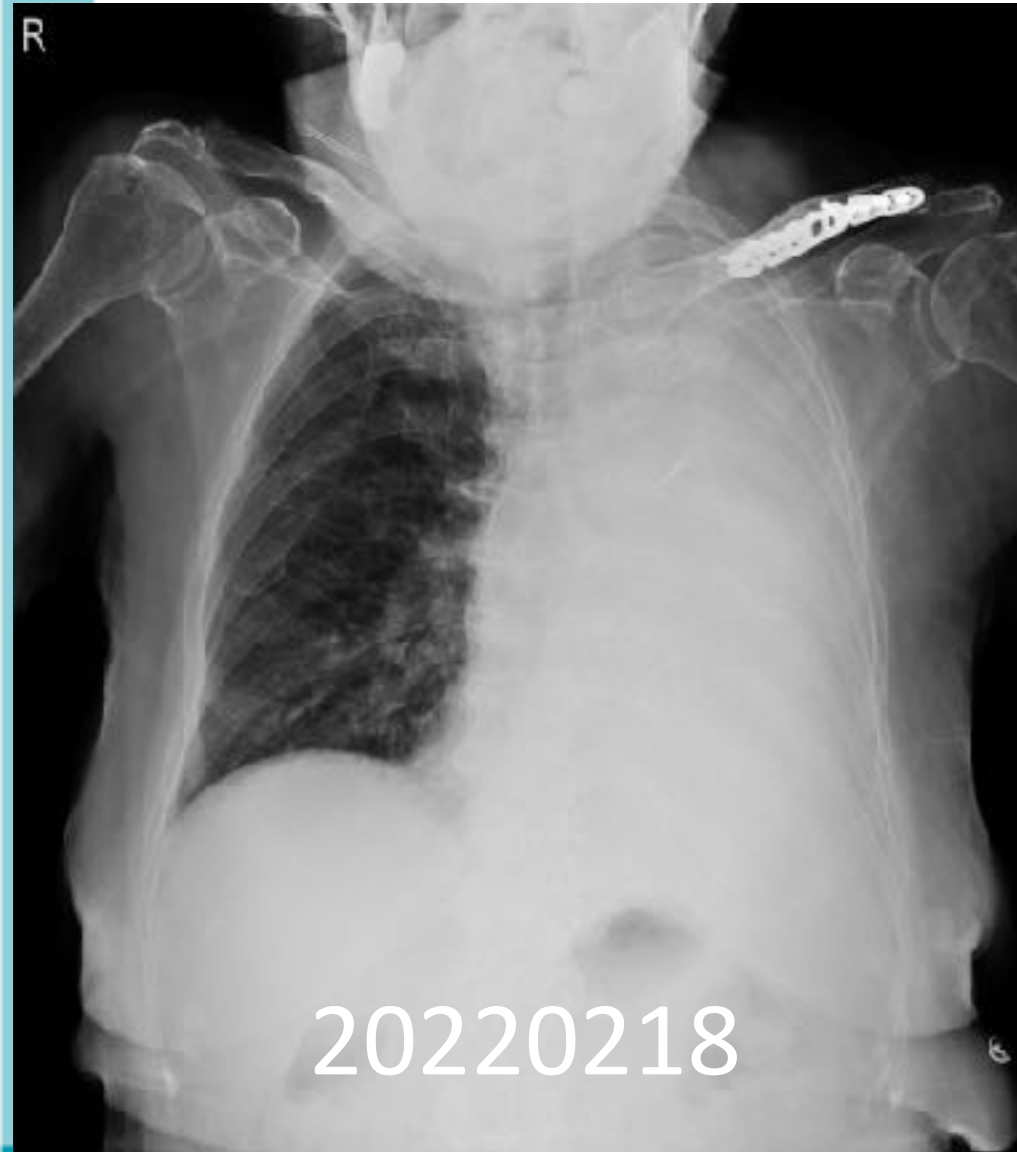MI L.1 2/21/2022
118 D.1 3:35:29 PM

15.D

20220218

Lung tumor with PLE

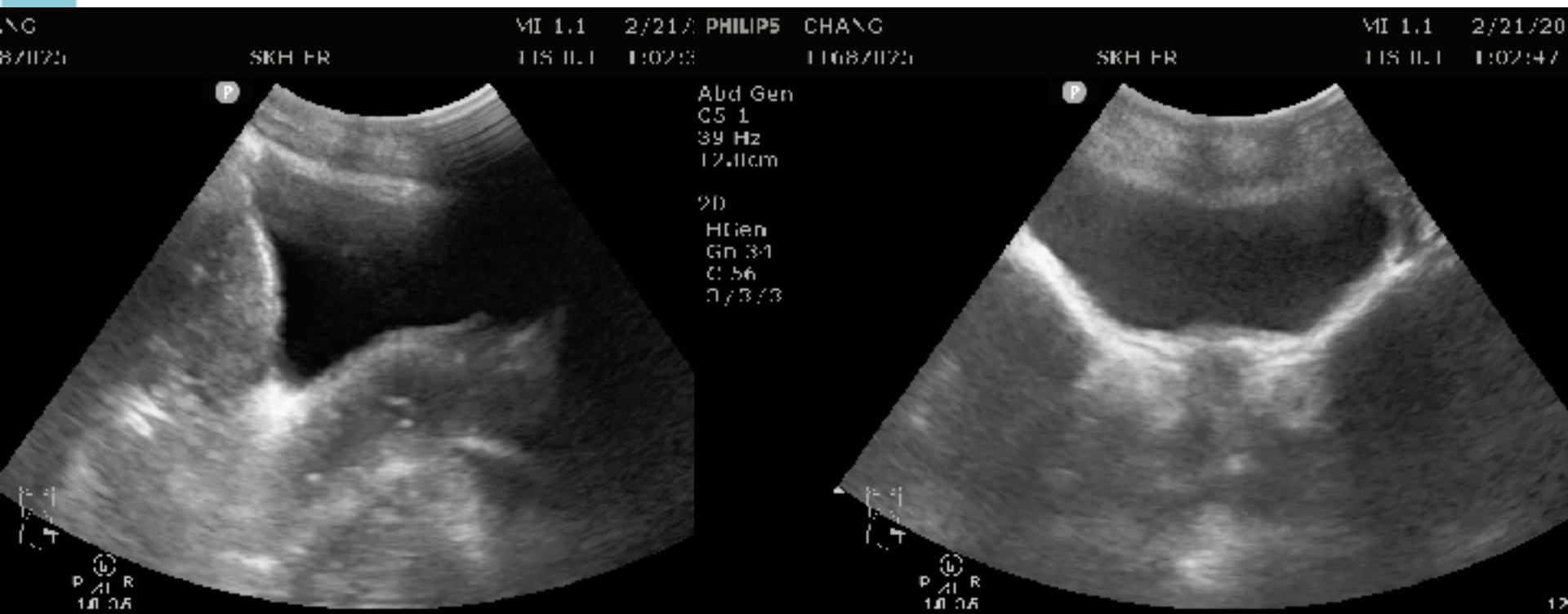


20220218



36F, lower abdominal pain

Bartholin cyst


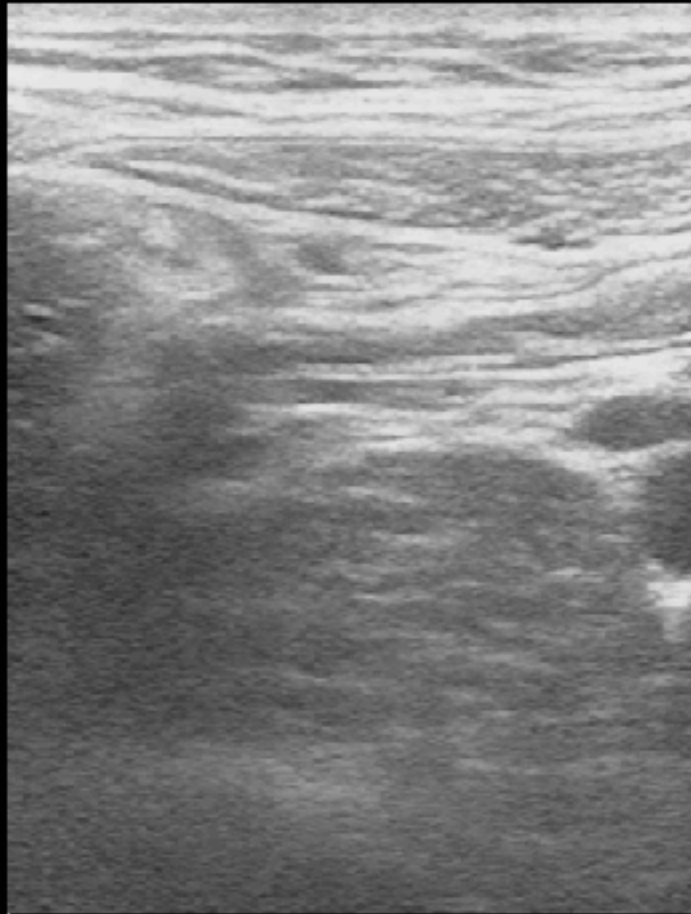


36F, lower abdominal pain



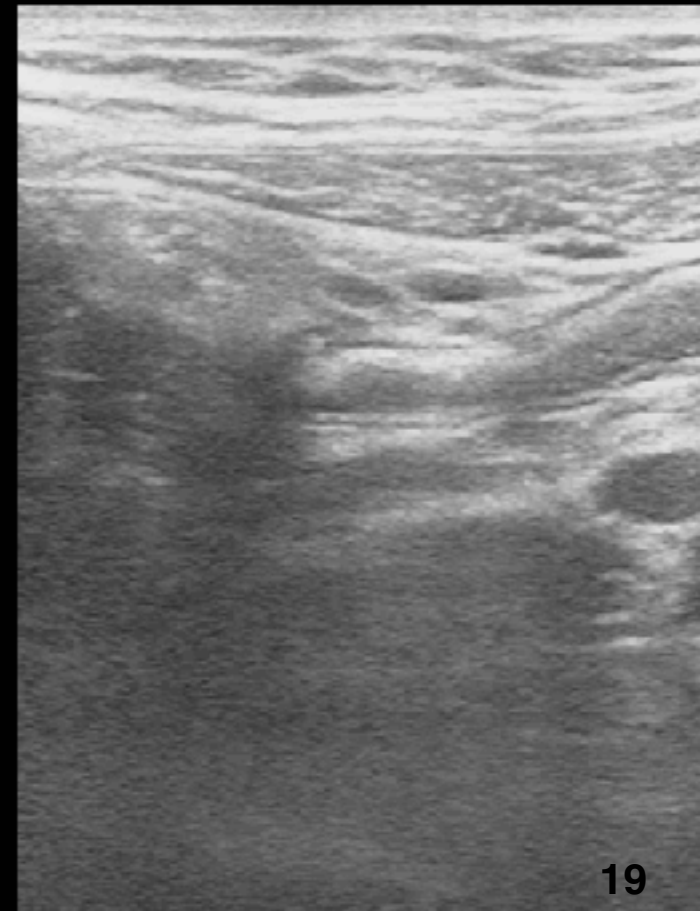
MI 1.2 2/21/2022
TIS 0.2 1:07:59 PM

SKII CR



SKII CR

MI 1.2
TIS 0.2



36F, lower abdominal pain

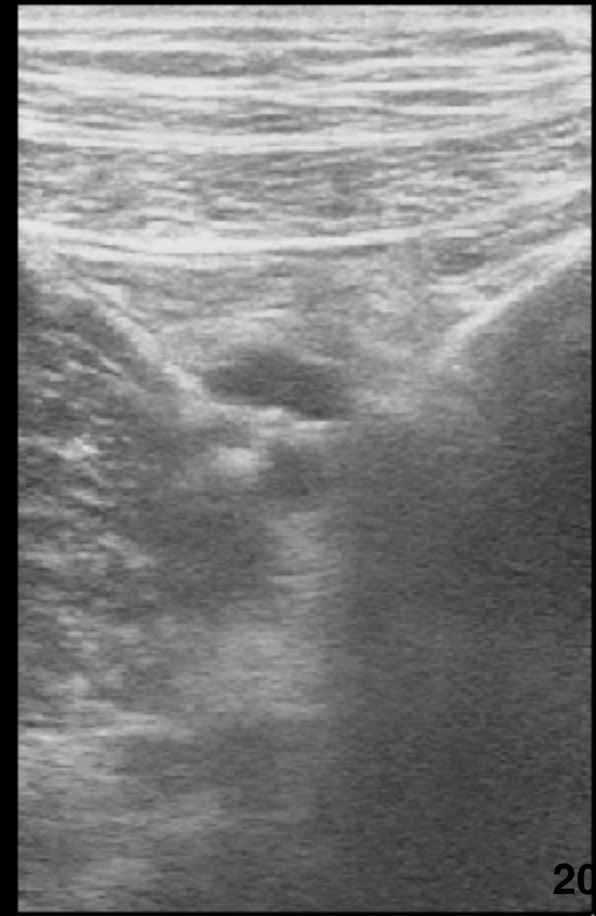
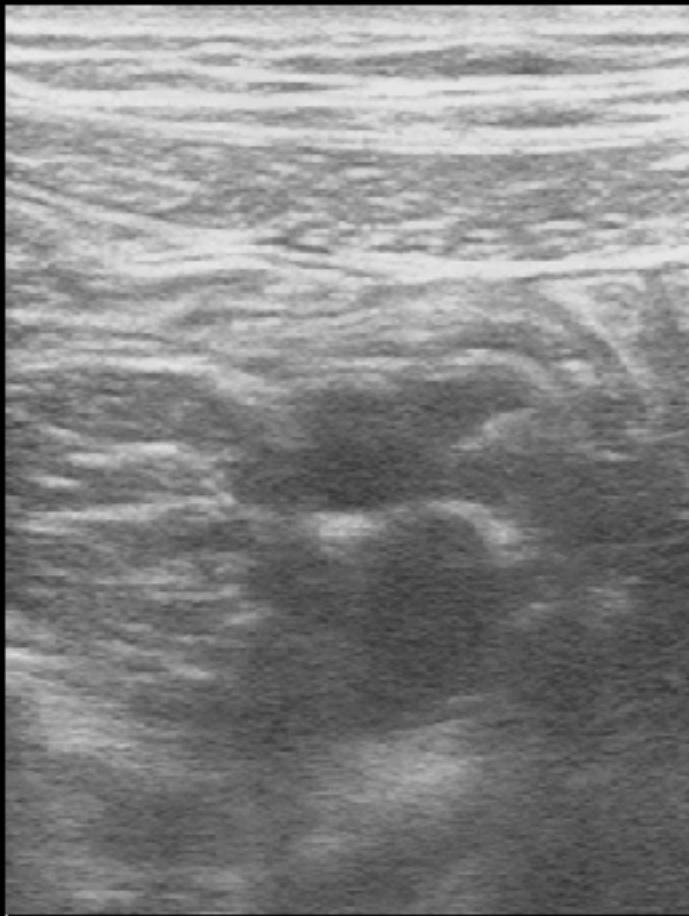


MI 1.2 2/21/2022
TIS 0.2 1:08:20 PM

SKII ER

MI 1.2
TIS 0.

SKII ER

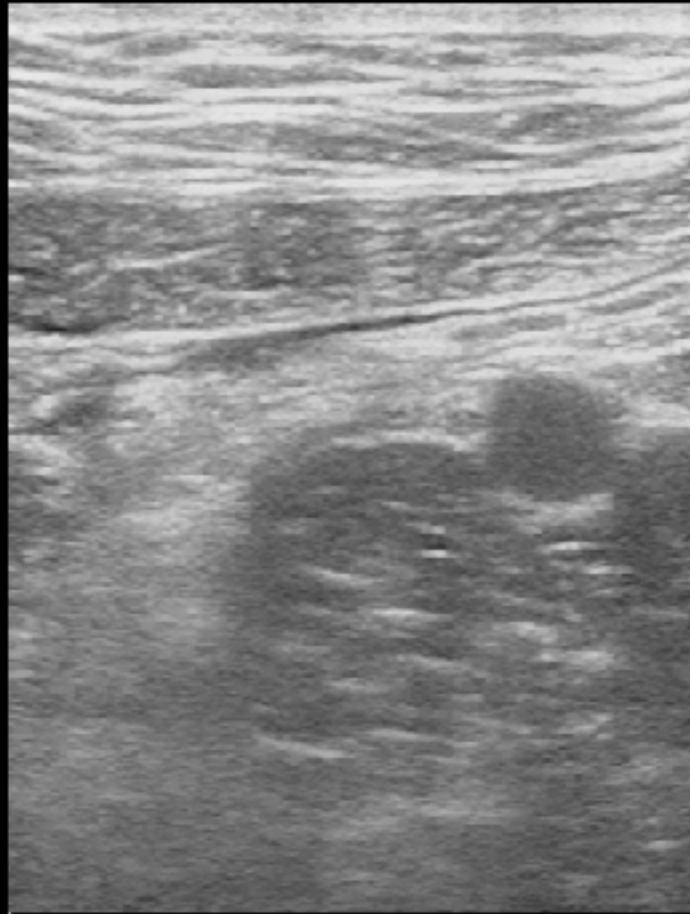


Normal appendix



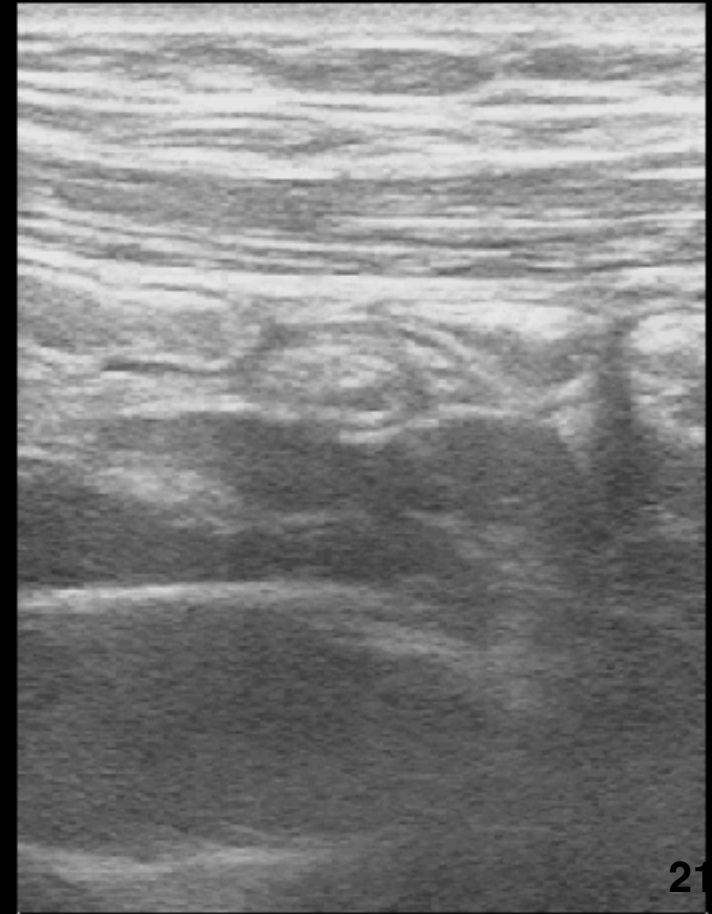
MI 1.1 2/21/2022
TIS 0.1 1:10:45 PM

SKII ER



SKII ER

MI 1.2
TIS 0.2



43M, severe epigastric pain



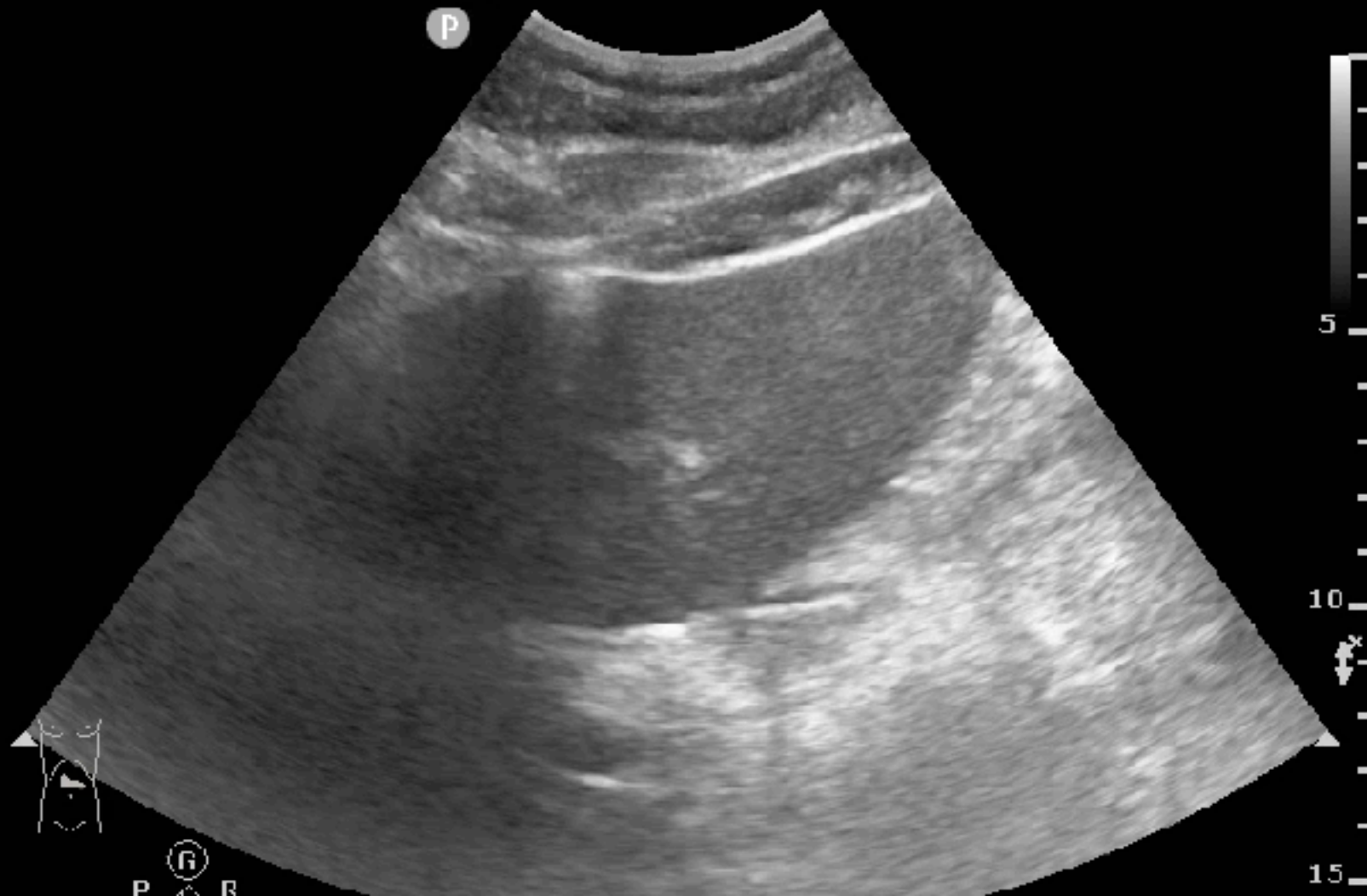PHILIPS TSAI
08458218

SKH ER

MI 1.0 2/21/2022
TIS 0.1 9:10:41 AM

Abd Gen
C5-1
32 Hz
16.0cm

2D
HGen
Gn 74
C. 56
3/3/3



43M, severe epigastric pain



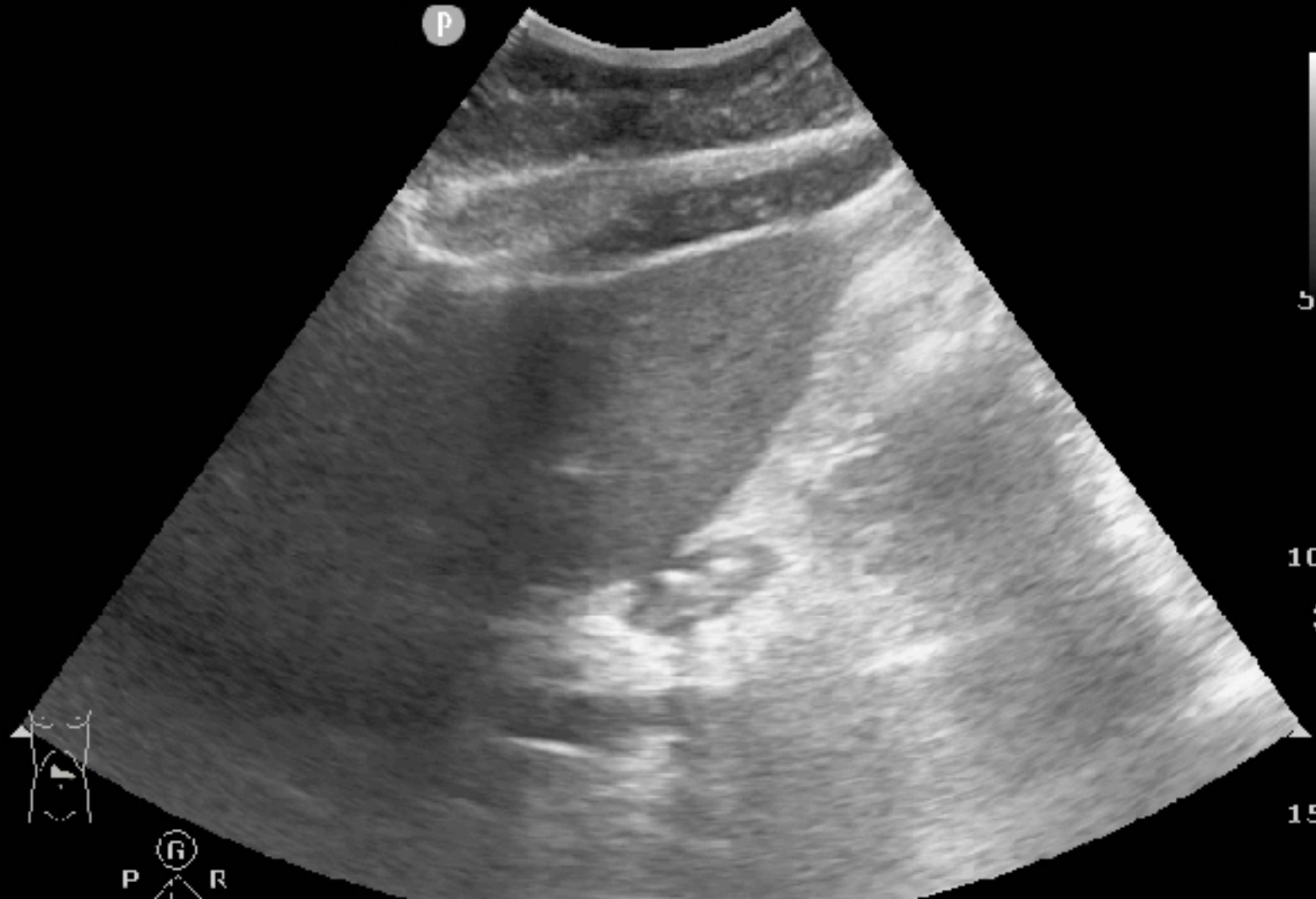PHILIPS TSAI
08458218

SKH ER

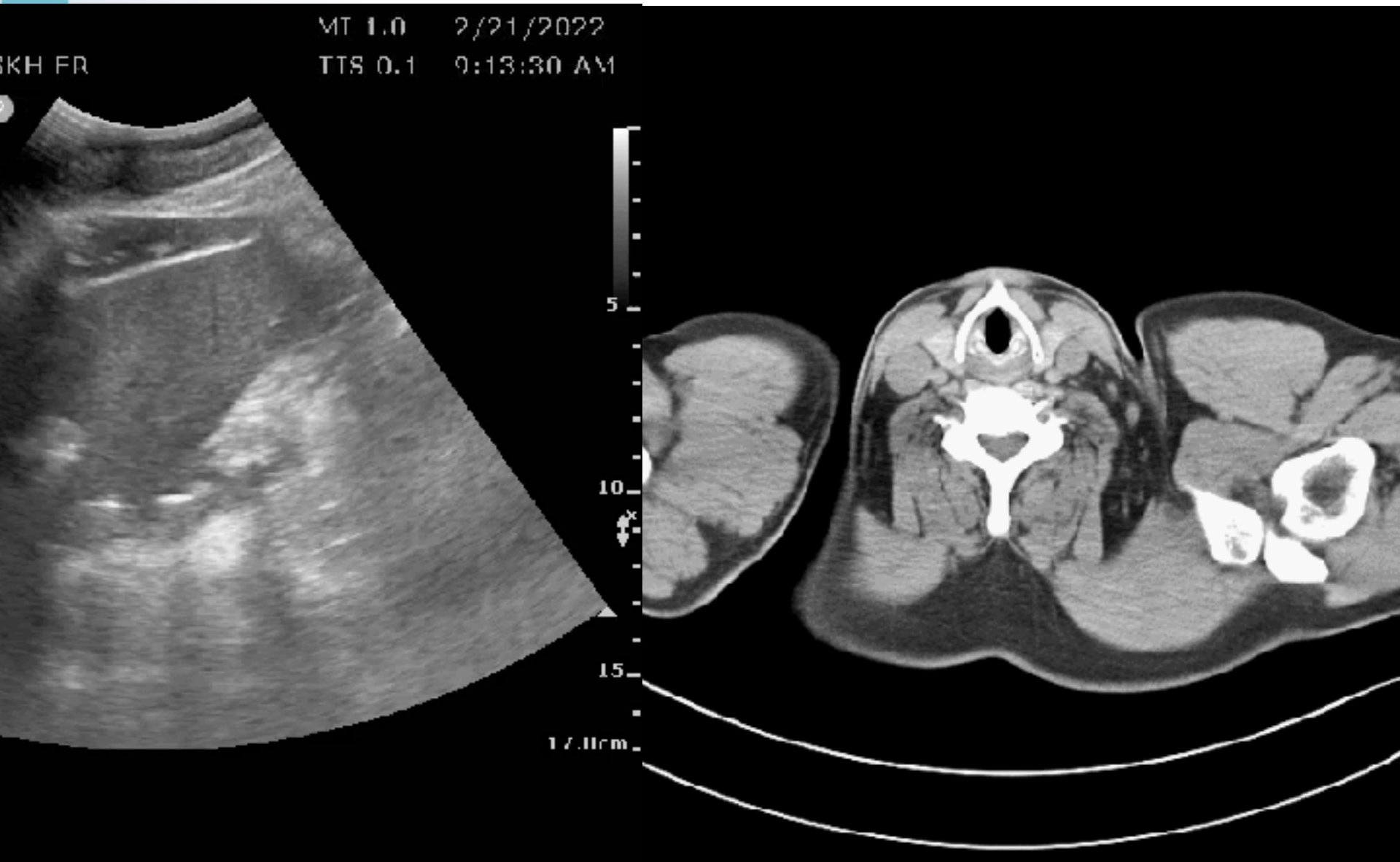MI 1.0 2/21/2022
TIS 0.1 9:12:20 AM

Abd Gen
C5-1
31 Hz
17.0cm

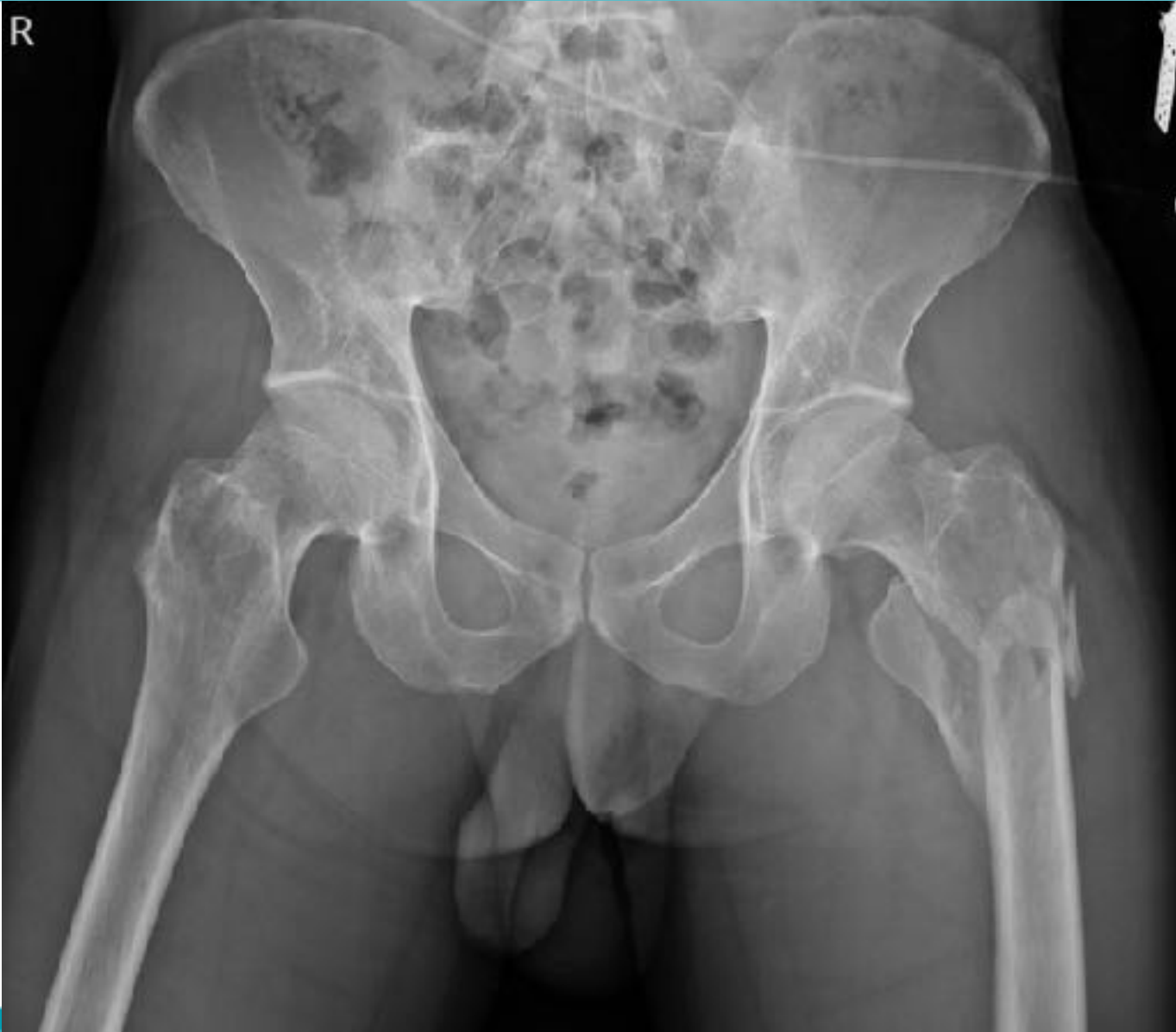2D
HGen
Gn 74
C. 56
3/3/3



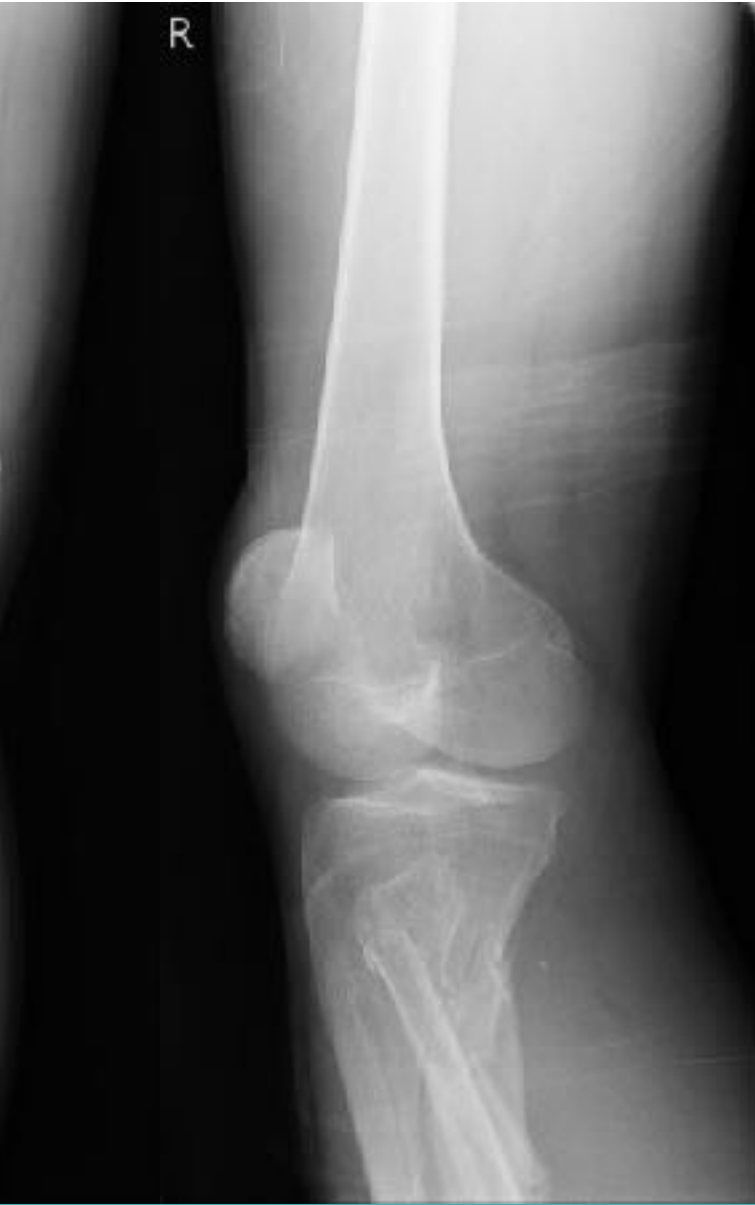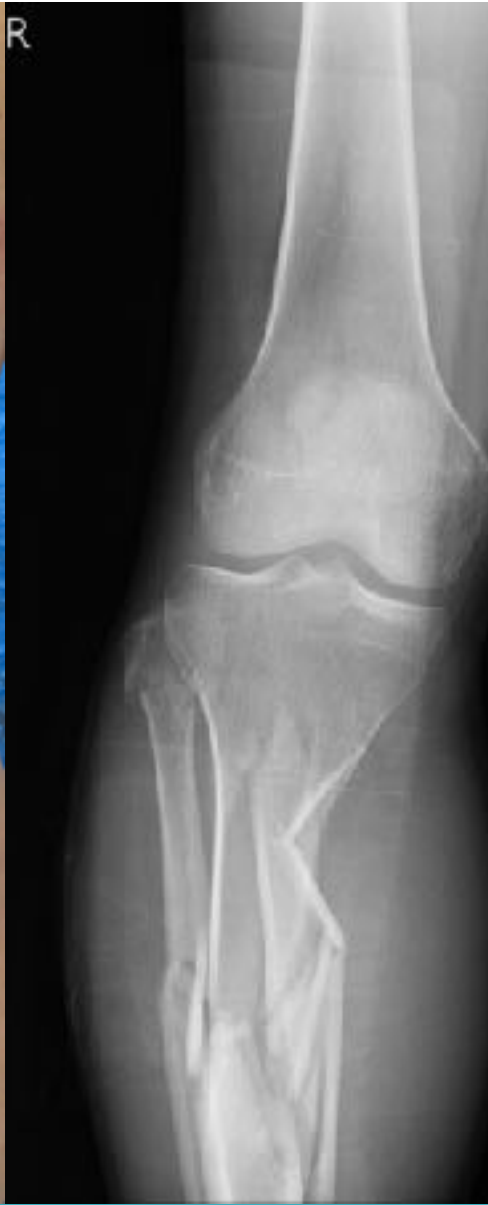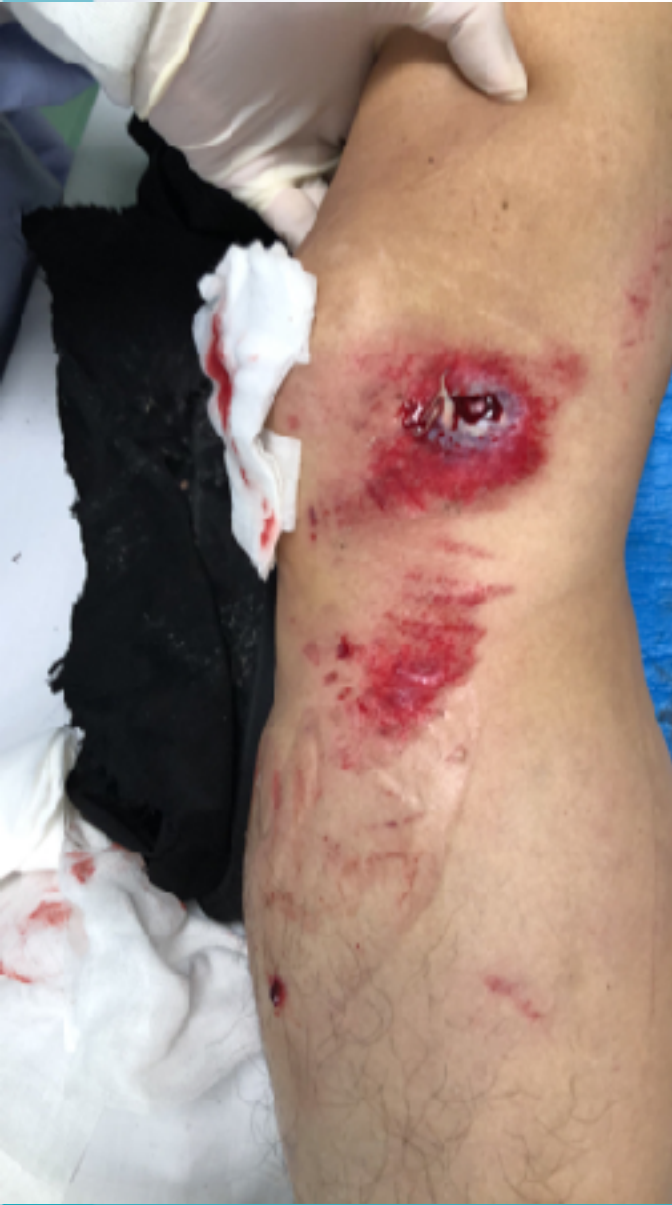Perforated peptic ulcer (PPU)



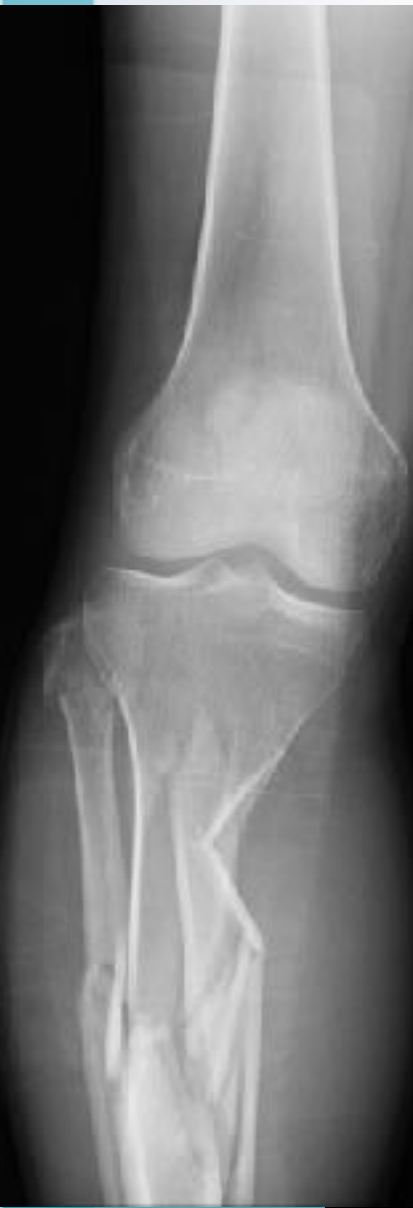37M, trauma w/ fracture (VAS 10)



37M, trauma w/ fracture (VAS 10)



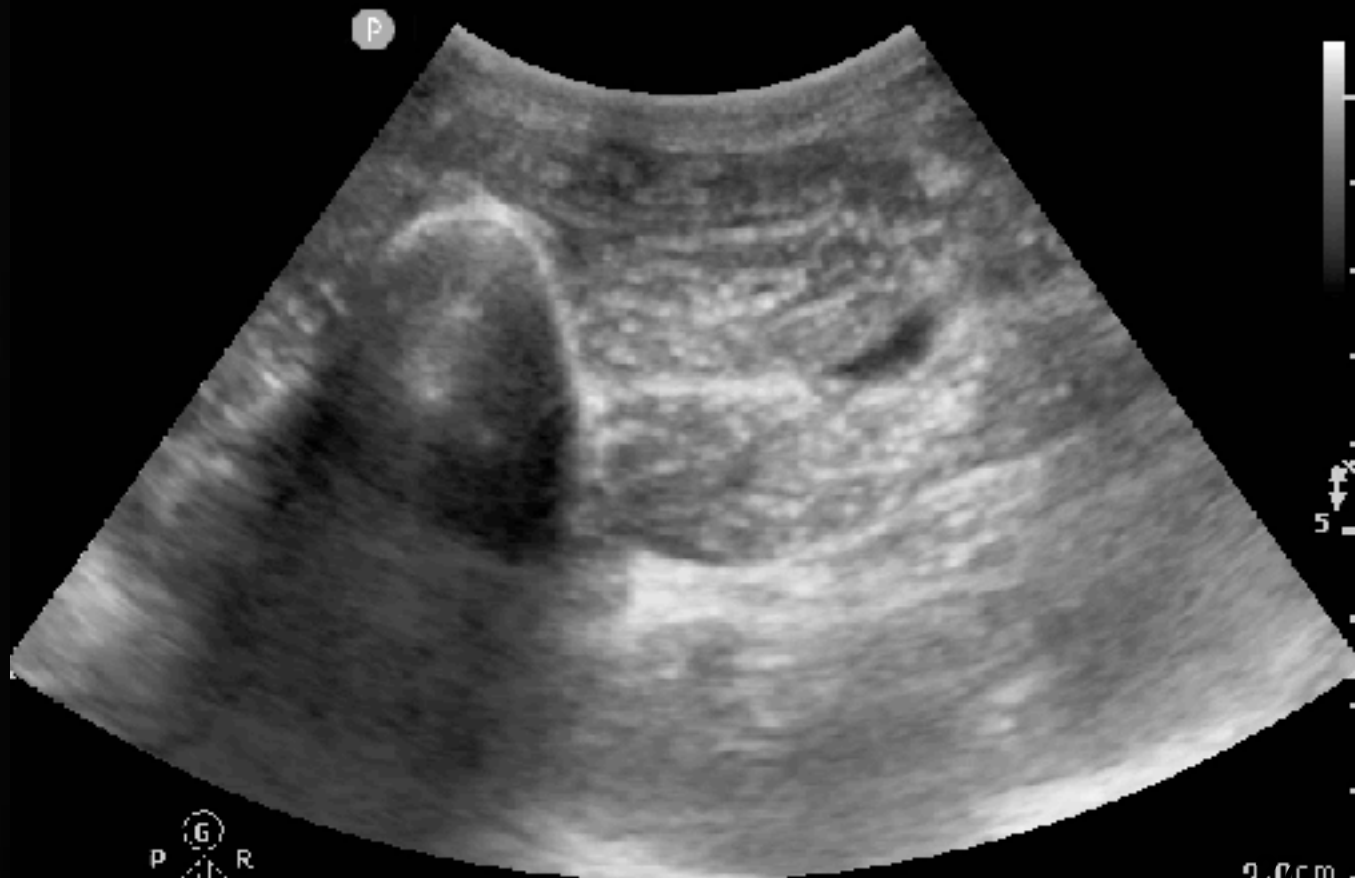37M, trauma with fracture



I
547696

SKII ER

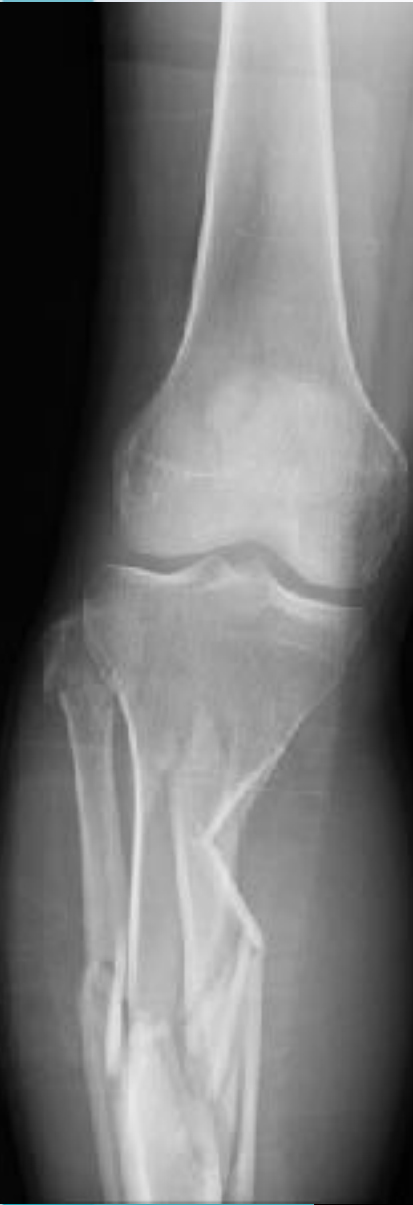MI 1.1 2/21/2022
TIS 0.1 10:24:46 AM



G
P R
1.0 1.6

9.0cm

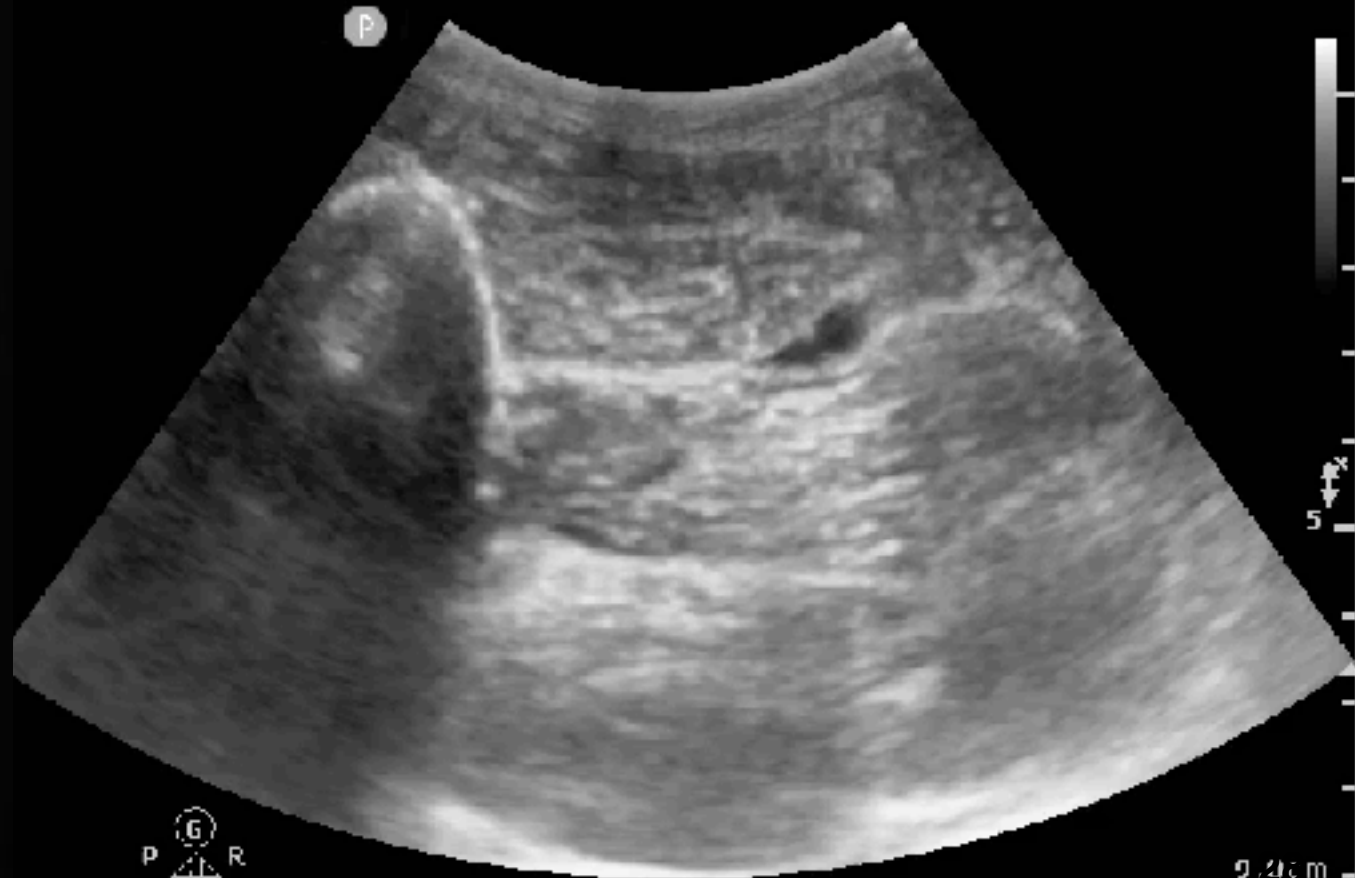Sciatic N block (anterior approach)



47696

SKILLER

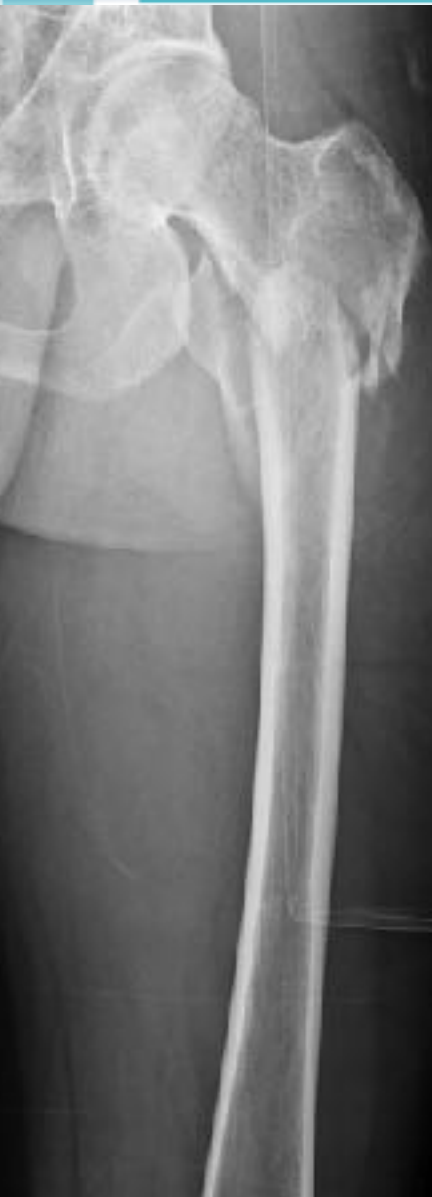MI 1.1 2/21/2022
TIS 0.1 10:25:47 AM



G
P R
1.0 1.6

9.0cm

37M, trauma with fracture

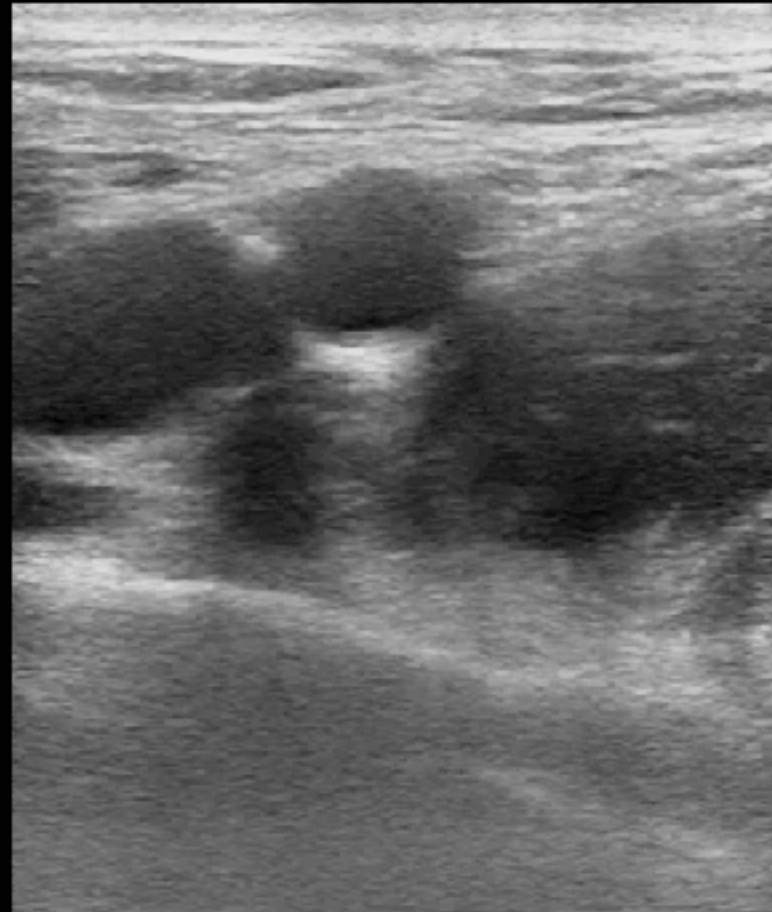


LU
1547696

SKII ER

MI 1.2 2/21/2022
TIS 0.2 10:35:03 A

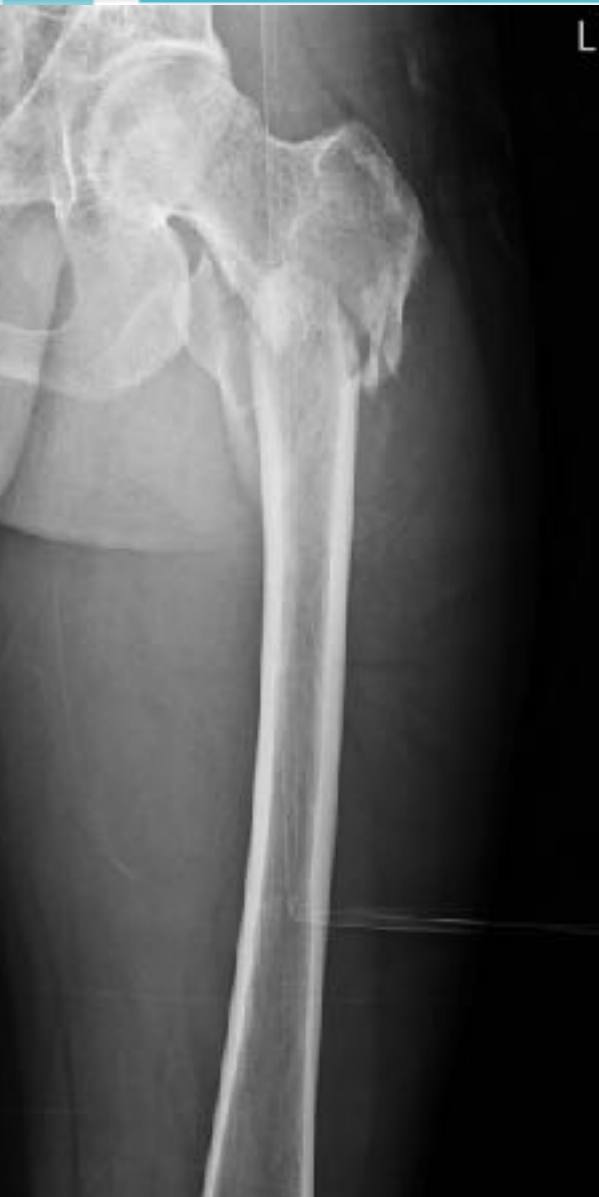P



G
P R
4.4 11.11

4.50

Femoral N block



L

17696

SKH ER

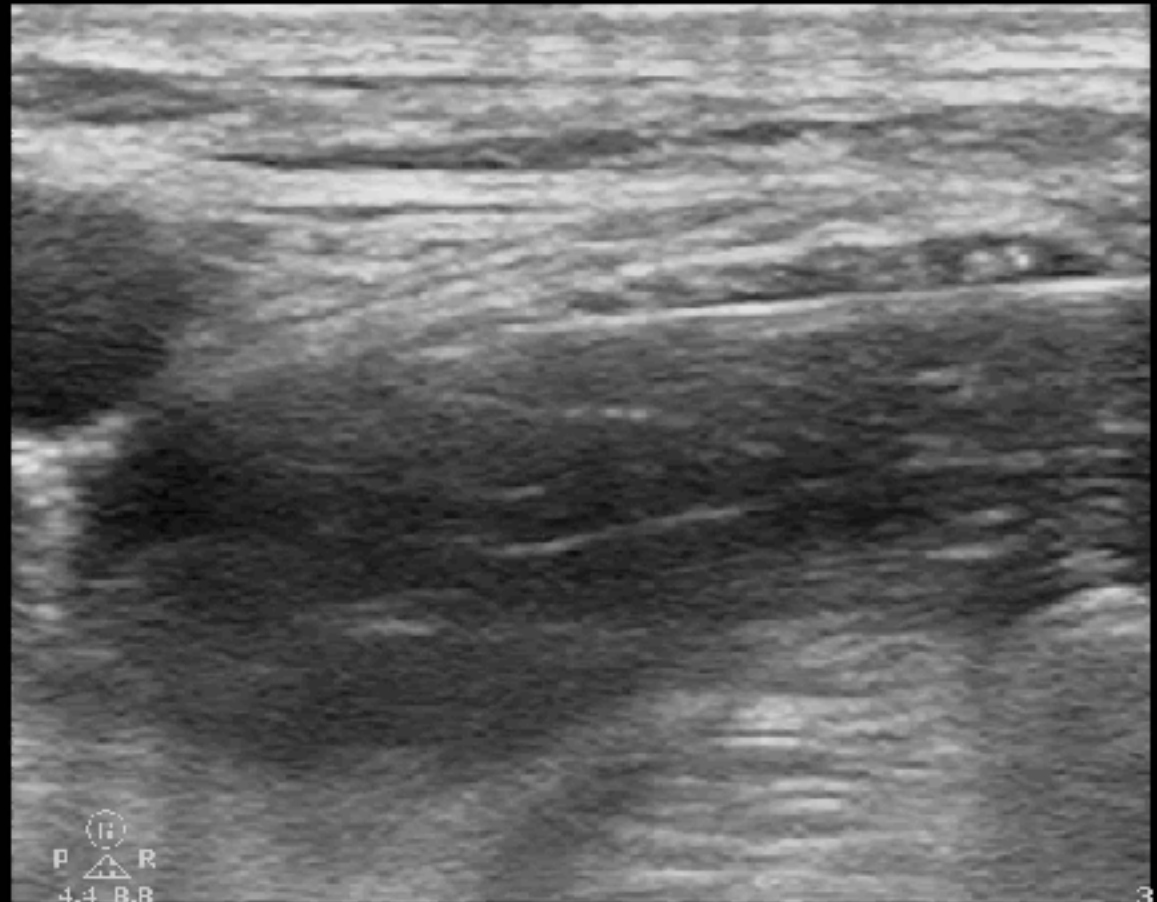MT 0.8

2/21/2022

11S 0.1

10:44:33 AM

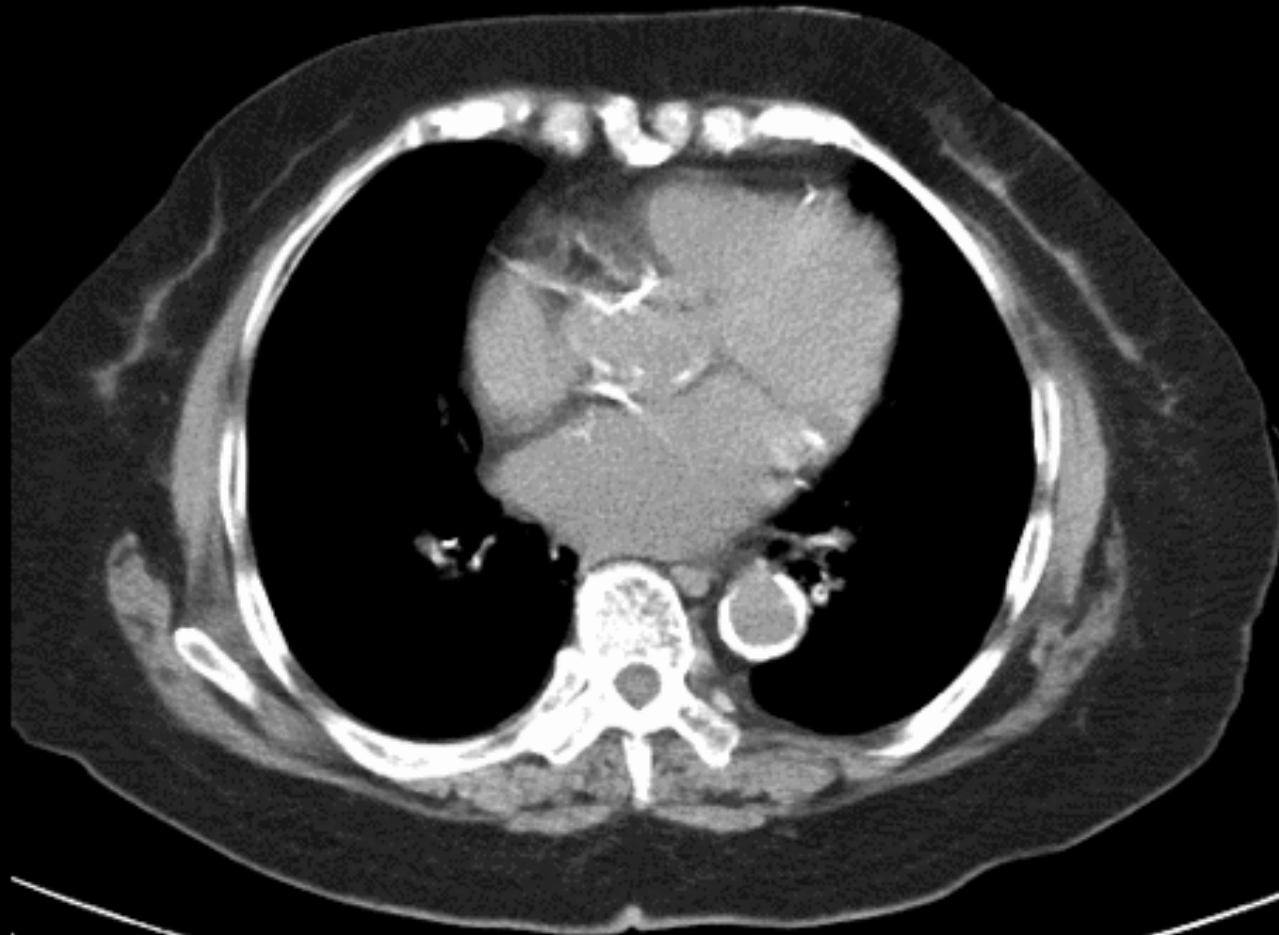
P



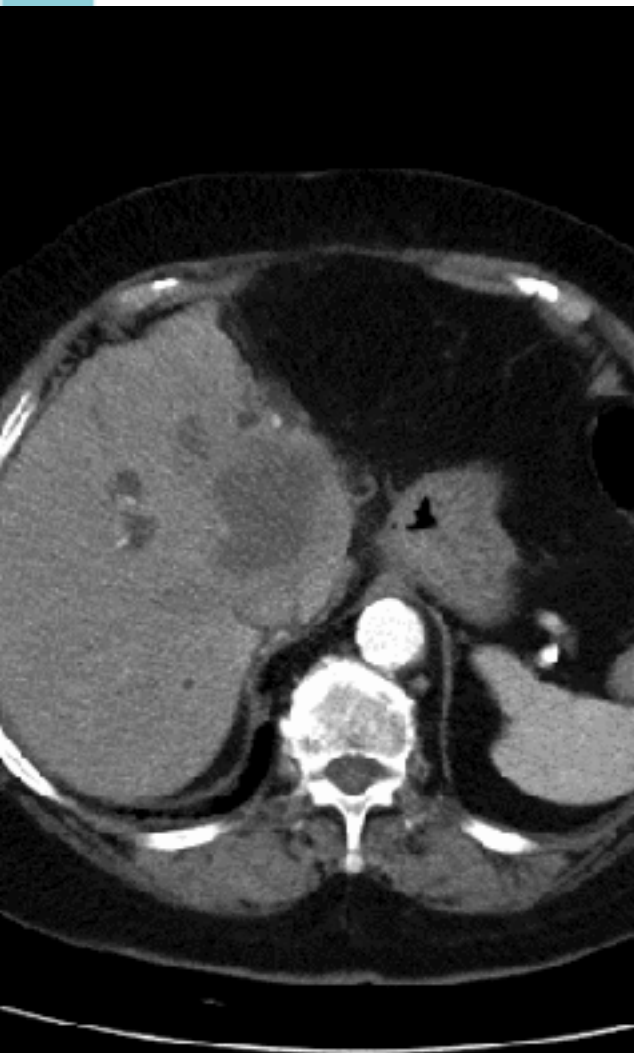Ⓜ
P R
4.4 8.8

3.0cm

85F, abdominal pain



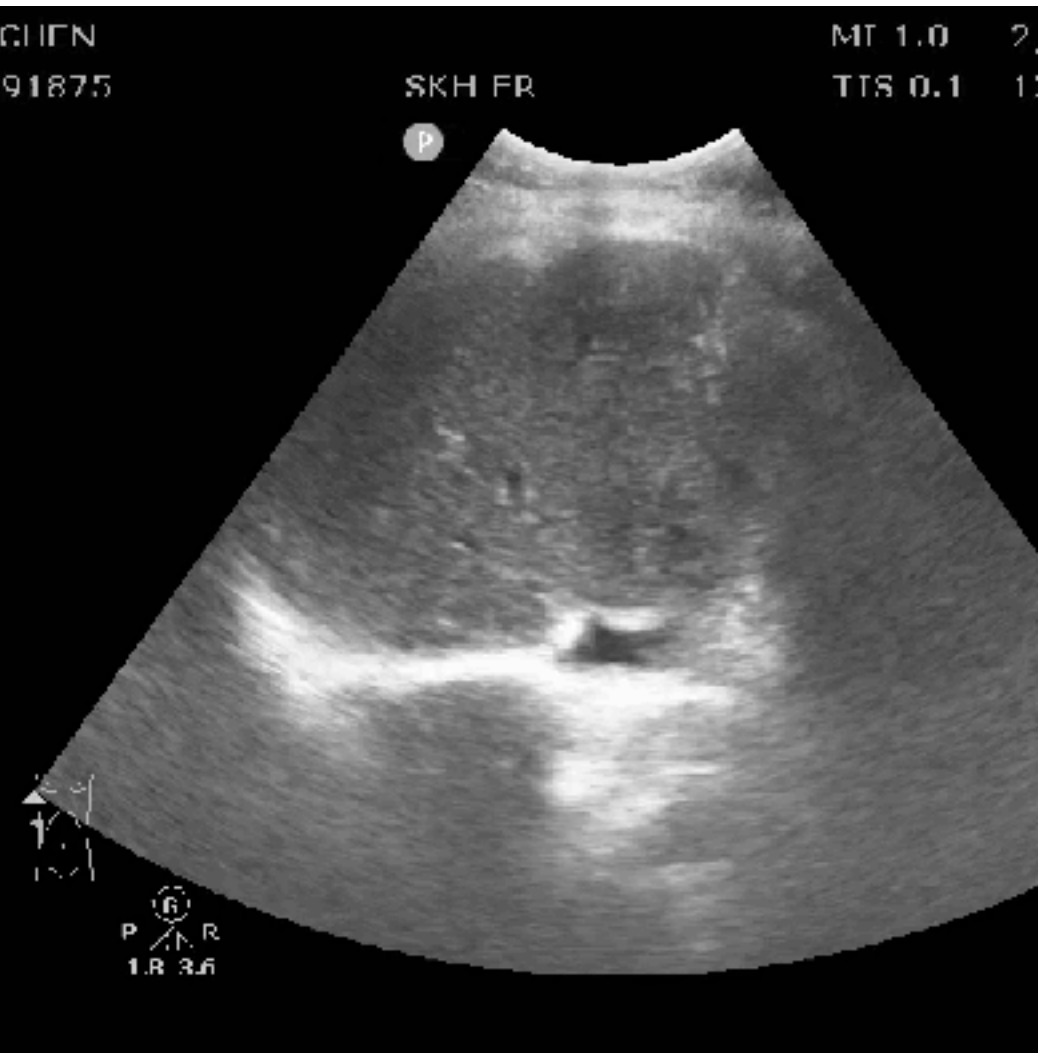Hepatic tumor



PHILIPS I TNGHEN
00991875

Abd Gen
C5-1
30 Hz
18.0cm

2D
HGen
Gn 76
C 56
3/3/3

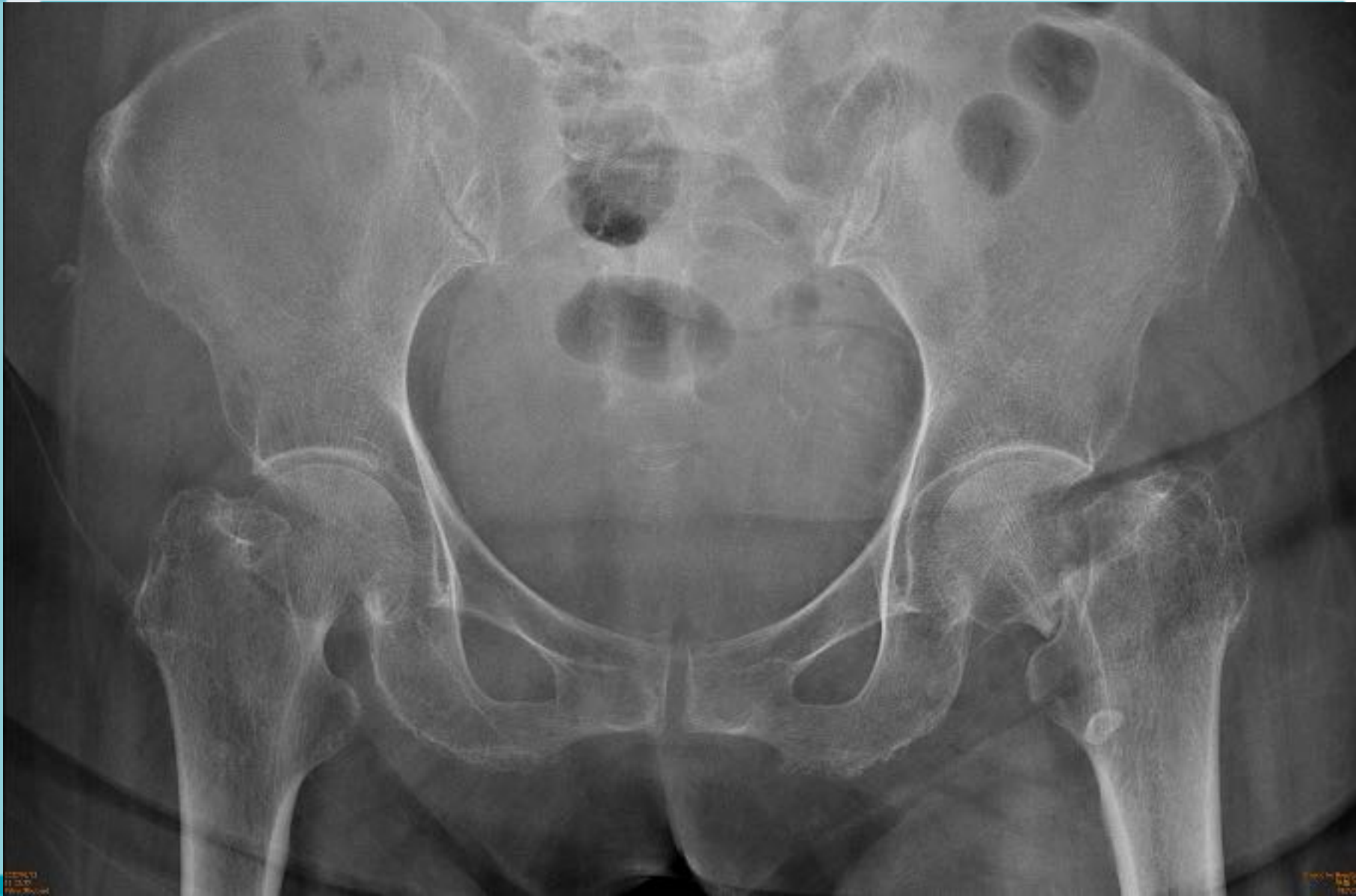

SKH FR

MT 1.0 2
TTS 0.1 1

⑥
P ↑ R
1.8 3.6

81F, Femoral neck fracture



Pericapsular Nerve Group block



05949591 2022Feb23 21:45

Res MB

Res

Patient

Auto Gain

Res

Clip

Page 1/3

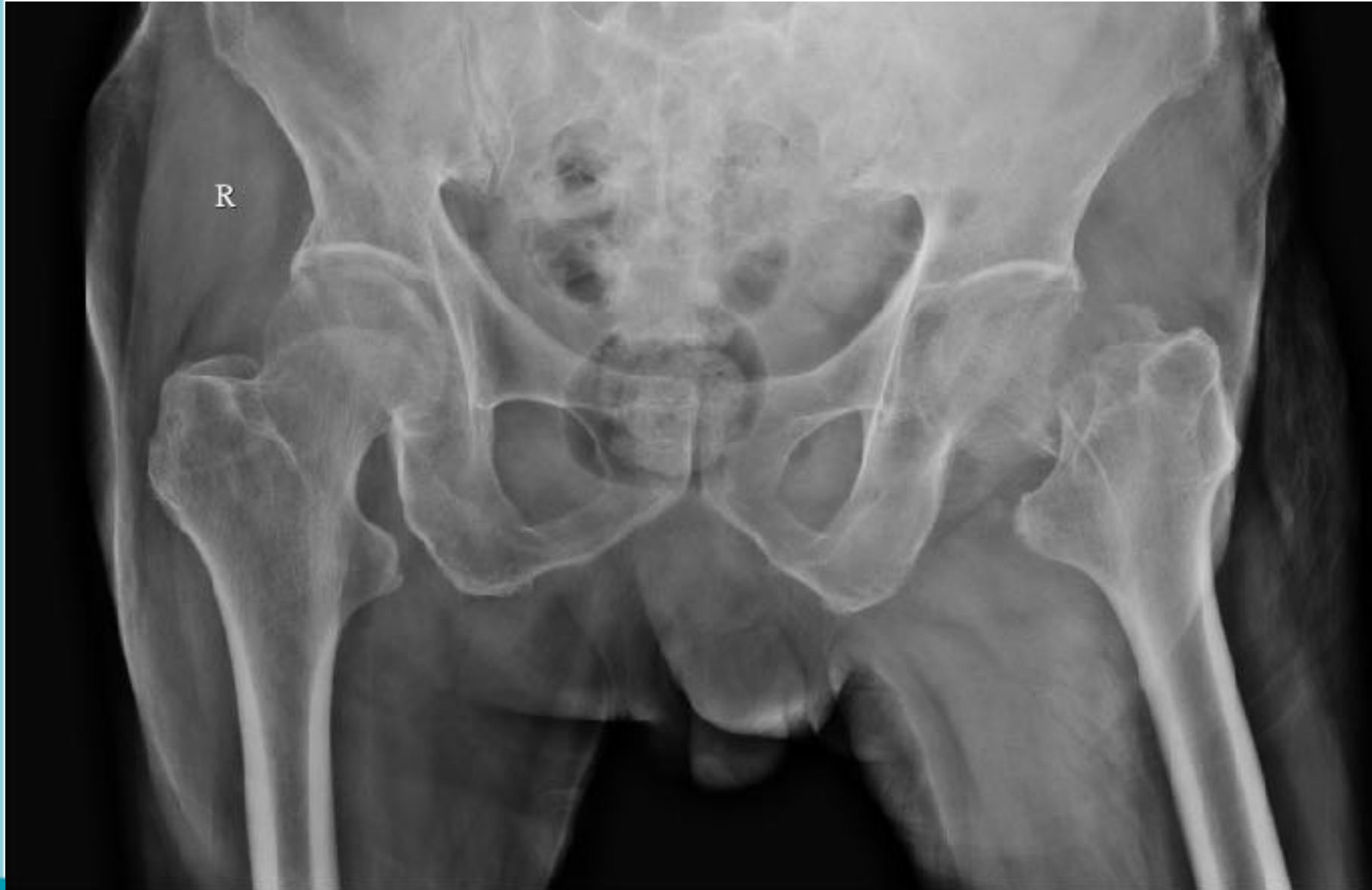4.9

Nrv
HFL
44%
MI
0.6
TIS
0.1

4.9

4.9

99M, Femoral neck fracture



PENG block



14148277 2022Feb23 22:02

Res MB

Res

Auto Gain

Res

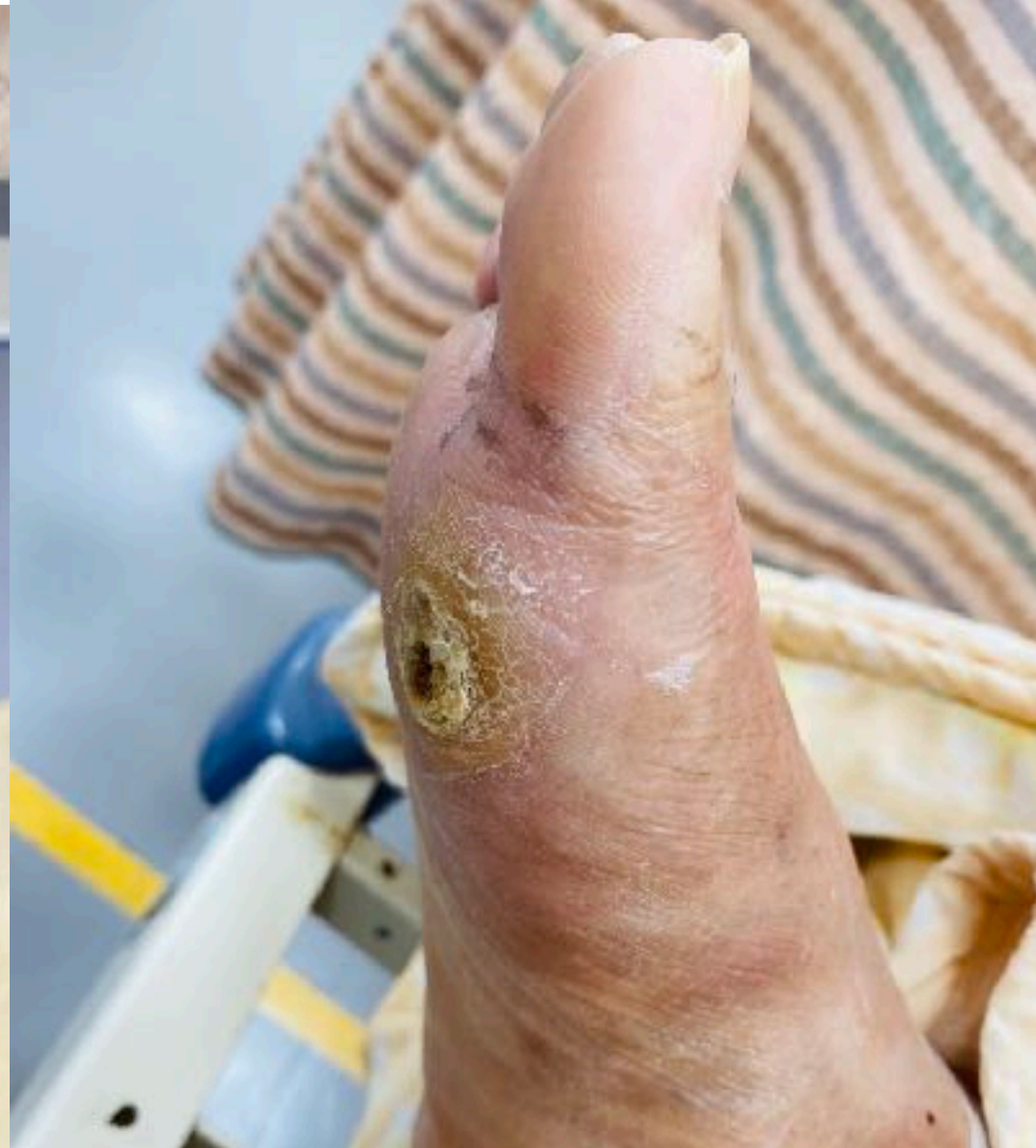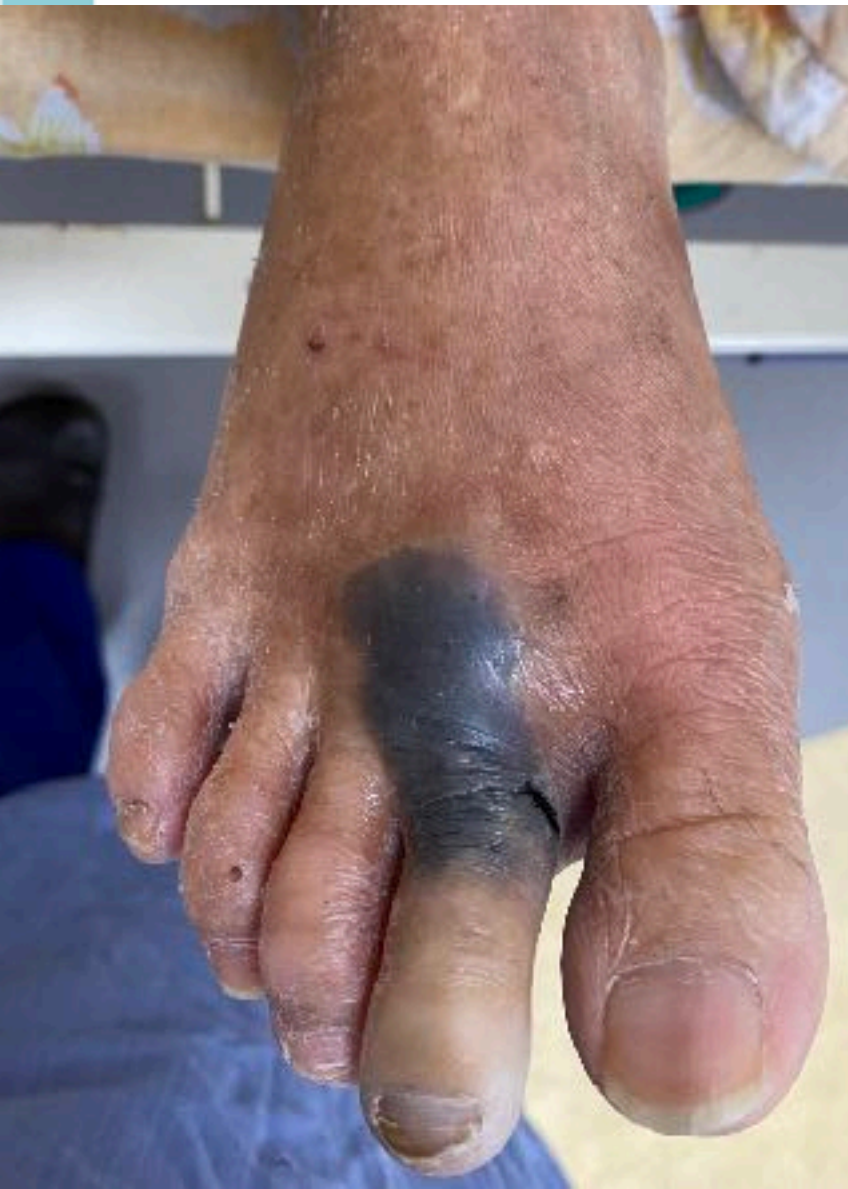Clip

MI 0.7
TIS 0.1

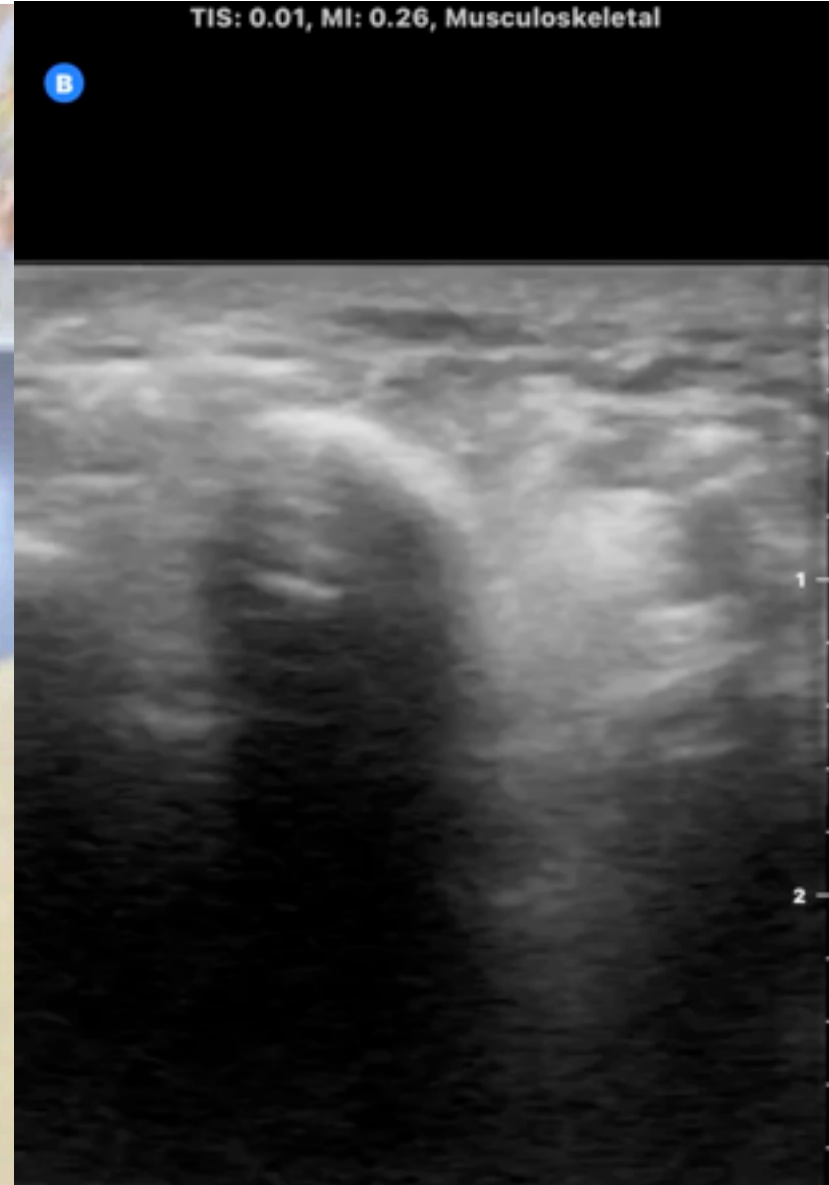
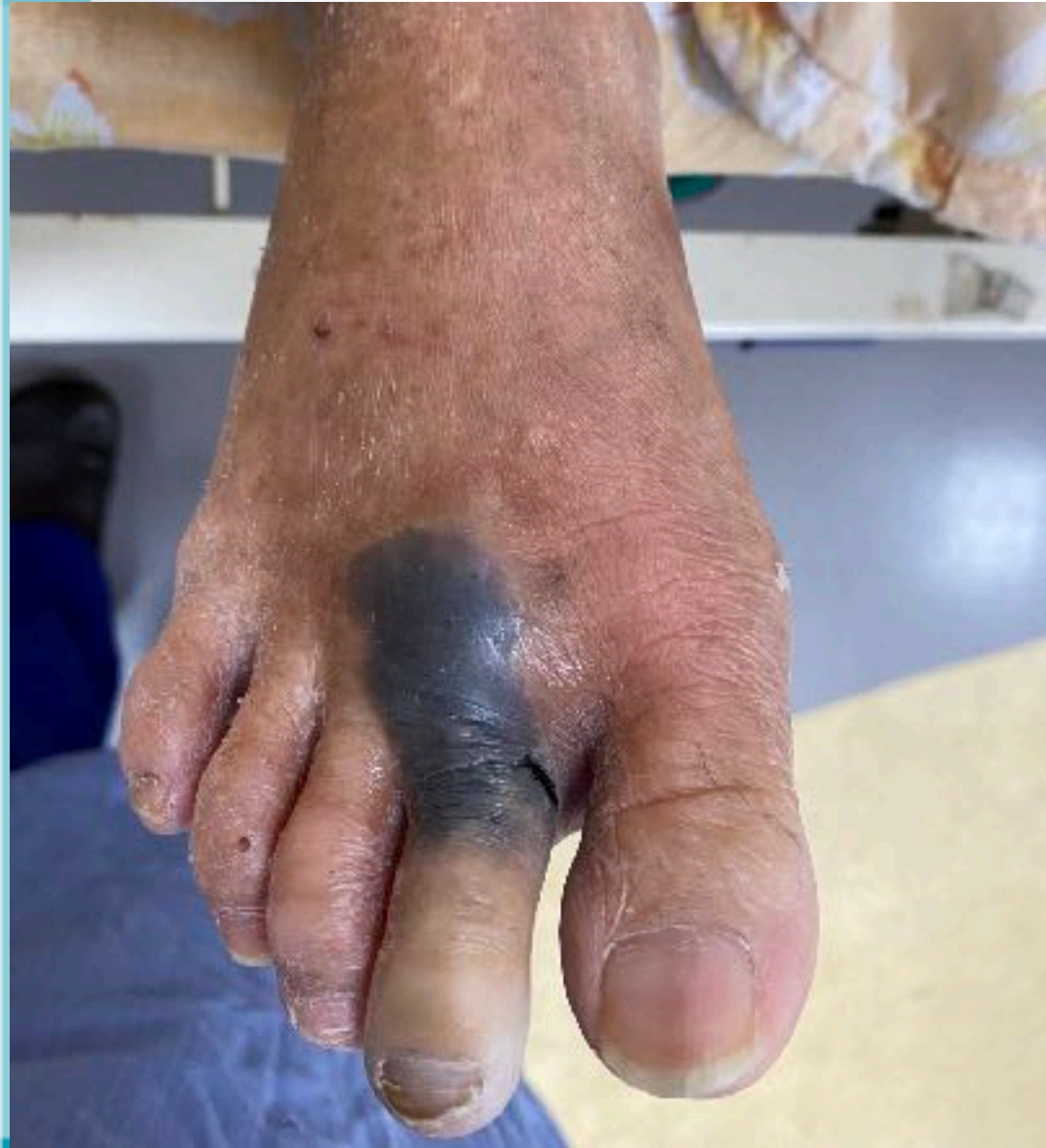42%

40

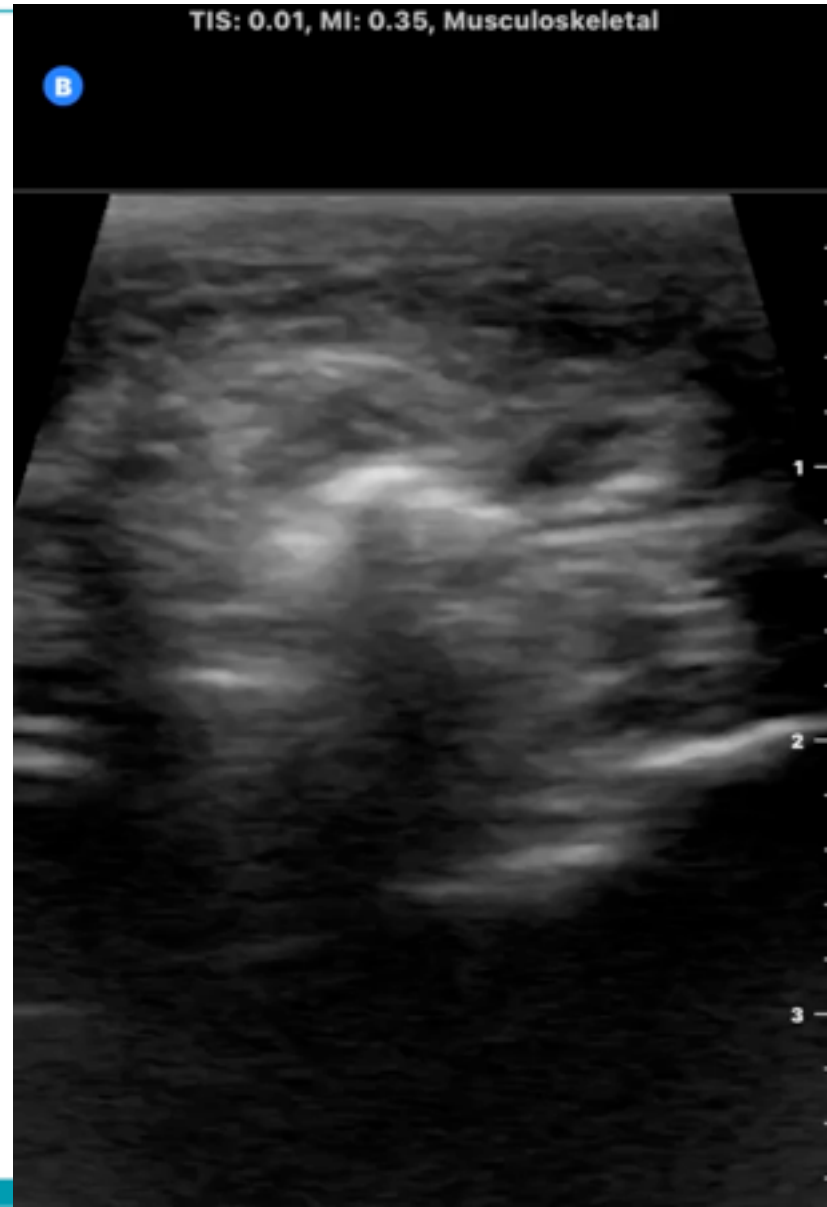
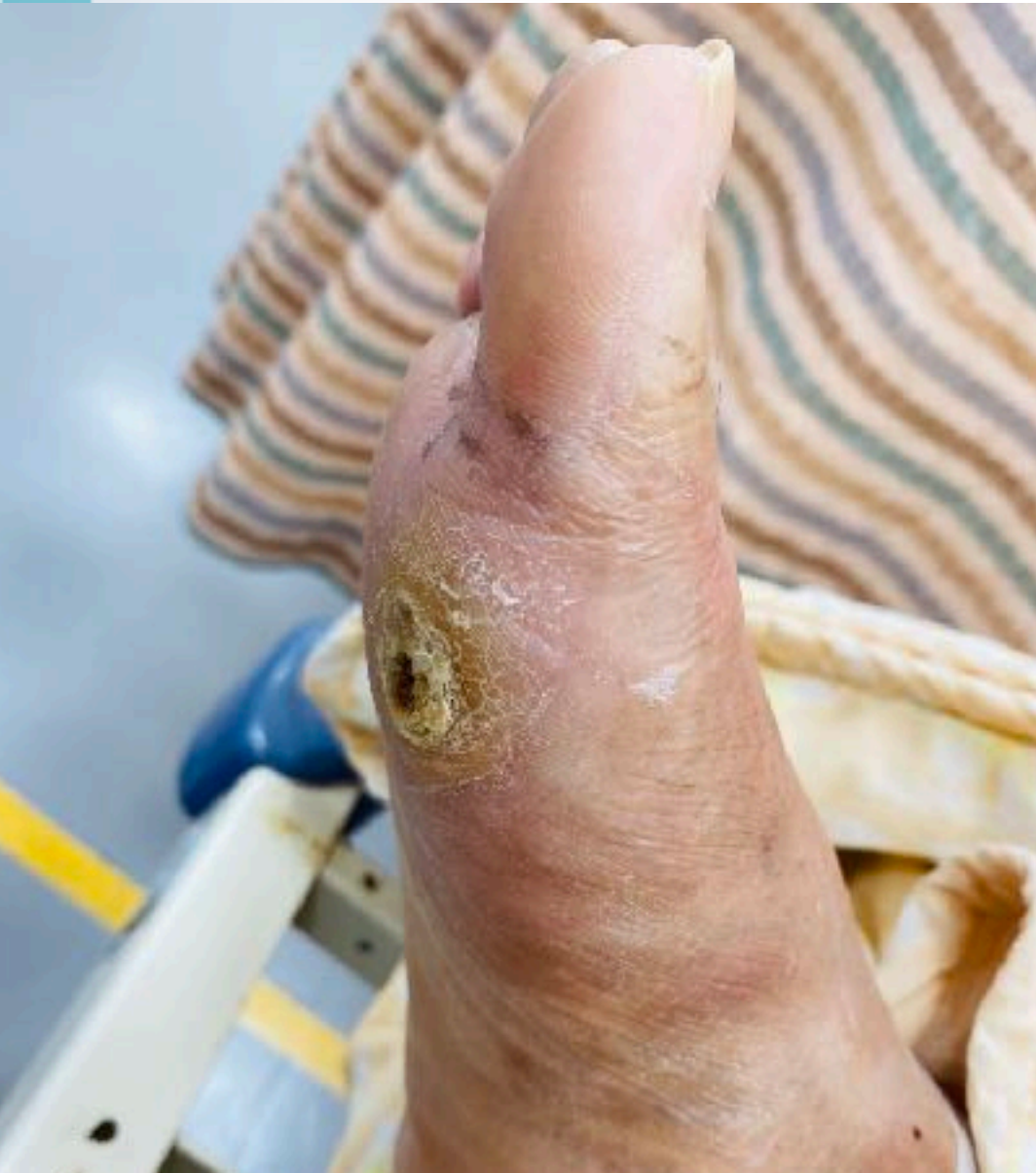59F, DM, Uremia on HD, Fever



59F, DM, Uremia on HD, Fever



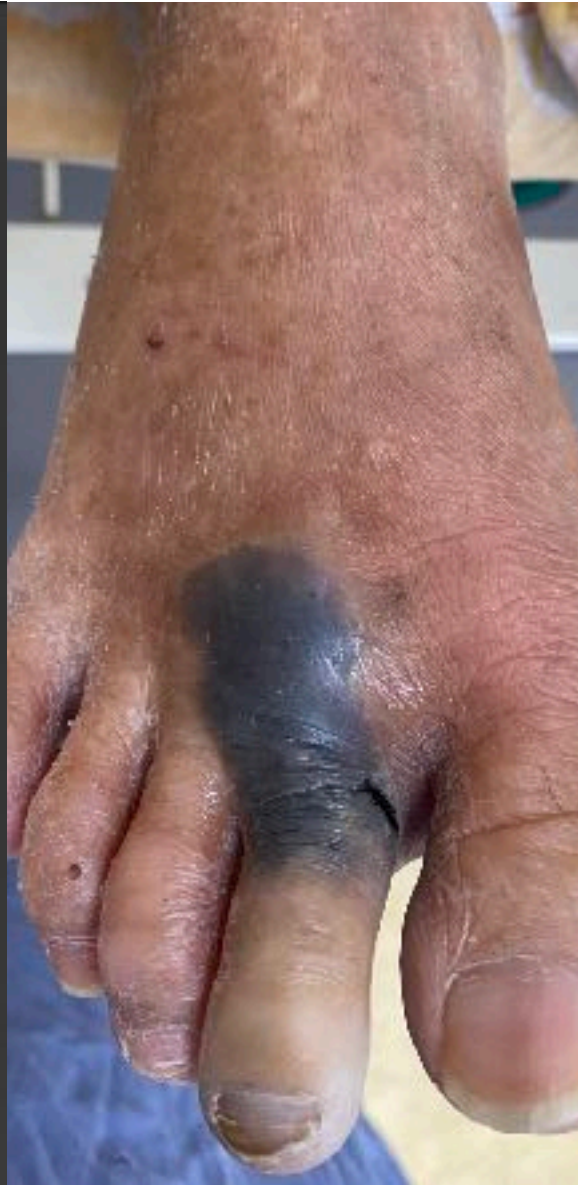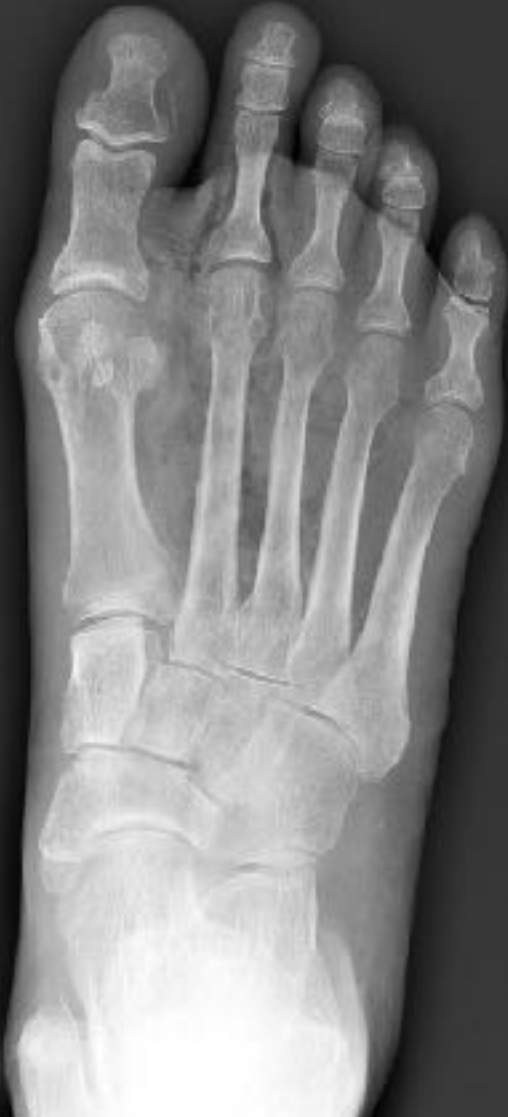59F, DM, Uremia on HD, Fever



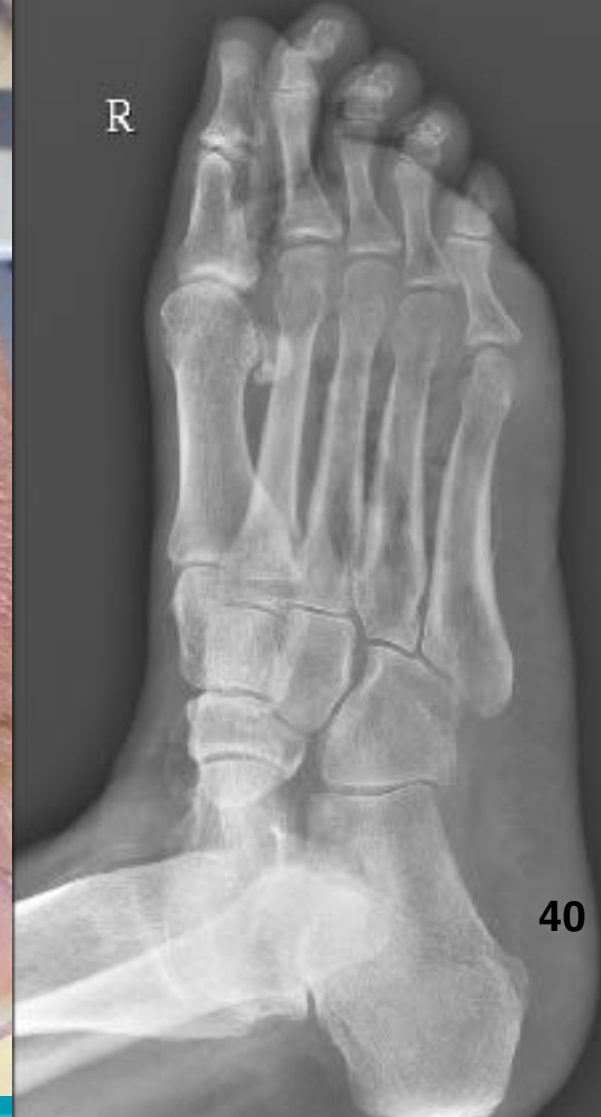Soft tissue gas



R



R

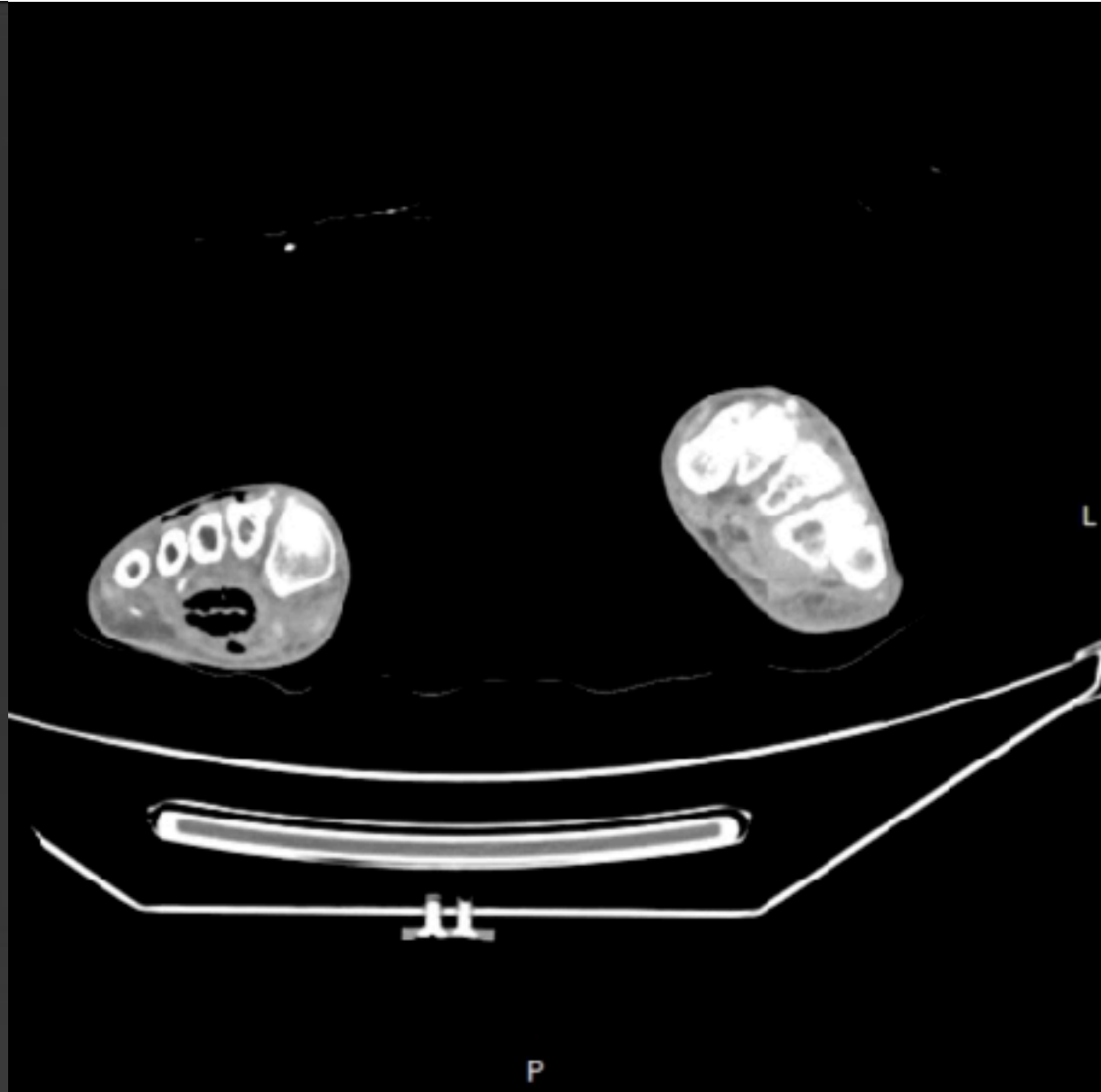
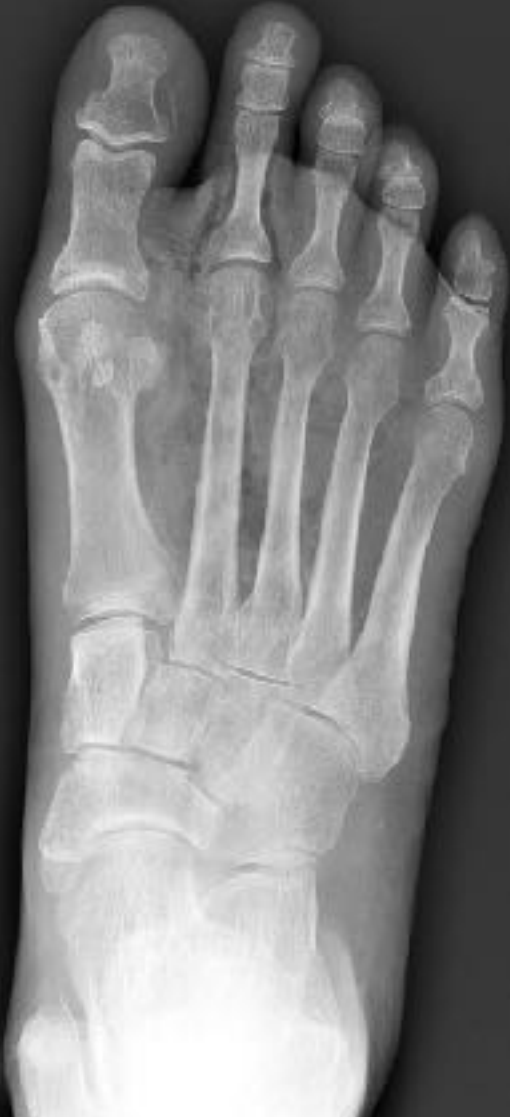

40

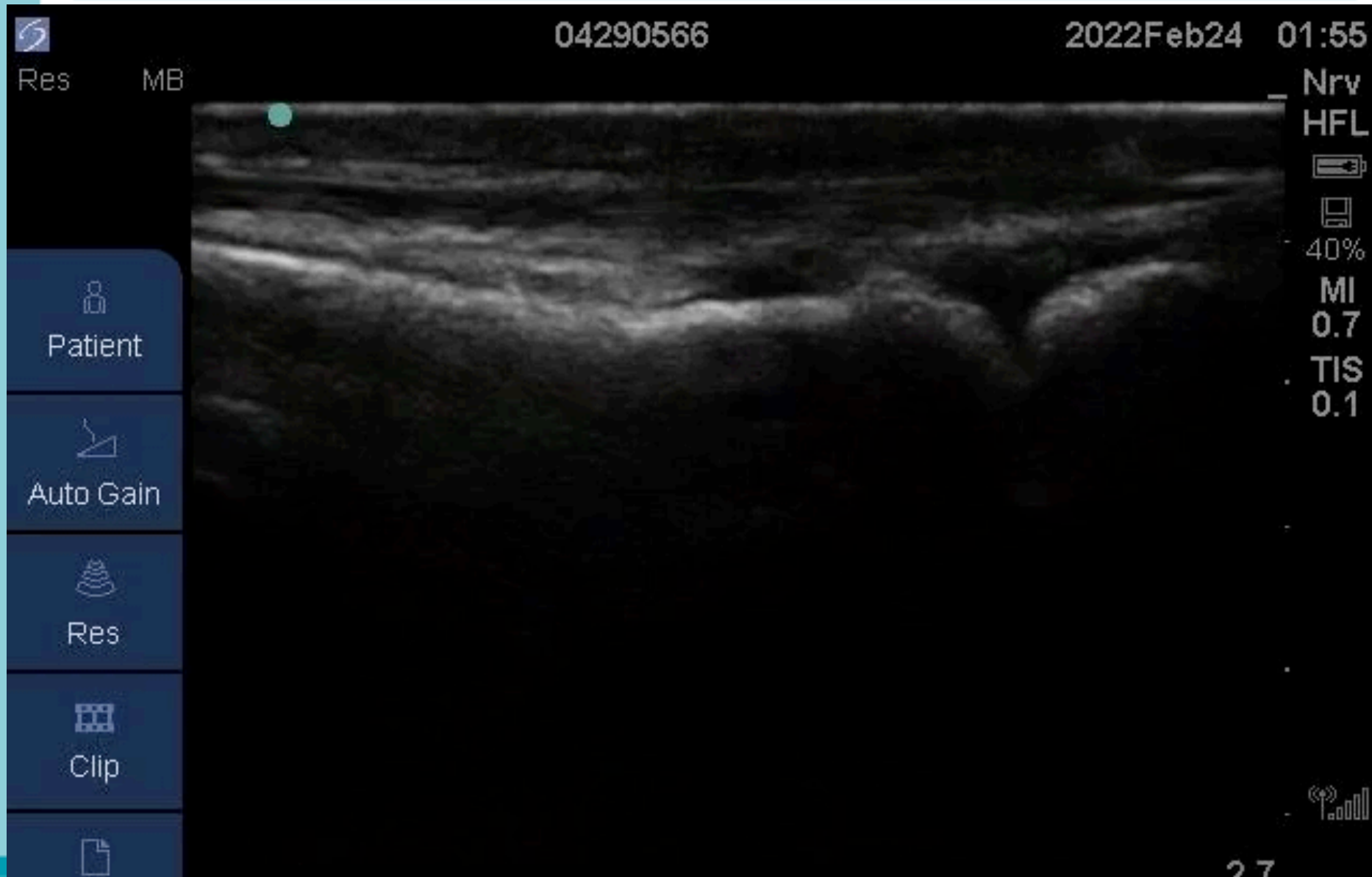
59F, DM, Uremia on HD, Fever



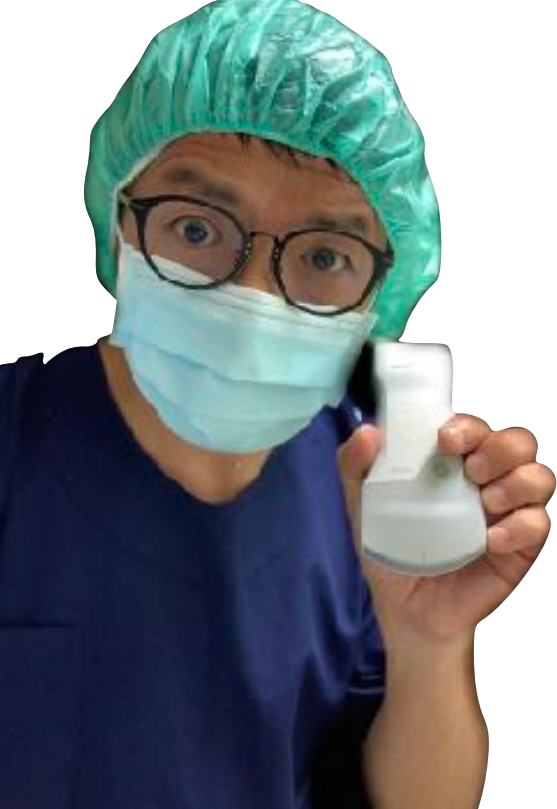R



Necrotizing fasciitis



20220304 END



努力可能會說謊，
但努力不會白費。

羽生結弦

HOLISTIC ULTRASOUND

juice119@gmail.com / POCUSacademy.com