



雙和急診POCUS訓練

陳國智 醫師



醫用超音波學會指導醫師
WINFOCUS director / instructor
急救加護醫學會重症超音波負責人

急診 / 重症 / 介入 / 急性疼痛

經歷

新光急診超音波訓練中心主任

西園醫院急診醫學科主任

急診醫學會超音波委員會主委

台灣疼痛醫學會大體模擬手術講師



LE joint effusion

01/07

Airway

01/14

Needling

01/21

VExUS protocol

01/28

雙和急診POCUS訓練



Central access

02/11

Peripheral access

02/18

EFAST

02/25

雙和急診POCUS訓練



Basic ECHO

03/04

Nerve block-UE(1)

03/11

Nerve block-LE(1)

03/25

雙和急診POCUS訓練

診
斷

監
測

介
入

POINT OF CARE ULTRASOUND

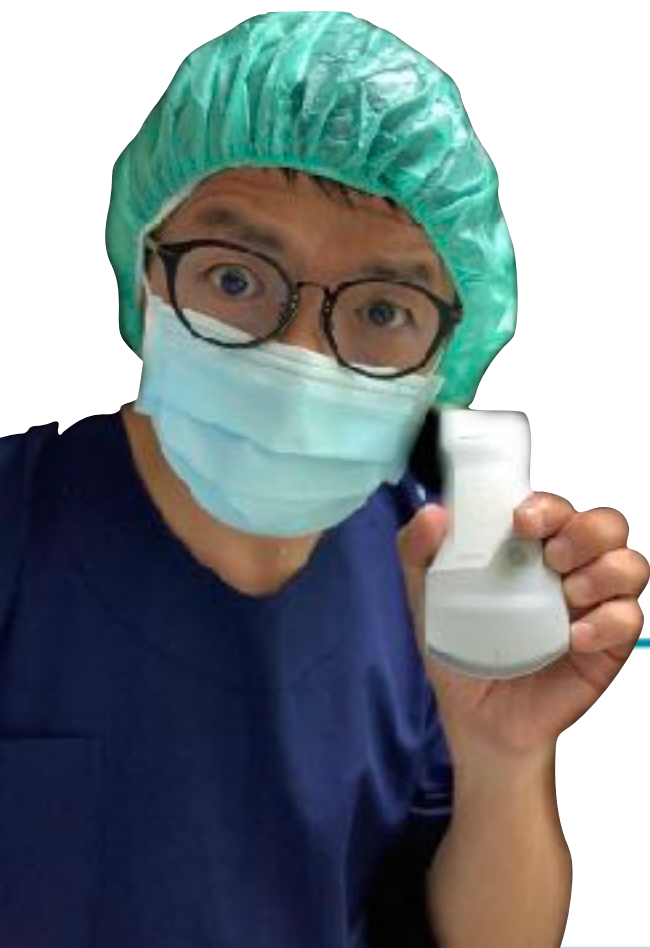~ 存在於臨床需求之所在 ~



衛生福利部雙和醫院
(委託臺北醫學大學興建經營)
Taipei Medical University · Shuang Ho Hospital,
Ministry of Health and Welfare



POCUS Imaging Reading



陳國智醫師

雙和醫院 急診醫學科

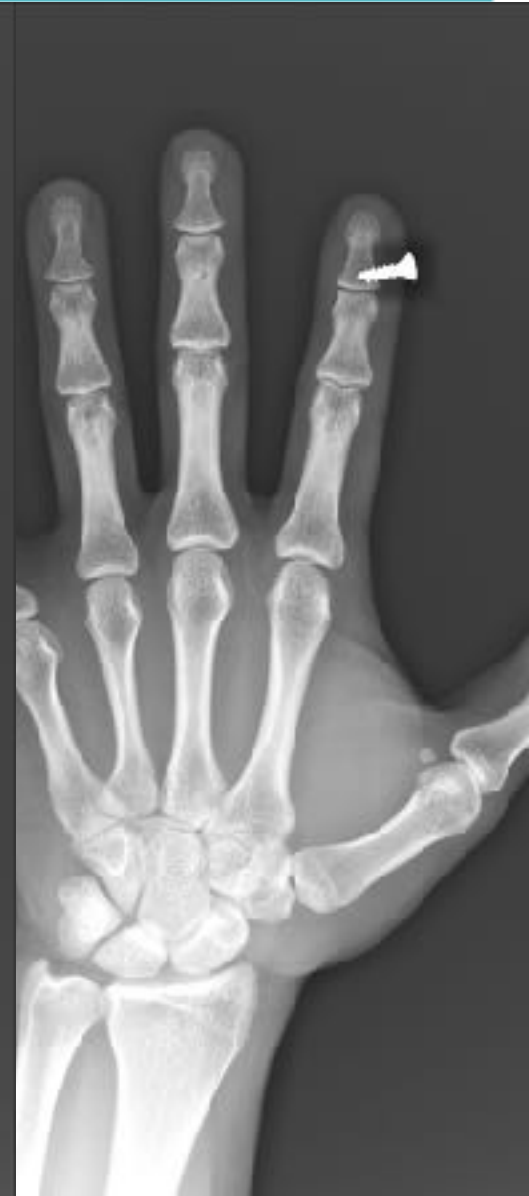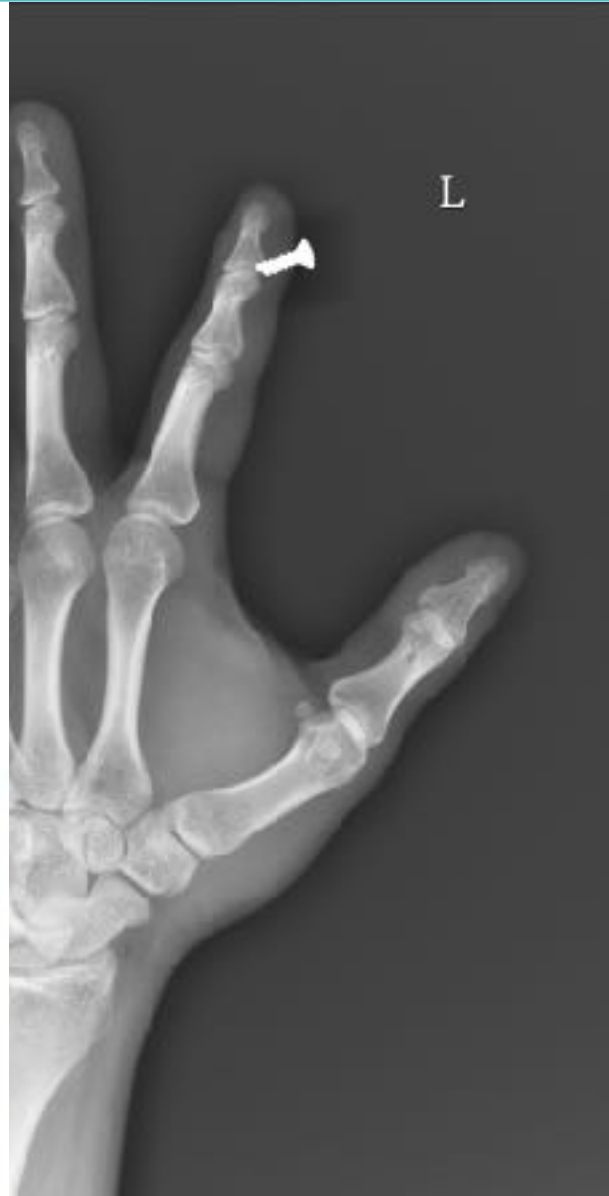36M, penetrating injury



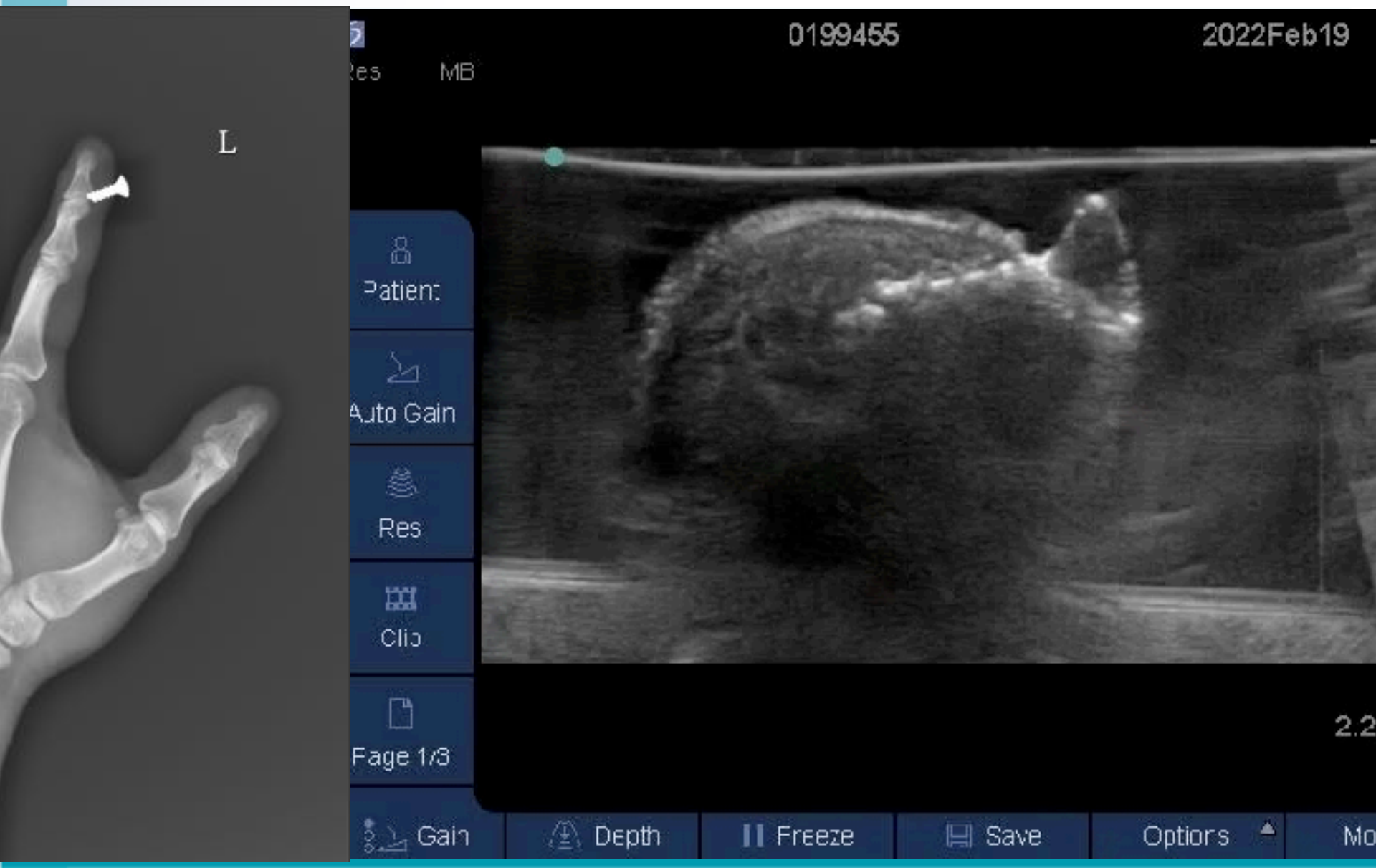< 黃泓勝
1天 · 公

...

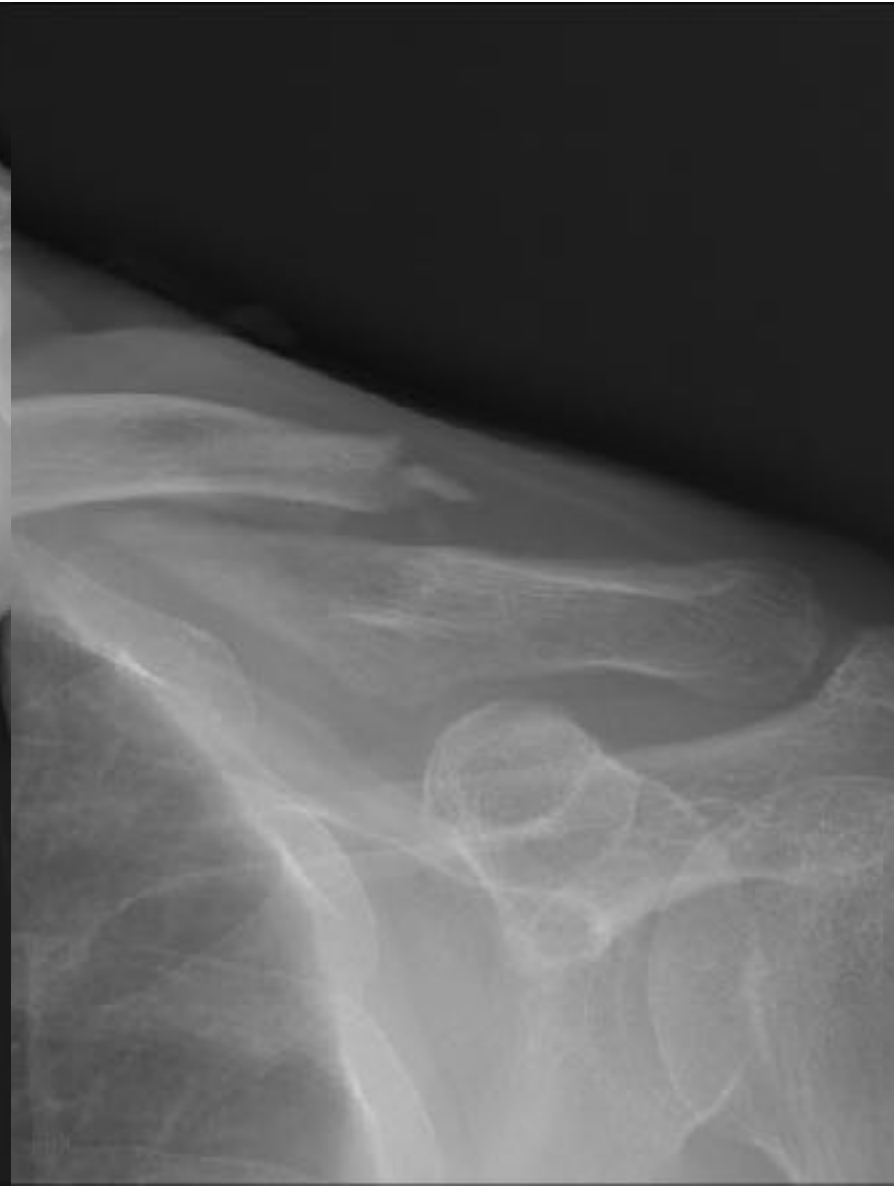
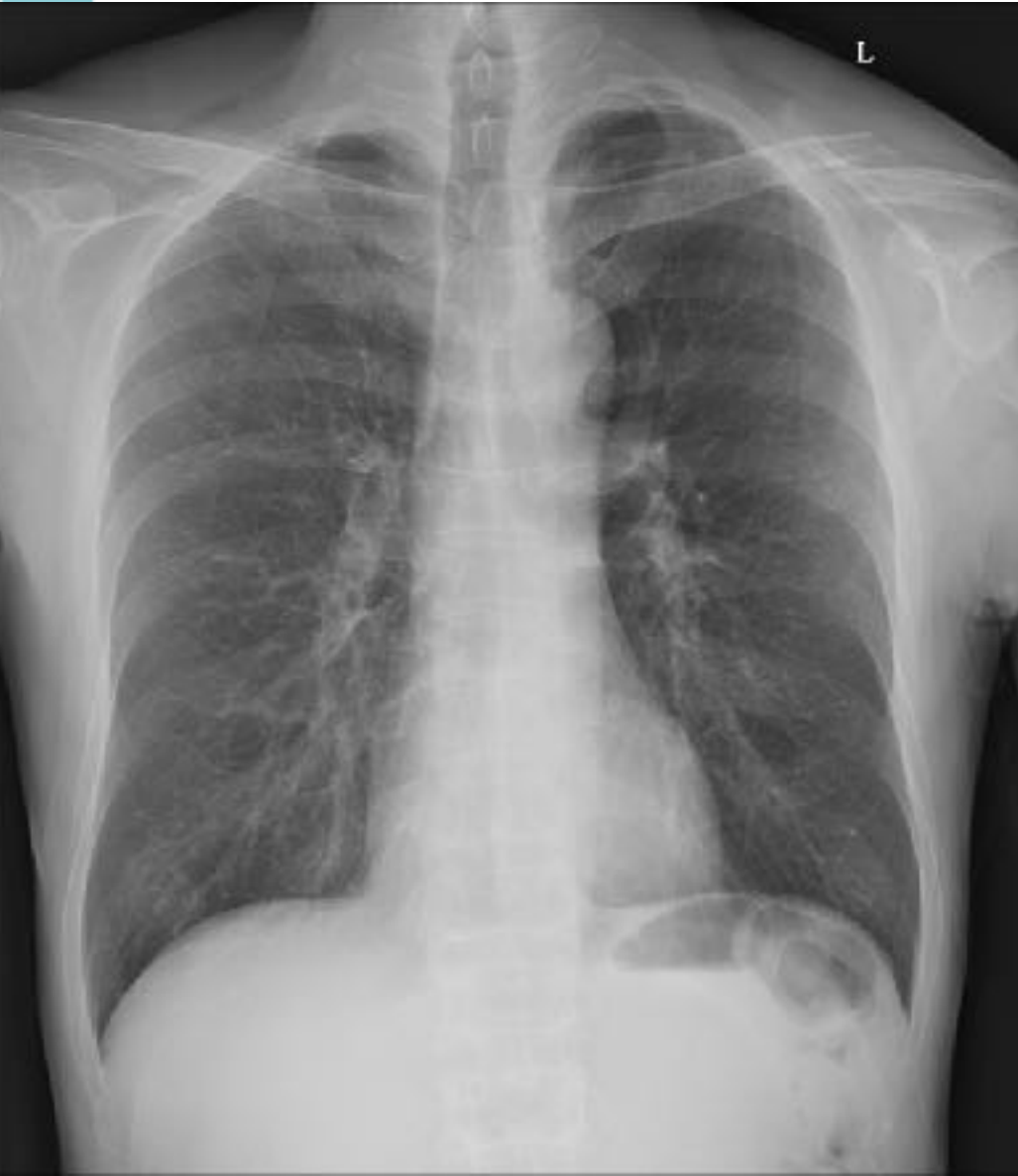人生成就達成
身為一位保養維修員
下班在家也不忘修東修西
重點溜手後還不忘在地上找螺絲
(家裡有小孩)
找著找著居然發現螺絲在...
居家附近診所請我找外科
去雙和急診3位醫生湊過來研究這手指頭
X光照外加超音波還是無法判斷
最後來招水中超音波
終於判定閃過骨頭



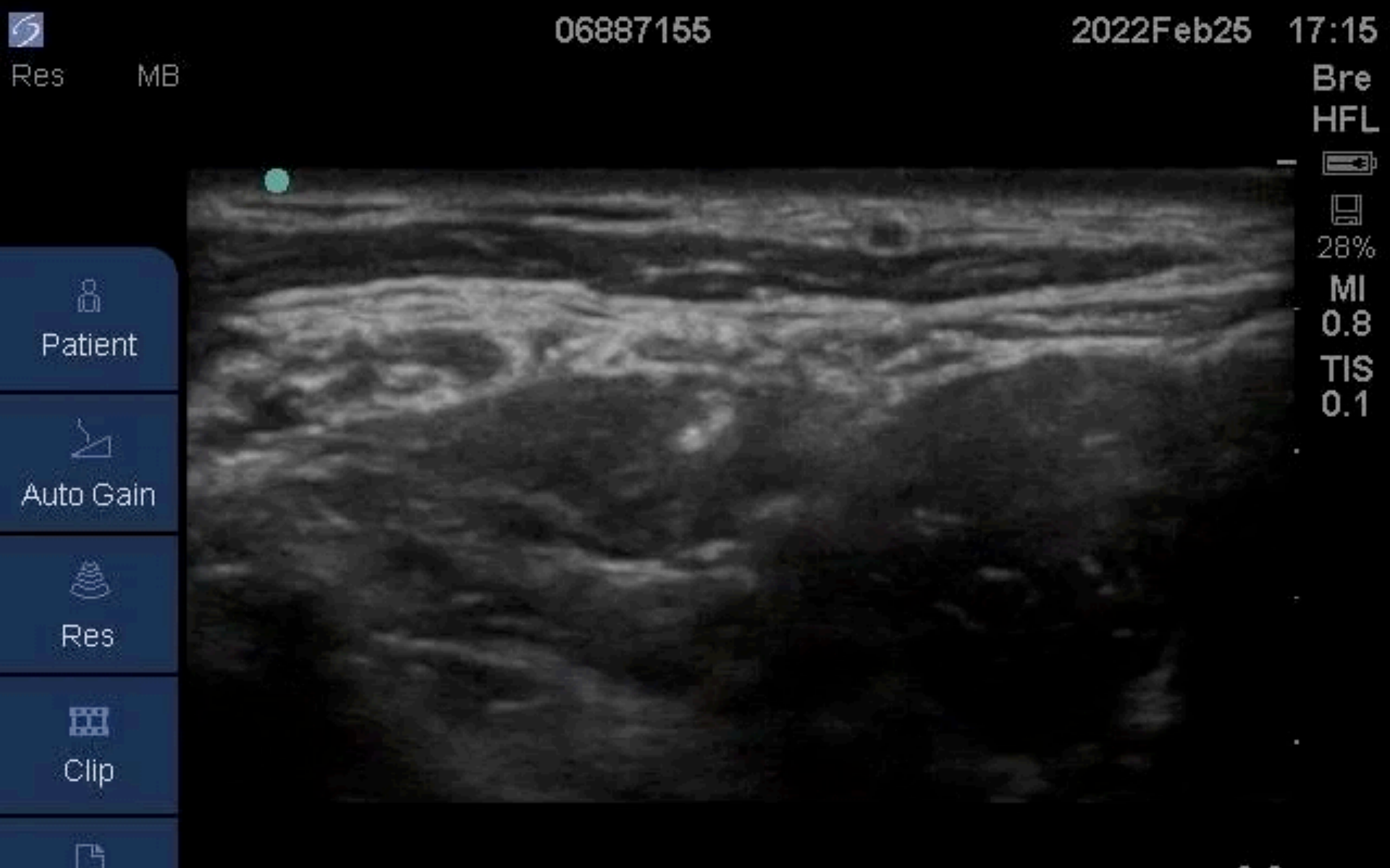36M, penetrating injury



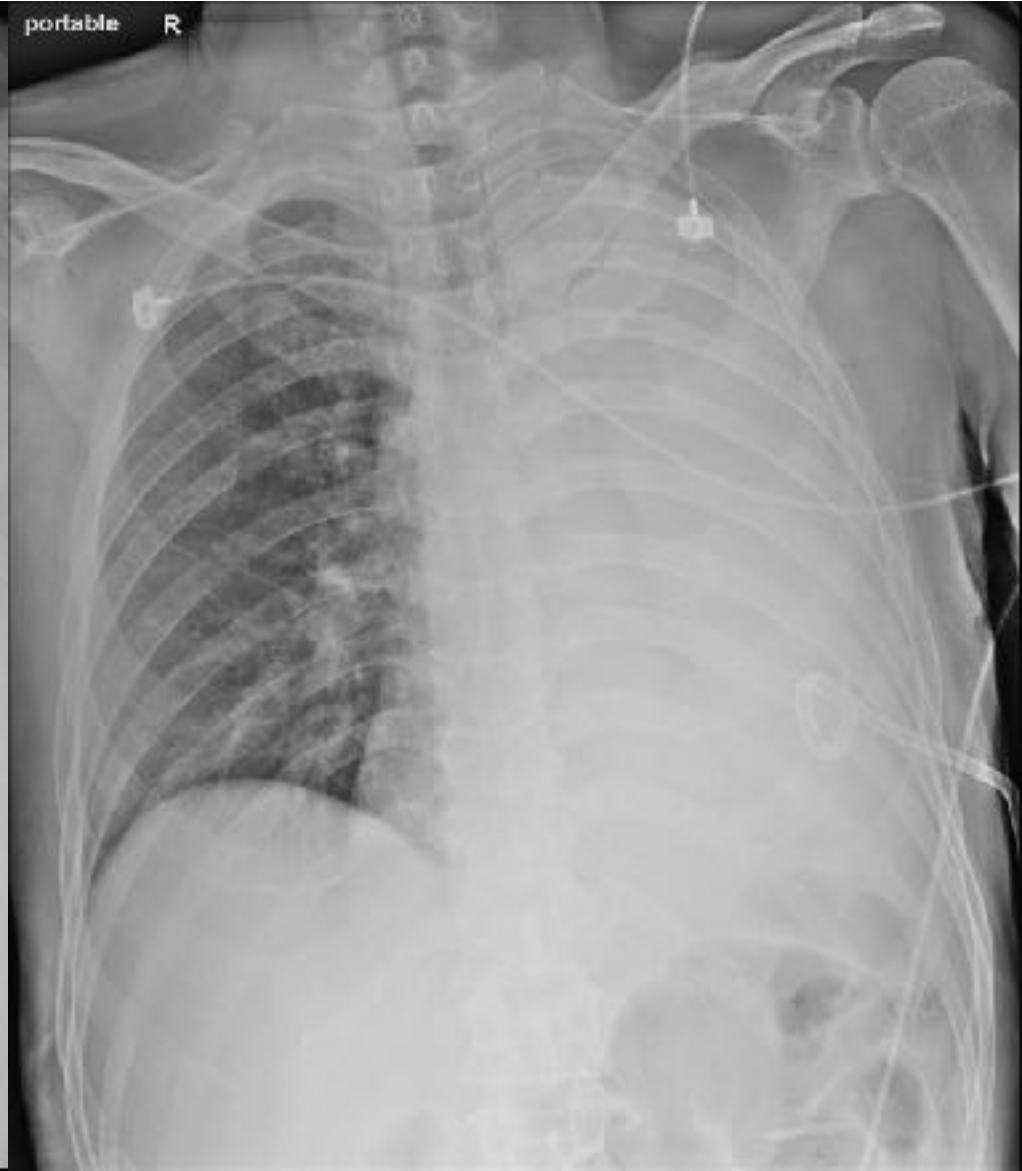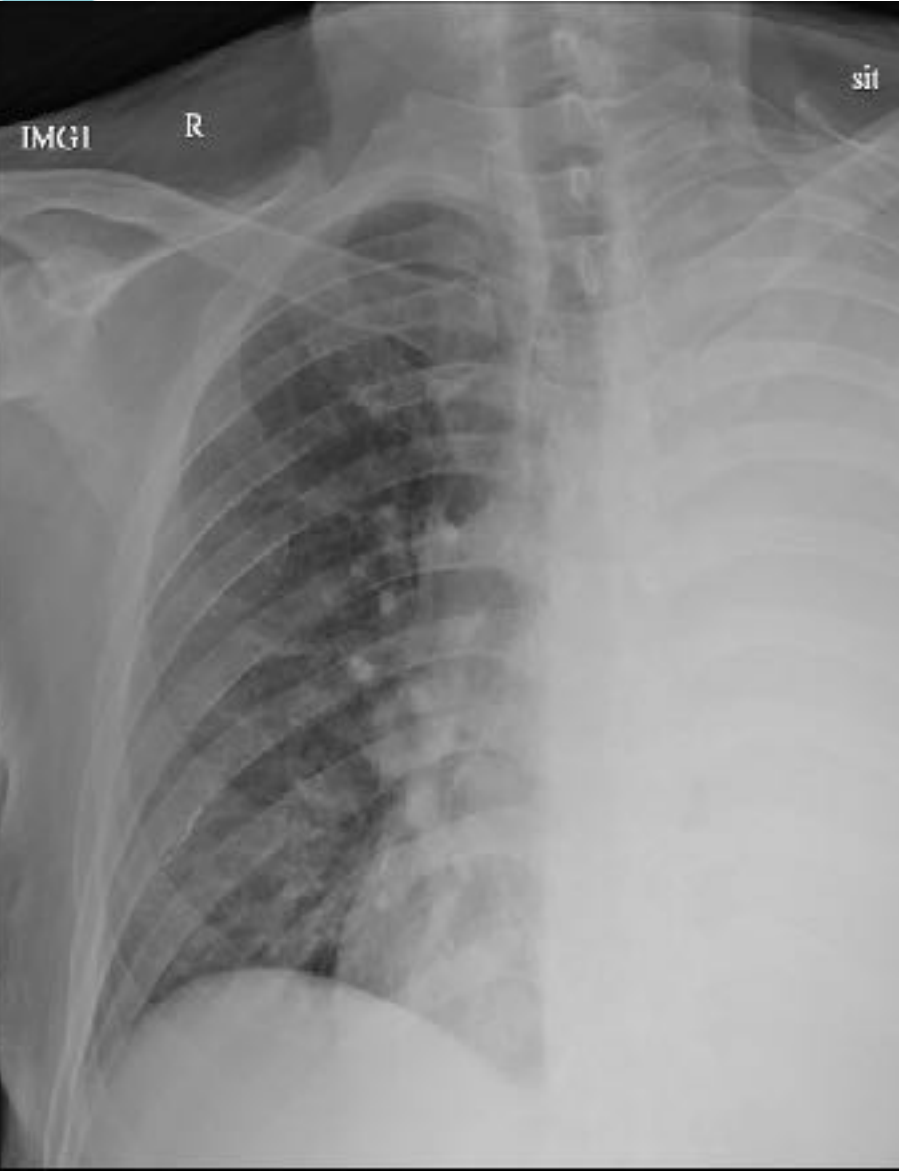55M, left clavicle fracture



Superficial cervical plexus block



59F, DM, Uremia on HD, Fever



59F, DM, Uremia on HD, Fever



TIS: 0.01, MI: 0.38, Abdomen

B

1
2
3
4
5
6
7
8
9
10
11
12
13
14
15
16
17
18
19
20

TIS: 0.01, MI: 0.38, Abdomen

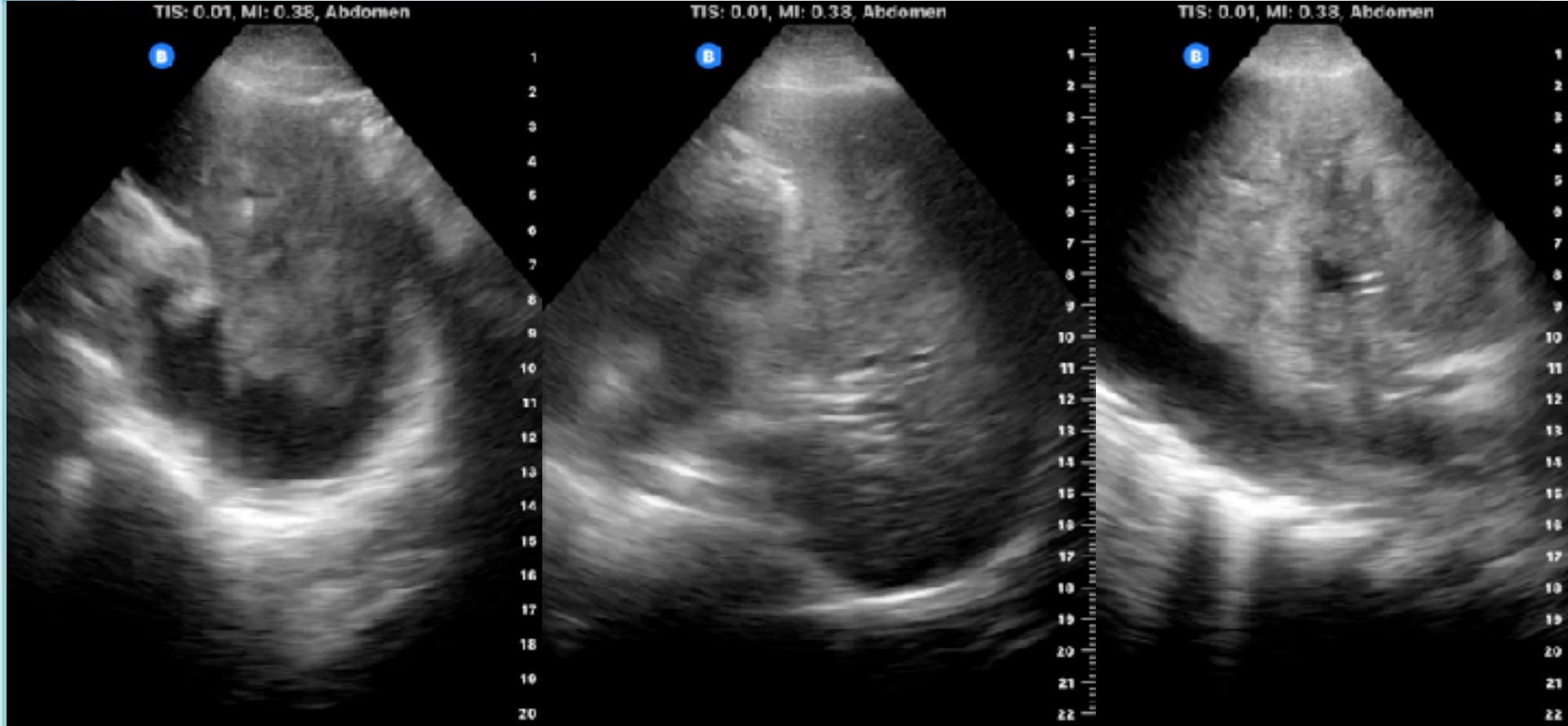
B

1
2
3
4
5
6
7
8
9
10
11
12
13
14
15
16
17
18
19
20
21
22

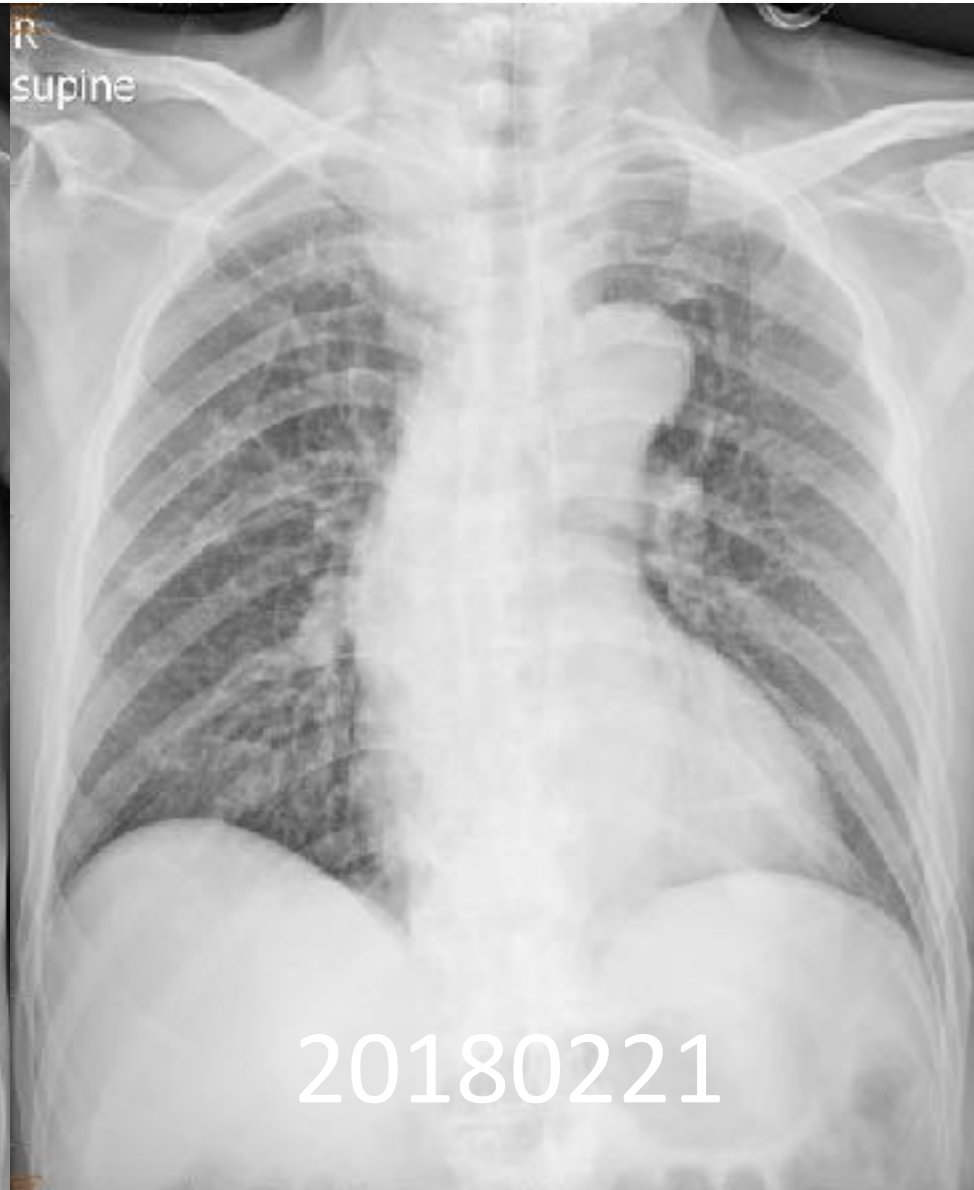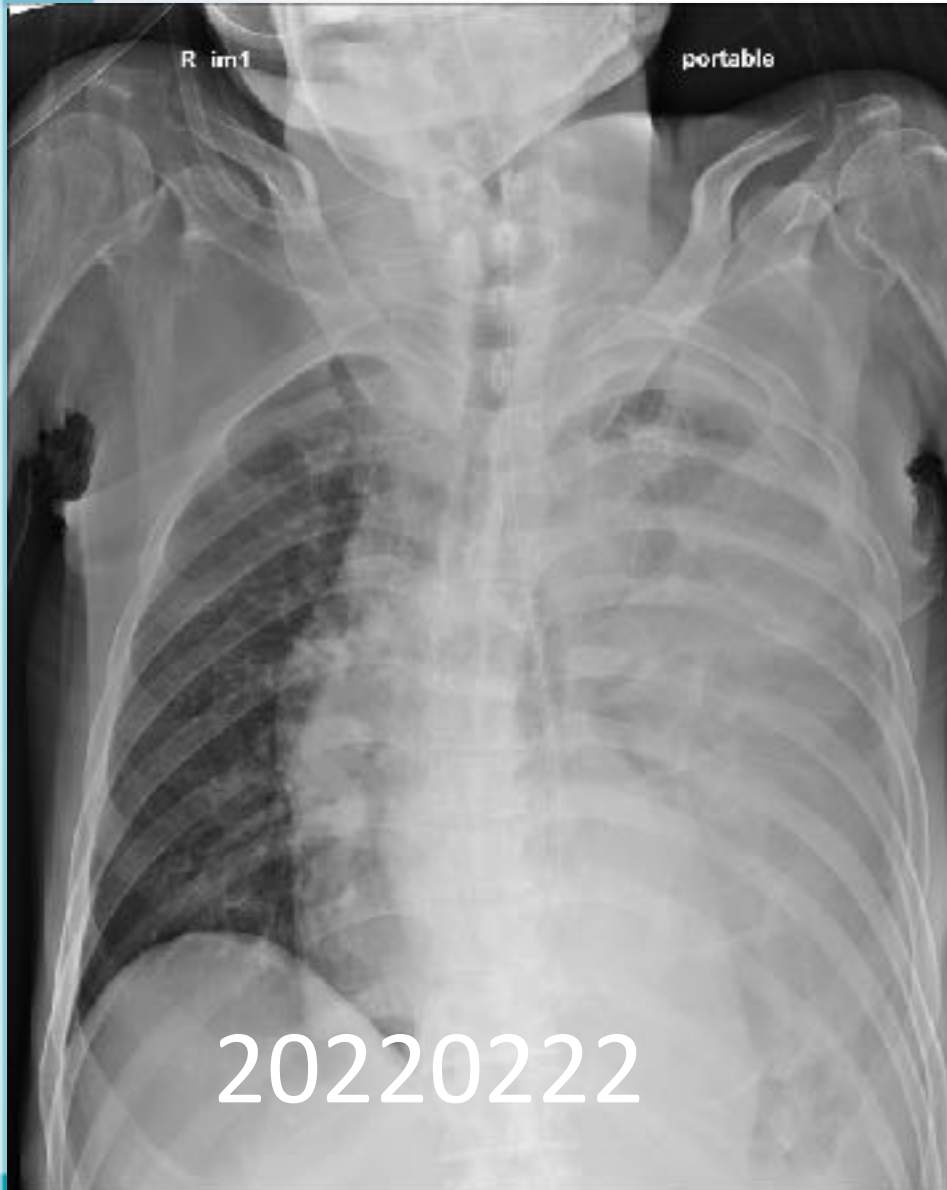TIS: 0.01, MI: 0.38, Abdomen

B

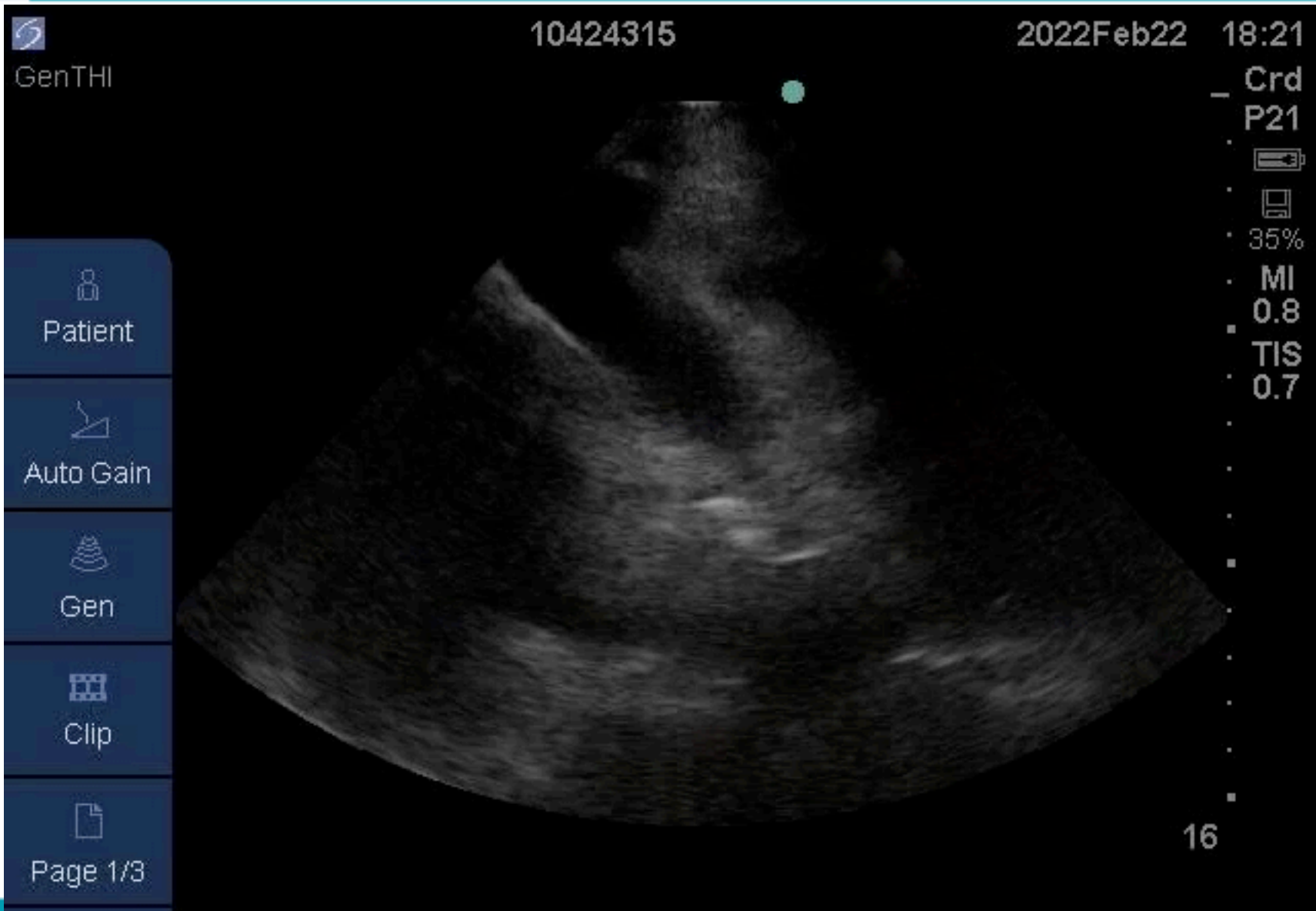1
2
3
4
5
6
7
8
9
10
11
12
13
14
15
16
17
18
19
20
21
22




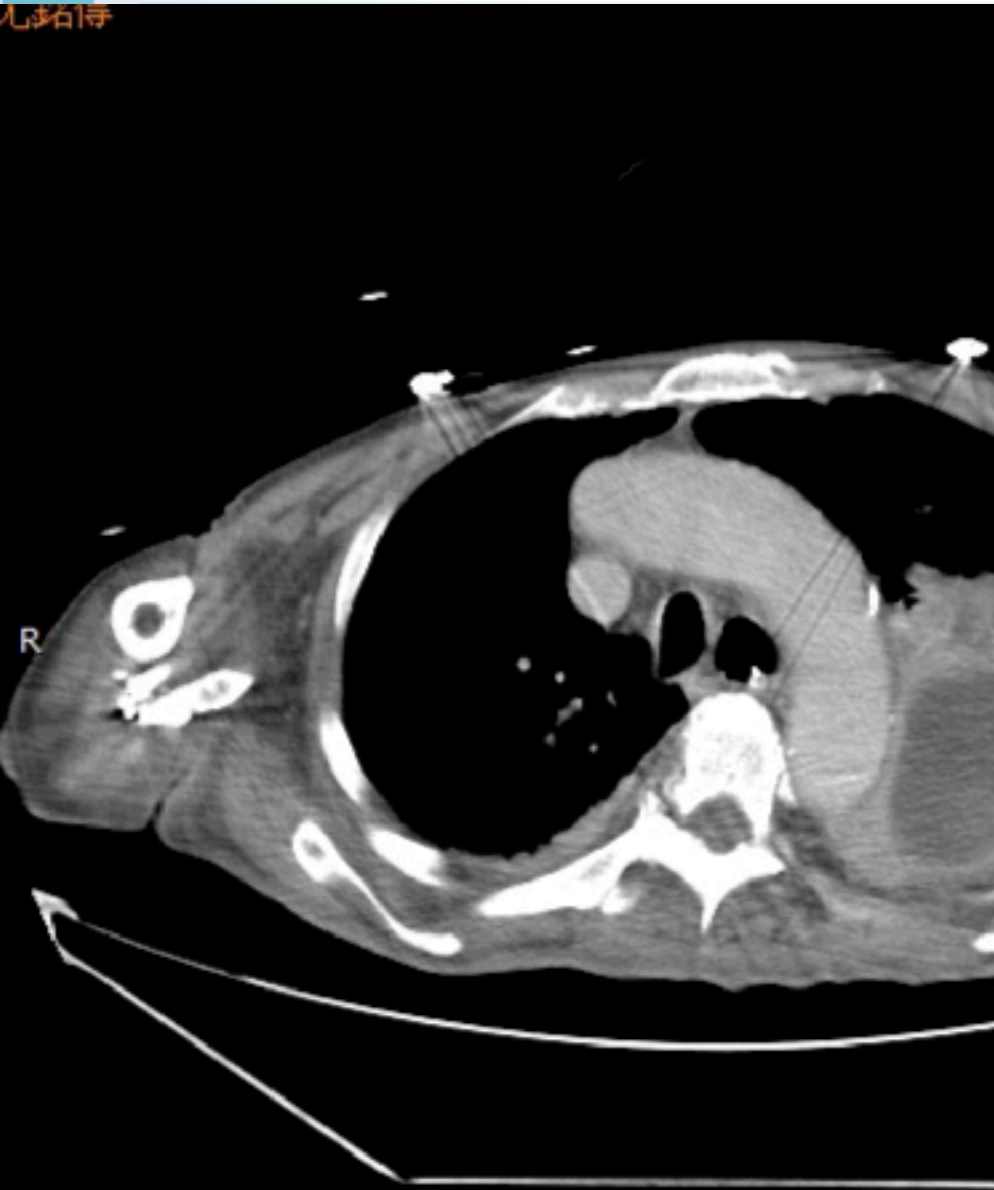
73M, Dyspnea & shock



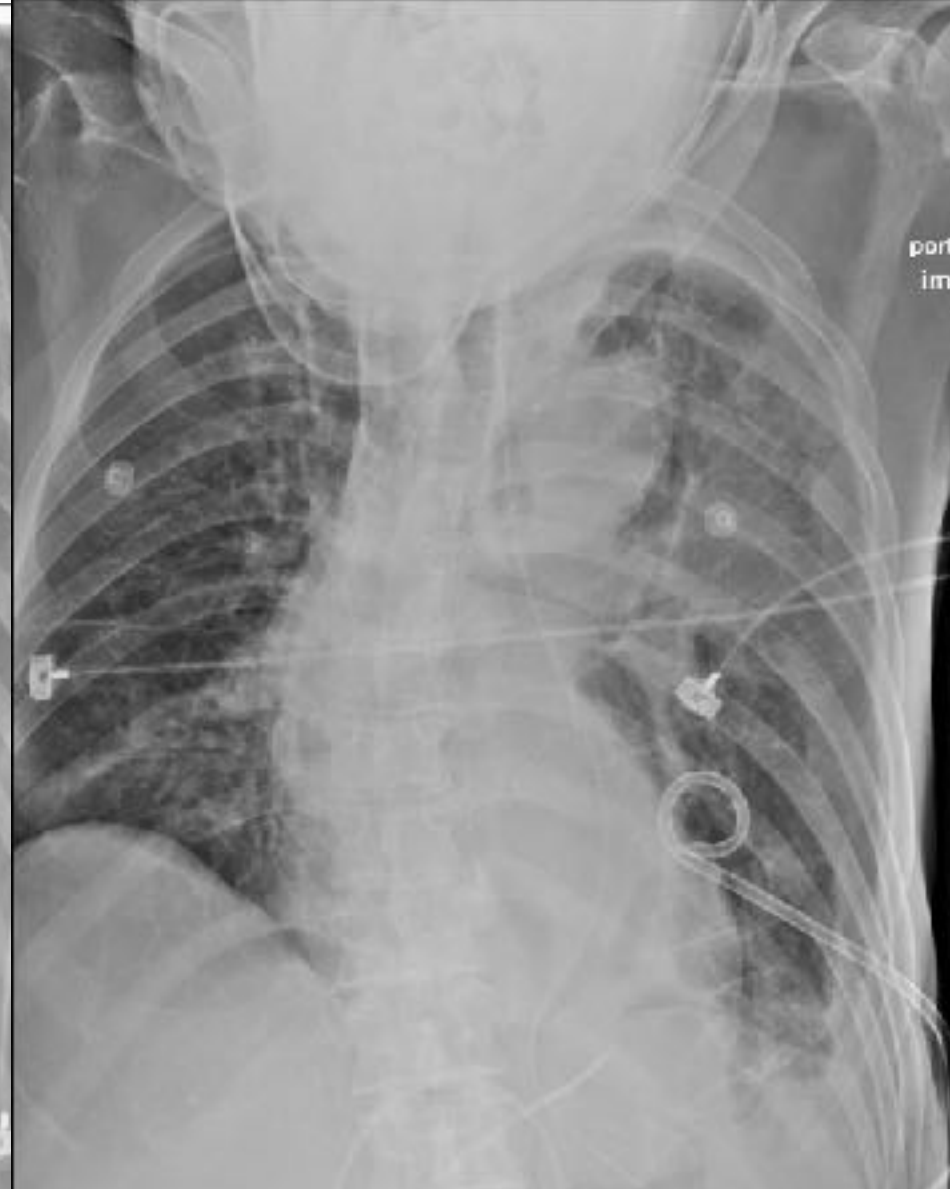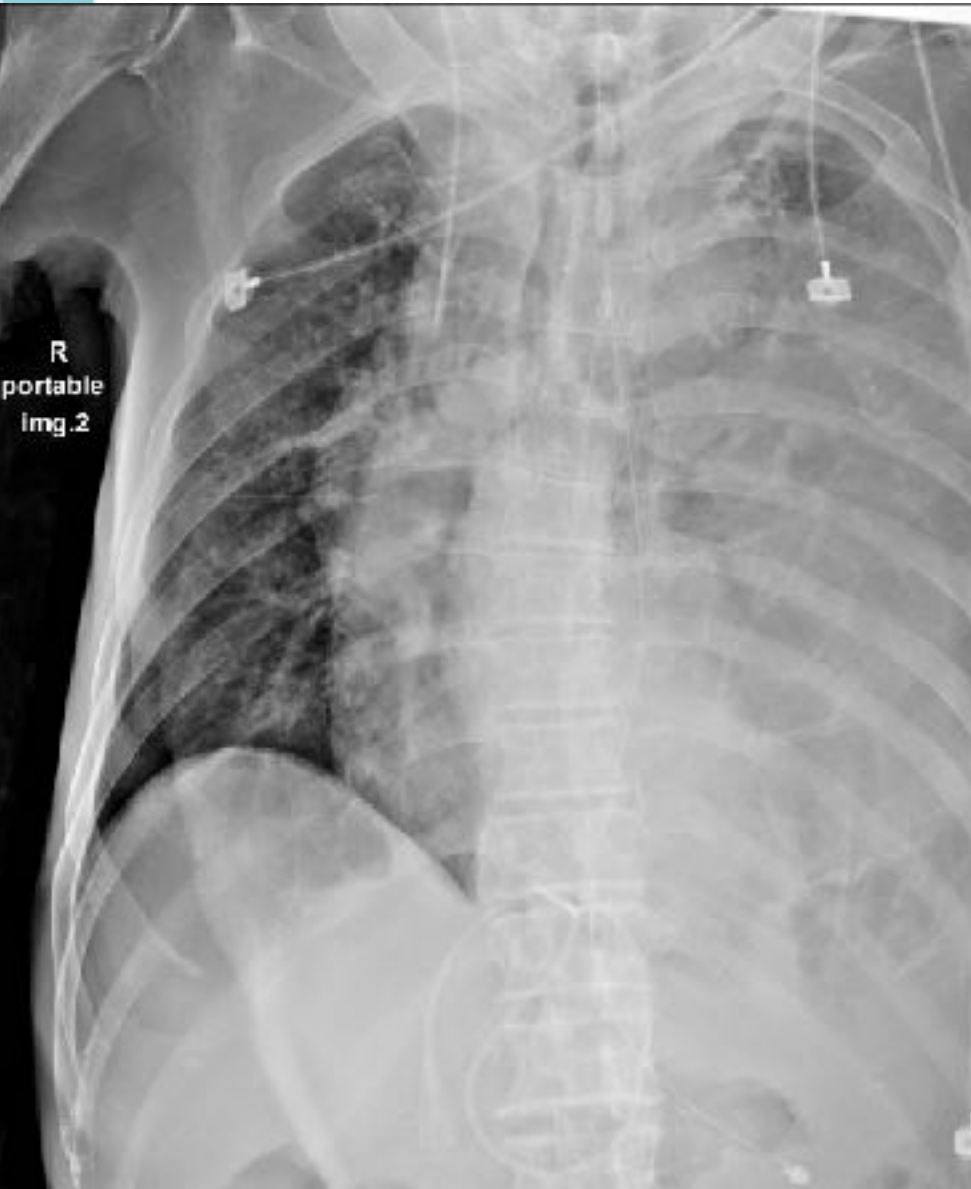Pericardiocentesis 160 ml (CVC)



Empyema



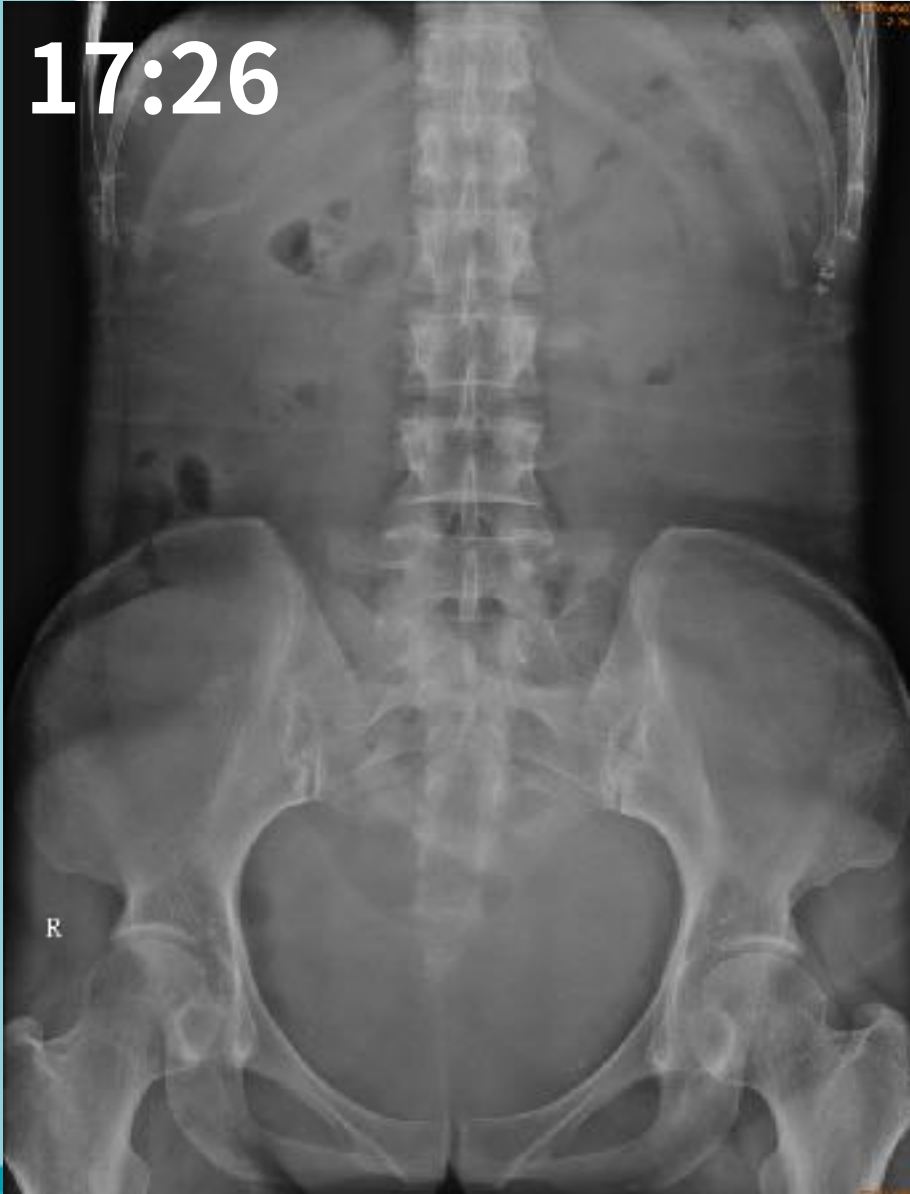Empyema drainage 1500ml



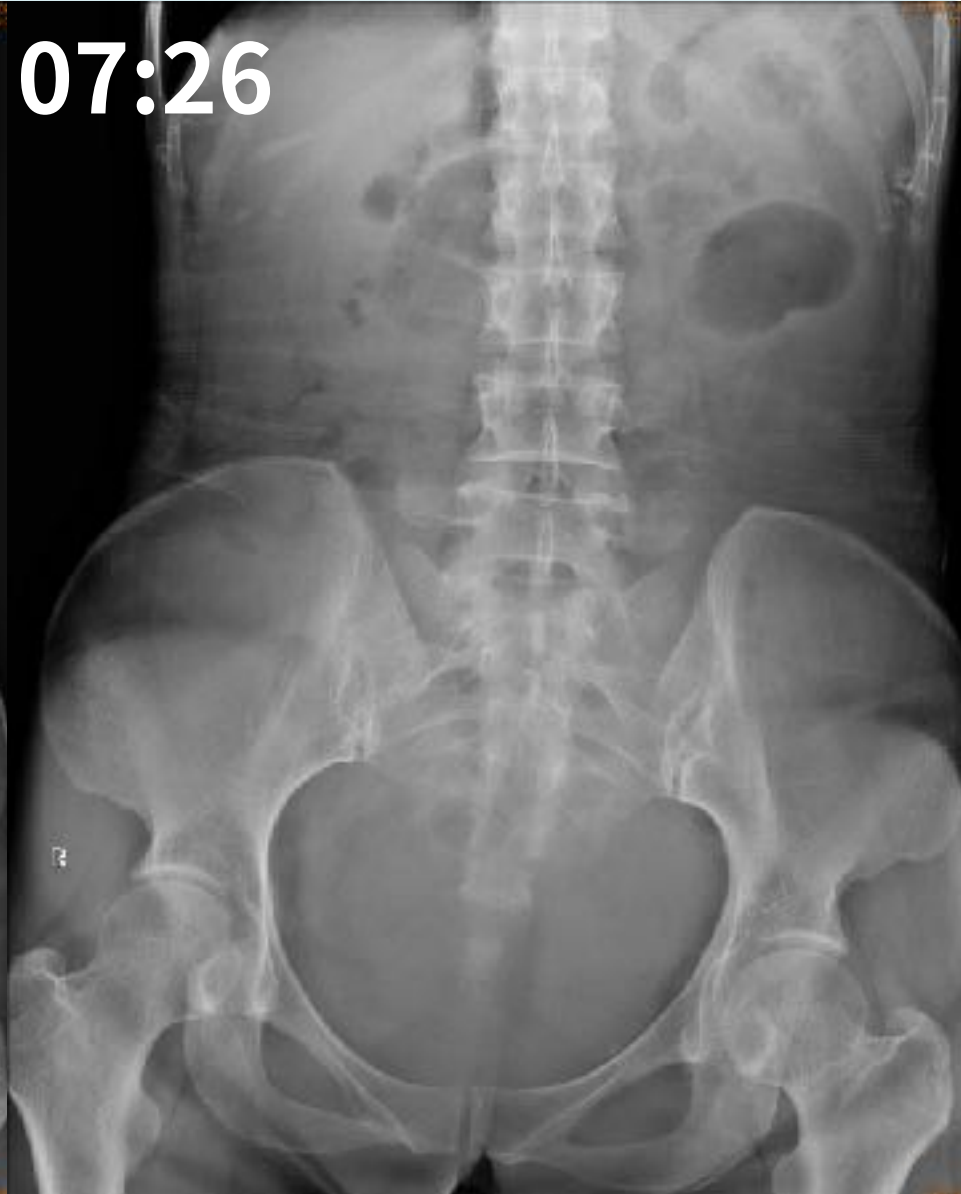44F, Adhesion ileus



17:26



07:26





44F, Adhesion ileus

02615442 2022Feb20 17:01

GenTHI MB

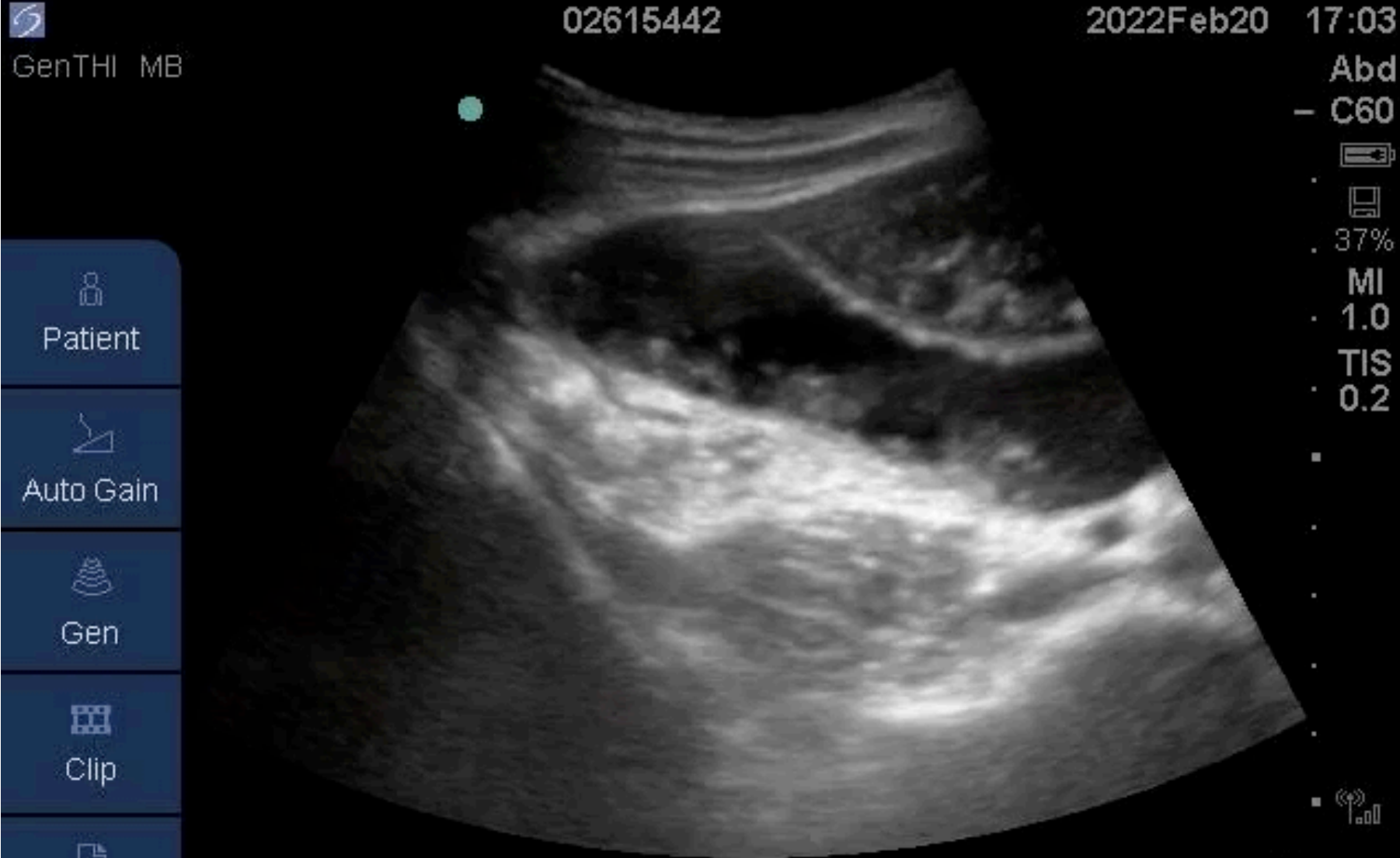
Abd
- C60
37%
MI 0.7
TIS 0.1

15

Patient
Auto Gain
Gen
Clip
Page 1/3



44F, Adhesion ileus



02615442

2022Feb20 17:03

GenTHI MB

Abd

- C60



37%

MI

1.0

TIS

0.2



Patient



Auto Gain



Gen



Clip



Page 1/3



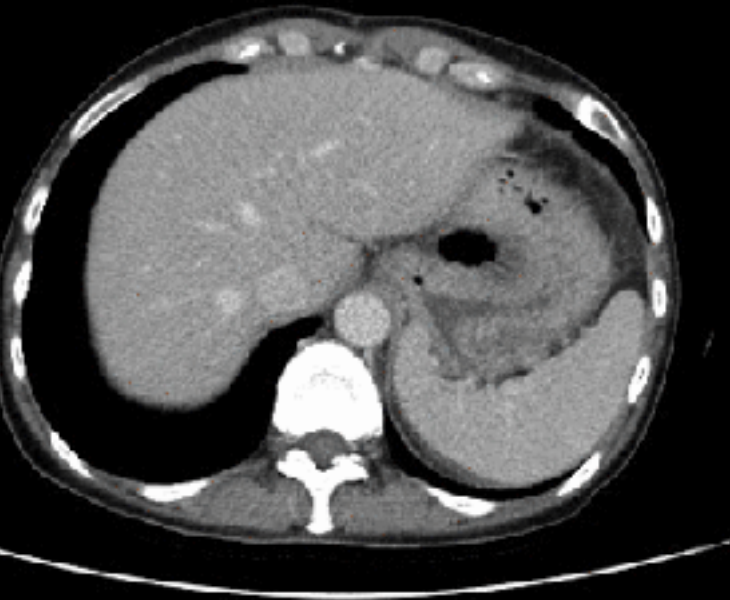44F, Adhesion ileus



STEMS

A

E MEDICAL SYSTEMS



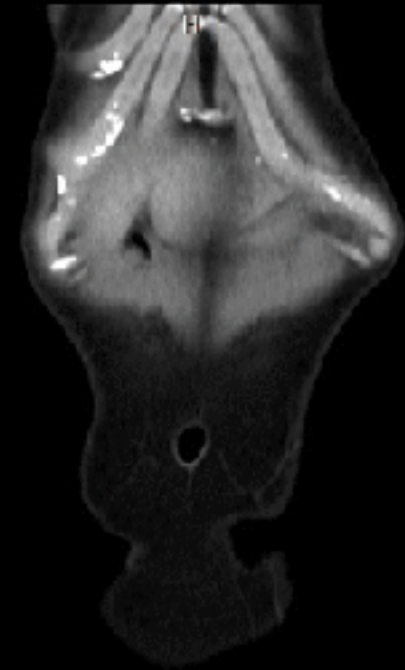
L

R

P

醫學部 放射科

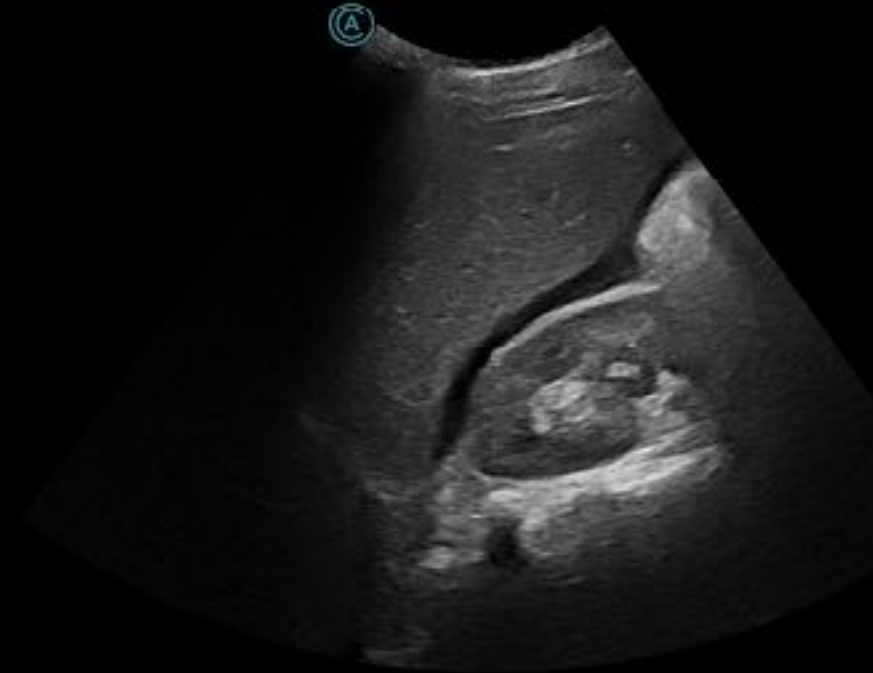
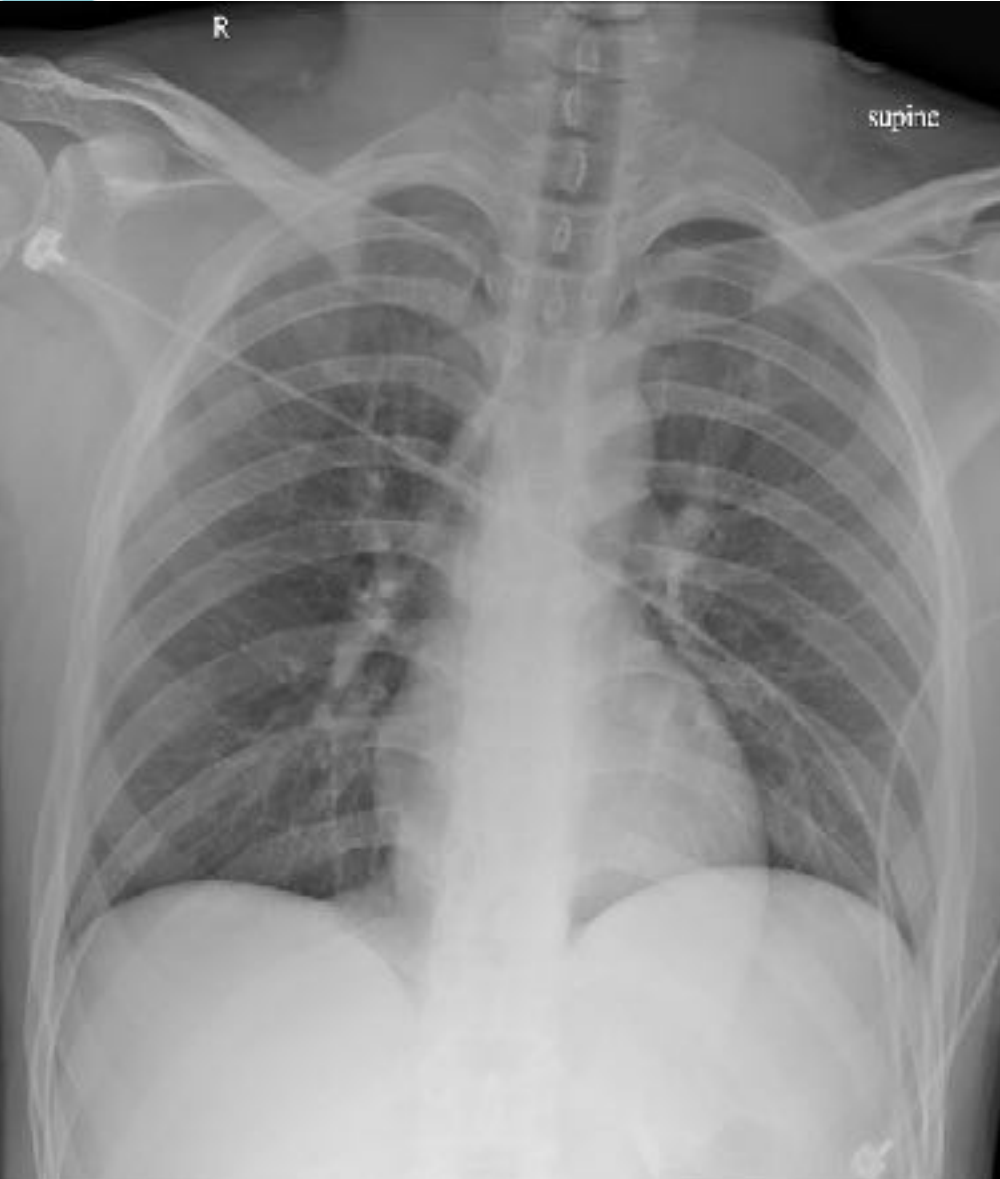977/10/16

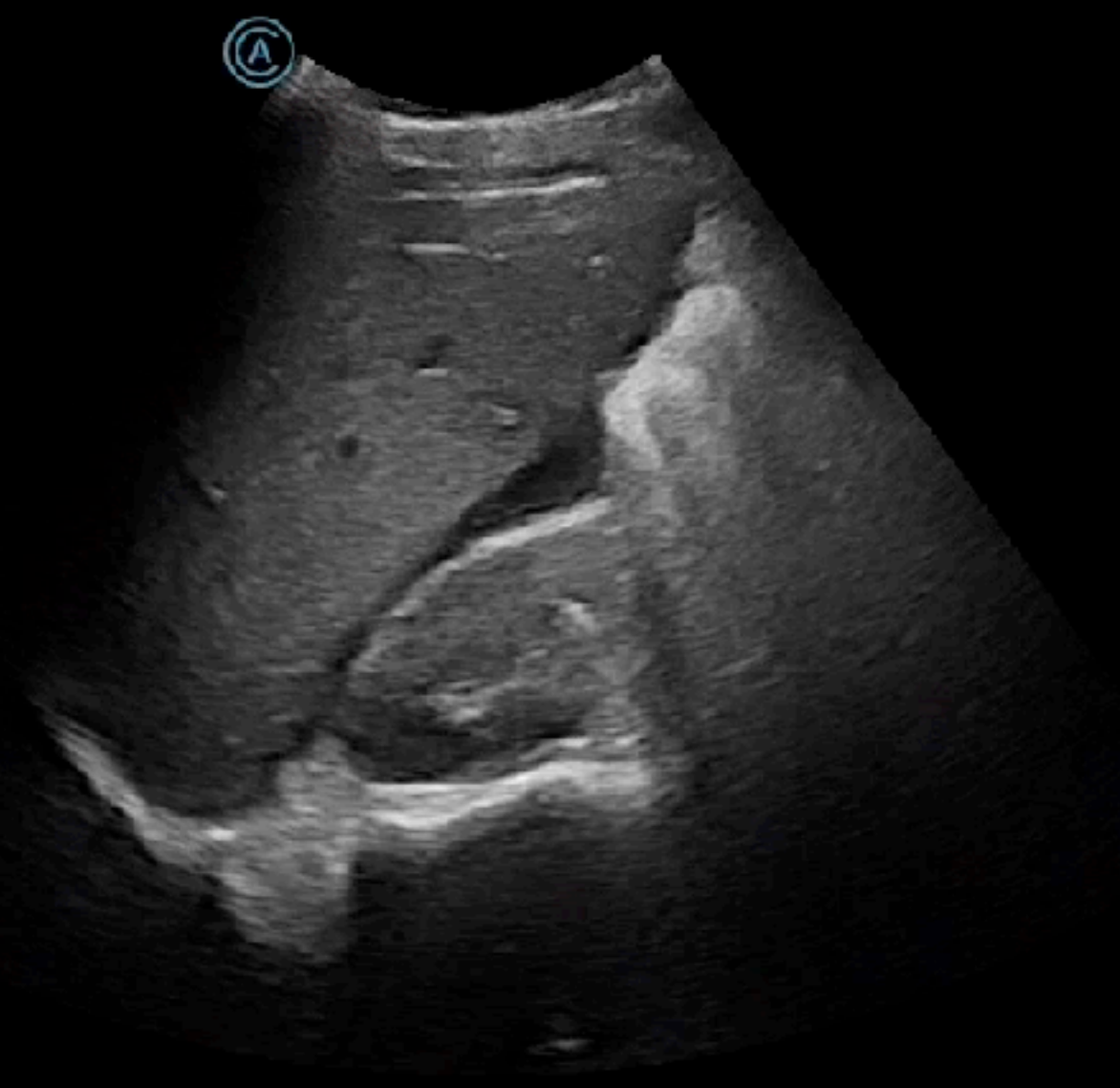


F

醫學部 放射科

23M, trauma with abdominal pain

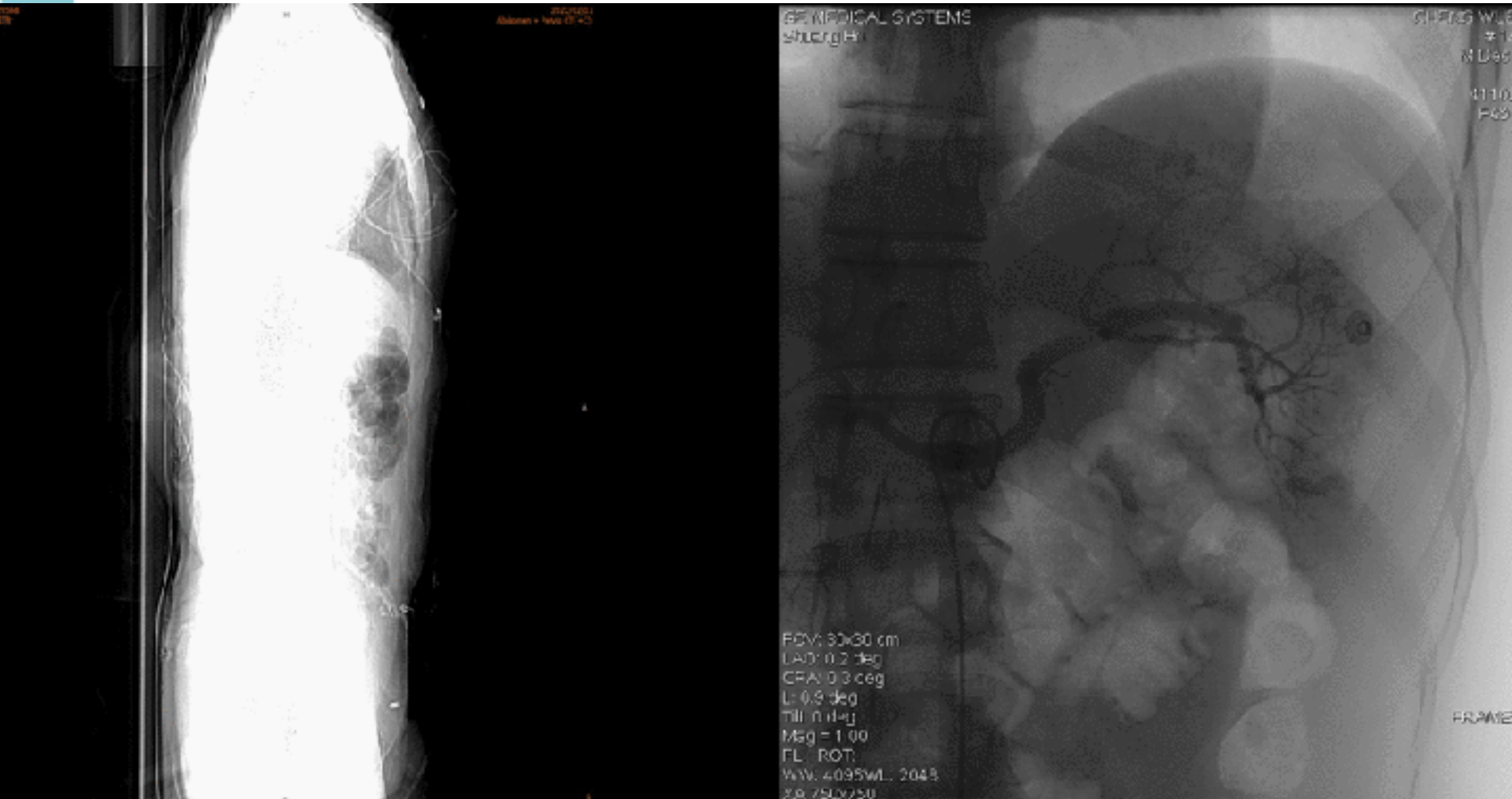



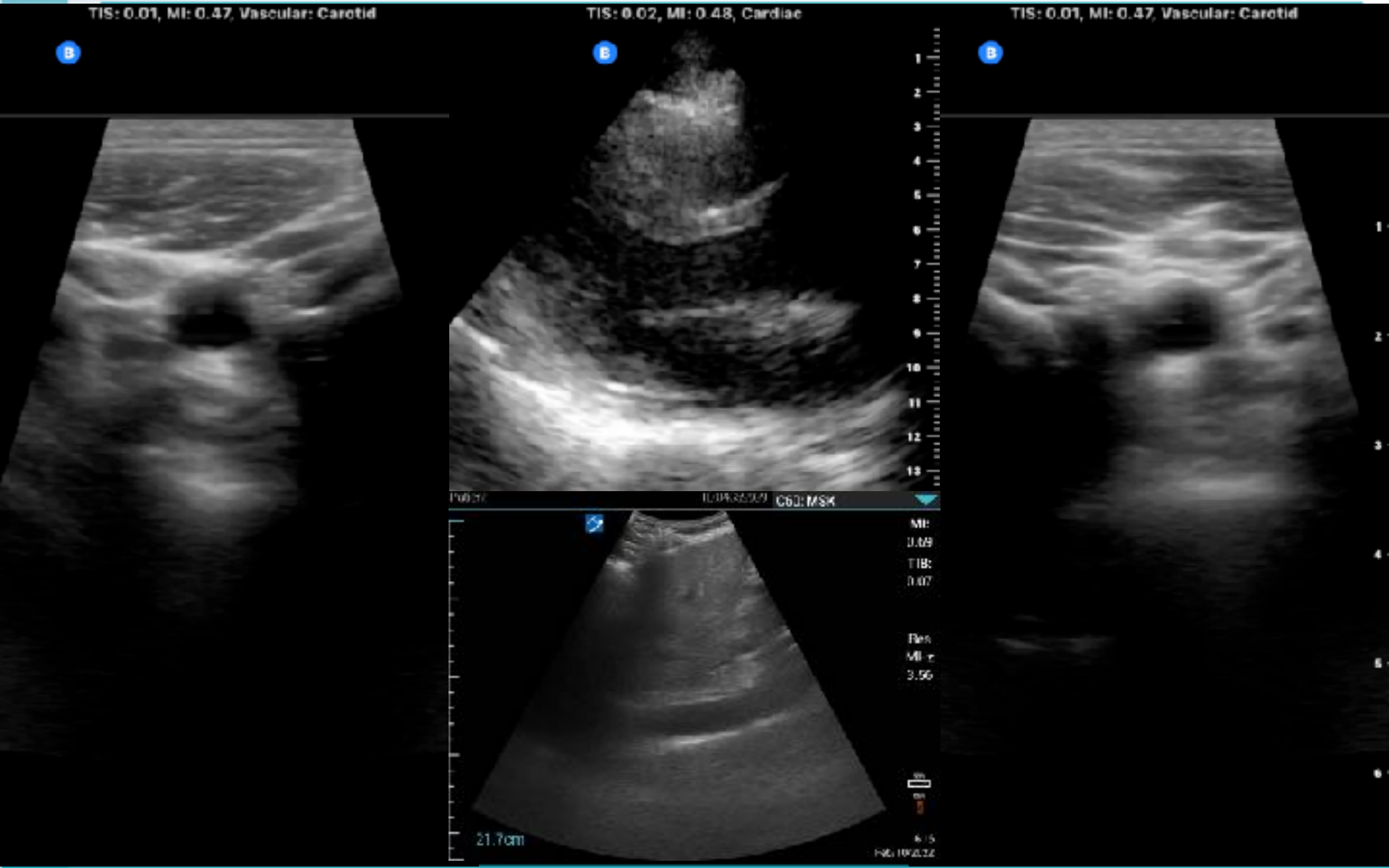
0.4
Prese
èß
FP
60.0
Dept
16.0
Gai
50.0
Powe
M
PR
0.0



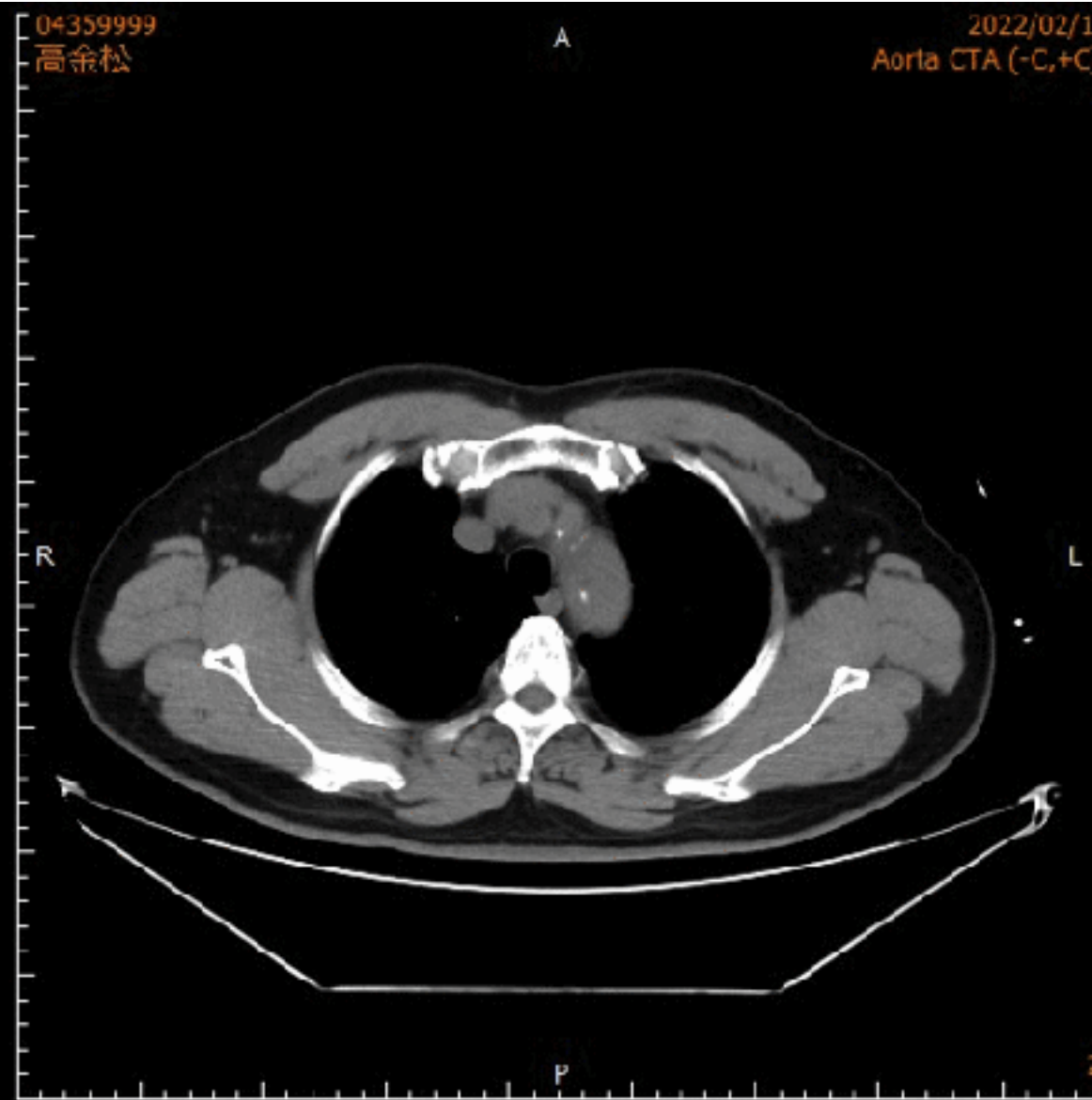
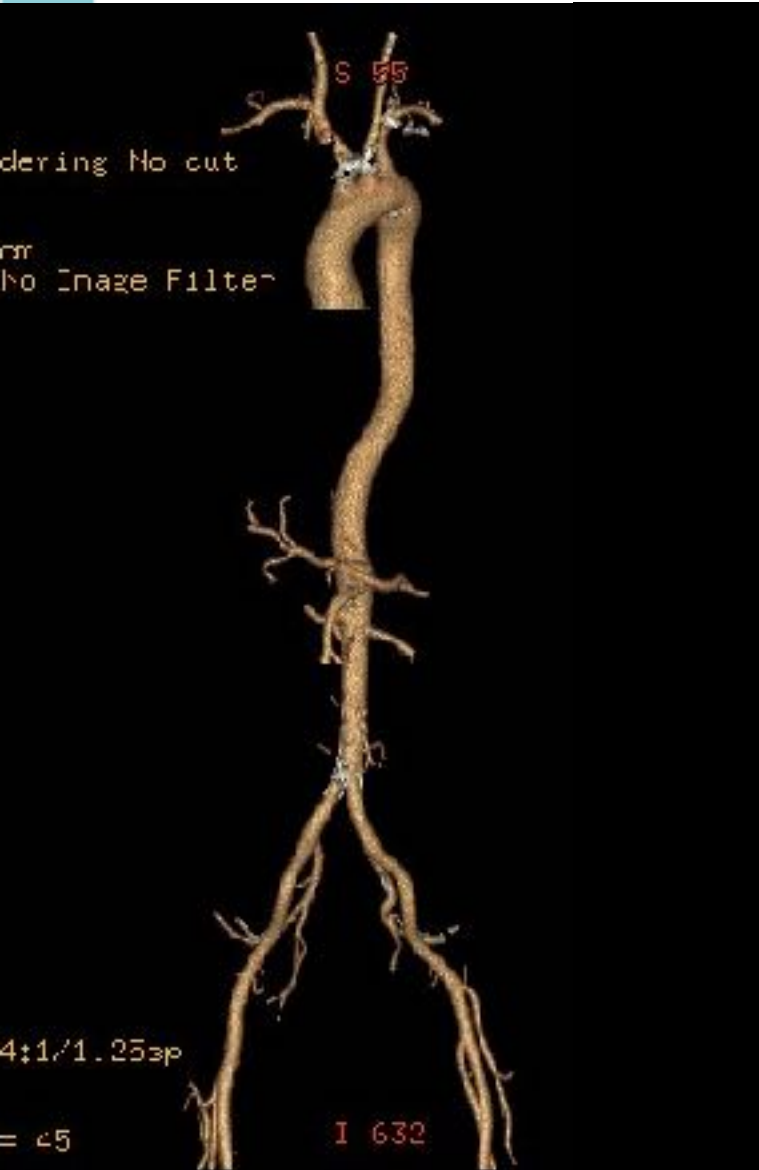Splenic laceration & TAE



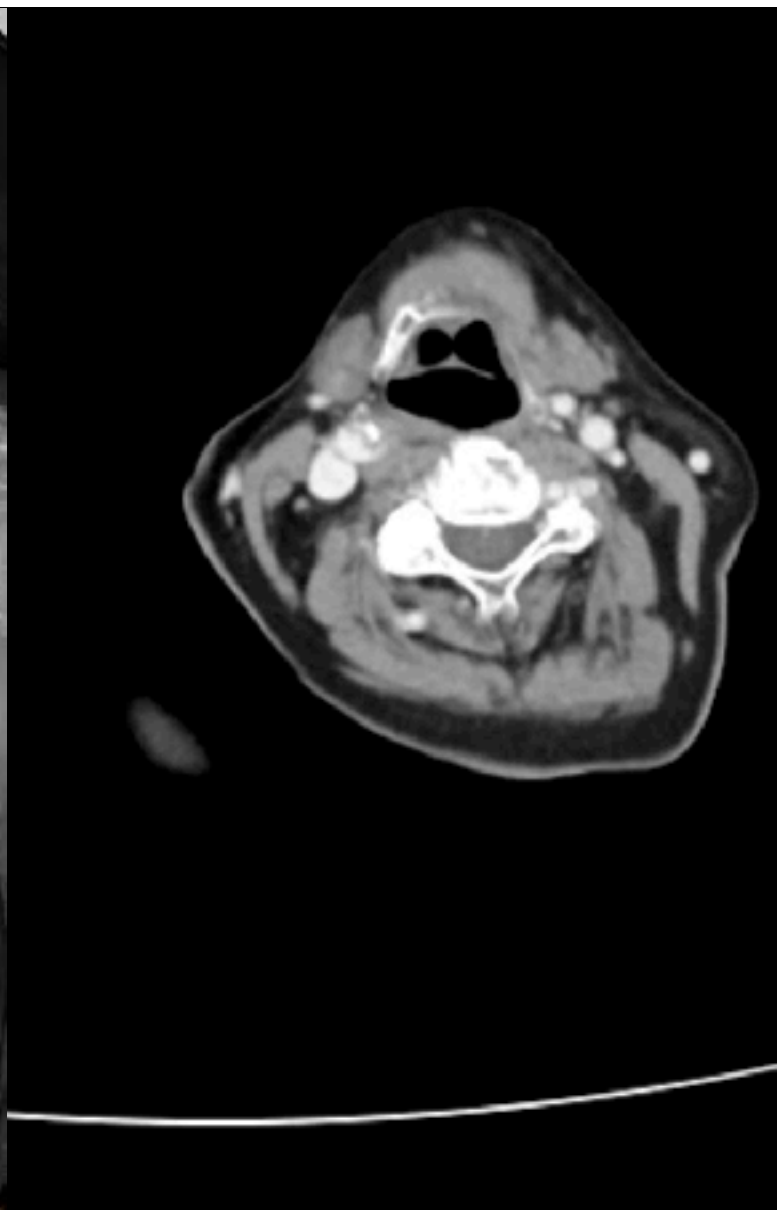
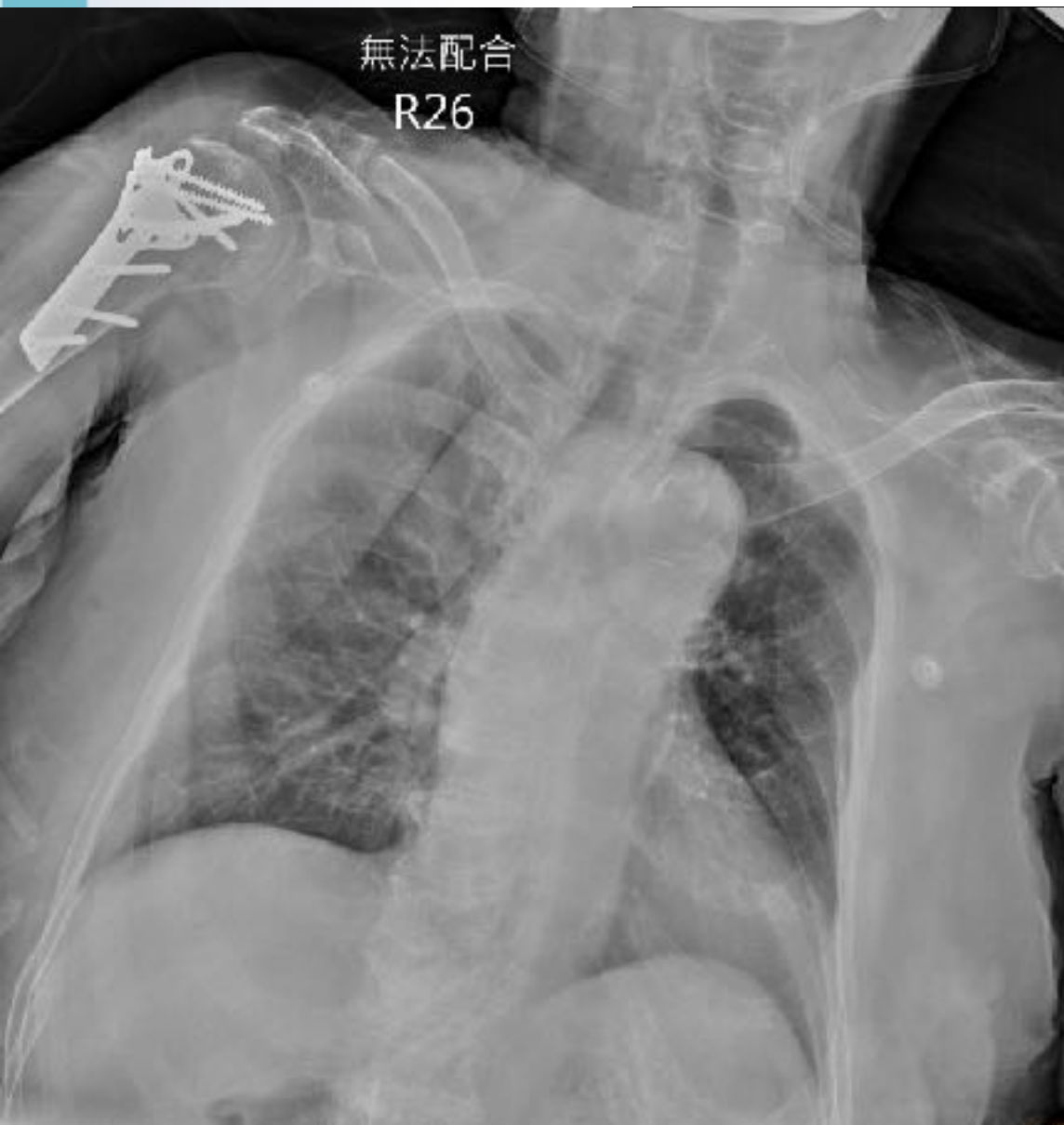54M, chest pain & back pain



54M, chest pain & back pain



79F, syncope at home



79F, syncope at home



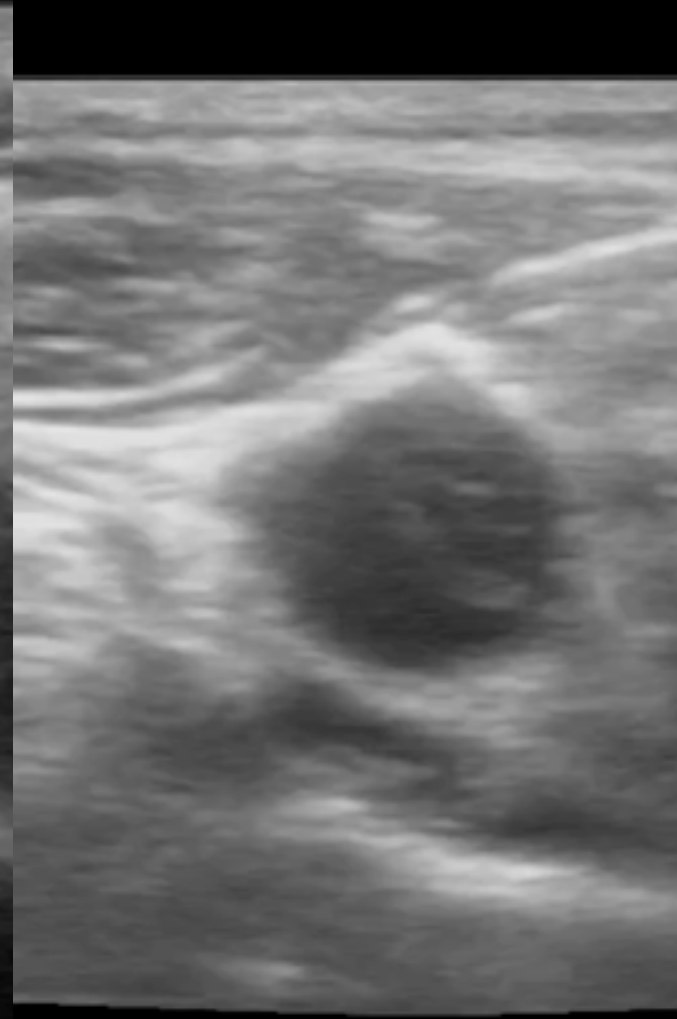
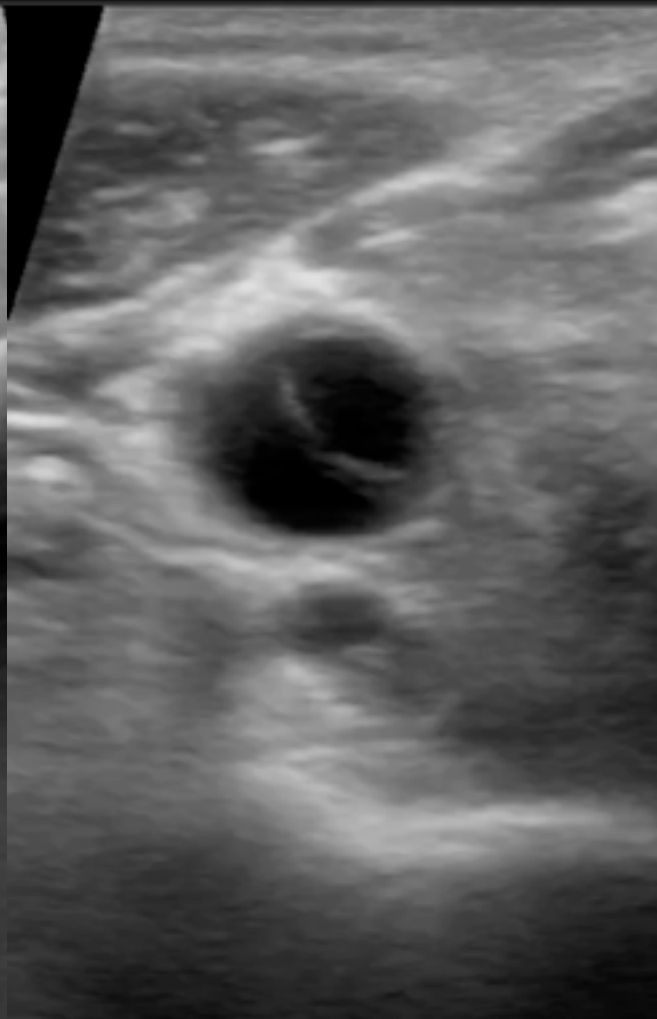
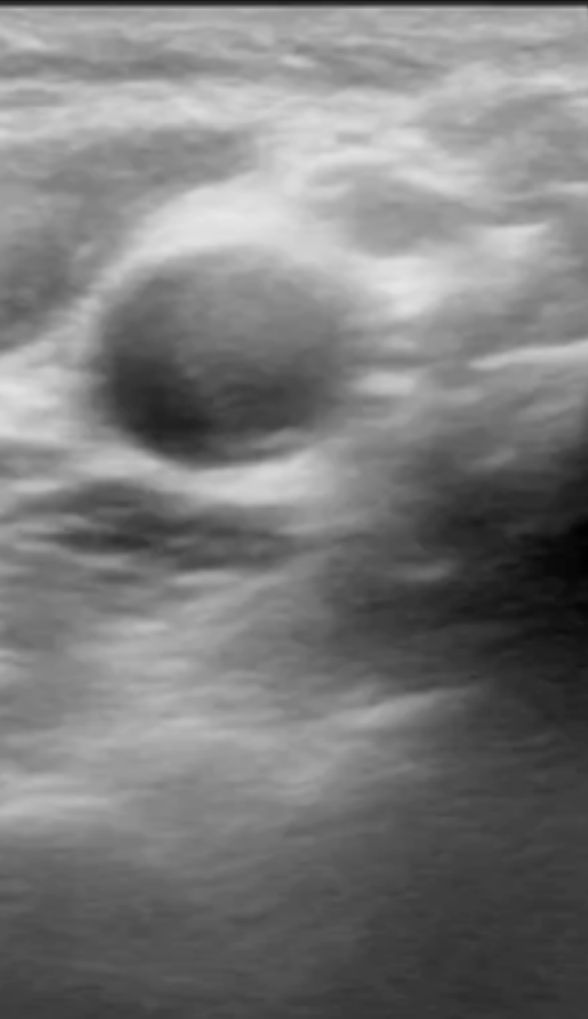TIS: 0.01, MI: 0.35, Vascular: Carotid

TIS: 0.01, MI: 0.35, Vascular: Carotid

TIS: 0.01, MI: 0.26, Vascular: Carotid

B

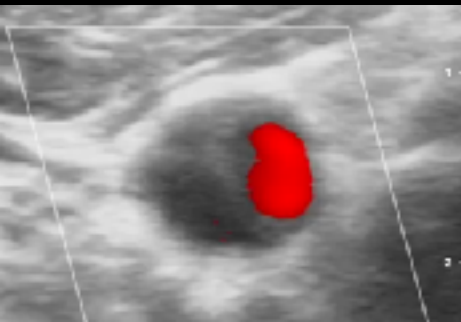
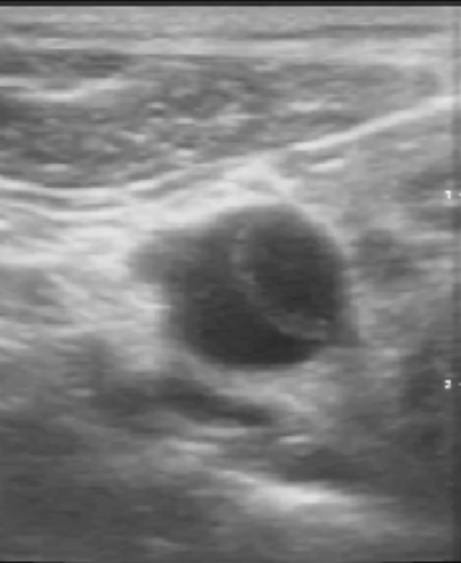
B



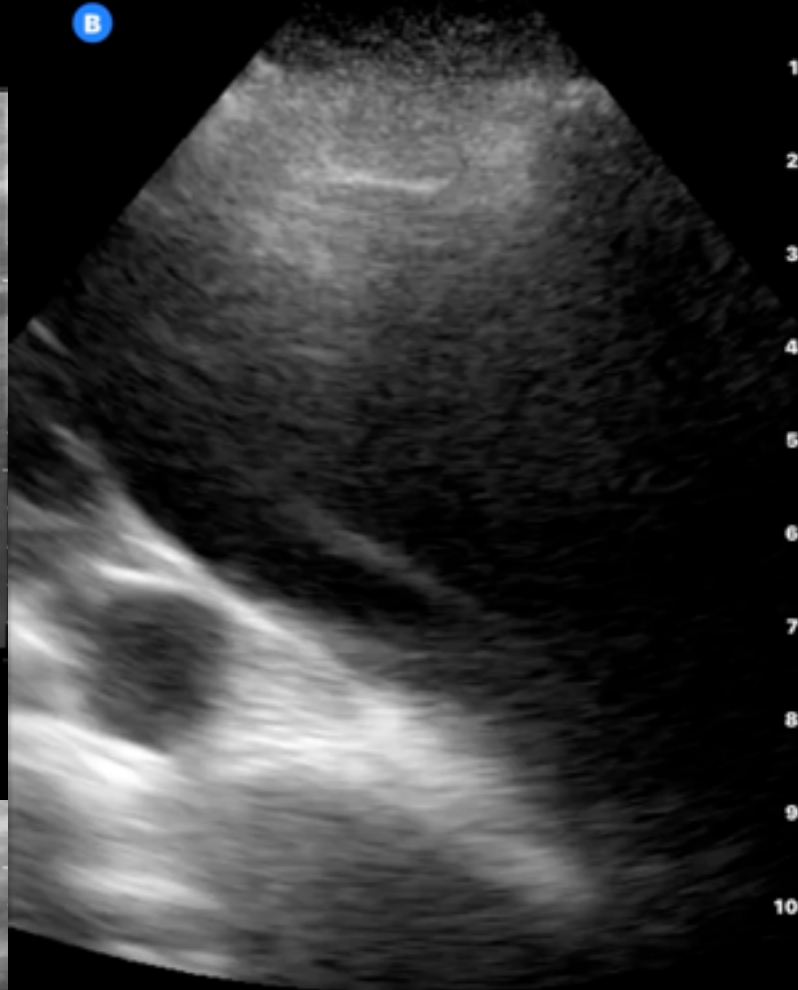
79F, syncope at home



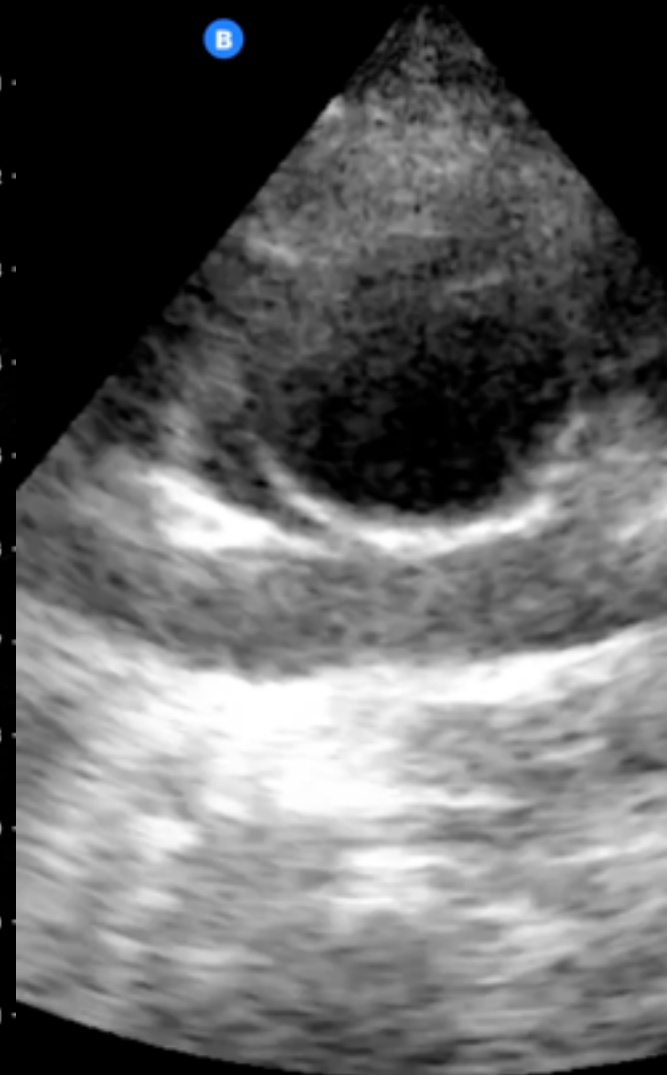
TIS: 0.01, MI: 0.26, Muscular Carotid



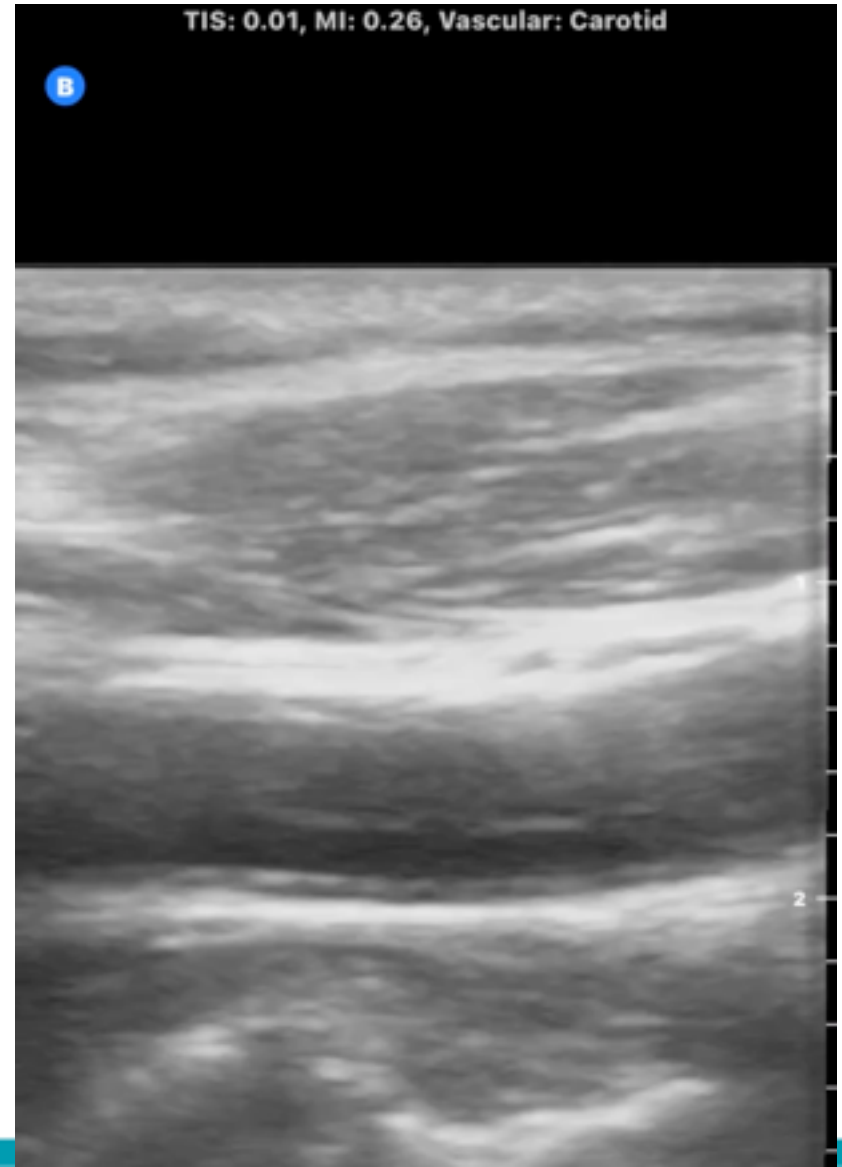
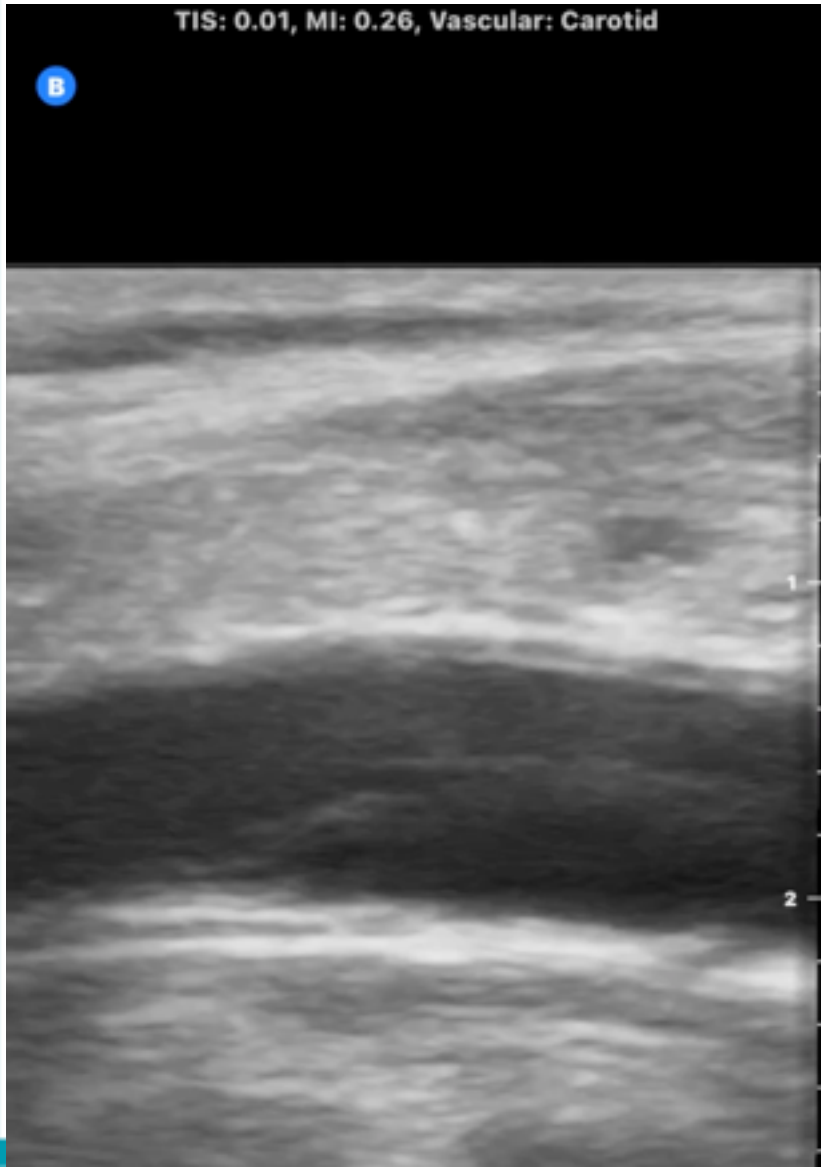
TIS: 0.01, MI: 0.4, Abdomen



TIS: 0.02, MI: 0.48, Cardiac



79F, syncope at home



55M, Chest pain 2H (BP 80/59)

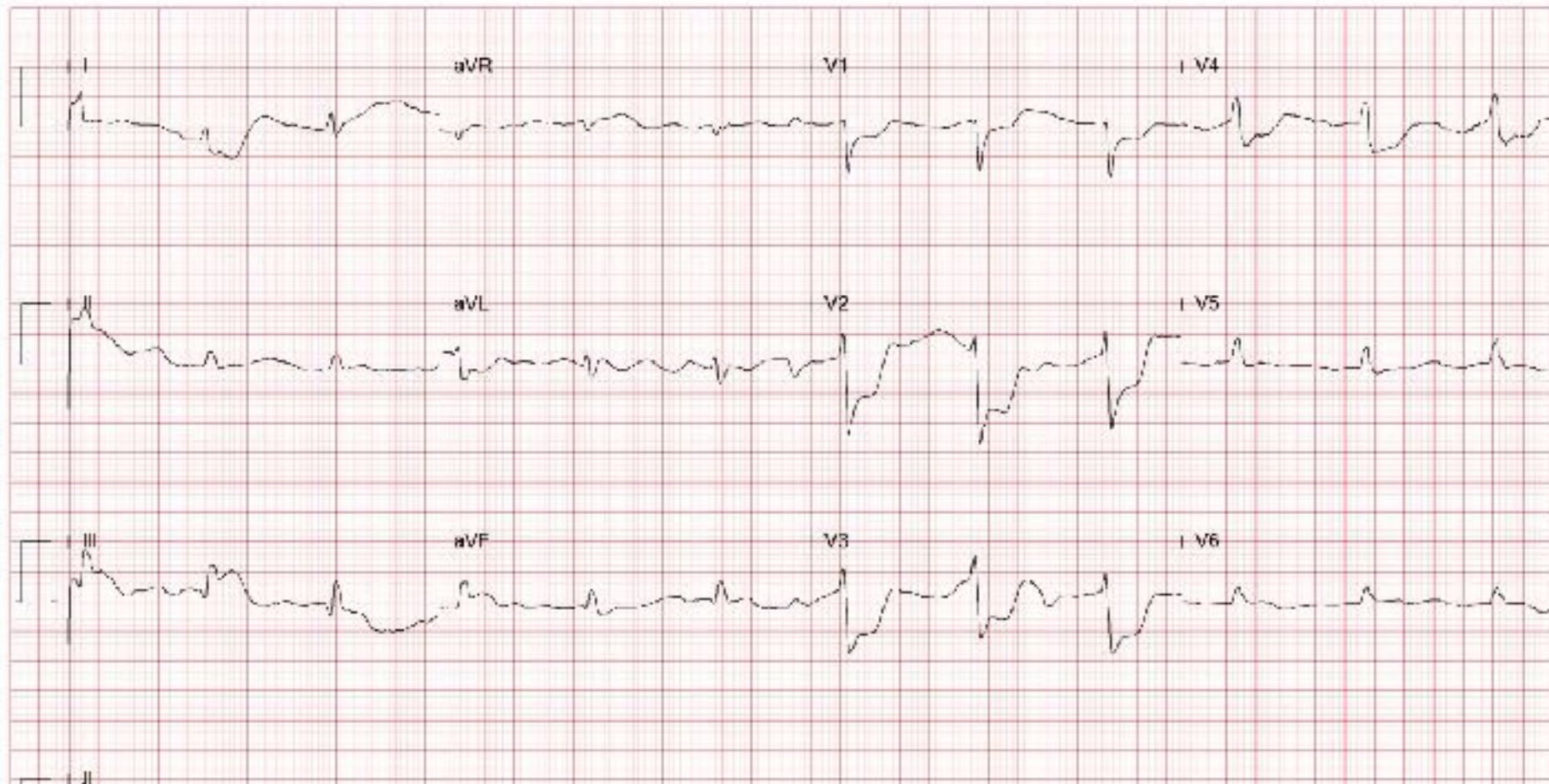


Patient ID: 14138647
Order Number:
Age:
Sex: O
Name:
Comment:

2022/02/19 07:45:24

Vent rate: 58 BPM
PR int: 287 ms
QRS dur: 129 ms
QT/QTc: 383 / 389 ms
P-R-T axes: -52 80 114

Age not entered, assumed to be 50 years old for purpose of ECG interpretation
Sinus or ectopic atrial rhythm...P axis (-45,135)
Prolonged PR interval...PR >210, V-rate 50-90
Nonspecific intraventricular conduction delay...QRSd >115ms, not LBBB/RBBB
Inferoposterior infarct, acute (RCA)...ST>.1 inf, <-.1 ant
Probable RV involvement, suggest recording right precordial leads
Baseline wander in lead(s) II,aVR



55M, Chest pain 2H (BP 80/59)

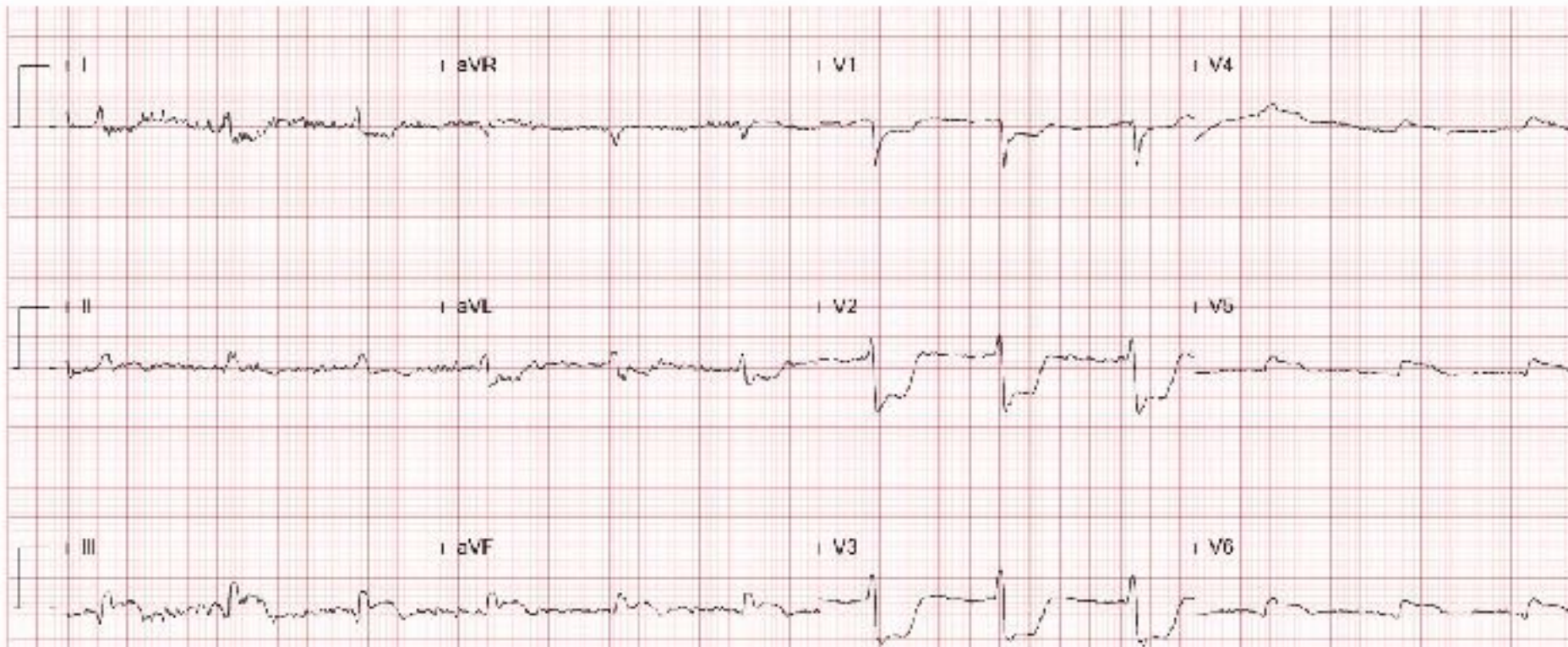


Patient ID: 14138842
Order Number:
Age:
Sex: O
Name:
Comment:

2022/02/19 07:48:48

Vent rate: 70 BPM
PR int: 69 ms
QRS dur: 131 ms
QT/QTc: 377 / 407 ms
P-R-T axes: 207 88 159

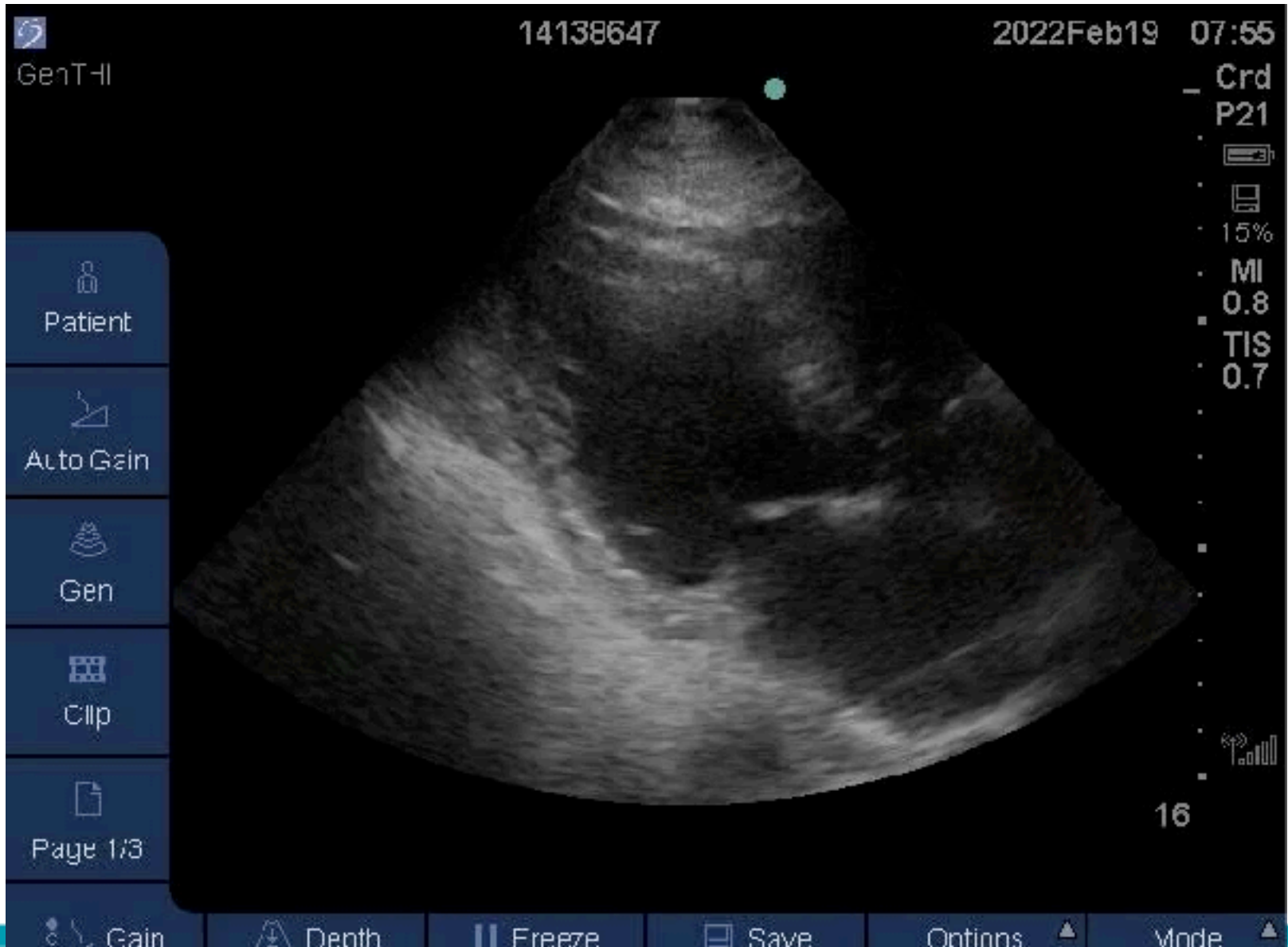Age not entered, assumed to be 50 years old for purpose of ECG interpretation
Sinus or ectopic atrial rhythm... P axis (-15, 135)
Short PR interval... PR <110ms
Nonspecific intraventricular conduction delay... QRSd >115ms, not LBBB/RBBB
Inferolateral infarct, acute (RCA)... ST>.10mv, inf-lat leads
Probable RV involvement, suggest recording right precordial leads
Baseline wander in lead(s) V1, V4



Posterior wall EKG



55M, Chest pain 2H (BP 80/59)





Intubation

14138647 2022Feb19 08:11

Res MB

— Nrv
HFL
13%
MI
0.6
TIS
0.1

Patient

Auto Gain

Res

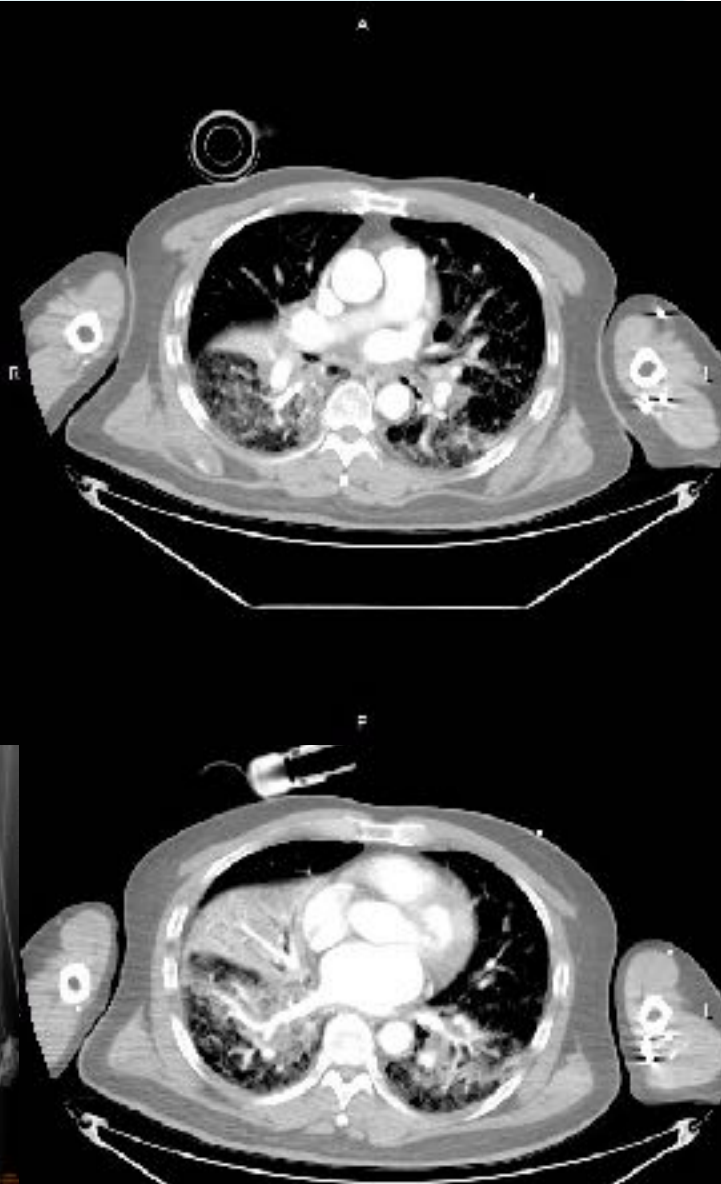
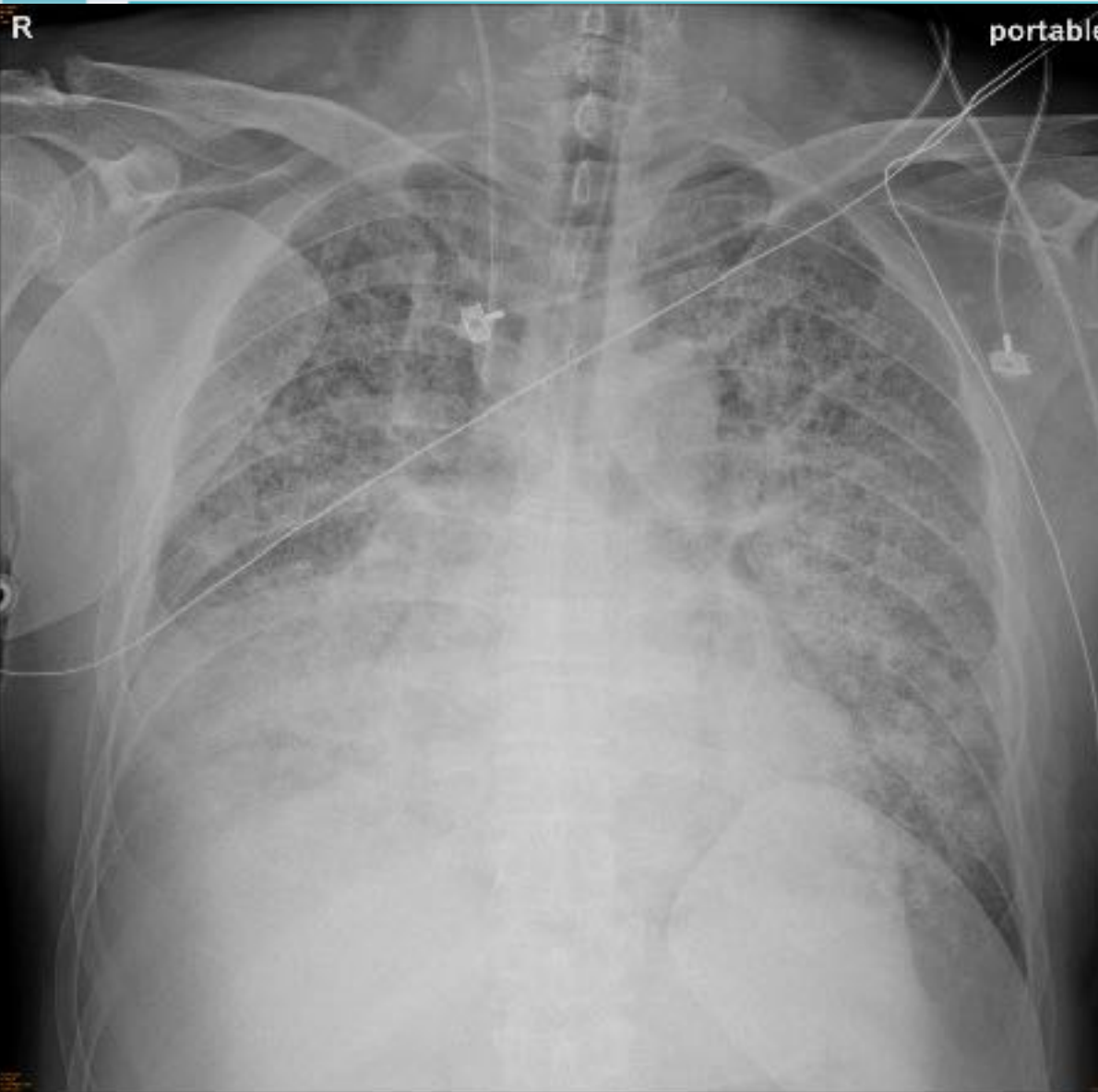Clip

Page 1/3

6.0



AMI & Cardiogenic shock



68F, left knee injury



00672151

2022Feb25

15:31

Res

MB

Msk

HFL



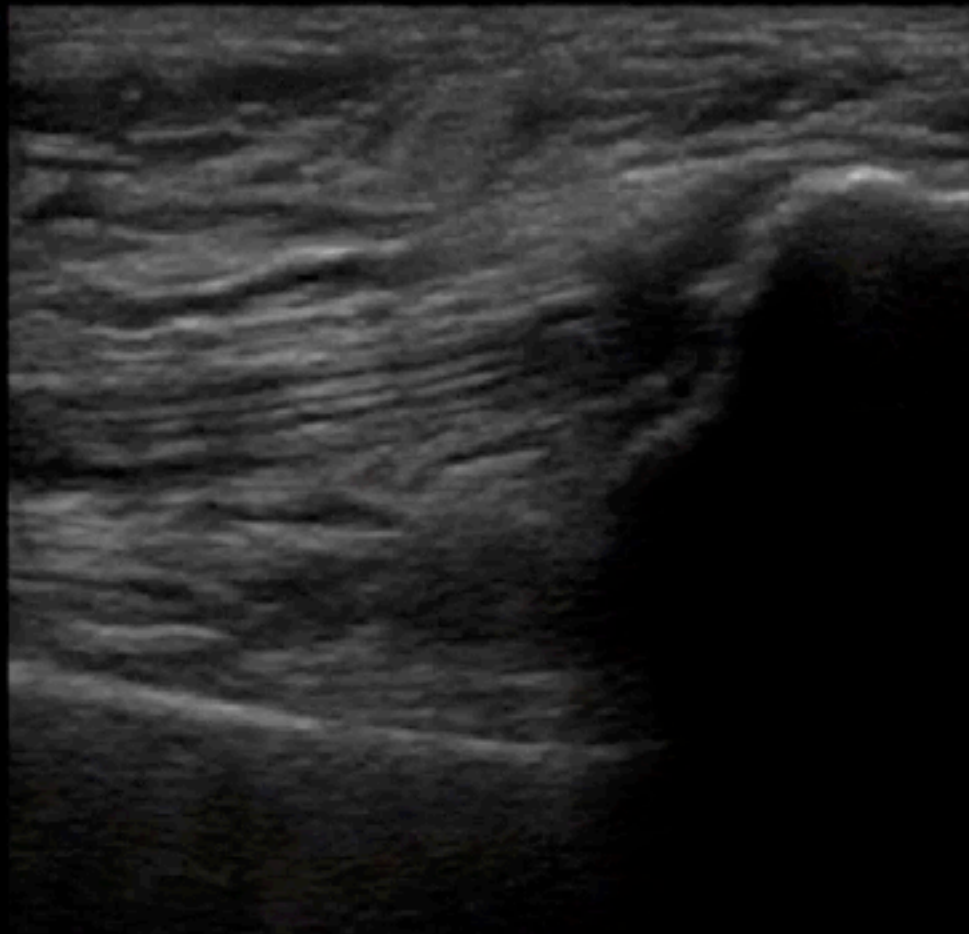
35%

MI

0.7

TIS

0.1



Patient



Auto Gain



Res



Clip

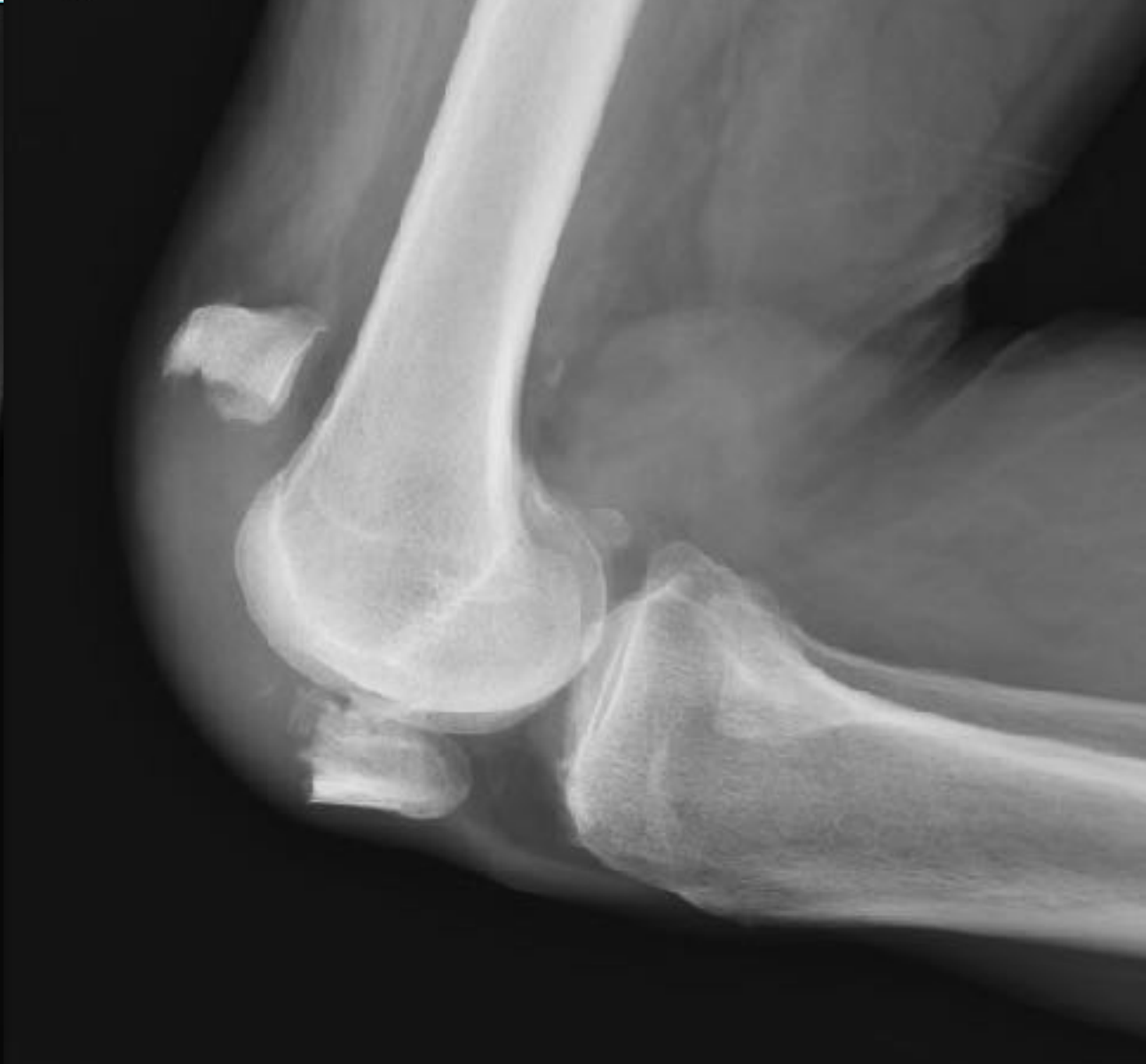
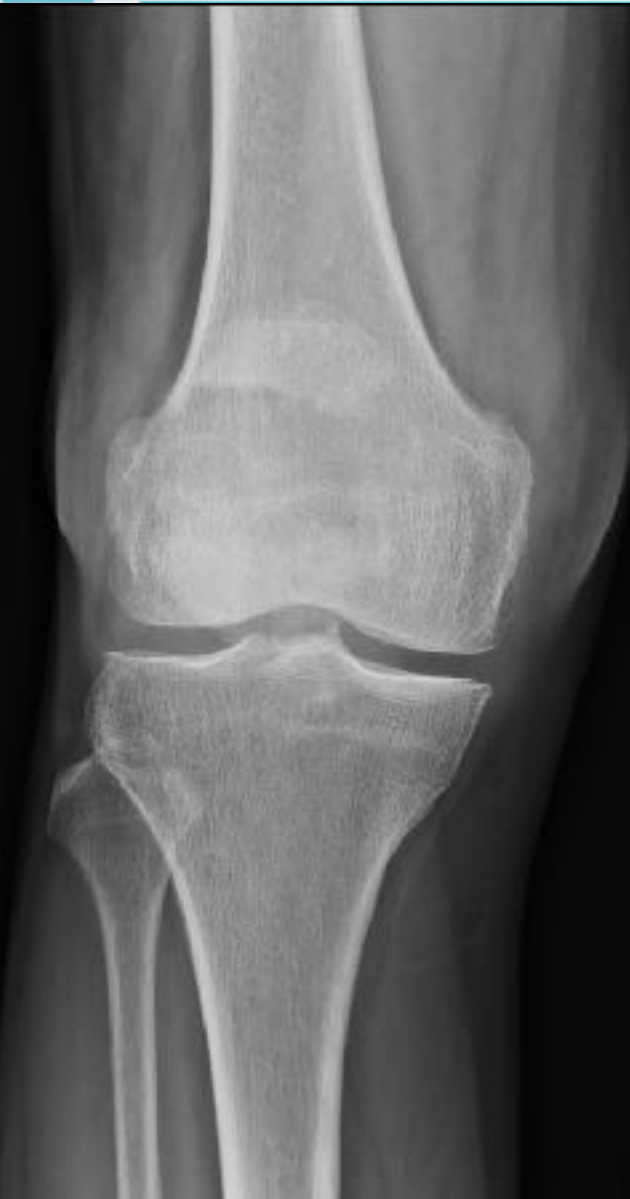
Page 1/3



4.0

68F, right knee injury



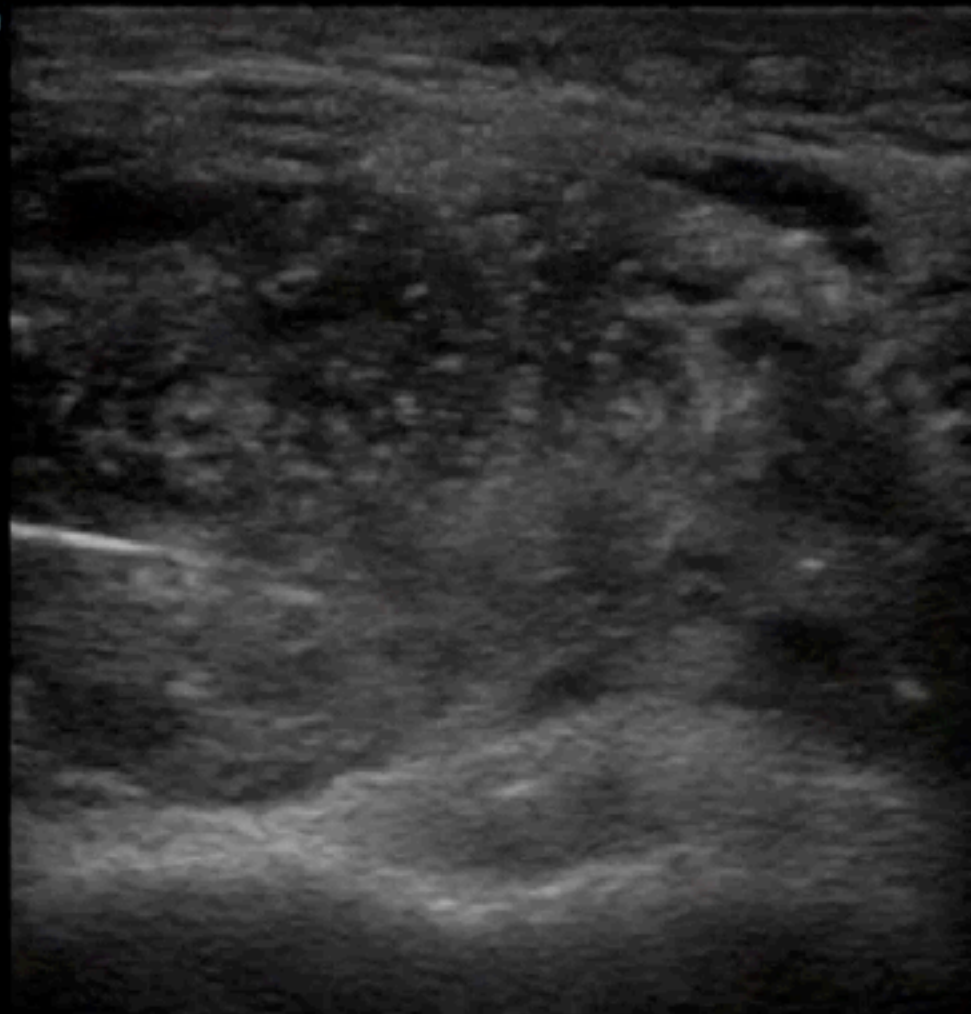
Needling



00672151

2022Feb25 15:37

Res MB



Msk
HFL
34%
MI
0.7
TIS
0.1



Patient



Auto Gain



Res



Clip



Page 1/3



4.0

Needling



00672151 2022Feb25 15:38

Res MB

— Msk
HFL
33%
MI
0.7
TIS
0.1

4.0

Patient
Auto Gain
Res
Clip
Page 1/3

The image is a B-mode ultrasound scan. A bright, curved line represents the needle shaft, which is inserted into a dark, heterogeneous tissue mass. The surrounding tissue shows various echogenic patterns, including some linear and speckled textures. The overall image is in grayscale, typical of medical ultrasound.

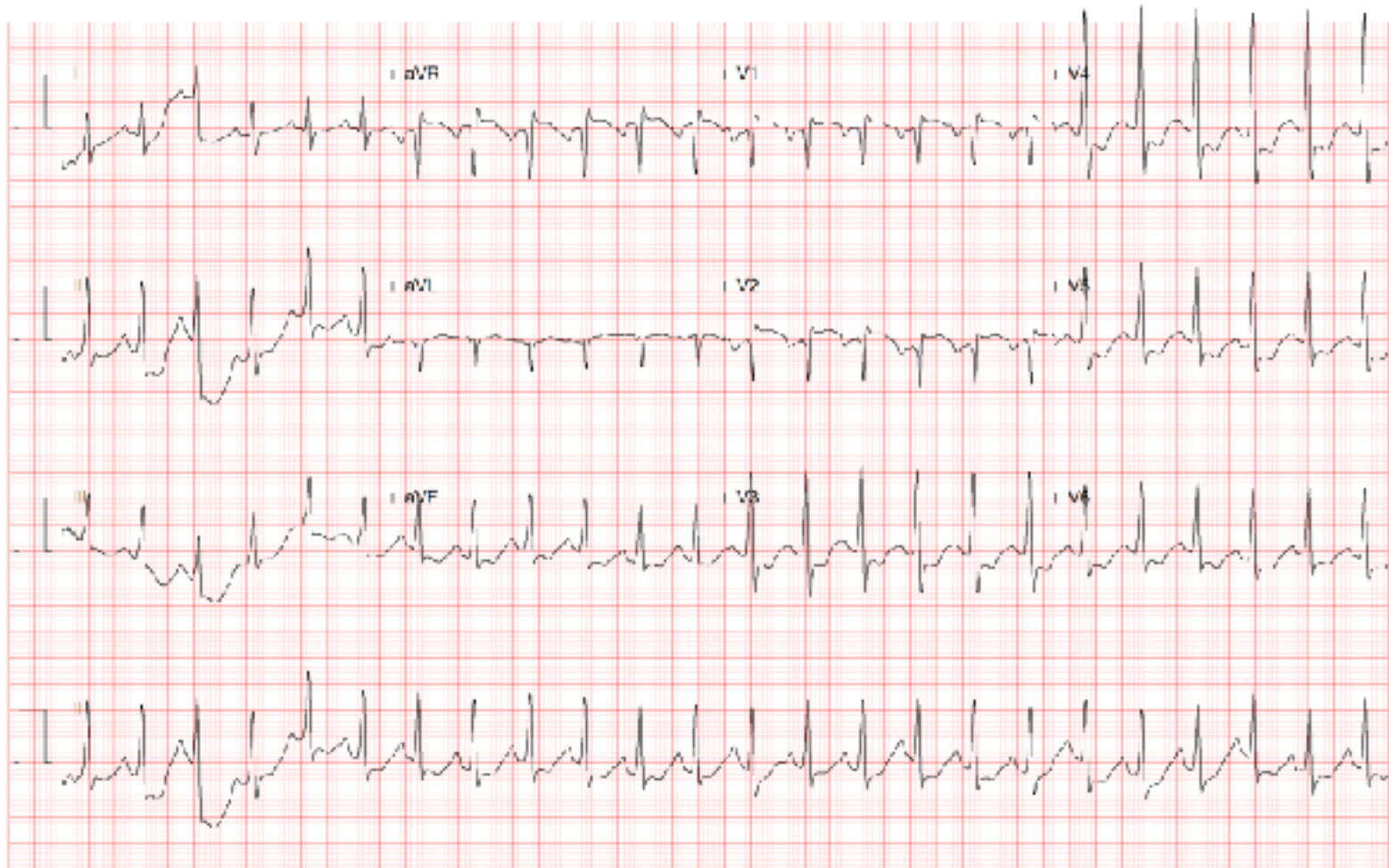
36M, Seizure then IHCA on arrival



Patient ID: 01985812
Order Number:
Age: 36 Years
Sex: M
Name: RRP
Comment:

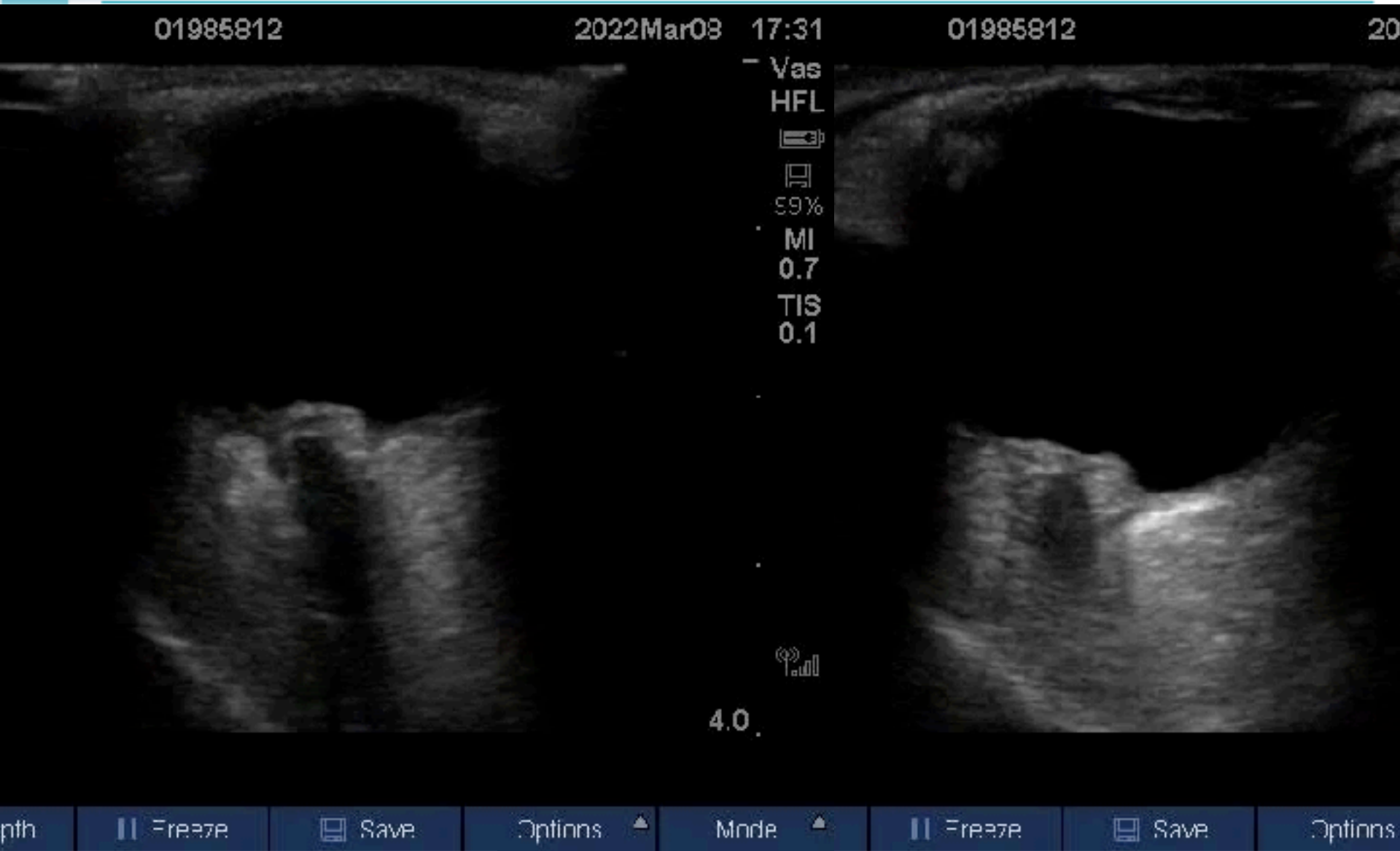2022/09/08 16:46:23
Vent rate: 142 BPM
PR int: 144 ms
QRS dur: 105 ms
QT/QTc: 299 / 461 ms
P-R-T axes: 68 85 255

Age not entered, assumed to be 50 years old for purpose of ECG interpretation
Sinus tachycardia...rate> 99
LAF, consider atrial enlargement...P>80ms <- 15mV V1x 25mV limb leads
RER in V1 or V2, right VCD or RVH...QRS area positive R V1V2
Repol abnm suggests ischemia...diffuse leads...ST-T neg. an/ta/inf



25mm/s 10mm/mV 40-0.5Hz

36M, Seizure then IHCA on arrival



Brainstem ICH & Papilledema



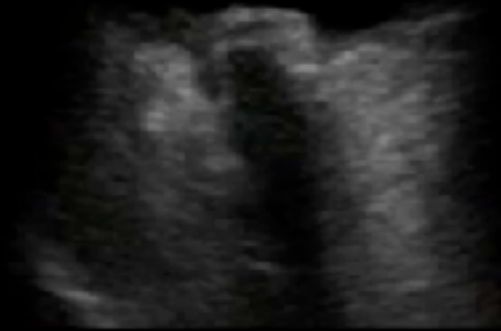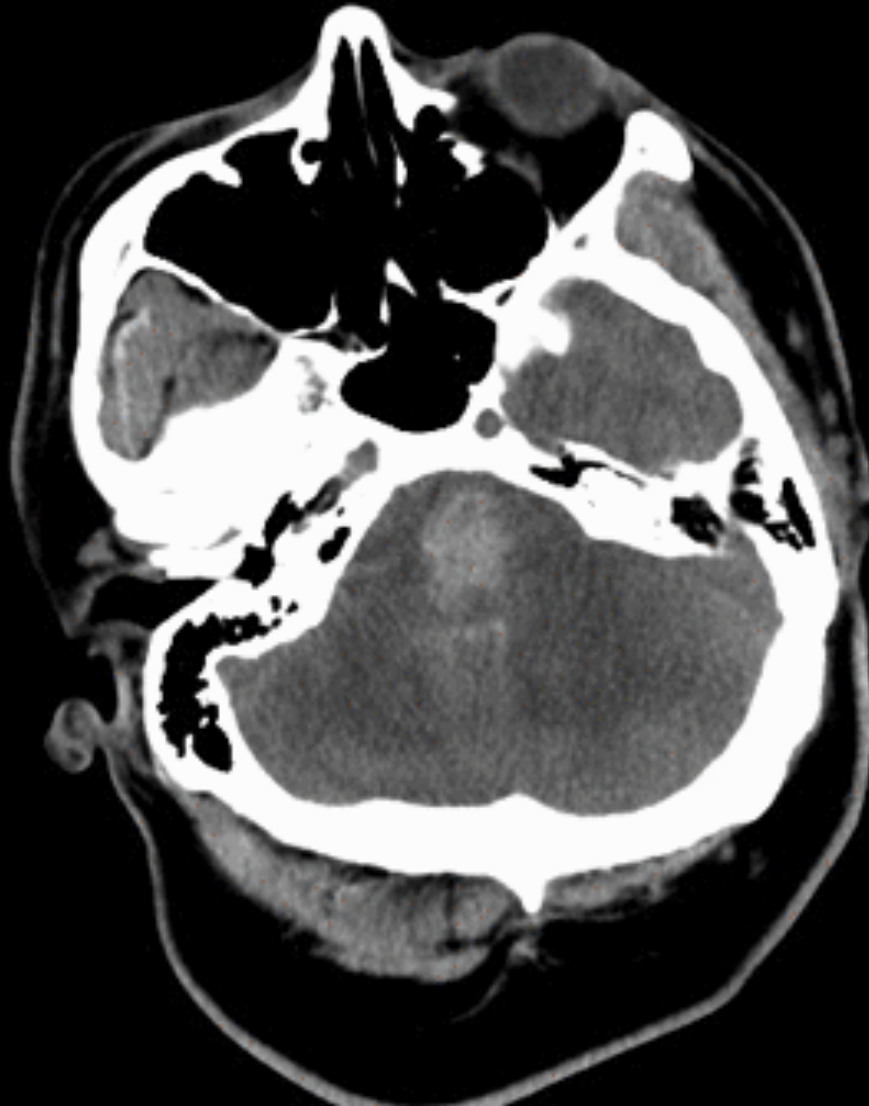01985812
張桓銘

A

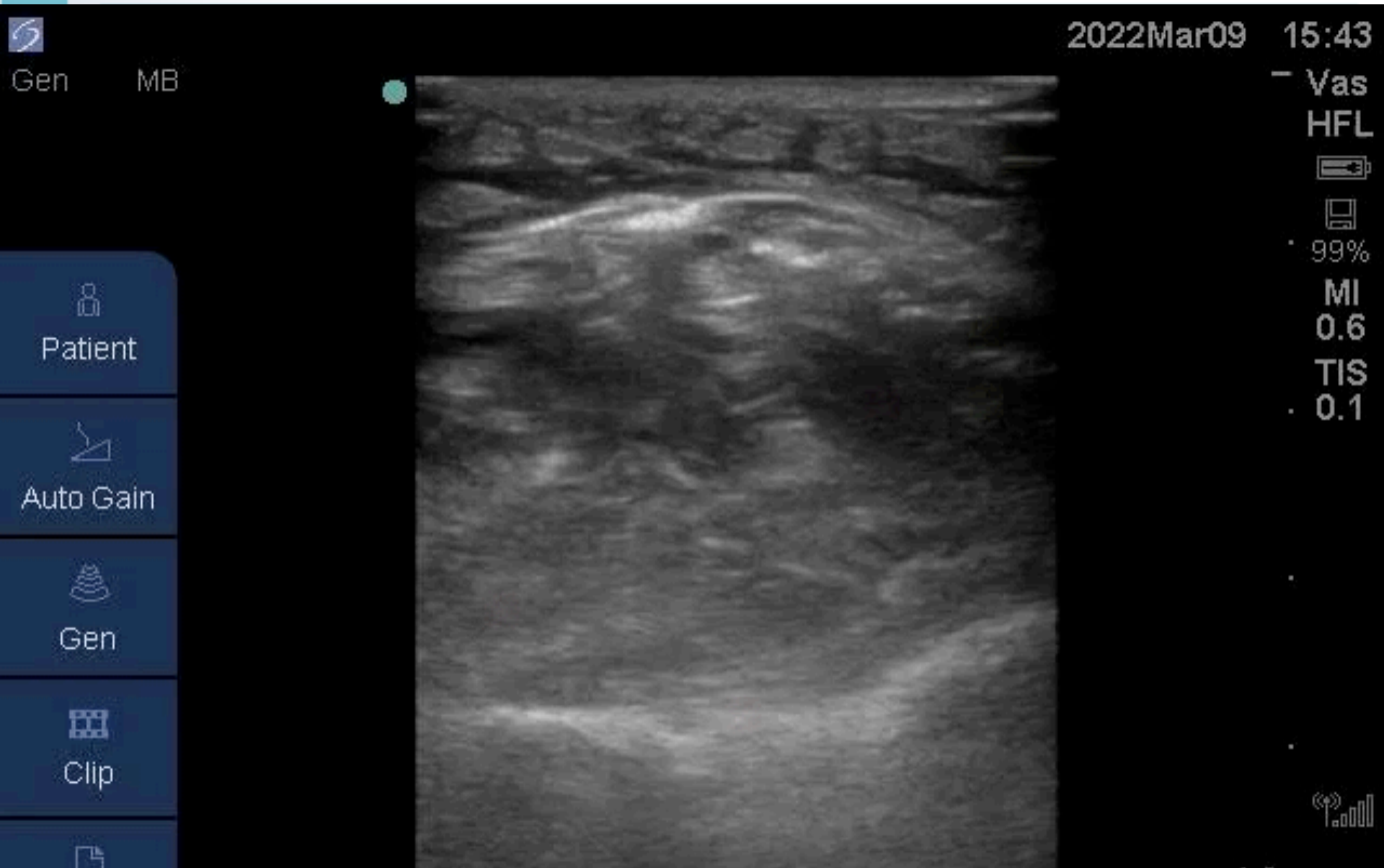Brain

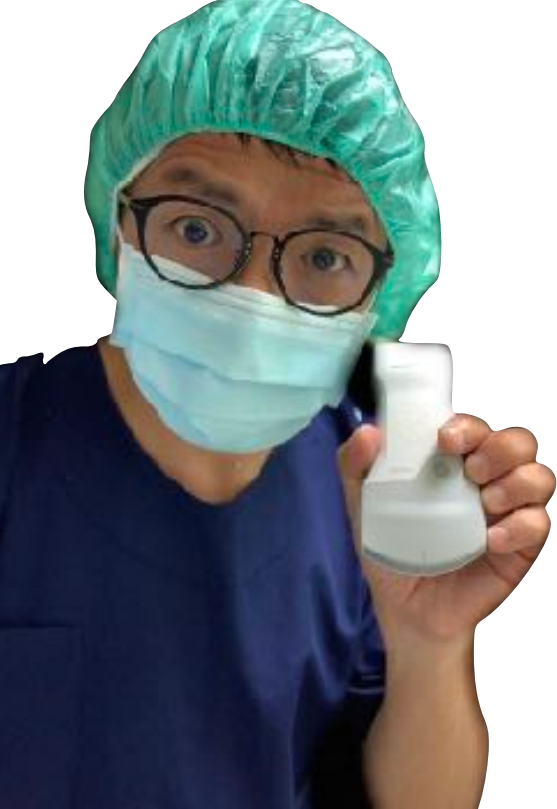R

L



74M, hypoglycemia, arm swelling after IV





努力可能會說謊，
但努力不會白費。

羽生結弦

HOLISTIC ULTRASOUND

juice119@gmail.com / POCUSacademy.com