



# 雙和急診POCUS訓練

# 陳國智 醫師



醫用超音波學會指導醫師  
WINFOCUS director / instructor  
急救加護醫學會重症超音波負責人

急診 / 重症 / 介入 / 急性疼痛

## 經歷

新光急診超音波訓練中心主任

西園醫院急診醫學科主任

急診醫學會超音波委員會主委

台灣疼痛醫學會大體模擬手術講師



**LE joint effusion**

01/07

**Airway**

01/14

**Needling**

01/21

**VExUS protocol**

01/28

**雙和急診POCUS訓練**



**Central access**

02/11

**Peripheral access**

02/18

**EFAST**

02/25

**雙和急診POCUS訓練**



**Basic ECHO**

03/04

**Nerve block-UE(1)**

03/11

**Nerve block-LE(1)**

03/25

**雙和急診POCUS訓練**



**Aorta & IVC**

**04/01**

**Liver & Biliary**

**04/08**

**Pancreas & Spleen**

**04/15**

**Kidney & UB**

**04/29**

**雙和急診POCUS訓練**

診  
斷

監  
測

介  
入

POINT OF CARE ULTRASOUND

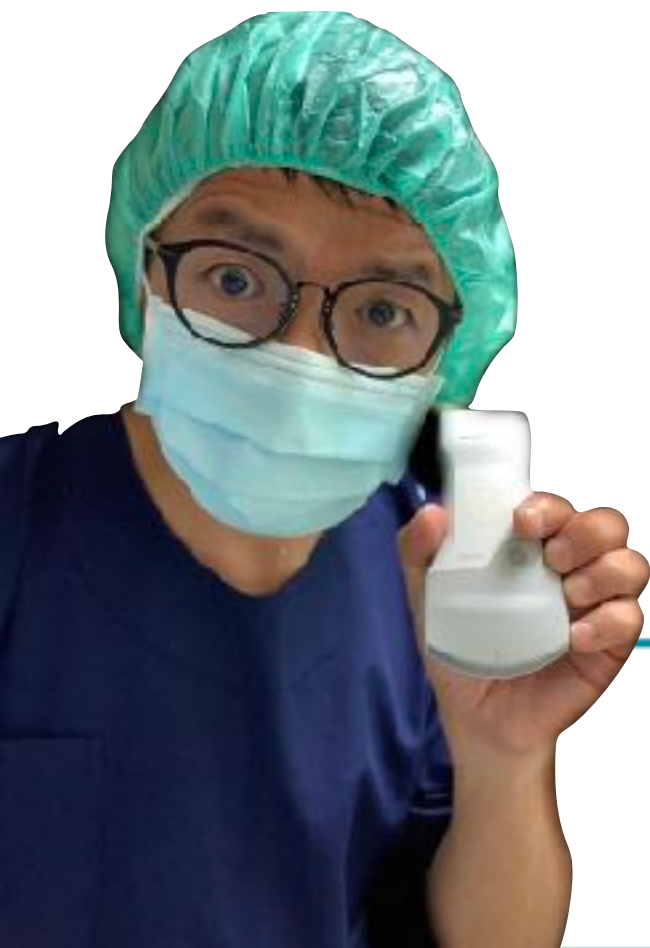~ 存在於臨床需求之所在 ~



衛生福利部雙和醫院  
(委託臺北醫學大學興建經營)  
Taipei Medical University · Shuang Ho Hospital,  
Ministry of Health and Welfare



# POCUS Imaging Reading

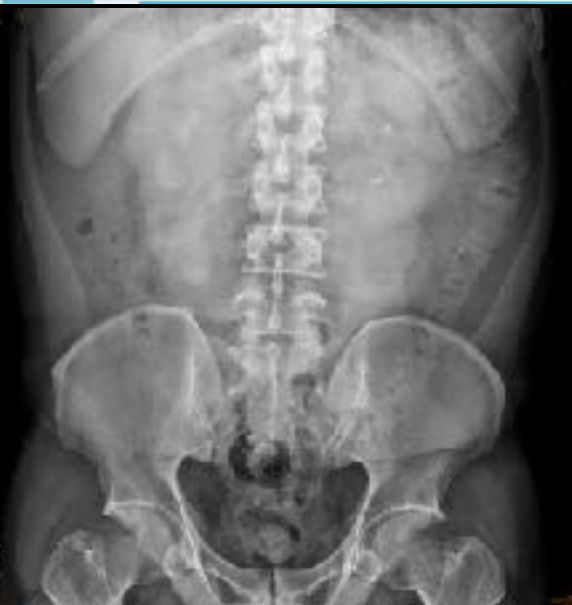

陳國智醫師

雙和醫院 急診醫學科

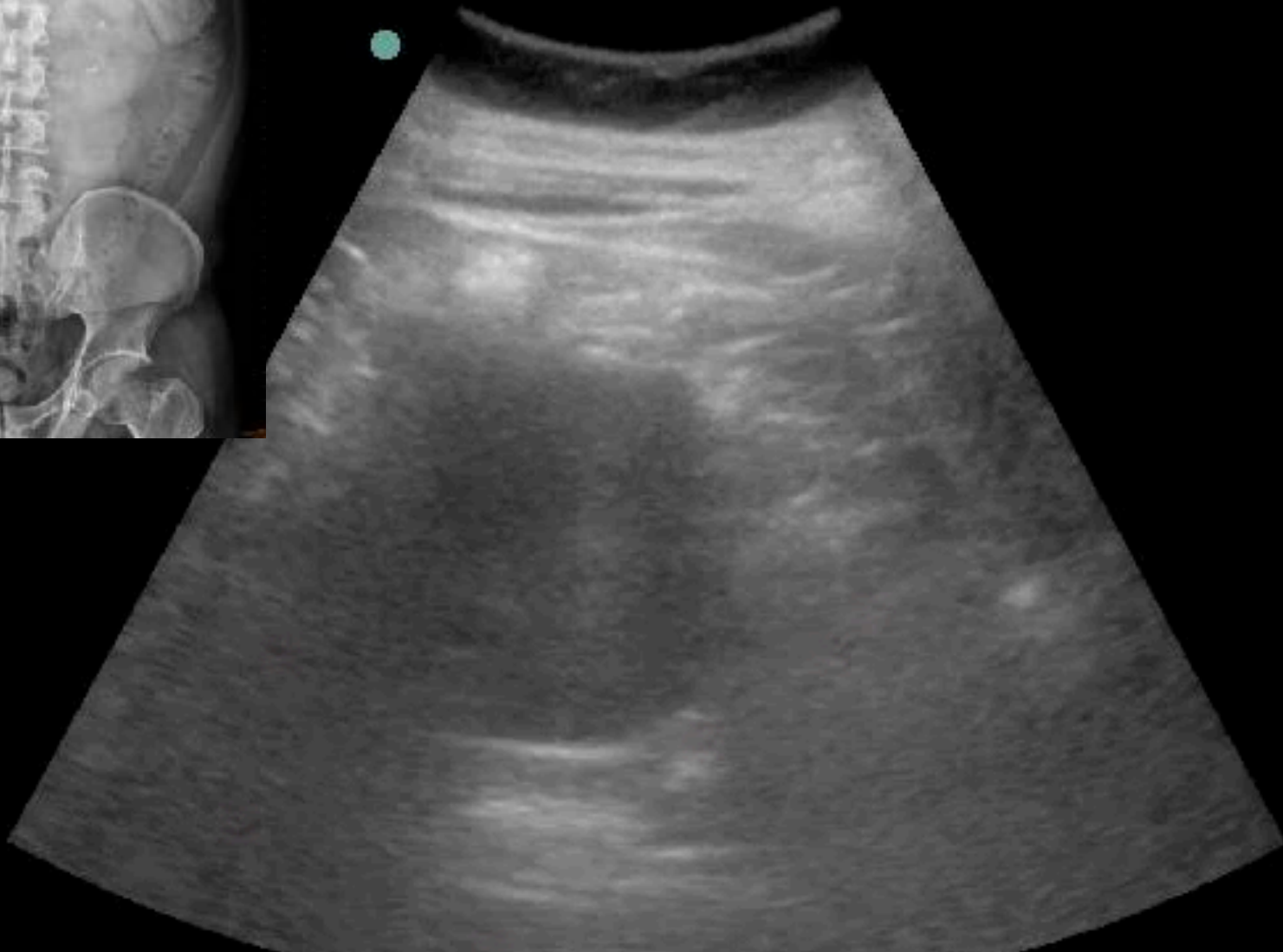

# 39M, left flank pain after ESWL



04723961

2022Mar04 16:53



Abd  
- C60  
·   
·   
23%  
MI  
0.7  
· TIS  
0.1

Auto Gain

Gen

Clip

[Unlabeled]



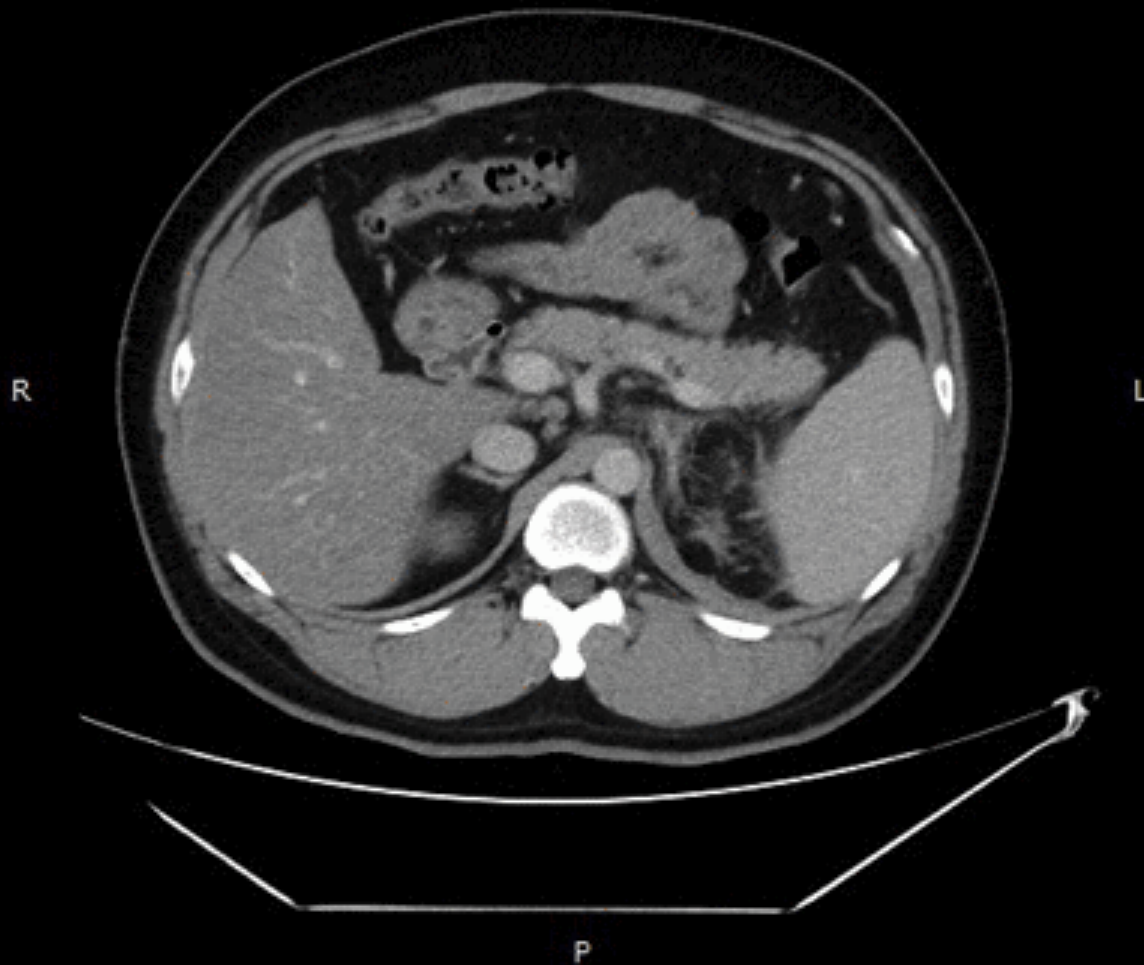
# 39M, left flank pain after ESWL



04723961  
詹國

A

2022/03/04  
Abdomen + Pelvis CT(-C,+C)



# 54M, DM, scrotal swelling for days



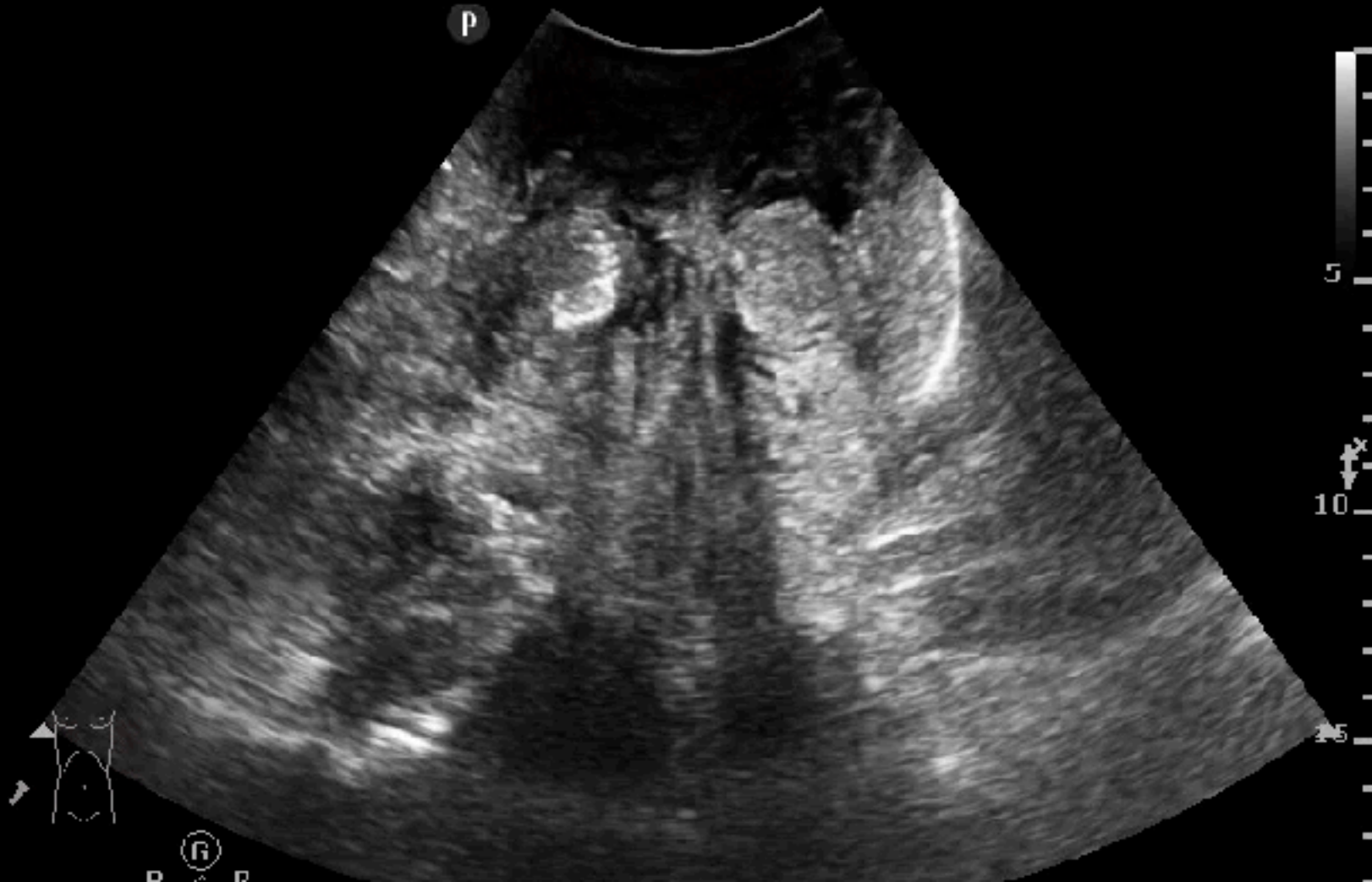PHILIPS shung  
11414135

SHH

MI 0.6 3/1/2022  
TIS 0.0 6:35:55 PM

ABD  
C6-2  
25Hz  
19.0cm

2D  
HGen  
Gn 100  
56  
1/3/3



# 54M, DM, scrotal swelling for days



PHILIPS shung  
11414135

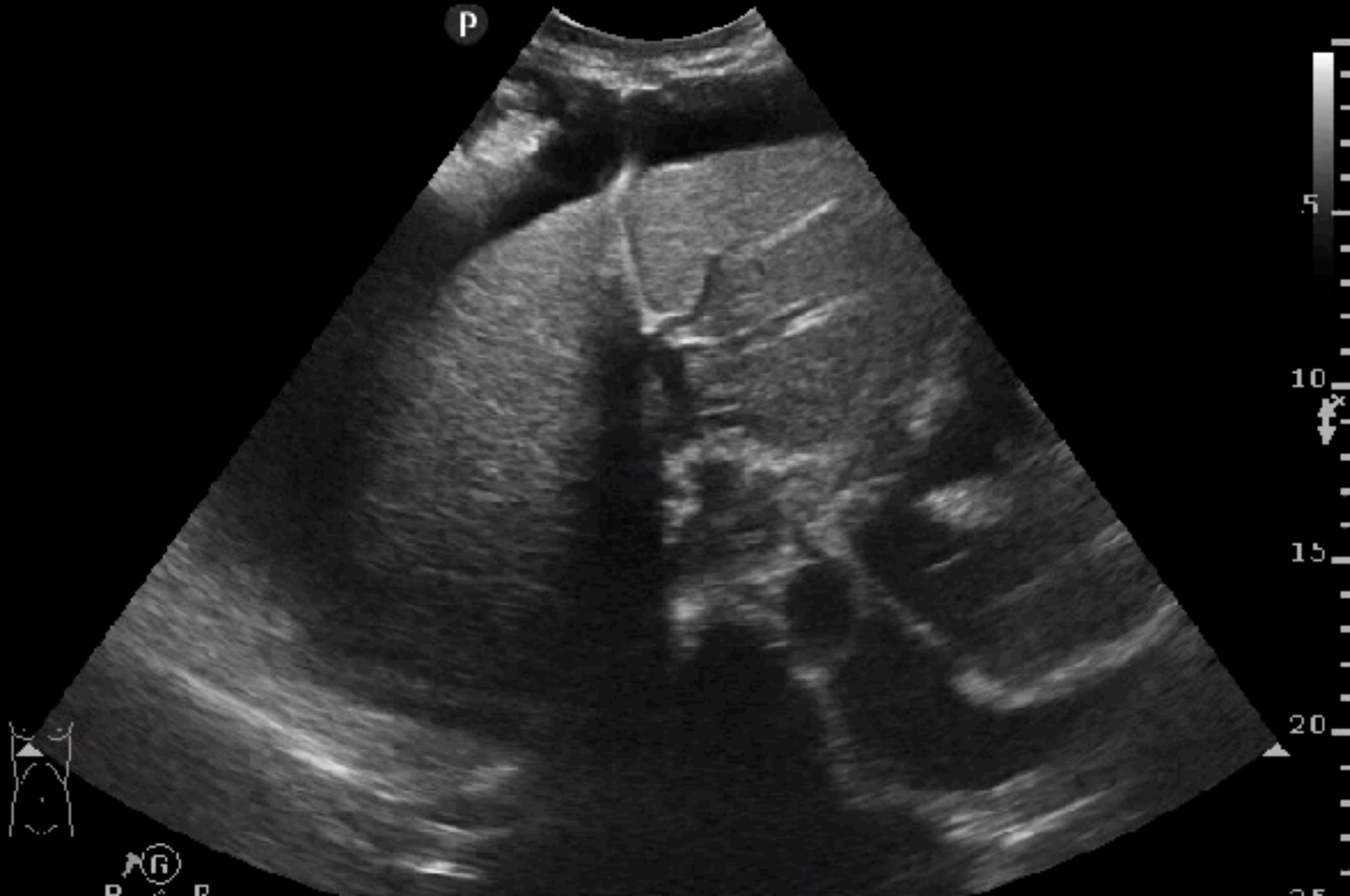MI 0.5 3/1/2022  
TIS 0.0 6:33:47 PM

SHH

P

ABD  
C6-2  
19Hz  
26.0cm

2D  
HGen  
Gn 100  
56  
1/3/3



# 55F, RLQ pain



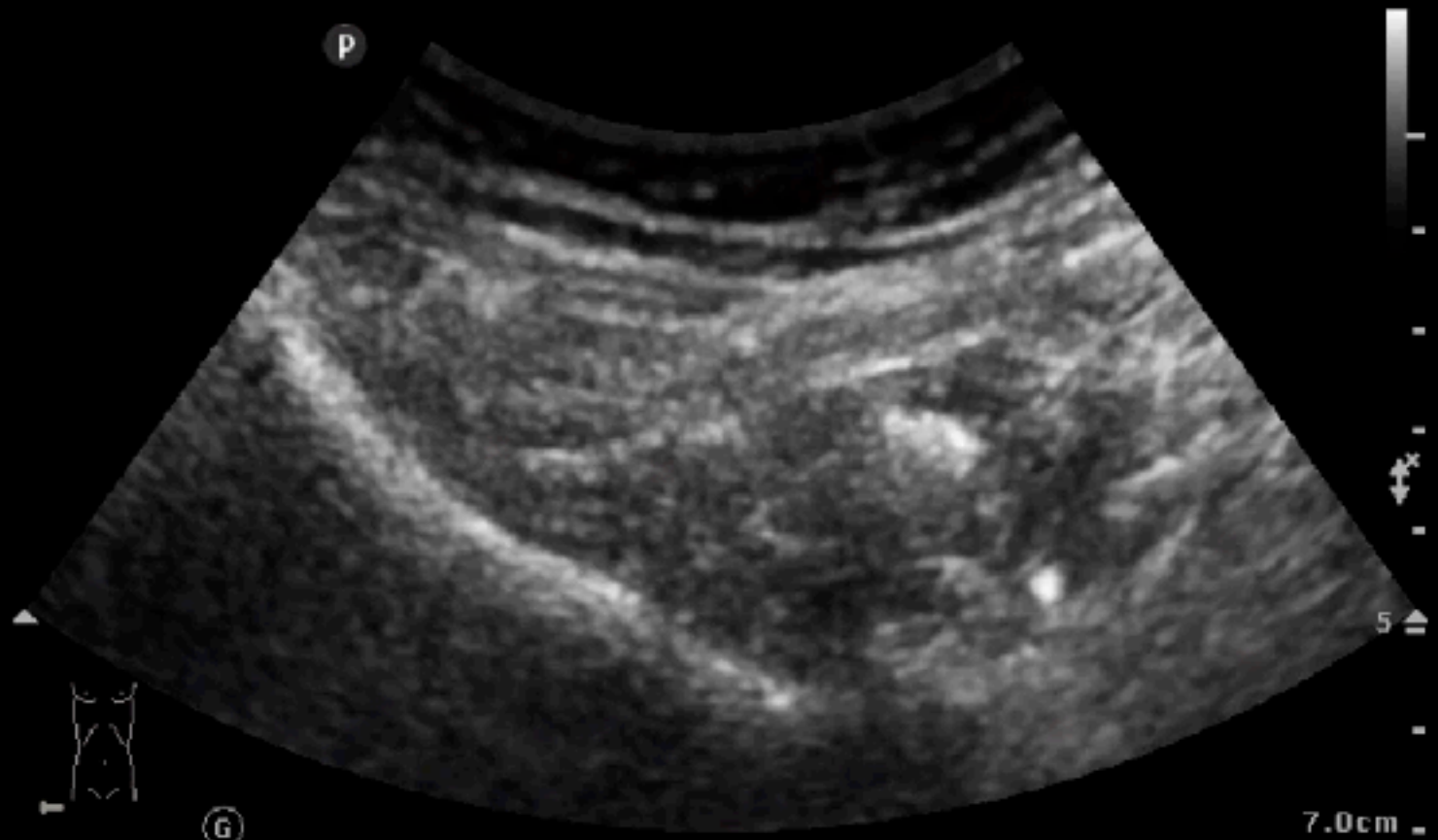
PHILIPS LIN  
00470214

SHH

MI 0.5 2/25/2022  
TIS 0.0 2:35:58 PM

ABD  
C6-2  
47Hz  
7.0cm

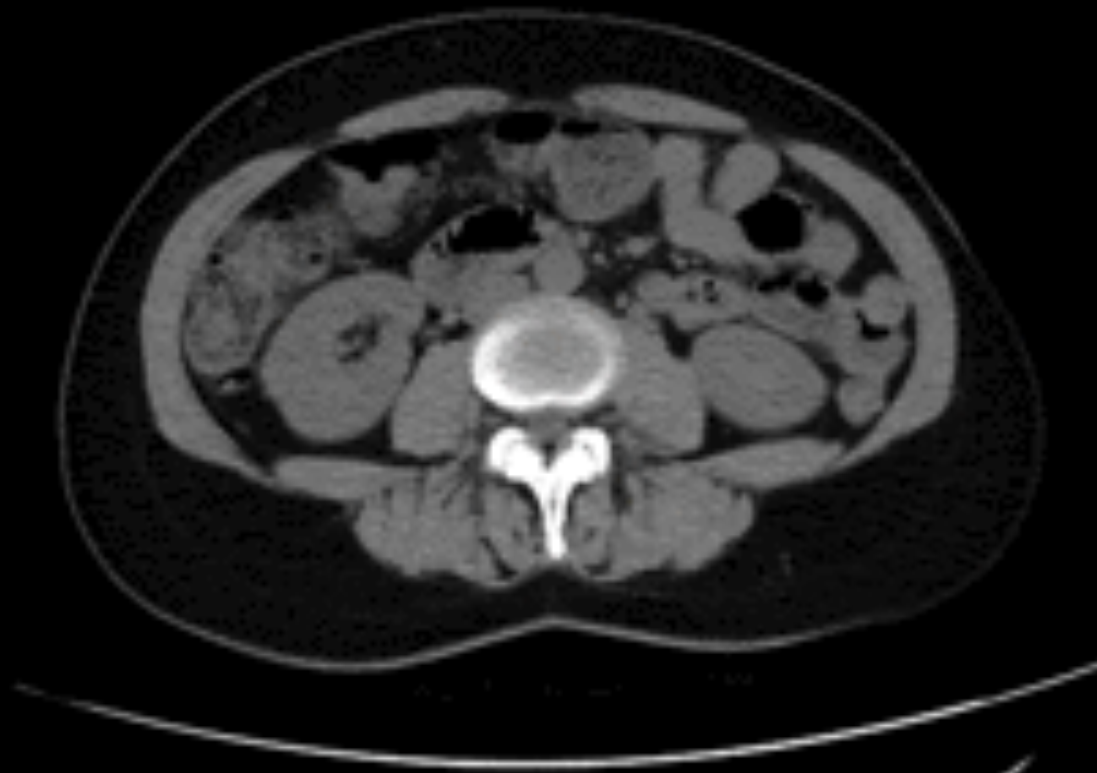2D  
HGen  
Gn 100  
56  
1/3/3



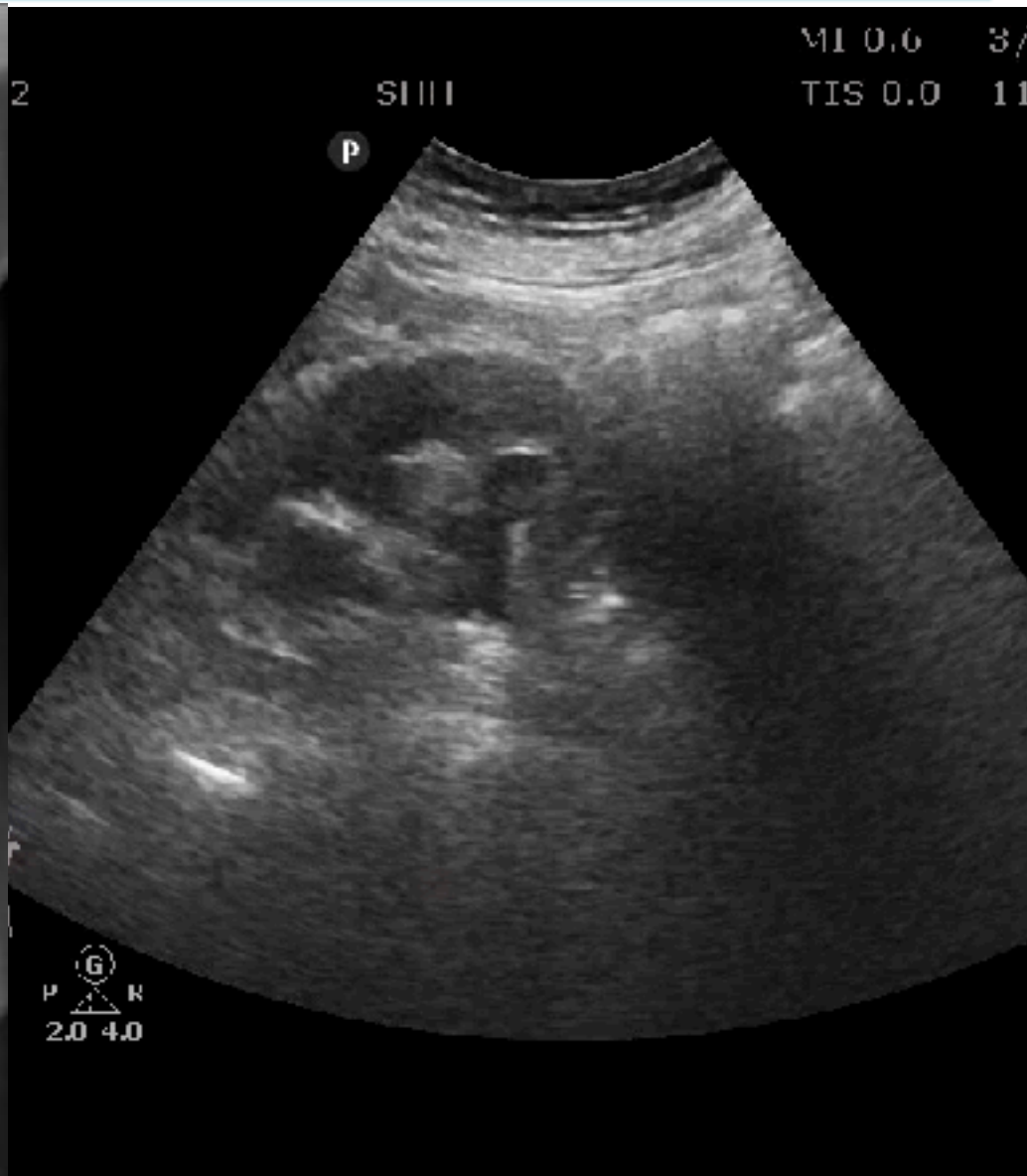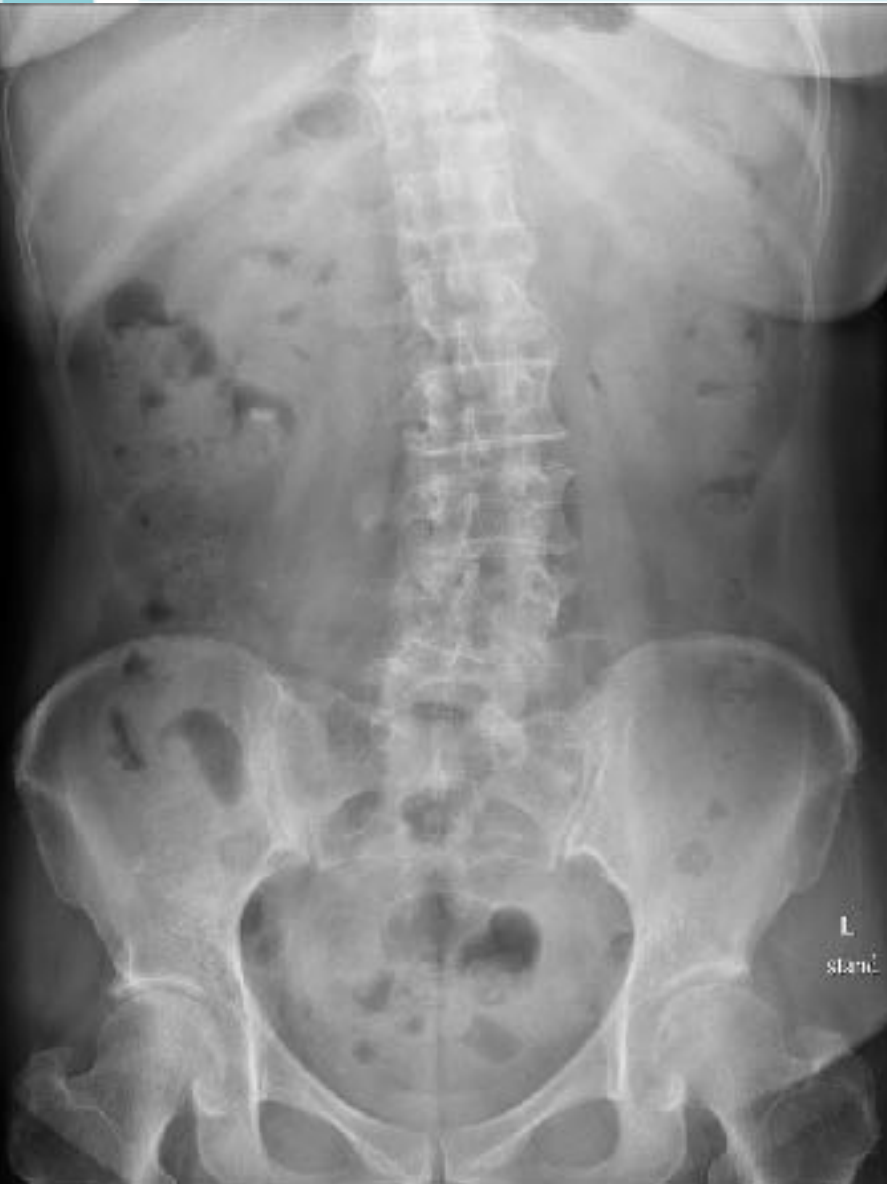①  
P R  
2.0 4.0

7.0cm

# 55F, RLQ pain



# 55F, Fever & chills



# 71F, high fever, chills



GenTHI MB

14159505

2022Feb25 16:31

Abd  
- C60



30%

MI

1.0

TIS

0.1



Patient



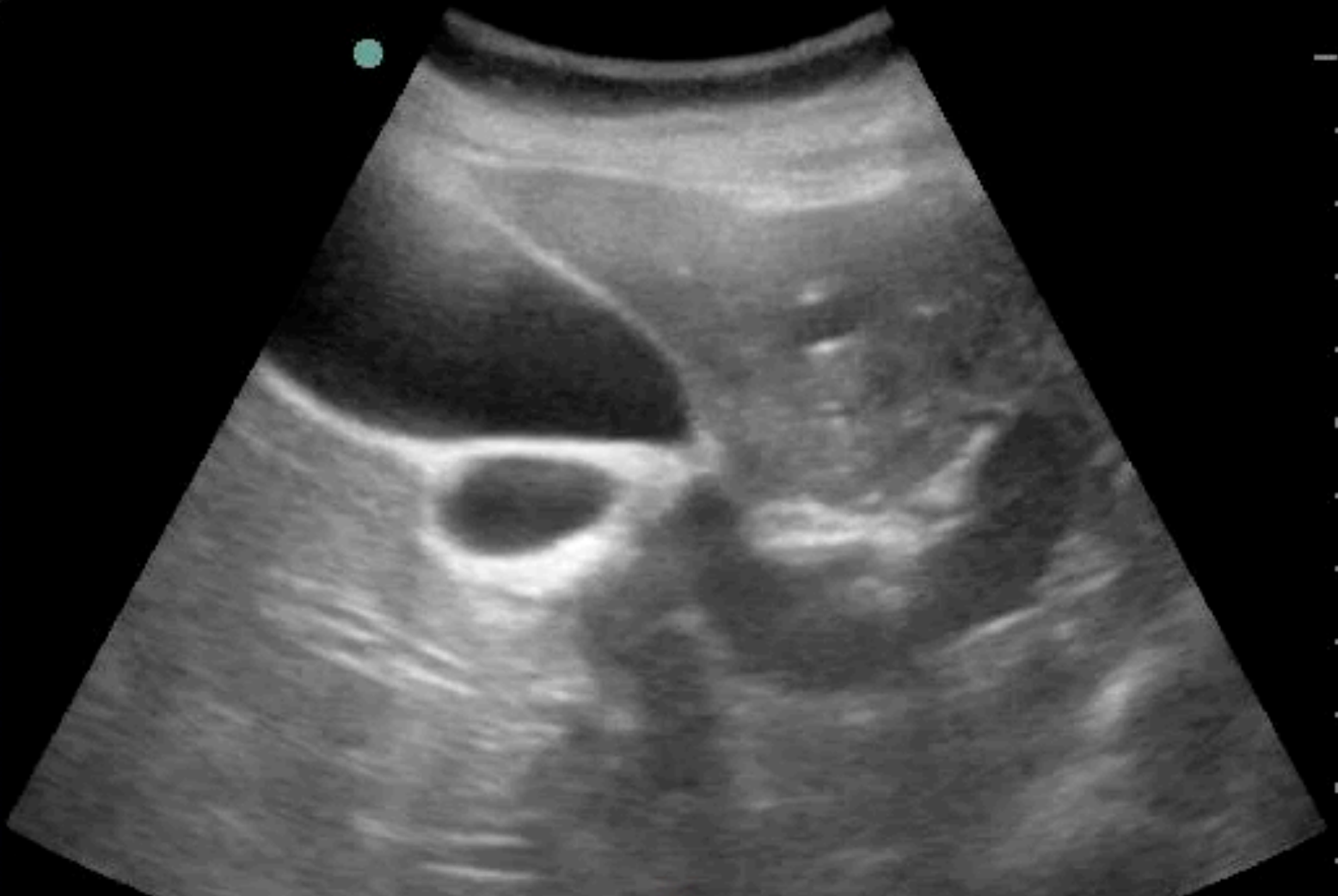Auto Gain



Gen



Clip





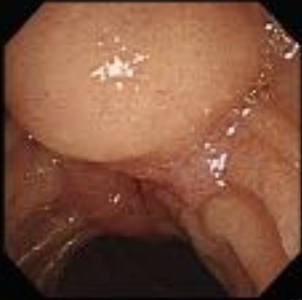# 71F, high fever, chills



14169505

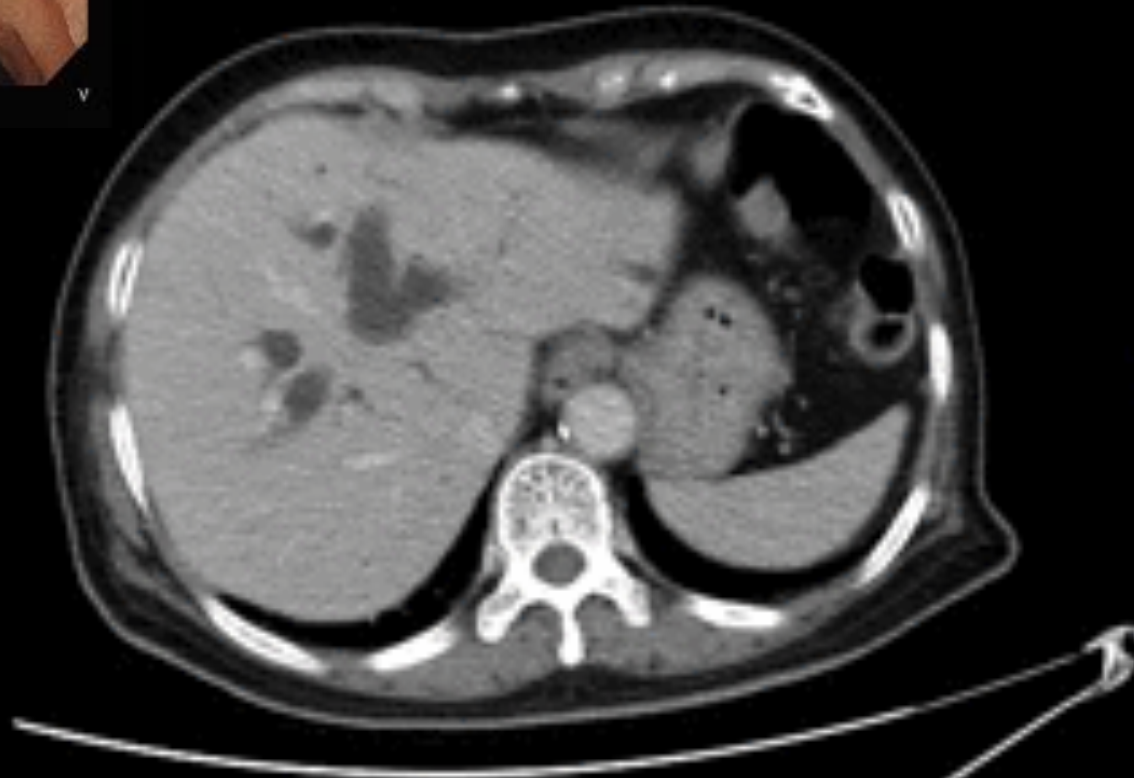
03/03/2022  
09:58:41

Q:1N Set:AS  
Q:1D



V

2022/02/25  
Abdomen + Pelvis CT(-C,+C)



R

L

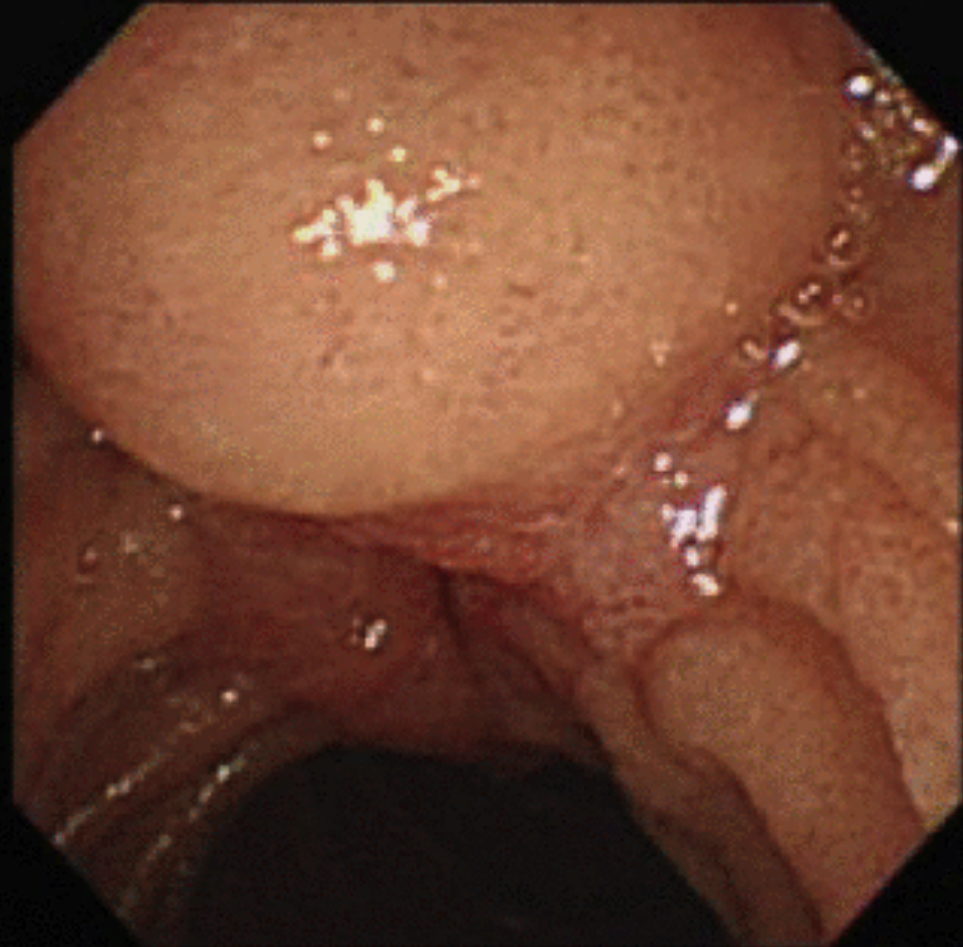


# Ampulla Vater tumor

14159505

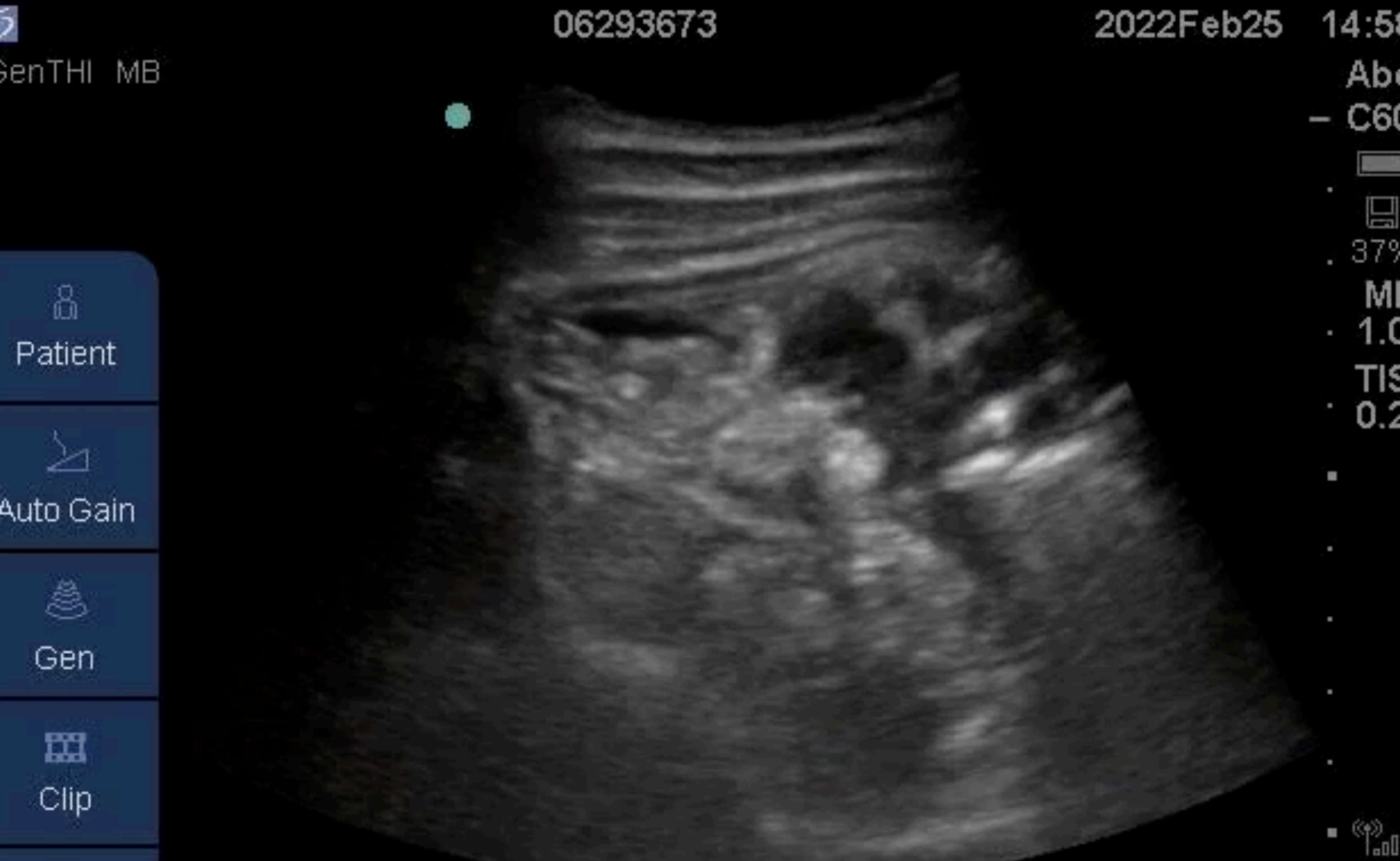03/03/2022  
09:56:41

Ct: N Eh: A5  
Ce: O



V

# 59M, RLQ pain



06293673

2022Feb25 14:50

GenTHI MB

Abd  
- C60

Patient

Auto Gain

Gen

Clip

37%  
MI  
1.0  
TIS  
0.2

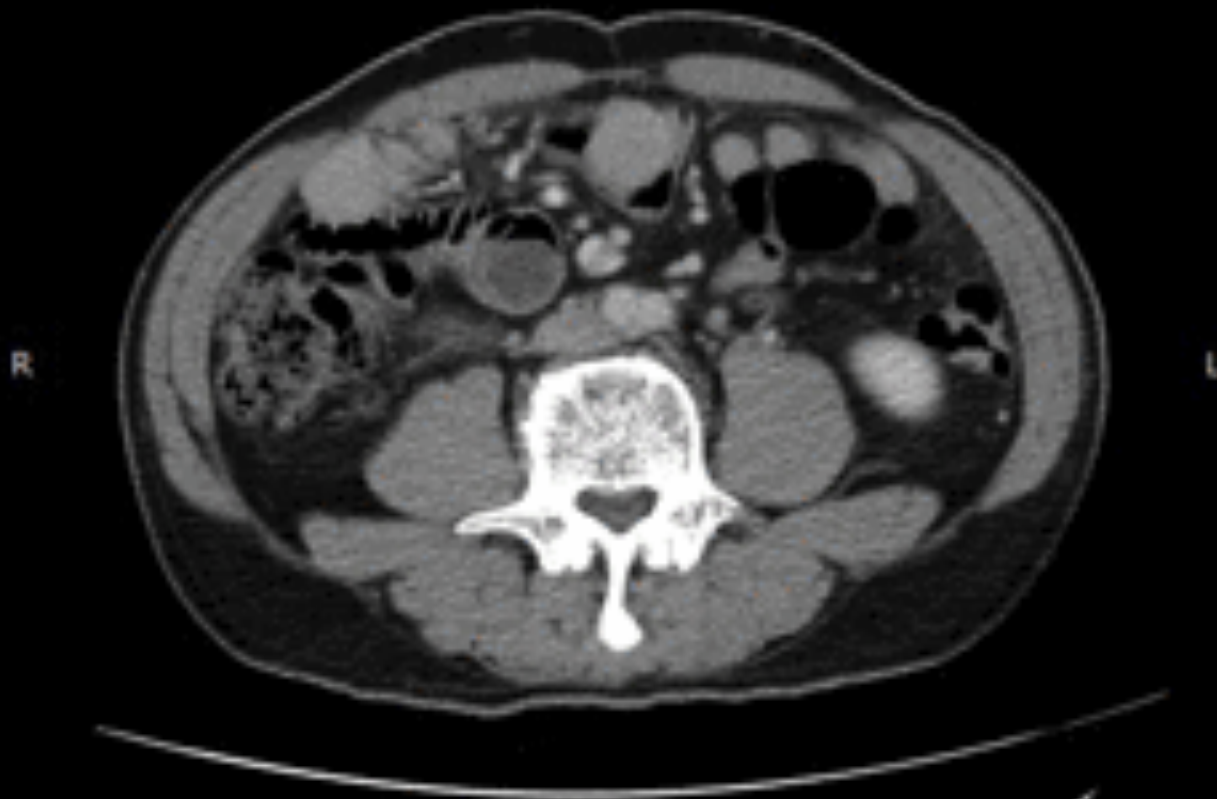

# 59M, RLQ pain



06293673  
林尚鏡

2022/02/25  
Abdomen + Pelvis CT(+C)





# 71M, left thigh redness



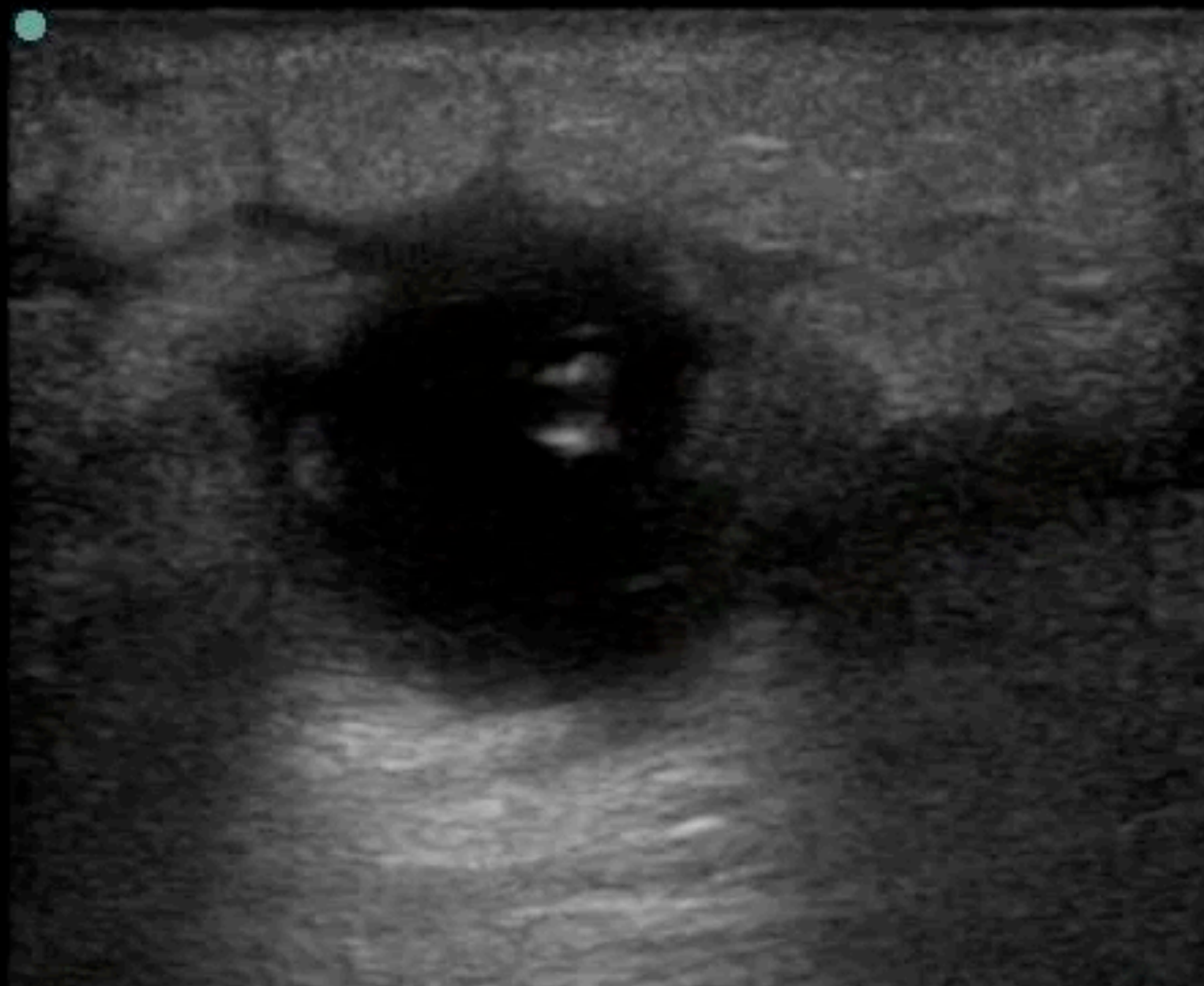
02388371

2022Mar09

19:19

Gen

MB



- Vas  
HFL  
98%  
MI  
0.8  
TIS  
0.1



Patient



Auto Gain



Gen



Clip



# 43F, epigastric pain



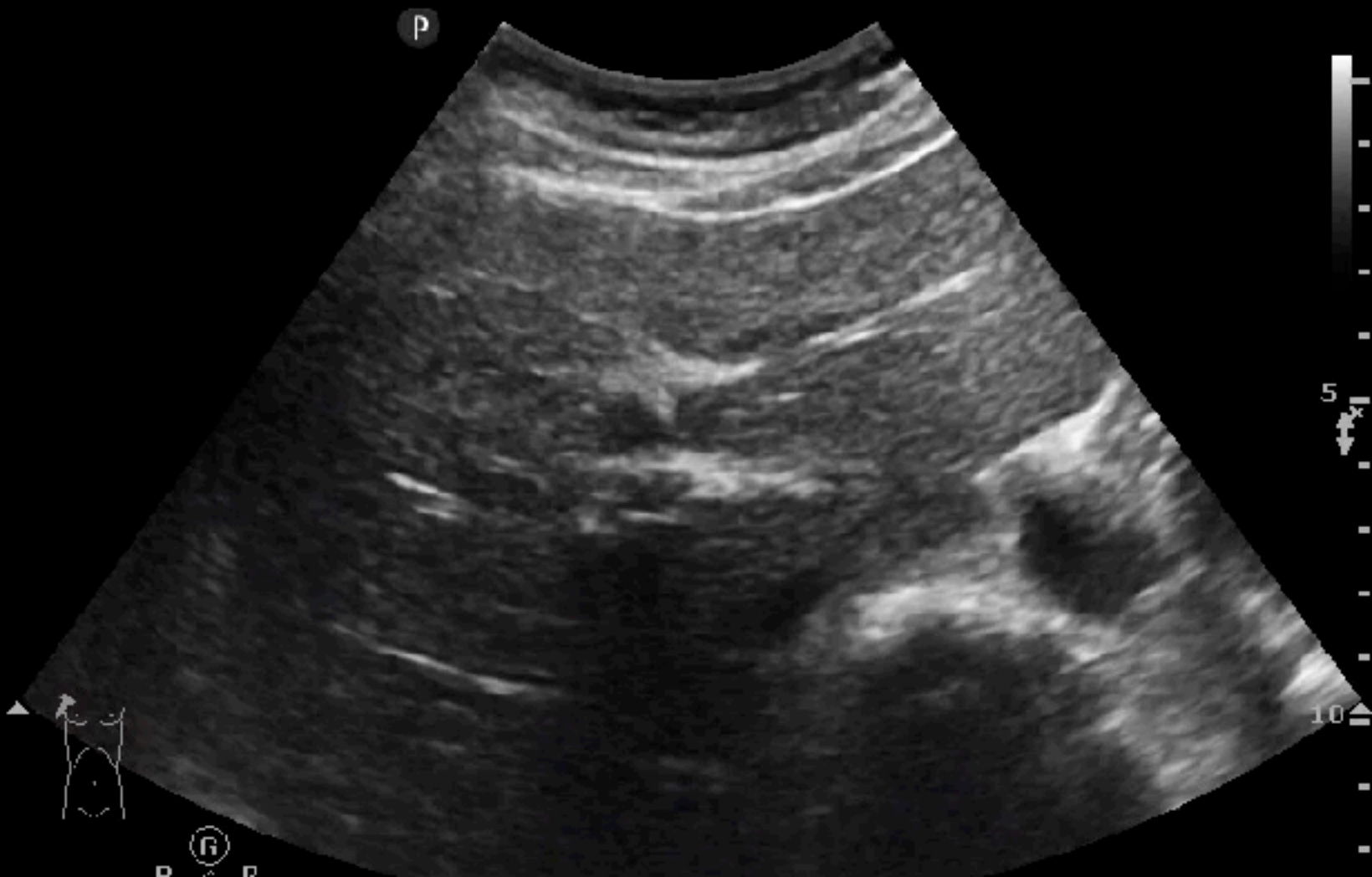
PHILIPS sun  
13727718

SHH

MI 0.6 3/1/2022  
TIS 0.0 9:26:50 AM

ABD  
C6-2  
32Hz  
13.0cm

2D  
HGen  
Gn 100  
56  
1/3/3



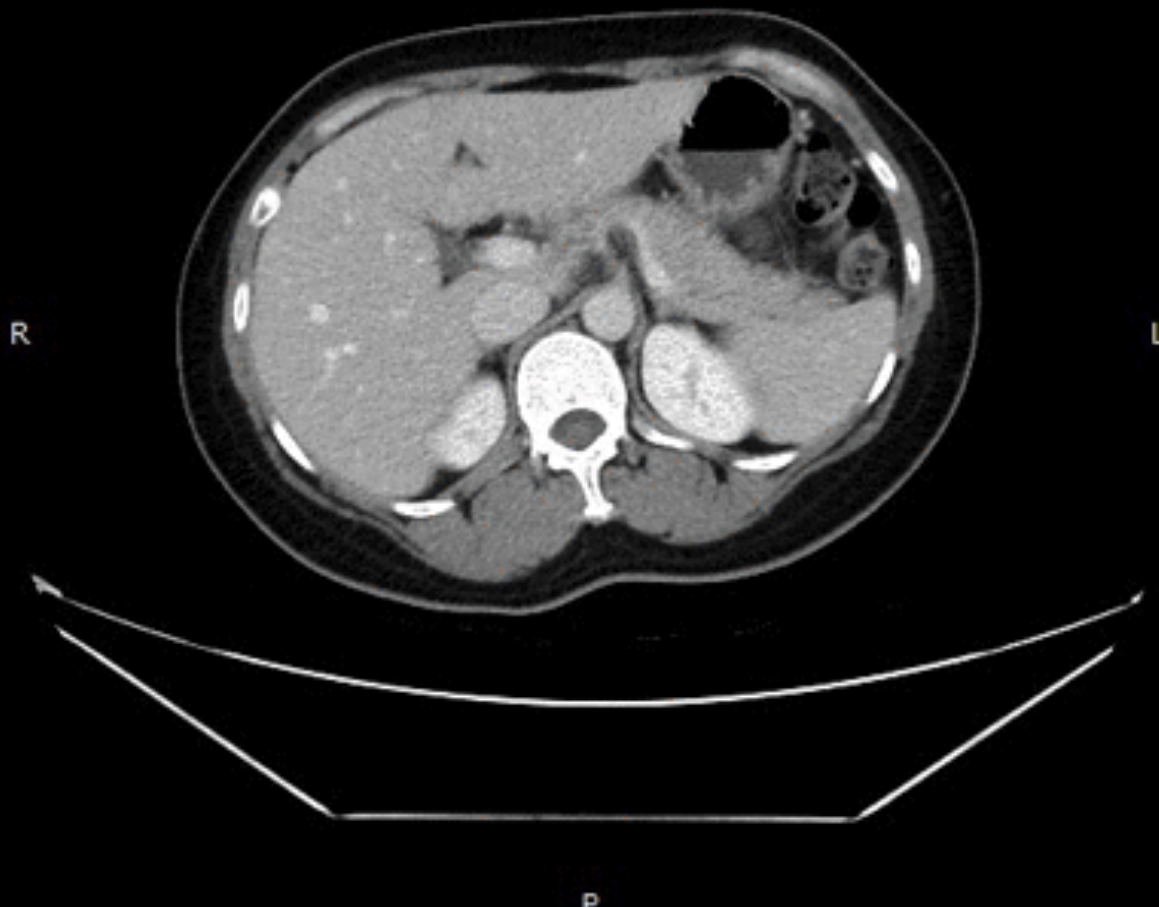# 43F, epigastric pain



13727718  
SURINH

A

2022/03/01  
Abdomen + Pelvis CT(-C,+C)





# 64F, abdominal pain & vomiting



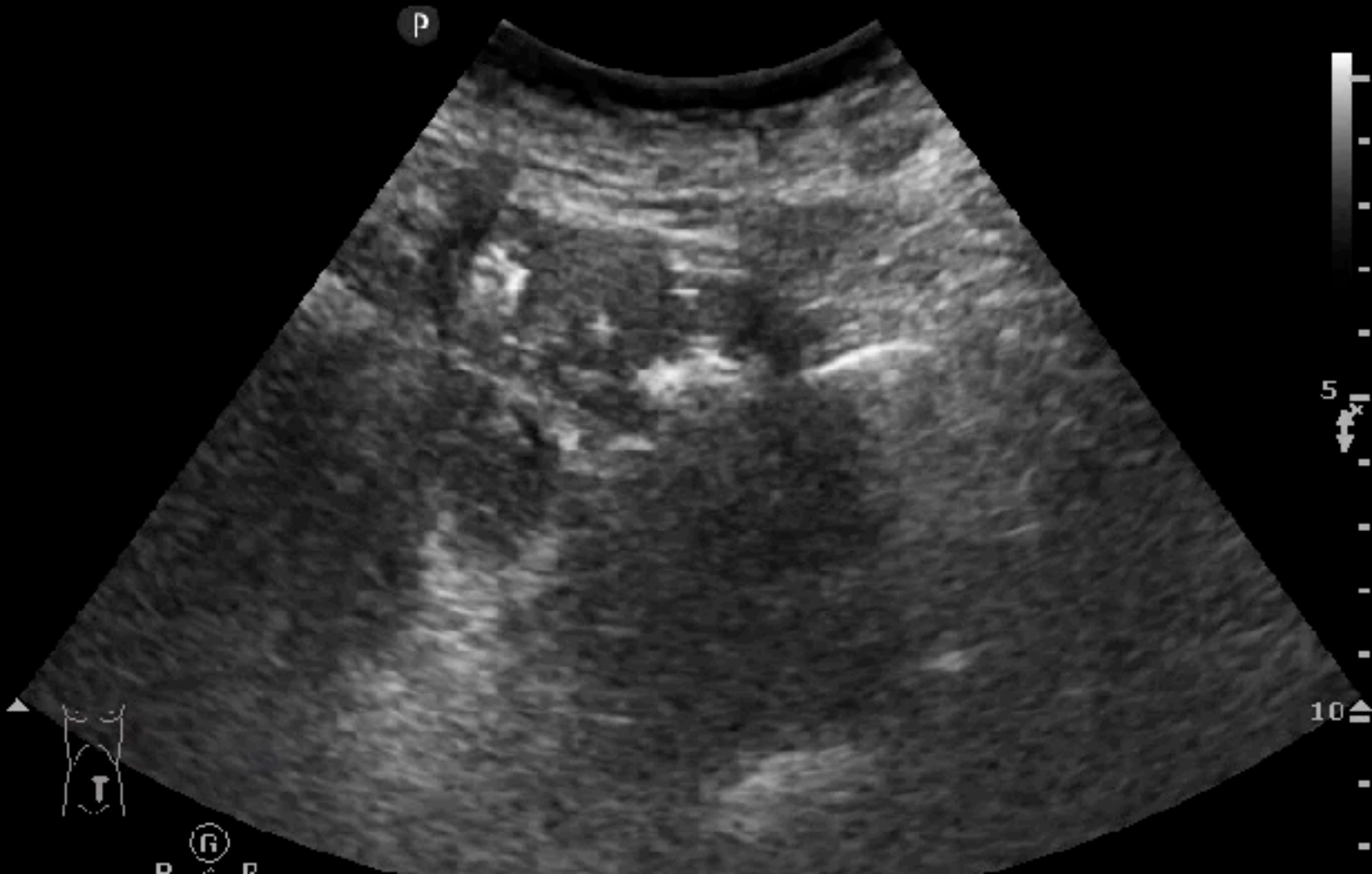
PHILIPS LIU  
00006804

SHH

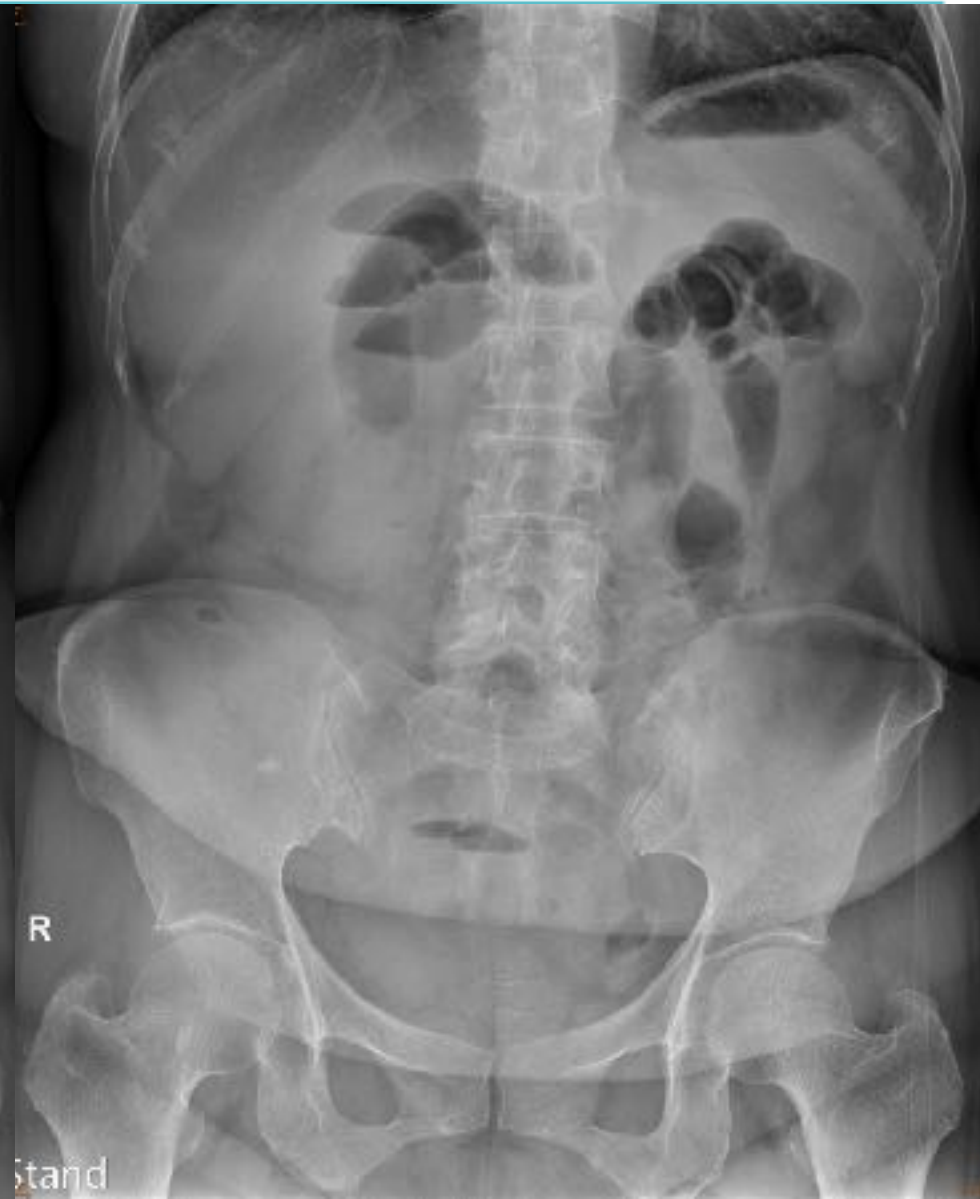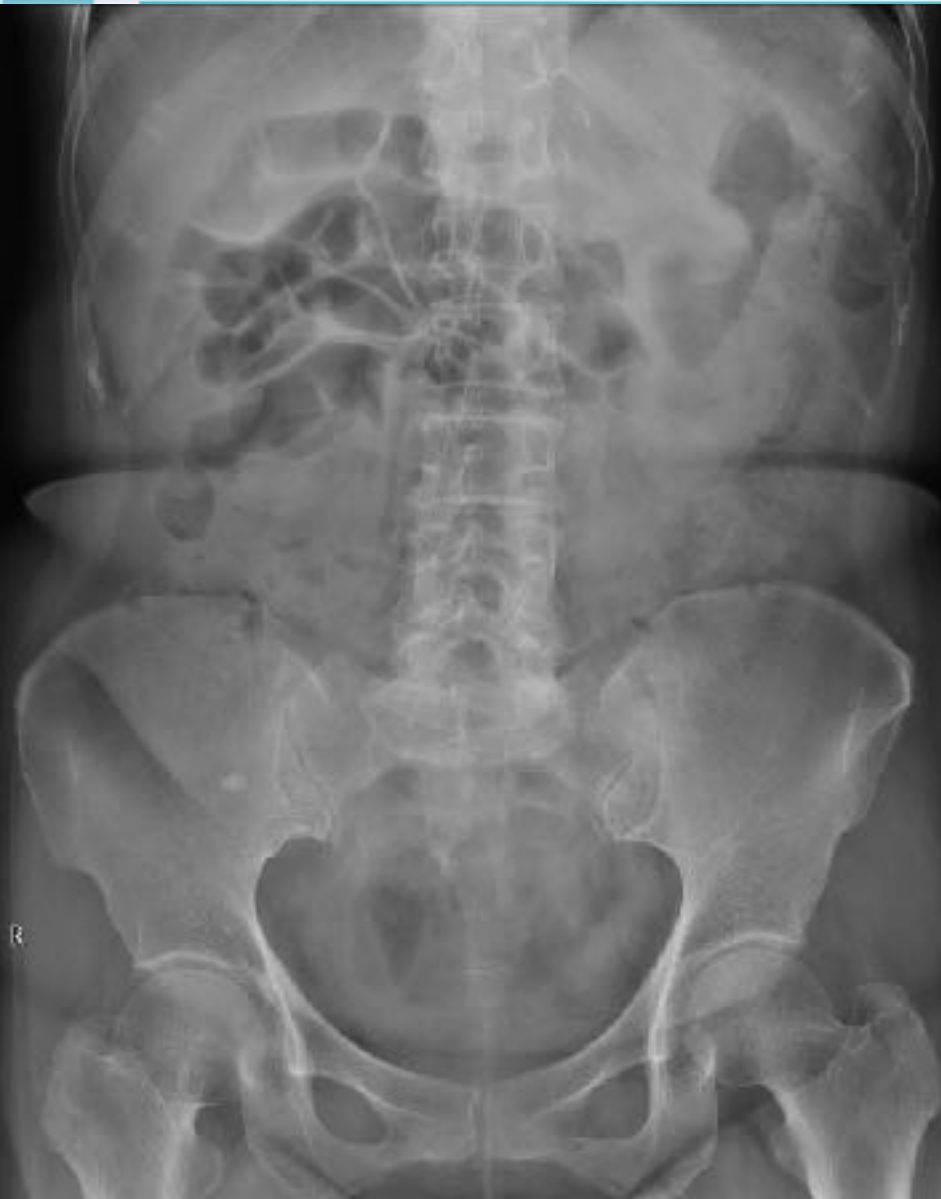MI 0.6 3/2/2022  
TIS 0.0 2:53:17 PM

ABD  
C6-2  
32Hz  
13.0cm

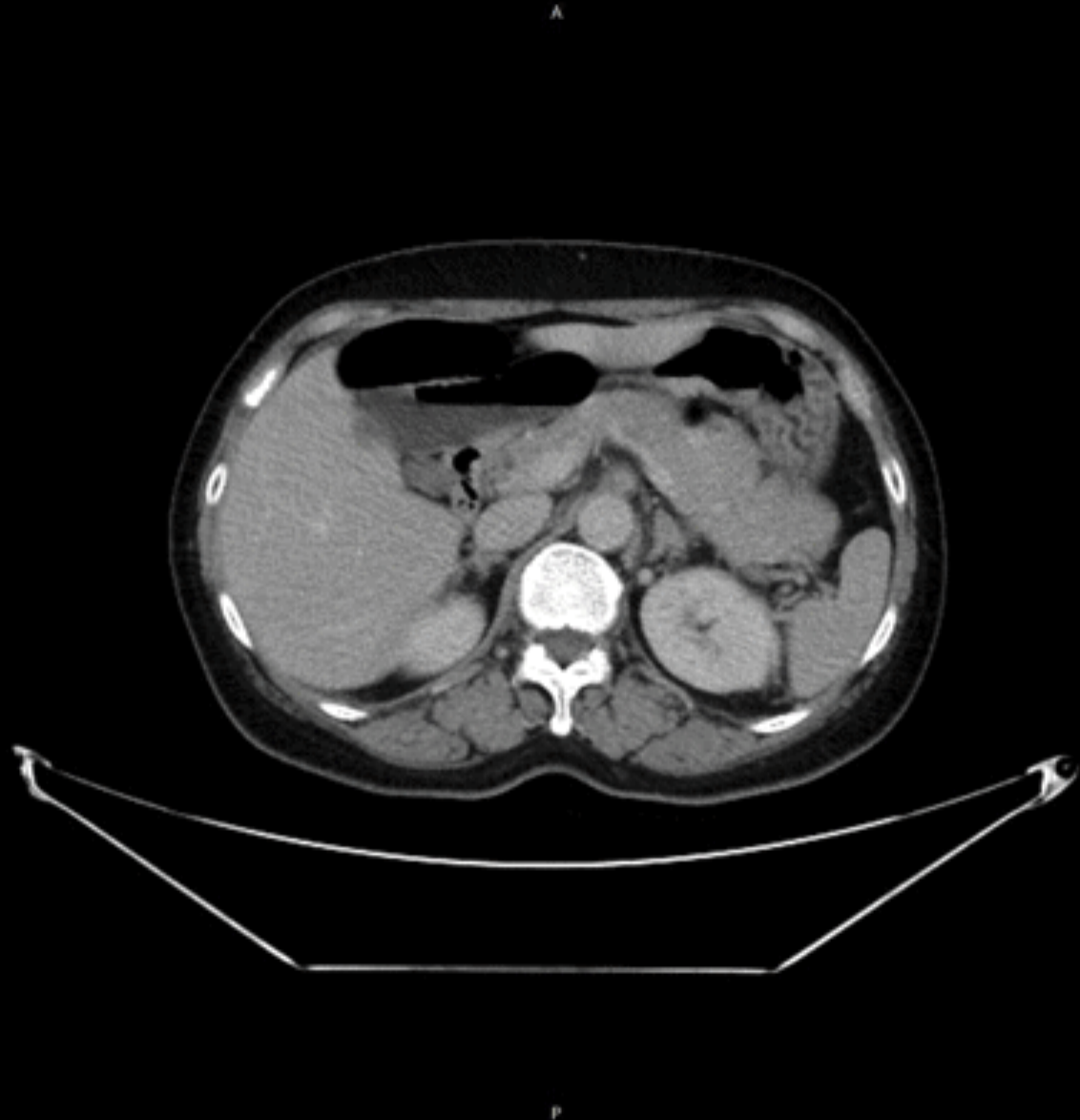
2D  
HGen  
Gn 100  
56  
1/3/3



# 64F, abdominal pain & vomiting



# SBO / Adhesion ileus



# 50M, HCC hx , abdominal pain



PHILIPS LIN  
02610278

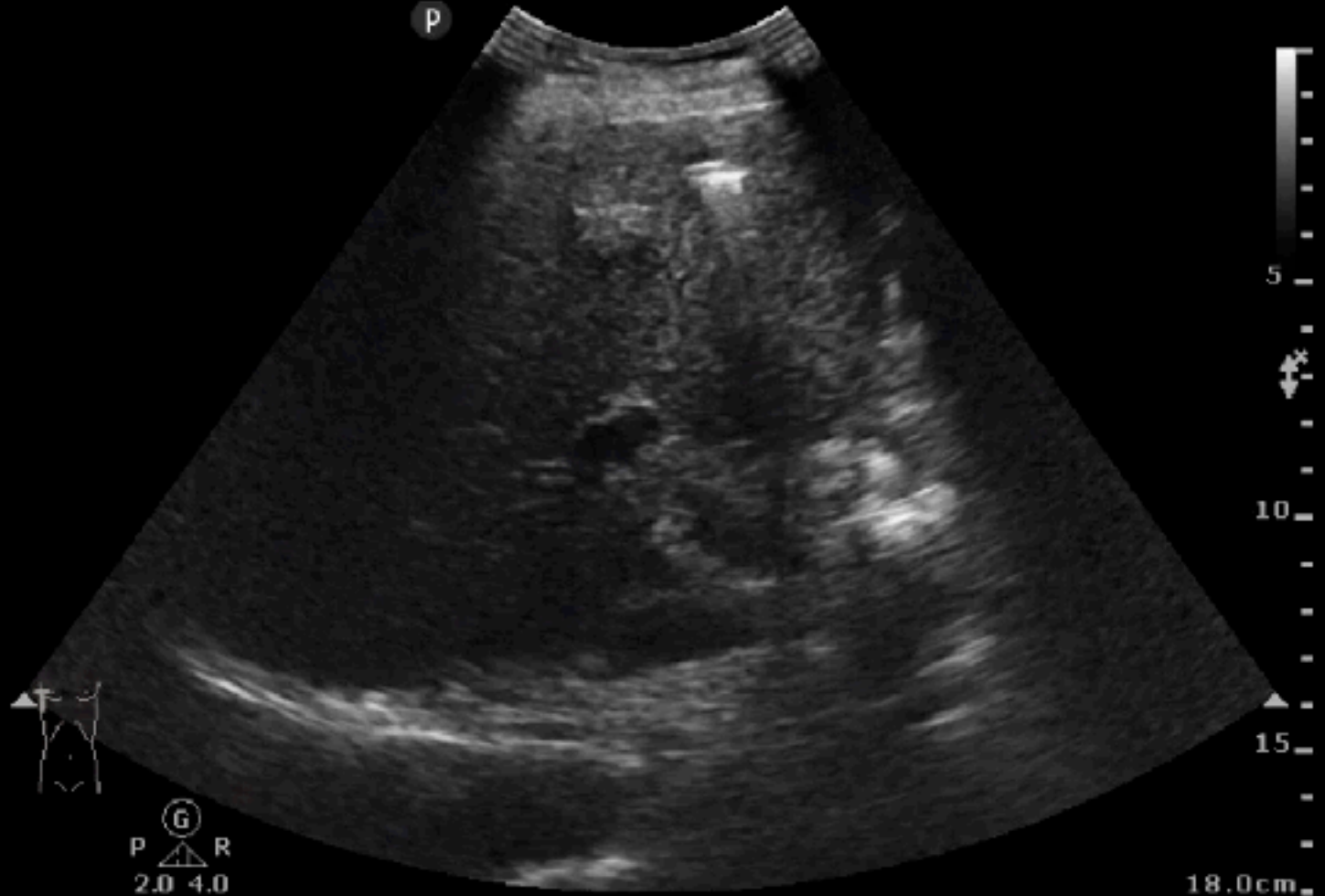
MI 0.6 3/2/2022  
TIS 0.0 3:15:38 PM

ABD  
C6-2  
25Hz  
18.0cm

2D  
HGen  
Gn 100  
56  
1/3/3

SHH

P



G  
P R  
2.0 4.0

18.0cm

# 50M, HCC hx , abdominal pain



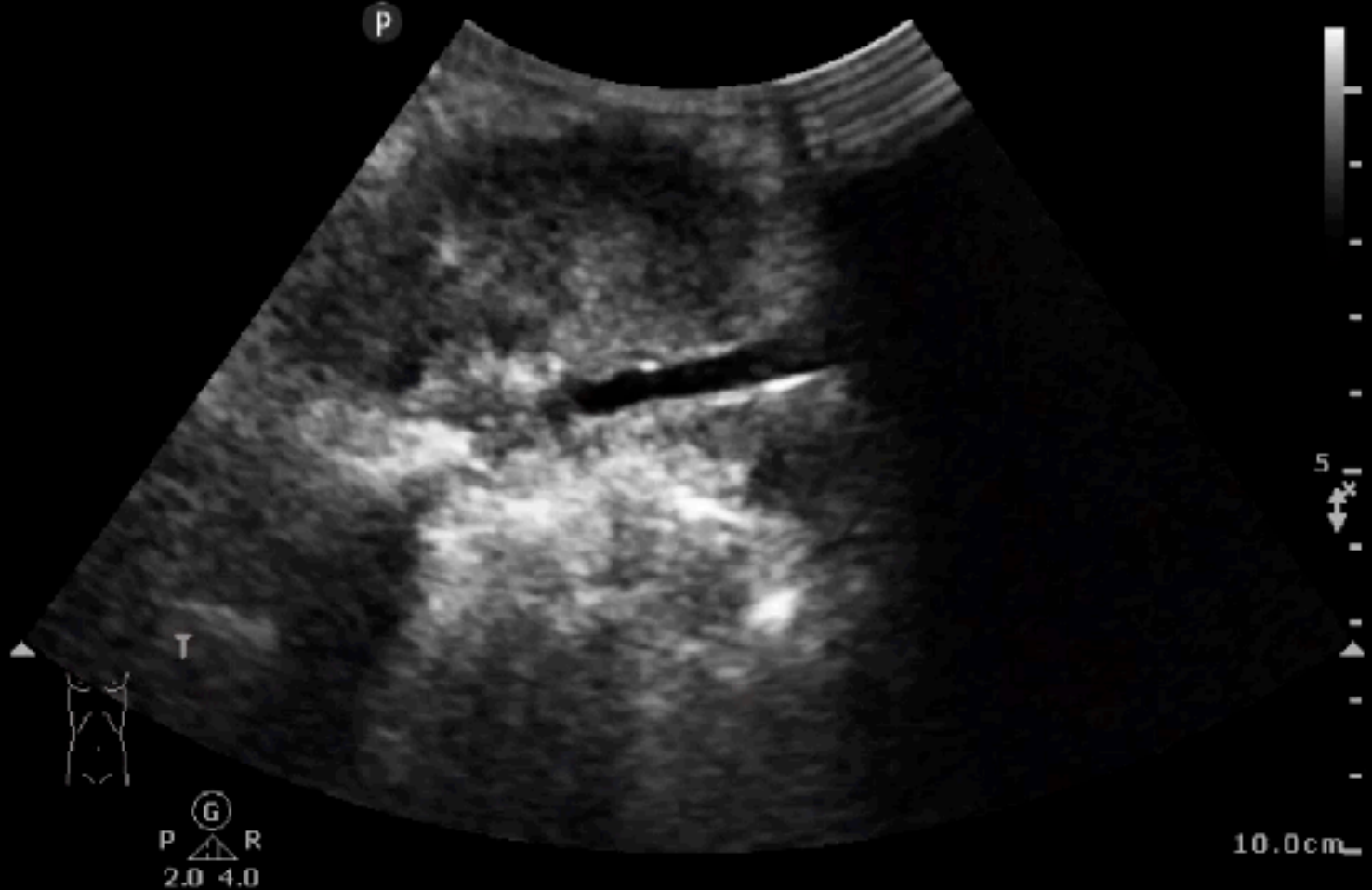
PHILIPS LIN  
02610278

SHH

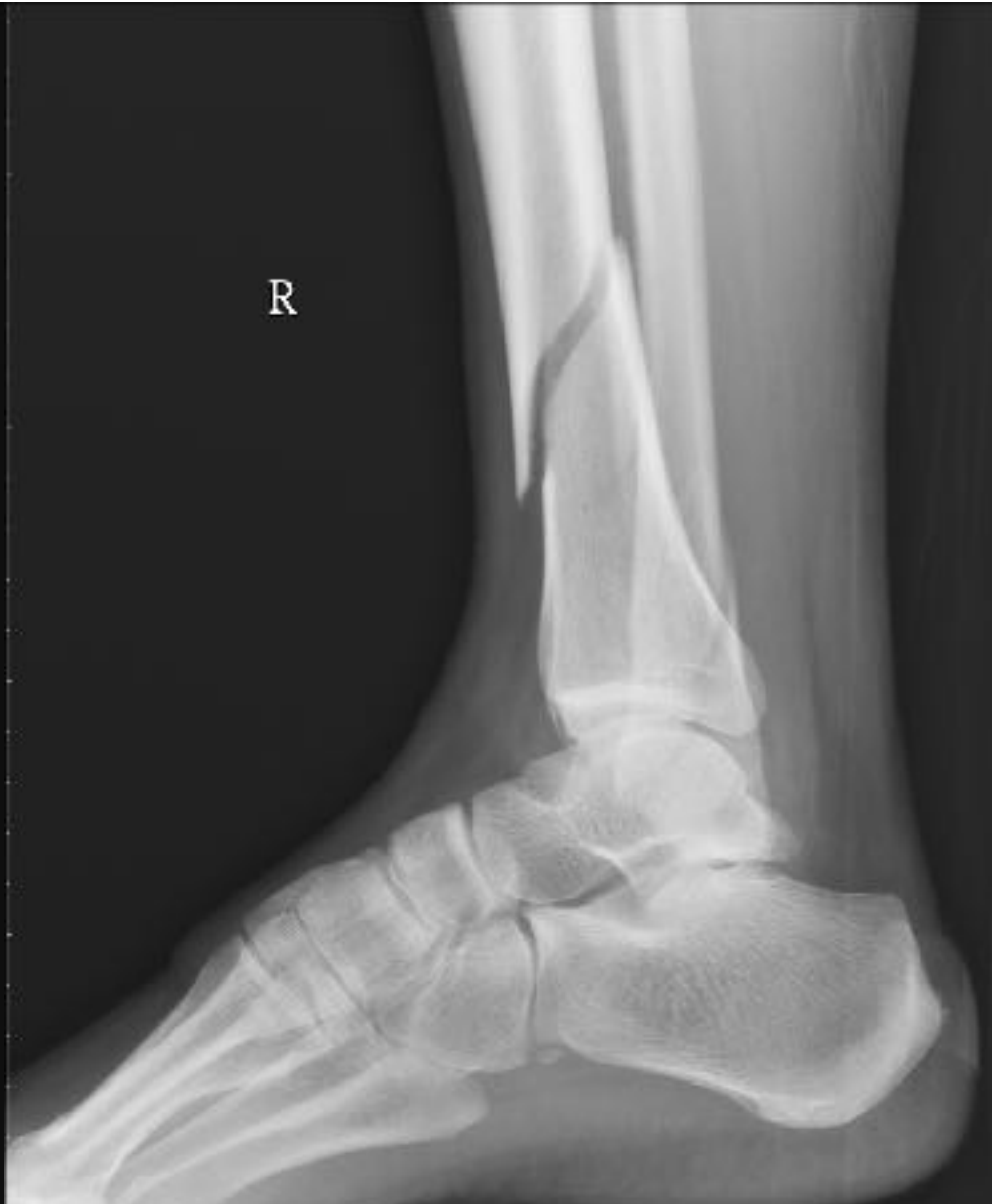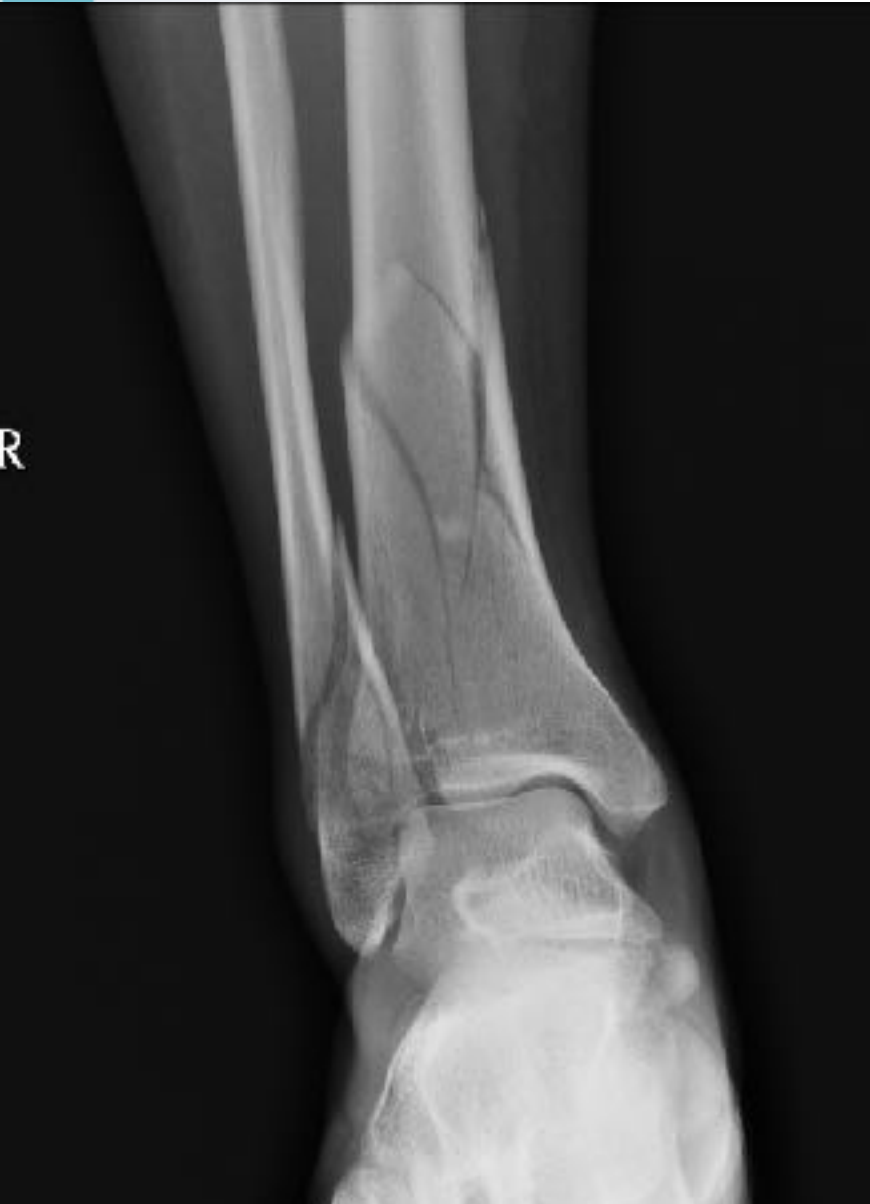MI 0.6 3/2/2022  
TIS 0.0 3:22:56 PM

ABD  
C6-2  
38Hz  
10.0cm

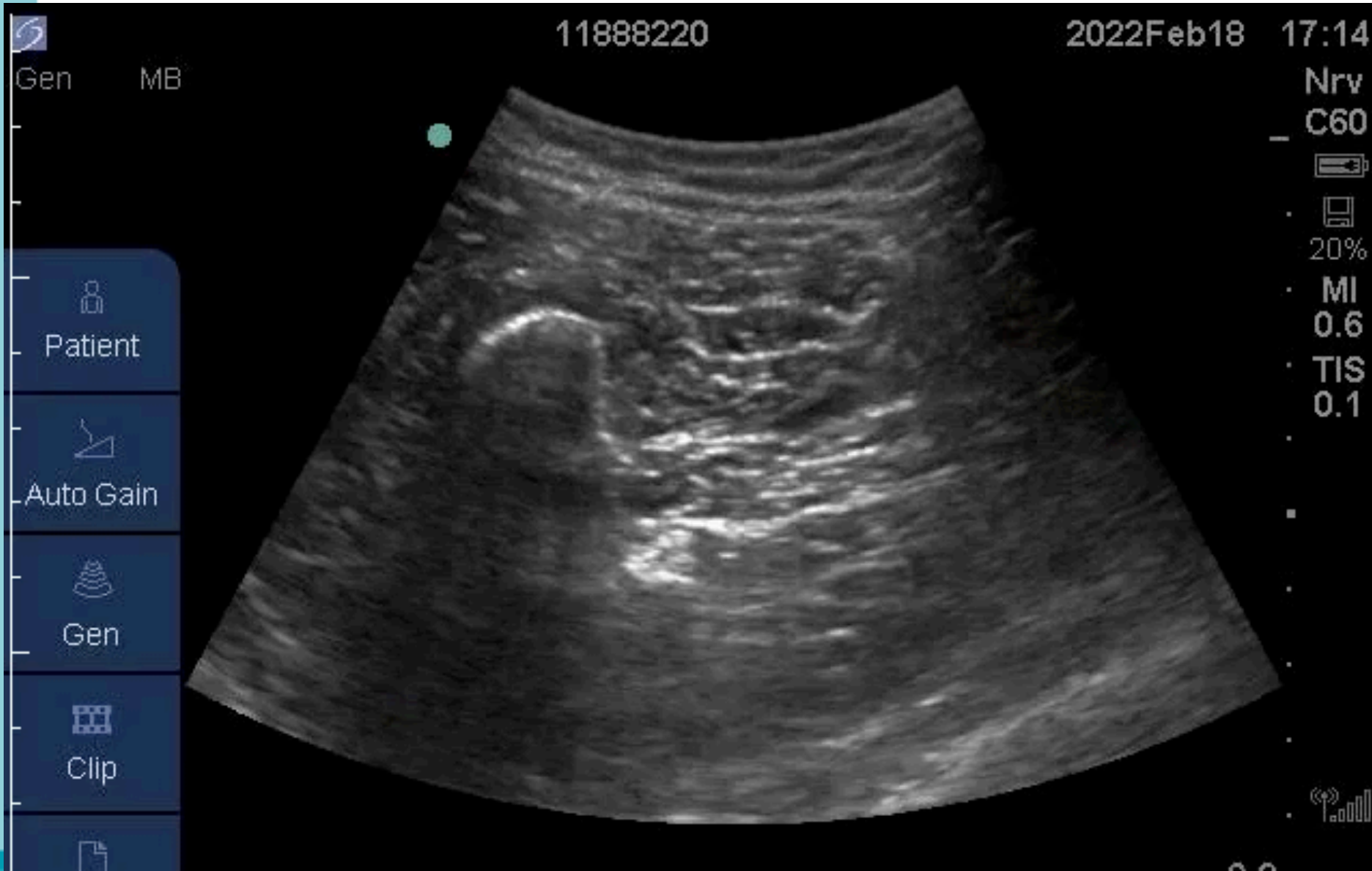
2D  
HGen  
Gn 100  
56  
1/3/3



# 42F, trauma with fracture

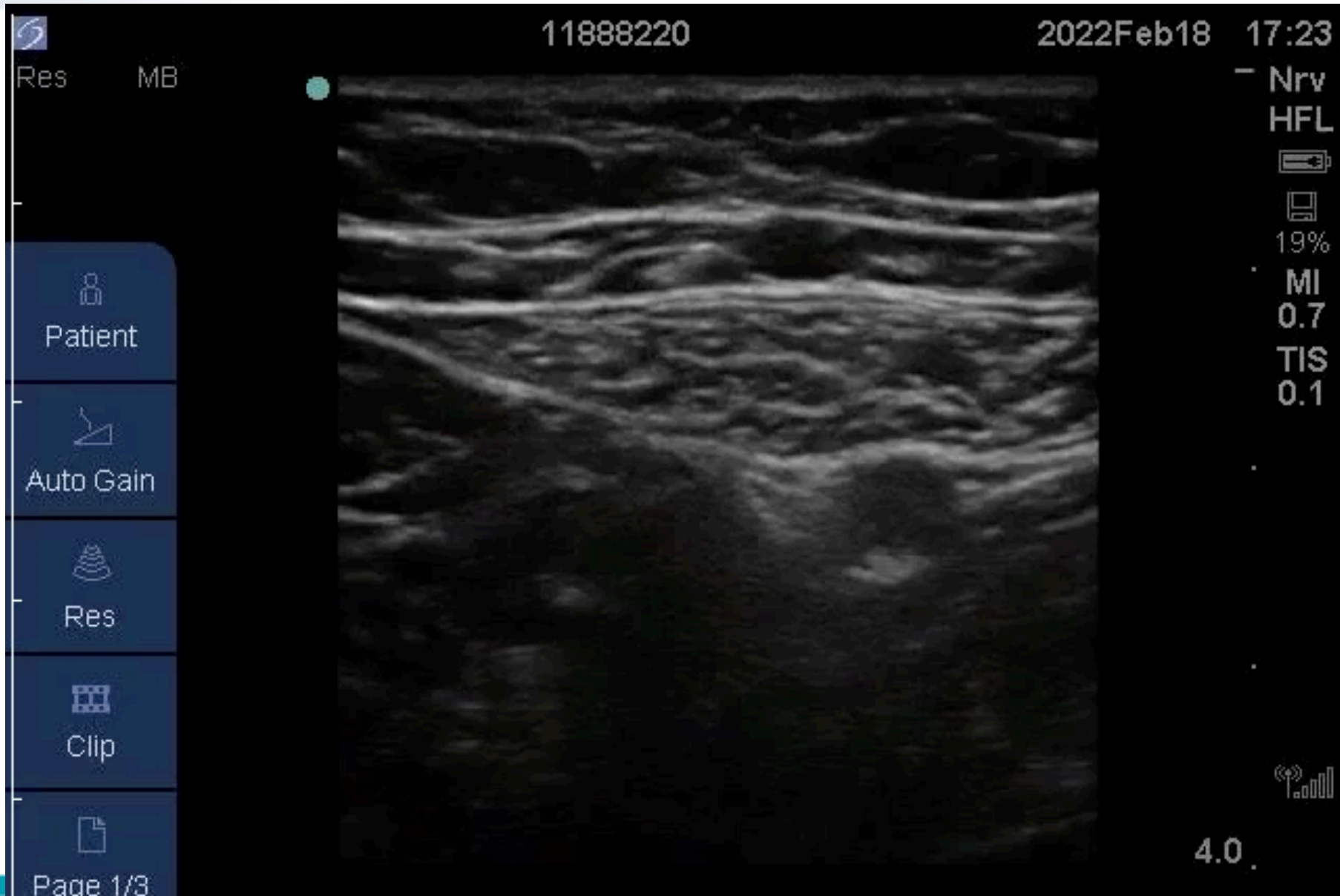


# Sciatic nerve block (anterior approach)



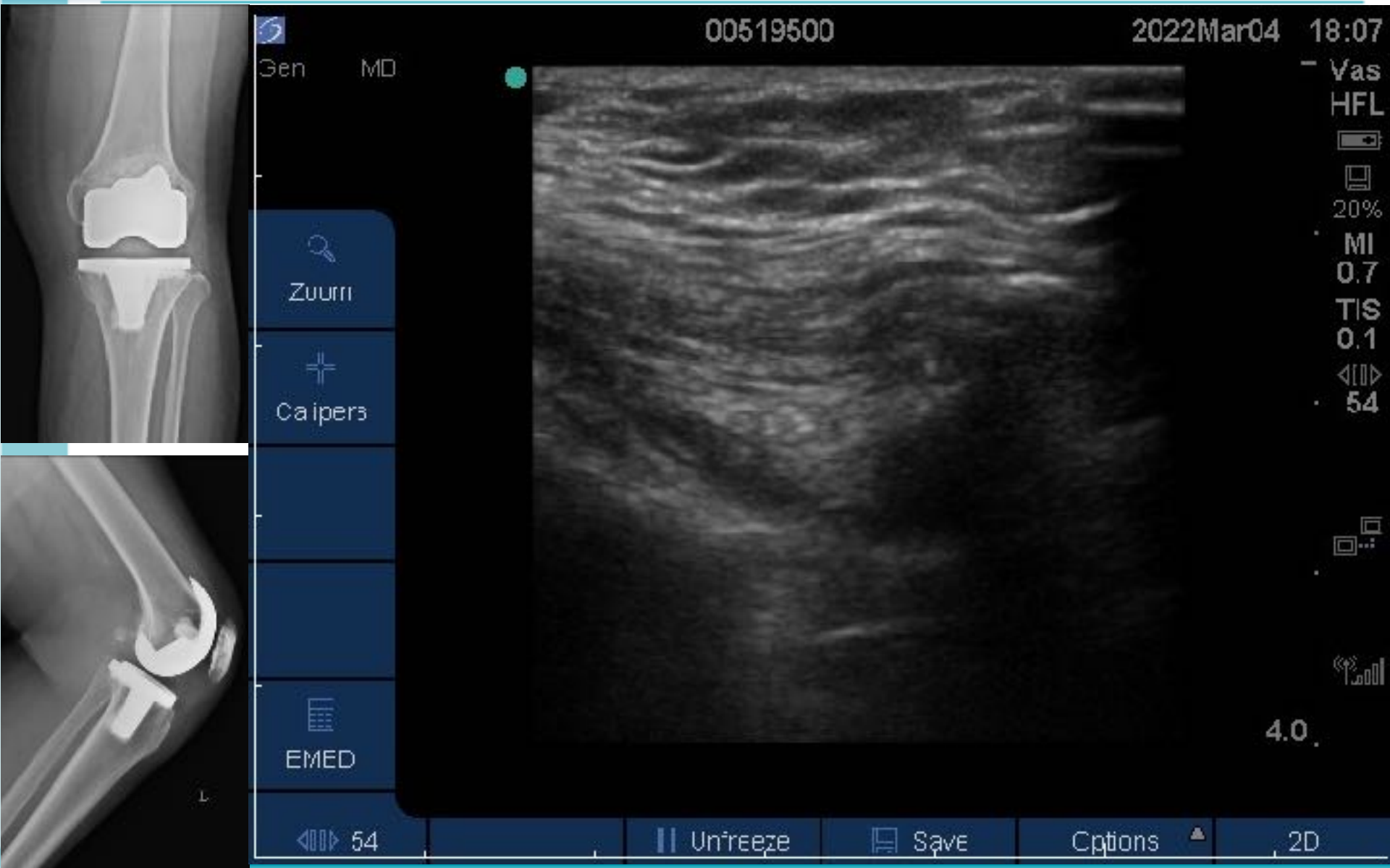

# Adductor canal block

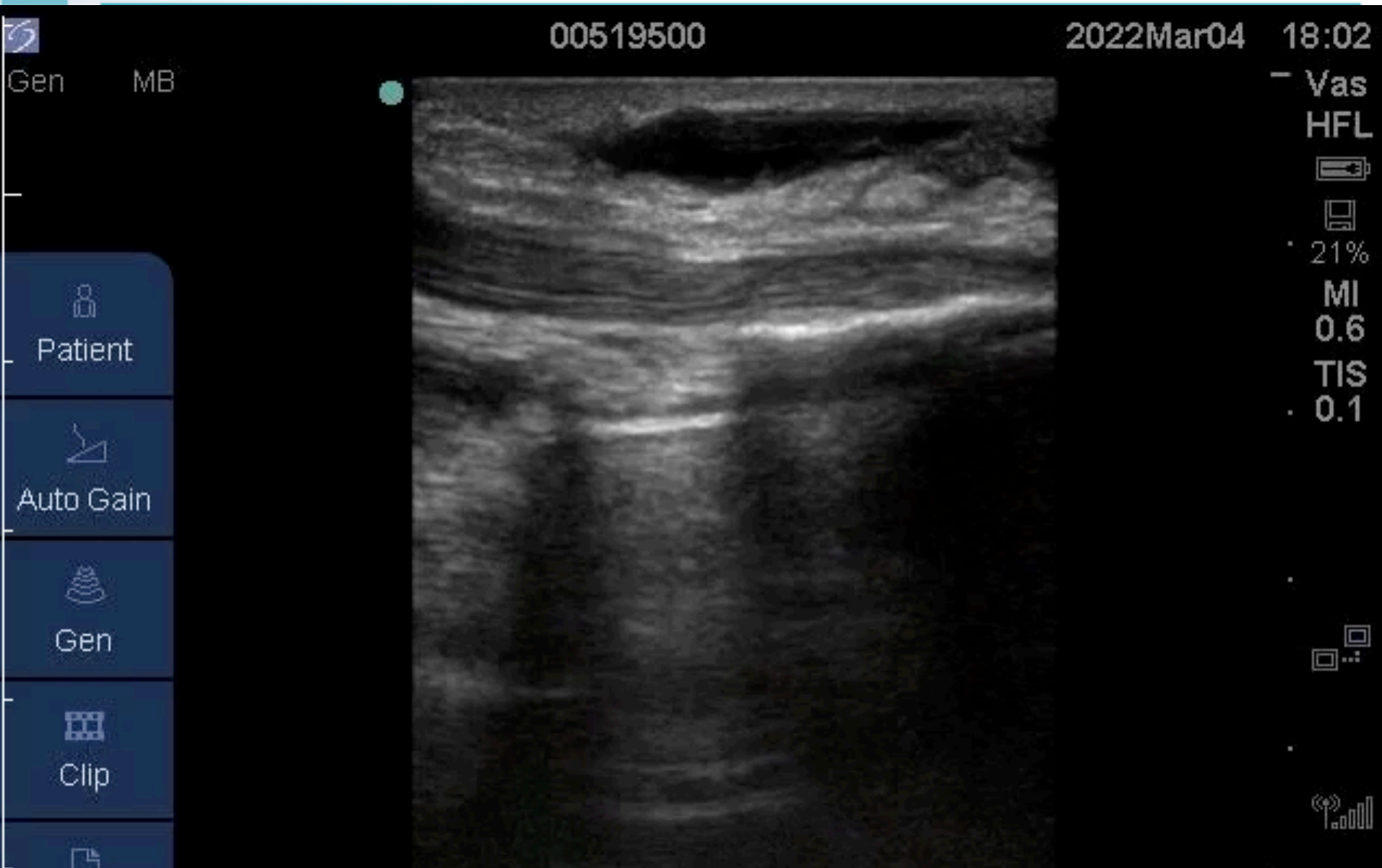



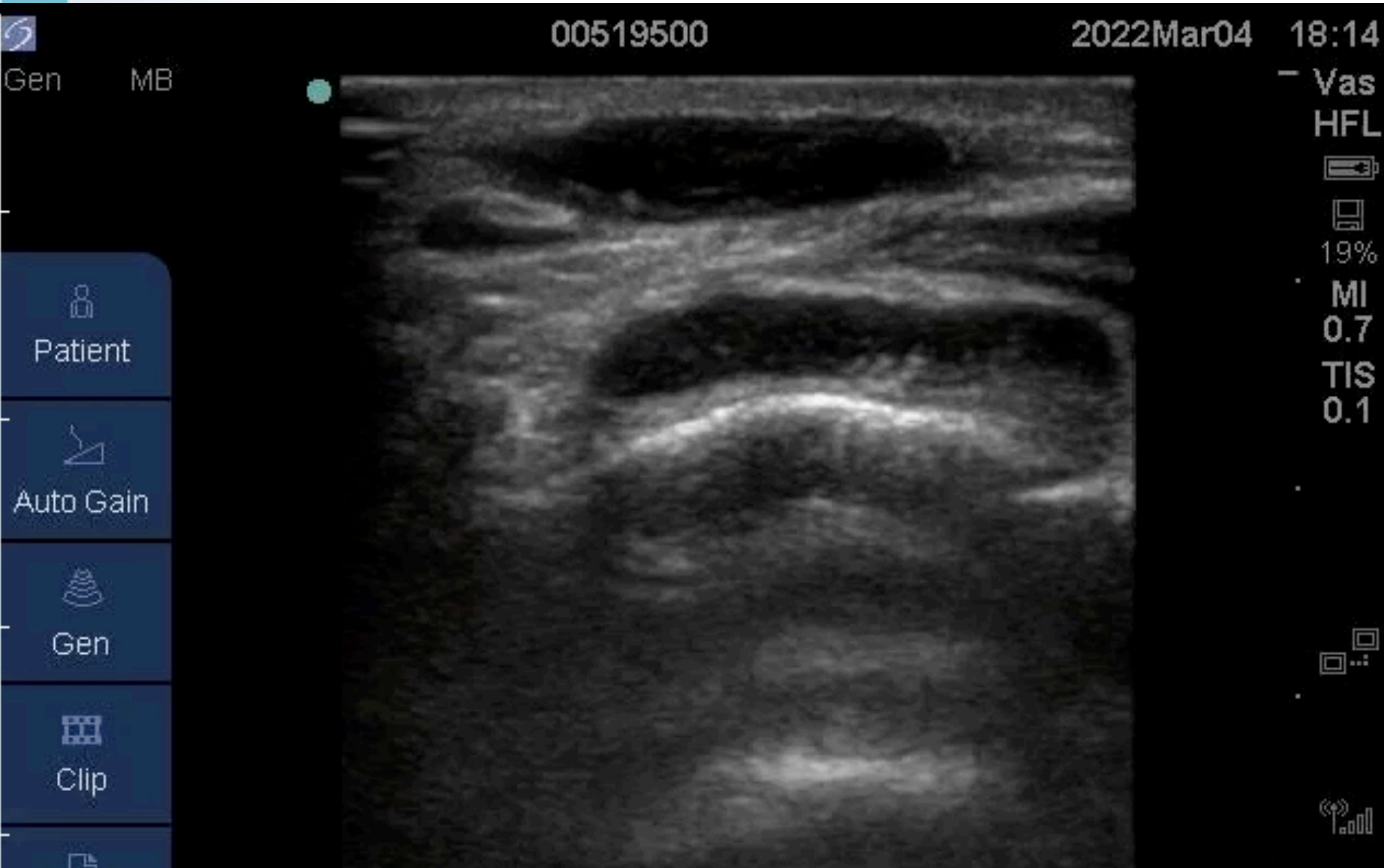
# 72F, left knee cellulitis



# 72F, left knee cellulitis



# Anisotropy



# 38M, RLQ pain (Dr. Lu)



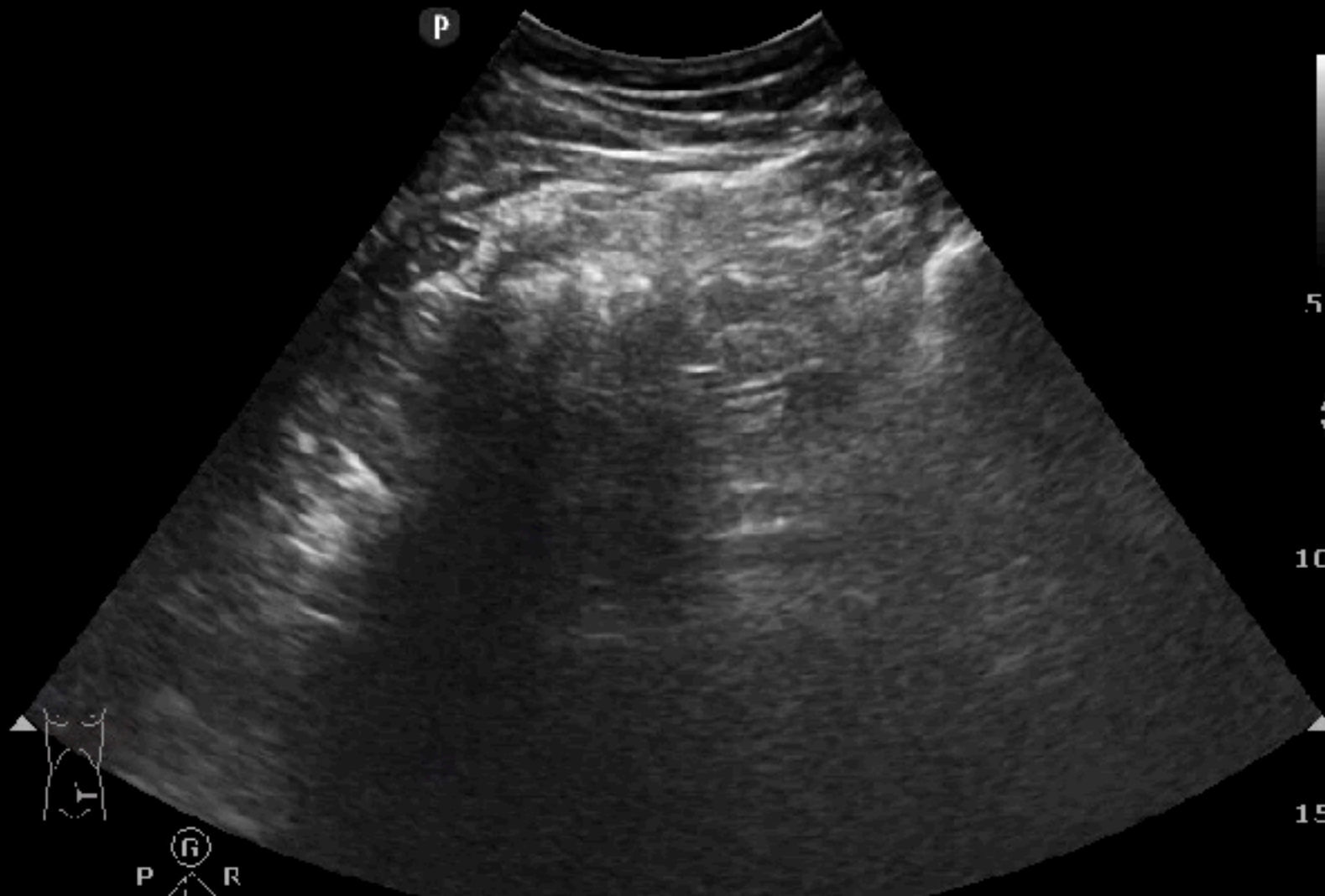PHILIPS LIAO  
12034987

SHH

MI 0.6 2/25/2022  
TIS 0.0 11:38:33 AM

ABD  
C6-2  
26Hz  
17.0cm

2D  
HGen  
Gn 100  
56  
1/3/3

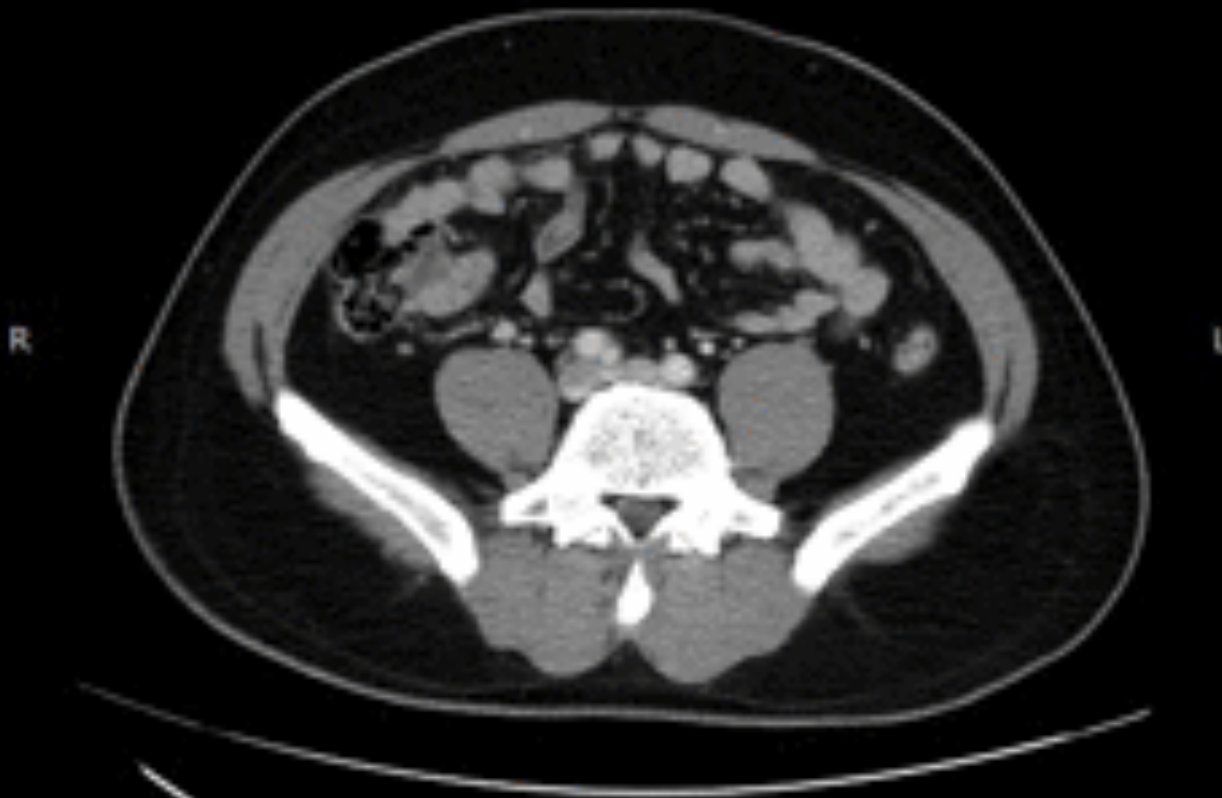


# 38M, RLQ pain



12034987  
廖育德

2022/02/25  
Abdomen + Pelvis CT(-C,+C)





# 58M, dyspnea for 2 days (3級)

到院時間: 20220308 134801

檢傷級數: 3

意識狀態: E4\_V5\_M6

體重: 68Kg 體溫: 36°C

脈搏: 109 呼吸次數: 25

血壓: 139/107

SP02: 92

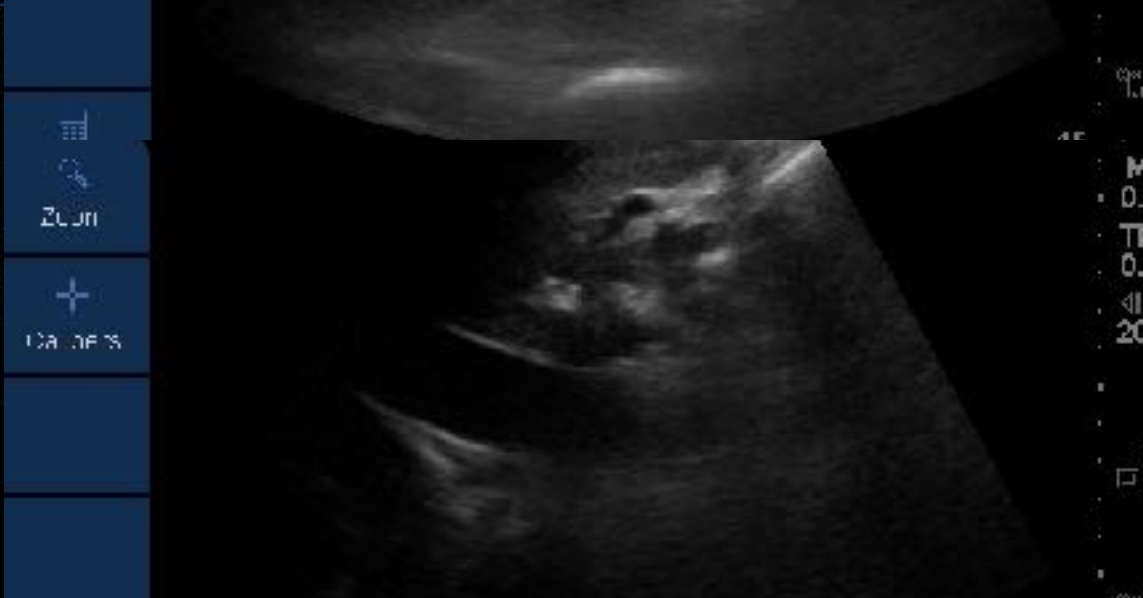
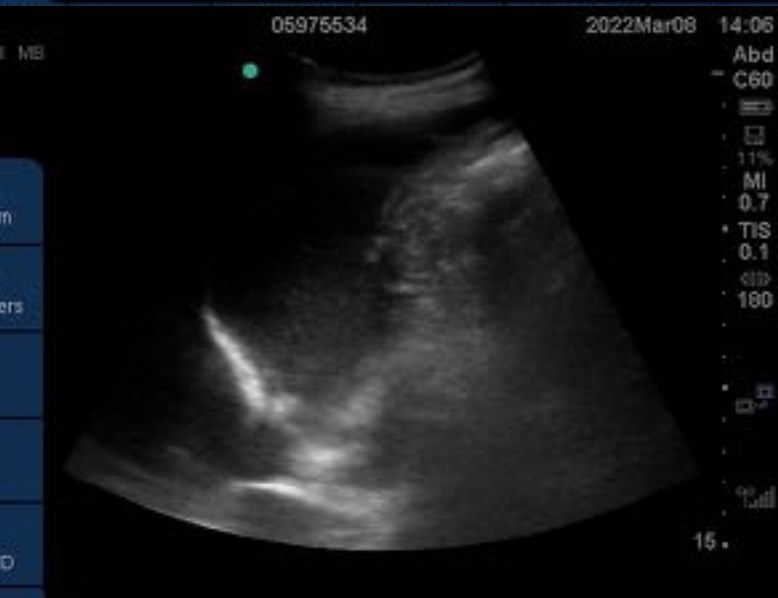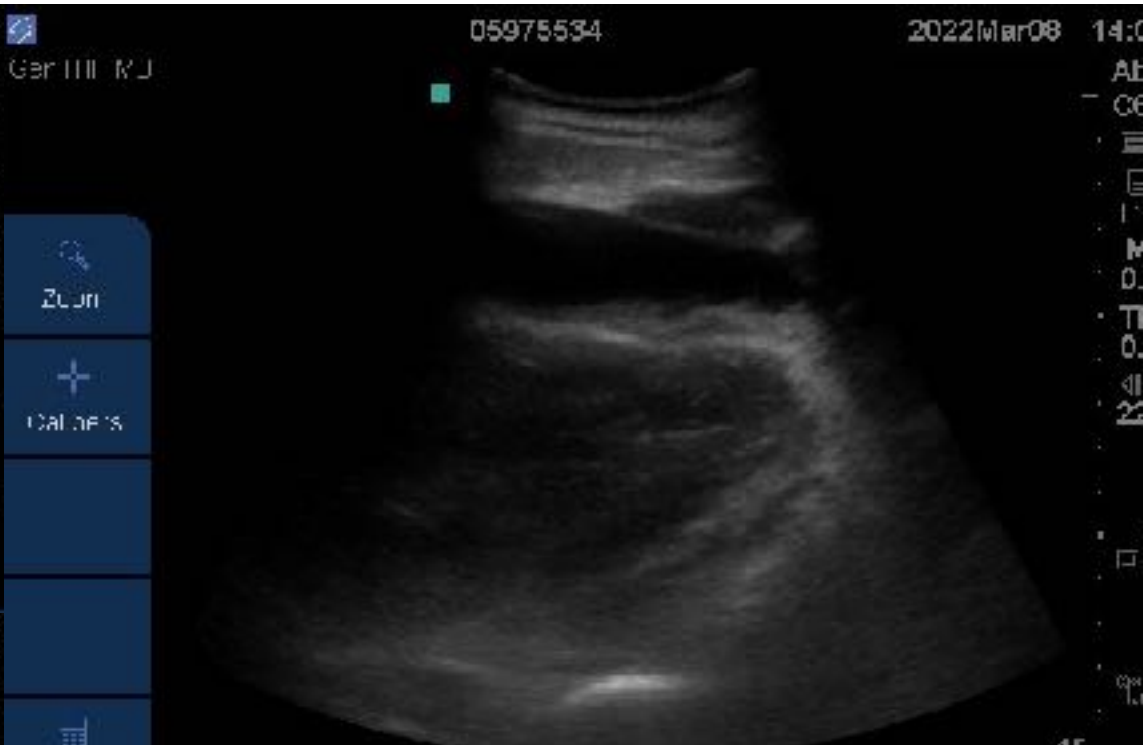
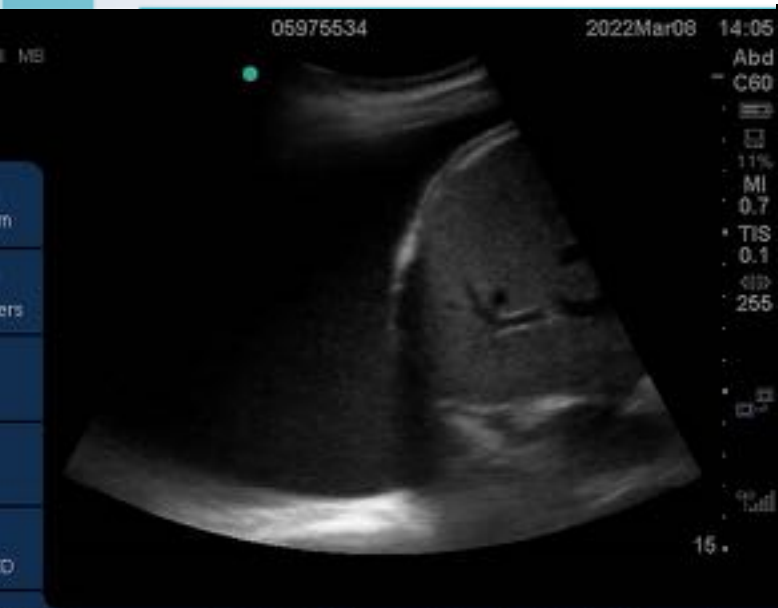過敏史: 無

過去病史: ;其他\_1:1;說明: B肝、肺腺癌

主述: 病患來診為呼吸短促, 喘2天

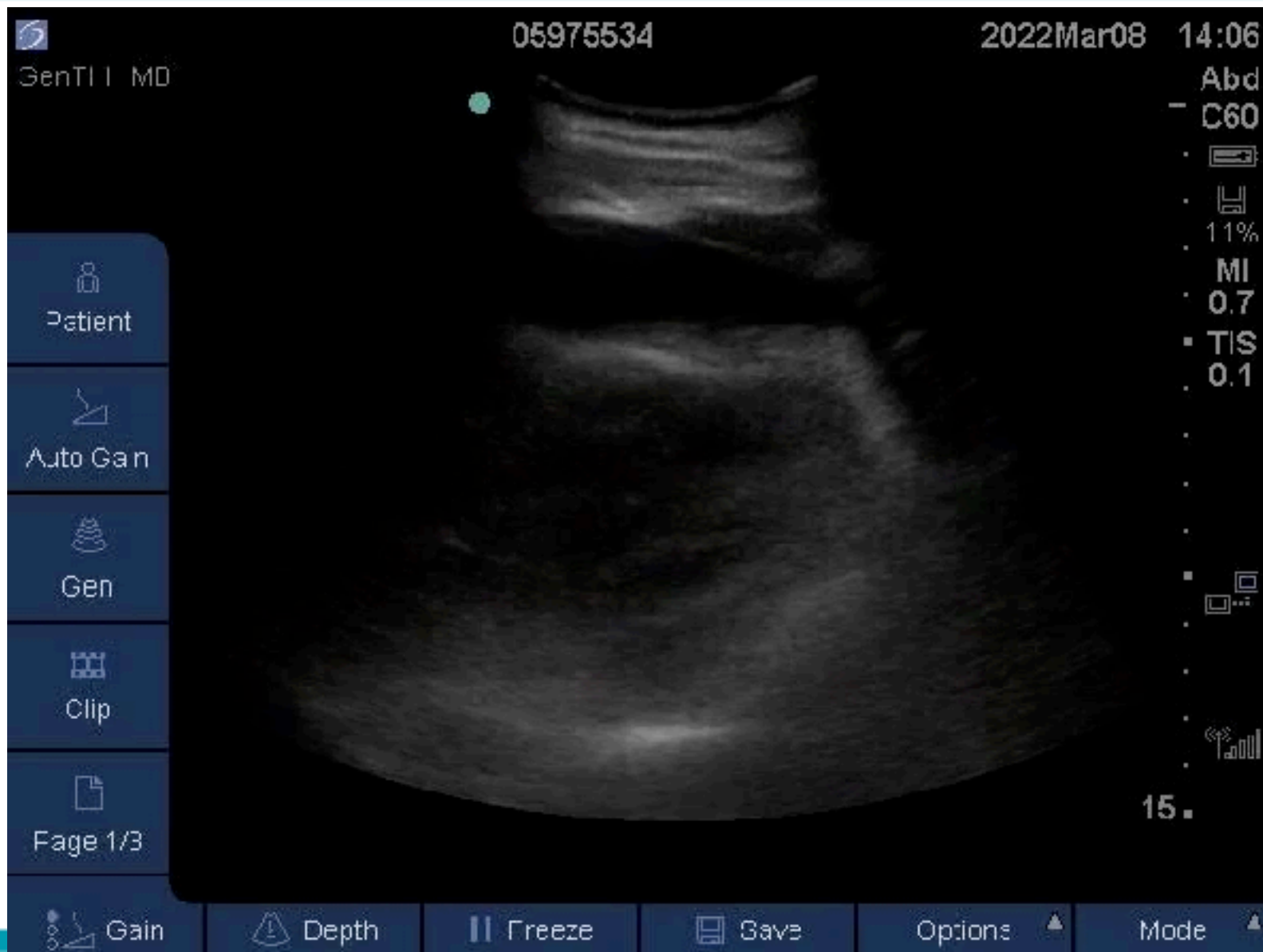

# 58M, dyspnea for 2 days (3級)



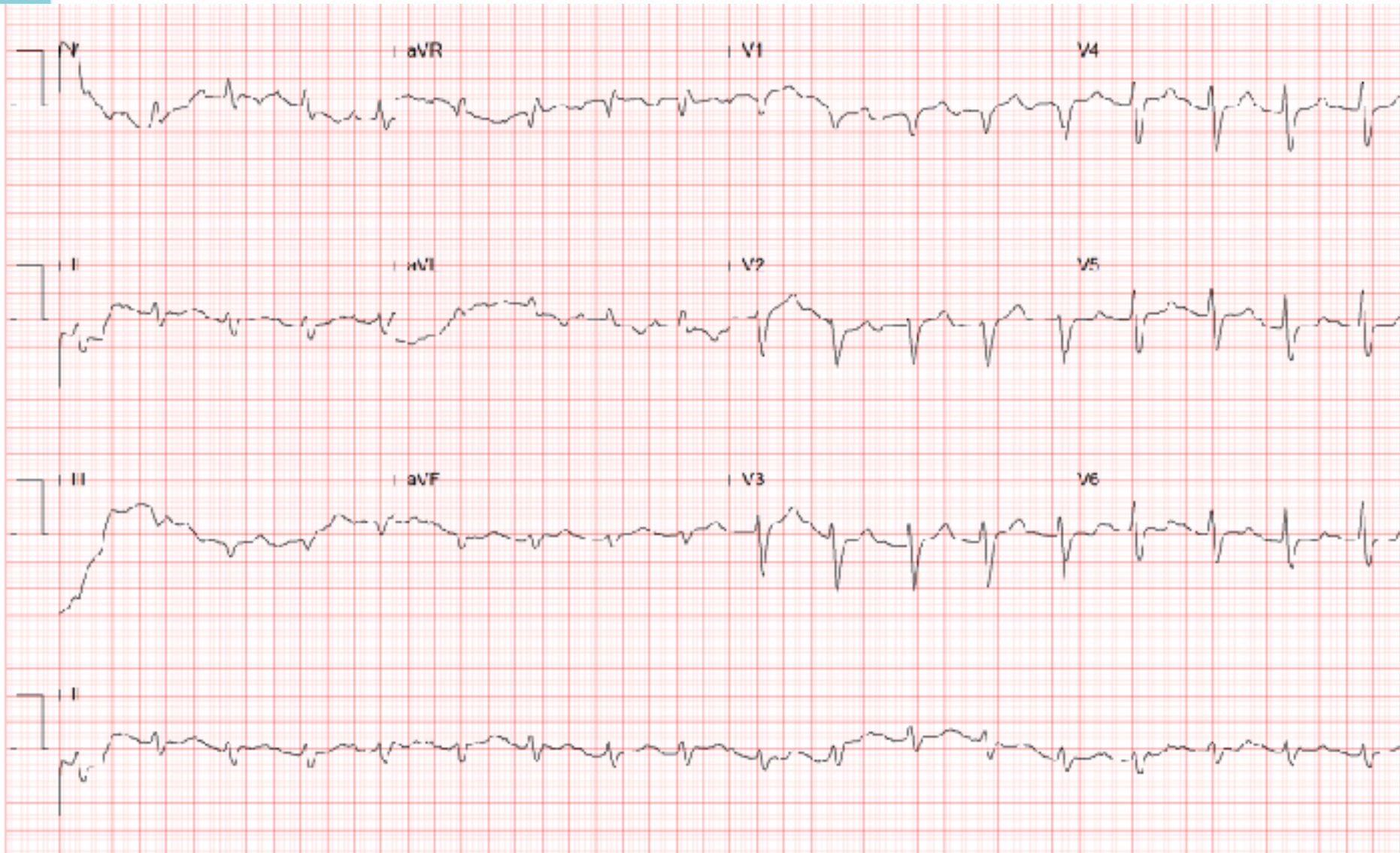


# 58M, dyspnea for 2 days (3級)

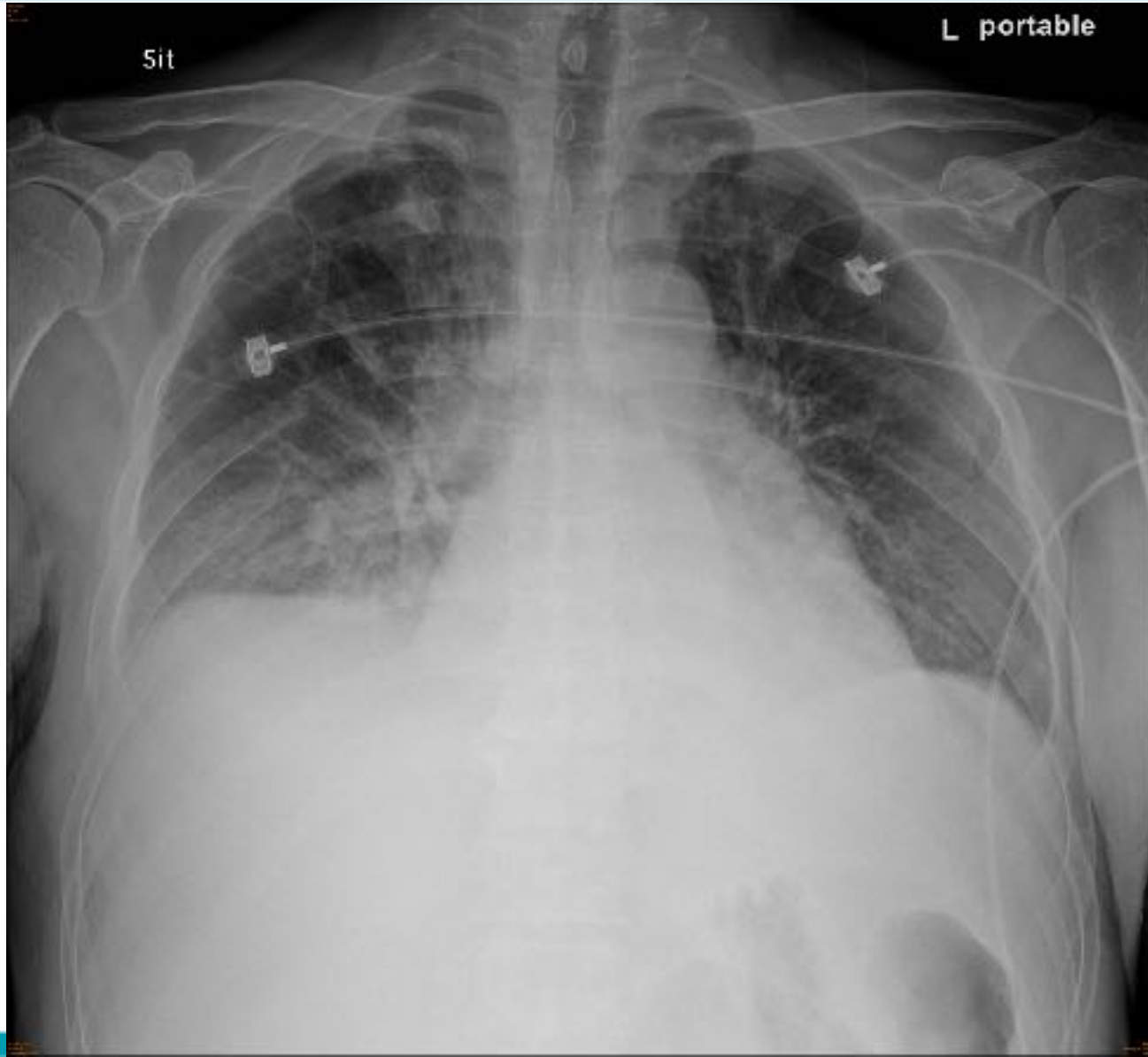



# 58M, dyspnea for 2 days (3級)



# 58M, dyspnea for 2 days (3級)



# 58M, dyspnea for 2 days (3級)



05975534 2022Mar08 14:27

Gen MB

— Vas  
HFL  
11%  
MI  
0.6  
TIS  
0.1

Patient

Auto Gain

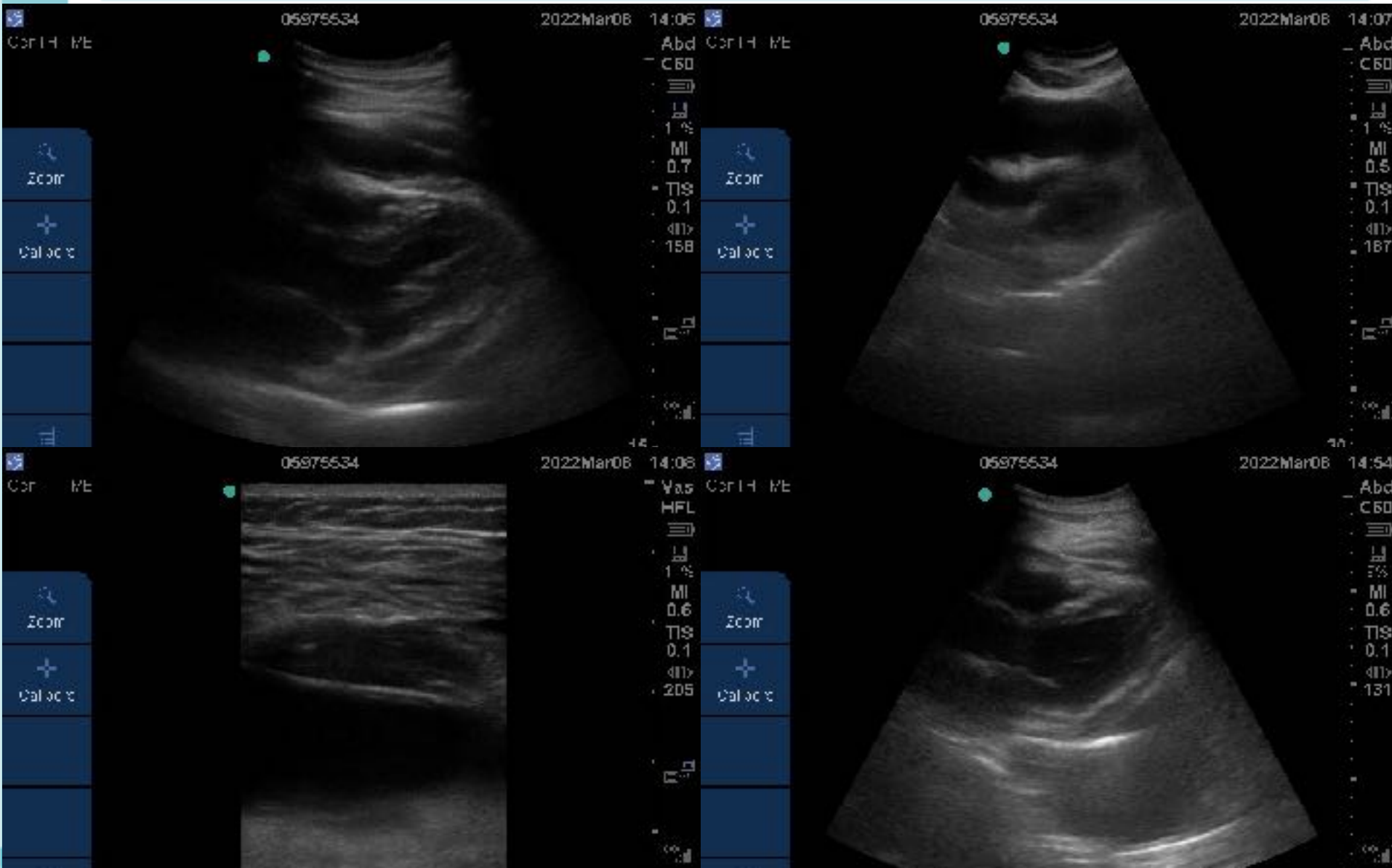
Gen

Clip

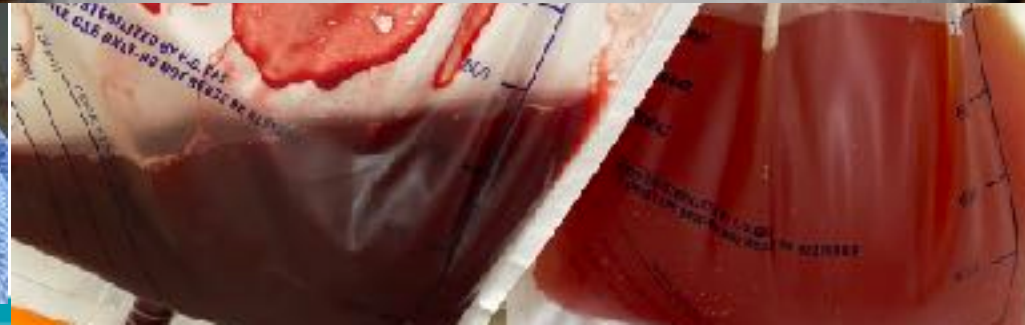
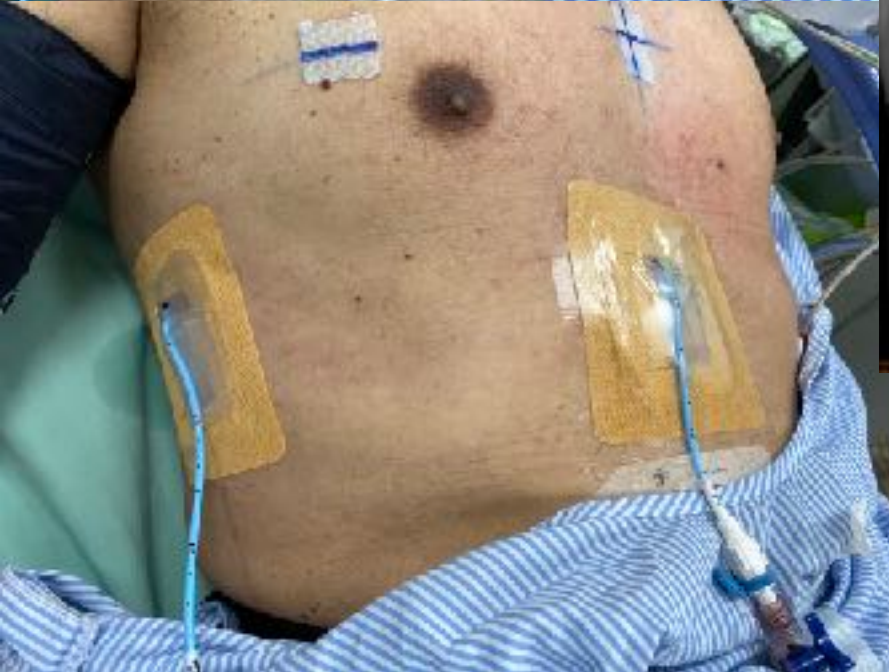
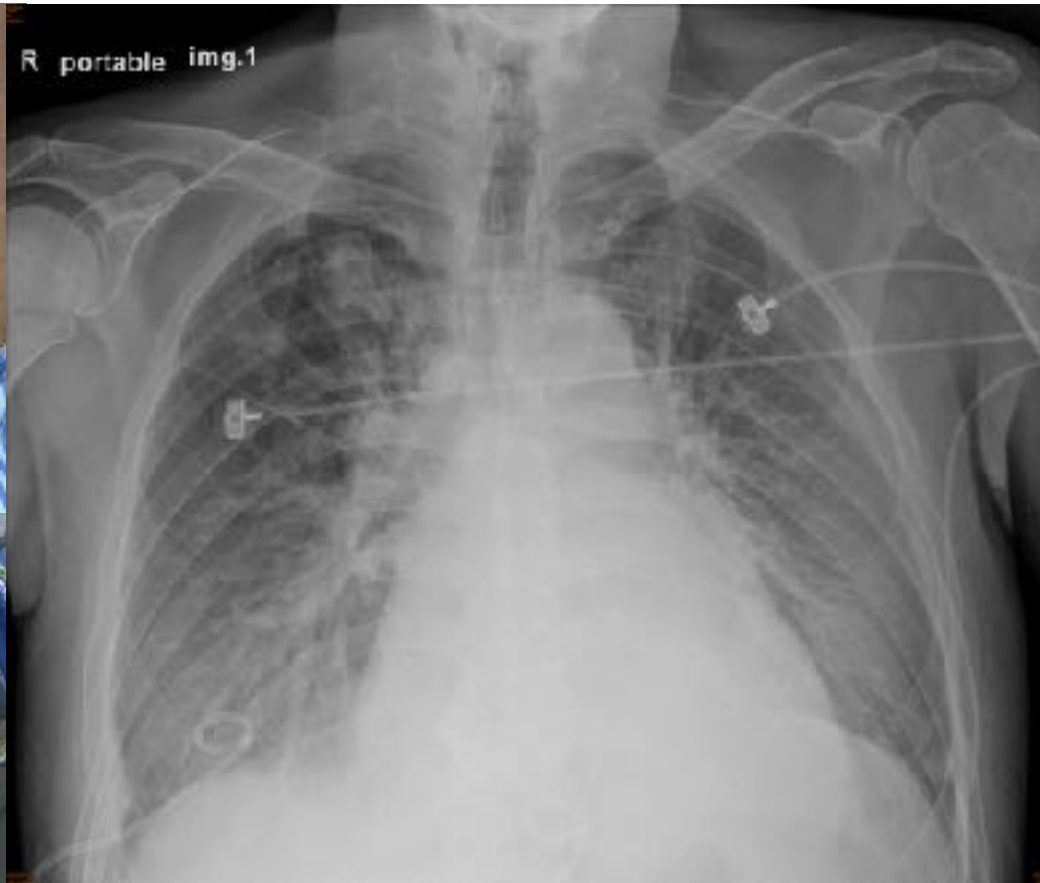

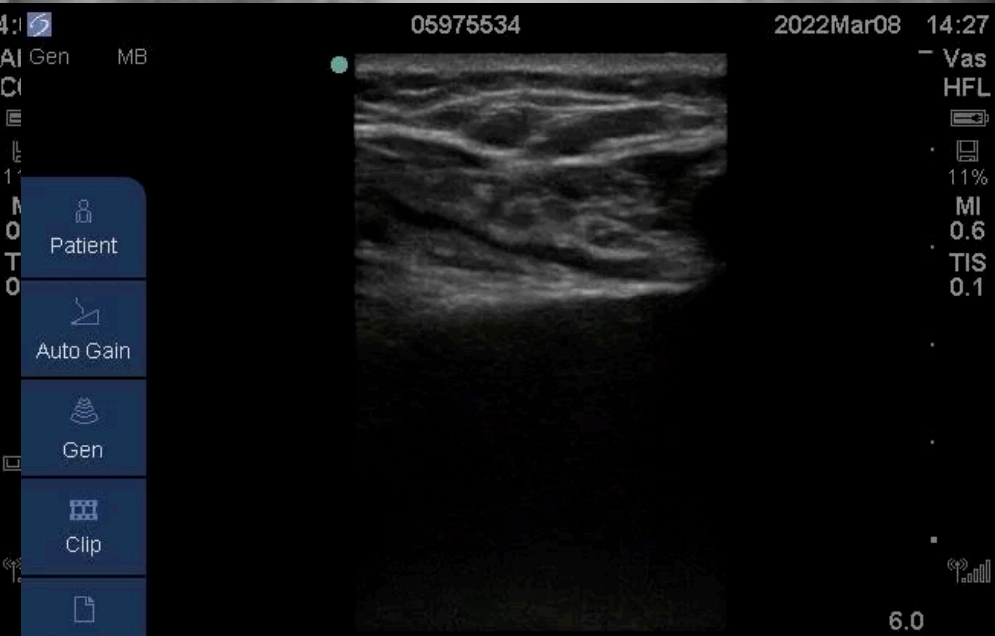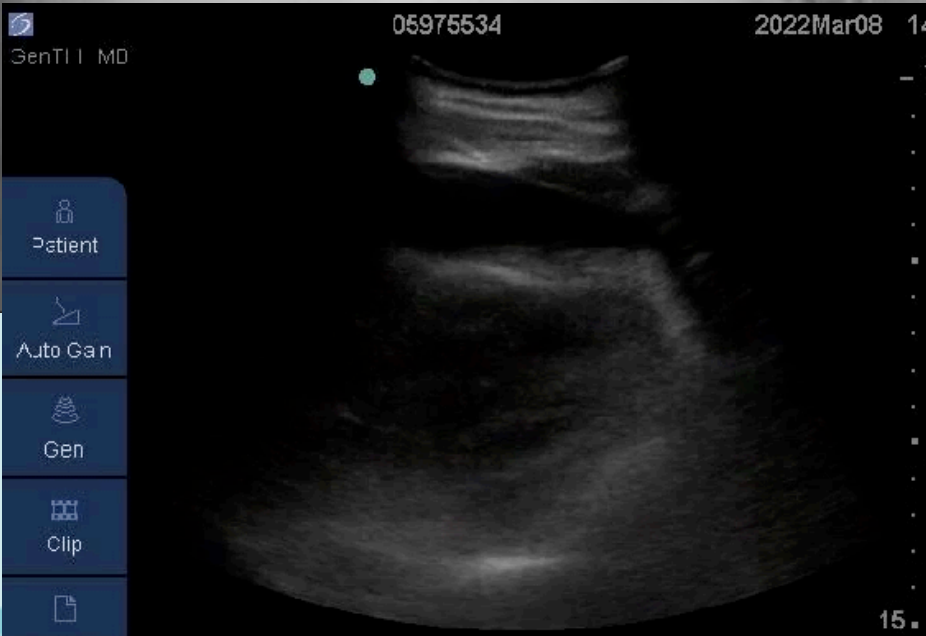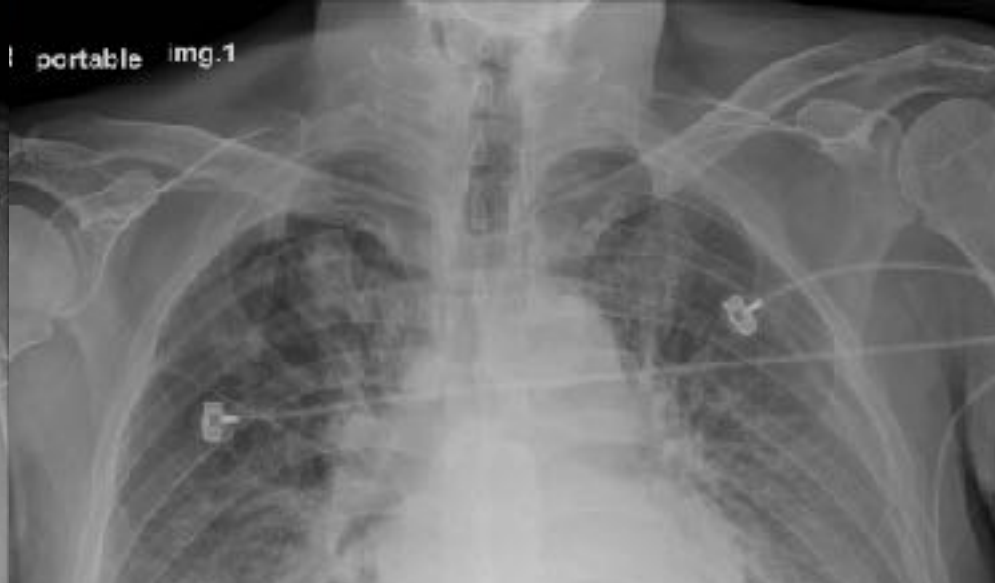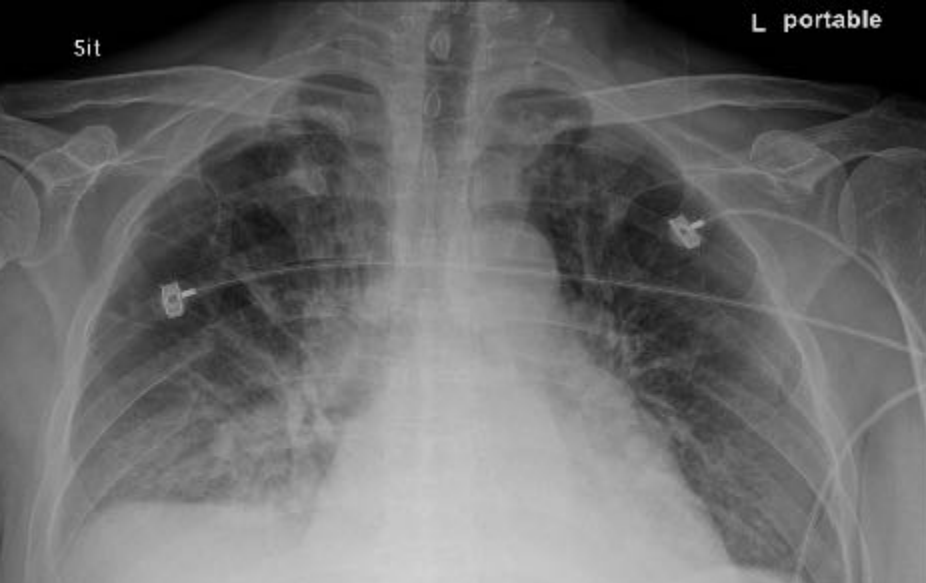# 58M, dyspnea for 2 days (3級)



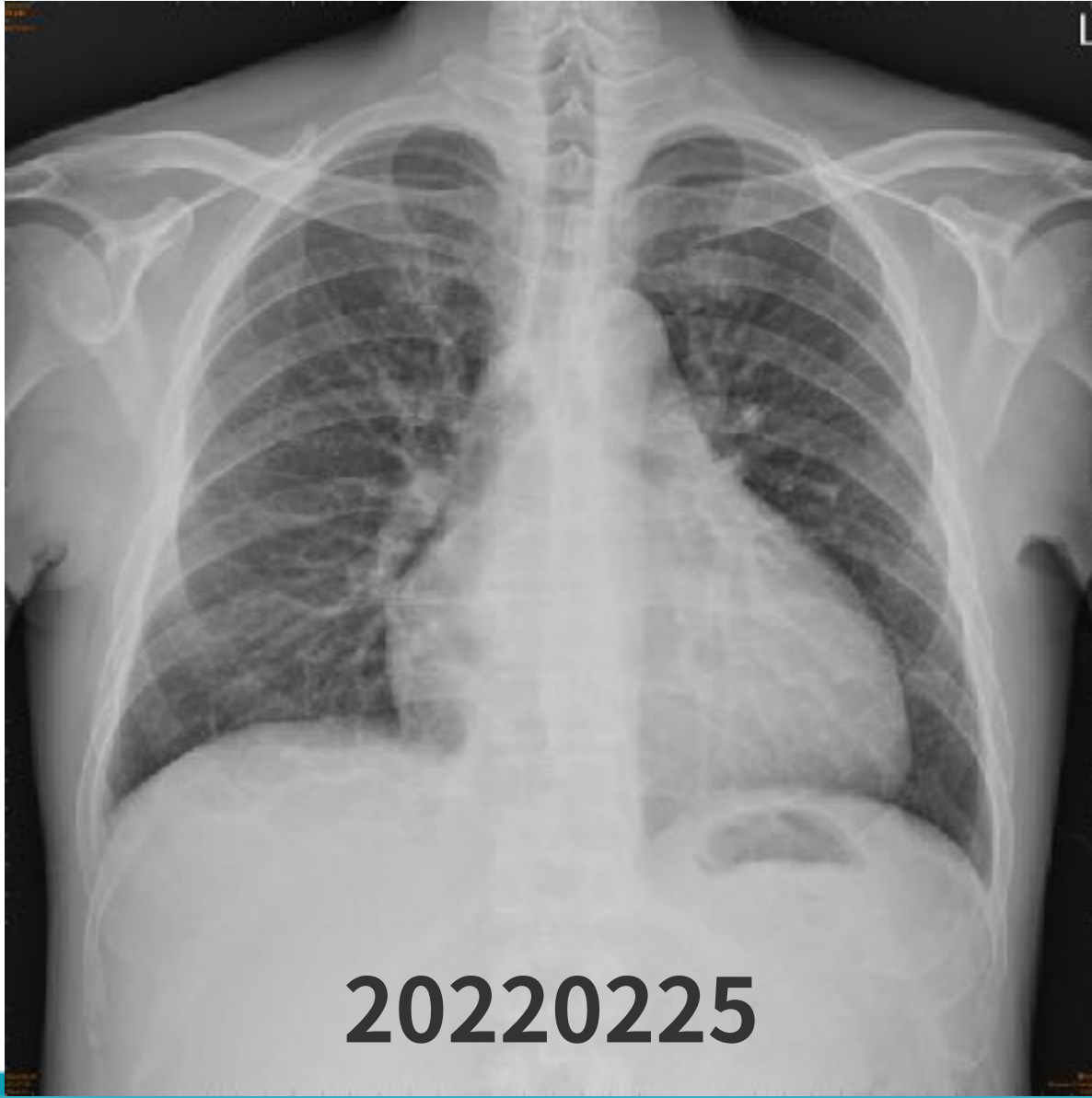# 58M, dyspnea for 2 days (3級)



# Tamponade & PLE , improved

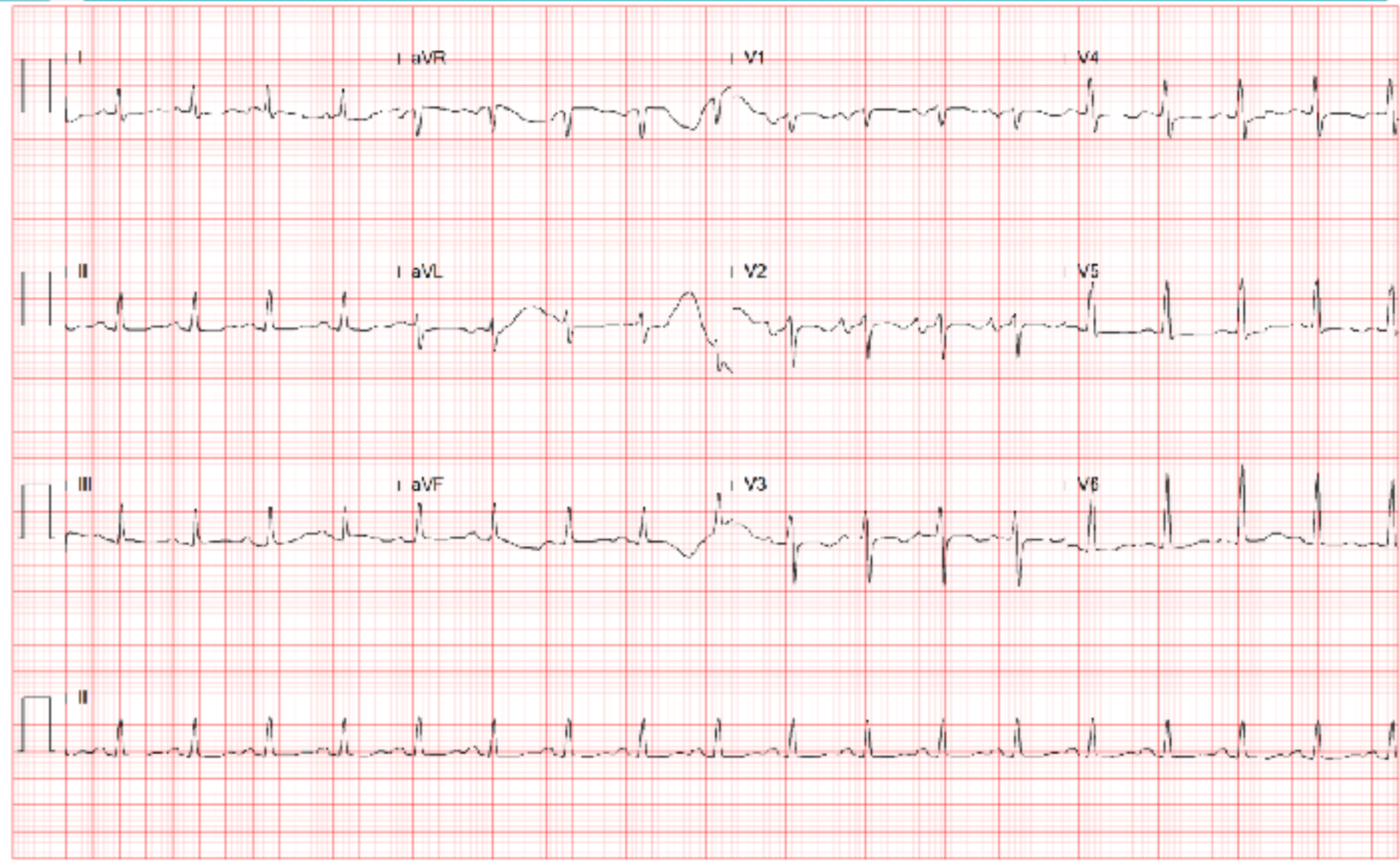


# 47M, SOB & edema for months



20220225

# 47M, SOB & edema for months

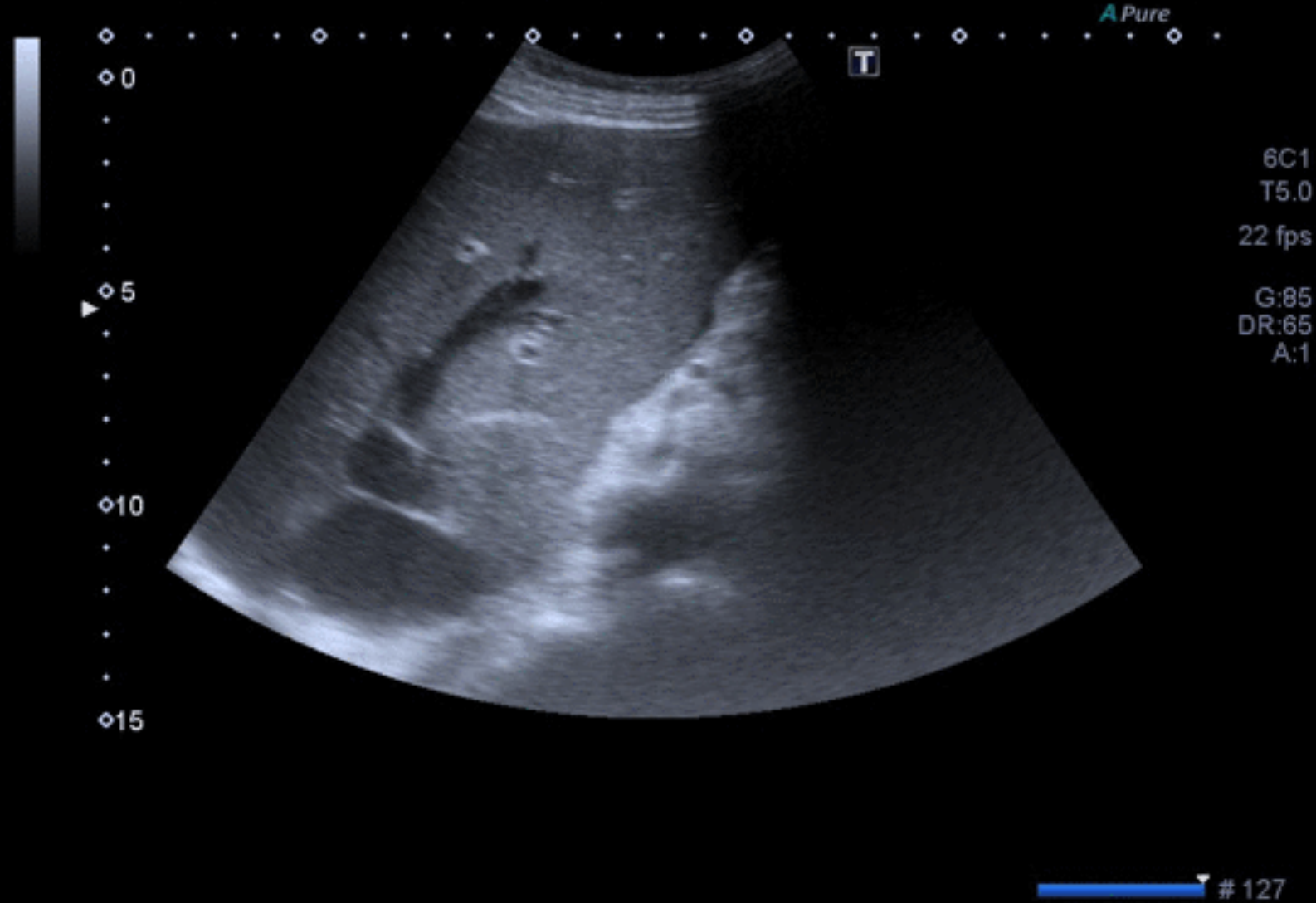




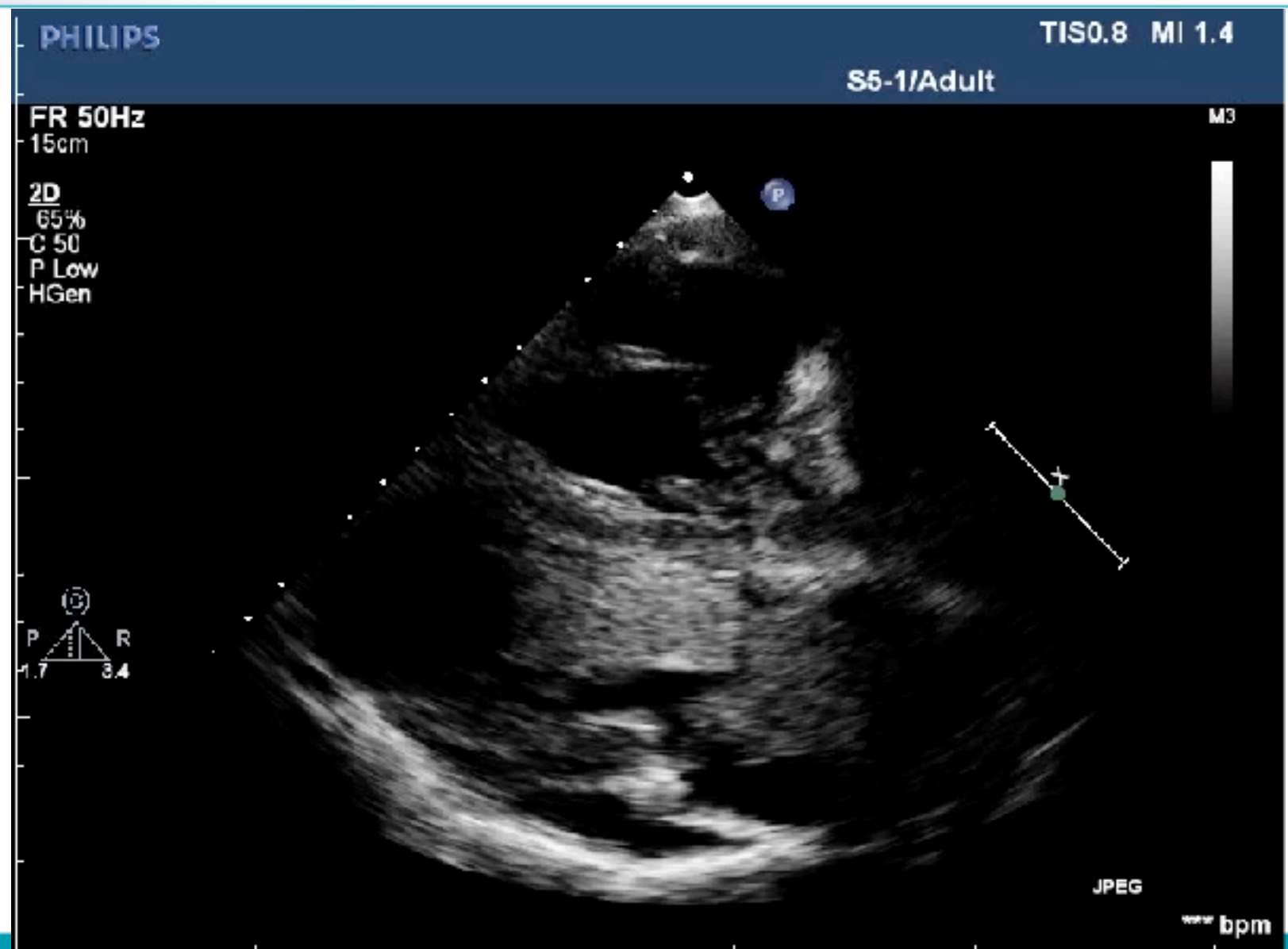
# 47M, SOB & edema for months



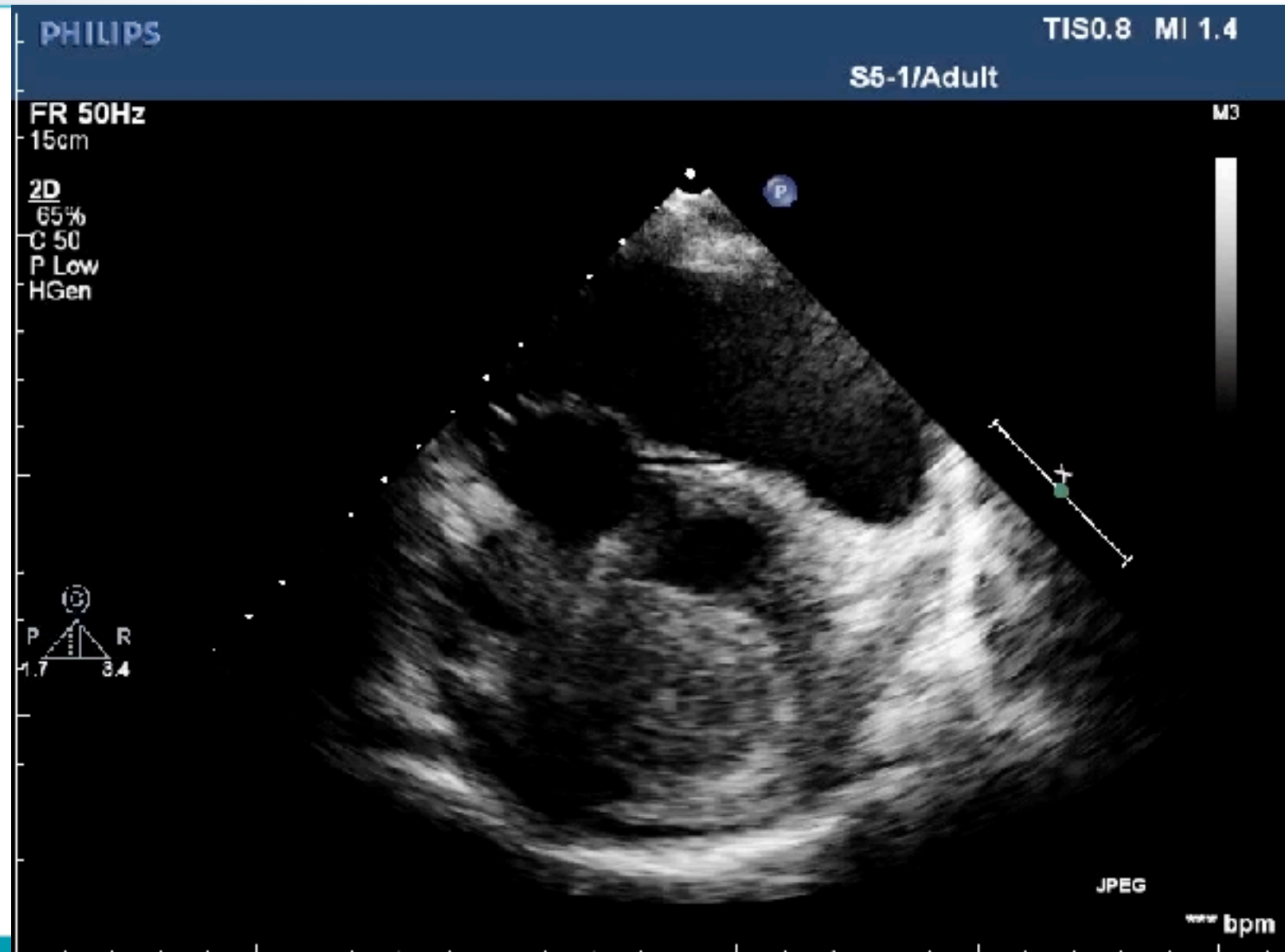
Canon 14165737:CHENG CHENG LUENG M 47 2022/03/11  
Aplio 500 HospitalName Abdomen 1:46:53 PM



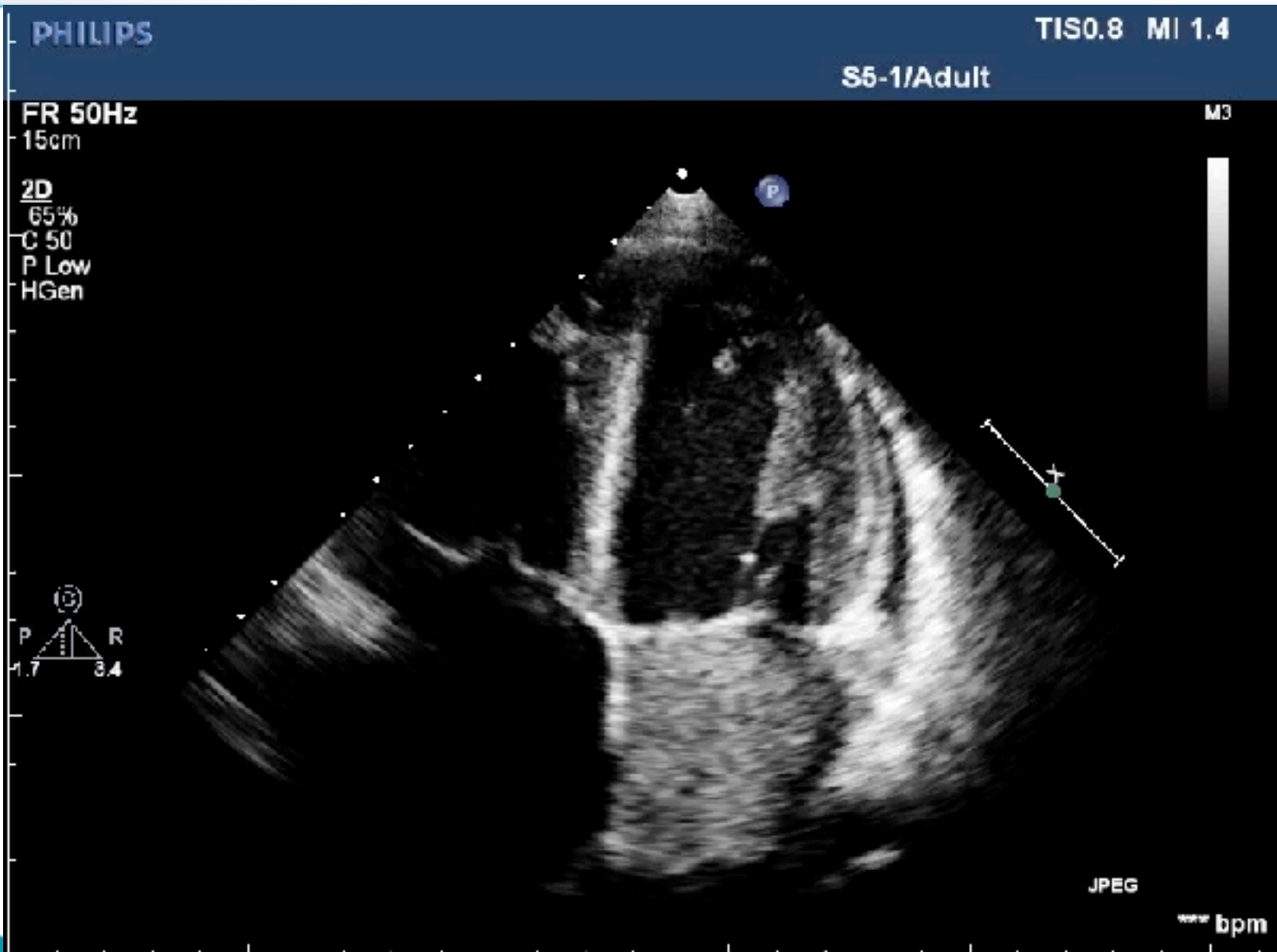
# 47M, SOB & edema for months



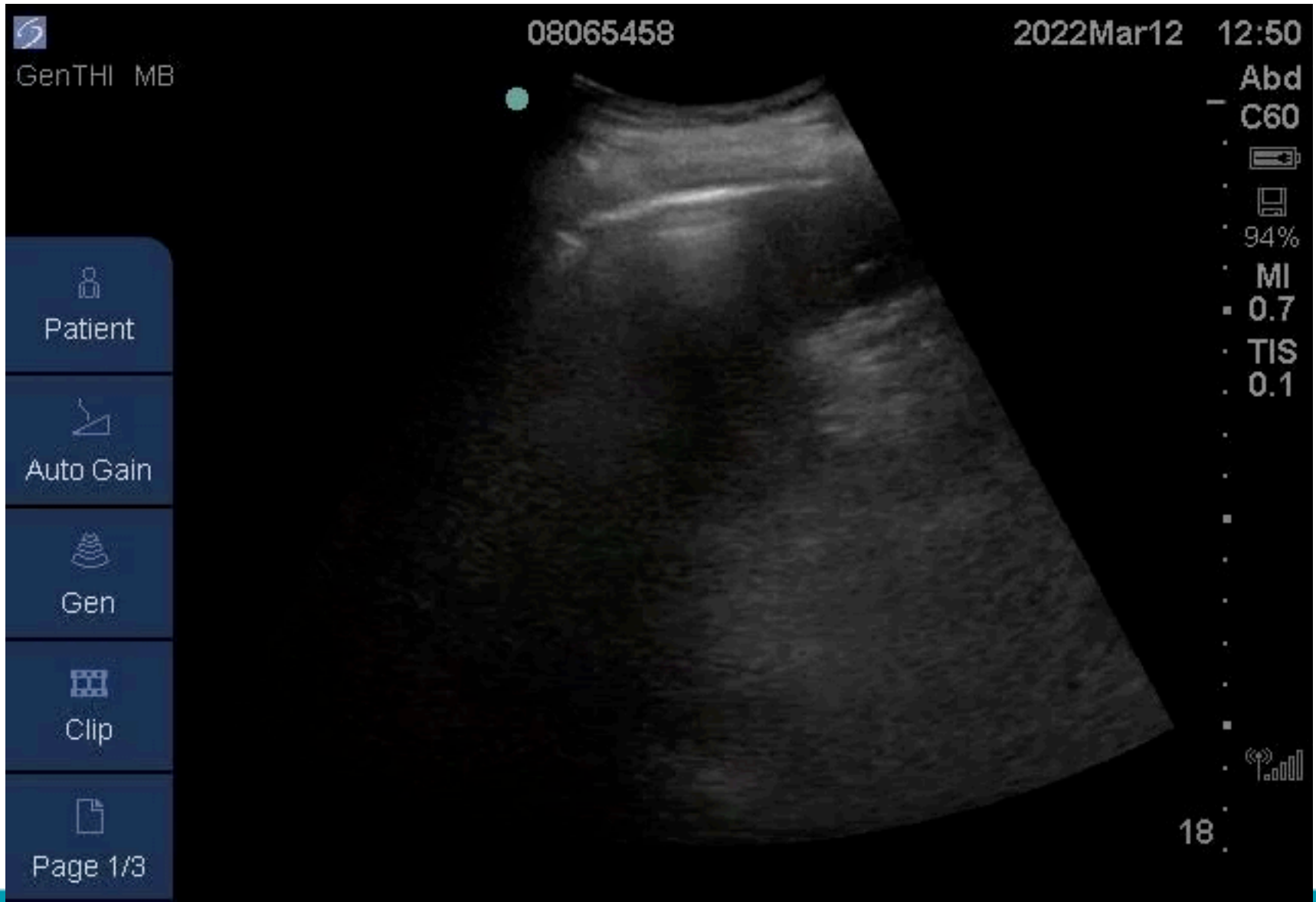
# 47M, SOB & edema for months



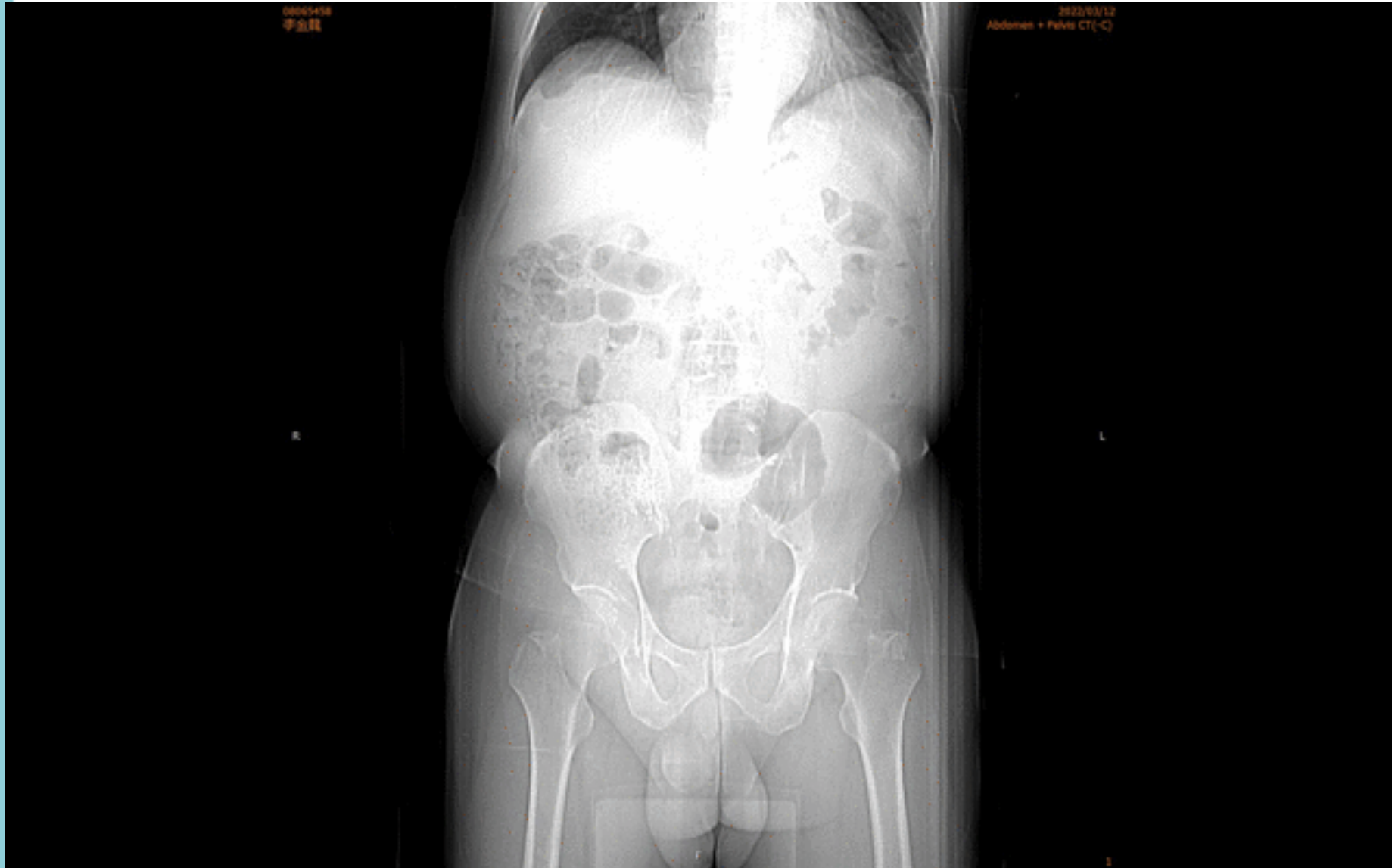
# 47M, SOB & edema for months



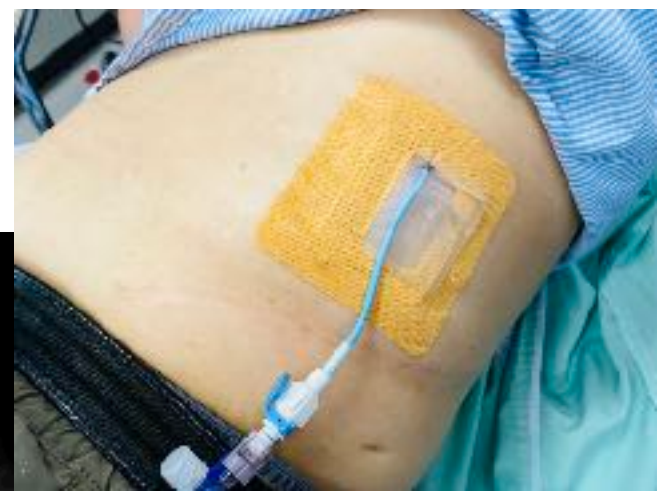# 65M, abdominal pain for one night



# 65M, abdominal pain for one night



# PCN for drainage



08065458

GenTHI MB

Patient

Auto Gain

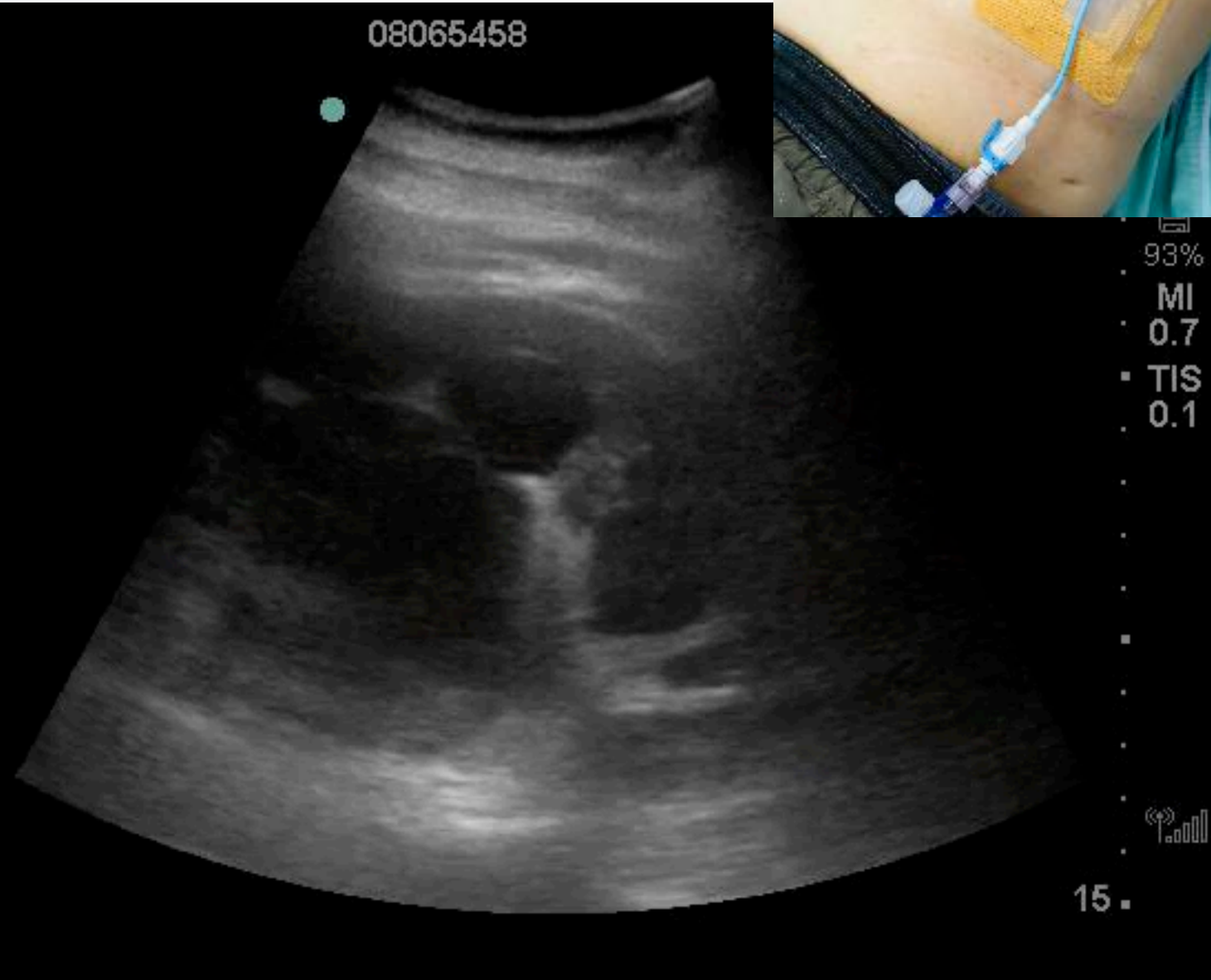
Gen

Clip

Page 1/3

93% MI 0.7 TIS 0.1

15





# 87M, found collapse in pool

2022Mar12 16:49

Abd  
- C60  
85%  
MI 0.7  
TIS 0.1

GenTHI MB

Patient

Auto Gain

Gen

Clip

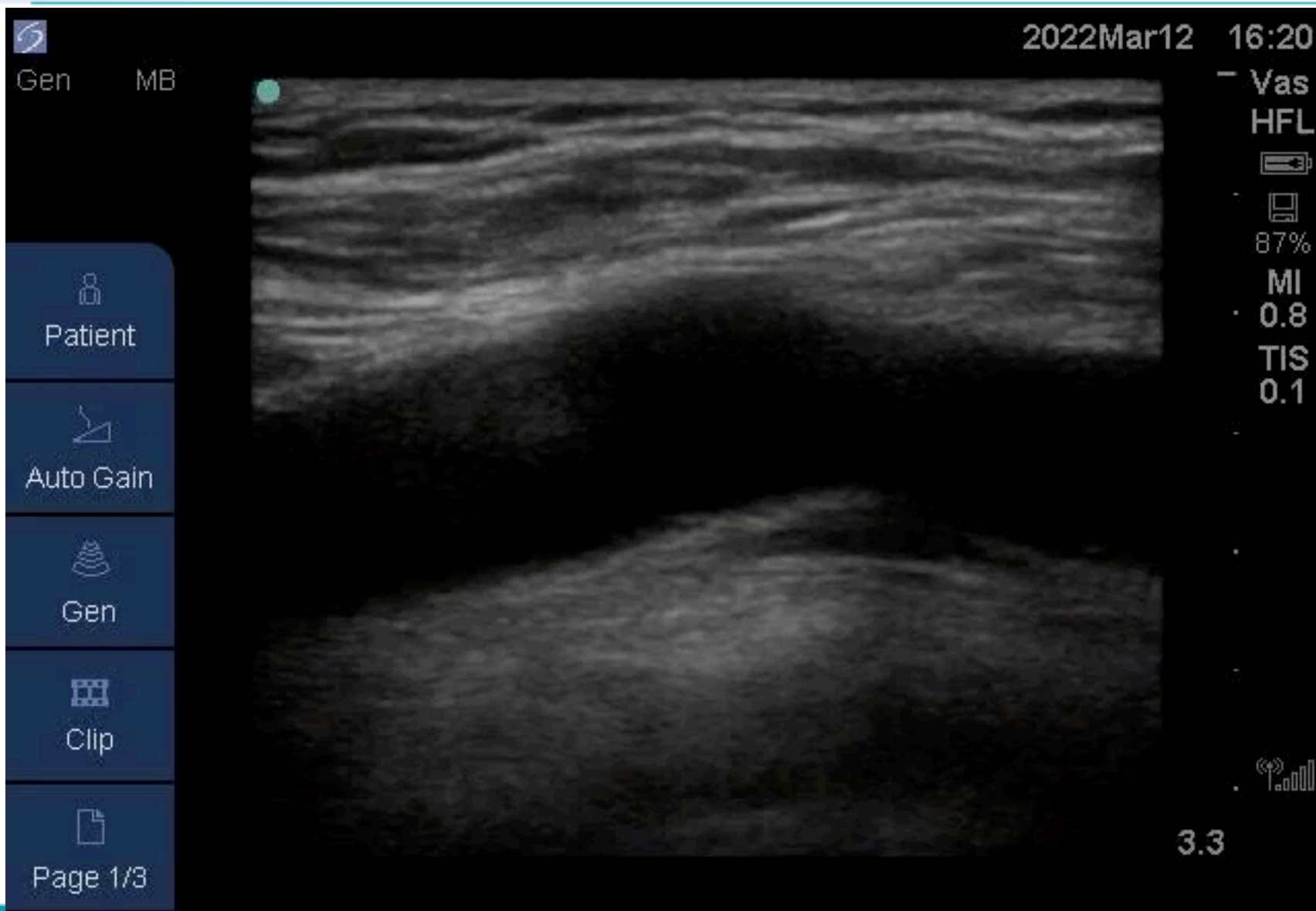Page 1/3

15

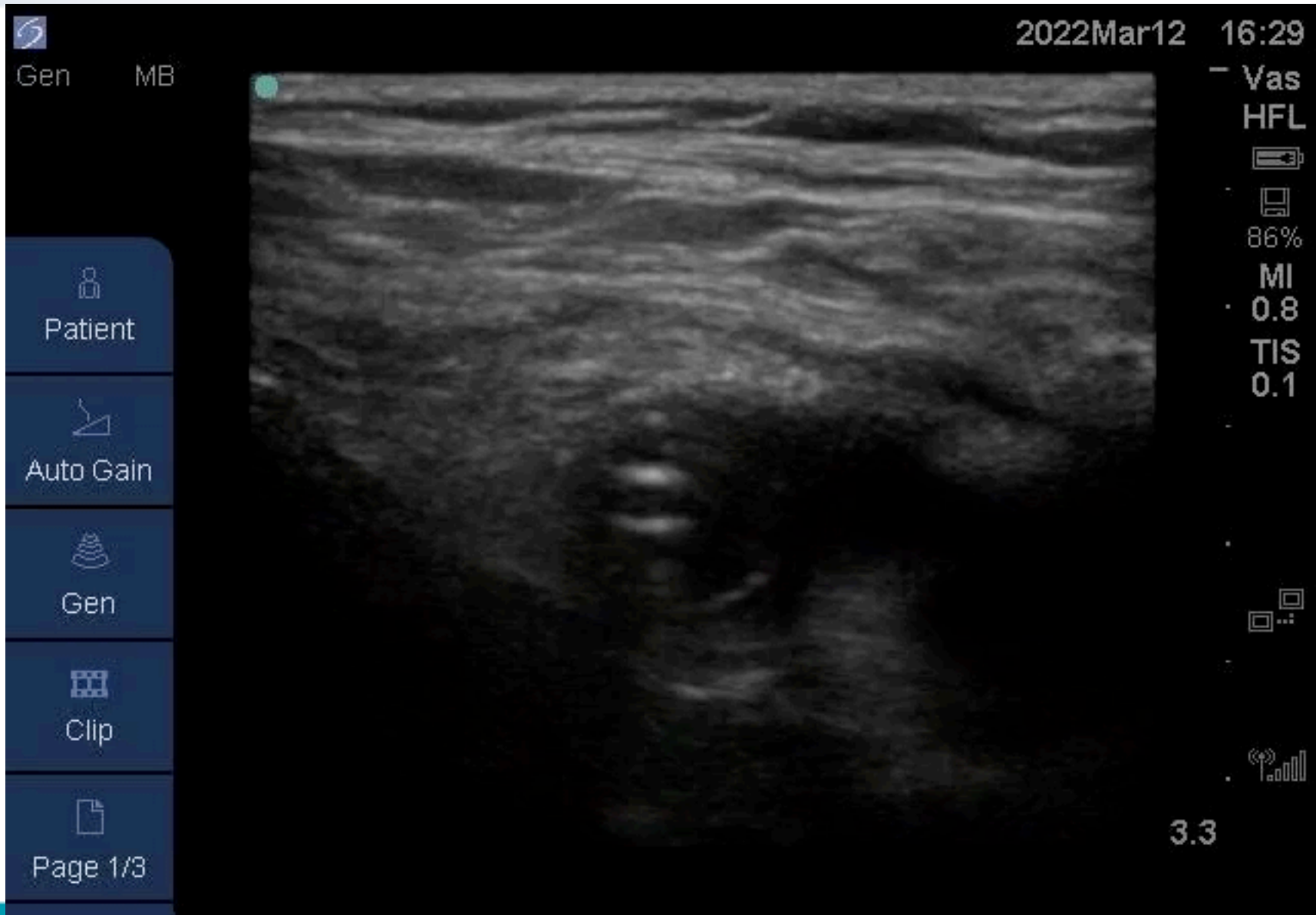



# For A line evaluation



# For A line confirmation (dark blood)





# Hepatic portal vein gas

2022Mar12 16:33

Abd  
C60

86%

MI  
0.7

TIS  
0.1

18

GenTHI MB

Patient

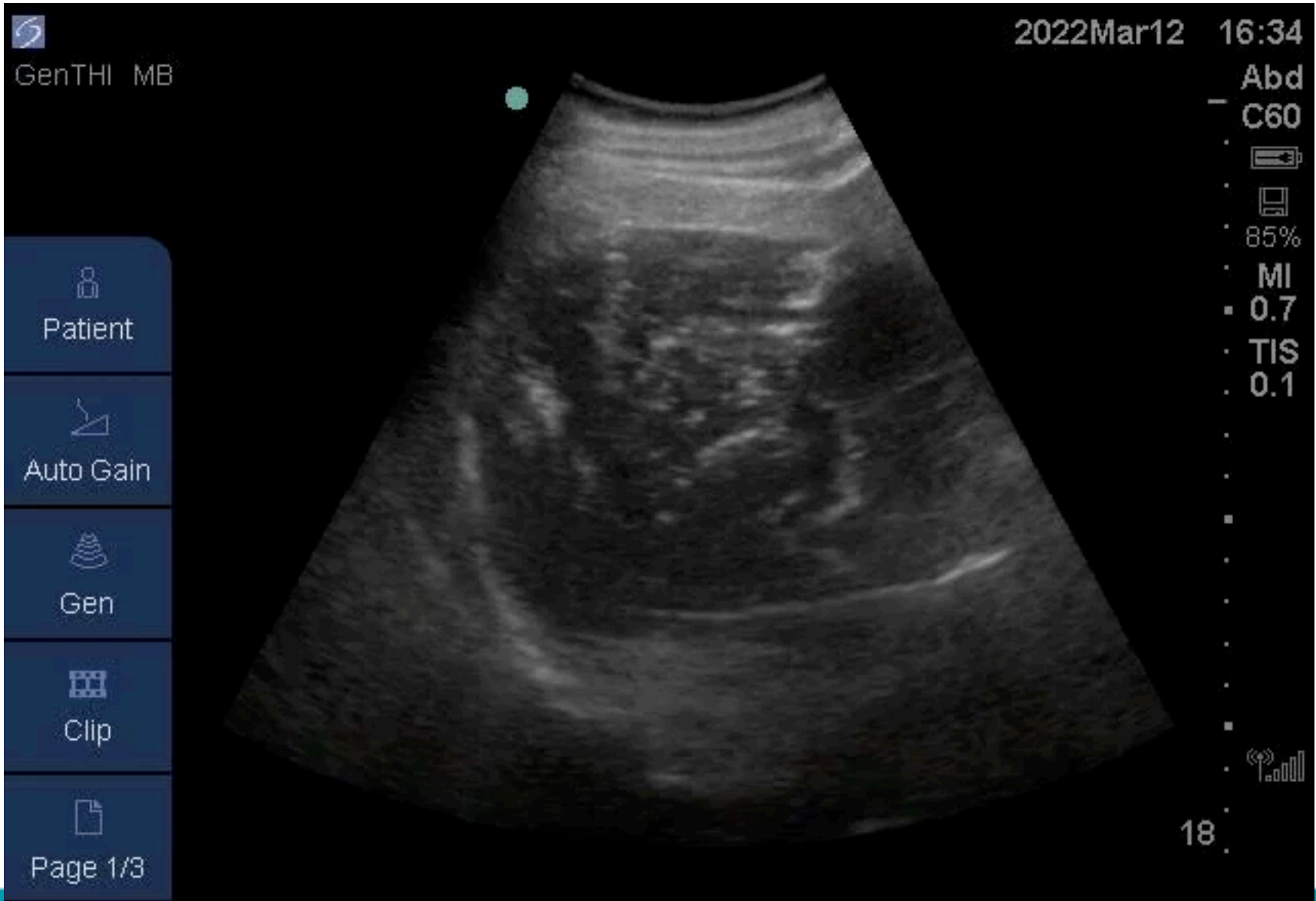
Auto Gain

Gen

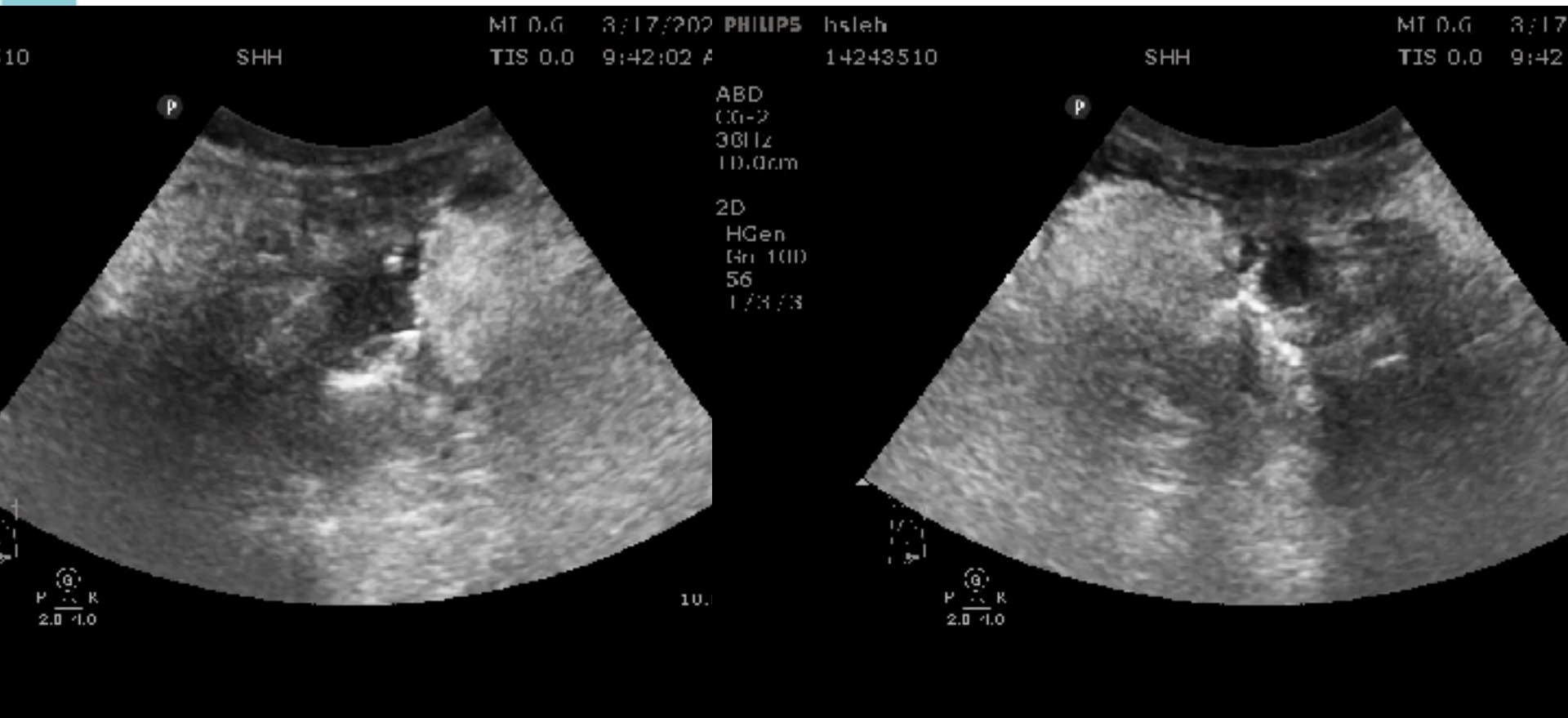
Clip

Page 1/3

# HPVG (poor prognosis)



# 29M, R sore throat



# Cervical lymphadenopathy

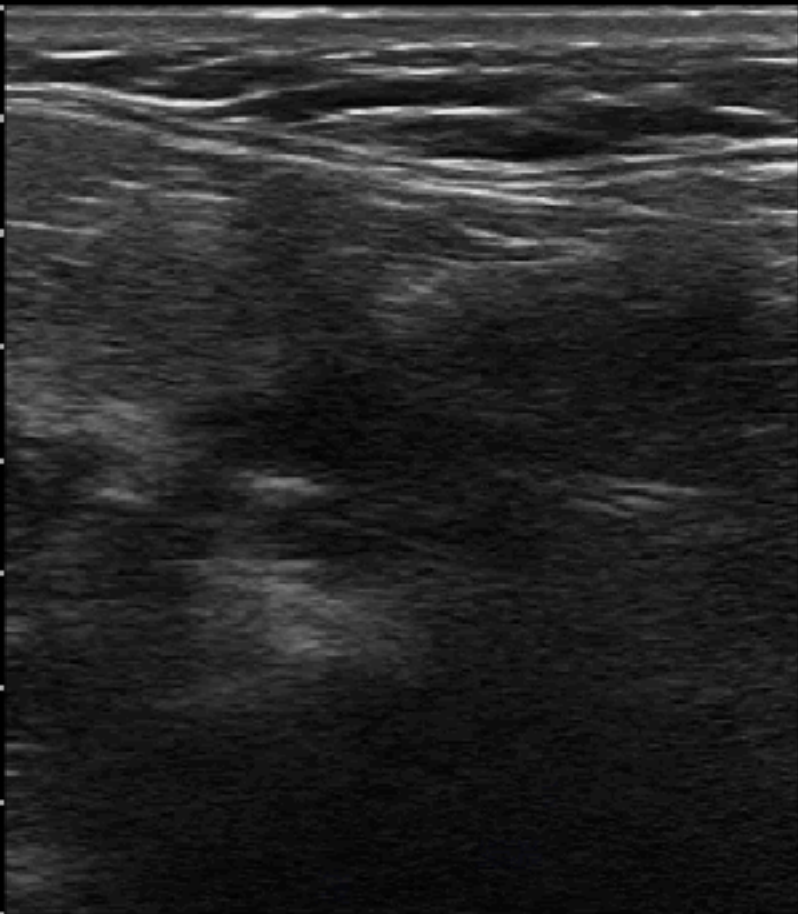
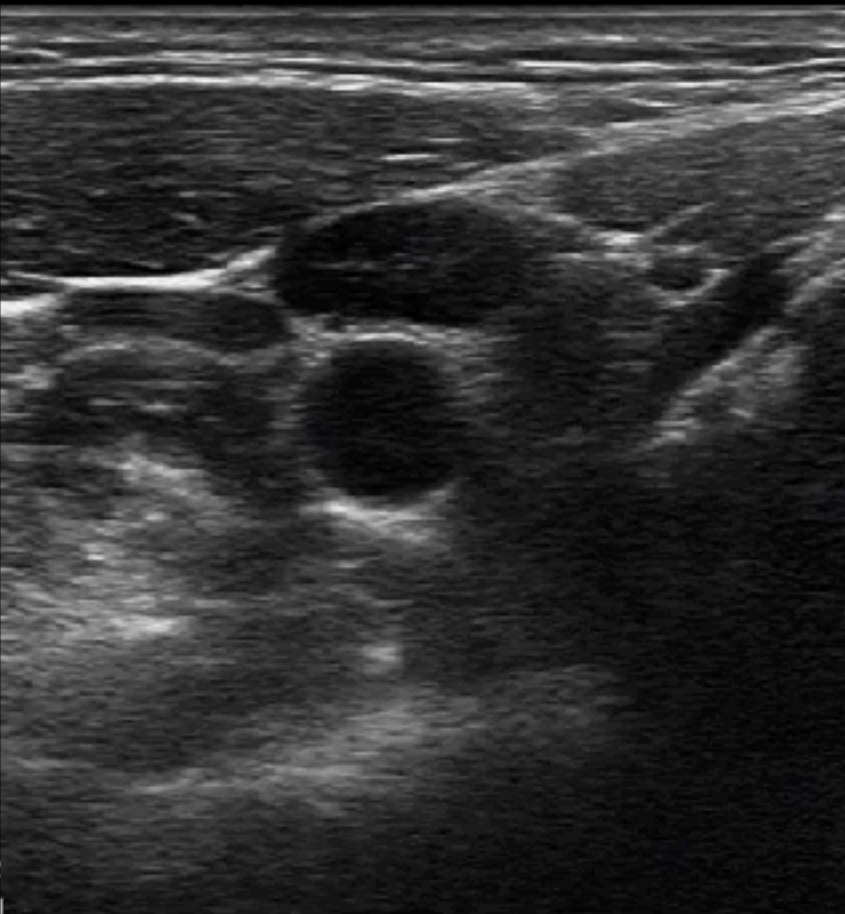


SI III

MI 0.5 3/17/2022  
TIS 0.0 9:45:08 AM

SI III

MI 0.5 3  
TIS 0.0 9



# Acute tonsillitis



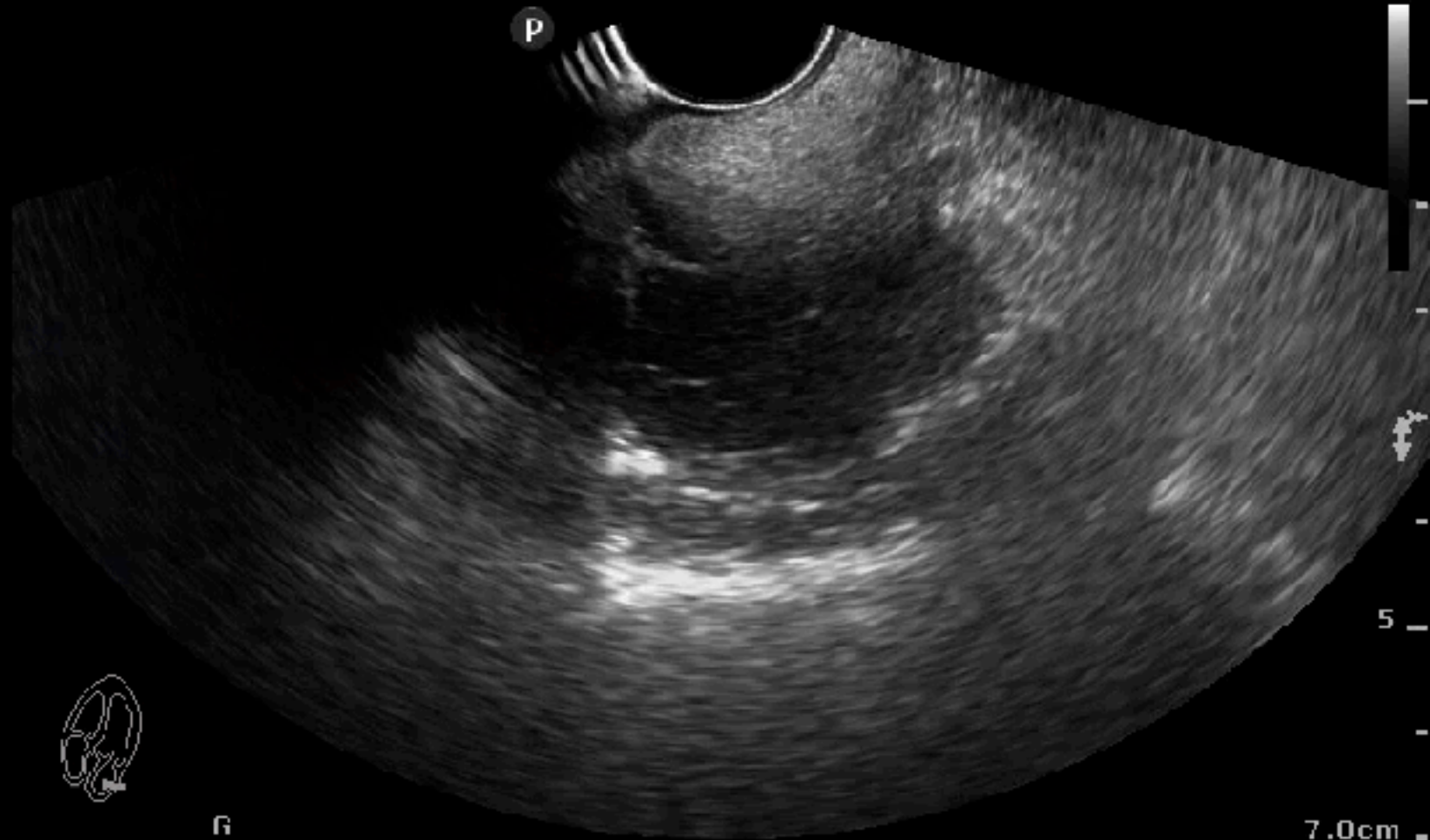
PHILIPS hsieh  
14243510

SHH

MI 0.9 3/17/2022  
TIS 0.2 9:48:52 AM

GYN1  
C9-4v  
74Hz  
7.0cm

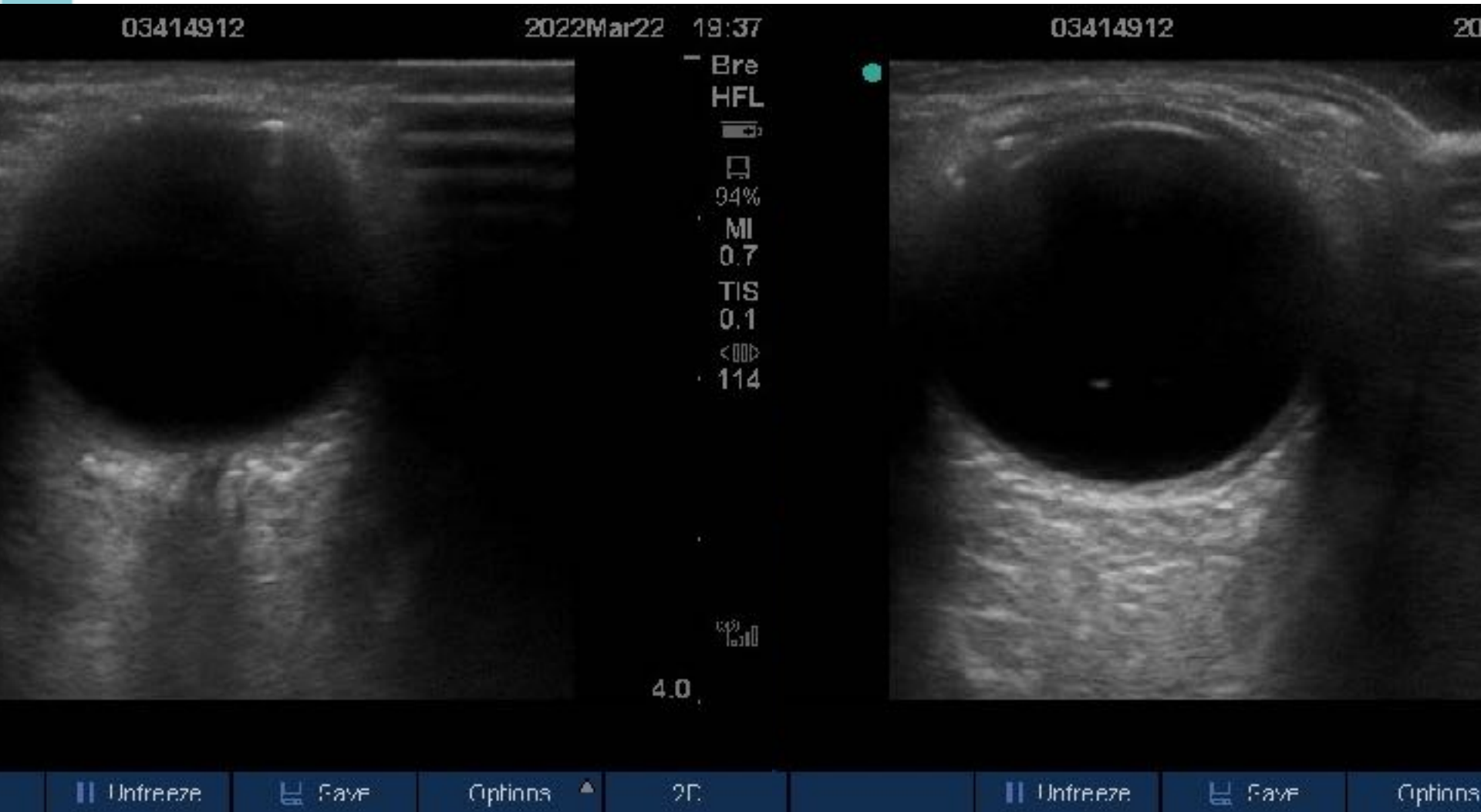
2D  
Pen  
Gn 63  
57  
3/2/2



R  
P R

7.0cm

# 69M, left eye blunt injury & blurred vision





# 69M, left eye blunt injury & blurred vision



03414912 2022Mar22 19:37

Res MB

— Bre  
HFL  
94%  
MI  
0.7  
TIS  
0.1

Patient

Auto Gain

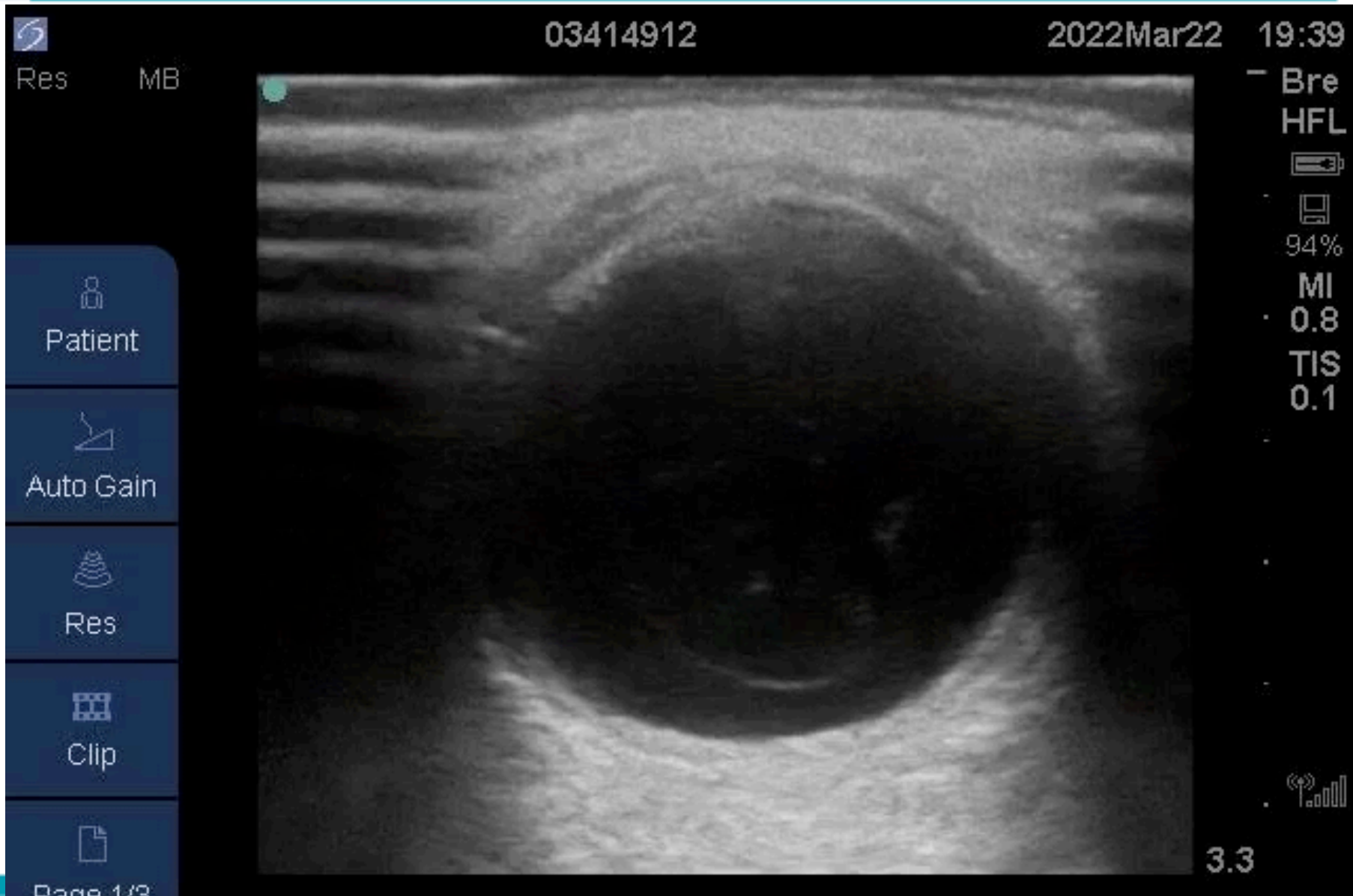
Res

Clip

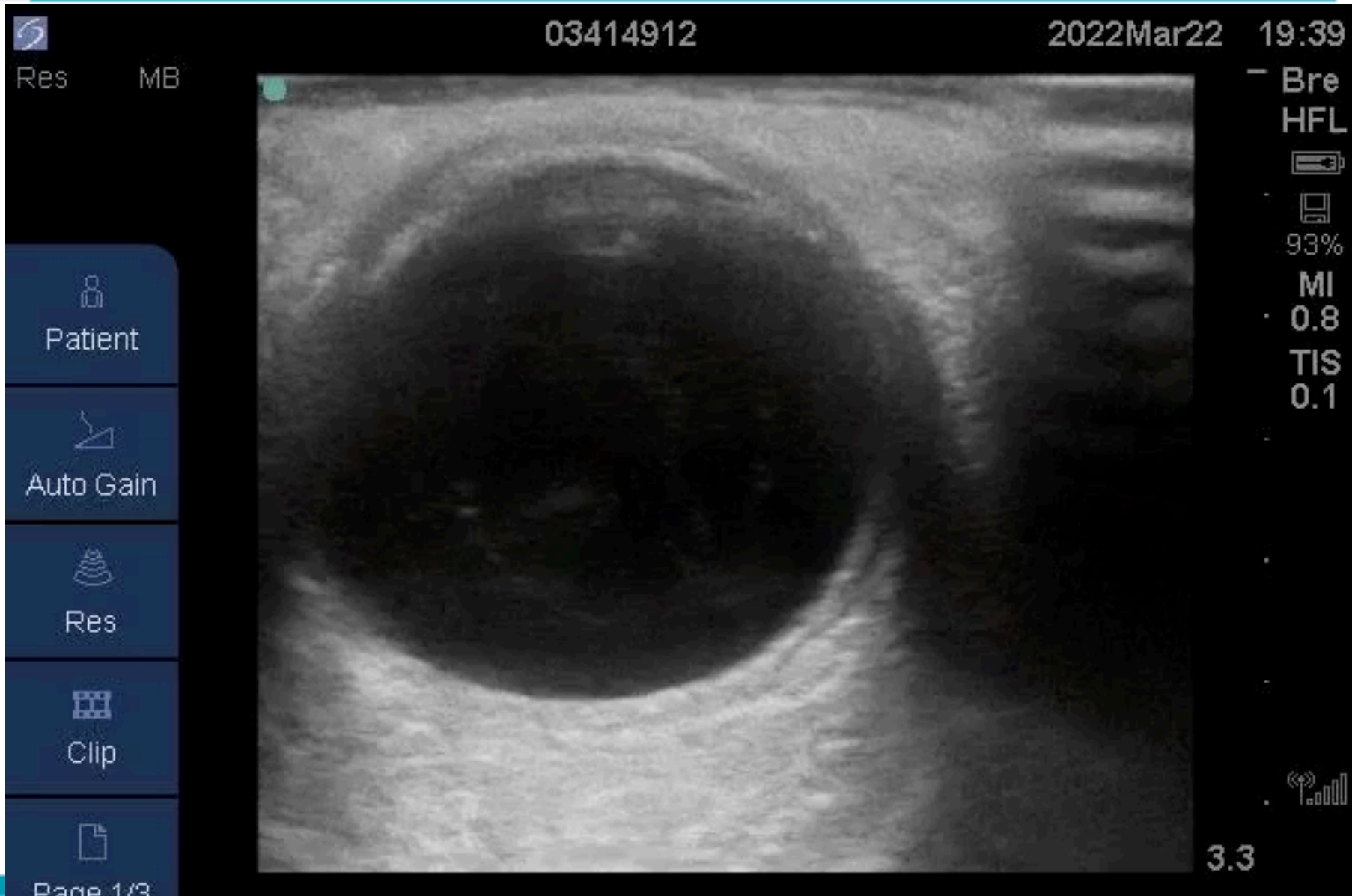
Page 1/3

4.0

# 69M, left eye blunt injury & blurred vision



# 69M, left eye blunt injury & blurred vision



# 32F, Preg 17wks, 羊膜穿刺後腹部不適



PHILIPS YANG  
03366971

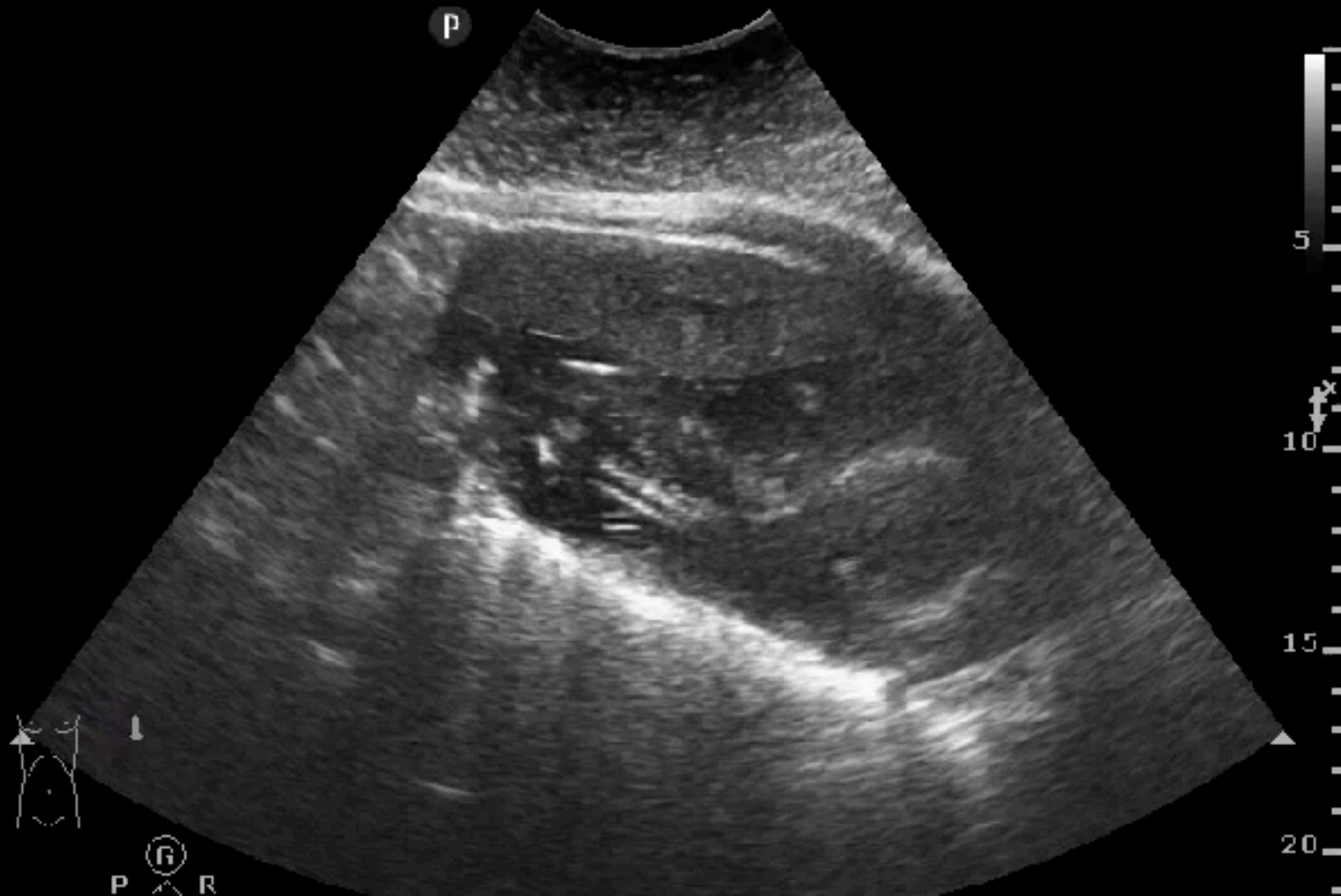MI 0.6 3/17/2022  
TIS 0.0 6:10:27 PM

ABD  
C6-2  
22Hz  
22.0cm

2D  
HGen  
Gn 100  
56  
1/3/3

SHH

P



# 32F, Preg 17wks, 羊膜穿刺後腹部不適



PHILIPS YANG  
03366971

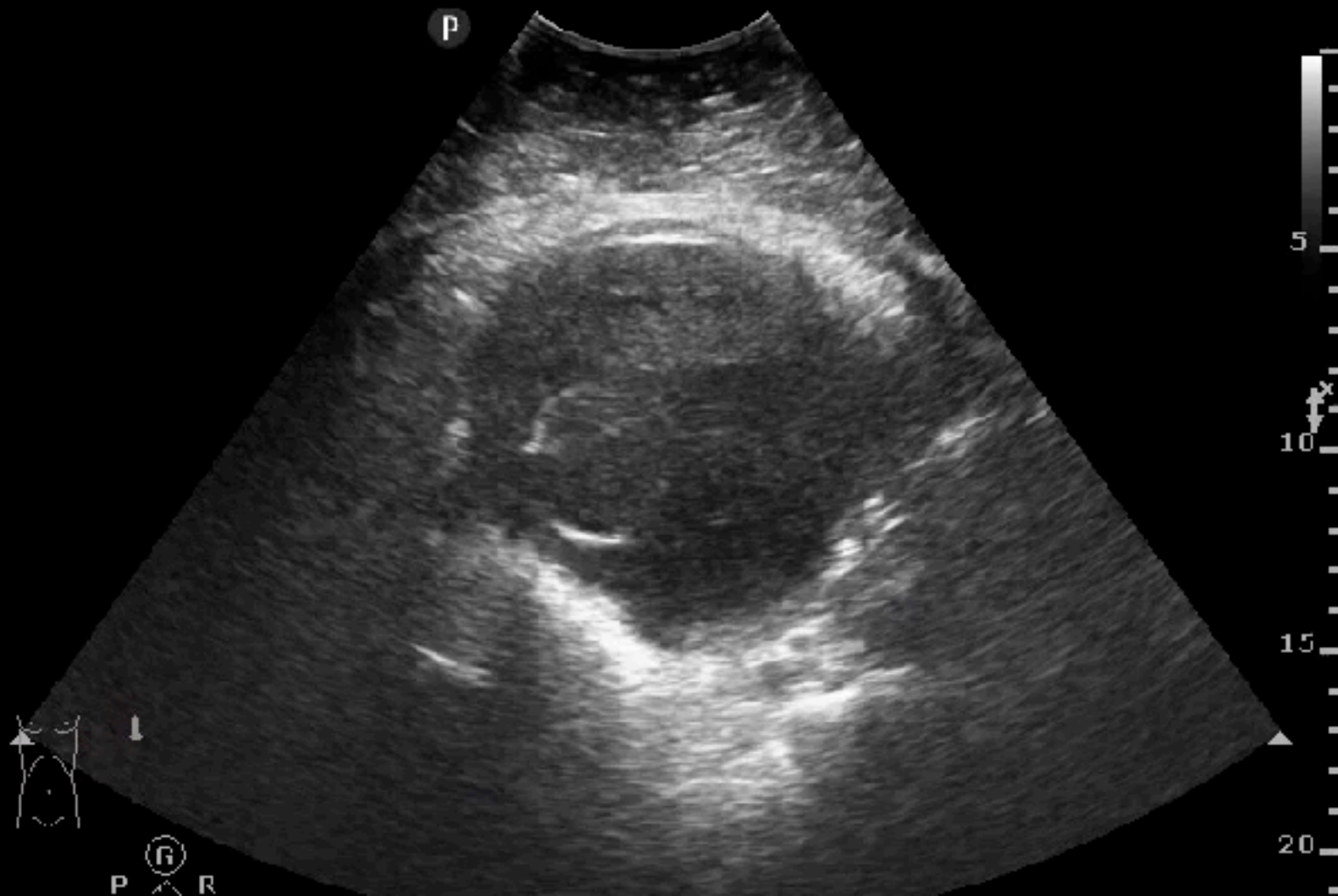
MI 0.6 3/17/2022  
TIS 0.0 6:10:40 PM

ABD  
C6-2  
22Hz  
22.0cm

2D  
HGen  
Gn 100  
56  
1/3/3

SHH

P



# 32F, Preg 17wks, 羊膜穿刺後腹部不適



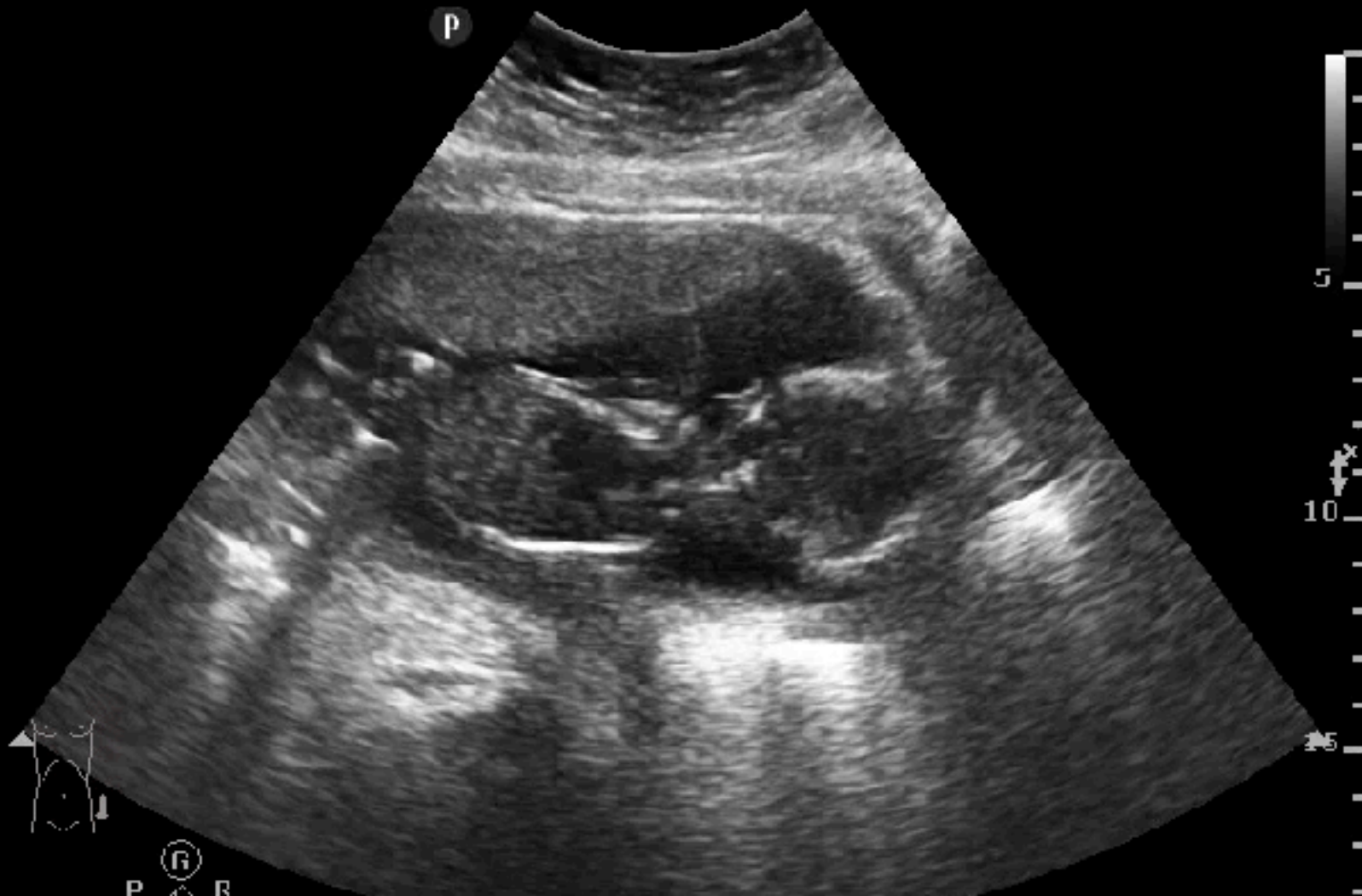PHILIPS YANG  
03366974

SHH

MI 0.6 3/17/2022  
TIS 0.0 6:11:17 PM

ABD  
C6-2  
25Hz  
19.0cm

2D  
HGen  
Gn 100  
56  
1/3/3



# 32F, Preg 17wks, 羊膜穿刺後腹部不適



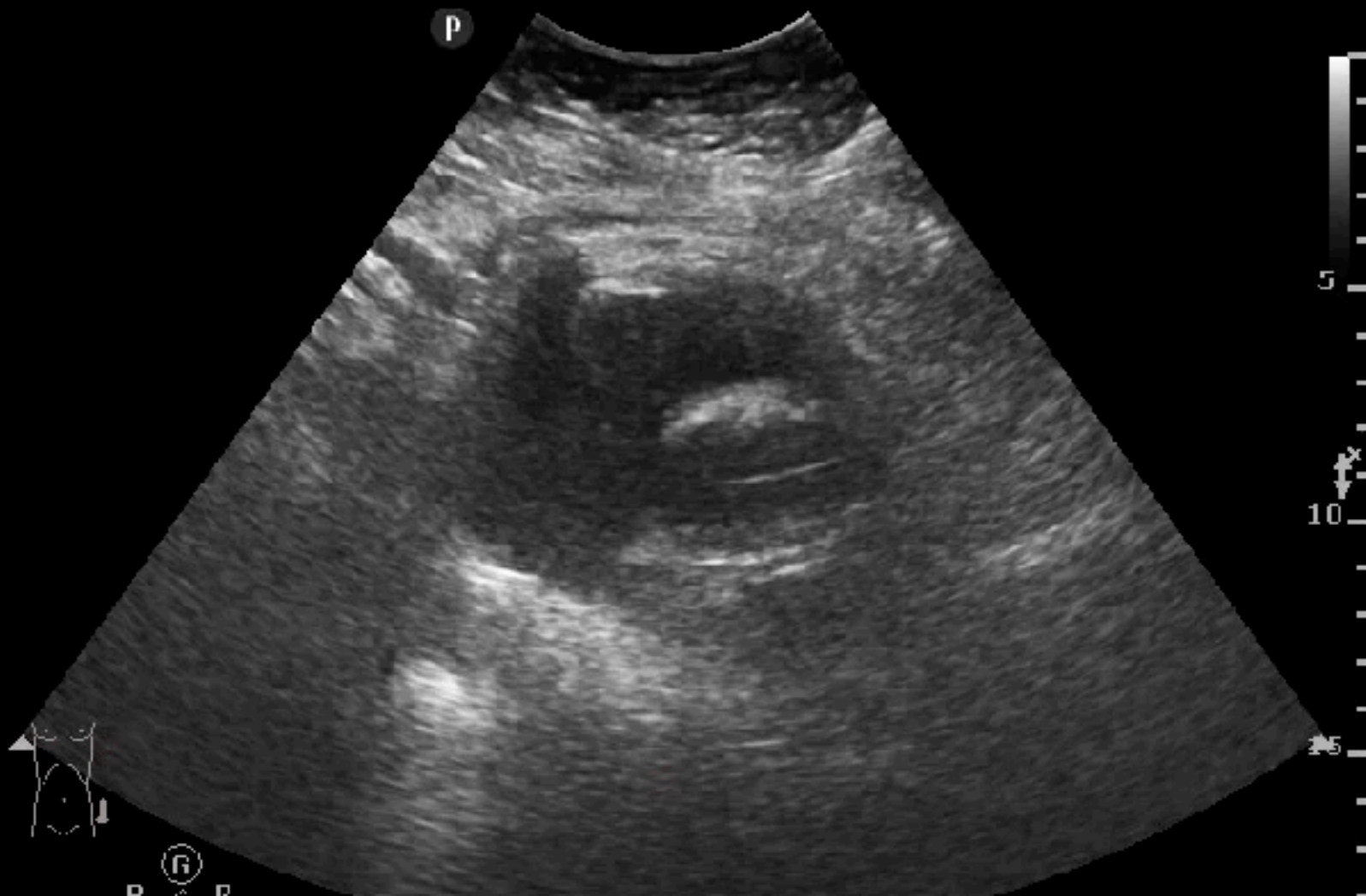PHILIPS YANG  
03366974

SHH

MI 0.6 3/17/2022  
TIS 0.0 6:11:32 PM

ABD  
C6-2  
25Hz  
19.0cm

2D  
HGen  
Gn 100  
56  
1/3/3



# 32F, Preg 17wks, 羊膜穿刺後腹部不適



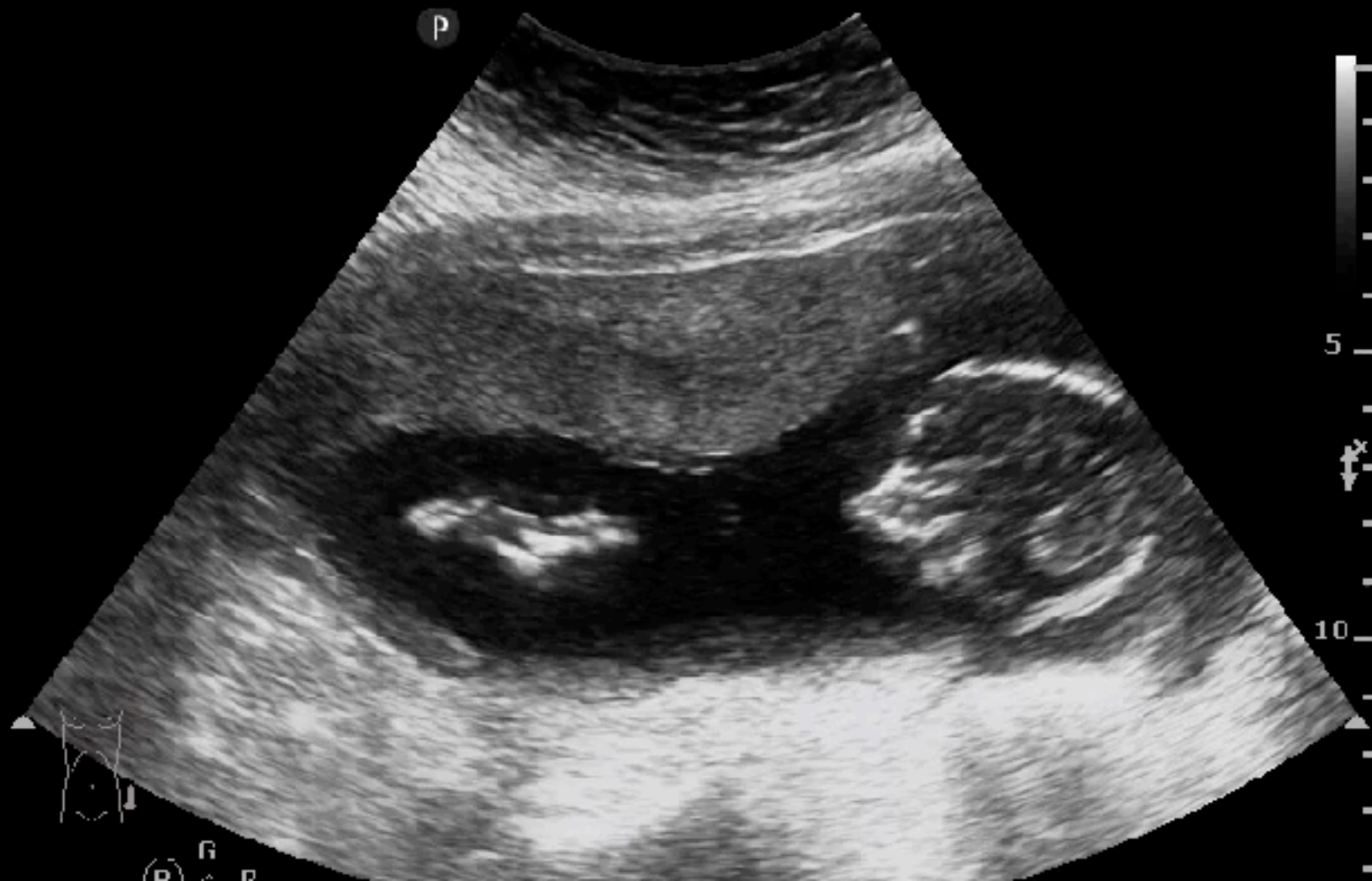PHILIPS YANG  
03366974

SHH

MI 0.6 3/17/2022  
TIS 0.0 6:15:31 PM

ABD  
C6-2  
29Hz  
15.0cm

2D  
HPen  
Gn 100  
56  
1/3/3





# 32F, Preg 17wks, 羊膜穿刺後腹部不適



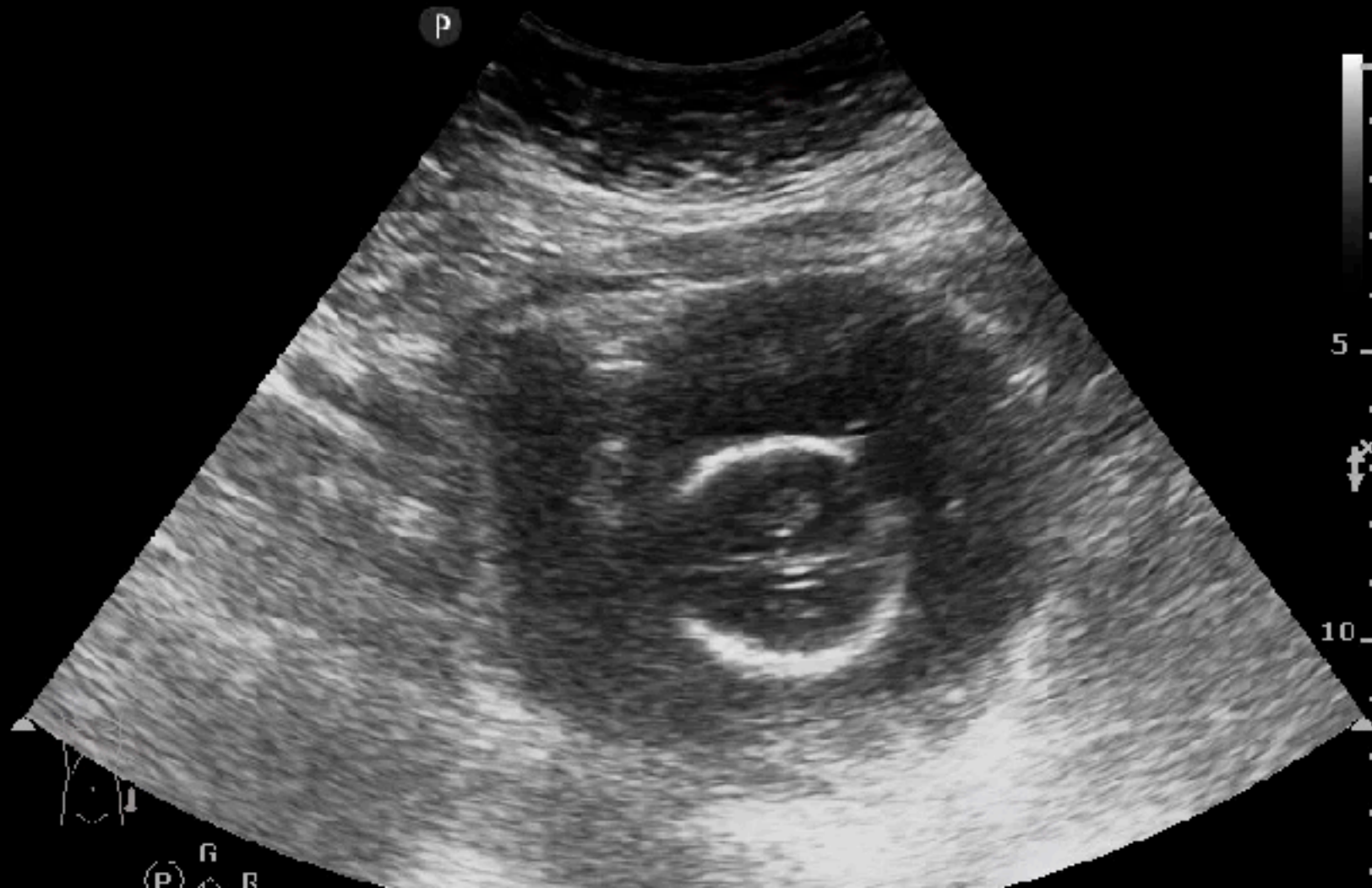PHILIPS YANG  
03366974

SHH

MI 0.6 3/17/2022  
TIS 0.0 6:15:43 PM

ABD  
C6-2  
29Hz  
15.0cm

2D  
HPen  
Gn 100  
56  
1/3/3



# 32F, Preg 17wks, 羊膜穿刺後腹部不適



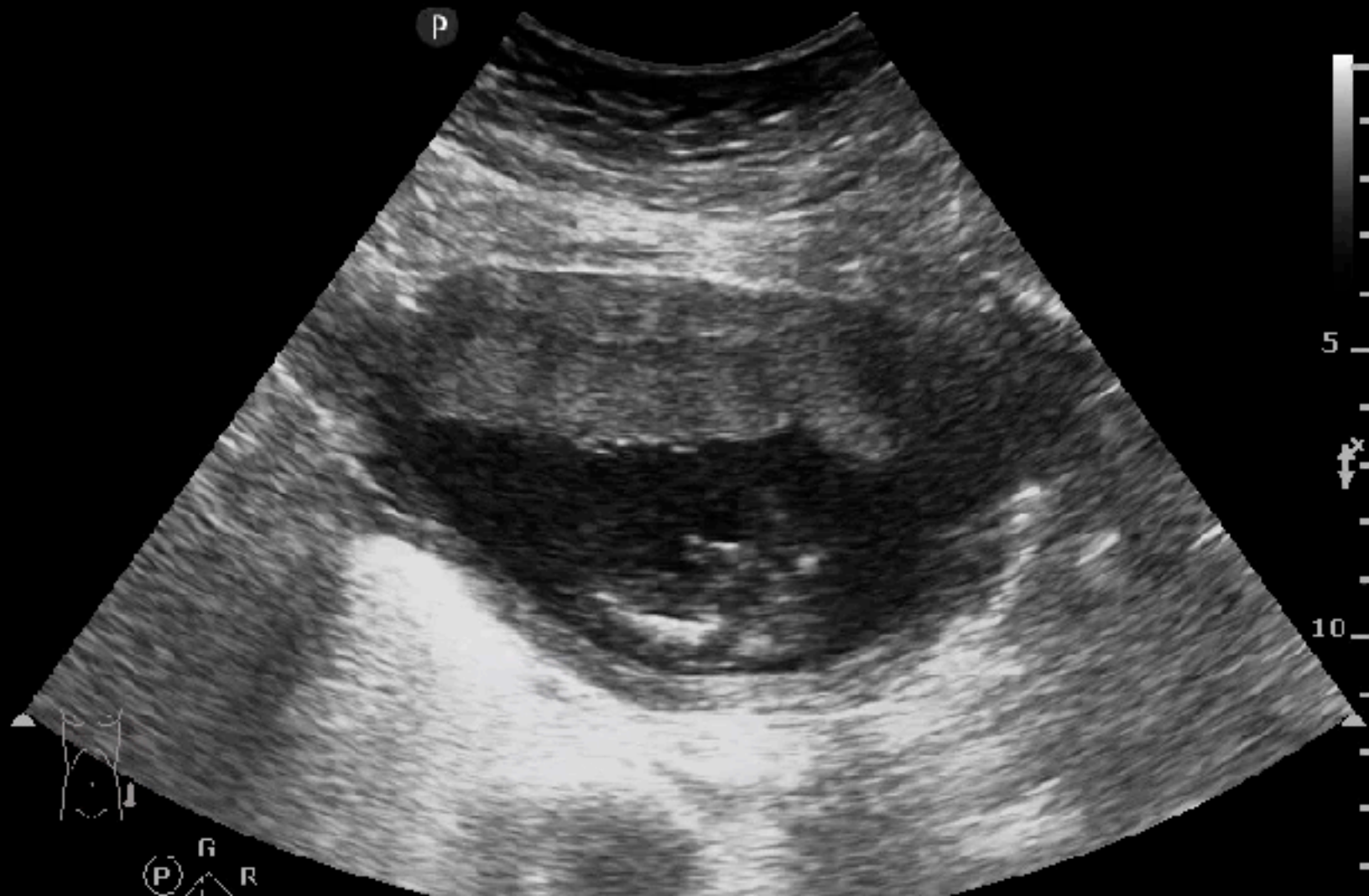PHILIPS YANG  
03366974

SHH

MI 0.6 3/17/2022  
TIS 0.0 6:16:12 PM

ABD  
C6-2  
29Hz  
15.0cm

2D  
HPen  
Gn 100  
56  
1/3/3



# 32F, Preg 17wks, 羊膜穿刺後腹部不適

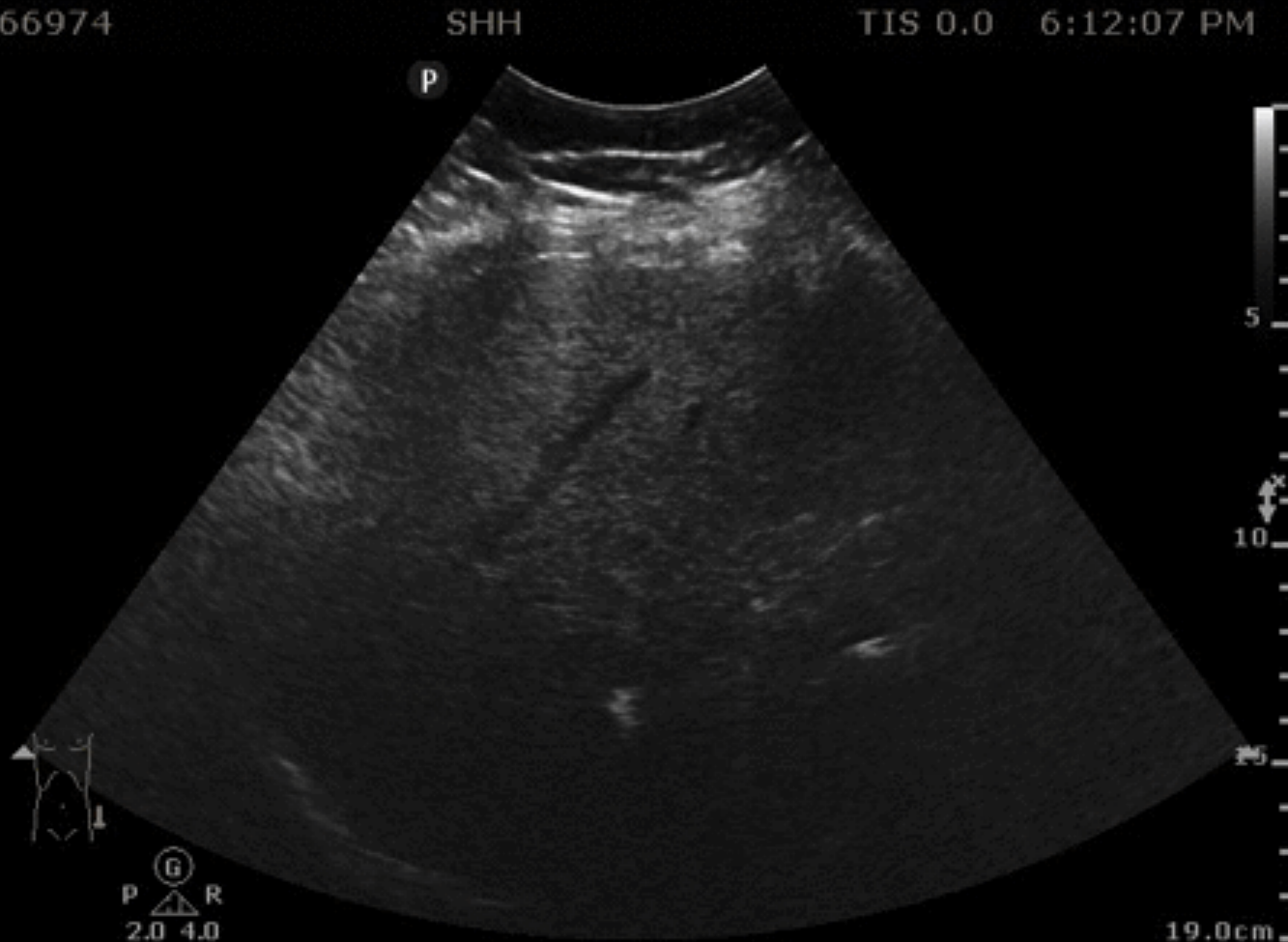


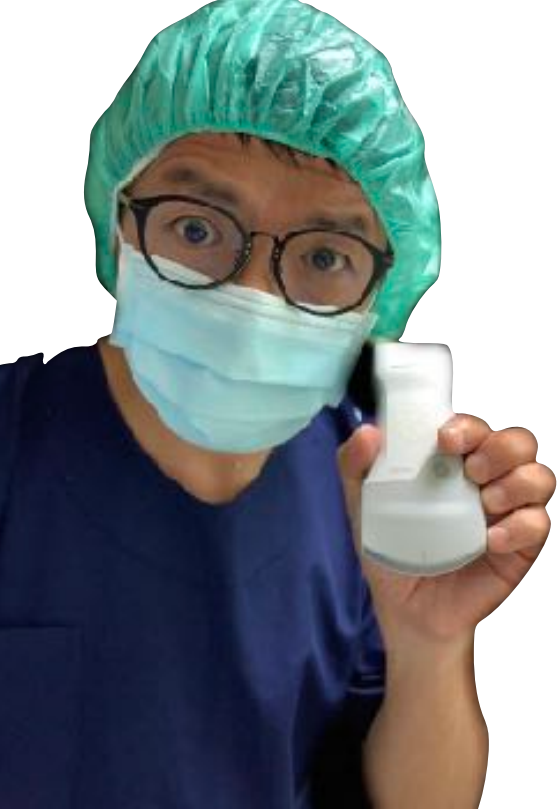PHILIPS YANG  
03366974

MI 0.6 3/17/2022  
TIS 0.0 6:12:07 PM

ABD  
C6-2  
25Hz  
19.0cm

2D  
HGen  
Gn 100  
56  
1/3/3





努力可能會說謊，  
但努力不會白費。

羽生結弦

**HOLISTIC ULTRASOUND**

[juice119@gmail.com](mailto:juice119@gmail.com) / [POCUSacademy.com](http://POCUSacademy.com)