



雙和急診POCUS訓練

診
斷

監
測

介
入

POINT OF CARE ULTRASOUND

~ 存在於臨床需求之所在 ~

陳國智 醫師



醫用超音波學會指導醫師
WINFOCUS director / instructor
急救加護醫學會重症超音波負責人

急診 / 重症 / 介入 / 急性疼痛

經歷

新光急診超音波訓練中心主任

西園醫院急診醫學科主任

急診醫學會超音波委員會主委

台灣疼痛醫學會大體模擬手術講師



LE joint effusion

01/07

Airway

01/14

Needling

01/21

VExUS protocol

01/28

雙和急診POCUS訓練



Central access

02/11

Peripheral access

02/18

EFAST

02/25

雙和急診POCUS訓練



Basic ECHO

03/04

Nerve block-UE(1)

03/11

Nerve block-LE(1)

03/25

雙和急診POCUS訓練



Aorta & IVC

04/01

Liver & Biliary

04/08

Pancreas & Spleen

04/15

Kidney & UB

04/29

雙和急診POCUS訓練



AORTA & IVC



Aorta - transverse tracing

PHILIPS Temporary ID-20160331172347

MI 1.1 3/31/2016

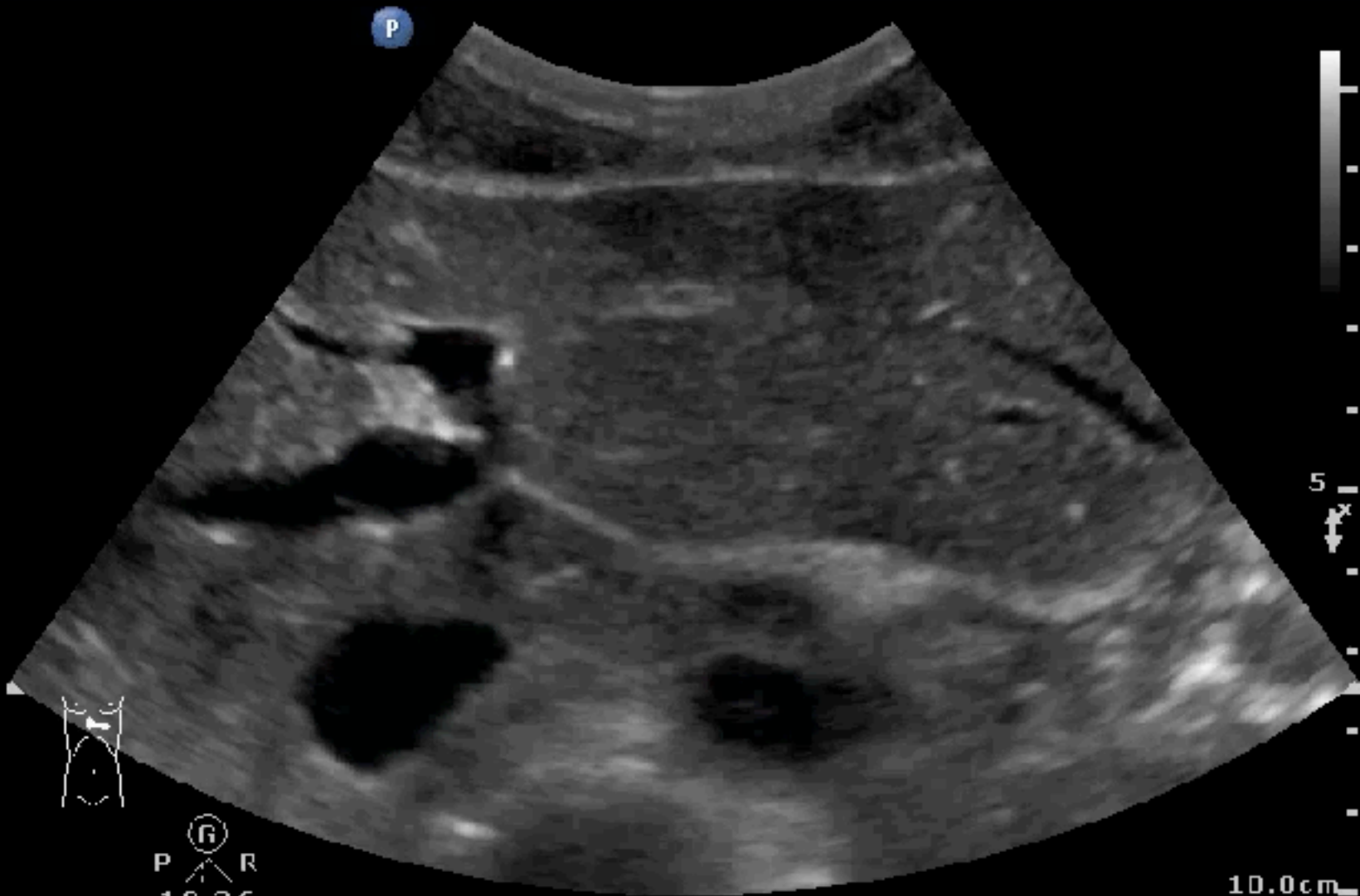
16-03-31-172347

SKH ER

TIS 0.1 5:26:34 PM

Abd Gen
C5-1
45 Hz
10.0cm

2D
HGen
Gn 60
C. 56
3/3/3





Aorta - longitudinal tracing

PHILIPS Temporary ID-20160331172347

MI 1.1 3/31/2016

16-03-31-172347

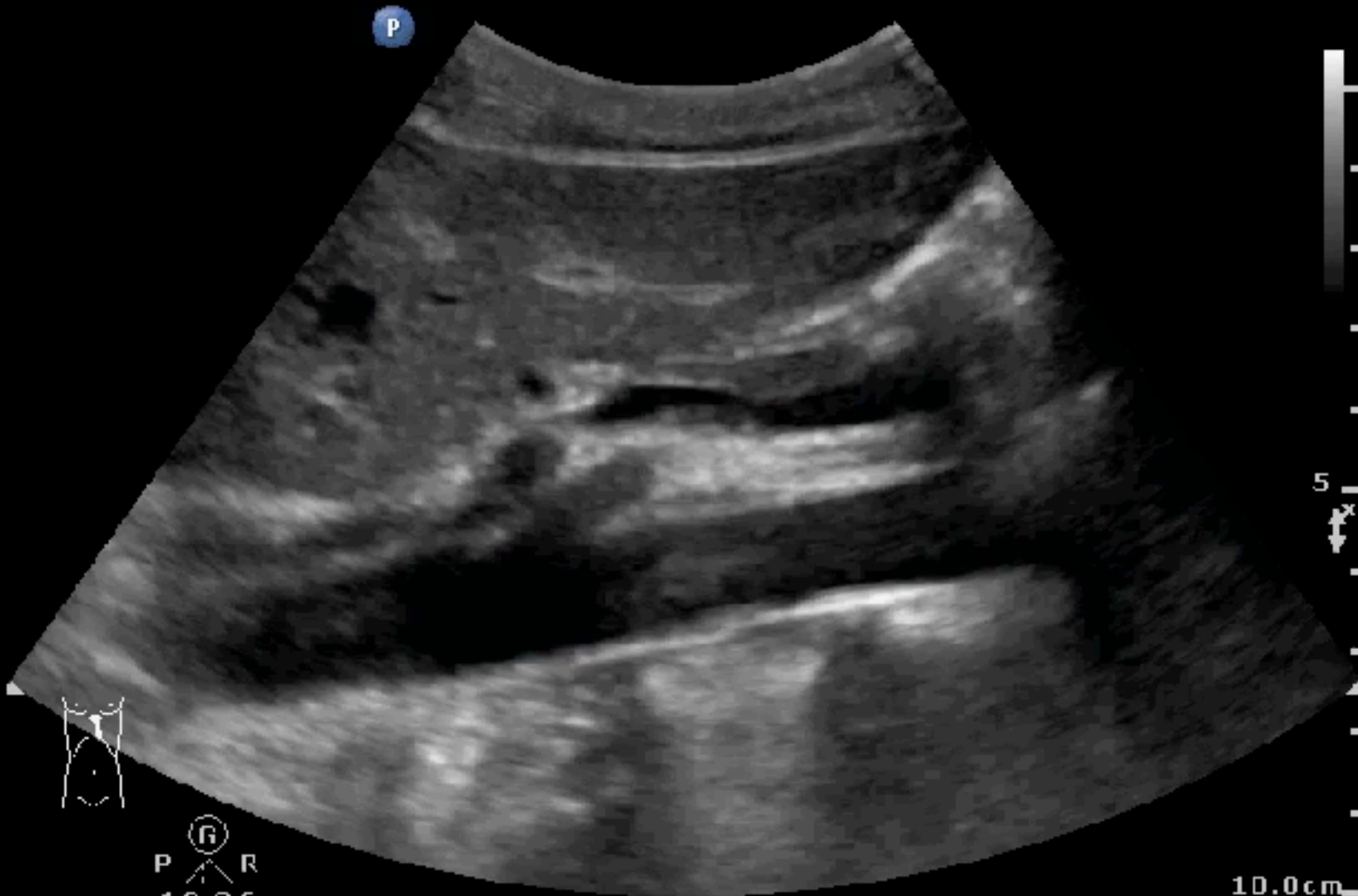SKH ER

TIS 0.1 5:27:00 PM

Abd Gen
C5-1
45 Hz
10.0cm

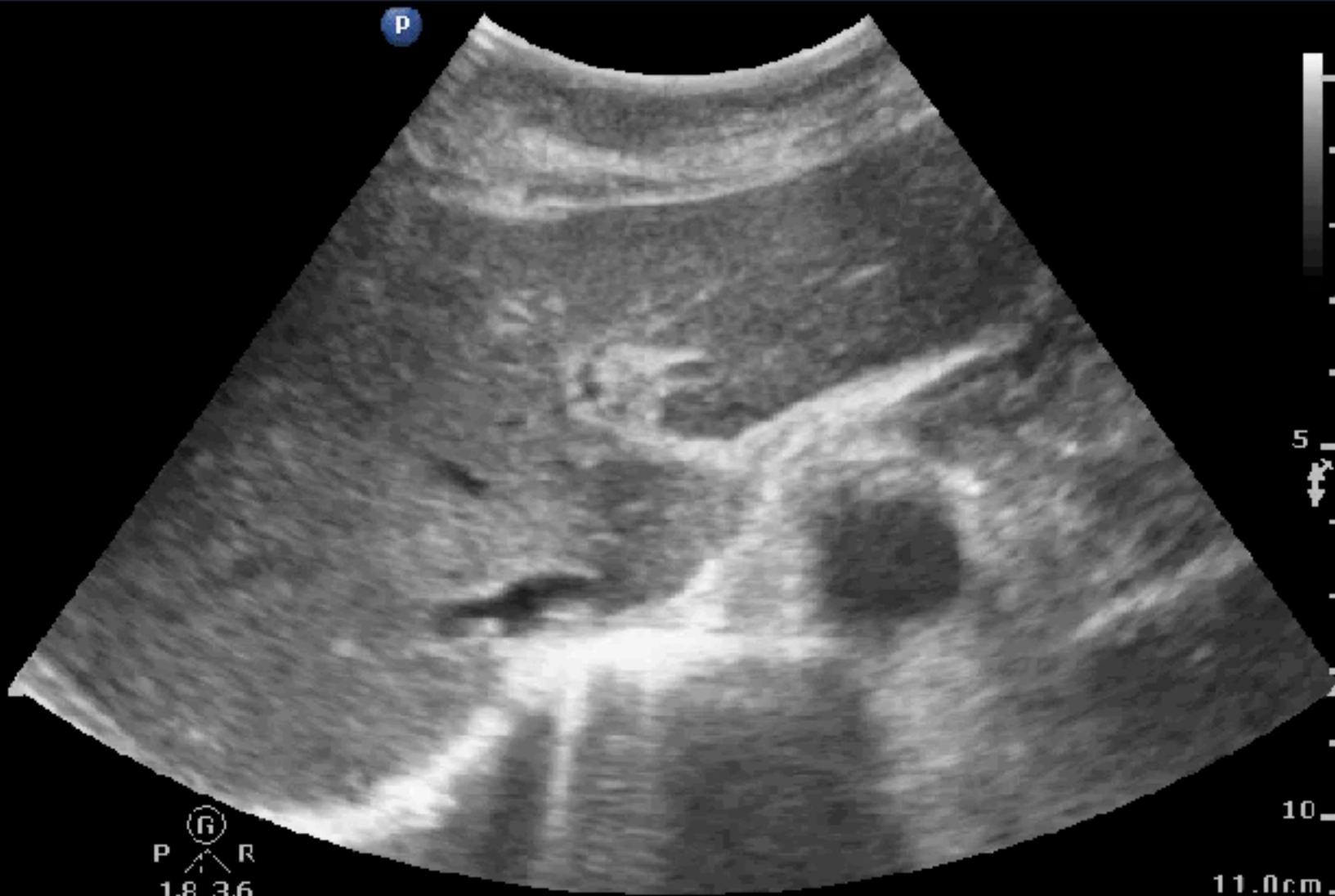2D

HGen
Gn 60
C. 56
3/3/3



10.0cm

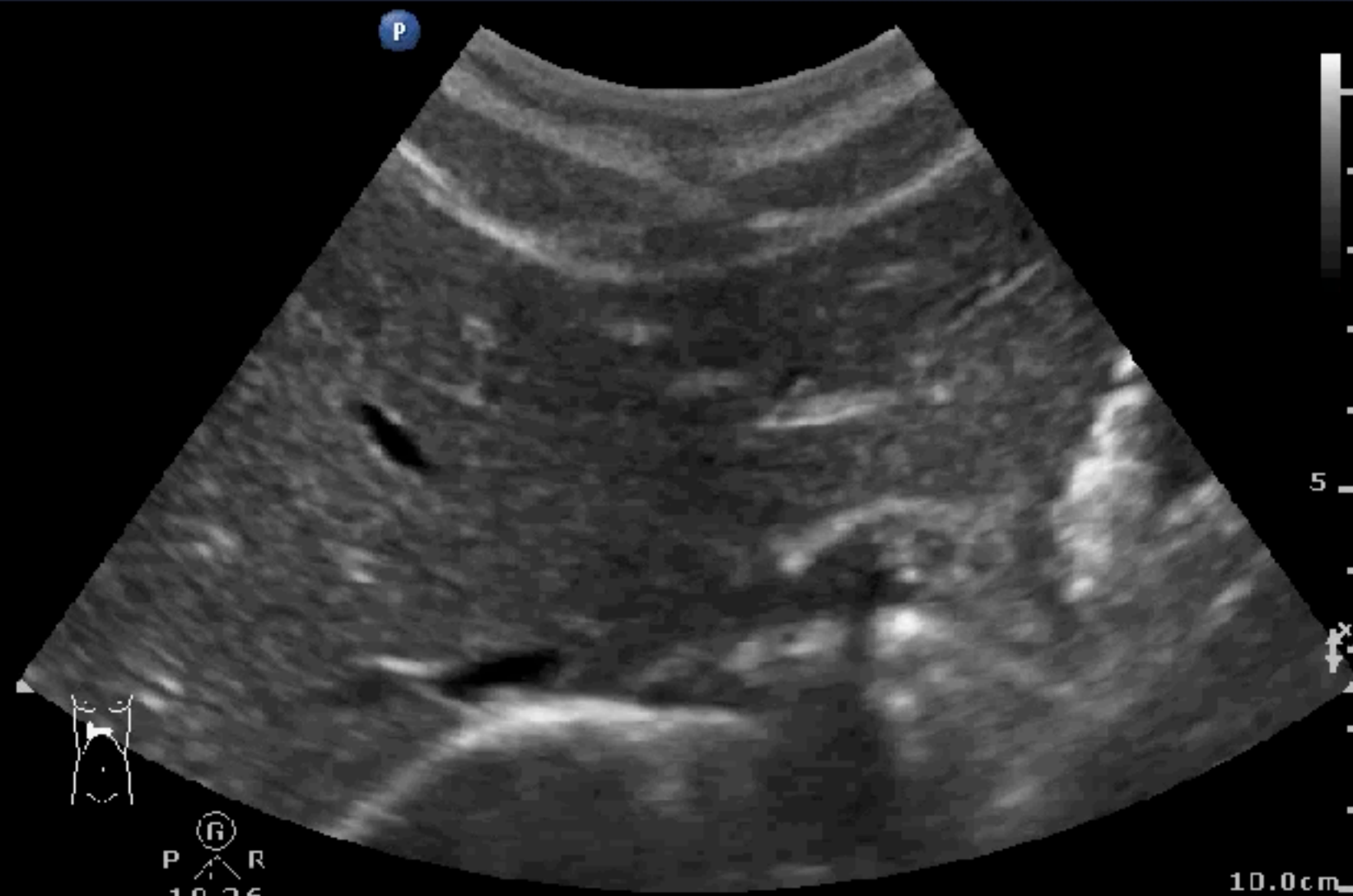Abd Gen
C5-1
42 Hz
11.0cm
2D
HGen
Gn 66
C. 56
3/3/3



11.0cm

Abd Gen
C5-1
45 Hz
10.0cm

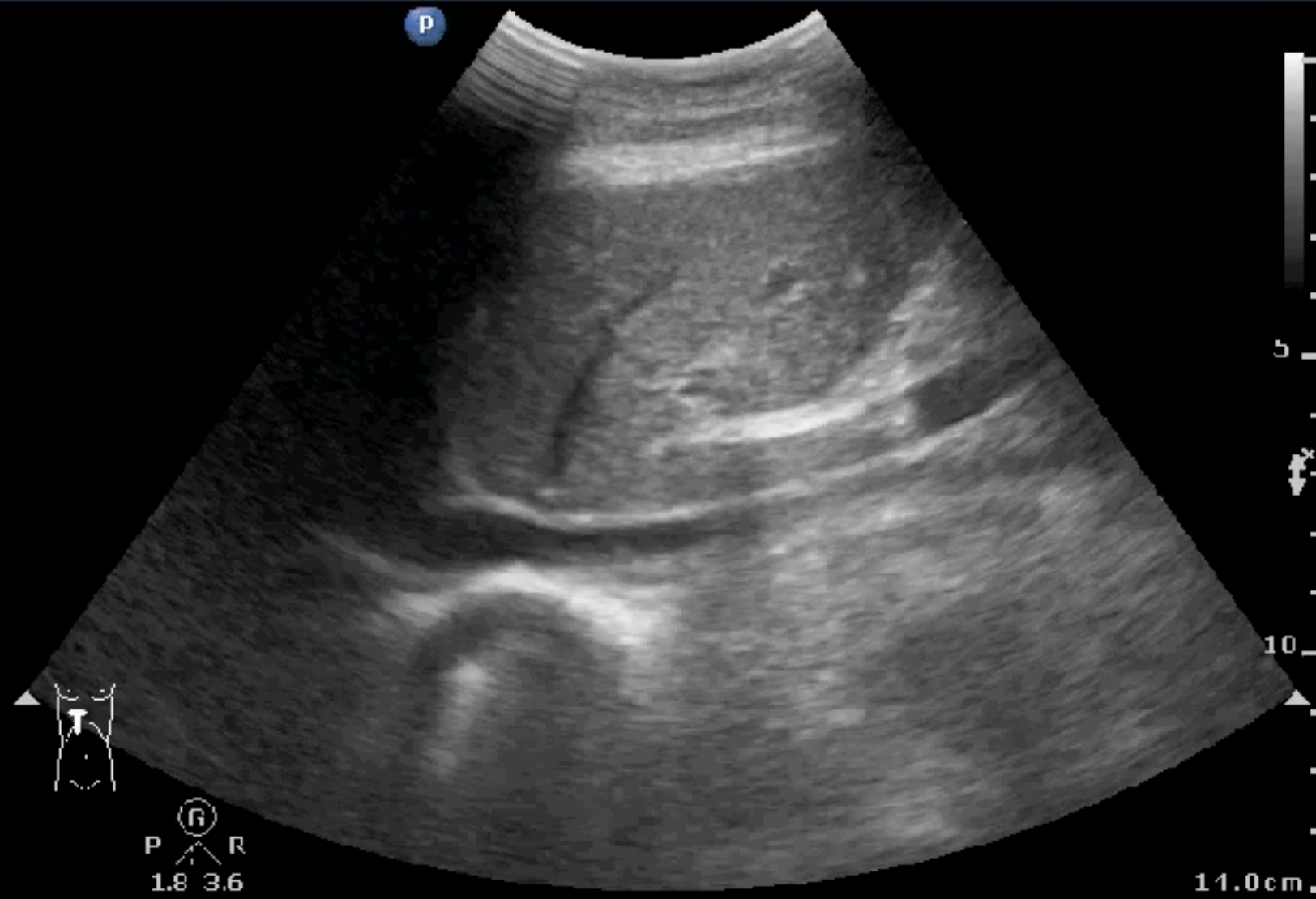
2D
HGen
Gn 81
C. 56
3/3/3



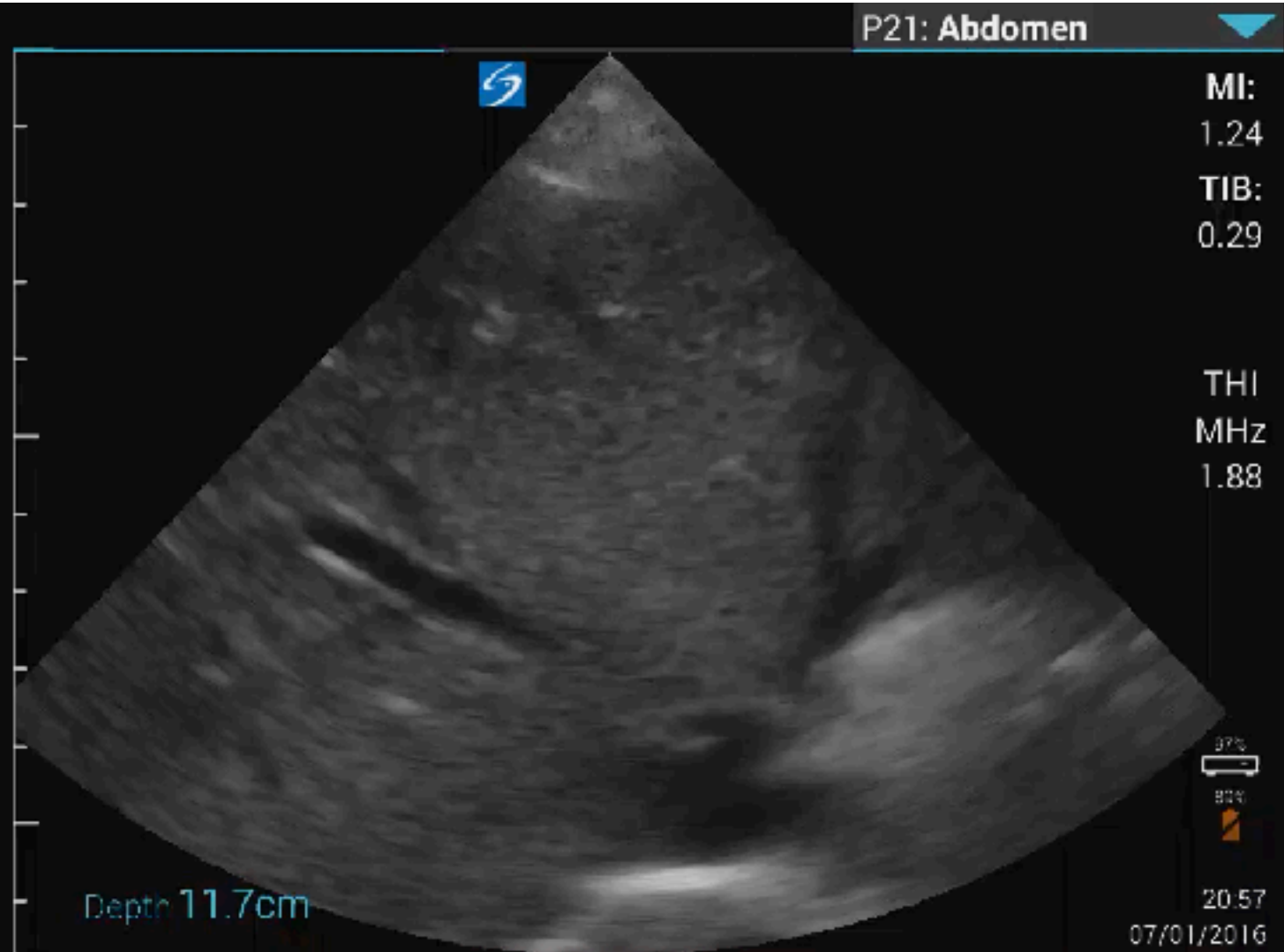
10.0 cm

Abd Gen
C5-1
36 Hz
14.0cm

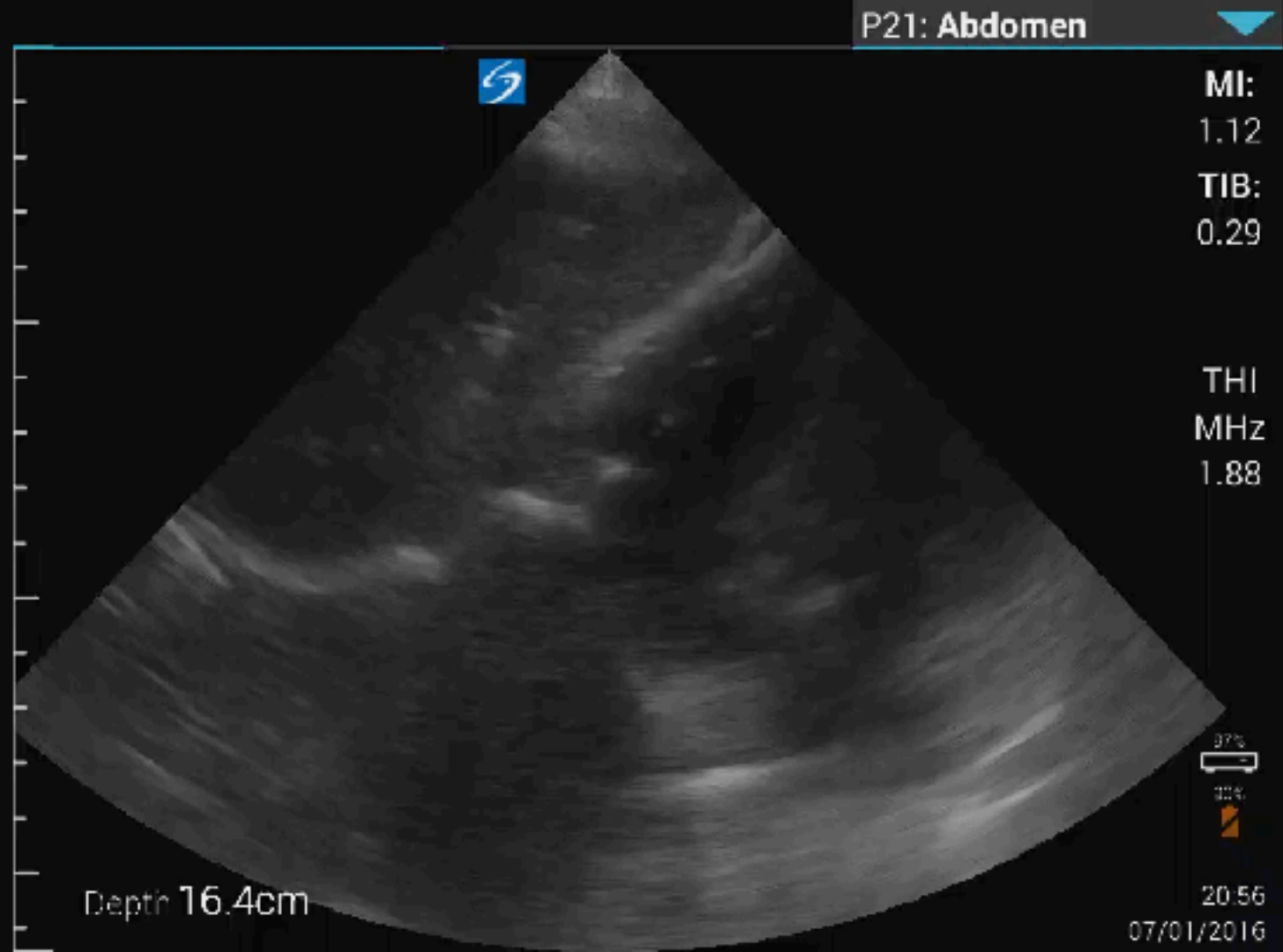2D
HGen
Gn 100
C. 56
3/3/3



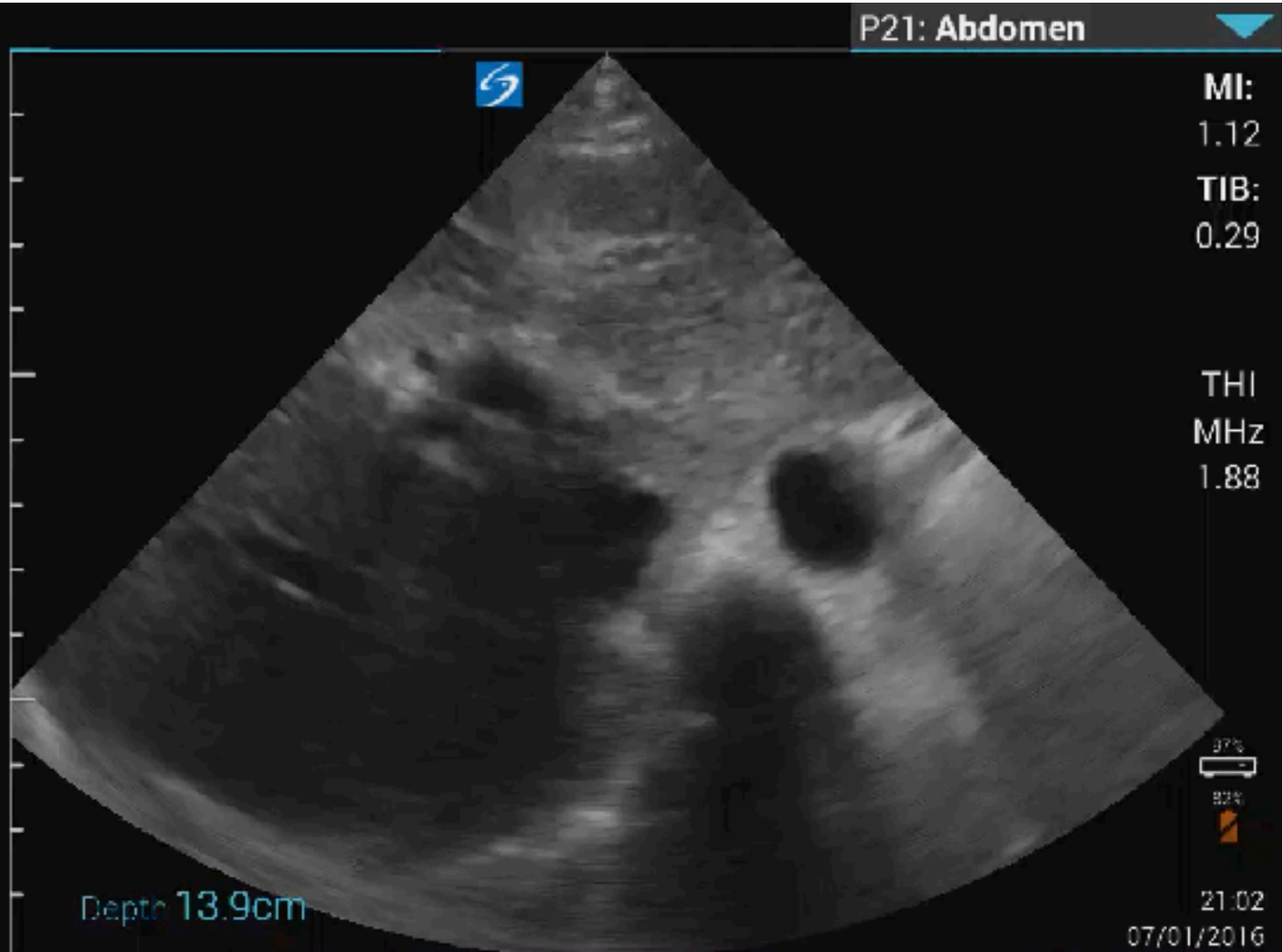
IVC & Hepatic veins



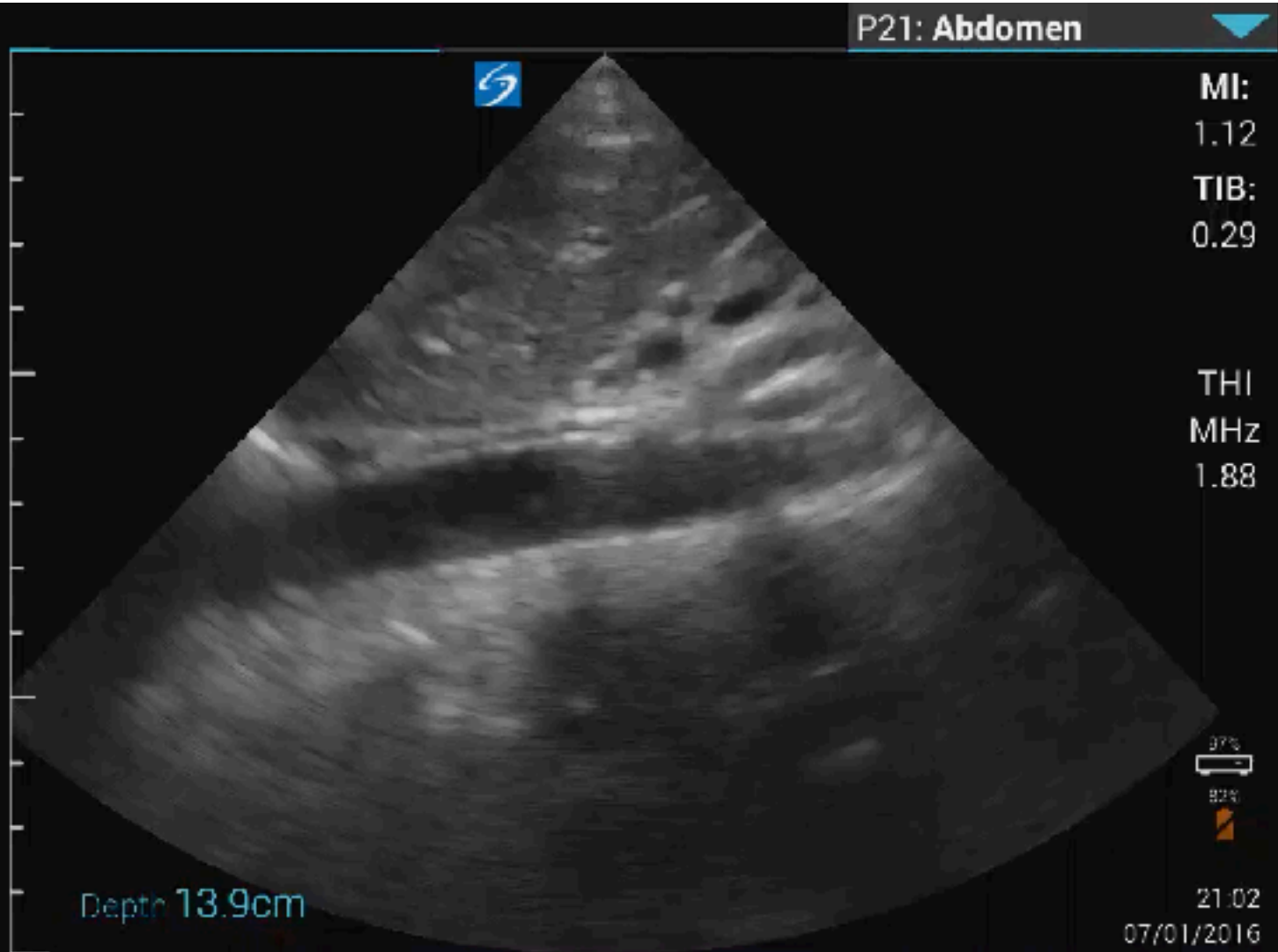
Subcostal 4 chamber & IVC



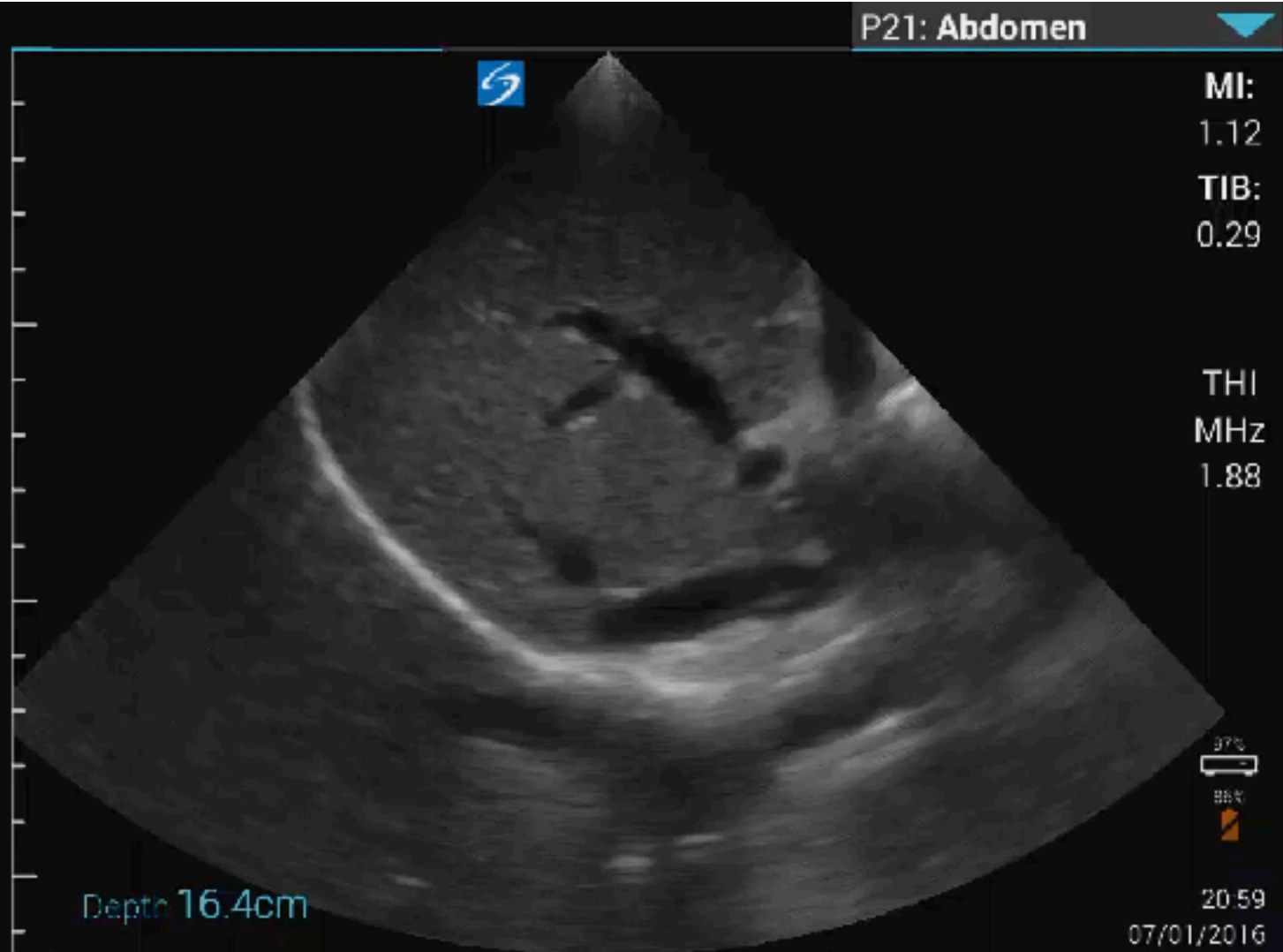Aorta & IVC ratio



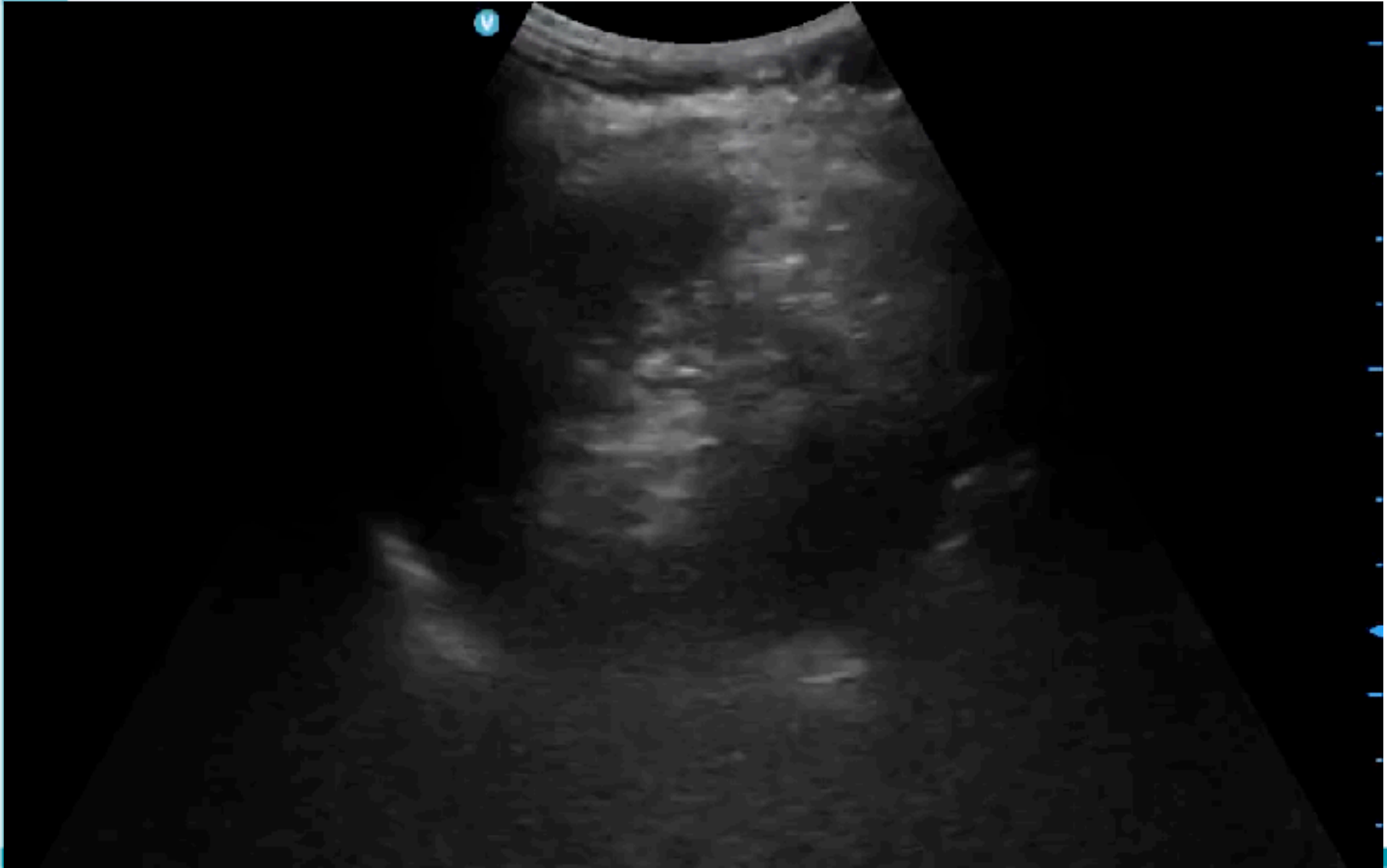Aorta & IVC -Tilt



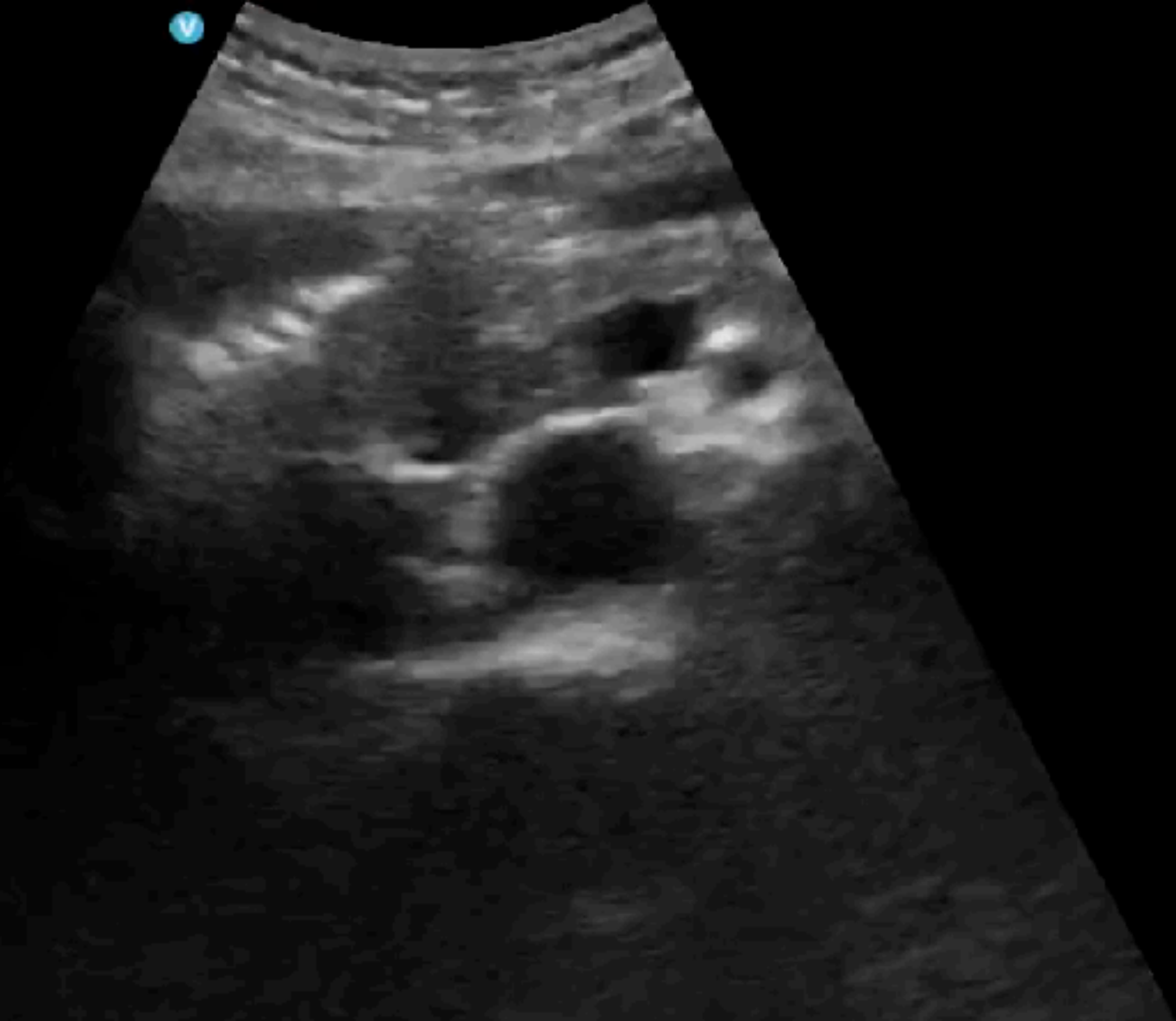Transhepatic scan for IVC



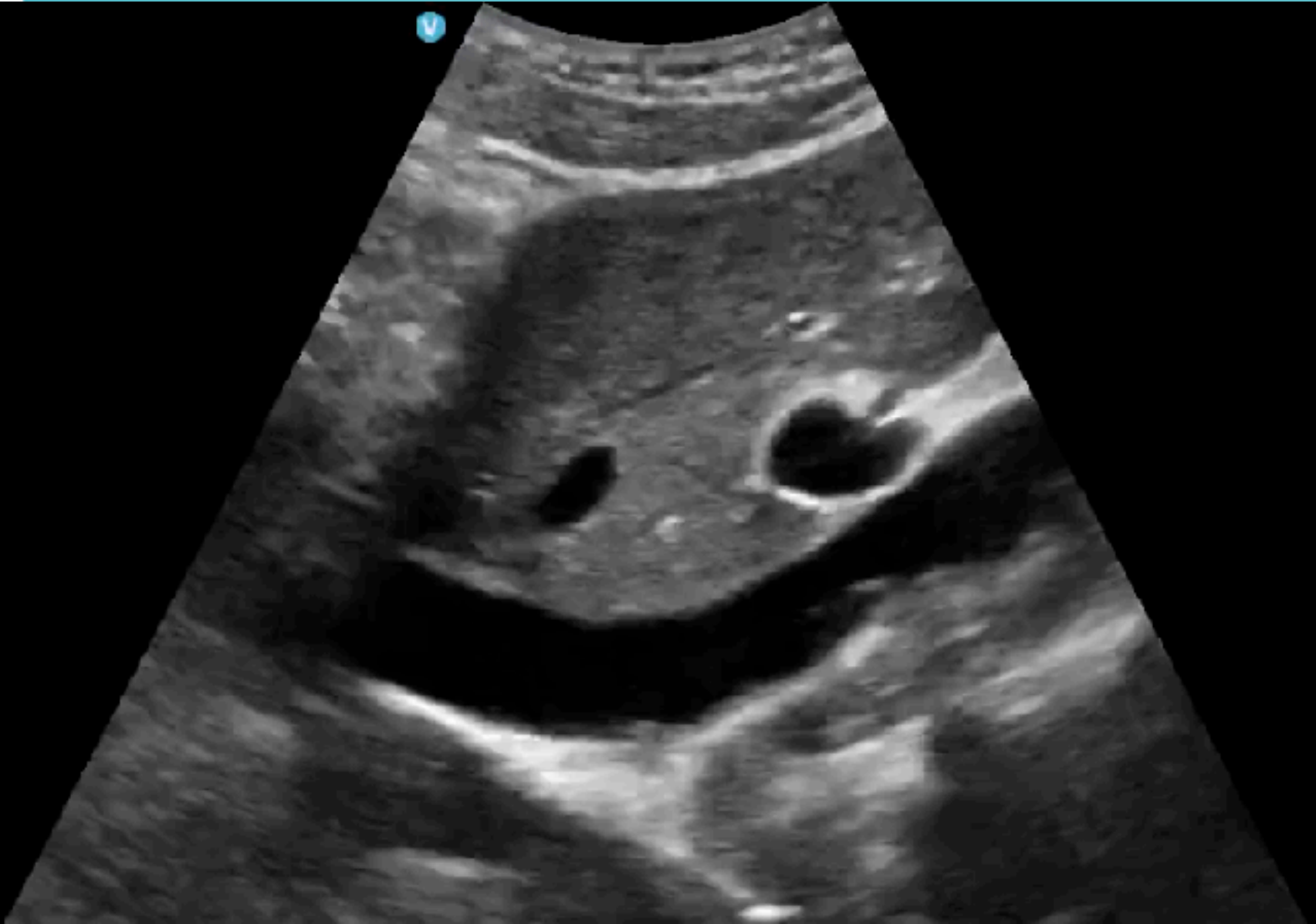Trans-splenic scan for aorta



Aorta- rotational skill



Name the vessels

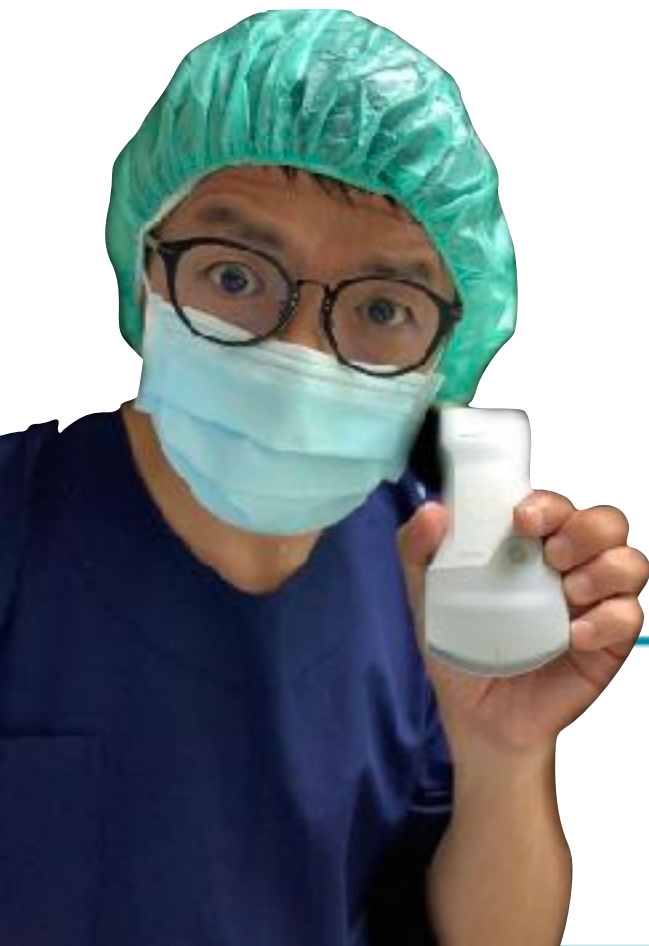



衛生福利部雙和醫院
(委託臺北醫學大學興建經營)
Taipei Medical University · Shuang Ho Hospital,
Ministry of Health and Welfare



POCUS Imaging Reading



陳國智醫師

雙和醫院 急診醫學科

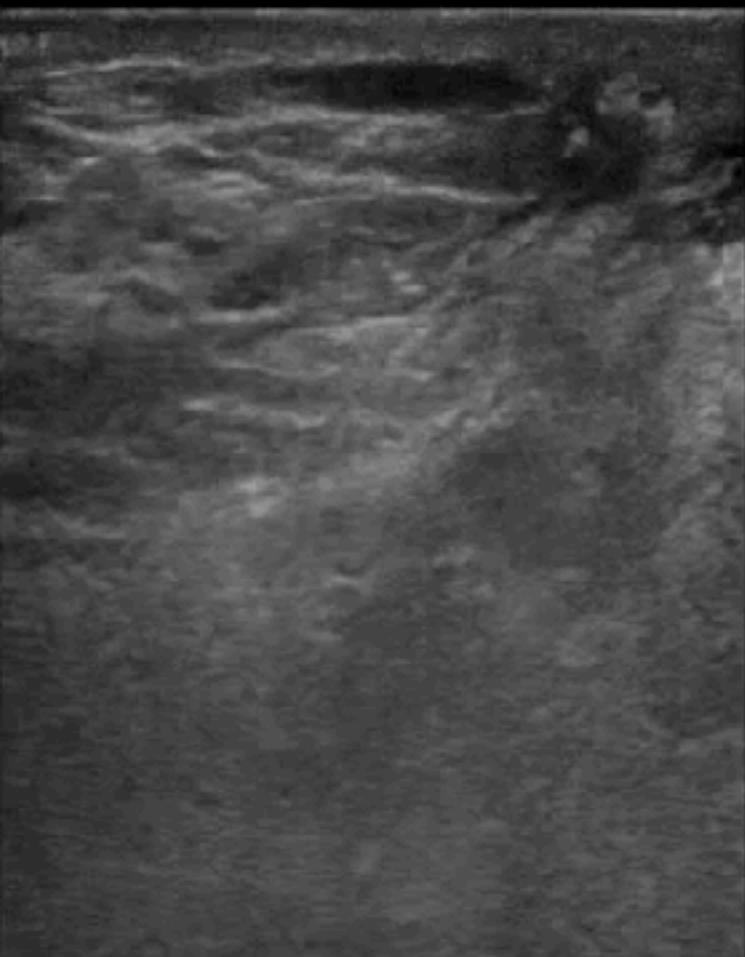63歲男性，陰囊腫痛



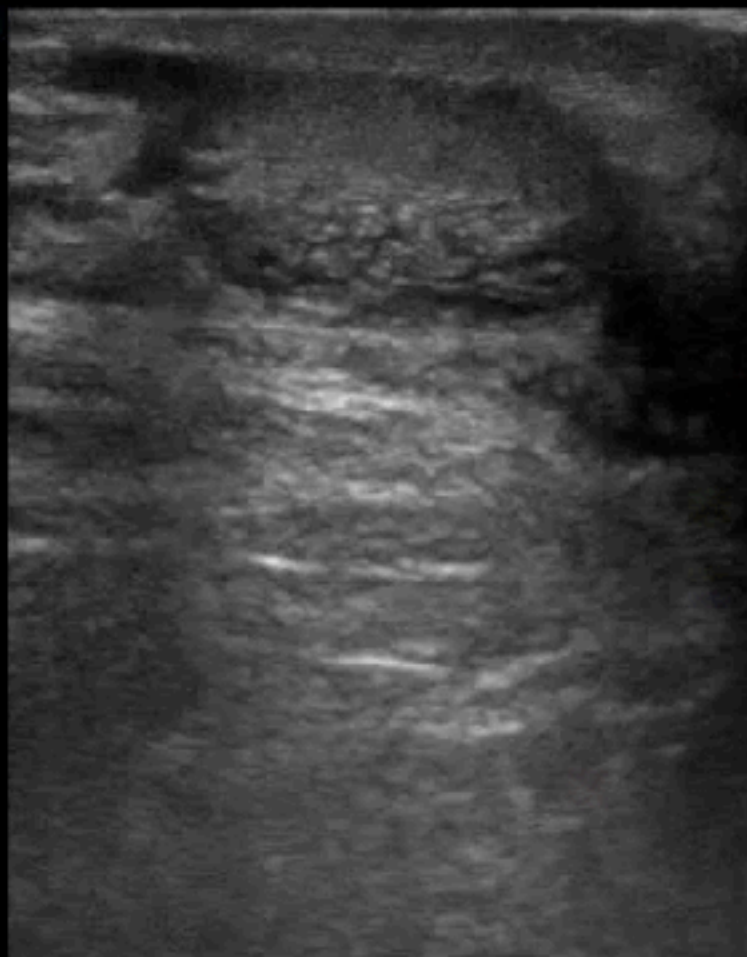00685863

2022Mar25 17:34

00685863



- SmP
HFL
MI
0.6
TIS
0.1



4.9

Freeze

Save

Options

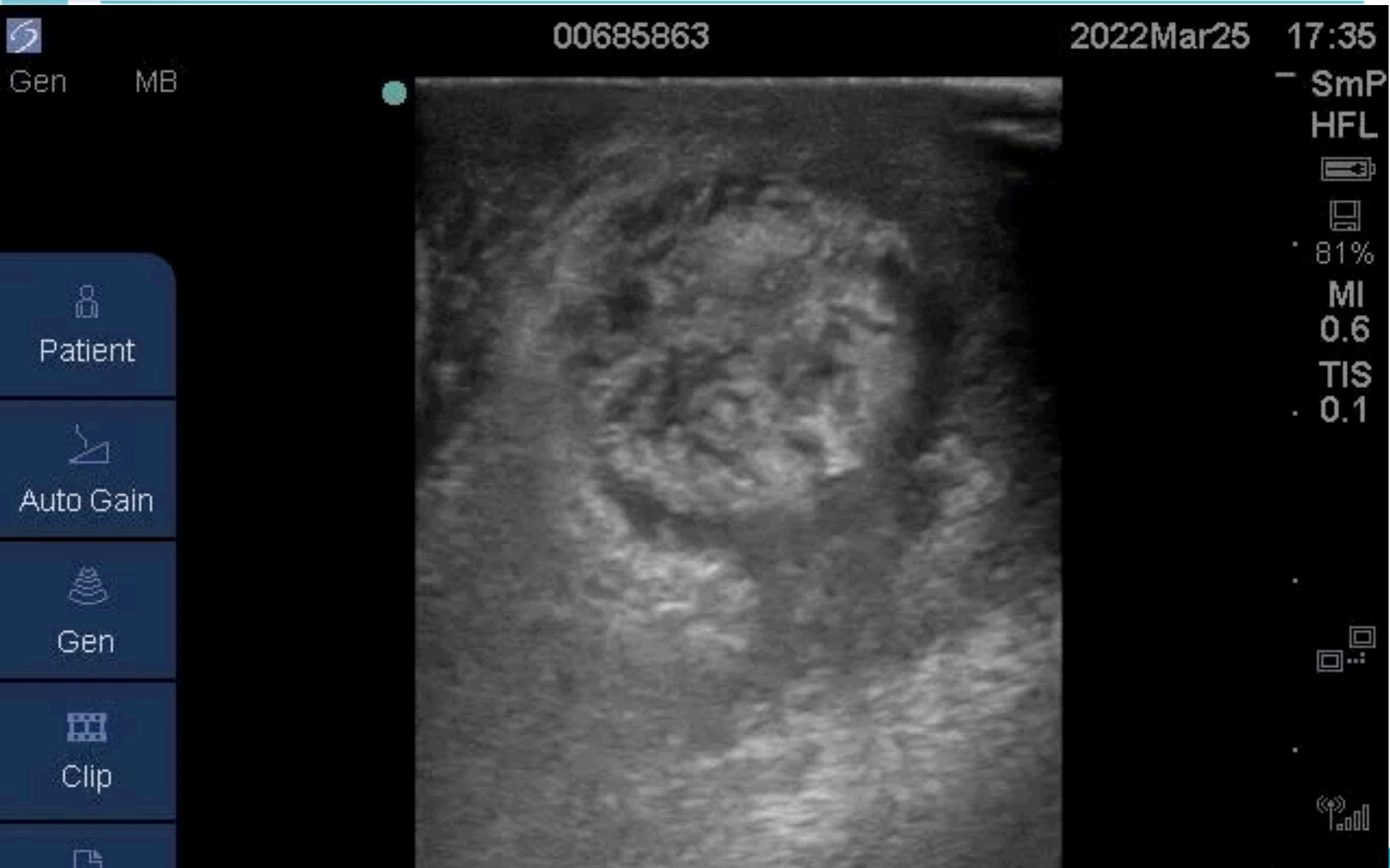Mode

Freeze

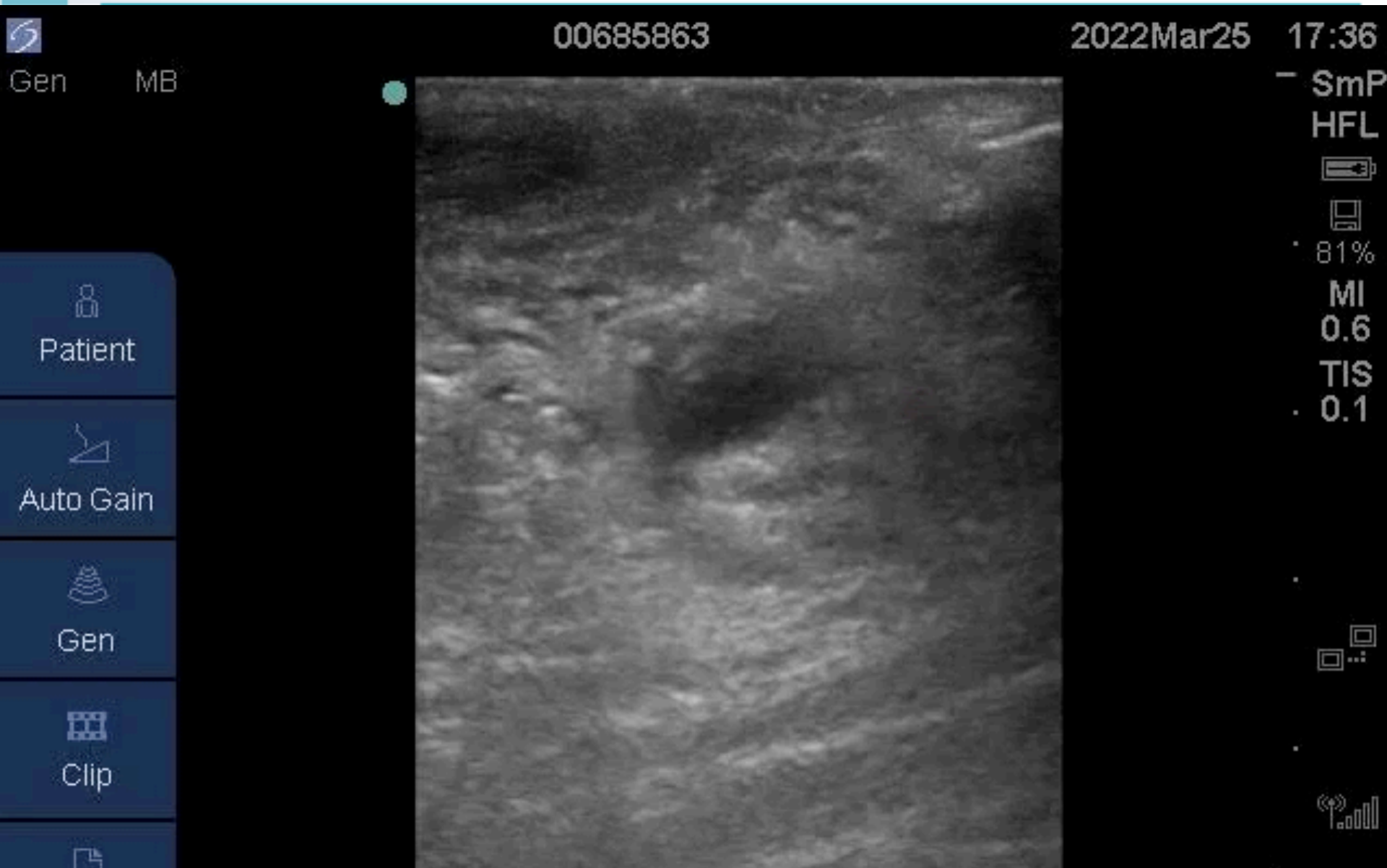Save

Options

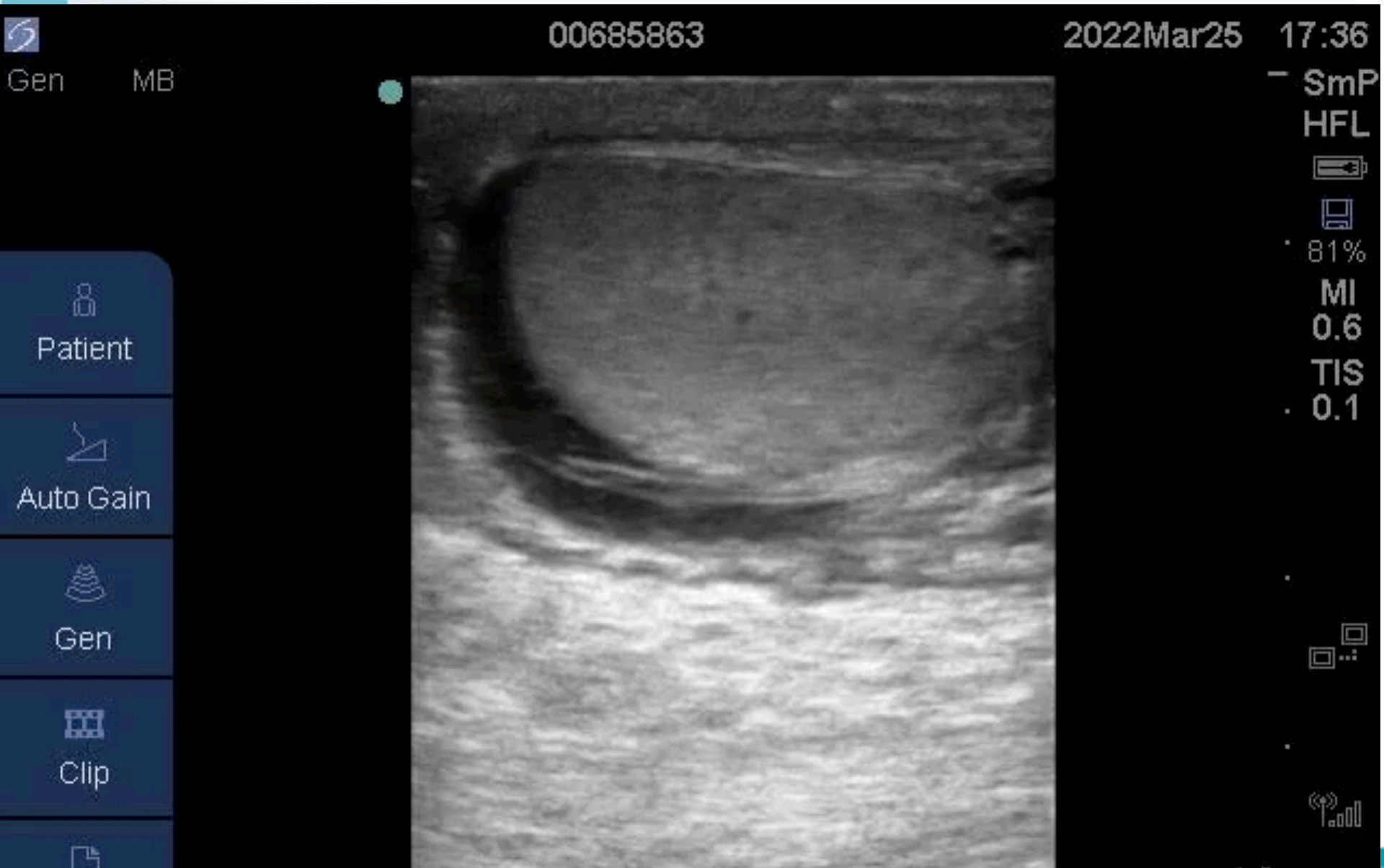63歲男性，陰囊腫痛



63歲男性，陰囊腫痛

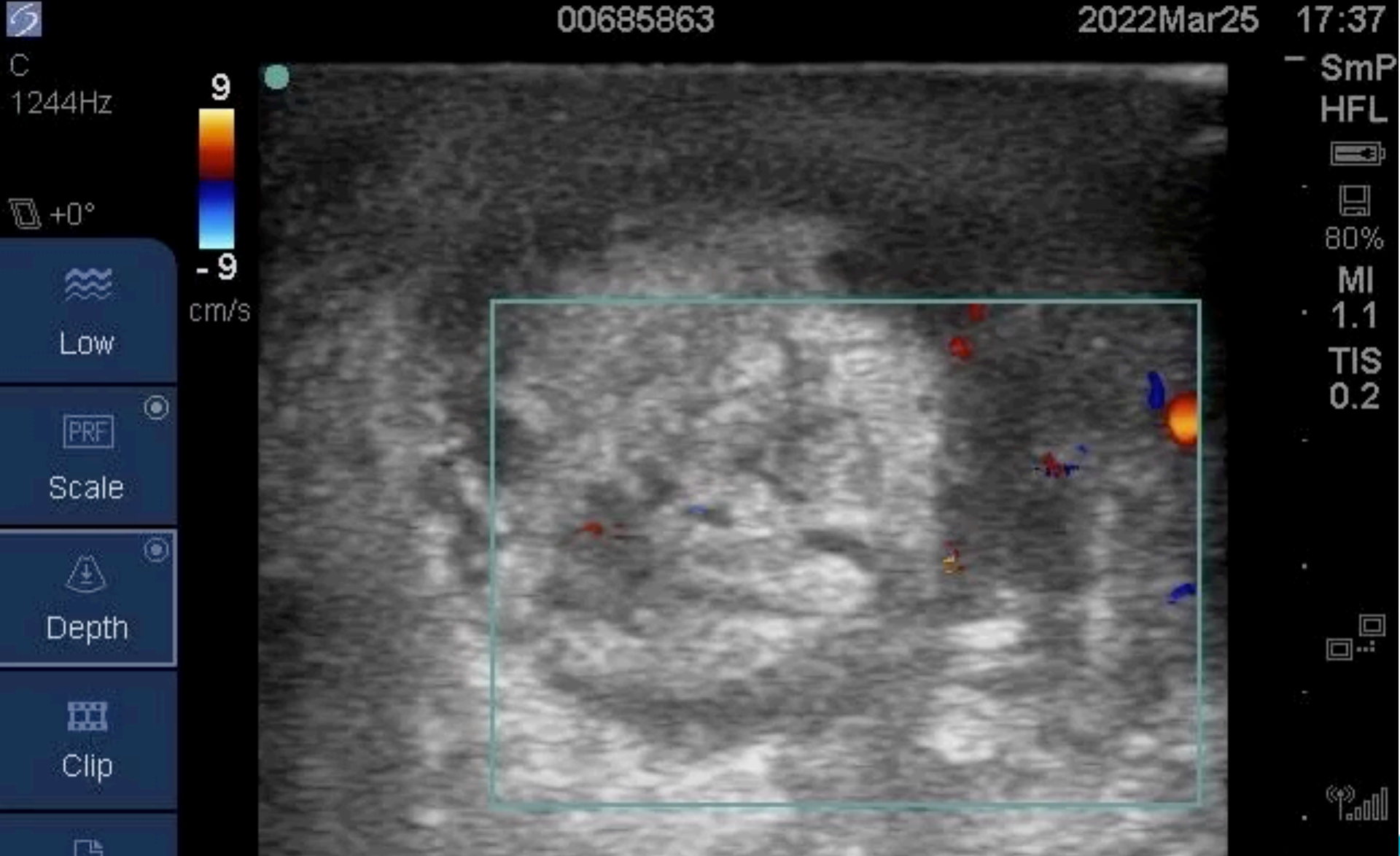


63歲男性，陰囊腫痛

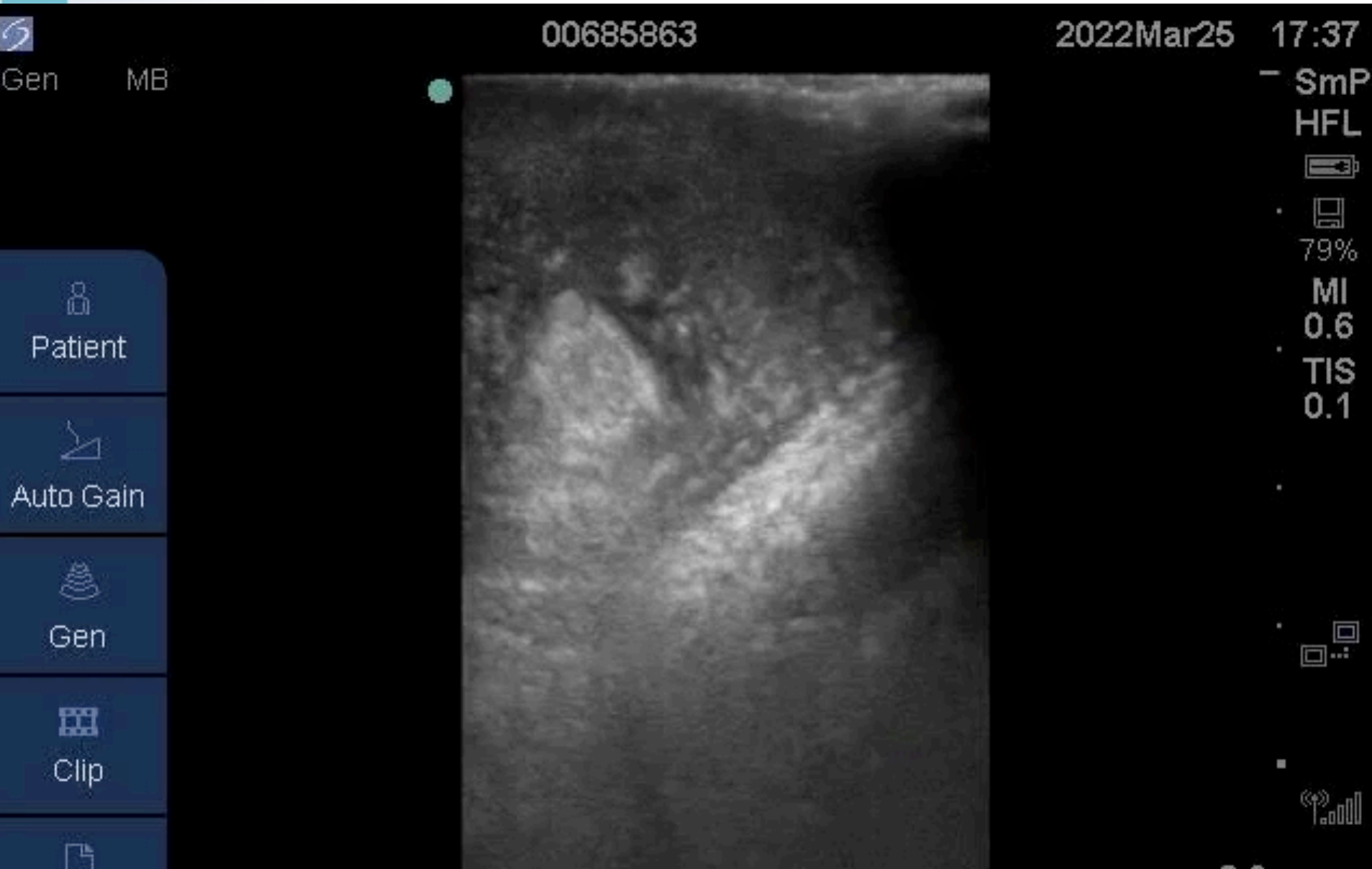



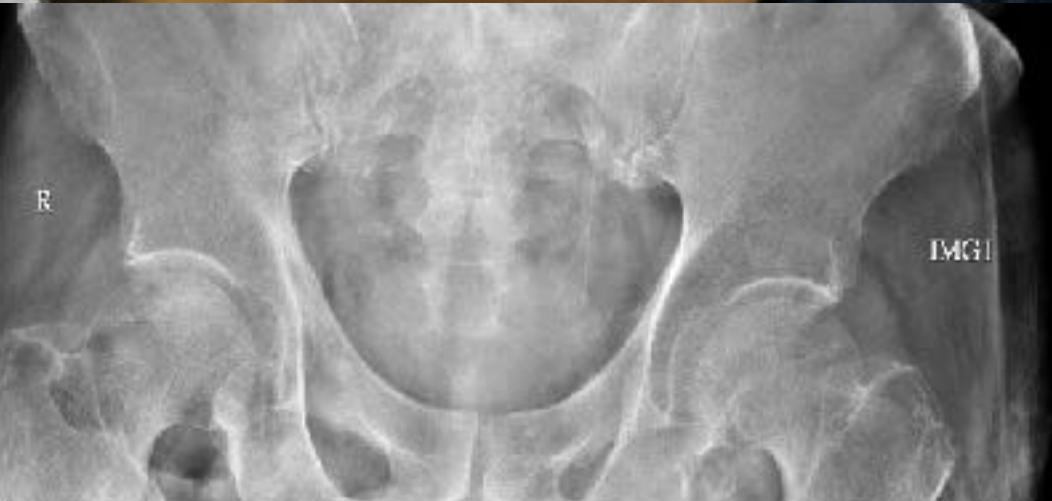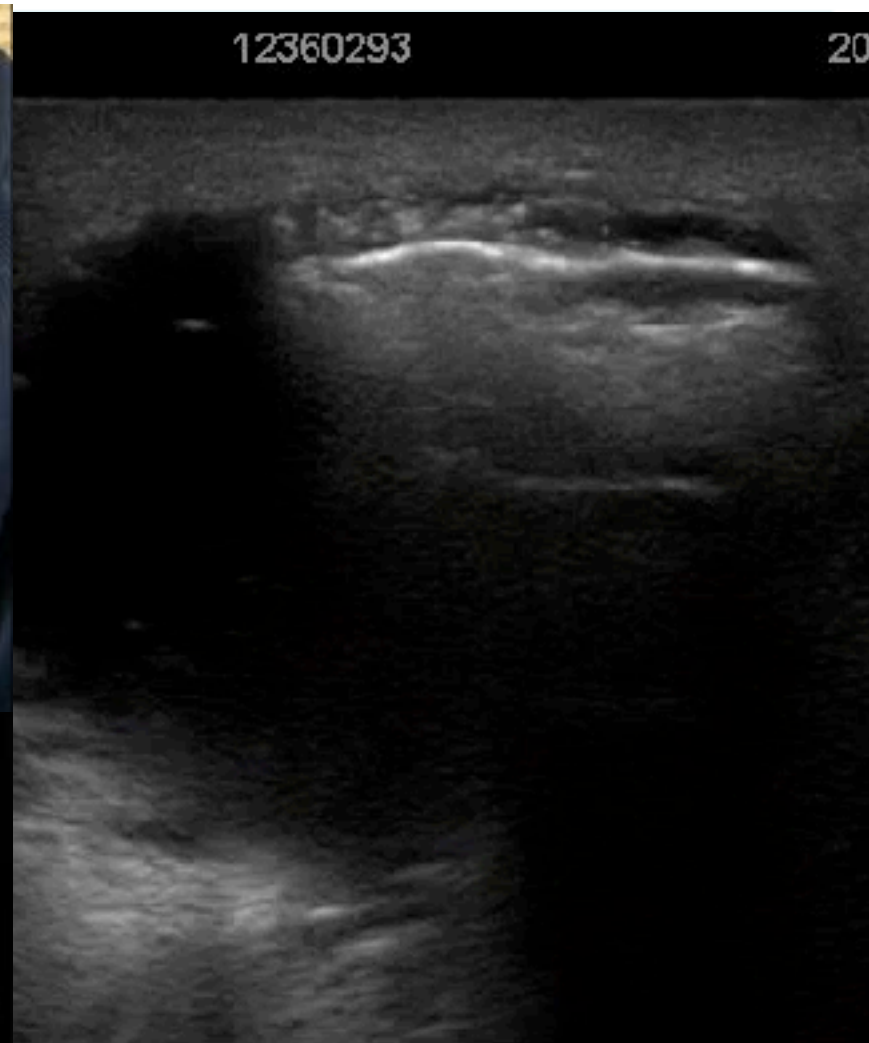
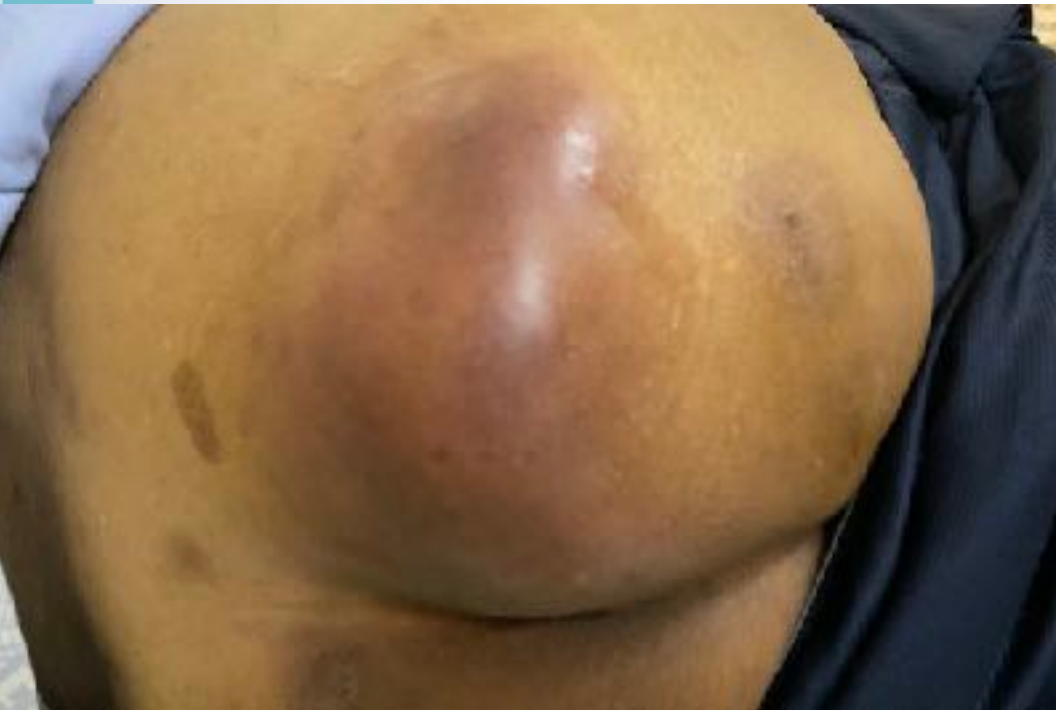63歲男性，陰囊腫痛



Epididymo-orchitis, left



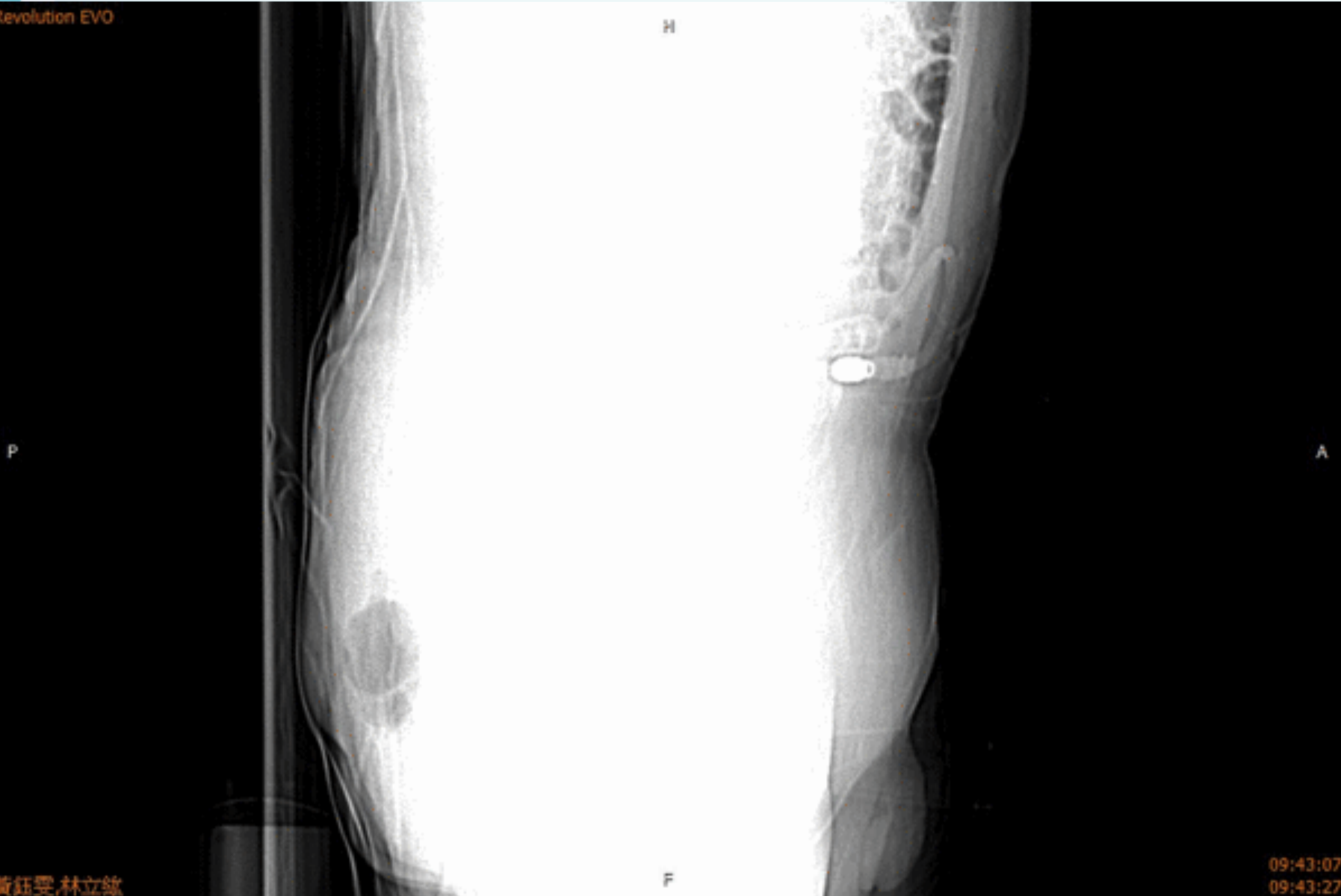
72M, ESRD on HD, DM, buttock lump



72M, ESRD on HD, DM, buttock lump



Revolution EVO



Gas-forming abscess



GenTHI MB

12360293

2022Mar26

13:39

Abd

C60



69%

MI

0.8

TIS

0.2



Patient



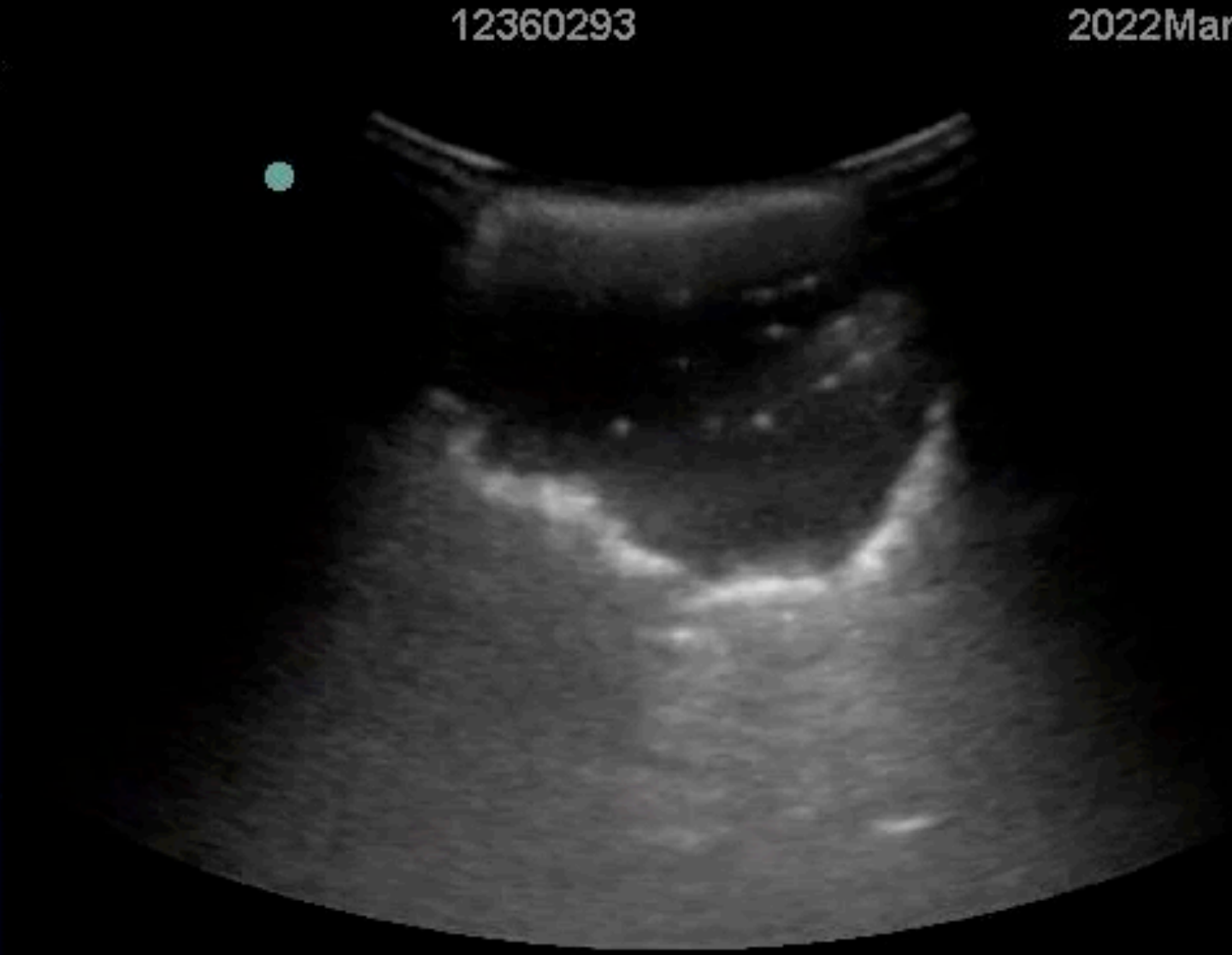Auto Gain



Gen



Clip



Bedside I & D



12360293

2022Mar26 13:40

GenTHI MB

Abd

C60



· 69%

MI

· 0.8

TIS

· 0.2



Patient



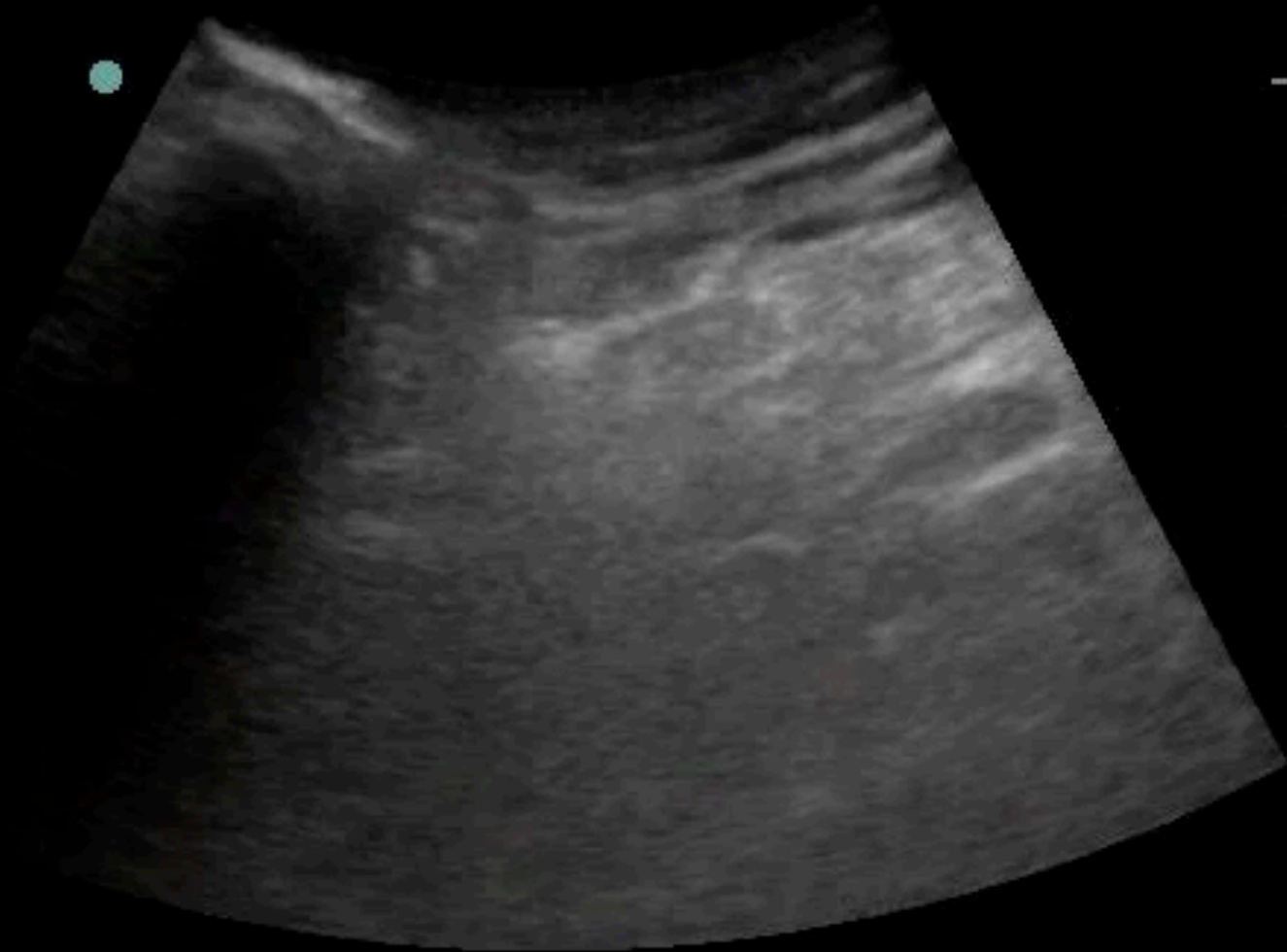Auto Gain



Gen



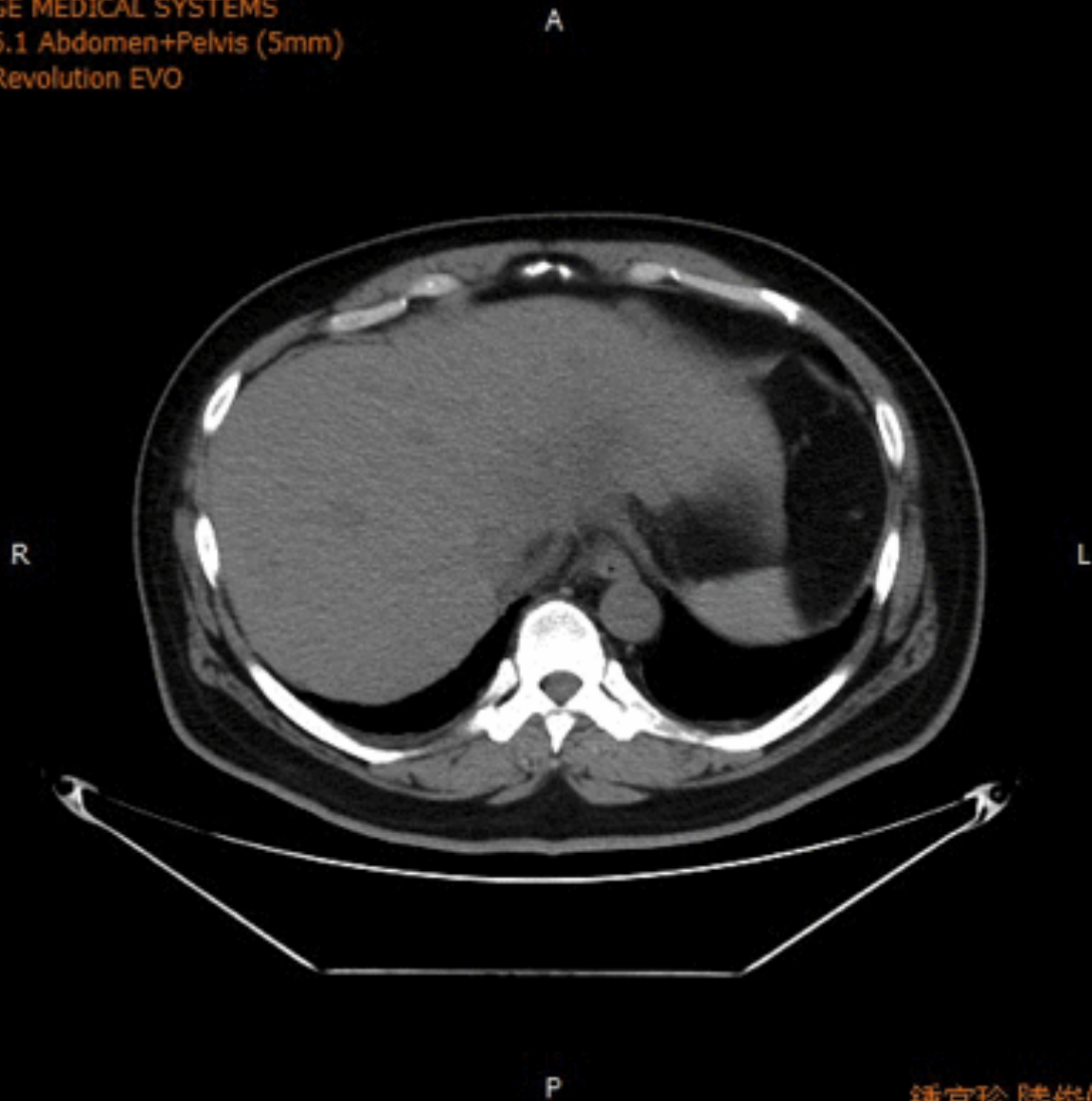
Clip



53M, 體重減輕, 發燒

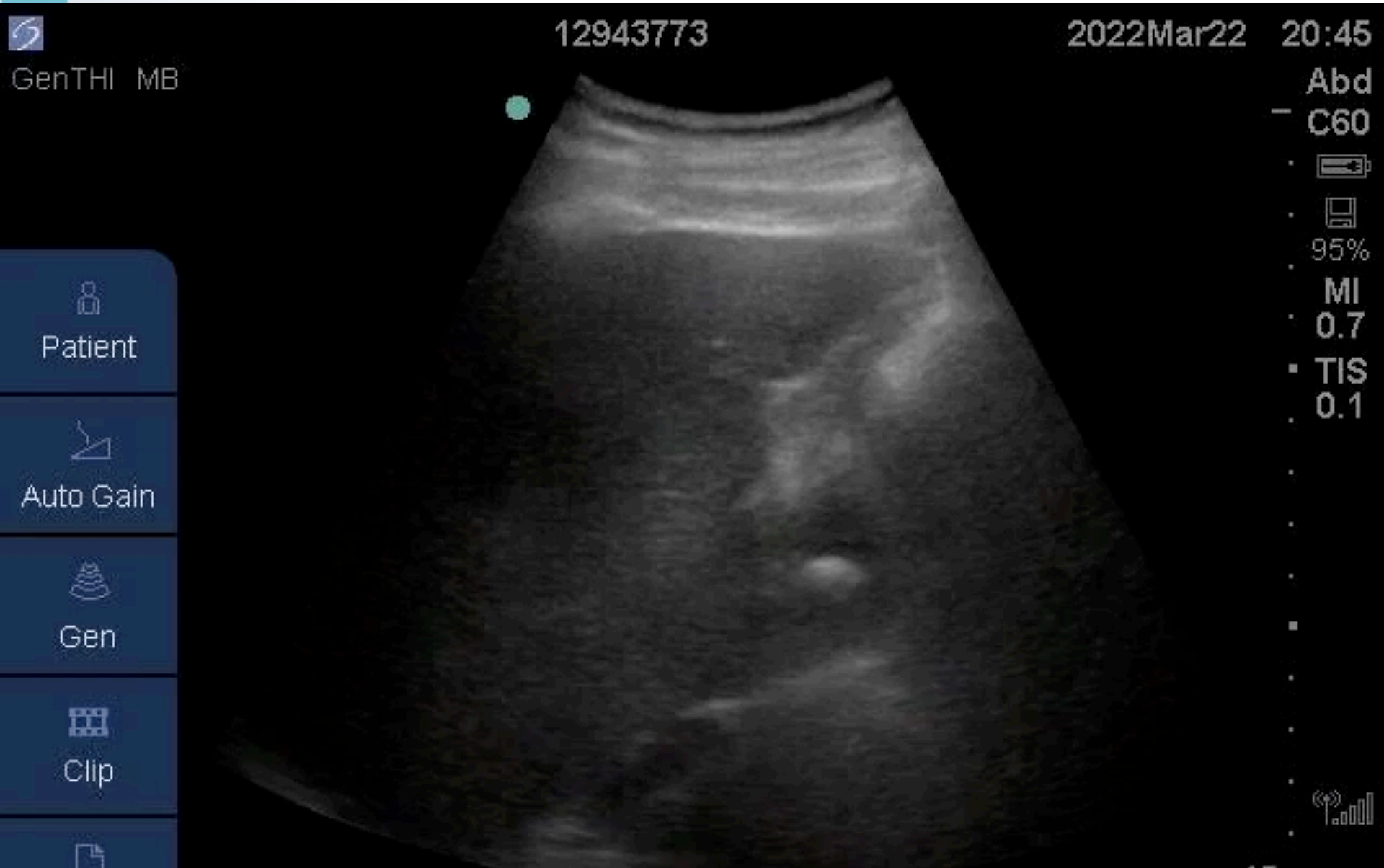

GE MEDICAL SYSTEMS
6.1 Abdomen+Pelvis (5mm)
Revolution EVO

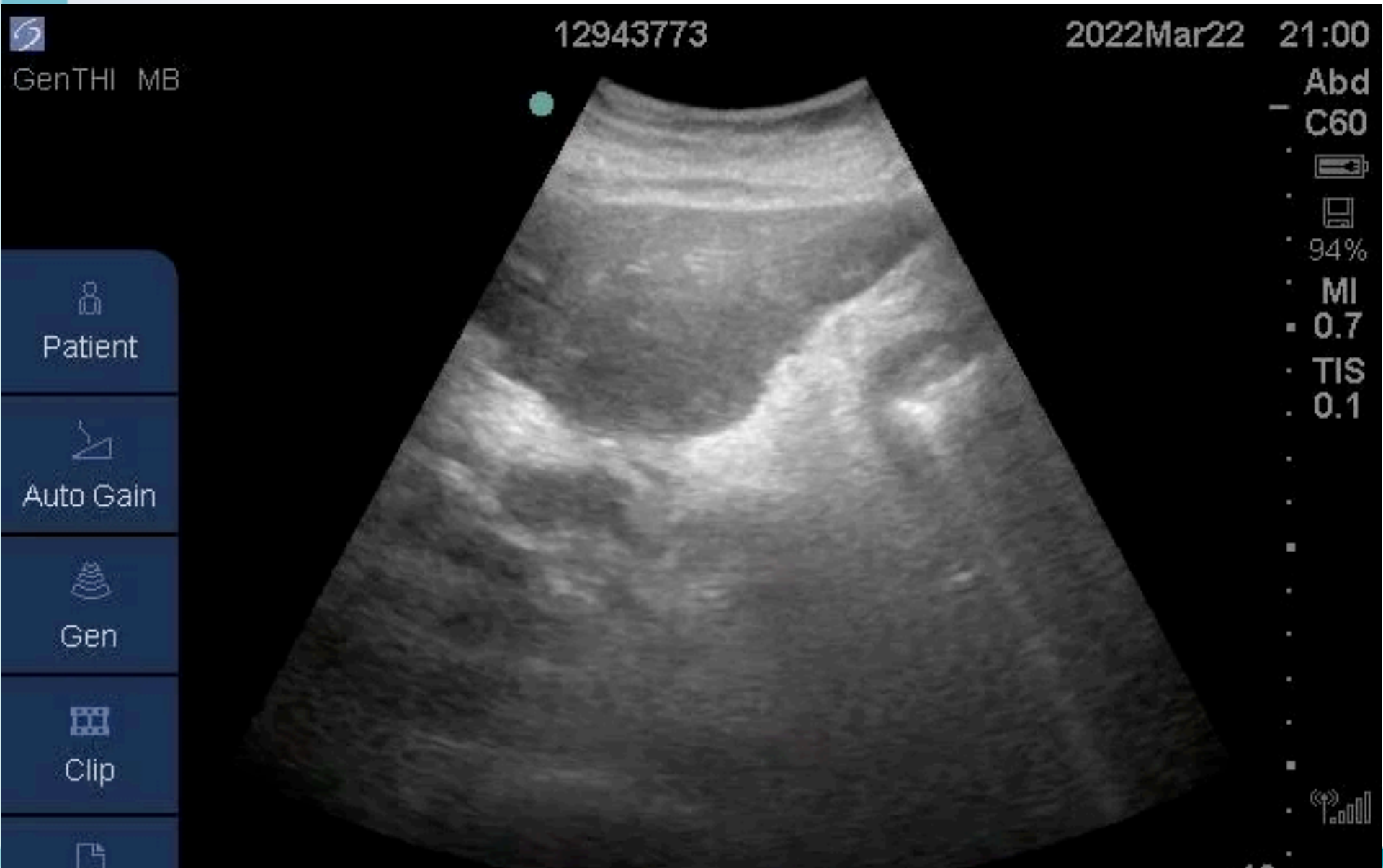


鍾宜珍, 陸俊偉

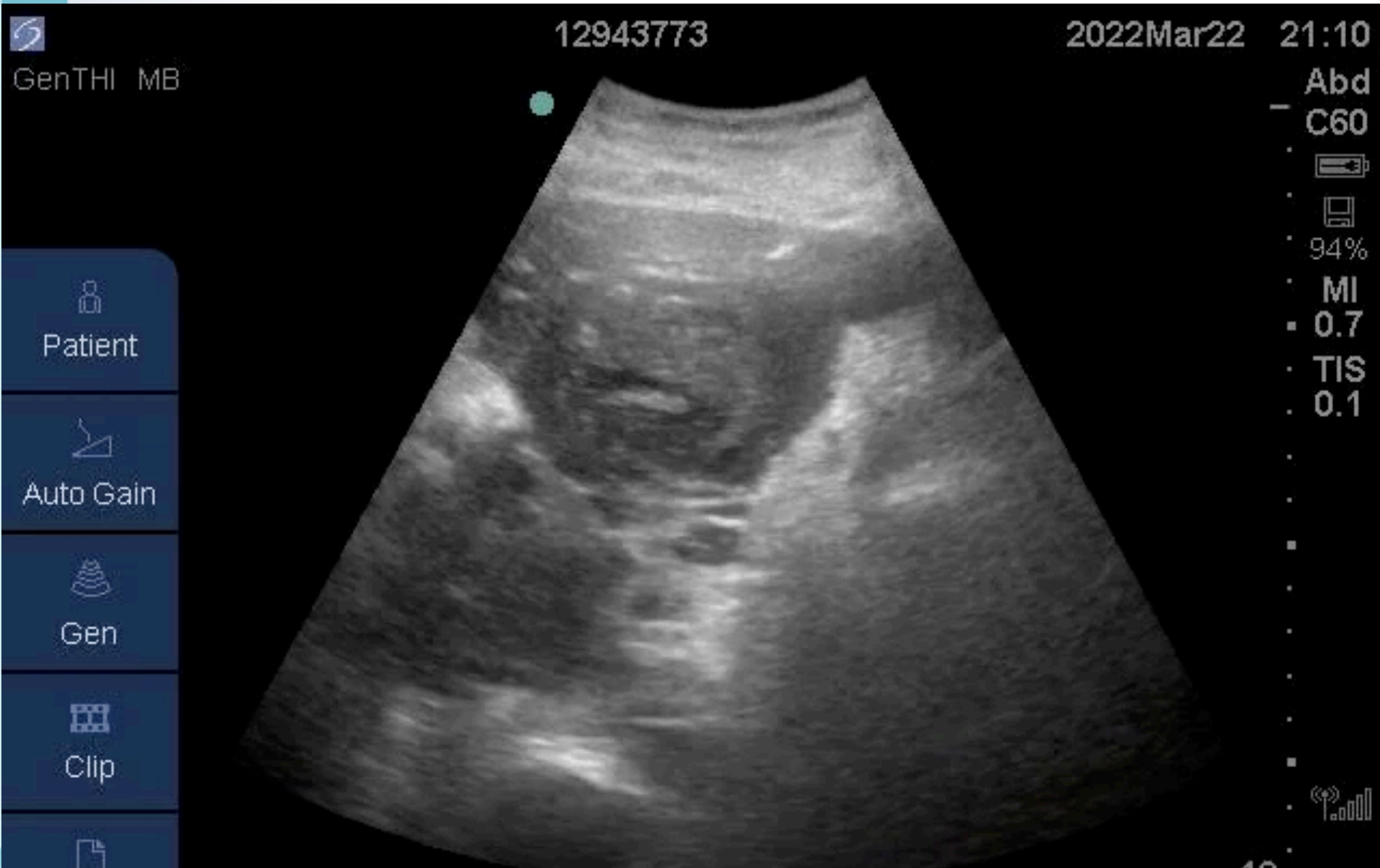
Liver abscess



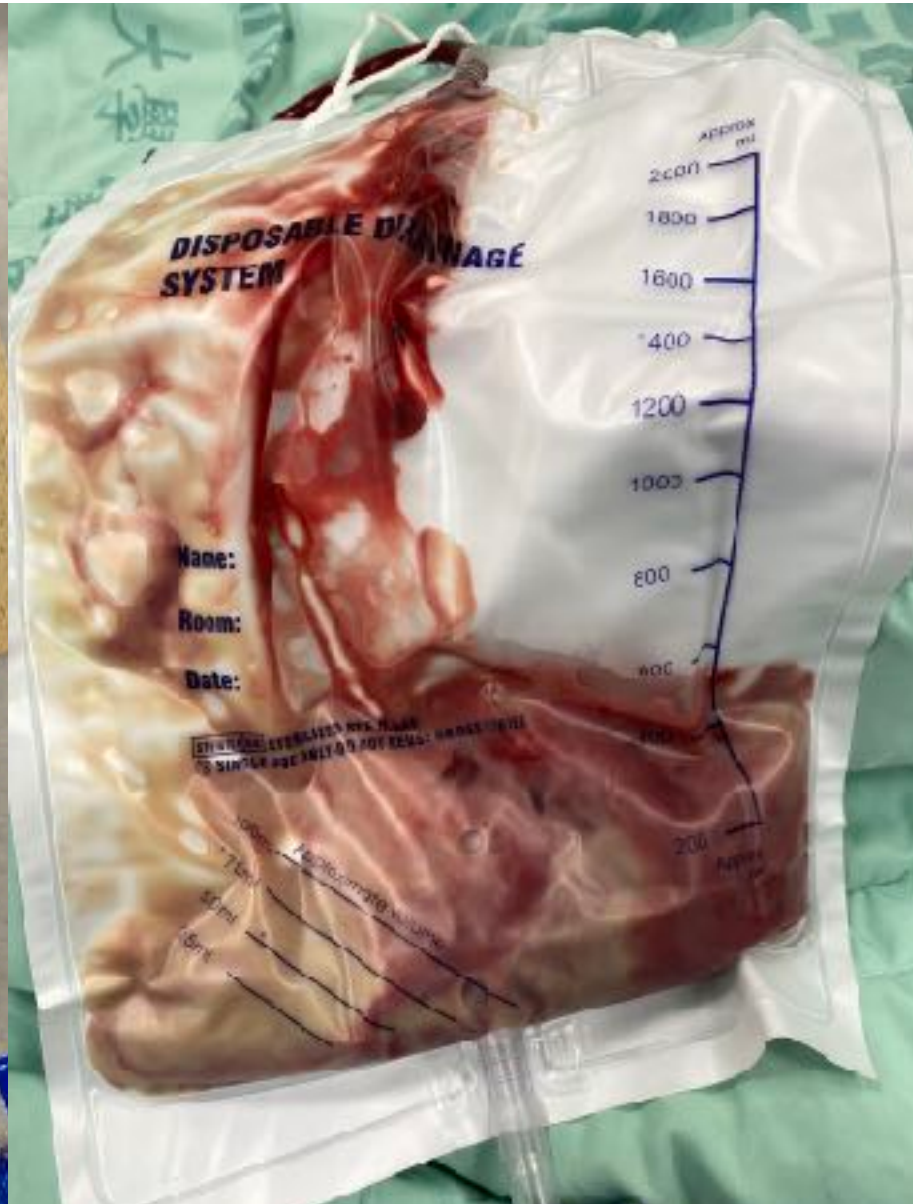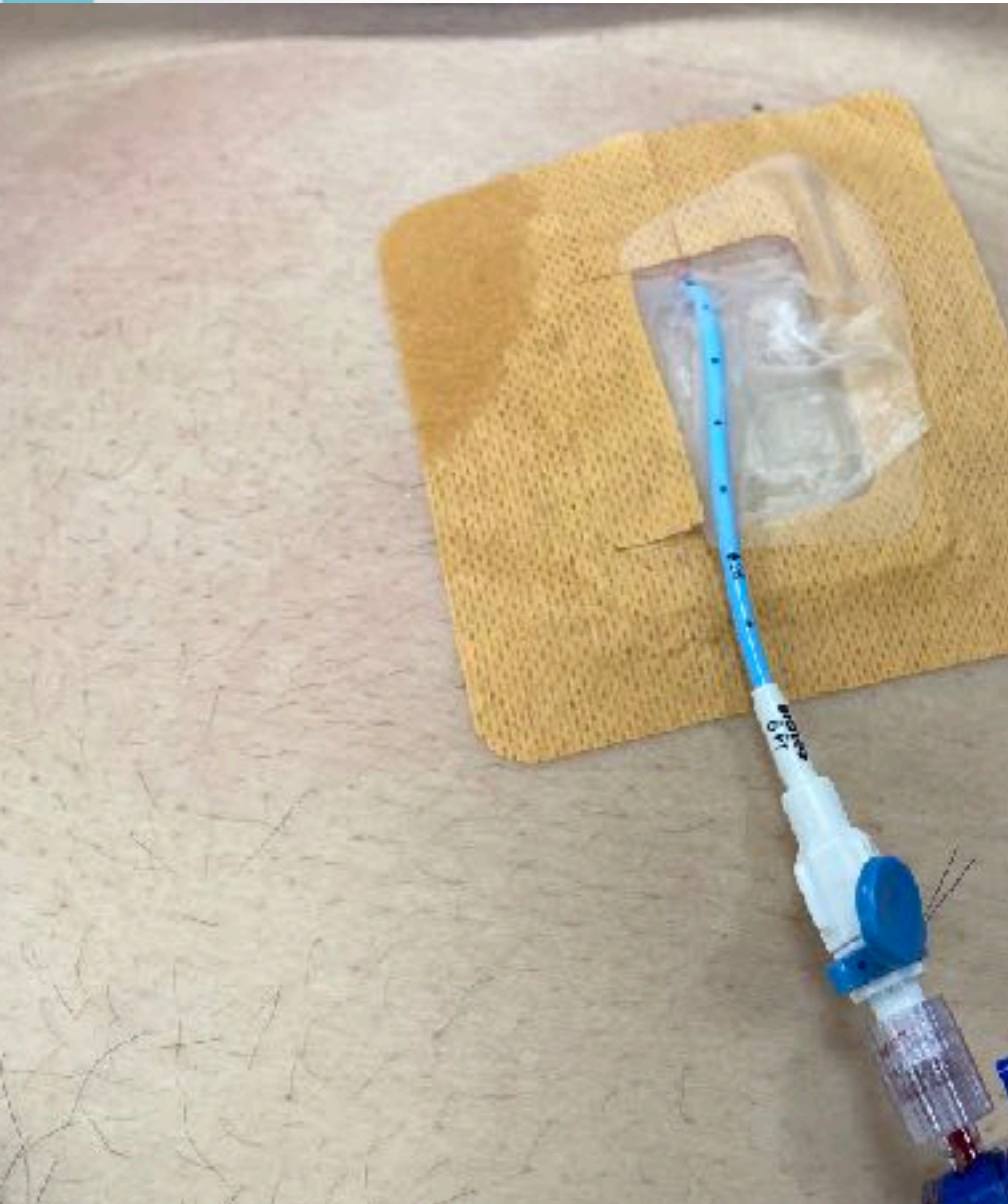53M, 體重減輕, 發燒



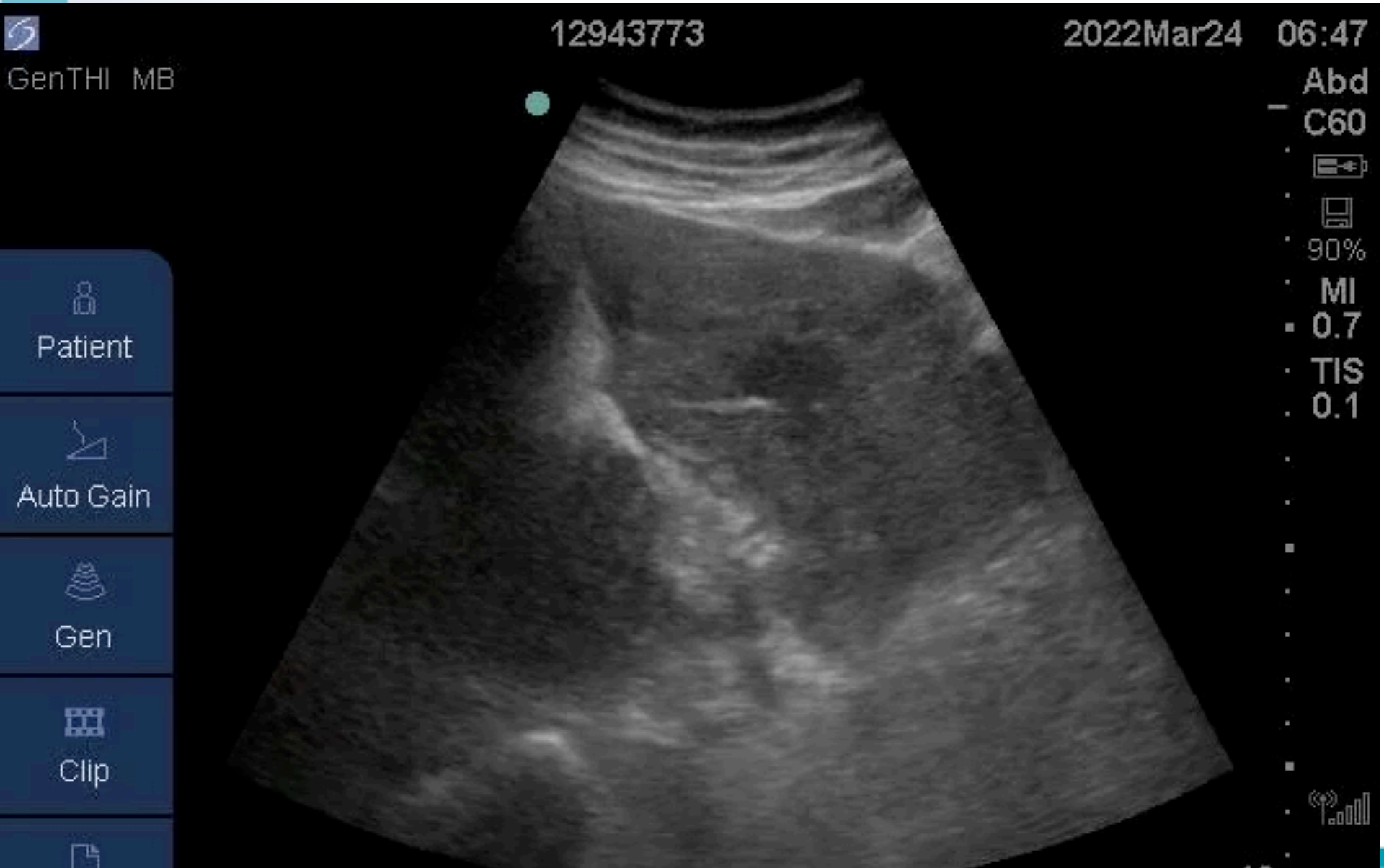Pigtail drainage



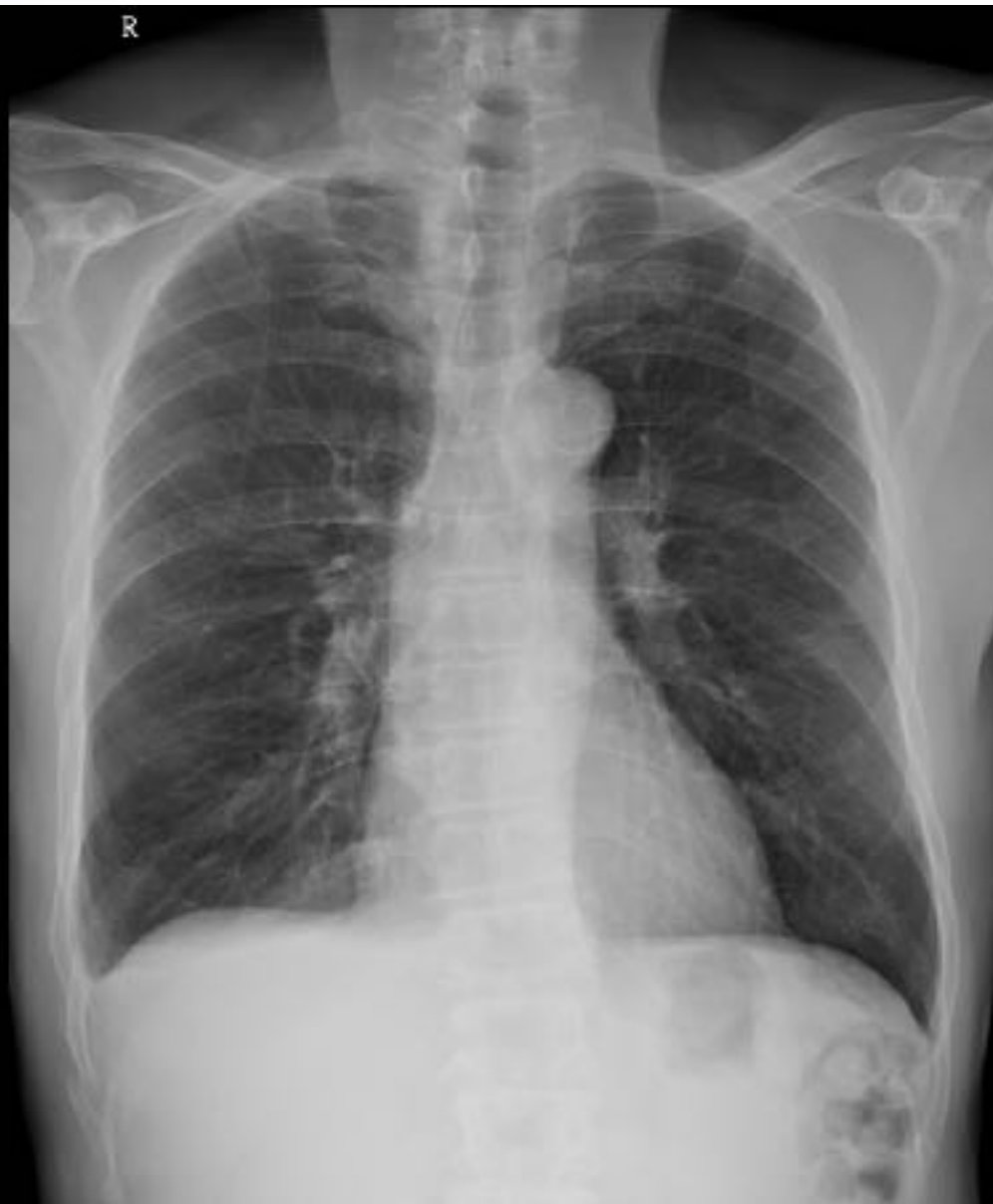39M, left flank pain after ESWL



Pigtail drainage > 1000 ml pus

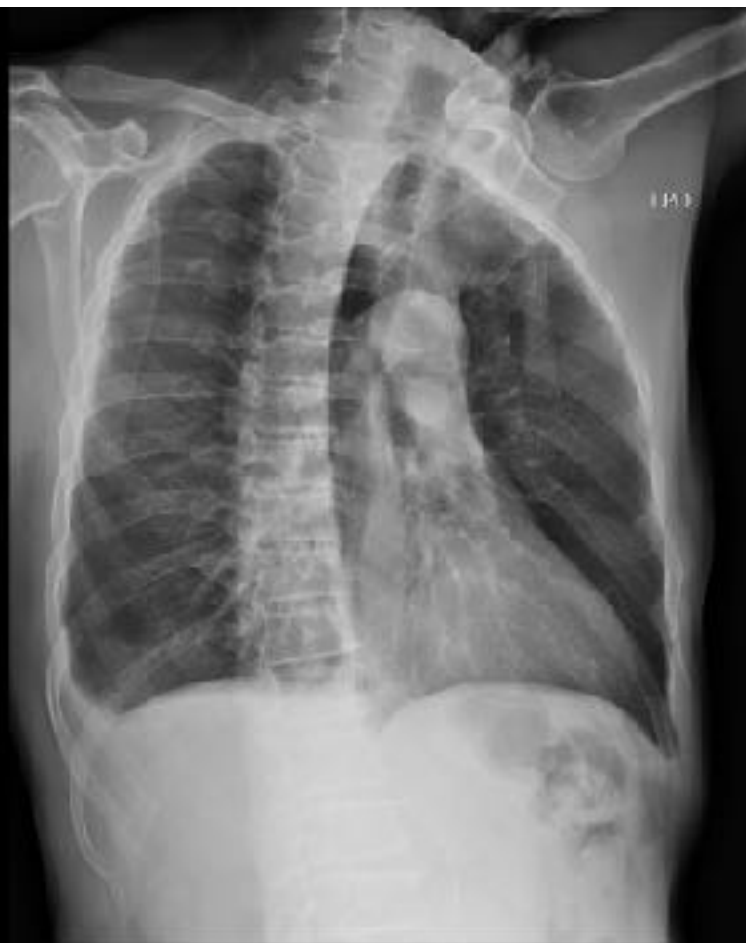

60M, 一週前工作滑倒撞到模板，右胸痛

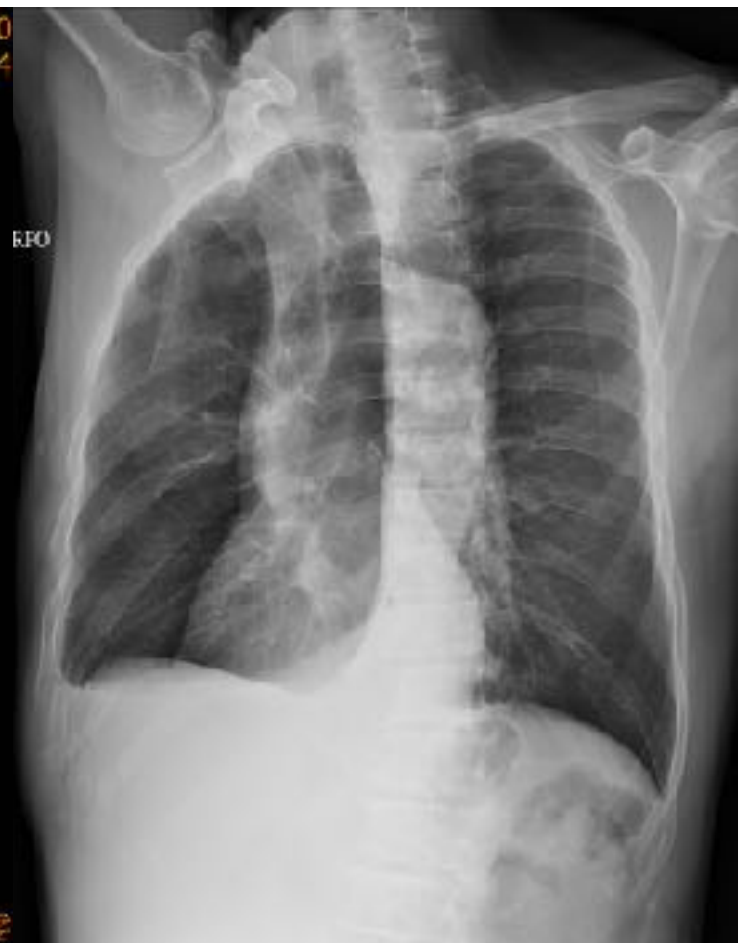

1110312014550001
09:53:28

60M, 一週前工作滑倒撞到模板，右胸痛



1110312014550020
09:54:14



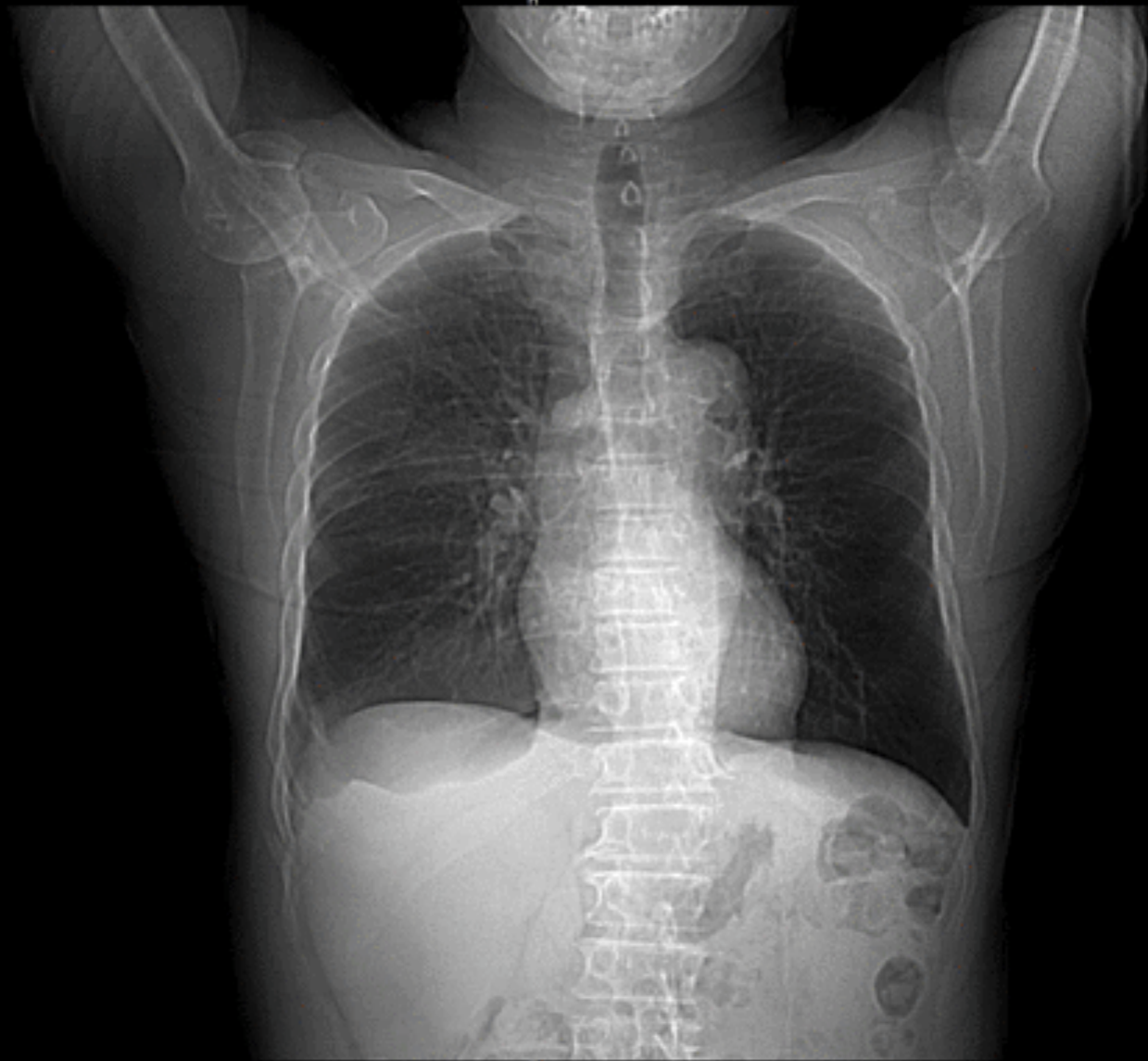
黃鈺雯, 黃鈺雯

60M, 一週前工作滑倒撞到模板，右胸痛



06624402
潘河俊

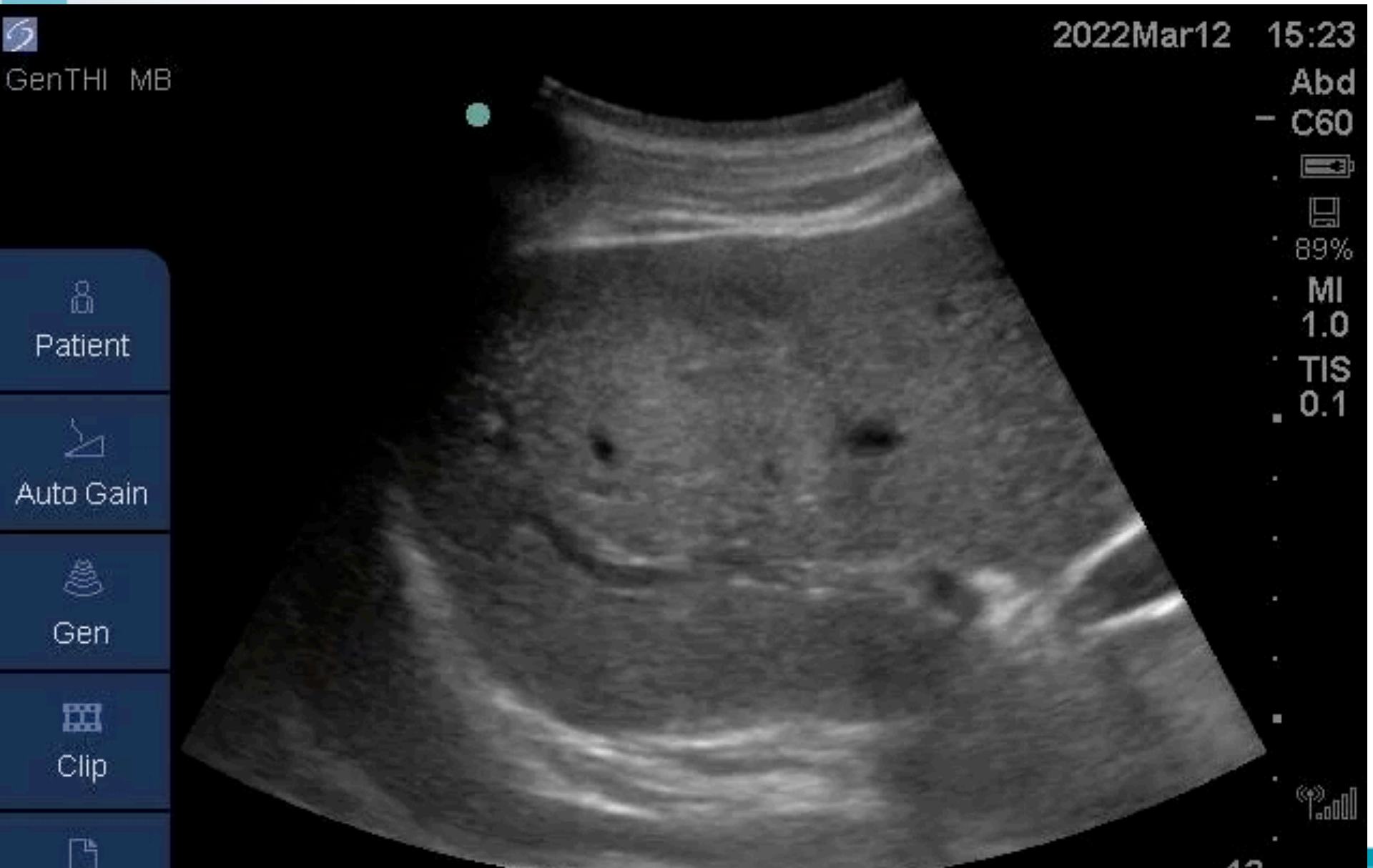2022/03/12
Chest/Heart CT(-C,+C)



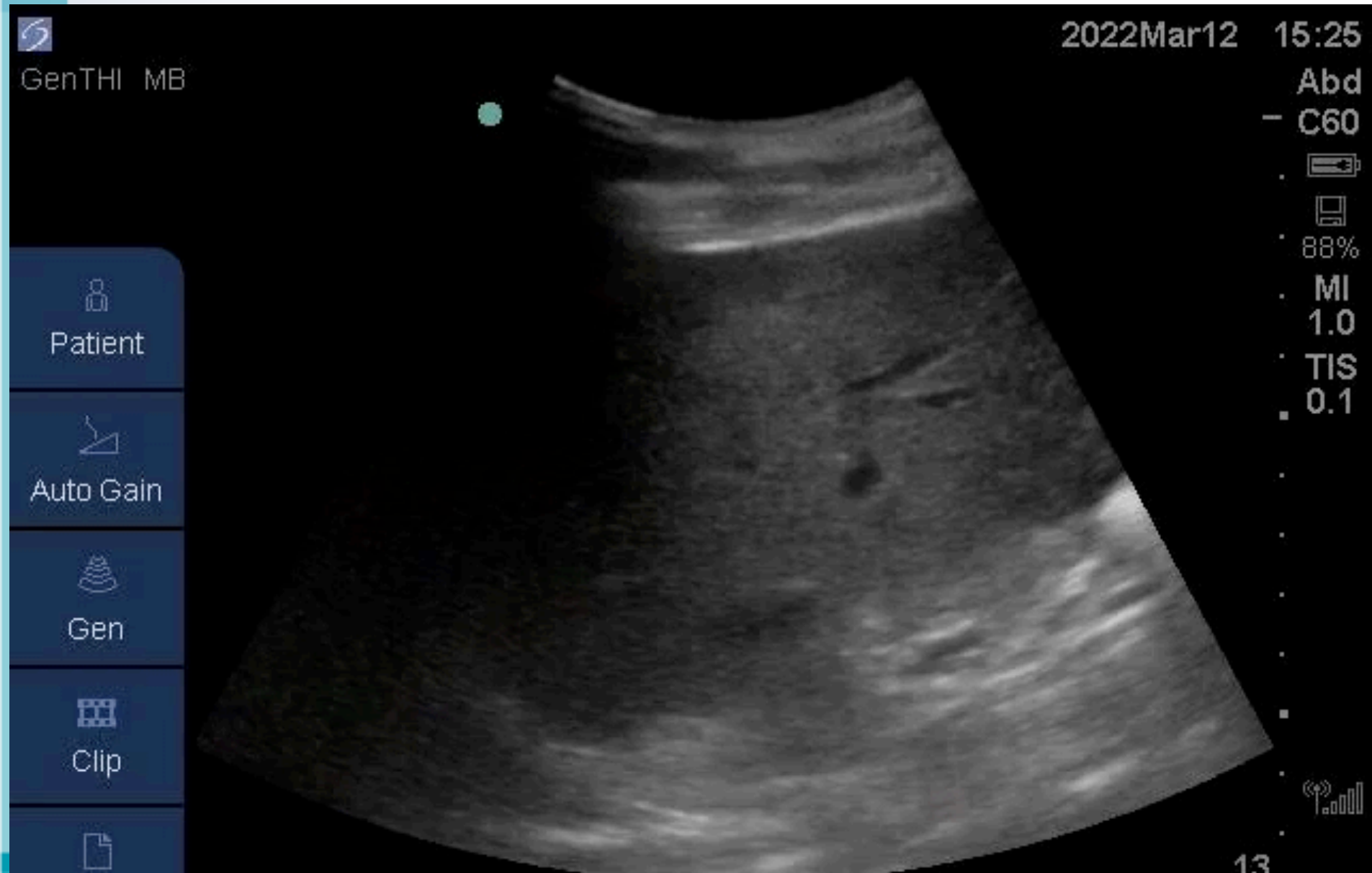
R

L

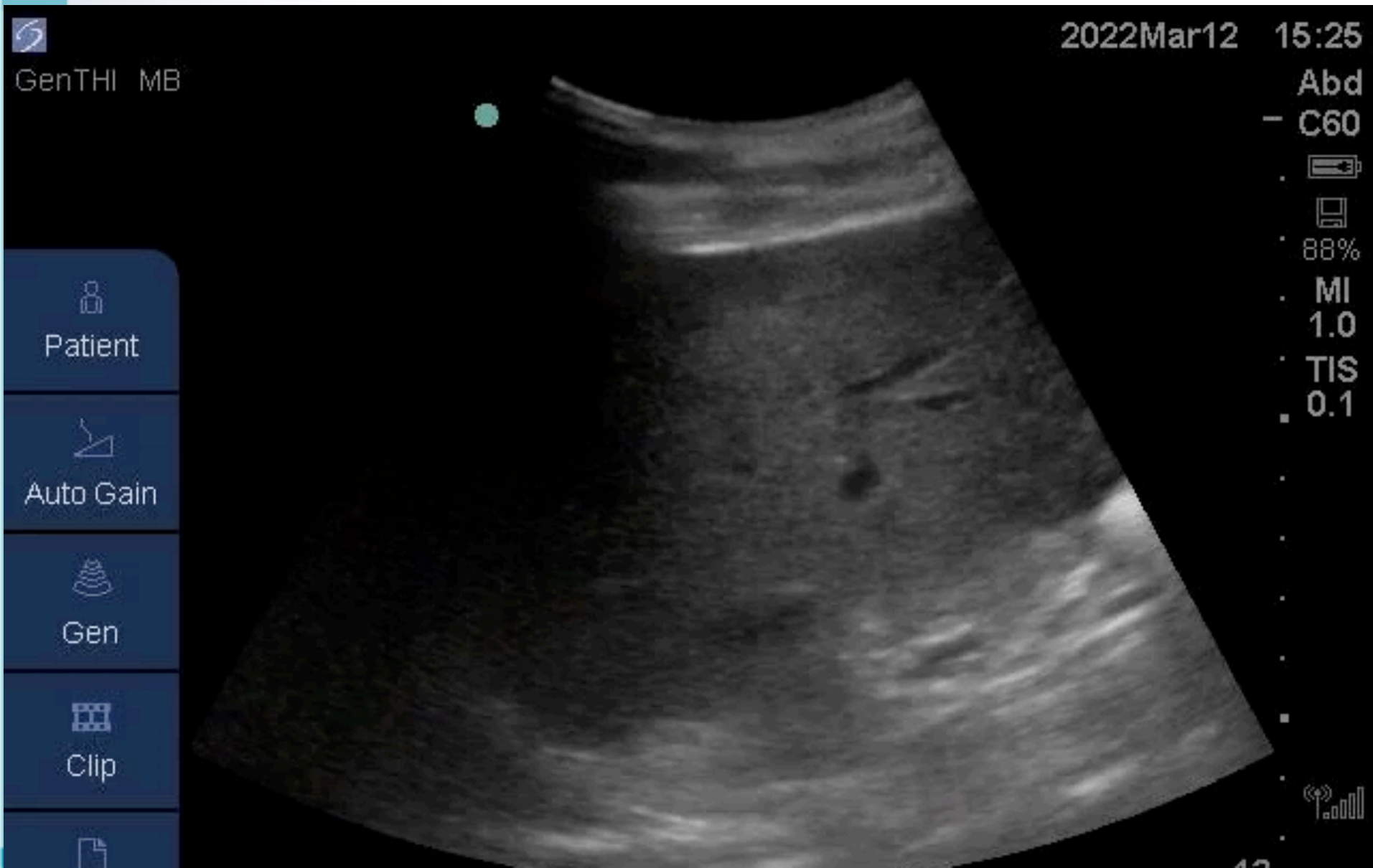
Liver laceration



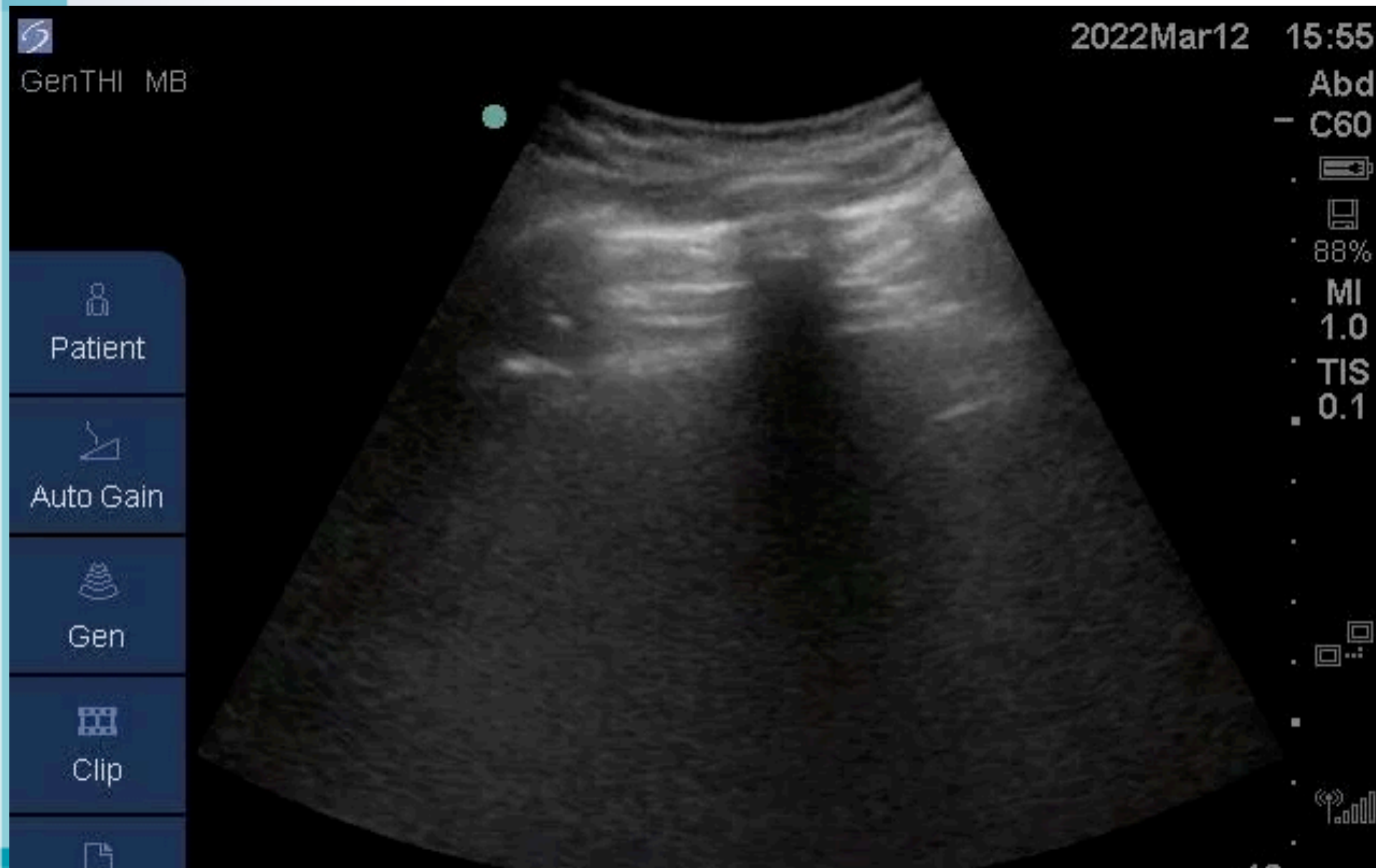
Rib fracture & liver laceration



60M, 一週前工作滑倒撞到模板，右胸痛



60M, 一週前工作滑倒撞到模板，右胸痛



2022Mar12 15:55

GenTHI MB

Abd

- C60



88%

MI

1.0

TIS

0.1



Patient



Auto Gain



Gen



Clip



60M, 一週前工作滑倒撞到模板，右胸痛



GenTHI MB

2022Mar12 16:03

Abd

- C60



88%

MI

1.0

TIS

0.1



Patient



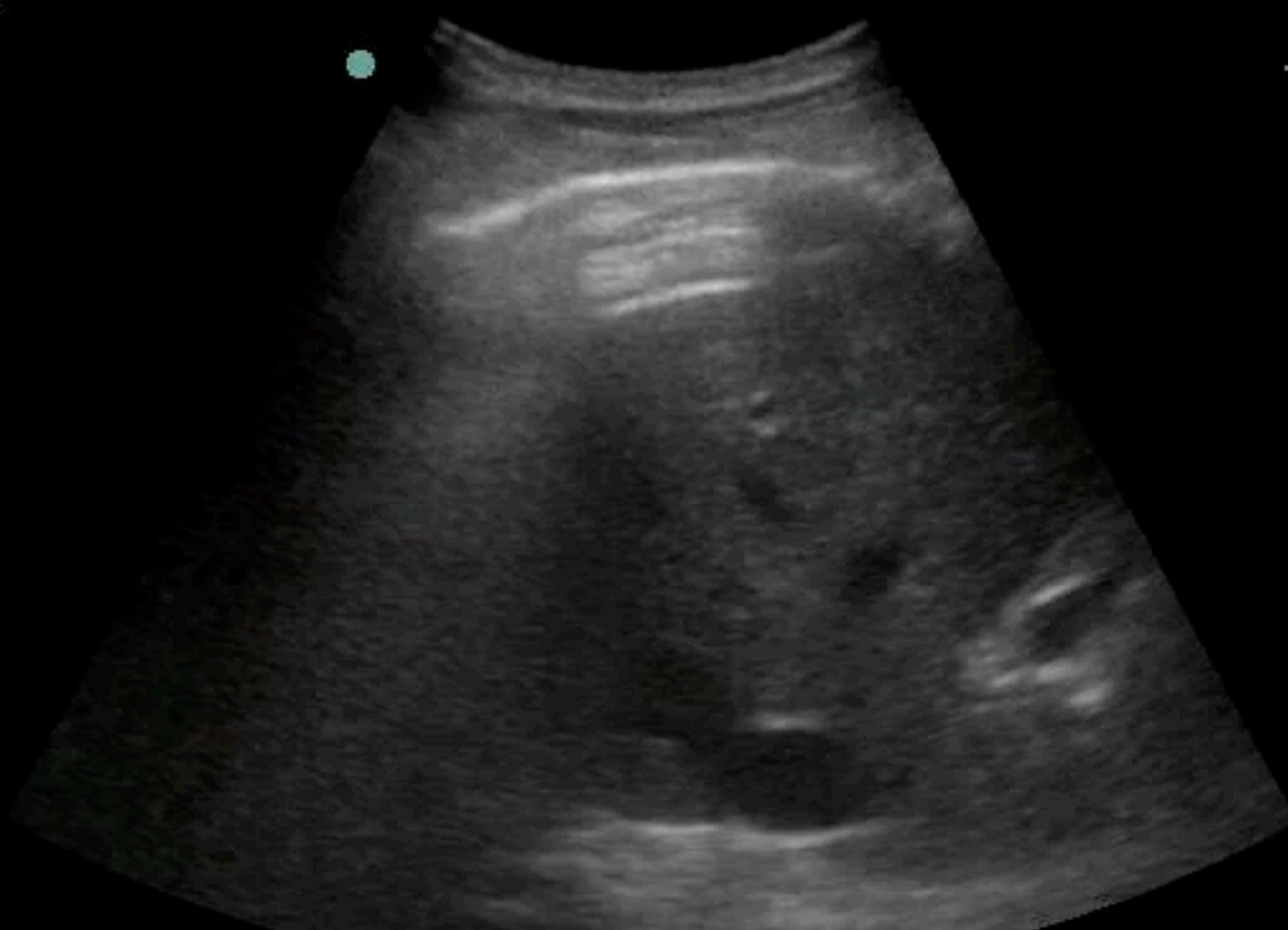Auto Gain



Gen



Clip



Lung point



2022Mar12 16:04



GenTHI MB

Abd

C60



87%

MI

0.8

TIS

0.2



Patient



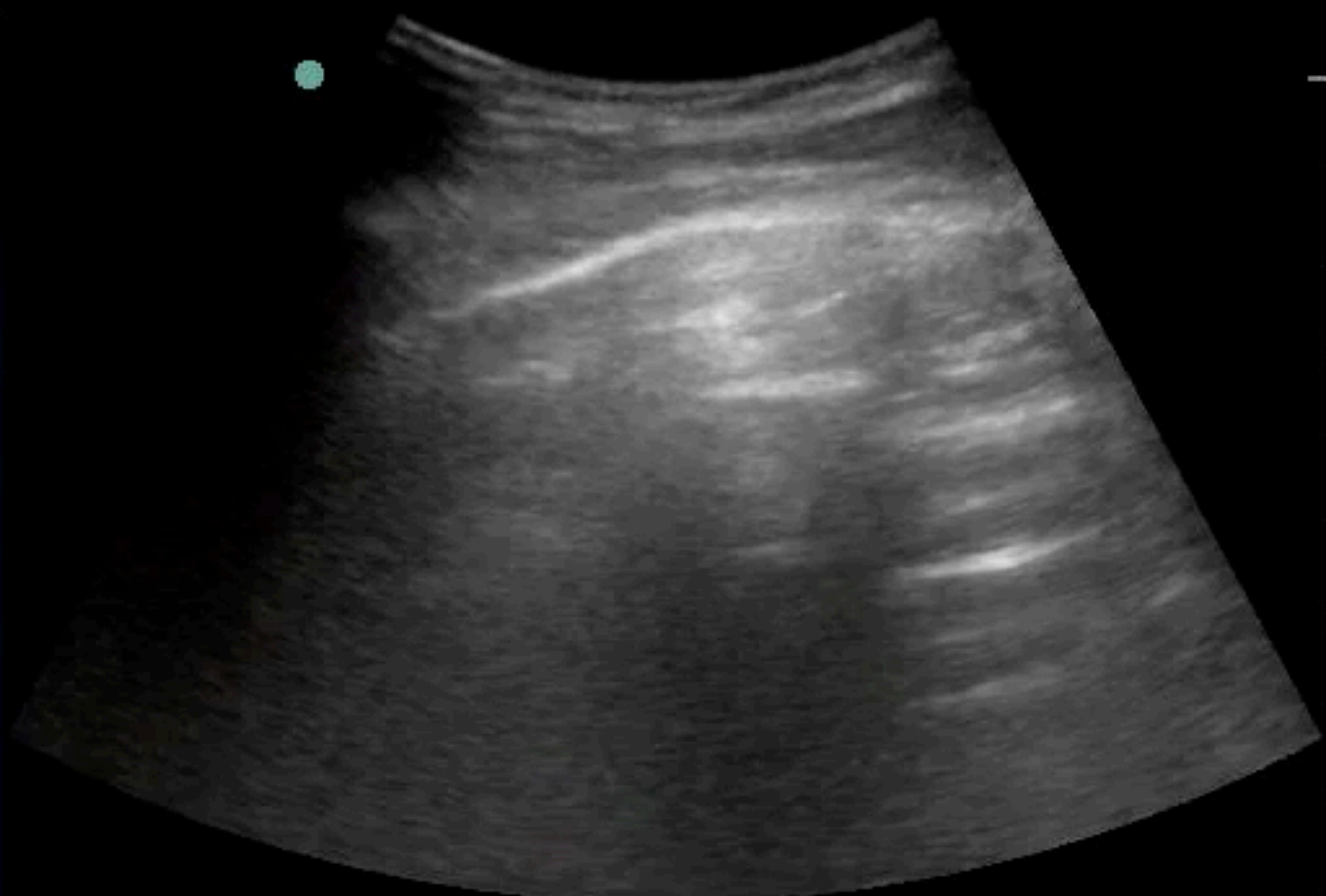Auto Gain



Gen



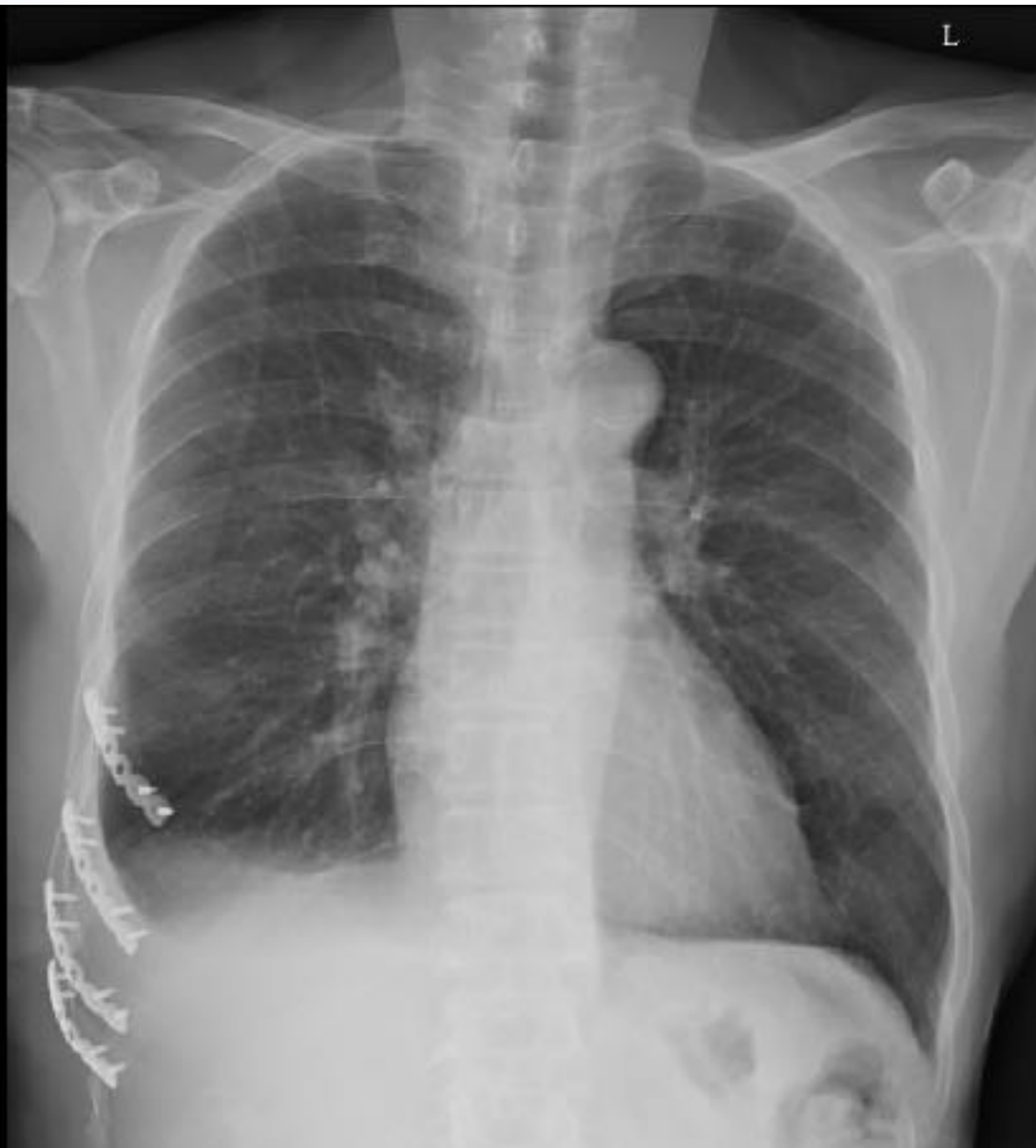Clip



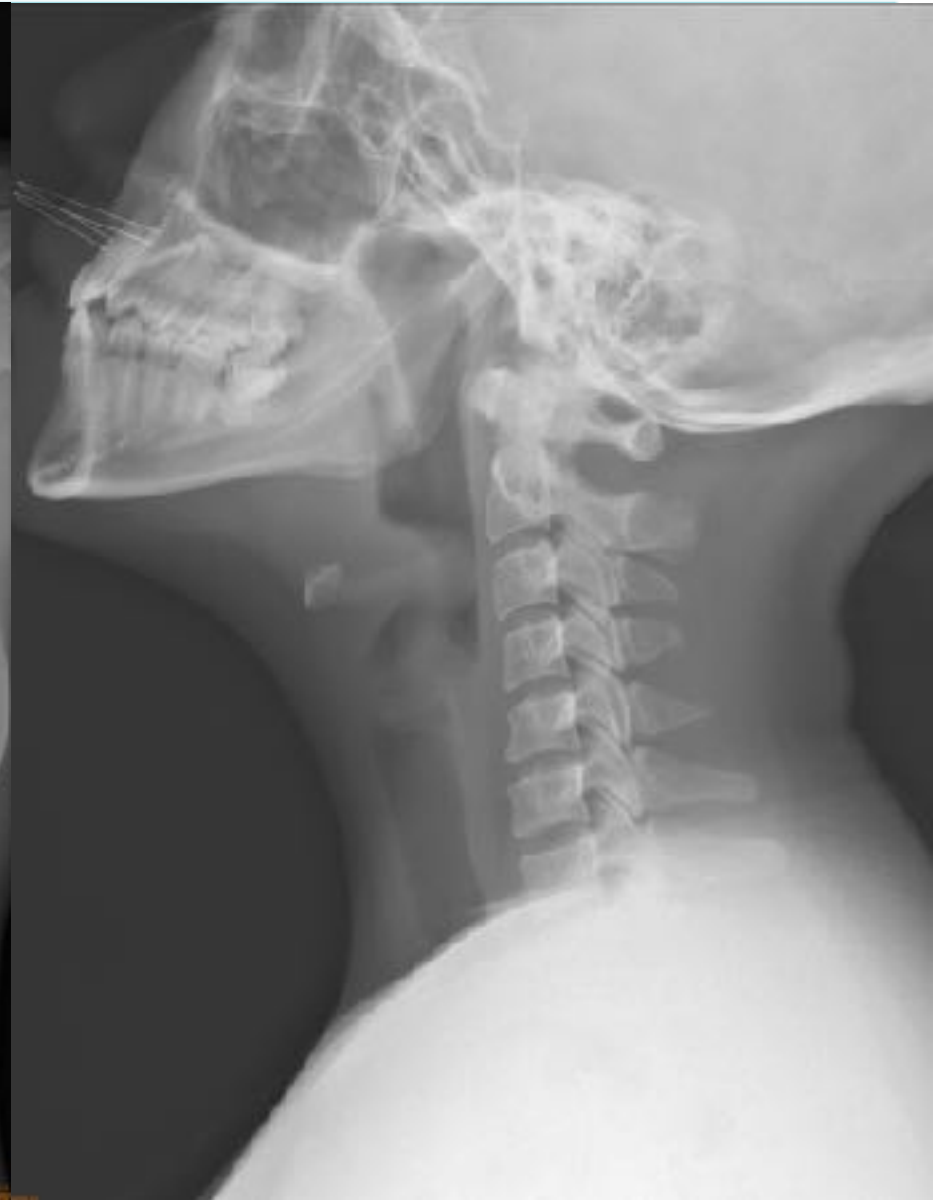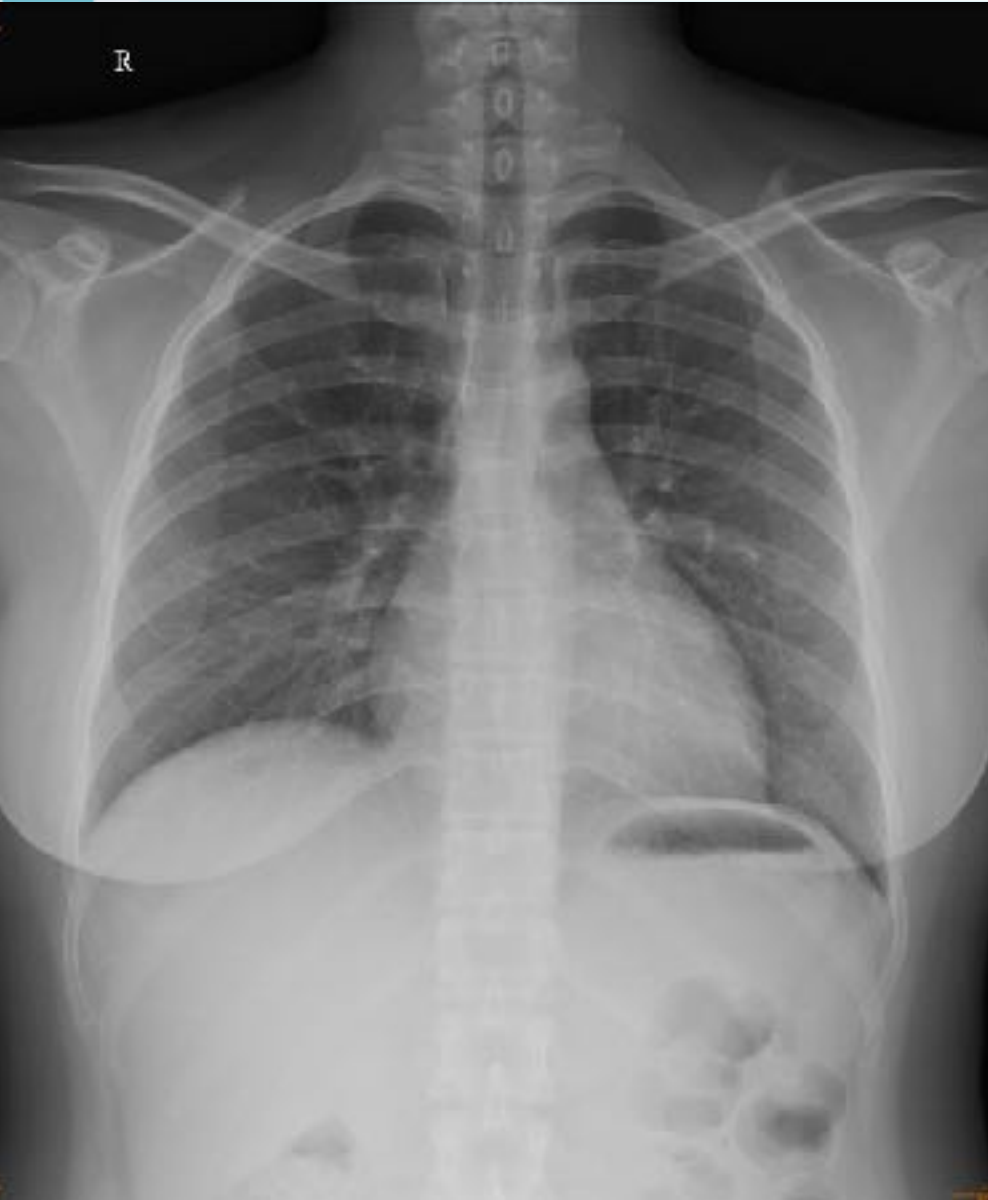60M, 一週前工作滑倒撞到模板，右胸痛



06614402
曾國威
M
1993/06/15
b1



30F, 喉嚨痛，嘔吐、呼吸困難

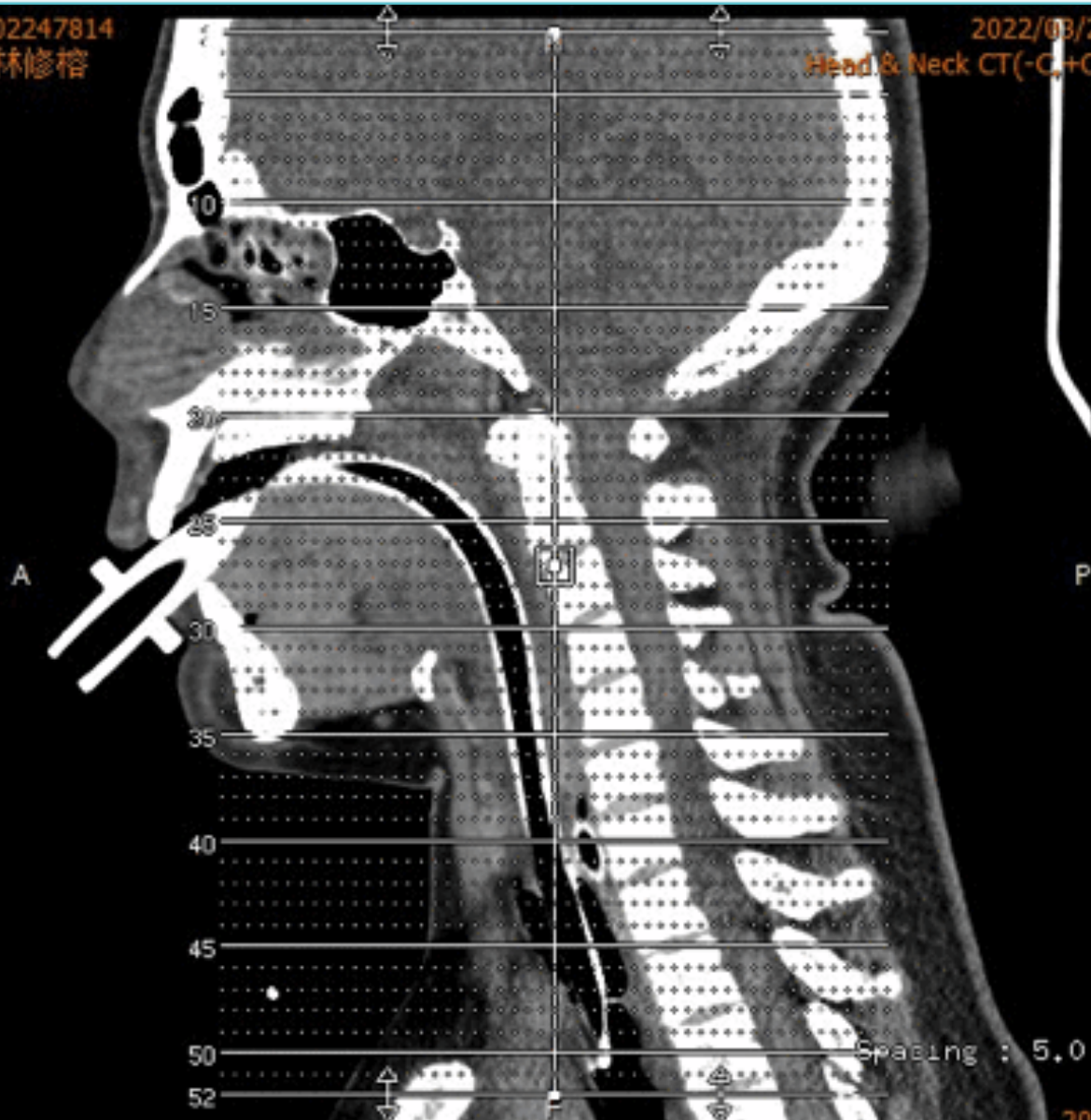




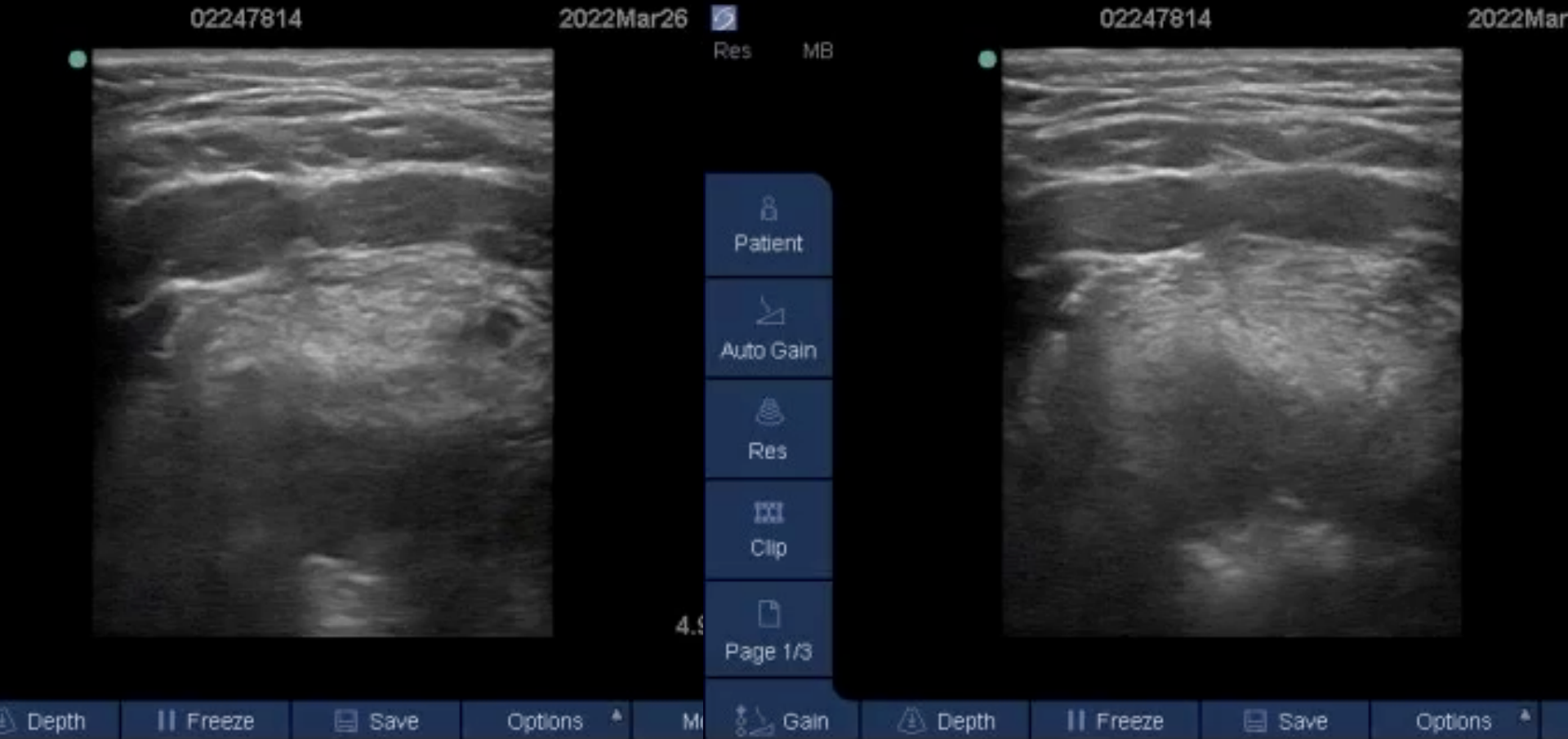
30F, 喉嚨痛，嘔吐、呼吸困難

02247814
林修榕

2022/03/26
Head & Neck CT(-C,+C)



30F, 喉嚨痛，嘔吐、呼吸困難





30F, 喉嚨痛，嘔吐、呼吸困難



02247814 2022Mar 02247814 2022Mar26 07:20

GenTHI MB



Patient

Auto Gain

Gen

Clip

Page 1/3

Abd C60

76%

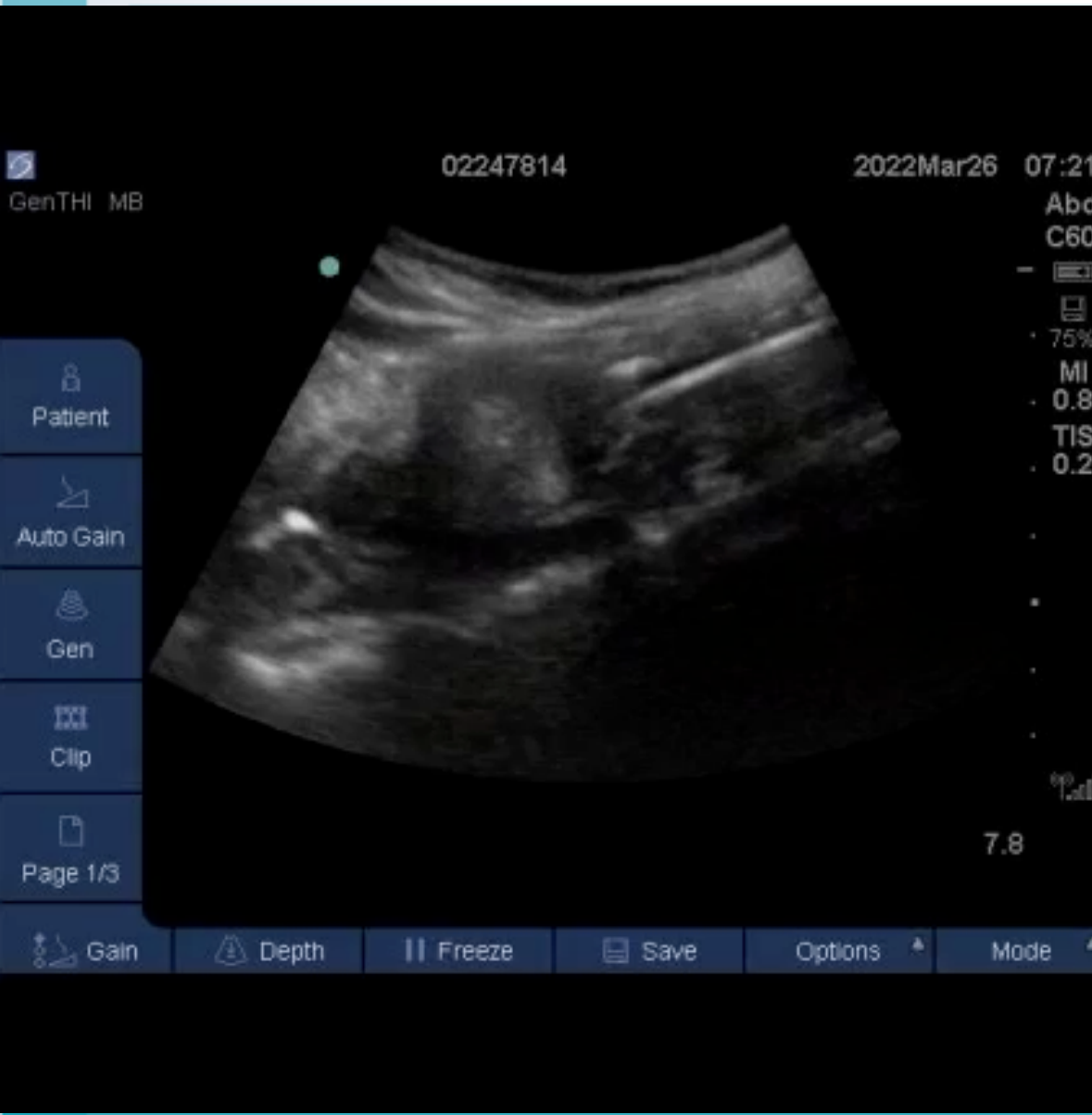
MI 0.8

TIS 0.2

7.8

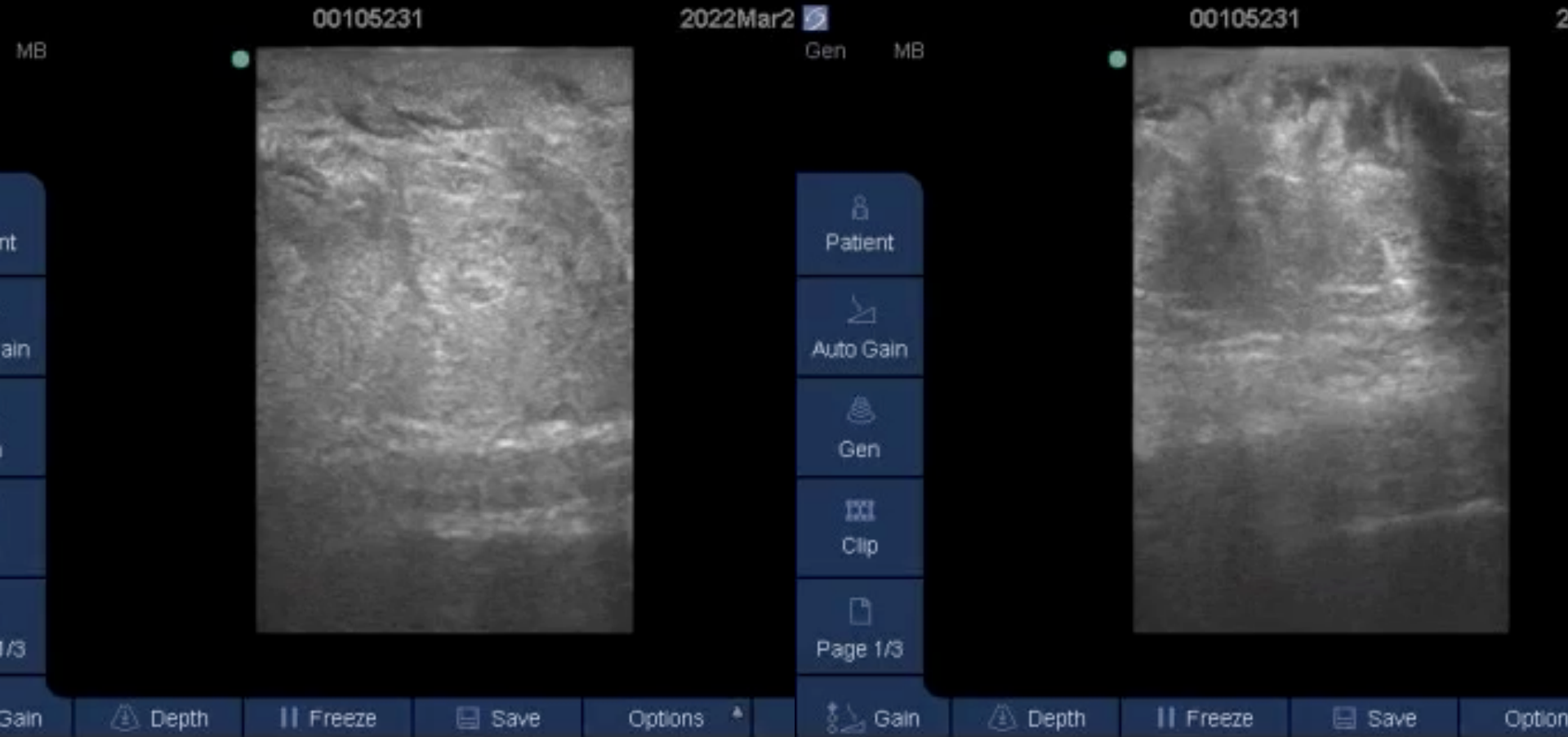
Freeze Save Options Gain Depth Freeze Save Options Mode

Epiglottitis

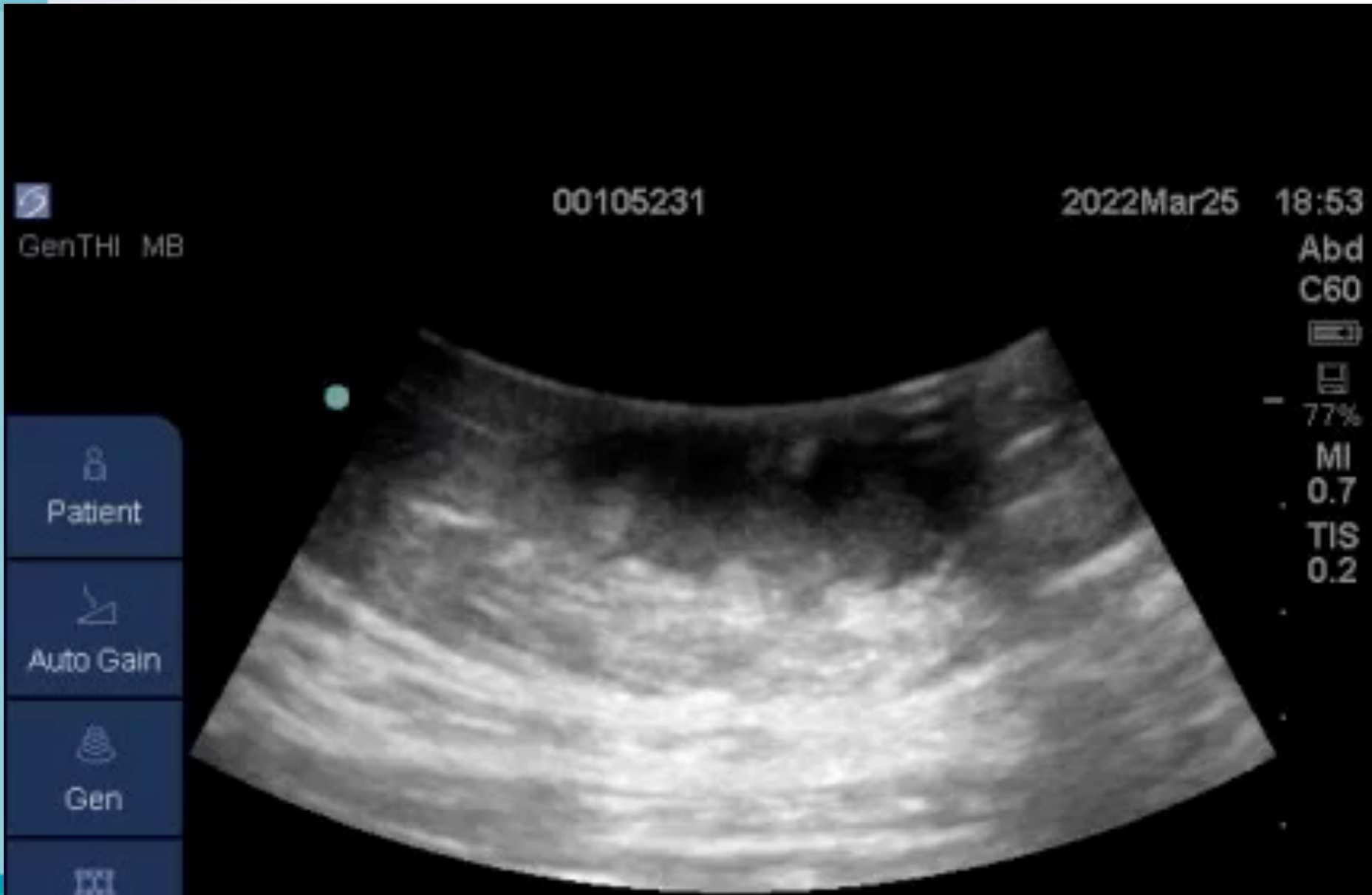

P

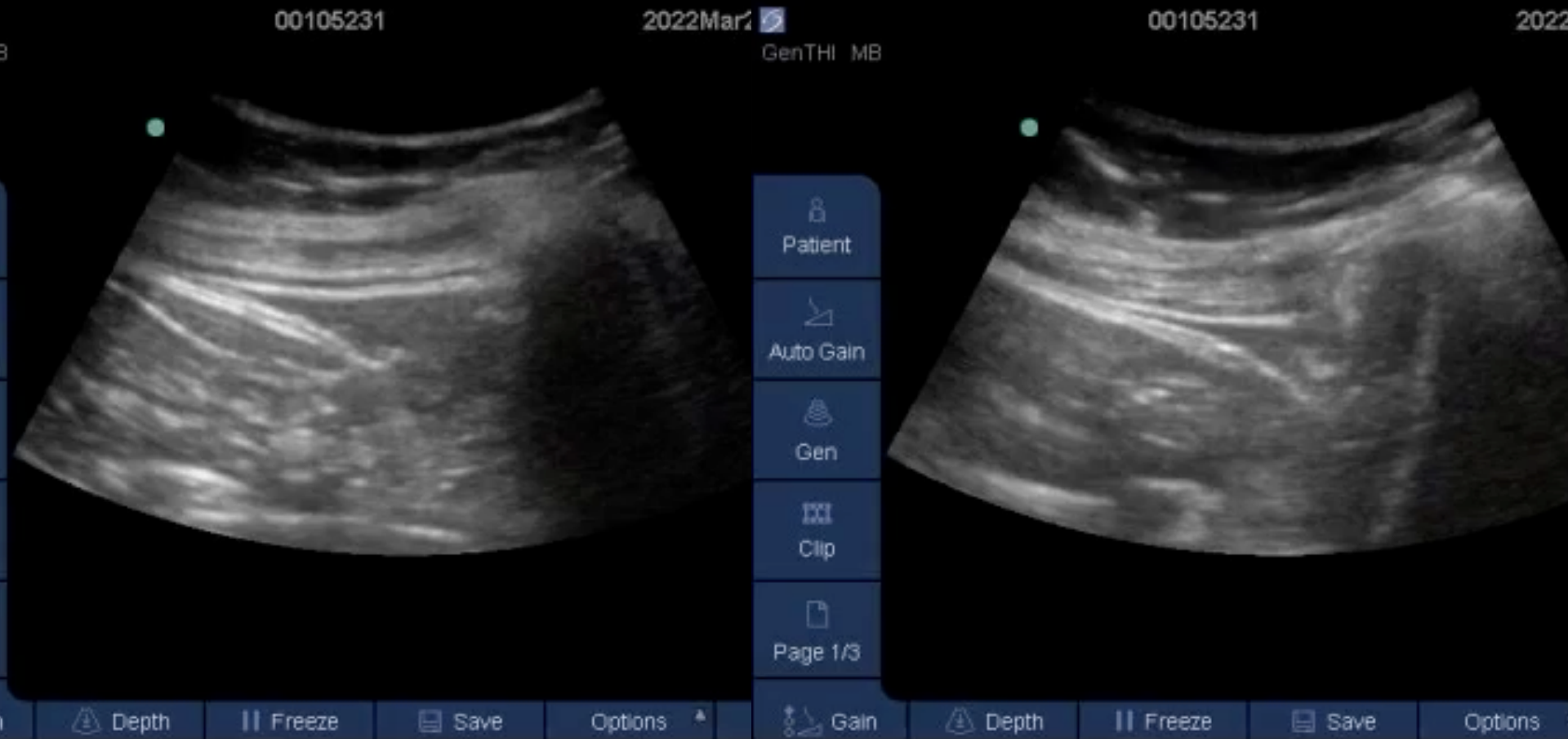
19F, abdominal wall cellulitis



Abdominal wall abscess



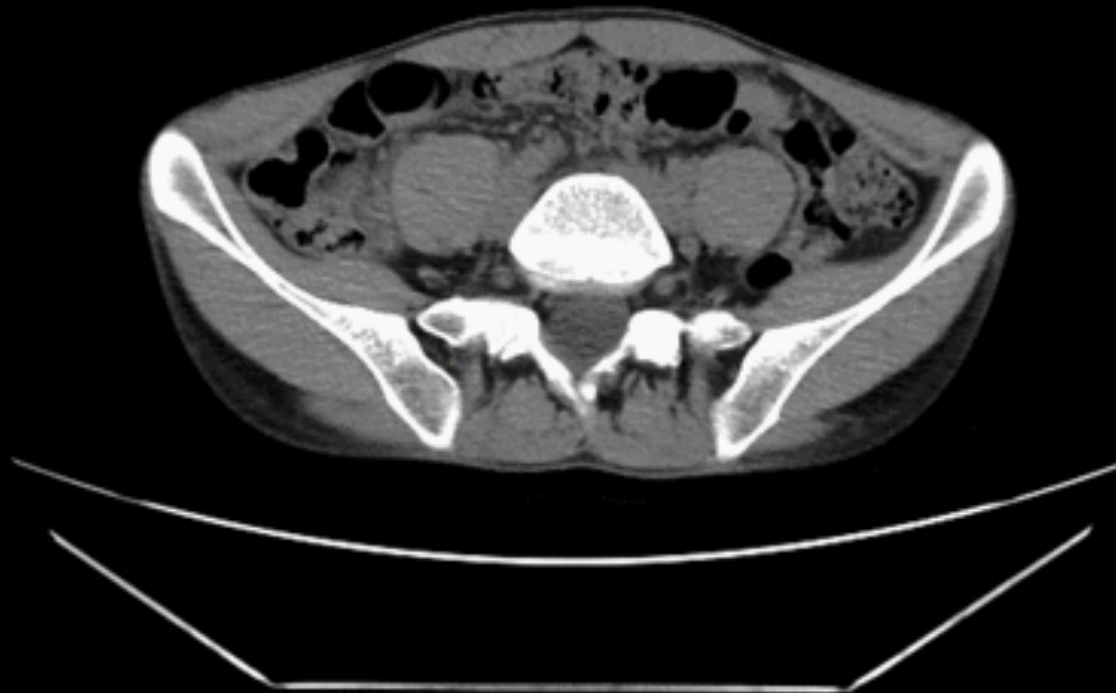Iliohypogastric & ilioinguinal block



23M, RLQ pain for 3 days



GE MEDICAL SYSTEMS
6.1 Abdomen+Pelvis (5mm)
Revolution EVO



23M, RLQ pain for 3 days



00591948

2022Mar25 17:06

GenTHI MB

Abd
C60



83%

MI

0.8

TIS

0.2



Patient



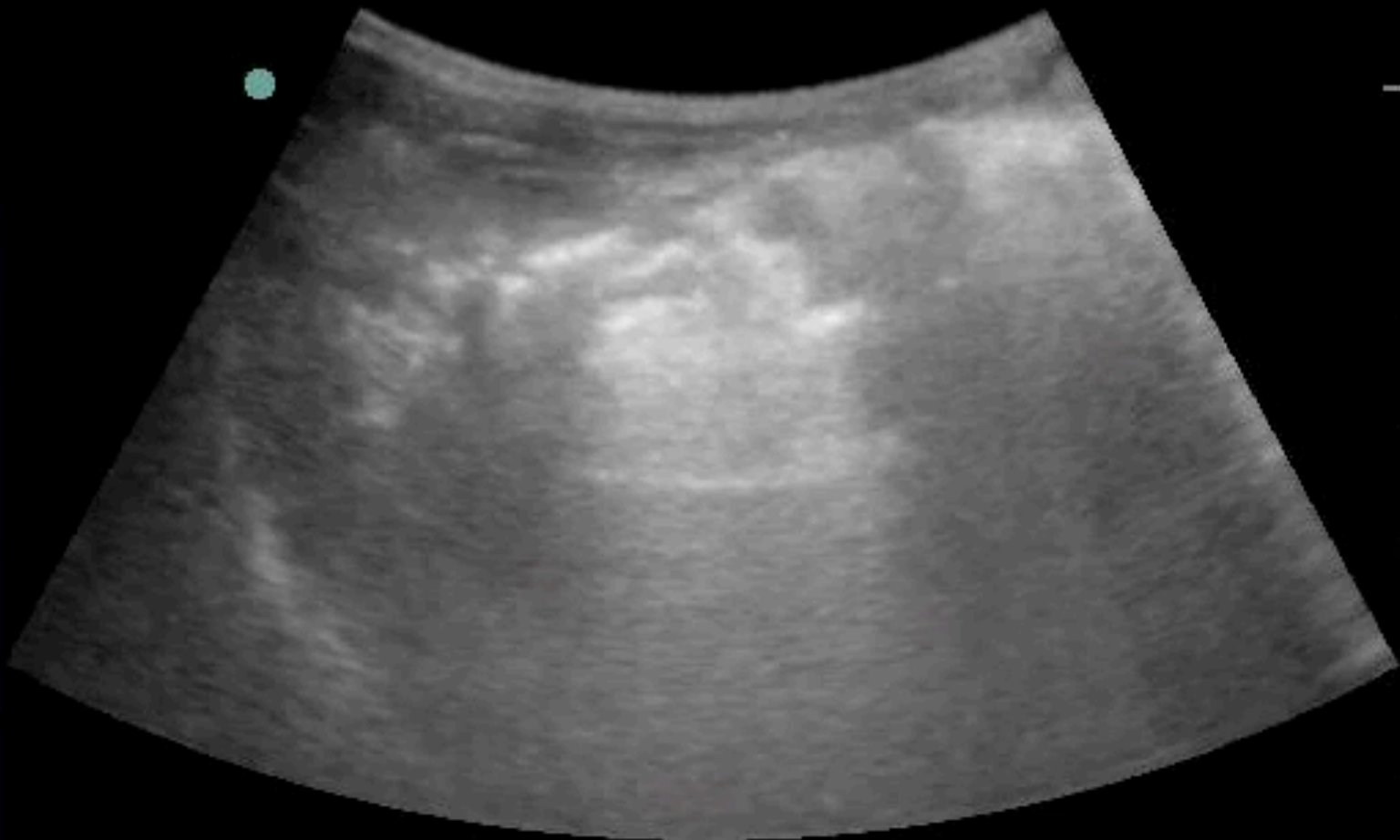Auto Gain



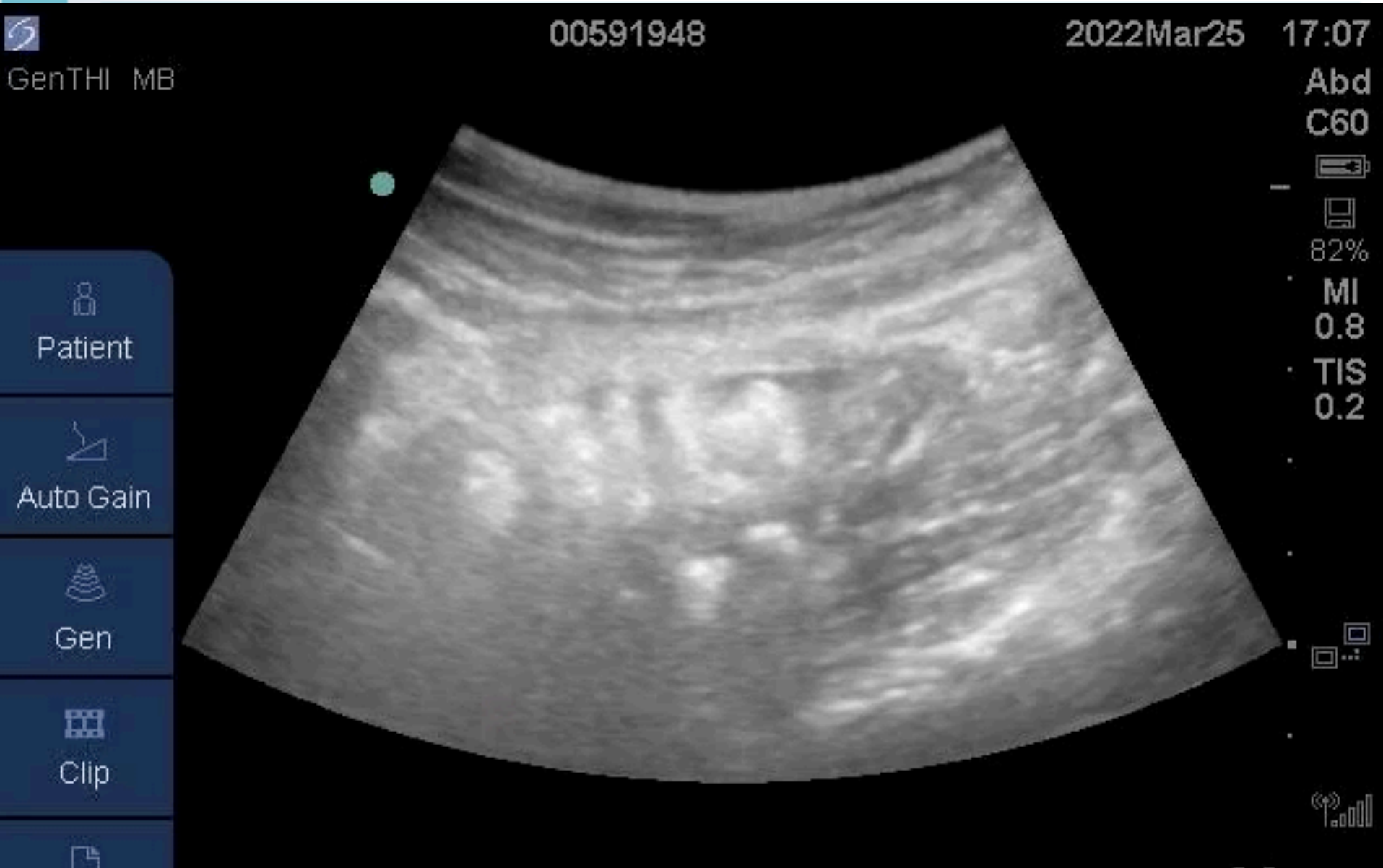Gen



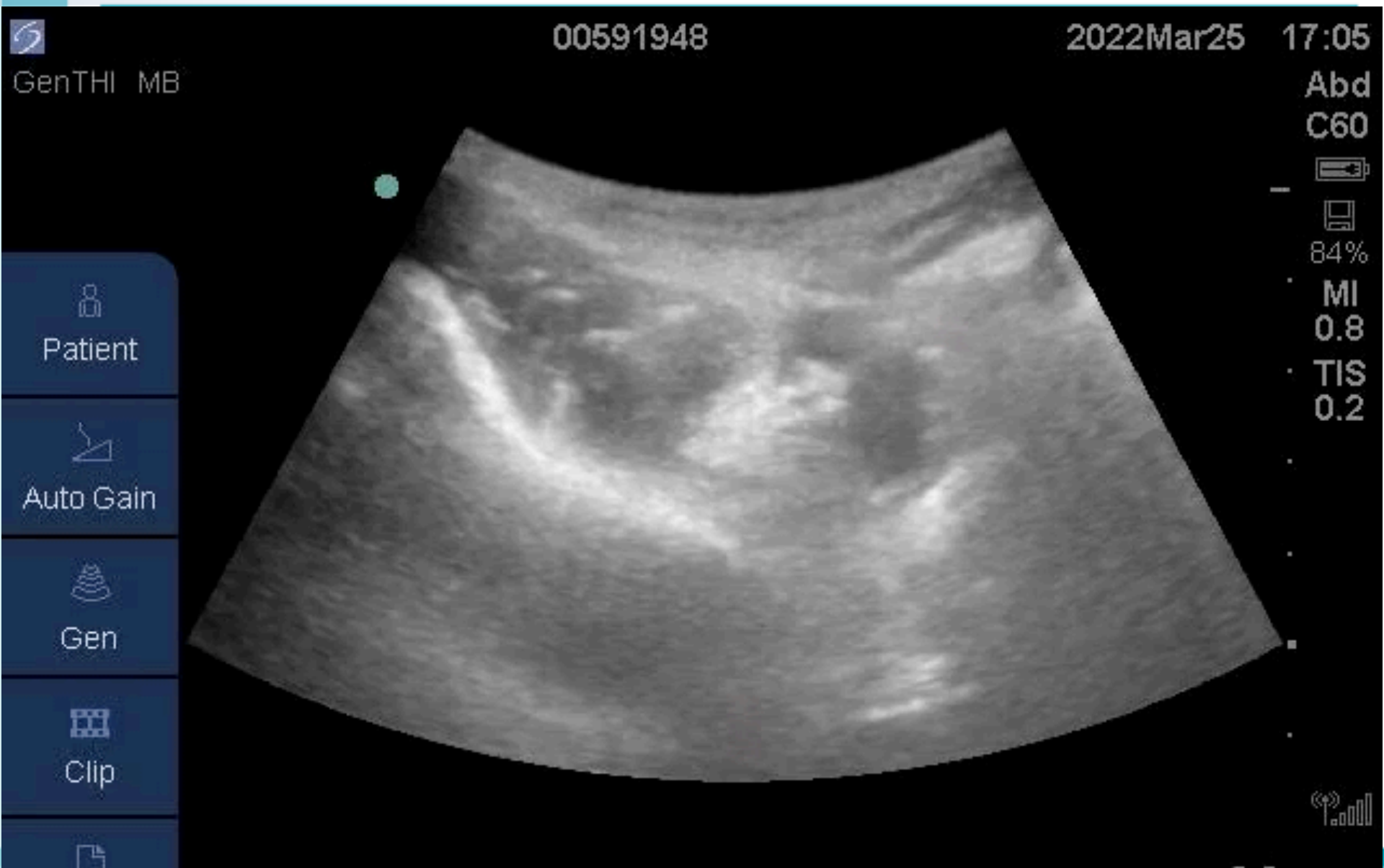
Clip



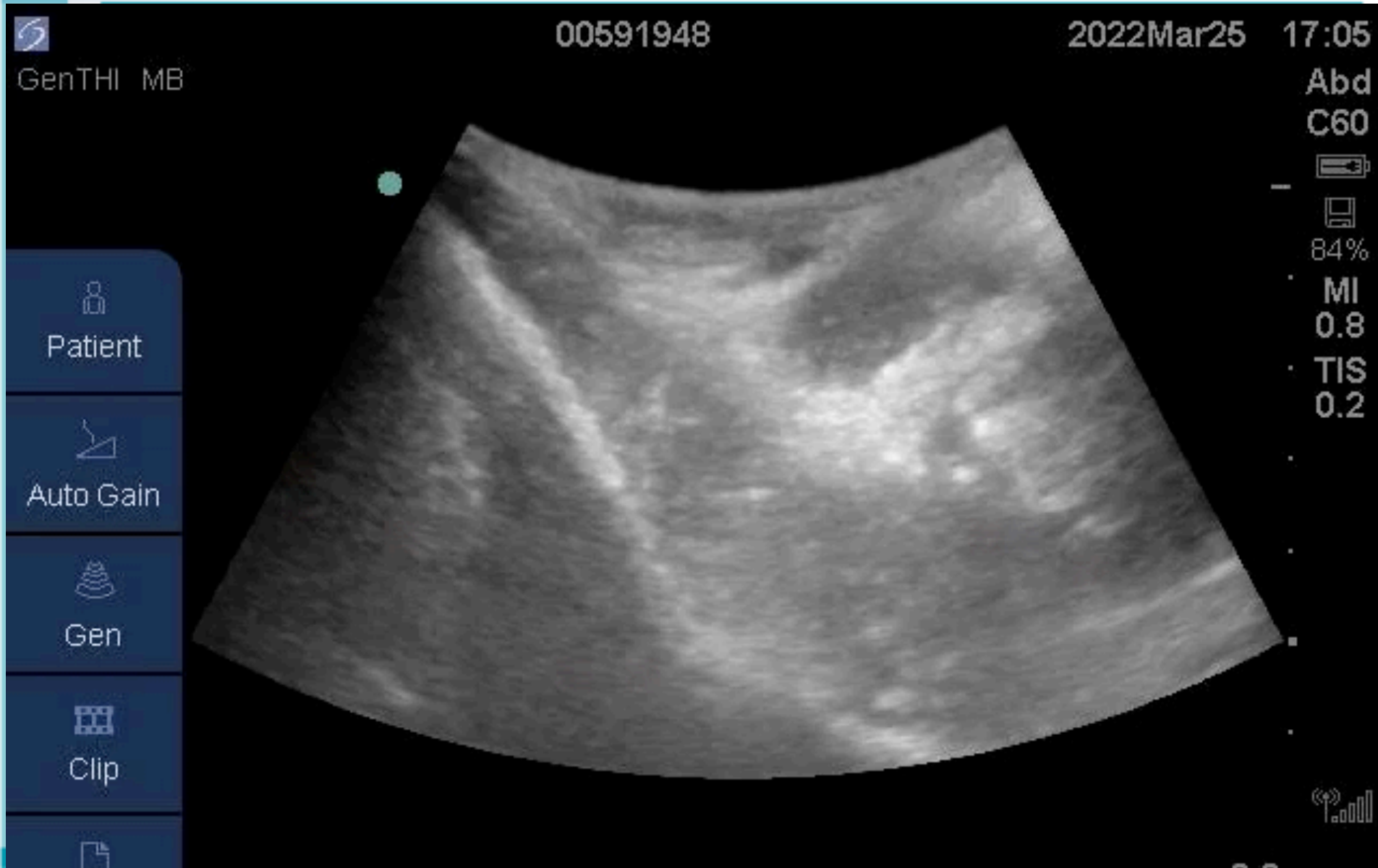23M, RLQ pain for 3 days



Appendicitis & appendicolith



Landmark for PENG block





59F, TA with elbow pain

到院時間: 20220308 152525

檢傷級數: 3

意識狀態: E4_V5_M6

體重: Kg 體溫: 36.2°C

脈搏: 86 呼吸次數: 18

血壓: 158/94

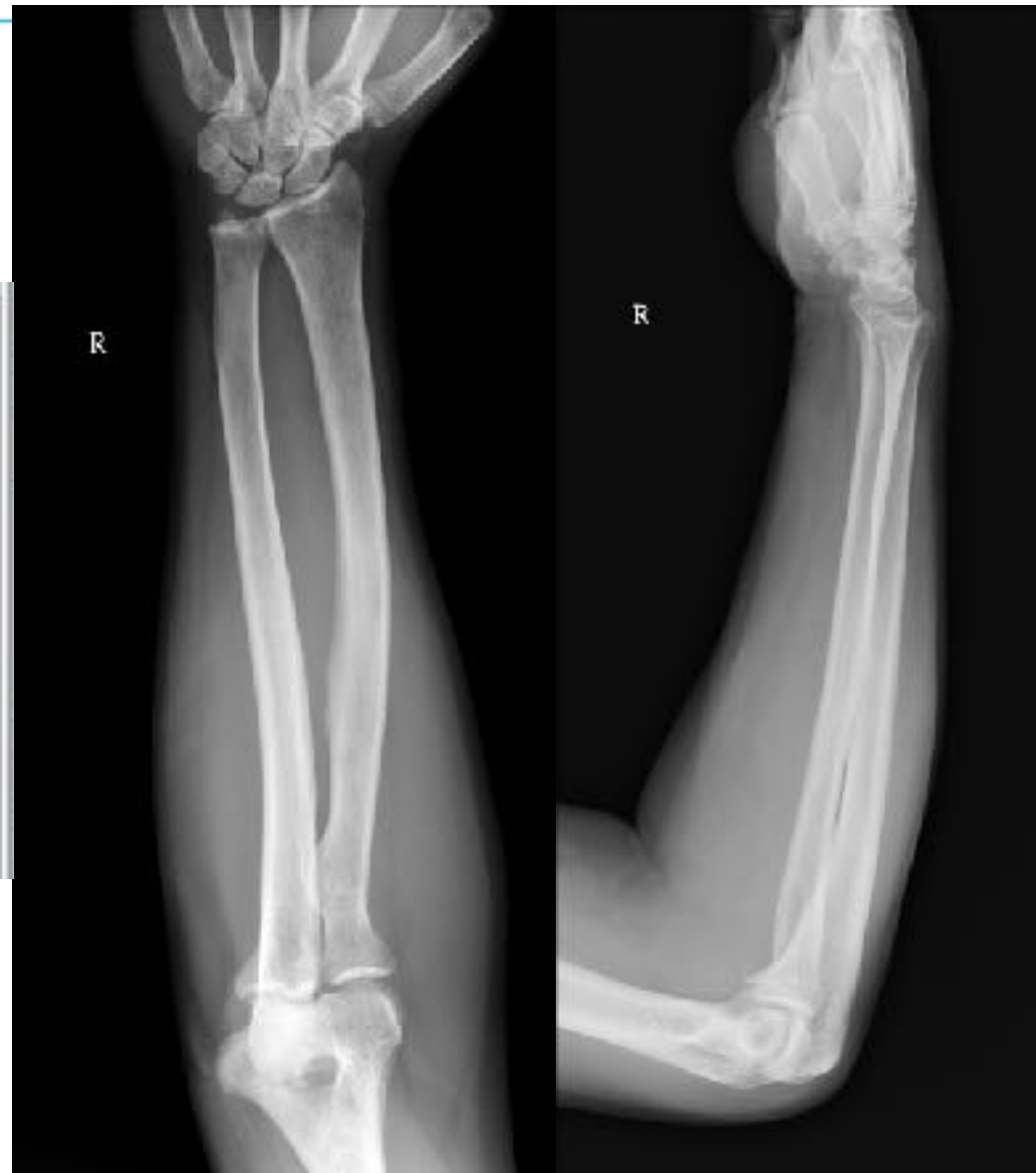SpO2: 98

過敏史: 無

疼痛強度: 6

主述: 病患來診為機車與機車車禍，
右手及雙膝痛 (25-159-1955)

※來院方式為119轉入



Radial head fracture



TIS: 0.01, MI: 0.45, Musculoskeletal

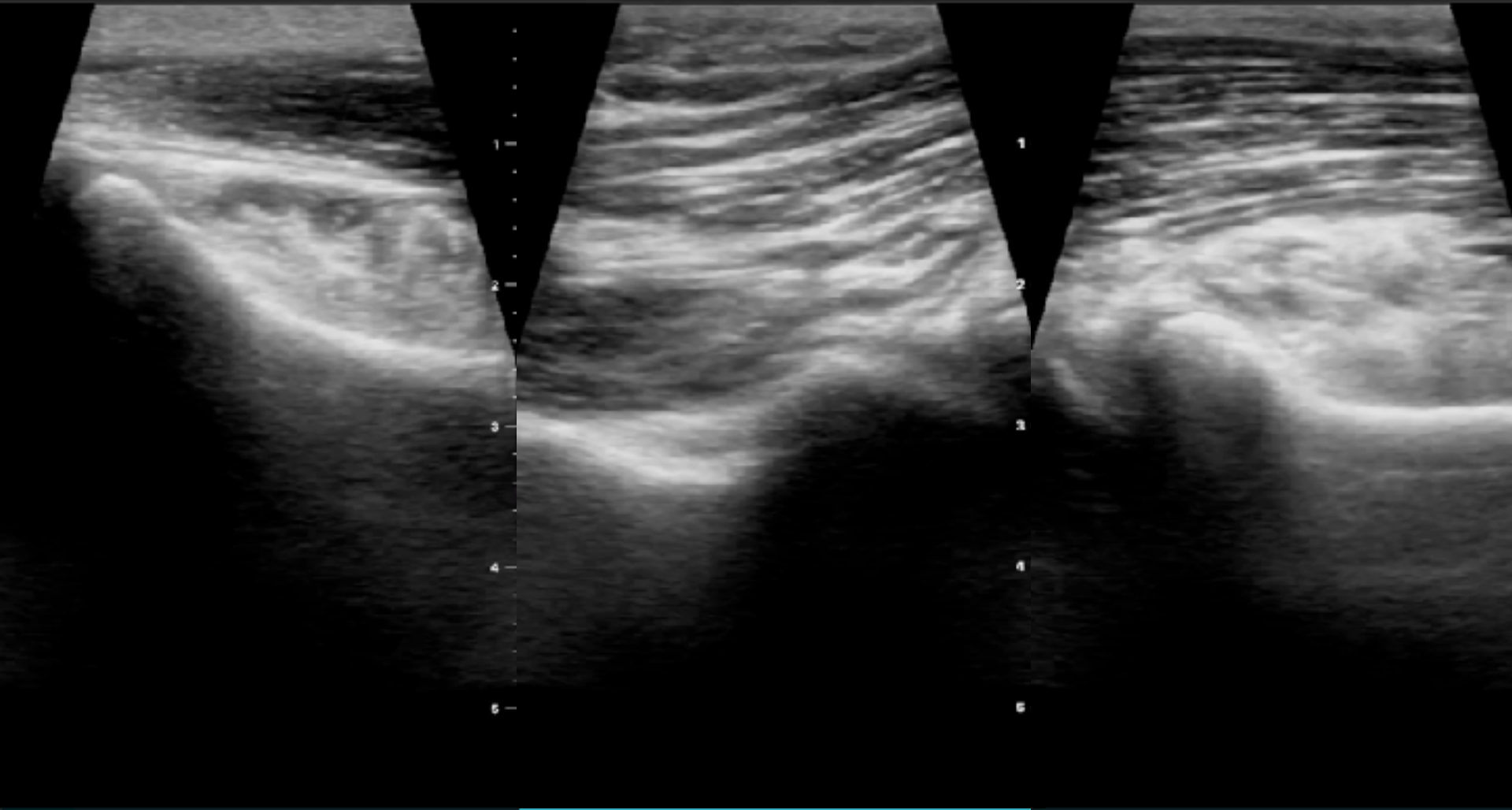
TIS: 0.01, MI: 0.45, Musculoskeletal

TIS: 0.01, MI: 0.45, Musculoskeletal

B

B

B



26M, peritonsillar abscess



ENG
90475

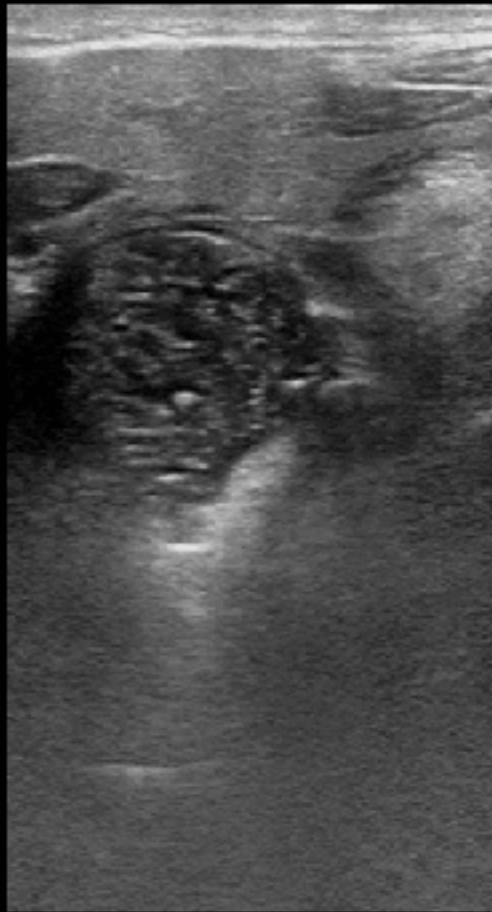
MI 1.2 3/21/2022
TIS 0.1 8:26:34 AM

MI
TIS

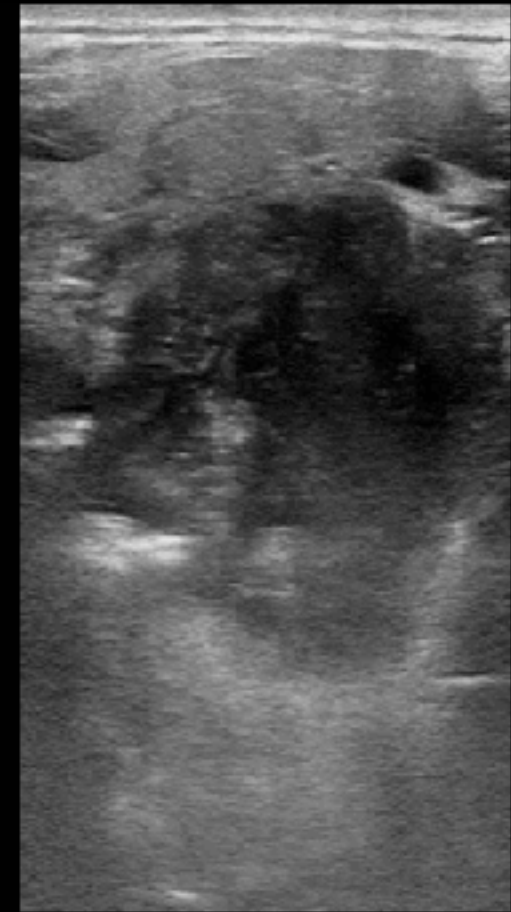SKII ER

SKII ER

P



7.11cm



26M, peritonsillar abscess



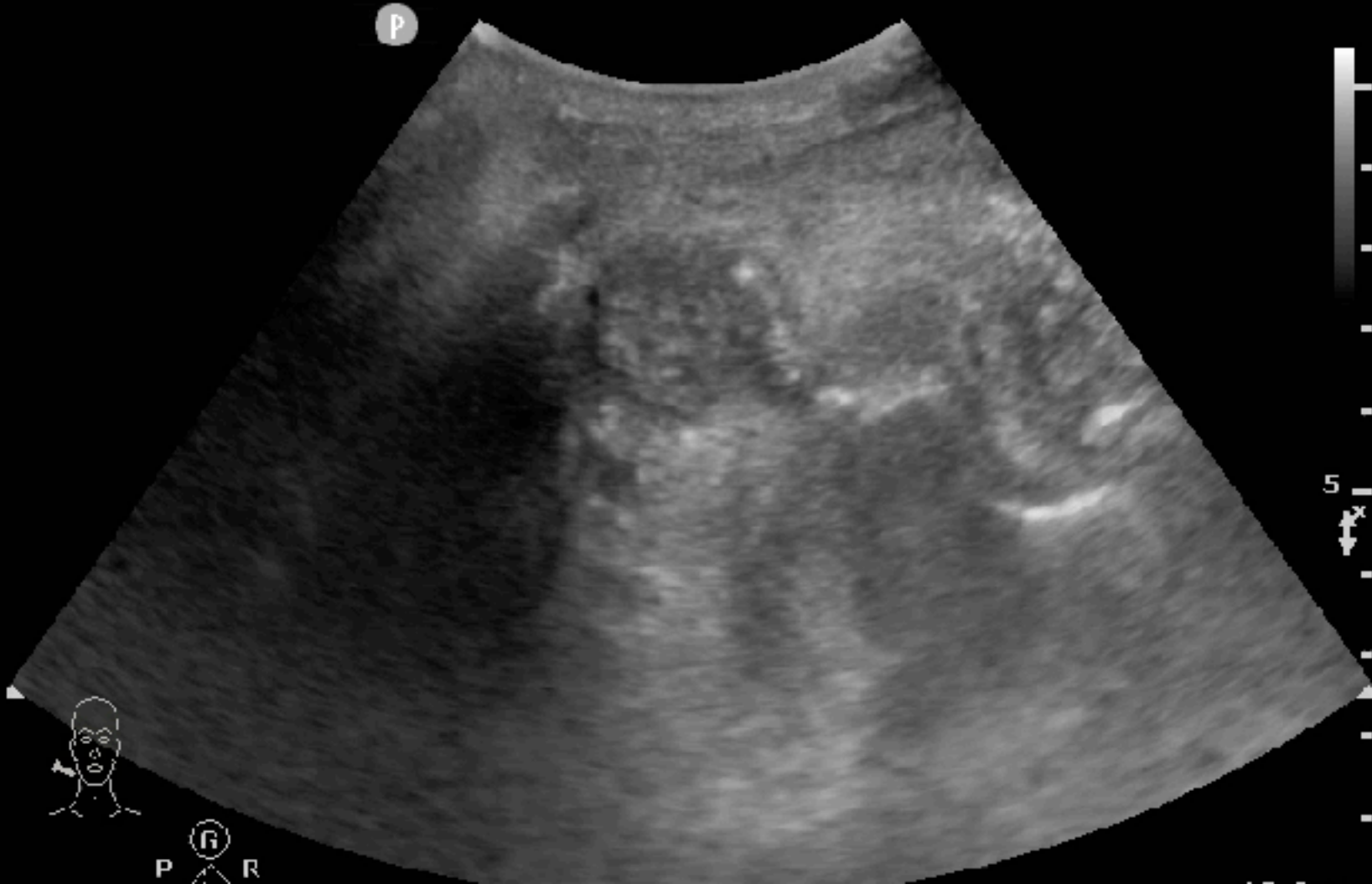
PHILIPS CHENG
22590475

SKH ER

MI 1.1 3/21/2022
TIS 0.1 8:27:56 AM

Abd Gen
C5-1
45 Hz
10.0cm

2D
HGen
Gn 92
C. 56
3/3/3



26M, peritonsillar abscess



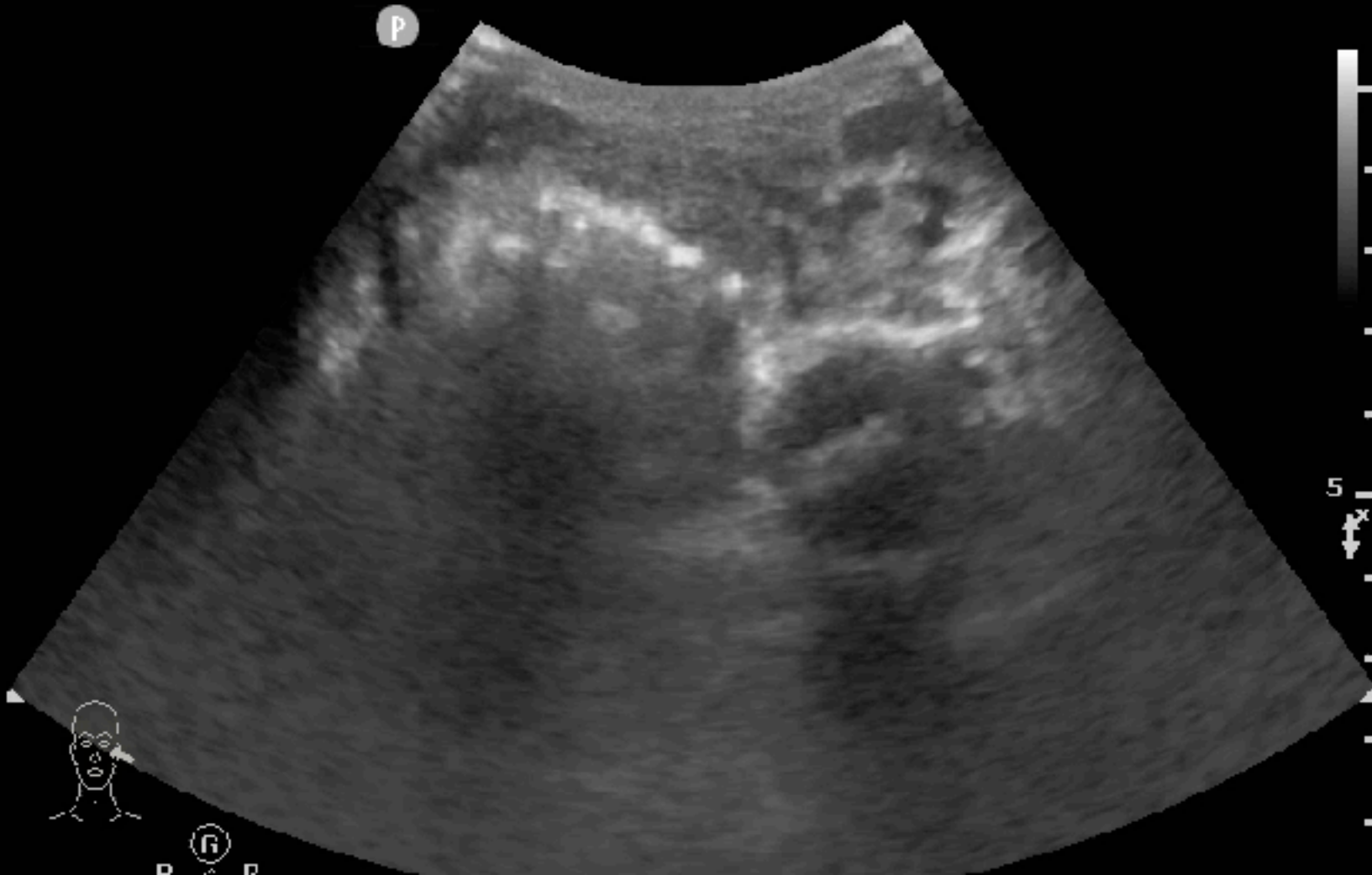PHILIPS CHENG
22590475

SKH ER

MI 1.1 3/21/2022
TIS 0.1 8:28:20 AM

Abd Gen
C5-1
45 Hz
10.0cm

2D
HGen
Gn 92
C. 56
3/3/3



26M, peritonsillar abscess



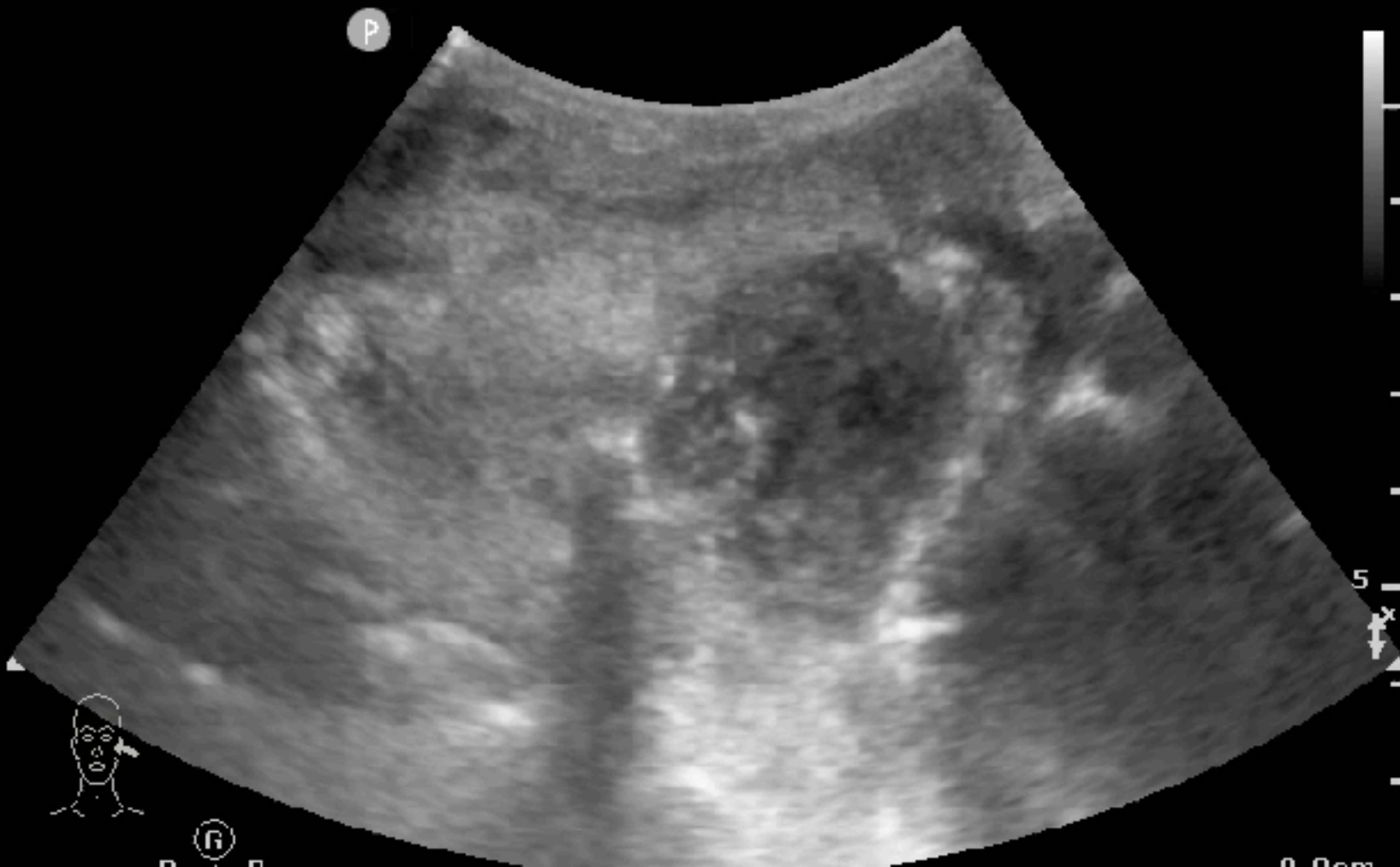
PHILIPS CHENG
22590475

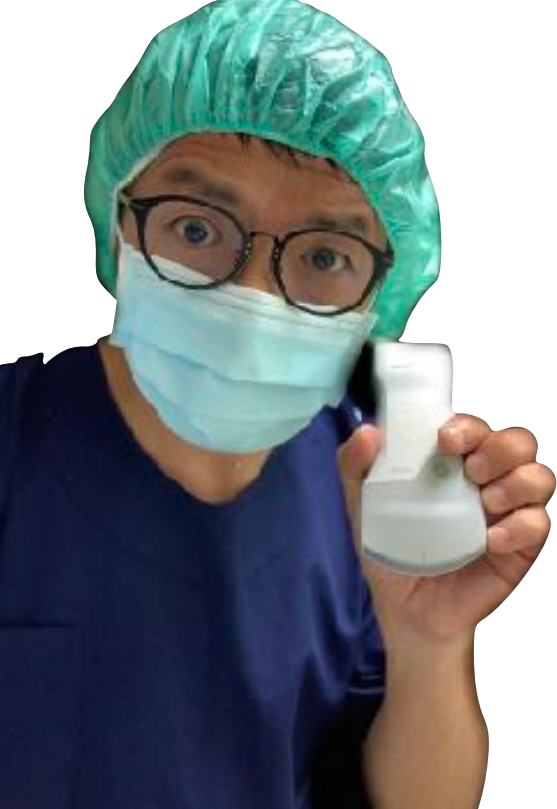SKH ER

MI 1.1 3/21/2022
TIS 0.1 8:29:14 AM

Abd Gen
C5-1
51 Hz
8.0cm

2D
HGen
Gn 98
C. 56
3/3/3





努力可能會說謊，
但努力不會白費。

羽生結弦

HOLISTIC ULTRASOUND

juice119@gmail.com / POCUSacademy.com