



雙和急診POCUS訓練

診
斷

監
測

介
入

POINT OF CARE ULTRASOUND

~ 存在於臨床需求之所在 ~

陳國智 醫師



醫用超音波學會指導醫師
WINFOCUS director / instructor
急救加護醫學會重症超音波負責人

急診 / 重症 / 介入 / 急性疼痛

經歷

新光急診超音波訓練中心主任

西園醫院急診醫學科主任

急診醫學會超音波委員會主委

台灣疼痛醫學會大體模擬手術講師



LE joint effusion

01/07

Airway

01/14

Needling

01/21

VExUS protocol

01/28

雙和急診POCUS訓練



Central access

02/11

Peripheral access

02/18

EFAST

02/25

雙和急診POCUS訓練



Basic ECHO

03/04

Nerve block-UE(1)

03/11

Nerve block-LE(1)

03/25

雙和急診POCUS訓練



Aorta & IVC

04/01

Liver & Biliary

04/08

Pancreas & Spleen

04/15

Kidney & UB

04/29

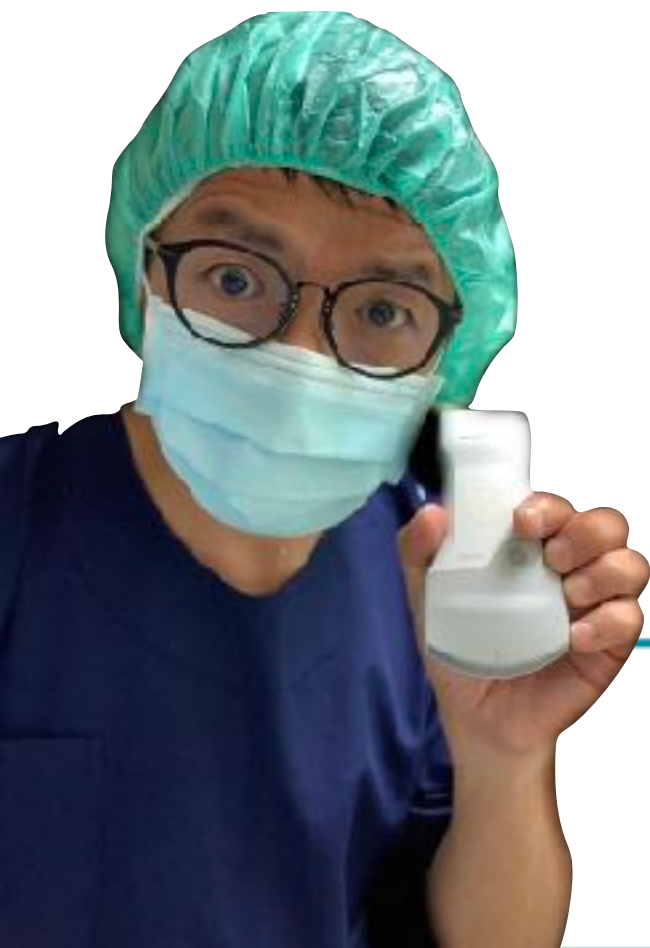雙和急診POCUS訓練



衛生福利部雙和醫院
(委託臺北醫學大學興建經營)
Taipei Medical University · Shuang Ho Hospital,
Ministry of Health and Welfare



POCUS Imaging Reading



陳國智醫師

雙和醫院 急診醫學科

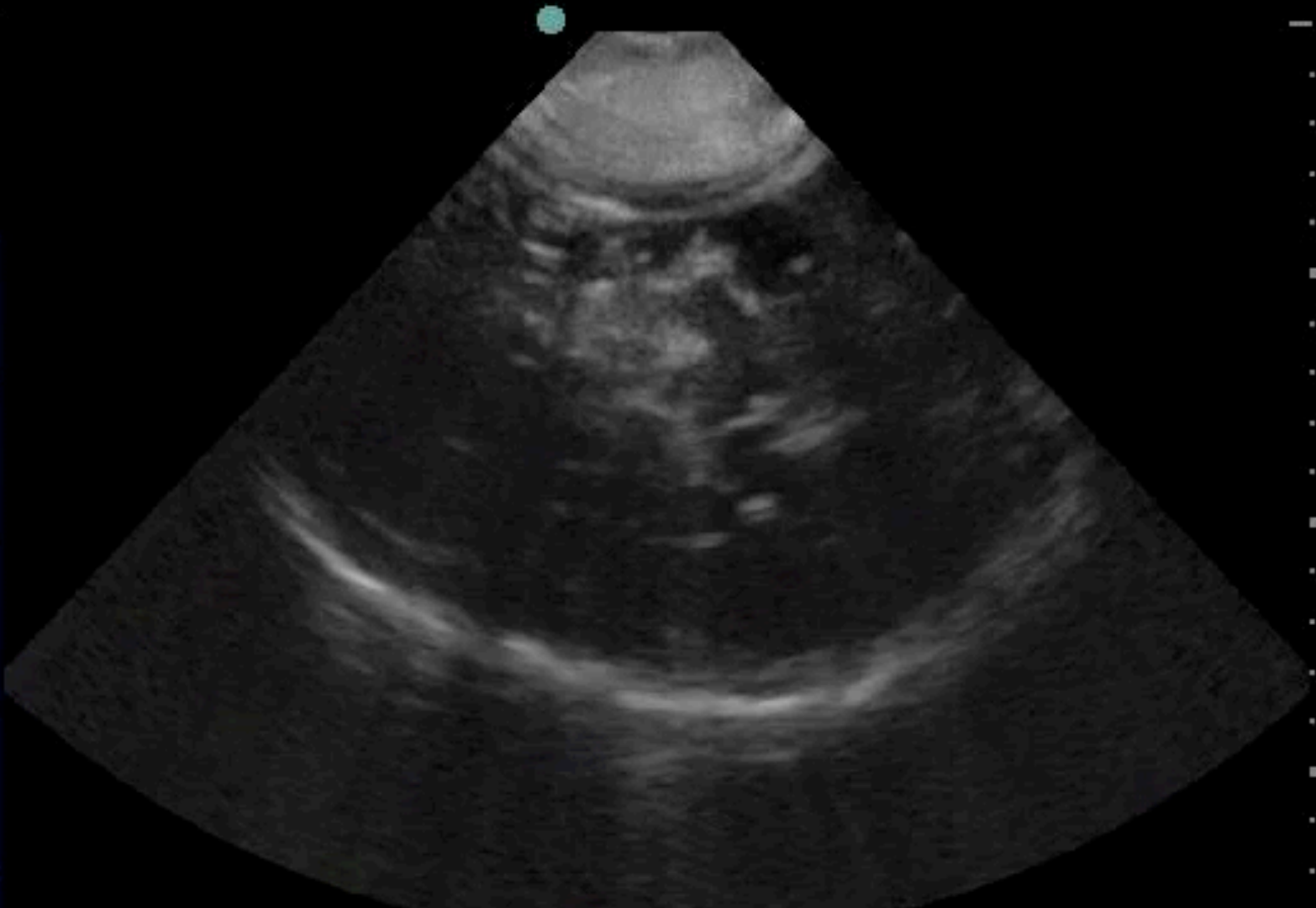
67M, AMS, F/S 487, BT 37.9



GenTHI MB

14306701

2022Apr05 12:47



Abd

P21



94%

MI

1.1

TIS

0.8



Patient



Auto Gain



Gen



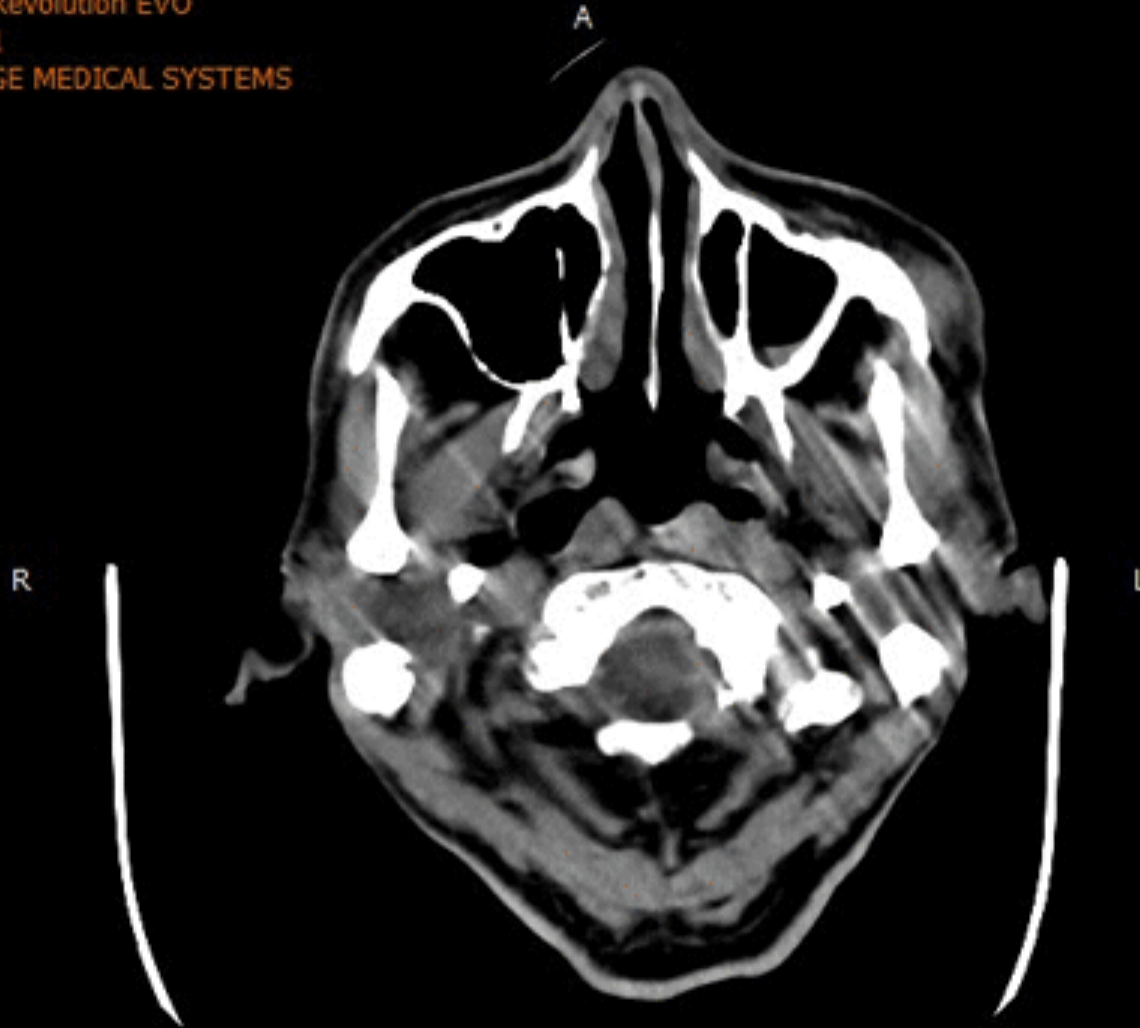
Clip



67M, AMS, F/S 487, BT 37.9



Revolution EVO
1
GE MEDICAL SYSTEMS



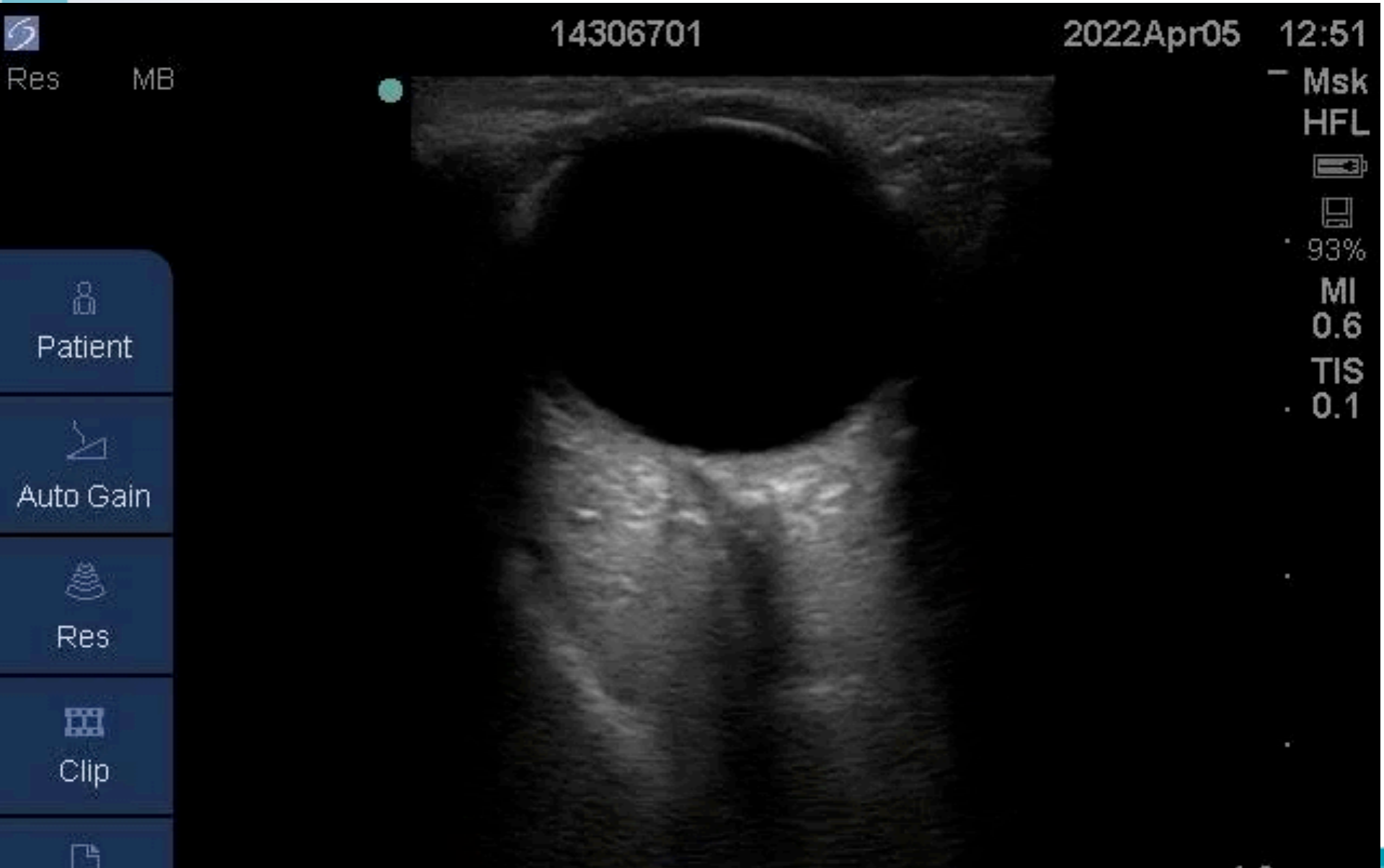何欣璋,何欣璋

P

12:00:03

12:00:52

ONSD (0.3cm depth, > 0.5cm)



Movement effect on ONSD



14306701 2022Apr05 12:49

Res MB

— Msk
HFL
94%
MI
0.7
TIS
0.1

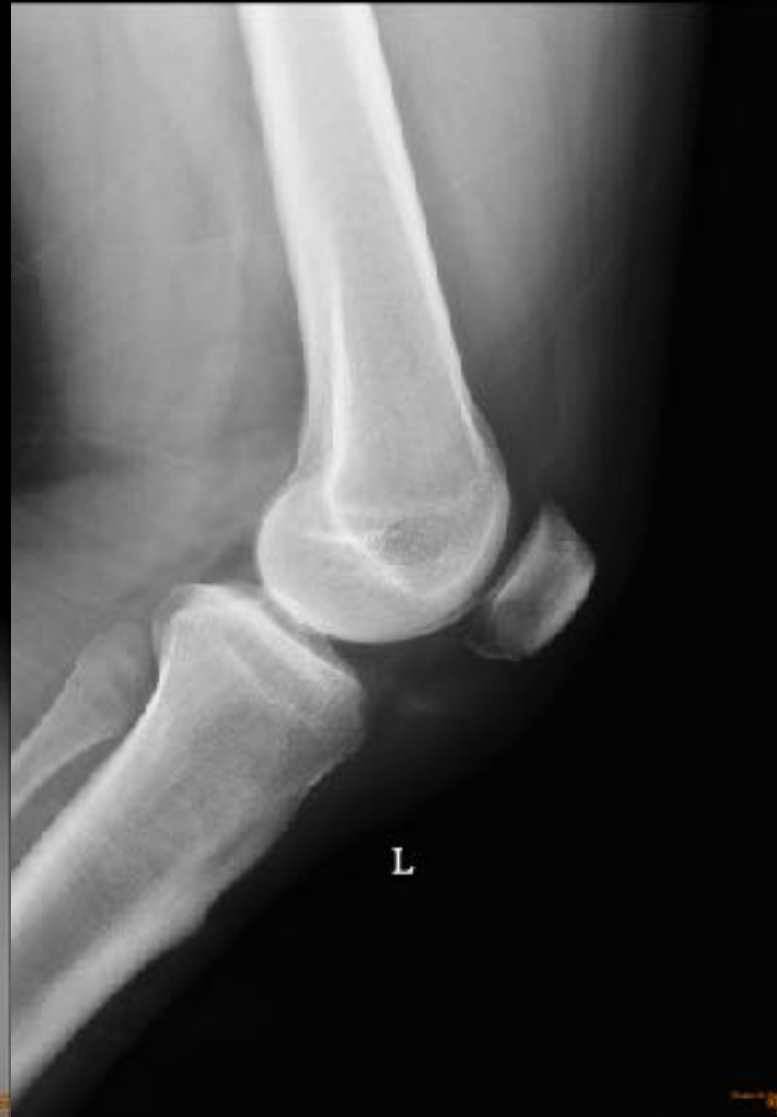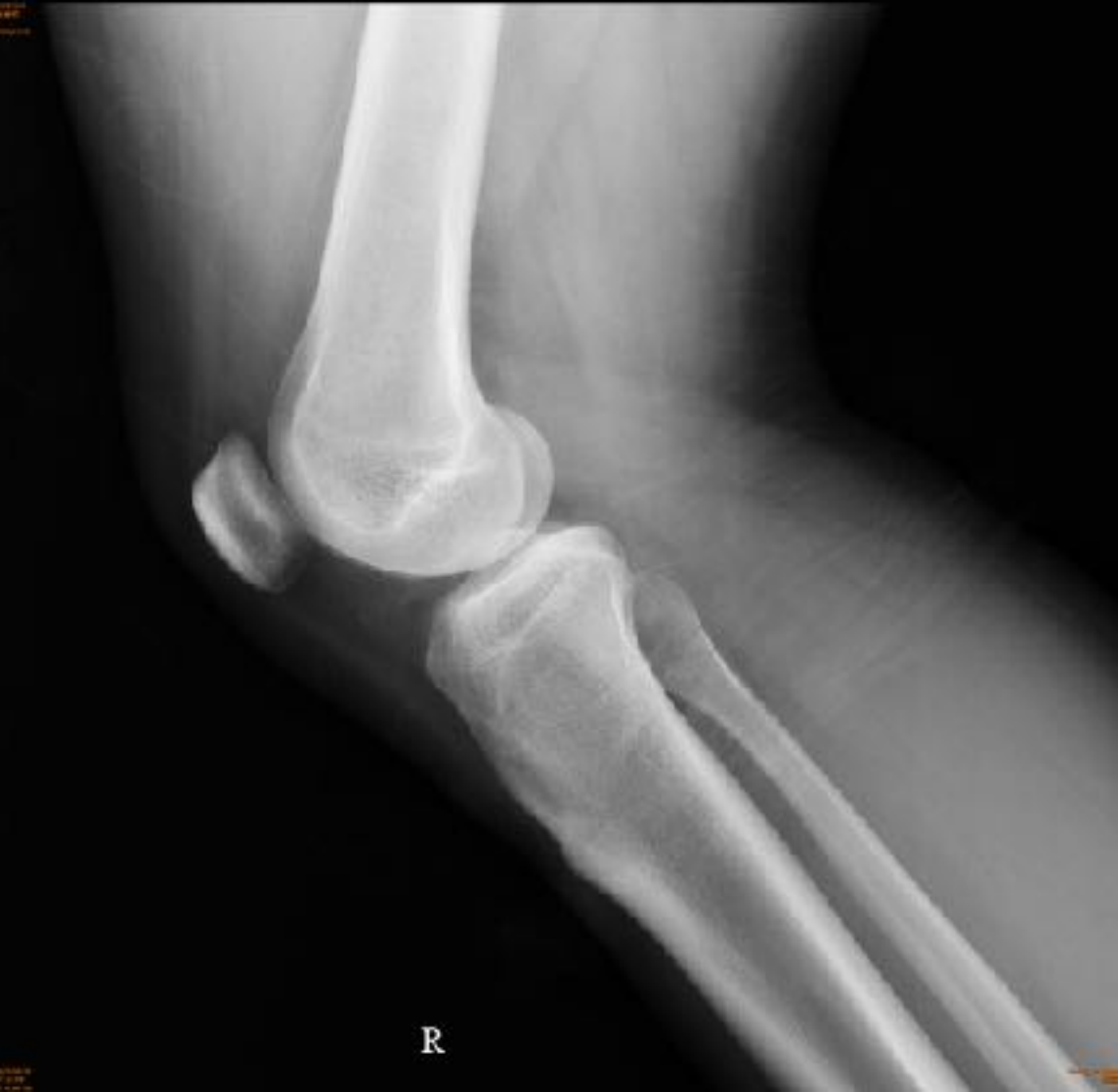Patient

Auto Gain

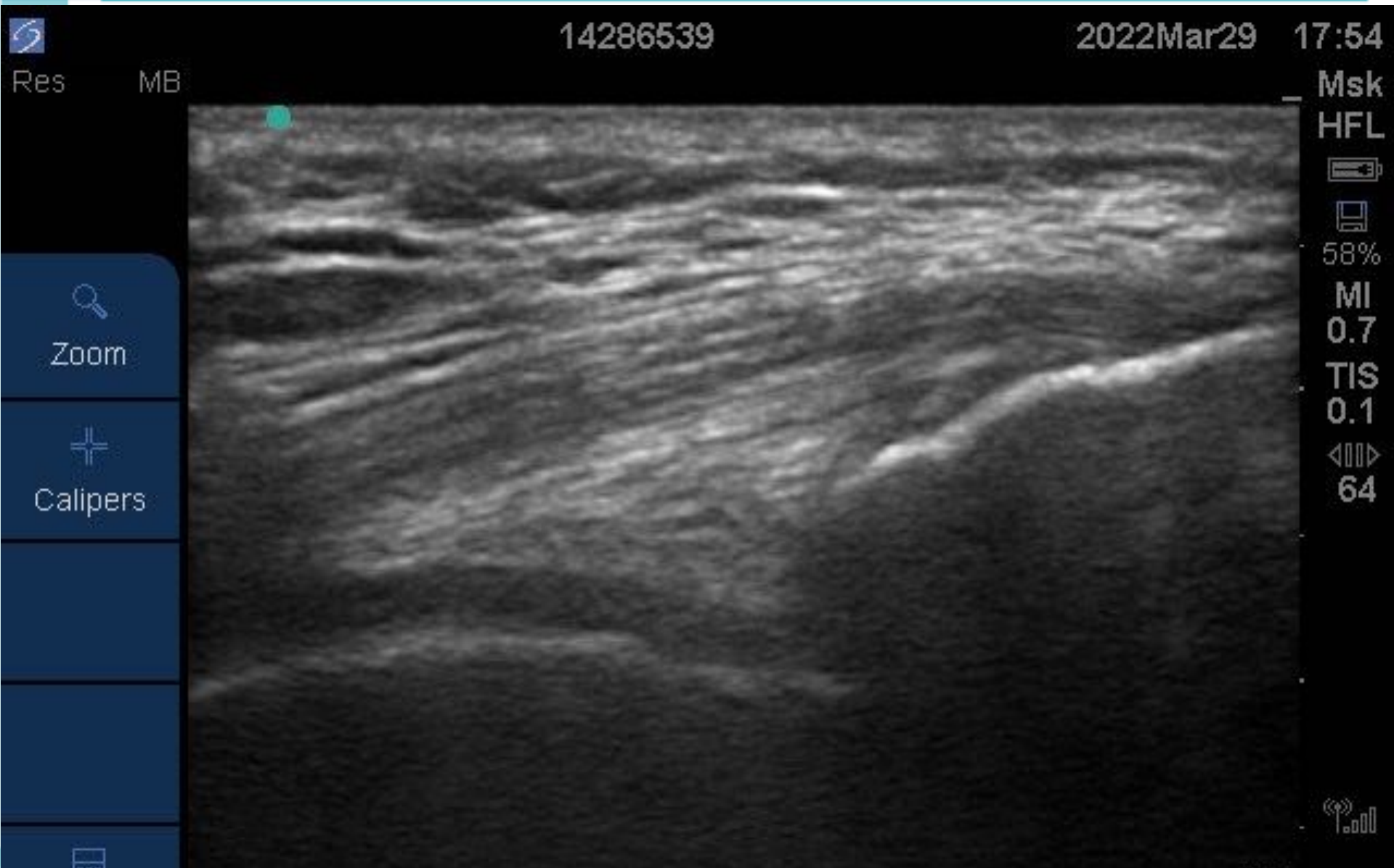Res

Clip

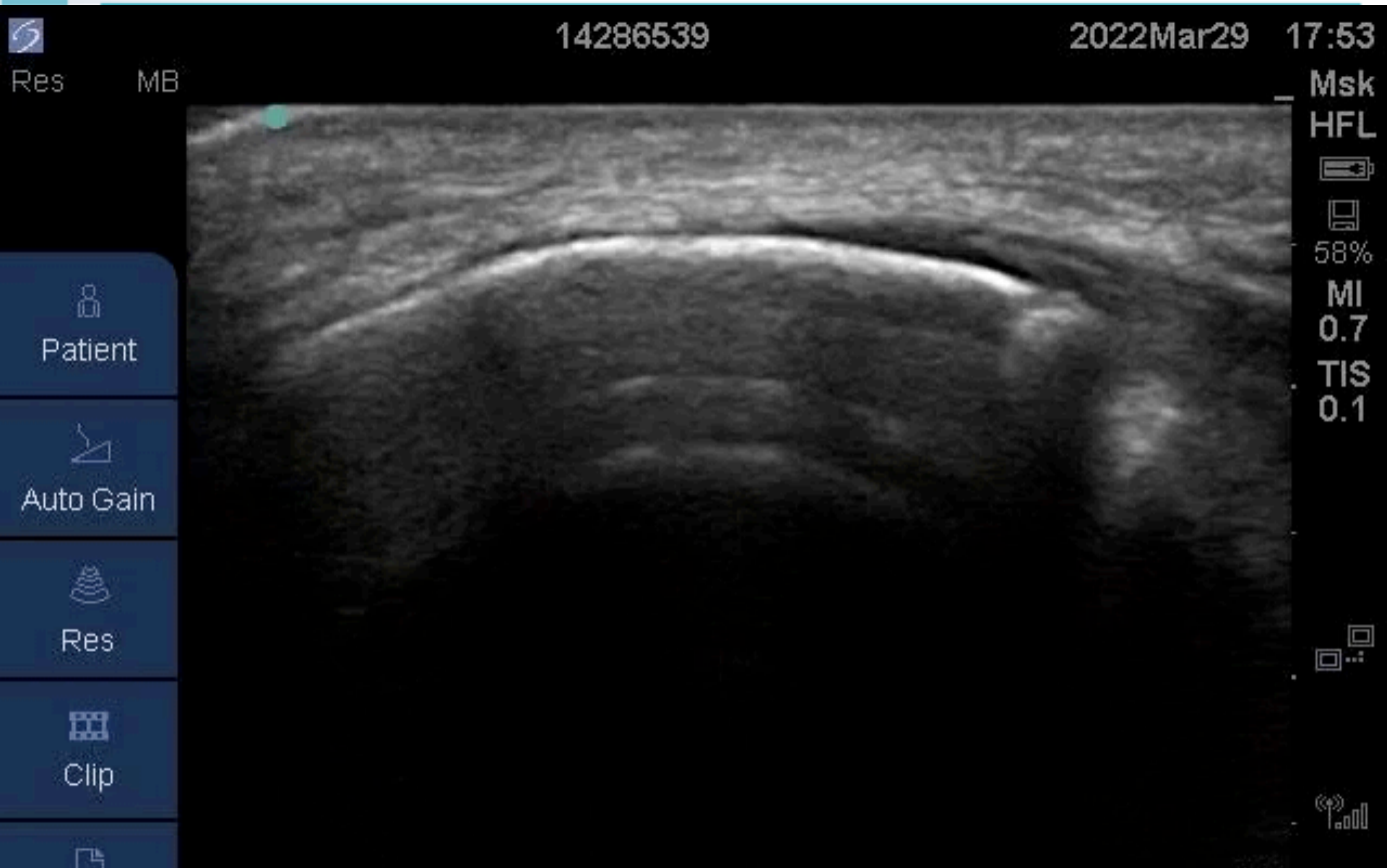20M, TA, both knee contusion



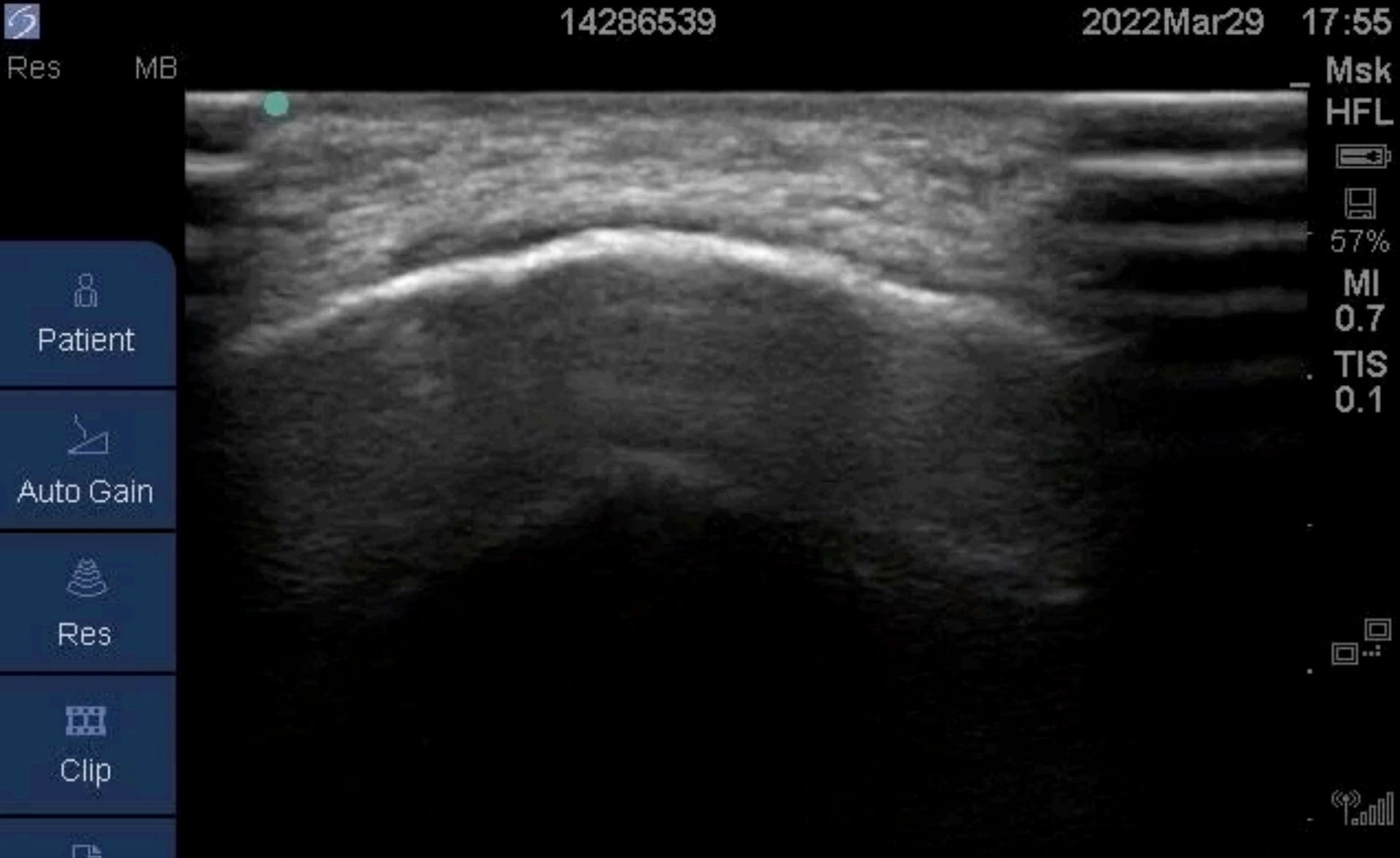No suprapatellar fossa fluid



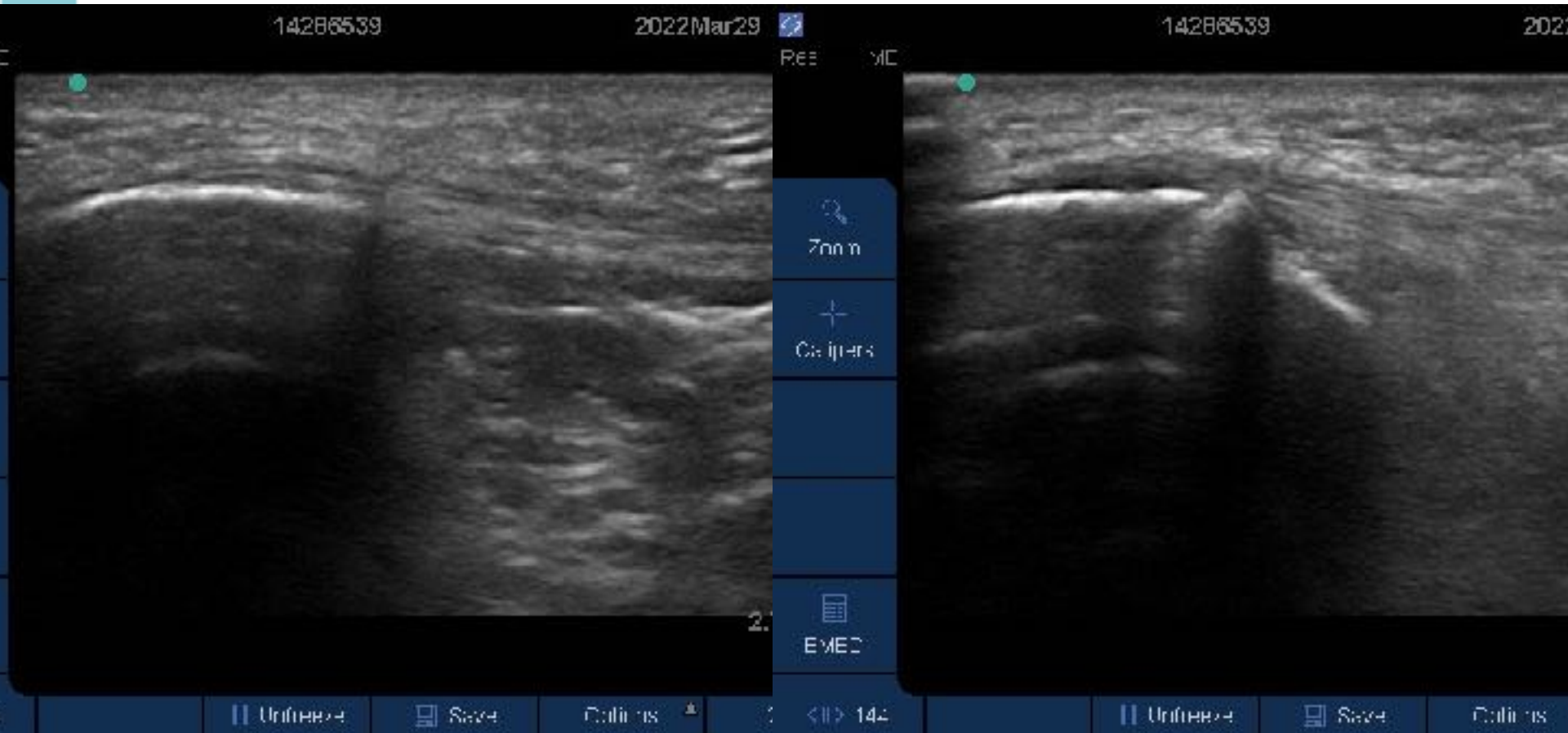
20M, TA, both knee contusion



20M, TA, both knee contusion



Comparison



23M, TA with knee painful swelling



GenTHI MB

14287530

2022Mar30 08:41

Abd

- C60



57%

MI

0.7

▪ TIS

0.1



121



Zoom



Calipers



EMED

121

Unfreeze

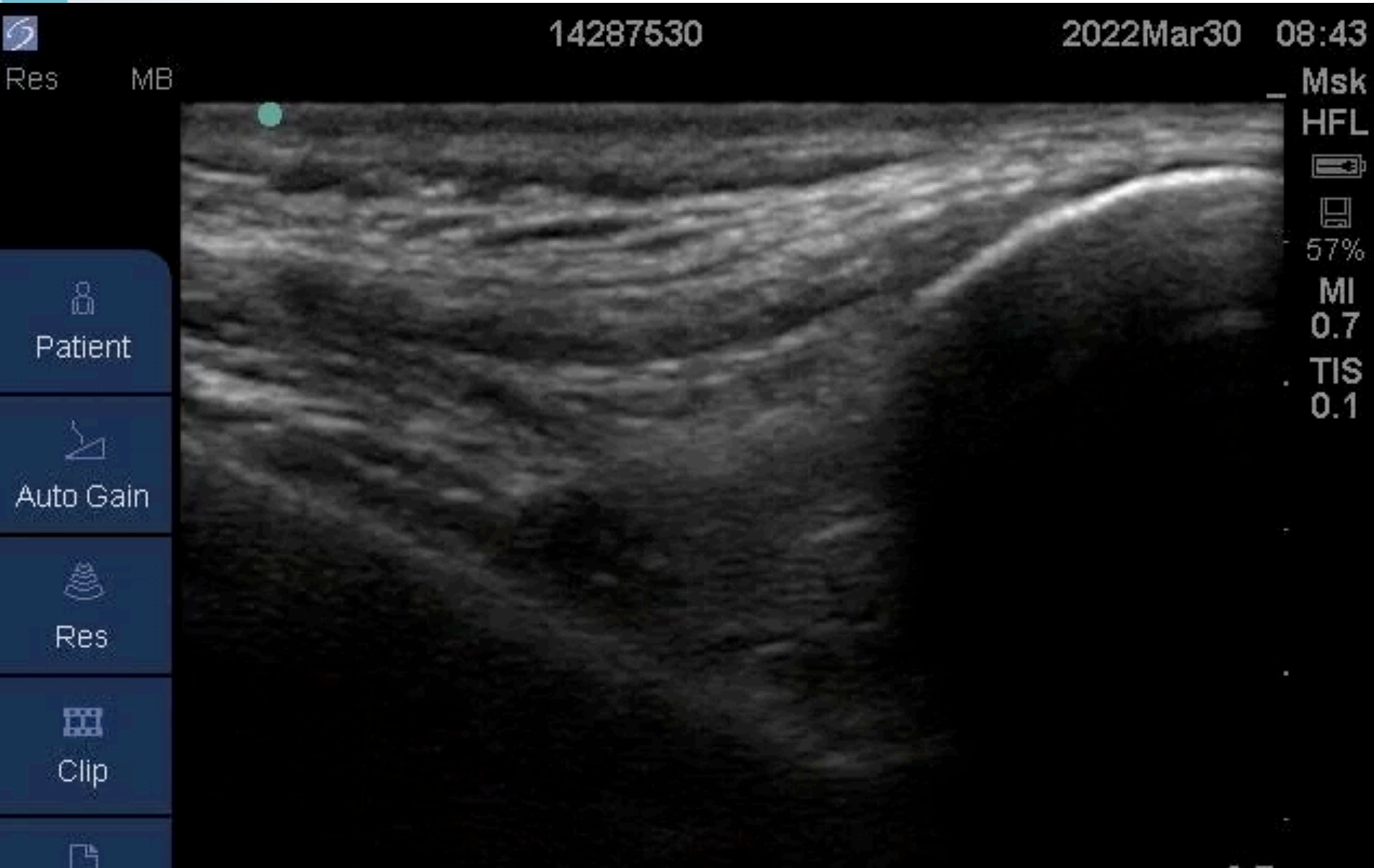Save

Options

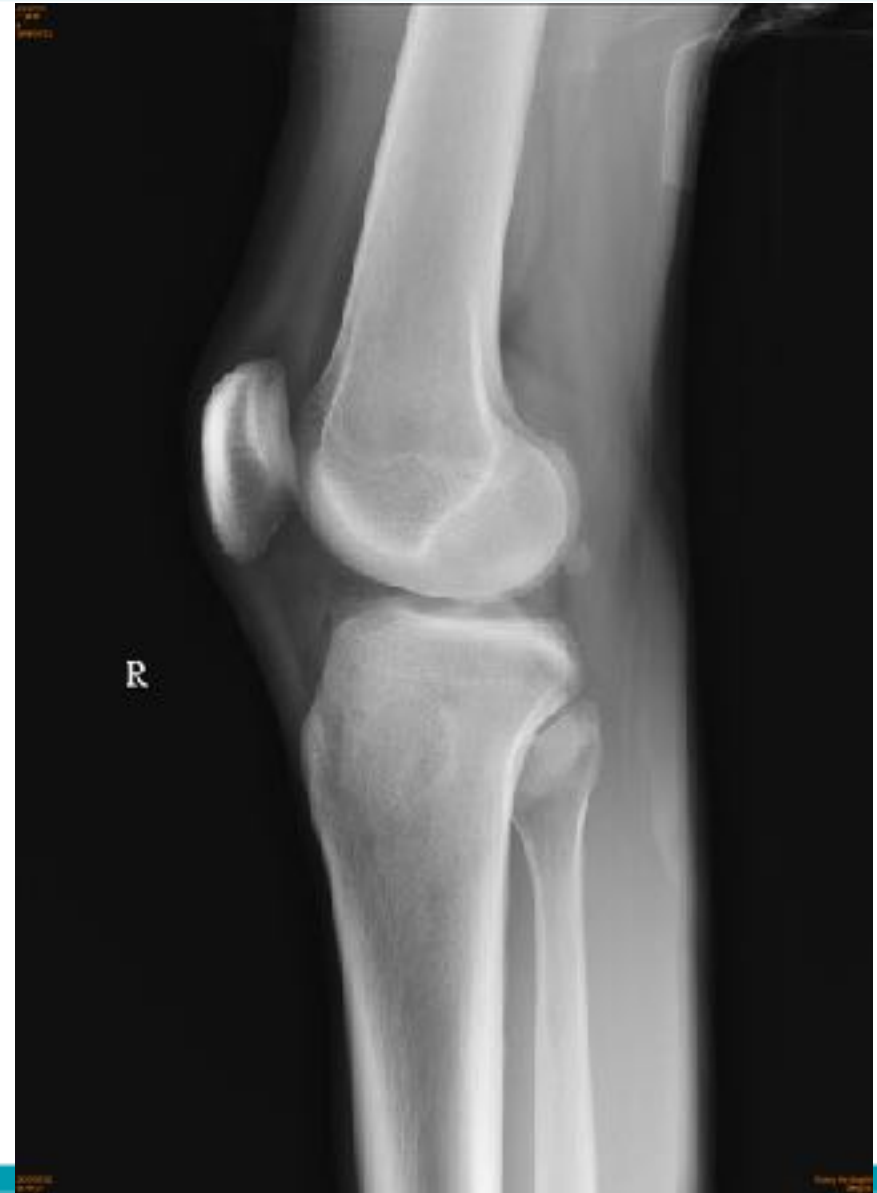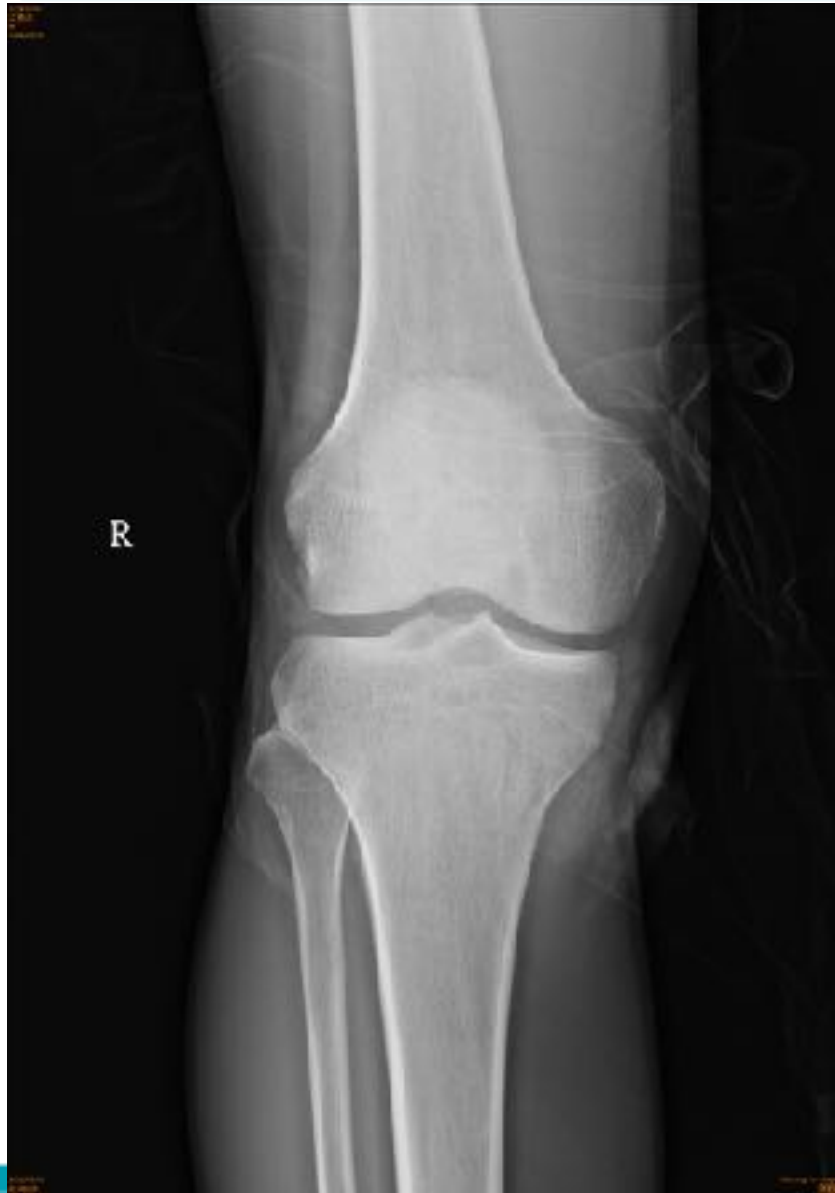2D

15

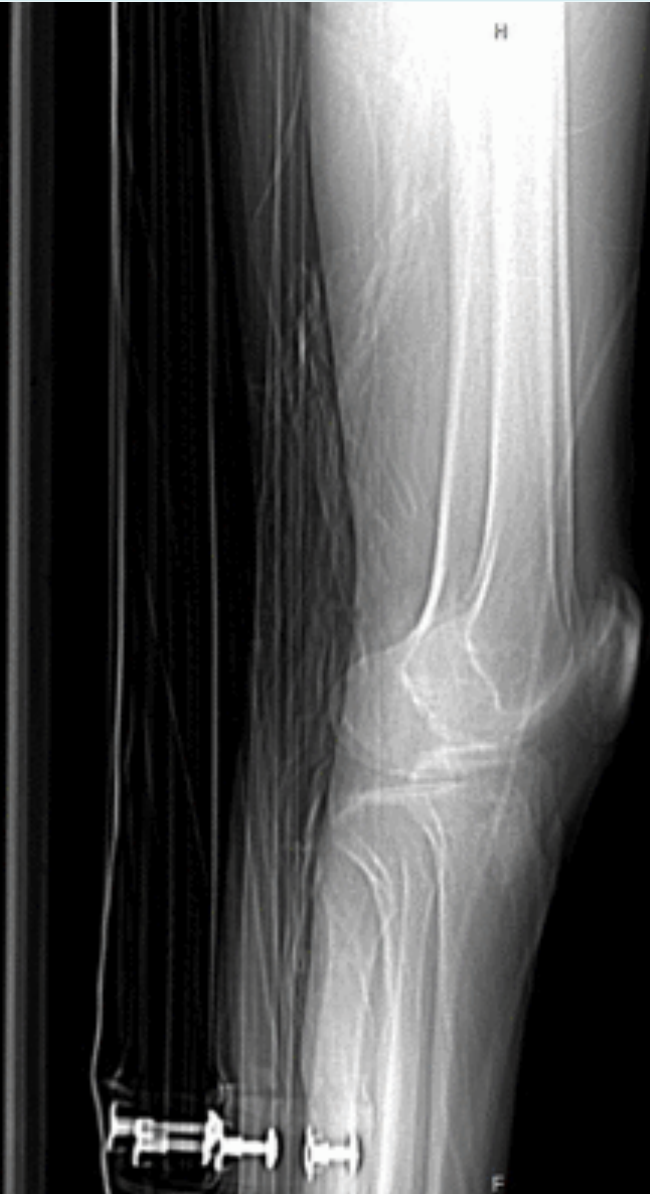
23M, TA with knee painful swelling



23M, TA with knee painful swelling



Open fracture



P

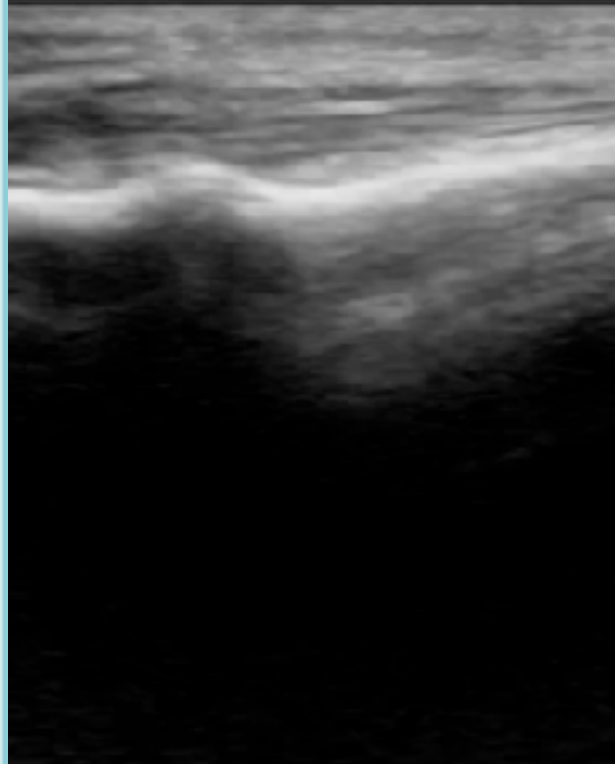
A

4M, wrist pain after a fall



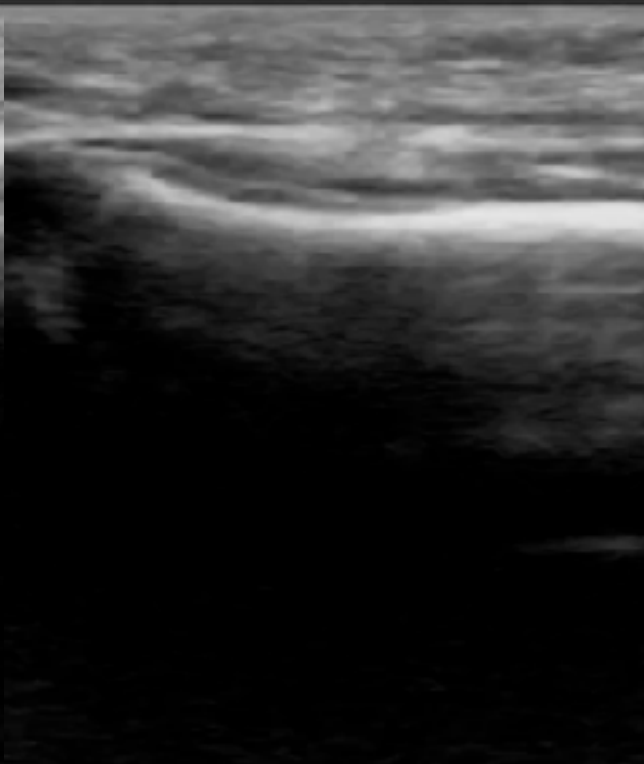
TIS: 0.01, MI: 0.26, Musculoskeletal

B



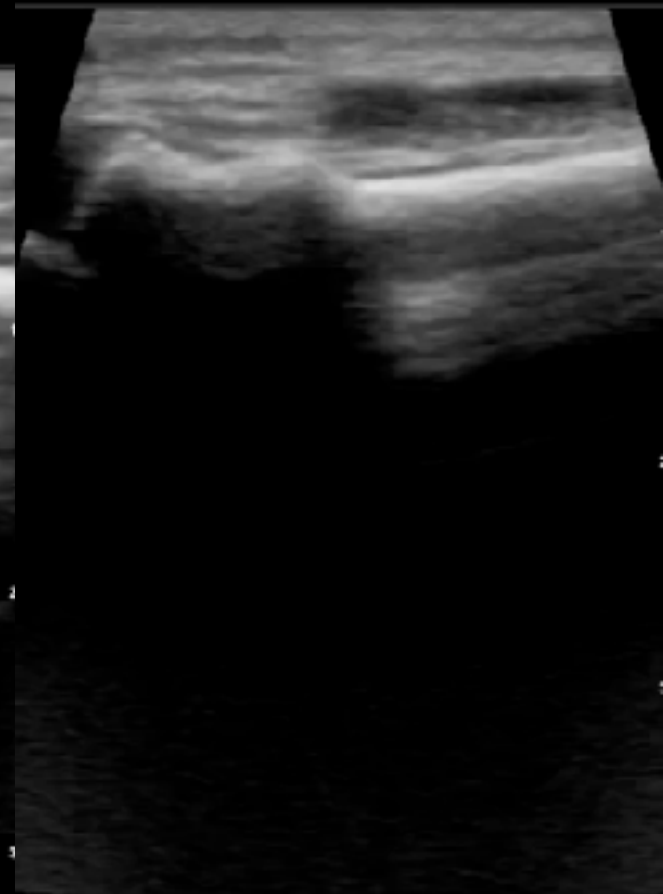
TIS: 0.01, MI: 0.26, Musculoskeletal

B

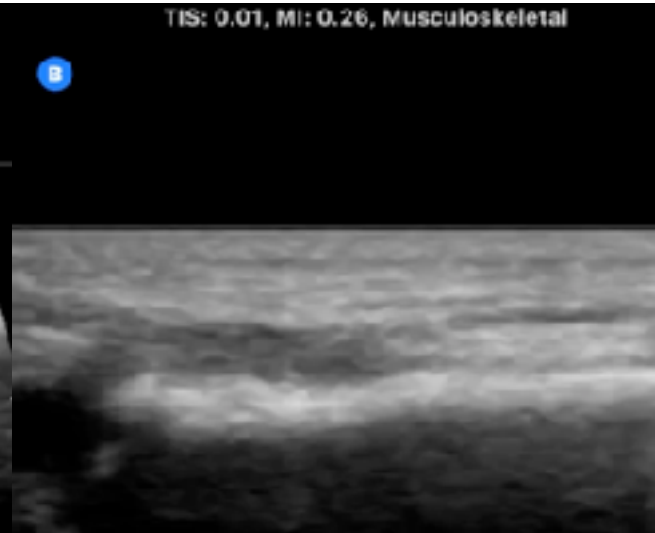
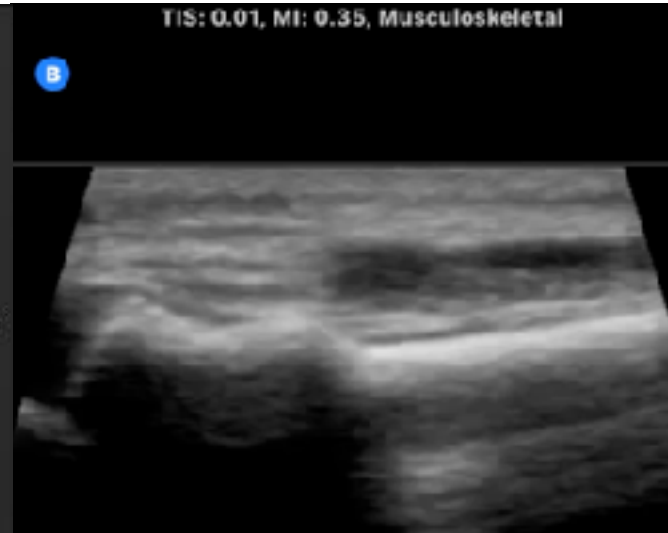
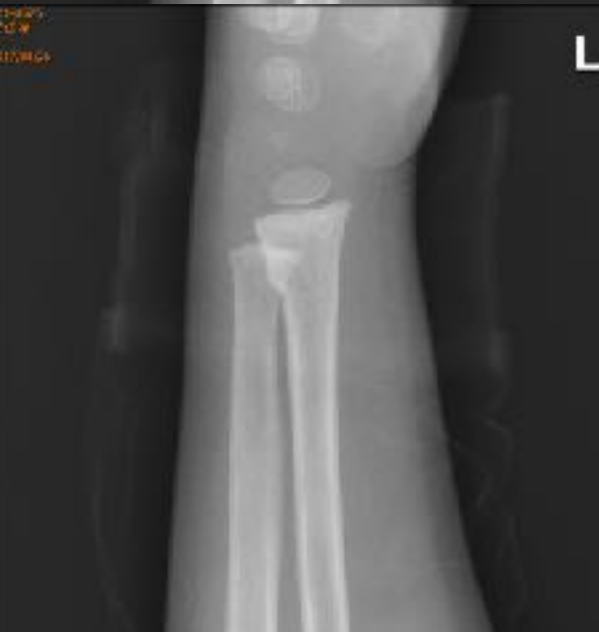
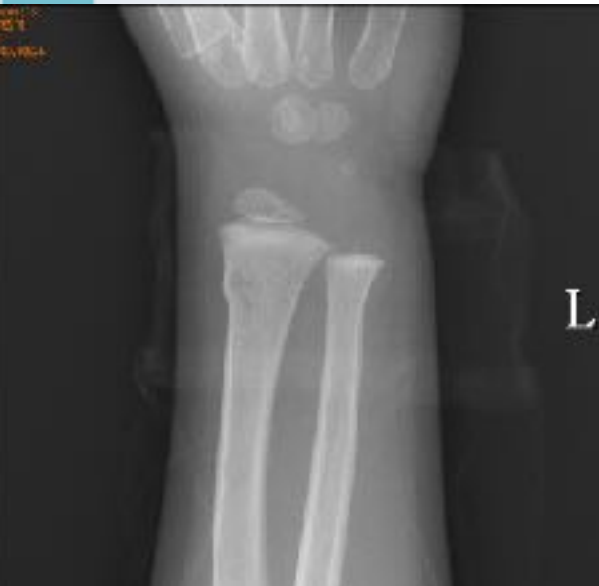
TIS: 0.01, MI: 0.35, Musculoskeletal

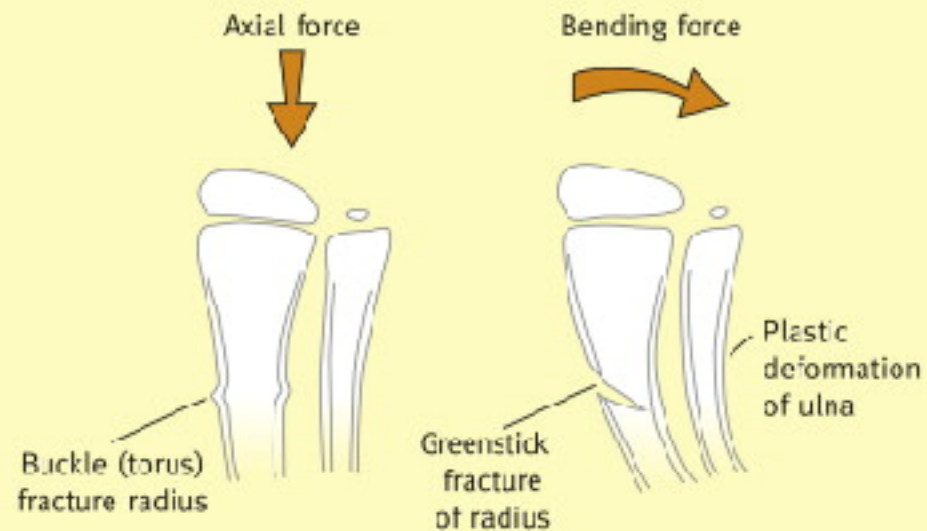
B



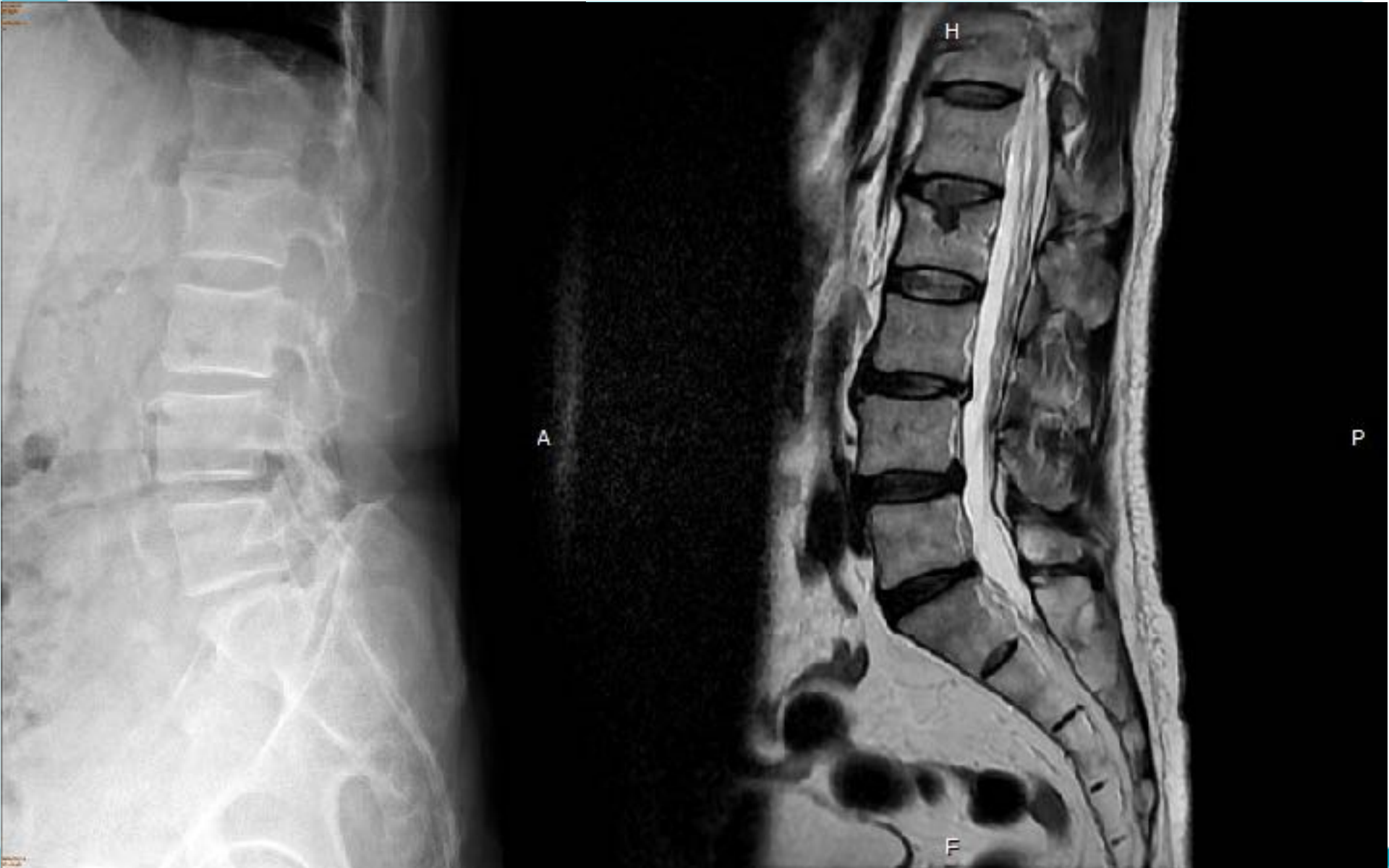Buckle fracture



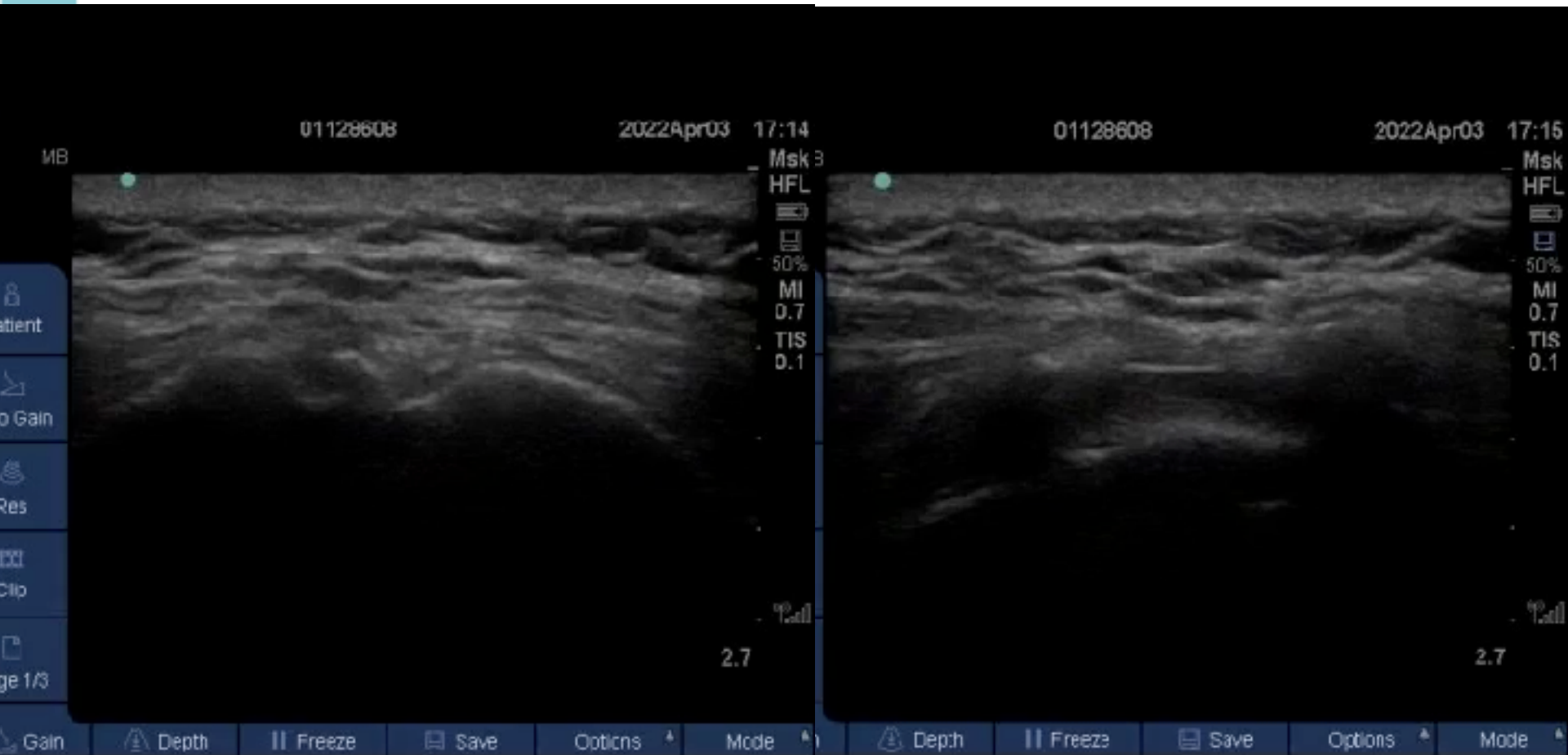
Paediatric fracture patterns



63M, LBP with right sciatica



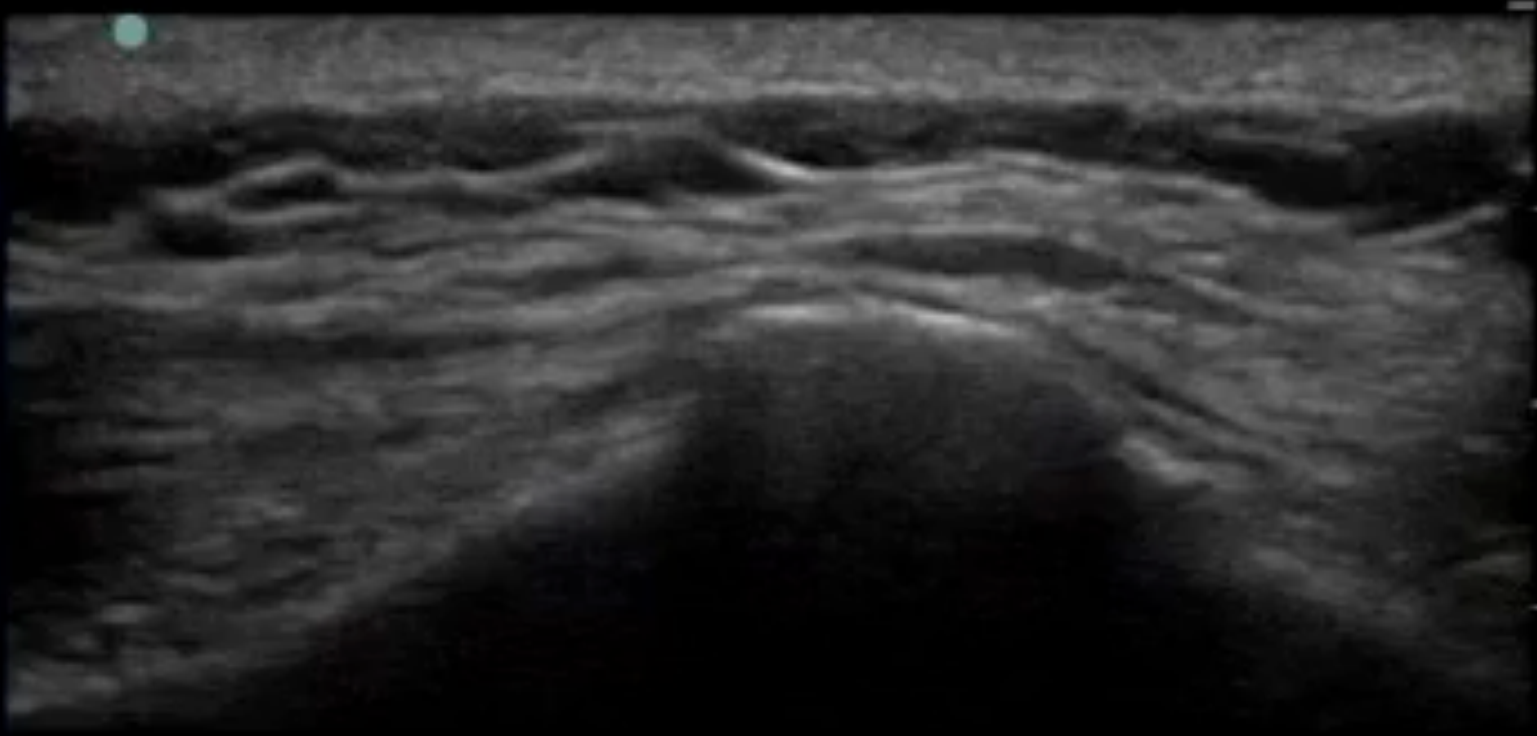
Caudal block for acute low back pain





49%

MI
0.7
TIS
0.1



1.8

Patient

Auto Gain

Res

Clip

Page 1/3

Gain

Depth

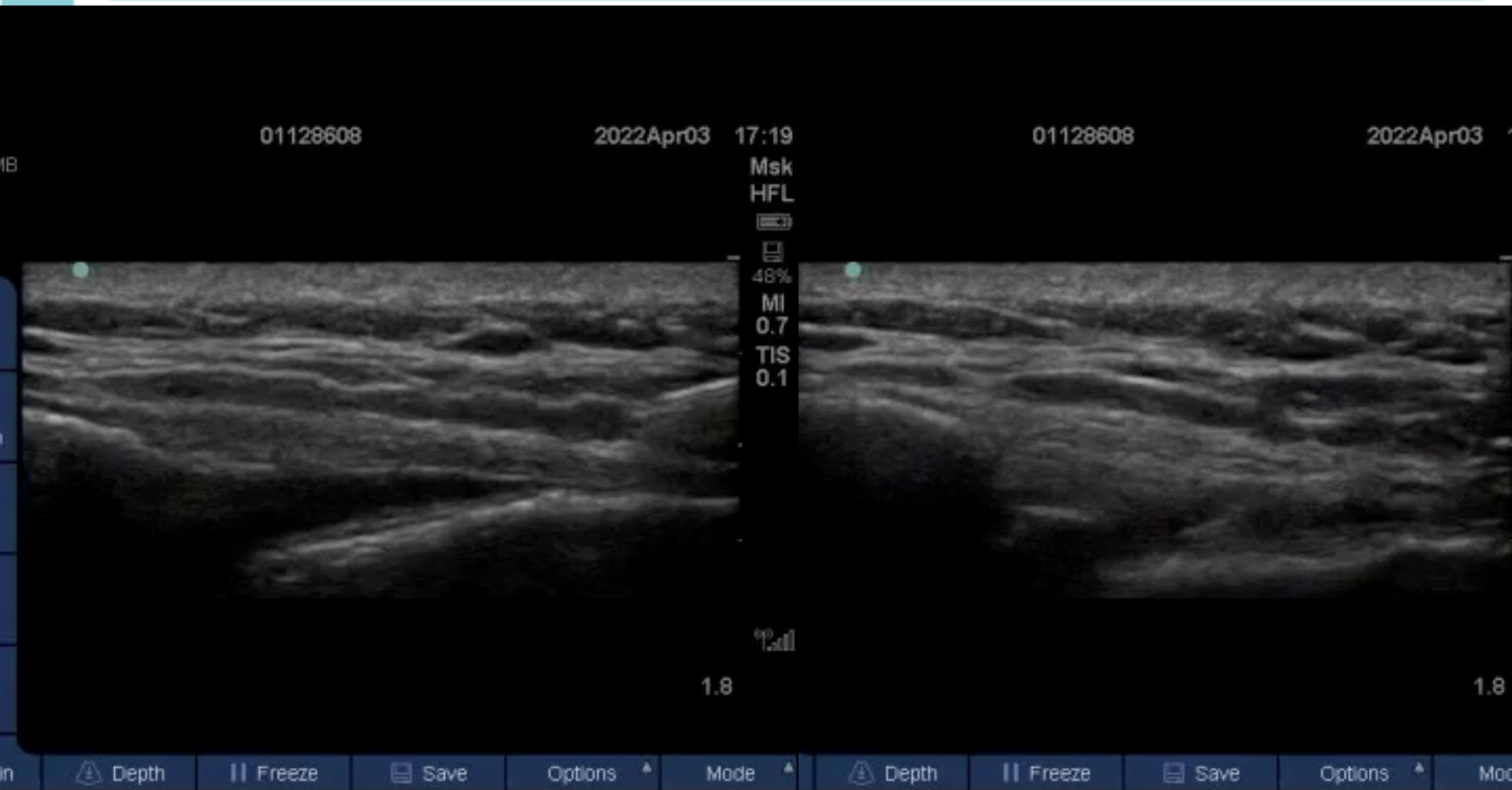Freeze

Save

Options

Mode

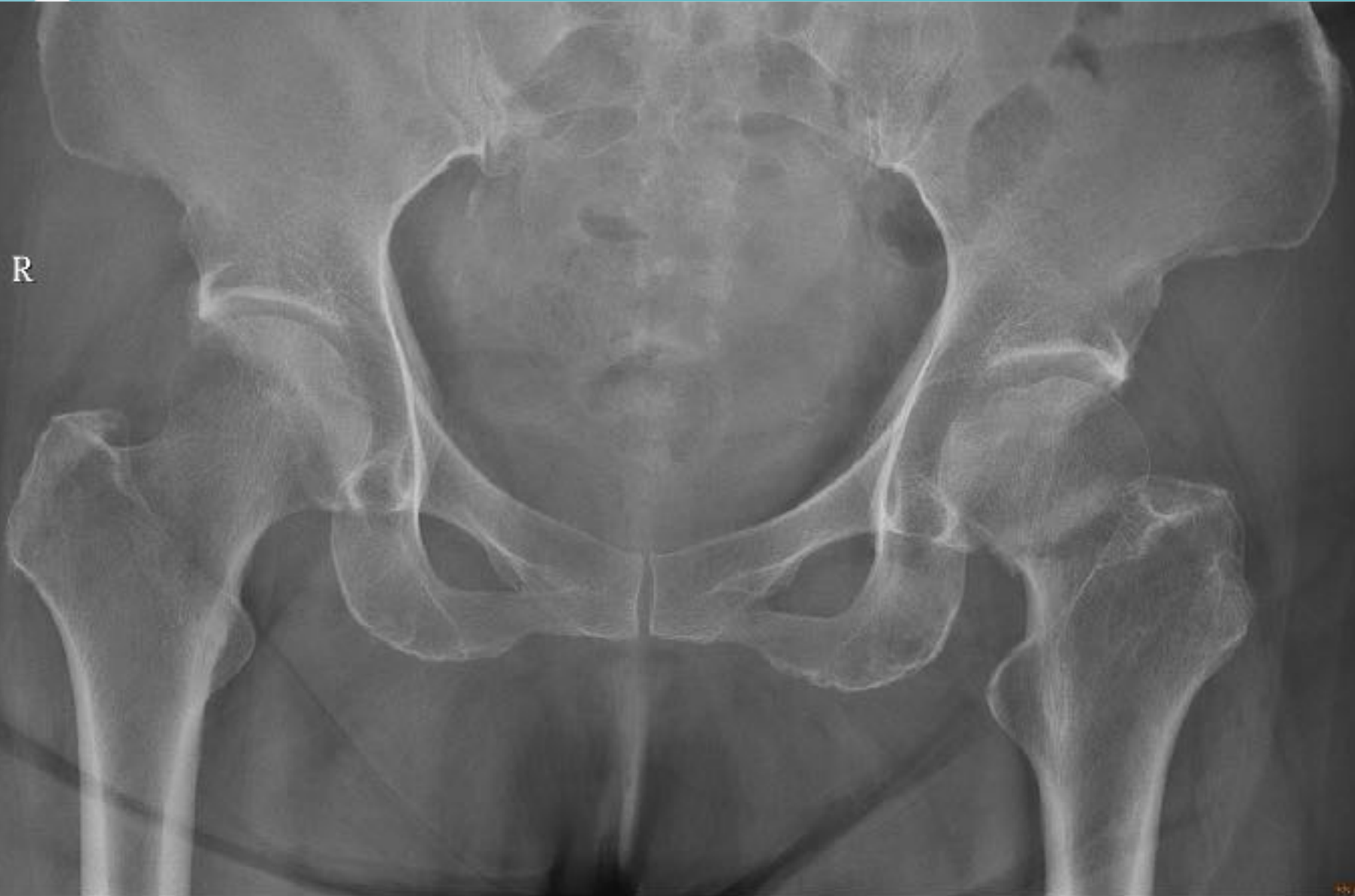Marcaine 0.5% 20 ml



70F, PENG block for FNF (妍方)



R



70F, PENG block for FNF (妍方)



00039260

2022Apr01

14:45

GenTHI MB

Msk

C60



46%

MI

0.7

TIS

0.2



Patient



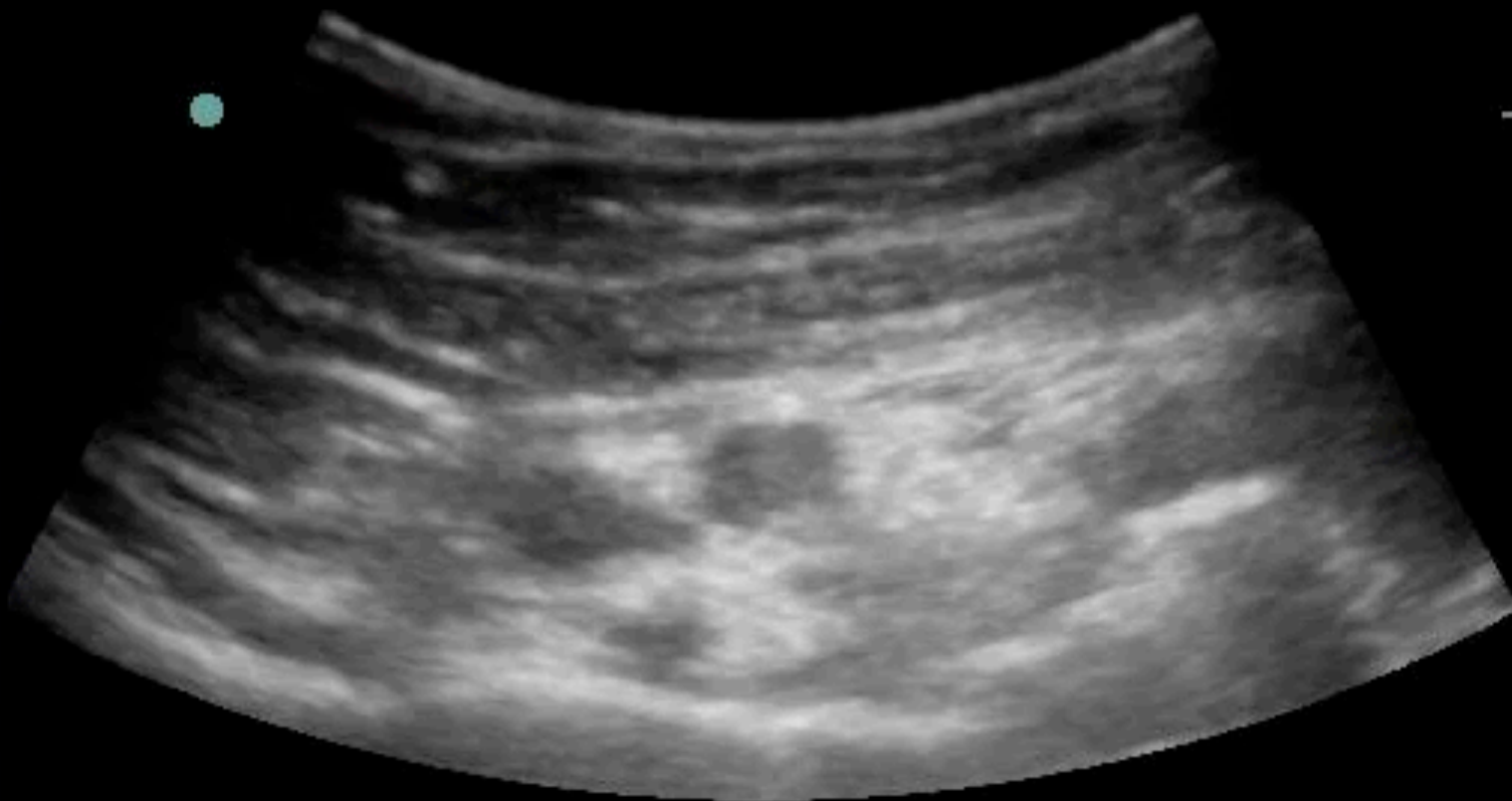Auto Gain



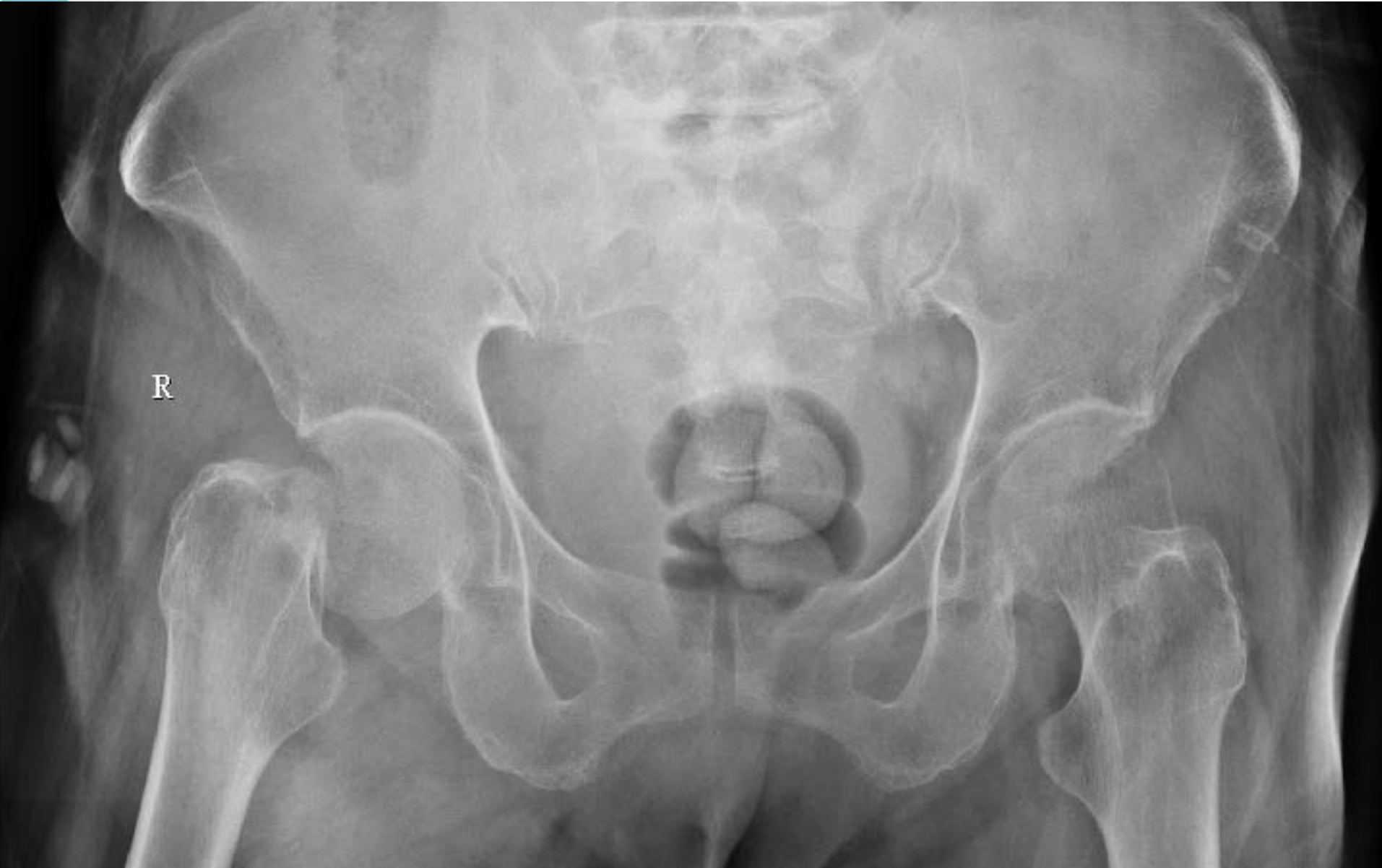Gen



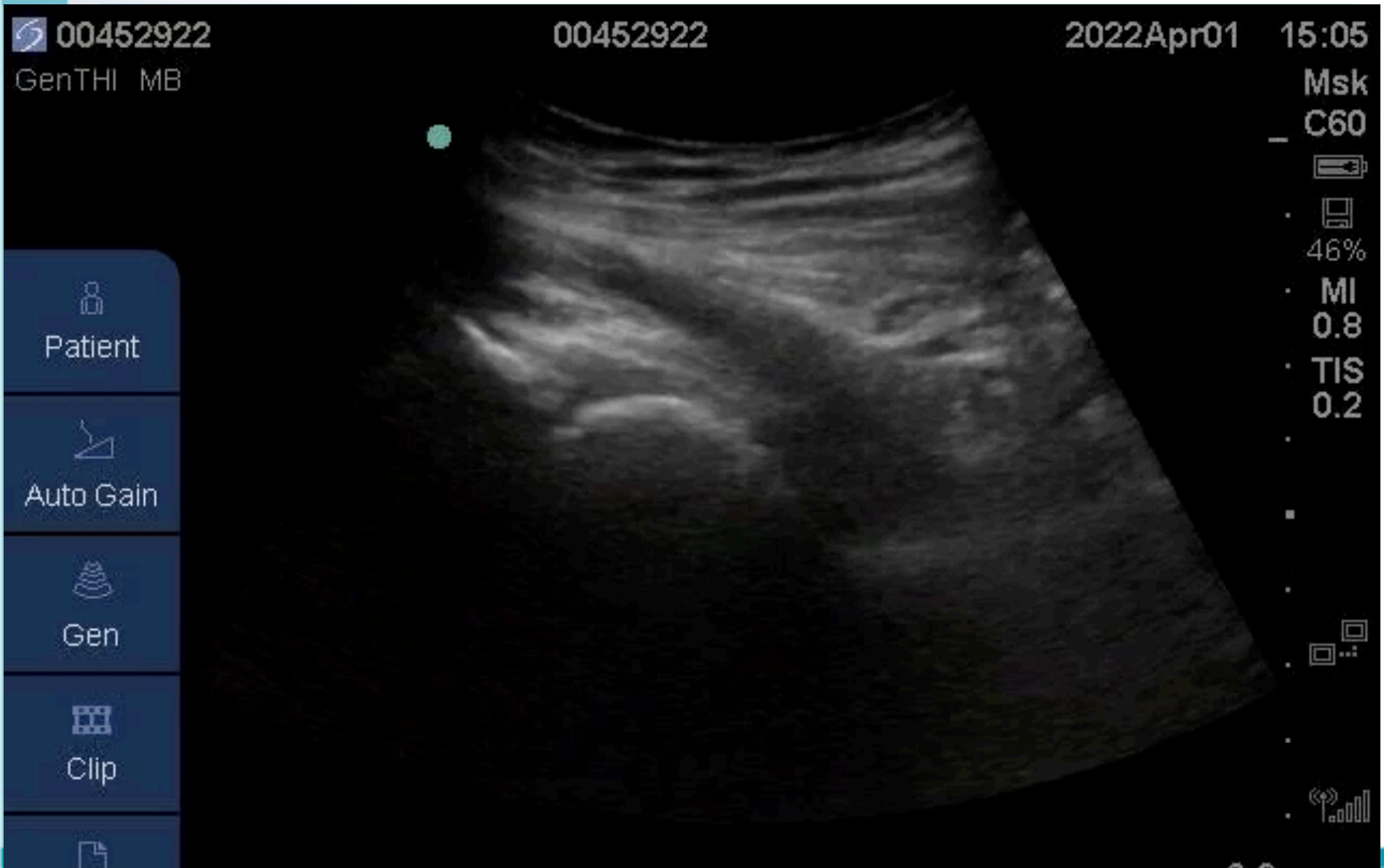Clip



81F, PENG block for FNF (閱皓)



FN fracture



PENG block landmark



00452922
GenTHI MB

00452922

2022Apr01 15:05

Msk

C60



45%

MI

0.7

TIS

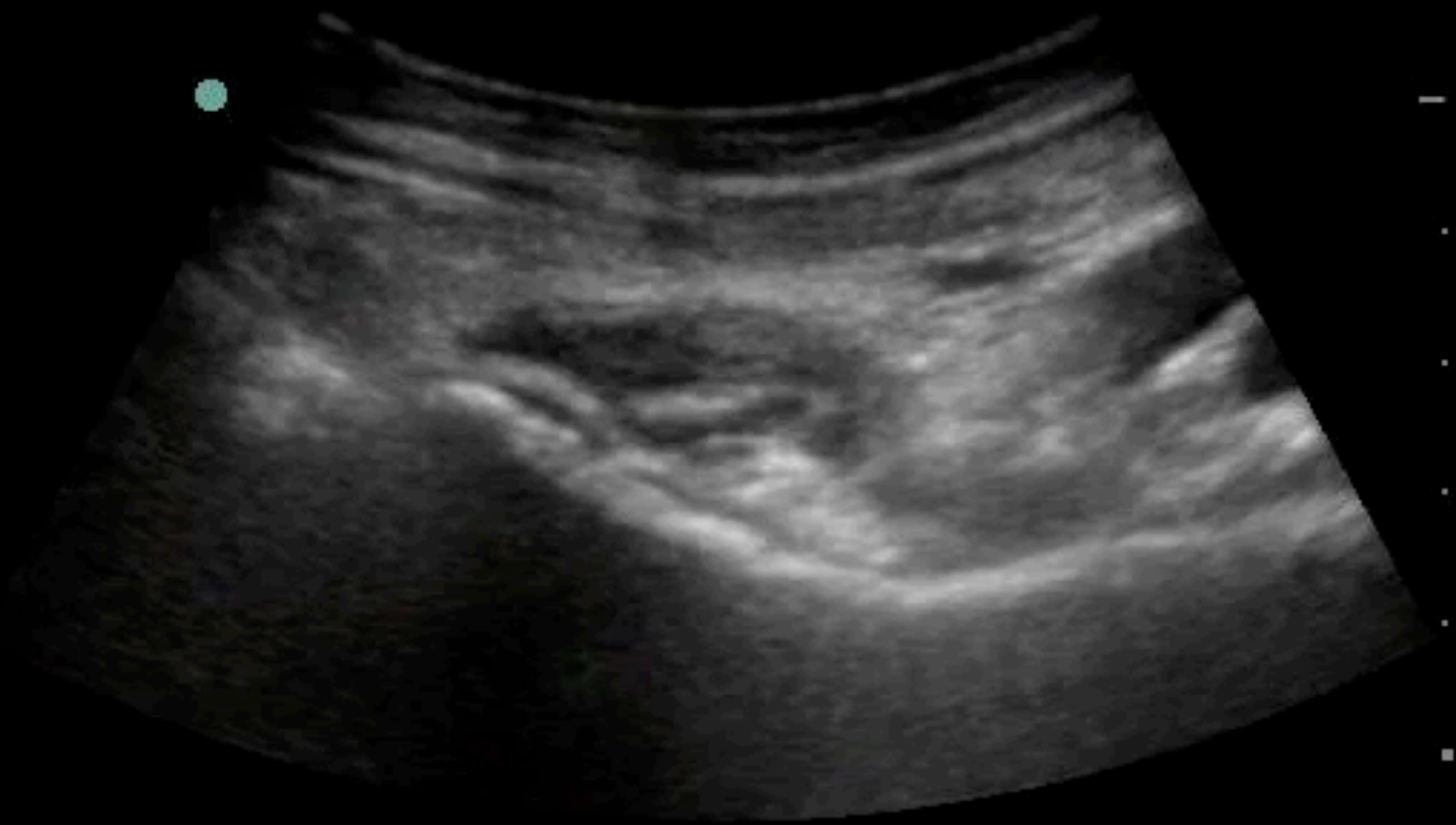
0.2

Patient

Auto Gain

Gen

Clip



PENG block



00452922

00452922

2022Apr01

15:05

GenTHI MB

Msk

C60



45%

MI

0.7

TIS

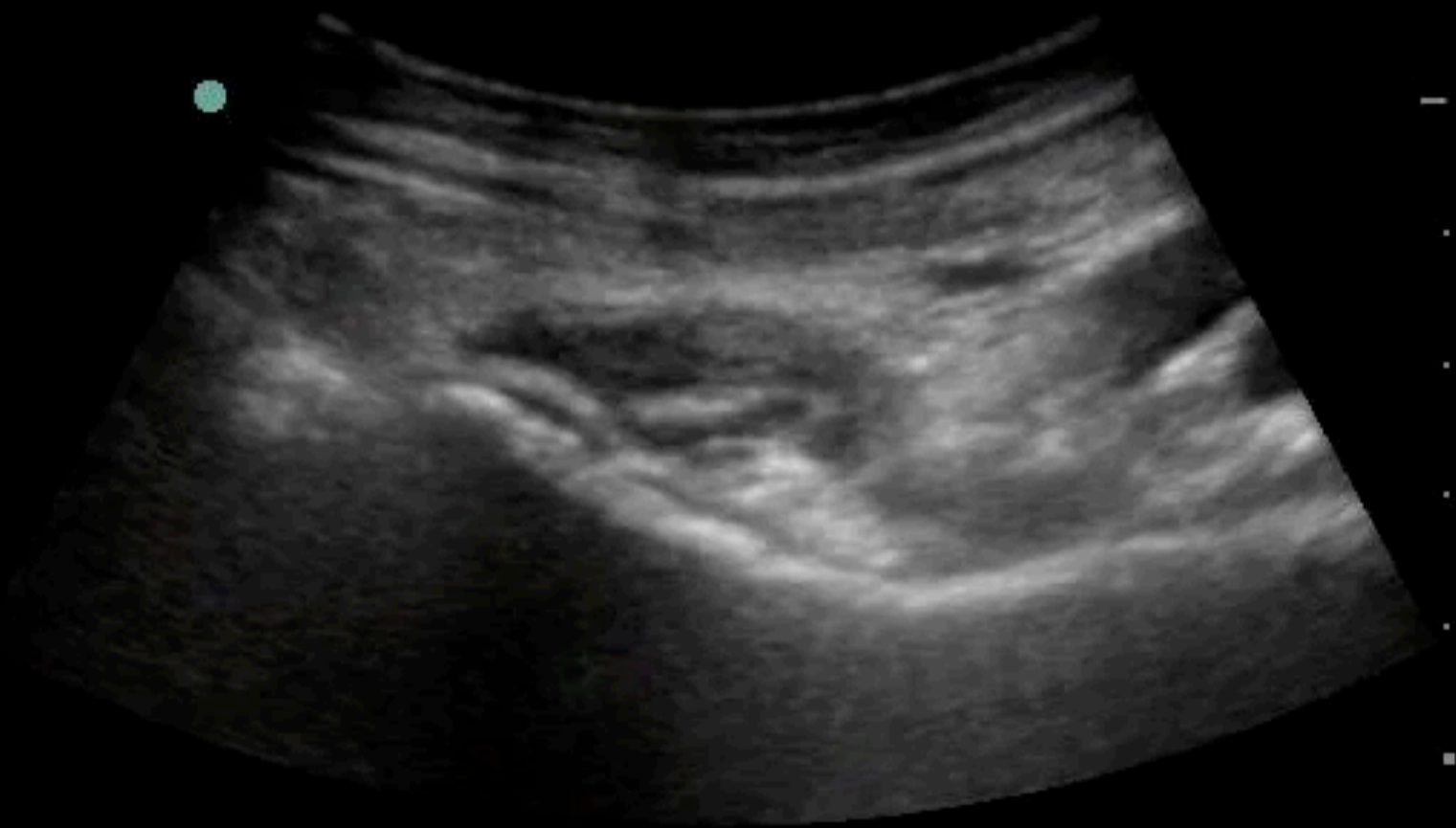0.2

Patient

Auto Gain

Gen

Clip



37F, forearm lump, heroin injection



PHILIPS li

01821417

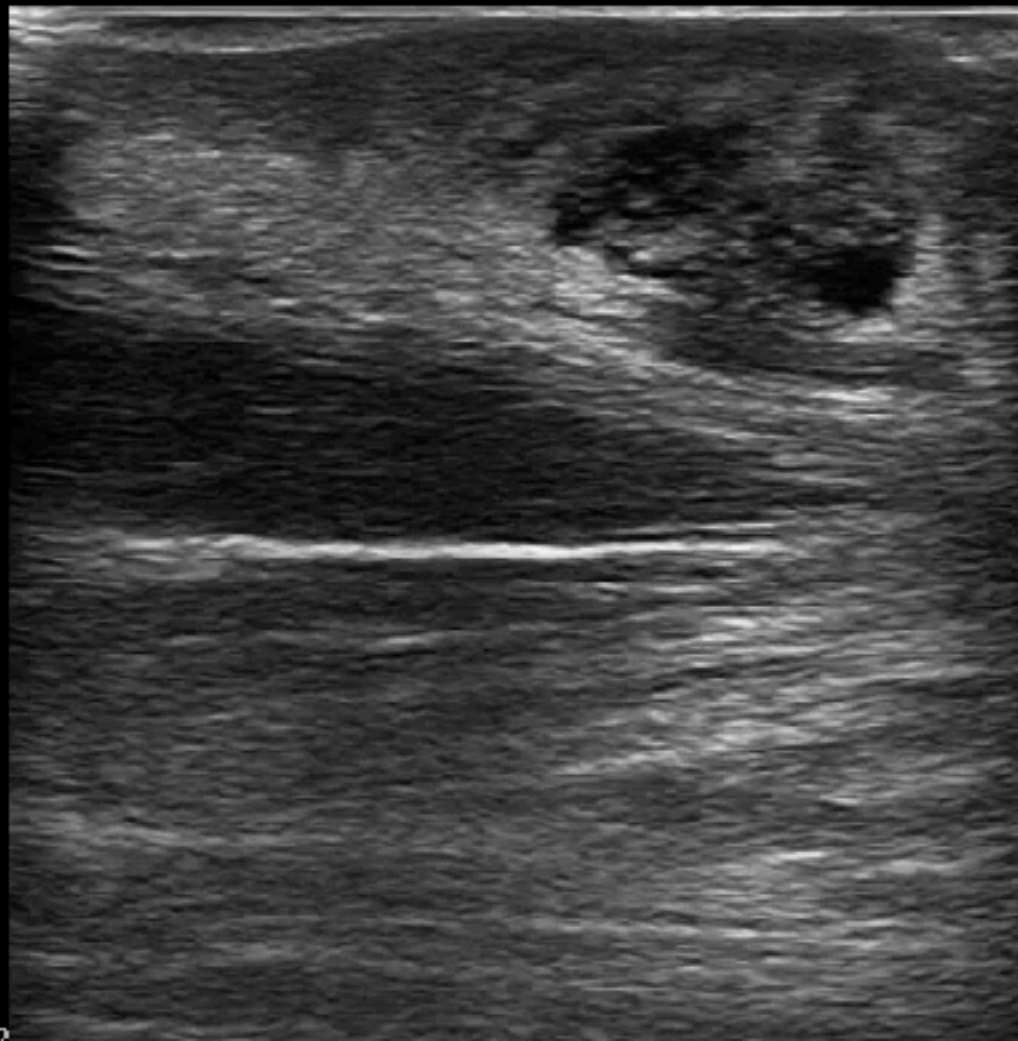
SHH

MI 0.5 3/30/2022

TIS 0.0 10:33:06 AM

Superficial
L12-4
25Hz
4.0cm

P



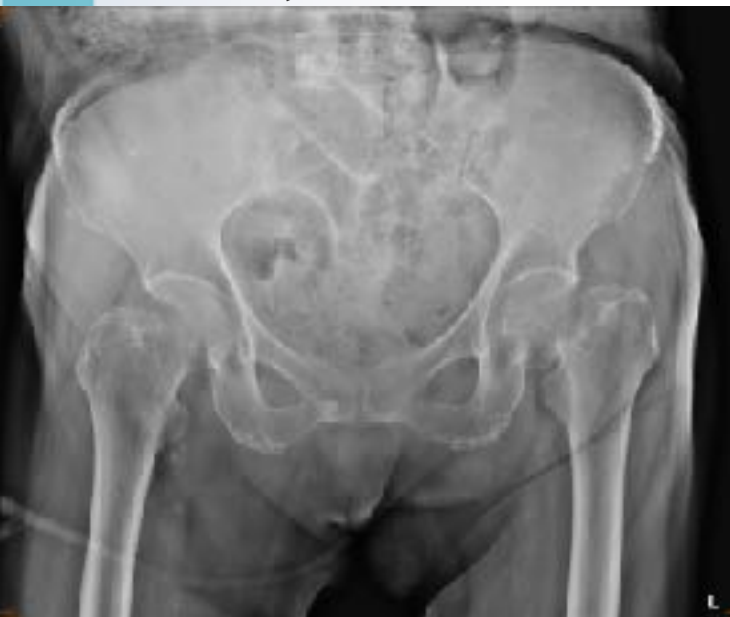2D
Res
Gn /3
60
3 / 1 / 3



P
G
P

2

89F, PENG block for FNF



07090275

2022Apr03 16:11

Msk

C60

54%

MI

0.8

TIS

0.2



Patient

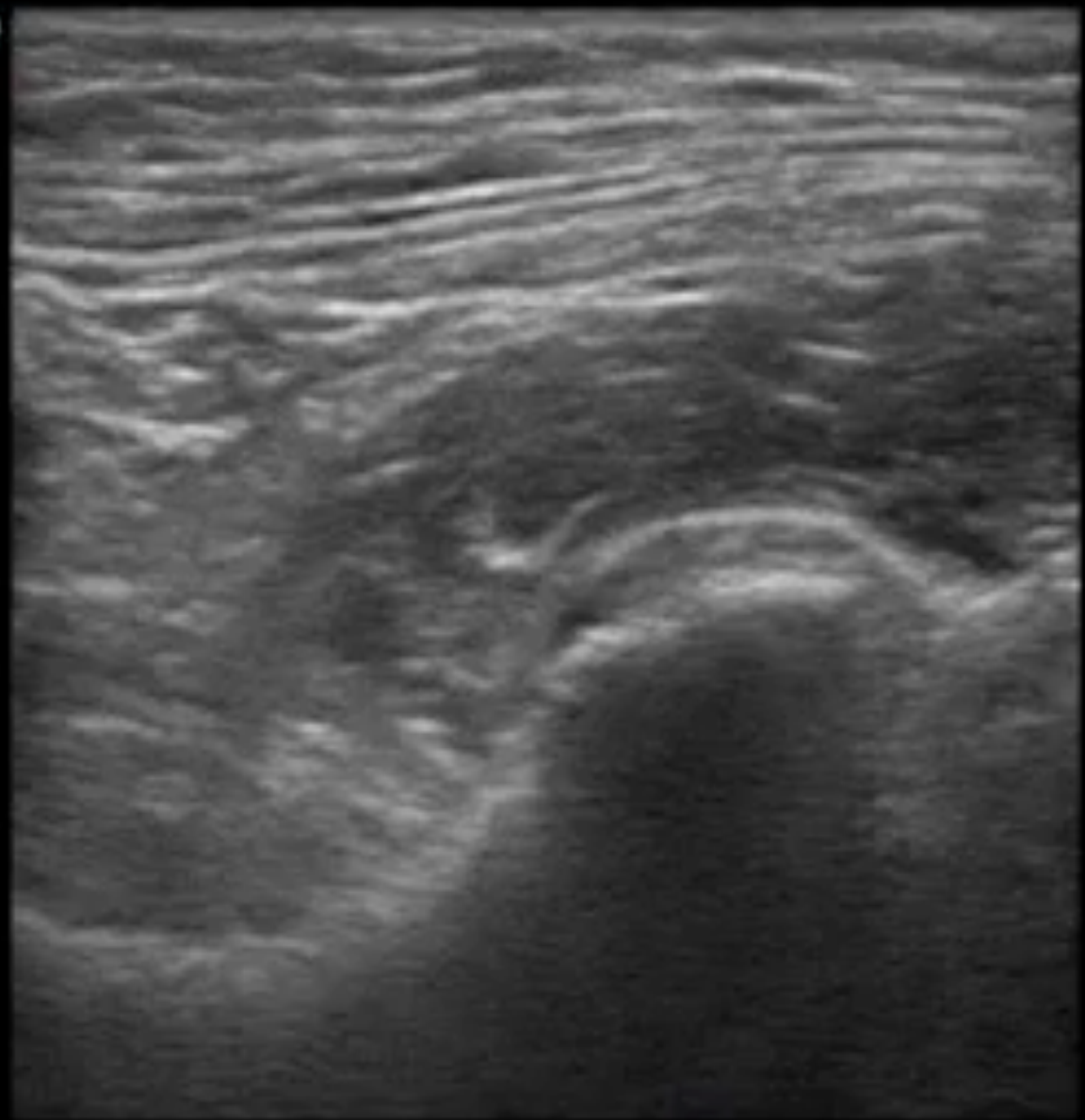


Auto Gain



Gen

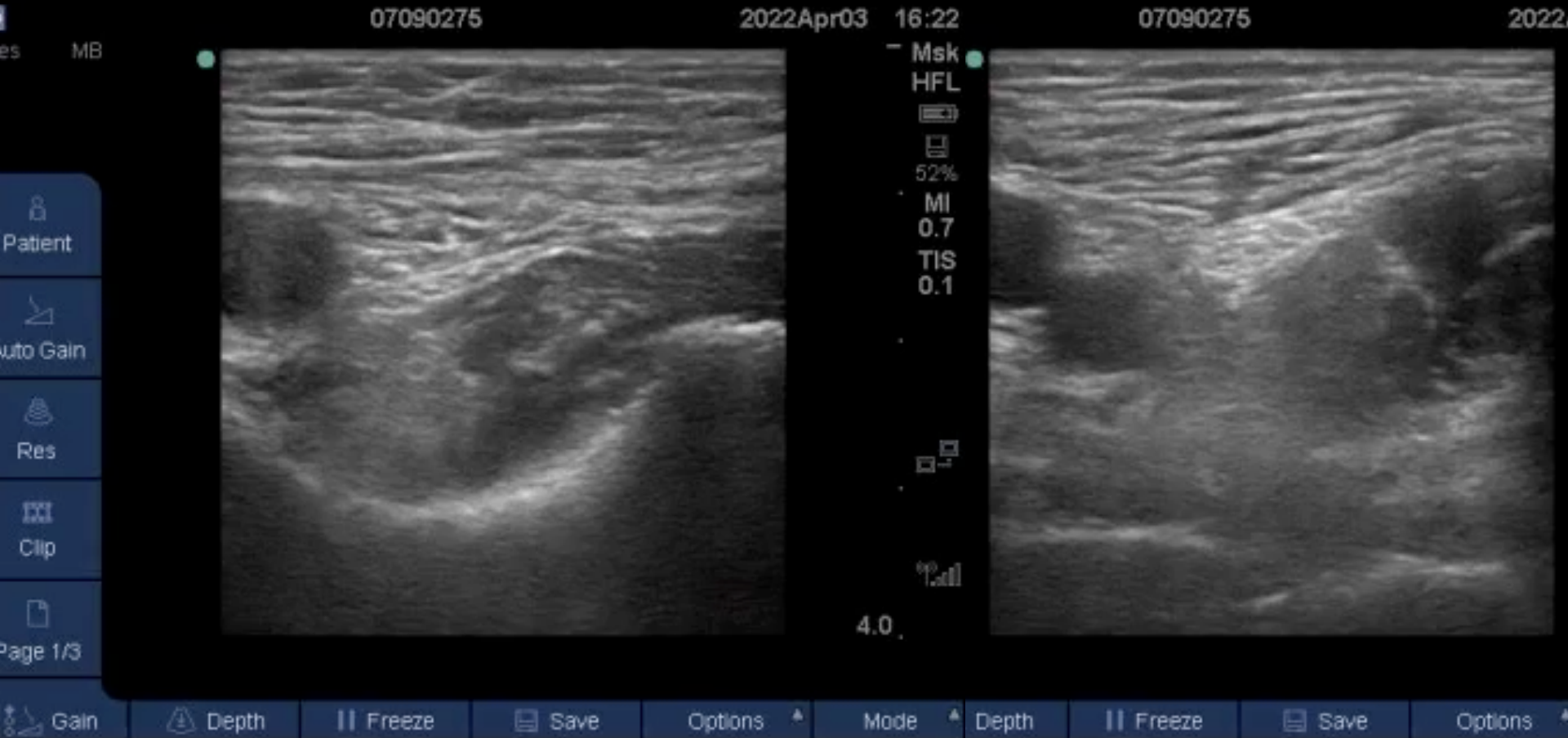- 
 Patient
- 
 Auto Gain
- 
 Res
- 
 Clip
- 
 Page 1/3



Ms
 HF
 53%
 M
 0.7
 TIS
 0.1

4.0

Post procedure / FN

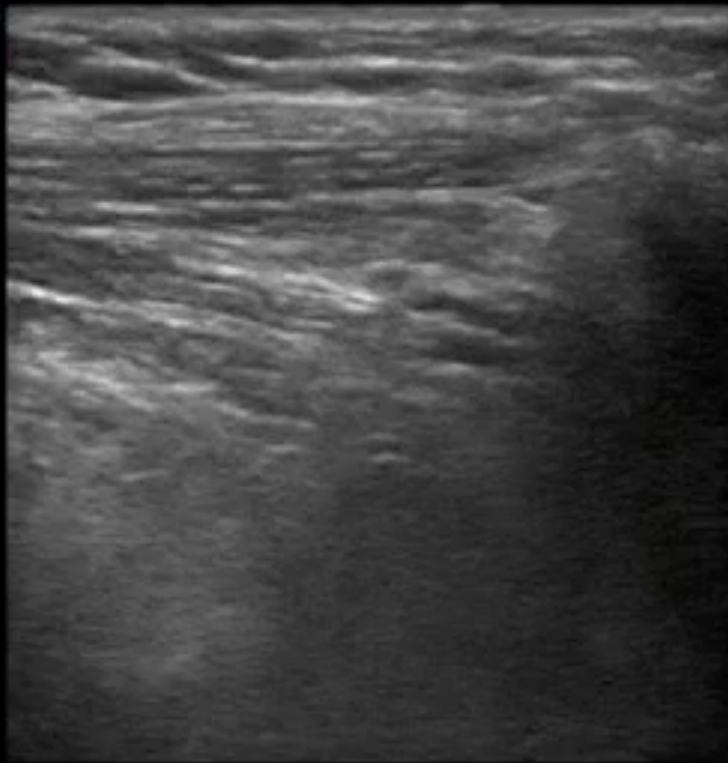


Lateral femoral cutaneous nerve (LFCN)



07090275

2022Apr03 16:24

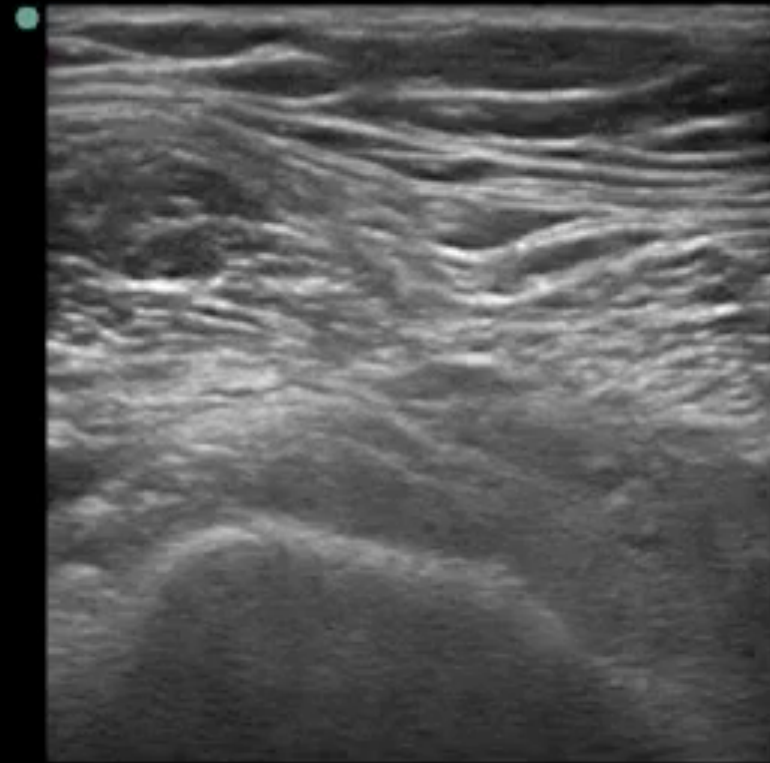



- Msk
HFL
51%
MI
0.7
TIS
0.1

4.0

07090275

2022A



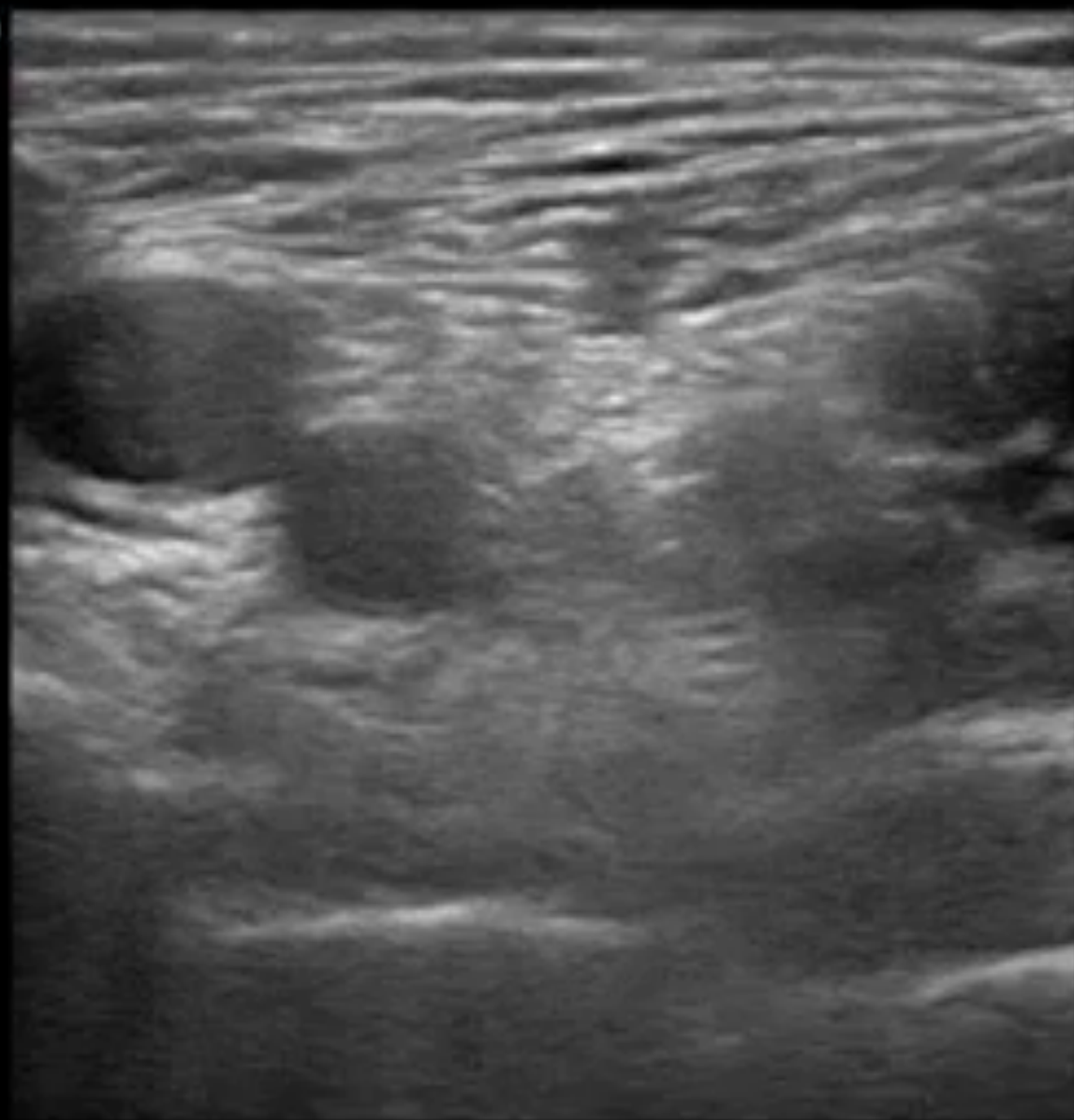
 Patient

 Auto Gain

 Res

 Clip

 Page 1/3



Ms
HF



51
M
0.7
TI
0.2





1.2


4.0


 Gain

 Depth

 Freeze

 Save

 Options

 Mode



75M, dizziness & sepsis

病歷號 **U3285895** 科別 **急診科** **3**
身分證 **R100773692** 血型 **0**
年 齡 **75歲 09個月** 體重 **83** kg
區 域 **留觀C** 檢傷 **第三級** 重大
床 號 **311** 返診 戶外

套餐 會診 病歷首頁 常用項 Ditto 現病史

Vital signs data:

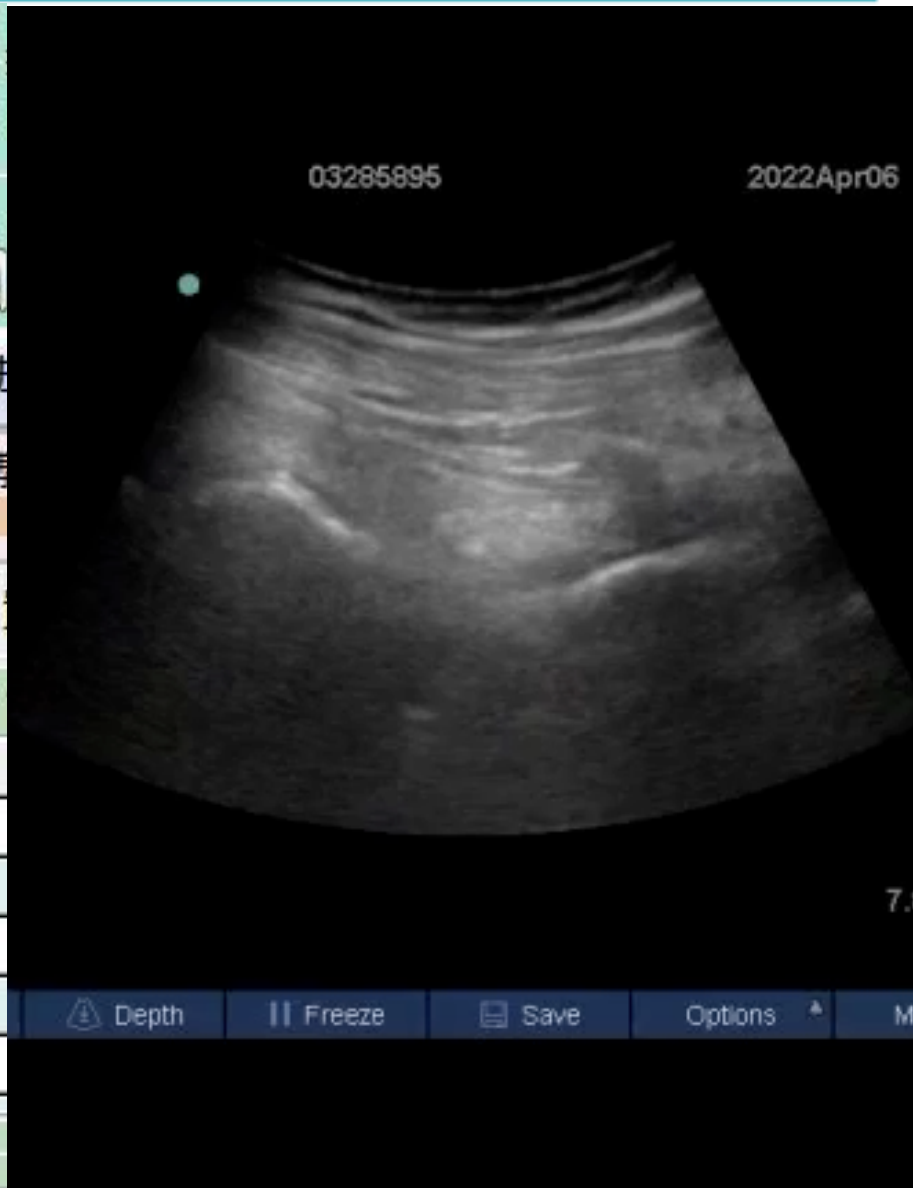E	V	M	體溫	脈搏
4	5	6	36.7	85

全部 | 診斷&病程 | 藥品 | 檢驗 | 放射 | 處

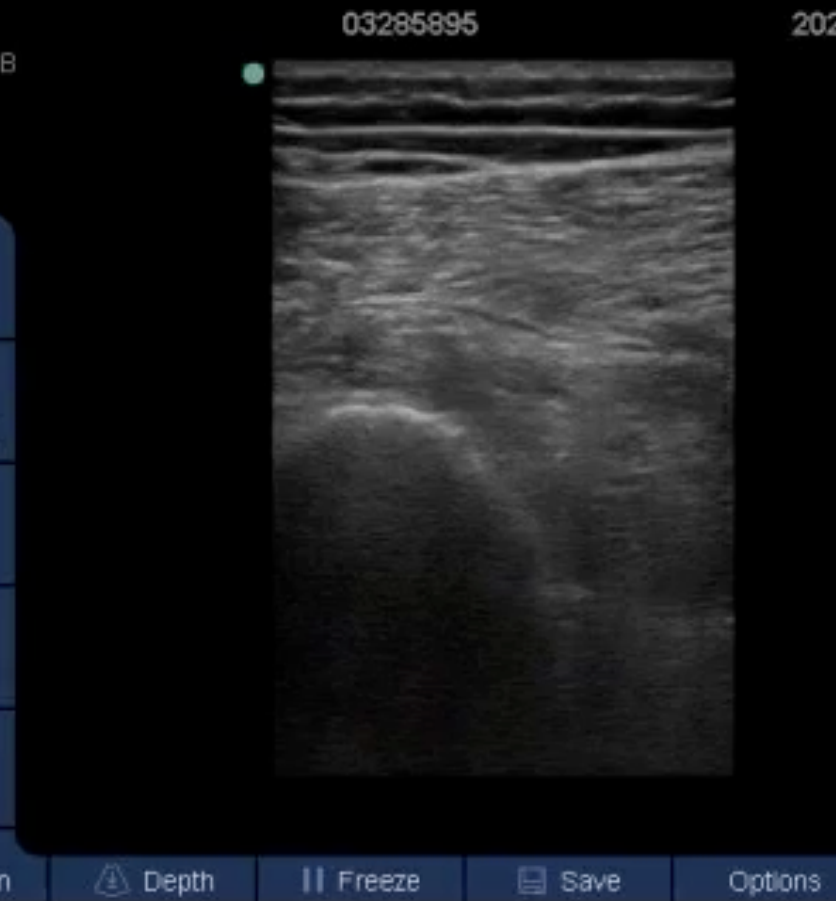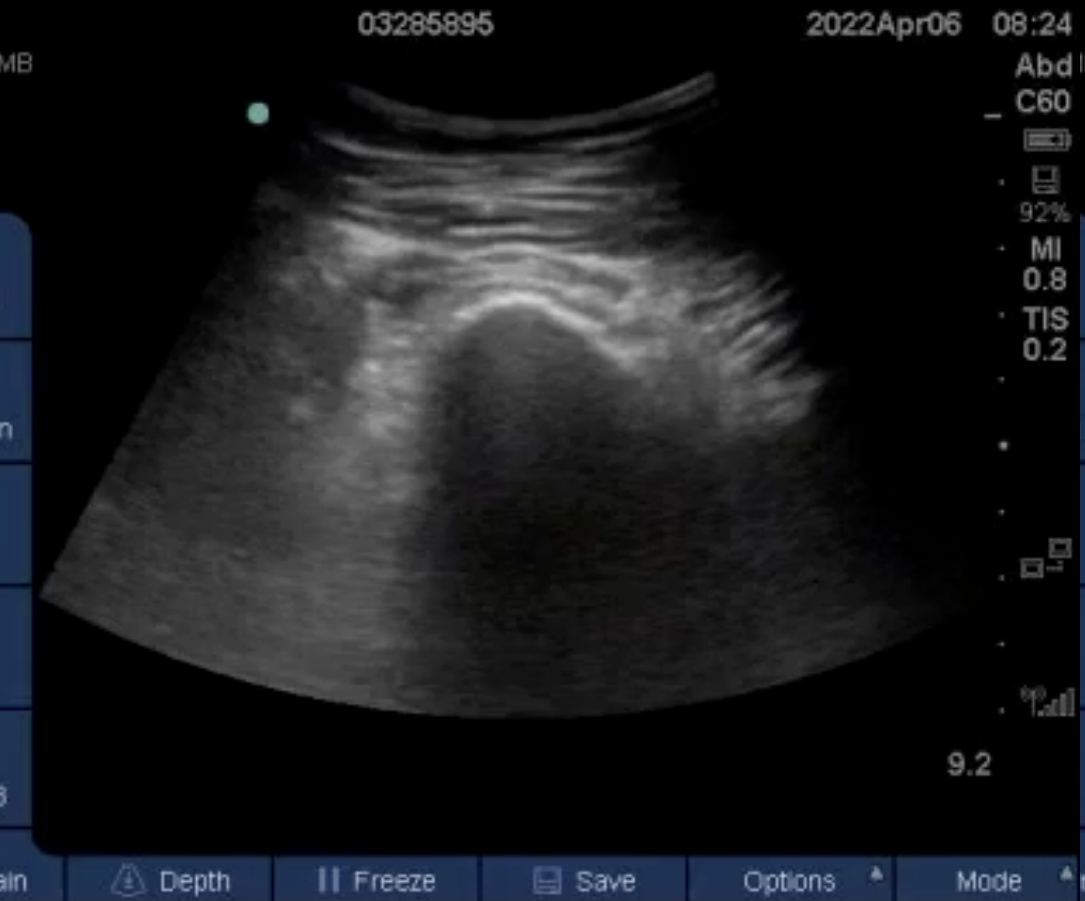檢傷

到院時間: 20220405 201307
檢傷級數: 3
意識狀態: E4_V5_M6
體重: 83Kg 體溫: 35.9°C
脈搏: 101 呼吸次數: 18
血壓: 149/78
SPO2: 100
過敏史: 無
過去病史: 高血壓; 心臟病
主述: 病患來診為眩暈/頭暈。

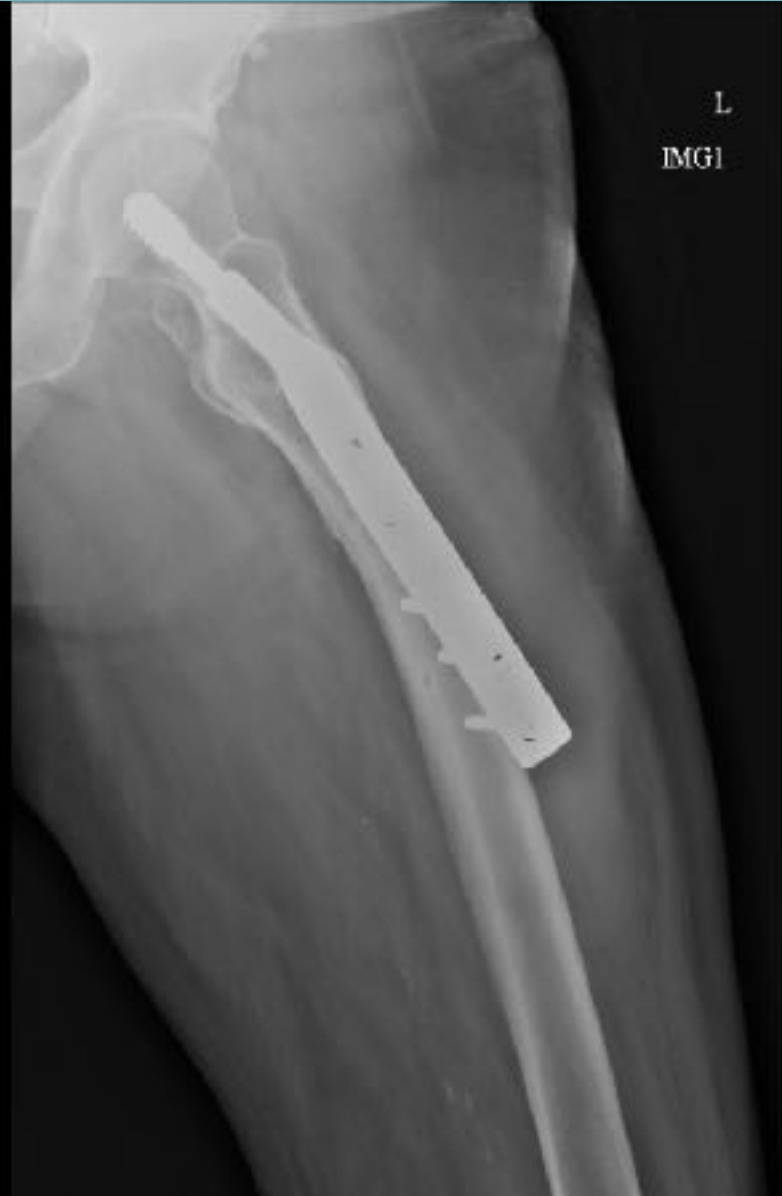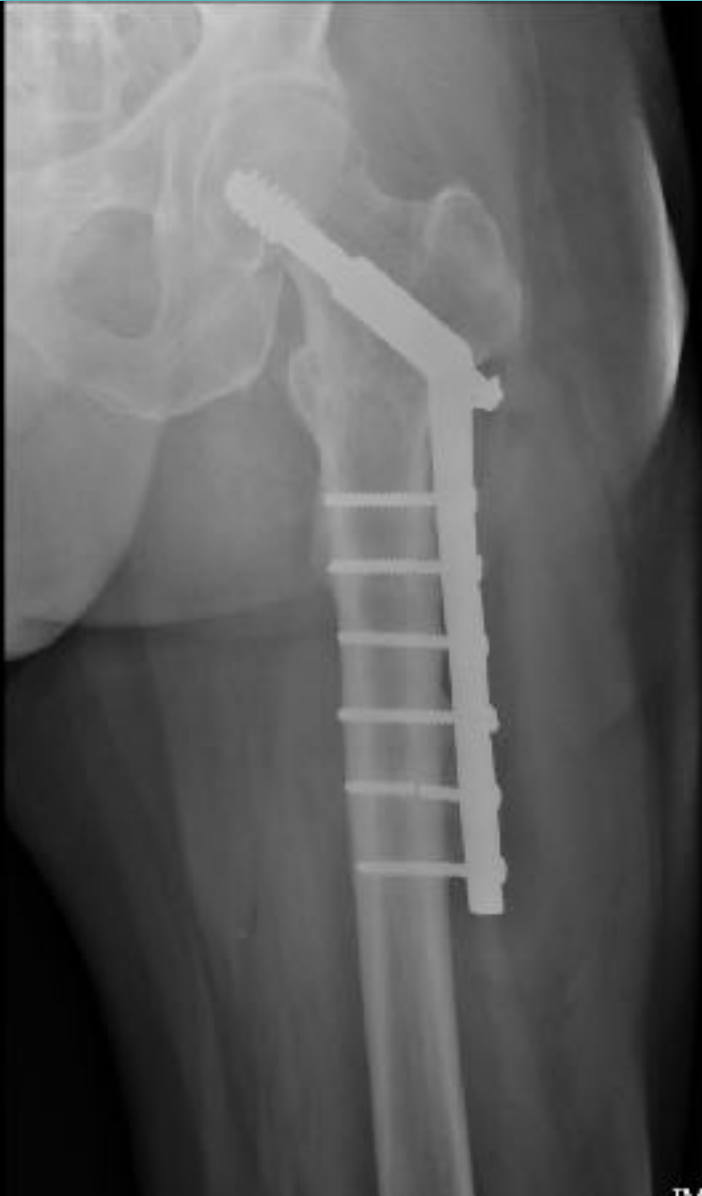檢驗
類別
檢查
檢查
檢查
檢驗
檢驗
藥品



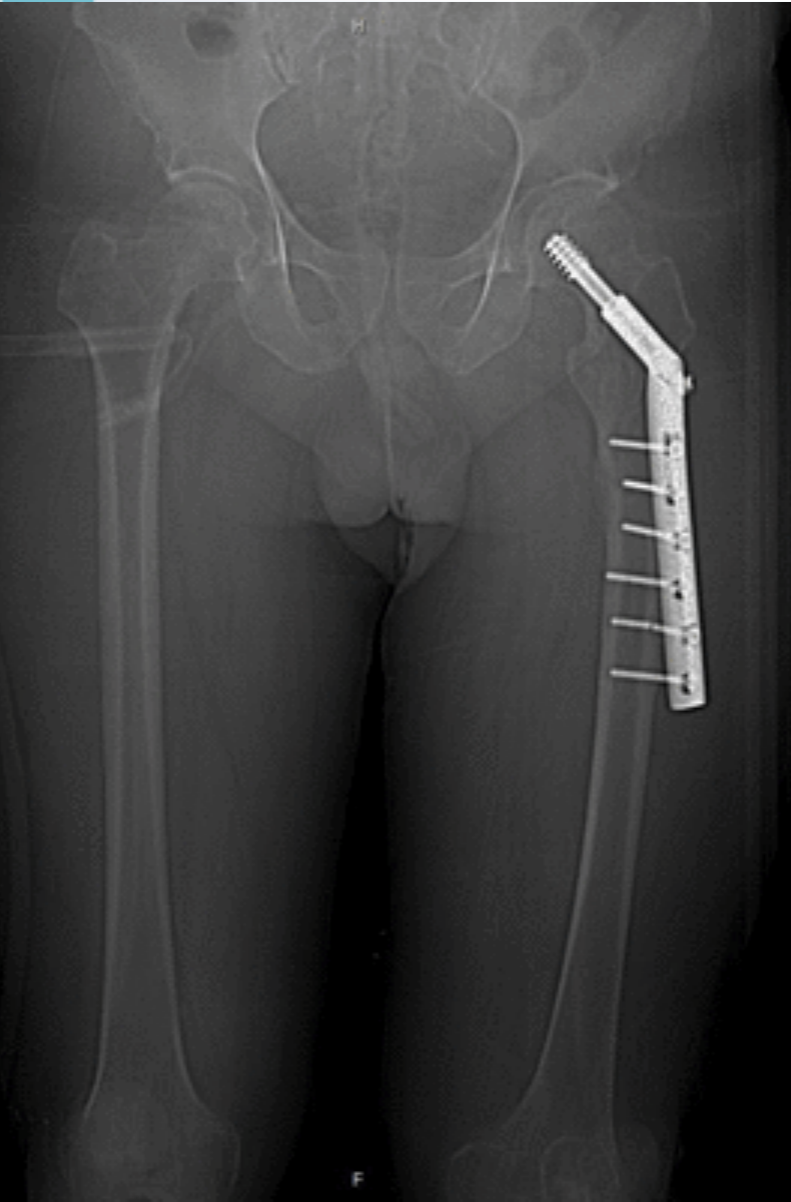
Thigh abscess



Thigh abscess



Thigh abscess

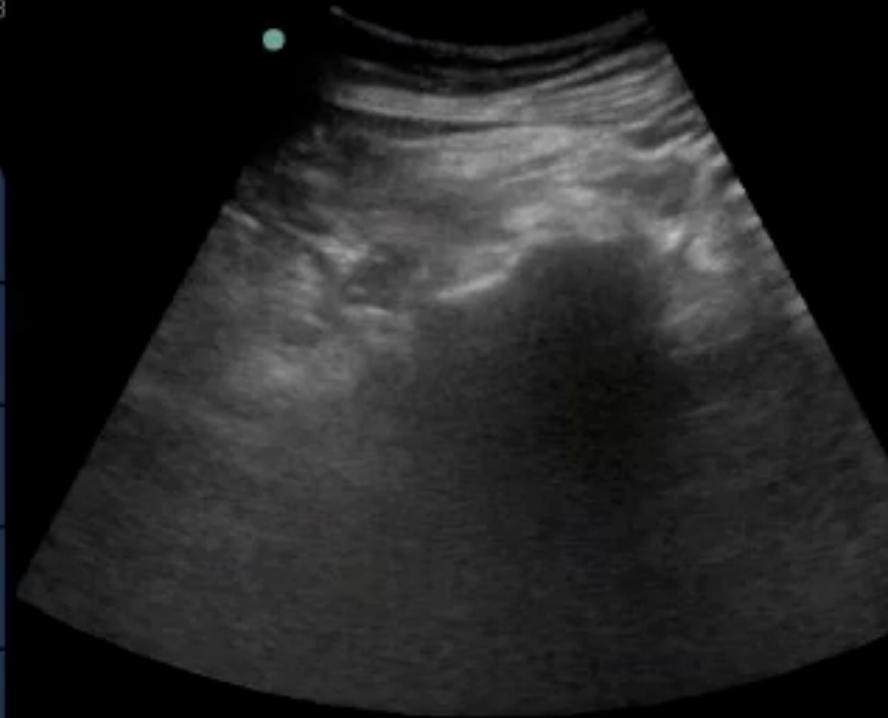

GenTHI MB

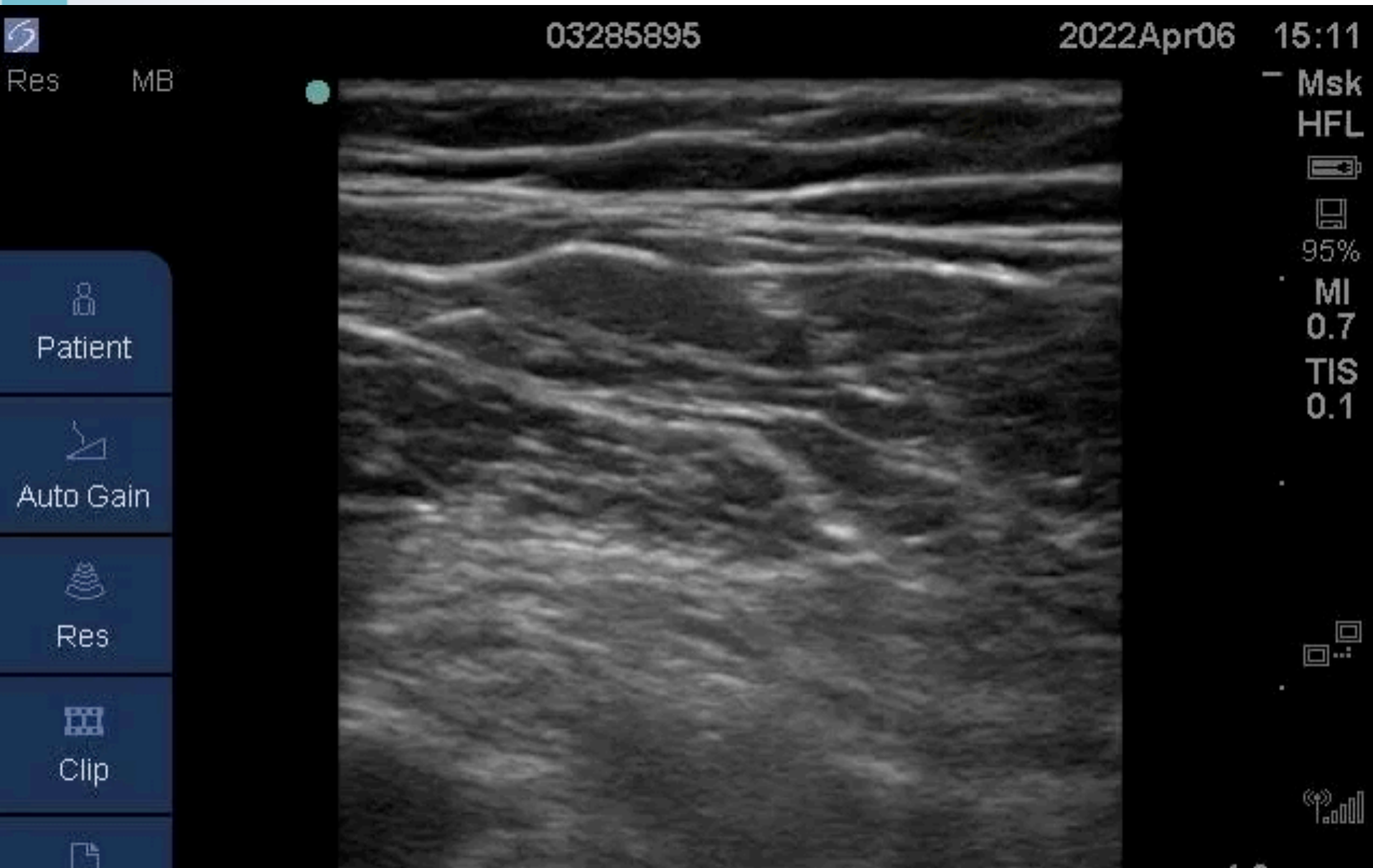
03285895

2022Apr

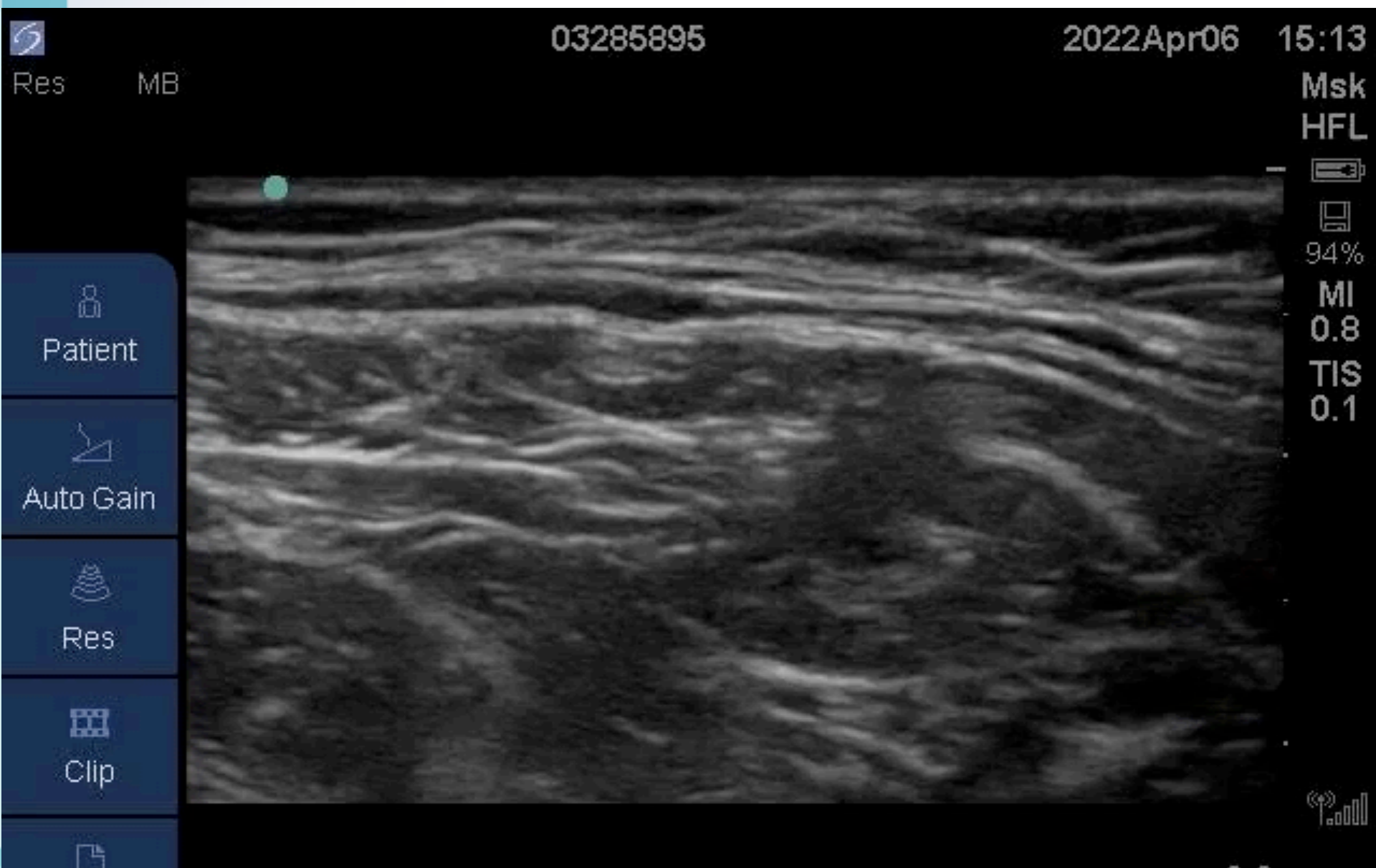
- Patient
- Auto Gain
- Gen
- Clip
- Page 1/3
- Gain
- Depth
- Freeze
- Save
- Options



Lateral femoral cutaneous nerve



LFCN block



03285895

2022Apr06

15:13

Res MB

Msk

HFL



94%

MI

0.8

TIS

0.1



Patient



Auto Gain



Res



Clip

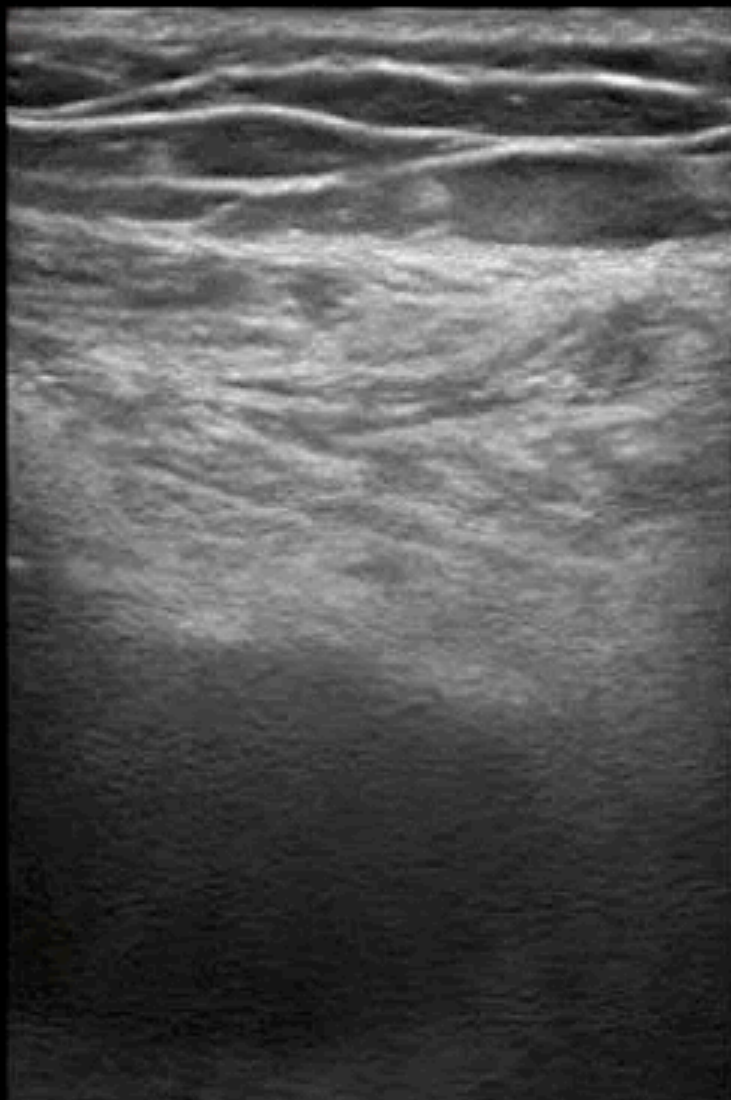
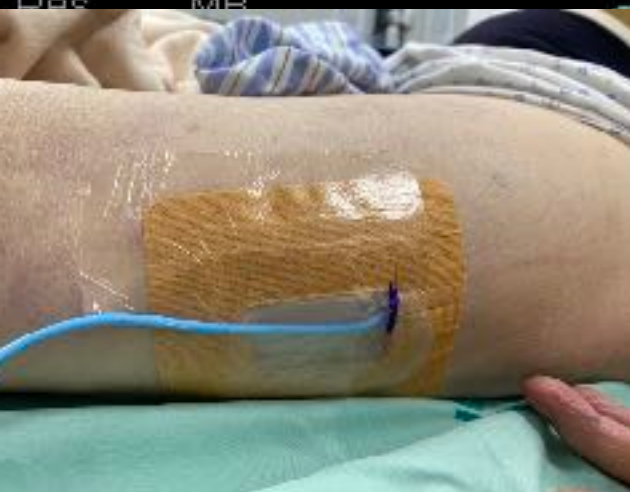

Thigh abscess



03285895

2022Apr06 15:21



Msk
HFL
93%
MI
0.6
TIS
0.1

Auto Gain



89M, Dyspnea

GenTHI MB

03756810

劉海輝 (03756810)
床號: 10
病室: 內科
職工: 醫師
性別: 男
年齡: 89
日期: 2014
時間: 10:00
設備: 10
檢查部位: 肺部
TIS: 0.1
MI: 1.0
97%

Patient

Auto Gain

Gen

Clip

ABD
- C60
97%
MI
1.0
TIS
0.1



89M, Dyspnea

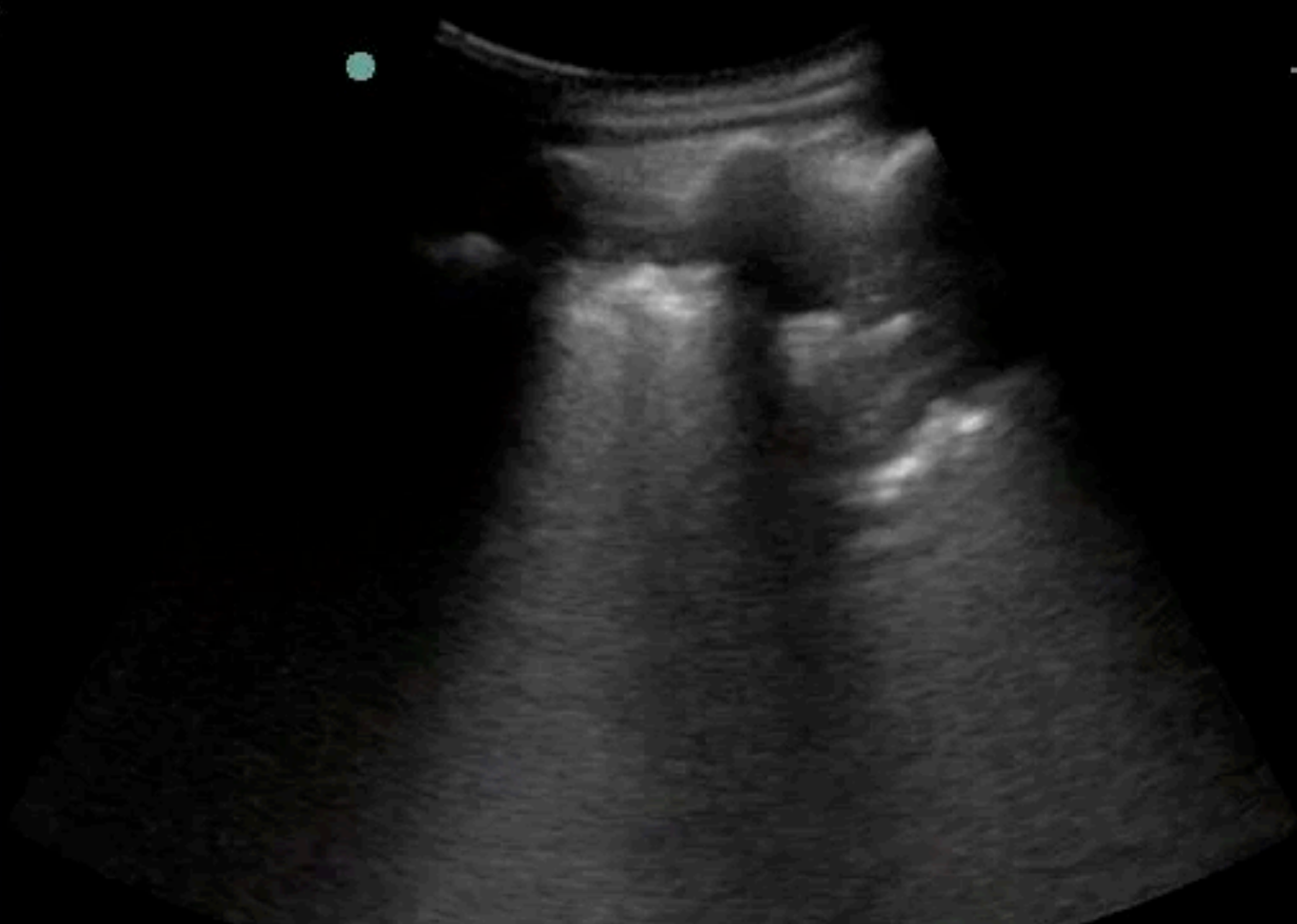
劉海濱醫師 (Liu Hai Bin)
醫師編號: 1111111111
醫院: 財團法人 聖保羅醫院
科別: 心臟內科
日期: 2022/04/05
時間: 09:46
設備: GE
患者姓名: 89M

GenTHI MB

03756810

2022Apr05 09:46

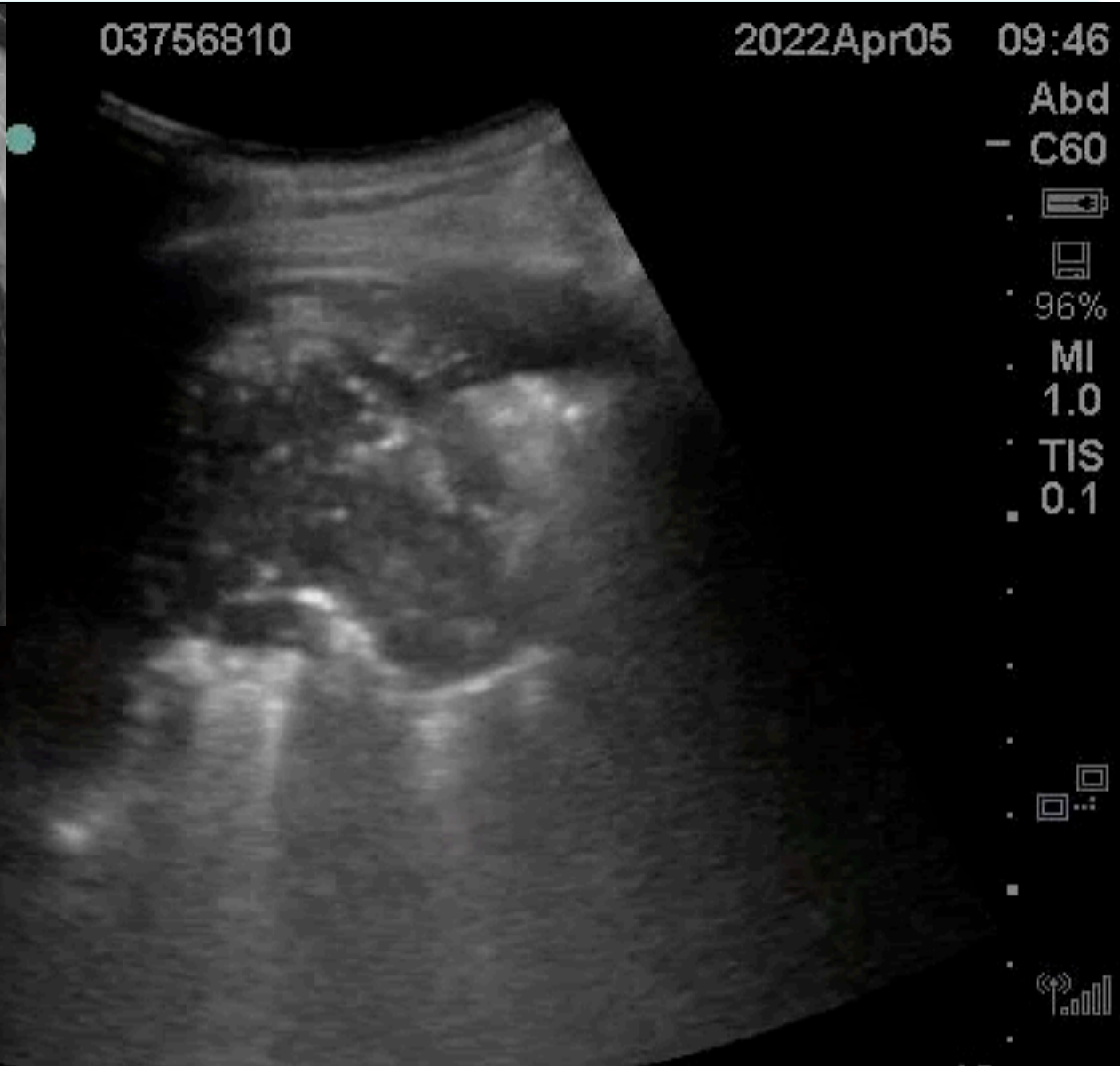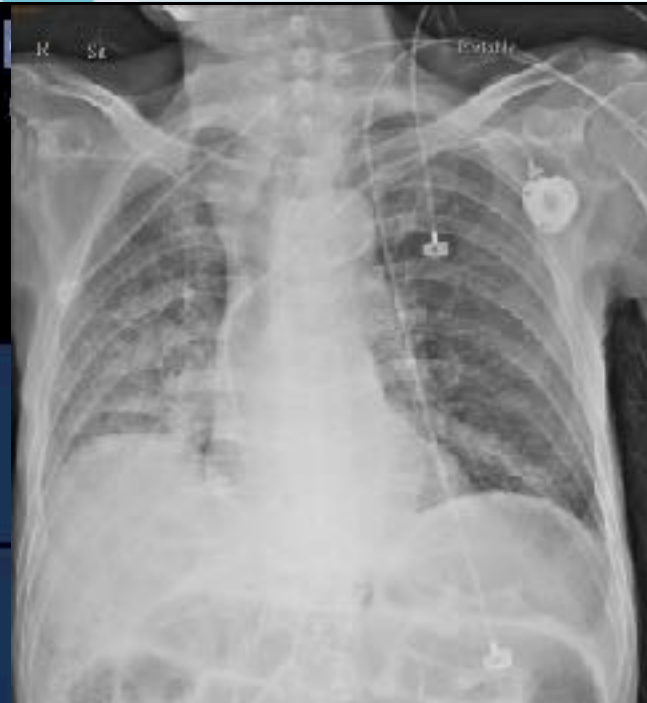Abd
- C60
97%
MI
1.0
TIS
0.1



- Person icon: Patient
- Graph icon: Auto Gain
- Waveform icon: Gen
- Clipboard icon: Clip
- Document icon: [Unlabeled]



Dynamic air-bronchogram



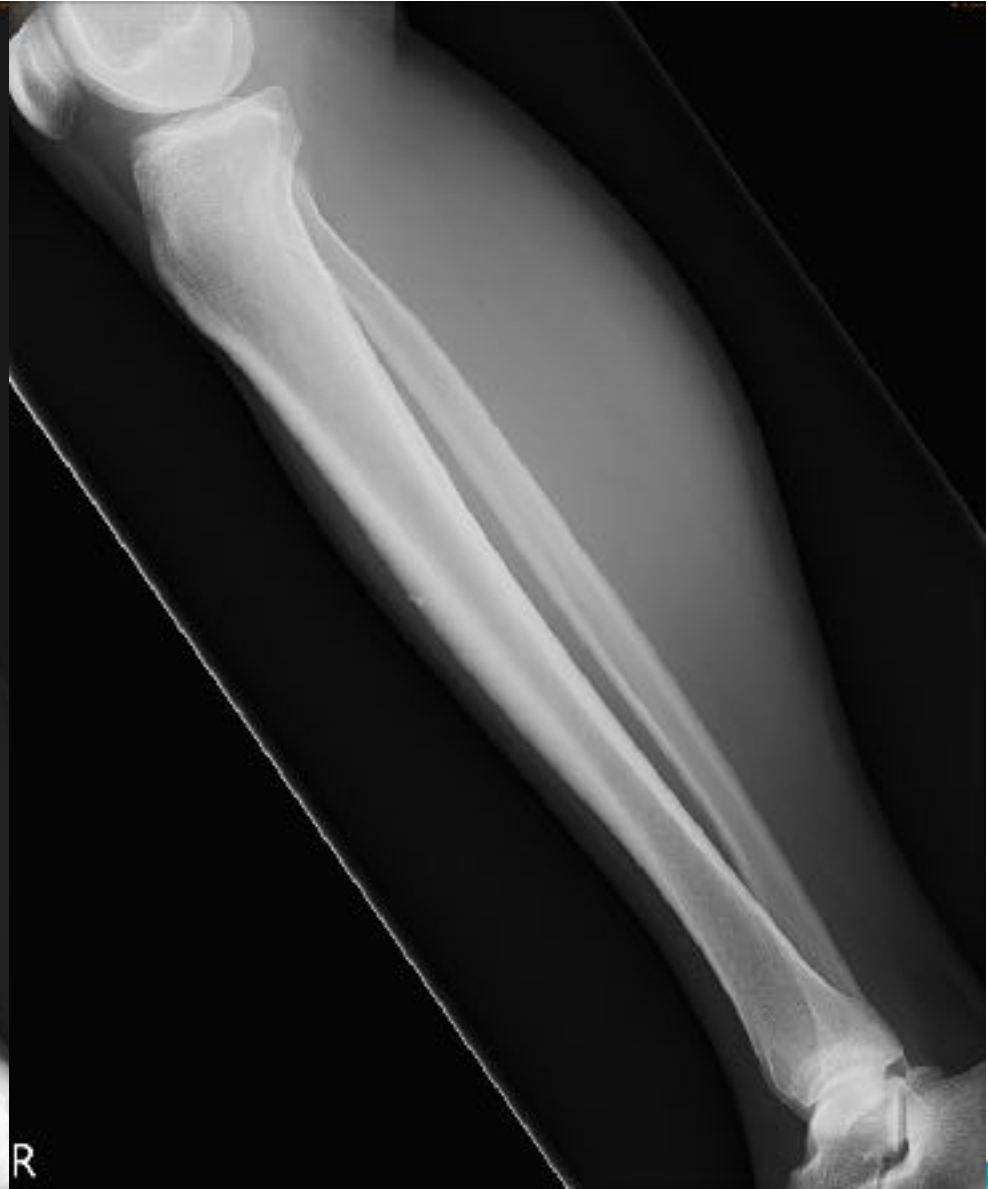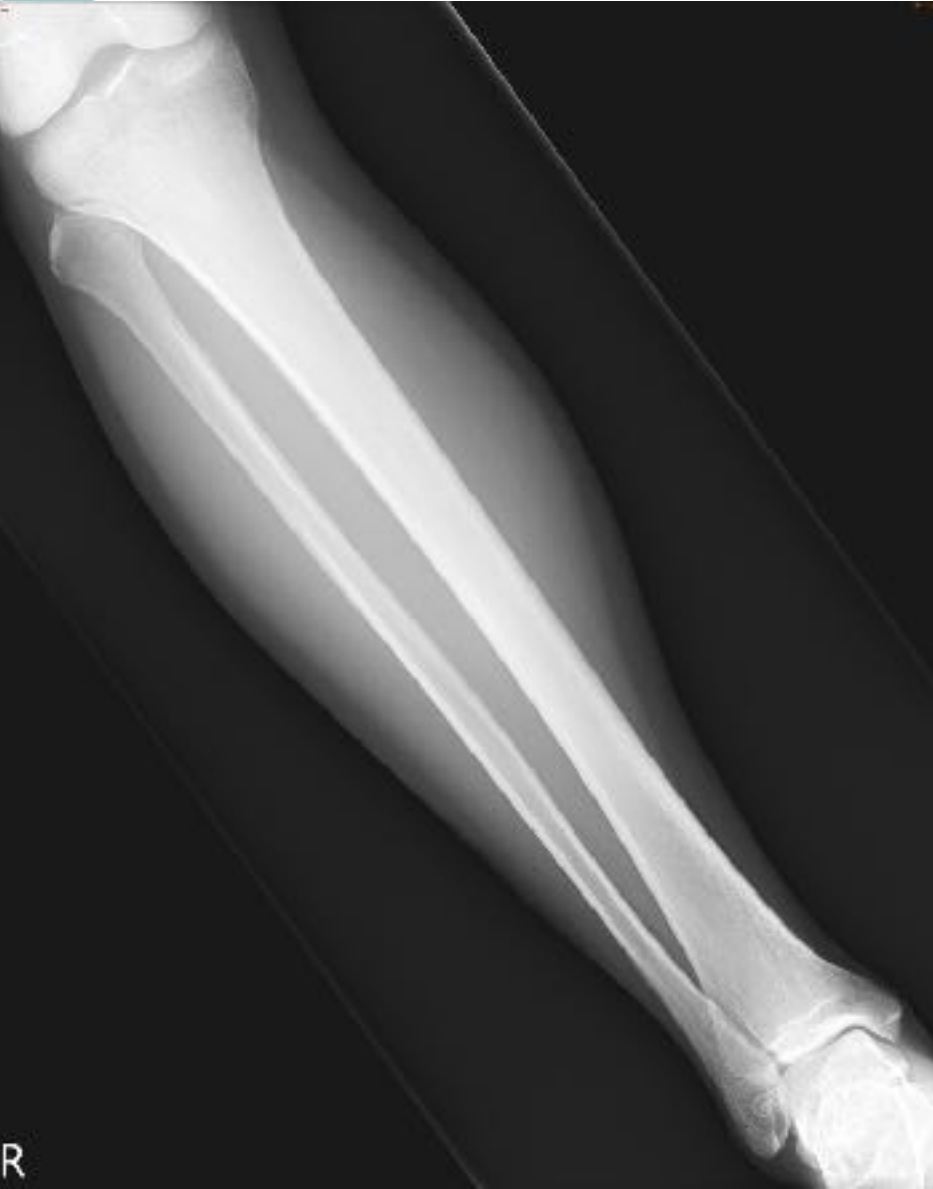Gen



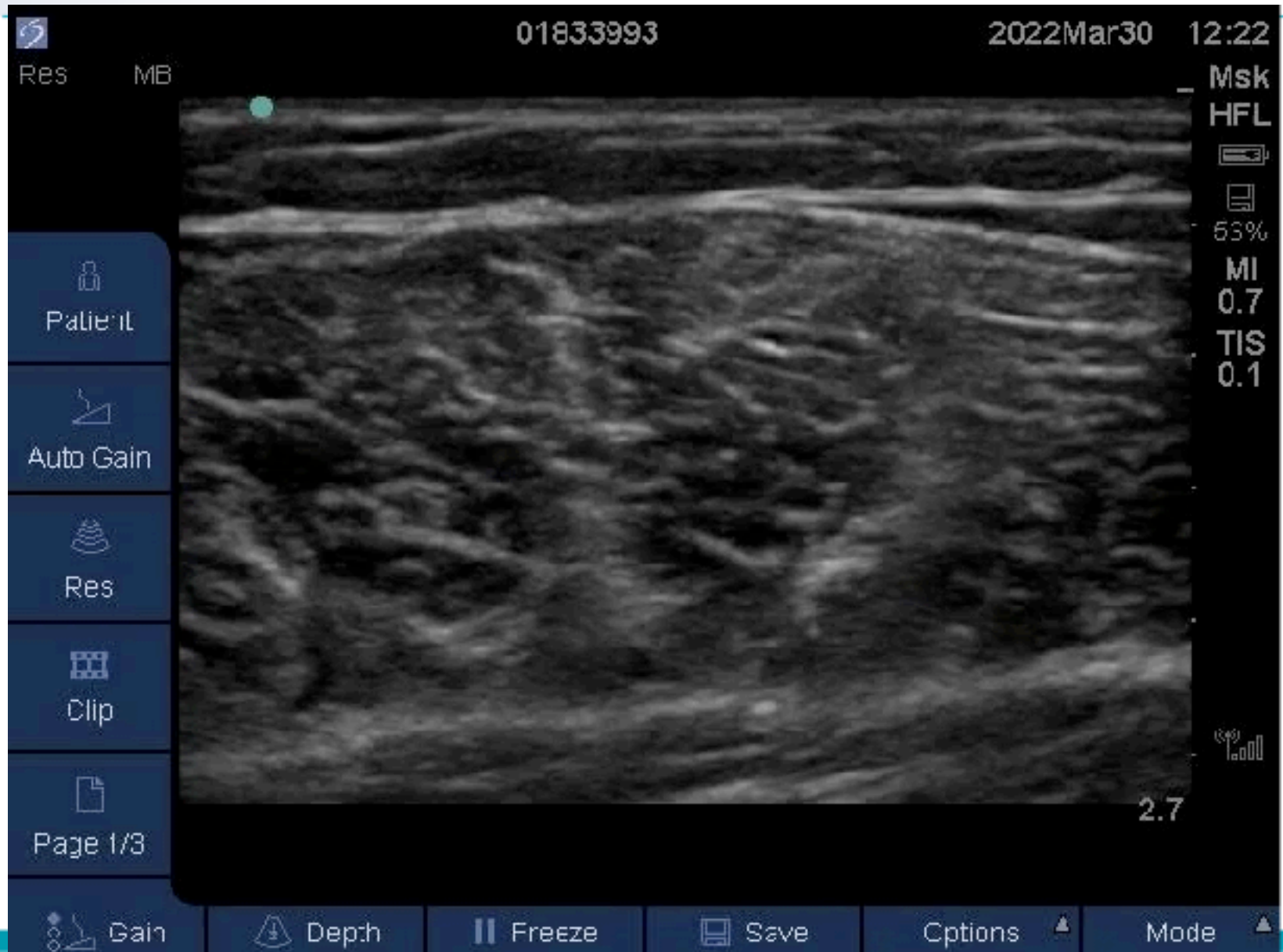
Clip



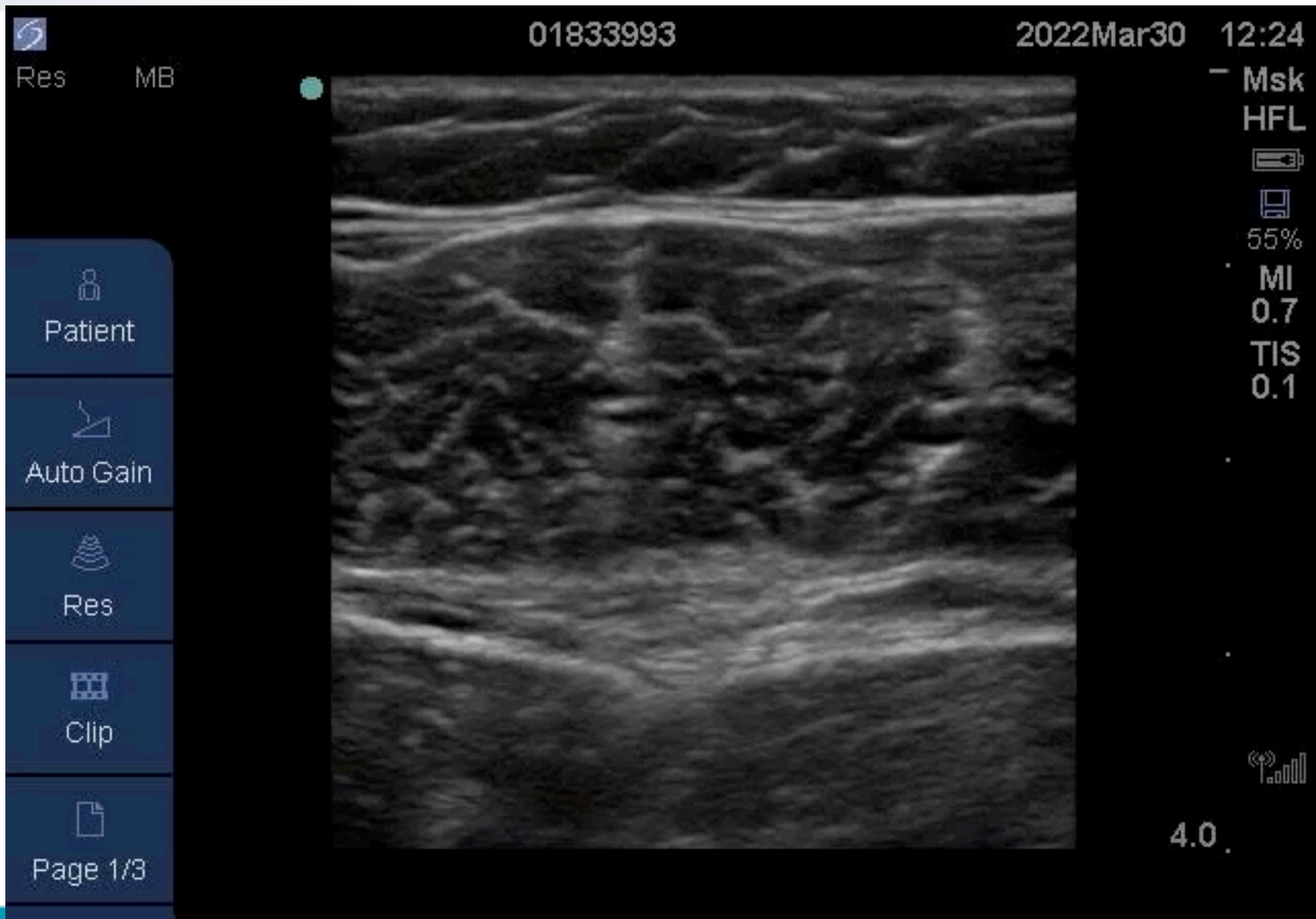41M, calf pain after during badminton



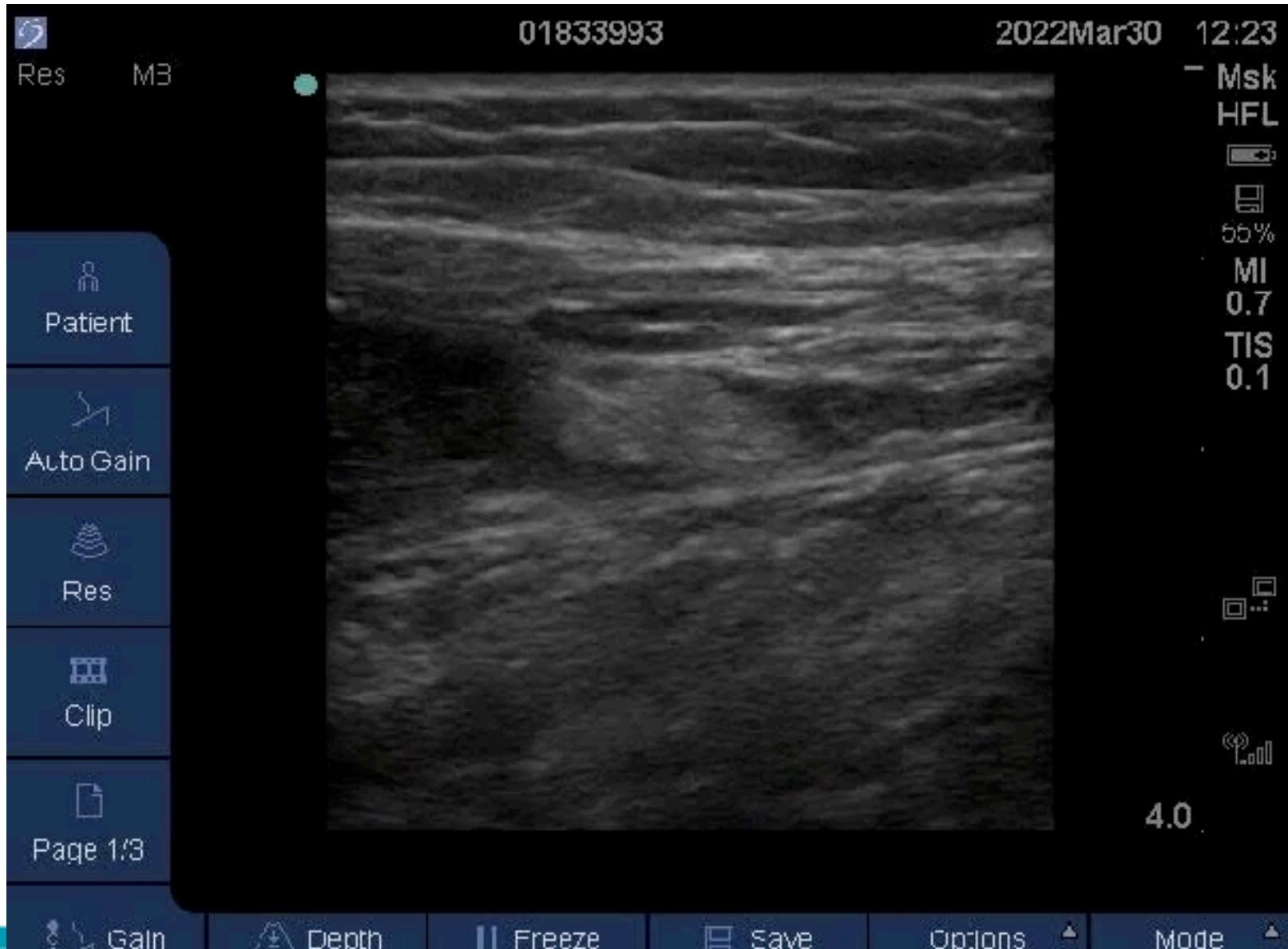41M, calf pain after during badminton



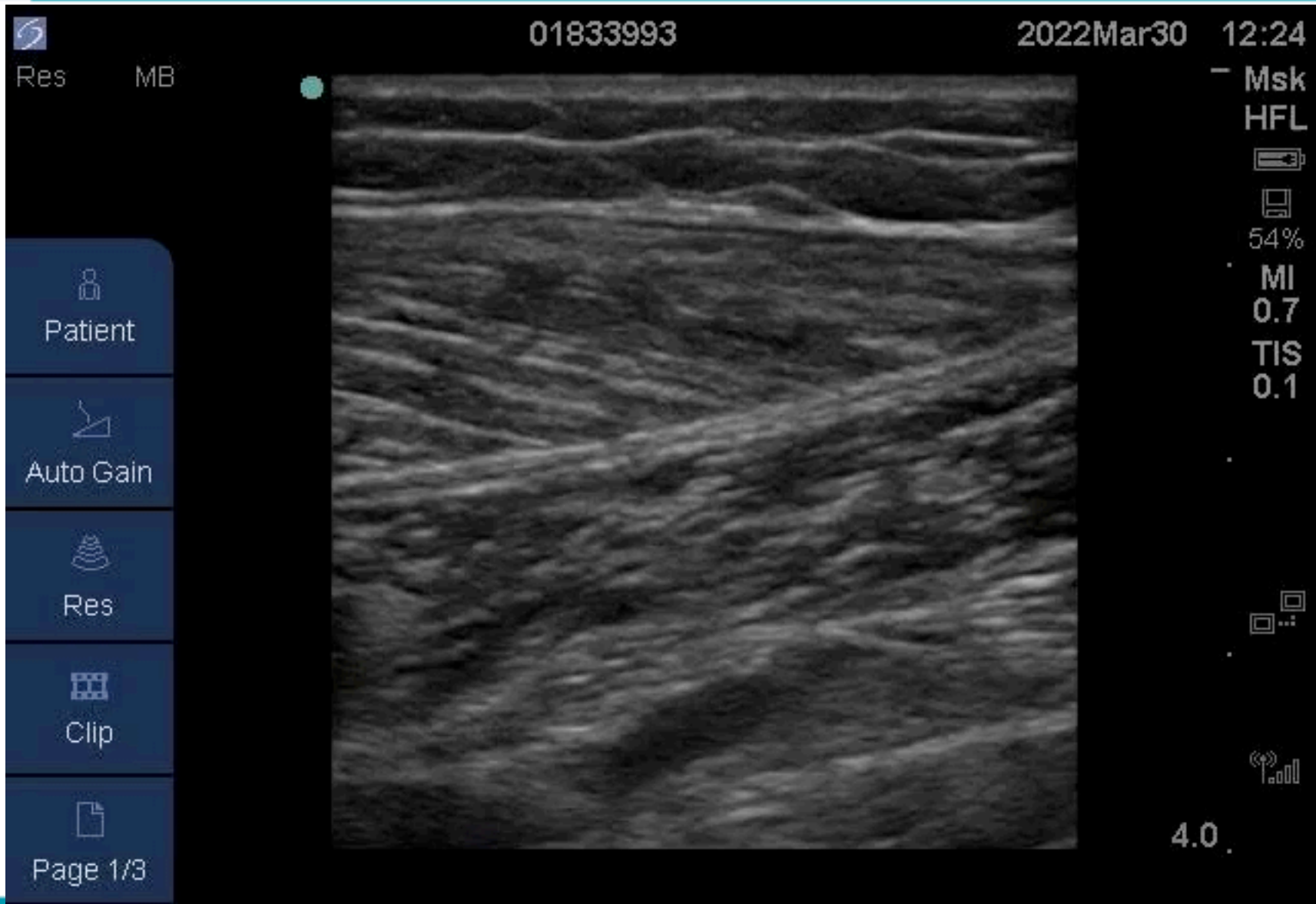
41M, calf pain after during badminton



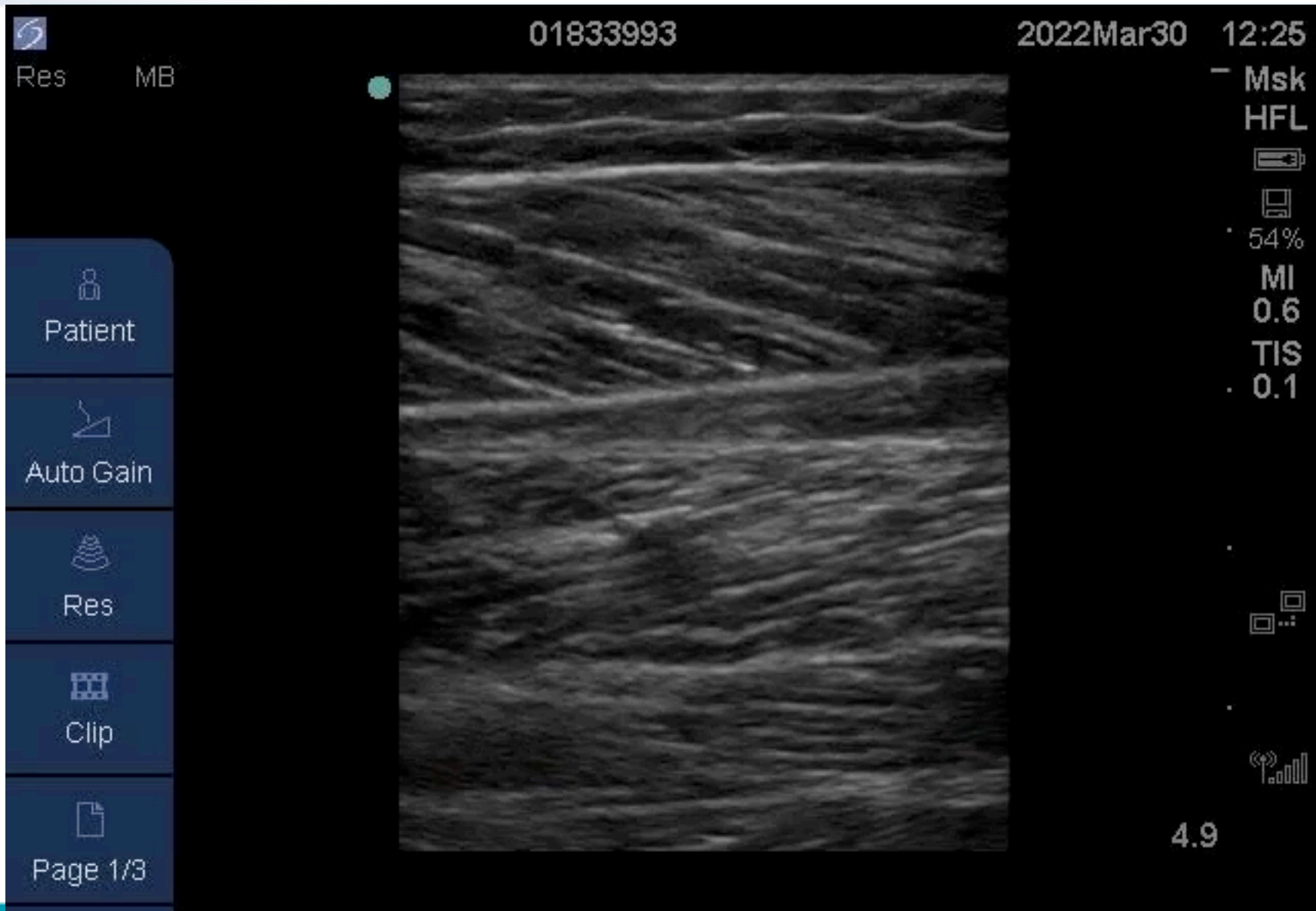
41M, calf pain after during badminton



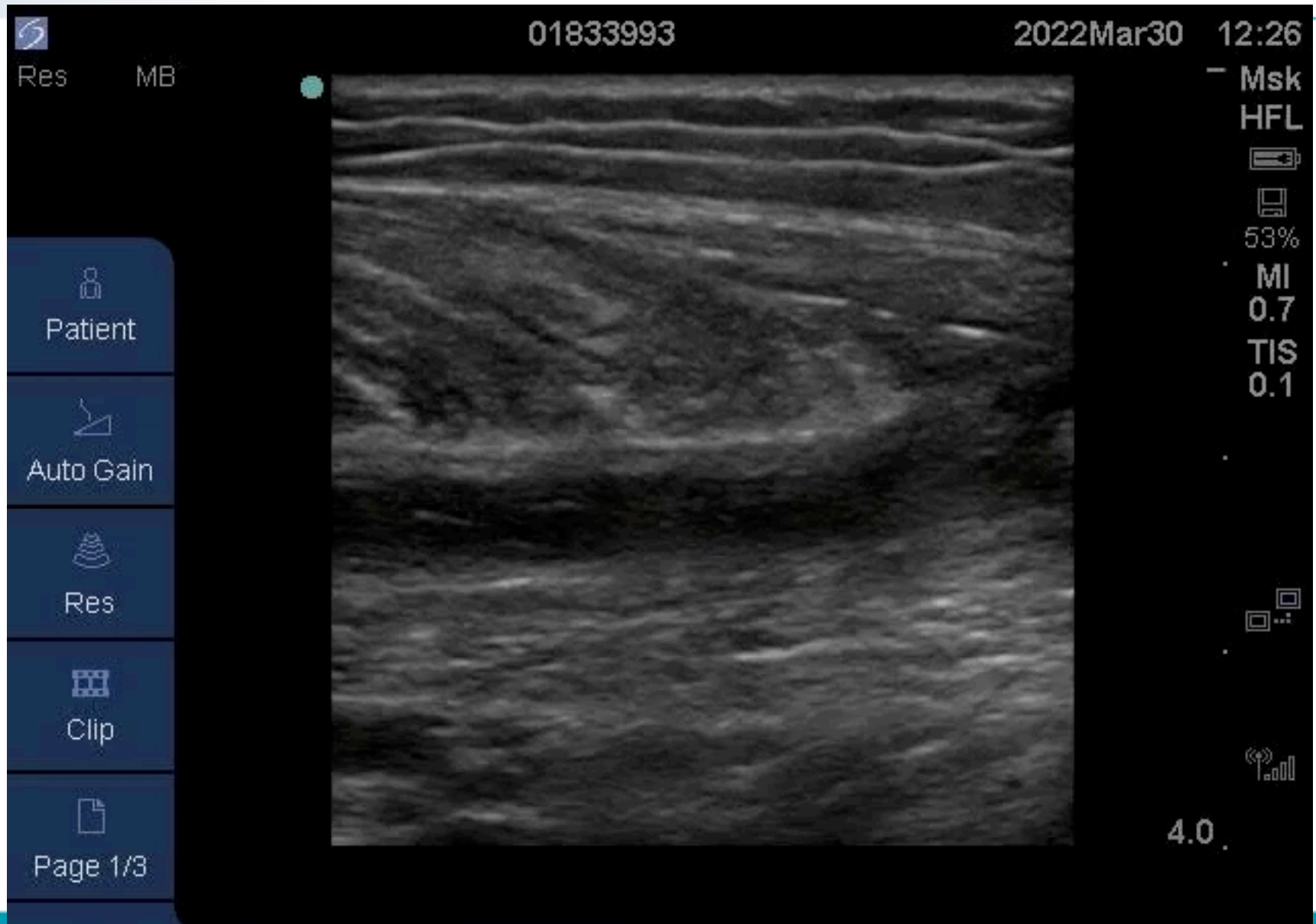41M, calf pain after during badminton



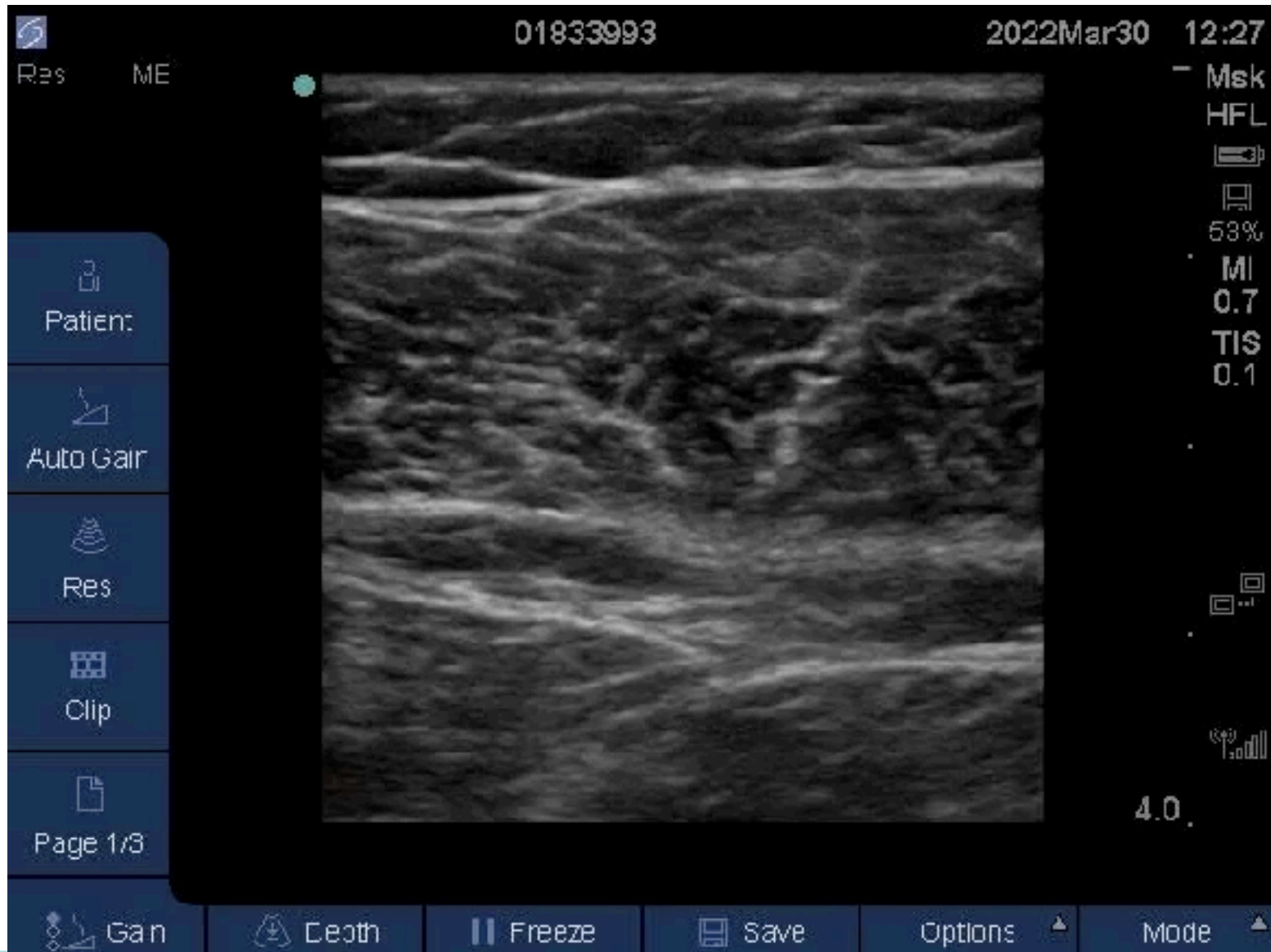41M, calf pain after during badminton



41M, calf pain after during badminton



Gastrocnemius muscle Gr III injury



41M, calf pain after during badminton



GE MEDICAL SYSTEMS

H

蕭名傑,蕭名傑

SIGNA Voyager

7.9-0 Leg Thigh C-

16AA+32PA

28\LX\MR Software release:VX28.0_R05_2127.a

R

L

2022/04/01

F

82F, RLQ pain



GenTHI MB

06143161

2022Mar29 08:44

Abd

- C60



64%

MI

1.0

TIS

0.1



27



13



Zoom



Calipers



EMED

27

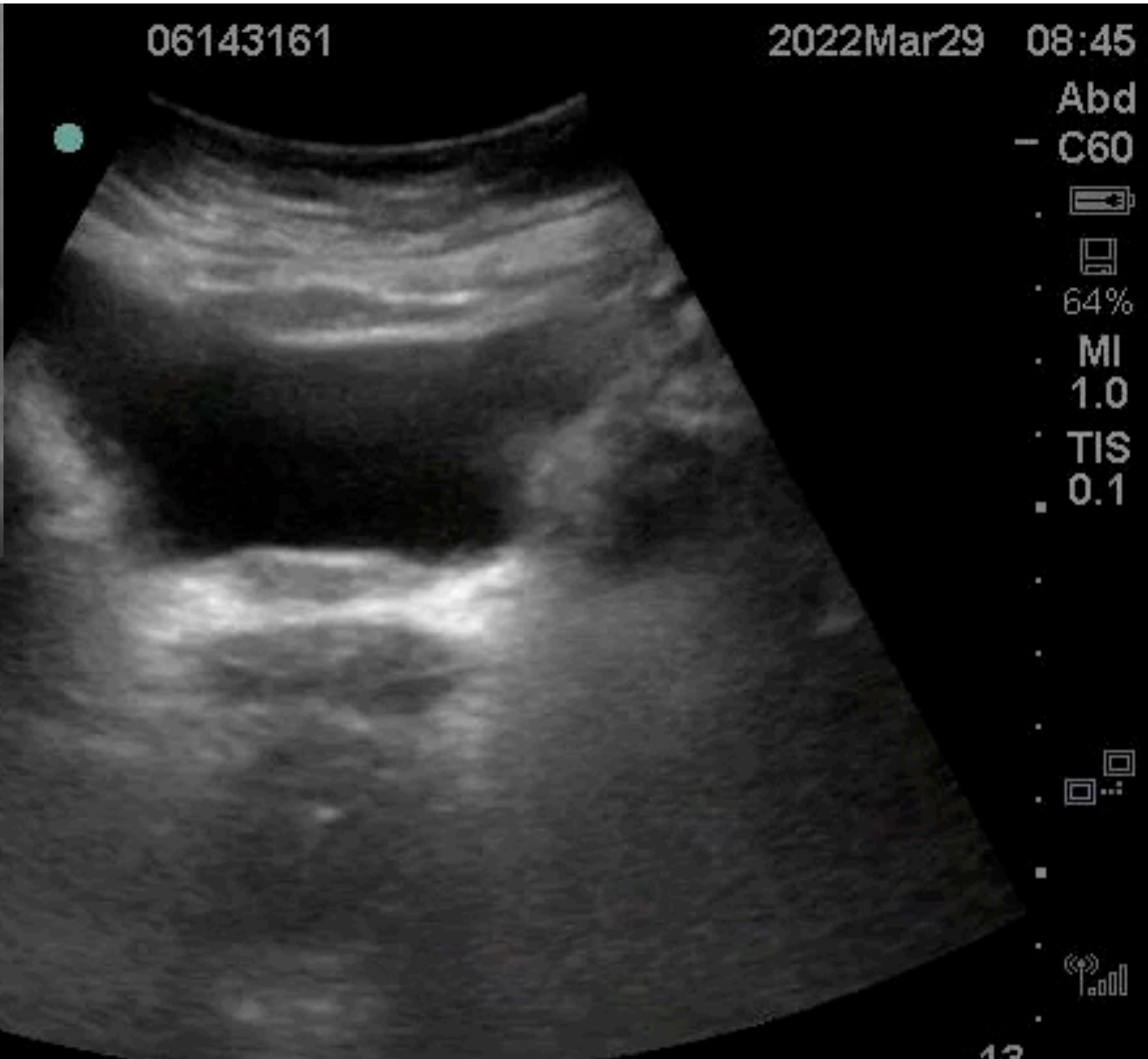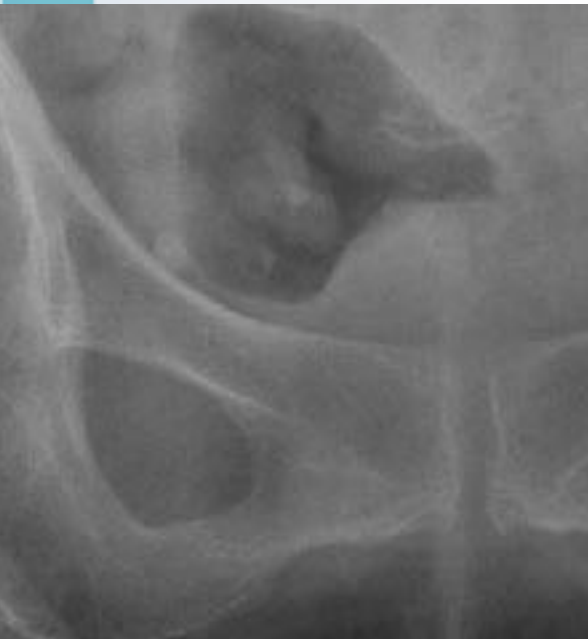Unfreeze

Save

Options

2D

UVJ stone

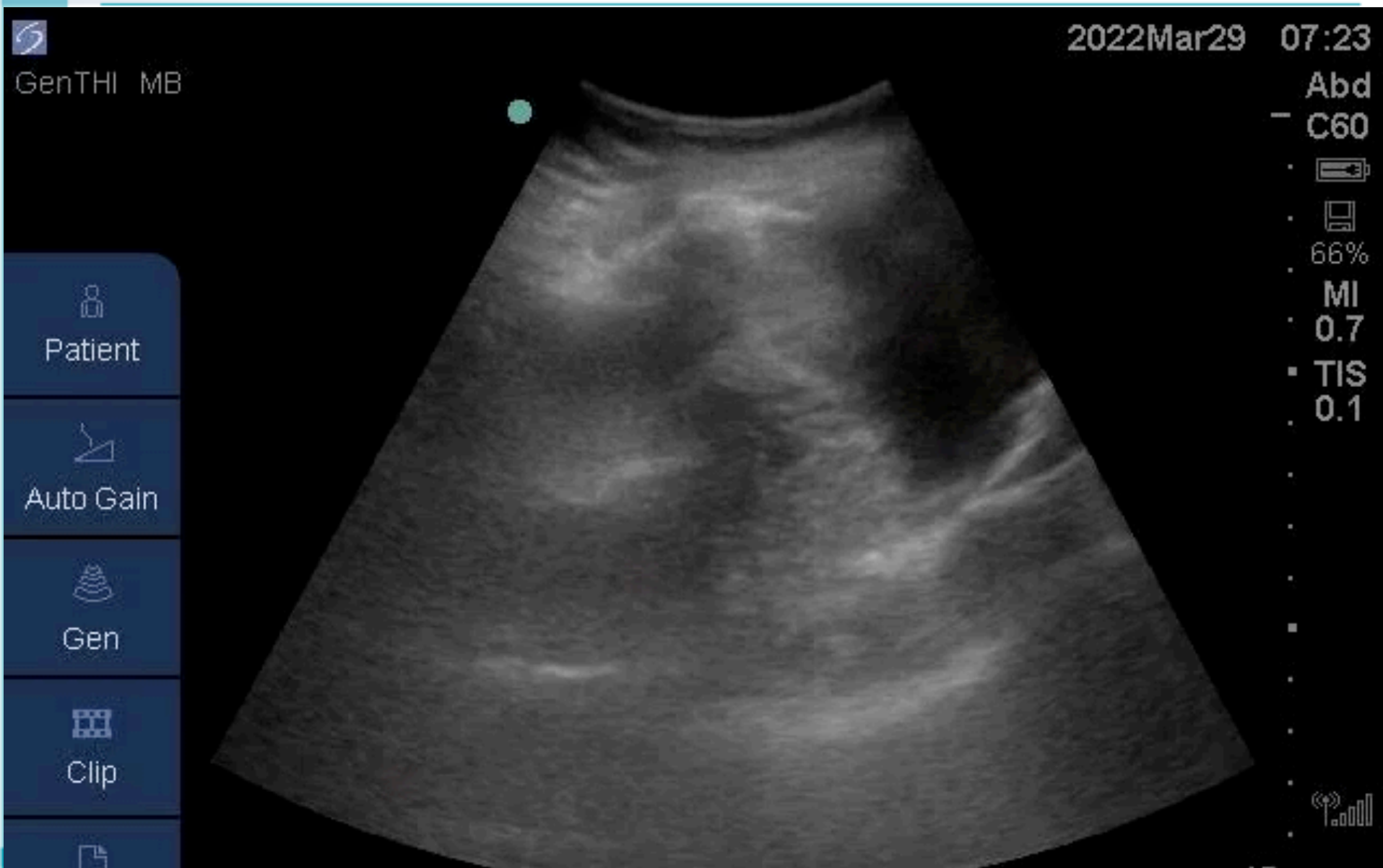


Auto Gain

Gen

Clip

50F, IHCA (外籍看護)

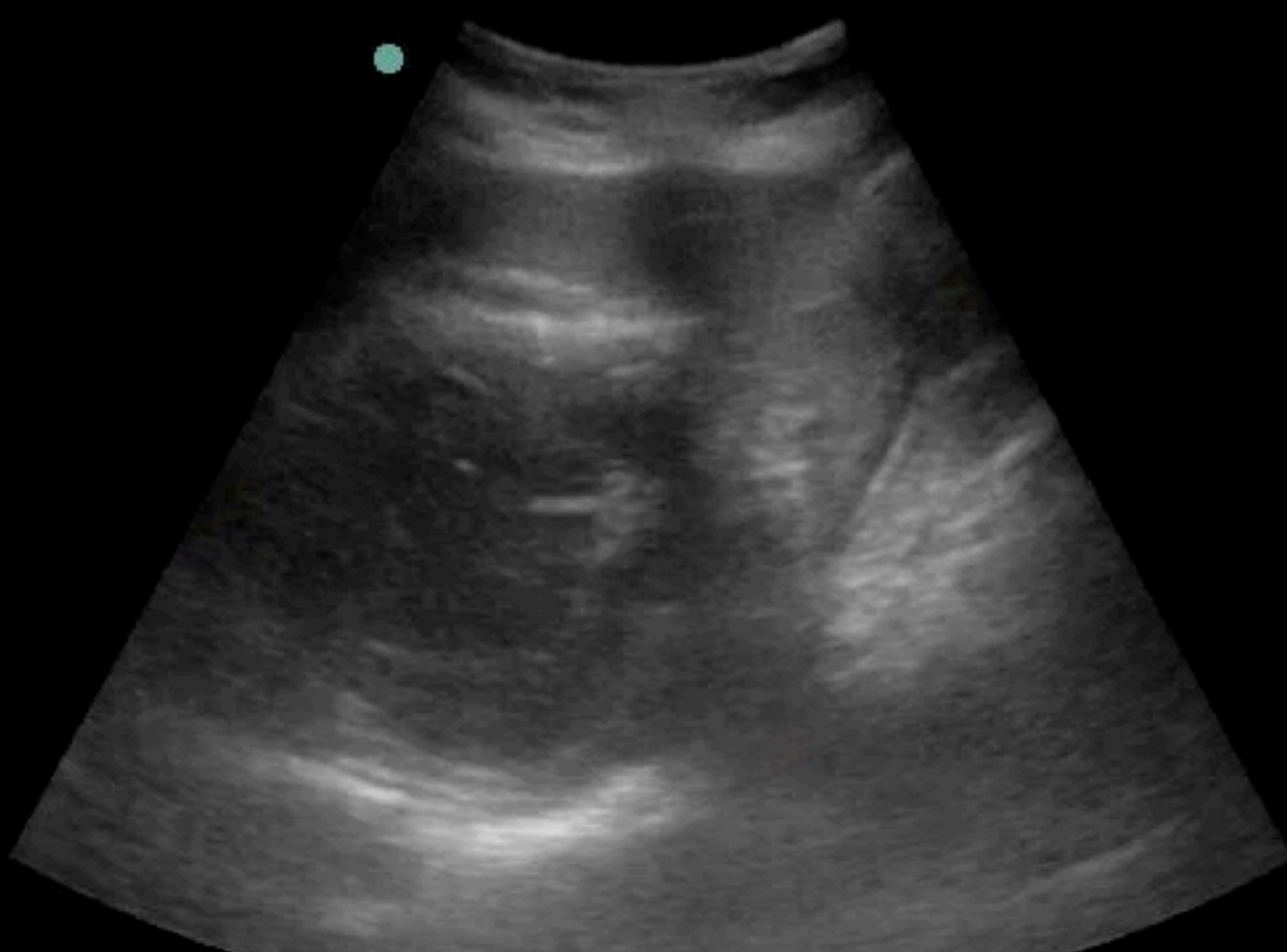


50F, IHCA (外籍看護)




GenTHI MB

2022Mar29 07:23



Abd

C60



66%

MI

0.7

TIS

0.1



Patient



Auto Gain



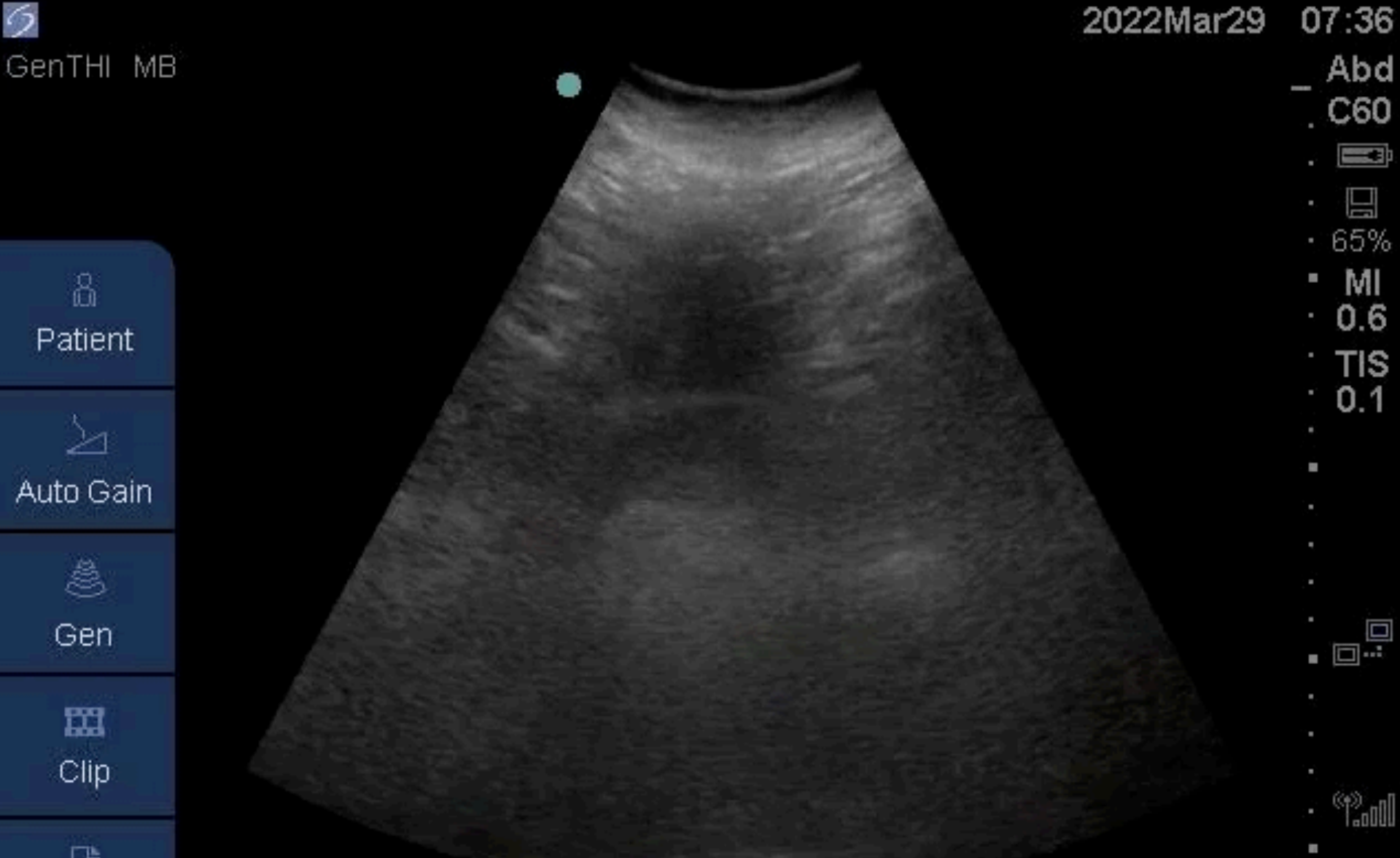Gen



Clip



14Fr pigtail from parasternal approach



150 ml blood drained



GenTHI MB

2022Mar29 07:36

Abd

C60



65%






MI

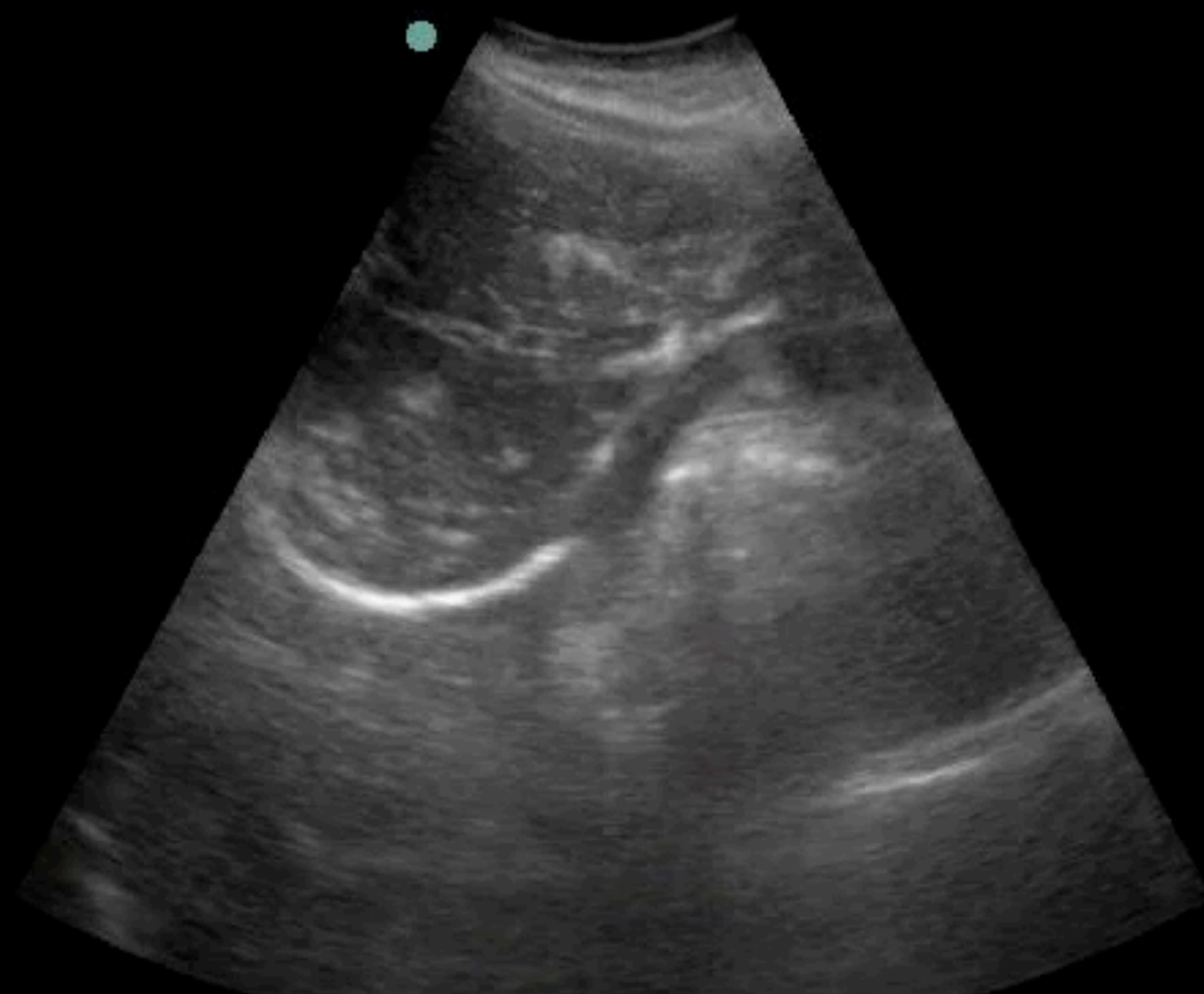
0.6

TIS

0.1



-  Patient
-  Auto Gain
-  Gen
-  Clip
- 

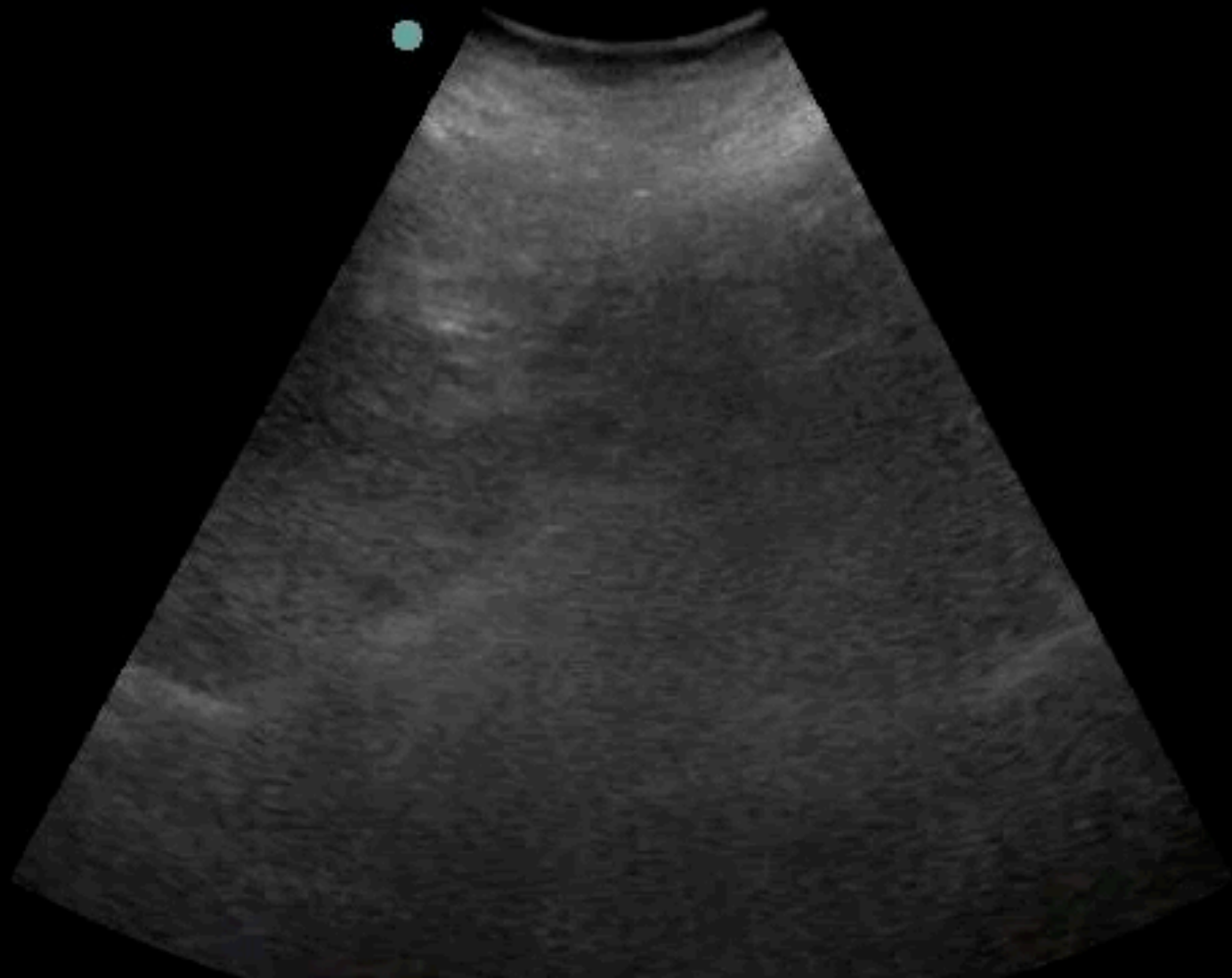

Perform pericardial window



GenTHI MB

2022Mar29 07:38



Patient



Auto Gain



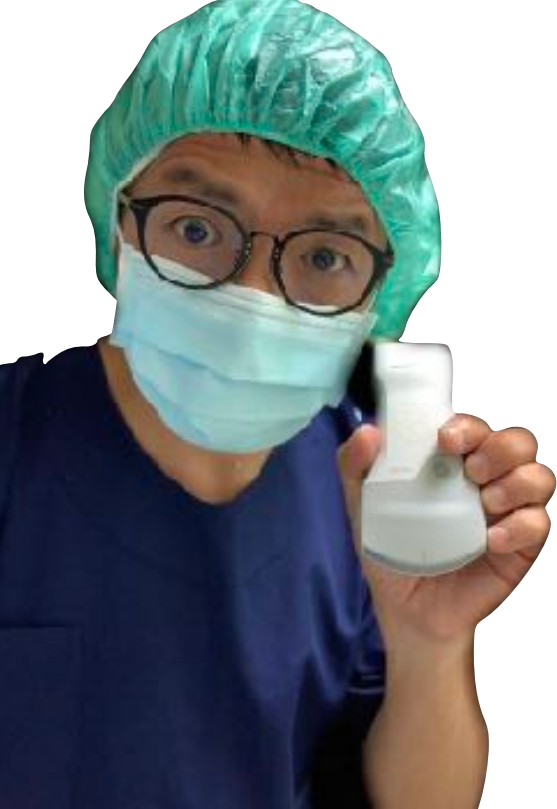Gen



Clip

Abd
C60
65%
MI
0.6
TIS
0.1





努力可能會說謊，
但努力不會白費。

羽生結弦

HOLISTIC ULTRASOUND

juice119@gmail.com / POCUSacademy.com