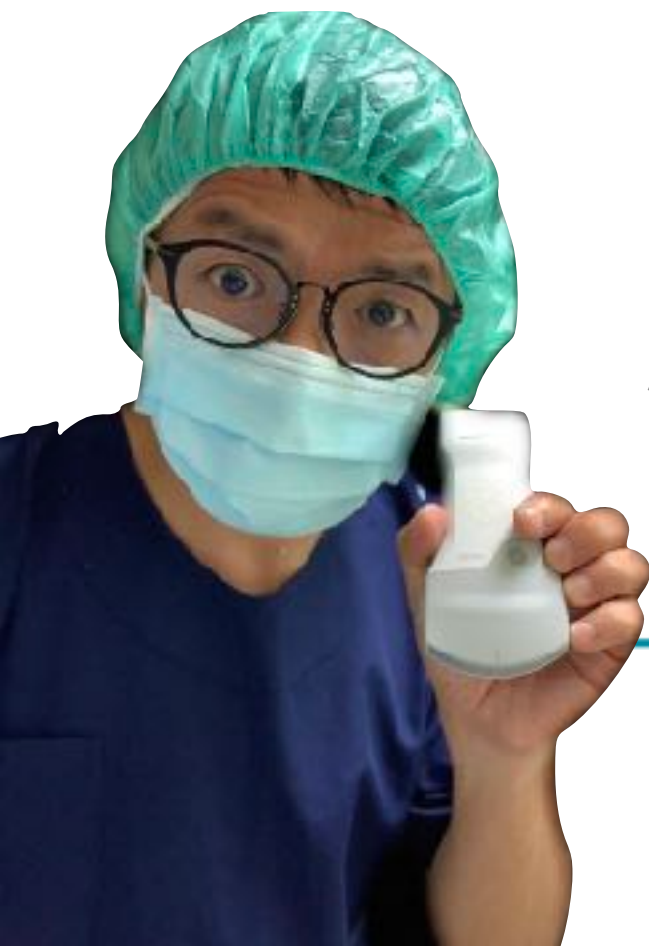



衛生福利部雙和醫院  
(委託臺北醫學大學興建經營)  
Taipei Medical University · Shuang Ho Hospital,  
Ministry of Health and Welfare



# How I Do It

## US-assisted procedures

### 超音波輔助之醫療處置經驗分享

20220808 台灣急診醫學會年會

陳國智醫師

雙和醫院 急診醫學科

# 陳國智 醫師



醫用超音波學會指導醫師  
WINFOCUS director / instructor  
急救加護醫學會重症超音波負責人

**急診 / 重症 / 介入 / 急性疼痛**

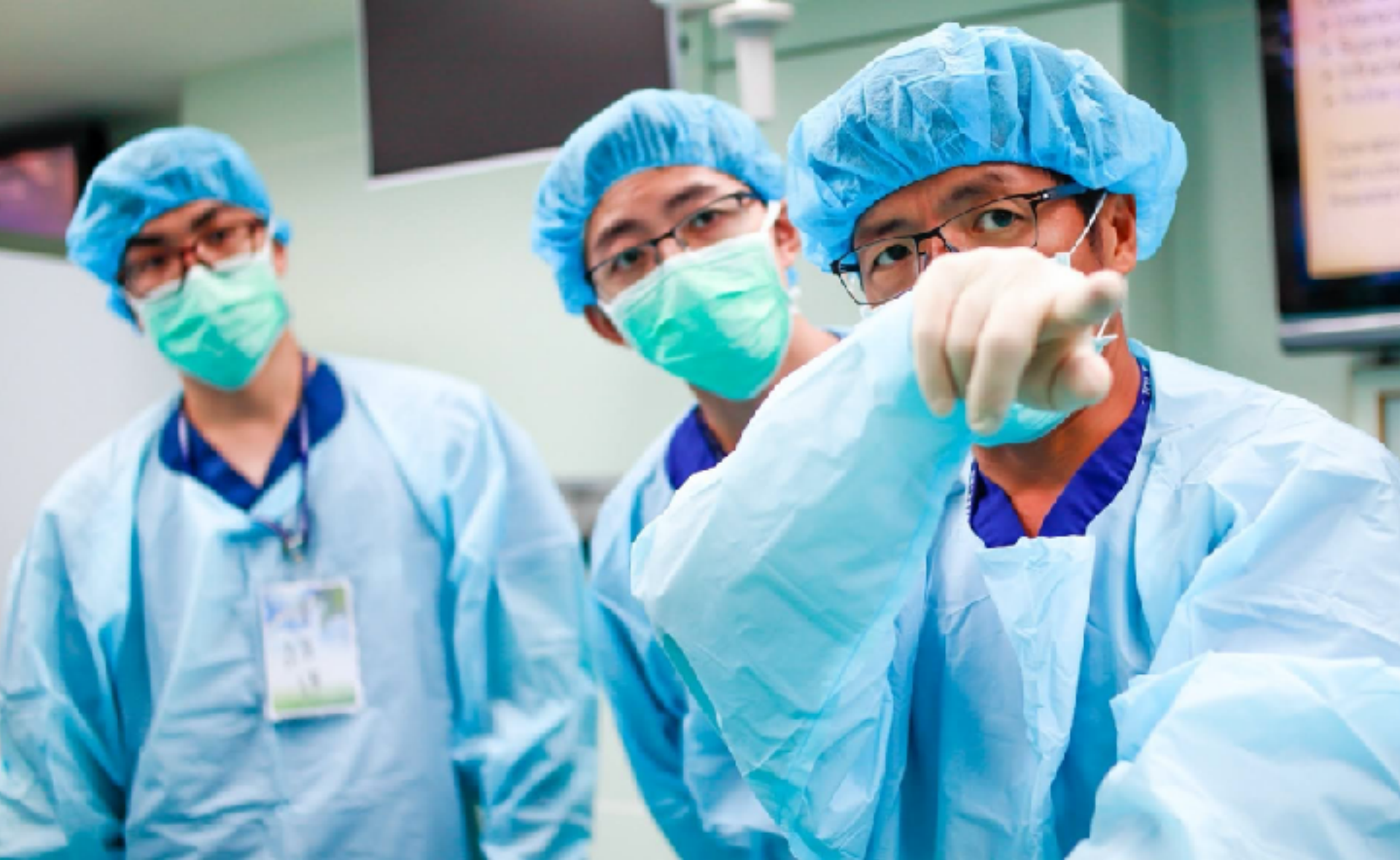經歷

新光急診超音波訓練中心主任

西園醫院急診醫學科主任

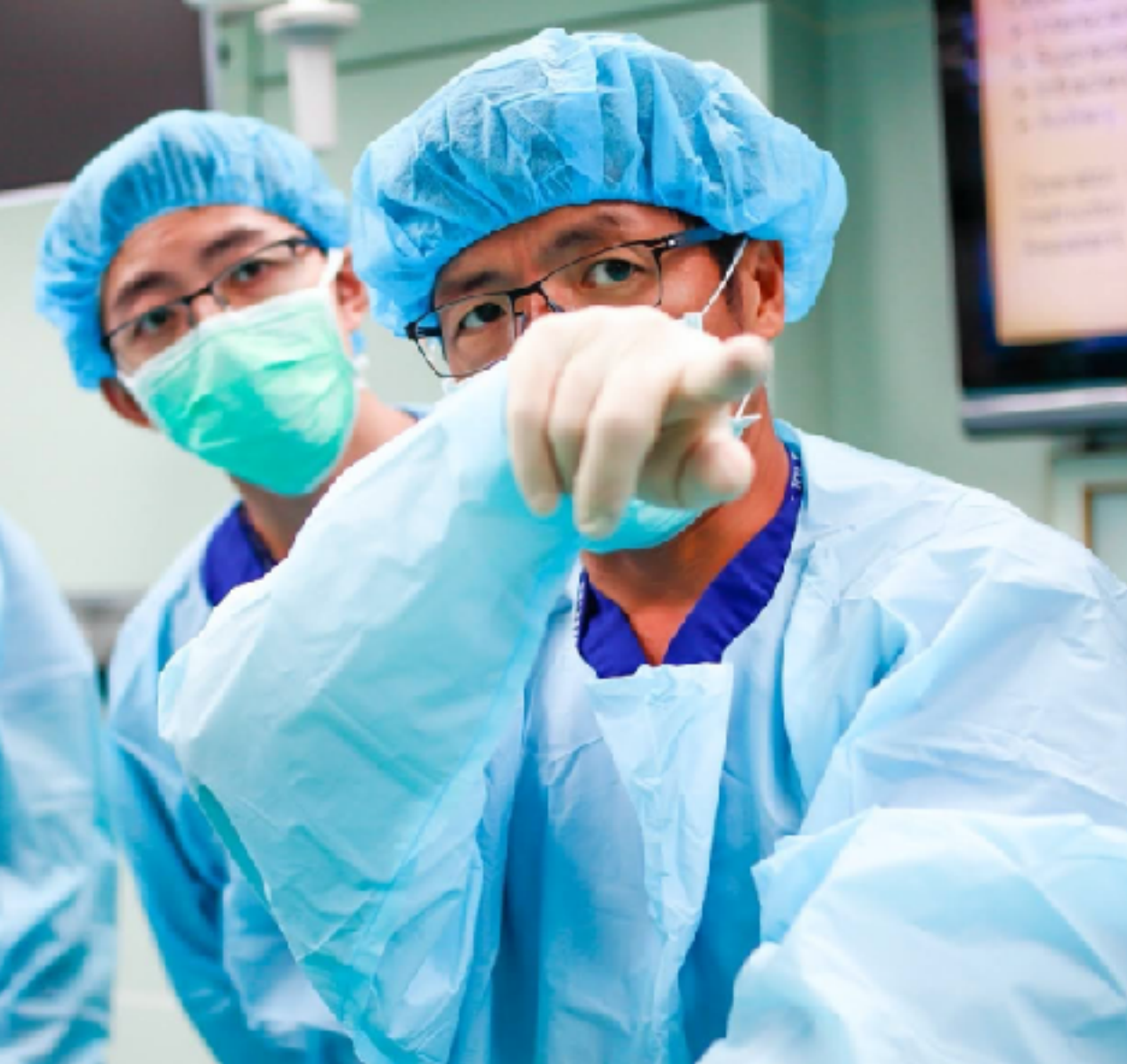急診醫學會超音波委員會主委

台灣疼痛醫學會大體模擬手術講師

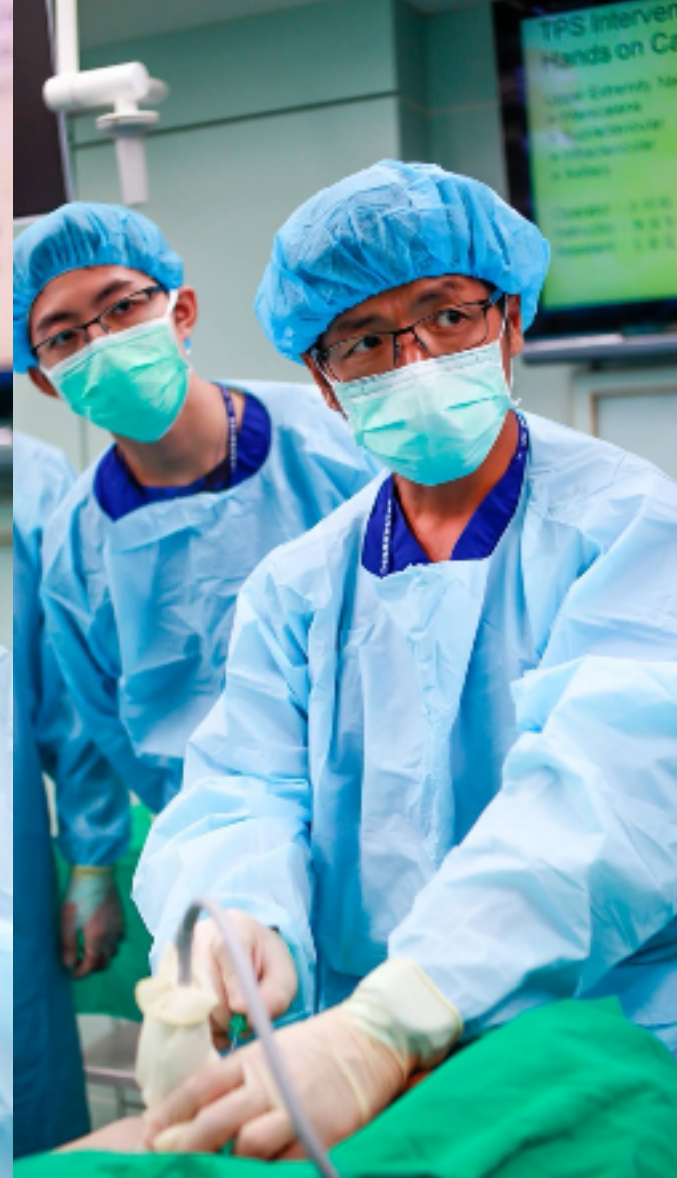

**Diagnostician**





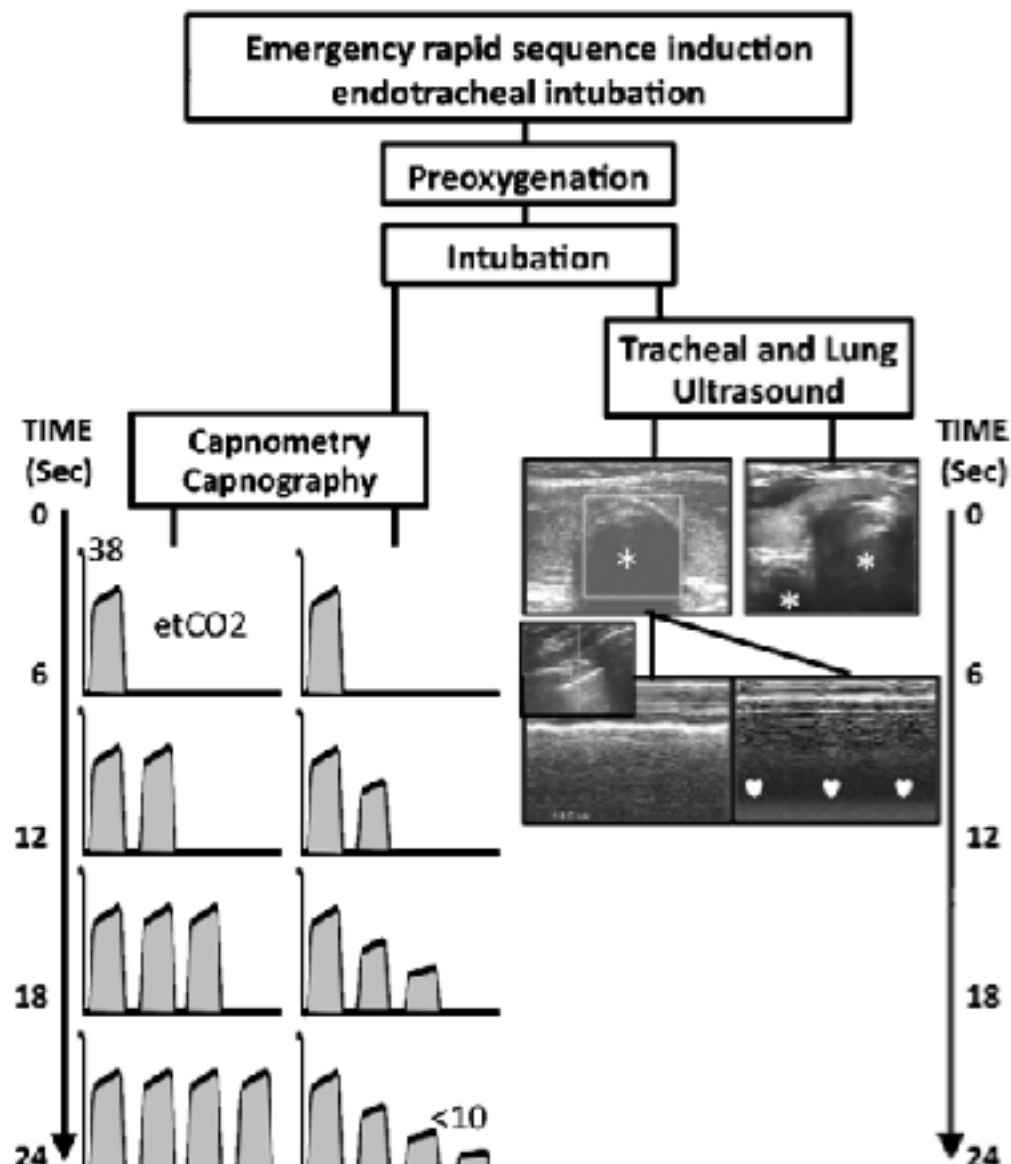
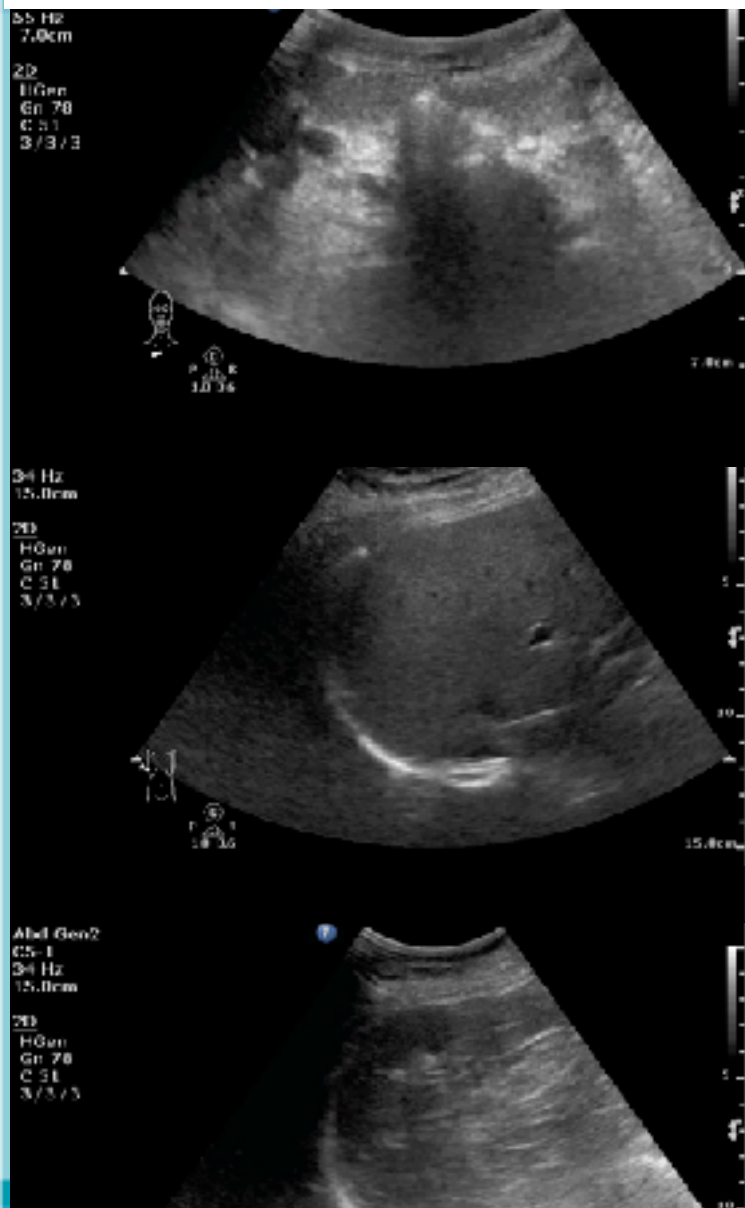**Diagnostician**



**Interventionist**



# TRUTH: 確認插管 & 雙側通氣



# TRUST



## Tracheal Rapid Ultrasound Saline Test confirming correct ET **Depth** in children

20160410190238

MI 0.5

4/10/2016

20160410190238

MI 0.5

-190238

SKH ER

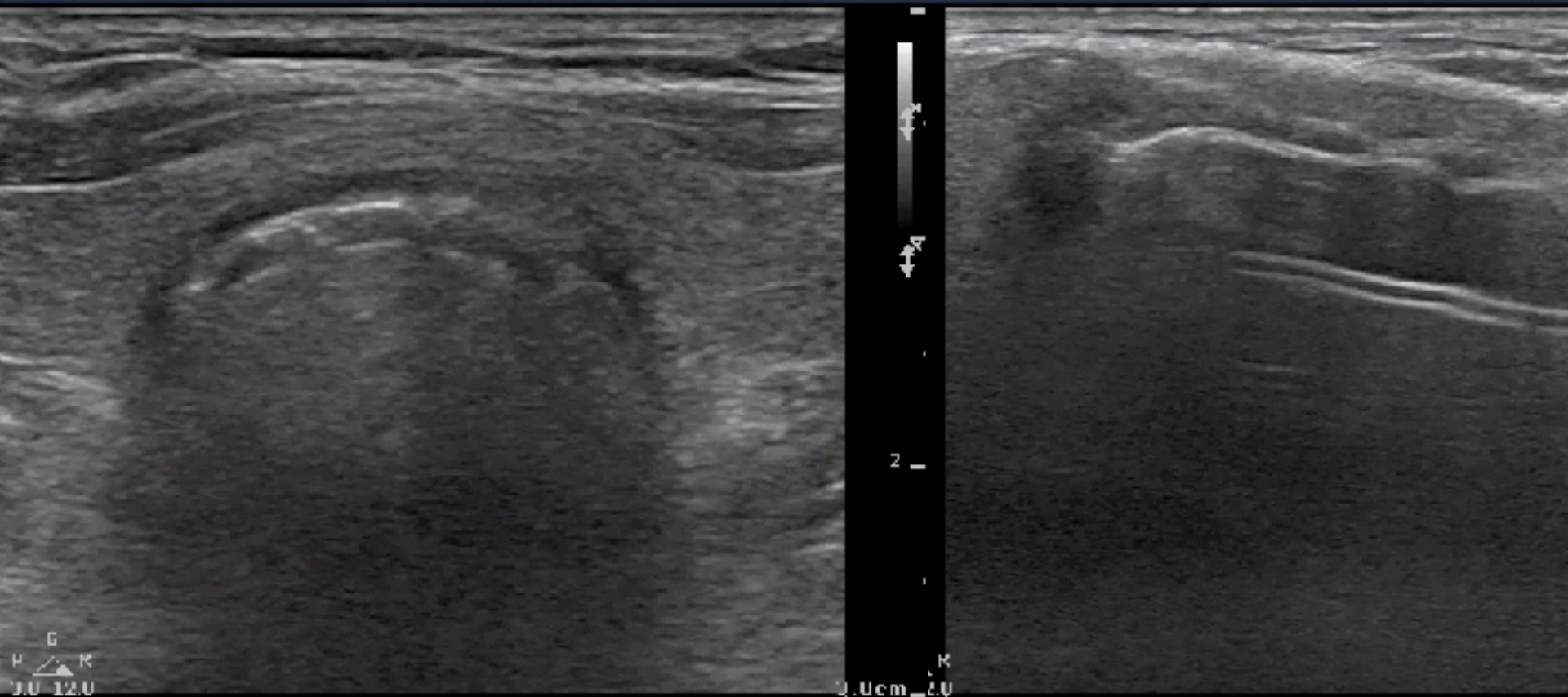
118 0.1

7:24:17 PM

238

SKH ER

118 0.1



G  
H K  
0.0 12.0

R  
2.0cm 2.0

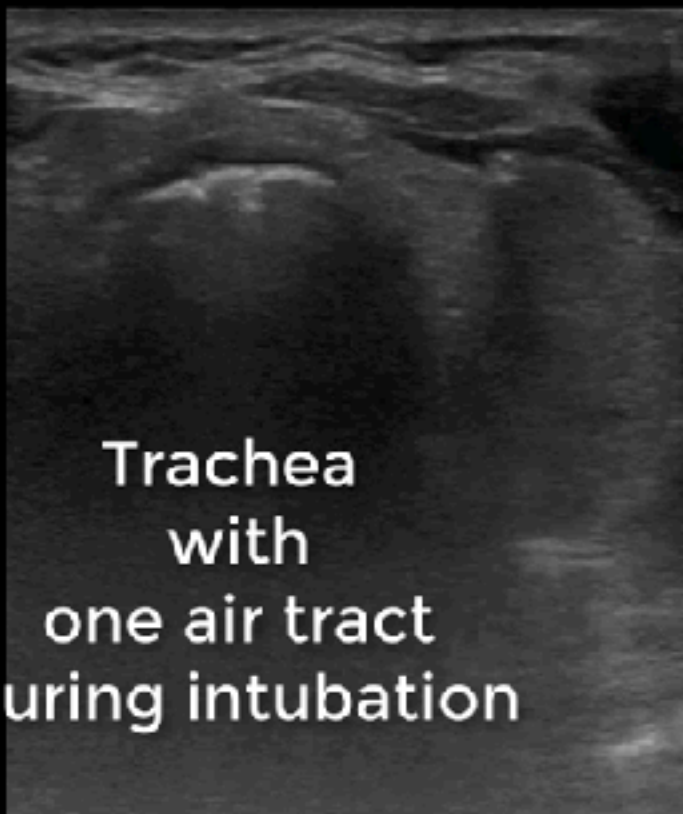

# 線形探頭 + Trachea compression

Small part1  
L12-3  
37 Hz  
4.5cm

2D  
HGen  
Gn 100  
C 56  
3/3/4

P



2

4

4.5cm



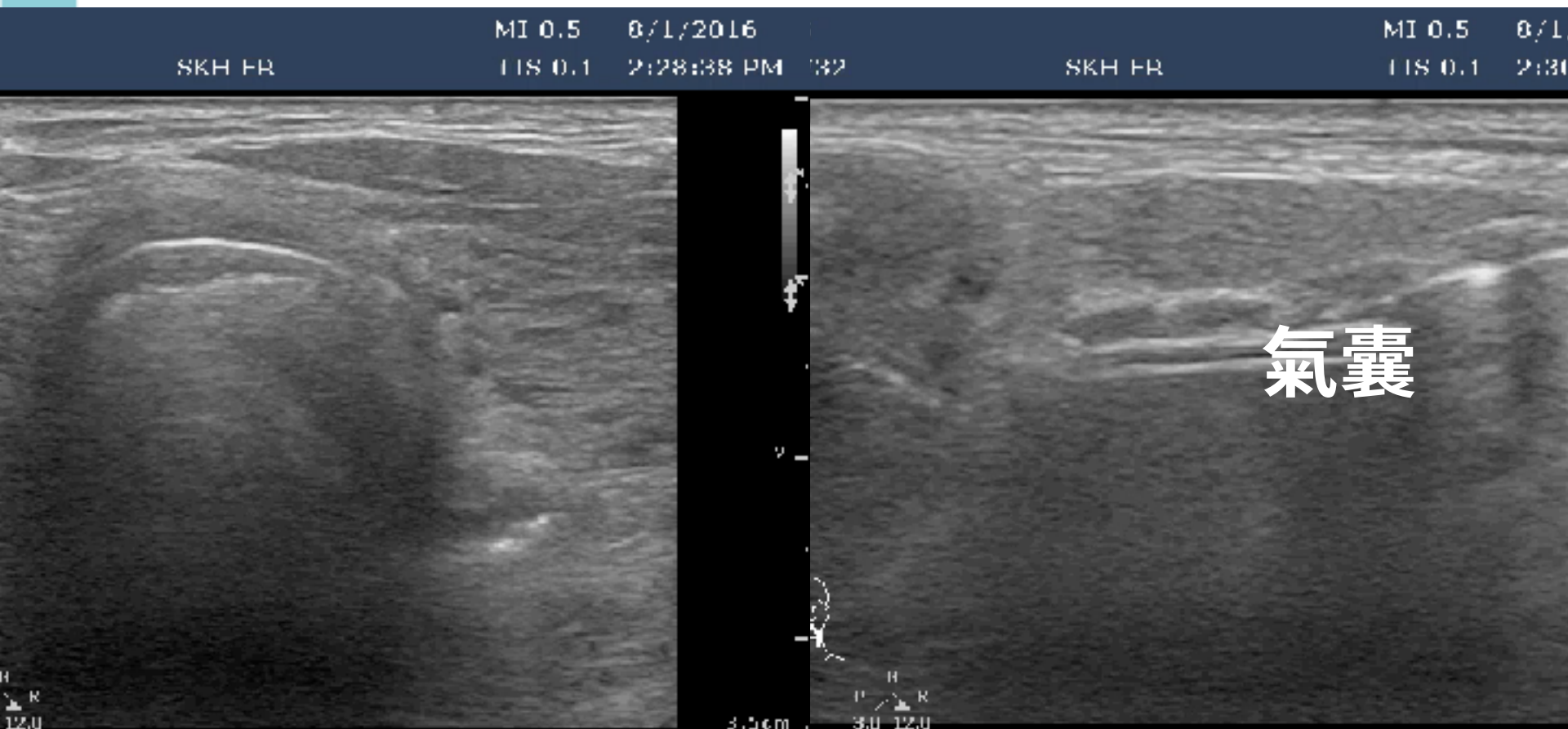
Right

Left

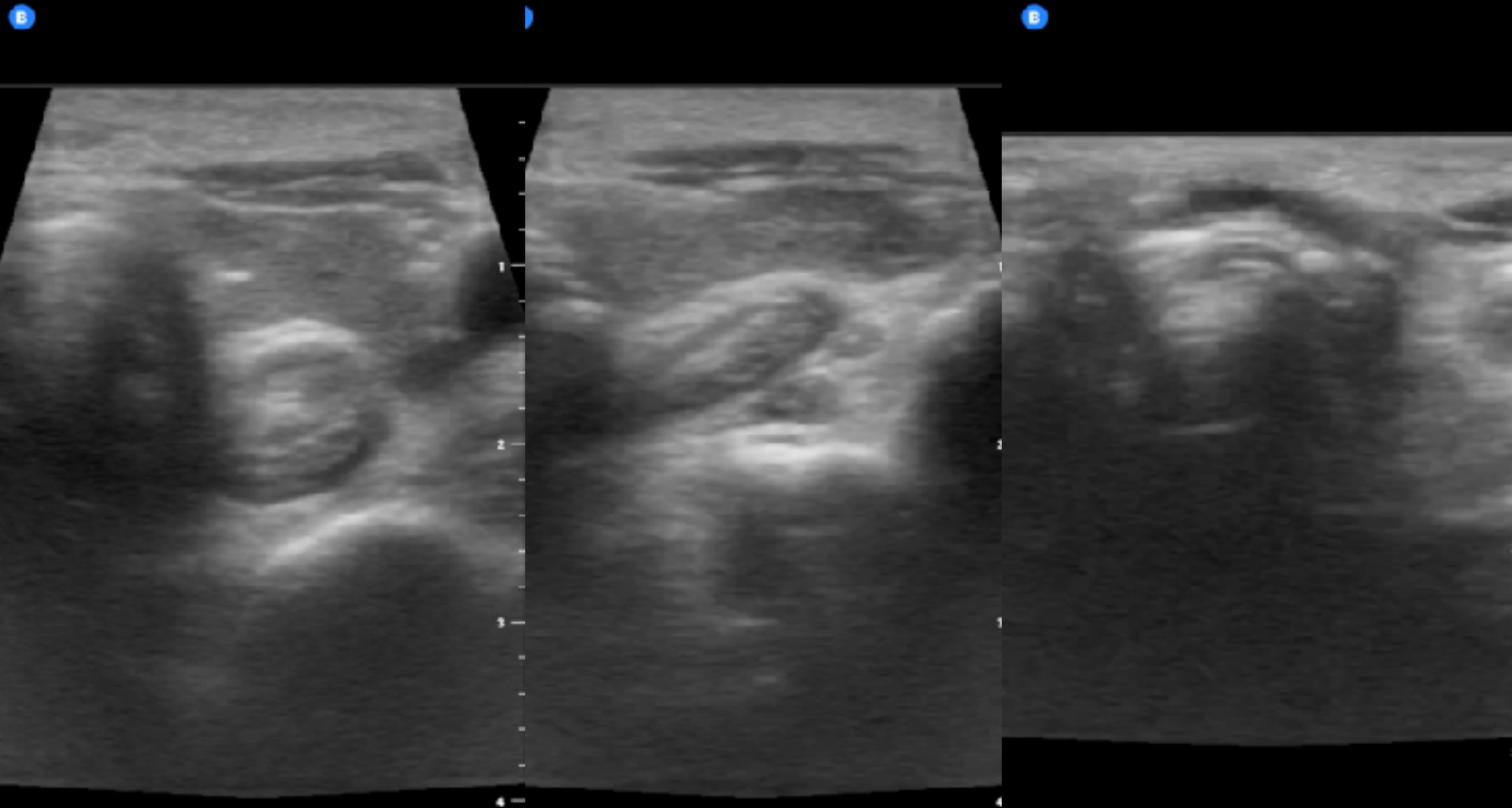


# Tracheal compression Direct visualization of ETT

# 要壓在氣囊頭側喔！



# 75F, shock & resuscitation



# 插管/CTM/PDT

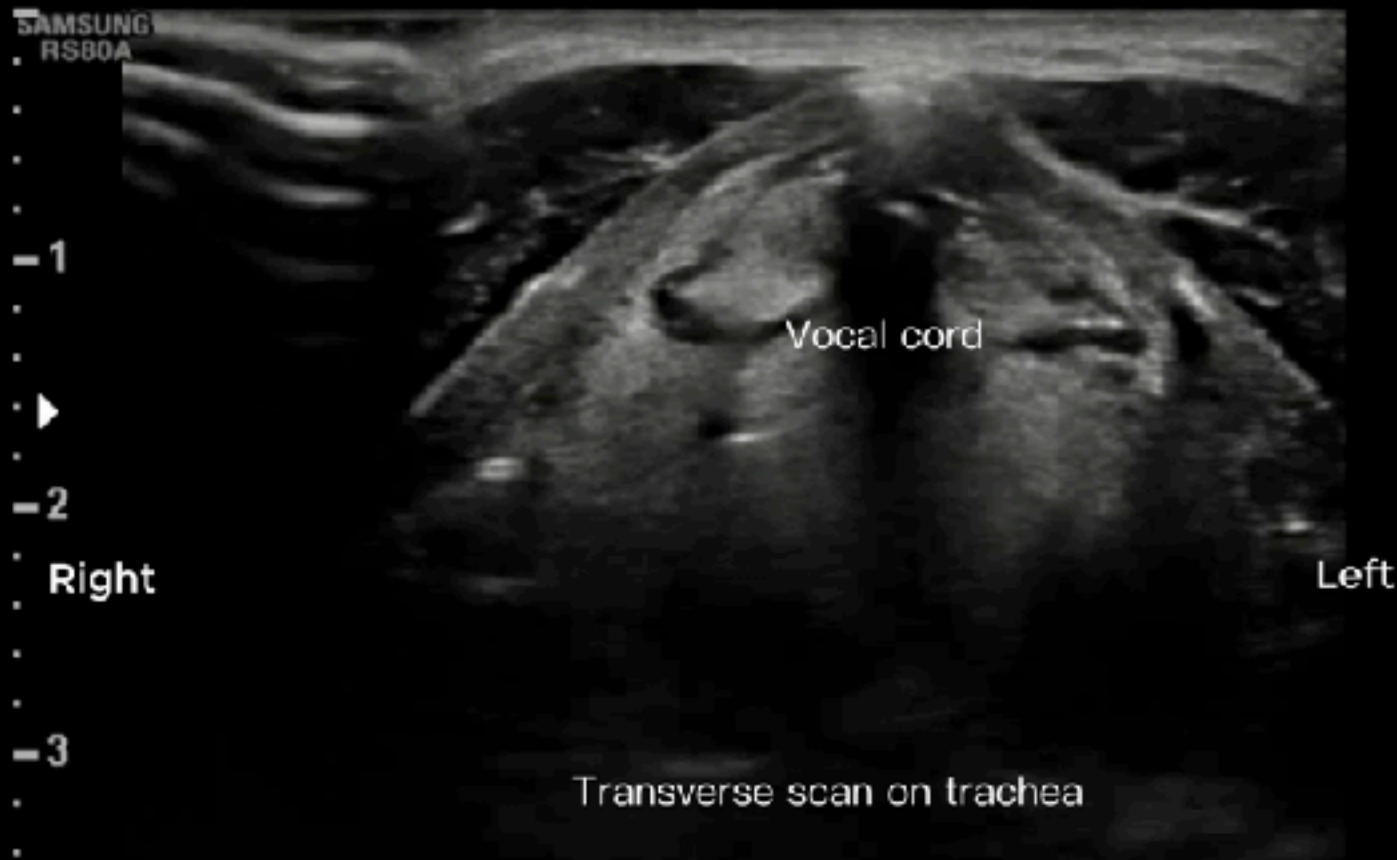


CTM: cryothyroid membrane

PDT: percutaneous dilatational tracheostomy

L3-12A / SmallParts / FPS40 / MI0.96 / TI0.1 / 01-09-2016 10:29:39 AM

2D G53/DR58/FA4/P90/2.7/Frq Pen./3.5cm

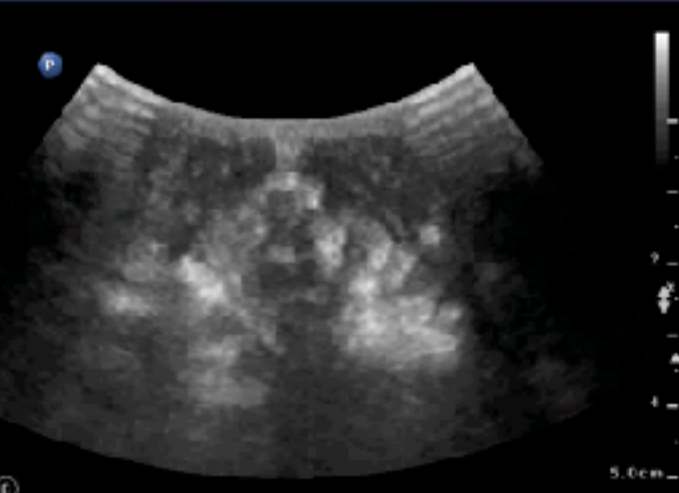



# Stridor & Dyspnea. Crico or PDT ?



SKH ER MI D.8 1/6/2016  
TIS 0.1 6:33:17 PM

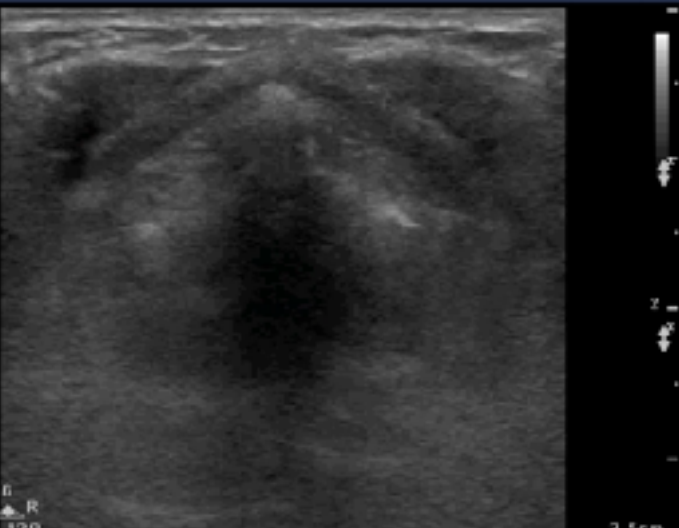


07 10

SKH ER

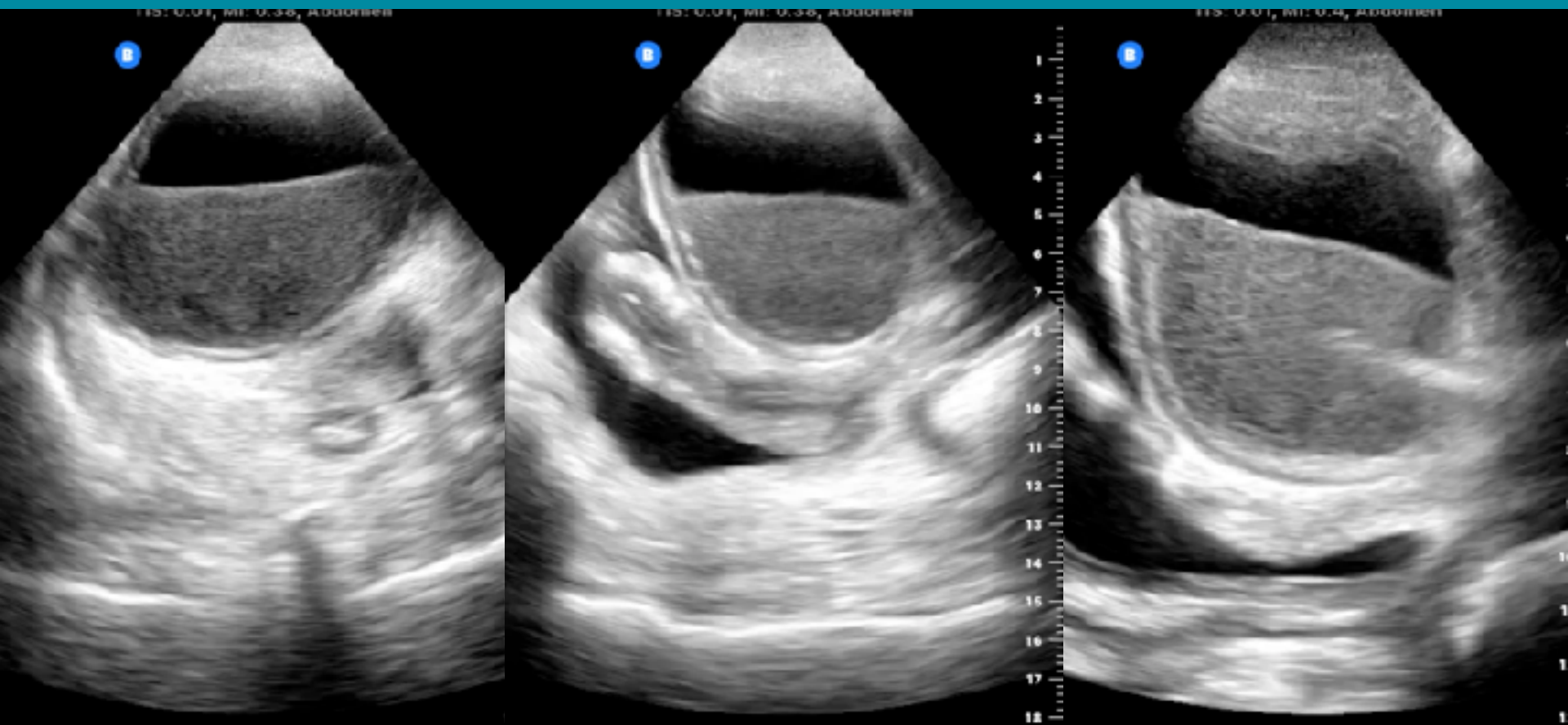
MI 0.9 1  
TIS 0.2 6

SKH ER MI D.9 1/6/2016  
TIS 0.2 6:37:25 PM



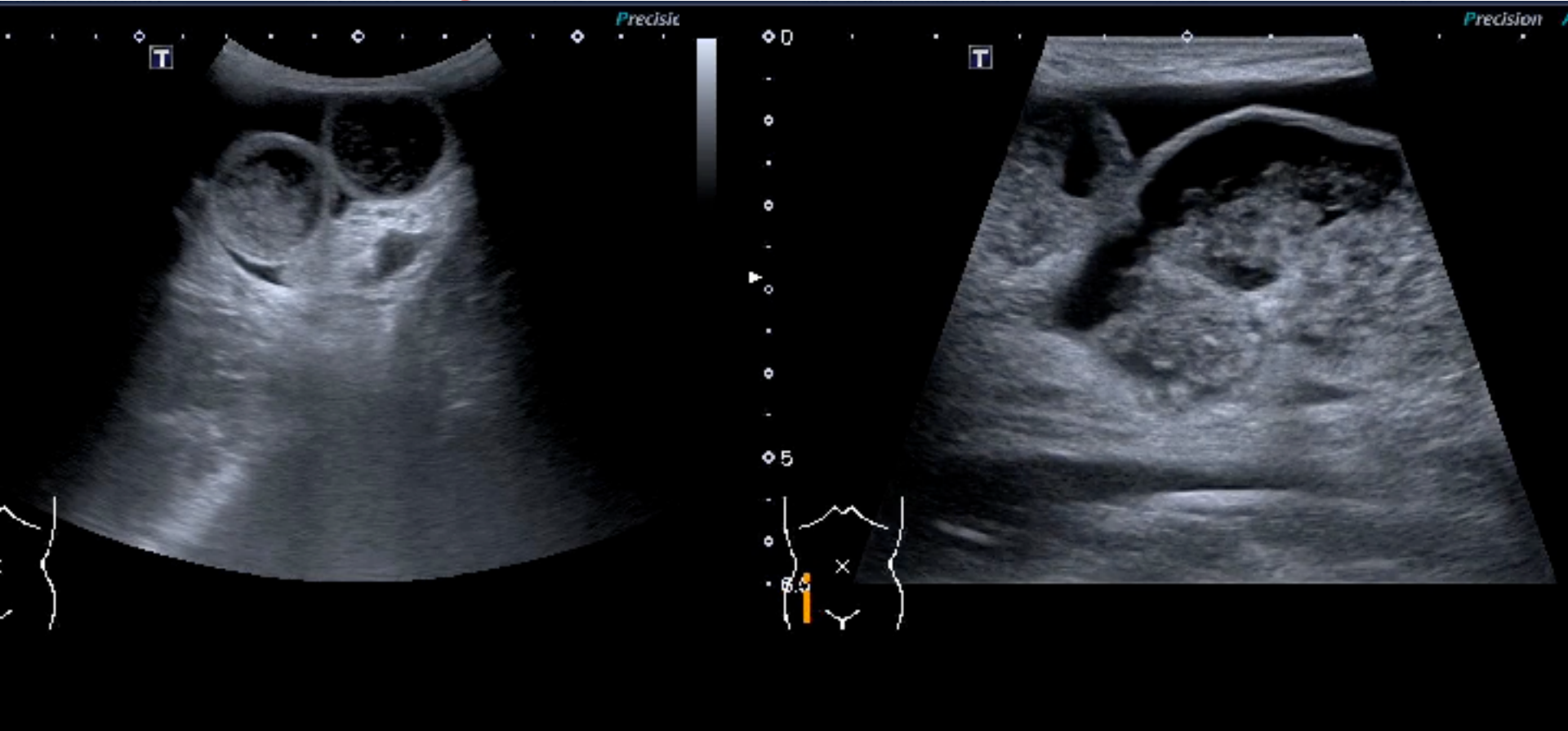
G  
P R  
3.0 12.0

# 75F, shock & resuscitation

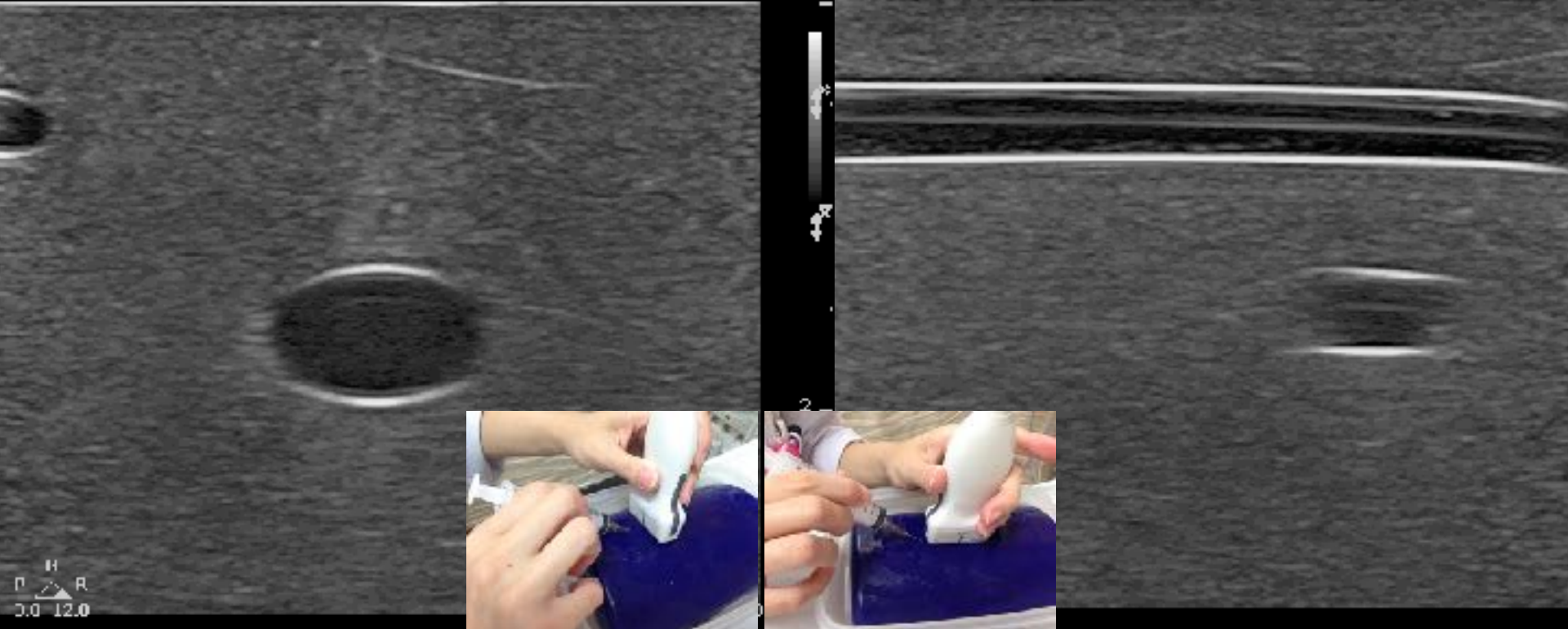


# 69M, right inguinal pain

**Hernia diagnosis & find best reduction path**





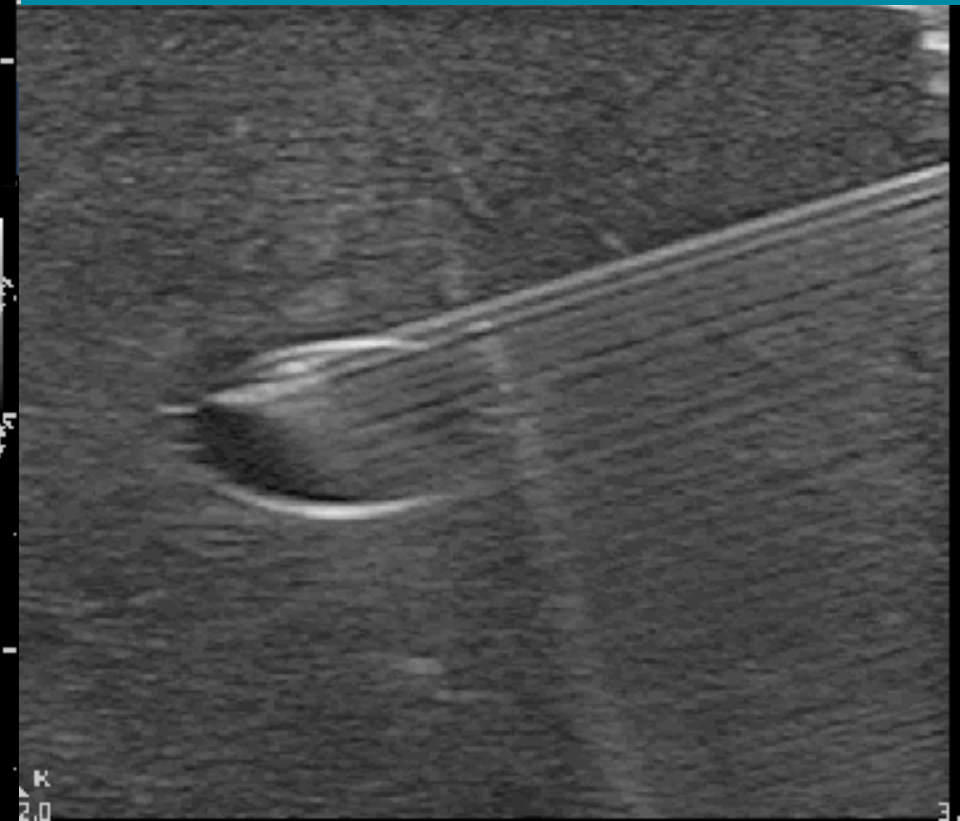
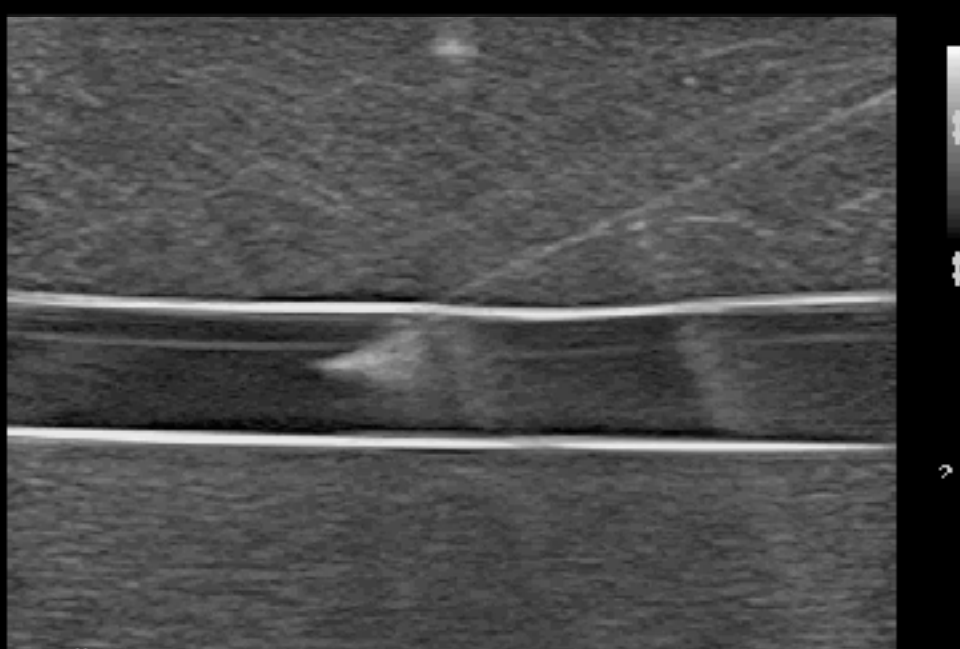
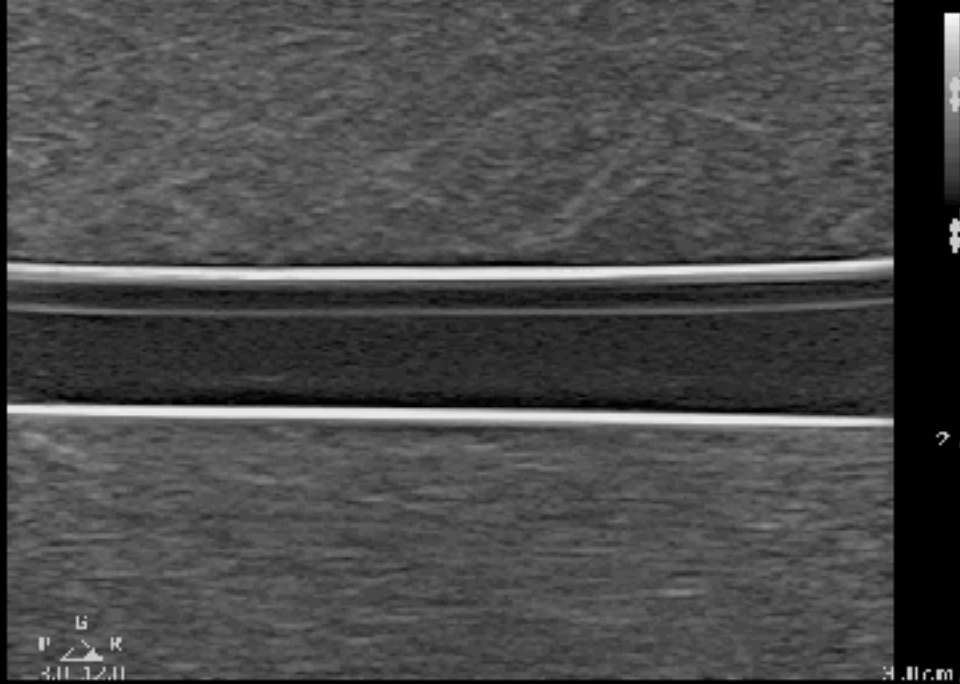


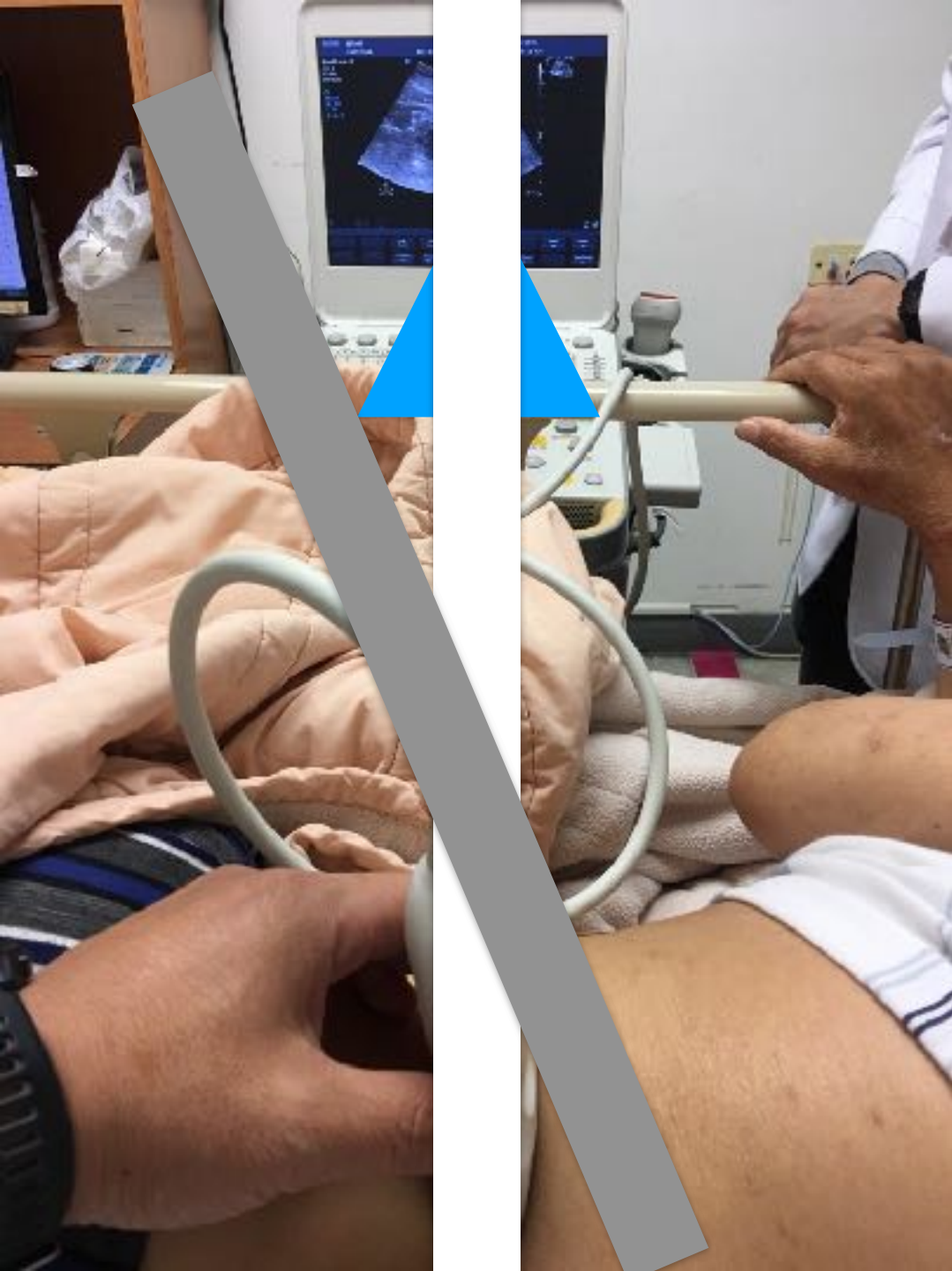# MASTER NEEDLING

**Off-plane**

**In-plane**

# NEEDLE OPTIMIZATION 探頭要垂直針身





保持軸線

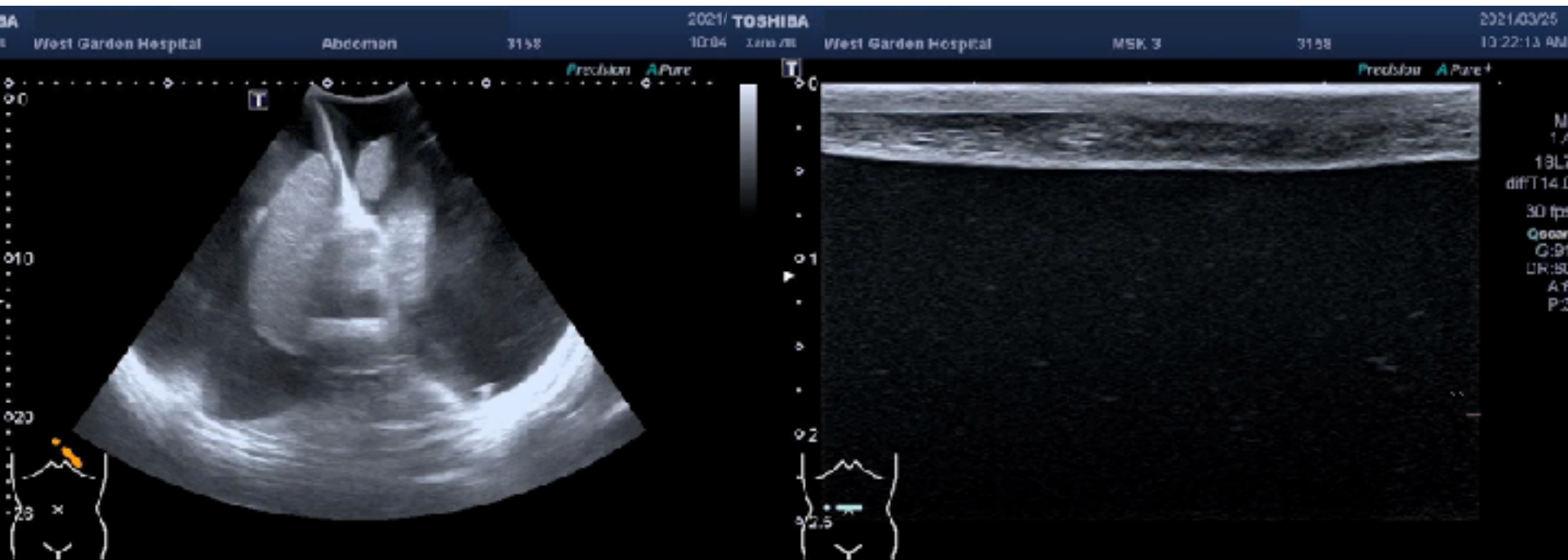
堅守切面

擬定路徑

# 61M, Cirrhosis & massive ascites

Find best location

Avoid bowel & vessels



IEA: inferior epigastric artery


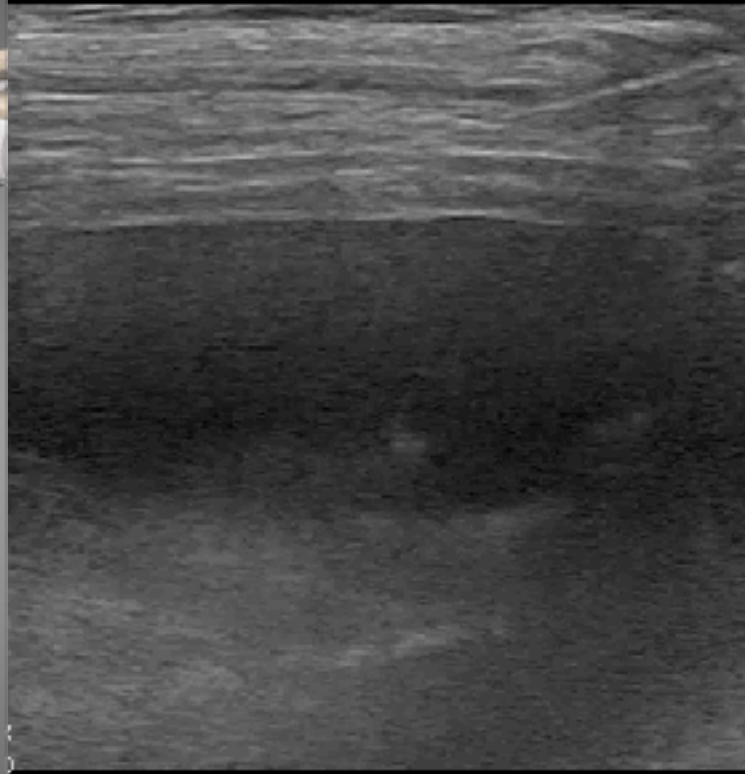
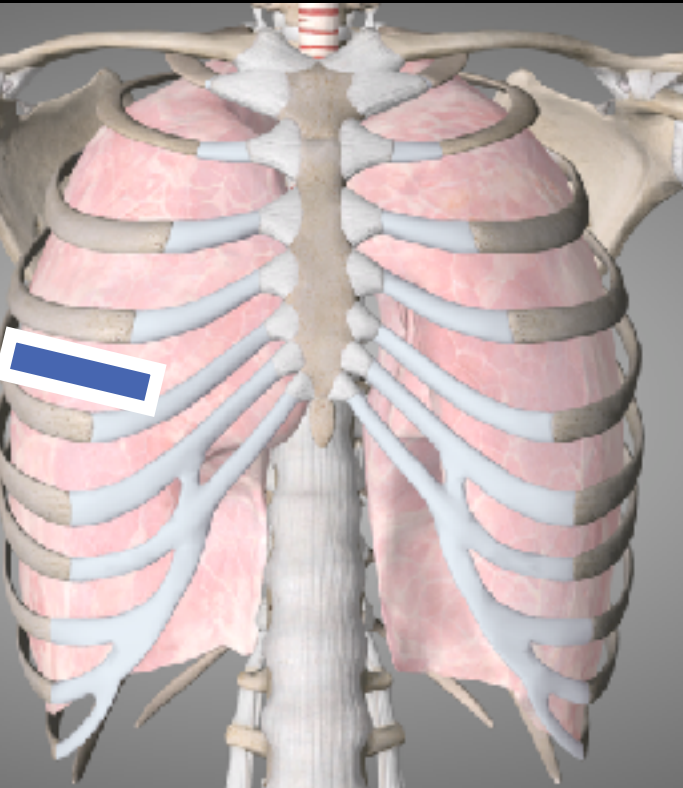
寬廣的空間適合【定位】更是絕佳的【安全精進區】



# In-plane drainage



SKH-EUTC©ChenKC



Catheter insertion

# Off-plane drainage



Superficial

L 12-3

43 Hz

4.5cm

2D

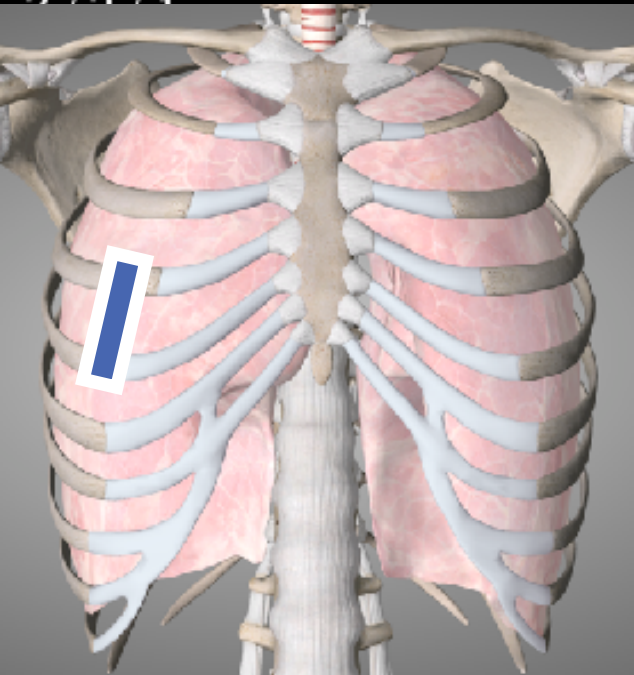
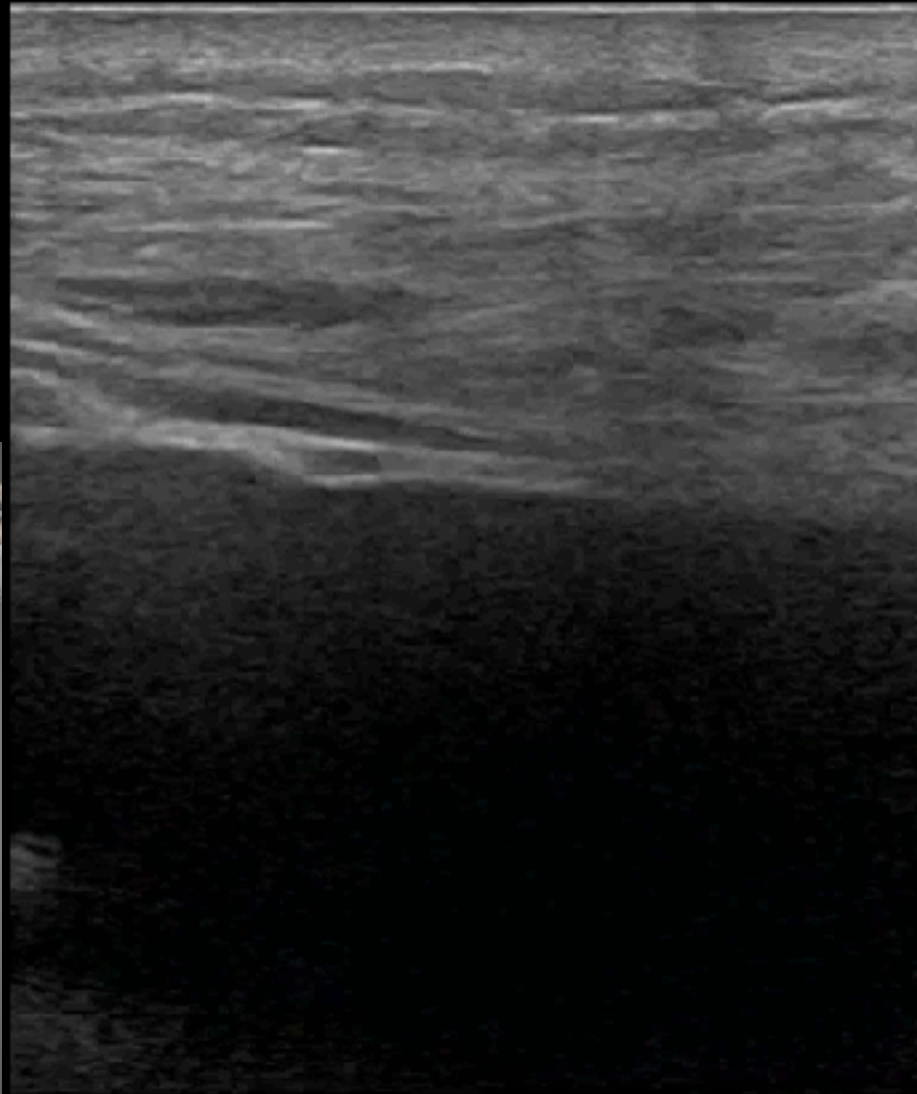
Res

Gn 100

C 56

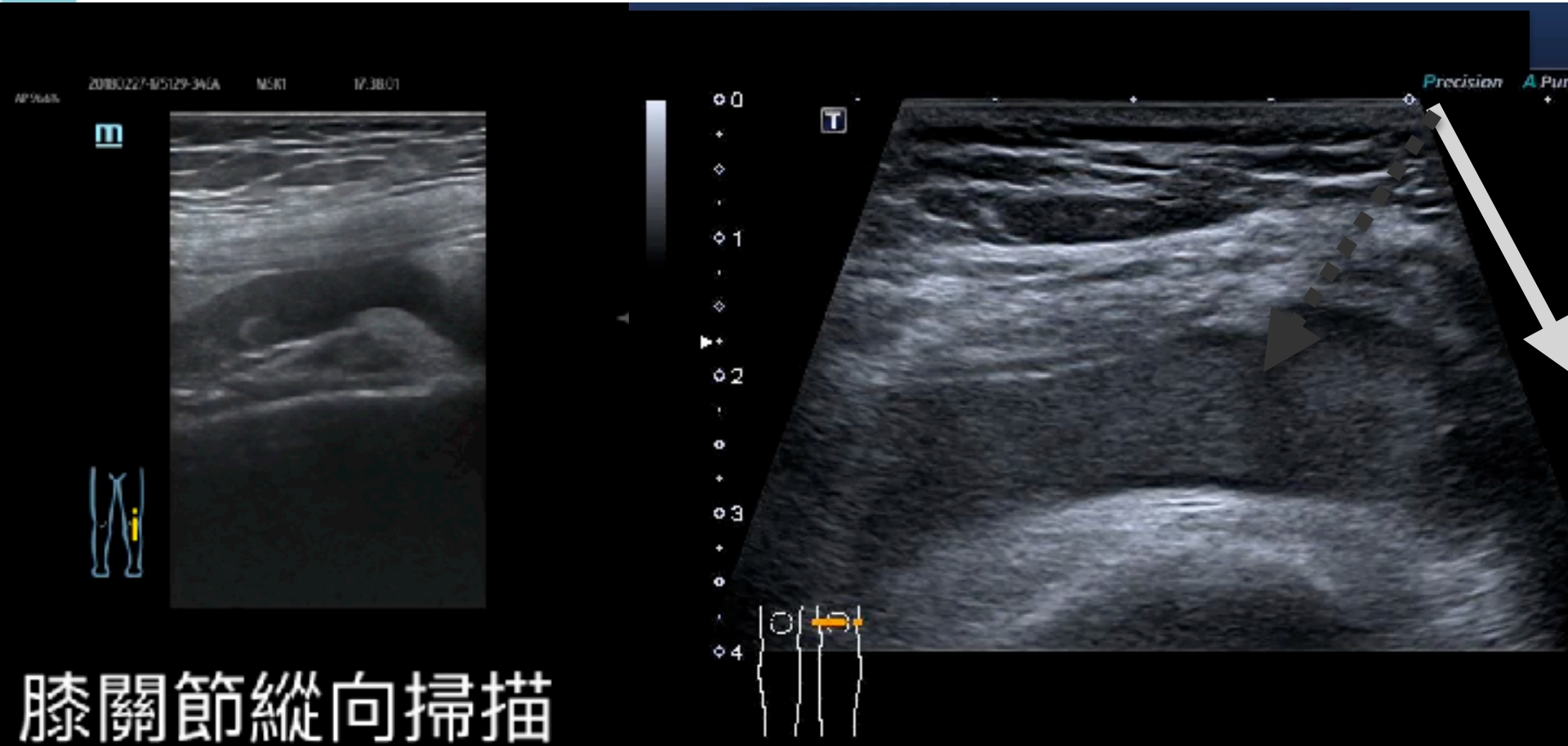
2 / 2 / 1

P

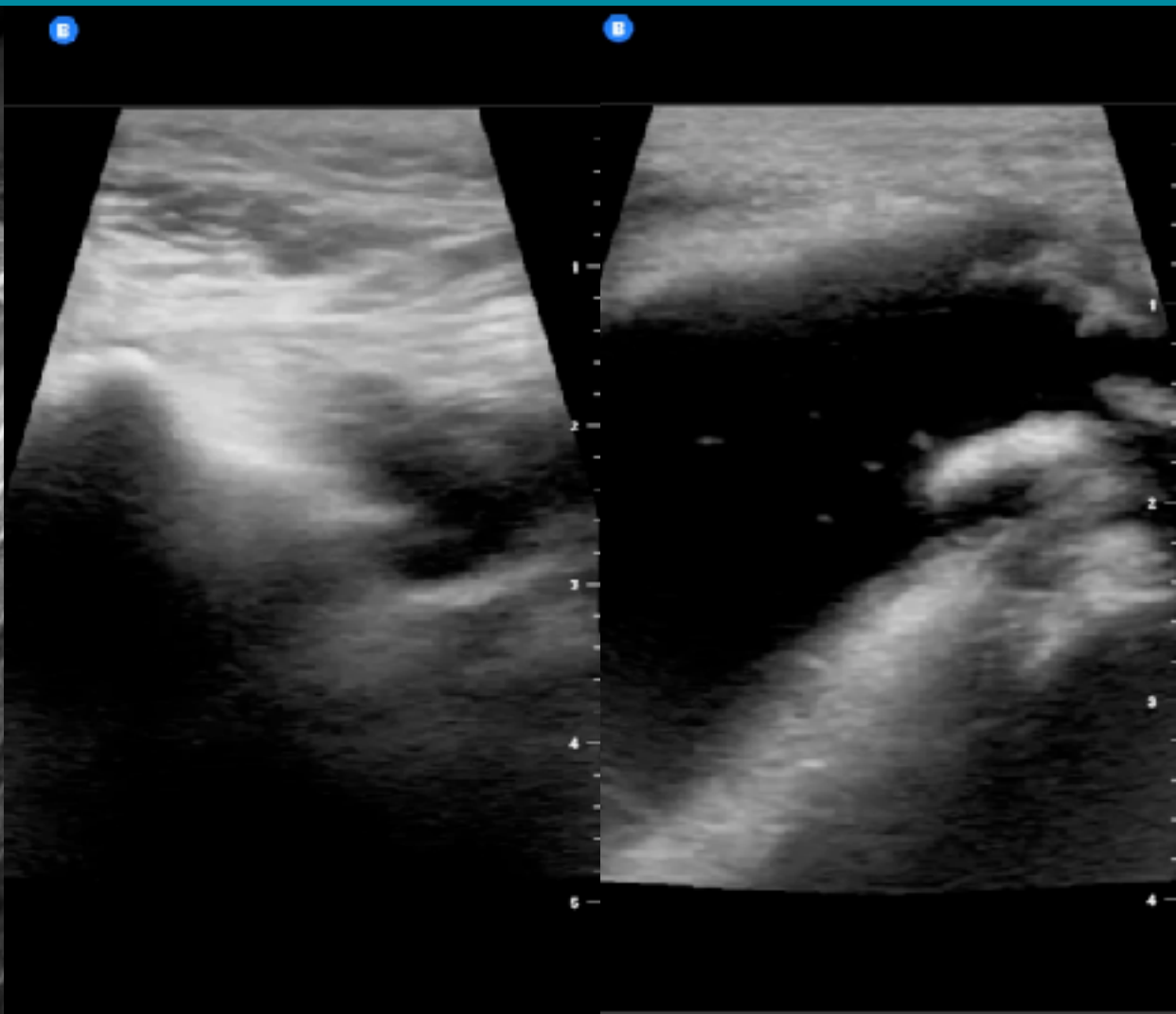
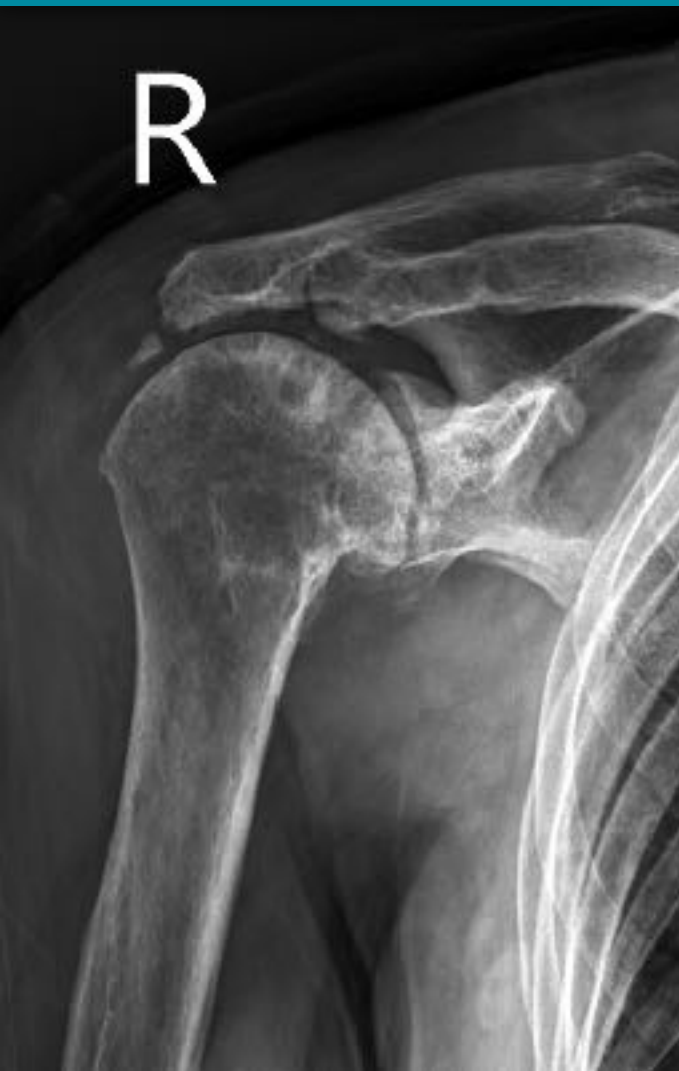


4.5cm

# Joint effusion & aspiration



93F, 原本躺著孫子要扶起來，  
不慎拉傷右肩，昨天右肩痛，右手無法上舉





# Pneumothorax

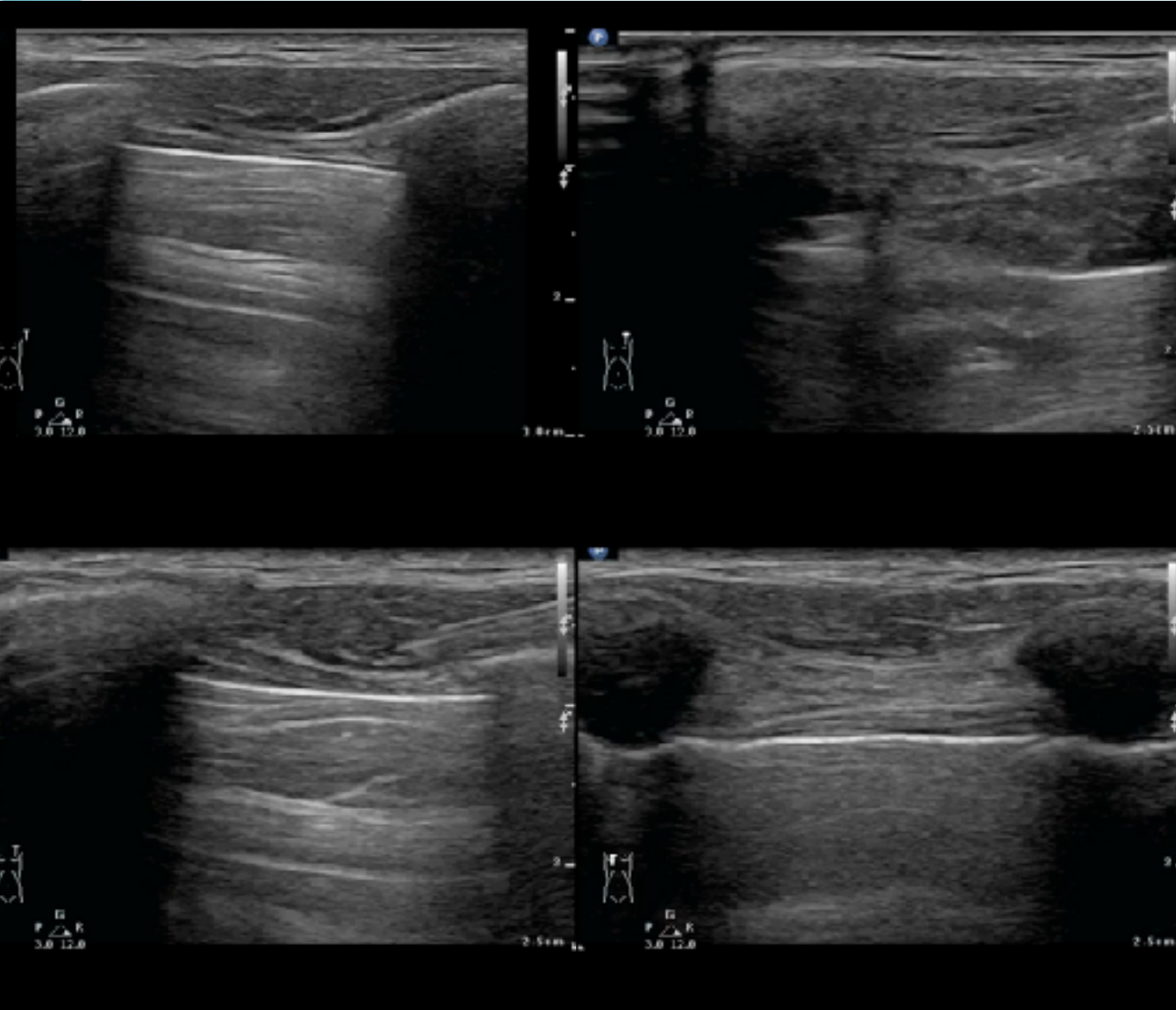


選定肋間

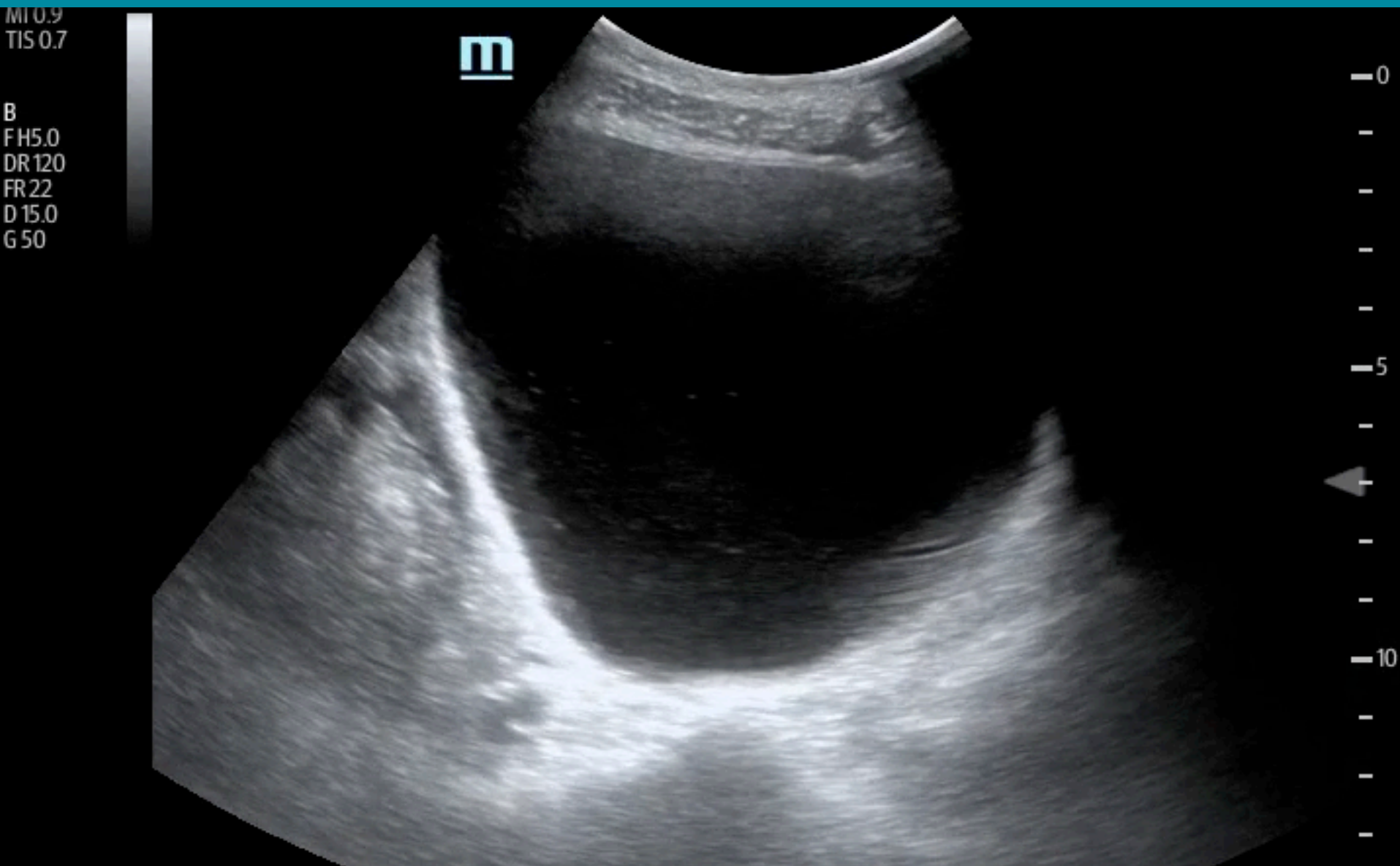
精準麻醉

導管置入

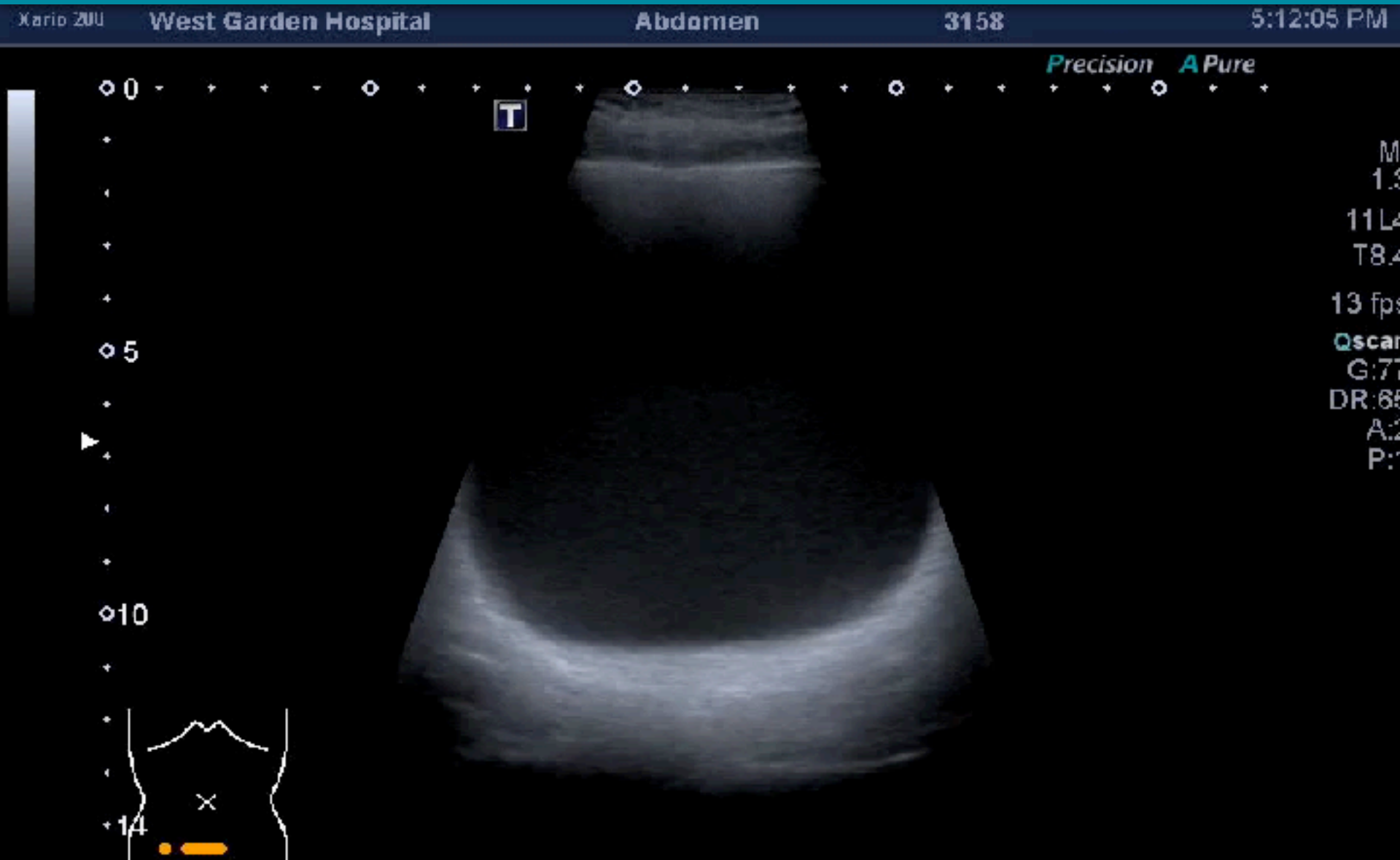
擴張評估<sup>22</sup>



# 66M, AUR due to urethral stone obstruction



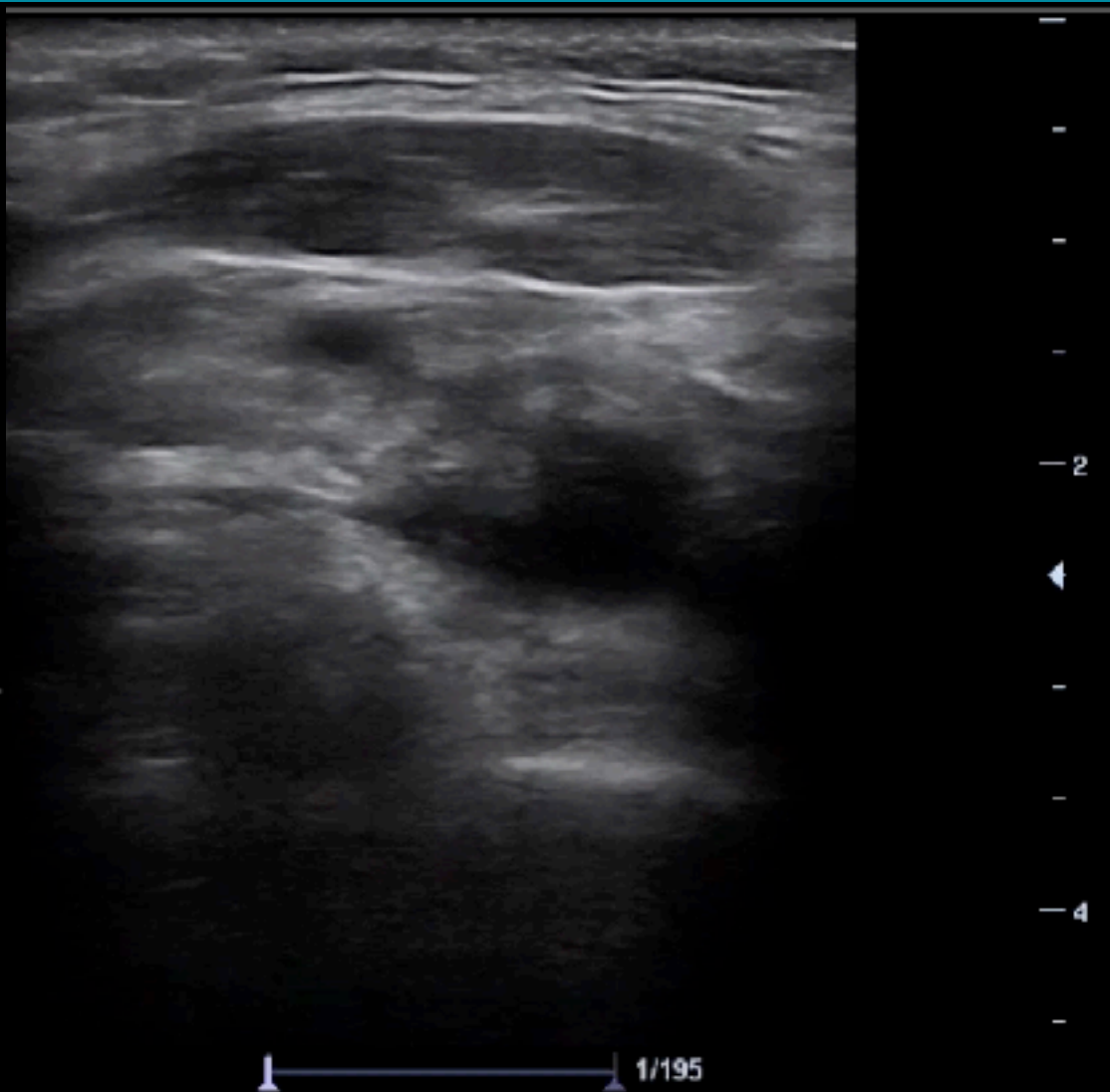
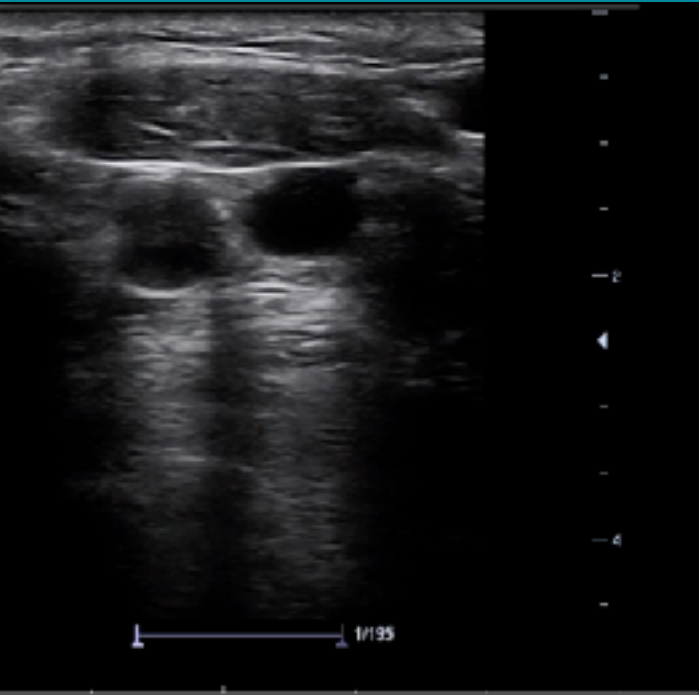
# 76M, AUR & urethral stricture



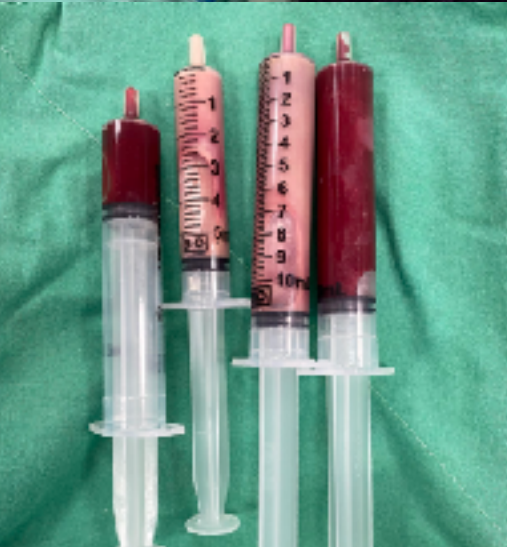
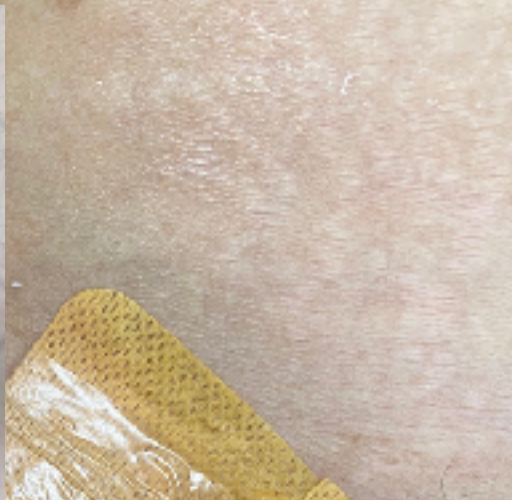
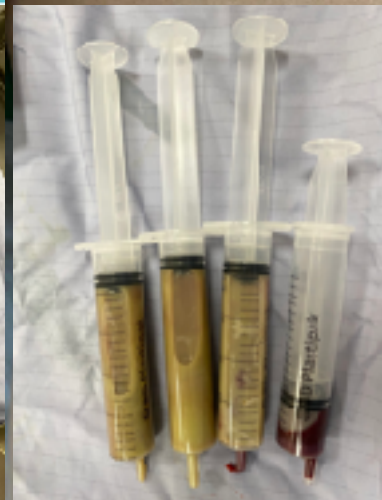
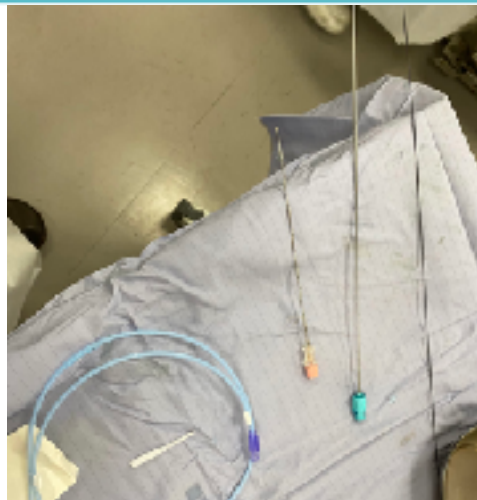
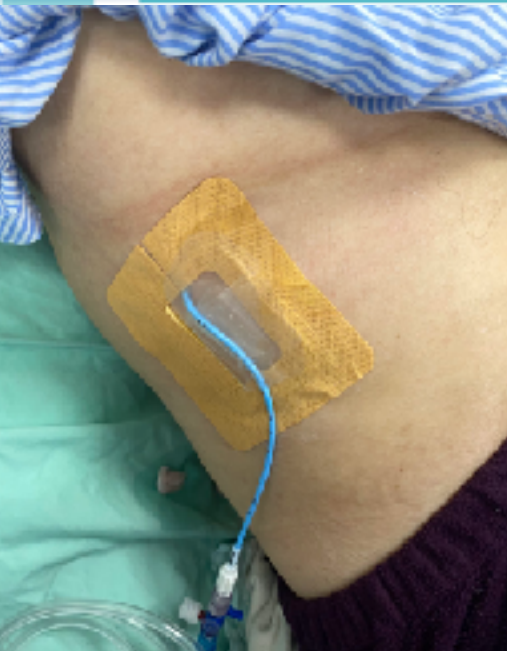# 穿刺前的三思: 合適? 安全? 容易?



# 超音波導引介入性治療



**NEO-SOF**  
Hydrophilic Drainage Catheters

\*和特®引流導管及穿刺導入系統

**引流導管組**  
Drainage Catheter Kit


規格：8FR - 帶線  
表面親水性塗層設計  
衛署醫器製字號00287D 號  
藥商：邦特生物科技股份有限公司

8FR (2.5mm)  
總長0.83M 帶線  
A=30cm B=25cm

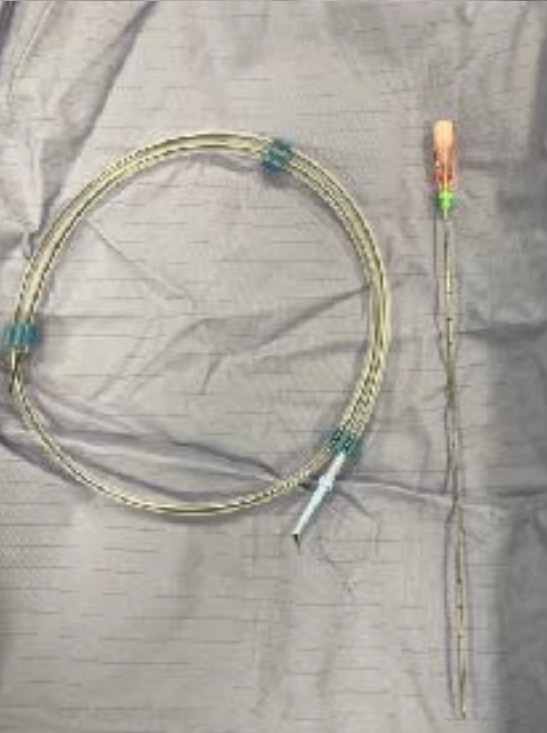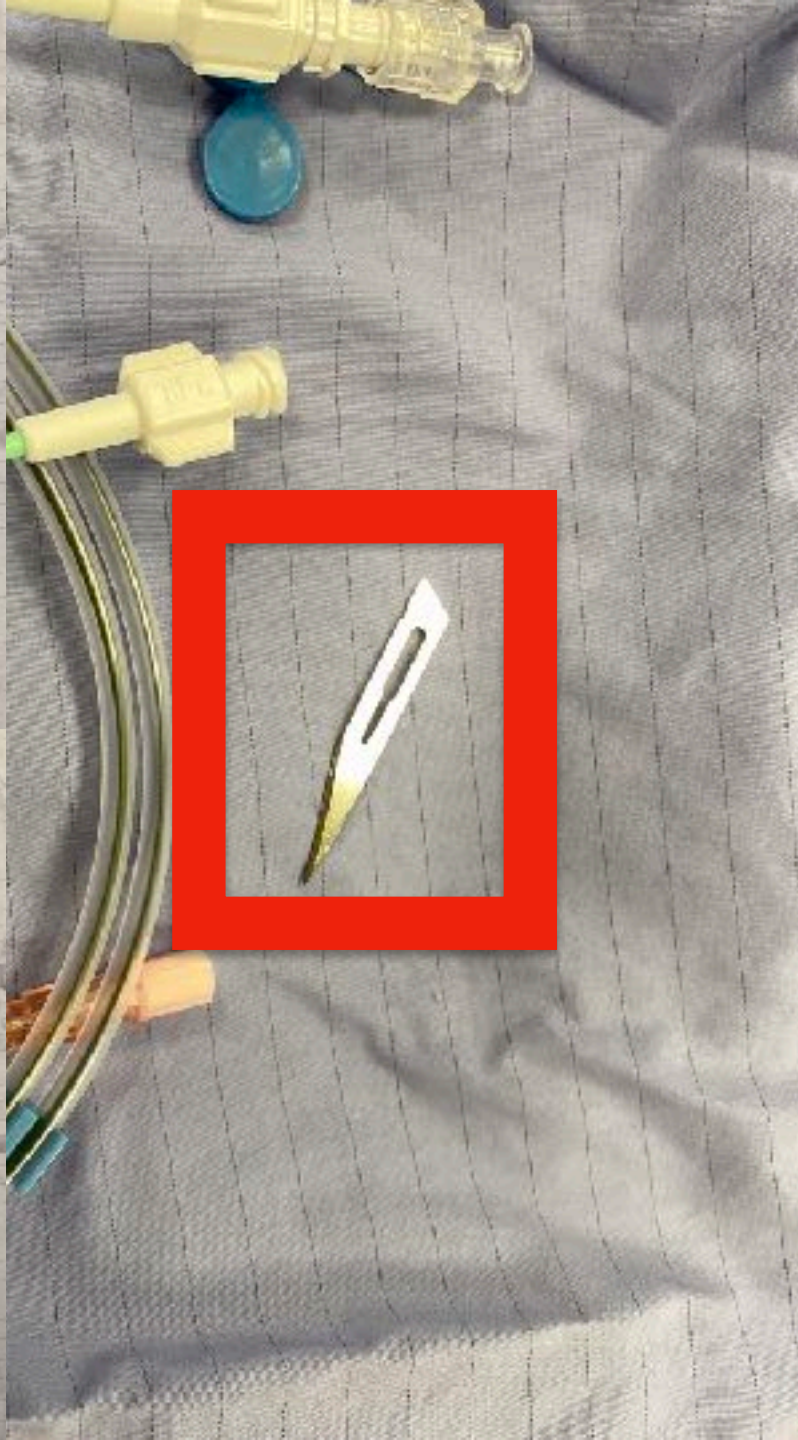
內容物：

(1) 導管	(1) 導管固定器
(1) 導管塞	(1) 導管帽
(1) 針筒	(1) 手洗液
(1) 膠尿管 (1.5x20cm)	(1) 蓋轉圈
(1) 膠尿管針座 (1.5)	
(1) 引流鋼線 (0.037)	

0 541 5880 5880 0 011014 0100000





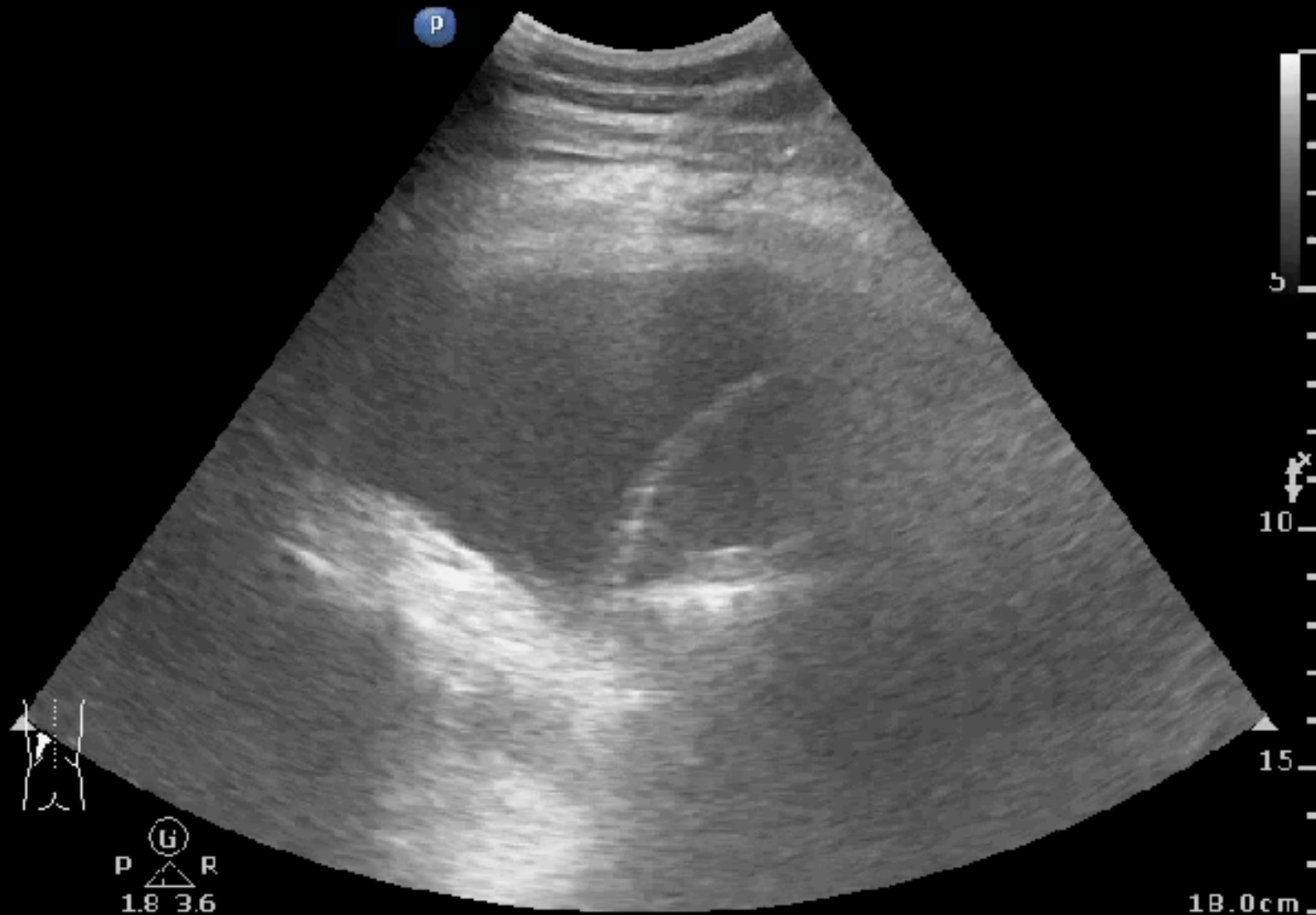

# Pigtail drainage with stylet



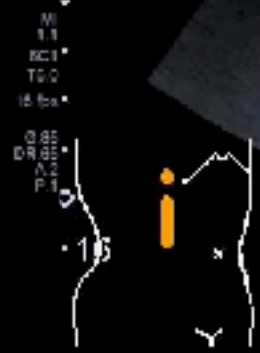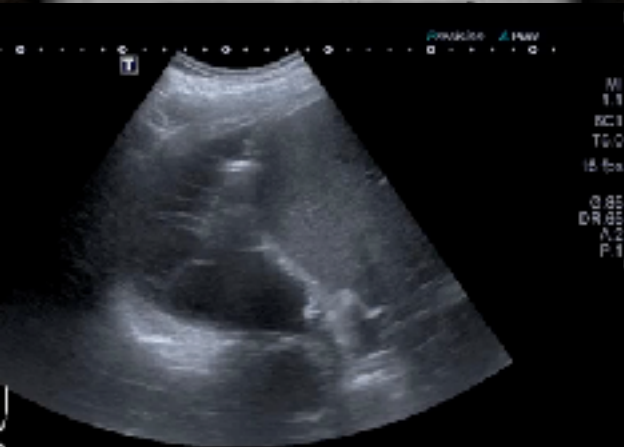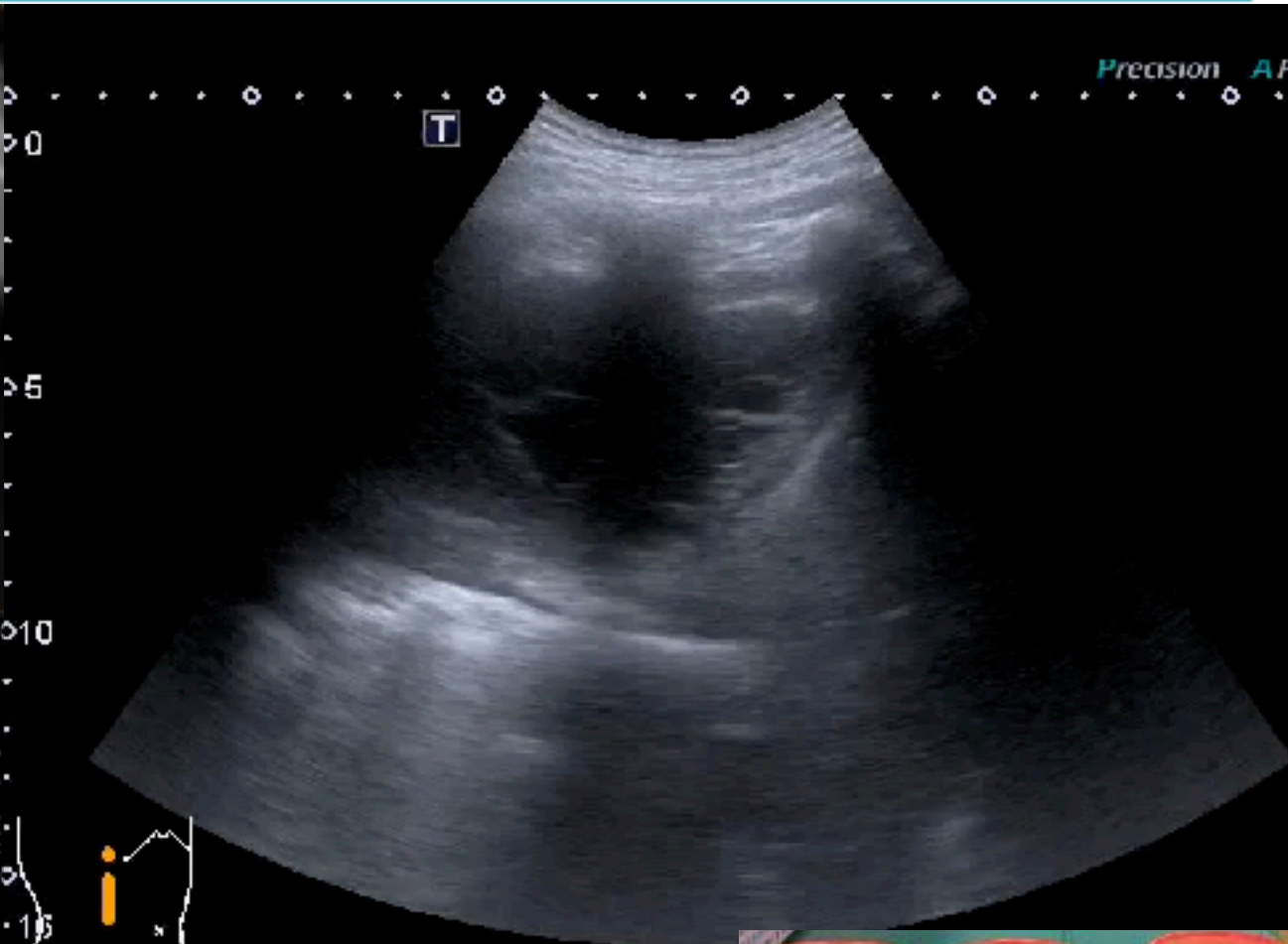
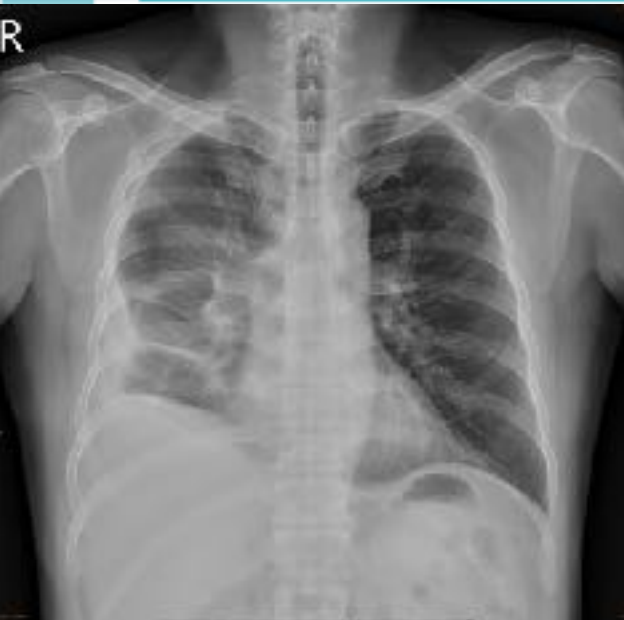Abd Gen2  
C5-1  
30 Hz  
18.0cm

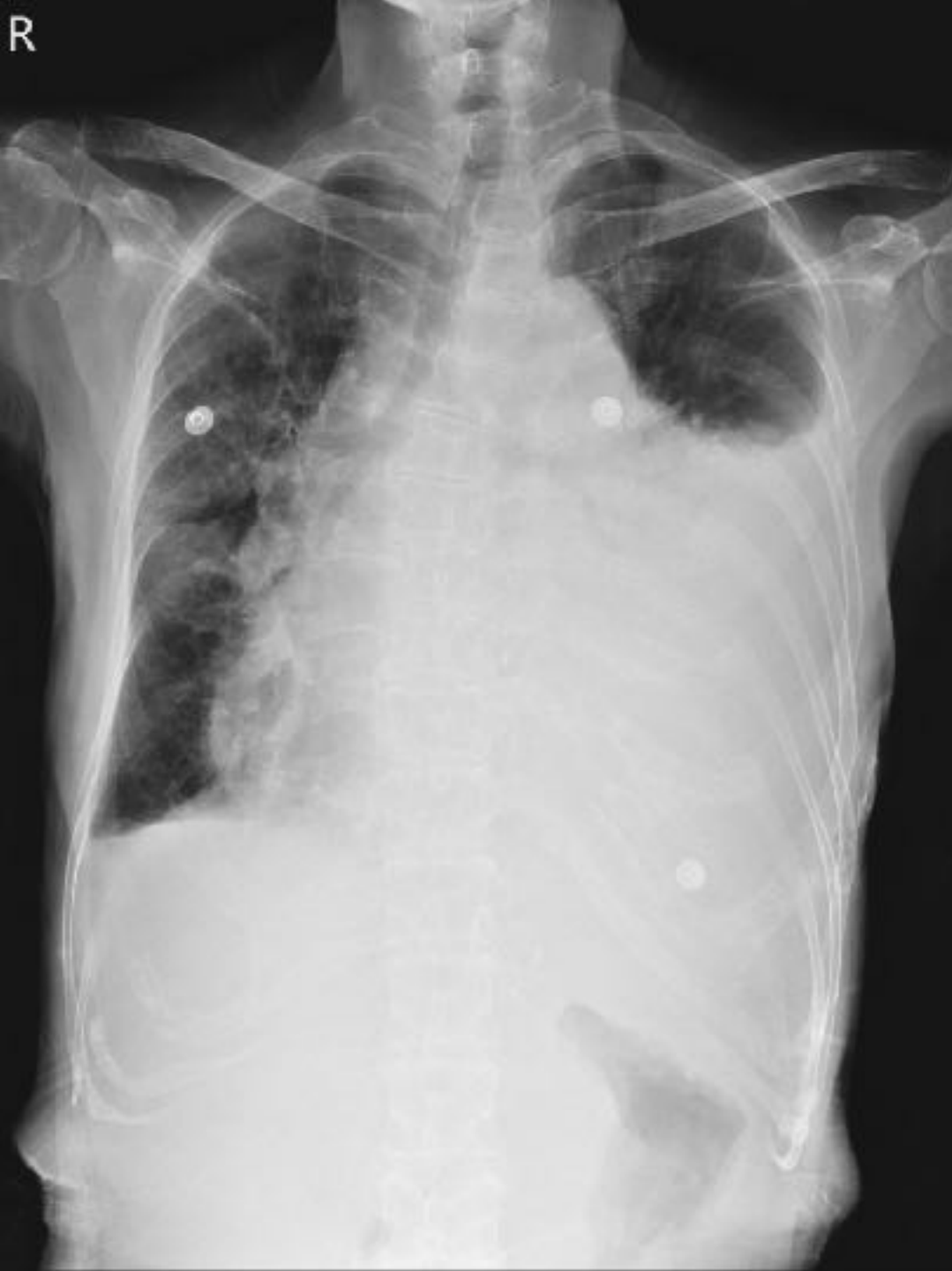2D  
HGen  
Gn 100  
C 56  
3 / 3 / 3





# Pigtail drainage with guidewire





# 個案

62F

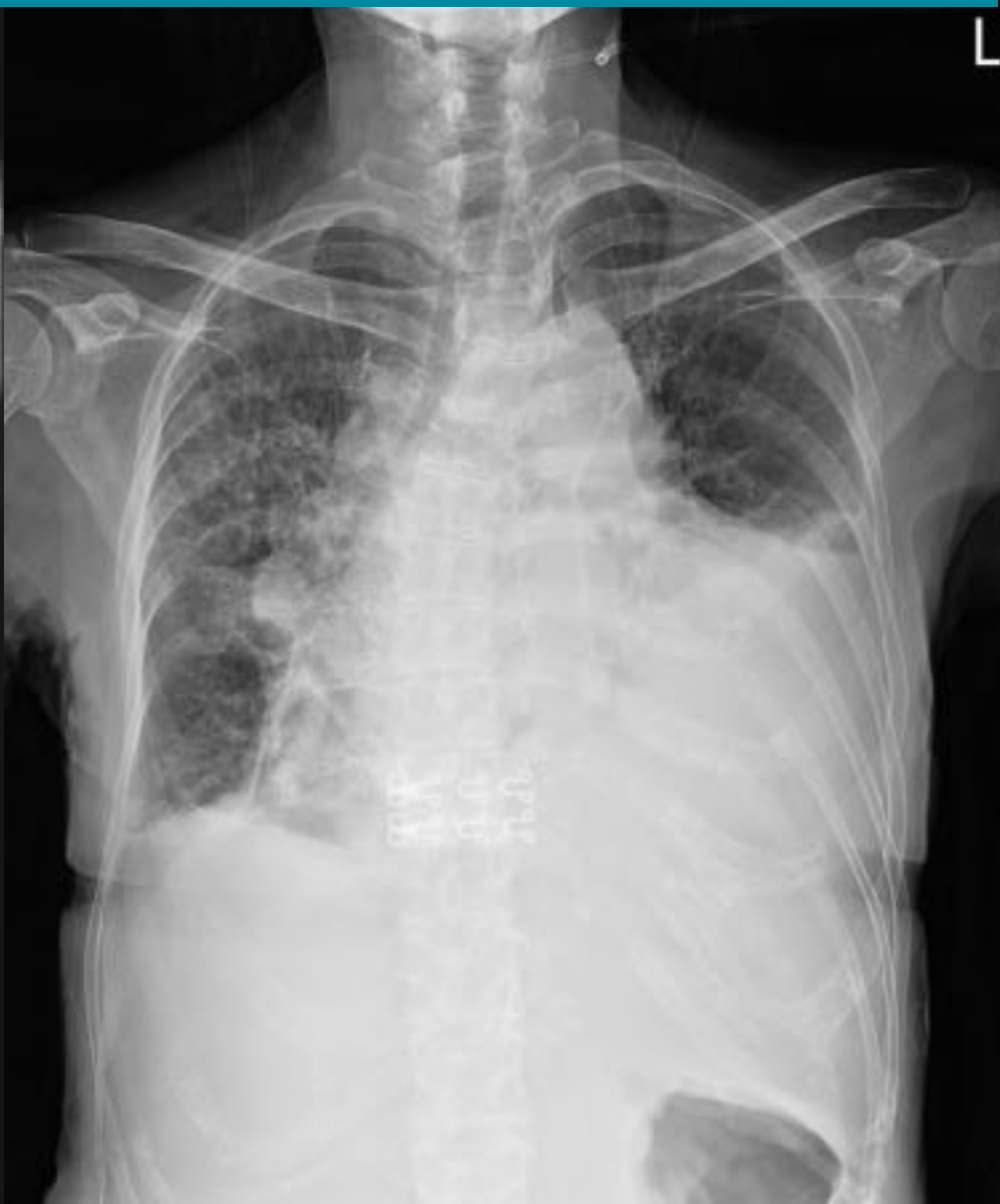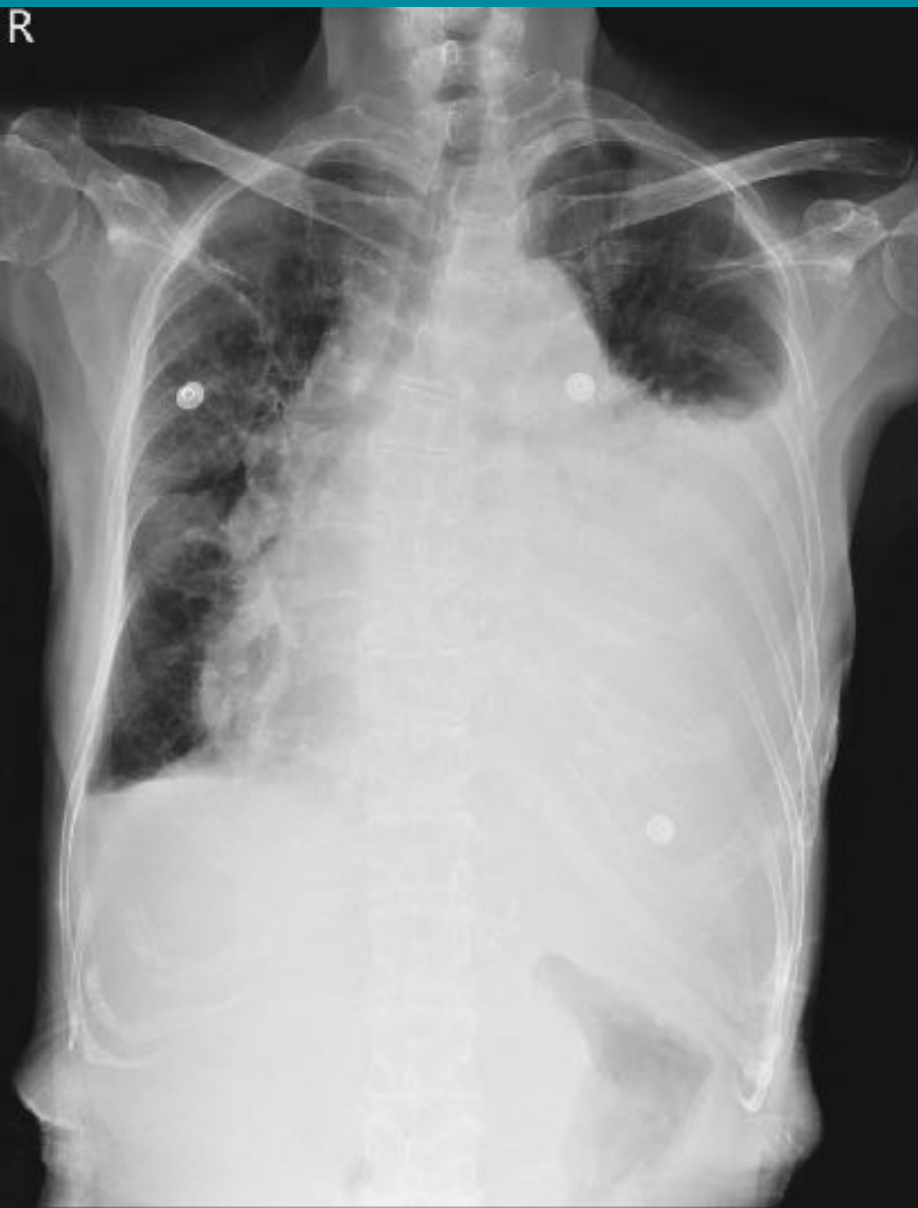Hx of breast cancer

4天前於急診進行  
Pleural effusion  
tapping 600 ml

主訴：  
呼吸困難 &  
心博過速

4天前

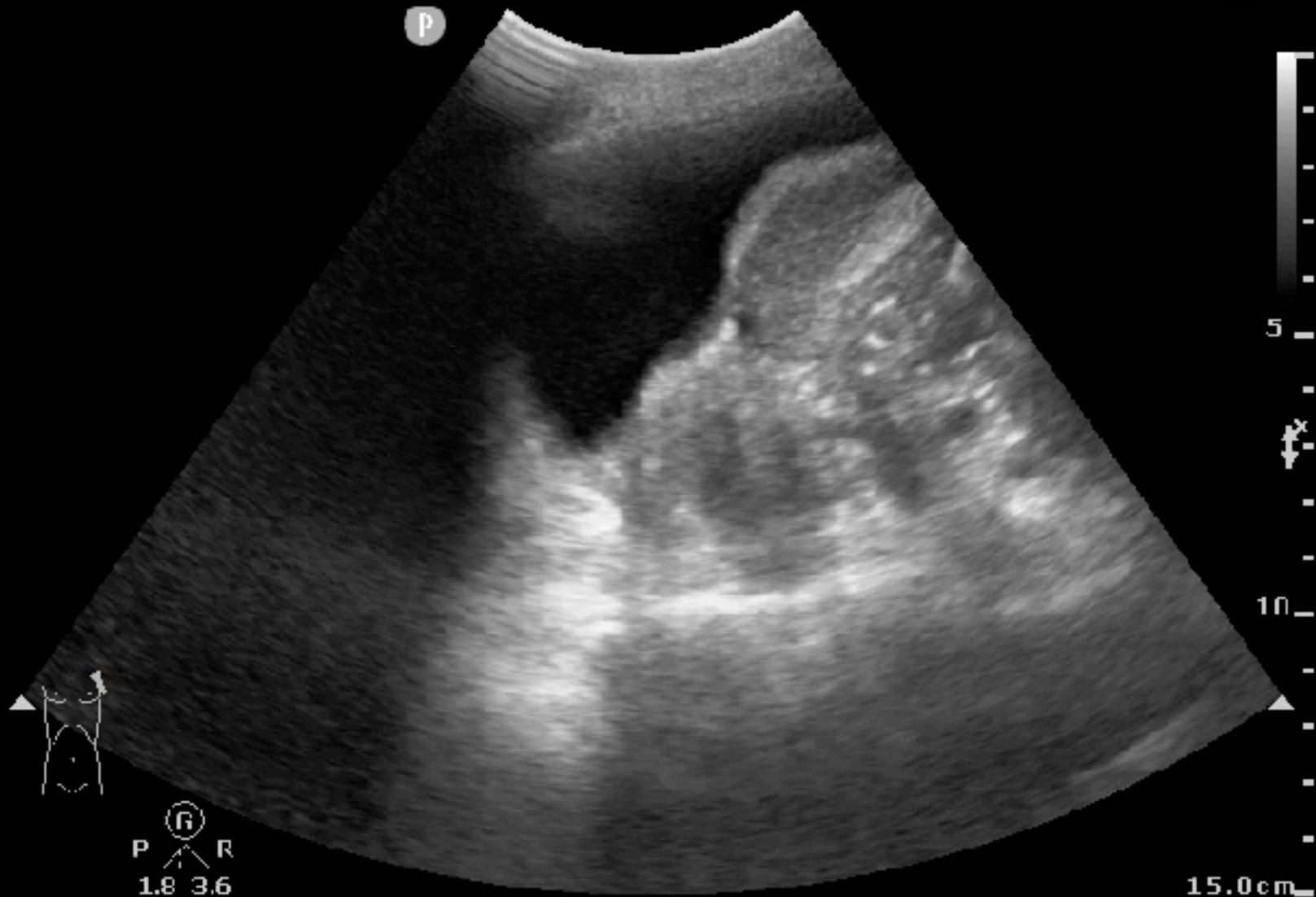
就診日



# PLE相關？

Abd Gen  
C5-1  
34 Hz  
15.0cm

2D  
HGen  
Gn 100  
C. 56  
3/3/3



P R  
1.8 3.6

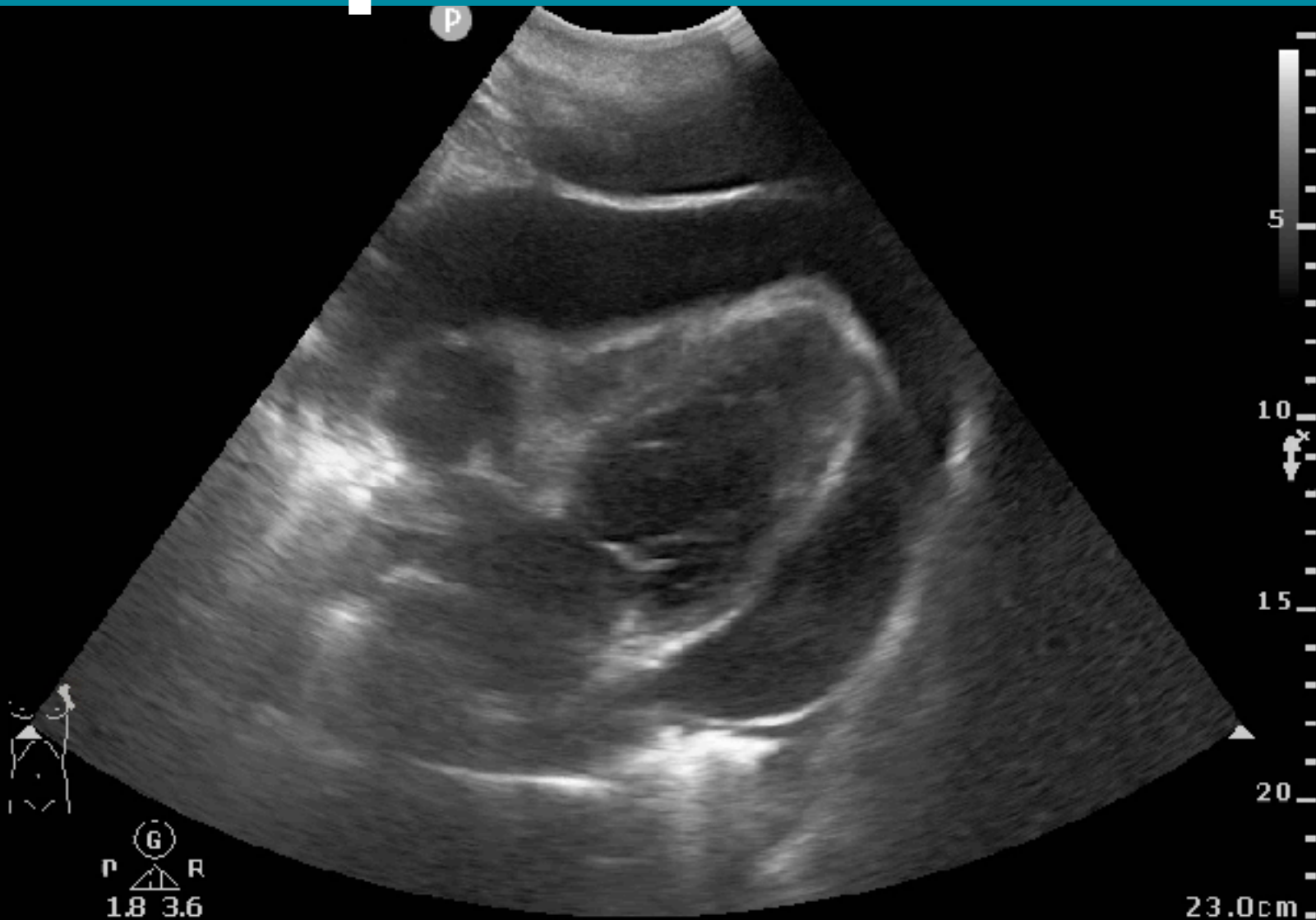
15.0cm



# Tamponade ?

bd Gen  
5-1  
5 Hz  
3.0cm

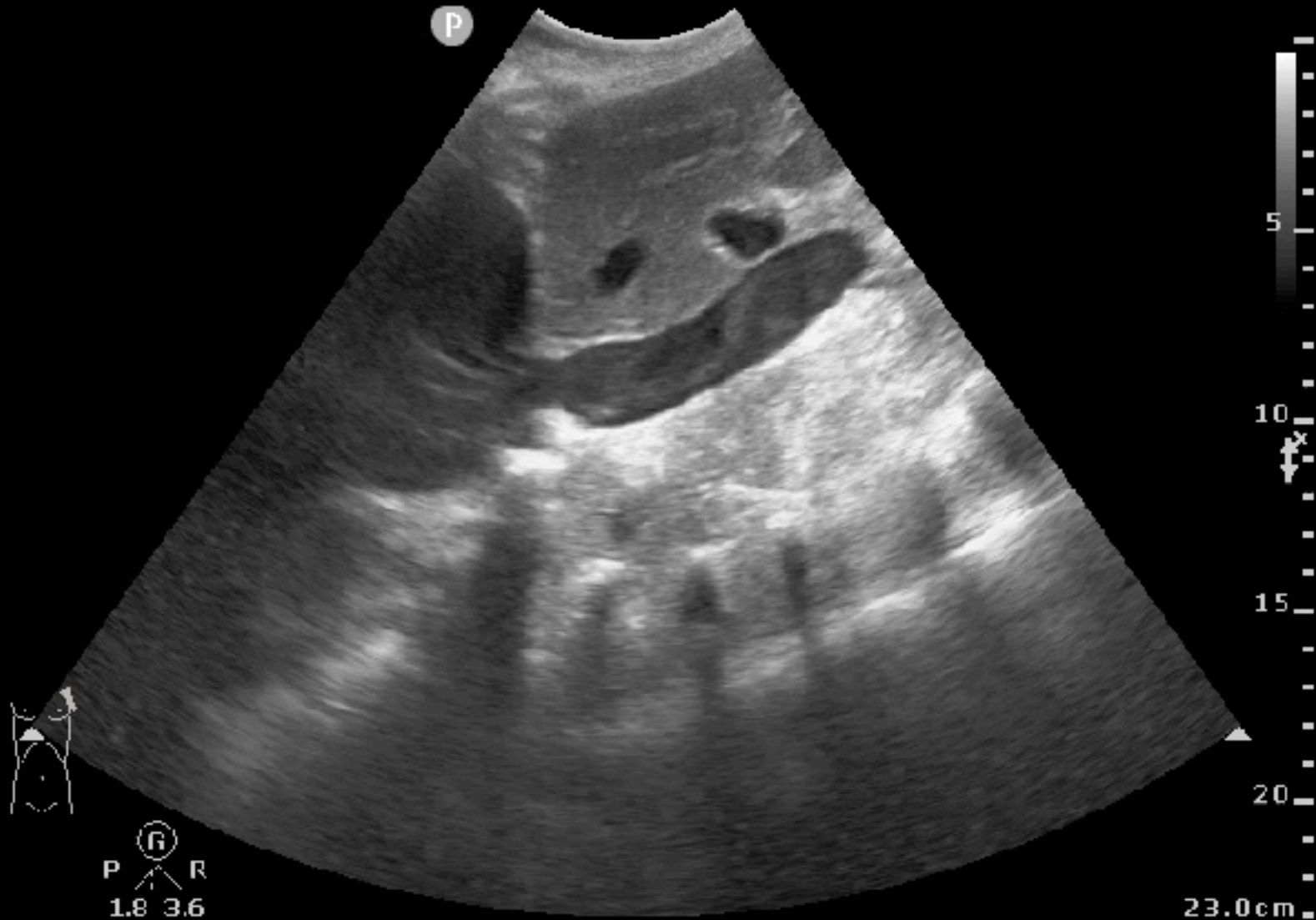D  
HGen  
Gn 100  
C 56  
3/3/3



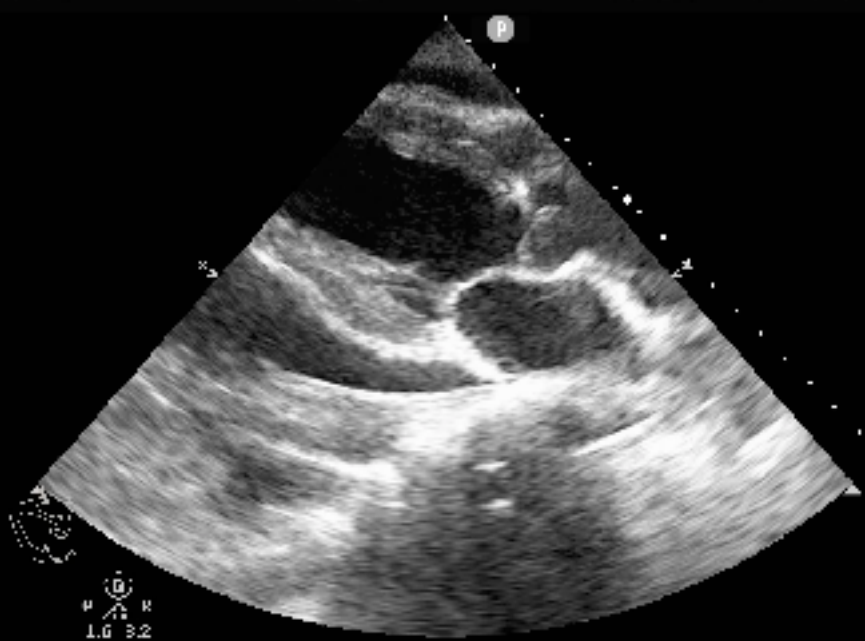
# 臨床/積液/鼓漲

Abd Gen  
C5-1  
25 Hz  
23.0cm

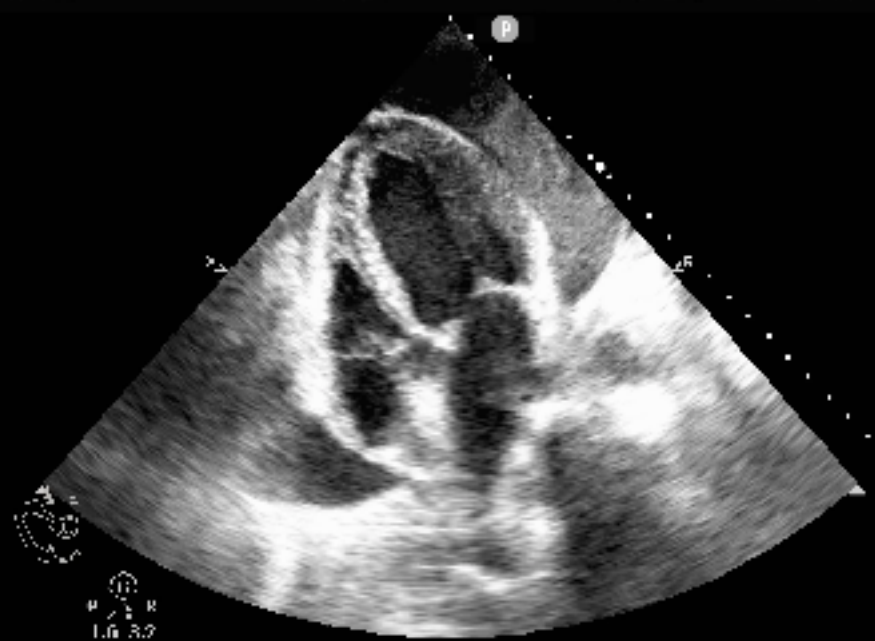
2D  
HGen  
Gn 100  
C. 56  
3/3/3



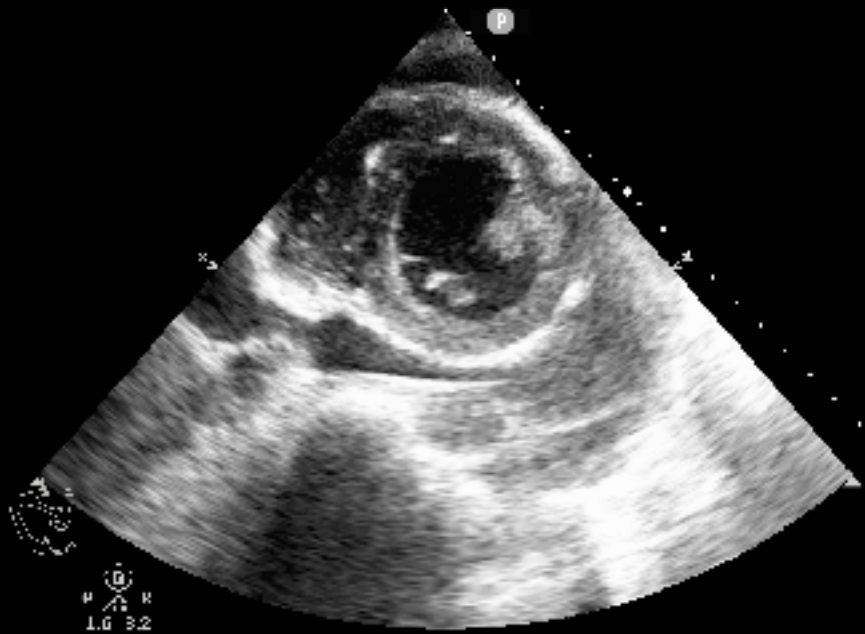cho



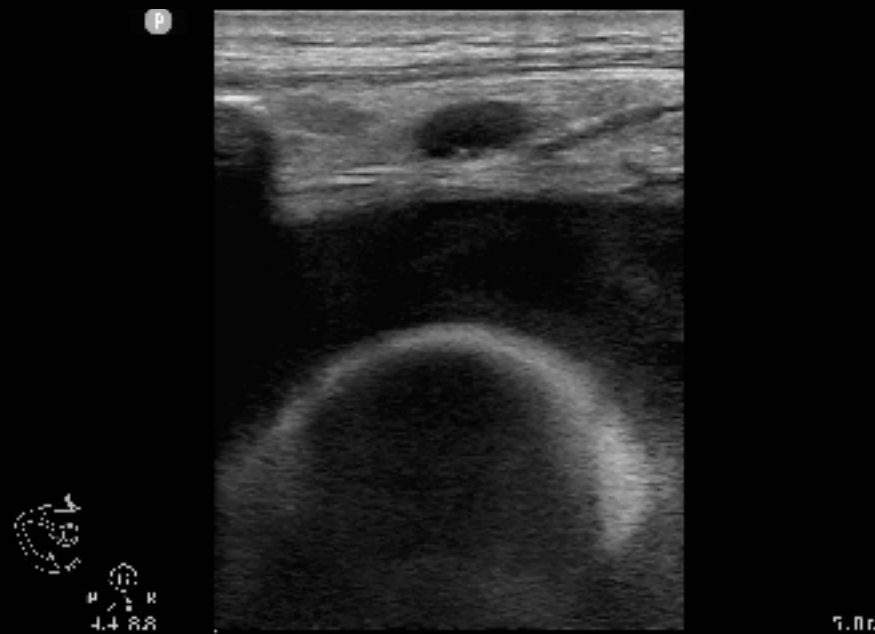
0



cho



0



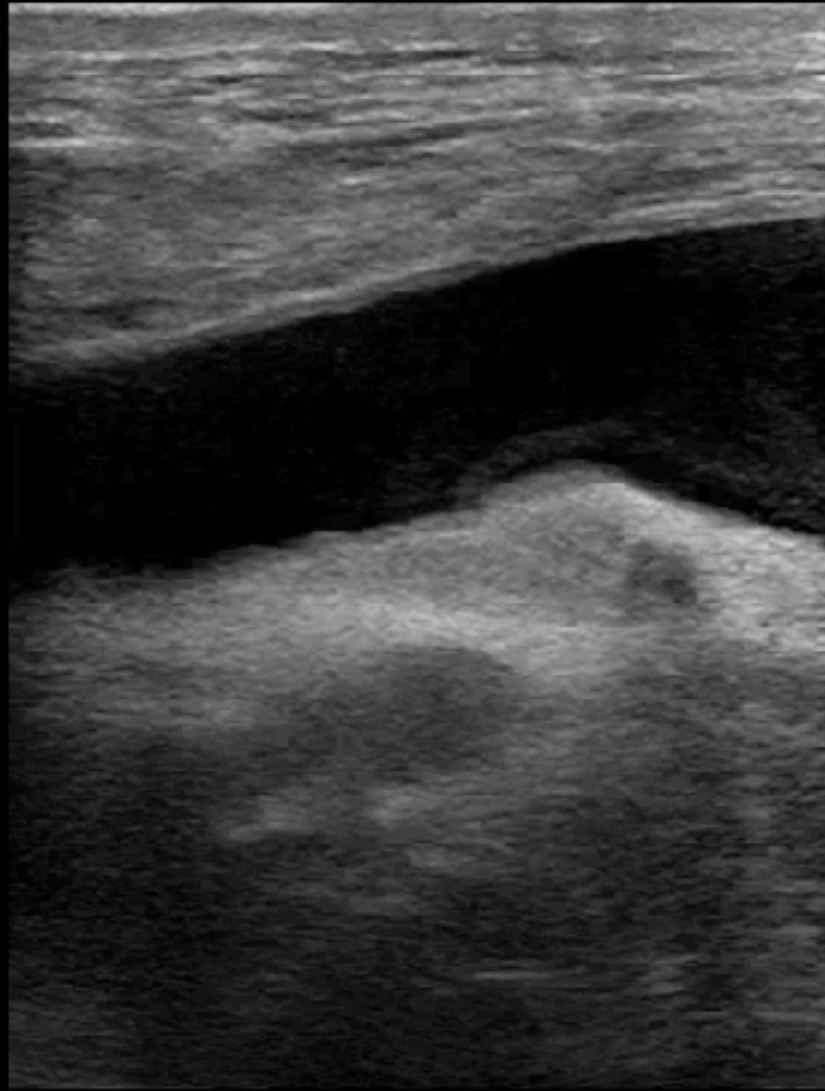
5.0 cm

# Step-by-step drainage

Arterial  
L12-3  
34 Hz  
5.0cm

2D

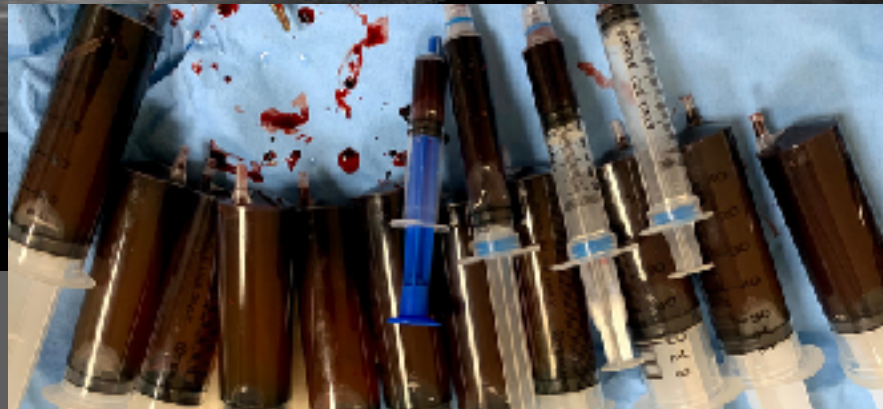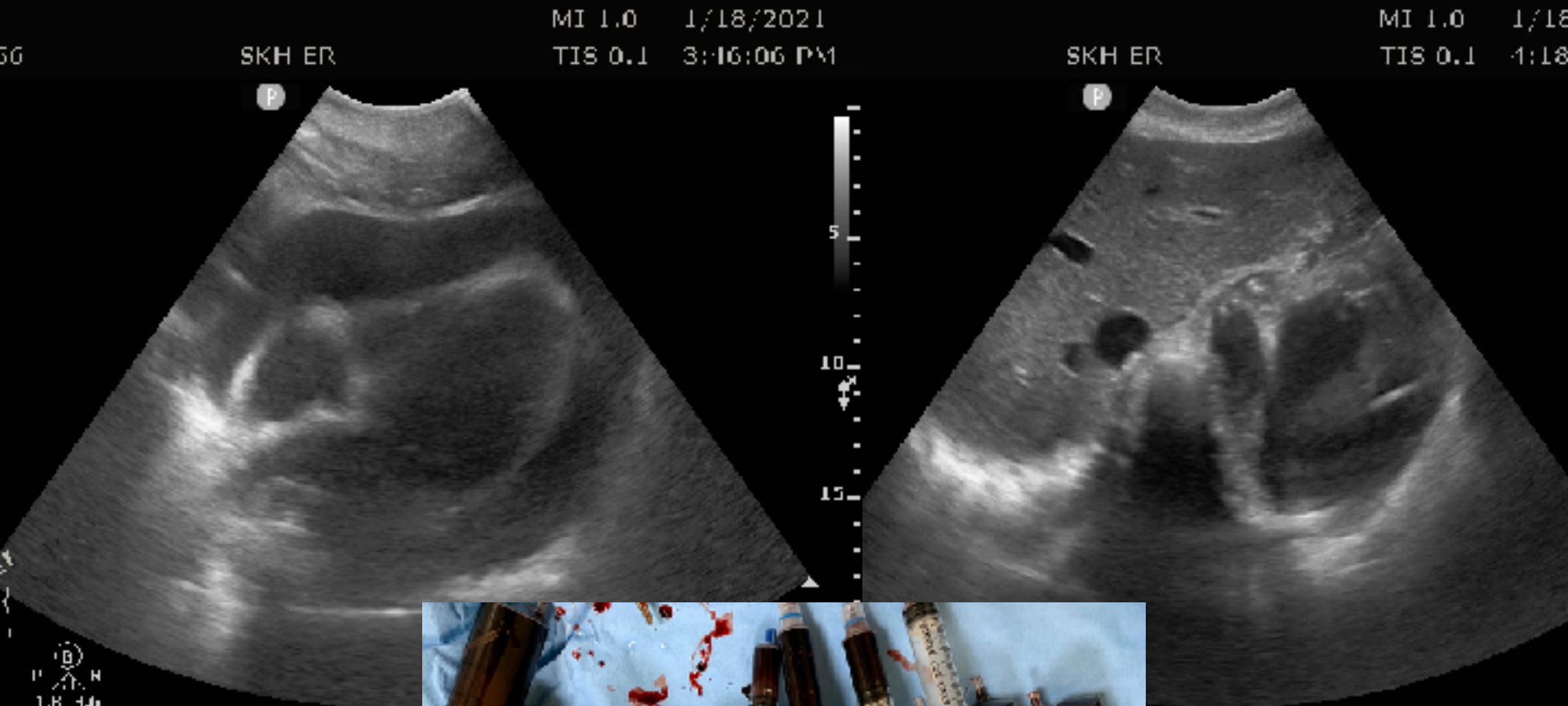
HGen  
Gn 66  
C. 41  
3/3/2



5.0cm



# Monitor after drainage





# 重點

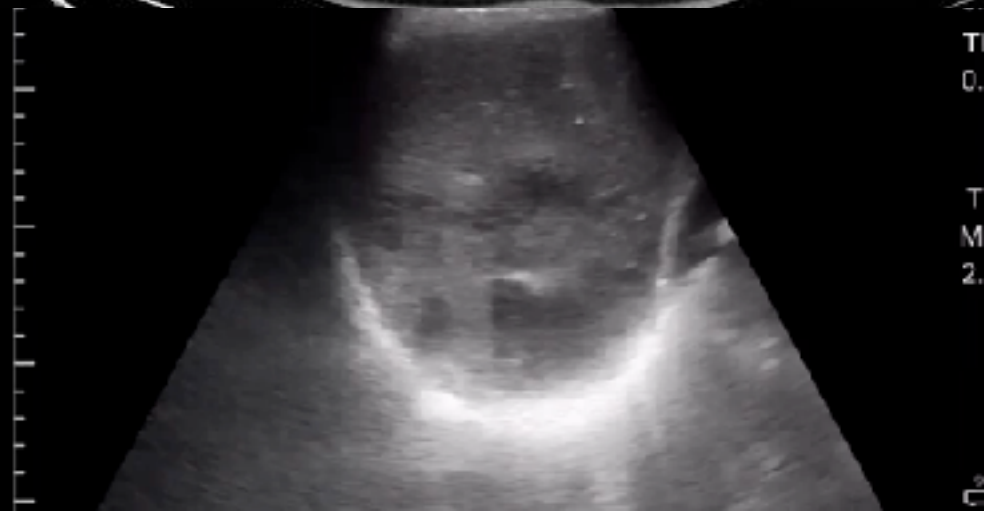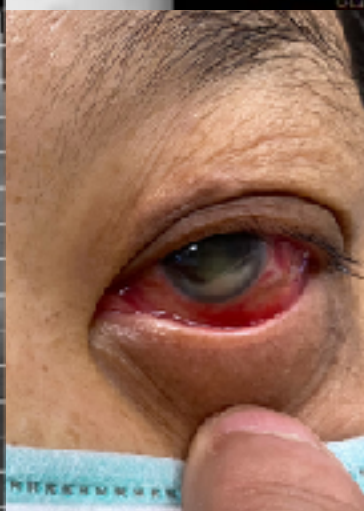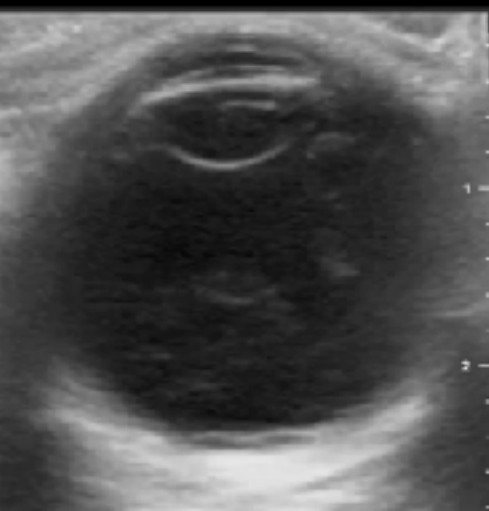
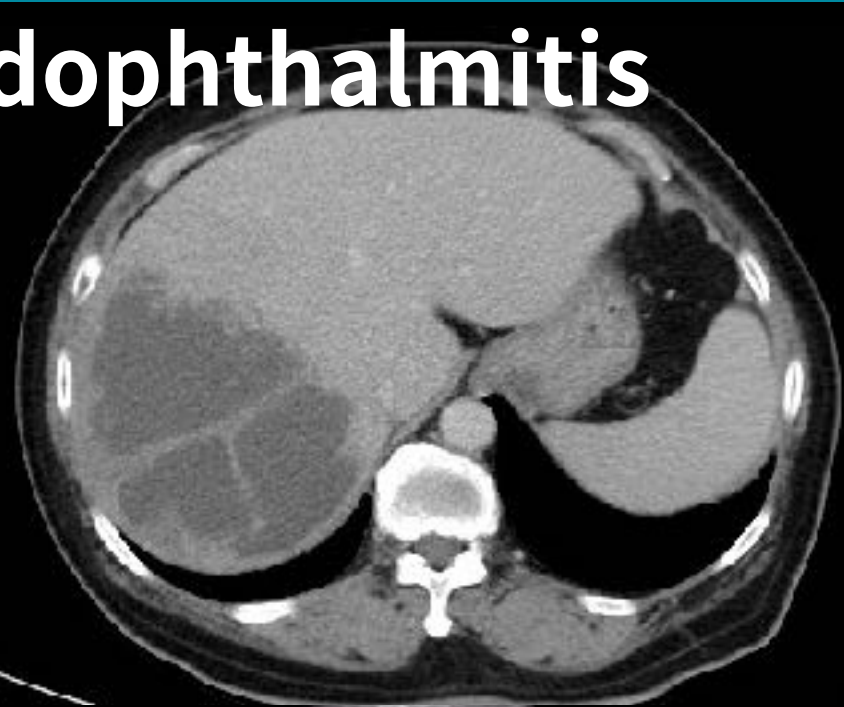
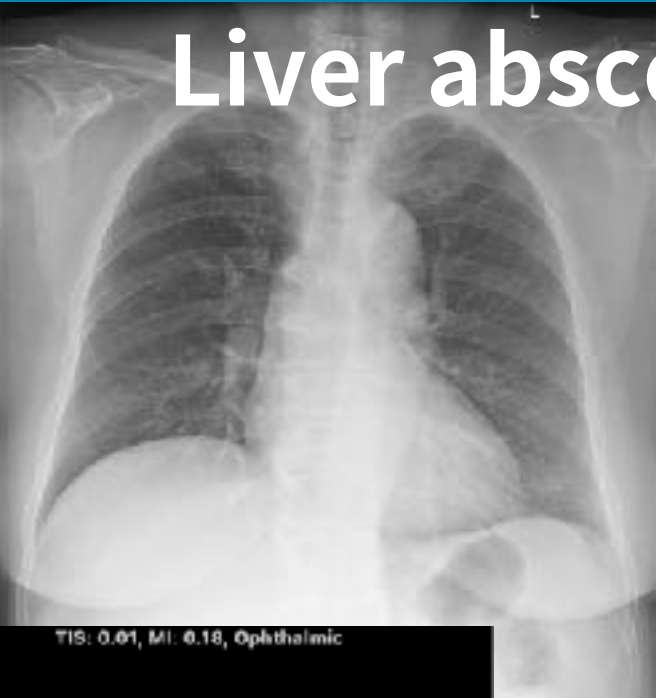引流三部曲

選最短路徑

精準的運針

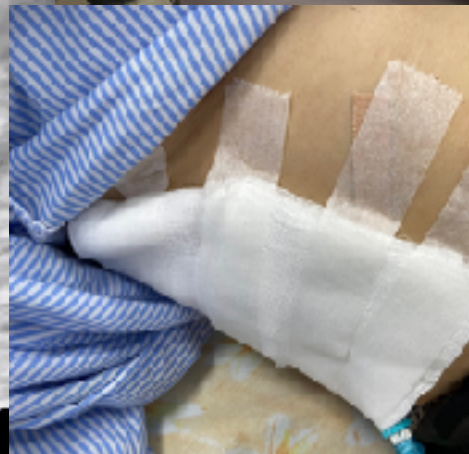
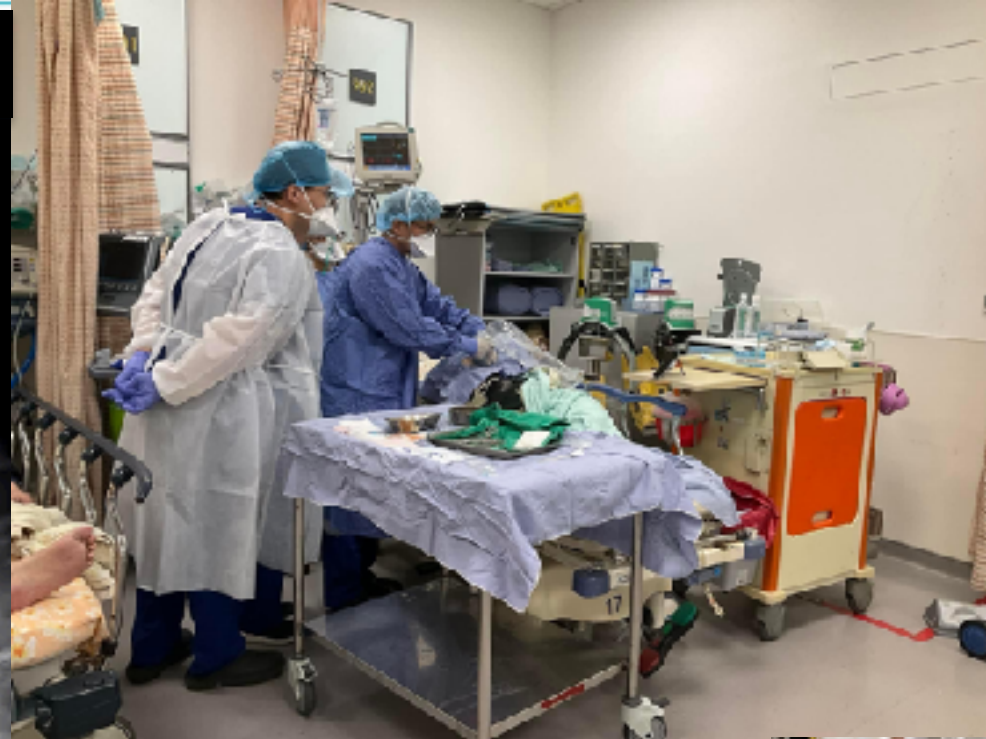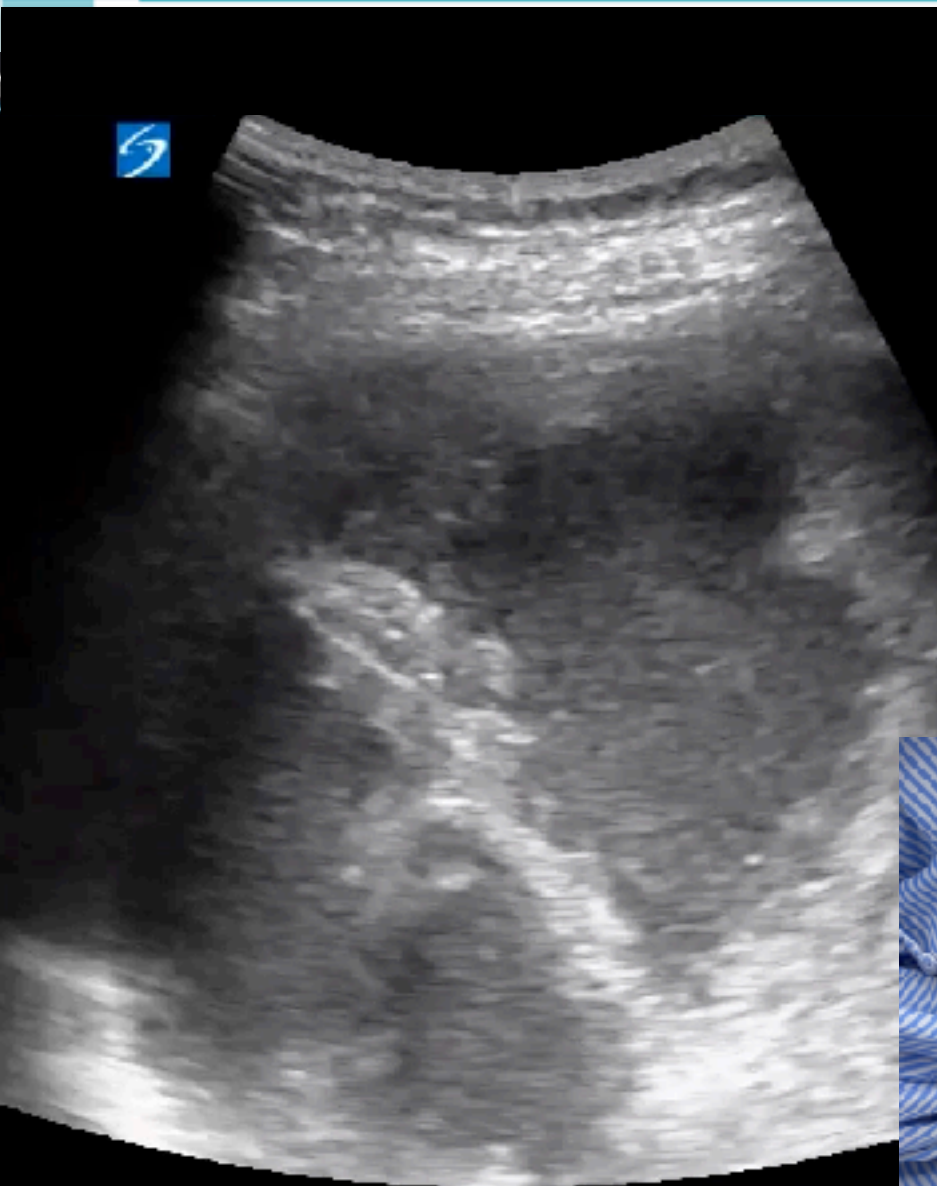
65F, left eye redness, pain; R chest pain

Liver abscess / Endophthalmitis



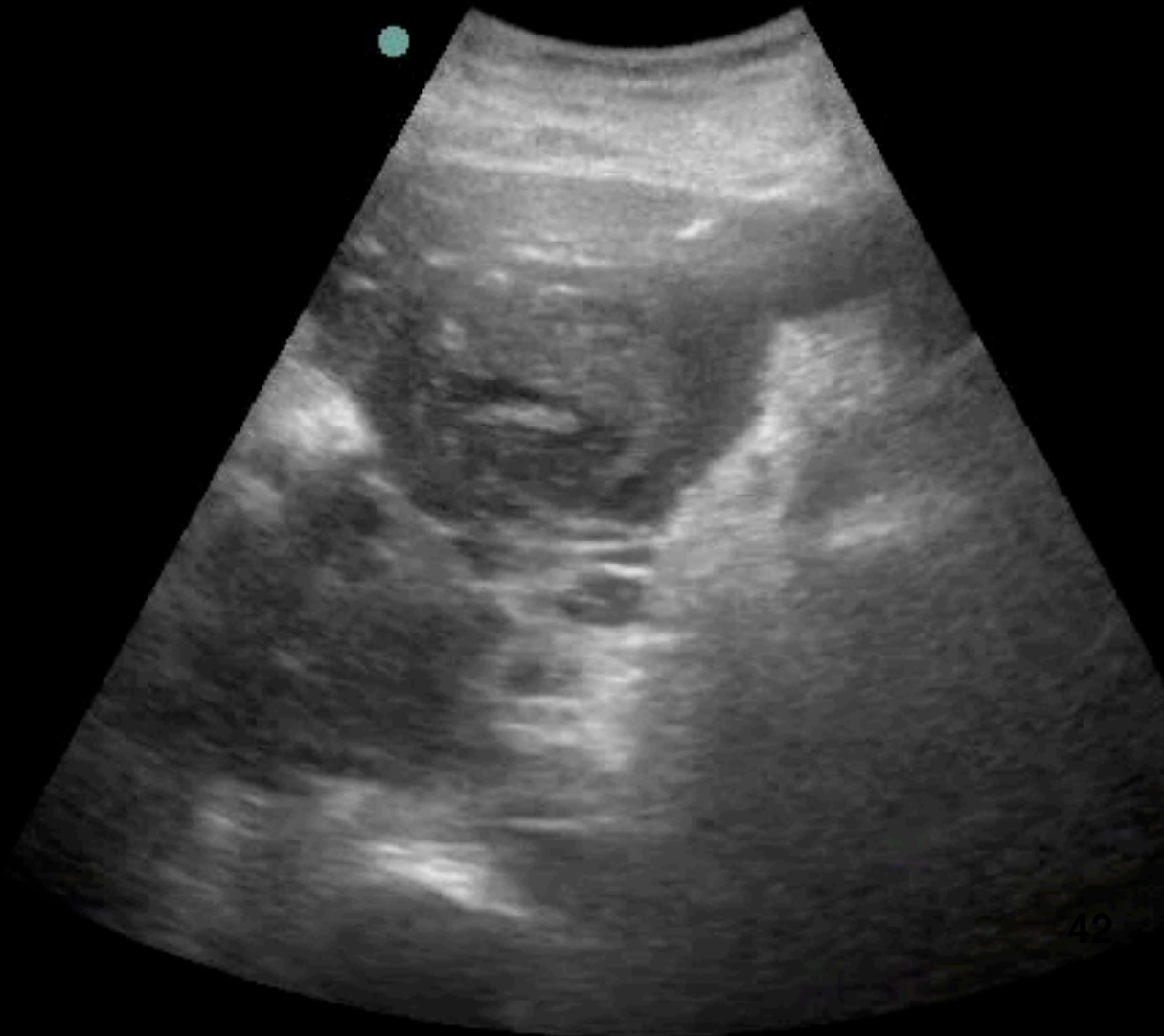
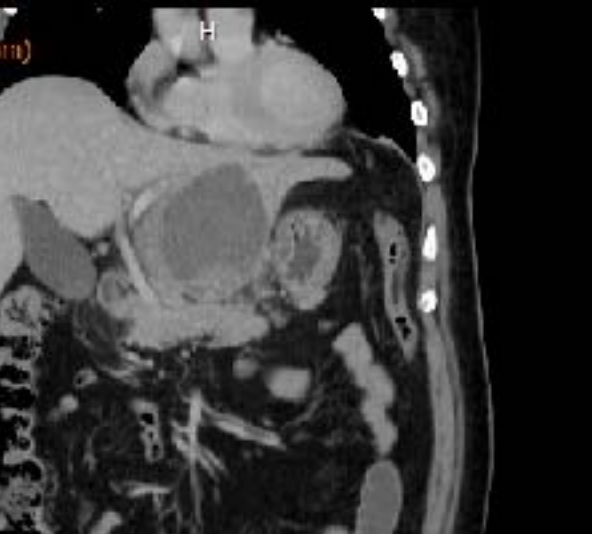
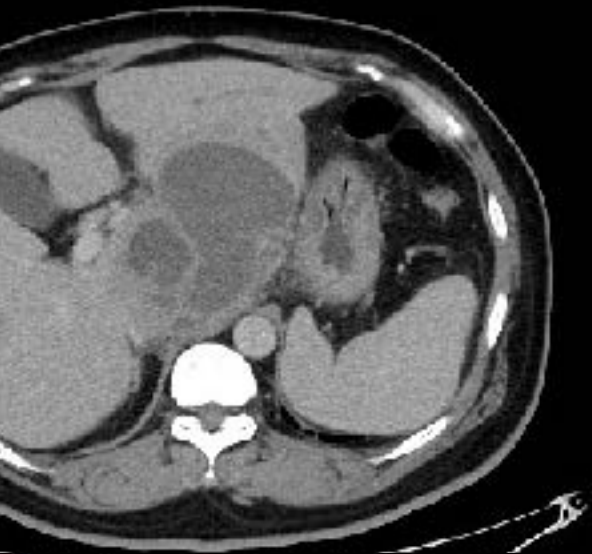

# Pigtail for liver abscess drainage



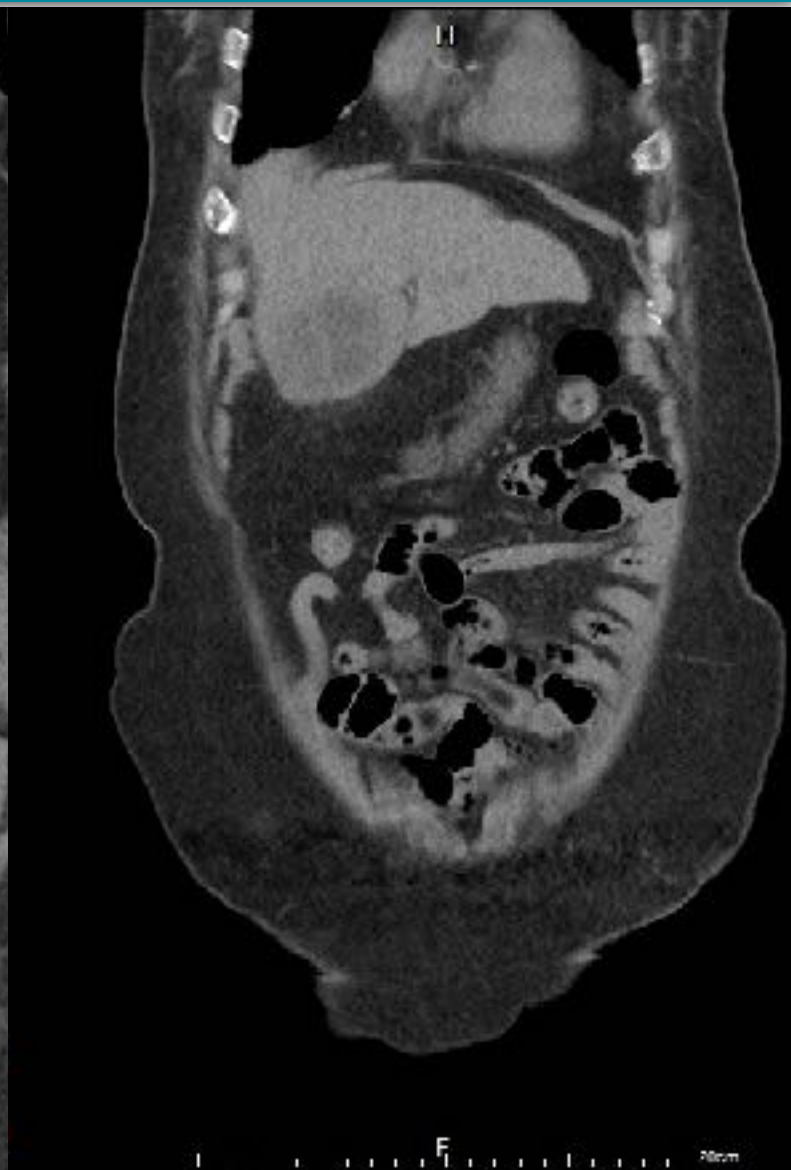
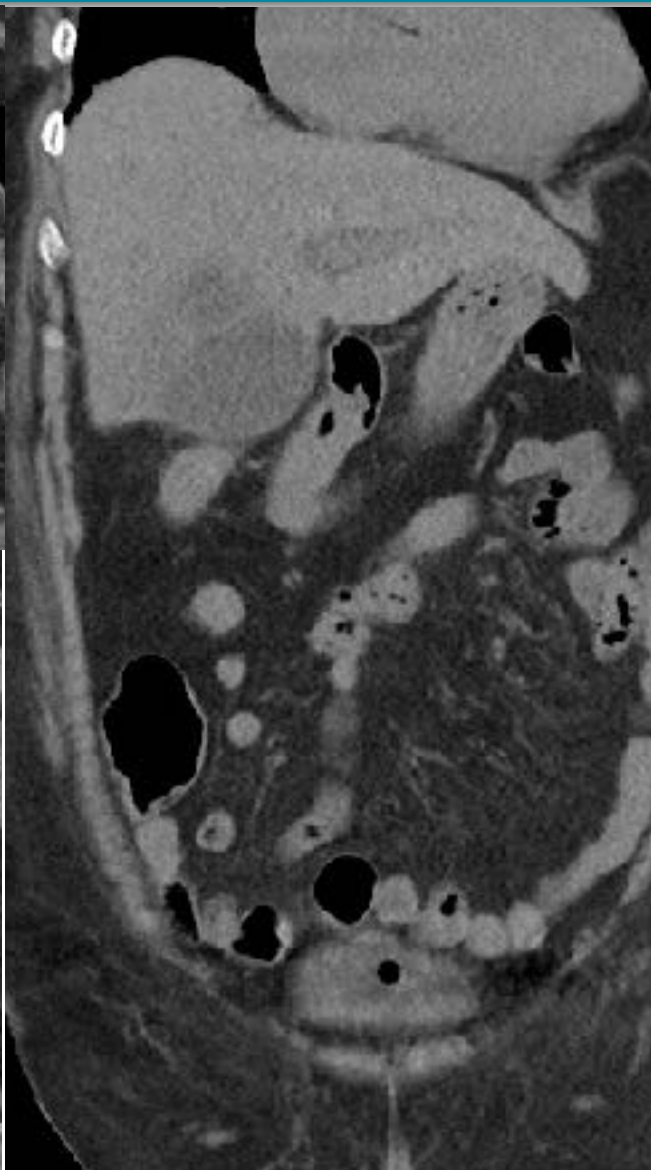
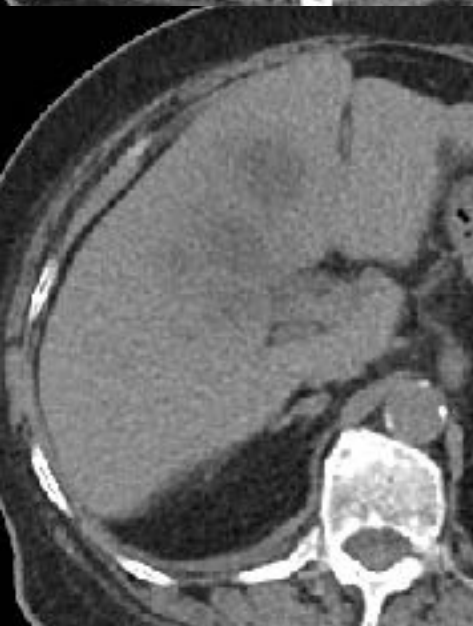
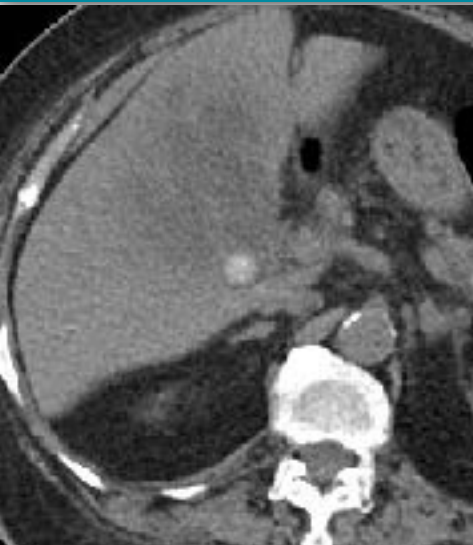
# 53M, liver abscess

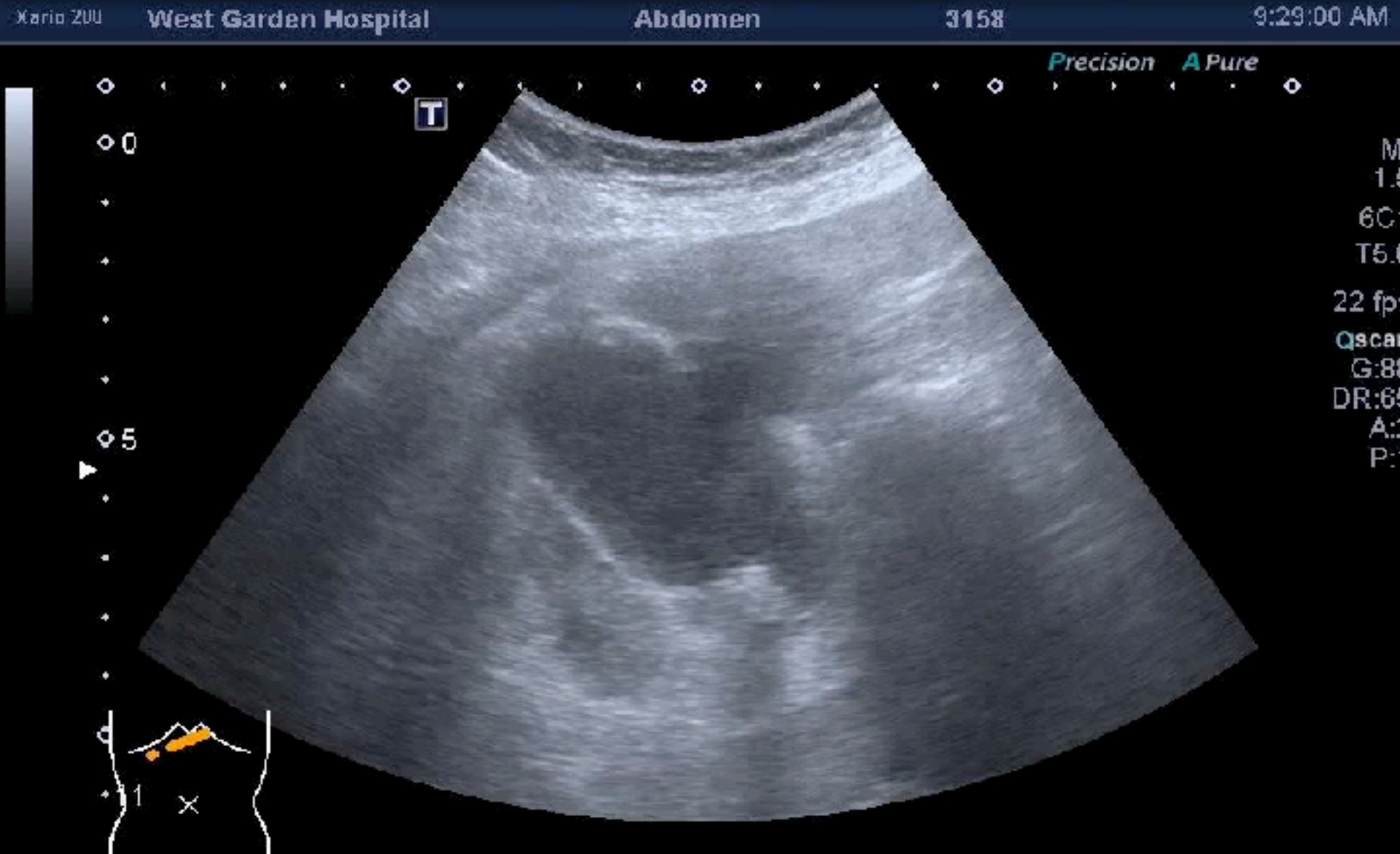

**Total amount > 1000ml**

# 94F, right abdominal pain with fever

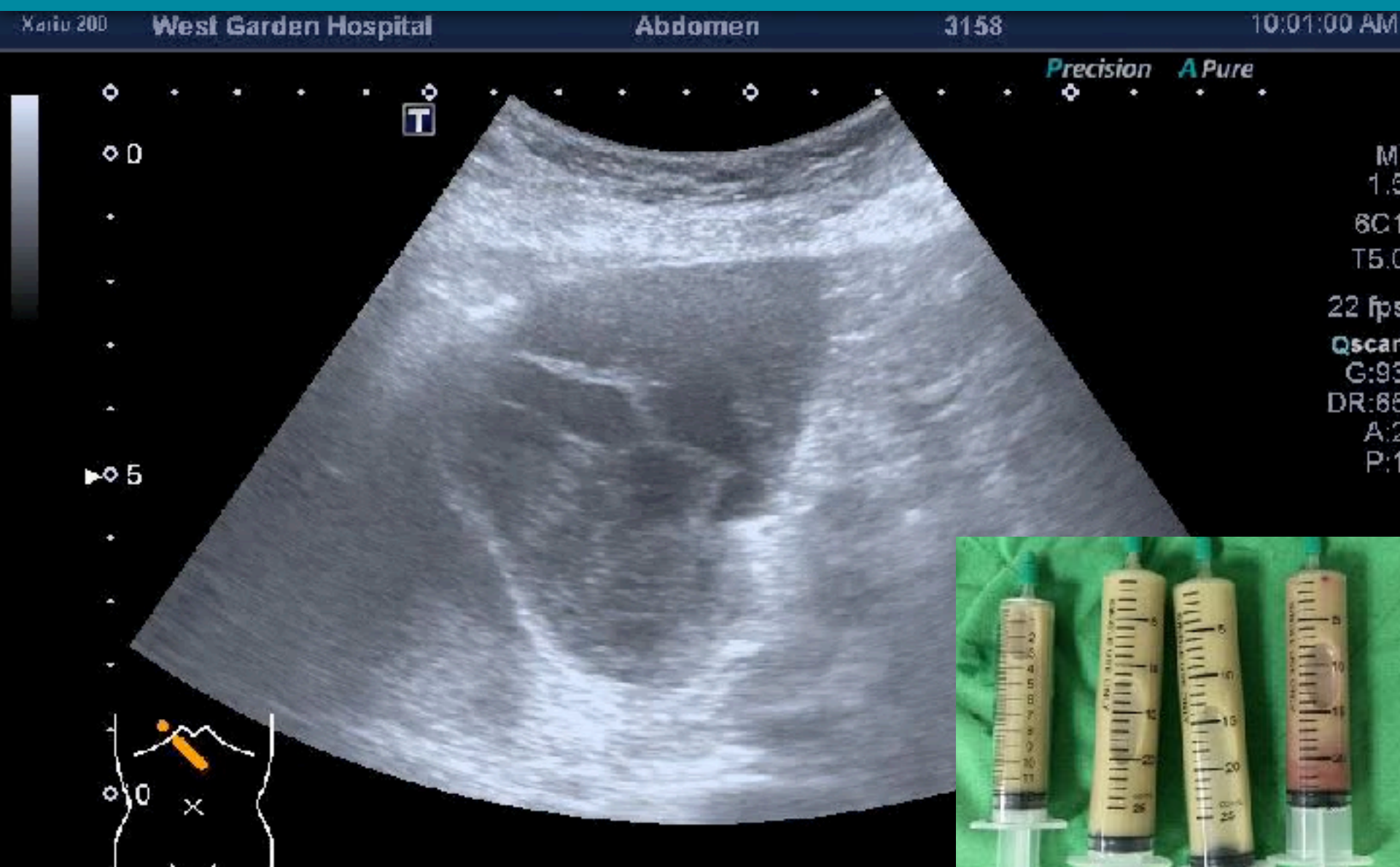


# GB empyema with rupture



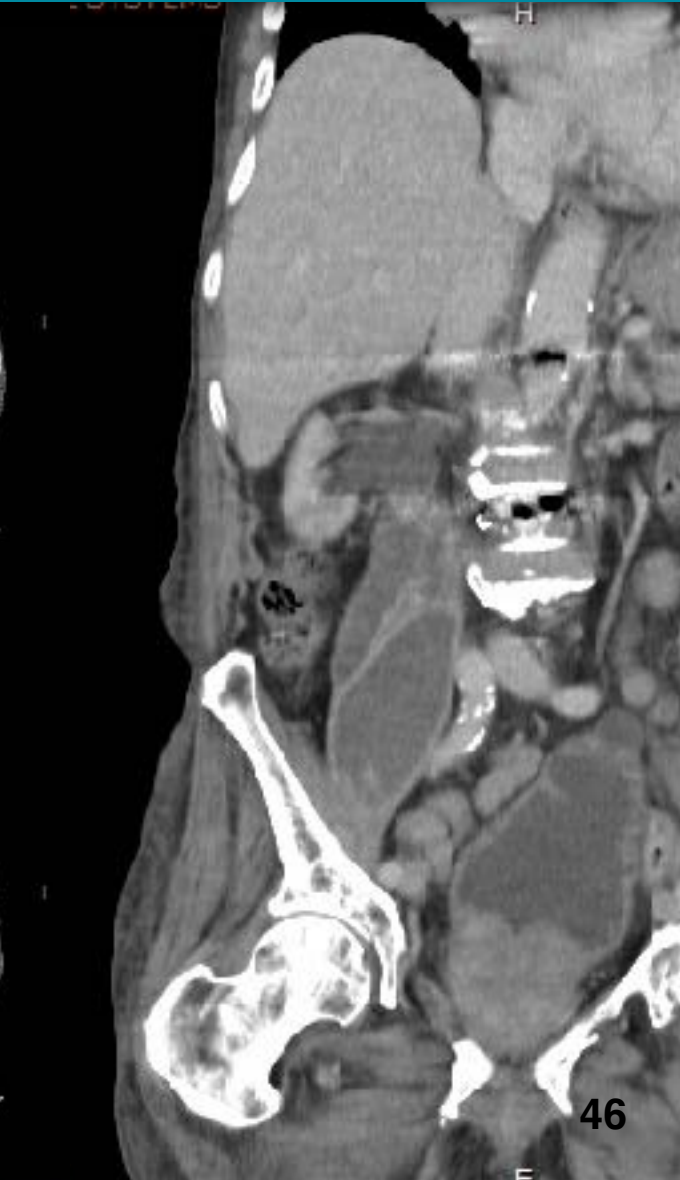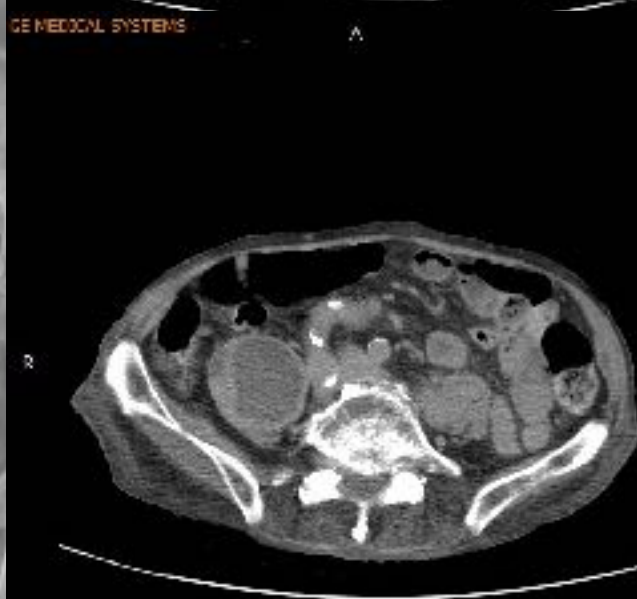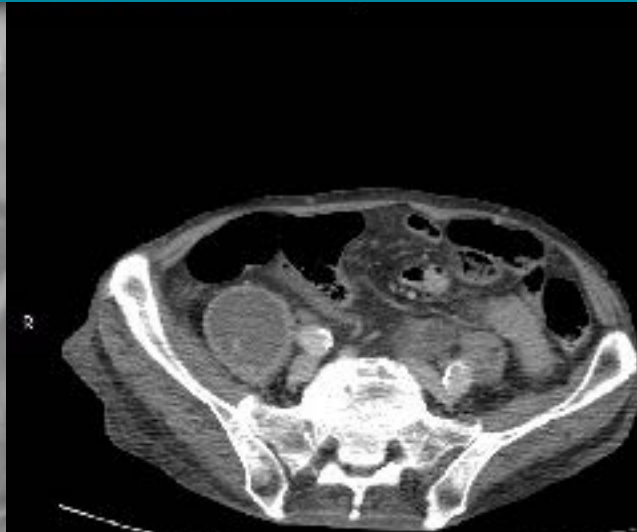


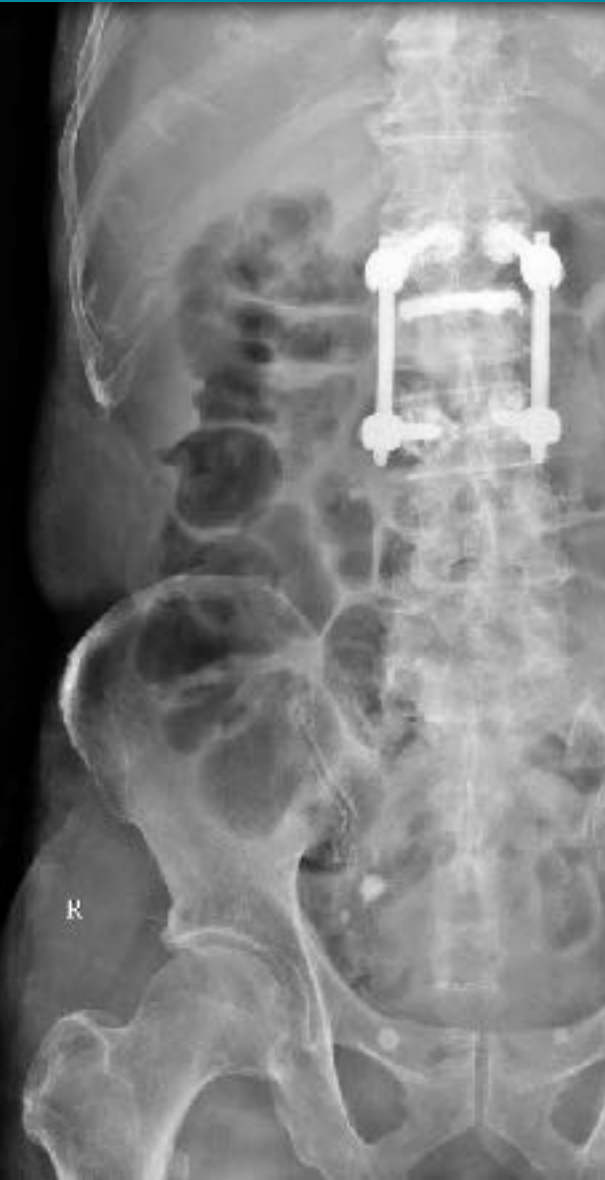# GB empyema with rupture

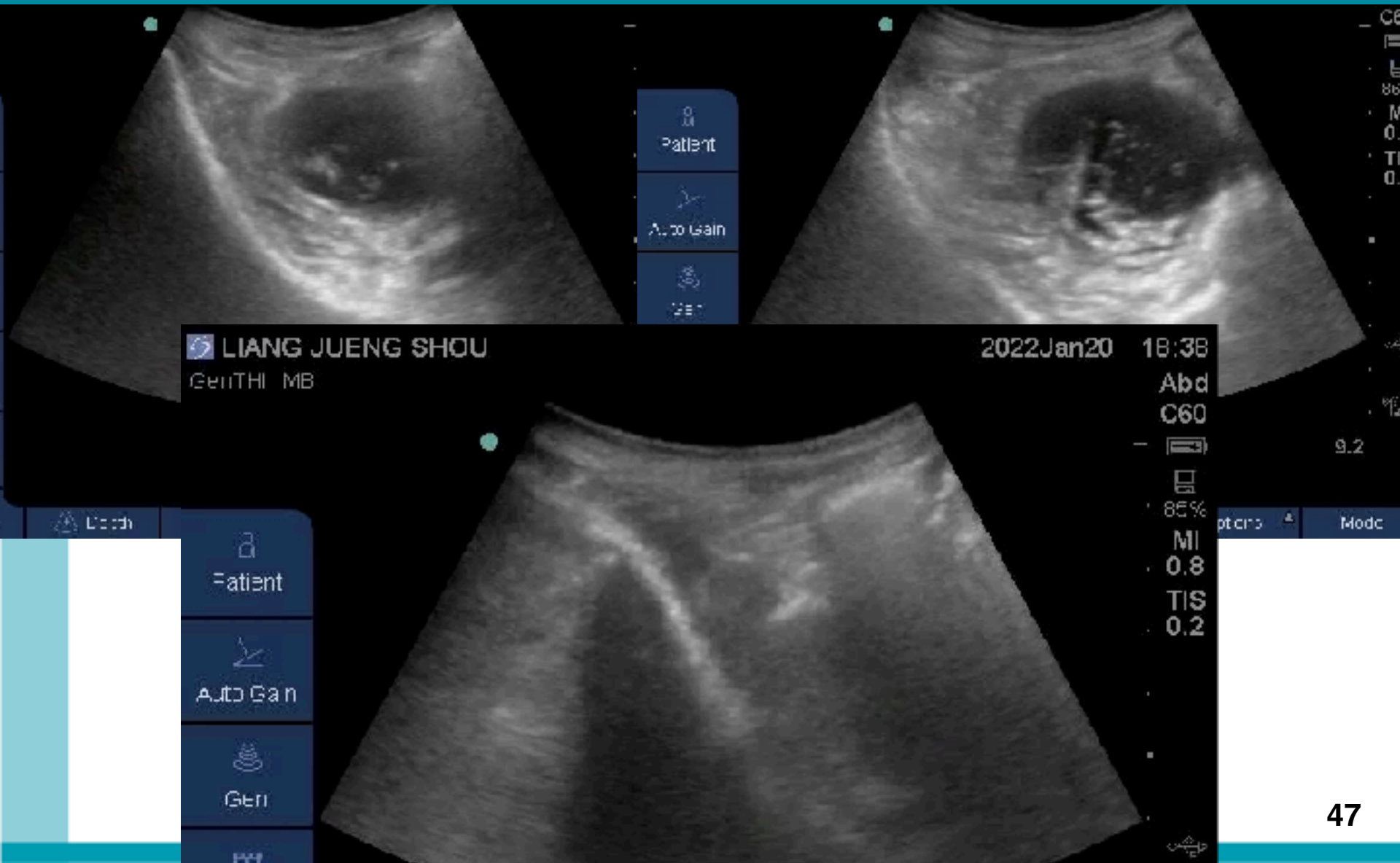




# 85, Psoas muscle abscess

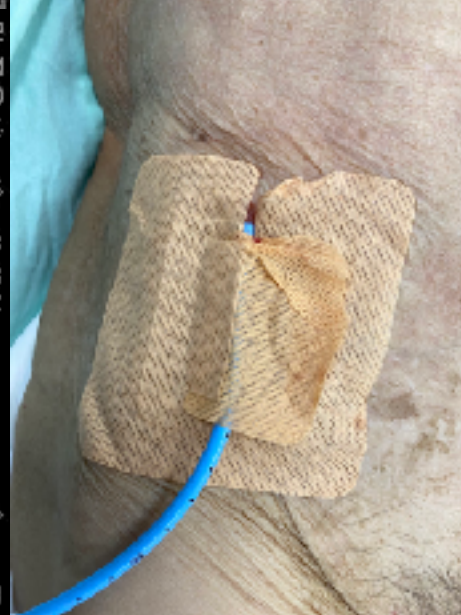
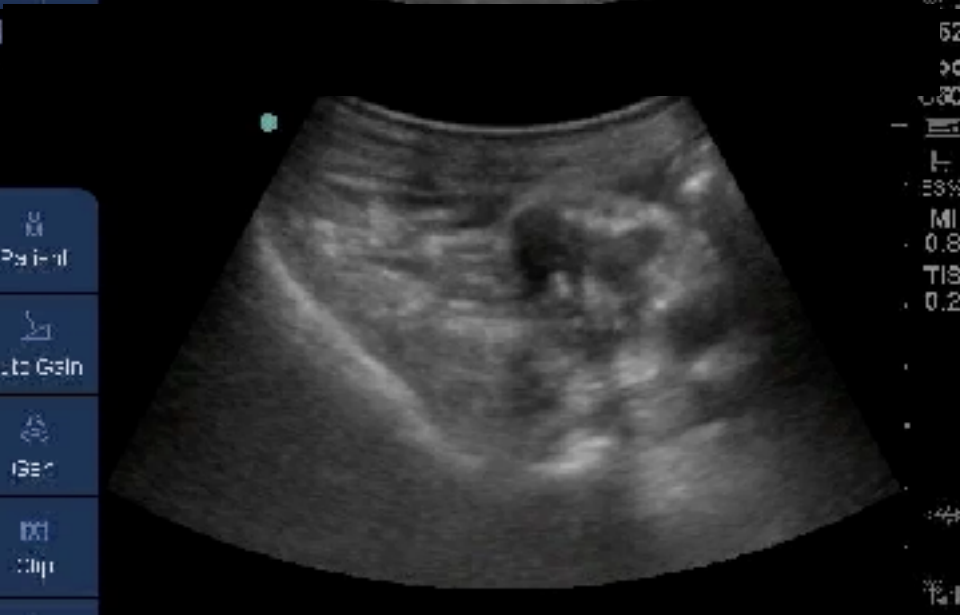
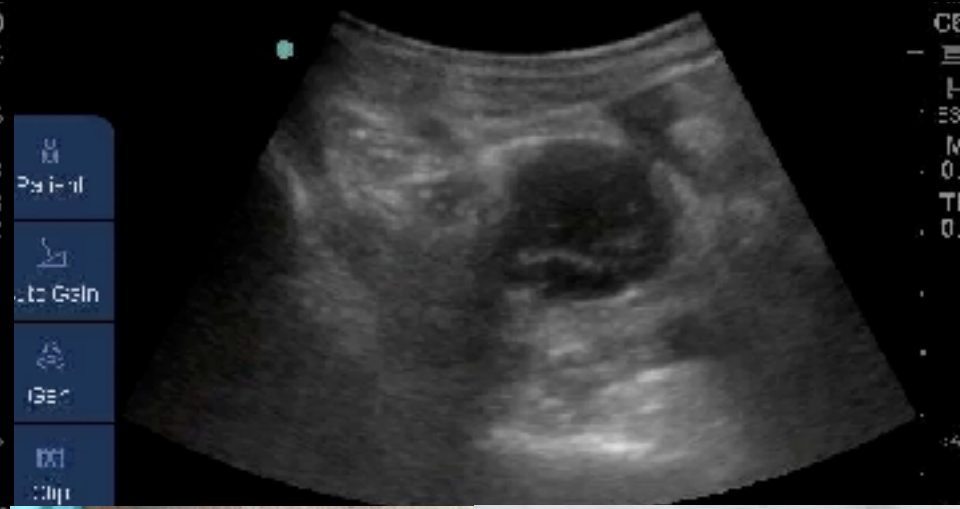
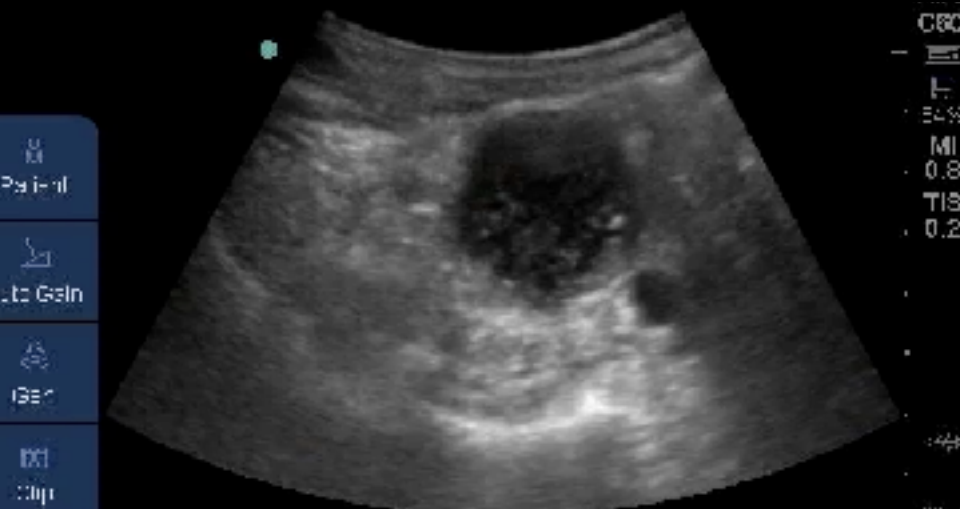# 85, Psoas muscle abscess



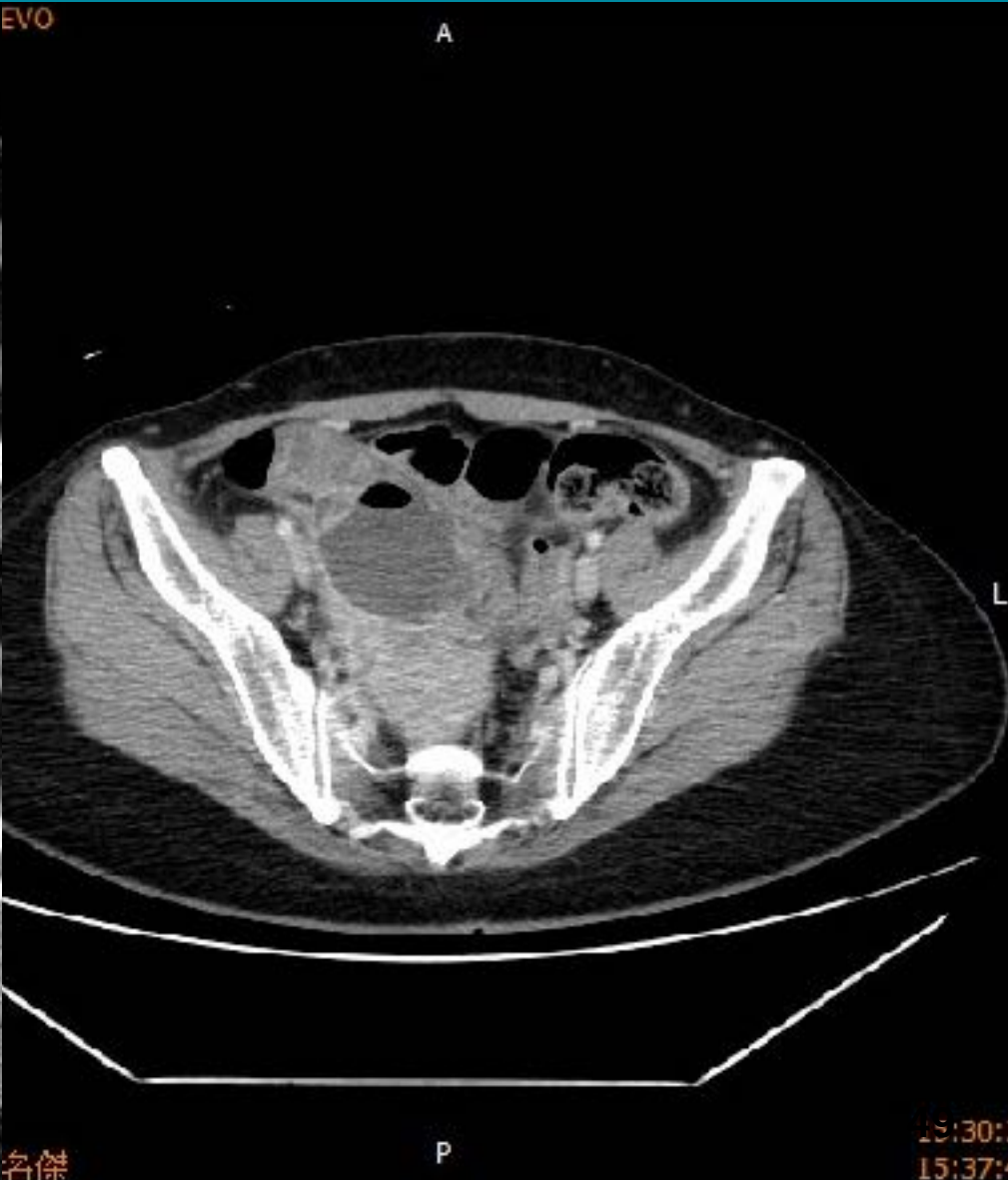
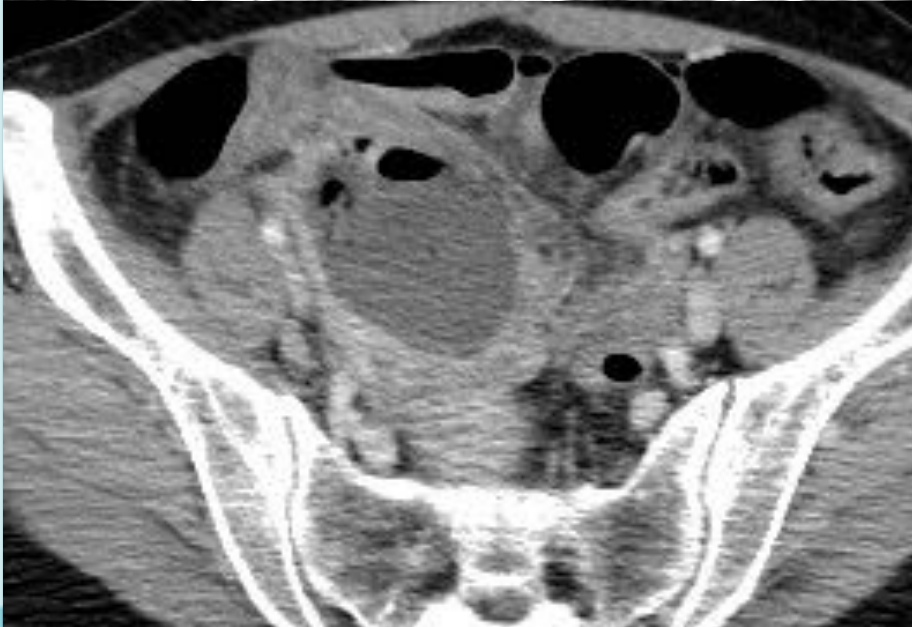
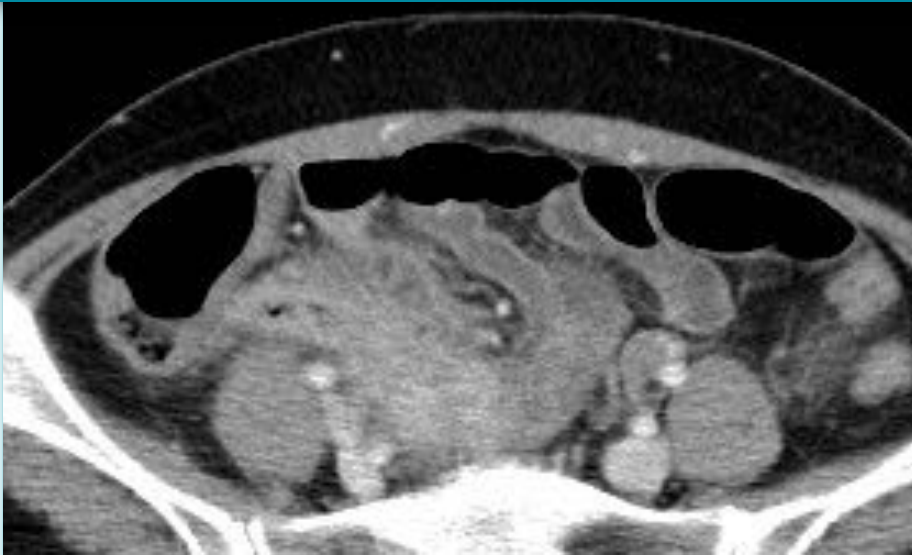# 14F pigtail with stylet



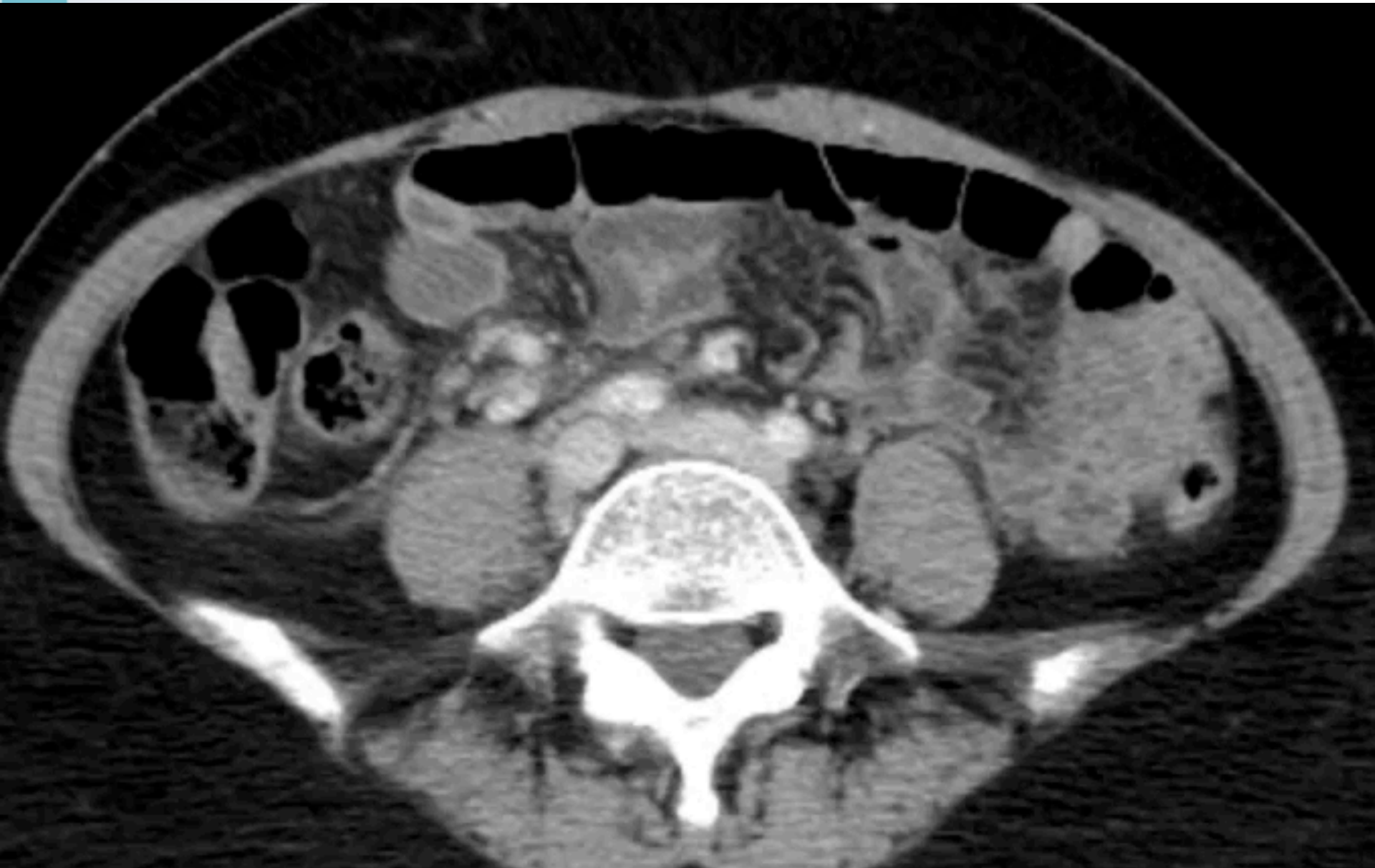

# 50F, RLQ pain for one week





# Radiology refused this drainage



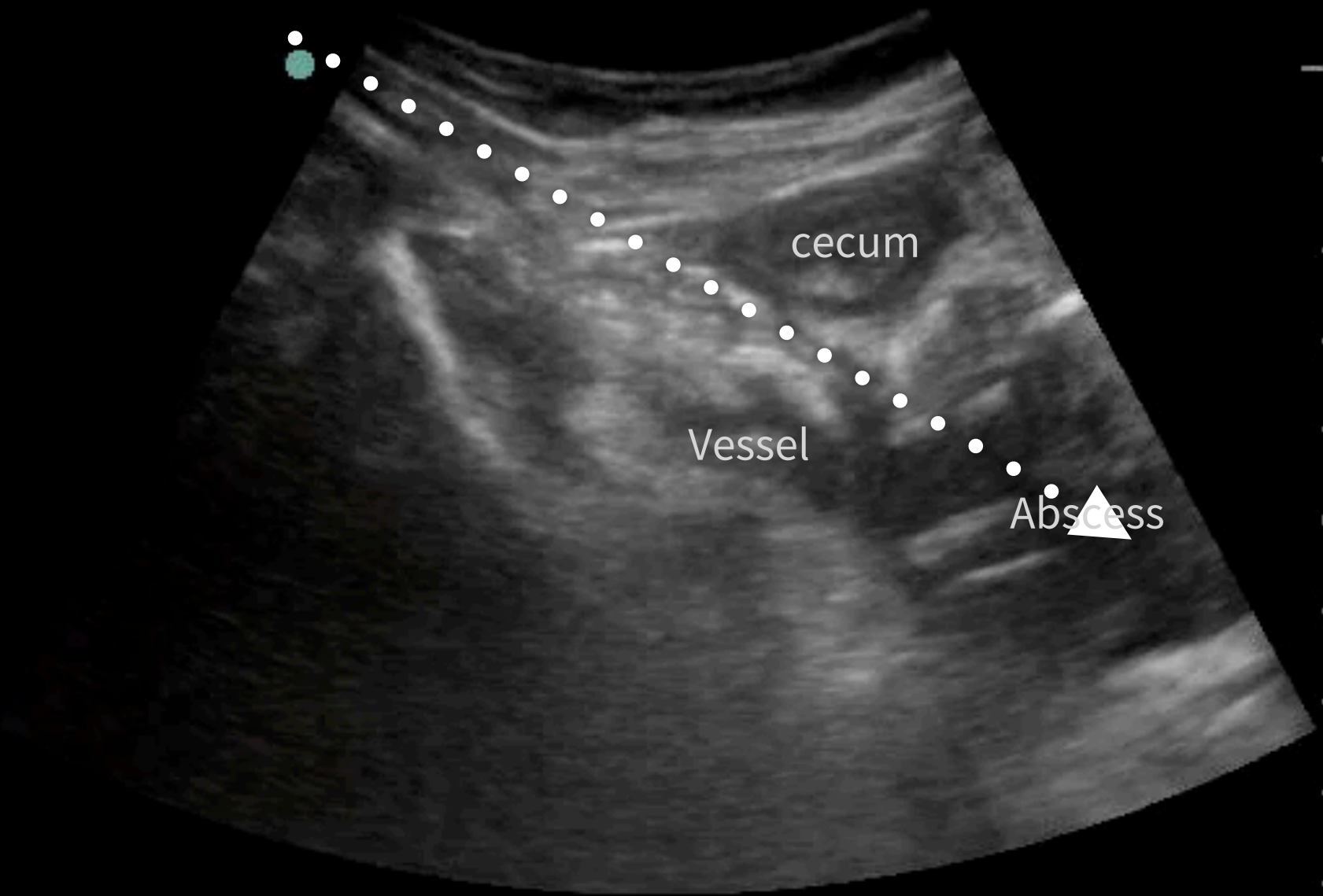
atient

to Gain

Gen

Clip

ge 1/3

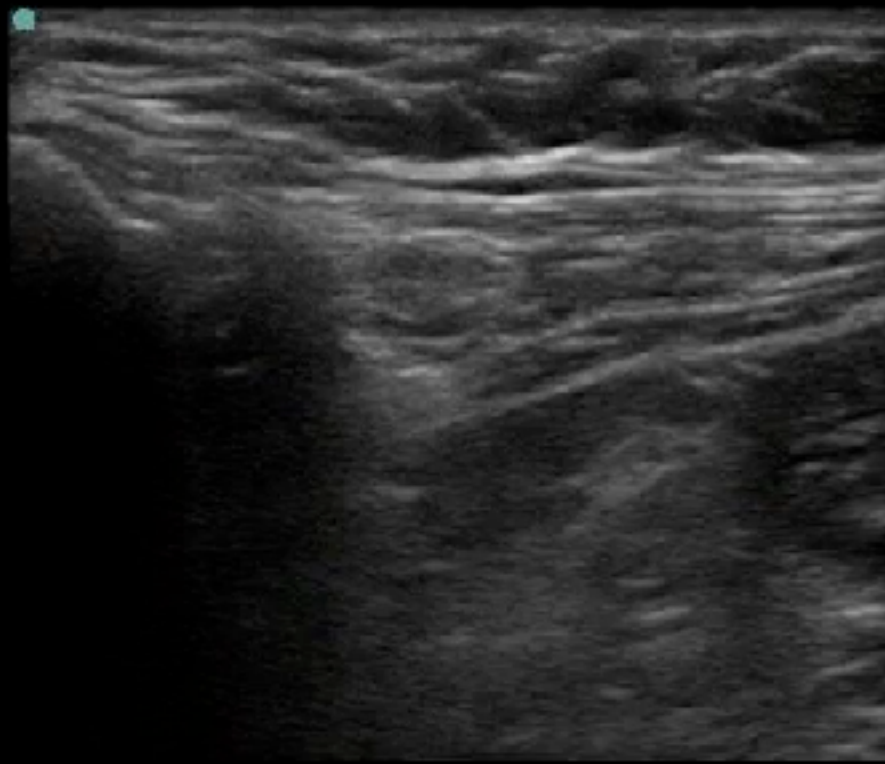


cecum

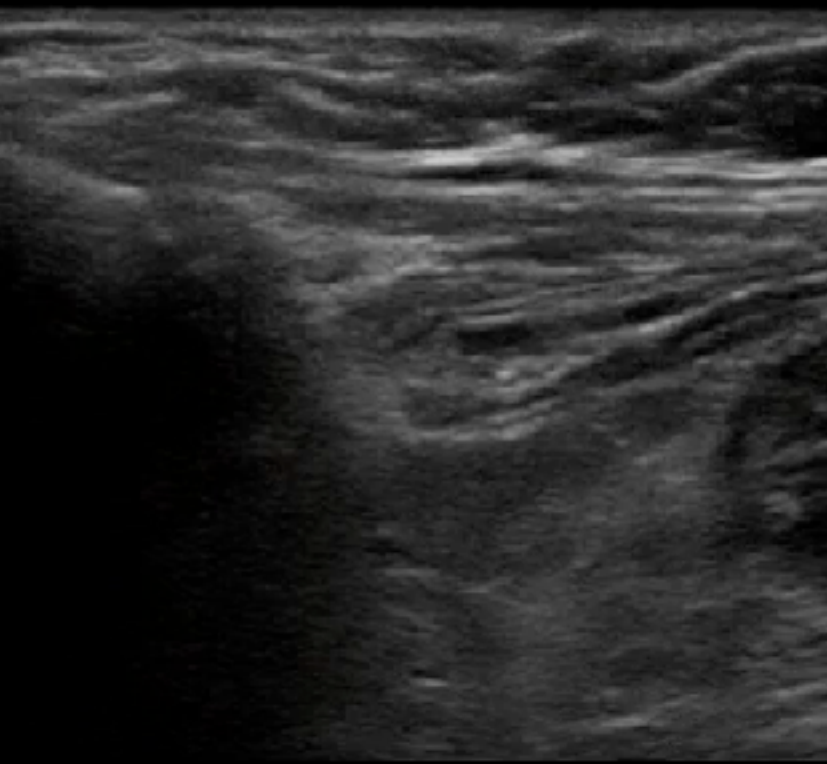
Vessel

Abscess

# Ilioinguinal & iliohypogastric nerve block



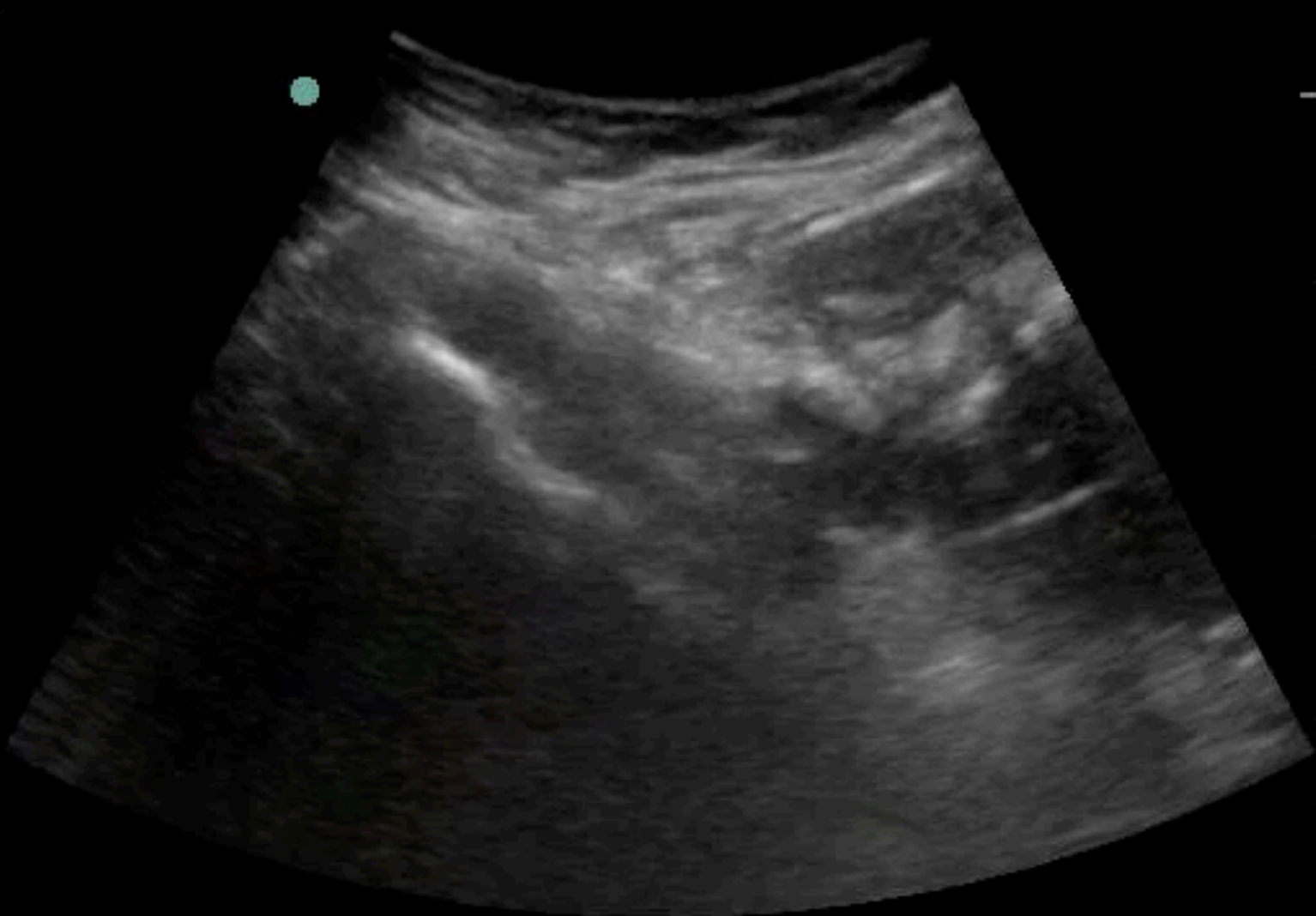
- Msk  
HFL  
E  
73%  
MI  
0.8  
TIS  
0.1  
3.3



# Pigtail drainage - guiding needle



GenTHI MB



Abd

C60



71%

MI

0.8

TIS

0.2



Patient



Auto Gain



Gen



Clip

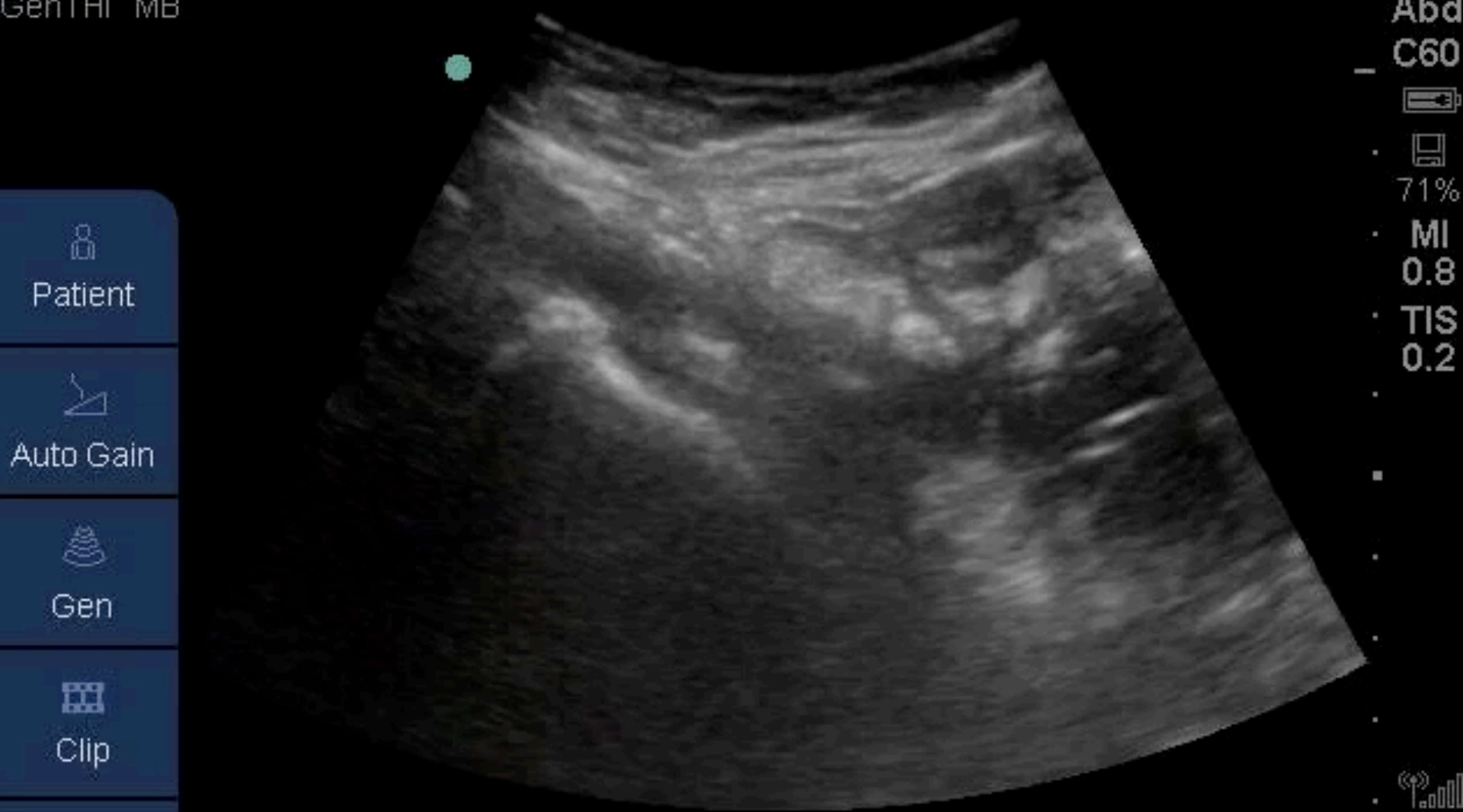




# Pigtail drainage - guiding needle



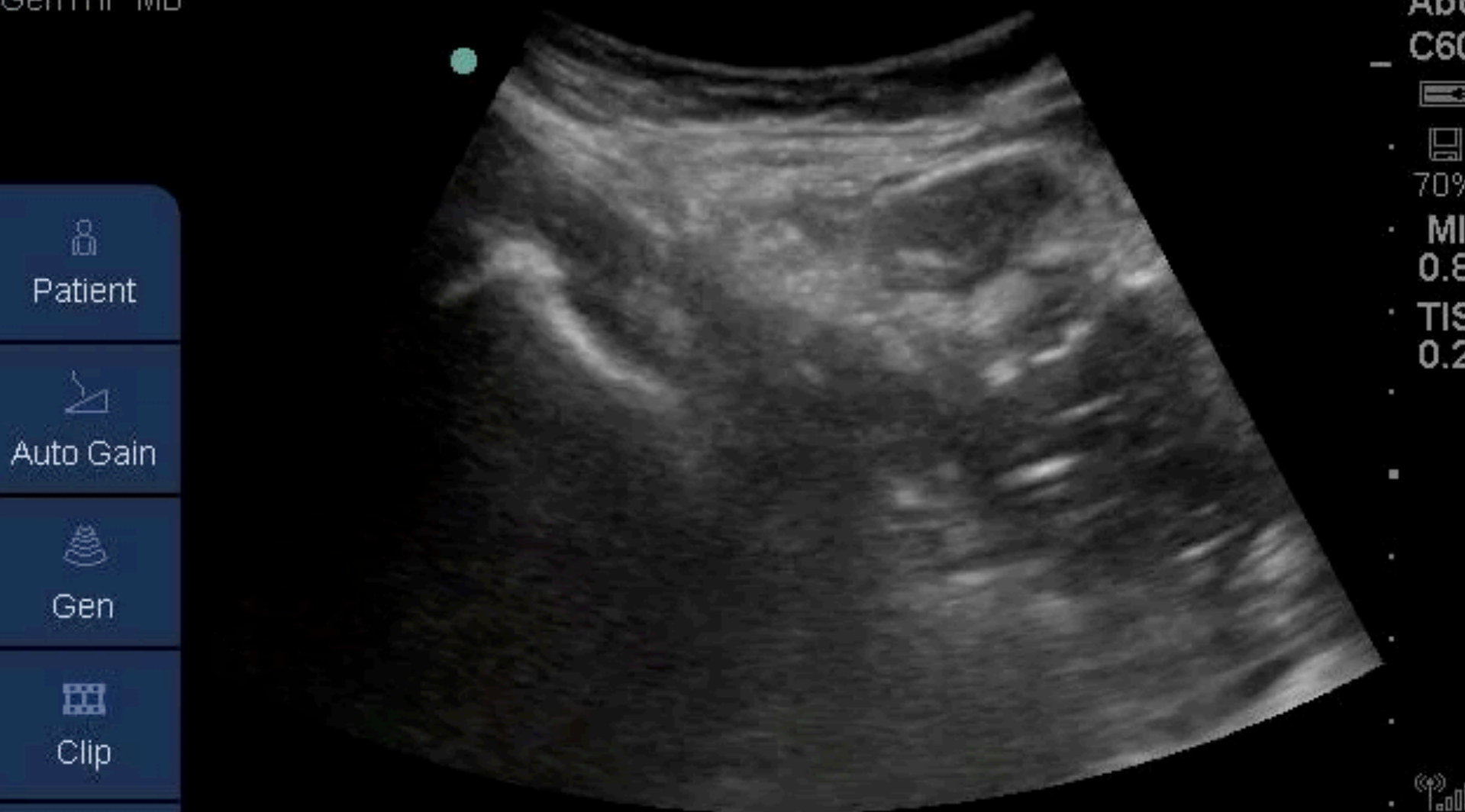
GenTHI MB



# Pigtail drainage - guidewire



GenTHI MB



Patient



Auto Gain



Gen



Clip

Abd

C60



70%

MI

0.8

TIS

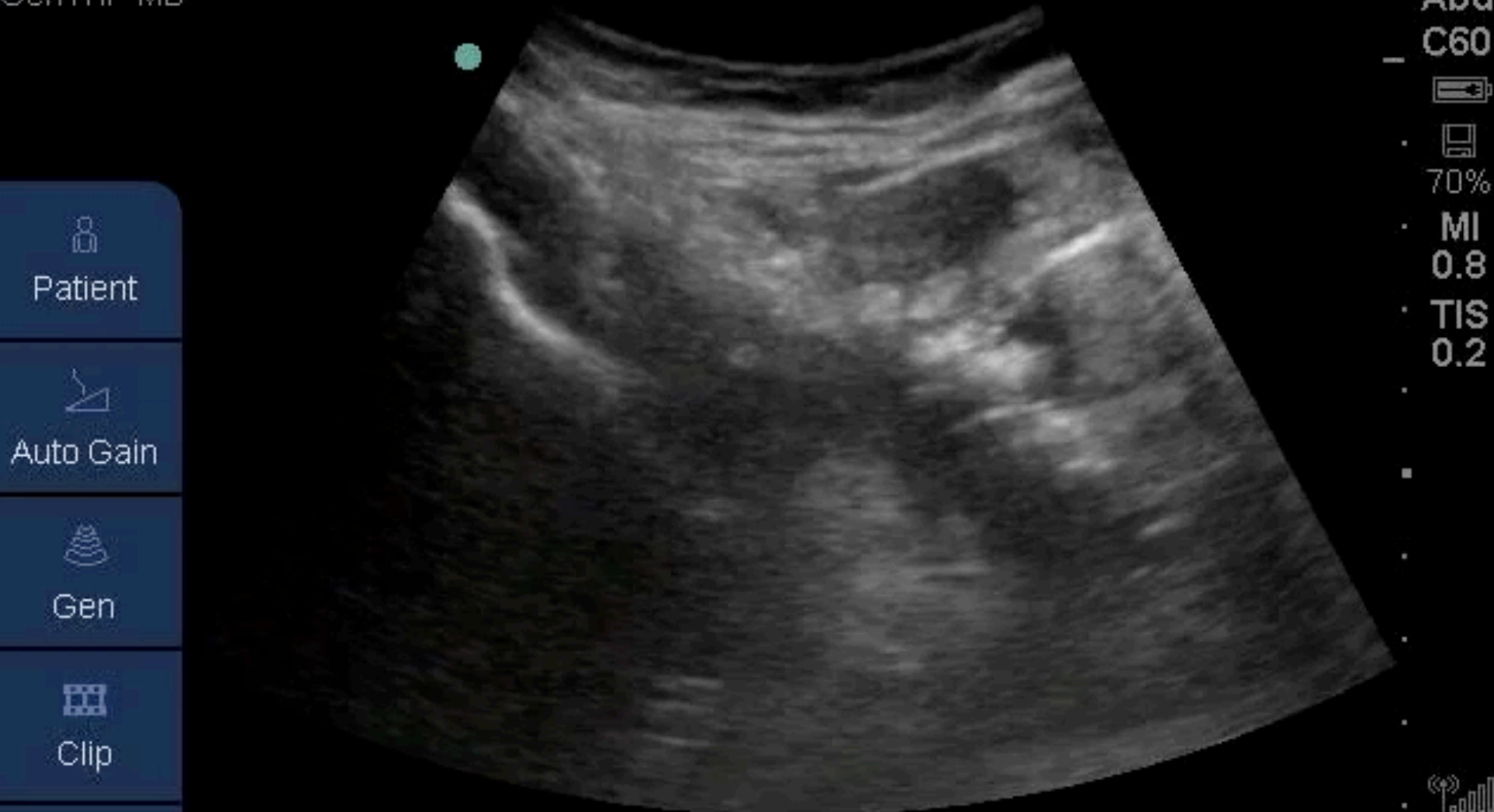
0.2



# Pigtail drainage - pigtail through guidewire



GenTHI MB



  
Patient

  
Auto Gain

  
Gen

  
Clip

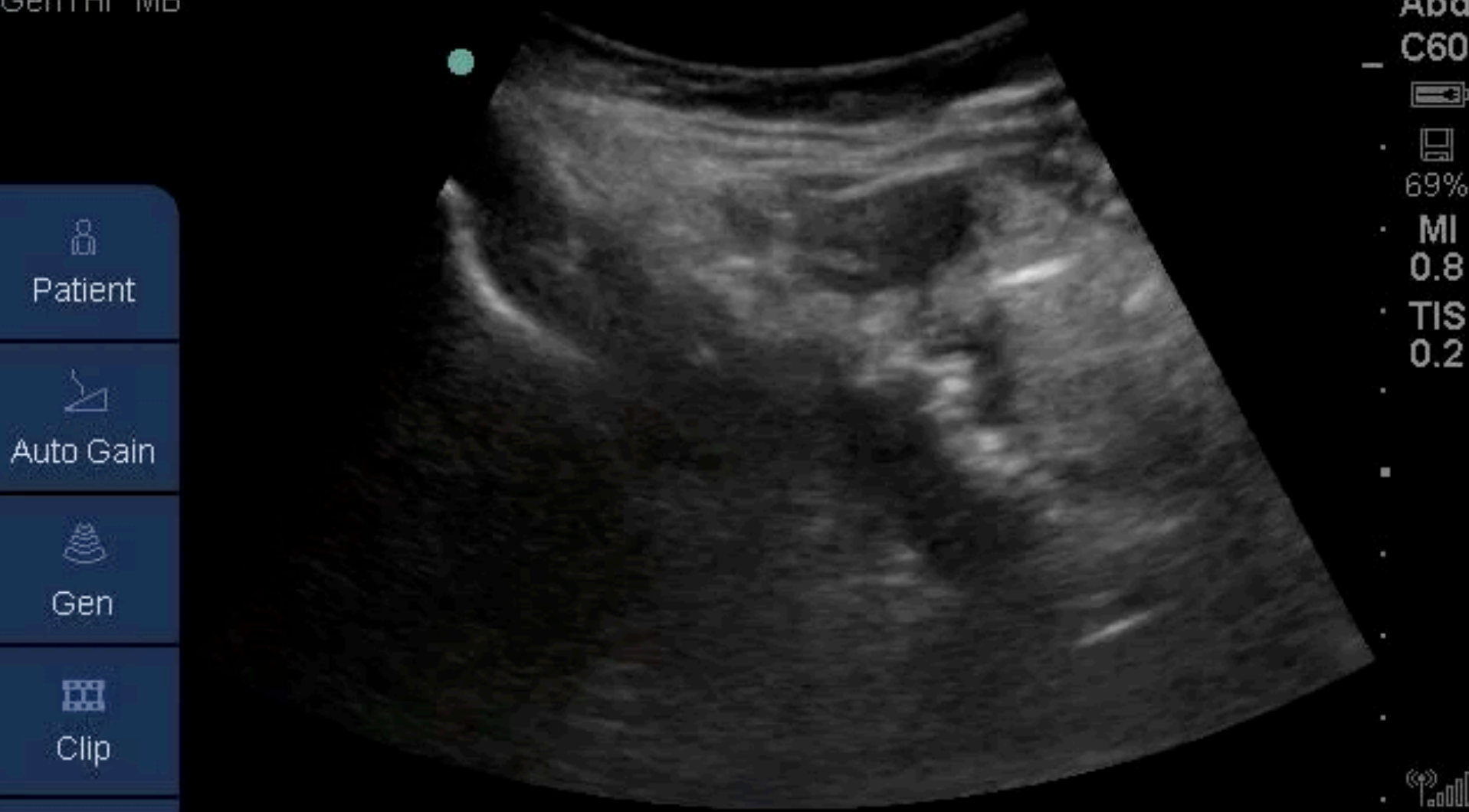
Abd  
C60  
  
70%  
MI  
0.8  
TIS  
0.2



# Pigtail drainage - pigtail through guidewire



GenTHI MB



Abd

C60



69%

MI

0.8

TIS

0.2



Patient



Auto Gain



Gen



Clip

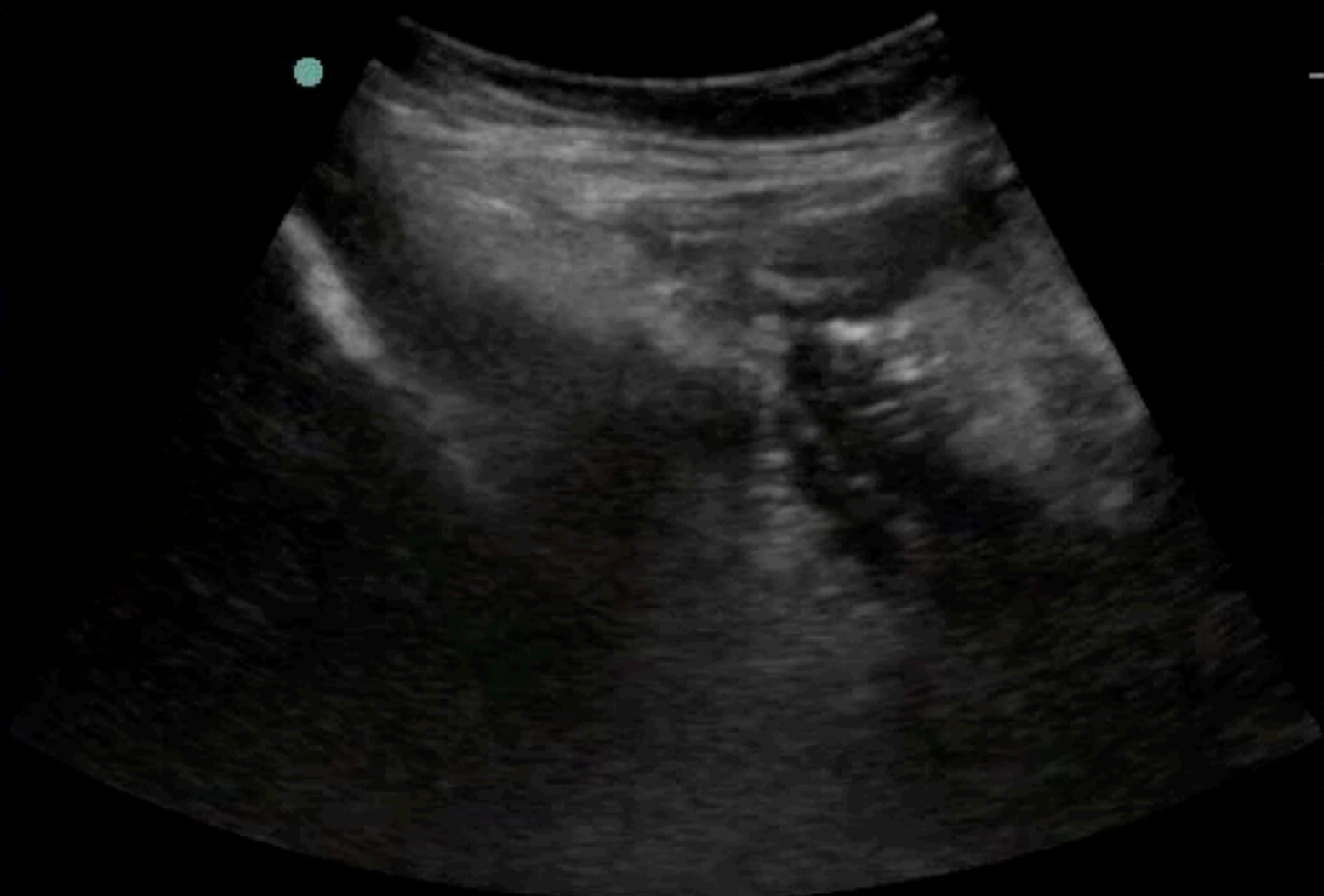




# Pigtail drainage - pigtail



GenTHI MB



Abd  
C60  
69%  
MI  
0.8  
TIS  
0.2

Patient

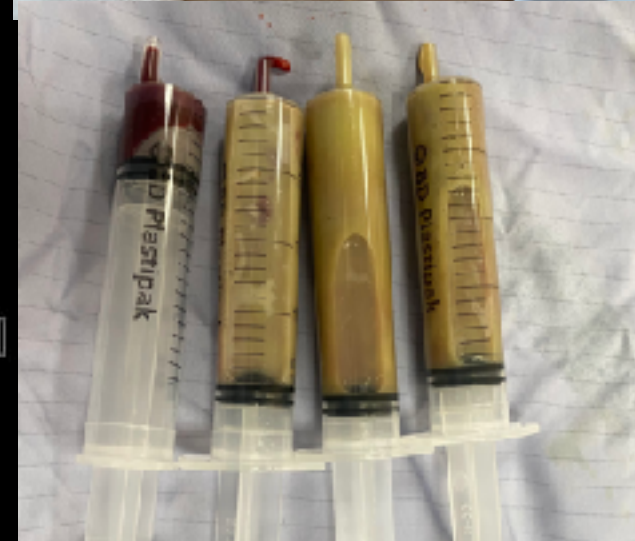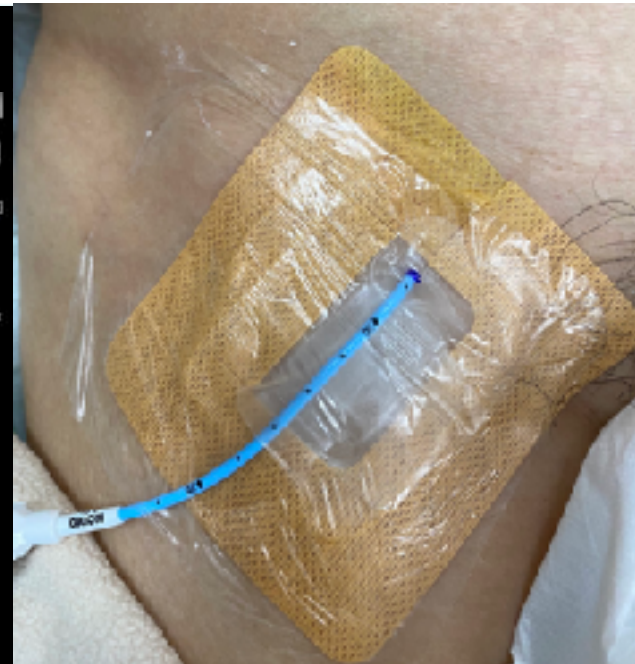
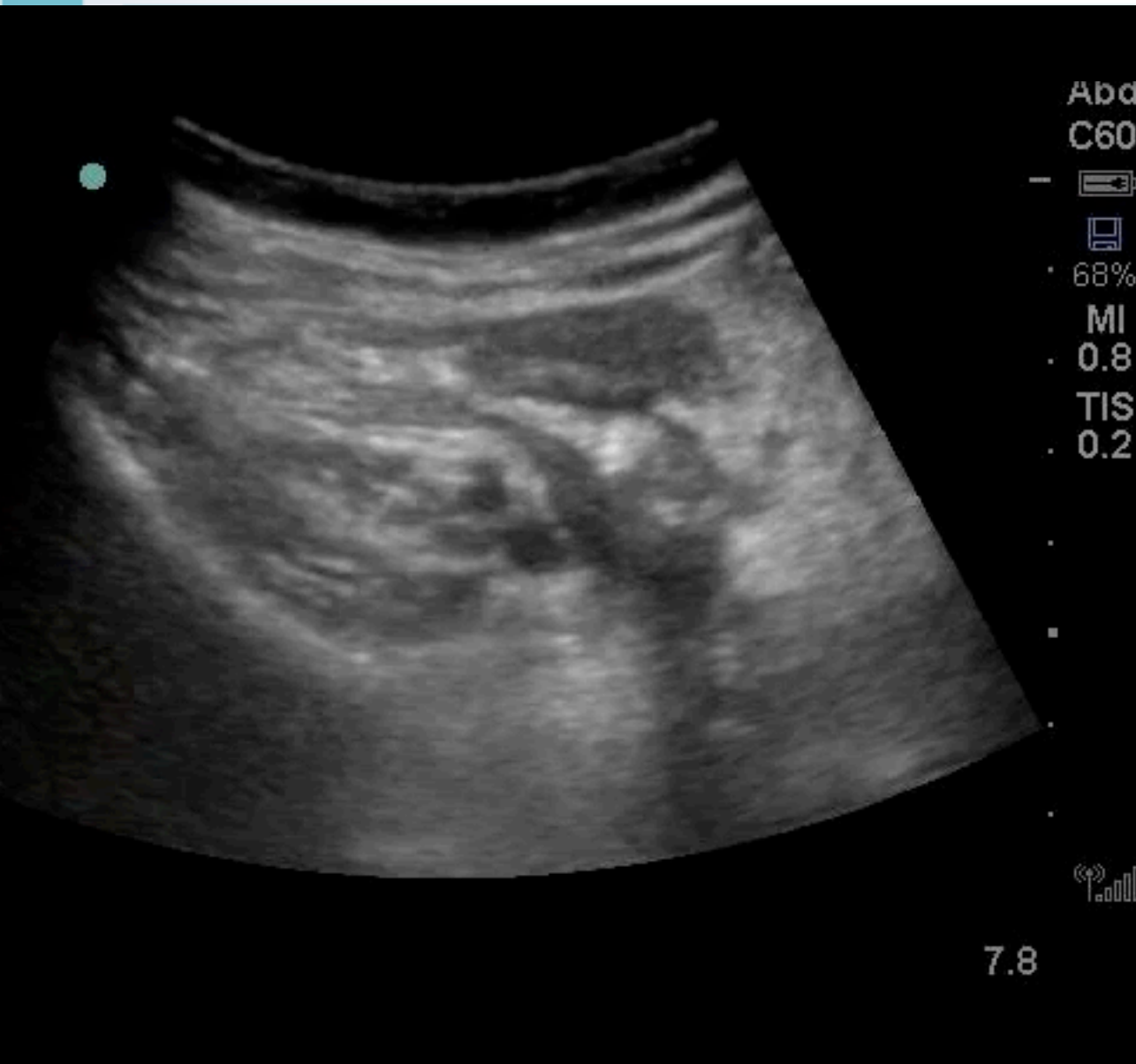
Auto Gain

Gen

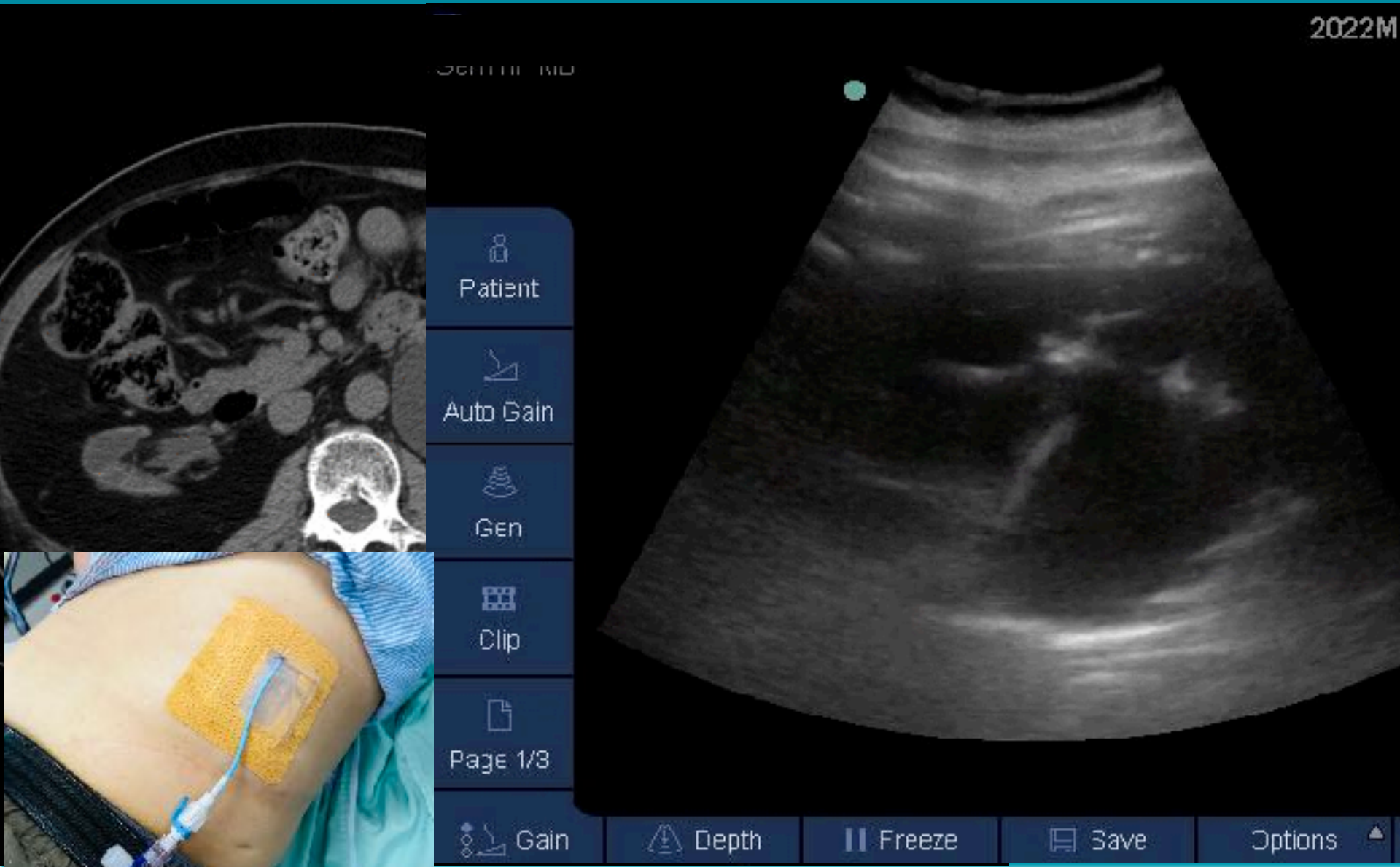
Clip



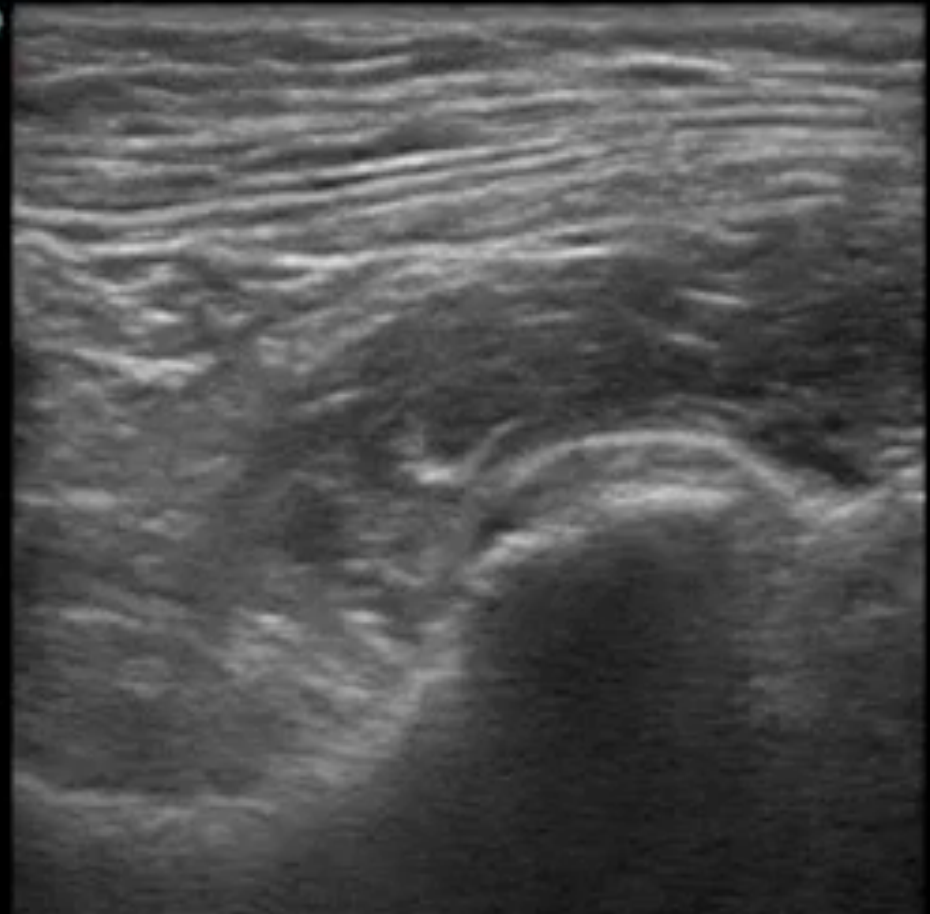
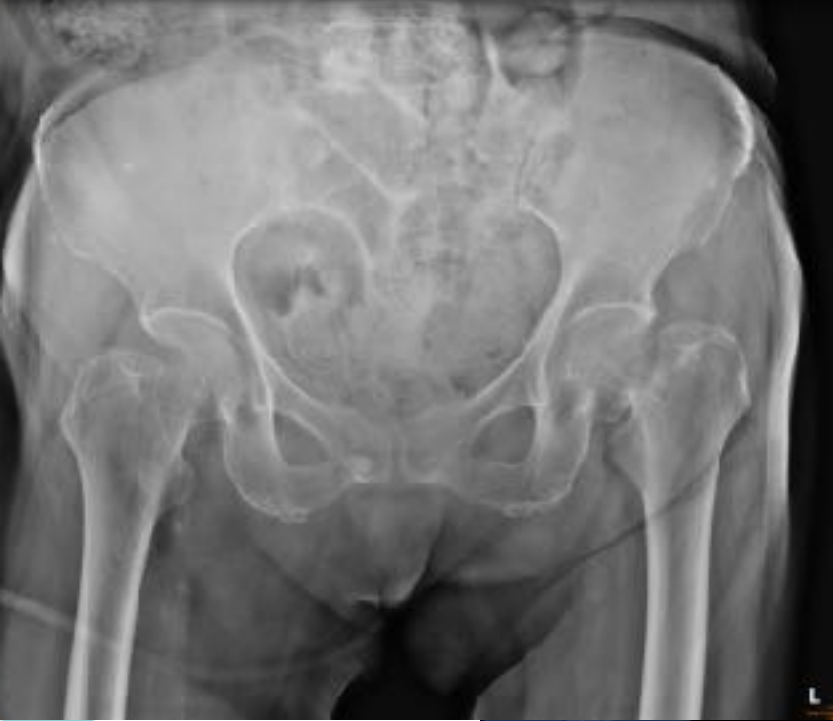# FIRST: master needling



# 65M, left side flank pain



# 89F, PENG block for FNF Pericapsular Nerve Group block



Auto Gain



Res

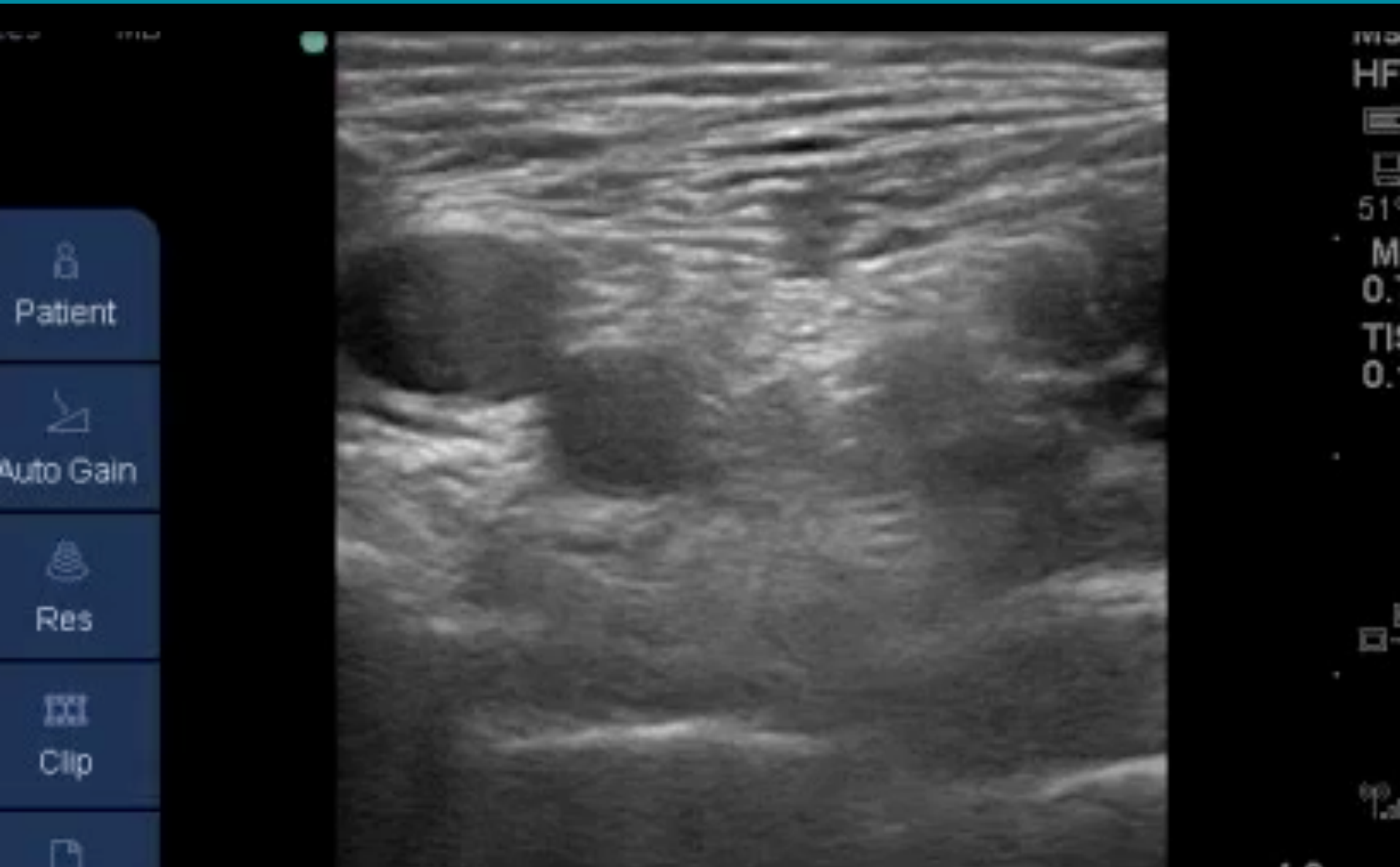


Clip





# FN & Lateral femoral cutaneous nerve



# LFCN block



RES MID

MSK

HFL



94%

MI

0.8

TIS

0.1



Patient



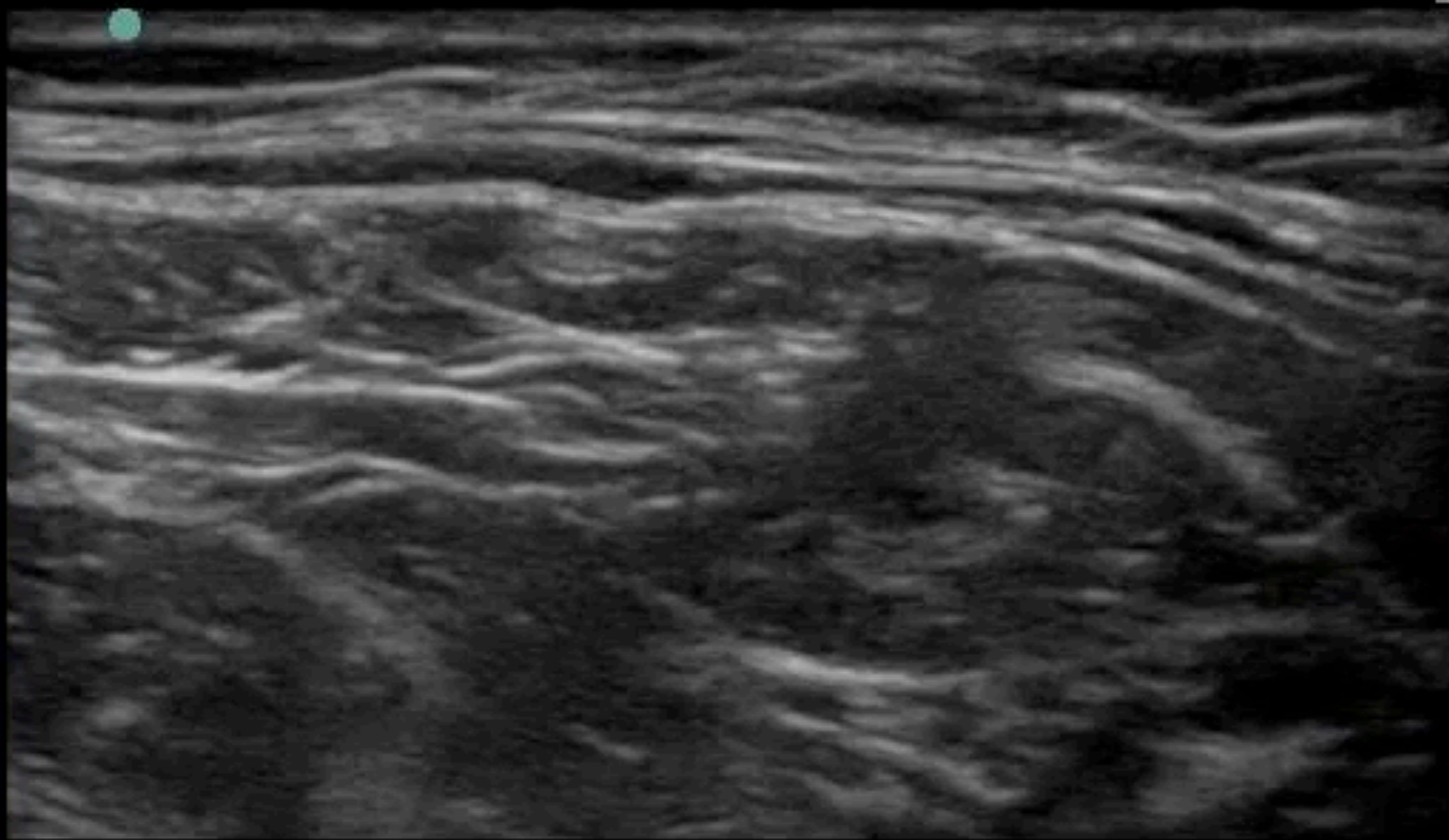
Auto Gain



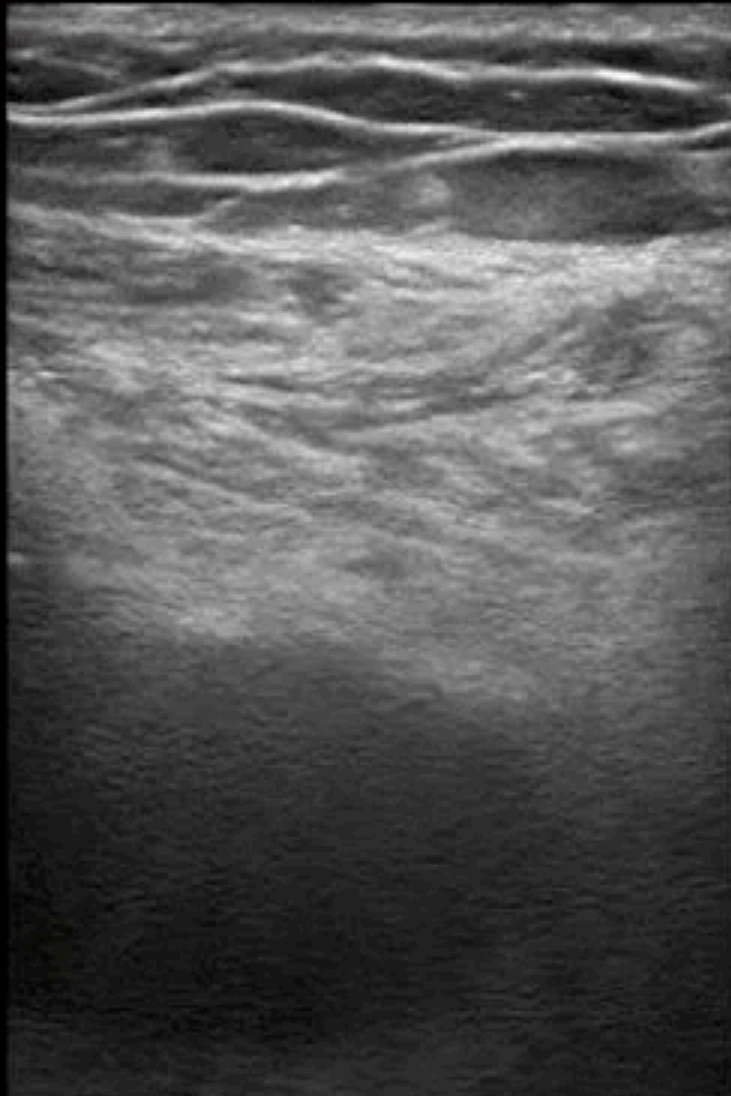
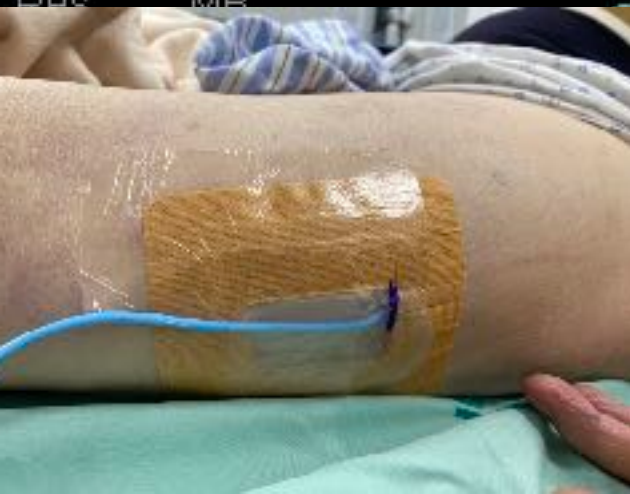Res



Clip

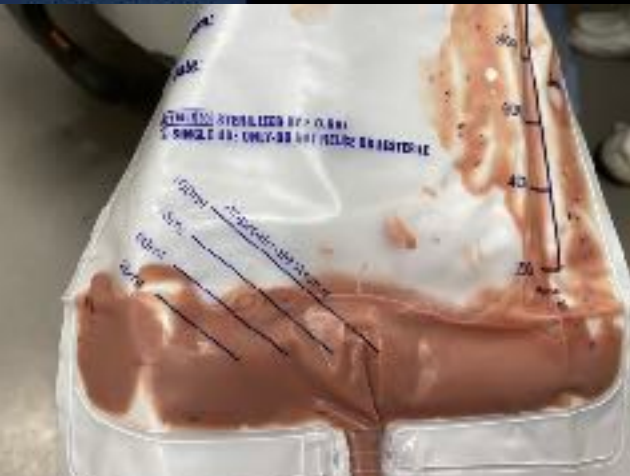

# Pigtail with stylet for thigh abscess

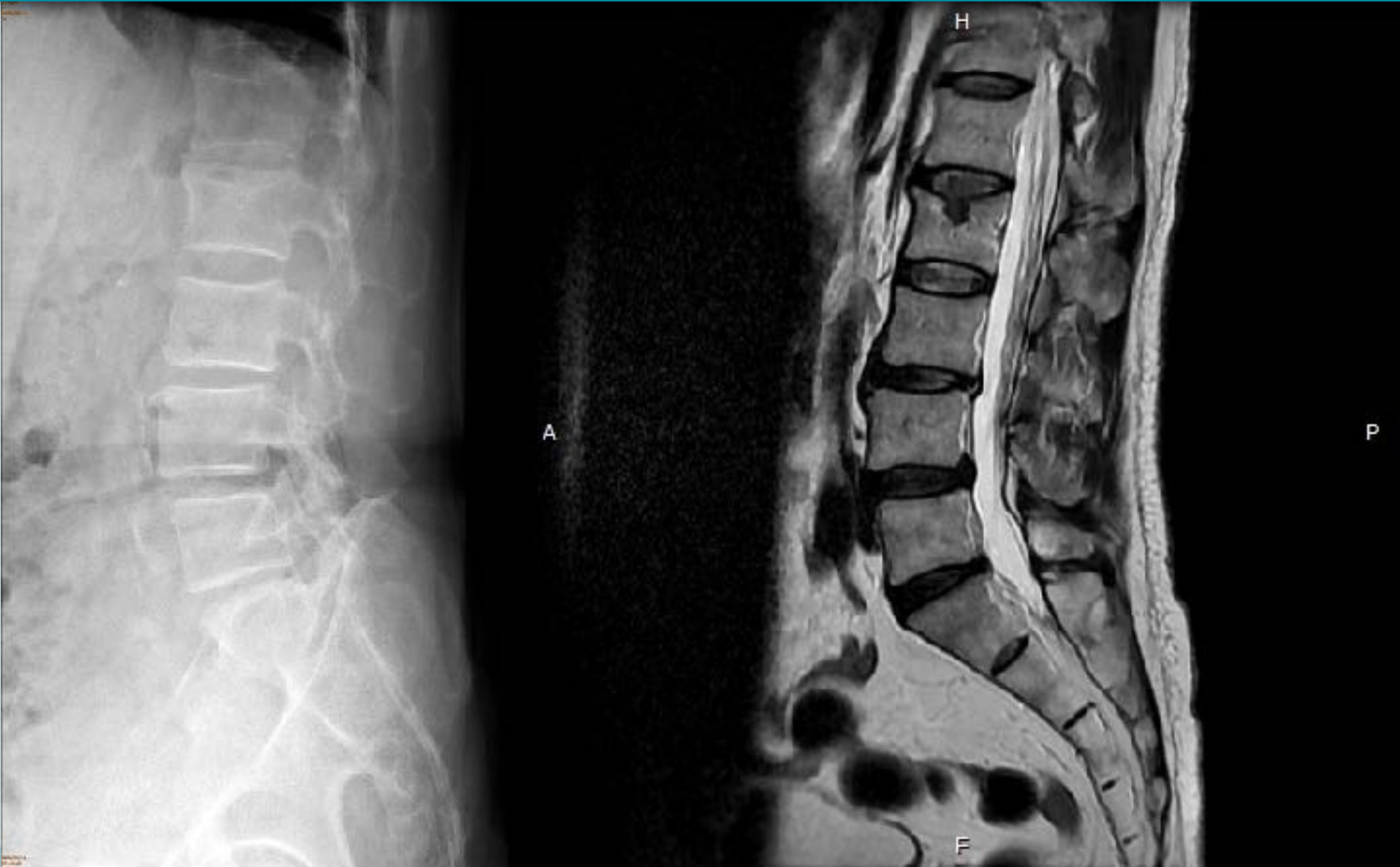

Msk  
HFL  
93%  
MI  
0.6  
TIS  
0.1

Auto Gain

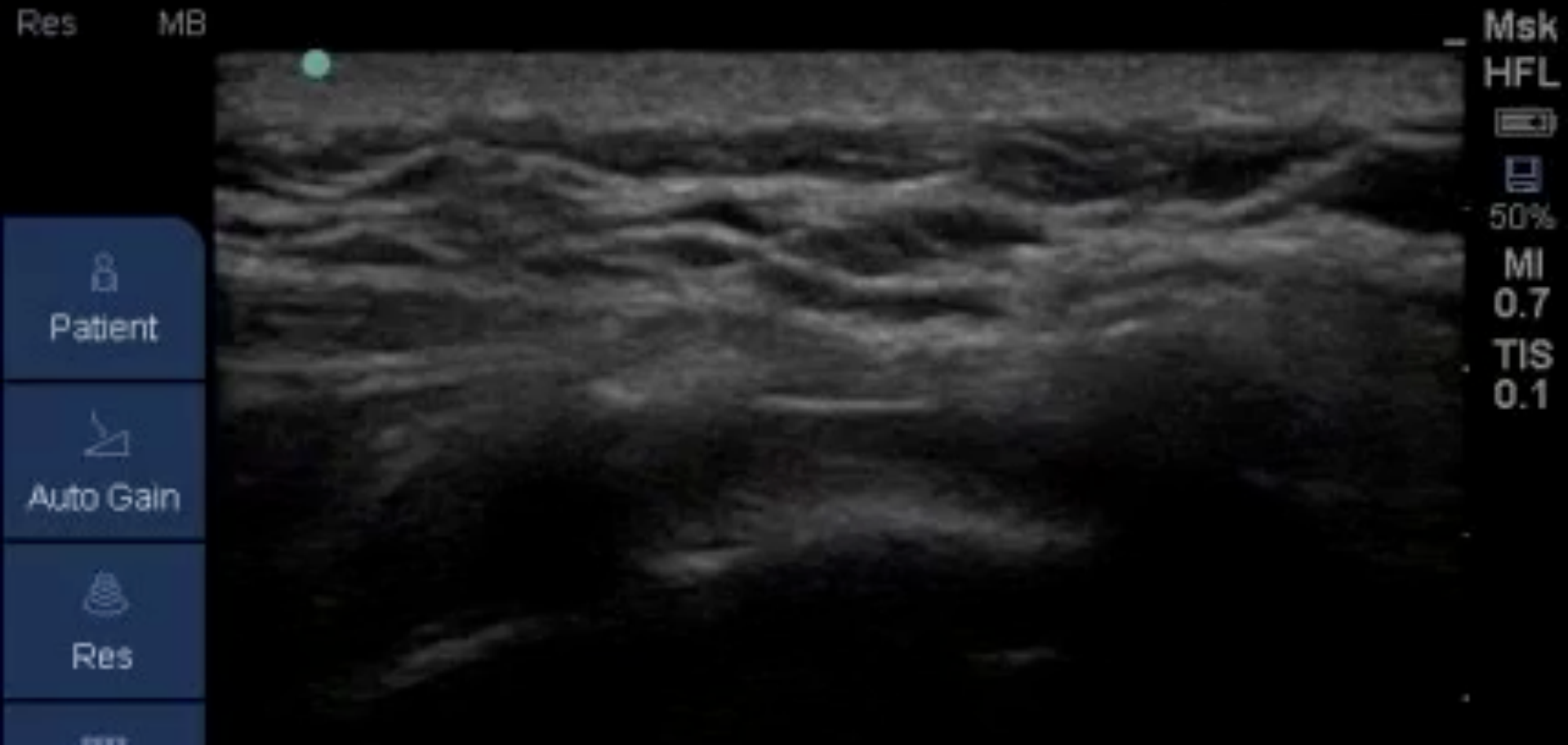


# 63M, LBP with right sciatica

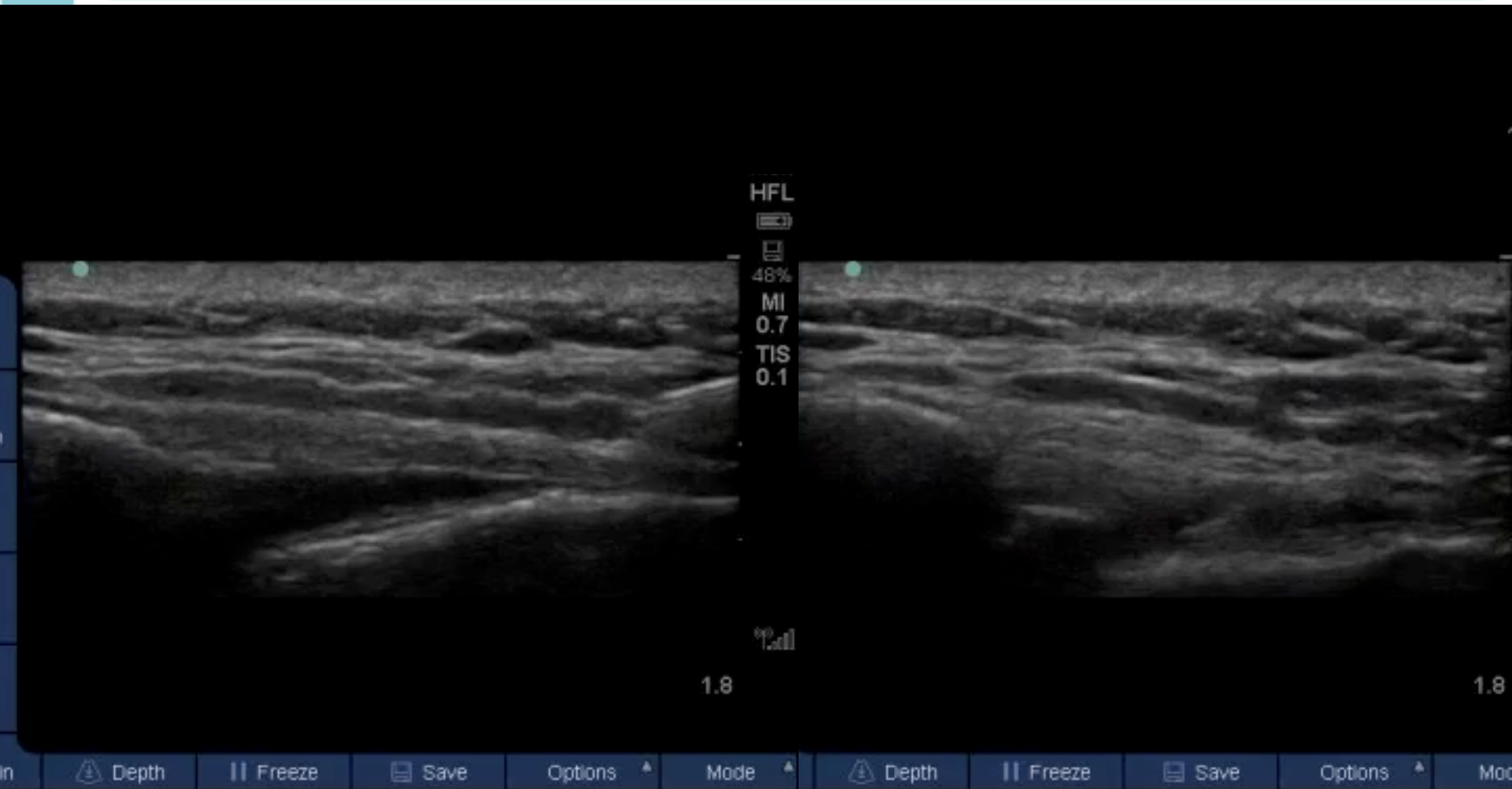



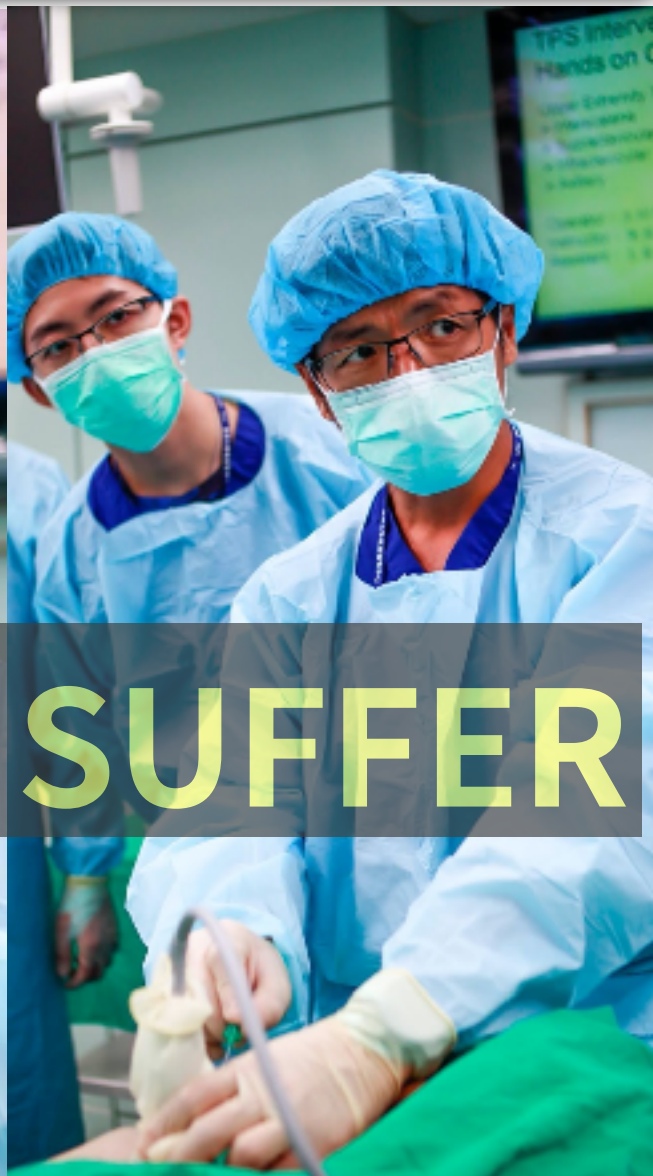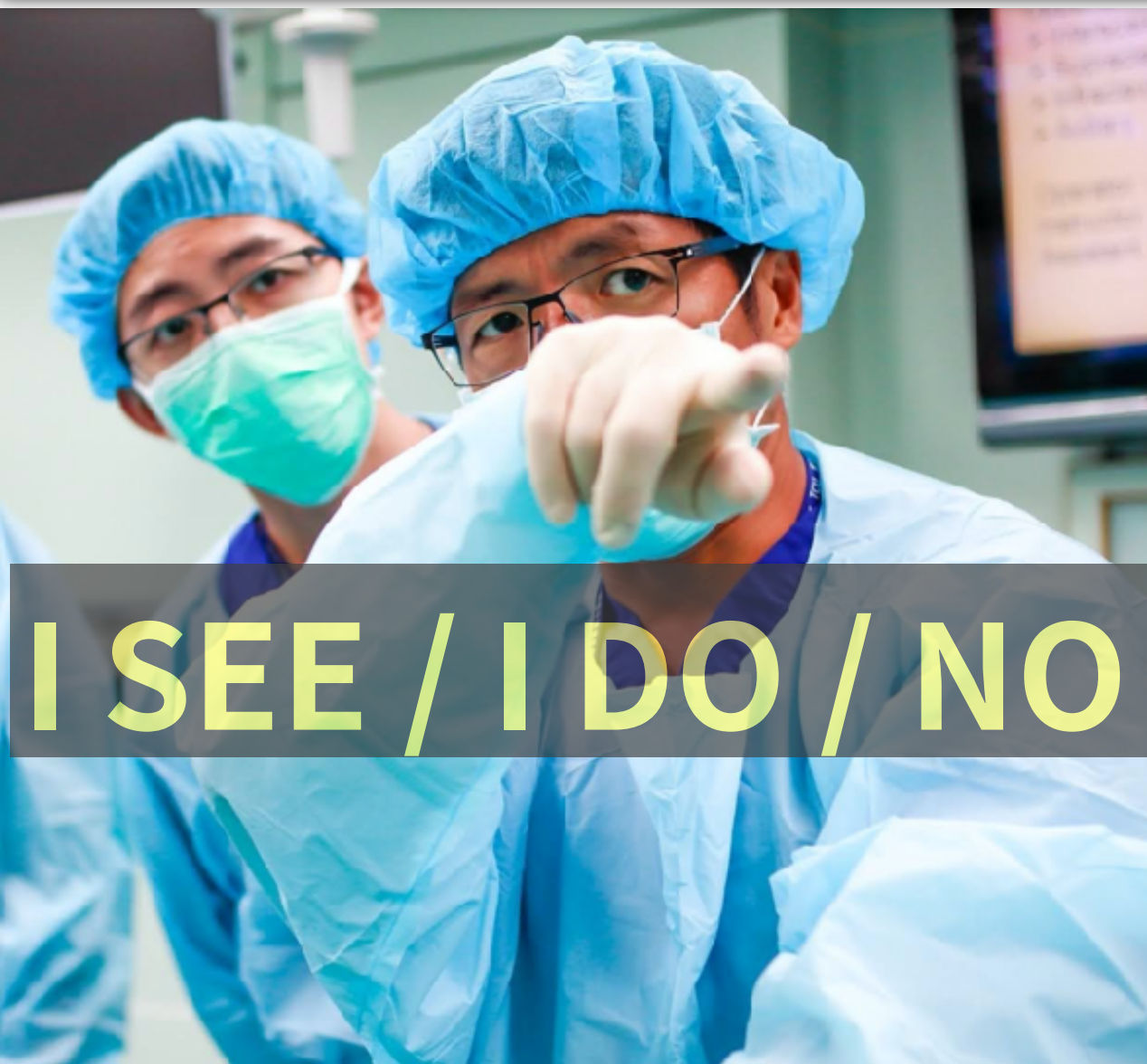# Caudal block for acute low back pain



# Marcaine 0.5% 20 ml



無痛的精準個人化急診醫療就在你我手中



I SEE / I DO / NO SUFFER