



# 雙和急診POCUS訓練

# 陳國智 醫師



急診超音波臨床評核醫師  
醫用超音波學會指導醫師  
雙和急診超音波教學負責人  
WINFOCUS director / instructor

**急診 / 重症 / 介入 / 急性疼痛**

經歷

新光急診超音波訓練中心主任  
西園醫院急診醫學科主任  
急診醫學會超音波委員會主委  
台灣疼痛醫學會大體模擬手術講師  
急救加護醫學會重症超音波負責人

診  
斷

監  
測

介  
入

POINT OF CARE ULTRASOUND

~ 存在於臨床需求之所在 ~



**LE joint effusion**

**01/07**

**Airway**

**01/14**

**Needling**

**01/21**

**VExUS protocol**

**01/28**

**雙和急診POCUS訓練**



**Central access**

02/11

**Peripheral access**

02/18

**EFAST**

02/25

**雙和急診POCUS訓練**



**Basic ECHO**

03/04

**Nerve block-UE(1)**

03/11

**Nerve block-LE(1)**

03/25

**雙和急診POCUS訓練**



**Aorta & IVC**

04/01

**Liver & Biliary**

04/08

**Kidney & UB**

07/08

**Pancreas & Spleen**

07/22

**雙和急診POCUS訓練**



**GI tract scan**

**08/05**

**Basic lung & heart (PGY)**

**08/05**

**Sternum & Ribs**

**08/19**

**UE joint effusion**

**08/26**

**雙和急診POCUS訓練**





**急診臨床掃描指導**

**09/16**

**CVC工作坊 (1)**

**09/16**

**8 POCUS skills for PGY**

**09/23**

**Ocular US**

**09/30**

**雙和急診POCUS訓練**



**8 POCUS skills for PGY**

**10/07**

**急診臨床掃描指導**

**10/14**

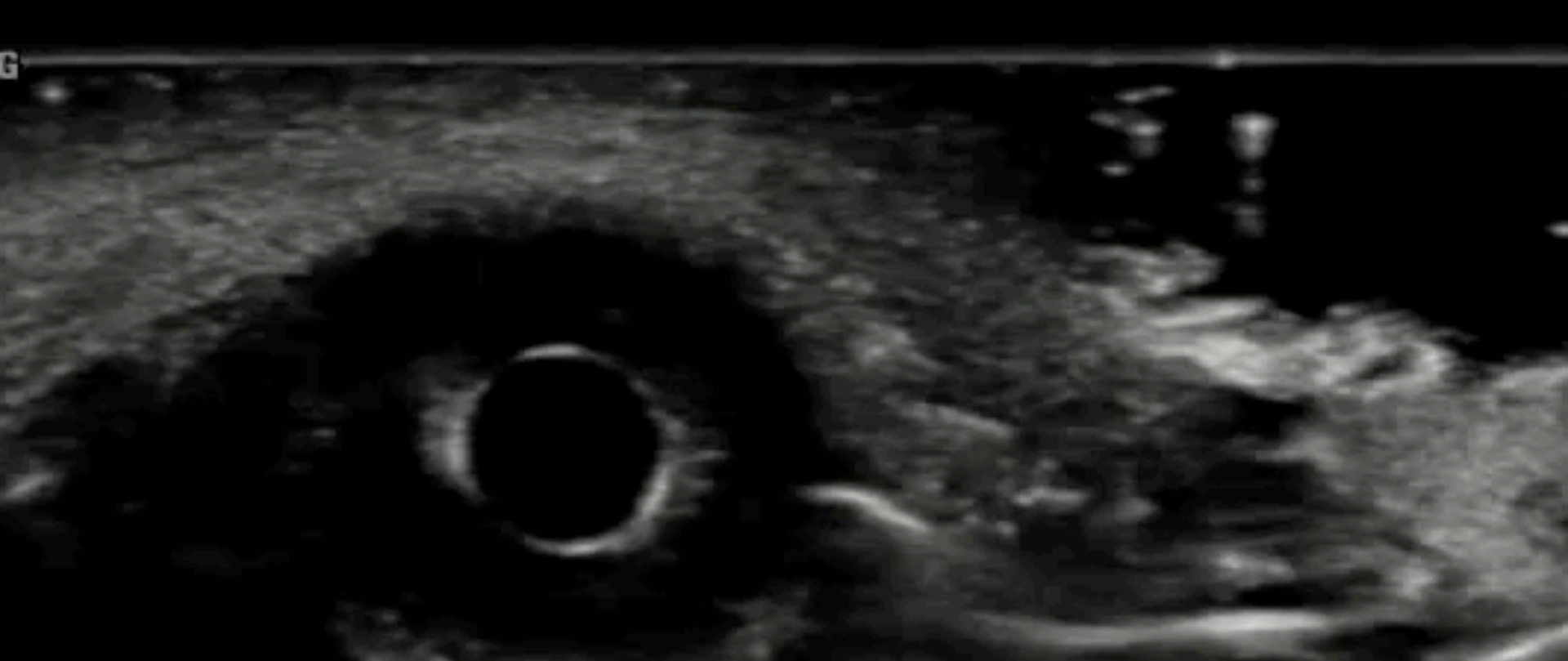
**CVC工作坊 (2)**

**10/14**

**ENT US**

**10/21**

**雙和急診POCUS訓練**



# OCULAR ULTRASOUND



# 臨床應用

**IICP**

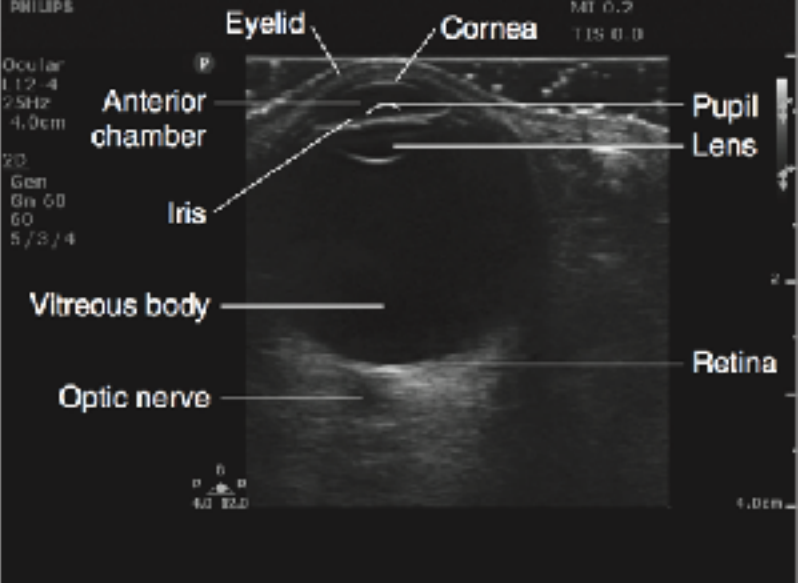
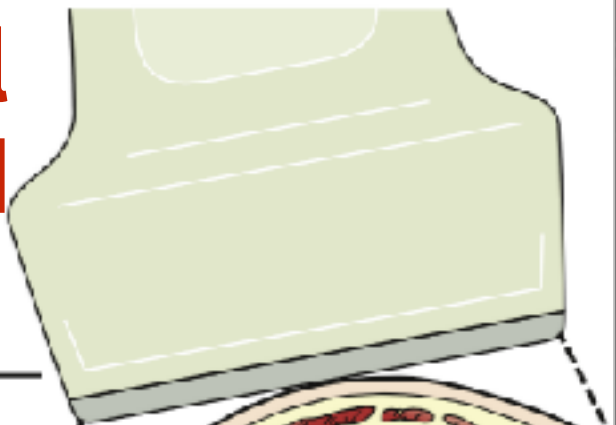
**Vision loss**

**Trauma**

**Infection**



# Superficial Fluid-filled



Closed upper lid

Iris

Ciliary body

Retina

Choroid

Sclera

Optic nerve

Optic nerve sheath

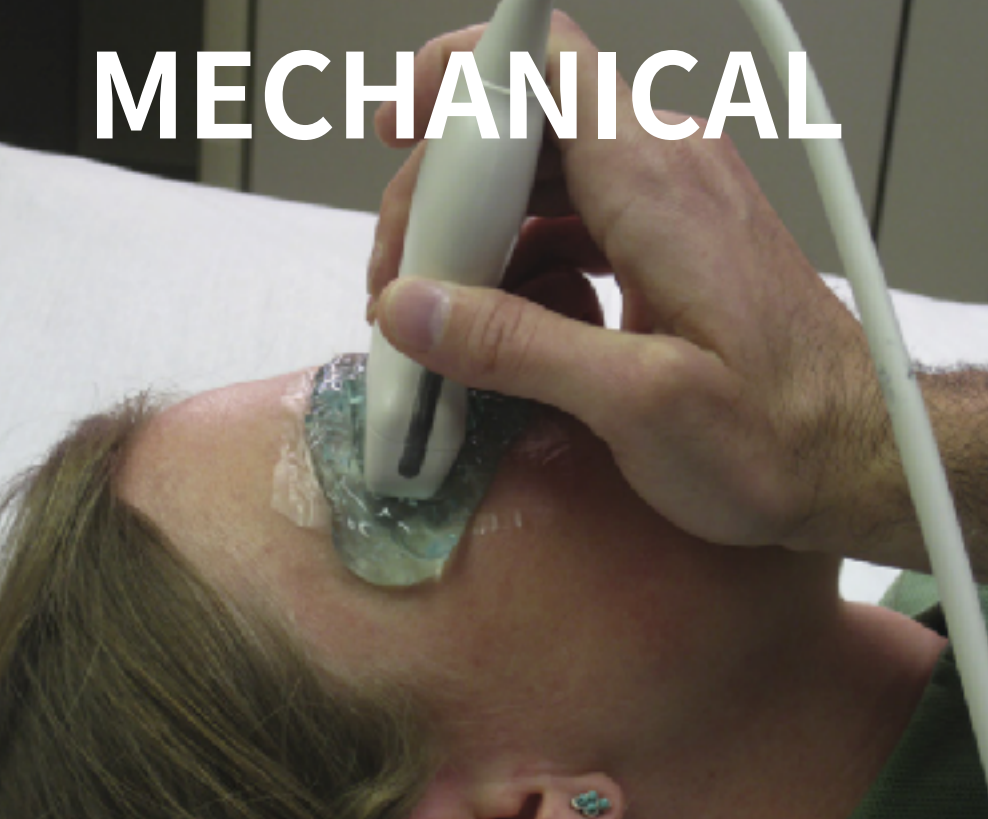Anterior chamber

Lens

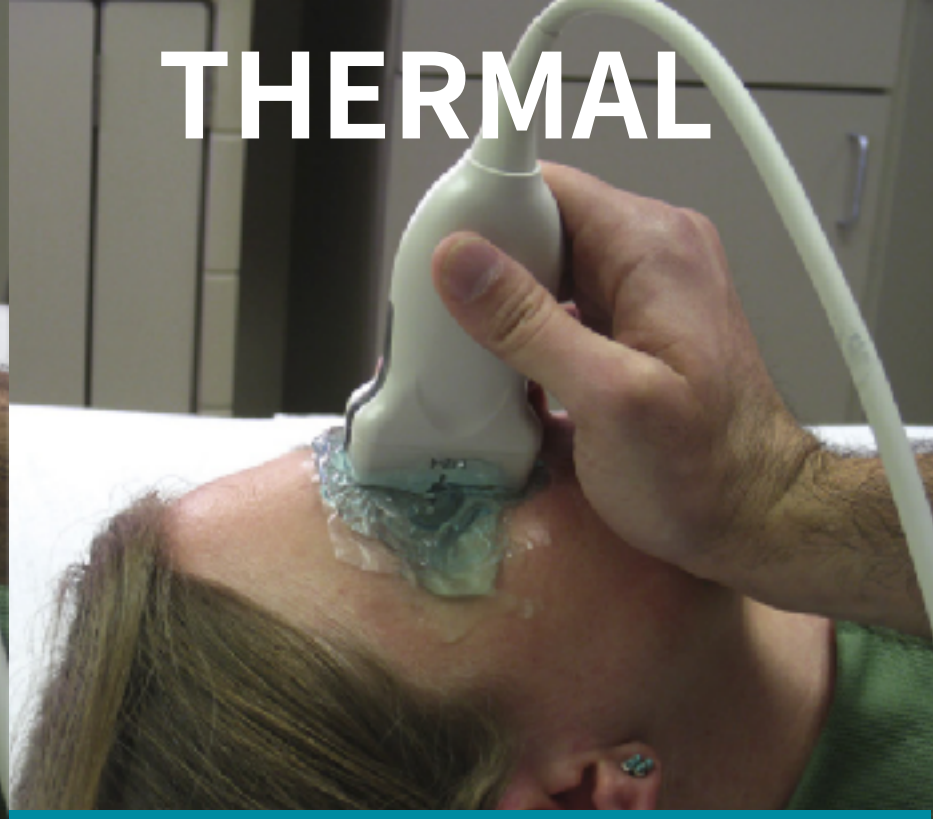Vitreous body

Central retinal artery and vein

**MECHANICAL**



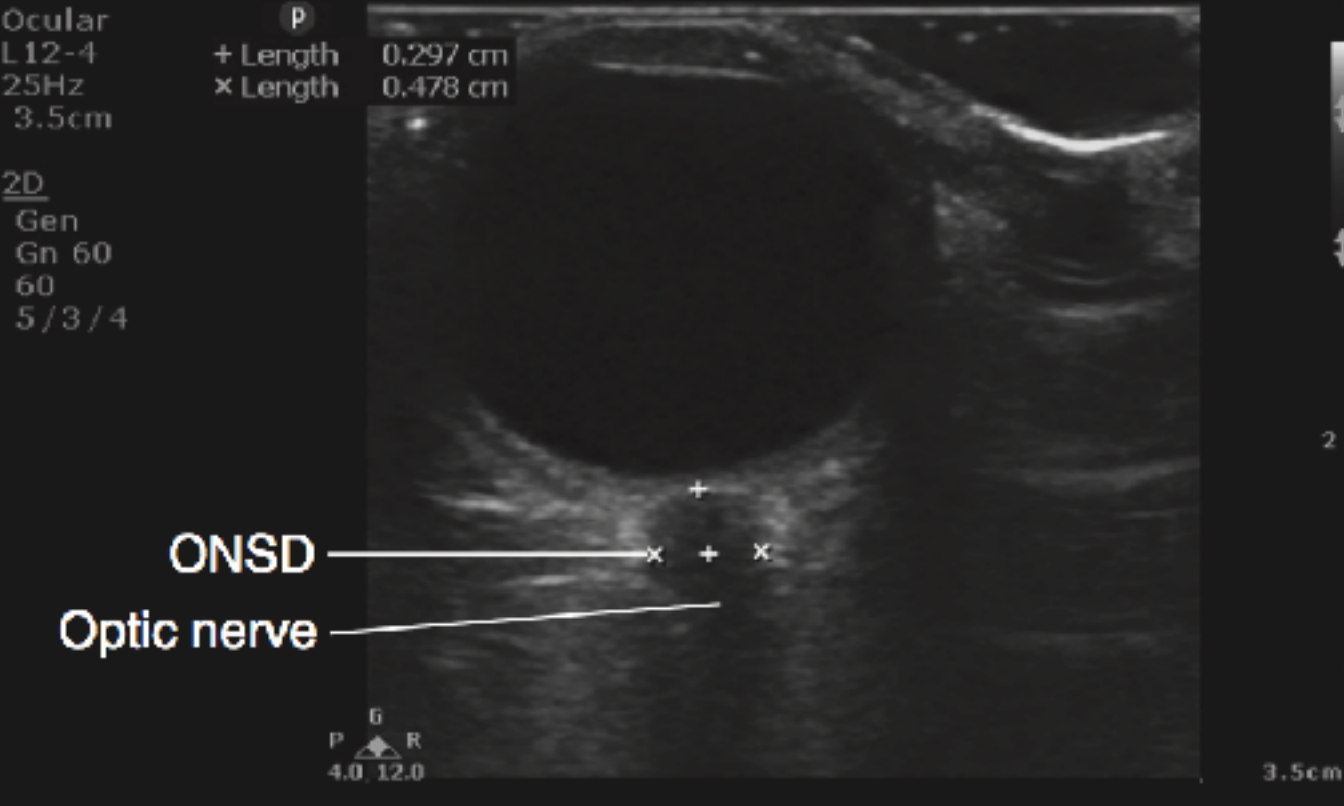
**THERMAL**



**ALARA**

AS LOW AS REASONABLY ACHIEVABLE

**線形探頭 + GEL + TEGADERM**



**3mm**

**5mm**

**ICP > 20 cmH2O**

# ONSD

OPTIC NERVE SHEATH DIAMETER

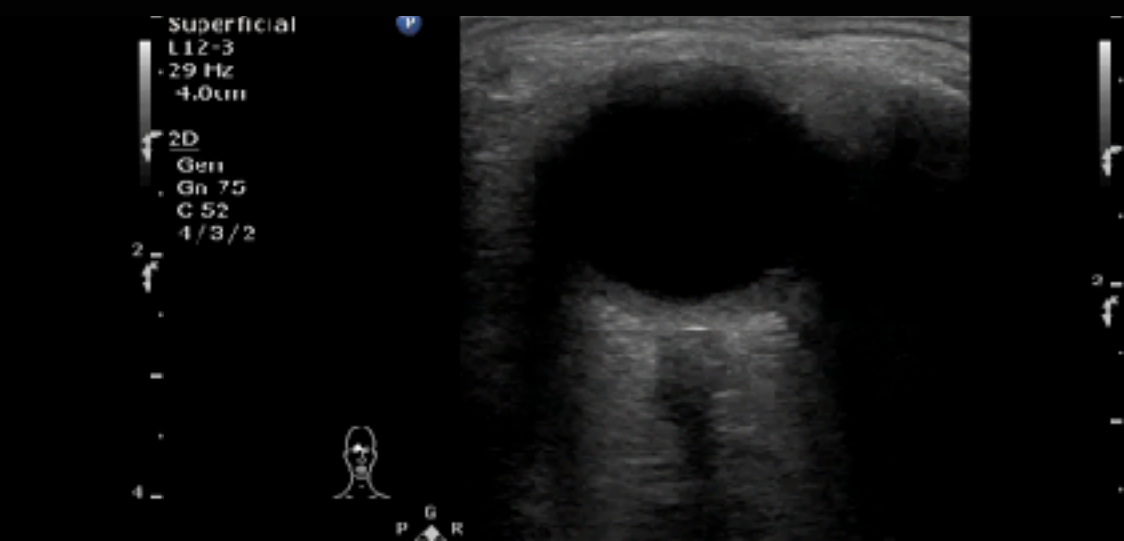
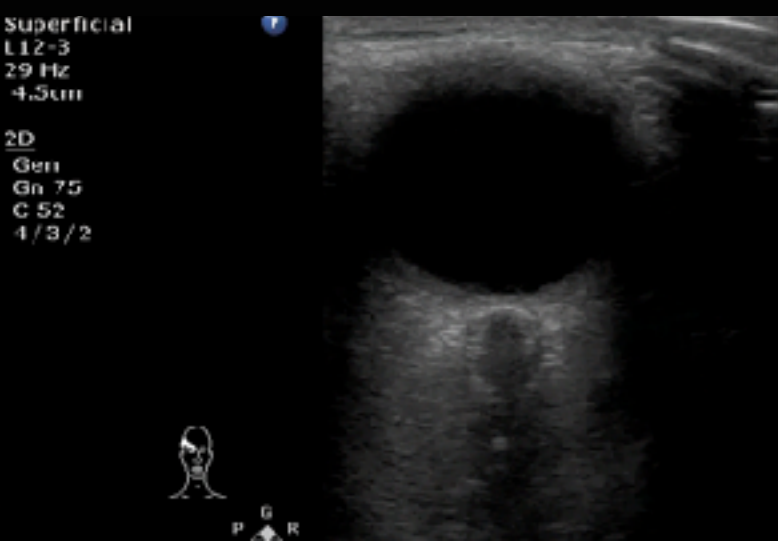
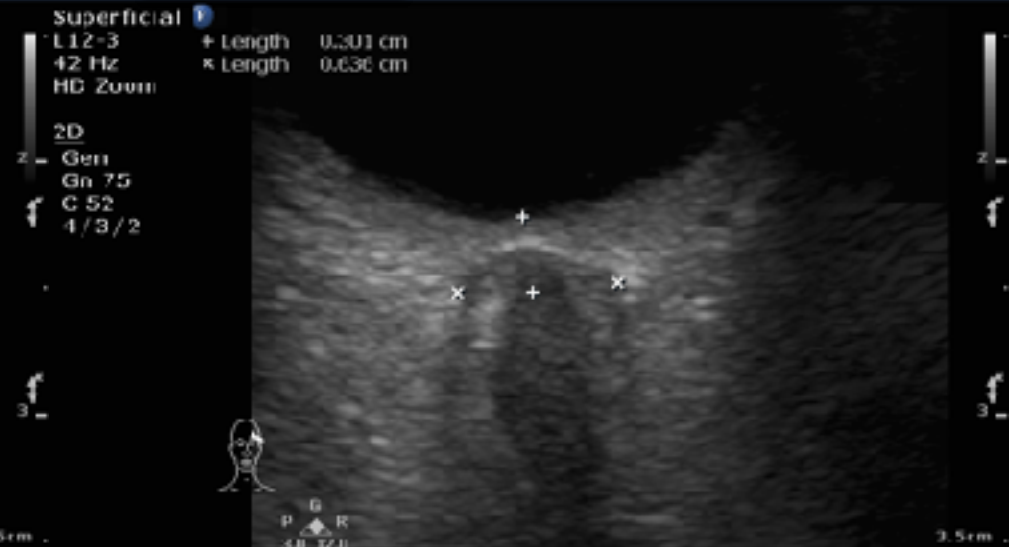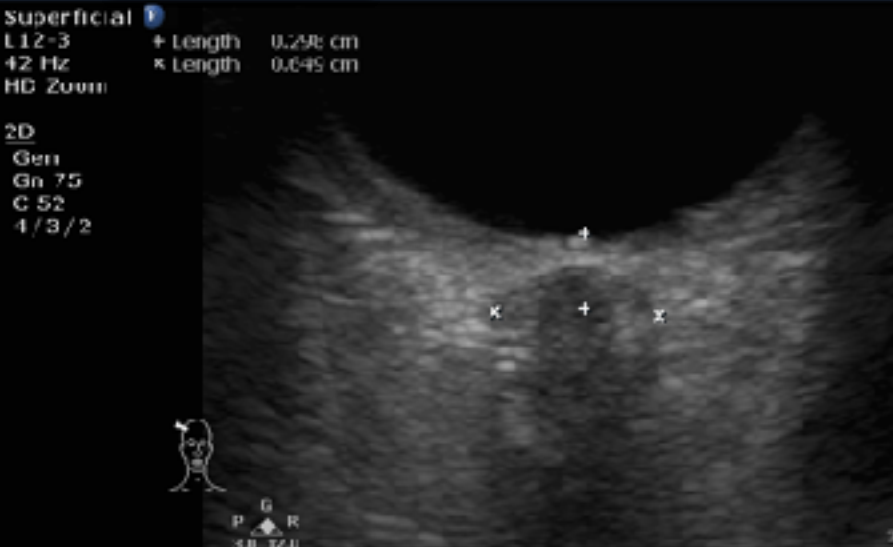**Sen 87-90% / Spe 79-85% (>4 y/o)**



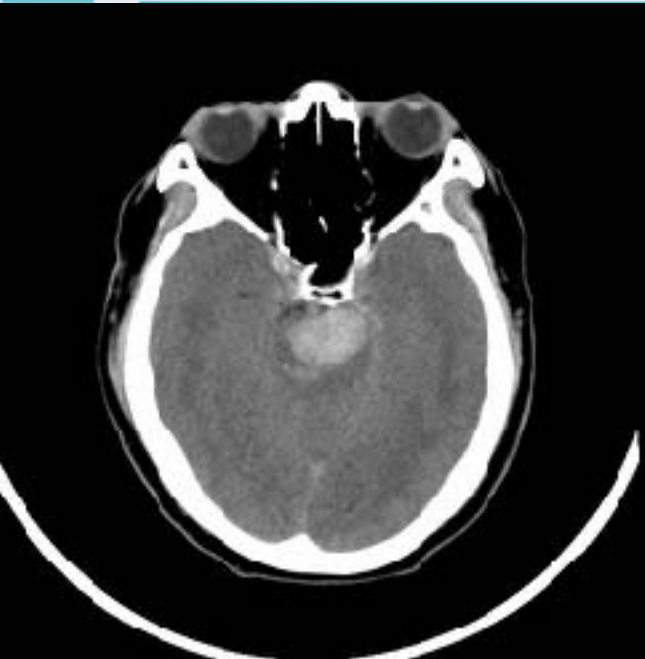
# 47M, unconsciousness with high BP



PHILIPS MI L.2 12/14/2015 PHILIPS SKH FR TIS 0.6 10:59:44 AM PHILIPS MI L.2 12/14/2015 SKH FR TIS 0.6 10:58:43 AM



# Pontine hemorrhage



SKH ER

MI 1.2

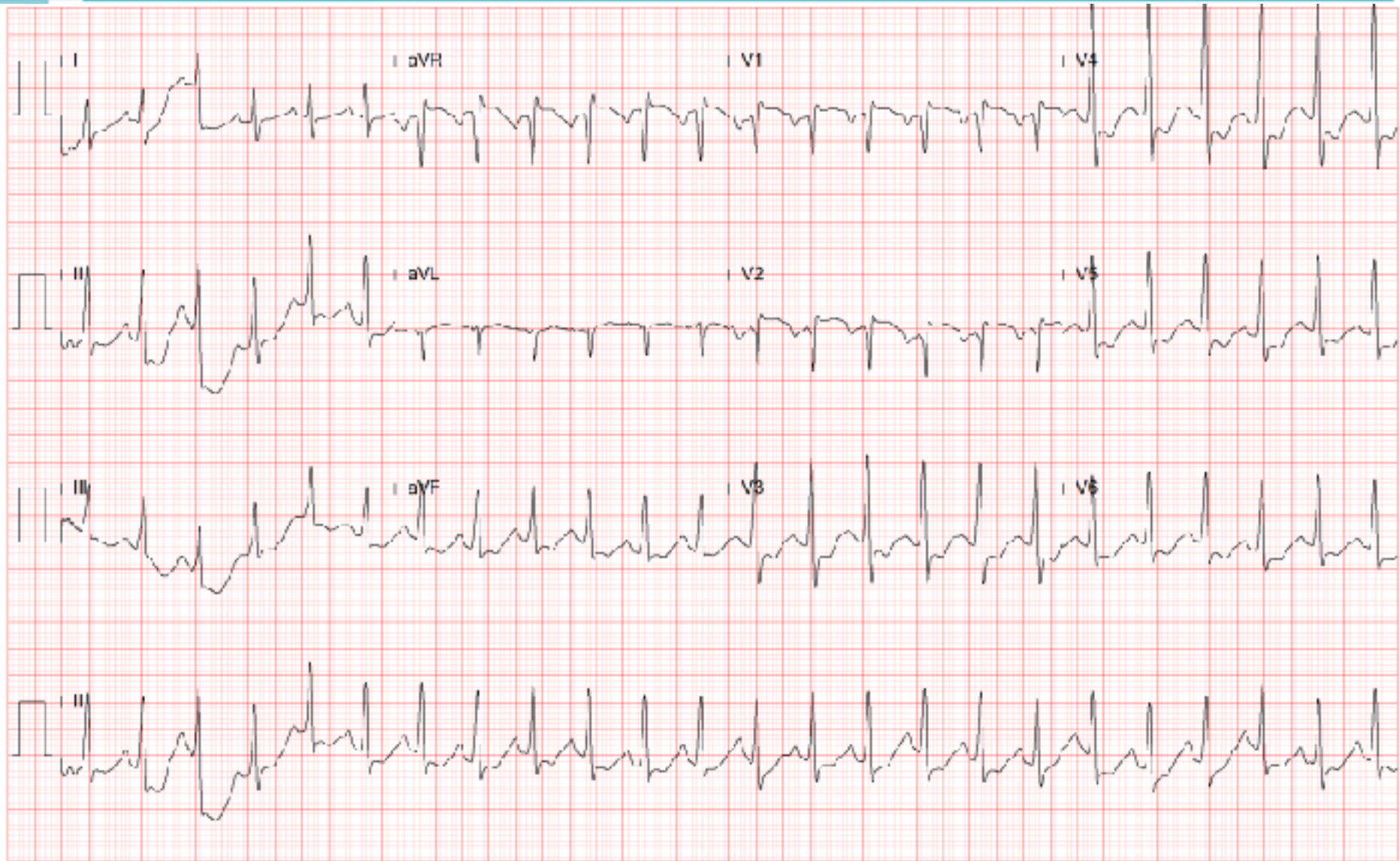
12/14/

TIS 0.6

10:28:



# 36M, Seizure & Coma (E1V1M1)

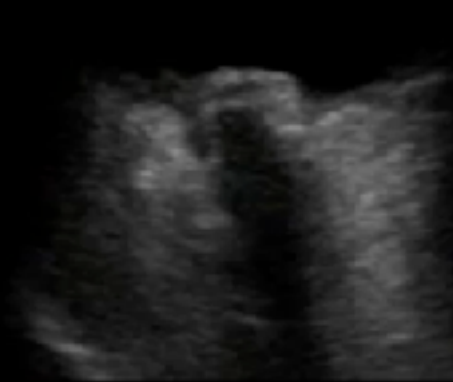
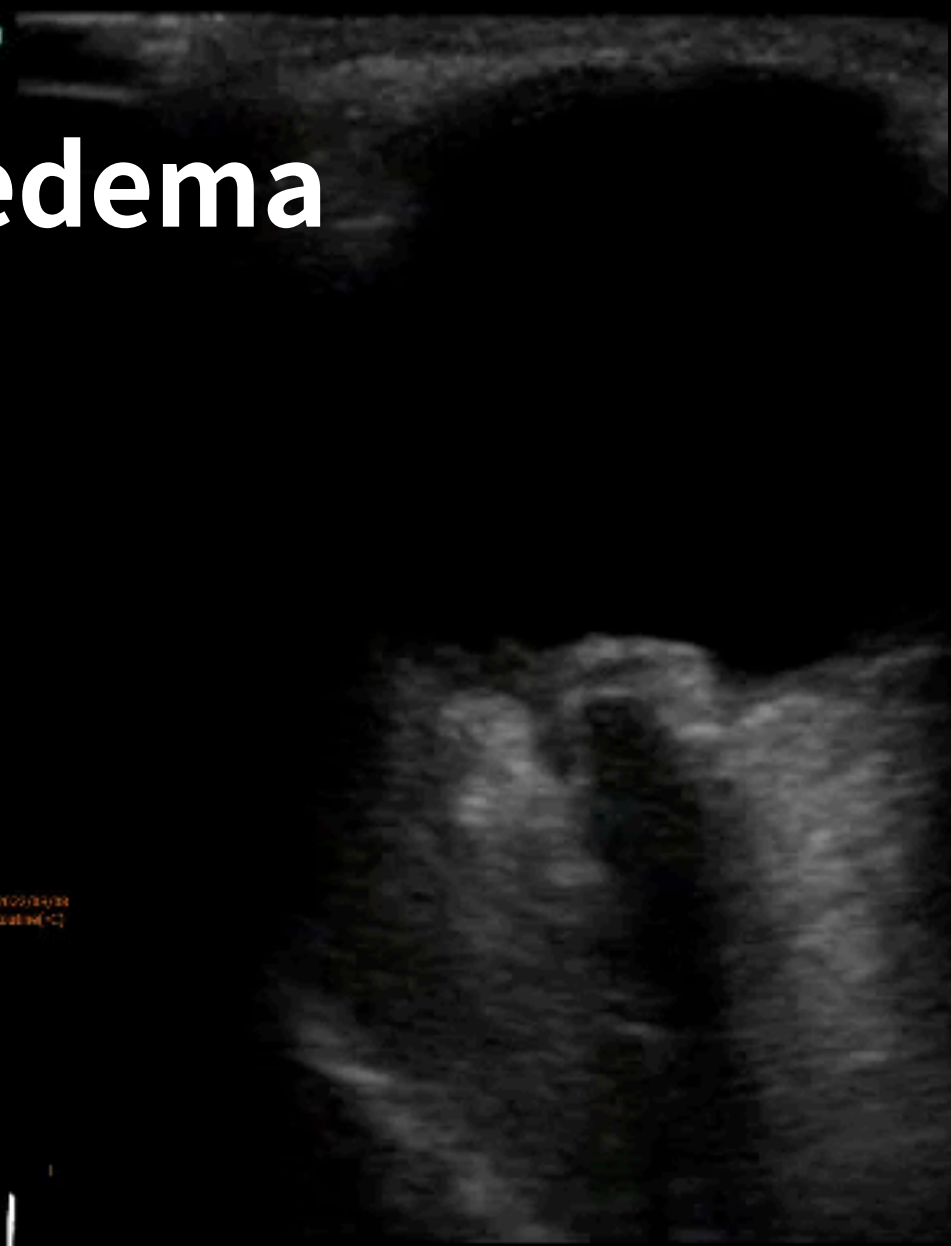
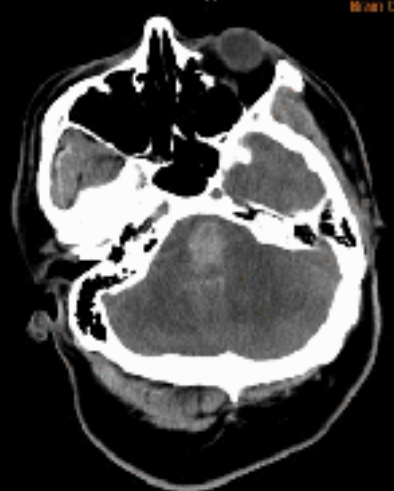# Papilledema

Patient

Auto Gain

Gen



4.0

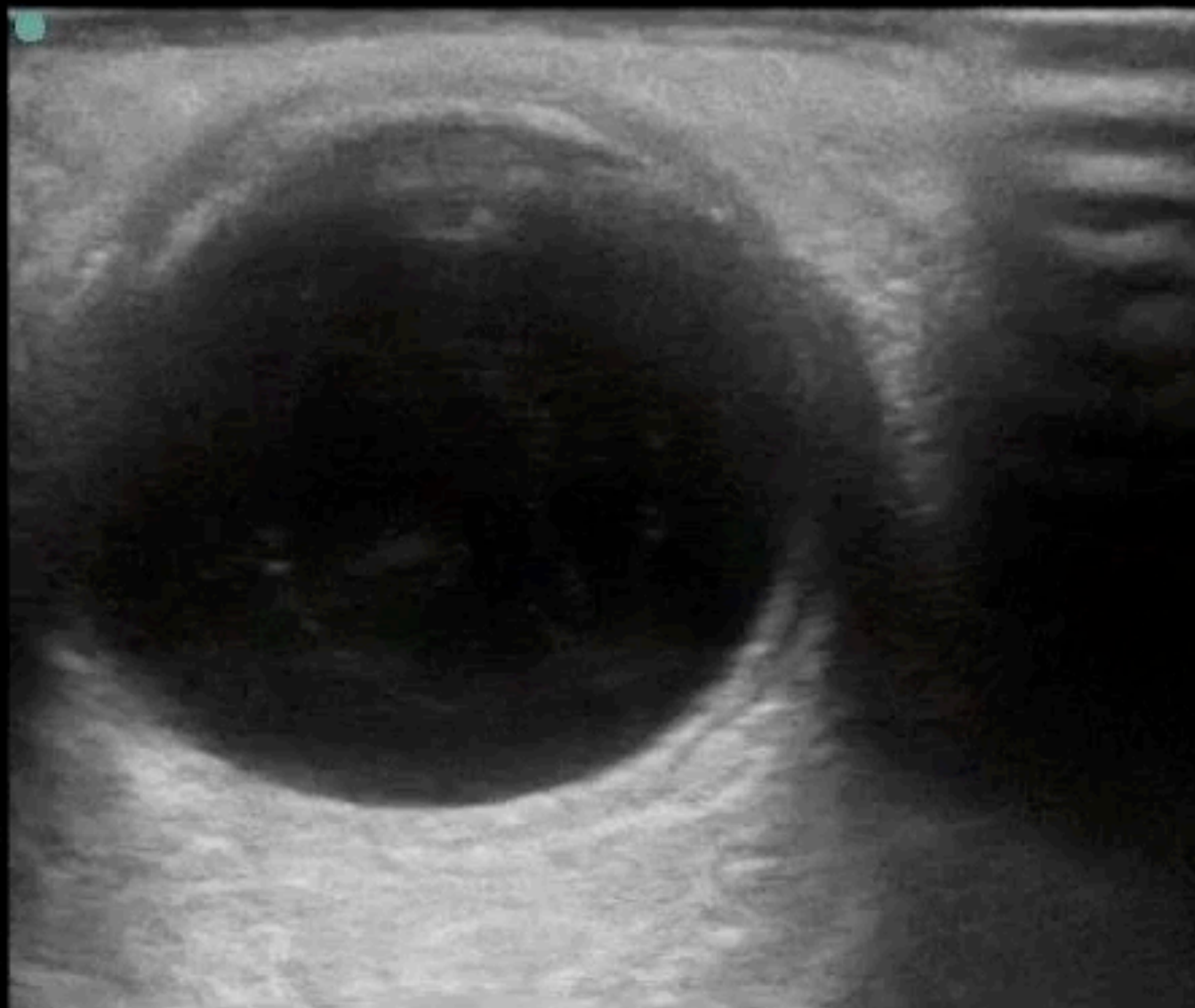
# 69M，被人用拳頭打左眼，視力模糊



Res

MB

2022Mar22 19:39



Bre

HFL



93%

MI

0.8

TIS

0.1



Patient



Auto Gain



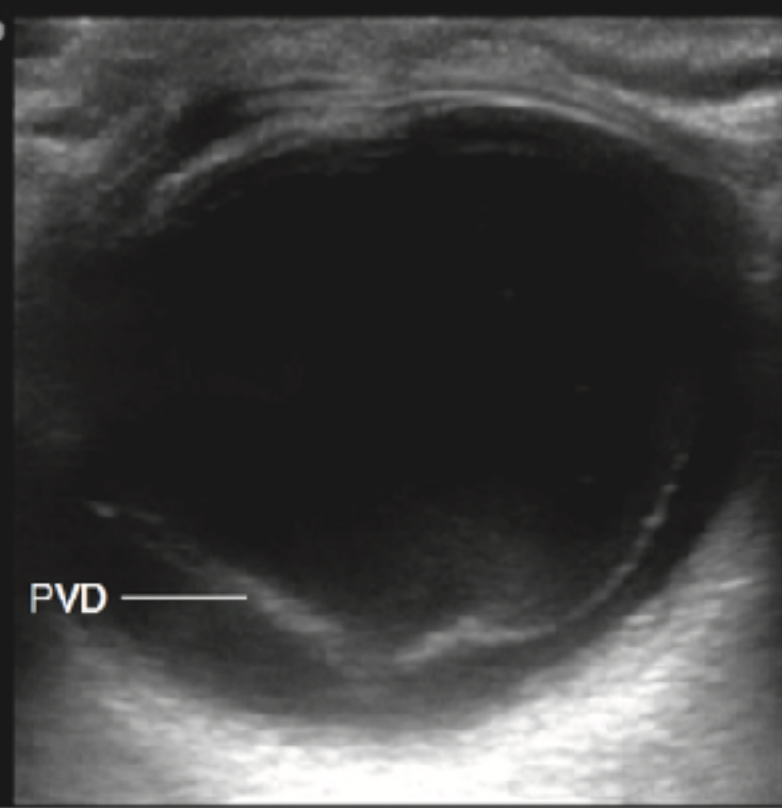
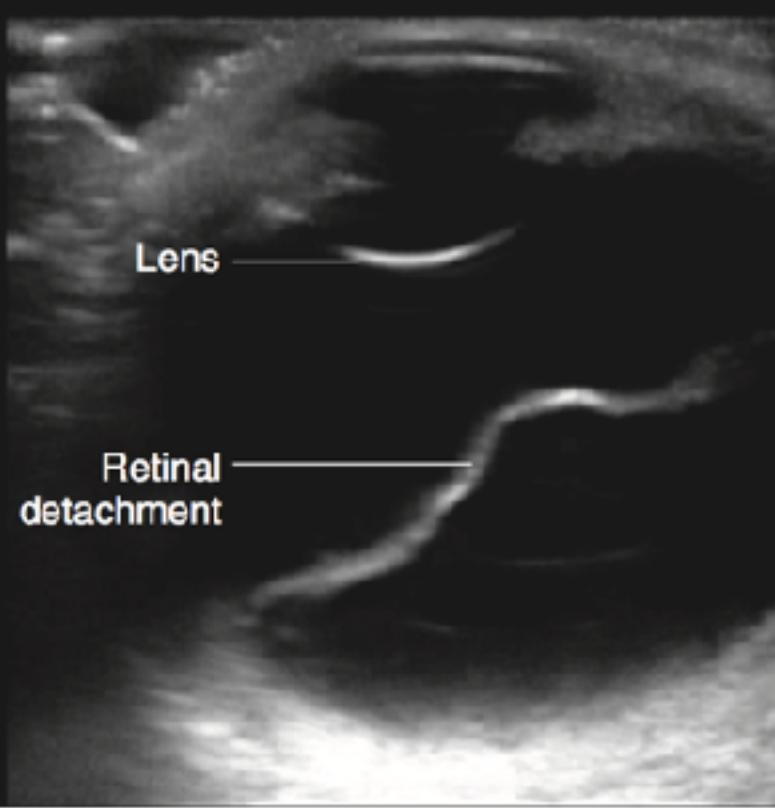
Res



Clip



33



# RETINAL DETACHMENT

POSTERIOR VITREOUS DETACHMENT WITH RETINAL TEAR

floaters, flashers, curtain, visual field loss

22

## Optic Nerve

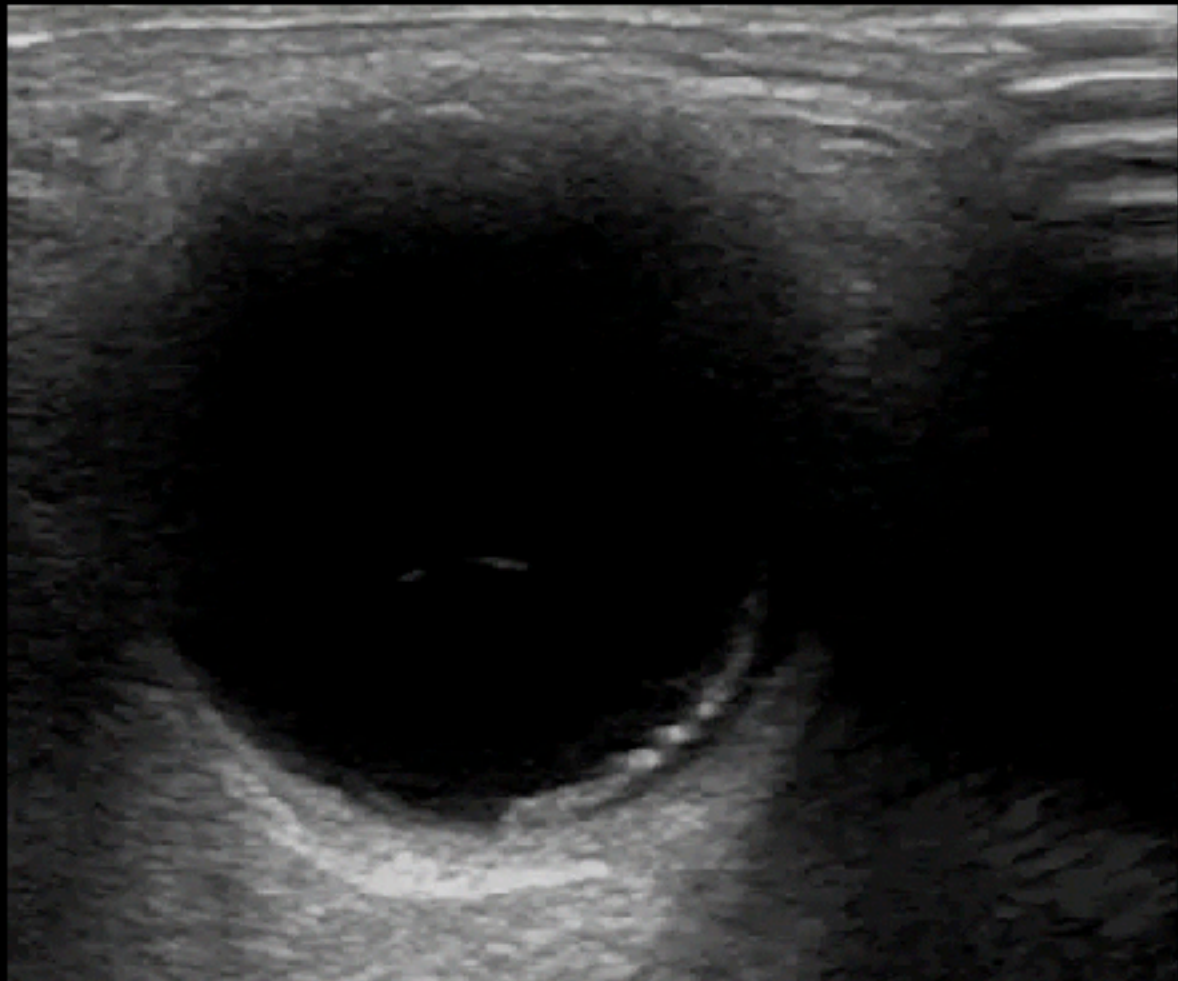
# 65M, floaters & visual field defect (OS)



PHILIPS SKH ER MI 0.9 11/25/2015  
TIS 0.2 7:29:12 PM

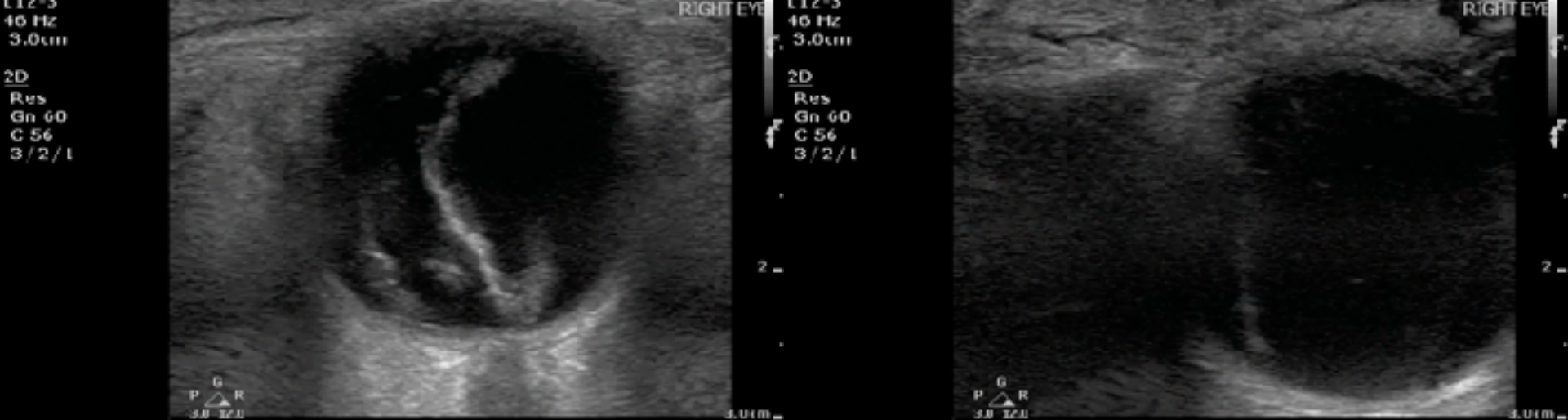
Superficial  
L12-3  
31 Hz  
3.5cm

2D  
Gen  
Gn 100  
C. 57  
4/3/2



P G R

2  
x  
↓



52M, sudden onset of blurred vision 3d

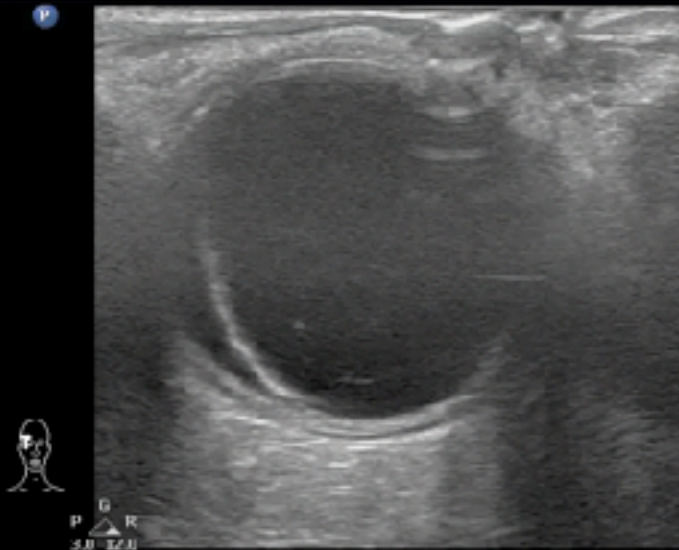
**RD OR PVD**

**Optic Nerve**



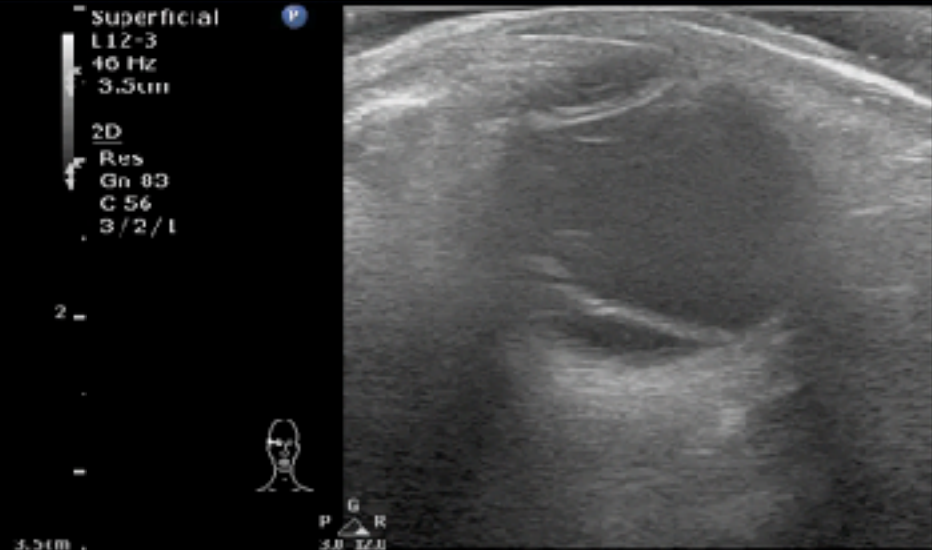
superficial  
L12-3  
40 Hz  
3.5cm

2D  
Res  
Gn 83  
C 56  
3/2/1



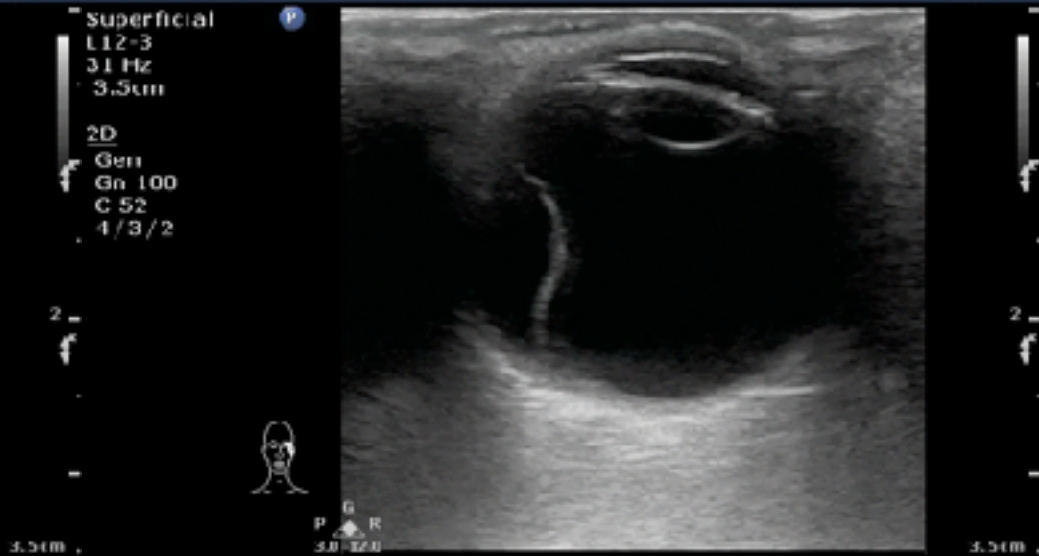
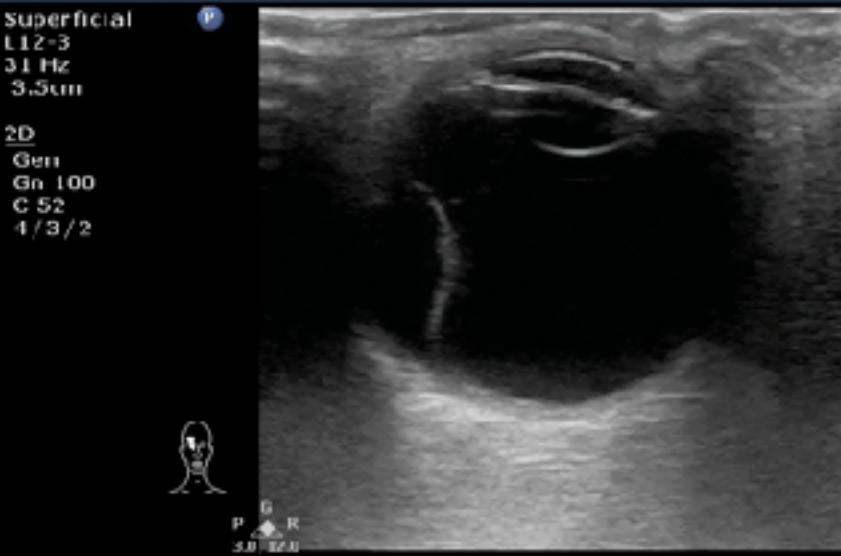
superficial  
L12-3  
40 Hz  
3.5cm

2D  
Res  
Gn 83  
C 56  
3/2/1



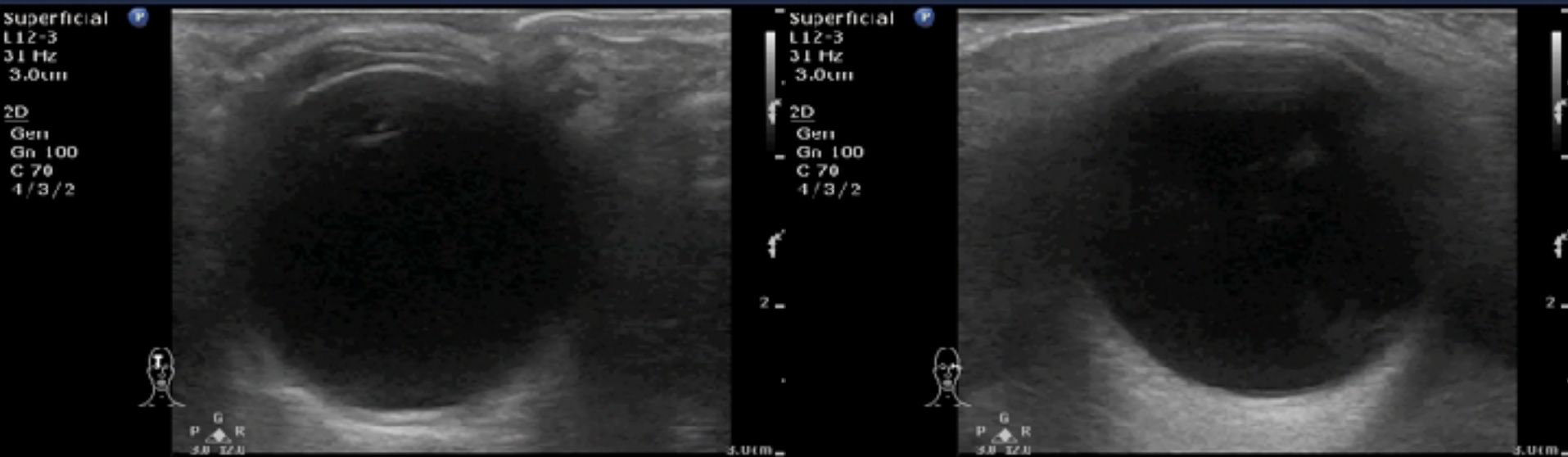
# RD & VH

# Optic Nerve



# RETINAL DETACHMENT

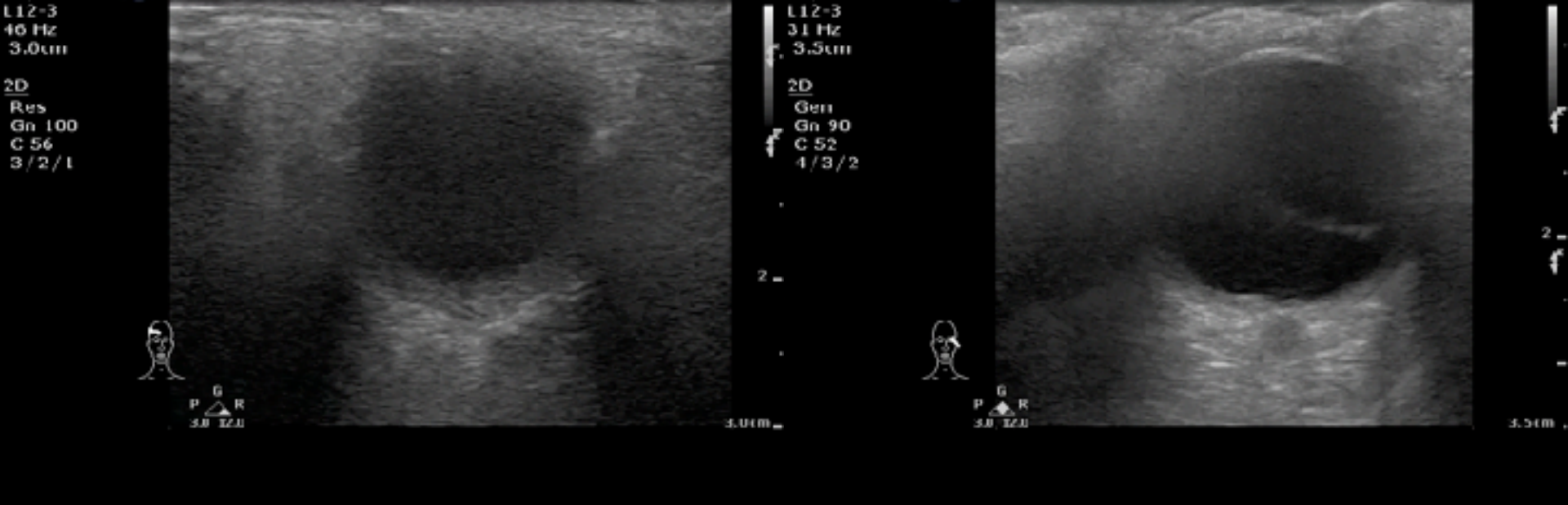
## Optic Nerve



61M, left eye blurred vision & floaters

## VITREOUS HEMORRHAGE

Washing machine sign

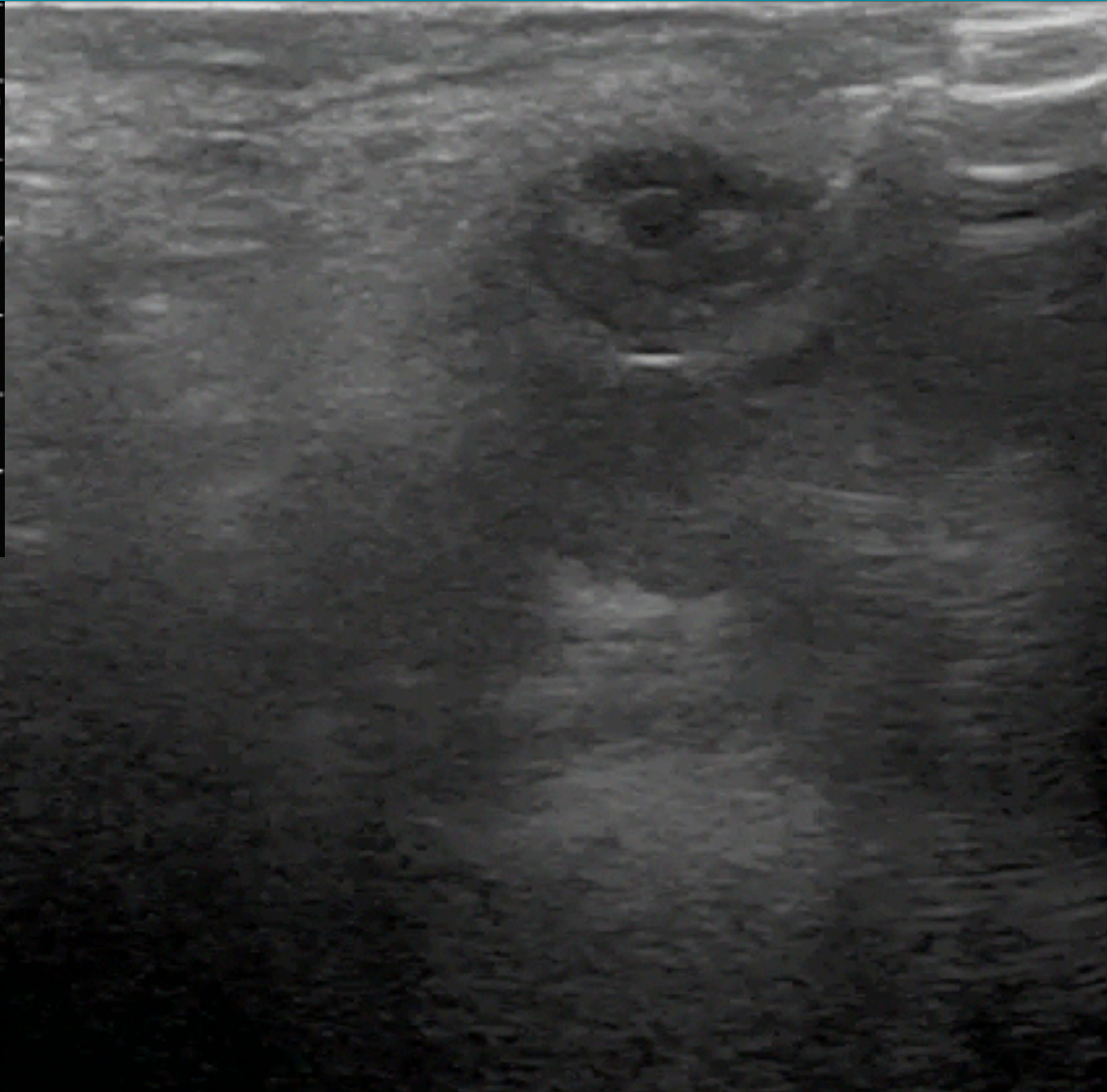
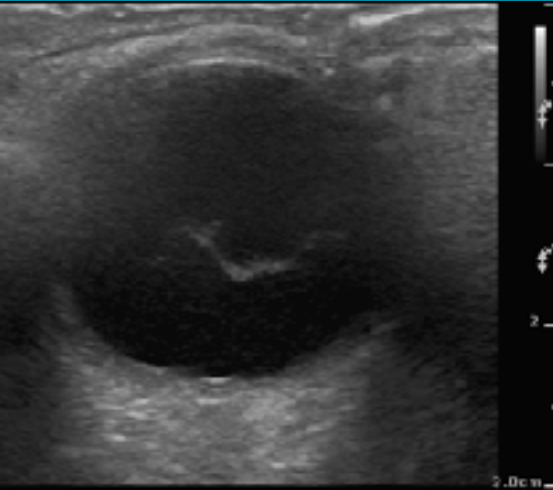


65F, left eye blindness for half year  
ESRD on HD

**RD , VD OR VH ?**

**Vitreous detachment & hemorrhage** <sup>28</sup>

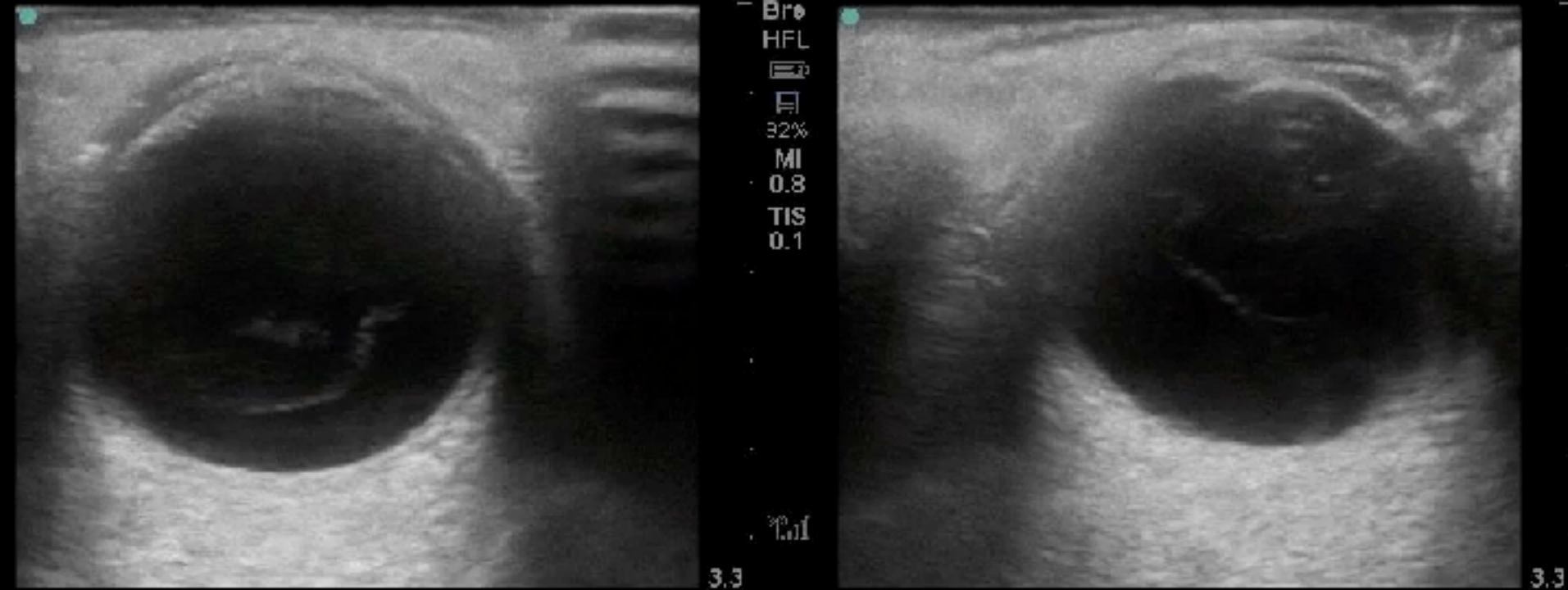
# RD , VD OR VH ?



**VD**

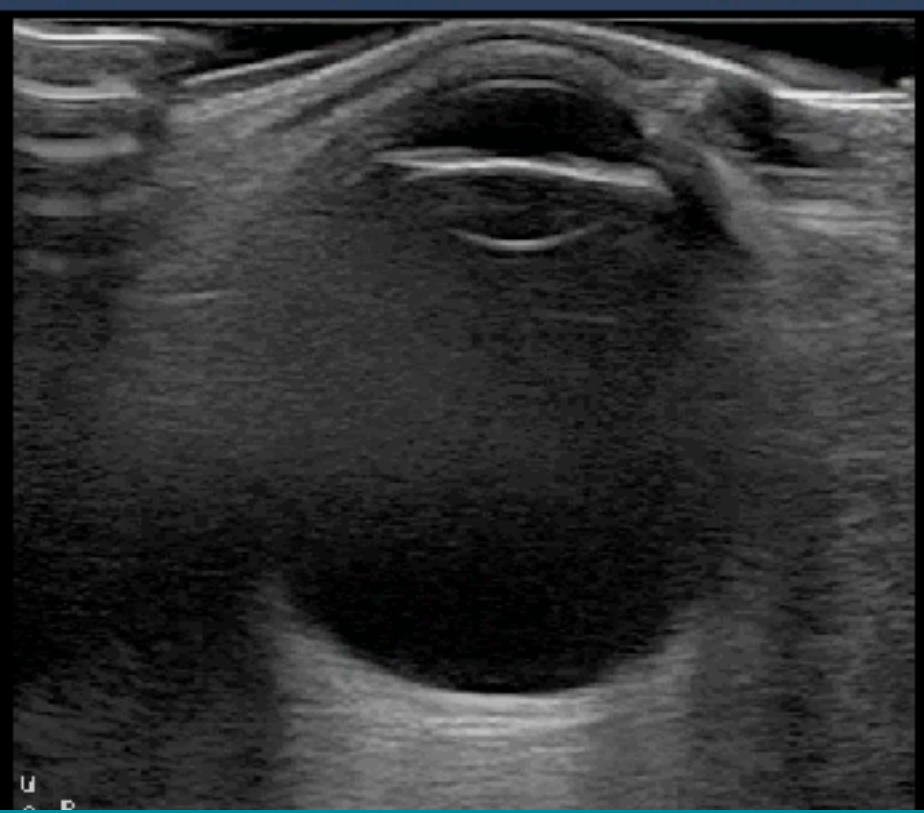
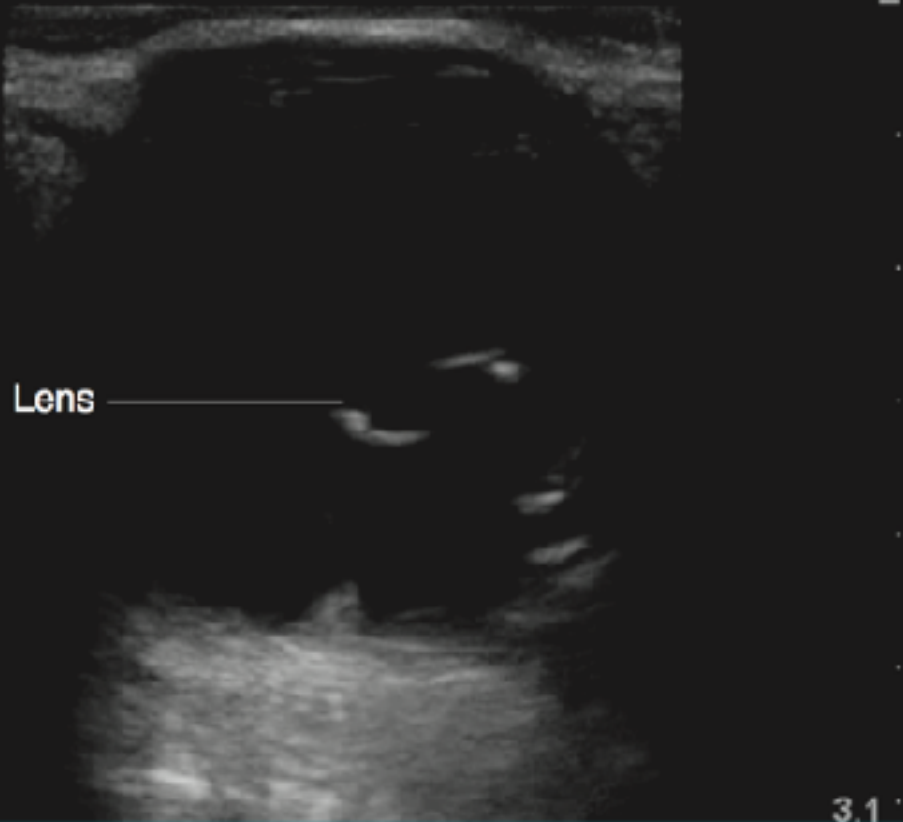**VH**



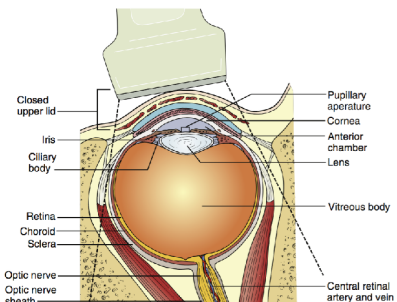


## VITREOUS DETACHMENT & HEMORRHAGE

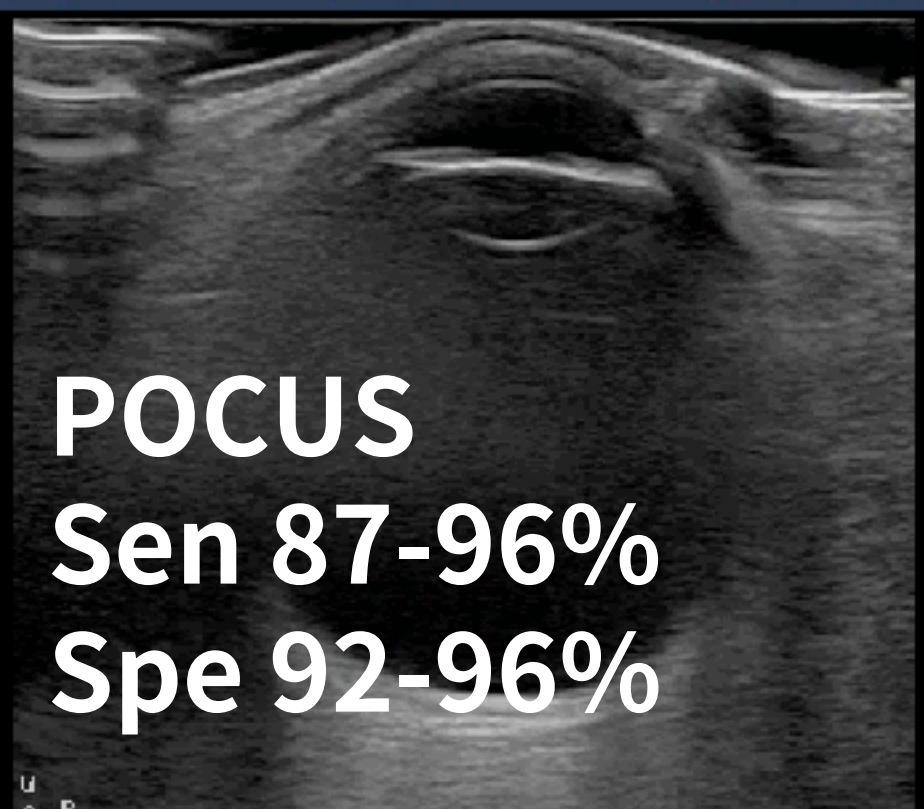
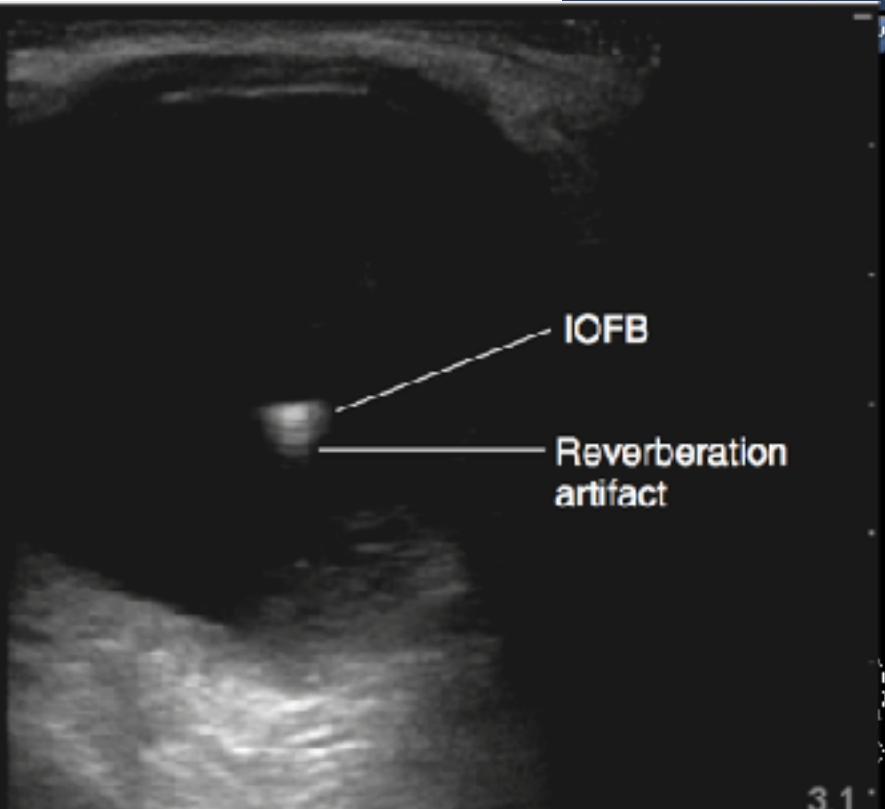
**ON & Washing machine sign** <sup>30</sup>



# TRAUMA



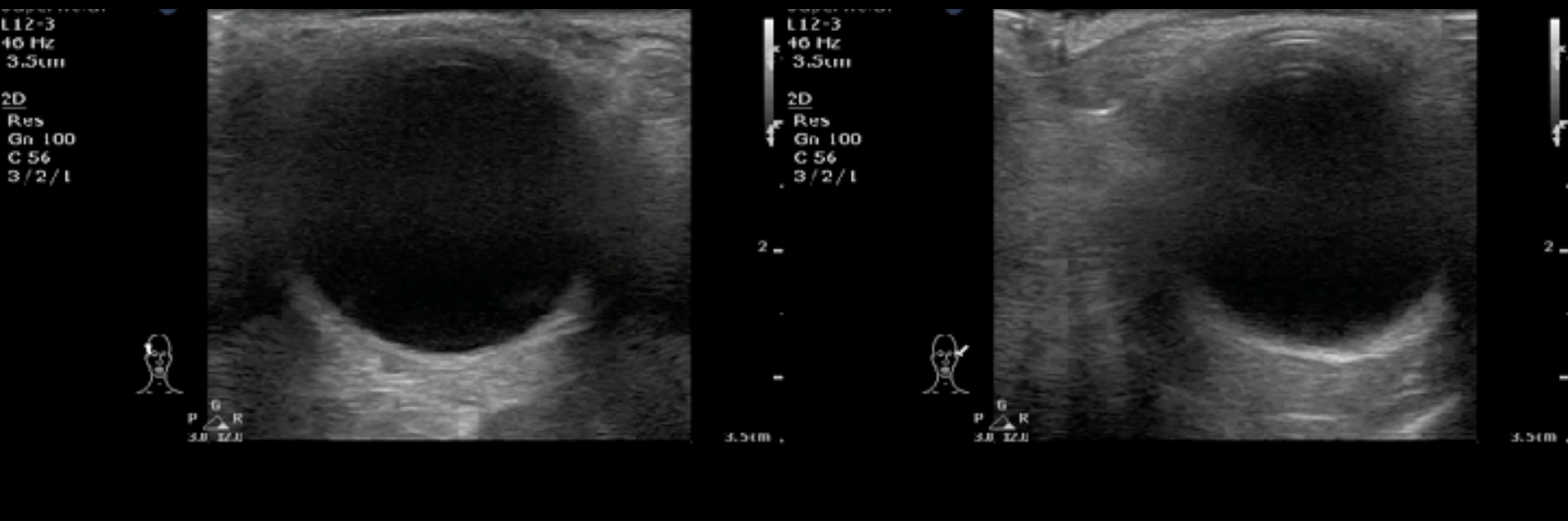
# Lens dislocation



## TRAUMA

Intraocular foreign body (CT)<sup>32</sup>



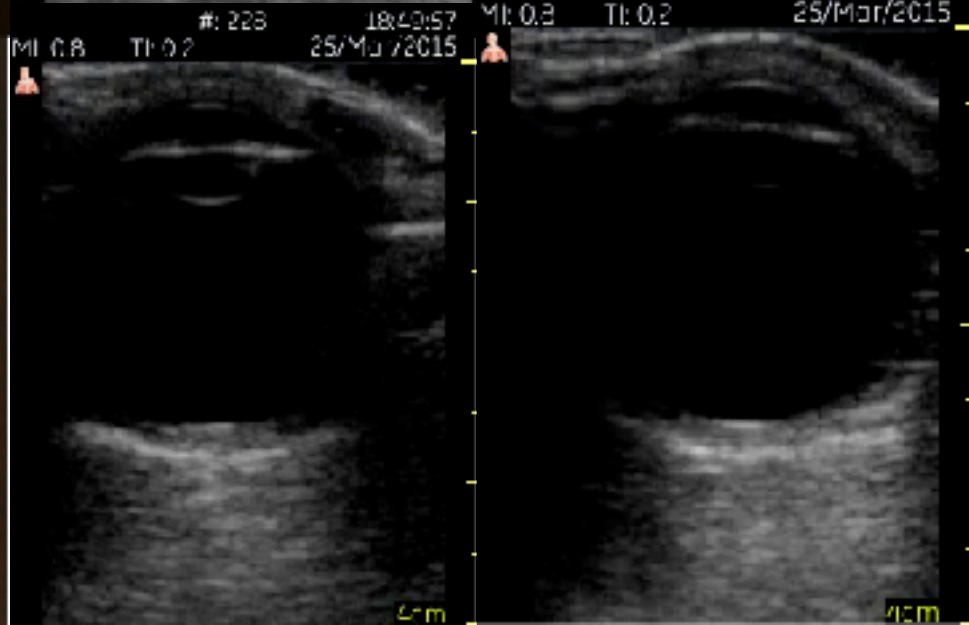
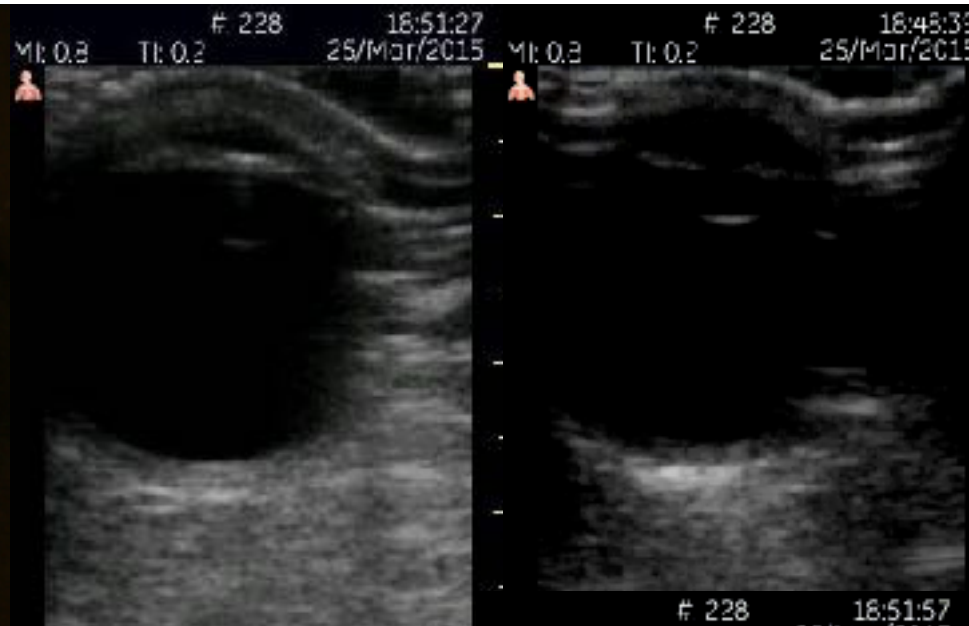
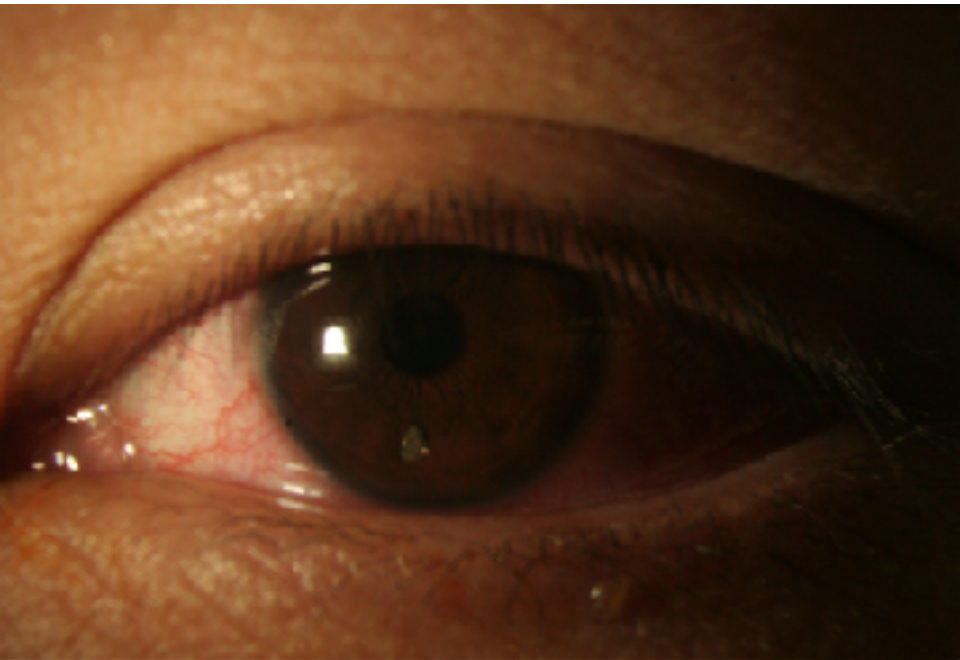


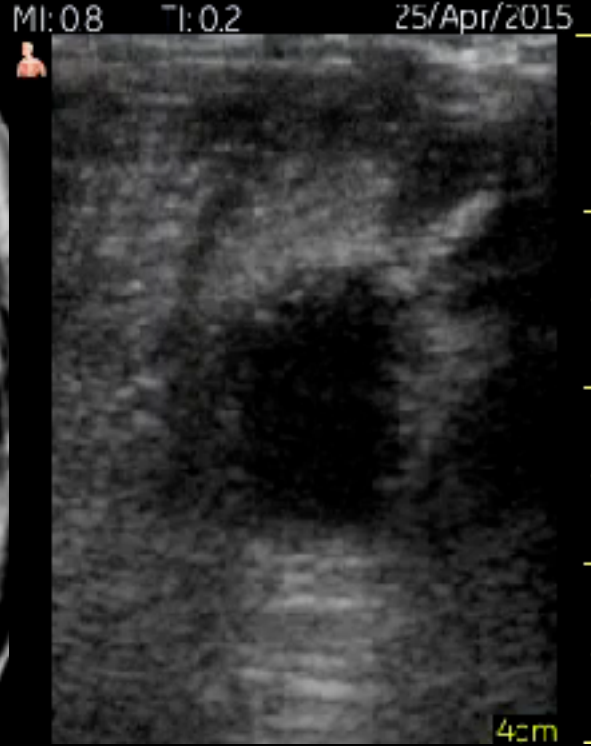
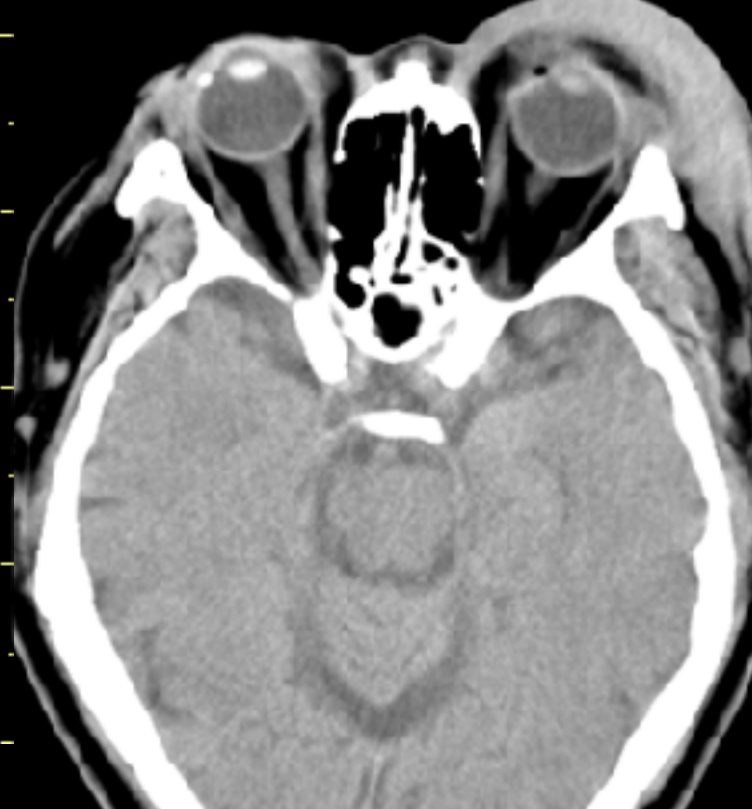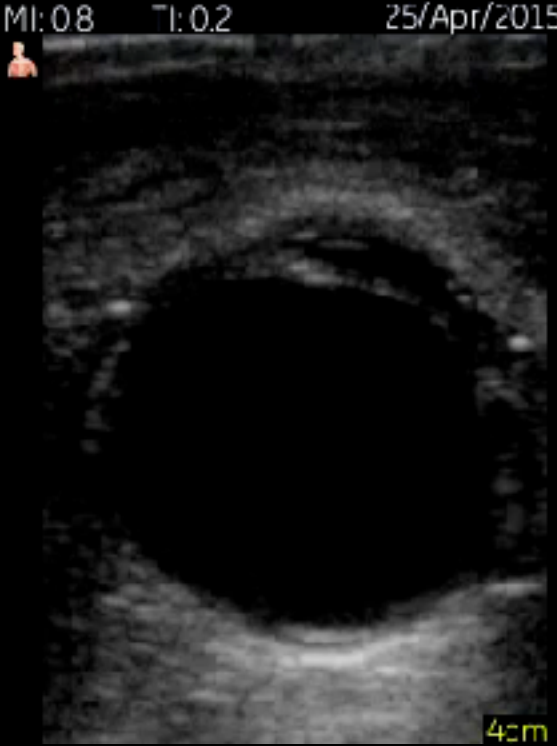
44M, 走路滑倒，右眼被箭竹刺傷

## TRAUMA

Conjunctival laceration (s/p suture by OPH)<sup>33</sup>

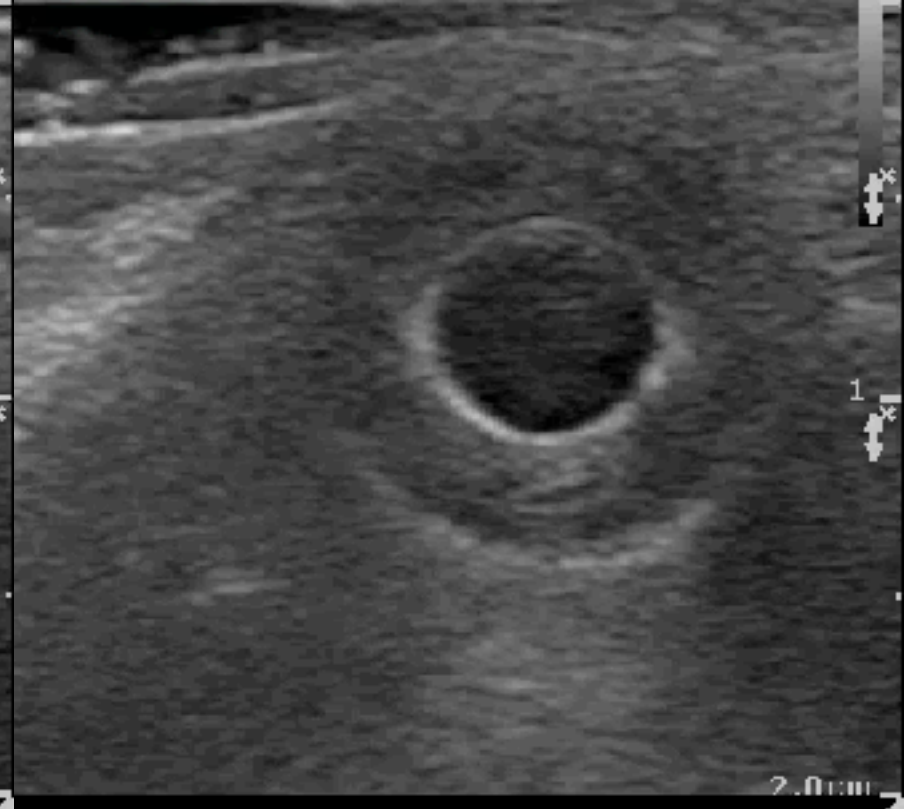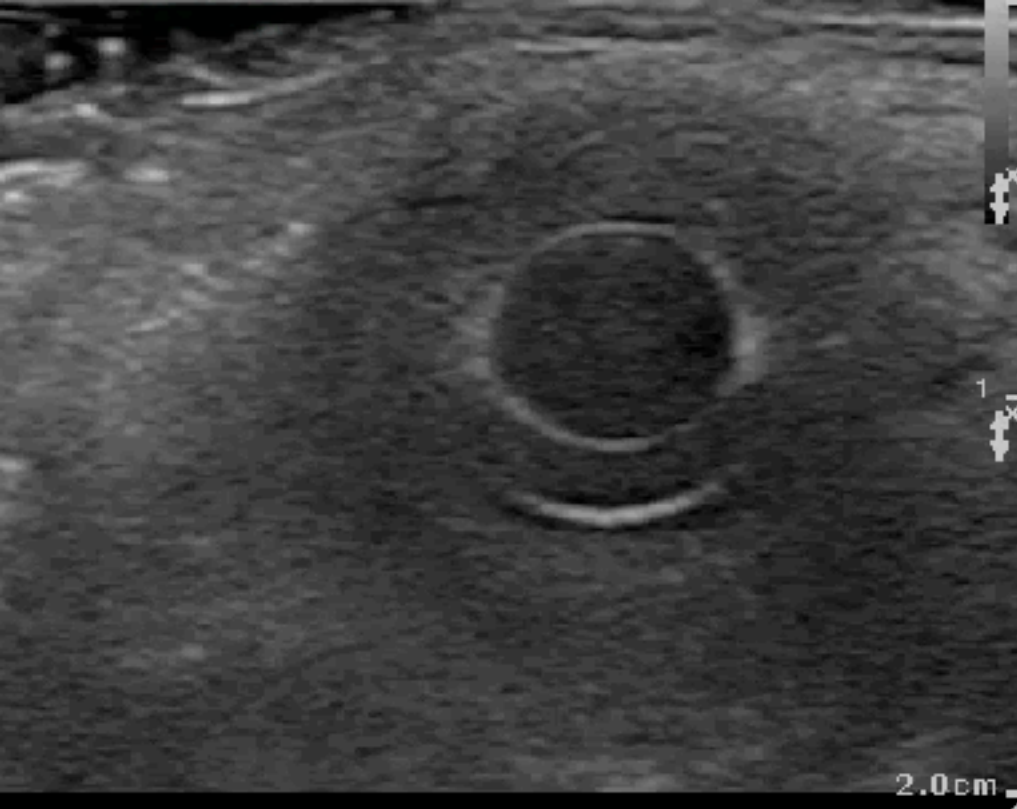# 36M, left eye FB sensation





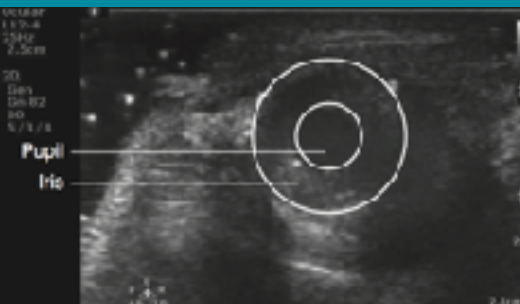
# TRAUMA

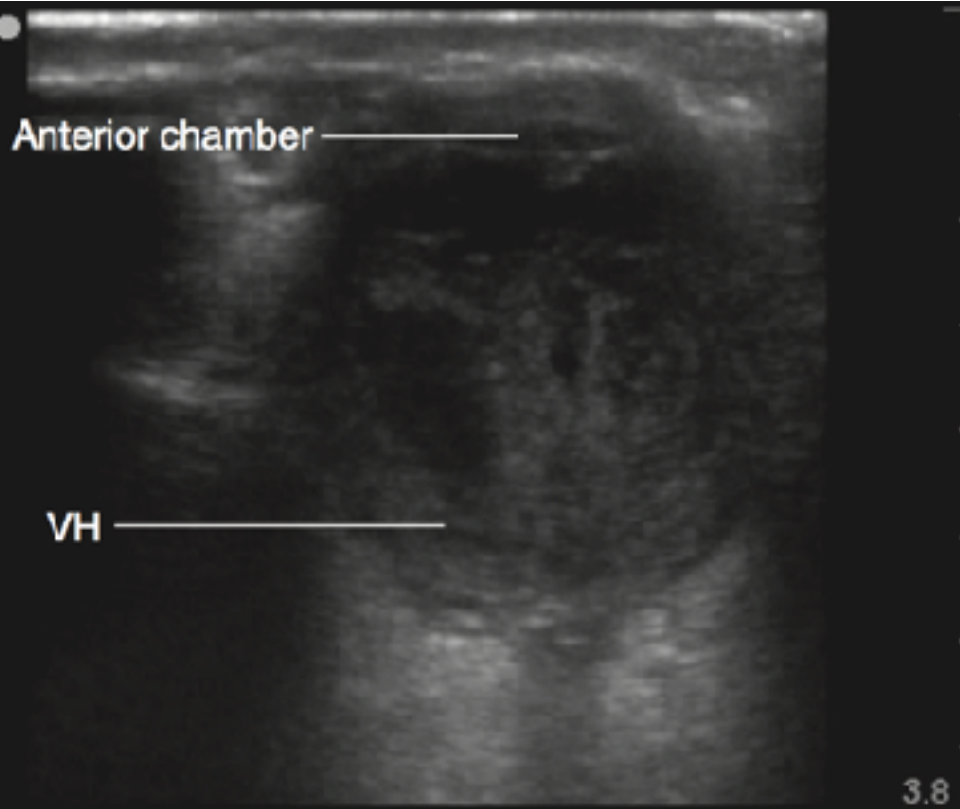
75M, MBA with left eye blunt injury



# PUPILLARY REFLEX

transverse scan  
along inferior eyelid





## Contraindication ?

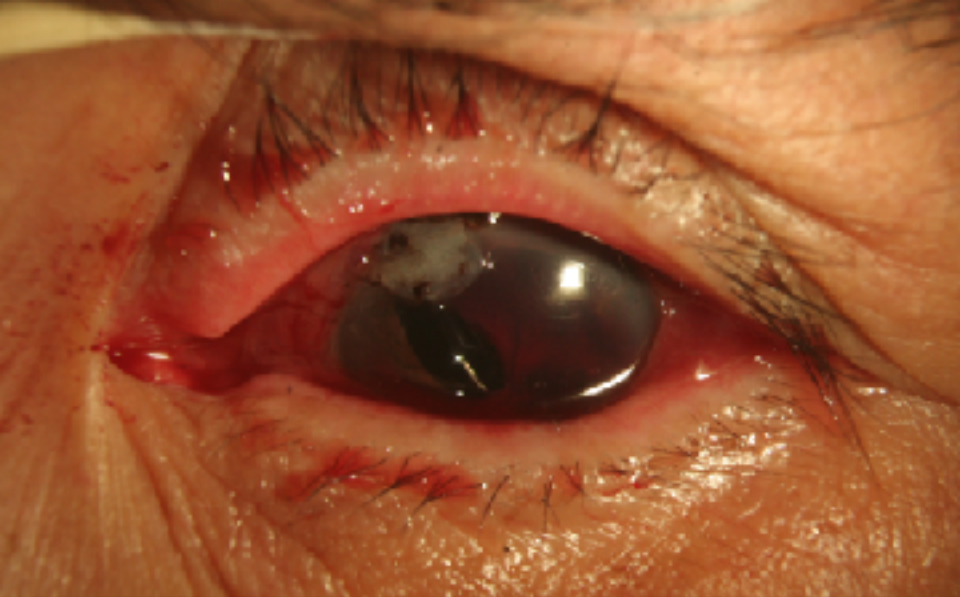
Sclera 變形

Eyeball 球形改變

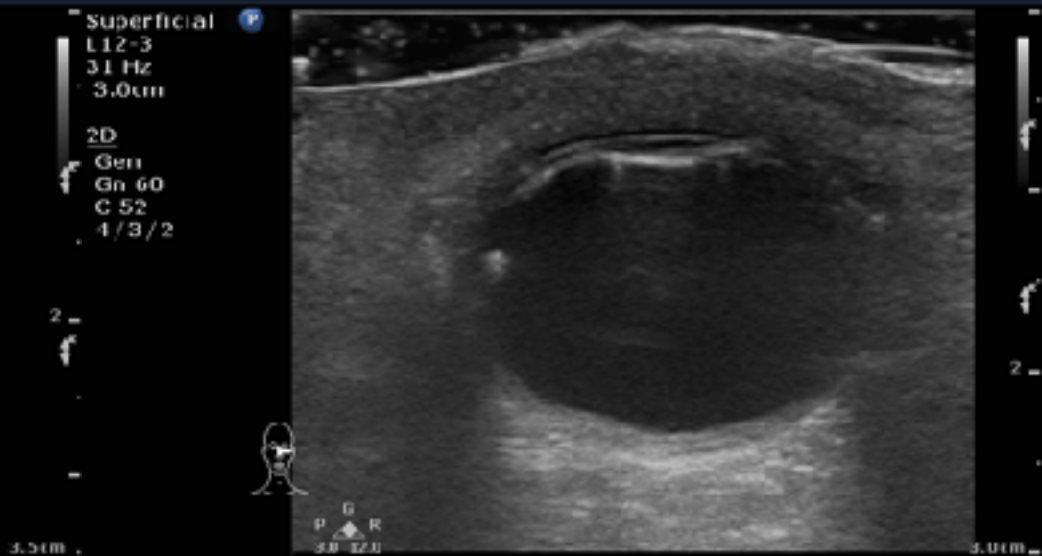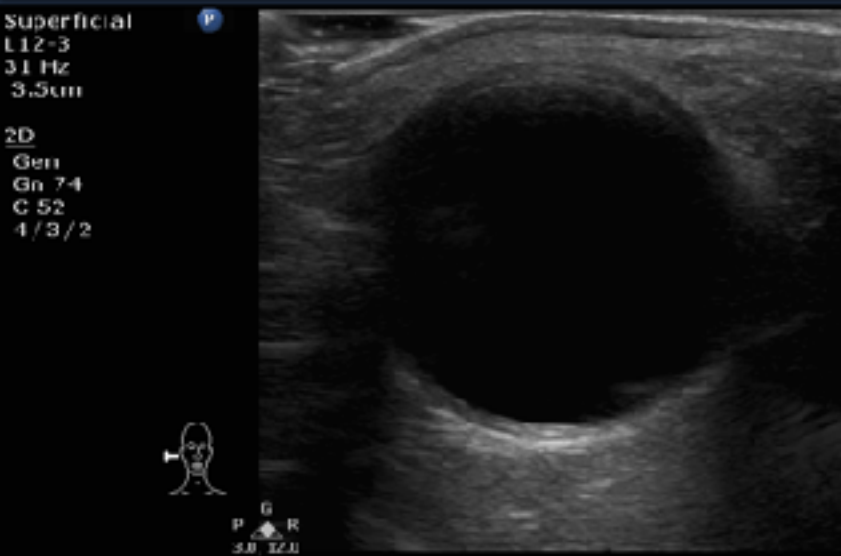
Anterior chamber 扁平壓縮

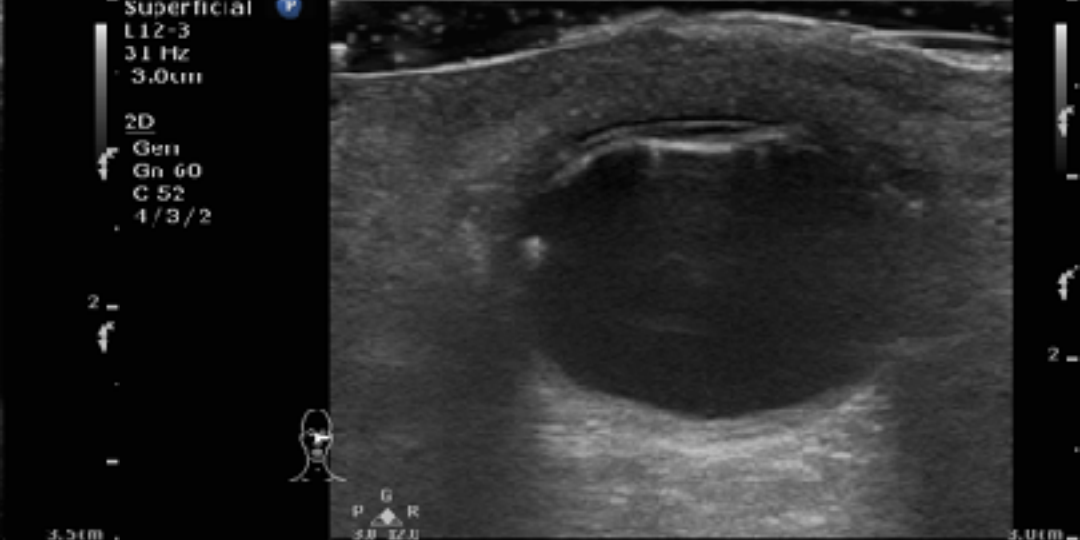
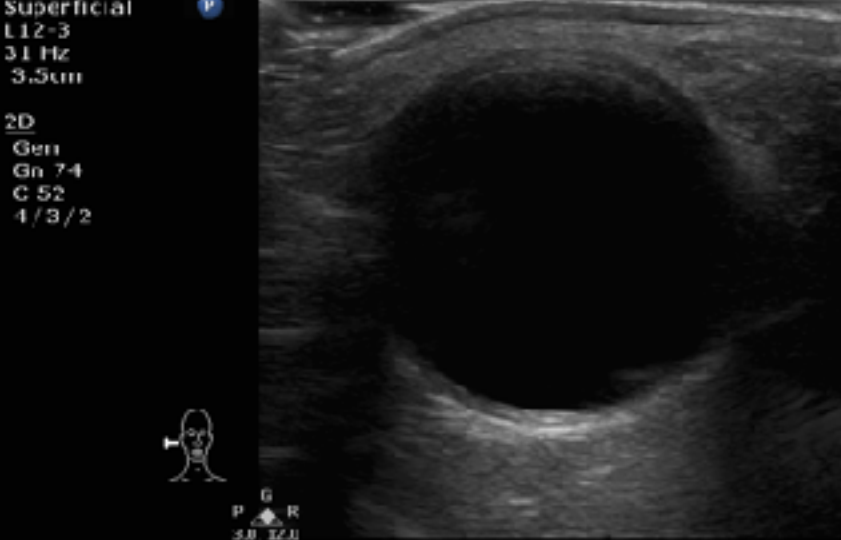
# TRAUMA

## Eyeball rupture

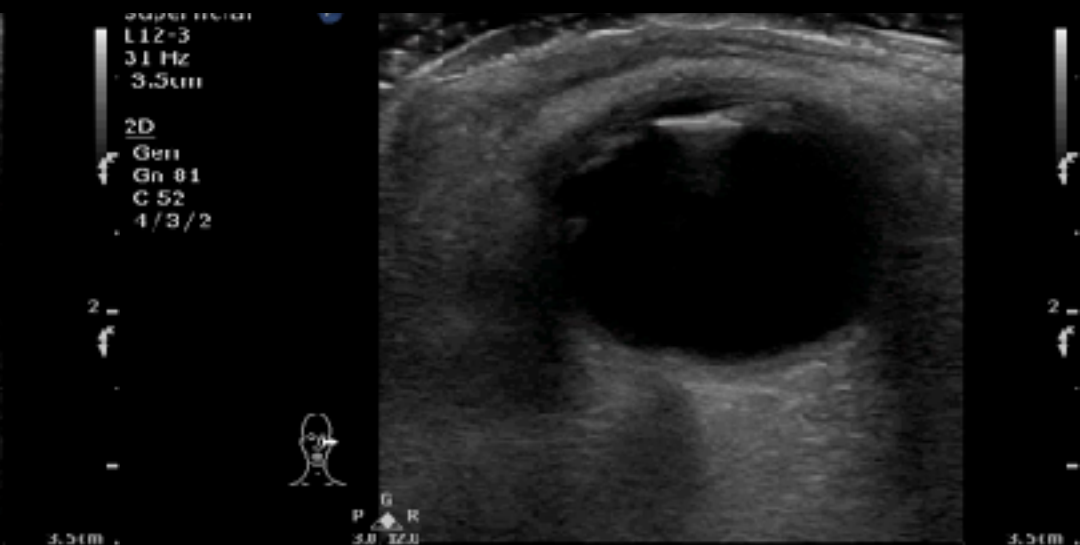
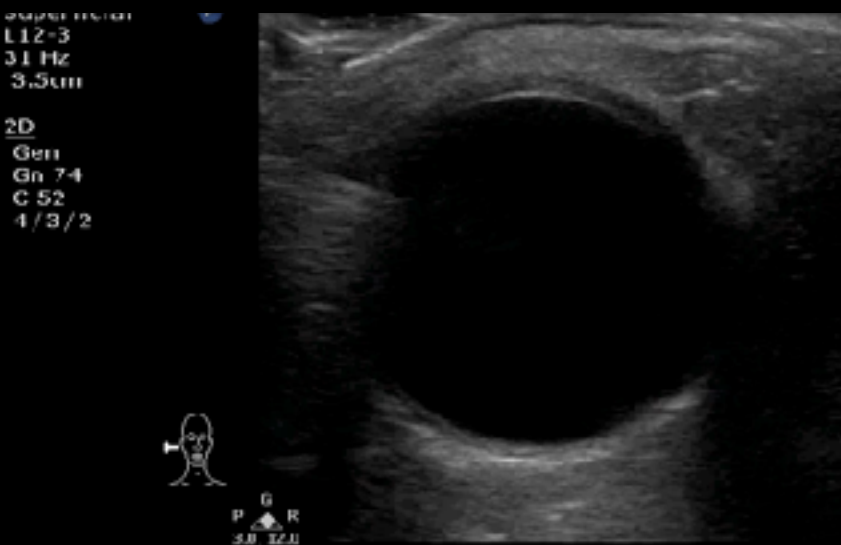


**77M, fell from bus  
hit left eye (HM)**

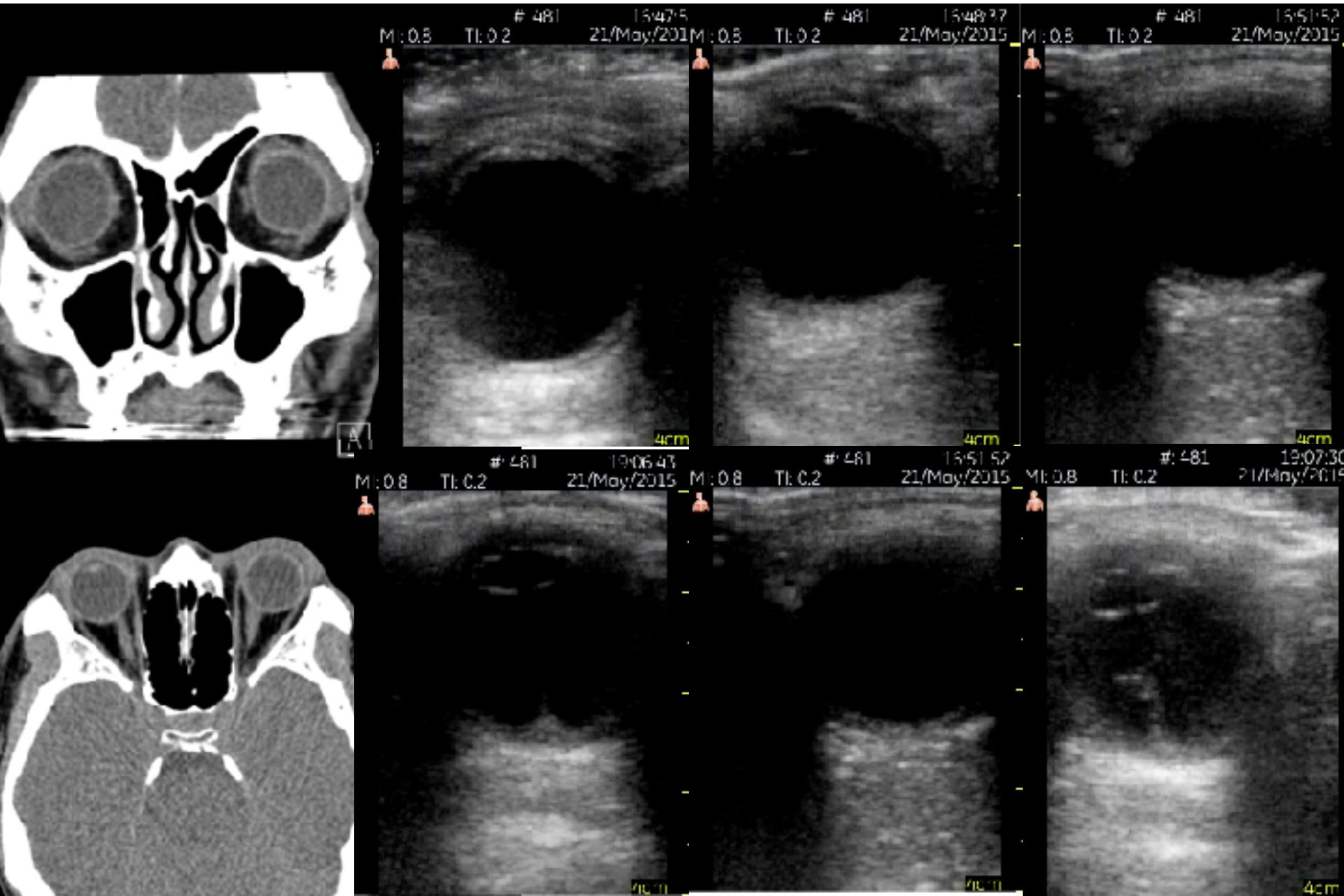




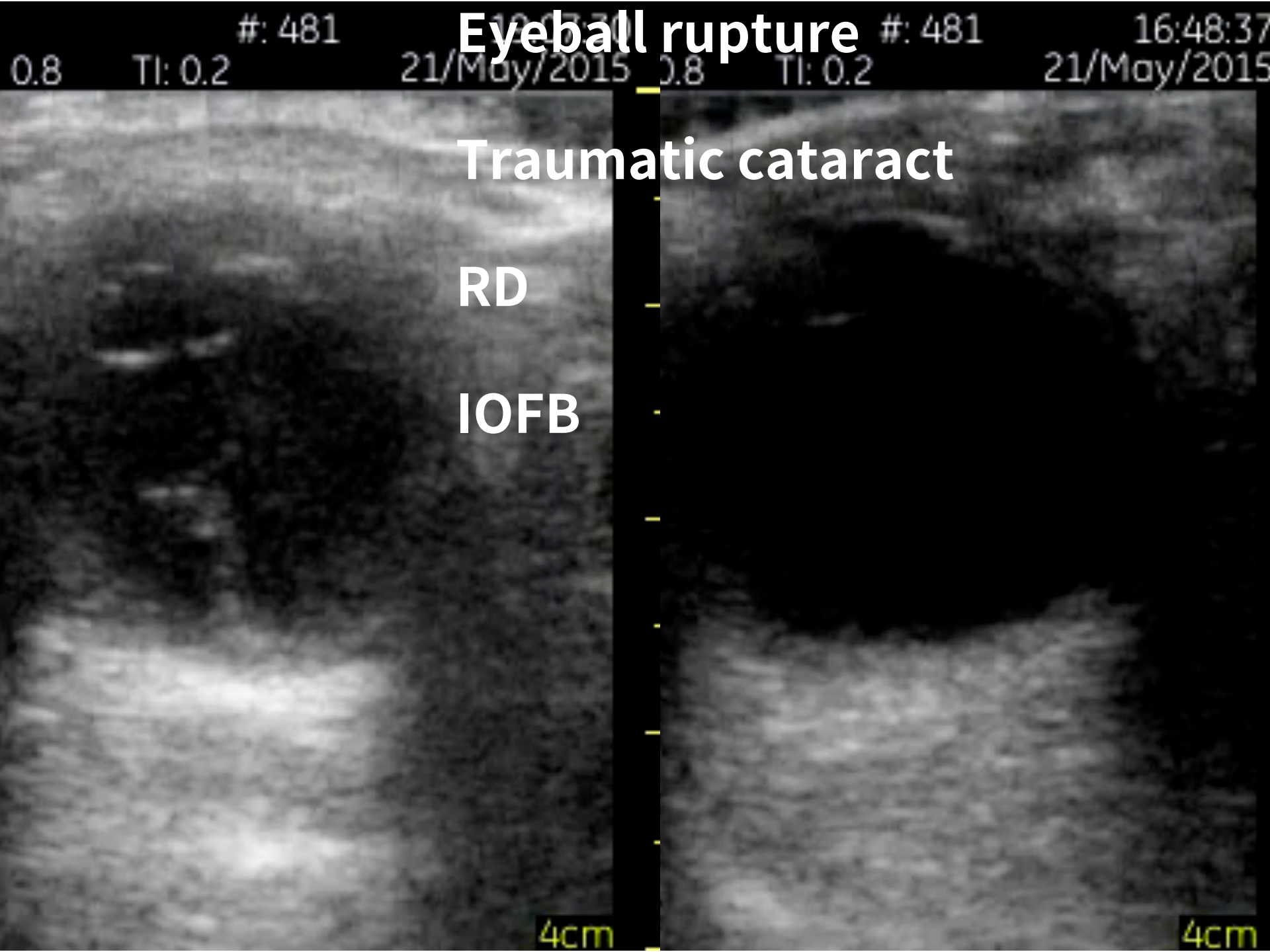
# Eyeball rupture



# 36M, 左眼鐵釘穿刺 (HM only)







# eyeball rupture

#: 481

#: 481

16:48:37

0.8

TI: 0.2

21/May/2015

0.8

TI: 0.2

21/May/2015

Traumatic cataract

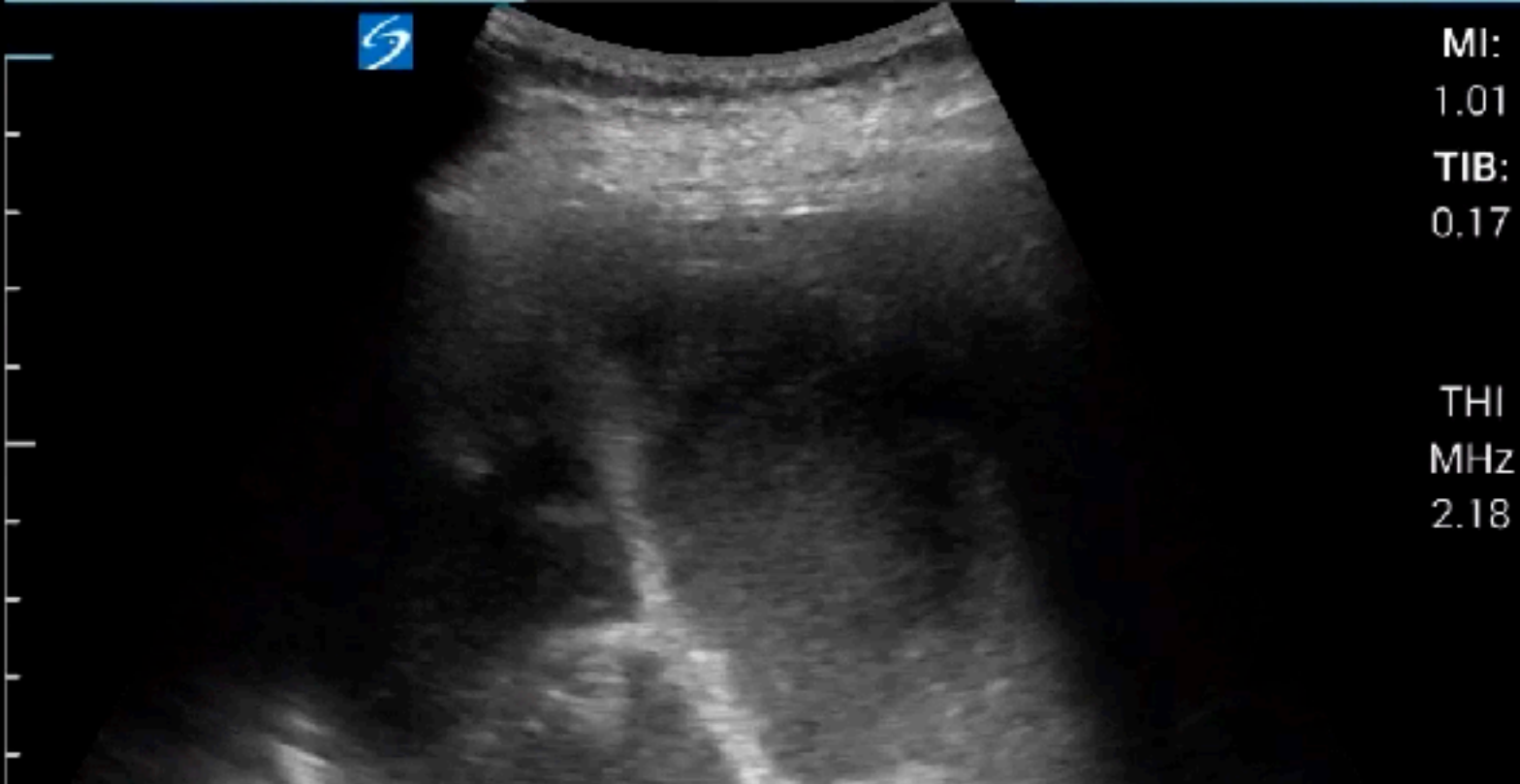
RD

IOFB

4cm

4cm

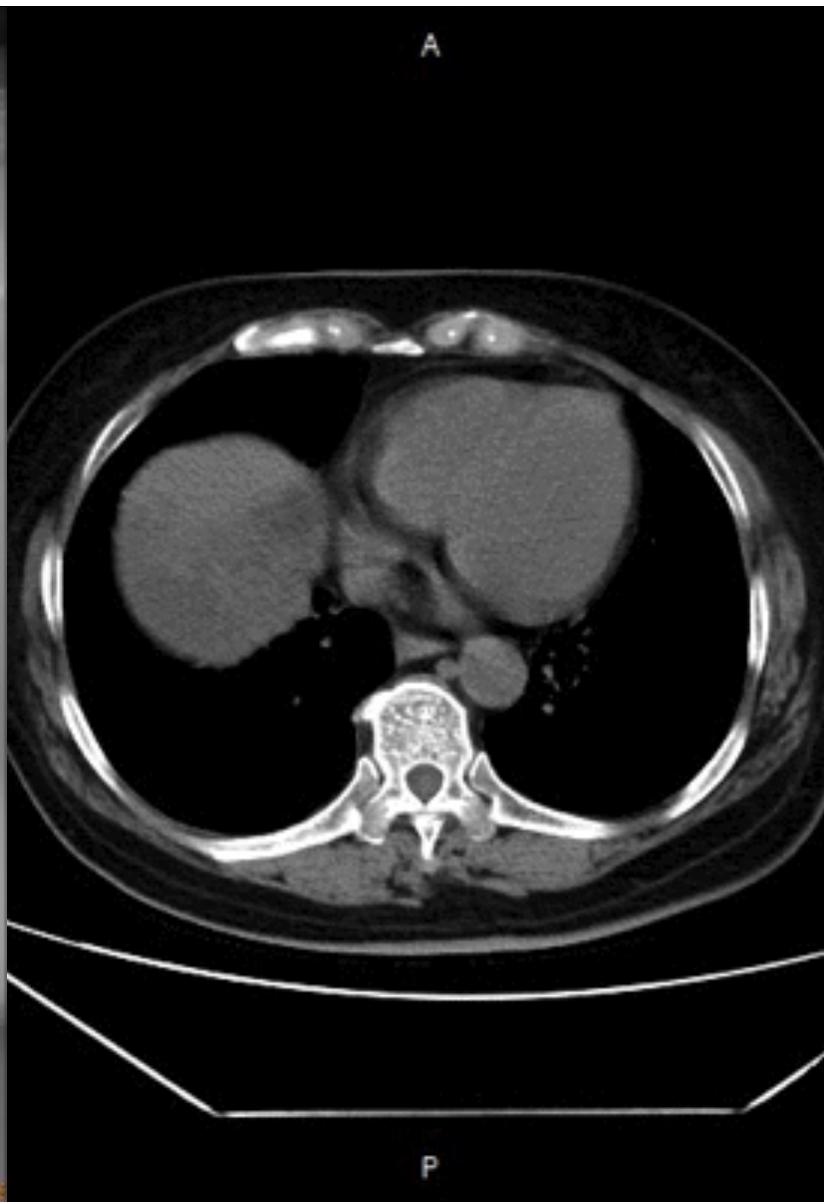
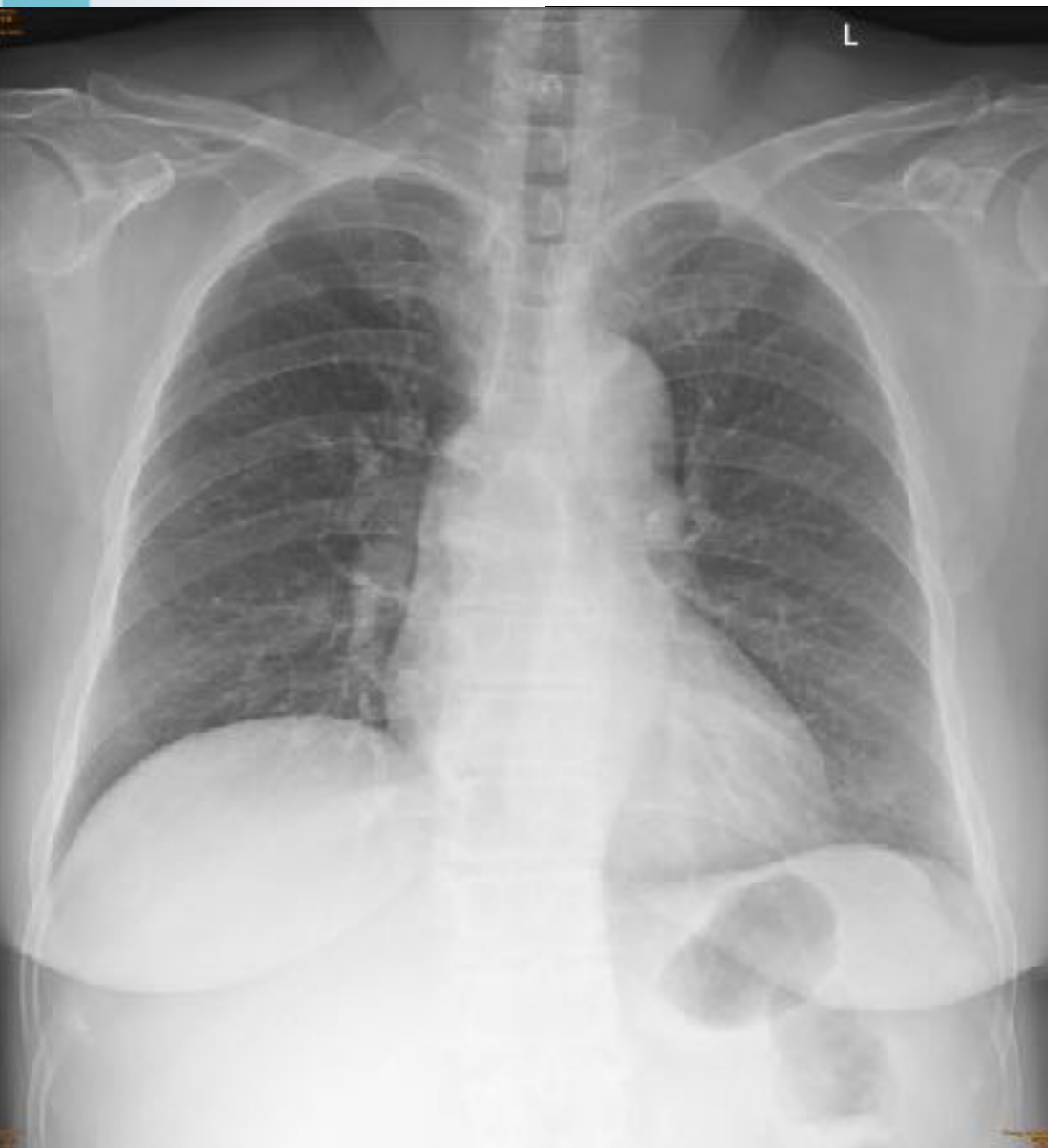

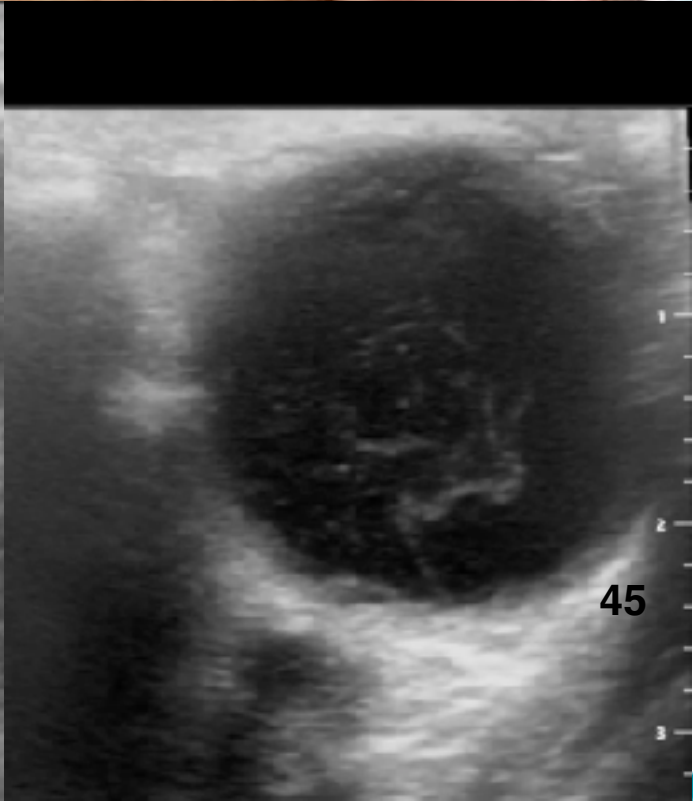
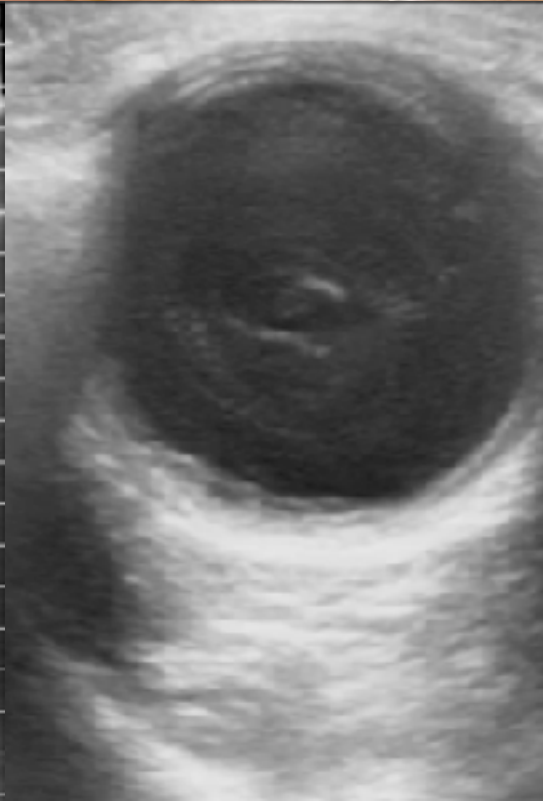
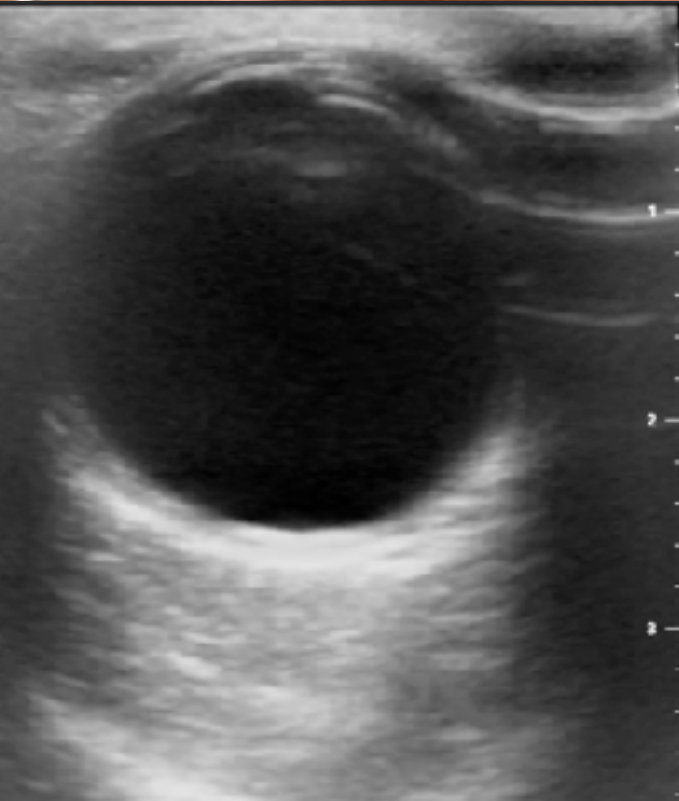

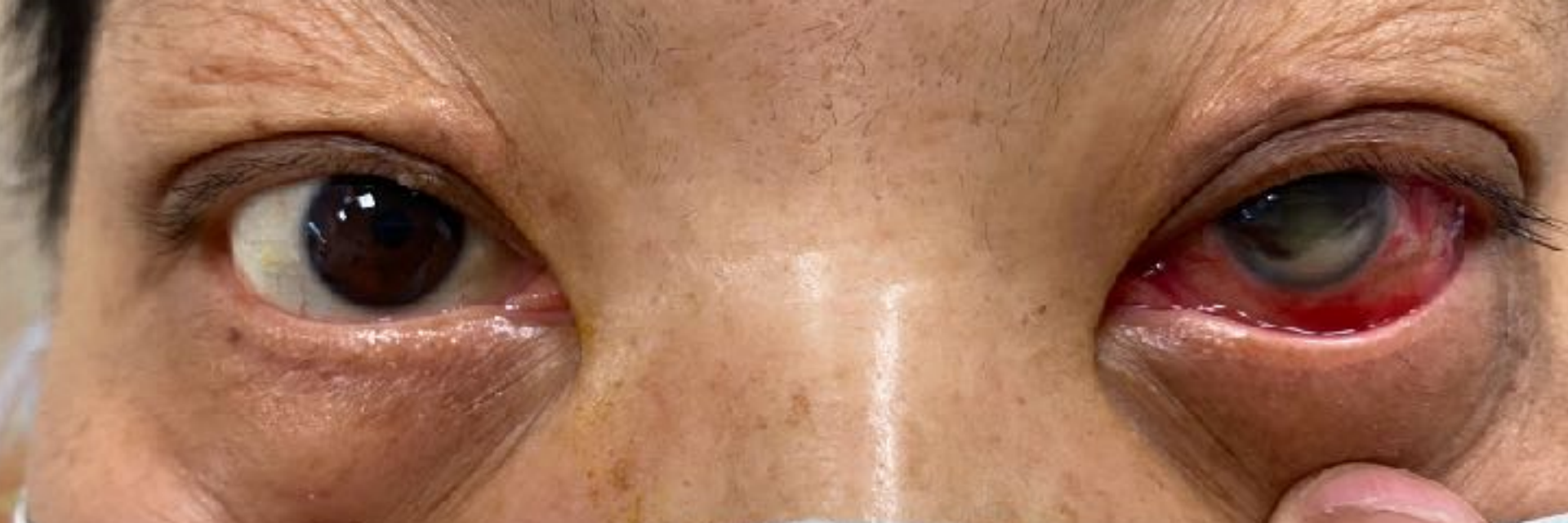
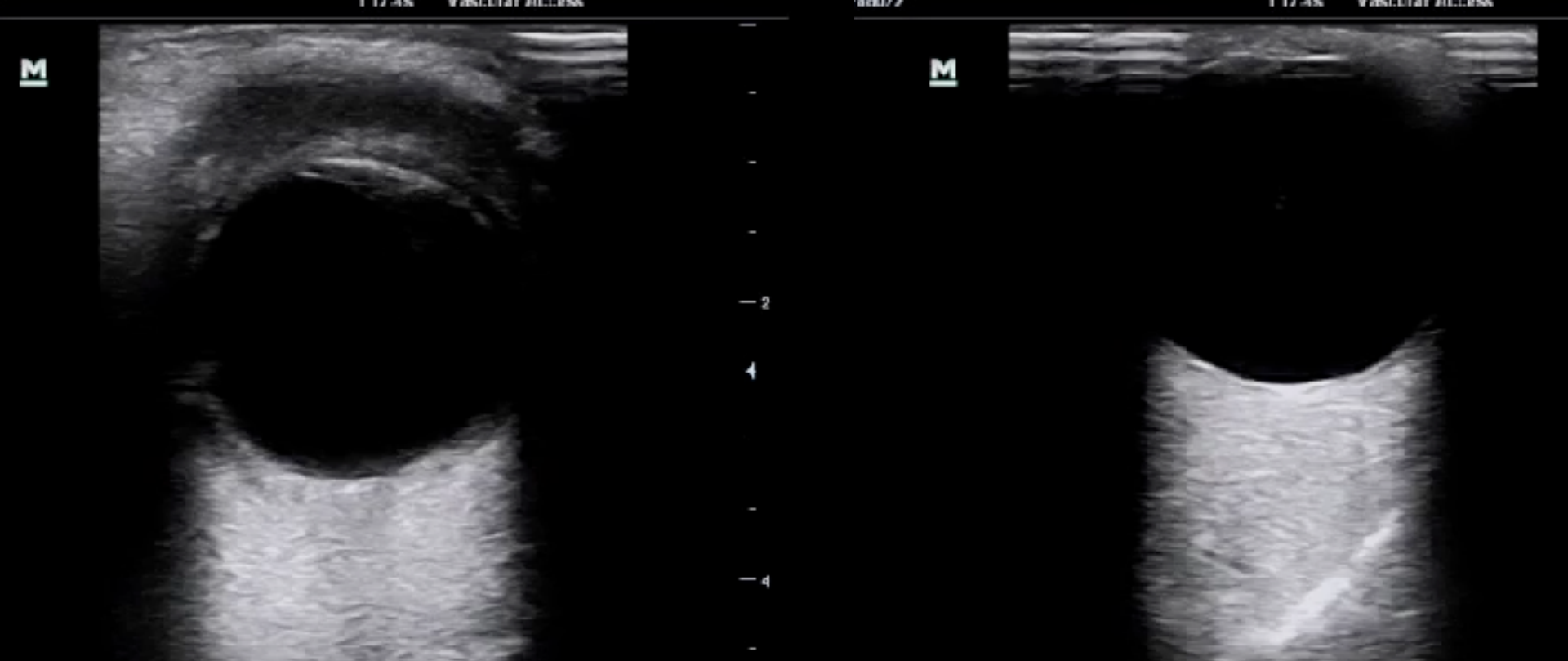## 雙和急診第一例肝膿瘍引流



65F, 交接班前5分鐘，右下胸部痛，左眼紅紅的







**71M, RIGHT EYE REDNESS & SWELLING**

**Preseptal cellulitis**

# PEARLS & PITFALLS

## Gain

For small FB & subtle RD

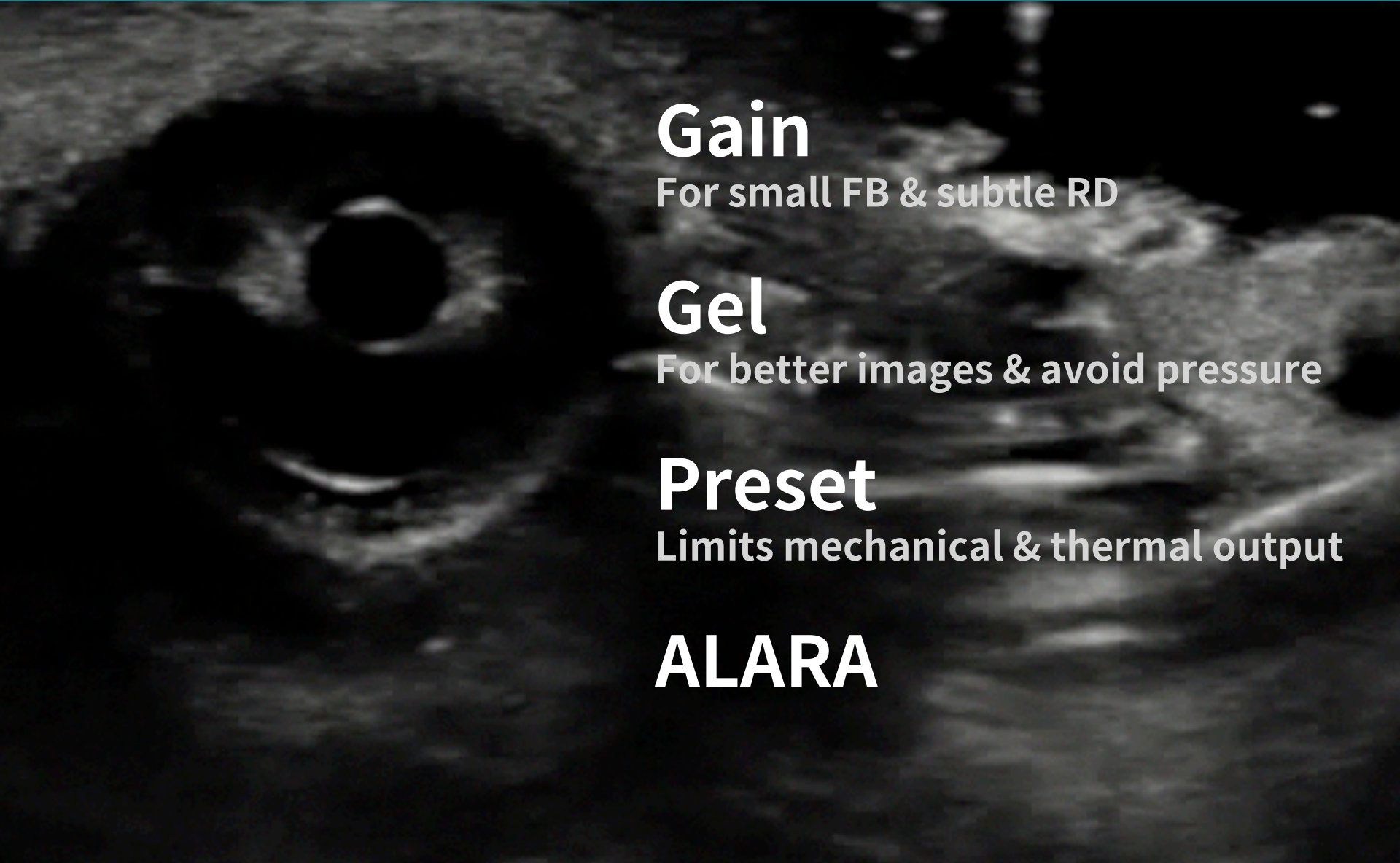
## Gel

For better images & avoid pressure

## Preset

Limits mechanical & thermal output

## ALARA



# IICP

3cm / 5mm / ICP 20

# Vision loss

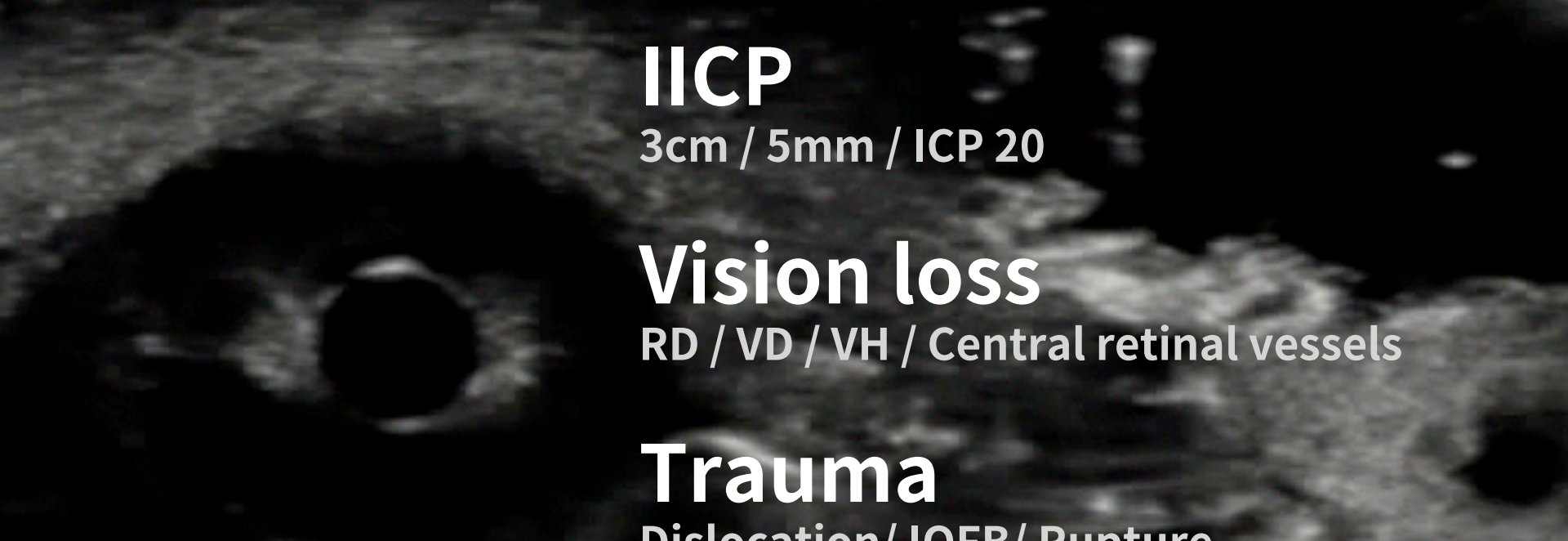
RD / VD / VH / Central retinal vessels

# Trauma

Dislocation/ IOFB/ Rupture

# Infection

Endophthalmitis



LG 12A7Gha Parts / FR910 / MD 96 / Te0.1 / 01 08 2016 10:43:42 AM  
[2D G54DR58 FA4P202.7/Eng Pen.2.com](#)

LG 12A7Gha Parts / FR910 / MD 96 / Te0.1 / 01 08 2016 10:43:42 AM  
[2D G54DR58 FA4P202.7/Eng Pen.2.com](#)

