A surgeon in a blue scrubs and mask is pointing upwards with his right hand. He is wearing a blue surgical cap and a green surgical mask. The background shows other surgeons in a sterile operating room environment.

超音波在急診 骨骼肌肉系統應用 陳國智雙和醫院急診醫學科

陳國智 醫師



醫用超音波學會指導醫師
WINFOCUS director / instructor

急診 / 重症 / 介入 / 急性疼痛

經歷

新光急診超音波訓練中心主任

西園醫院急診醫學科主任

急診醫學會超音波委員會主委

台灣疼痛醫學會大體模擬手術講師

急救加護醫學會重症超音波負責人

Blog: POCUSacademy.com

juice119@gmail.com

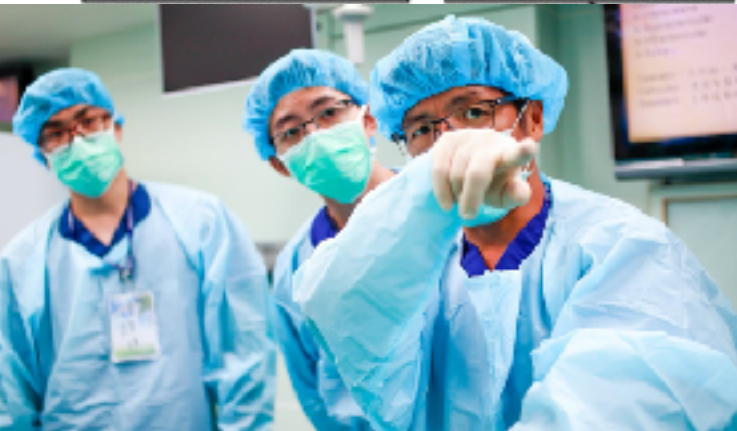Resuscitative

Diagnostic

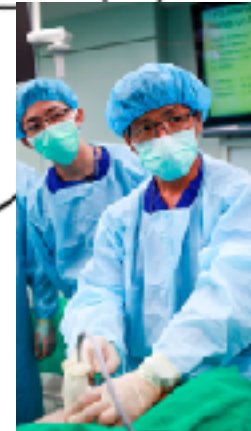Procedural
Guidance

Symptom- or
Sign-Based

Therapeutic



Diagnostician



Interventionist

Core Applications

- Trauma
- Intrauterine Pregnancy
- AAA
- Cardiac/HD Assessment
- Biliary
- Urinary Tract
- DVT
- Soft-tissue/Musculoskeletal
- Thoracic/Airway
- Ocular
- Bowel
- Procedural Guidance

ACEP

2016

12 核心

5大應用

REVIEW

Open Access



An overview of point-of-care ultrasound for soft tissue and musculoskeletal applications in the emergency department

Kuo-Chih Chen^{1,2}, Aning Chor-Ming Lin^{1,2*}, Chee-Fah Chong^{1,2} and Tzong-Luen Wang^{1,2}

Musculoskeletal Ultrasound in the Emergency Department

Vito Chianca, MD¹ Francesco Di Pietto, MD, PhD² Marcello Zappia, MD, PhD³
Domenico Albano, MD^{1,4} Carmelo Messina, MD^{1,5} Luca Maria Sconfienza, MD, PhD^{1,5}

¹IRCCS Istituto Ortopedico Galeazzi, Milano, Italy

²Dipartimento di Diagnostica per immagini, Pineta Grande Hospital, Castel Volturno (CE), Italy

³Department of Medicine and Health Sciences, Università del Molise, Campobasso, Italy

⁴Section of Radiological Sciences, Department of Biomedicine, Neurosciences and Advanced Diagnostics, University of Palermo, Palermo, Italy

⁵Dipartimento di Scienze Biomediche per la Salute, Università degli Studi di Milano, Milano, Italy

Semin Musculoskelet Radiol 2020;24:167–174.



Address for correspondence Vito Chianca, MD, IRCCS Istituto Ortopedico Galeazzi, via Riccardo Galeazzi 4, 20161 Milano, Italy (e-mail: vitochianca@gmail.com).

Soft tissue infection
Joint effusion
Foreign body
Long bone fracture
Muscle & Tendon injury
Vascular occlusion
Procedures

Seminars in

ROENTGENOLOGY

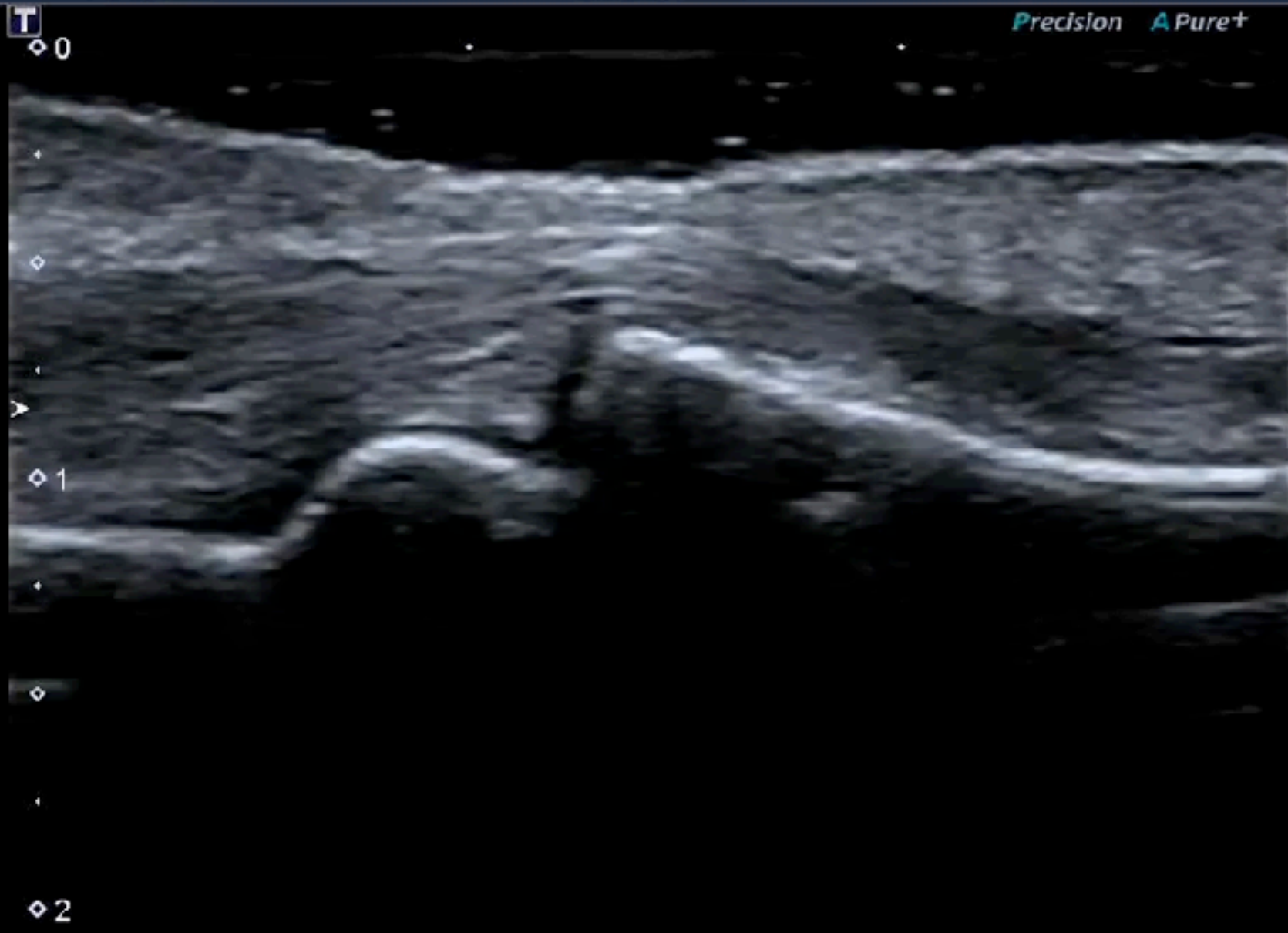
Musculoskeletal Ultrasound in the Emergency Department: Is There a Role?

Michael V. Perone, MD, and Corrie M. Yablon, MD <https://doi.org/10.1053/j.ro.2020.09.004>

Limitations of US

In the hands of highly skilled practitioners, the performance of MSK US in the assessment of superficial soft tissue and tendon injury is equal to MRI. A barrier to the performance of MSK US in the ED is the high degree of training that is required of personnel, both to scan and to interpret the images. Sonographers must be able to recognize the artifacts inherent to MSK US and must be able to manipulate the various parameters in order to optimize image quality. It is vital to have a sophisticated understanding of MSK anatomy and the varied sonographic appearances of tissues such as skin, subcutaneous fat, muscle, tendon, ligament, and synovium, both when normal and abnormal. Without this high level of understanding, the resulting images can be confusing at best, and cause missed diagnoses at worst. <https://doi.org/10.1053/j.ro.2020.09.004>

Precision A Pure+



MI
1.5
14L5
diff14M
44 fps
G:78
DR:65
A:7
P:5



FORMOSA XTREME TRIATHLON

WAYPOINT



FAT




XTRI

4天前
左腳不小心
撞到石頭。
致血腫疼痛



MSK 常用探頭

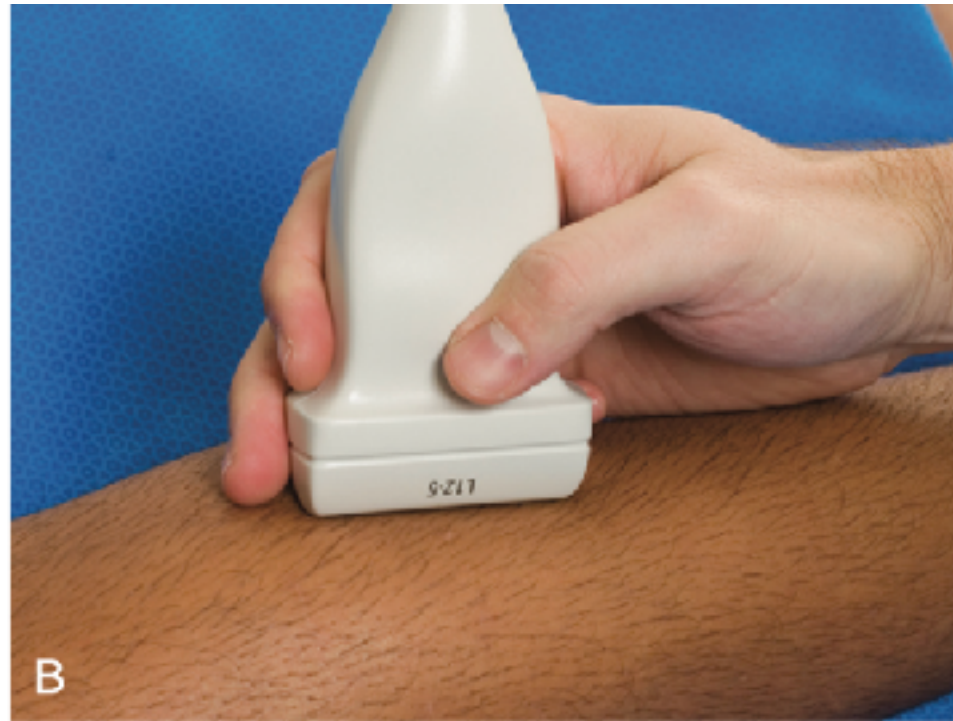
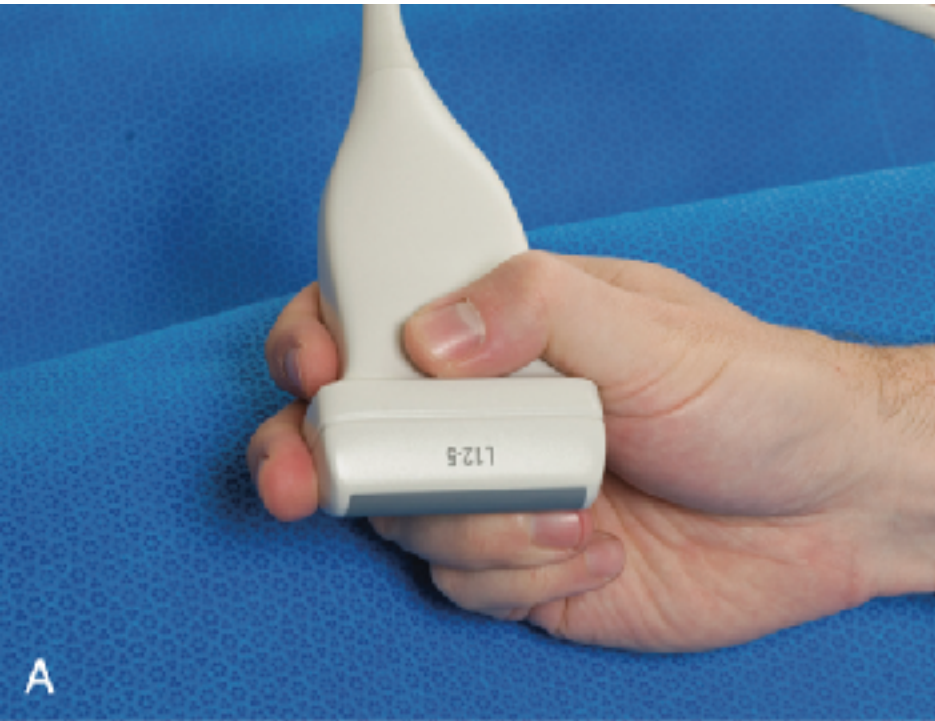
Transducer Positioning

探頭

操作者的手

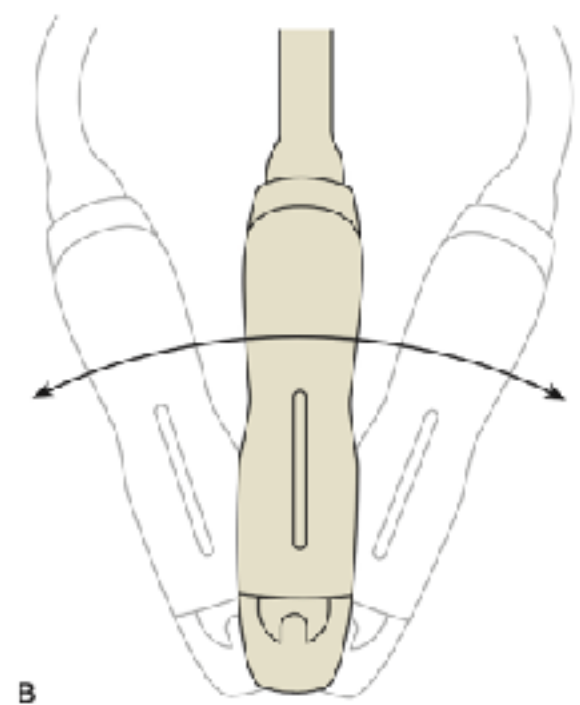
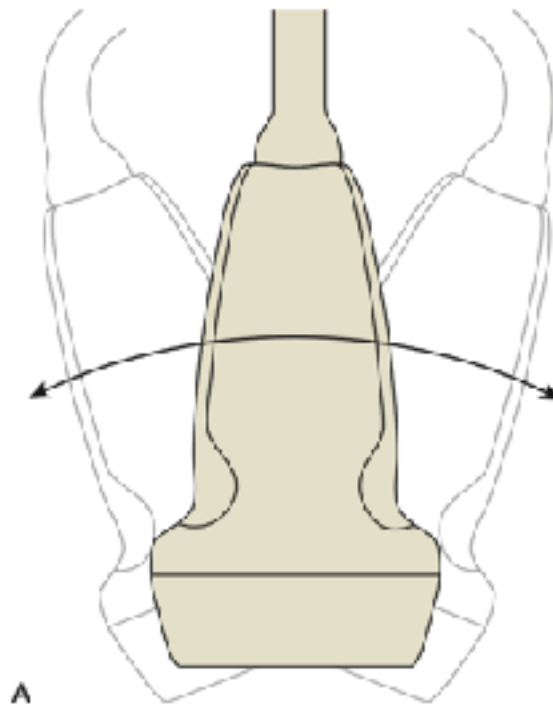
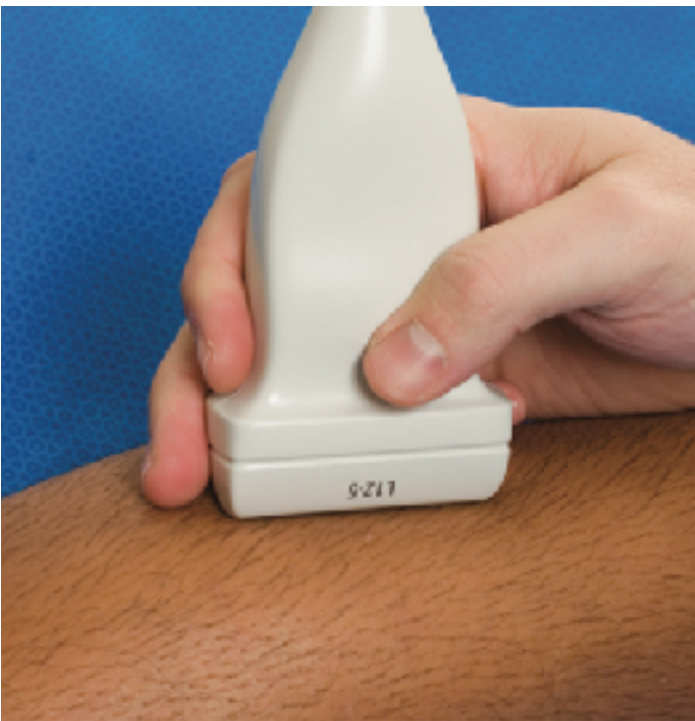皮膚



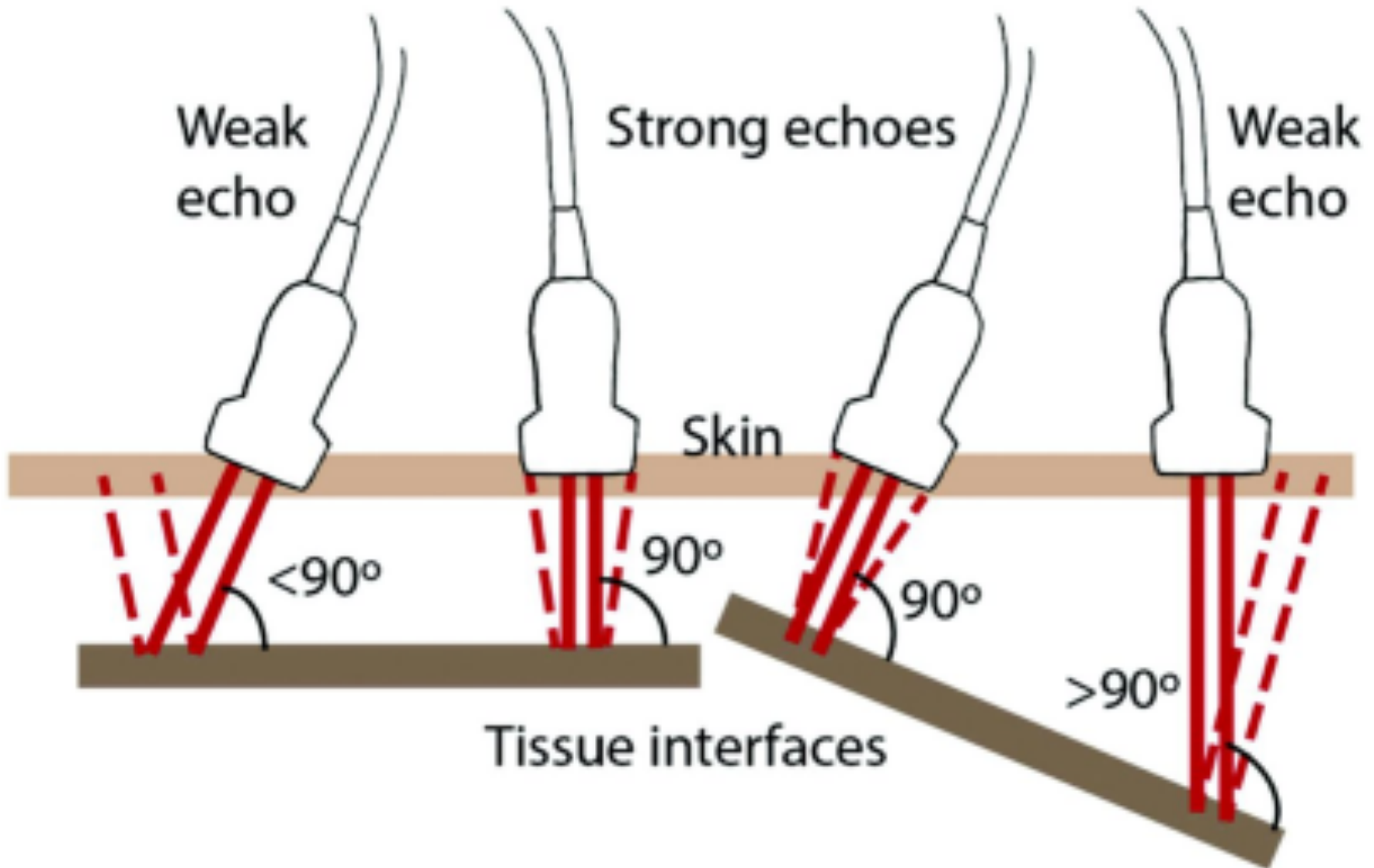
Transducer maneuver

探頭的操控

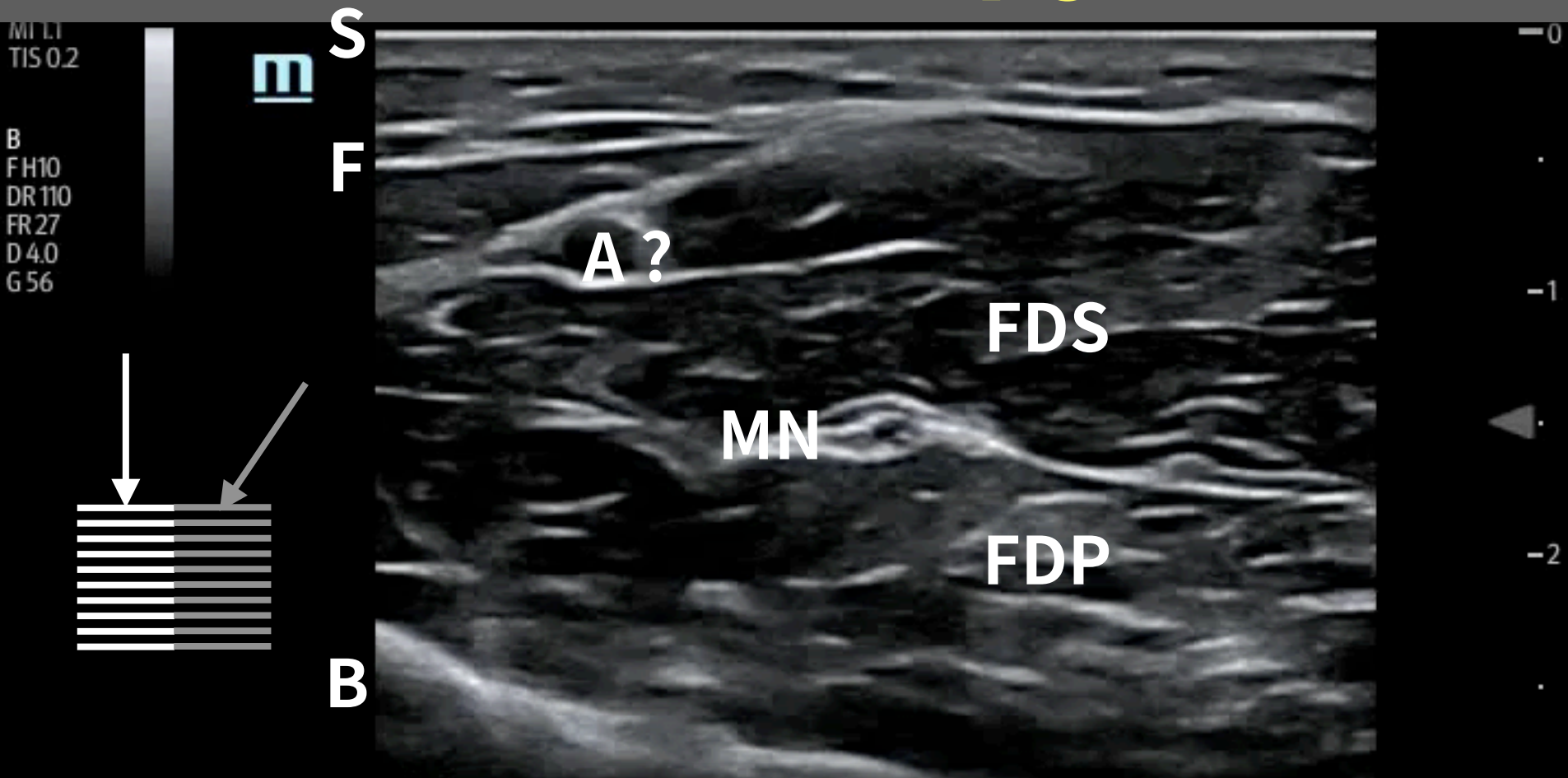
Rock 扇 Tilt



Perpendicular to Target



Anisotropy

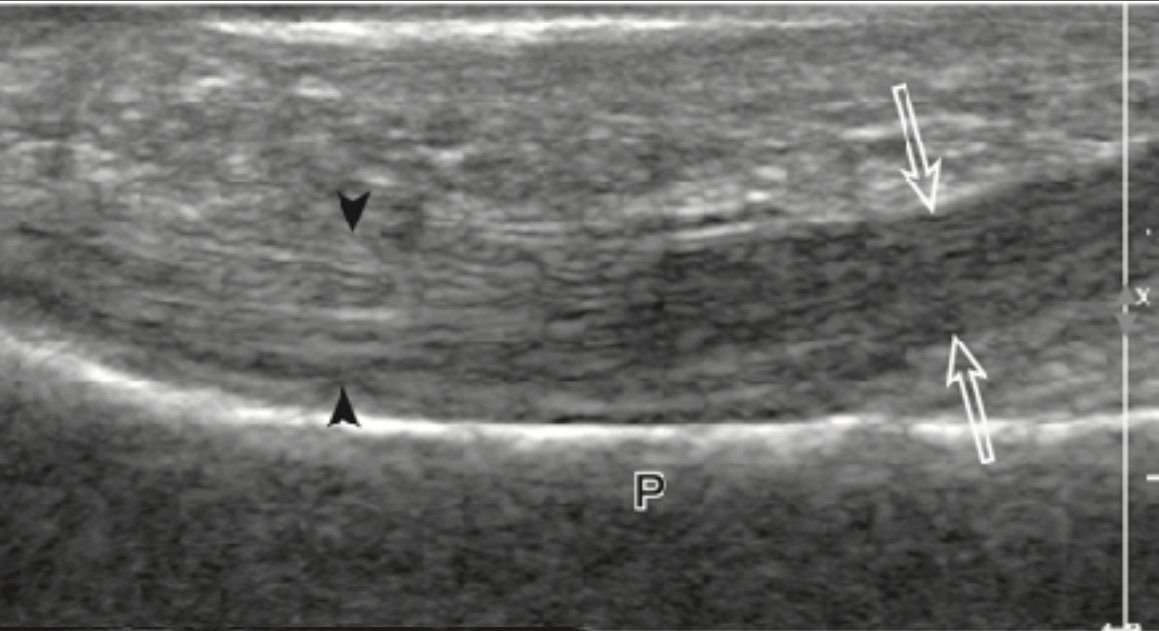


Tendon

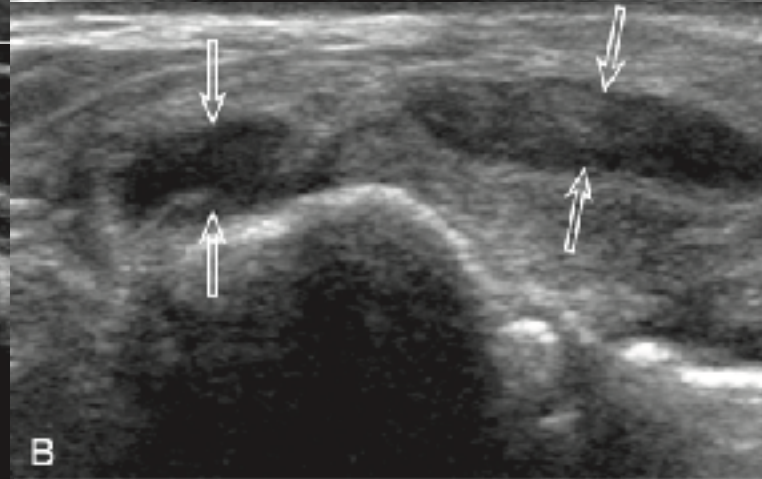
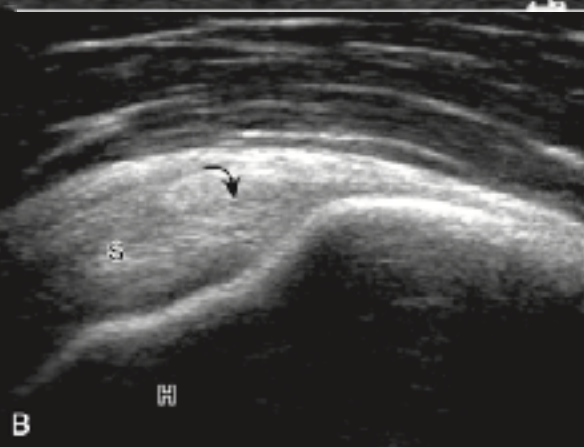
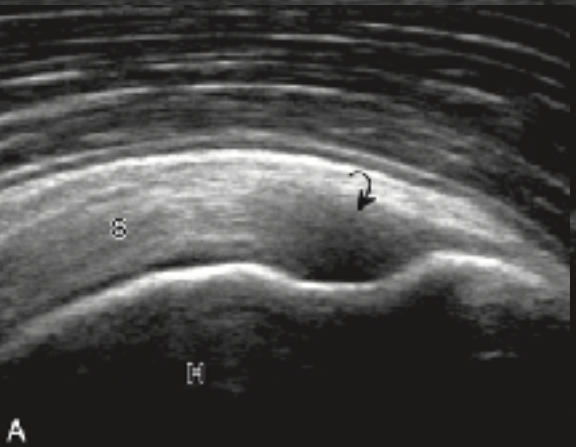
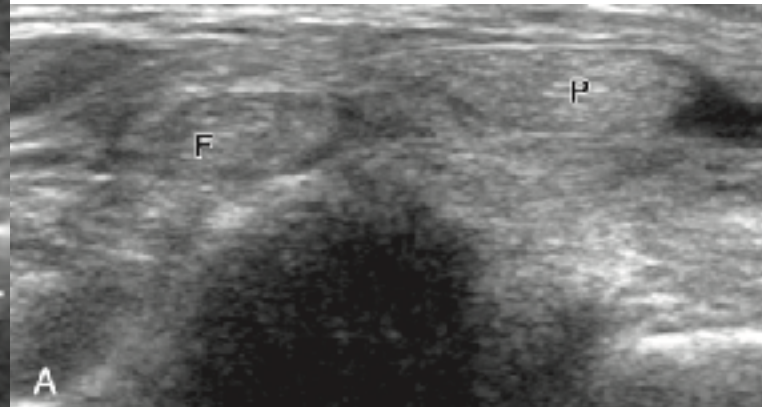
Nerve

Muscle

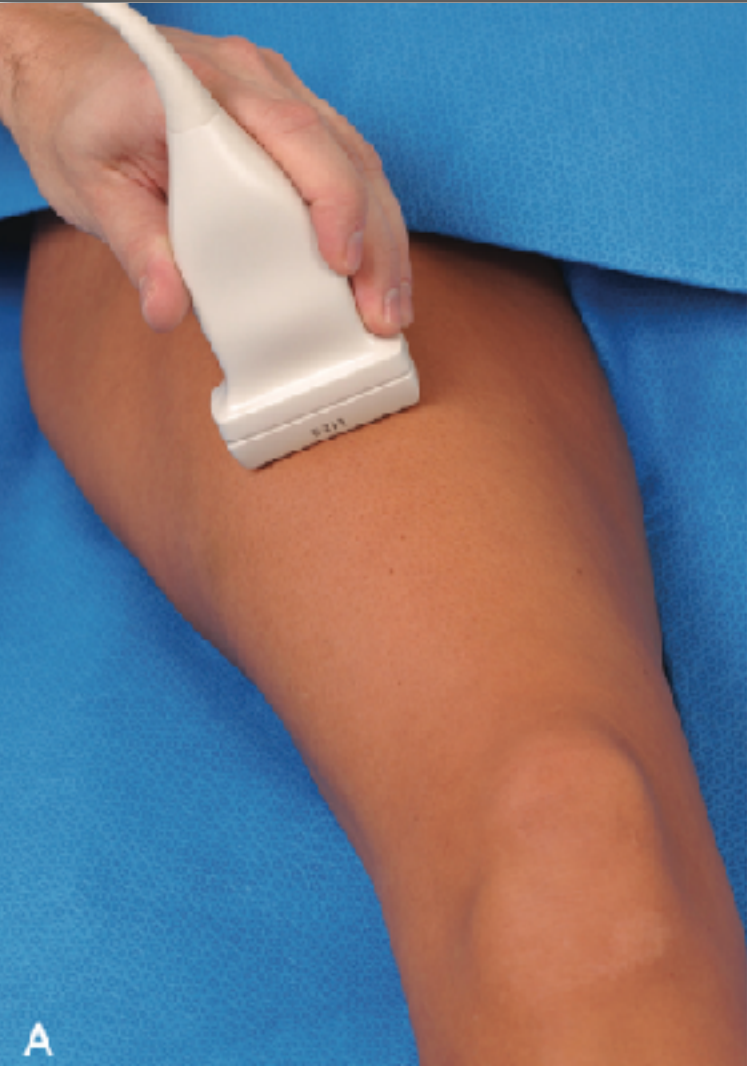Anisotropy



角度/垂直



MSK掃描原則

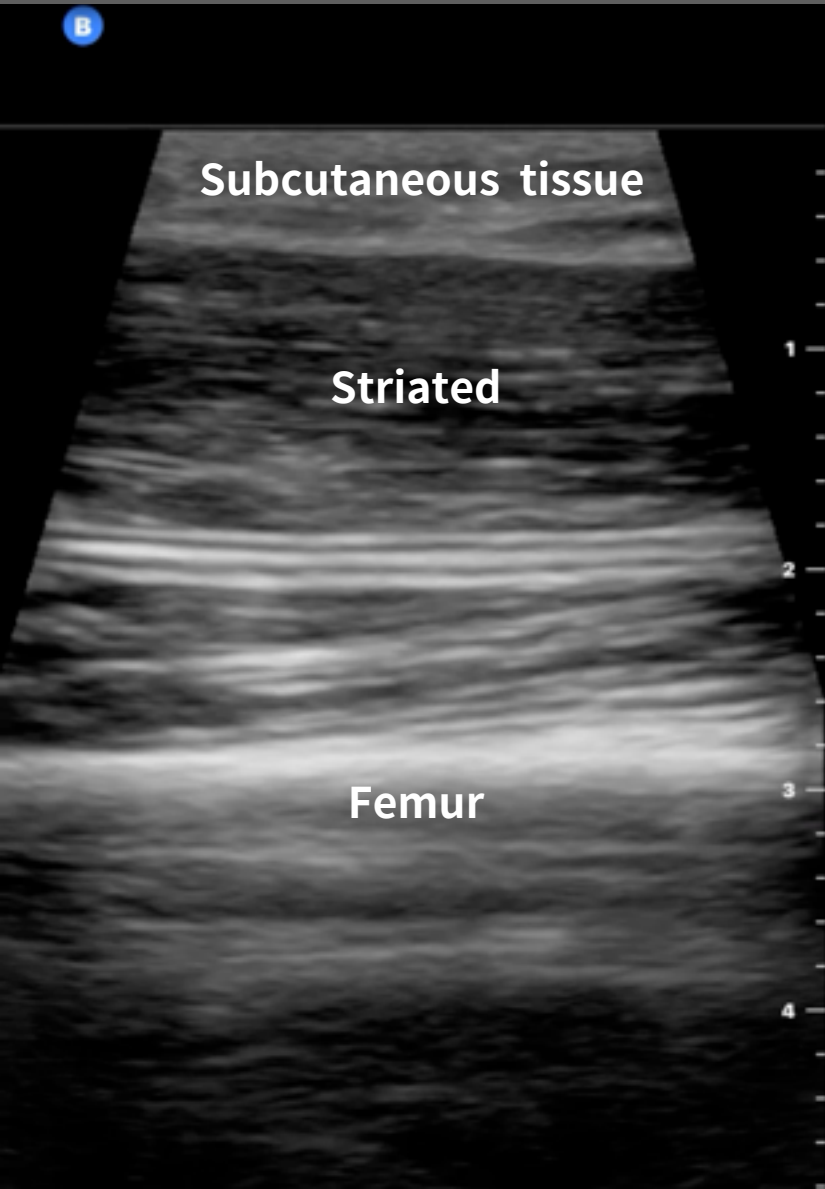


管狀構造橫掃優先

先找外在明顯定位

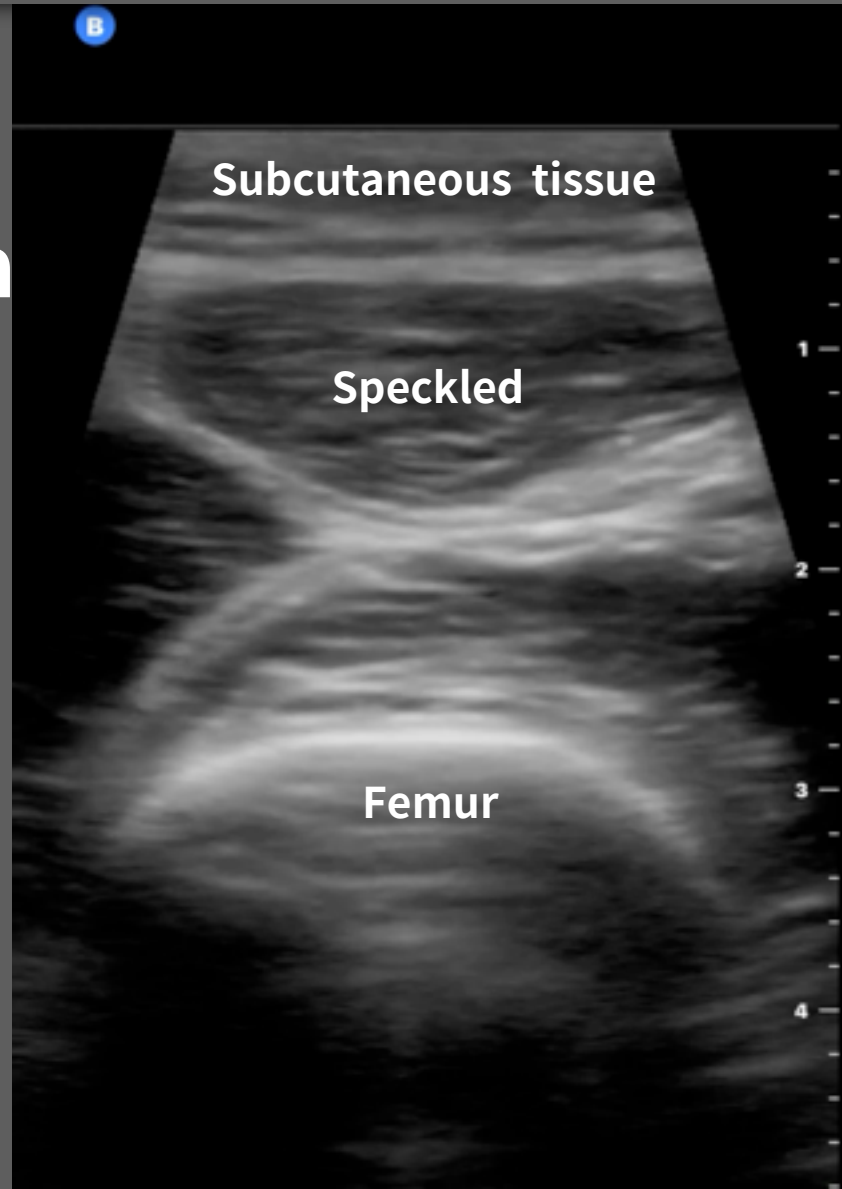
確認內在明顯標的

MSK的重要三界線(白線)

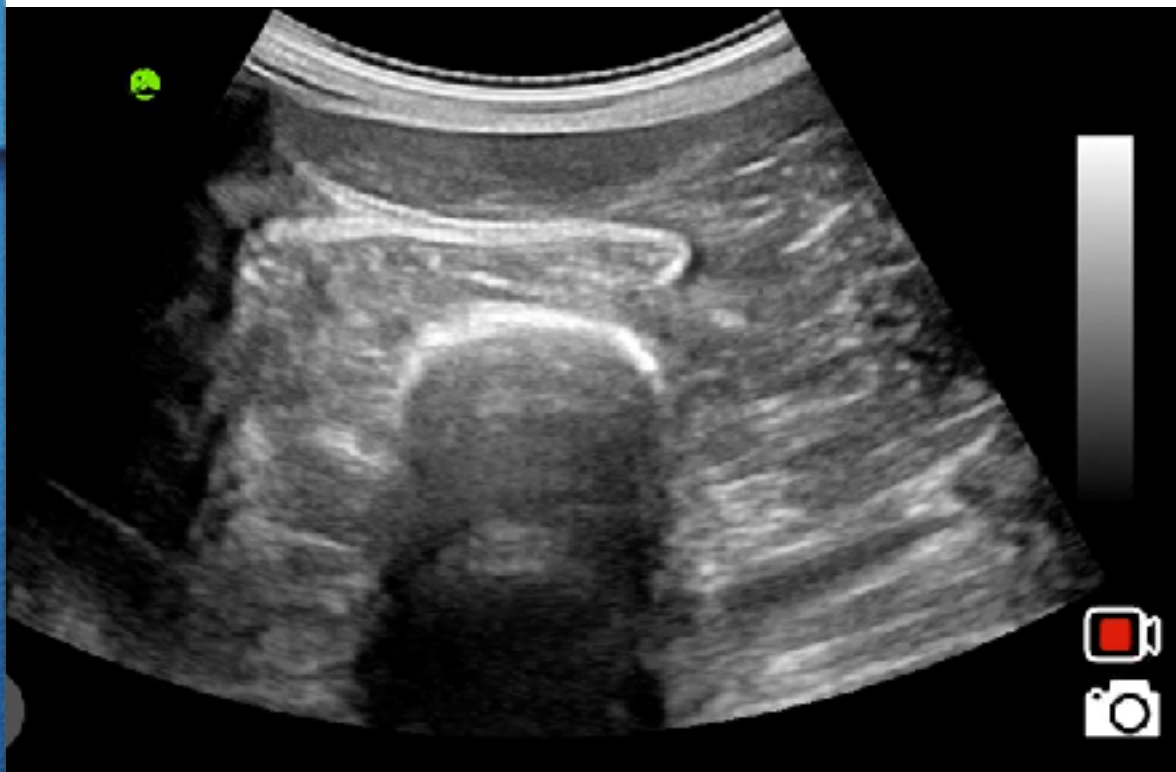
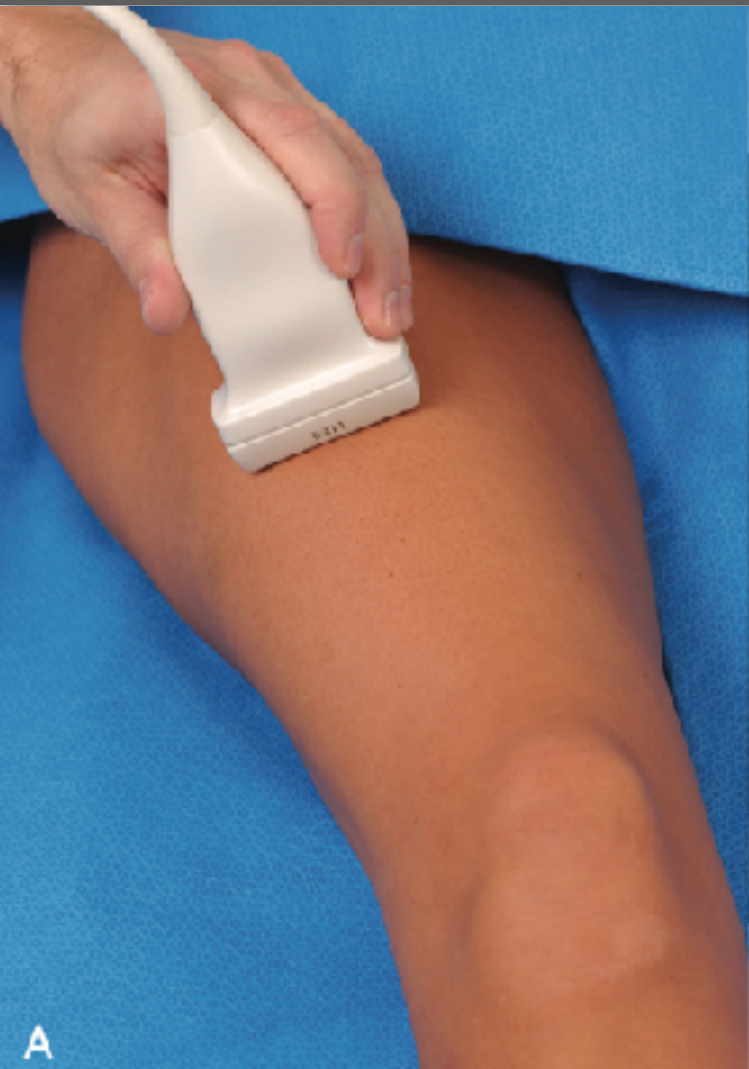
Skin
Fascia

Bone



股骨 / 股四頭肌



大腿前側肌肉縱向掃描

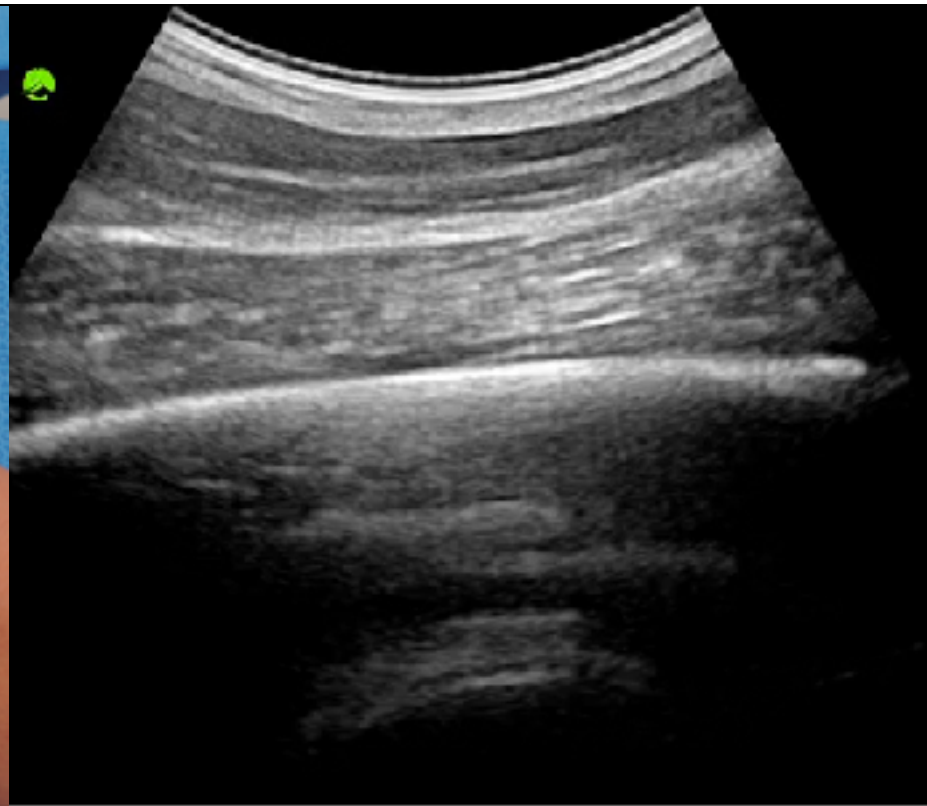
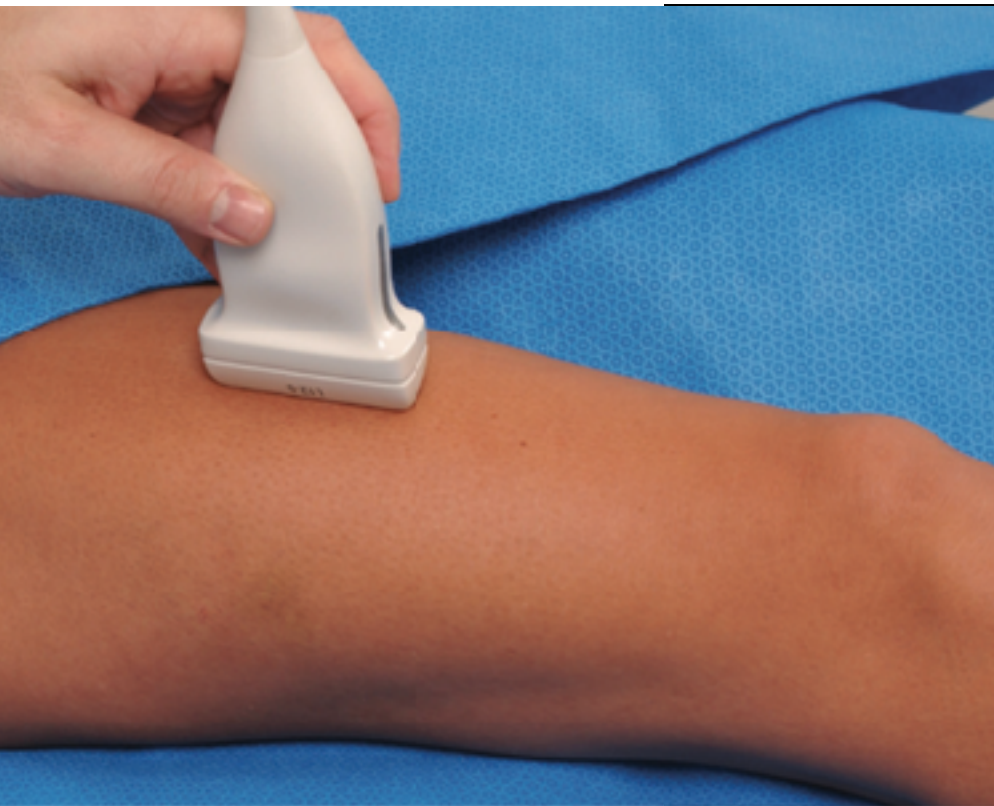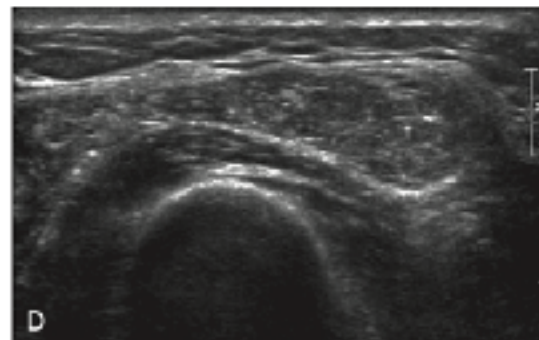
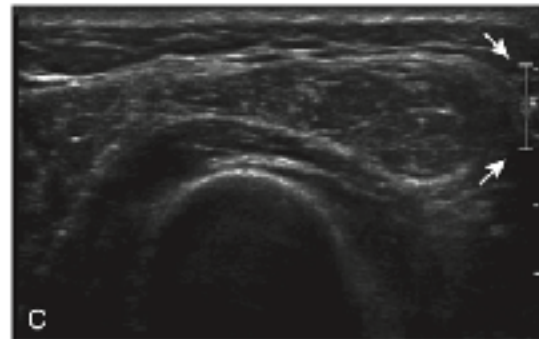
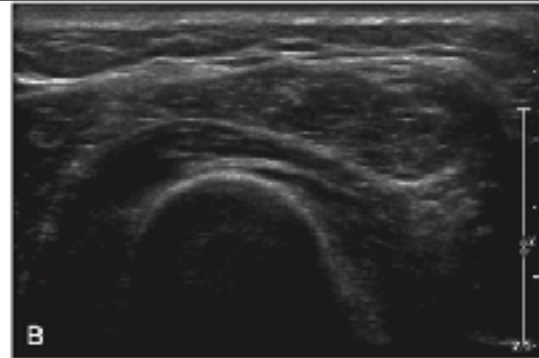


Image optimization

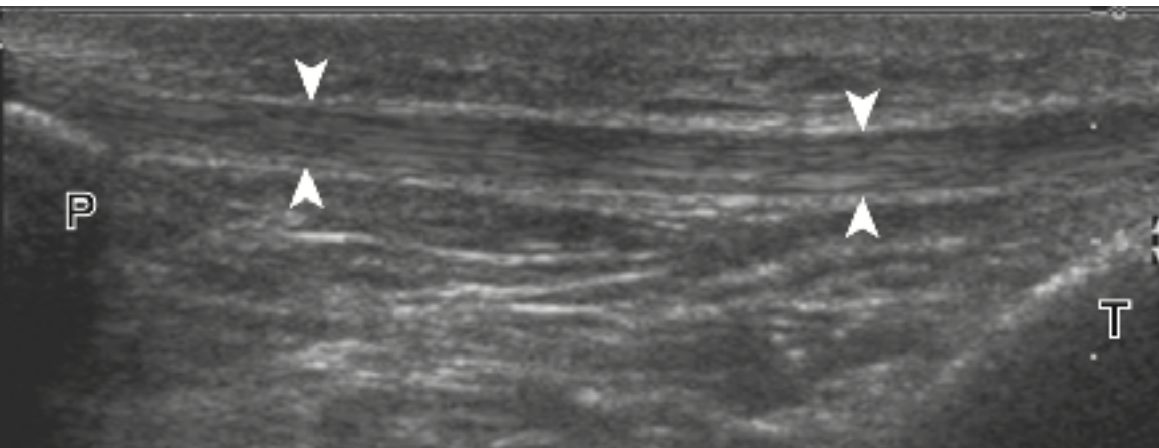


深度/Depth

焦點/Focus

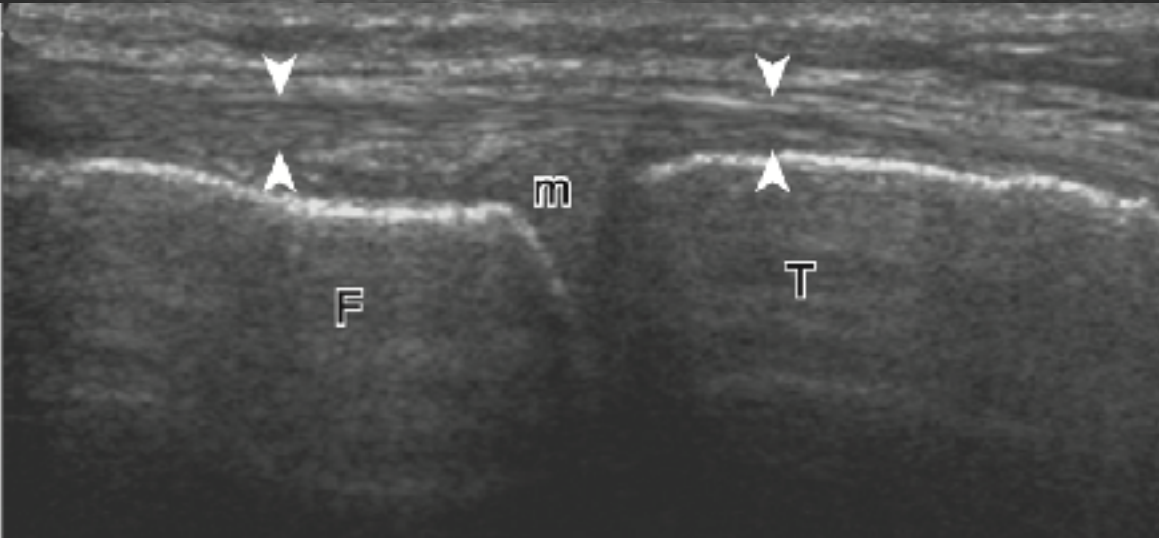
亮度/Gain

Tendon 韌帶



高回音

Fibrillar



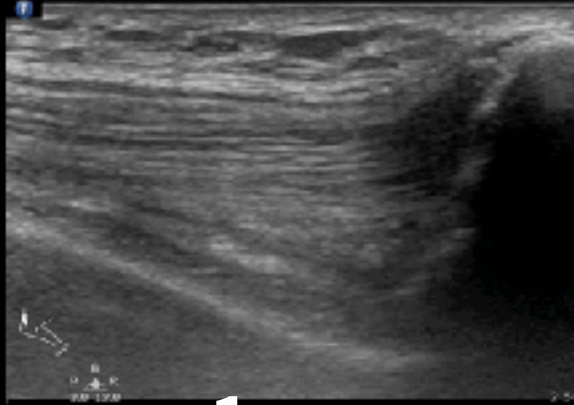Grade of Injury

I : no fiber disruption

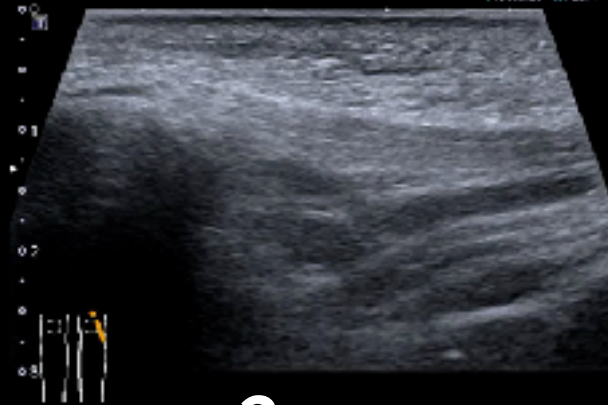
II : partial fiber disruption

III: complete fiber disruption

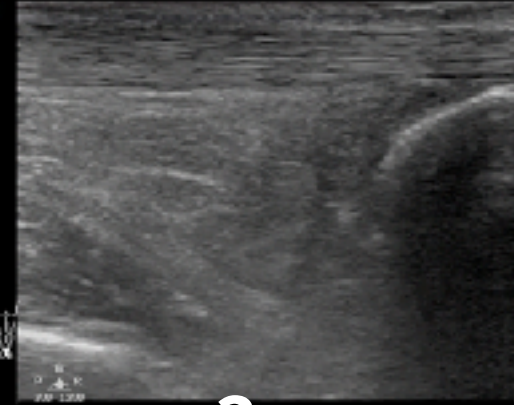
Tendon



1



2

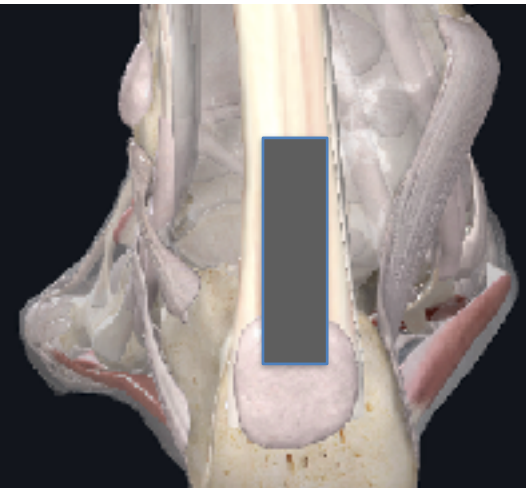
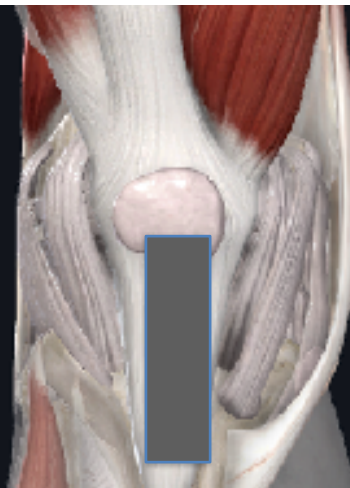
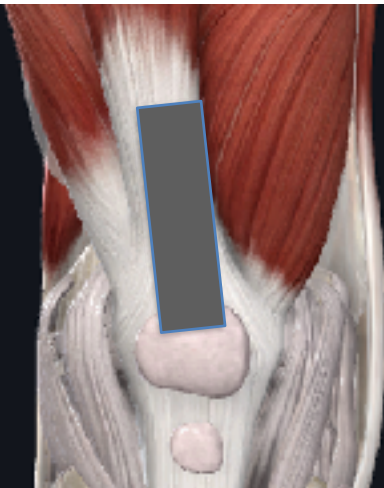
3

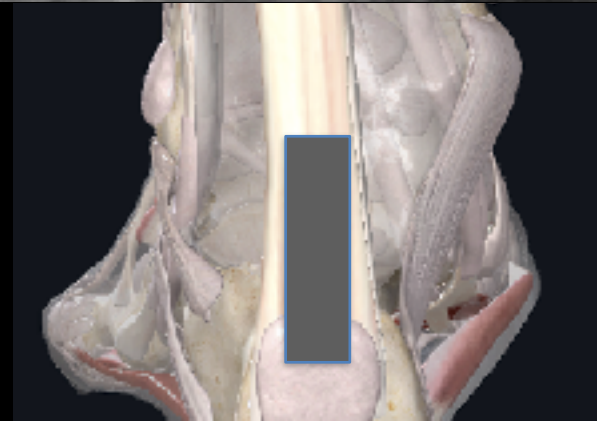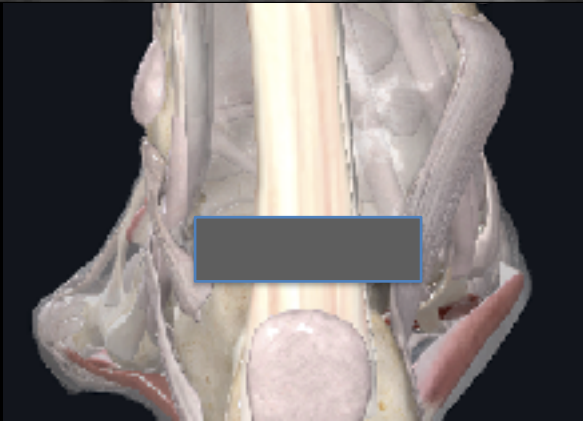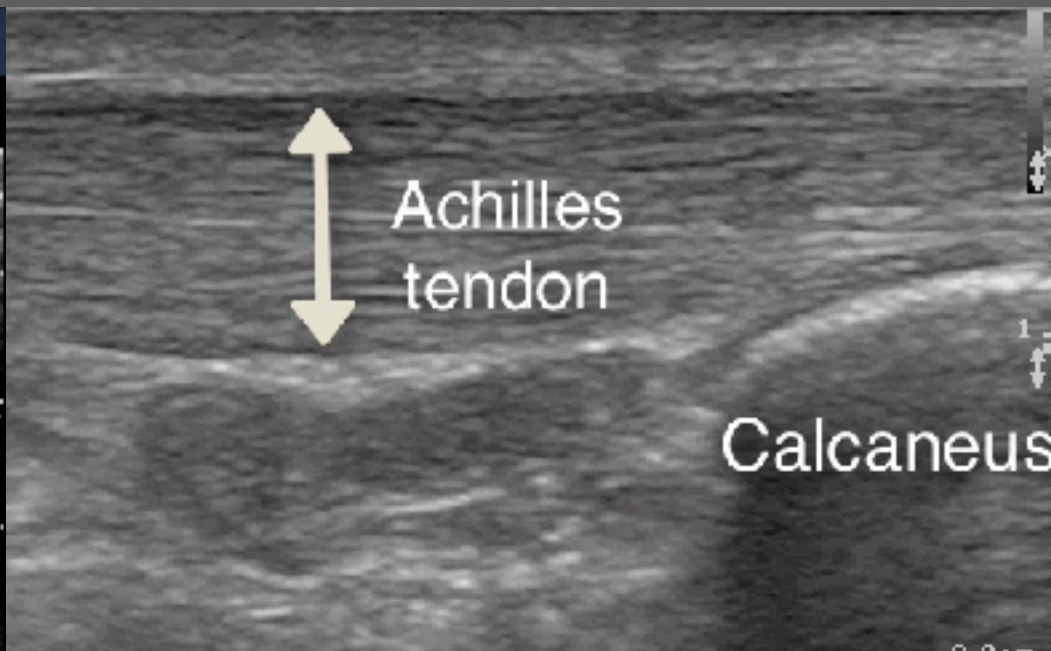
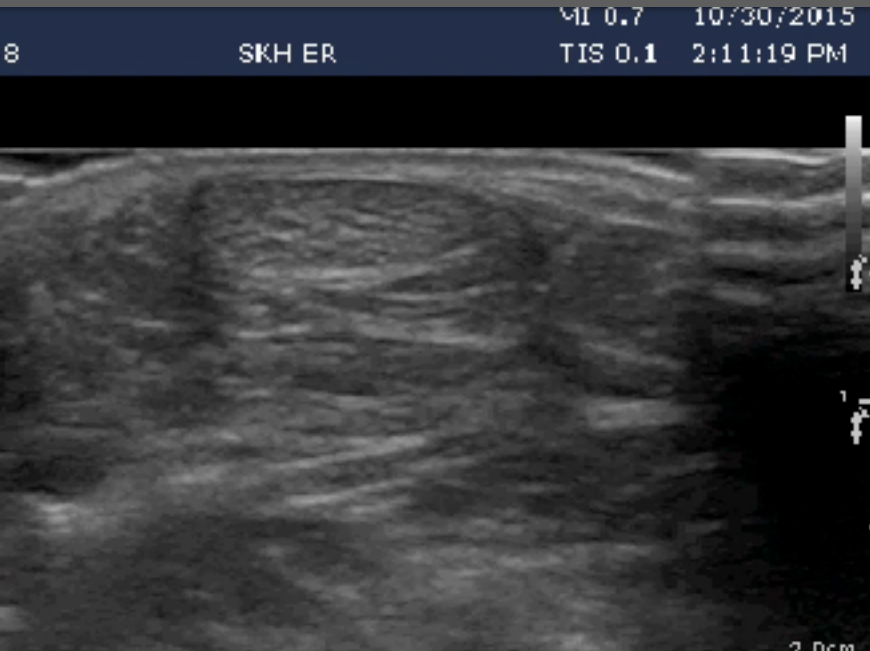
**Quadriceps
Tendon**

**Patellar
Tendon**

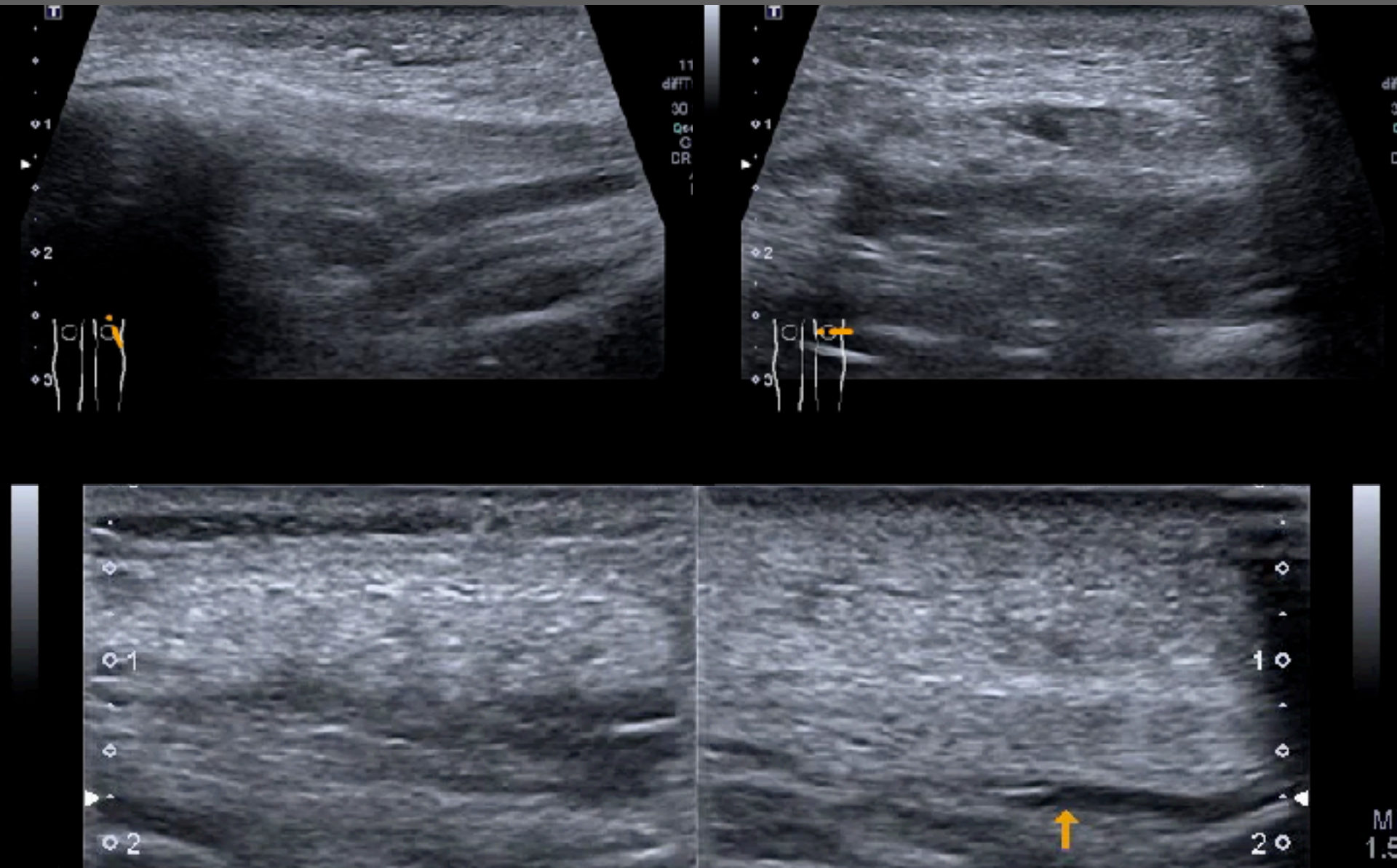
**Achilles
Tendon**



Achilles tendon rupture



Patellar tendon injury



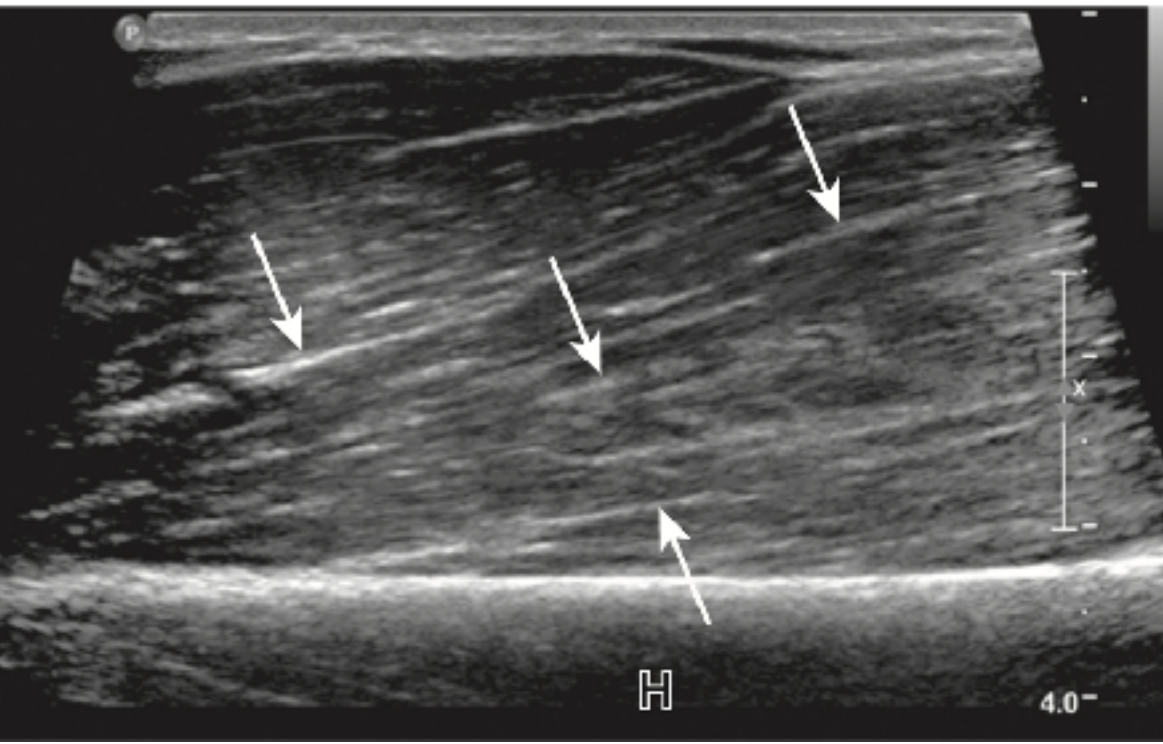
Muscle 肌肉

Grade of Injury

I : no fiber disruption

II : partial fiber disruption

III: complete fiber disruption

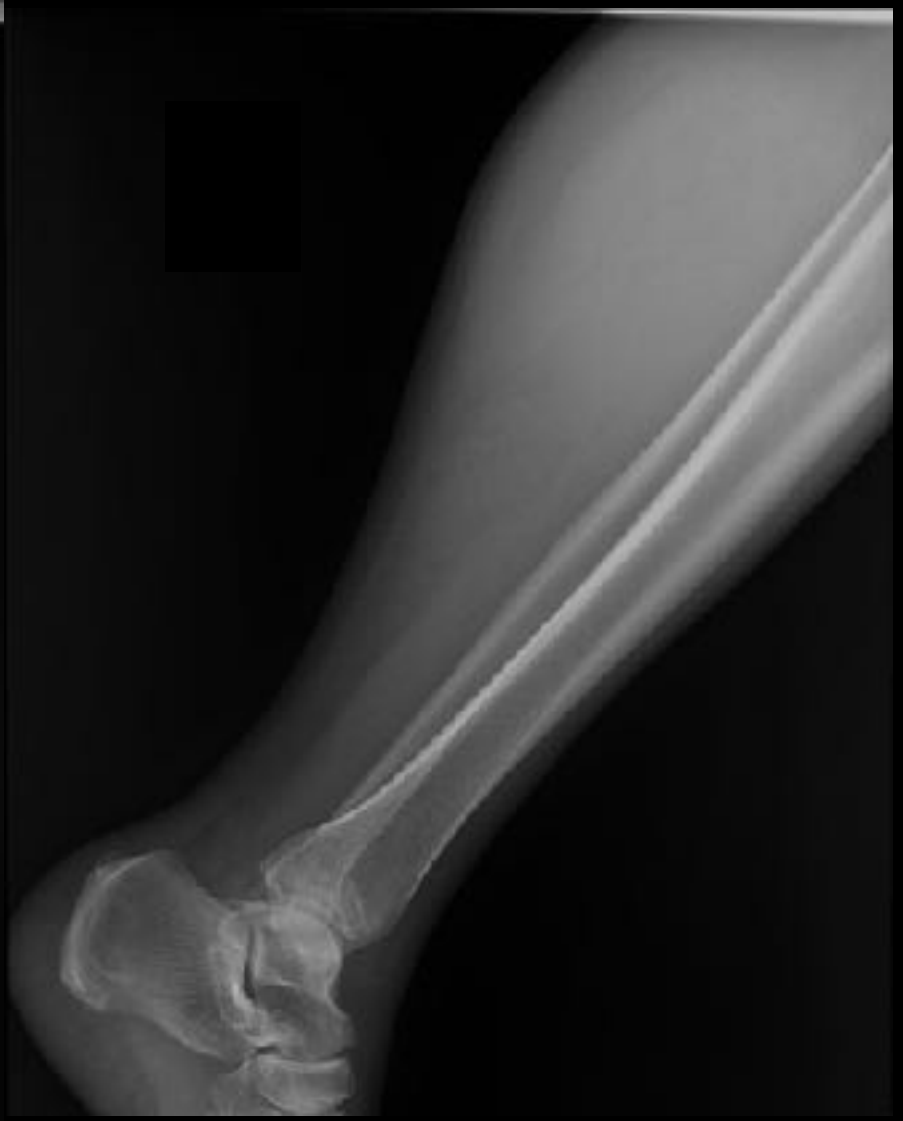
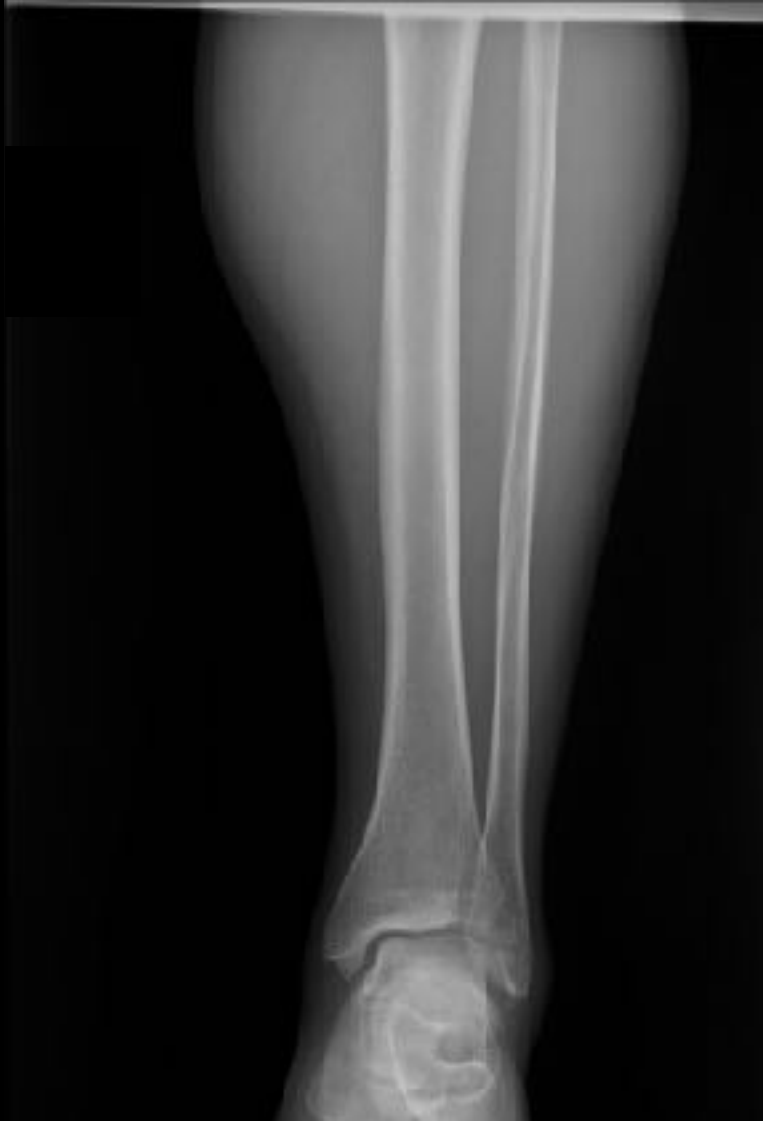
Bristal brush

**Hypoechoic
mucle**

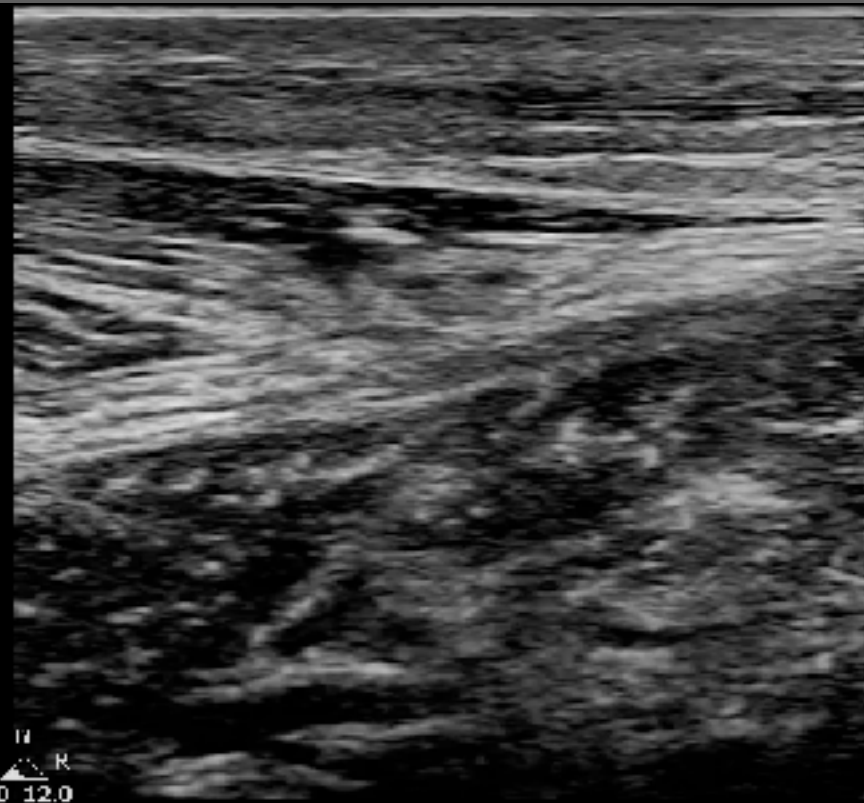**Hyperechoic
fibroadipose tissue**

58M, right leg pain while running

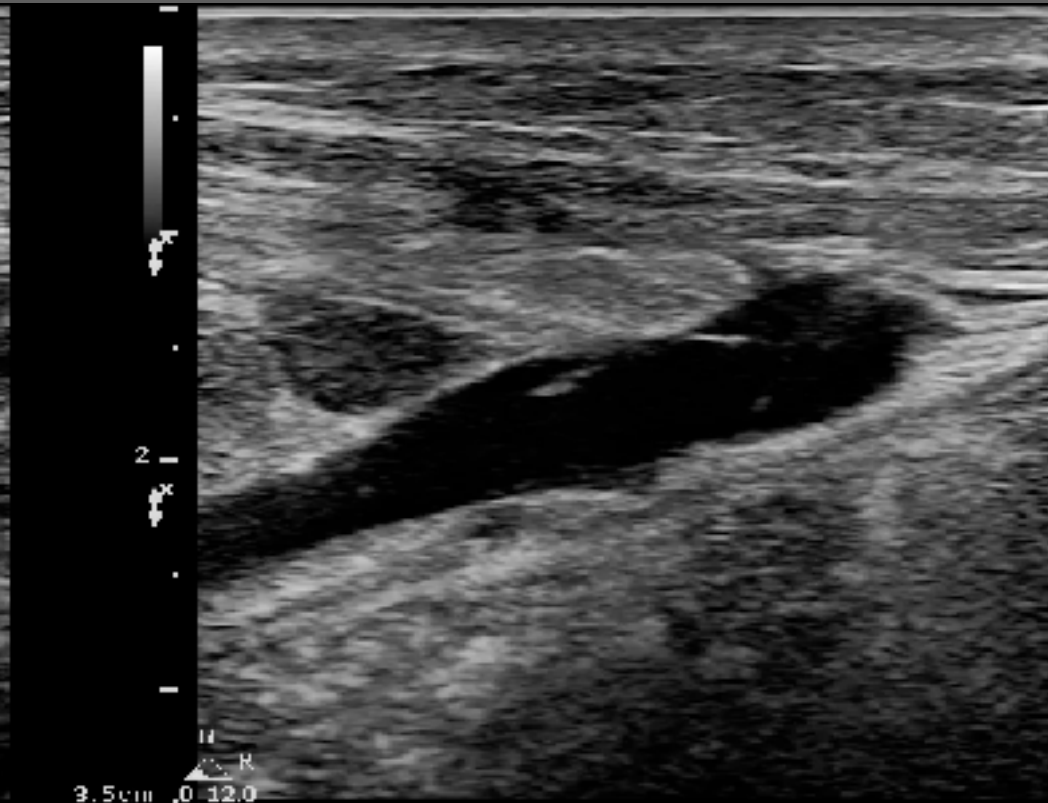

Calf muscle tear

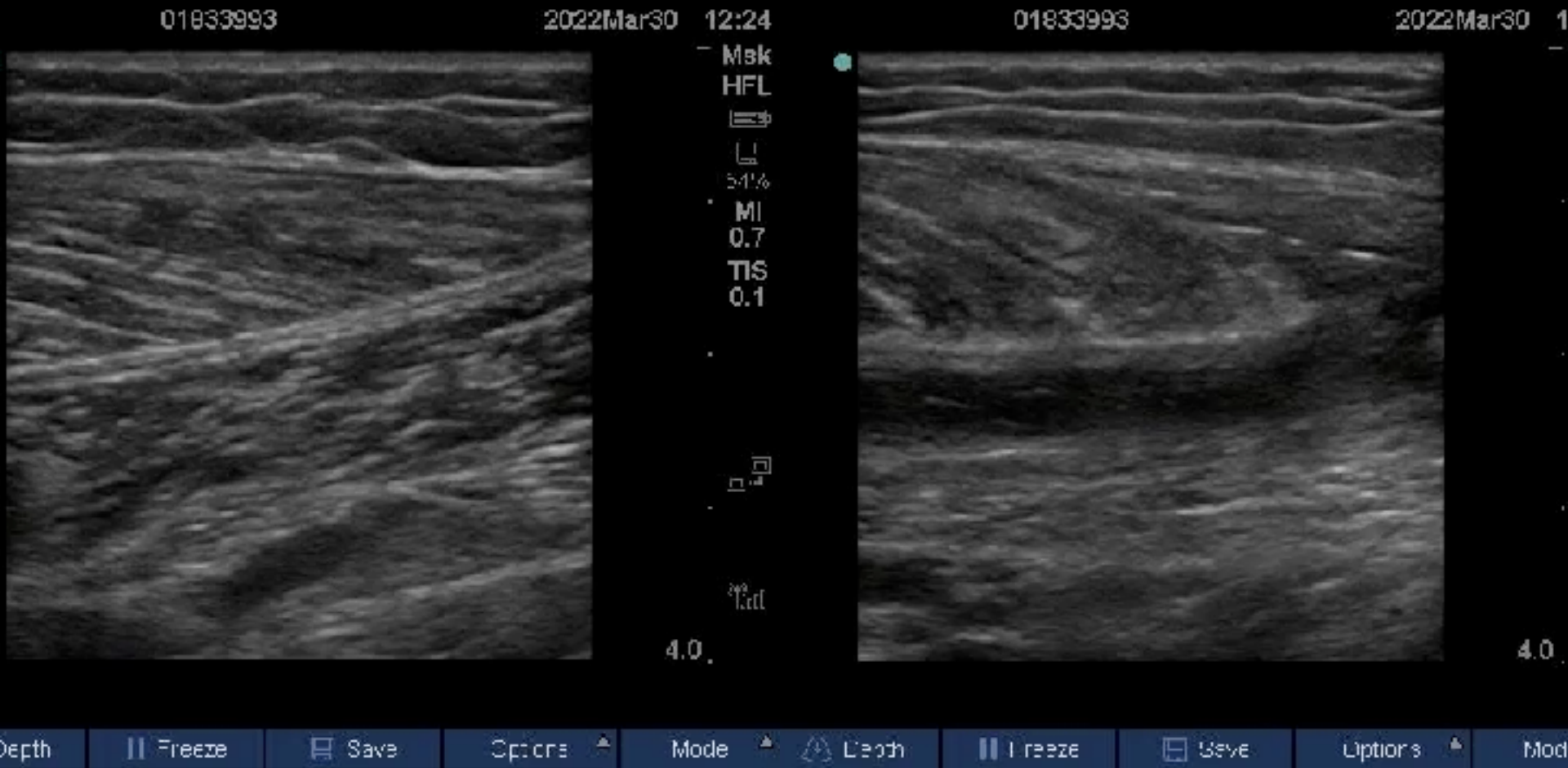
Left calf



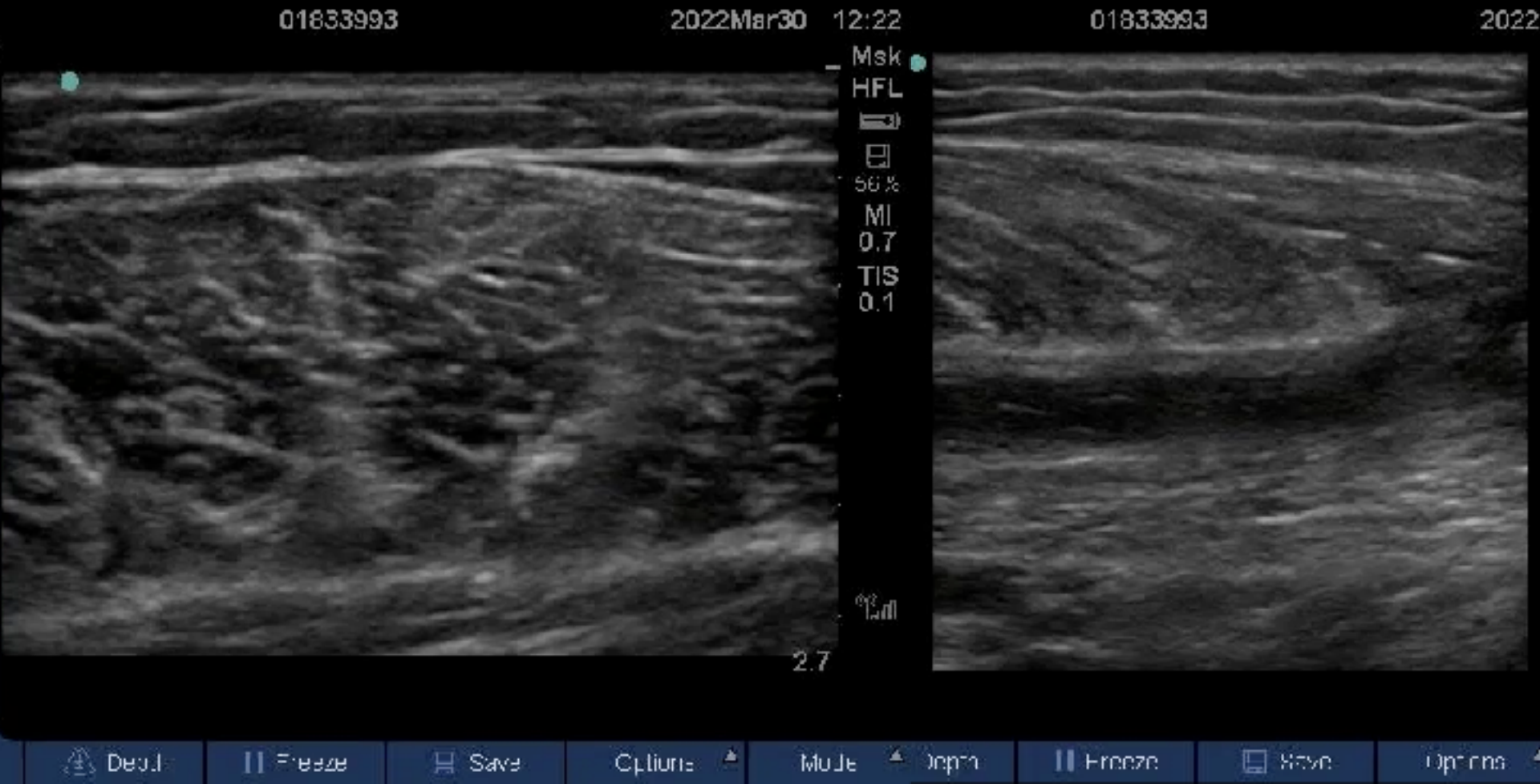
Right calf



Calf muscle tear



Calf muscle tear





FORMOSA XTREME TRIATHLON

WAYPOINT

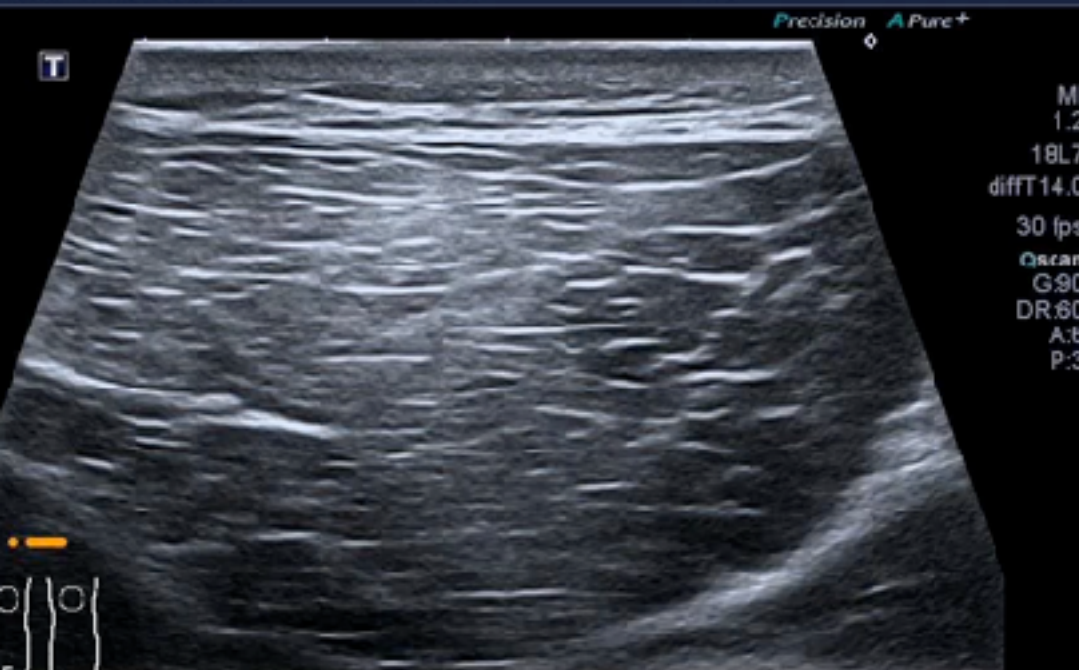FAT

XTRI
WORLD
2018

4天前
左腳不小心
撞到石頭。
致血腫疼痛



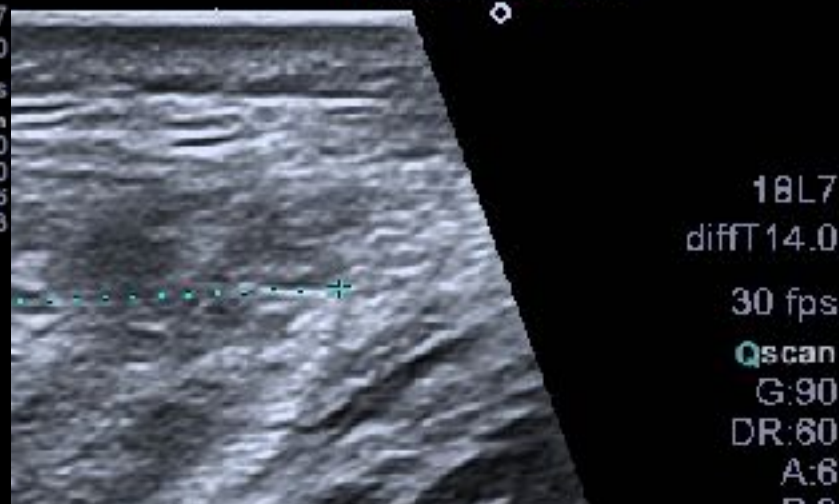T



MI
1.2
18L7
diffT 14.0
30 fps
Qscan
G:90
DR:60
A:6
P:3

3158

Precision A Pure+



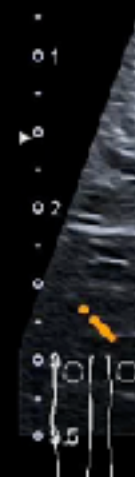
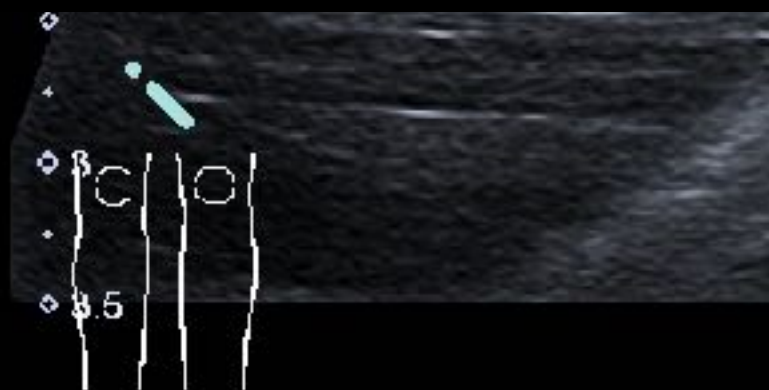

2021/12/01

11:51:07 AM

West Garden Hospital

MSK 3

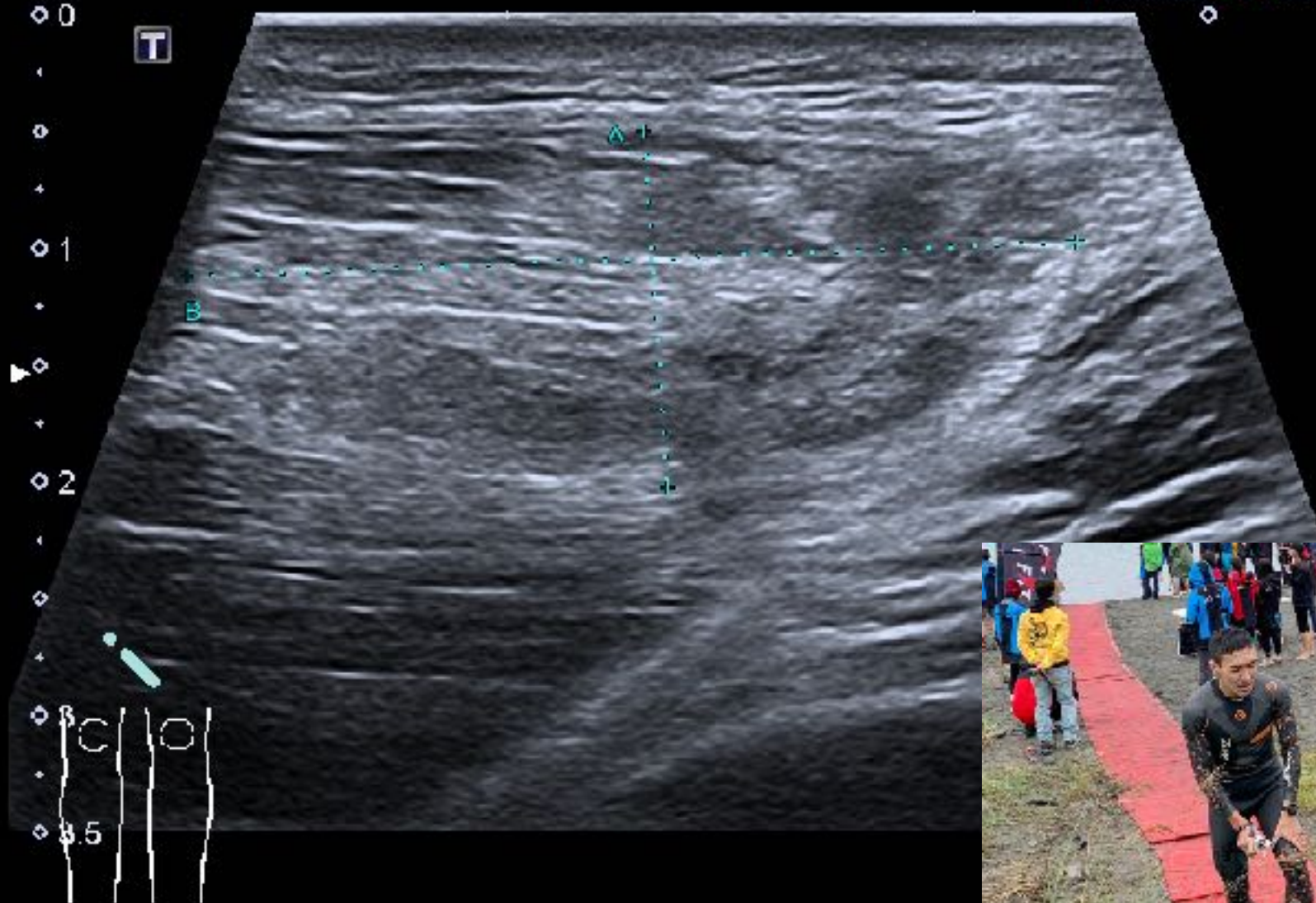
3158



MI
1.2
18L7
diffT 14.0
30 fps
Qscan
G:90
DR:60
A:6
P:3

Dist A	15.3mm
Dist B	38.1mm

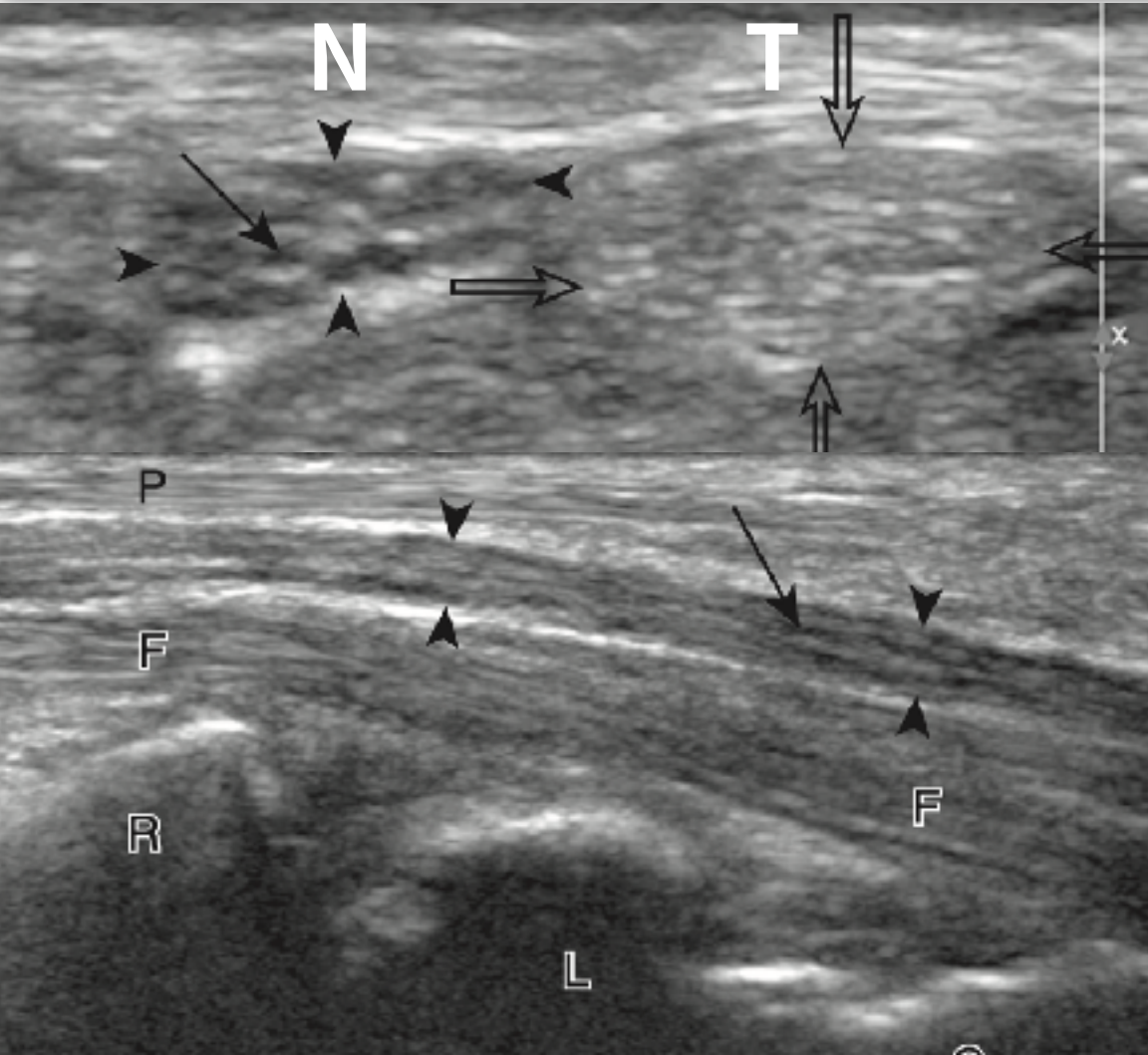
Precision A Pure+



18L7
diffT 14.0
30 fps
Qscan
G:90
DR:60
A:6
P:3

Dist A	15.3mm
Dist B	38.1mm

Nerve



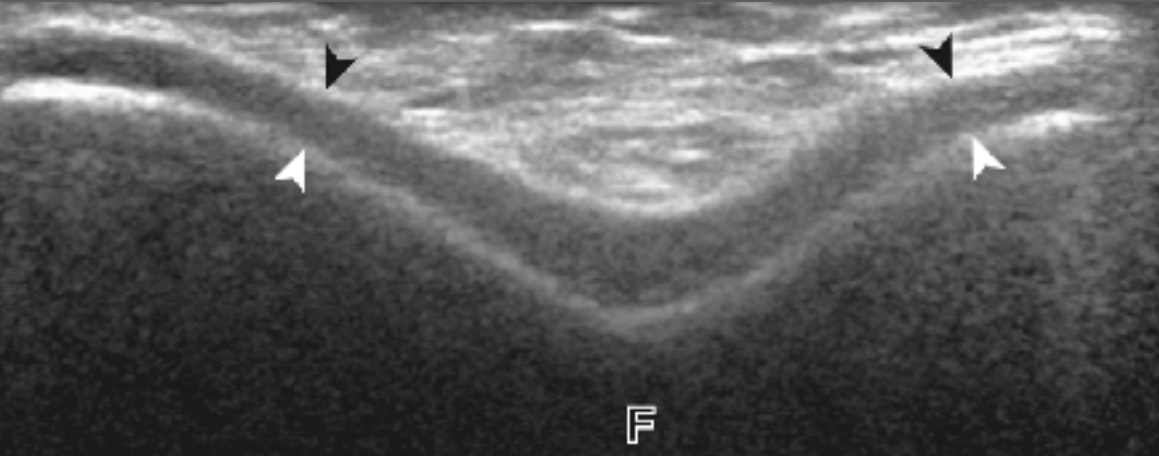
Hypoechoic

Hyperechoic

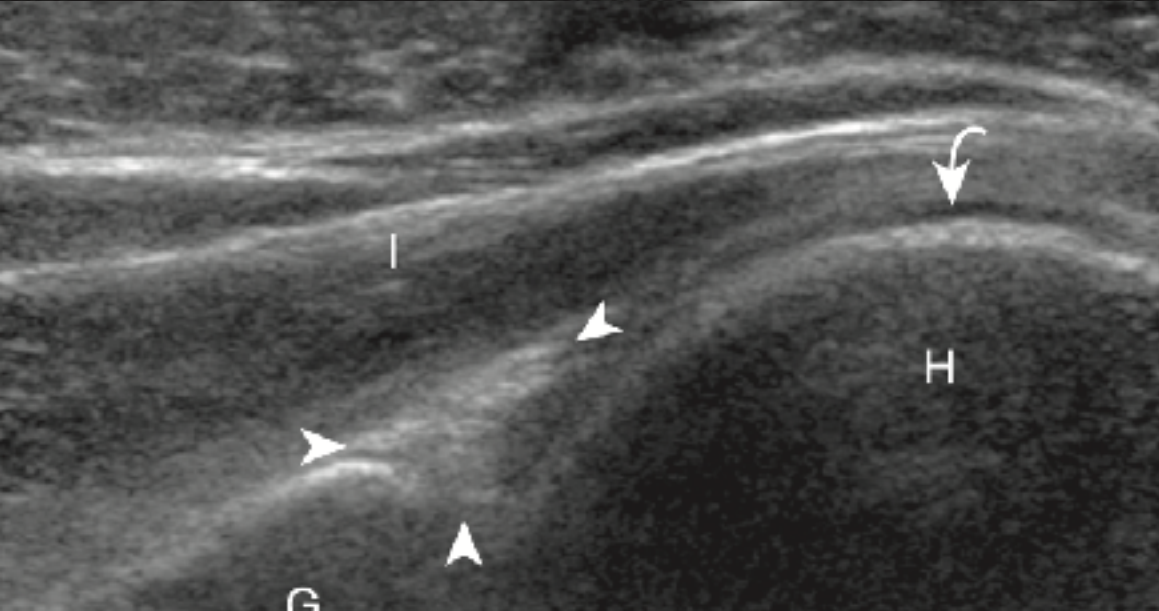
Honeycomb

Fibrillar

Cartilage



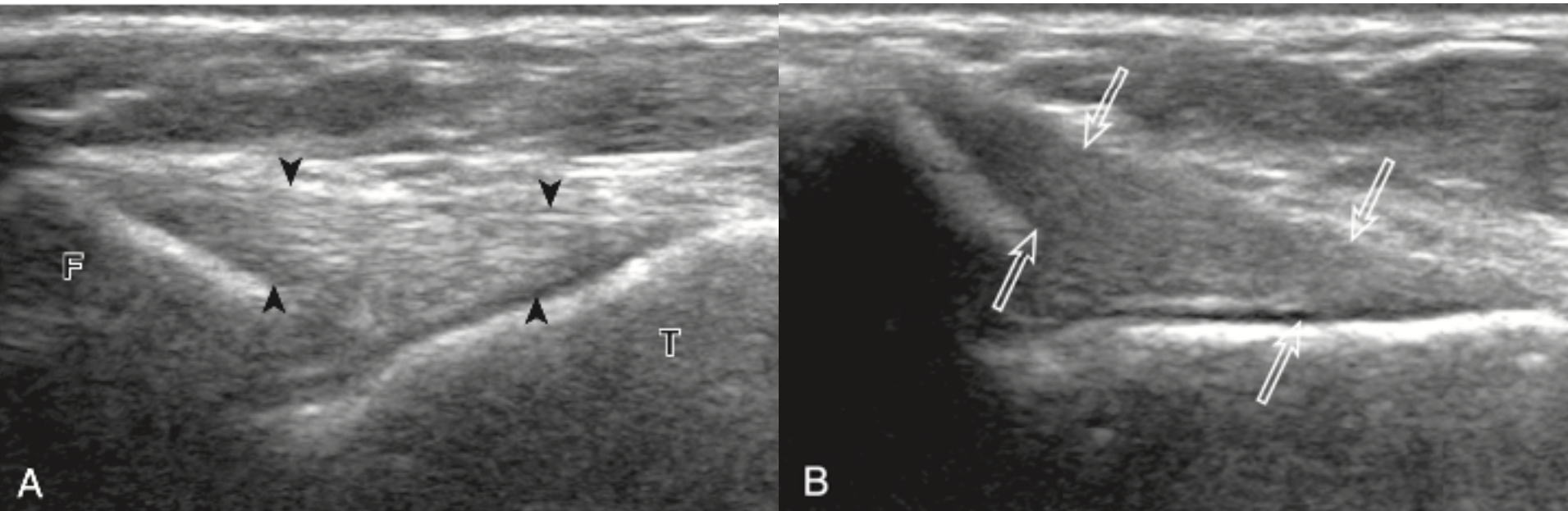
**Hypoechoic
hyaline
cartilage**



**Hyperechoic
fibrocartilage**

Artifact ?

Anisotropy



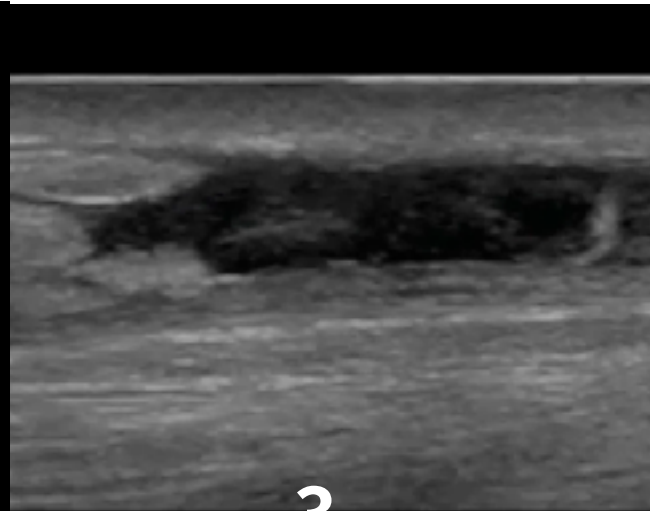
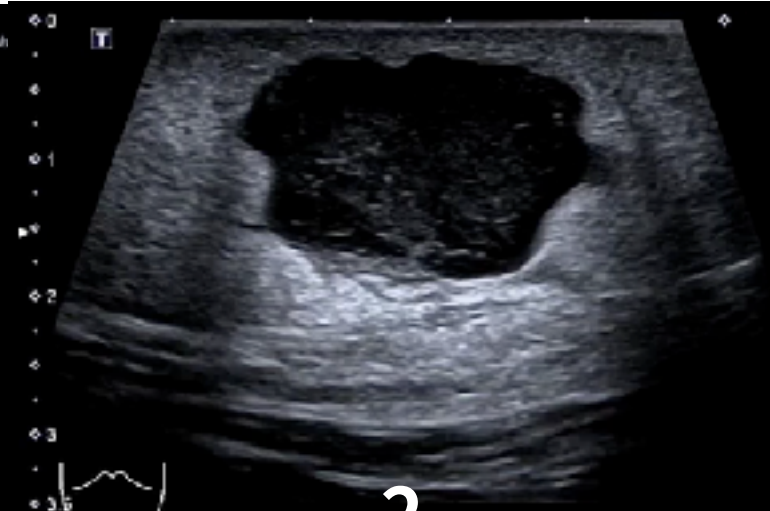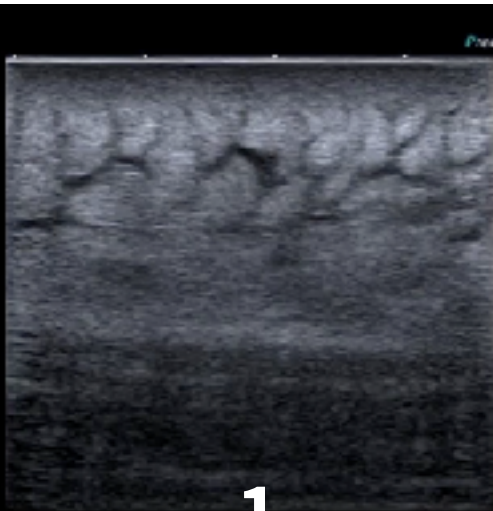Anterior talofibular ligament

軟組織感染症

蜂窩性組織炎

膿瘍

壞死性筋膜炎



Cobblestone

Collection

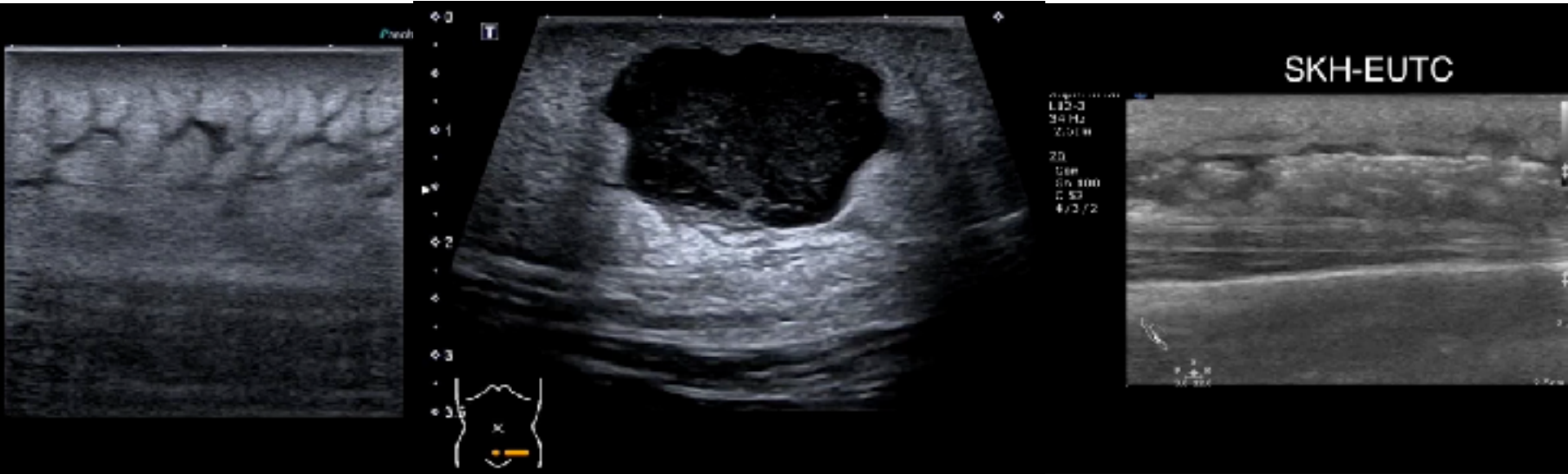Fascial fluid >4mm

軟組織感染症

蜂窩性組織炎

膿瘍

壞死性筋膜炎

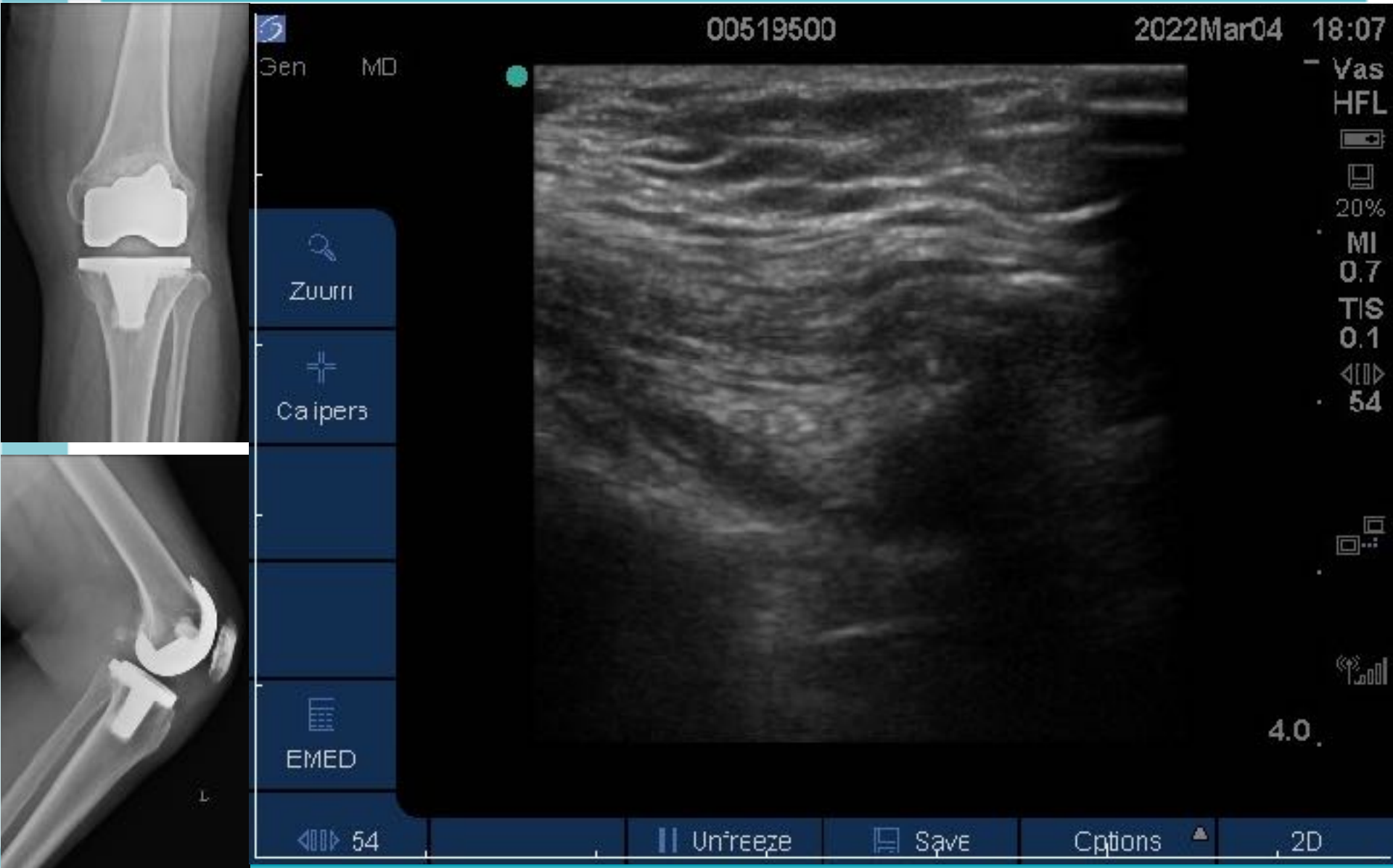

Cobblestone

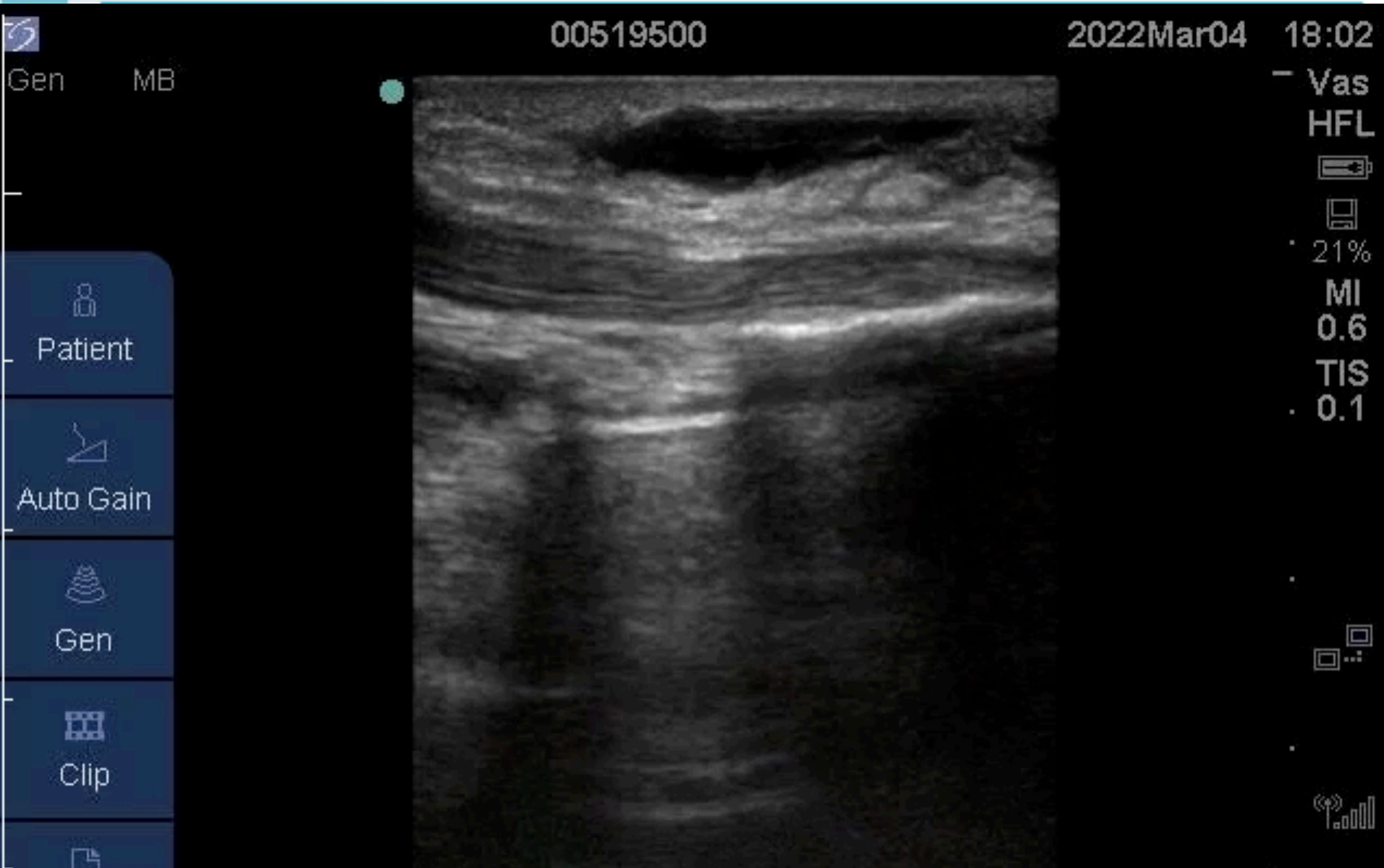Collection

STAFF

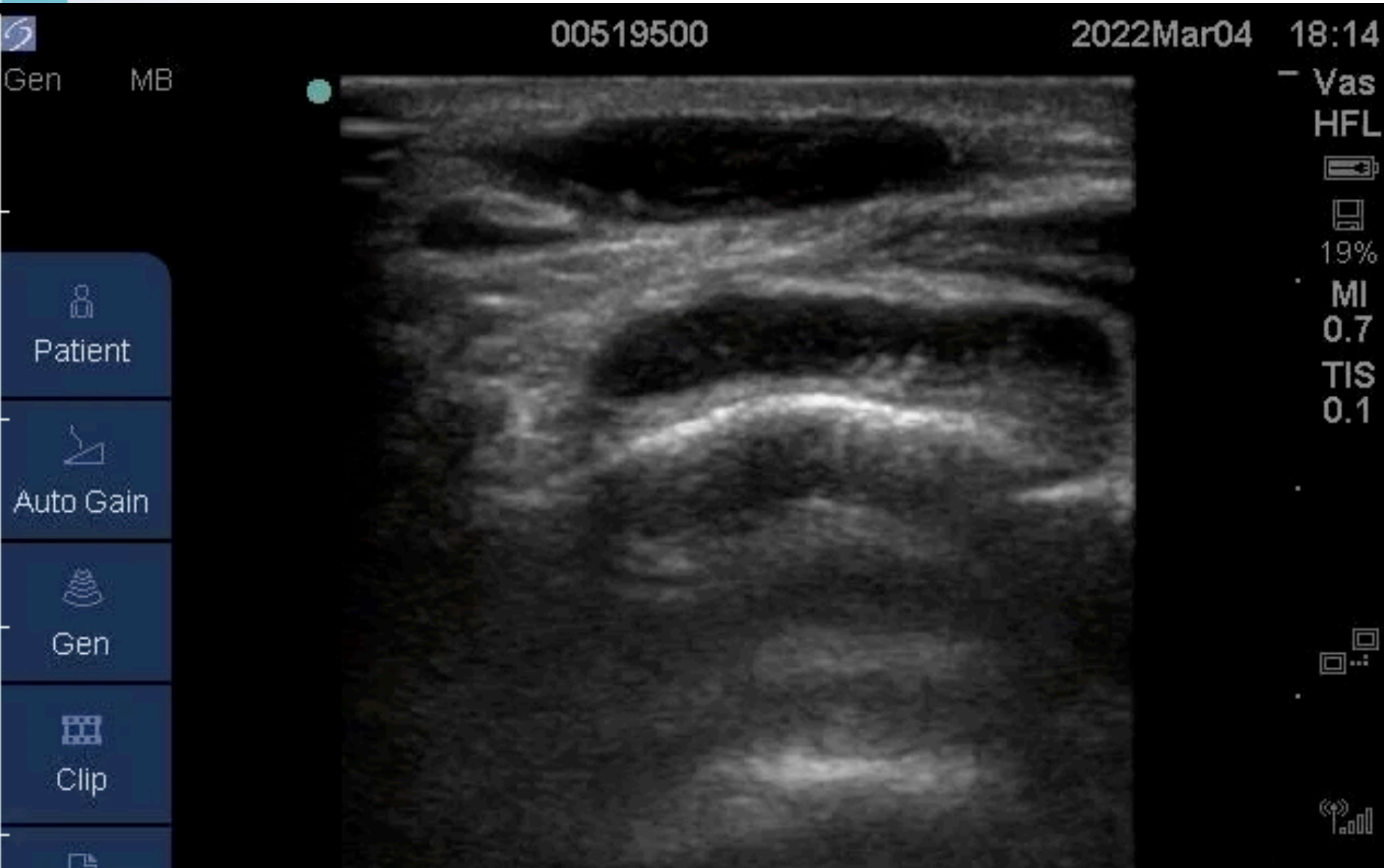
72F, left knee cellulitis



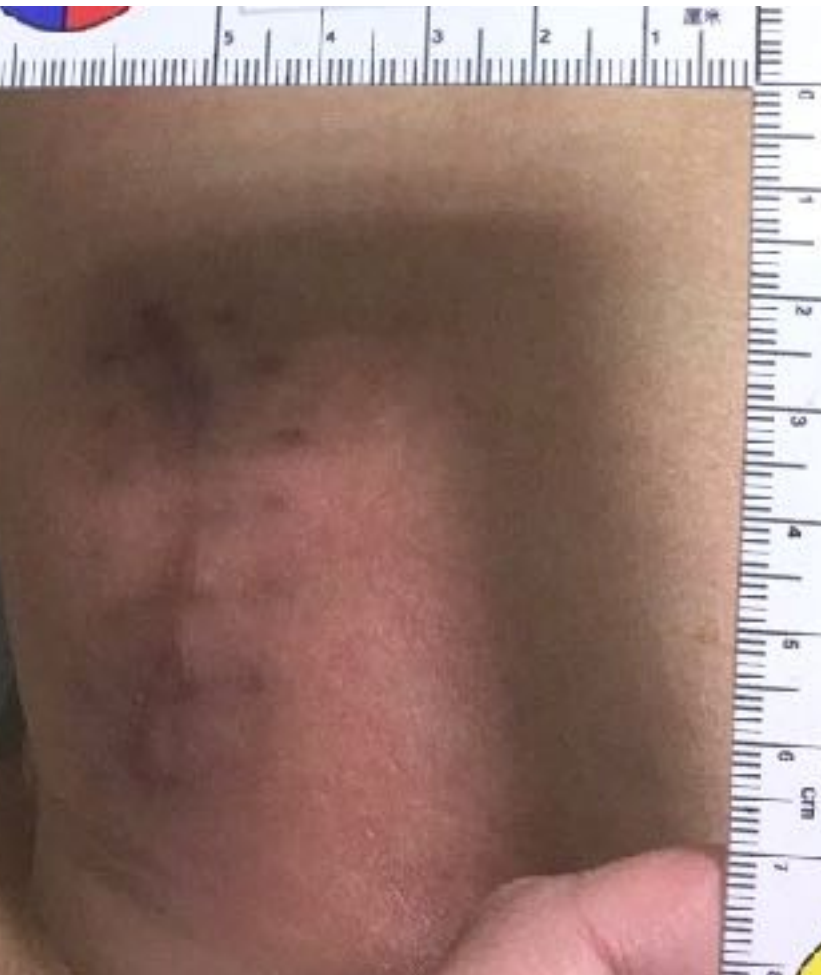72F, left knee cellulitis



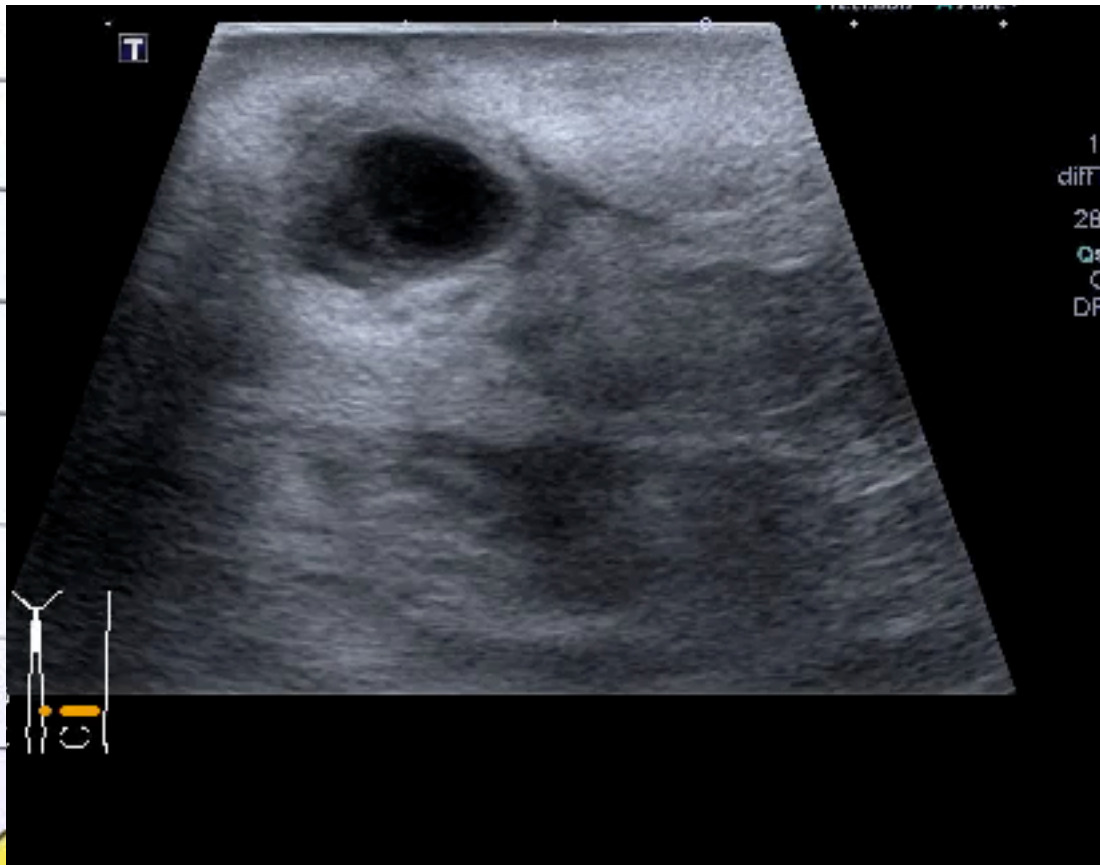
Anisotropy



71M, 2個月前CABG，近一週左大腿紅腫

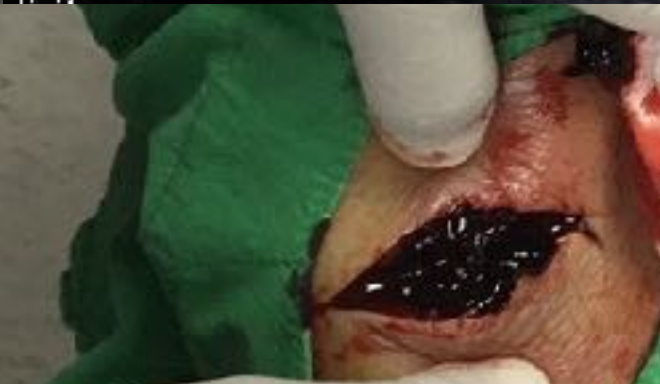
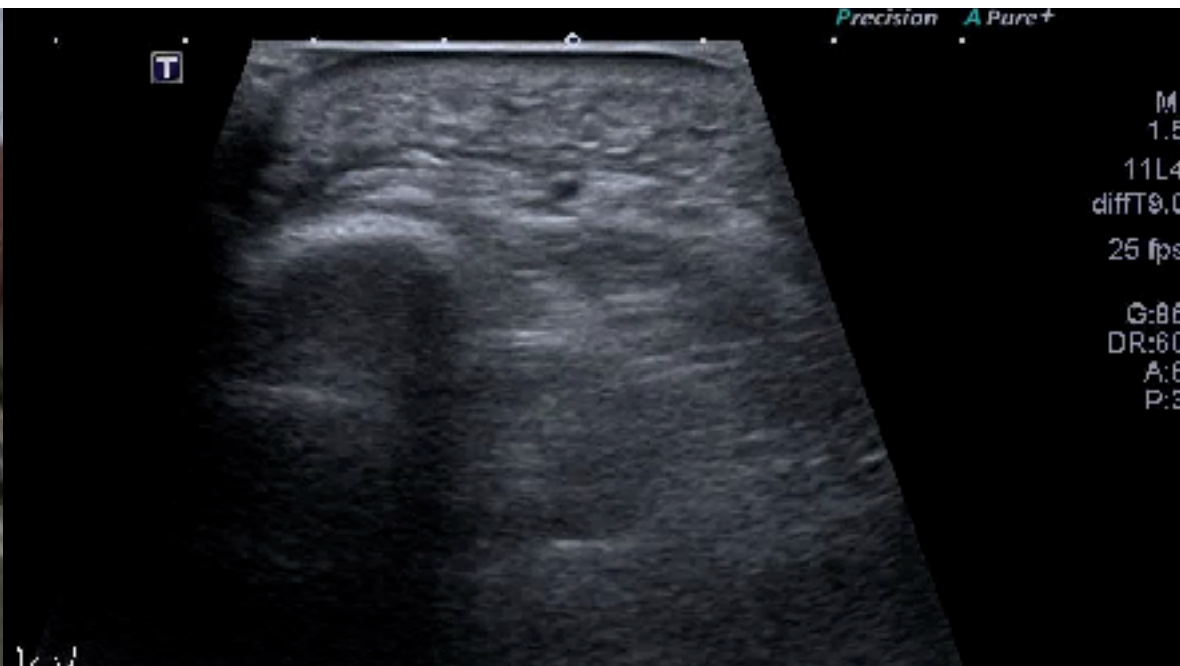
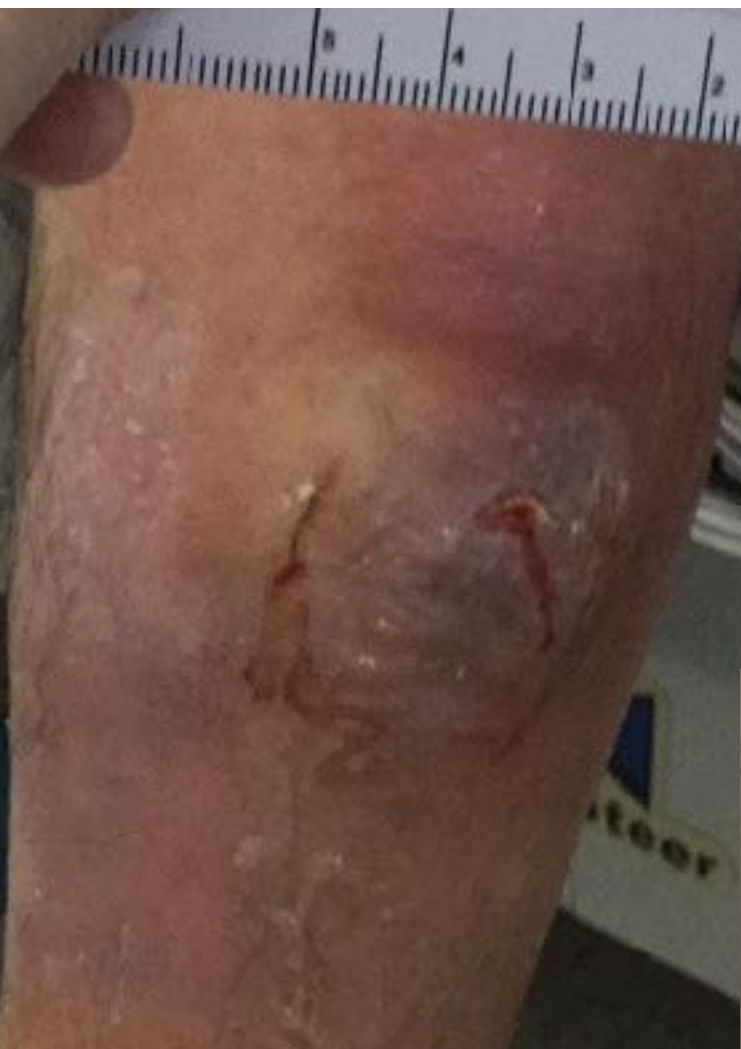Abscess (S. aureus)

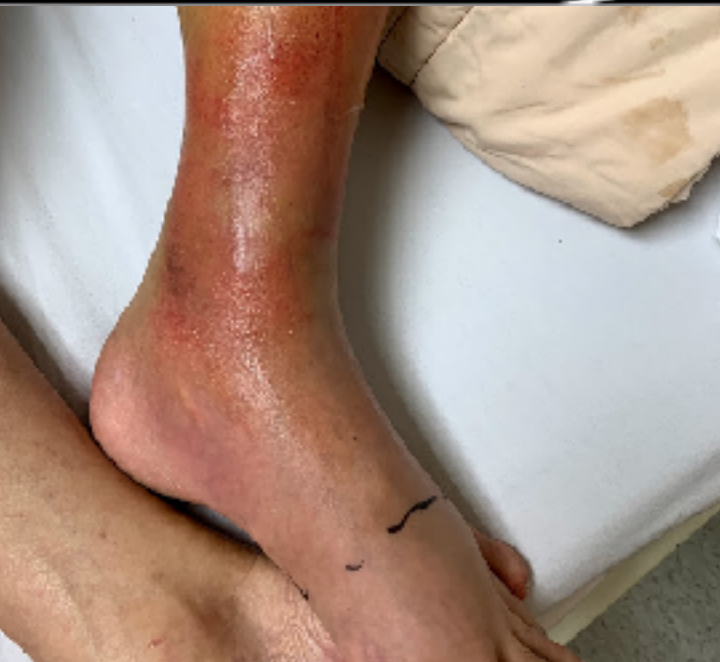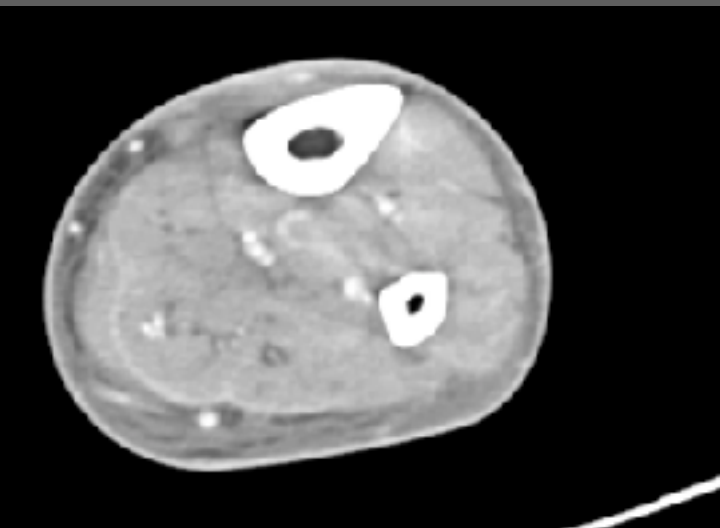


60M, Right leg contusion & swelling 1wk

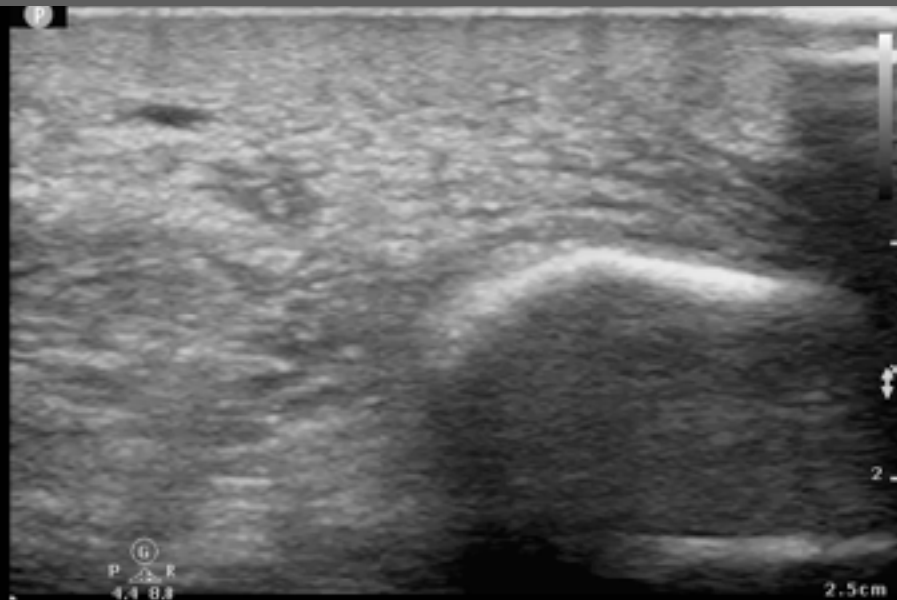
Diagnosis → Adductor canal block → I & D



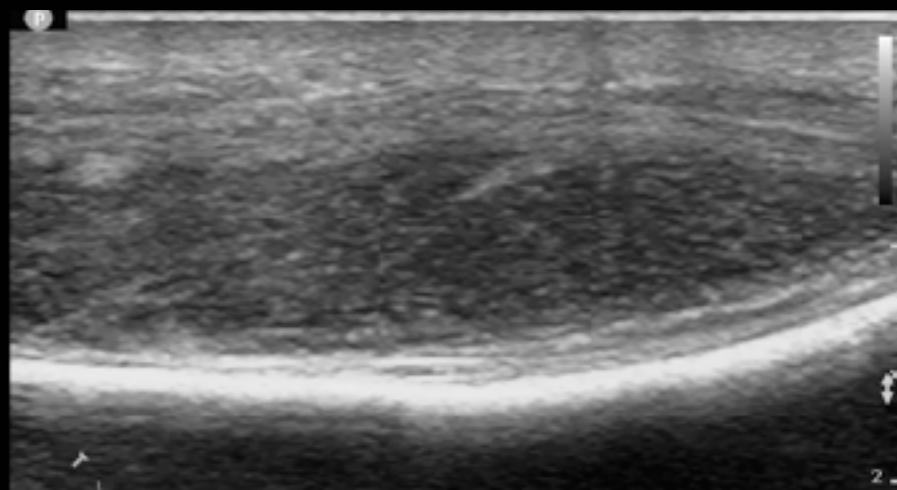
60M, L leg swelling & redness for 2 weeks



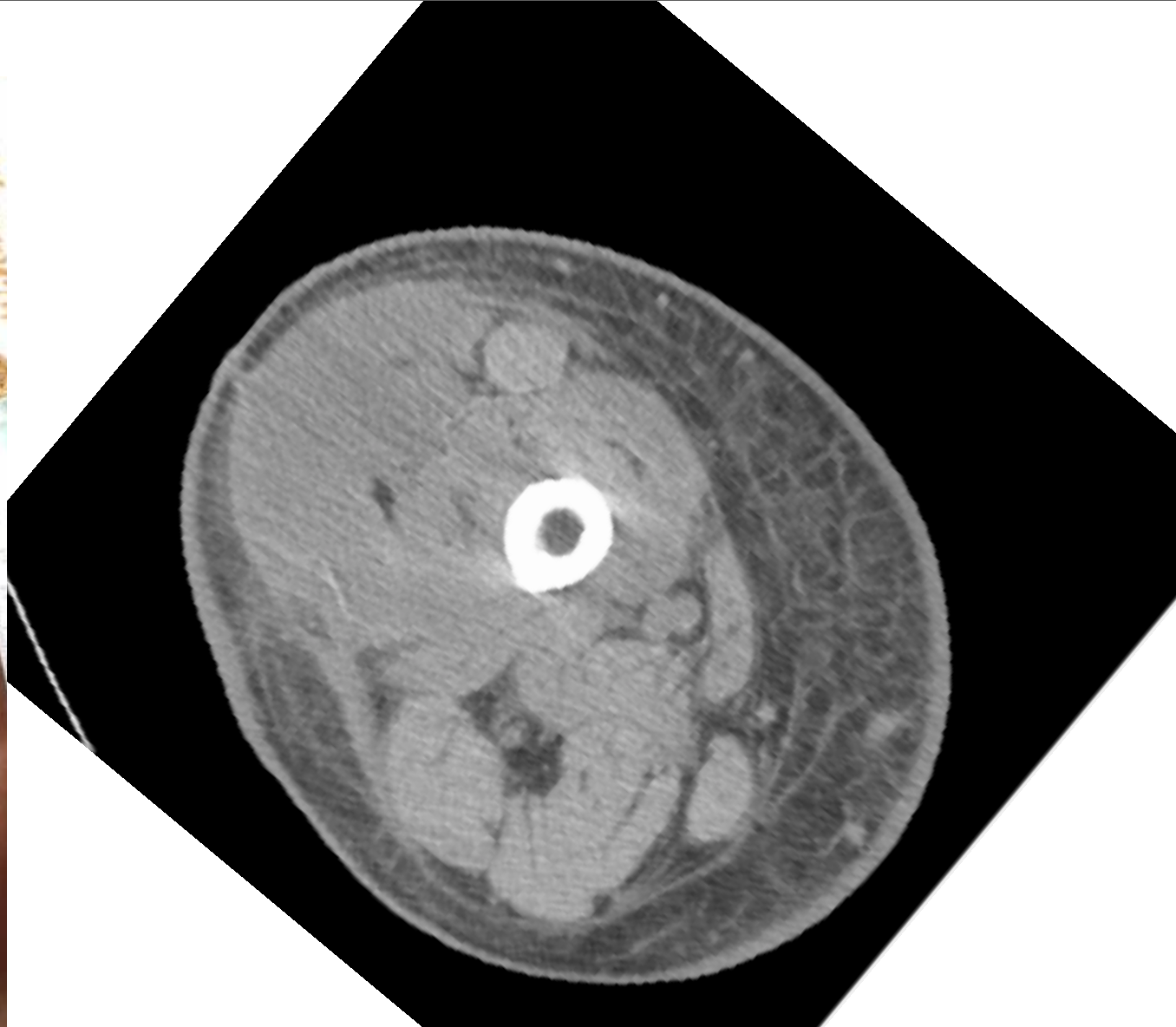
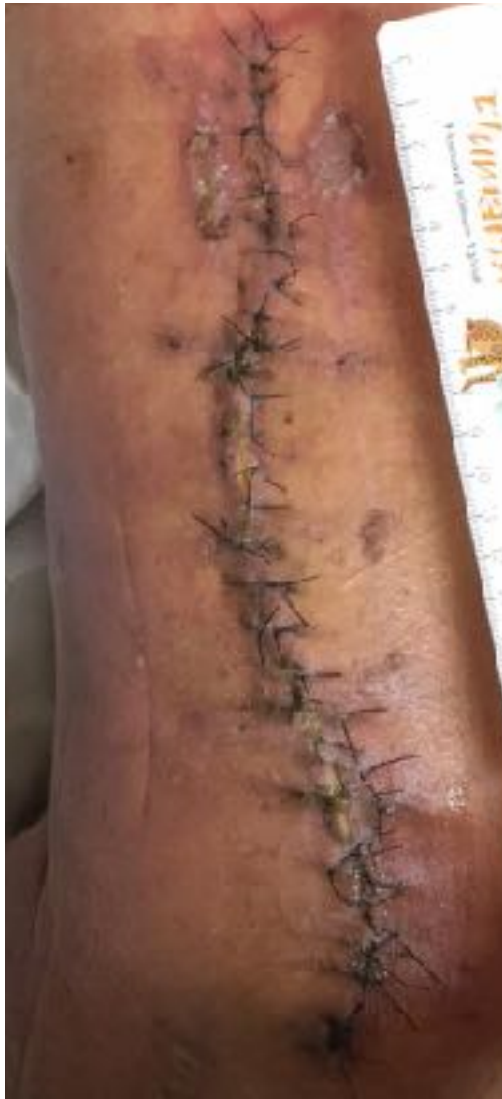Arterial
L12-3
49 Hz
2.5cm
2D
HGen
Gn 78
C 41
3/3/2



Arterial
L12-3
49 Hz
2.5cm
2D
HGen
Gn 76
C 41
3/3/2



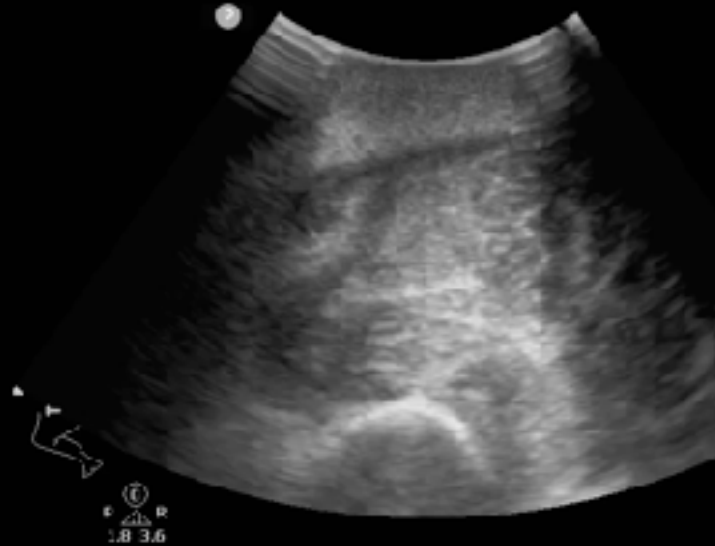38M, recurrent thigh painful swelling



Necrotizing fasciitis

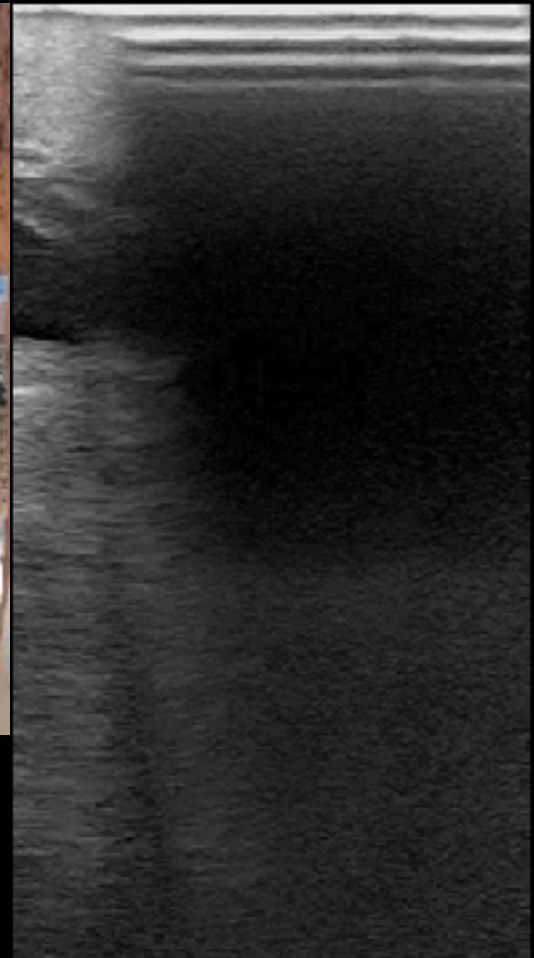
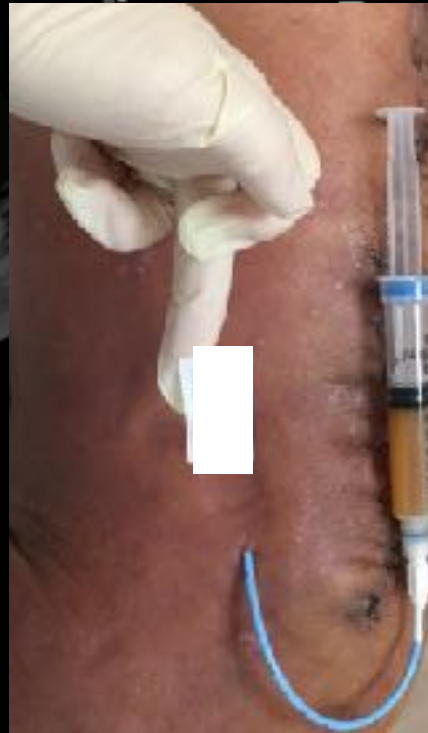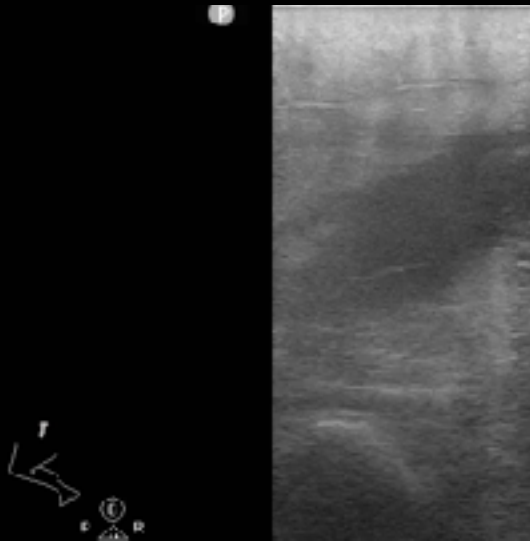
Abd Gen
C5-1
51 Hz
8.0cm

2D
HGen
Gn 65
C 56
3/3/3

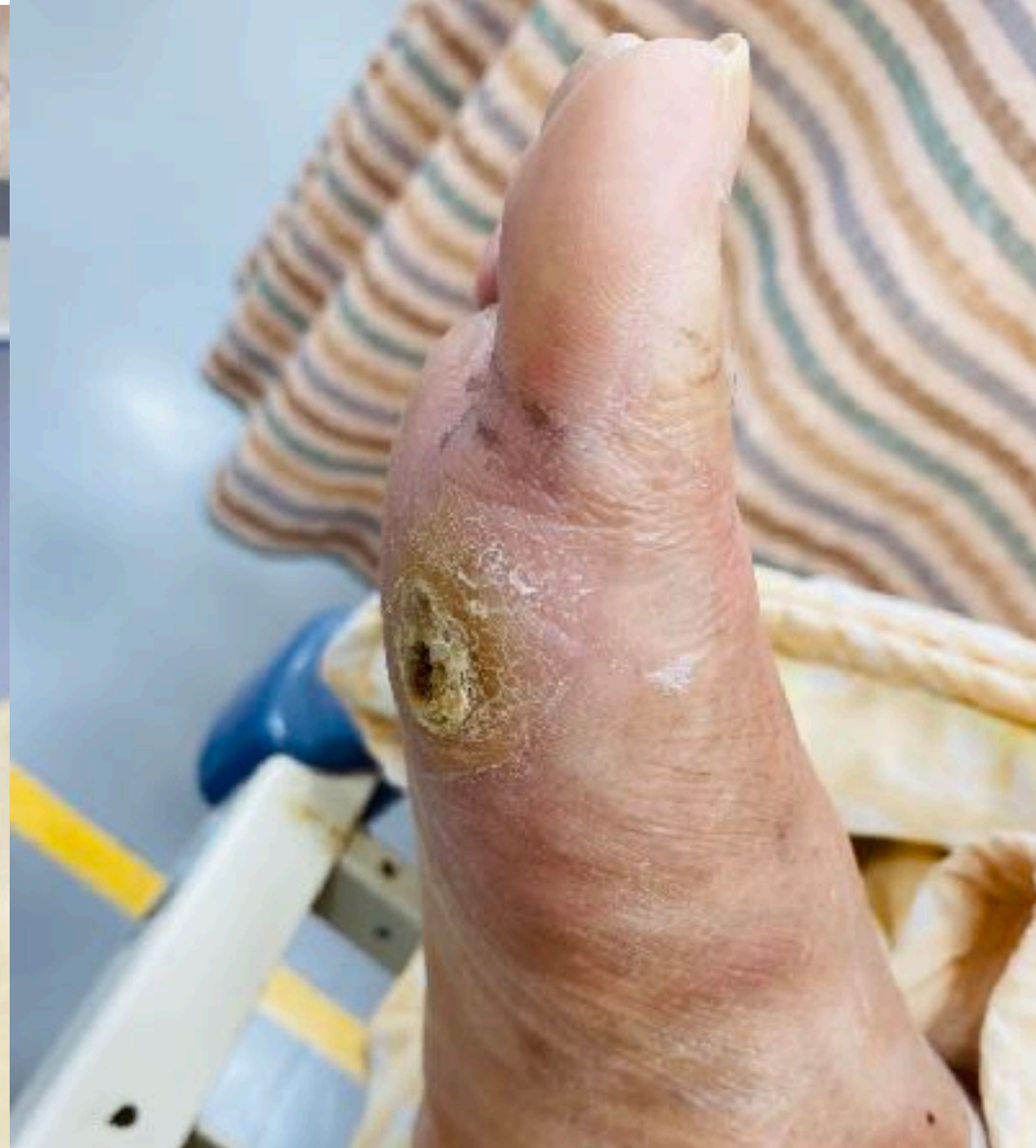
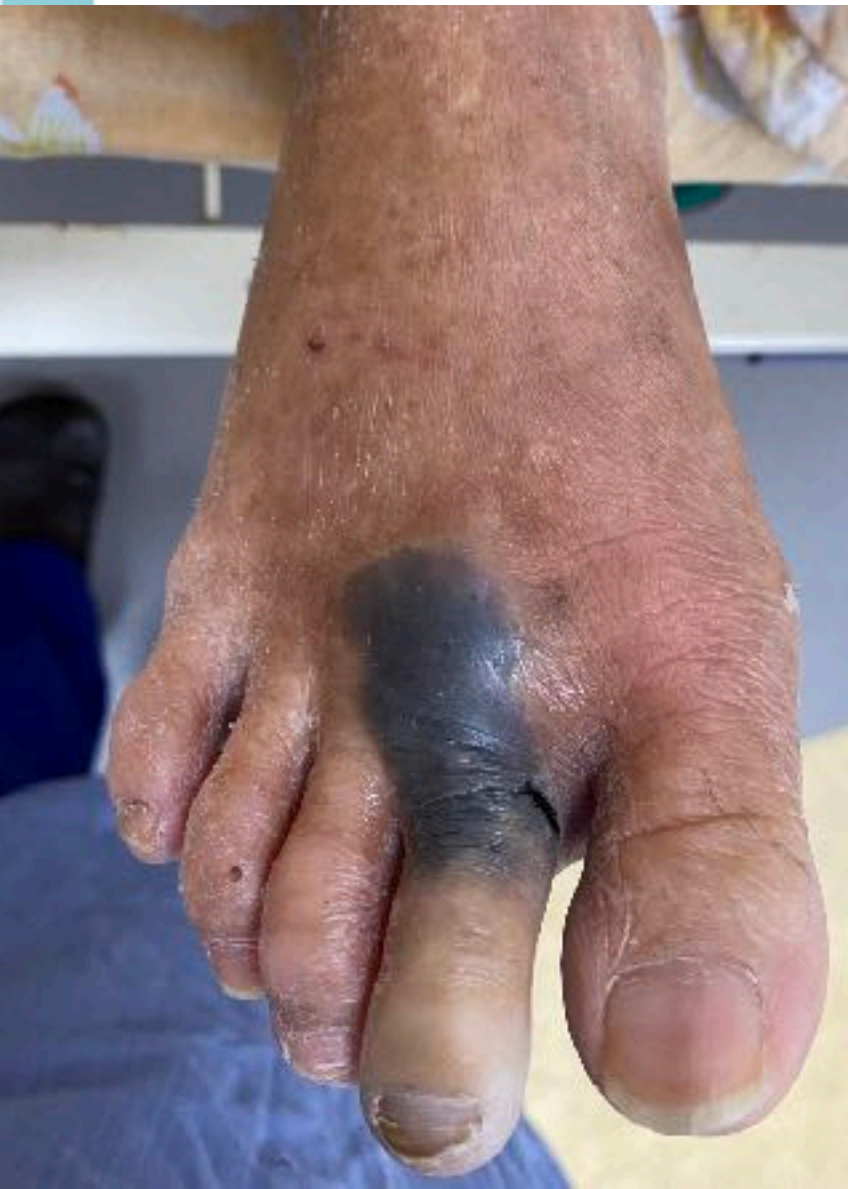
Arterial
L12-3
26 Hz
8.0cm

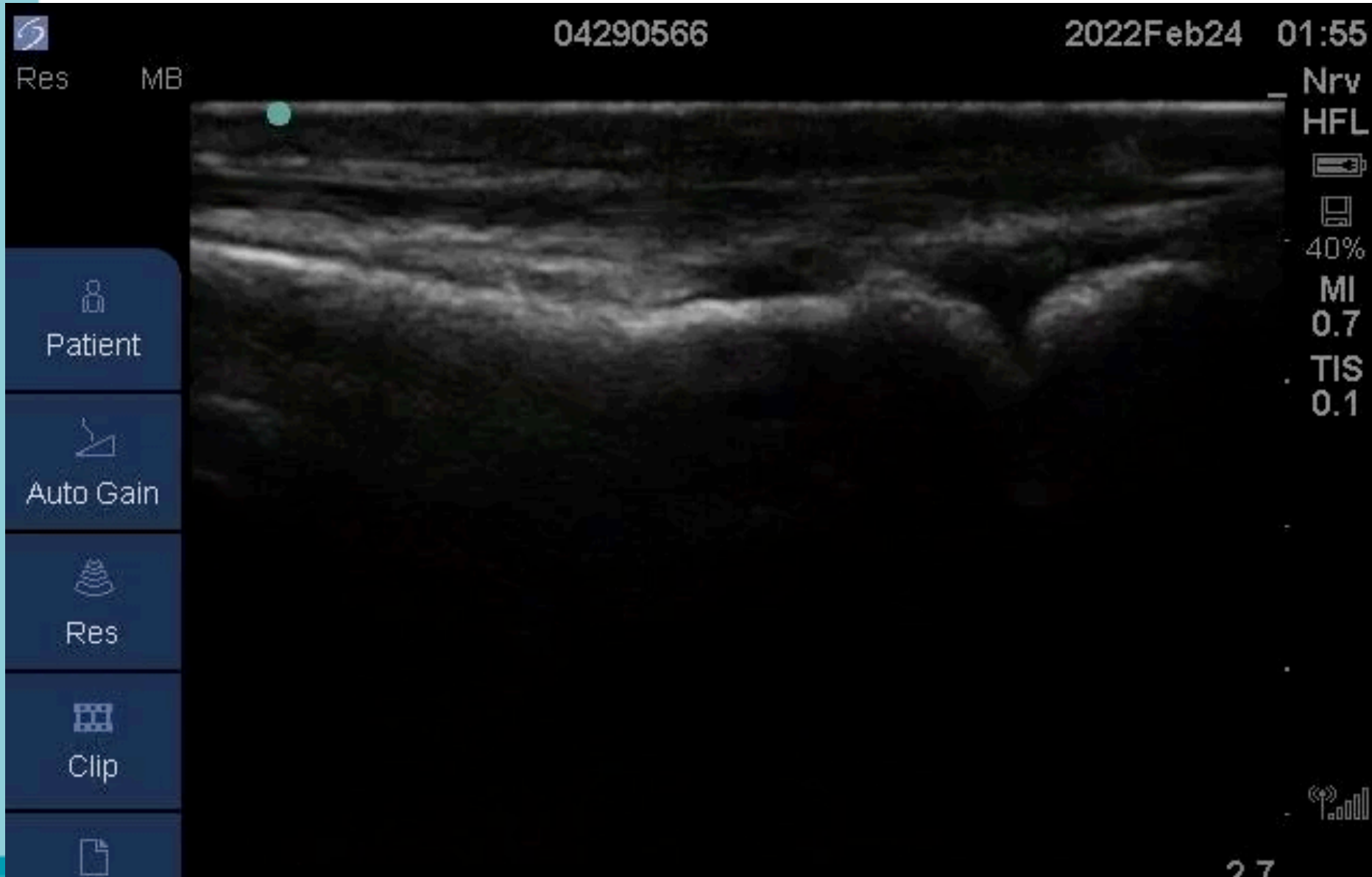2D
HGen
Gn 100
C 41
3/3/2



59F, DM, Uremia on HD, Fever



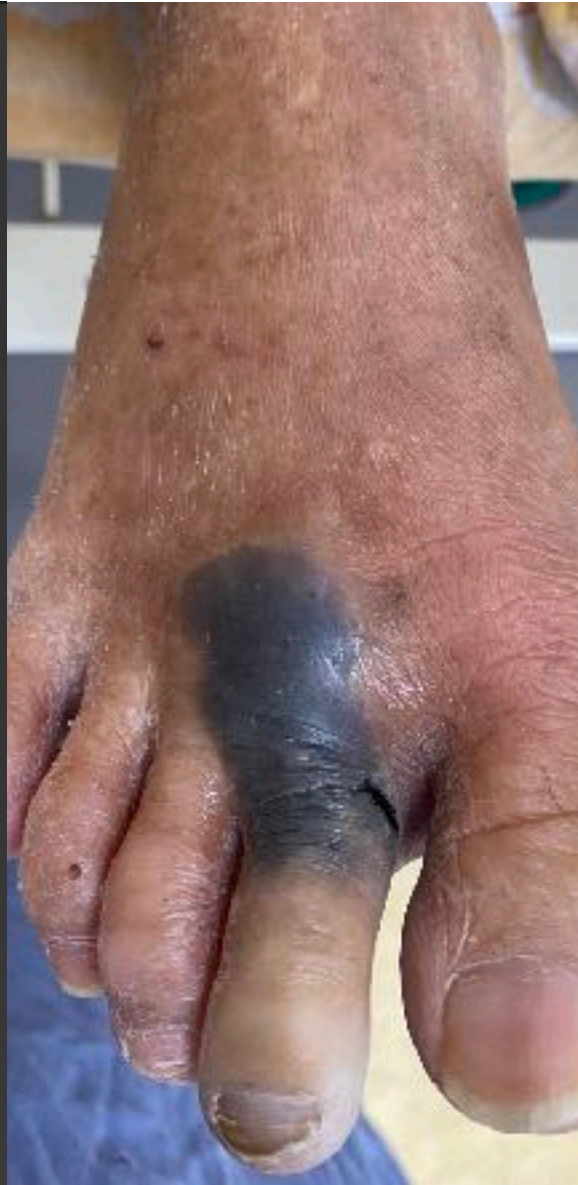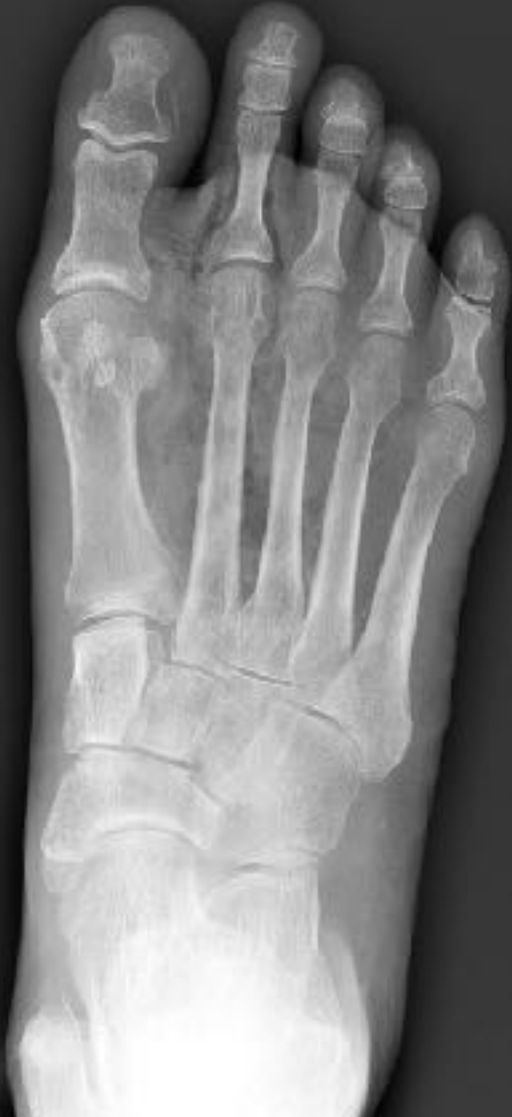Necrotizing fasciitis



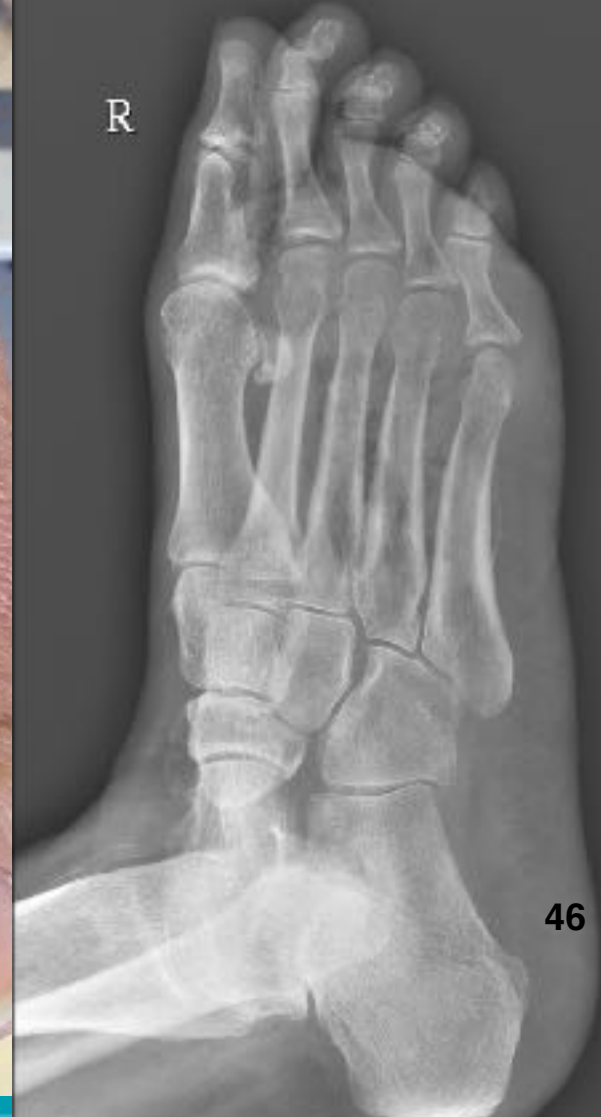Soft tissue gas



R



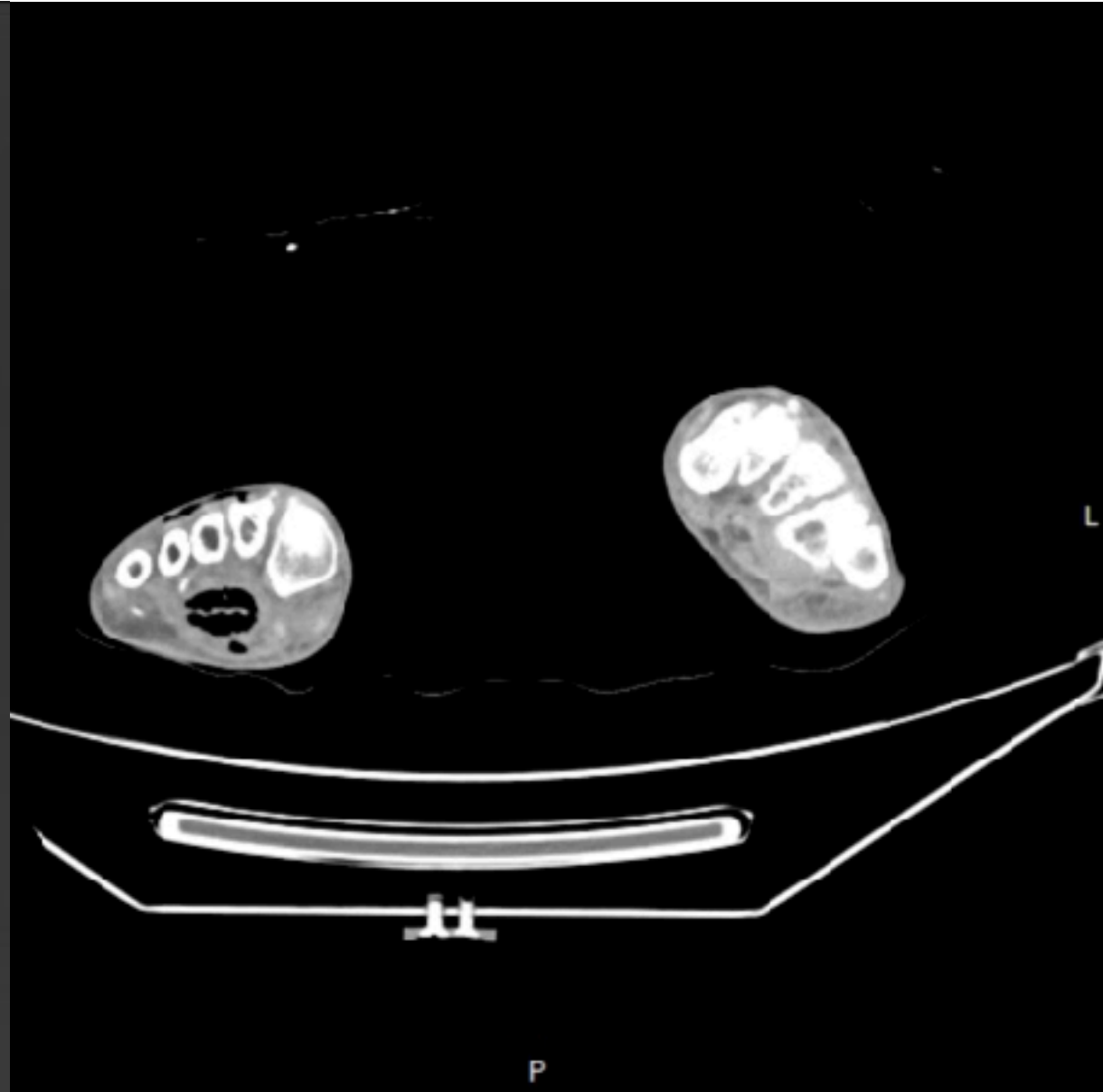
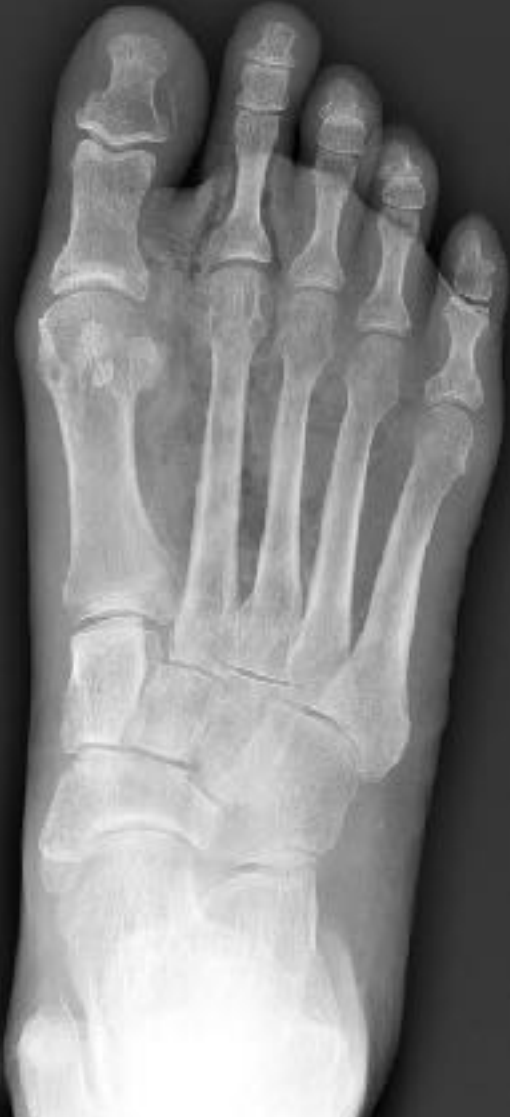R



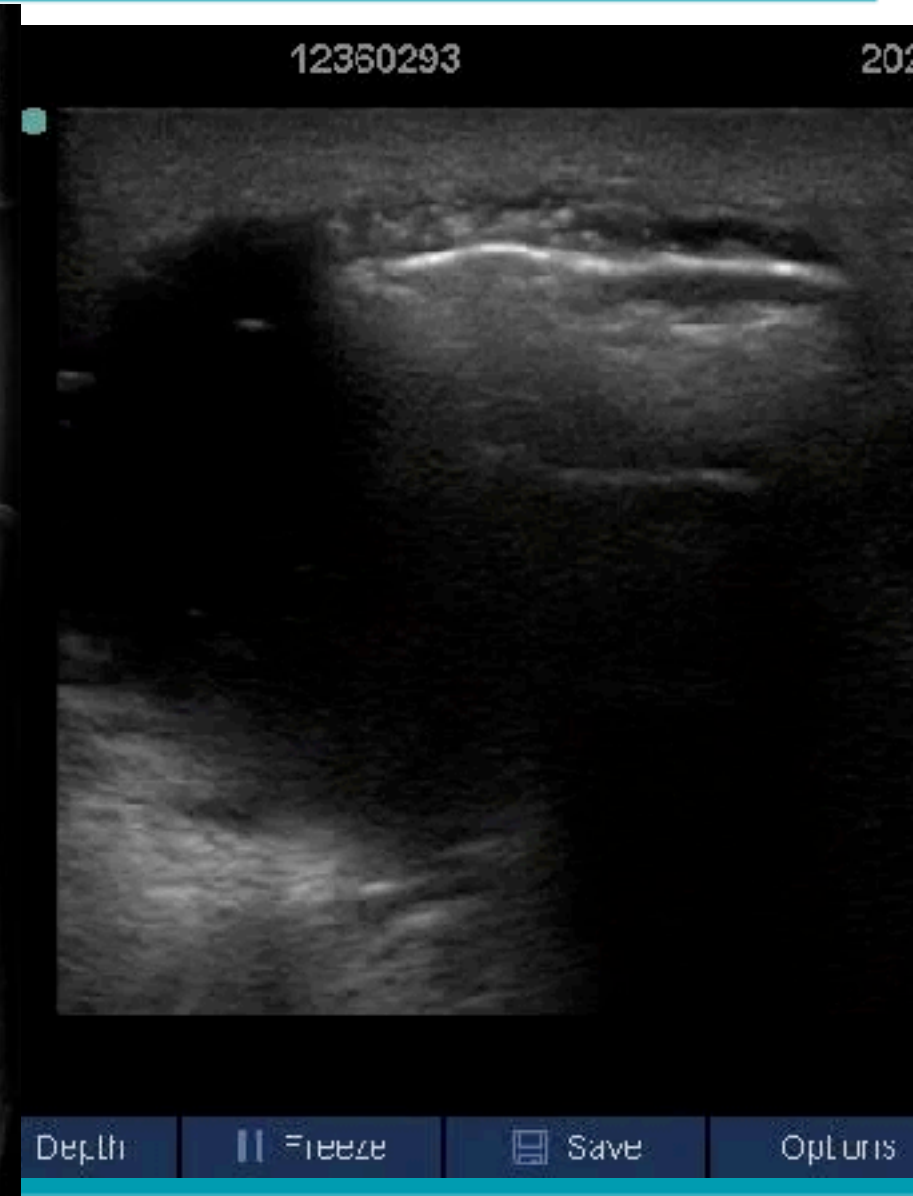
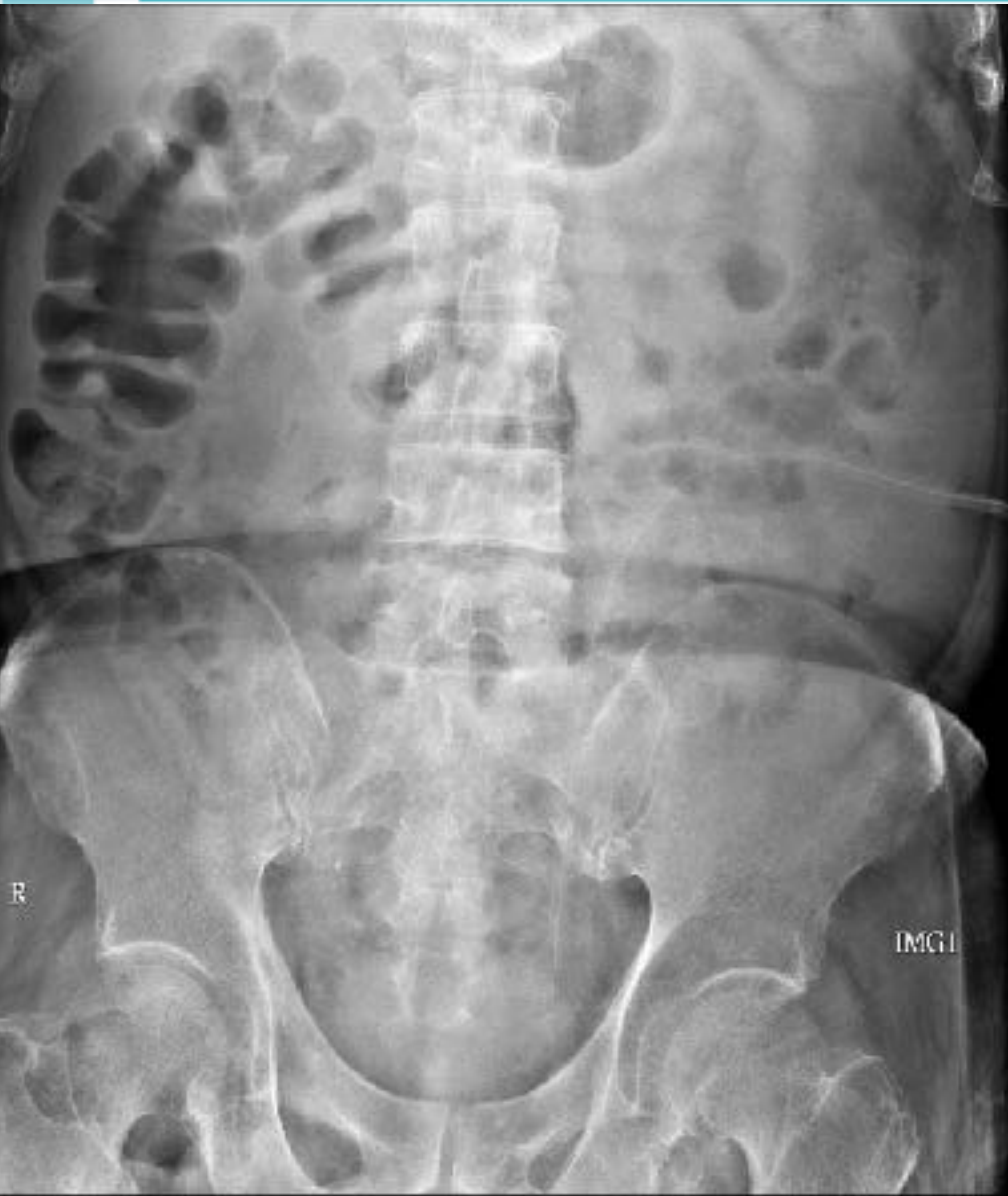59F, DM, Uremia on HD, Fever



R



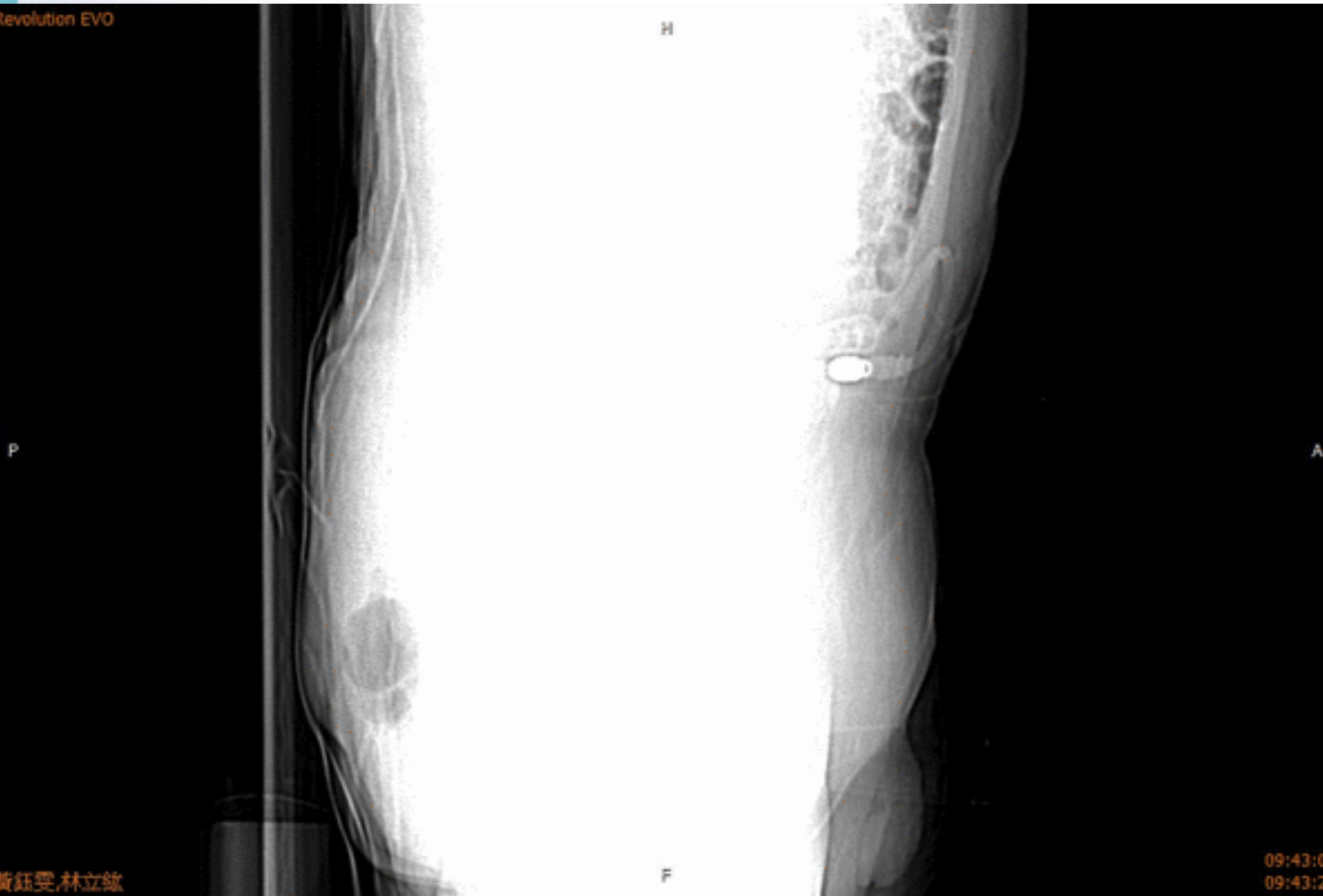
72M, buttock painful swelling



72M, buttock painful swelling



Revolution EVO



Pattern recognition

Axillary pain

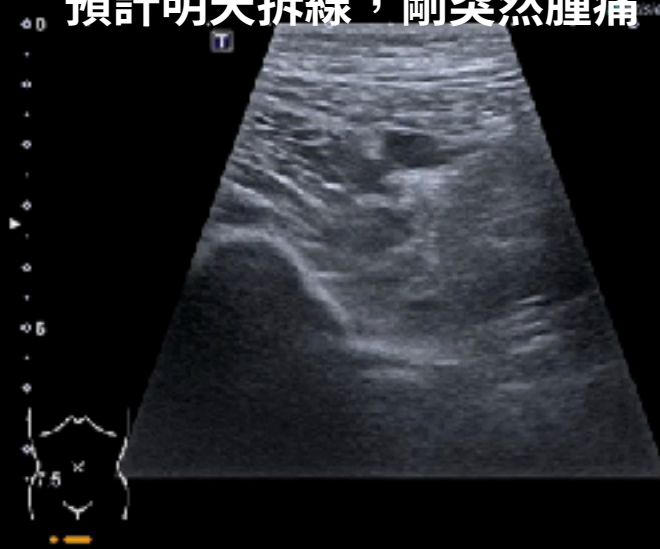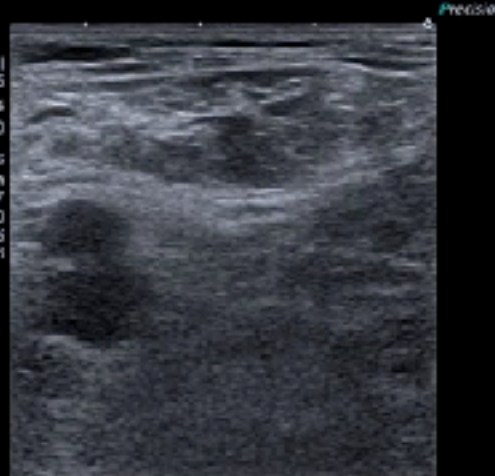
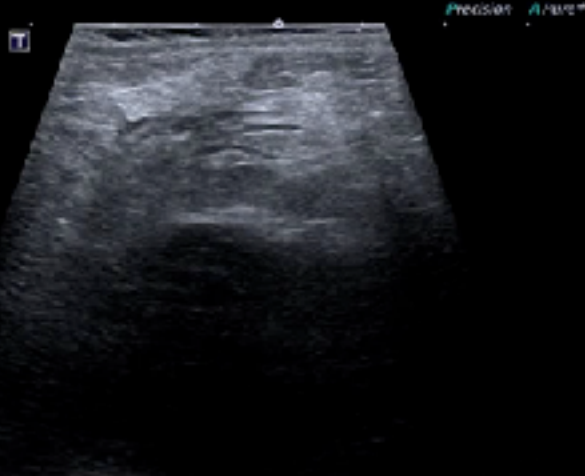Inguinal pain

Thigh pain

前幾天腋下長一顆東西

右腳和鼠蹊痛1天

上個月拔右髌釘子，
預計明天拆線，剛突然腫痛



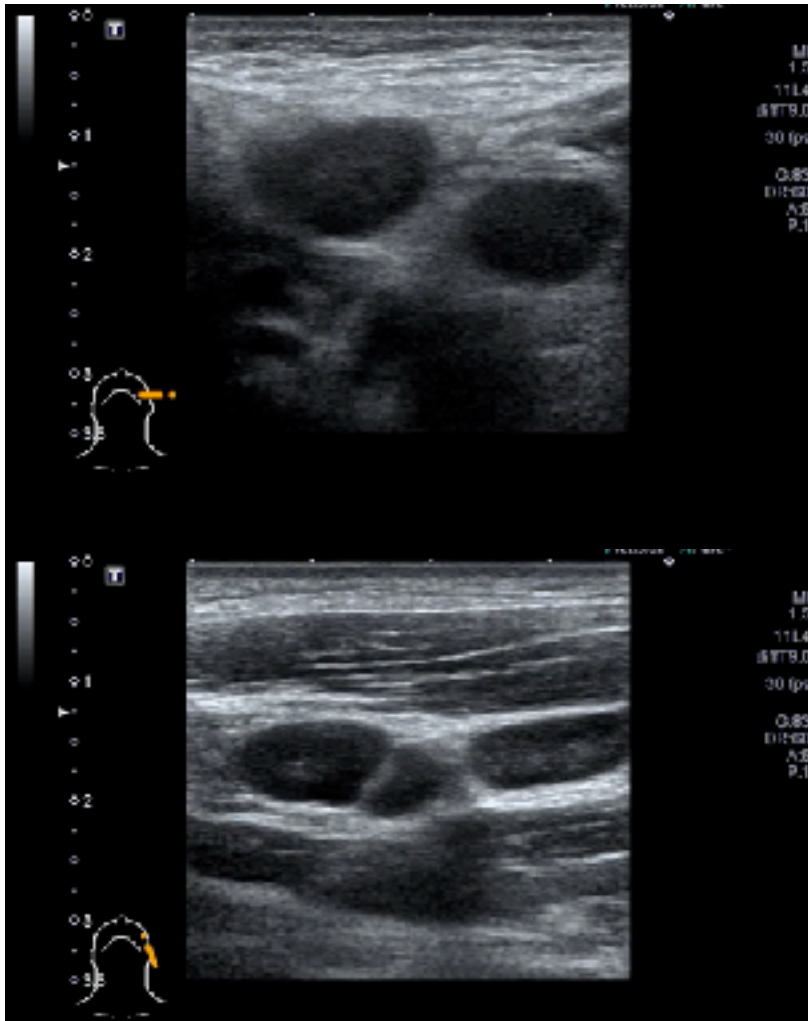
Abscess

Lymphadenitis

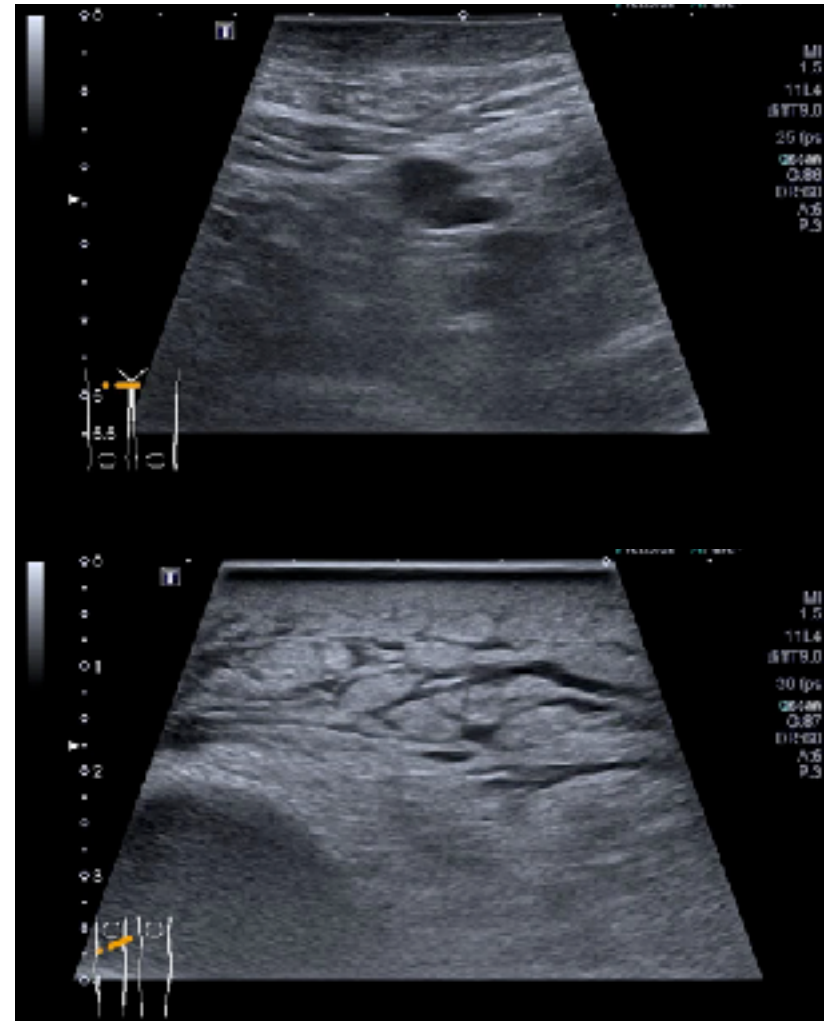
Hematoma

Lymphadenopathy

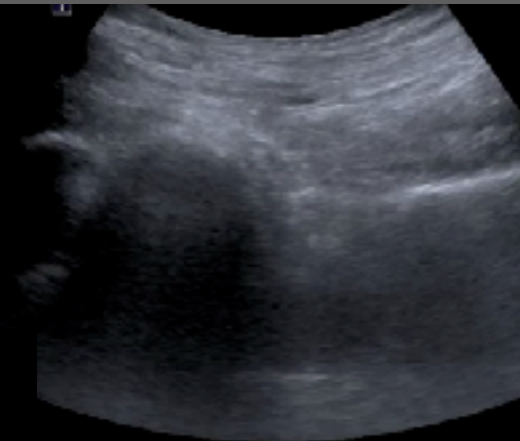39M, fever & neck pain



86M, F & R leg redness

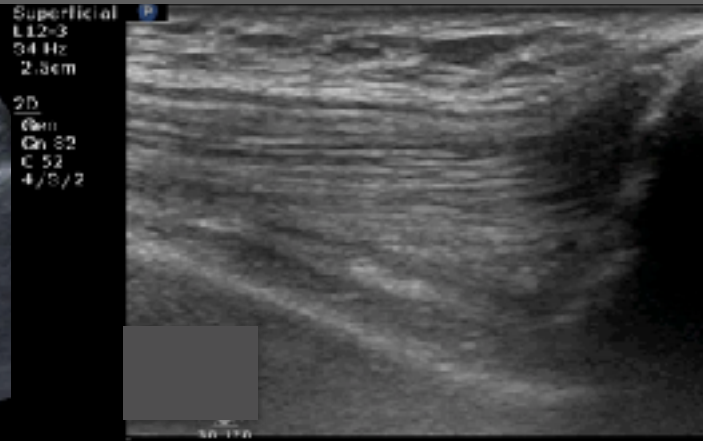

Lower extremity joints



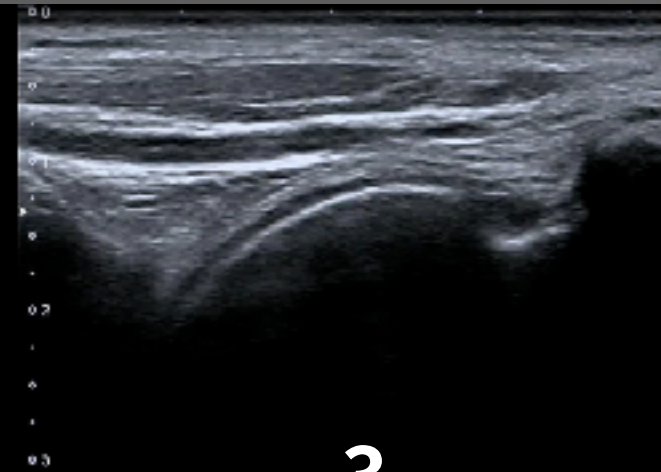
1

Hip



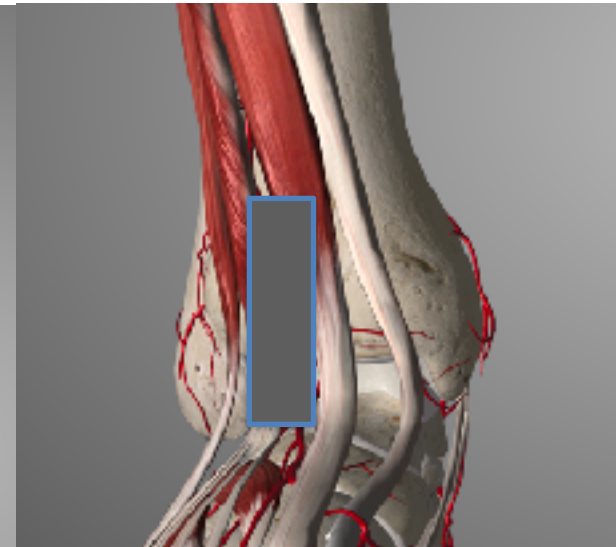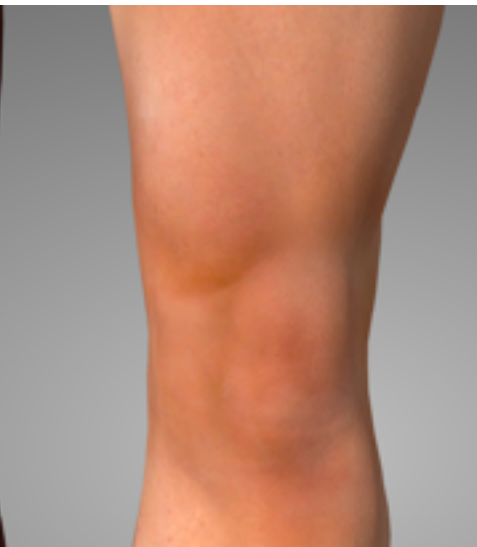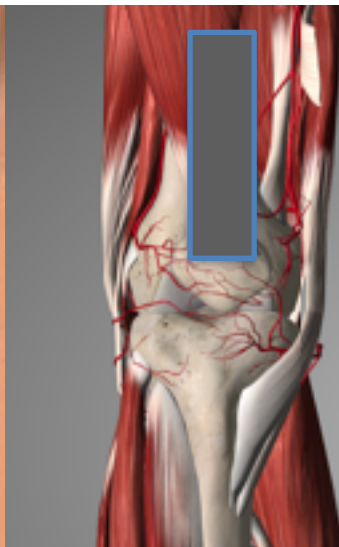
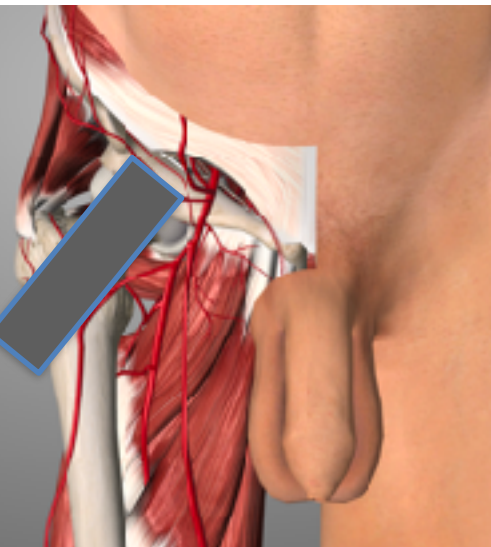
2

Knee

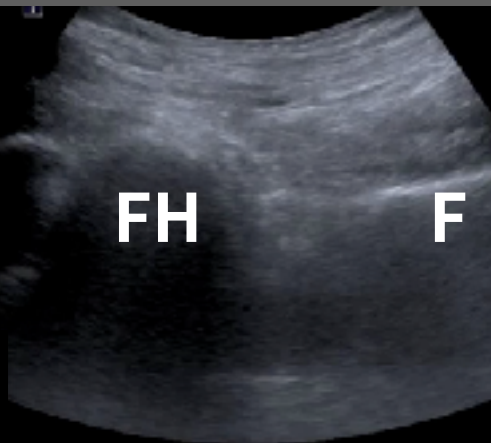


3

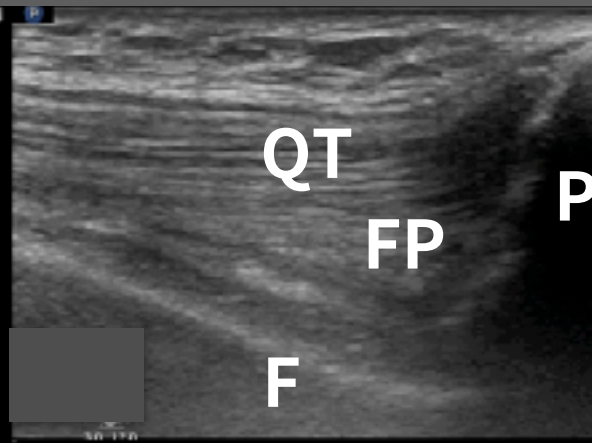
Ankle



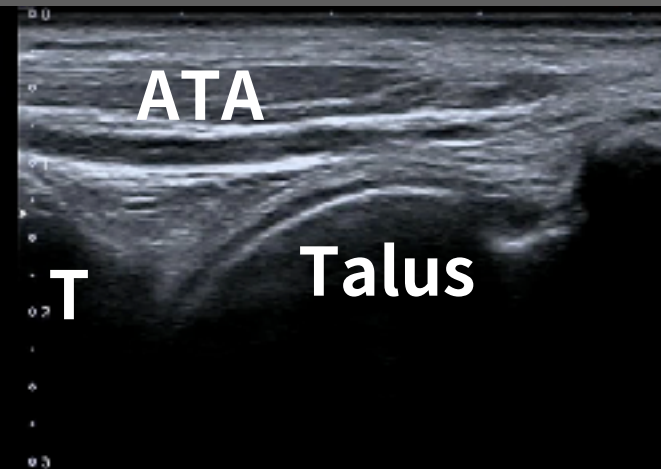
LE Joint effusion



Hip

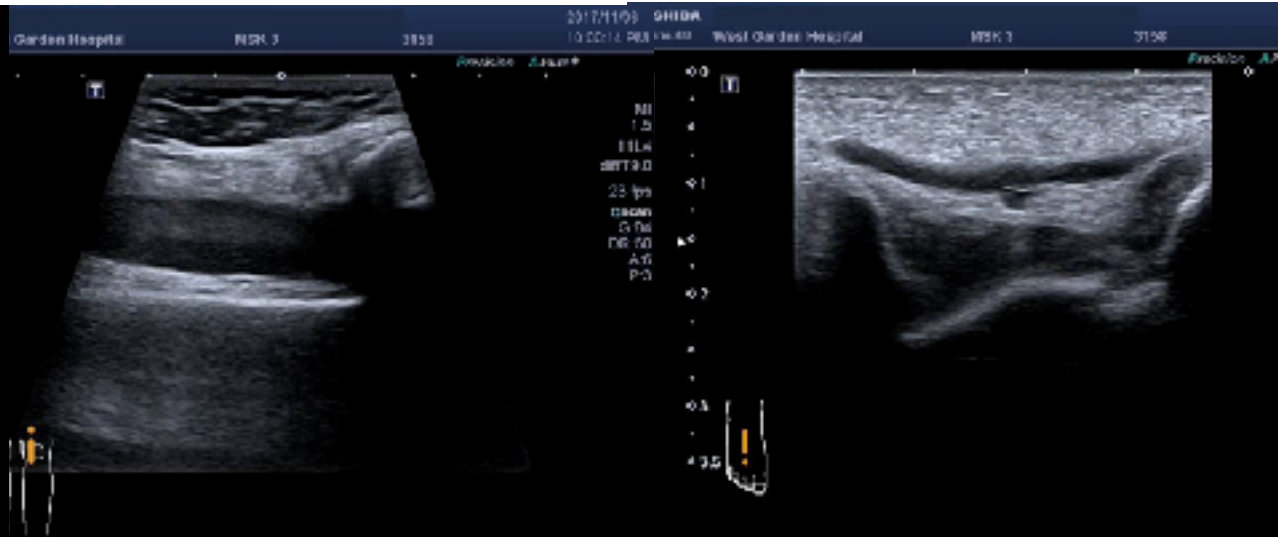
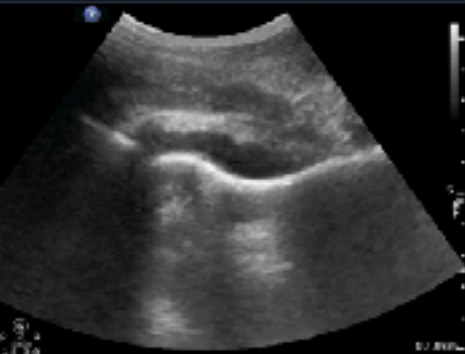

Knee

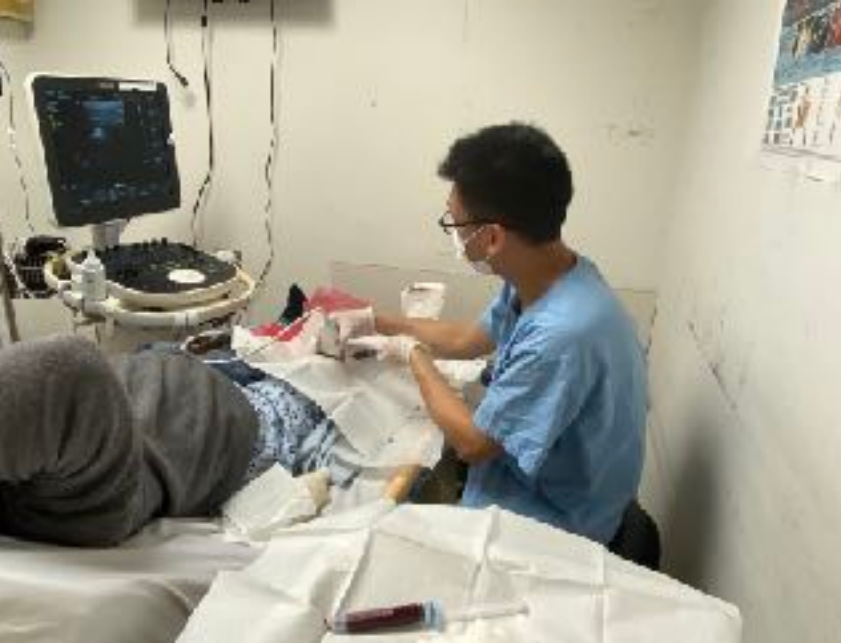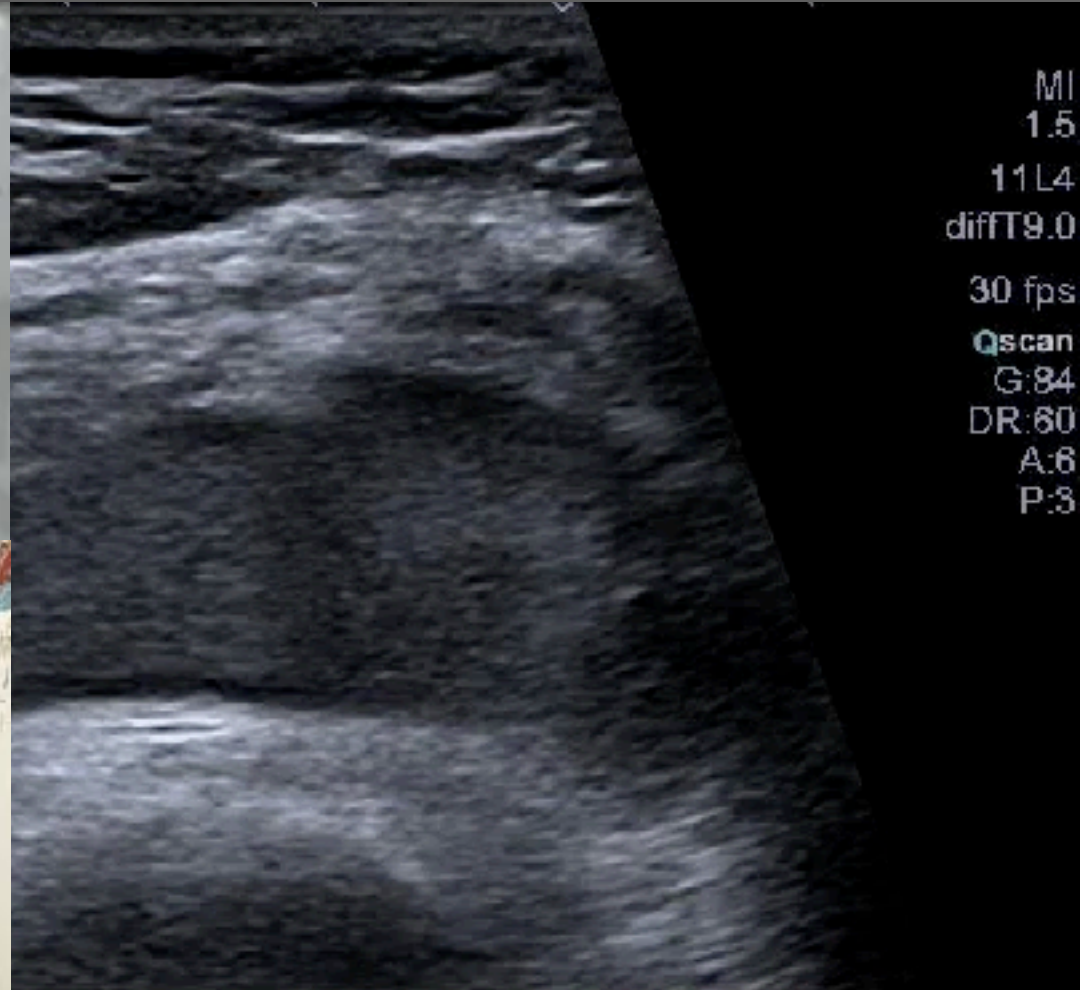


Ankle

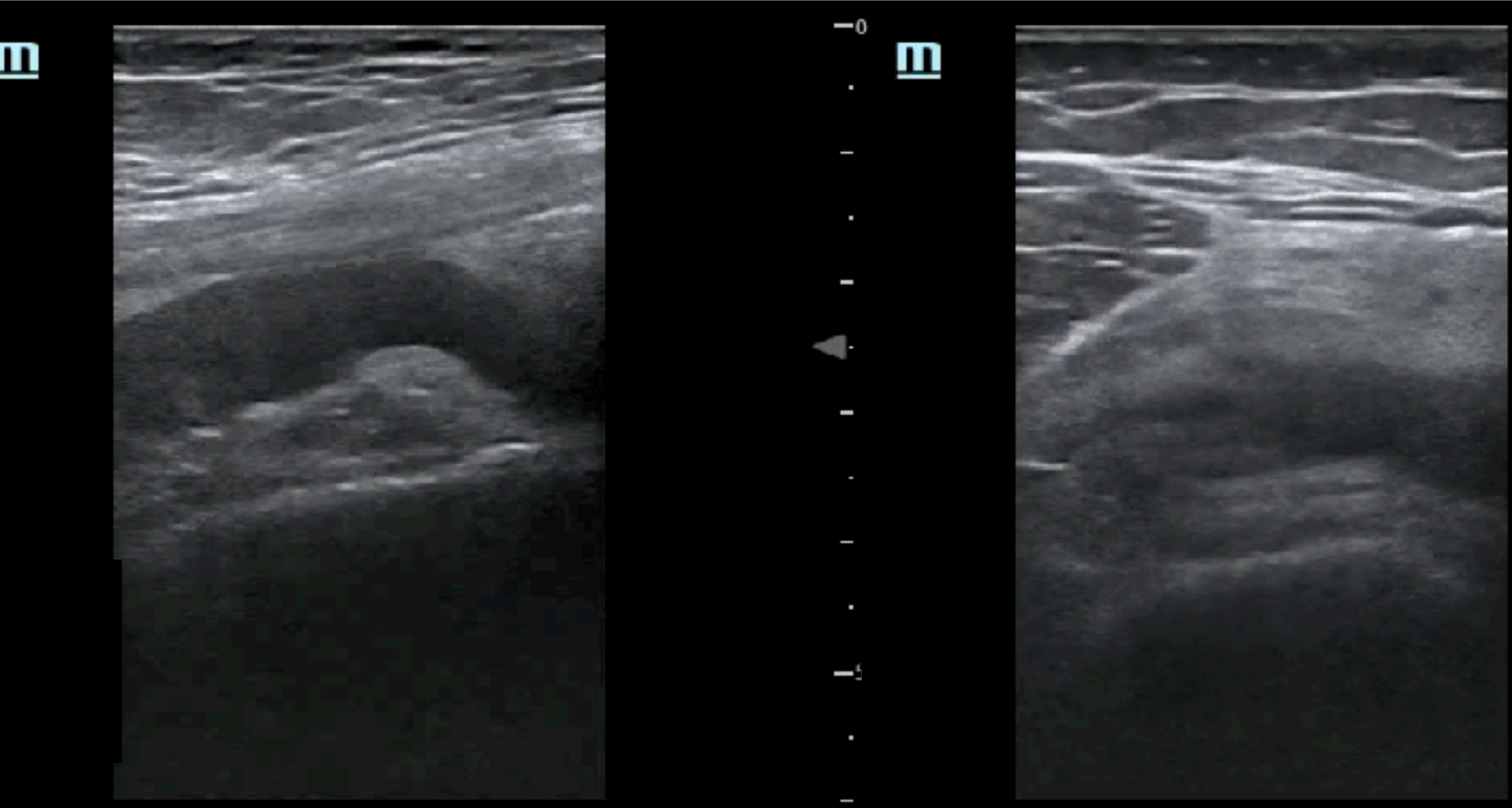
SKH-EUTC@ChenKC



Needling for hemarthrosis

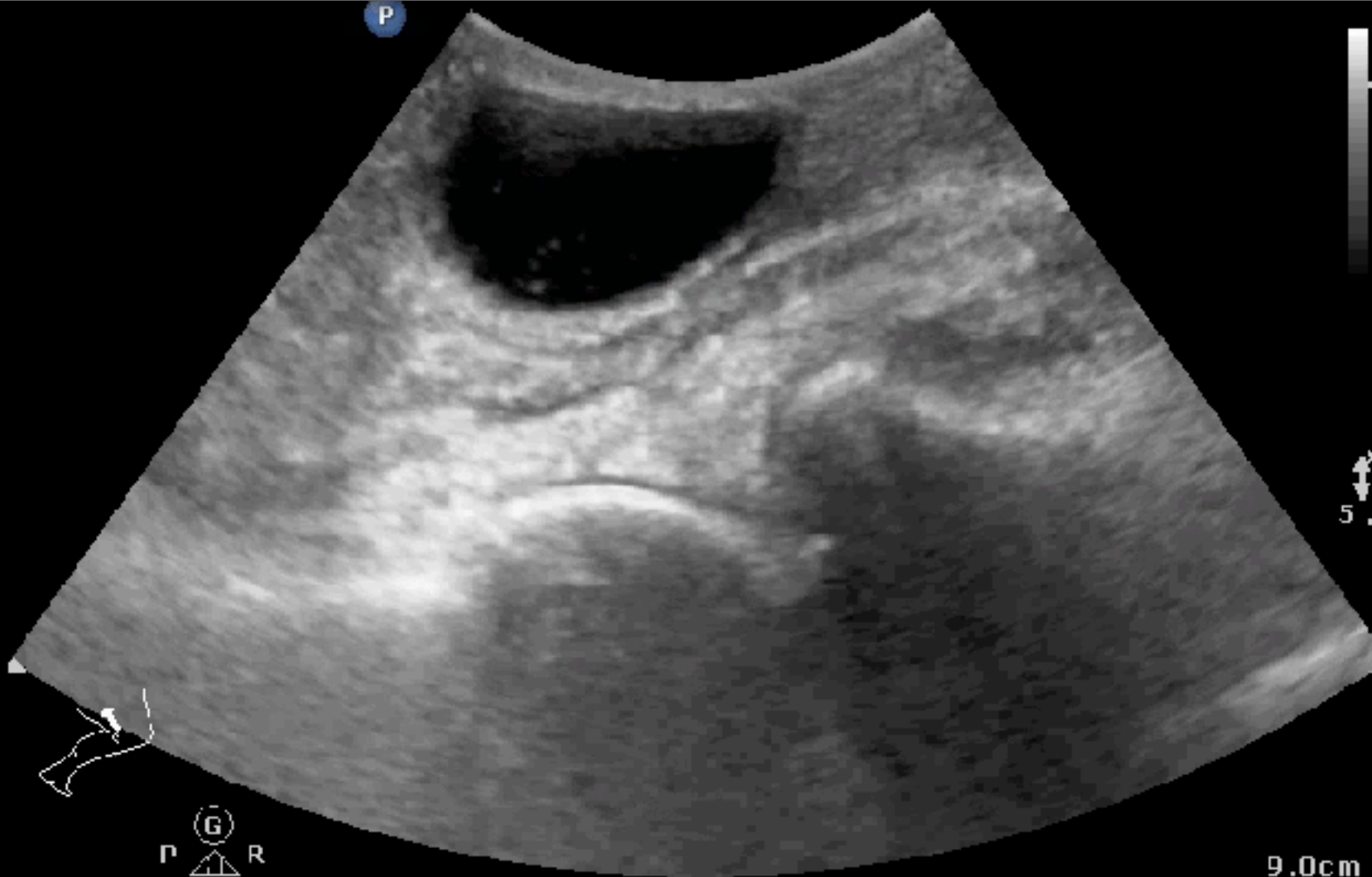

Lipohemarthrosis



Baker's cyst

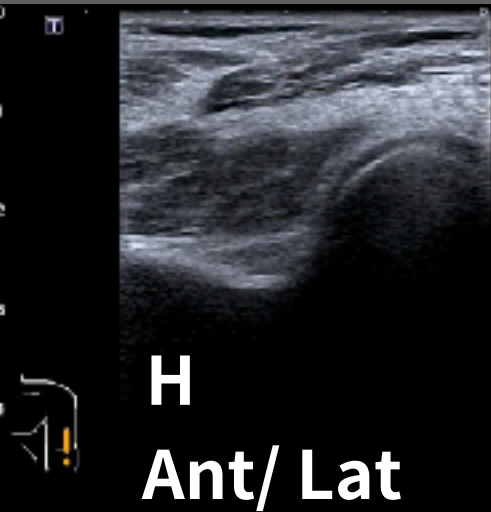
ADU Gen7
C5-1
47 Hz
9.0cm
2D
HGen
Gn 85
C 56
3 / 3 / 3



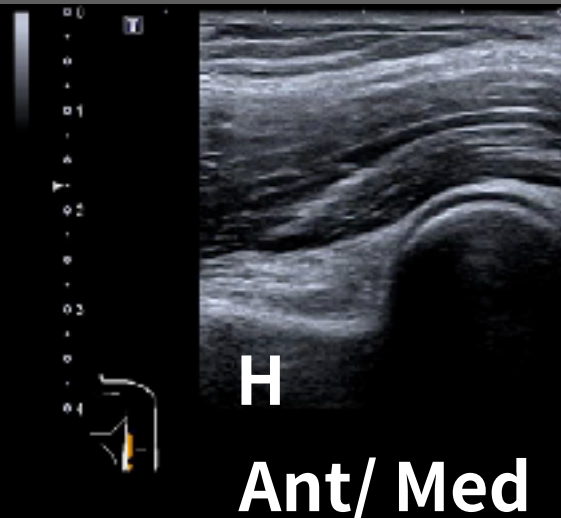
Ⓞ
P R
1.8 3.6

9.0cm

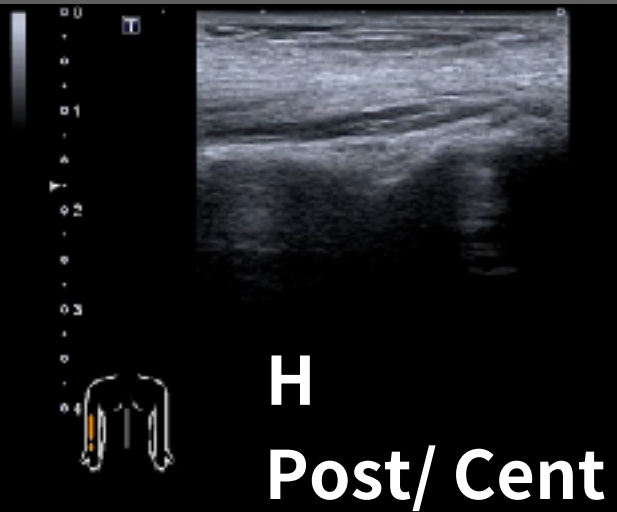
Elbow fossa



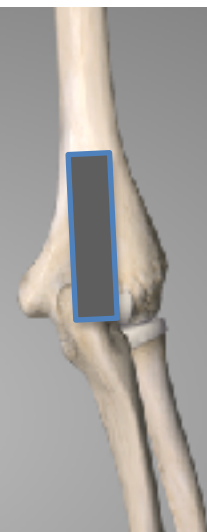
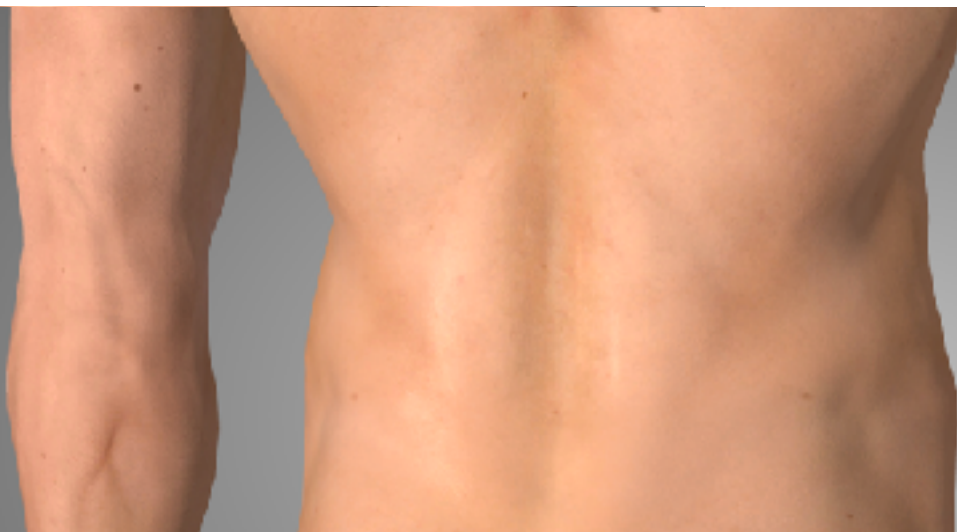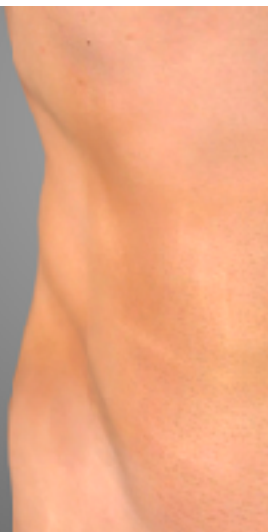Radial fossa



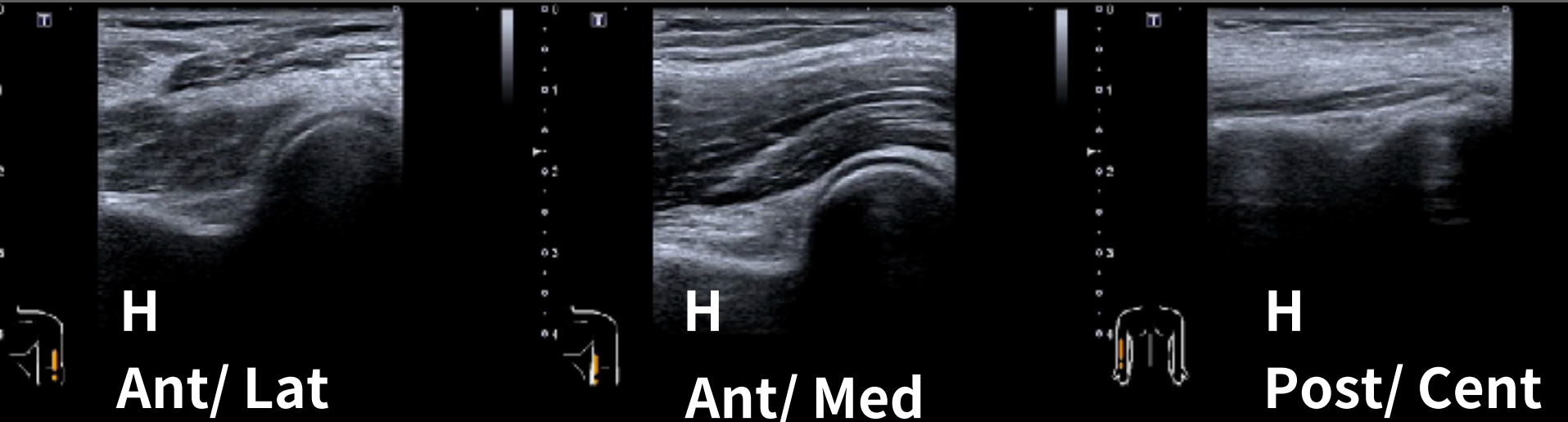
Coronoid fossa



Olecranon fossa



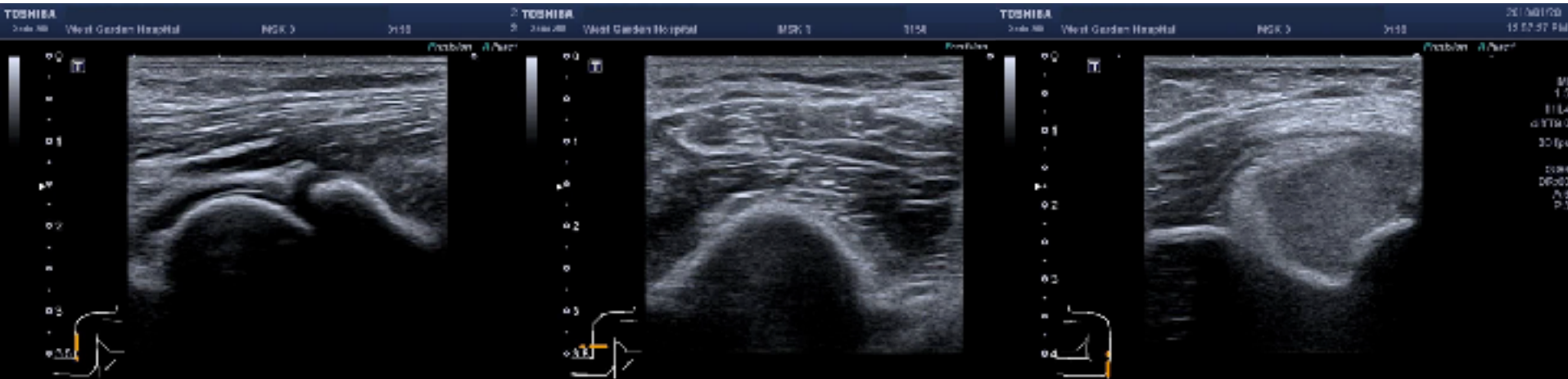Elbow effusion



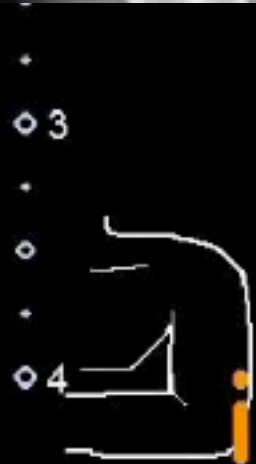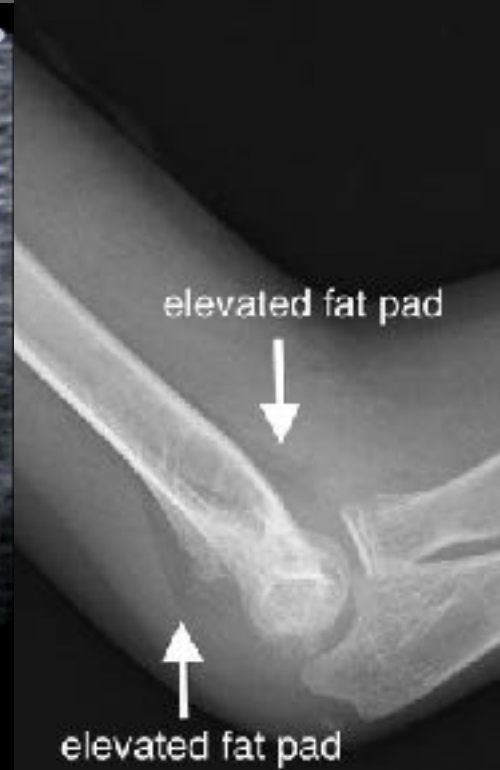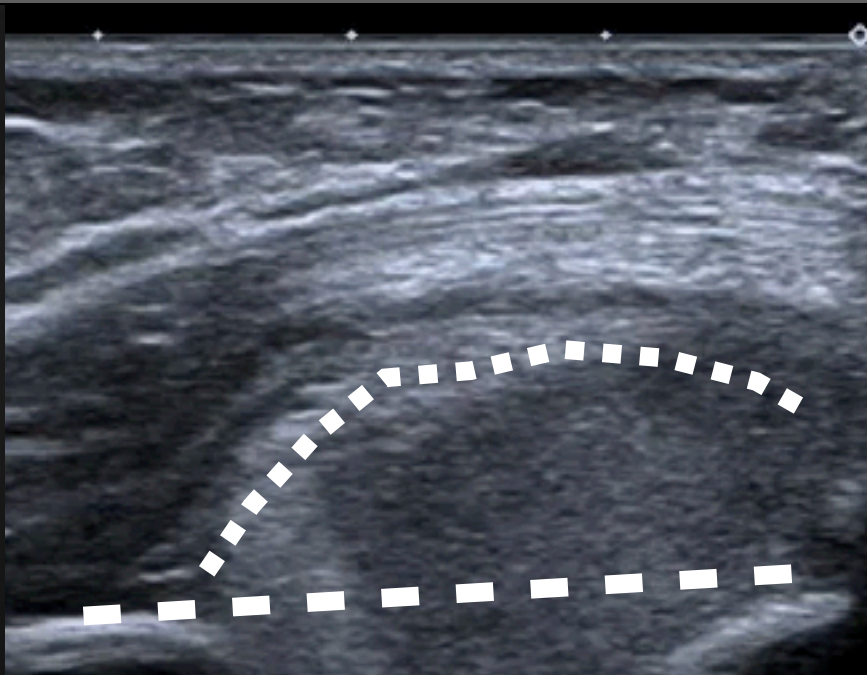
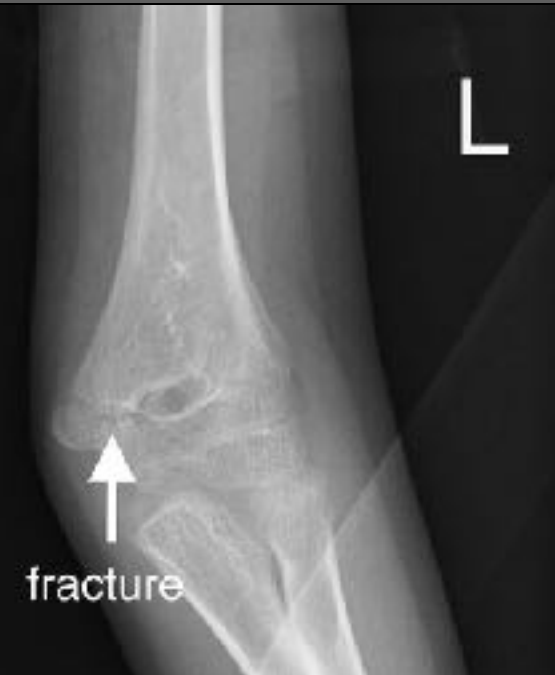Radial fossa

Coronoid fossa

Olecranon fossa

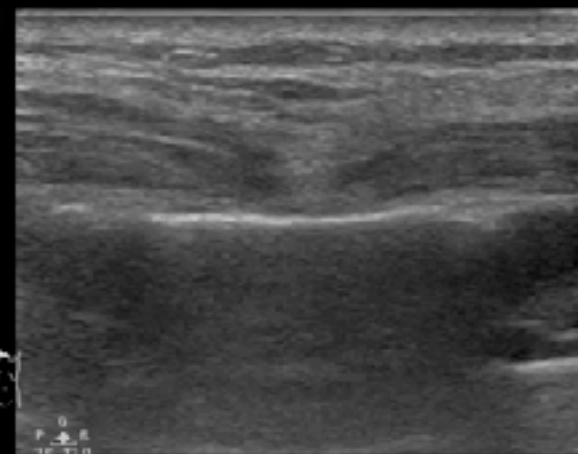
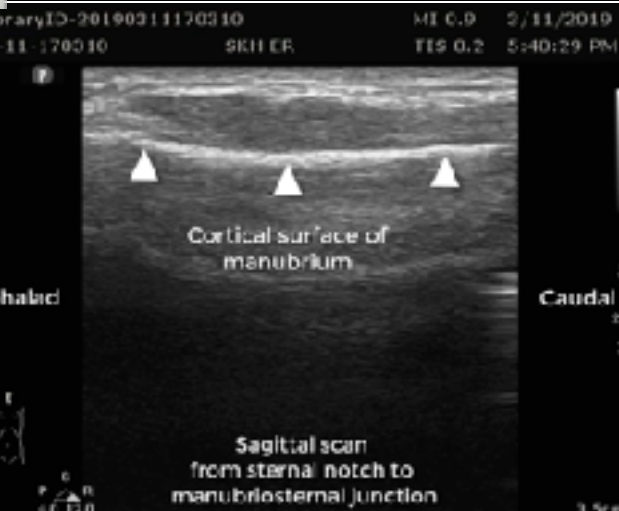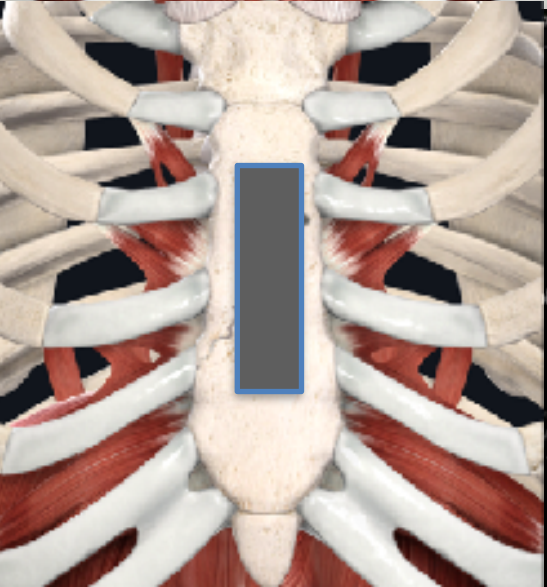
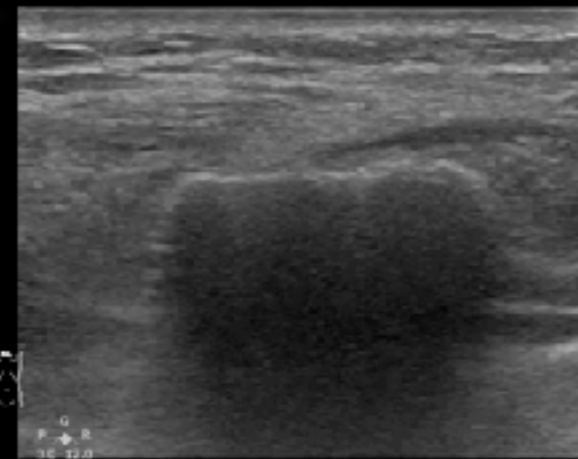
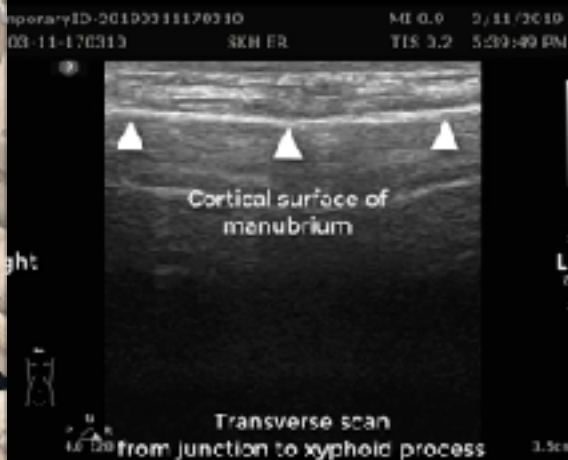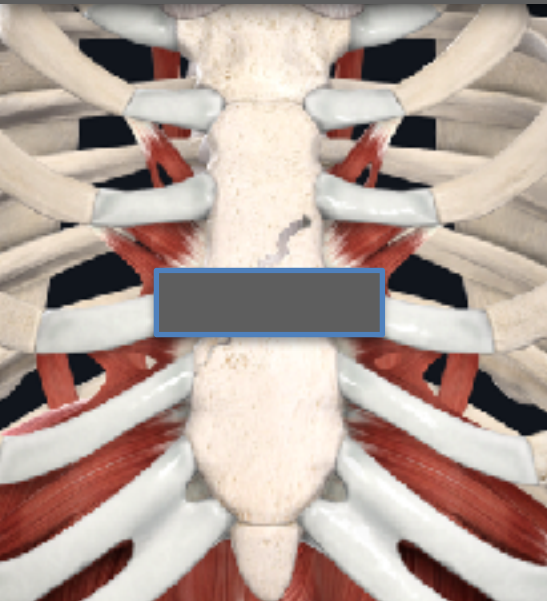


Elevated fat pad sign

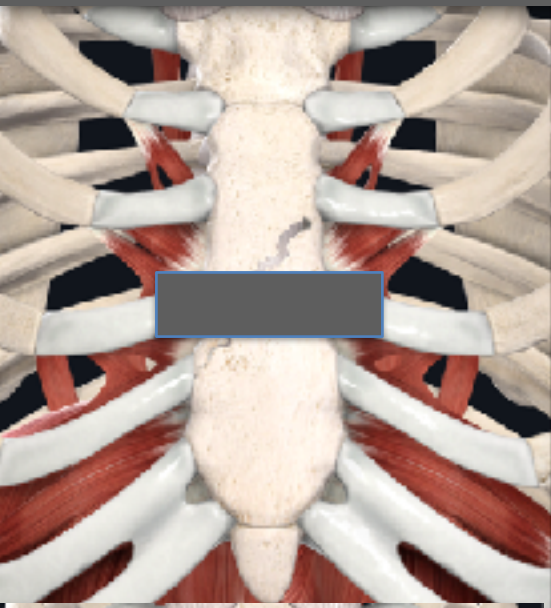

olecranon fossa

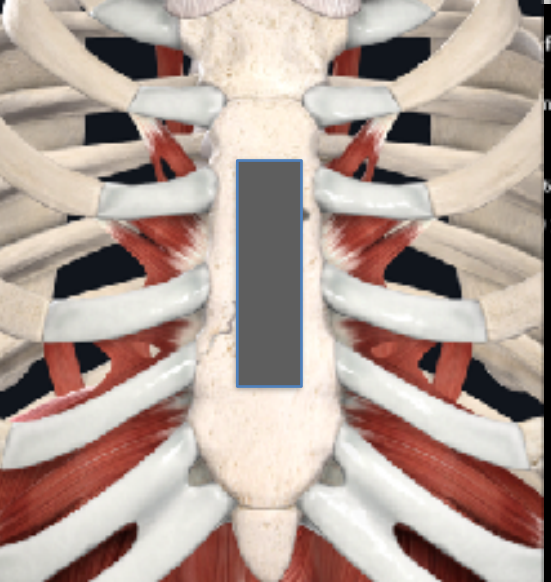
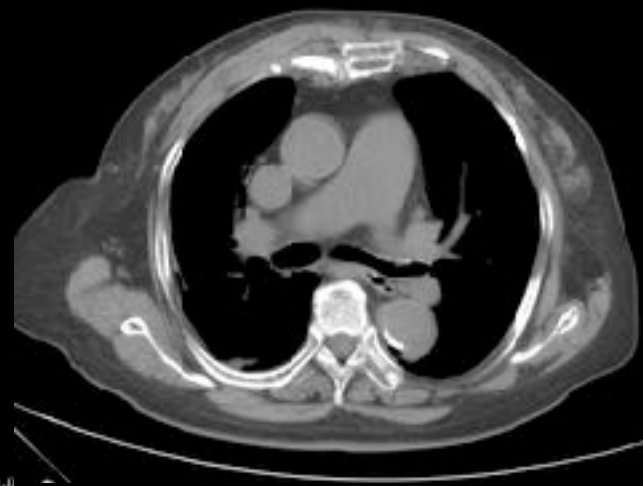
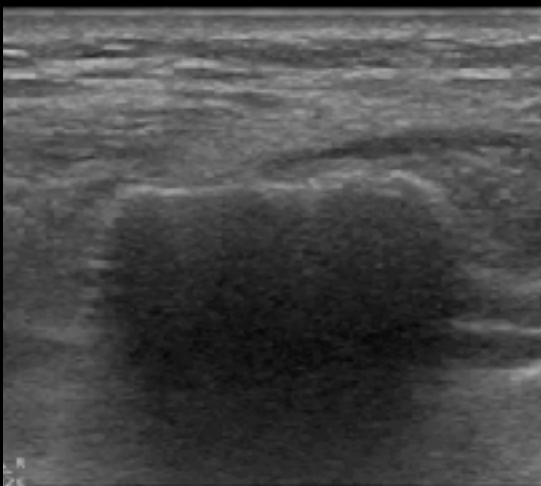
Sternal fracture



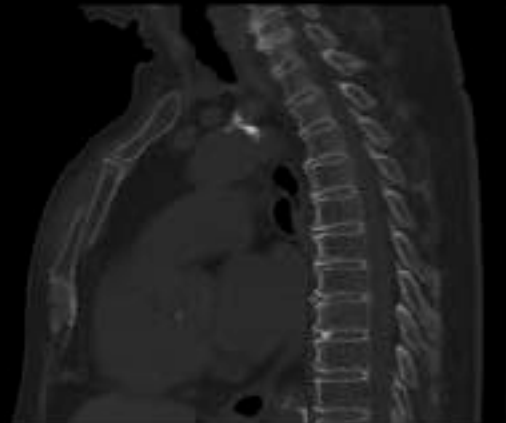
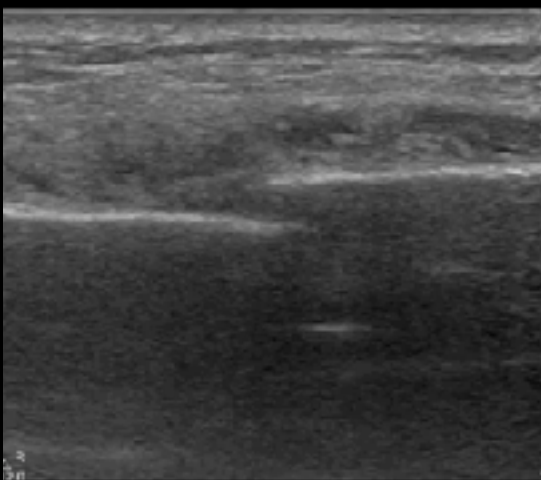
骨折判斷 - 適用長骨&平骨



高低落差

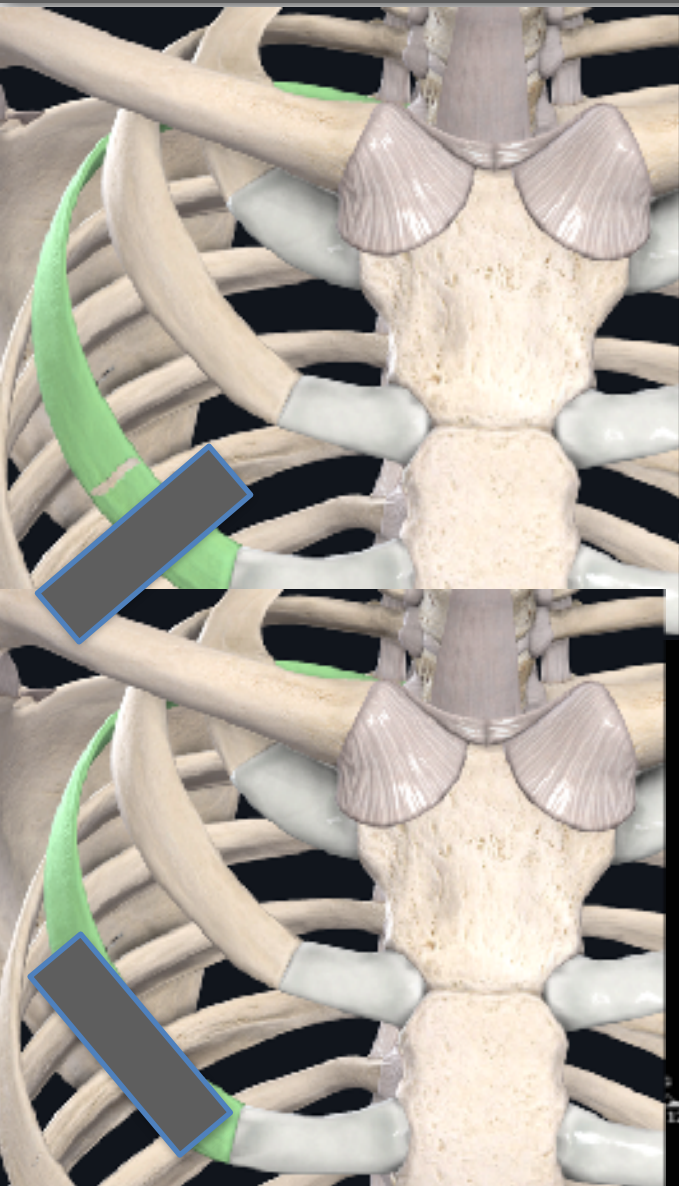


不連續

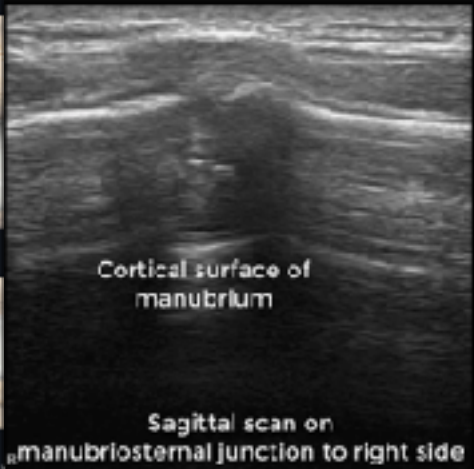

血腫

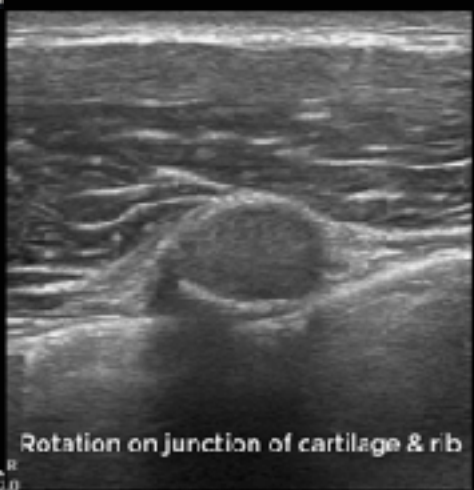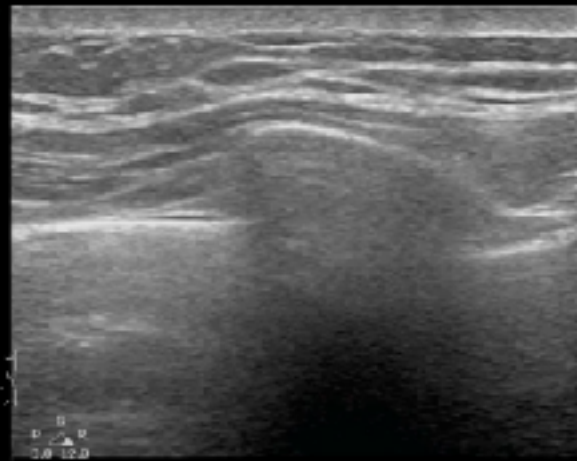
Rib fracture



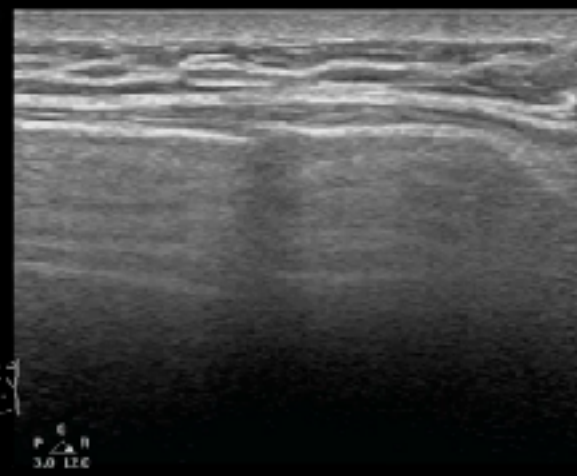
20190311170310 MI 0.9 3/11
SKH-ER TIS 0.2 5:40



Superficial
L12-3
46 Hz
3.0cm
2D
Res
Gn 96
C 56
3/2 / 1



Superficial
L12-3
46 Hz
3.0cm
2D
Res
Gn 96
C 56
3/2 / 1

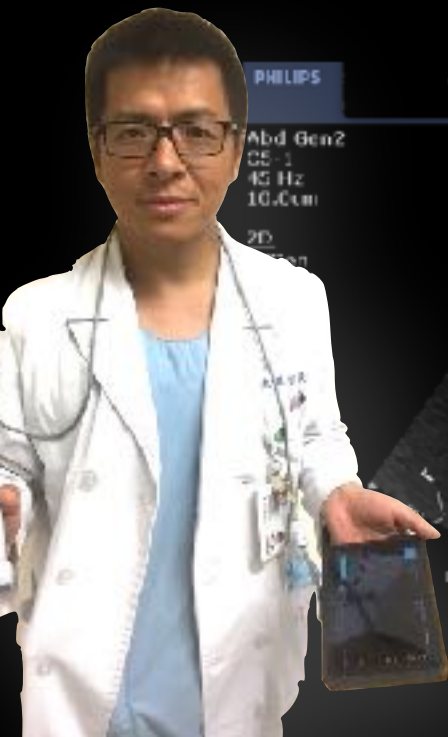


How to interpret ?

Consult

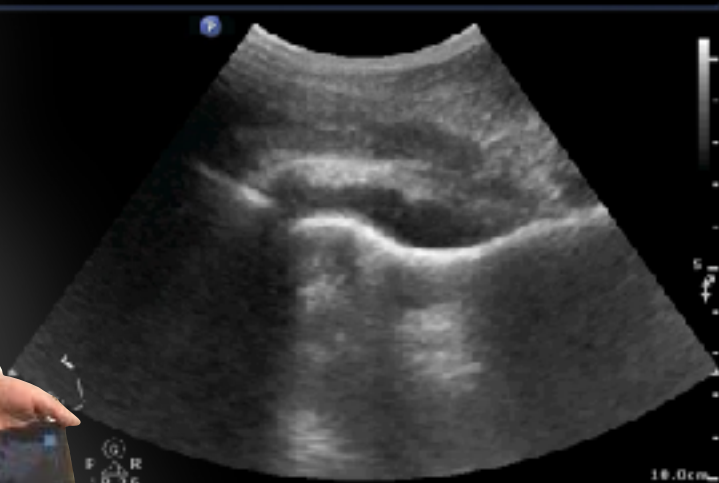Capture

Compare



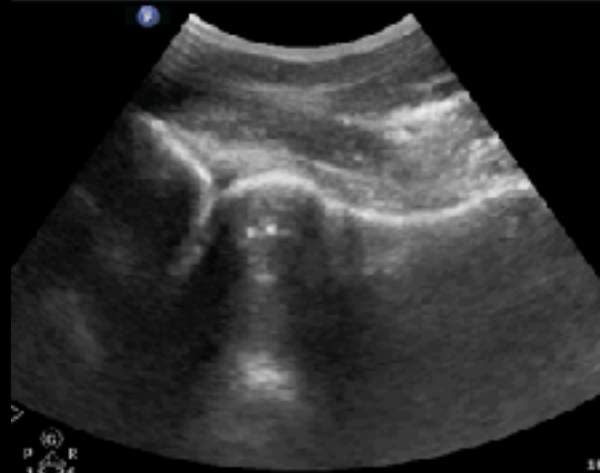SKH-EUTC©ChenKC

PHILIPS
Abd Gen2
C5-1
45 Hz
10.0cm
2D
12.07



left hip

SKH-EUTC©ChenKC

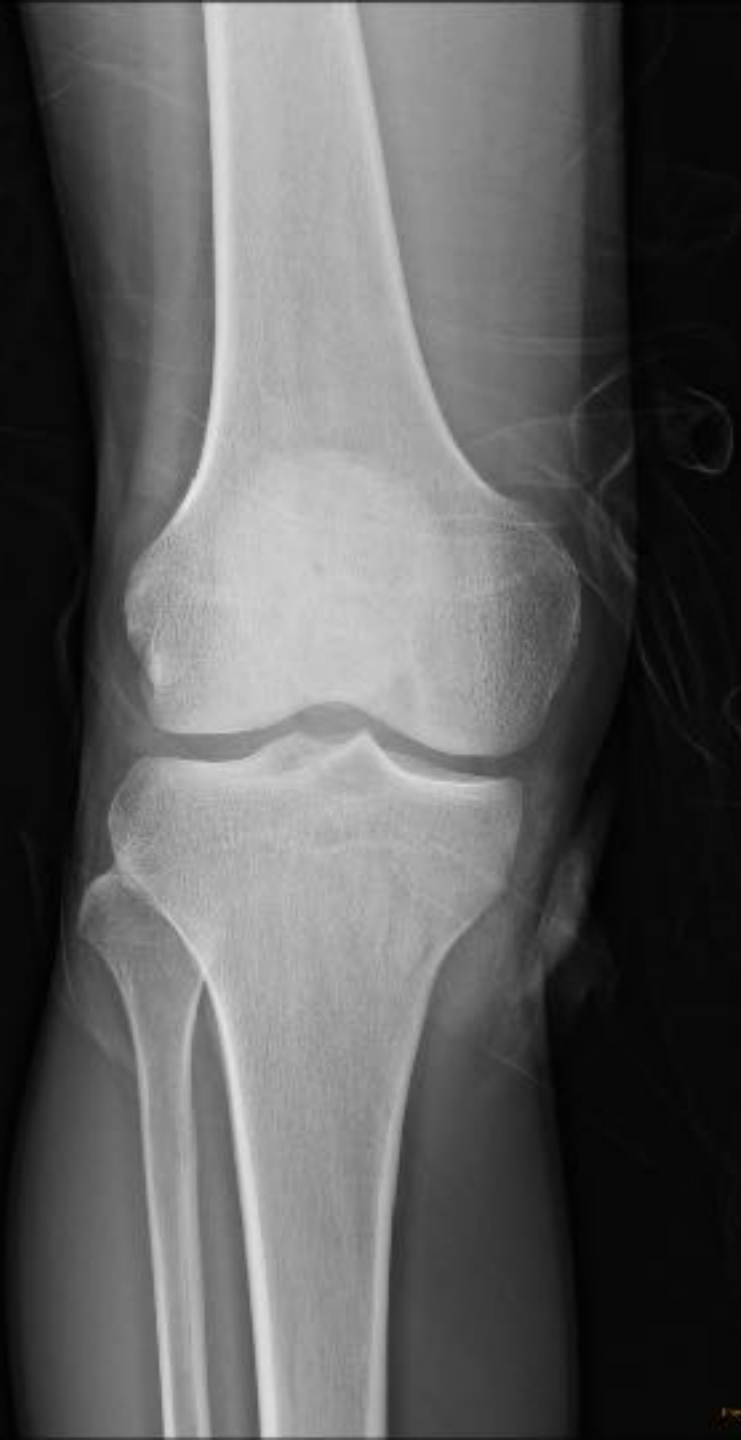

right hip

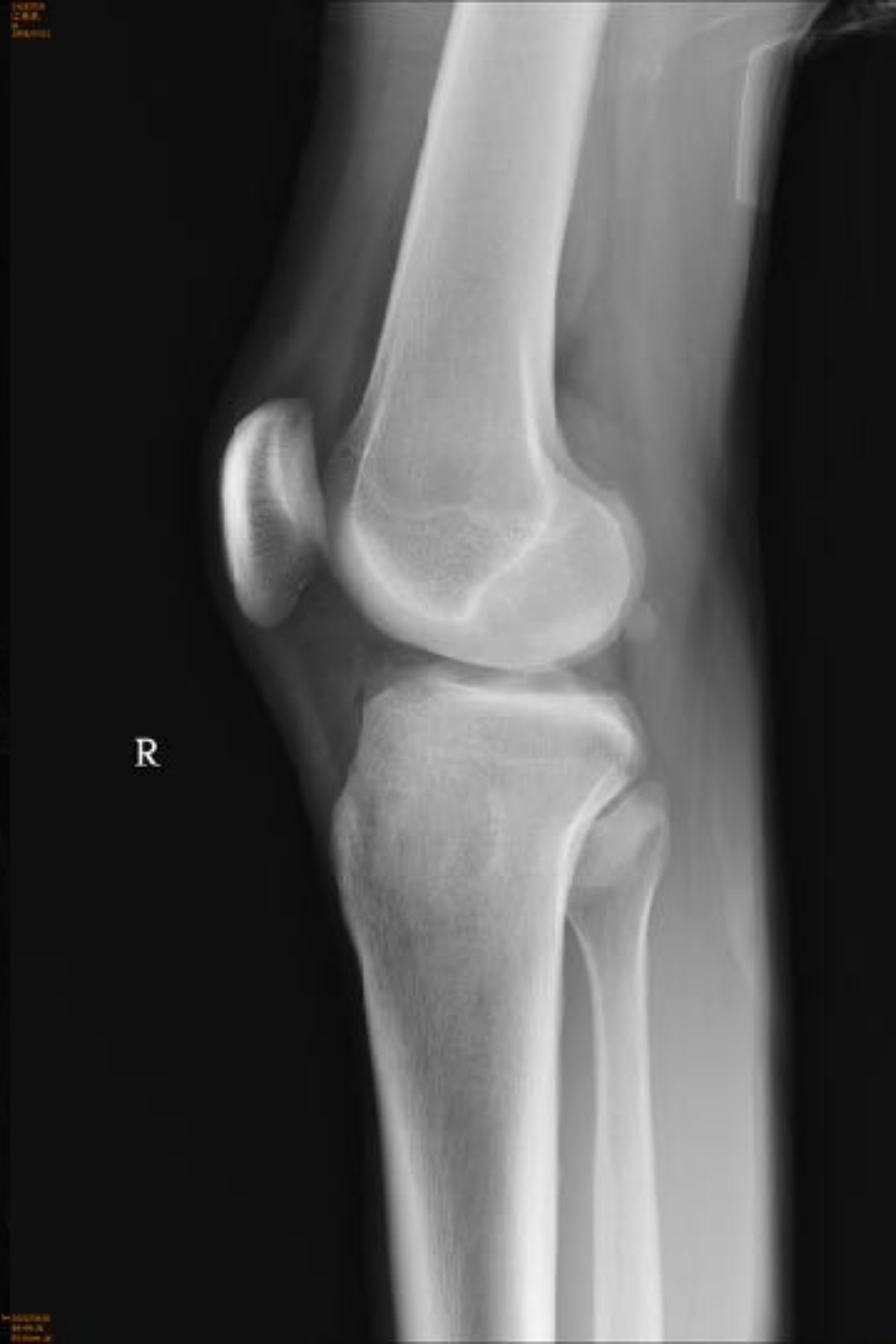Sono-Anatomy Sono-Pattern Sono-Diagnosis

看不懂時就橫縱都錄一段影片事後看或問專家

R



R





14287530

2022Mar30 08:43

Res MB

Msk

HFL



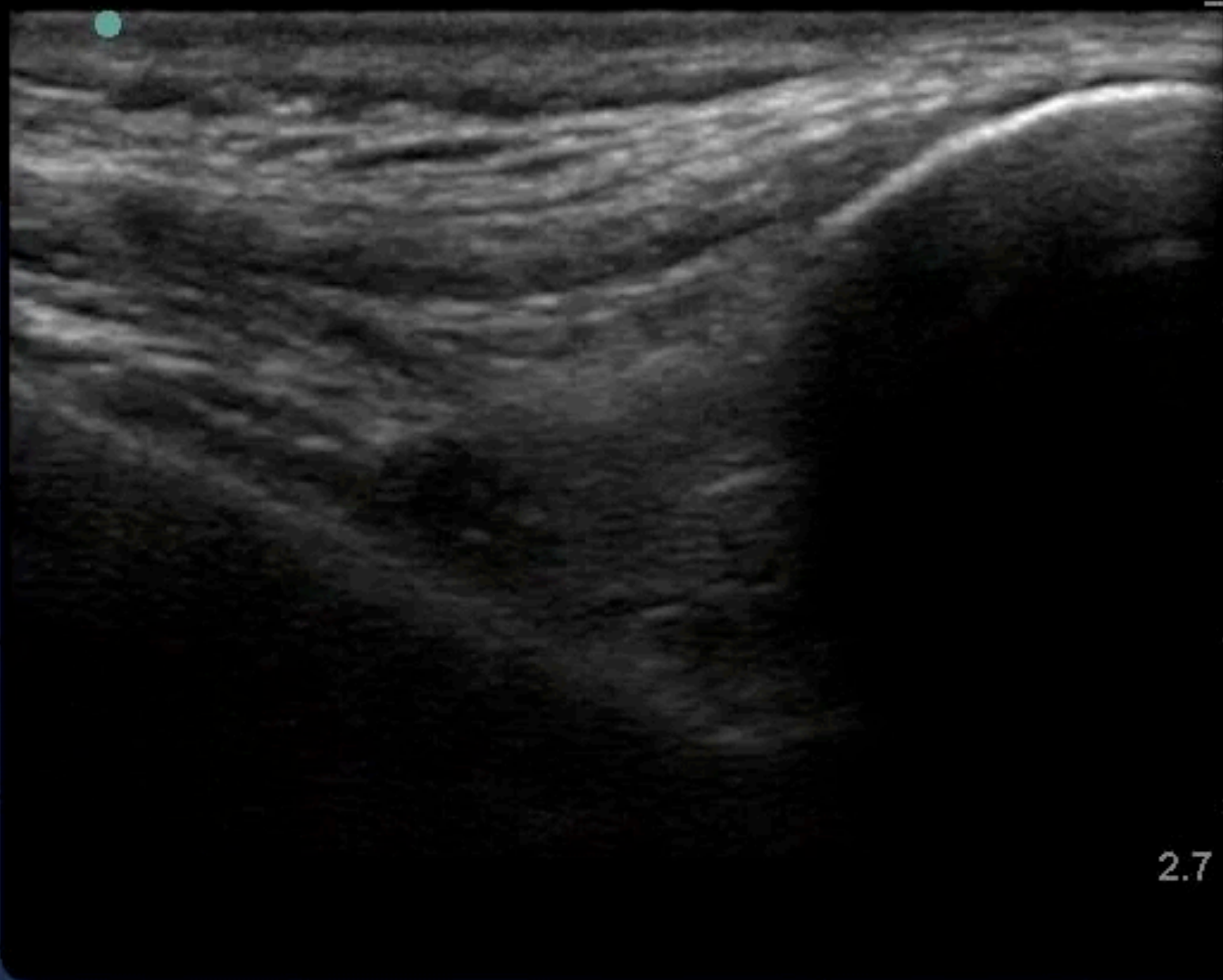
57%

MI

0.7


TIS

0.1




2.7

 Patient

 Auto Gain


 Res


 Clip

 Page 1/3

 Gain

 Depth

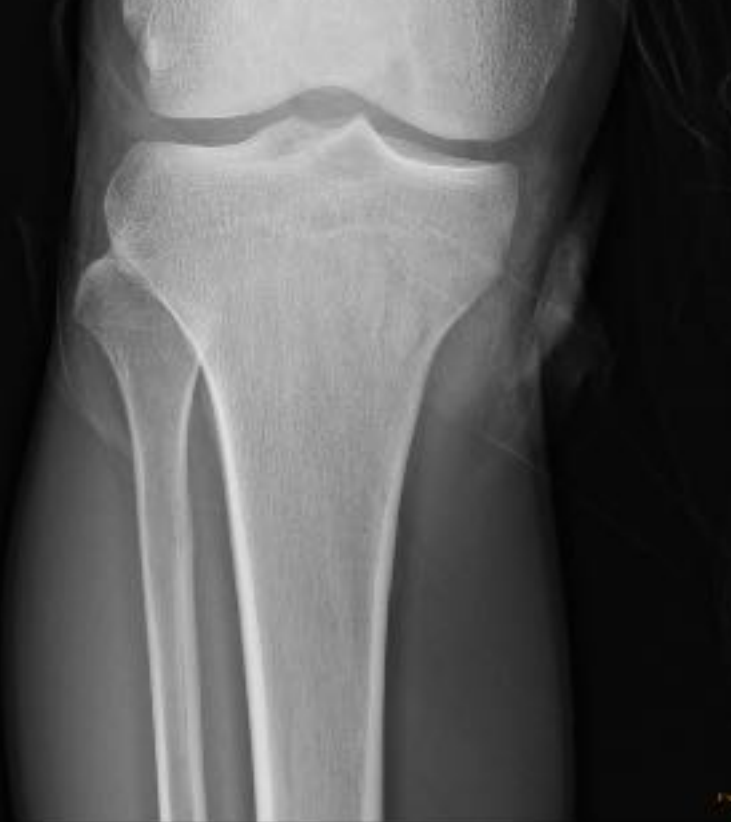 Freeze

 Save

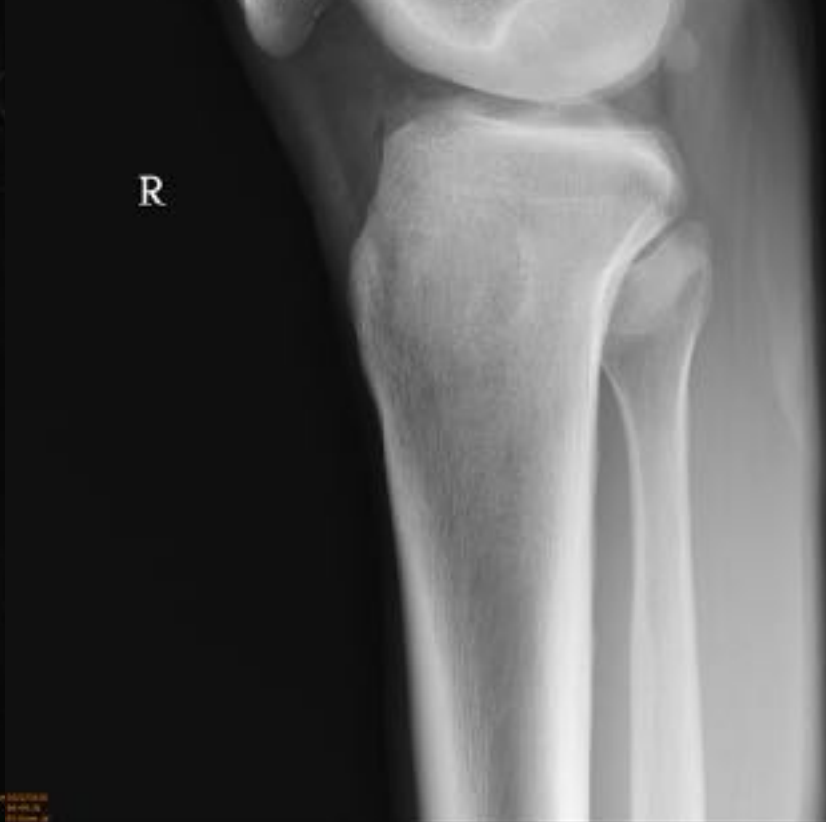Options 

Mode 

R



R



12/08/11
14:34
0.0000

12/08/11
14:34
0.0000



Patient



Auto Gain



57%

MI

0.7

TIS

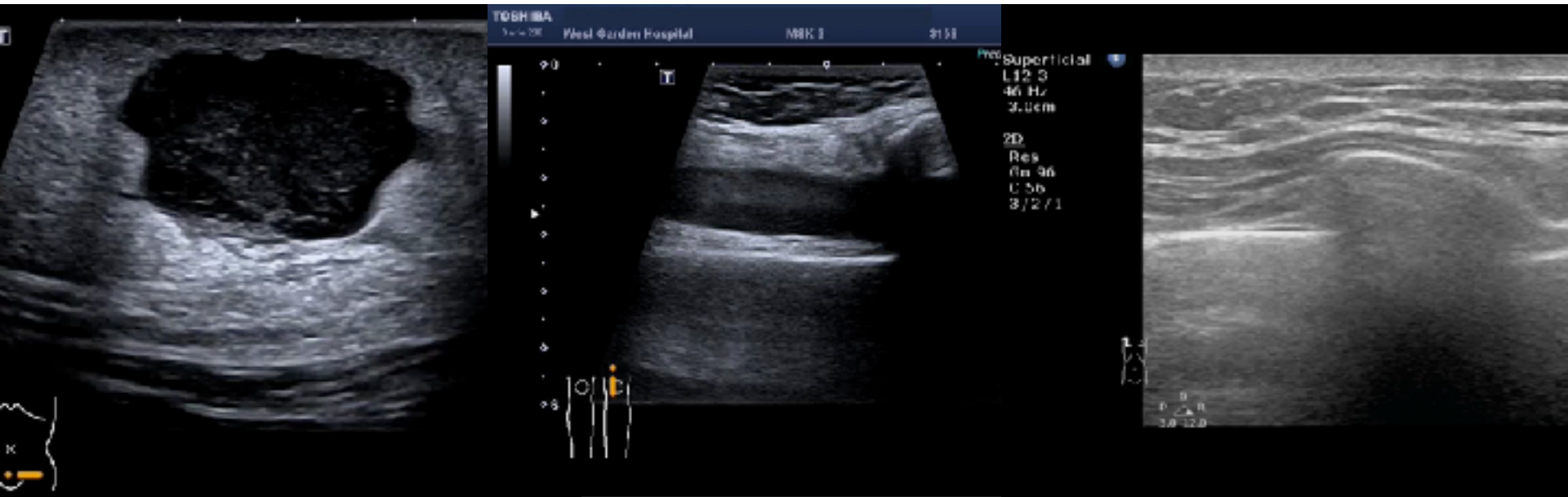
0.1

Essential ER MSK POCUS

Soft tissue

Joint

Bone



Abscess

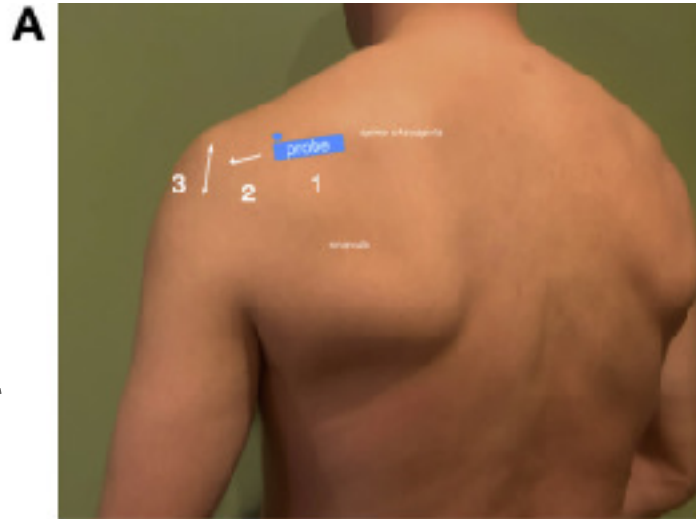
Effusion

Occult

Musculoskeletal Ultrasonography to Diagnose Dislocated Shoulders: A Prospective Cohort

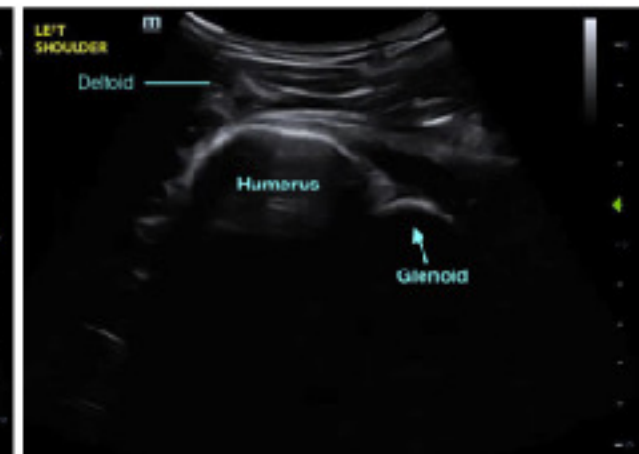
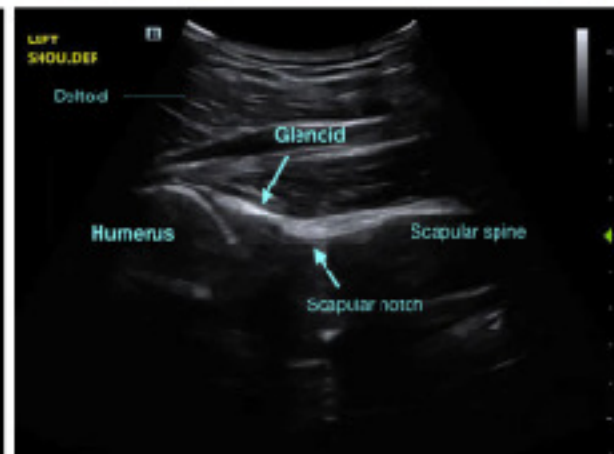
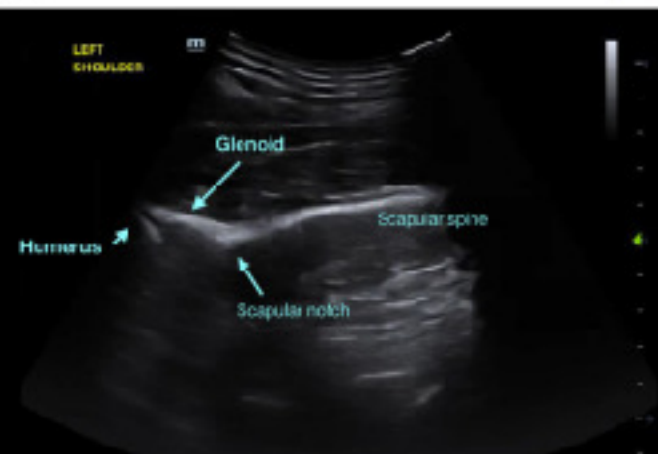Michael A. Secko, MD, RDMS*; Lindsay Reardon, MD; Michael Gottlieb, MD; Eric J. Morley, MD; Mathew R. Lohse, MD
Henry C. Thode, Jr, PhD; Adam J. Singer, MD

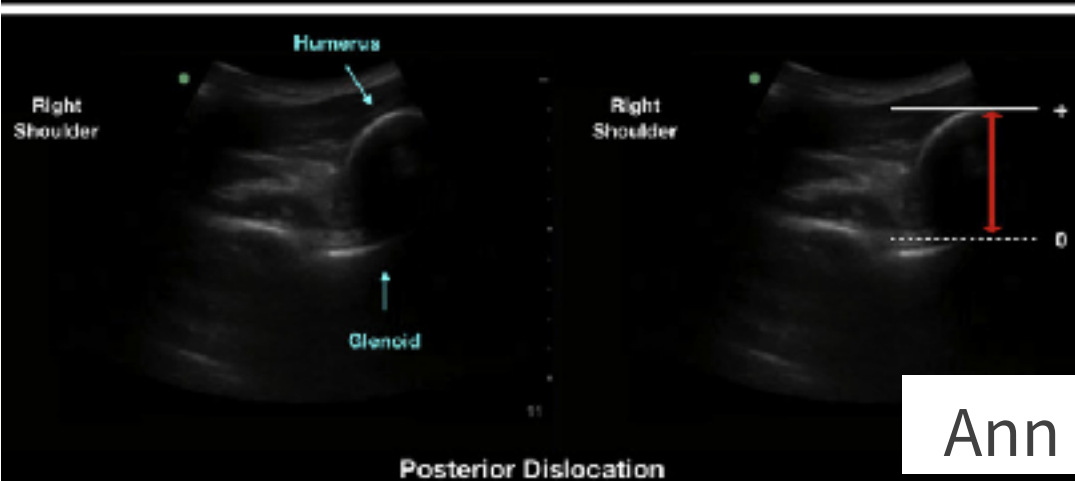
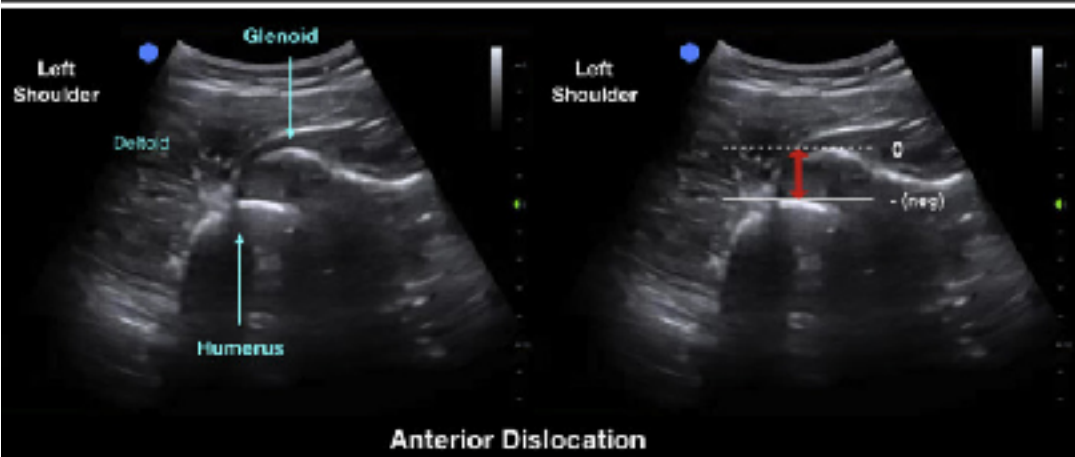
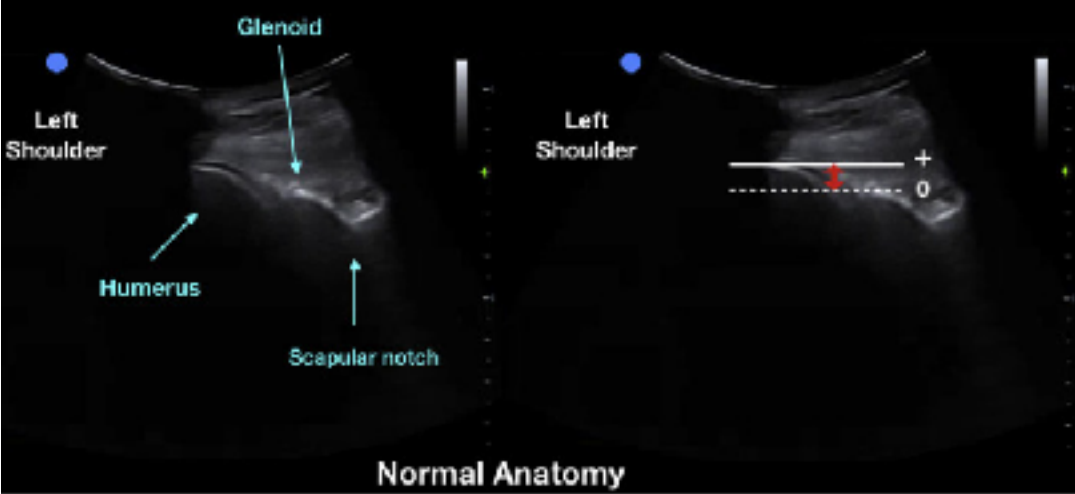
Multicenter
Prospective
Observational



65 patients

B





Sensitivity 100%
 Specificity 100%

Sens (Fx) 92%
 Spes (Fx) 100%

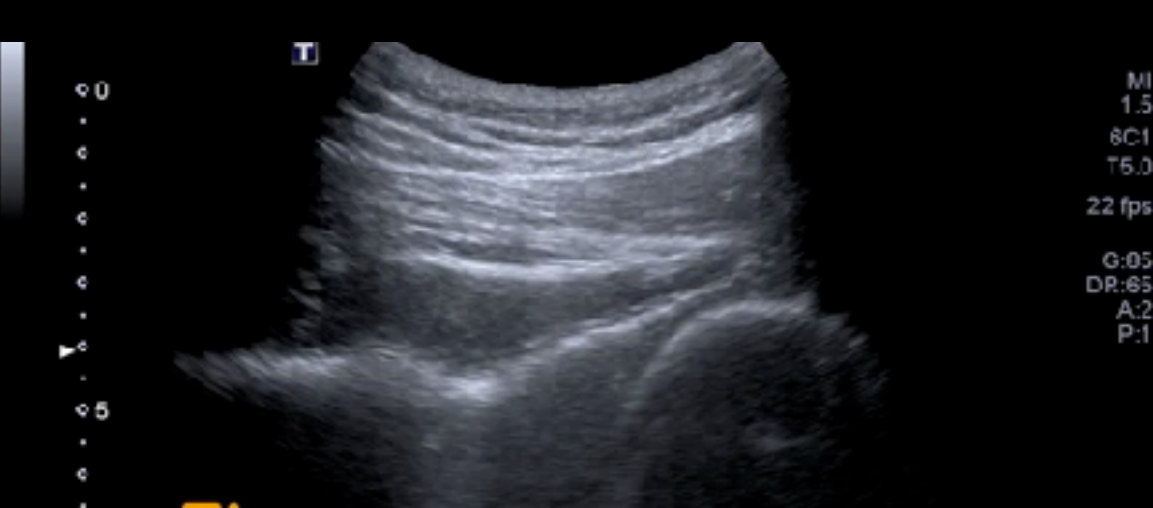
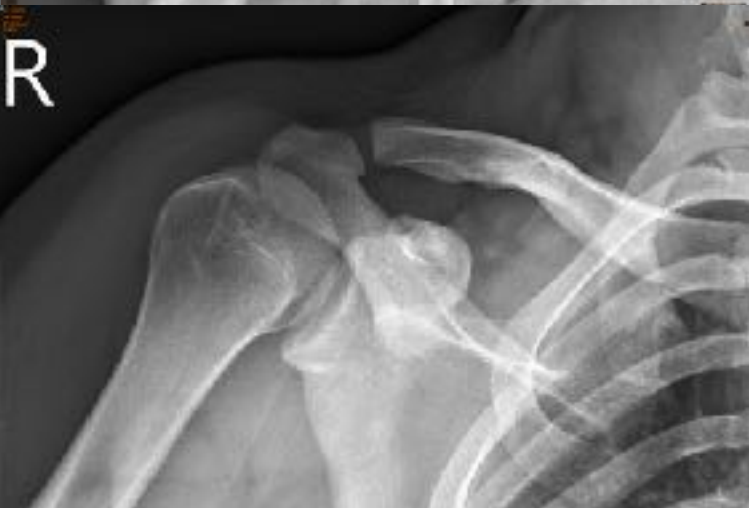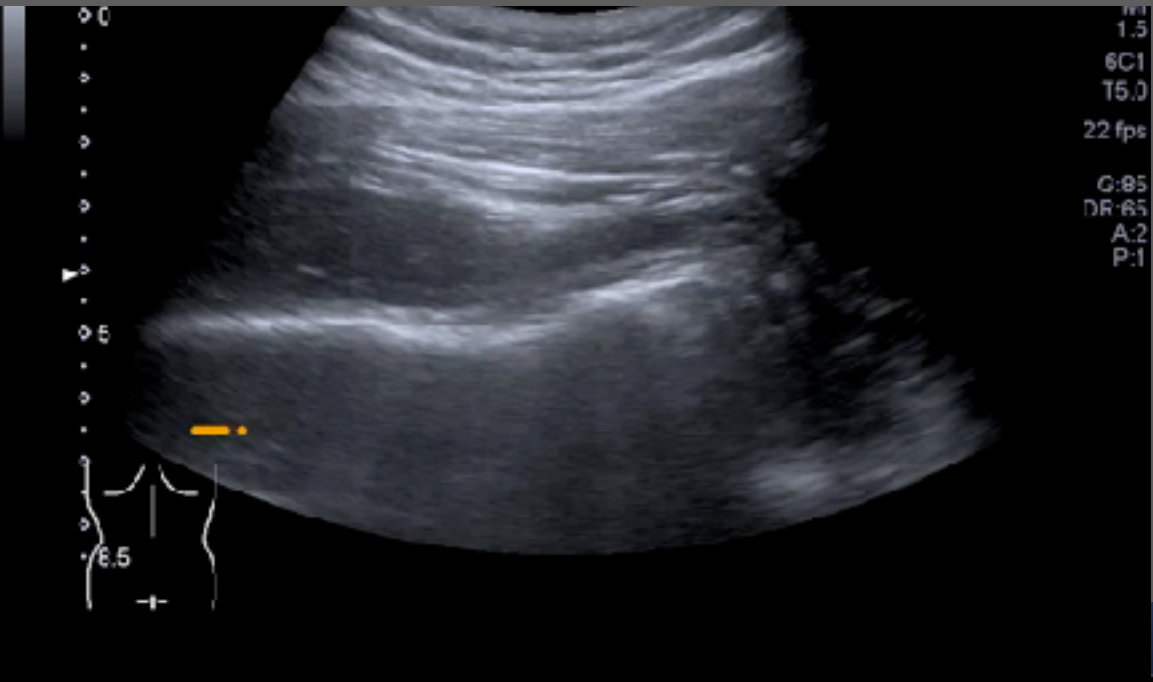
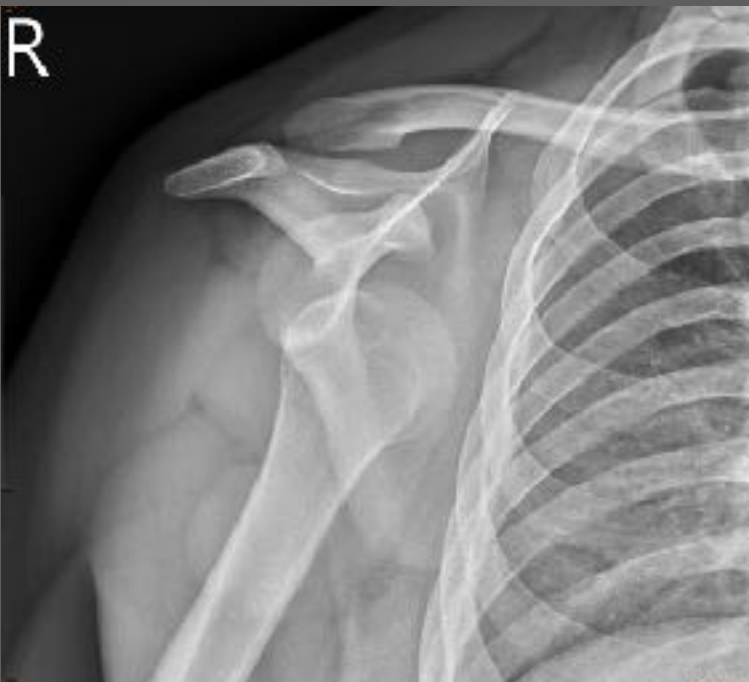Median 19s

GH(d-A) -1.83cm

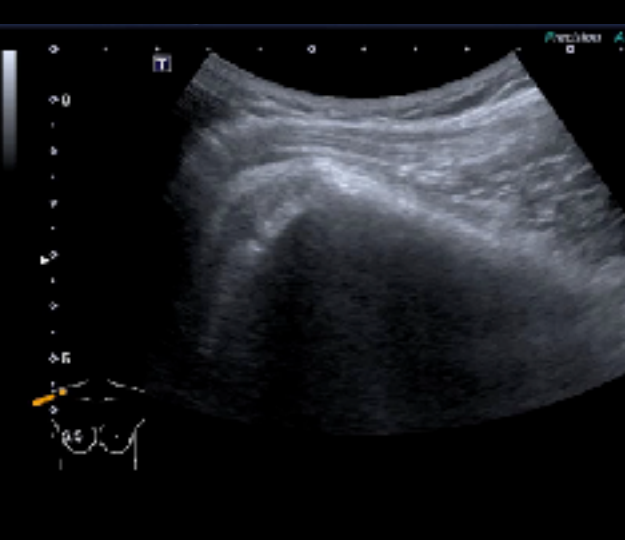
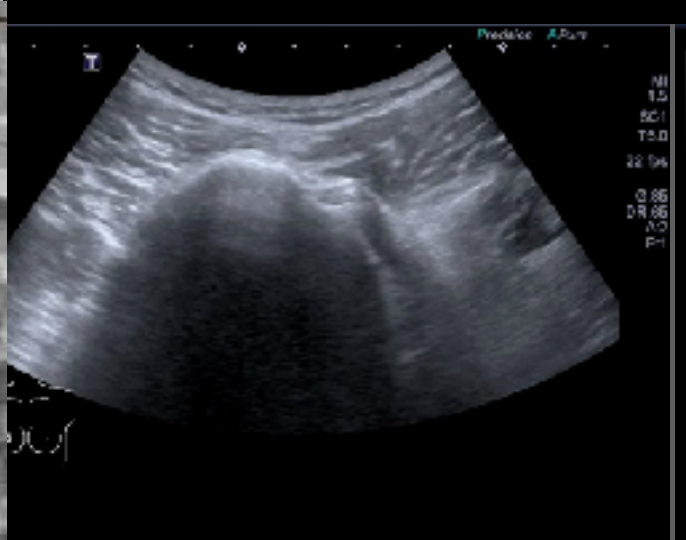
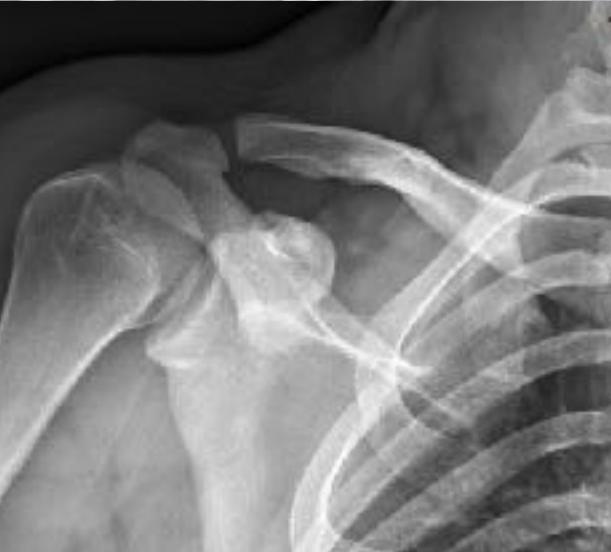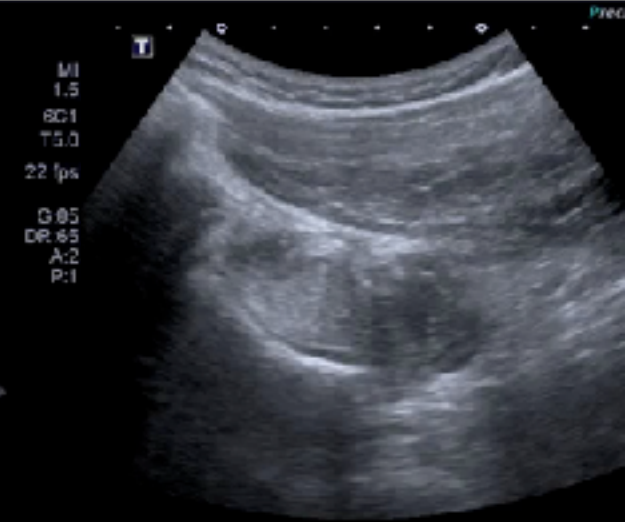
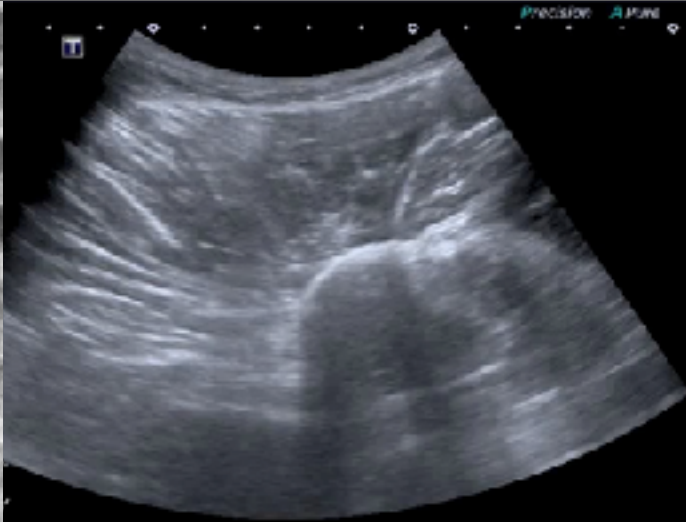
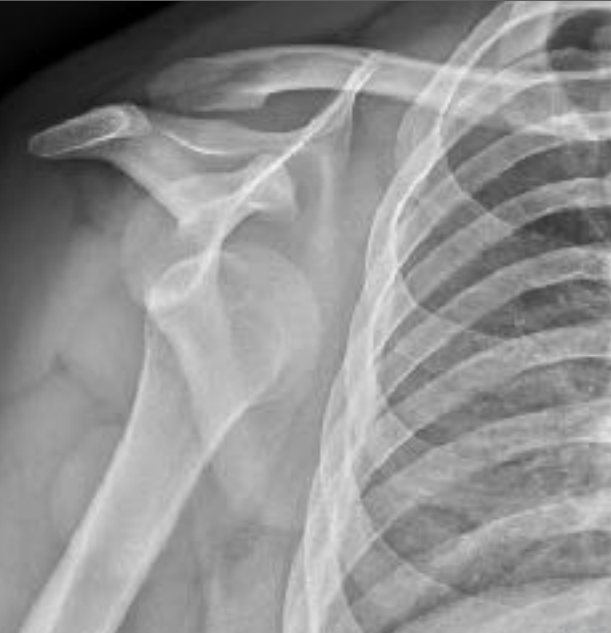GH(d-N) 0.22cm

GH(d-P) 3.3cm

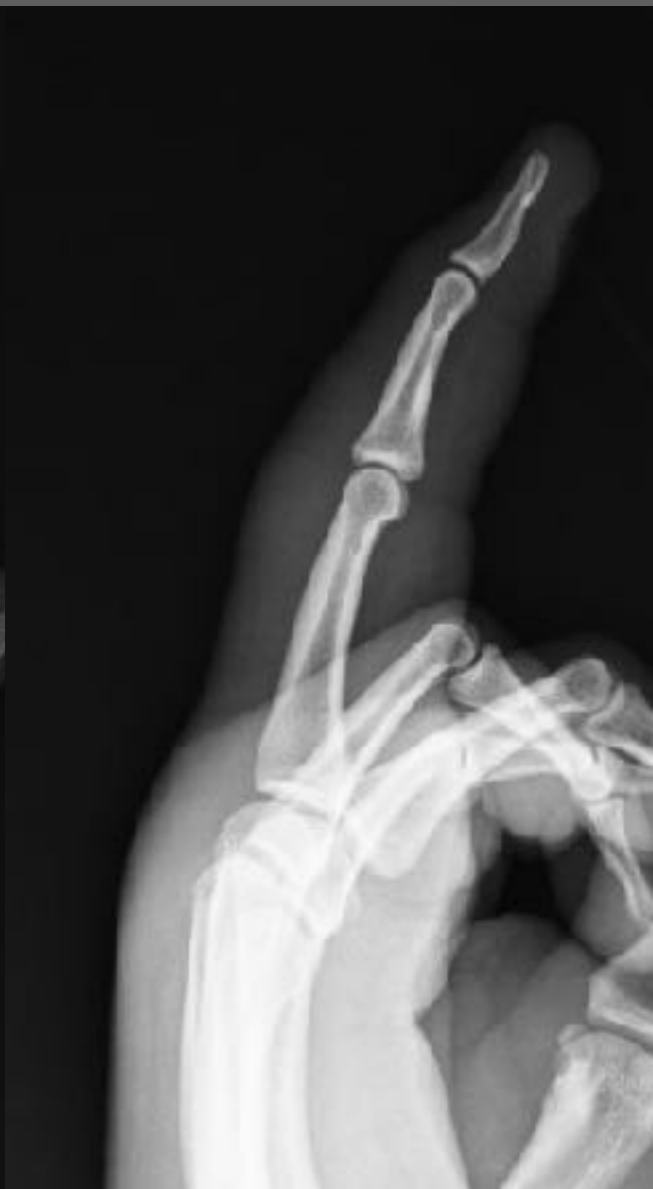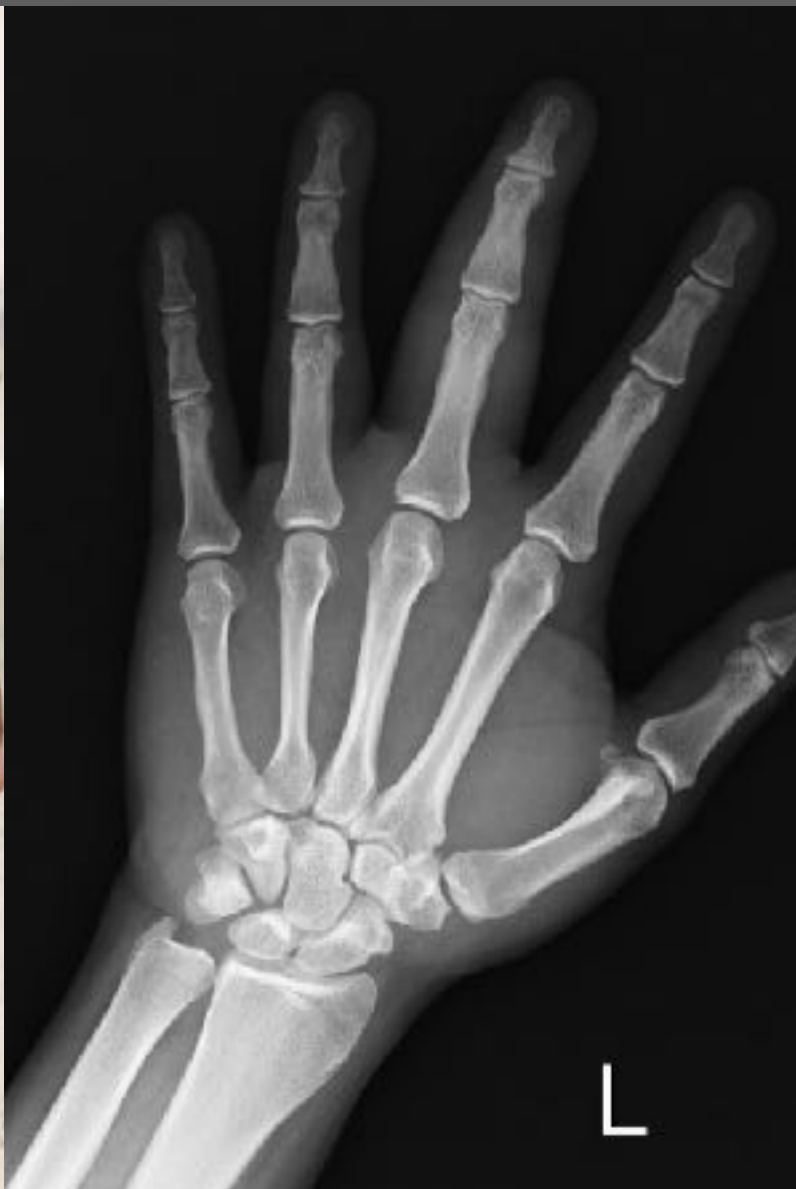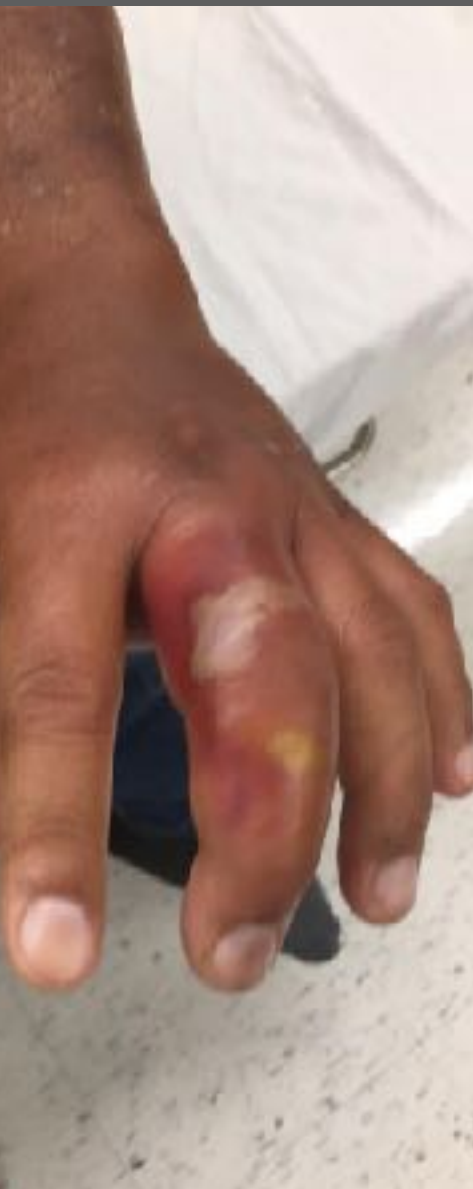M/20, 工作時從階梯滑下用手去抓致右肩脫位



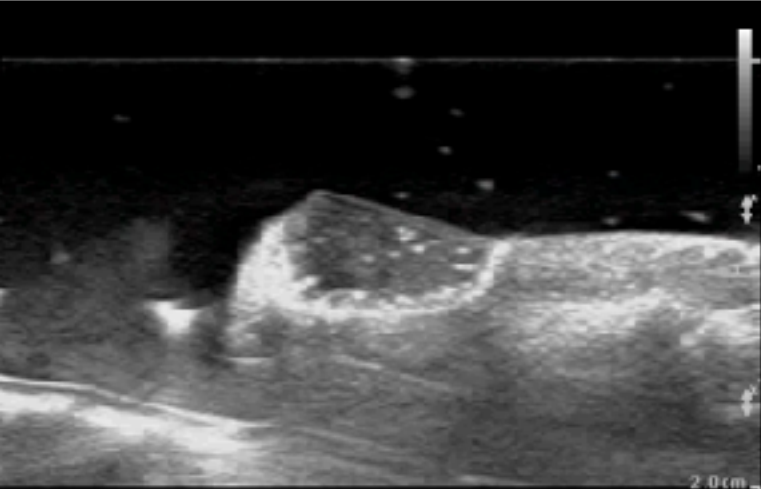
Anterior approach for diagnosis, block & reduction



左手中指腫痛

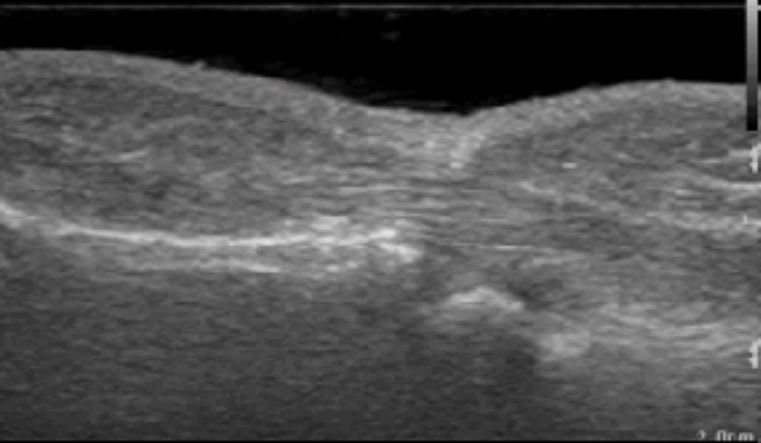


Water bath method



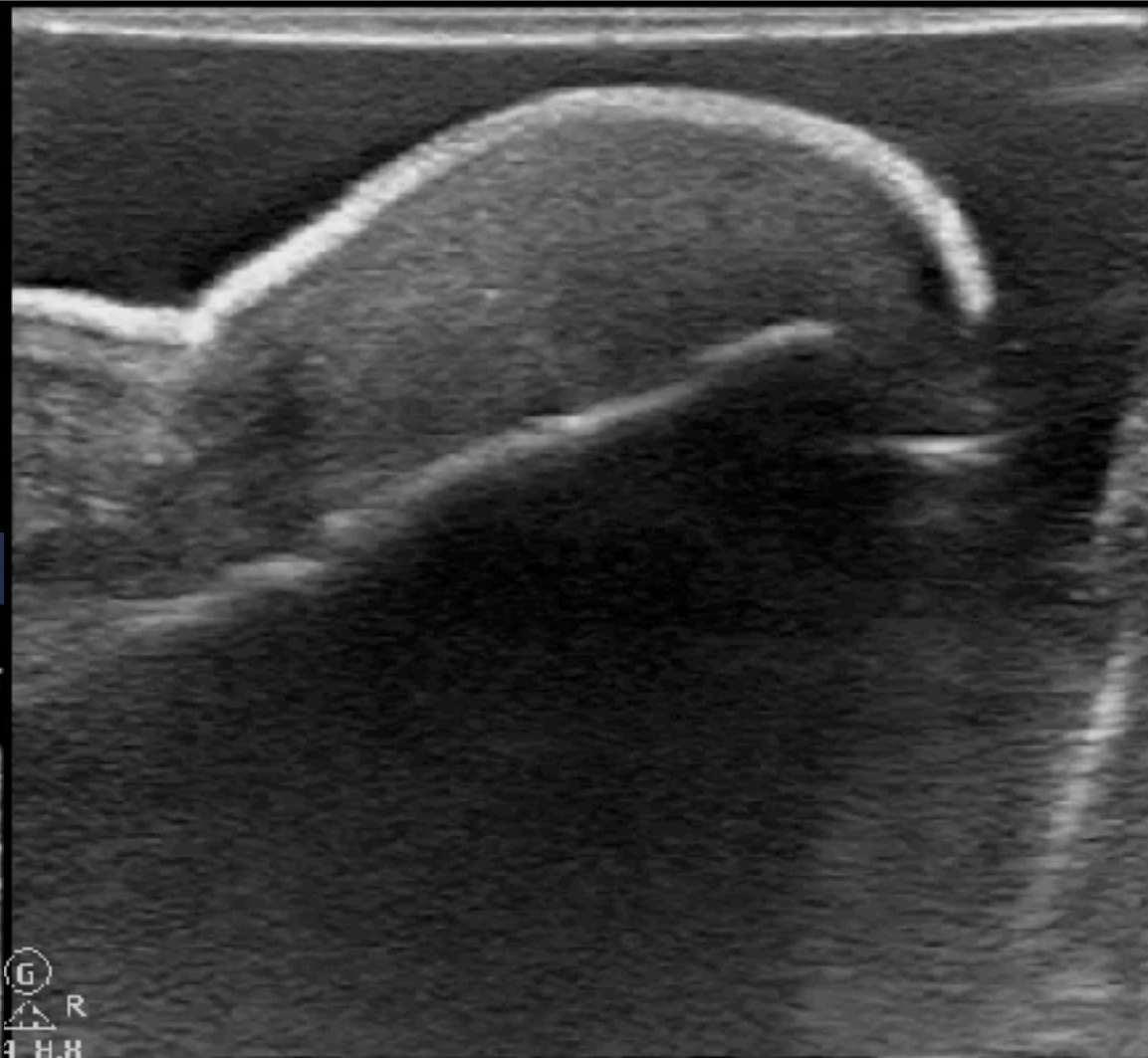G
D R
3.0 12.3

2.0cm



G
P R
2.0 12.0

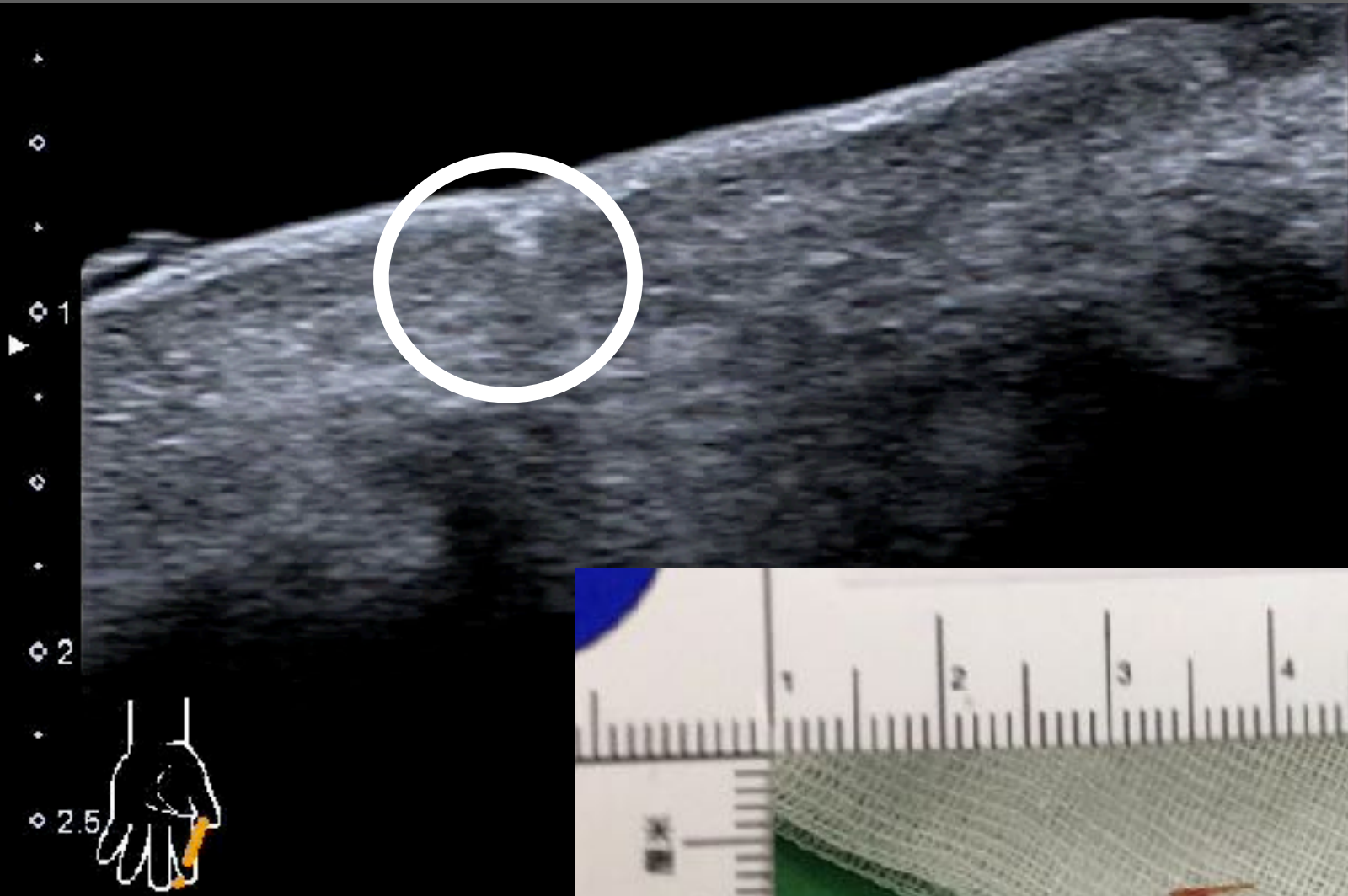
2.0cm




G
R
4 H.H

2.0cm

Water bath

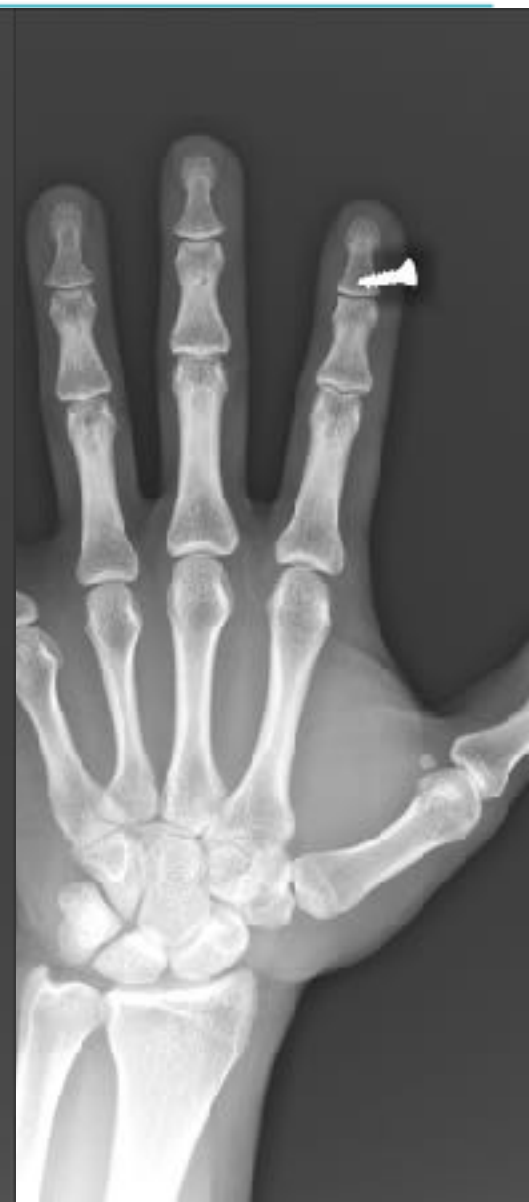
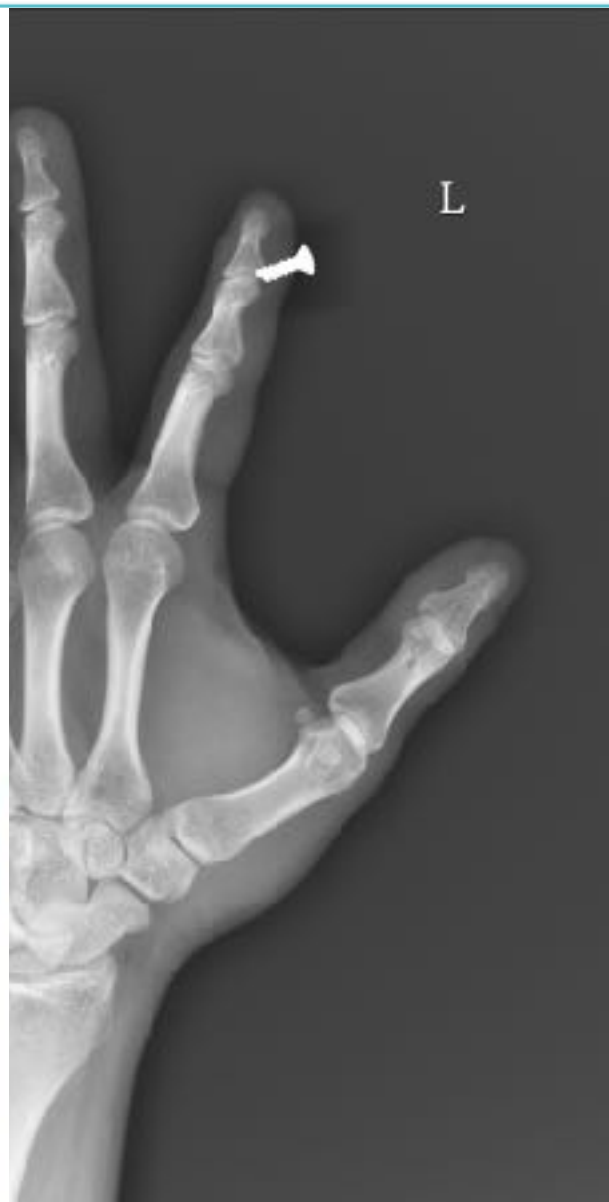
M
1.5
11L4
diffT9.0
30 fps
G:86
DR:60
A:6
P:3

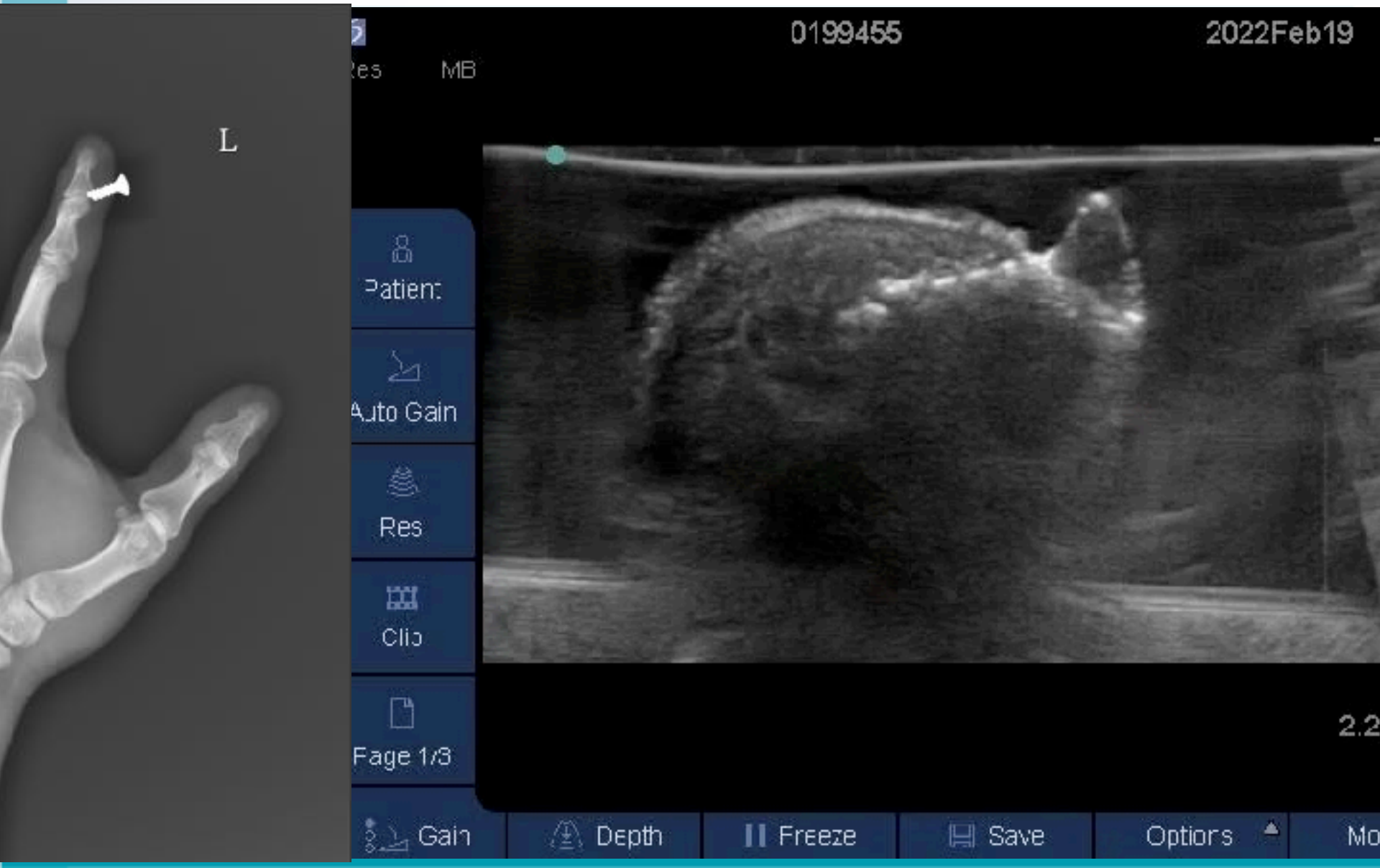

36M, penetrating injury

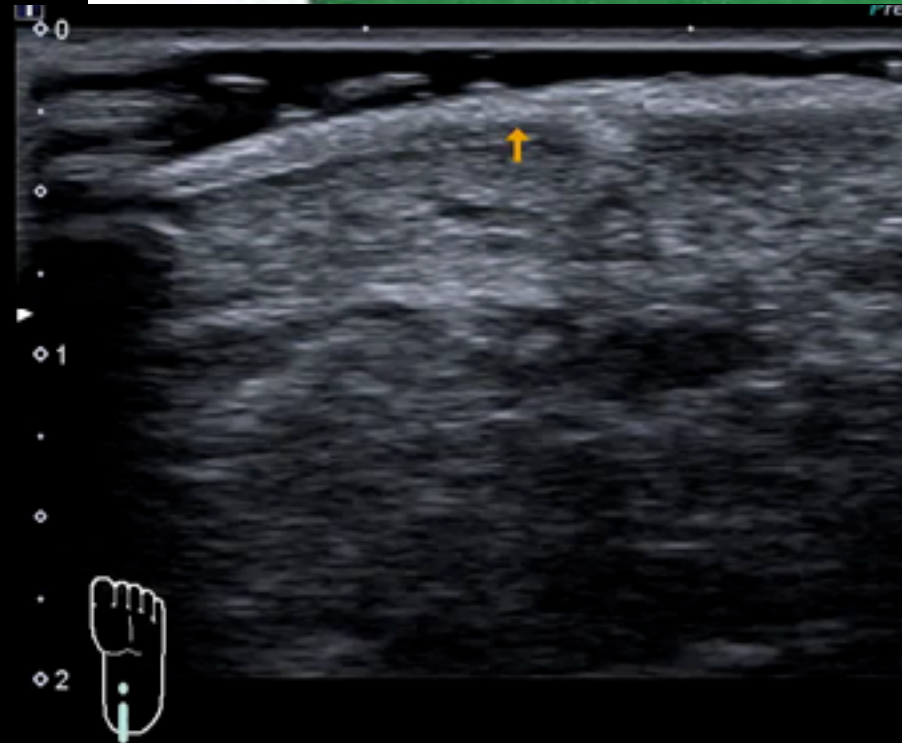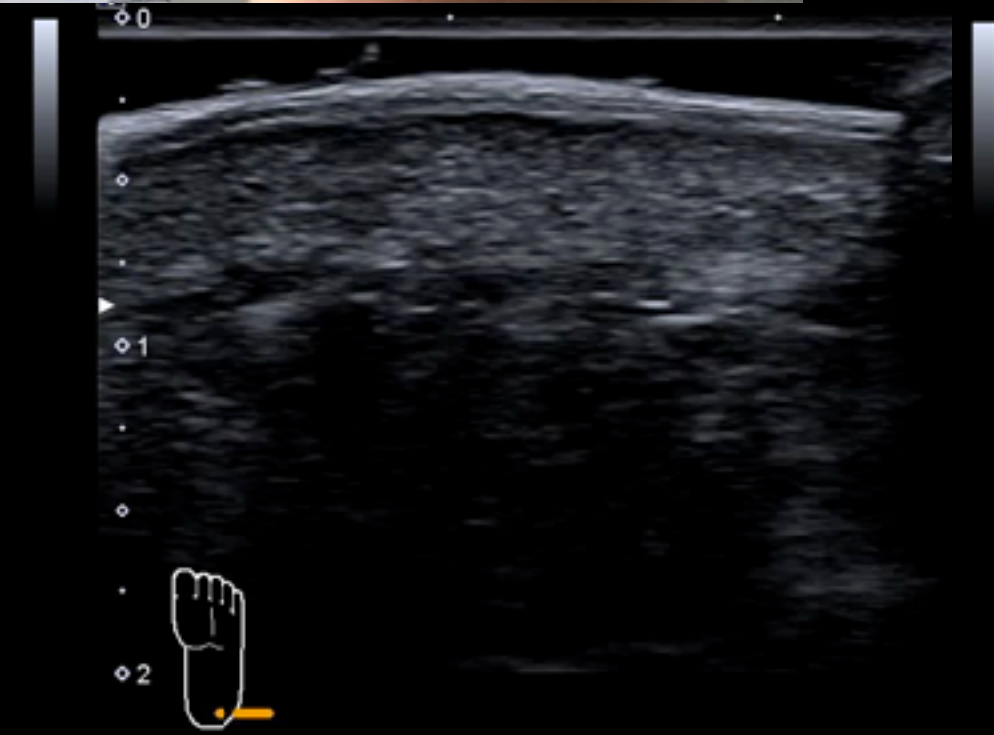
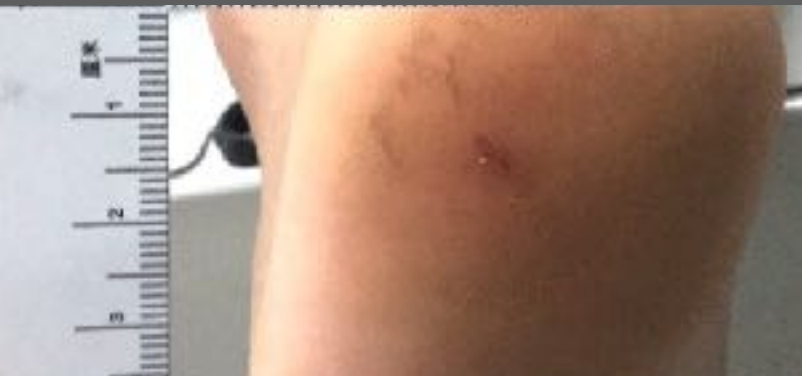人生成就達成
身為一位保養維修員
下班在家也不忘修東修西
重點溜手後還不忘在地上找螺絲
(家裡有小孩)
找著找著居然發現螺絲在...
居家附近診所請我找外科
去雙和急診3位醫生湊過來研究這手指頭
X光照外加超音波還是無法判斷
最後來招水中超音波
終於判定閃過骨頭

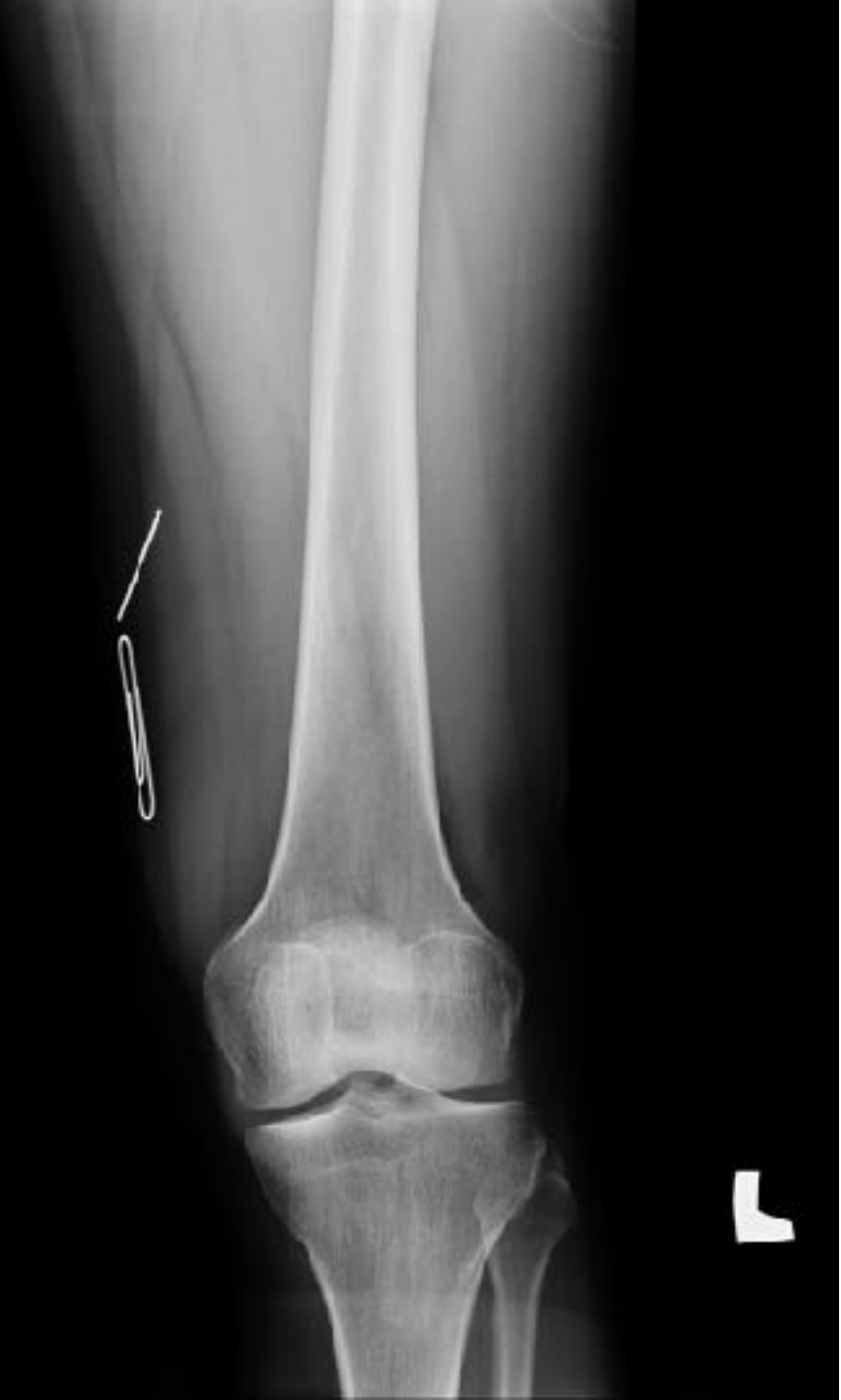
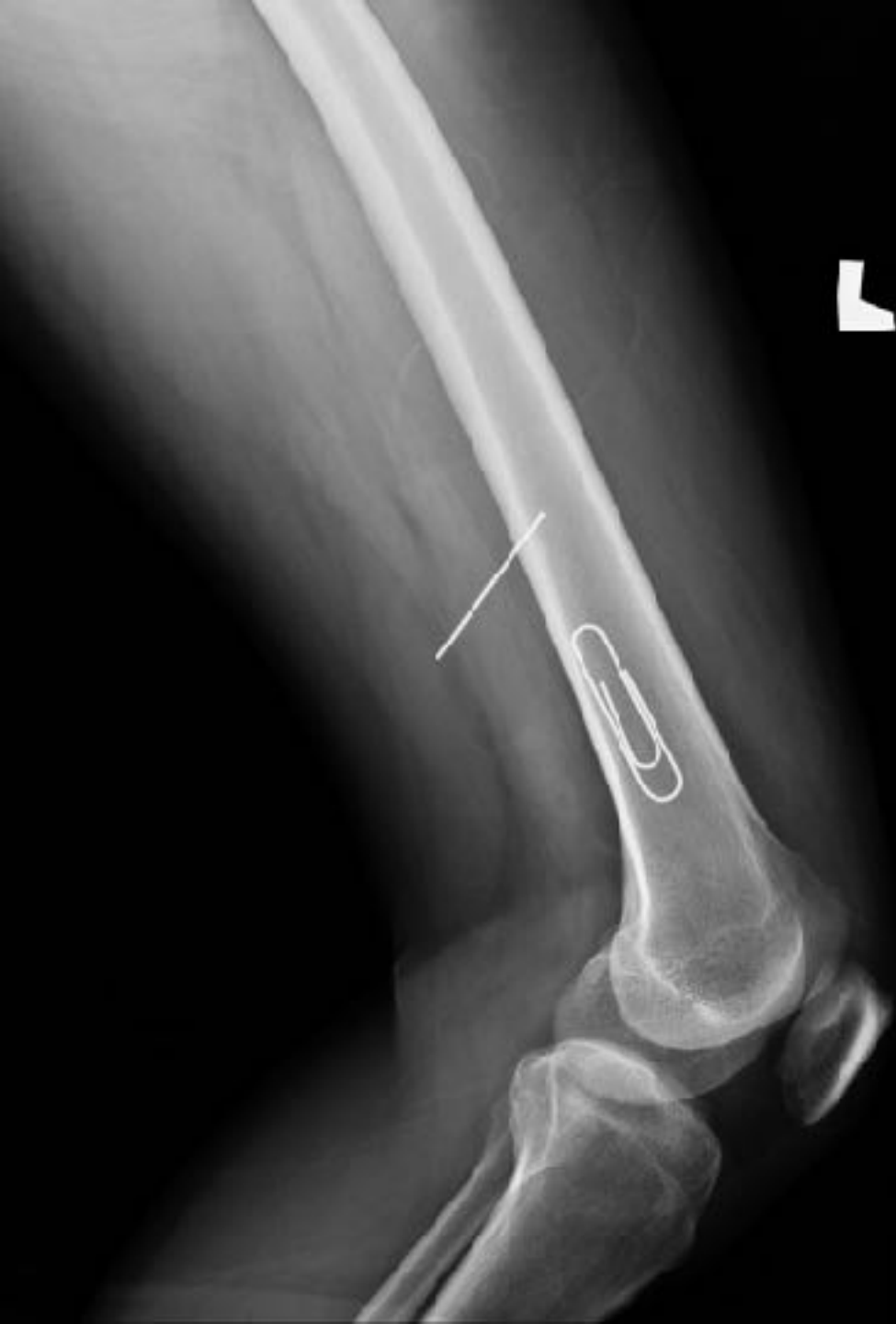
36M, penetrating injury



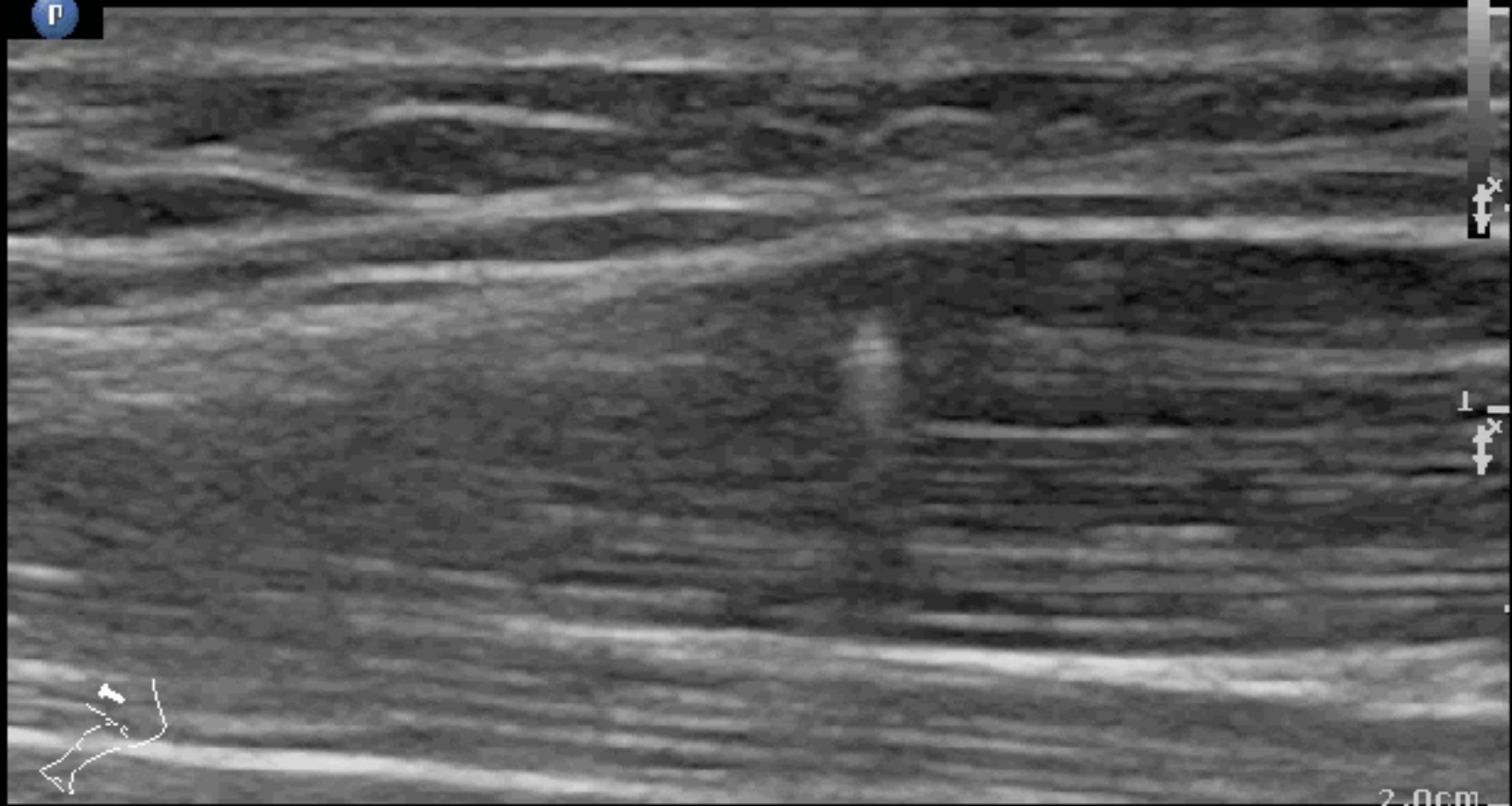
踩到碎玻璃，覺得有異物





superficial
L12-3
34 Hz
2.0cm

2D
Gen
Gn 60
C. 57
4/3/2

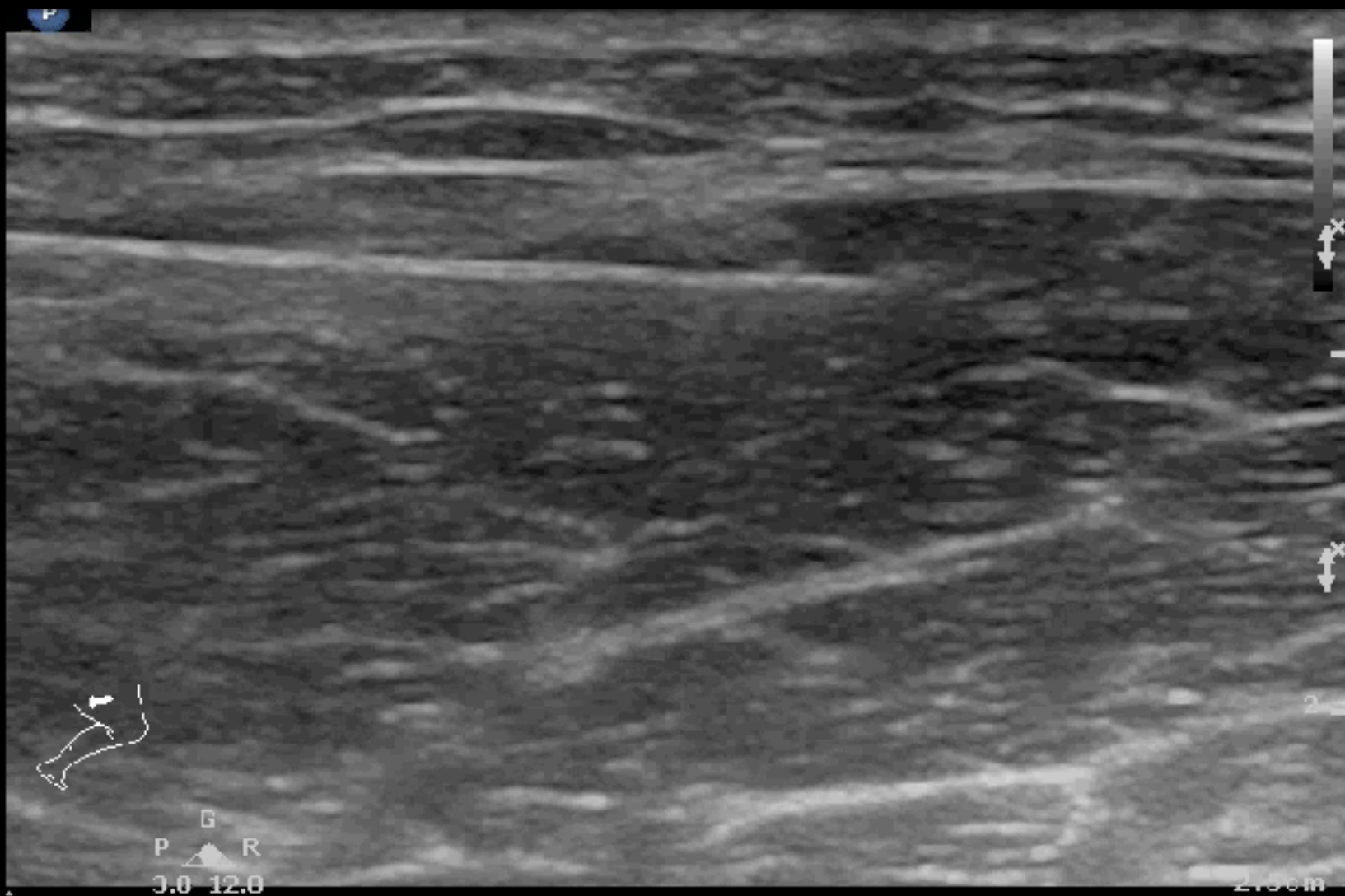


P R
3.0 12.0

2.0cm

Superficial
L12-3
34 Hz
2.5cm

2D
Gen
Gn 60
C 52
1/3/2



G
P R
3.0 12.0

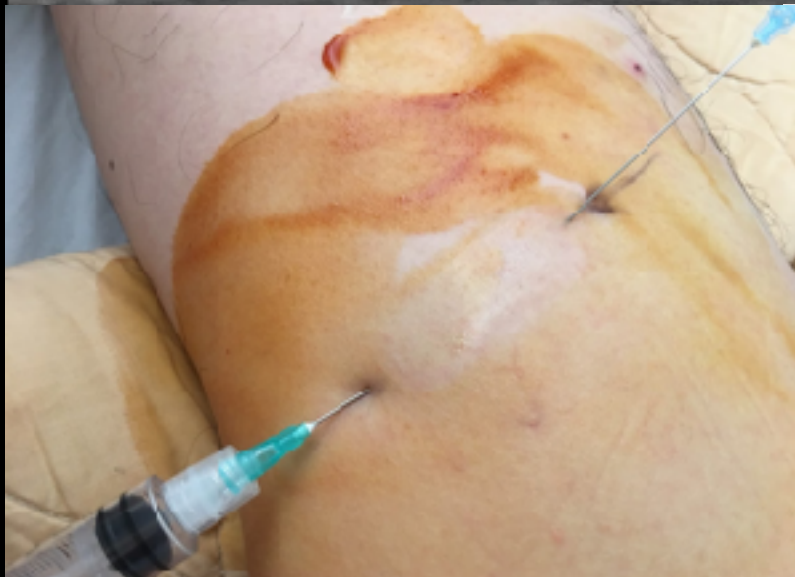
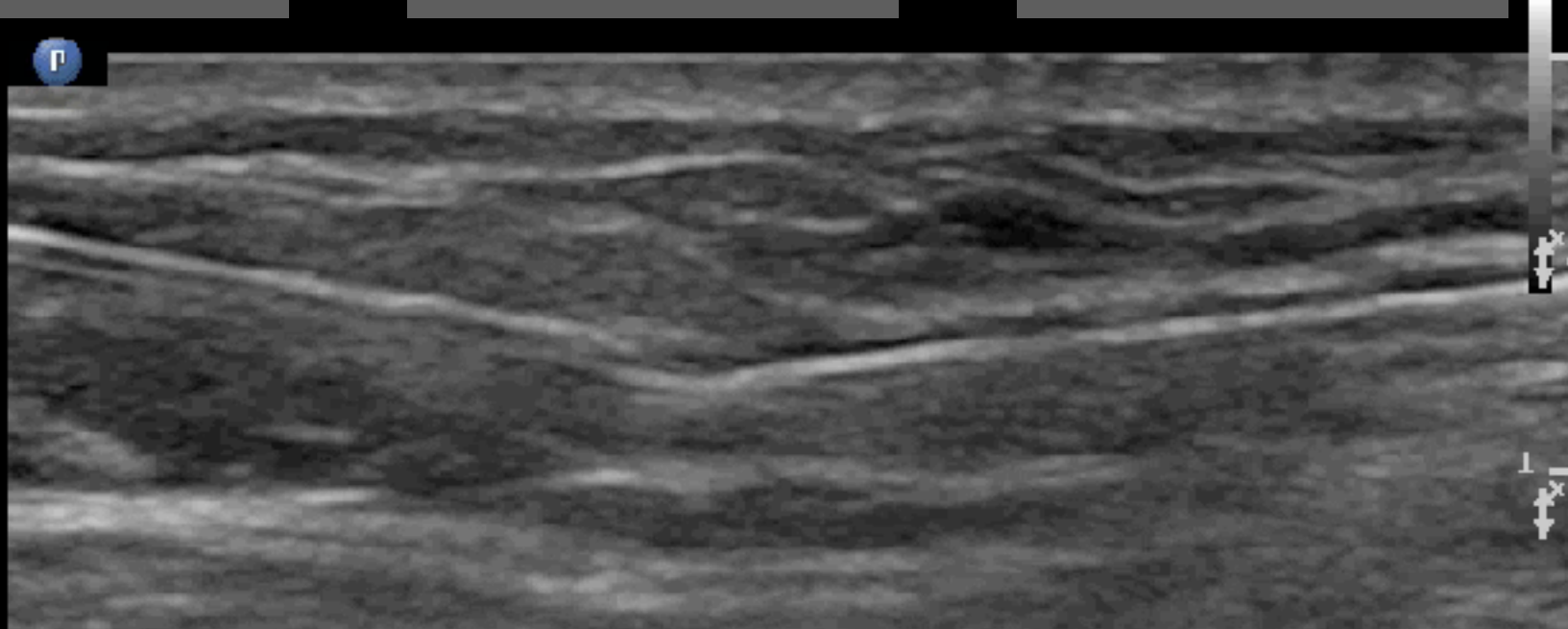
2.5cm

Localization

2 needle

Removal

L12
34 Hz
2.0cm
7D
Gen
Gn 60
C. 57
4/3/2



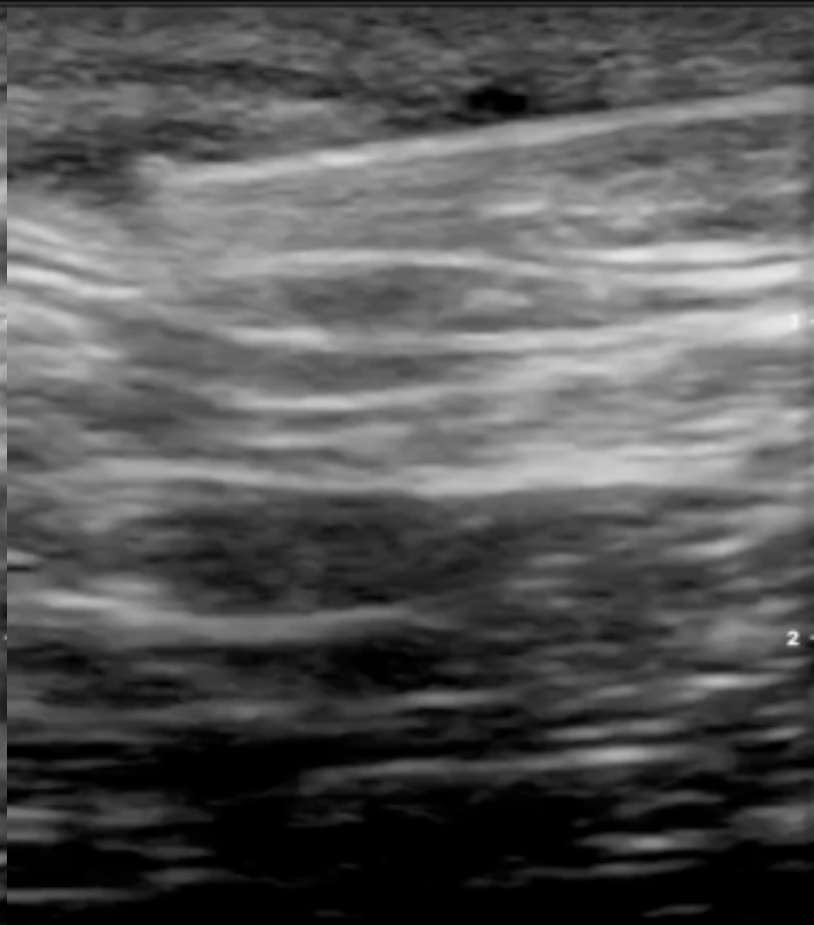
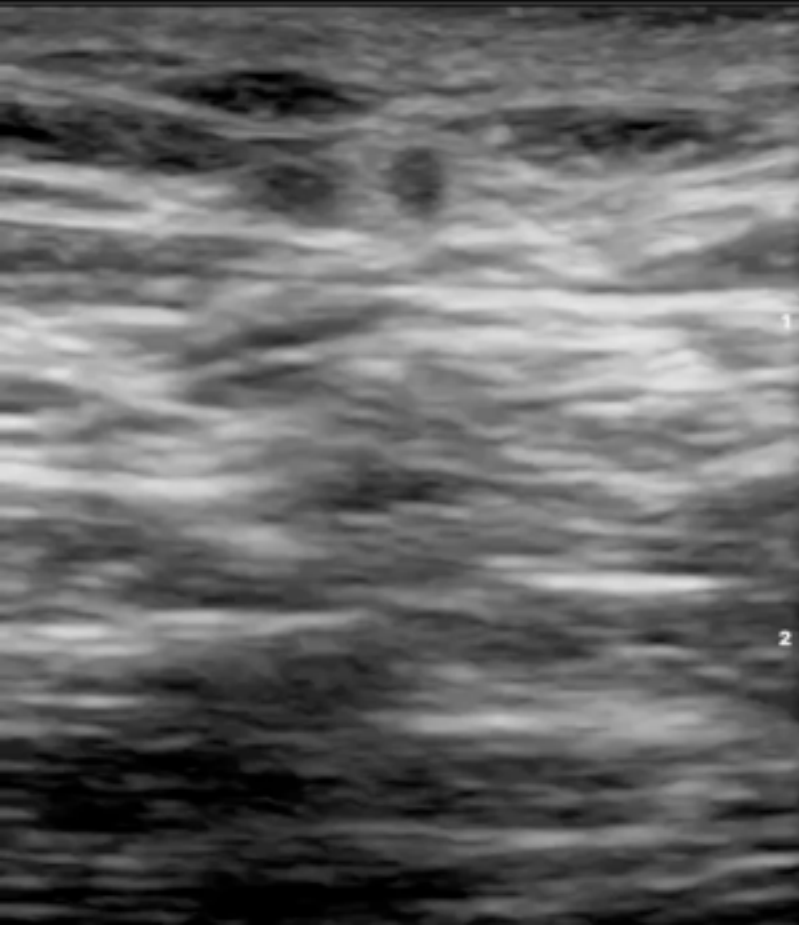
大腿痛和異物感

TIS: 0.01, MI: 0.26, Small Organ

TIS: 0.01, MI: 0.26, Small Organ

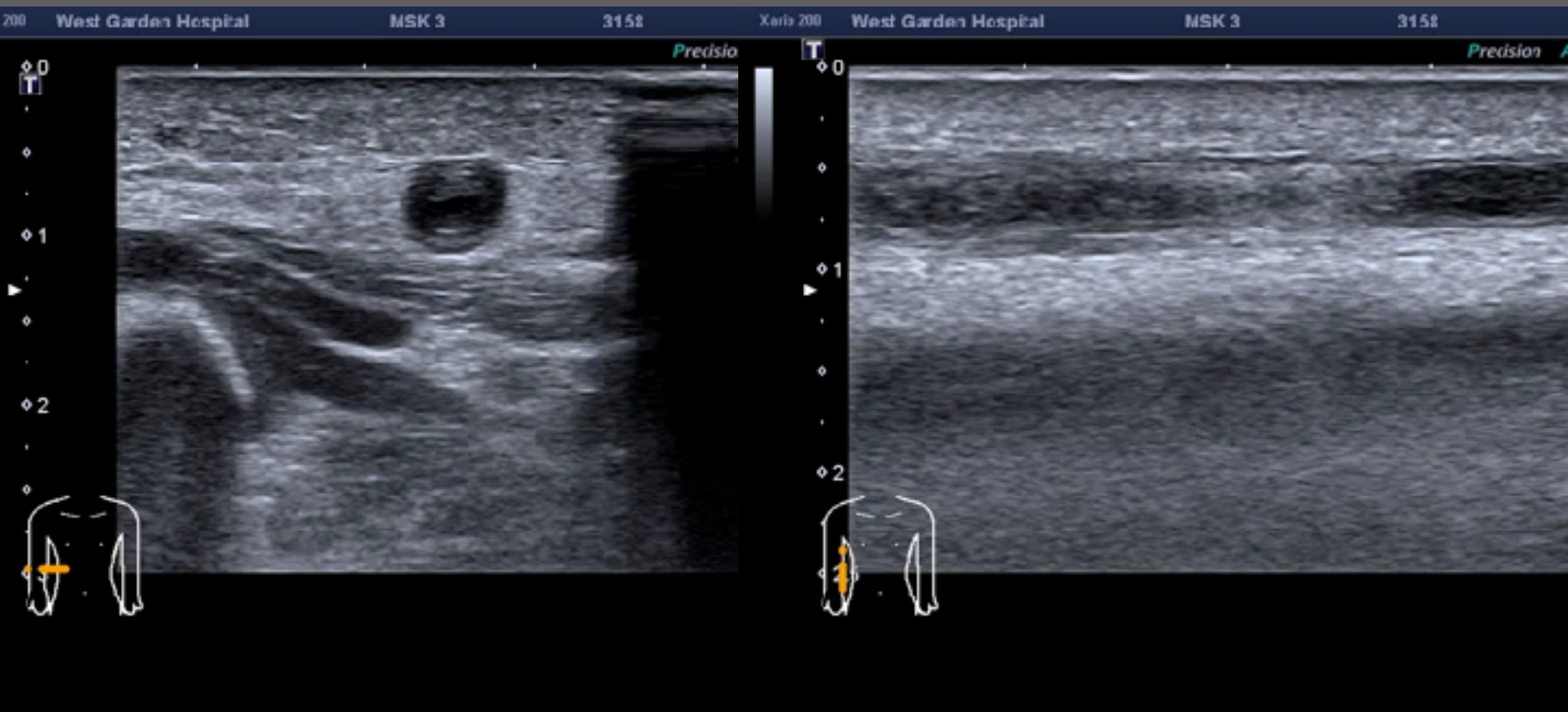
B

B

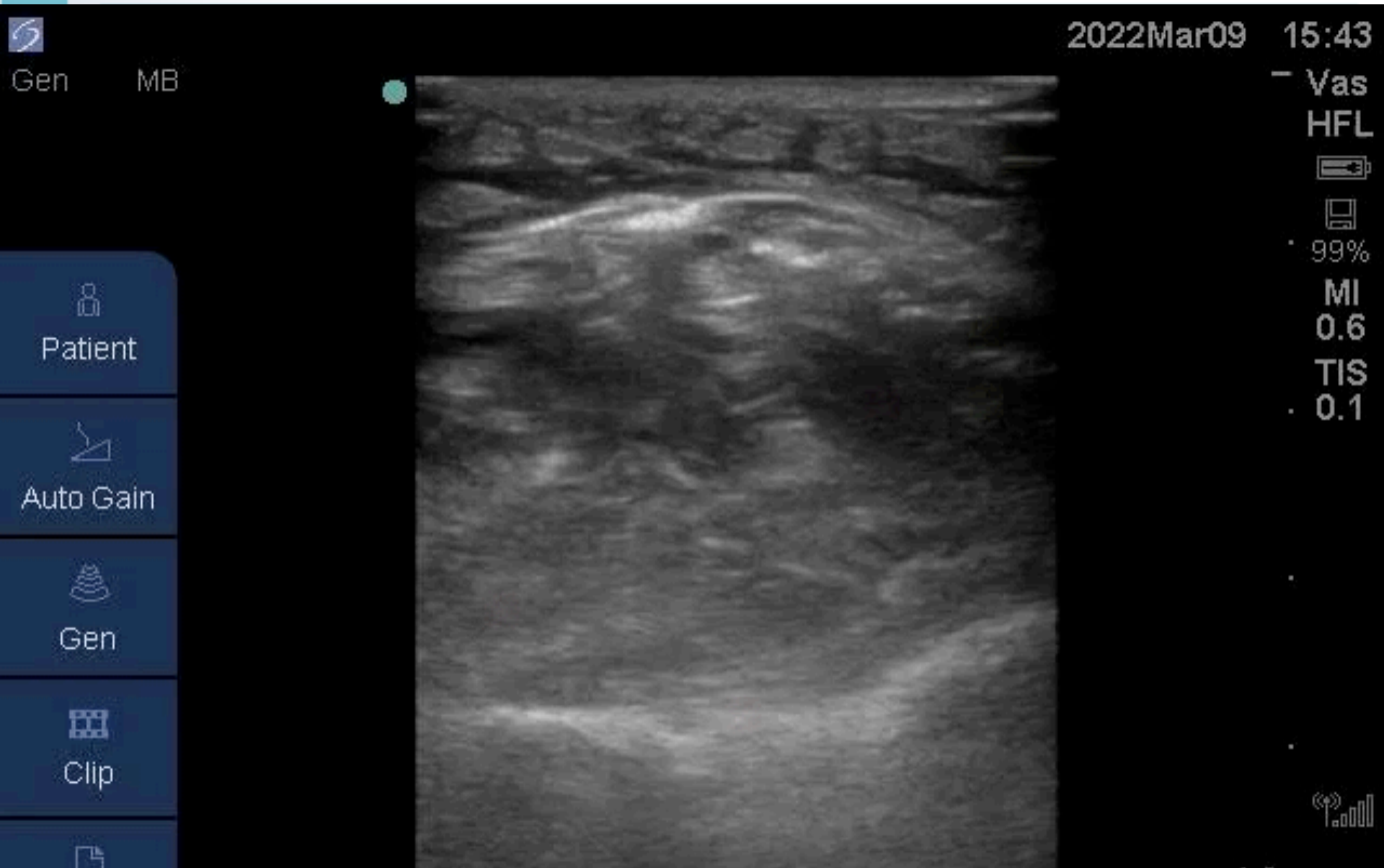

54歲男，注射處腫痛

Superficial thrombophlebitis



74M, hypoglycemia, arm swelling after IV



76F, Leg pain

Superficial

L12-3

50 Hz

2.5cm

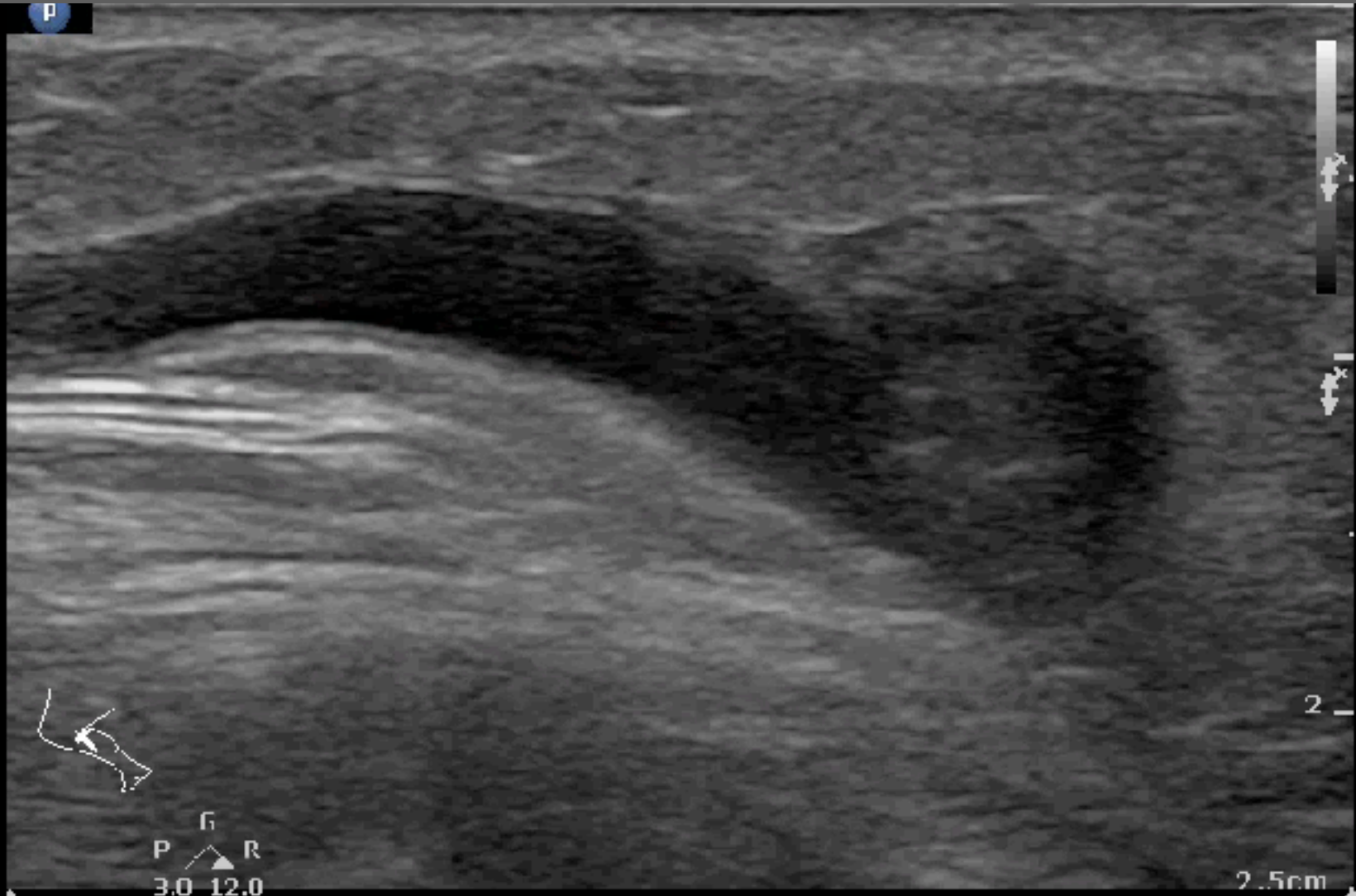2D

Res

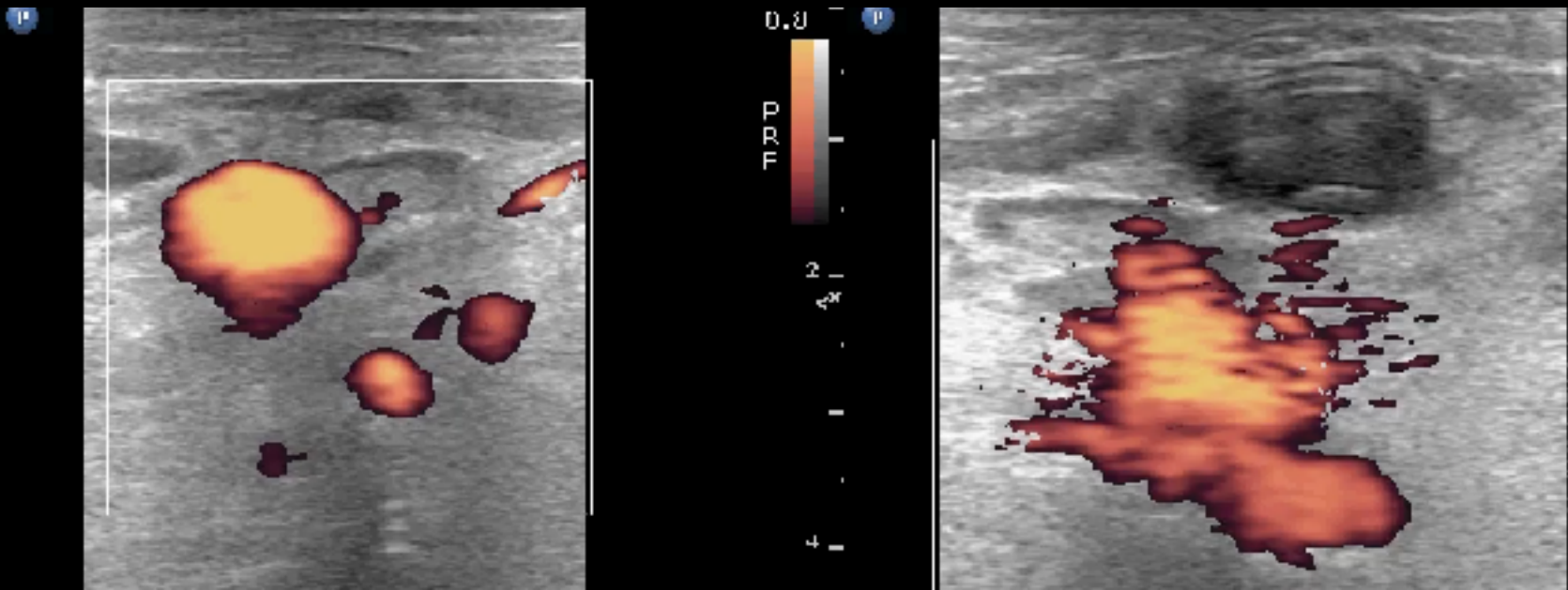
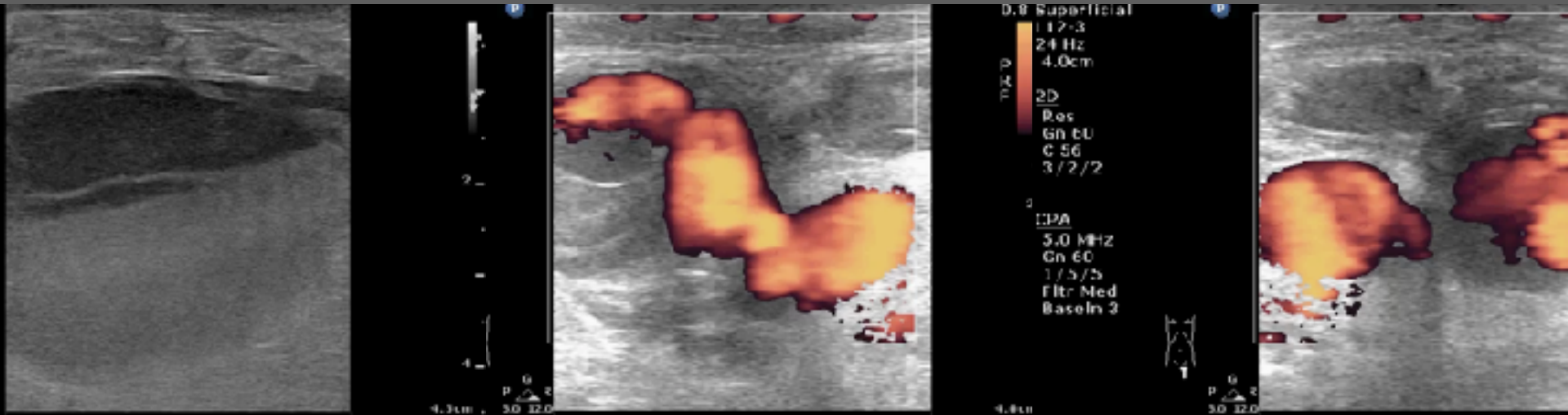
Gn //

C. 56

3 / 2 / 1

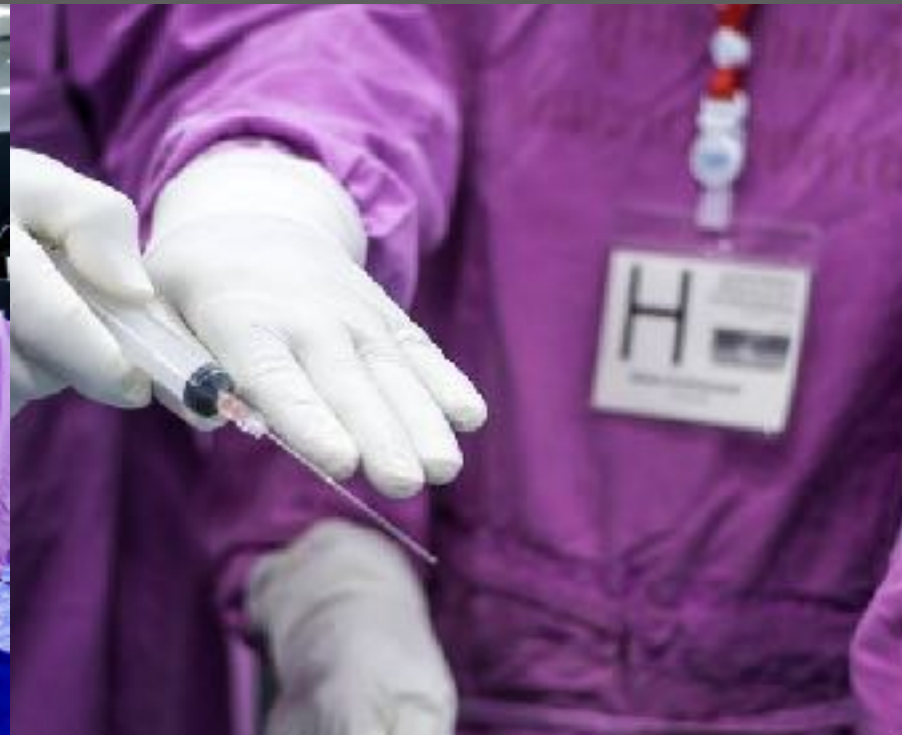

Left femoral painful swelling



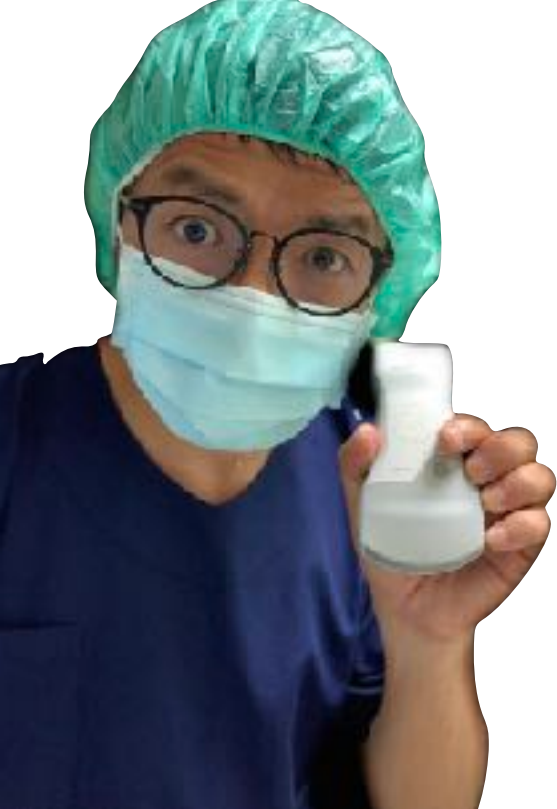Diagnostician

沒被骨頭空氣擋到的都看得到



Interventionist

只要找到縫隙針就送得到



努力可能會說謊，
但努力不會白費。

羽生結弦

HOLISTIC ULTRASOUND

juice119@gmail.com / POCUSacademy.com