



雙和急診POCUS訓練

陳國智 醫師



急診超音波臨床評核醫師
醫用超音波學會指導醫師
雙和急診超音波教學負責人
WINFOCUS director / instructor

急診 / 重症 / 介入 / 急性疼痛

經歷

新光急診超音波訓練中心主任
西園醫院急診醫學科主任
急診醫學會超音波委員會主委
台灣疼痛醫學會大體模擬手術講師
急救加護醫學會重症超音波負責人

診
斷

監
測

介
入

POINT OF CARE ULTRASOUND

~ 存在於臨床需求之所在 ~



LE joint effusion

01/07

Airway

01/14

Needling

01/21

VExUS protocol

01/28

雙和急診POCUS訓練



Central access

02/11

Peripheral access

02/18

EFAST

02/25

雙和急診POCUS訓練



Basic ECHO

03/04

Nerve block-UE(1)

03/11

Nerve block-LE(1)

03/25

雙和急診POCUS訓練



Aorta & IVC

04/01

Liver & Biliary

04/08

Kidney & UB

07/08

Pancreas & Spleen

07/22

雙和急診POCUS訓練



GI tract scan

08/05

Basic lung & heart (PGY)

08/05

Sternum & Ribs

08/19

UE joint effusion

08/26

雙和急診POCUS訓練



急診臨床掃描指導

09/16

CVC工作坊 (1)

09/16

8 POCUS skills for PGY

09/23

Ocular US

09/30

雙和急診POCUS訓練



8 POCUS skills for PGY

10/07

急診臨床掃描指導

10/14

CVC工作坊 (2)

10/14

ENT US

10/21

雙和急診POCUS訓練



8 POCUS skills for PGY

11/04

急診臨床掃描指導

11/11

CVC工作坊 (3)

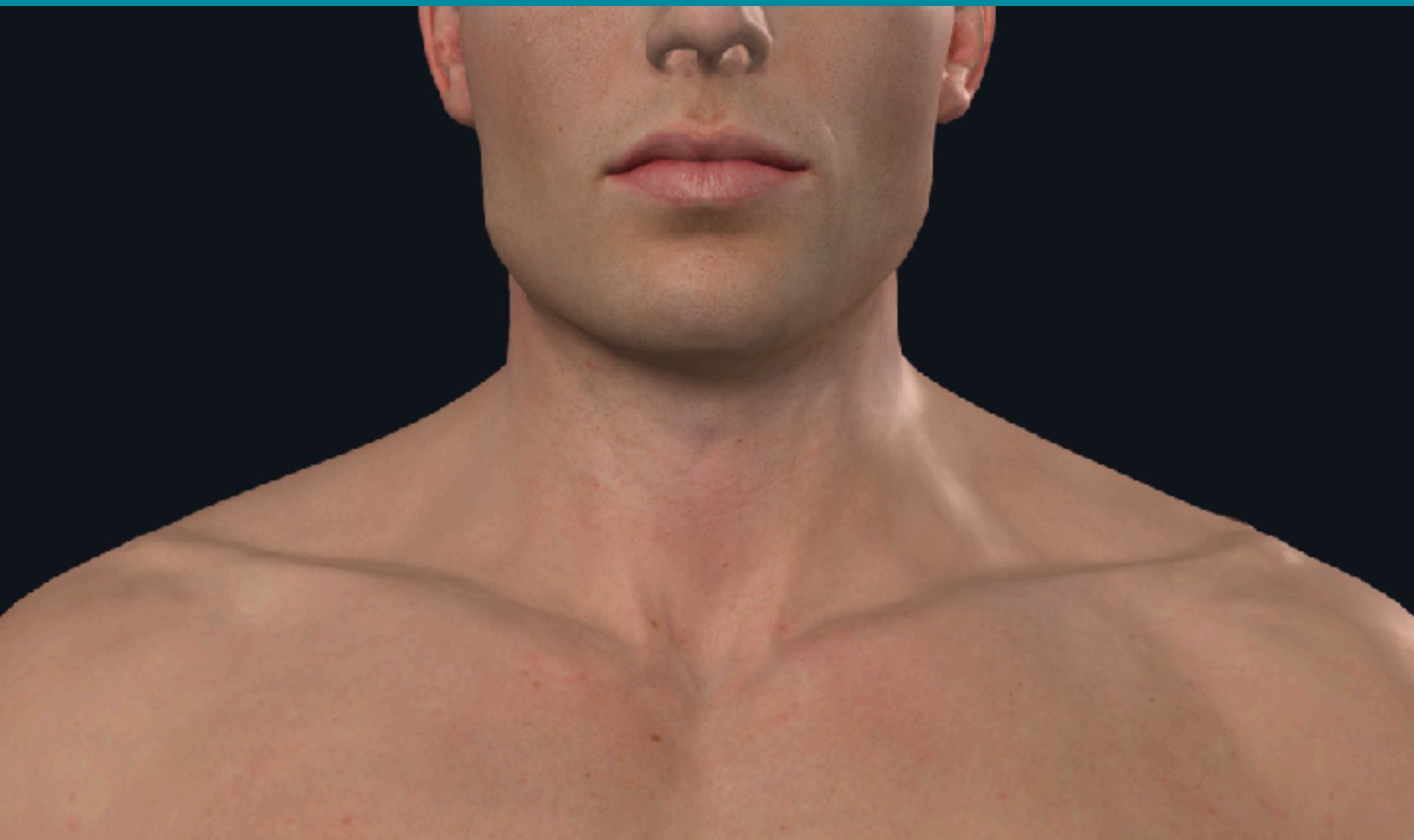
11/11

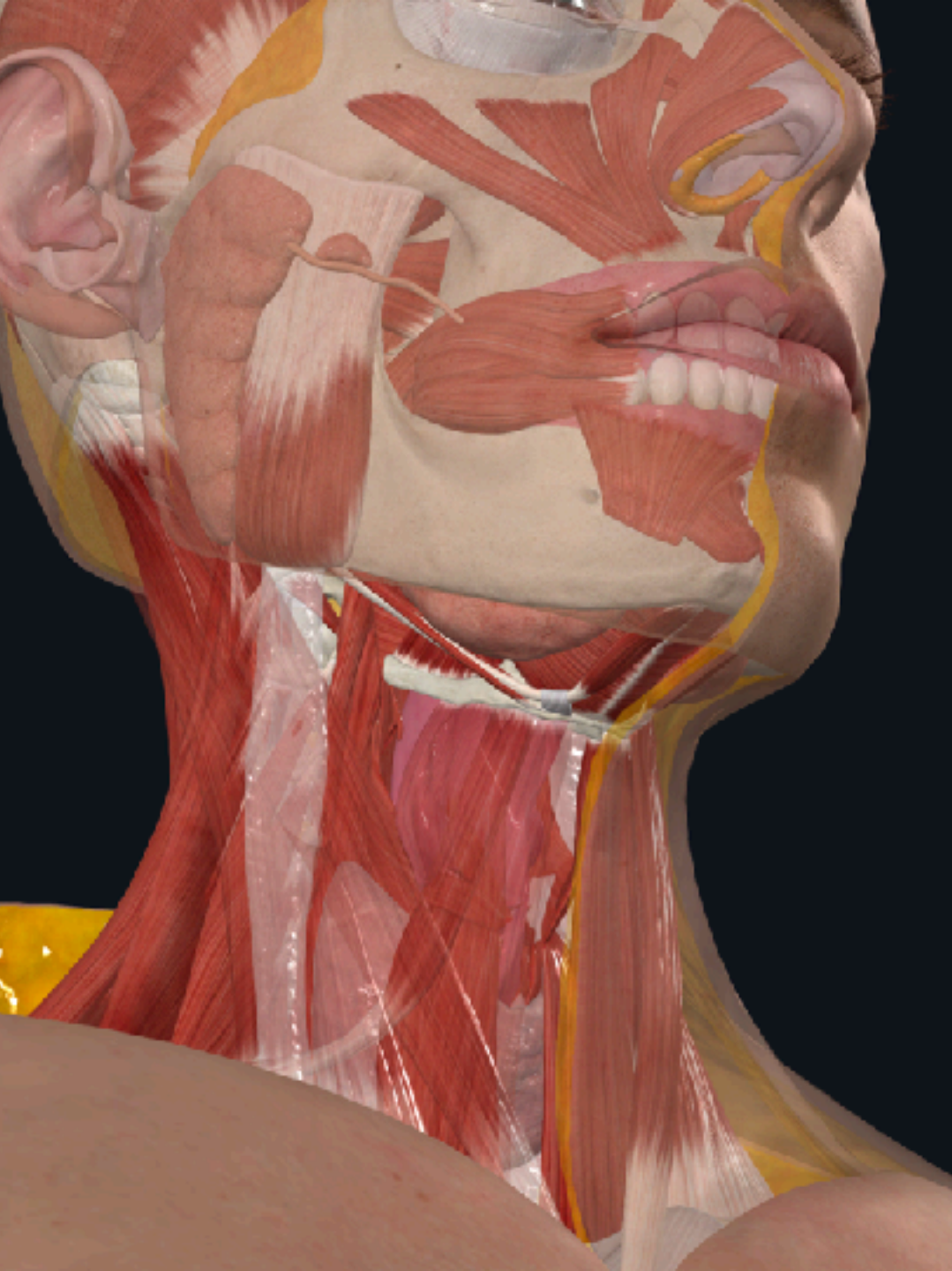ECD in ER

11/25

雙和急診POCUS訓練

ENT POCUS IN ER





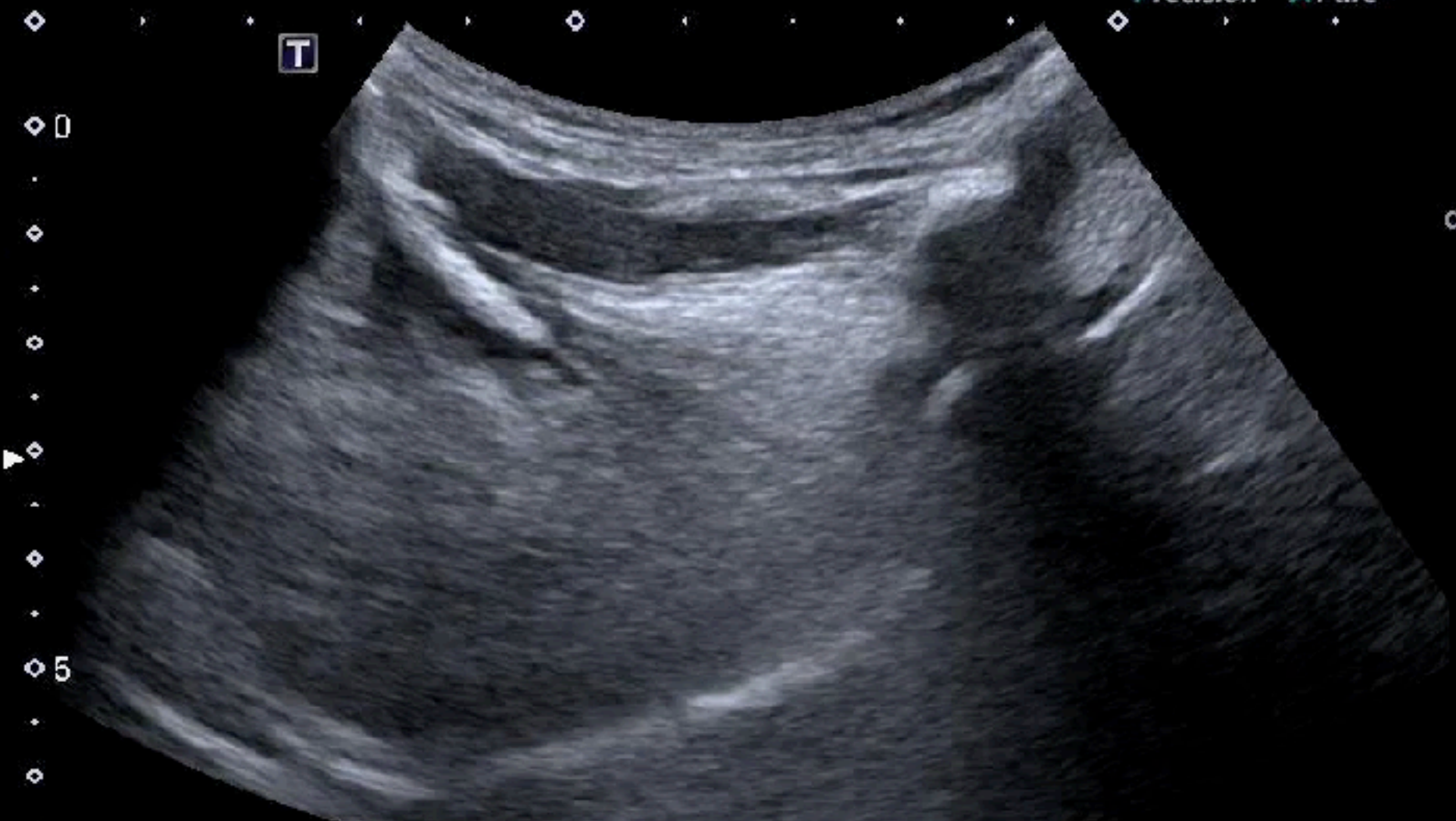
1 Epiglottis

2 Tonsils

3 Glands

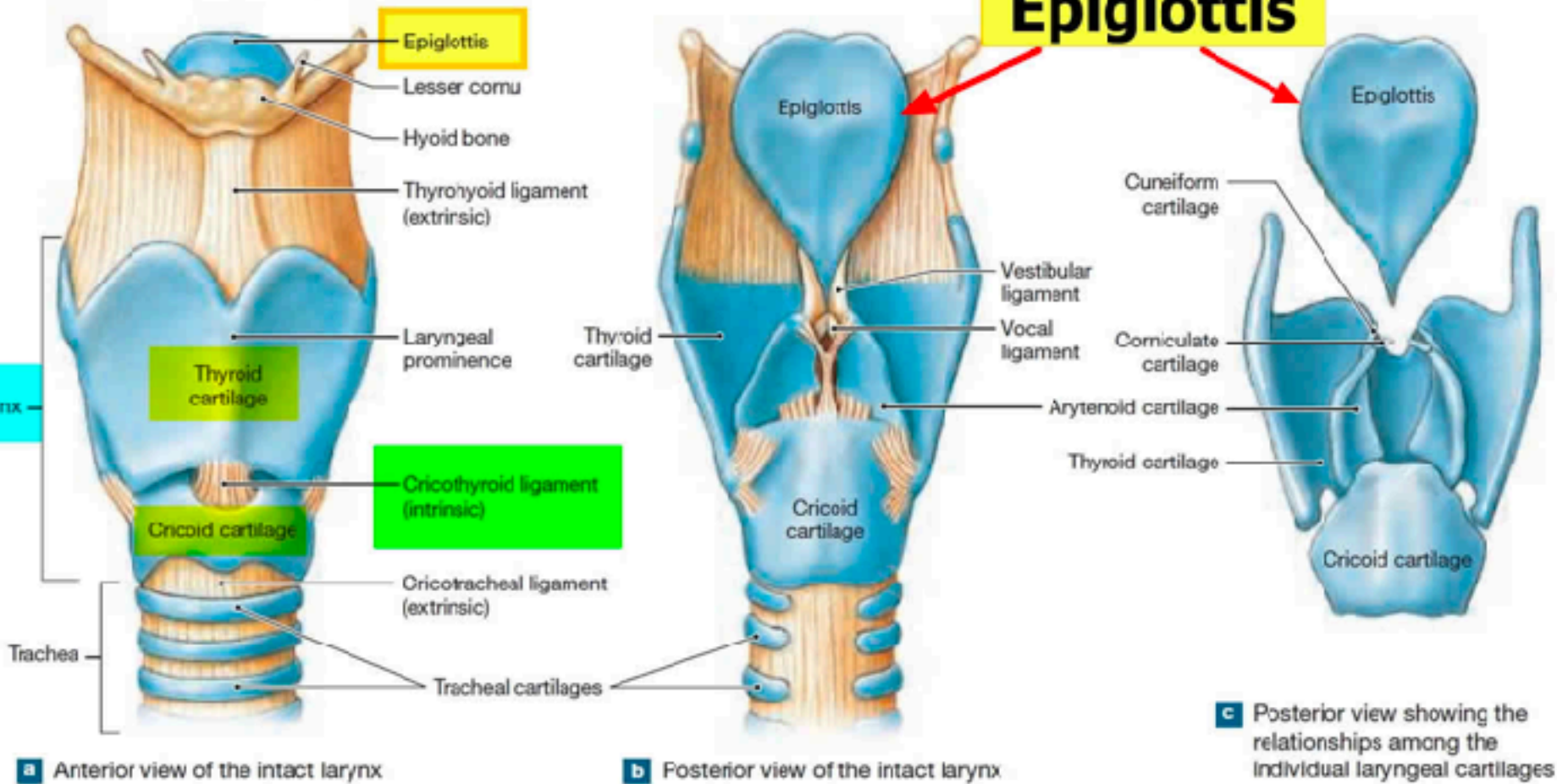
T

Precision A Pure+



SONOANATOMY

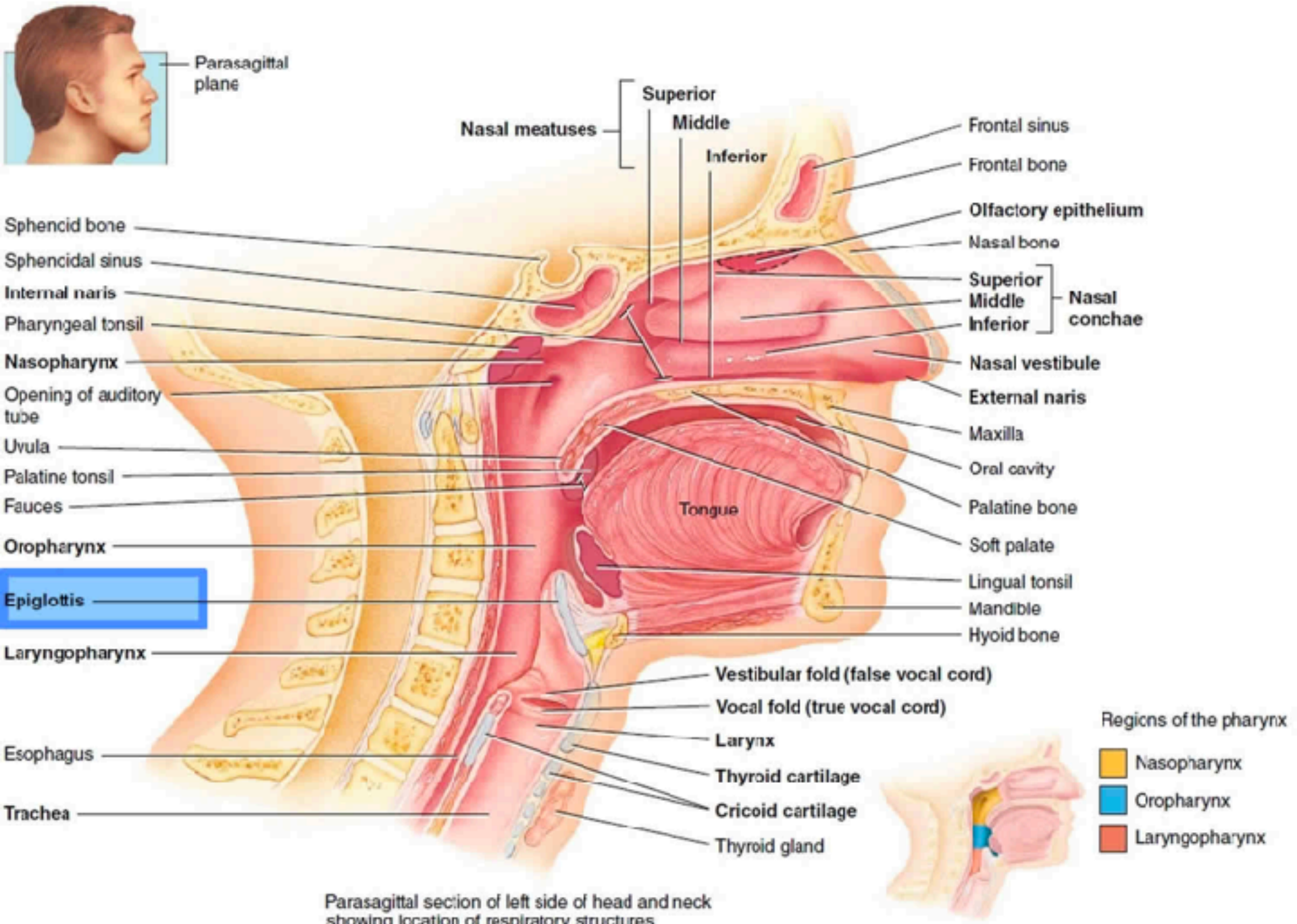
Anatomy of the Larynx



a Anterior view of the intact larynx

b Posterior view of the intact larynx

c Posterior view showing the relationships among the individual laryngeal cartilages

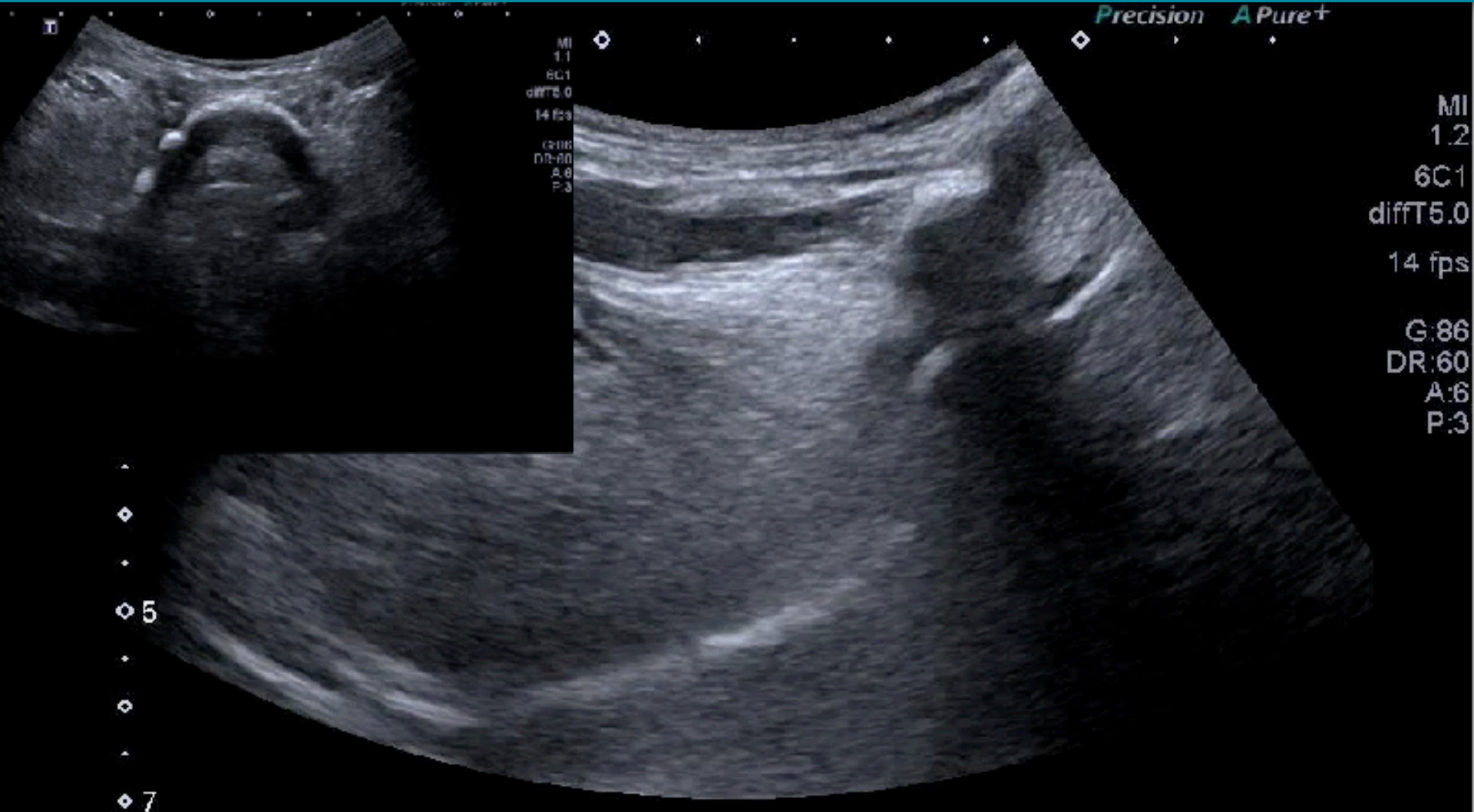


Parasagittal section of left side of head and neck showing location of respiratory structures

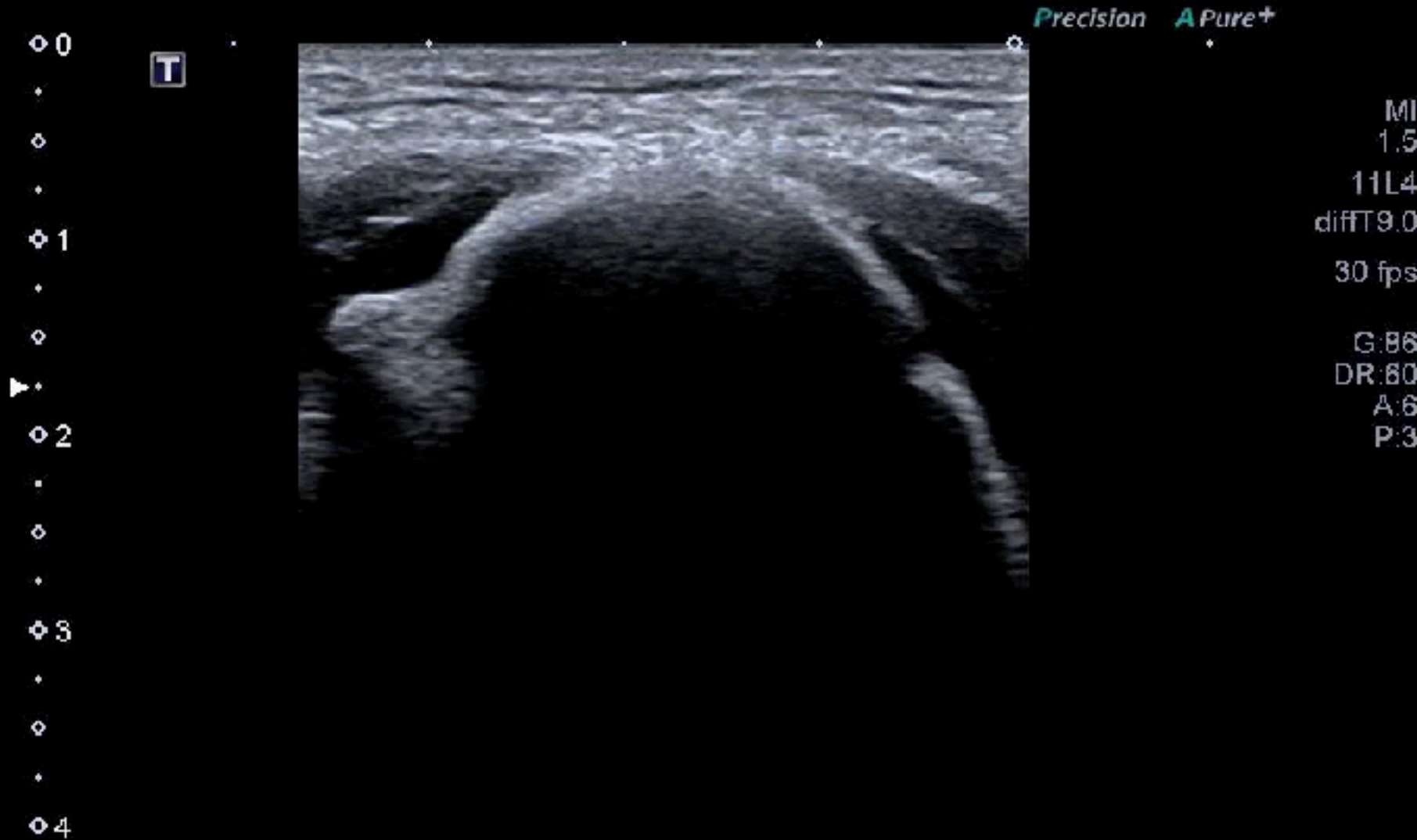Regions of the pharynx

- Nasopharynx
- Oropharynx
- Laryngopharynx

Hyoid bone: landmark for epiglottitis



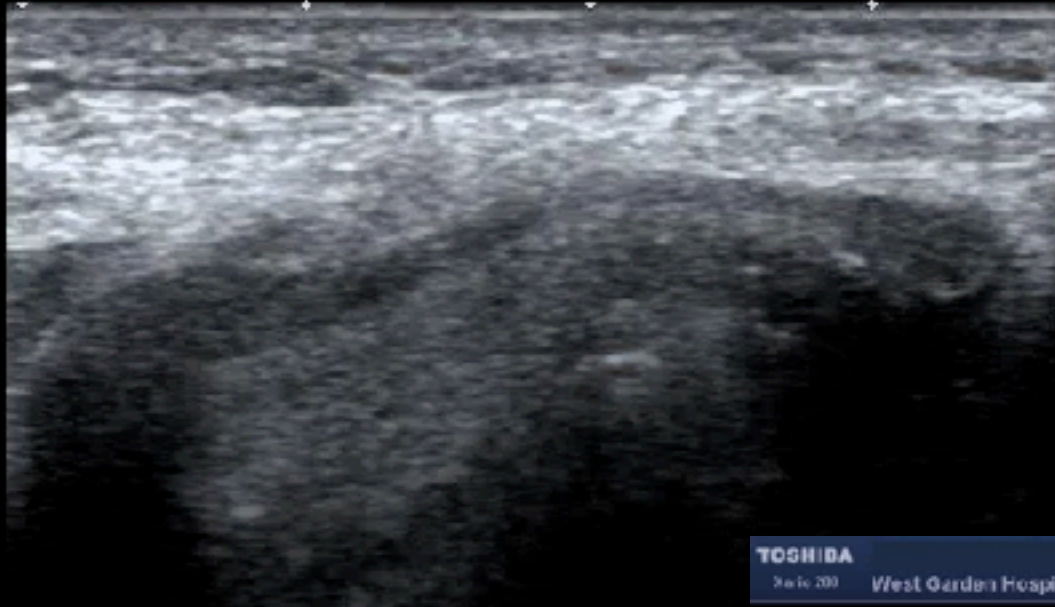
Epiglottis



Landmark: hyoid bone

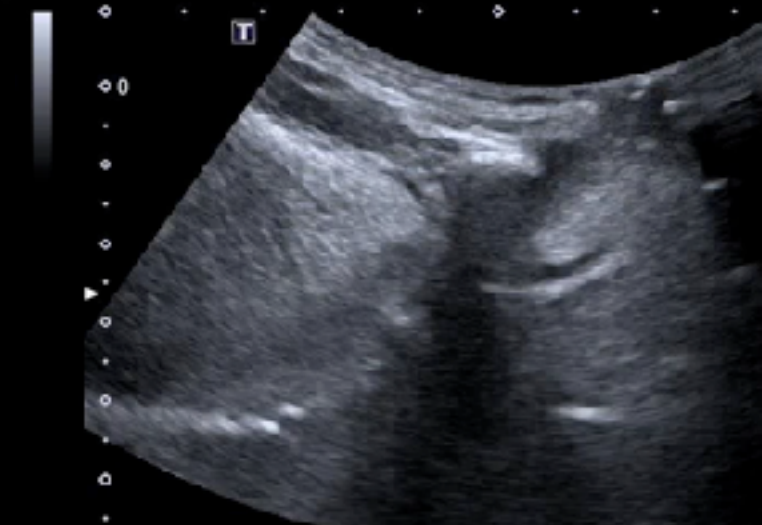
Epiglottis

0
T
1
2
3
3.5



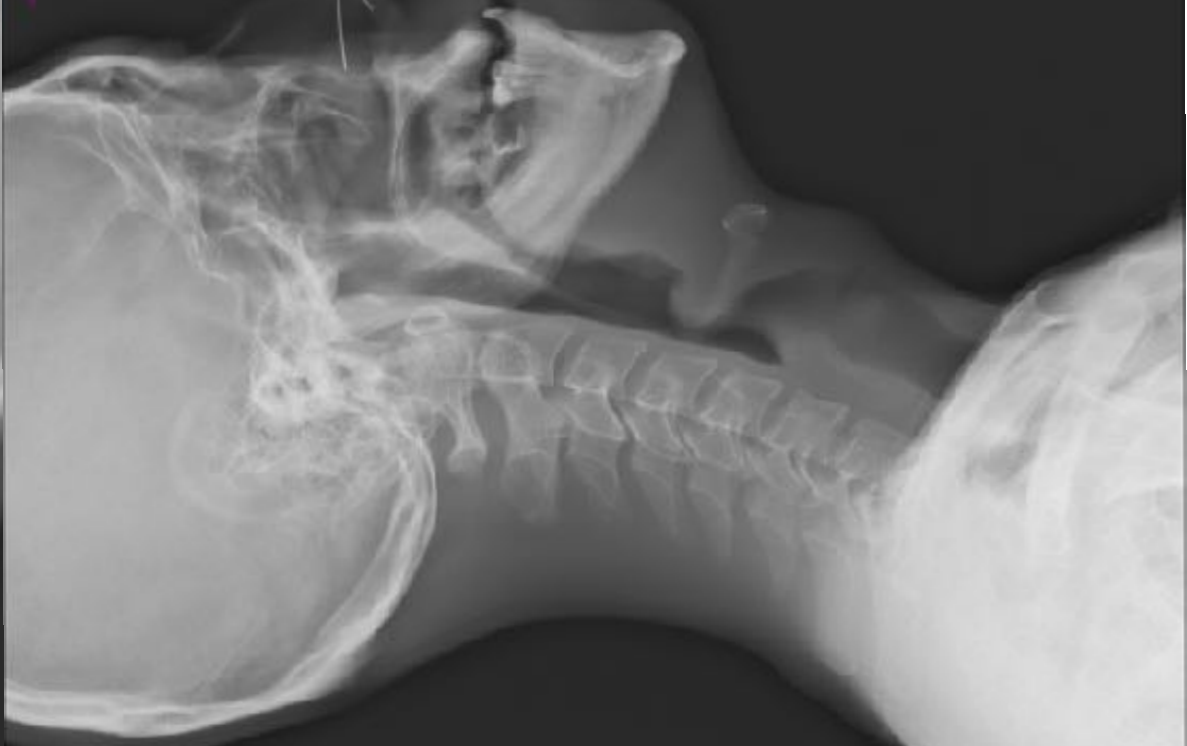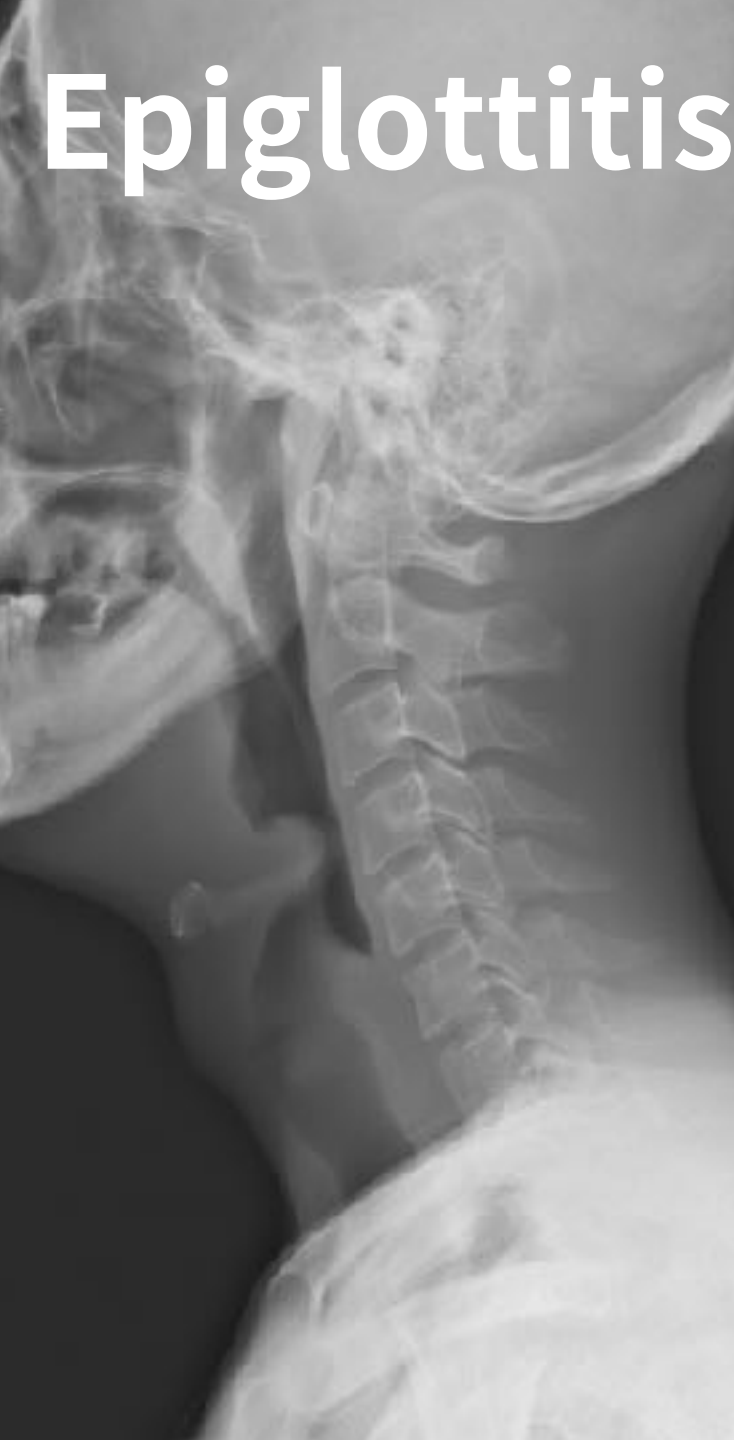MI
1.5
11L4
diffT9.0
30 fps
G:92
DR:80
A:5
P:1

TOSHIBA
Pac 200 West Garden Hospital MSK 3 313



Landmark: hyoid bone

Epiglottitis



mindray

llu01577831

14/10/2022

11:10:51

AP 92.0% MI 0.6 IIS 0.3

C5-2s

Adult ADD

M7

H1

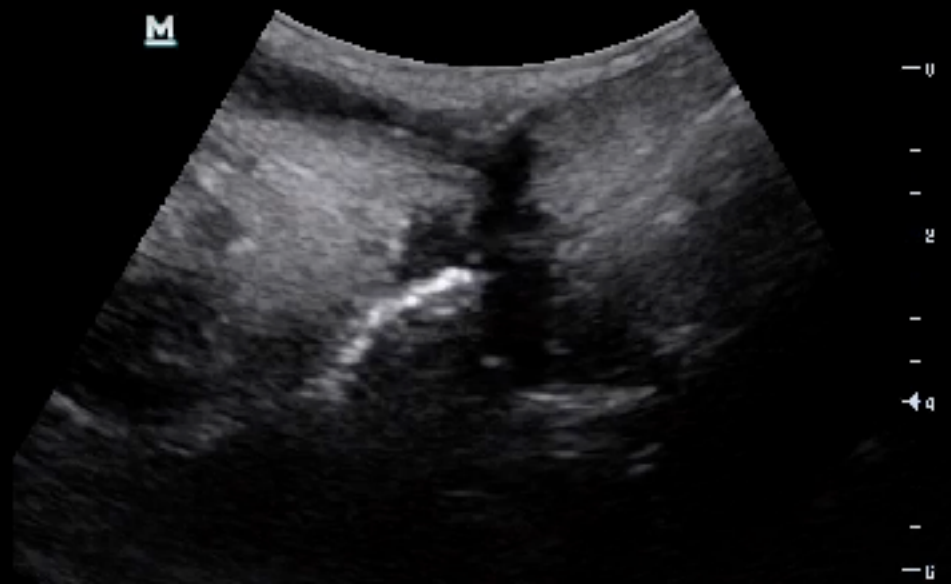
FRE 2 / 117.4

C51 / 17856

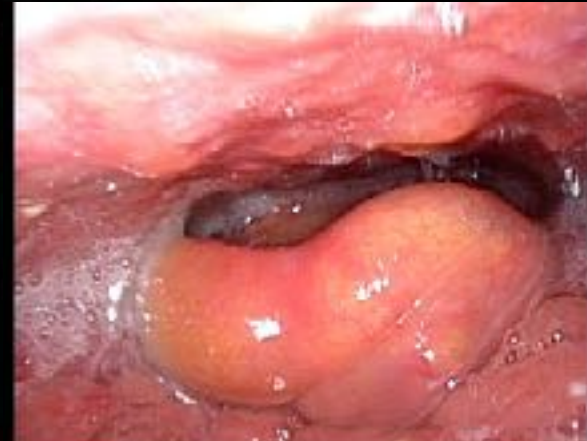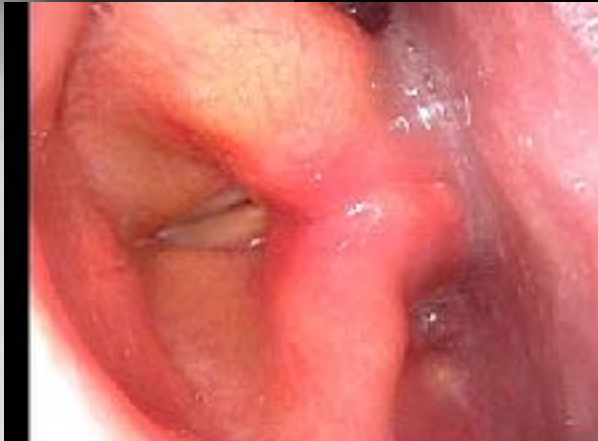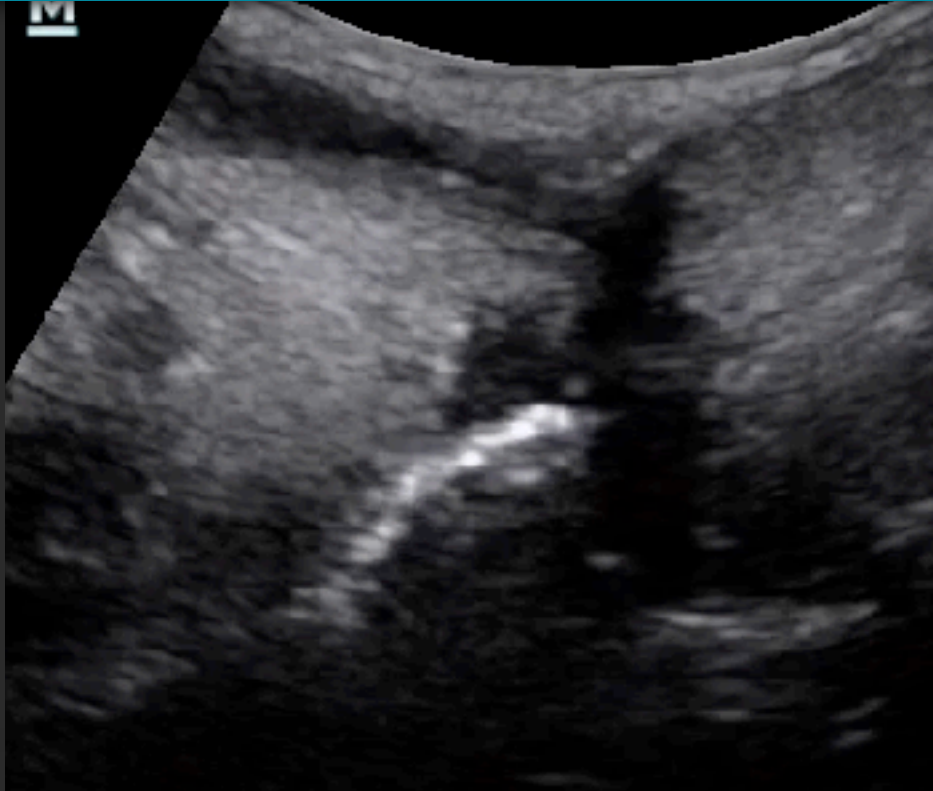
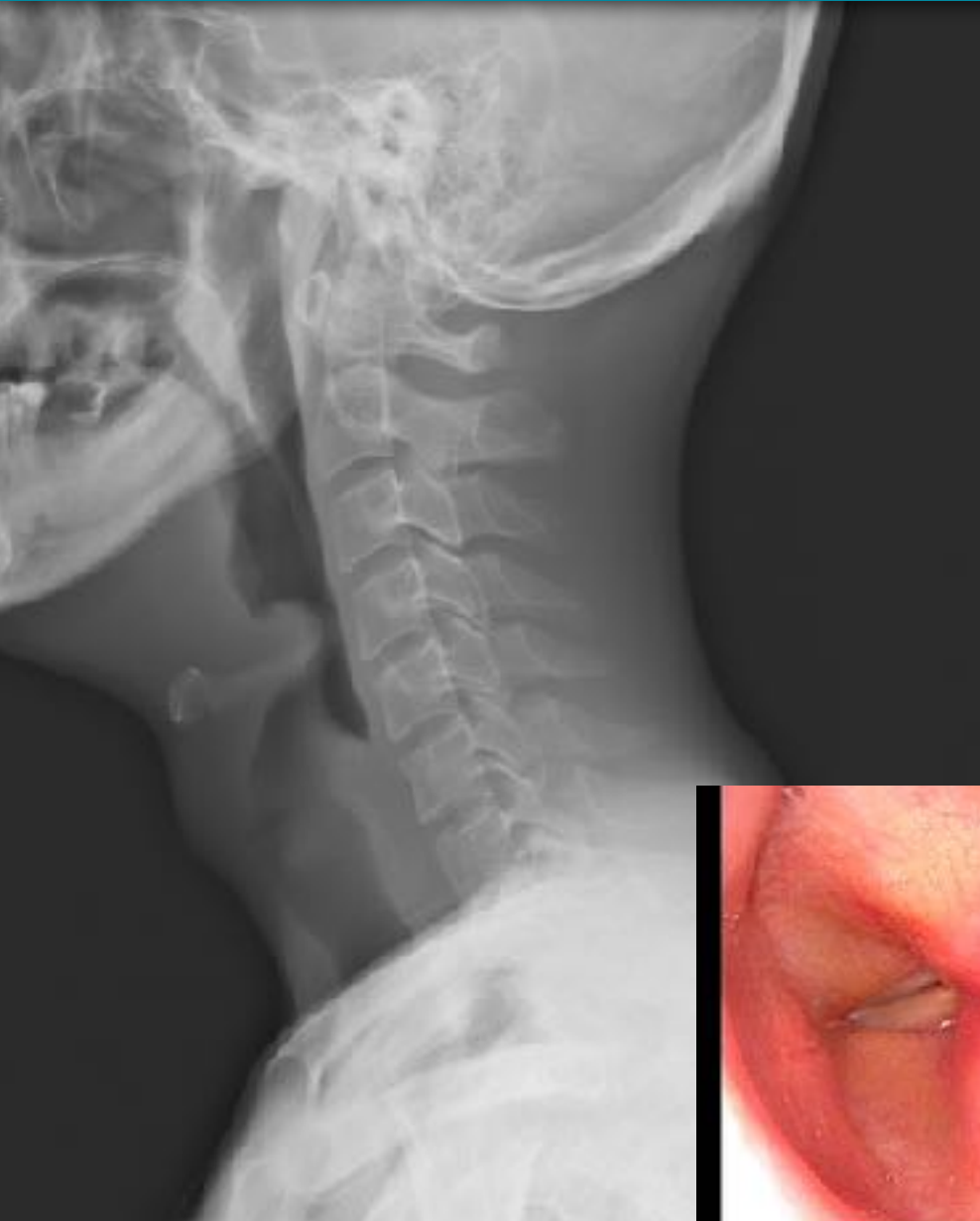IP1 / DR143



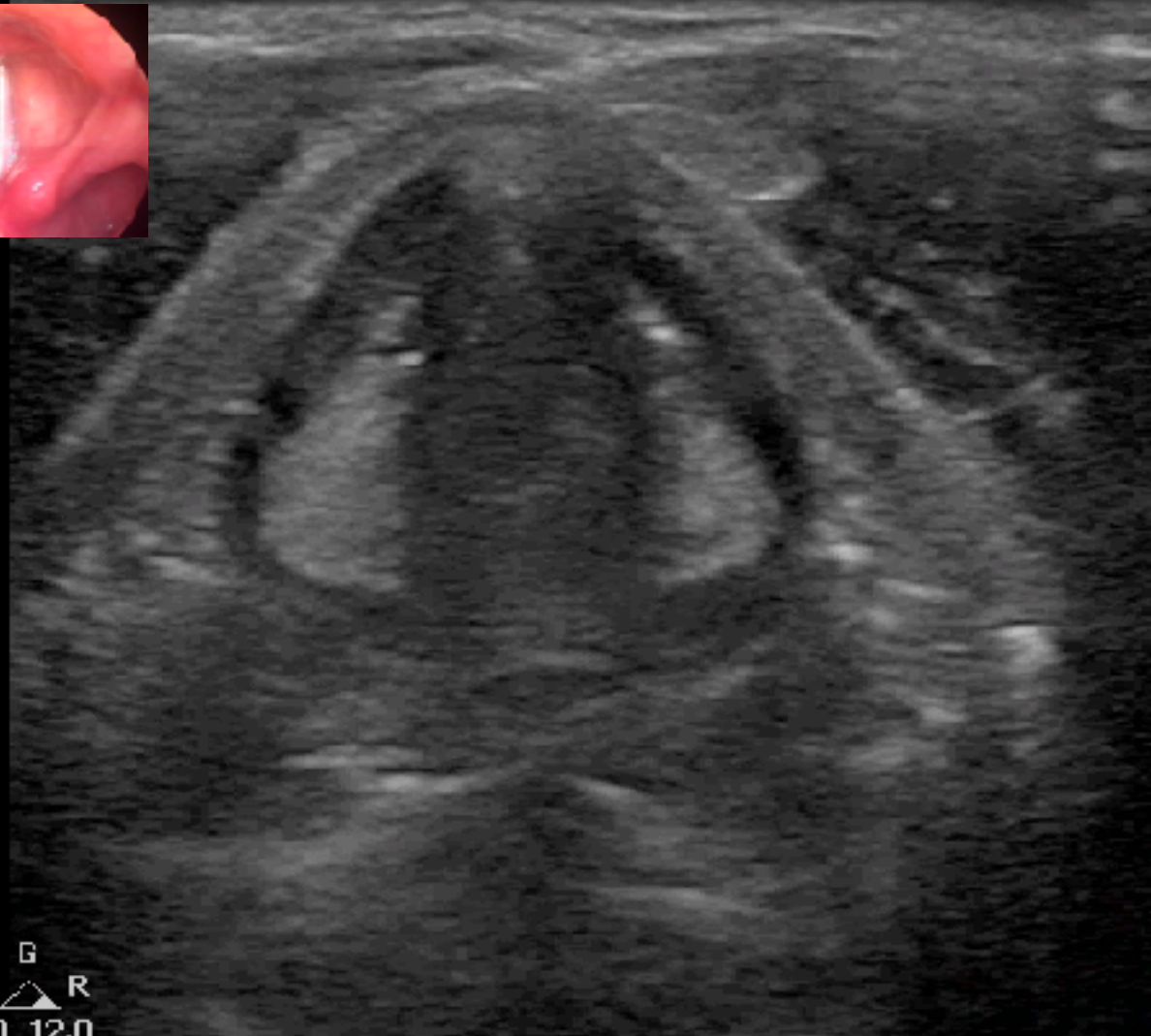
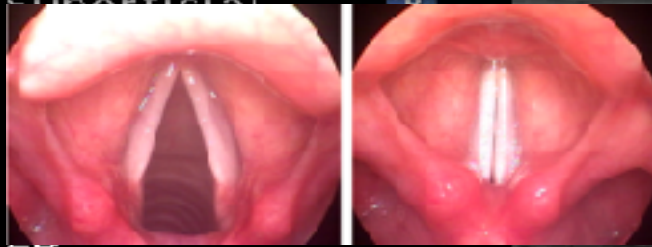M



Acute epiglottitis



Vocal cords



Res
Gn 100
C 56
3 / 2 / 1


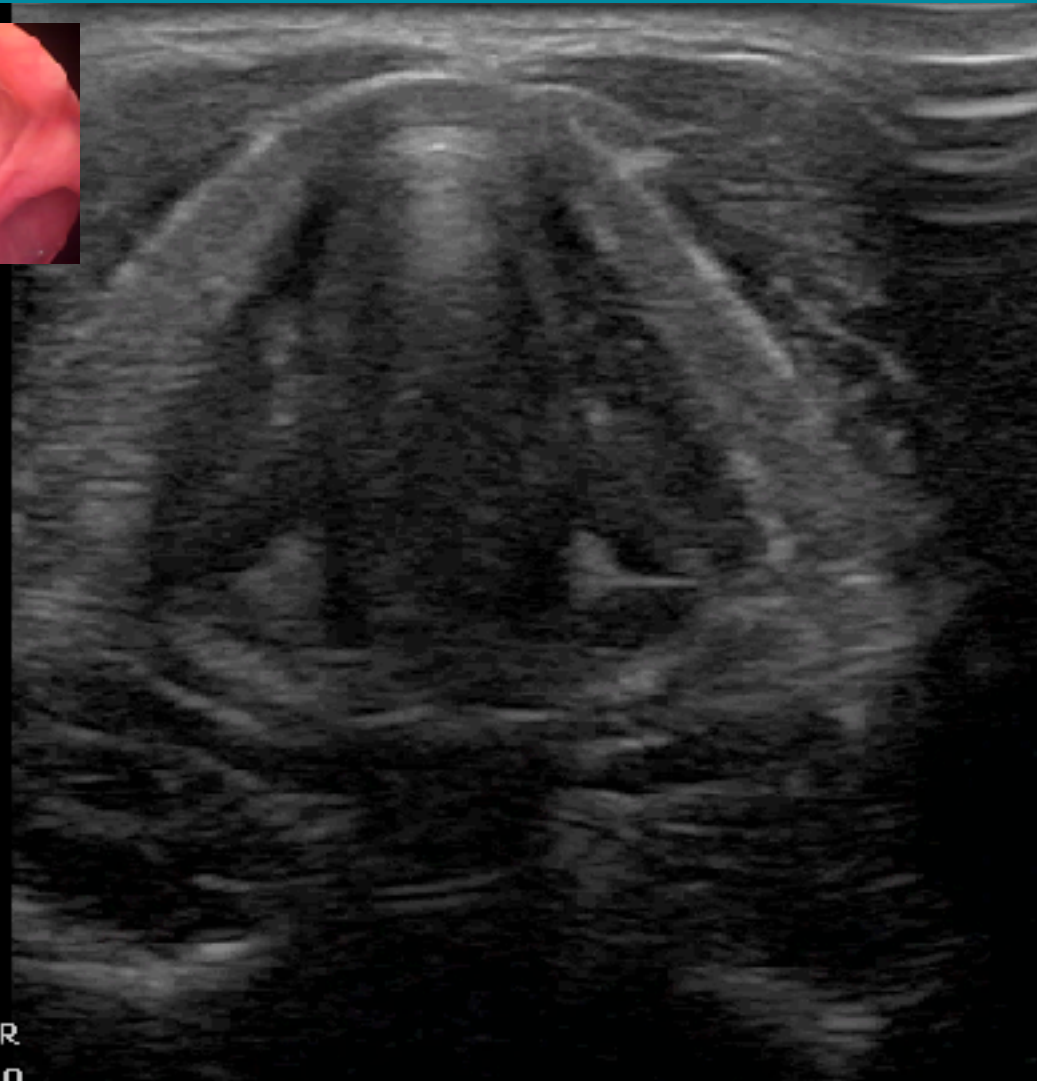
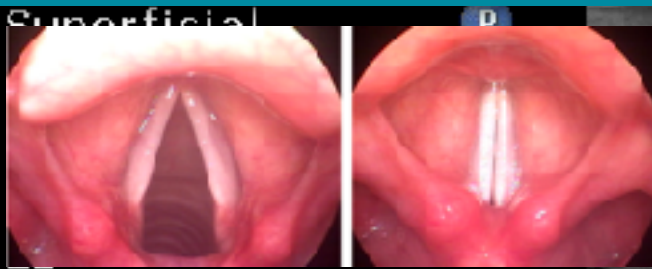


G
P R
3.0, 12.0

0.5cm

Landmark: thyroid cartilage

Phonation

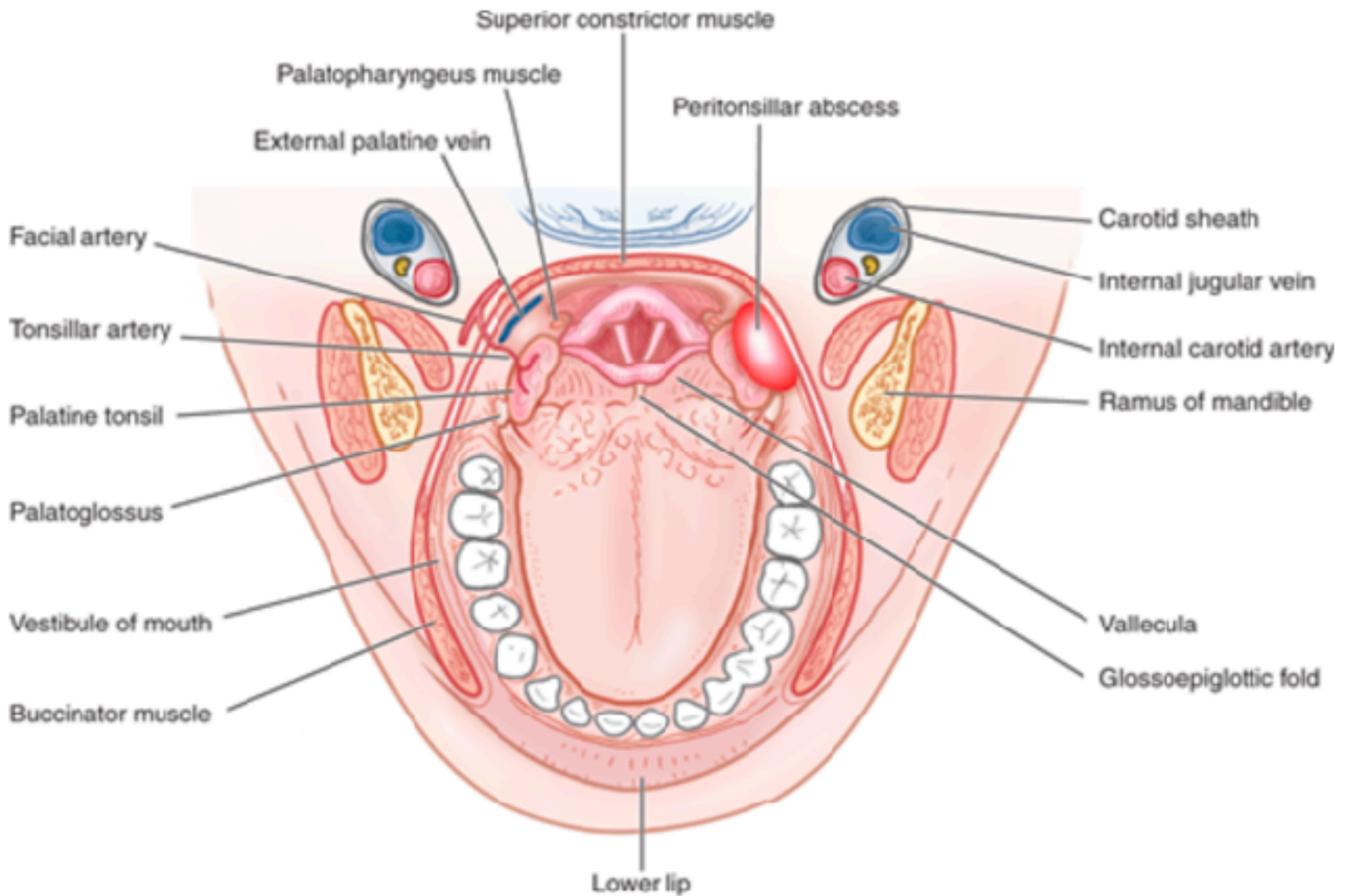


Res
Gn 100
C 56
3 / 2 / 1



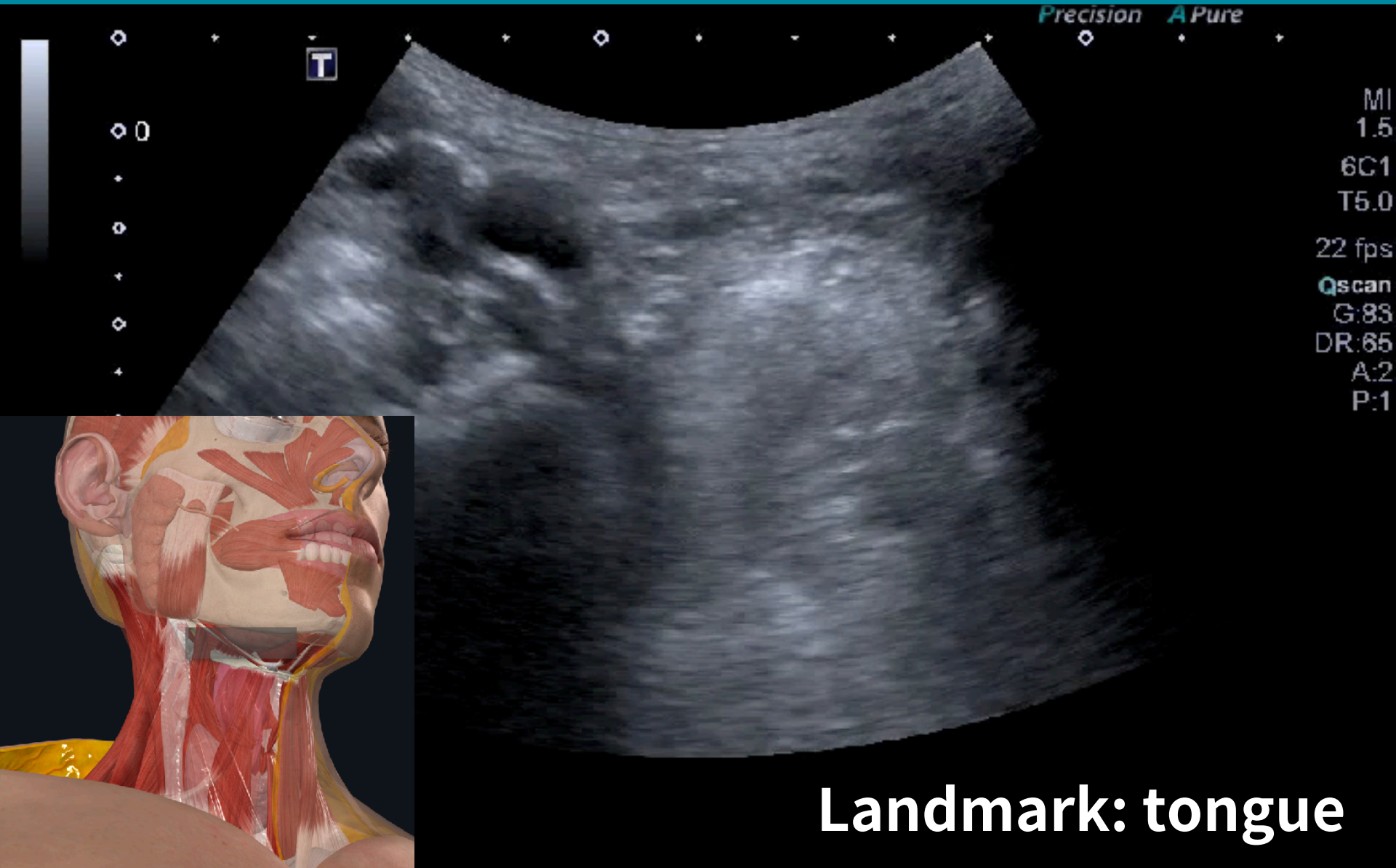
U
P R
3.0 12.0

Landmark: thyroid cartilage



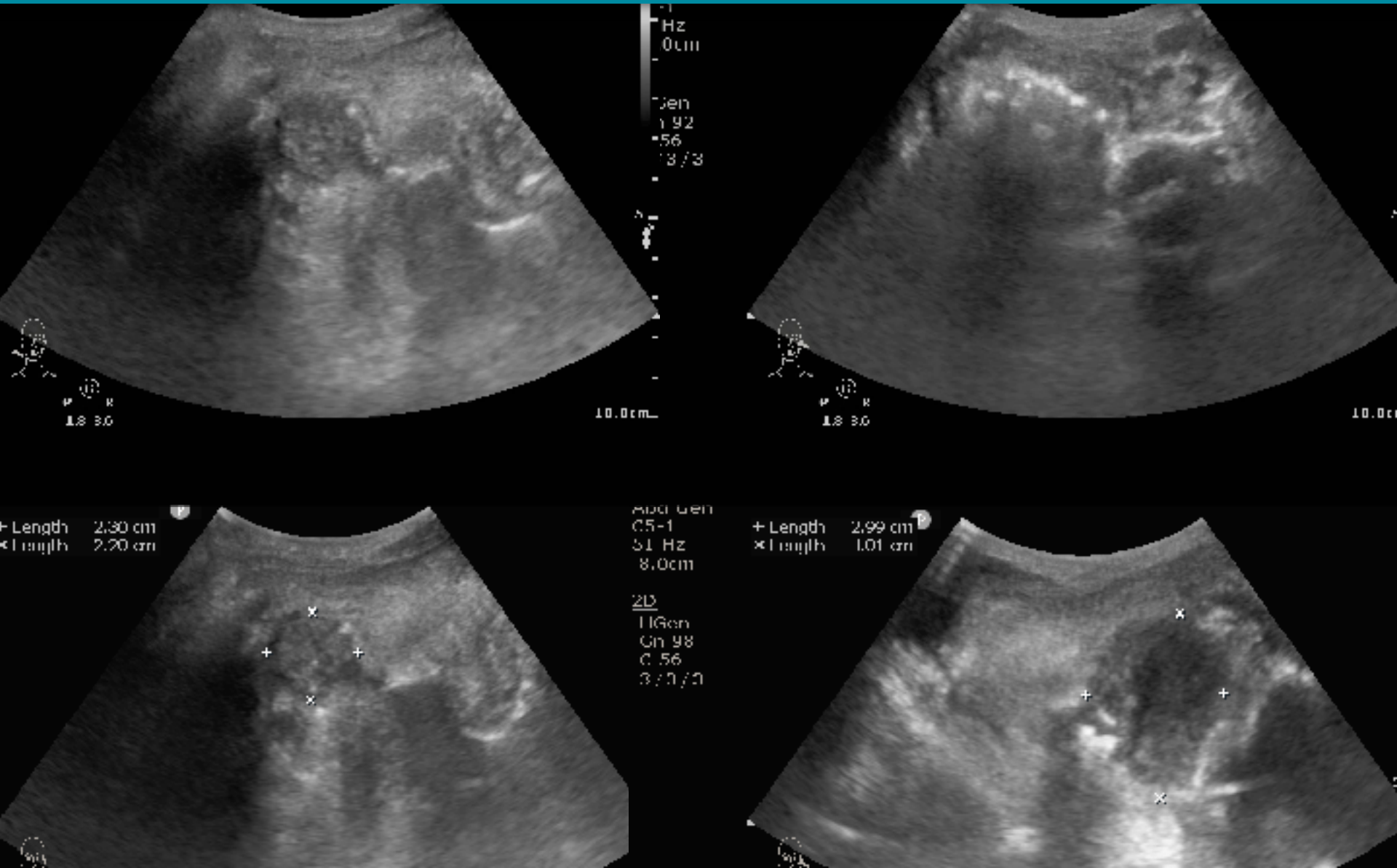
Source: Tintinalli ET: Emergency Medicine Procedures, Second Edition: www.accesssurgery.com
 Copyright © The McGraw-Hill Companies, Inc. All rights reserved.

Tonsil

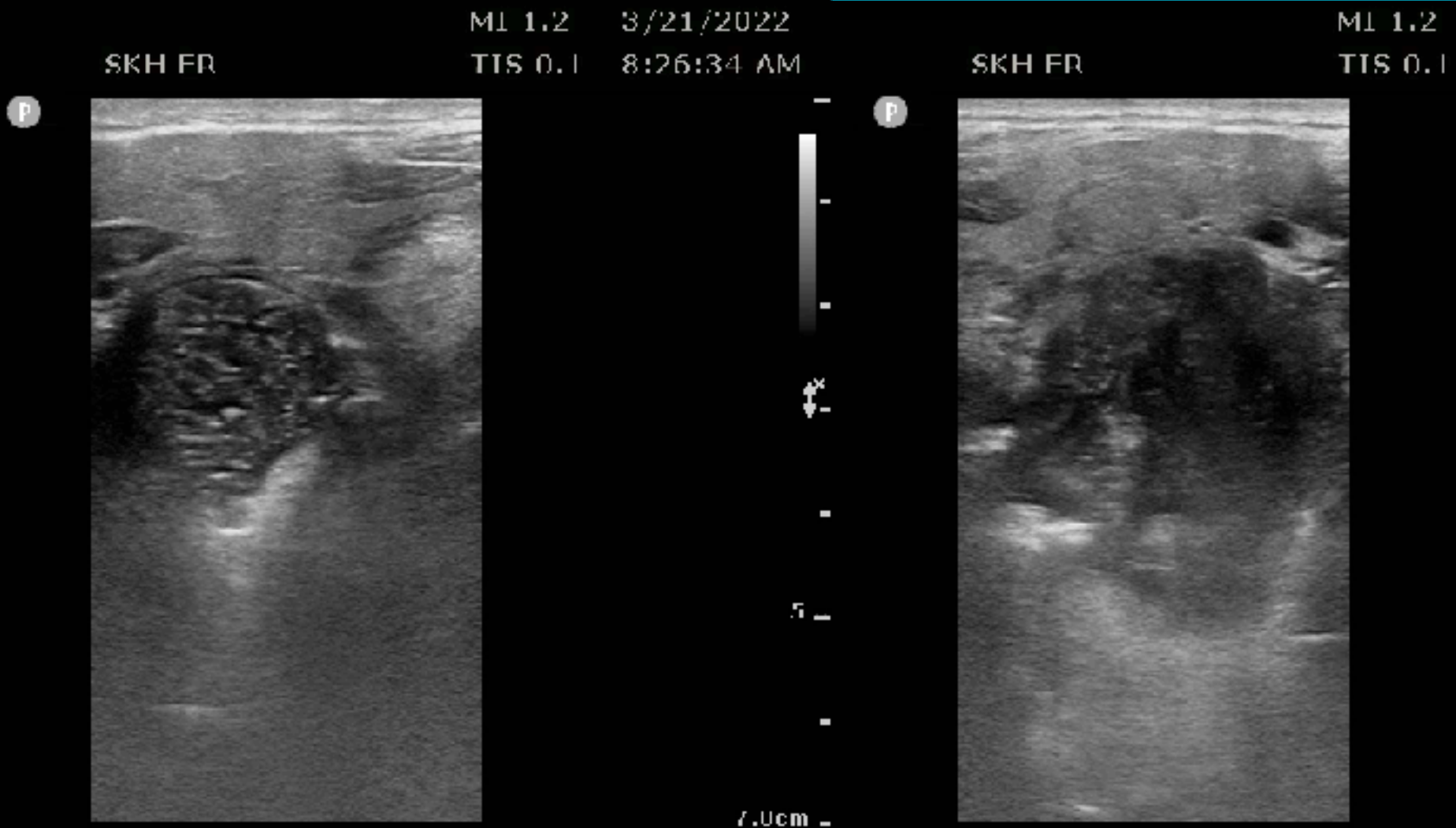


Landmark: tongue

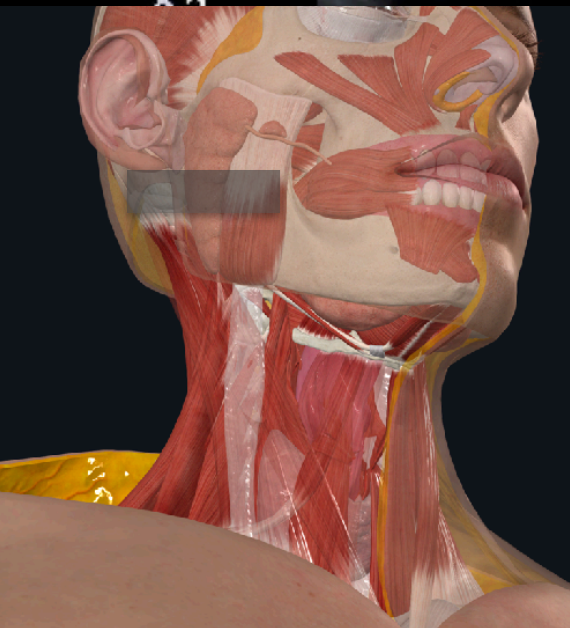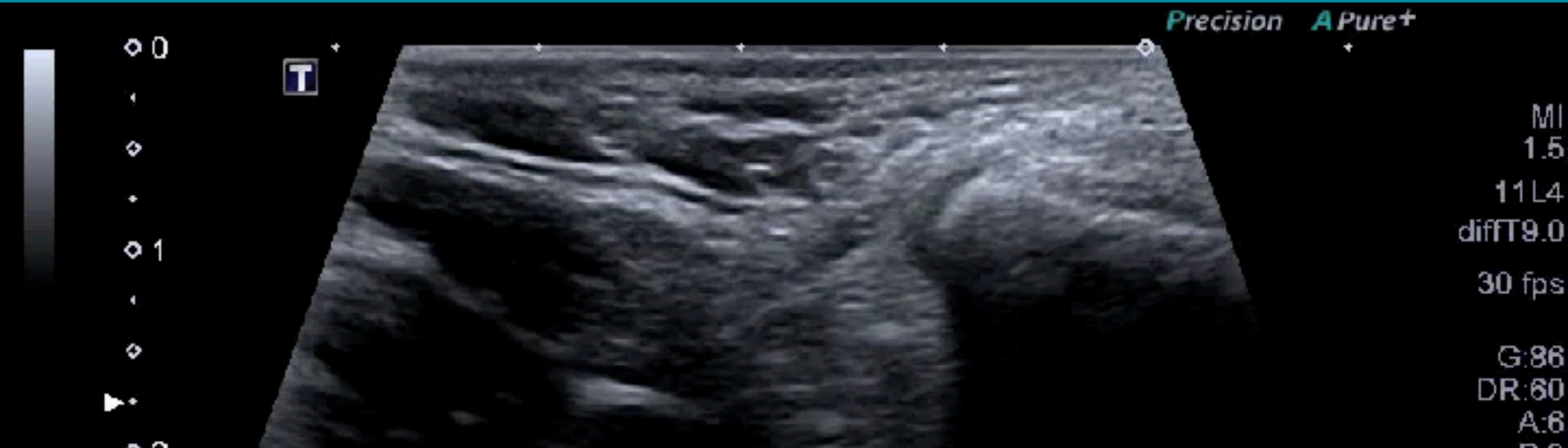26M, severe left throat pain



Peritonsillar abscess

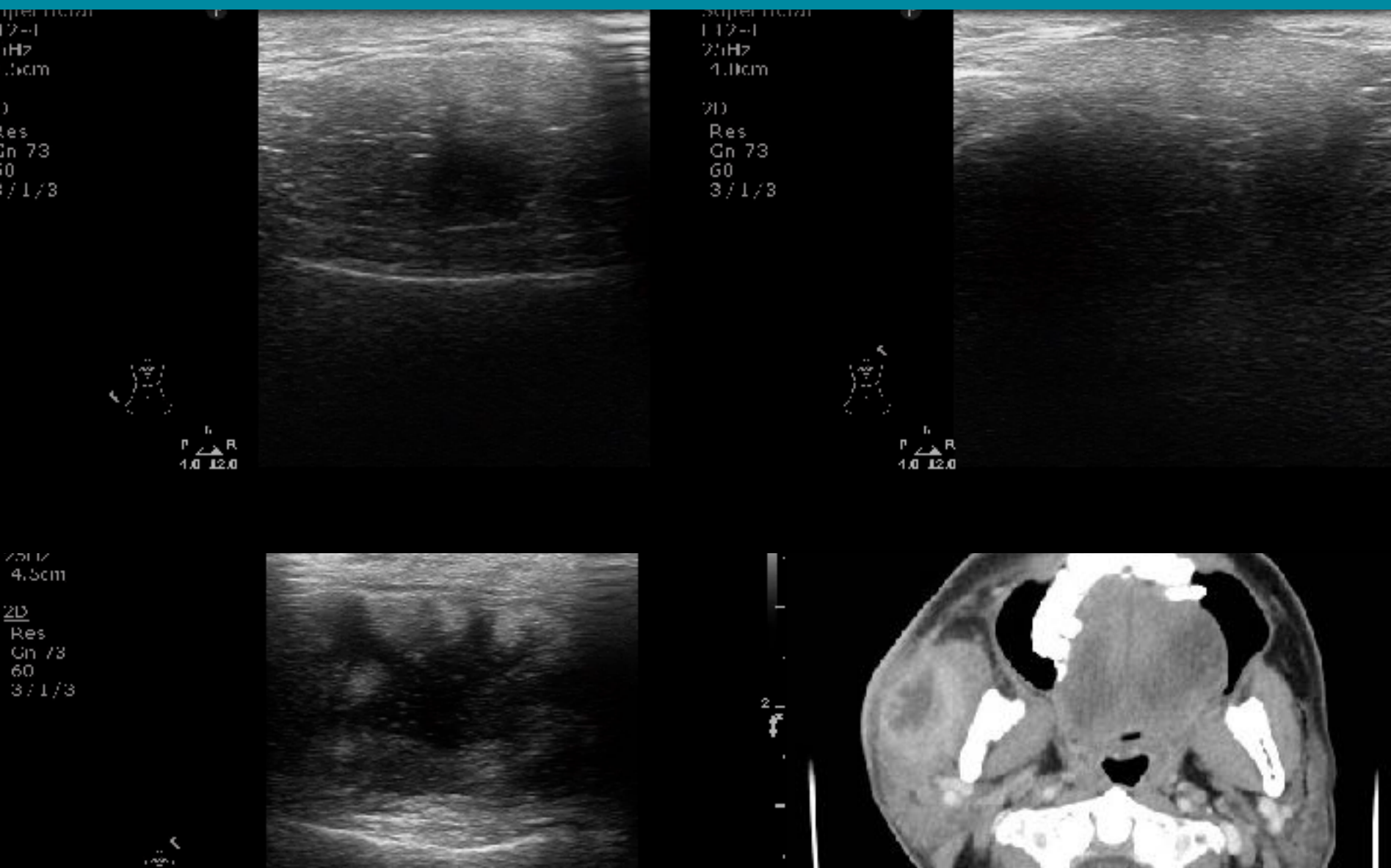


Parotid gland

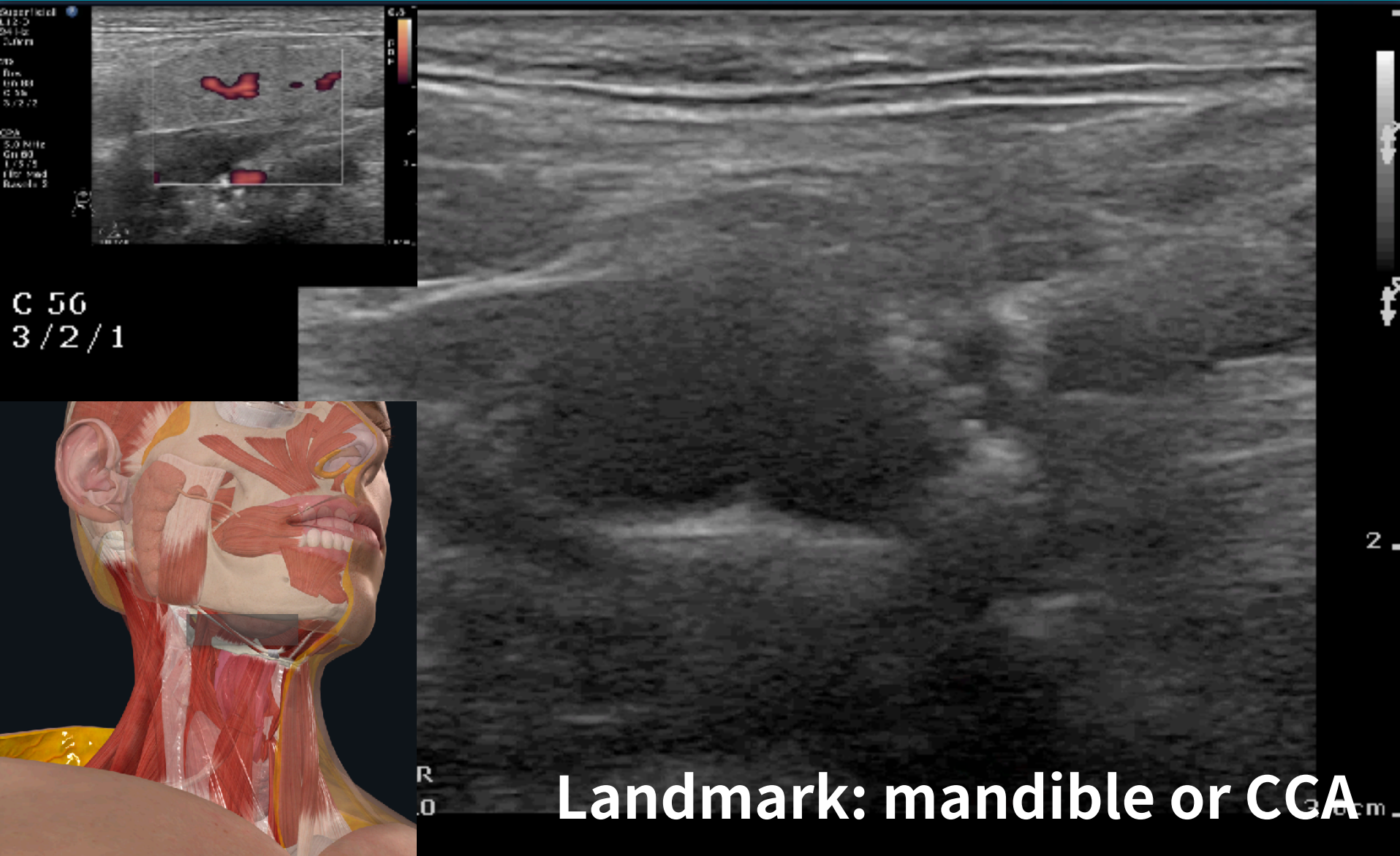


Landmark: mandible & mastoid

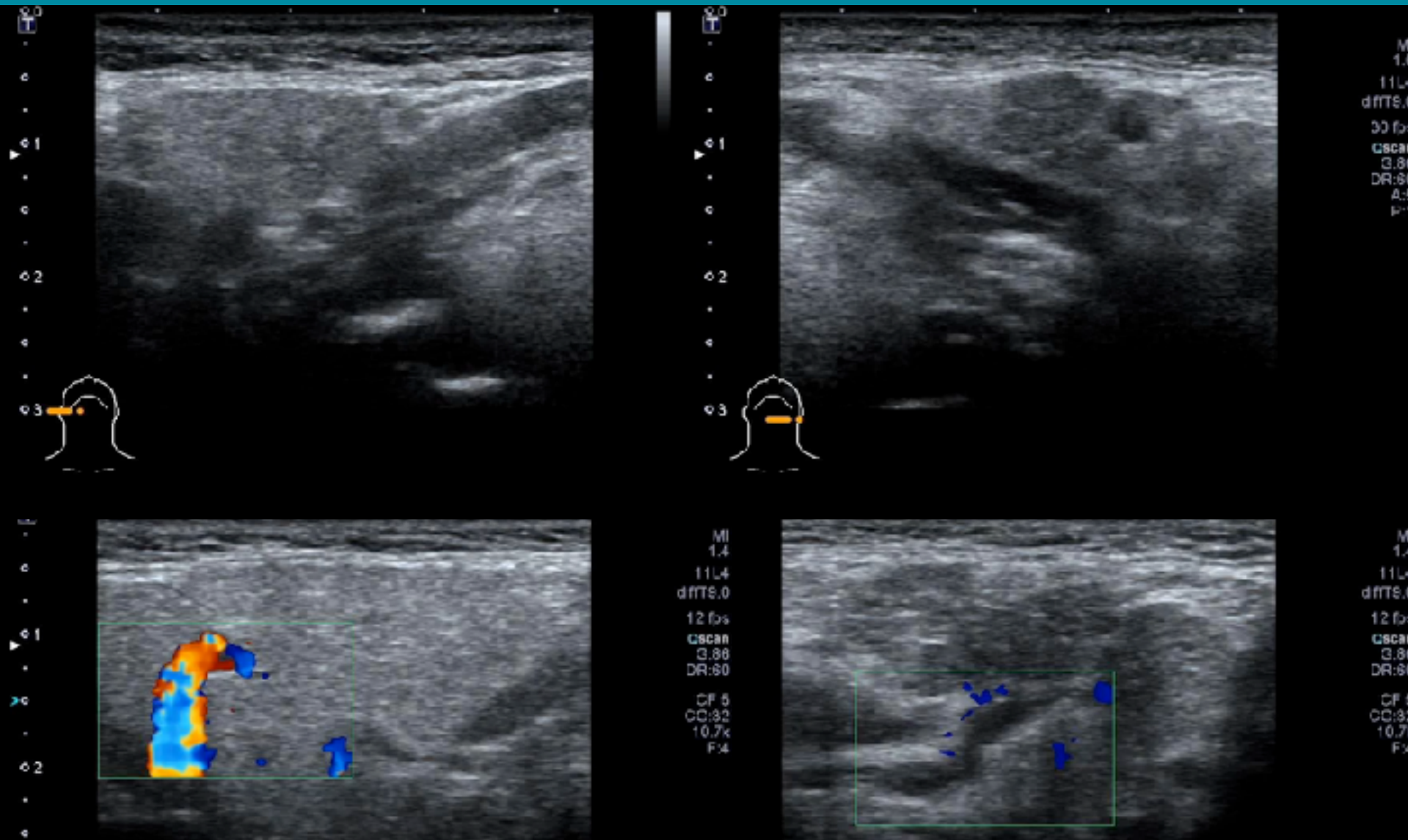
69M, 右臉腫，門診轉入腮腺炎



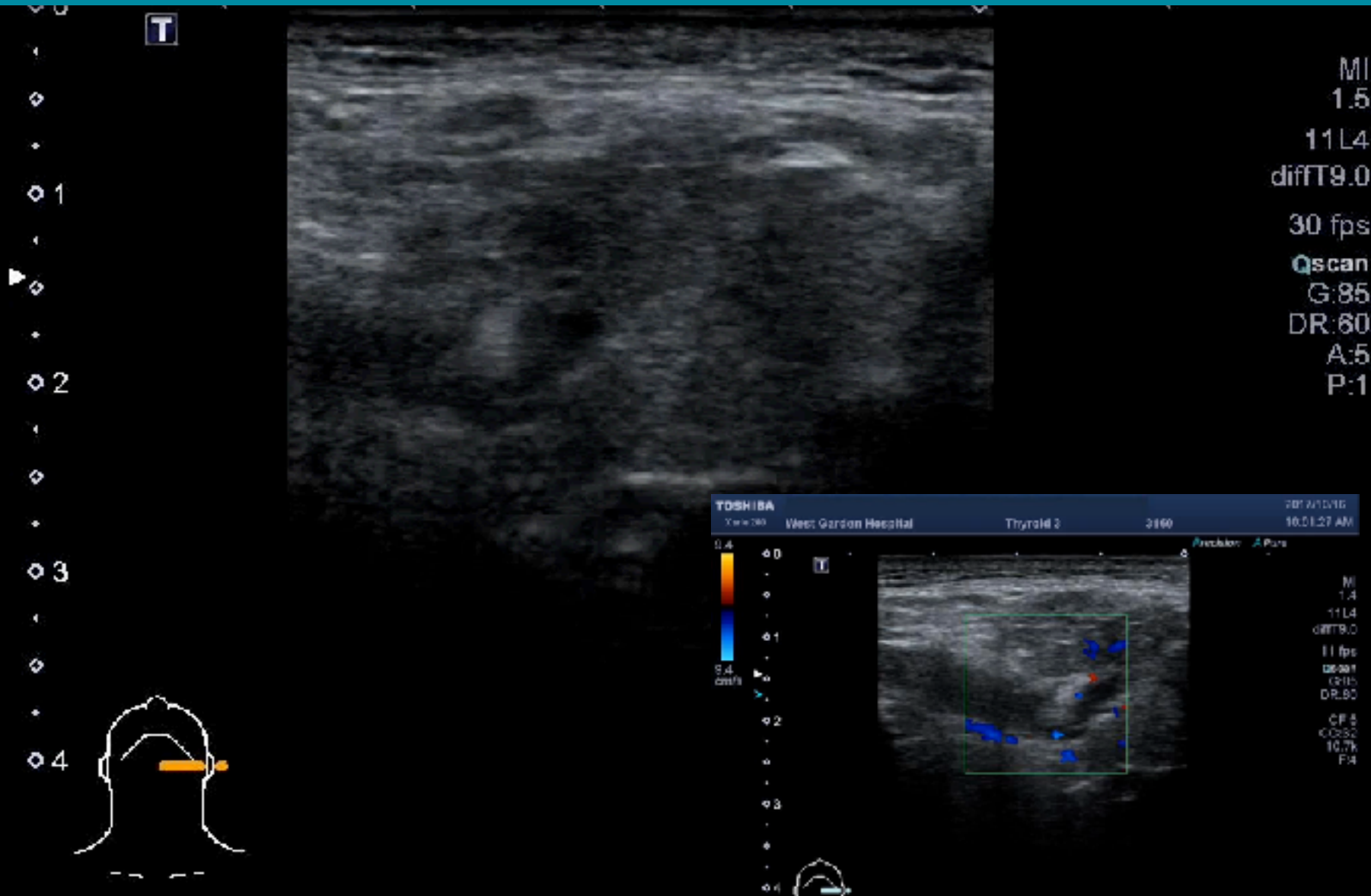
Submandibular gland



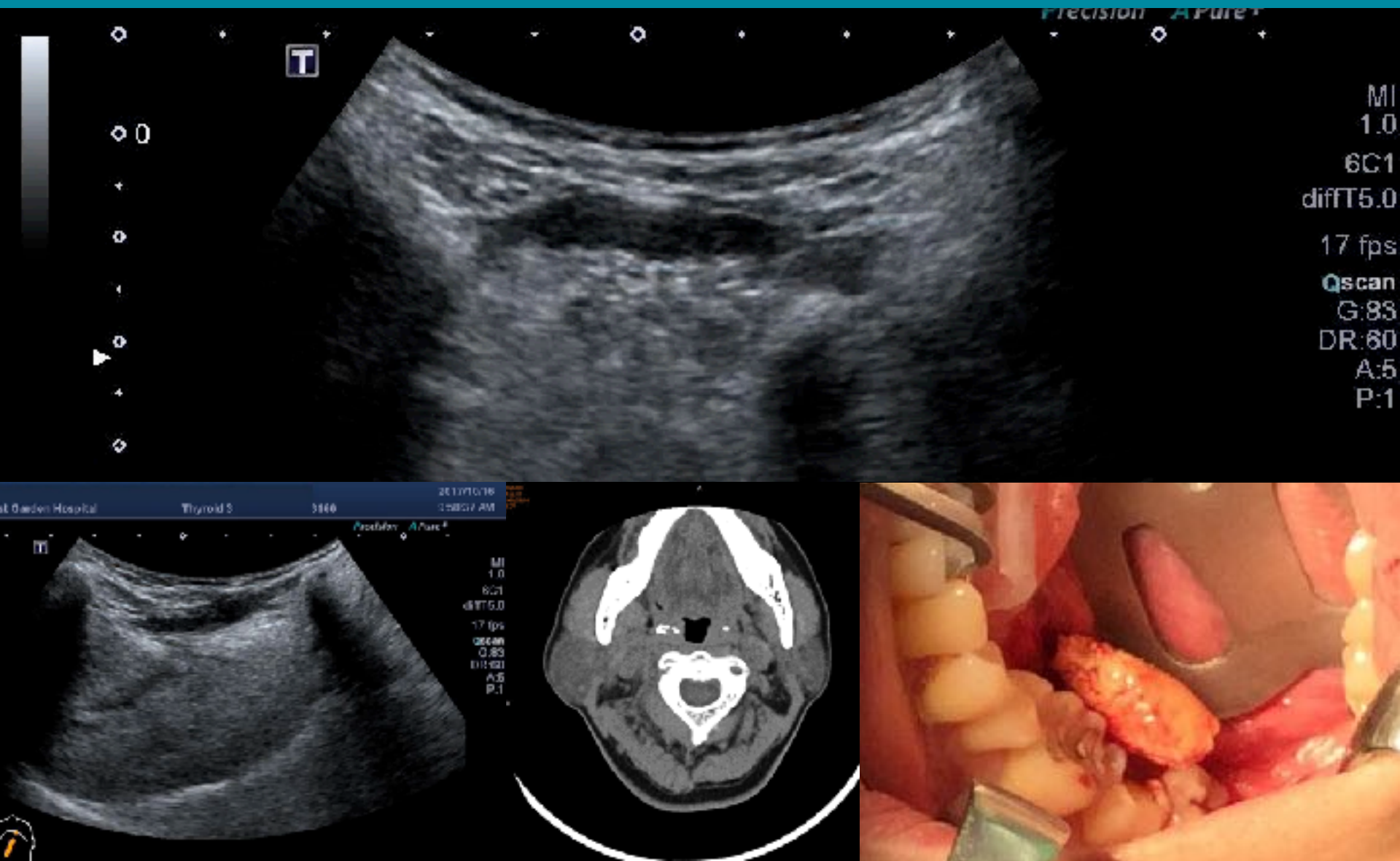
57F, 左下巴痛好幾週



57F, 左下巴痛好幾週



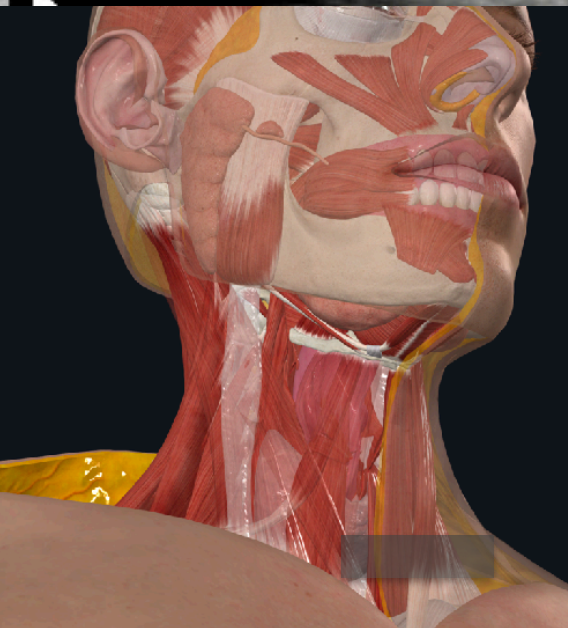Sialolithiasis



Thyroid gland

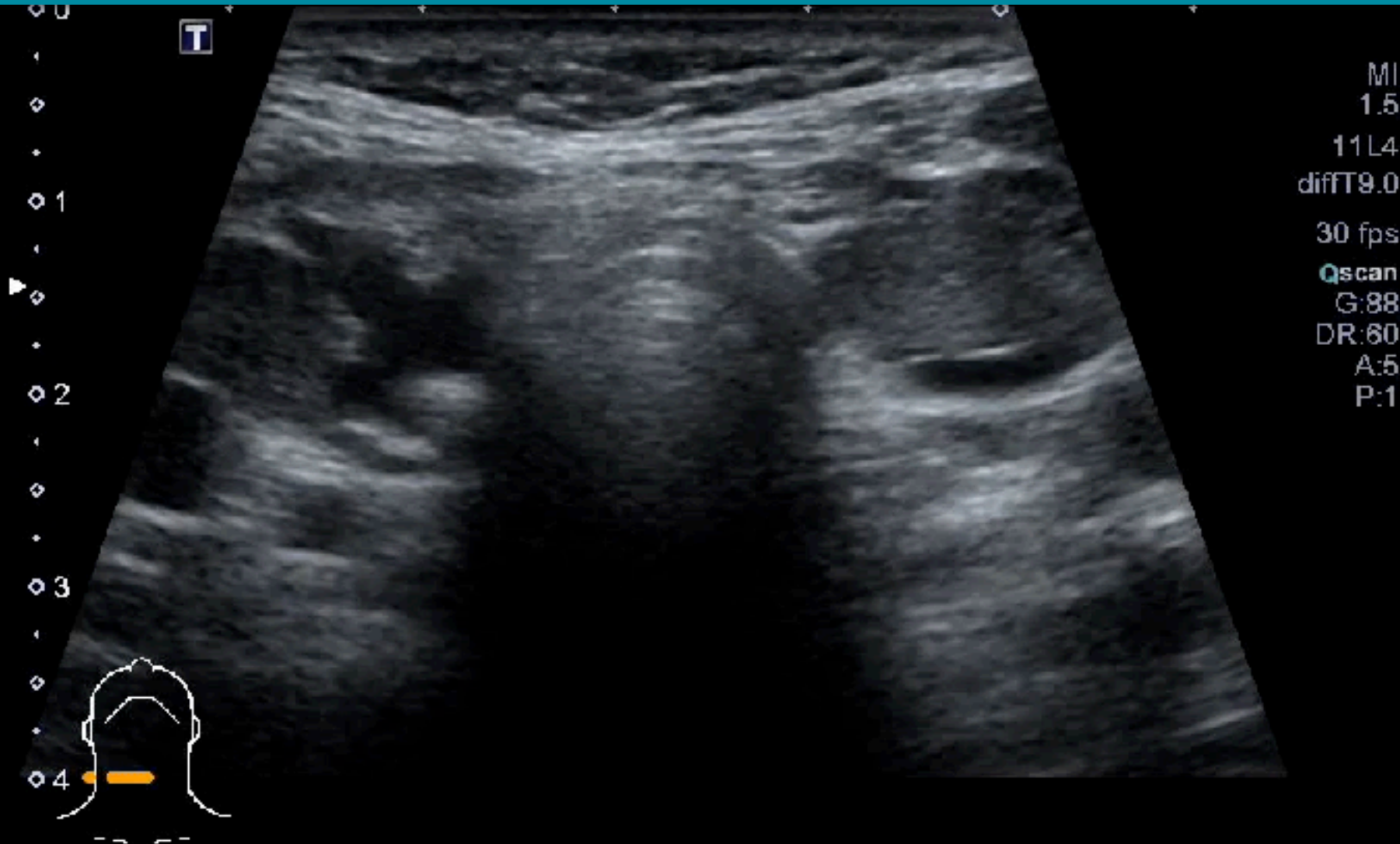
SAMSUNG
RS80A

1

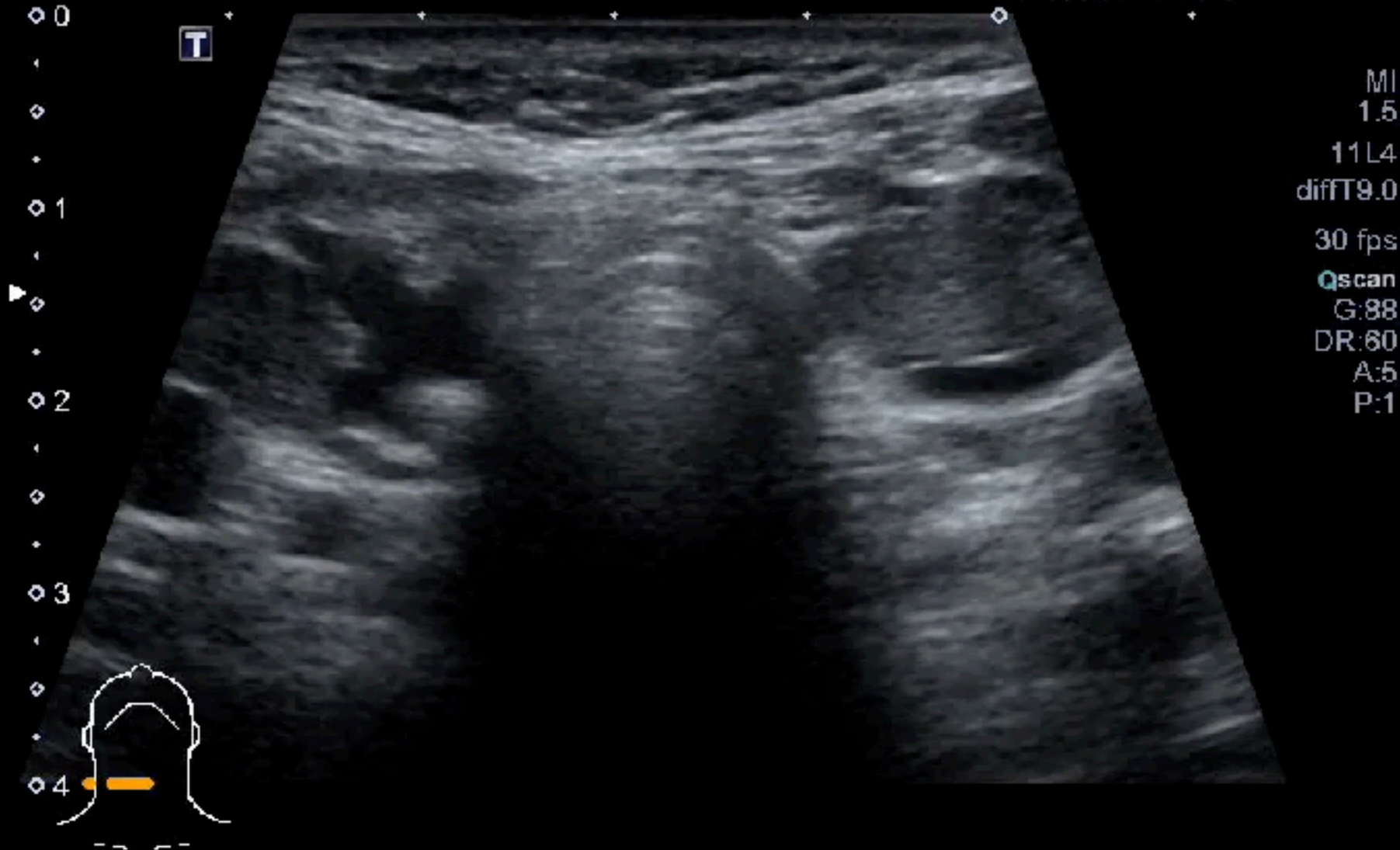


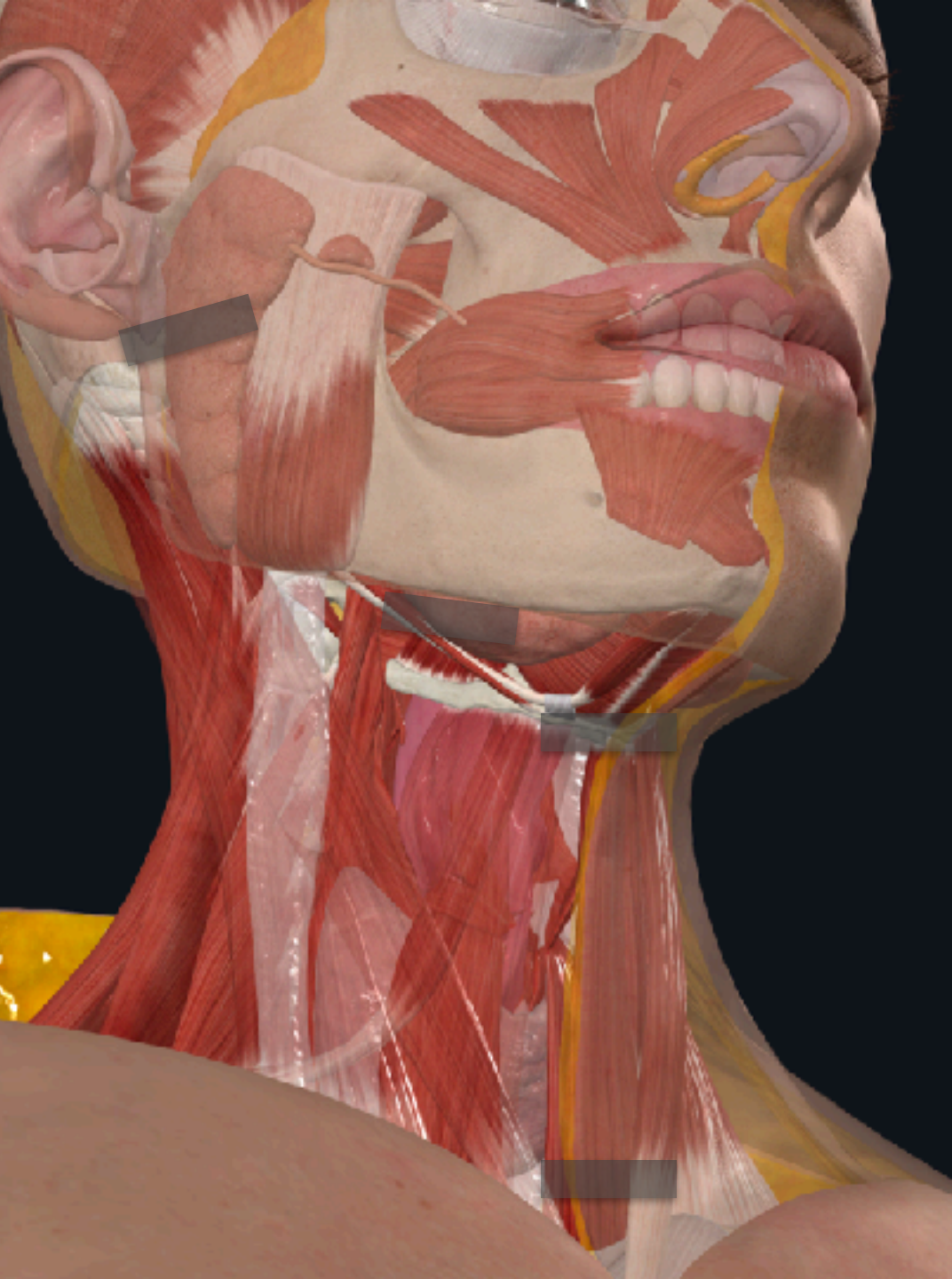
Landmark: suprasternal notch & trachea

36F, 雙腳無力低血鉀



Hyperthyroidism





1 Epiglottitis

2 Tonsils

3 Glands

