



衛生福利部雙和醫院
(委託臺北醫學大學興建經營)
Taipei Medical University · Shuang Ho Hospital,
Ministry of Health and Welfare



Basic pulmonary ultrasonography & “DYSPNEA approach” the BLUE protocol

2022 神經急重症照護 POCUS工作坊

陳國智醫師

雙和醫院急診醫學科

陳國智 醫師

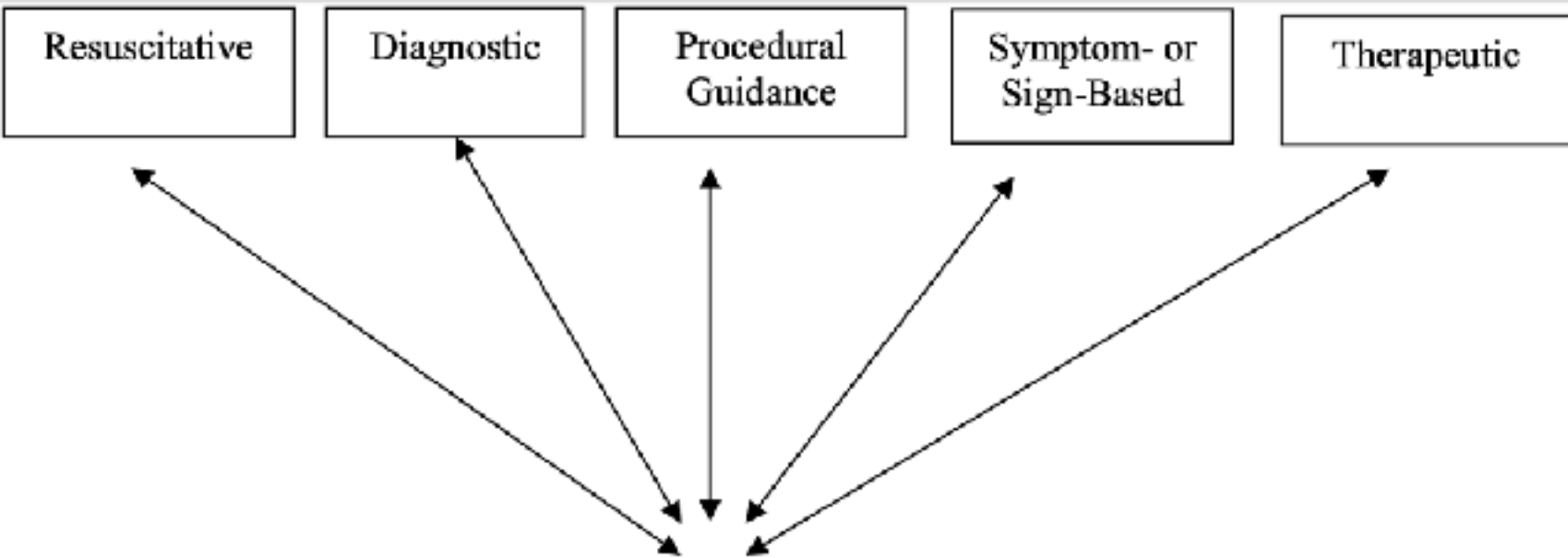


急診超音波臨床評核醫師
醫用超音波學會指導醫師
WINFOCUS director / instructor

急診 / 重症 / 介入 / 急性疼痛

經歷

新光急診超音波訓練中心主任
西園醫院急診醫學科主任
急診醫學會超音波委員會主委
台灣疼痛醫學會大體模擬手術講師
急救加護醫學會重症超音波負責人



2016 ACEP Policy

- Core Applications
- Trauma
 - Intrauterine Pregnancy
 - AAA
 - Cardiac/HD Assessment
 - Biliary
 - Urinary Tract
 - DVT
 - Soft-tissue/Musculoskeletal
 - Thoracic/Airway**
 - Ocular
 - Bowel
 - Procedural Guidance



Normal
PTX
AIS
PLE
Consolidation

Lung US 常用探頭



弧



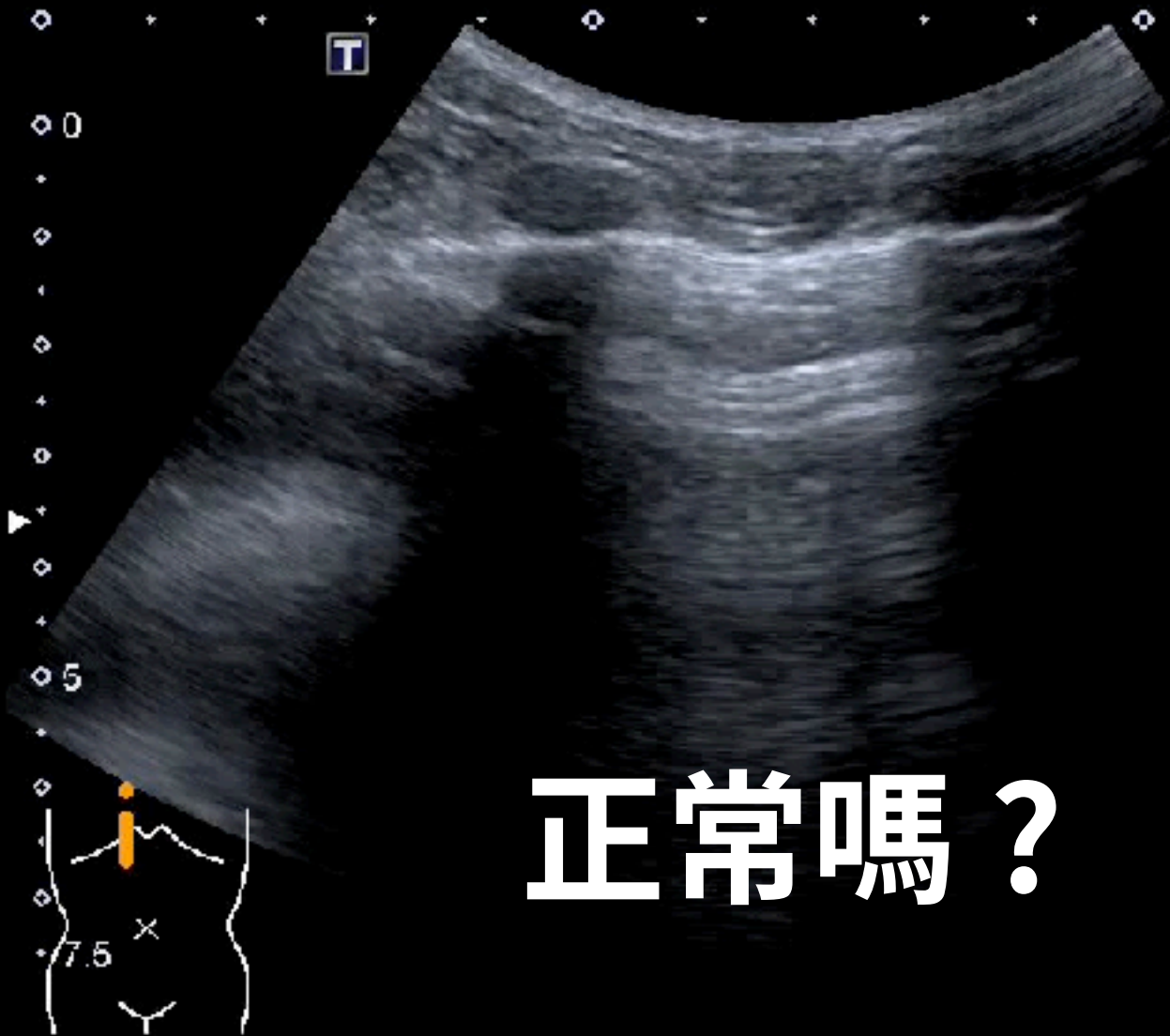
線



扇



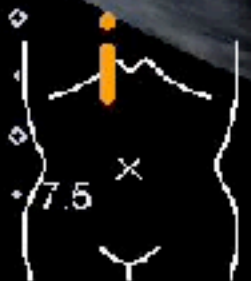LUNG



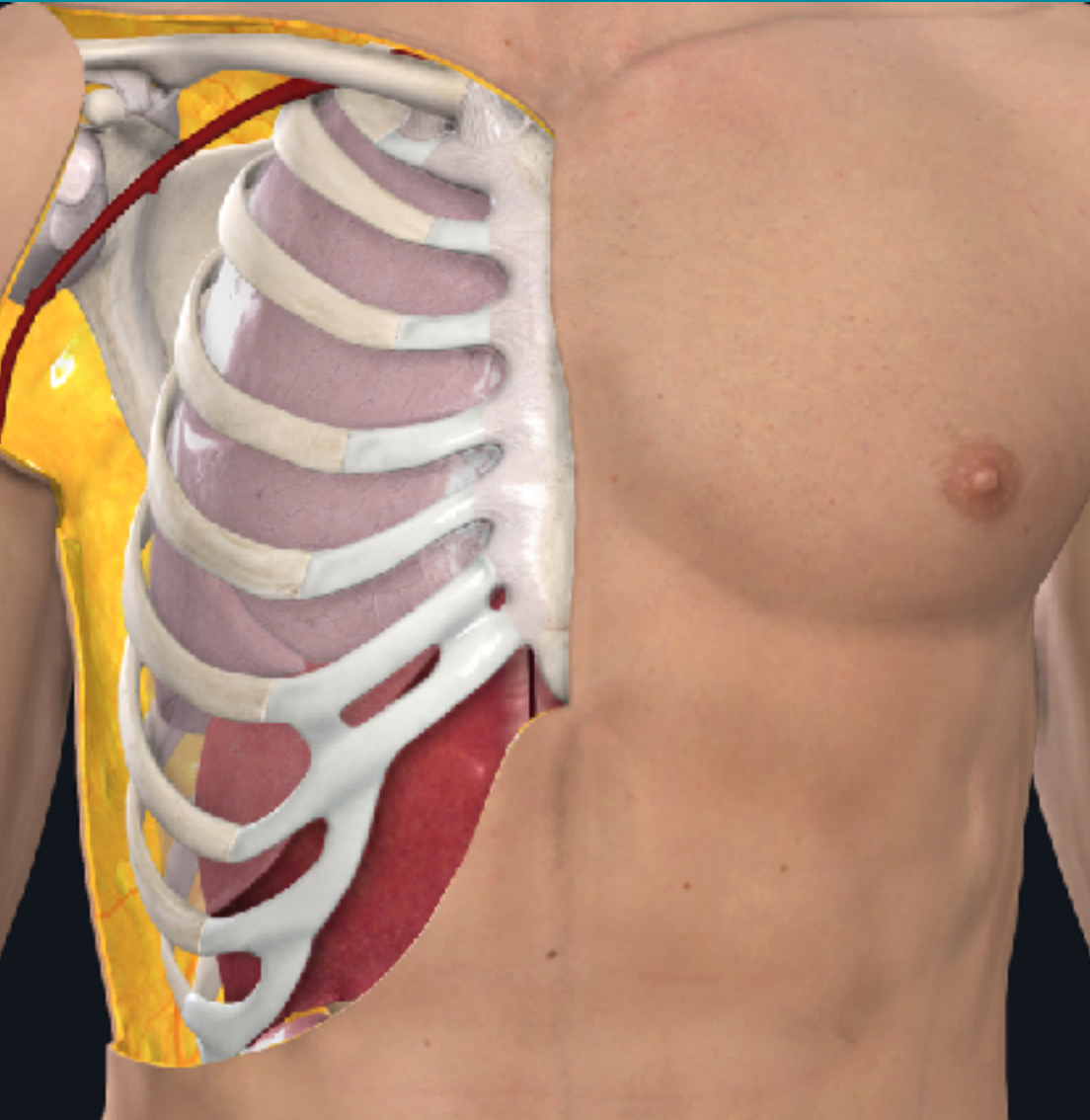
Precision Apure

MI
1.5
6C1
T5.0
22 fps
G:85
DR:65
A:2
P:1

正常嗎？



LUNG USG APPLICATIONS



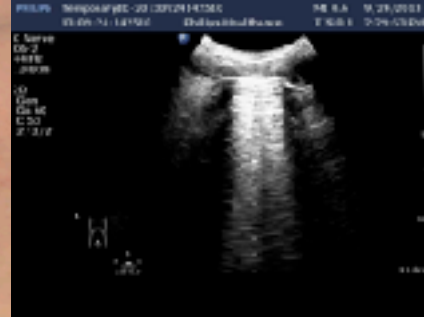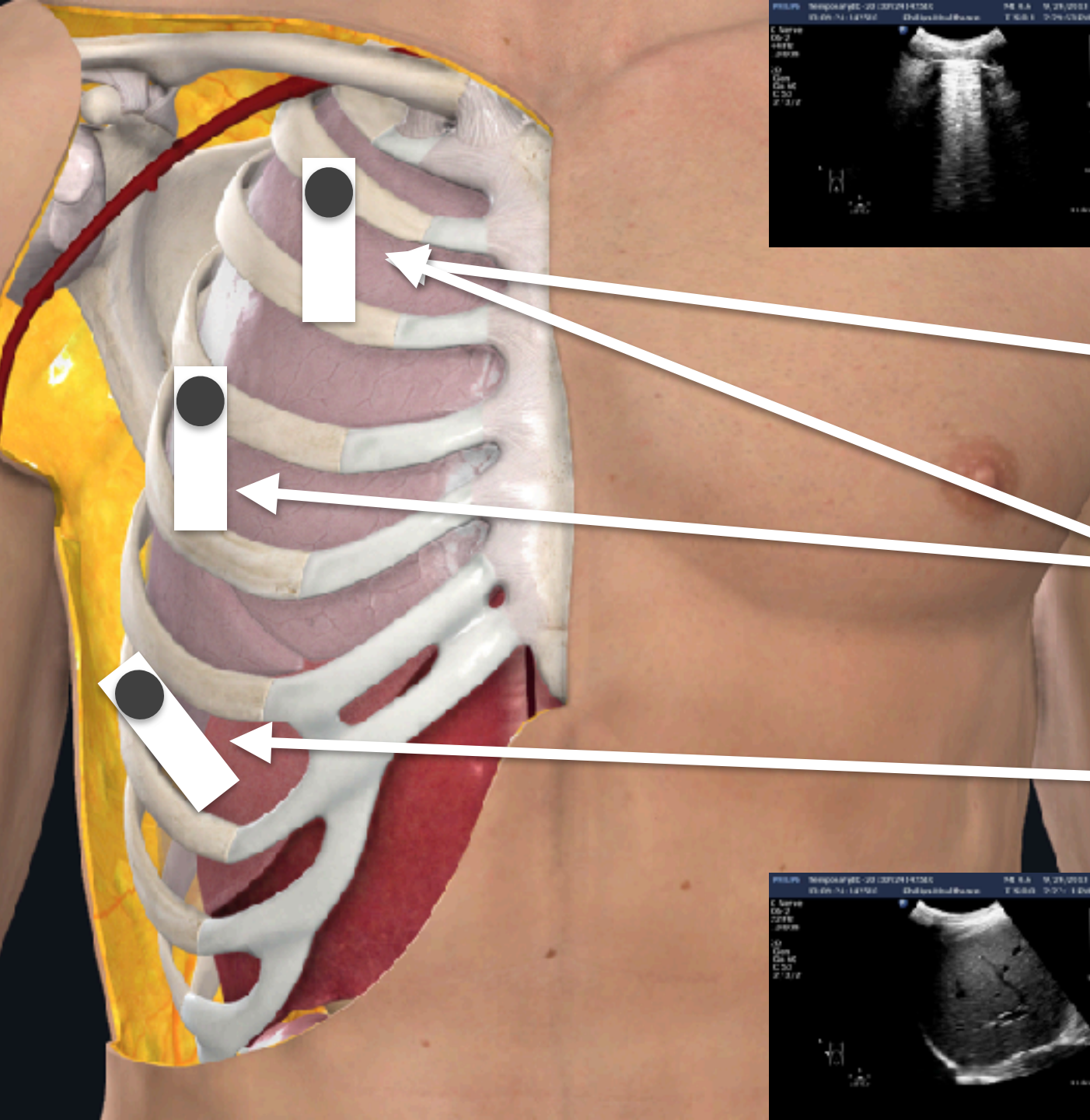
Dyspnea
Chest pain
Infections

PTX

AIS

PLE

Consolidation⁶

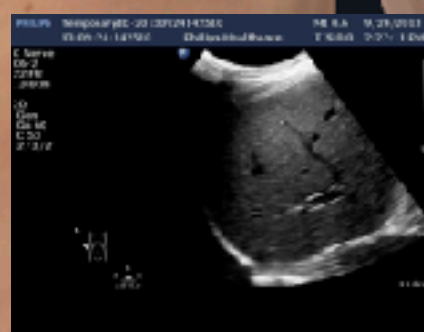


AIR

PTX

AIS

PLE



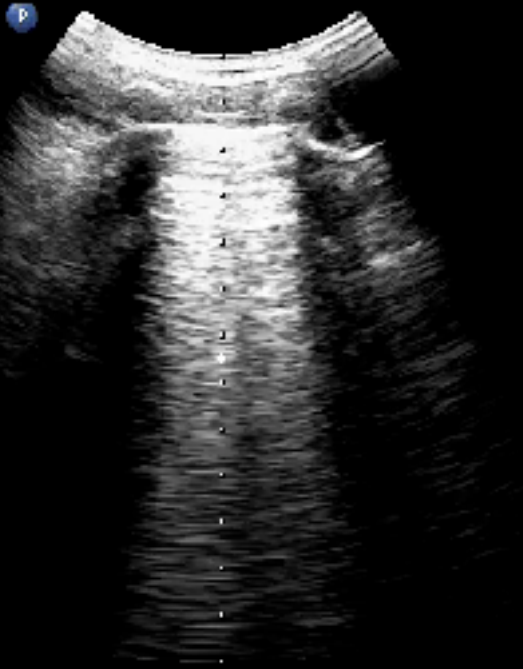FLUID

NORMAL LUNG

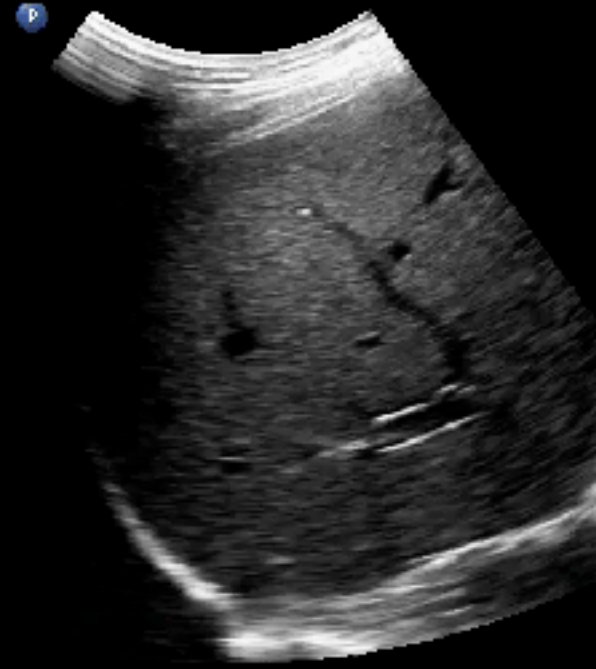
肋膜/滑動

橫膈膜/移動

TemporaryID 20130924142510 MT 0.6 9: PHILIPS 13 09 24 142510 Philips Healthcare TIS 0.1 2: TemporaryID 20130924142510 MT 0.6 9:24 13 09 24 142510 Philips Healthcare TIS 0.0 2:27



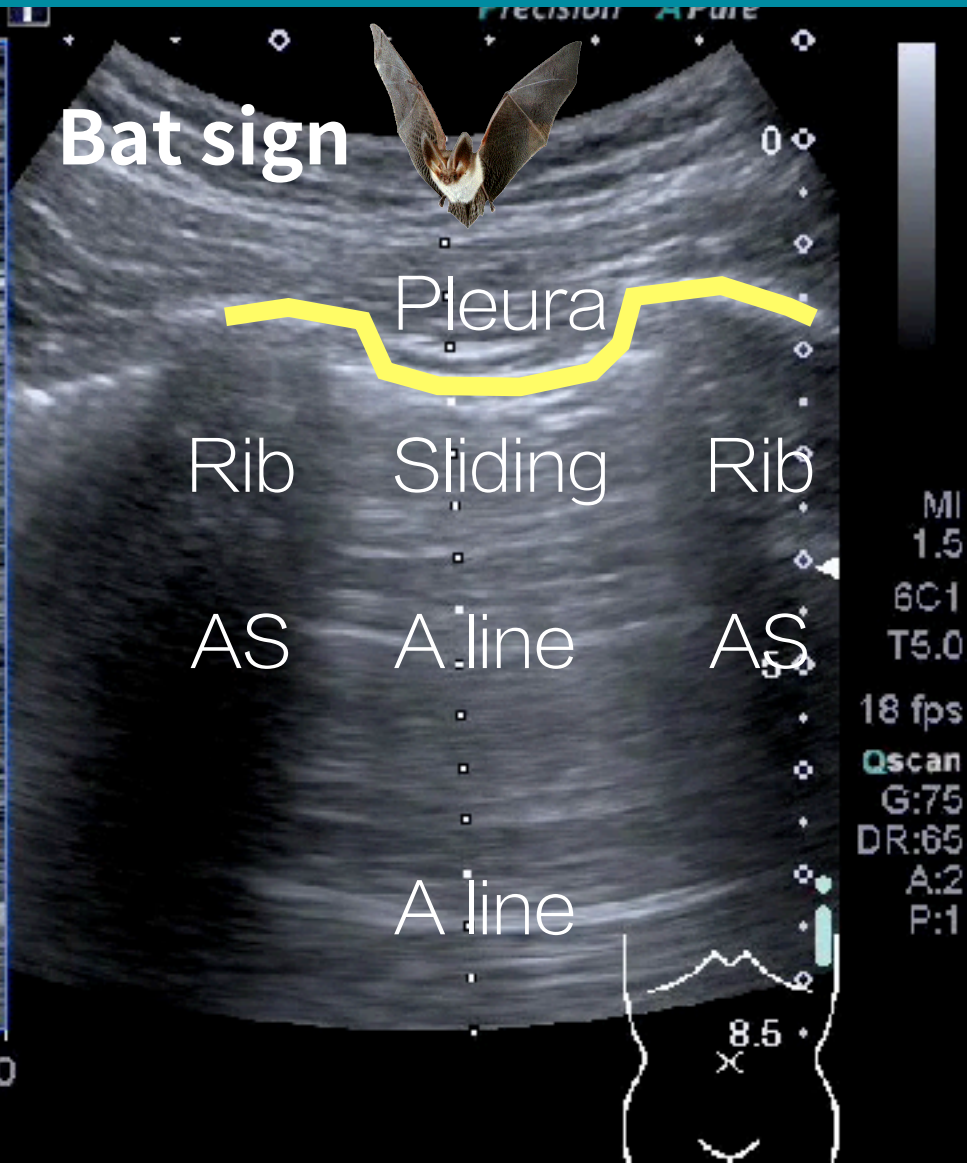
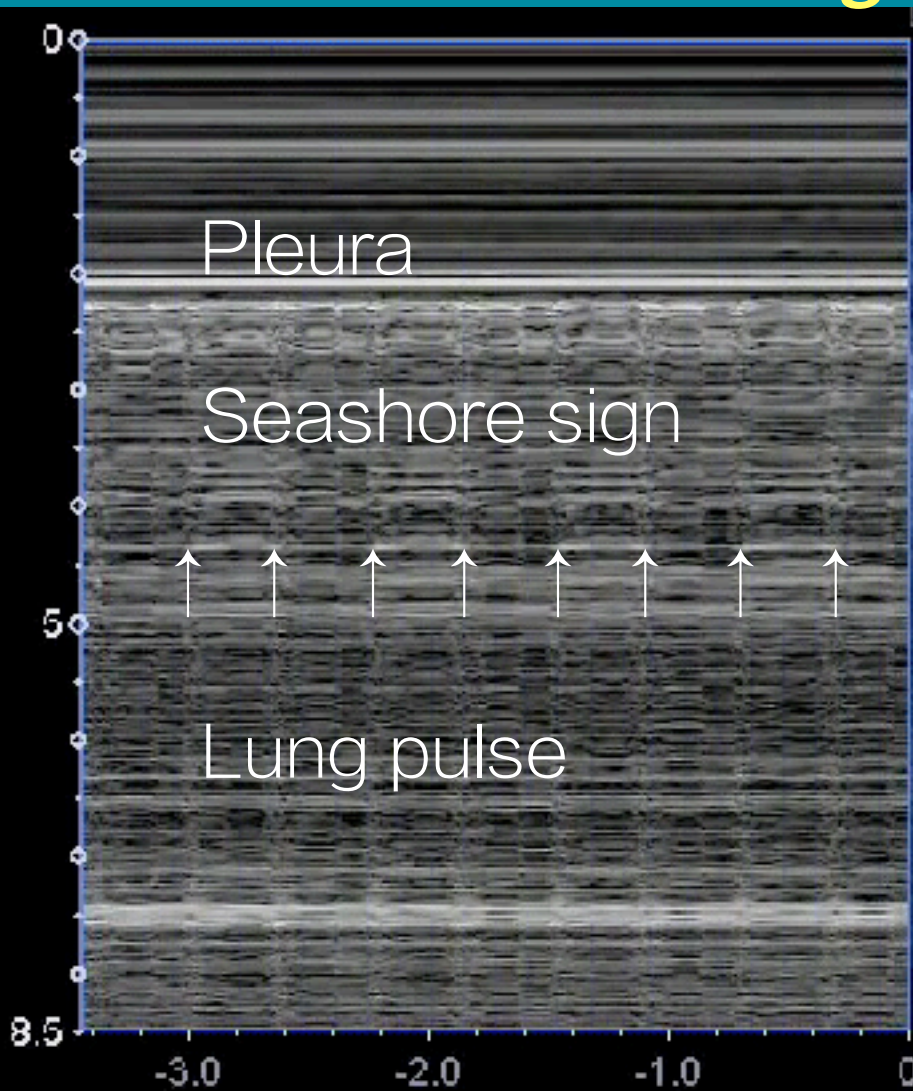
C Nerve
CG-2
22 Hz
13.0cm
2D
Gen
Gr 60
C 53
2/3/2



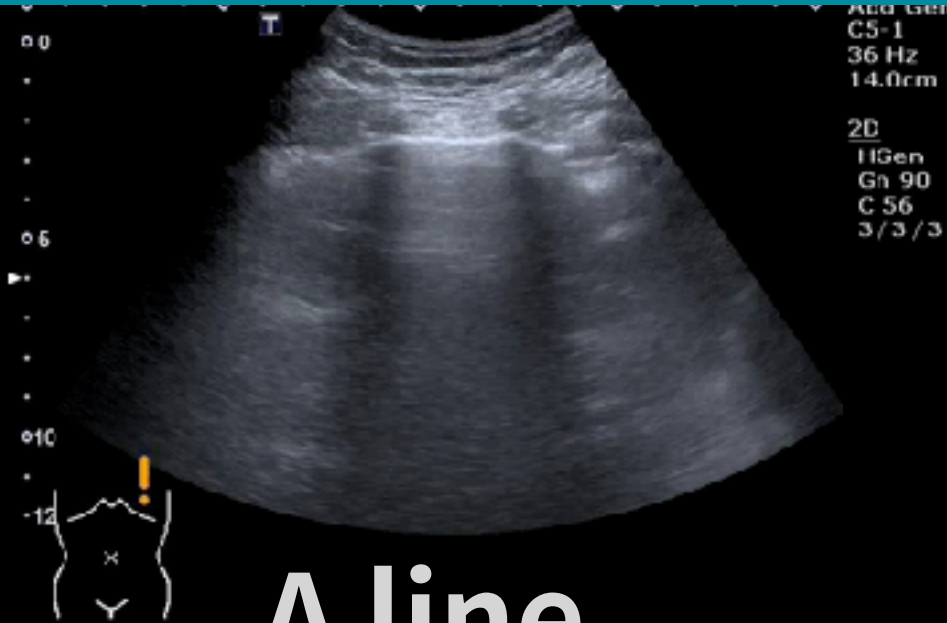G
P K
2.0 6.0

NORMAL LUNG

Sliding + A lines

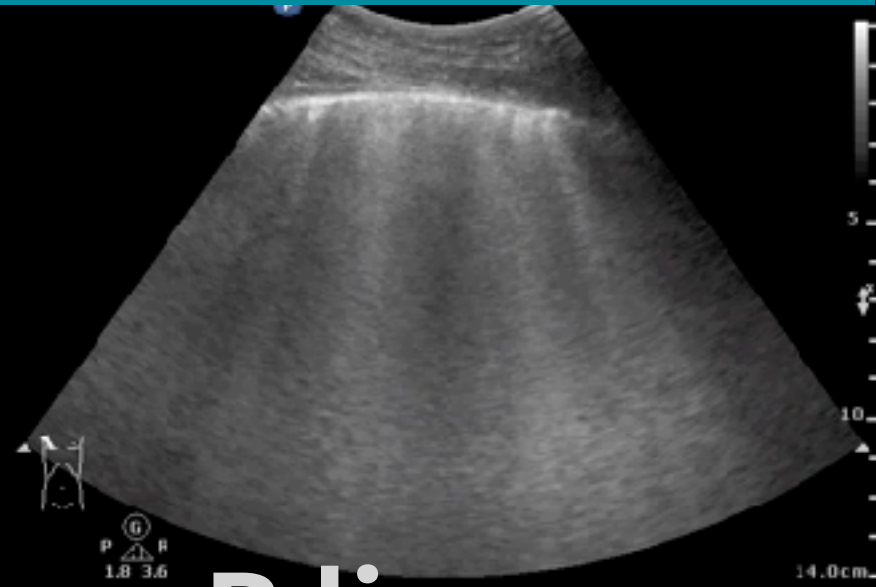

SLIDING FIRST



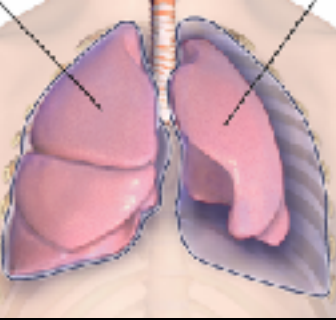
A line

肋膜下
水平線
等距離



B line

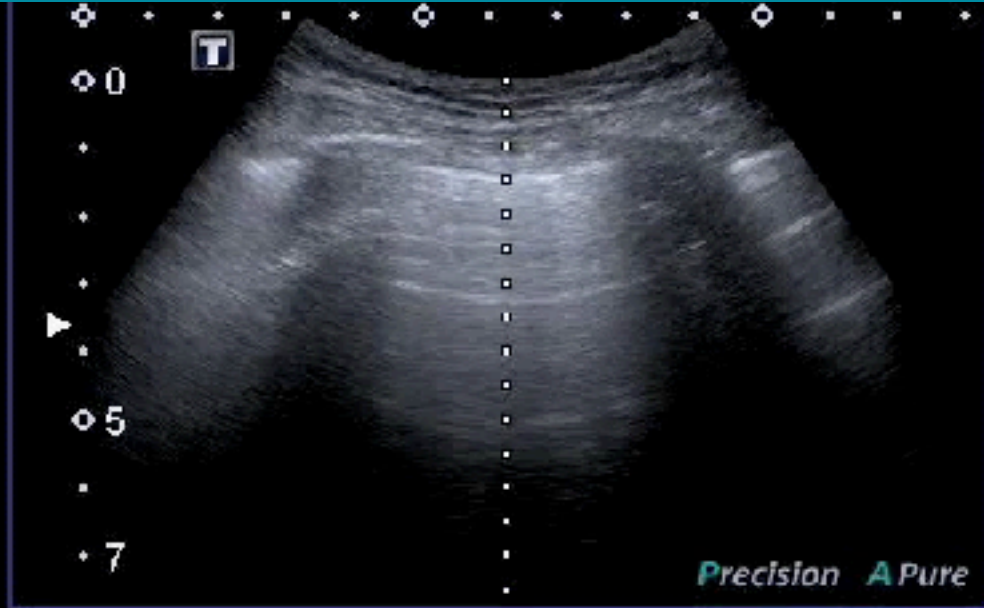
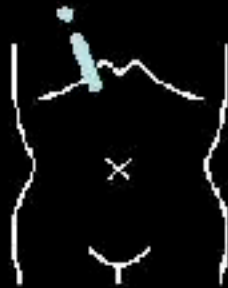肋膜下
垂直線
大於三



PNEUMOTHORAX ?

Sliding + A lines = Normal pleura

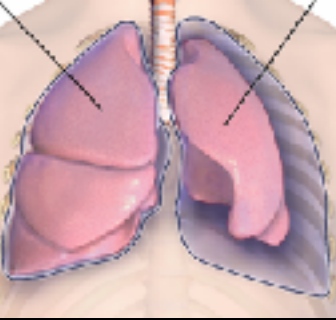
Seashore sign



MI:1.5
6C1
T5.0
18 fps
Qscan
G:71
DR:65
A:2
P:1



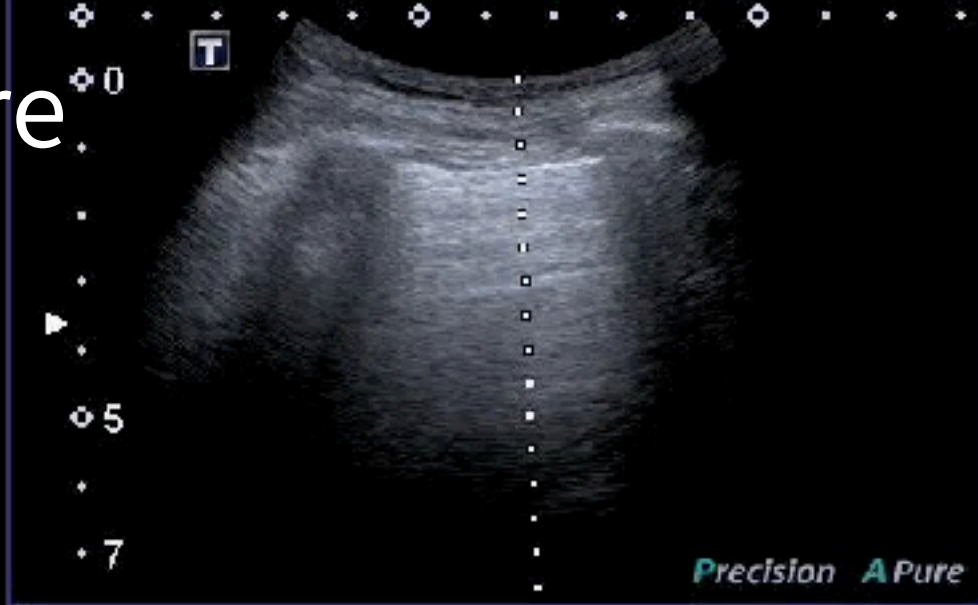
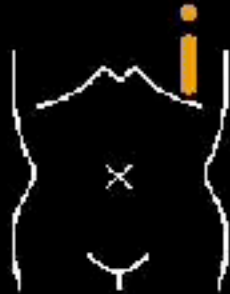0
5
7



PNEUMOTHORAX ?


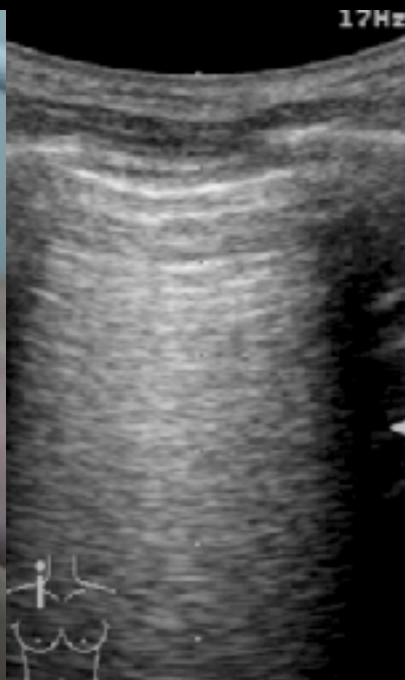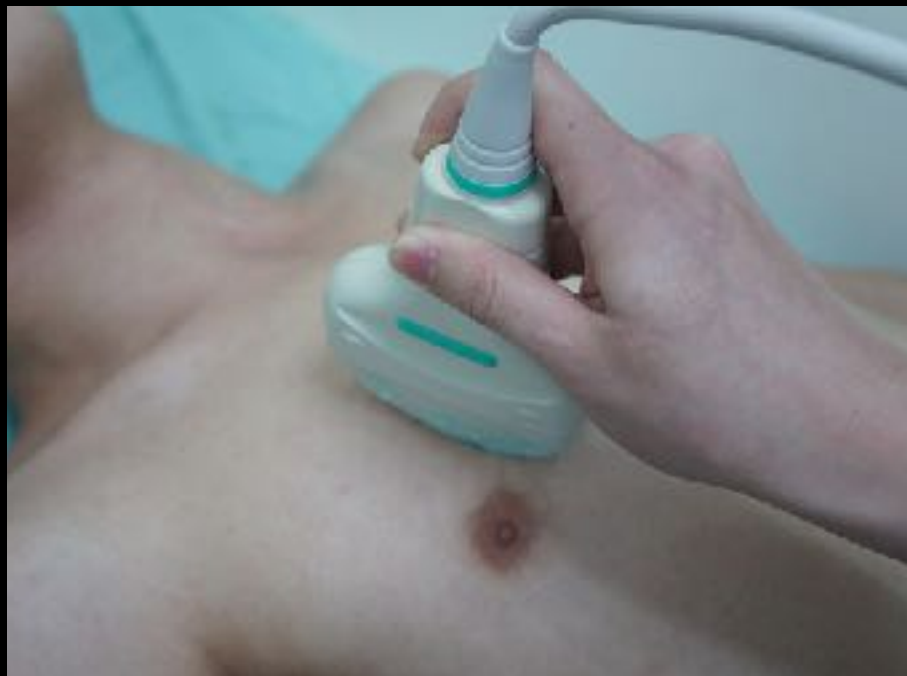
No Sliding + A lines >> Consider PTX

Stratosphere
sign

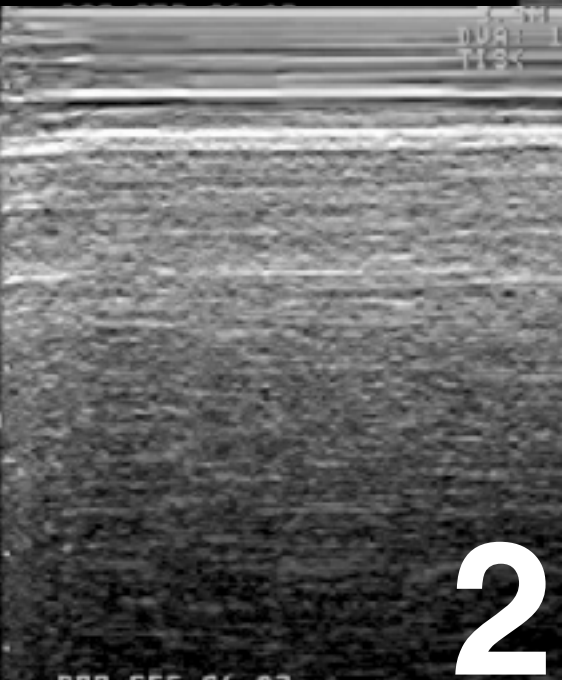
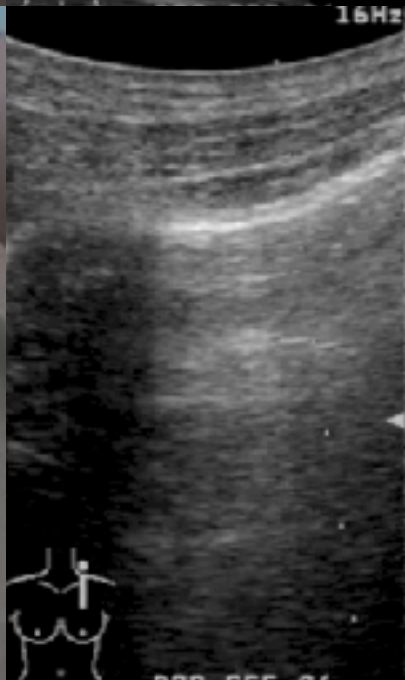
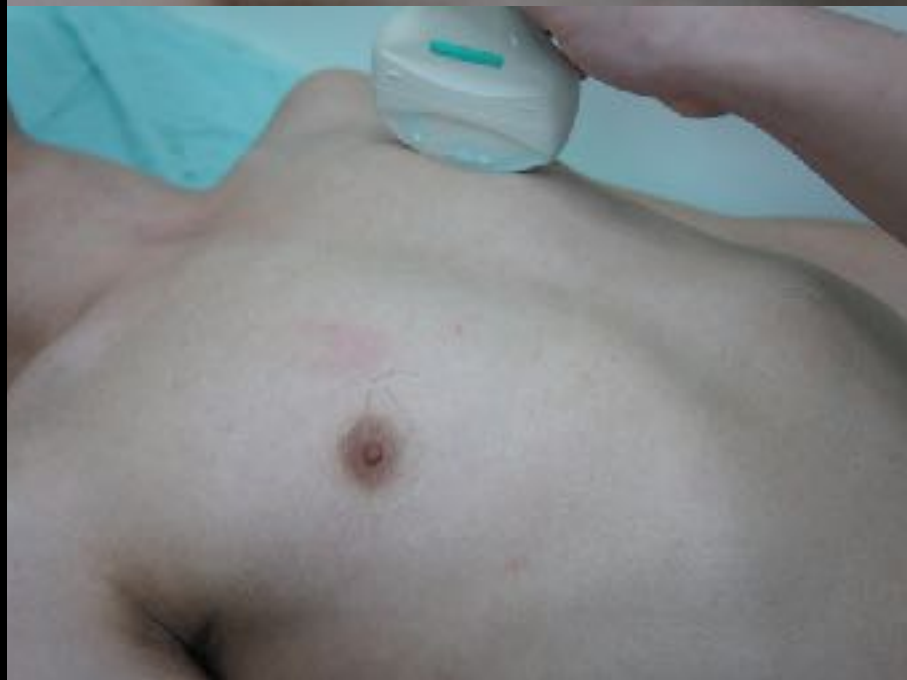
MI:1.5
6C1
T5.0
18 fps
Qscan
G:71
DR:65
A:2
P:1





1



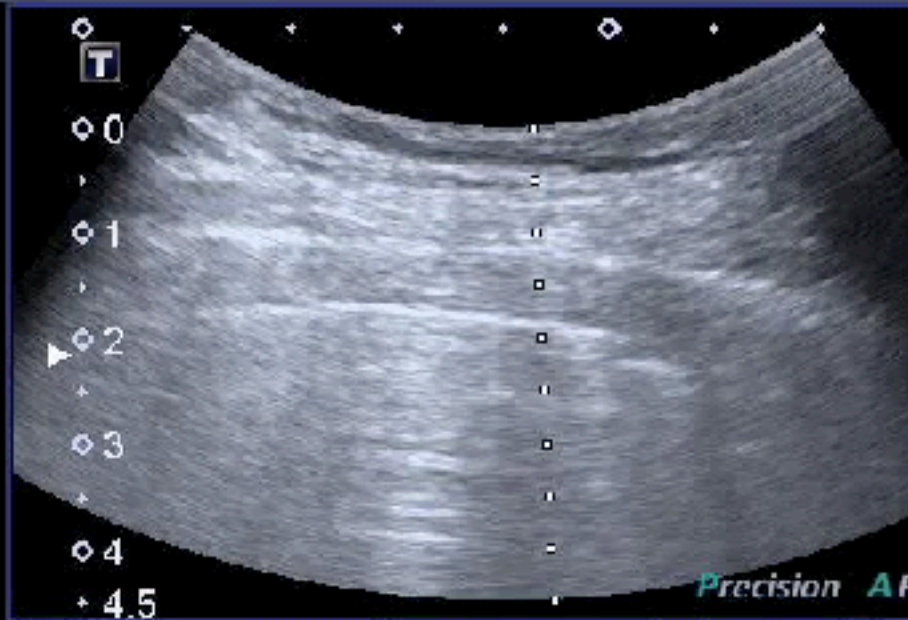
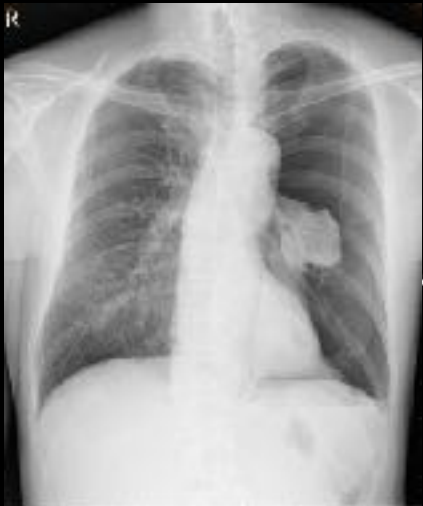2

R08 055 C4

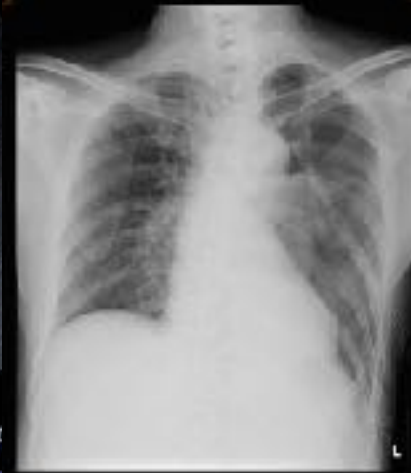
R08 055 C6 A3

Lung Point

A



B

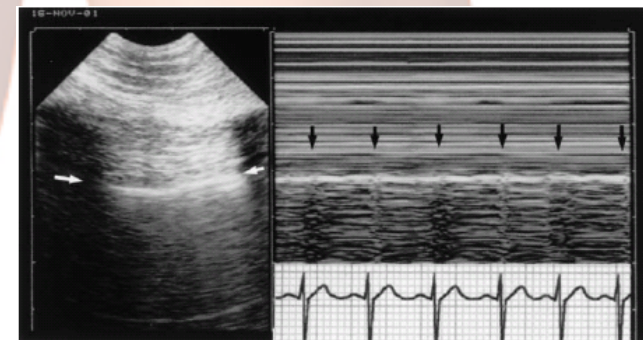
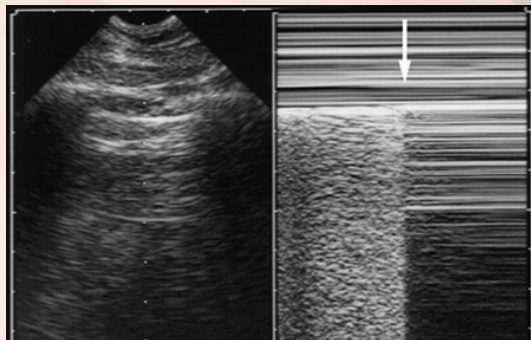
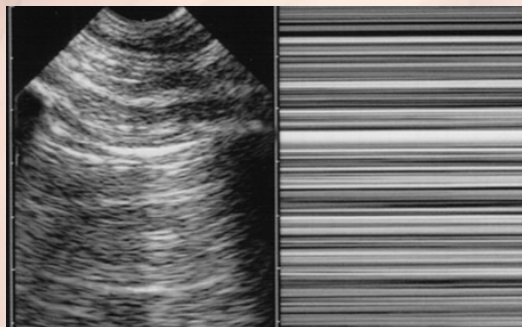
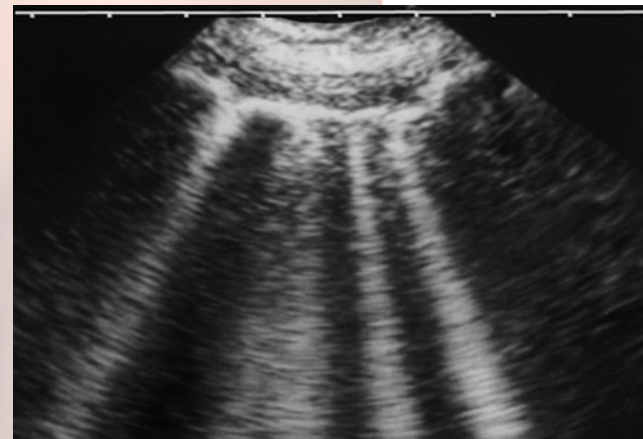
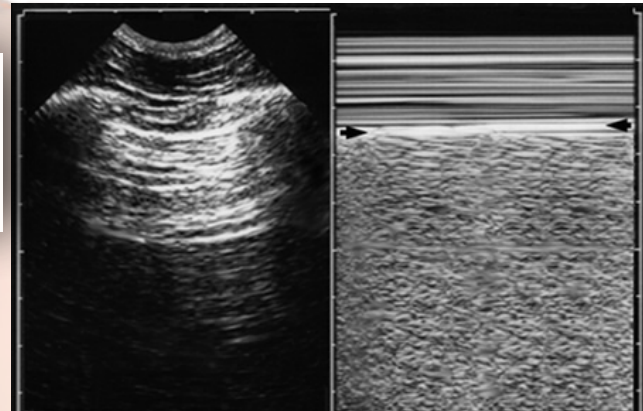


PTX

SBP Point

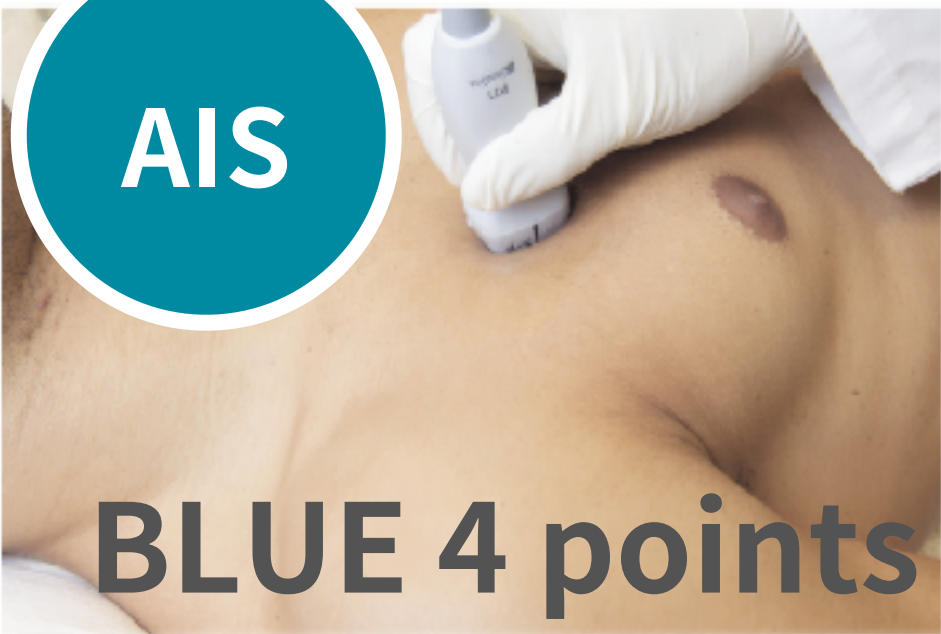4

No sliding
No B lines
No pulse
Lung point



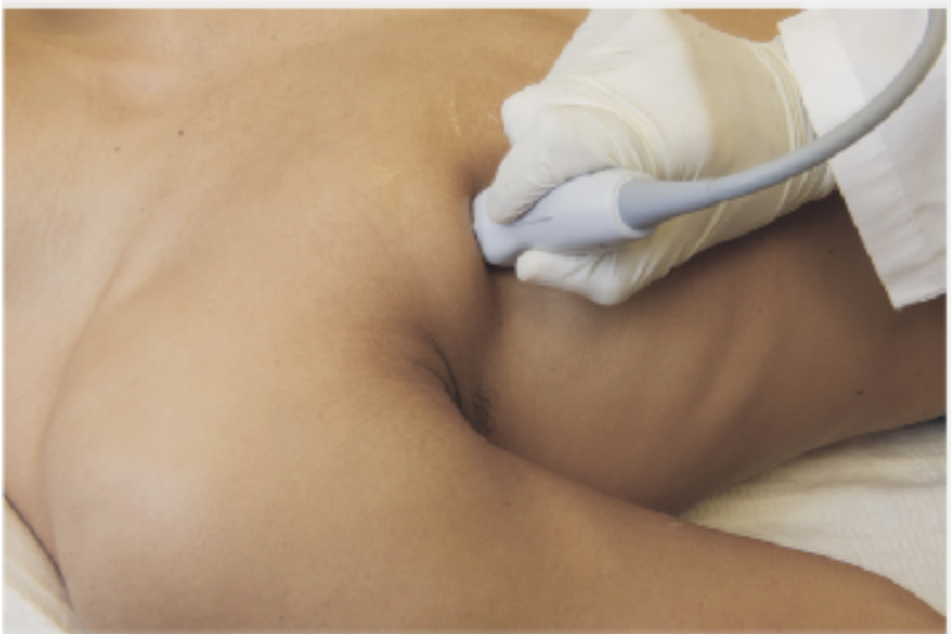AIS

Point 1

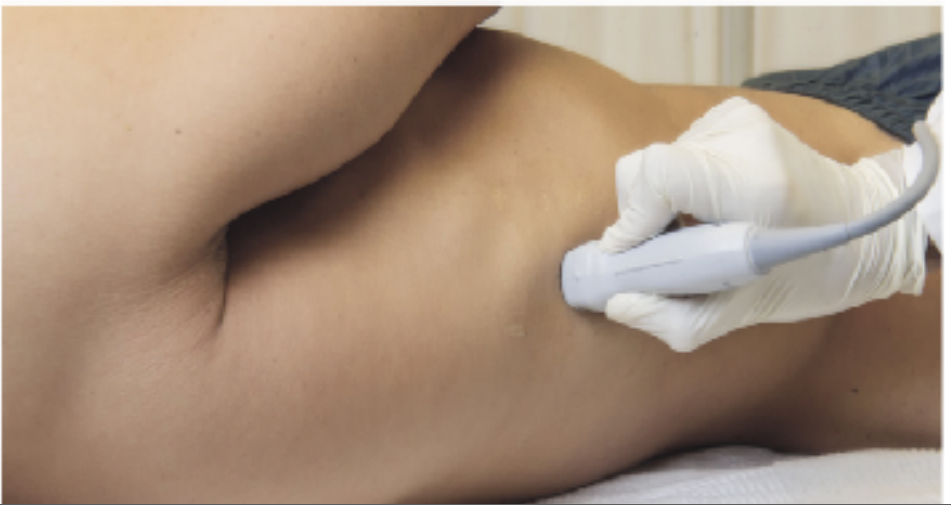


BLUE 4 points

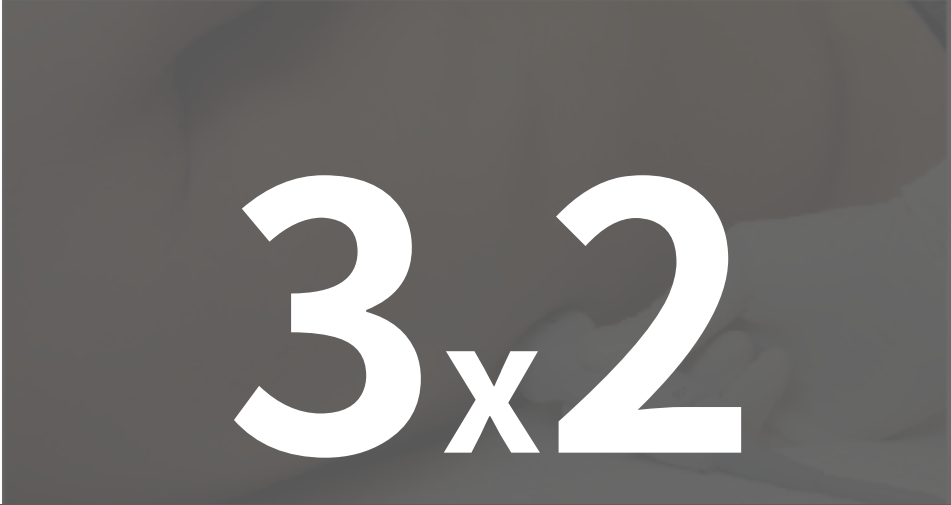Point 2



Point 3



Point 4

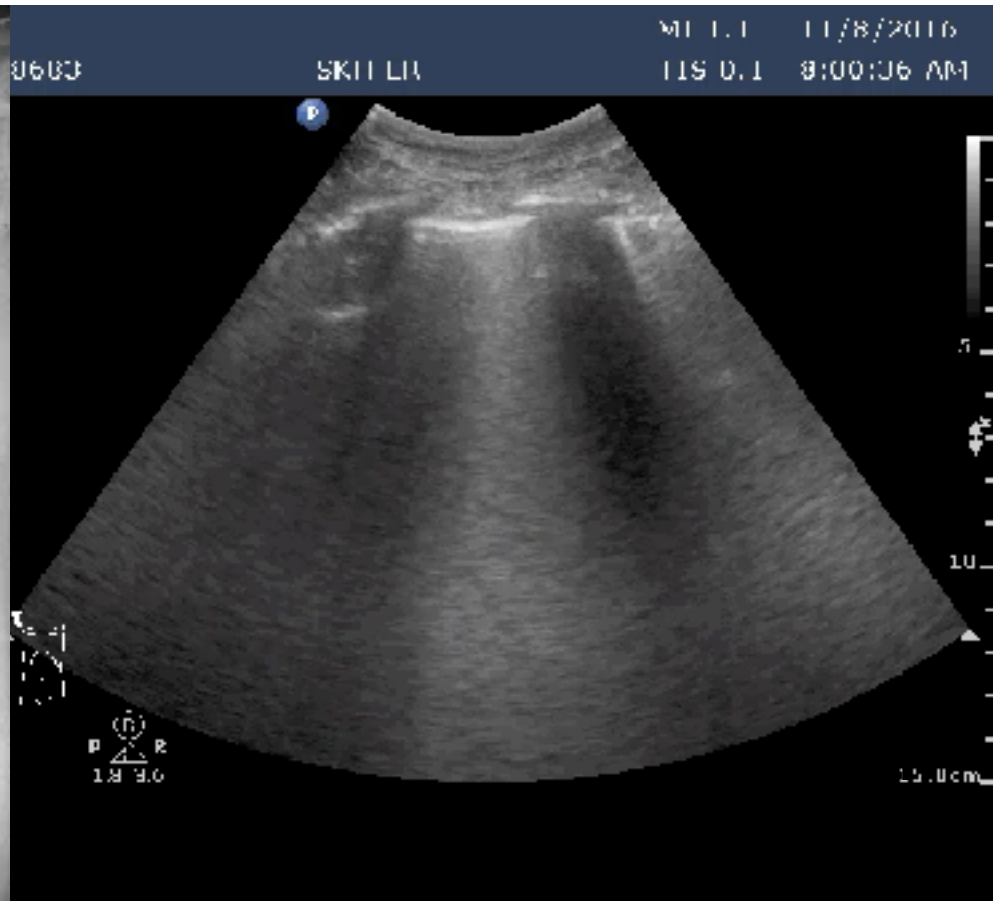
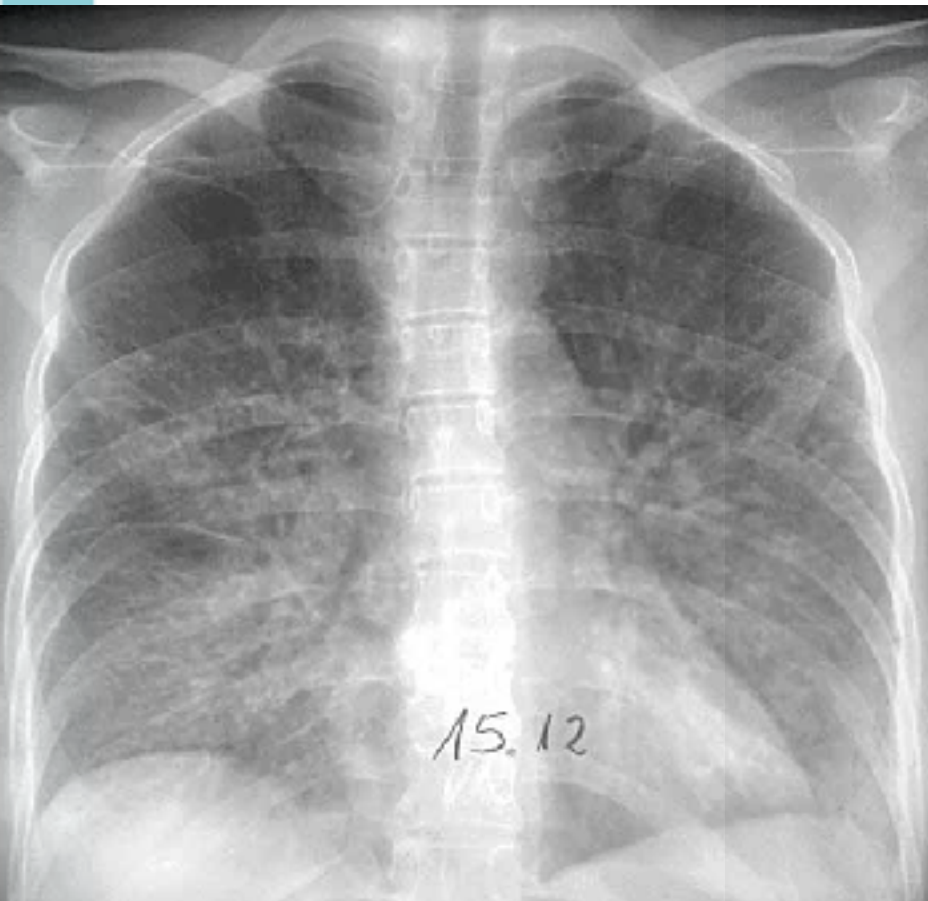


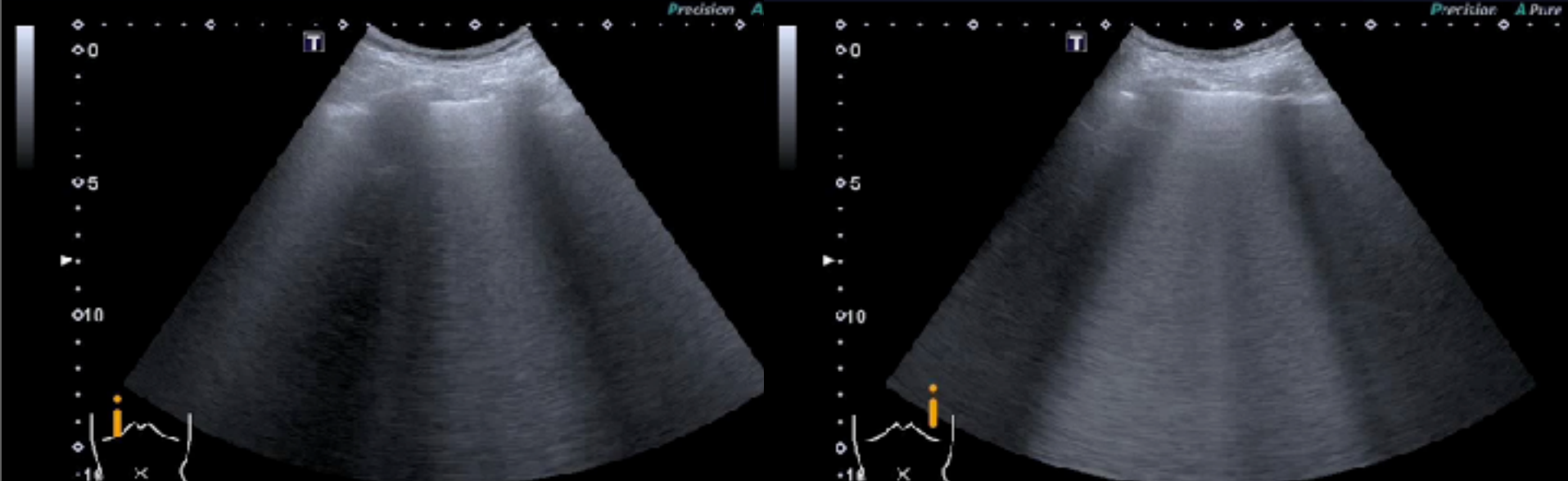
3x2

Alveolar Interstitial Syndrome

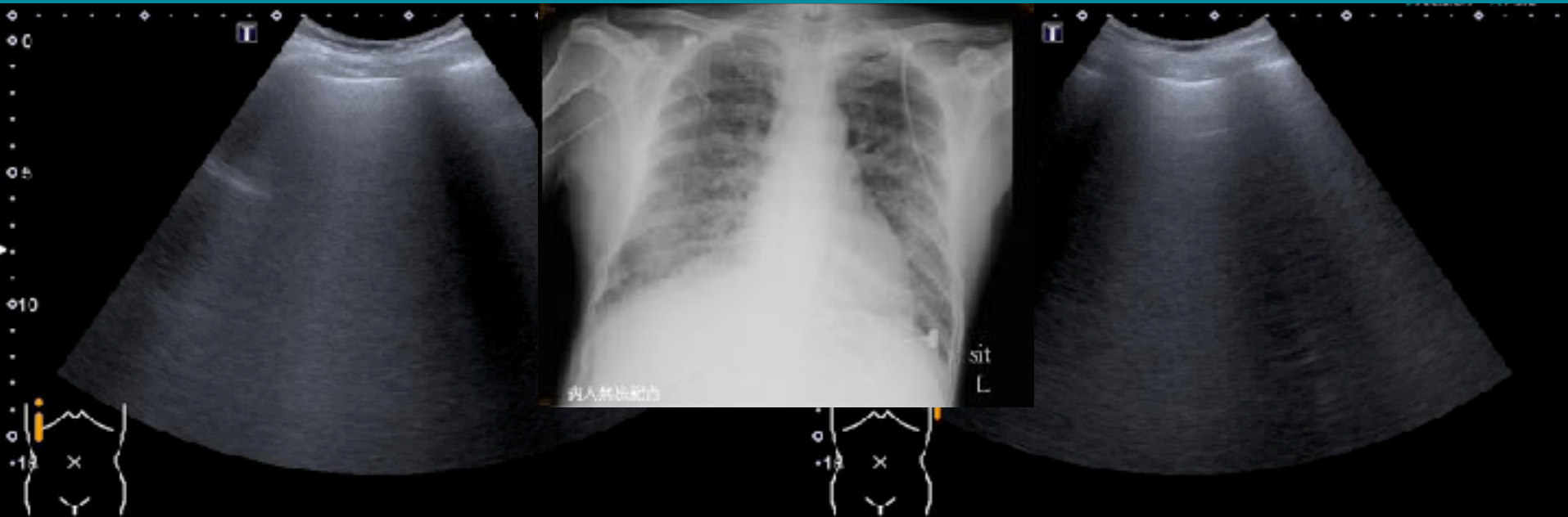
LUNG ROCKETS

ICS > 3 B lines

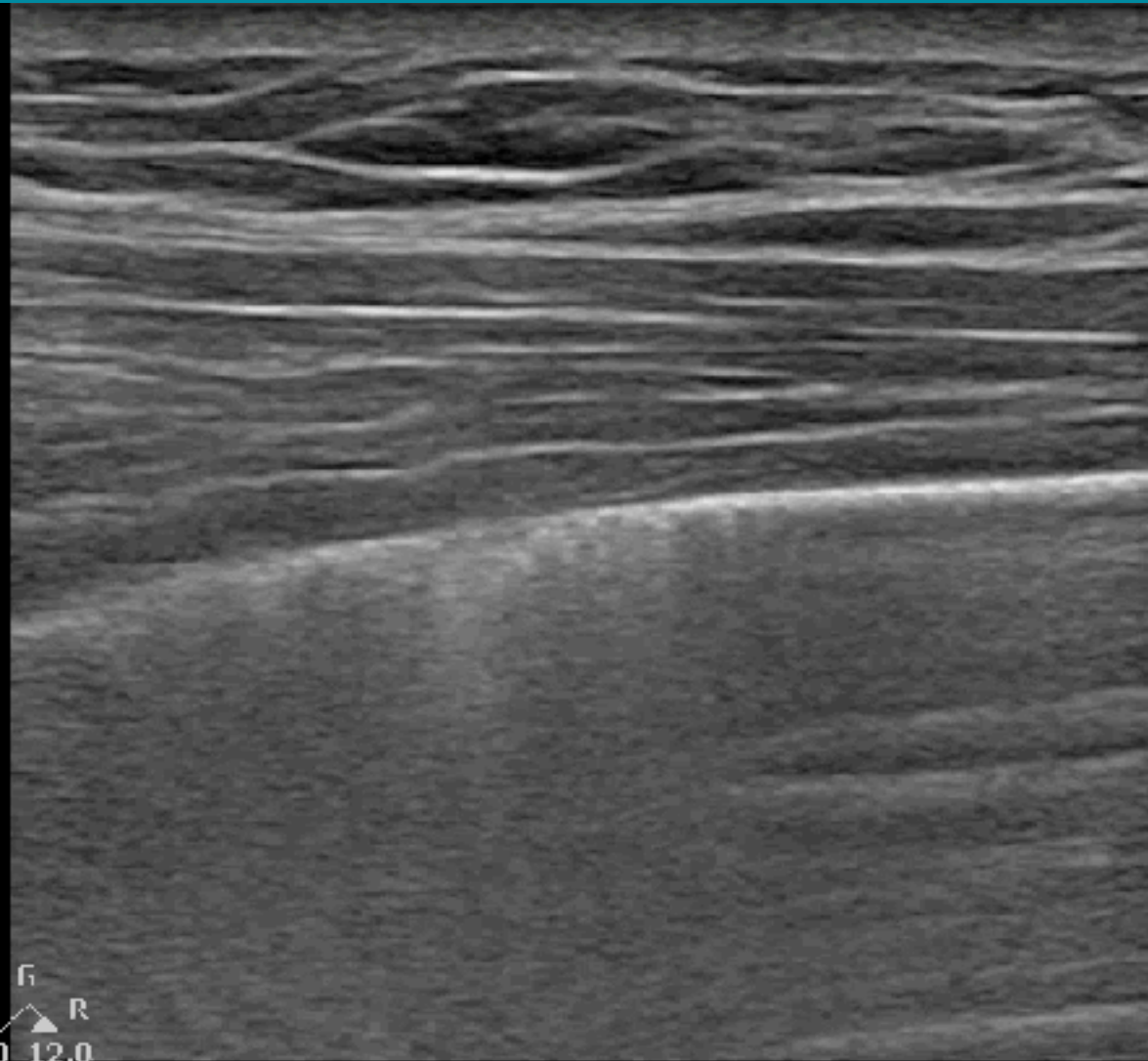




ALEVOLAR INTERSTITIAL SYNDROME



AIS: Localized



Pneumonia

Pneumonitis

Atelectasis

Contusion

Infarction

Pleural disease

Neoplasia

Normal lung

PLEURAL EFFUSION

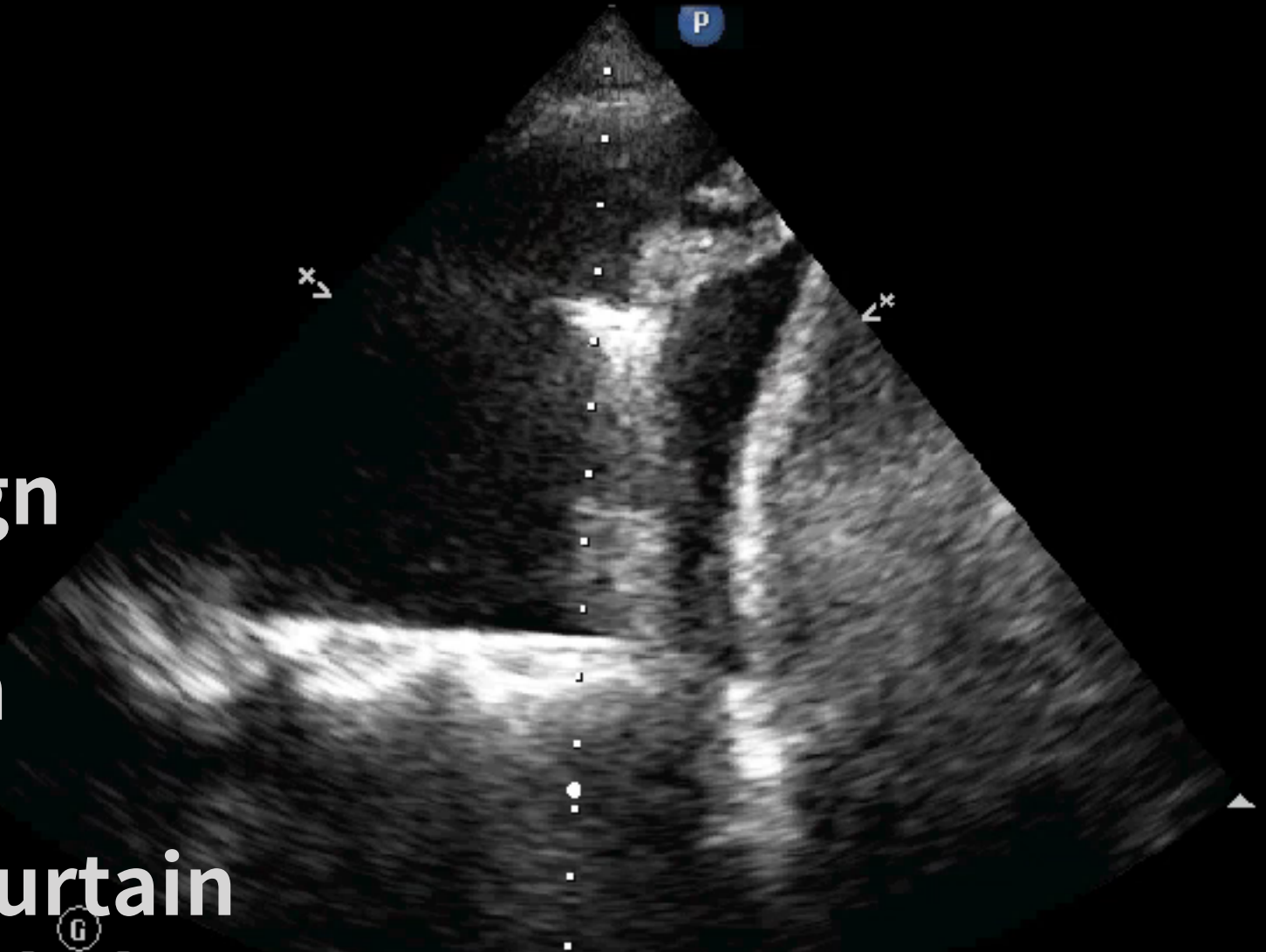
Adult Echo2
G-1
: Hz
5.0cm

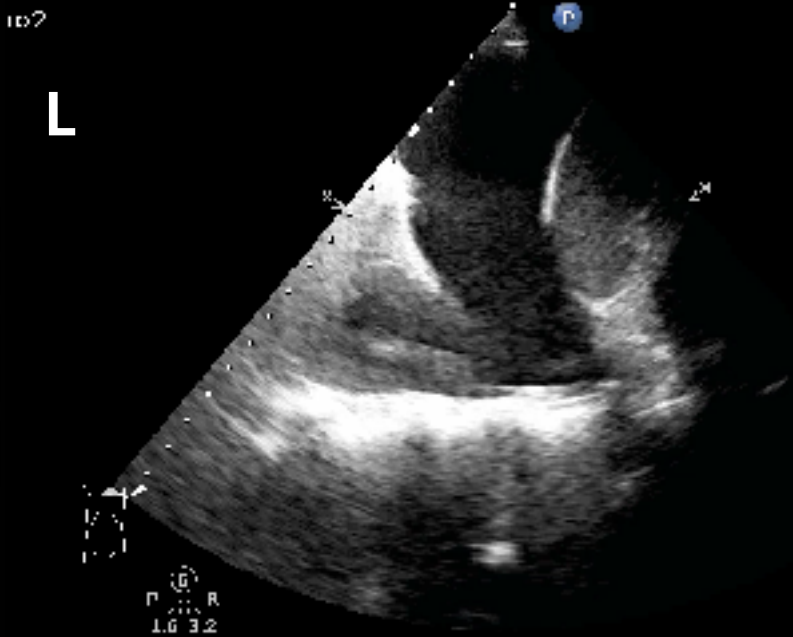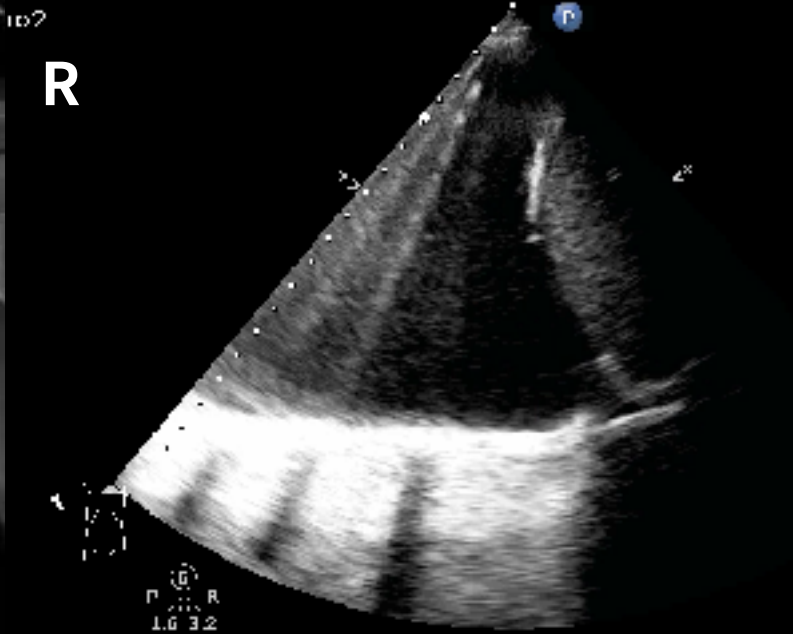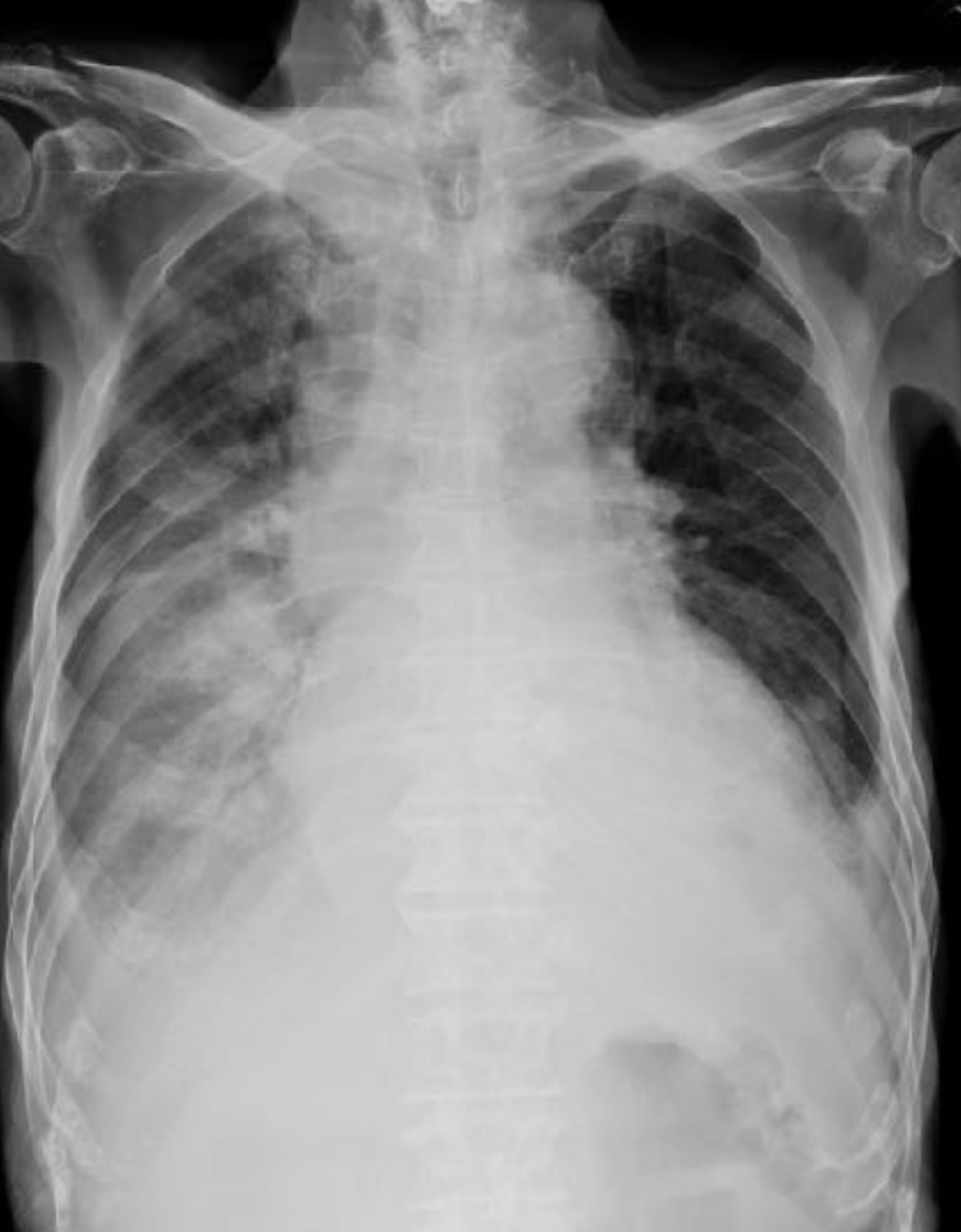Gen
n 30
50
/ 2 / 0

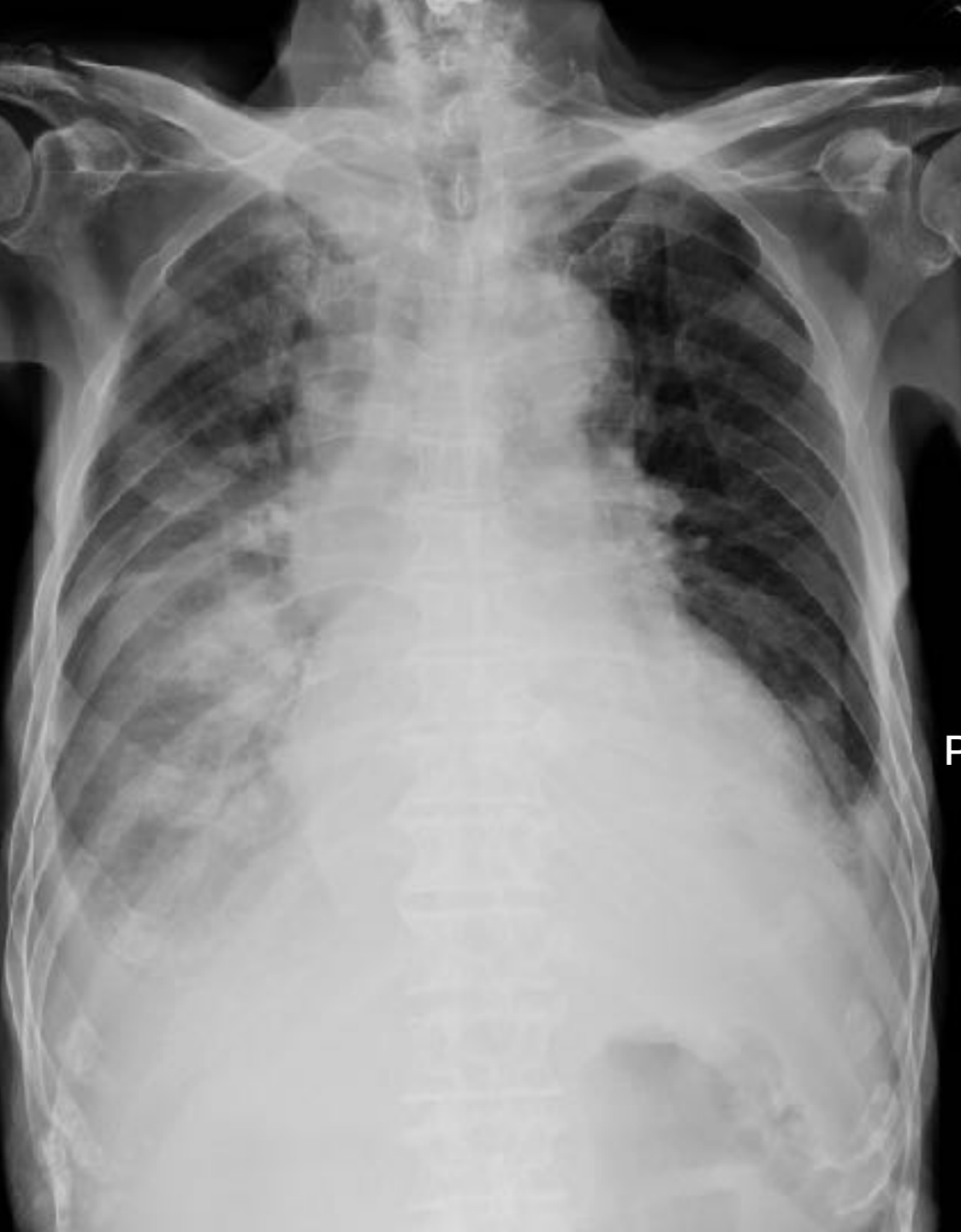Spine sign

Jelly fish

Loss of curtain



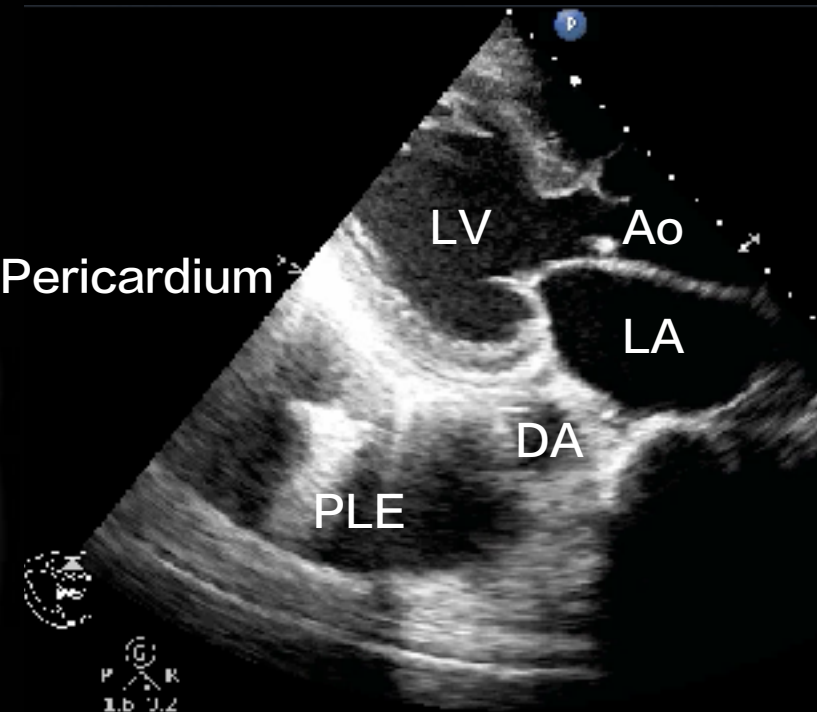




D aorta

Pericardial vs Pleural

Pericardium



LV

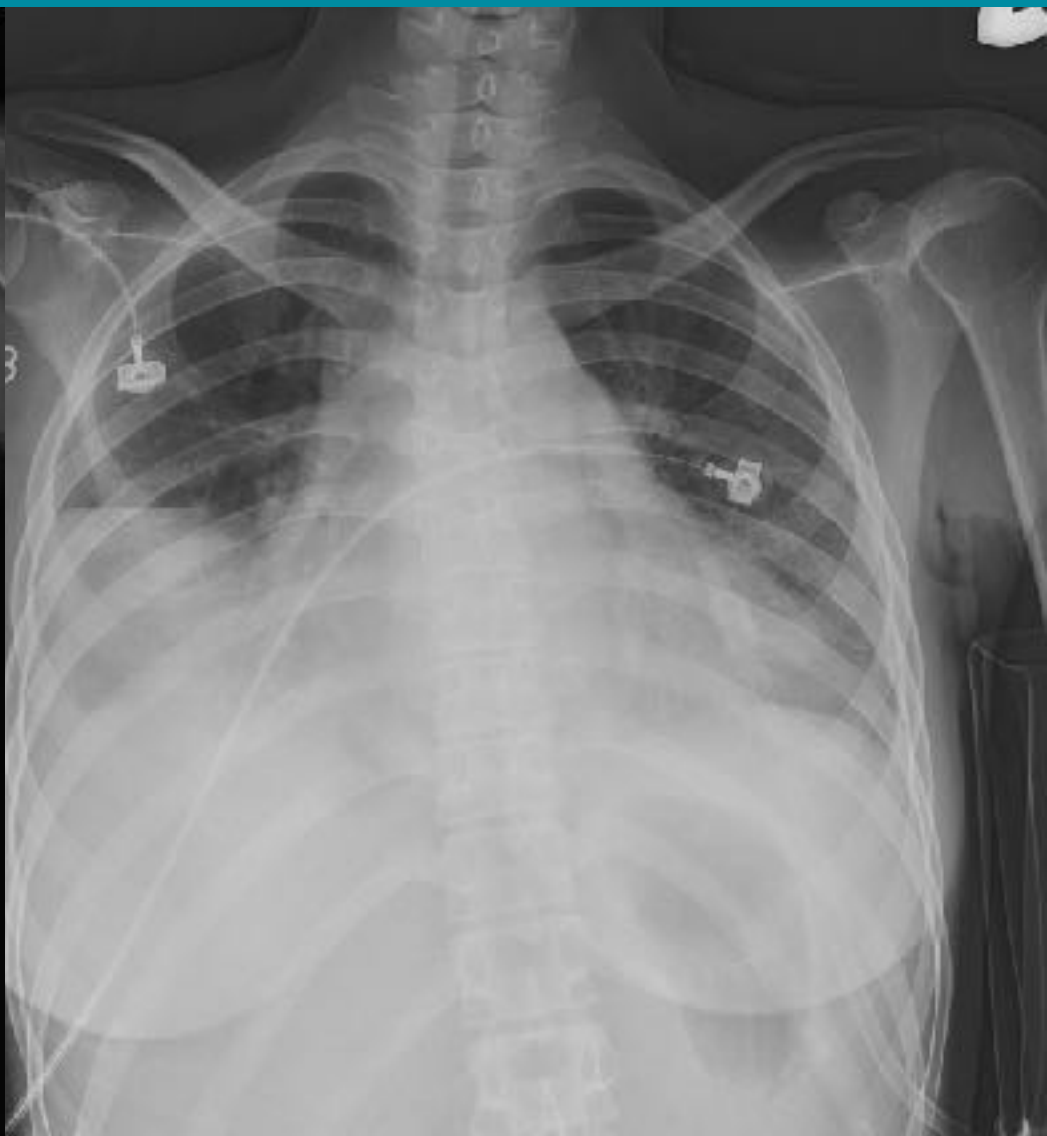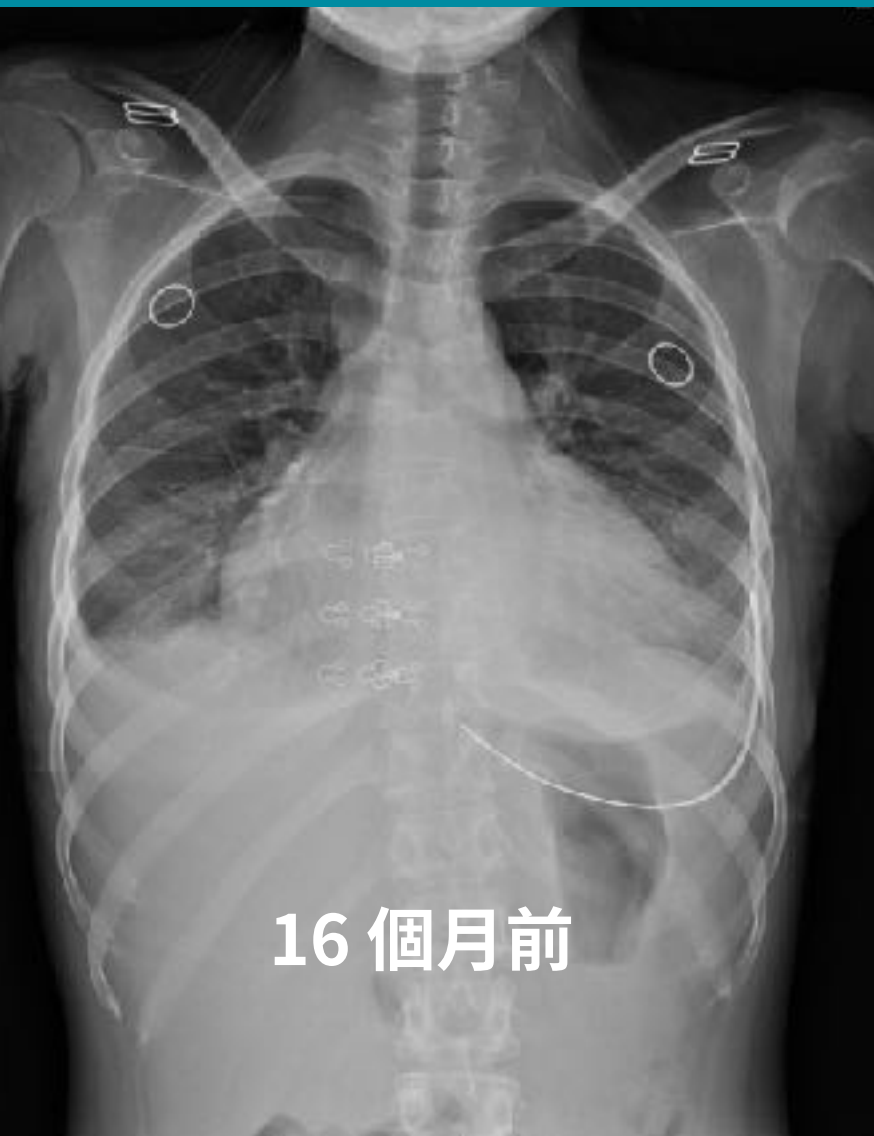Ao

LA

DA

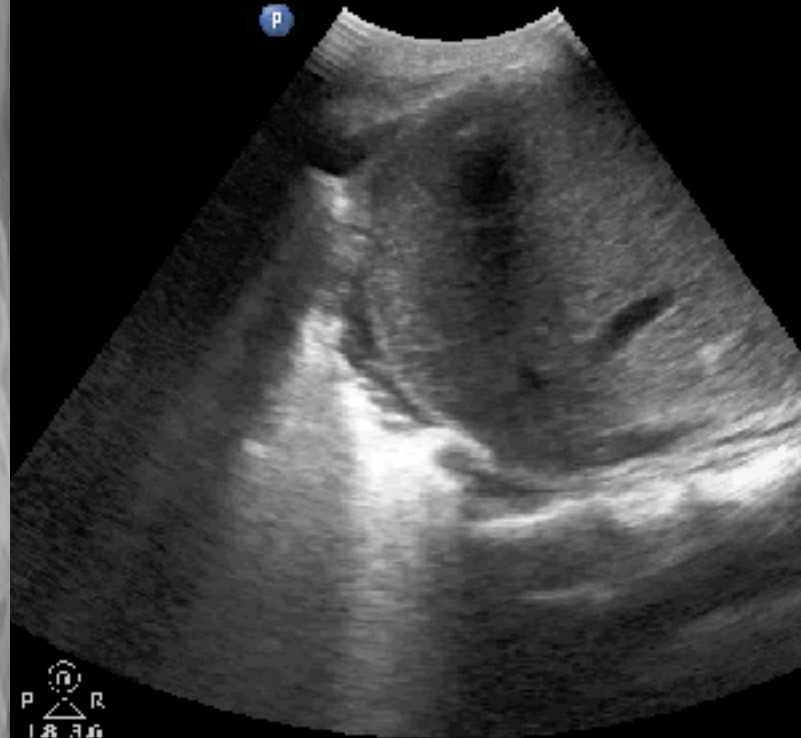
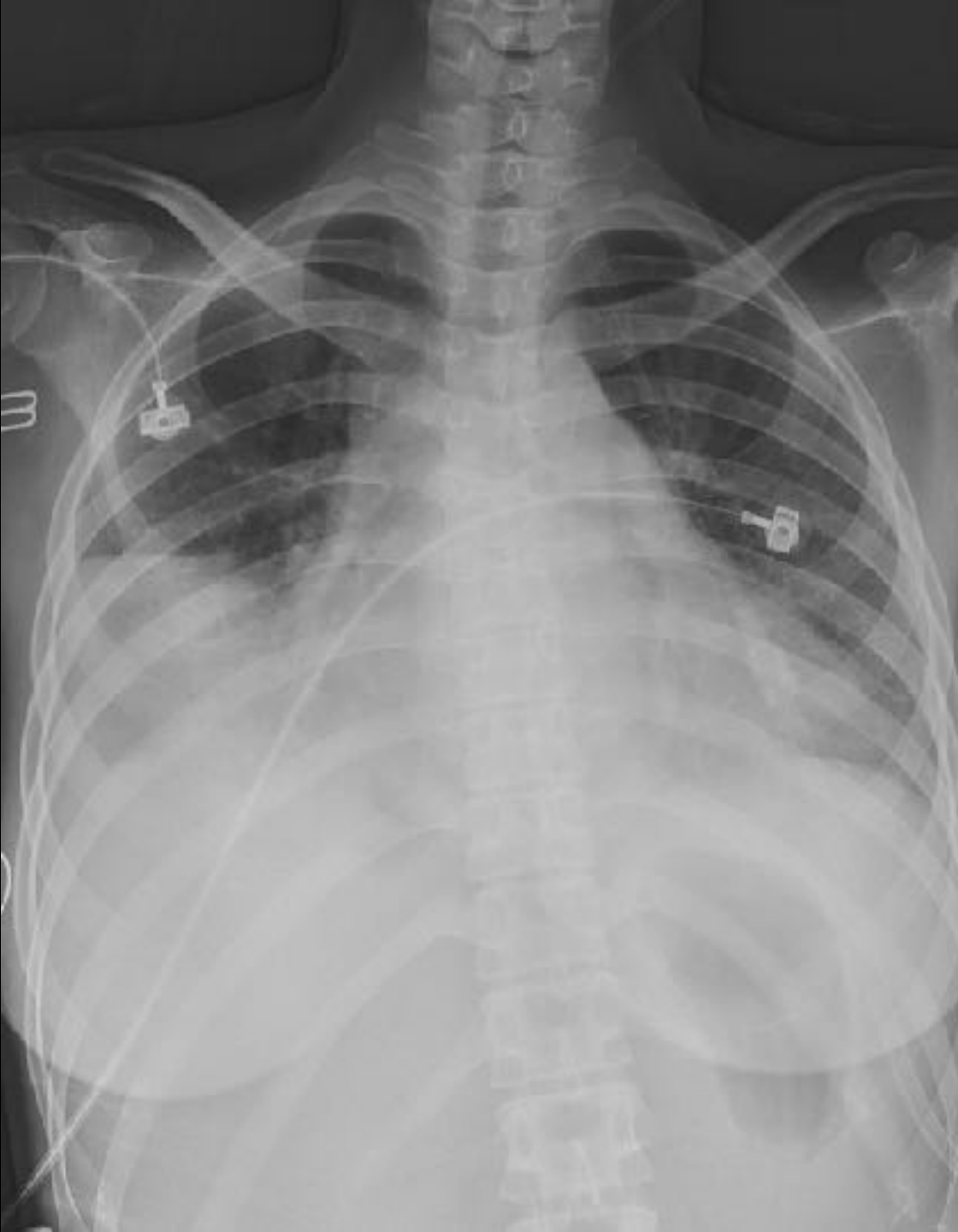PLE

28F, 來抽肋膜積液吧!?



Pneumonia

Consolidation
Air-bronchogram



C profile

Abd Gen
C5-1
45 Hz
10.0cm

2D
HGen
Gn 85
C. 56
3/3/3

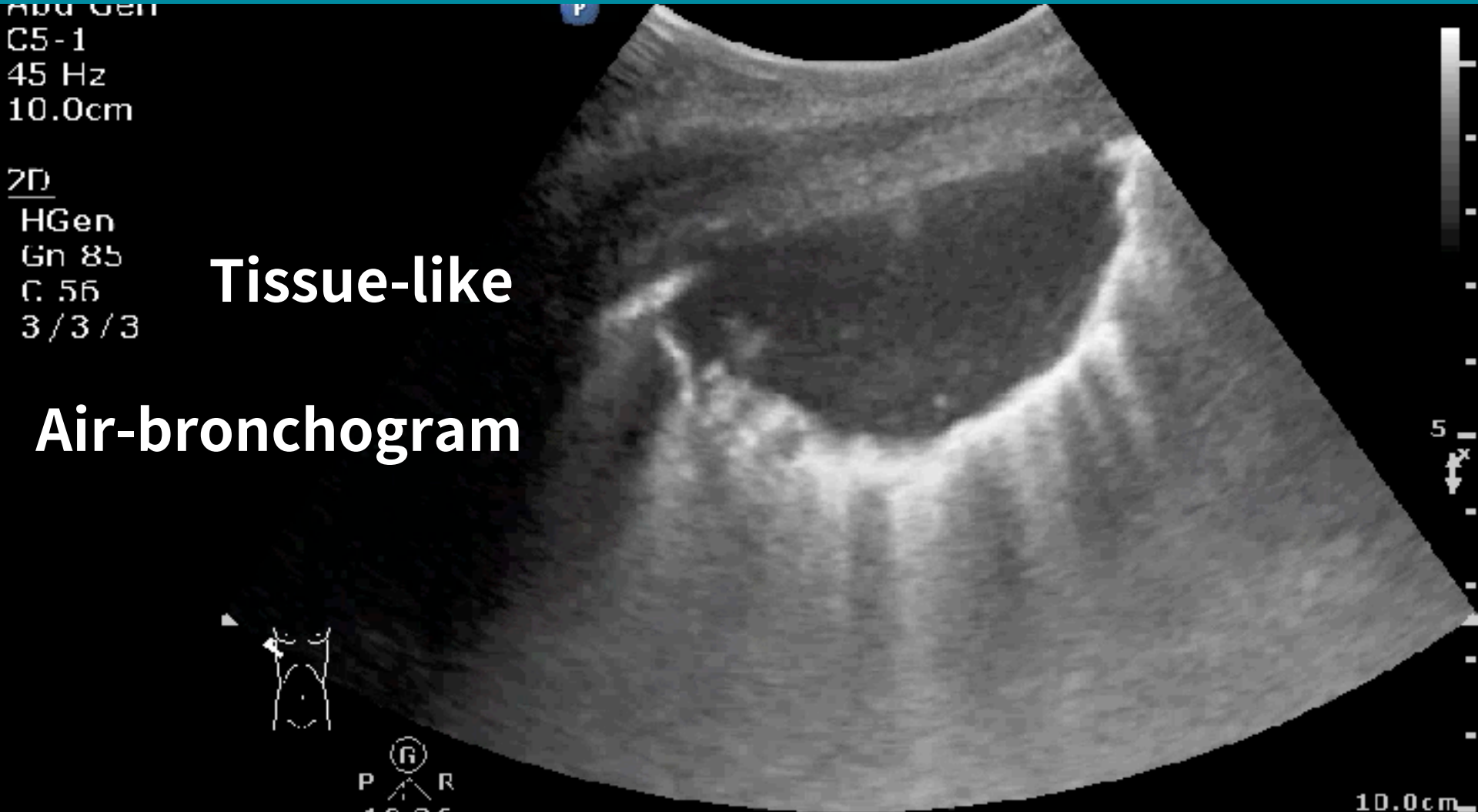
Tissue-like

Air-bronchogram

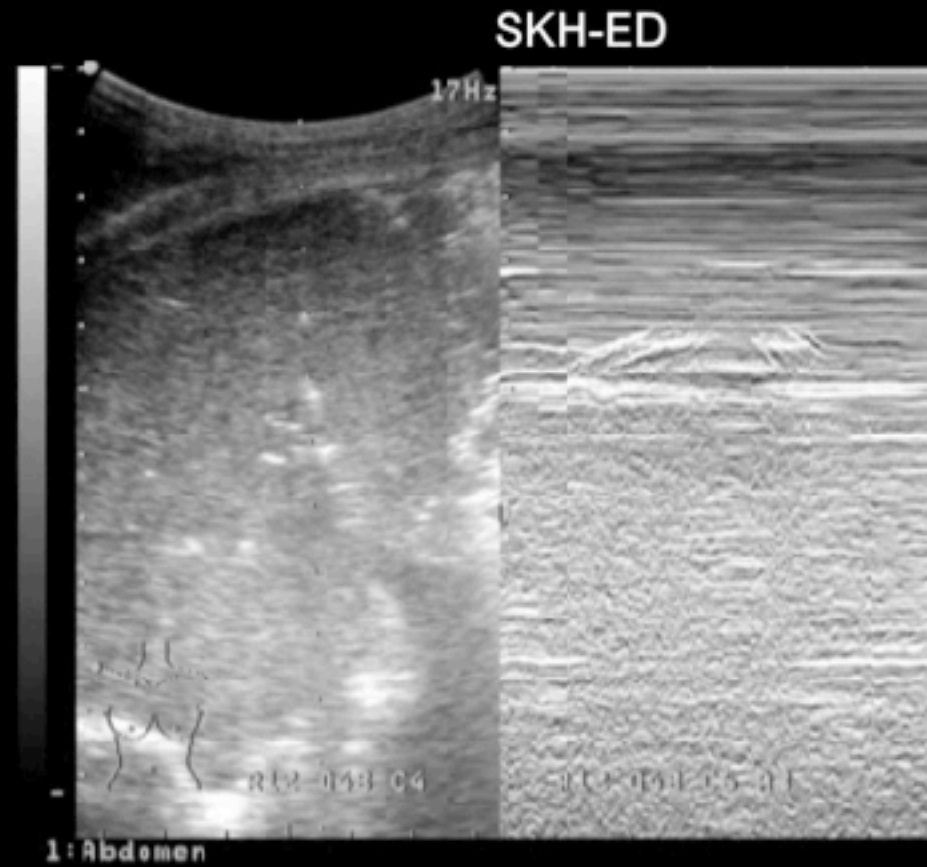
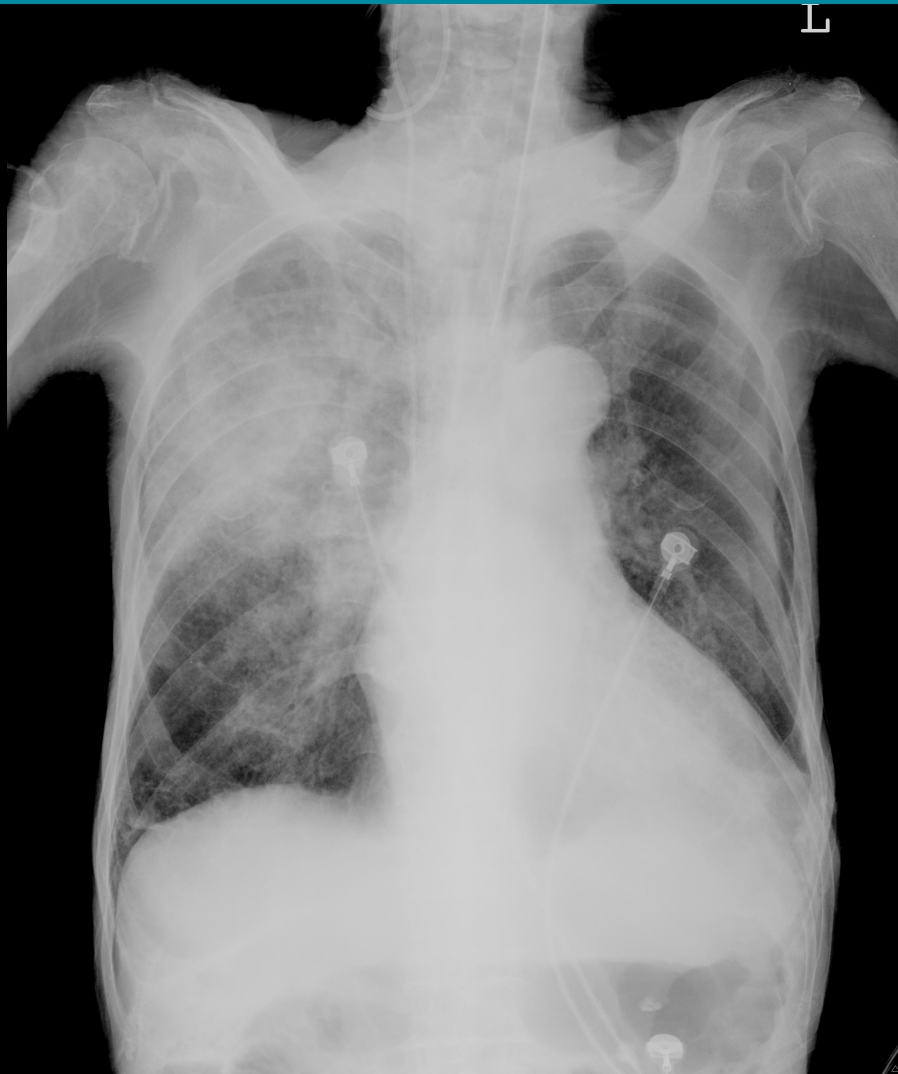

⑥
P R
1.8 3.6

10.0cm

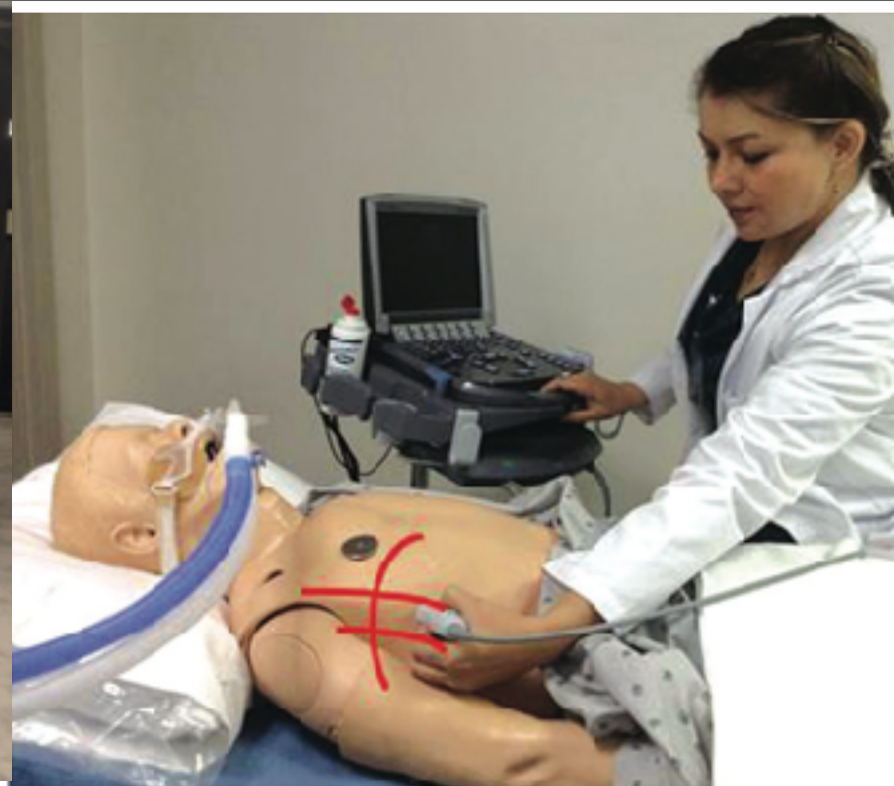


Dynamic air-bronchogram



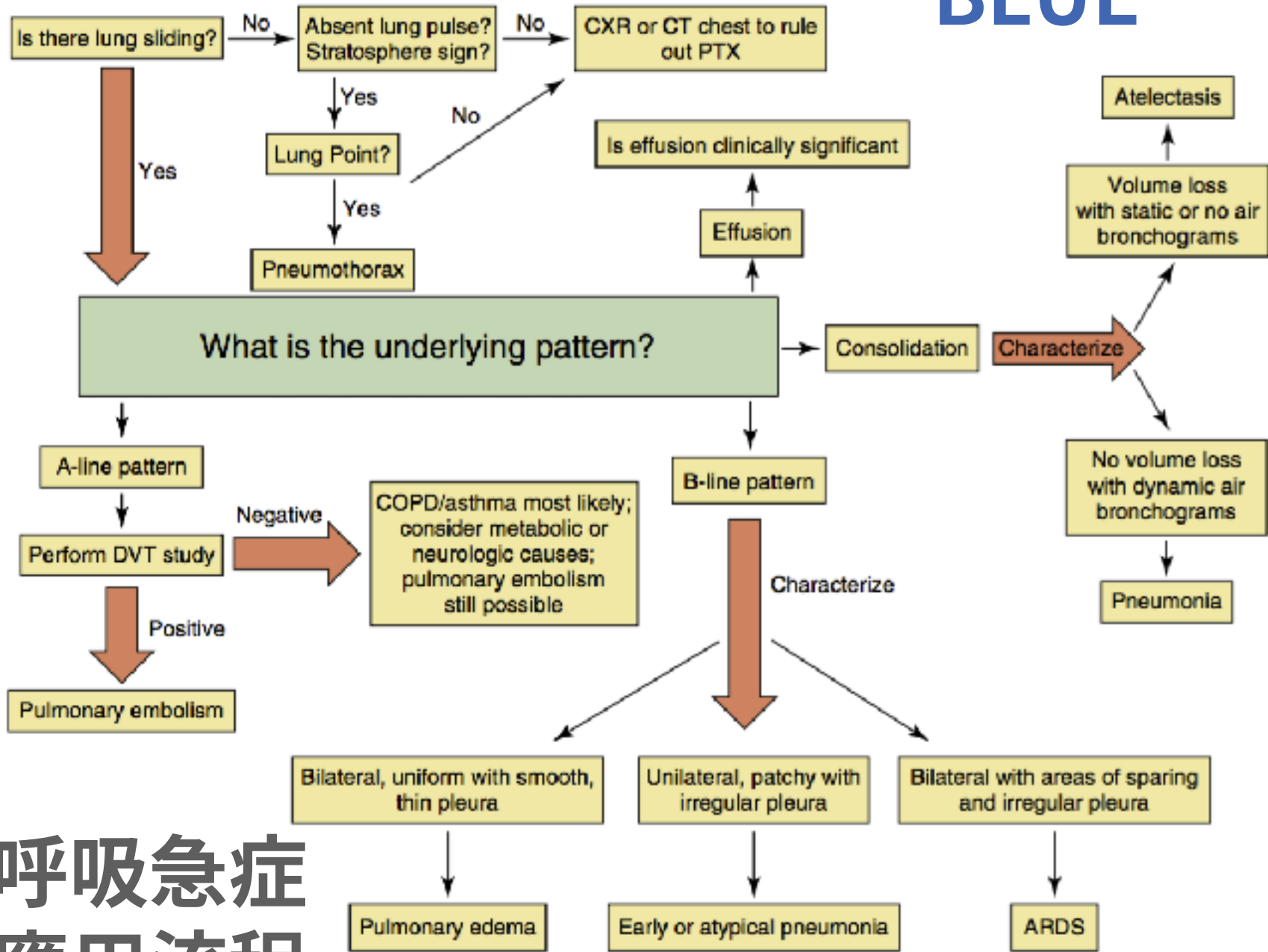
BLUE Protocol

(Bedside Lung Ultrasound in Emergency Protocol)



Daniel Lichtenstein

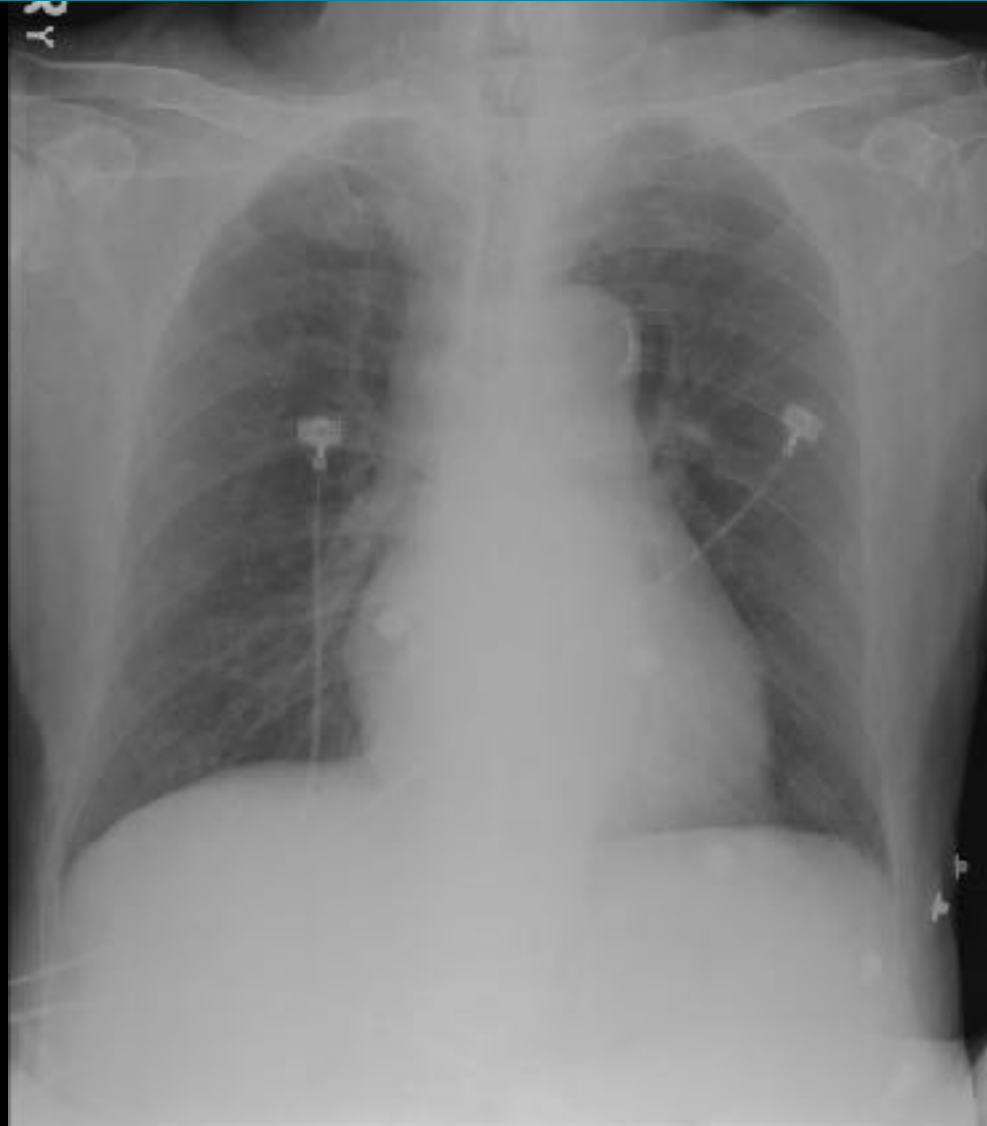BLUE



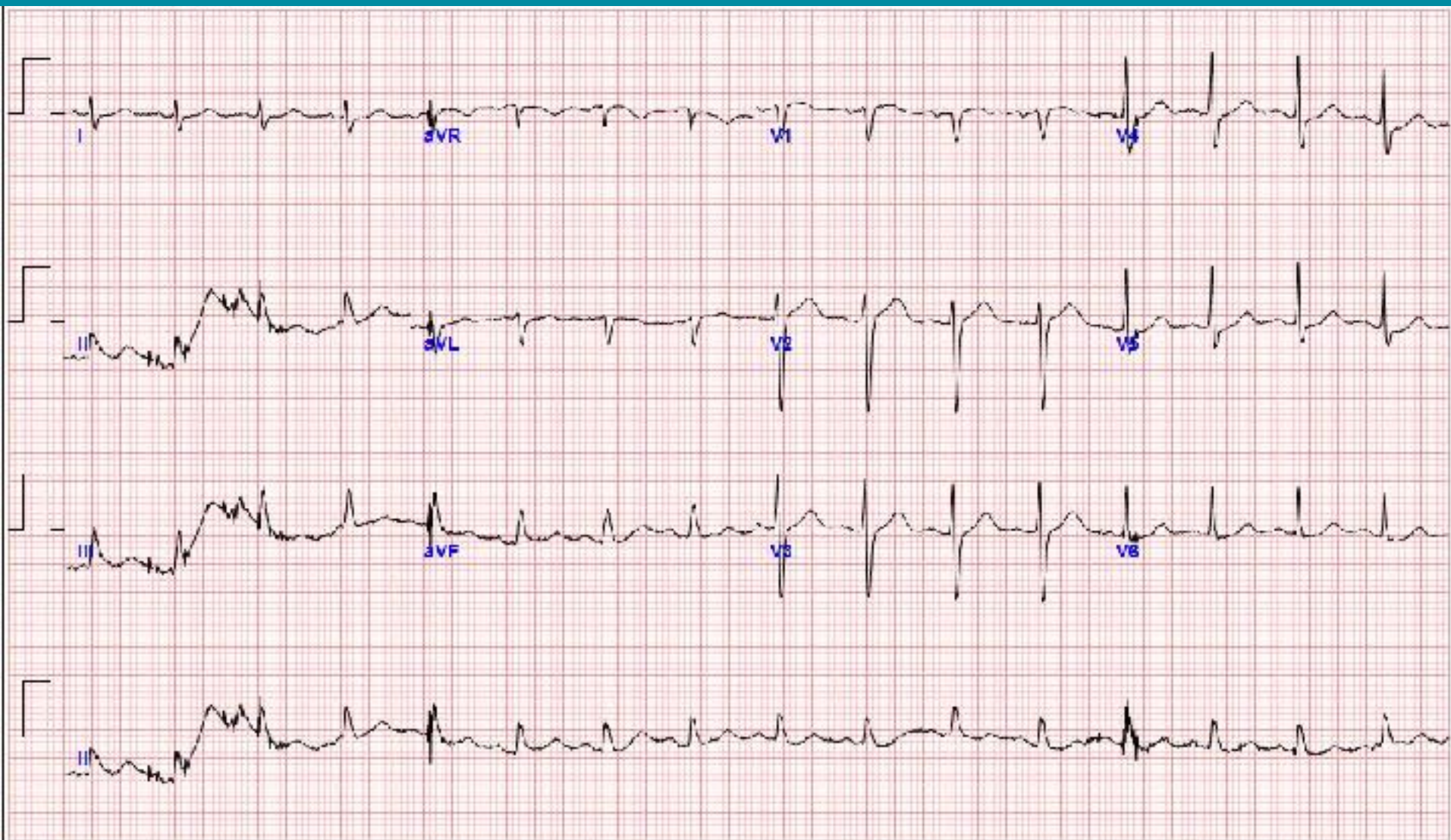
S
A
B
E
C

呼吸急症 應用流程

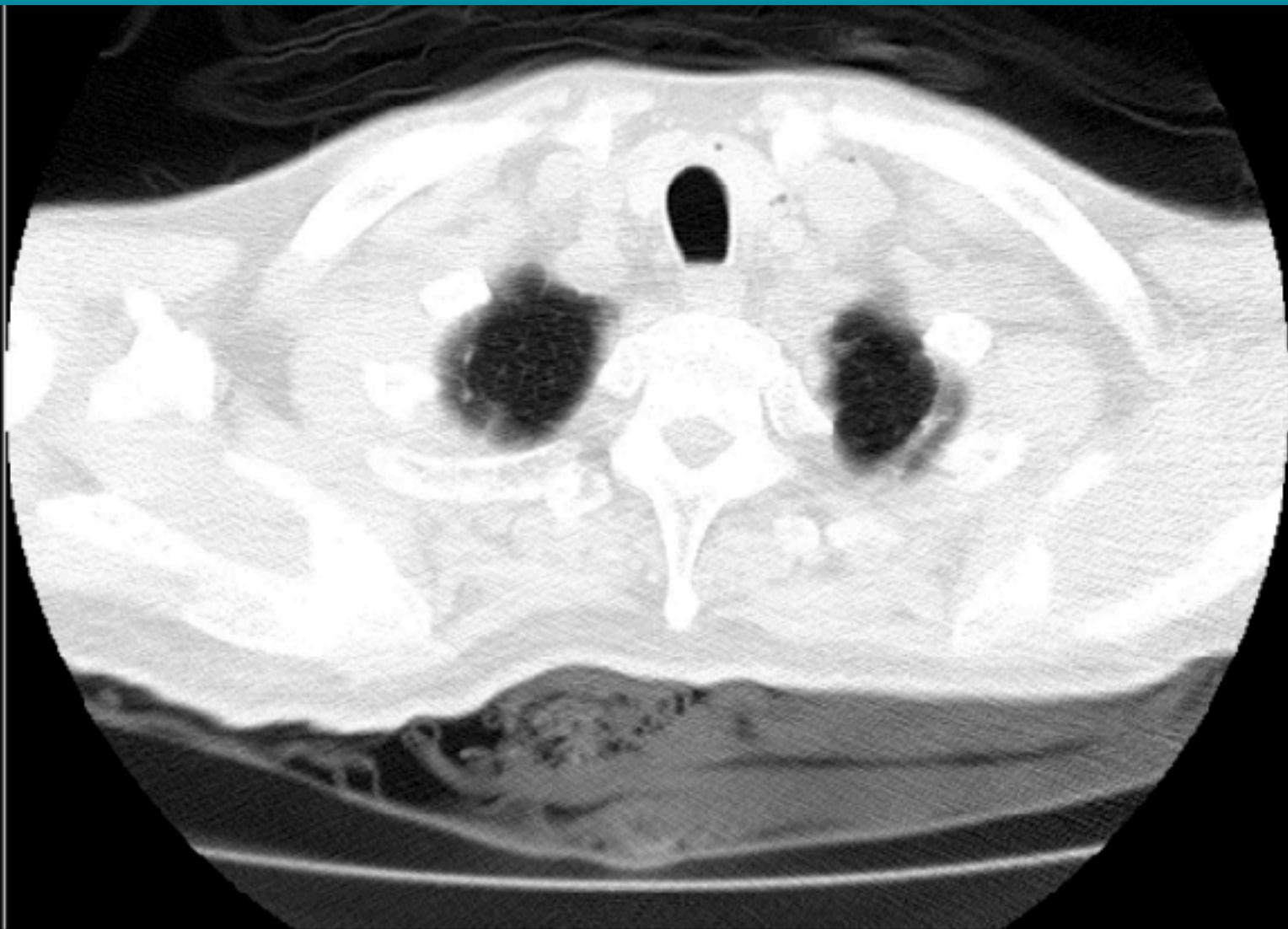76M, Dyspnea & desaturation



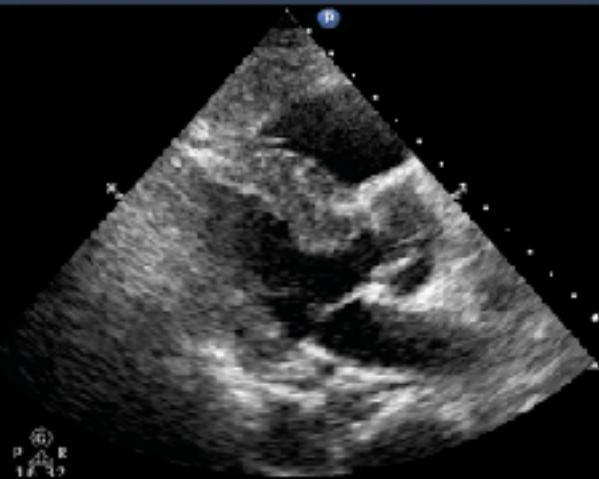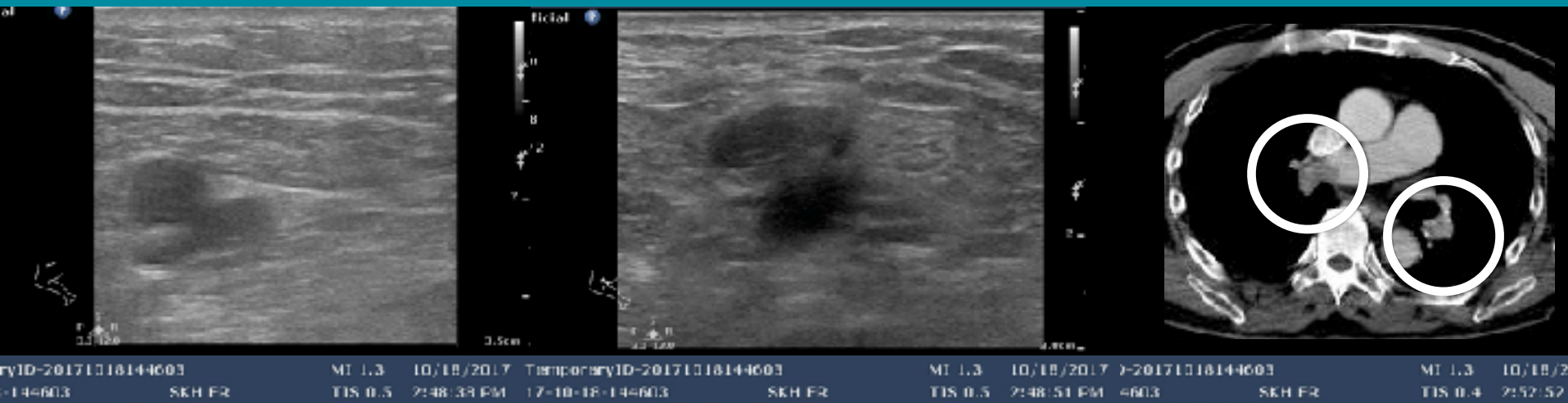76M, Dyspnea & desaturation



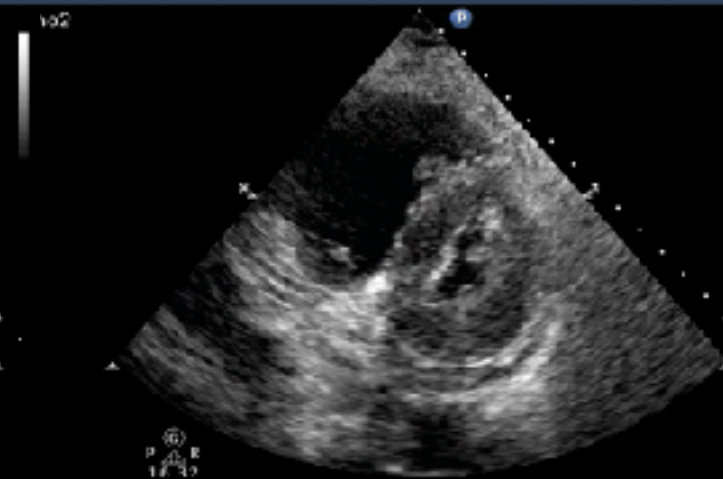76M, Dyspnea & desaturation



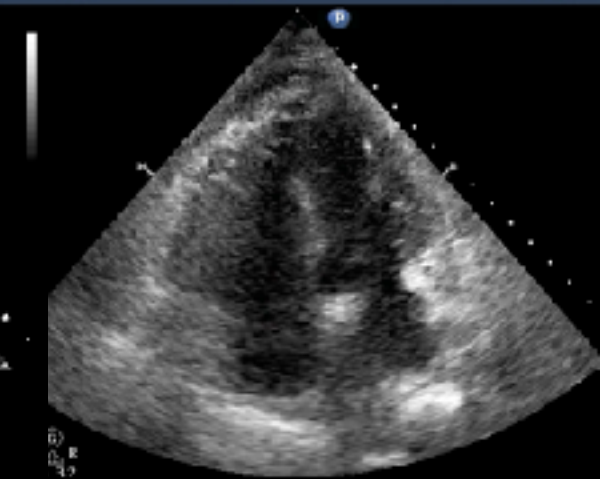76M, Dyspnea & desaturation



PSLA

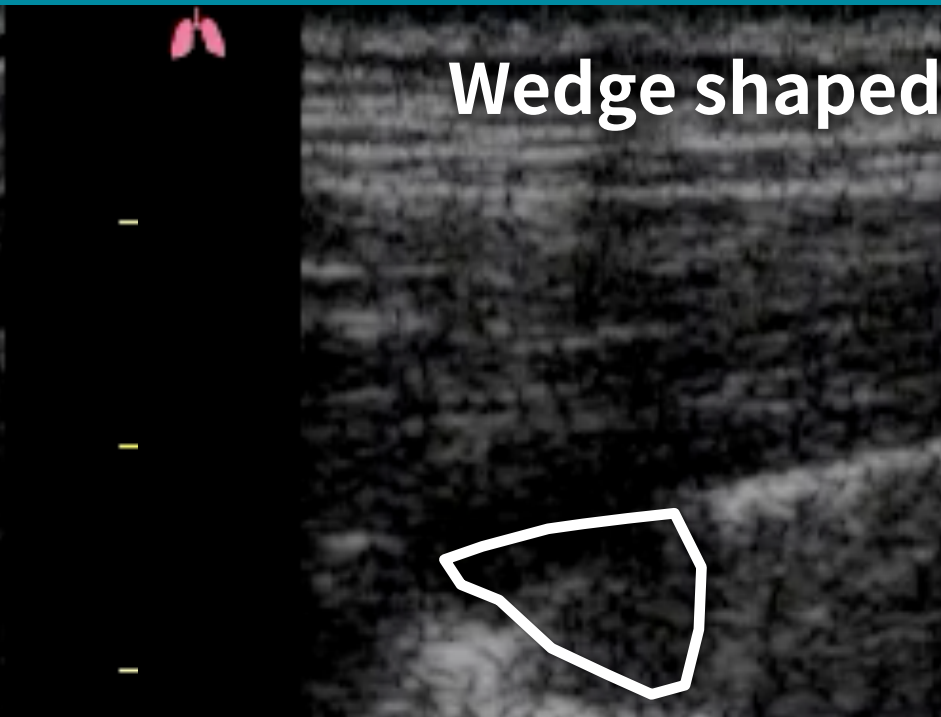
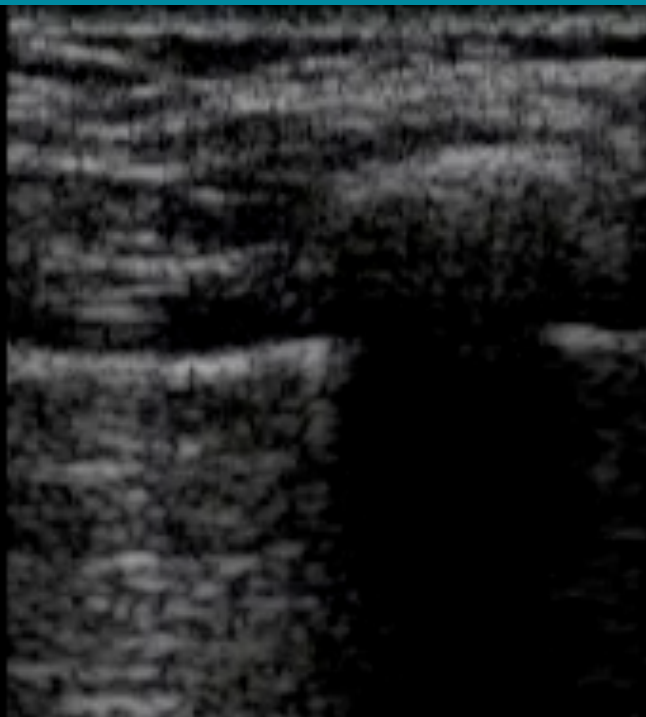


D sign



McConnell's sign

Pulmonary infarction



Wedge shaped



呼吸喘看肺—心—靜

肺栓塞看靜—心—肺

4.9cm

LUS for critically ill patients

ARJCCM 2018

ACUTE RESPIRATORY FAILURE – DIFFERENTIAL DIAGNOSIS

Start with anterior fields examination

A-lines

B-lines[#]

Consolidations

No sliding

Sliding

Focal

Diffuse

Subpleural consolidations

Thin regular pleura
Normal sliding

Subpleural consolidation
Irregular and thickened pleura
Reduced sliding

Move to postero-lateral fields or other point-of-care ultrasound techniques

Lung point

Eventual consolidations

Subpleural consolidations
DVT+

Eventual consolidations

Eventual consolidation &
eventual pleural effusion

Eventual consolidation

Pneumothorax

COPD

Pulmonary
Embolism

Pneumonia

Cardiogenic
edema

Interstitial
disease

ARDS
Pneumonia

Indication

- Respiratory symptoms and/or signs
- Unclear chest radiograph findings
- Monitoring and prognosis

- History
- Physical examination
- ABG
- ECG

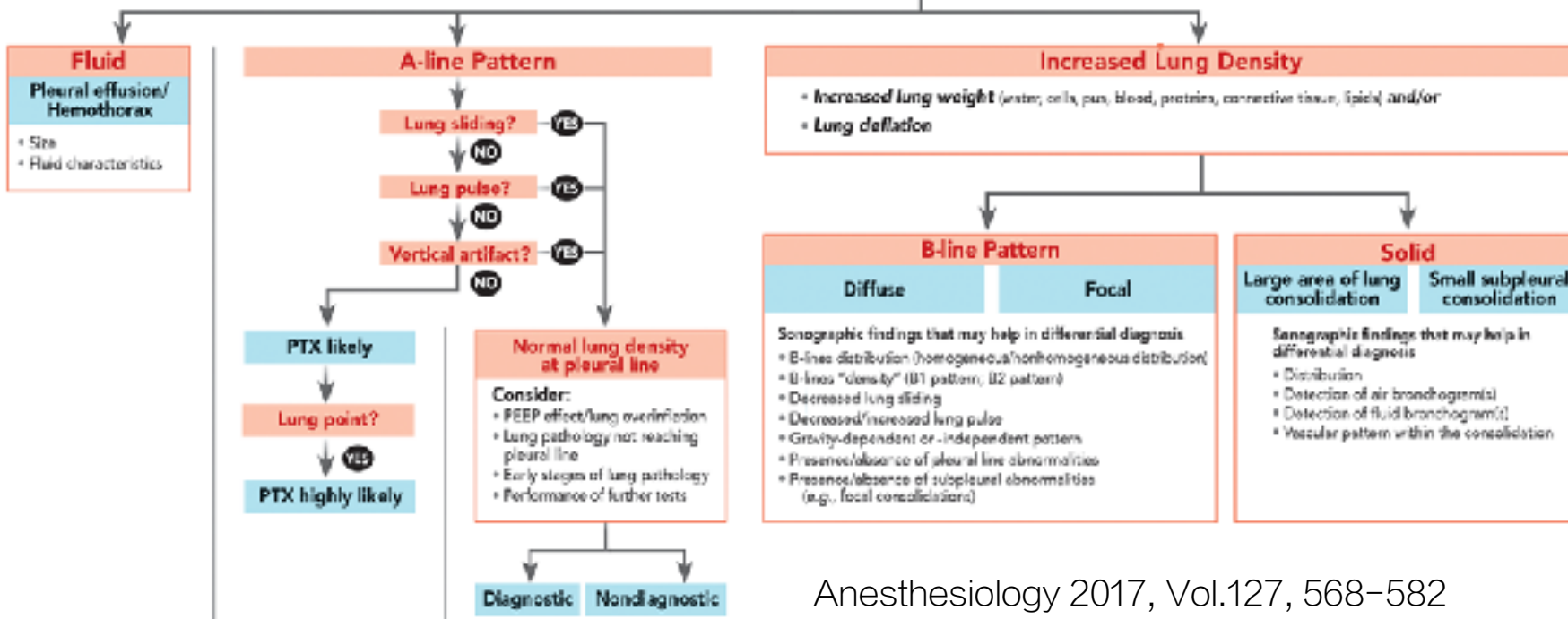
← Pretest probability

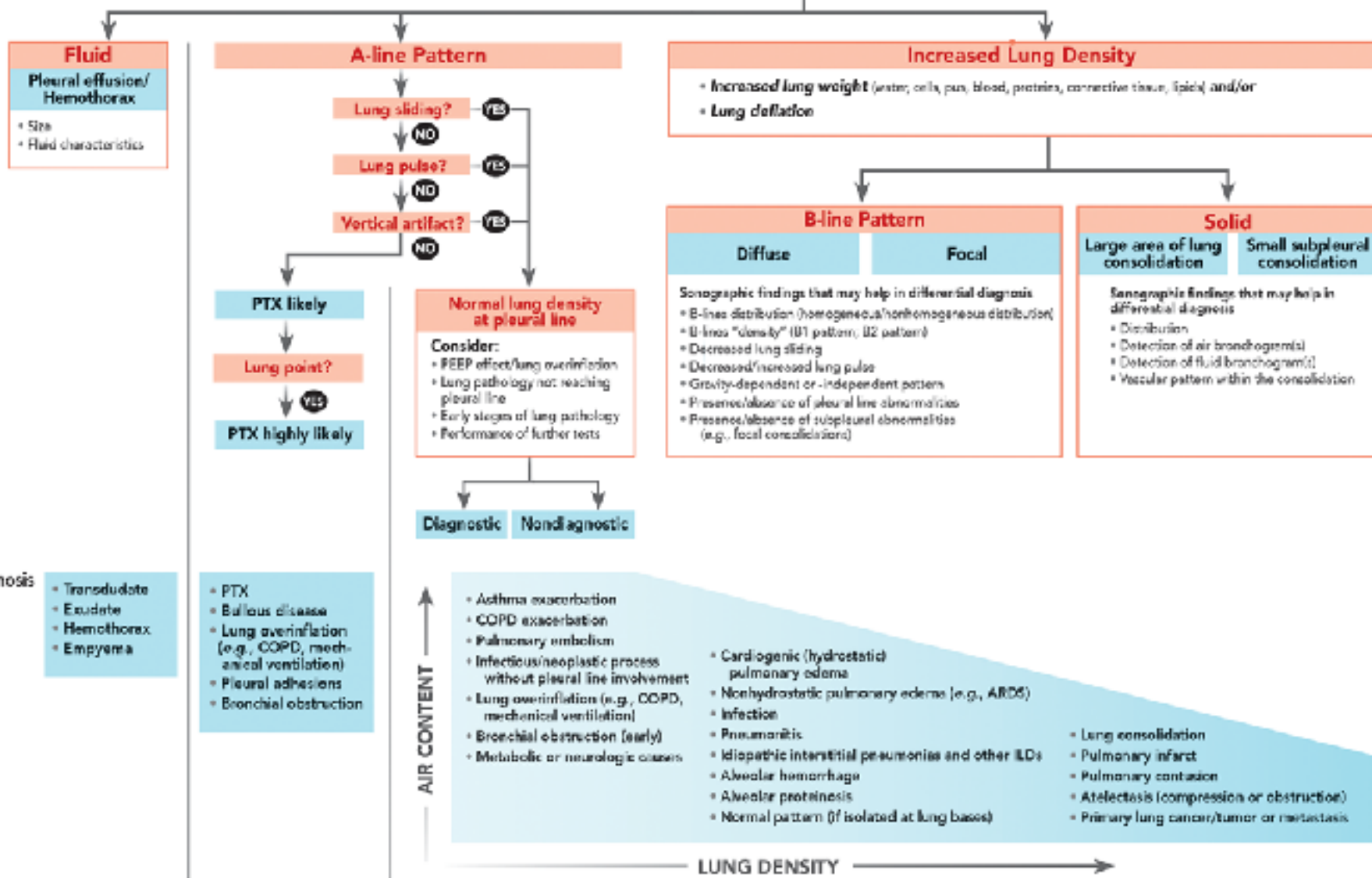
Acquisition

	DIAGNOSTIC HYPOTHESIS		
	Pleural effusion suspected	PTX suspected	Increased lung density suspected
Patient position Probe selection & orientation Protocol selection Picture optimization	<ul style="list-style-type: none"> • Semi-erect (or supine) • Low-frequency probe • Maintain post-processing artifacts reduction algorithms • Start examination from lung bases; identify diaphragm and spine 	<ul style="list-style-type: none"> • Ideally supine • If possible, high-frequency probe • Consider M-mode and Power Doppler • Identify least dependent zone 	<ul style="list-style-type: none"> • Semi-erect or supine • Low-frequency and high-frequency probes • If B-line pattern analysis, deactivate post-processing artifacts reduction algorithms • Complete lung examination (anterior, lateral, and posterior surfaces, bilaterally)

Interpretation

PLEURAL LINE INTERFACE

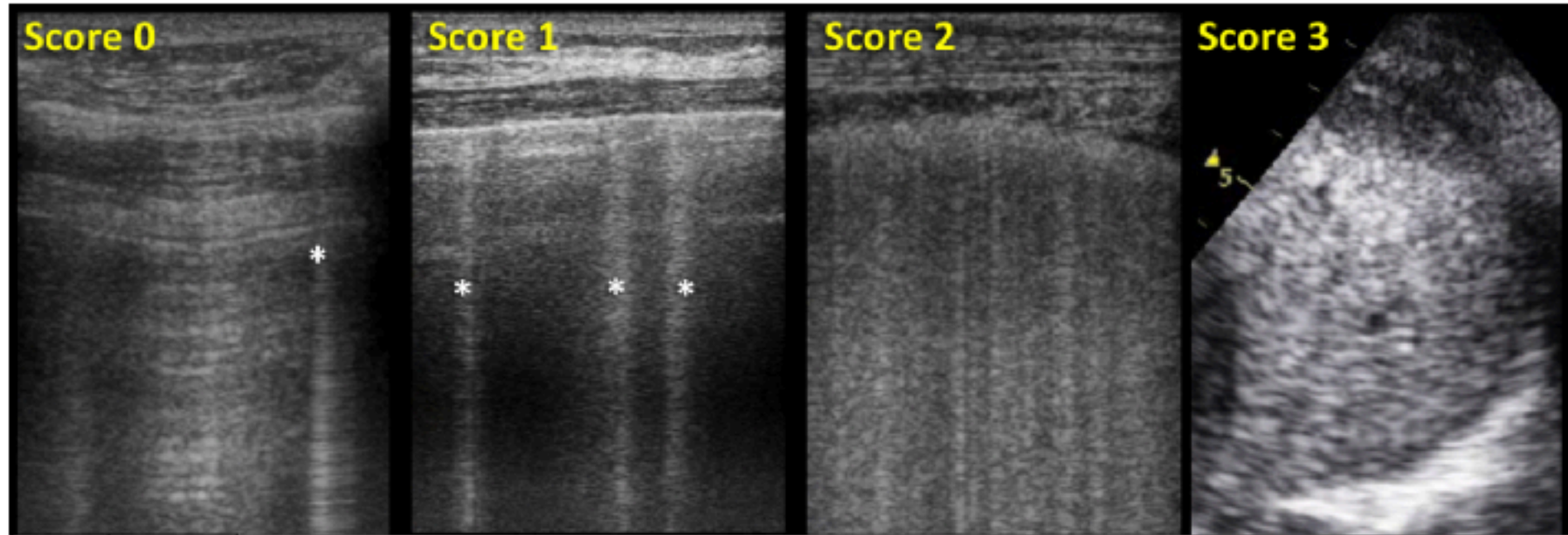




- Integration with clinical context (pretest probability)
- Consistency or inconsistency of findings with pretest diagnostic hypothesis
- LUS diagnostic or nondiagnostic
- Changes in diagnostic and therapeutic approach

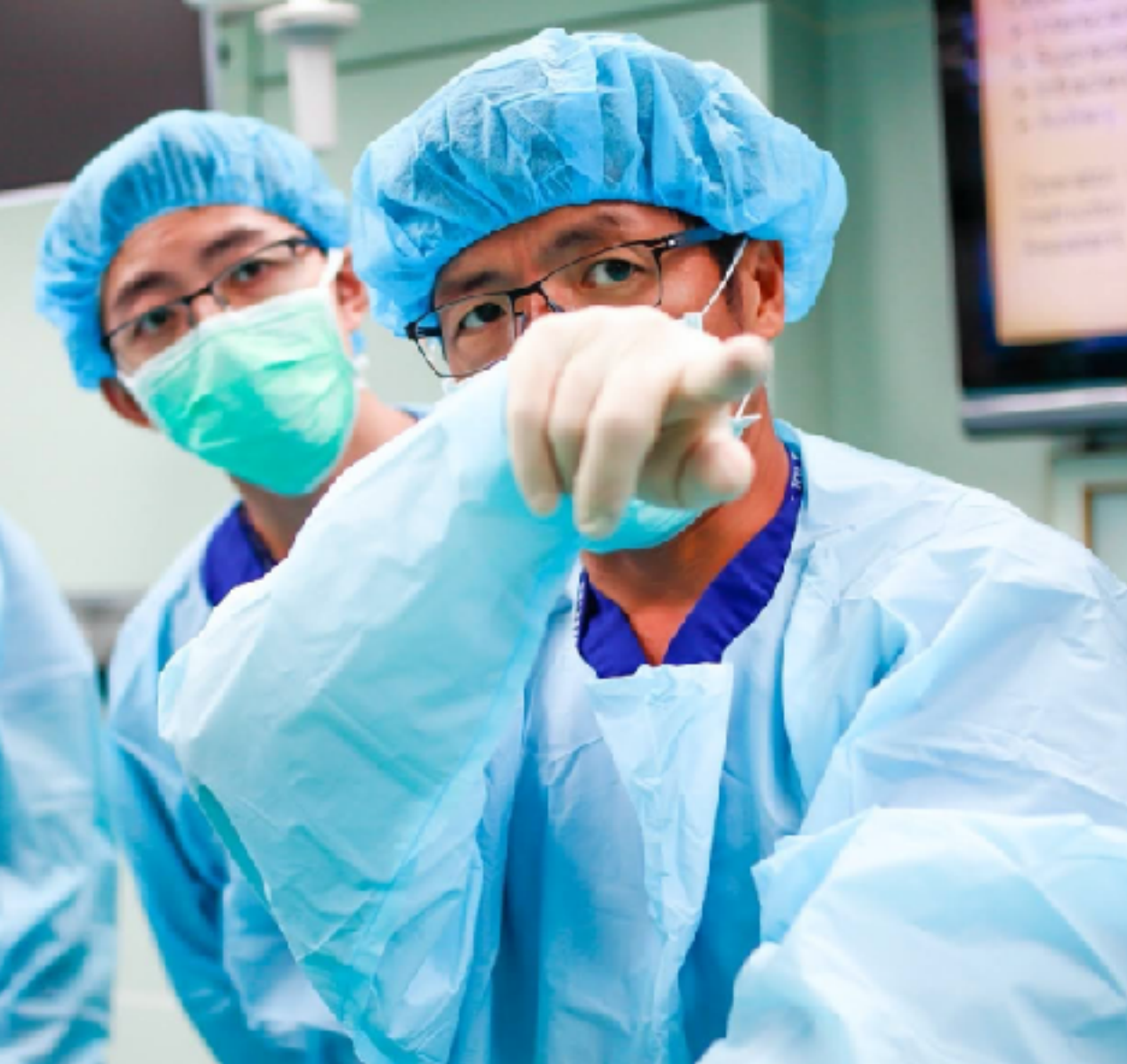Lung Aeration Score

12 regions: 0 ~ 36

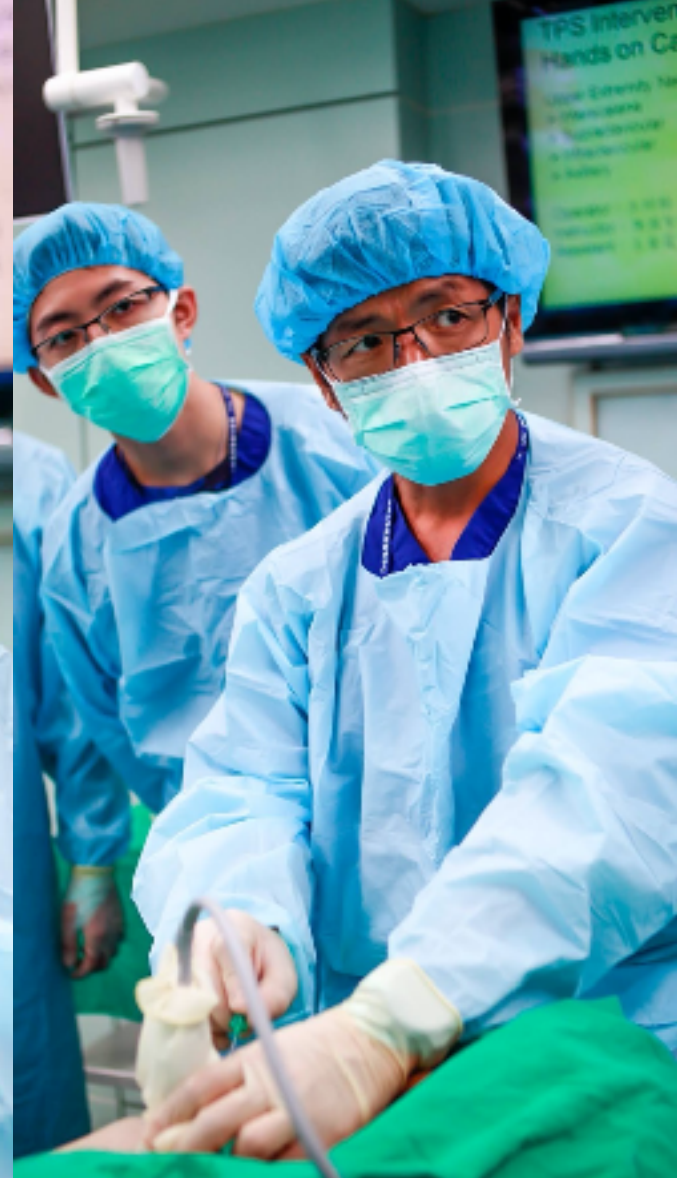

Reaeration score	+1	←	←	←
	+3	←	←	←
	+5	←	←	←
	-1	→	→	→
	-3	→	→	→
	-5	→	→	→





Diagnostician


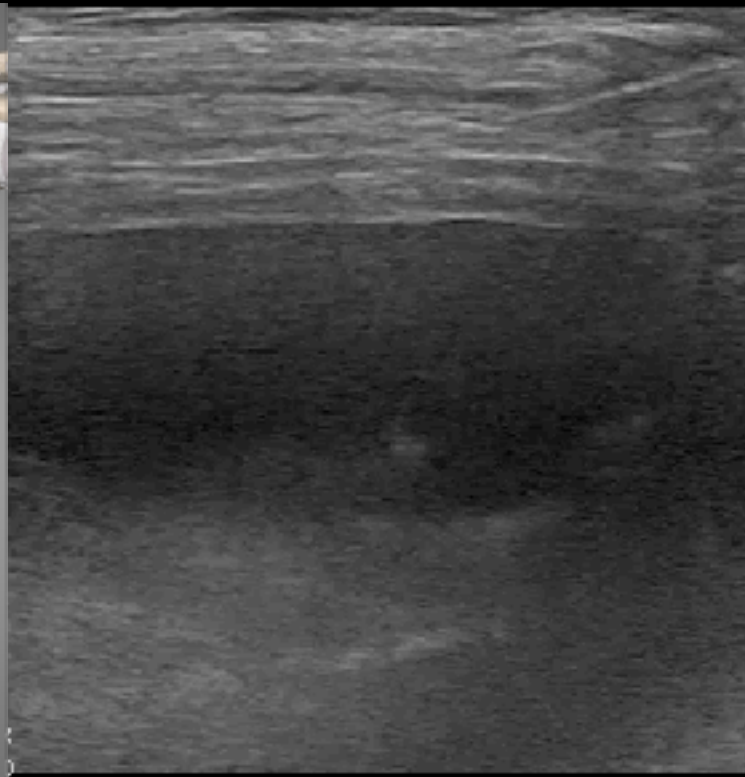
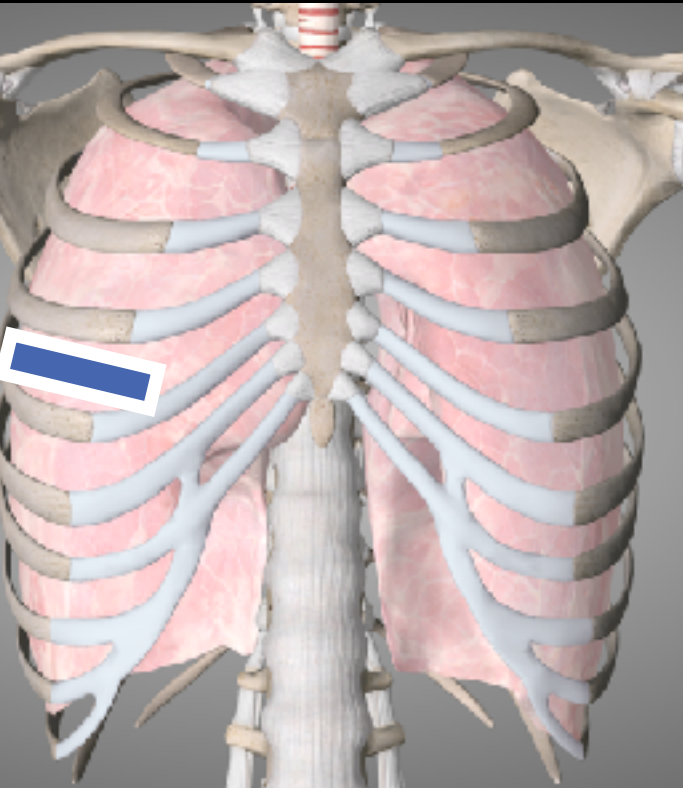


Interventionist

In-plane drainage



SKH-EUTC©ChenKC



Catheter insertion

Off-plane drainage



Superficial

L 12-3

43 Hz

4.5cm

P

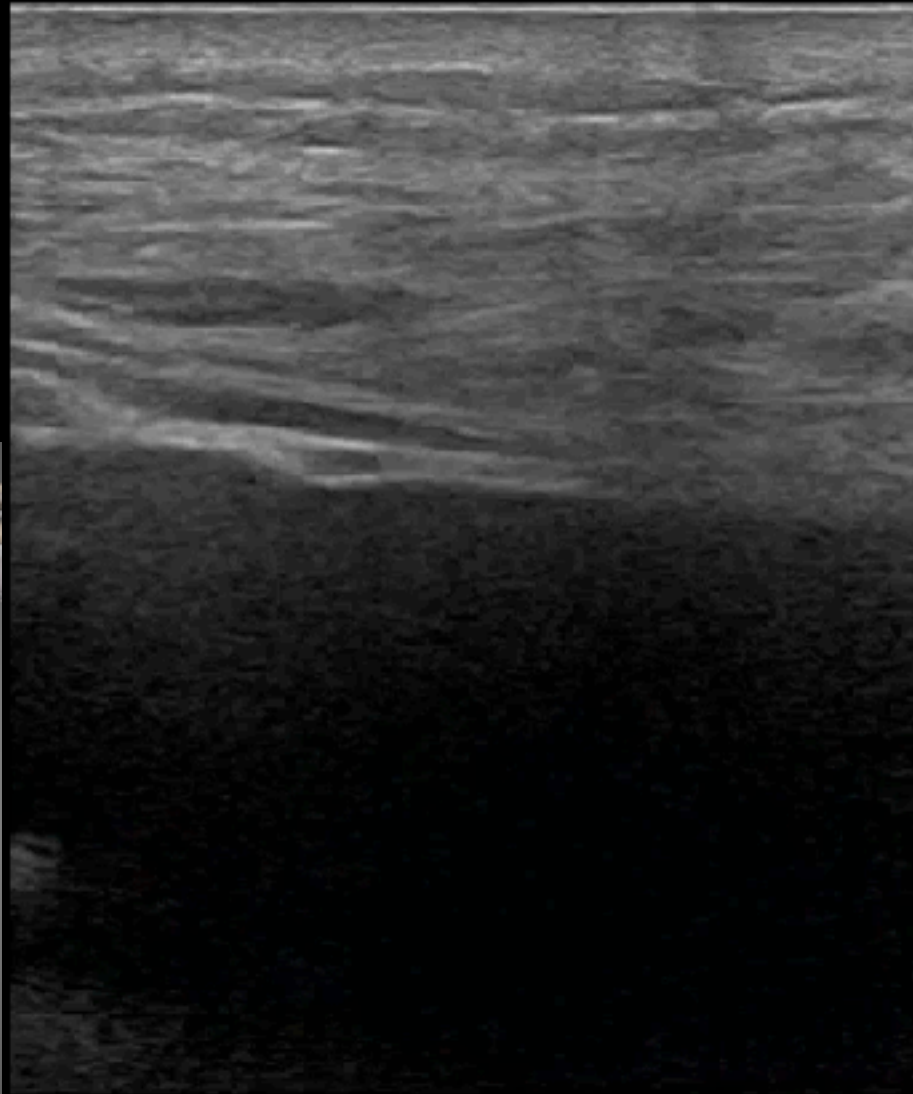
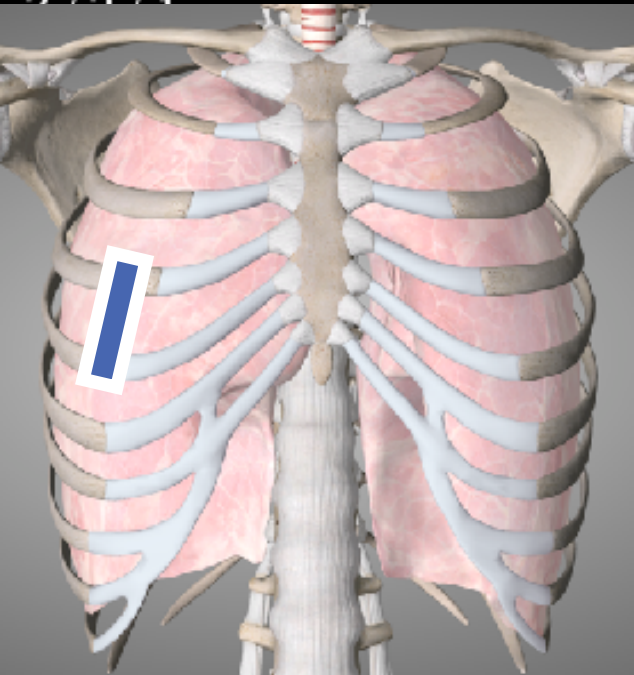
2D

Res

Gn 100

C 56

2 / 2 / 1



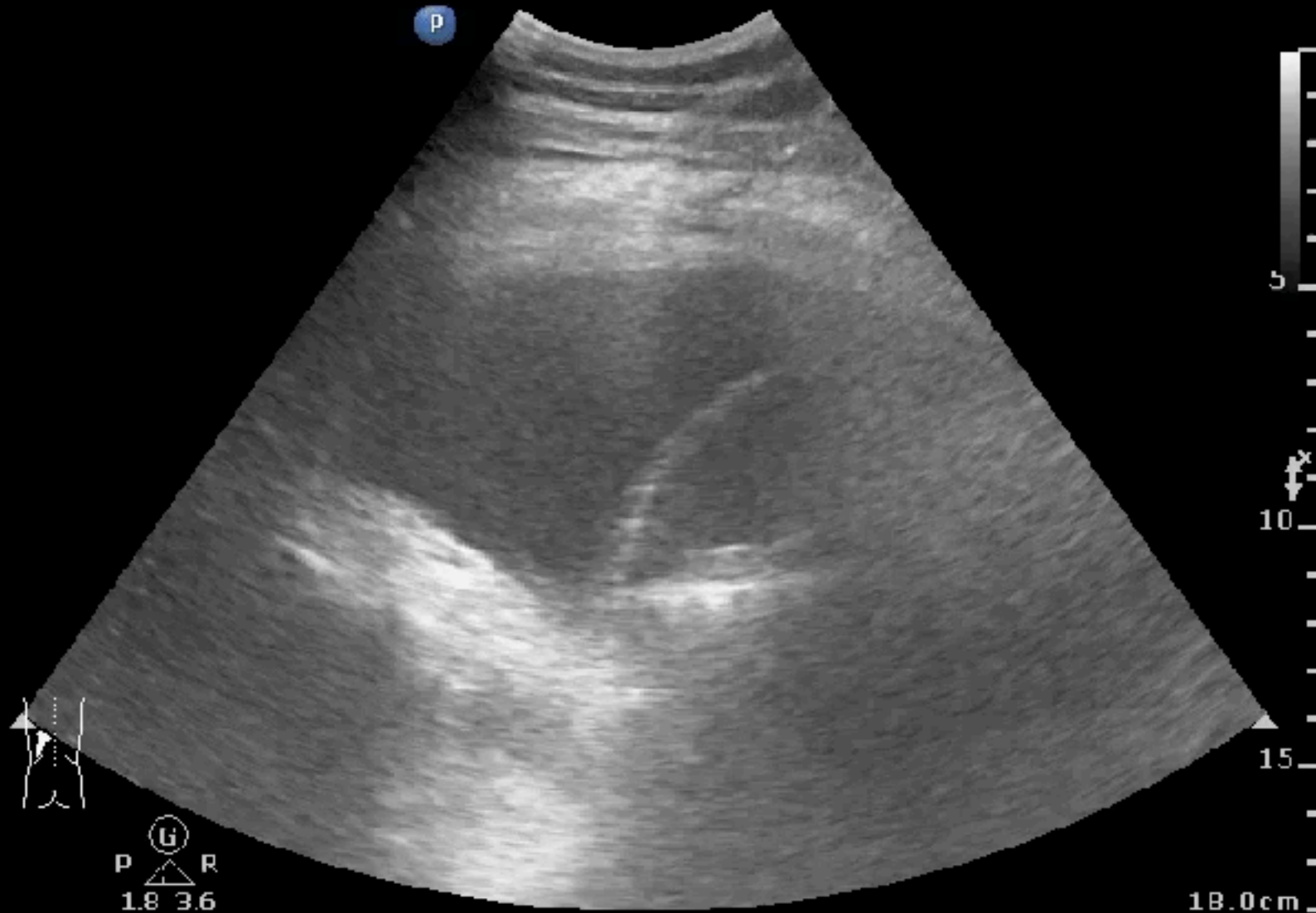4.5cm

Pigtail drainage with stylet

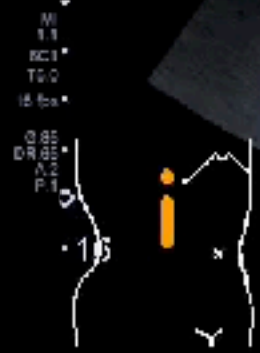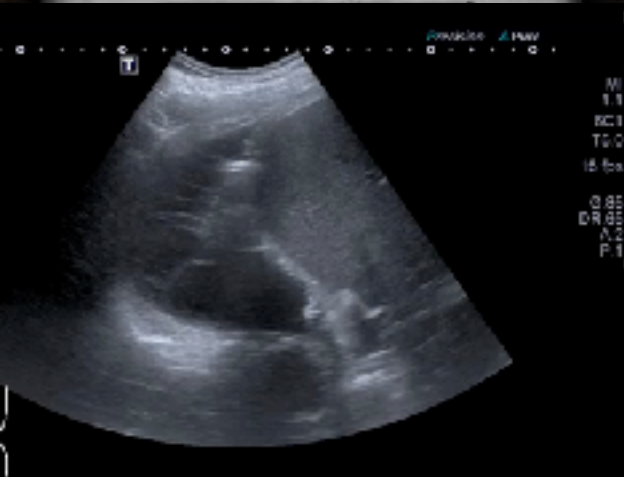
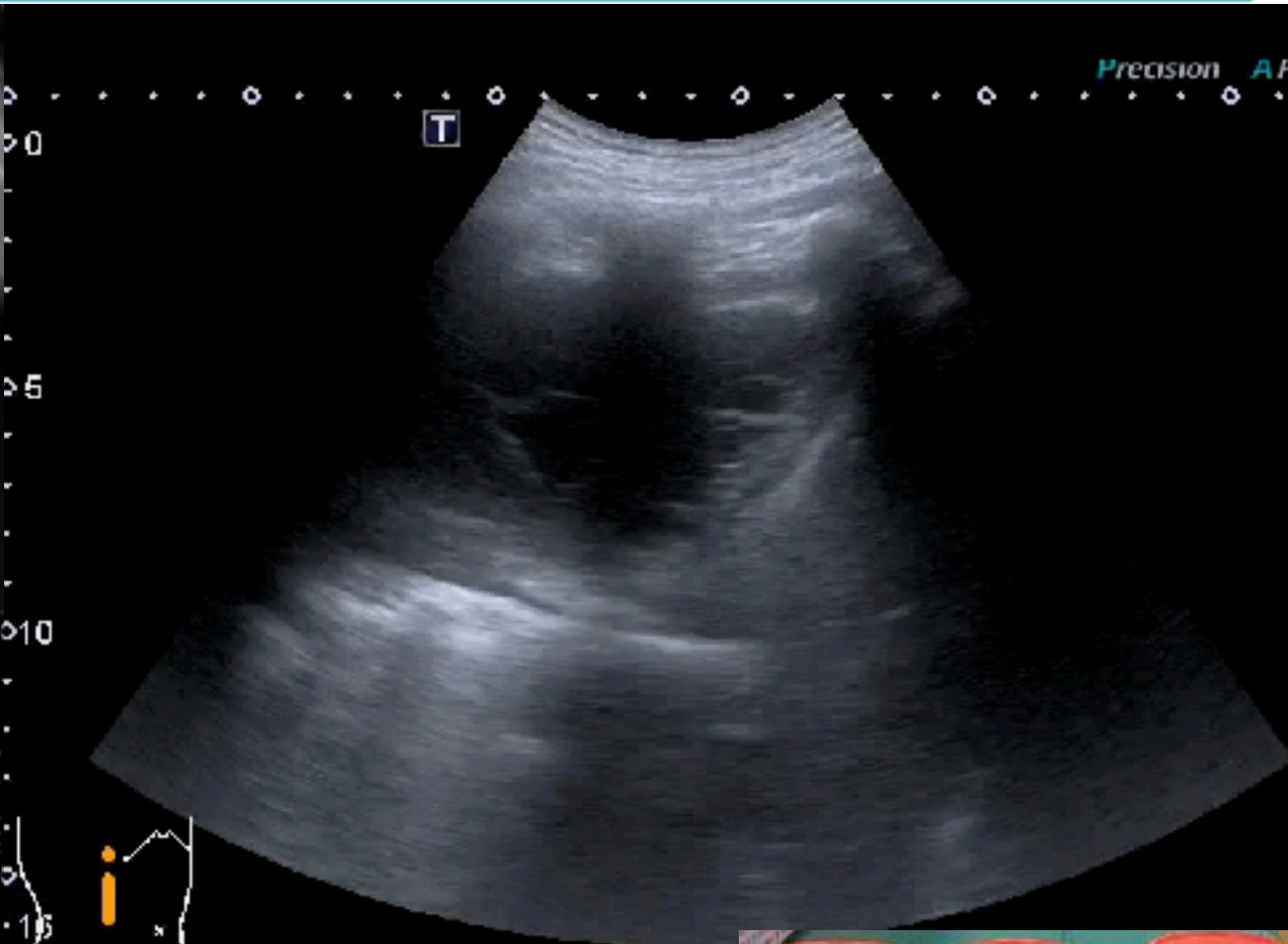

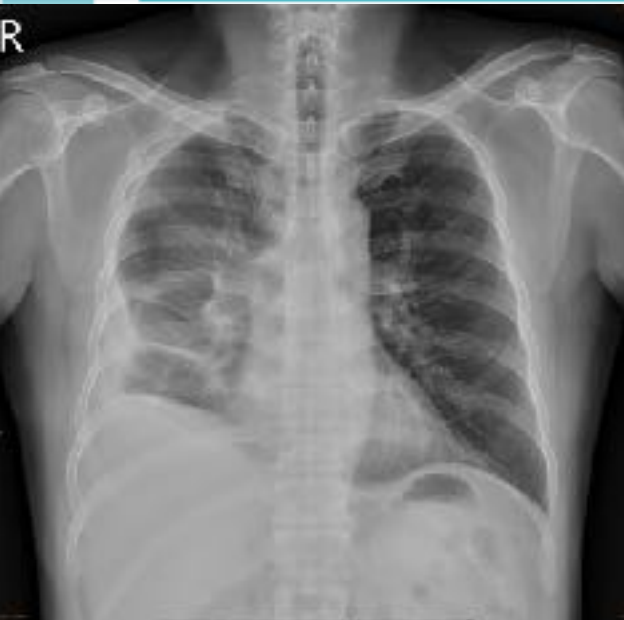
Abd Gen2
C5-1
30 Hz
18.0cm

2D
HGen
Gn 100
C 56
3 / 3 / 3

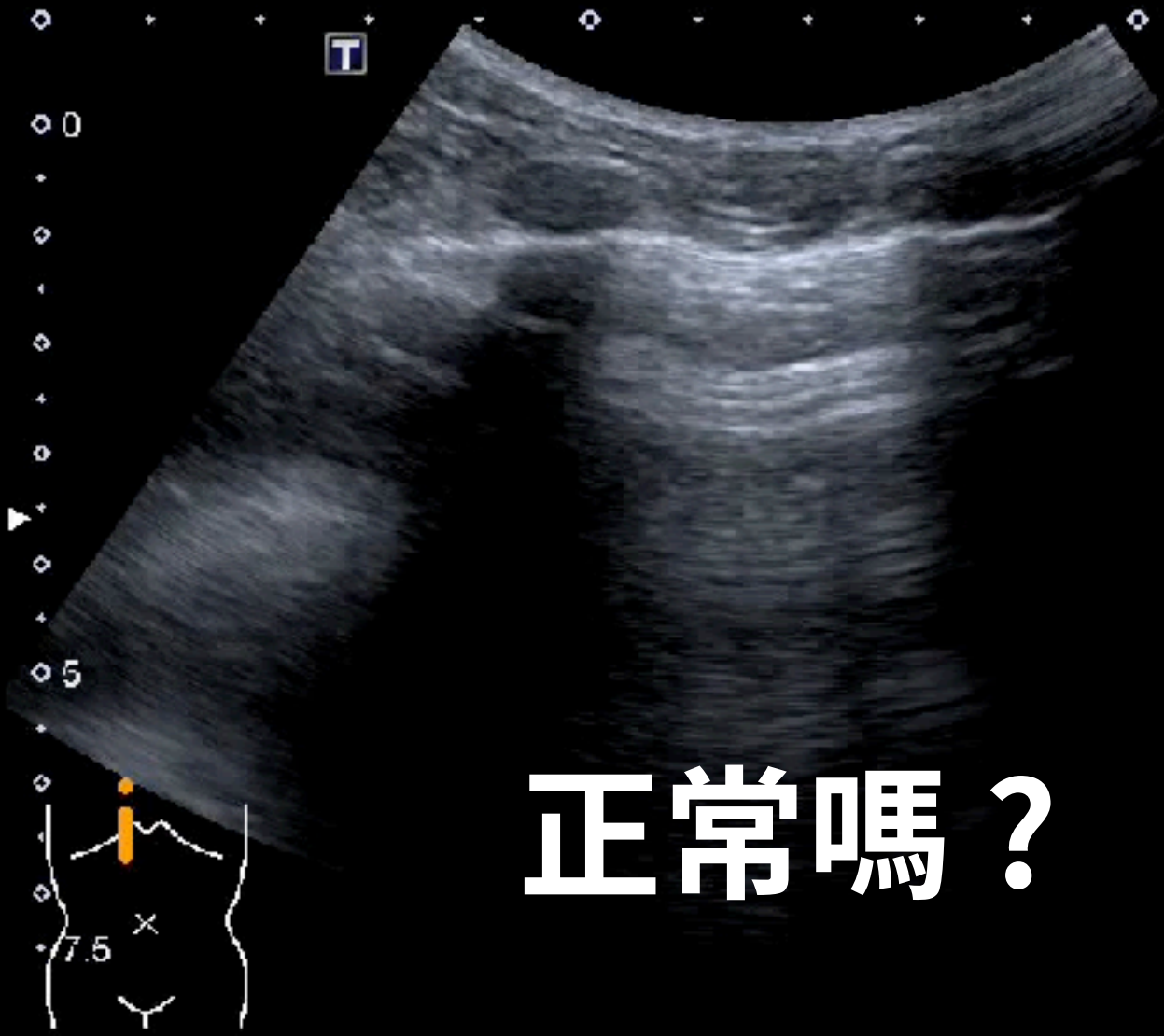


Pigtail drainage with guidewire





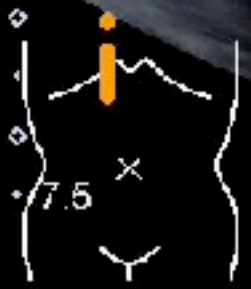LUNG



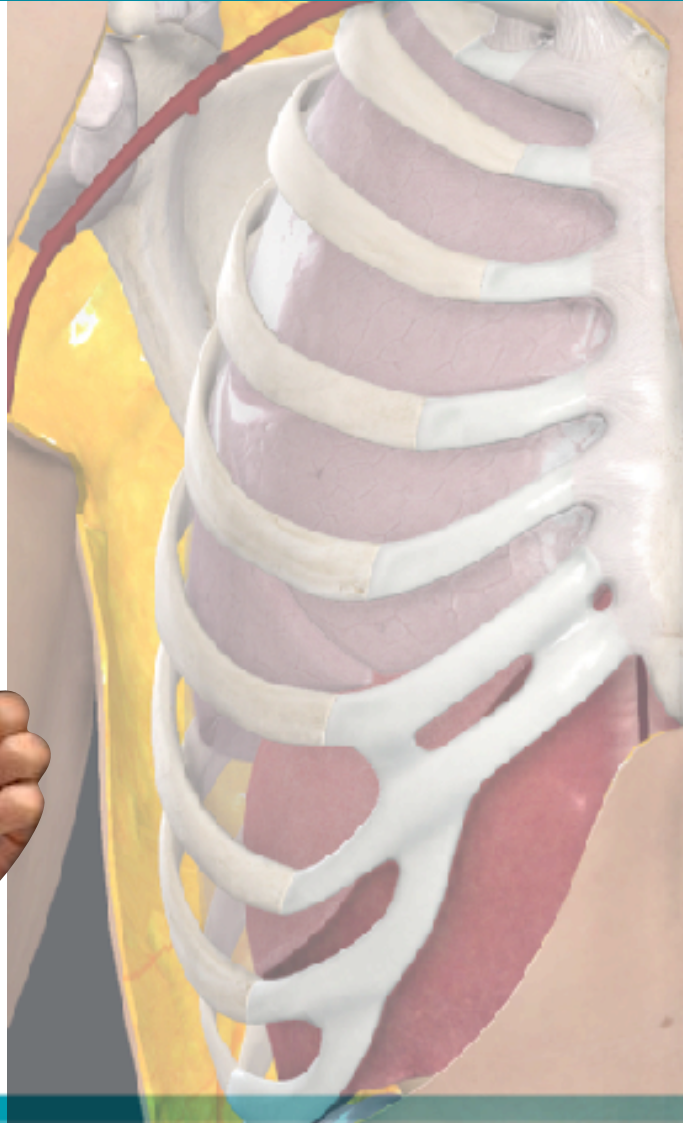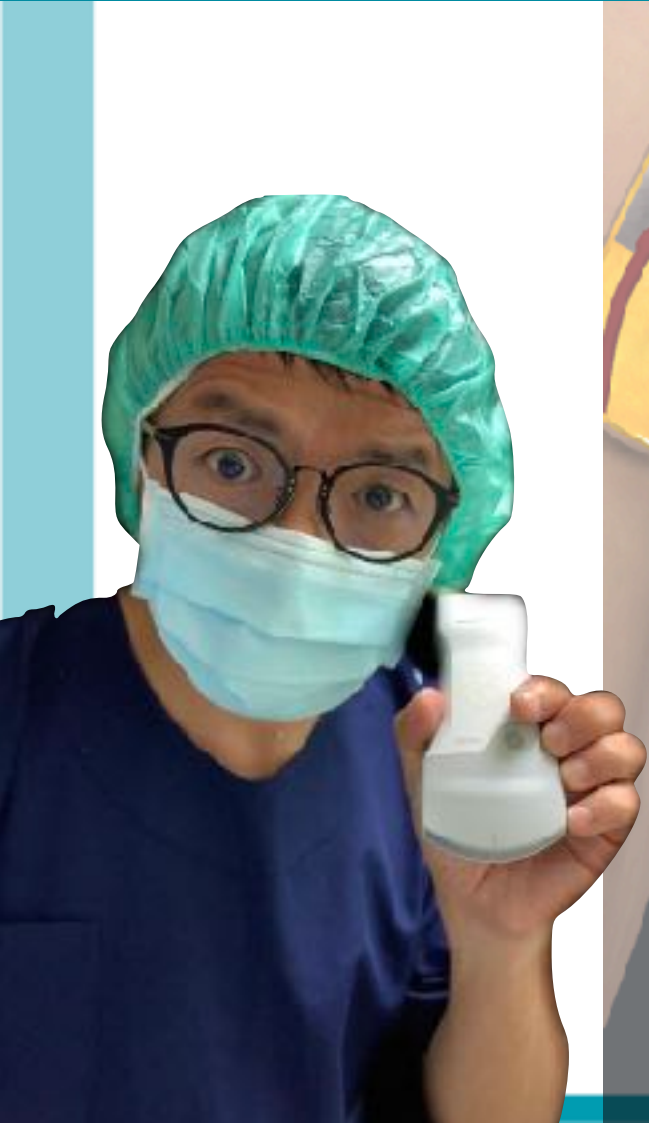Precision Apure

MI
1.5
6C1
T5.0
22 fps
G:85
DR:65
A:2
P:1

正常嗎？



LUNG USG : S - ABCDE



Dyspnea
Chest pain
Infections

PTX
AIS
PLE
Consolidation
DVT