



POCUS

急性腹痛的應用

陳國智雙和急診醫學科

陳國智 醫師



醫用超音波學會指導醫師
WINFOCUS director / instructor

急診 / 重症 / 介入 / 急性疼痛

經歷

新光急診超音波訓練中心主任

西園醫院急診醫學科主任

急診醫學會超音波委員會主委

台灣疼痛醫學會大體模擬手術講師

急救加護醫學會重症超音波負責人

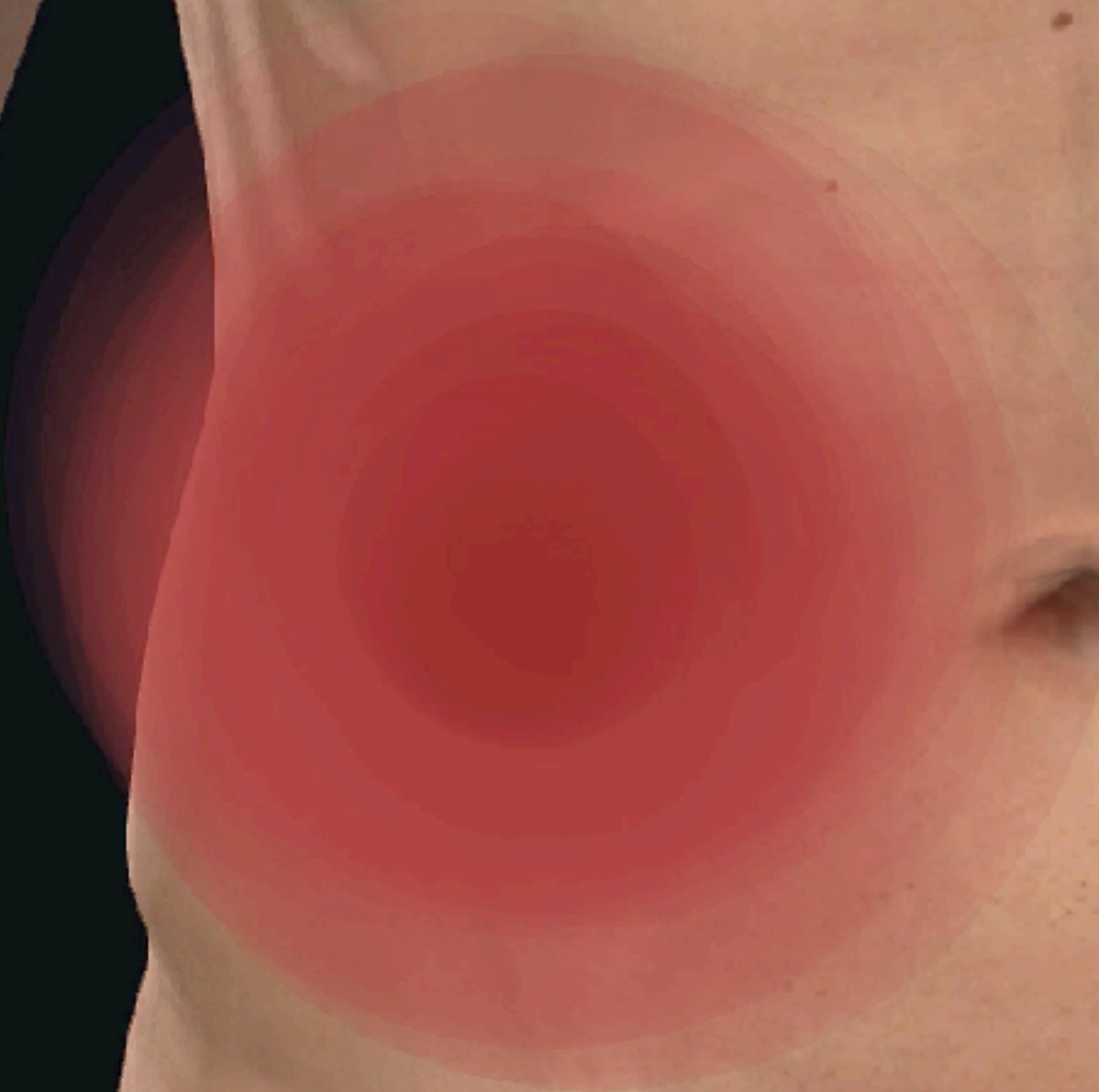
juice119@gmail.com

POCUSacademy.com

病史
詢問

理學
檢查

ECHO
評估



Approach to Abdominal Pain

Location

Onset

Type

Severity

Other locations (radiation)

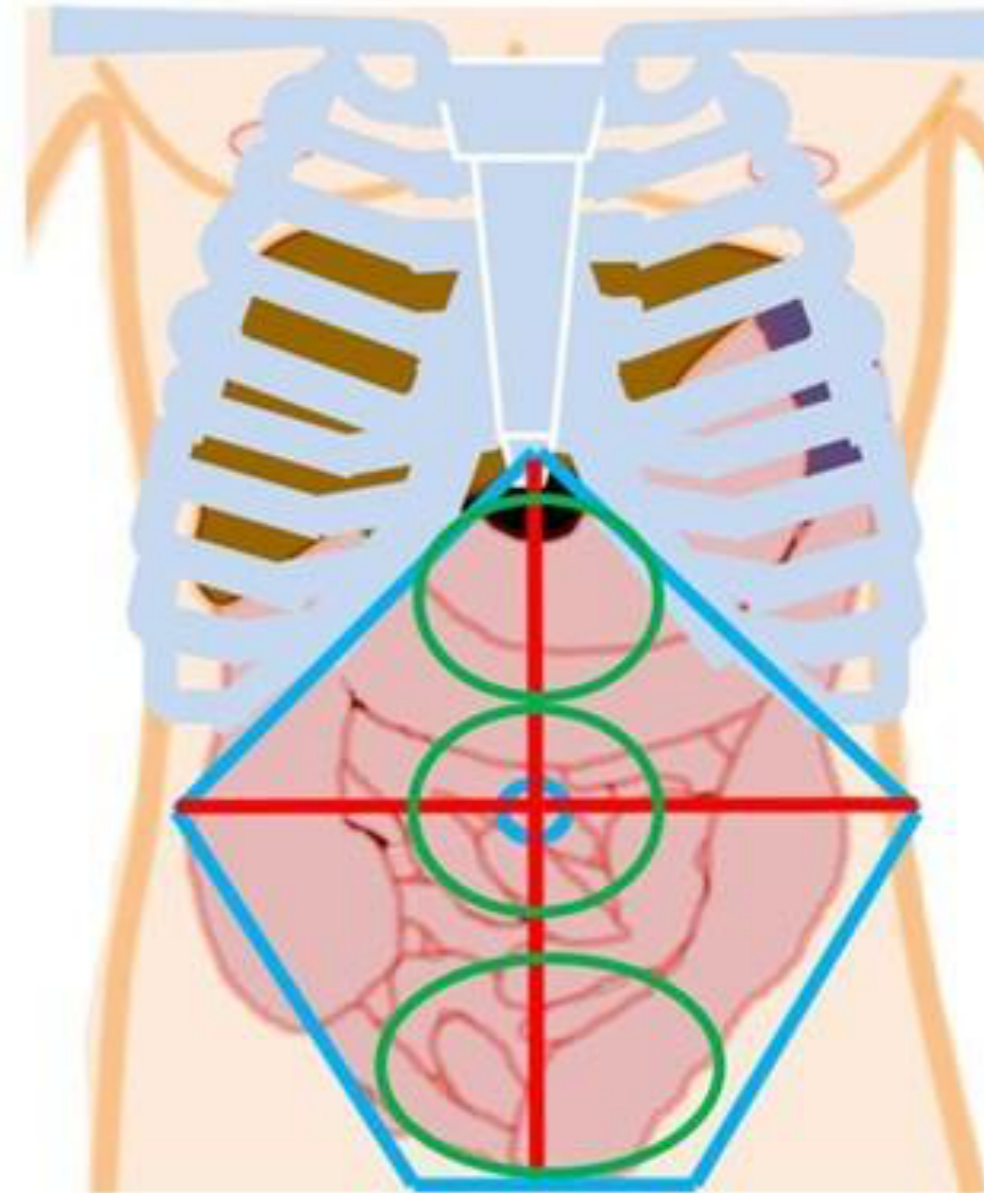
Factors (aggravating / alleviating)

Progression

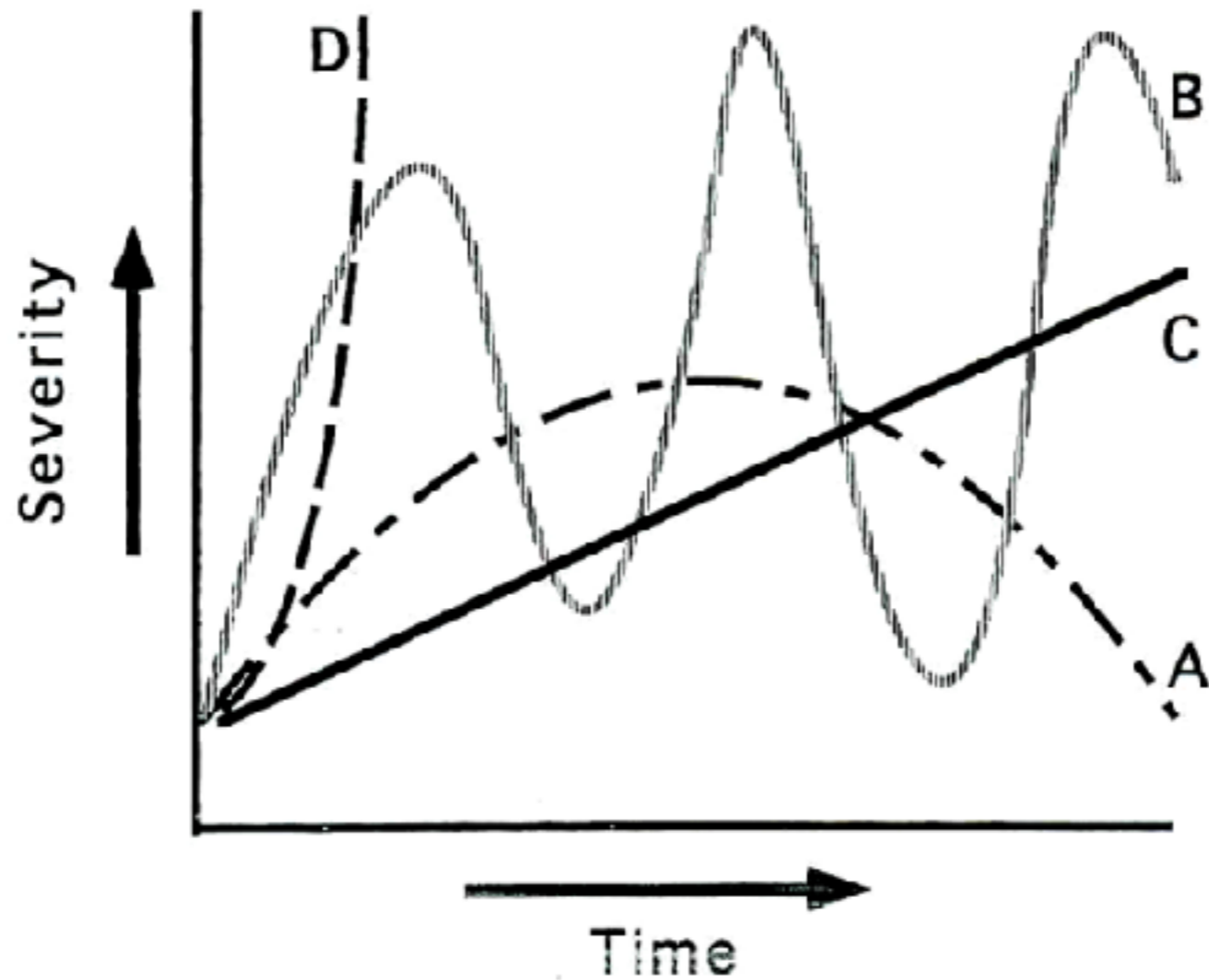
Associated symptoms







Insight (what do they think it is)

Need relief (what have they taken)



@kwburak



0	1	2	3	4	5	6	7	8	9	10
No Pain	Mild	Moderate	Severe	Very Severe	Worst Pain Possible					
										
0	1-3	4-6		7-9	10					

I-AIM

POINT



Acquire



Interpret



**Make
decision**

Acute Abdomen

Internal bleeding ?



FAST



Free Fluid



CT/TAE/OP

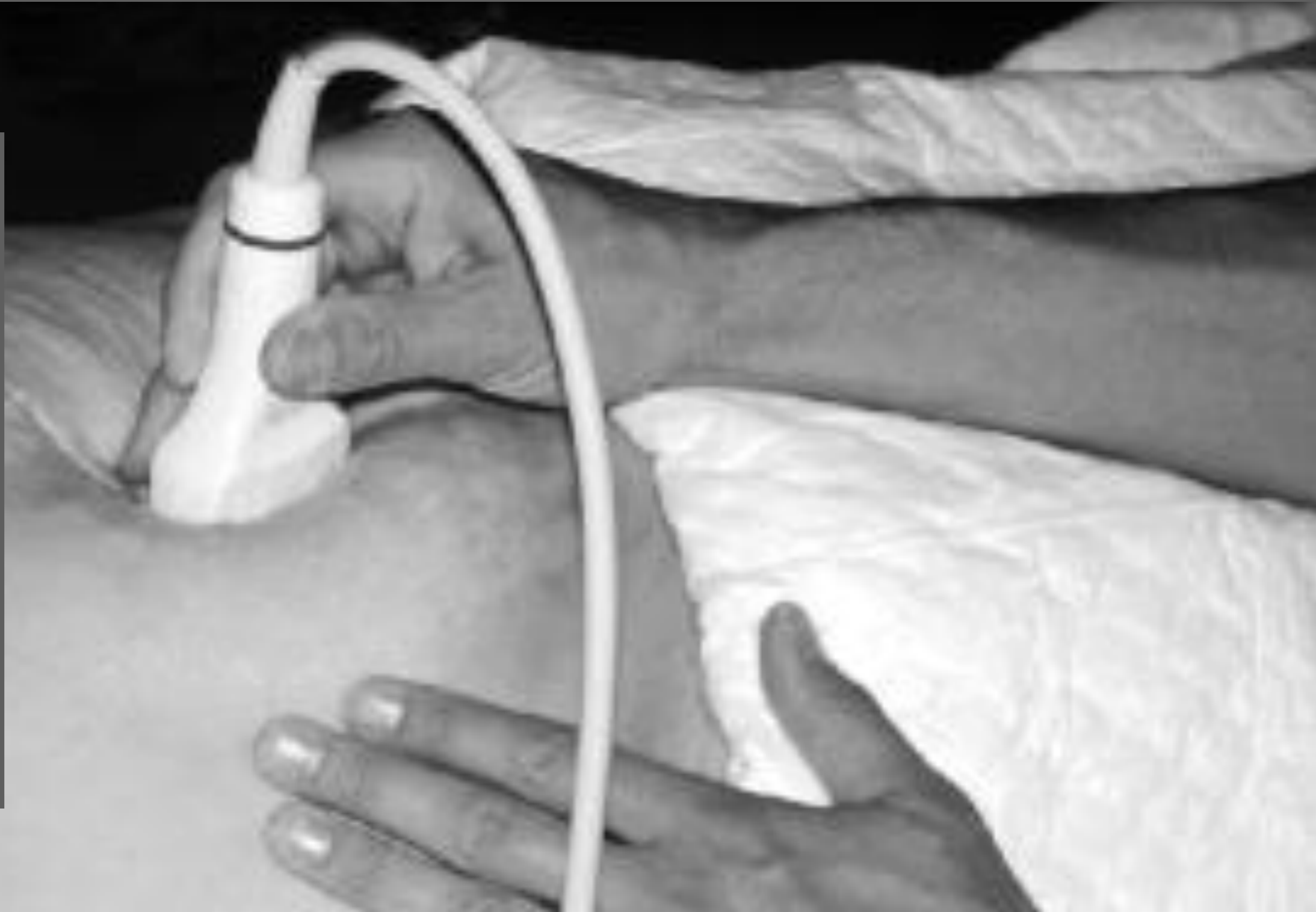探頭選擇：腹為主／線為輔



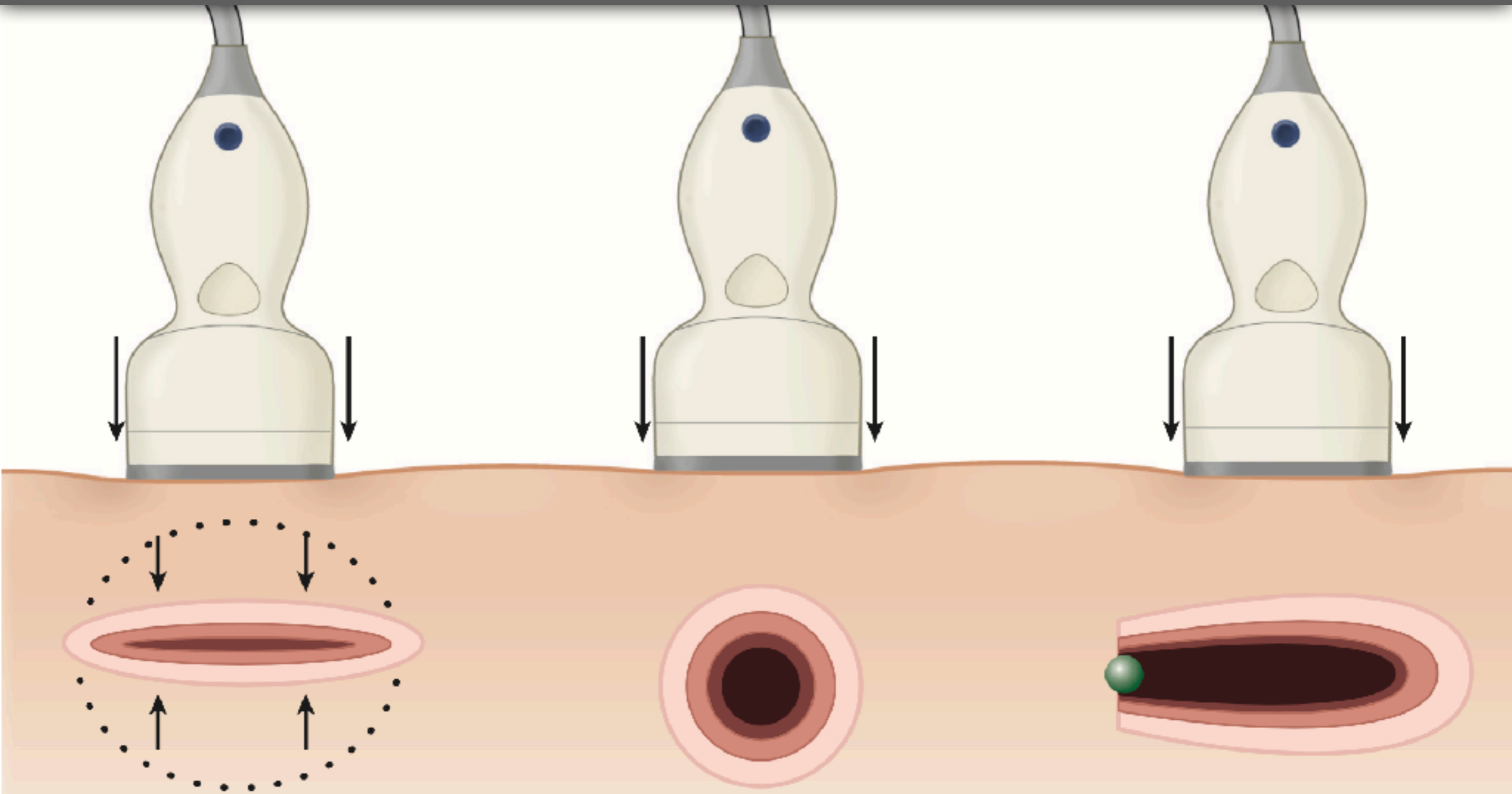
急診POCUS不用NP0
系統性掃描之後再聚焦

Graded compression

溫柔
穩定
施壓
停留
觀察



Compression很重要!!!

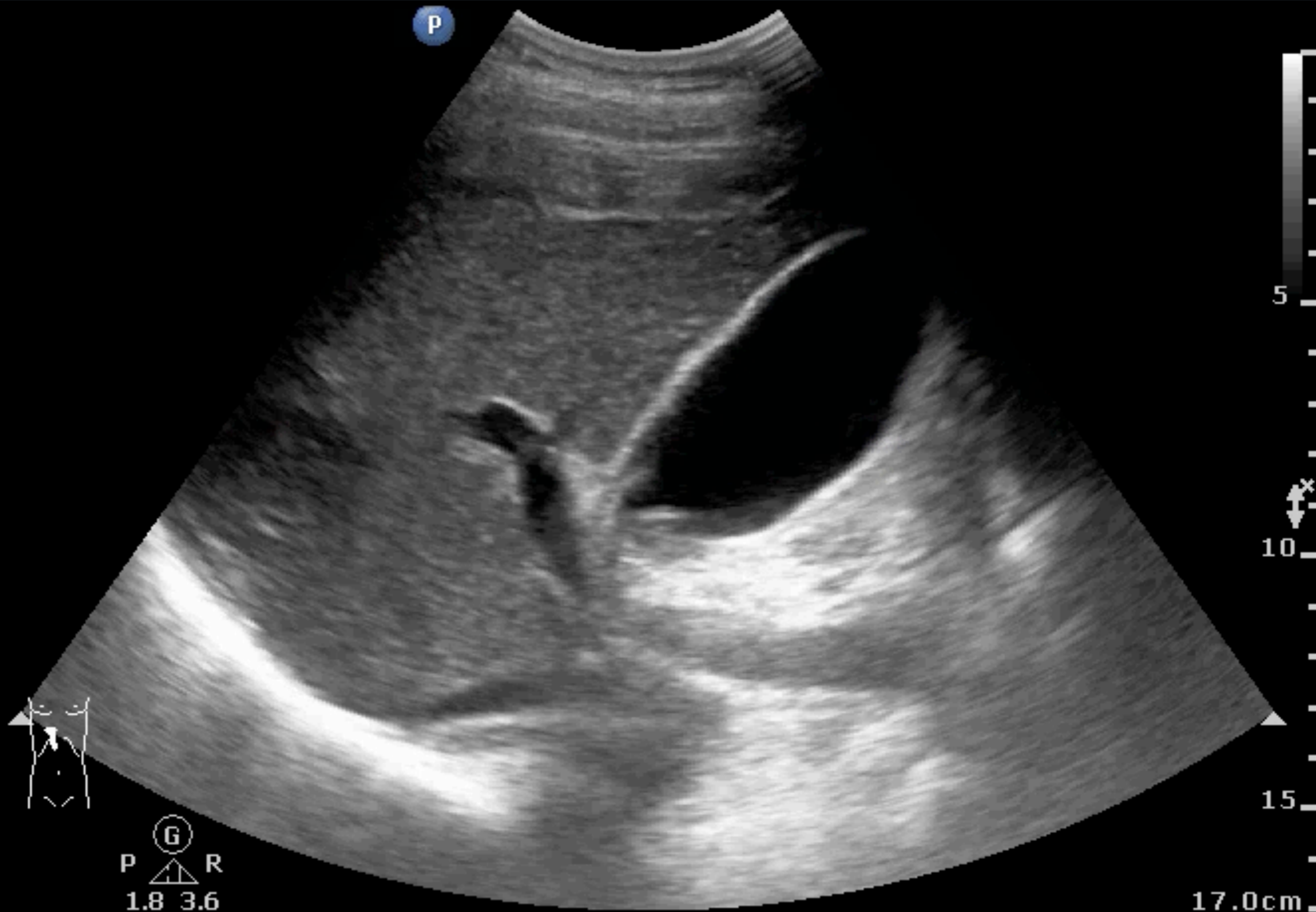

52M, RUQ pain, your diagnosis ?

Abd Gen2
C5-1
31 Hz
17.0cm

2D

HGen
Gn 86
C 56
3 / 3 / 3



POCUS

for

Acute

ABDOMEN

A for aorta

B for biliary

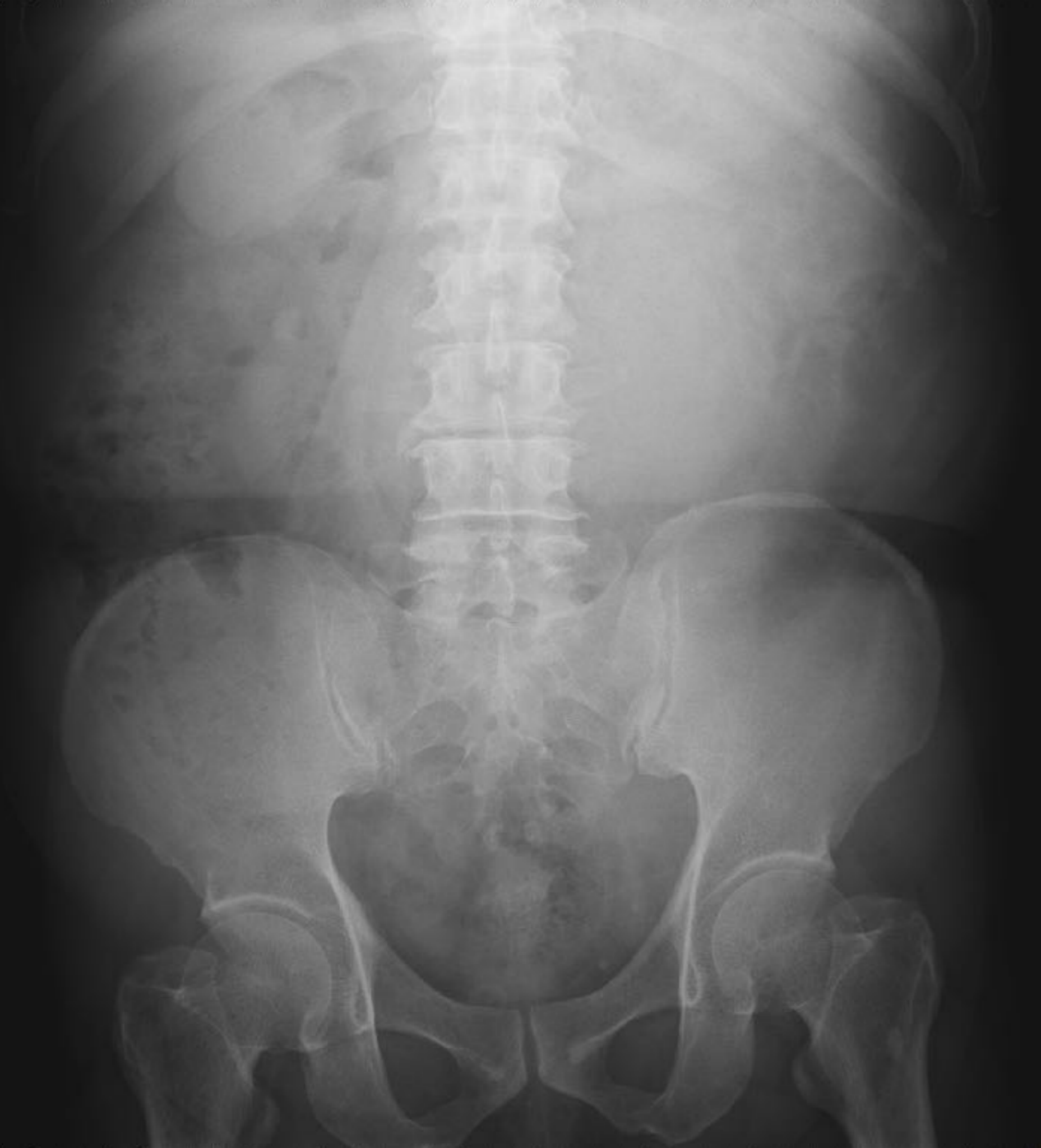D for diaphragm

O for bowel obstruction

M for moving fluid & air

E for ectopic pregnancy

N for nephropathy

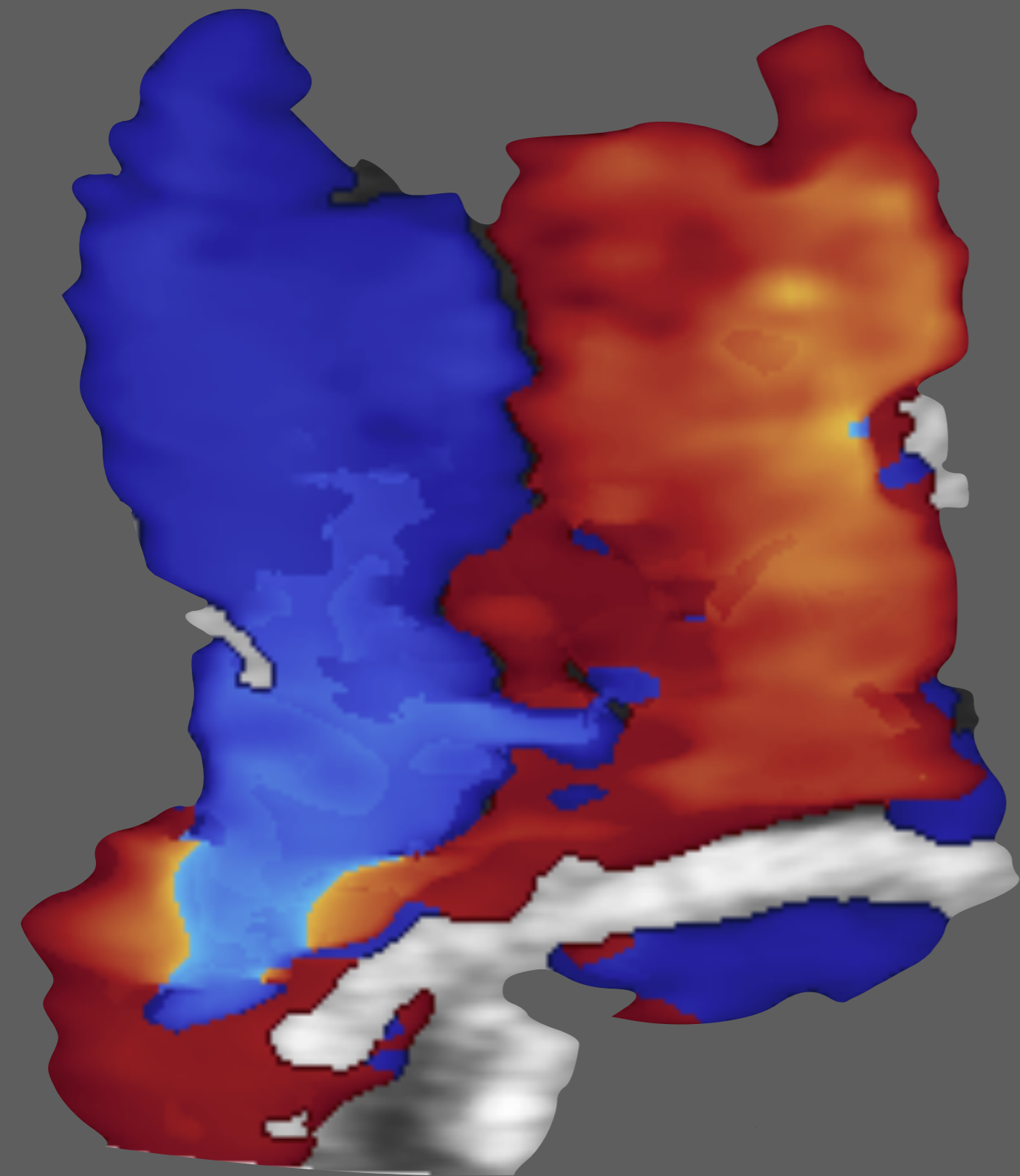


**64M,
左下腹痛
1小時
冒冷汗
結石病史**

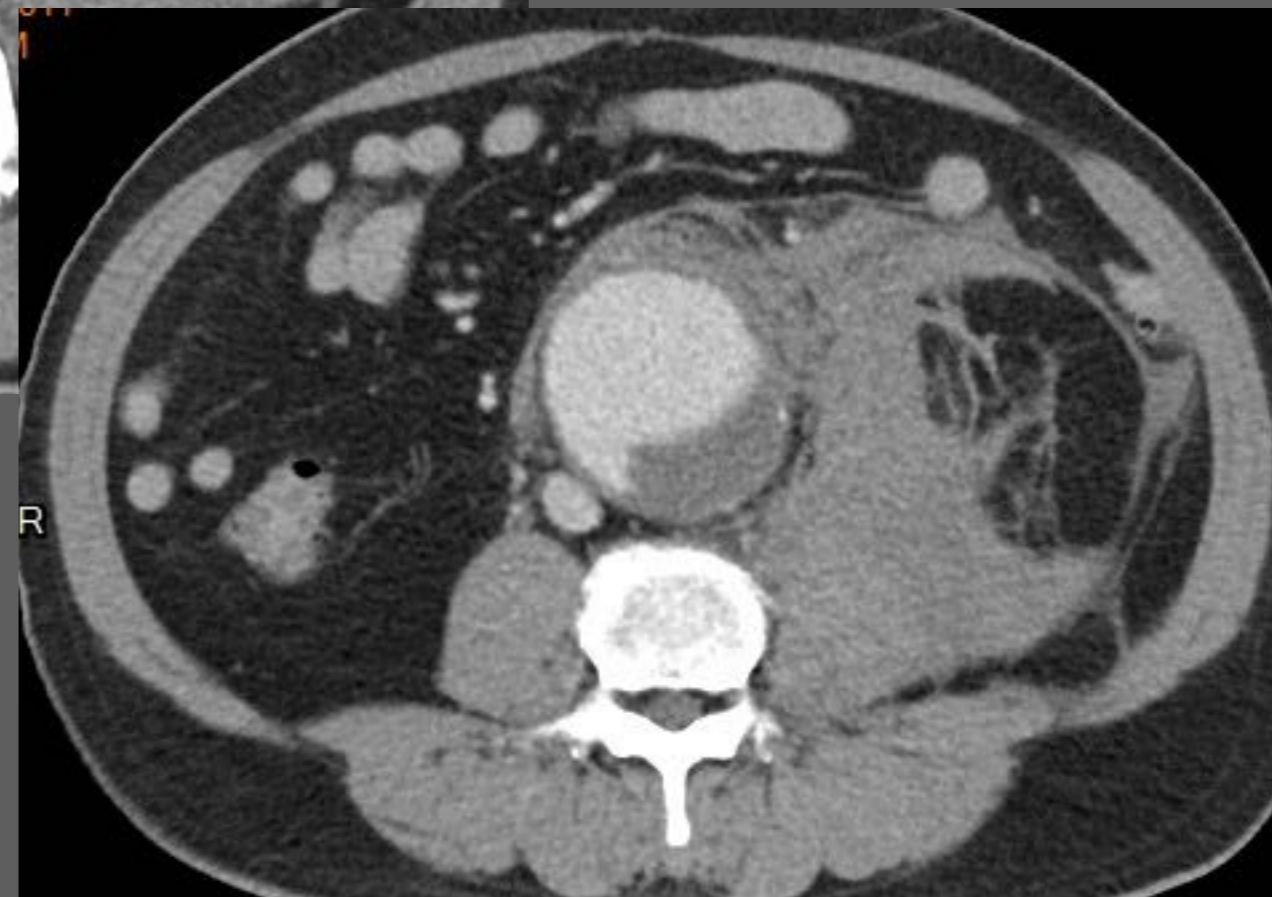
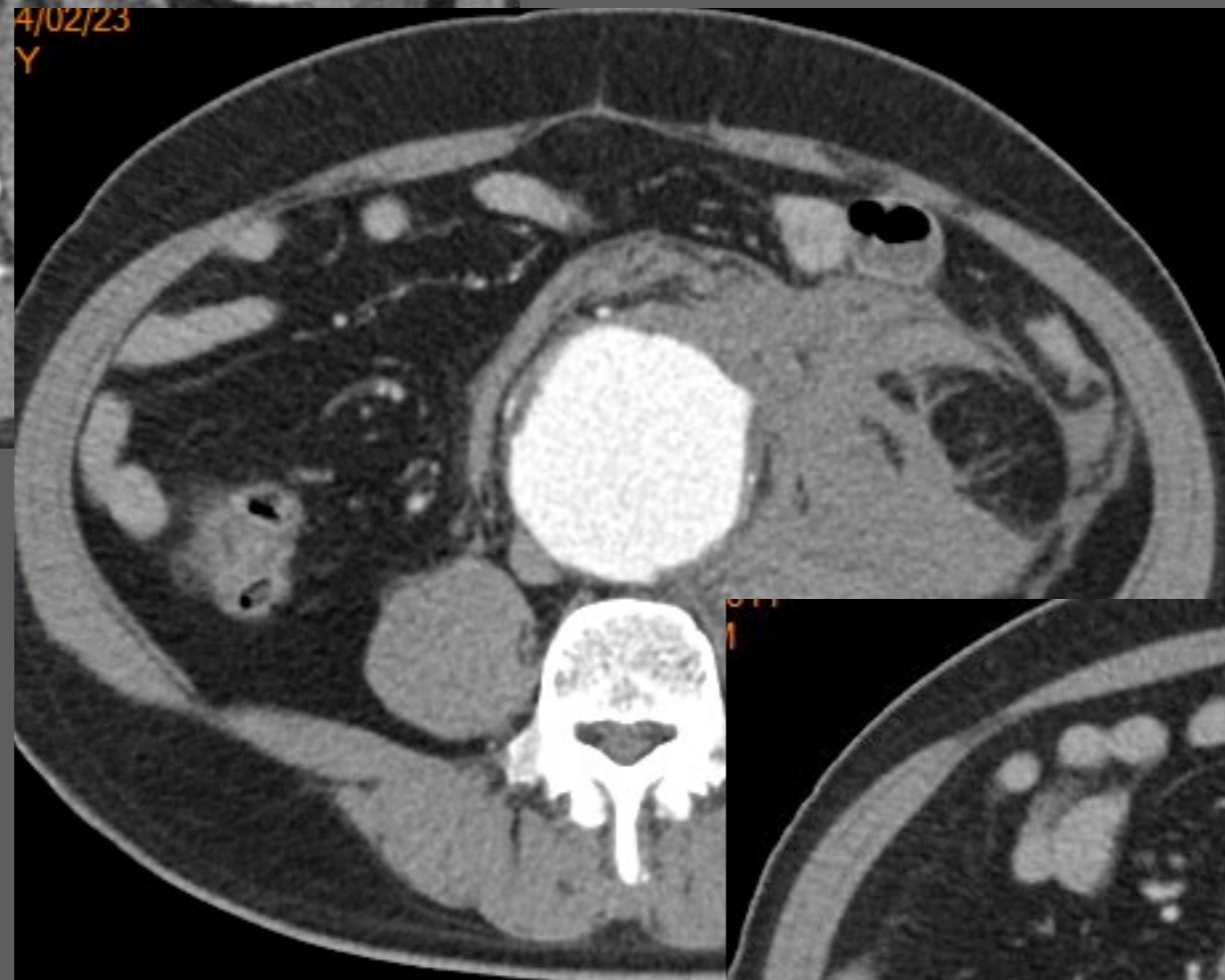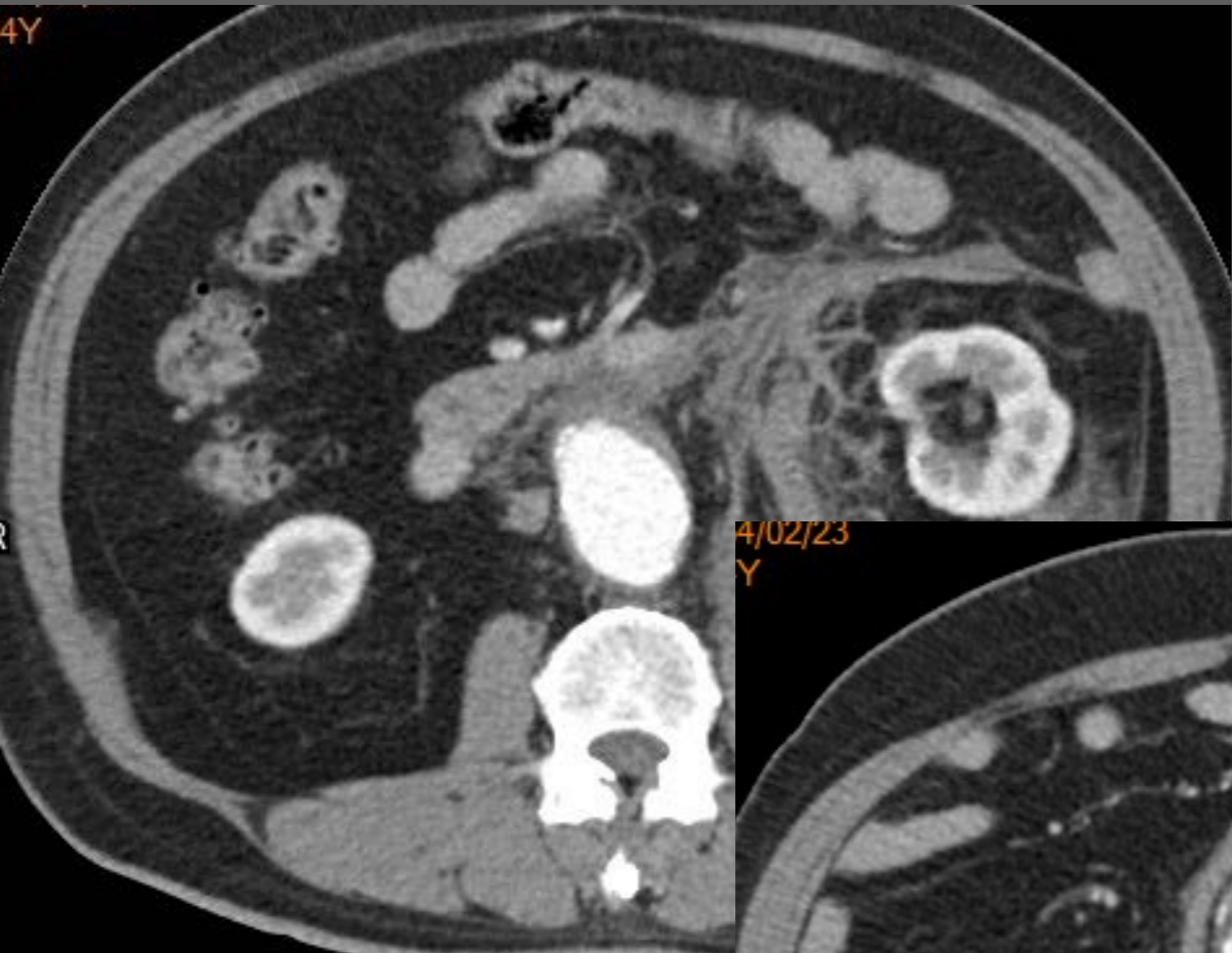PR 117

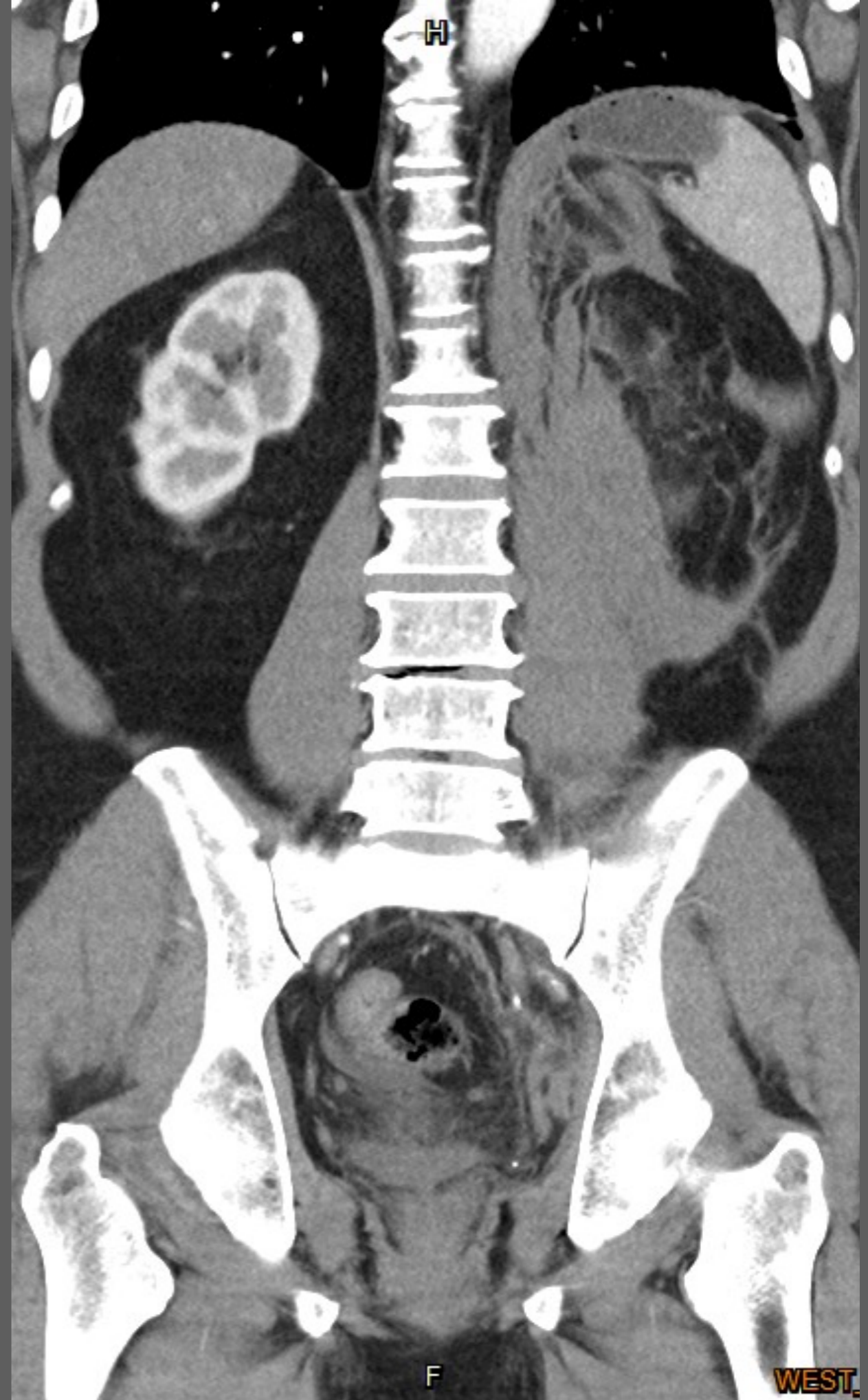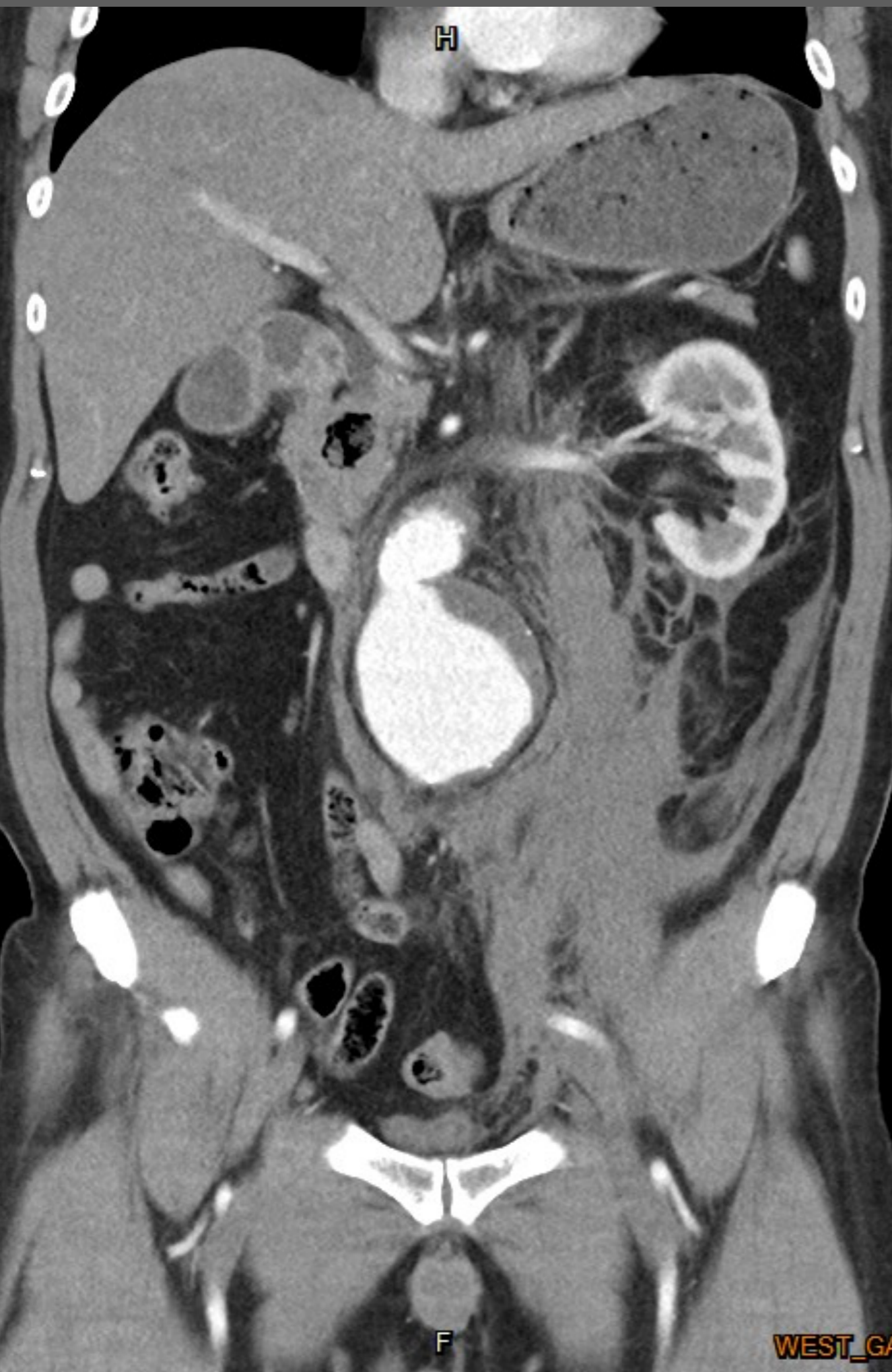BP

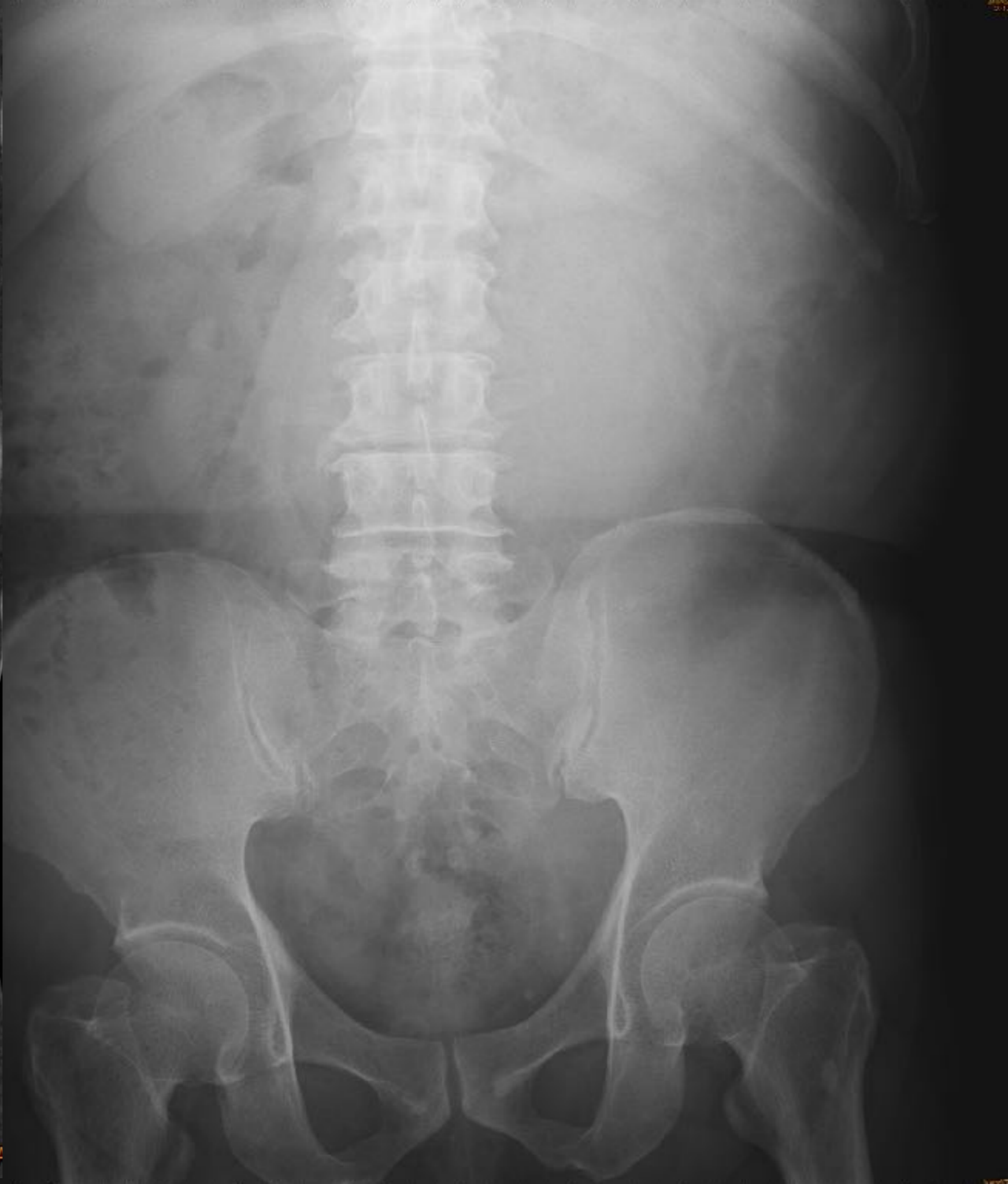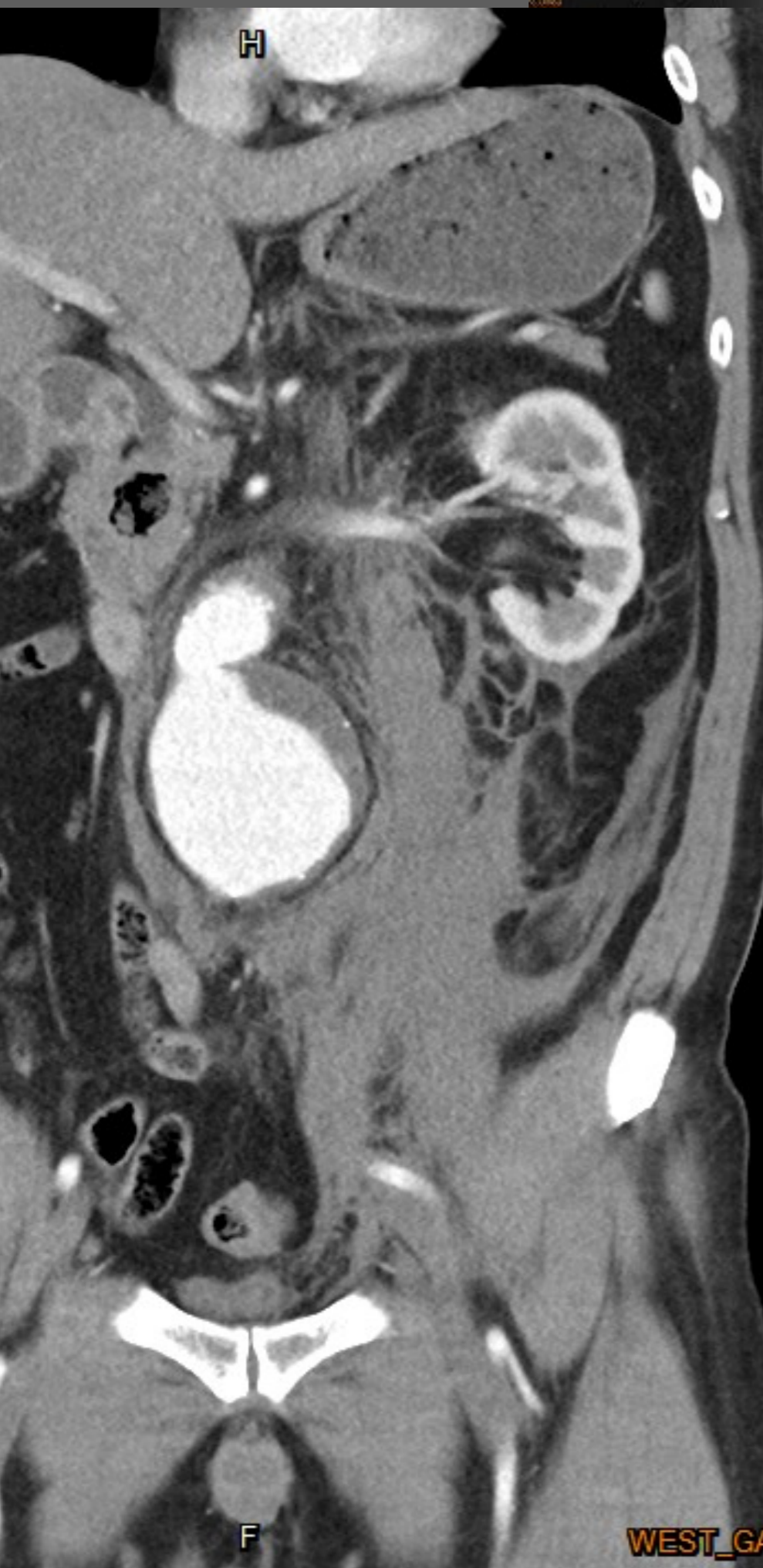
88/62



腰痛 + 冒冷汗，
我的病人可能是
主動脈瘤破裂？



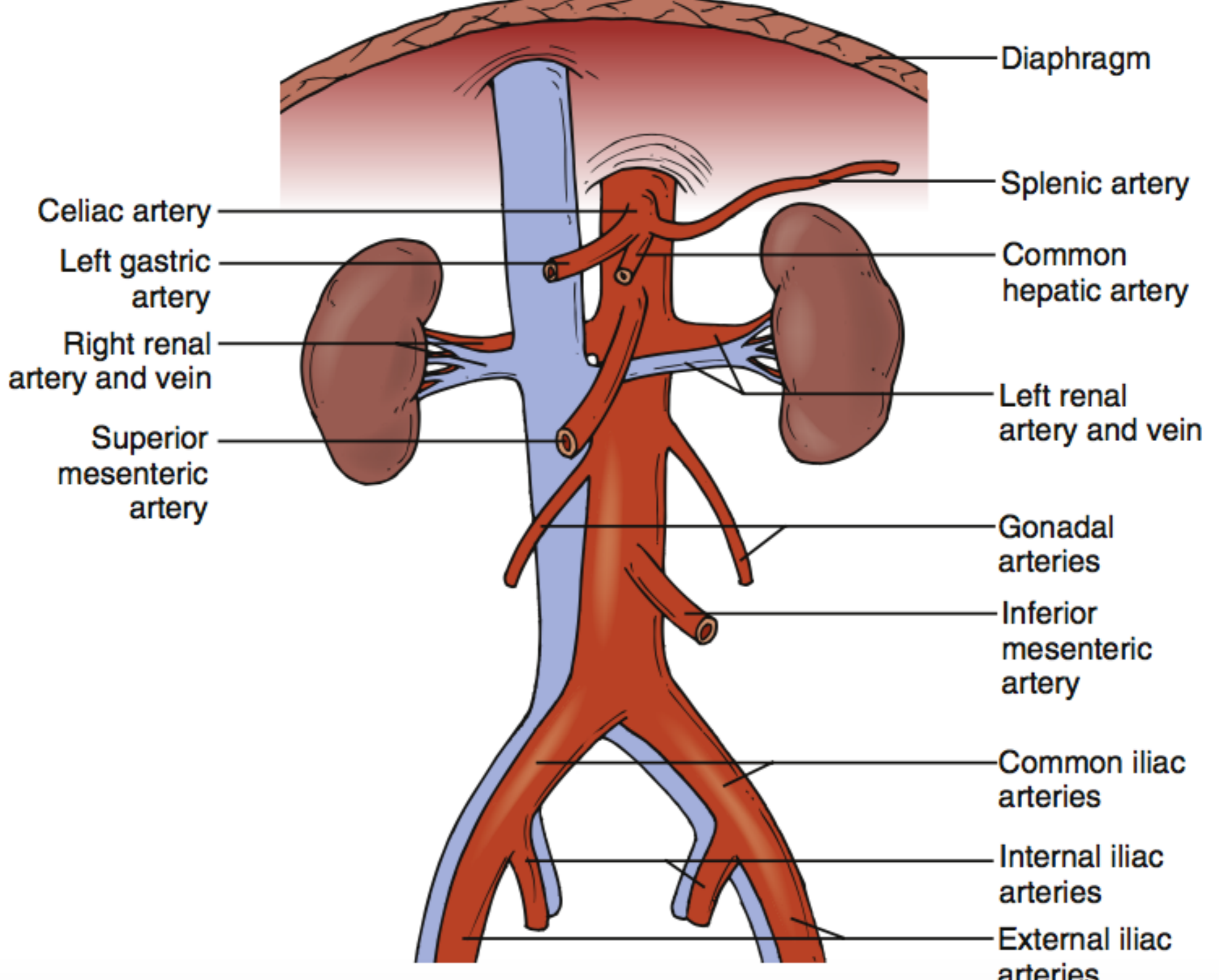


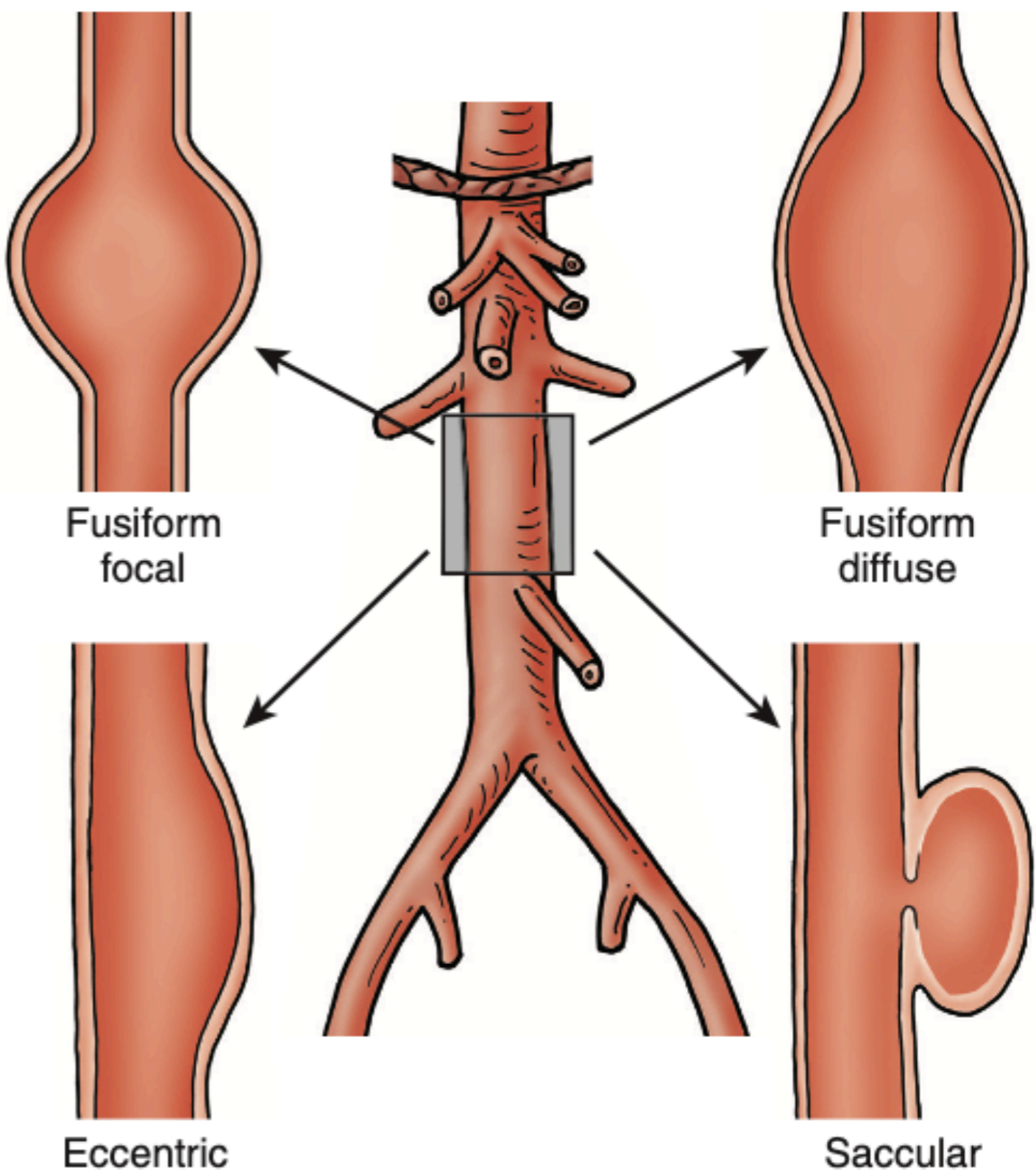
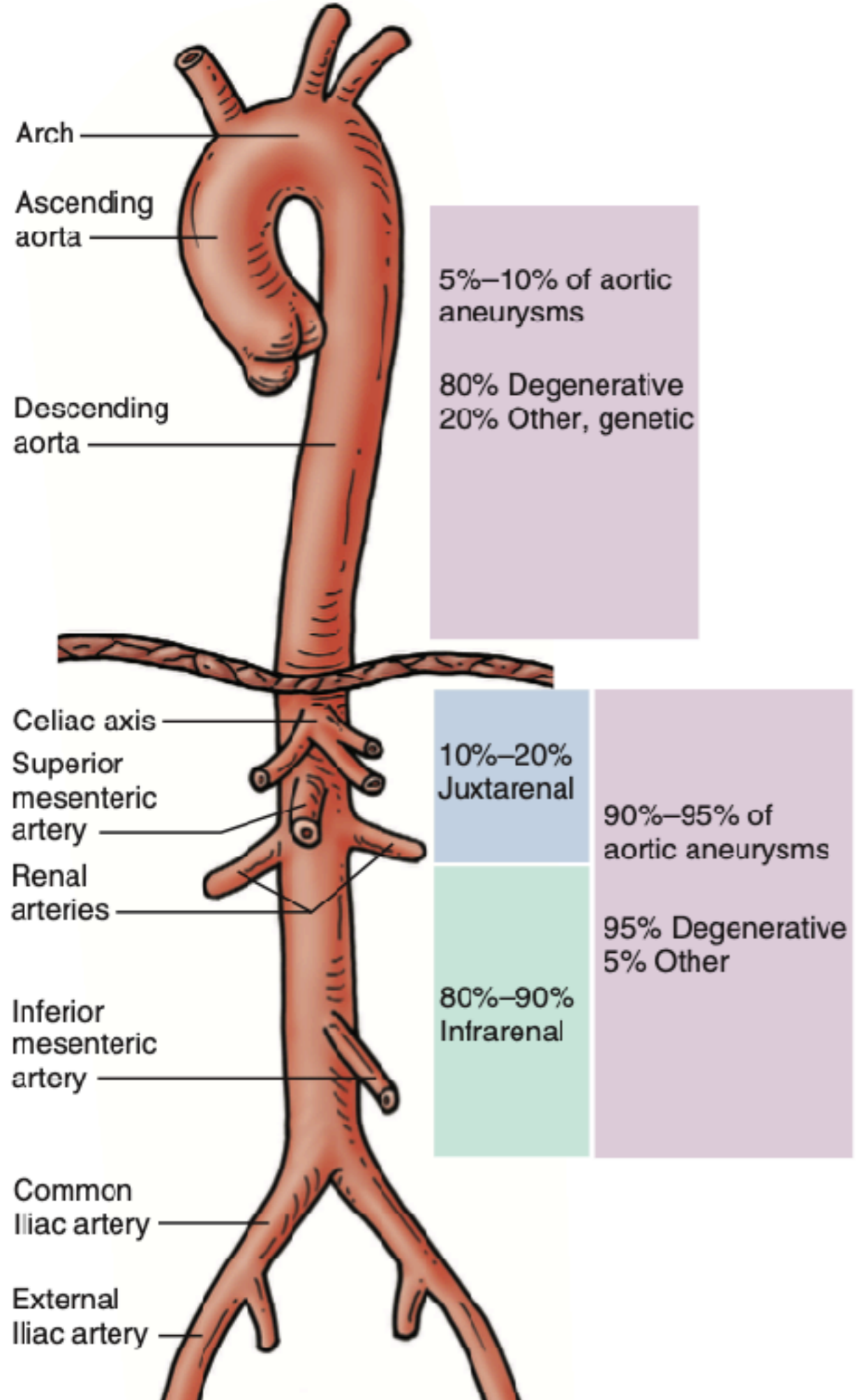


ABDOMEN

A for AAA

3_{cm}

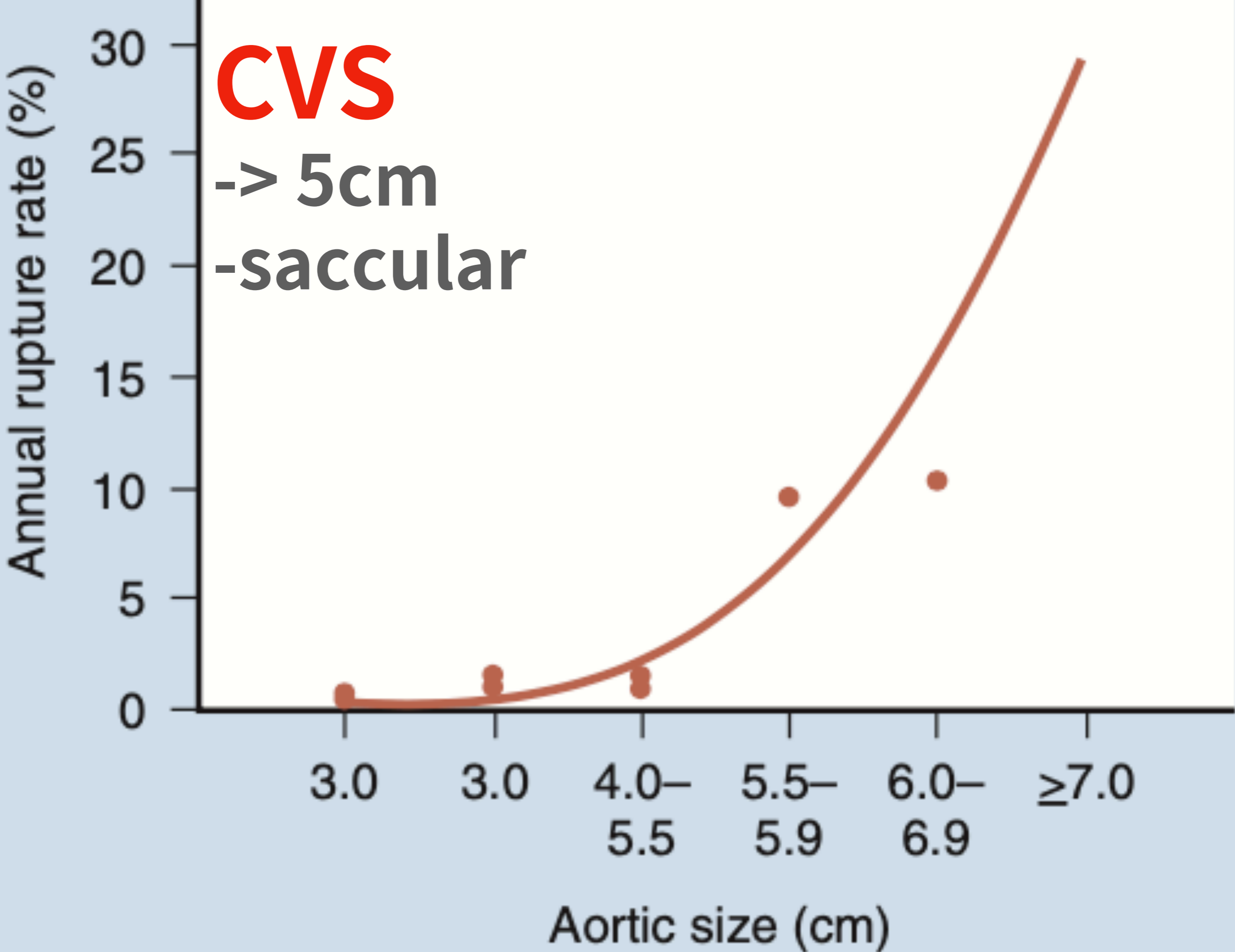




CVS

-> 5cm

-saccular



AAA

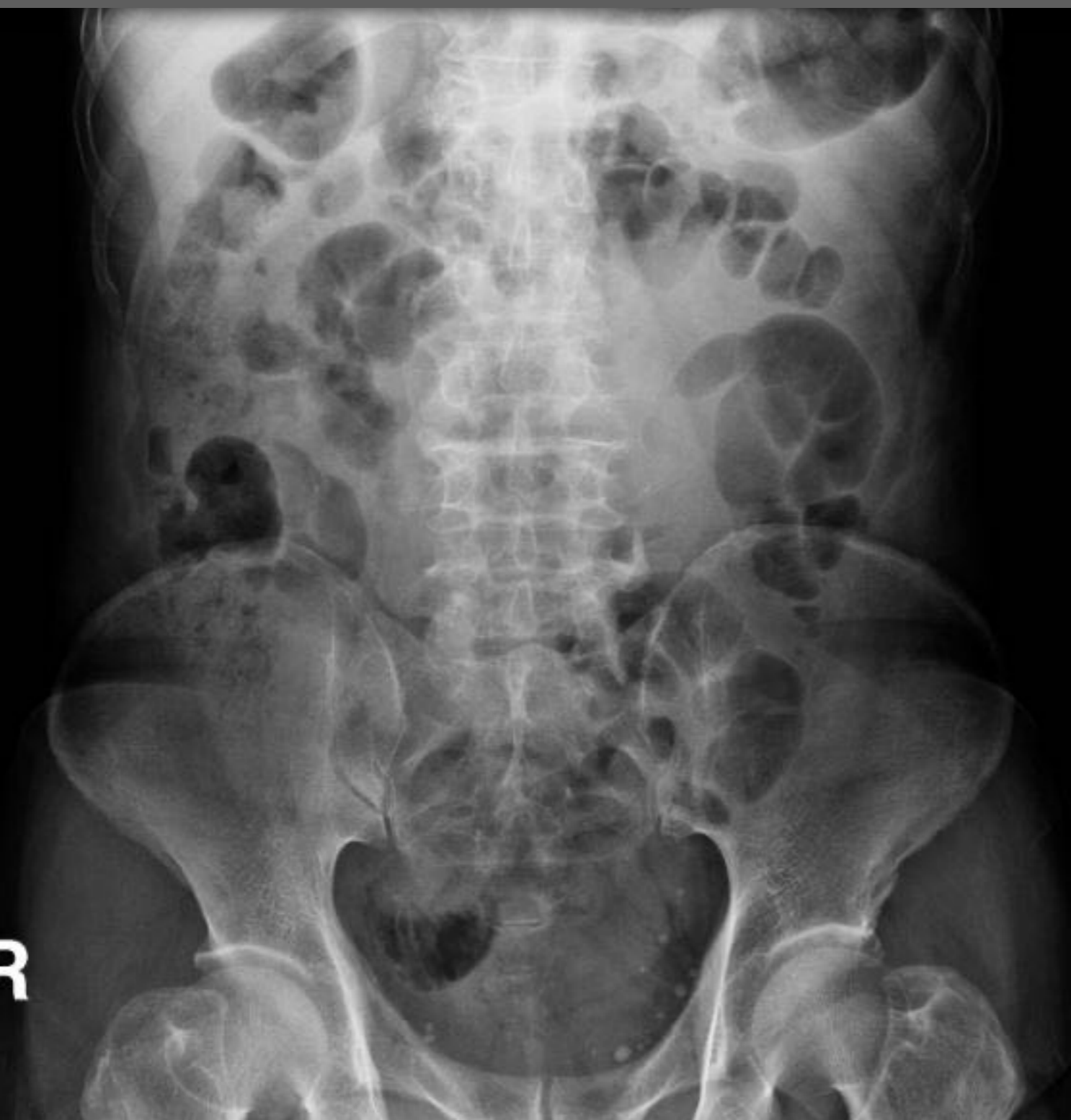

3 cm

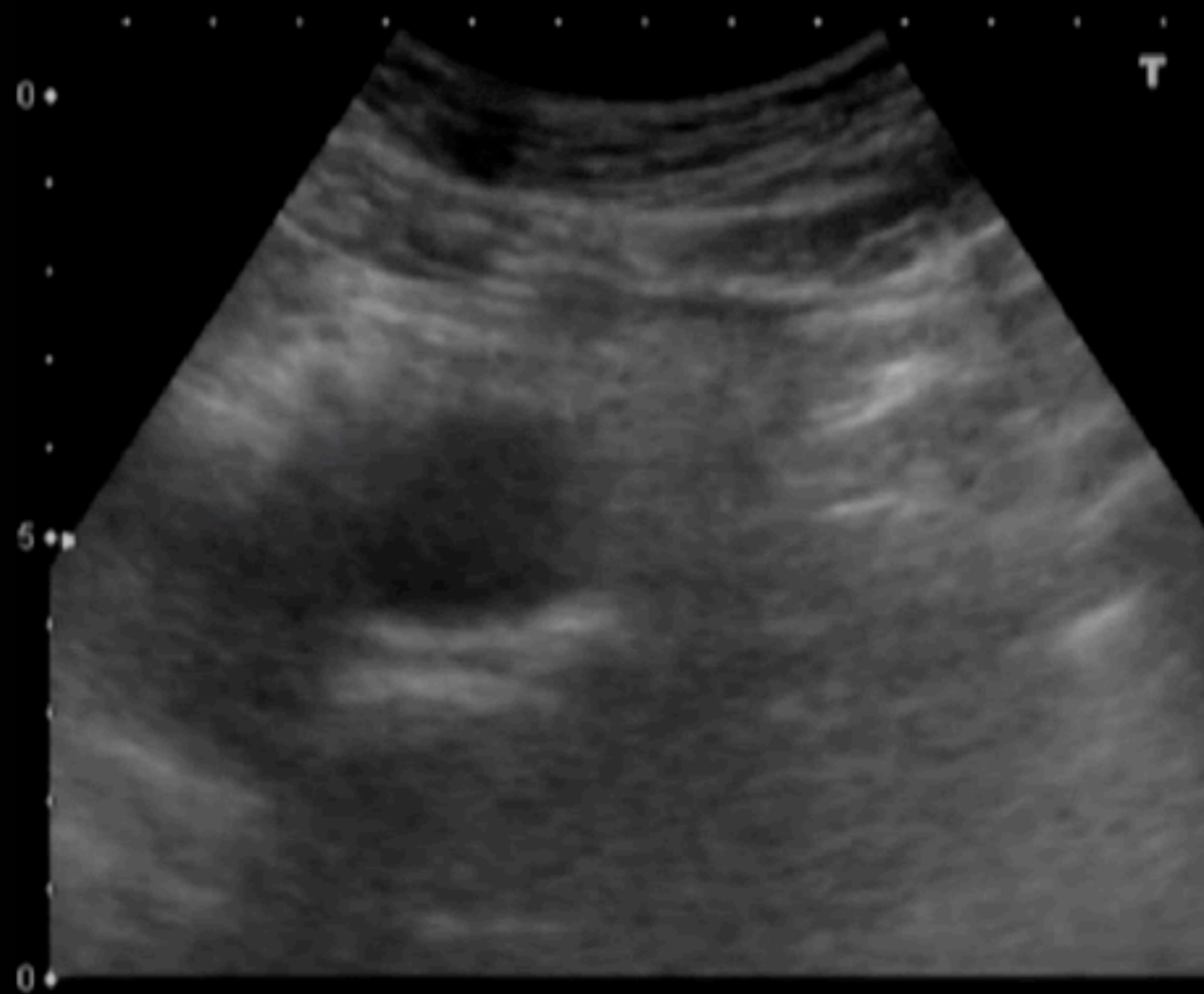> 50 y/o
Syncope
Hypotension
ABD/Flank/Back/Groin

Sensitivity **97.5-100%**
Specificity **94.1-100%**

59M, Abd pain & hematuria



POCUS Academy©ChenK



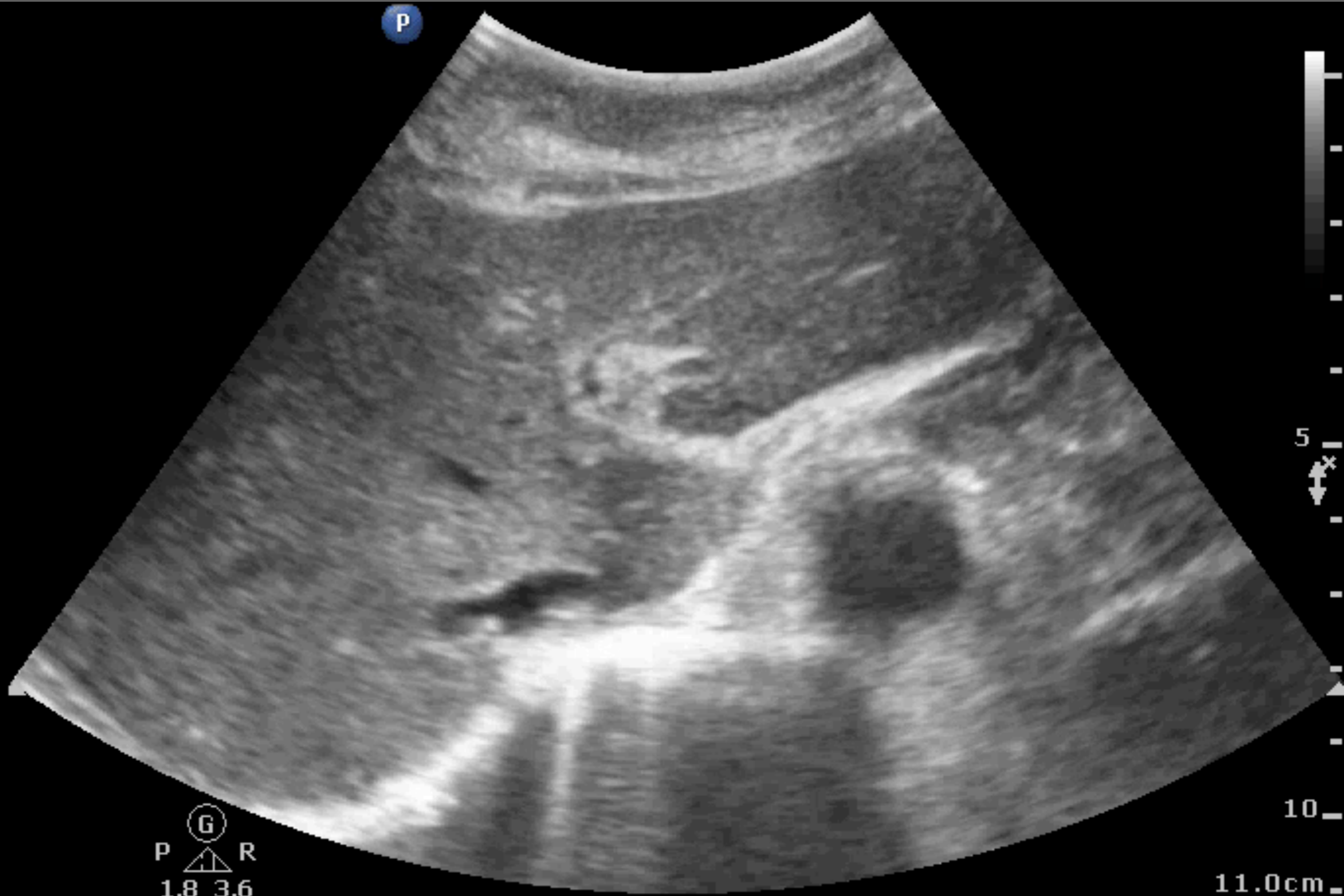Free 8

Abdominal aorta

Abd Gen
C5-1
42 Hz
11.0cm

2D

HGen
Gn 66
C 56
3 / 3 / 3



Ⓜ
P △ R
1.8 3.6

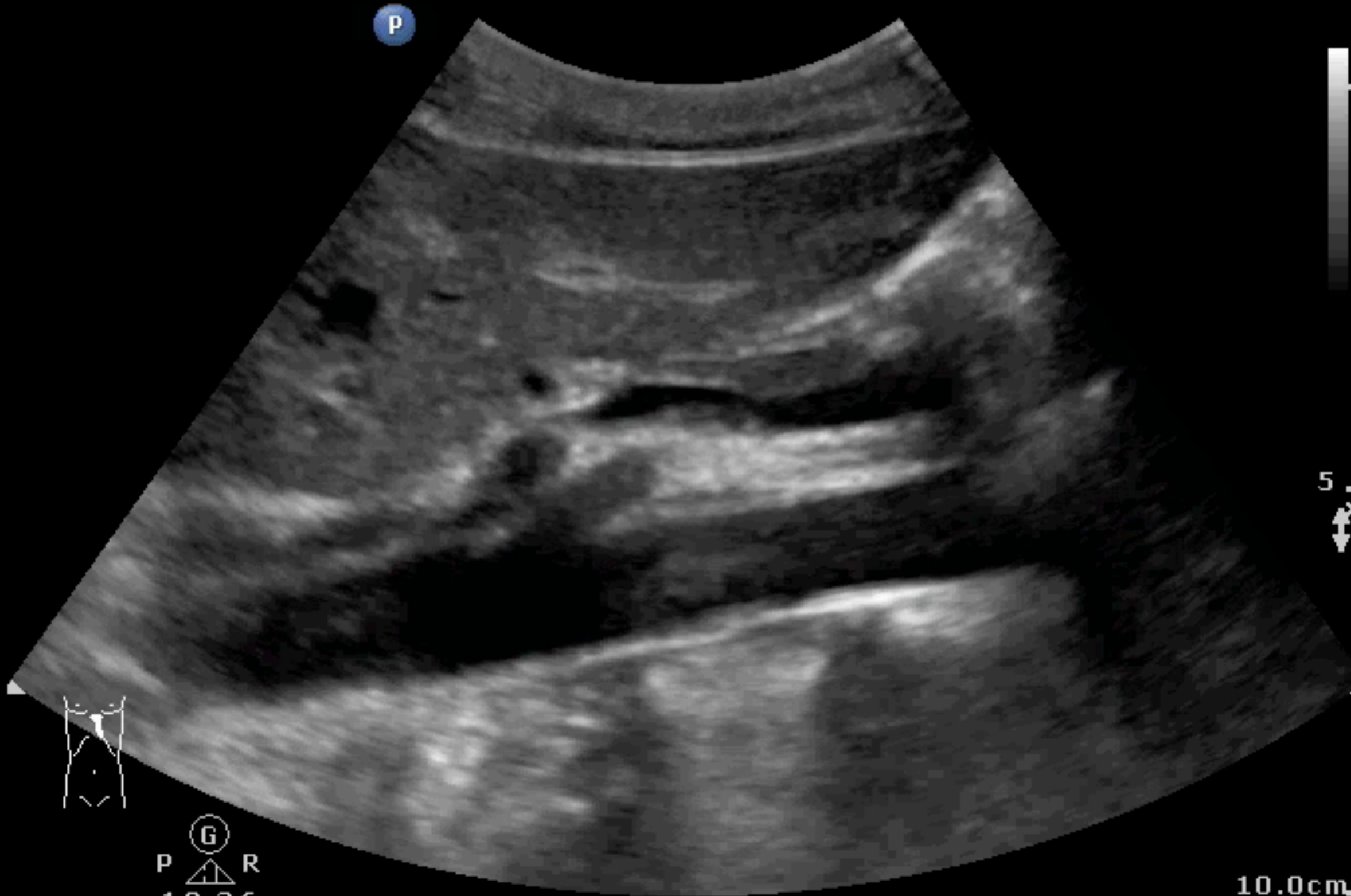11.0cm

Abdominal aorta

Abd Gen
C5-1
45 Hz
10.0cm

2D

HGen
Gn 60
C 56
3/3/3



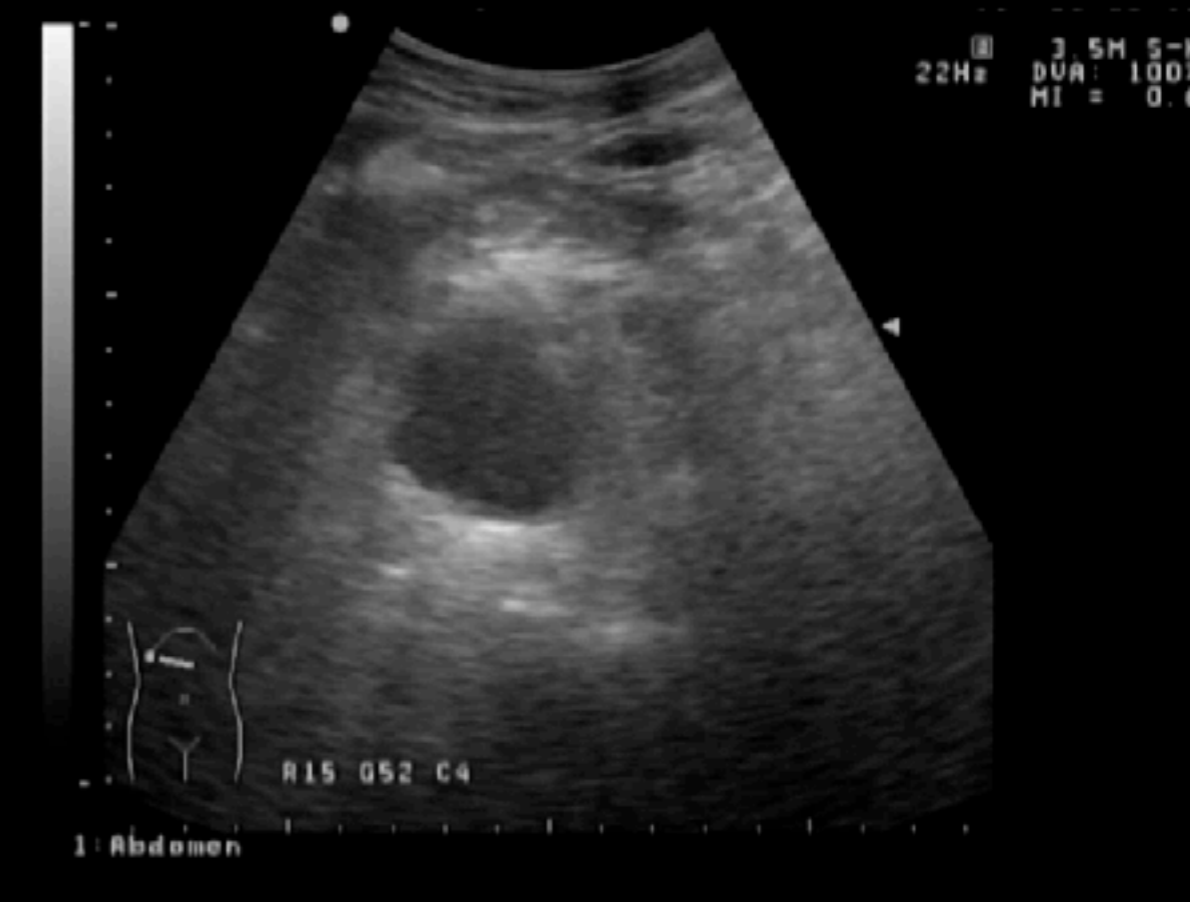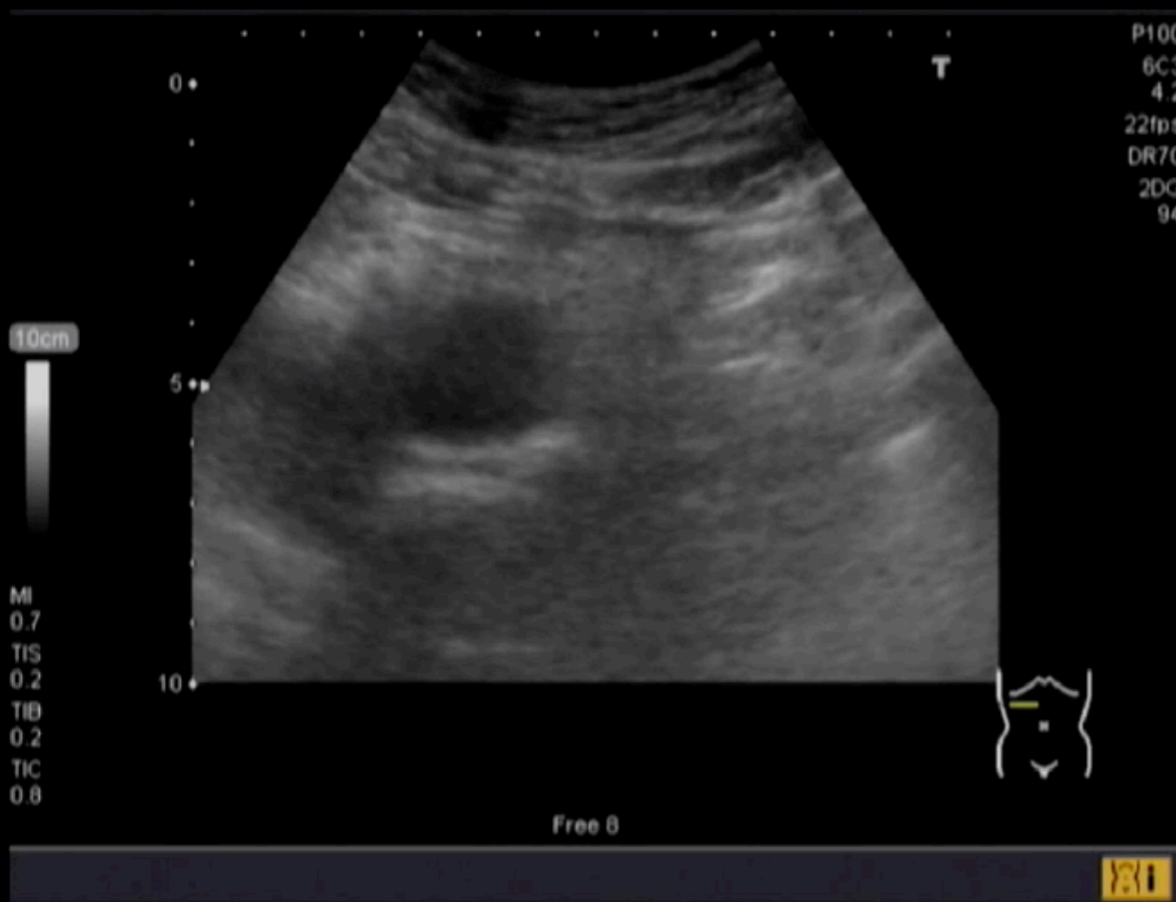G
P R
1.8 3.6

10.0cm

A for AAA, not for rupture

POCUS Academy©ChenKC

POCUS Academy©ChenKC

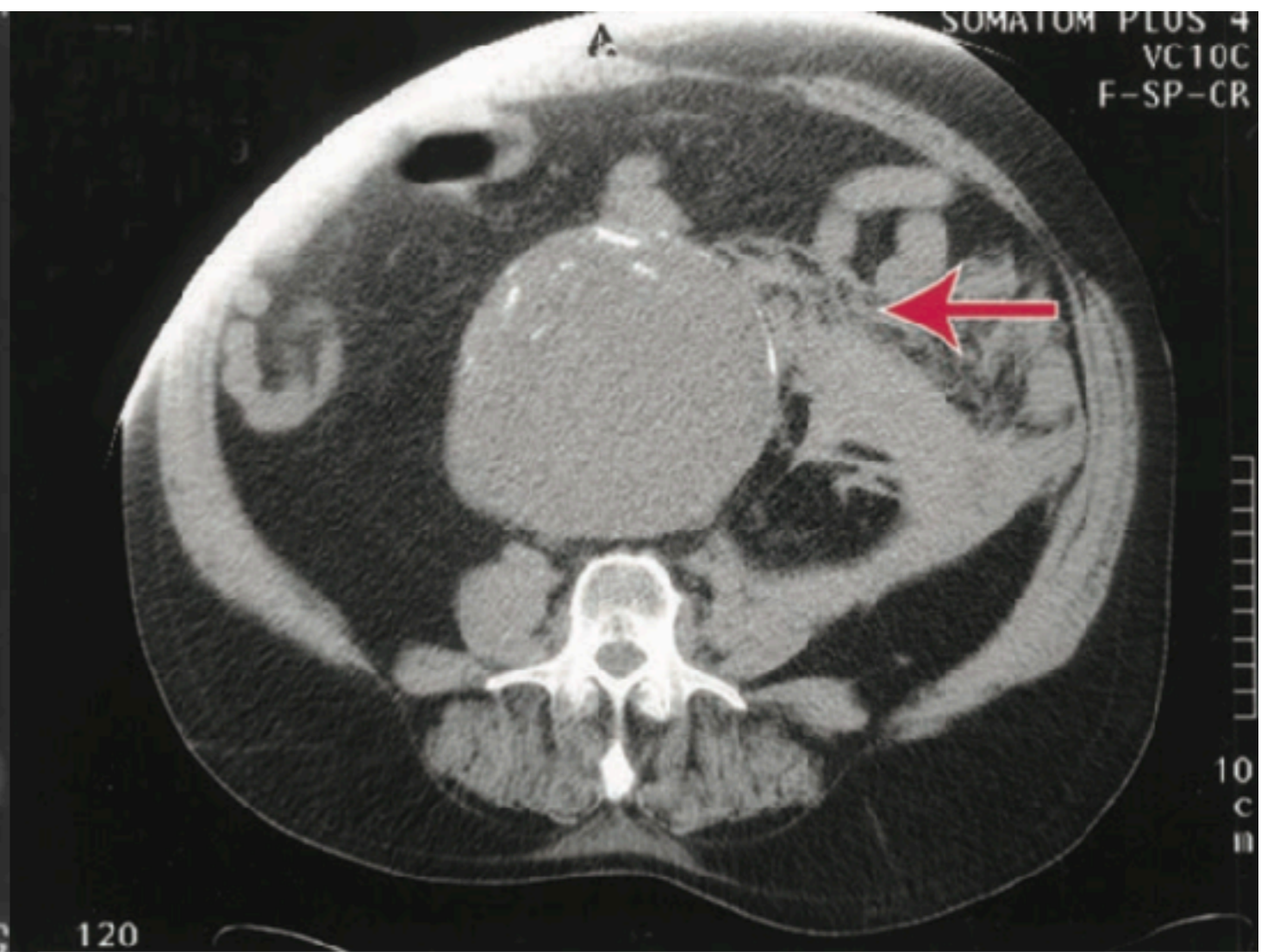
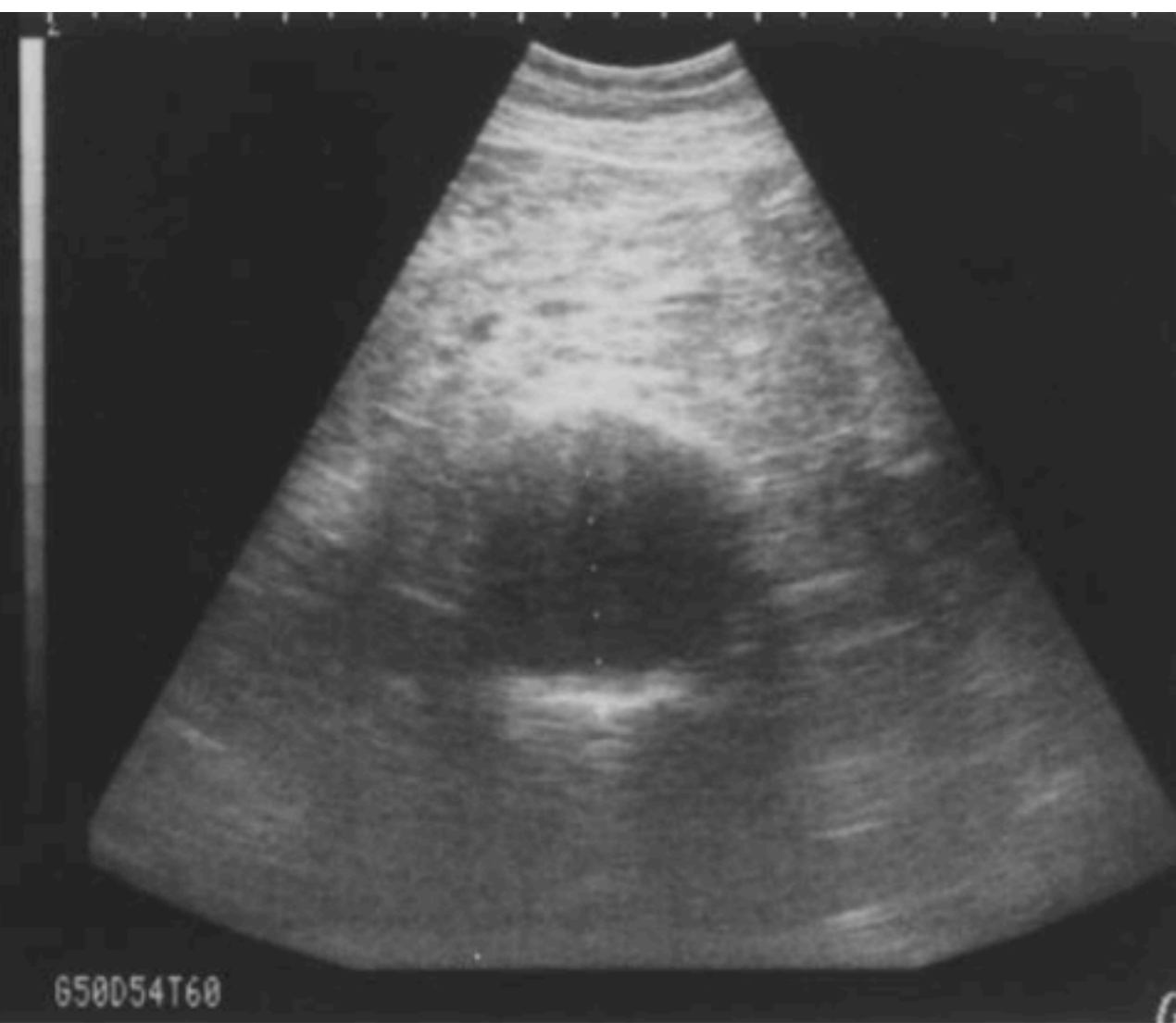


A

B

Echo for AAA (3~5cm)

Not for rupture



Eyeballing

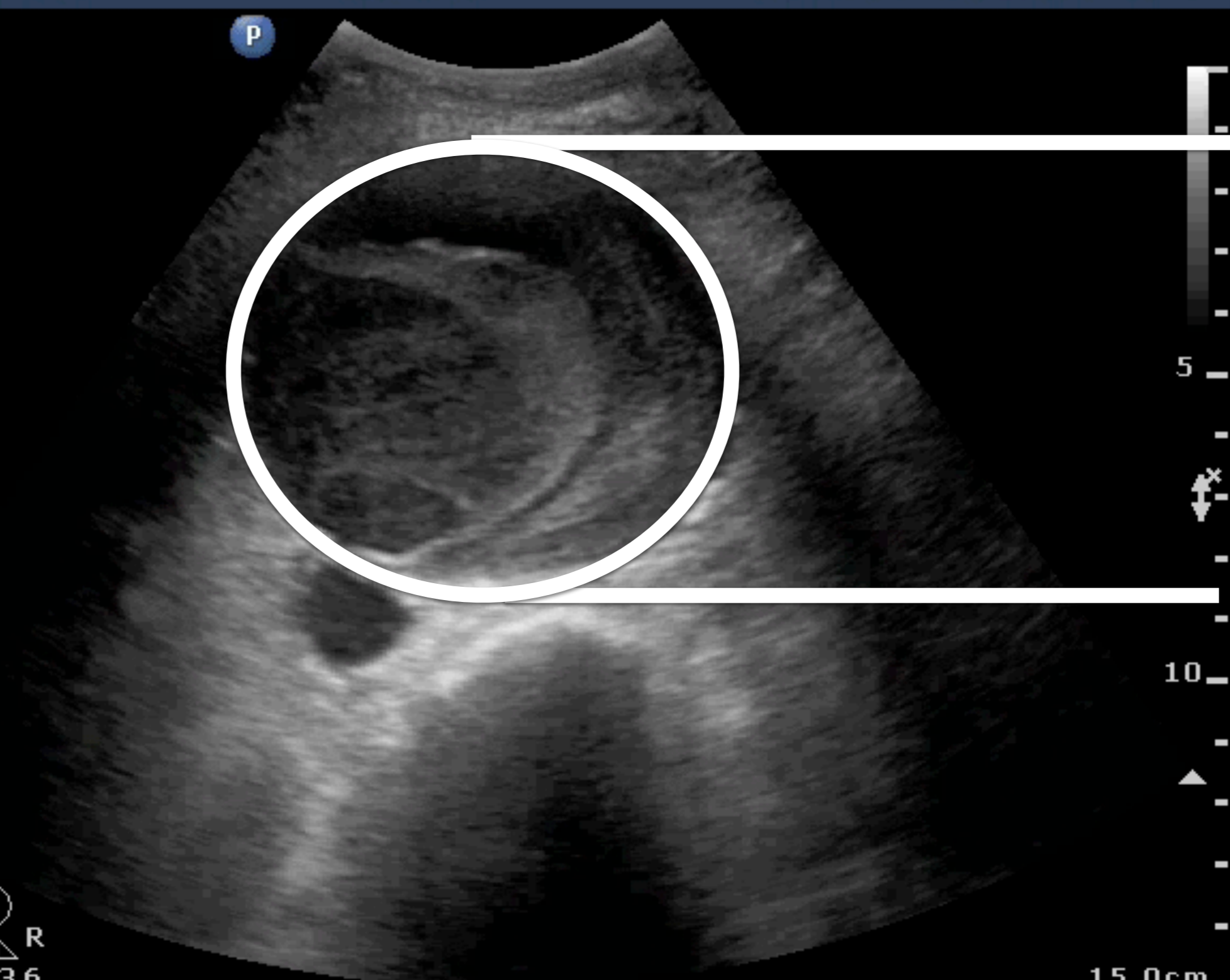
Abd Gen
C5-1
34 Hz
15.0cm

2D

HGen
Gn 57
C 56
3 / 3 / 3

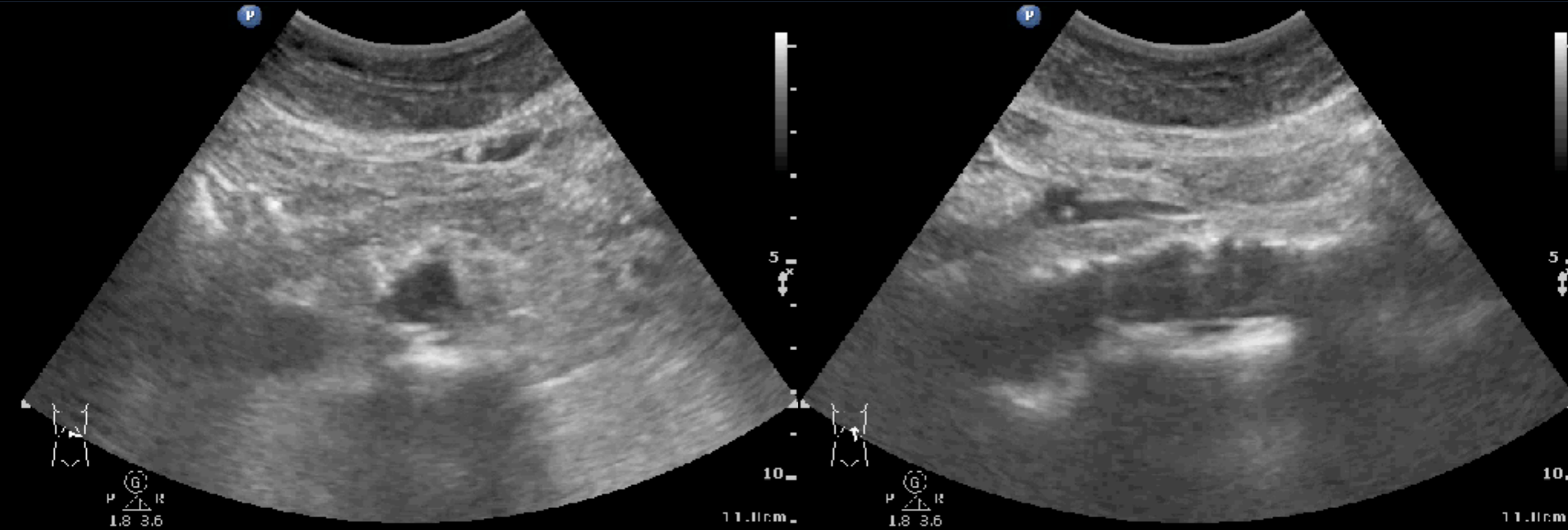
P  R
1.8 3.6

15.0cm



63M, chest/abd pain & low BP

Aortic dissection

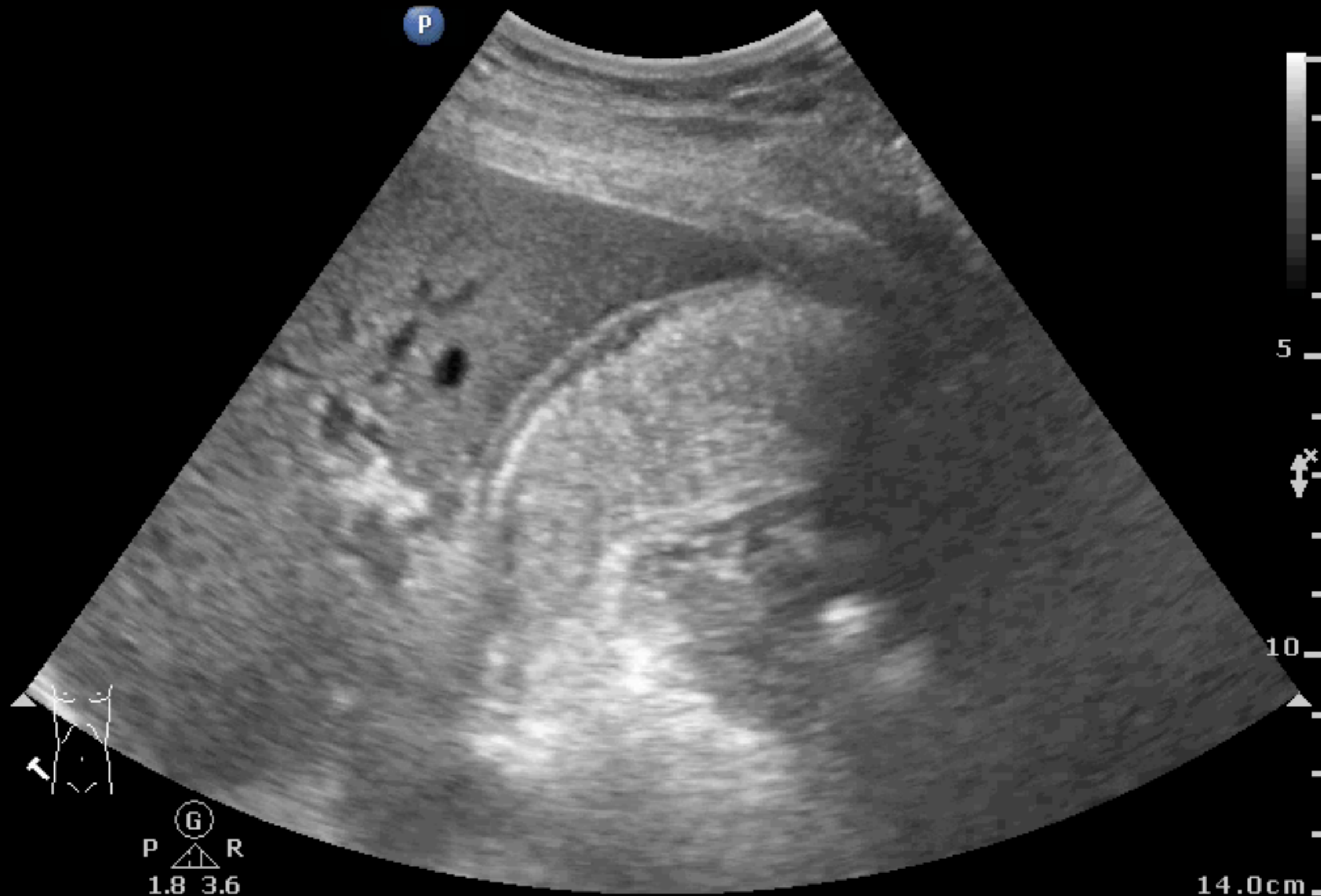

59M, epigastric pain at midnight

Abd Gen2
C5-1
36 Hz
14.0cm

2D

HGen
Gn 100
C 56
3 / 3 / 3



ABDOMEN

B for GB stone & dilatation

3

mm

7

mm

11

1

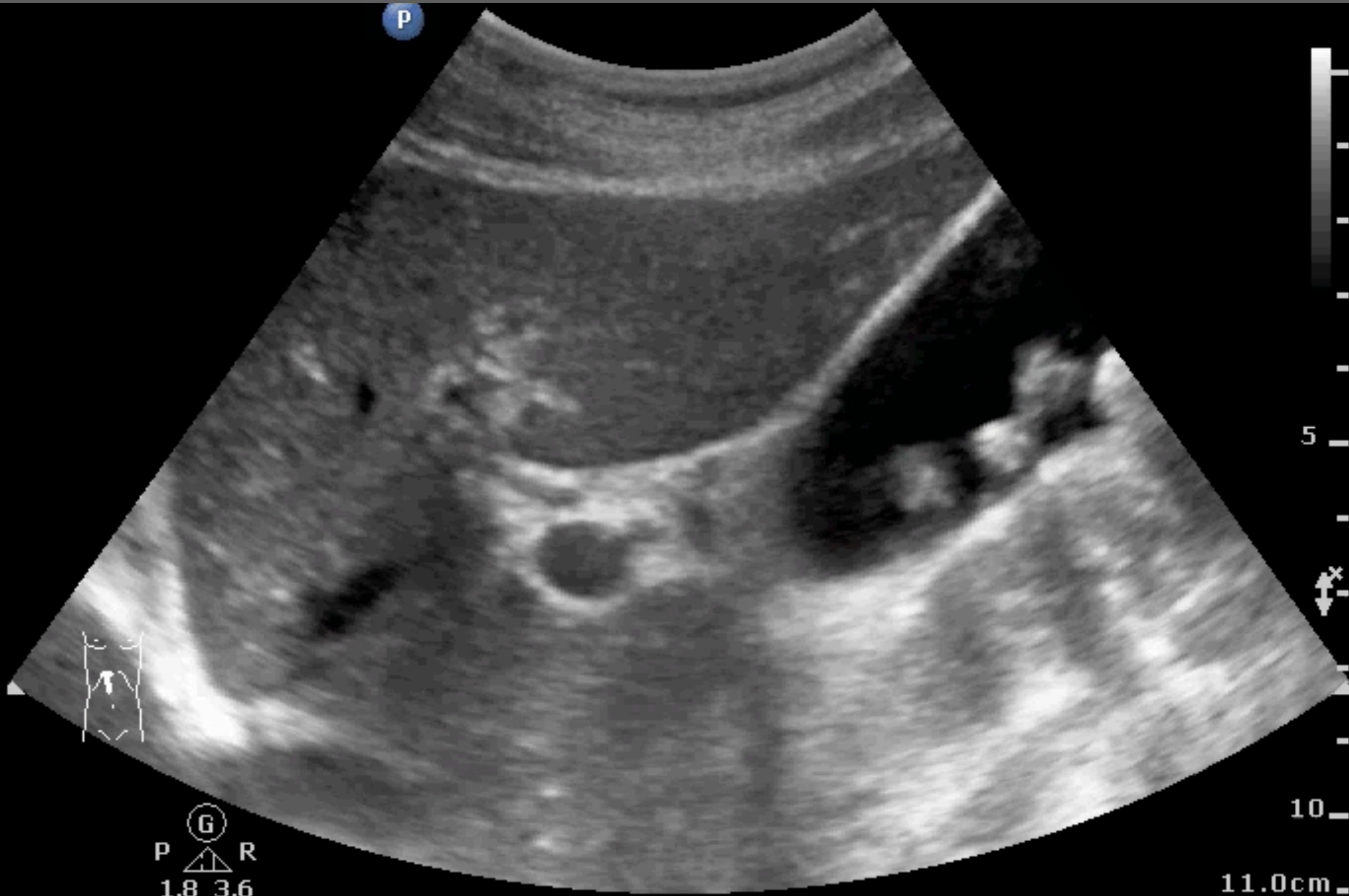
mm

讀讀看，你看到了什麼？

Abd Gen
C5-1
42 Hz
11.0cm

2D

HGen
Gn 80
C 56
3 / 3 / 3



G
P R
1.8 3.6

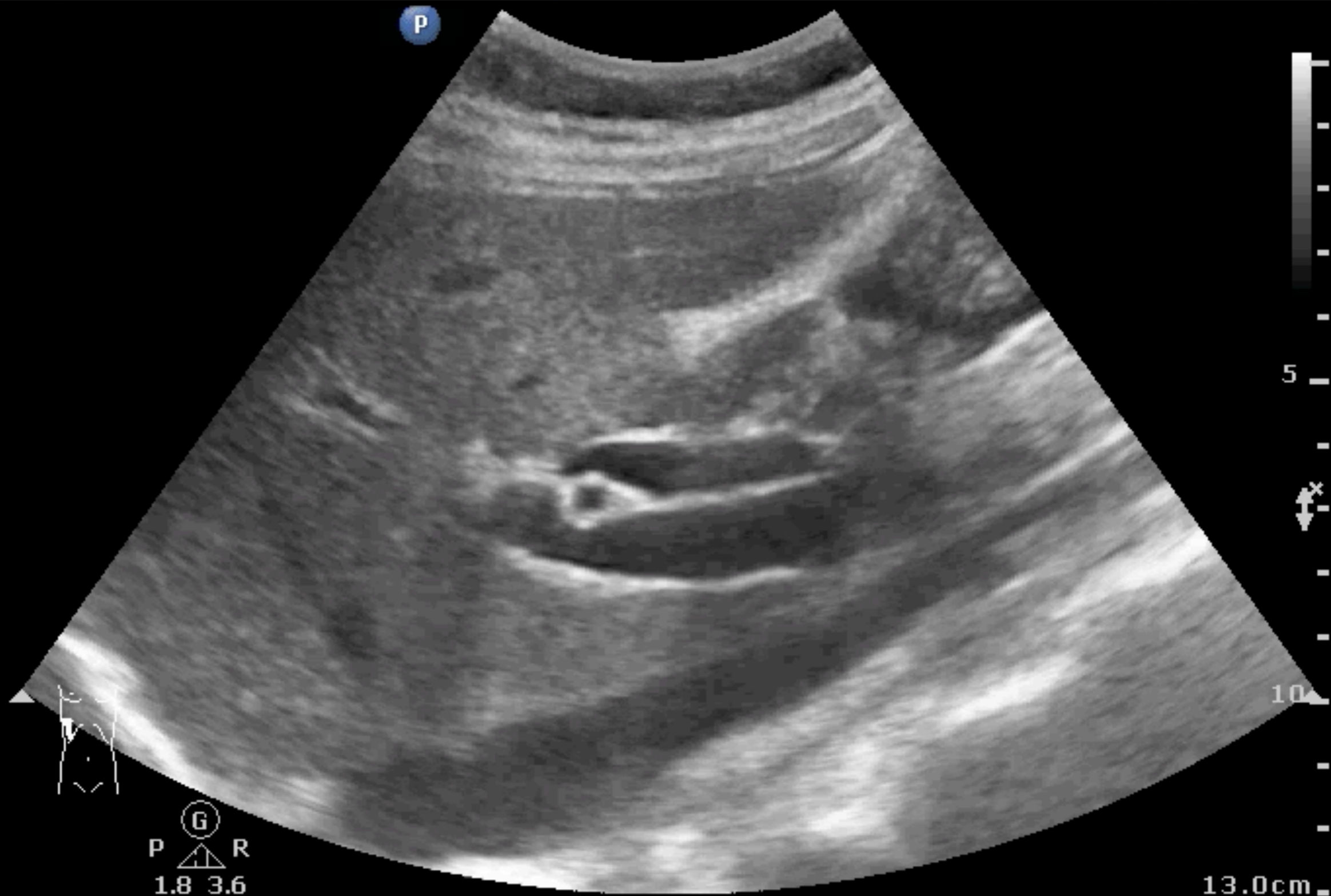11.0cm

讀讀看，你看到了什麼？

Abd Gen
C5-1
38 Hz
13.0cm

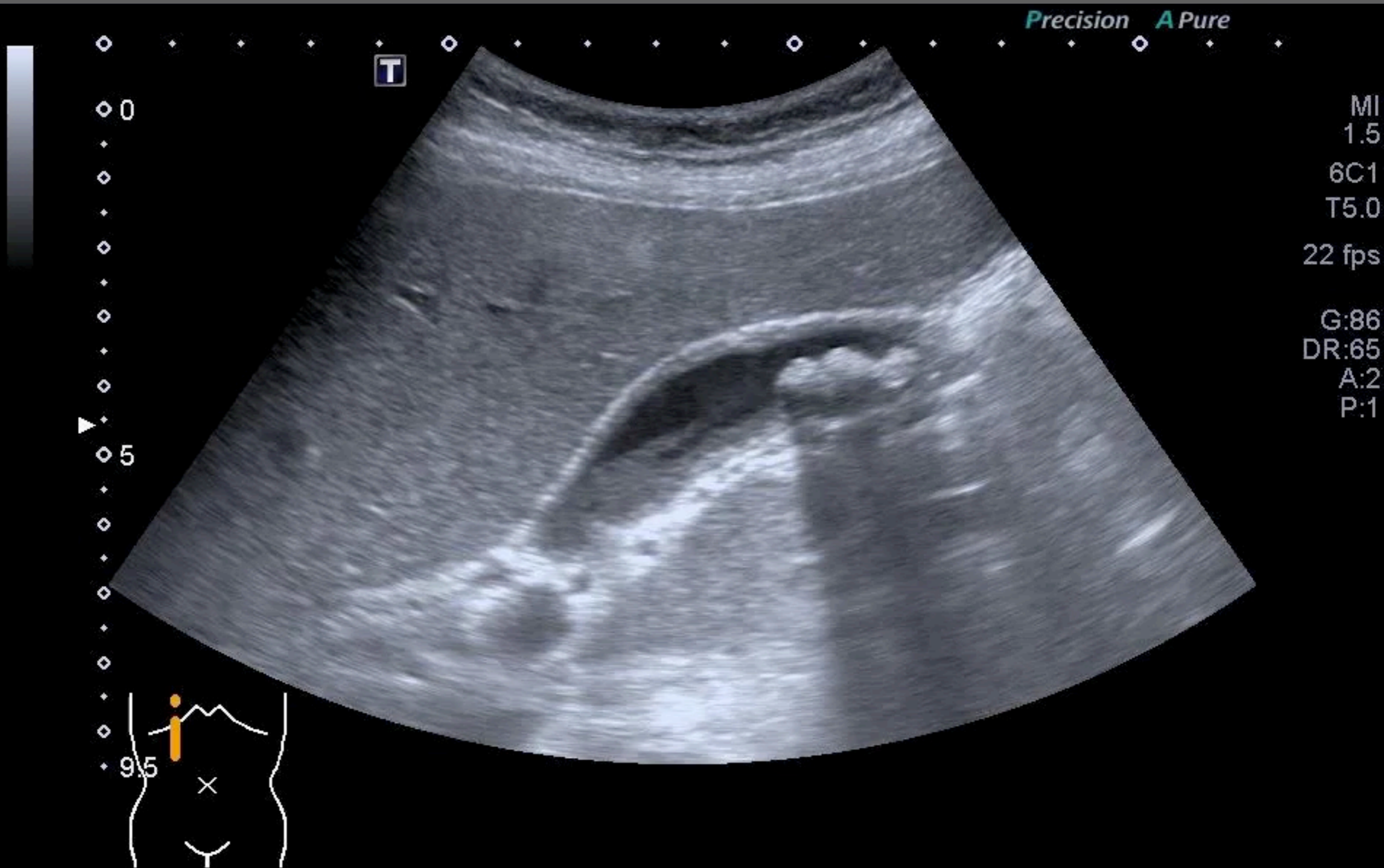
2D

HGen
Gn 82
C 56
3 / 3 / 3

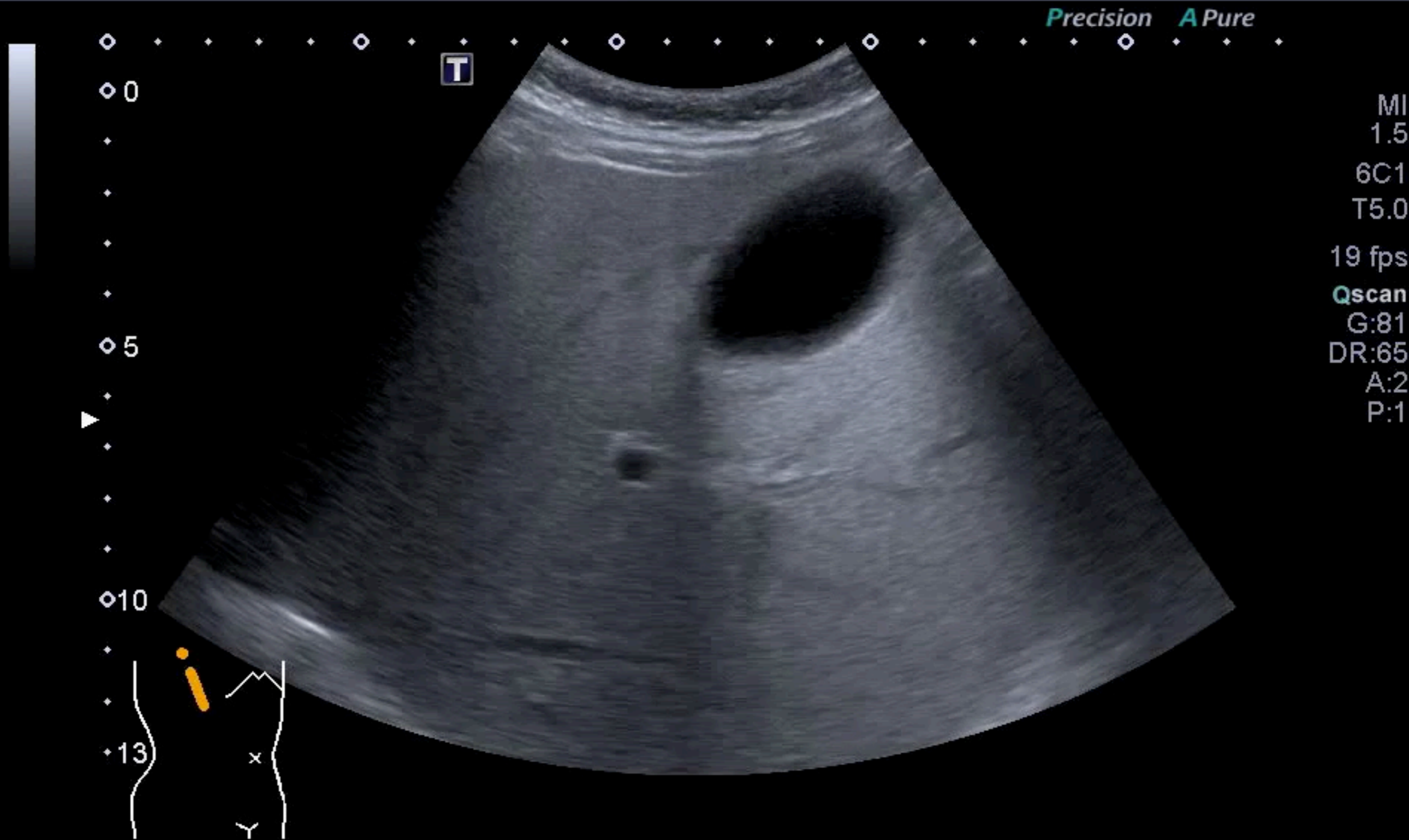


13.0cm

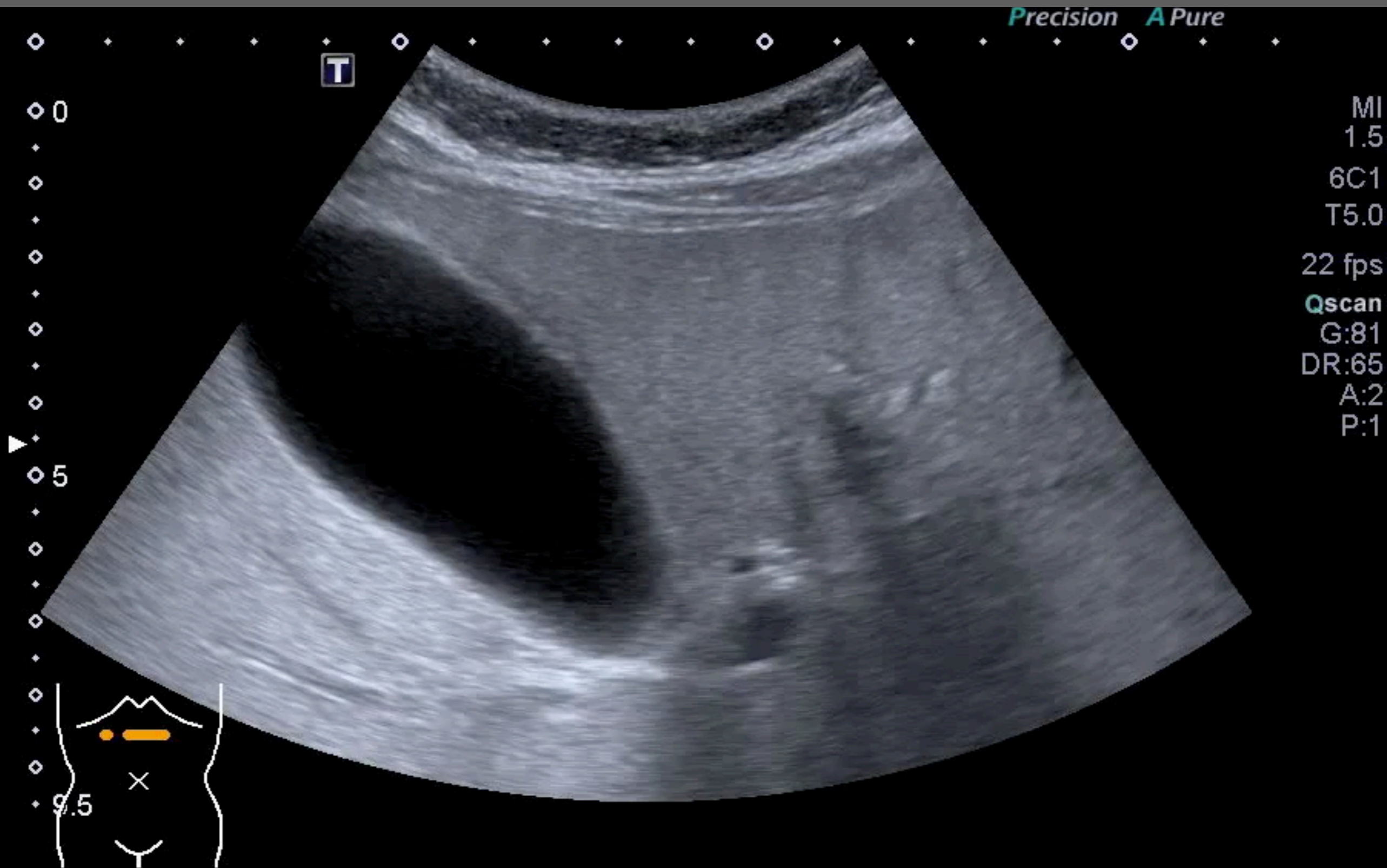
讀讀看，你看到了什麼？



61F , ABD pain for 3-4 days



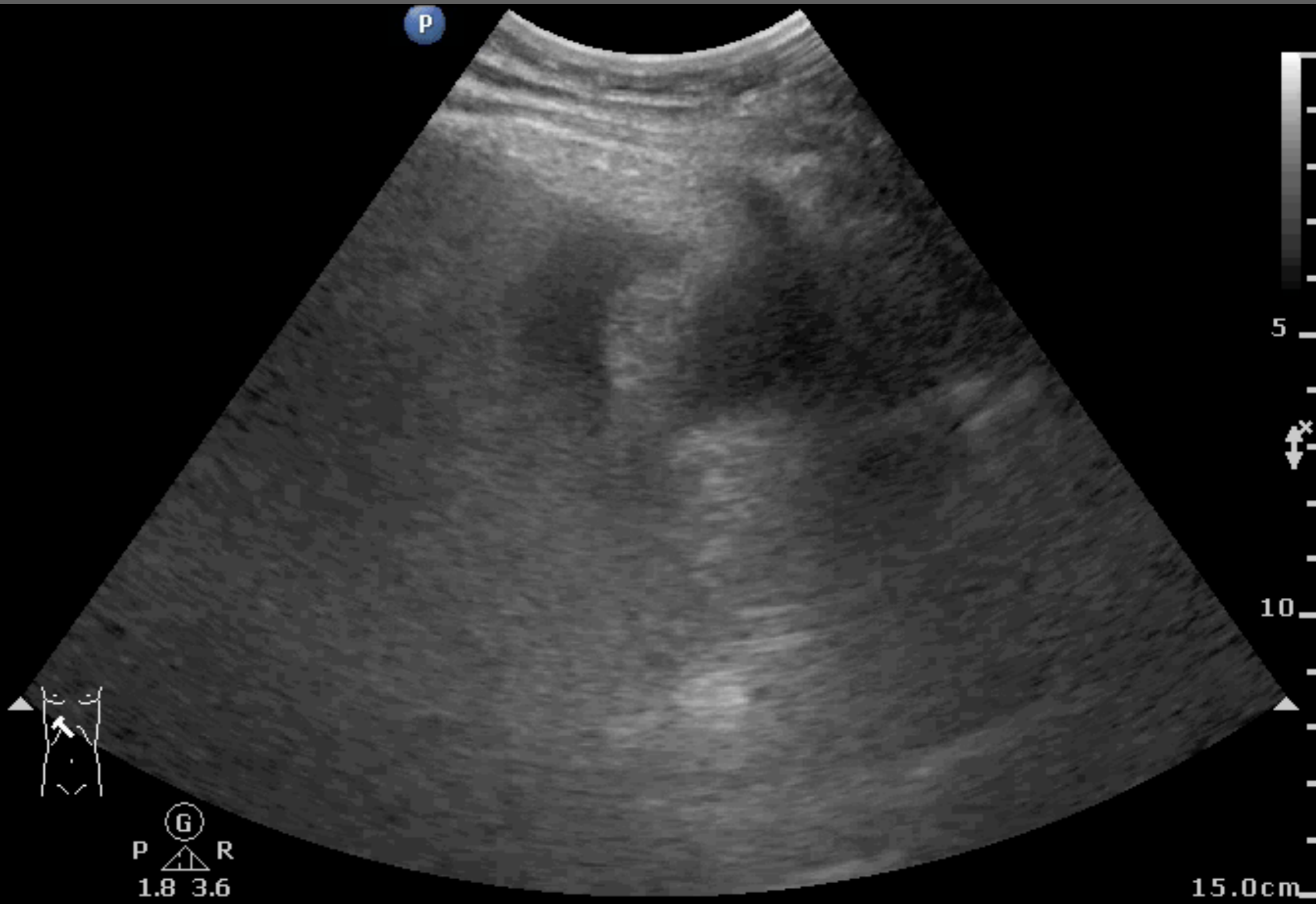GB stones & Cholecystitis



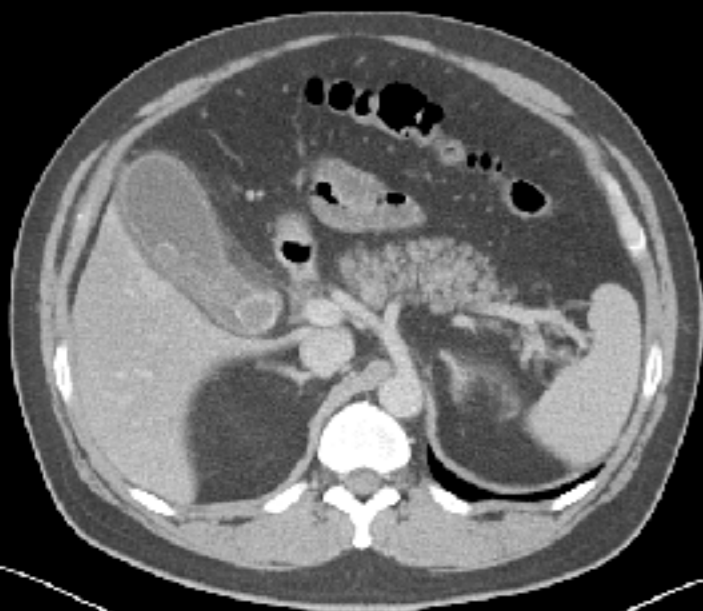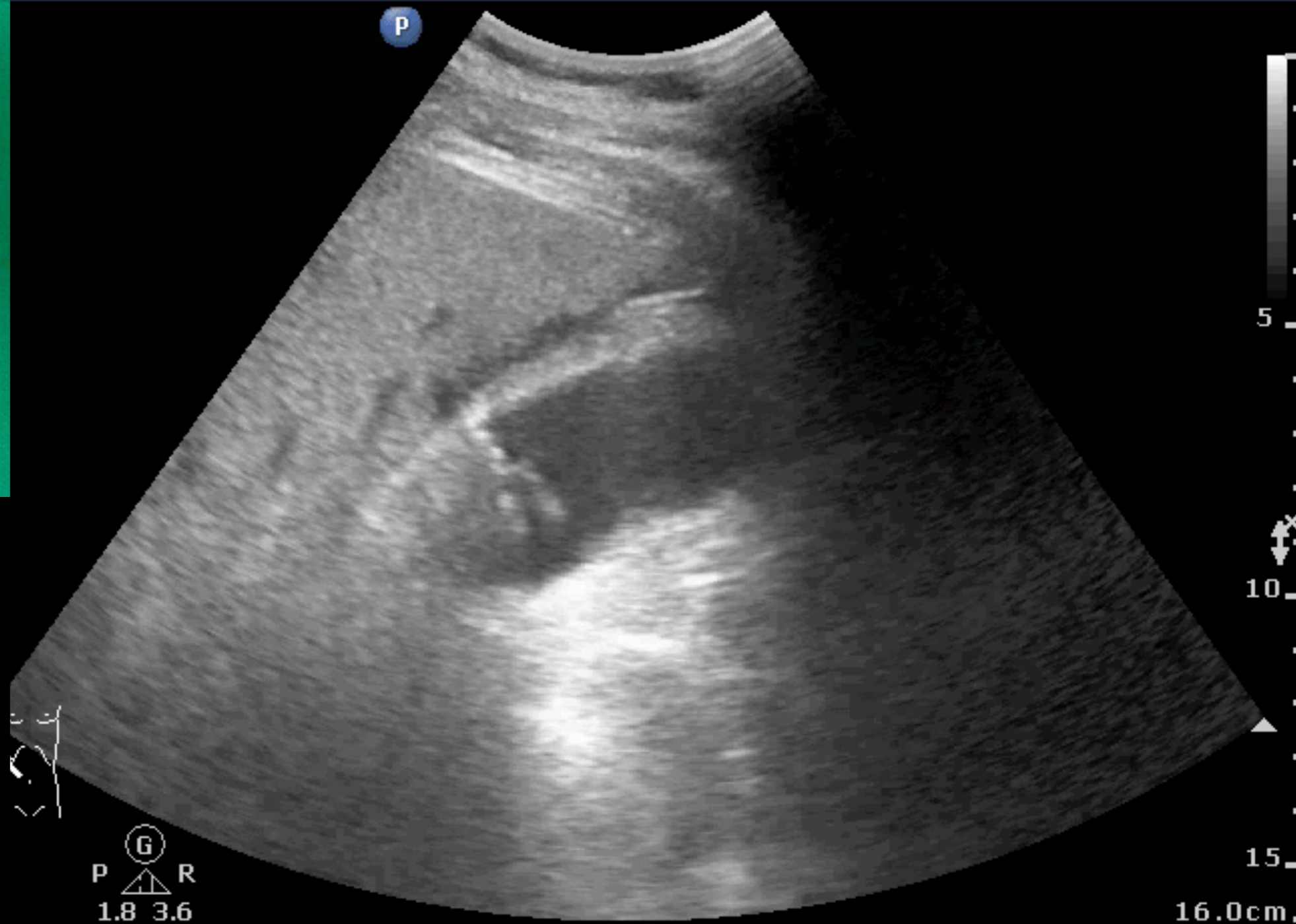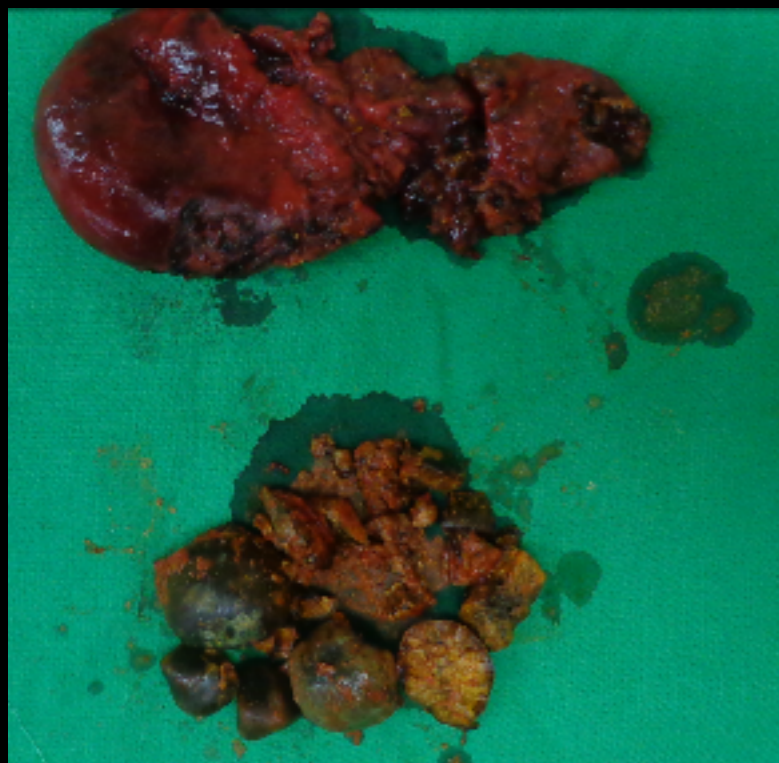
45M, RUQ pain & fever

Abd Gen2
C5-1
34 Hz
15.0cm

2D
HGen
Gn 100
C 56
3 / 3 / 3



Acute calculous cholecystitis

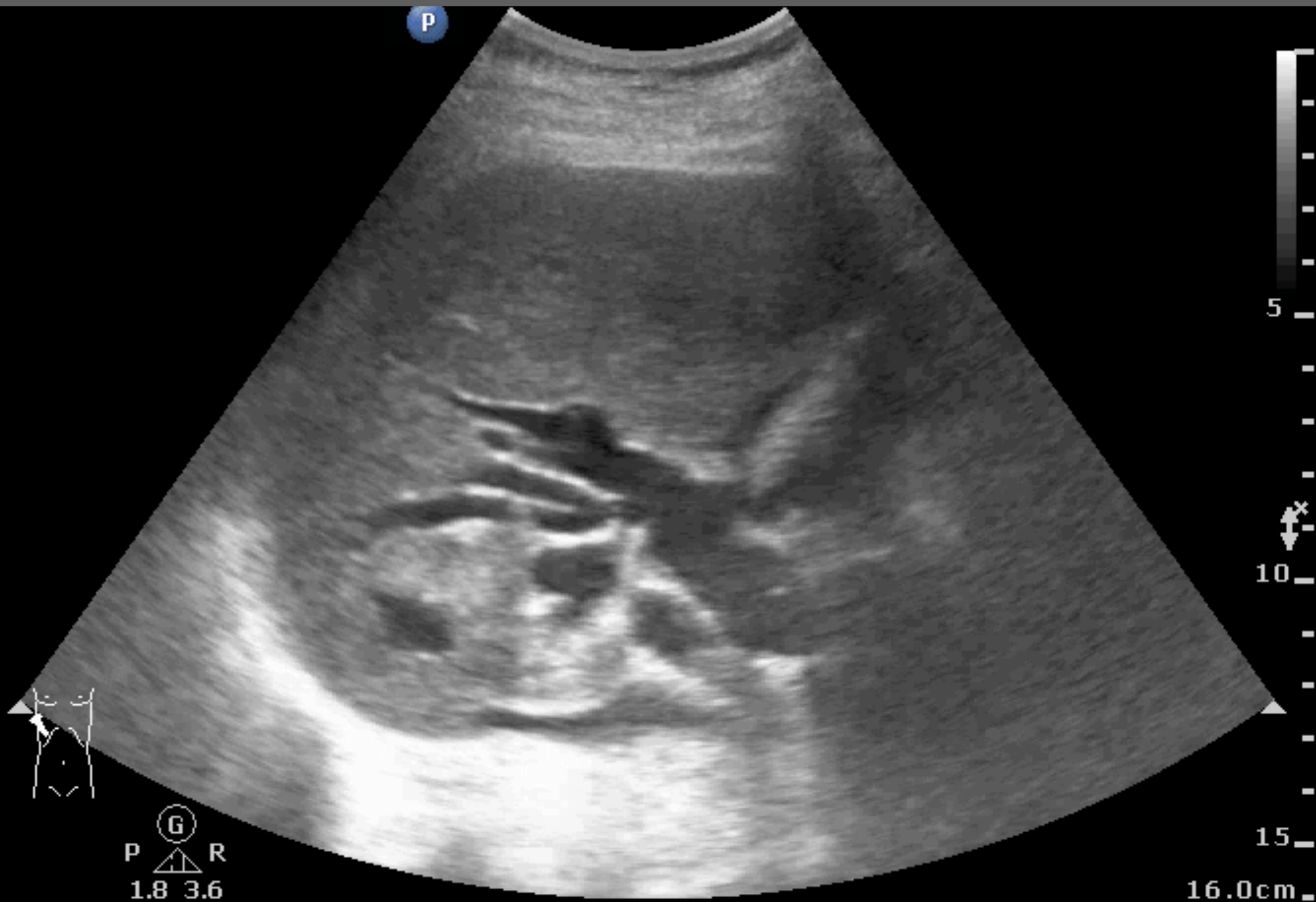

76F, Fever & Chills

Abd Gen2
C5-1
32 Hz
16.0cm

2D

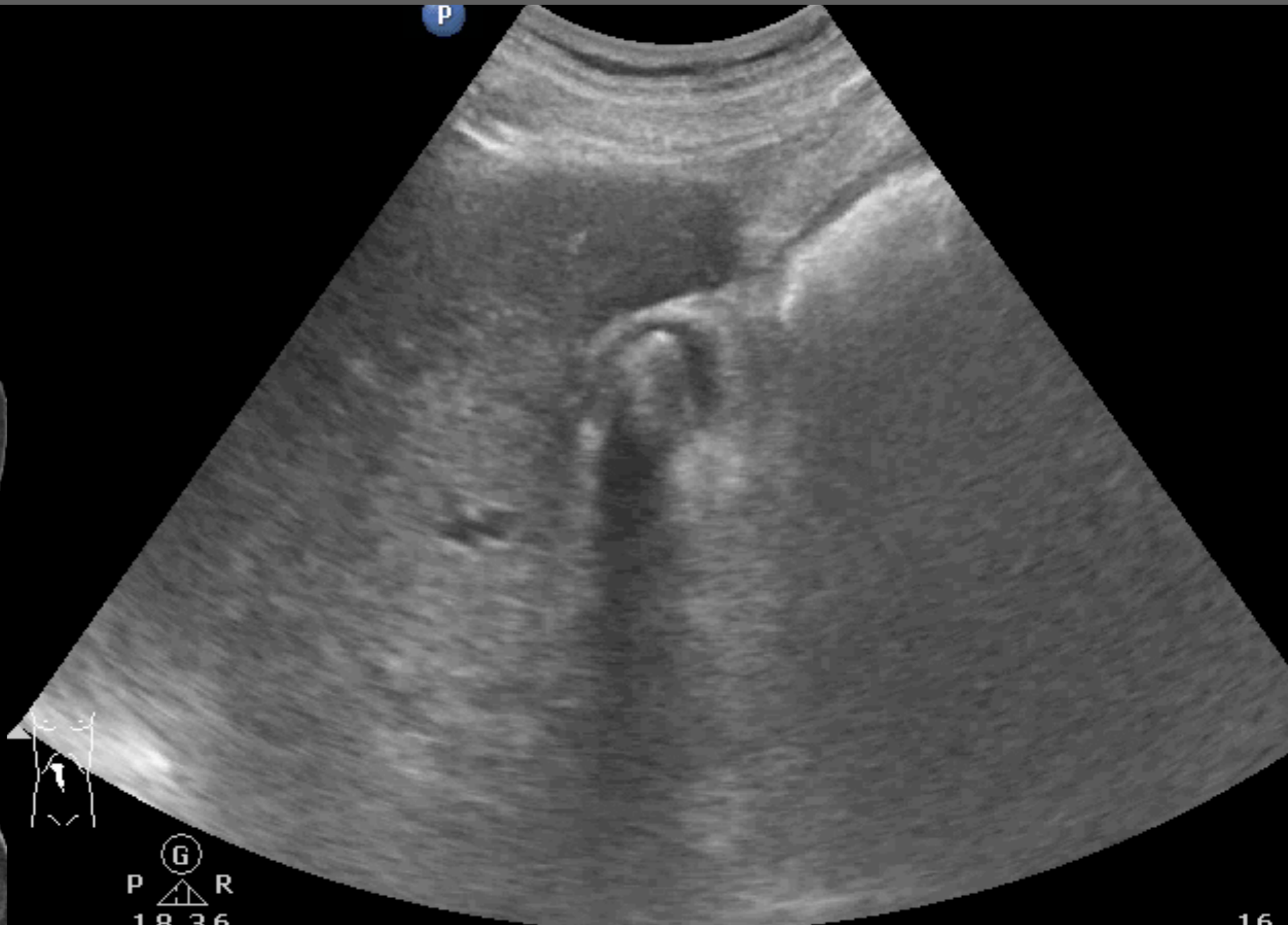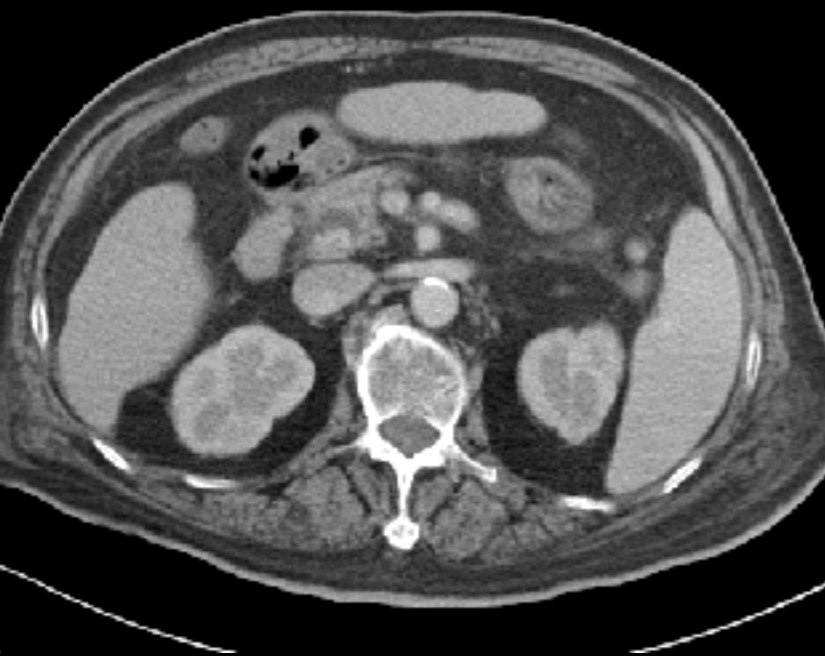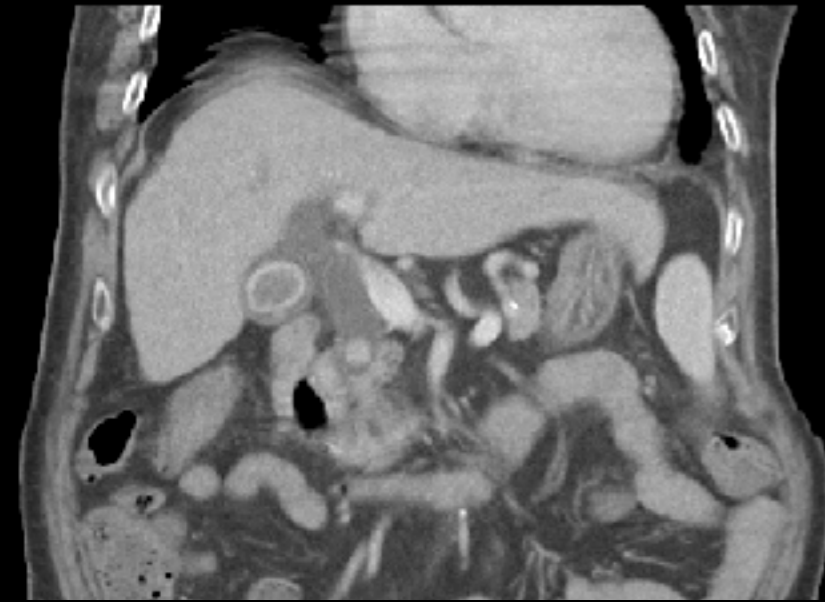
HGen
Gn 100
C 56
3 / 3 / 3



CBD dilatation & stone

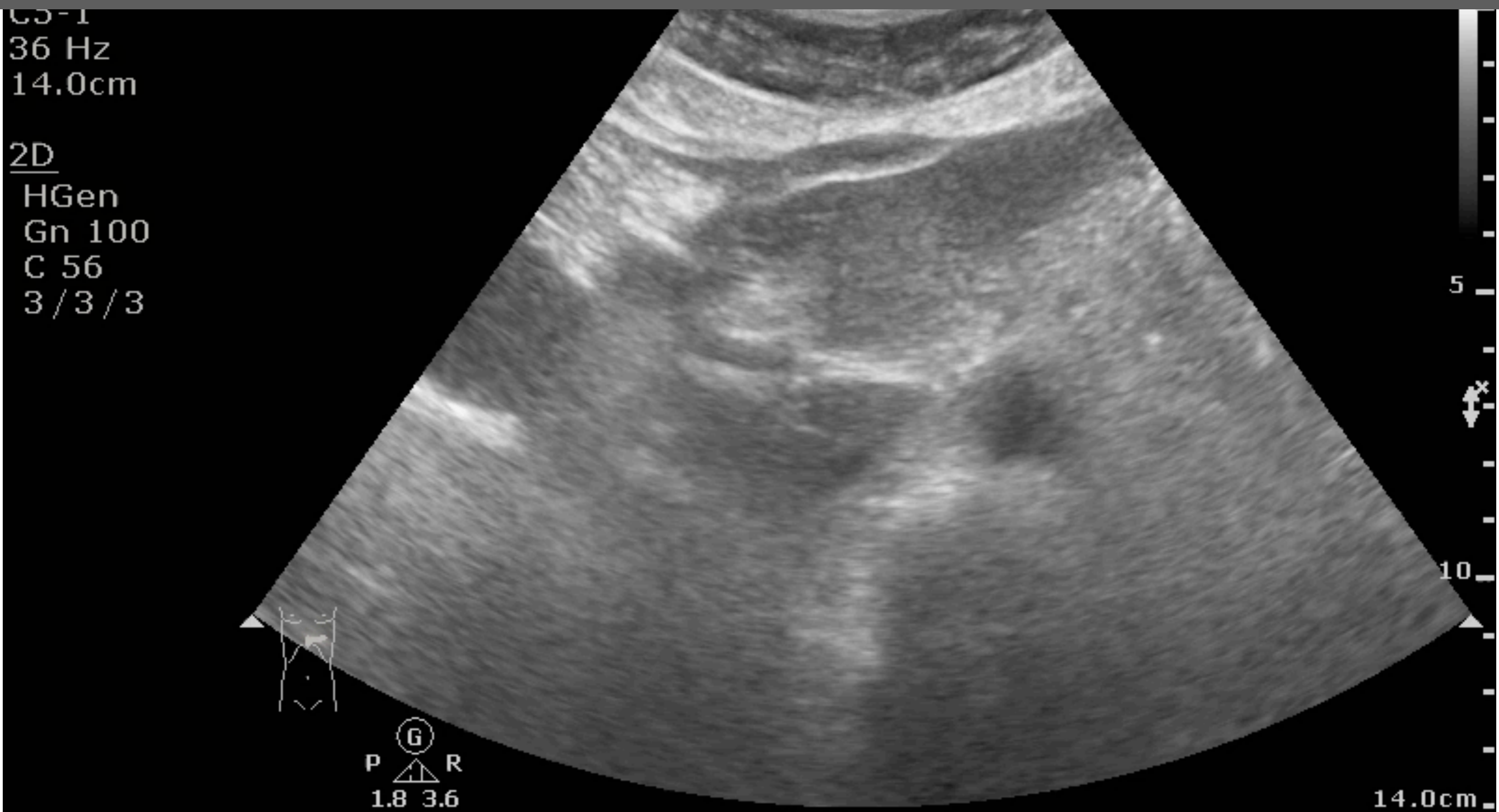Abd Gen2
C5-1

P

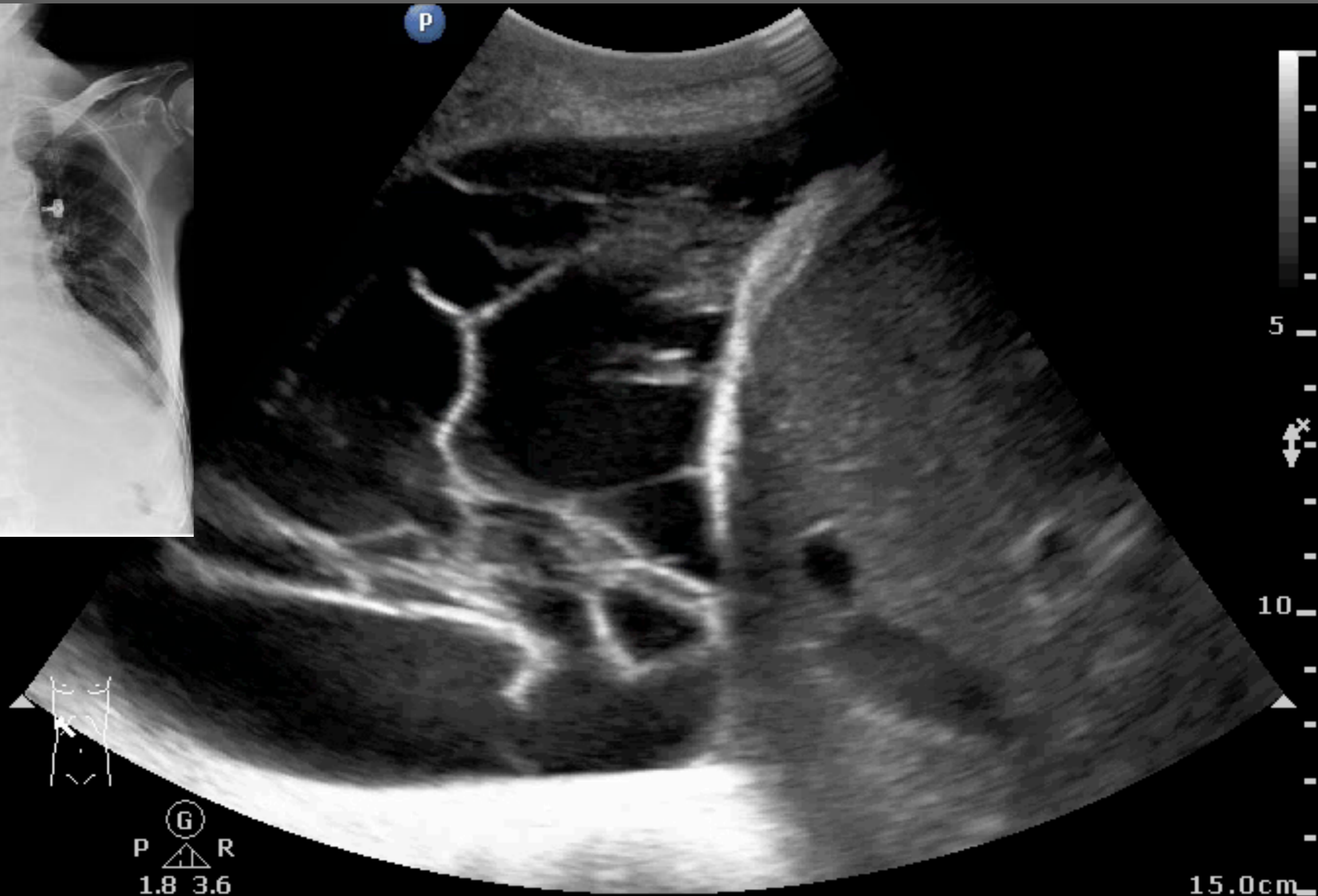
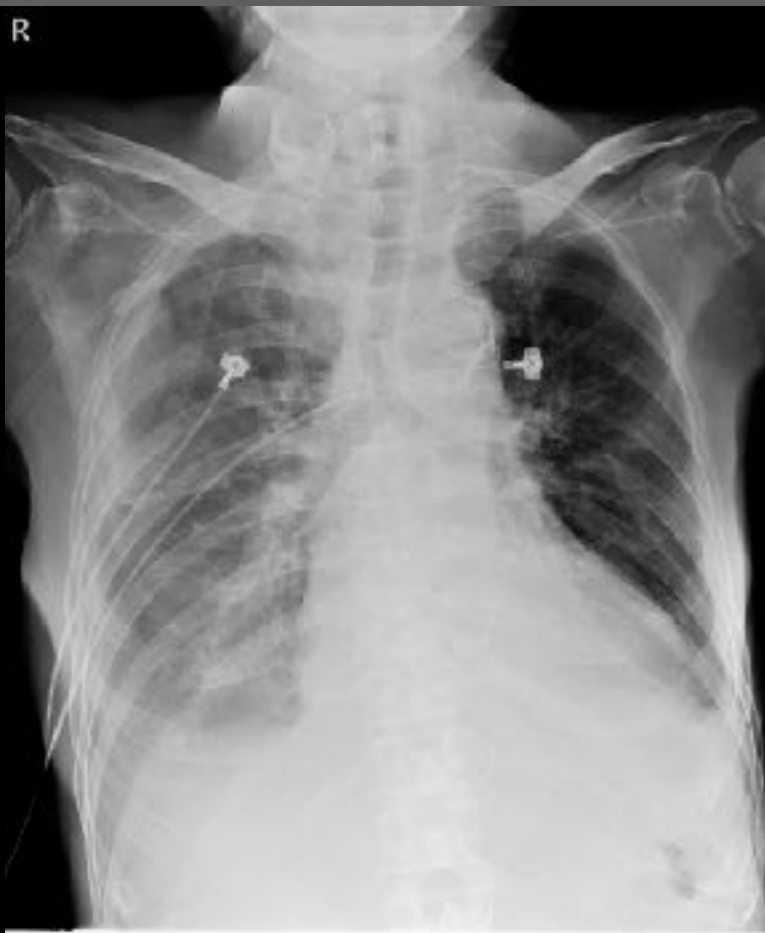

G
P R
1.8 3.6

CBD stone



73M, chest/abd pain & SOB



ABDOMEN

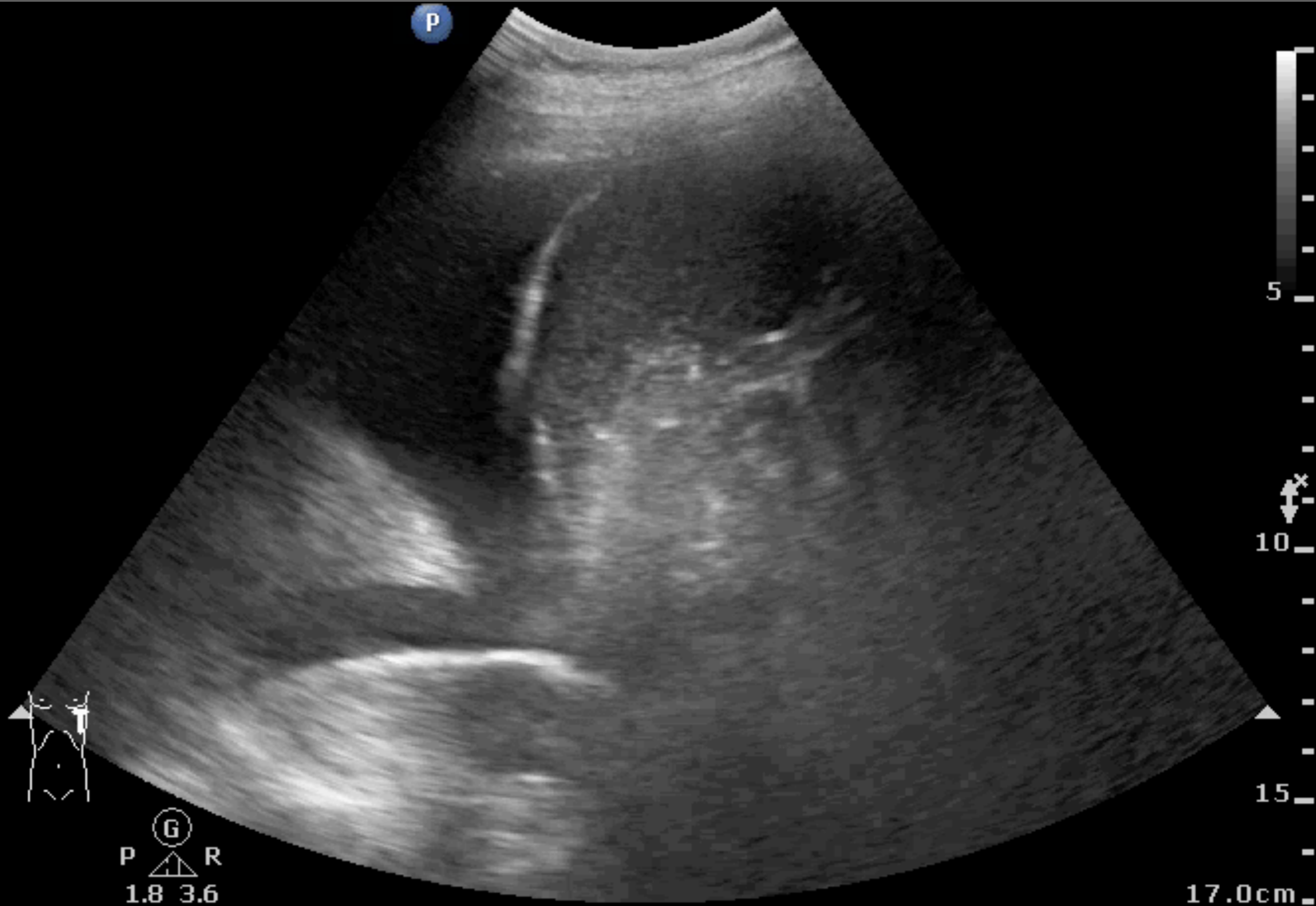D for diaphragm

Outsider

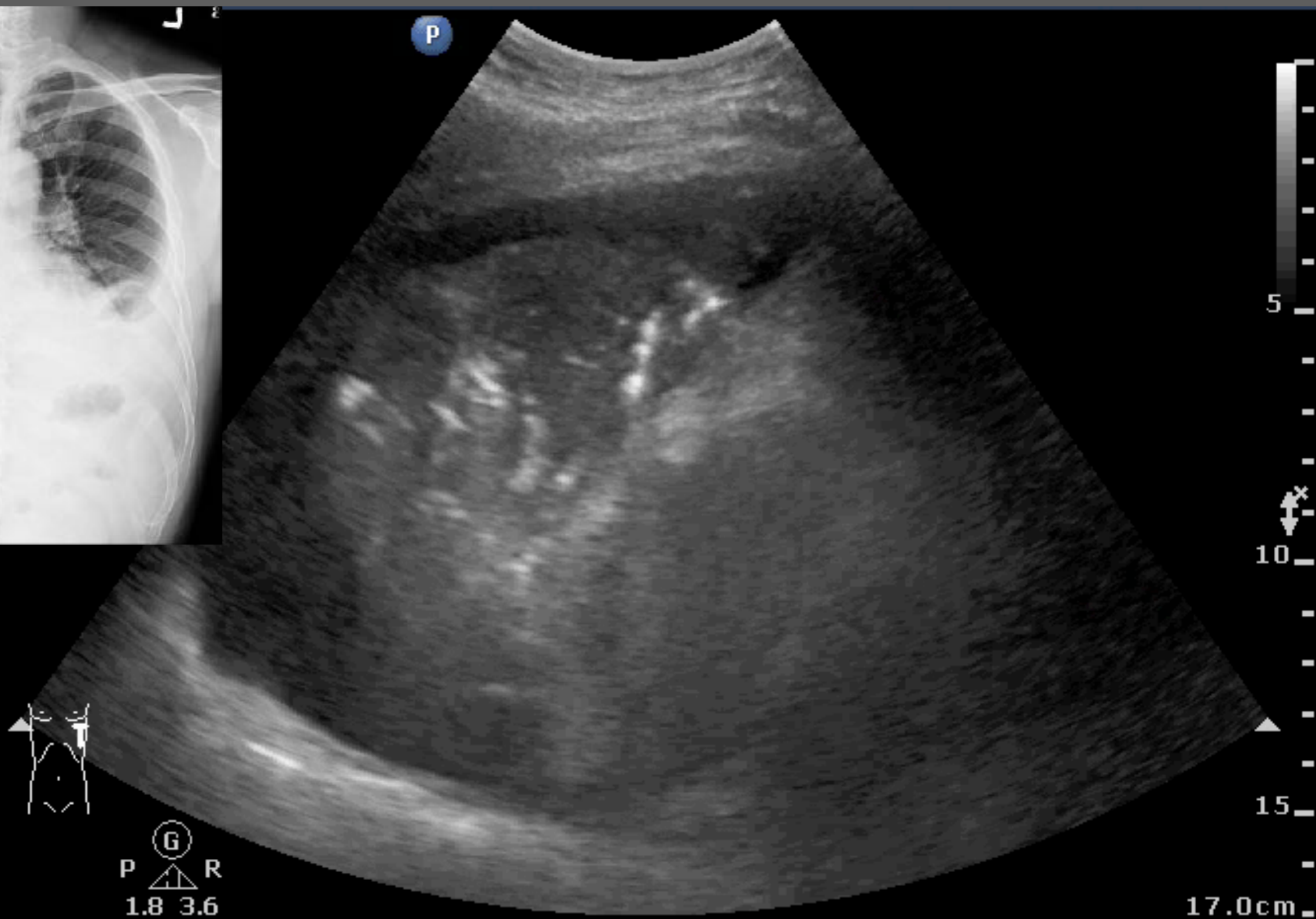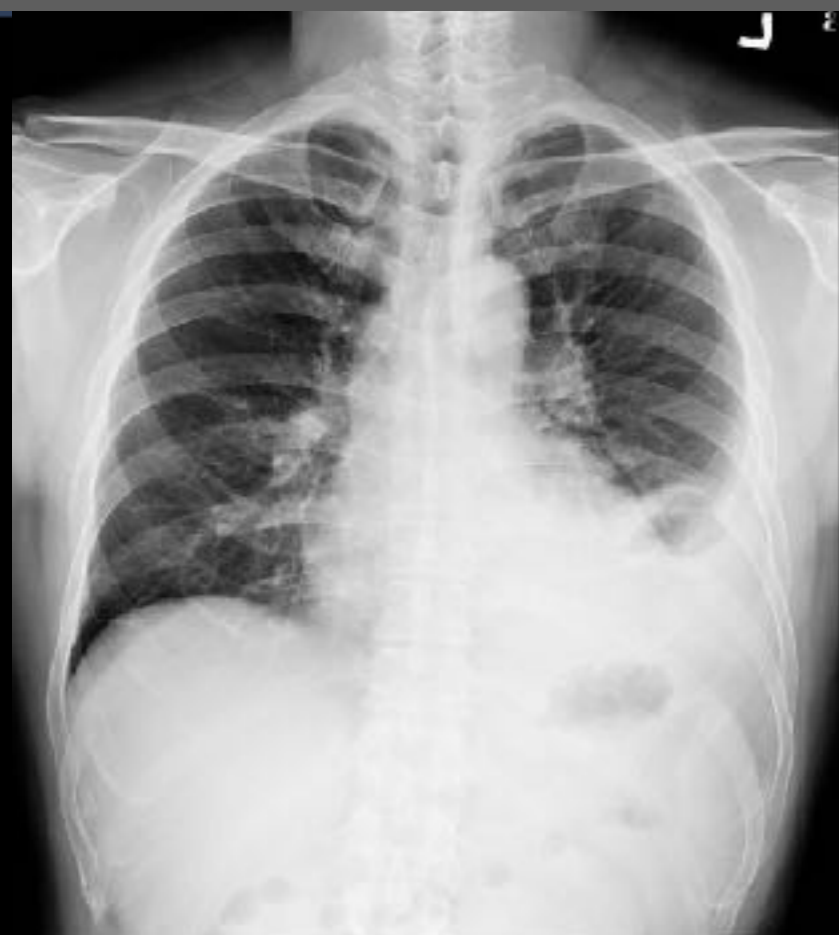45M, LUQ pain

Abd Gen
C5-1
31 Hz
17.0cm

2D
HGen
Gn 100
C 56
3/3/3



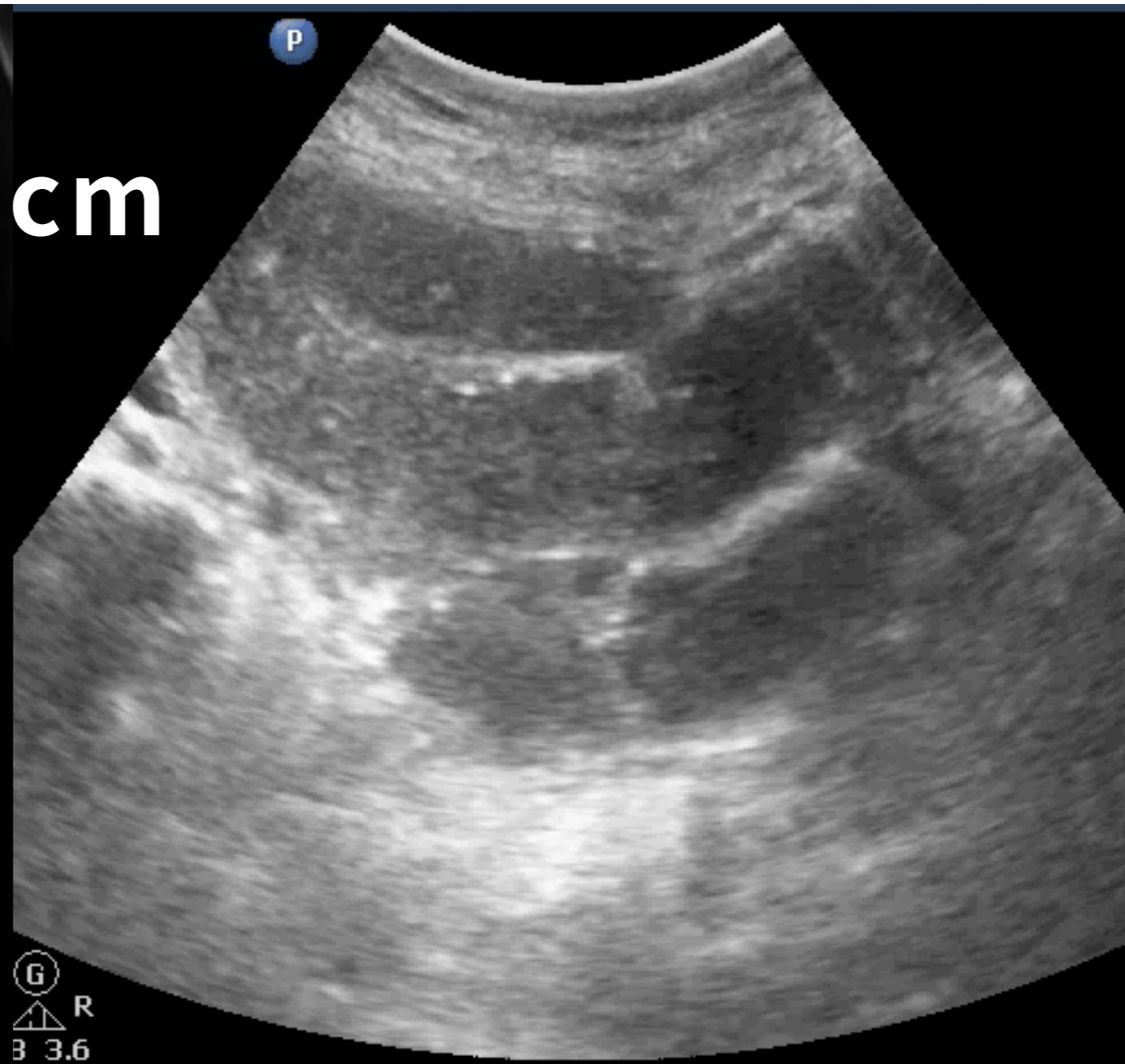
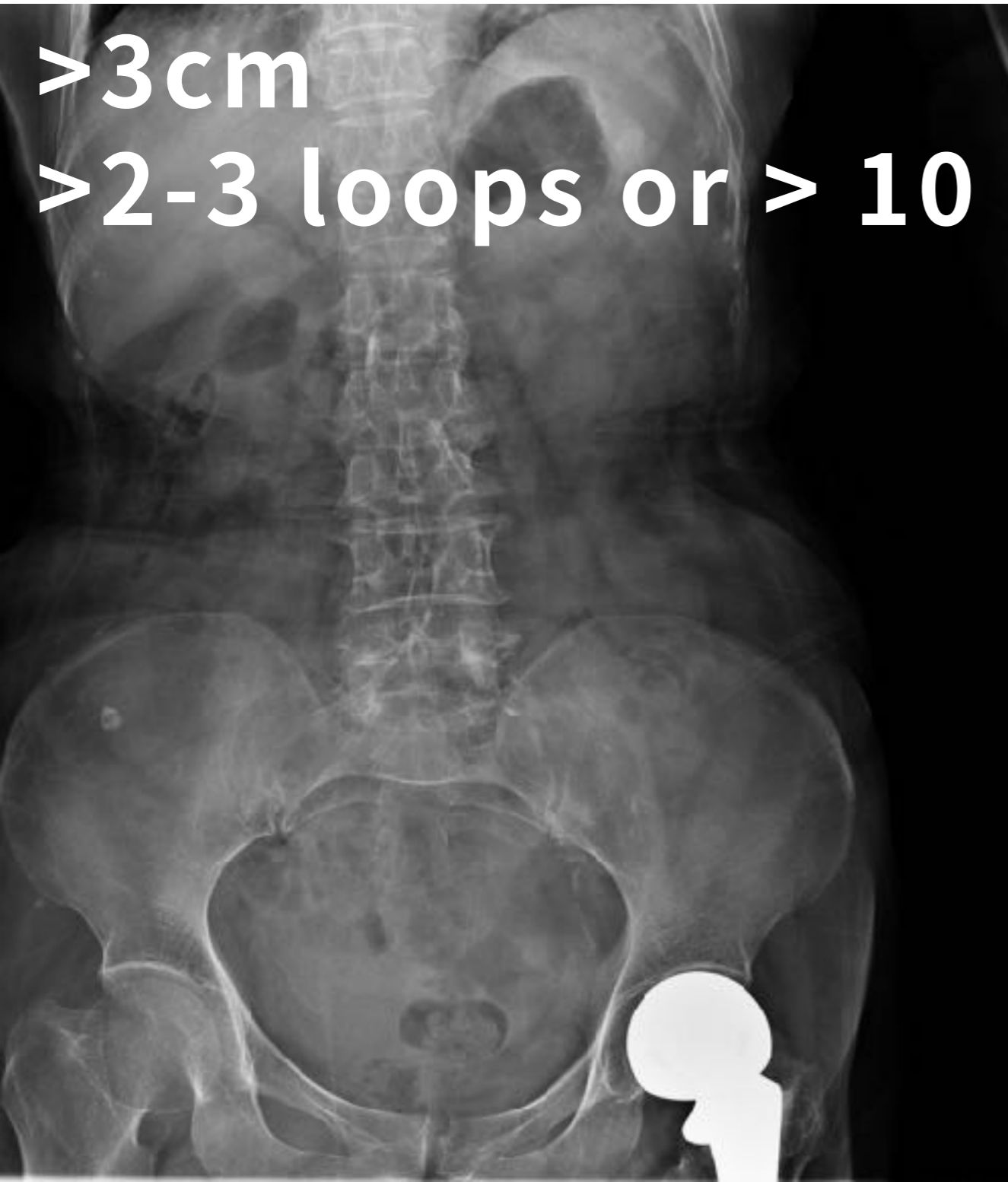
PN & parapneumonic effusion



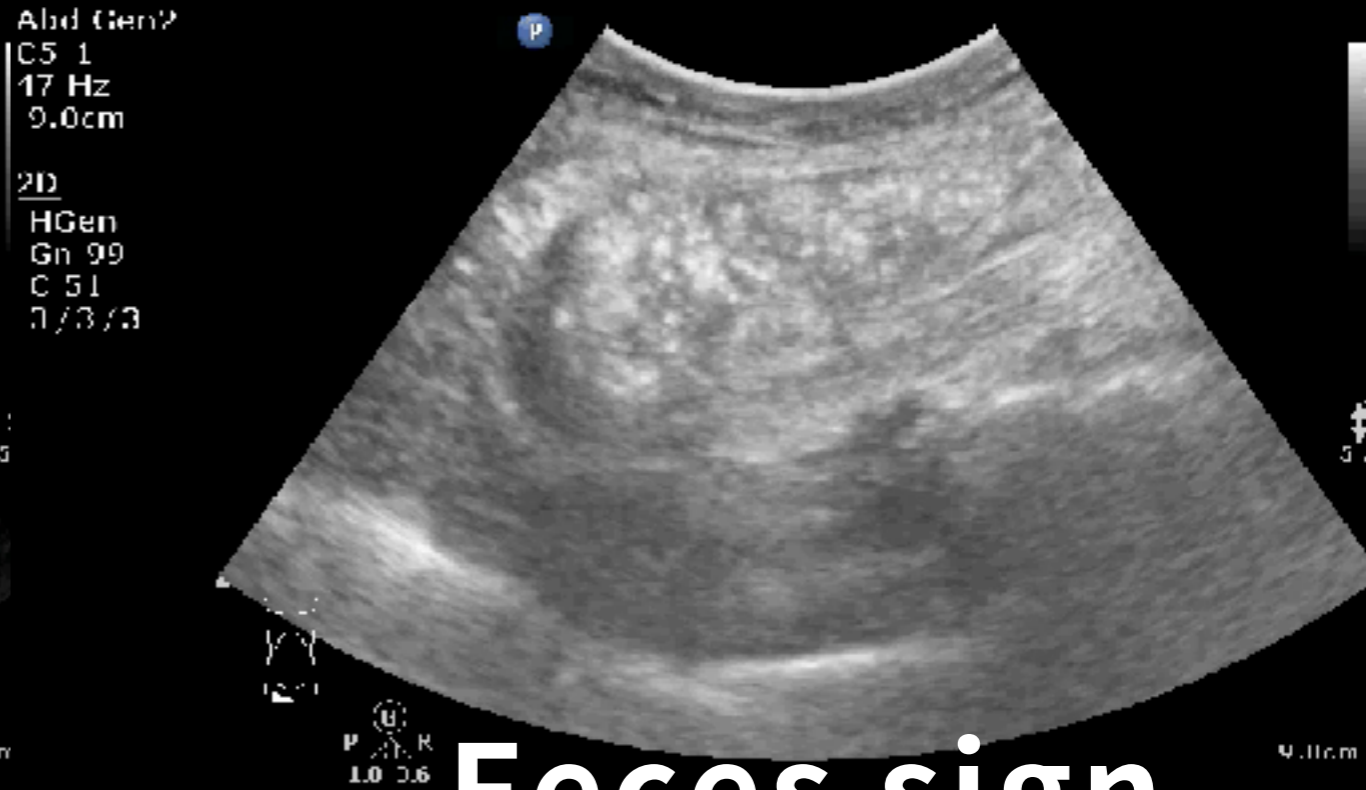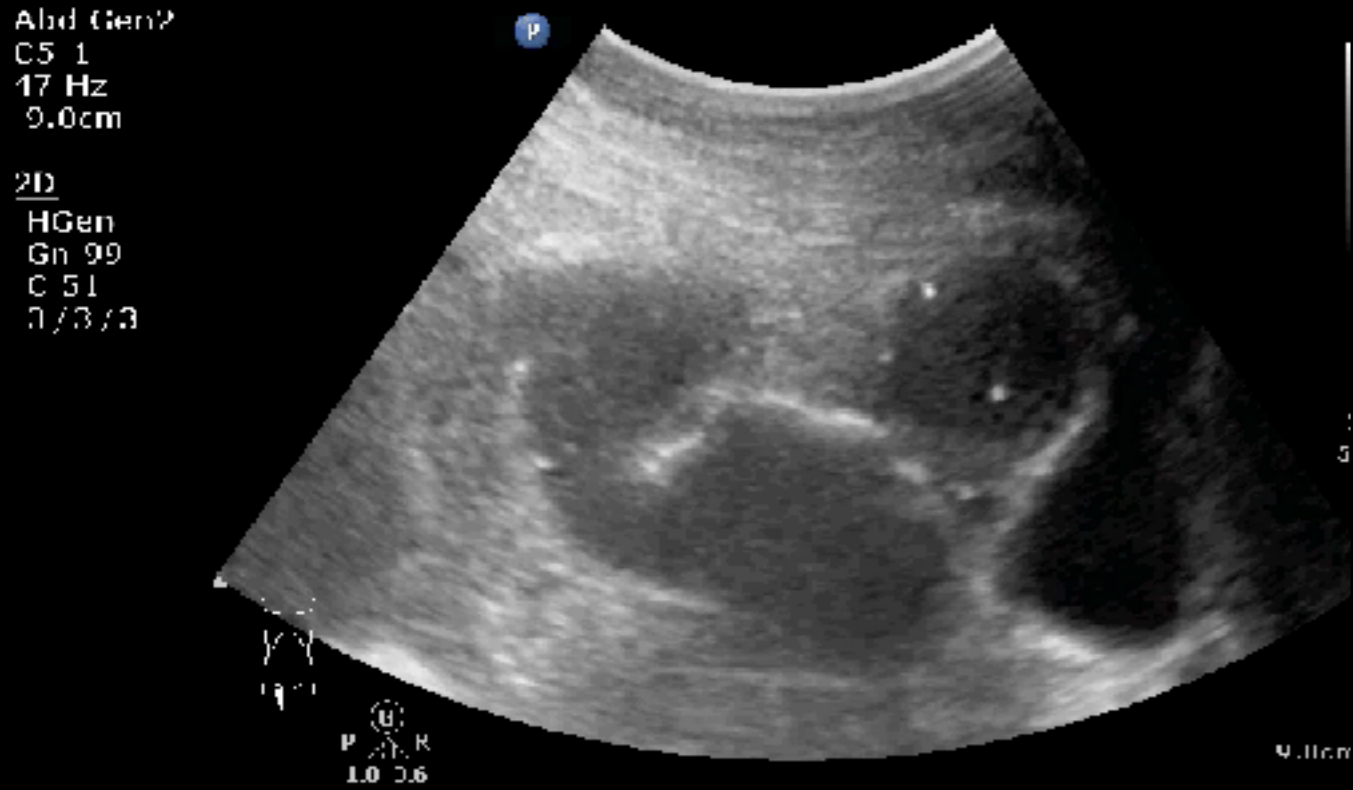88F, diffuse abdominal pain

> 3 cm

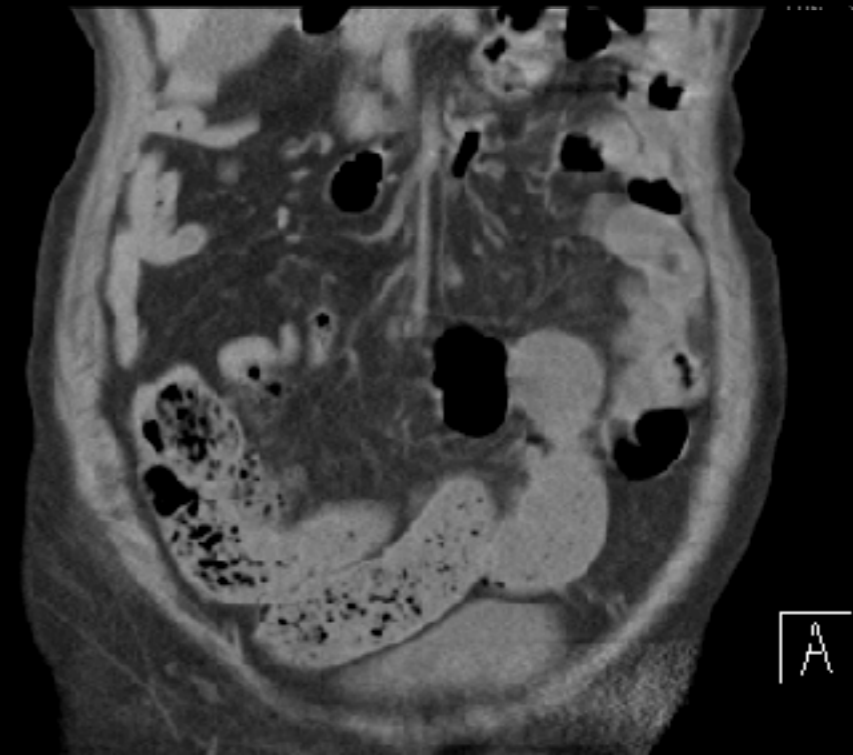
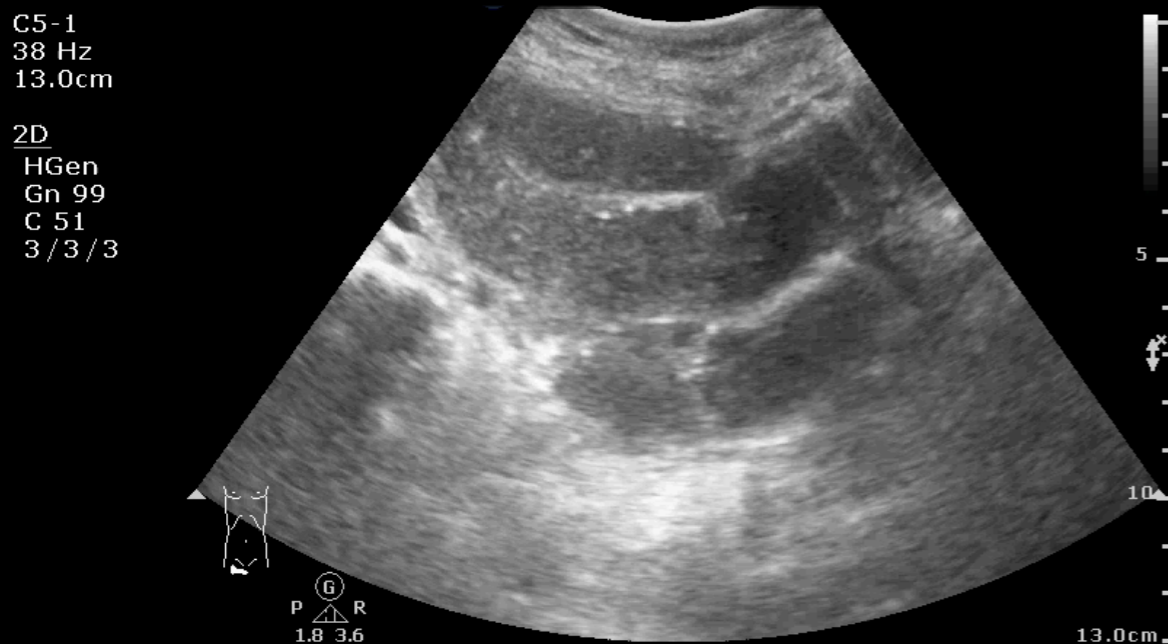> 2-3 loops or > 10 cm



88F, diffuse abdominal pain



Feces sign



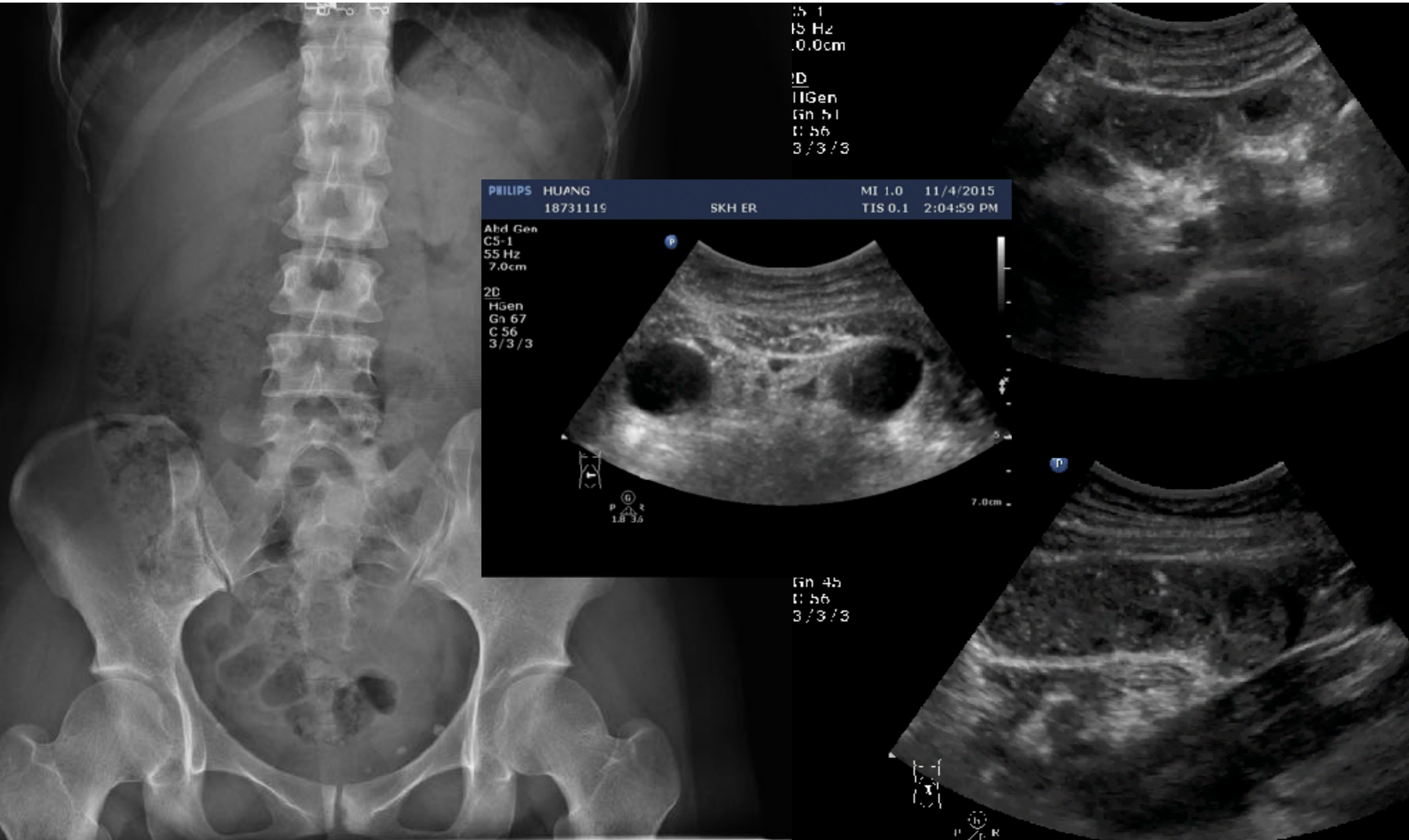
ABDOMEN

O for obstruction
(SBO & Intussusception)

3
cm

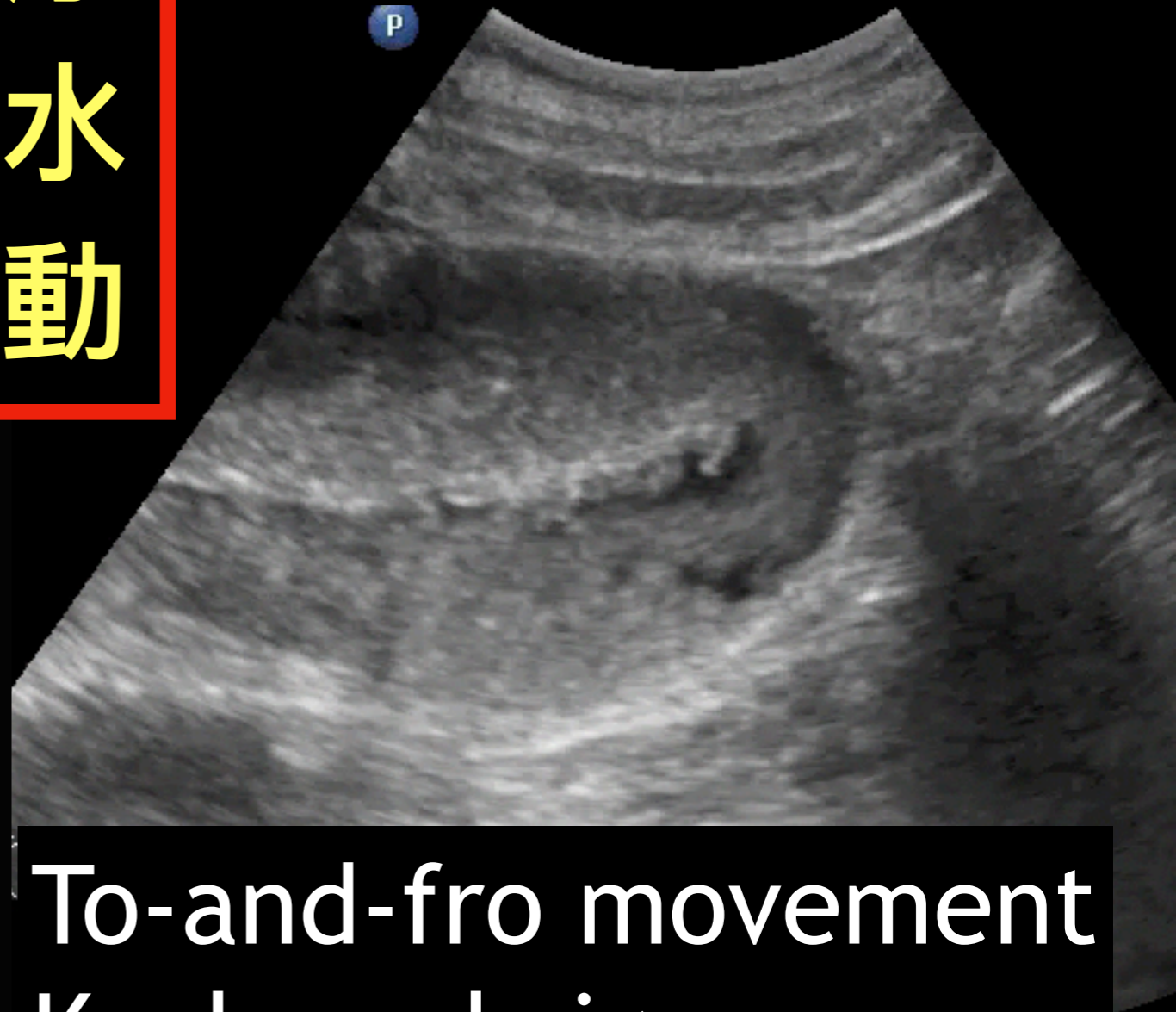
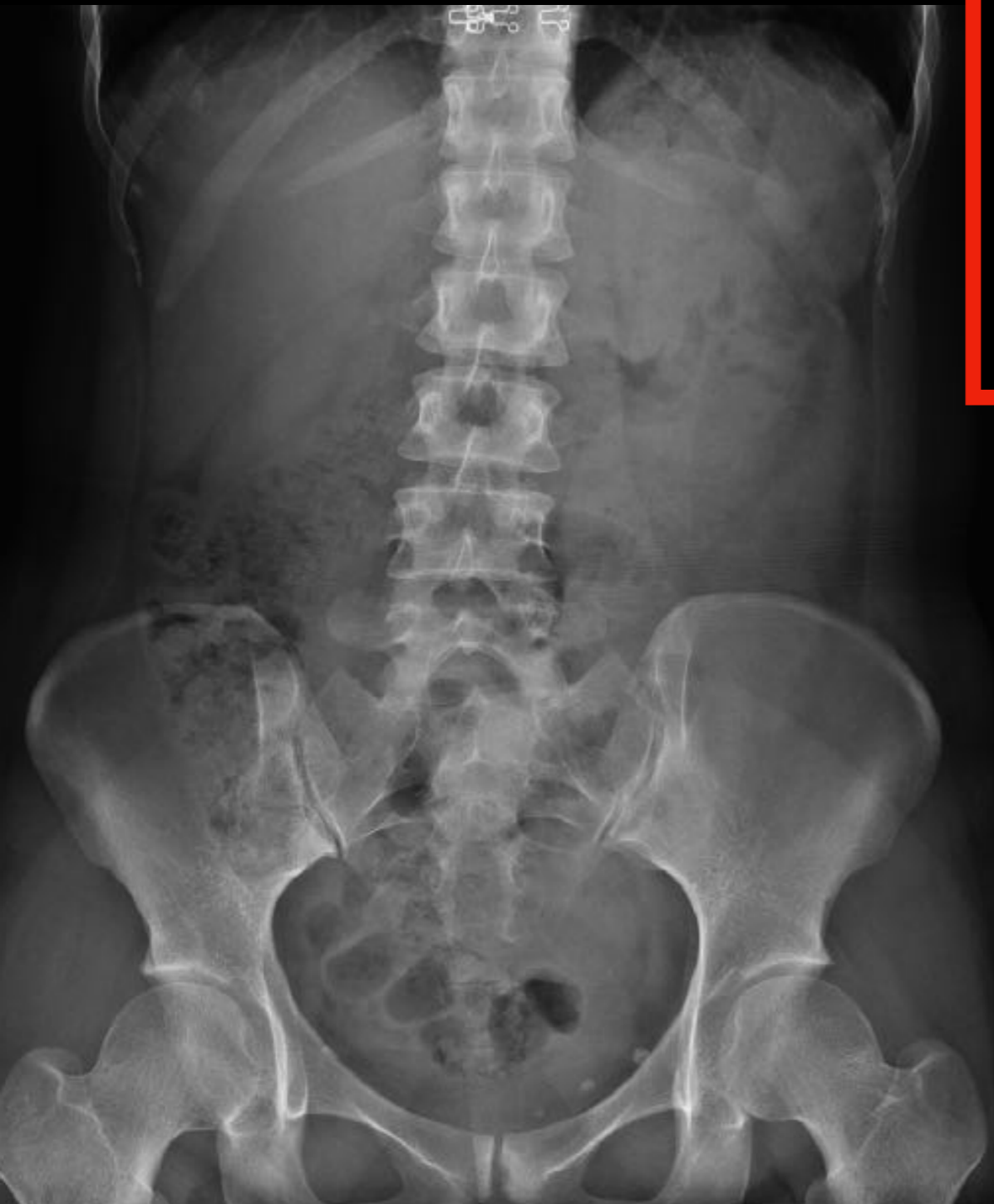5
cm

F/31, ABD pain & vomiting for 2Ds



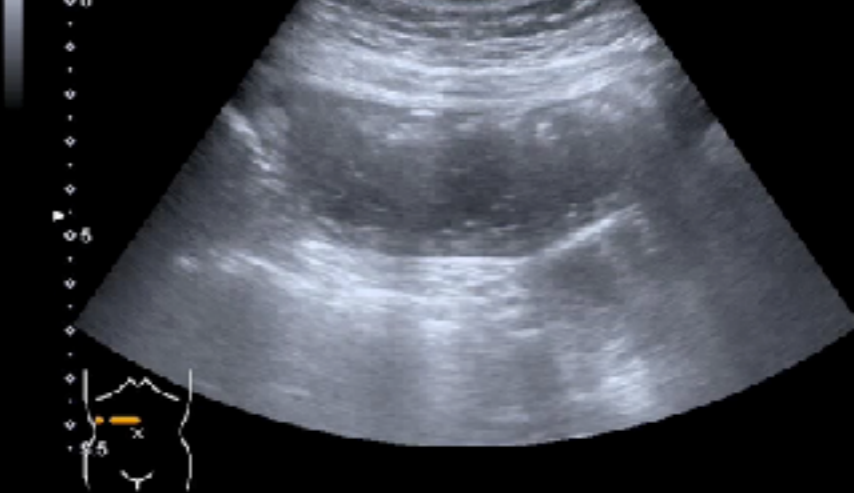
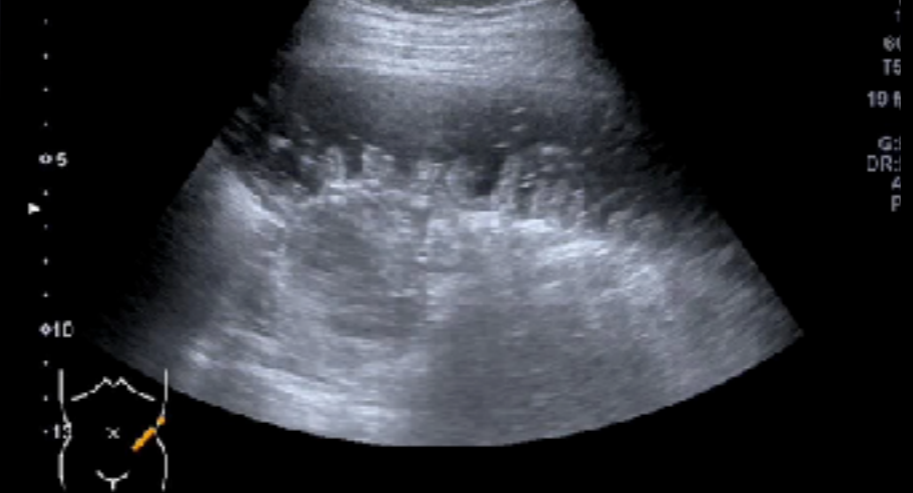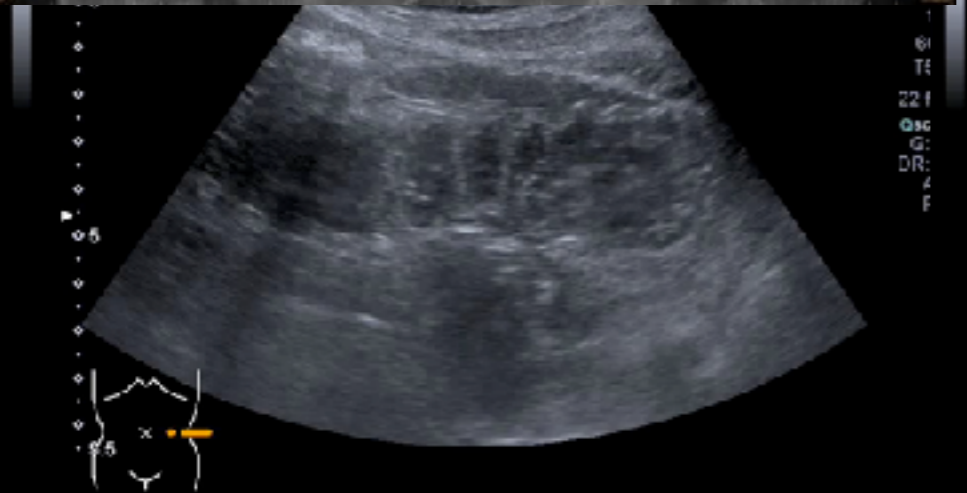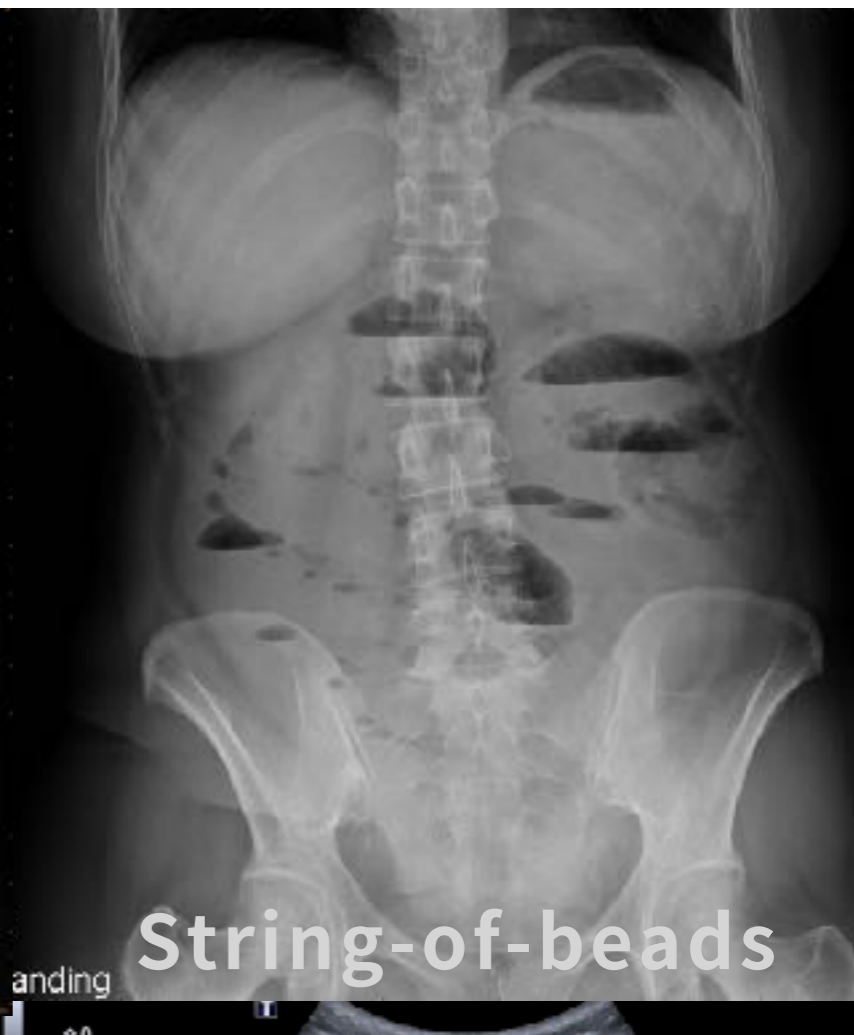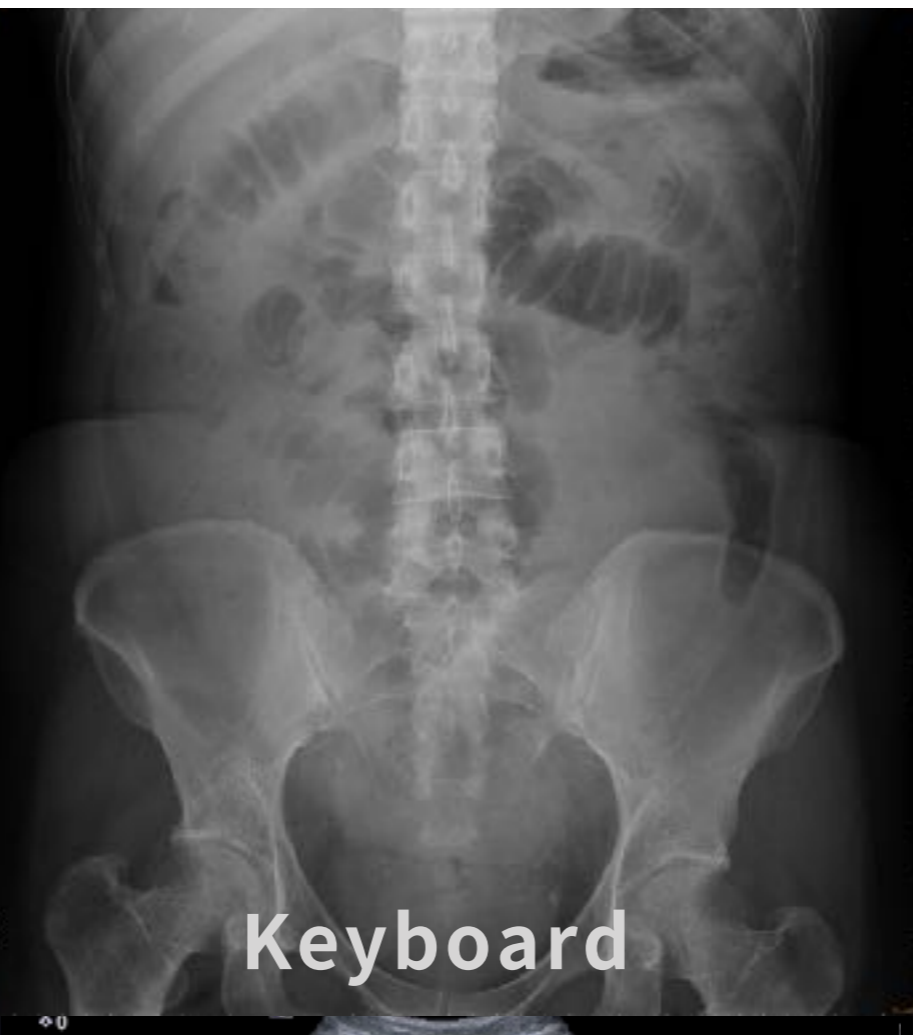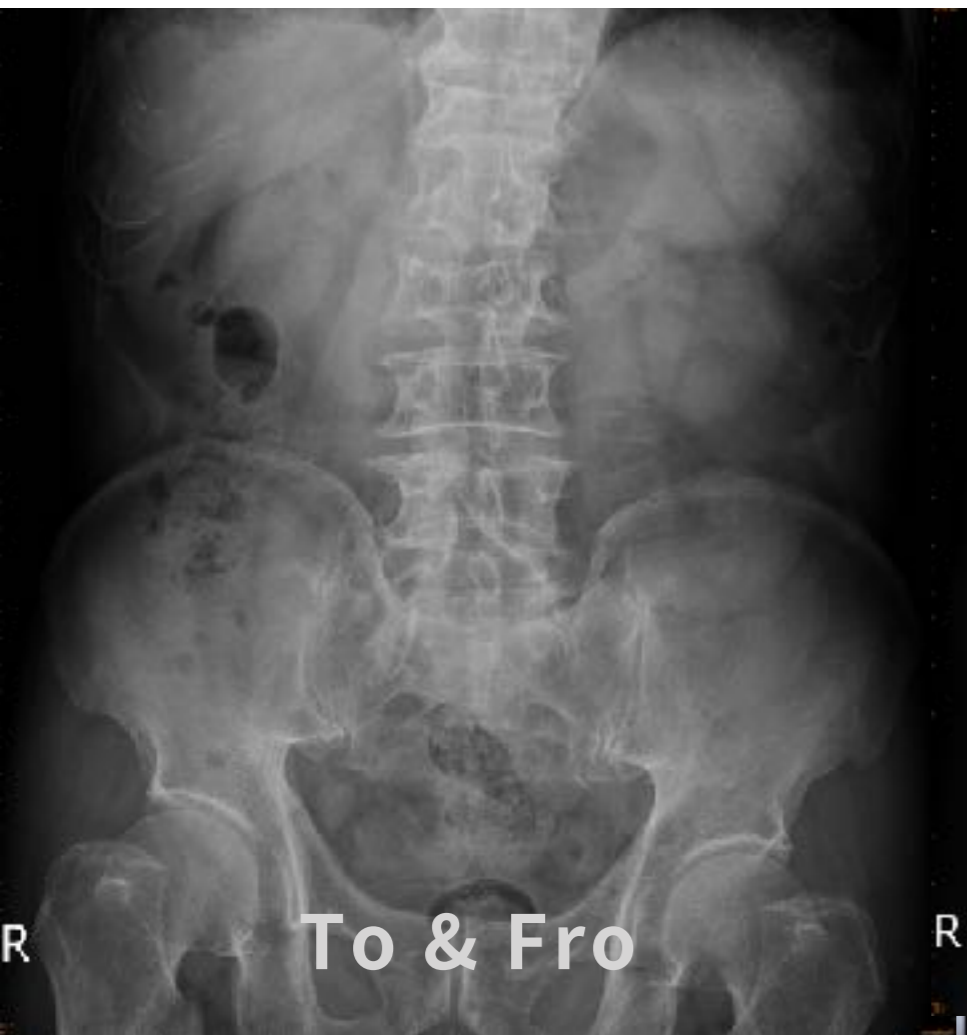POCUS is useful for gasless ileus

壁厚
腹水
蠕動



To-and-fro movement
Keyboard sign
Tanga sign

Small Bowel Obstruction



TAKE-HOME MESSAGE

For trained operators, ultrasonography possesses sensitivity and specificity comparable to that of abdominal computed tomography (CT) for the diagnosis of small bowel obstruction.

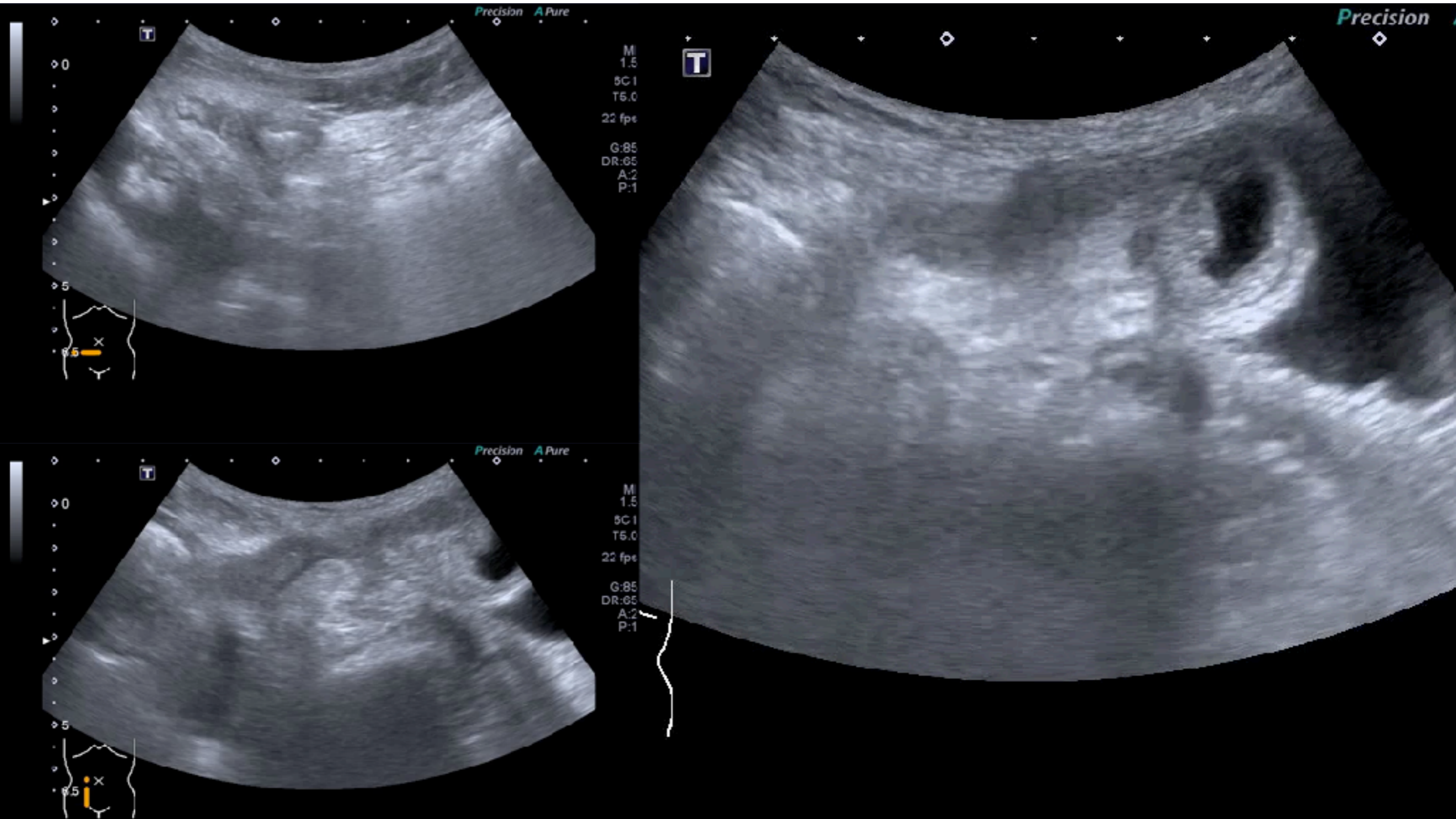
US for SBO diagnosis LR + >20起跳

Ultrasonographic Diagnosis of SBO	Specificity (95% CI)	Sensitivity (95% CI)	+LR (95% CI)	-LR (95% CI)	SROC AUC (95% CI)
Overall	0.97 (0.88–0.99)	0.92 (0.89–0.95)	27.5 (7.7–98.4)	0.08 (0.06–0.11)	0.96 (0.94–0.97)
ED	0.96 (0.86–0.99)	0.93 (0.89–0.95)	21.1 (6.5–68.9)	0.08 (0.05–0.12)	0.96 (0.94–0.97)
Non-ED	0.99 (0.60–1.00)	0.92 (0.85–0.96)	70.8 (1.5–3279.7)	0.08 (0.05–0.15)	0.96 (0.94–0.98)

CI, Confidence interval; *+LR*, positive likelihood ratio; *-LR*, negative likelihood ratio; *SBO*, small bowel obstruction; *SROC*, summary receiver operating characteristic; *AUC*, area under the curve.

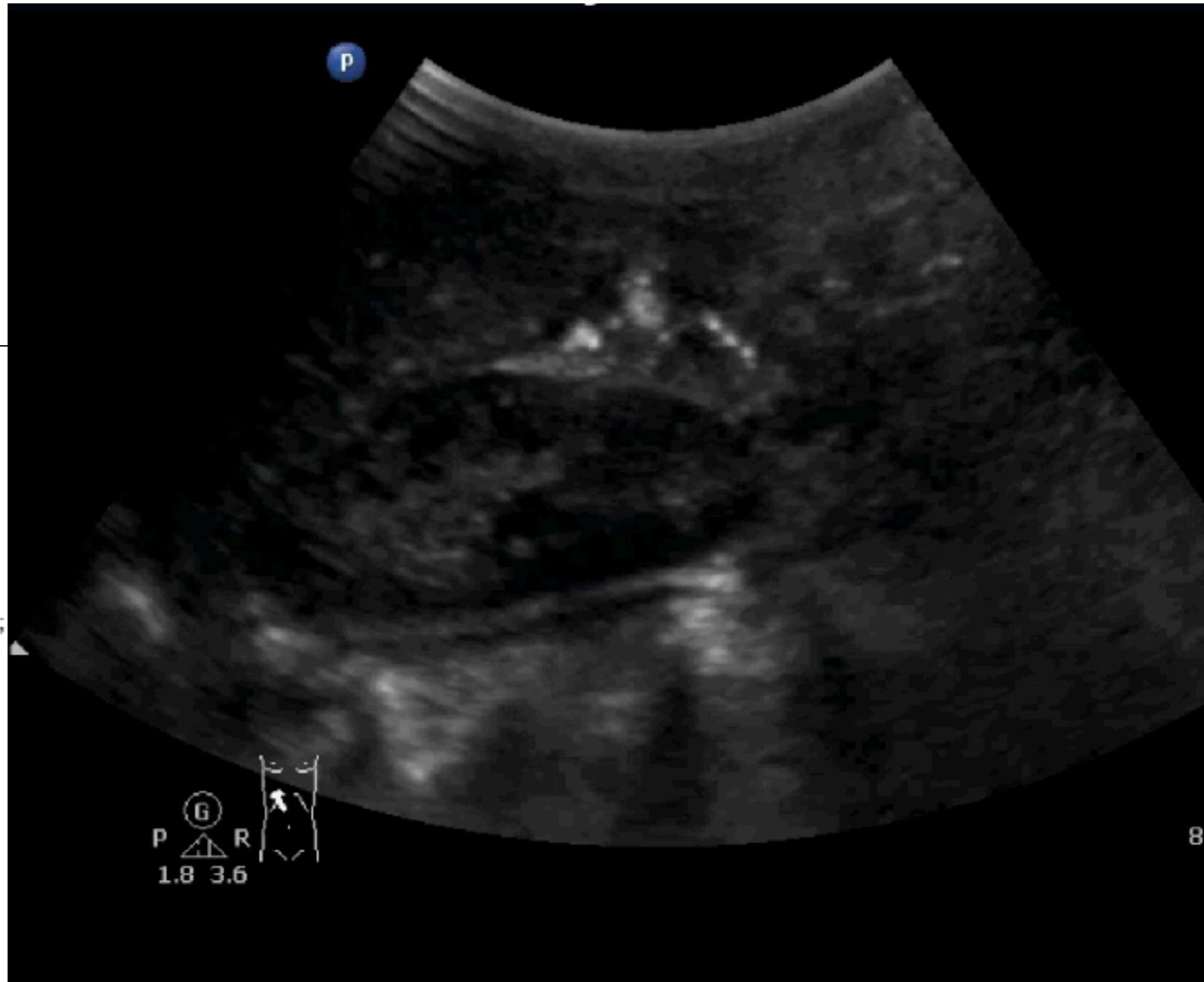
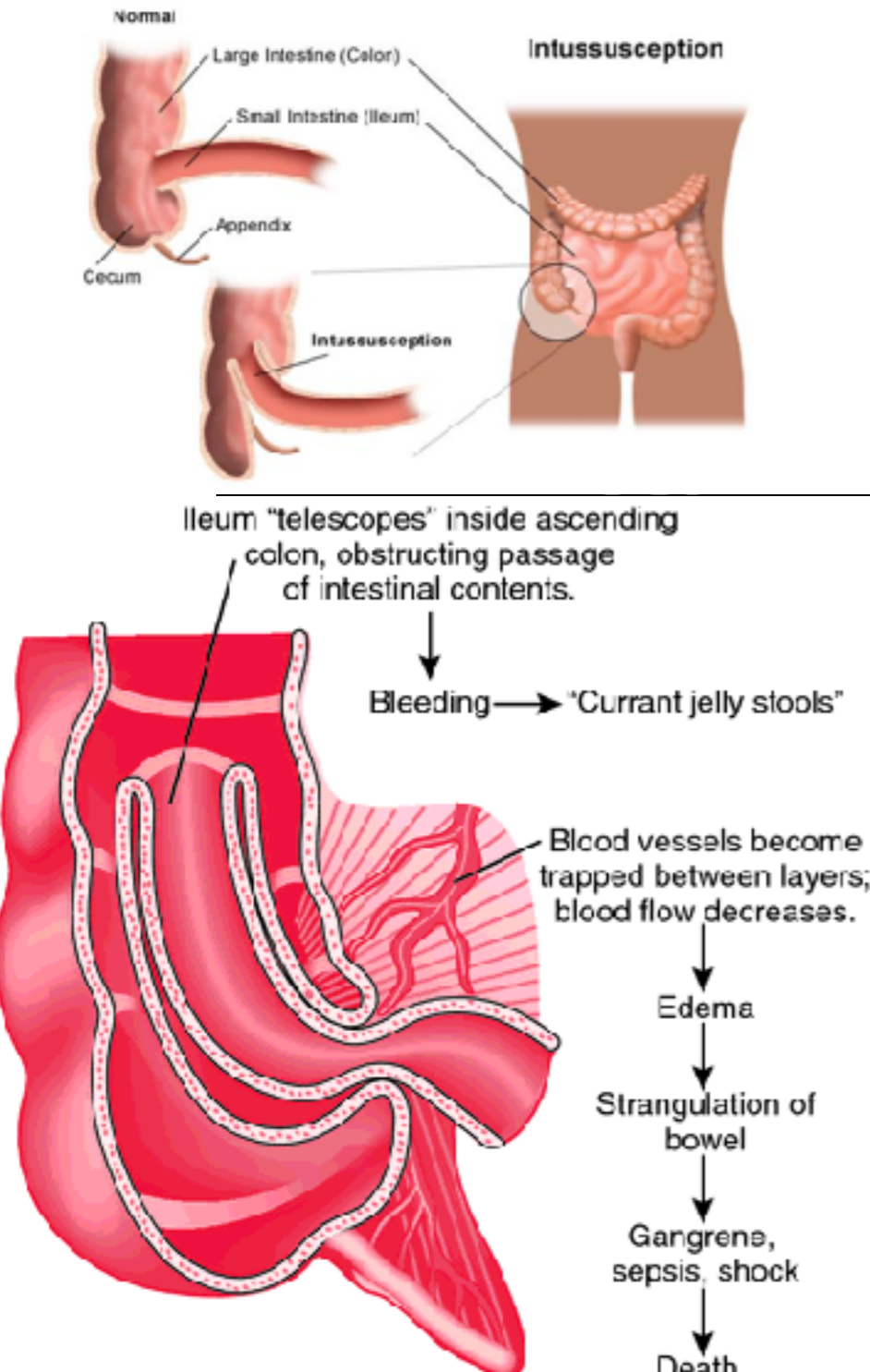
66M, right inguinal painful swelling

診斷 & 協助擬定復位路徑



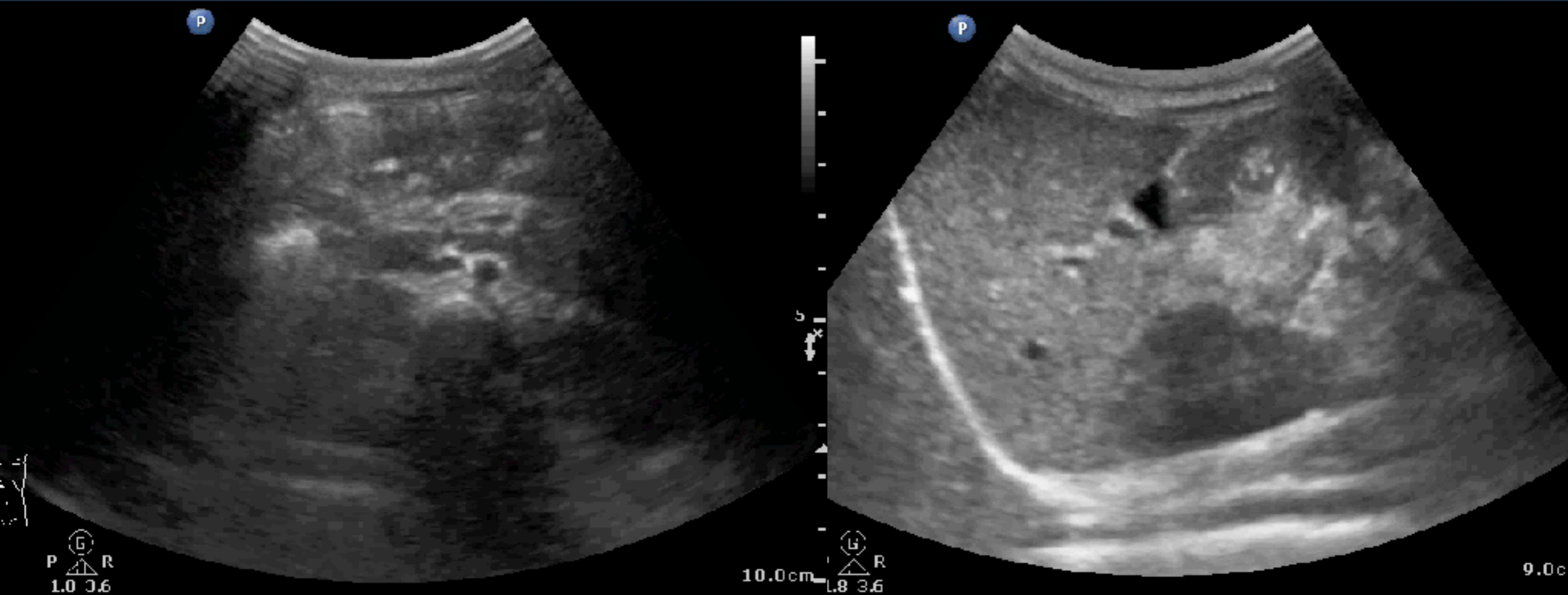
Intussusception

小孩優先找右上腹

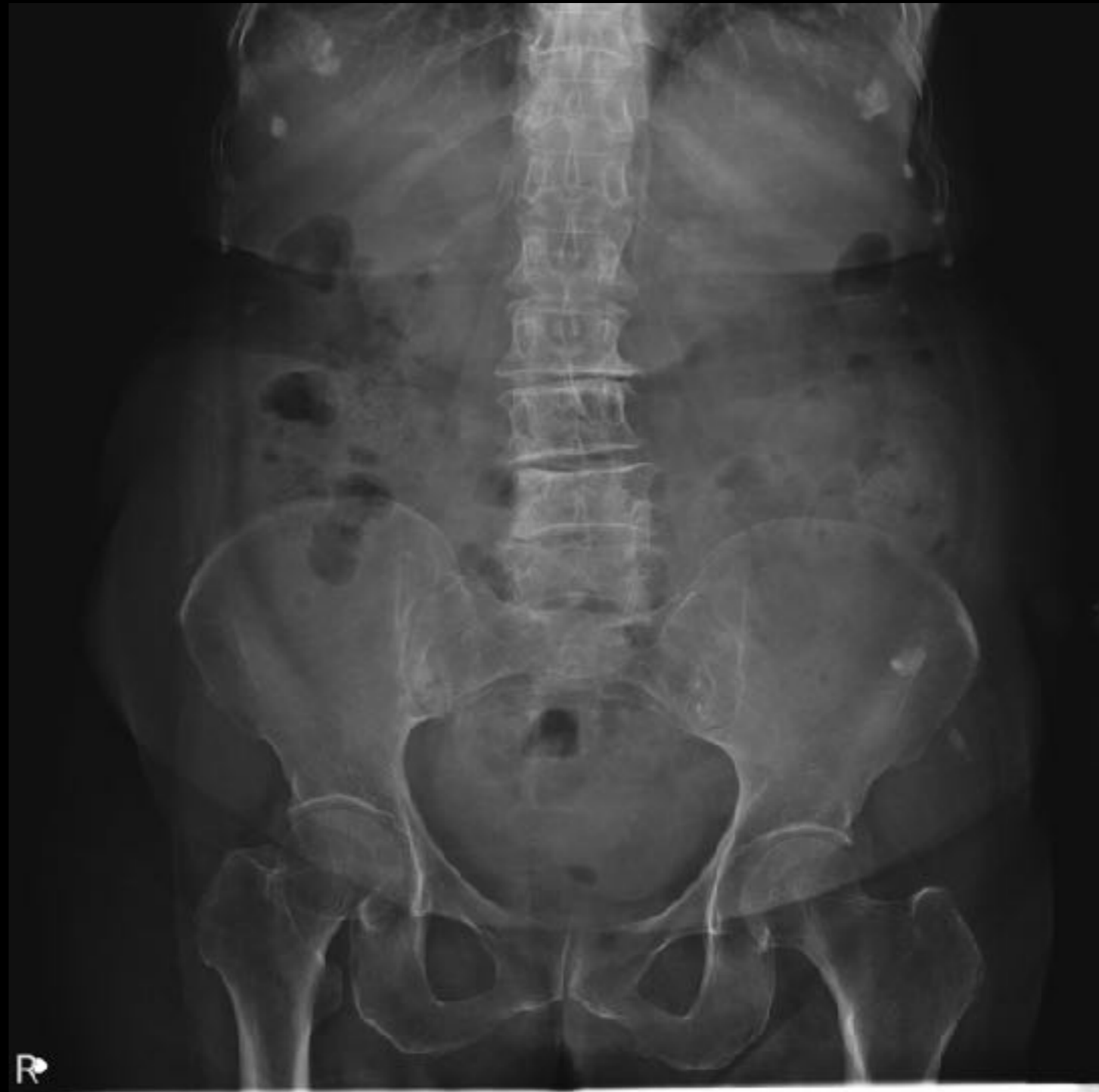
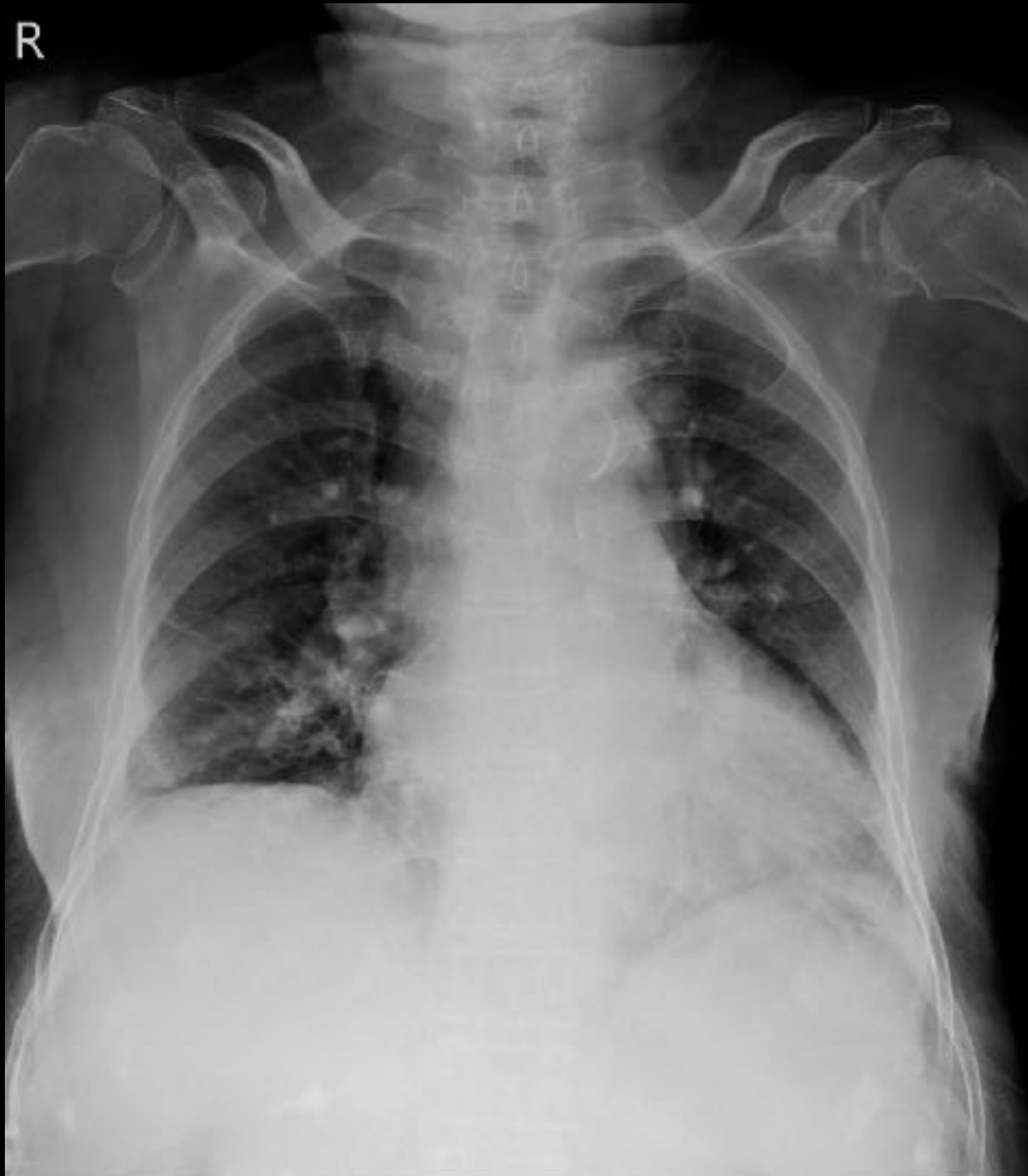
7個月大男童，間歇性溢奶

間歇性或周期性都要小心



80F, diffuse abdominal pain

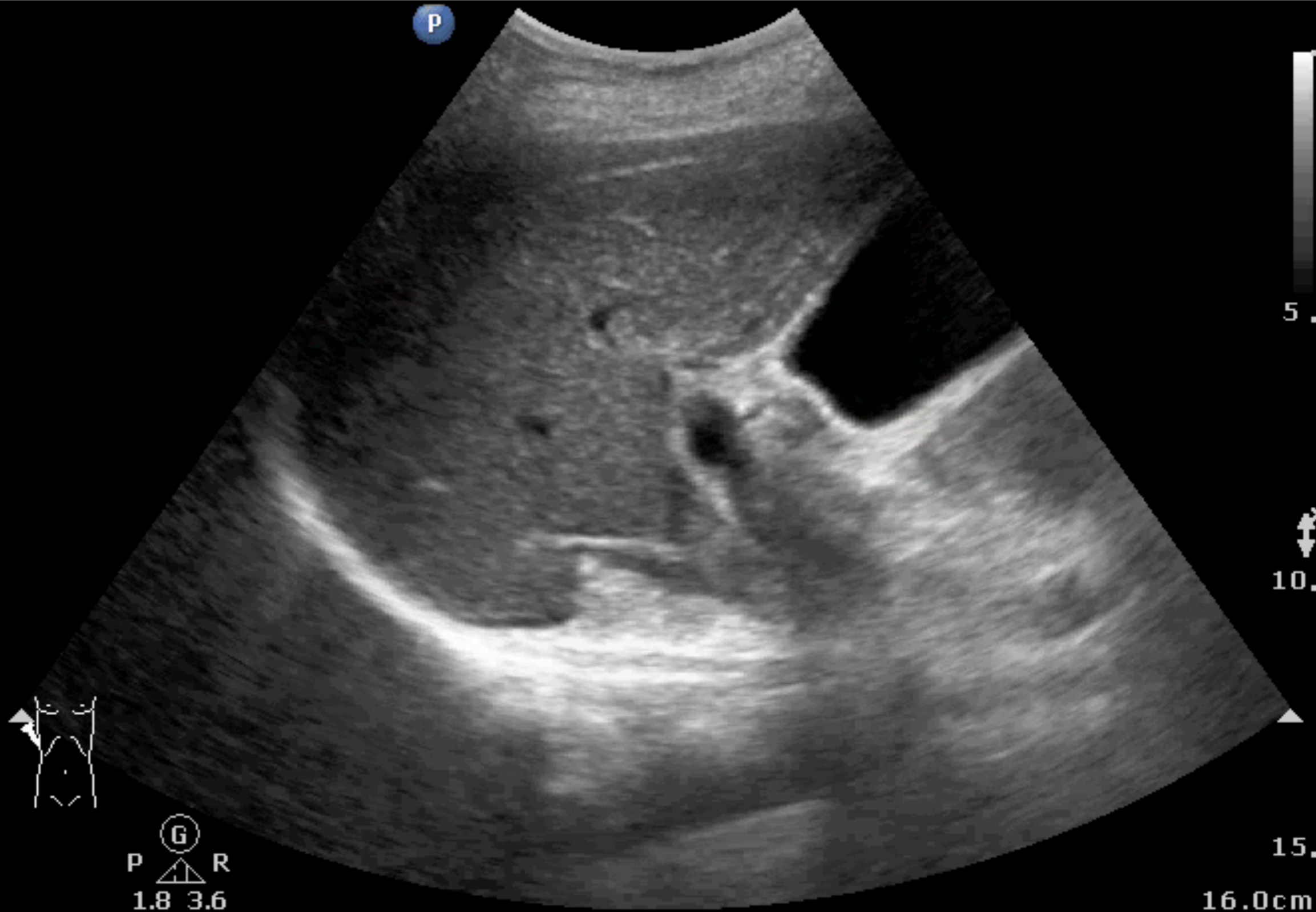

80F, diffuse abdominal pain

Abd Gen2
C5-1
32 Hz
16.0cm

2D

HGen
Gn 90
C 56
3/3/3



G
P R
1.8 3.6

15.
16.0cm

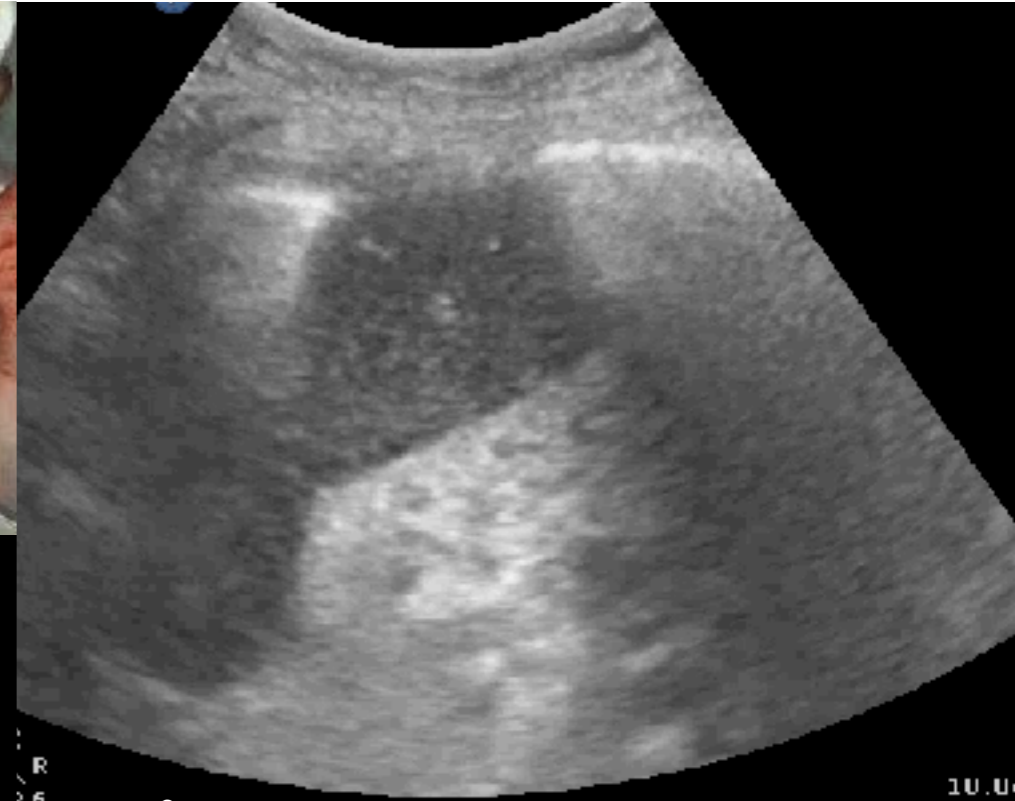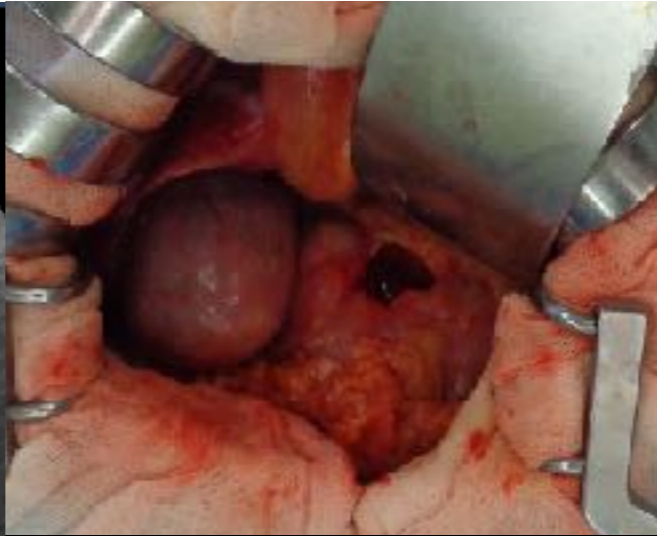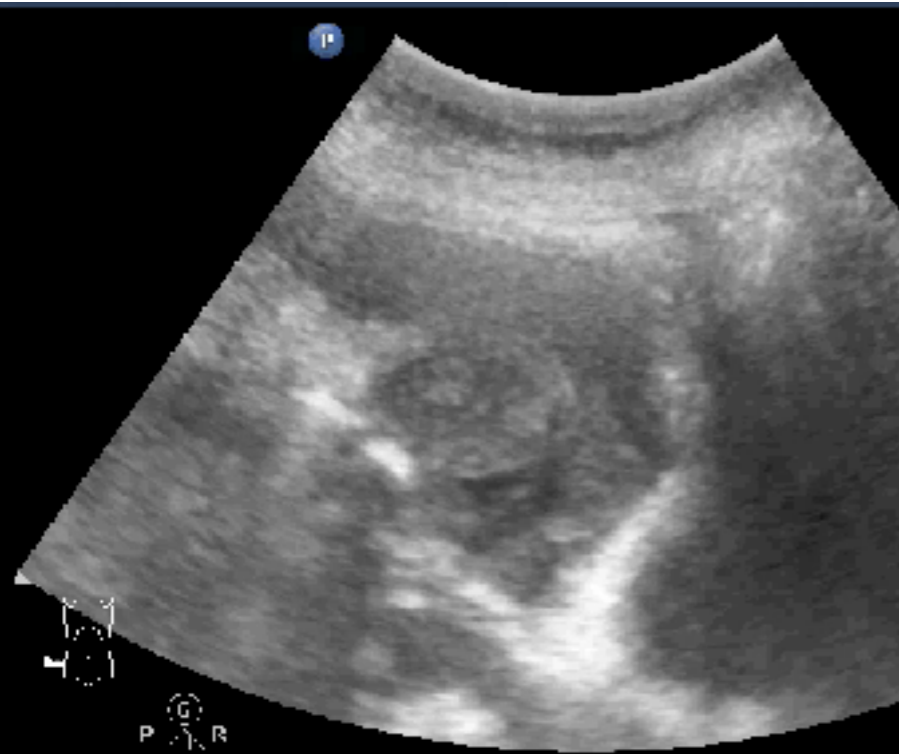
ABDOMEN

M for moving fluid or air

FAST / Liver surface

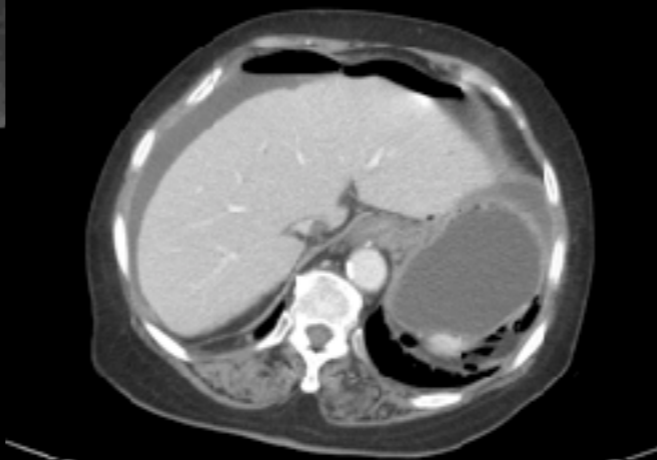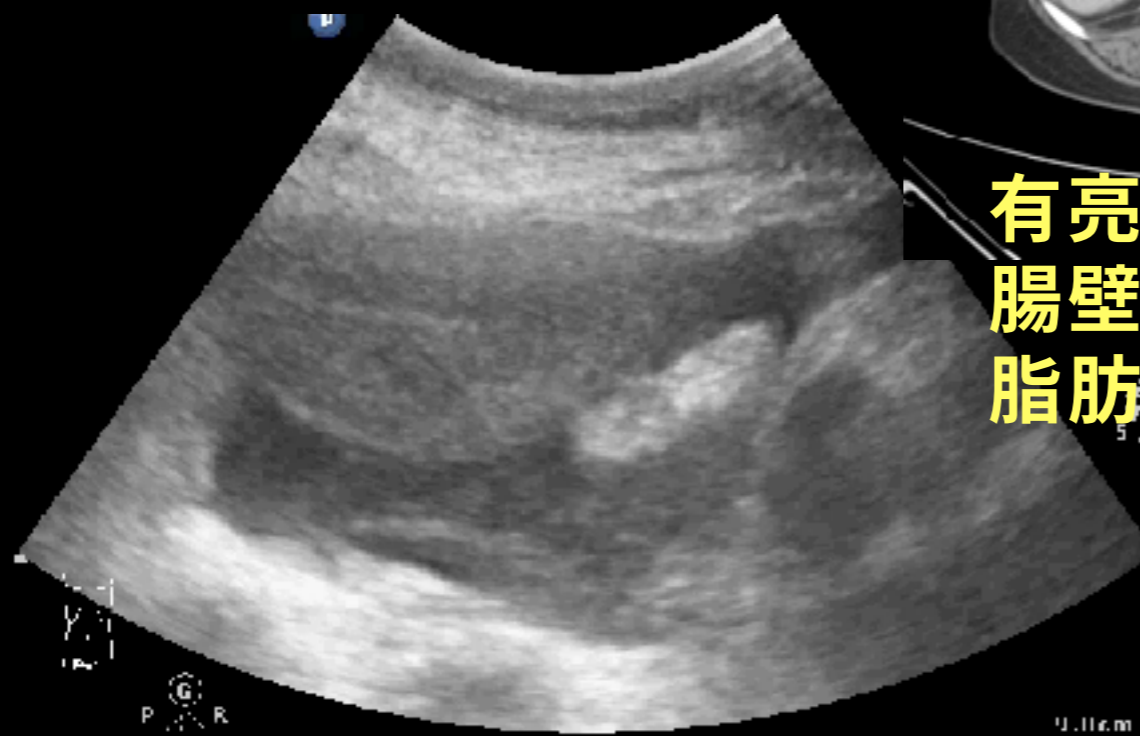80F, diffuse abdominal pain

Abd Gen2
C5-1
17 Hz
9.0cm
2D
HGen
Gn 100
C 56
3/3/3

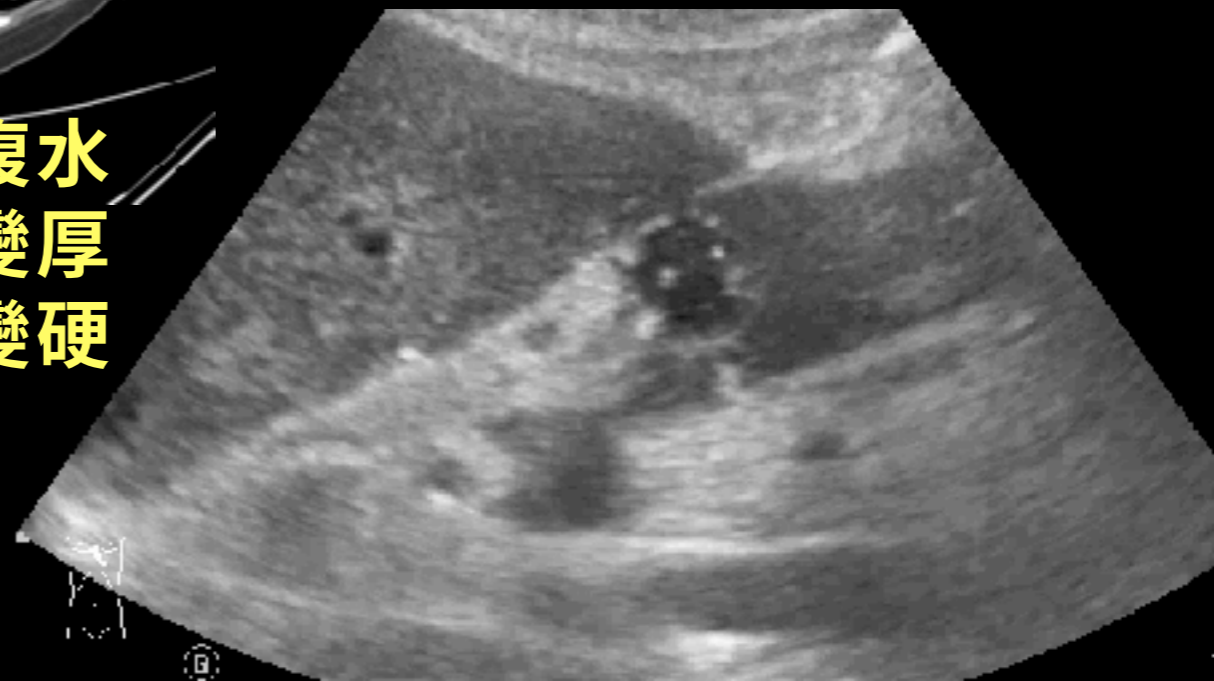


Scissors maneuver

Abd Gen2
C5-1
17 Hz
9.0cm
2D
HGen
Gn 100
C 56
3/3/3

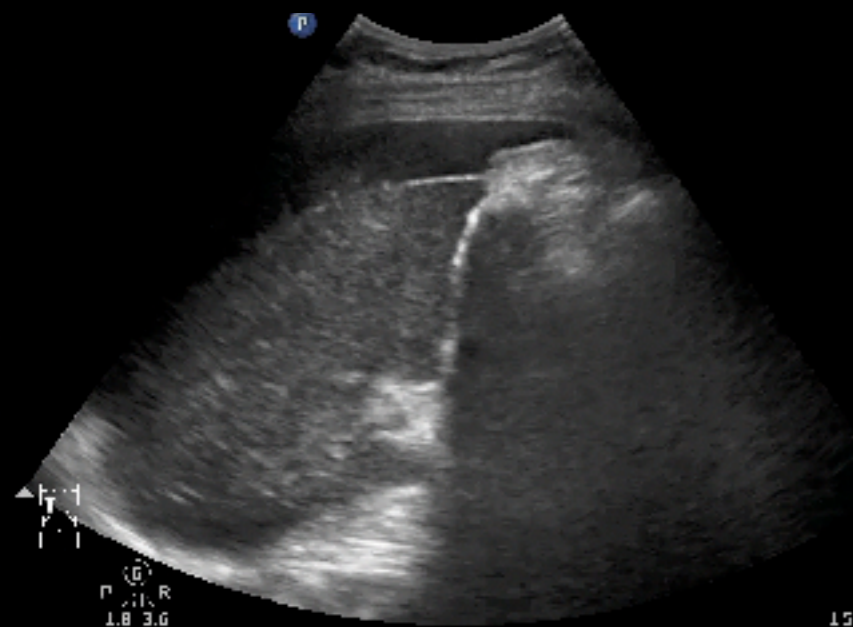


有亮度的腹水
腸壁異常變厚
脂肪變亮變硬

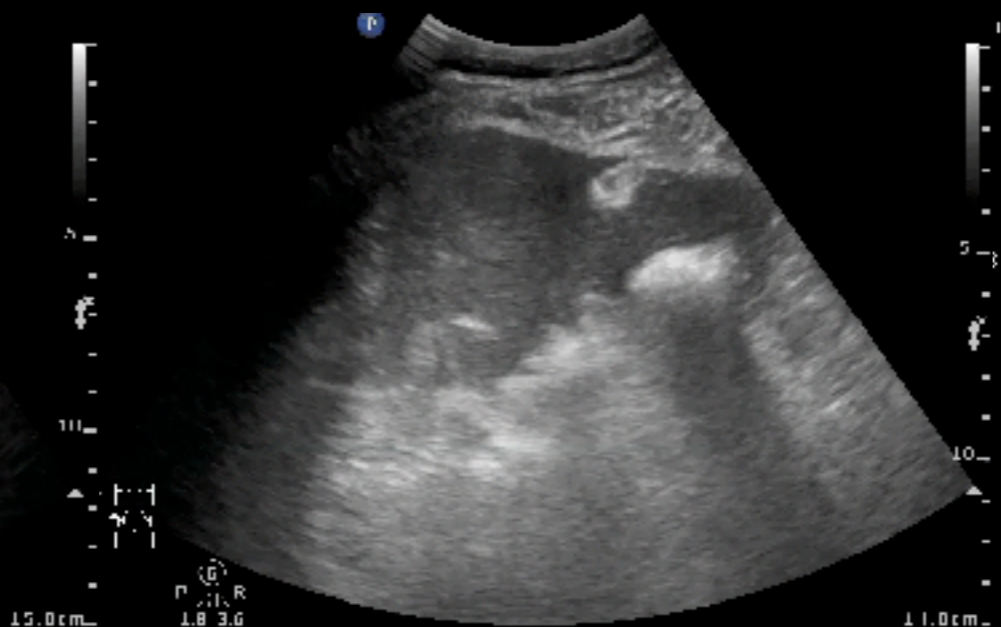

Dirty ascites: 水往下流

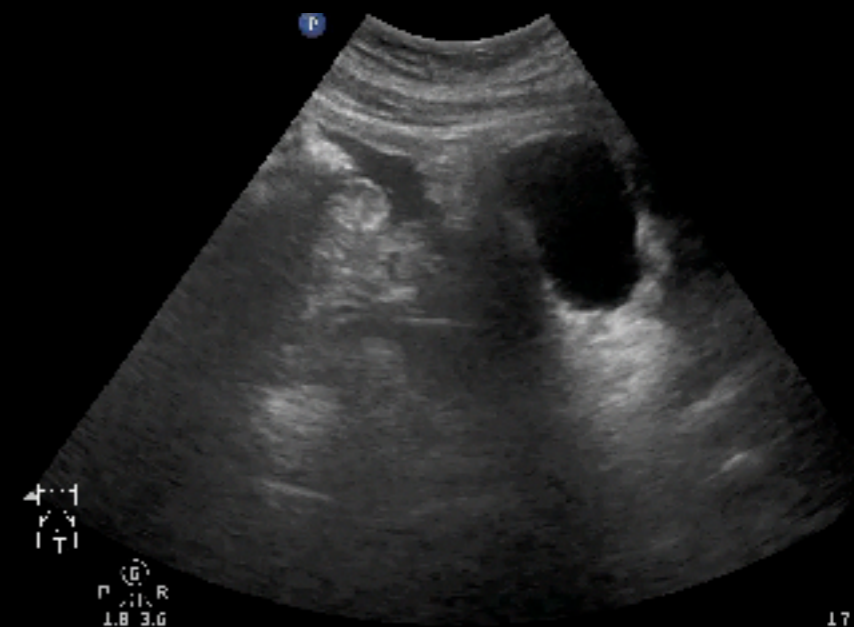
Around liver



Paracolic gutter



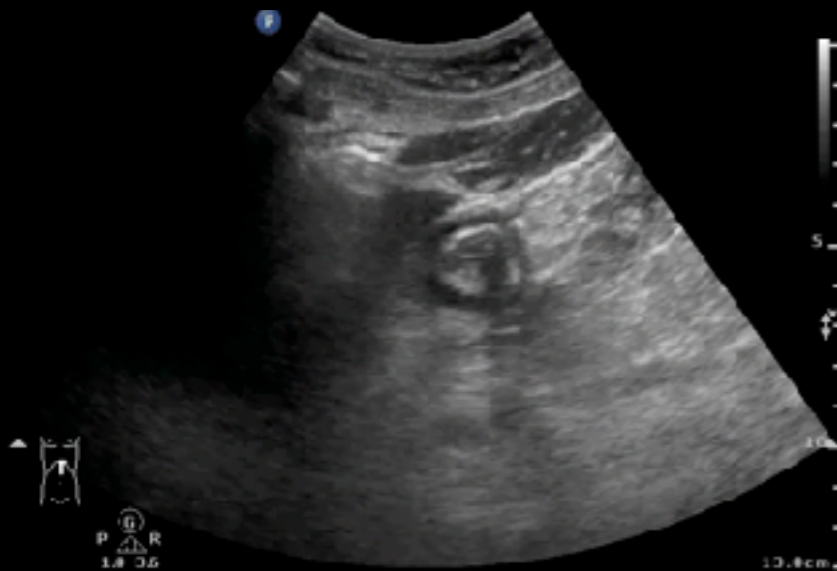Pelvis



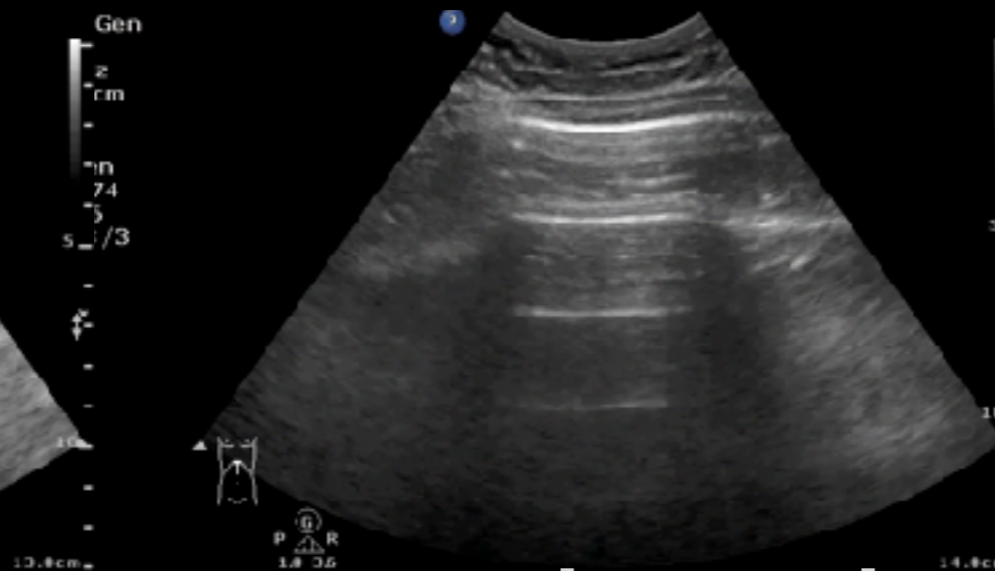
FAST倒三角是最基本的

Free air: 往上找

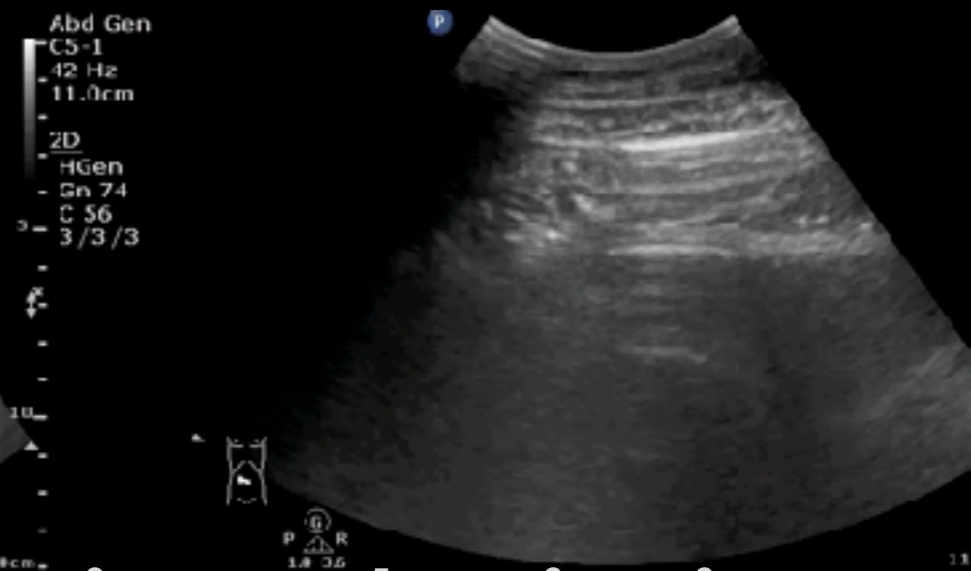
Liver surface



Curtain sign



EPSS

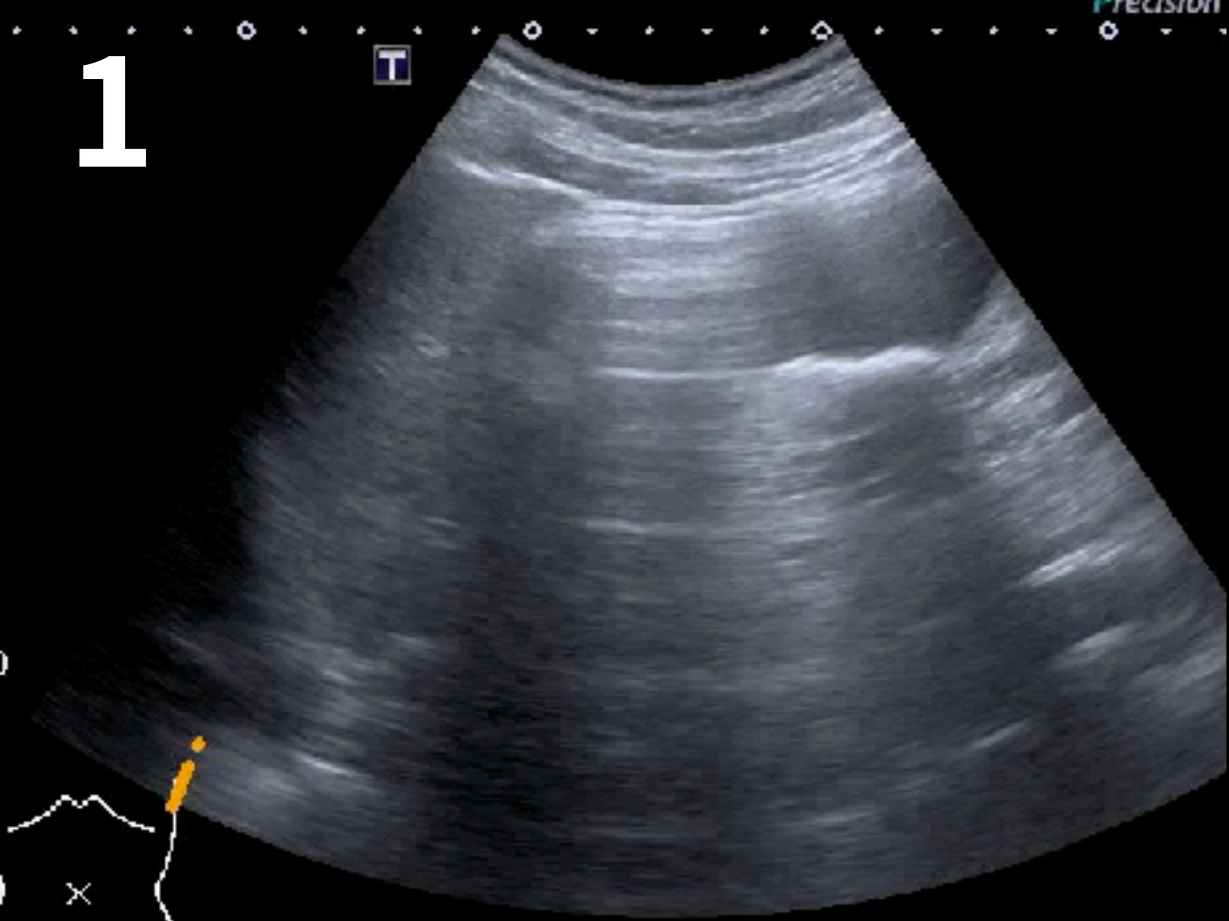


EPSS: Enhanced peritoneal strip sign

游離氣存在界面變亮
跟肺部的氣胸一個樣
不要忘了可以壓一壓

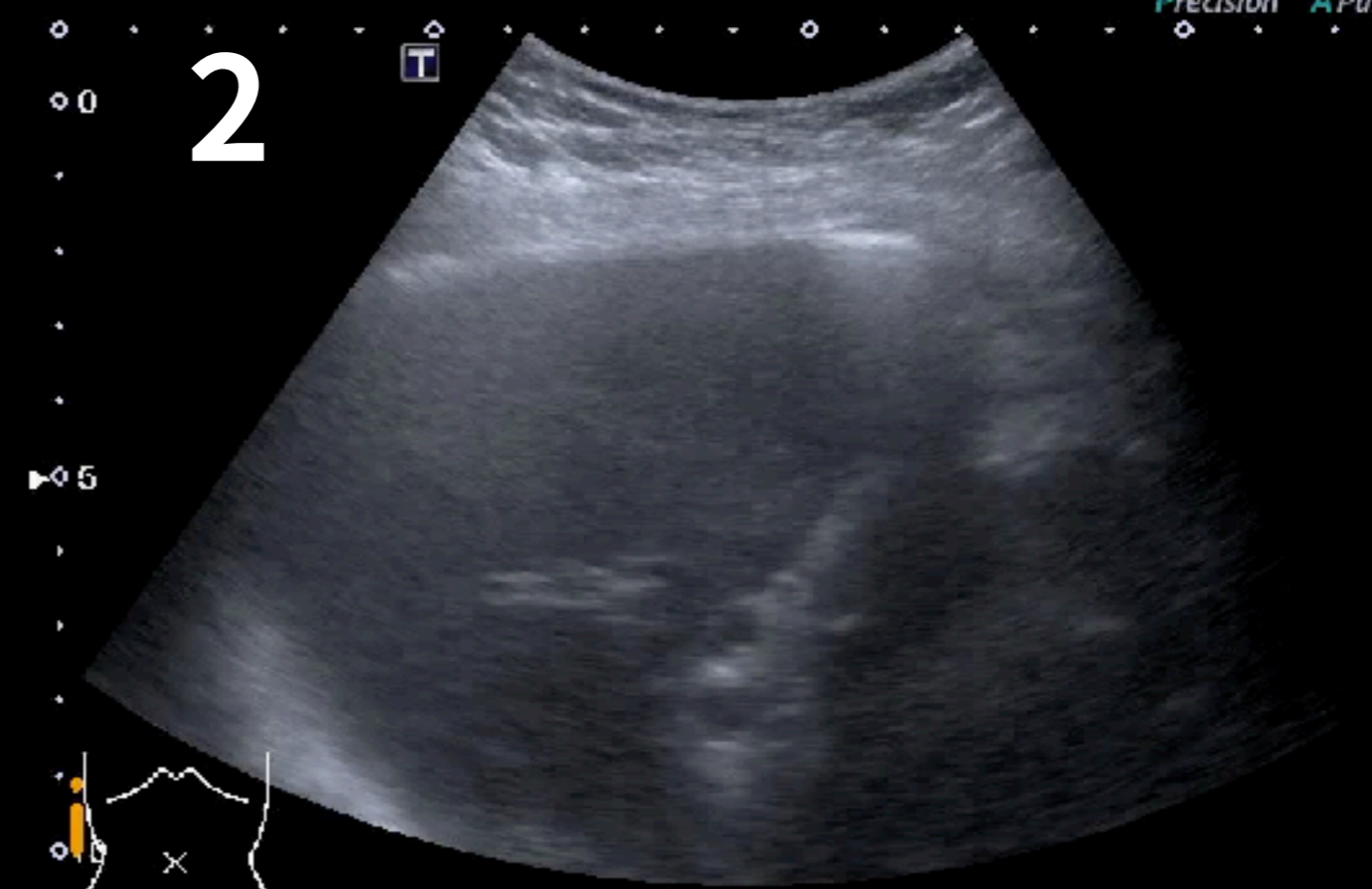
1

T



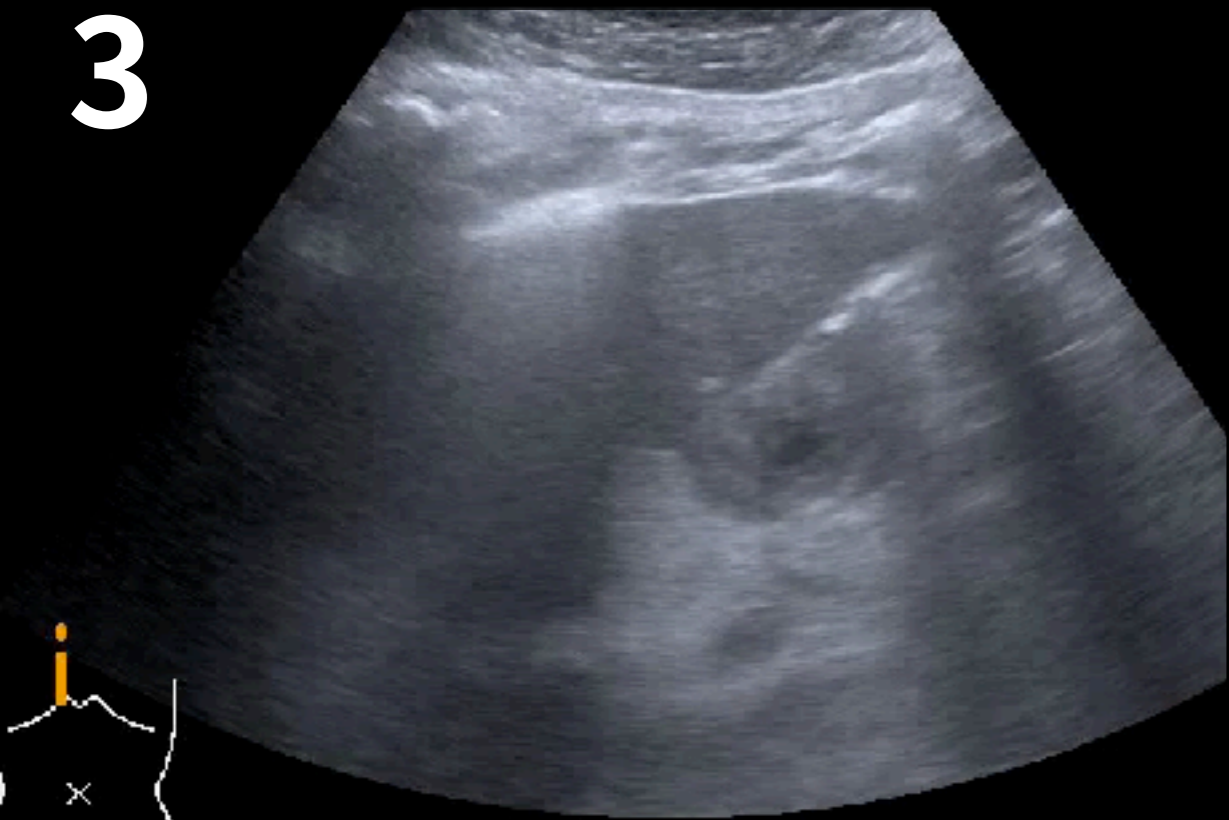
2

T

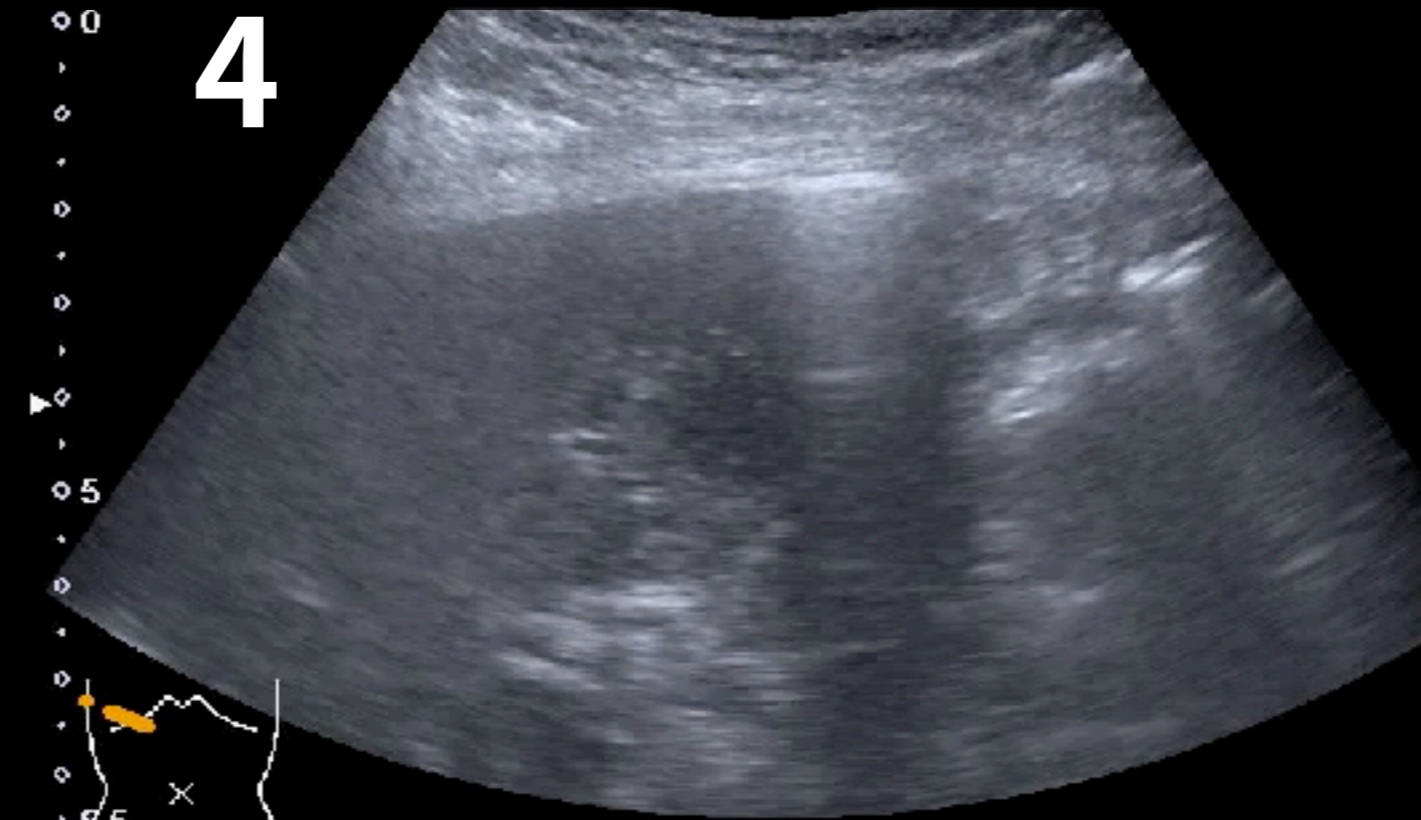


請問那一段影片不是Pneumoperitoneum？

3



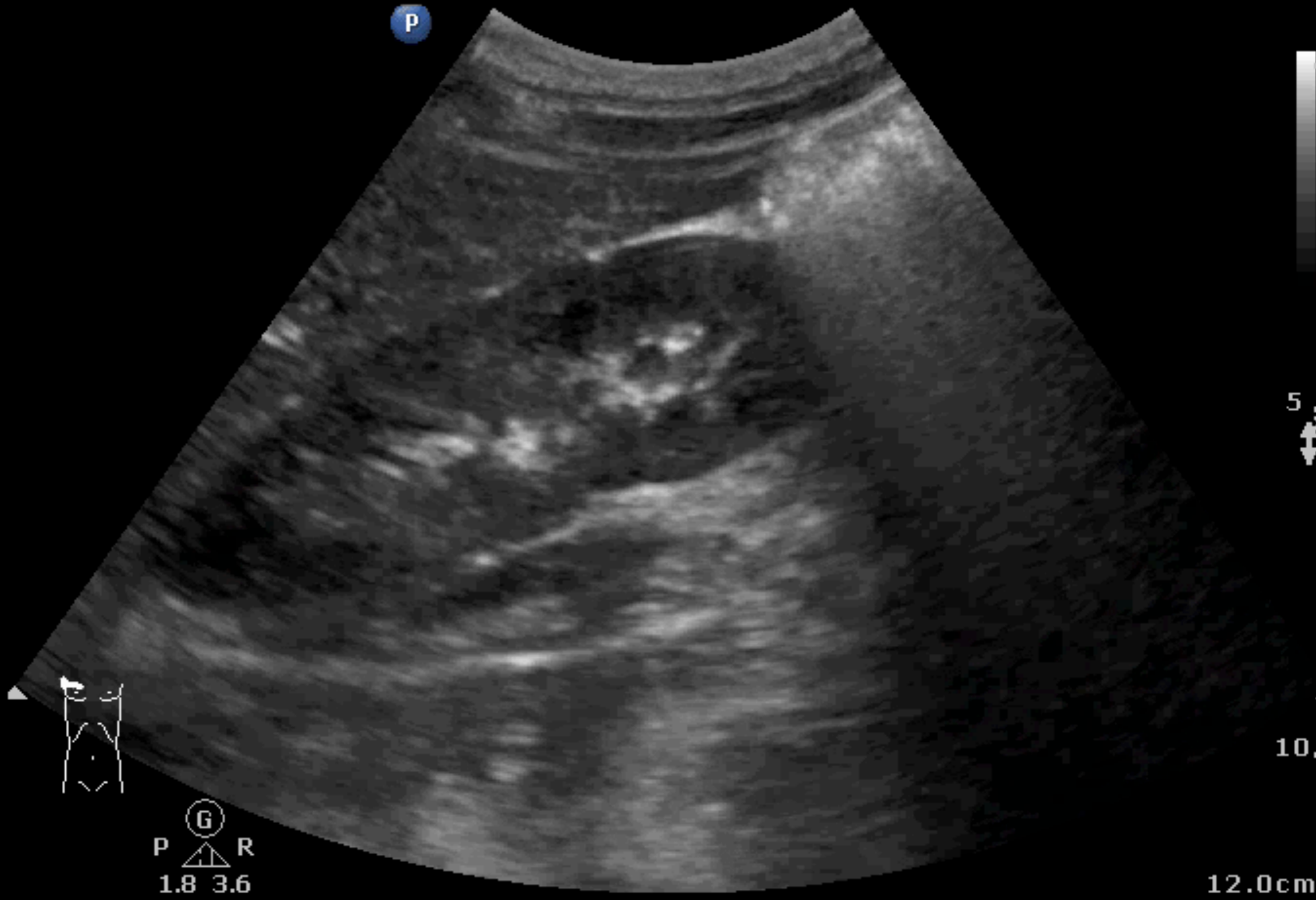
4



33F, low abdominal pain & shock

Abd Gen
C5-1
39 Hz
12.0cm

2D
HGen
Gn 71
C 56
3/3/3



G
P R
1.8 3.6

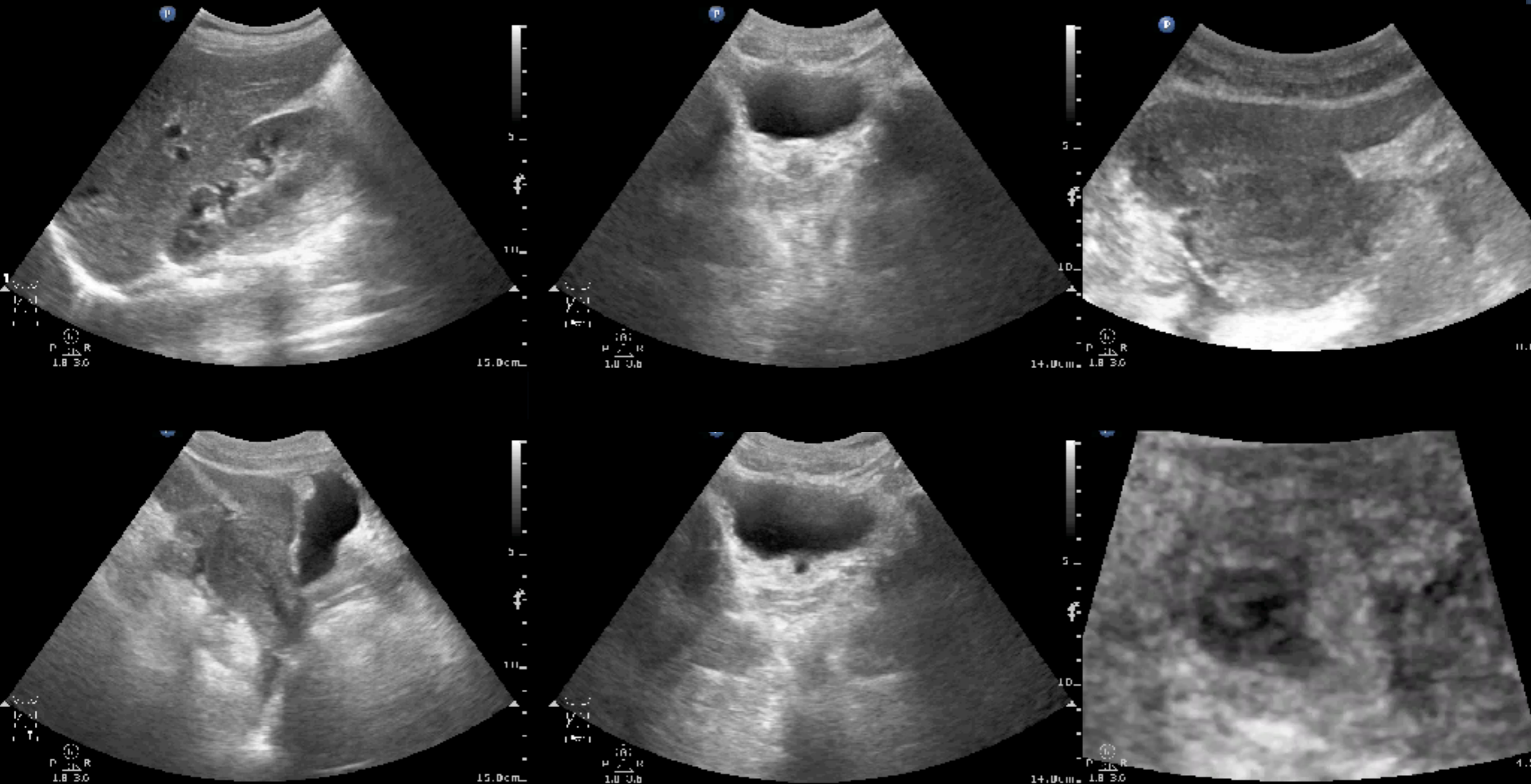
12.0cm

ABDOMEN

E for ectopic pregnancy

Ascites & IUUP

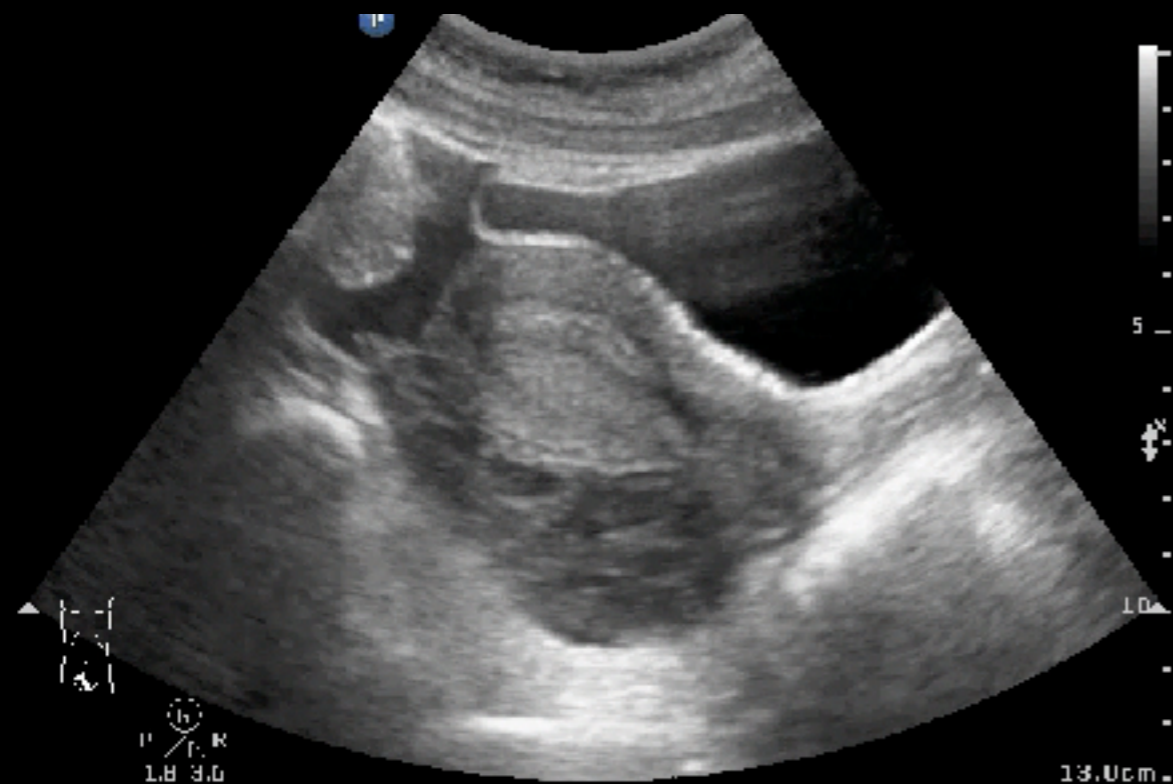
25F, abdominal pain



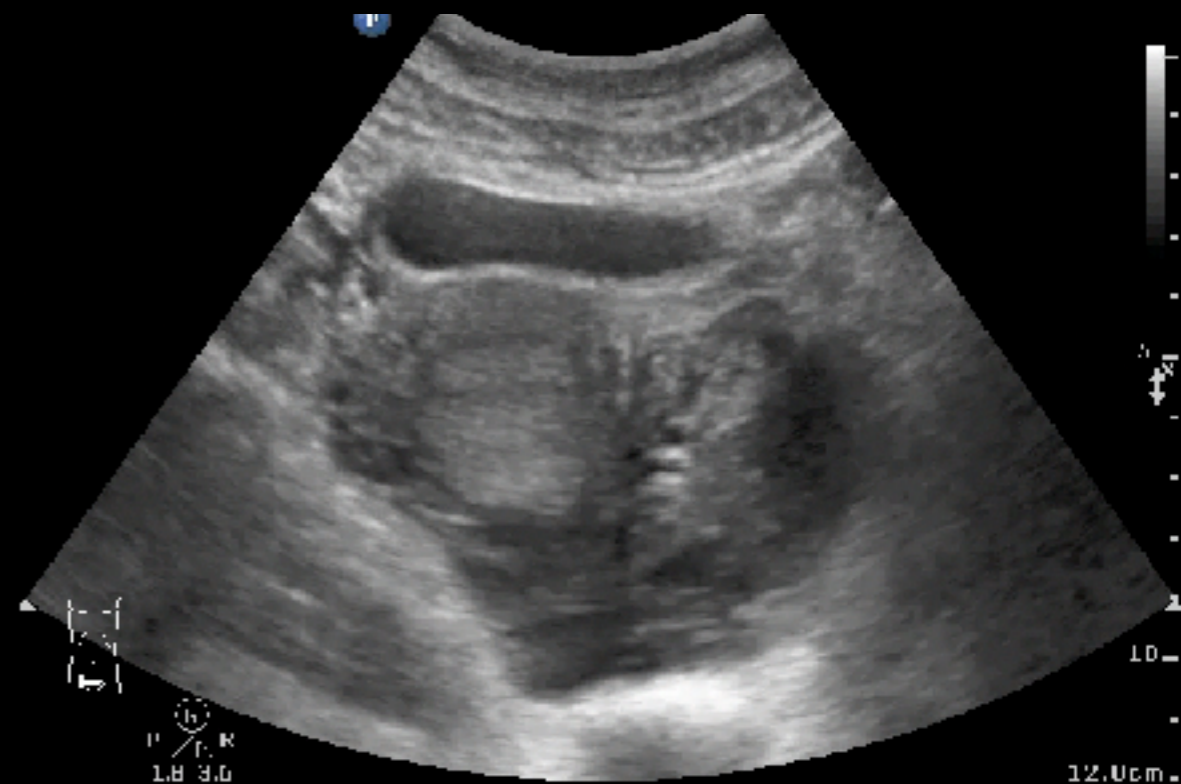
14F, acute lower abdominal pain with cold sweating

Female acute abdomen or shock consider **ovarian cyst rupture**

Abd Gen
[15 1
38 Hz
13.0cm
2D
11Gen
[in 7/8
[1 56
3/3/3



Abd Gen
[15 1
39 Hz
12.0cm
2D
11Gen
[in 7/8
[1 56
3/3/3



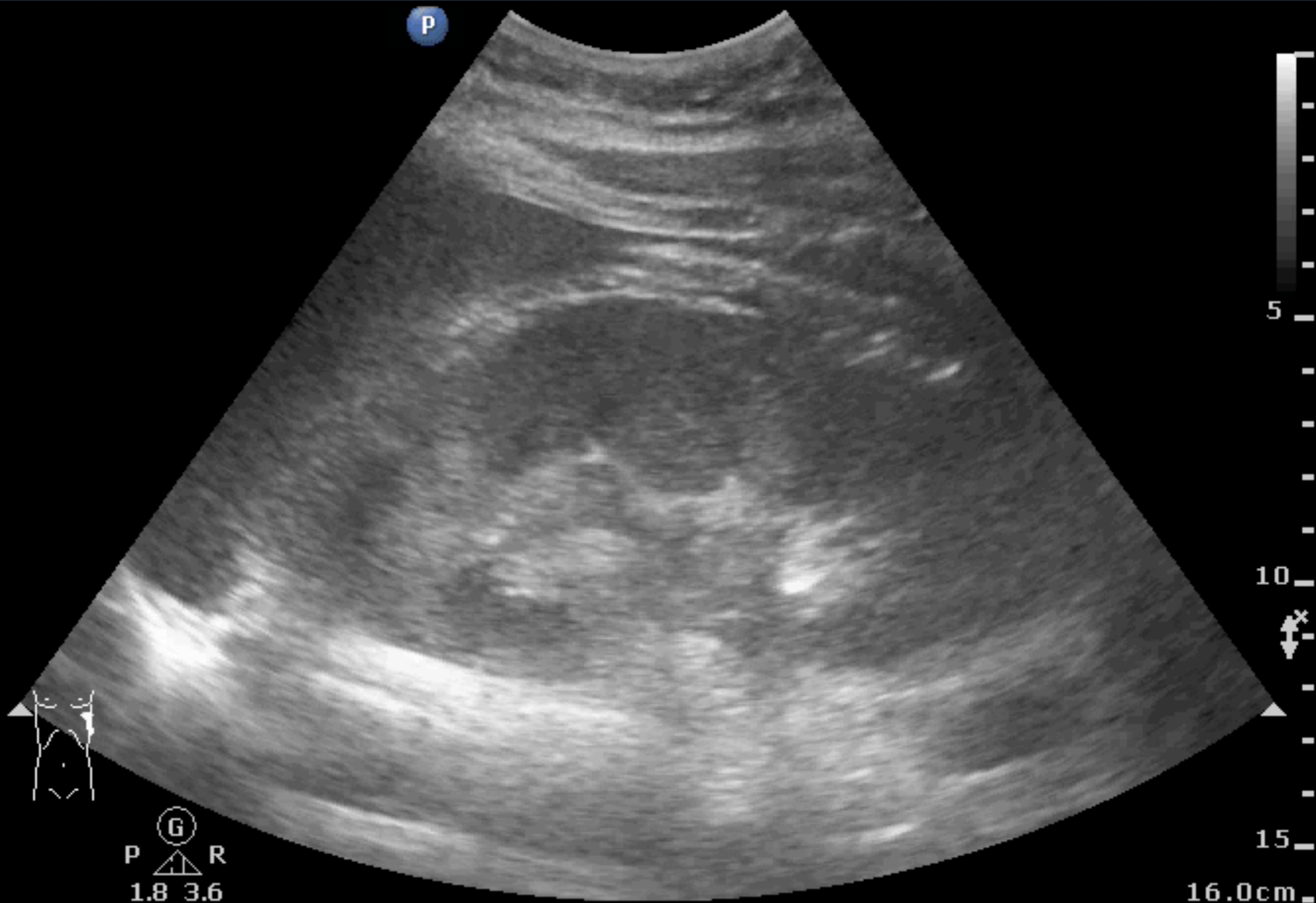
Echo first then Urine pregnancy test

25M, left flank pain

Abd Gen2
C5-1
32 Hz
16.0cm

2D

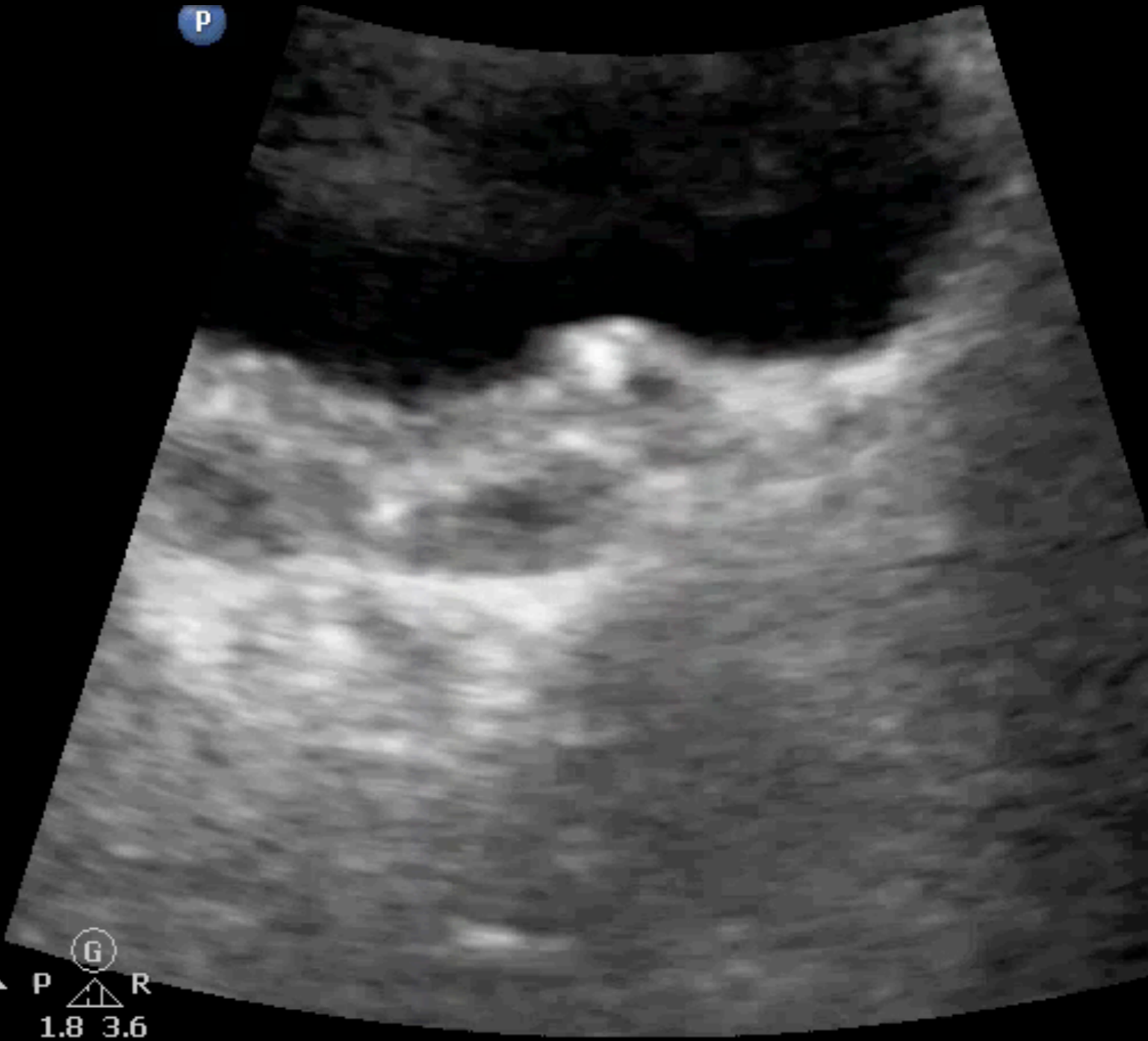
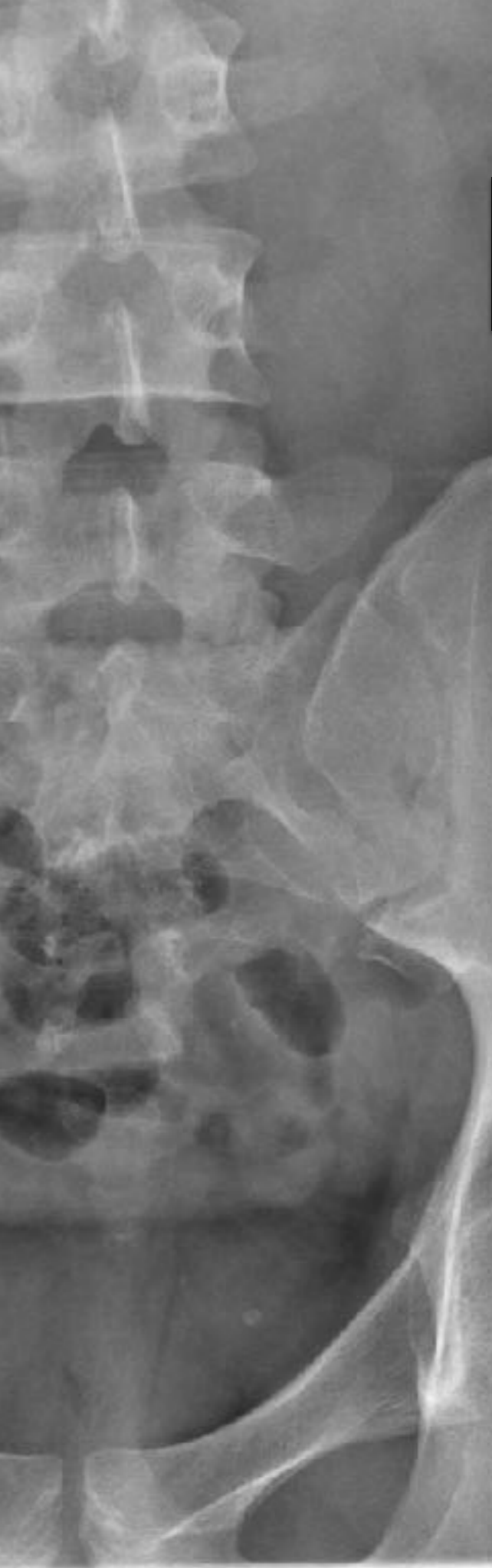
HGen
Gn 93
C 56
3/3/3



L UJV stone

Abd Gen2
C5-1
73 Hz
HD Zoom

2D
HGen
Gn 58
C 56
3 / 3 / 3

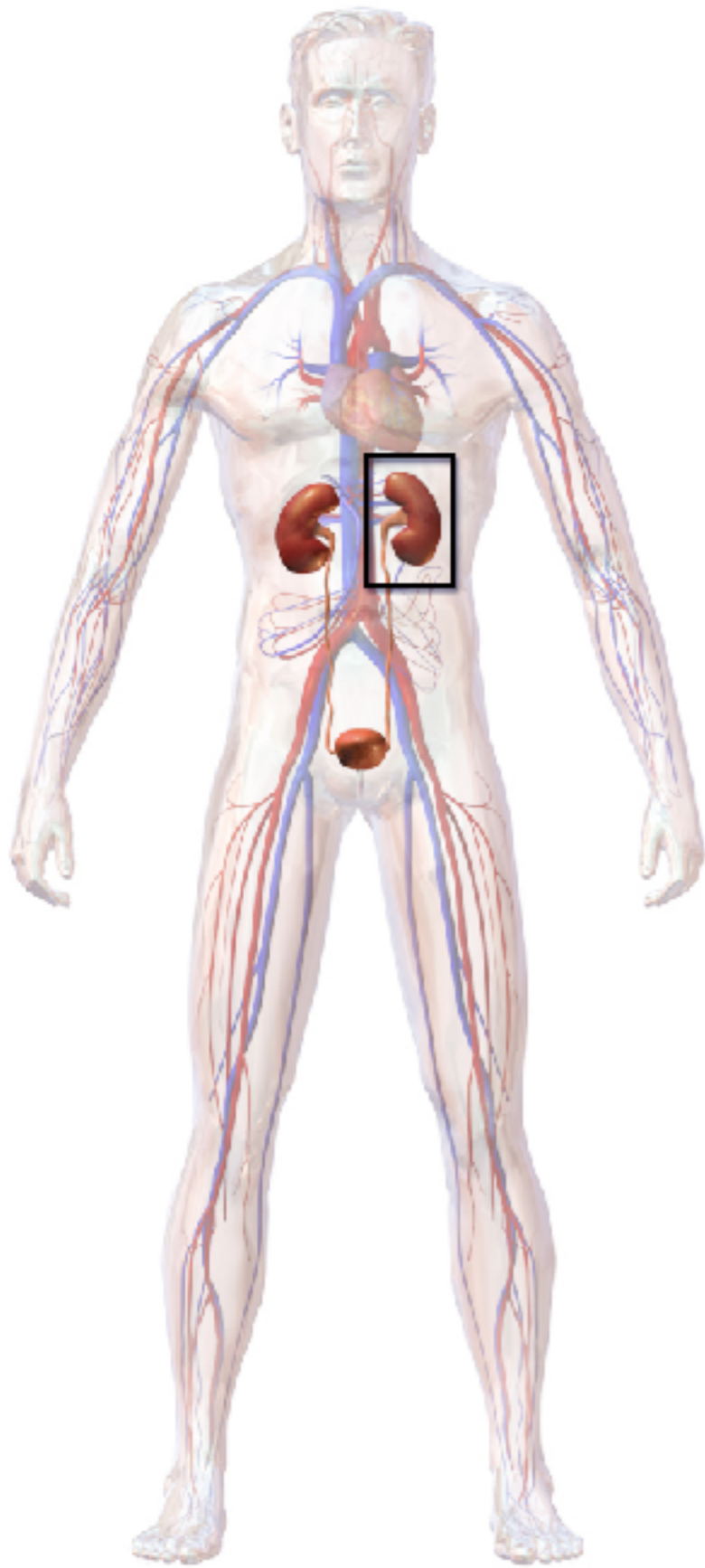


▲ P R
1.8 3.6

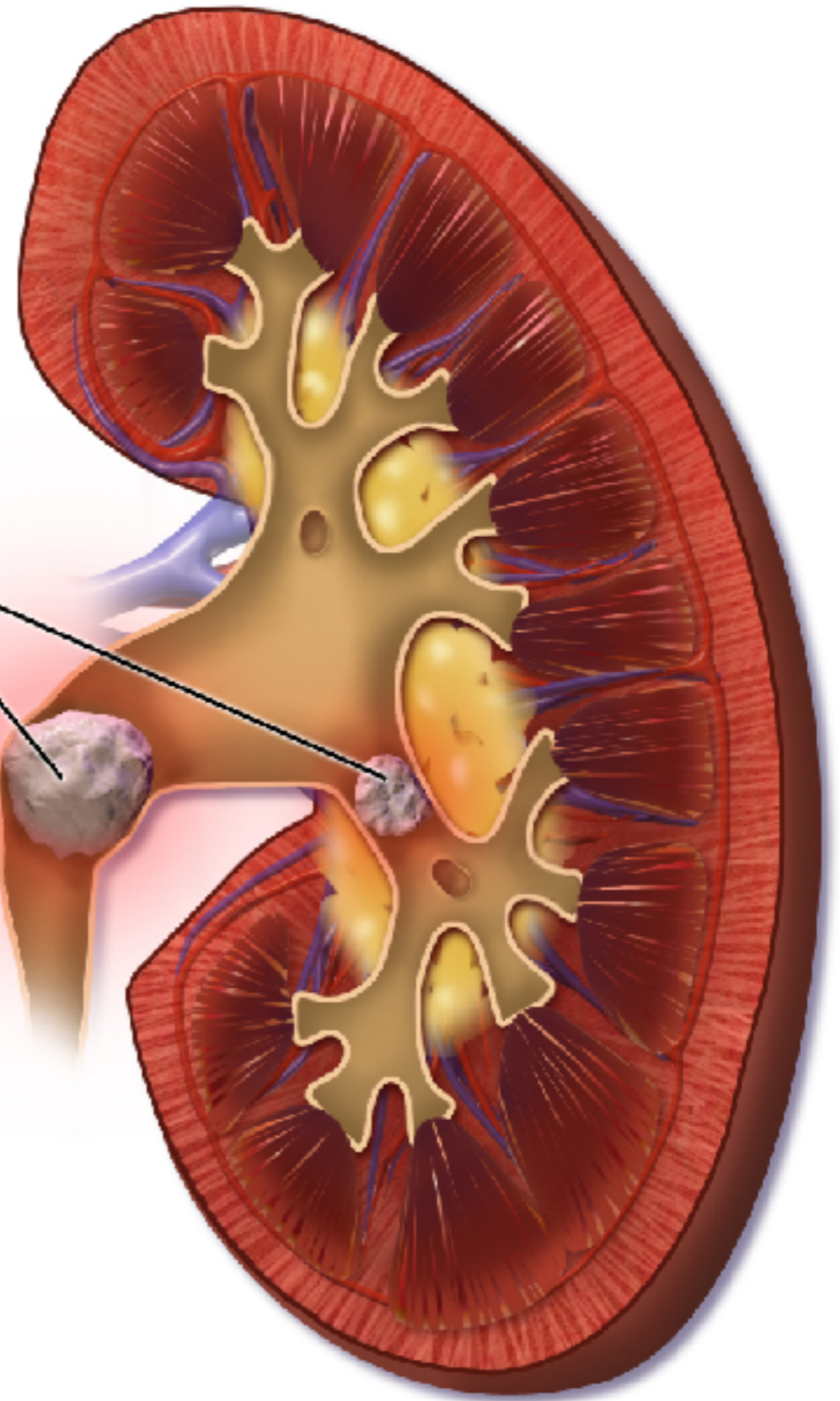
ABDOMEN

N for nephropathy

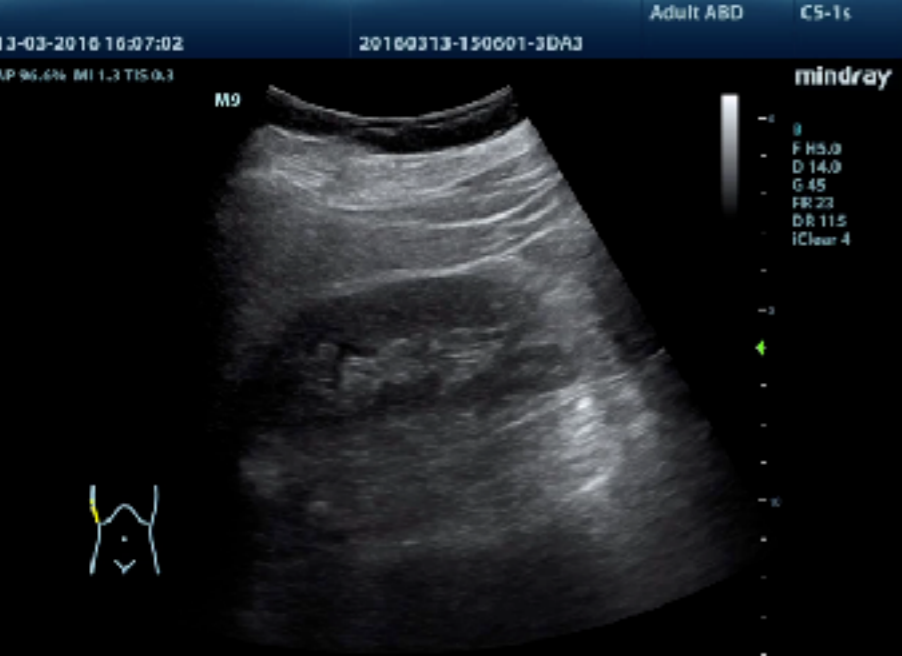Hydronephrosis & KuB



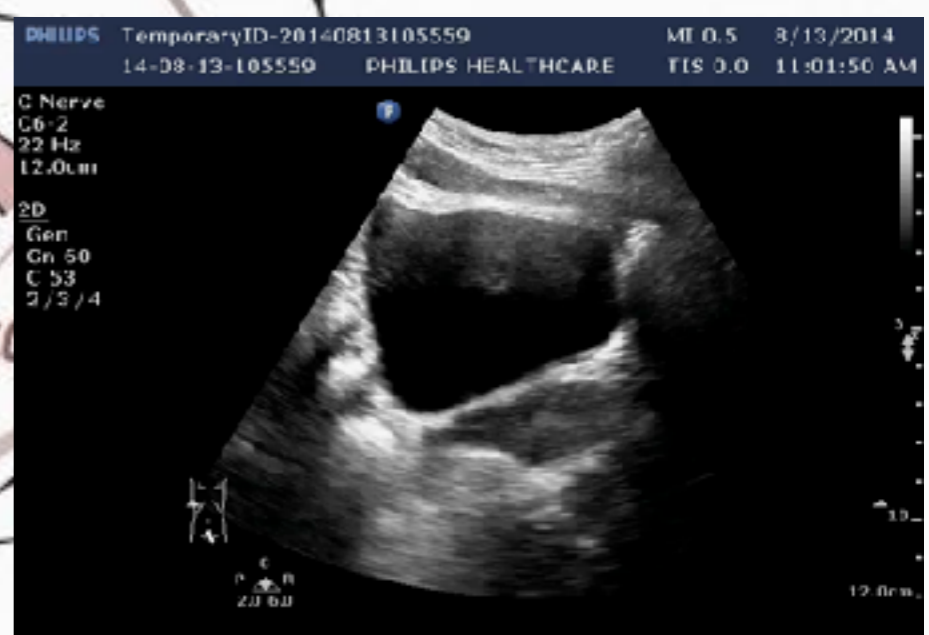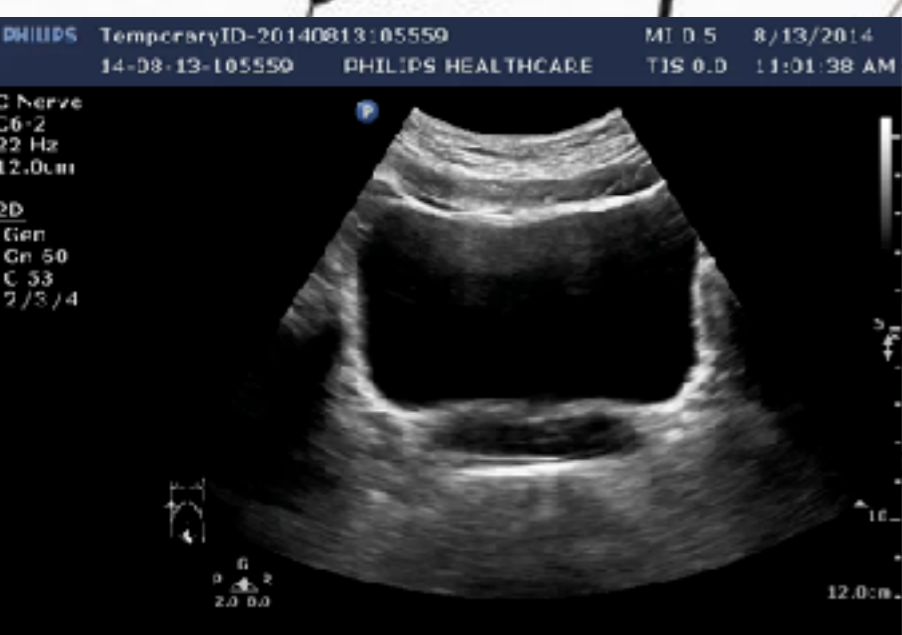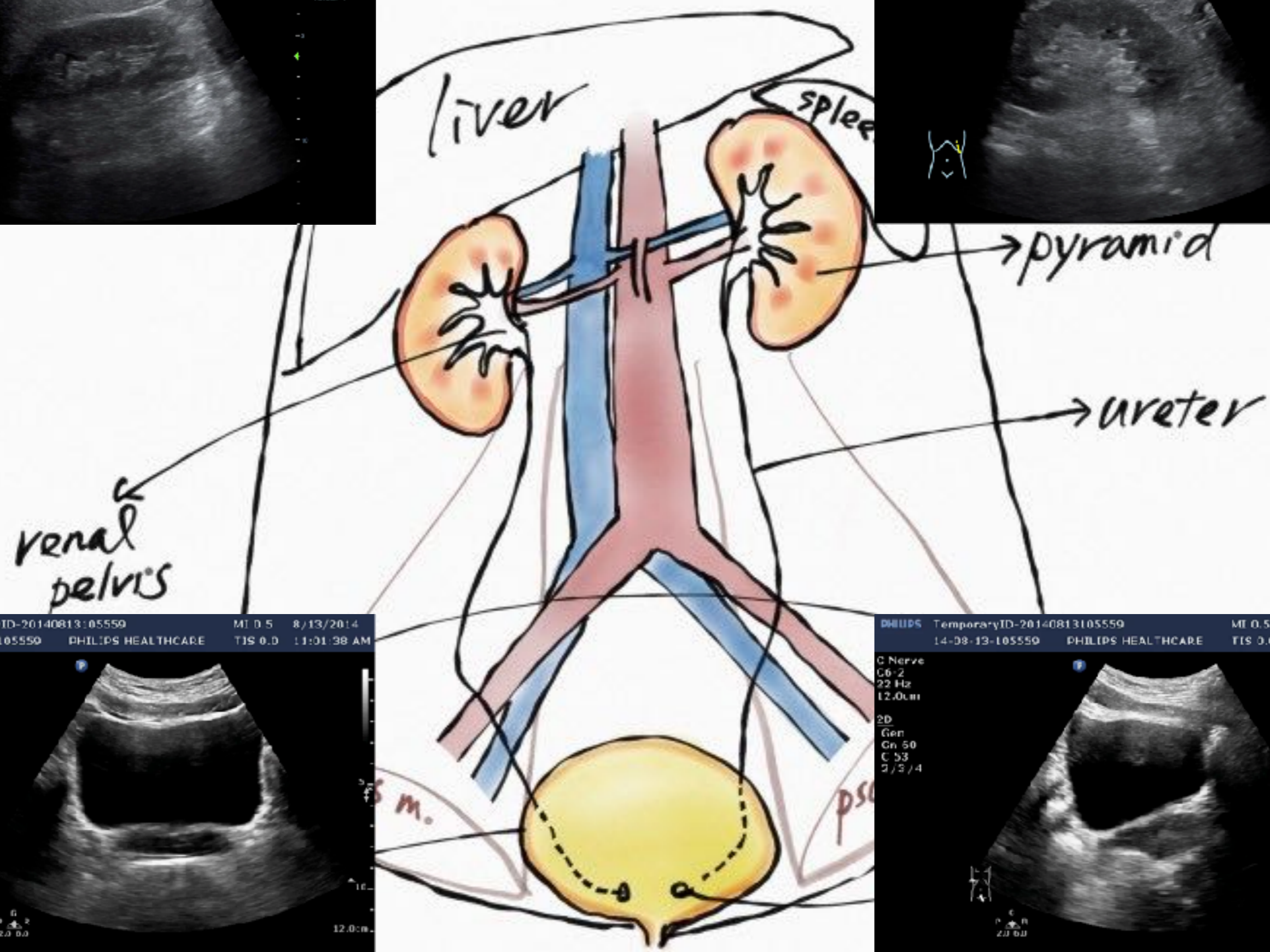
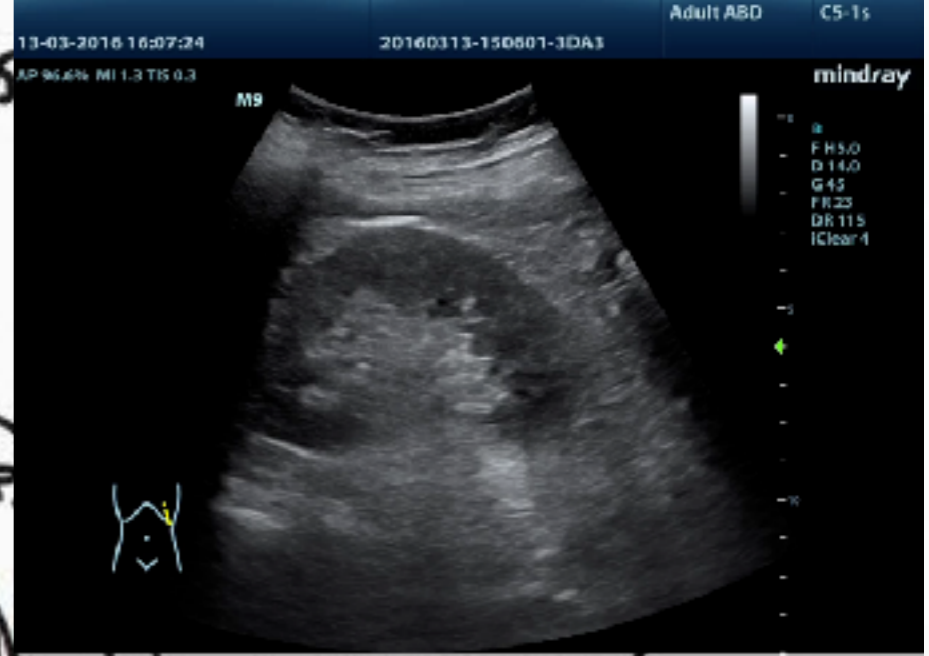Kidney stones



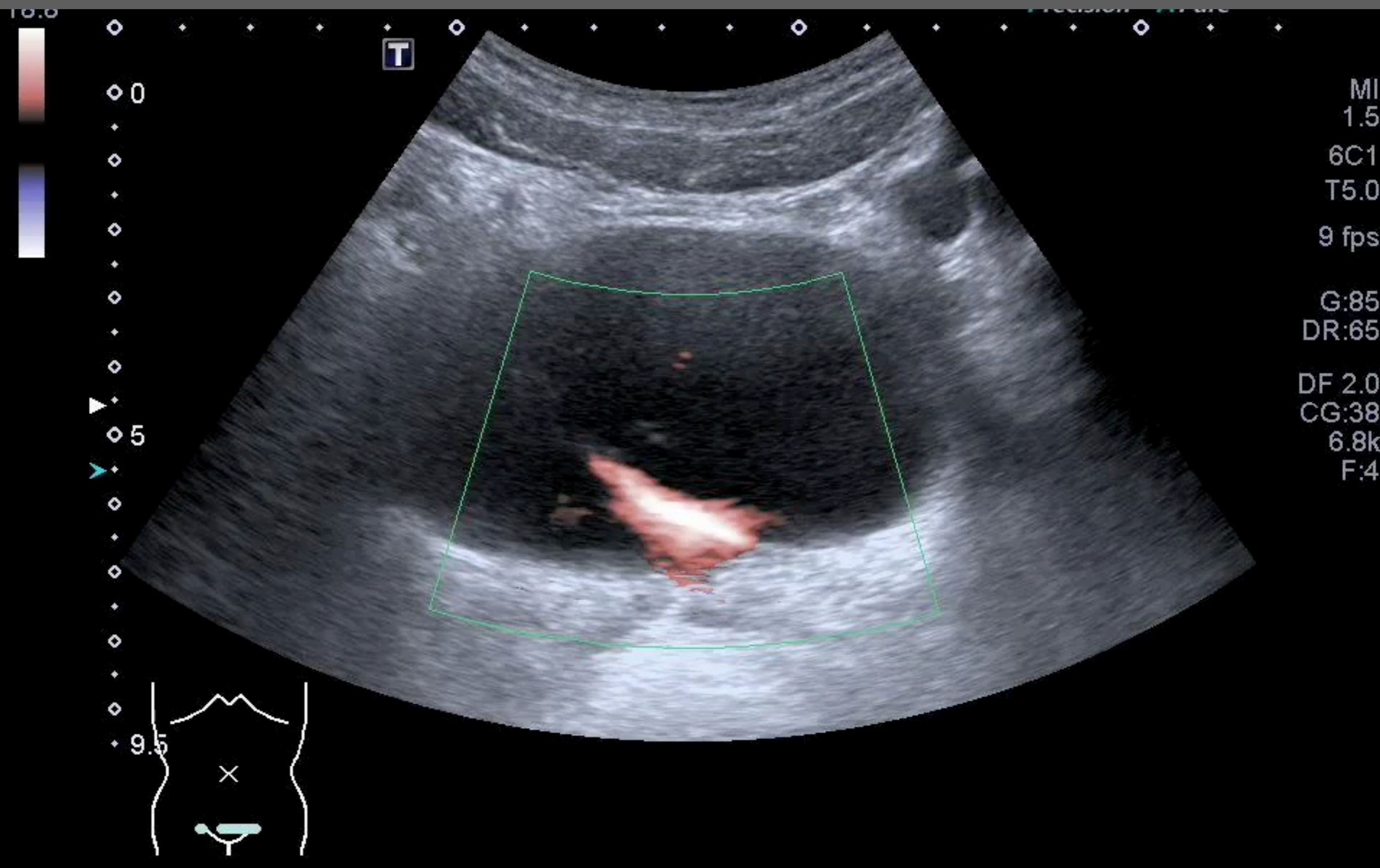
Kidney Stones



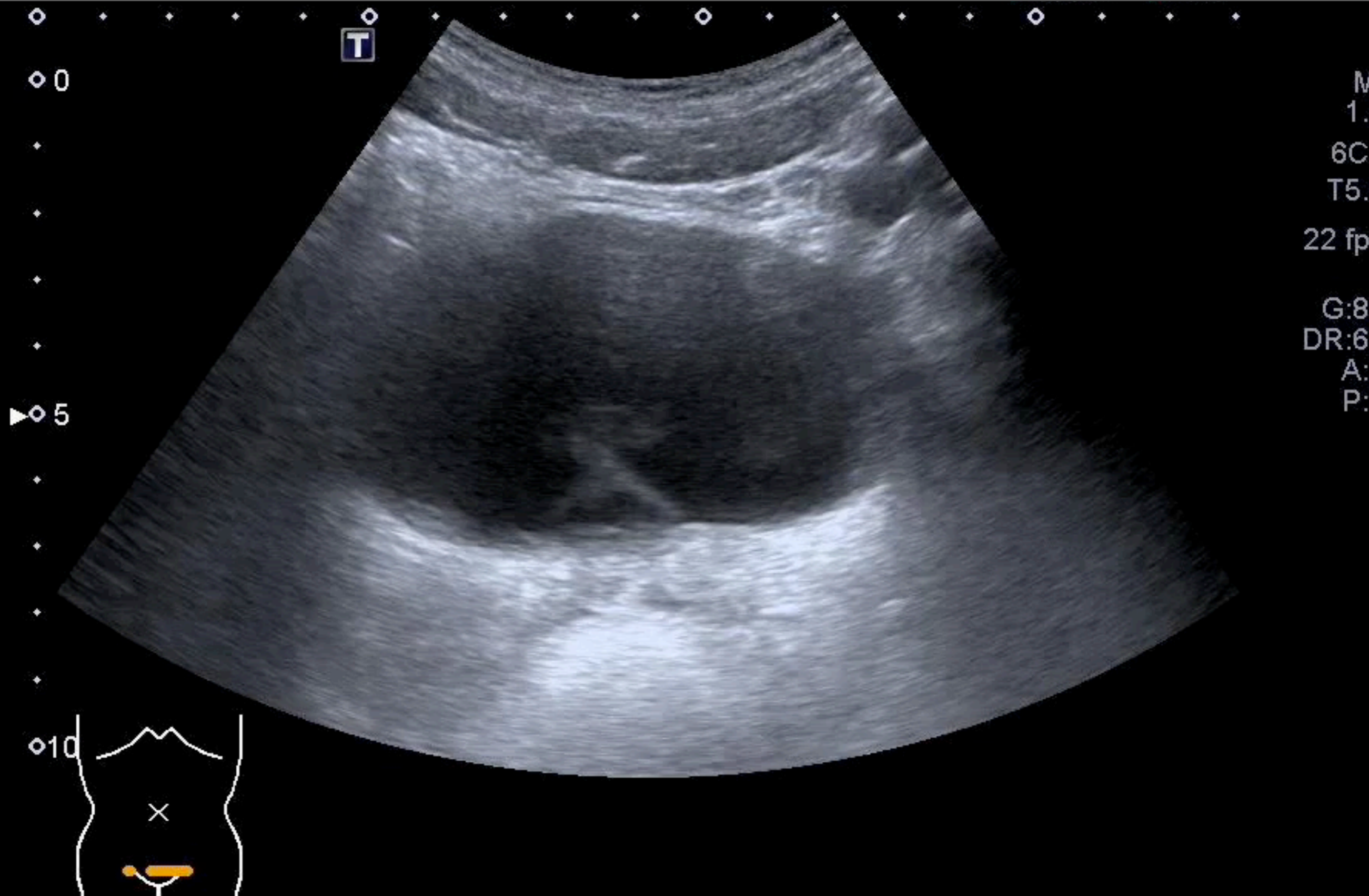
SOULZ CHAN GT. All rights res



Urinary jet



Urinary jet

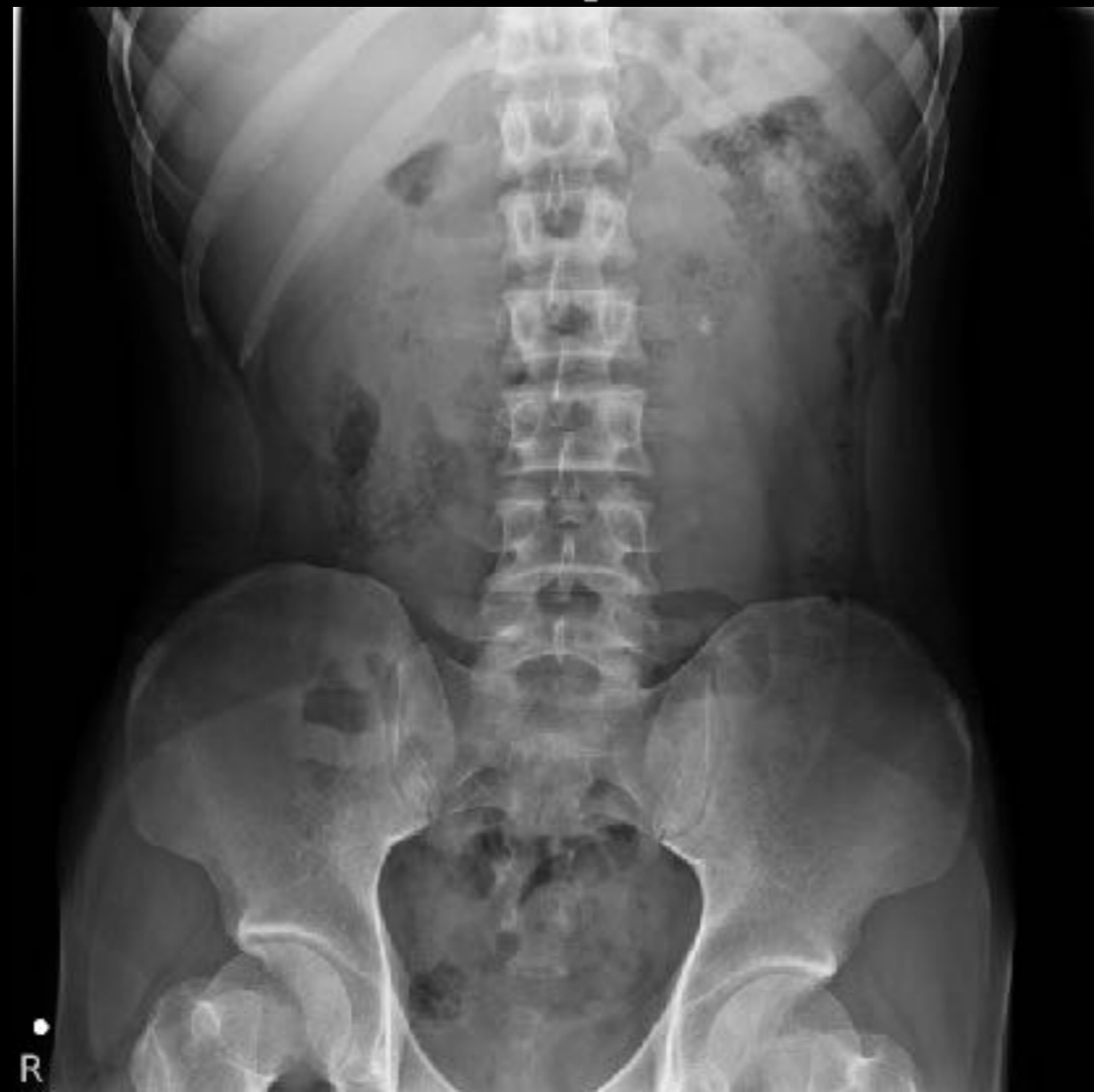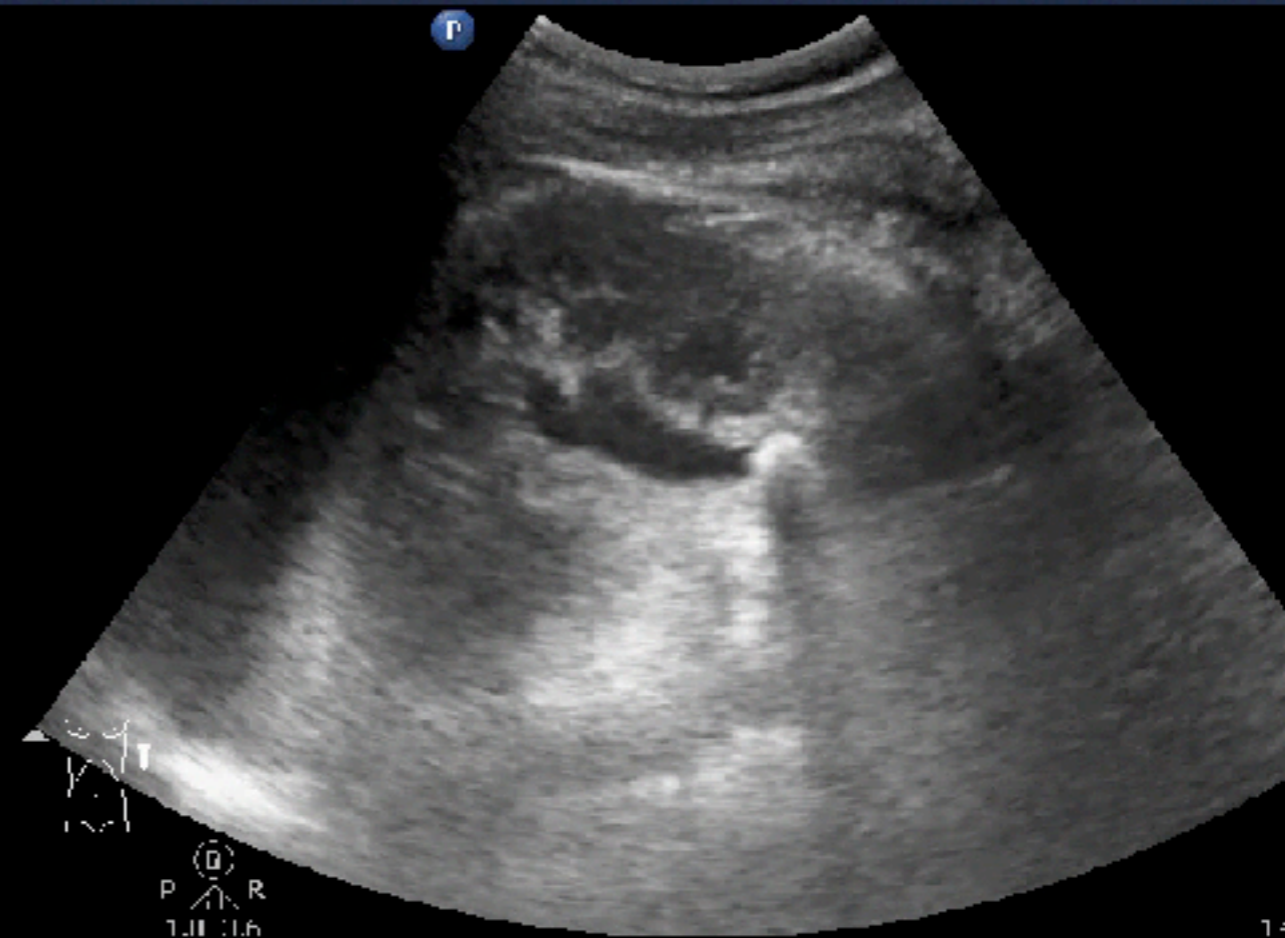
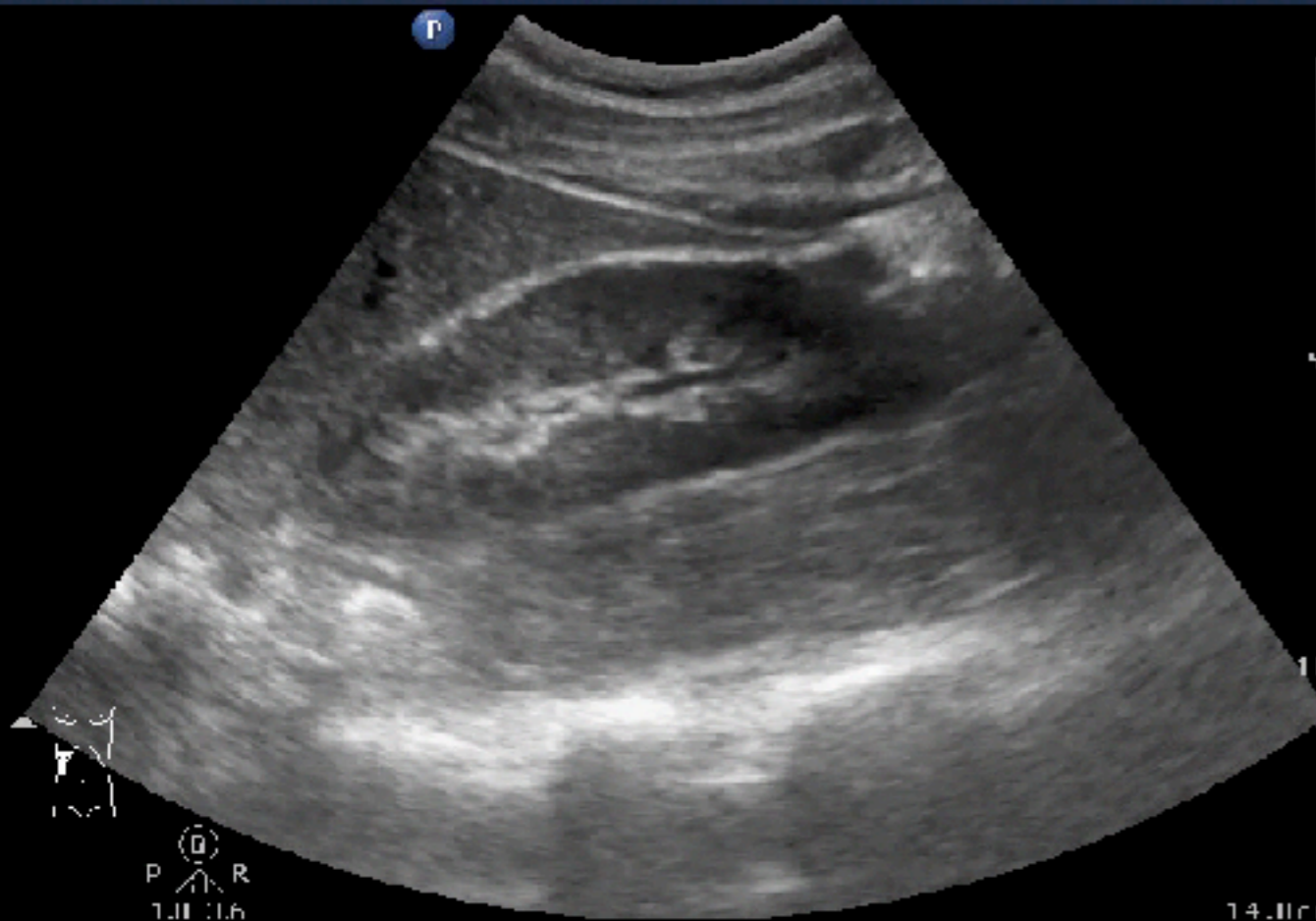


When will you use US for GU emergency?

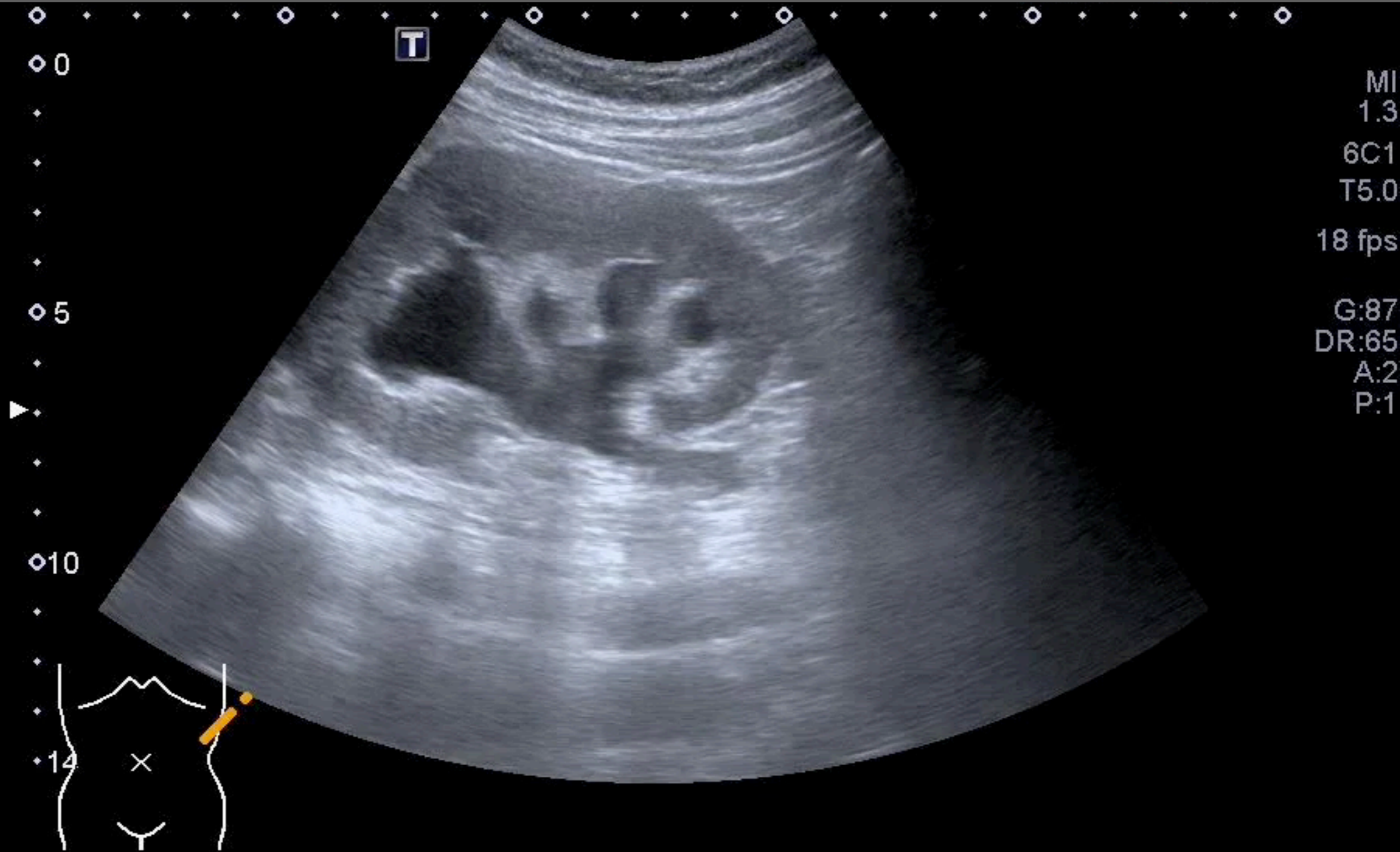Pain

Infection

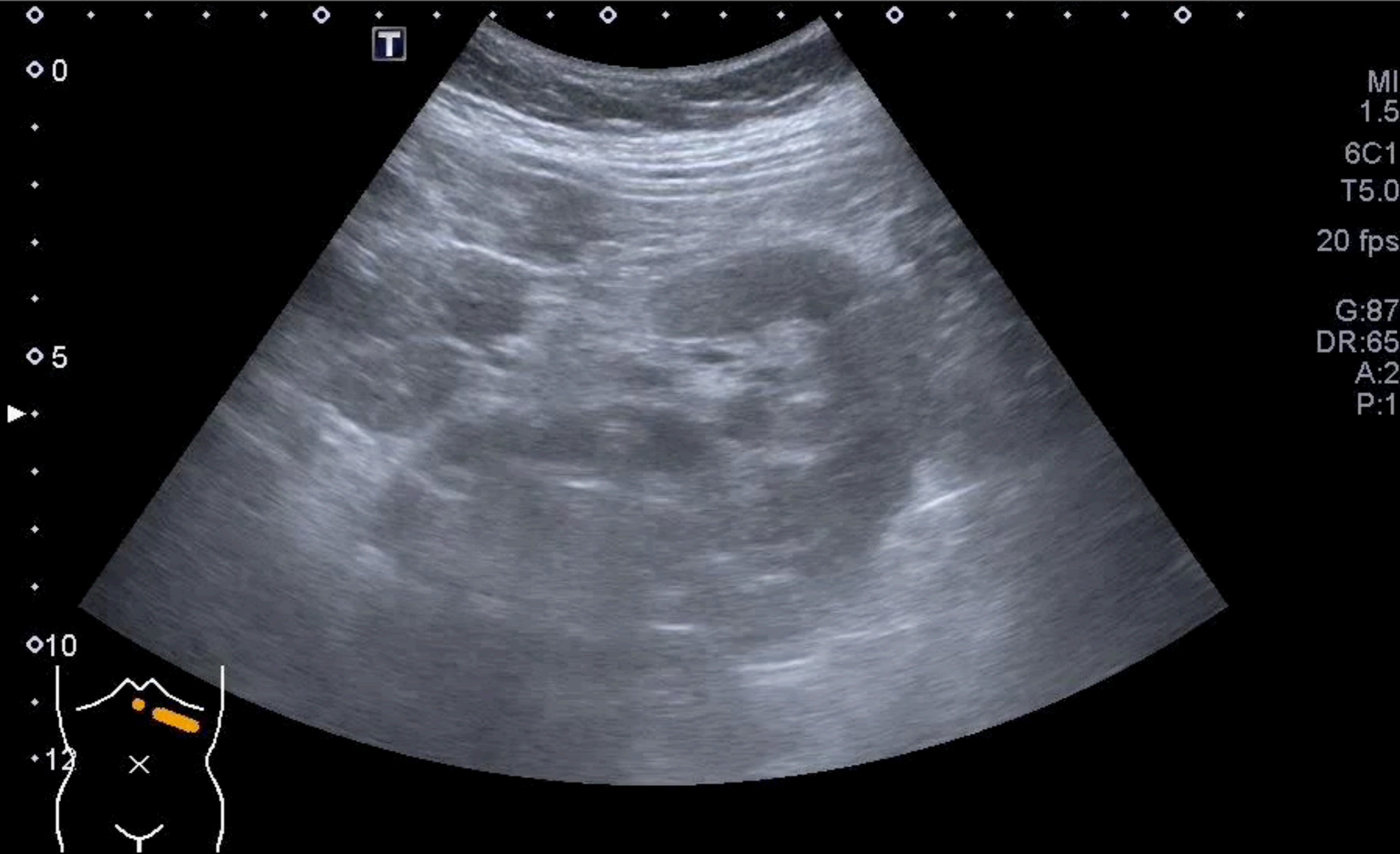
Failure



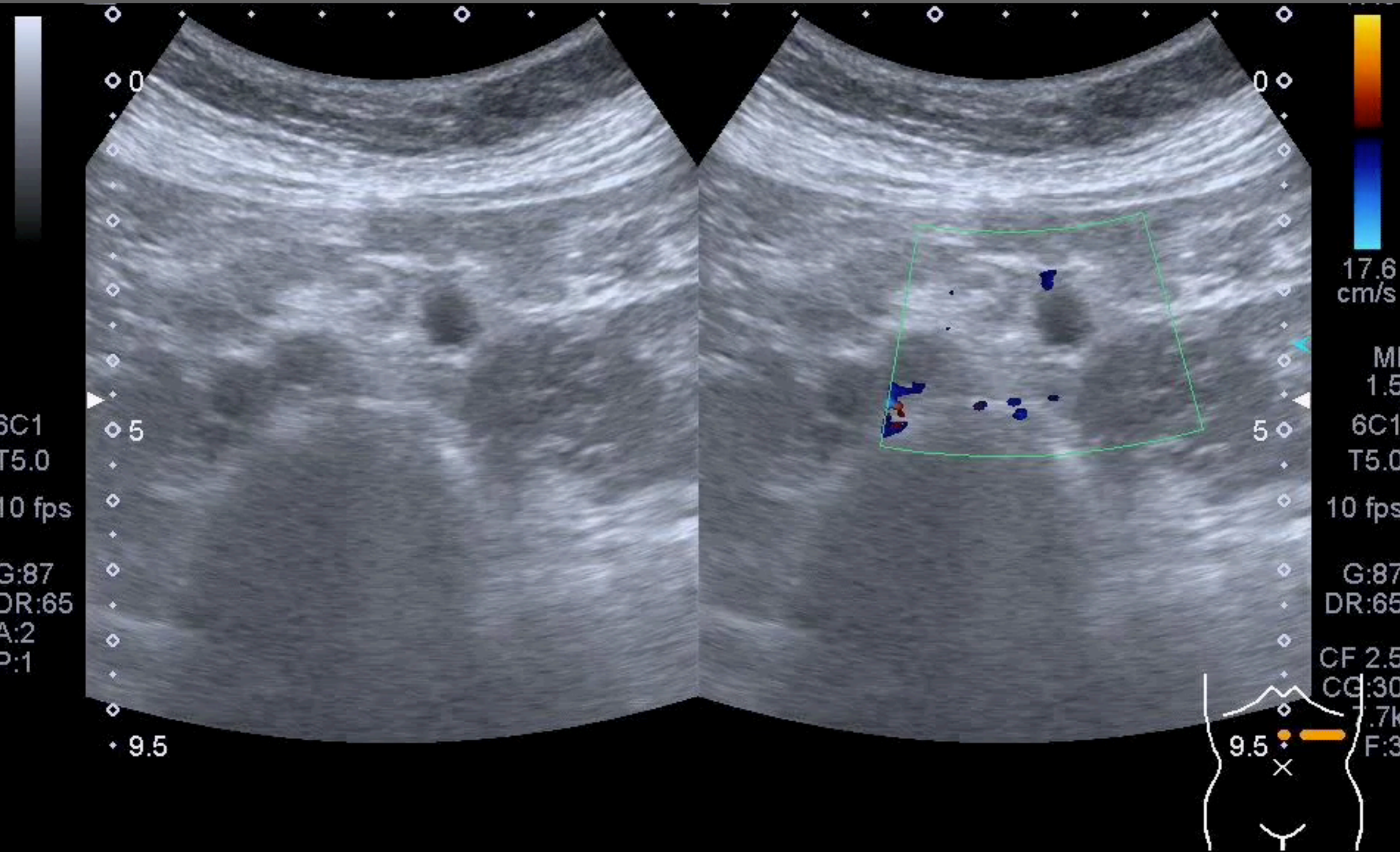
Hydronephrosis (Coronal)



Transverse (medial to colon)



Twinkling artifact



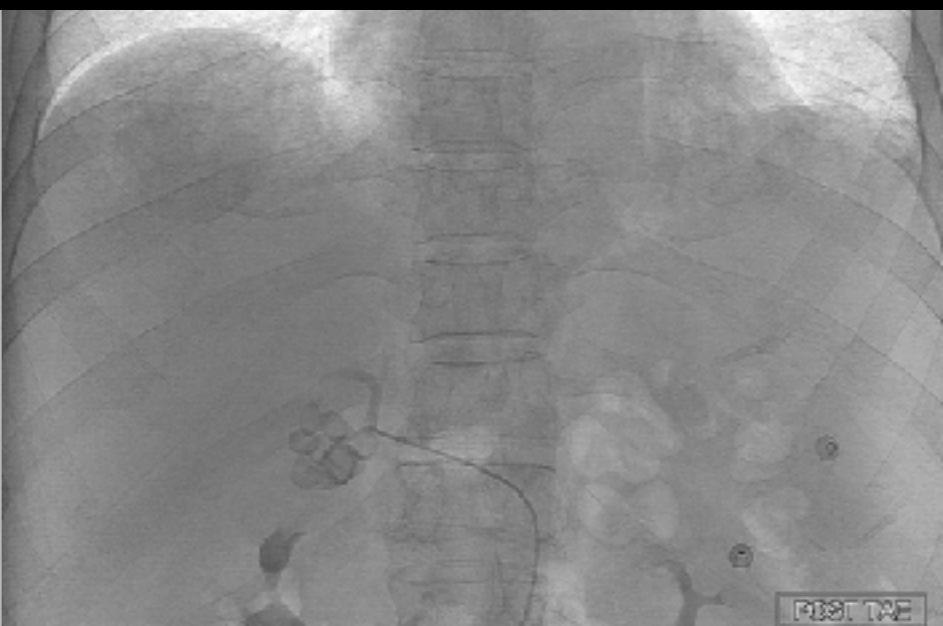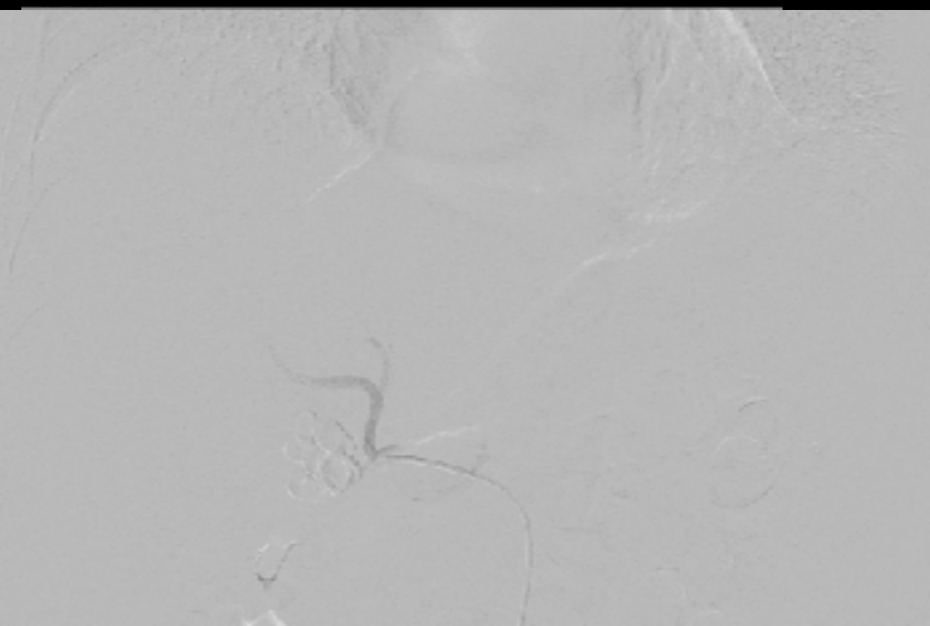
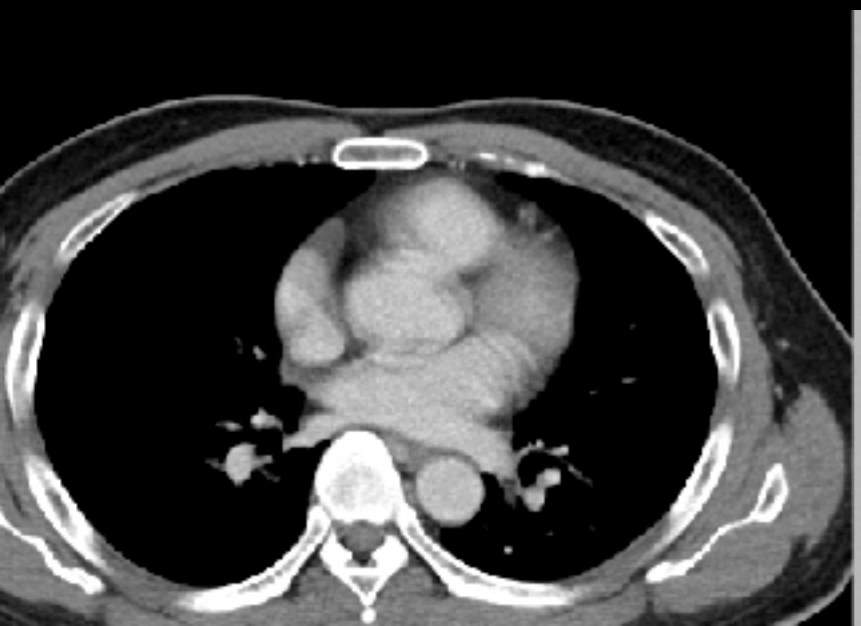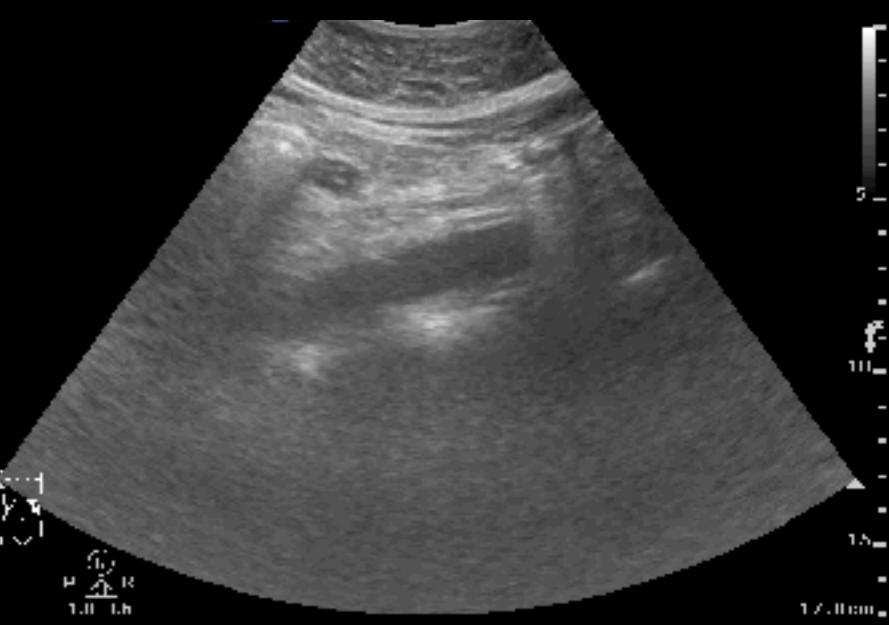
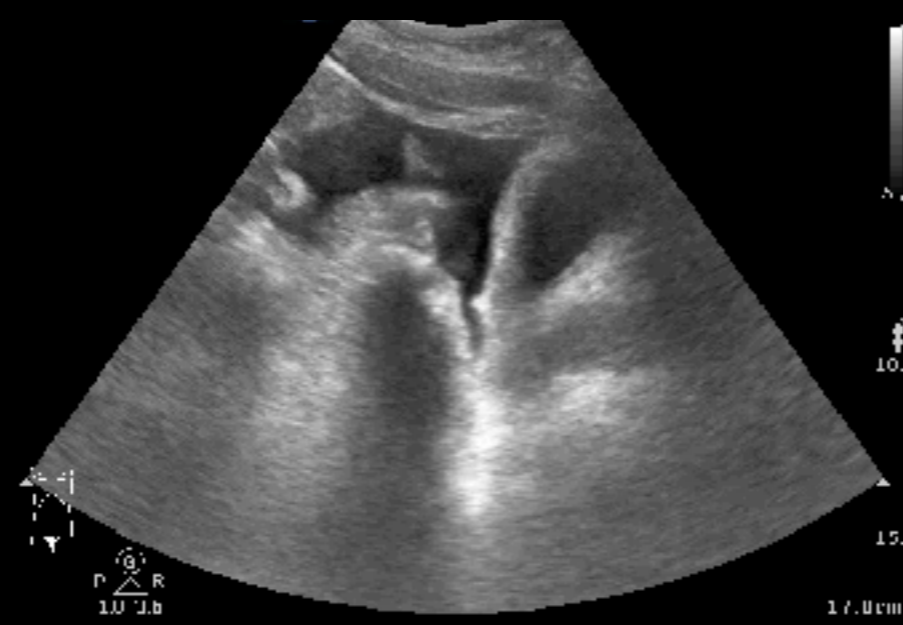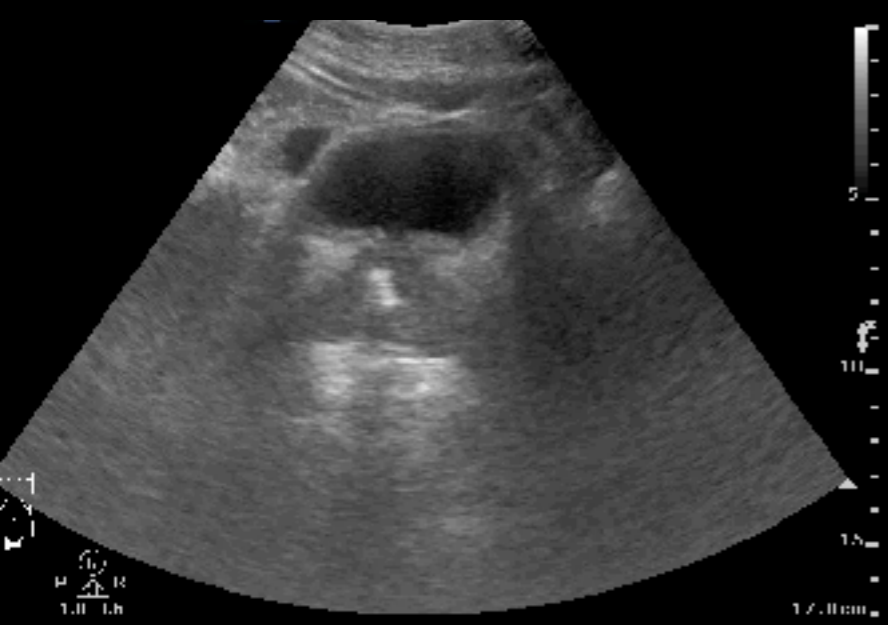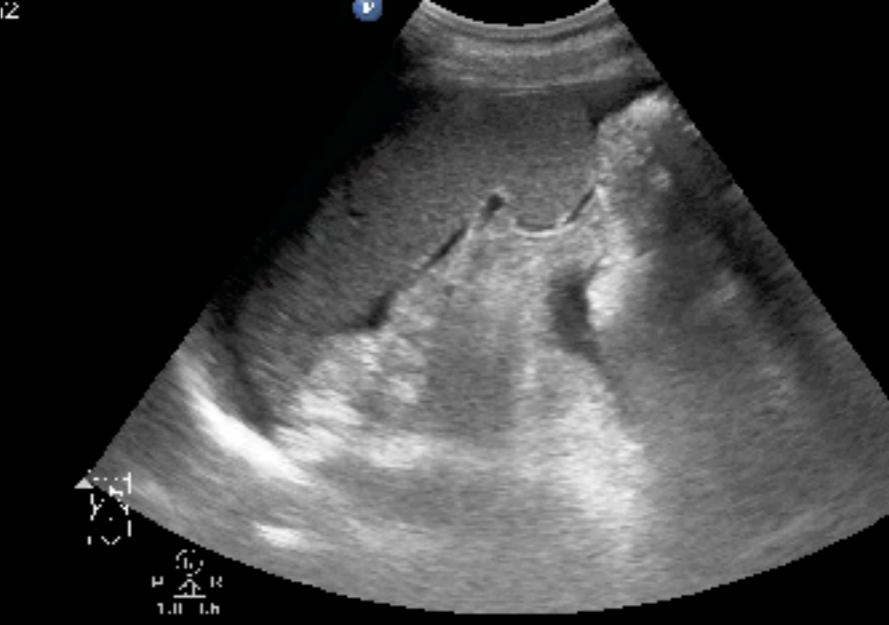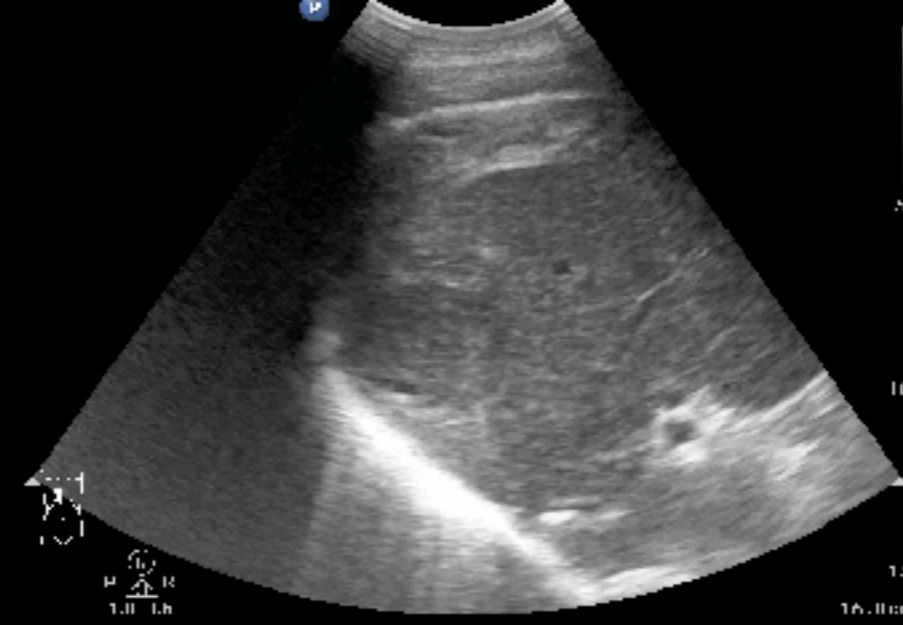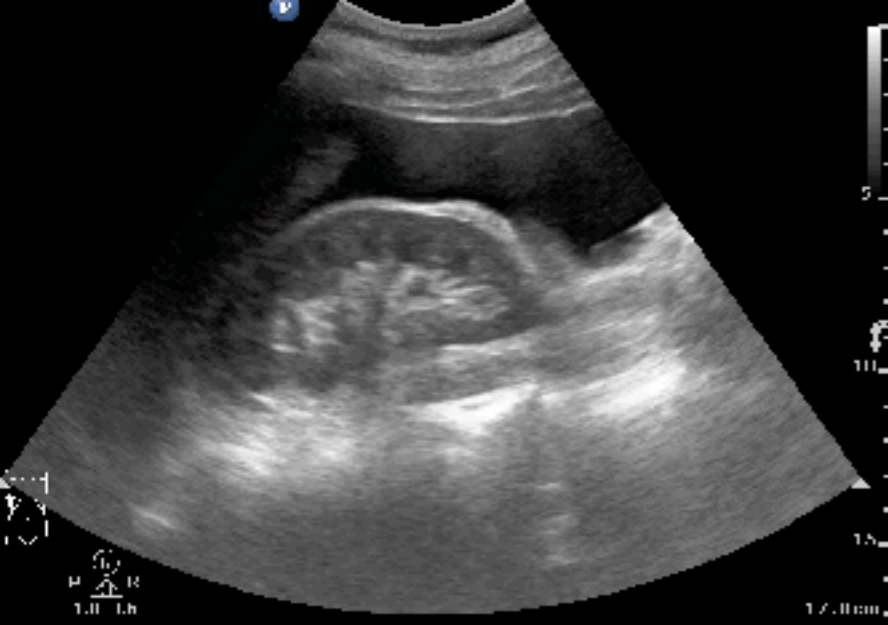52M, RUQ pain

Abd Gen2
C5-1
31 Hz
17.0cm

2D

HGen
Gn 86
C 56
3/3/3



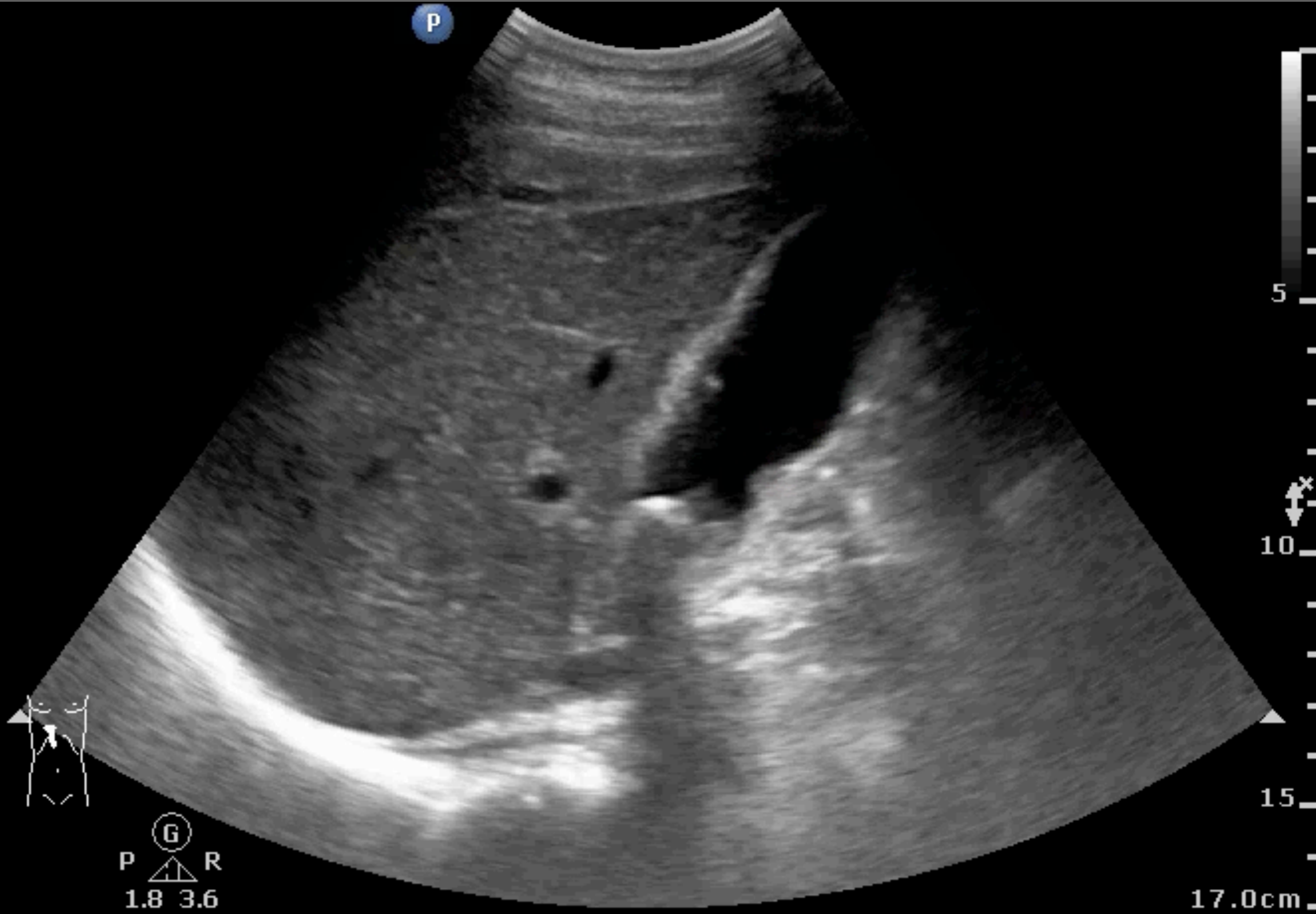

Premature closure

Abd Gen2
C5-1
31 Hz
17.0cm

2D

HGen
Gn 86
C 56
3/3/3





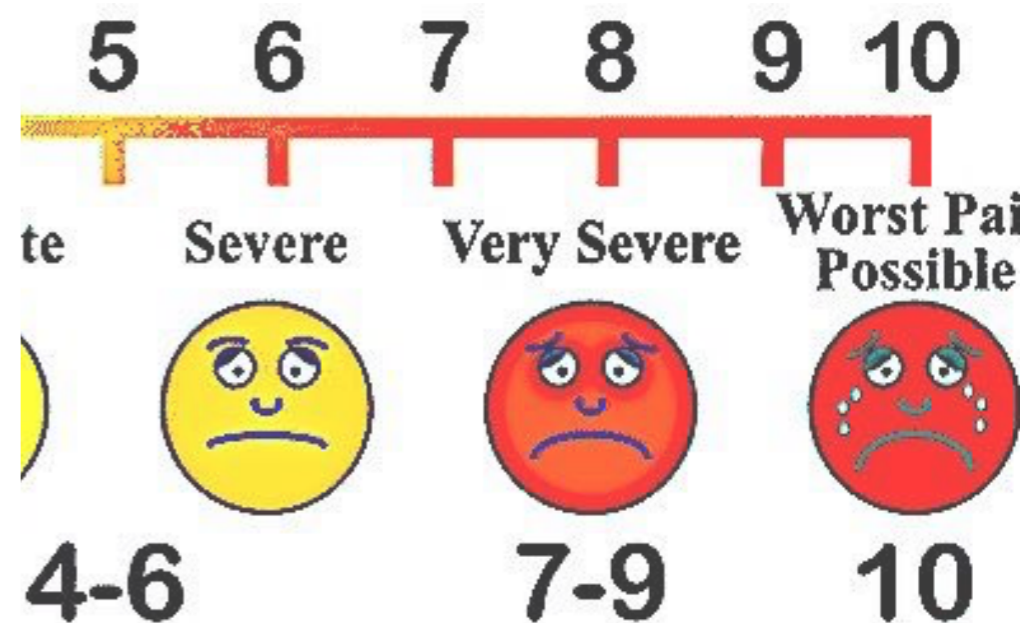
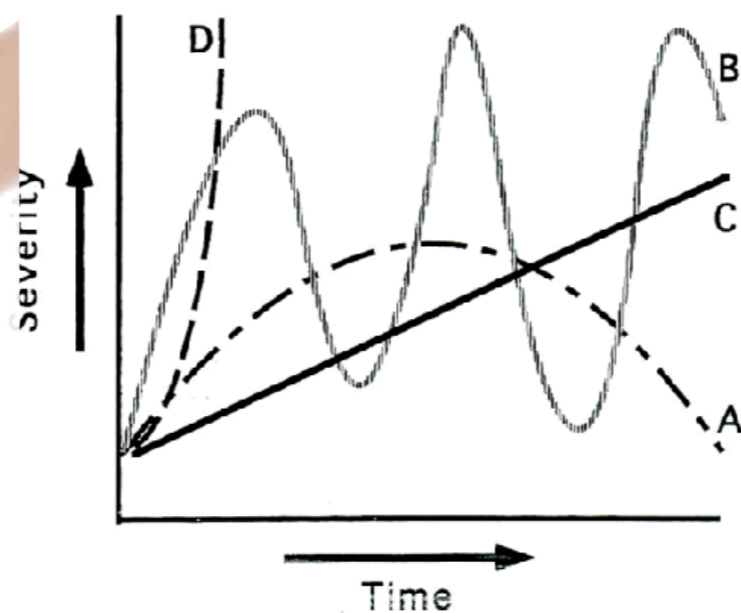
病史詢問



POCUS



理學檢查



POCUS

for

Acute

ABDOMEN

A for aorta

B for biliary

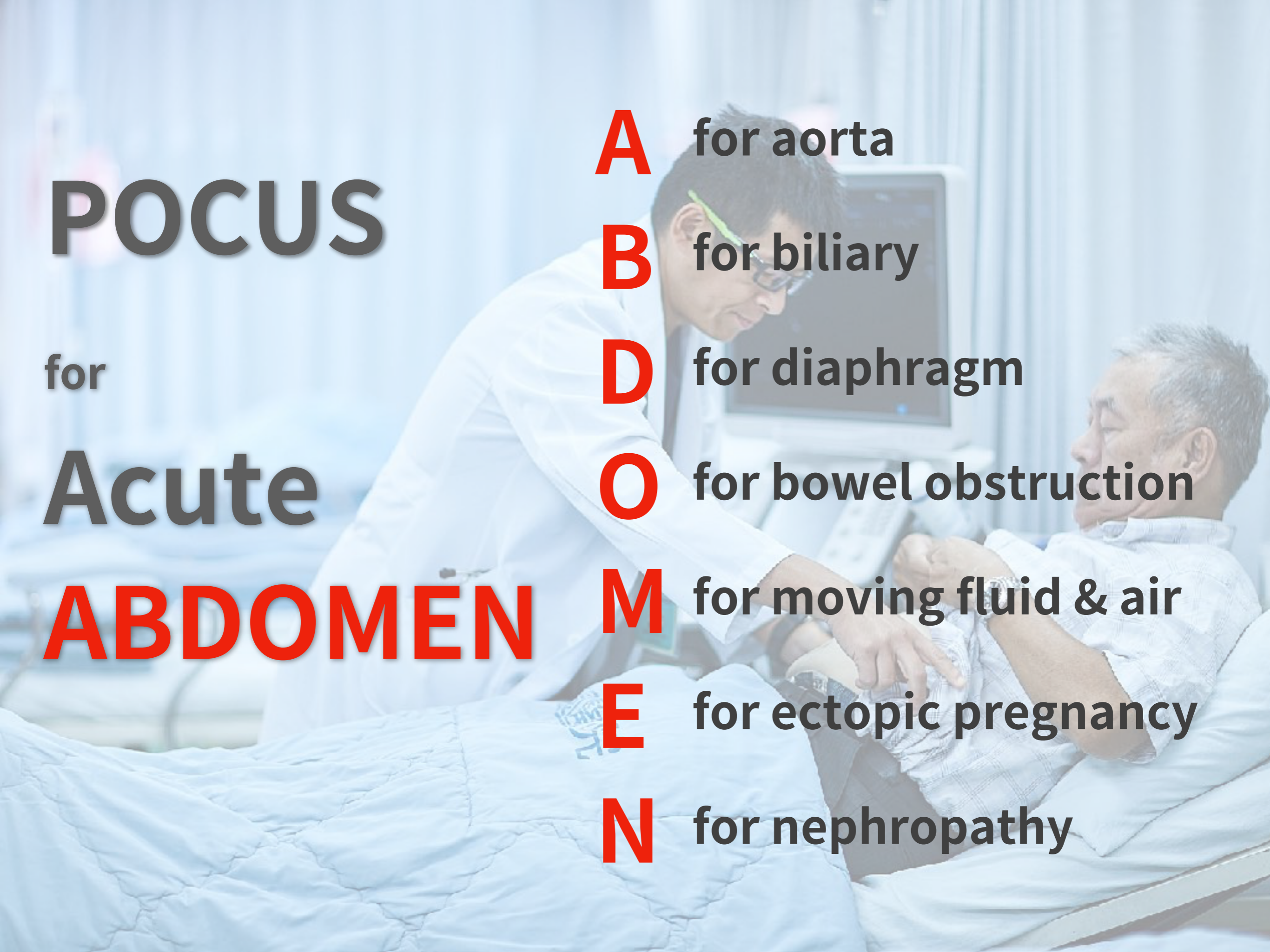
D for diaphragm

O for bowel obstruction

M for moving fluid & air

E for ectopic pregnancy

N for nephropathy



POCUS幫你【透視】急性腹痛

