



衛生福利部雙和醫院
(委託臺北醫學大學興建經營)
Taipei Medical University · Shuang Ho Hospital,
Ministry of Health and Welfare

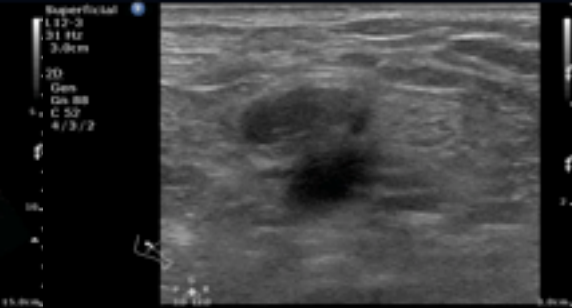
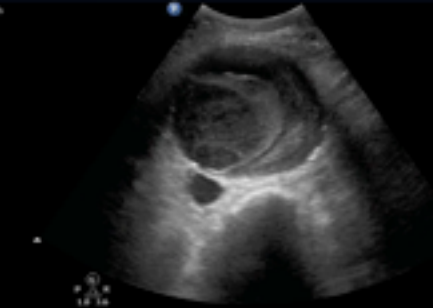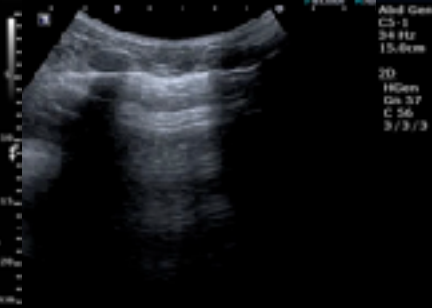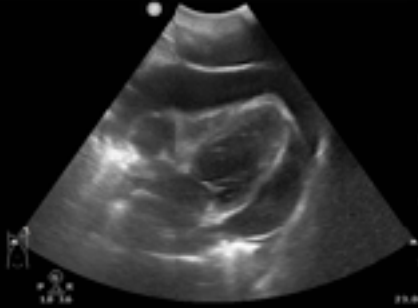


急診基礎超音波

20221227

陳國智醫師

雙和醫院急診醫學科



HEART

LUNG

AORTA

DVT

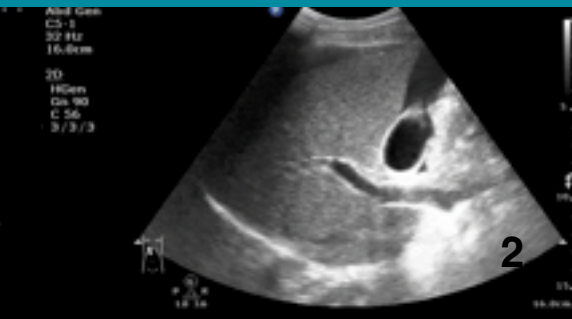
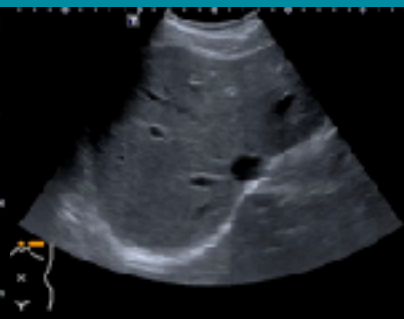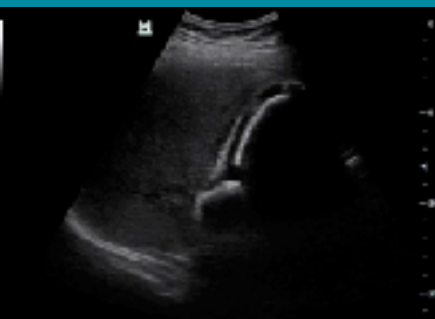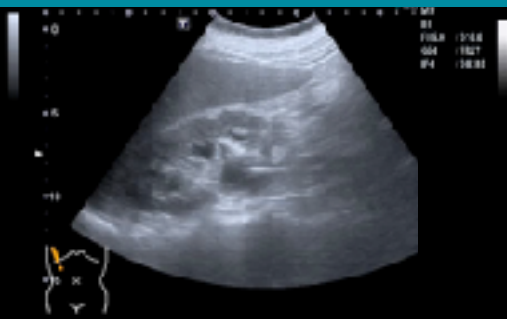KIDNEY

GB

Liver

FAST

急診基礎超音波工作坊



陳國智 醫師

POCUSacademy.com



急診超音波臨床評核醫師
醫用超音波學會指導醫師
WINFOCUS director / instructor

急診 / 重症 / 介入 / 急性疼痛

經歷

新光急診超音波訓練中心主任
西園醫院急診醫學科主任
急診醫學會超音波委員會主委
台灣疼痛醫學會大體模擬手術講師
急救加護醫學會重症超音波負責人

juice119@gmail.com

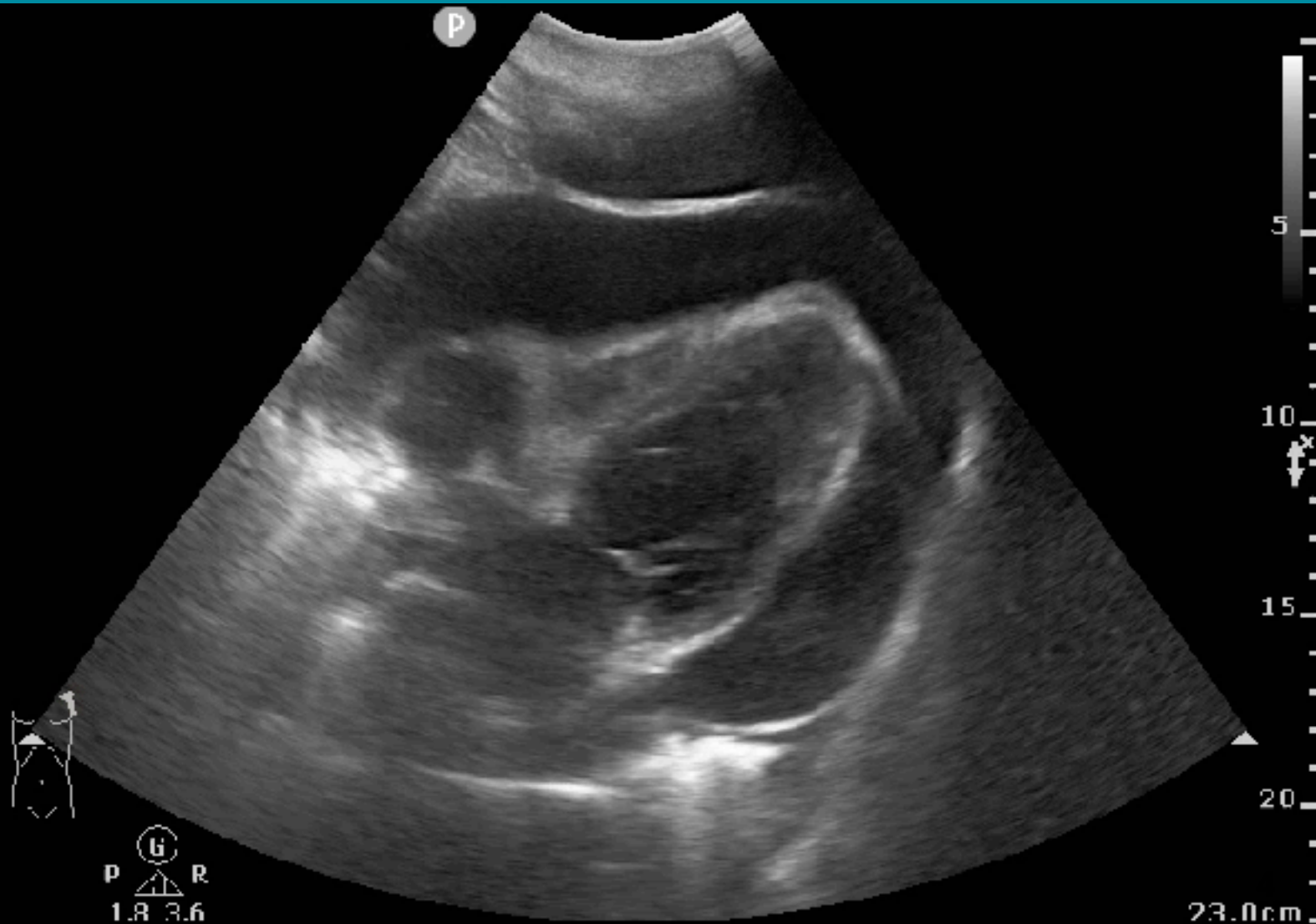


HEART

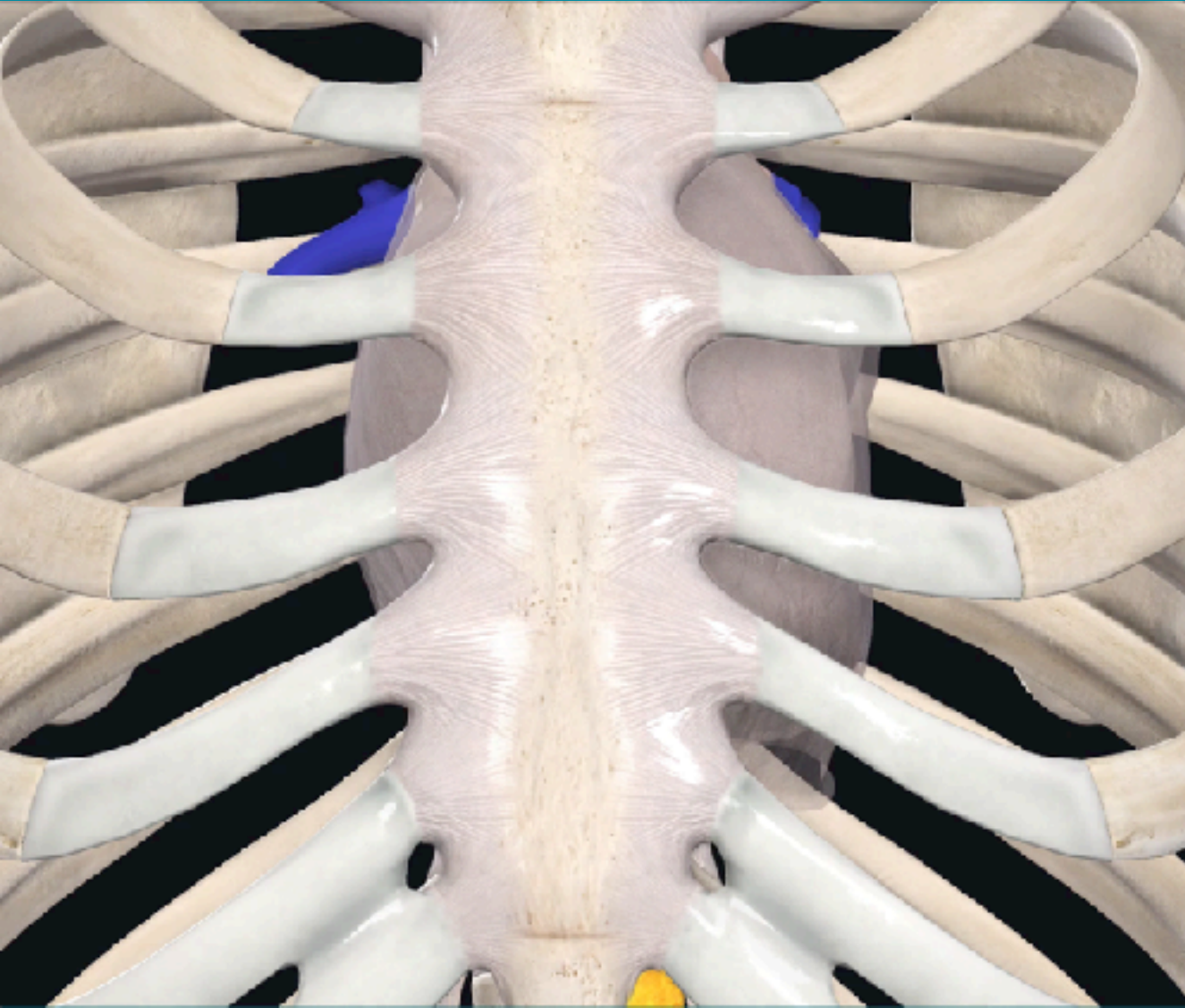
Abd Gen
C5-1
75 H7
23.0cm

2D

HGen
Gn 100
C 56
3 / 3 / 3



HEART



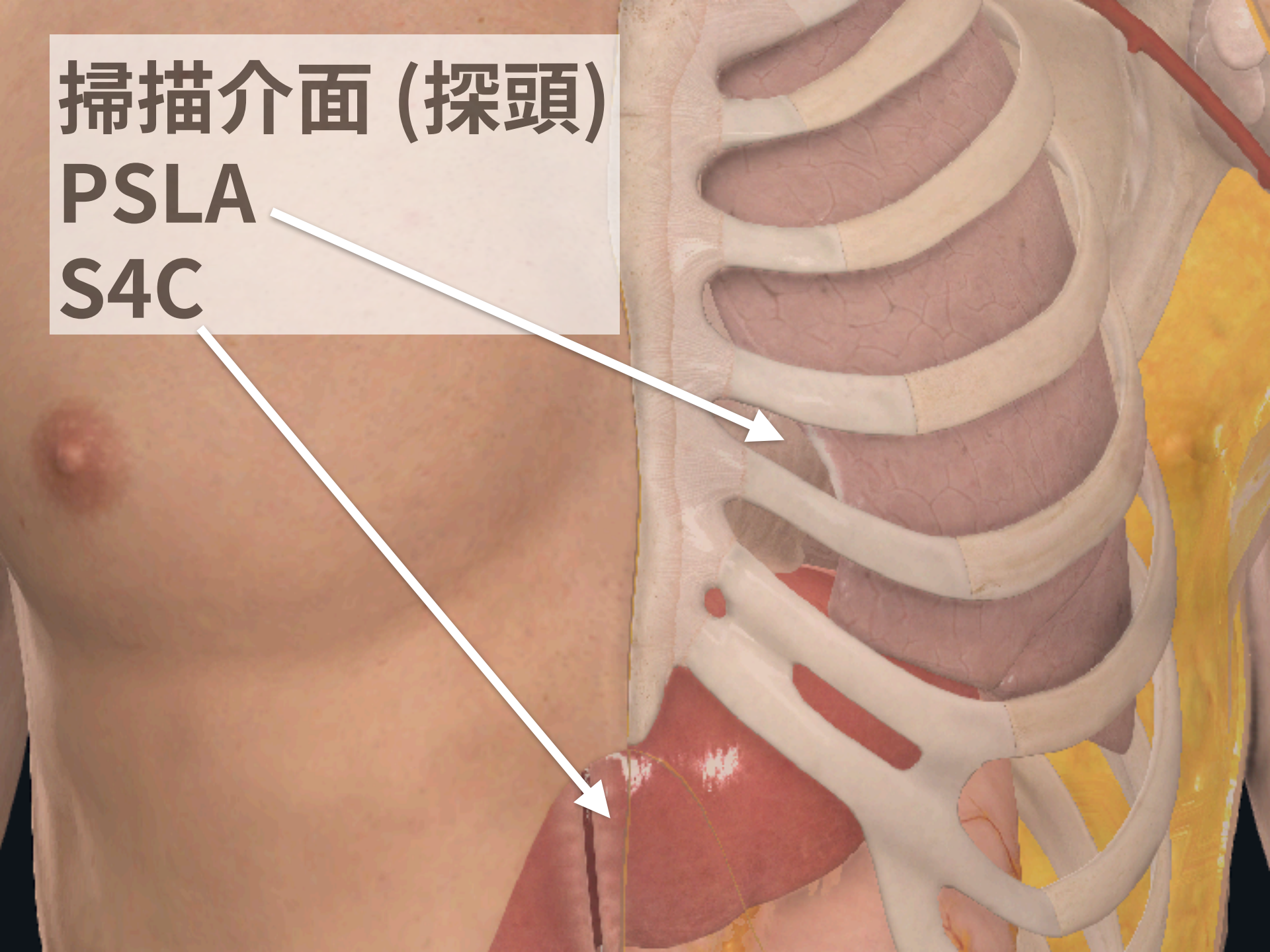
Arrest
Activity

Shock
Effusion
5

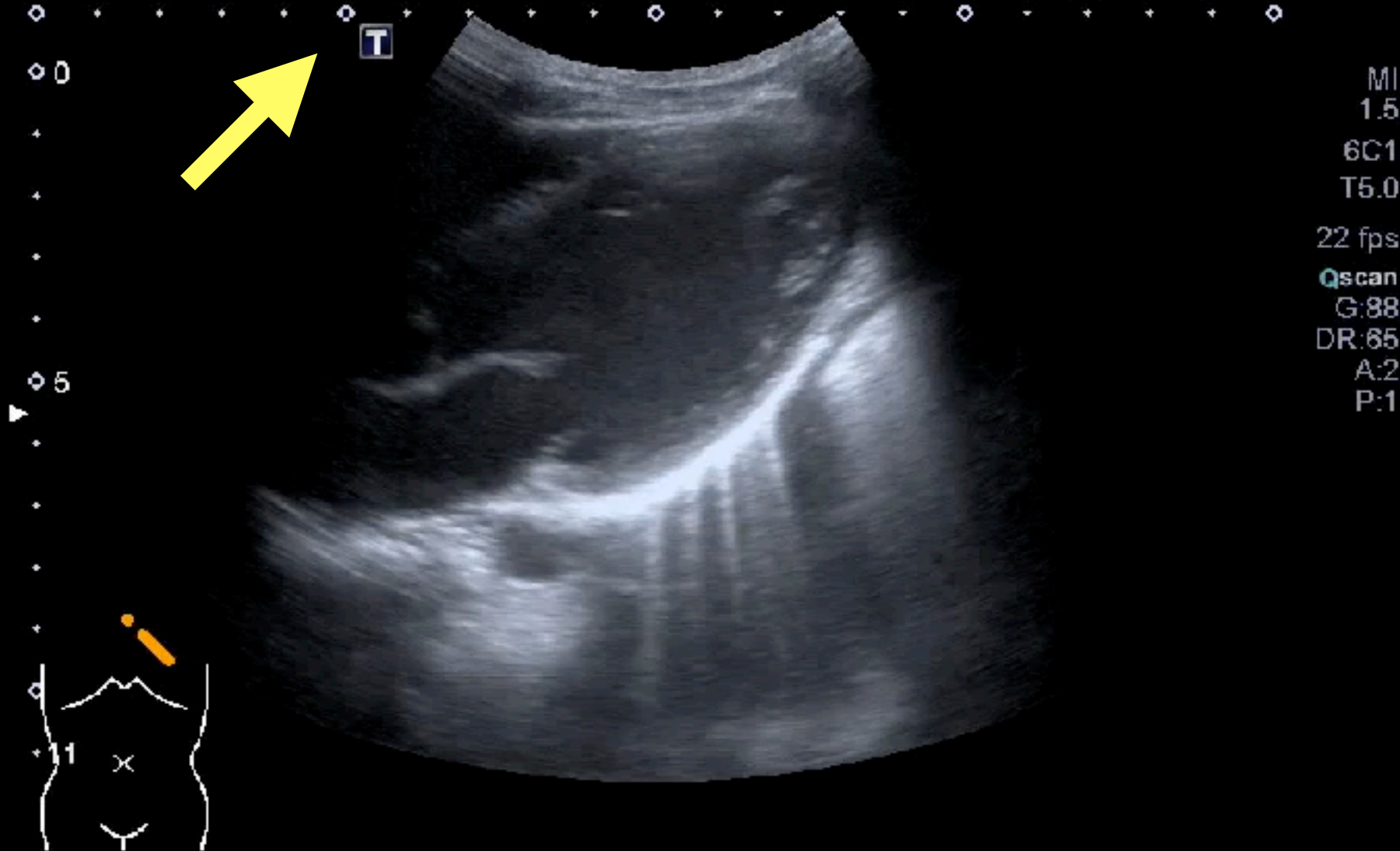
掃描介面 (探頭)

PSLA

S4C



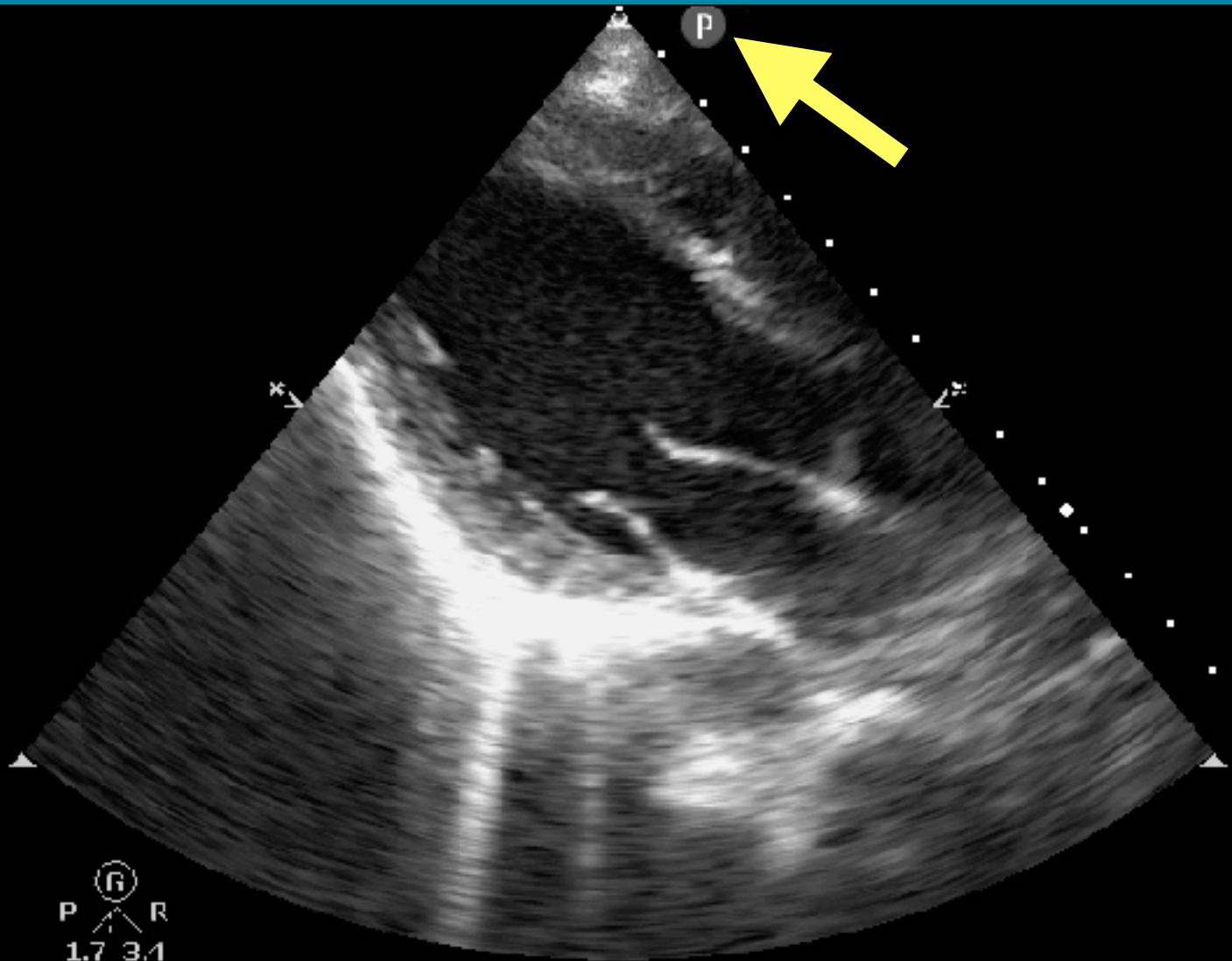
PARASTERNAL LONG AXIS



PARASTERNAL LONG AXIS

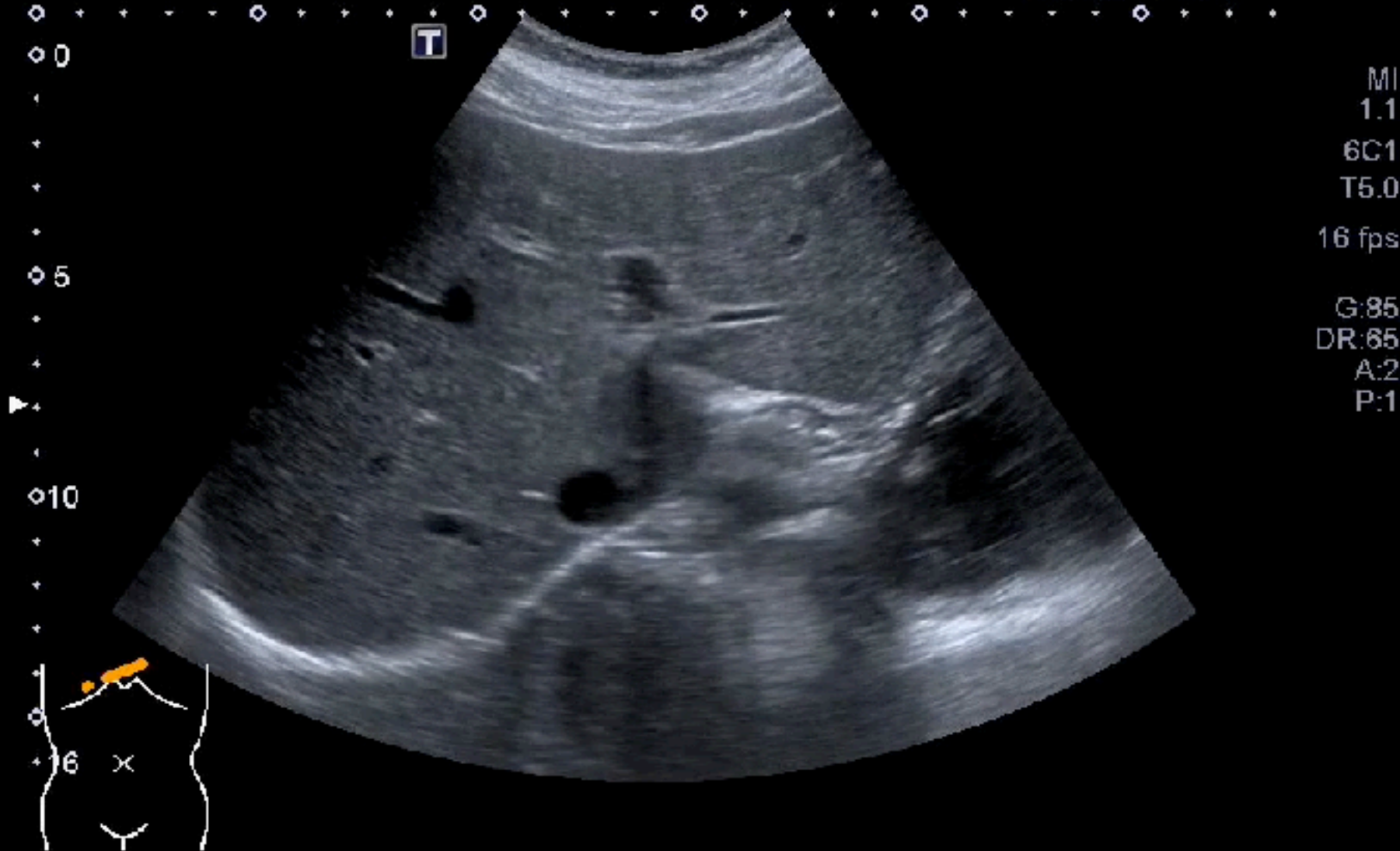
Adult Echo
S1-1
77 Hz
15.0cm

2D
HGen
Gn 100
55
3/2/0
50 mm/s

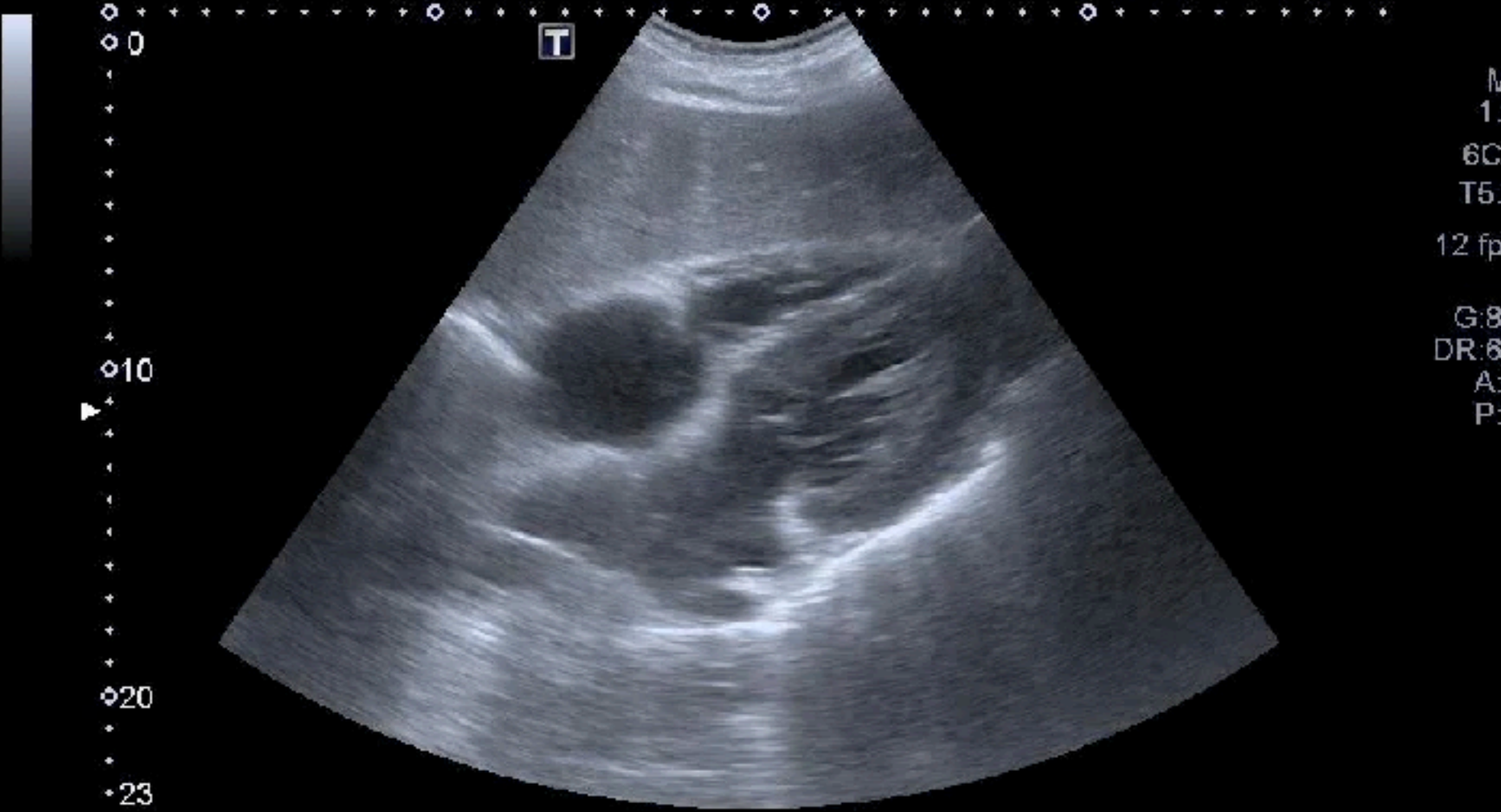

Ⓜ
P R
1.7 3.1

SUBCOSTAL 4 CHAMBER



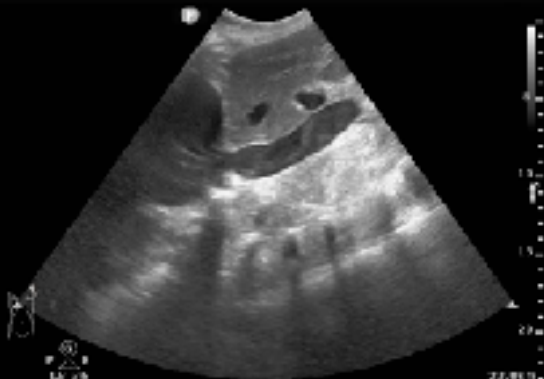CARDIAC ARREST



CARDIAC TAMPONADE

1.5d Con
3-1
3.8Hz
7.0cm

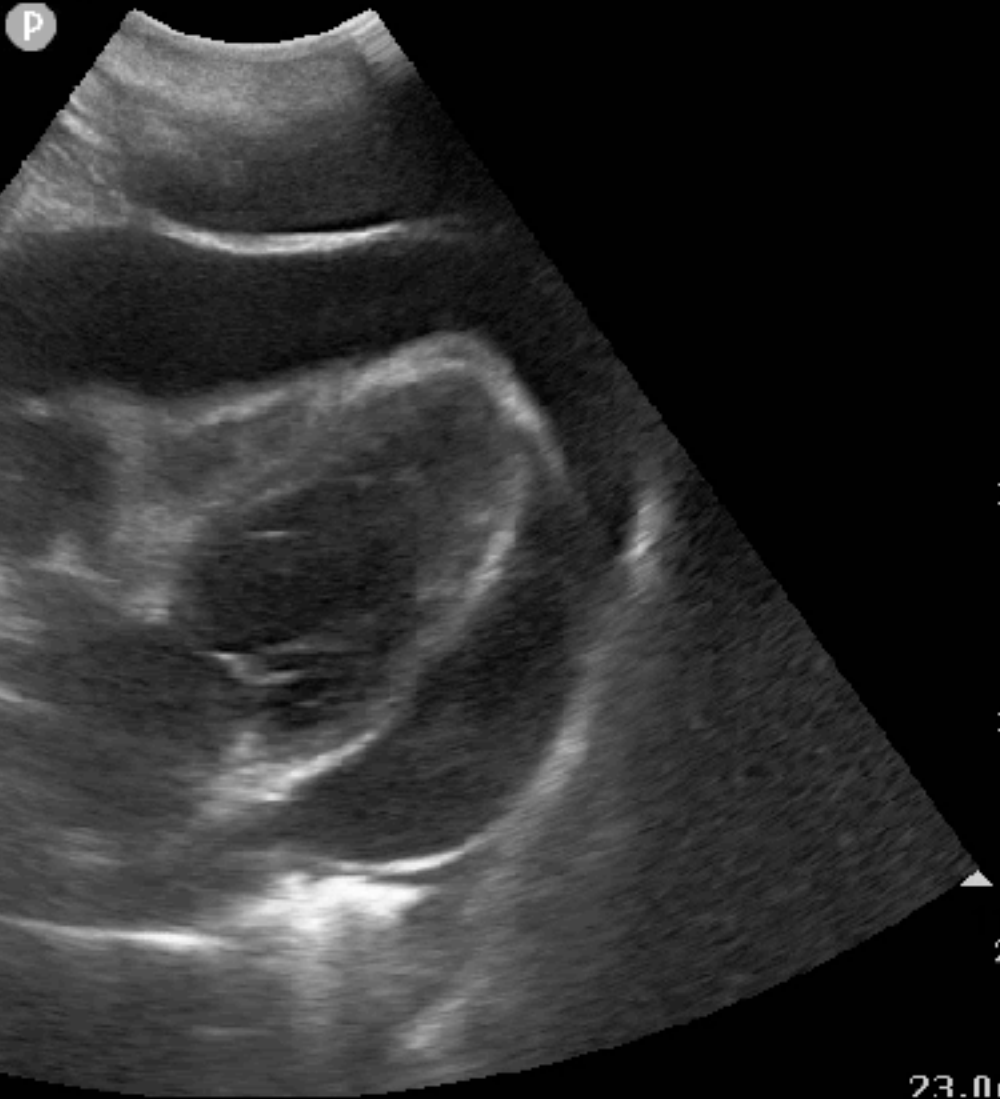
HD
H0cm
10.0cm
0.56
3/3/3



3/3/3



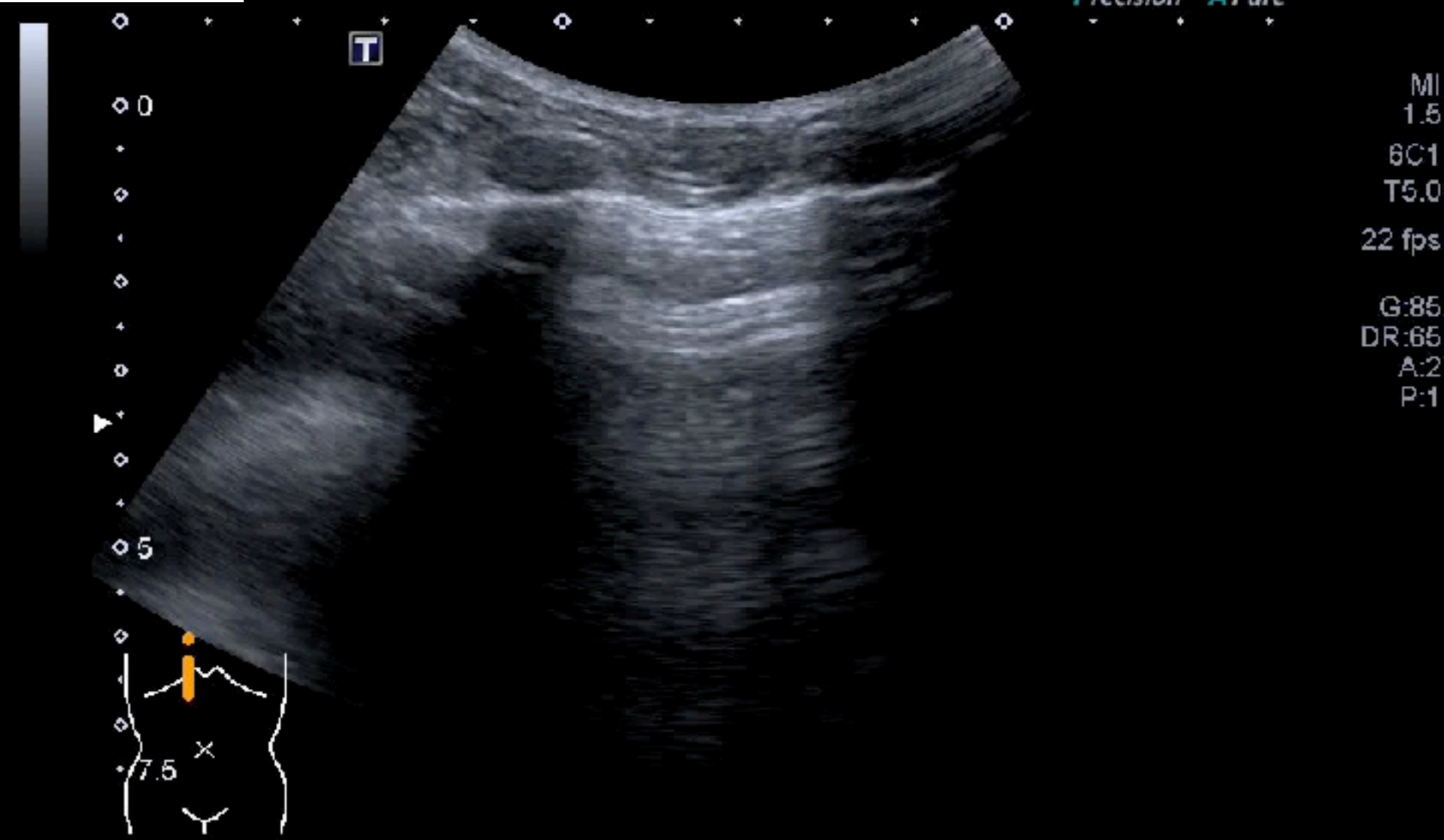
P R
1.8 3.6



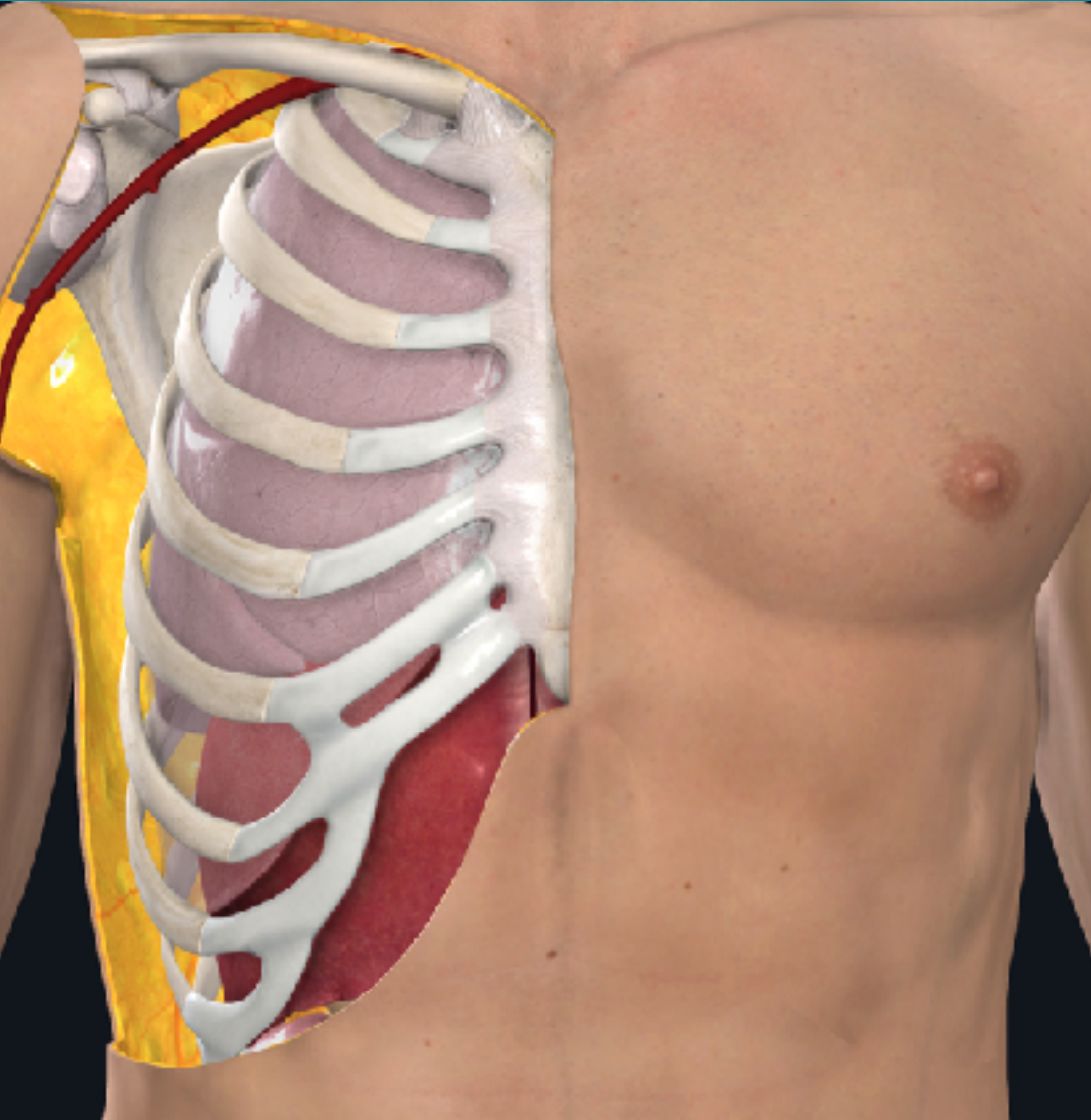
23.0cm



LUNG

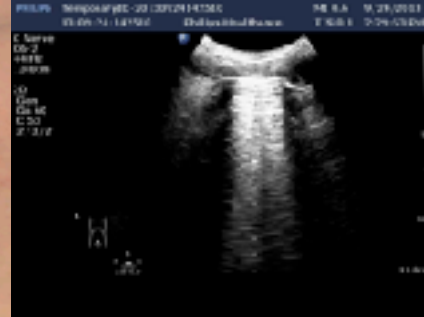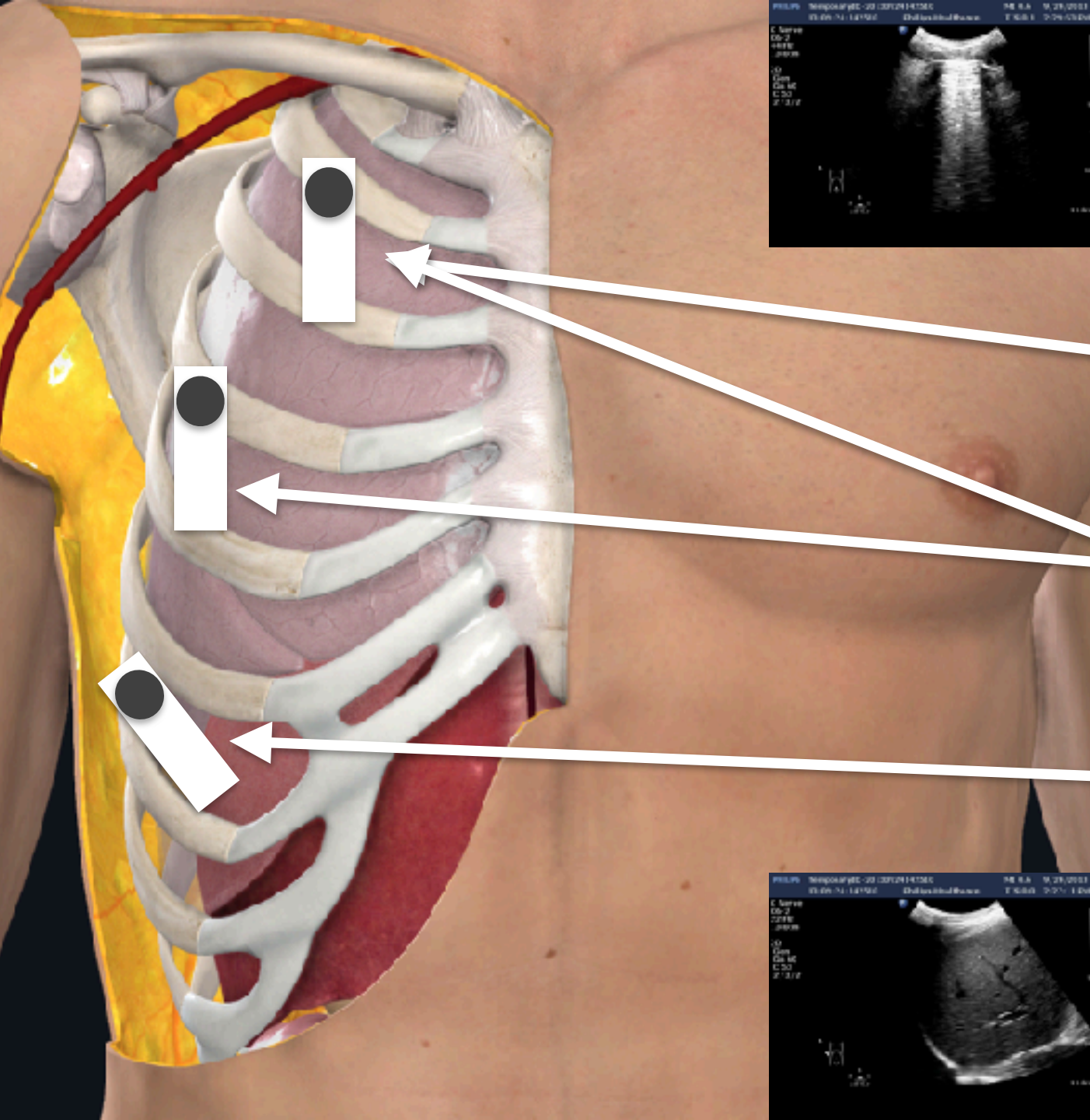


LUNG



Dyspnea
Chest pain

PTX
AIS
PLE

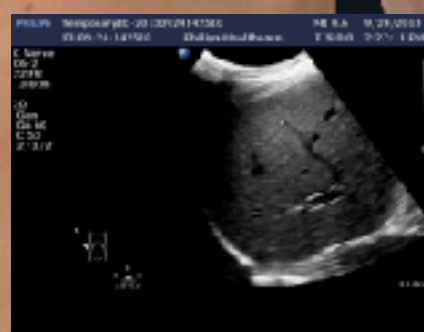


AIR

PTX

AIS

PLE



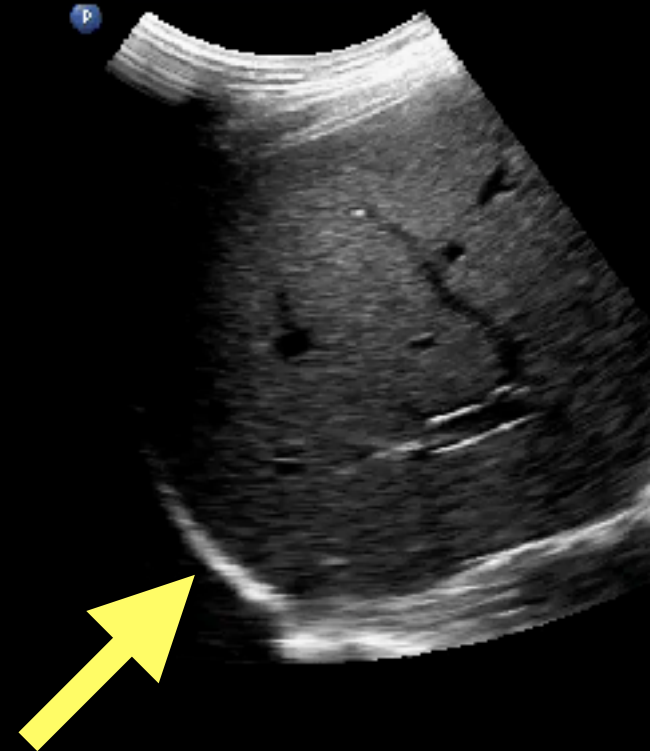
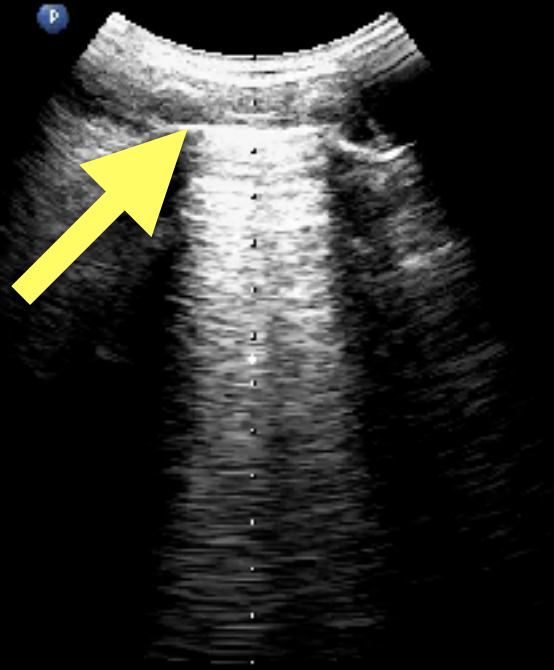FLUID

NORMAL LUNG

肋膜/滑動

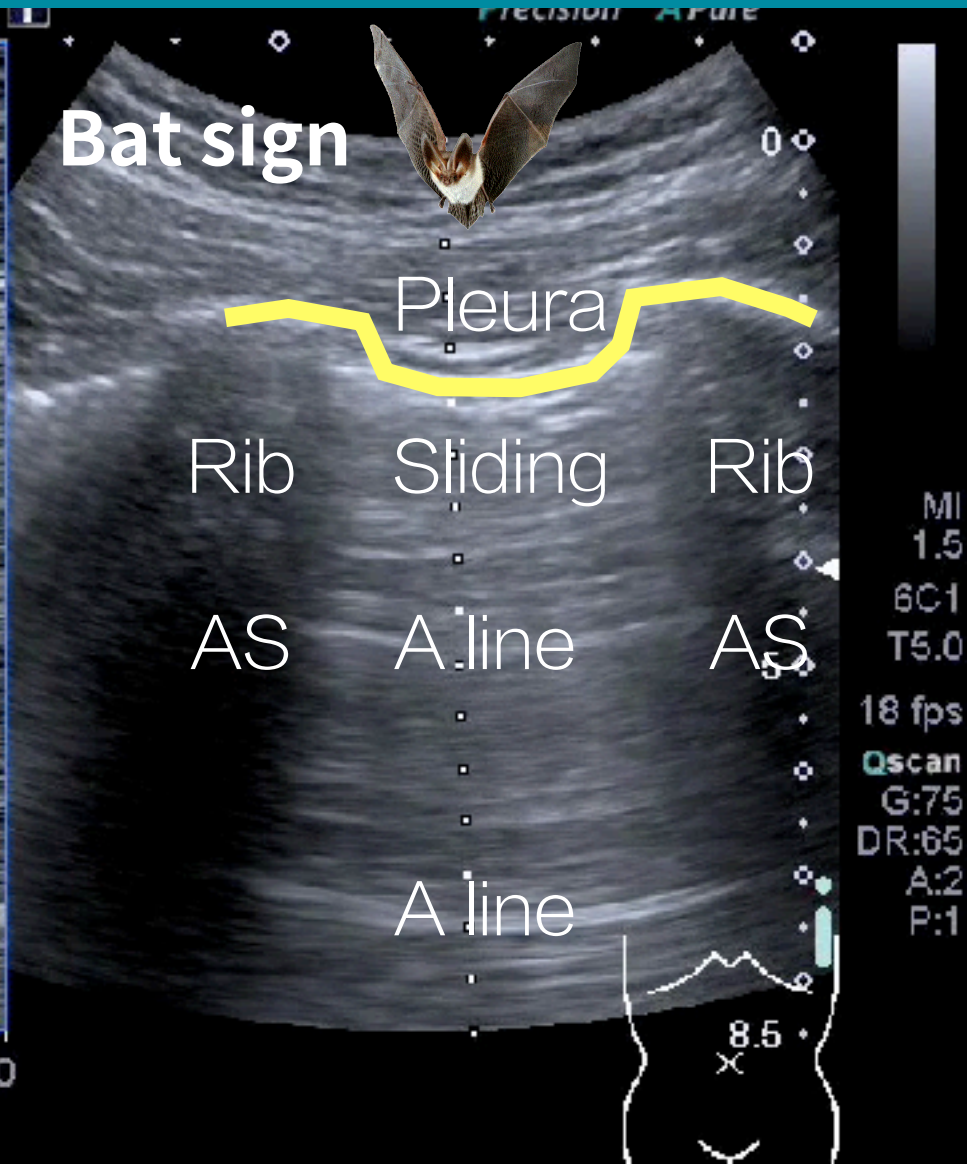
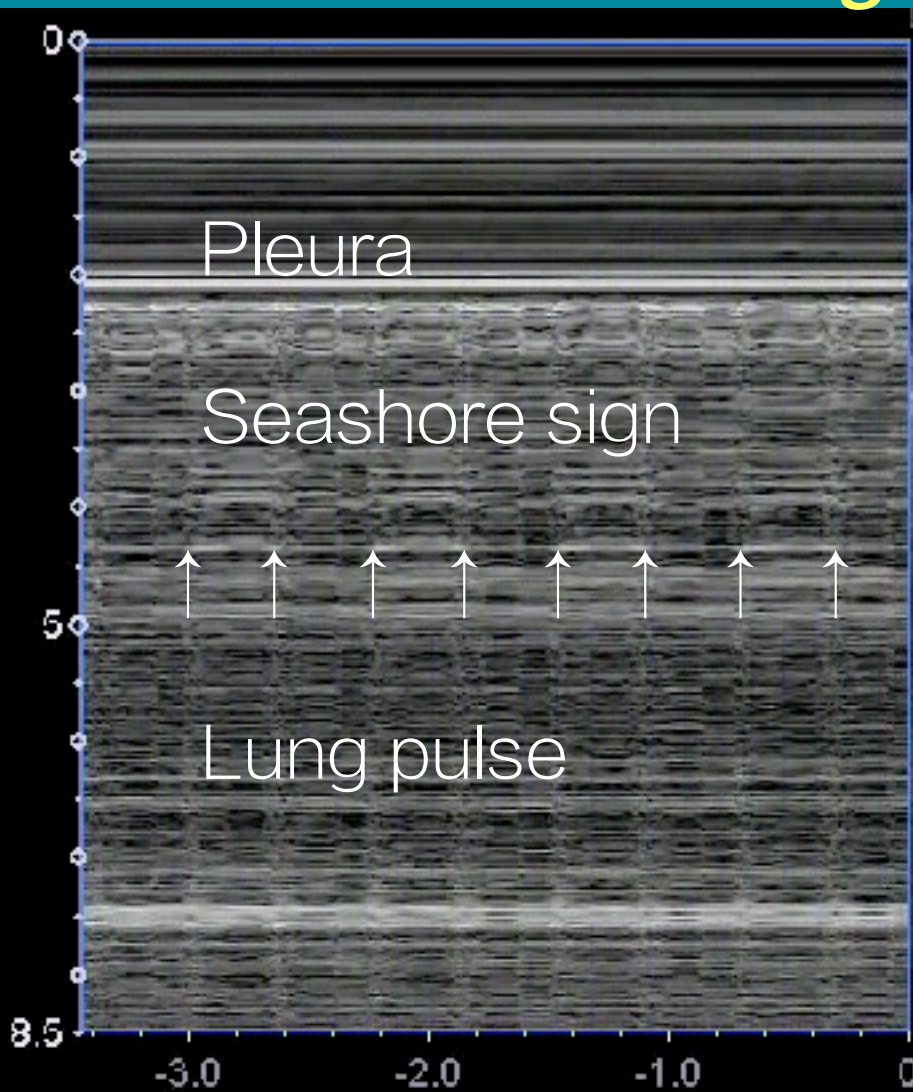
橫膈膜/移動

TemporaryID 20130924142510 MT 0.6 9: PHILIPS 13 09 24 142510 Philips Healthcare TIS 0.1 2: TemporaryID 20130924142510 MT 0.6 9:2 13 09 24 142510 Philips Healthcare TIS 0.0 2:27

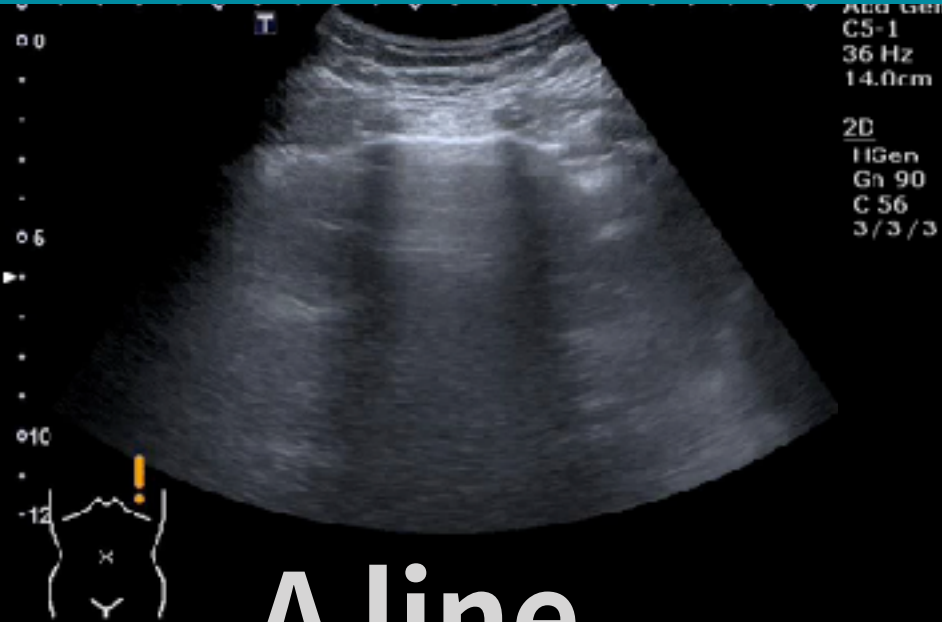

NORMAL LUNG

Sliding + A lines

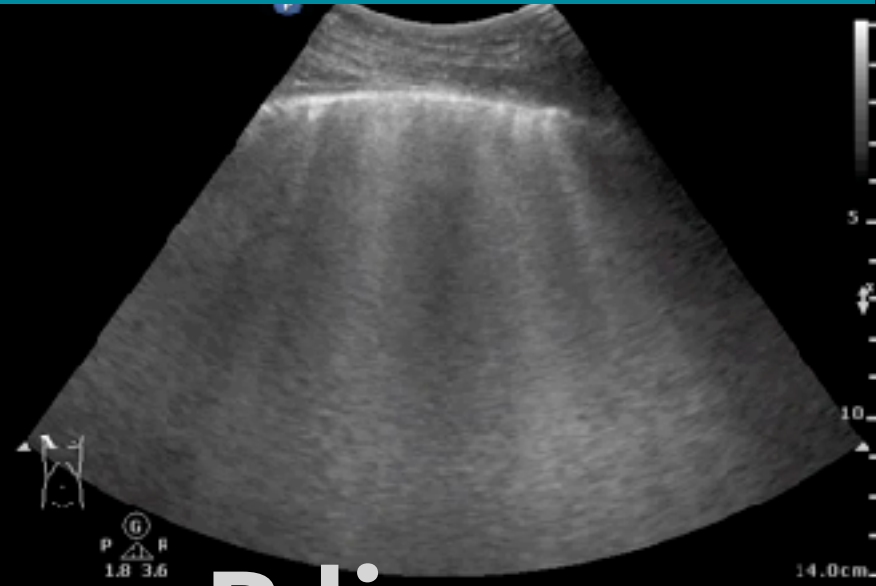

SLIDING FIRST



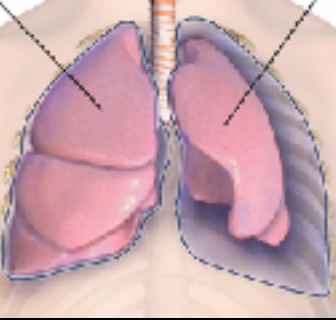
A line

肋膜下
水平線
等距離



B line

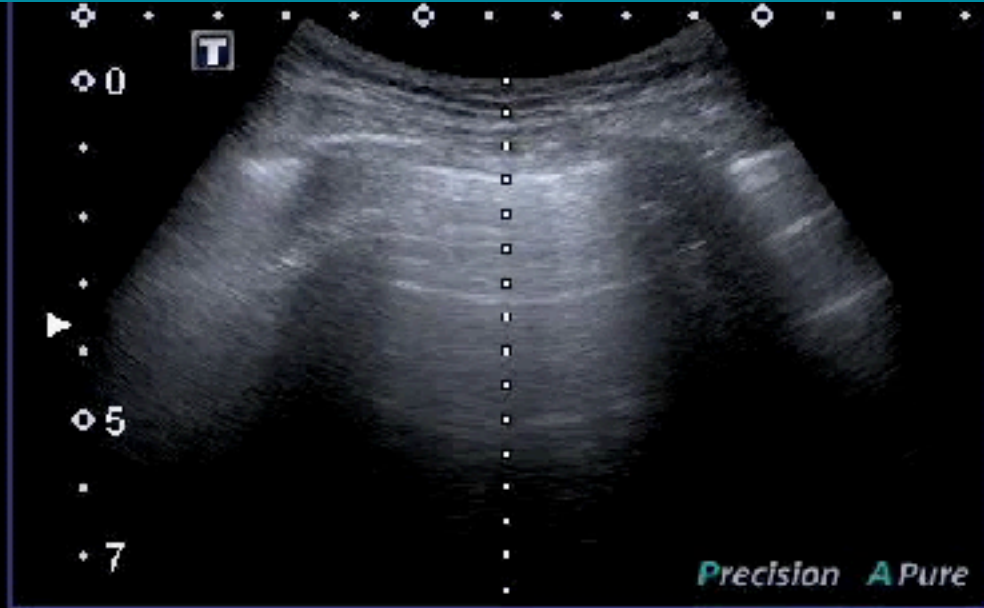
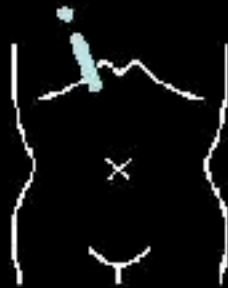肋膜下
垂直線
大於三



PNEUMOTHORAX ?

Sliding + A lines = Normal pleura

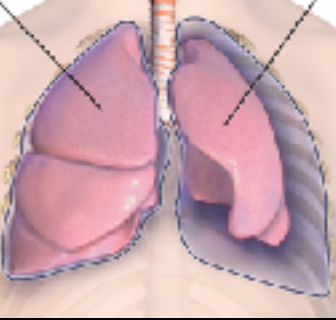
Seashore sign



MI:1.5
6C1
T5.0
18 fps
Qscan
G:71
DR:65
A:2
P:1



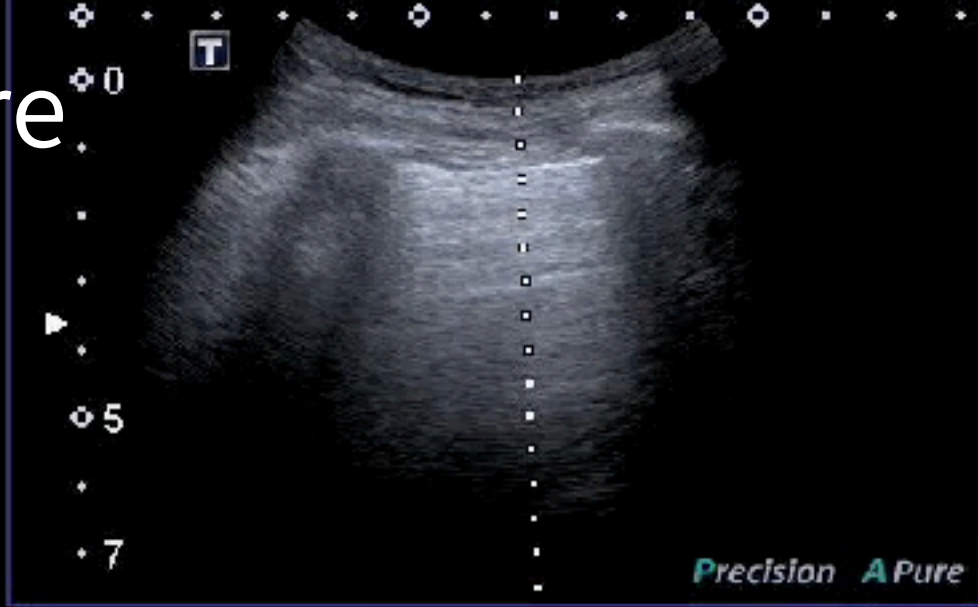
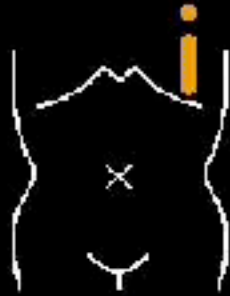0
5
7



PNEUMOTHORAX ?

No Sliding + A lines >> Consider PTX

Stratosphere
sign

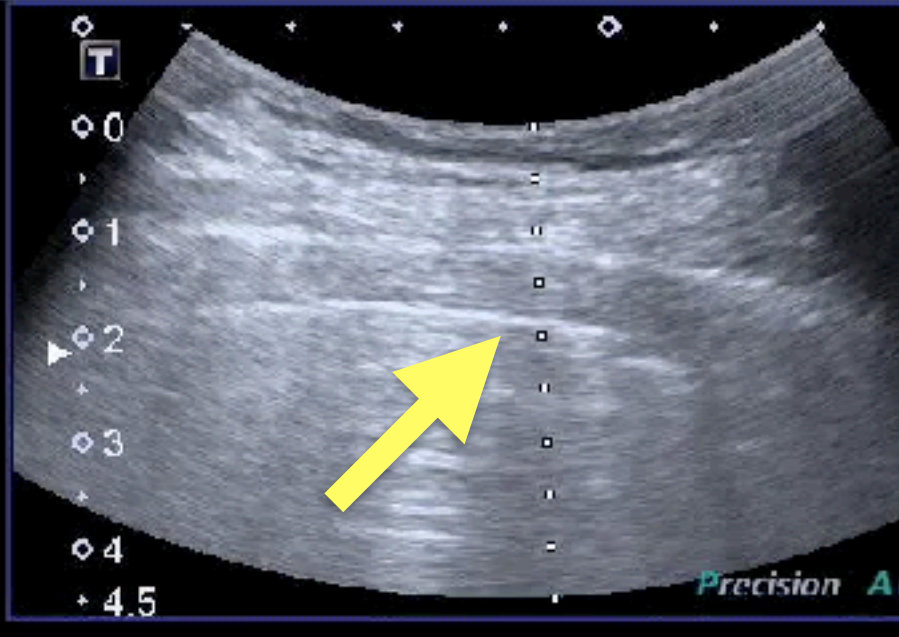
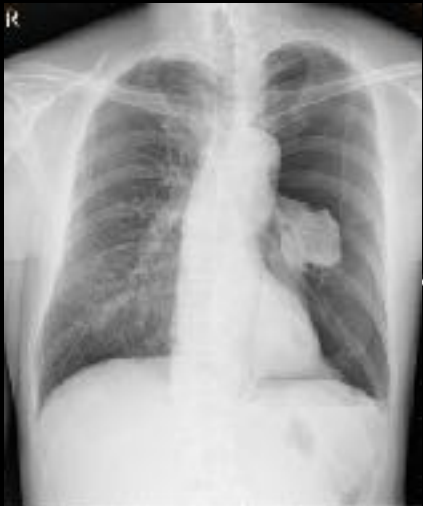

MI:1.5
6C1
T5.0
18 fps
Qscan
G:71
DR:65
A:2
P:1

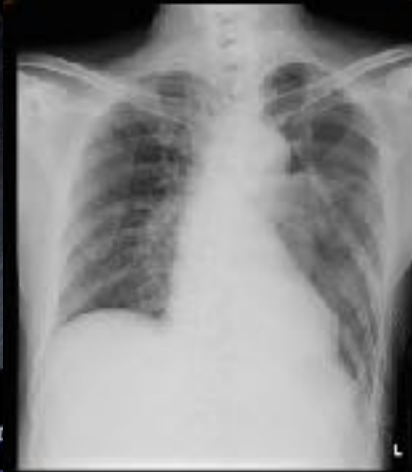


Lung Point

A

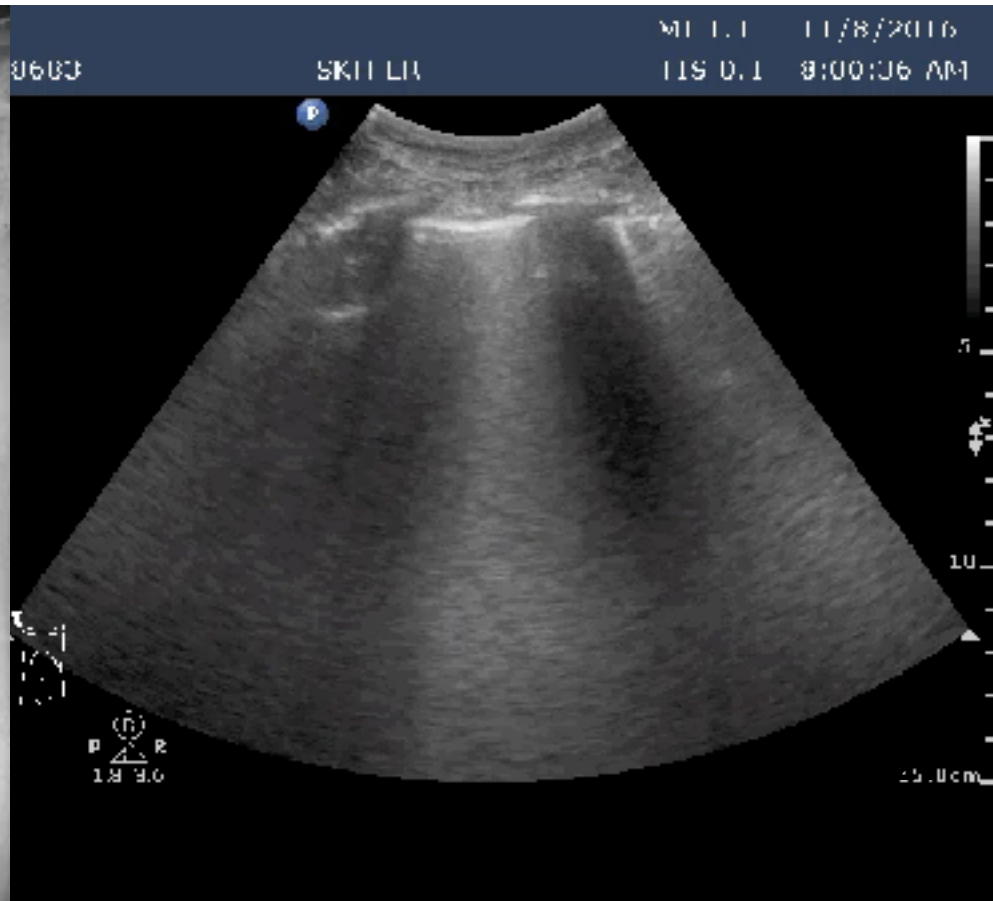
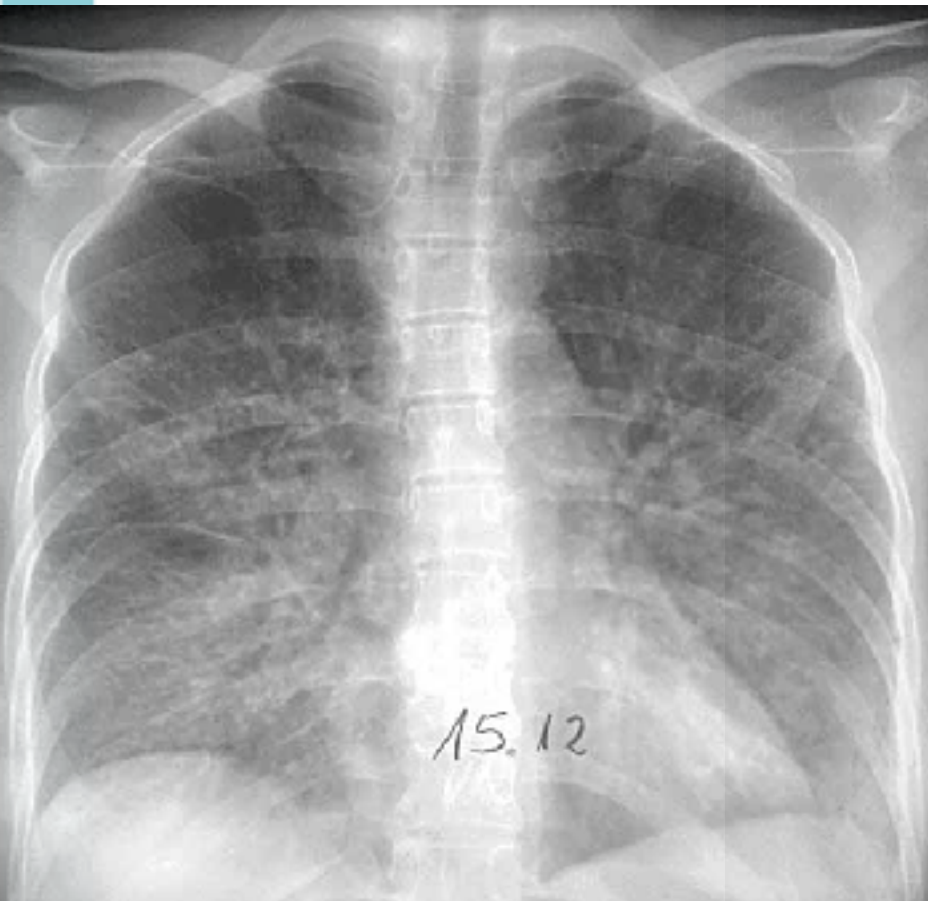


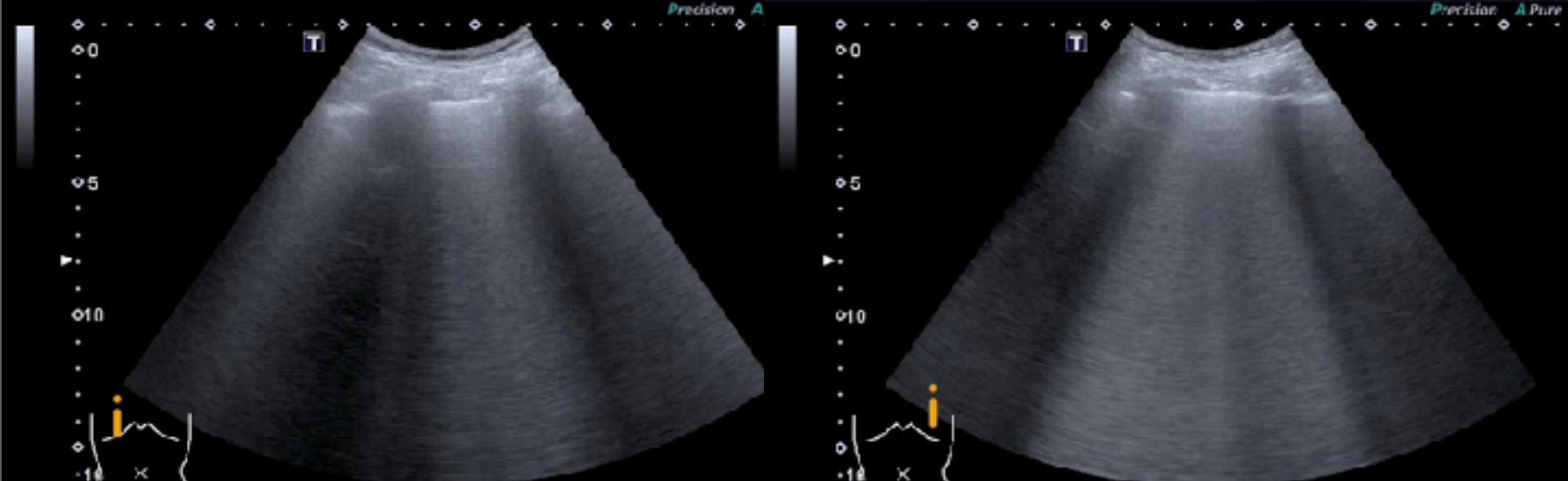
B



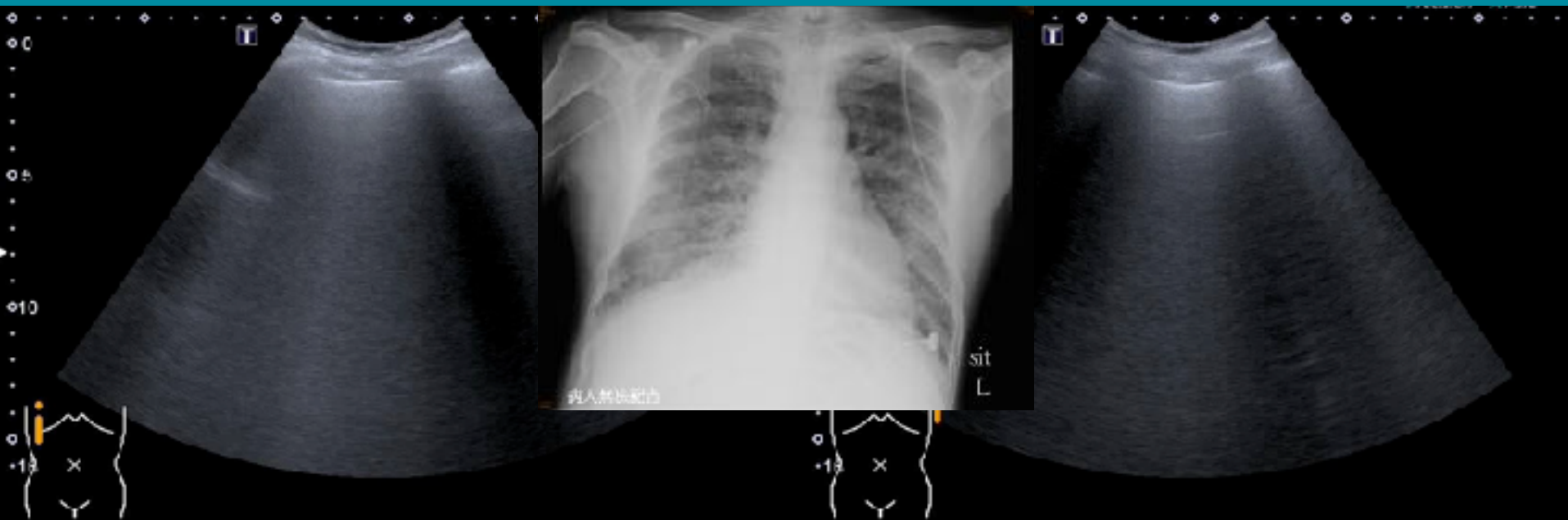
LUNG ROCKETS

ICS > 3 B lines

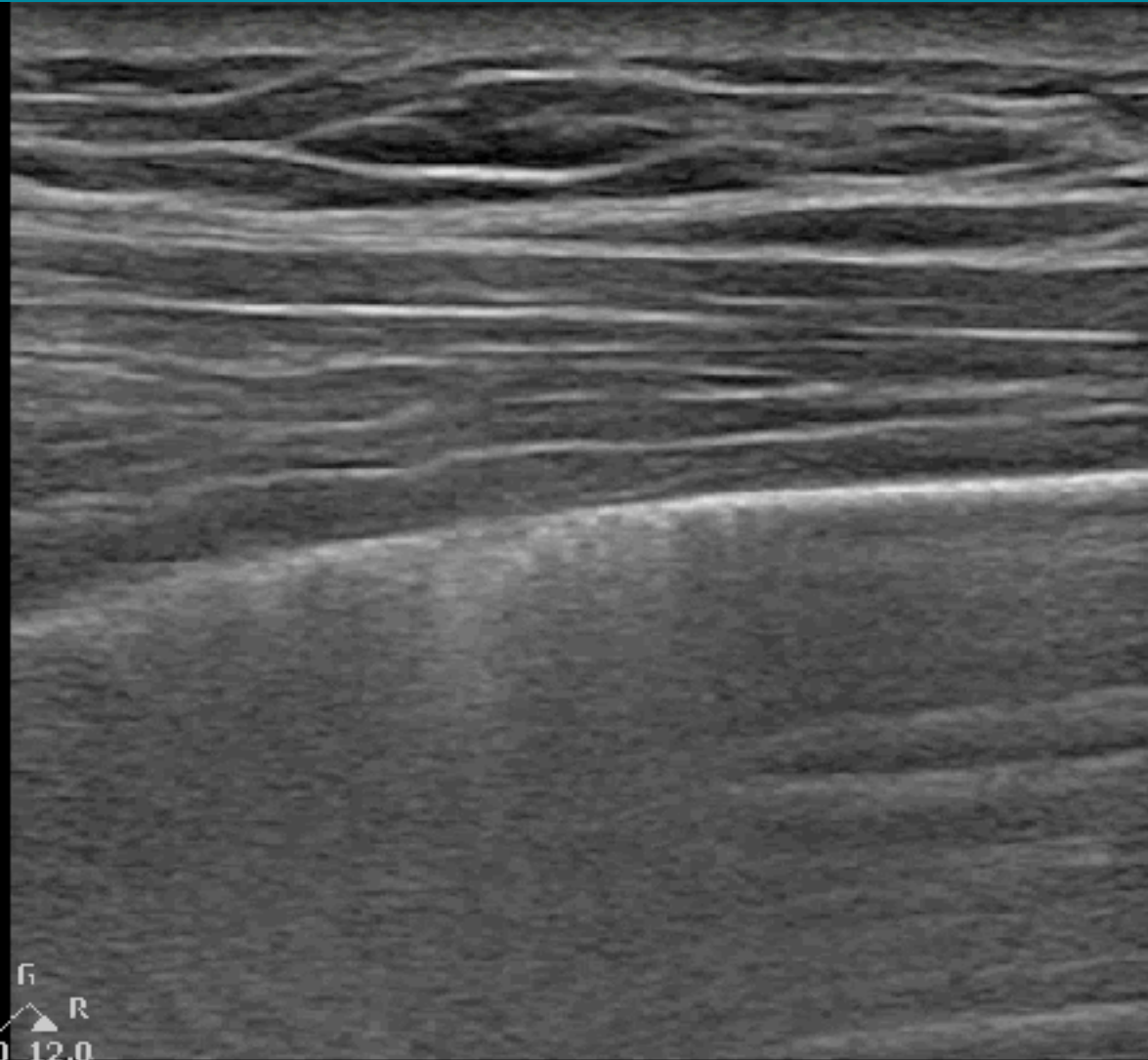




ALEVOLAR INTERSTITIAL SYNDROME



AIS: Localized



Pneumonia

Pneumonitis

Atelectasis

Contusion

Infarction

Pleural disease

Neoplasia

Normal lung

PLEURAL EFFUSION

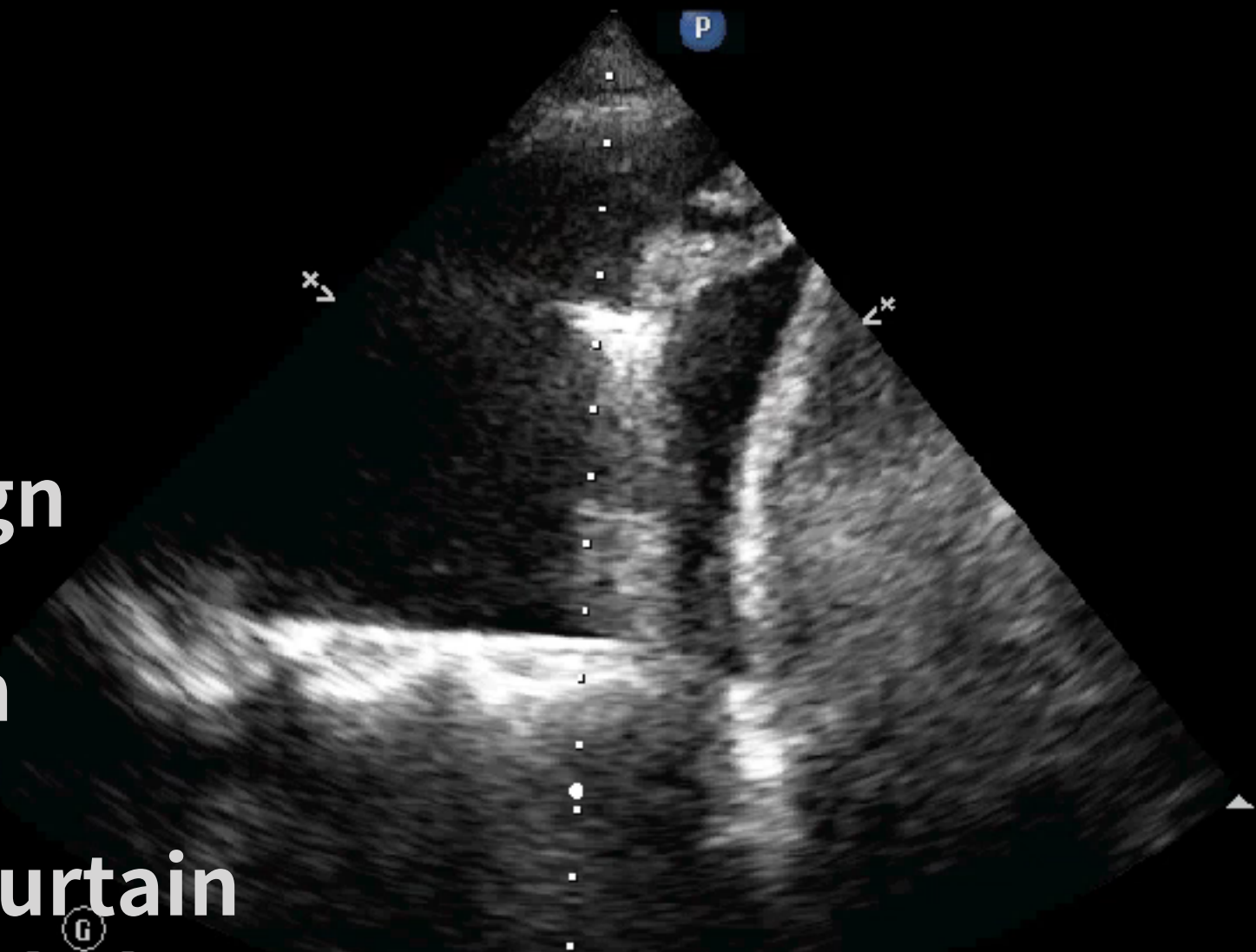
Adult Echo2
G-1
: Hz
5.0cm

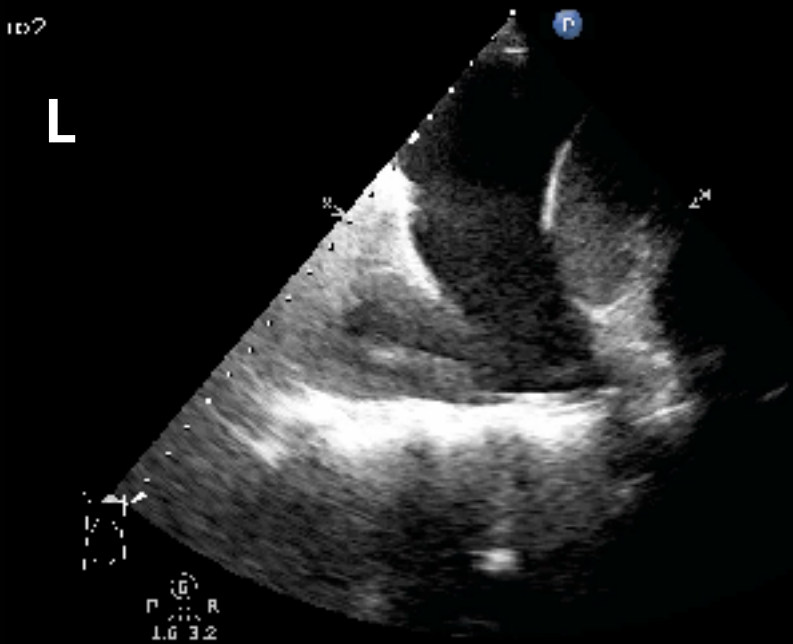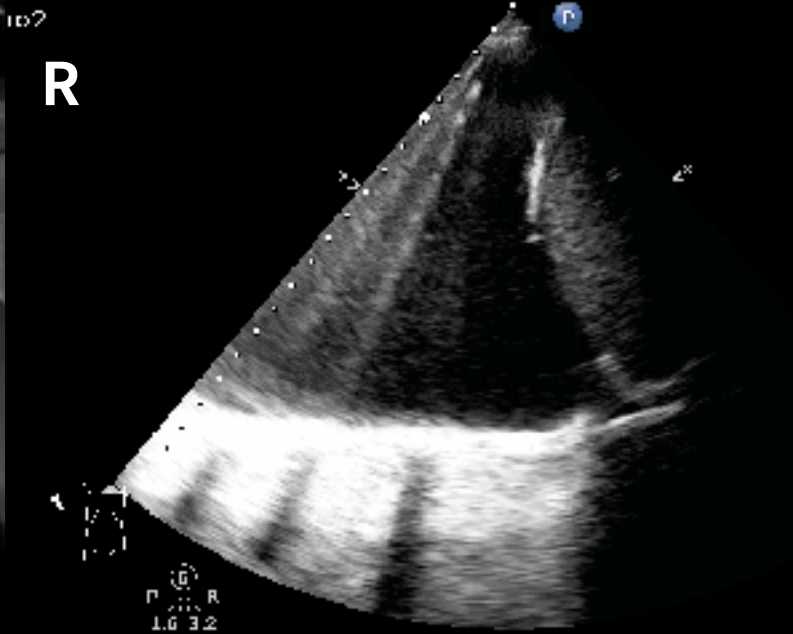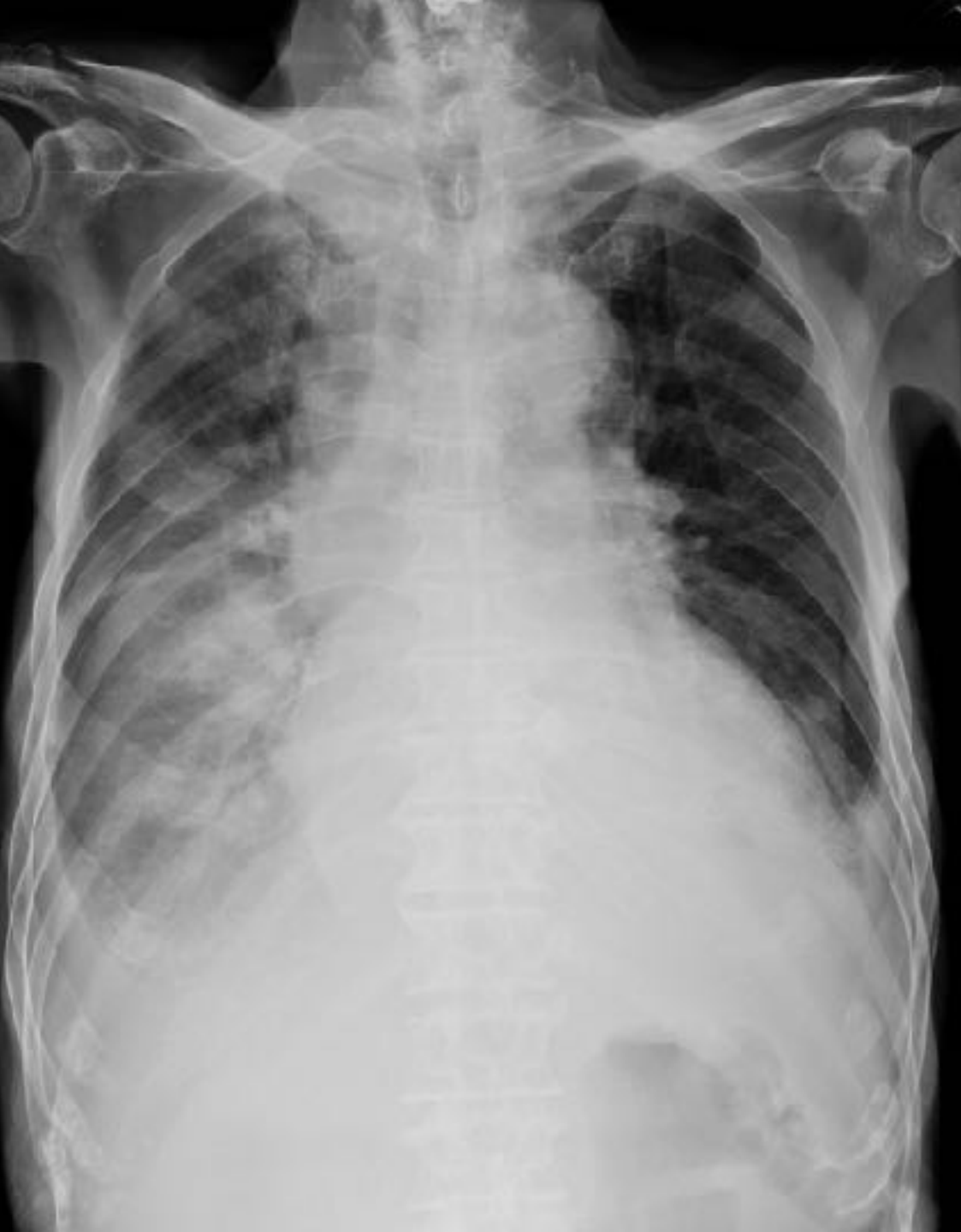Gen
n 30
50
/ 2 / 0

Spine sign

Jelly fish

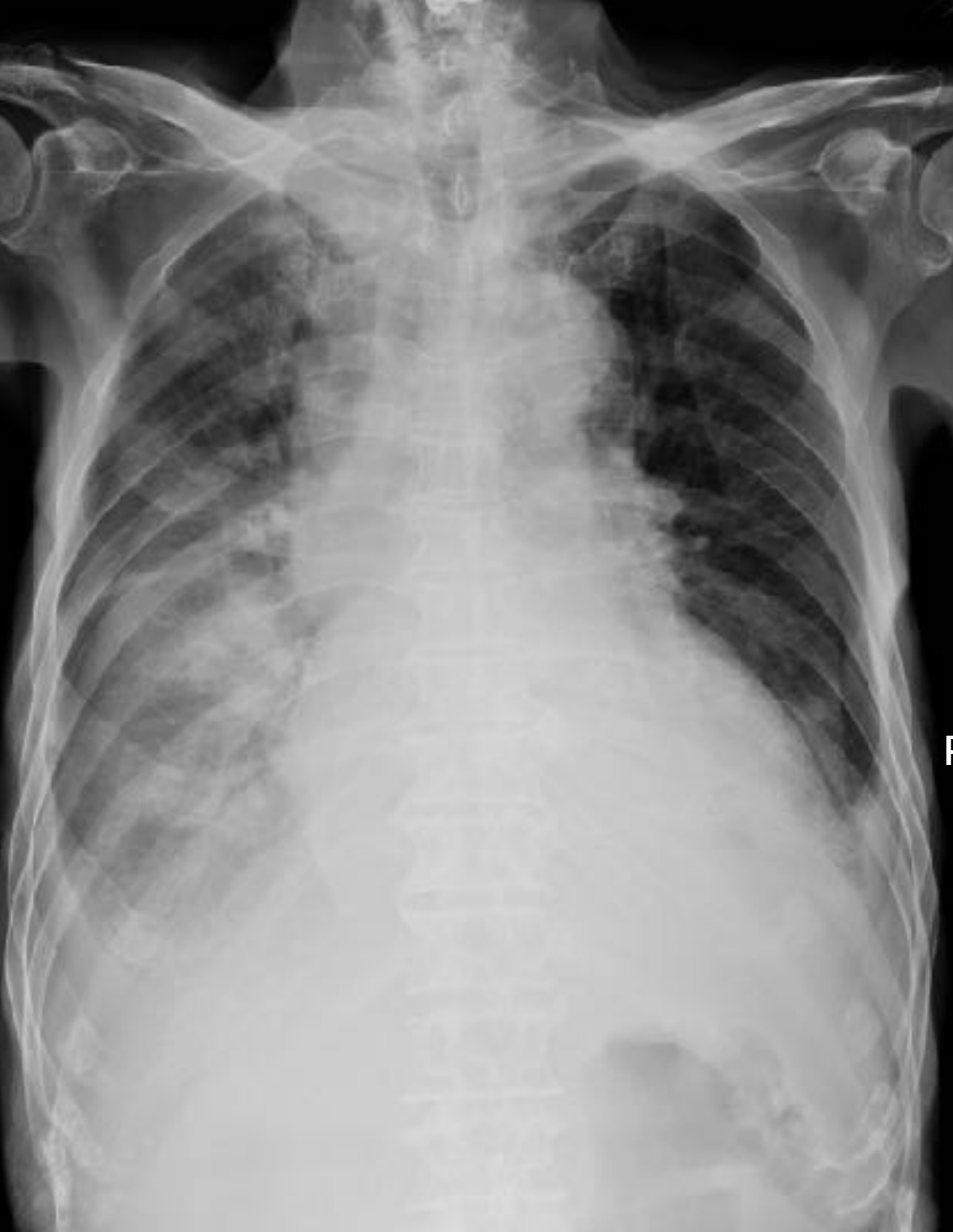Loss of curtain



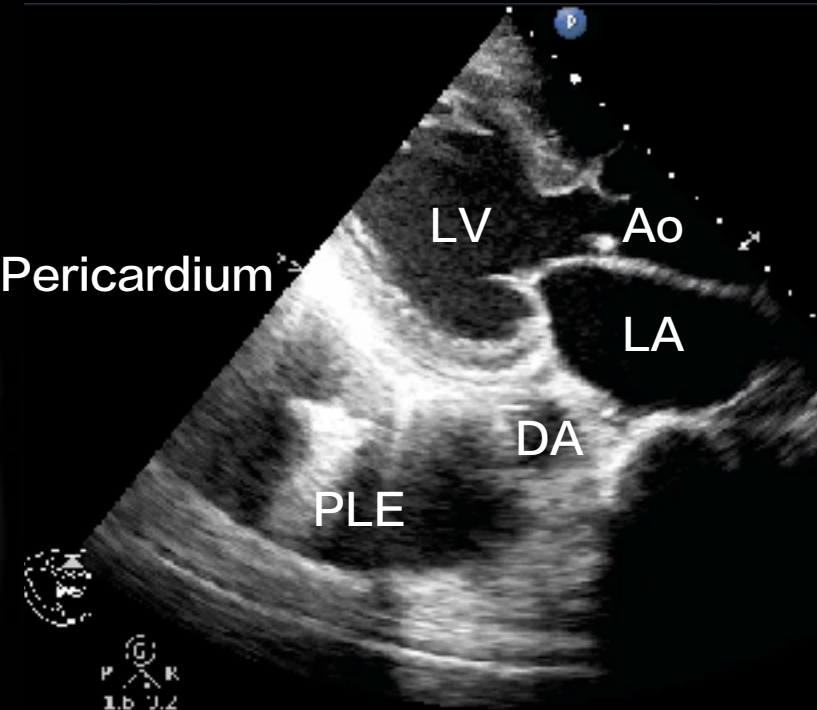


D aorta

Pericardial vs Pleural



Pericardium



LV

Ao

LA

DA

PLE

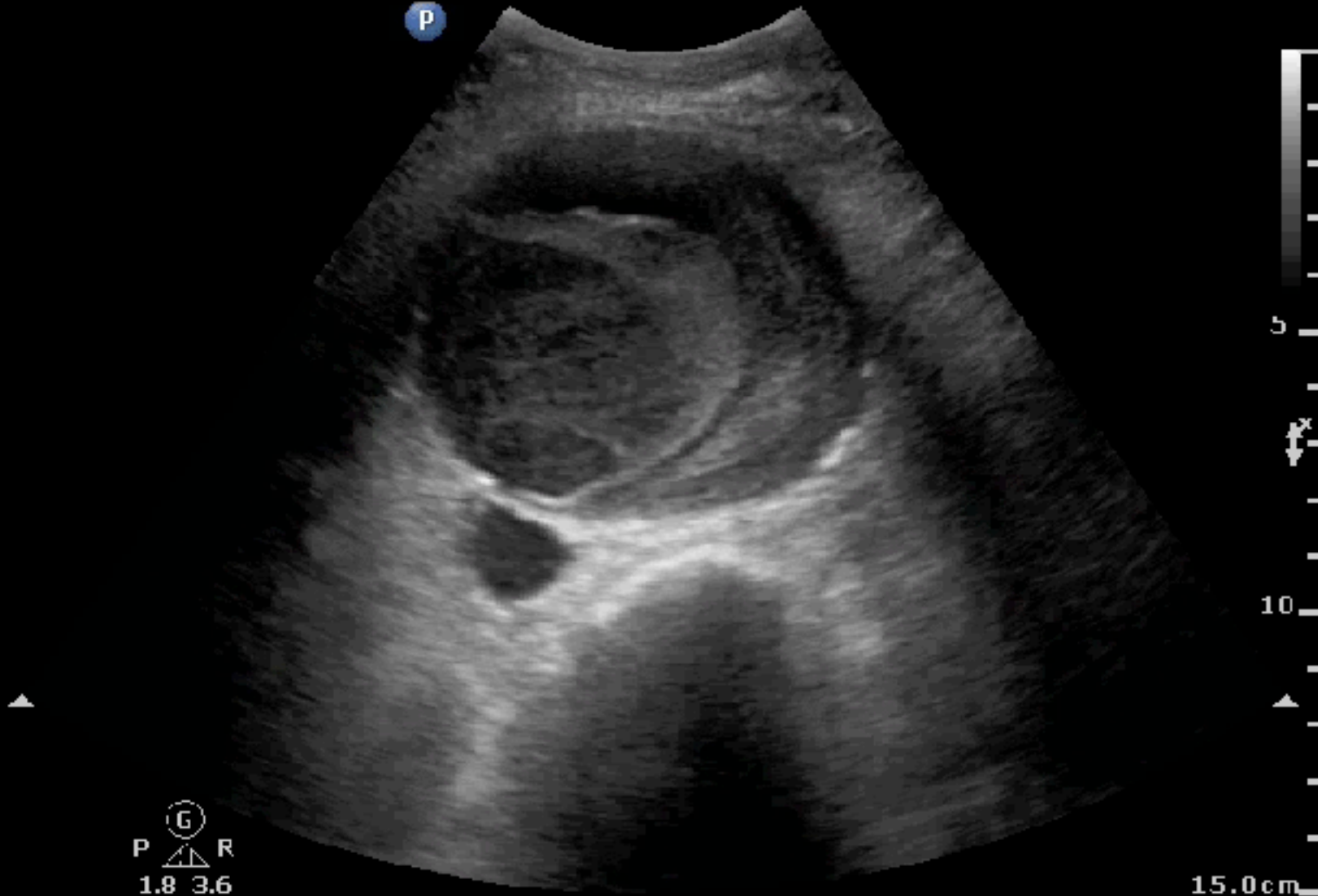


AORTA

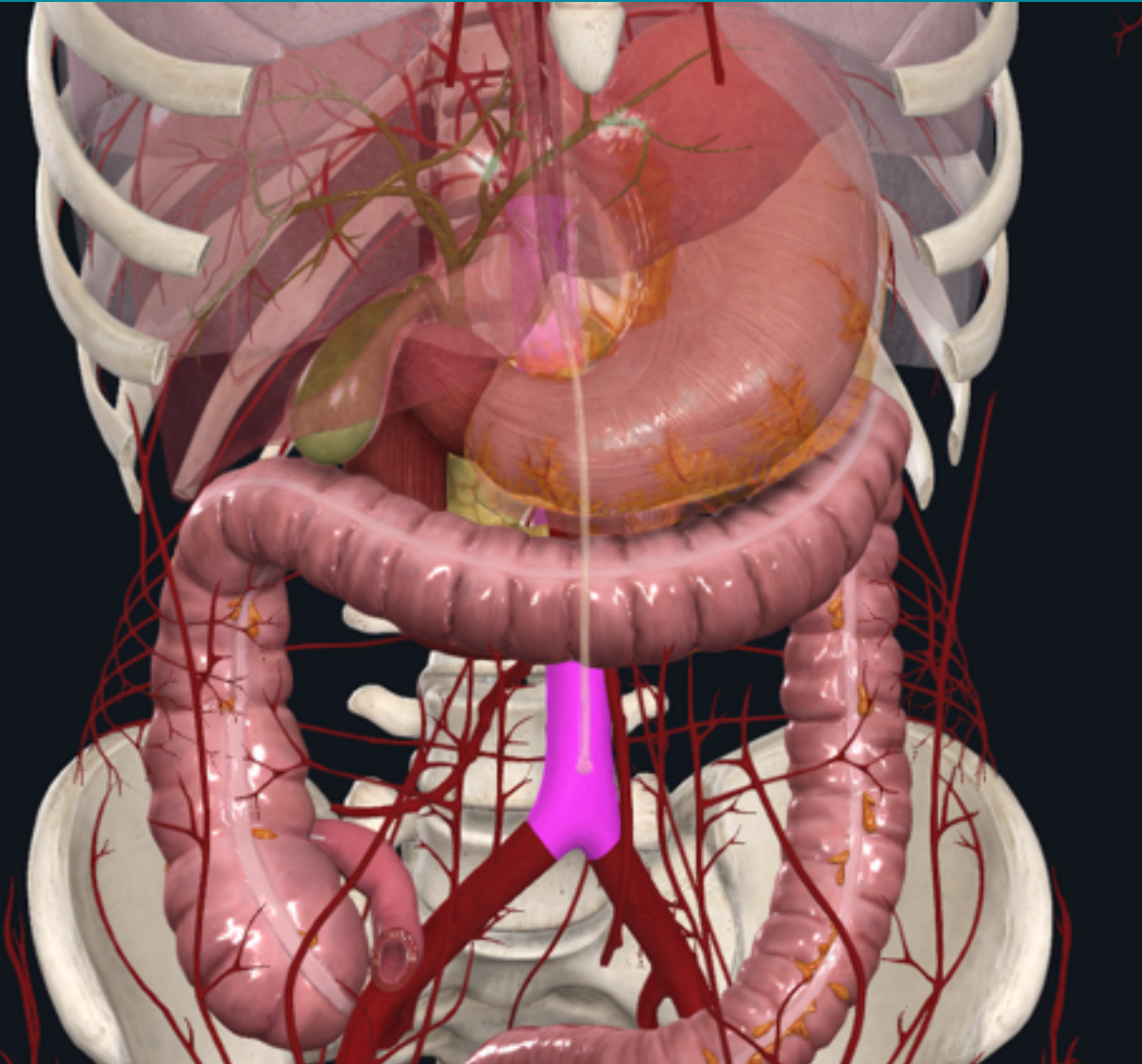
Abd Gen
C.5-1
34 Hz
15.0cm

2D

HGen
Gn 57
C 56
3 / 3 / 3



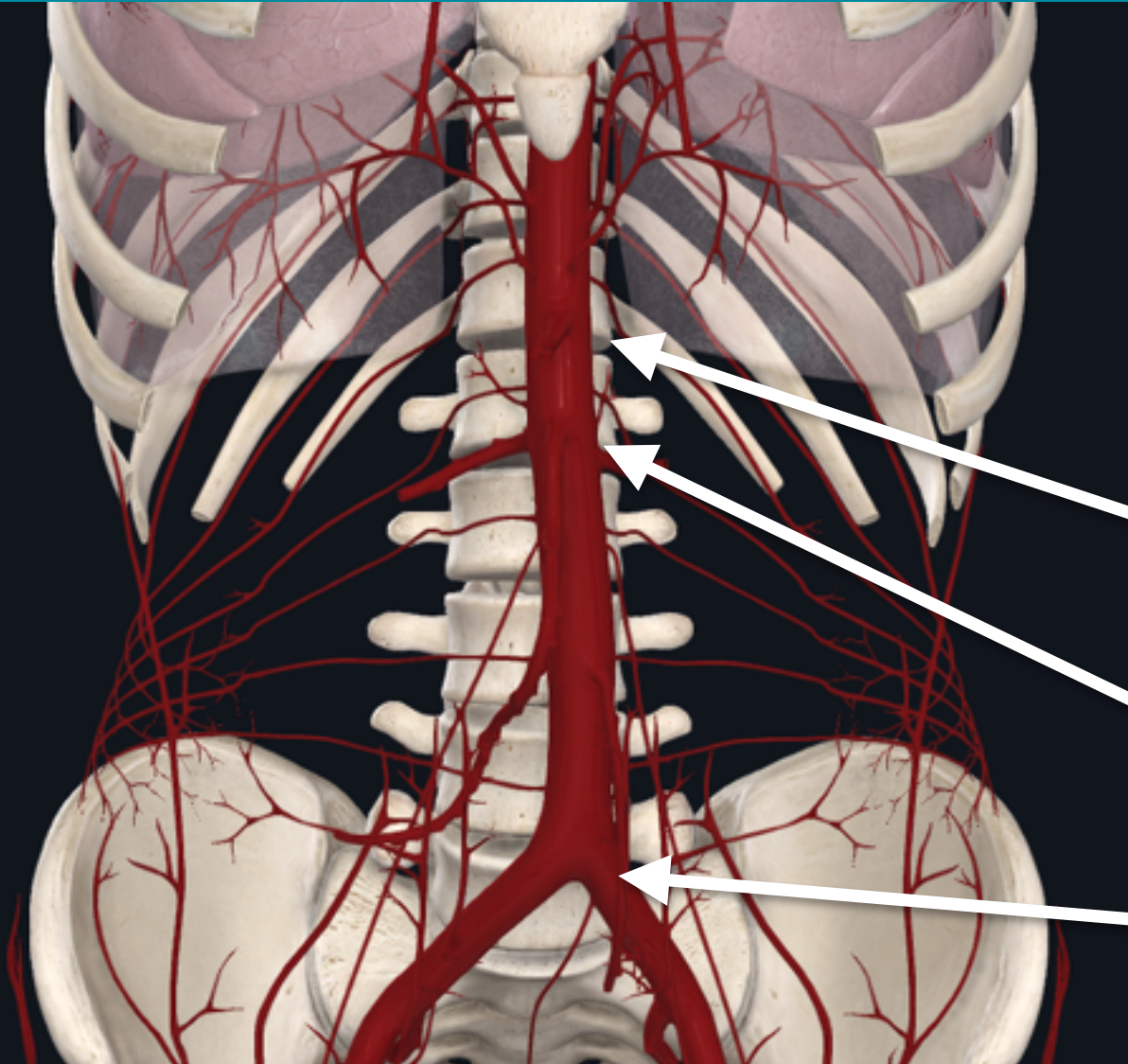
AORTA



Pain
Shock

AAA

AORTA



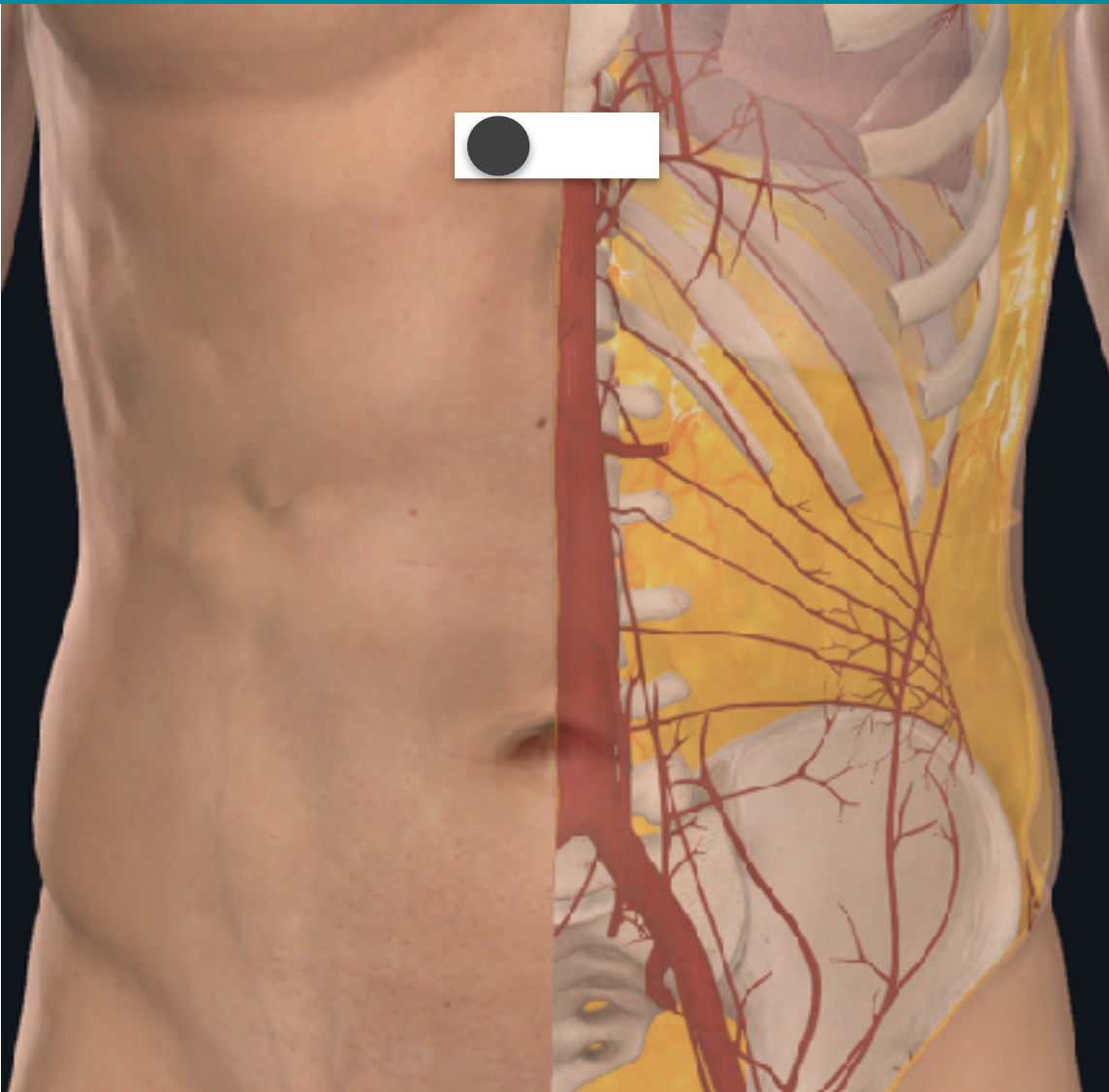
**Abdominal
Aorta (3cm)**

Celiac trunk

SMA

Bifurcation

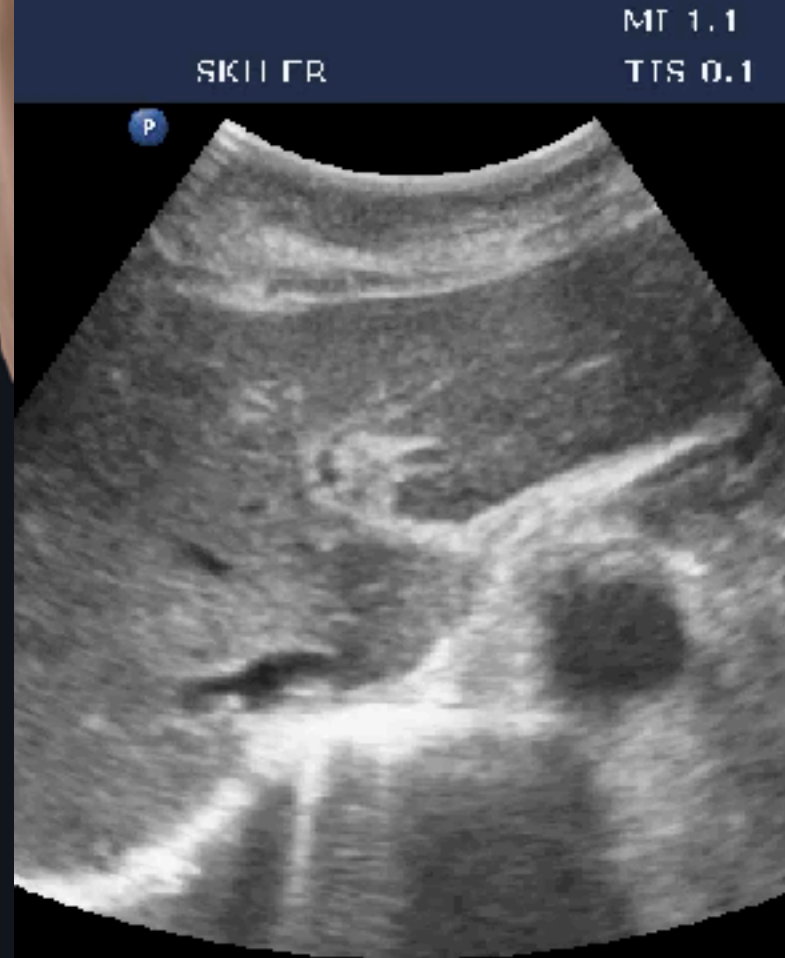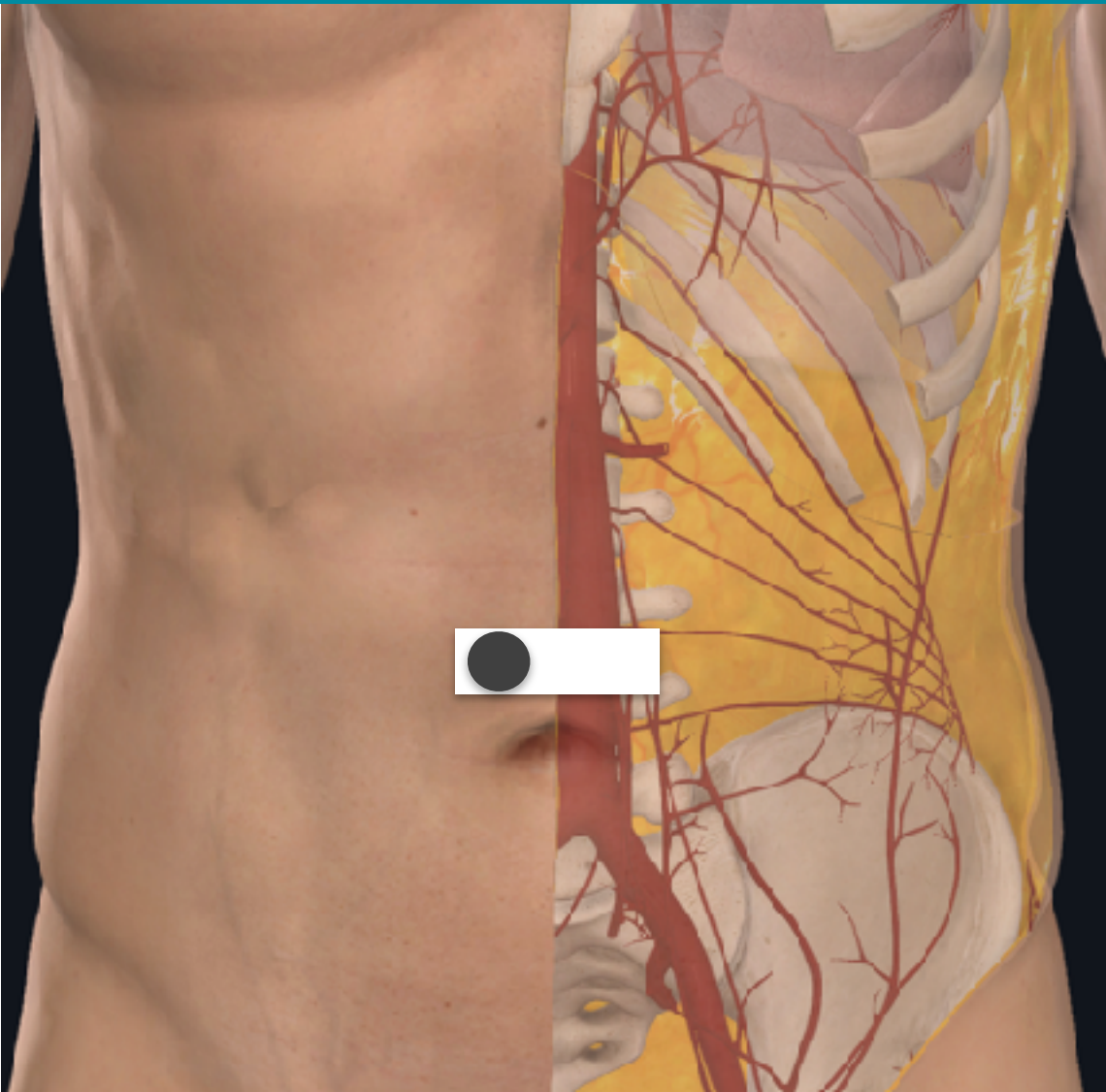
AORTA



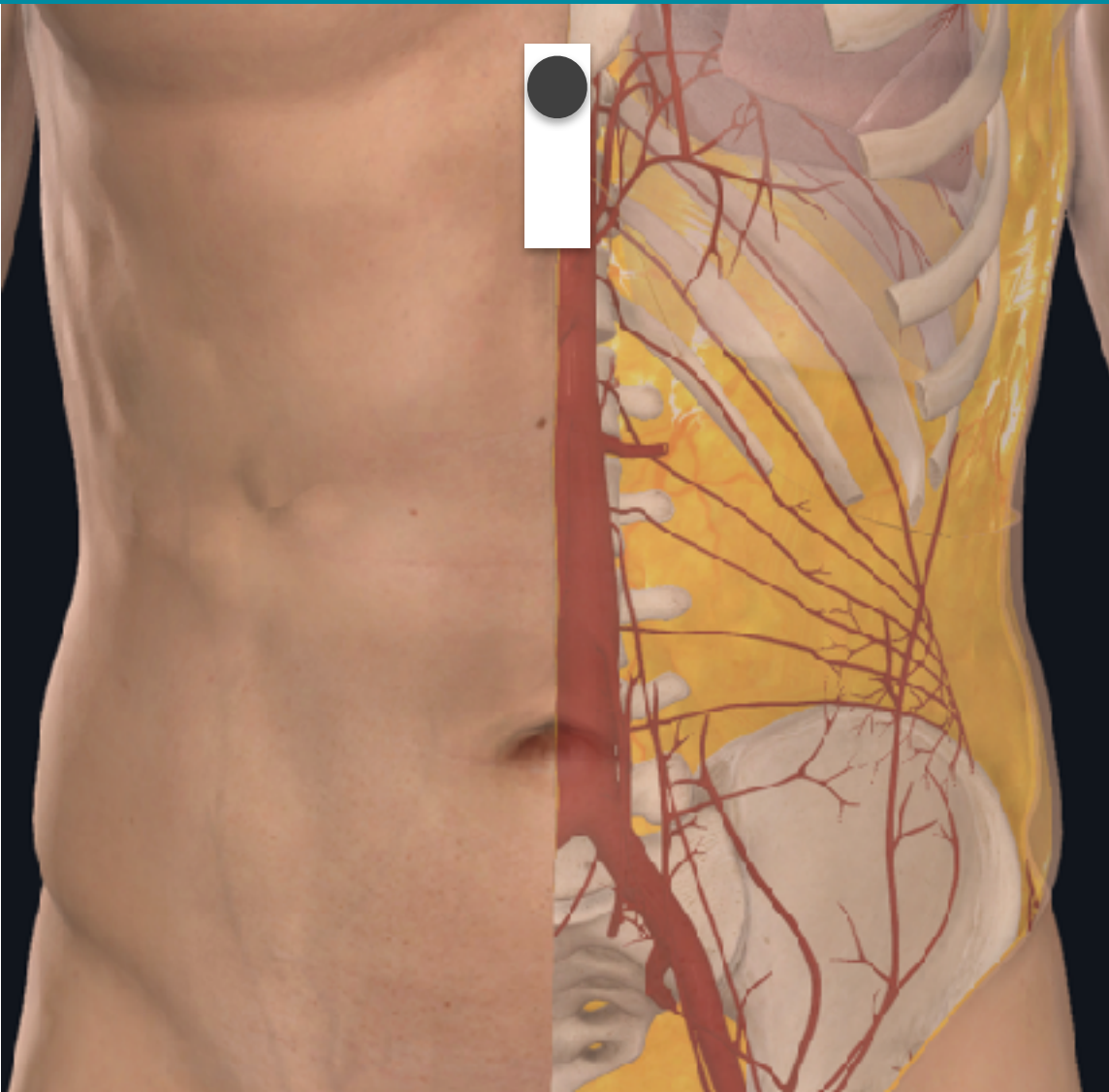
探頭: 弧形

位置: 劍突下

AORTA



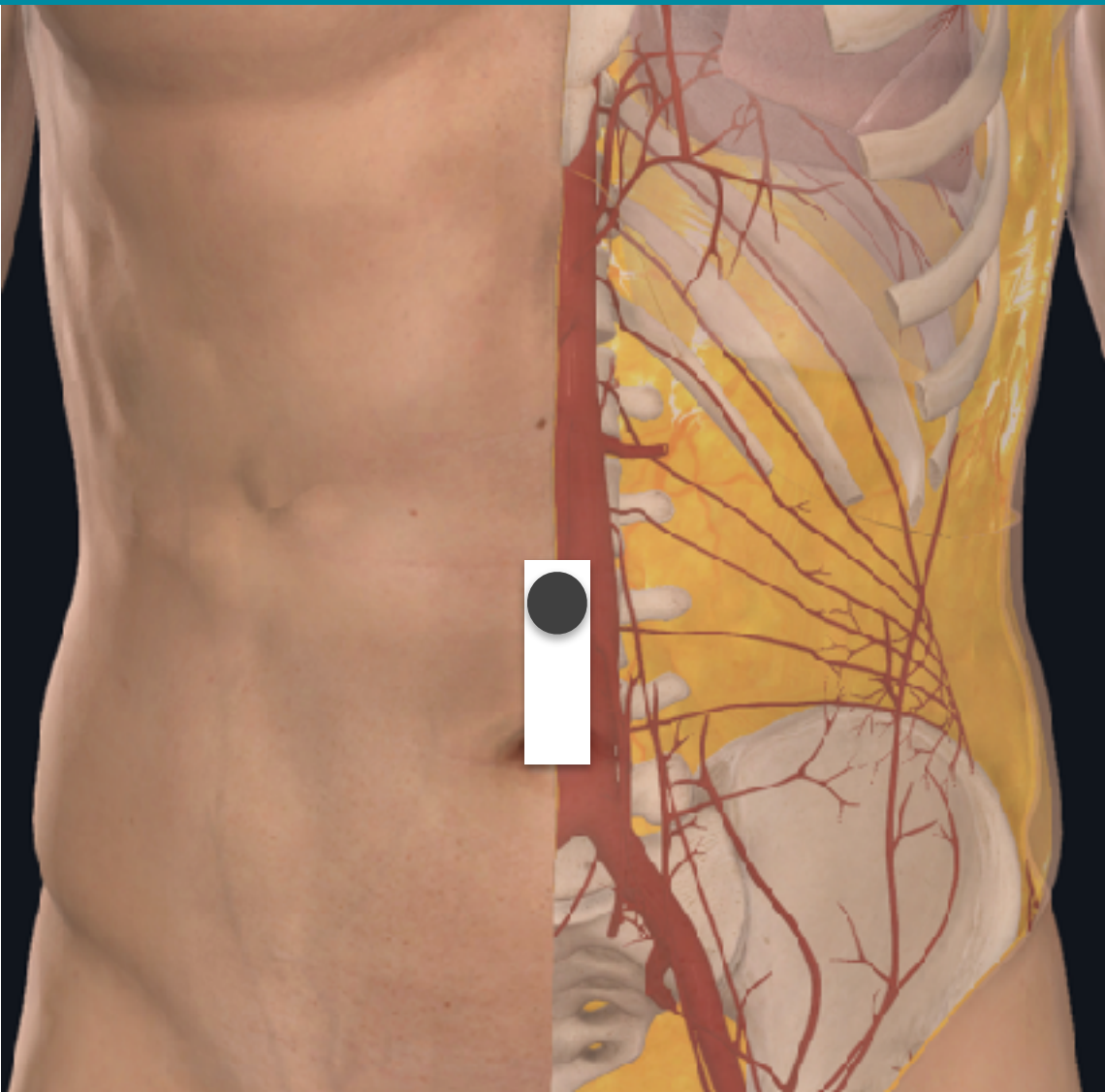
AORTA



探頭: 弧形

位置: 劍突下

AORTA

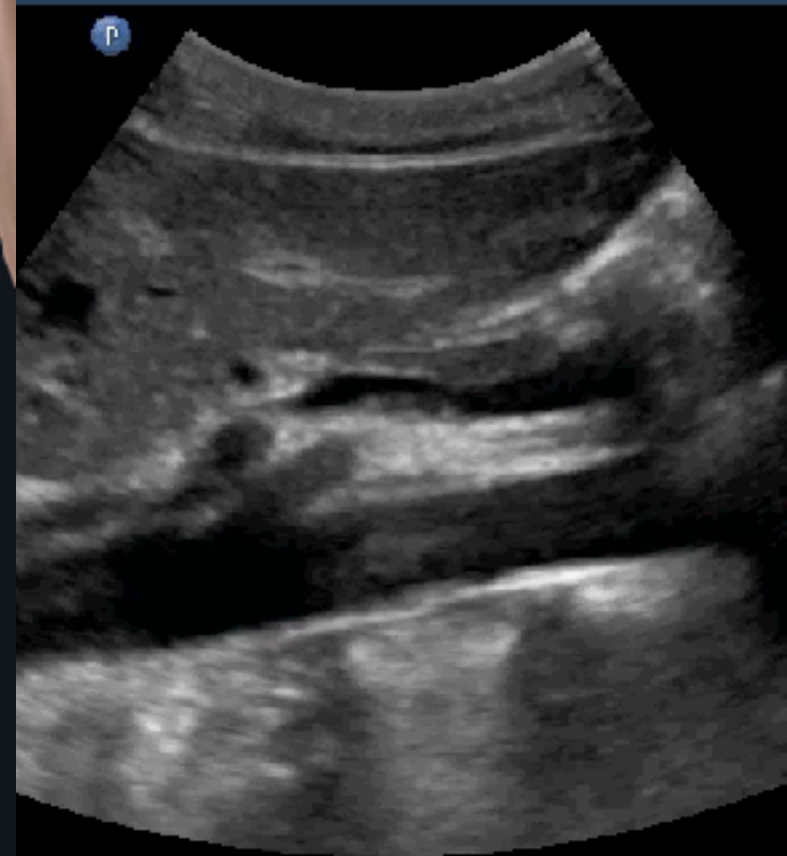

160331172347

SKII ER

MI 1.1

TIS 0.1

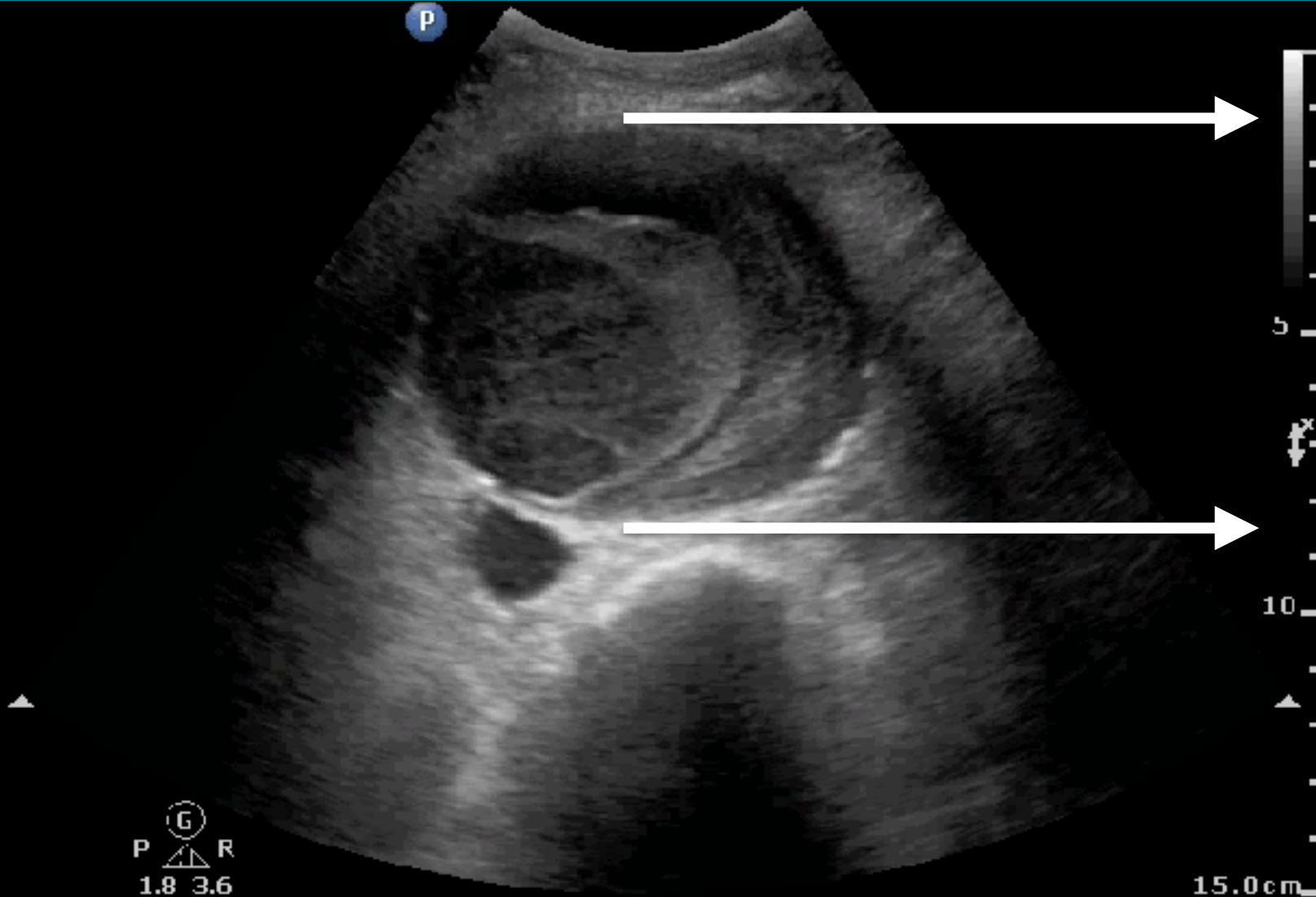


AAA: EYEBALLING

Abd Gen
C.5-1
34 Hz
15.0cm

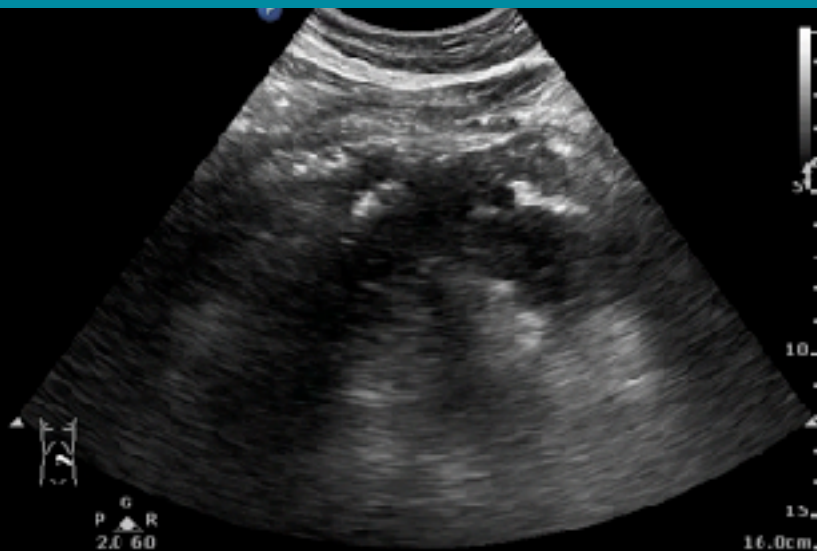
2D

HGen
Gn 57
C 56
3/3/3

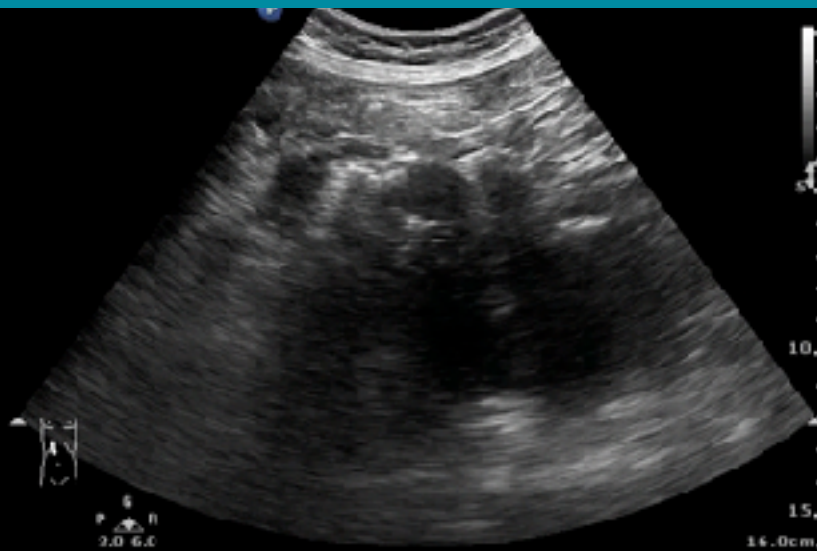


AAA ? RUPTURE ?

C Nerve
C6-2
22 Hz
16.0cm

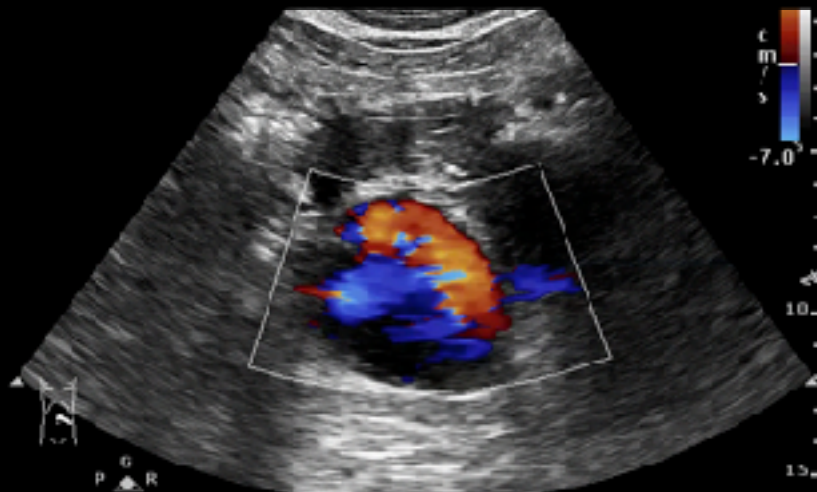


C Nerve
C6-2
22 Hz
16.0cm



11 Hz
16.0cm

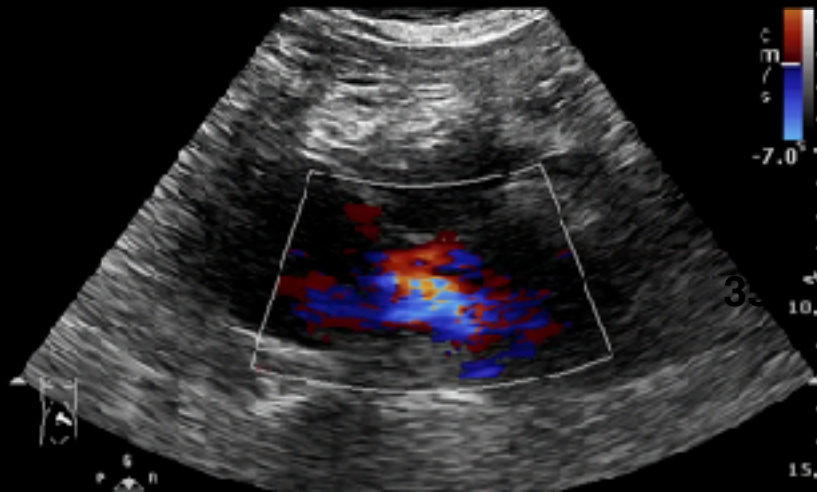
2D
Gen
Gh 60
C 53
2/3/3



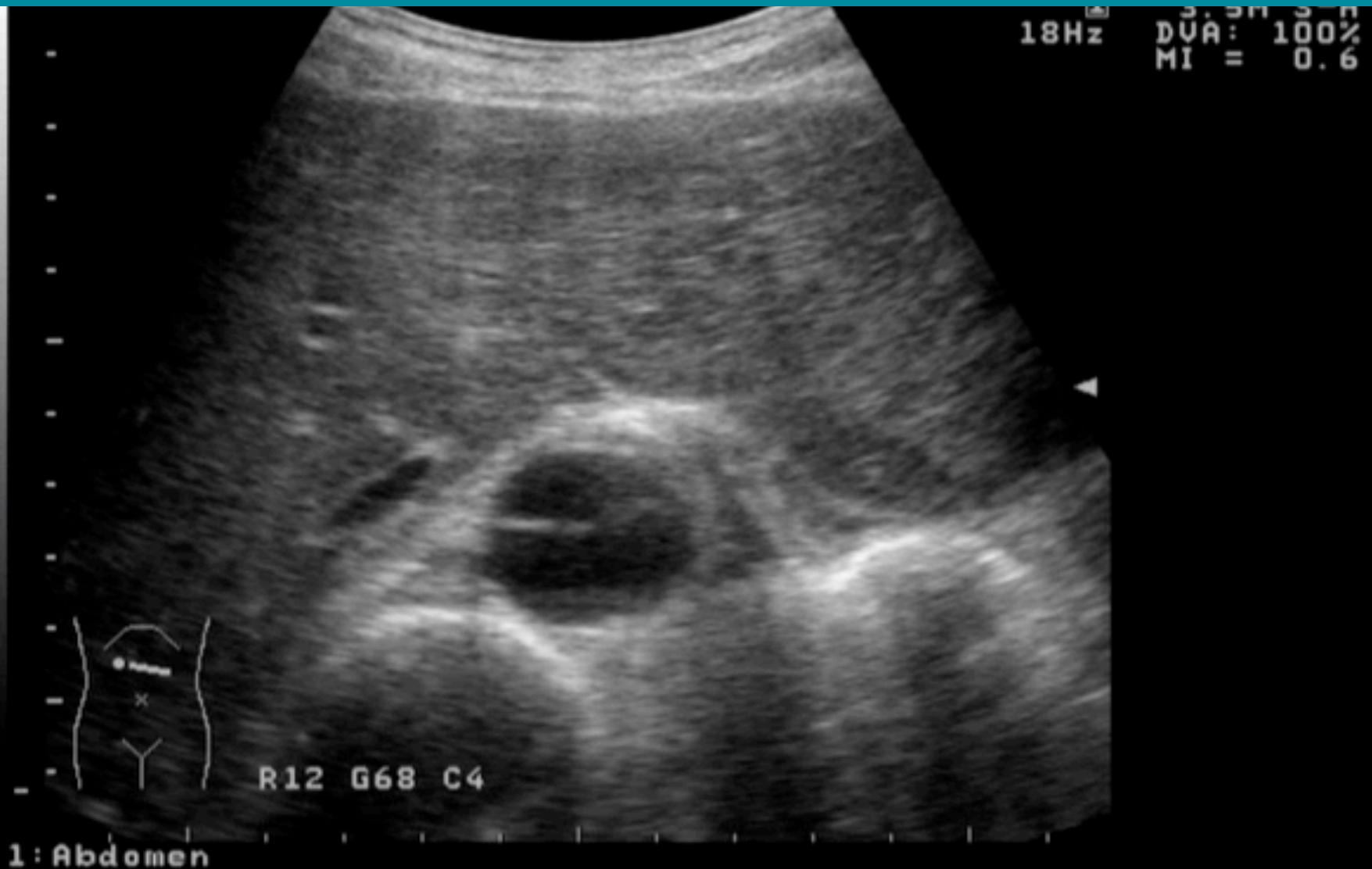
11 Hz
16.0cm

2D
Gen
Gh 60
C 53
2/3/3

Color
2.5 MHz
Gh 66
3/5/4
Filtr Med



AAA ?



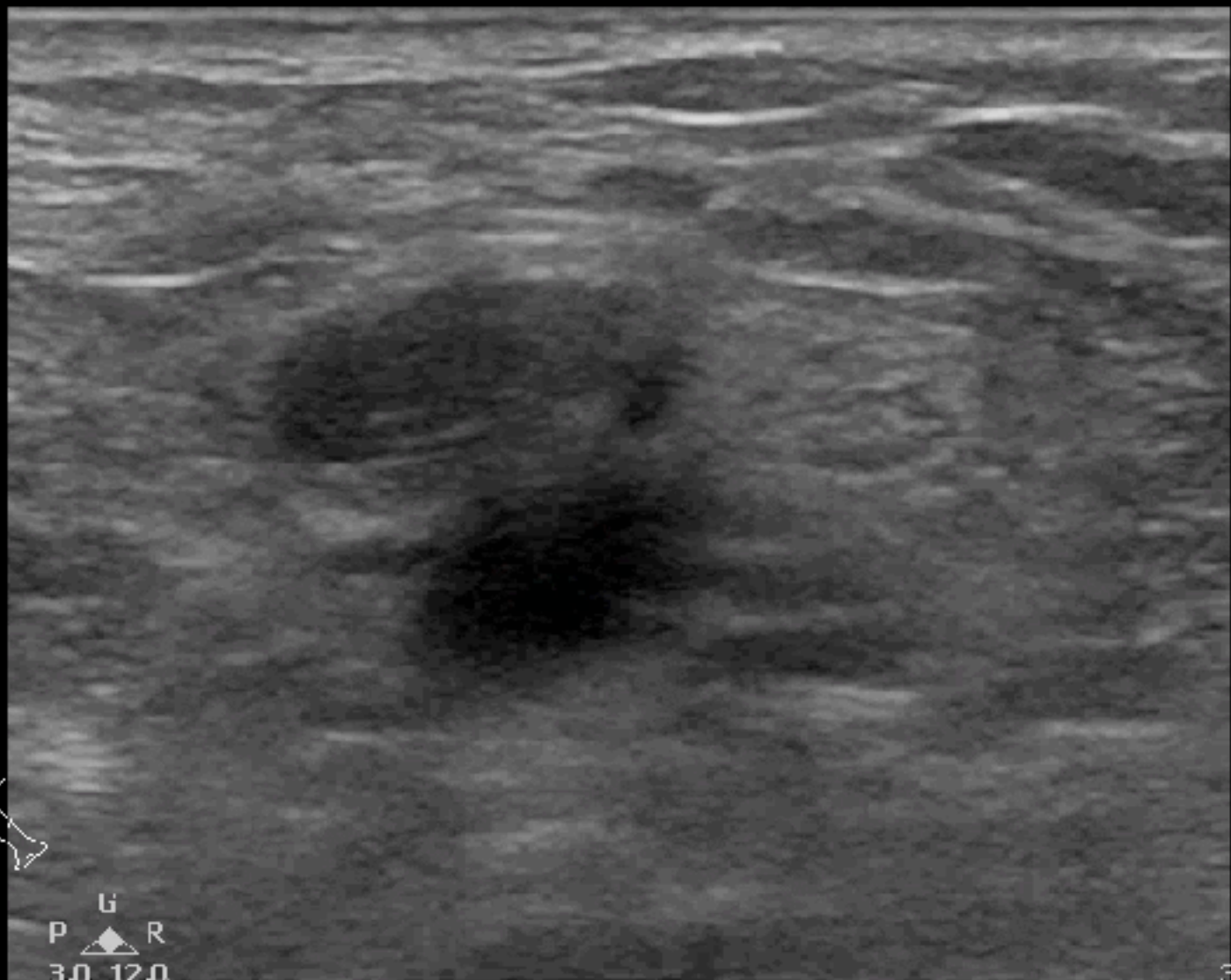
DVT



Superficial
_12-3
31 Hz
3.0cm

P

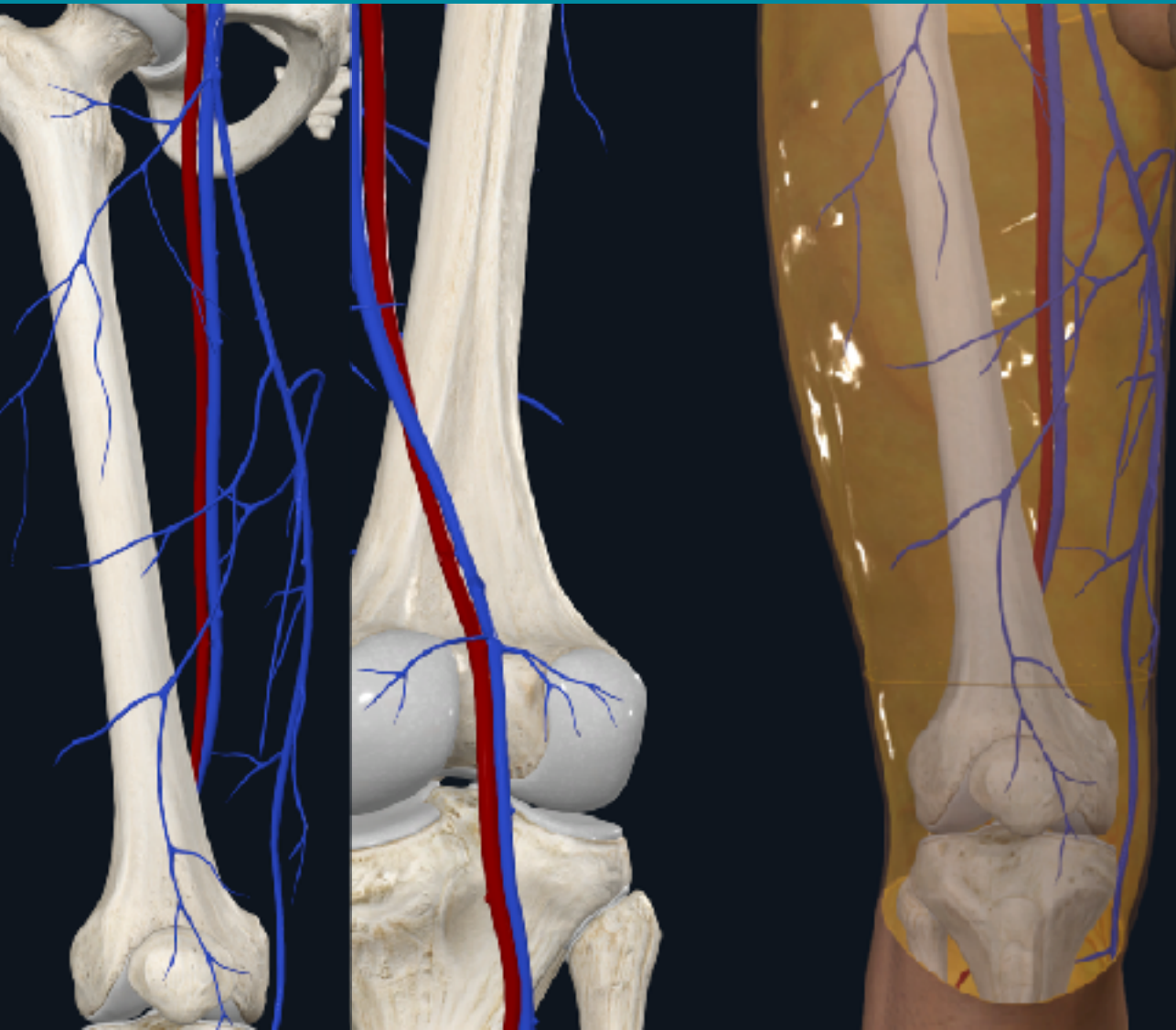
2D
Gen
Gn 88
C 52
4/3/2



G
P ▲ R
3.0 12.0

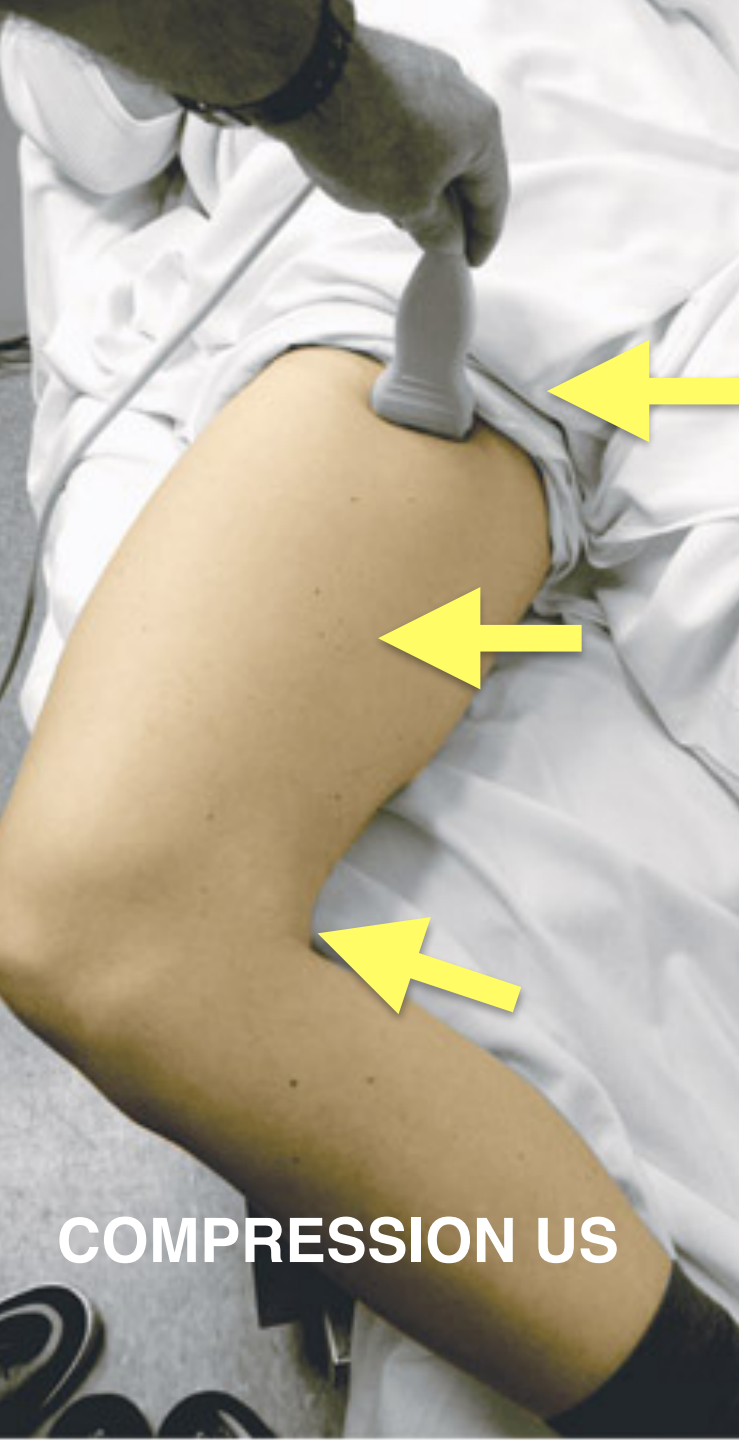
3.0cm

DVT

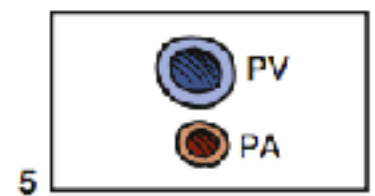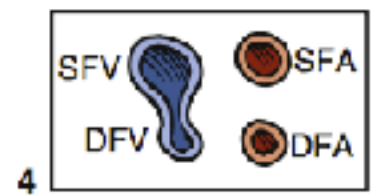
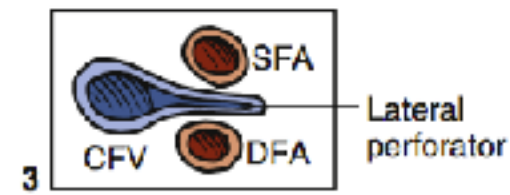
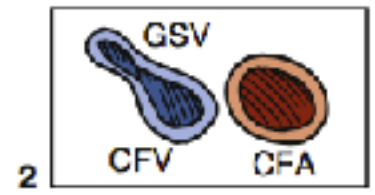
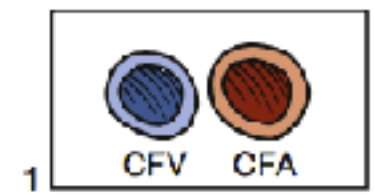
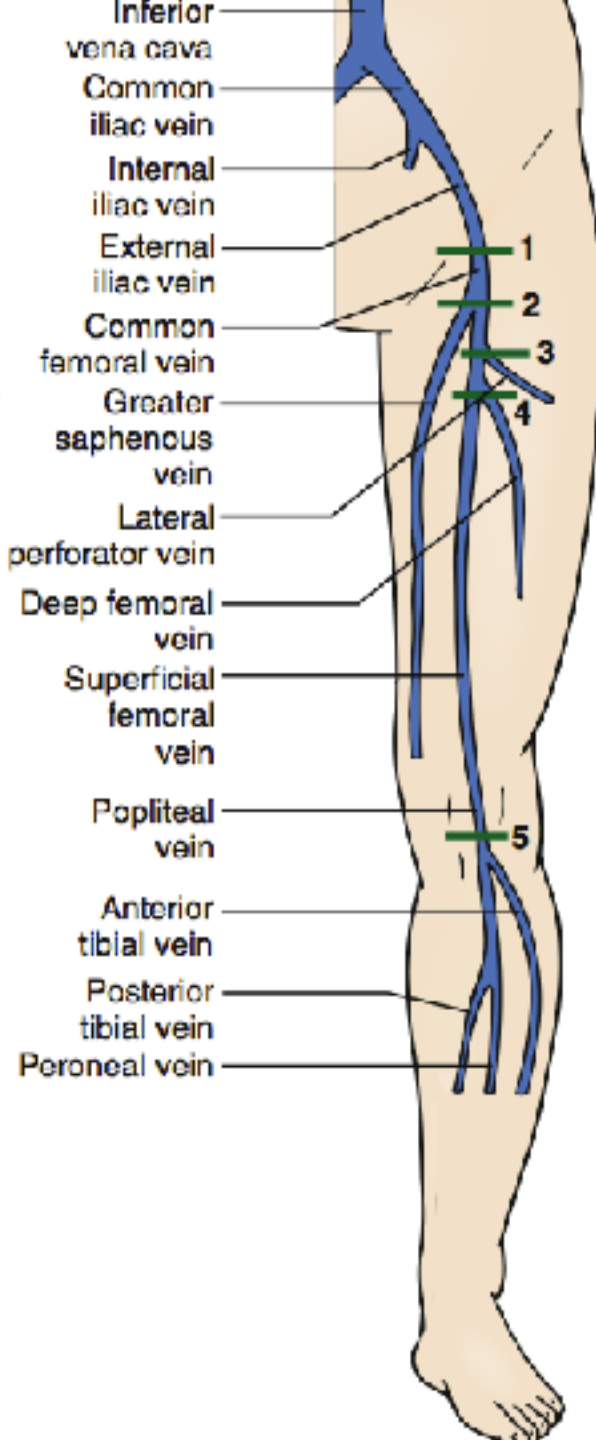


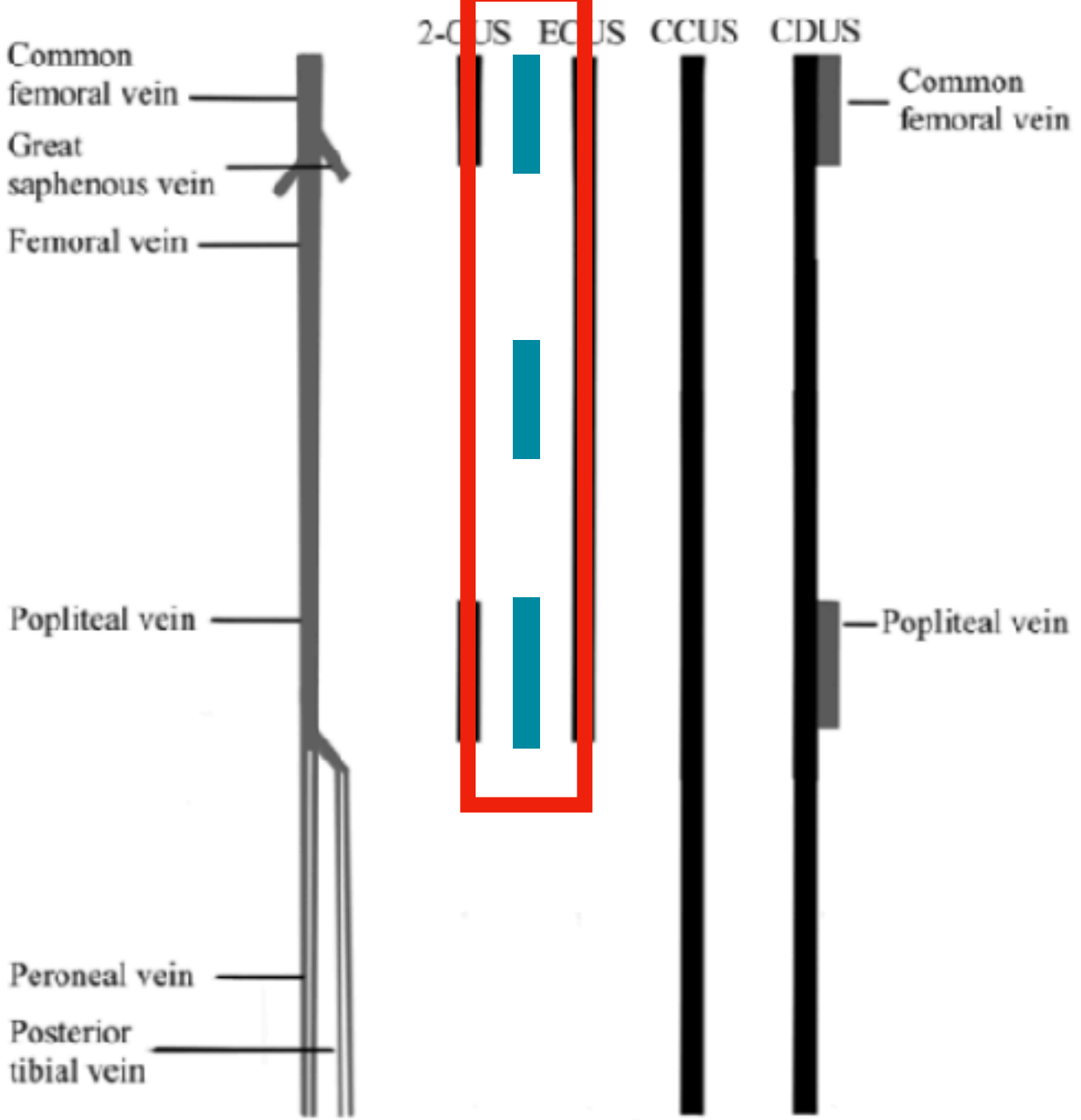
Swelling
Dyspnea
Shock

DVT



COMPRESSION US



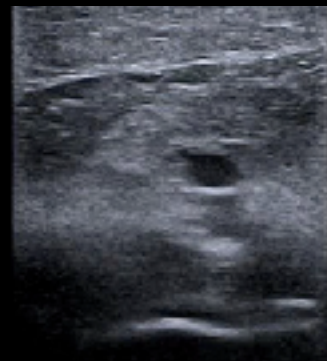
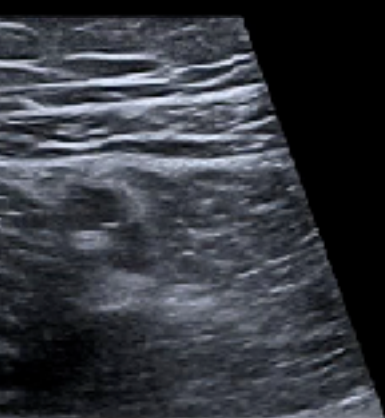
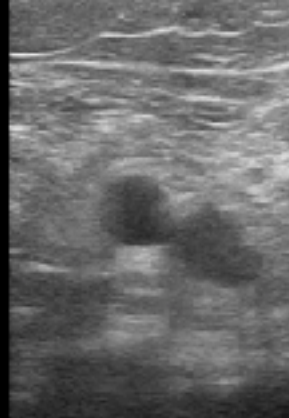


3 regions
Sen 90.57%
Spe 98.52%

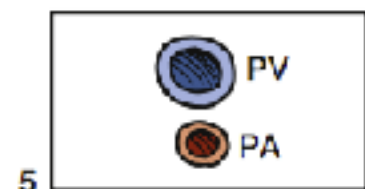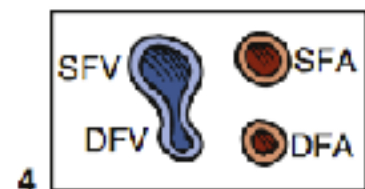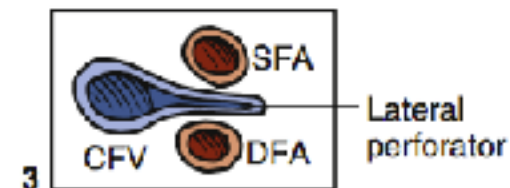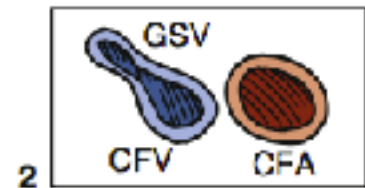
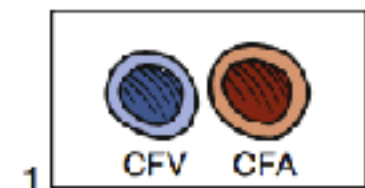
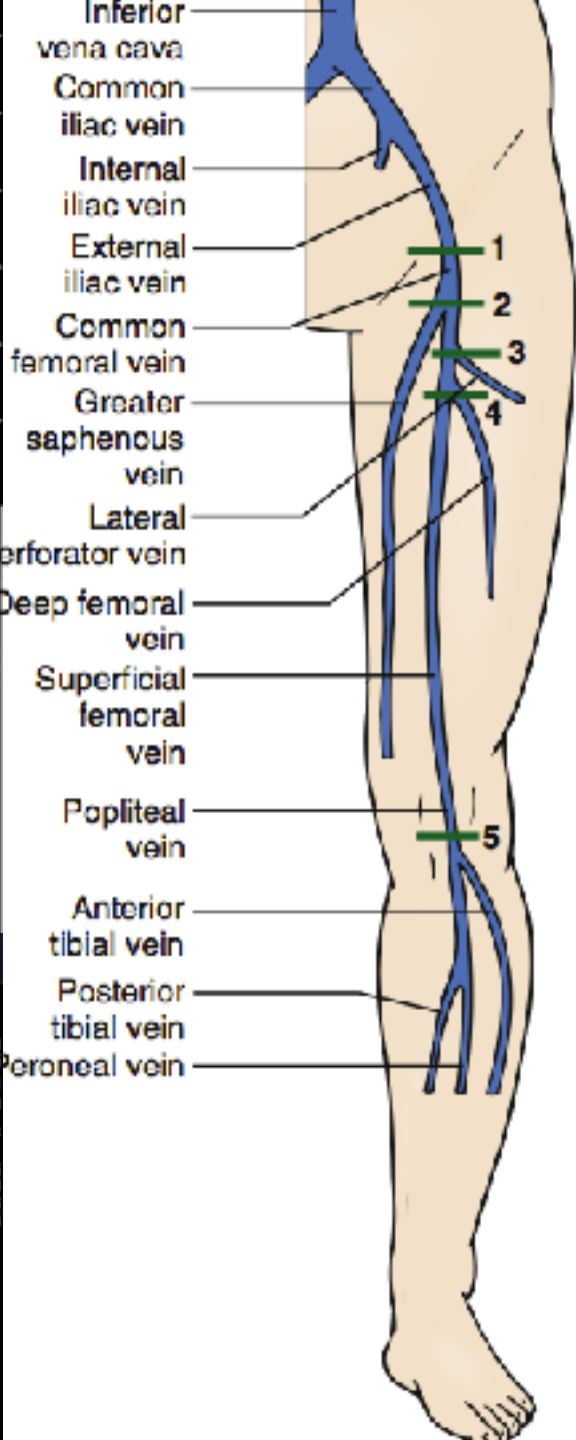
2 regions
Sen 82.76%
Spe 98.52%

Heather Hale, MD

0cm
Gen
n 32
41
7/3/12

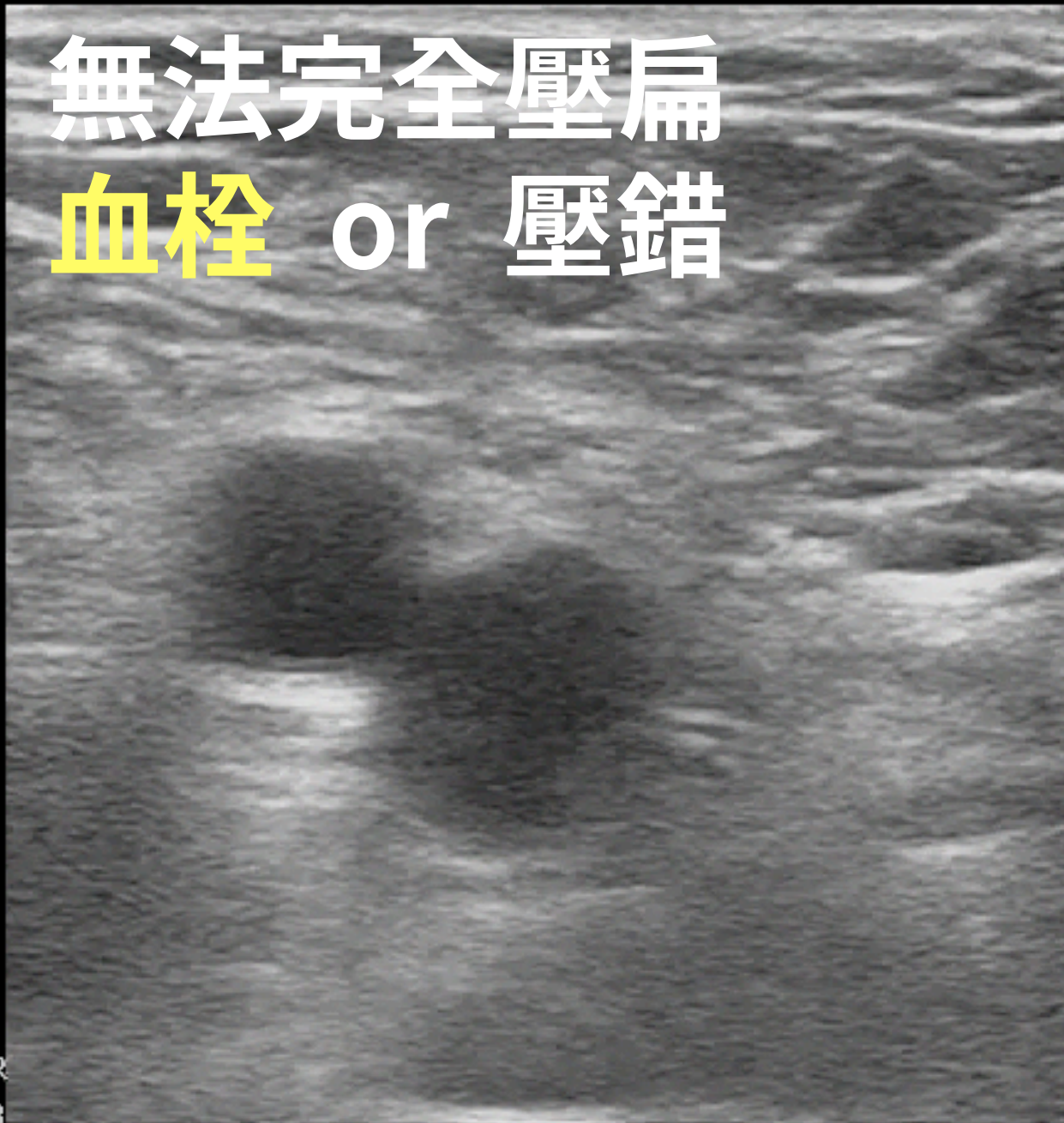


6.0cm
MI 1.5
11L4
dWT0.0
25 fps
G86
DR.80
A15
P3



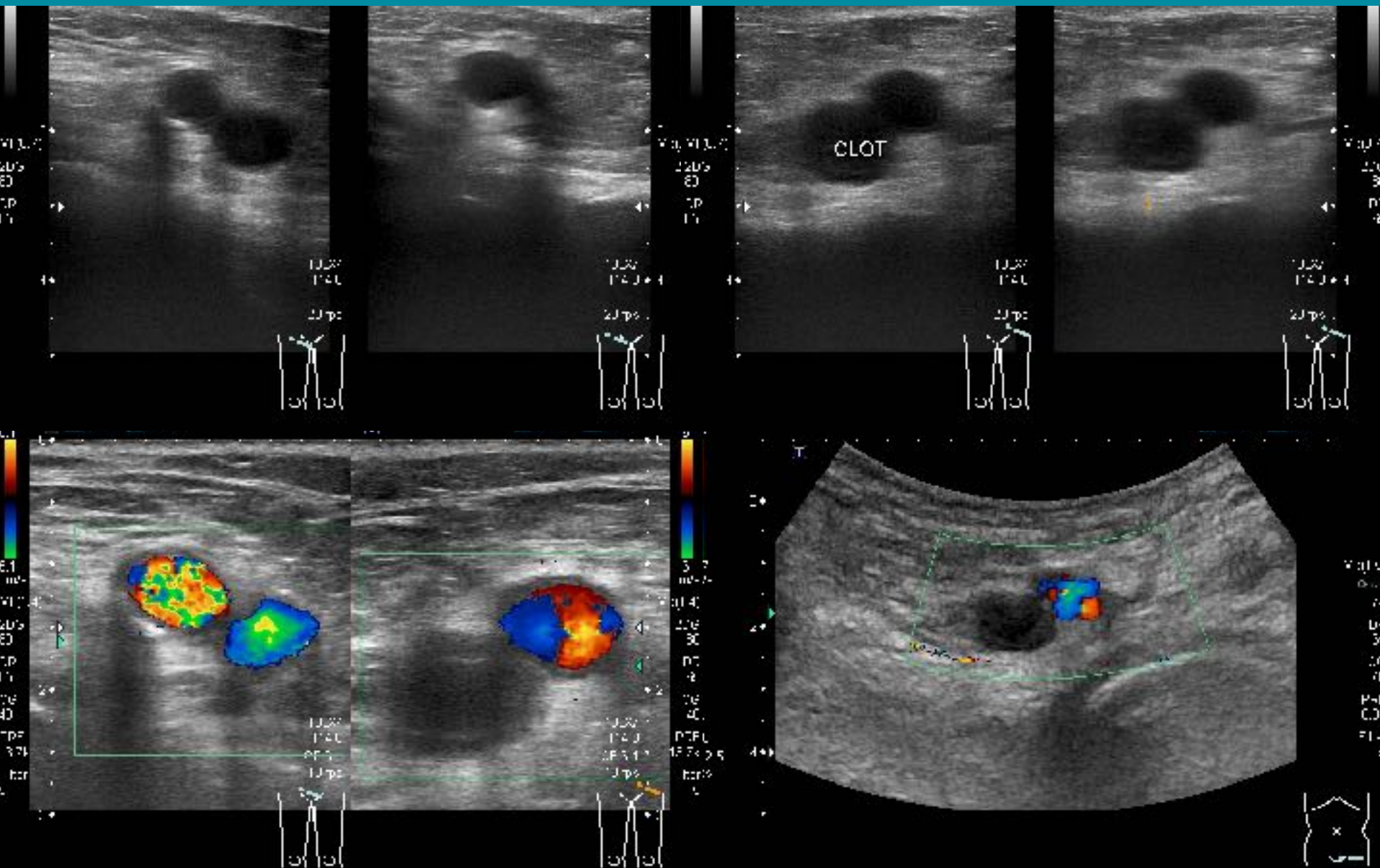
P

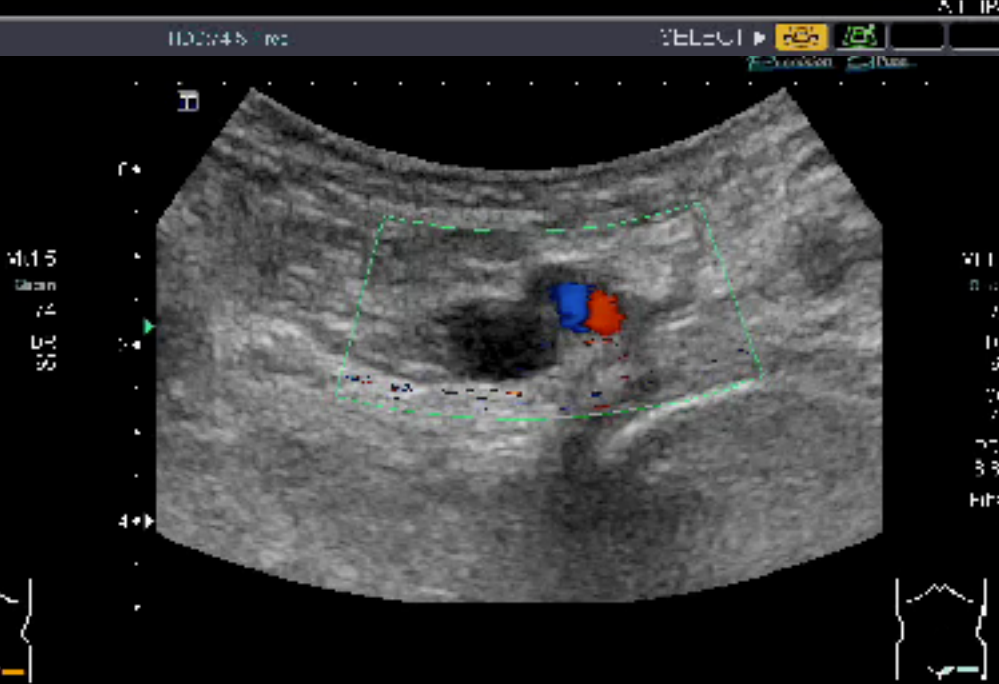
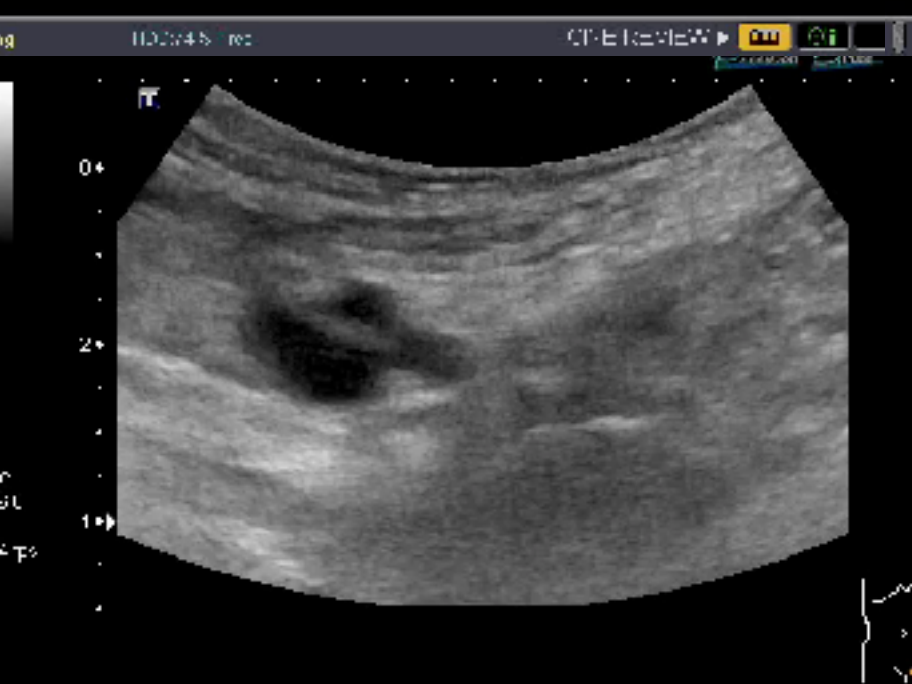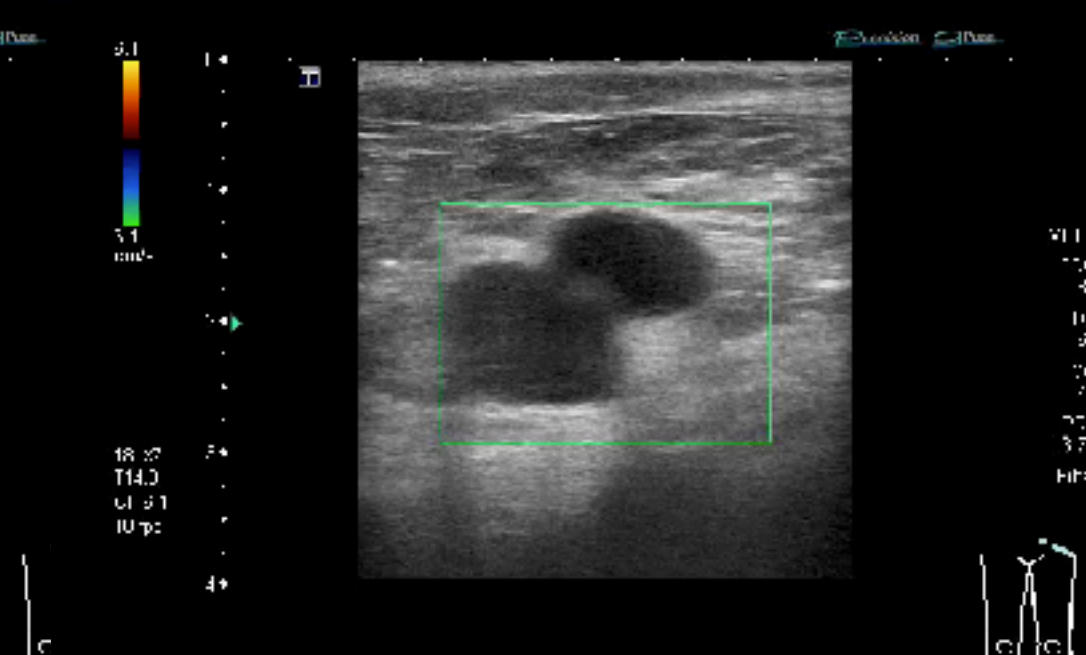
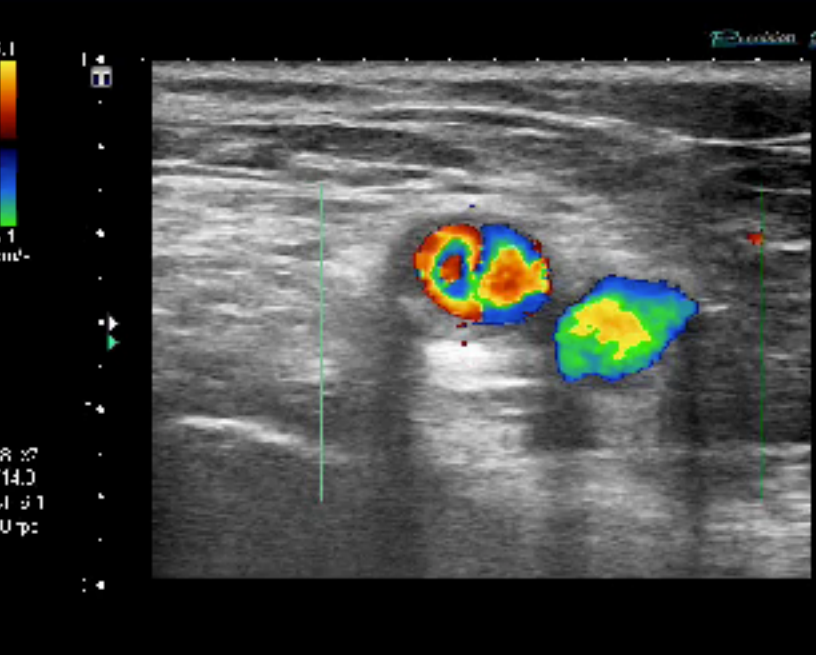
無法完全壓扁
血栓 or 壓錯



G
P R
4.4 8.8

DVT的記錄





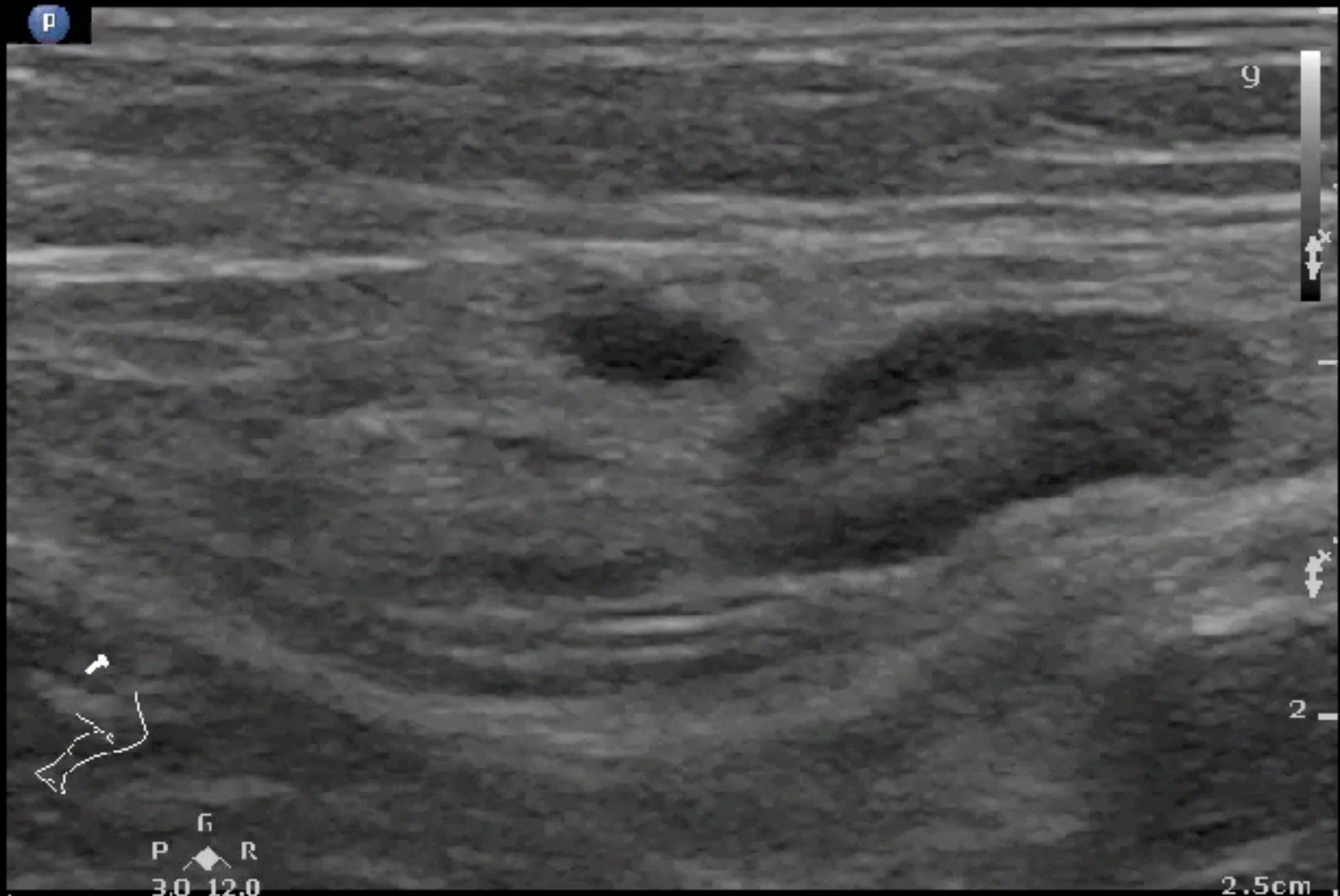
DVT ?

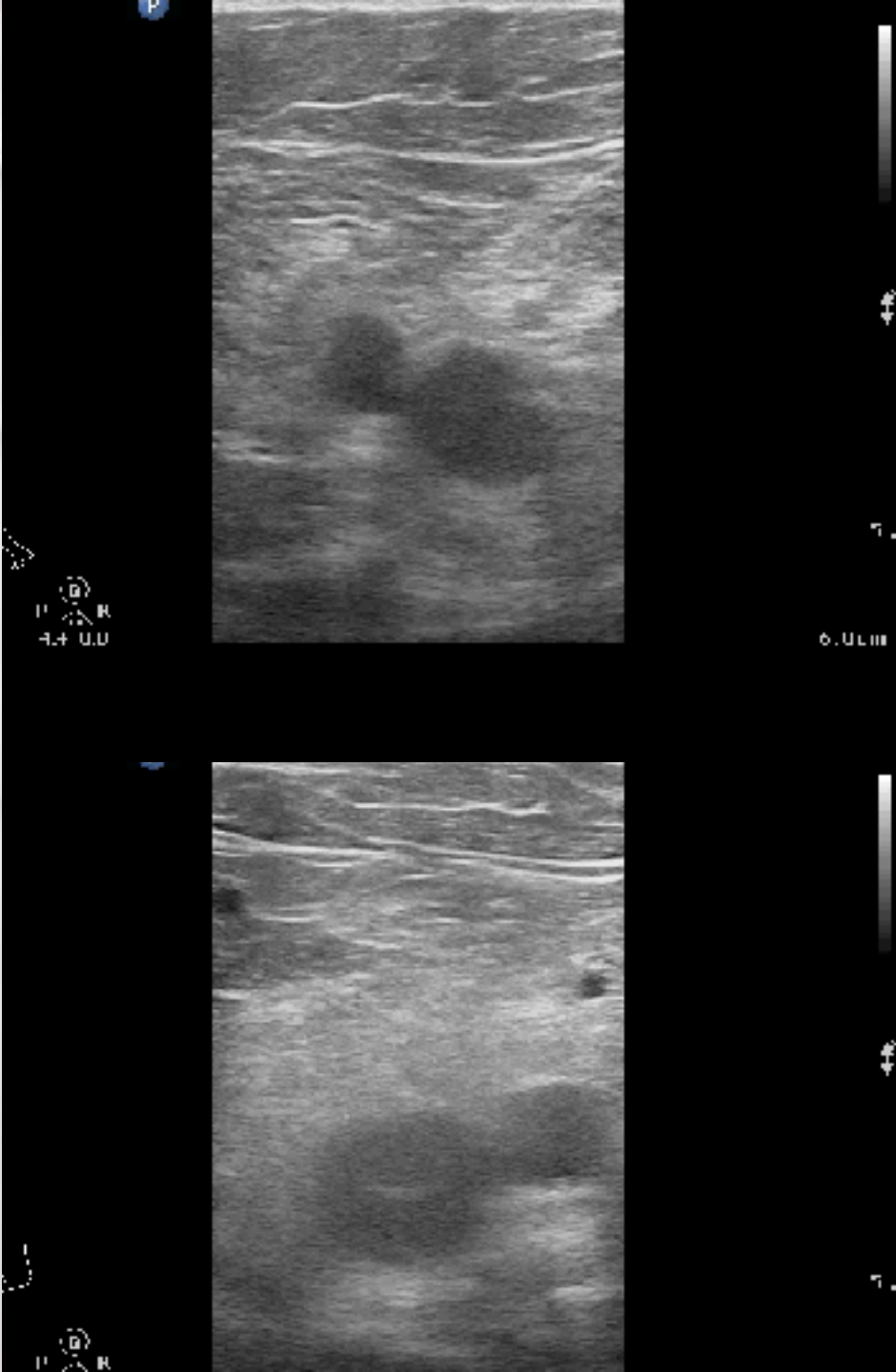
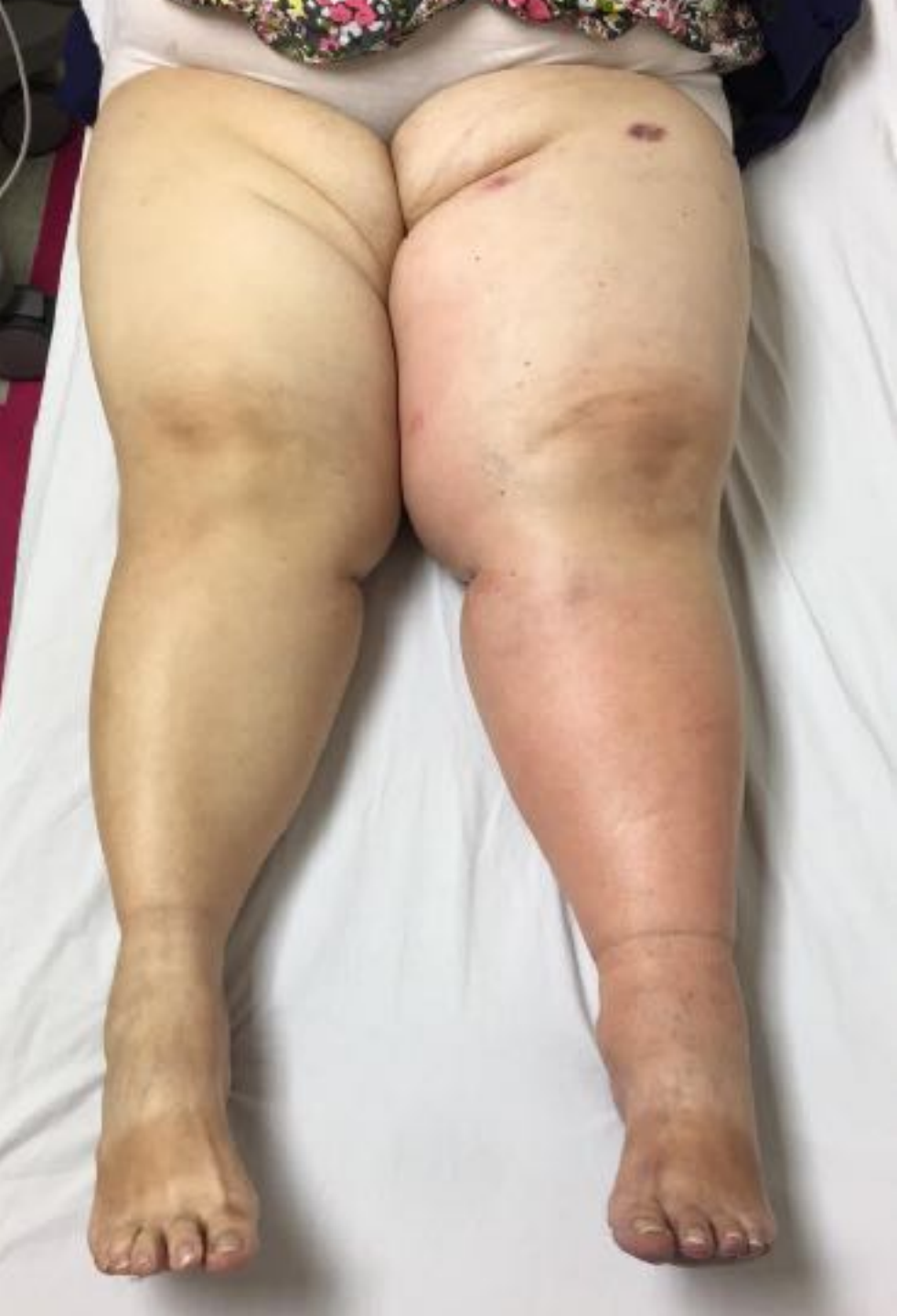Superficial

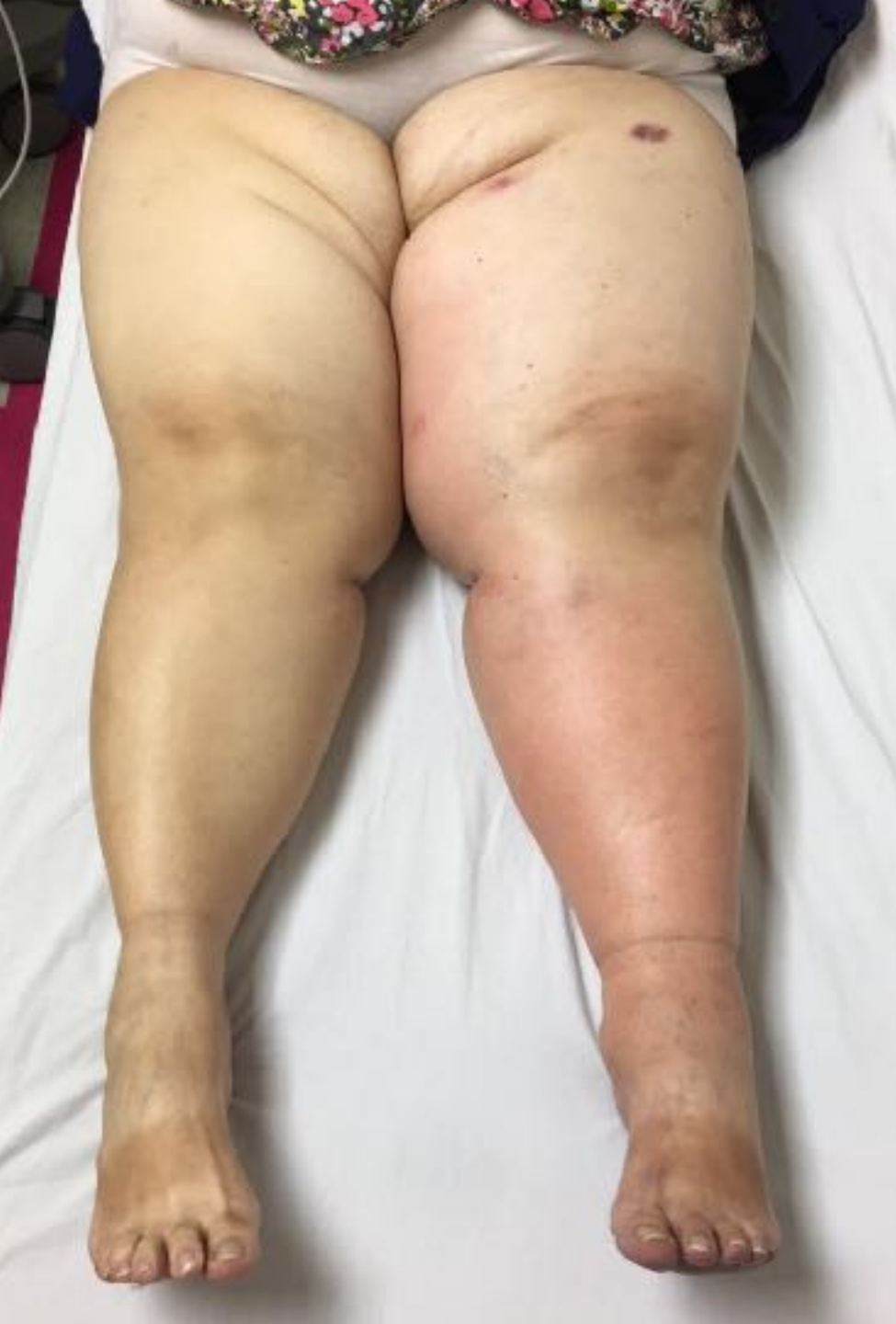L12-3
34 Hz
2.5cm

2D

Gen
Gn 60
C. 57
4/3/2

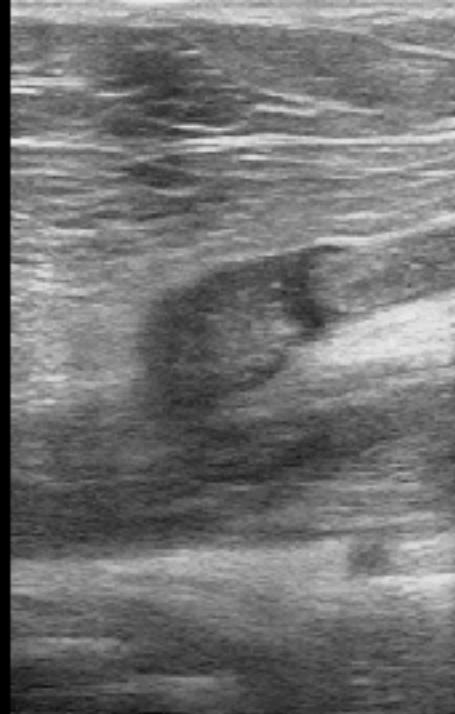




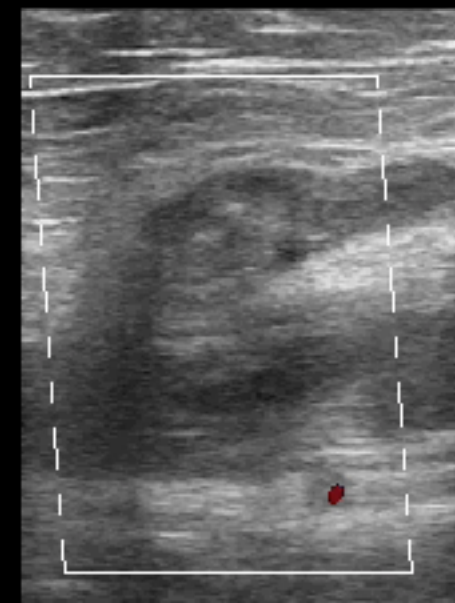


P
R
D.D

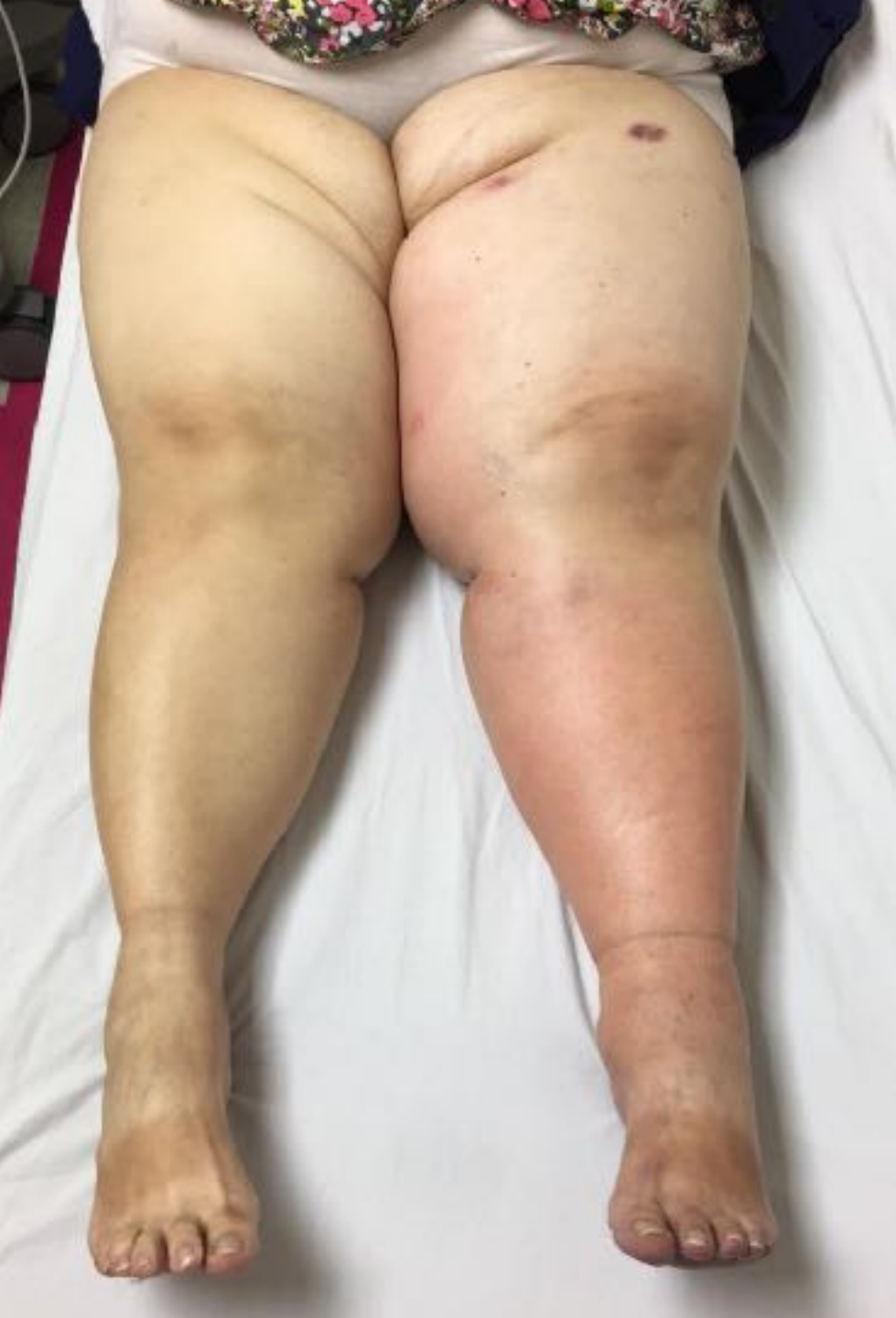P
R
D.D



6.0cm

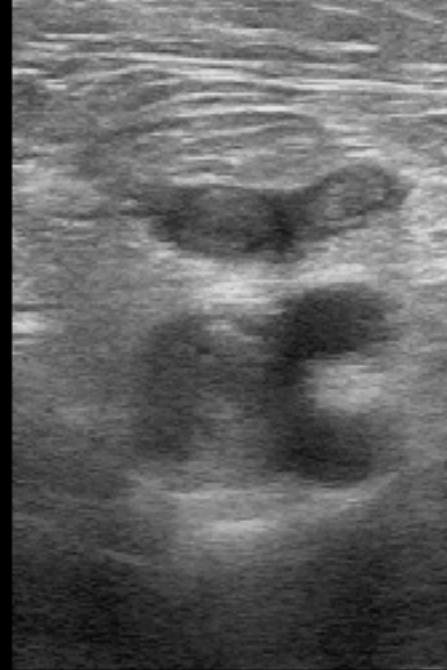

cm/s
-1.0

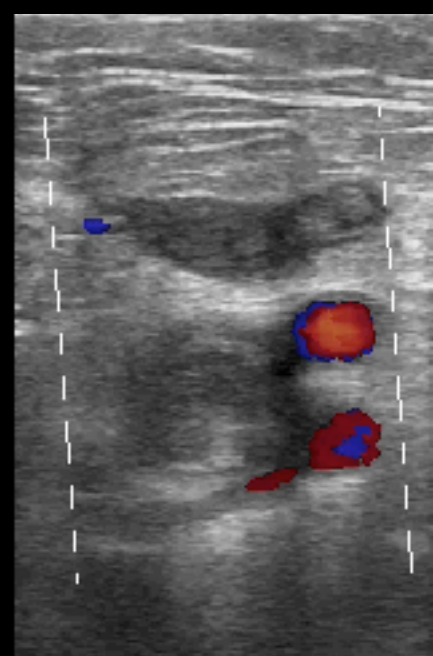


P
R
4.1 8.8

P
R



0.0cm



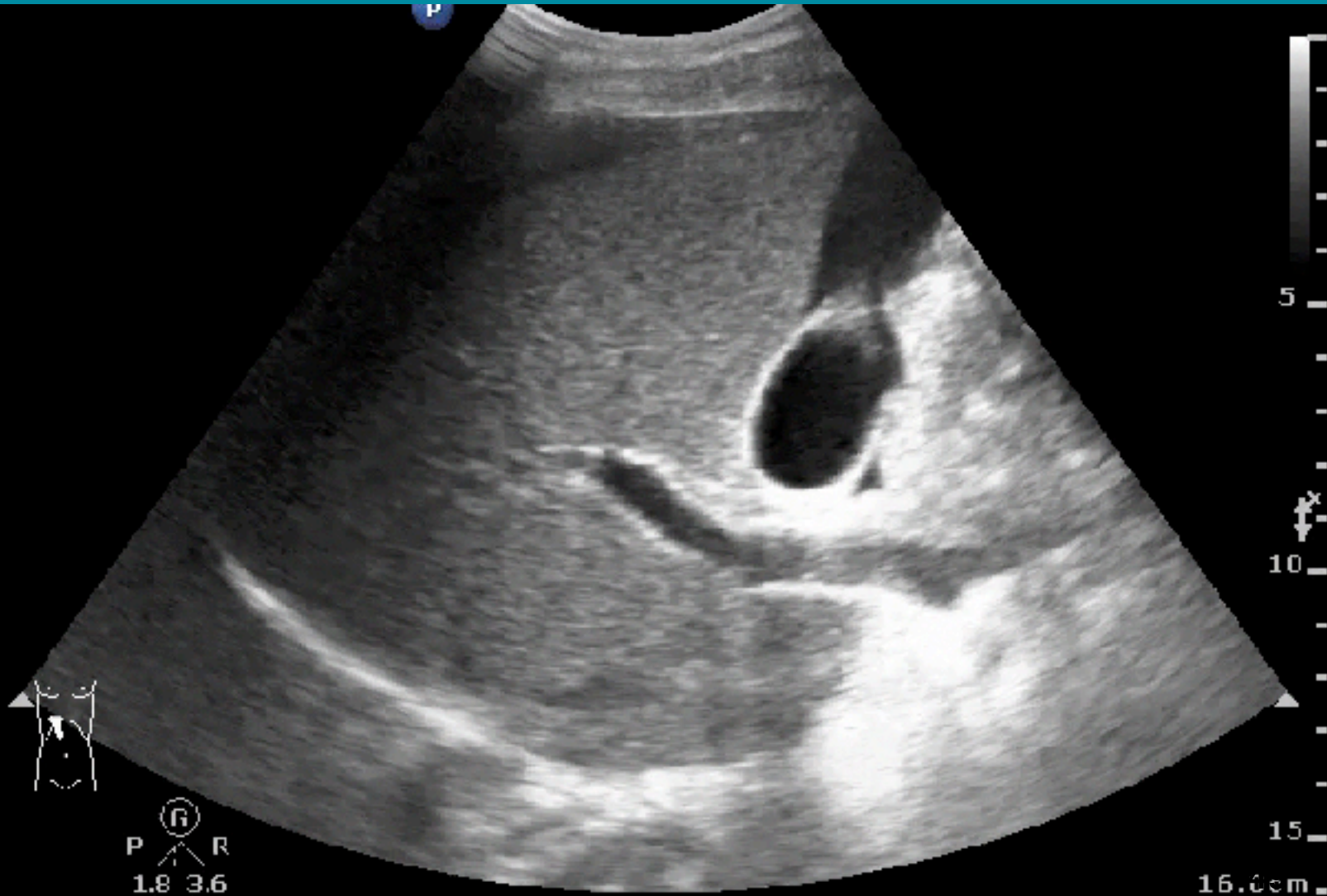
7.0
cm/s
-7.0

FAST

FOCUSED ASSESSMENT WITH SONOGRAPHY FOR TRAUMA

Abd Gen
C5-1
32 Hz
16.0cm

2D
HGen
Gn 90
C. 56
3 / 3 / 3



P R
1.8 3.6

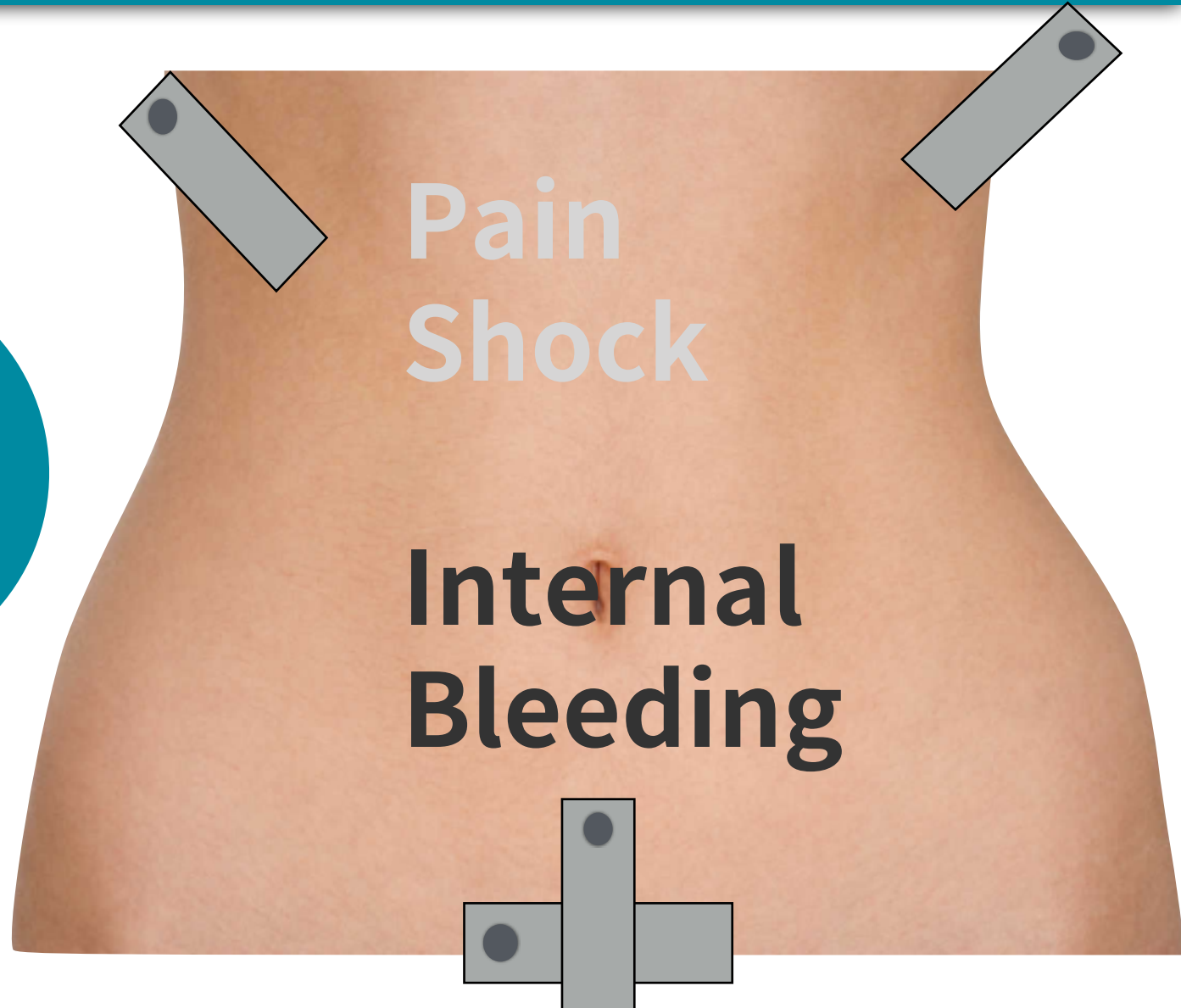
16.0cm



Free fluid



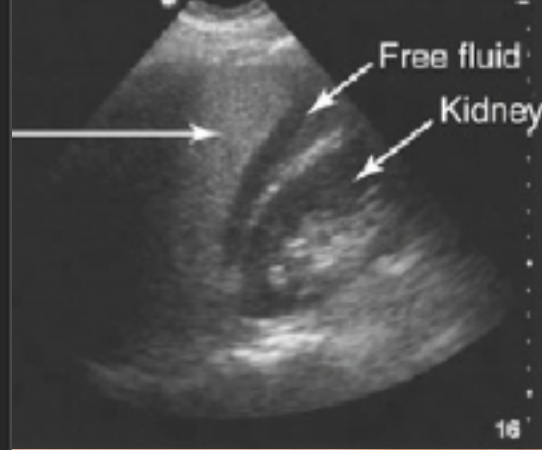
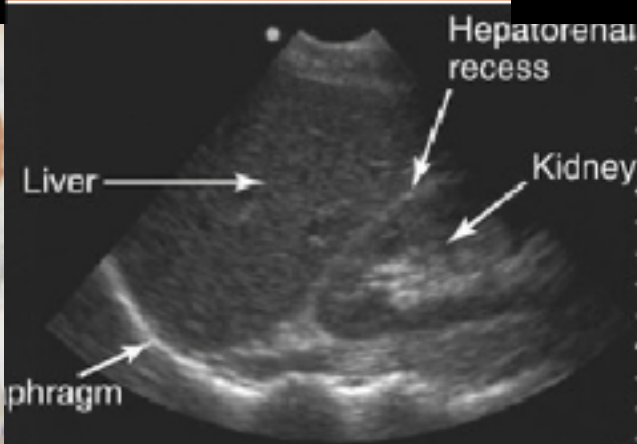
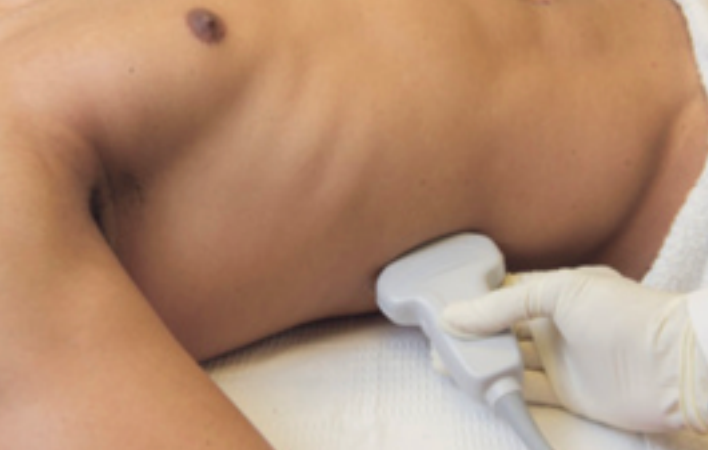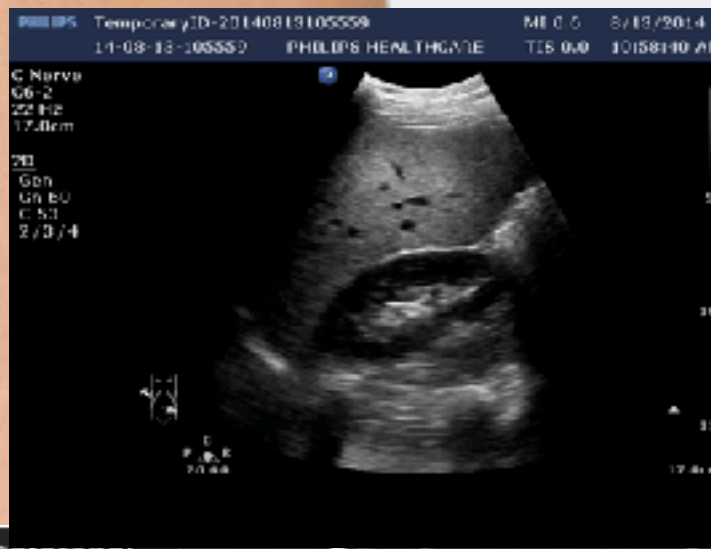
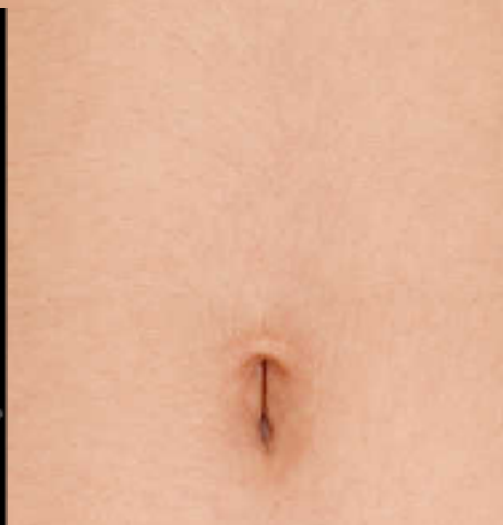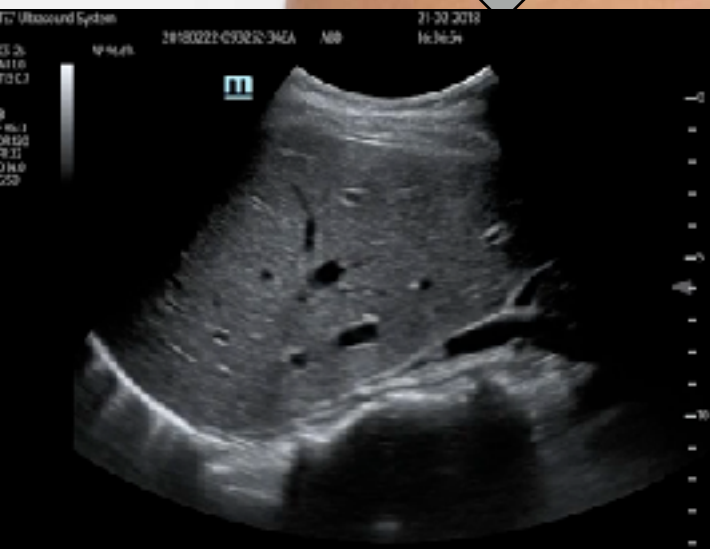倒三角
掃描介面



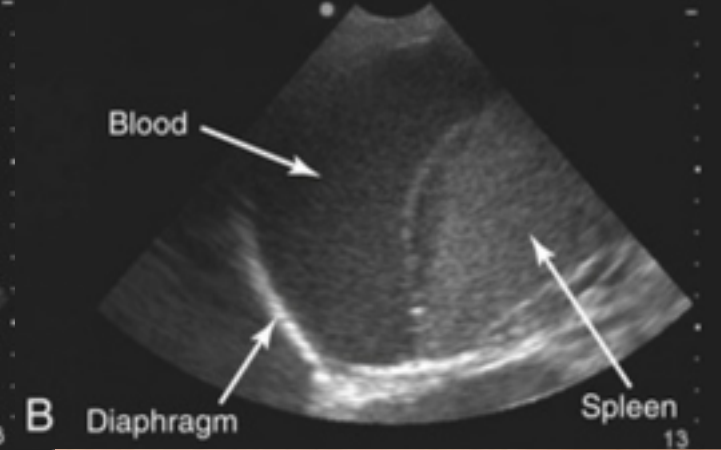
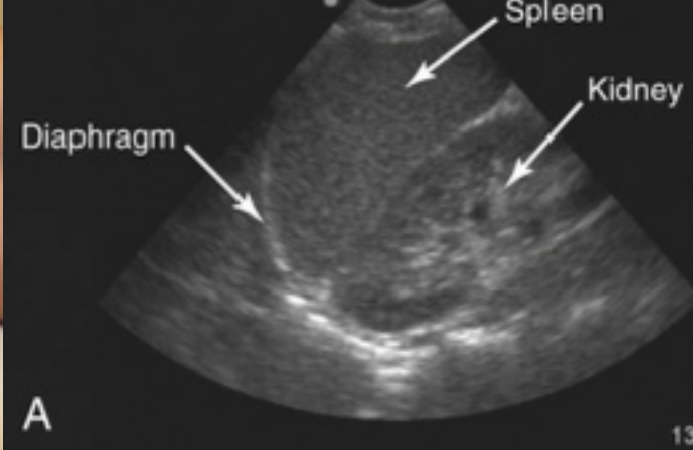
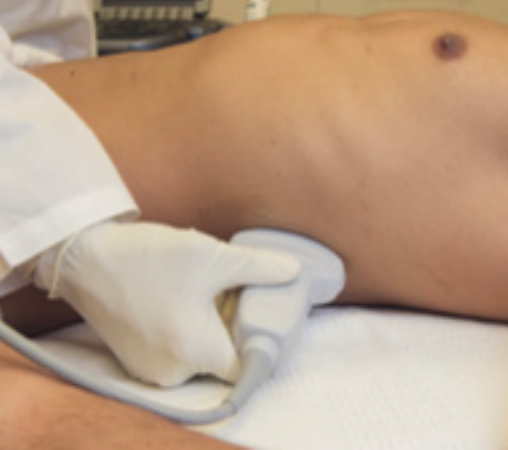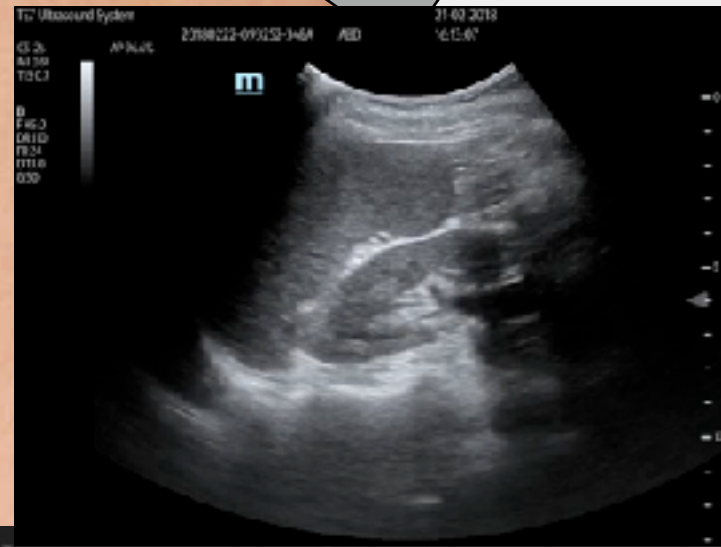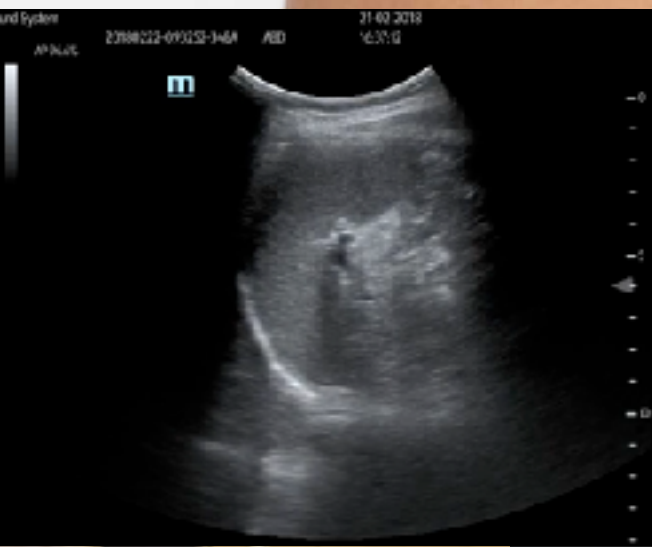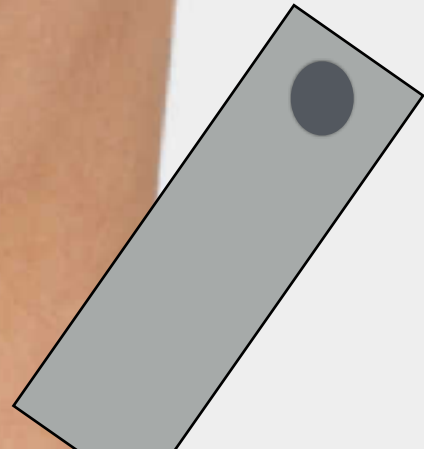
Pain
Shock

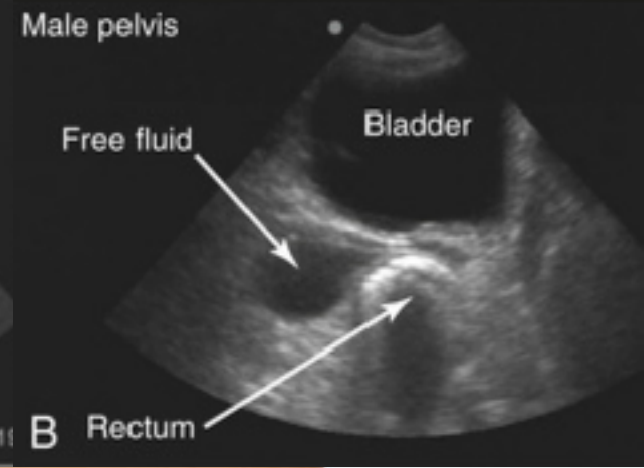
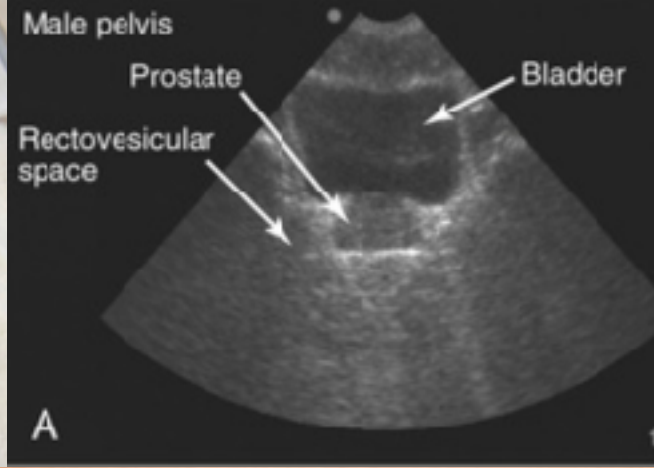
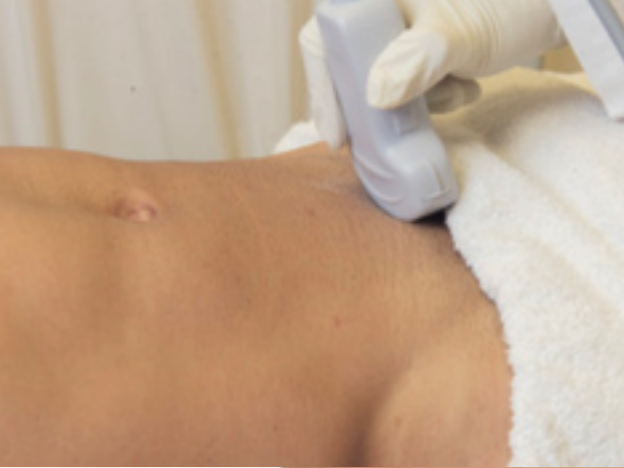Internal
Bleeding

劍突-腋前線交界點
平行肋間掃描以避開肋骨
第一目標:肝腎介面(Morrison's pouch)
第二目標:橫膈膜

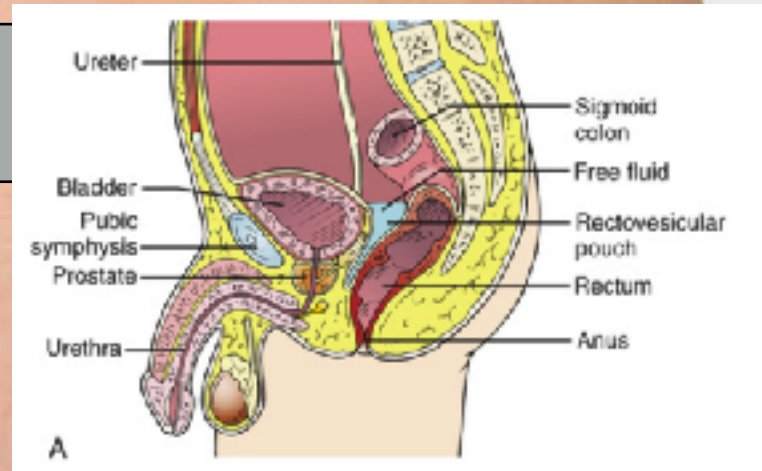
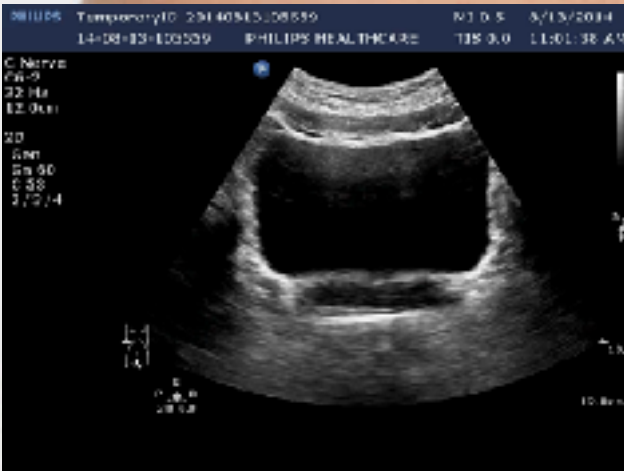

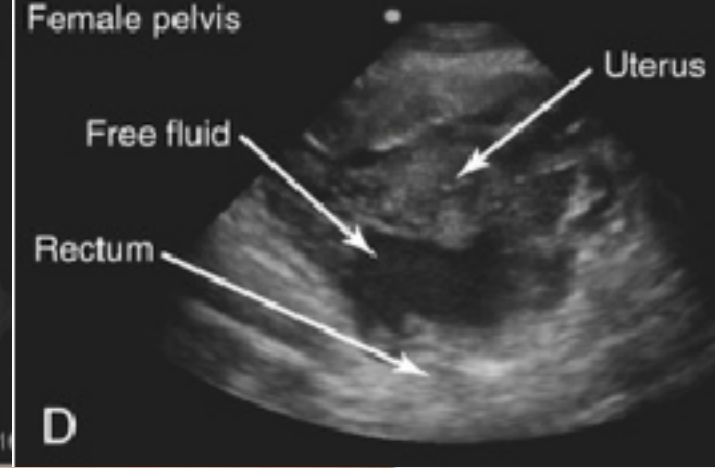
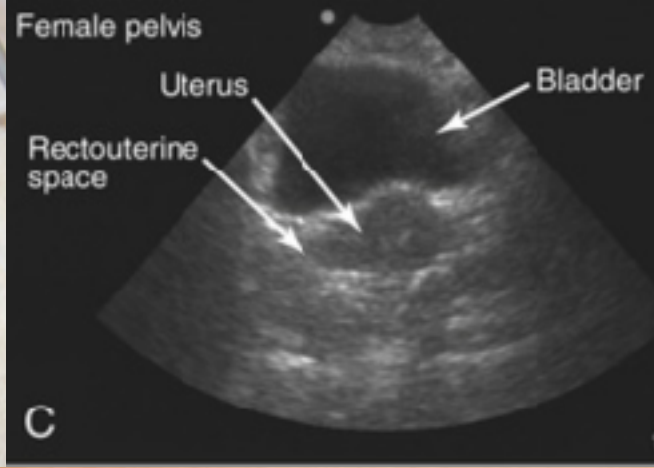
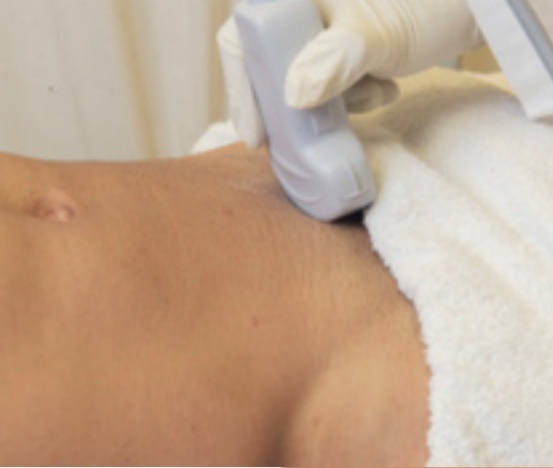劍突-腋後線交界點
平行肋間掃描以避開肋骨
第一目標:橫膈膜下
第二目標:脾腎交界



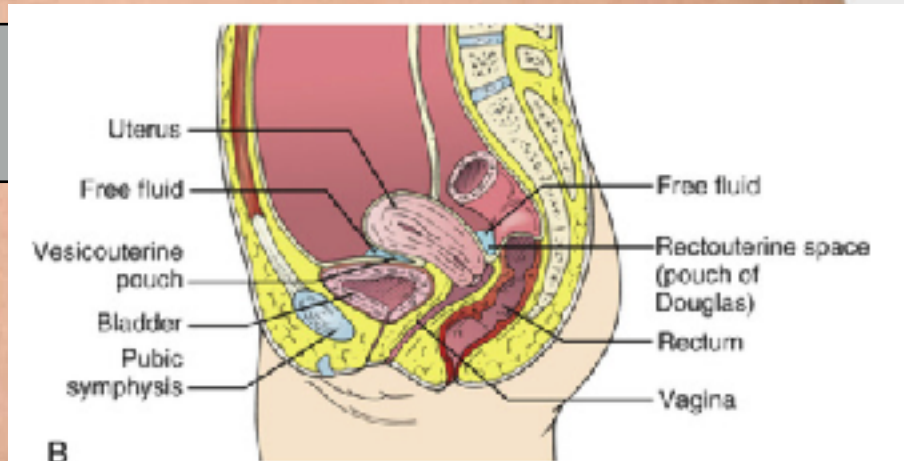
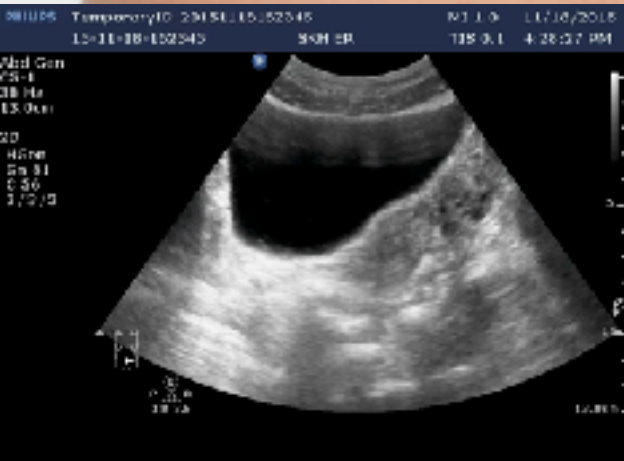


恥骨聯合上方
Tilt探頭進行掃描
要有好的視窗(尿液)
主要目標: 膀胱下方



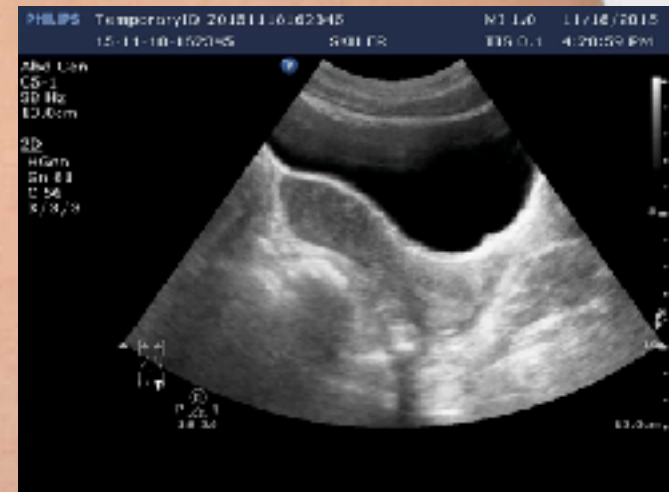
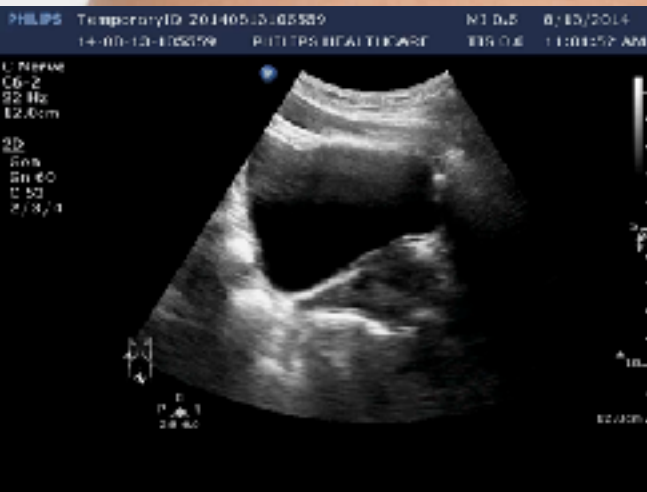

恥骨聯合上方
Tilt探頭進行掃描(頭腳)
要有好的視窗(尿液)
第一目標:子宮下方
第二目標:膀胱子宮間



為什麼一定要有這個介面呢？

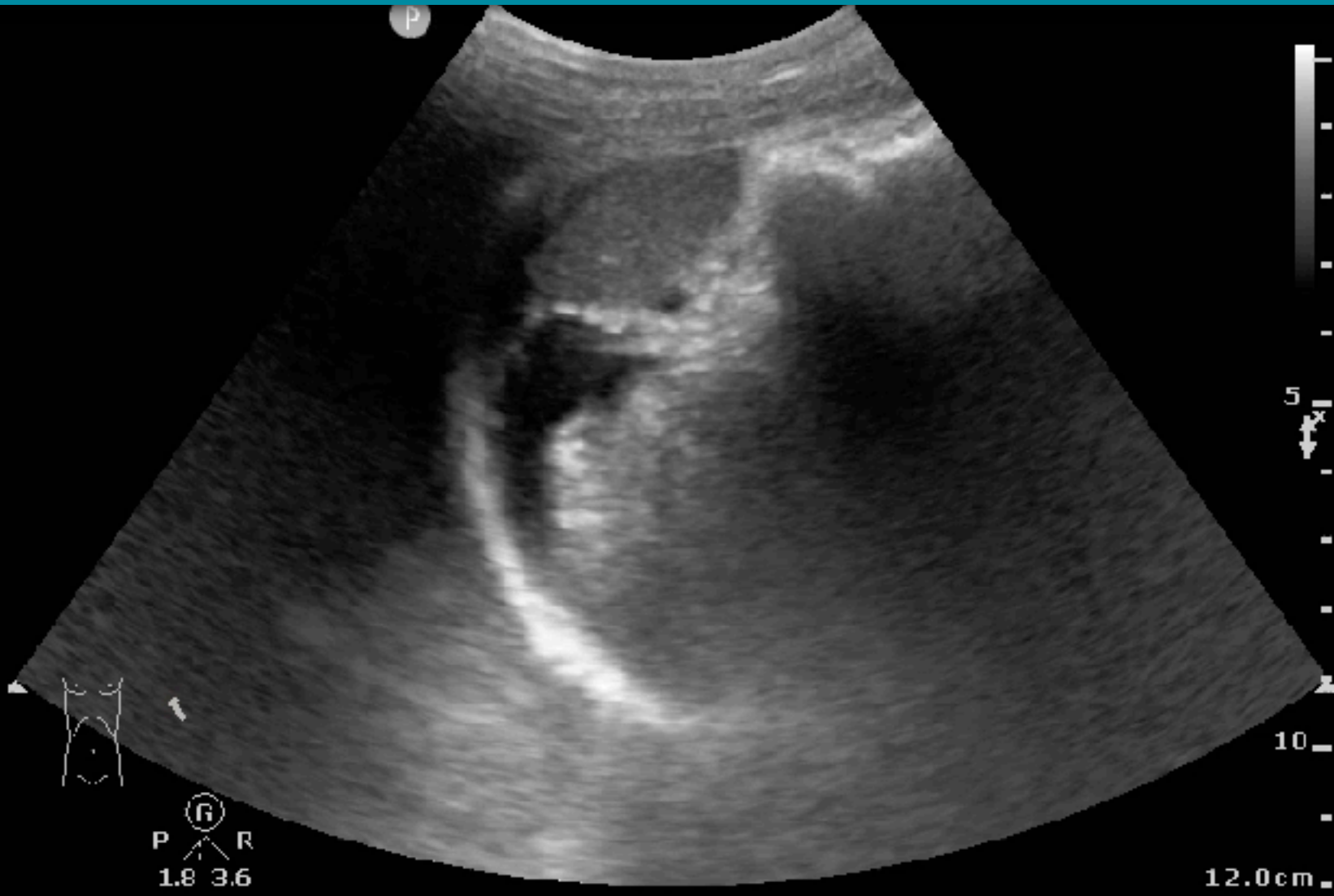
恥骨聯合上方
Tilt探頭進行掃描(左右)
要有好的介面(尿液)
第一目標:子宮下方
第二目標:膀胱子宮間
男:膀胱下方



Free fluid ?

Abd Gen
C5-1
39 Hz
12.0cm

2D
HGen
Gn 100
C. 56
3/3/3



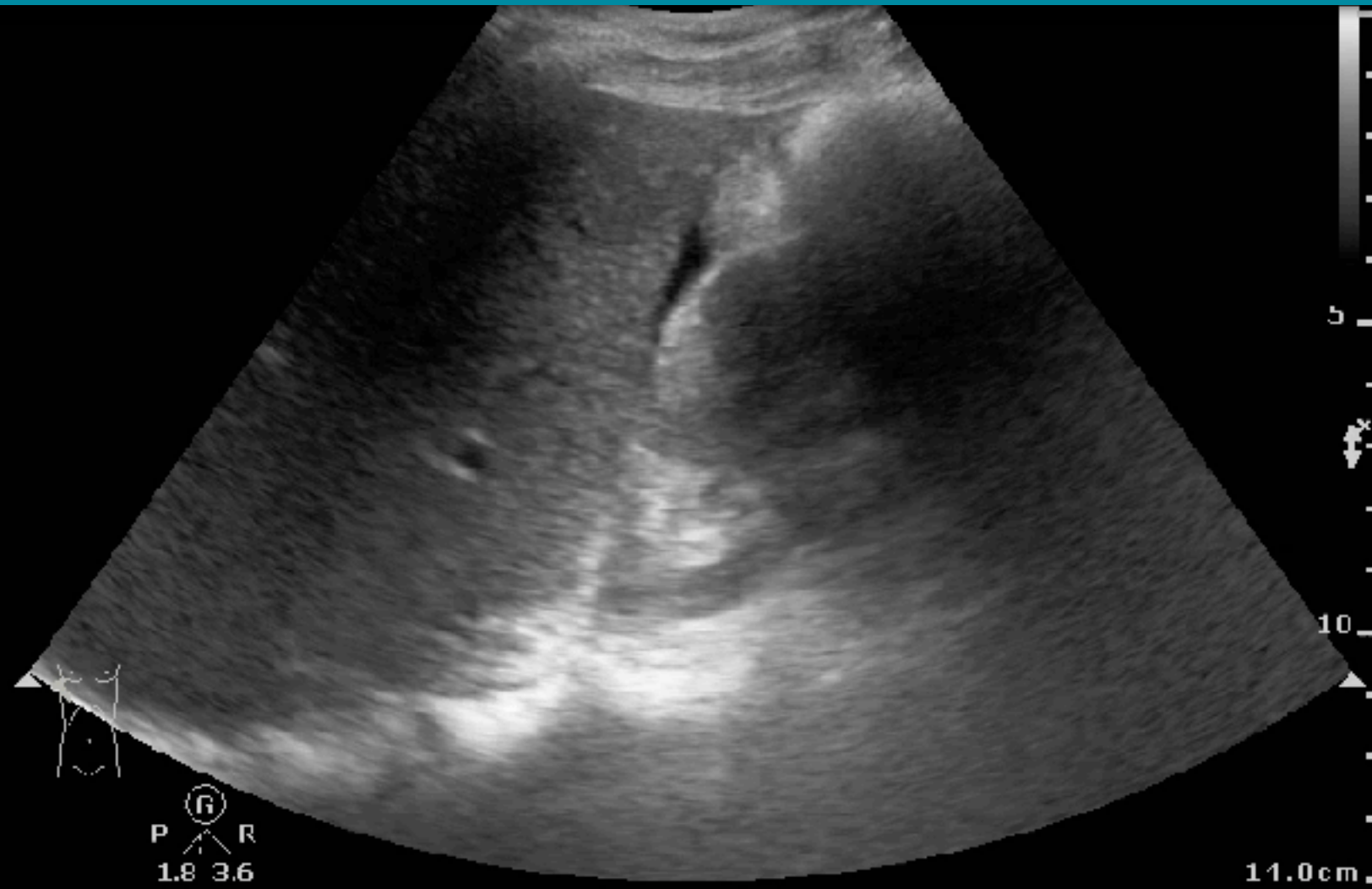
P R
1.8 3.6

12.0cm

Free fluid ?

C5-1
36 Hz
14.0cm

2D
HGen
Gn 100
C. 56
3 / 3 / 3

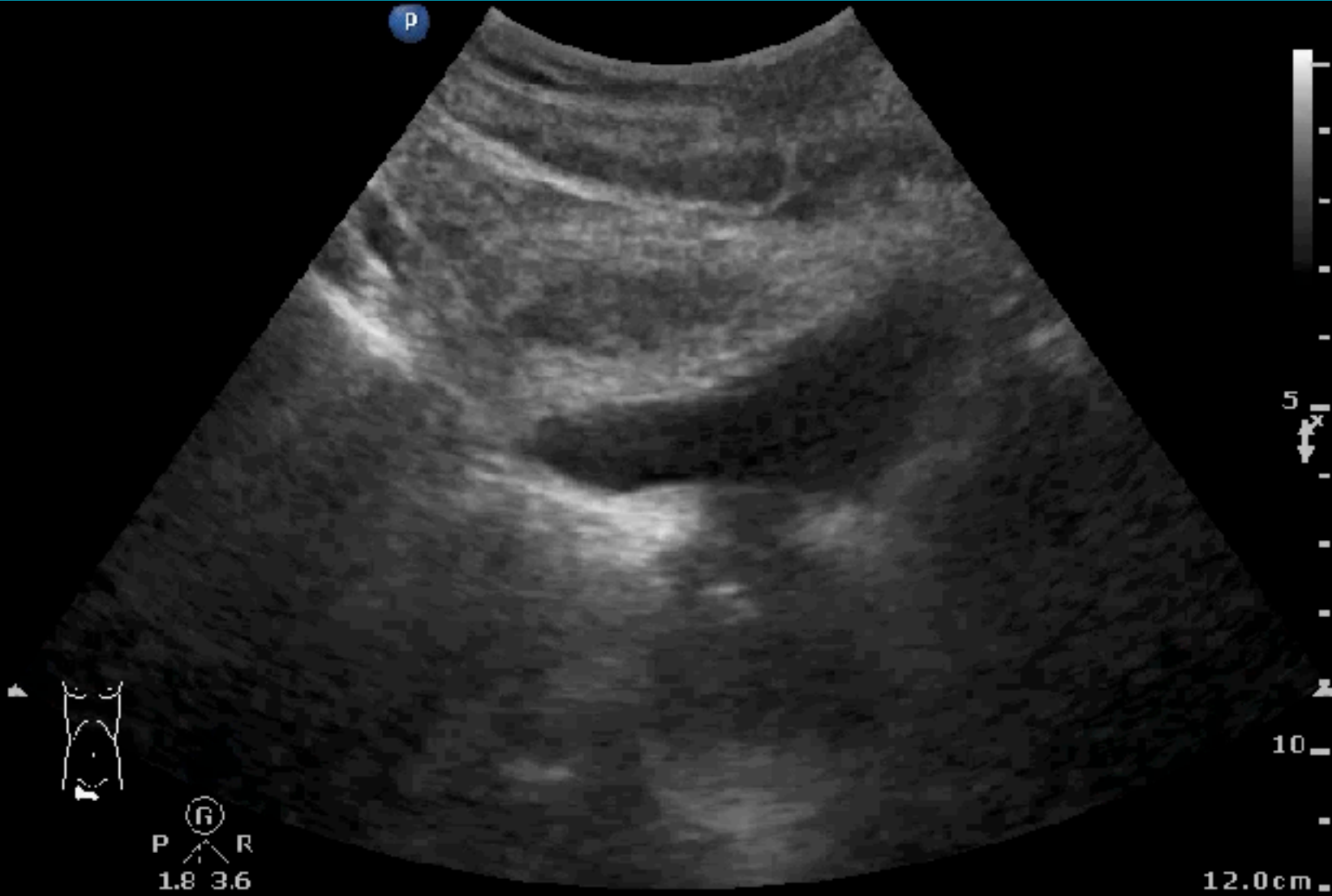

14.0cm

Free fluid ?

Abd Gen
C5-1
39 Hz
12.0cm

2D
HGen
Gn 66
C. 58
3 / 3 / 3

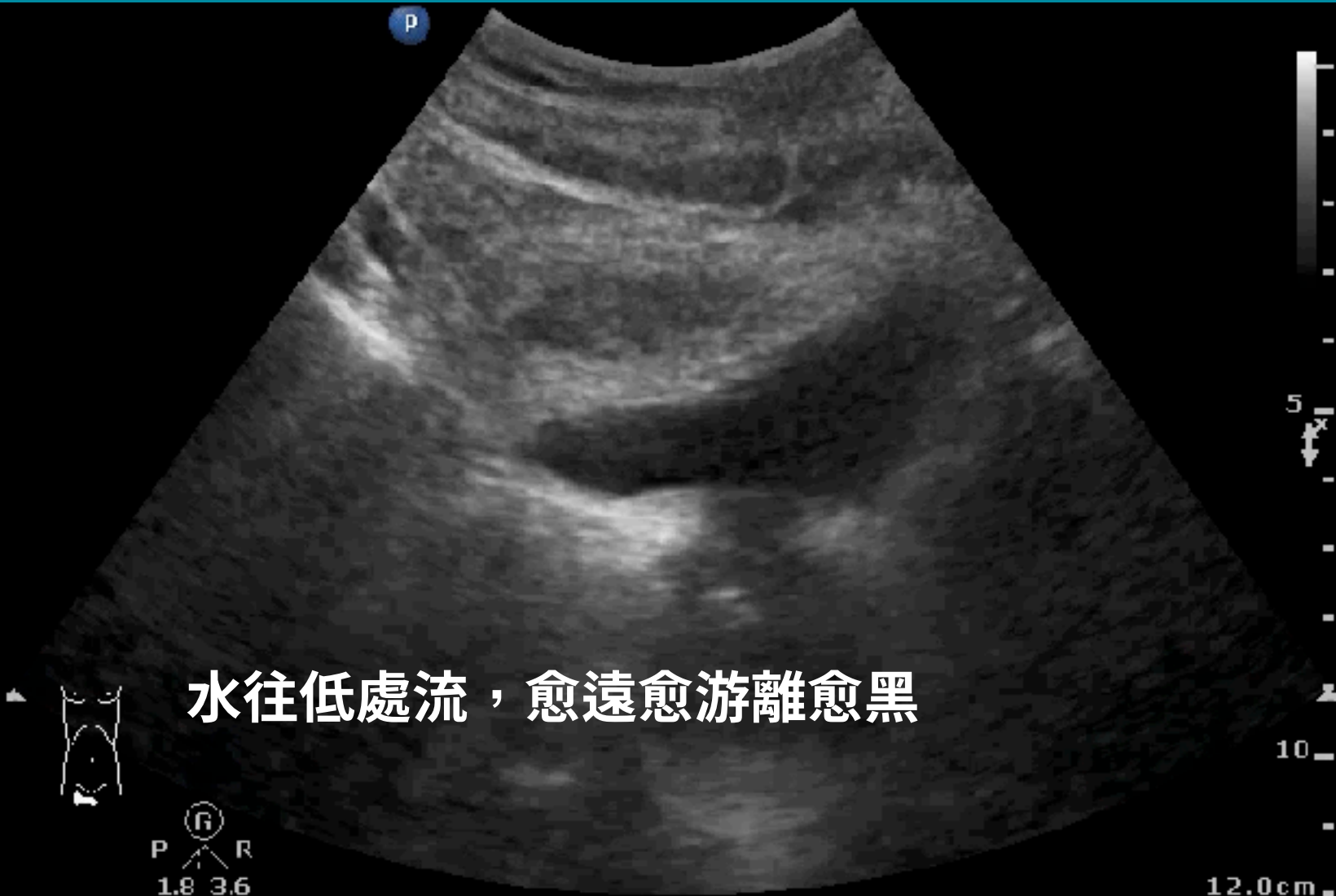

Free fluid ?

Abd Gen
C5-1
39 Hz
12.0cm

2D

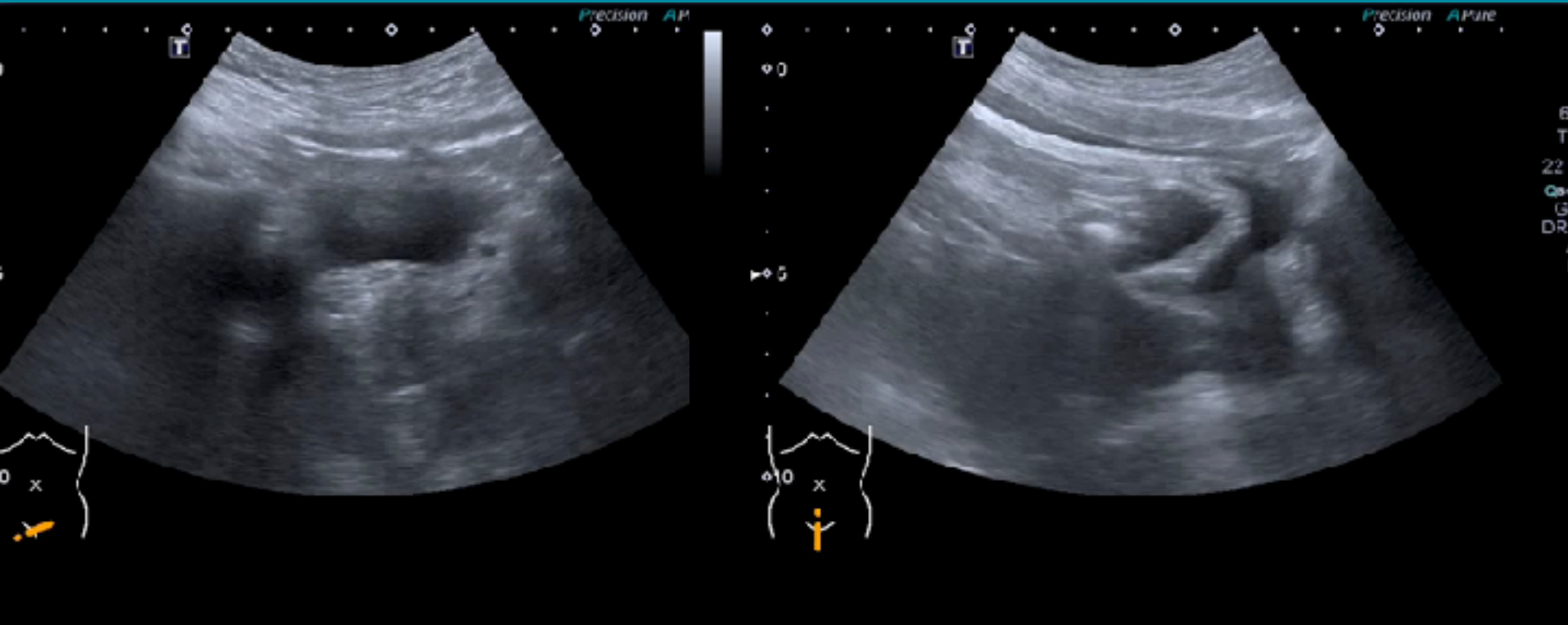
HGen
Gn 66
C. 58
3 / 3 / 3



水往低處流，愈遠愈游離愈黑

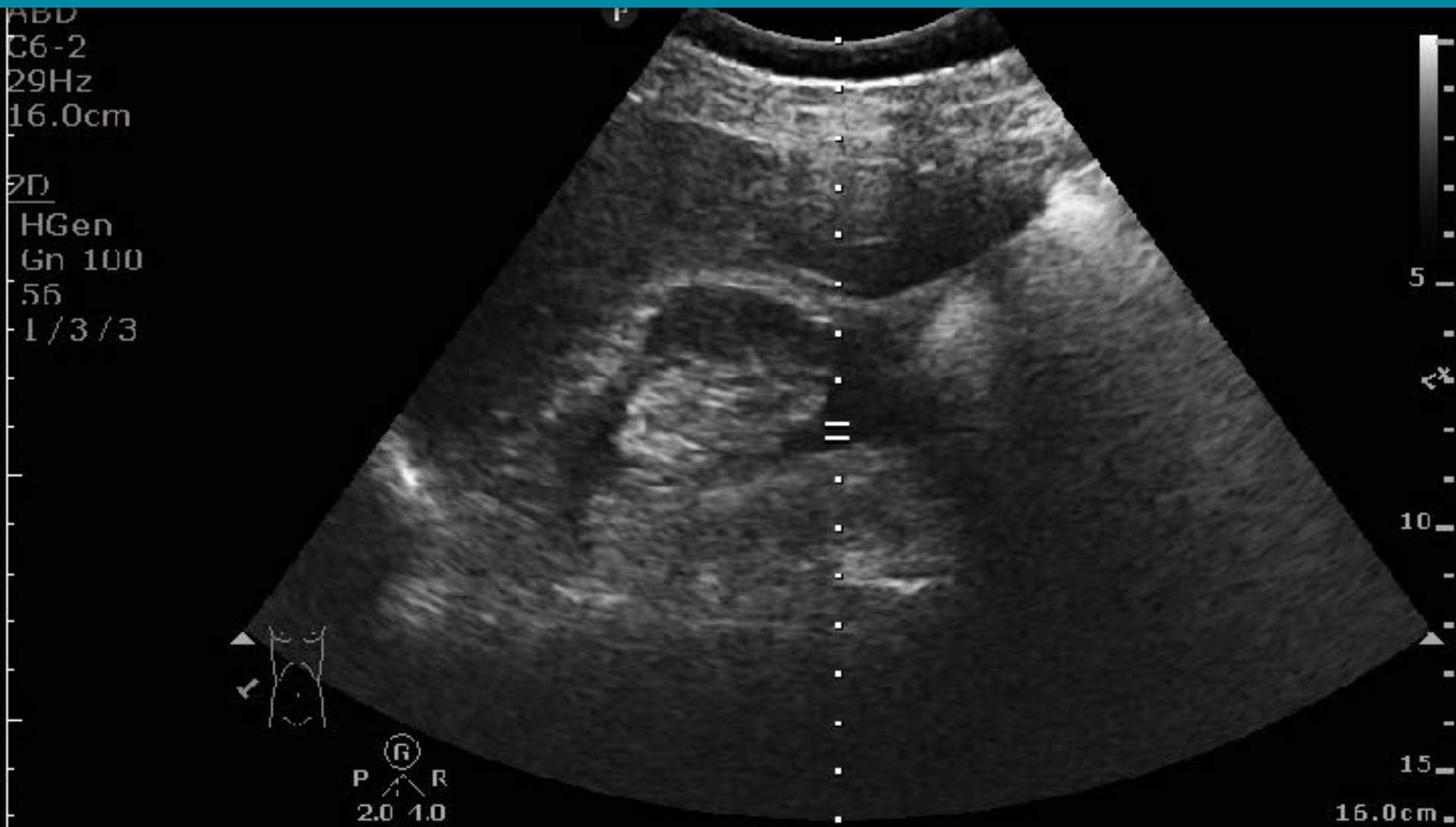
12.0cm

Free fluid ?

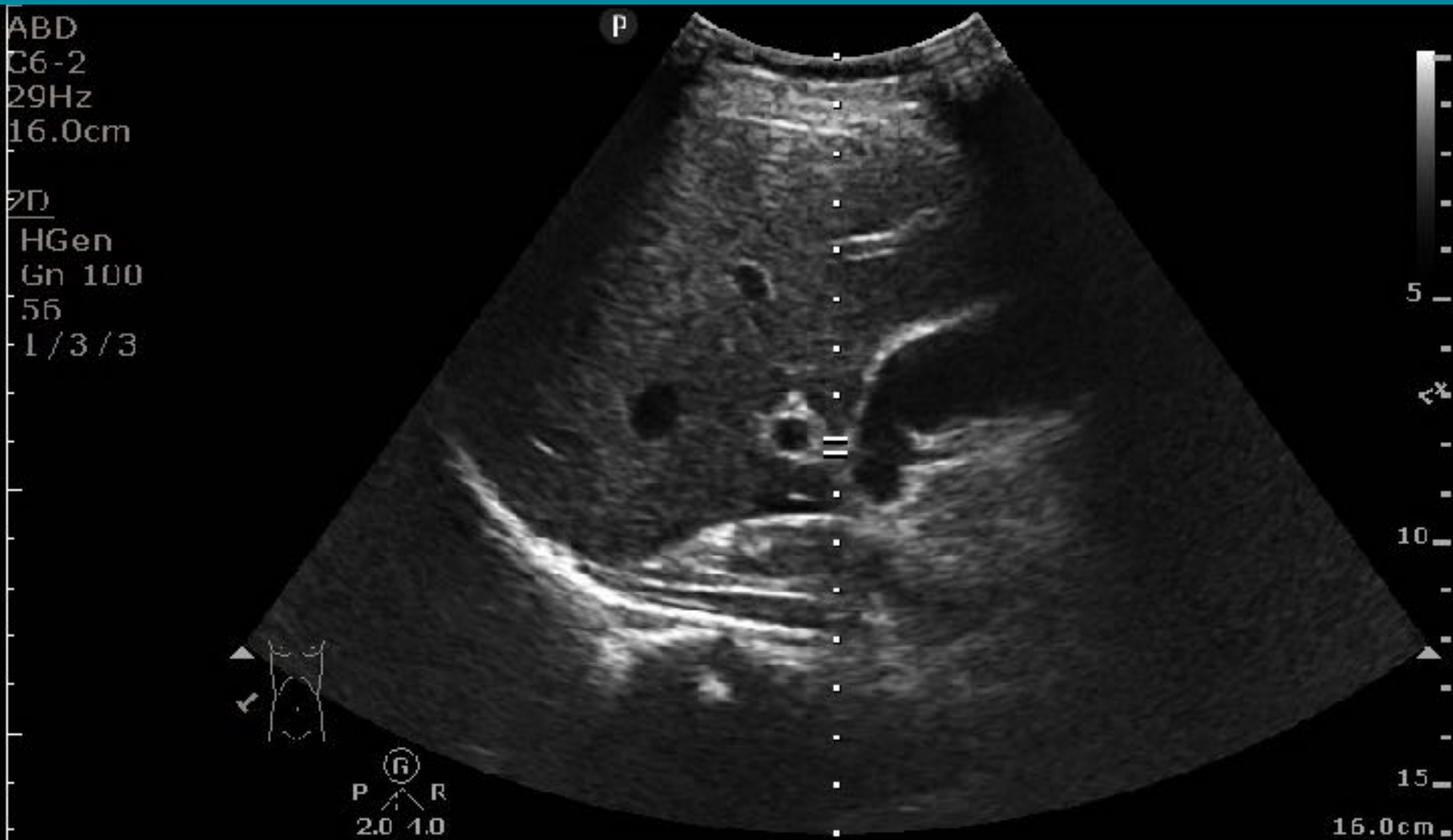

Transverse + Sagittal views = Standard

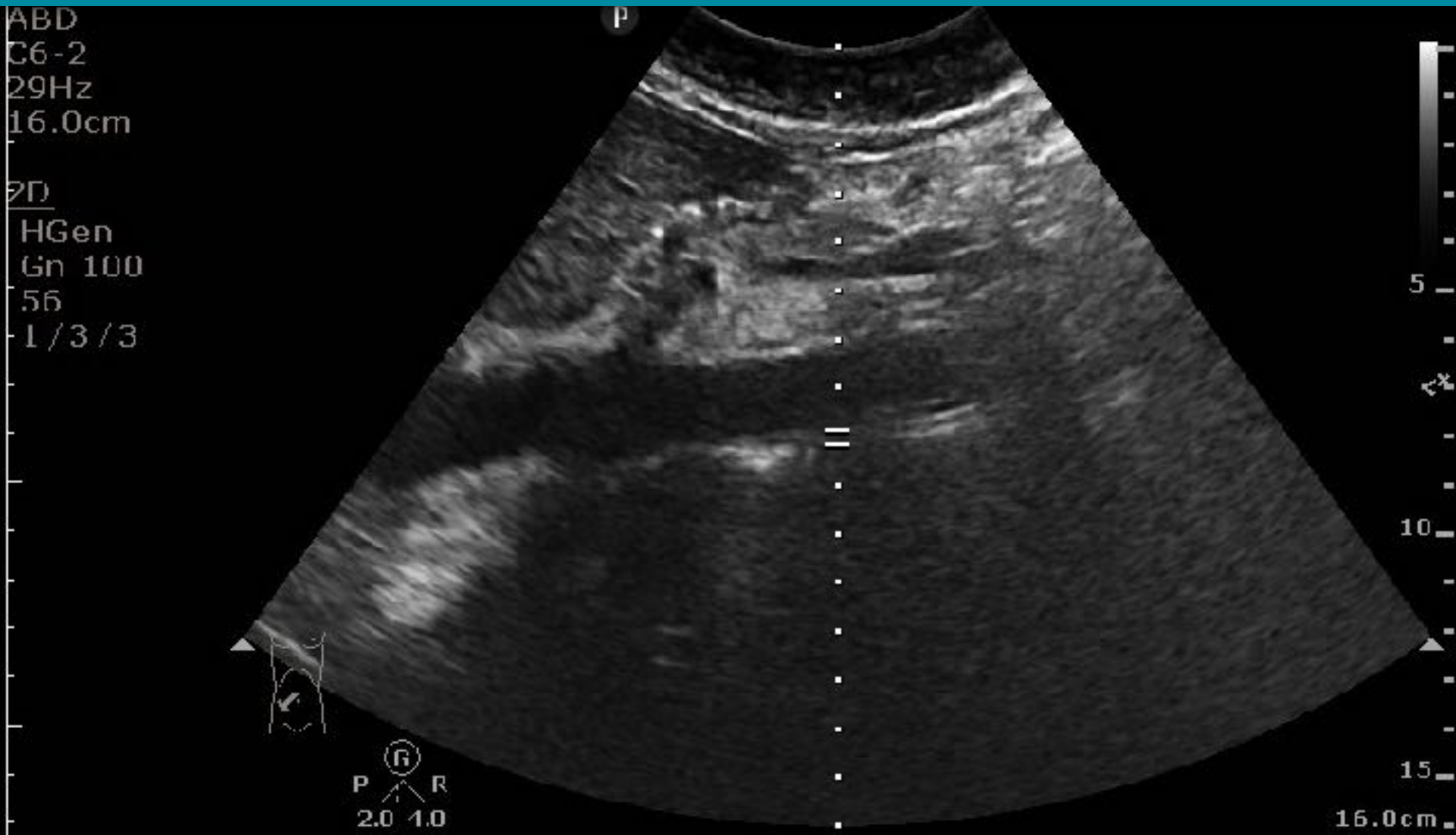45M , abdominal pain



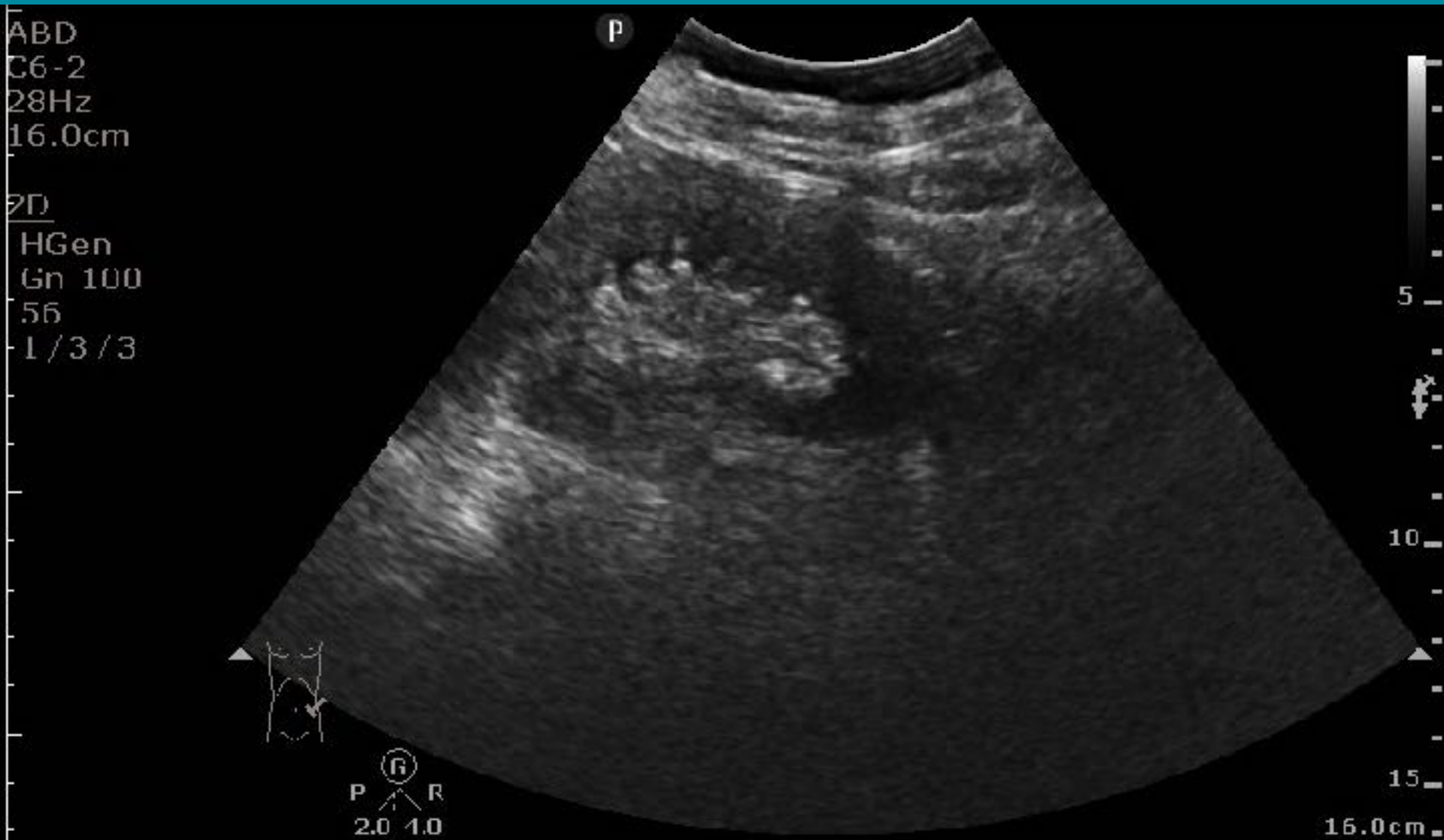
45M , abdominal pain



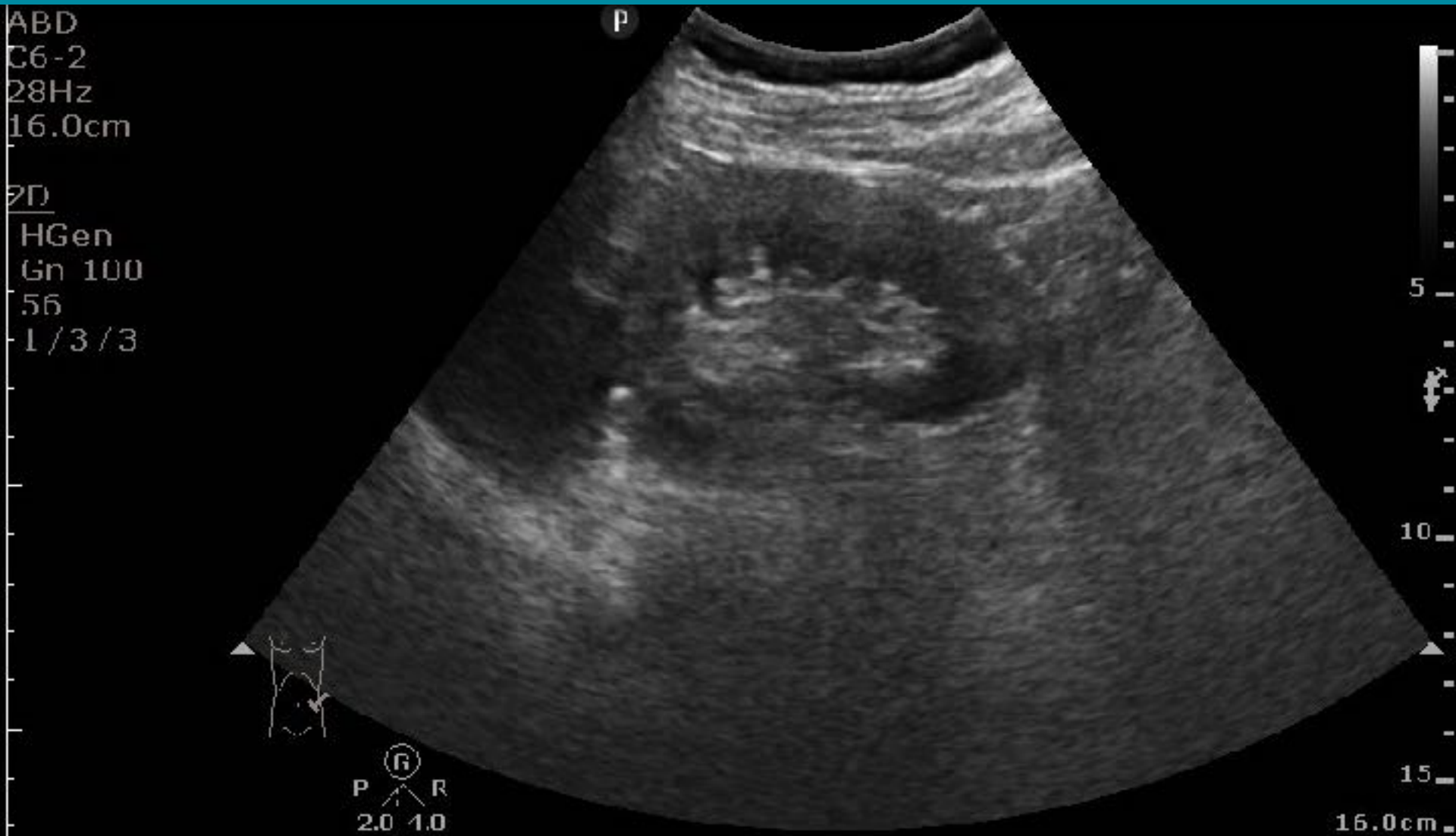45M , abdominal pain



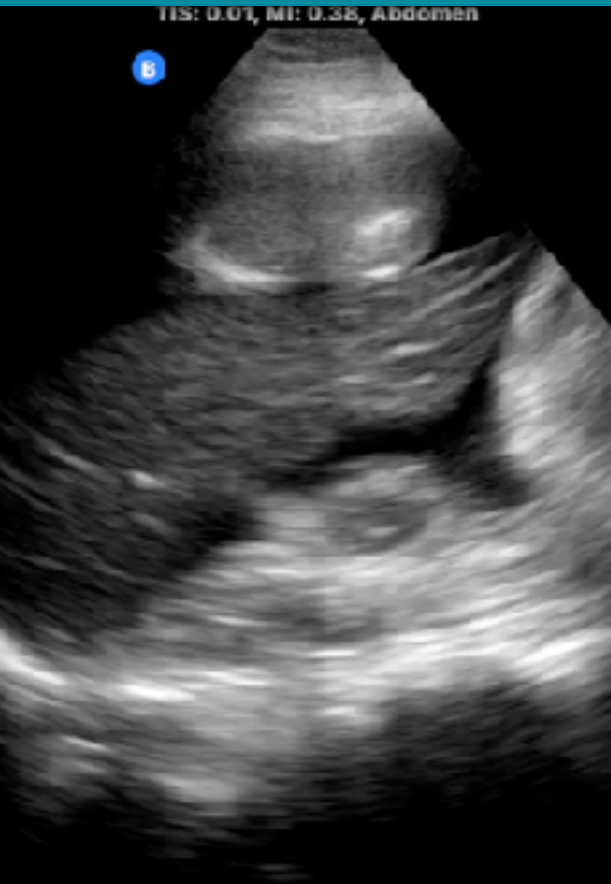45M , abdominal pain



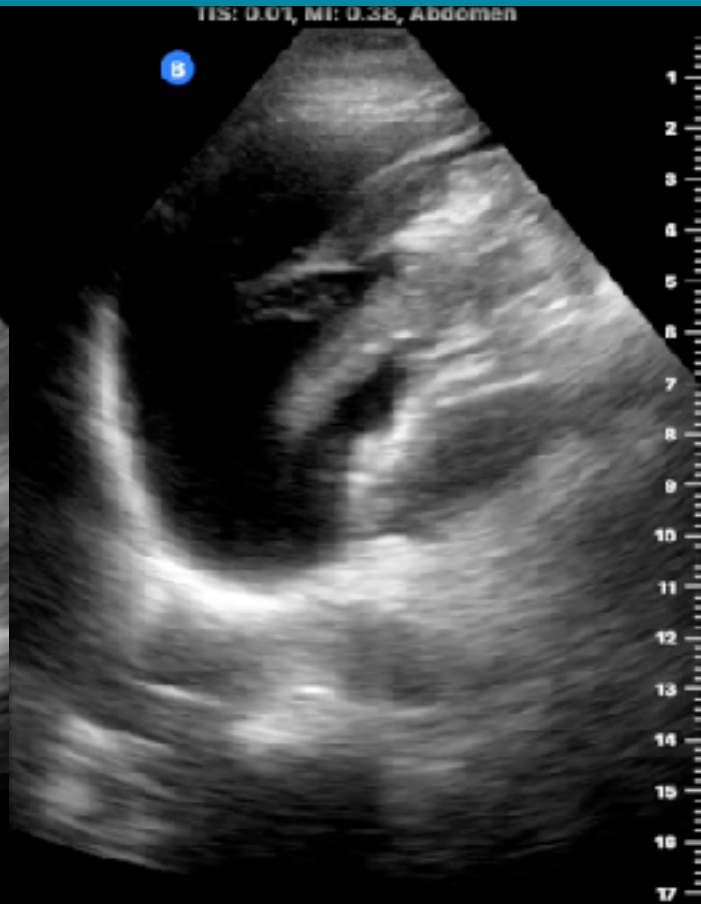45M , abdominal pain



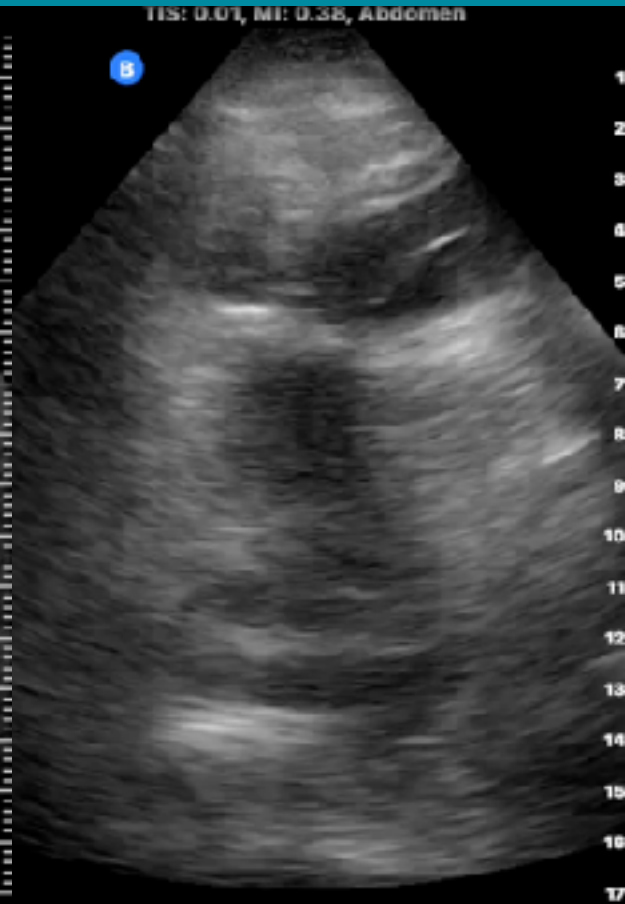Free fluid ?



右上腹



左上腹



骨盆横

腹腔積液Free fluid



有無游離液體

患者姿勢
患者體形
積液來源
經過時間
影像品質
掃描技術

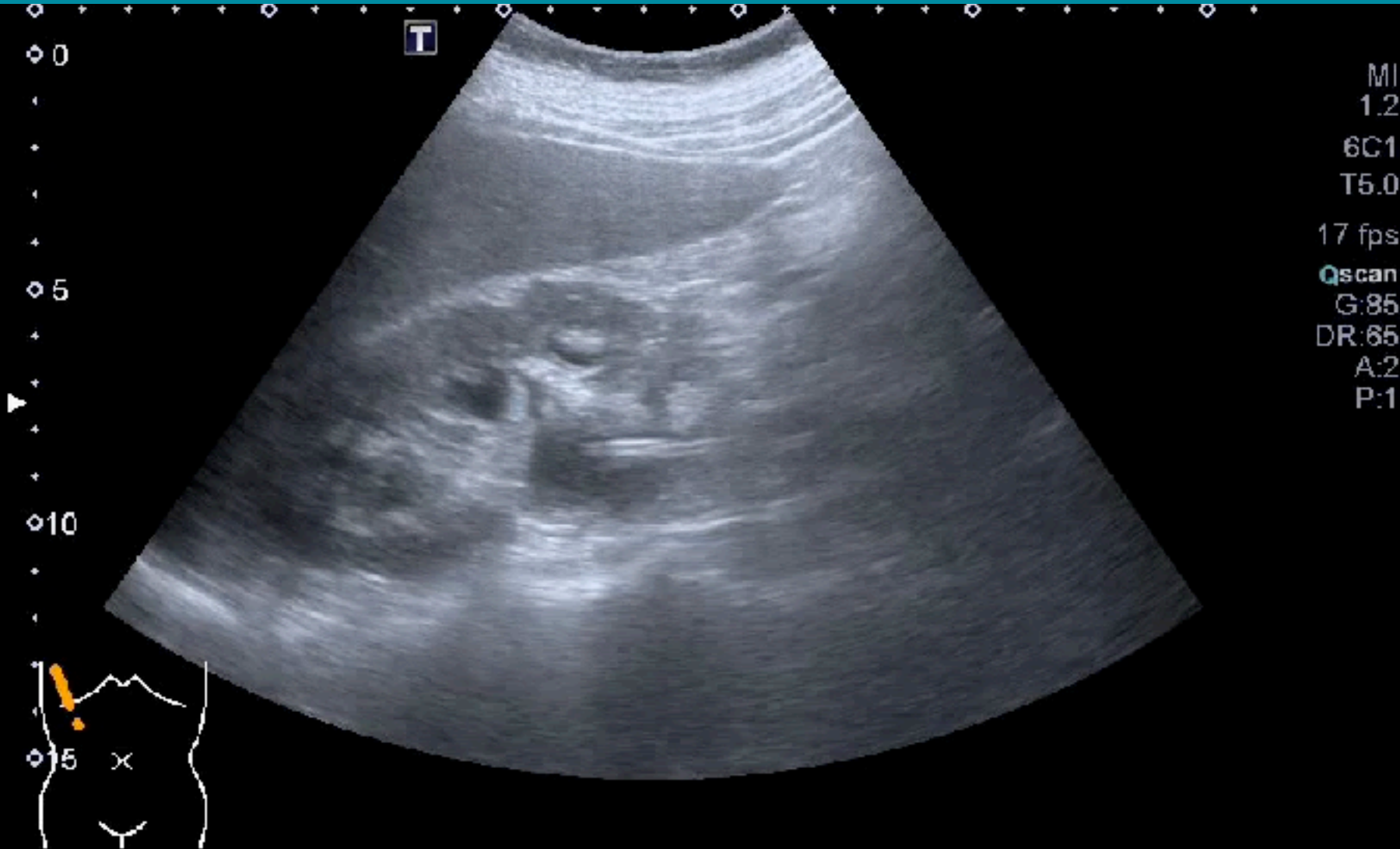
增加介面

增加頻次

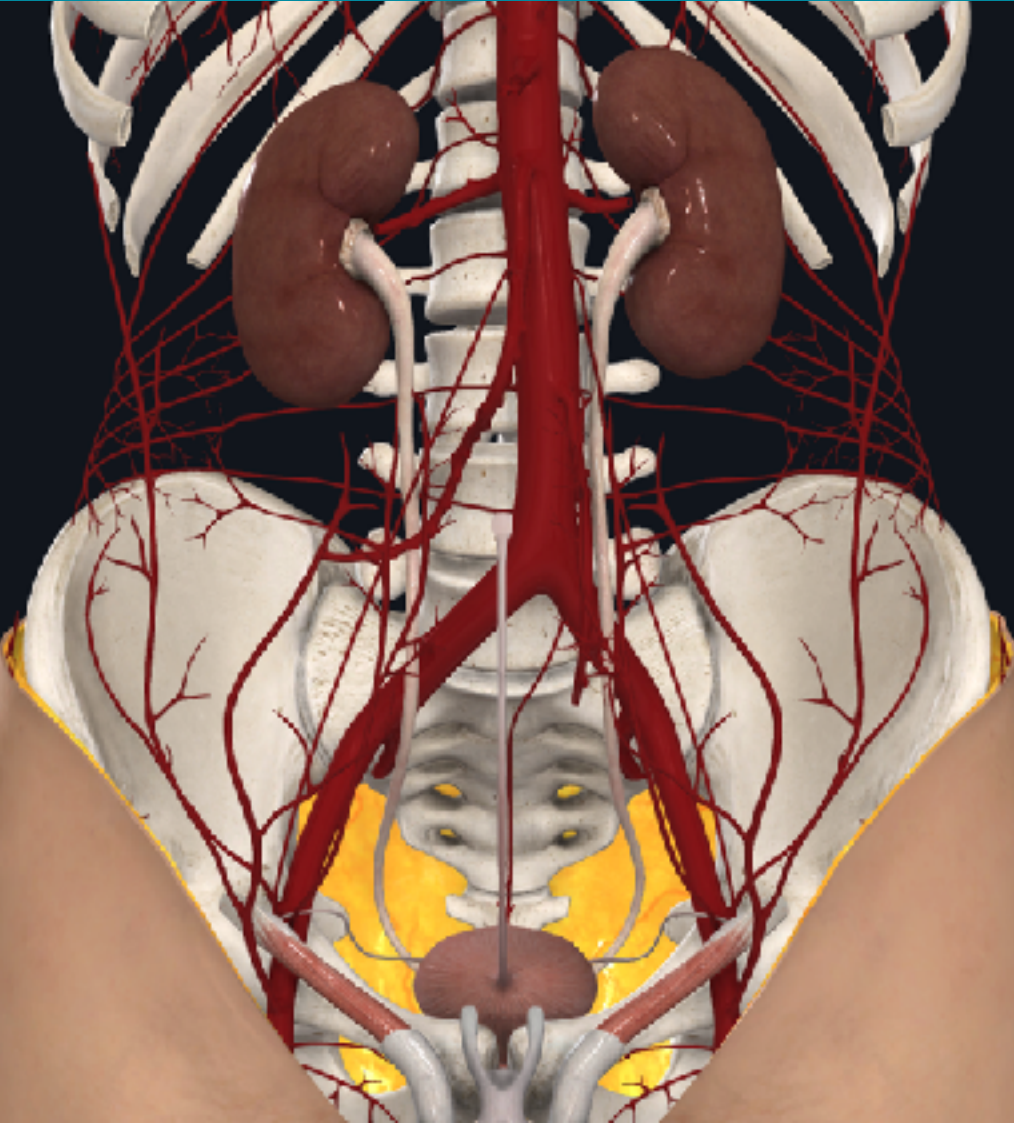替代影像



KIDNEY



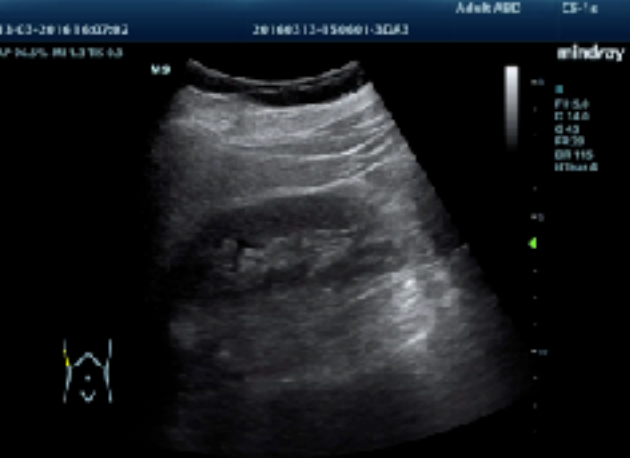KIDNEY & UB



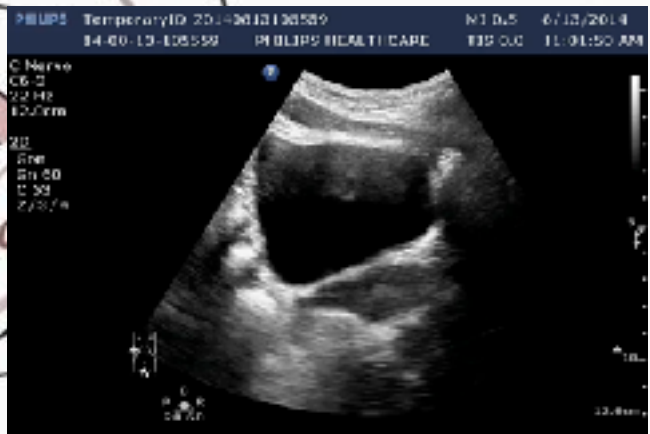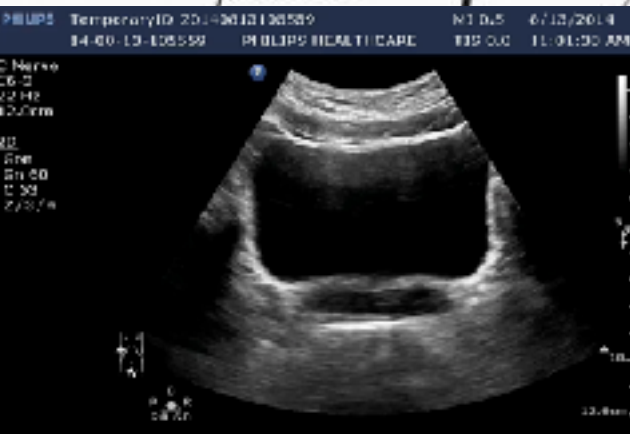
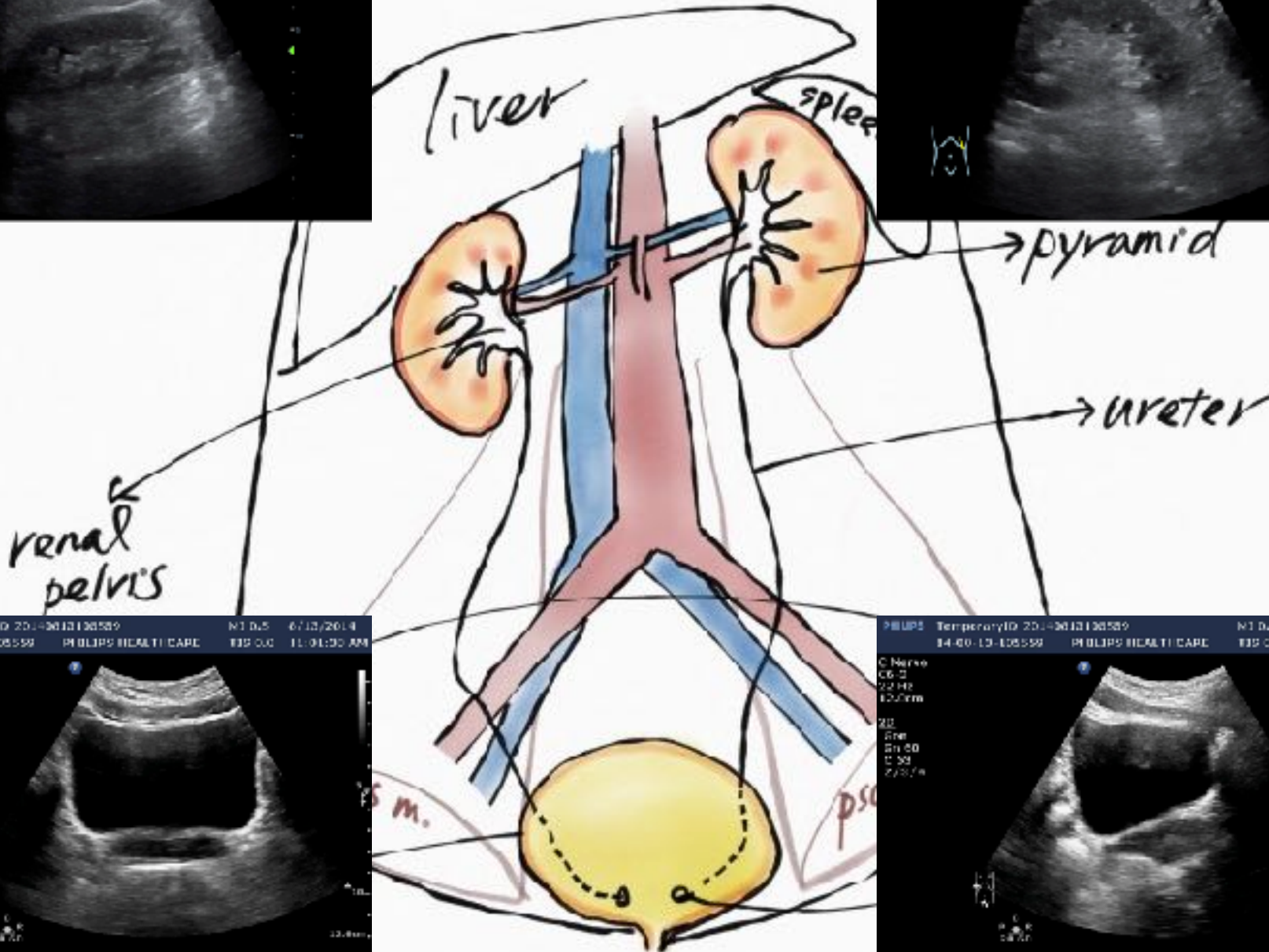
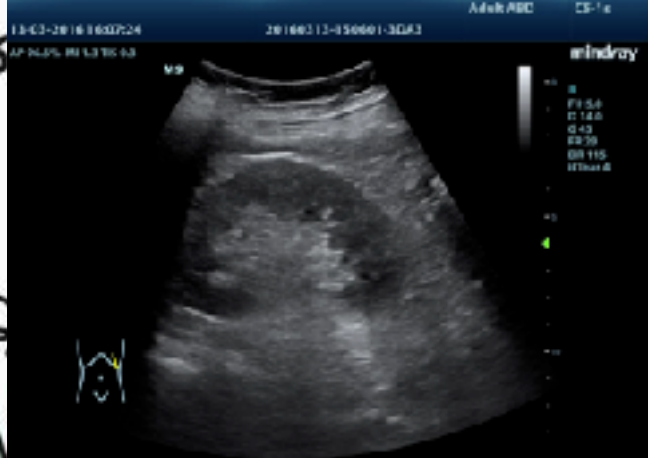Pain
Infection
Renal failure

Obstruction

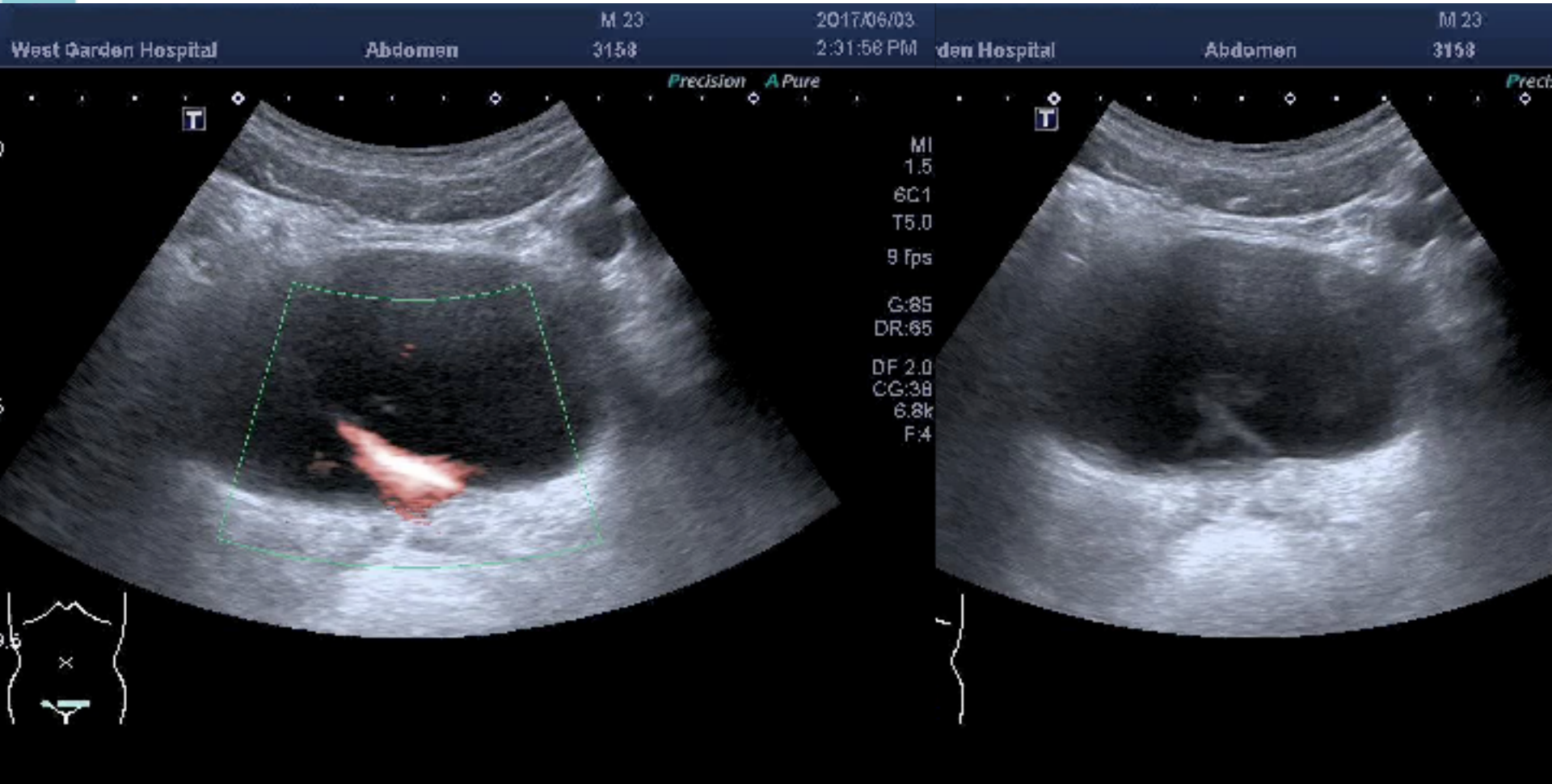
永遠要想到AAA



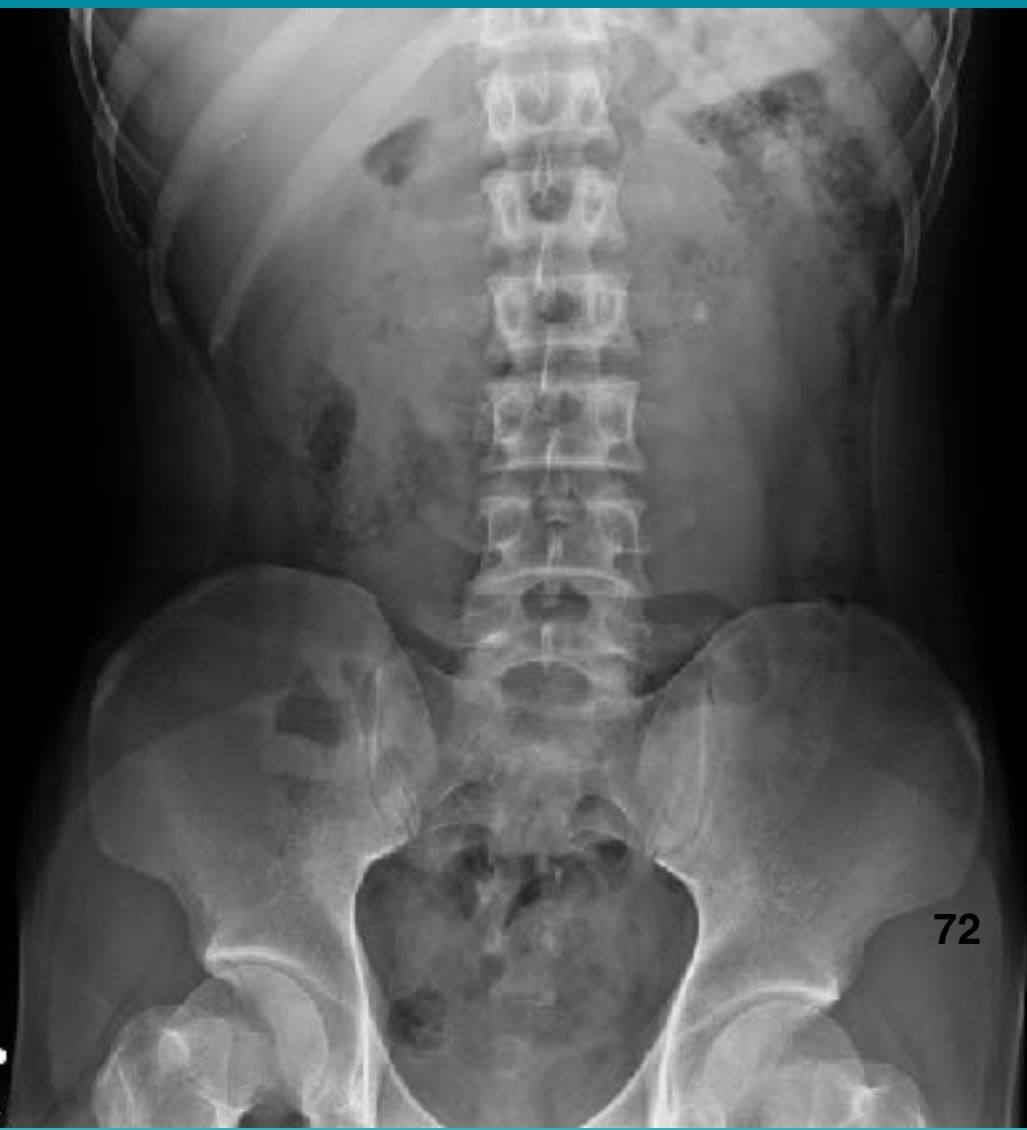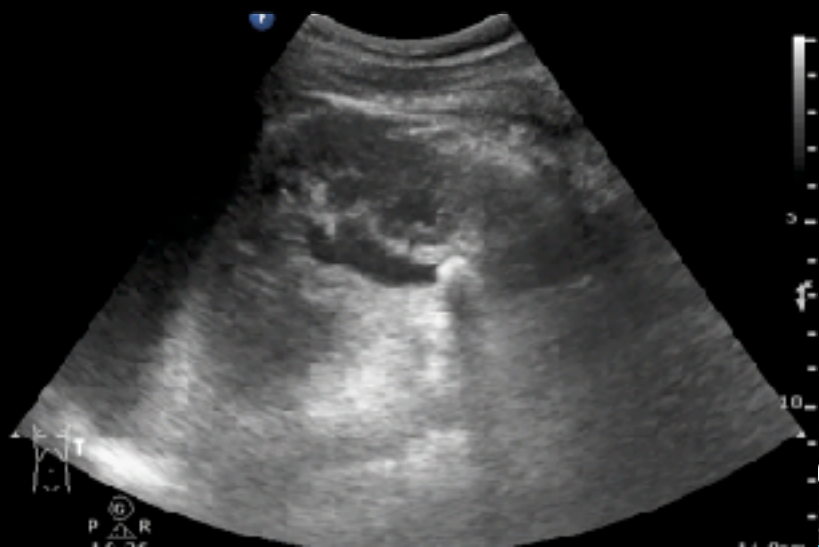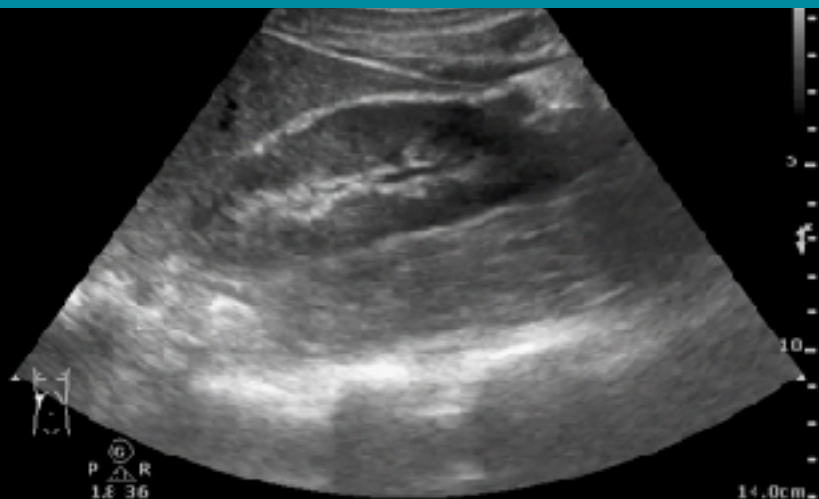
SIZE CHANGE. All rights reserved



URINARY JET

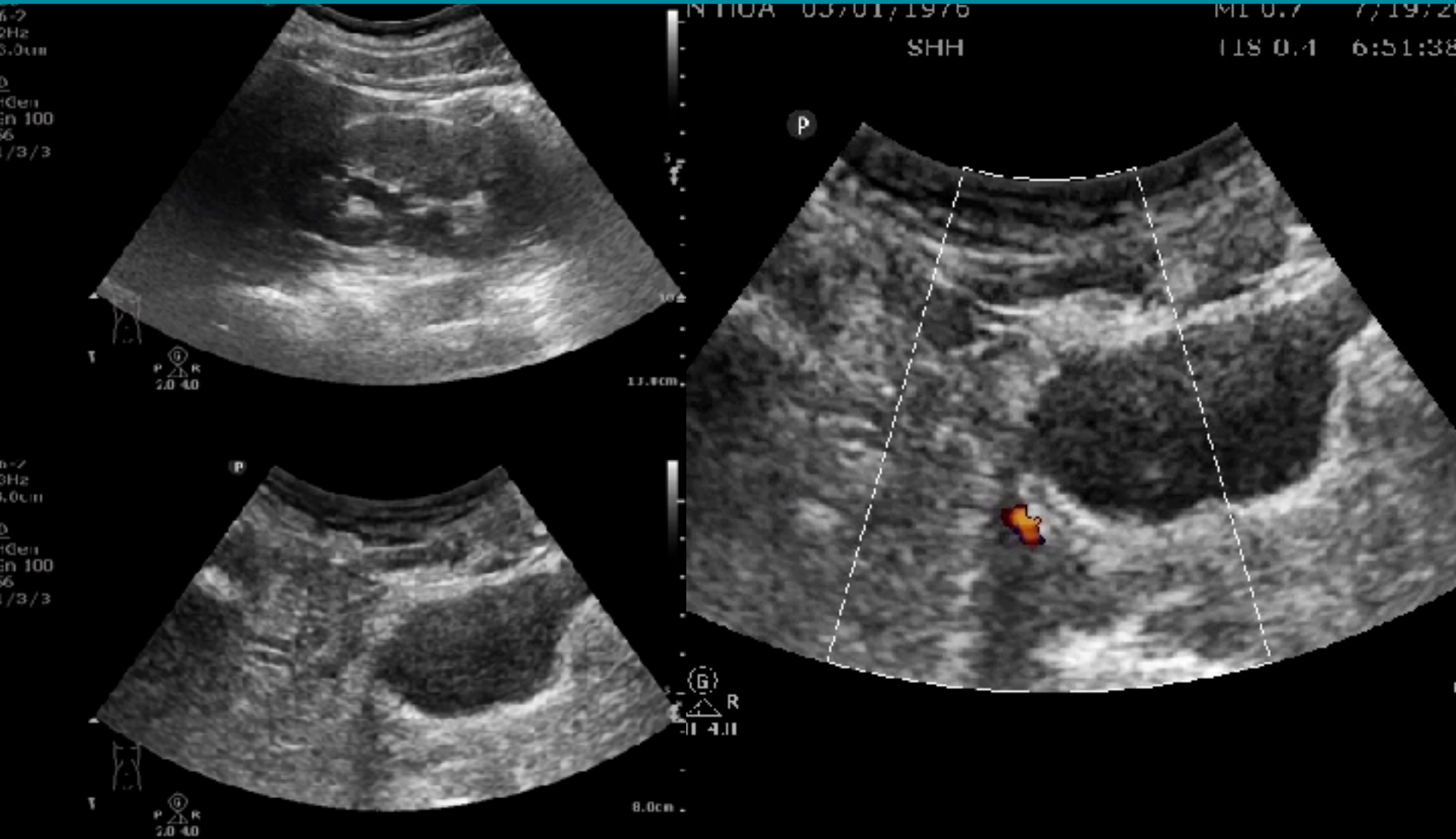


LEFT FLANK PAIN



R ABDOMINAL PAIN

TWINKLING ARTIFACT

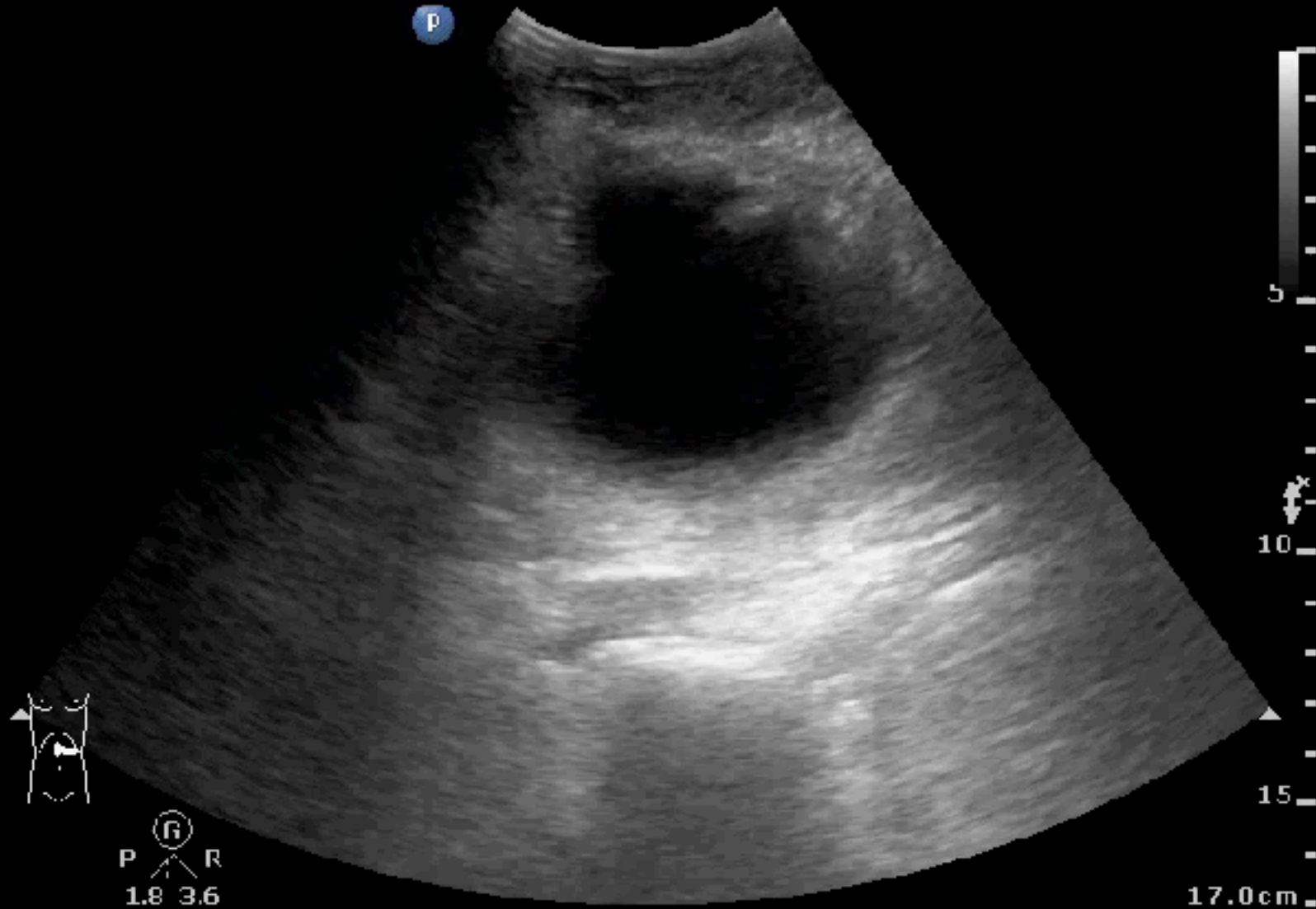


AUR

Abd Gen
C5-1
31 Hz
17.0cm

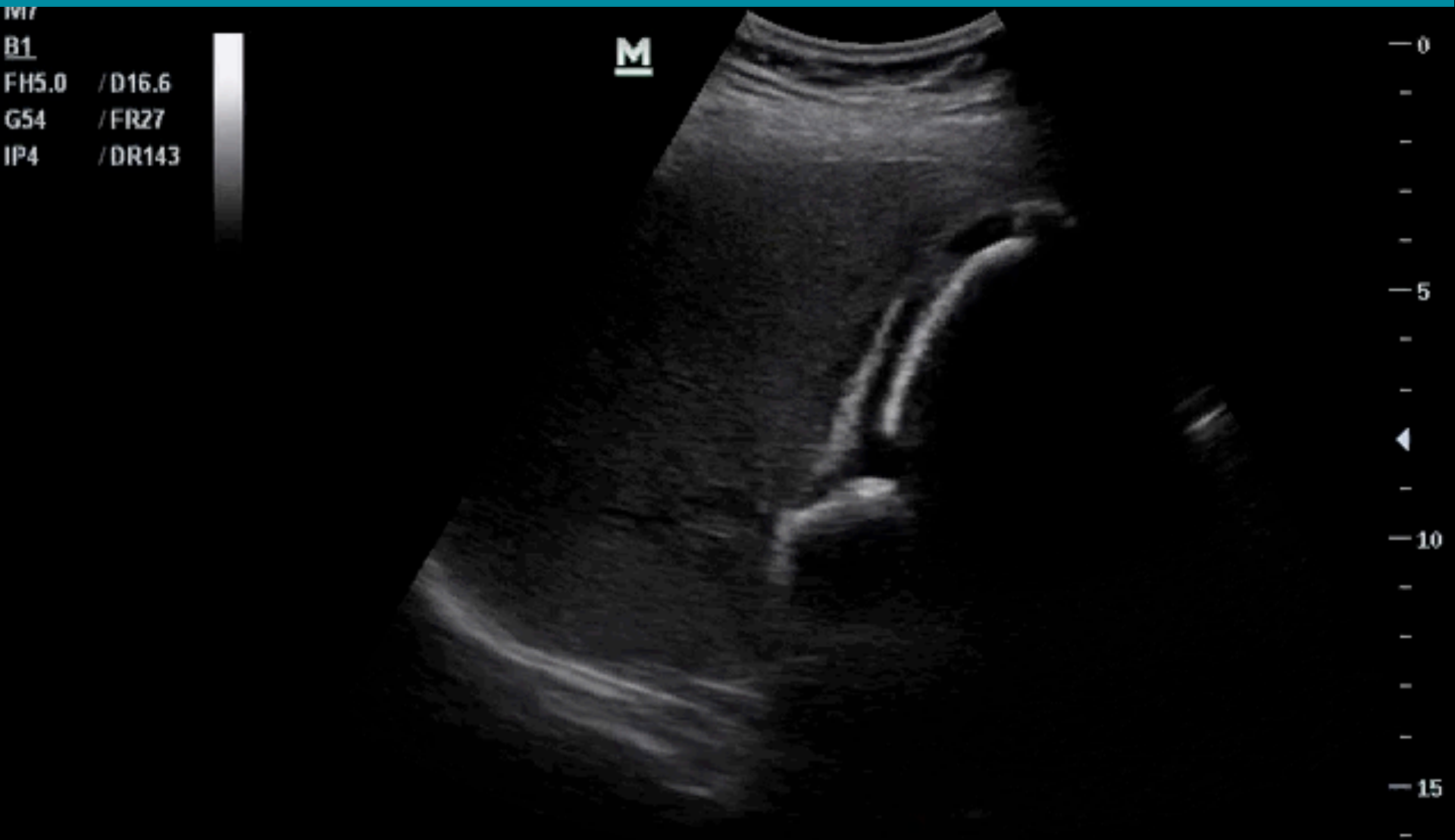
2D

HGen
Gn 60
C. 56
3 / 3 / 3



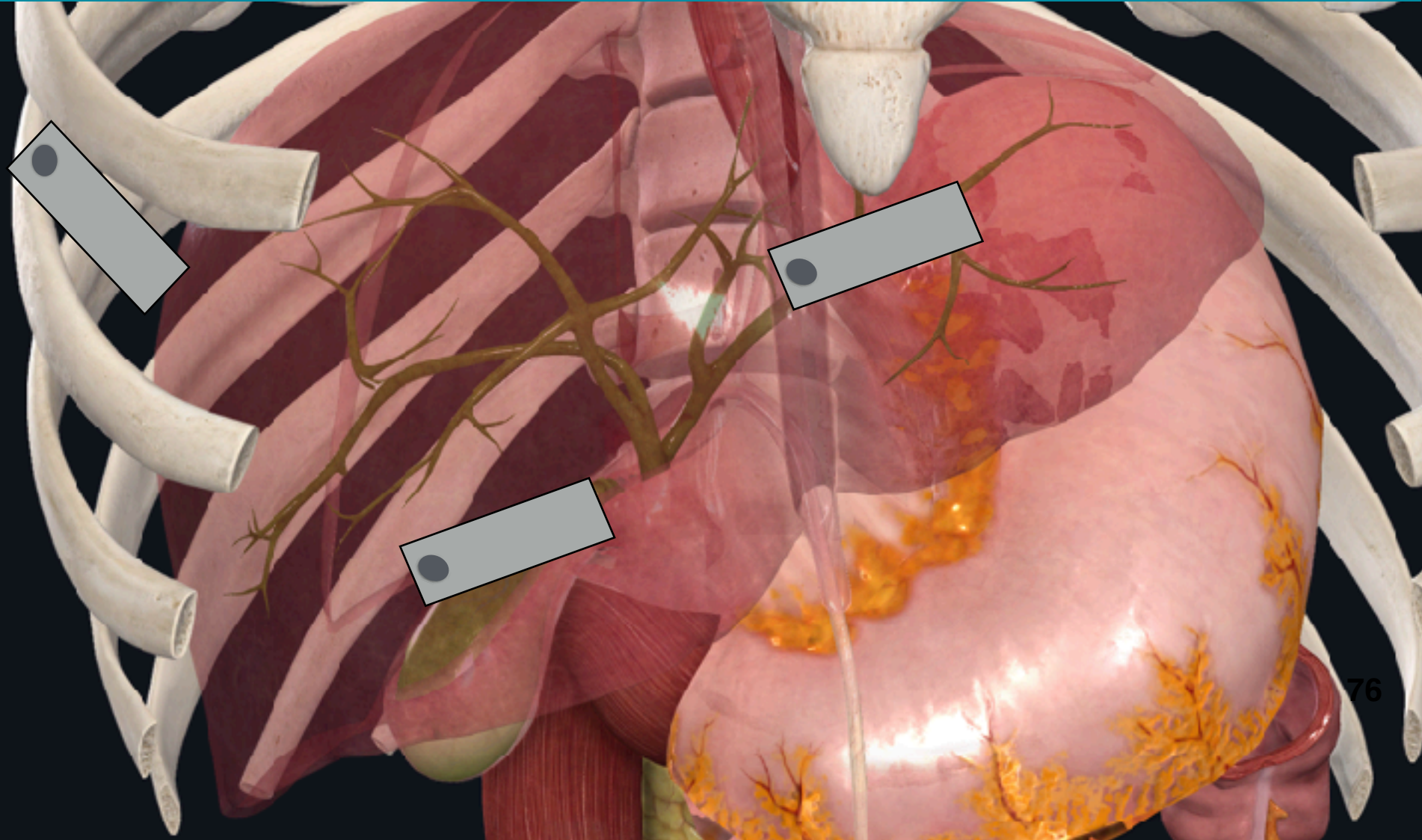
17.0cm

HEPATO-BILIARY



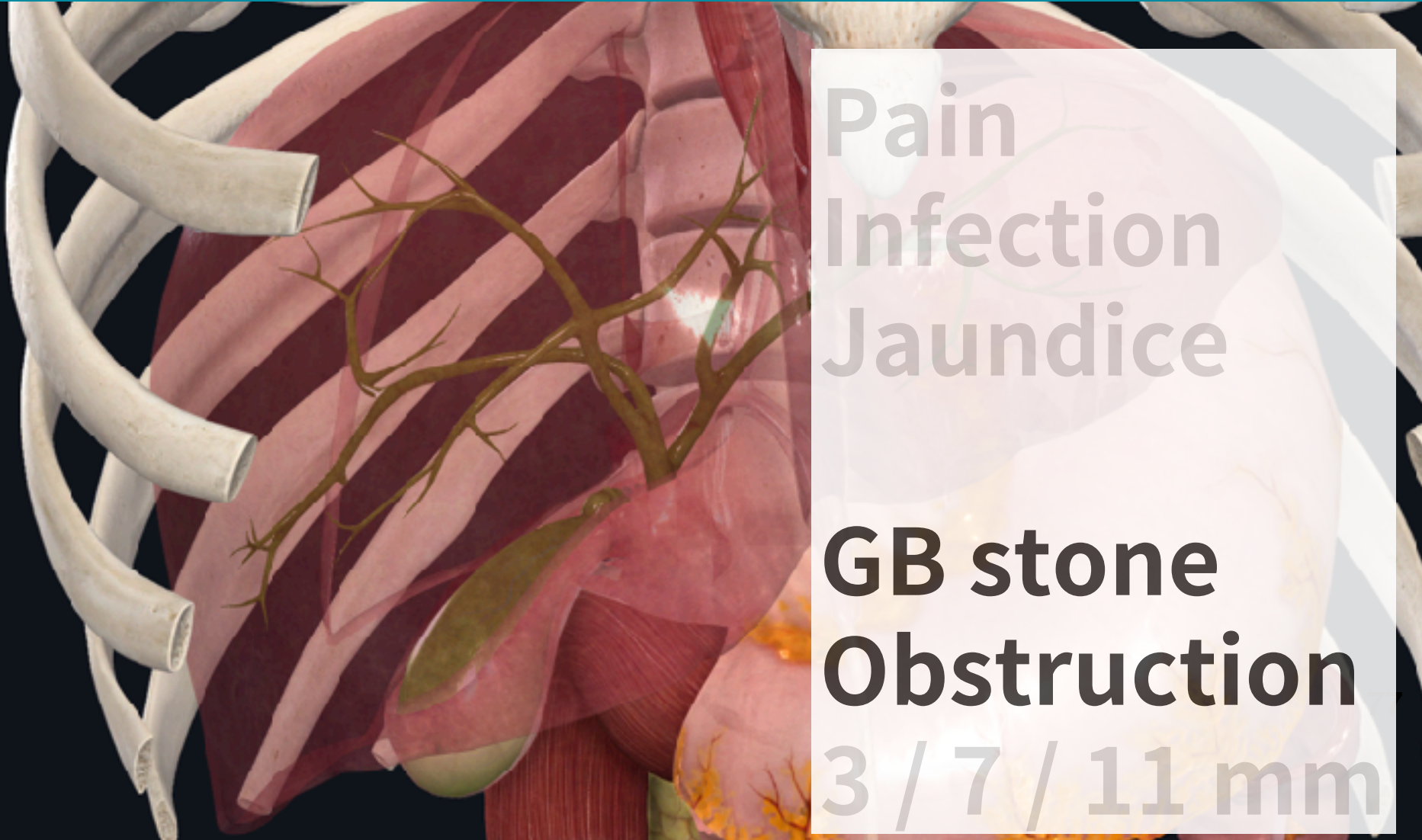


HEPATO-BILIARY





HEPATO-BILIARY



Pain
Infection
Jaundice

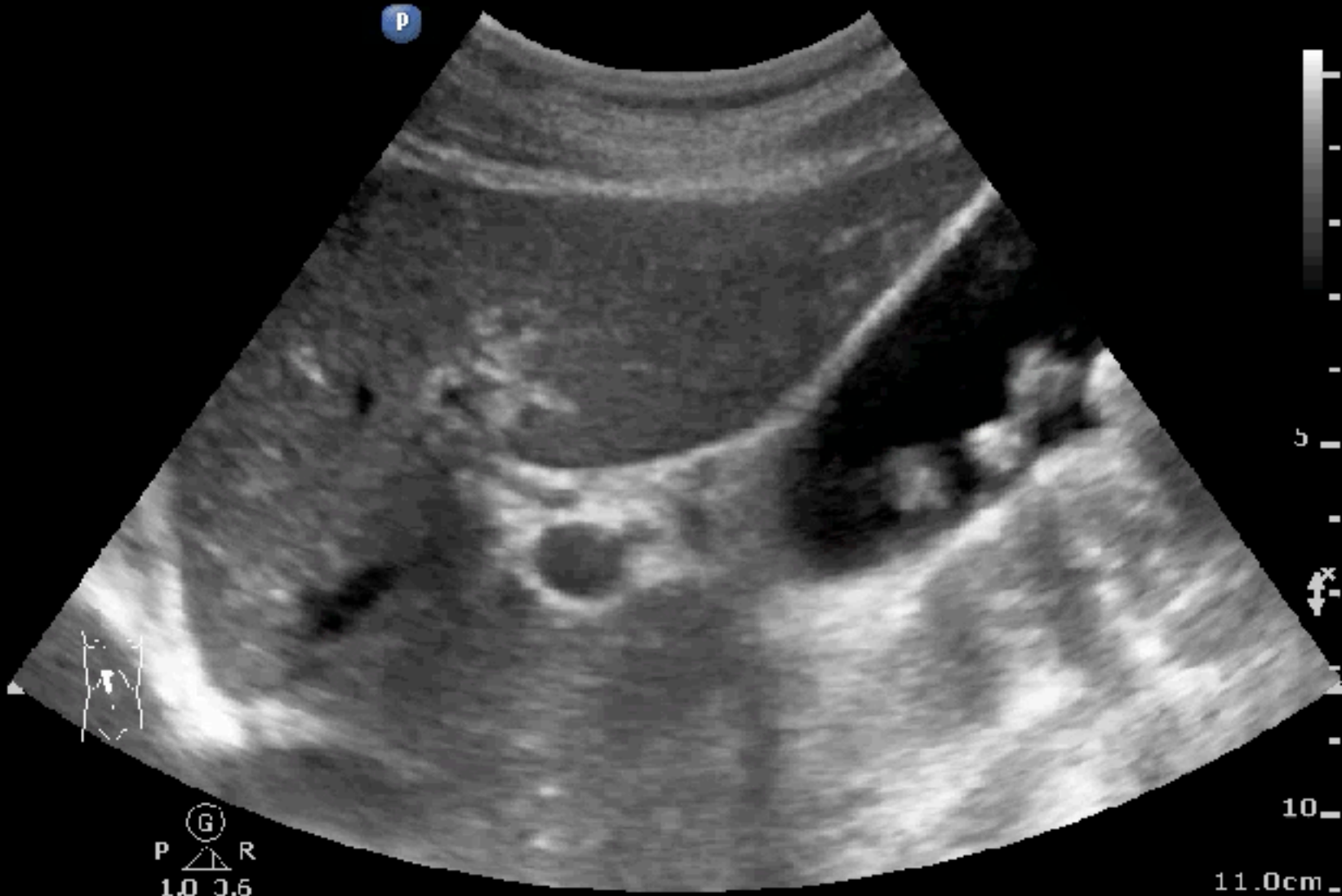GB stone
Obstruction
3 / 7 / 11 mm

Mickey Mouse sign

Abd Gen
C5-1
42 Hz
11.0cm

2D

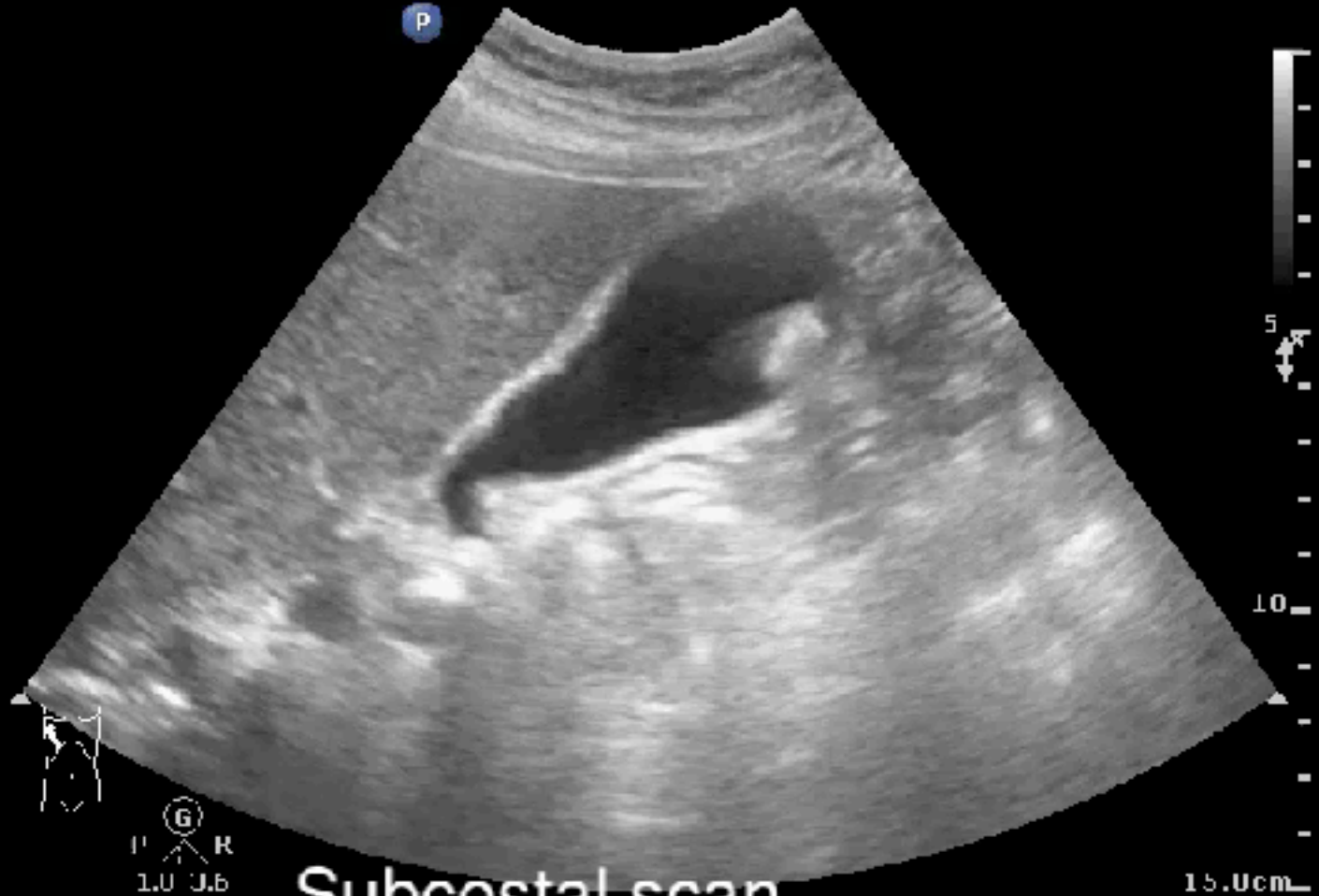HGen
Gn 80
C 56
3 / 3 / 3



GB stone ?

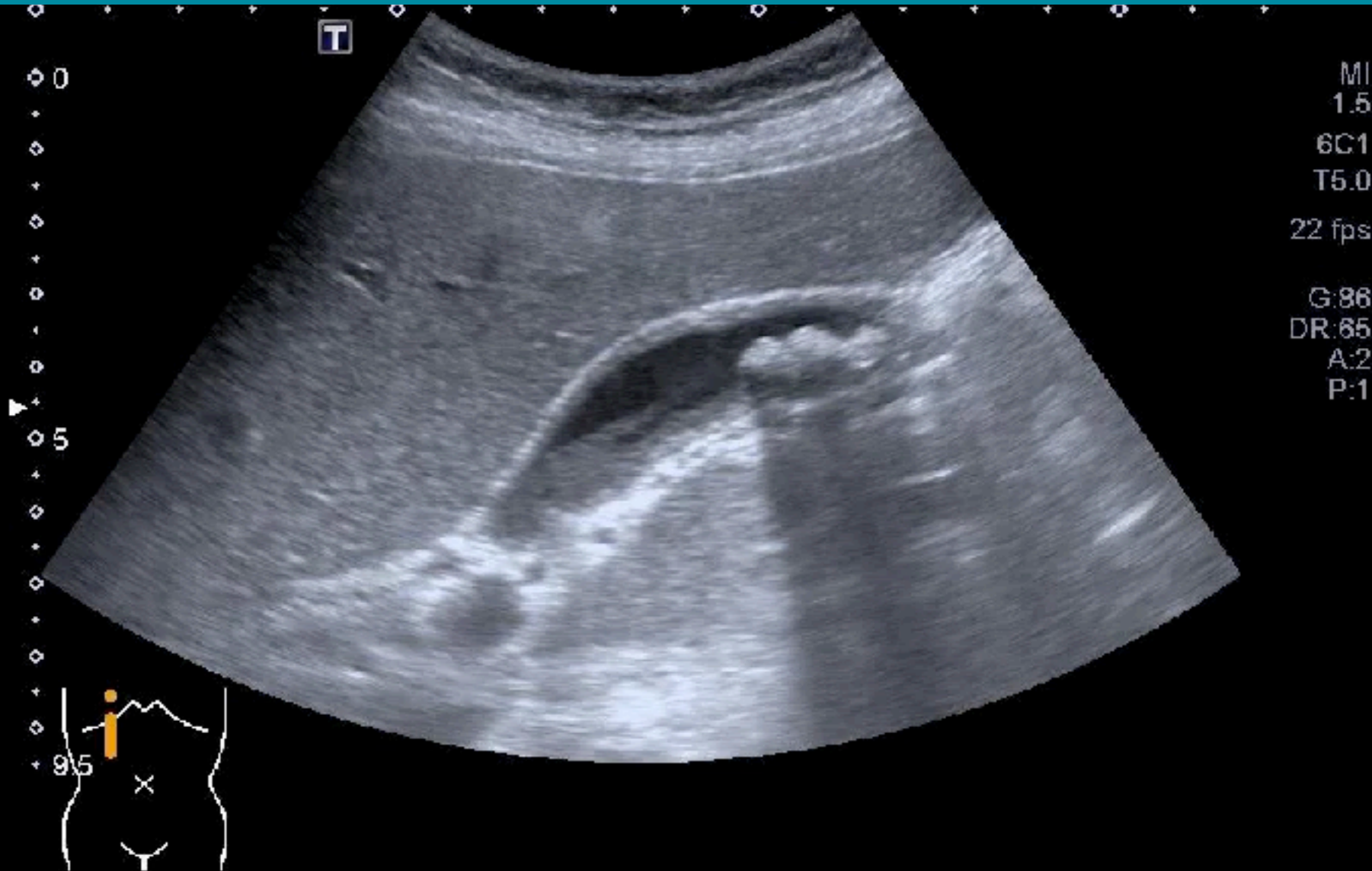Abd Gen
C5 1
34 Hz
15.0cm

2D
HGen
Gn 100
C 63
3 / 3 / 3

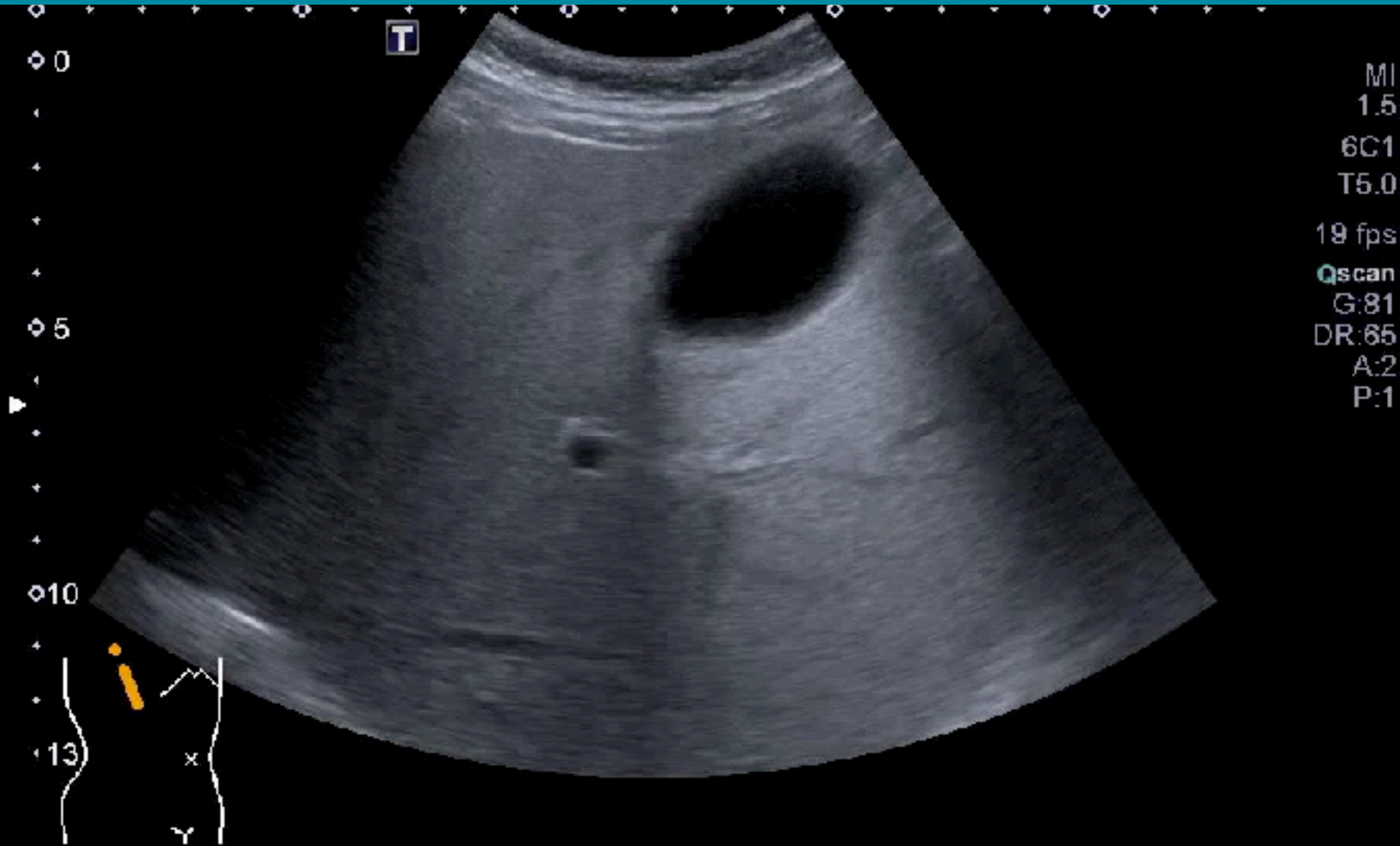


Subcostal scan
L decubitus position

GB stone / polyp / sludges



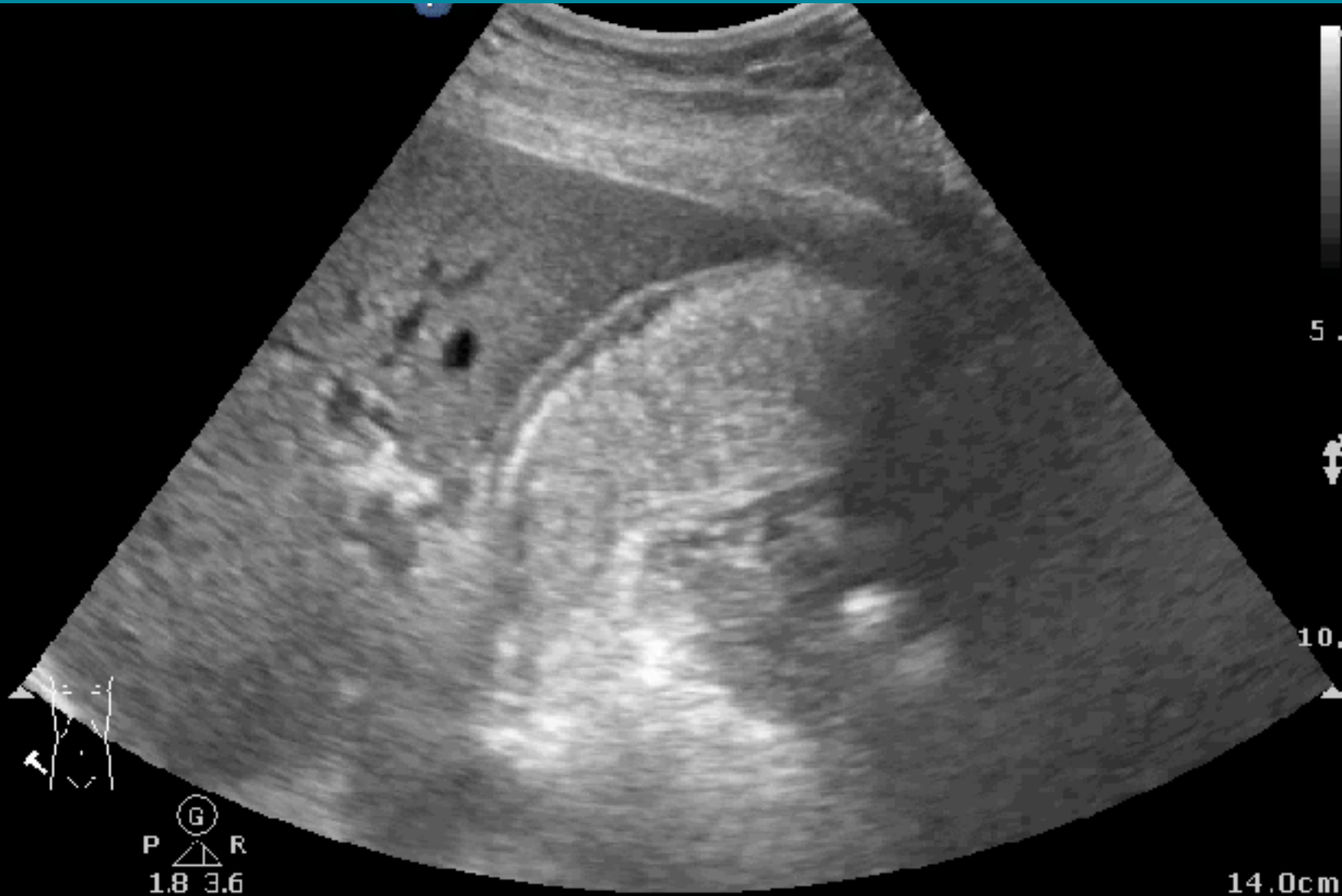
GB stone ?



GB stone ?

100 MHz
25 1
36 Hz
14.0cm

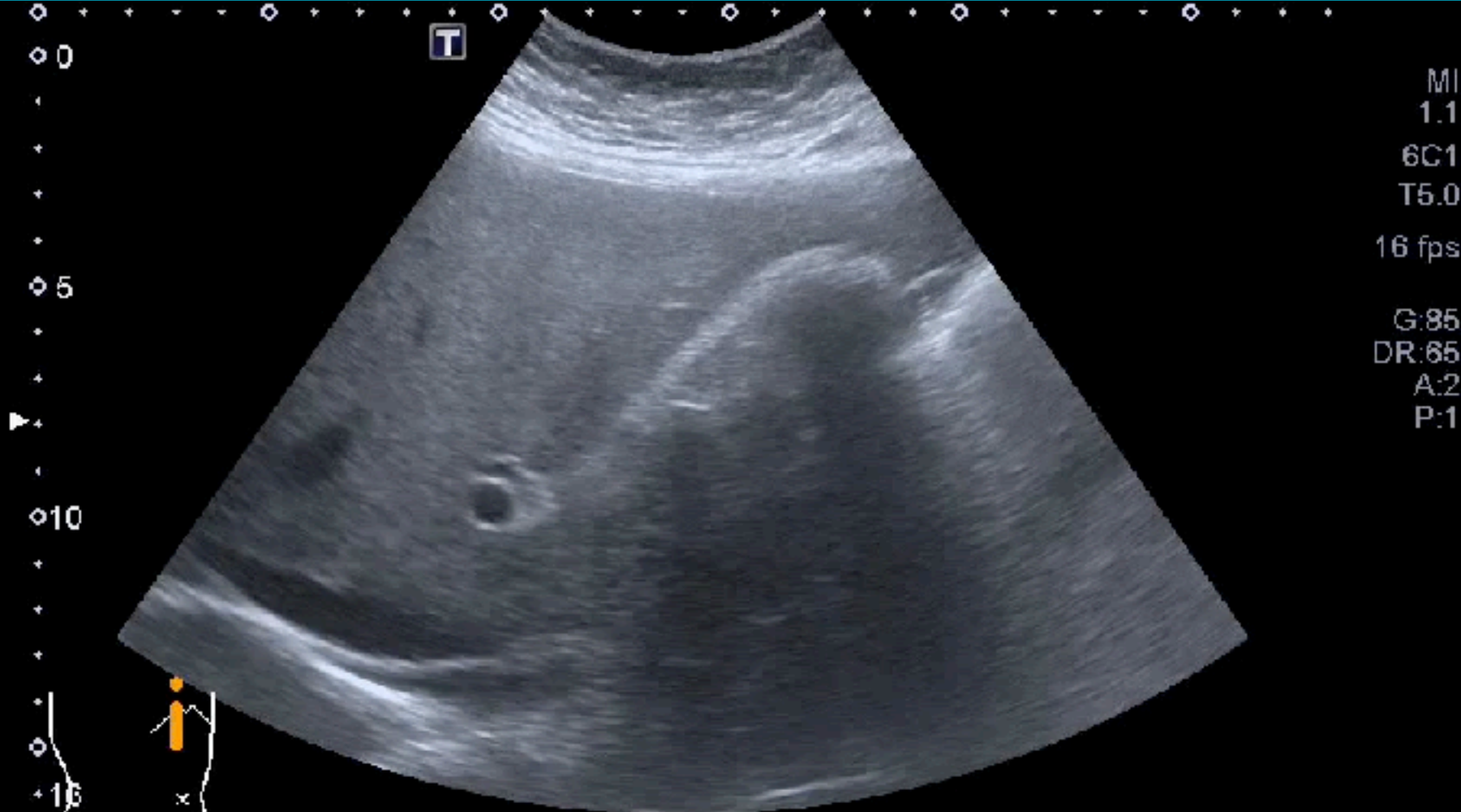2D
HGen
Gn 100
C 56
3 / 3 / 3



G
P R
1.8 3.6

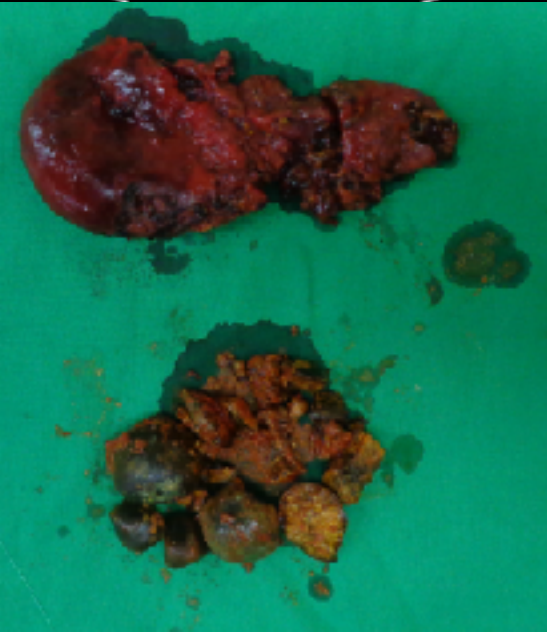
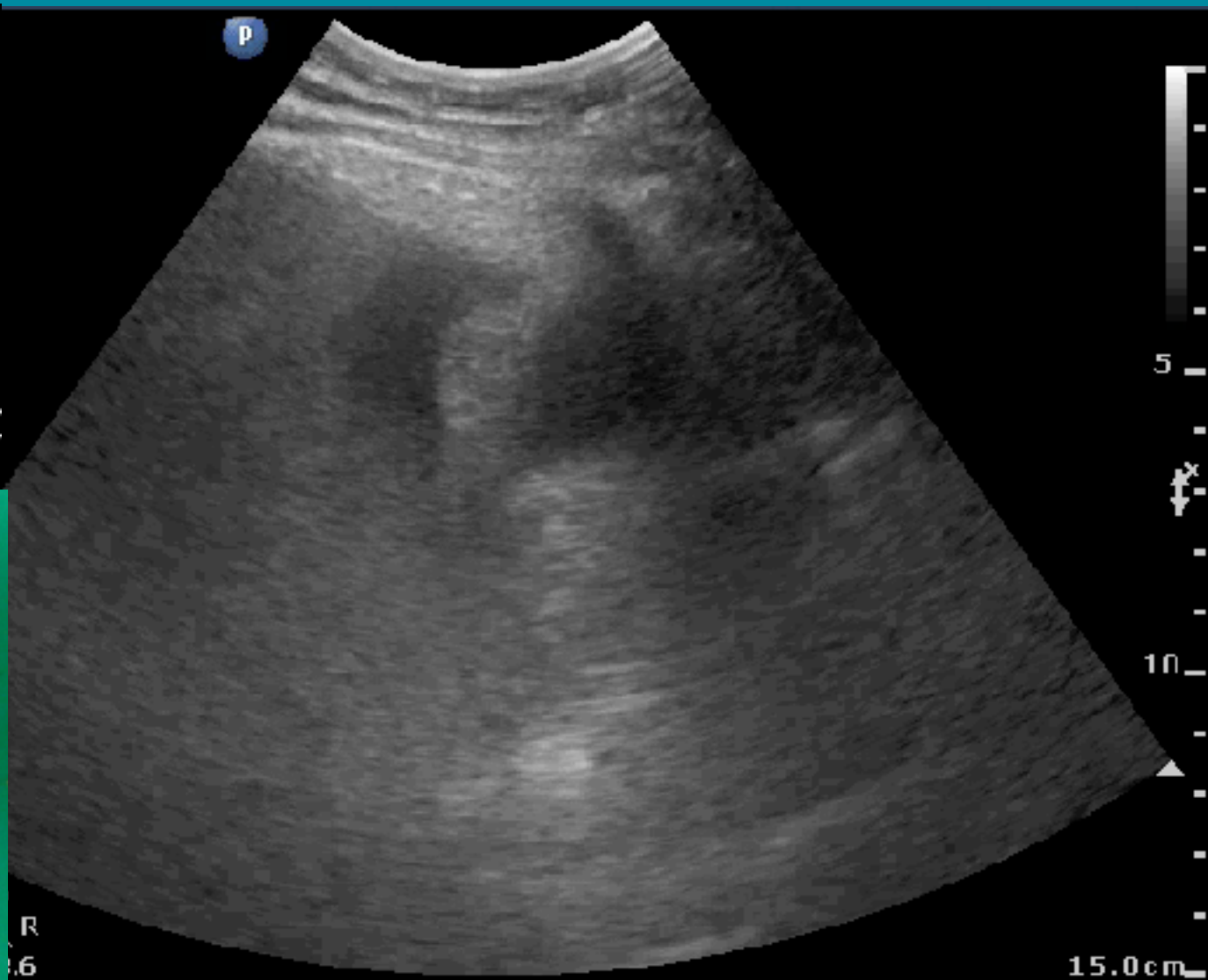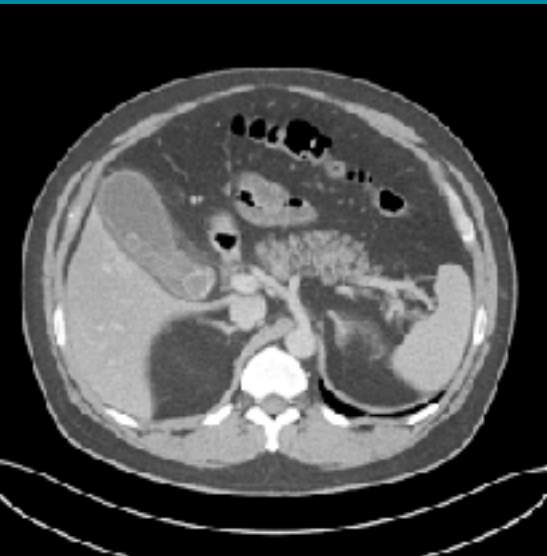
14.0cm

GB stone ?



Wall Echo Shadow (WES) sign

45M, RUQ pain & fever



R
6

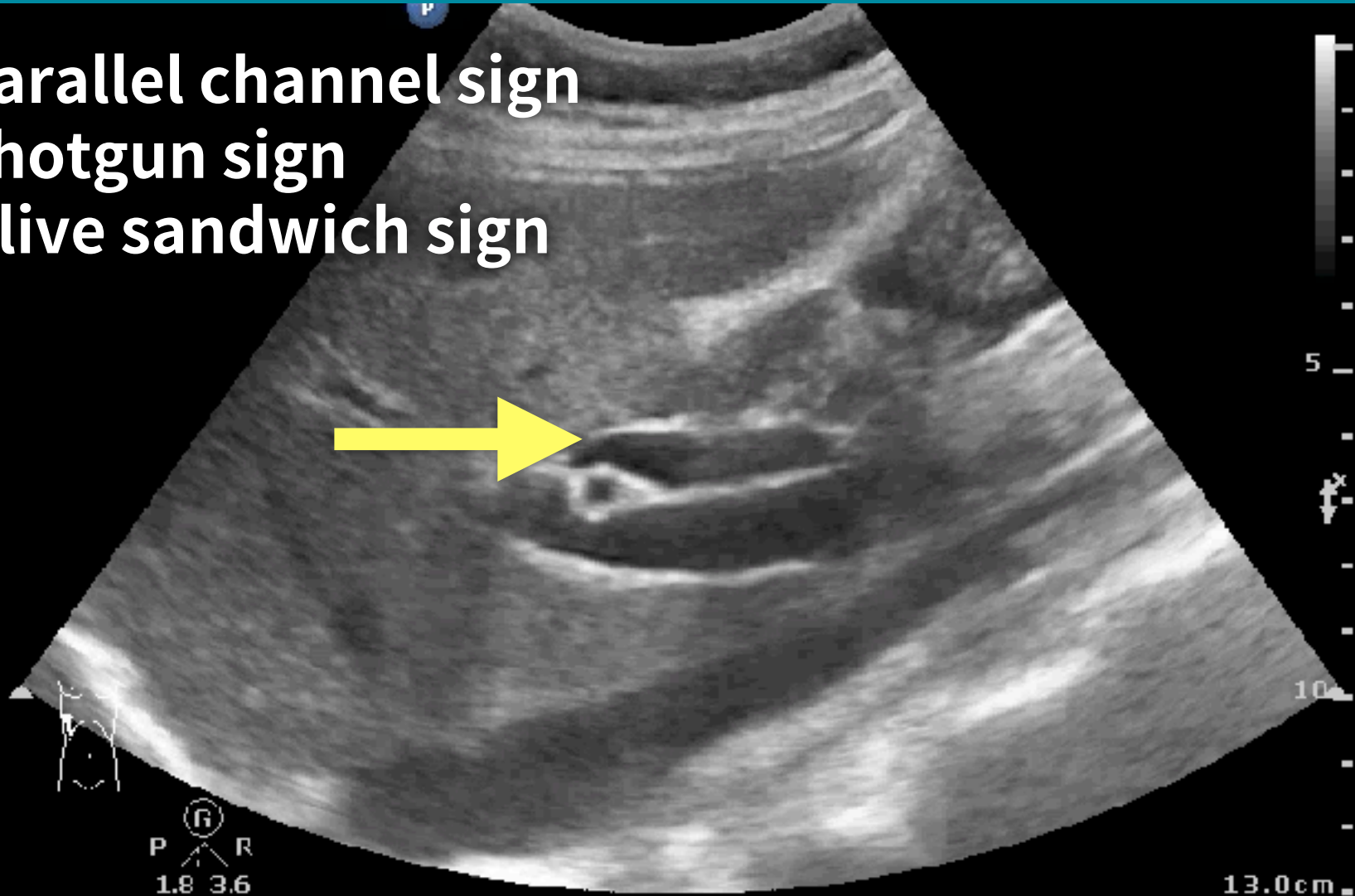
15.0 cm

Biliary dilatation ?

Abd Gen
C5-1
38 Hz
13.0cm

2D
HGen
Gn 82
C. 56
3/3/3

Parallel channel sign
Shotgun sign
Olive sandwich sign



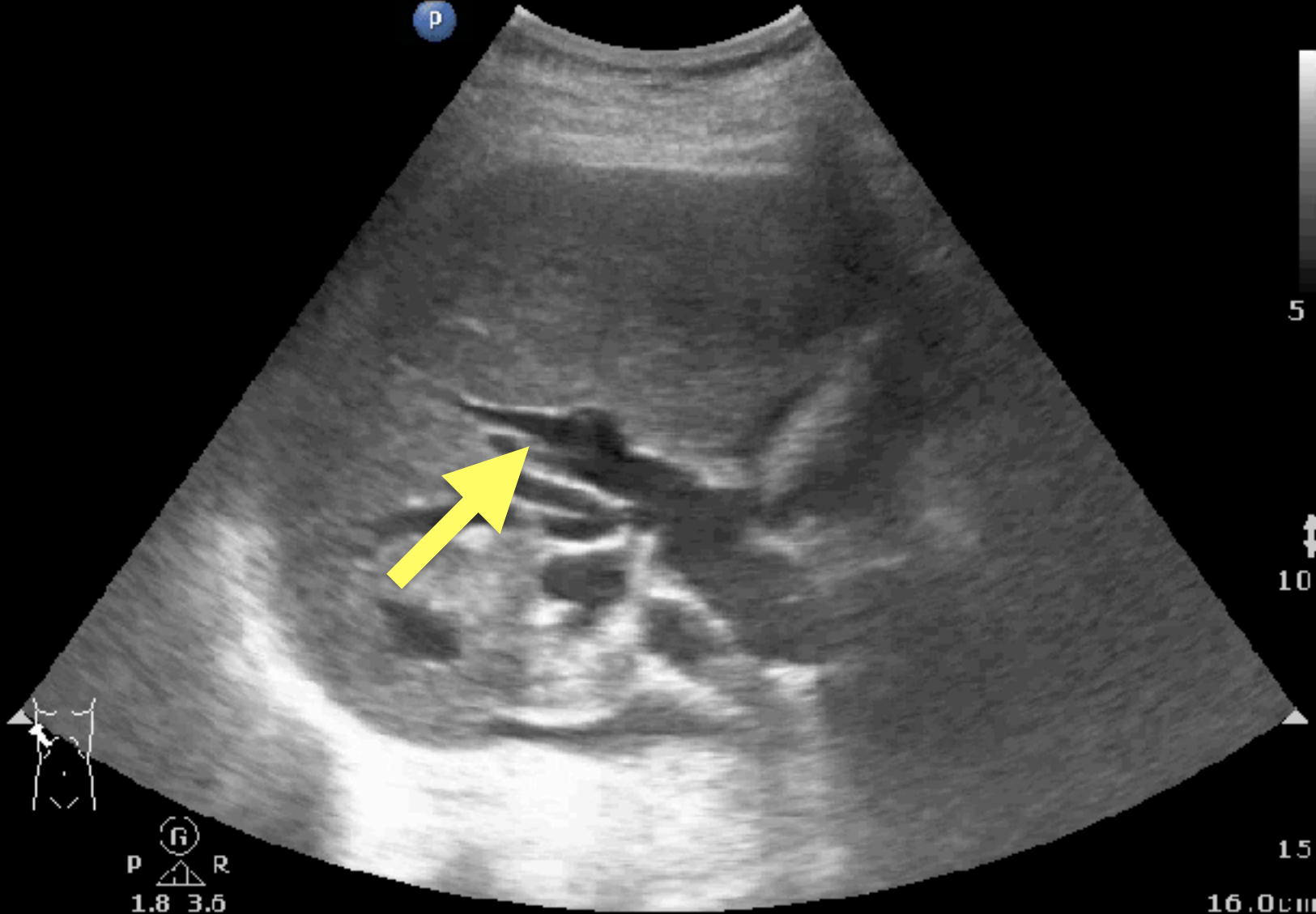
P
R
1.8 3.6

13.0cm

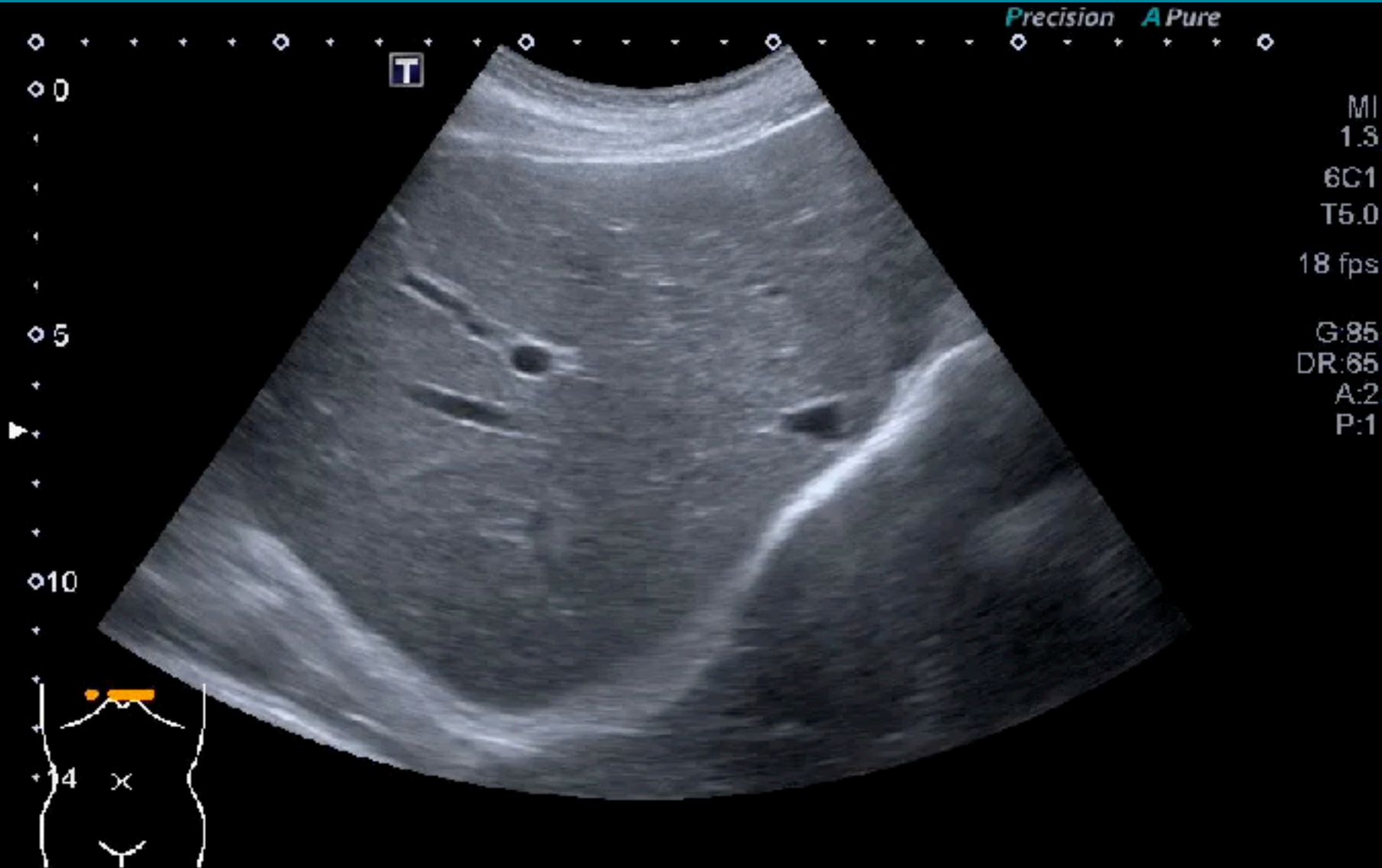
76F, Fever & Chills Biliary dilatation ?

Abd Gen2
C5-1
2 Hz
6.0cm

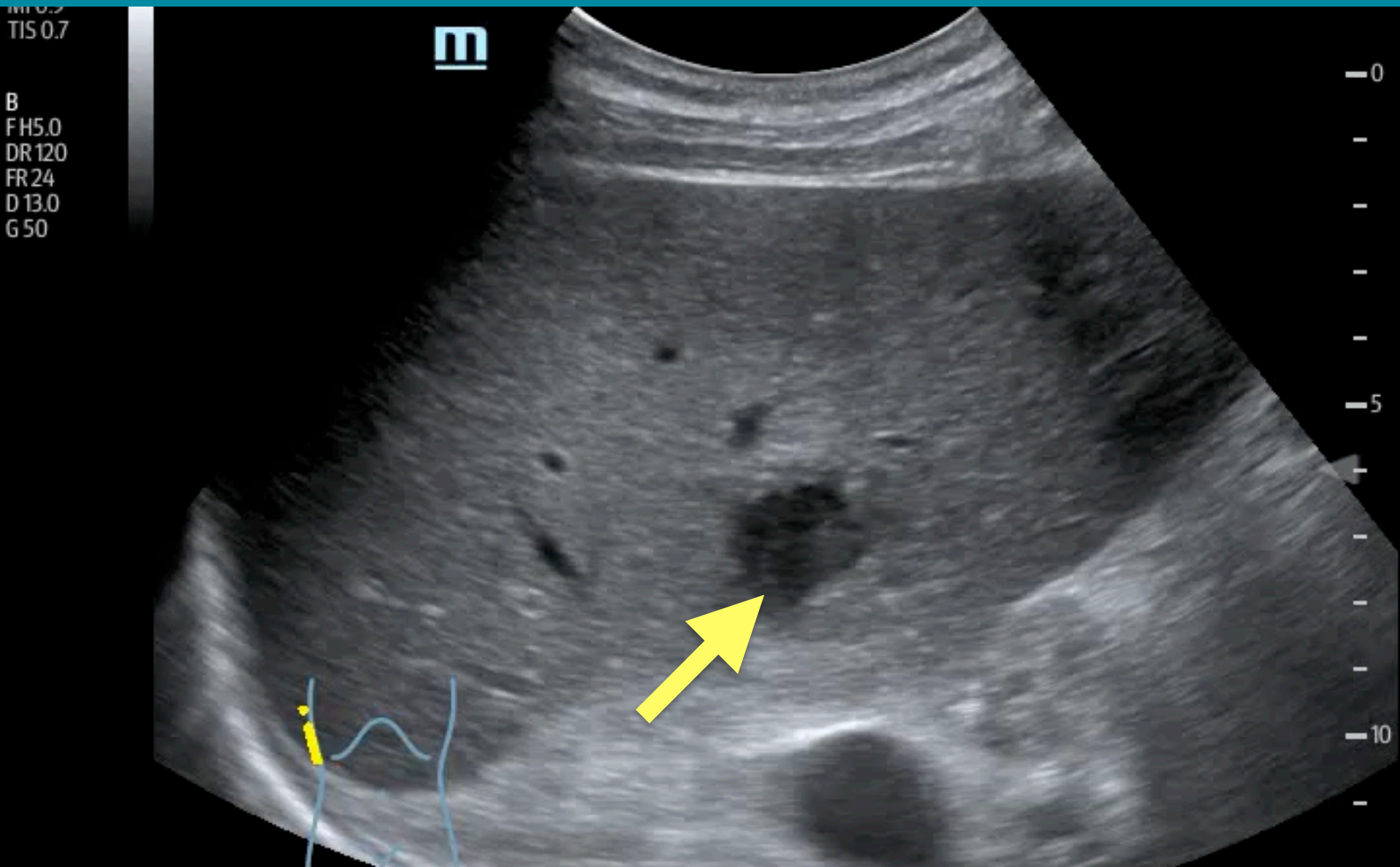
D
HGen
Gn 100
C 56
3/3/3



Subcostal liver scan



Liver abscess

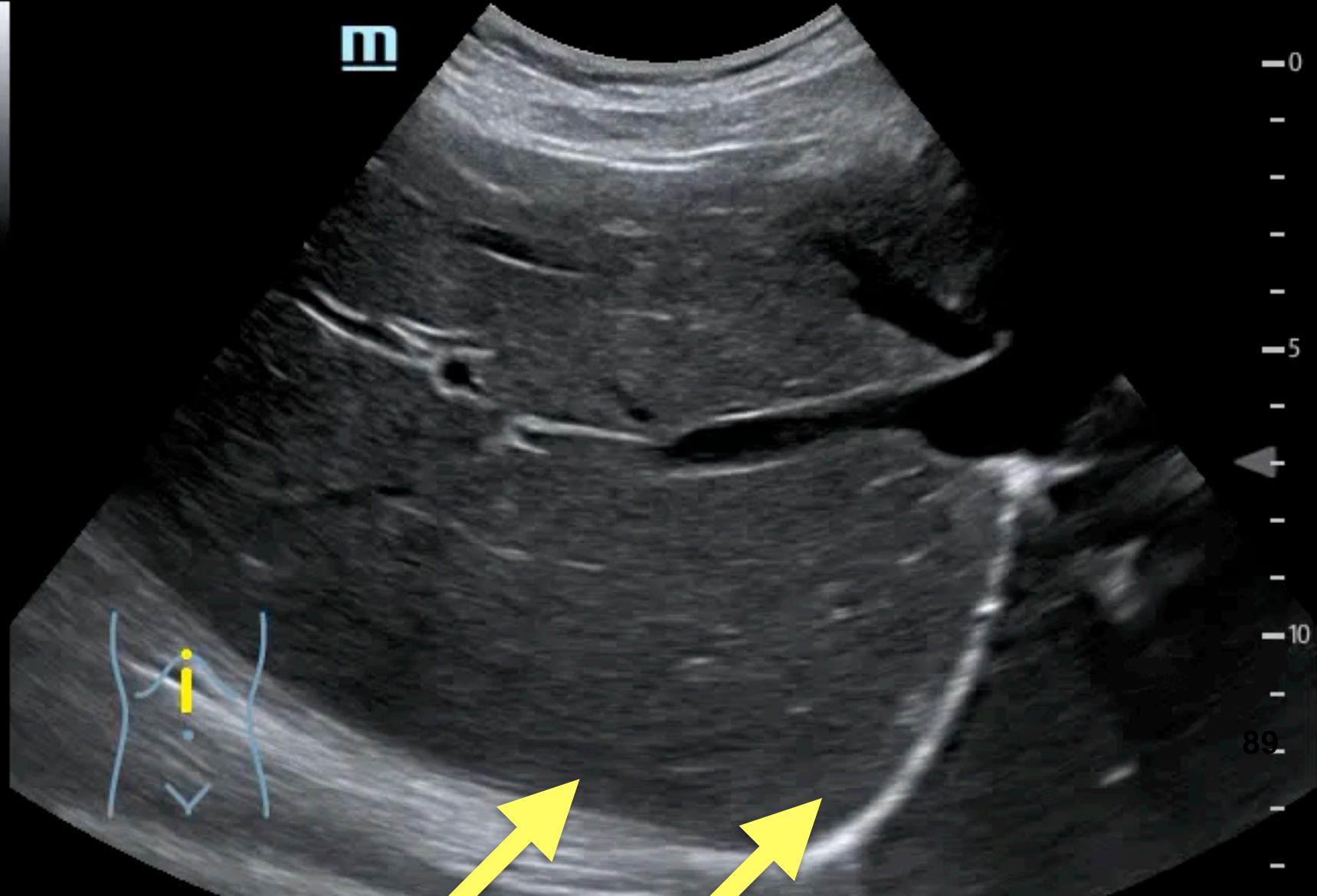


Hemangioma

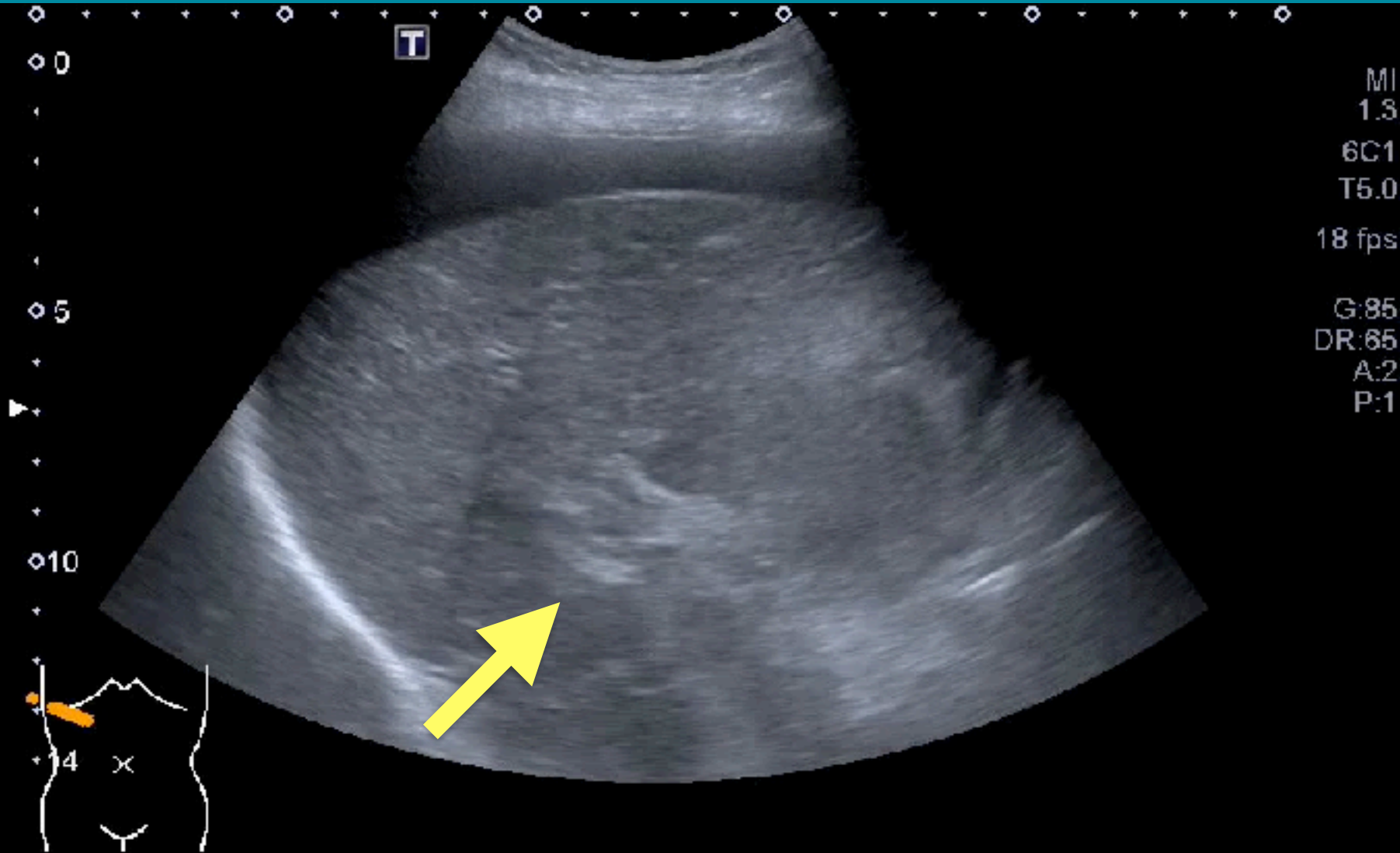
MI 0.9
TIS 0.7

B
FH5.0
DR120
FR 21
D 16.0
G 47

m



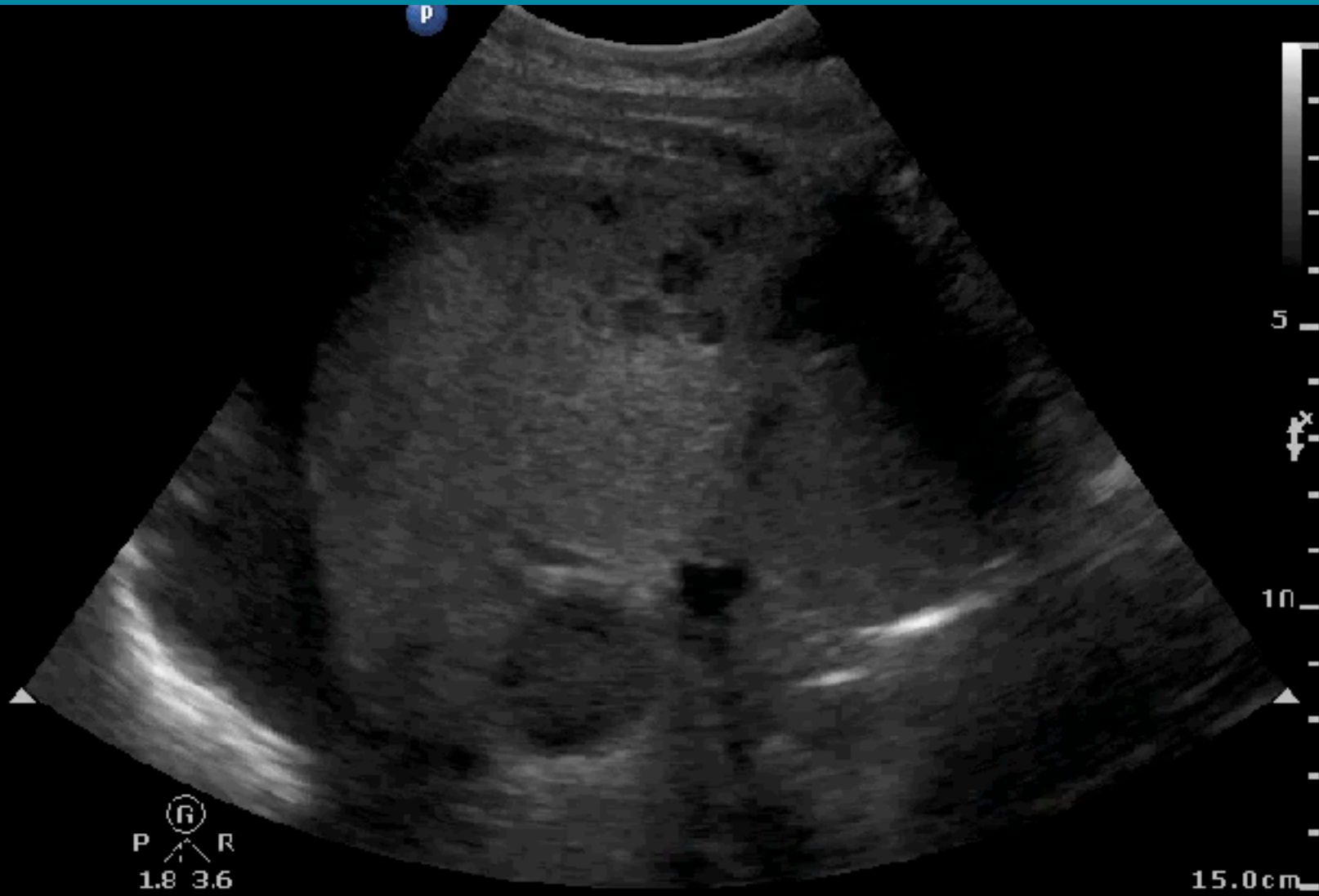
PVT



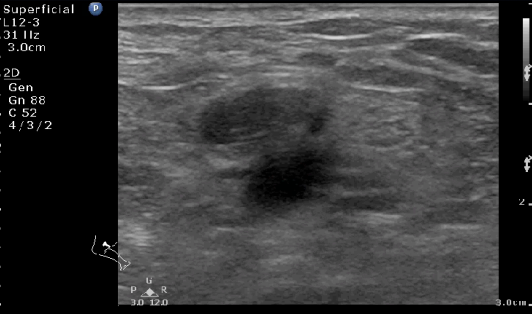
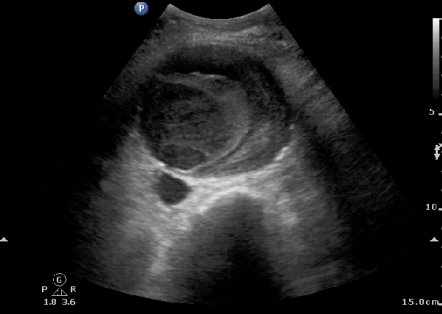
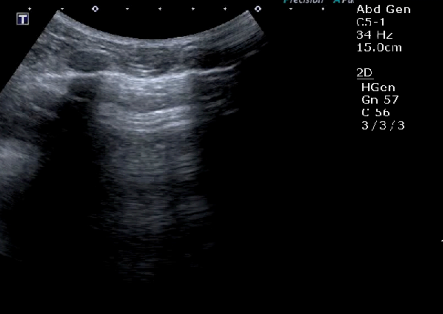
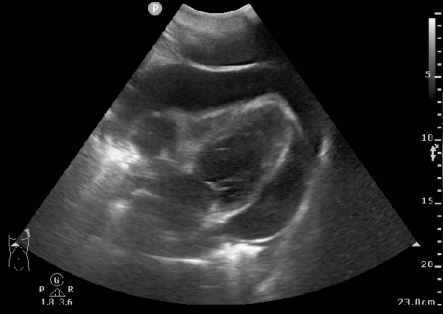
Metastatic liver tumor

Abd Gen
C5-1
34 Hz
15.0cm

2D
HGen
Gn 82
C. 56
3 / 3 / 3



15.0cm



HEART

LUNG

AORTA

DVT

KIDNEY

GB

Liver

FAST

TAKE HOME IMAGES

