



衛生福利部雙和醫院
(委託臺北醫學大學興建經營)
Taipei Medical University · Shuang Ho Hospital,
Ministry of Health and Welfare



重點式腹超:你該知道的大小事

Apache POCUS Workshop

陳國智醫師 雙和醫院急診醫學科

juice119@gmail.com

POCUSacademy.com

陳國智 醫師



急診超音波臨床評核醫師
醫用超音波學會指導醫師



WINFOCUS director / instructor
Certified Interventional Pain Sonologist

急診 / 重症 / 介入 / 急性疼痛

經歷

新光急診超音波訓練中心主任

西園醫院急診醫學科主任

急診醫學會超音波委員會主委

台灣疼痛醫學會大體模擬手術講師

急救加護醫學會重症超音波負責人

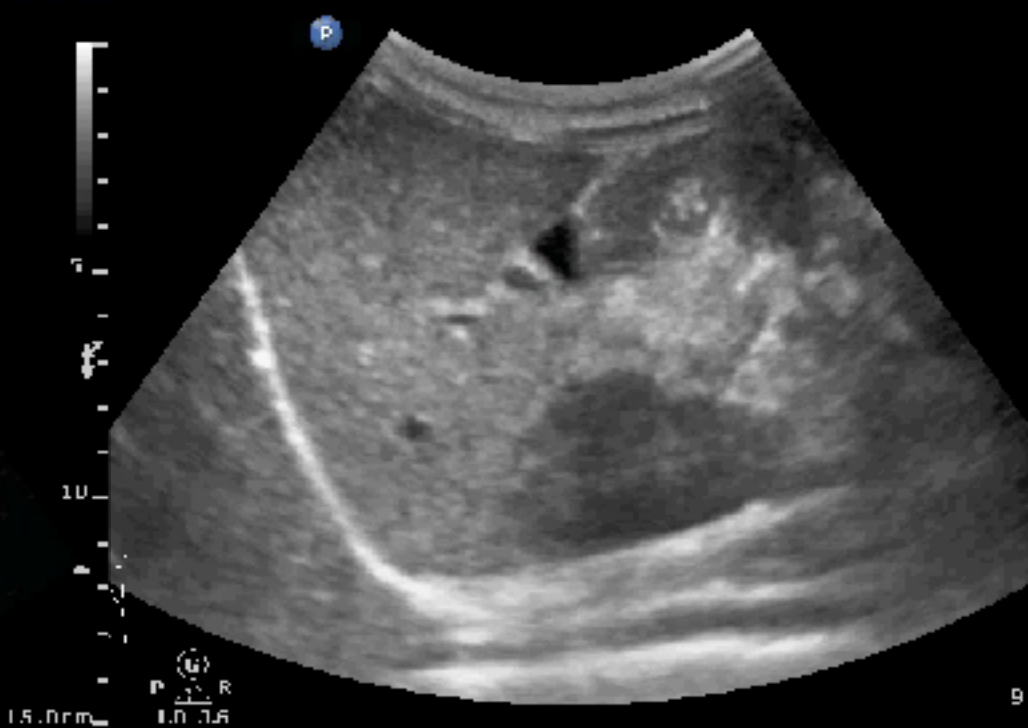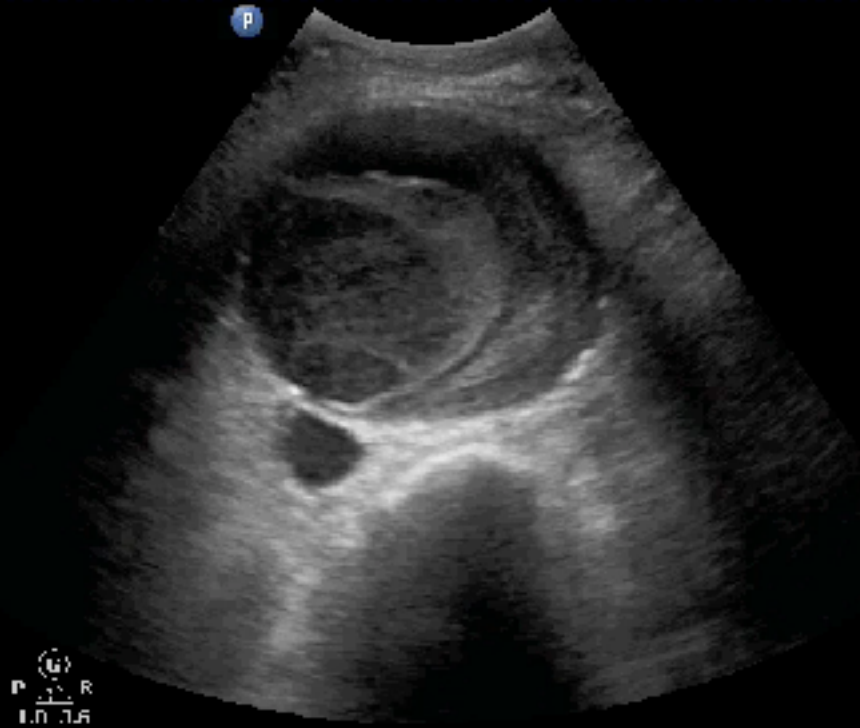診
斷

監
測

介
入

POINT OF CARE ULTRASOUND

~ 存在於臨床需求之所在 ~



重點式腹超:你該知道的大小事？

~ 你/妳和患者臨床需求所在 ~

I-AIM

POINT



Acquire



Interpret



**Make
decision**

Acute Abdomen

Internal bleeding ?



FAST

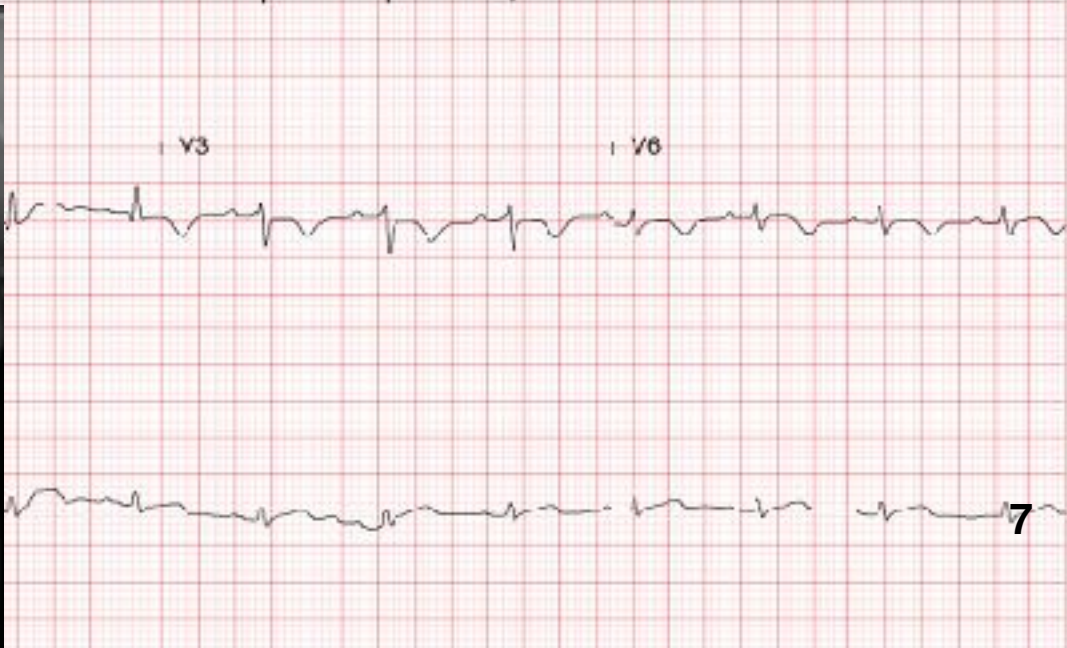
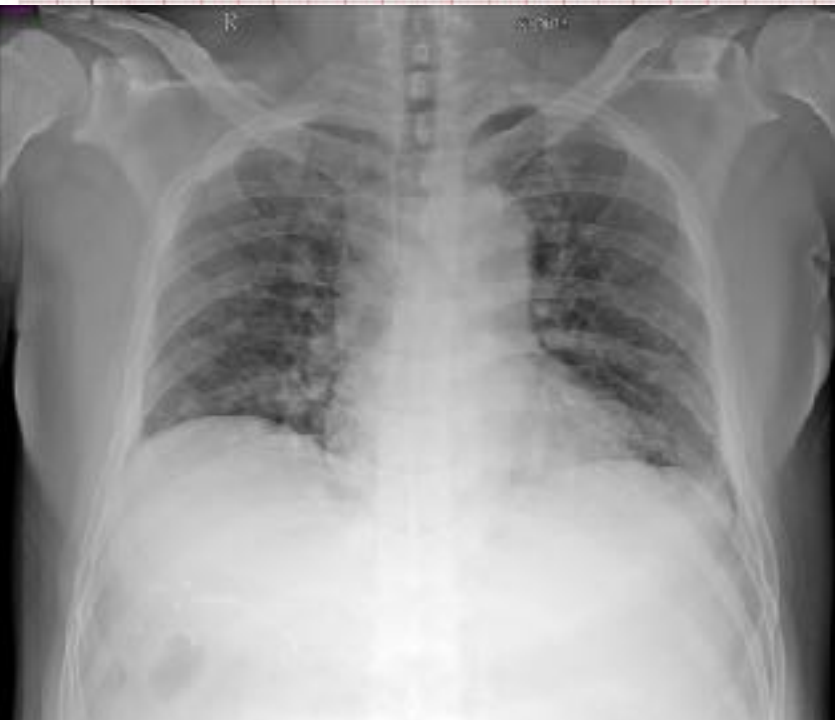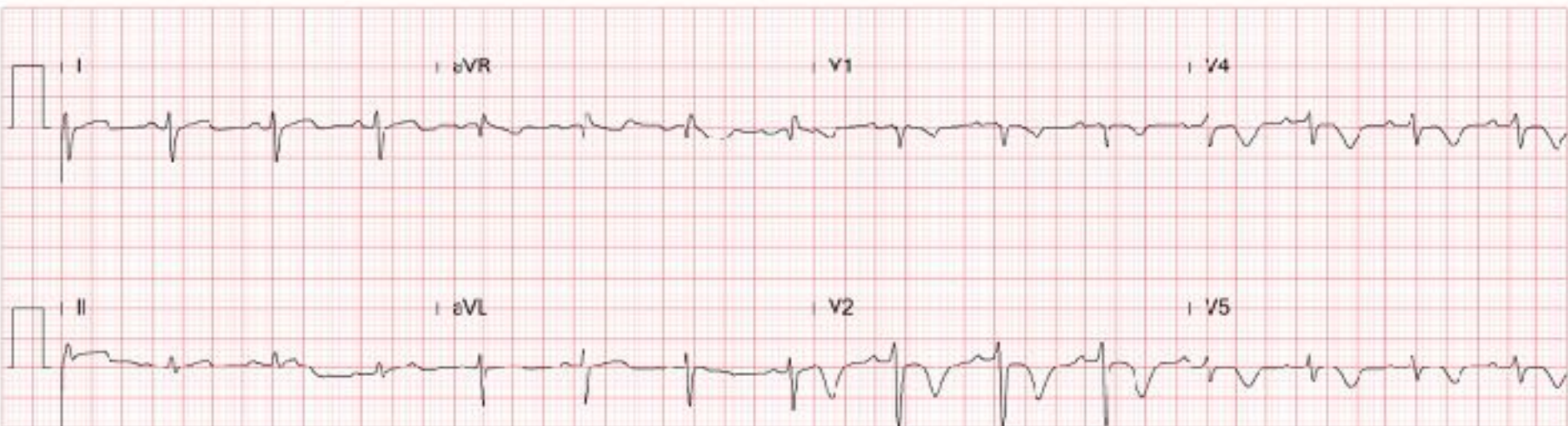


Free Fluid



CT/TAE/OP

52M, left chest pain



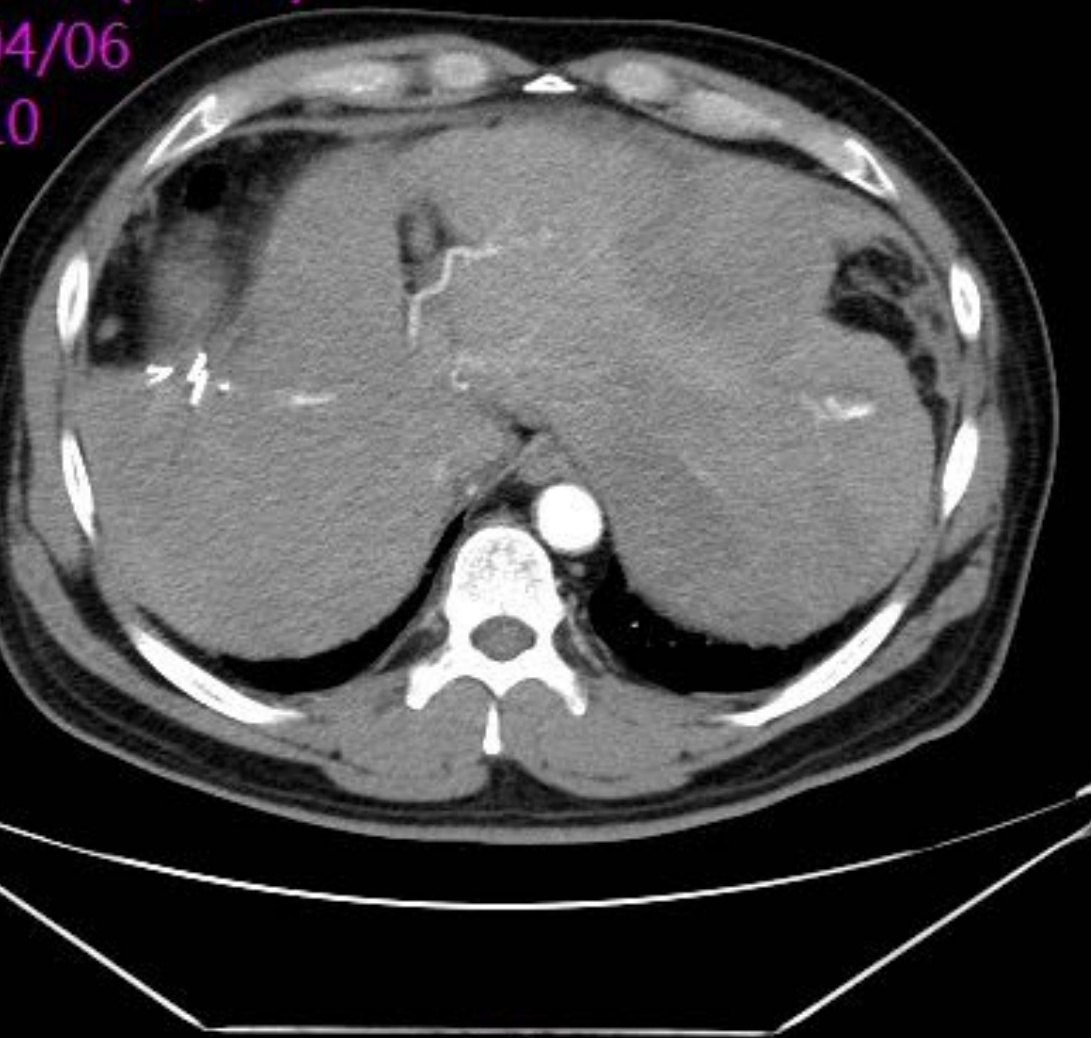
410

A

CTA (-C,+C)

4/06

0



P

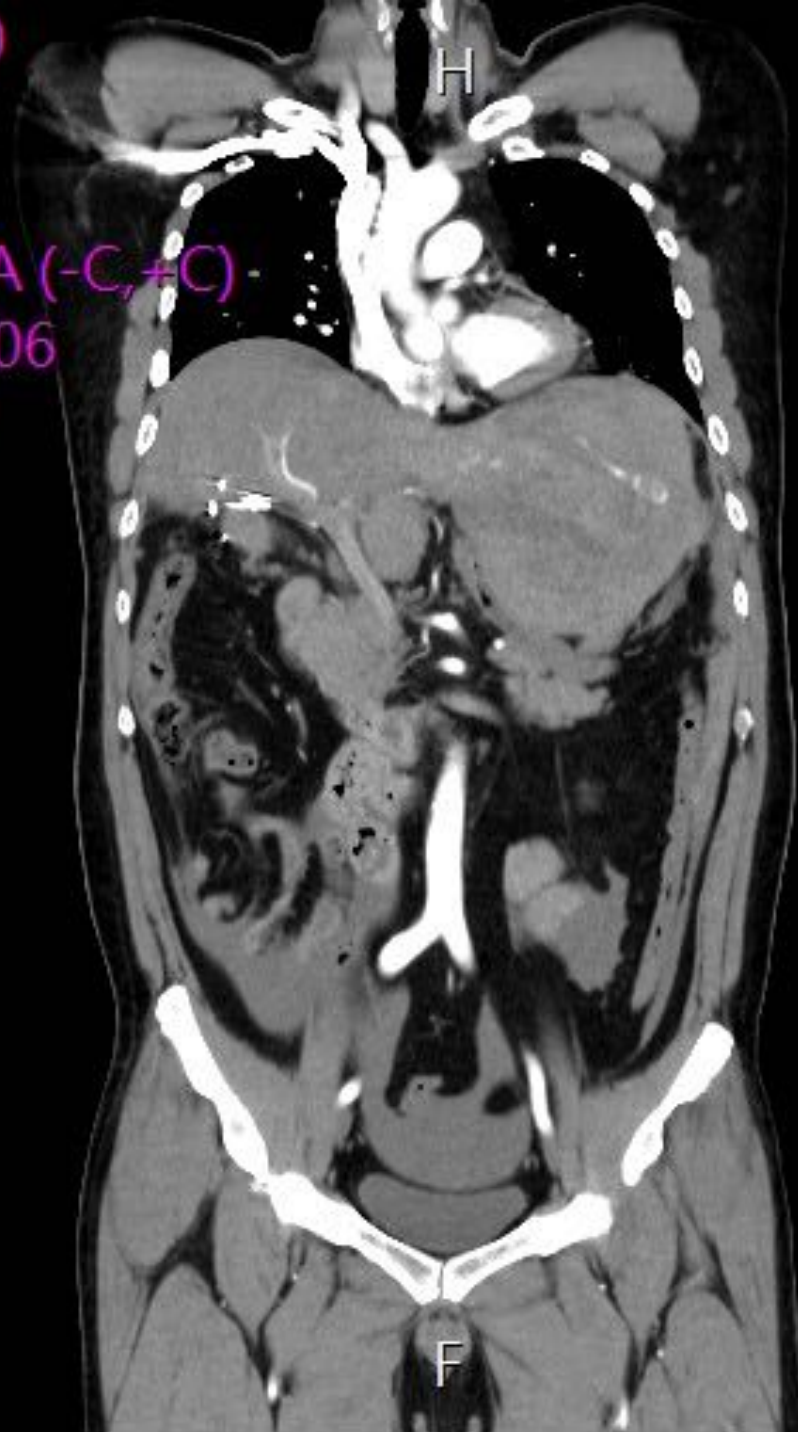0

H

CTA (-C,+C)

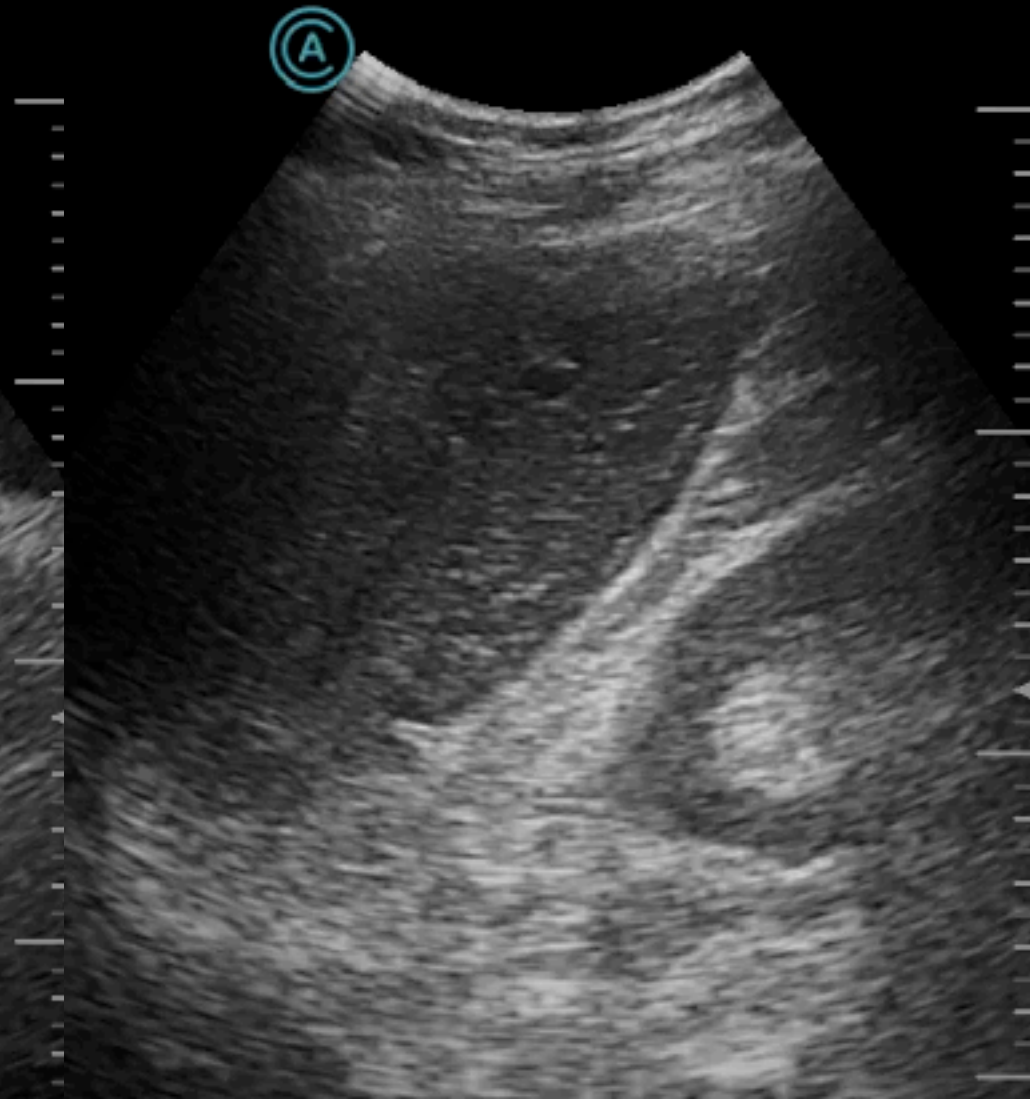
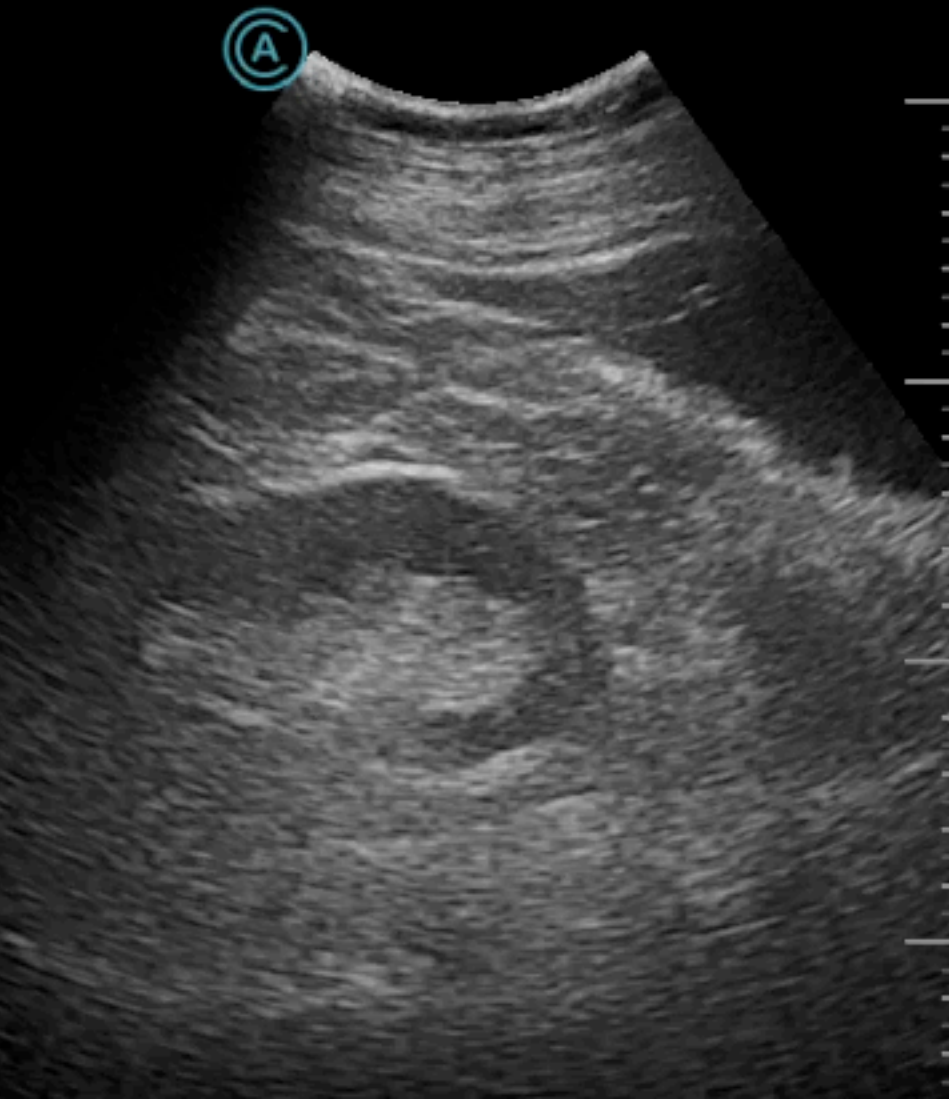
4/06

0

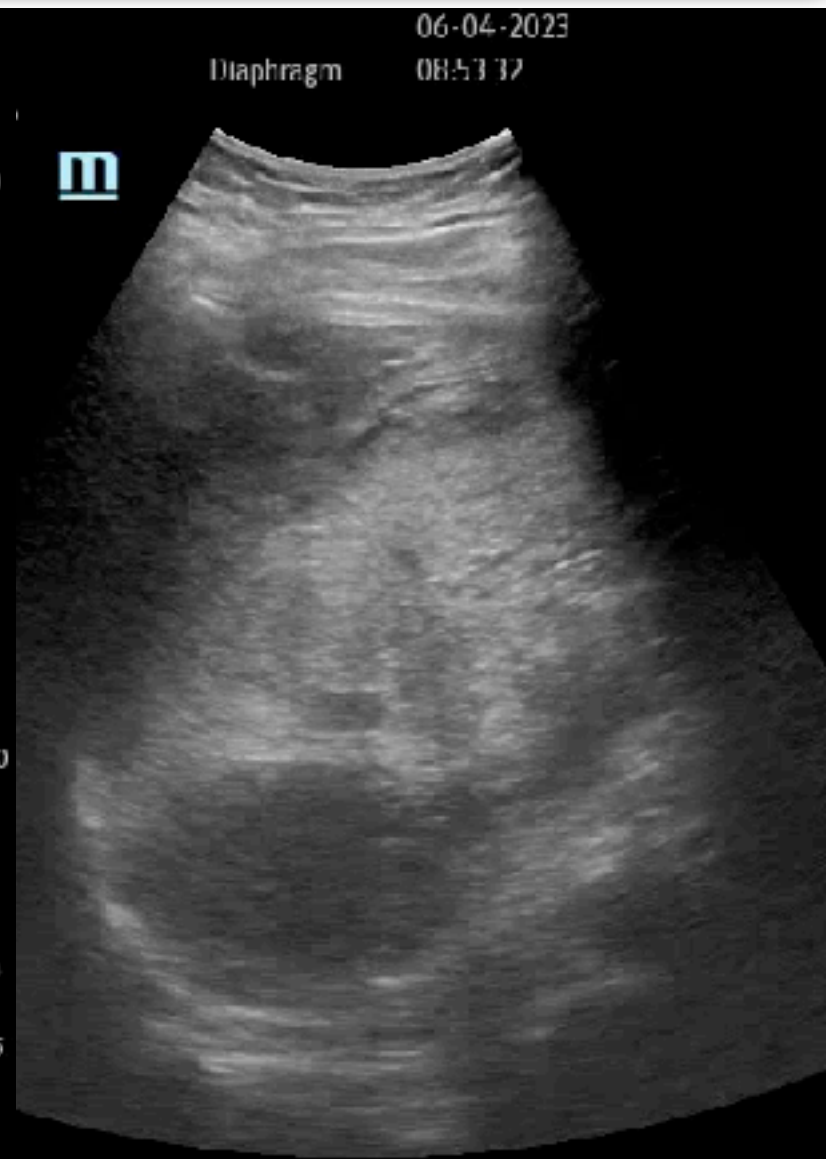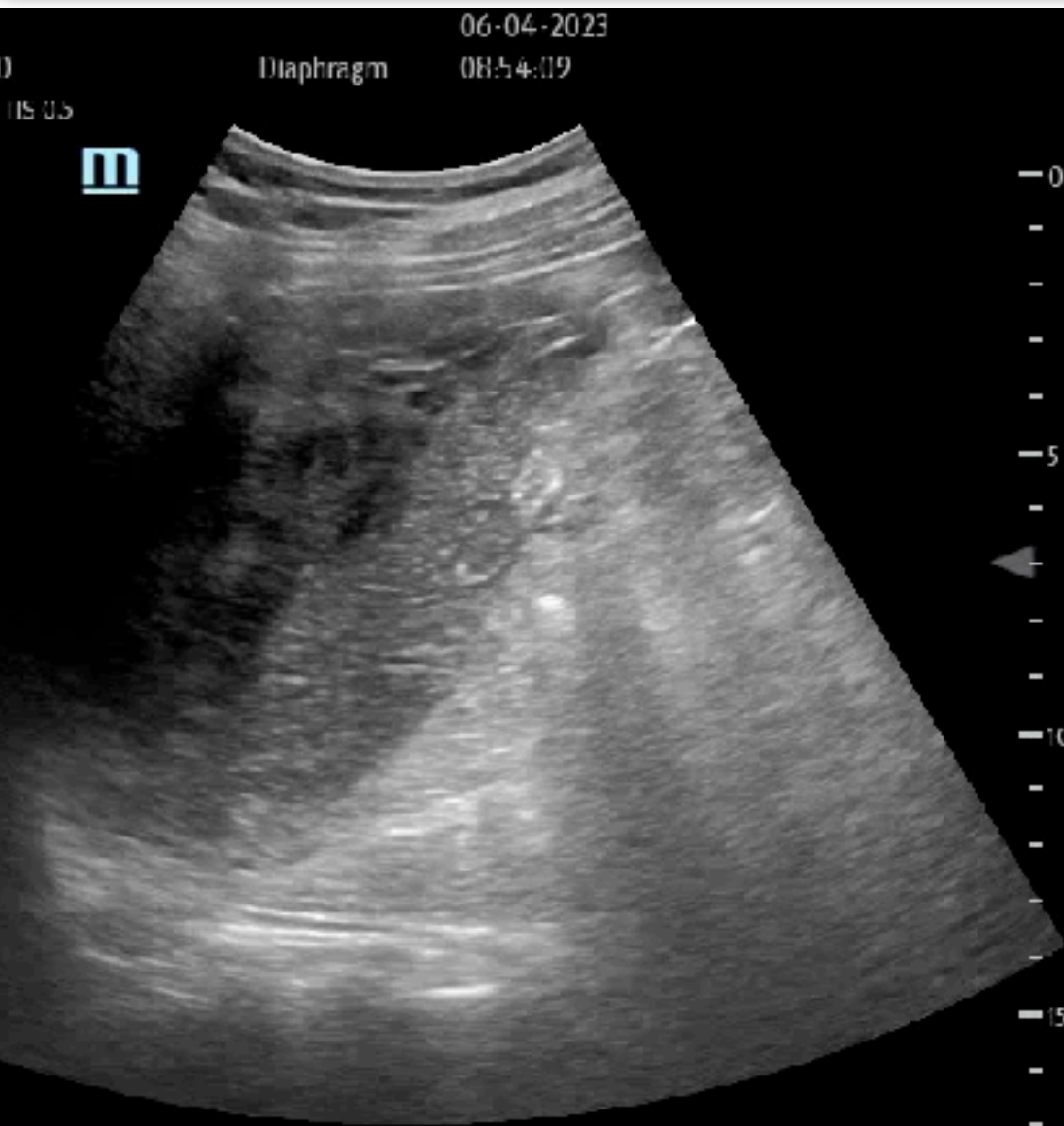


F

52M, left chest pain



Liver tumor rupture

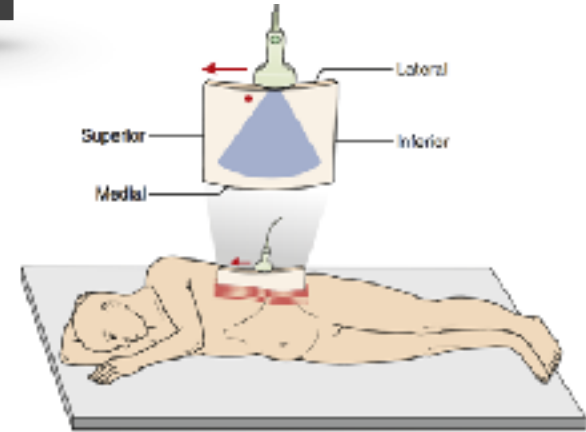
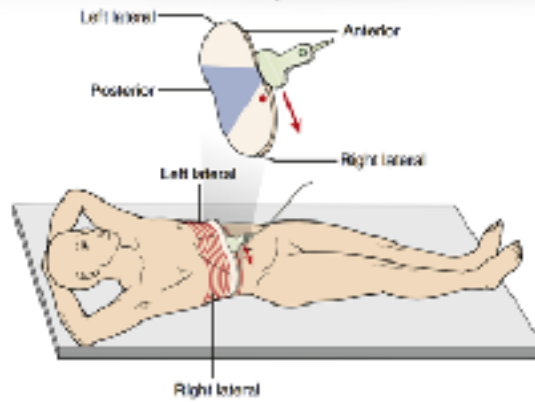
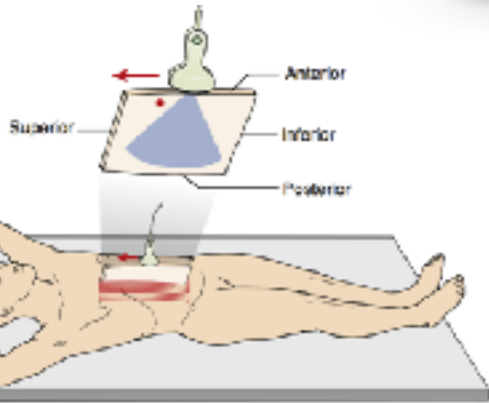


探頭選擇：腹為主／線為輔



急診POCUS不用NPO
系統性掃描之後再聚焦

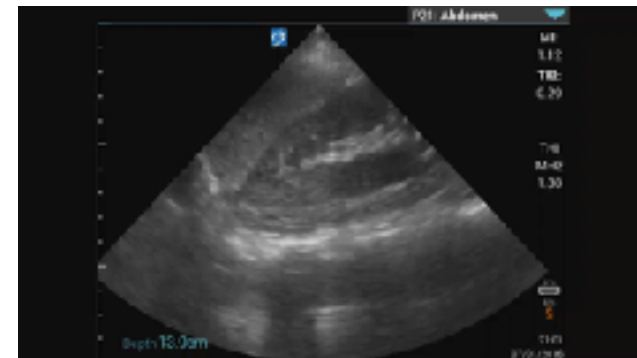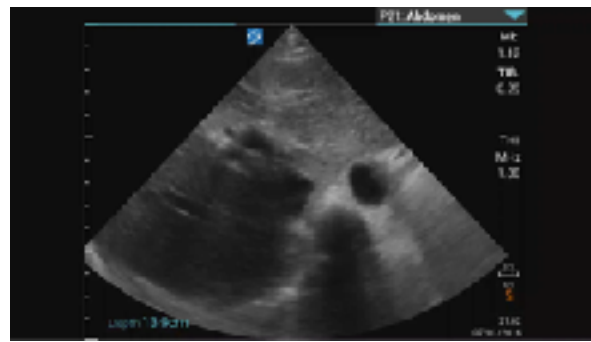
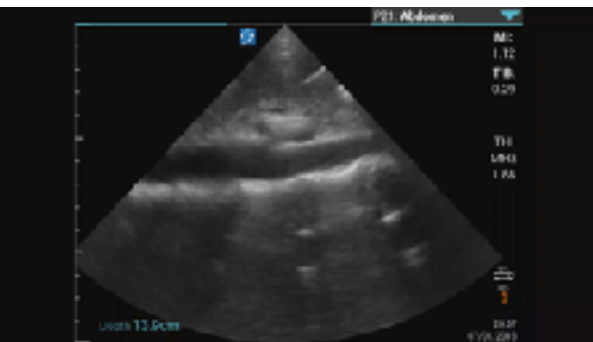3D 立體掃描



Sagittal 縱

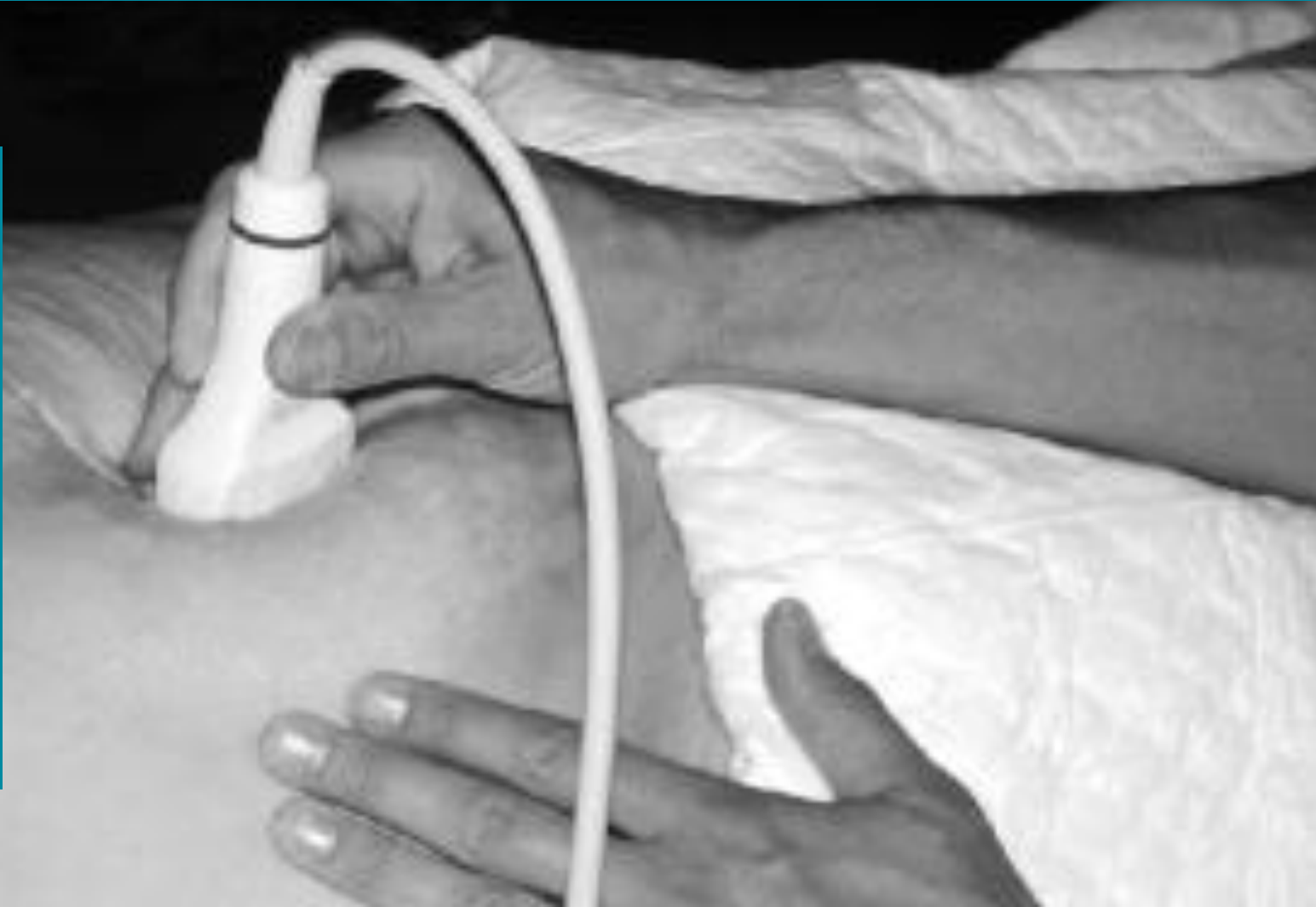Transverse 橫

Coronal 側

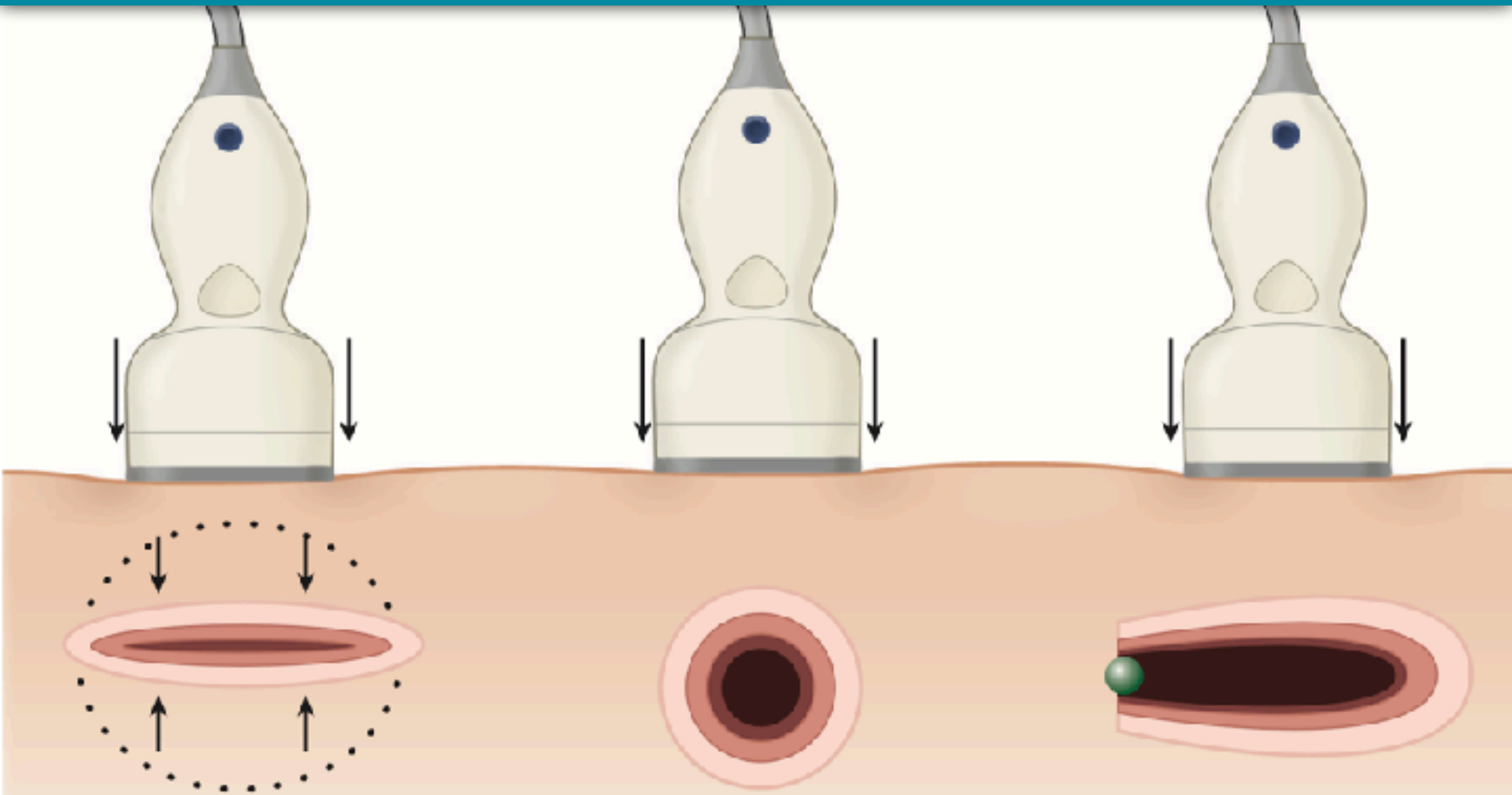


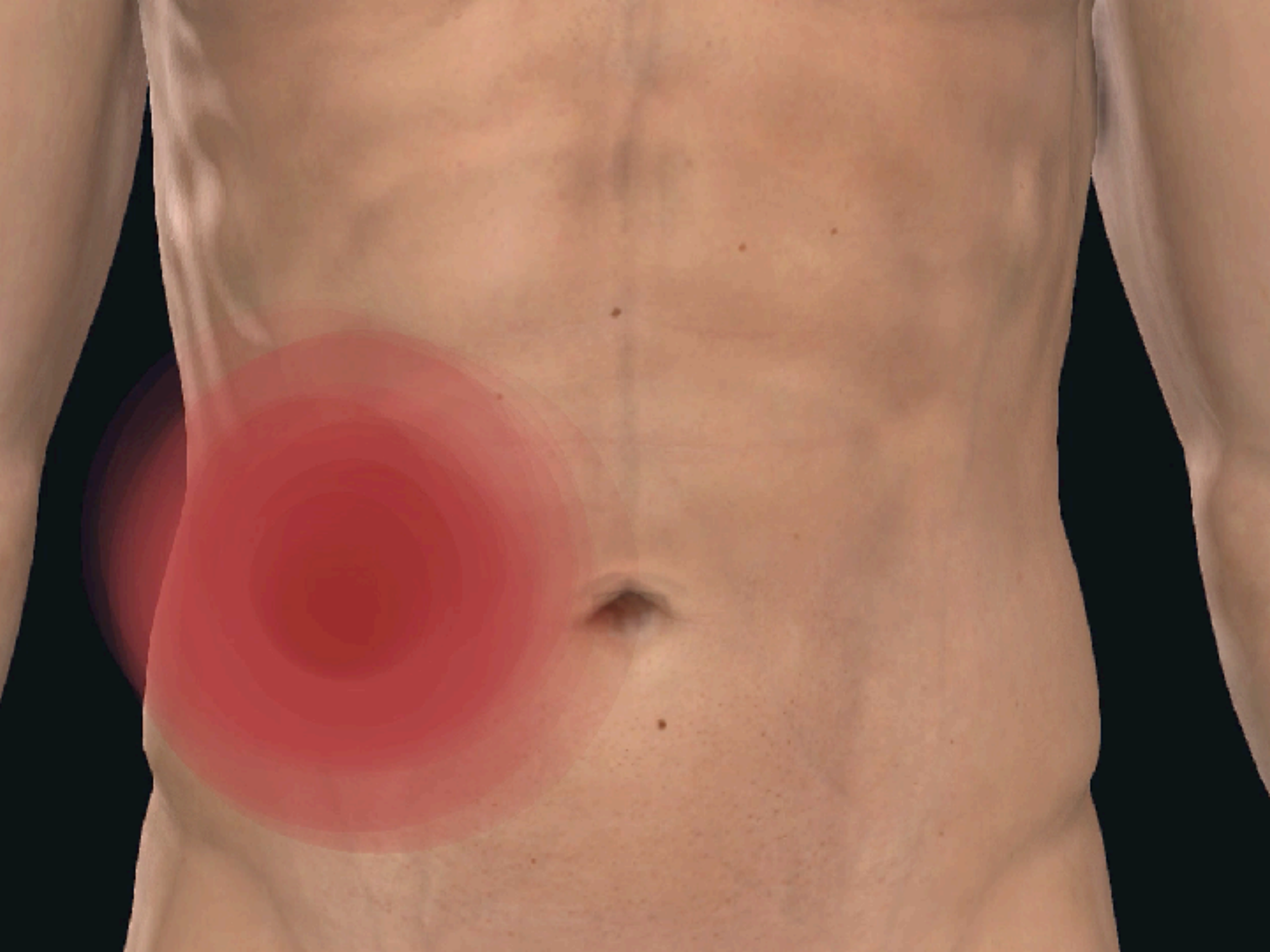
Graded compression

溫柔
穩定
施壓
停留
觀察



Compression很重要!!!



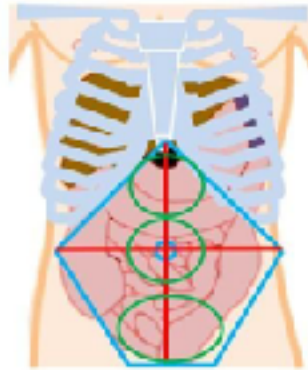


Approach to Abdominal Pain

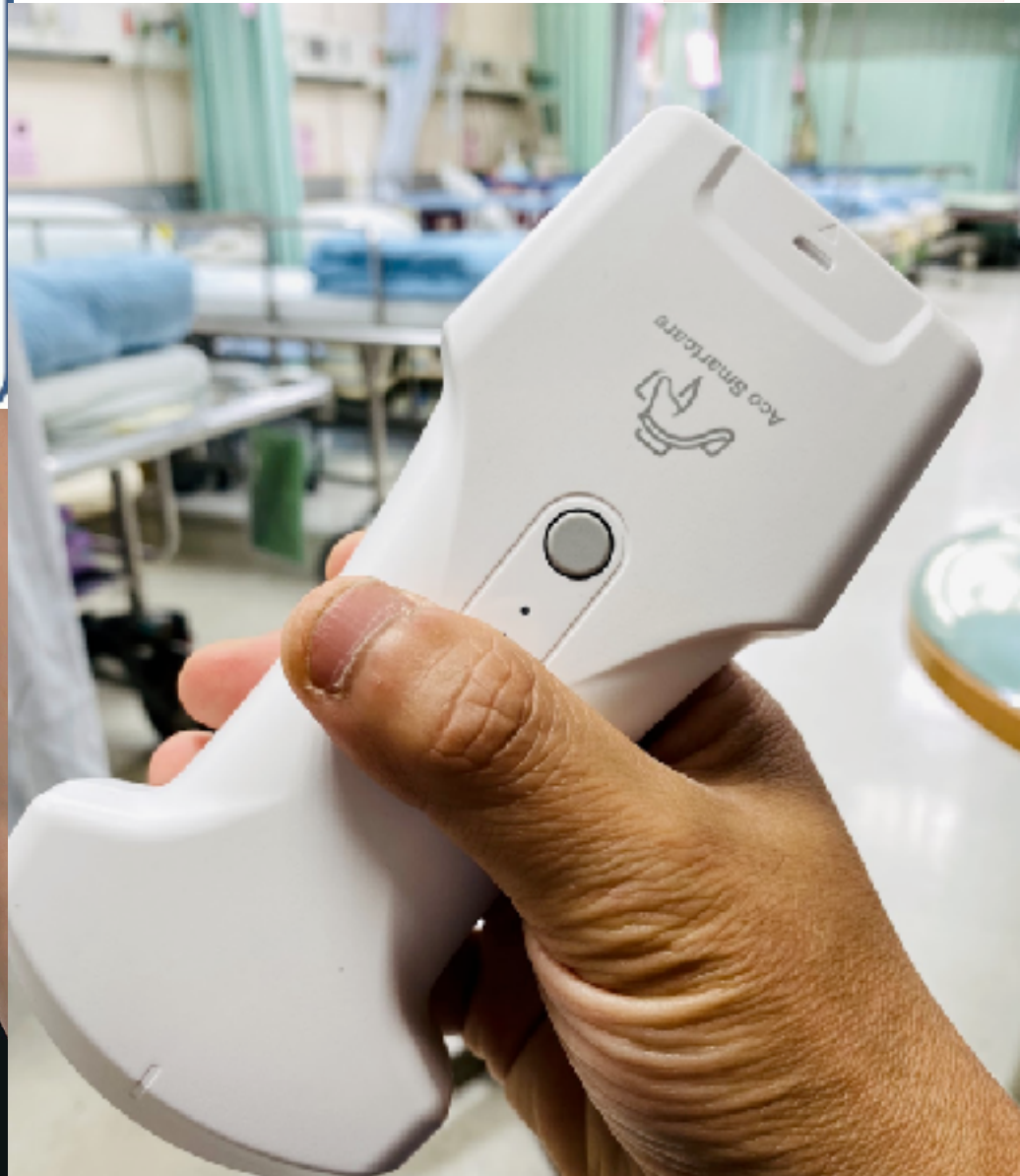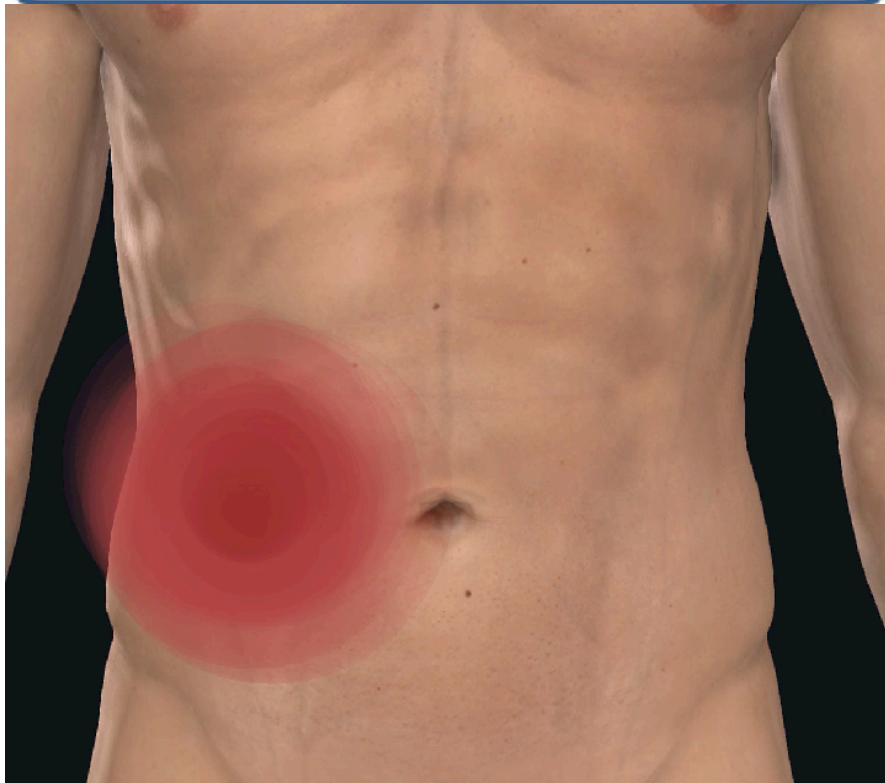
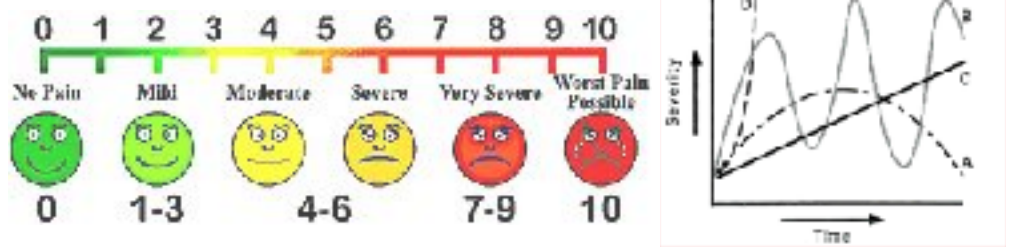
Location
Onset
Type
Severity

Other locations (radiation)
Factors (aggravating / alleviating)

Progression
Associated symptoms
Insight (what do they think it is)
Need relief (what have they taken)



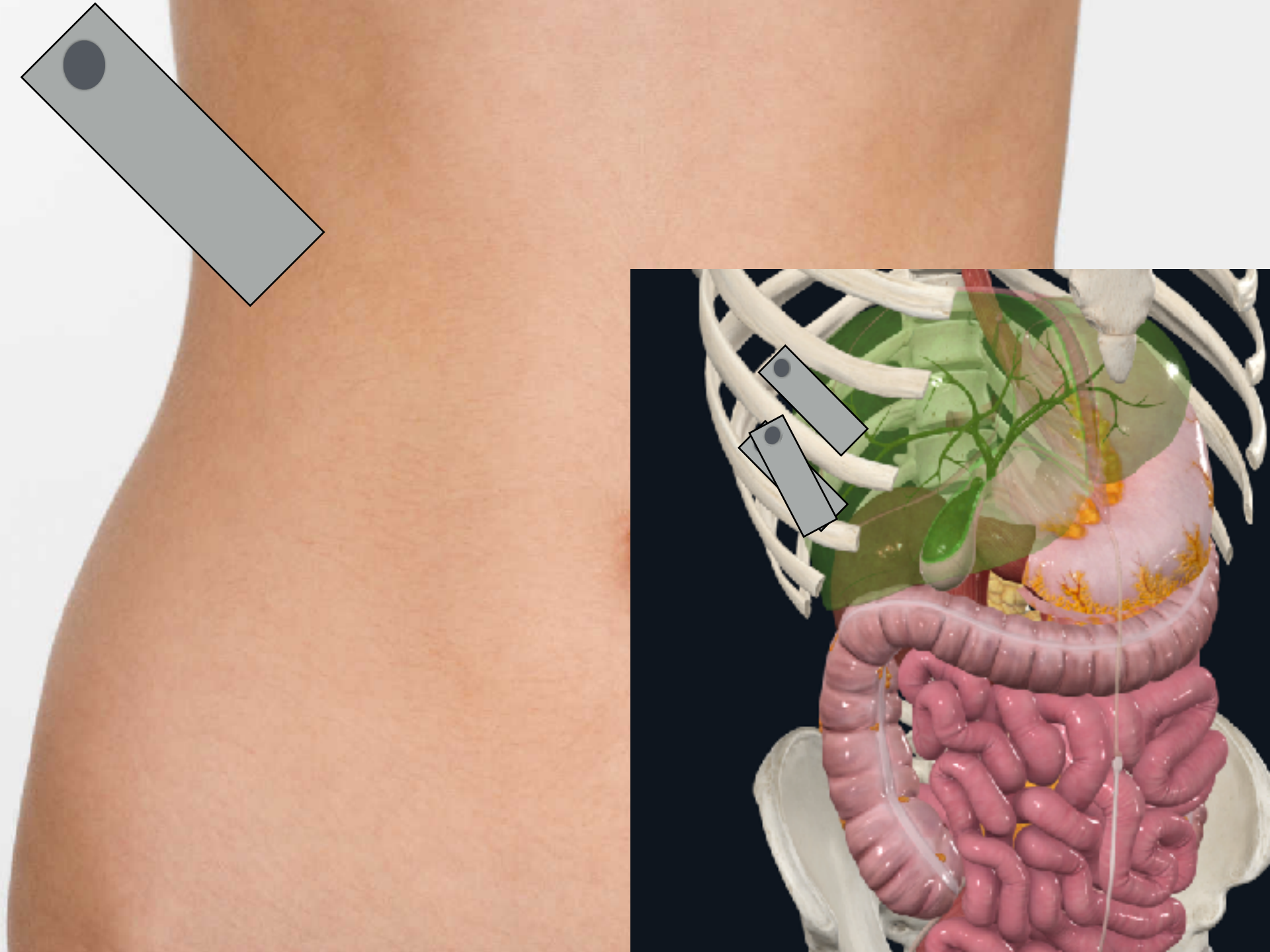
@kwburak

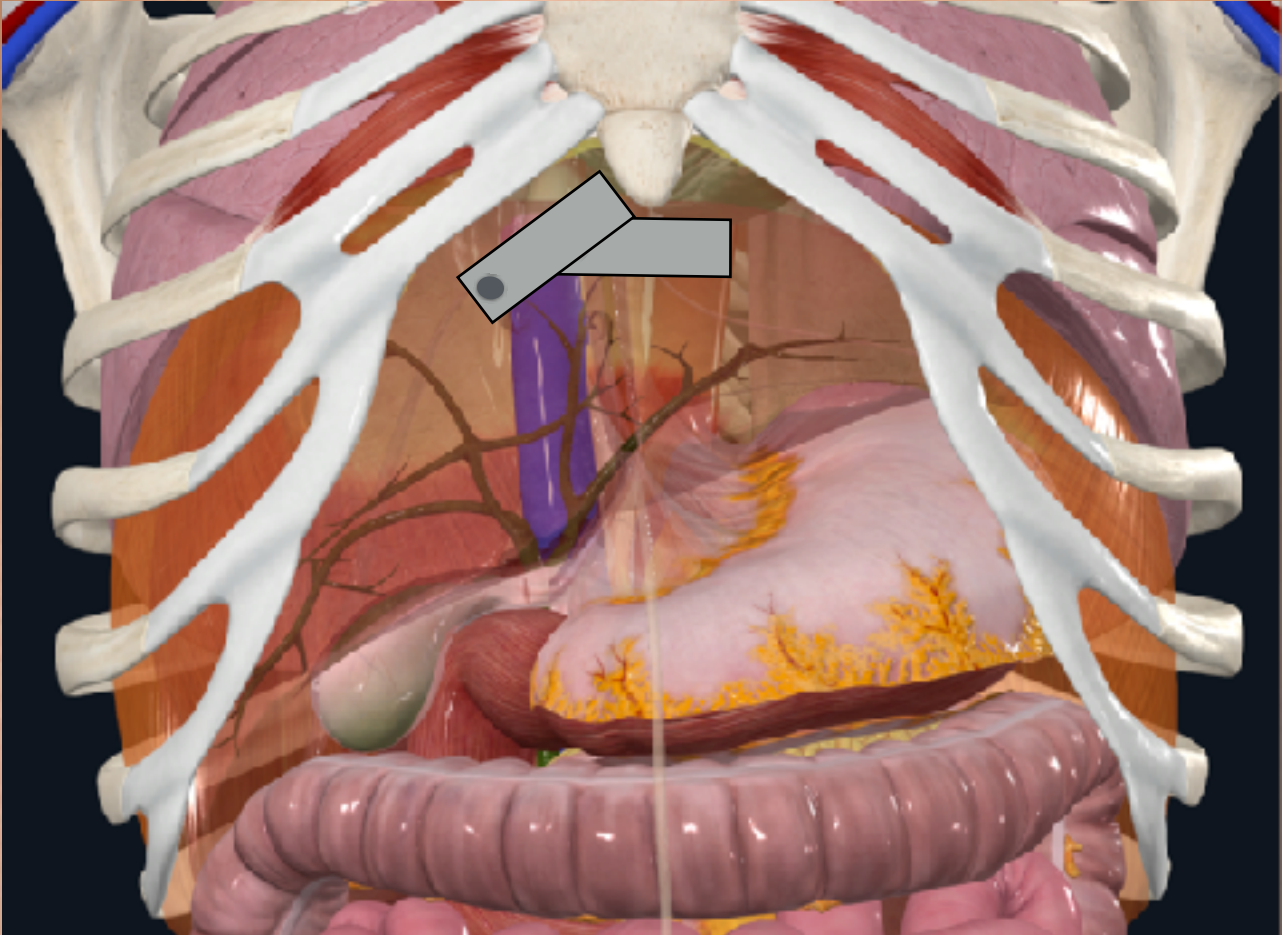



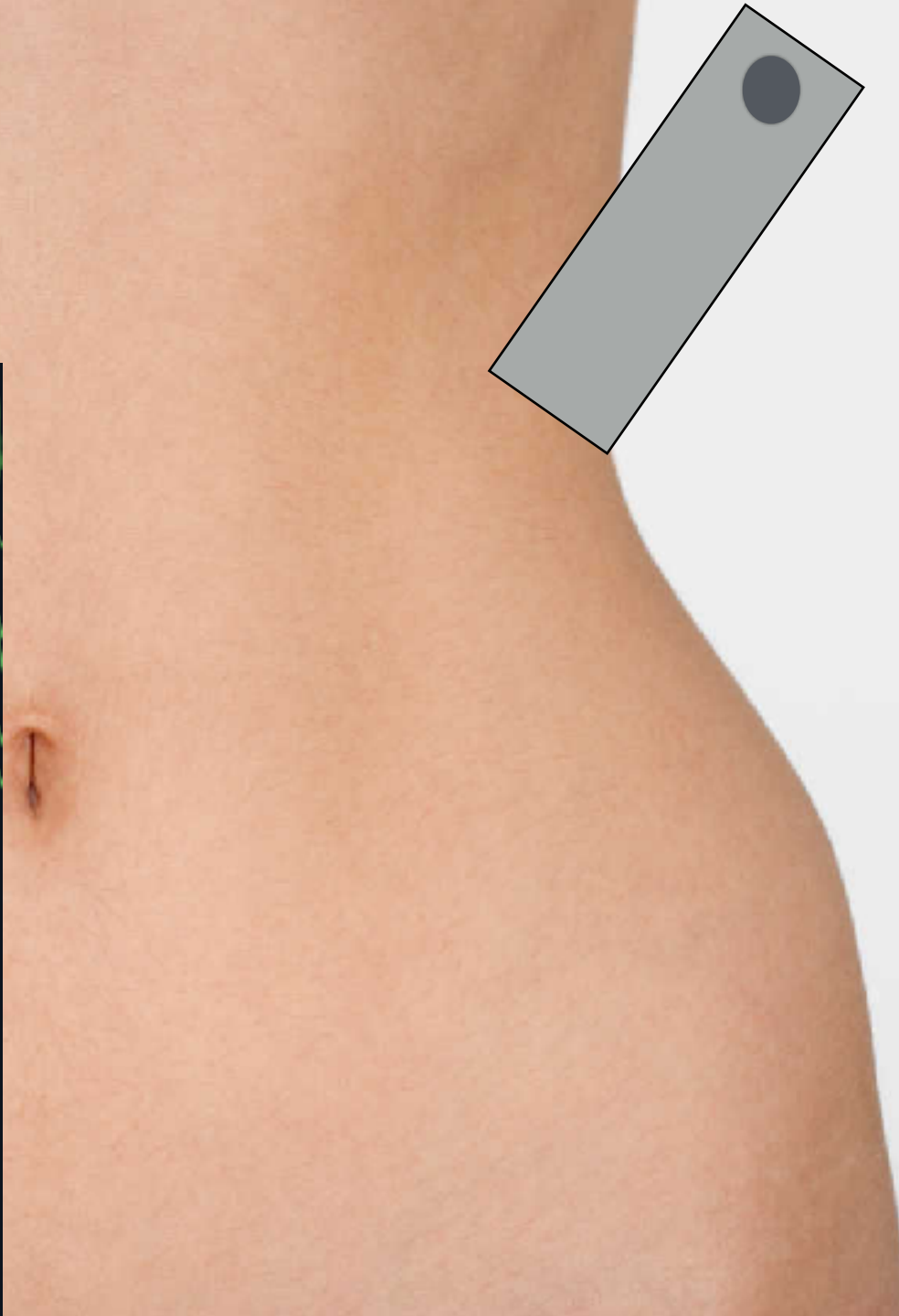
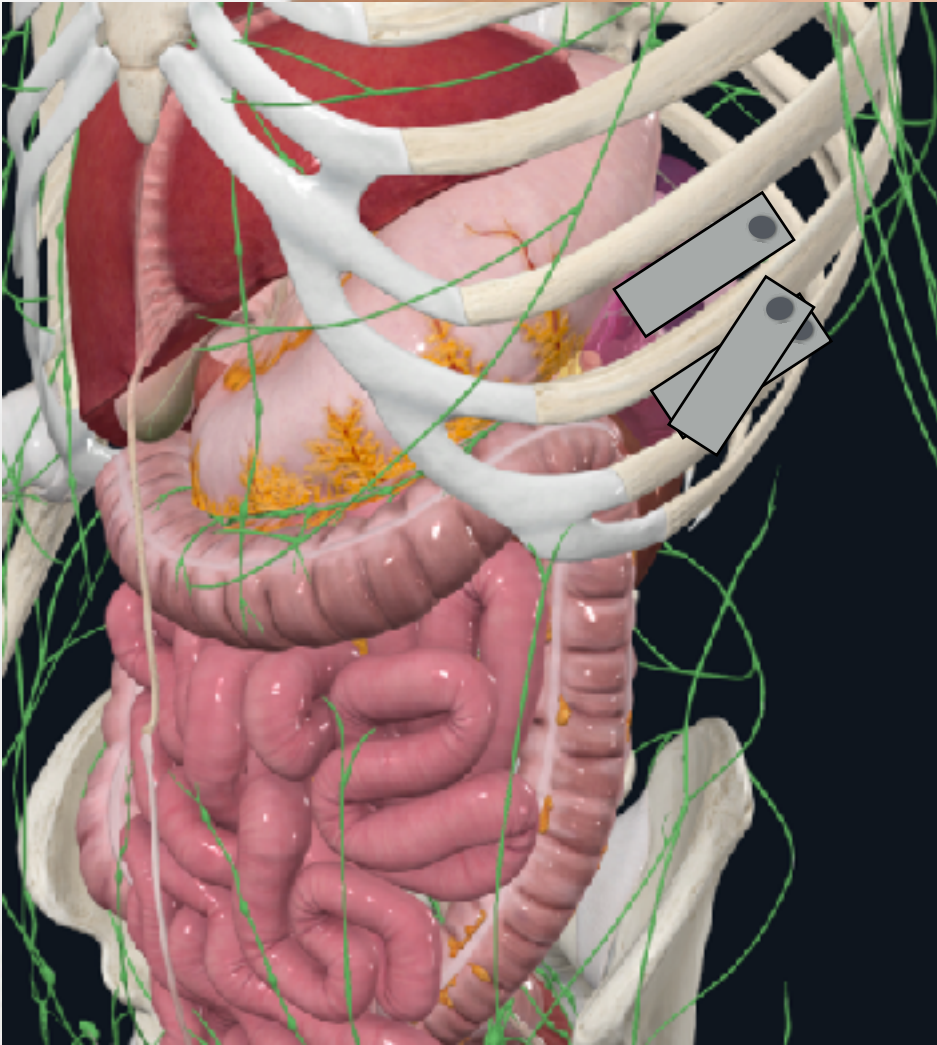
掃描前先想探頭該怎麼擺效果最好

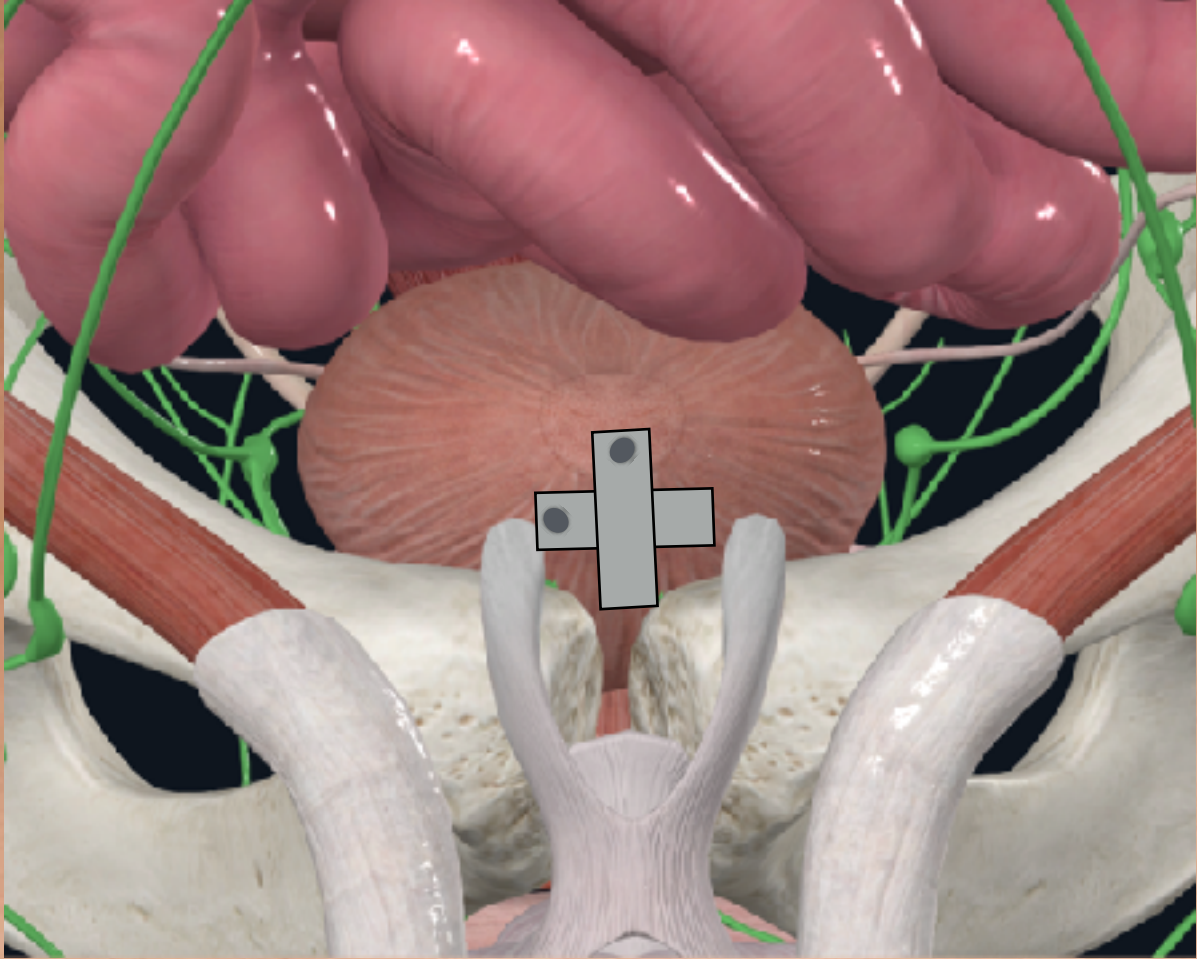
最佳視野
最大視窗
最好路線
最小調整

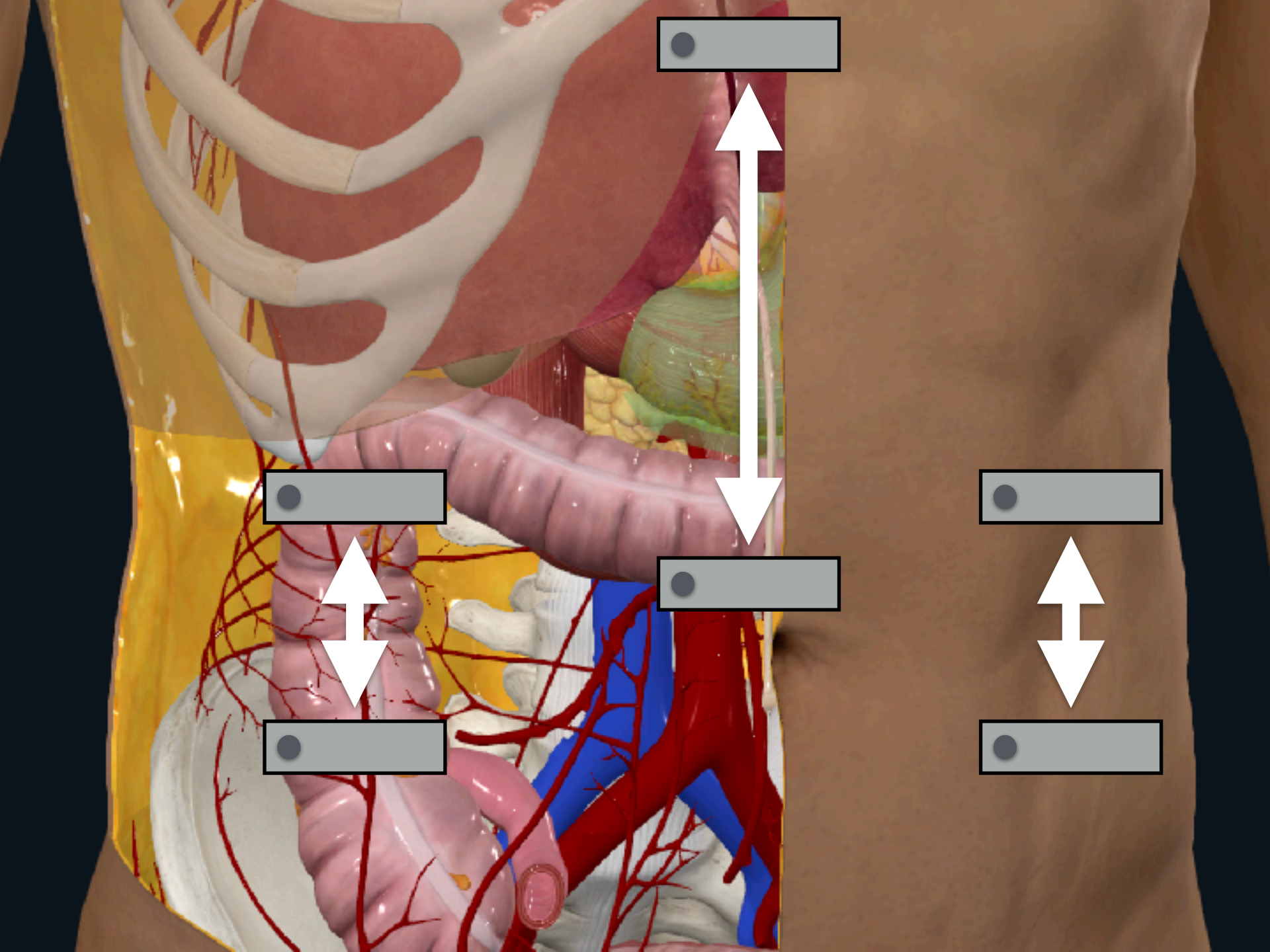
隨身設備用來
看最重要發現











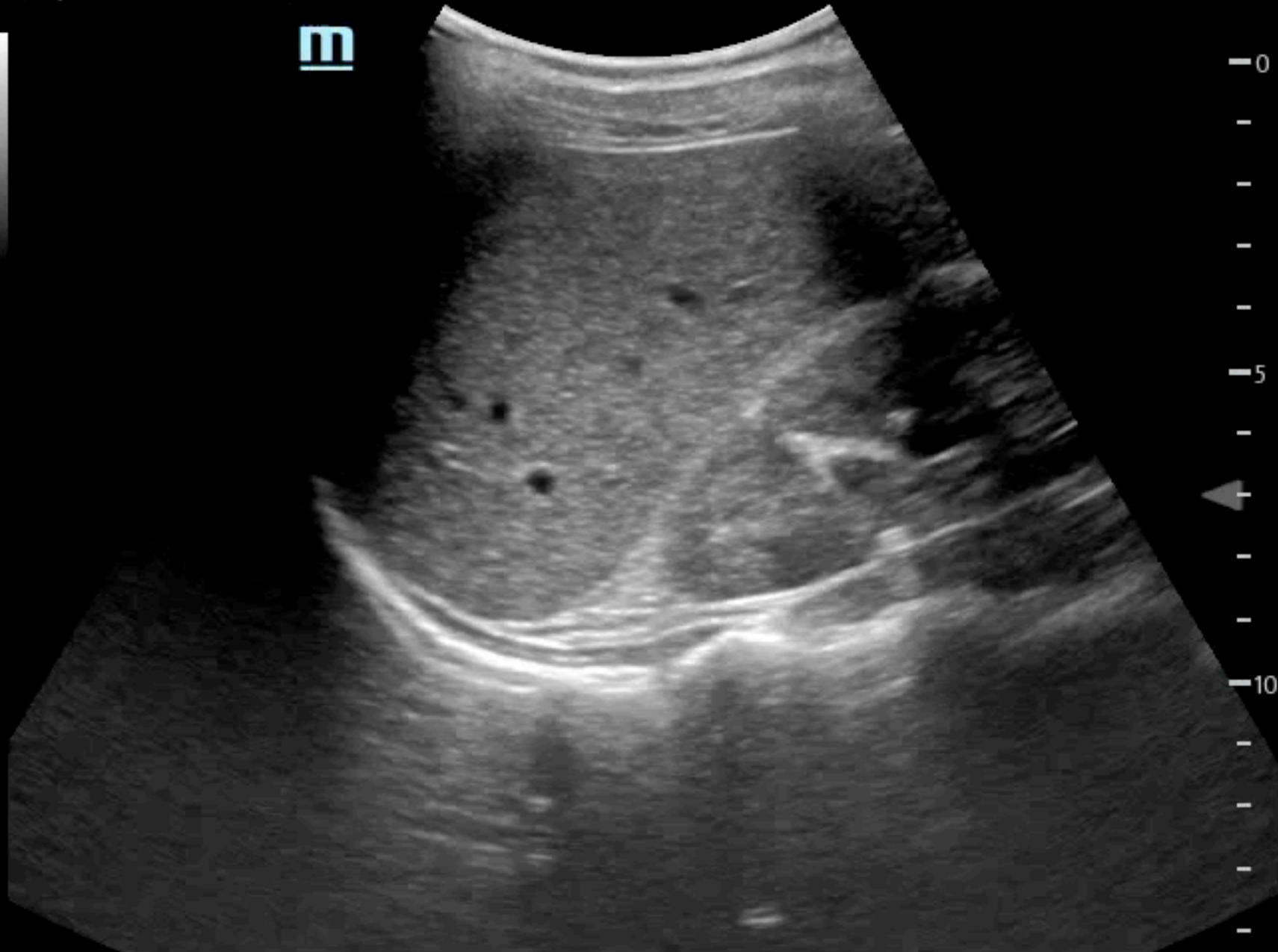
C5-1s

AP 96.6%

MI 130

TIS 0.5

B
FH6.0
DR 130
FR 18
D 16.0
G 71
Z 1.10



iNeedle

iTouch

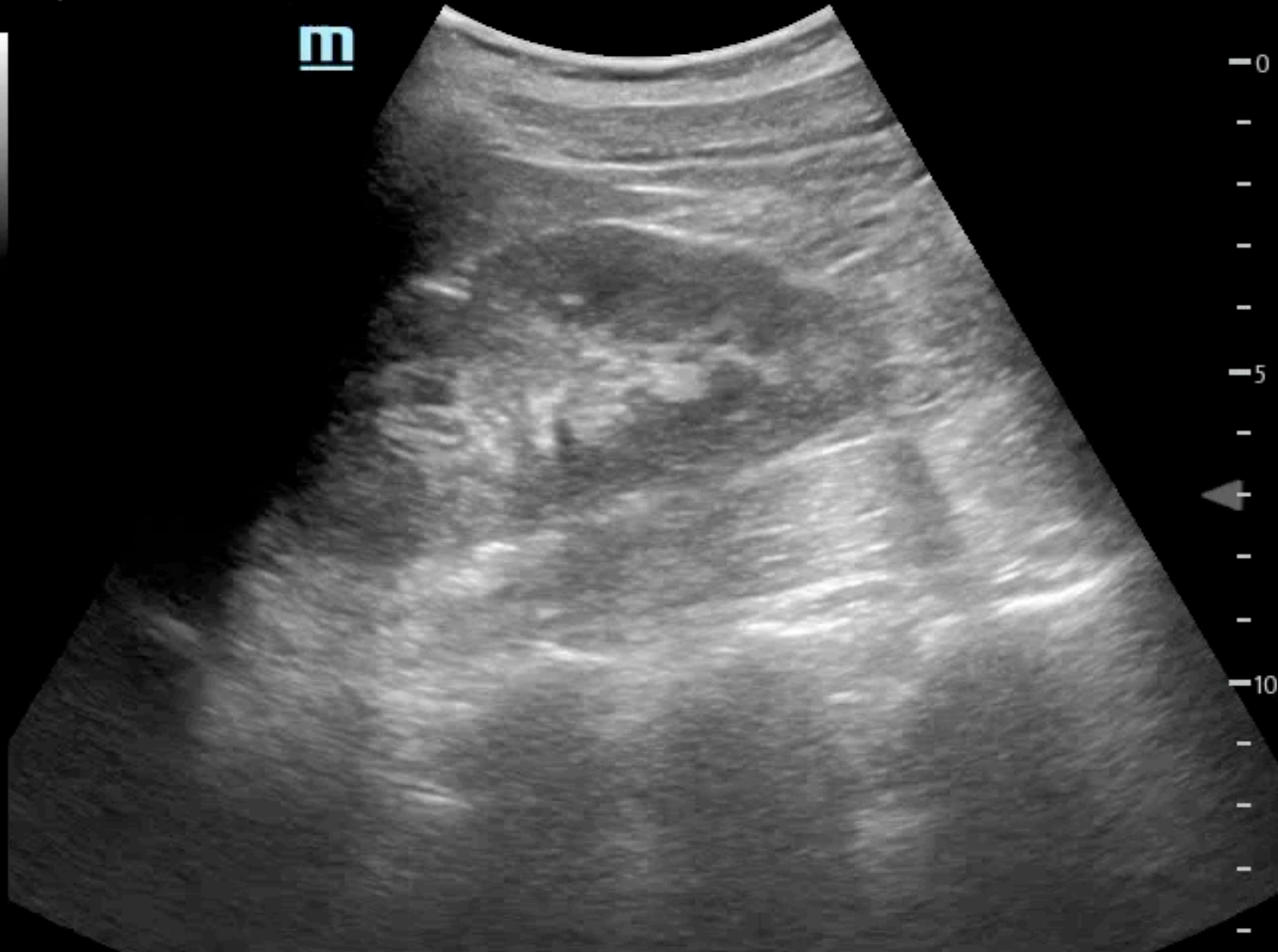
C5-1s

AP 96.6%

MI 130

TIS 0.5

B
FH6.0
DR 130
FR 18
D 16.0
G 71
Z 1.10



0
-
-
-
-
5
-
-
-
10
-
-
-

iNeedle

iTouch

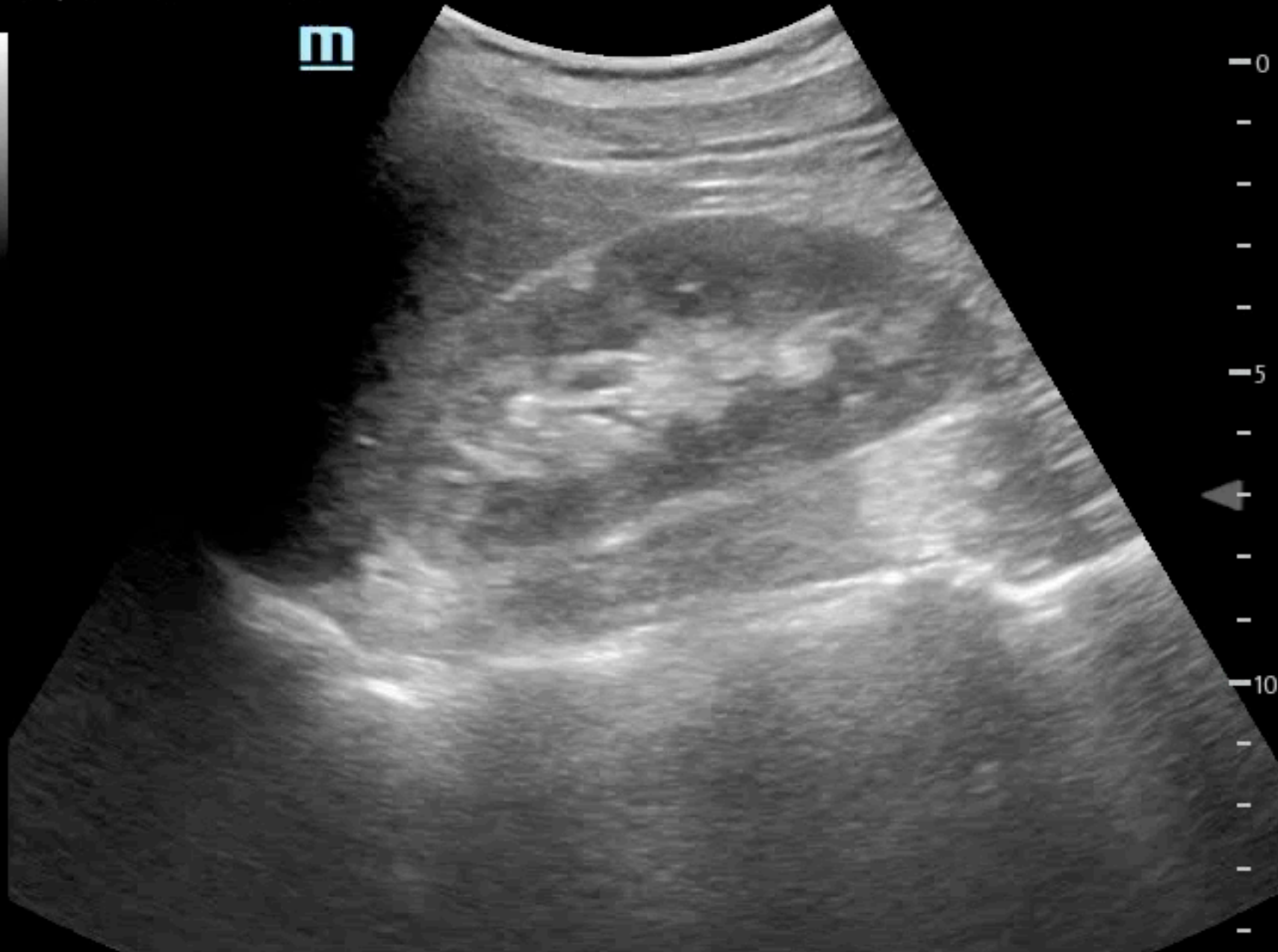C5-1s

AP 96.6%

MI 130

TIS 0.5

B
FH6.0
DR 130
FR 18
D 16.0
G 71
Z 1.10



iNeedle

iTouch


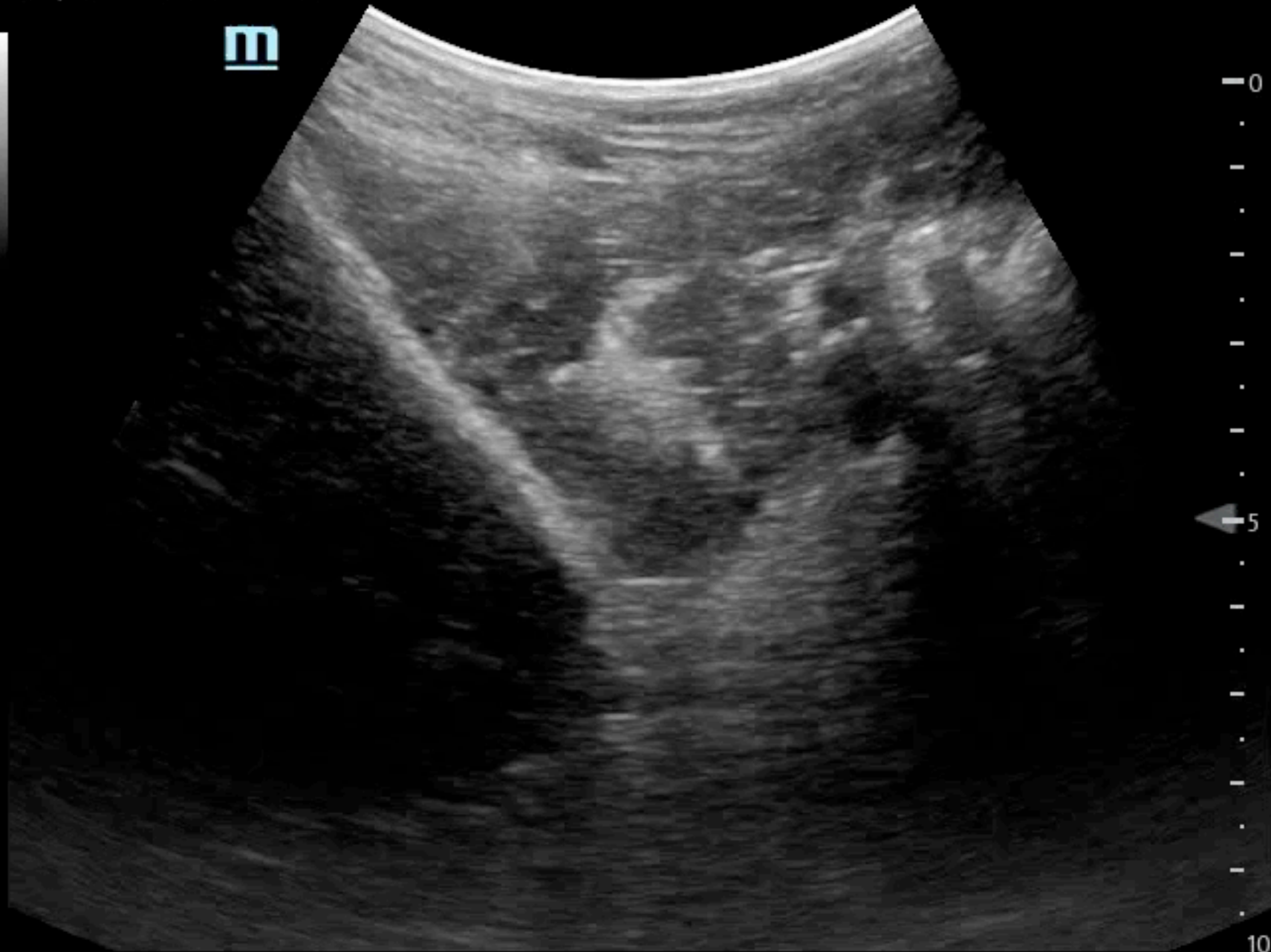
C5-1s

AP 96.6%

MI 1.18

TIS 0.5

B
FH6.0
DR 130
FR 24
D 11.0
G 81
Z 1.10



iNeedle

iTouch

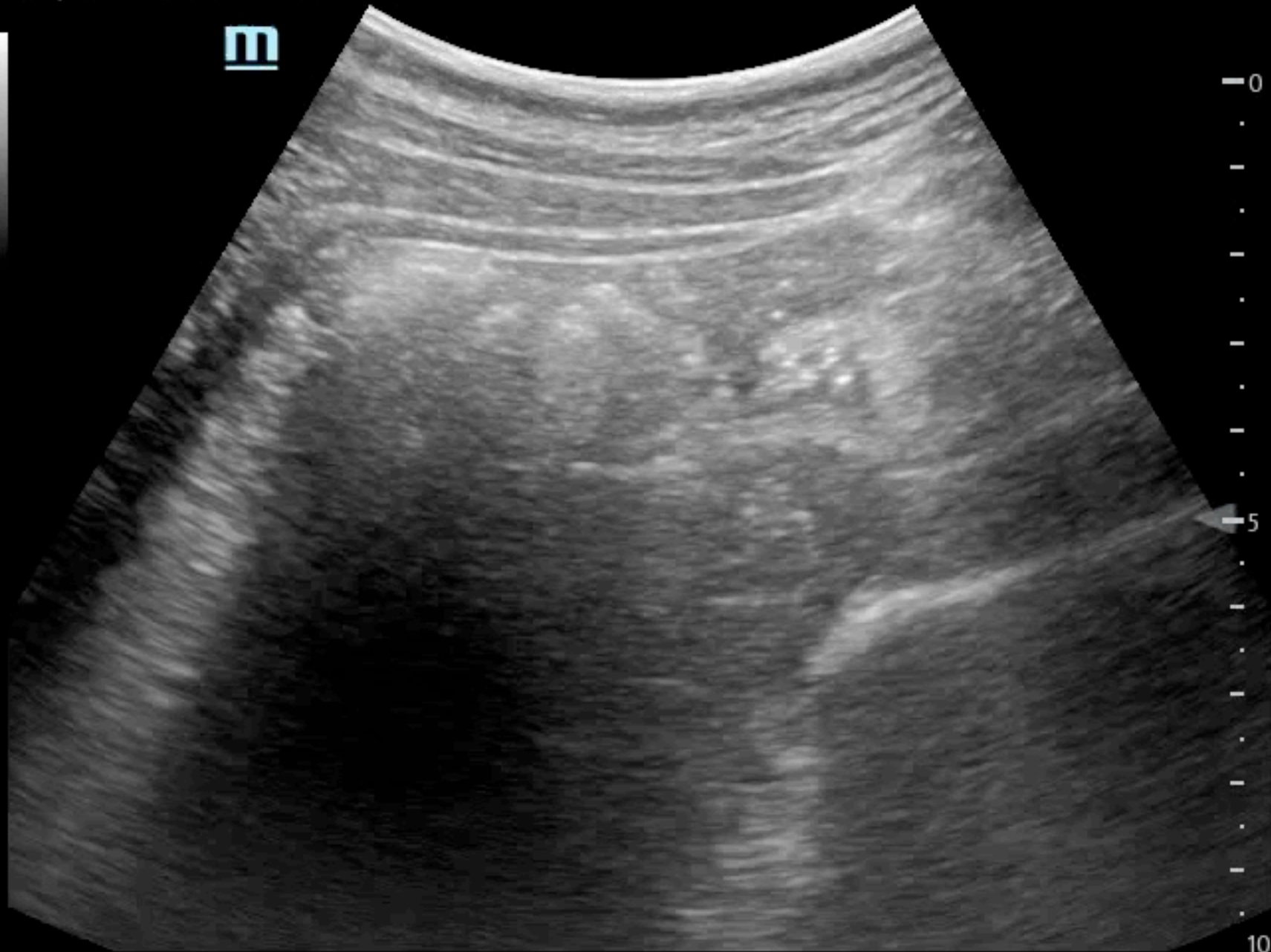C5-1s

AP 96.6%

MI 1.18

TIS 0.5

B
FH6.0
DR 130
FR 24
D 11.0
G 81
Z 1.10



iNeedle

iTouch

0
.
.
.
.
.
.
.
5
.
.
.
.
.
.
10

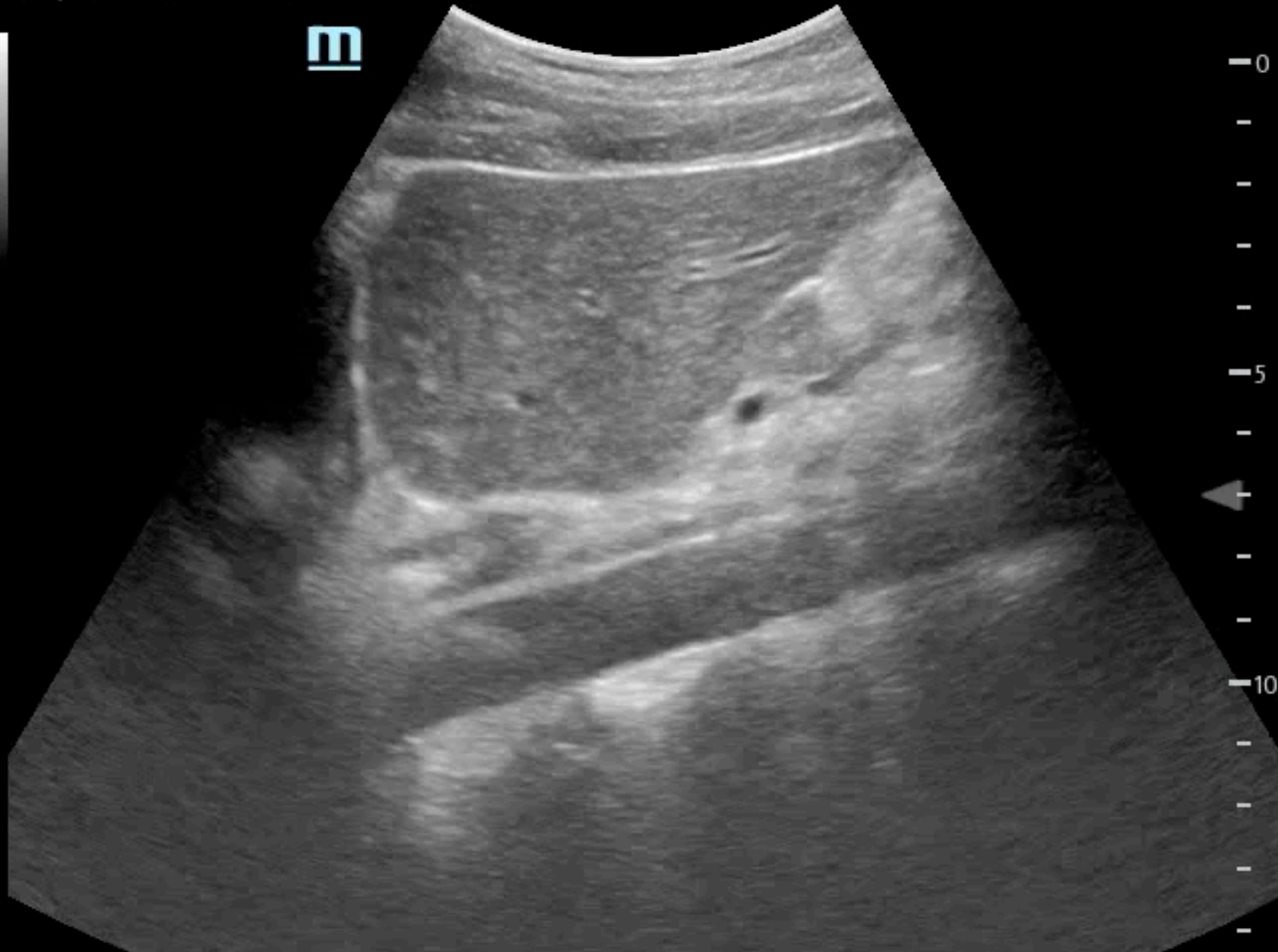
C5-1s

AP 96.6%

MI 130

TIS 0.5

B
FH6.0
DR 130
FR 18
D 16.0
G 81
Z 1.10



iNeedle

iTouch

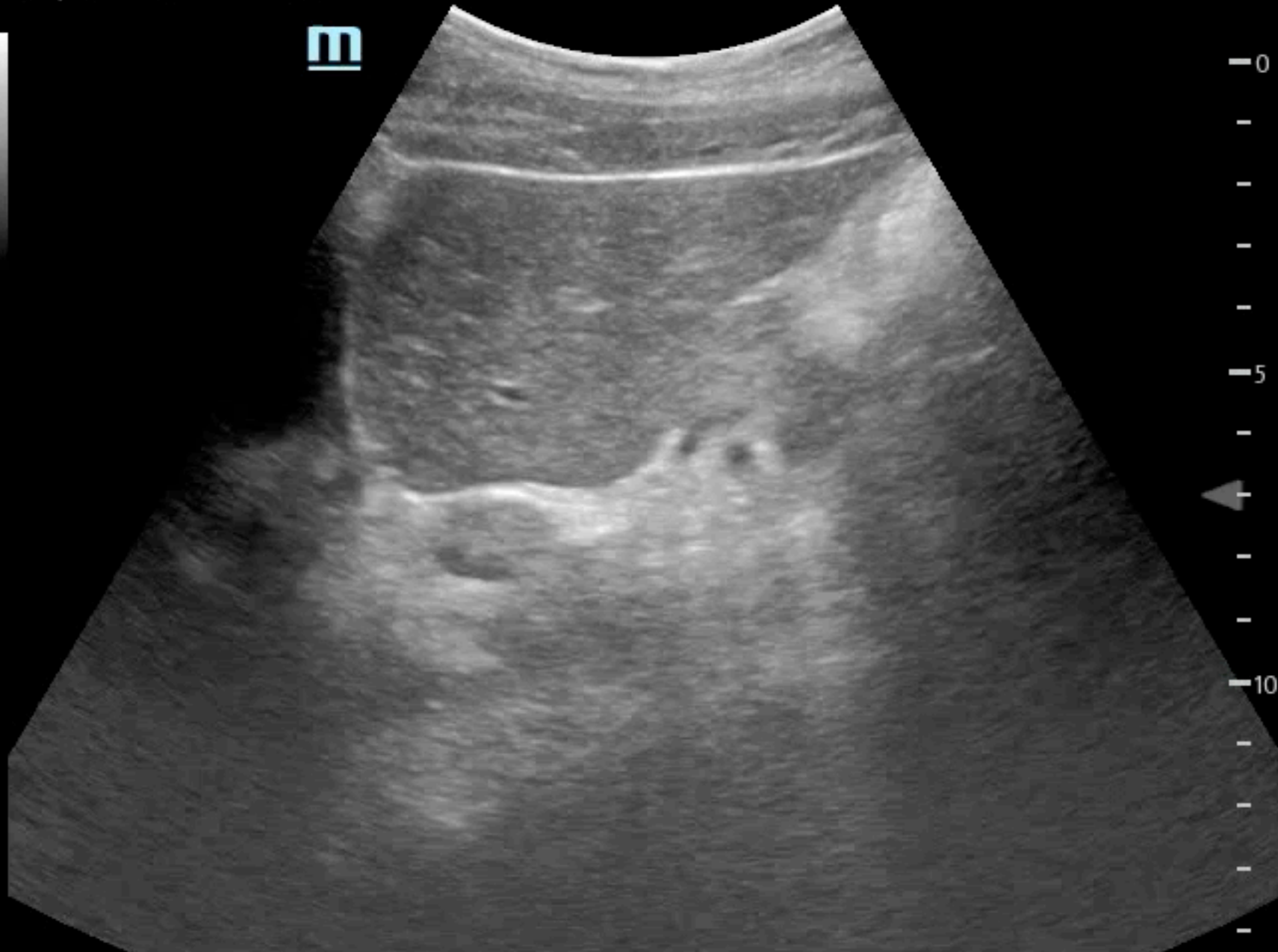
C5-1s

AP 96.6%

MI 130

TIS 0.5

B
FH6.0
DR 130
FR 18
D 16.0
G 81
Z 1.10



iNeedle

iTouch

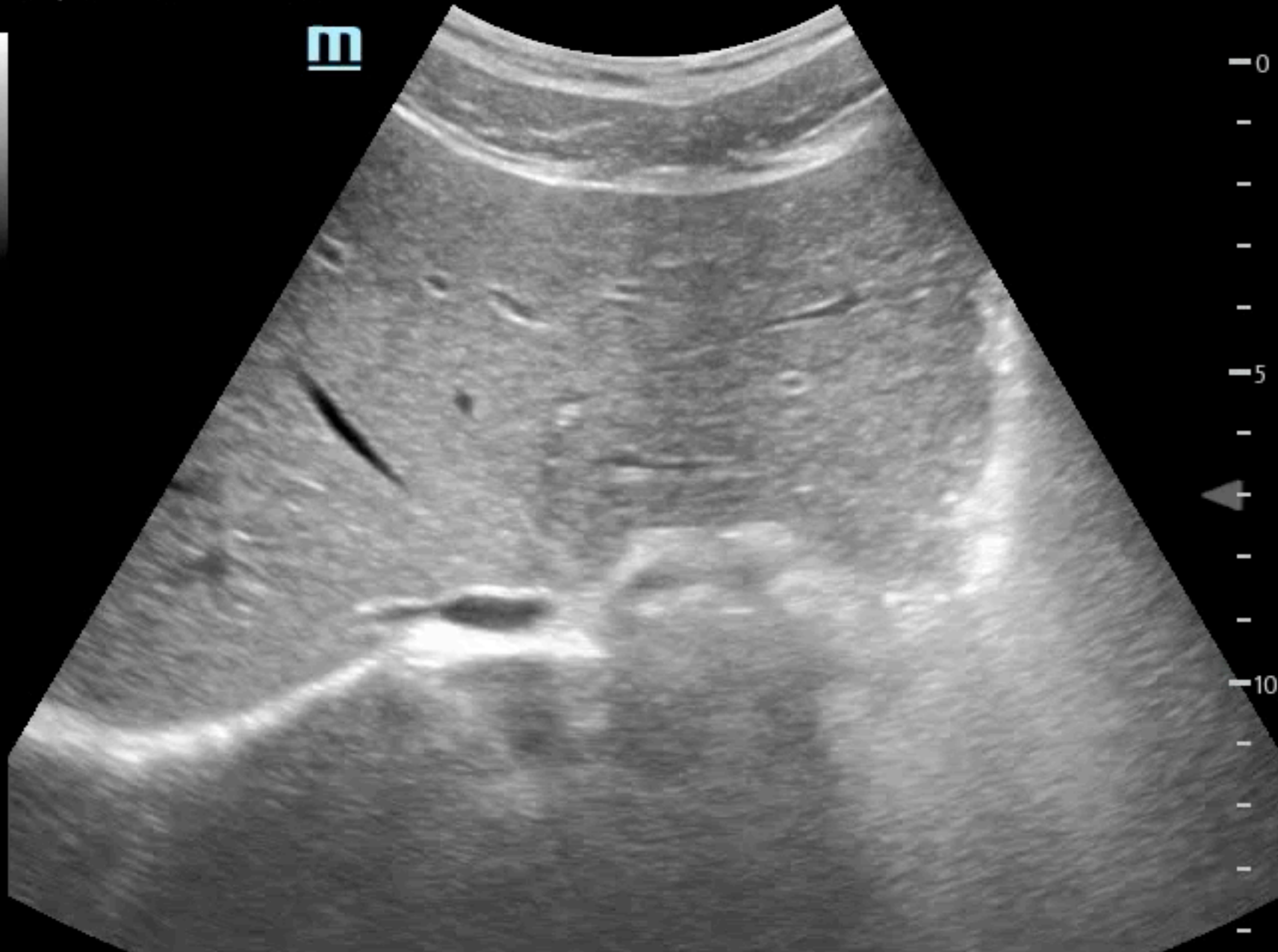
C5-1s

AP 96.6%

MI 130

TIS 0.5

B
FH6.0
DR 130
FR 18
D 16.0
G 81
Z 1.10



0
-
-
-
-
-
5
-
-
-
-
-
10
-
-
-
-

iNeedle

iTouch

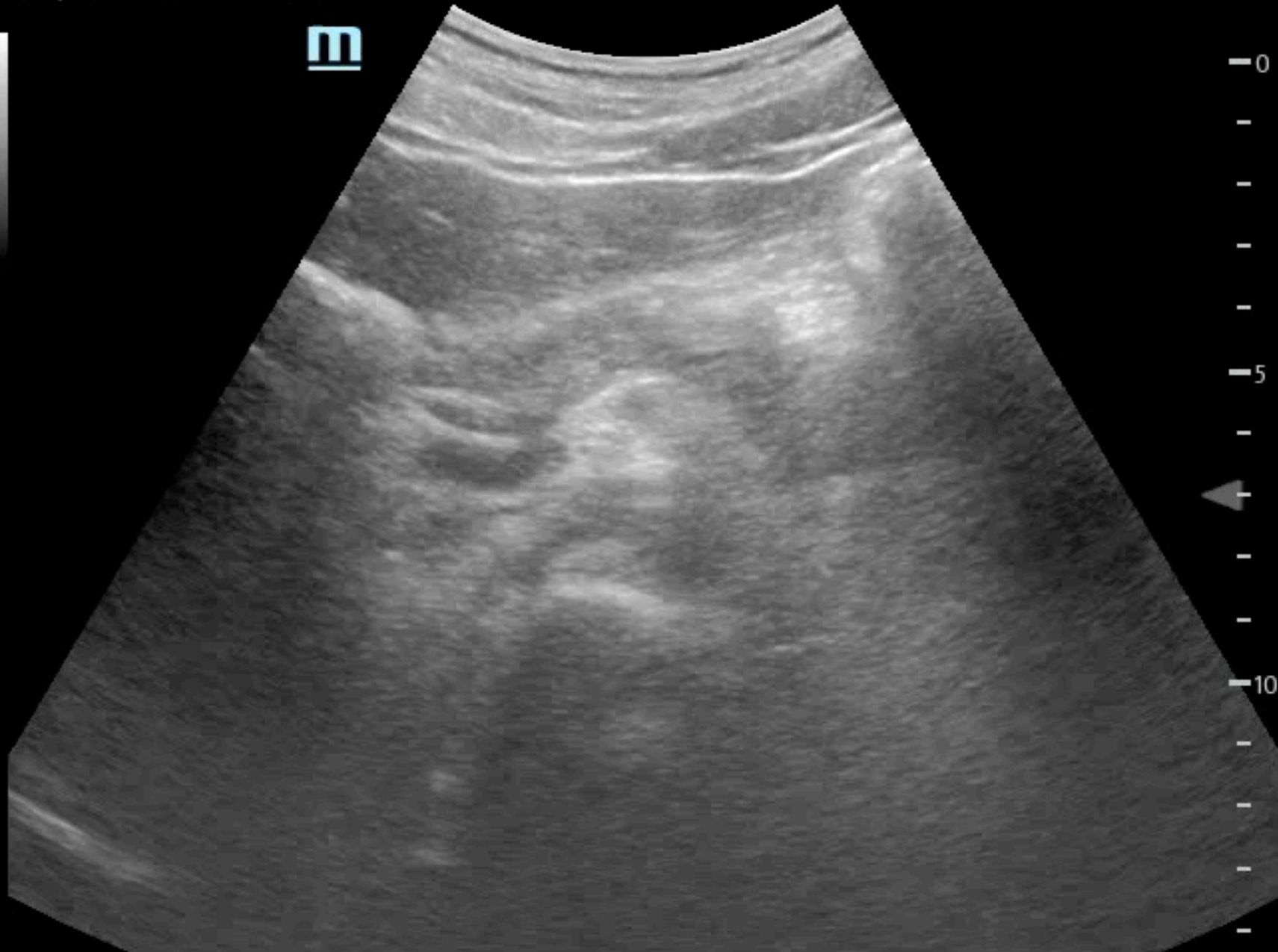C5-1s

AP 96.6%

MI 130

TIS 0.5

B
FH6.0
DR 130
FR 18
D 16.0
G 81
Z 1.10



0
-
-
-
-
-
5
-
-
-
-
10
-
-
-
-

iNeedle

iTouch



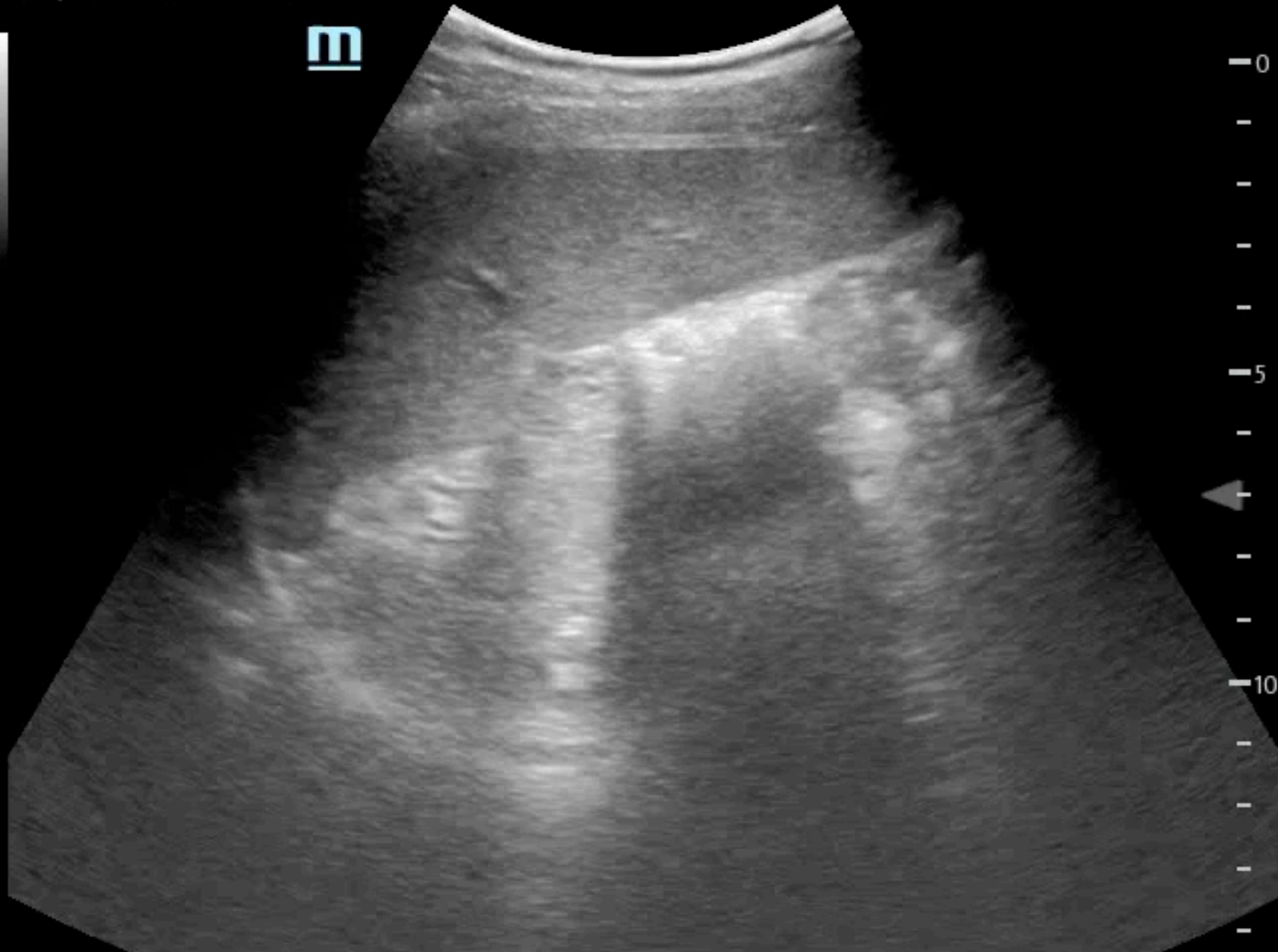
C5-1s

AP 96.6%

MI 130

TIS 0.5

B
FH6.0
DR 130
FR 18
D 16.0
G 81
Z 1.10



0
-
-
-
-
5
-
-
-
-
10
-
-
-
-

iNeedle

iTouch



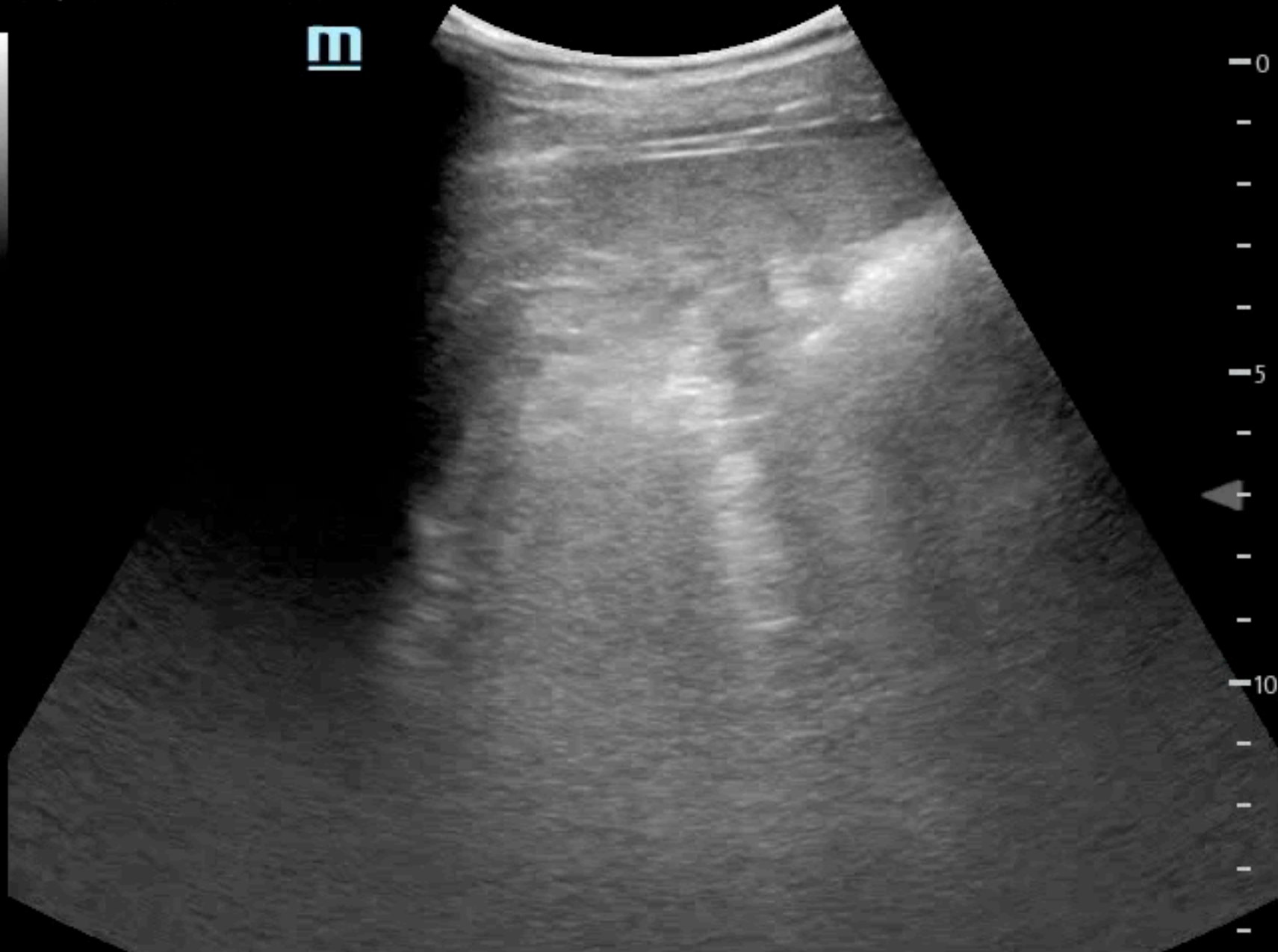C5-1s

AP 96.6%

MI 130

TIS 0.5

B
FH6.0
DR 130
FR 18
D 16.0
G 81
Z 1.10



iNeedle

iTouch

C5-1s

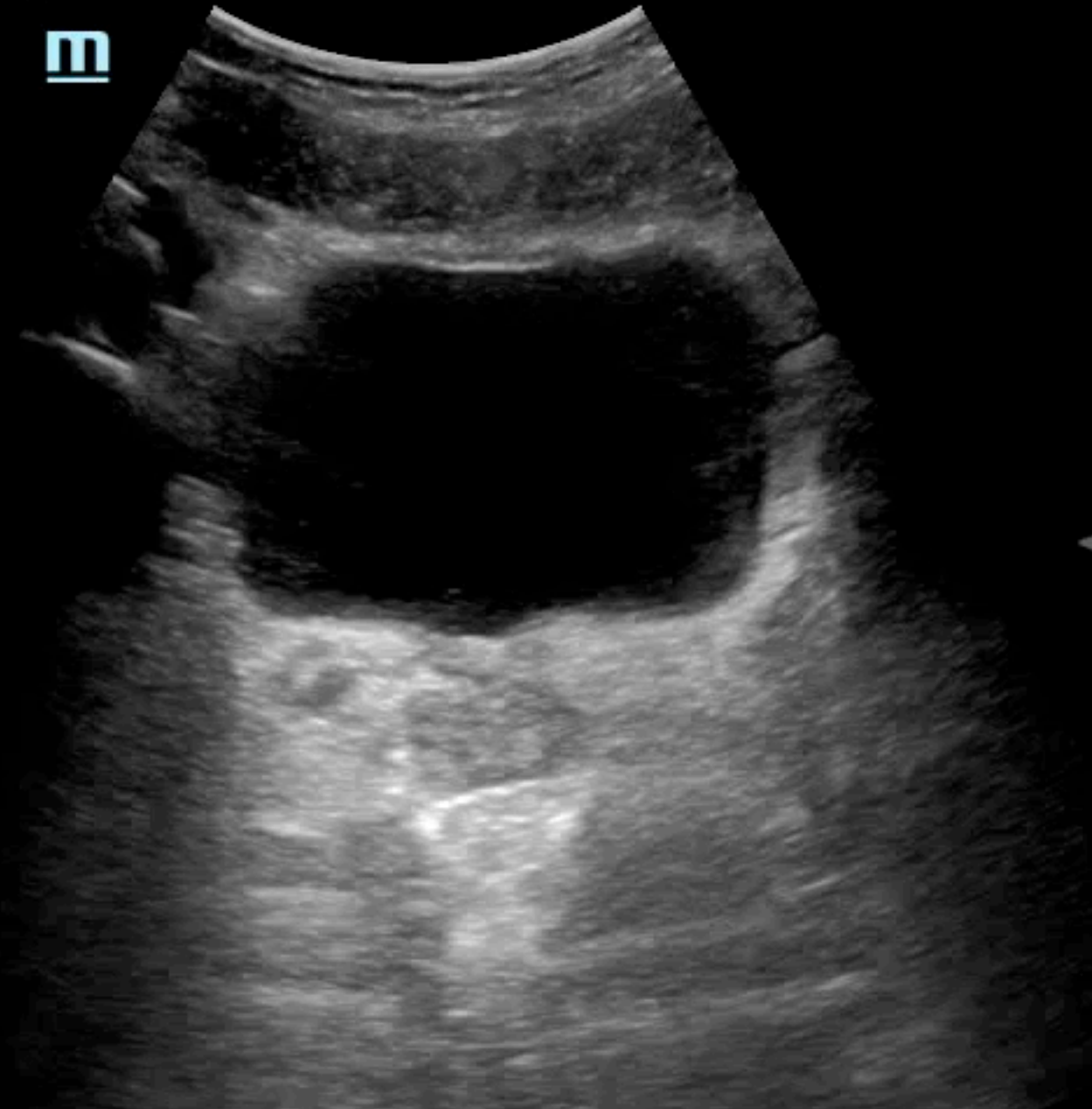AP 96.6%

MI 134

TIS 0.5

B

FH6.0
DR 130
FR 17
D 17.0
G 40
Z 1.10

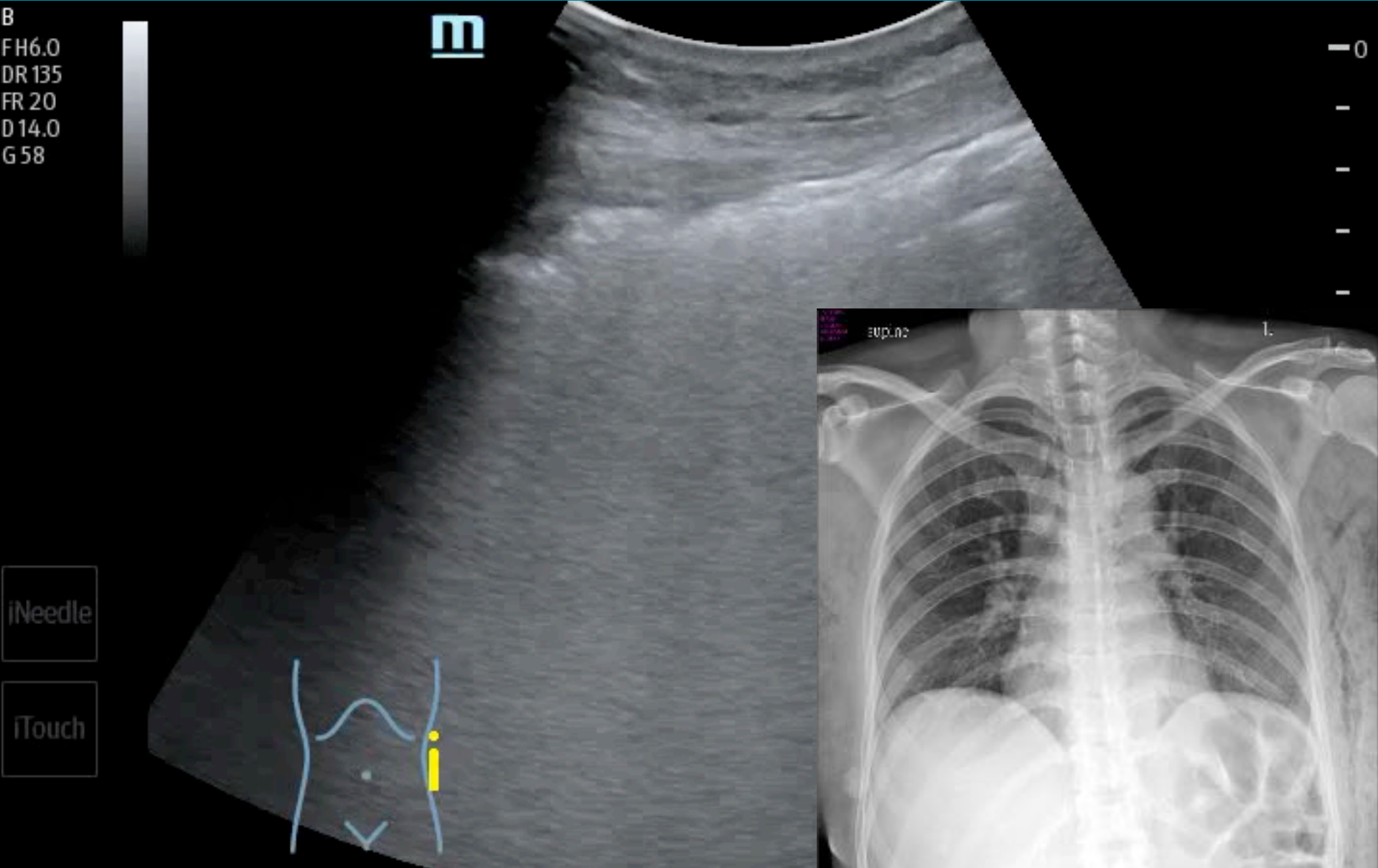


0
-
-
-
-
5
-
-
-
-
10
-
-
-
-
15

iNeedle

iTouch

50F, L chest pain, fever

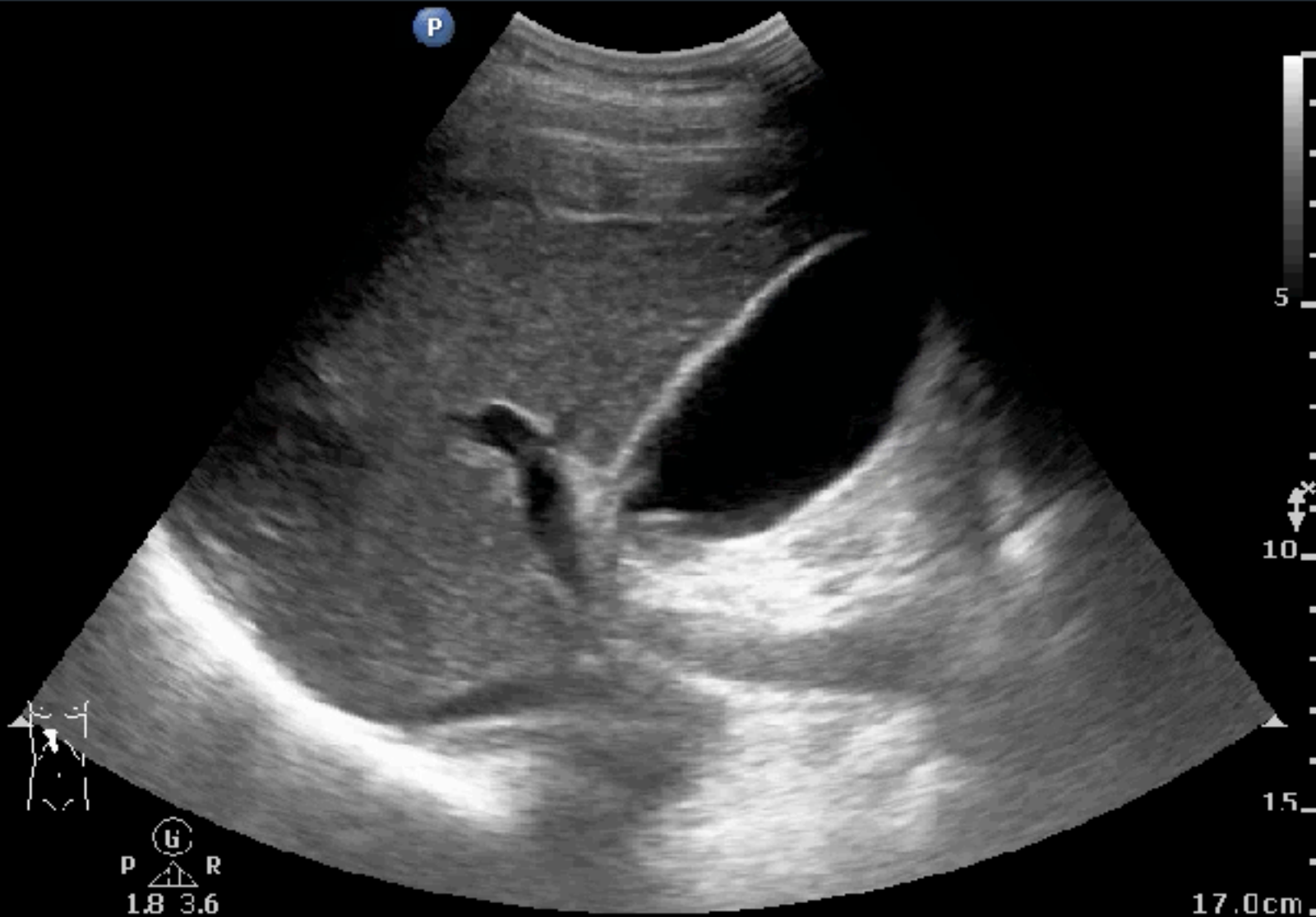

52M, RUQ pain, your diagnosis ?

Abd Gen2
C5-1
31 Hz
17.0cm

2D

HGen
Gn 86
C 56
3/3/3



POCUS

for

Acute

ABDOMEN

A for aorta

B for biliary


D for diaphragm

O for bowel obstruction

M for moving fluid & air

E for ectopic pregnancy

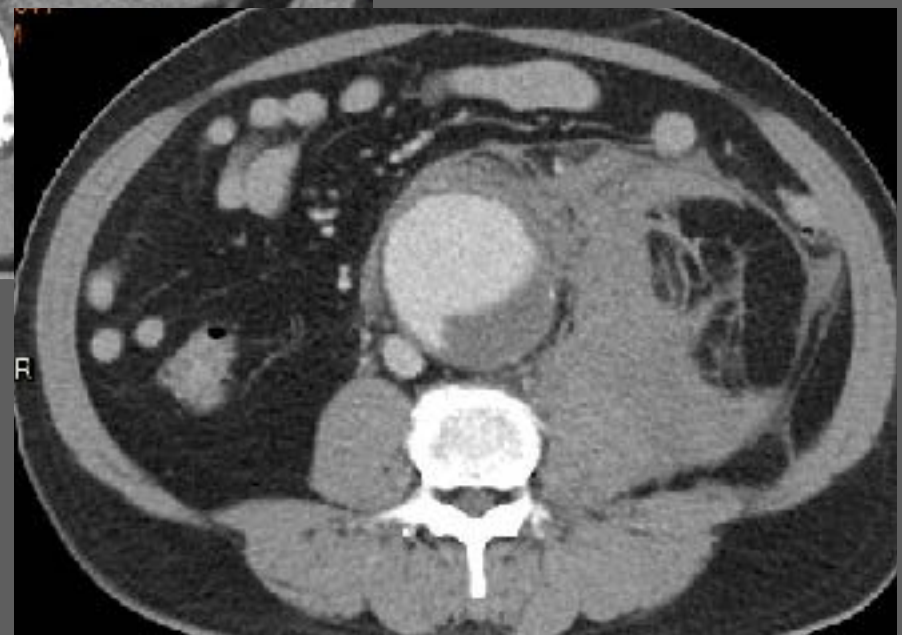
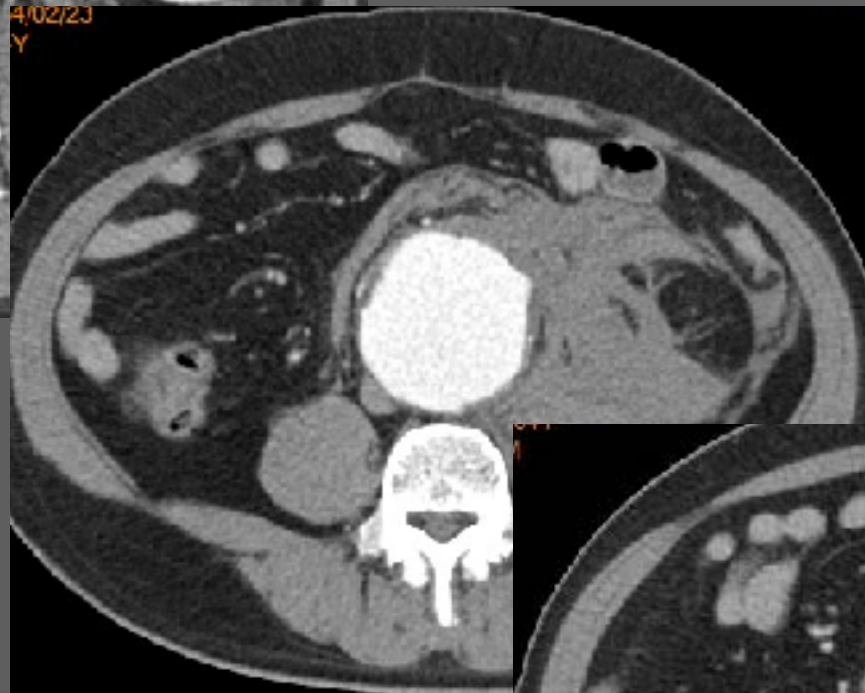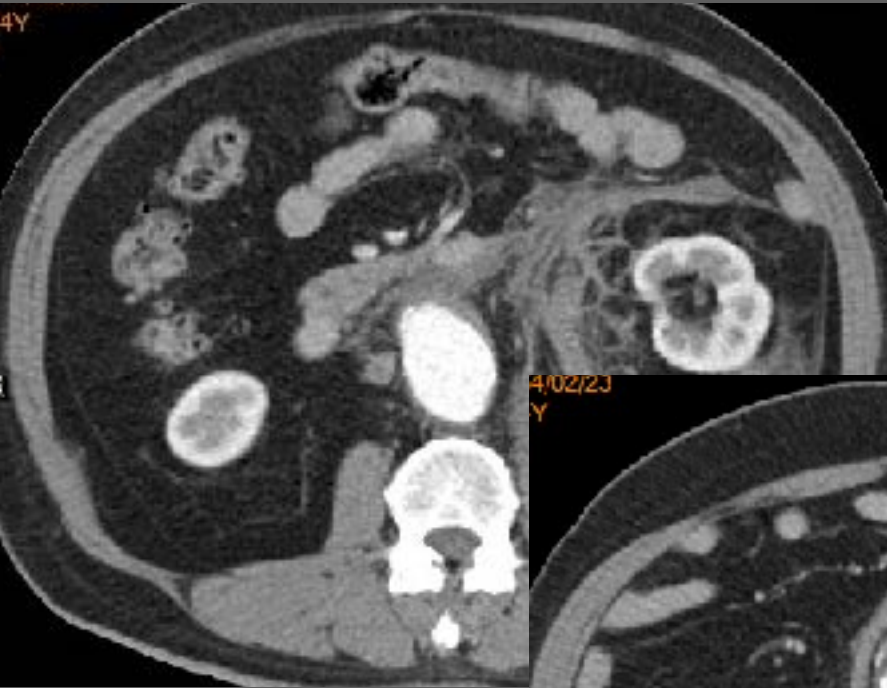N for nephropathy

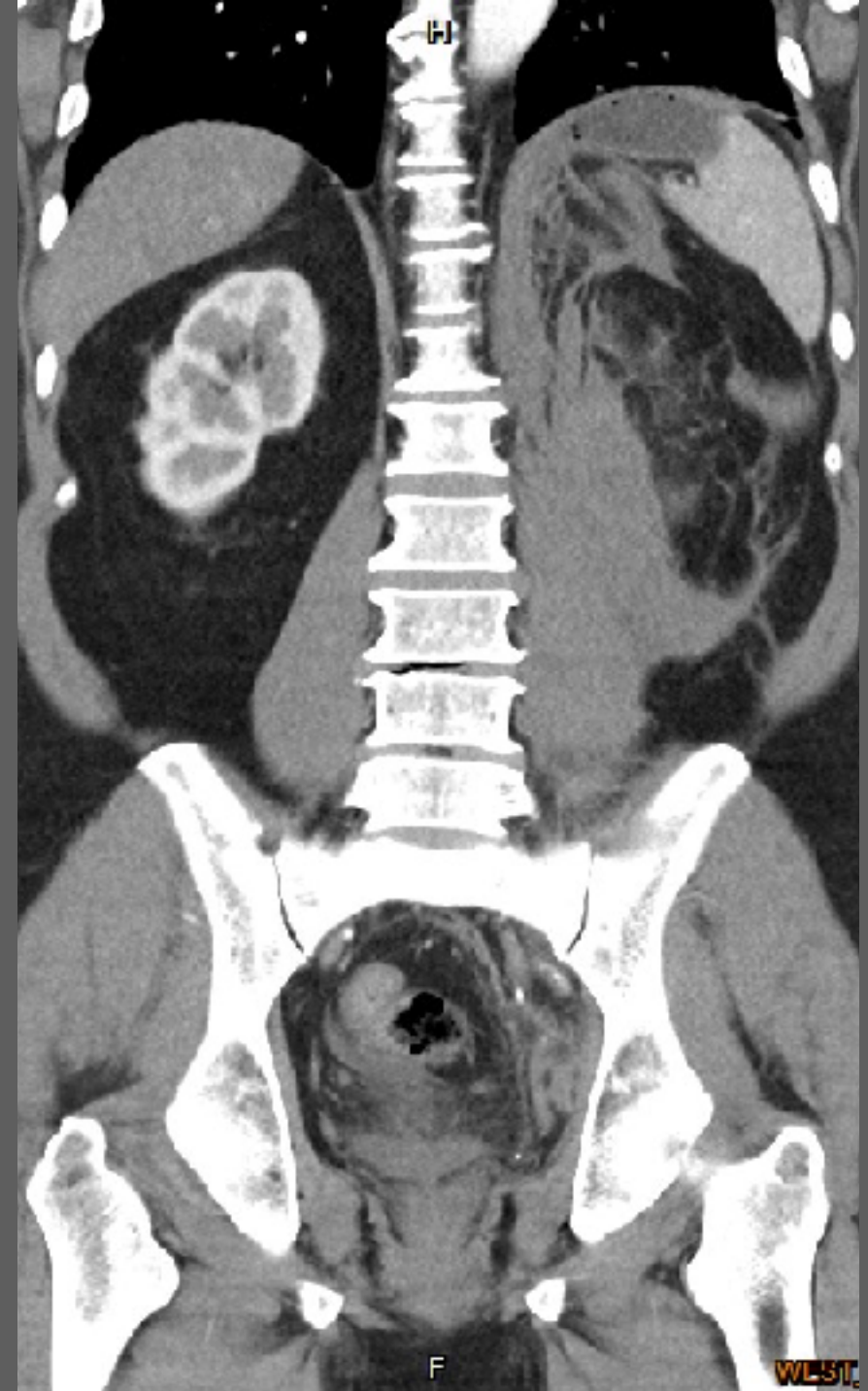
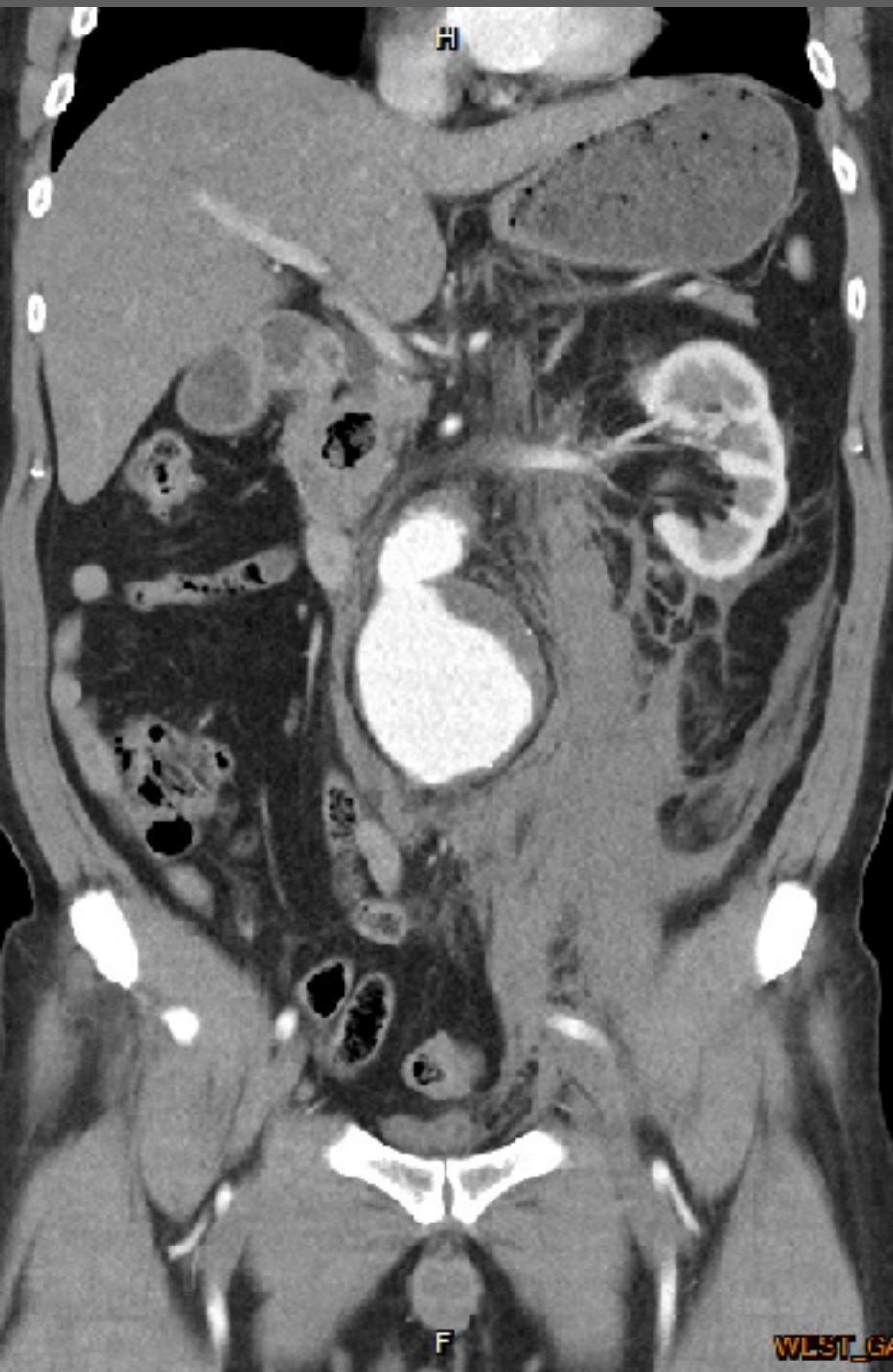
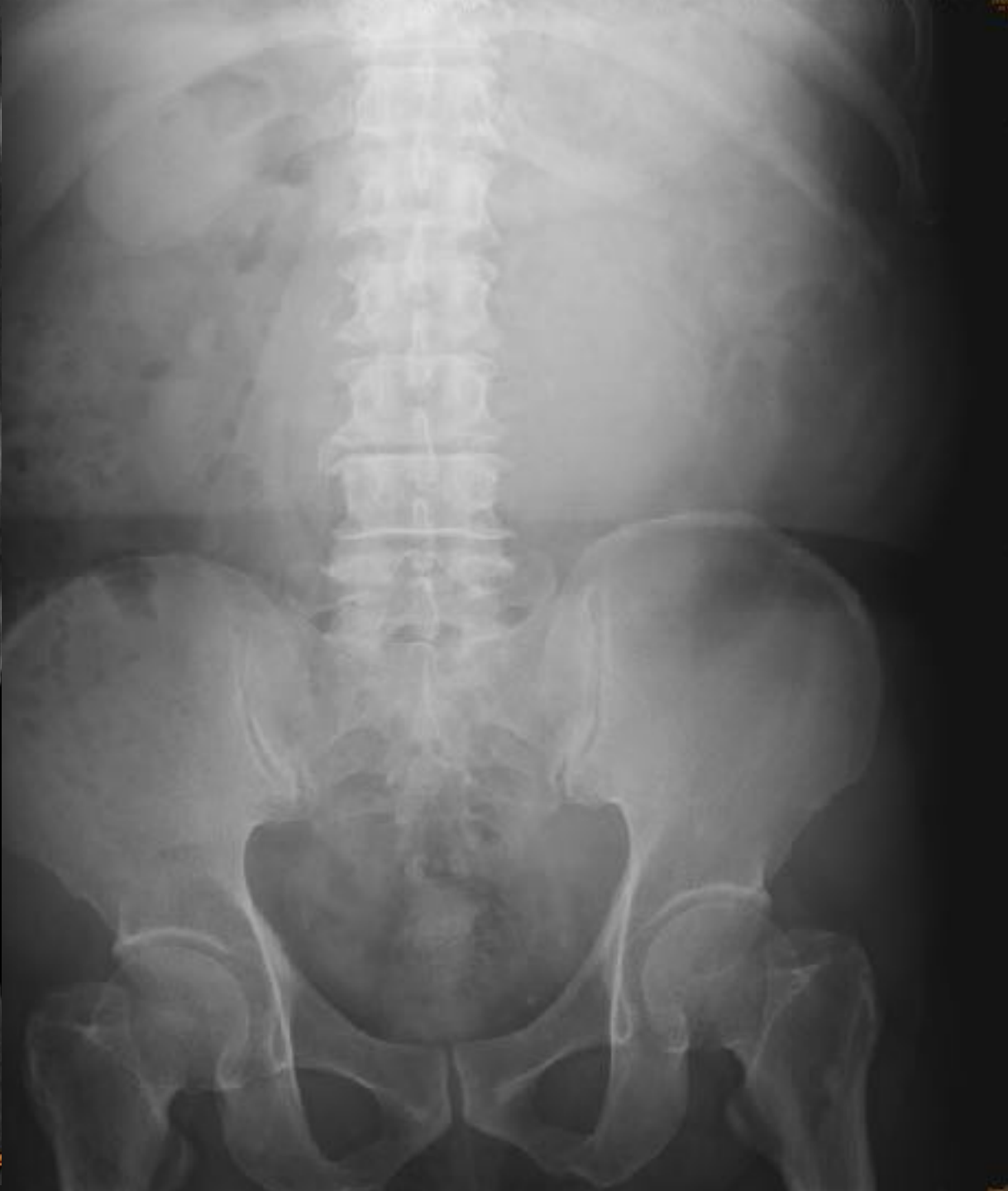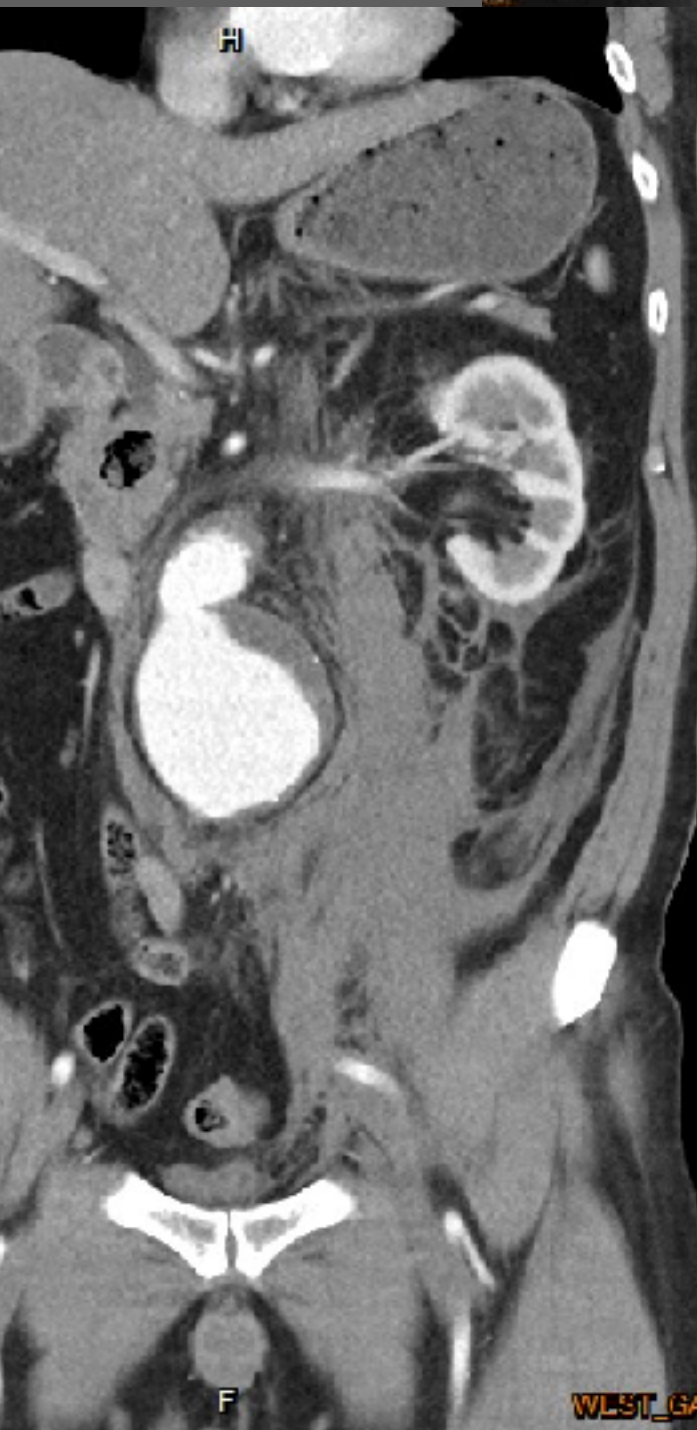
64M,
左下腹痛
1小時
冒冷汗
結石病史

PR 117
BP 88/62

腰痛 + 冒冷汗，
我的病人可能是
主動脈瘤破裂？



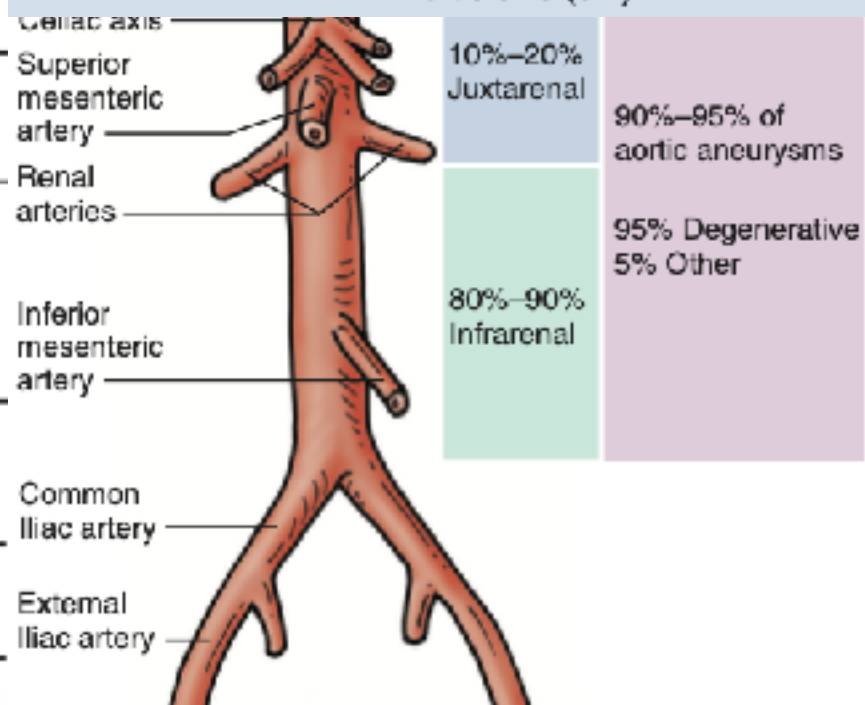
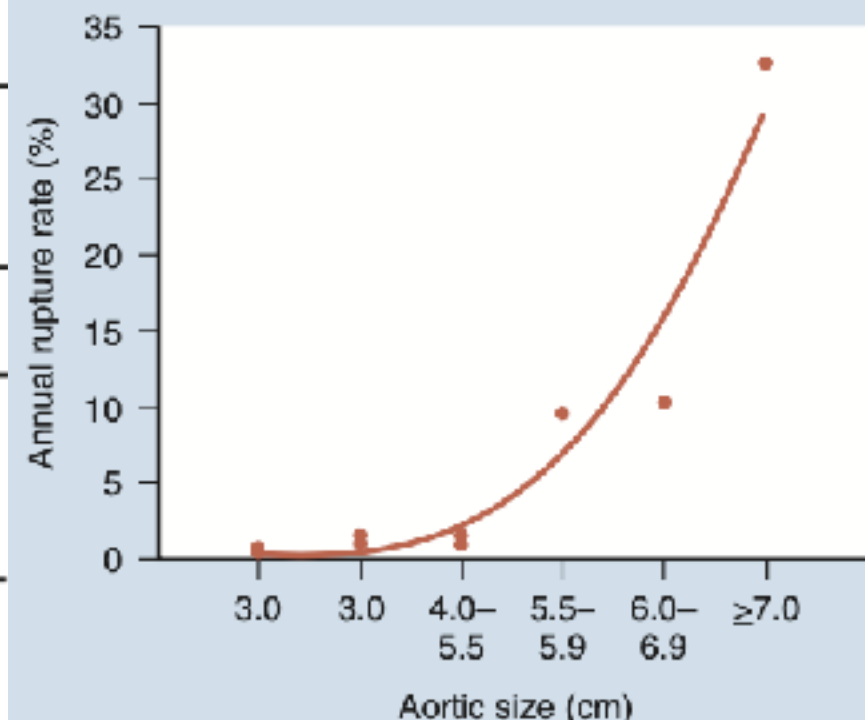
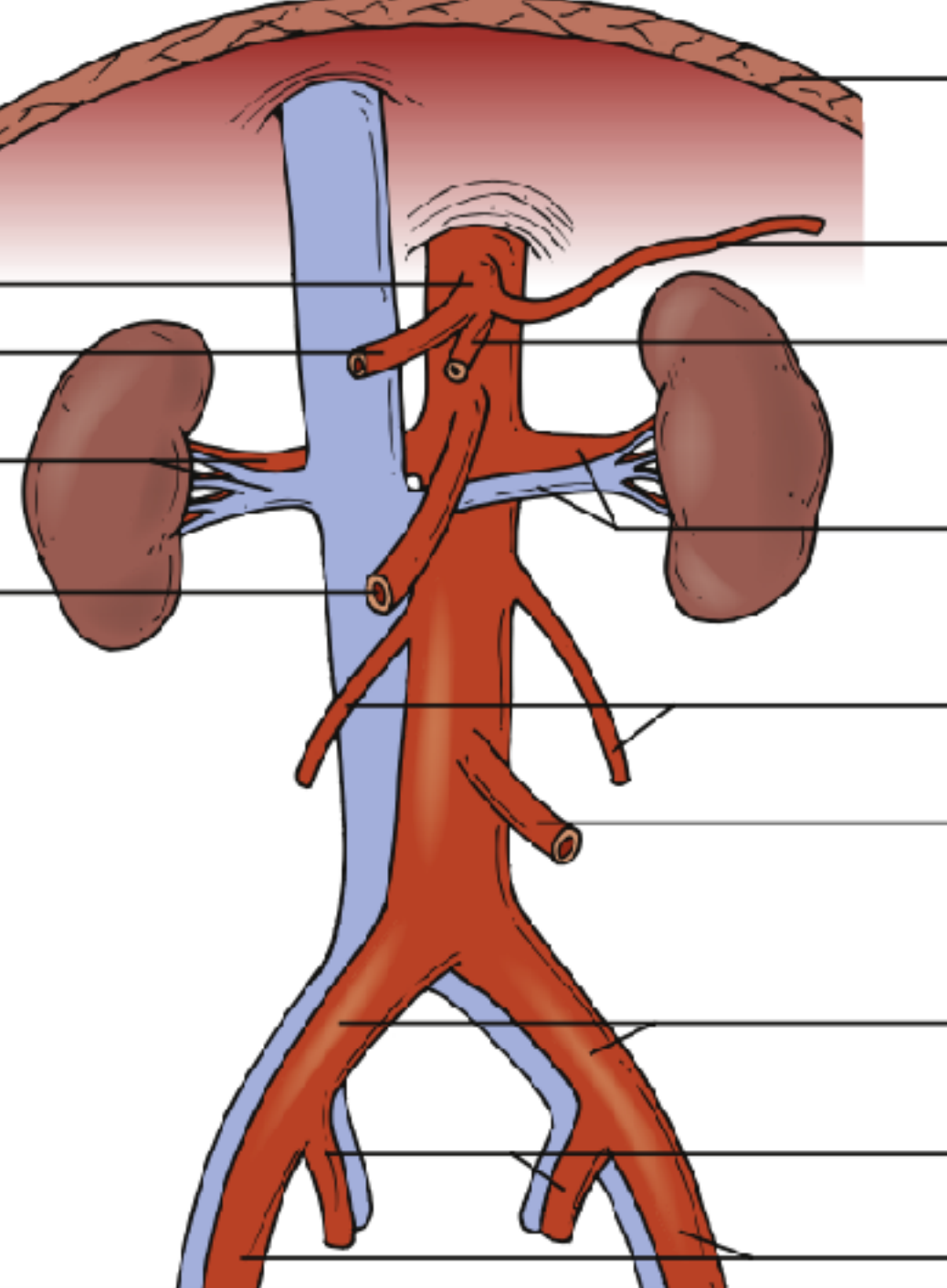




ABDOMEN

A for AAA

3_{cm}

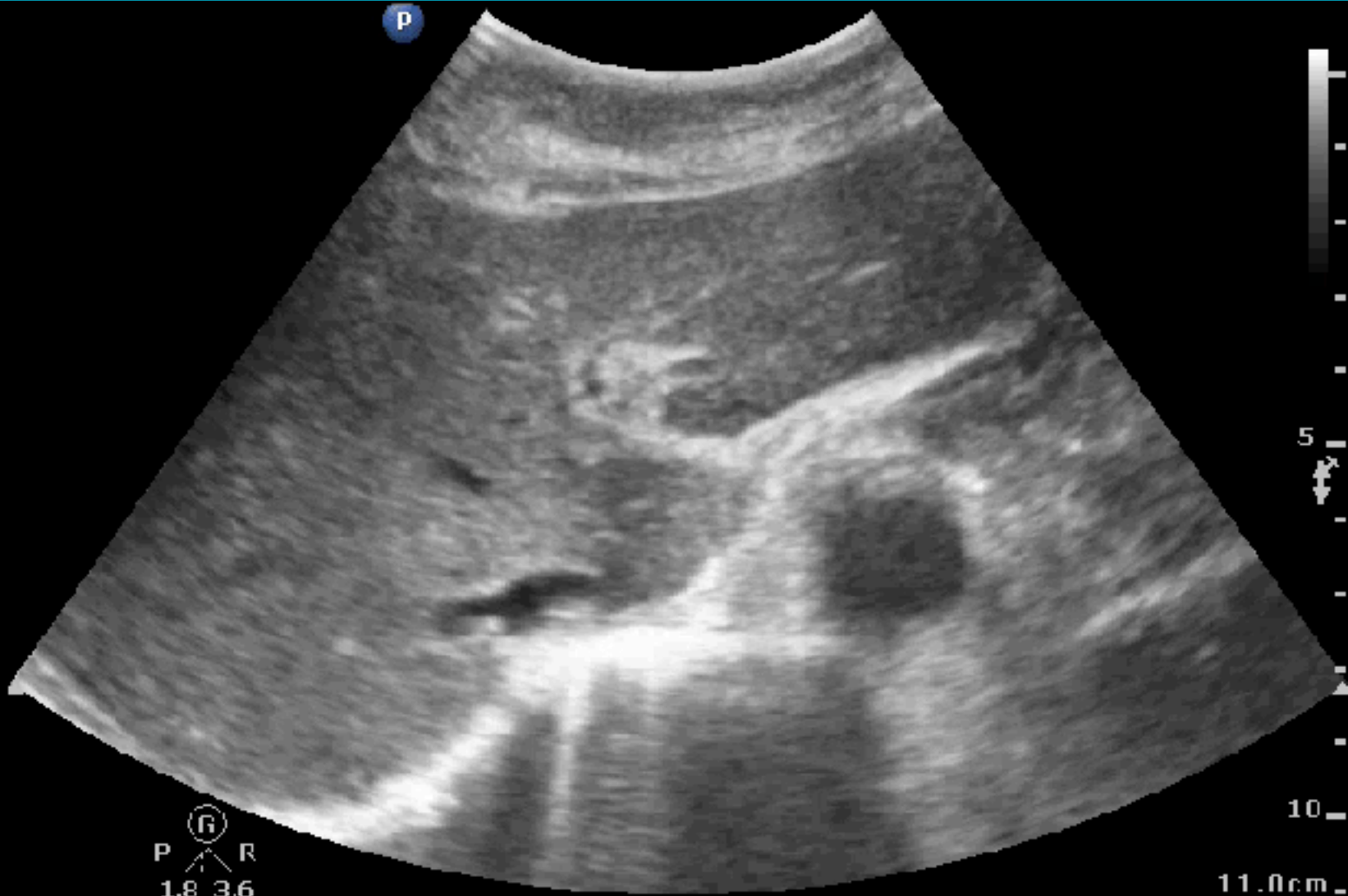

Abdominal aorta

Abd Gen
C5-1
42 Hz
11.0cm

2D

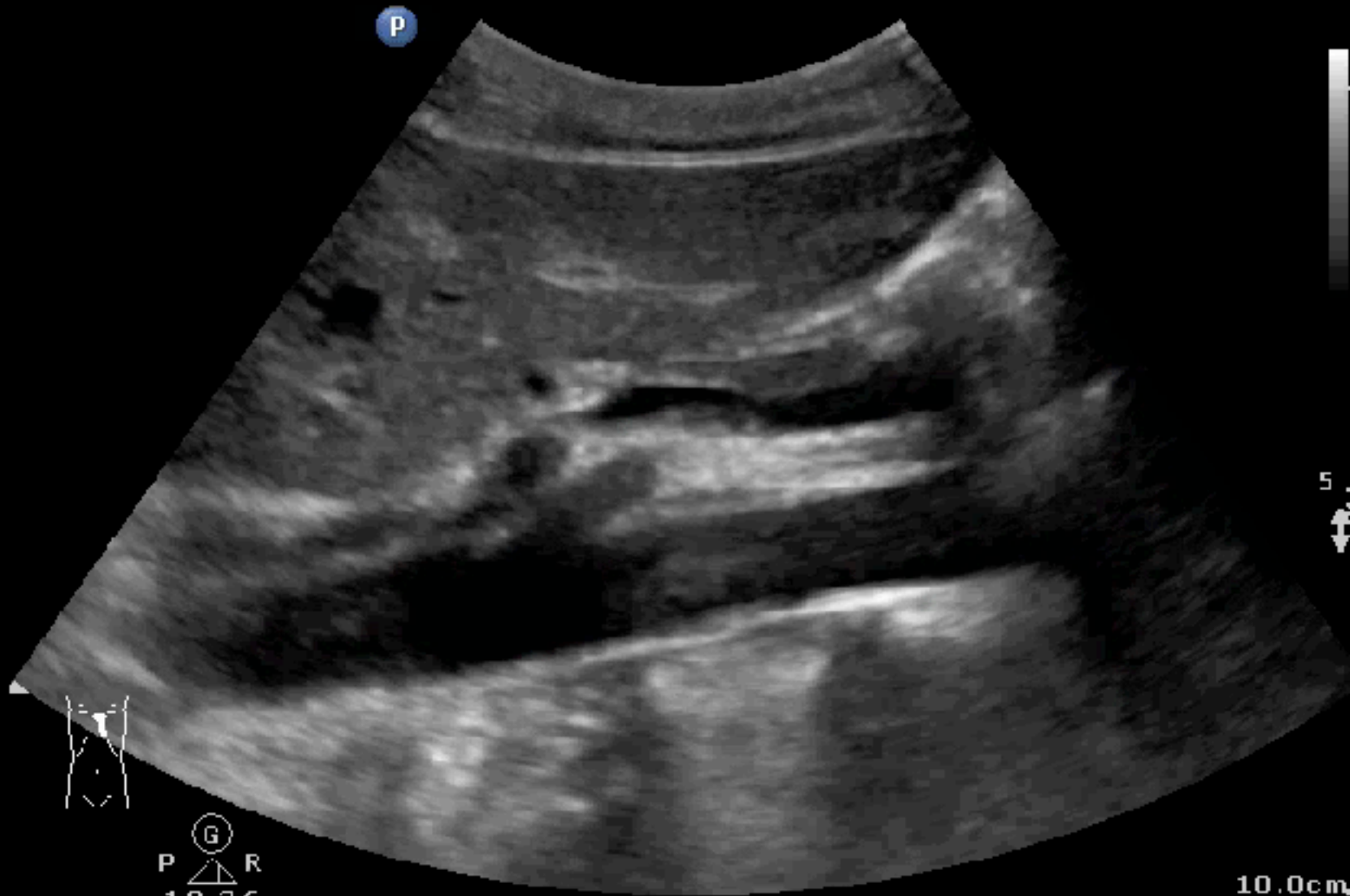HGen
Gn 66
C. 56
3 / 3 / 3



Abdominal aorta

Abd Gen
C5 1
45 Hz
10.0cm

2D
HGen
Gn 60
C 56
3 / 3 / 3



G
P R
1.8 3.6

10.0cm

AAA



3 cm

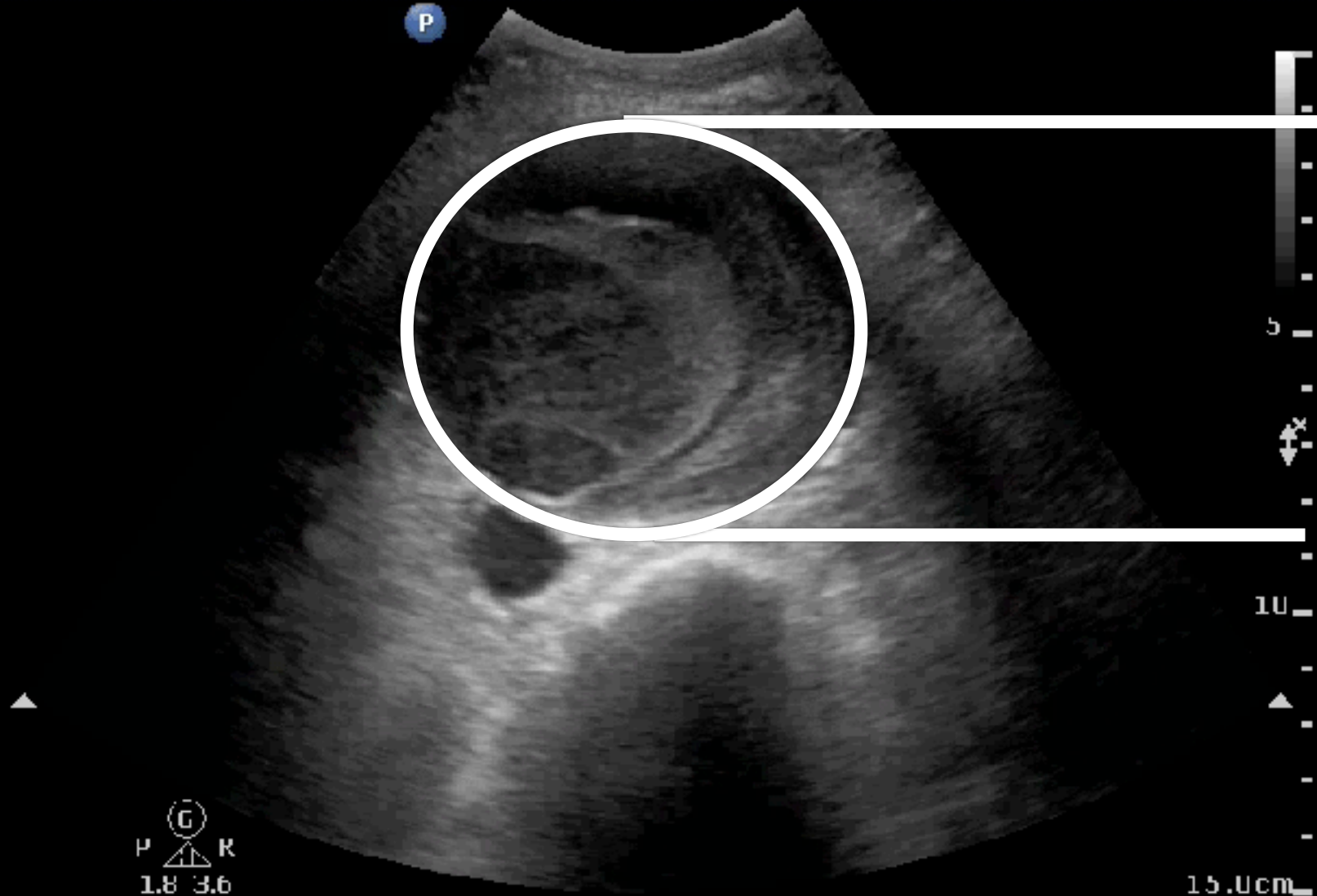
> 50 y/o
Syncope
Hypotension
ABD/Flank/Back/Groin

Sensitivity **97.5-100%**
Specificity **94.1-100%**

Eyeballing

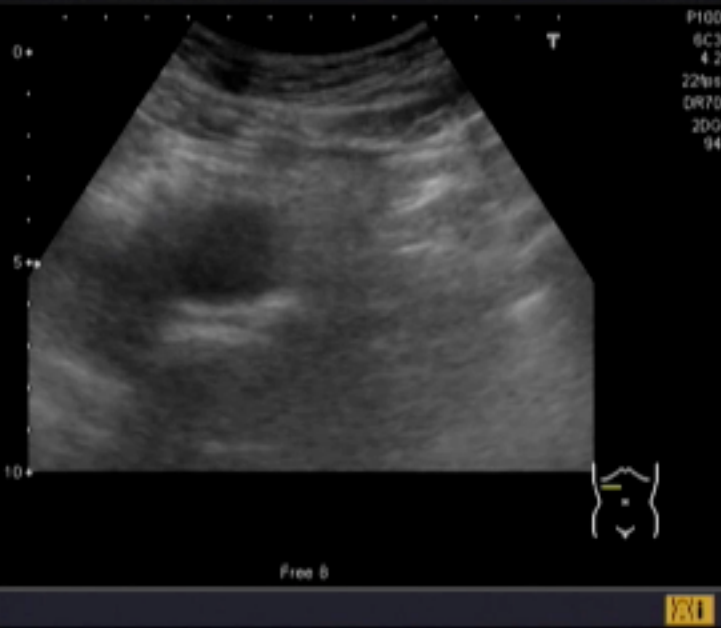
Abd Gen
C5-1
34 Hz
15.0cm

2D
HGen
Gn 5/
C 56
3/3/3



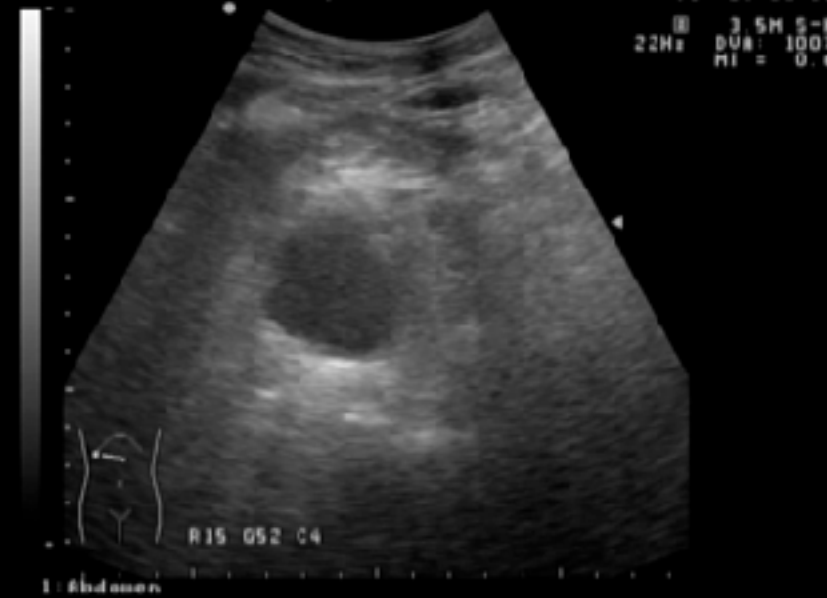A for AAA, not for rupture

POCUS Academy©ChenKC



A

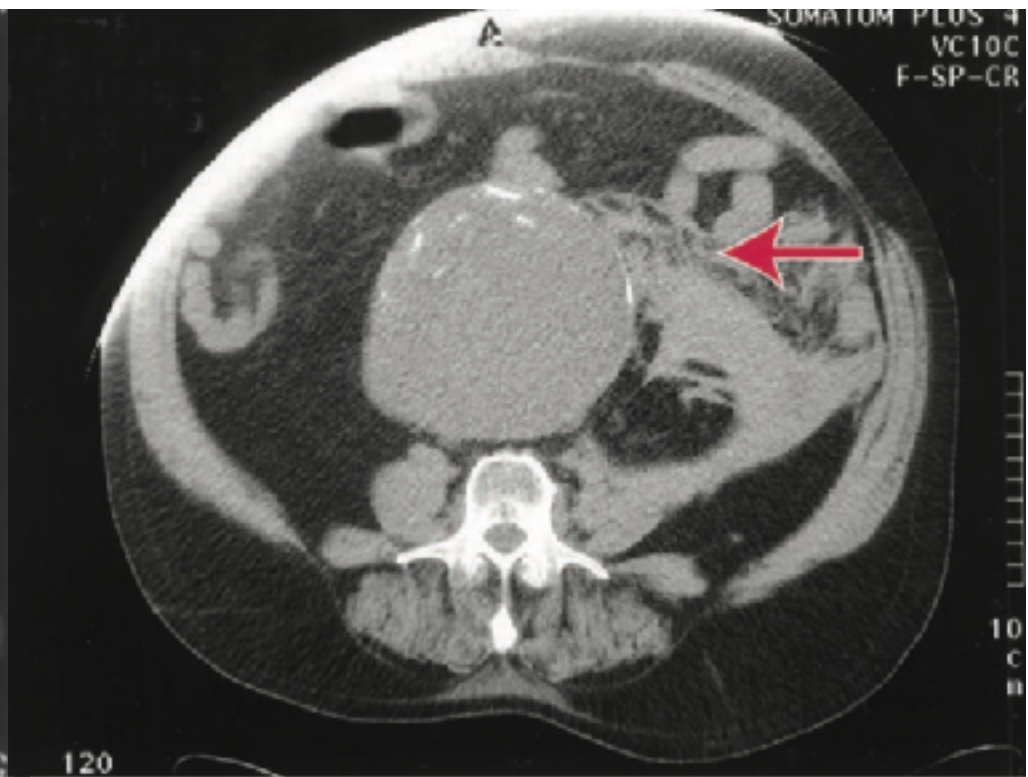
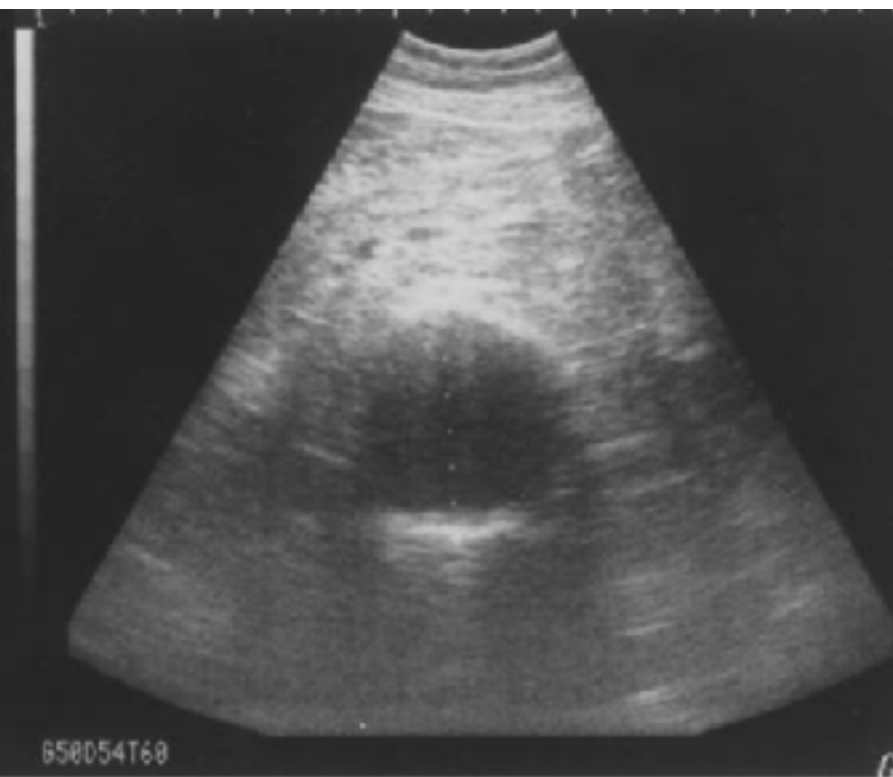POCUS Academy©ChenKC



B

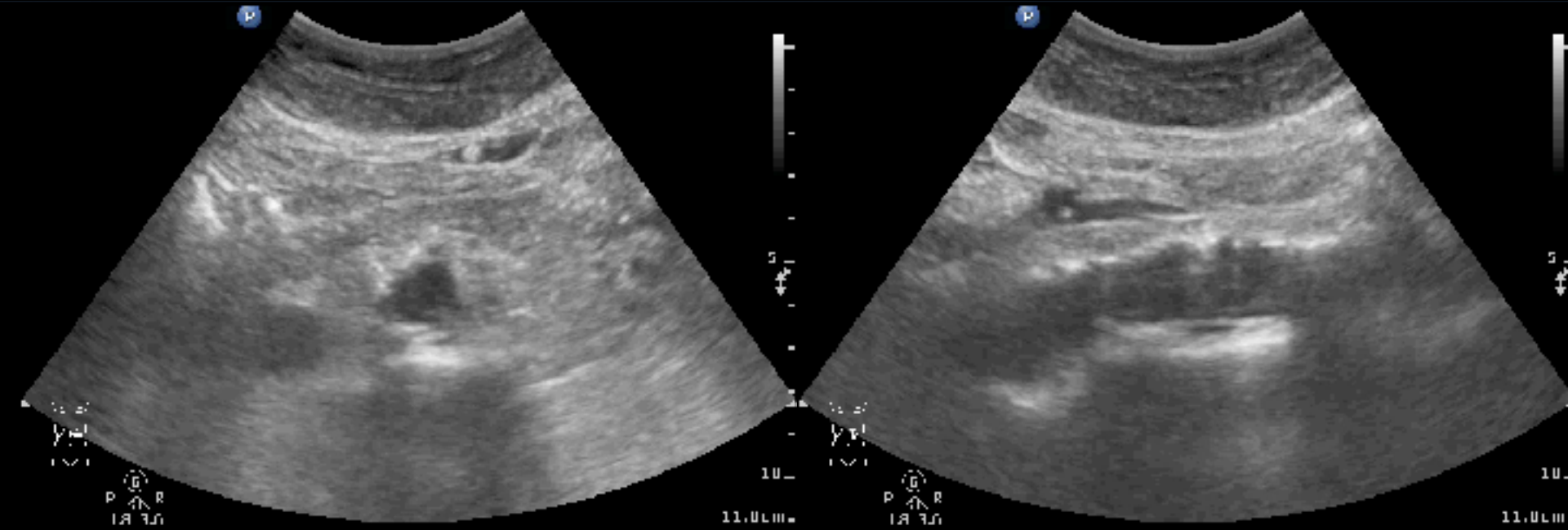
Echo for AAA (3~5cm)

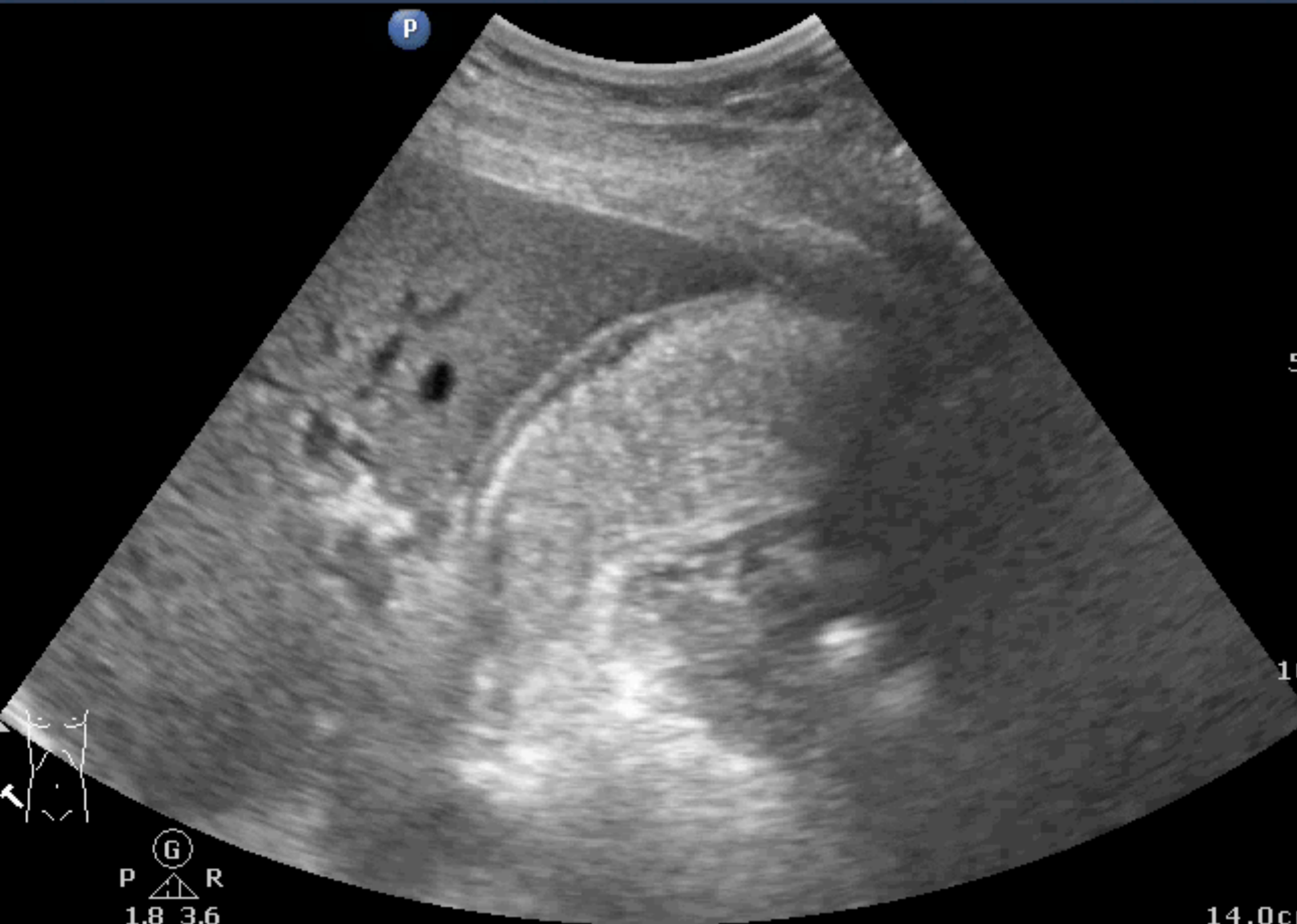
Not for rupture



63M, chest/abd pain & low BP

Aortic dissection





P

T

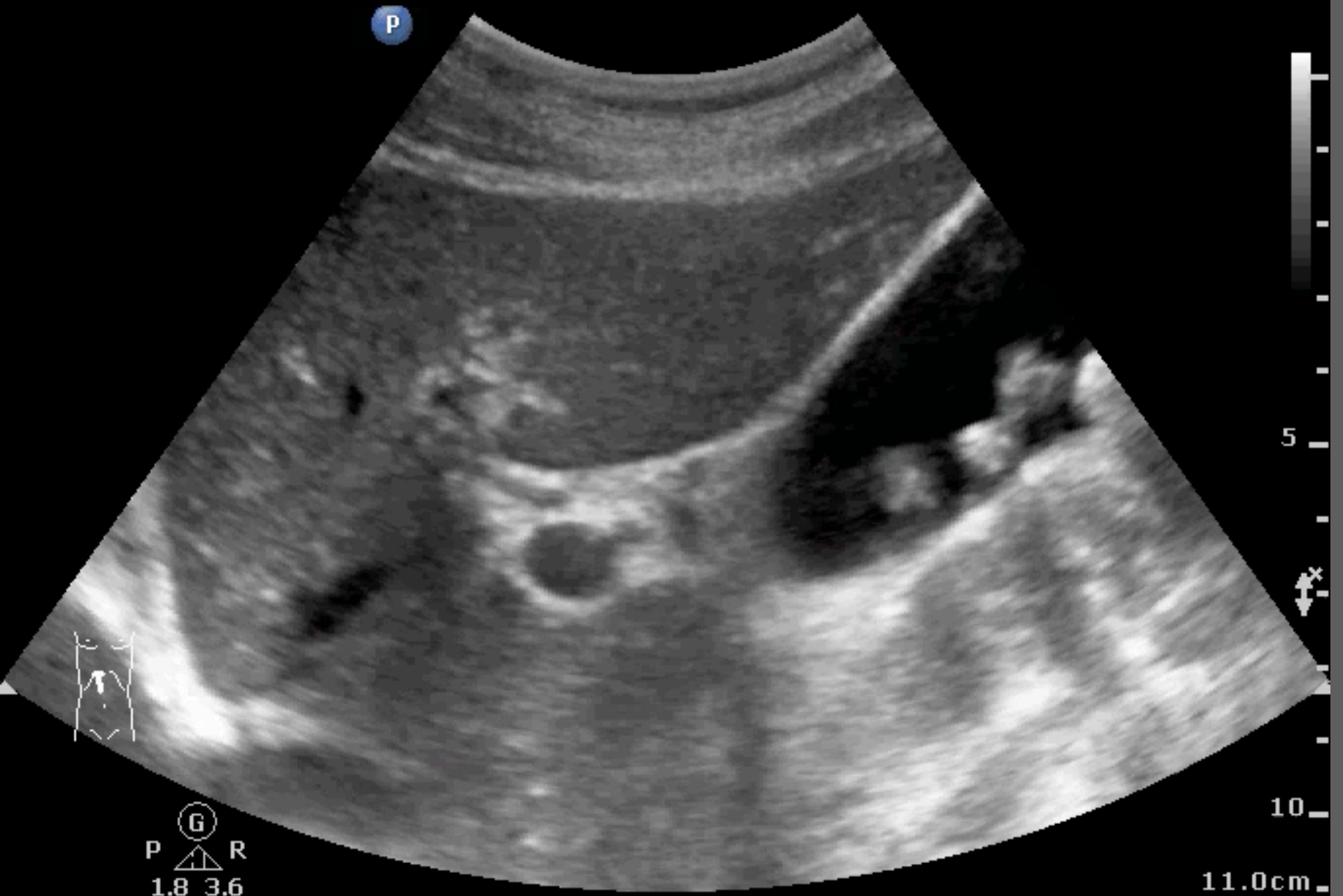
G
P R
1.8 3.6

14.0c

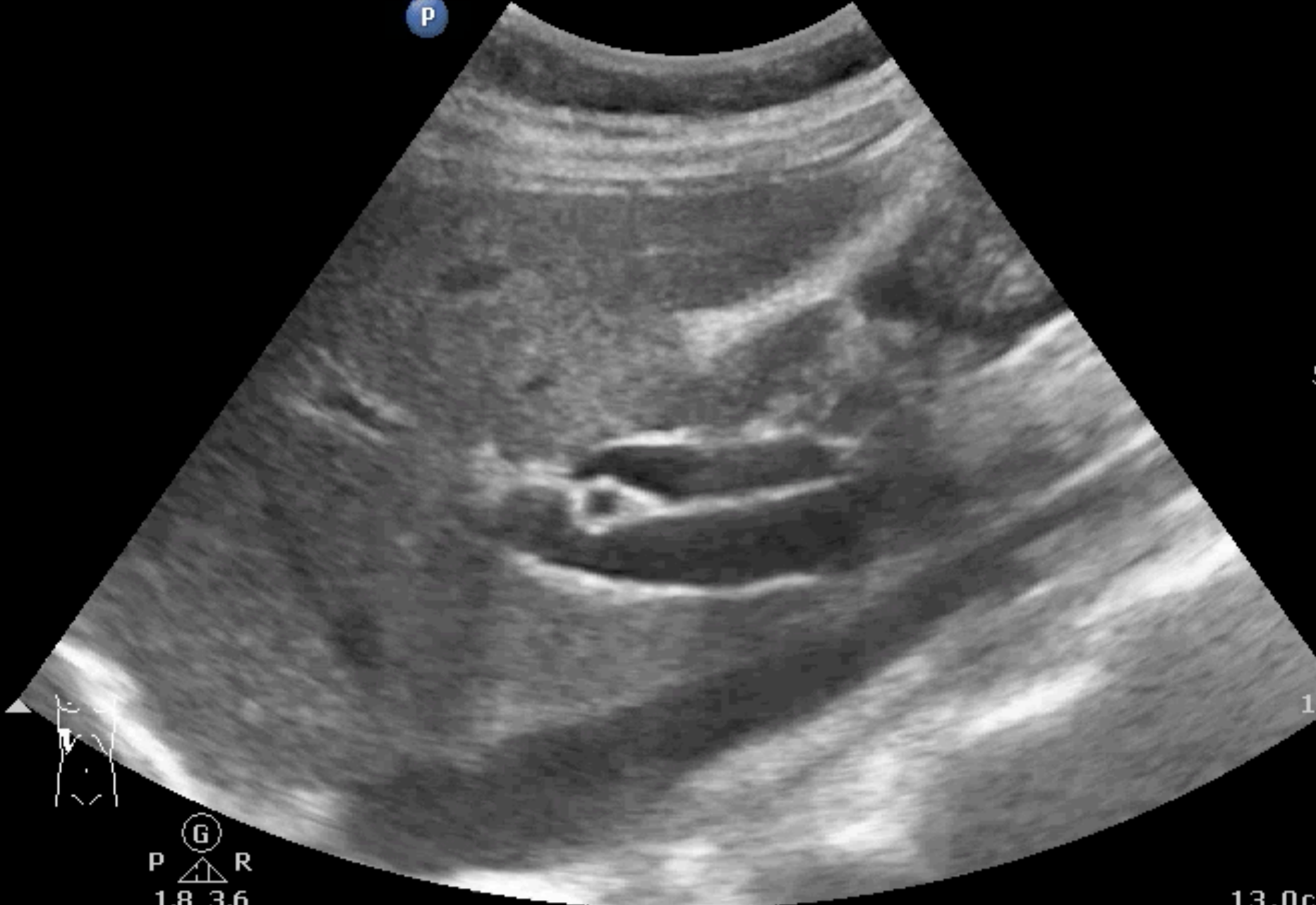ABDOMEN

B for GB stone & dilatation

3 mm 7 mm 11 mm



P



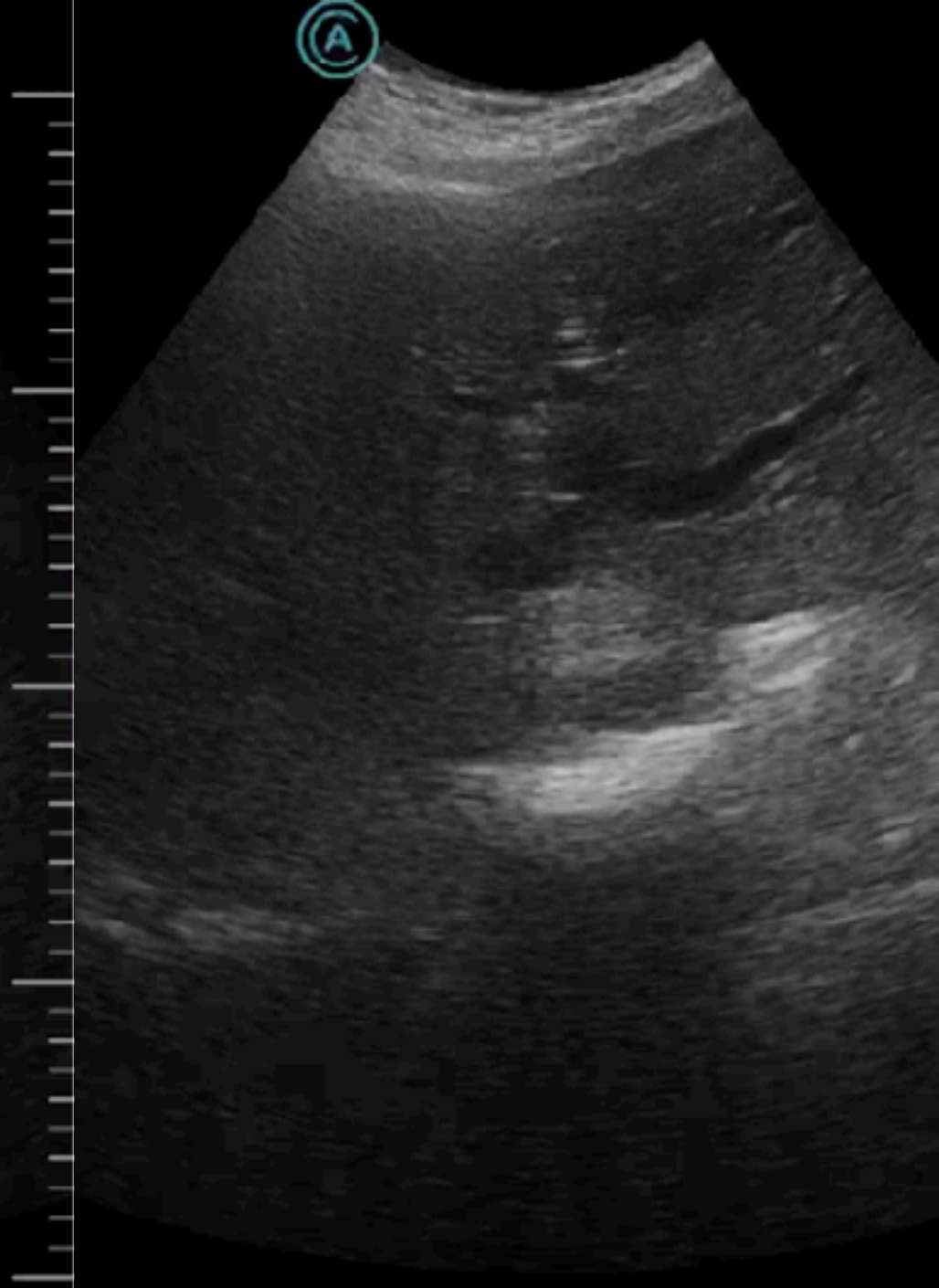
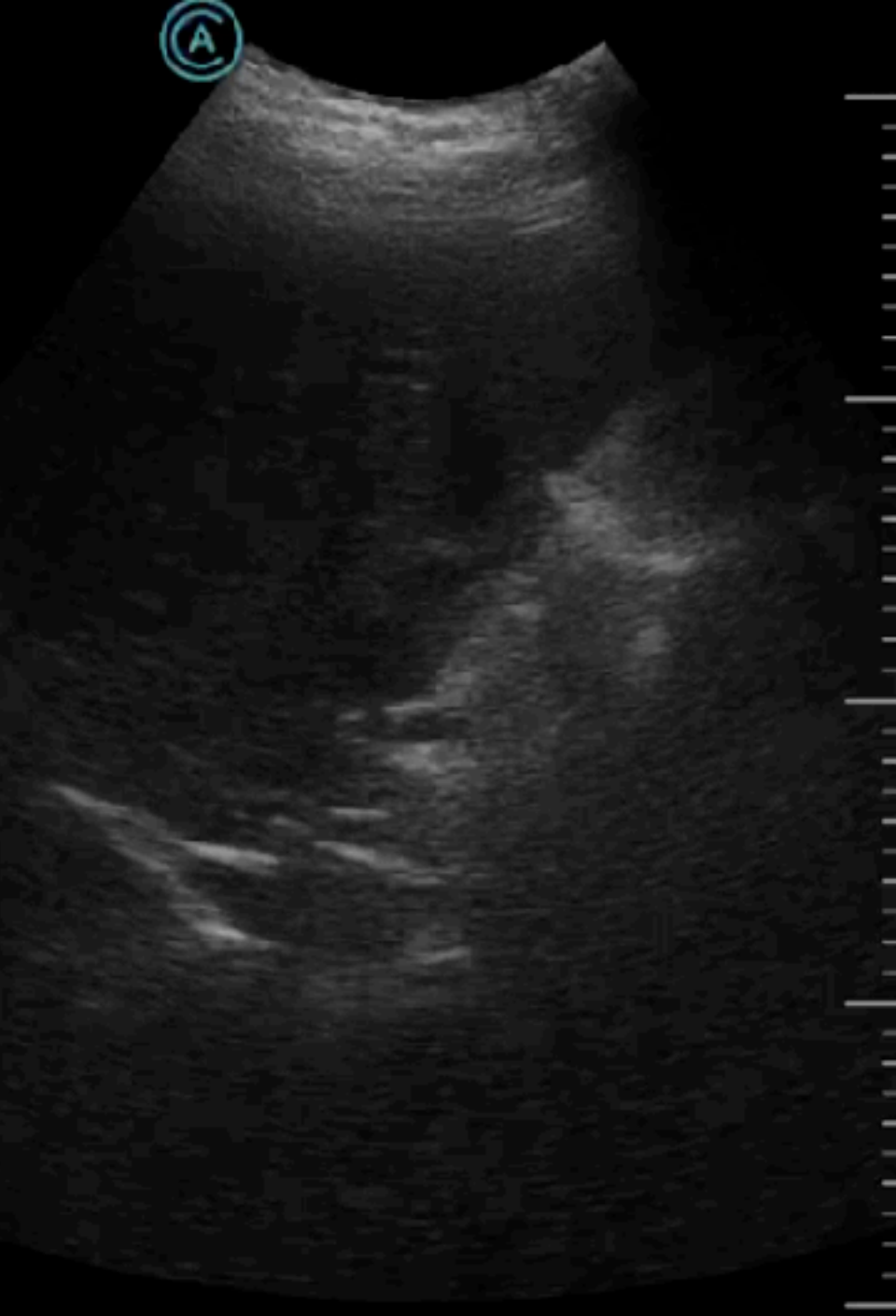
5

4

10



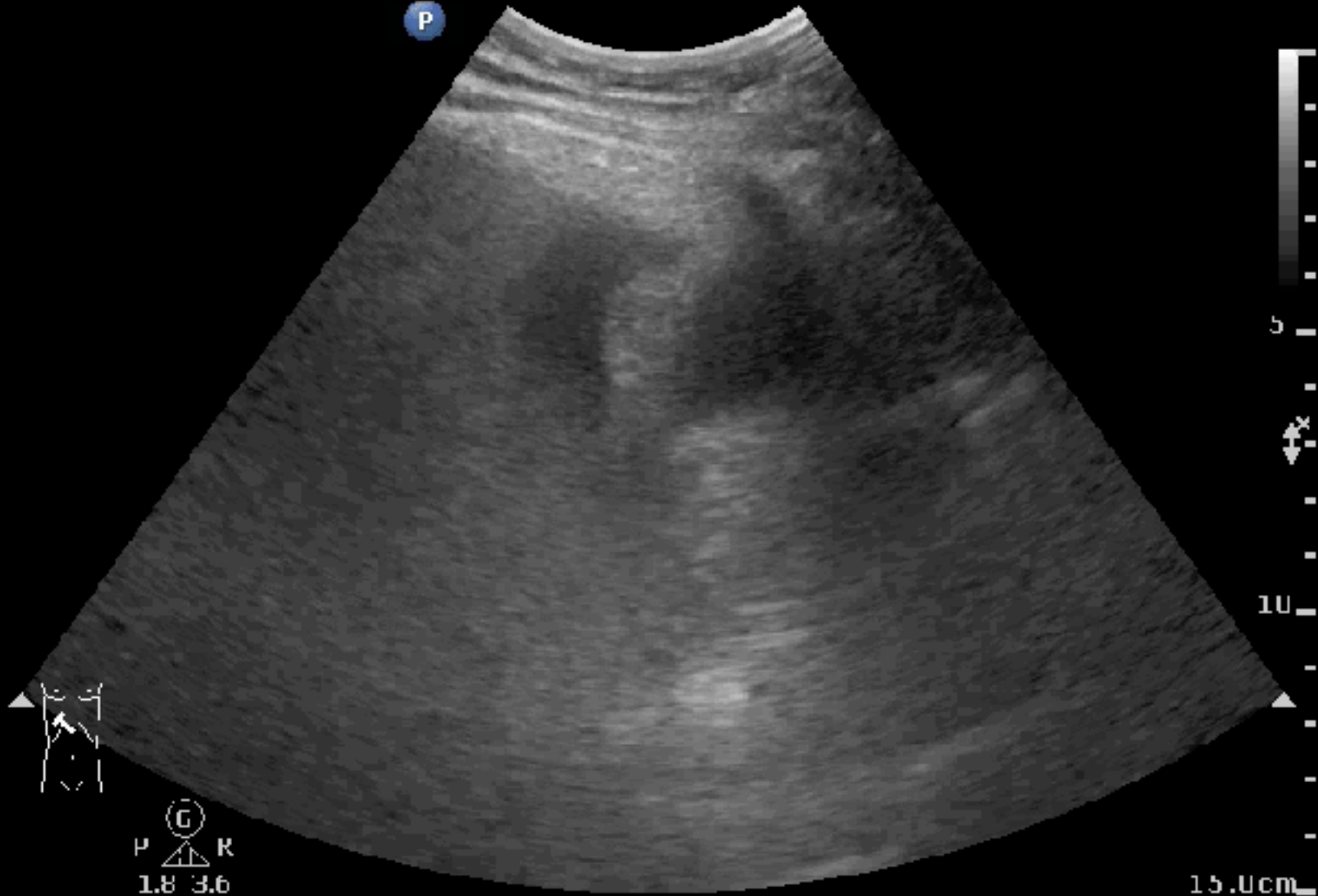13.0cm



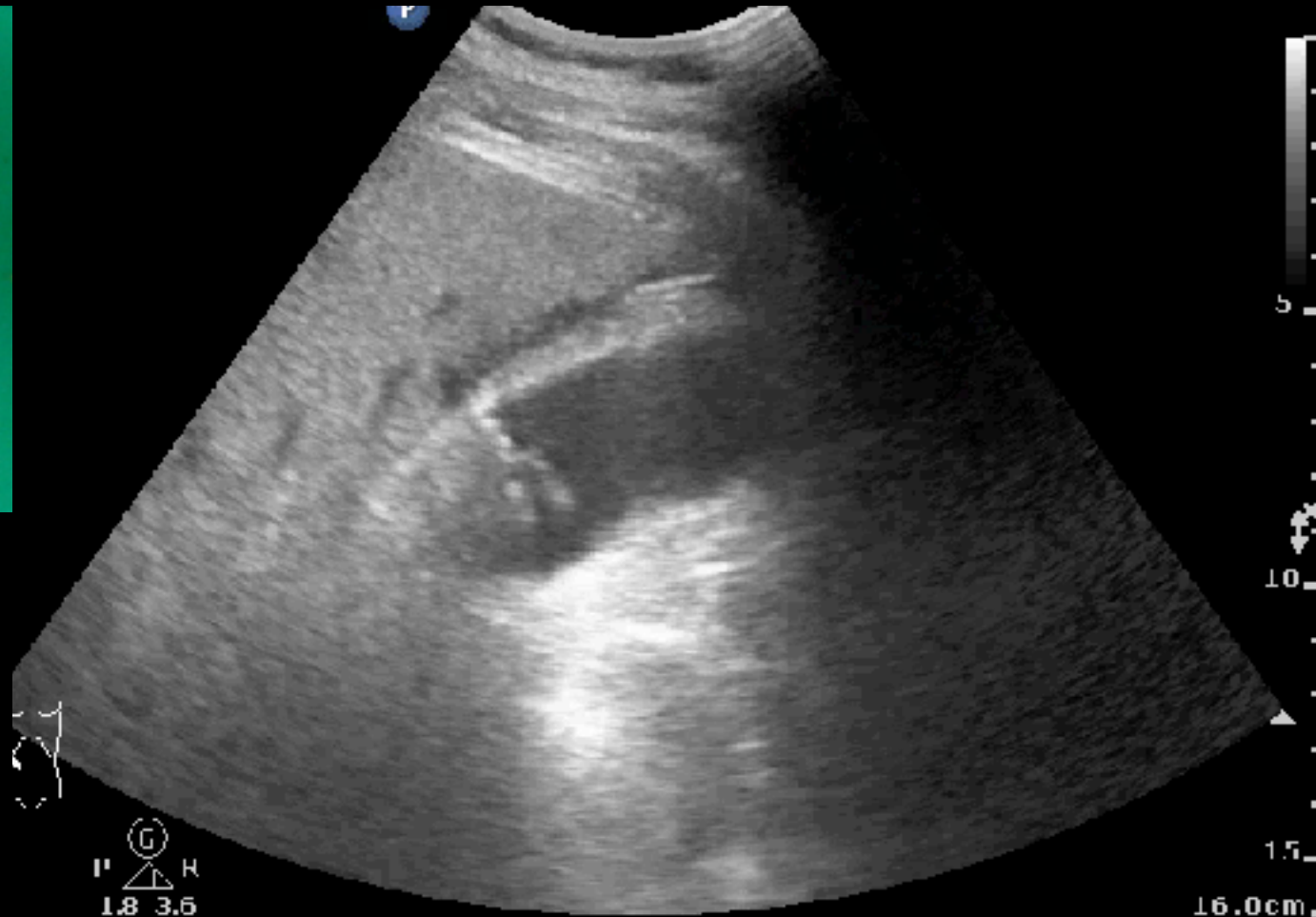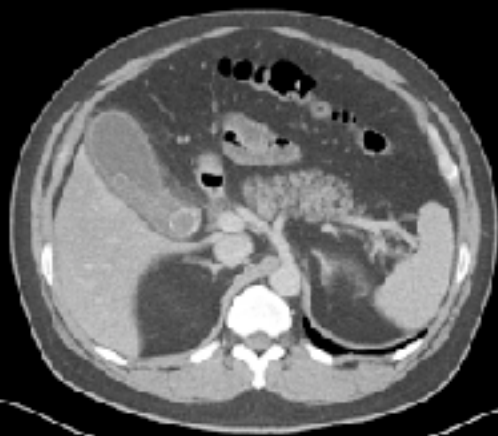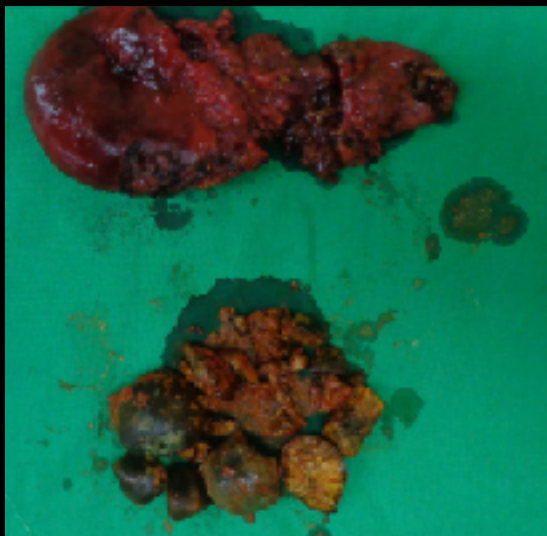
45M, RUQ pain & fever

Abd Gen2
C5-1
34 Hz
15.0cm

2D
HGen
Gn 100
C 56
3/3/3



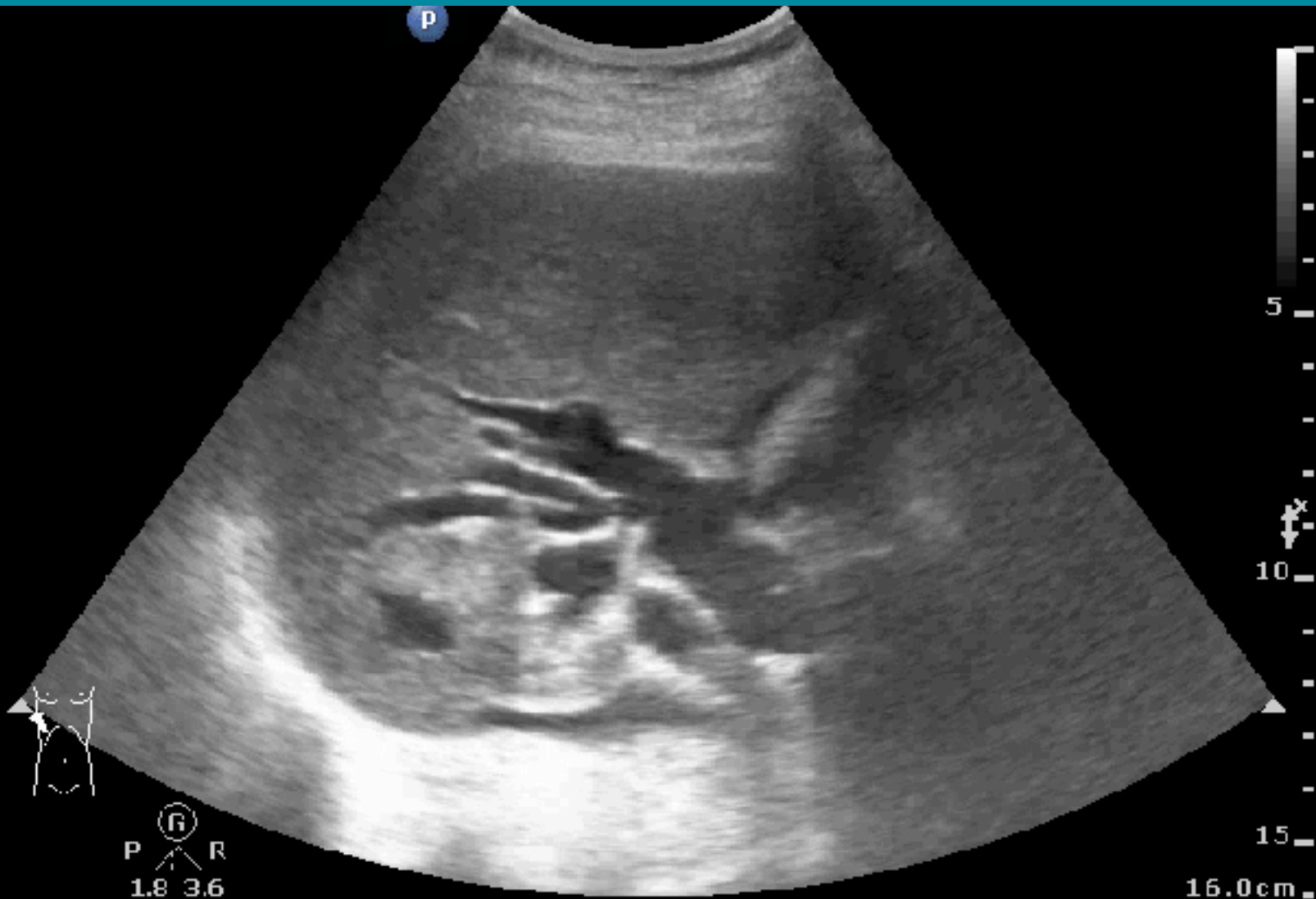Acute calculous cholecystitis



76F, Fever & Chills

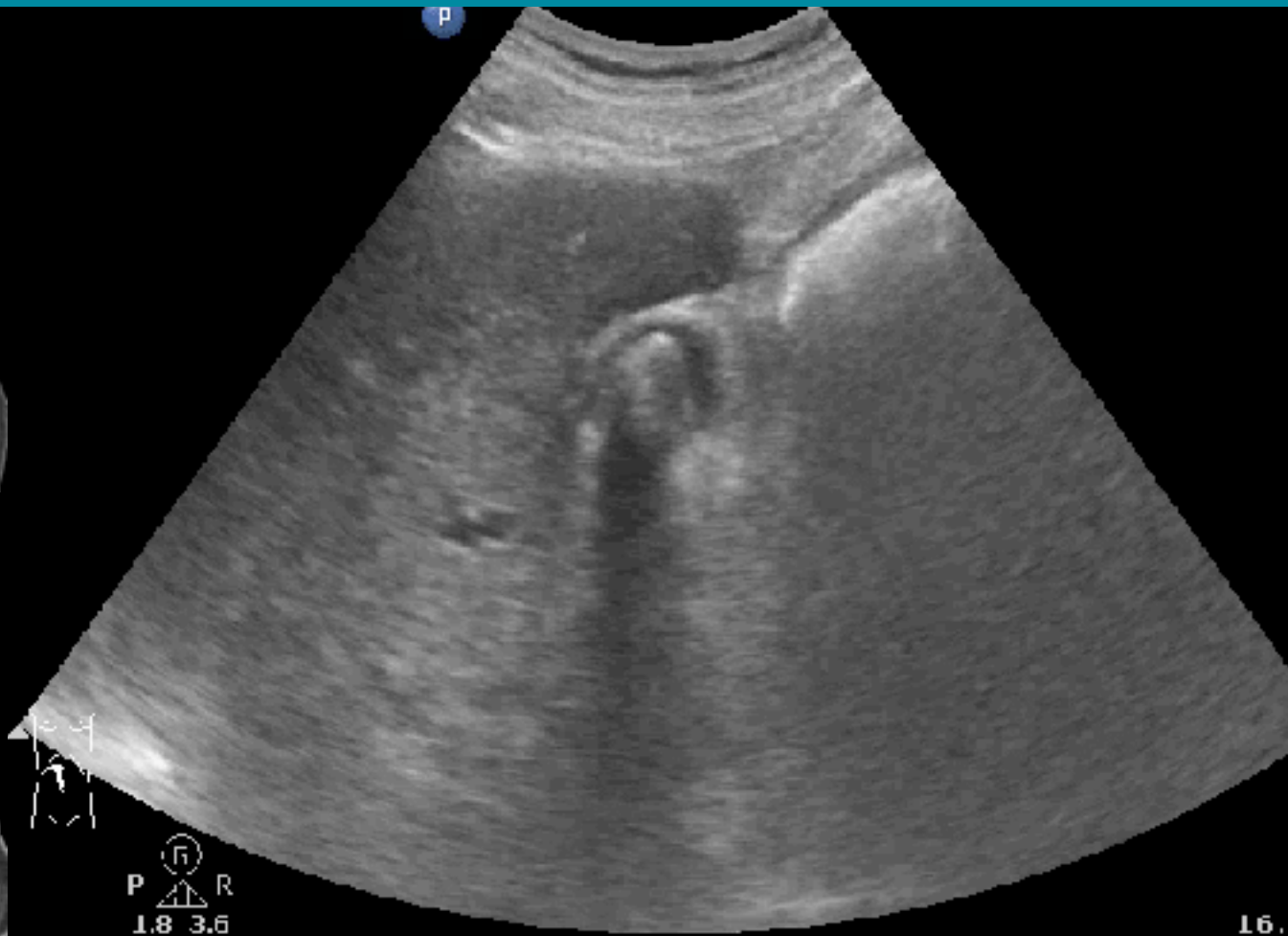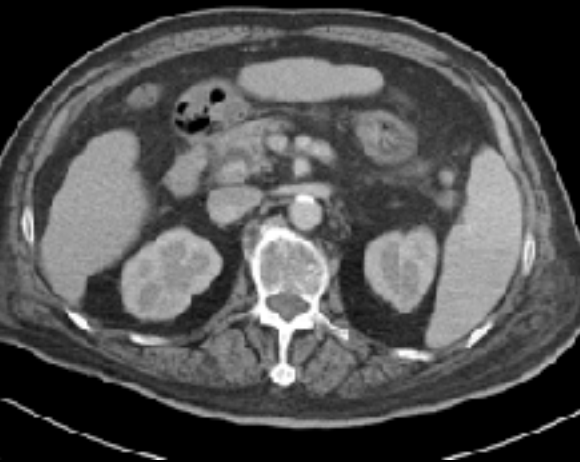
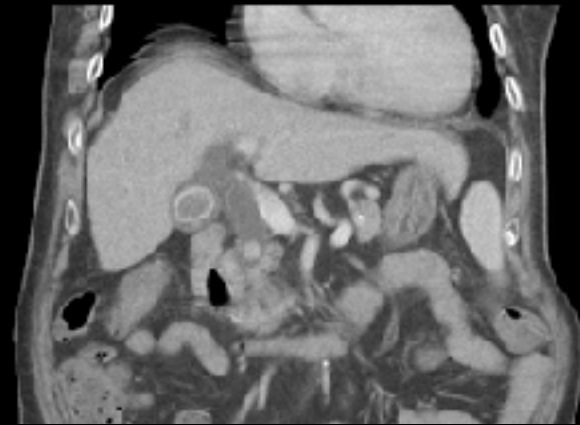
Abd Gen2
C5-1
32 Hz
16.0cm

2D
HGen
Gn 100
C. 56
3/3/3

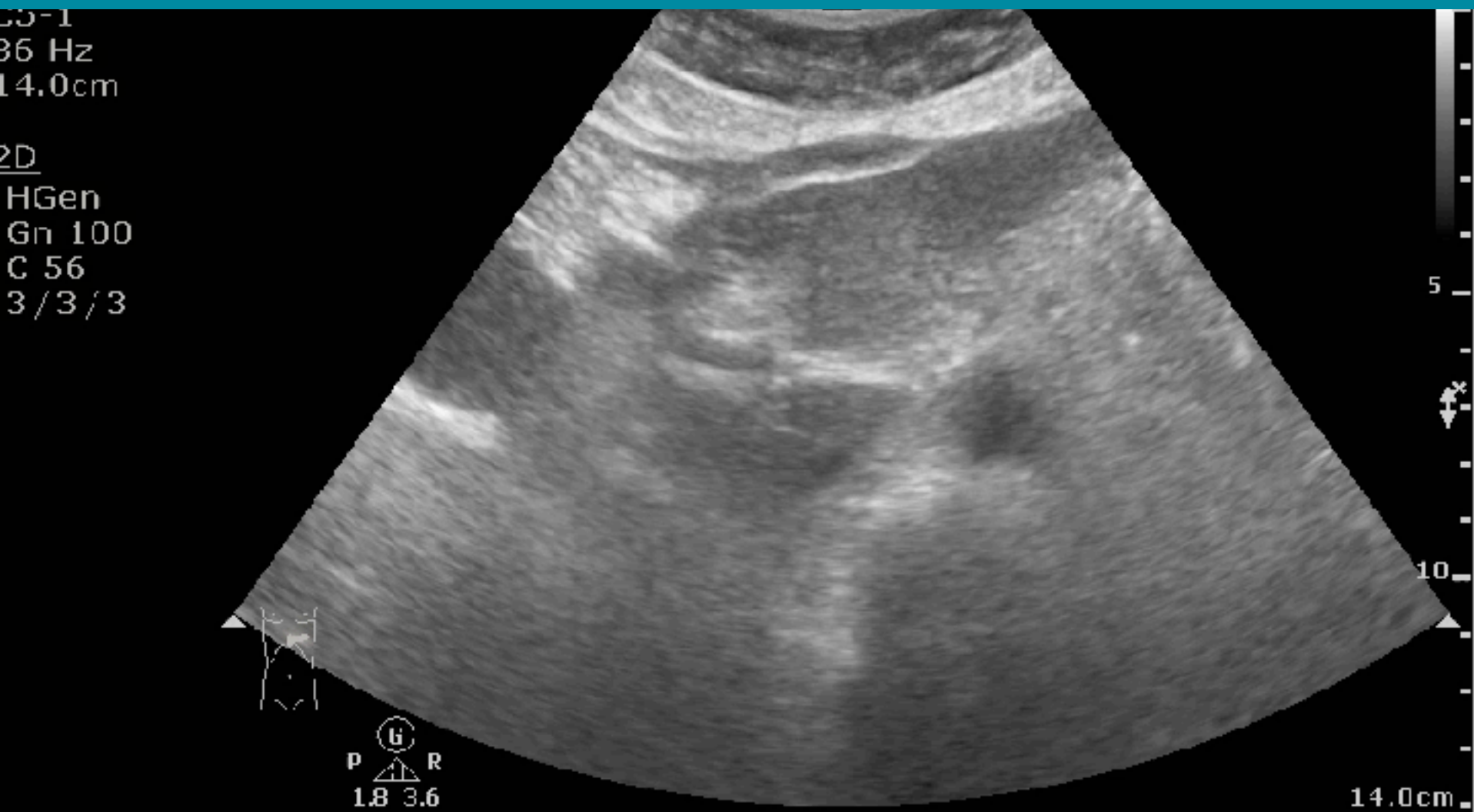

CBD dilatation & stone

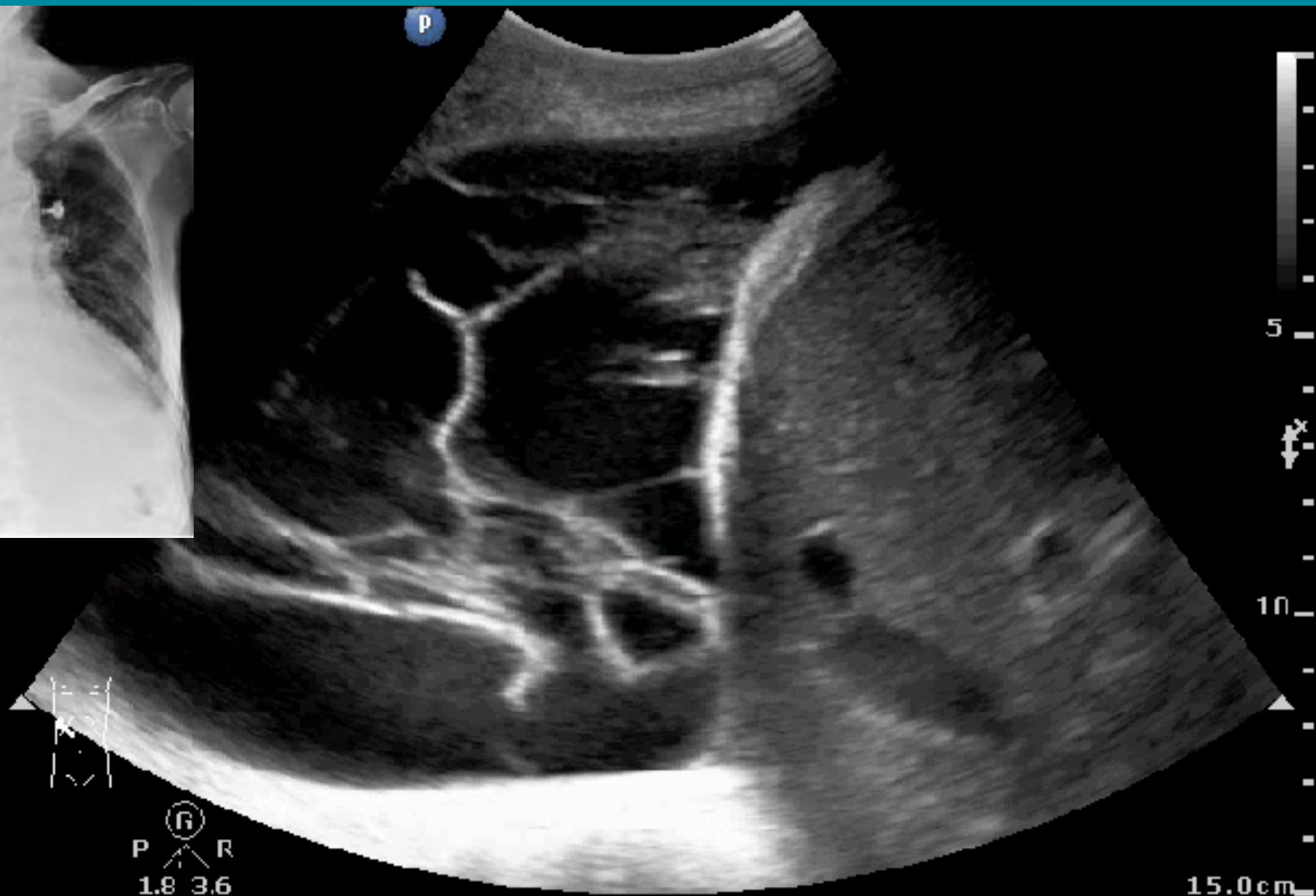
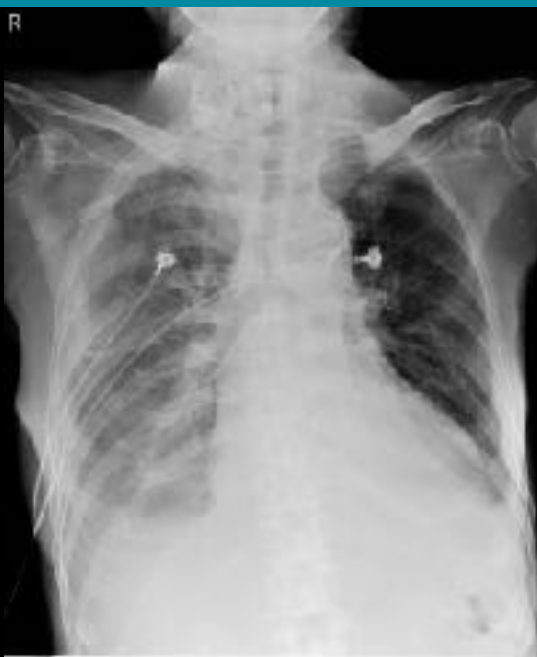Abd Gen2
C5-1



CBD stone



73M, chest/abd pain & SOB



ABDDOMEN

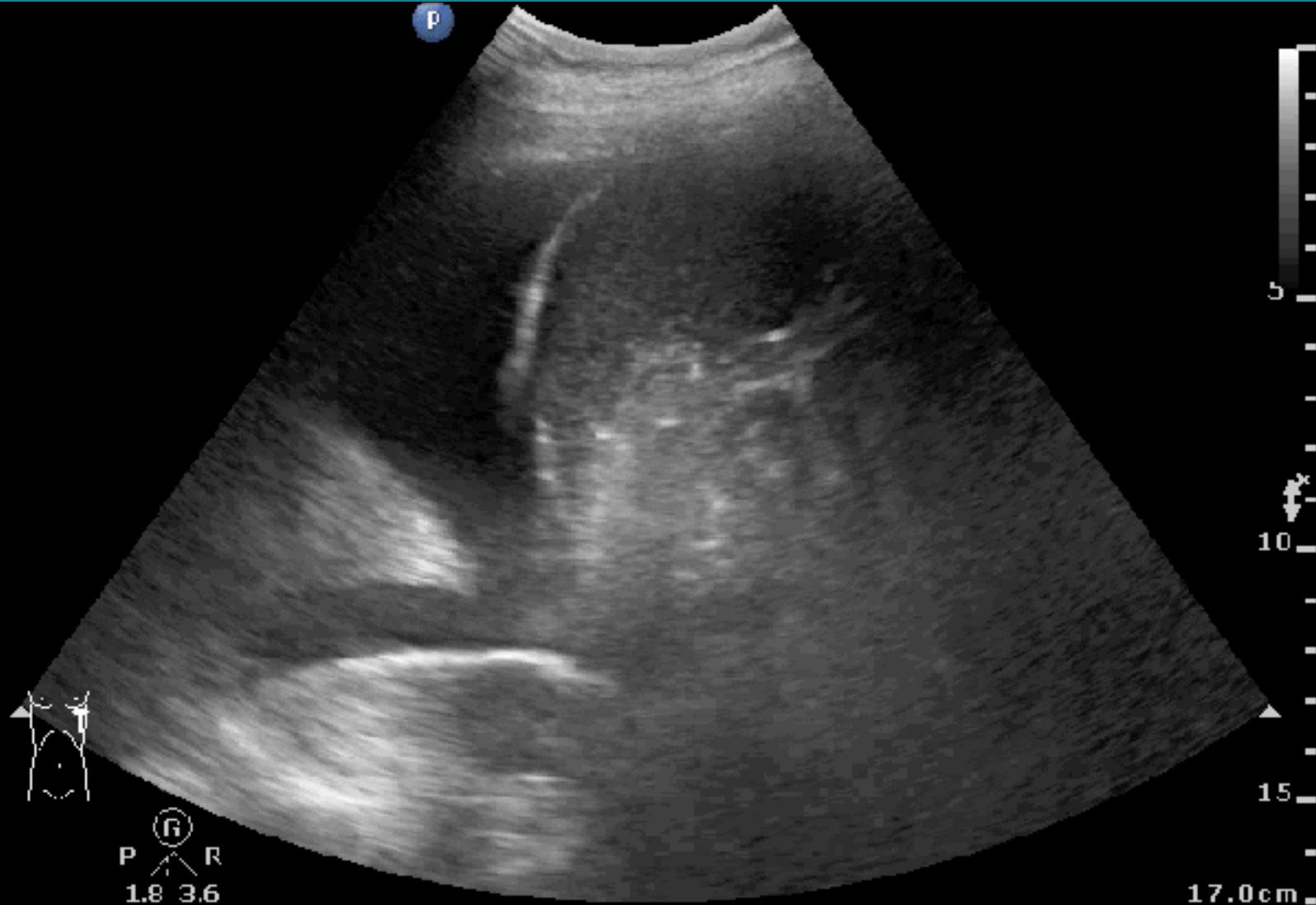
D for diaphragm

Outsider

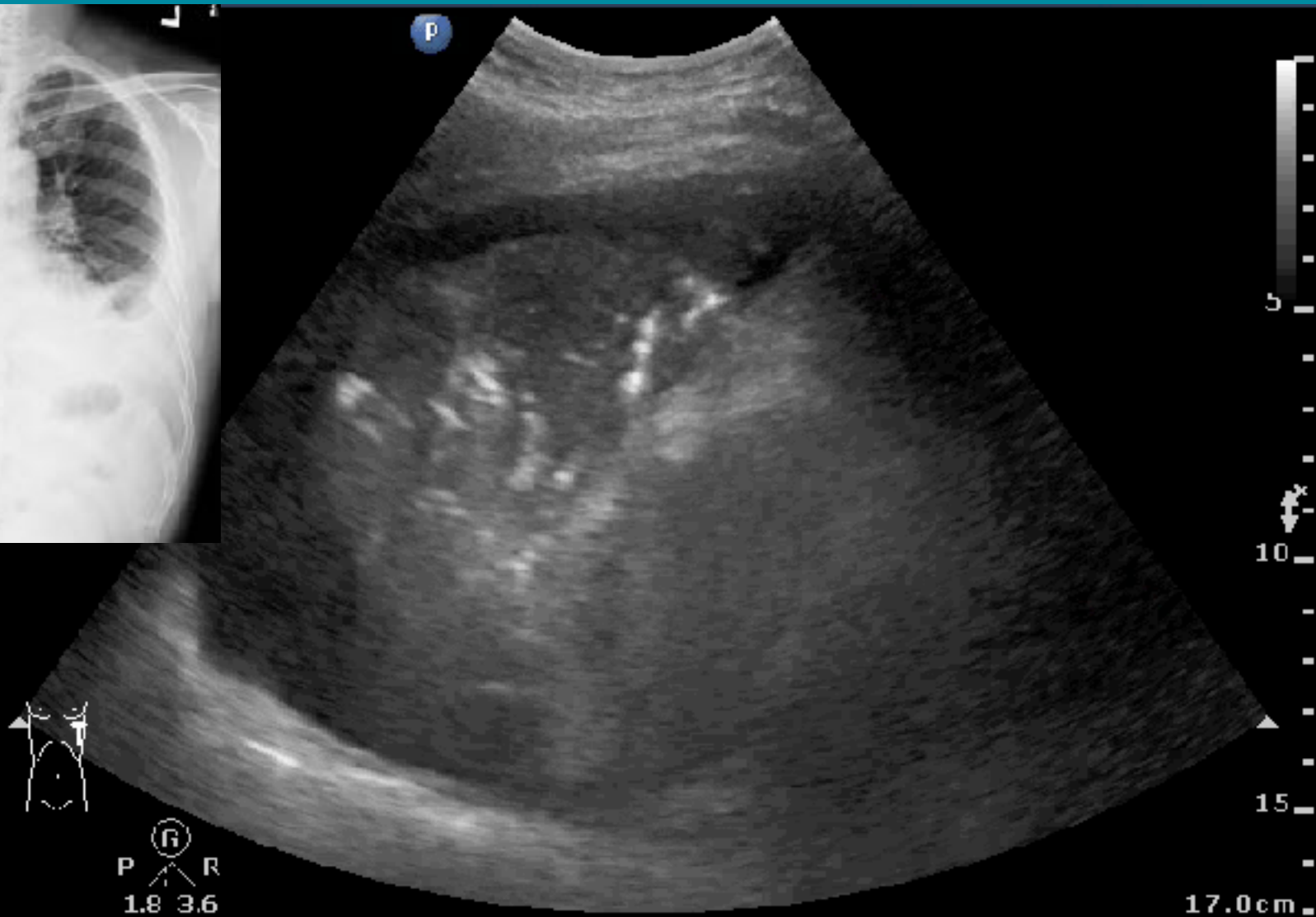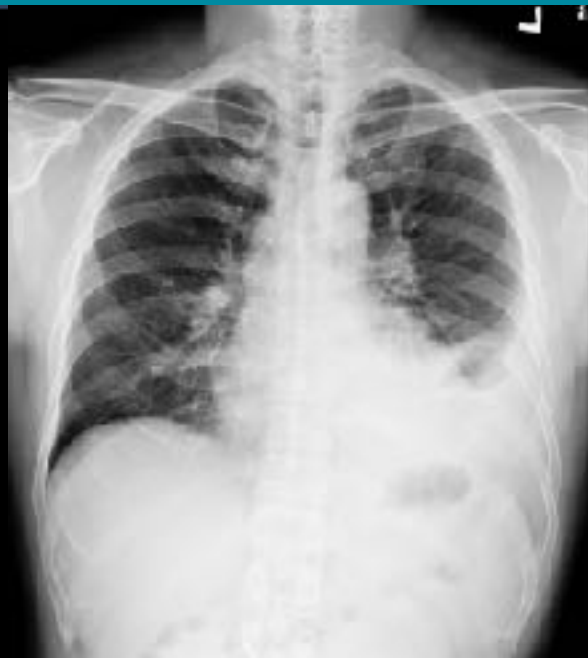45M, LUQ pain

Abd Gen
C5-1
31 Hz
17.0cm

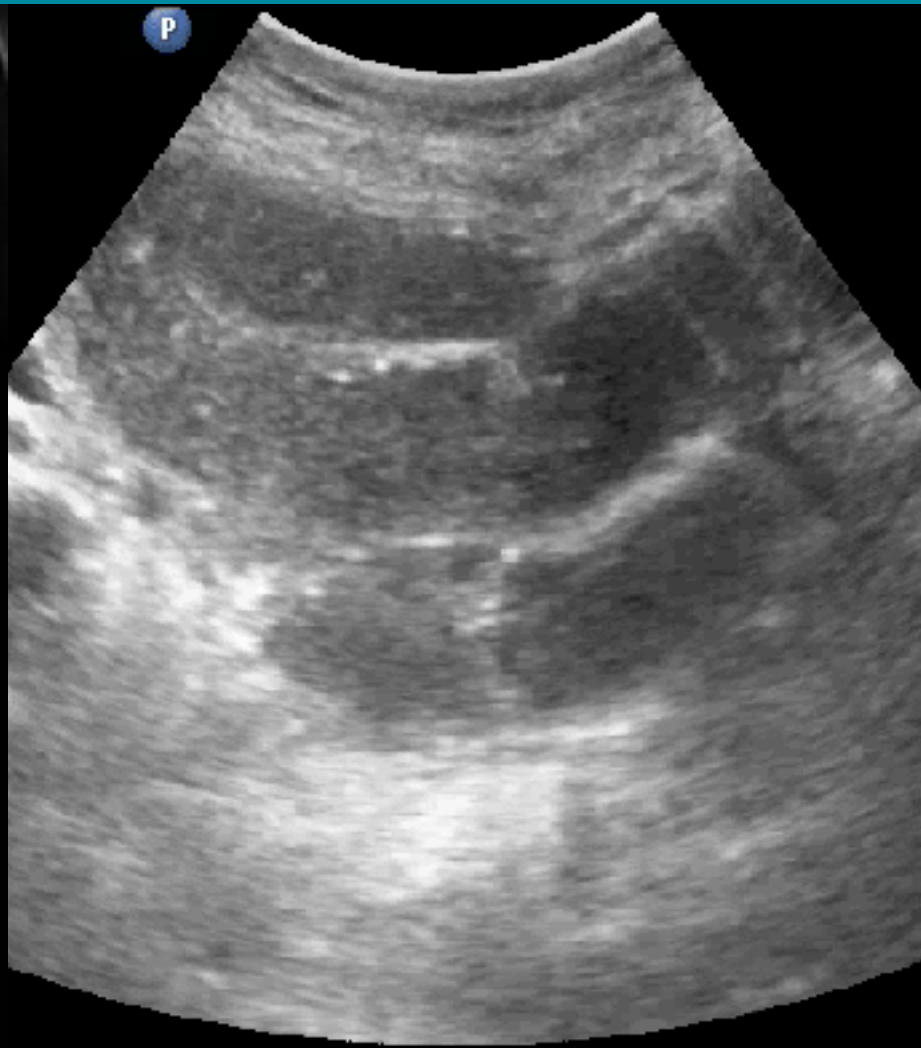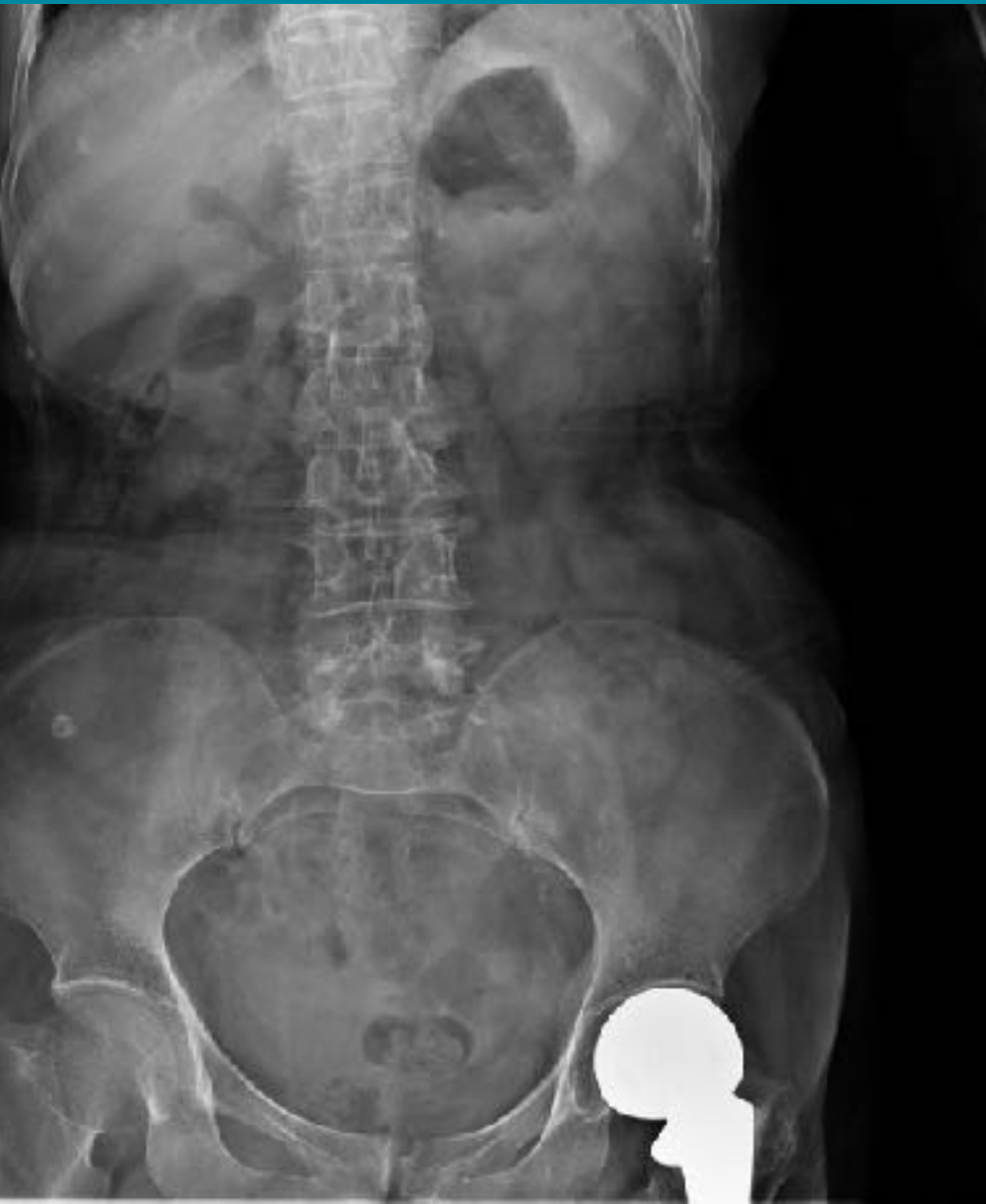2D
HGen
Gn 100
C. 56
3/3/3



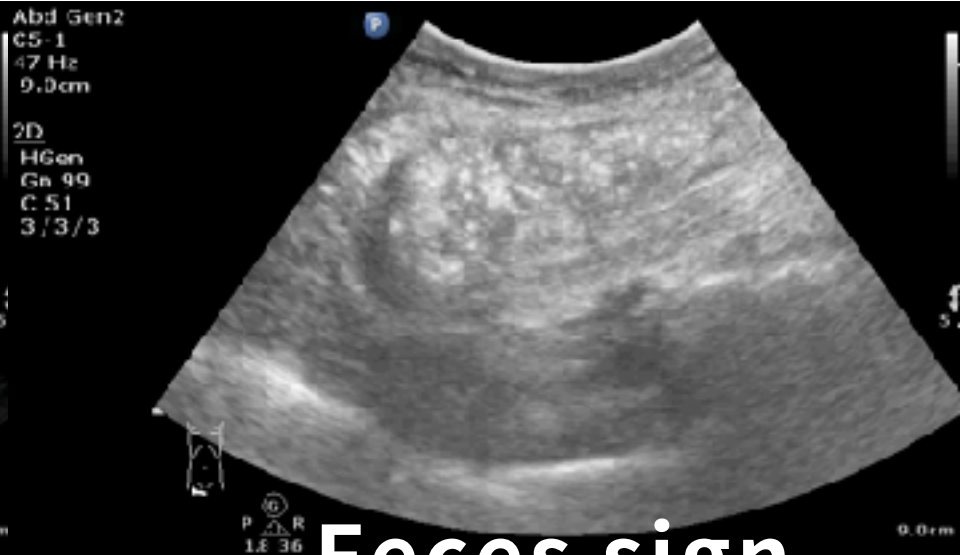
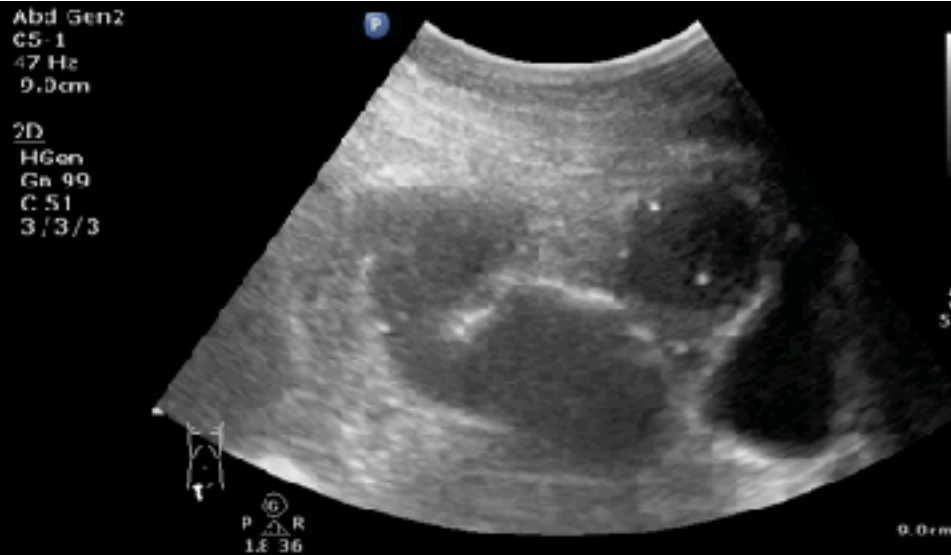
PN & parapneumonic effusion



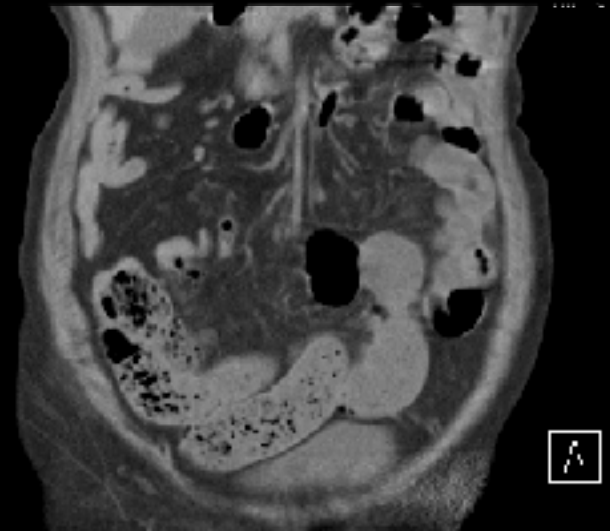
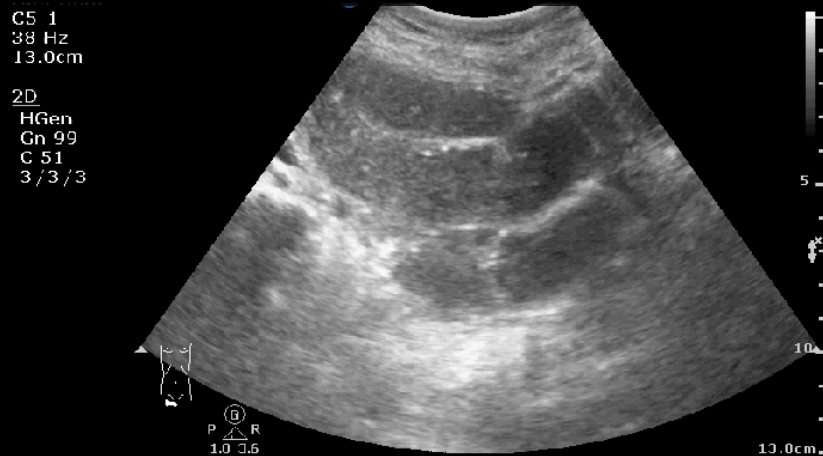
88F, diffuse abdominal pain



88F, diffuse abdominal pain



Feces sign



ABDOMEN

O for obstruction
(SBO & Intussusception)

3
cm

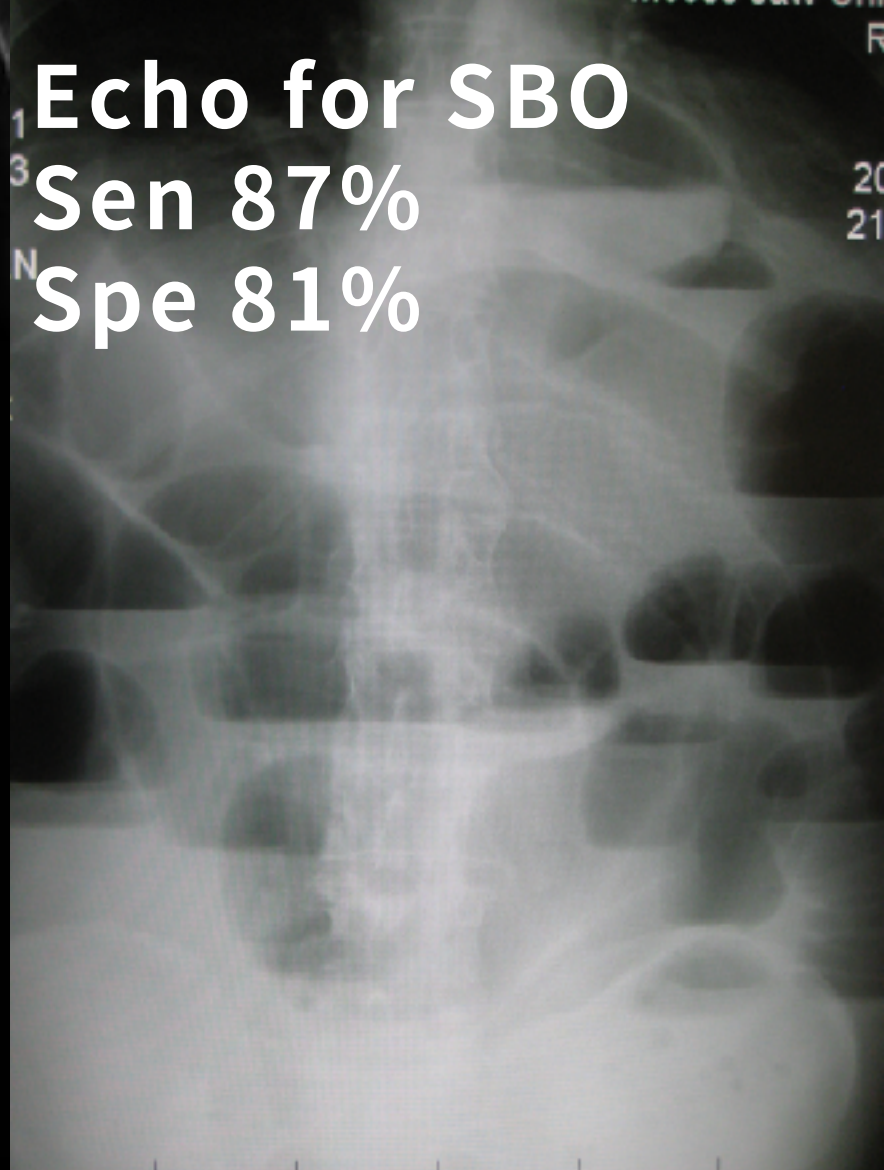
5
cm

X光要開【對】的條件才有用啊

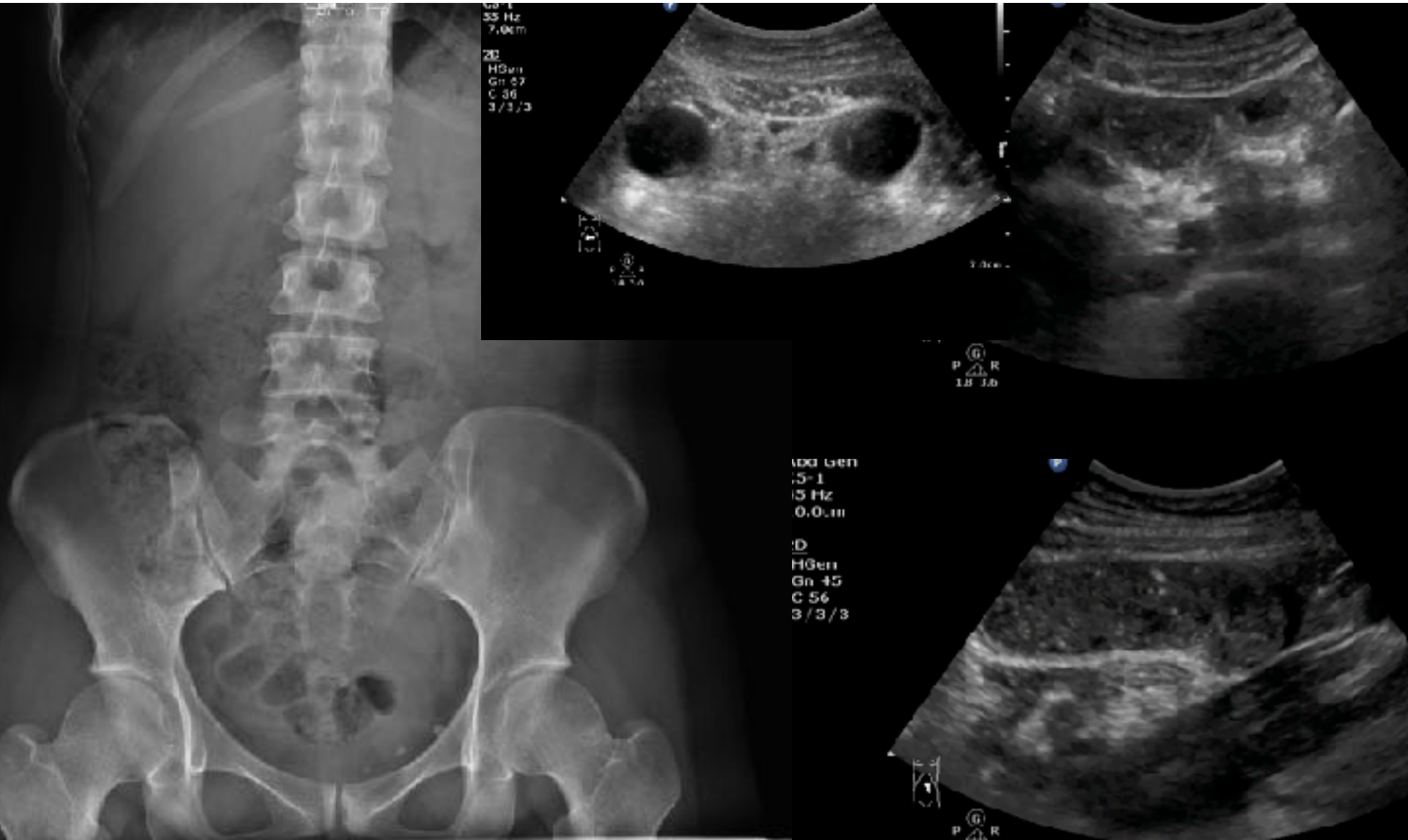
X-ray for SBO
Sen 75%
Spe 66%



Echo for SBO
Sen 87%
Spe 81%

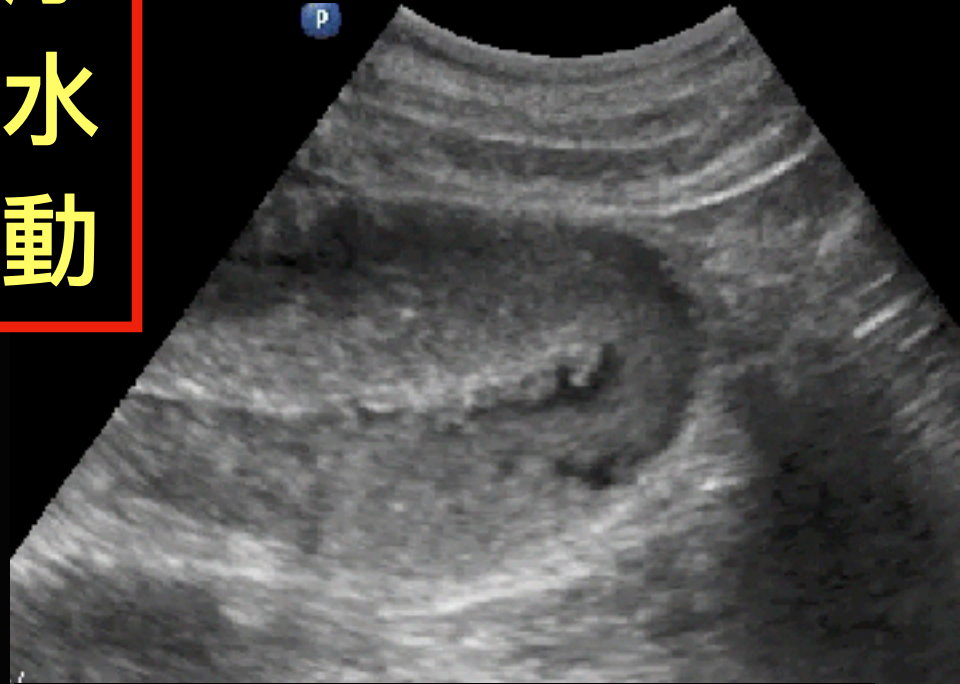
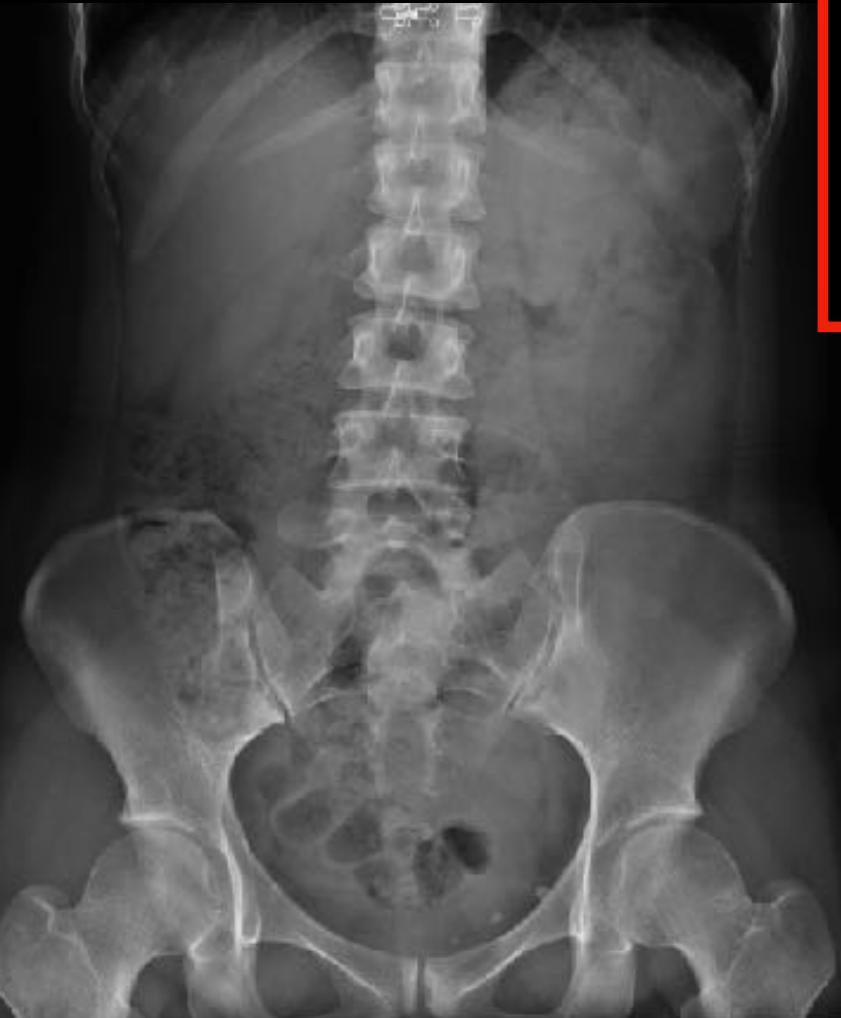

F/31, ABD pain & vomiting for 2Ds



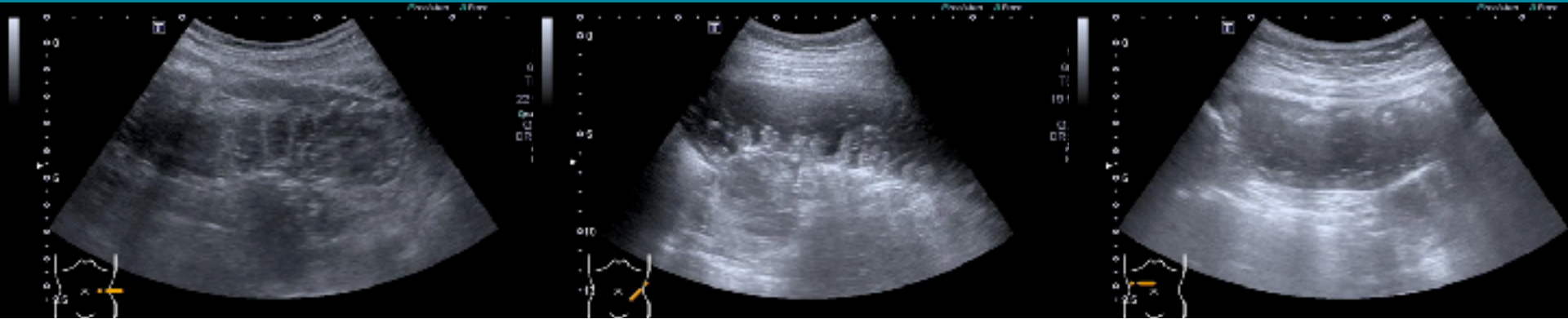
POCUS is useful for gasless ileus

壁厚
腹水
蠕動



To-and-fro movement
Keyboard sign
Tanga sign

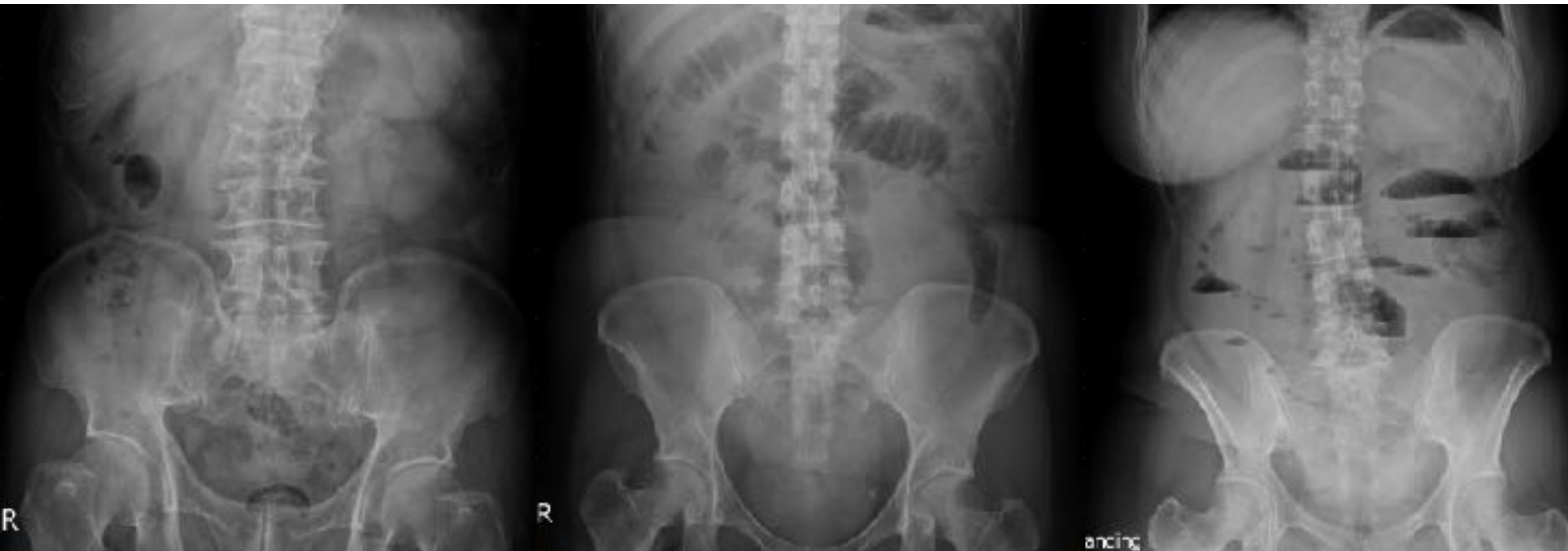Small Bowel Obstruction



To & Fro

Keyboard

String-of-beads



R

R

ancing

TAKE-HOME MESSAGE

For trained operators, ultrasonography possesses sensitivity and specificity comparable to that of abdominal computed tomography (CT) for the diagnosis of small bowel obstruction.

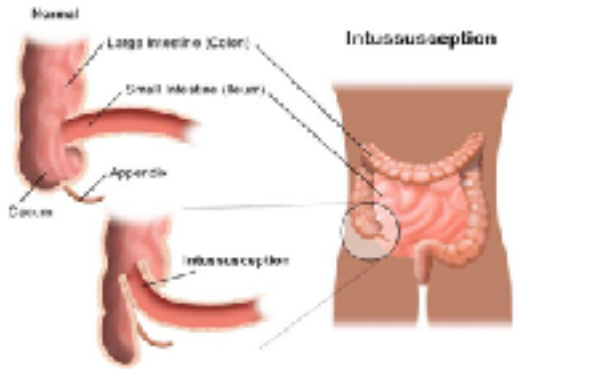
US for SBO diagnosis **LR + >20**起跳

Ultrasonographic Diagnosis of SBO	Specificity (95% CI)	Sensitivity (95% CI)	+LR (95% CI)	-LR (95% CI)	SROC AUC (95% CI)
Overall	0.97 (0.88–0.99)	0.92 (0.89–0.95)	27.5 (7.7–98.4)	0.08 (0.06–0.11)	0.96 (0.94–0.97)
ED	0.96 (0.86–0.99)	0.93 (0.89–0.95)	21.1 (6.5–68.9)	0.08 (0.05–0.12)	0.96 (0.94–0.97)
Non-ED	0.99 (0.60–1.00)	0.92 (0.85–0.96)	70.8 (1.5–3279.7)	0.08 (0.05–0.15)	0.96 (0.94–0.98)

CI, Confidence interval; +LR, positive likelihood ratio; -LR, negative likelihood ratio; SBO, small bowel obstruction; SROC, summary receiver operating characteristic; AUC, area under the curve.

Intussusception

小孩優先找右上腹



Ileum "telescopes" inside ascending colon, obstructing passage of intestinal contents.

Bleeding → "Currant jelly stools"

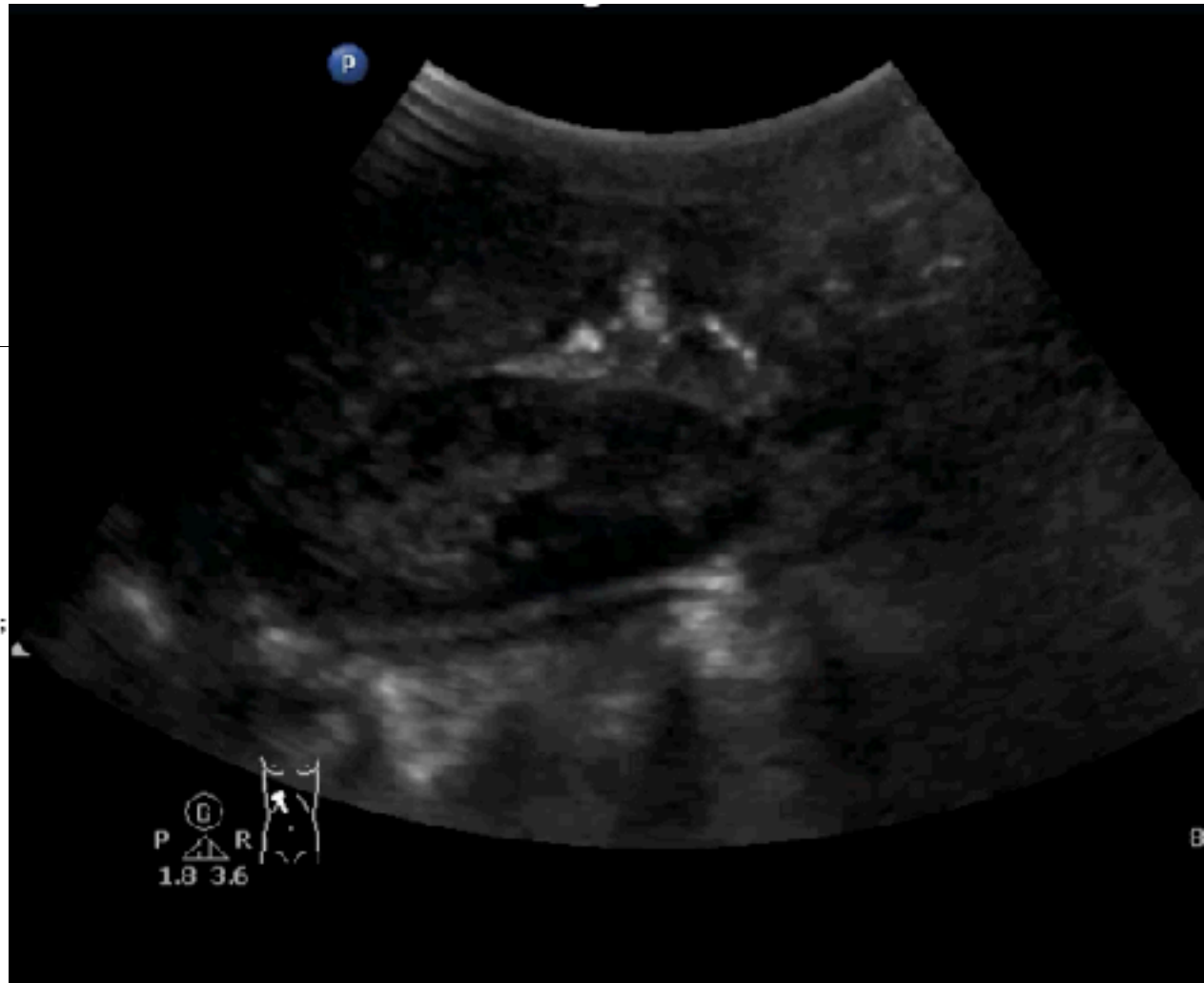
Blood vessels become trapped between layers; blood flow decreases.

Edema

Strangulation of bowel

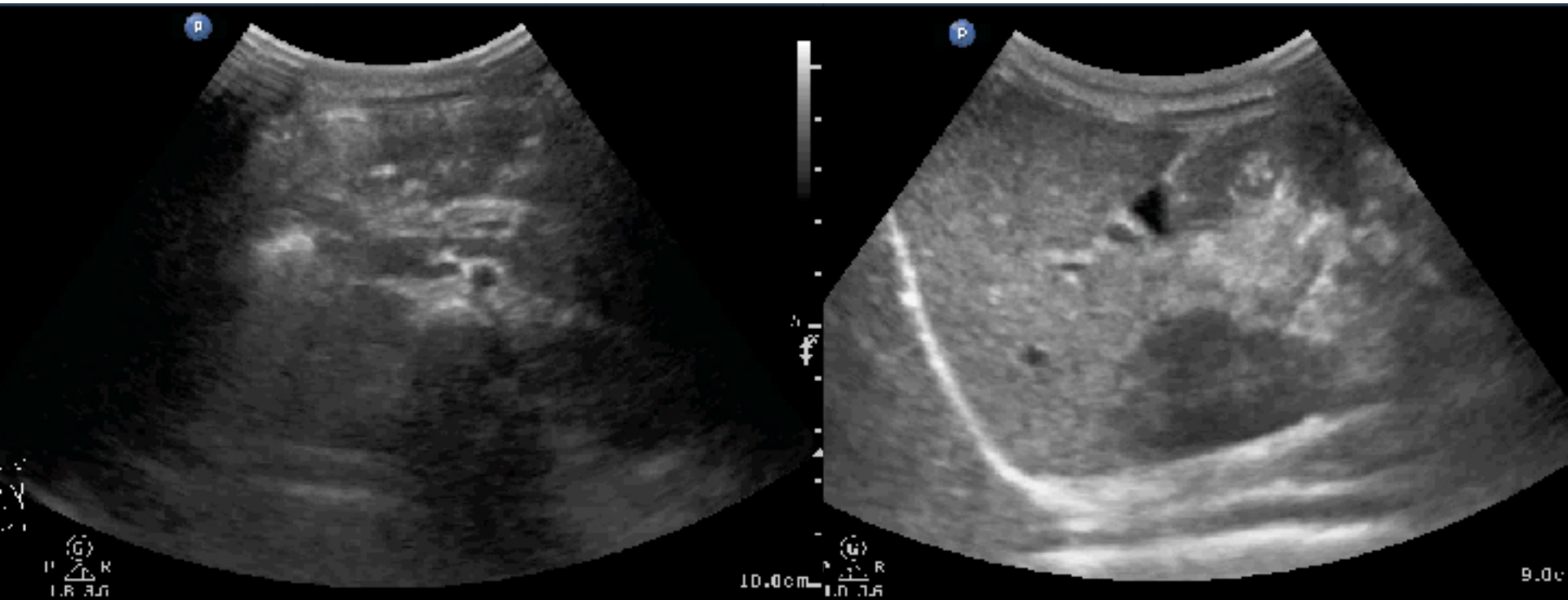
Gangrene, sepsis, shock

Death



7個月大男童，間歇性溢奶

間歇性或周期性都要小心

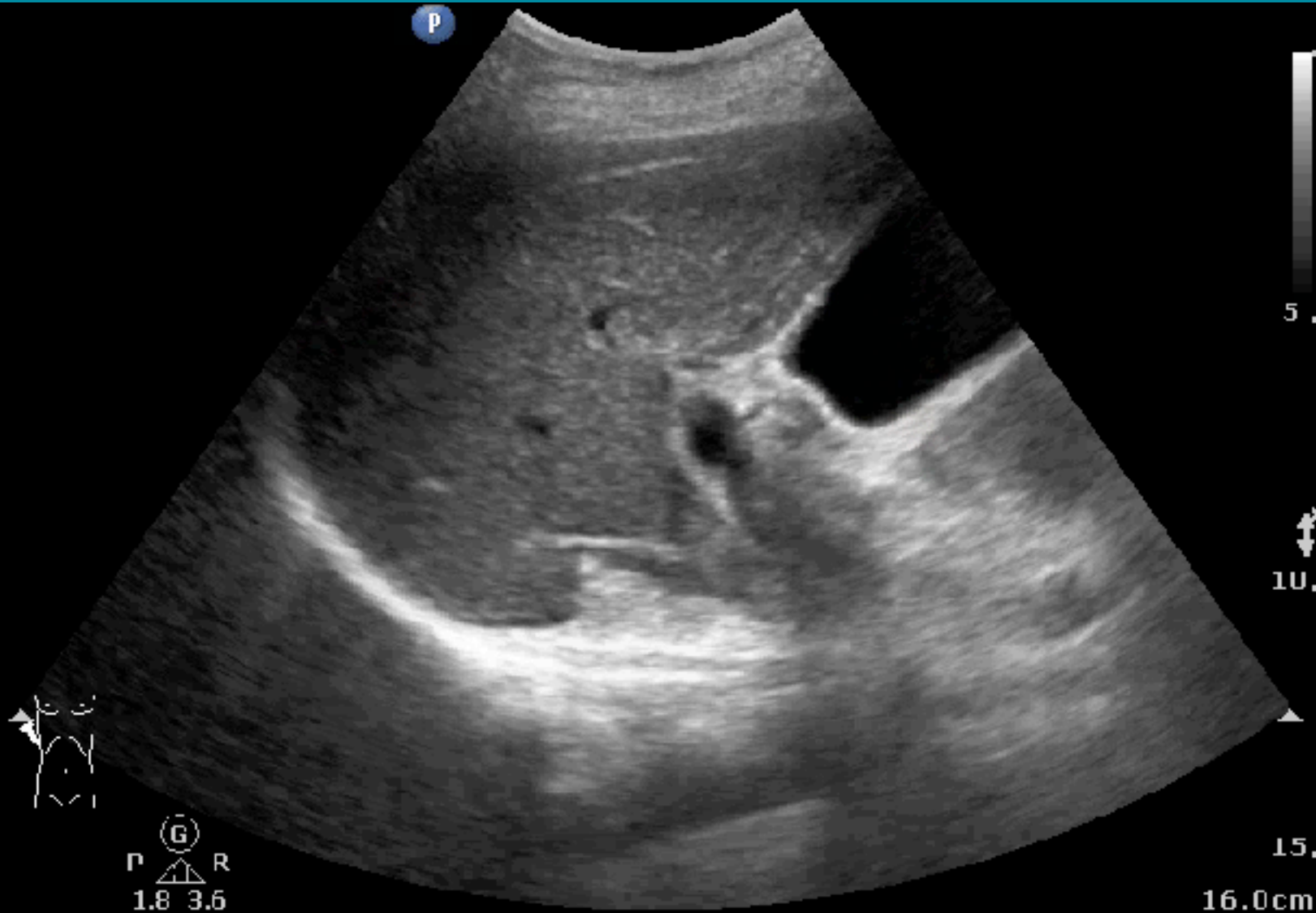


80F, diffuse abdominal pain

Abd Gen2
C5-1
32 Hz
16.0cm

2D

HGen
Gn 90
C 56
3/3/3



15.
16.0cm

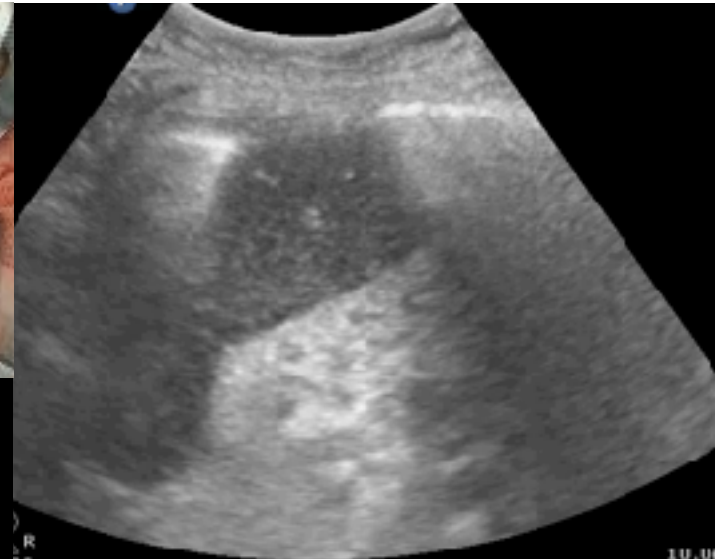
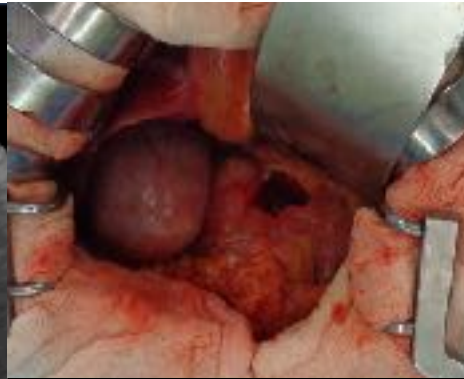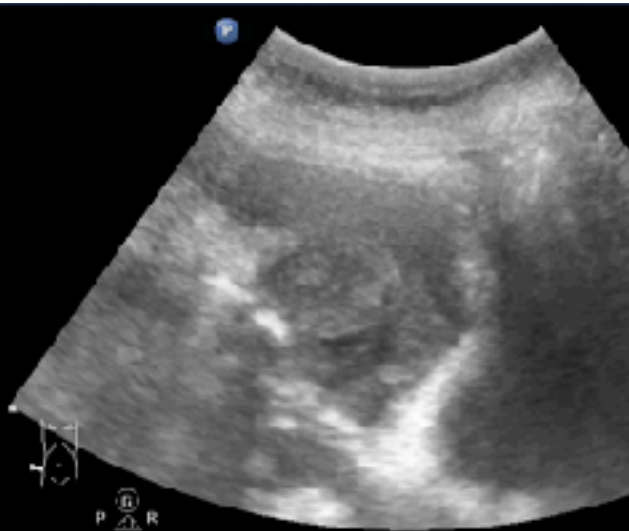
ABDOMEN

M for moving fluid or air

FAST / Liver surface

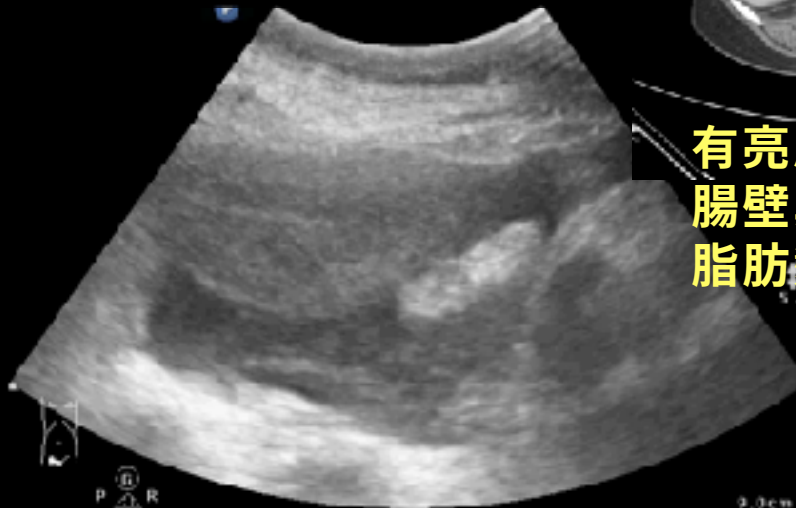80F, diffuse abdominal pain

Abd Gen2
C5-1
17 Hz
9.0cm
PD
HGen
Cn 100
C 56
3/3/3

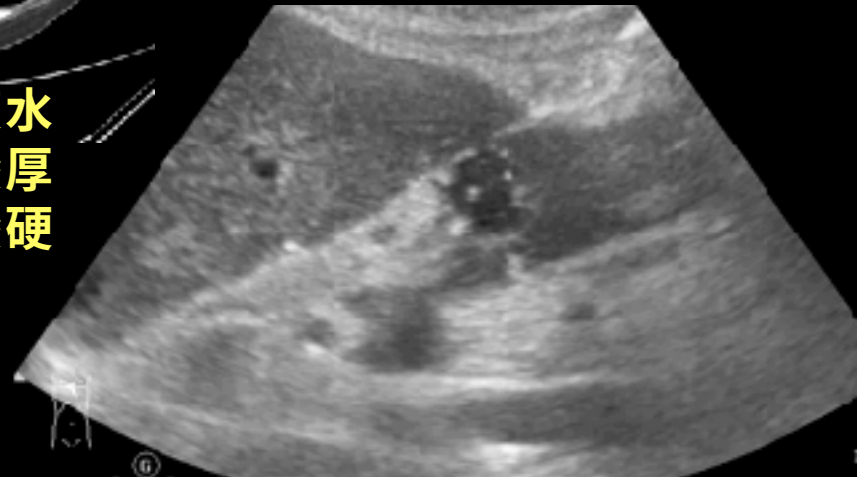


Scissors maneuver

C5-1
17 Hz
9.0cm
PD
HGen
Cn 100
C 56
3/3/3

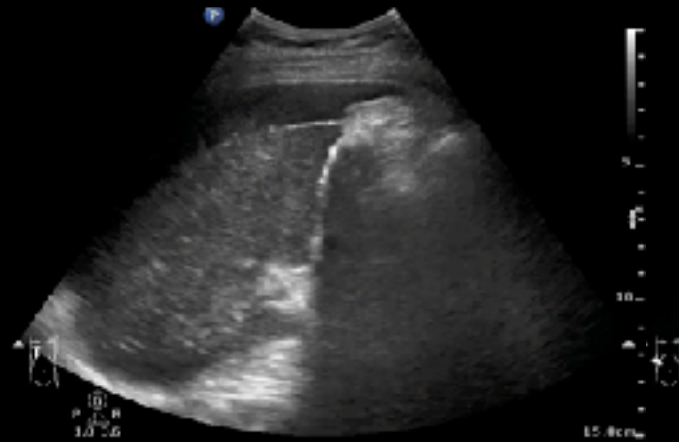

有亮度的腹水
腸壁異常變厚
脂肪變亮變硬

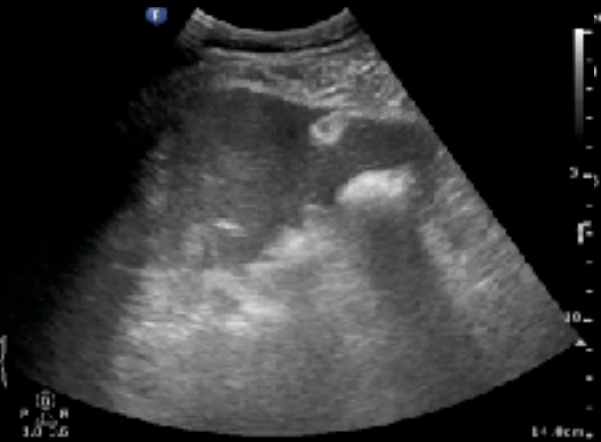

Dirty ascites: 水往下流

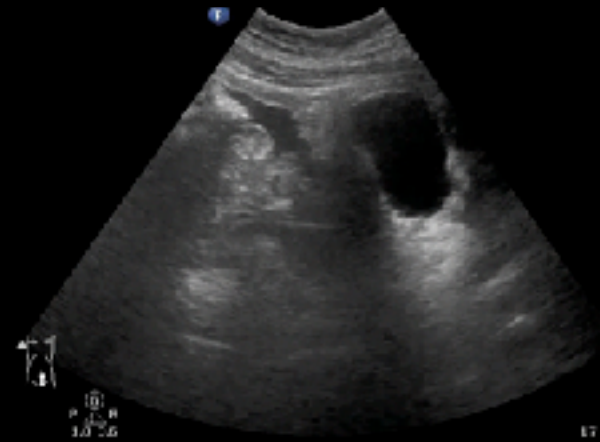Around liver



Paracolic gutter



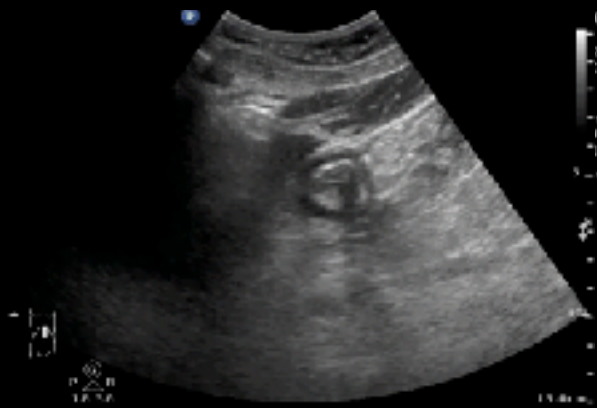Pelvis



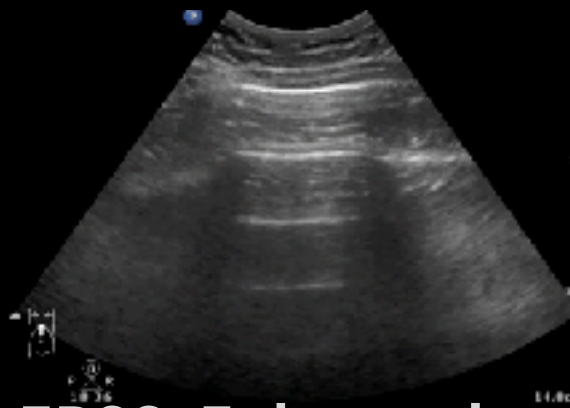
FAST倒三角是最基本的

Free air: 往上找

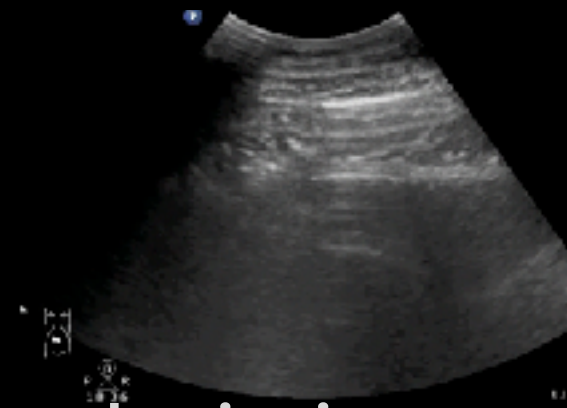Liver surface



Curtain sign



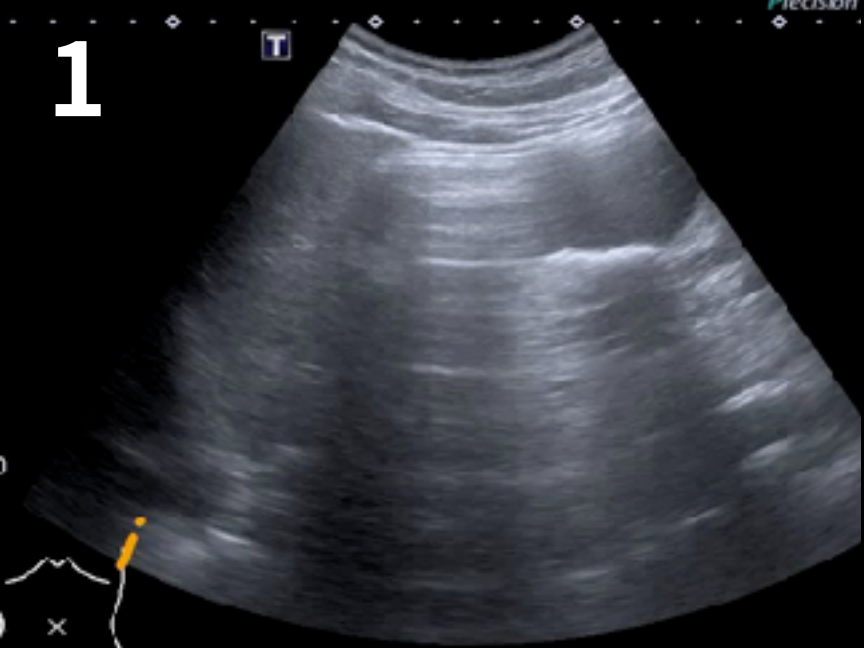
EPSS



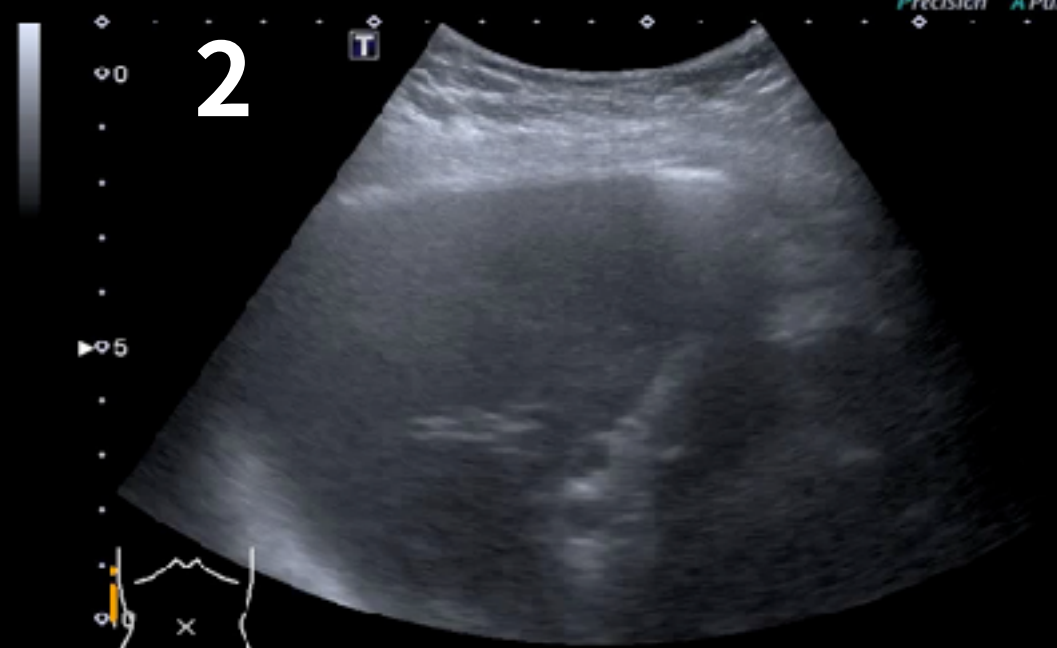
EPSS: Enhanced peritoneal strip sign

游離氣存在界面變亮
跟肺部的氣胸一個樣
不要忘了可以壓一壓

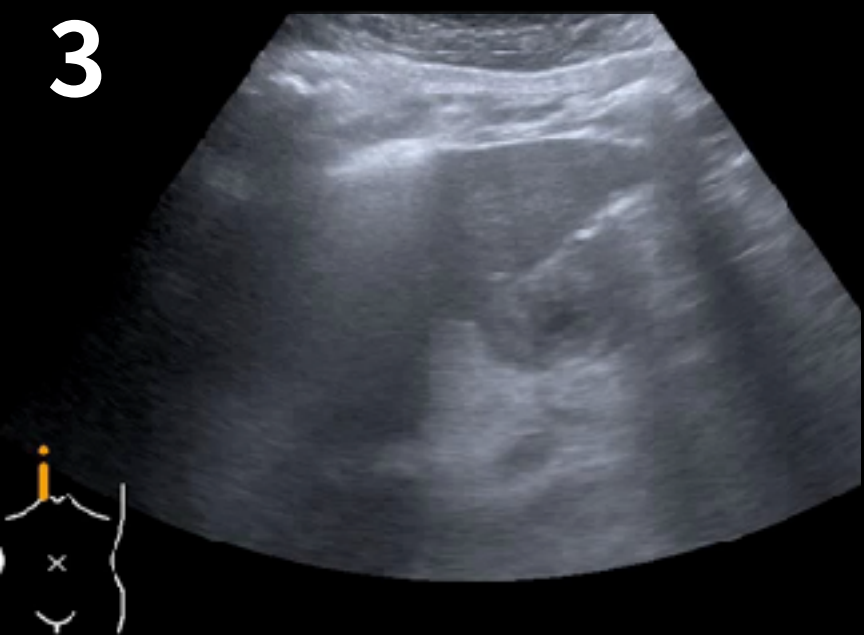
1



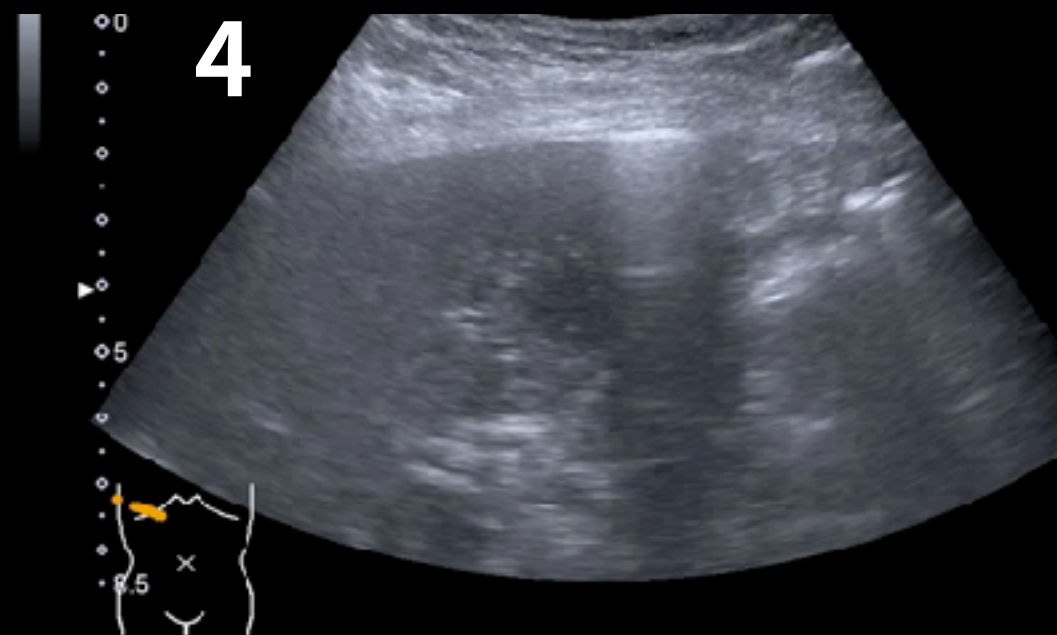
2



3



4



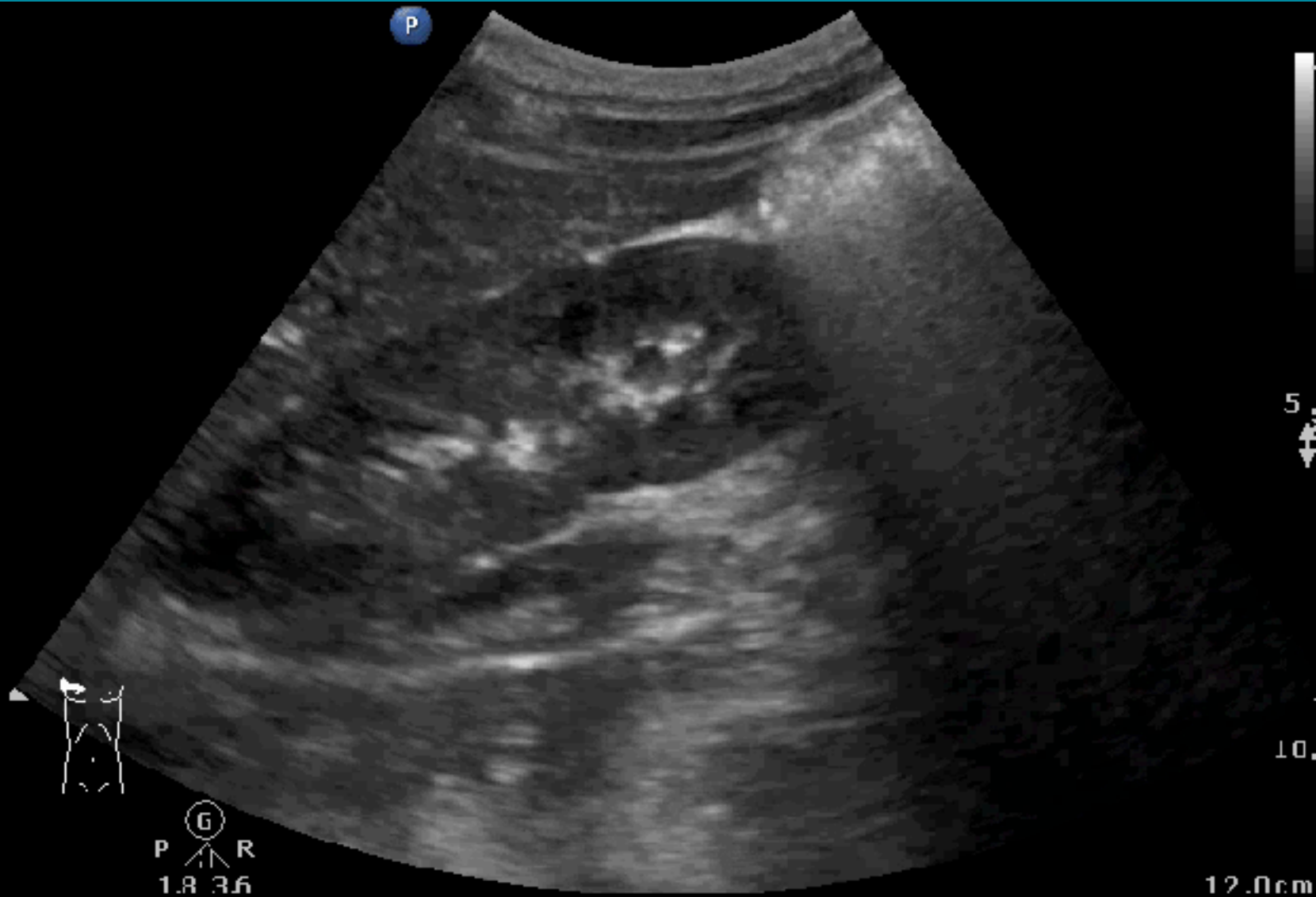
請問那一段影片不是Pneumoperitoneum ?

33F, low abdominal pain & shock

Abd Gen
C5-1
39 Hz
2.0cm

2D

HGen
Gn 71
C 56
3/3/3

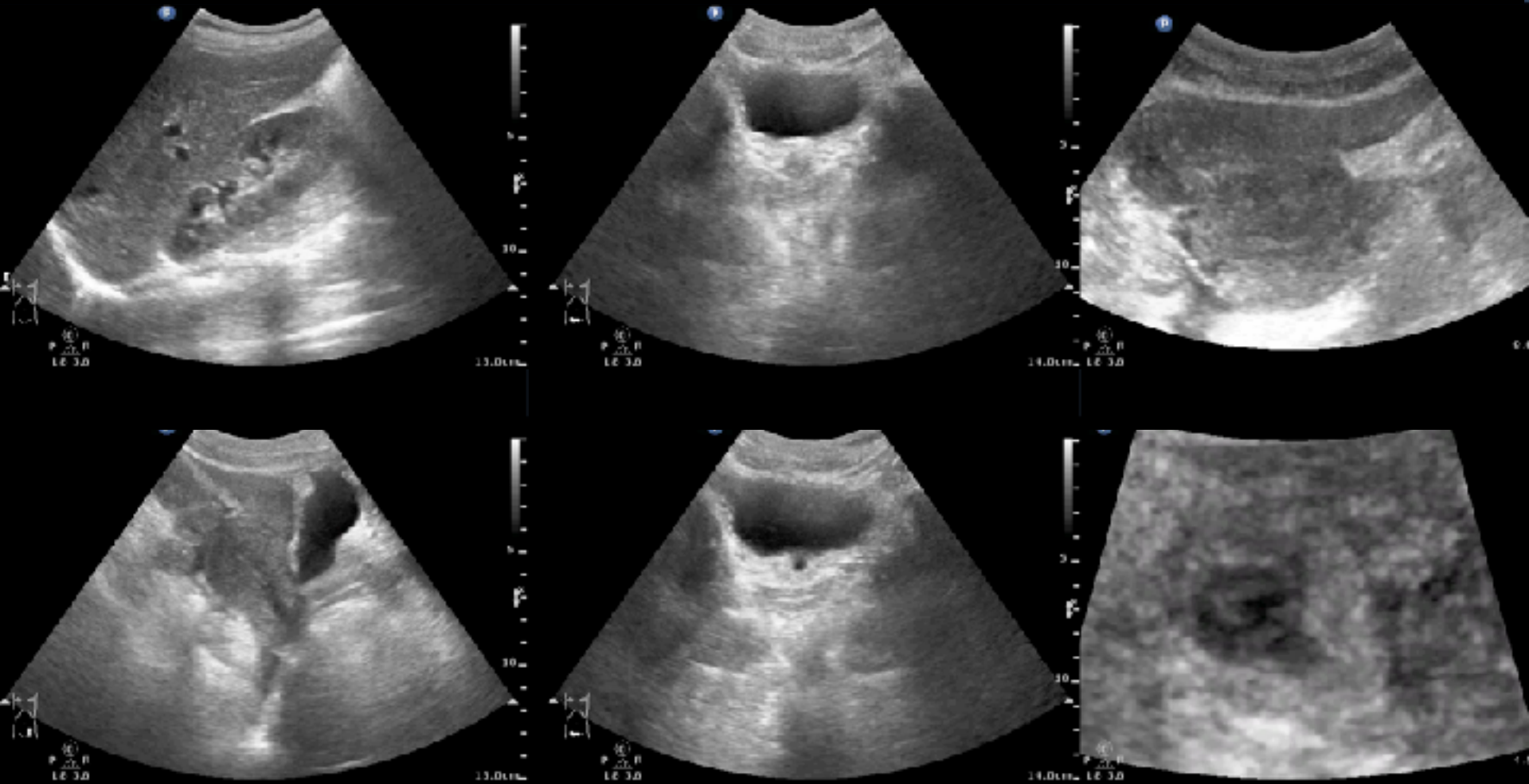


ABDOMEN

E for ectopic pregnancy

Ascites & IUP

25F, abdominal pain

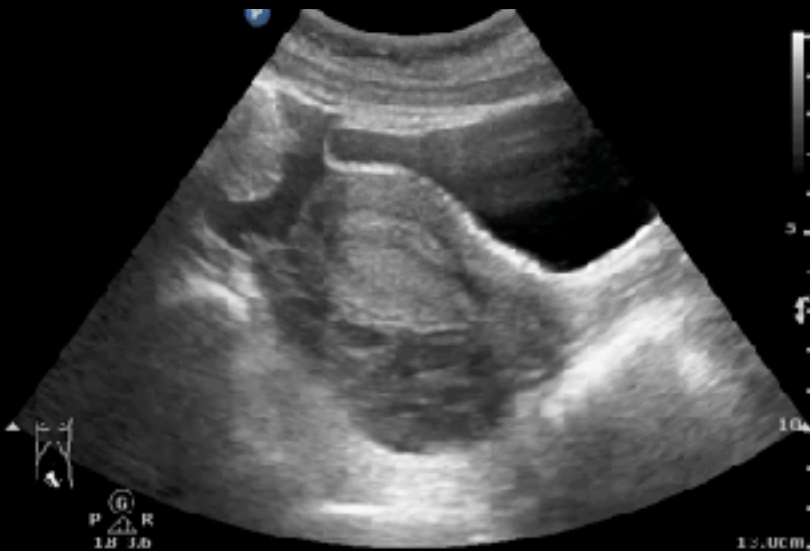

14F, acute lower abdominal pain with cold sweating

Female acute abdomen or shock consider **ovarian cyst rupture**

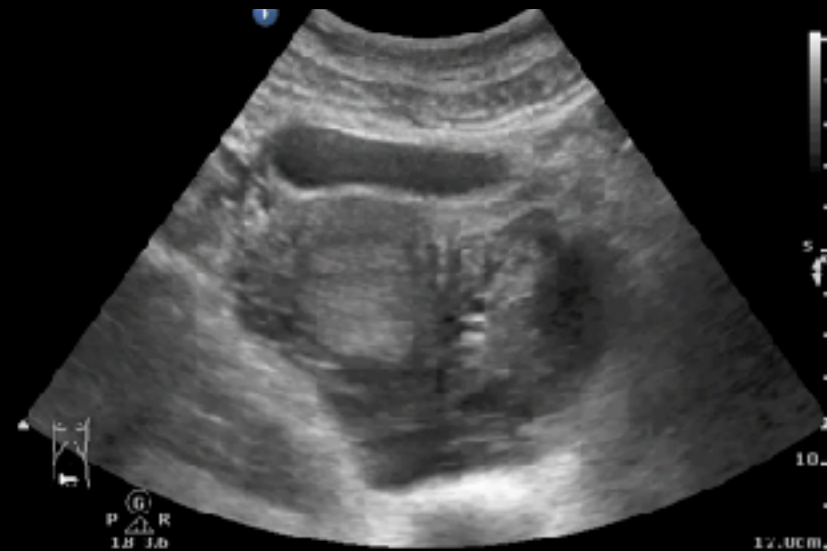
Abd Gen
C5-1
38 Hz
13.0cm

2D
HGen
Gn 78
C 56
3/3/3



Abd Gen
C5-1
39 Hz
12.0cm

2D
HGen
Gn 78
C 56
3/3/3

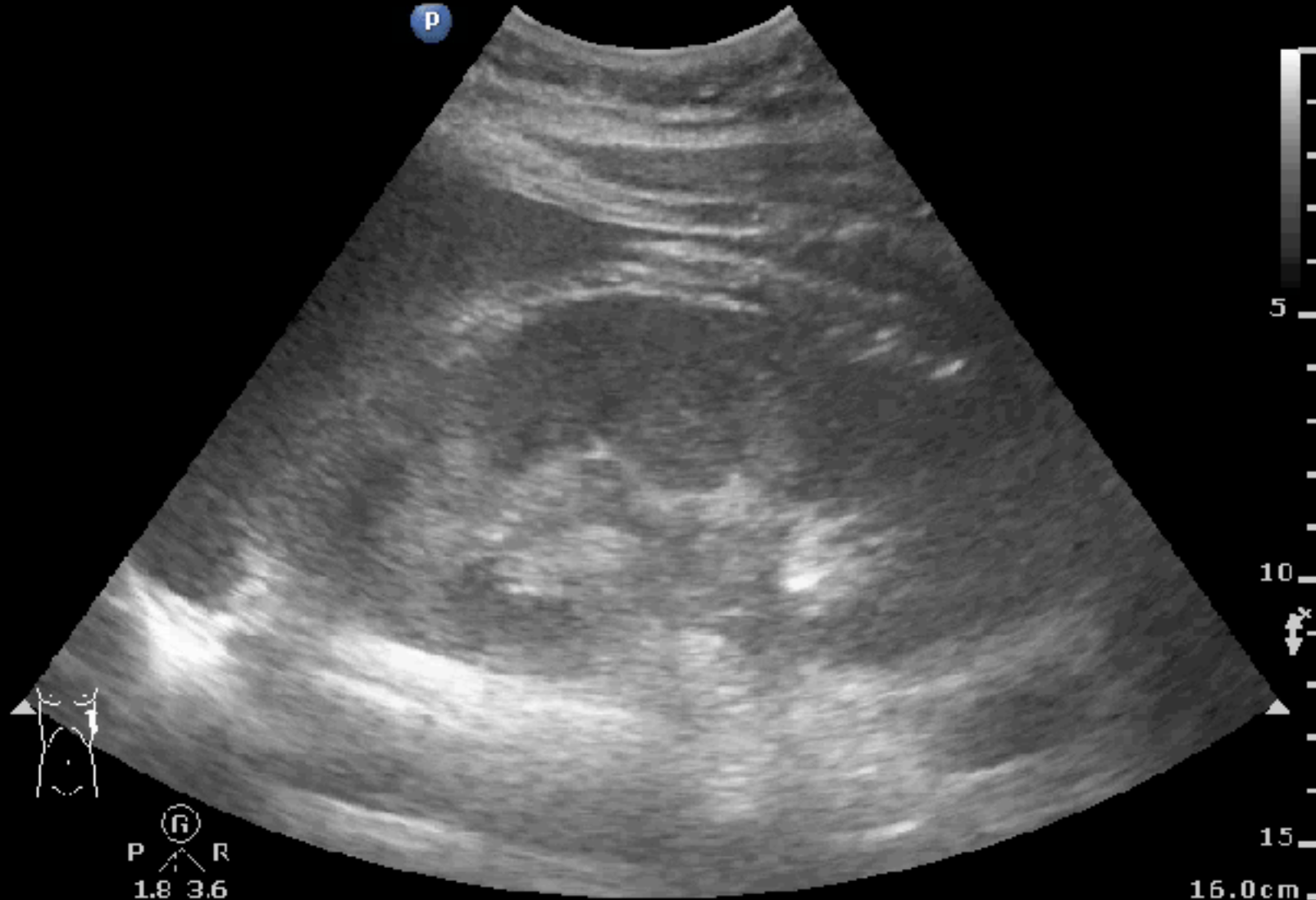

Echo first then Urine pregnancy test

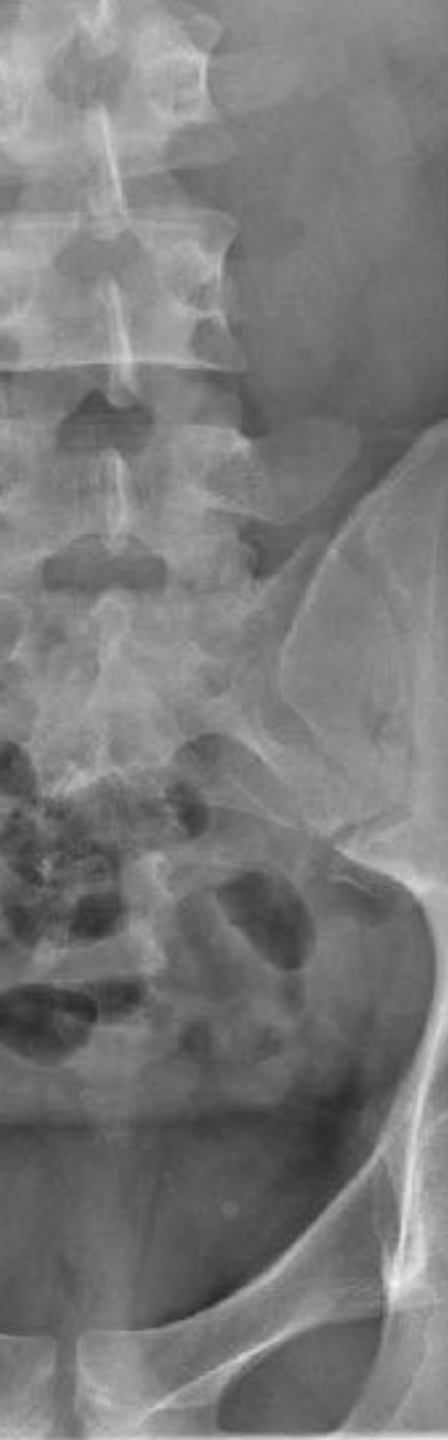25M, left flank pain

Abd Gen2
C5-1
32 Hz
16.0cm

2D
HGen
Gn 93
C. 56
3/3/3



L UJV stone

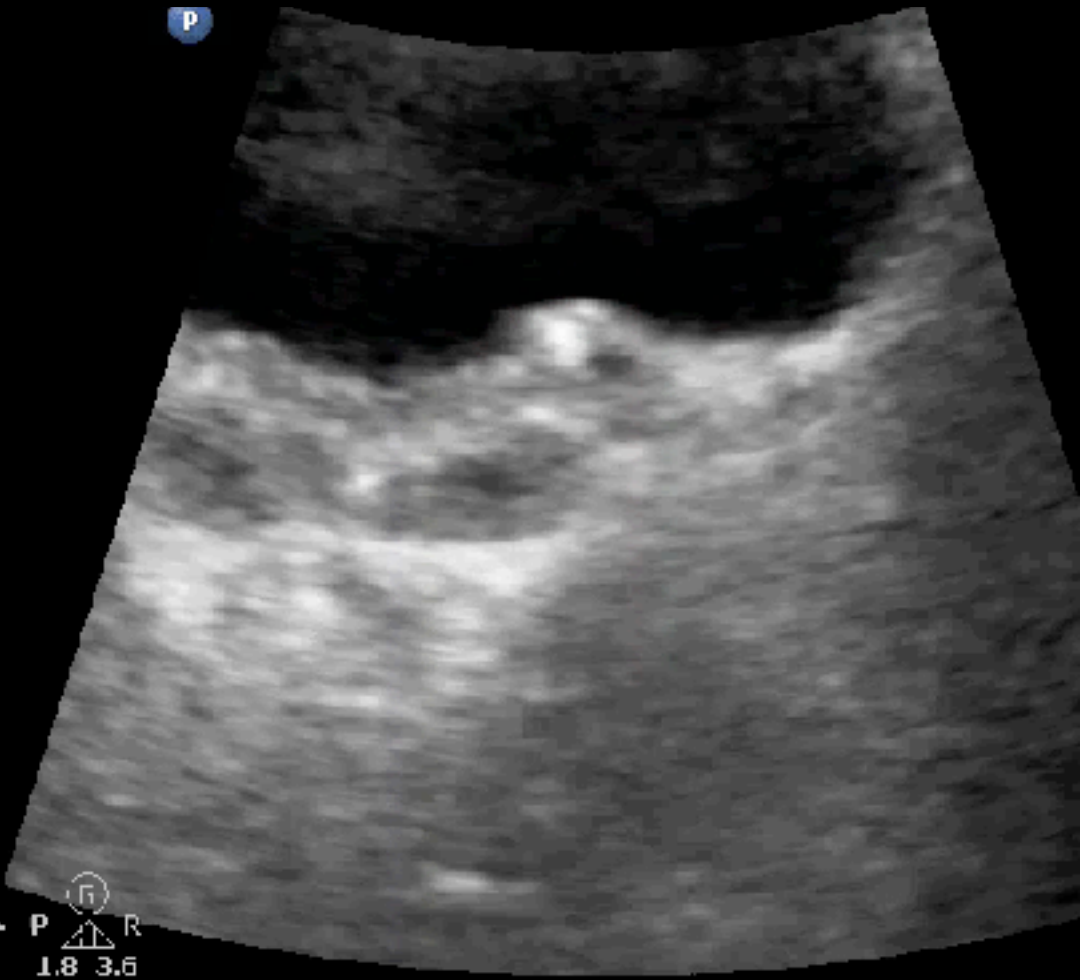


Abd Gen2
C5-1
7.8 Hz
IID Zoom

2D
HGen
Gn 58
C 56
3 / 3 / 3



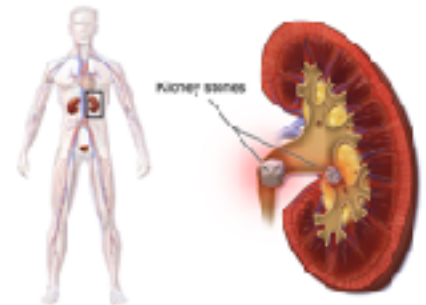
▲ P R
1.8 3.6



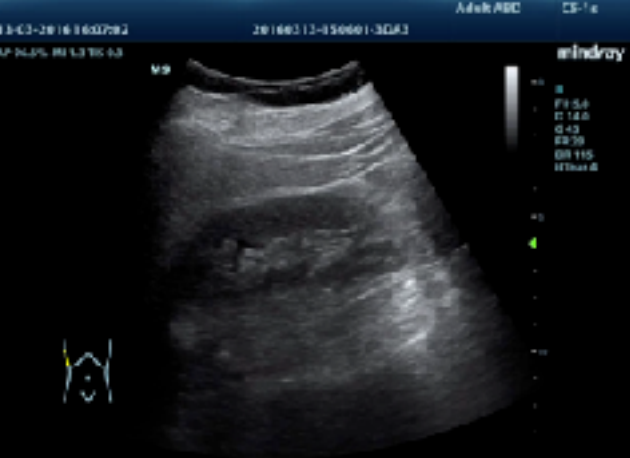ABDOMEN **N**

N for nephropathy

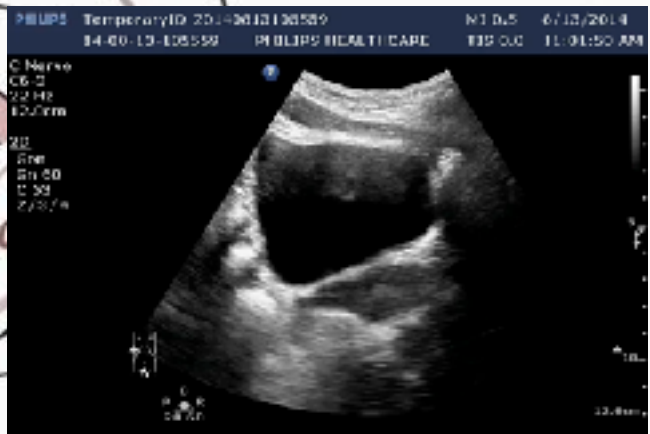
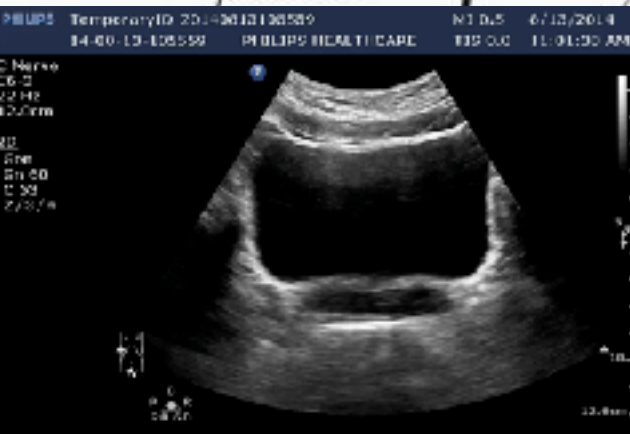
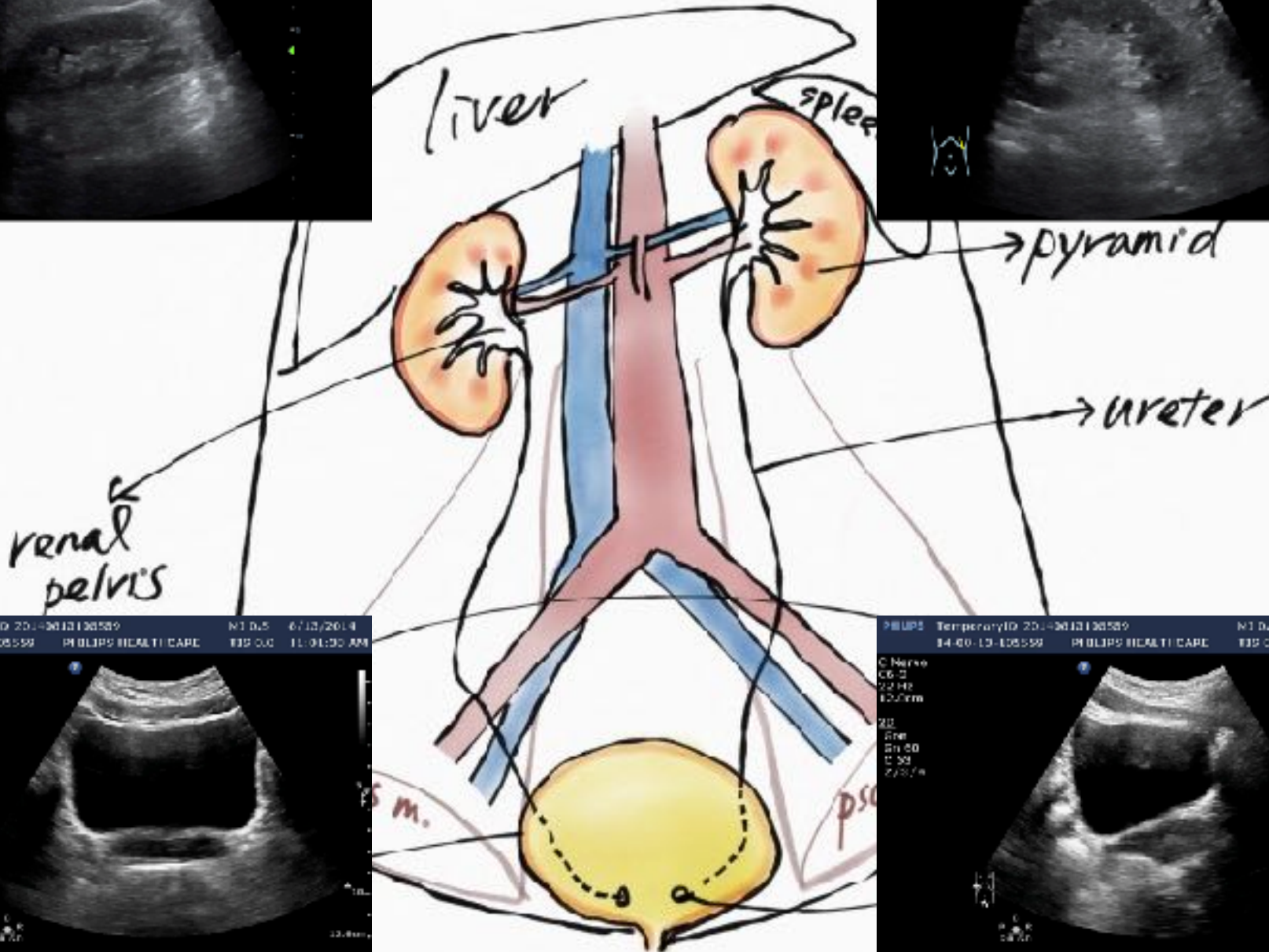
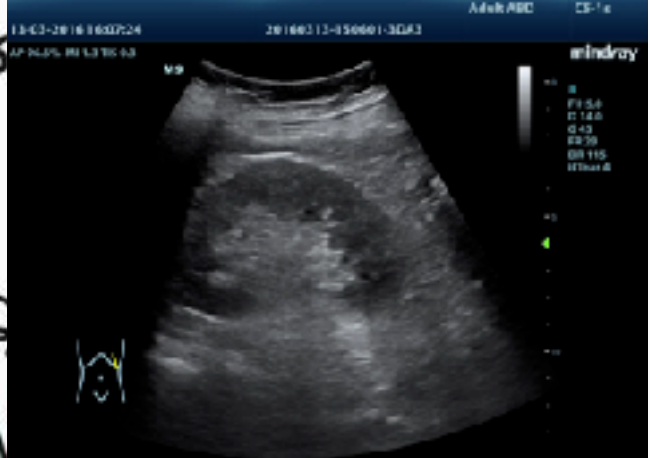Hydronephrosis & KuB



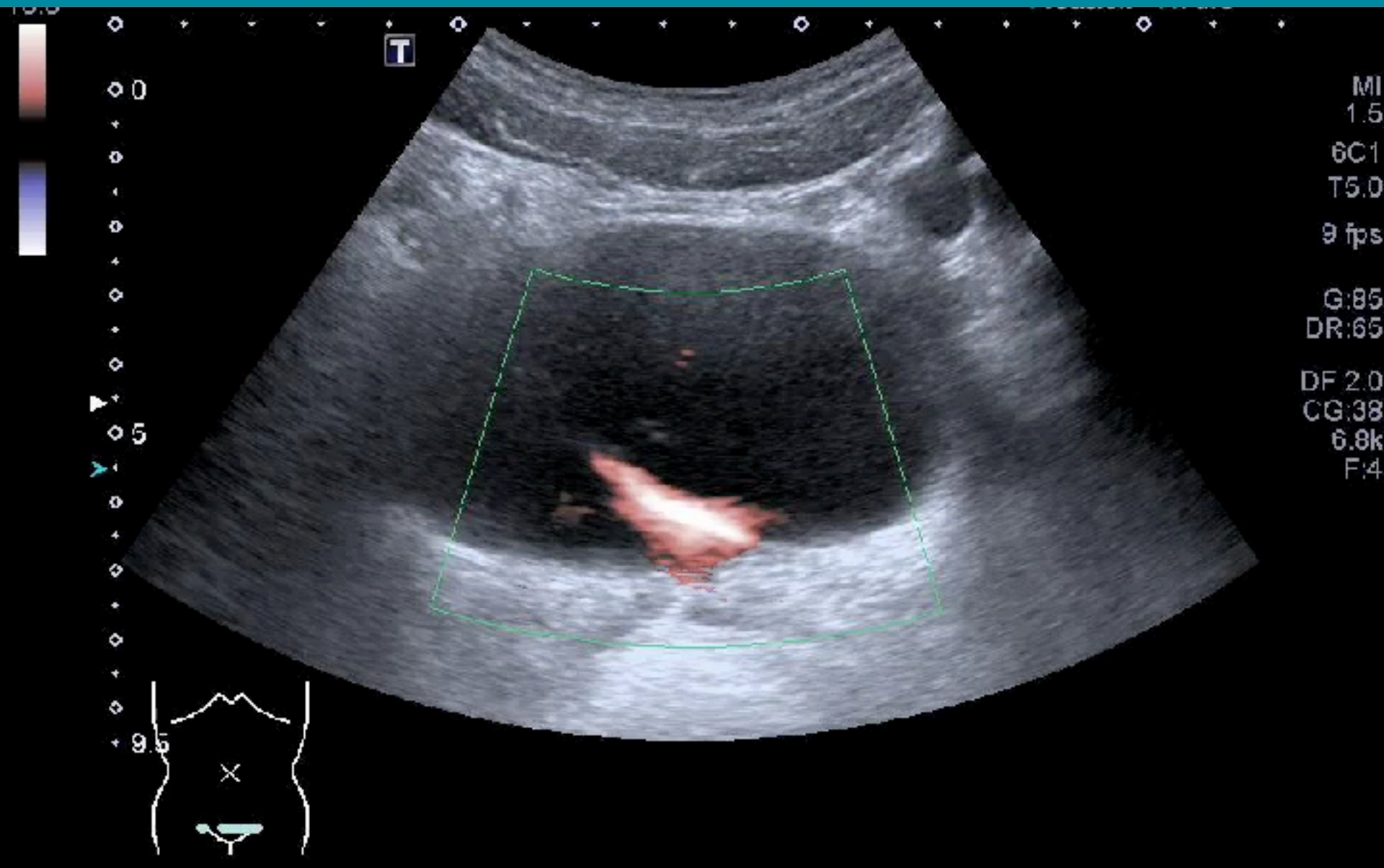
Kidney Stones



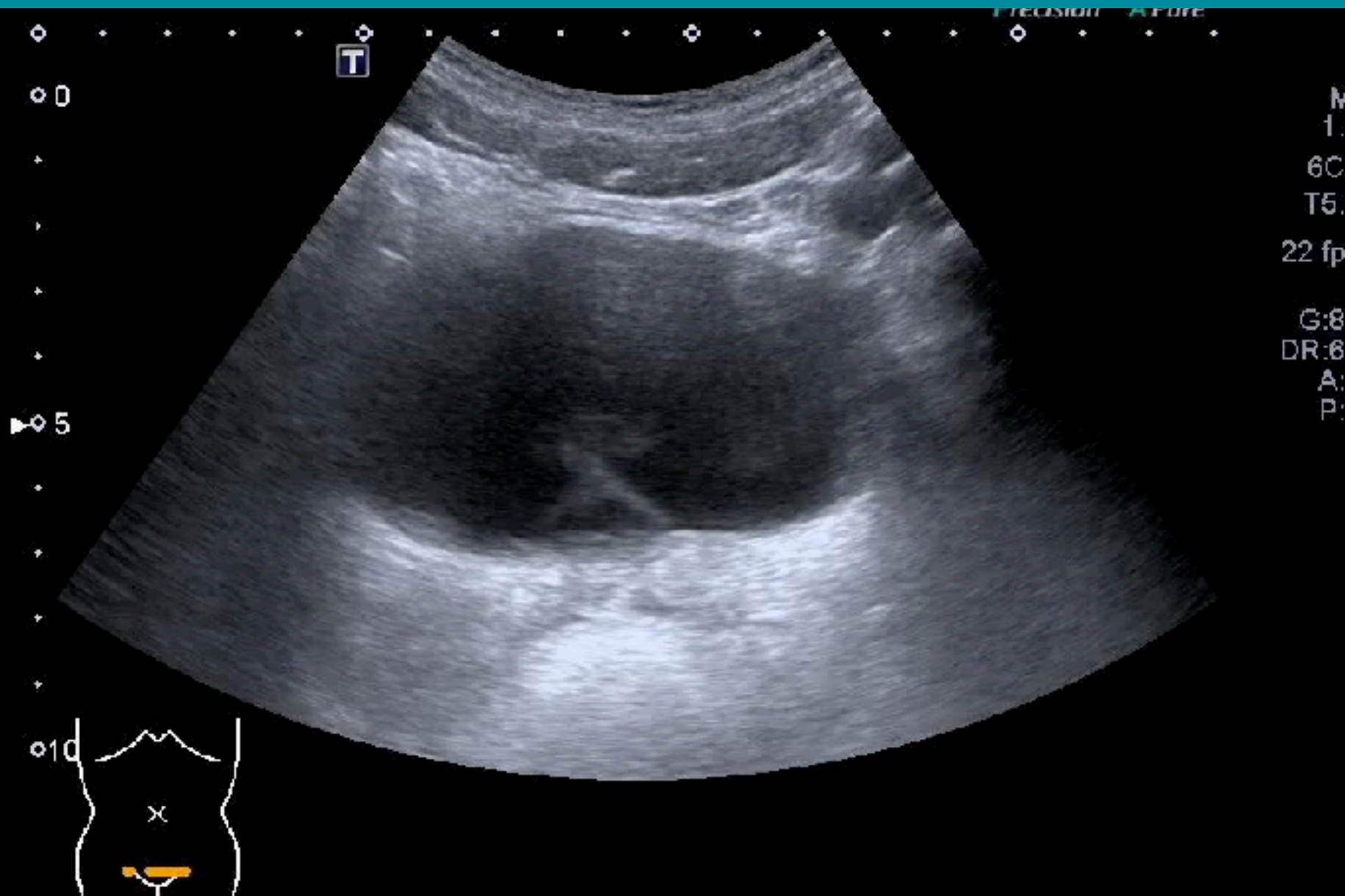
SIZE CHANG. All rights res

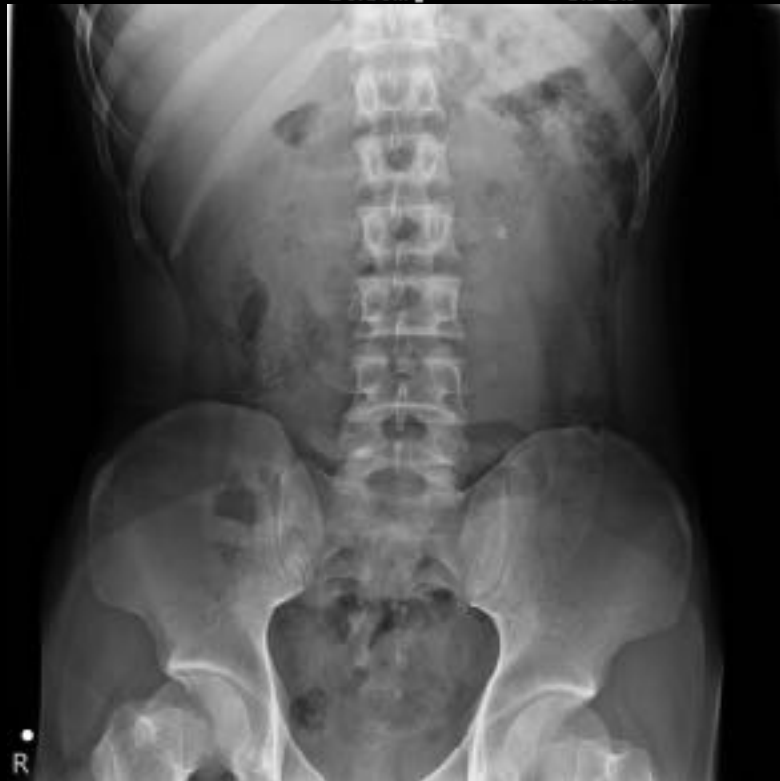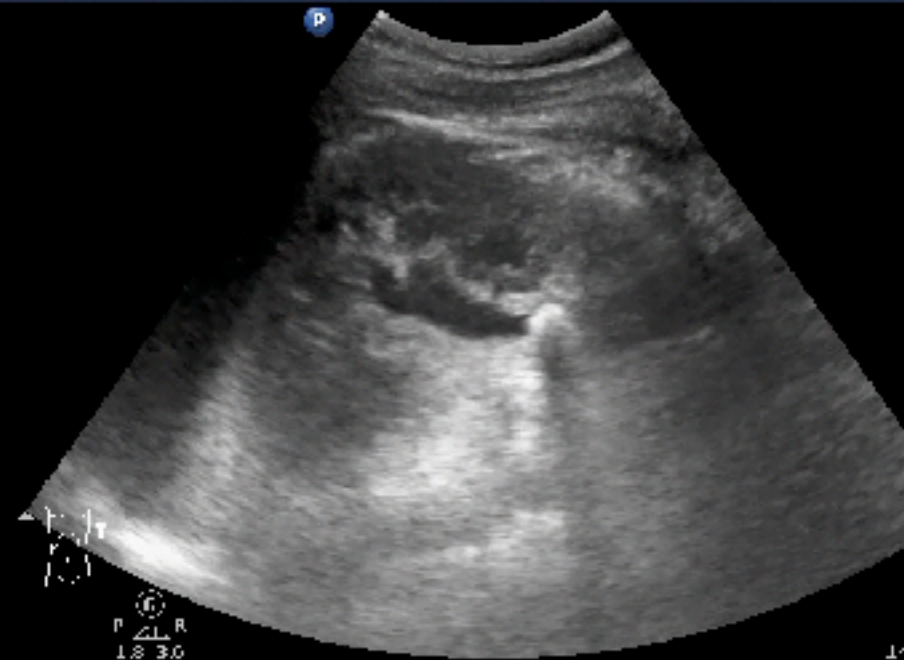
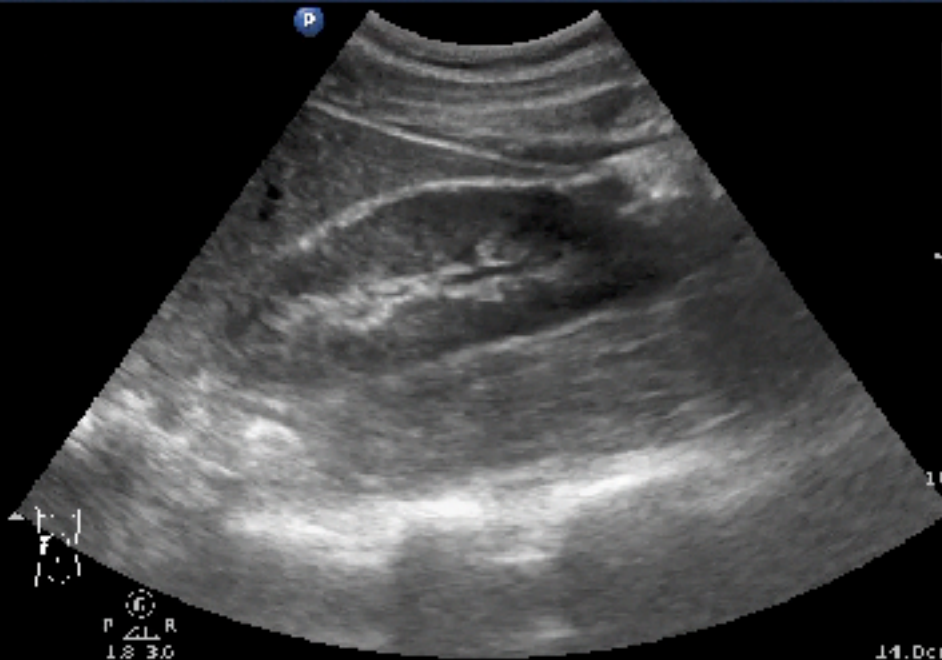


Urinary jet

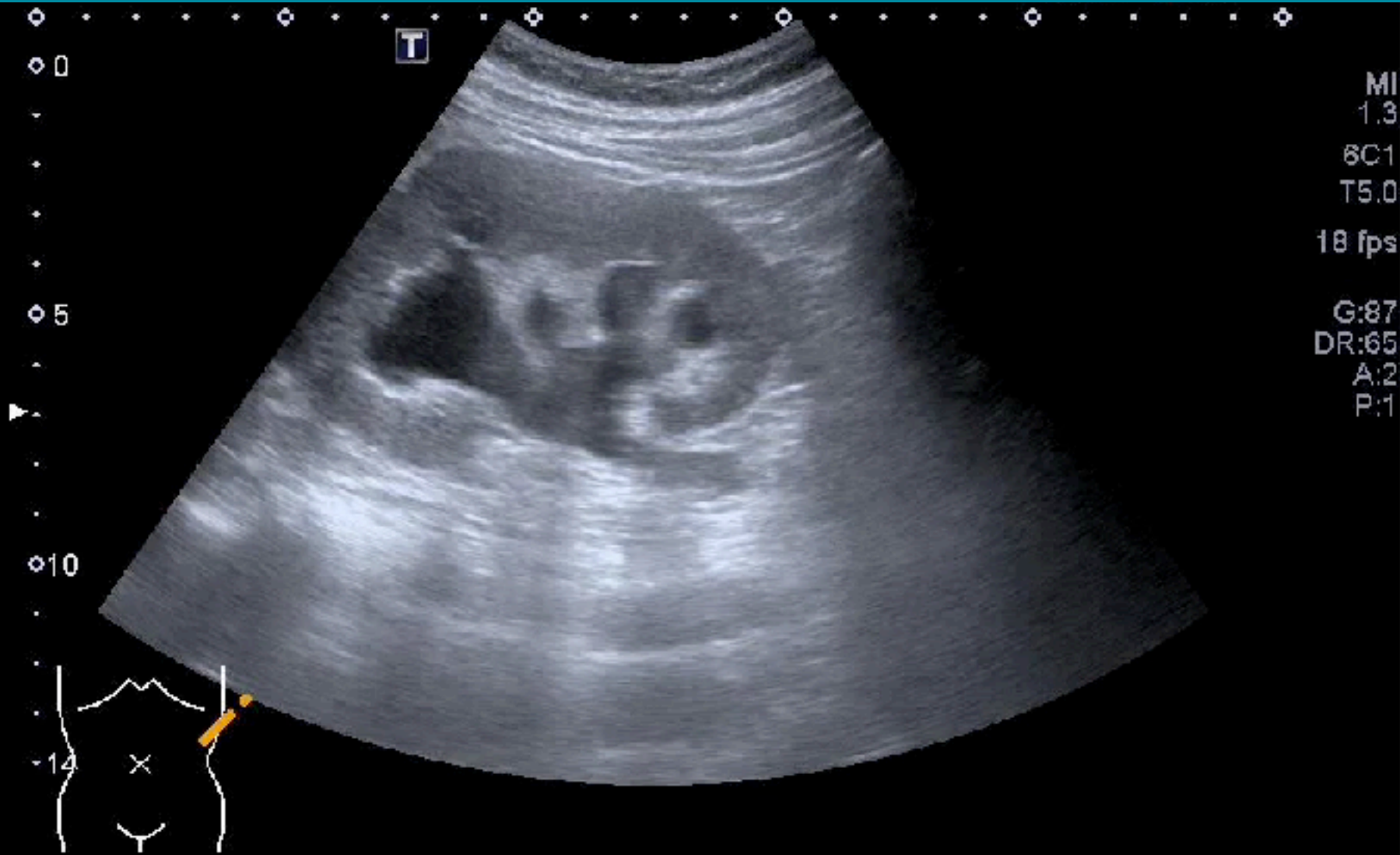

Urinary jet

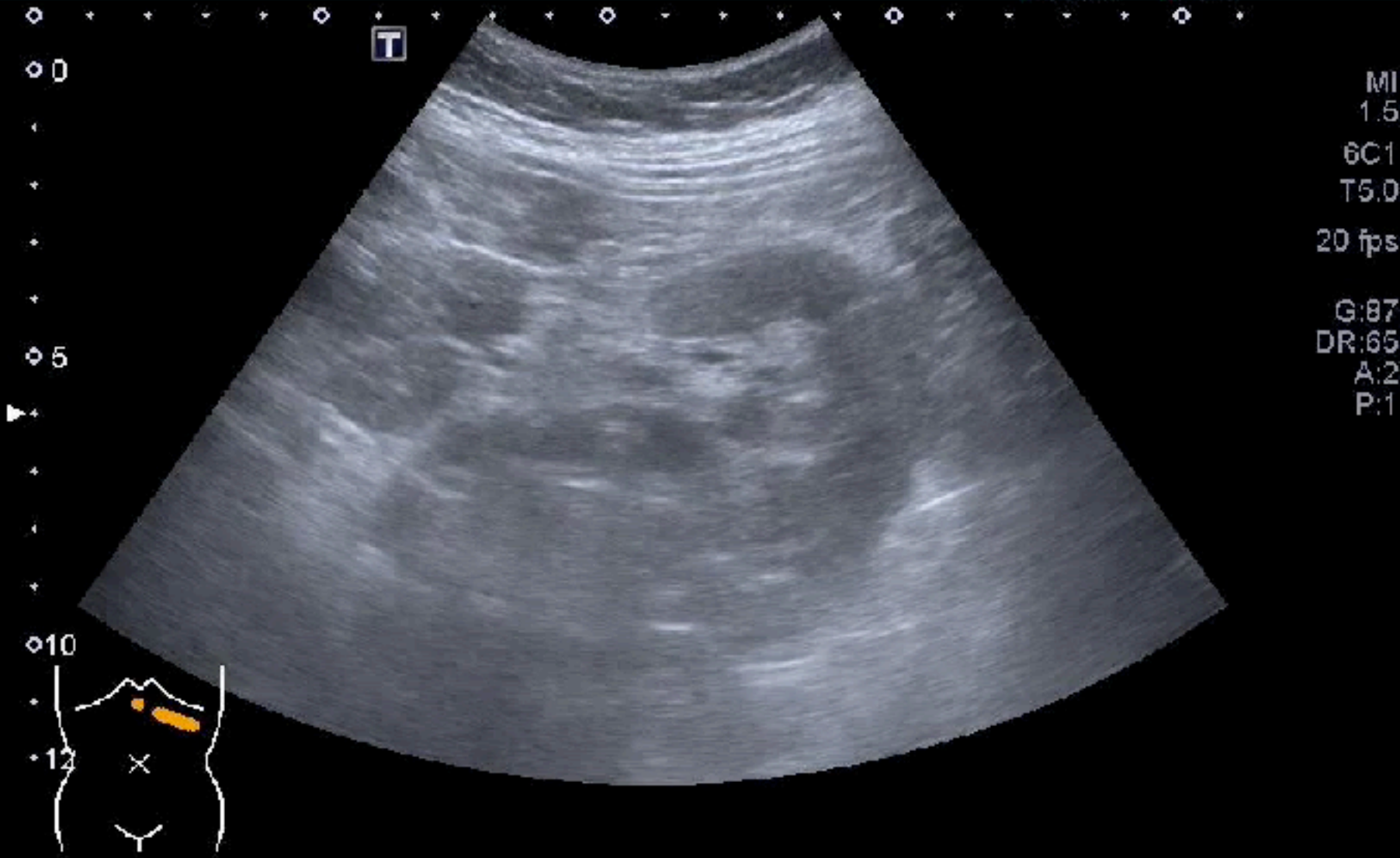




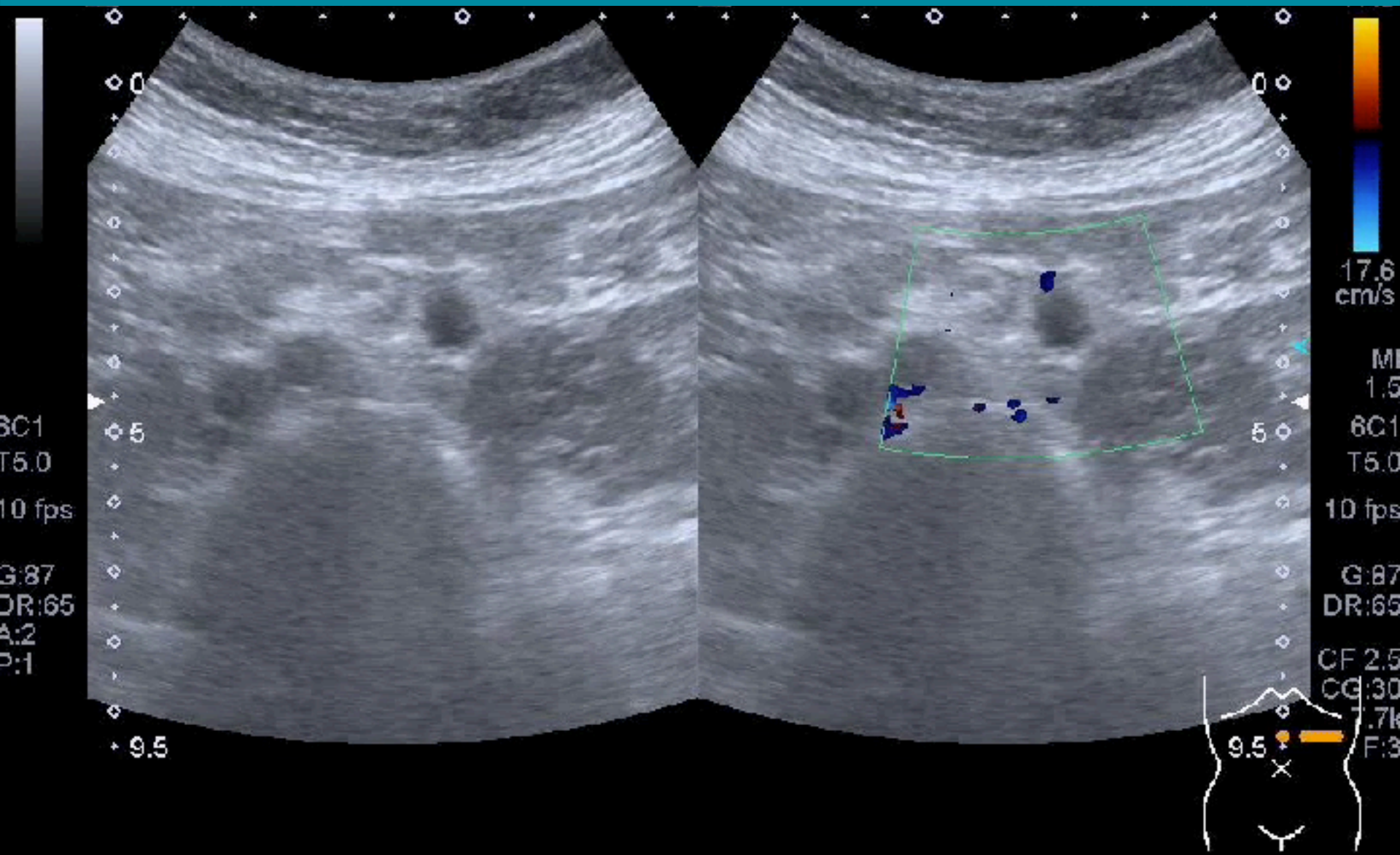
Hydronephrosis (Coronal)

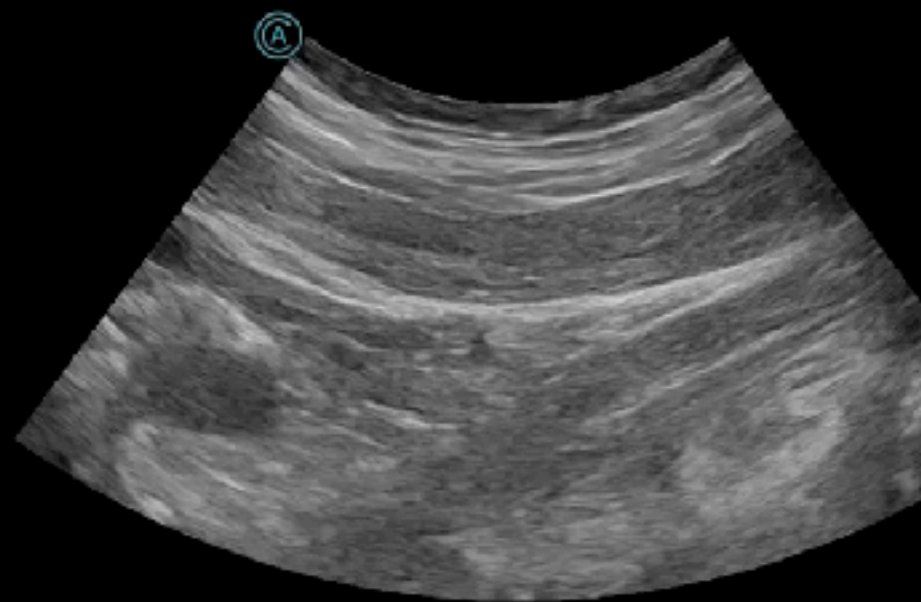

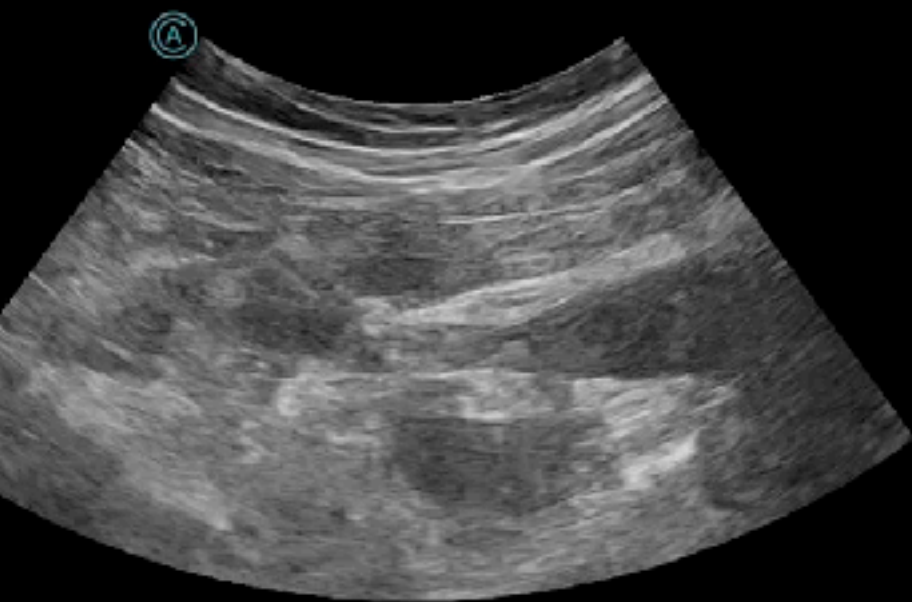


Transverse (medial to colon)



Twinkling artifact



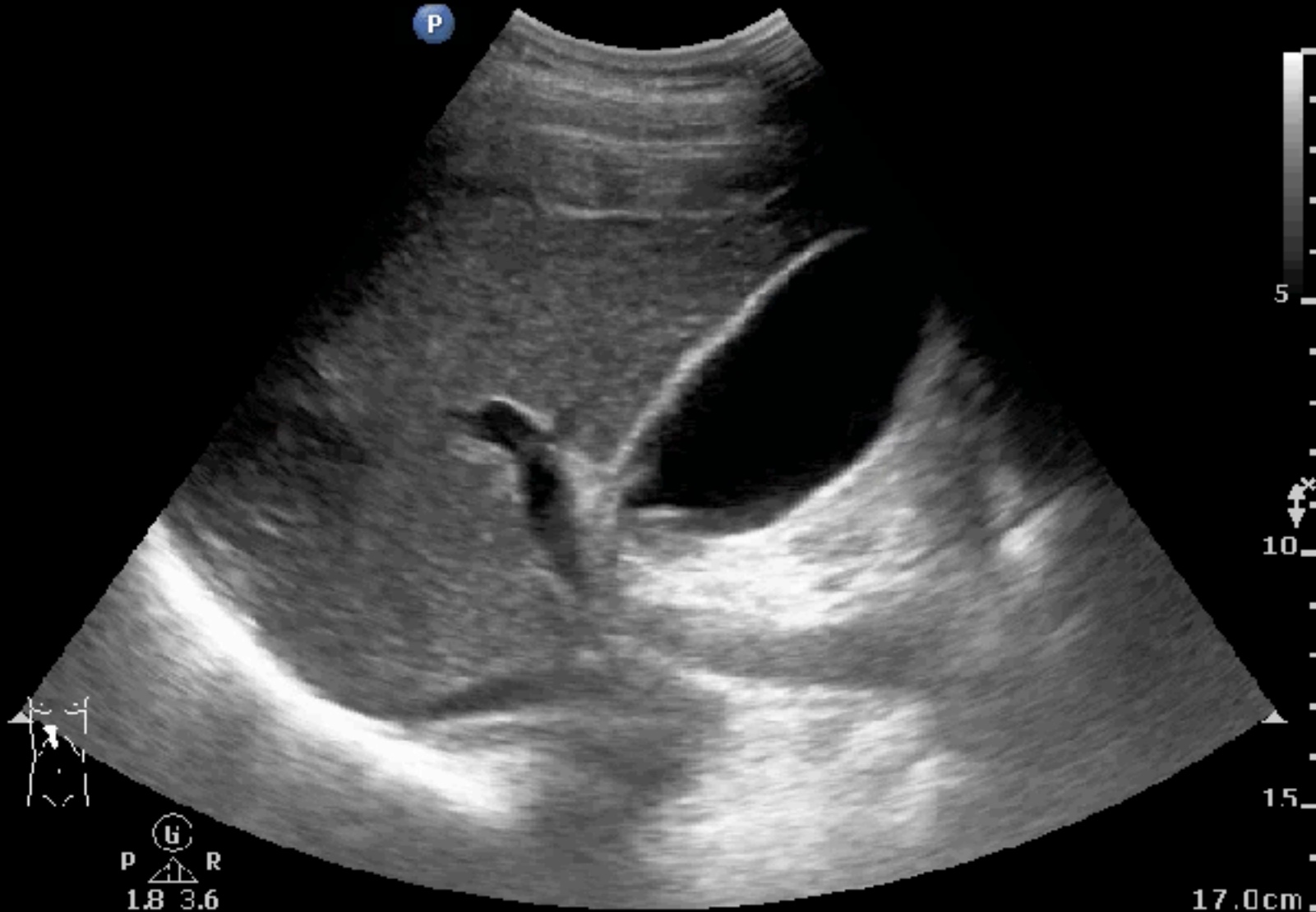

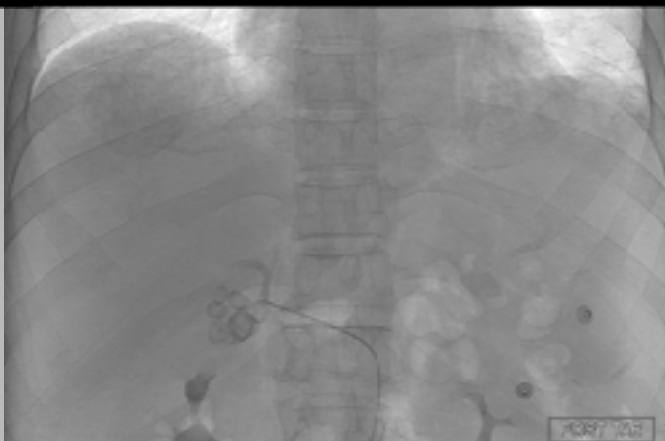
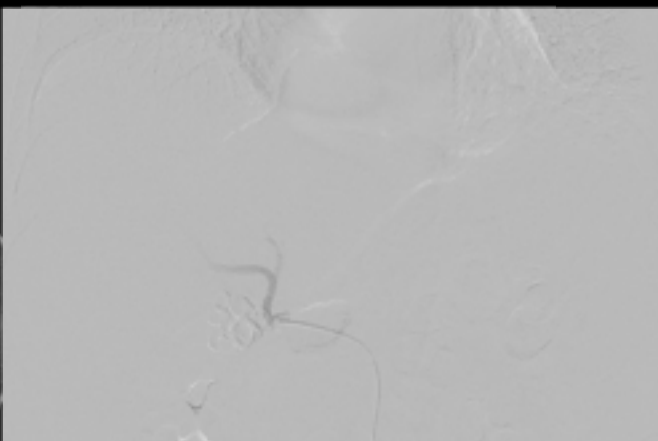
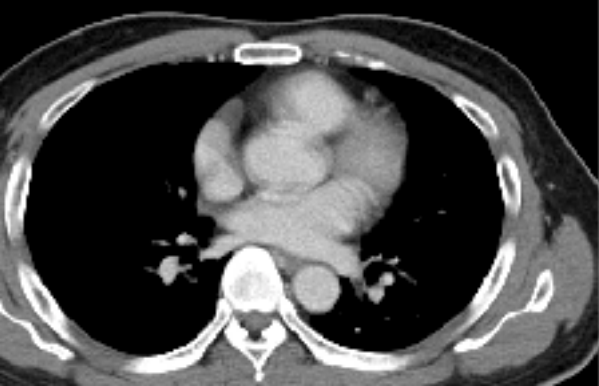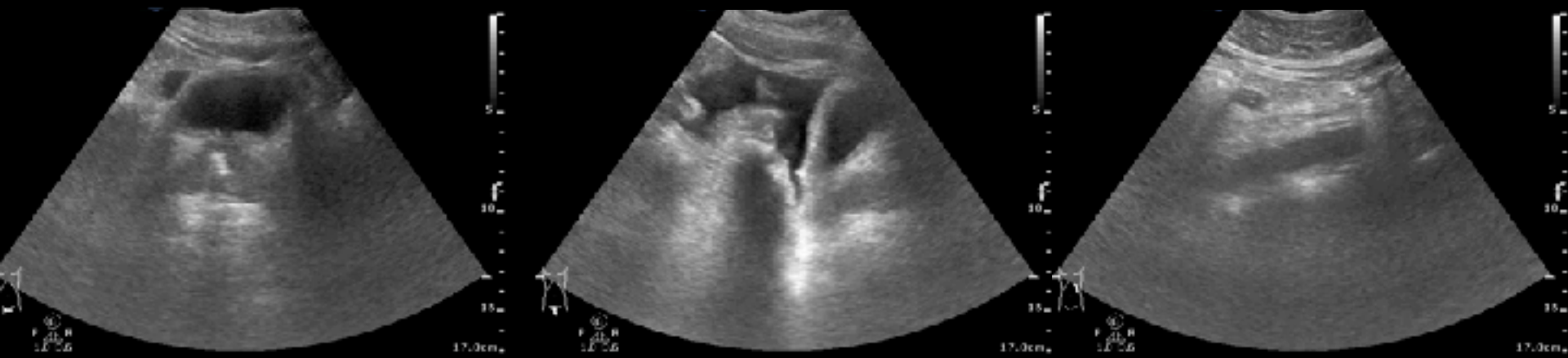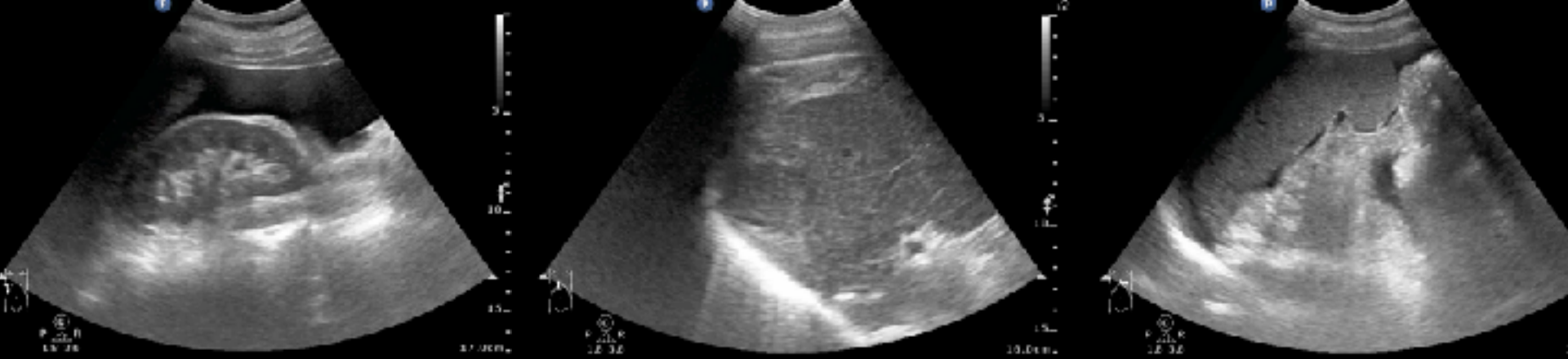52M, RUQ pain

Abd Gen2
C5-1
31 Hz
17.0cm

2D

HGen
Gn 86
C 56
3/3/3

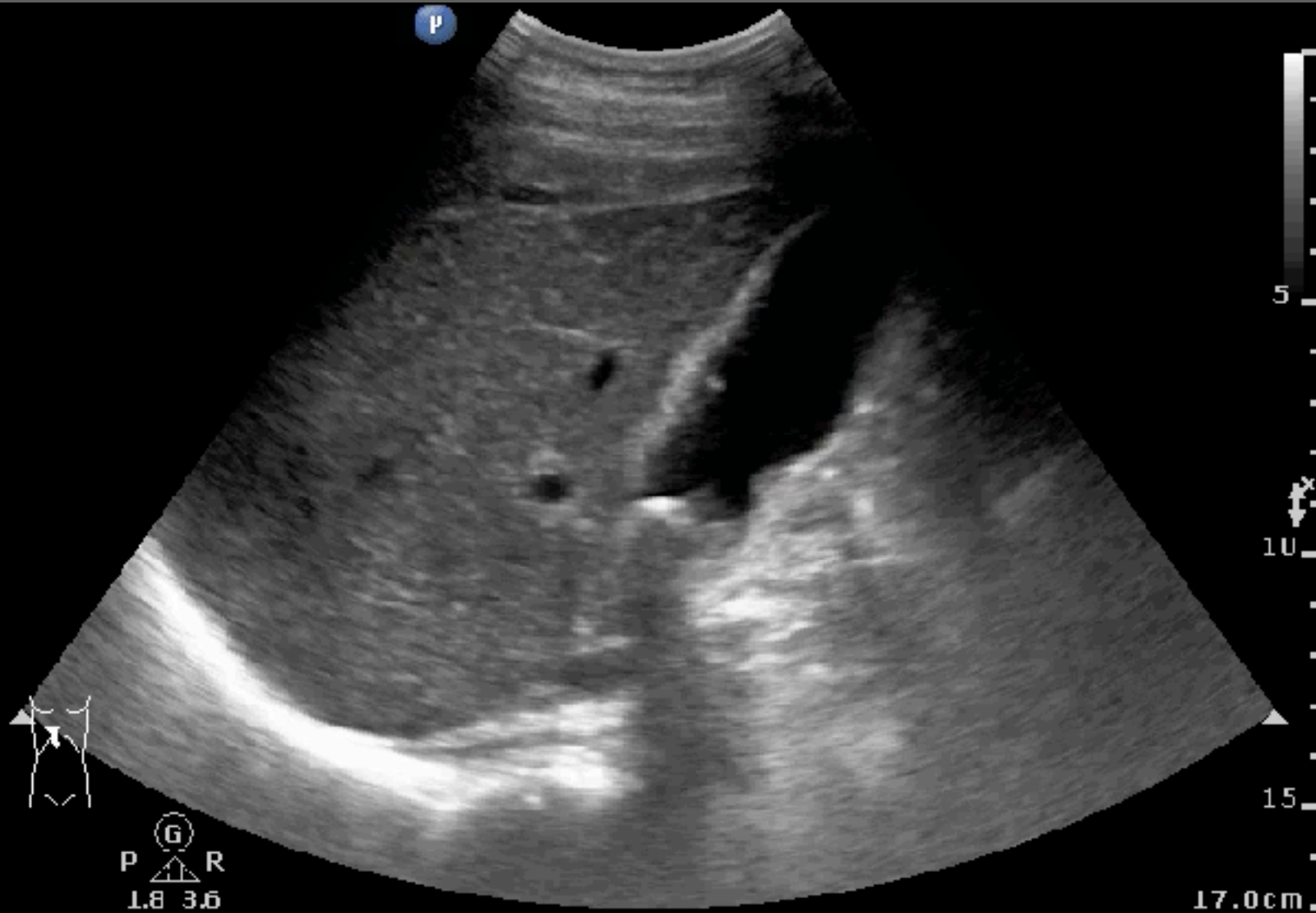




Premature closure

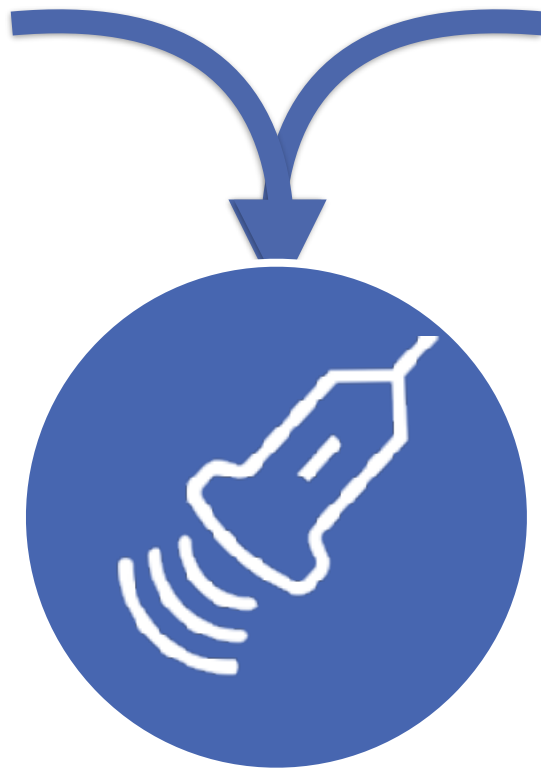Abd Gen2
C5-1
31 Hz
17.0cm

2D
HGen
Gn 86
C 56
3/3/3



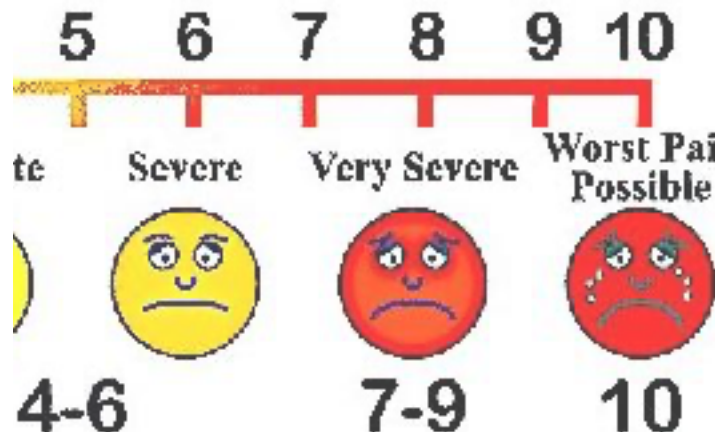
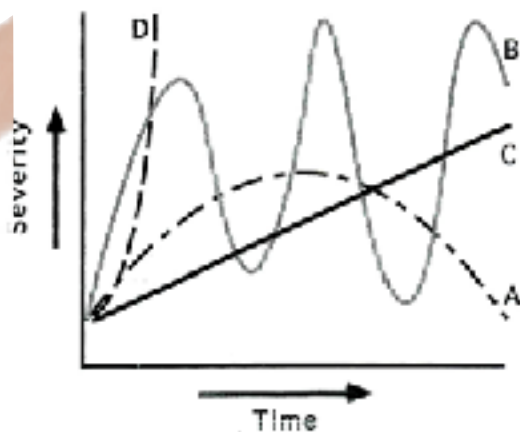


病史詢問



理學檢查

POCUS



POCUS

for

Acute

ABDOMEN

A for aorta

B for biliary

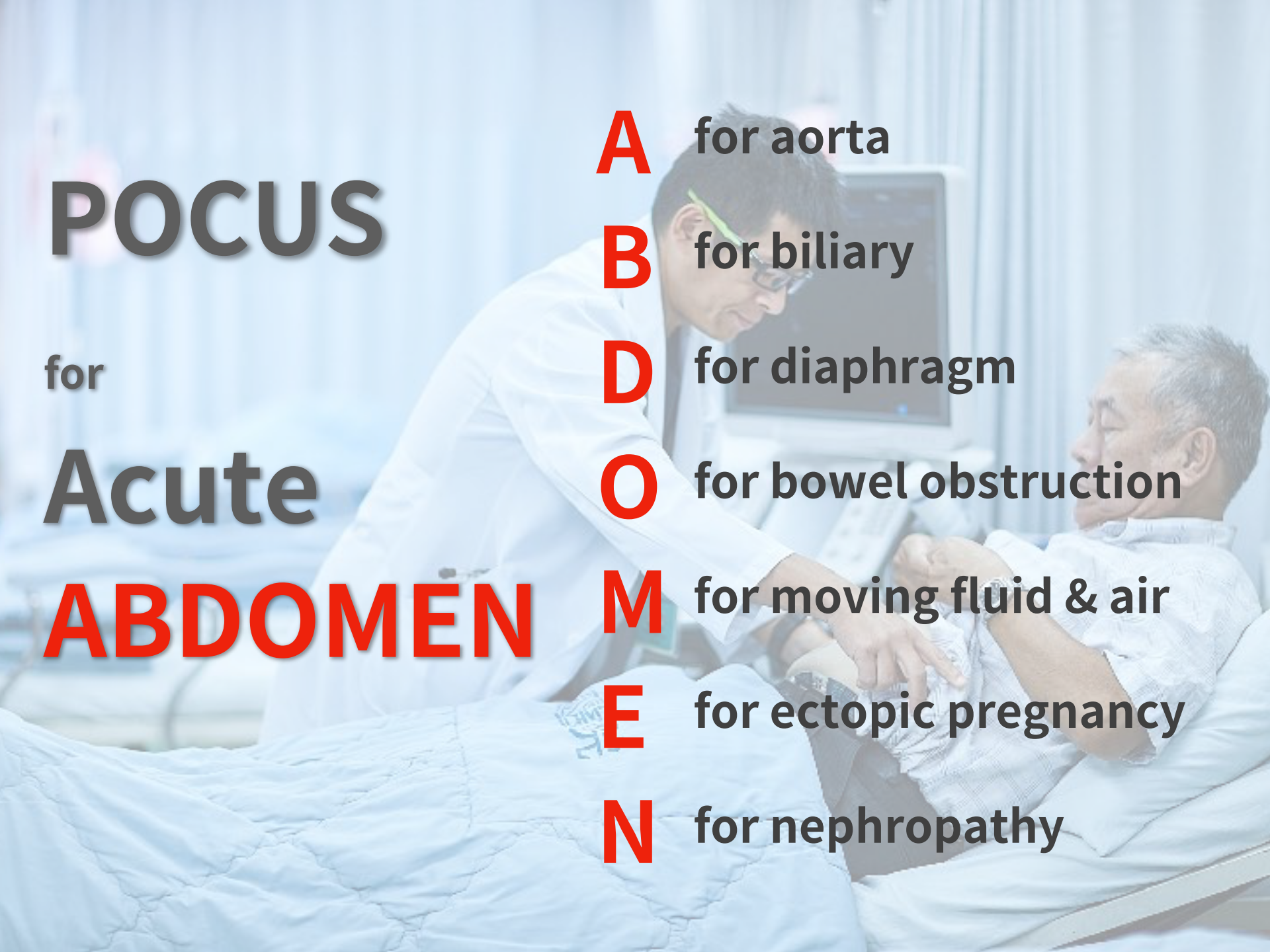D for diaphragm

O for bowel obstruction

M for moving fluid & air

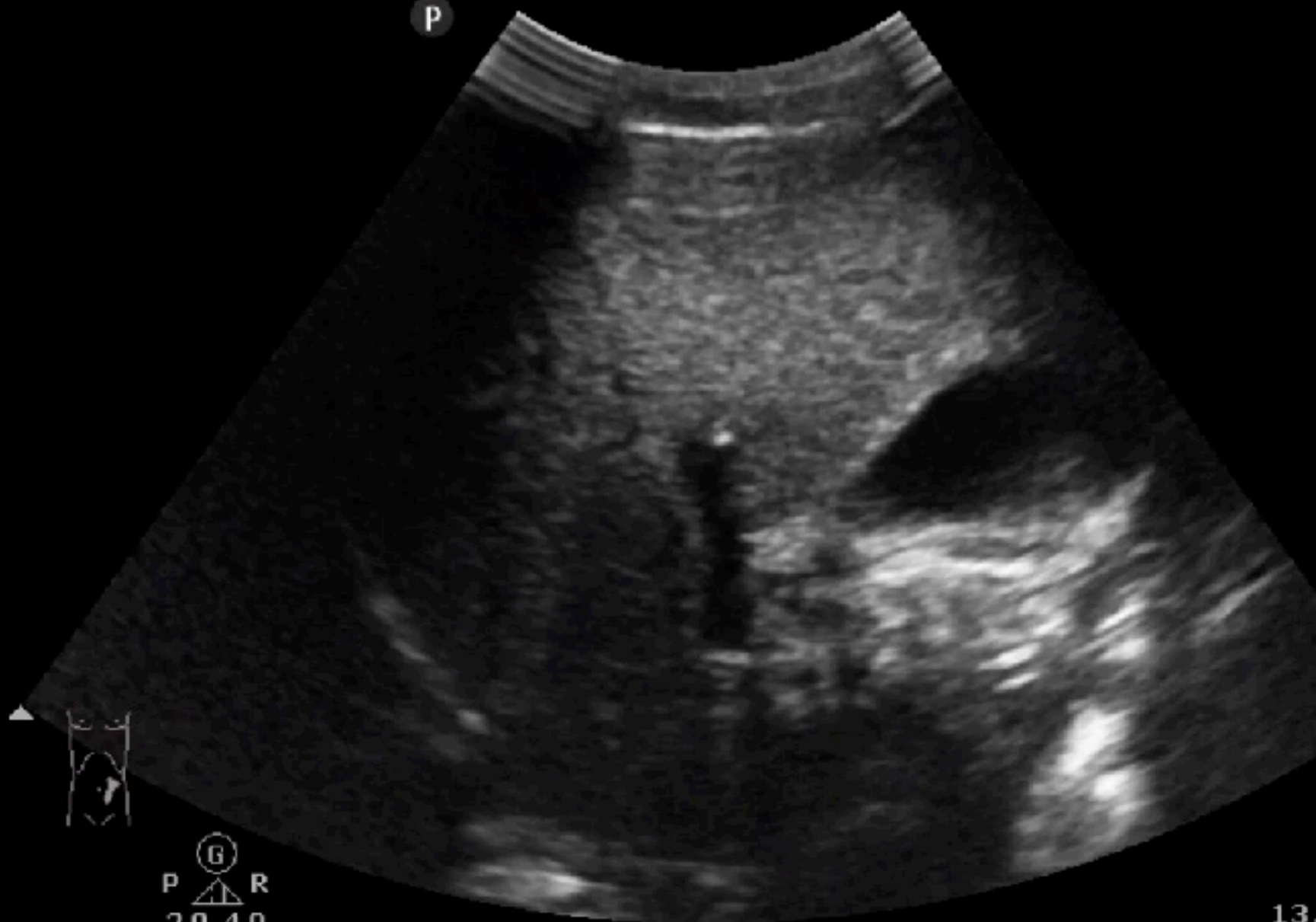
E for ectopic pregnancy

N for nephropathy



2
Z
cm
en
100
3/3

P



G
P R
2.0 4.0

cm

n
100

/3

P

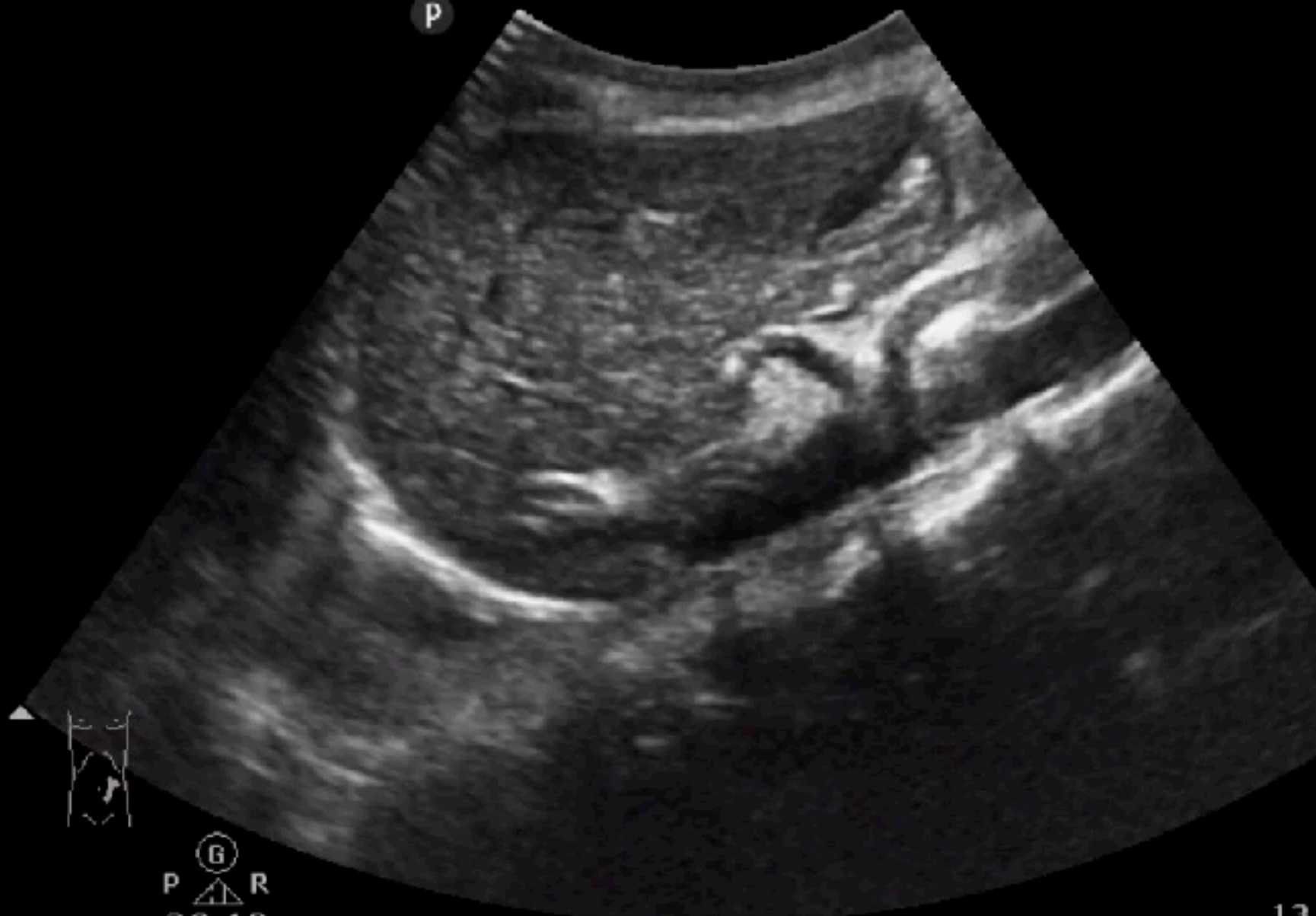


G
P R
2.0 4.0

2
Z
cm

en
100
3/3

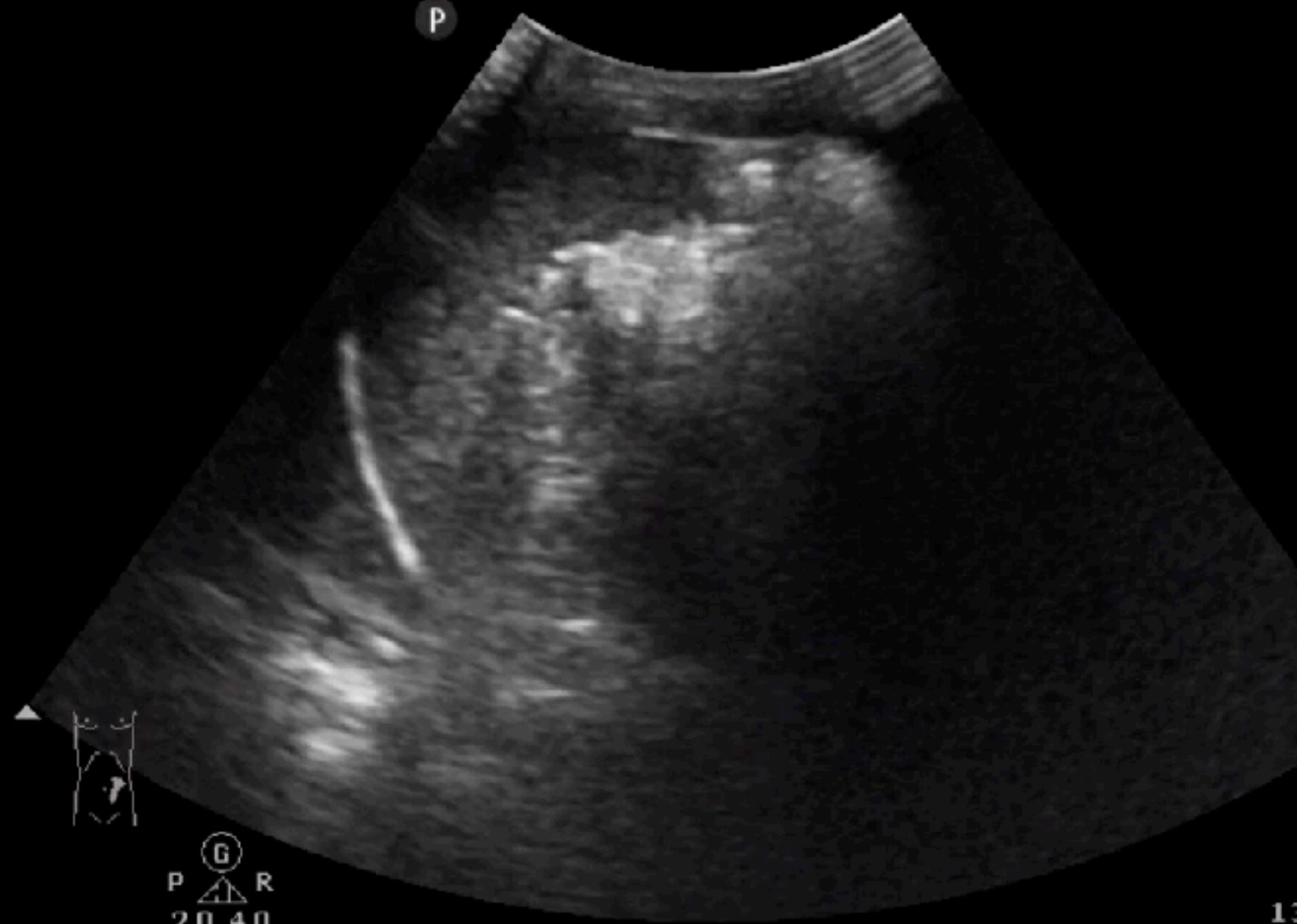
P



G
P R
2.0 4.0

m
n
00
/3

P



G
P R
2.0 4.0

m

1

00

3

P

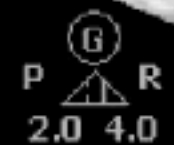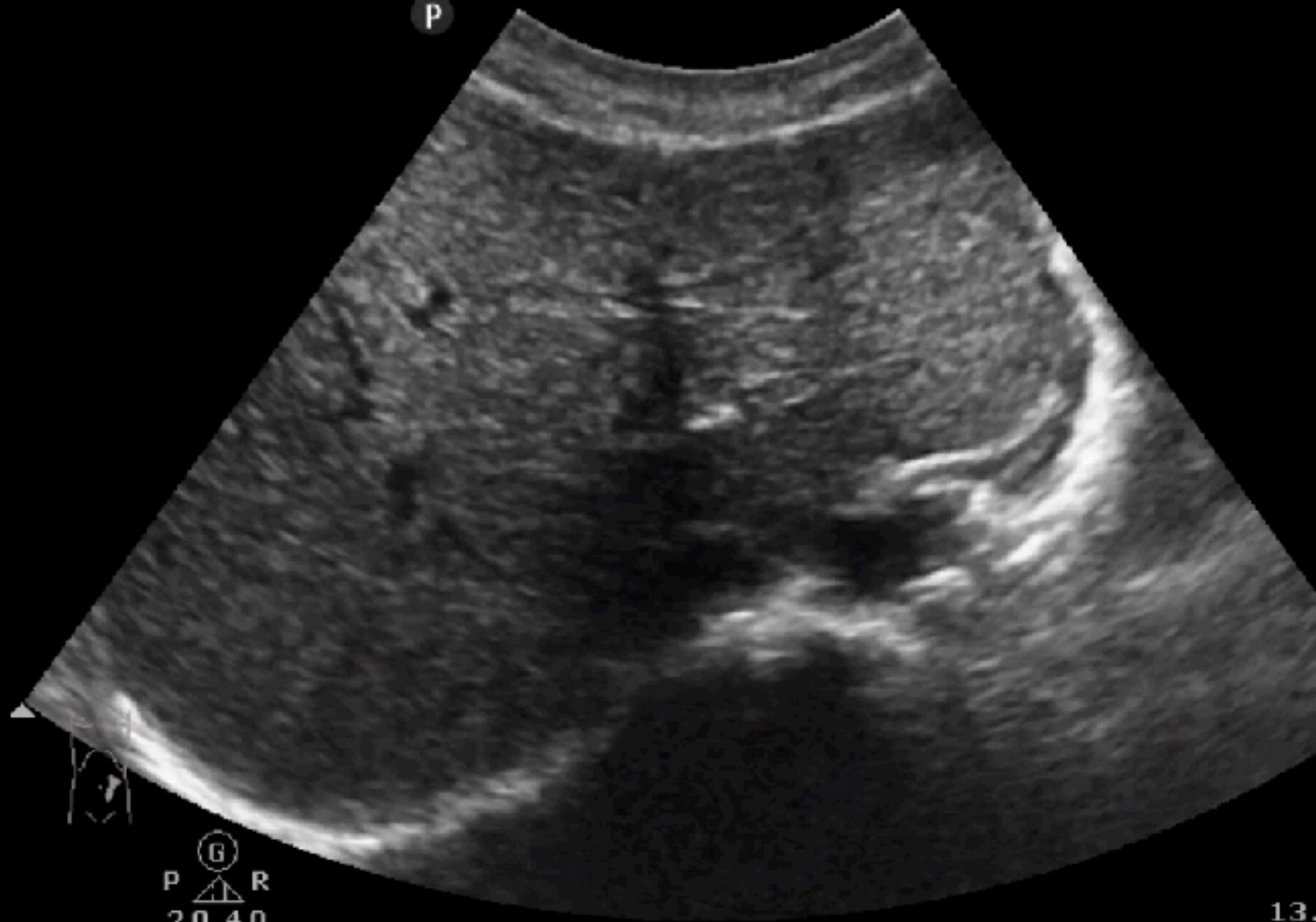


G
P R
2.0 4.0

1

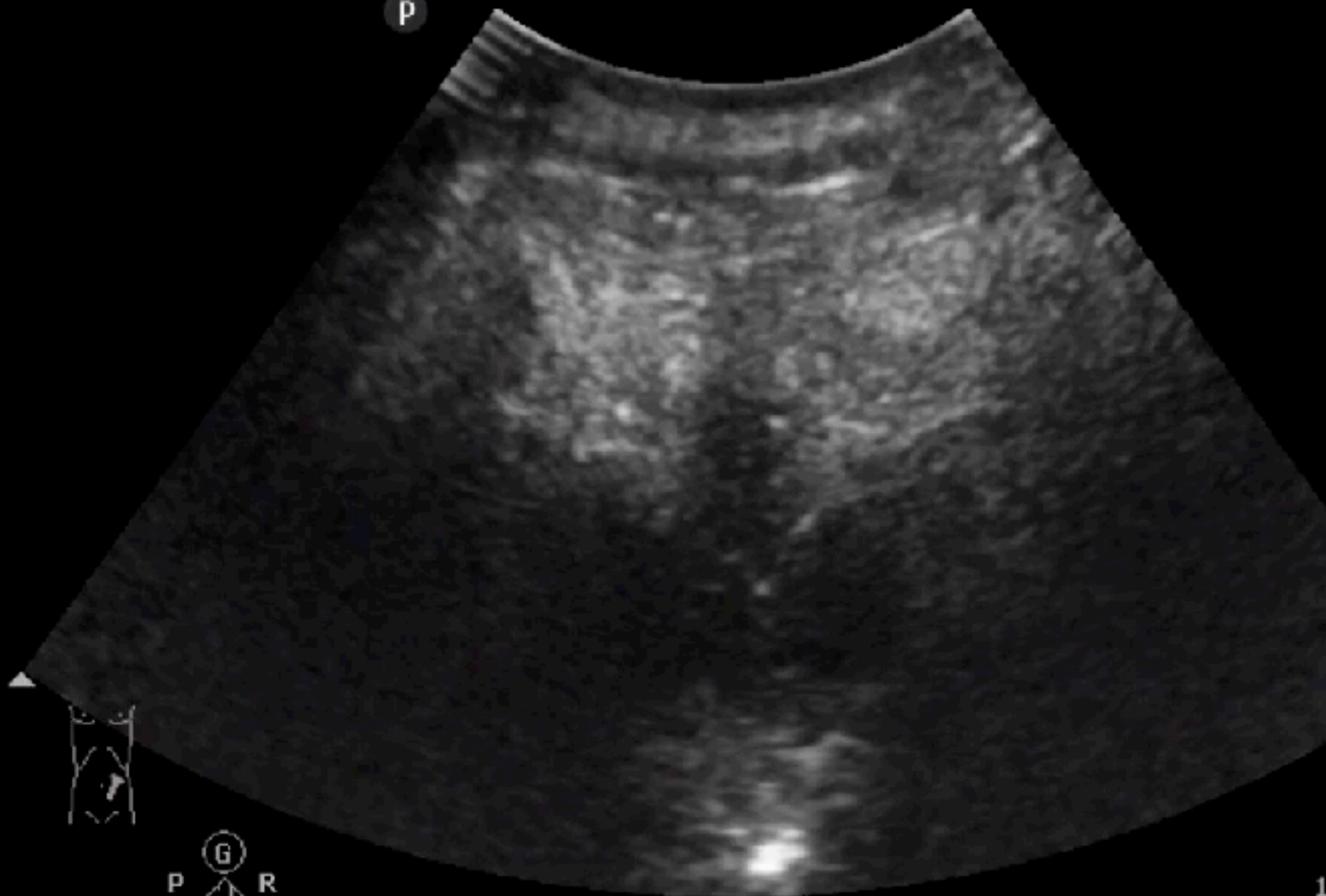
2
Z
cm
en
100
3/3

P



m
n
00
/3

P

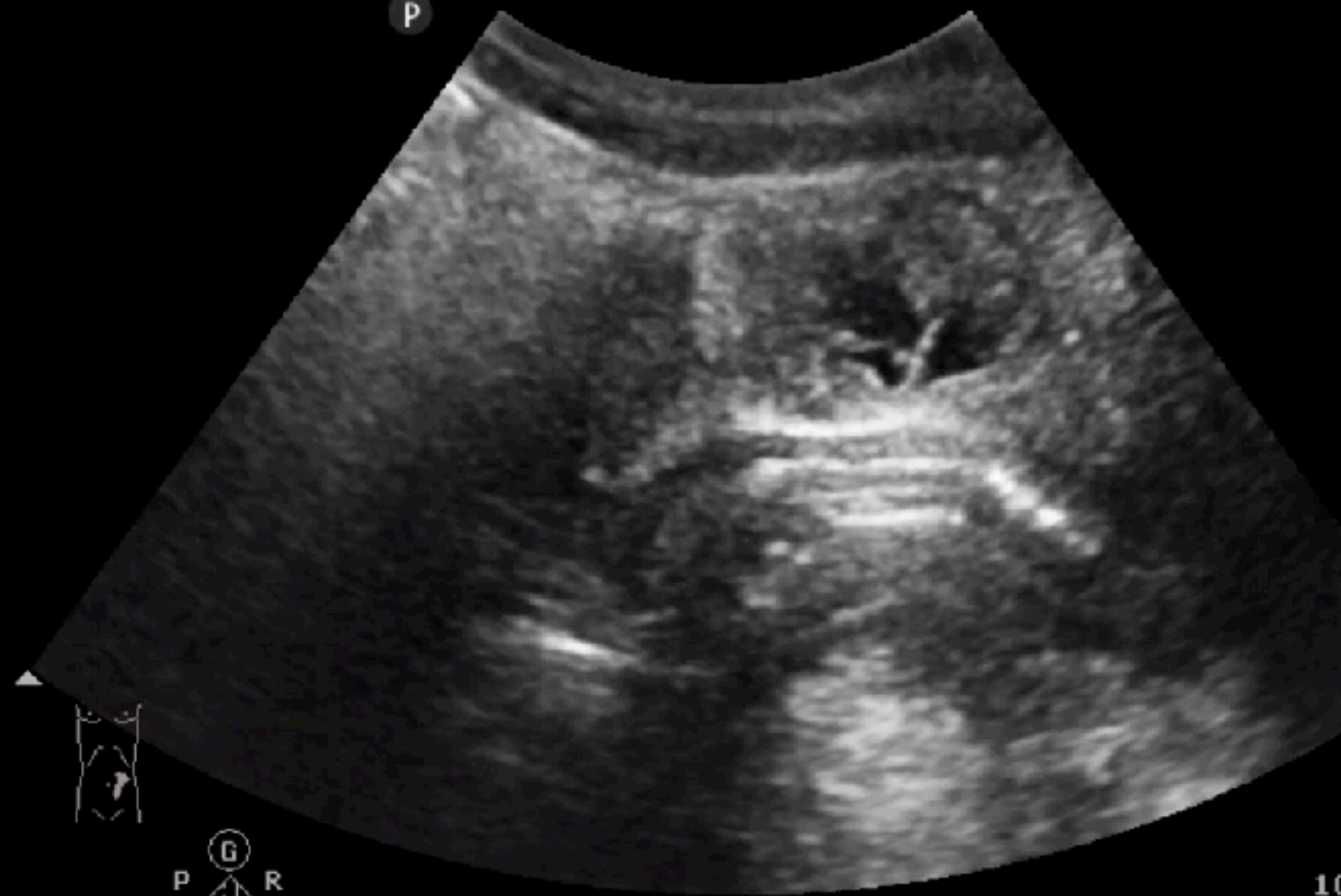


G
P R
2.0 4.0

1

m
n
00
/3

P



G
P R
2.0 4.0

10

cm

n
100

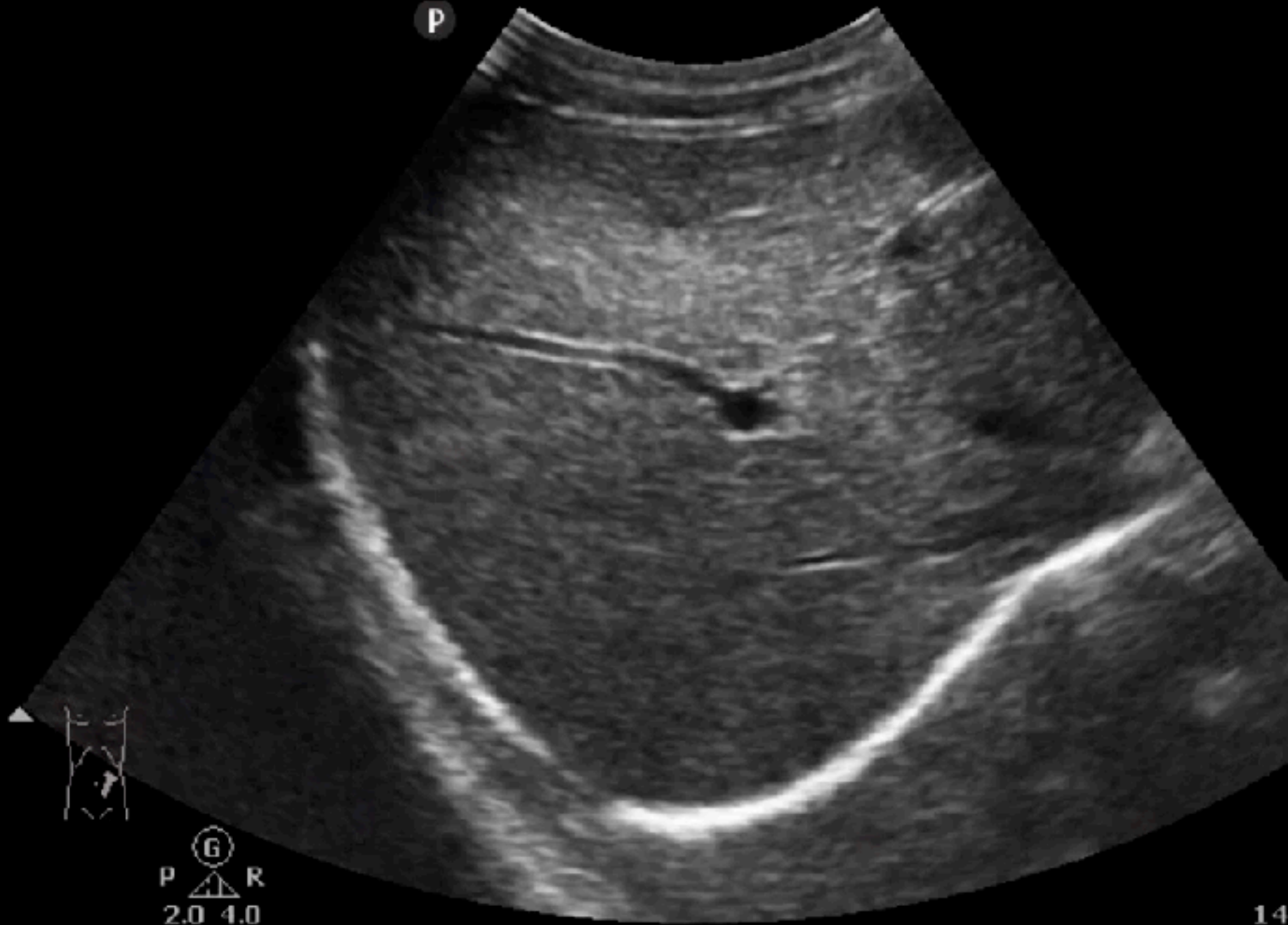/3

P



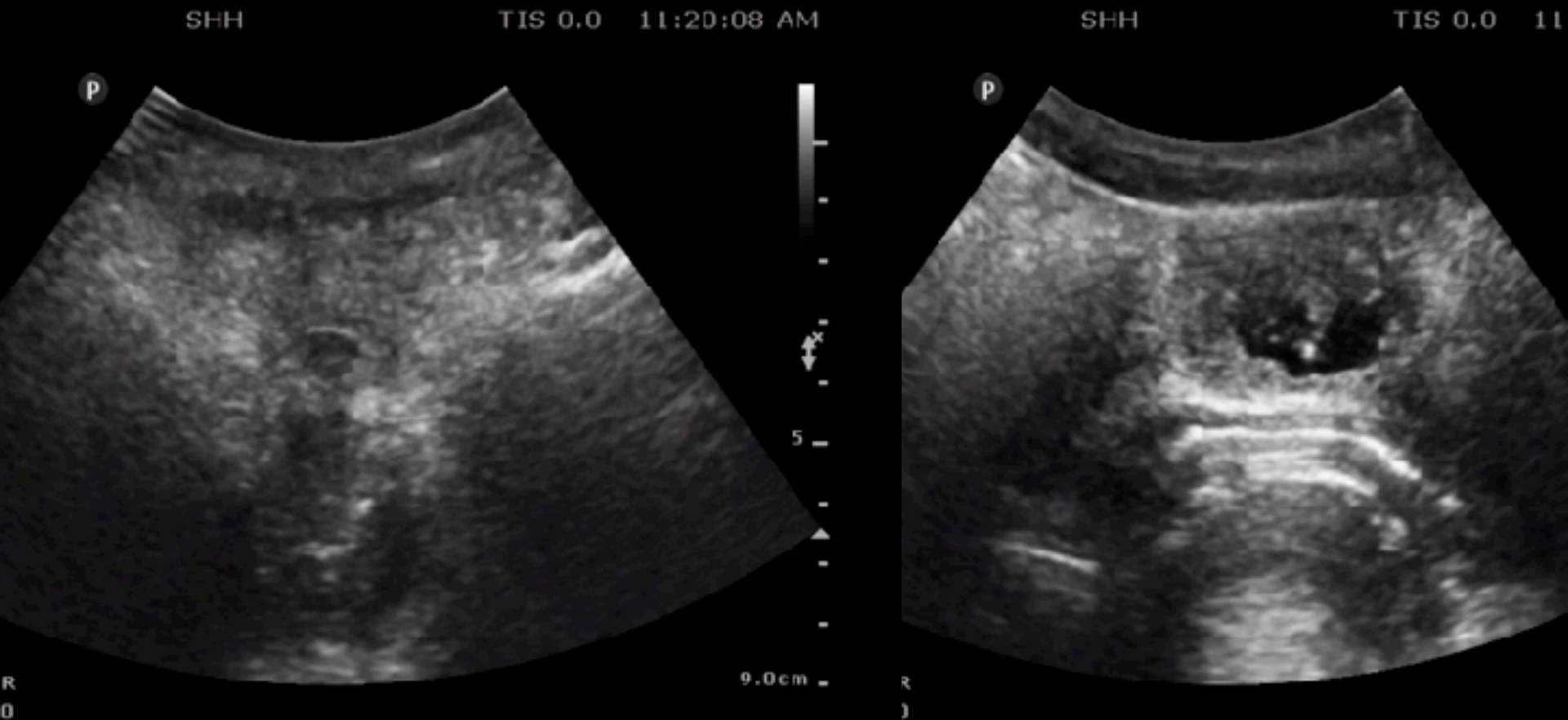
G
P R
2.0 4.0

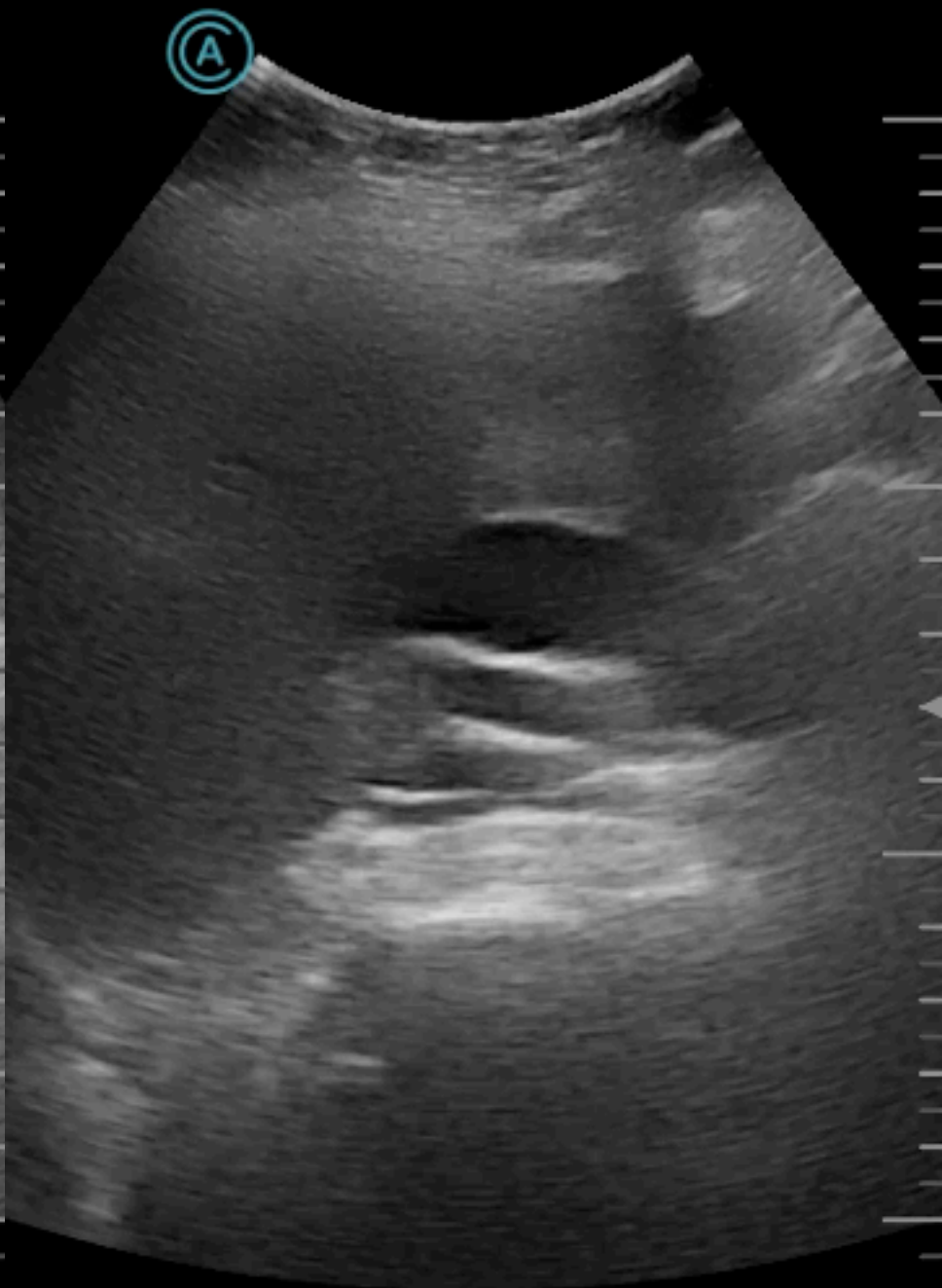
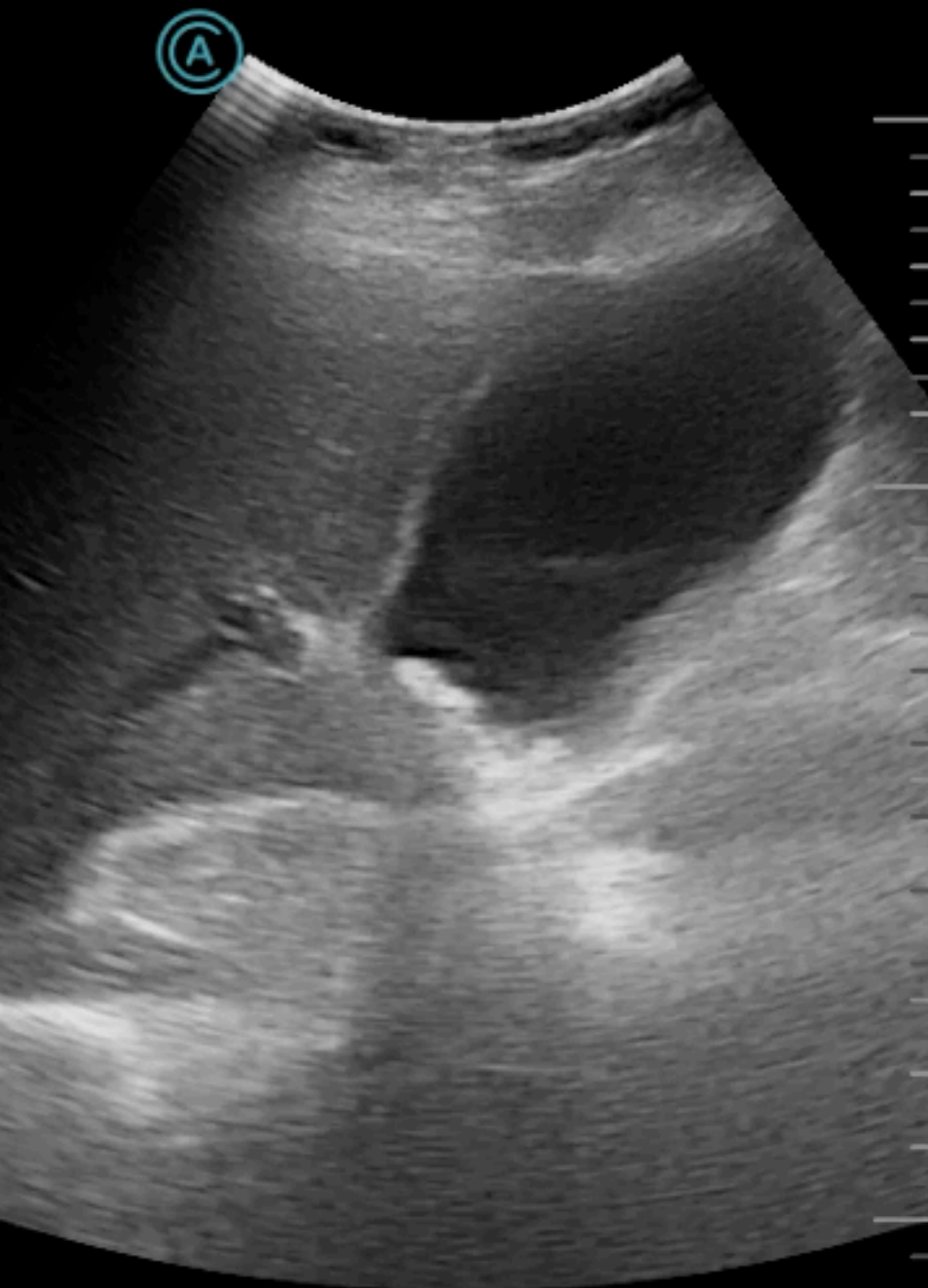
P



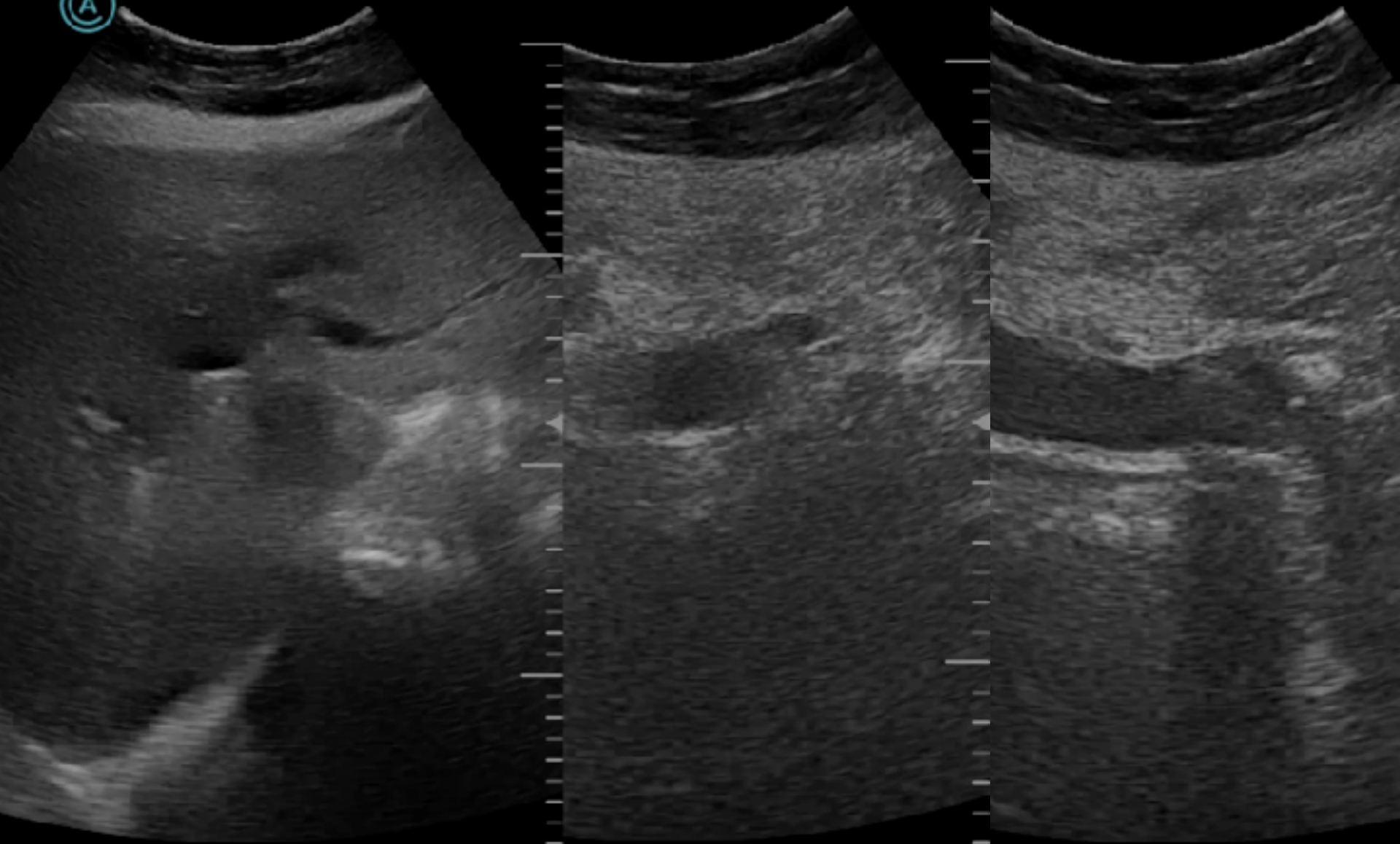
G
P R
2.0 4.0

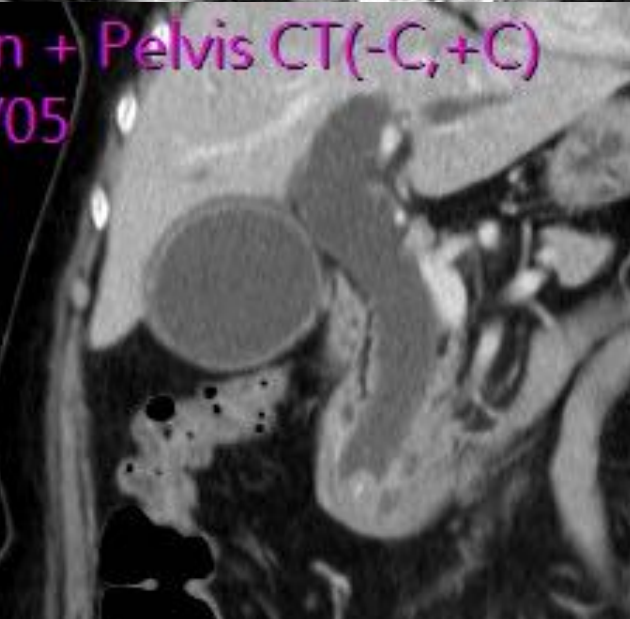
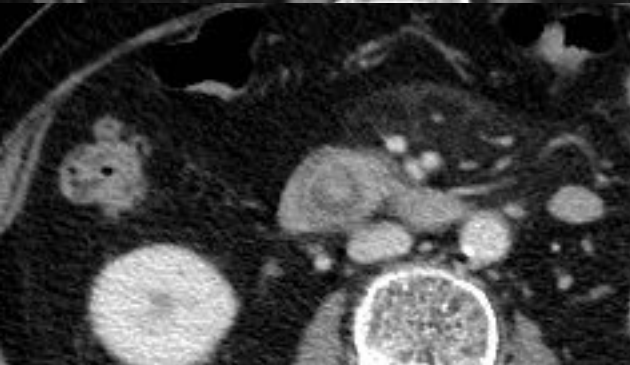
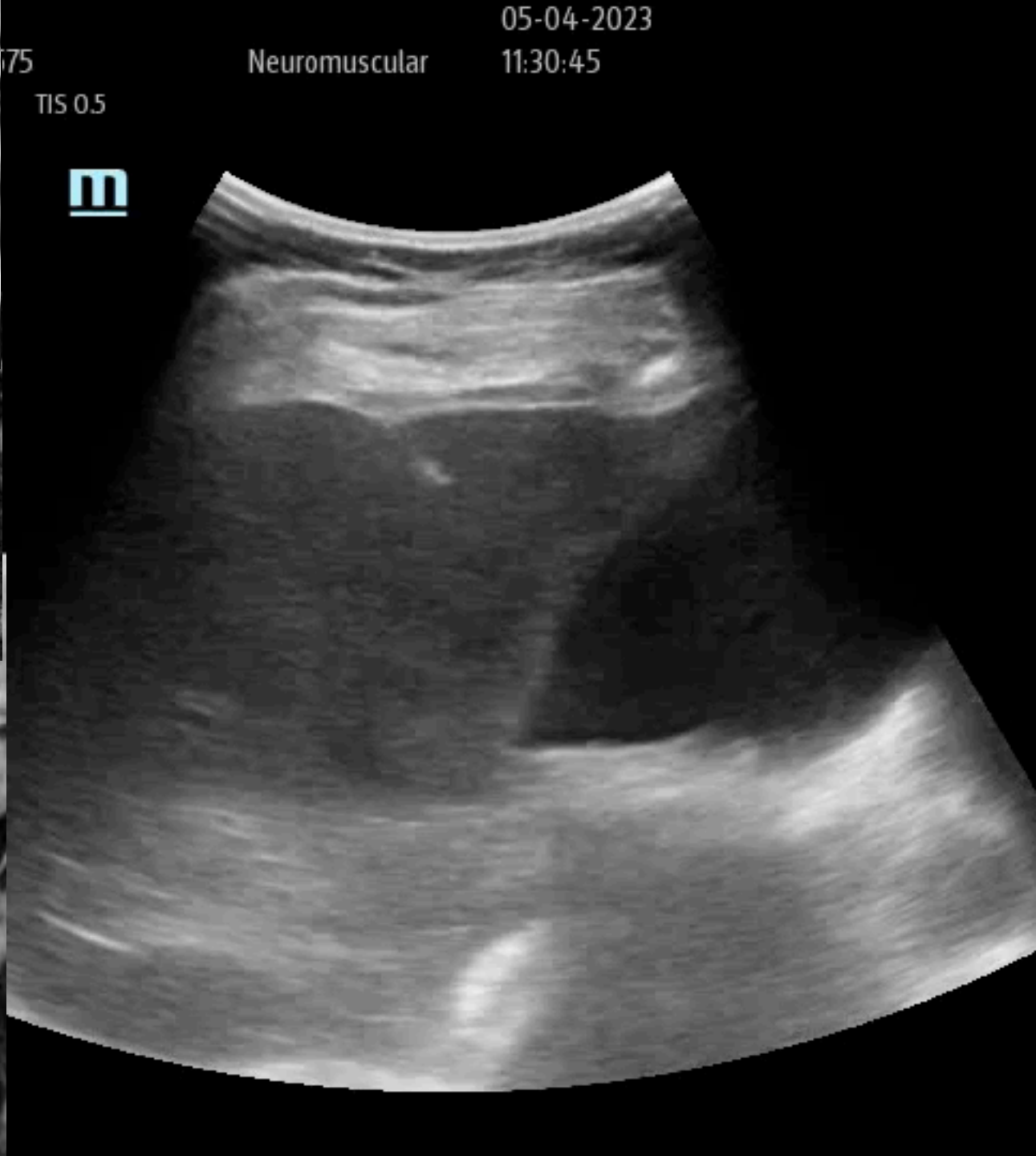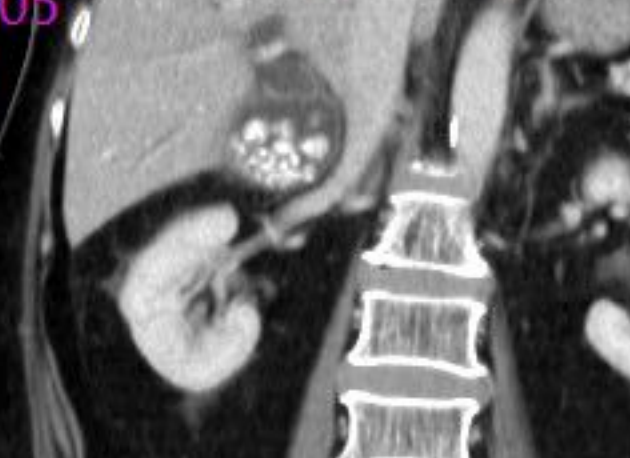
Interstitial cystitis





(A)

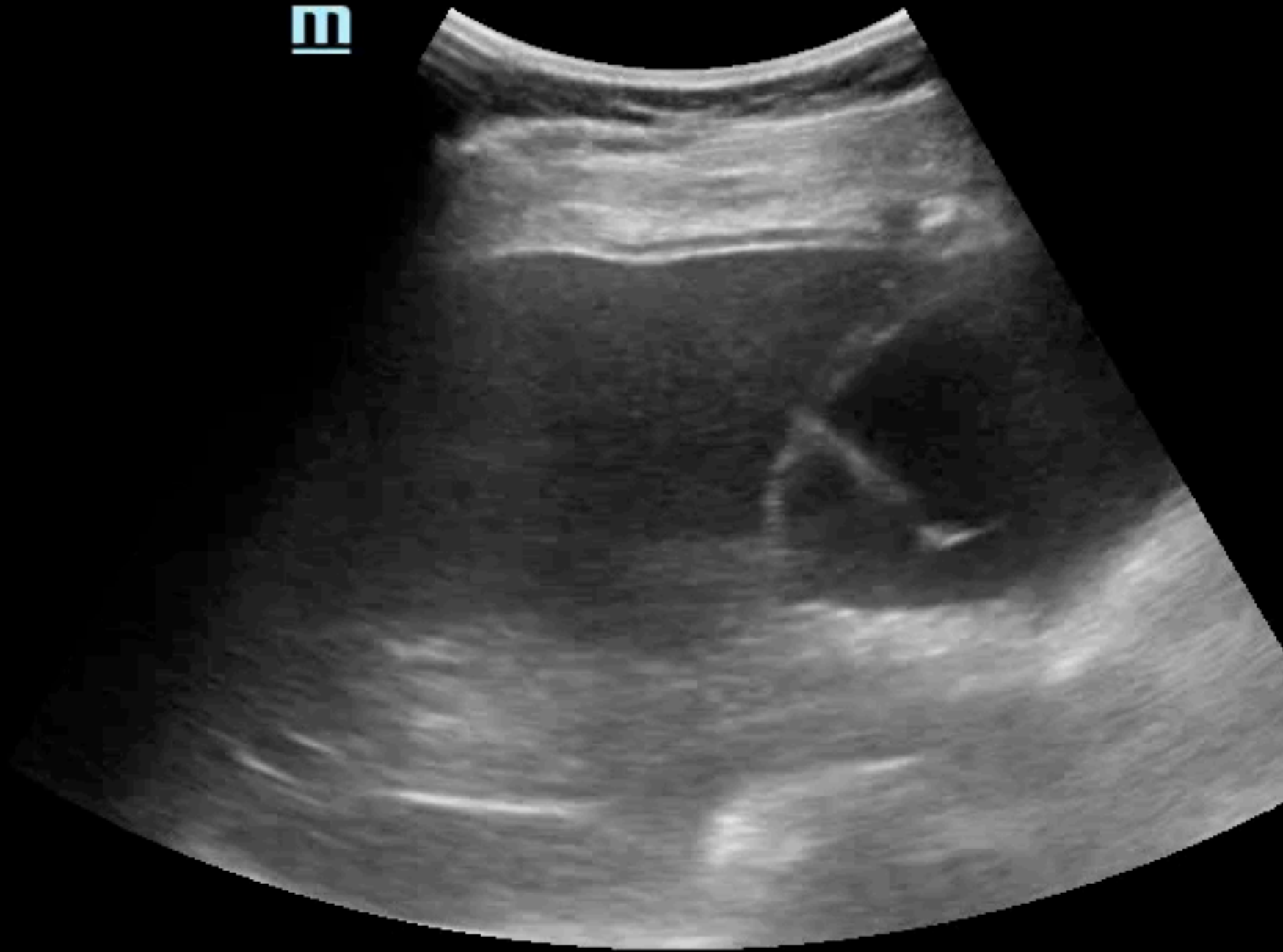



m

le

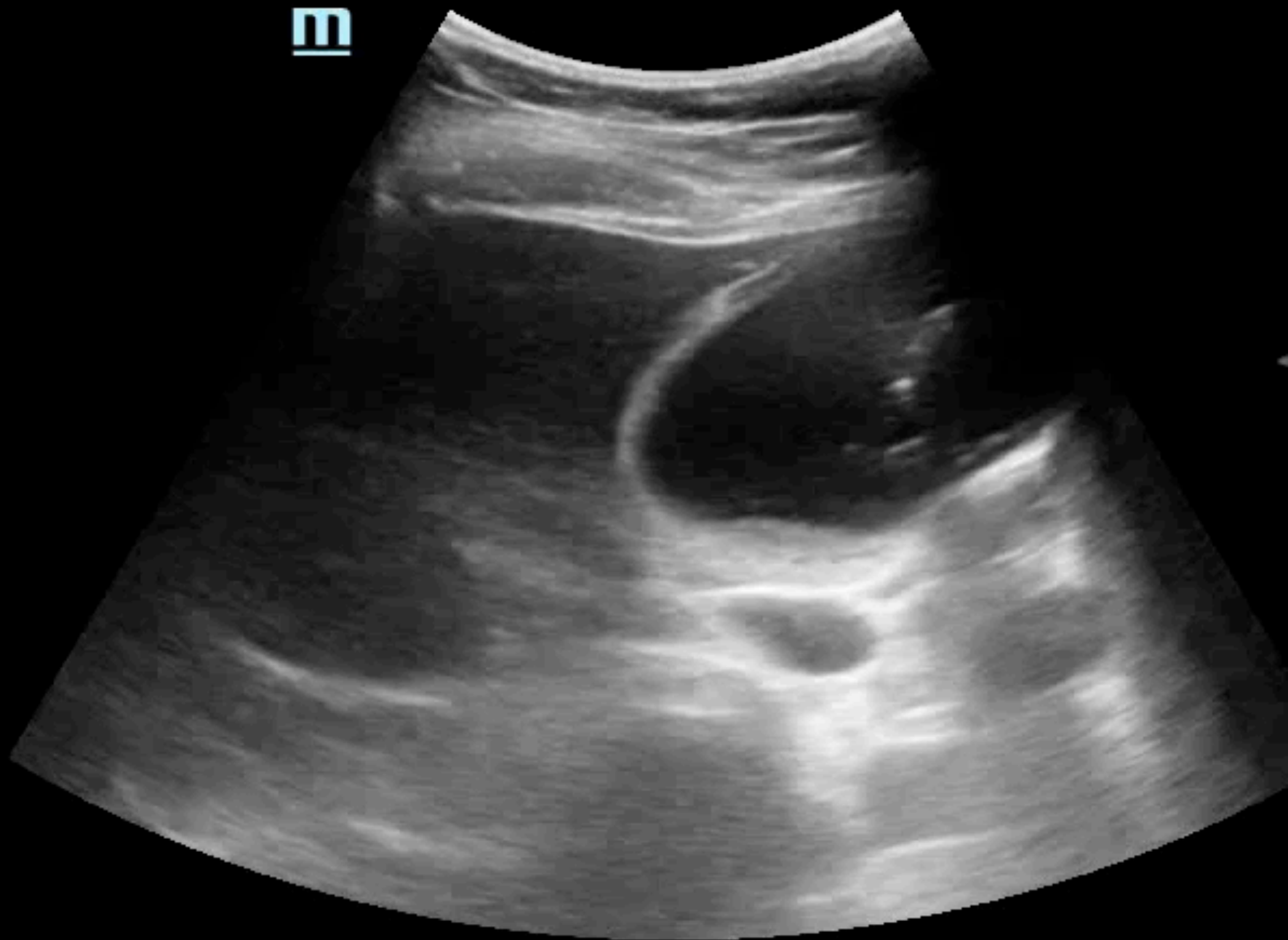ch

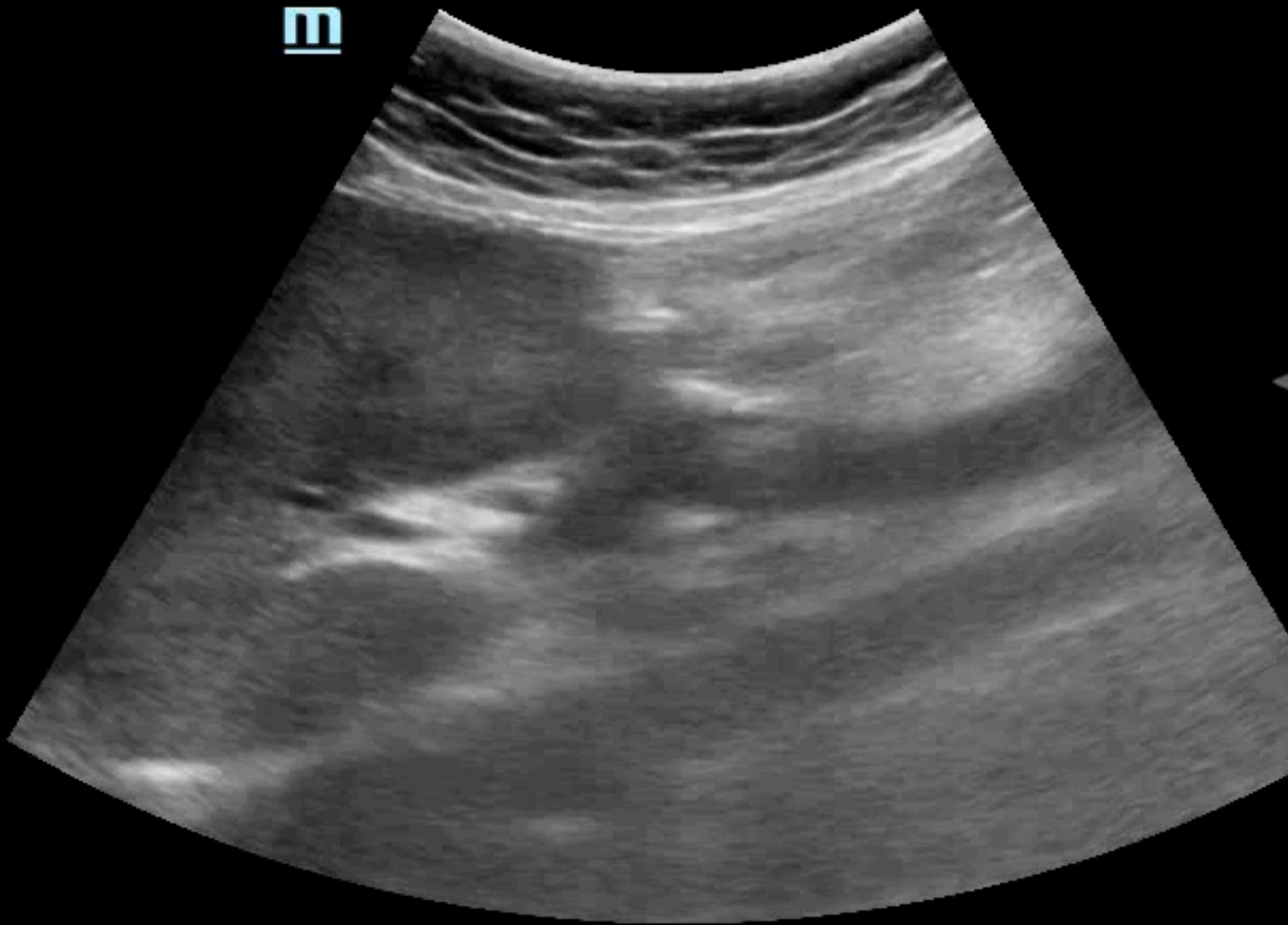


m

le

ch





dle

ch