



衛生福利部雙和醫院
(委託臺北醫學大學興建經營)
Taipei Medical University · Shuang Ho Hospital,
Ministry of Health and Welfare



經超音波引導之 緊急臨床處置之應用

急診進階超音波課程-第三場 2023/05/04

陳國智醫師 雙和醫院急診醫學科

juice119@gmail.com

POCUSacademy.com

陳國智 醫師



急診超音波臨床評核醫師
醫用超音波學會指導醫師



WINFOCUS director / instructor
Certified Interventional Pain Sonologist

急診 / 重症 / 介入 / 急性疼痛

經歷

新光急診超音波訓練中心主任

西園醫院急診醫學科主任

急診醫學會超音波委員會主委

台灣疼痛醫學會大體模擬手術講師

急救加護醫學會重症超音波負責人

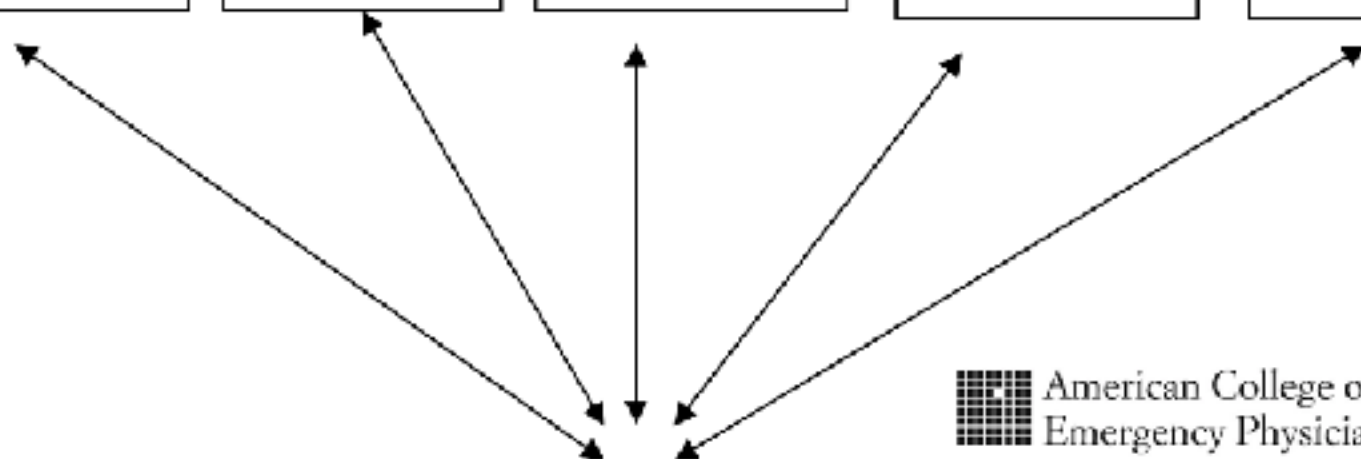
Resuscitative

Diagnostic

Procedural
Guidance

Symptom- or
Sign-Based

Therapeutic



American College of
Emergency Physicians®

ADVANCING EMERGENCY CARE

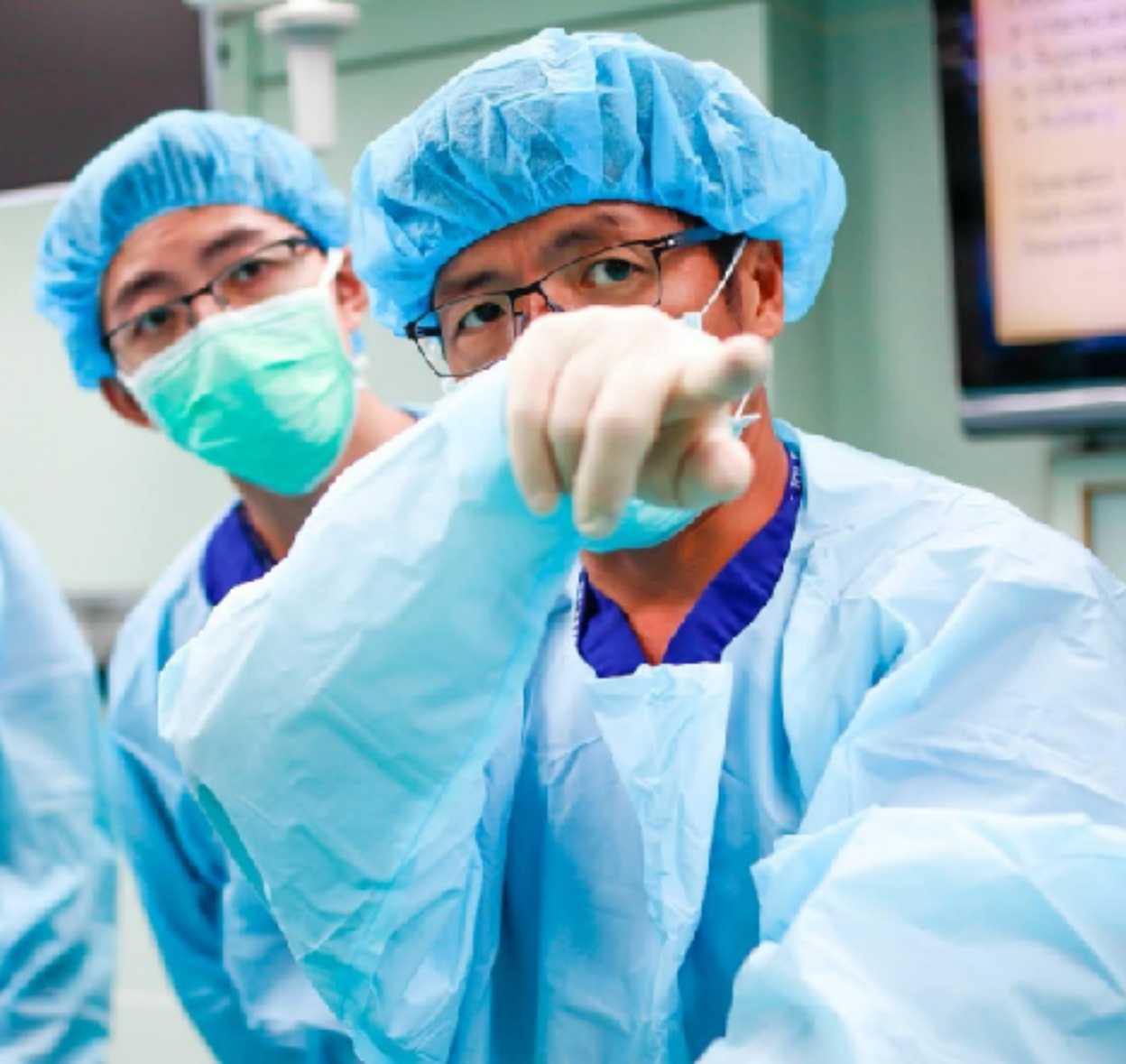**POLICY
STATEMENT**

Core Applications

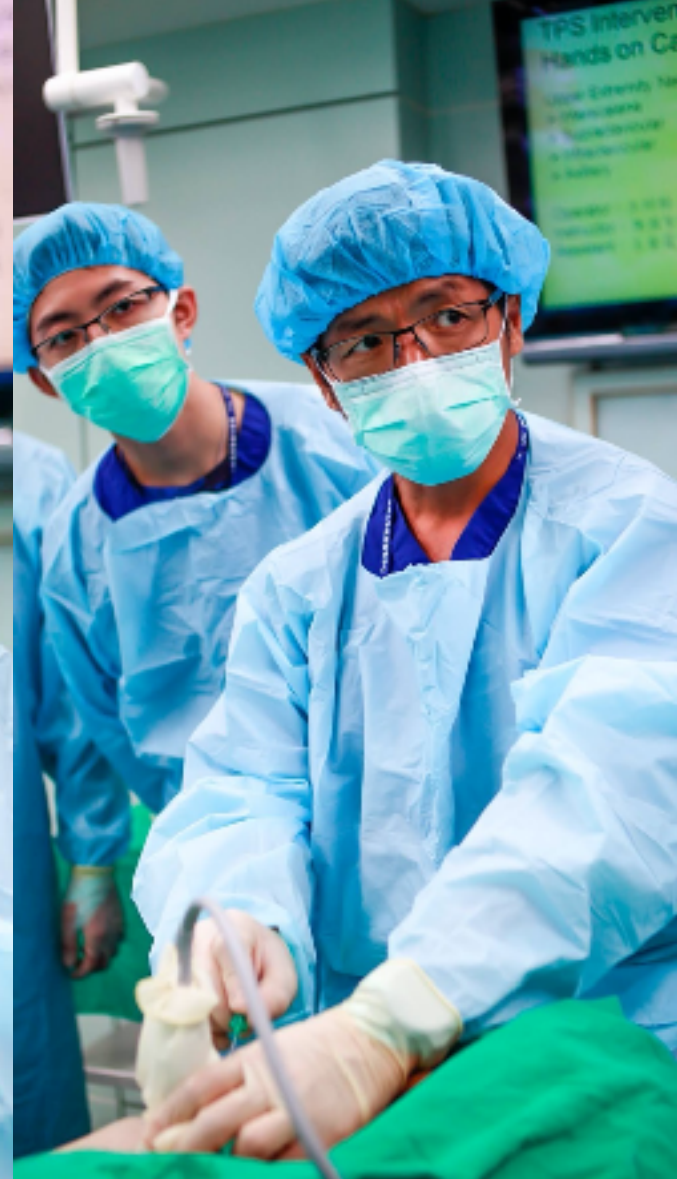Trauma
Intrauterine Pregnancy
AAA
Cardiac/HD Assessment
Biliary
Urinary Tract
DVT
Soft-tissue/Musculoskeletal
Thoracic/Airway
Ocular
Bowel
Procedural Guidance

Approved June 2016

***Ultrasound Guidelines:
Emergency, Point-of-care, and
Clinical Ultrasound Guidelines in
Medicine***



Diagnostician



Interventionist

診
斷

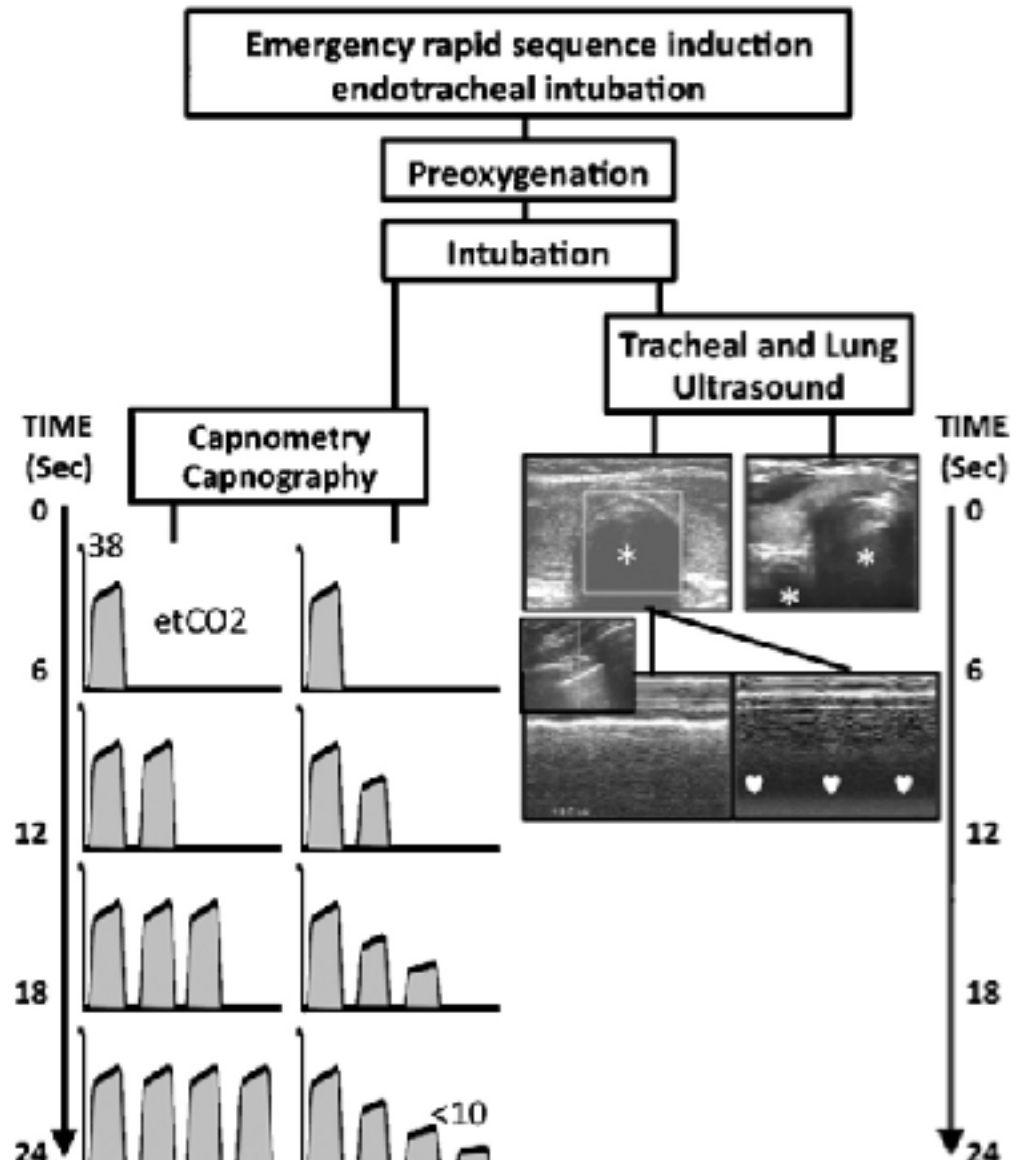
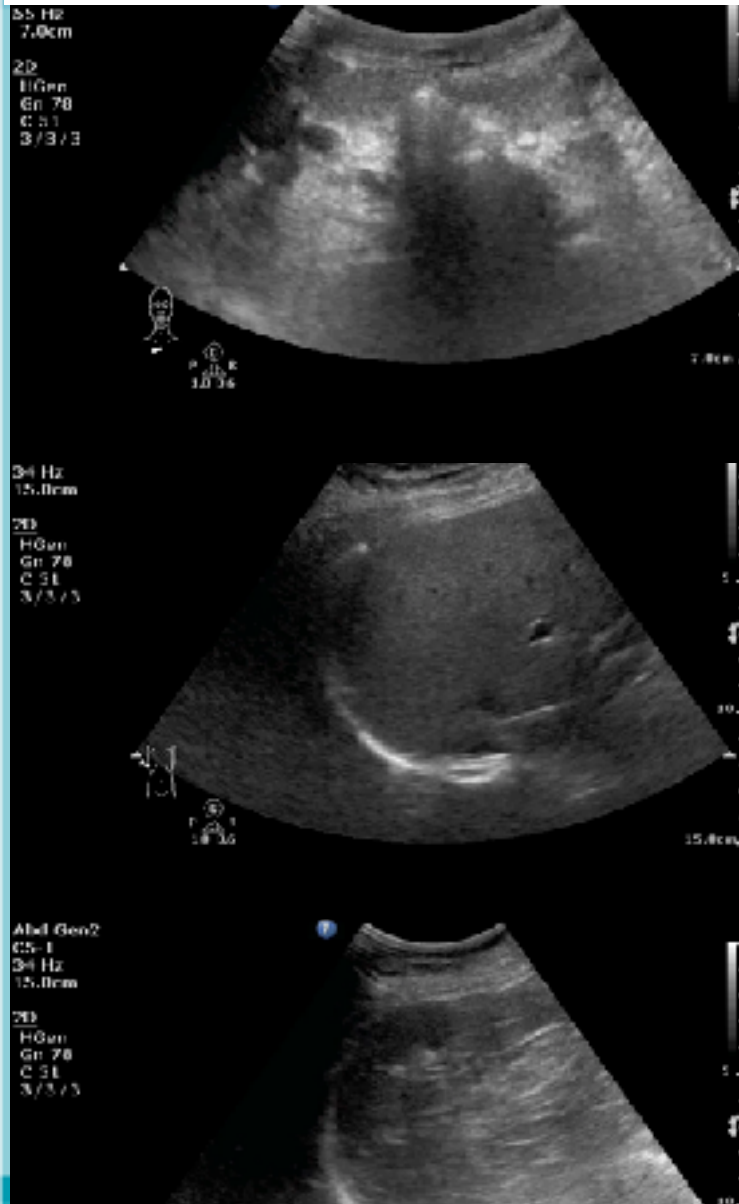監
測

介
入

POINT OF CARE ULTRASOUND

~ 存在於臨床需求之所在 ~

TRUTH: 確認插管 & 雙側通氣



TRUST



Tracheal Rapid Ultrasound Saline Test confirming correct ET **Depth** in children

20160410190238

MT 0.5

4/10/2016

20160410190238

MT 0.5

-190238

SKH ER

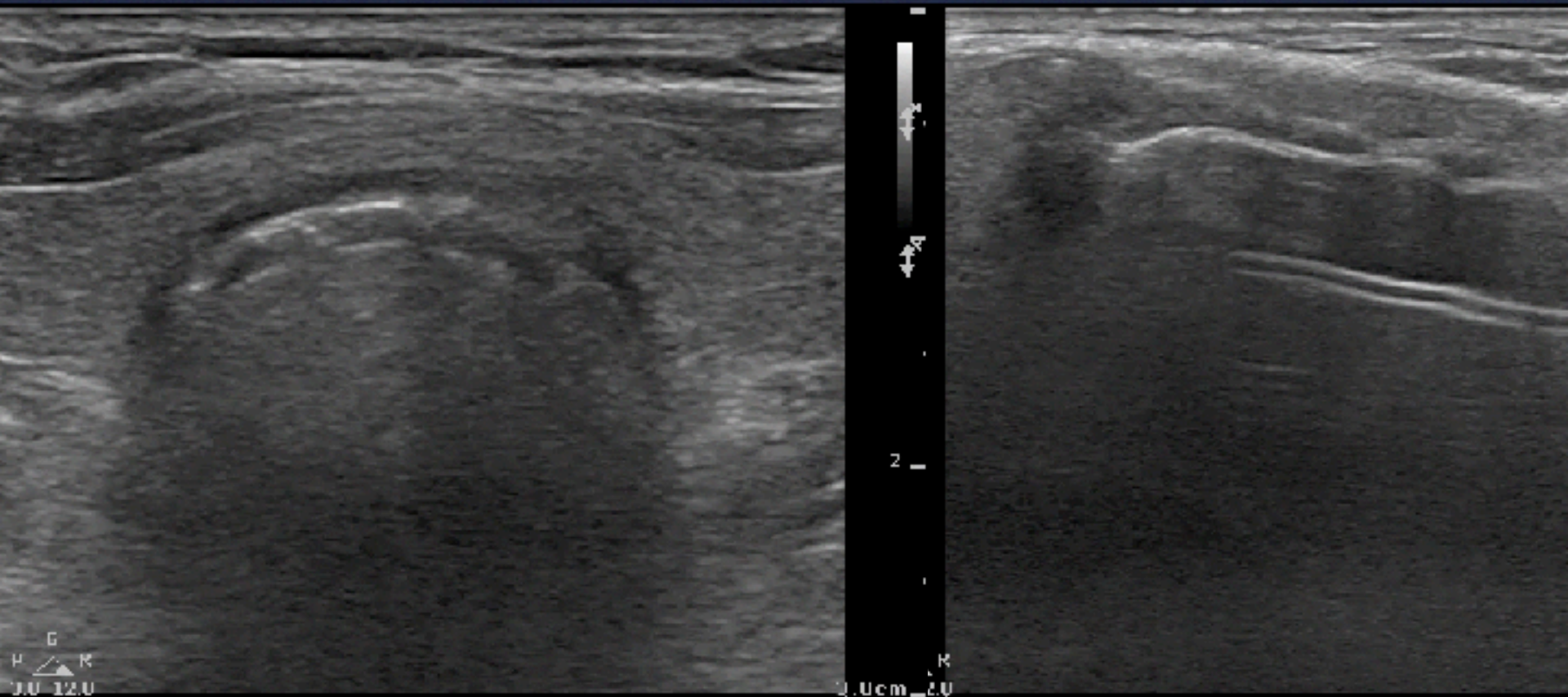
118 0.1

7:24:17 PM

238

SKH ER

118 0.1



G
H K
0.0 12.0

R
2.0cm

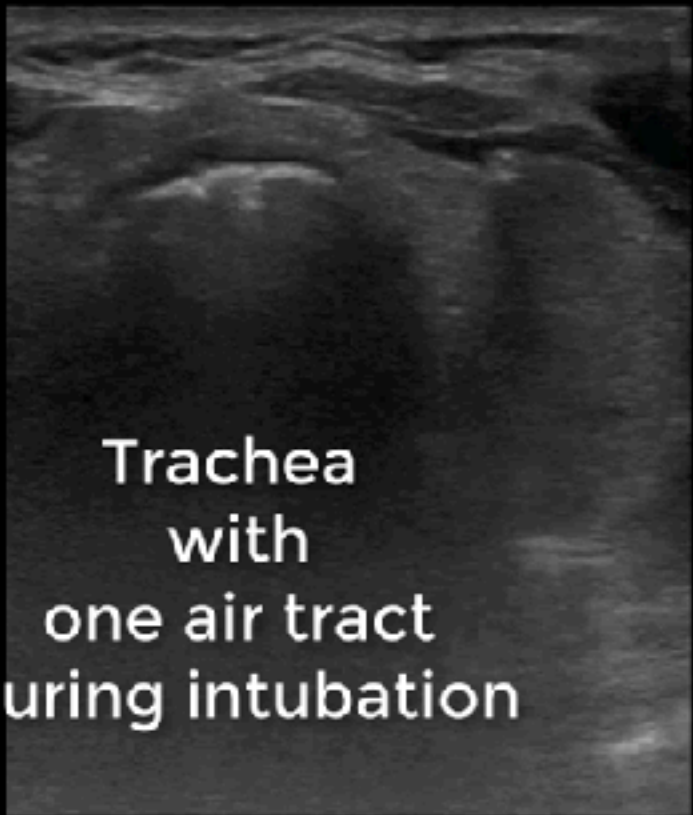

線形探頭 + Trachea compression

Small part1
L12-3
37 Hz
4.5cm

2D
HGen
Gn 100
C 56
3/3/4

P



2

4

4.5cm

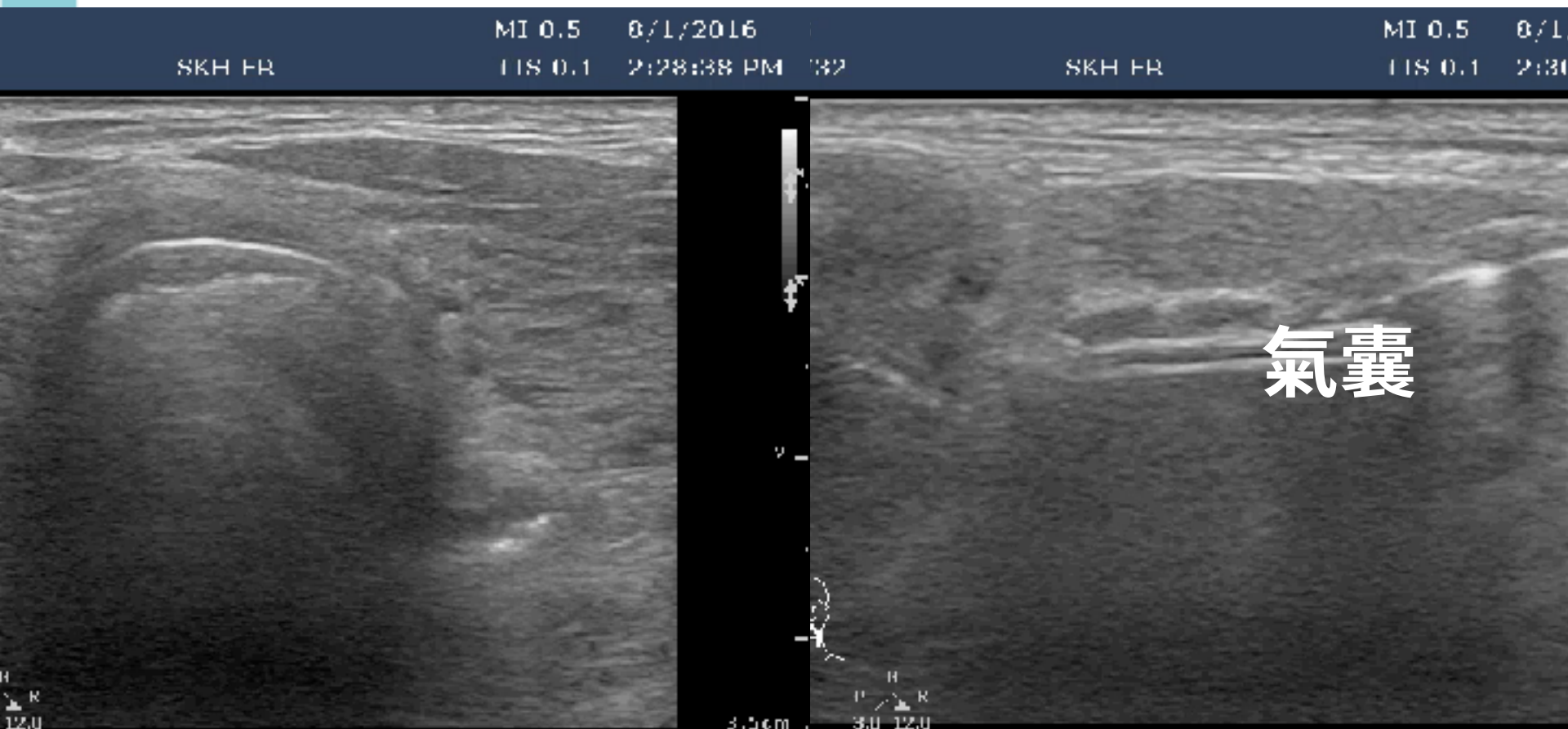


Right

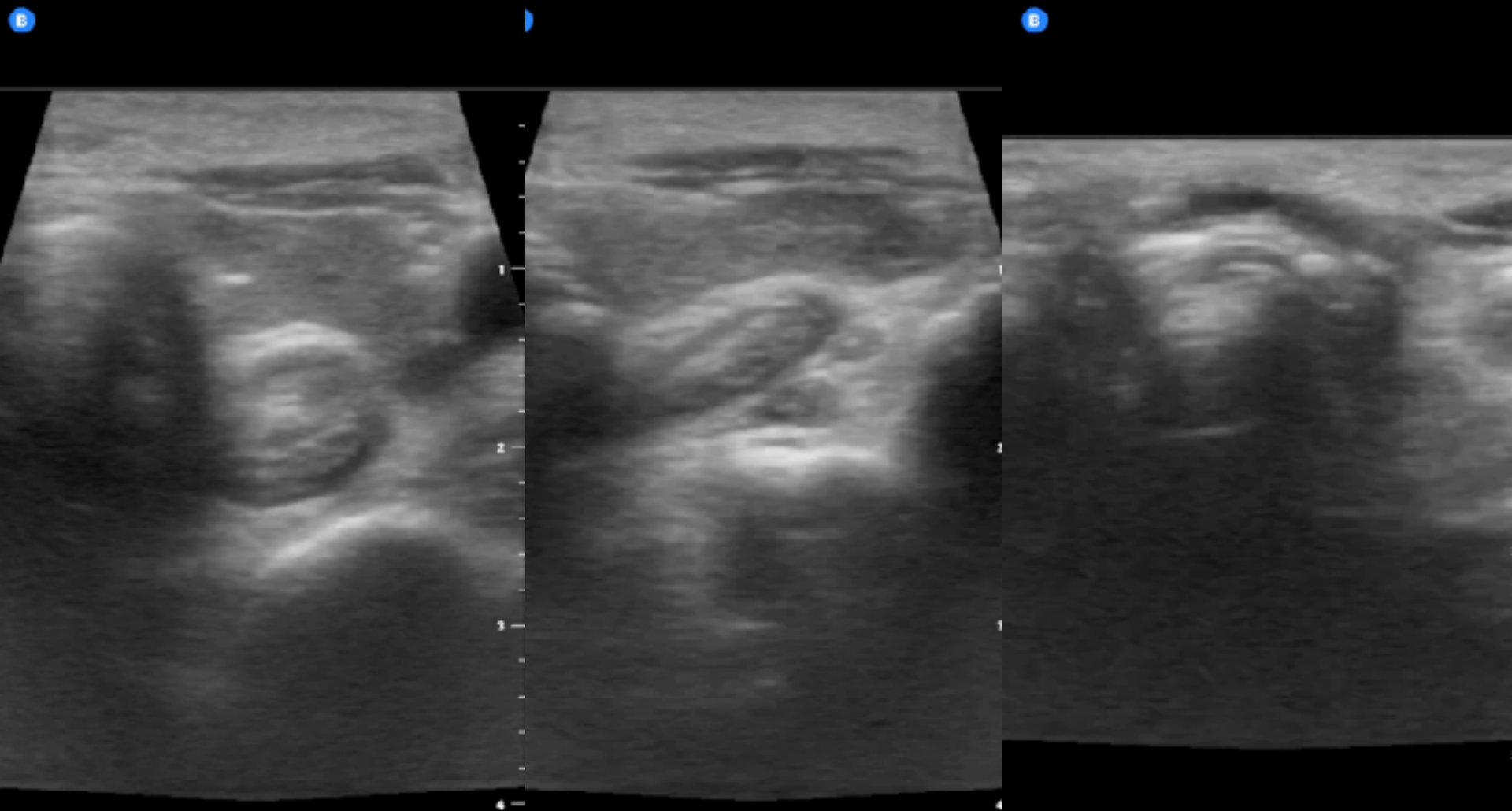
Left

Tracheal compression Direct visualization of ETT

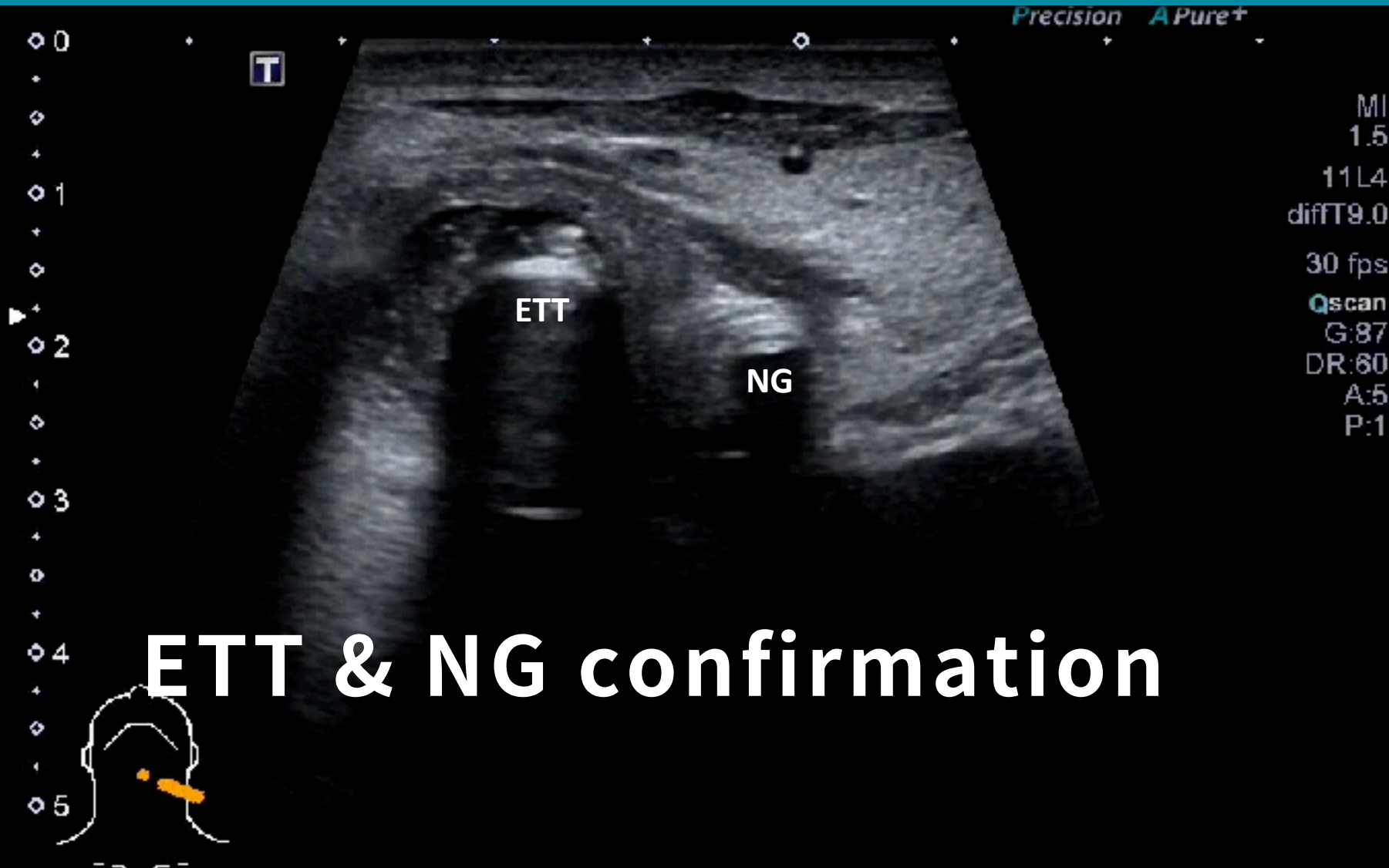
要壓在氣囊頭側喔！



75F, shock & resuscitation



68M , Respiratory failure



插管/CTM/PDT

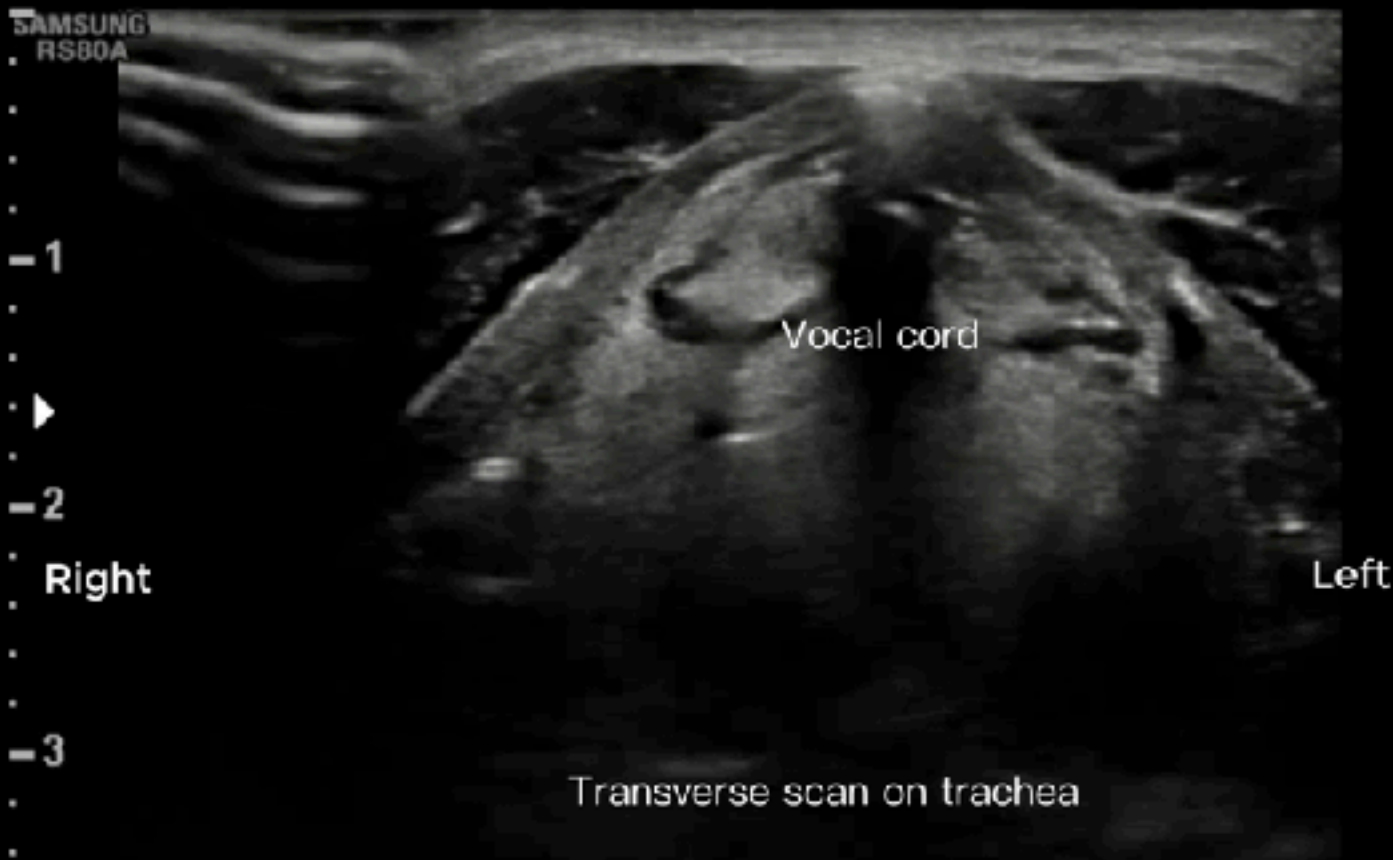


CTM: cryothyroid membrane

PDT: percutaneous dilatational tracheostomy

L3-12A / SmallParts / FPS40 / MI0.96 / TIs0.1 / 01-09-2016 10:29:39 AM

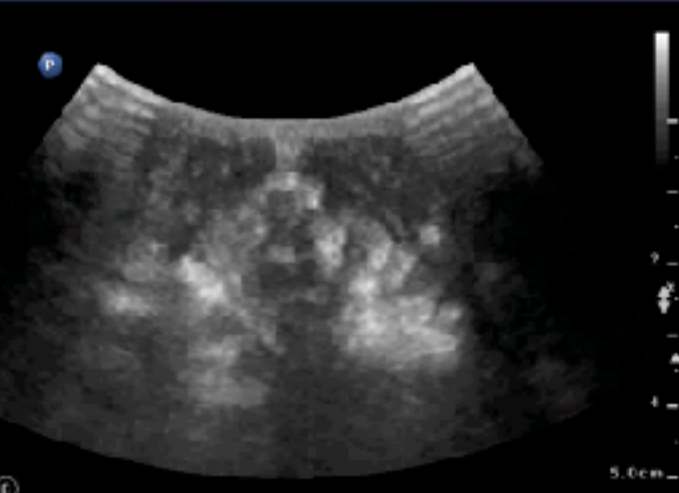2D G53/DR58/FA4/P90/2.7/Frq Pen./3.5cm



Stridor & Dyspnea. Crico or PDT ?



SKH ER MI D.8 1/6/2016
TIS 0.1 6:33:17 PM

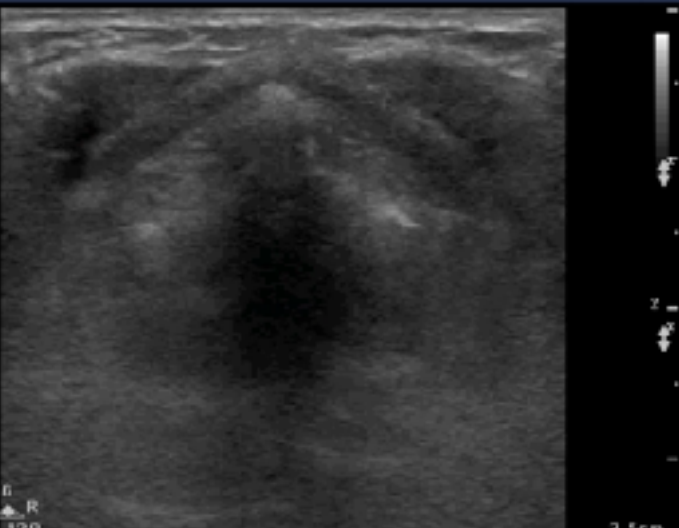


07 10

SKH ER

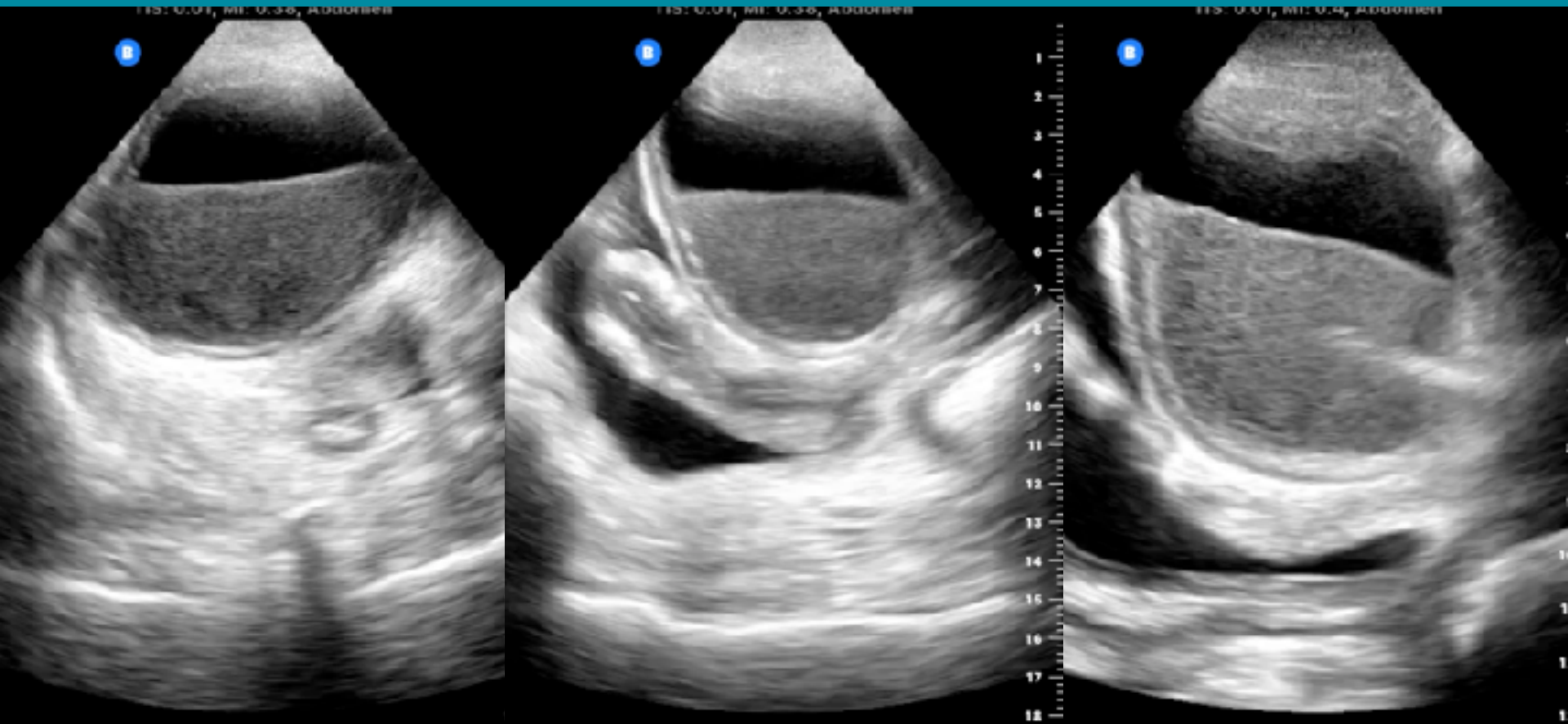
MI 0.9 1
TIS 0.2 6

SKH ER MI D.9 1/6/2016
TIS 0.2 6:37:25 PM



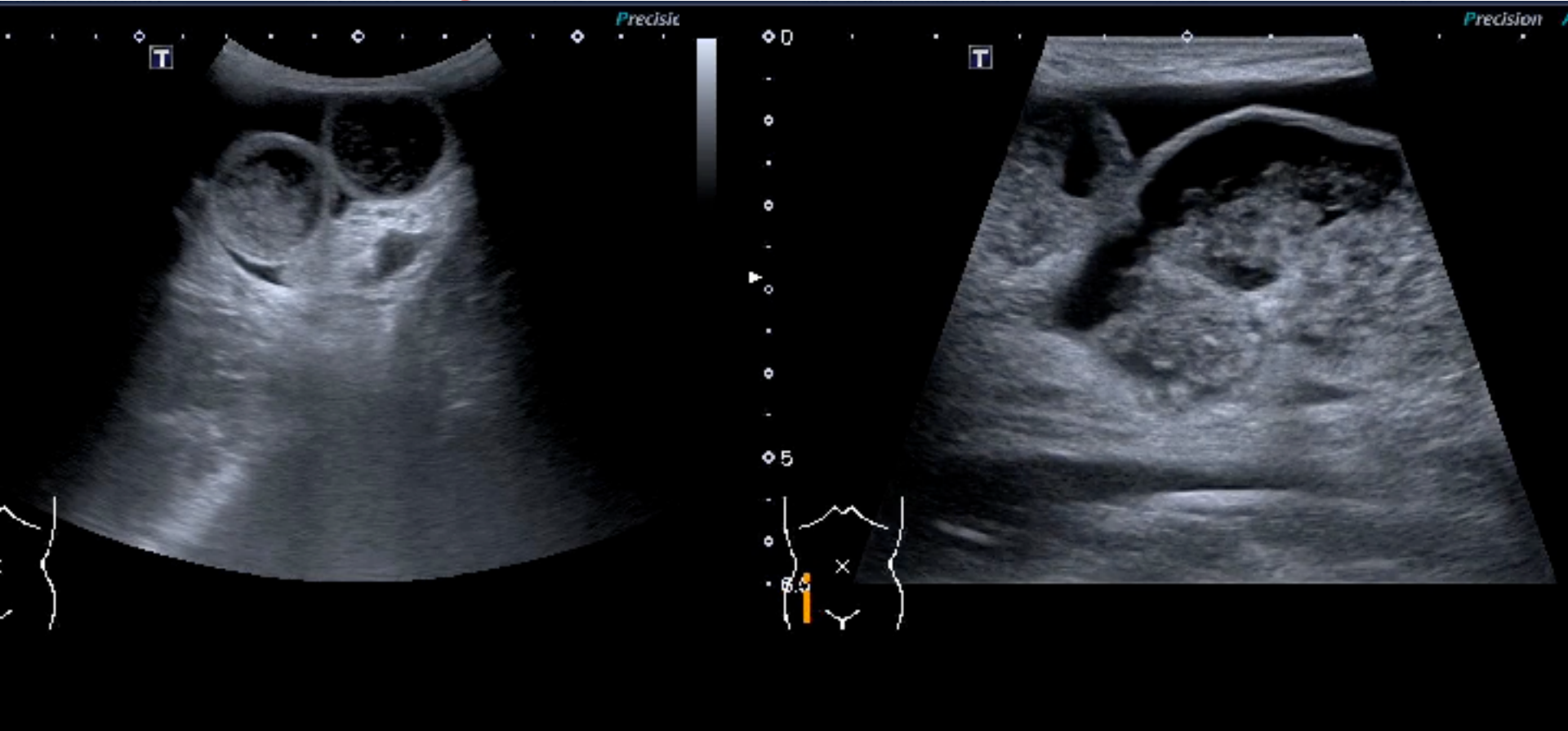
G
P R
3.0 12.0

75F, shock & resuscitation

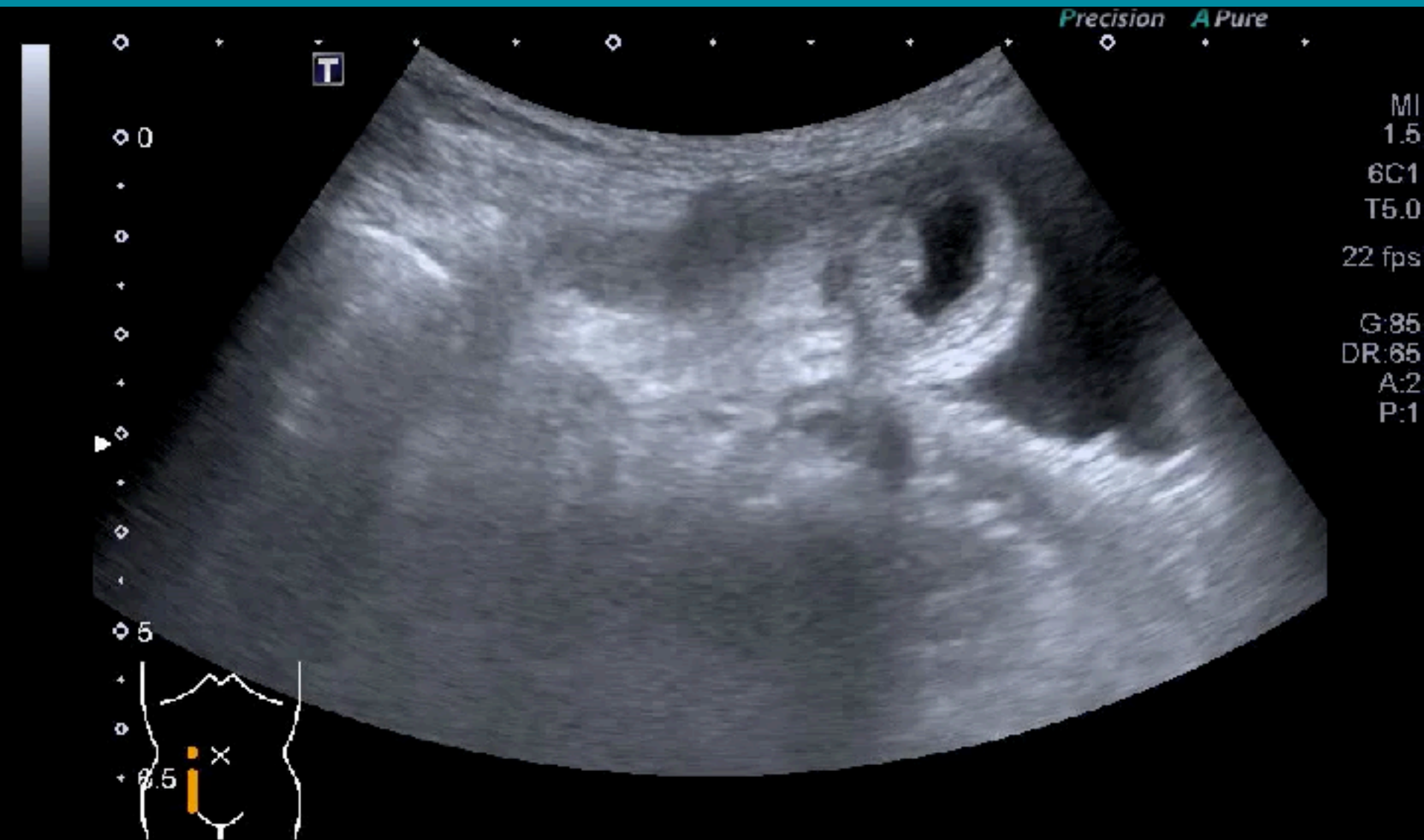

69M, right inguinal pain

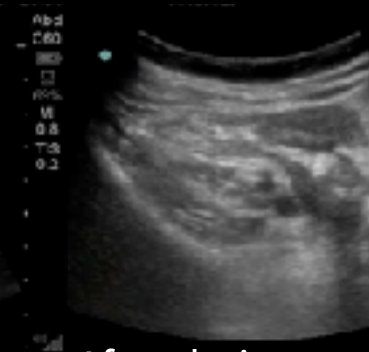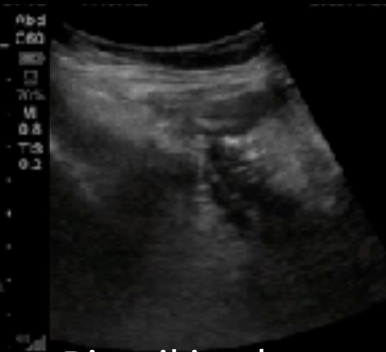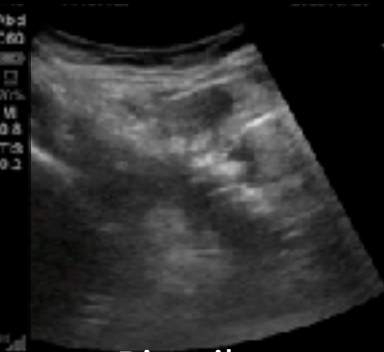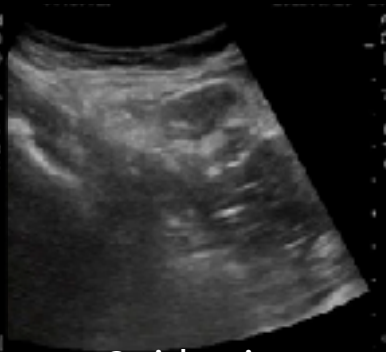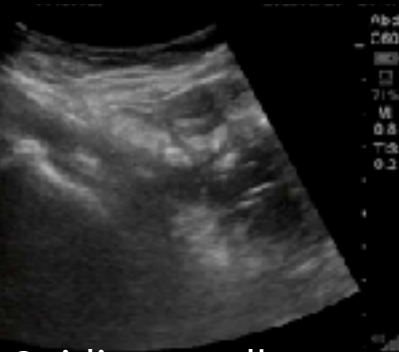
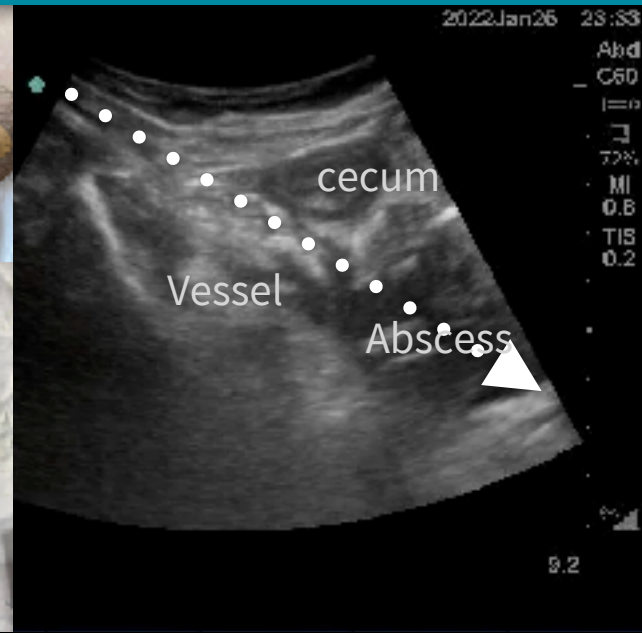
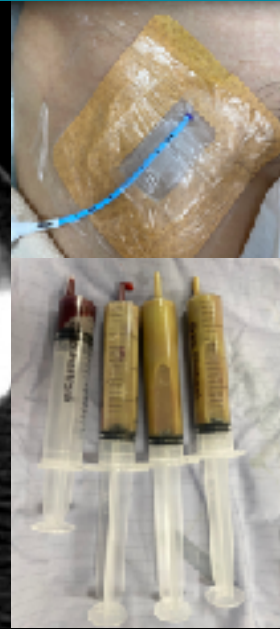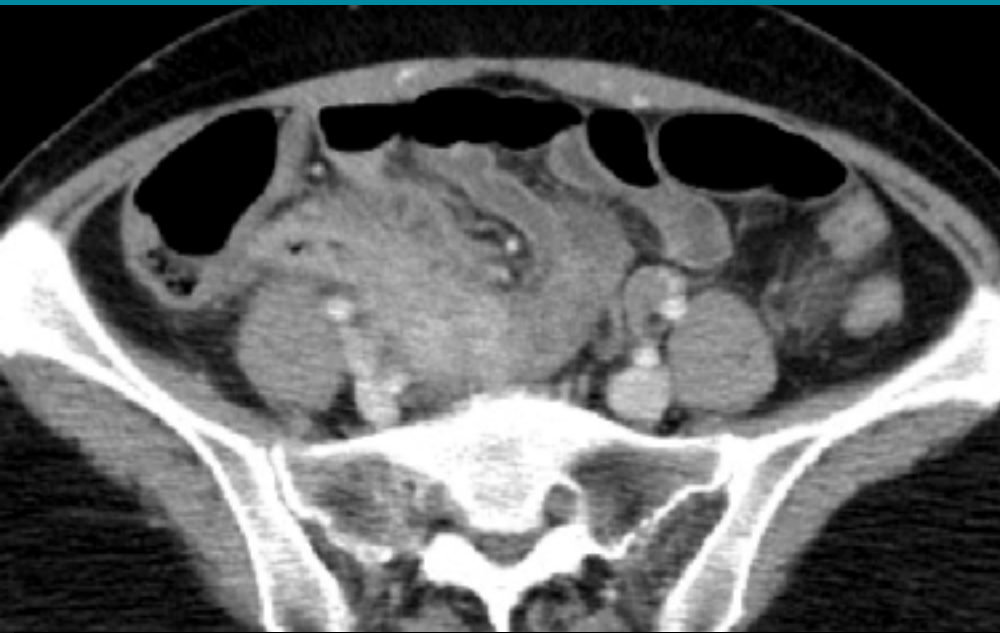Hernia diagnosis & find best reduction path



Ultrasound guided hernia reduction



Ultrasound guided pigtail for abscess drainage



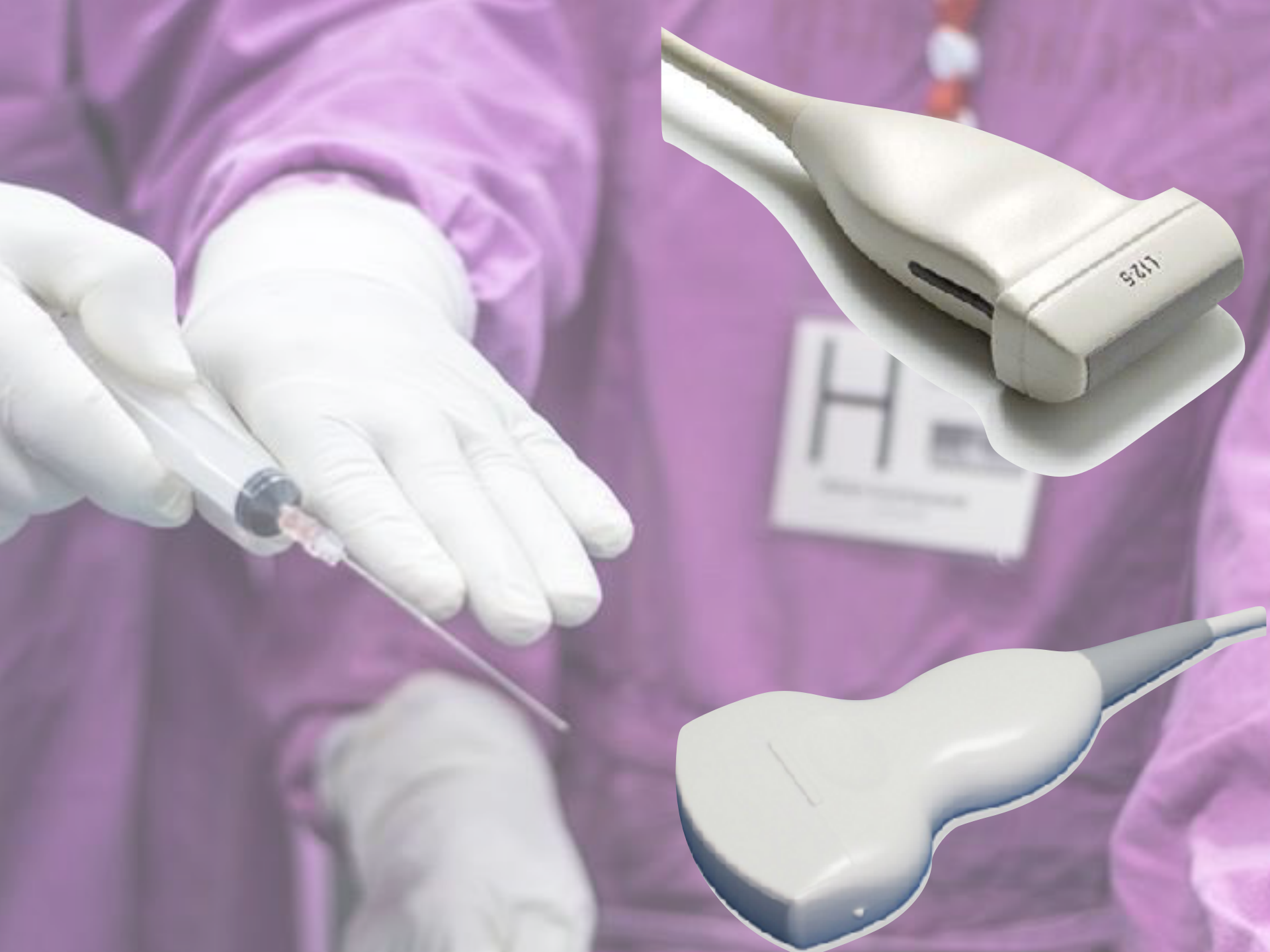Guiding needle

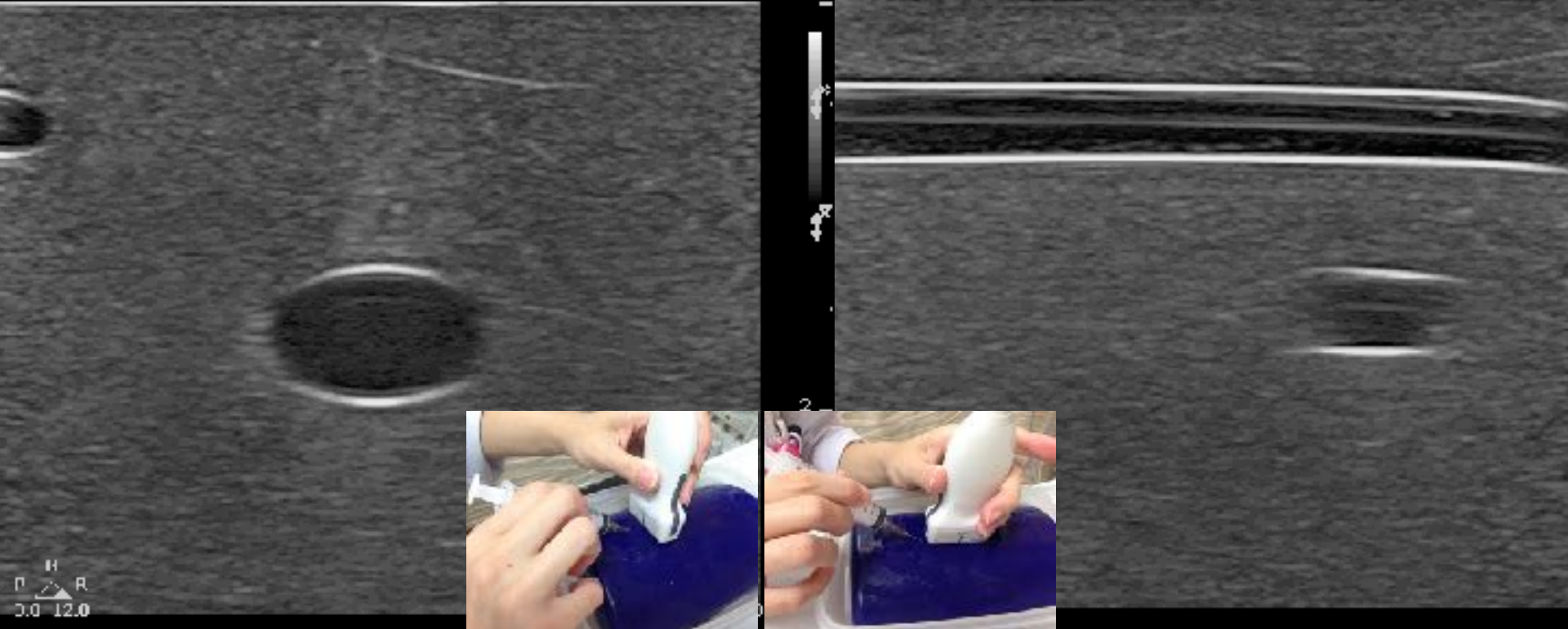
Guidewire

Pigtail

Pigtail in abscess

After drainage



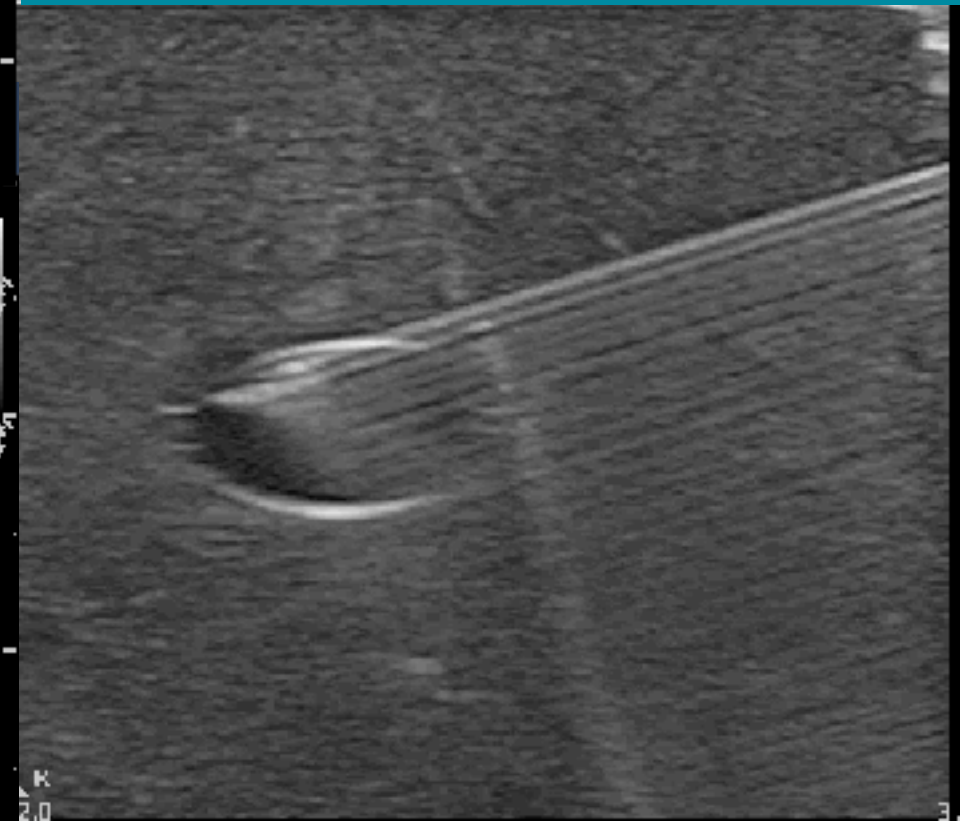
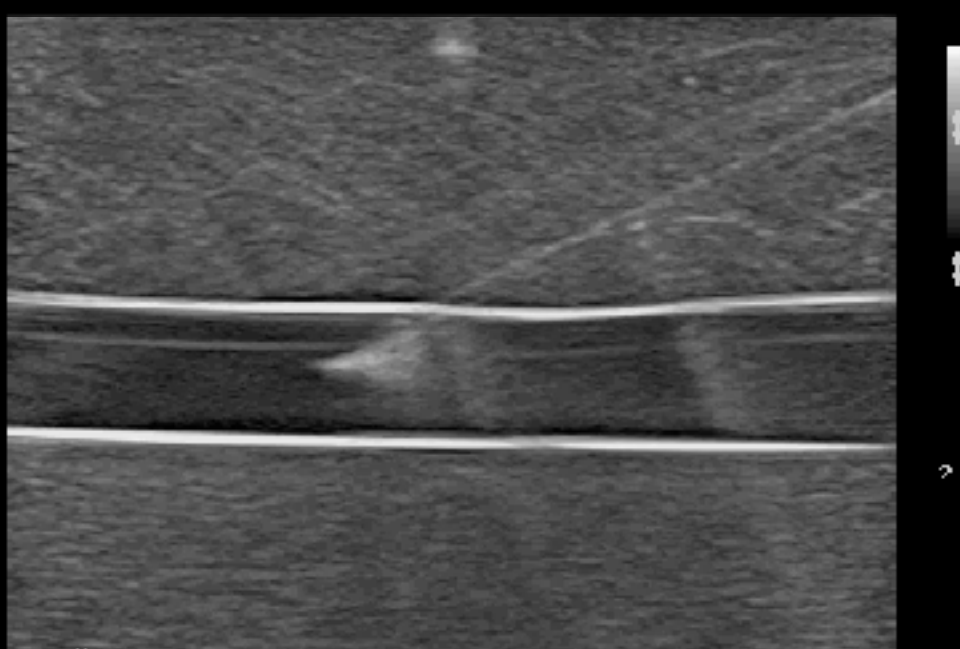
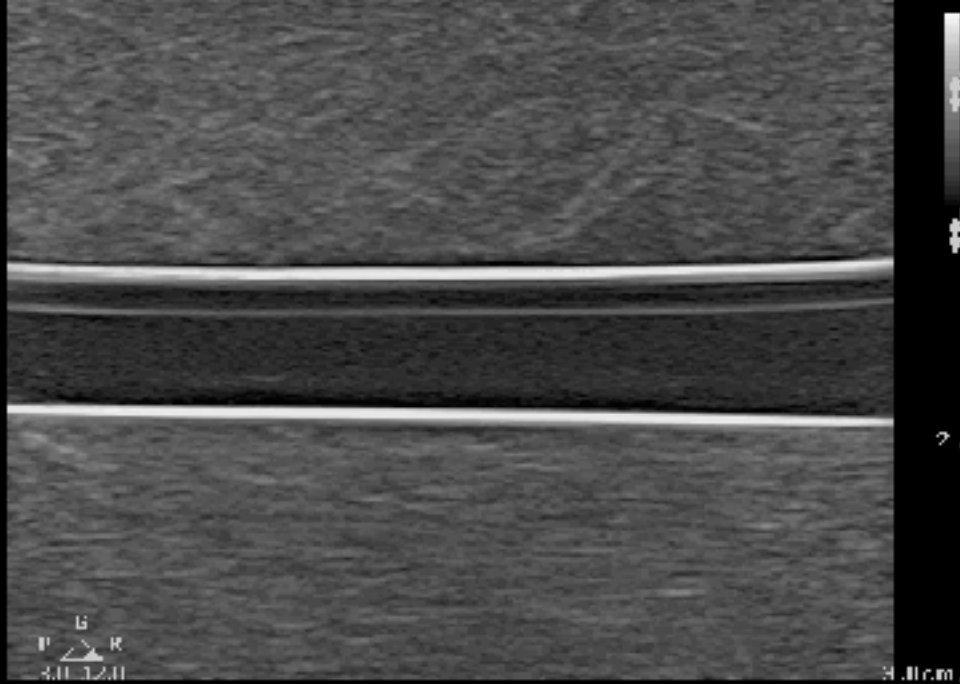


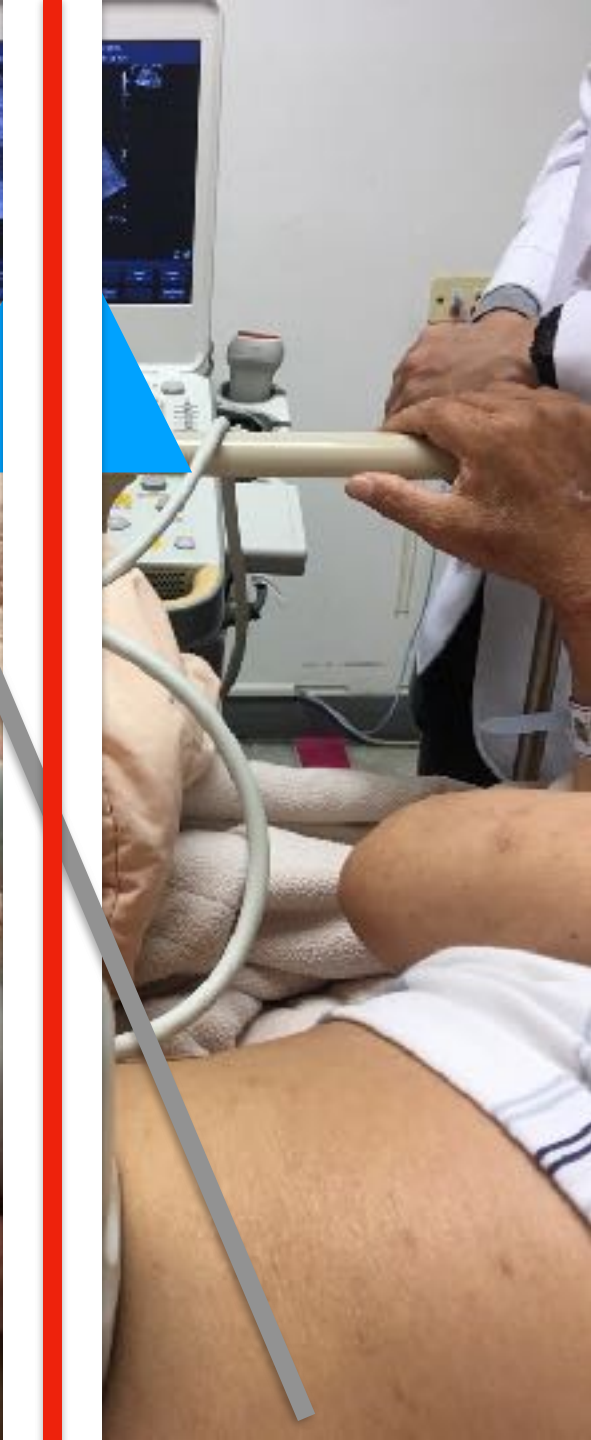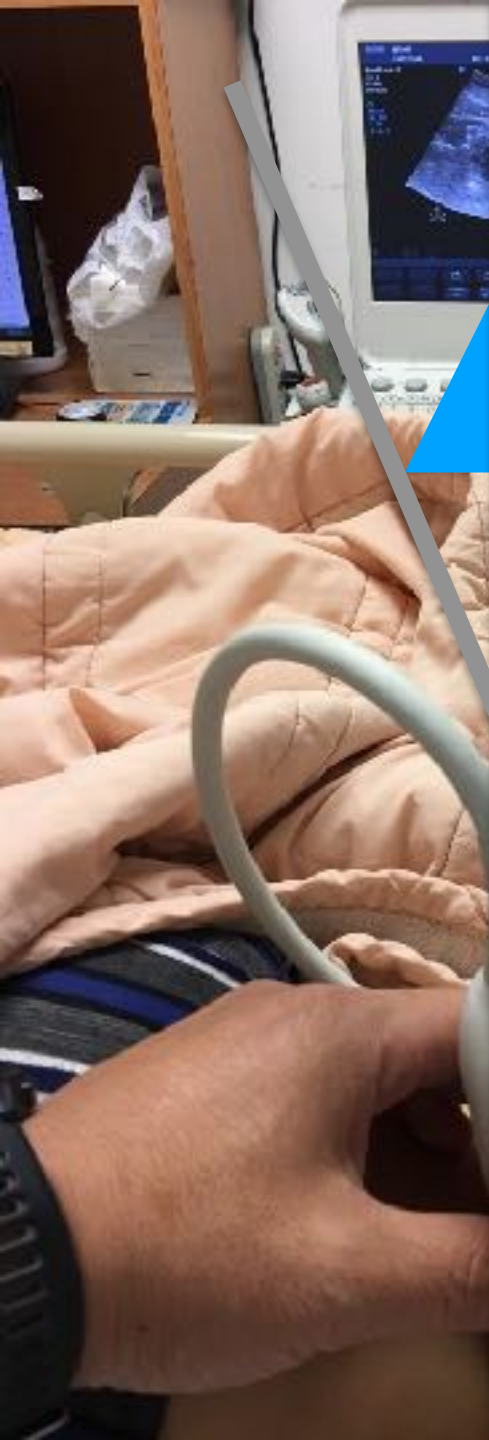MASTER NEEDLING (基本功)

Off-plane

In-plane

NEEDLE OPTIMIZATION 探頭要垂直針身



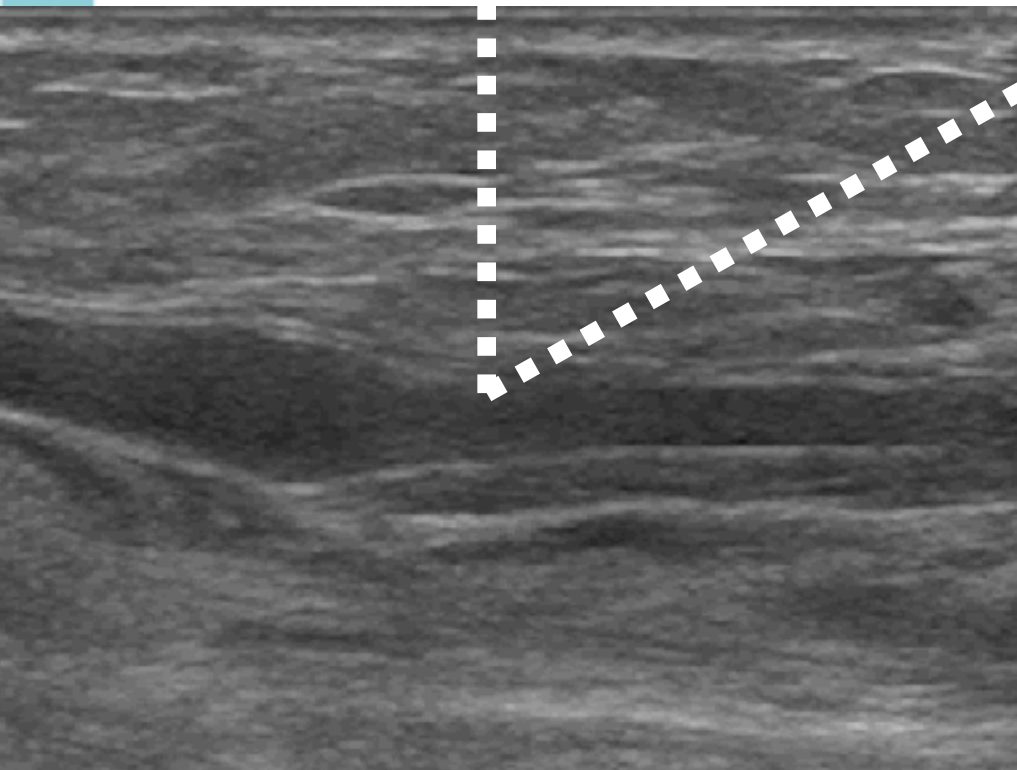
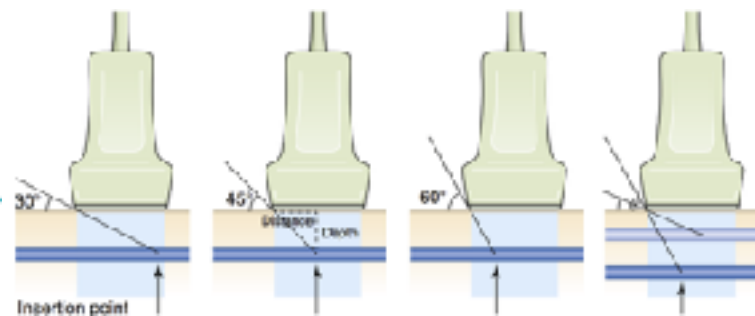


保持軸線

堅守切面

擬定路徑

長軸進針先計算

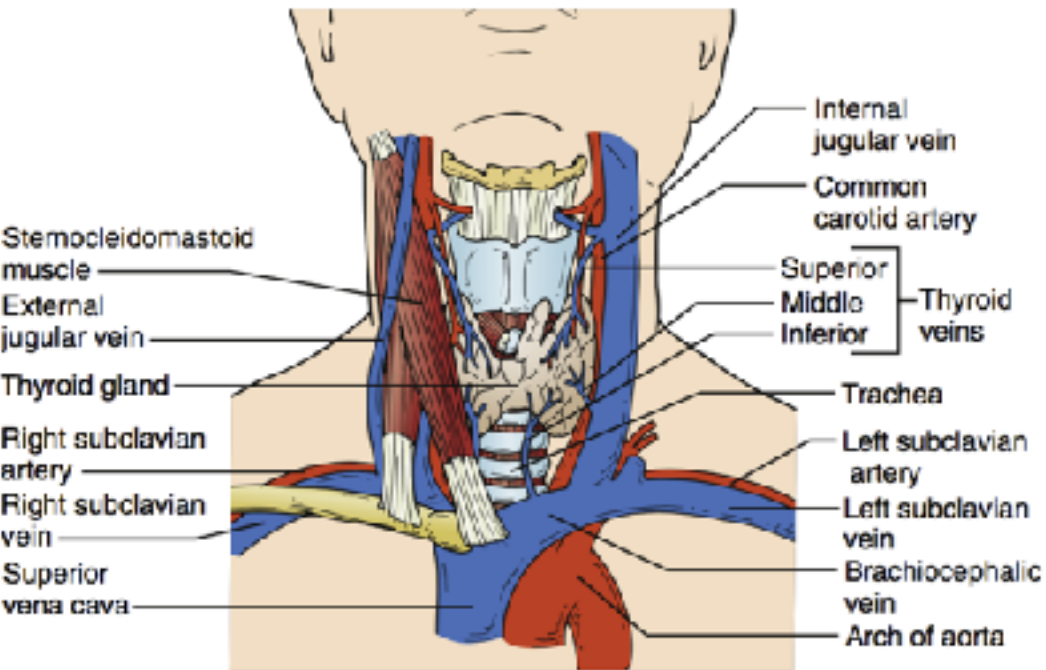
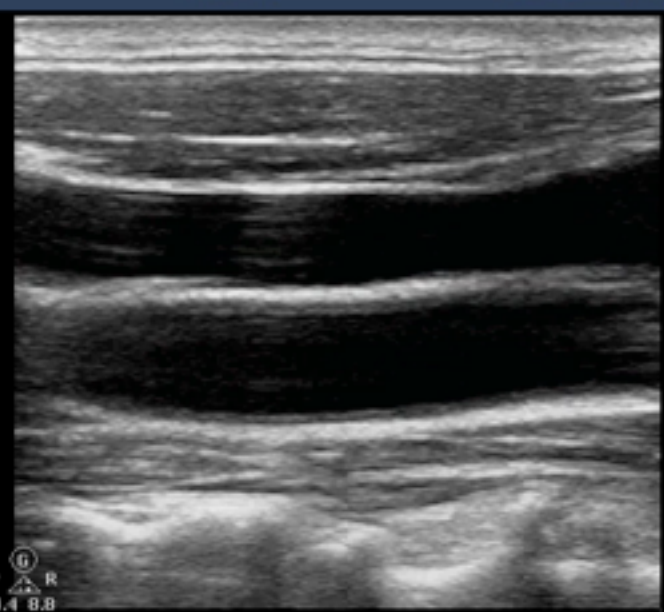
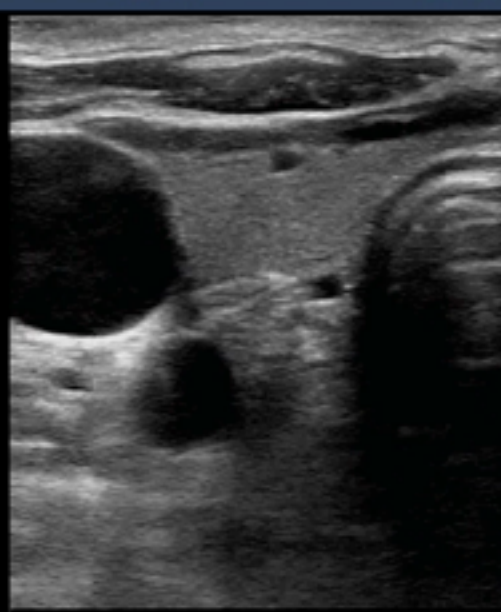


目標深度
入針位置
進針角度
導管長度

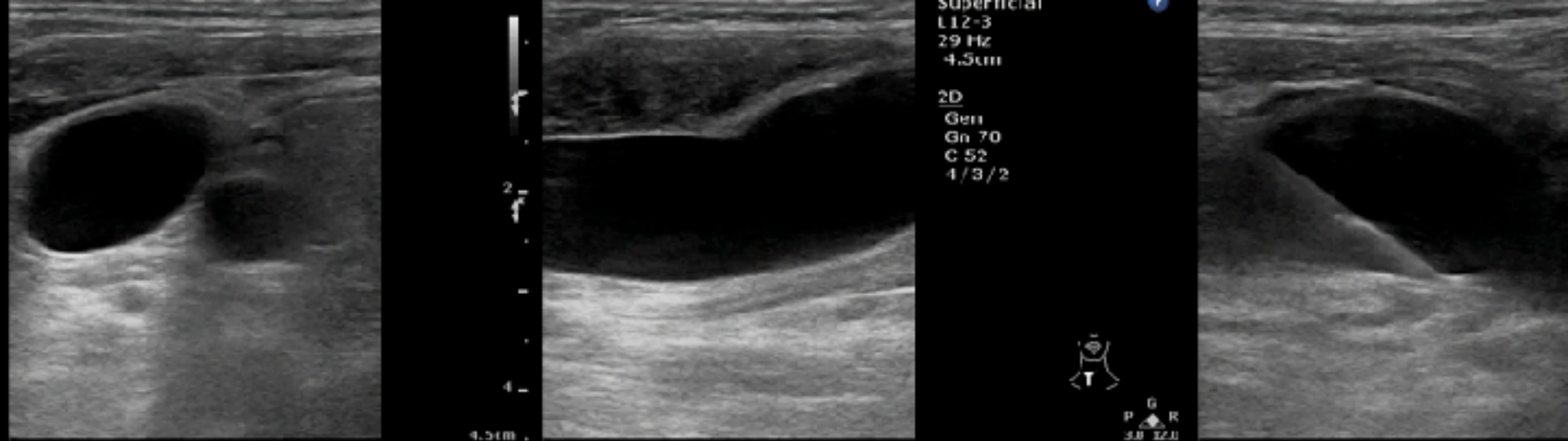
DEPTH OF VEIN (CM)	ENTRY DISTANCE AWAY FROM PROBE (CM) FOR PROPER VISUALIZATION	TRUE DISTANCE TO VEIN (CM)	SUGGESTED CATHETER LENGTH (CM)
0.5	0.5	0.6	2.4
1.0	1.0	1.2	3.2
1.5	1.5	1.8	6.35
2.0	2.0	2.4	6.35

Arterial
L12-3
37 Hz
4.5cm

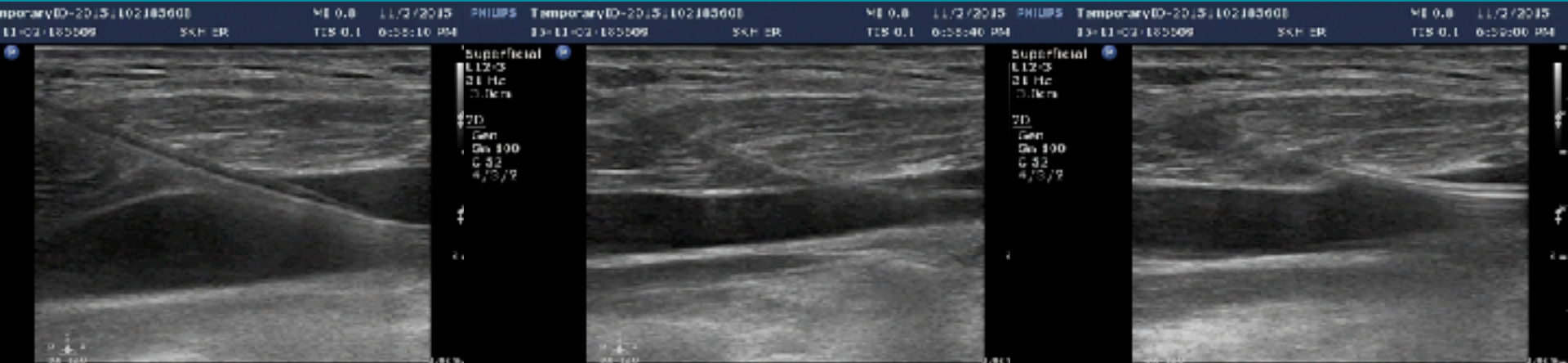
2D
HGen
Gn 50
C 41
3/3/2

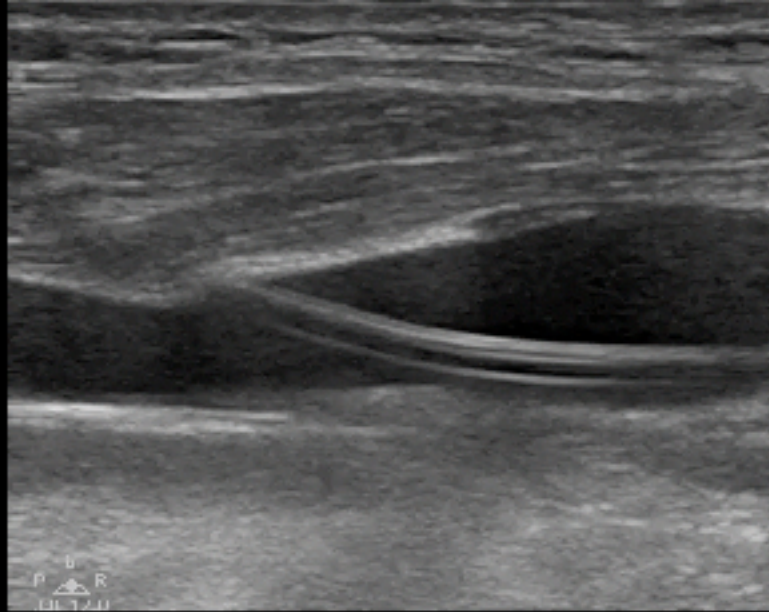


- Size
- Shape
- Depth
- Compressibility**
- Proximity to CCA
- Distal anastomosis with SCV
- Respiratory variation



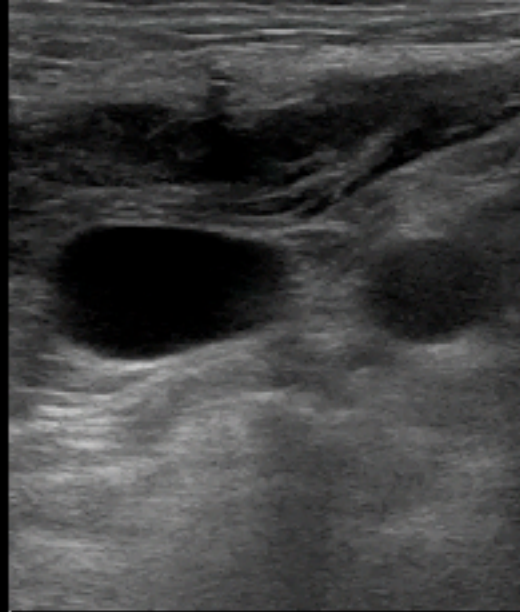
US-GUIDED CVC STEPS



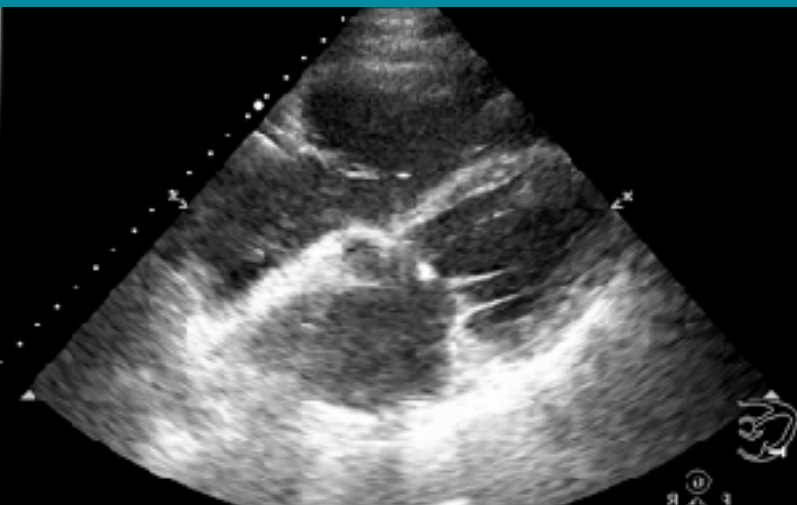


Superficial
112-3
29 Hz
4.3cm

2D
Gen
Ch 70
C 52
1/1/2

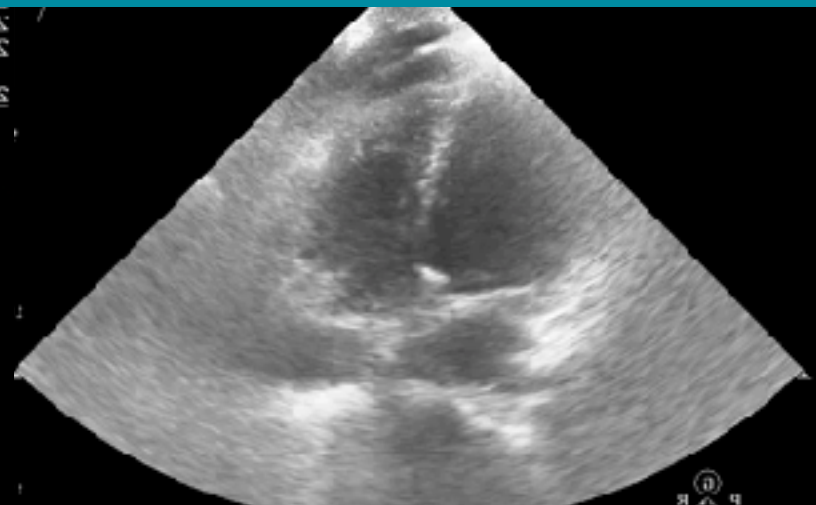


CVC CONFIRMATION



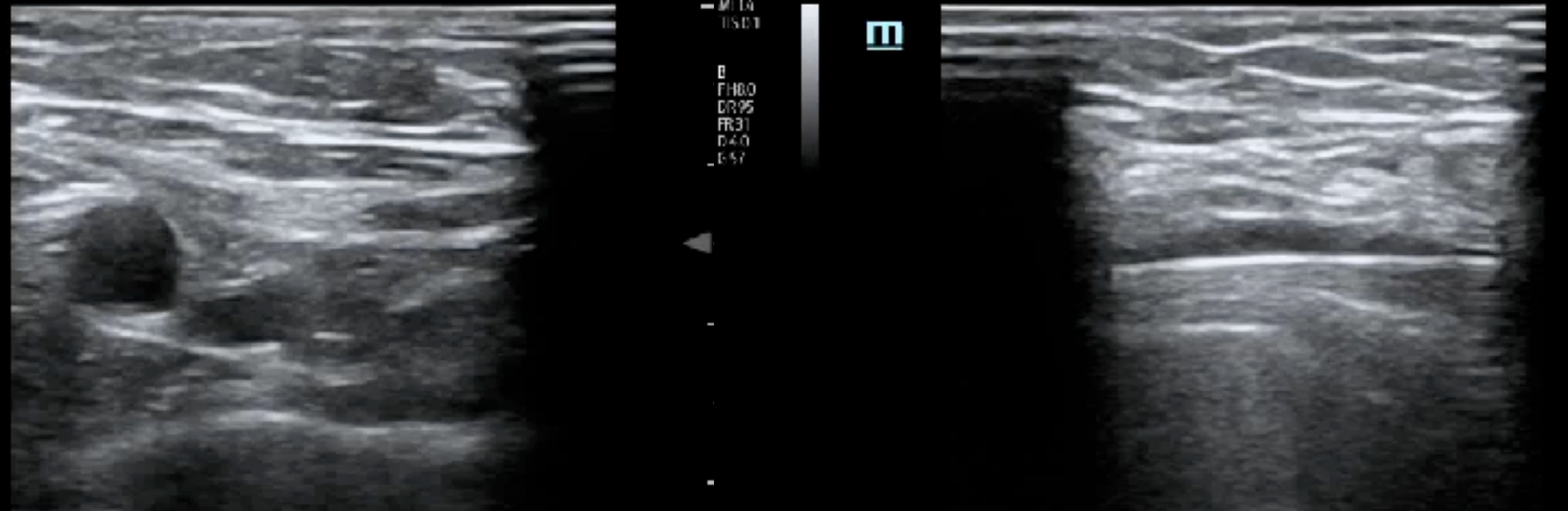
SH 12
21.0cm

2D
HGen
Ch 20
C 20
3/2/0

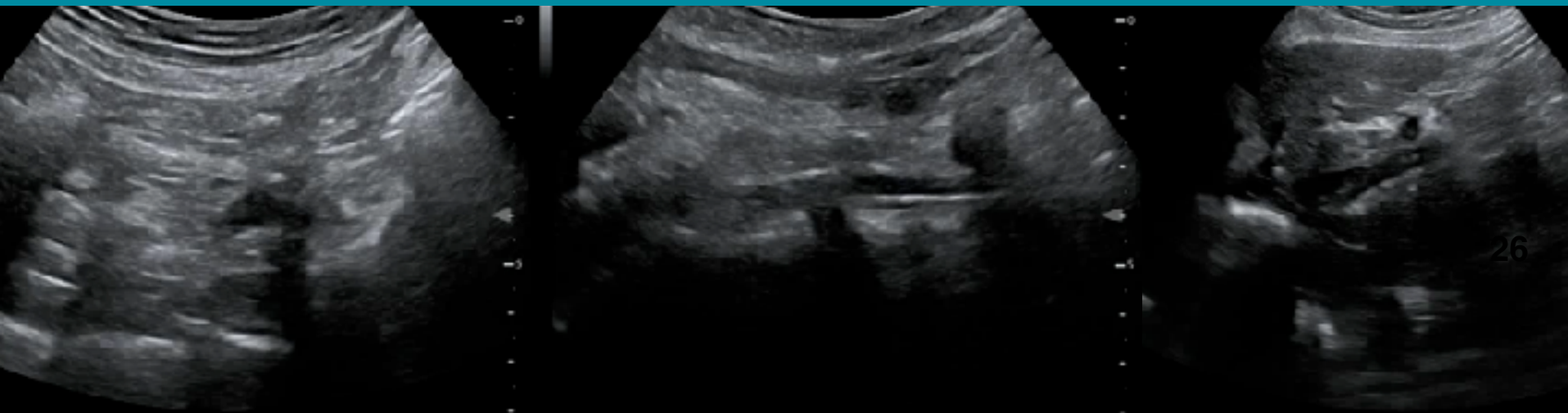

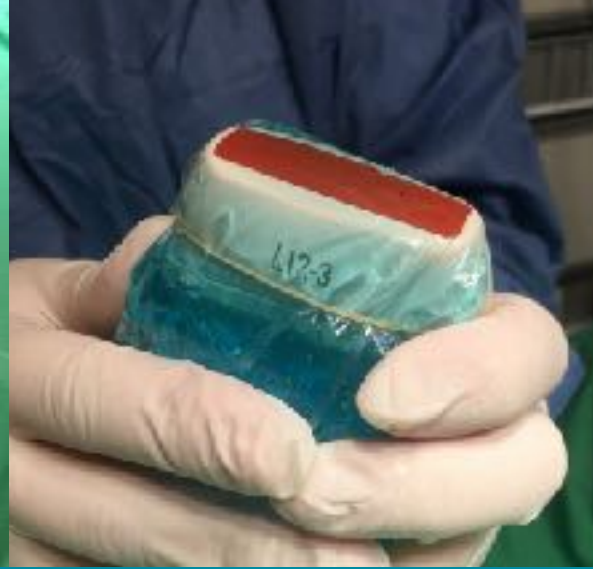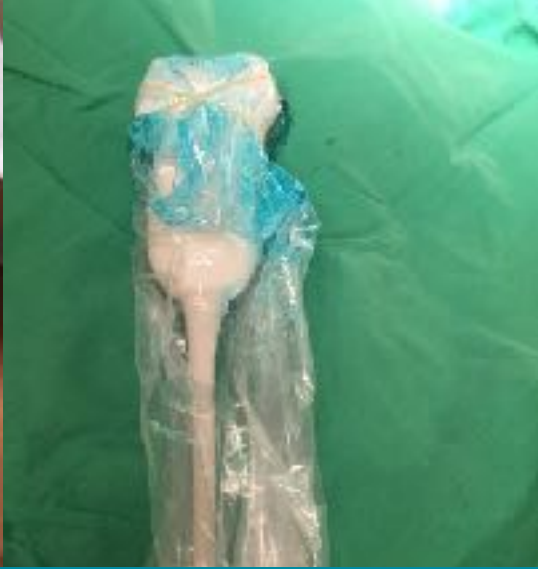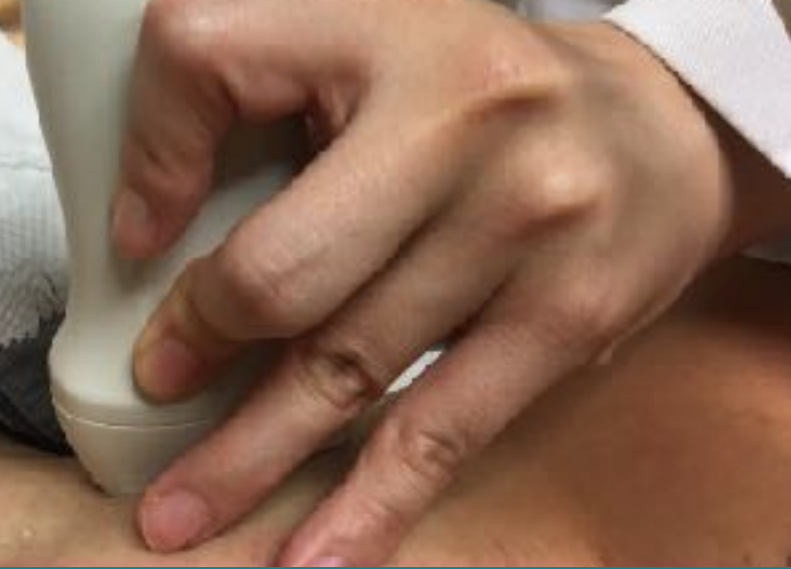SH 12
21.0cm

2D
HGen
Ch 20
C 20
3/2/0

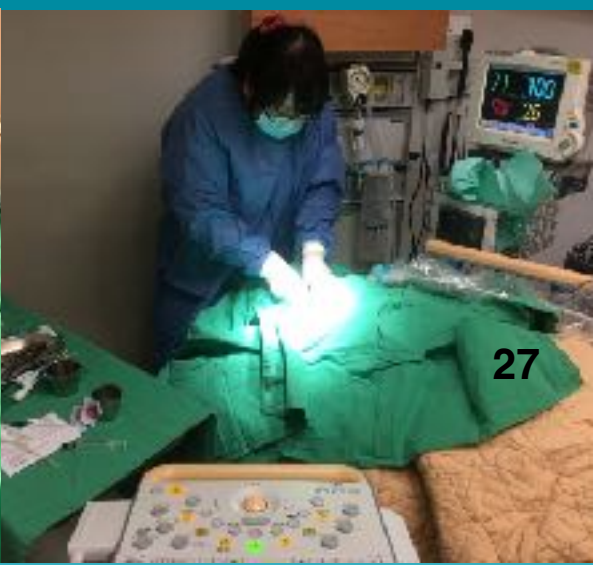
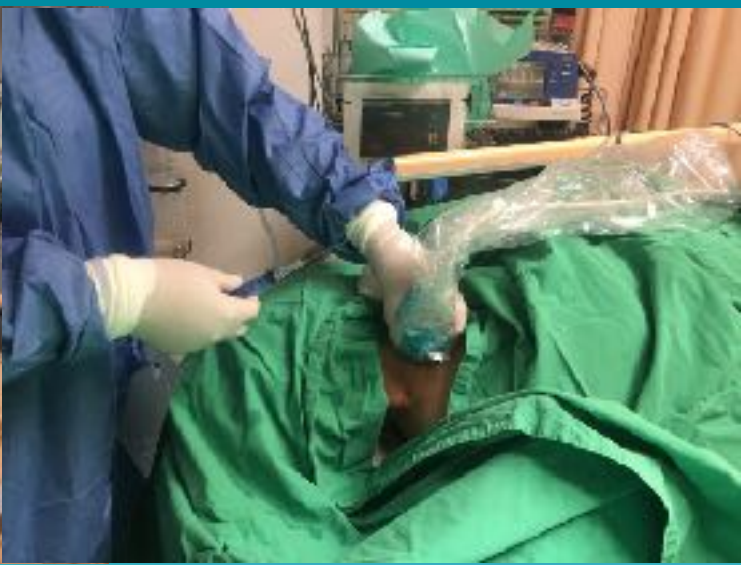
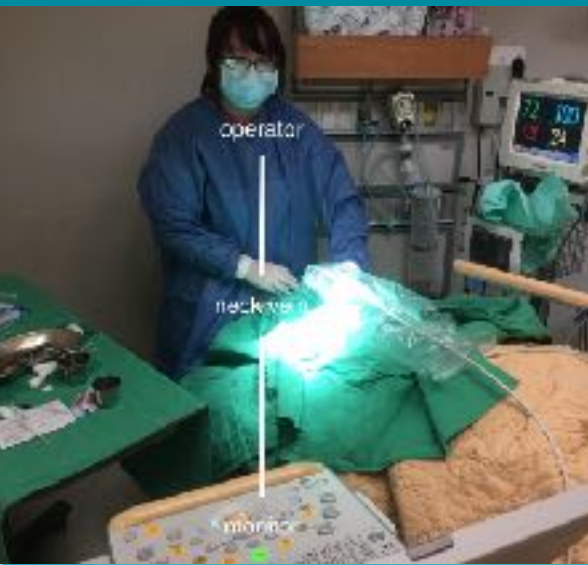CVC CONFIRMATION

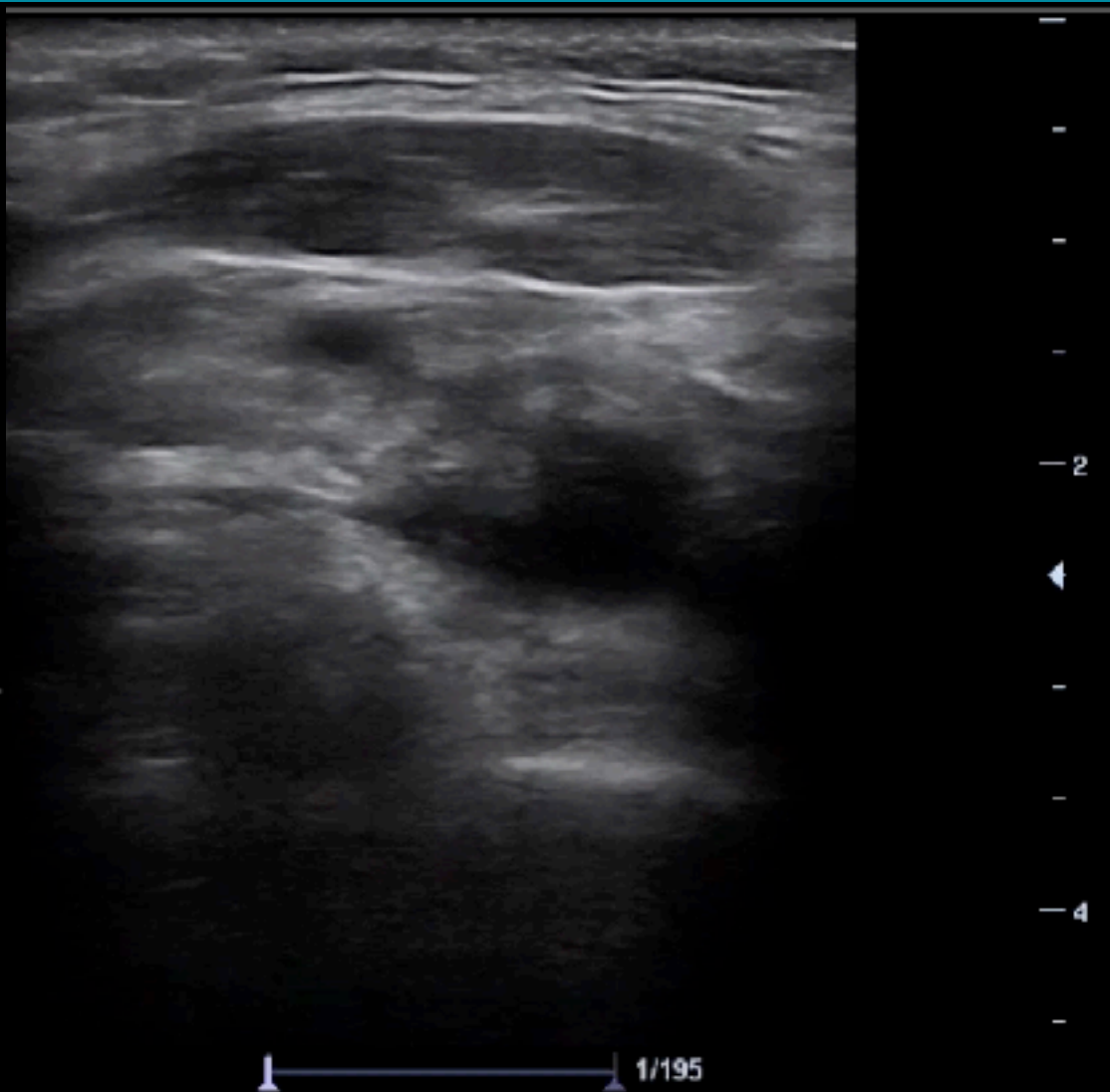
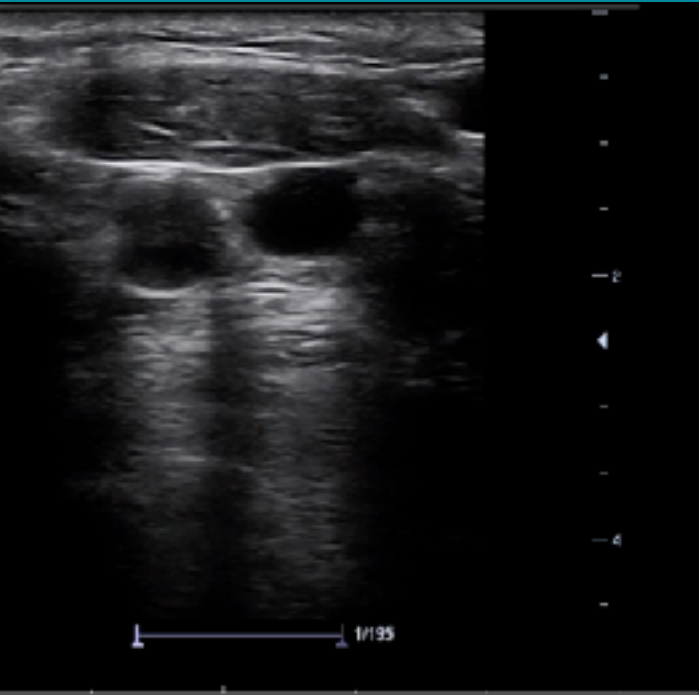




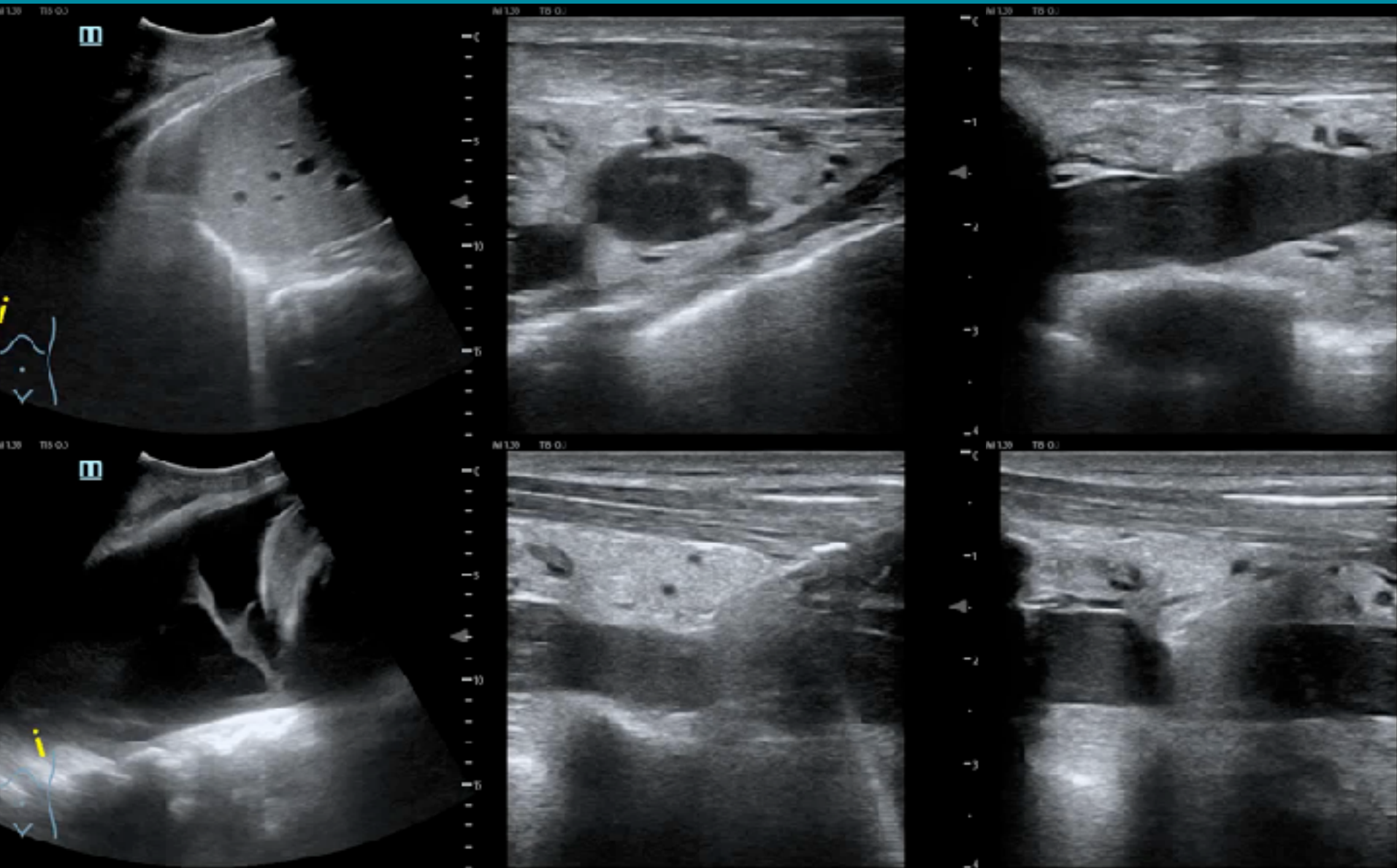
US-GUIDED CVC

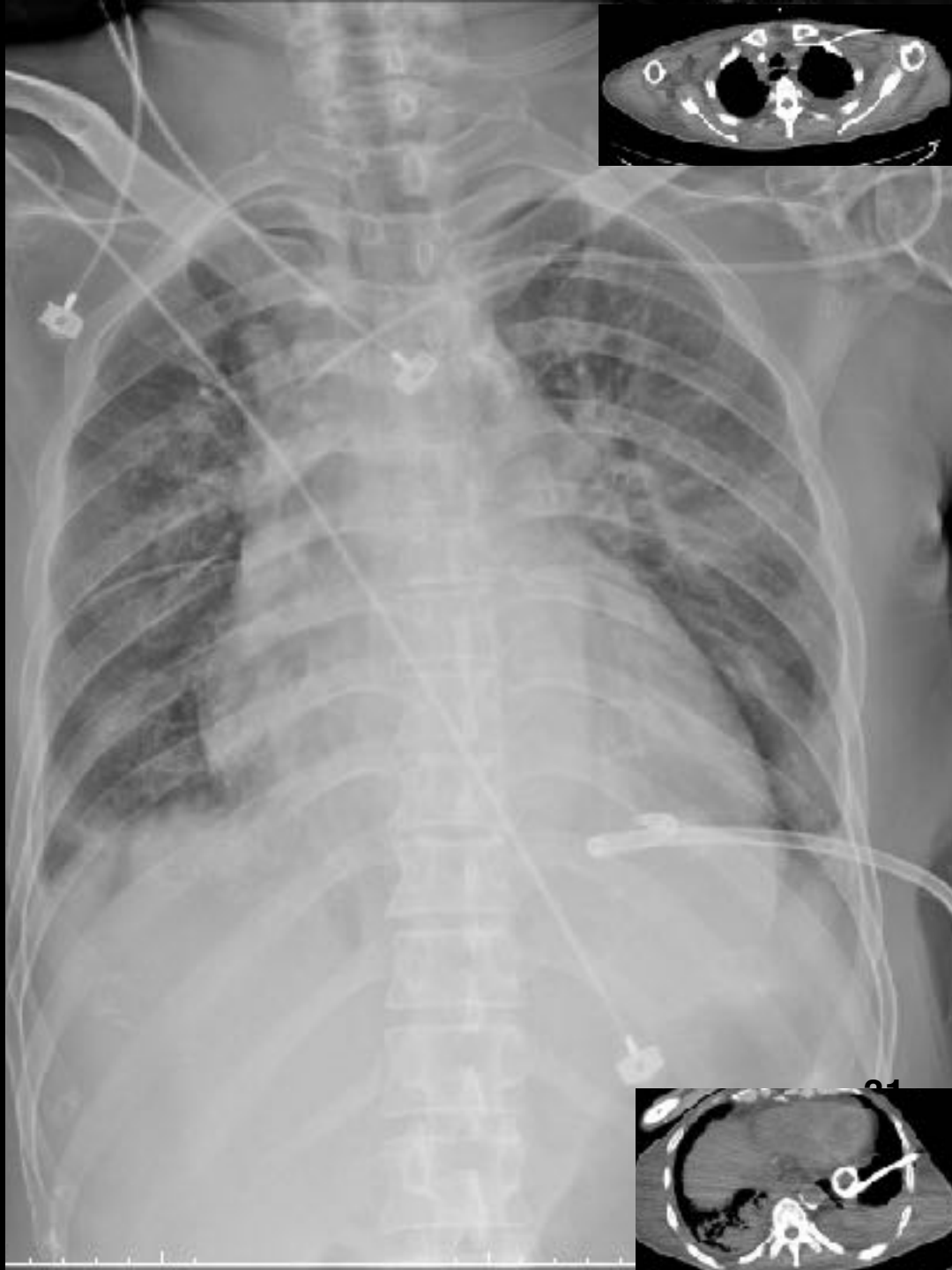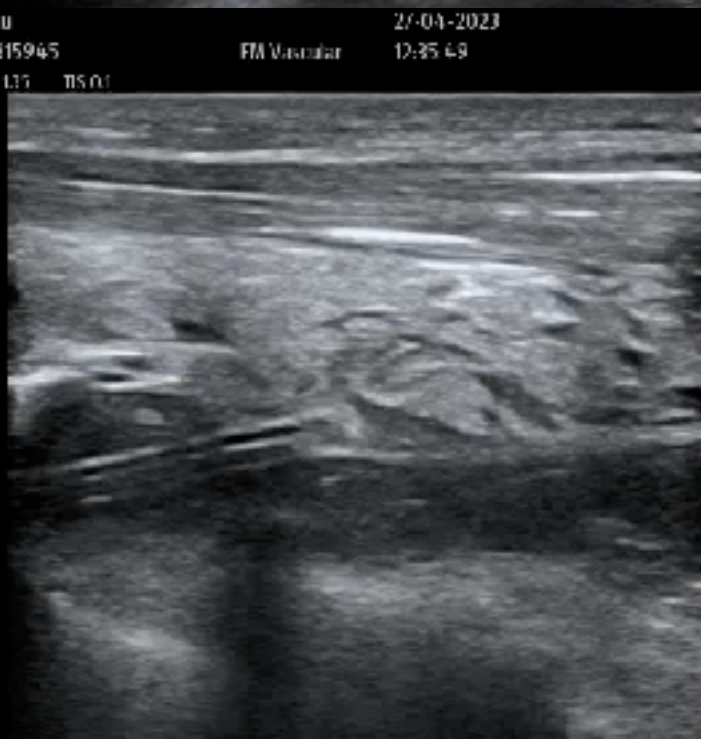

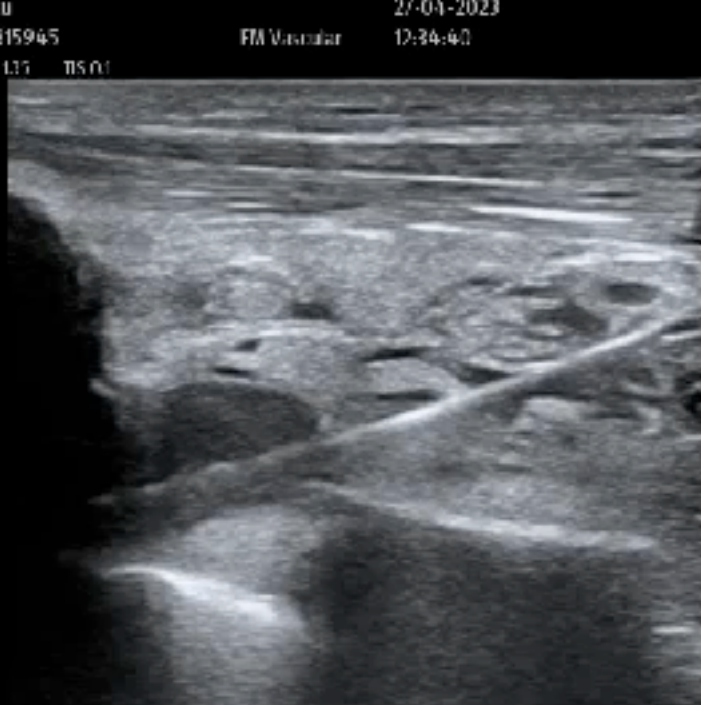
穿刺前的三思: 合適? 安全? 容易?



64M, 安中轉入，Shock & AMS





PIV: Basilic & Cephalic V



Landmark: humerus & brachial aretery

D-20170705165331

MI 1.1 7/5/2017

55331

SKH ER

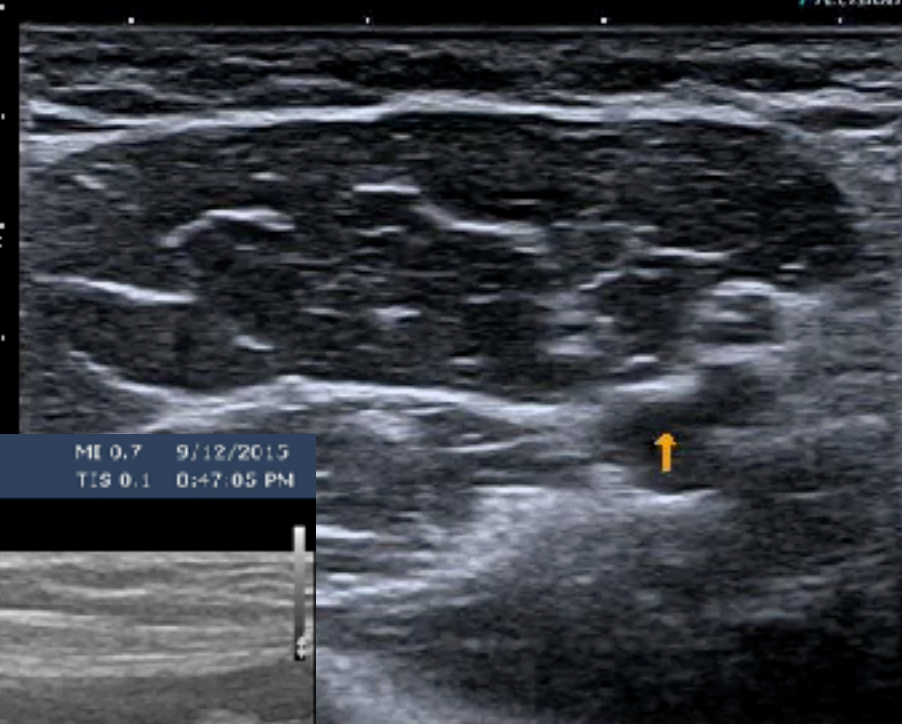
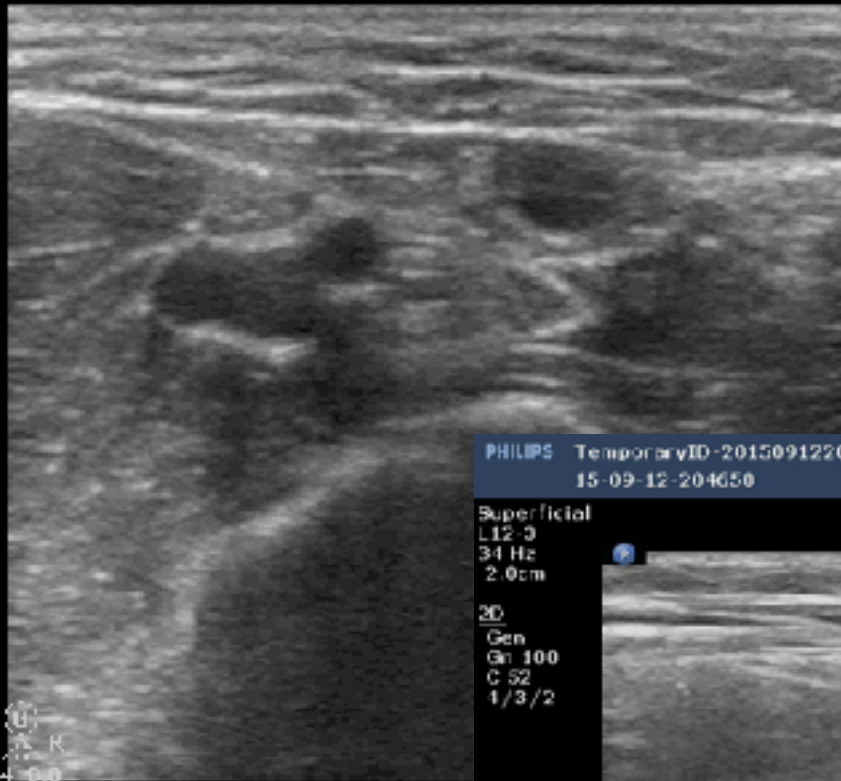
TIS 0.1 5:29:12 PM

Garden Hospital

MSK 3

3085

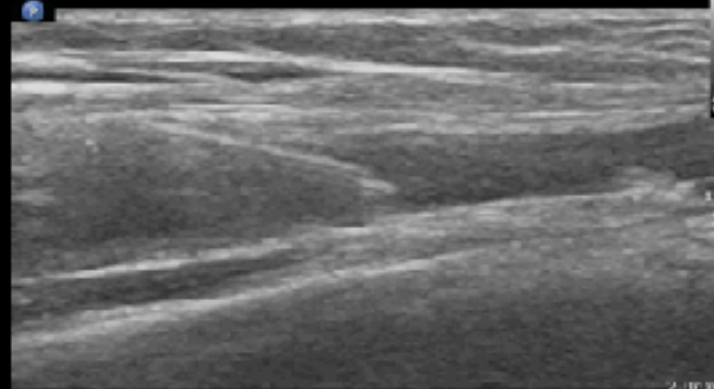
Precision


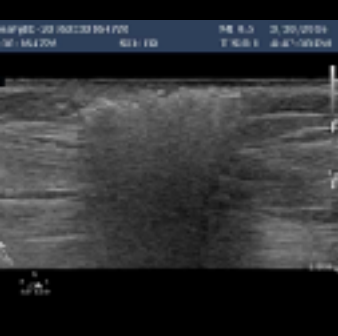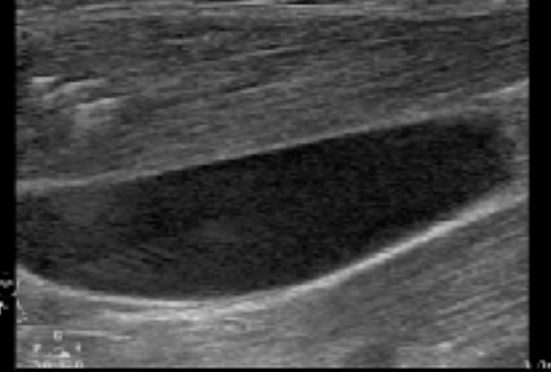
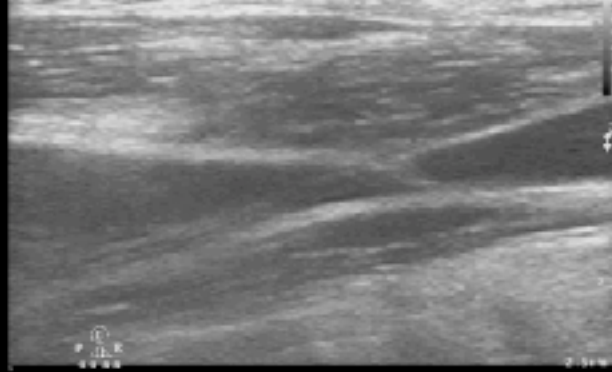
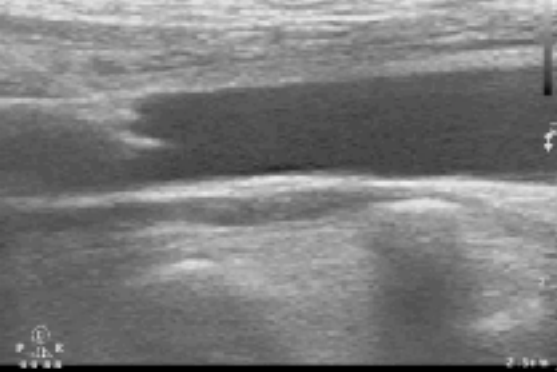


PHILIPS TemporaryID-20150912204658
15-09-12-204650 SKH ER

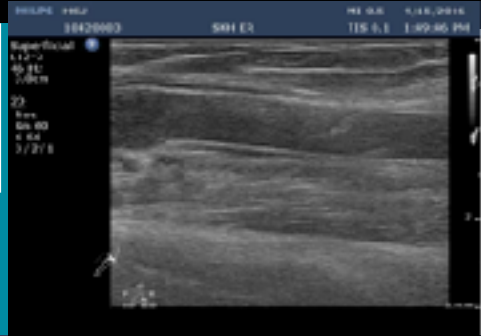
MI 0.7 9/12/2015
TIS 0.1 0:47:05 PM

Superficial
L12-0
34 Hz
2.0cm
2D
Gen
Gn 100
C 52
1/3/2





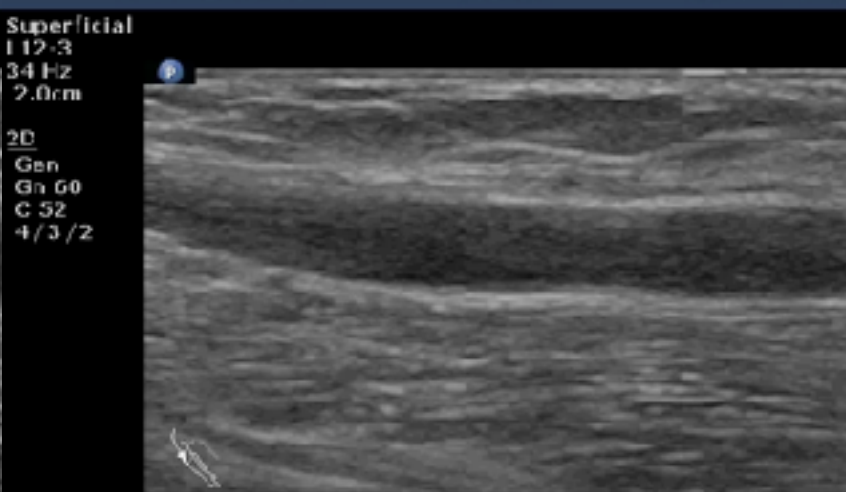
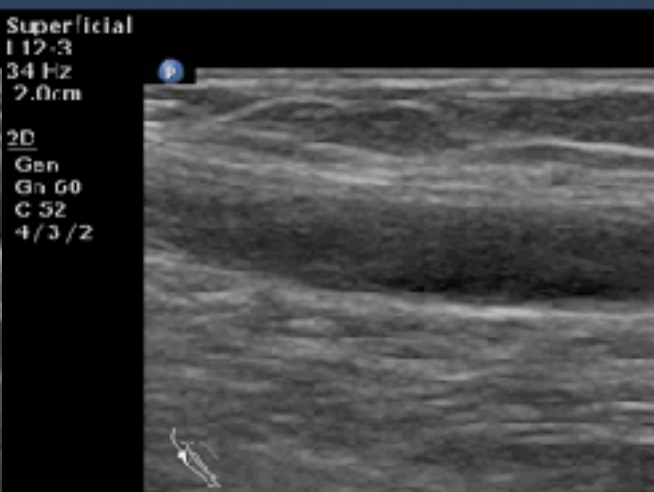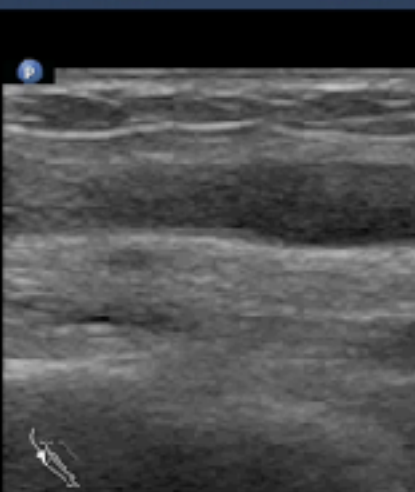TROUBLE SHOOTING



TemporaryID-20:50828131428
-08-28-131428 8KH ER

PHILIPS TemporaryID-20:50828131428
15-08-28-131428 8KH ER

PHILIPS TemporaryID-20:50828131428
15-08-28-131428 8KH ER TIS 0.1 1:30



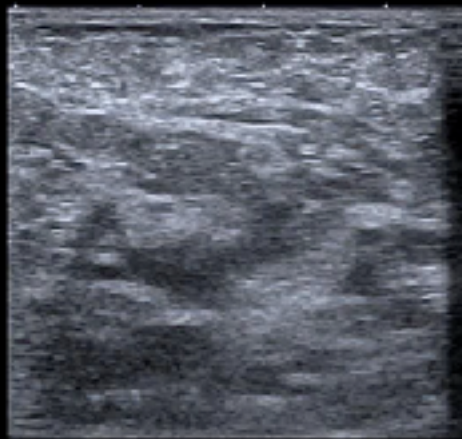

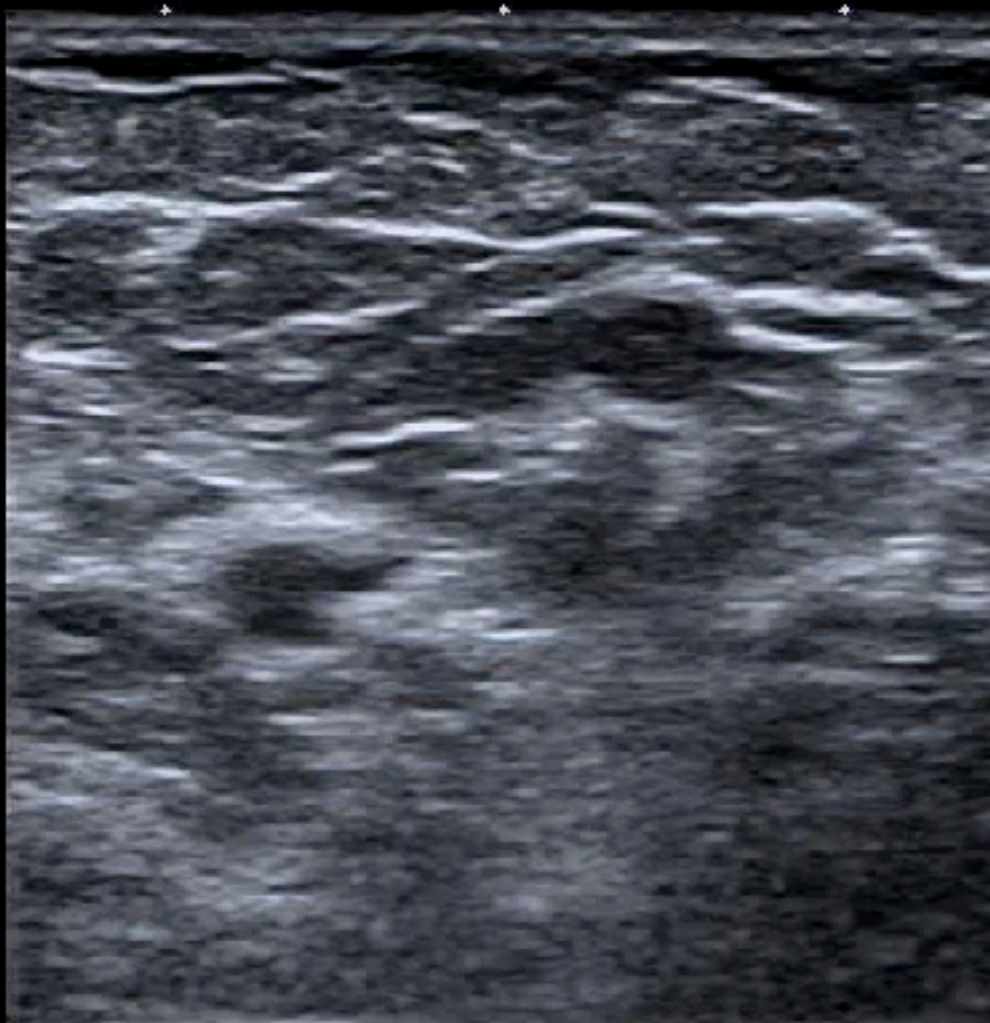
G
P R
3.0 12.0

G
P R
3.0 12.0

G
P R
3.0 12.0

0
T

- +
- ◇
- +
- ◇ 1
- +
- ◇
- +
- ◇ 2
- +
- ◇
- +
- ◇ 3



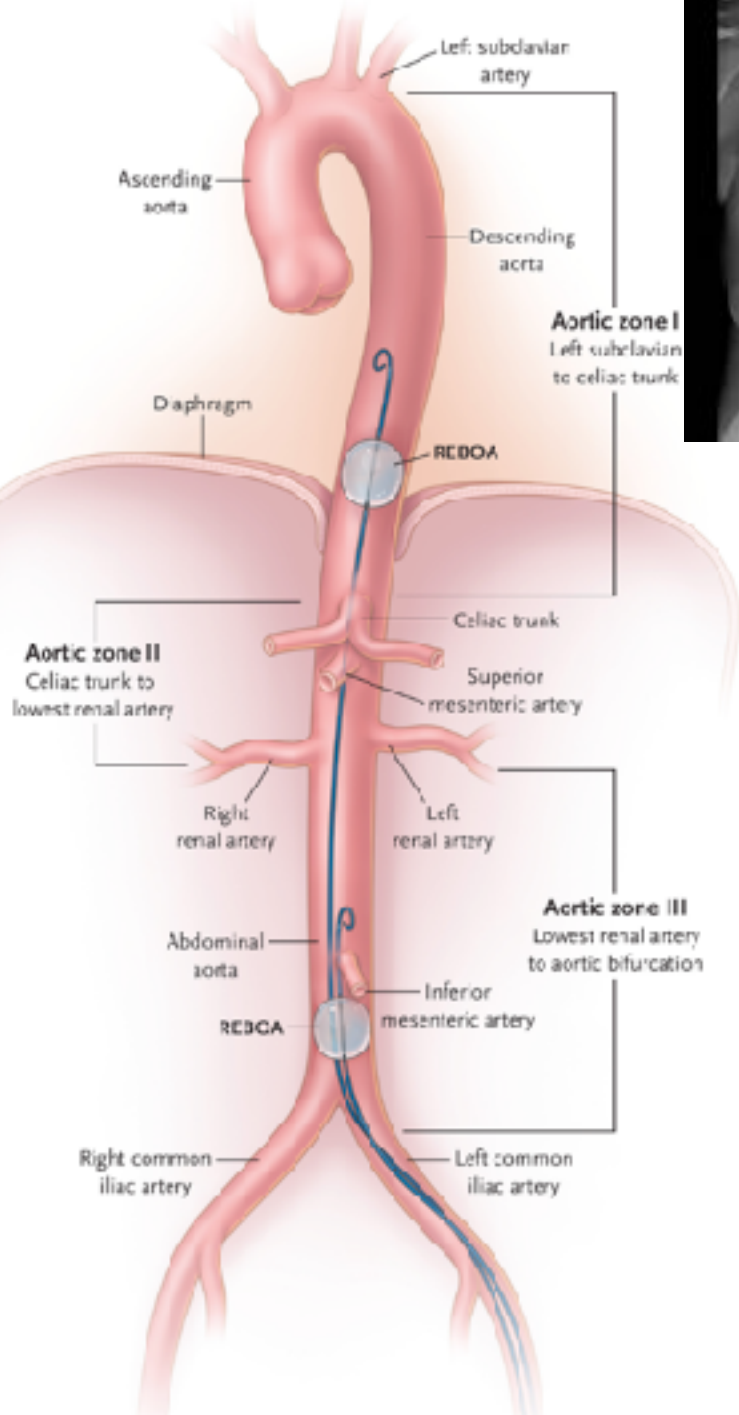
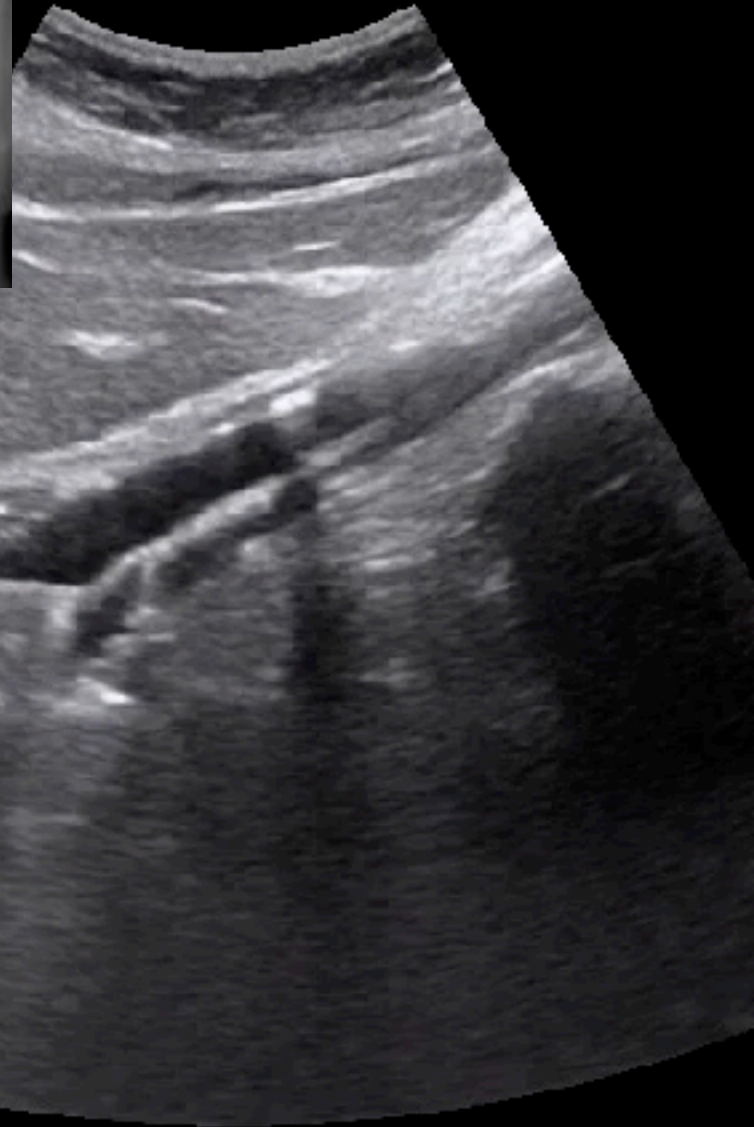
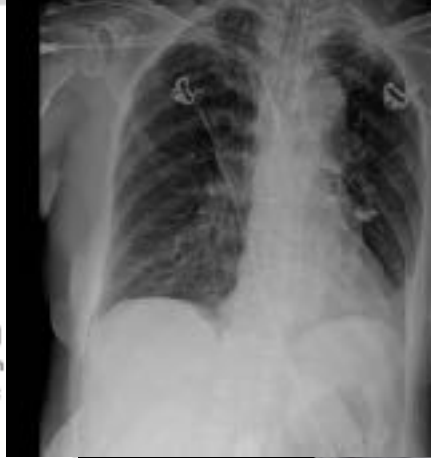DR:60
A:6
P:3

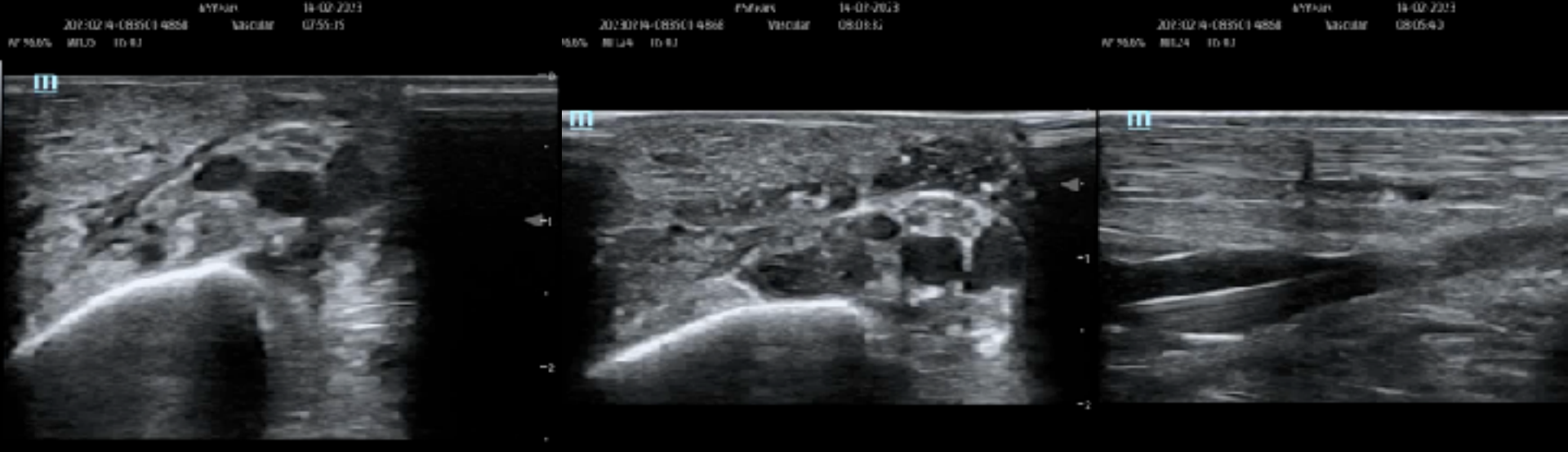09:28:55

AP 92.0% MI 0.8 TIS 0.7

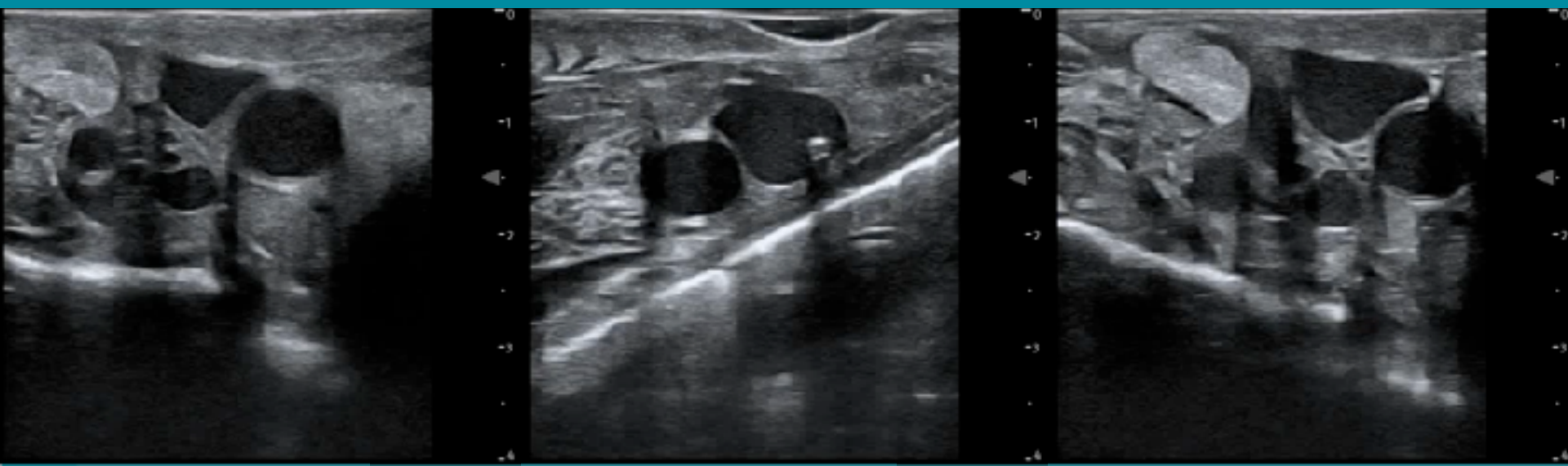
C5 2s

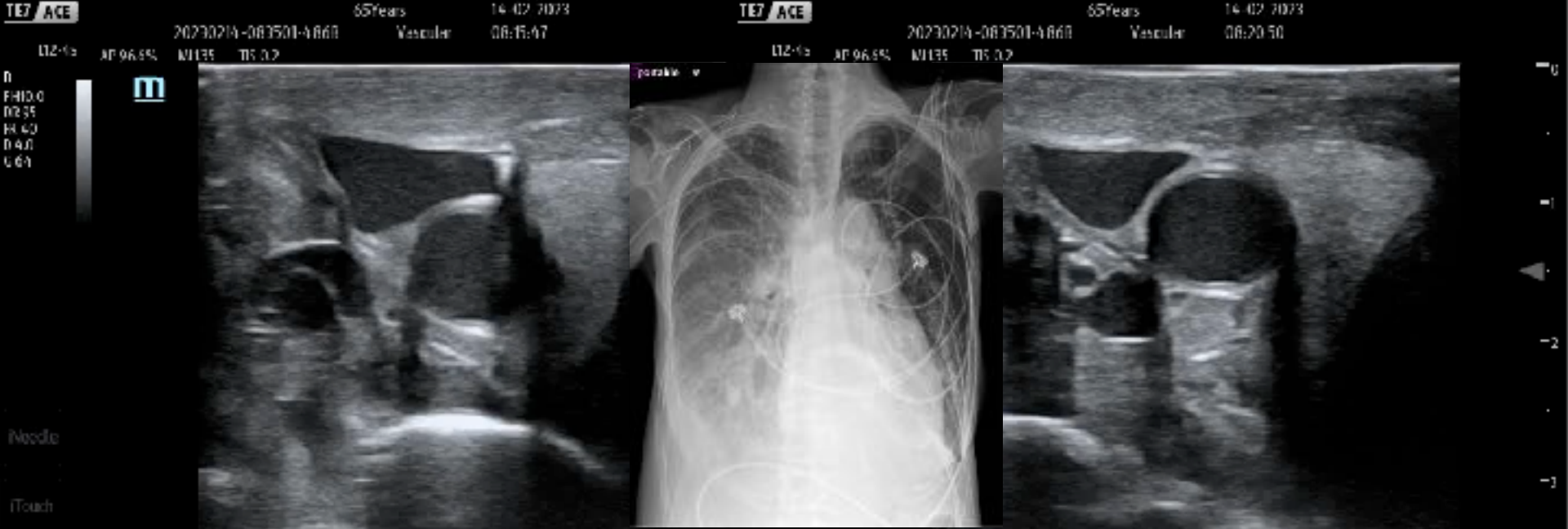Adult ABD



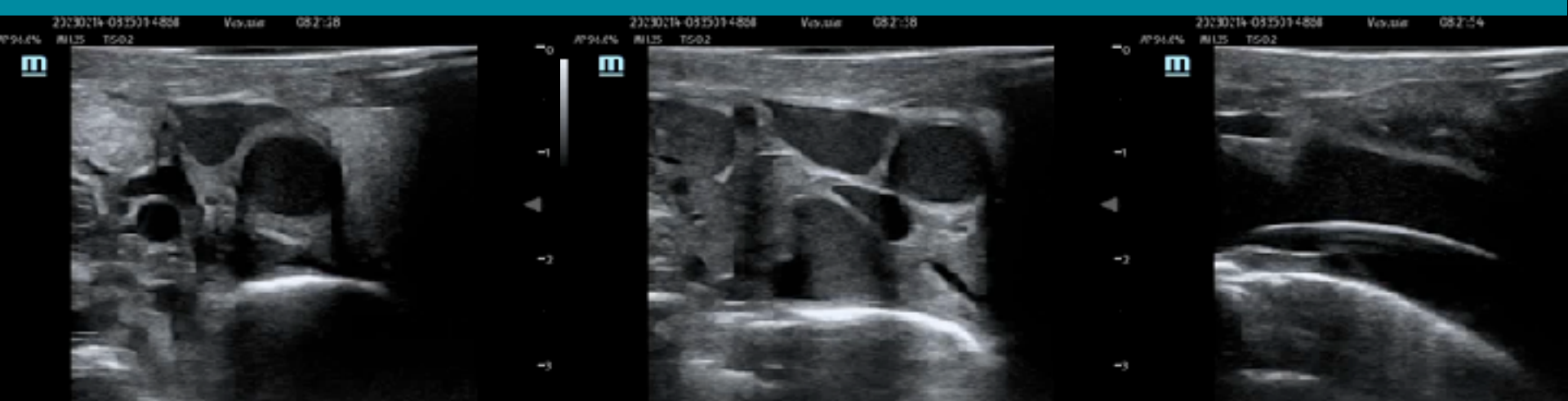

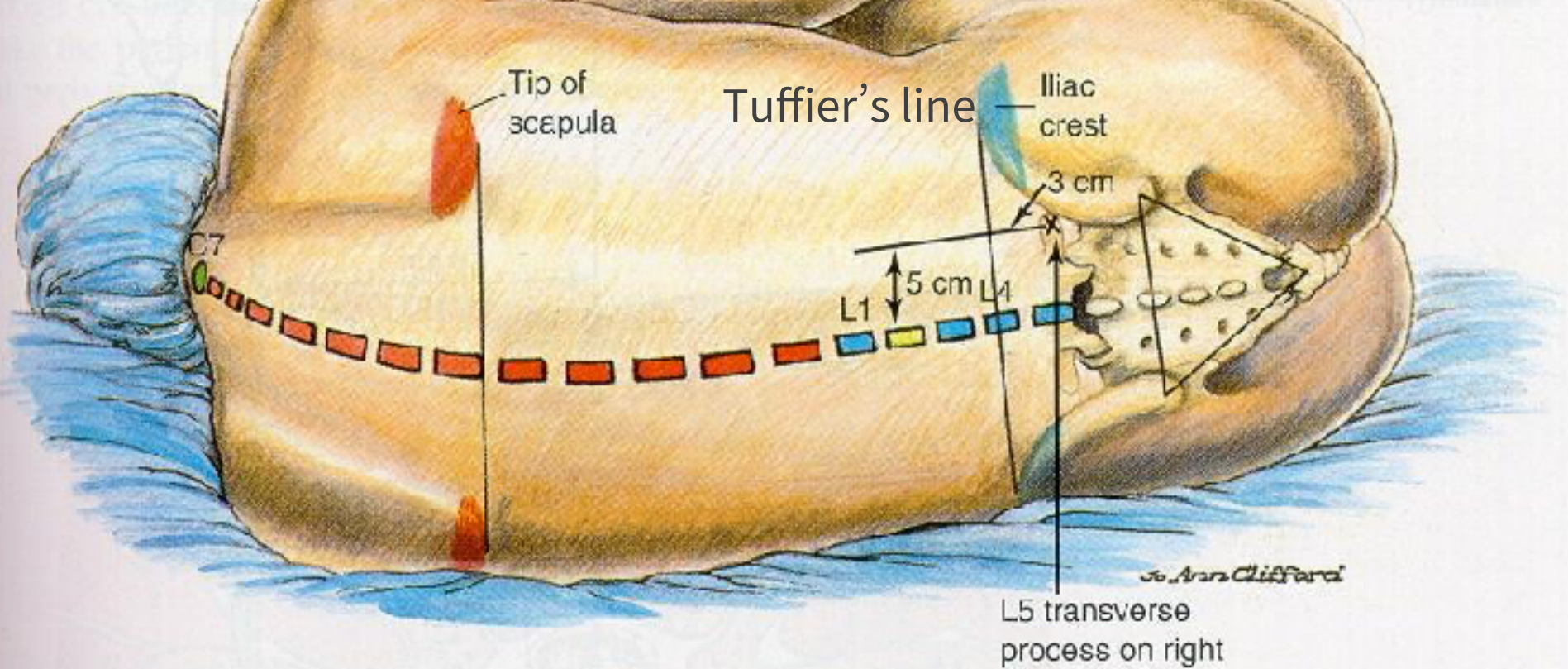
US-GUIDED PICC



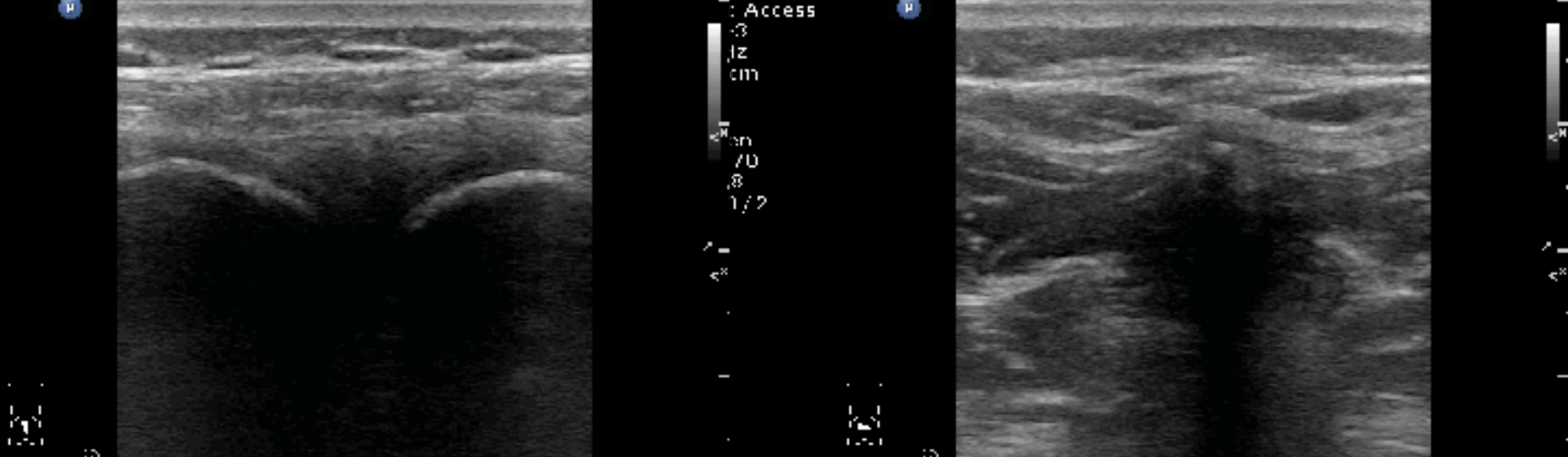

US-GUIDED PICC

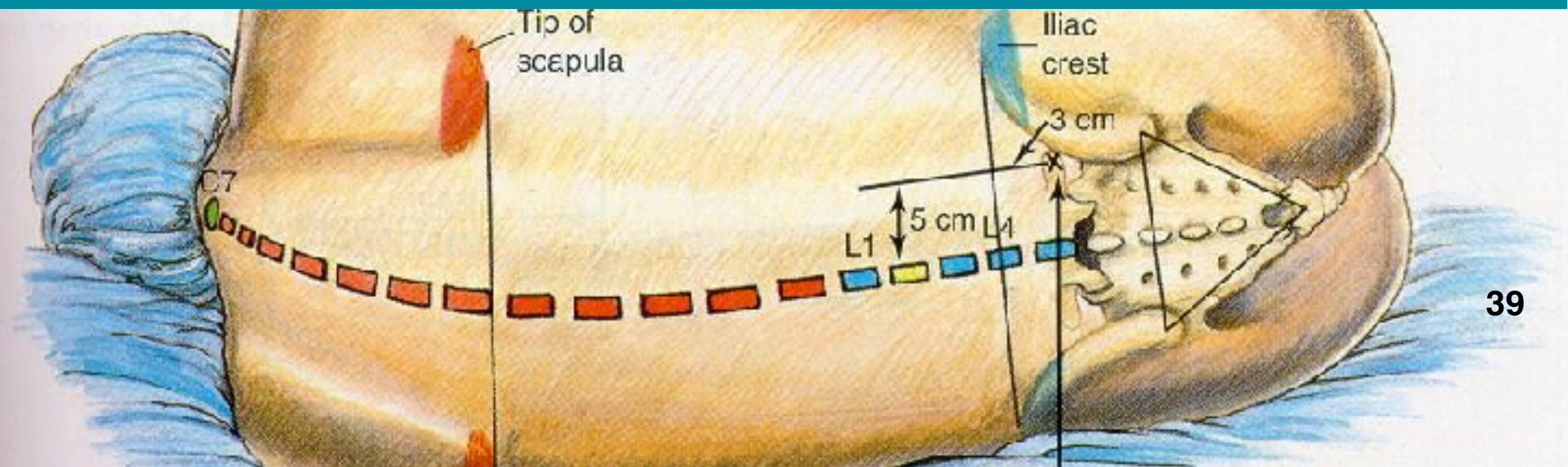




LUMBAR PUNCTURE

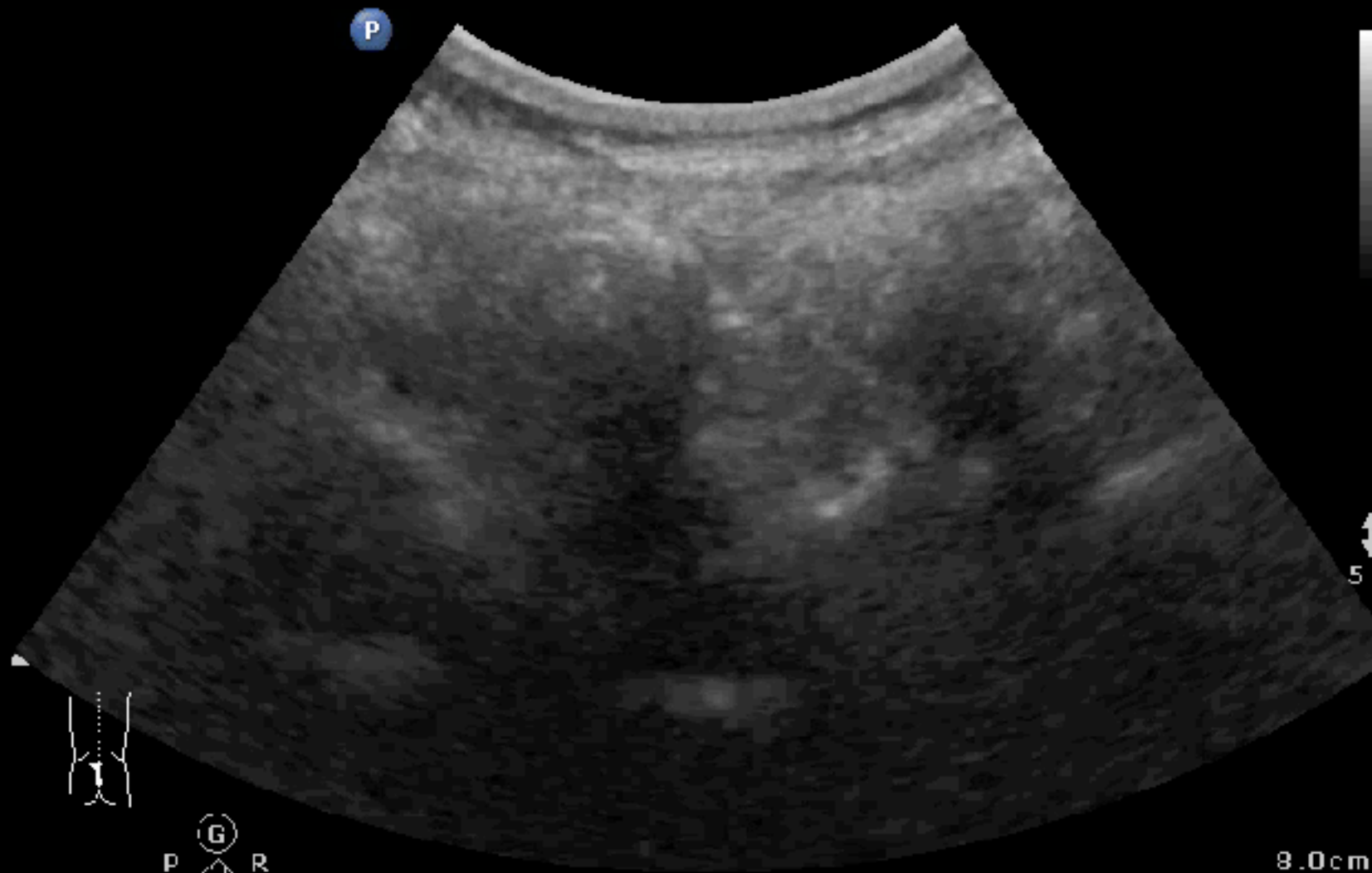

LUMBAR PUNCTURE

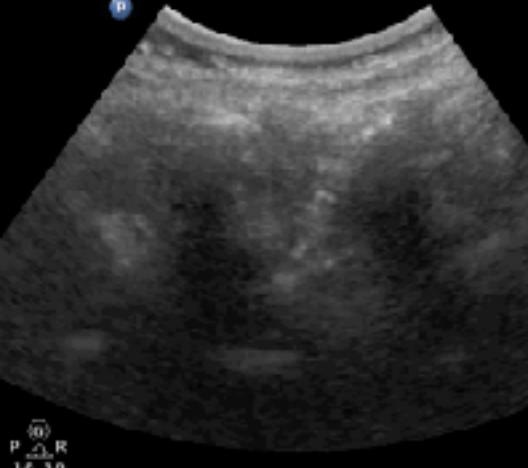

Abd Gen2
C5-1
51 Hz
8.0cm

PD
HGen
Gn 97
C 56
3/3/3

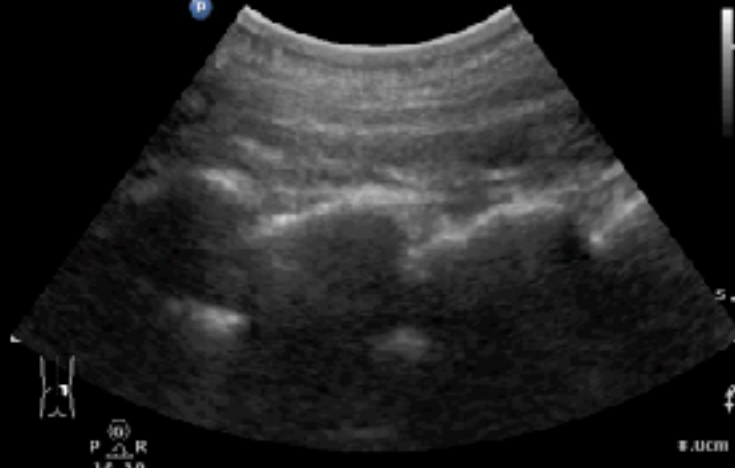


8.0cm

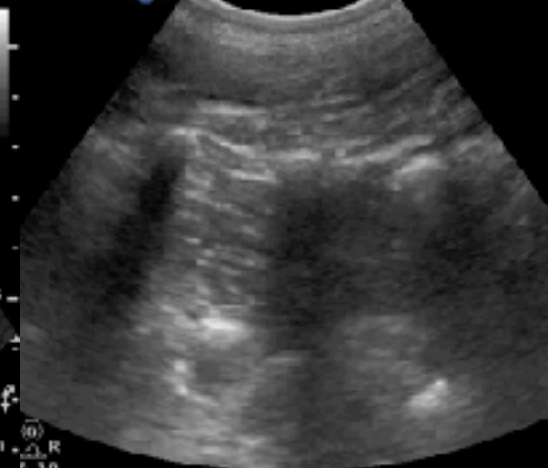

C5-1
51 Hz
0.0cm
HGen
15h 47
C 56
3/3/3

Spinal process

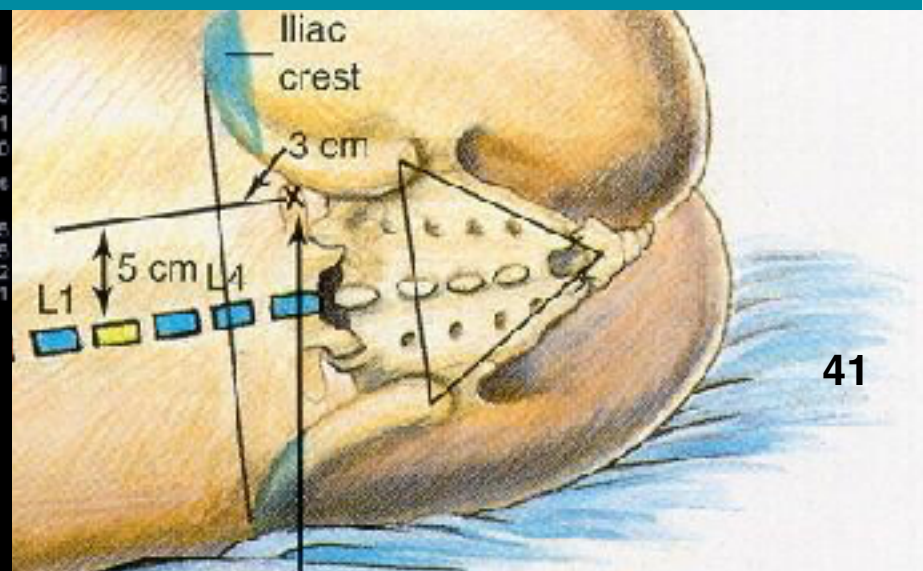
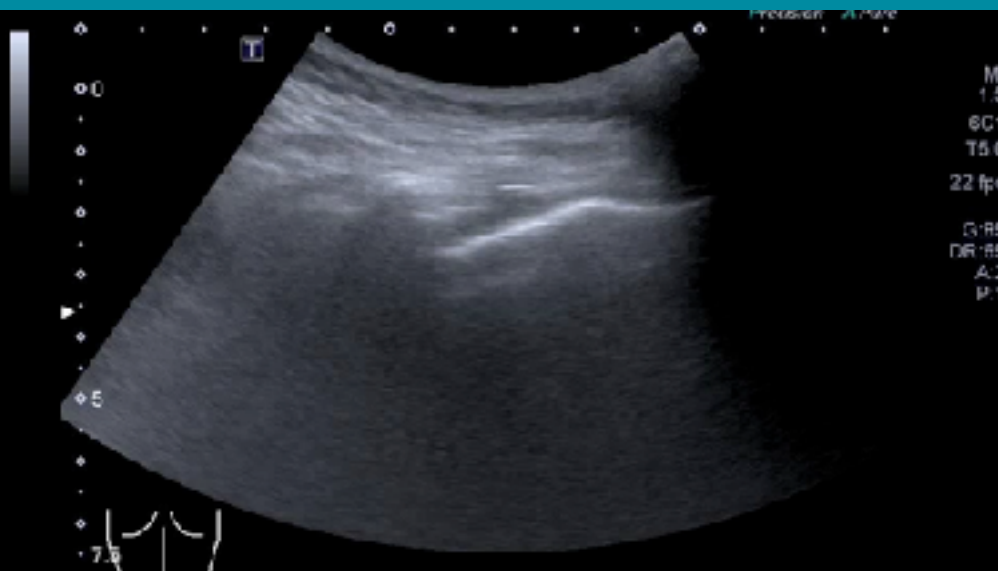

Lamina

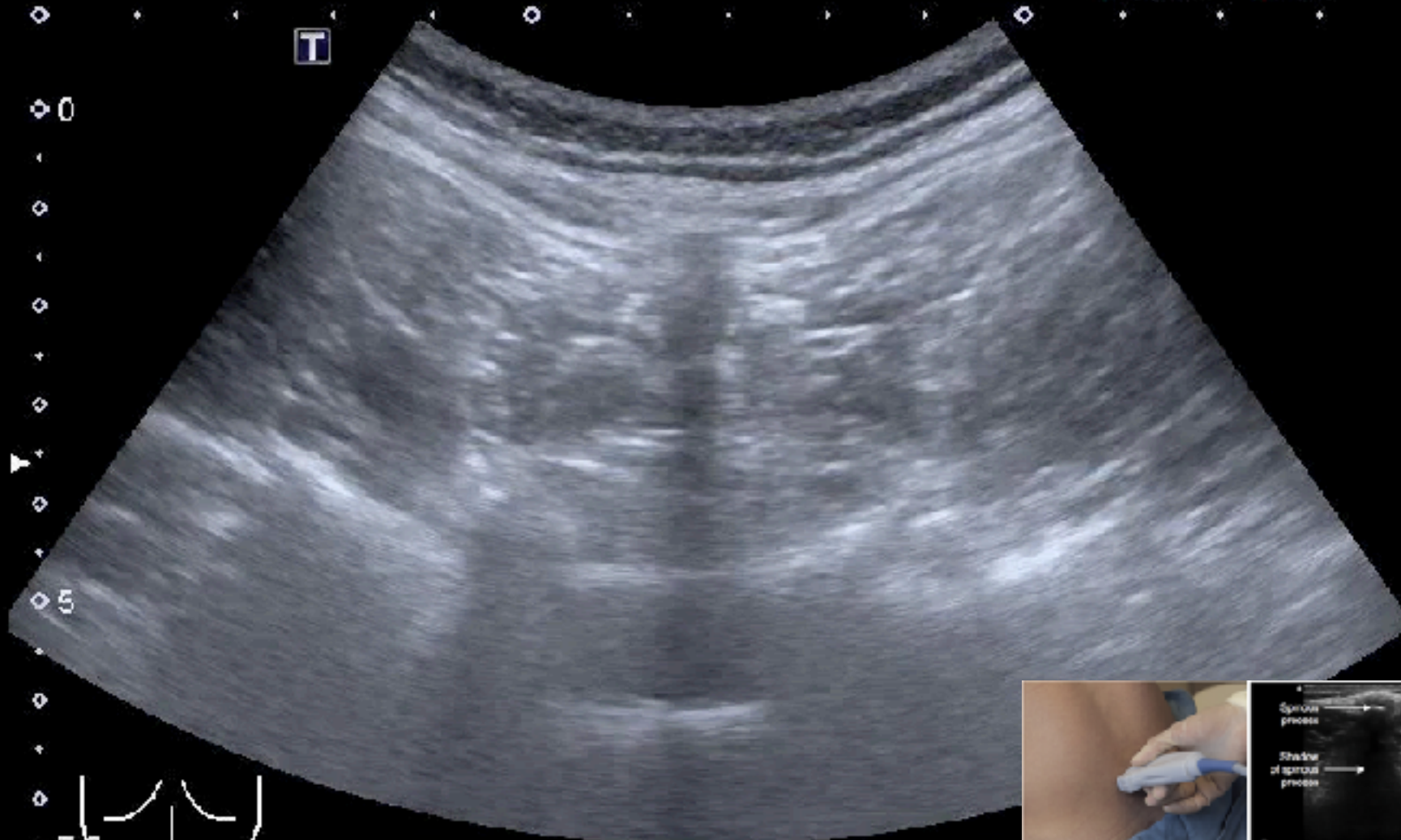


Transverse process

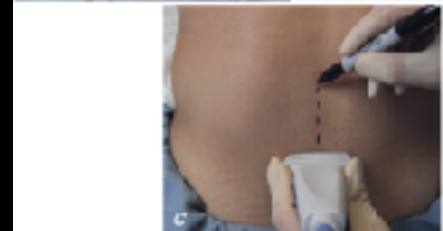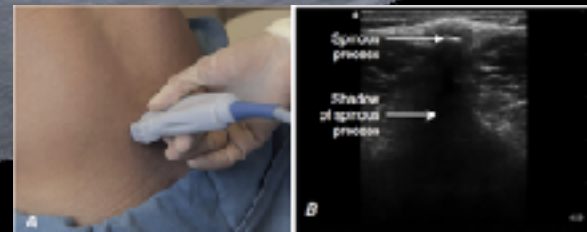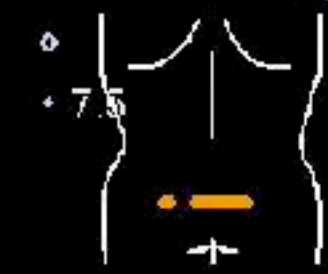LUMBAR PUNCTURE



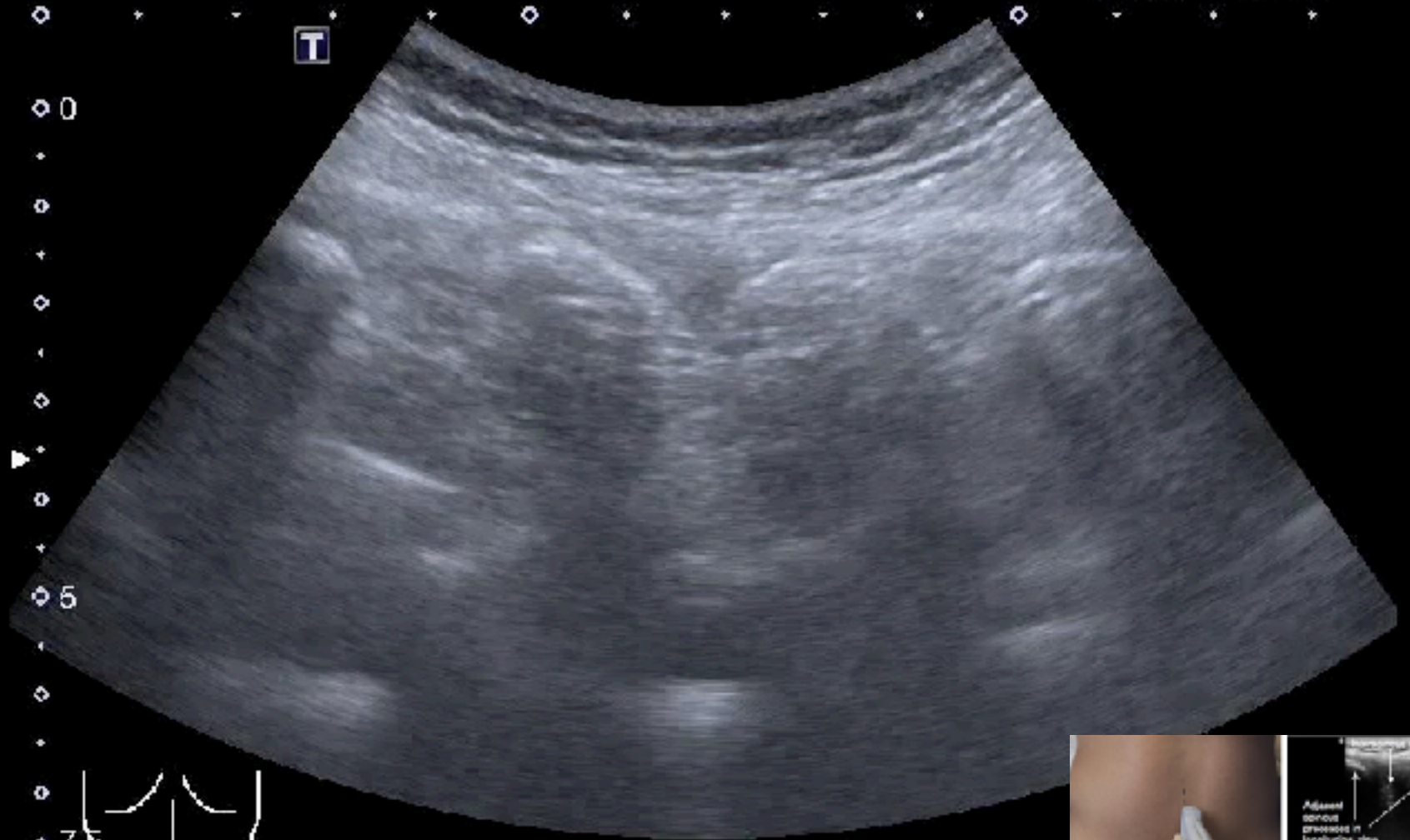
Precision A Pure



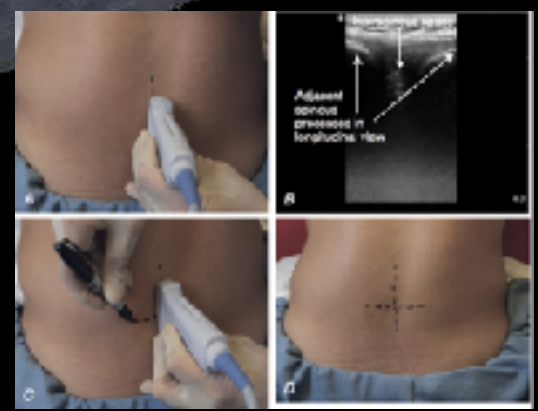
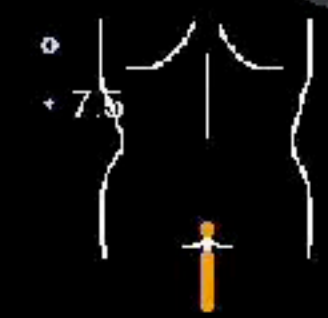
M
1
60
T5
22 f
G:8
DR:6
A
P



Precision A Pure

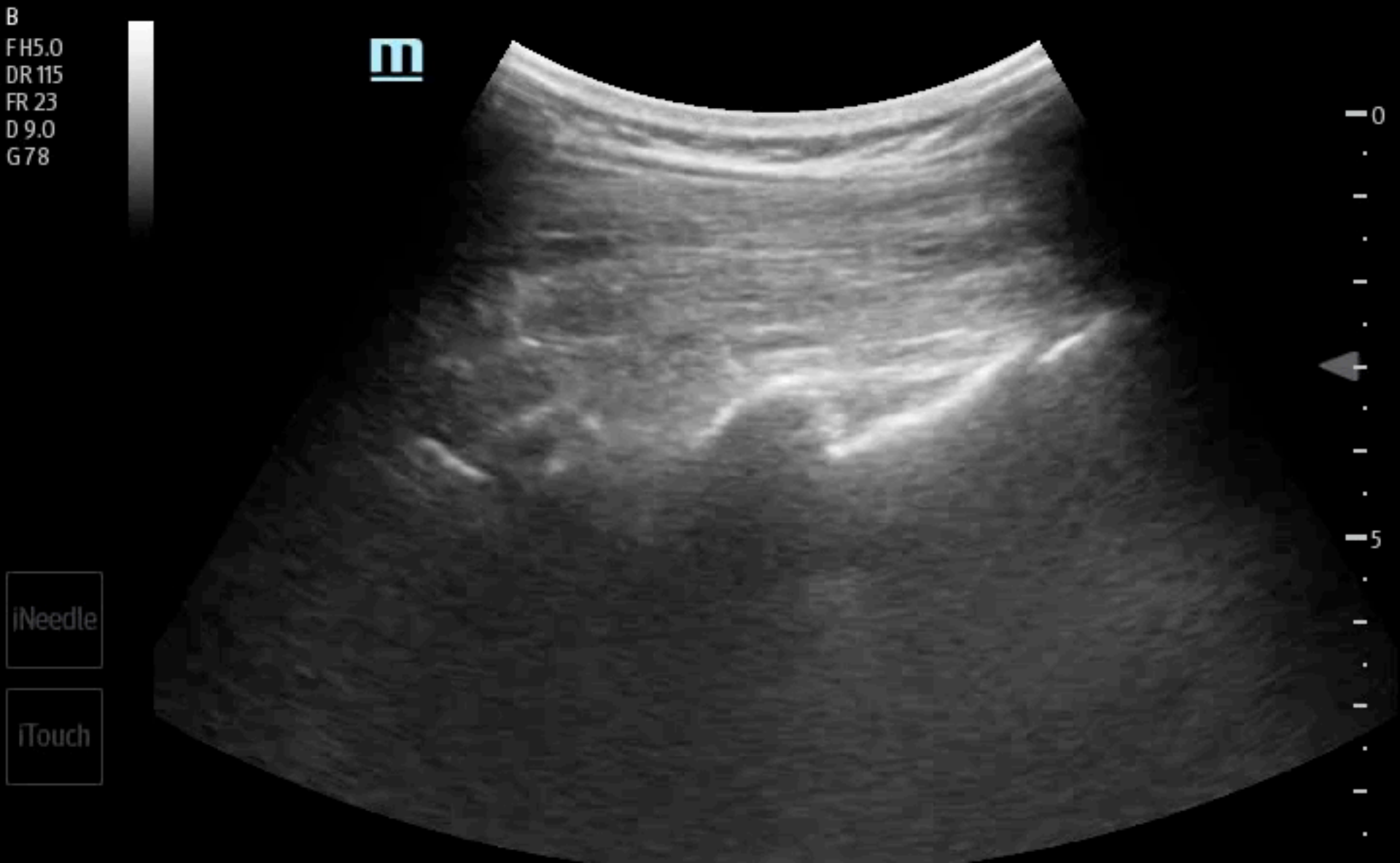


MI
1.5
6C1
T5.0
22 fps
G:85
DR:65
A:2
P:1



71M, Suspect CNS infection

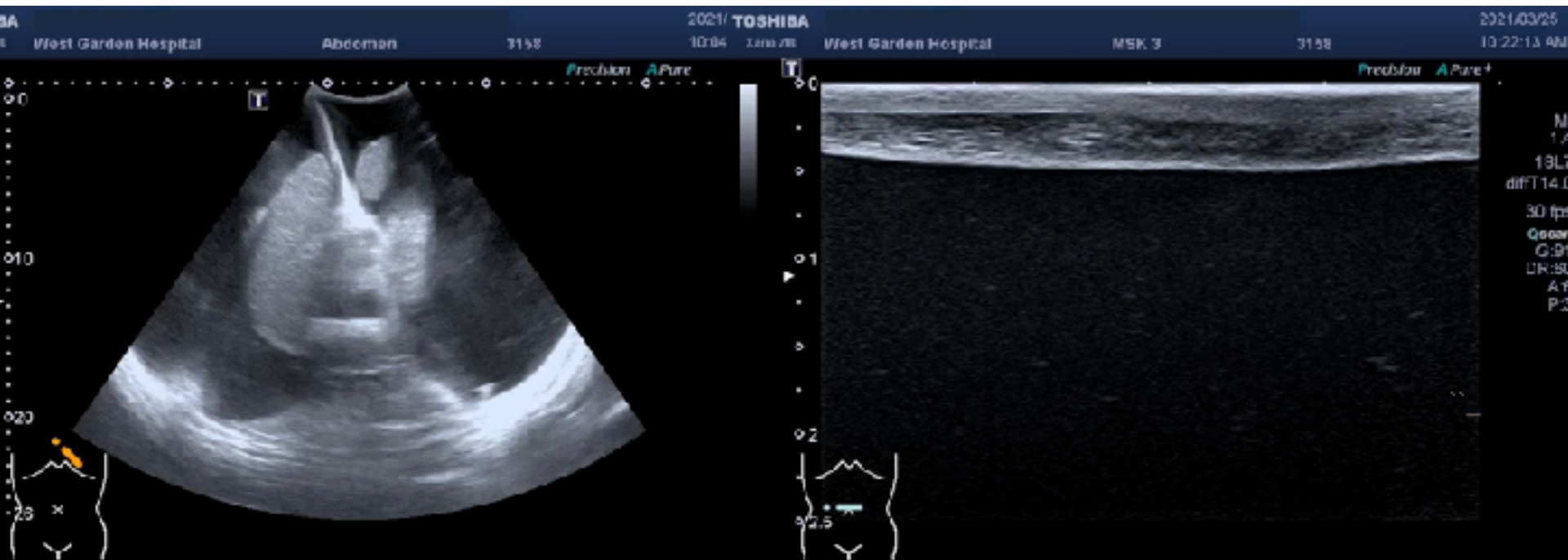
Failed CSF attempts



61M, Cirrhosis & massive ascites

Find best location

Avoid bowel & vessels




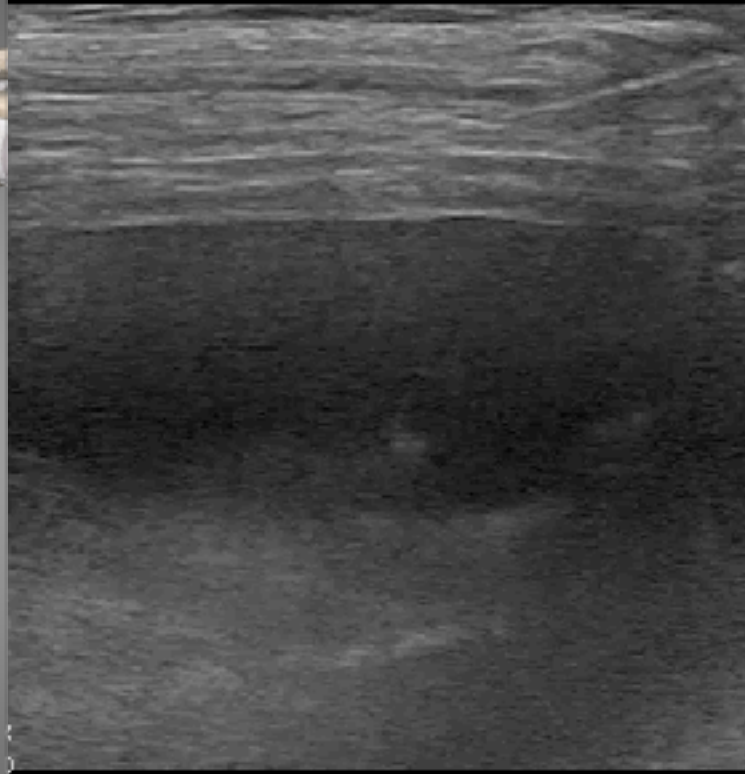
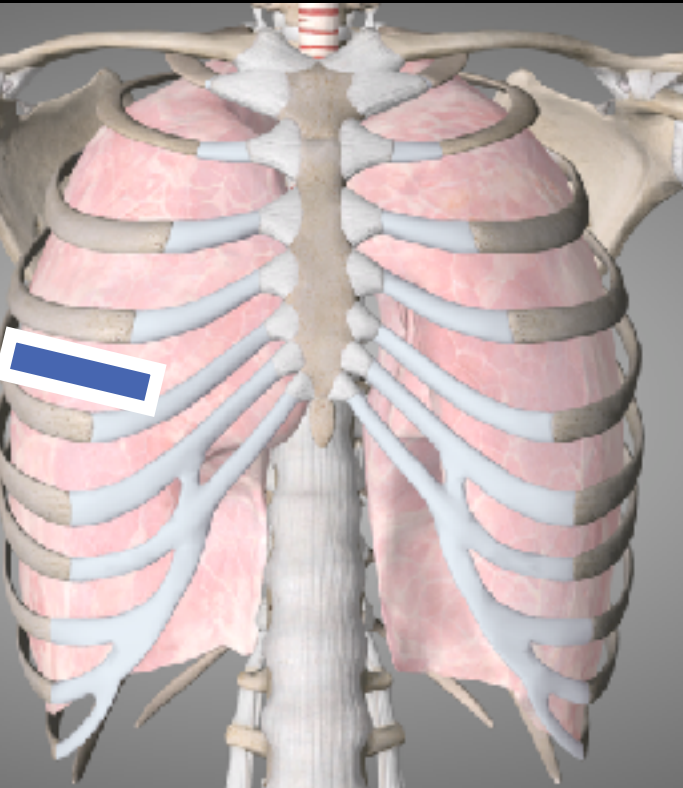
IEA: inferior epigastric artery

寬廣的空間適合【定位】更是絕佳的【安全精進區】

In-plane drainage



SKH-EUTC©ChenKC



Catheter insertion

Off-plane drainage



Superficial

L 12-3

43 Hz

4.5cm

2D

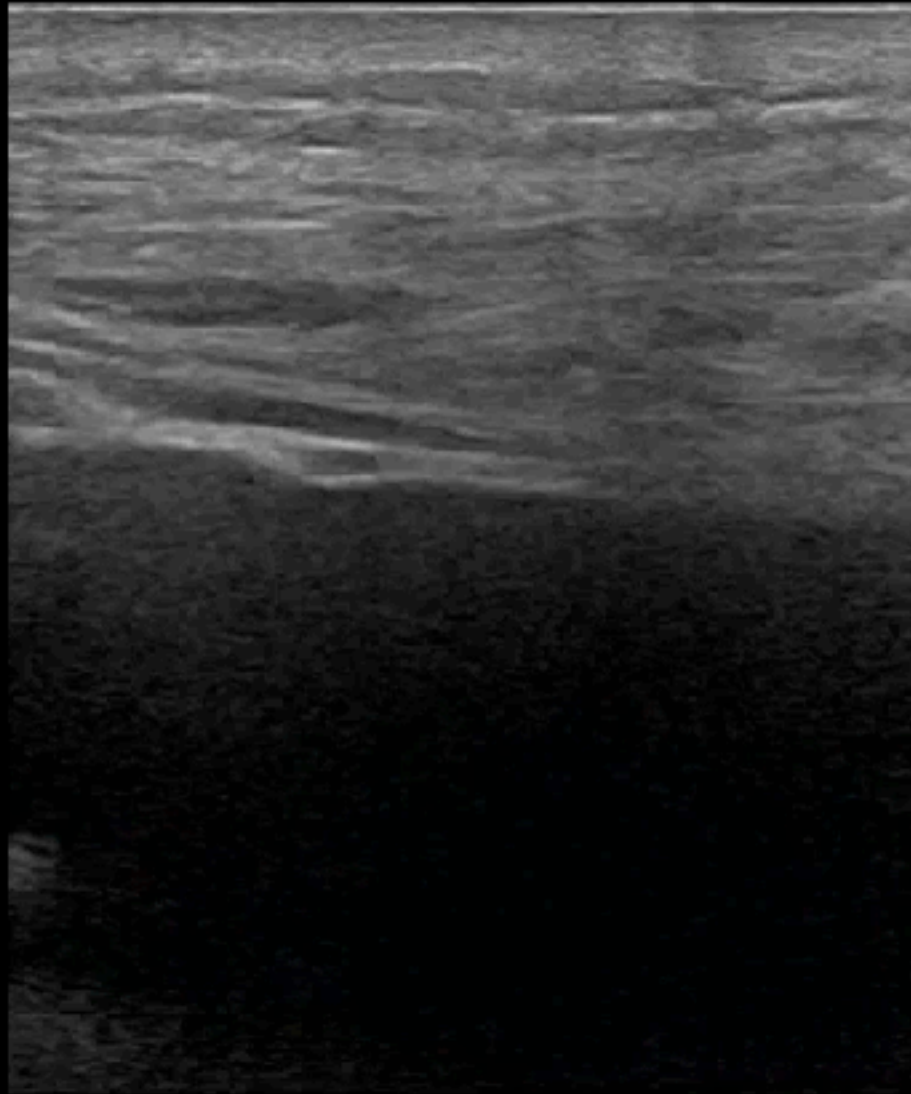
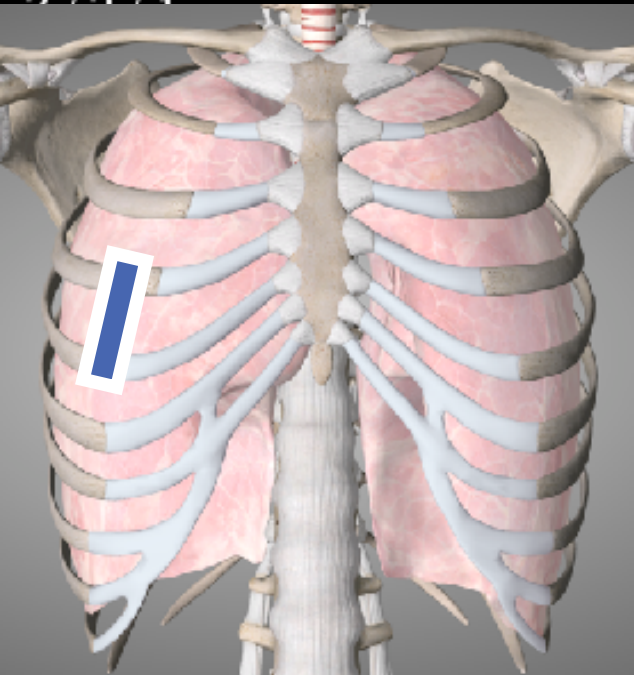
Res

Gn 100

C 56

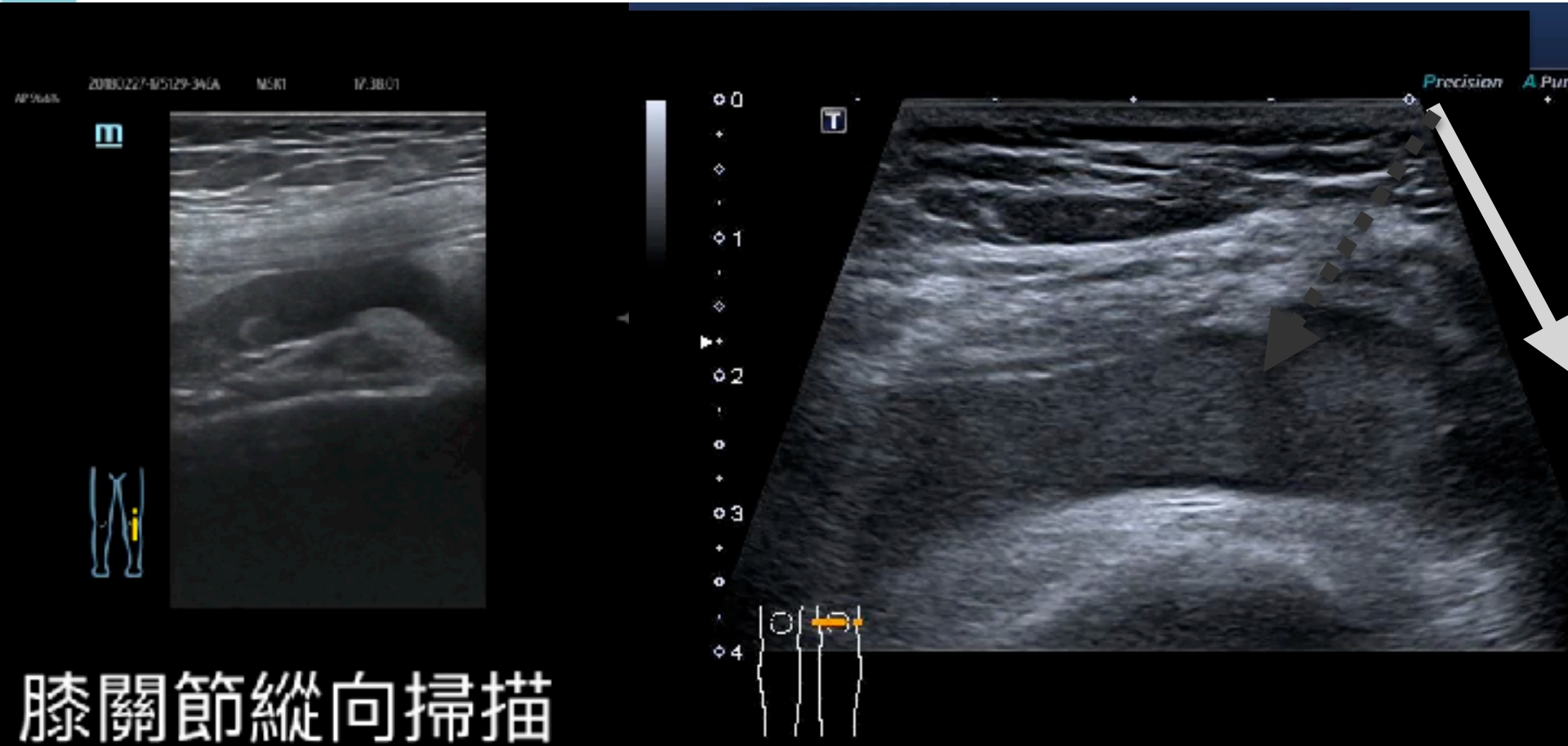
2 / 2 / 1

P

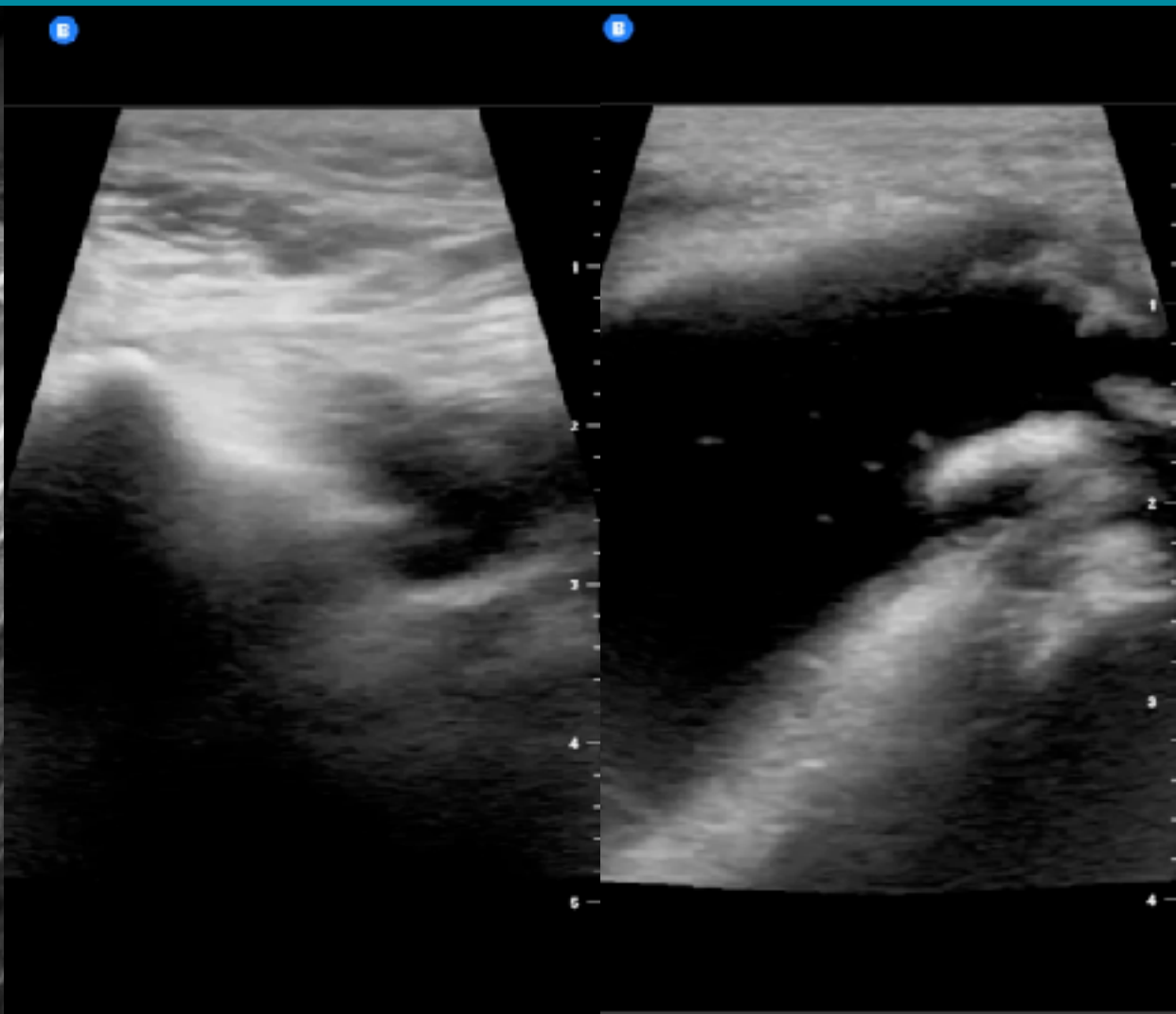
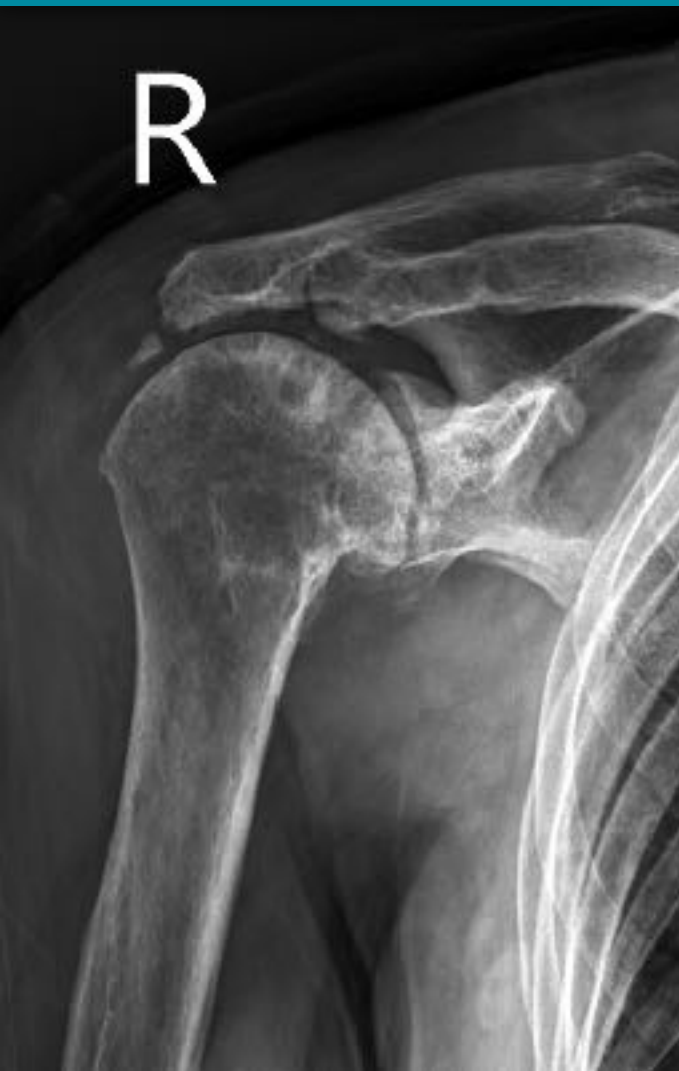


4.5cm

Joint effusion & aspiration



93F, 原本躺著孫子要扶起來，
不慎拉傷右肩，昨天右肩痛，右手無法上舉



Pneumothorax

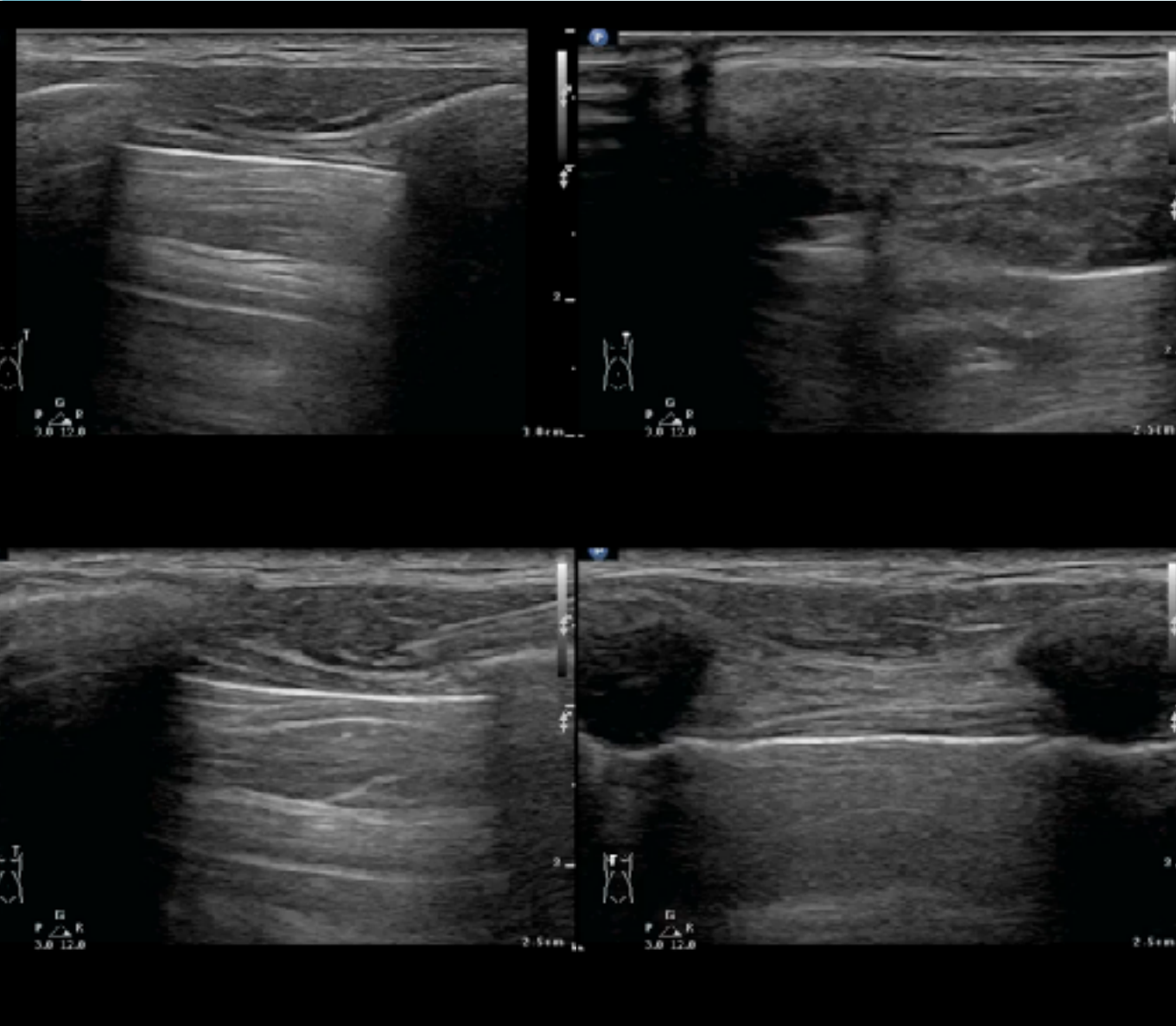


選定肋間

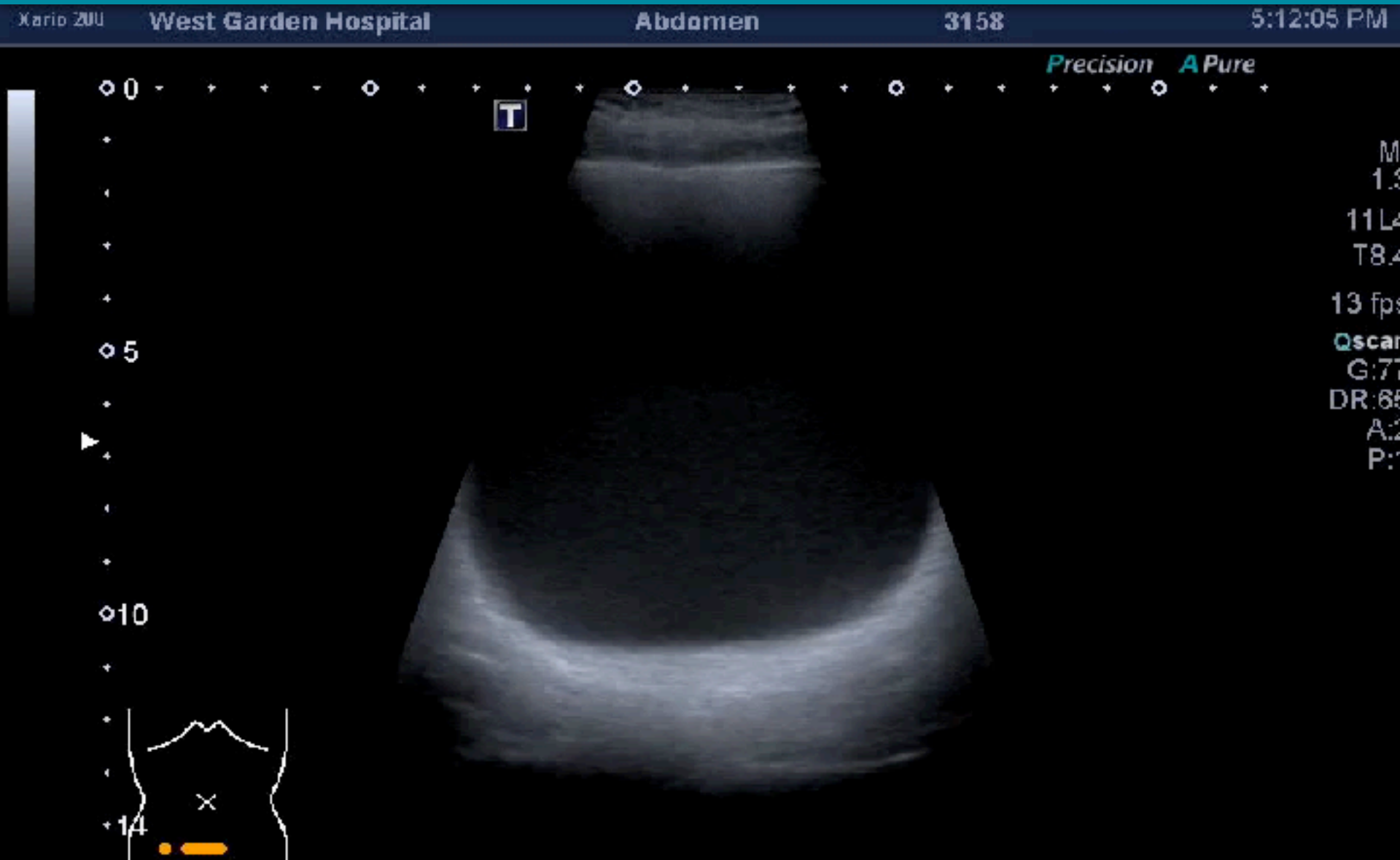
精準麻醉

導管置入

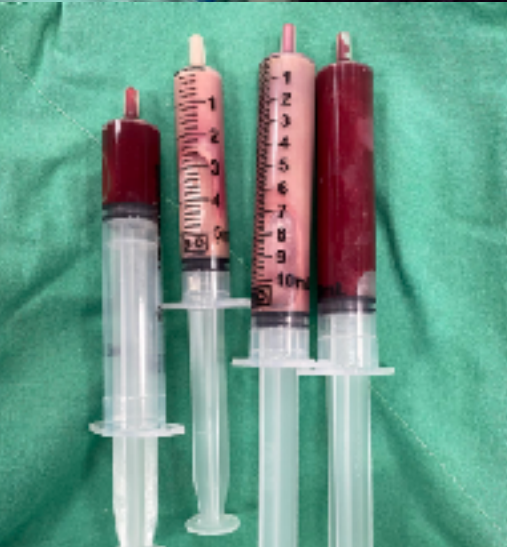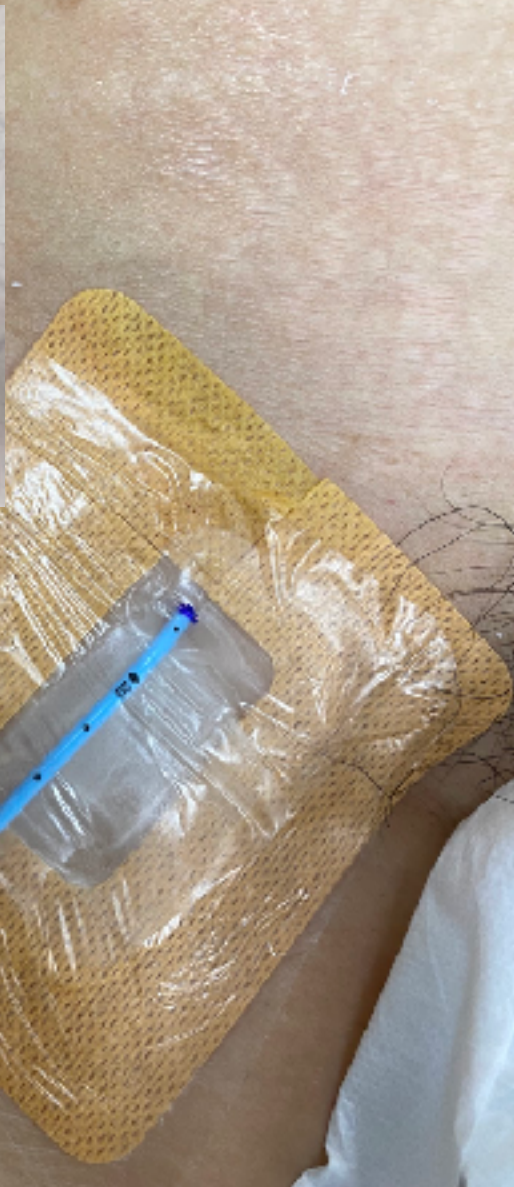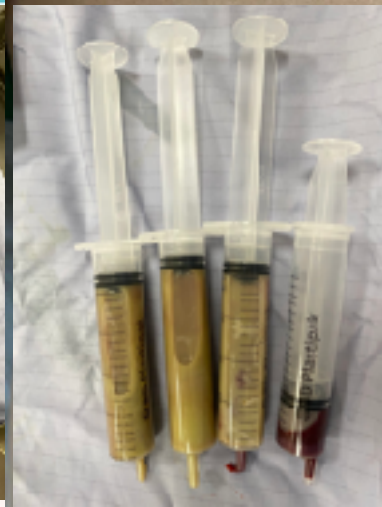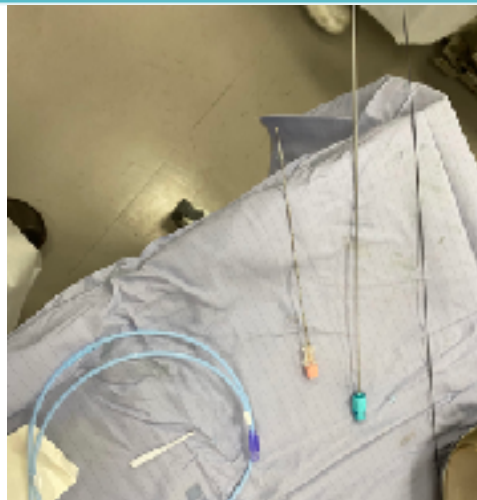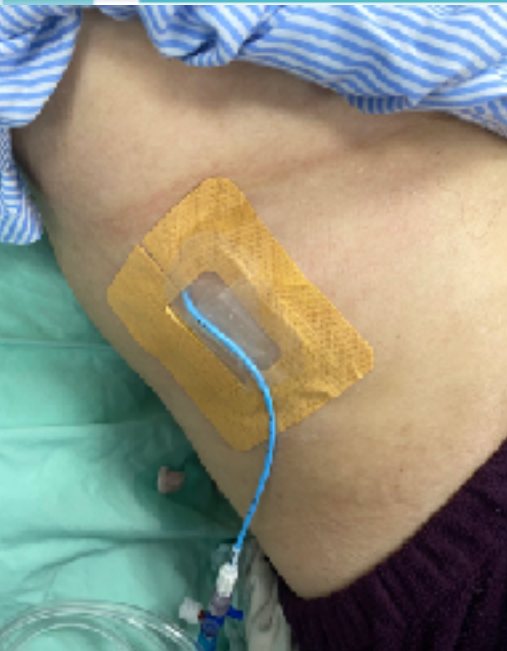擴張評估⁵⁰



76M, AUR & urethral stricture



超音波導引介入性處置



NEO-SOF
Hydrophilic Drainage Catheters

*和特®引流導管及穿刺導入系統

引流導管組
Drainage Catheter Kit

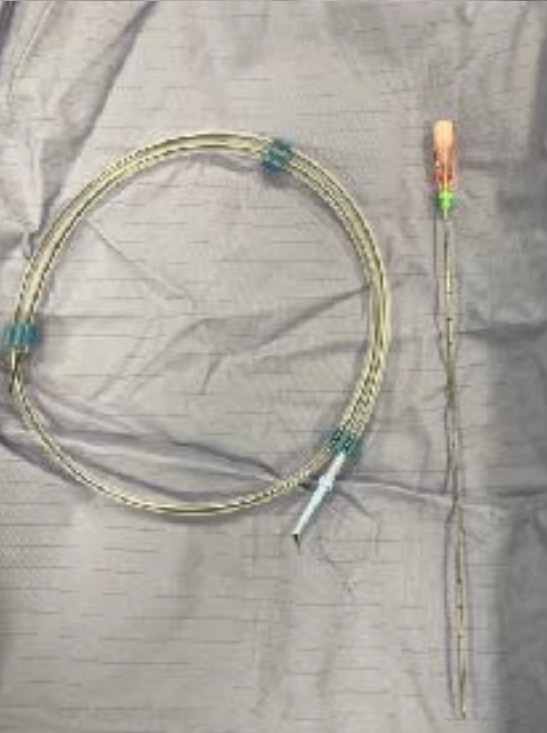
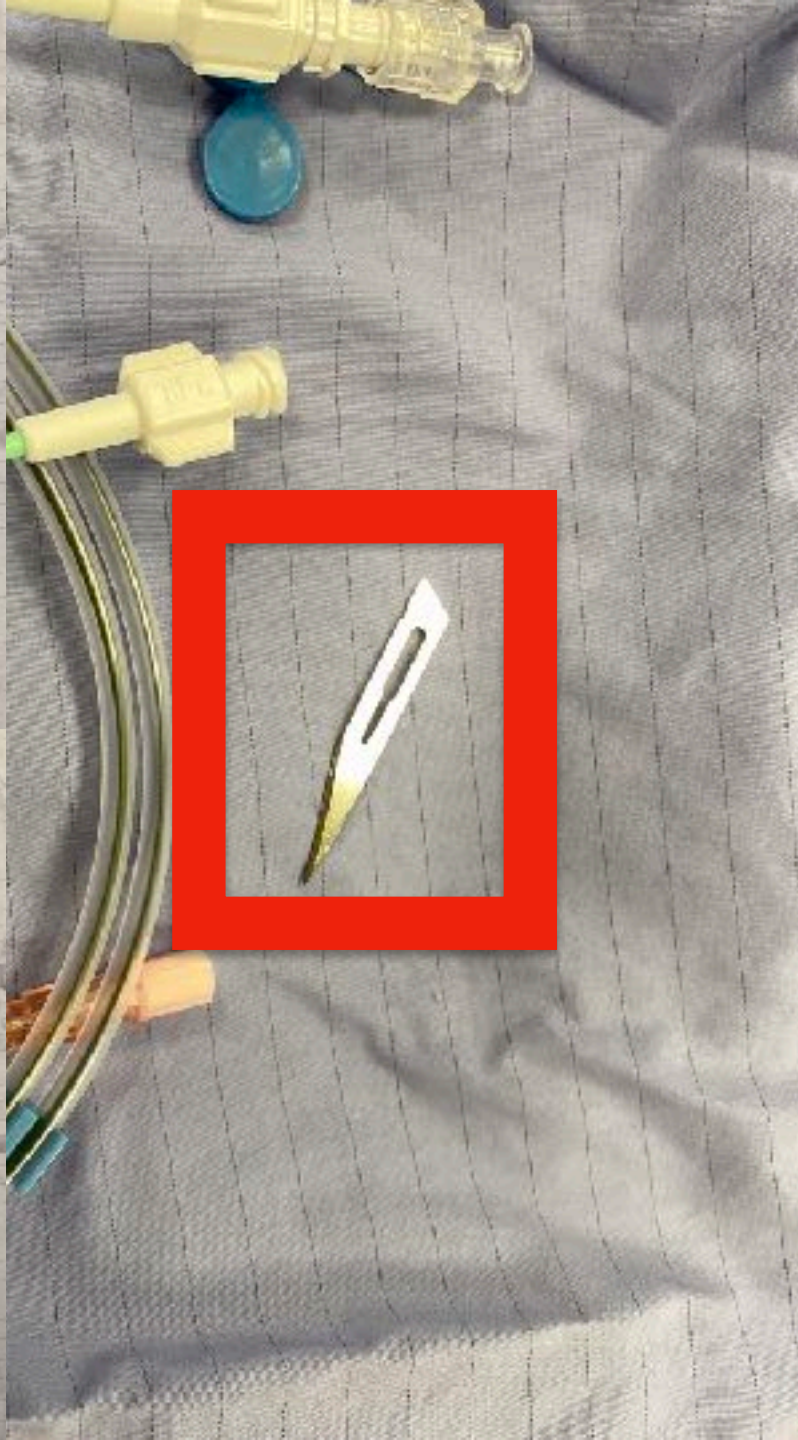
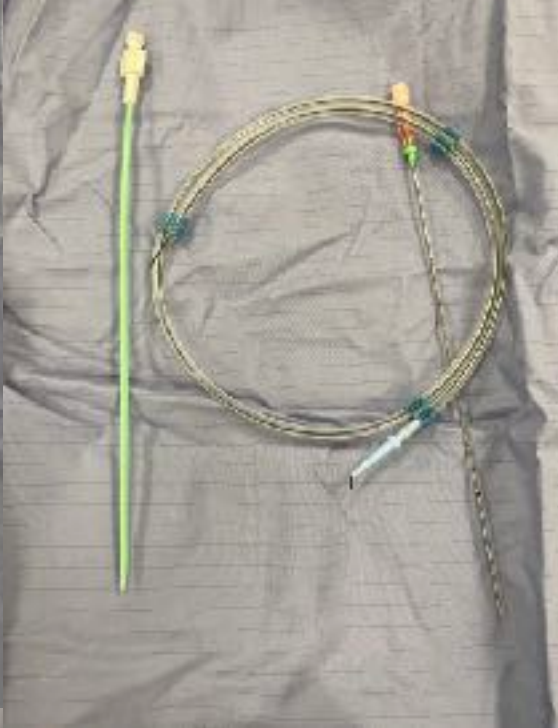規格：8FR - 帶線
表面親水性塗層設計
附齊醫器製字號00287D 號
藥商：邦特生物科技股份有限公司

8FR (2.5mm)
總長0.83M 導線
A=30cm B=25cm

內容物：

(1) 導管	(1) 消毒面紗(紗)
(1) 導管管	(1) 導管管
(1) 針管	(1) 手袋
(1) 膠尿管 (1.5x20cm)	(1) 蓋帽
(1) 膠尿管 (1.5x10cm)	(1) 蓋帽
(1) 引流管 (1.5x10cm)	

0 541 5888 5888 0 011014 010000

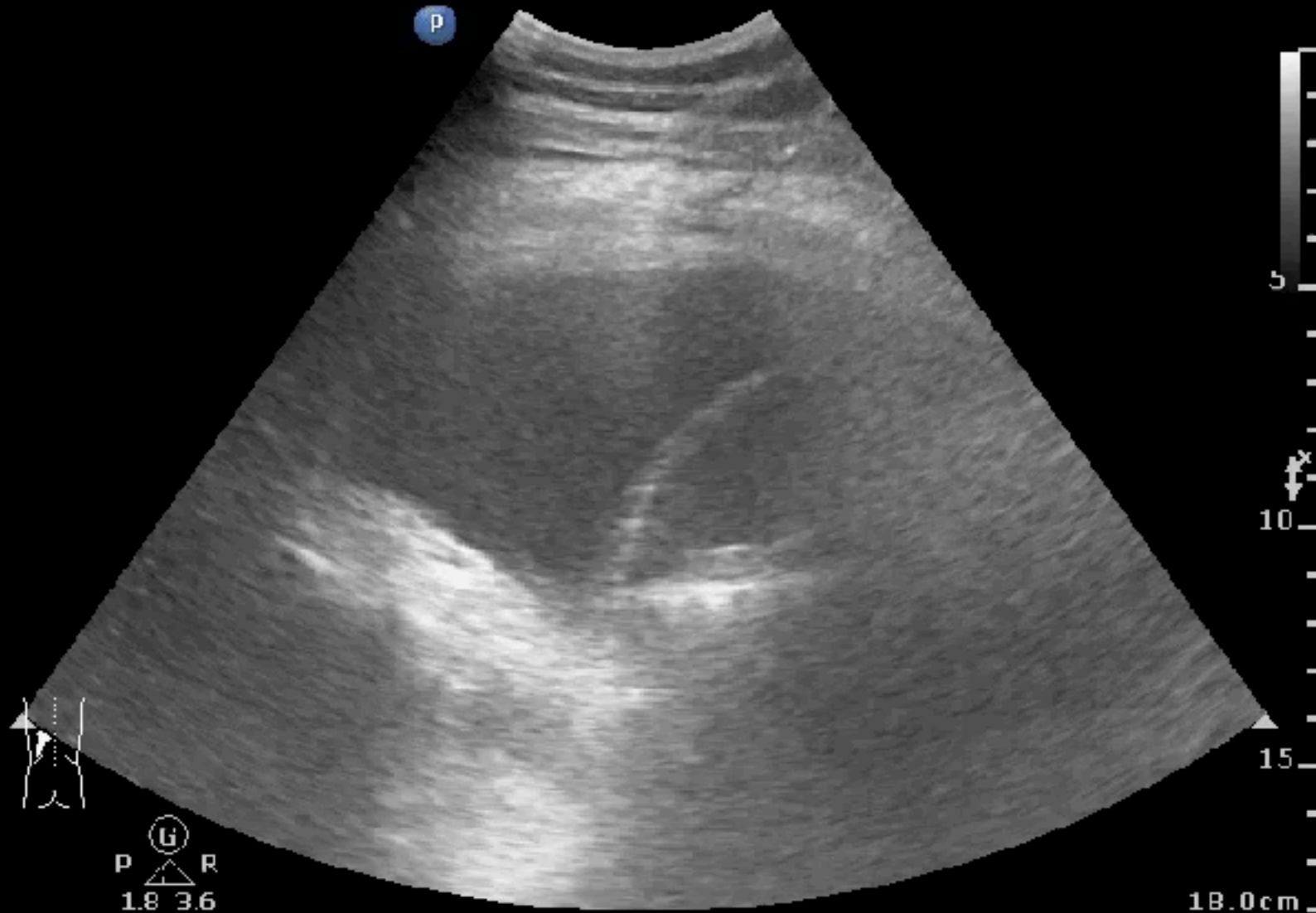

Pigtail drainage with stylet

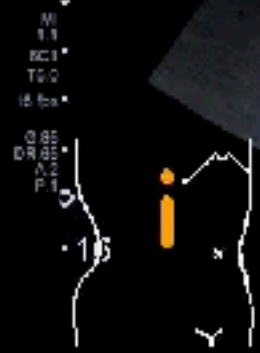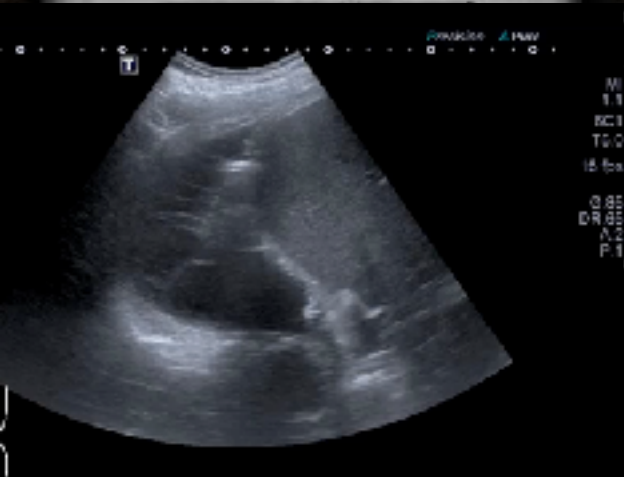
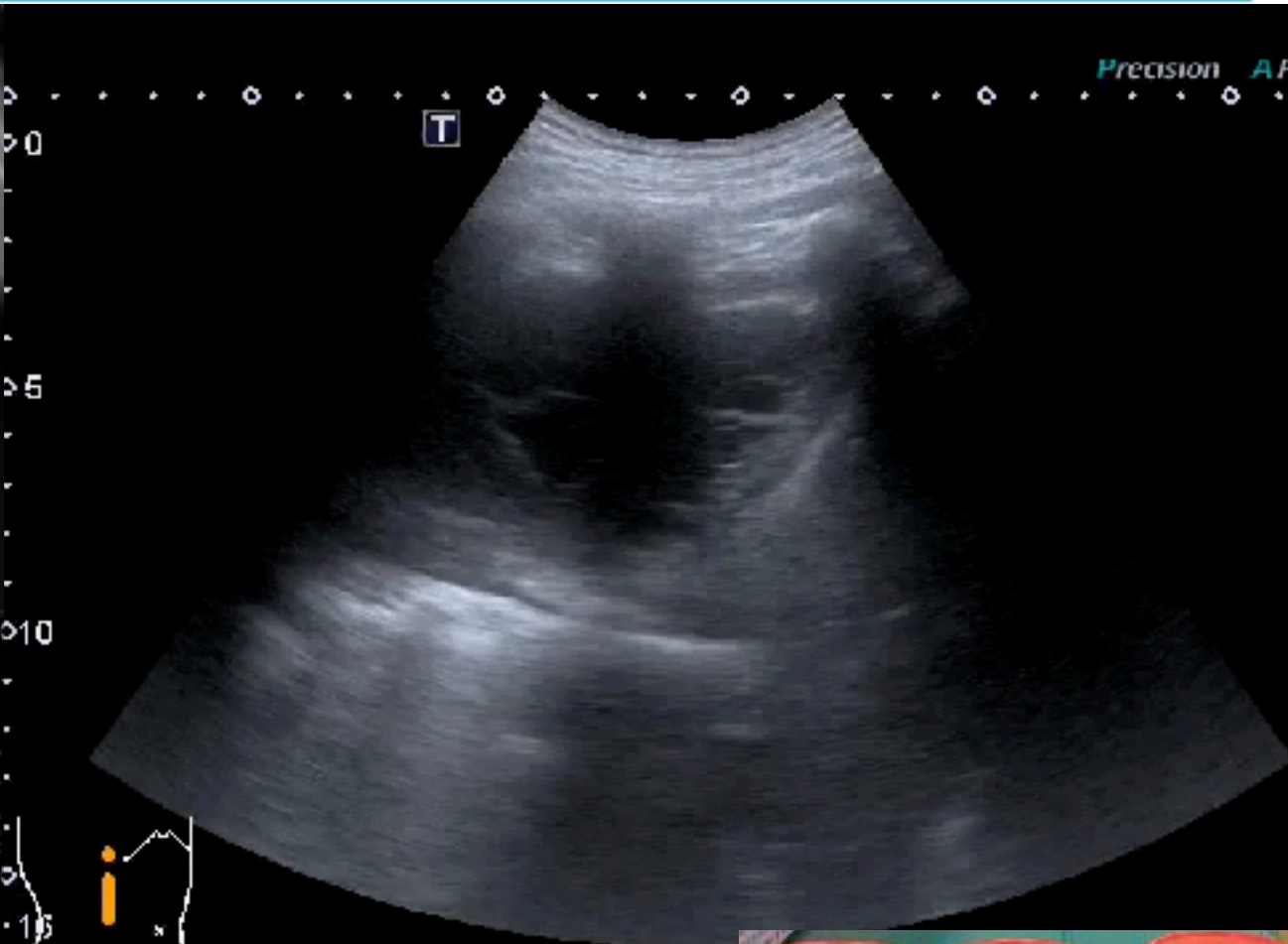

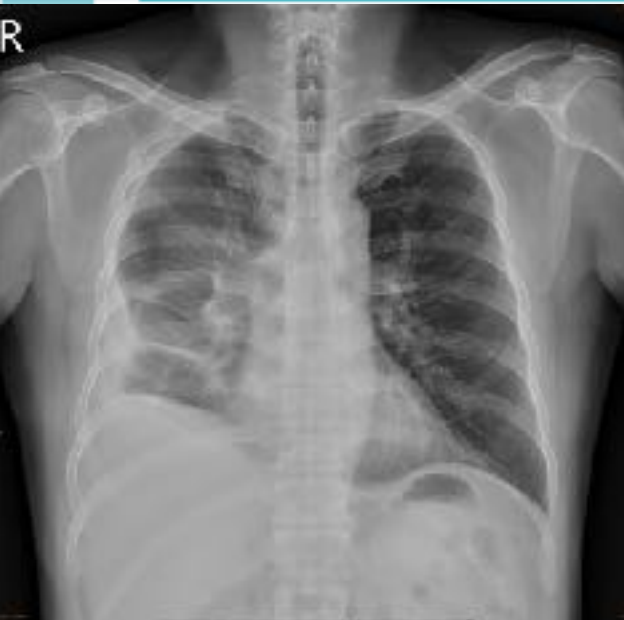
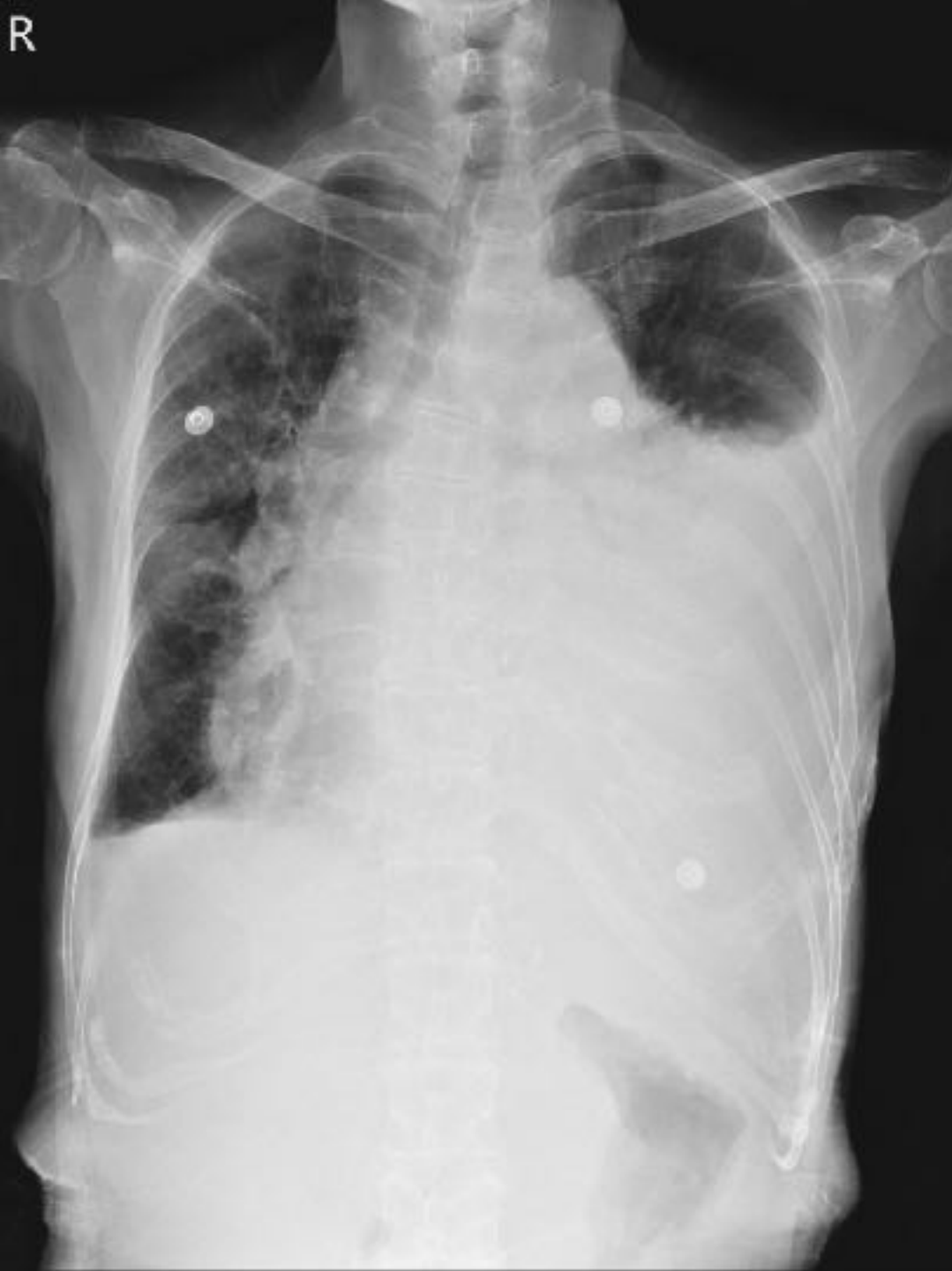Abd Gen2
C5-1
30 Hz
18.0cm

2D
HGen
Gn 100
C 56
3 / 3 / 3



Pigtail drainage with guidewire





個案

62F

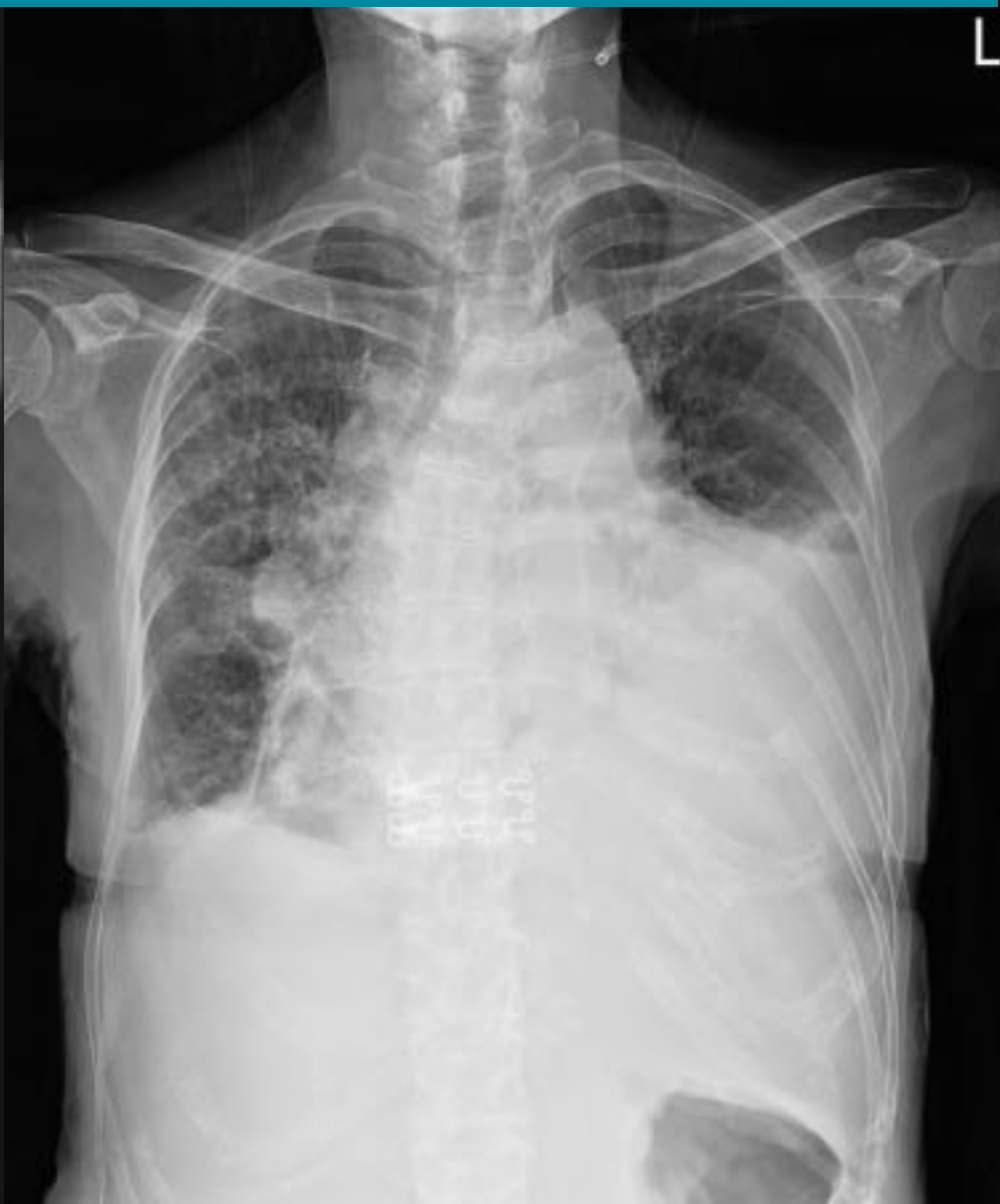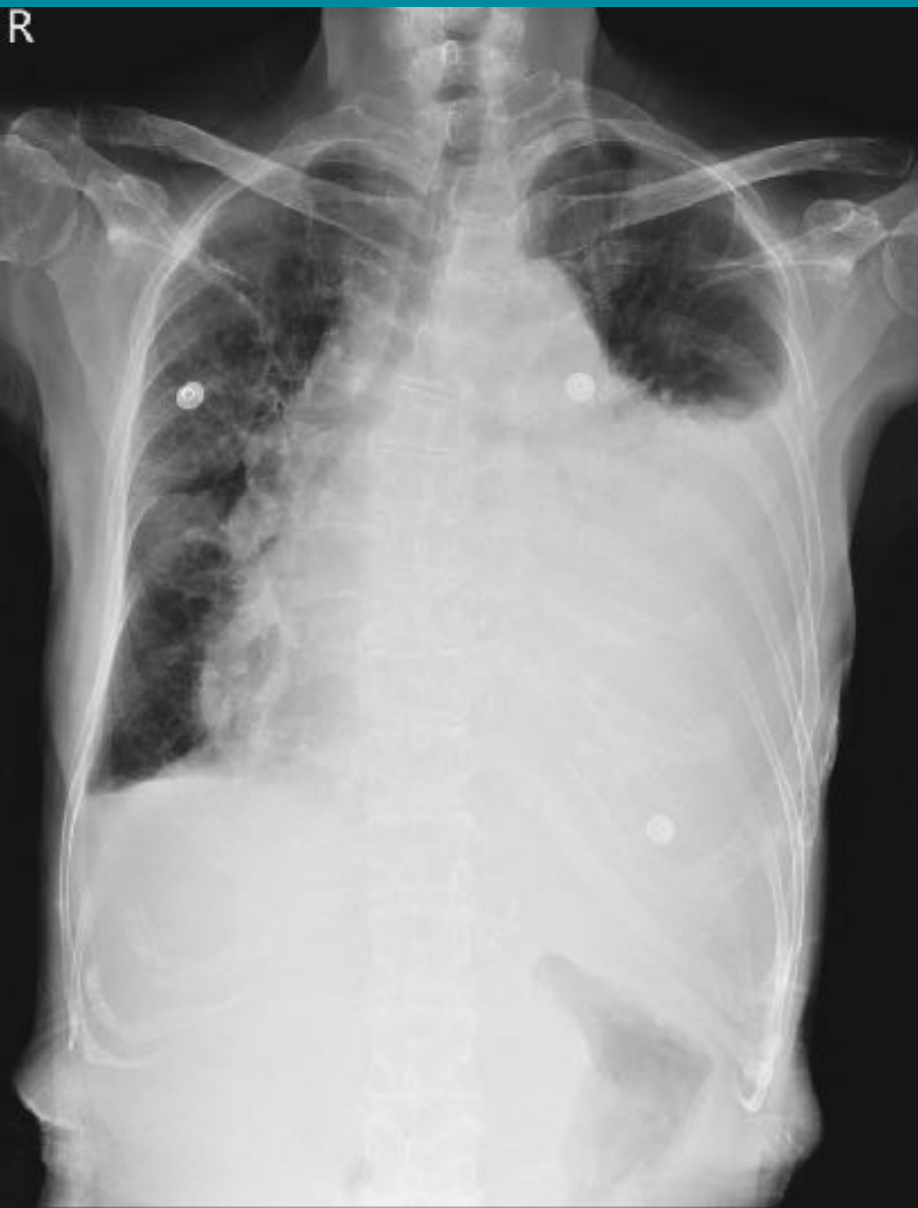Hx of breast cancer

4天前於急診進行
Pleural effusion
tapping 600 ml

主訴:
呼吸困難 &
心博過速

4天前

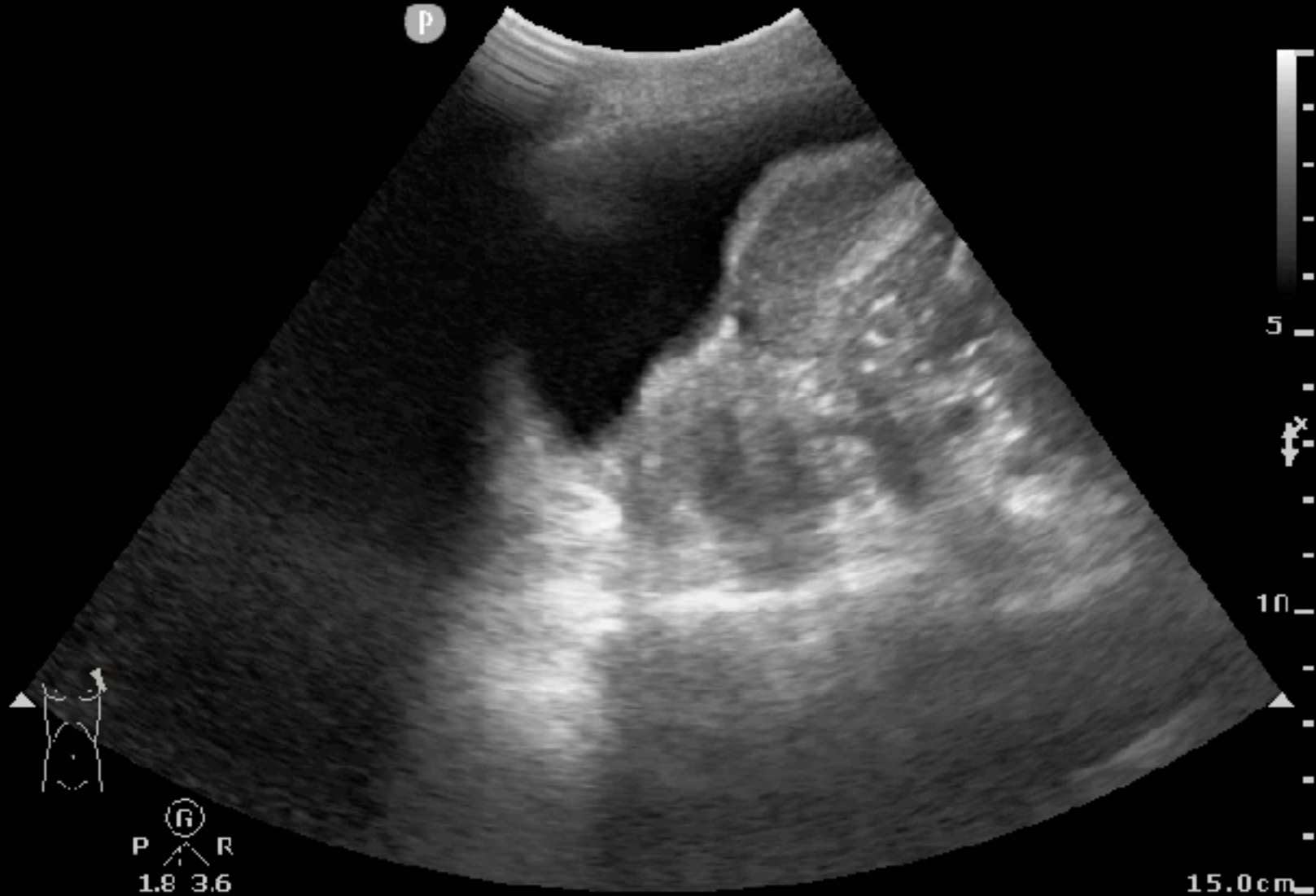
就診日



PLE相關？

Abd Gen
C5-1
34 Hz
15.0cm

2D
HGen
Gn 100
C. 56
3/3/3

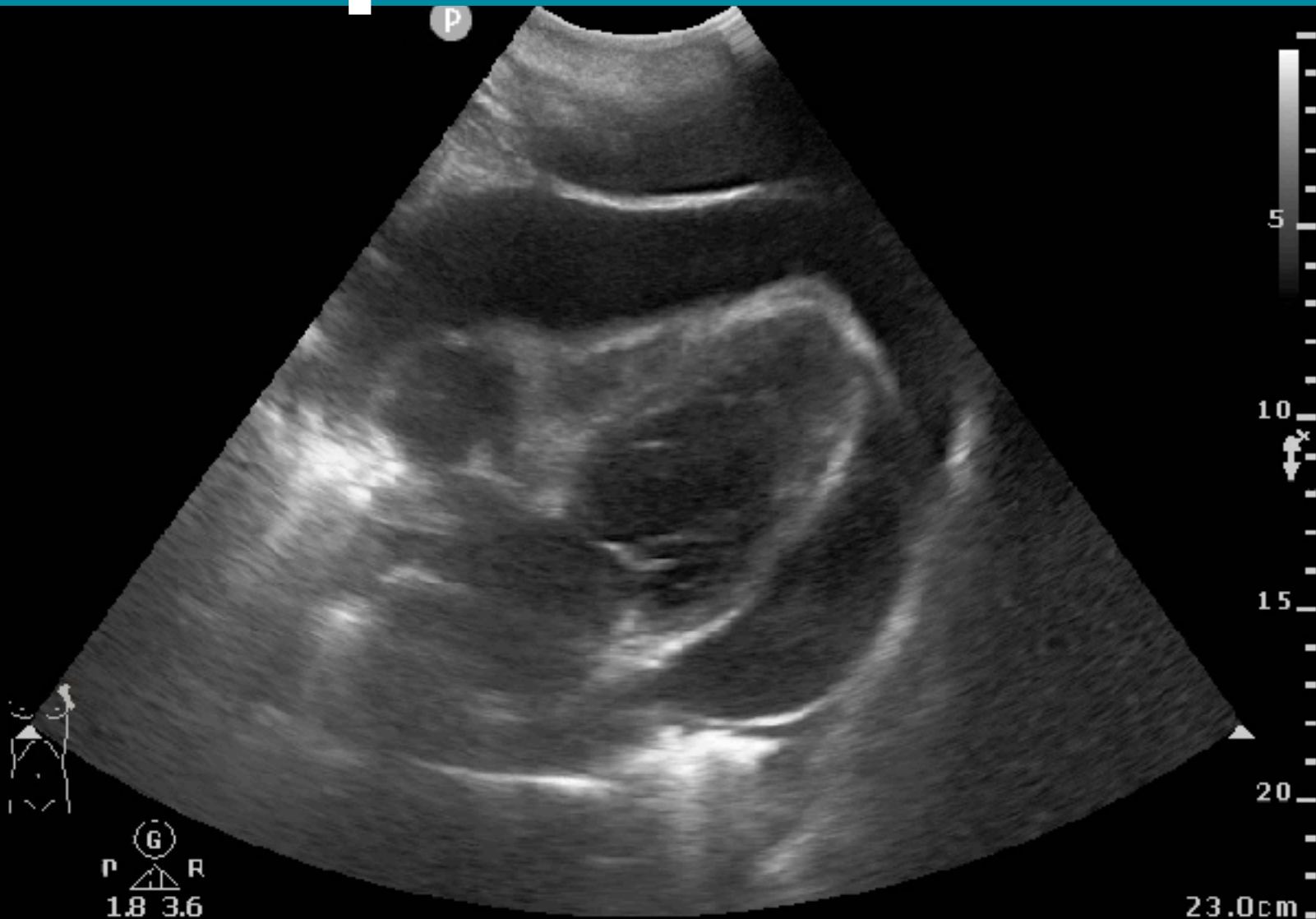


15.0cm

Tamponade ?

bd Gen
5-1
5 Hz
3.0cm

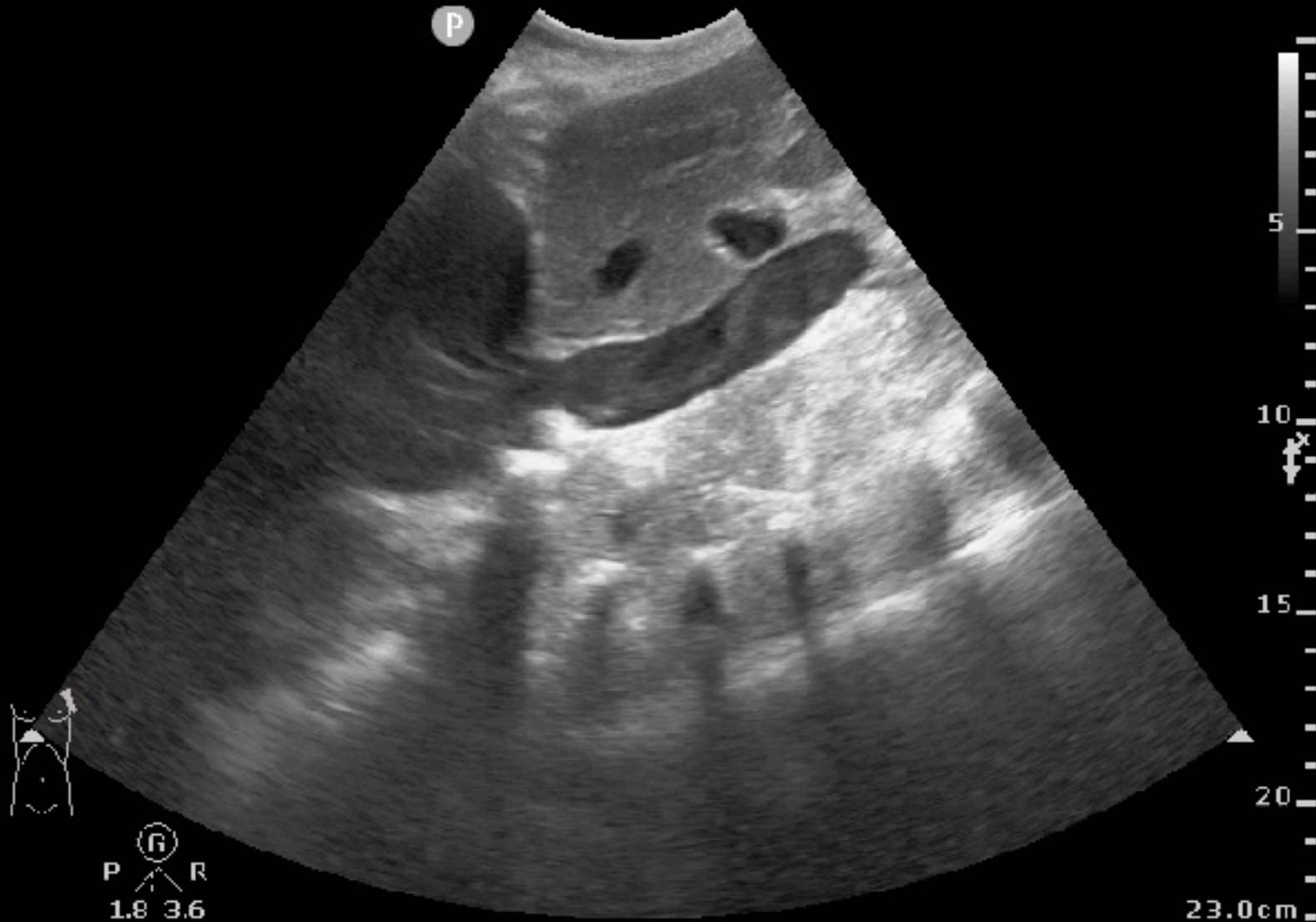D
HGen
Gn 100
C 56
3/3/3



臨床/積液/鼓漲

Abd Gen
C5-1
25 Hz
23.0cm

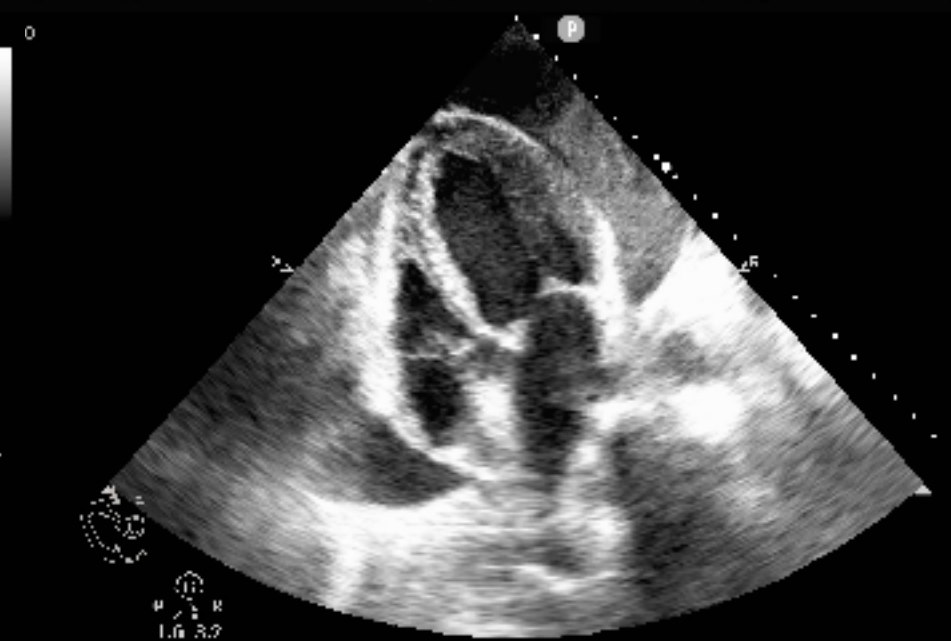
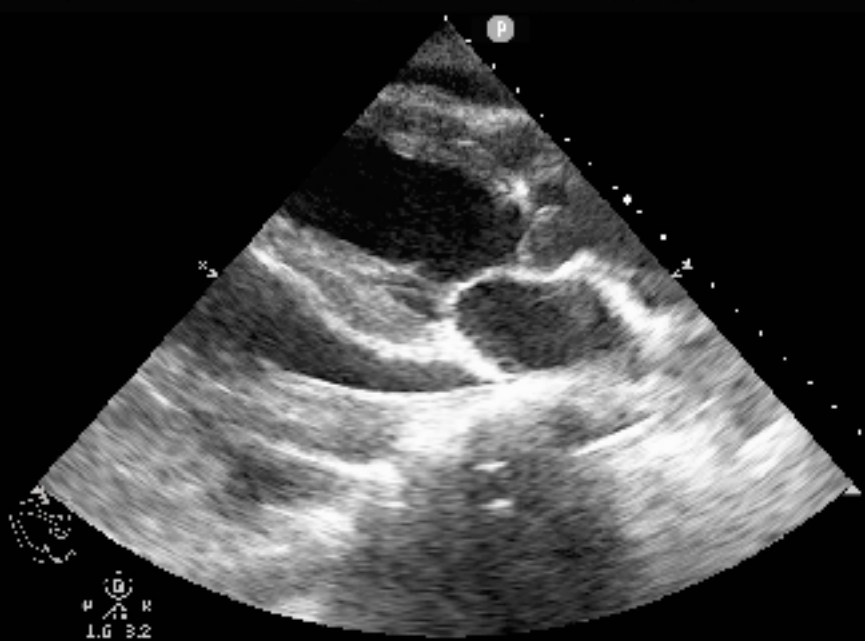
2D
HGen
Gn 100
C. 56
3/3/3



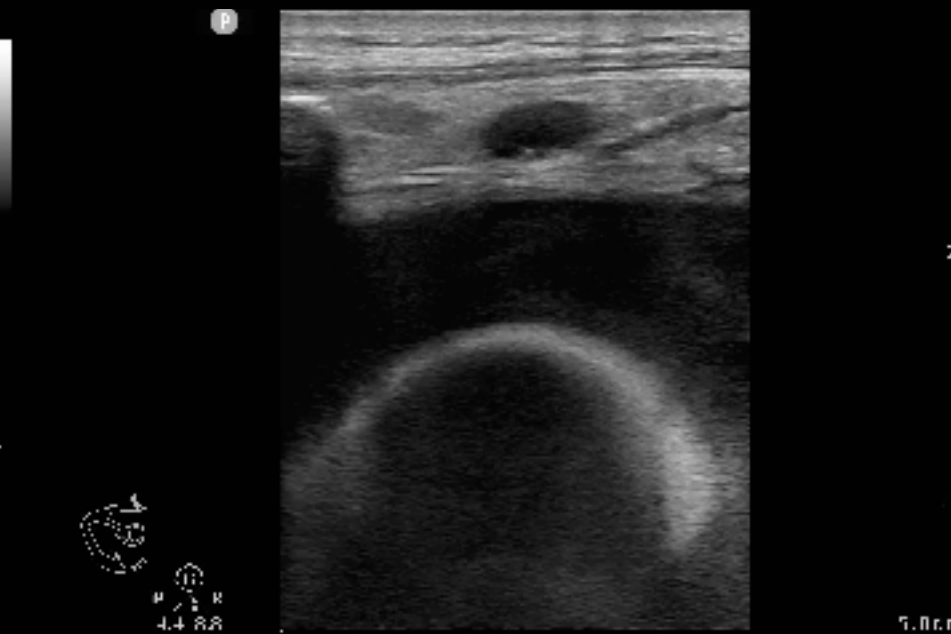
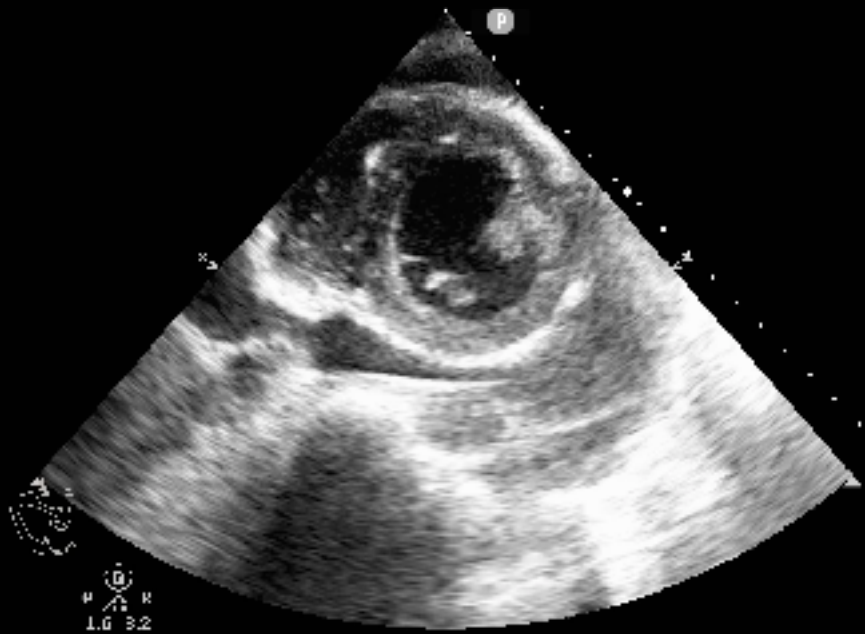①
P R
1.8 3.6

23.0cm

cho



cho

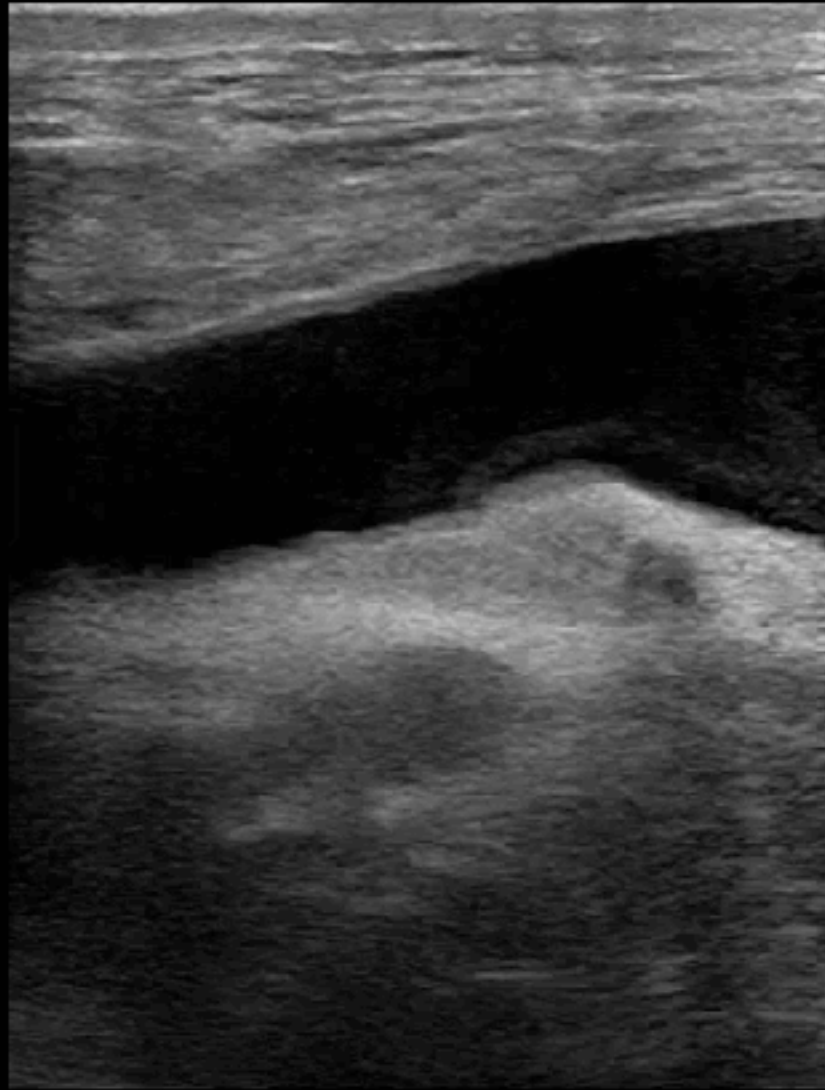


Step-by-step drainage

Arterial
L12-3
34 Hz
5.0cm

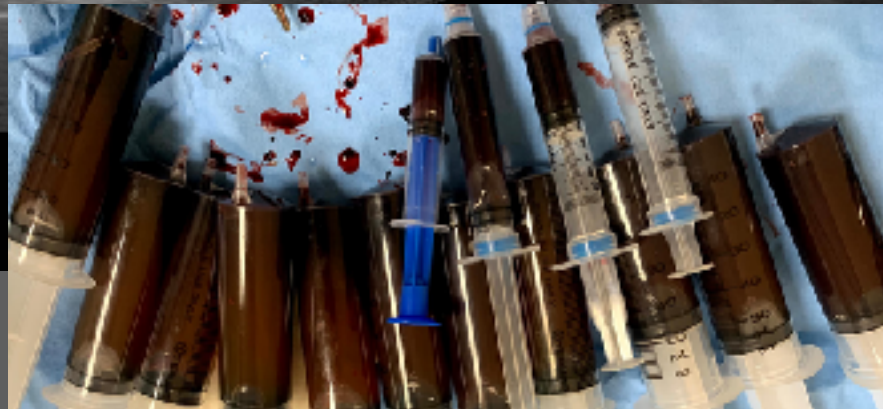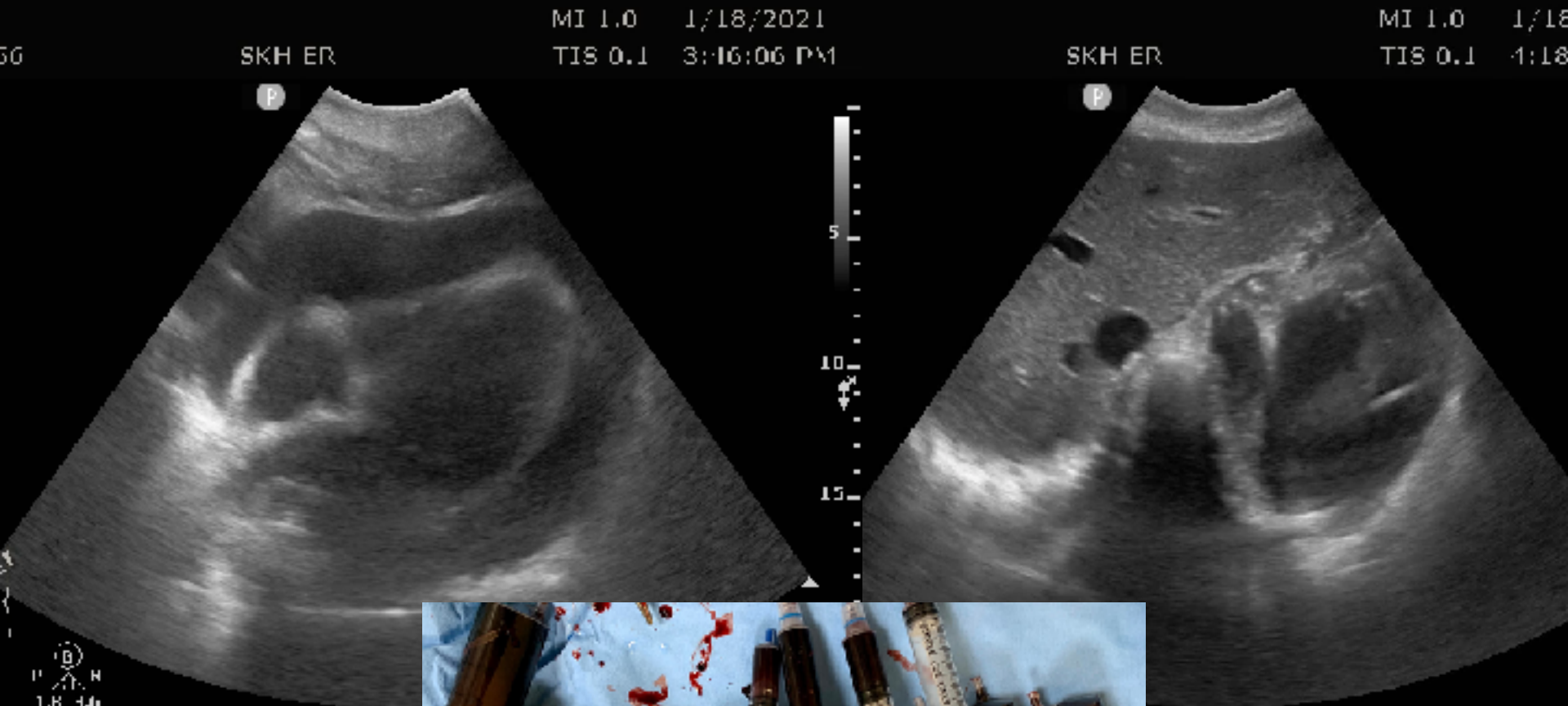
2D

HGen
Gn 66
C. 41
3/3/2

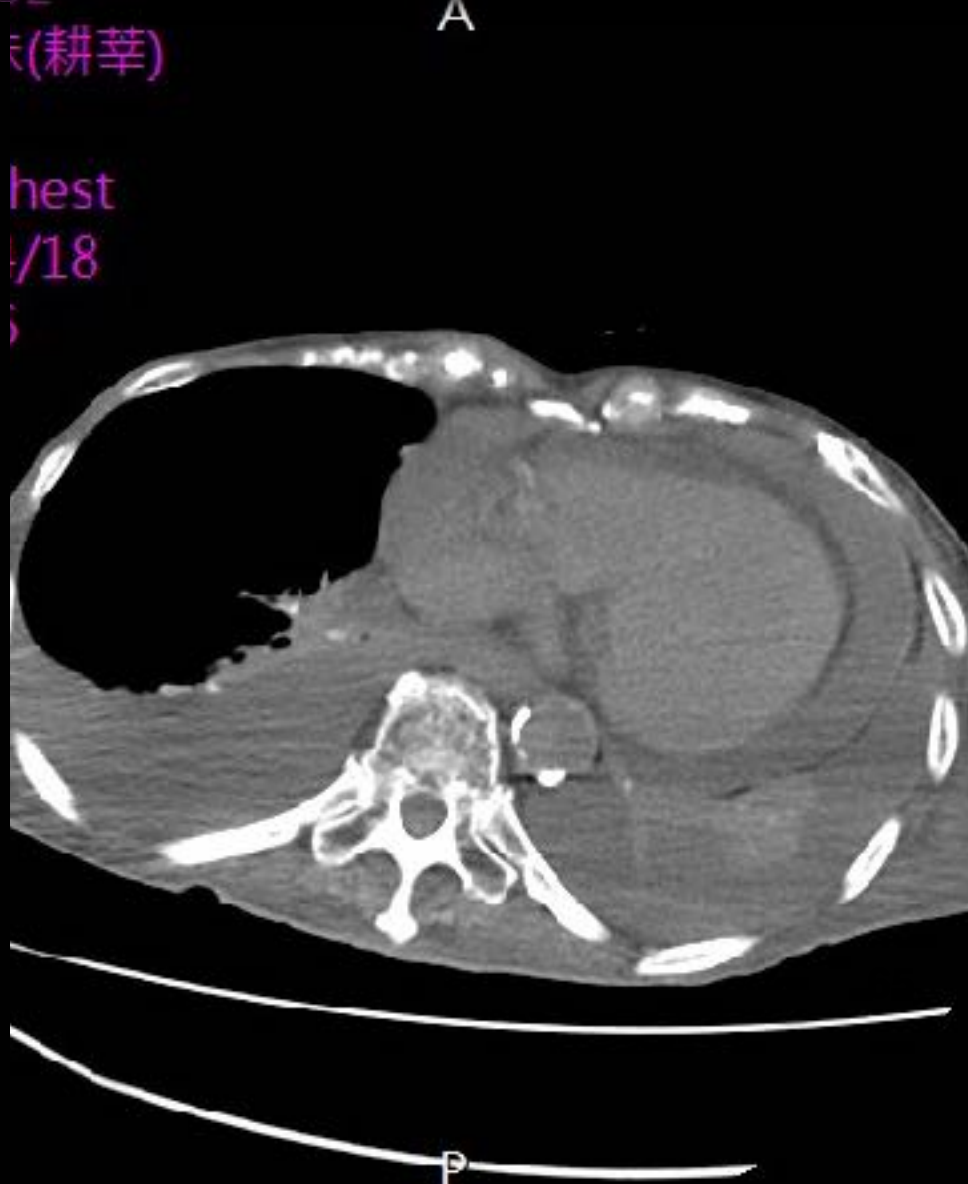
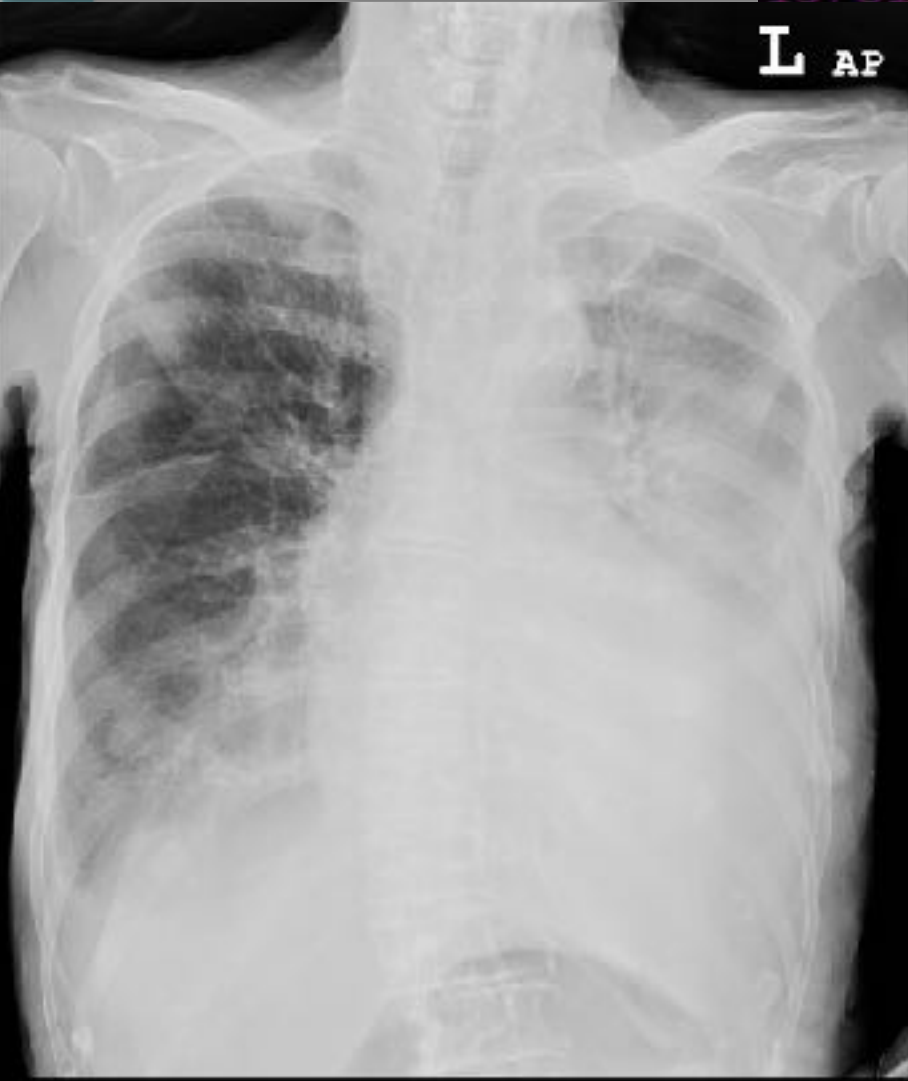
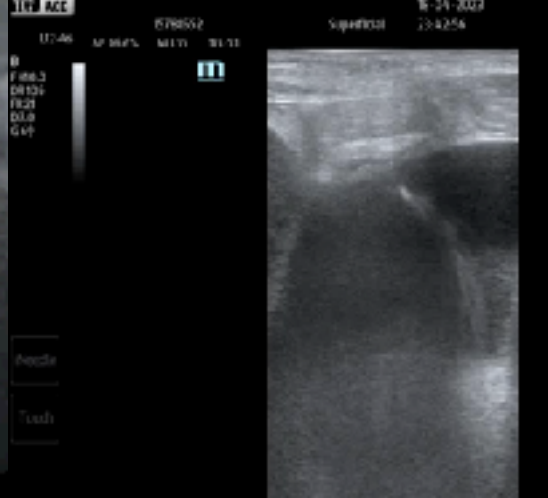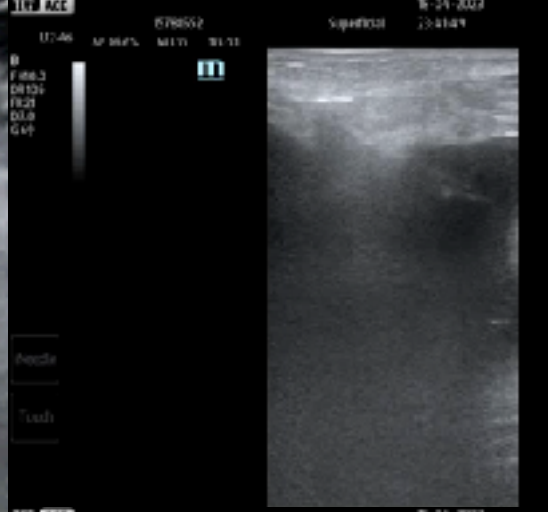
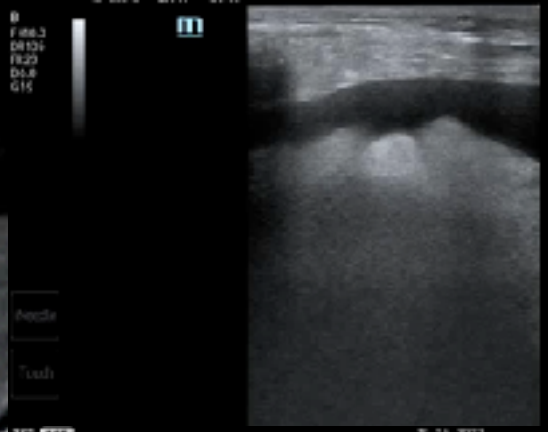
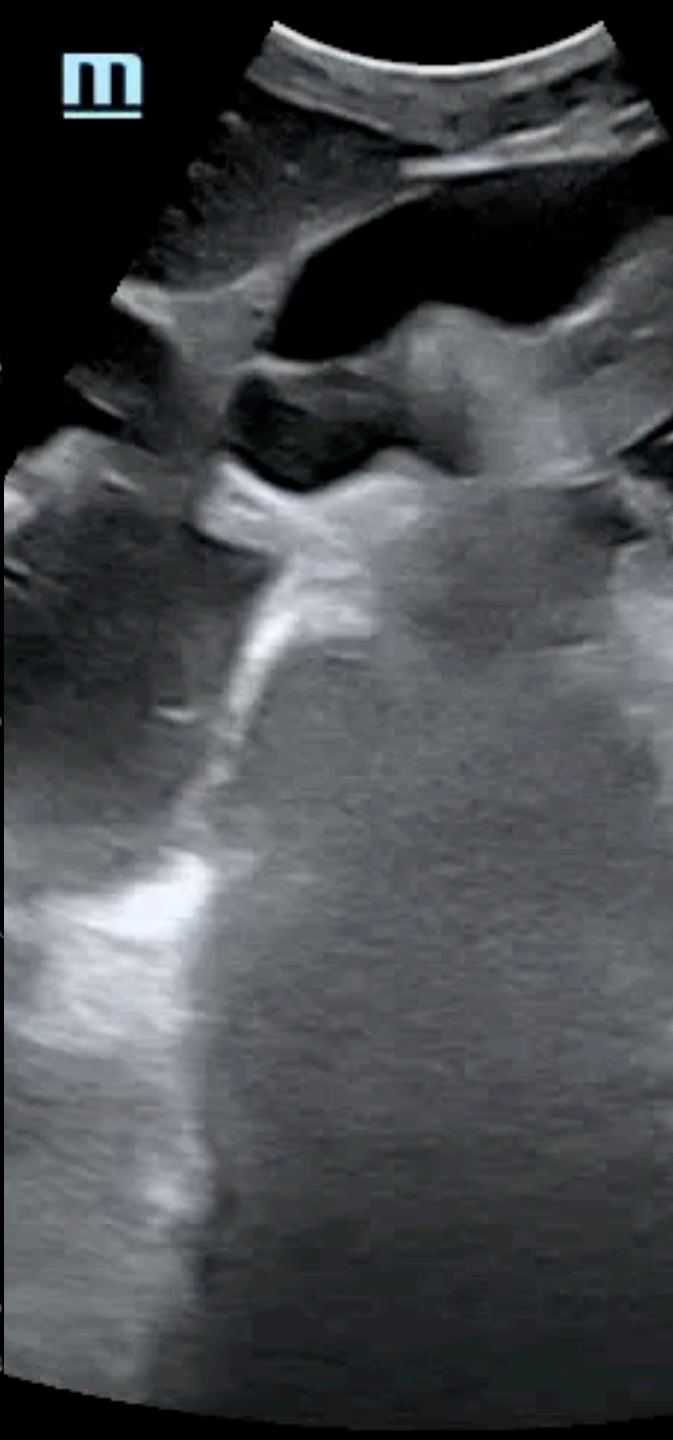
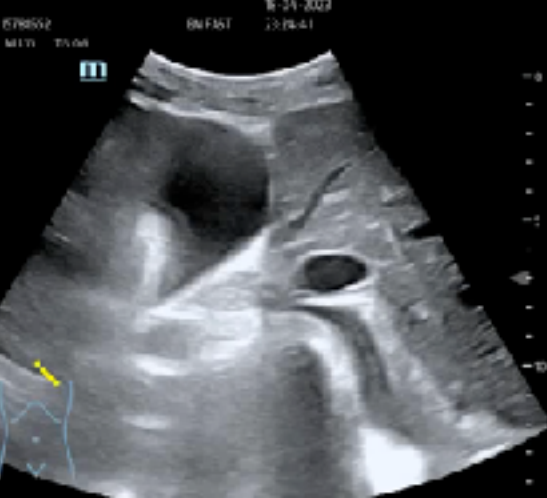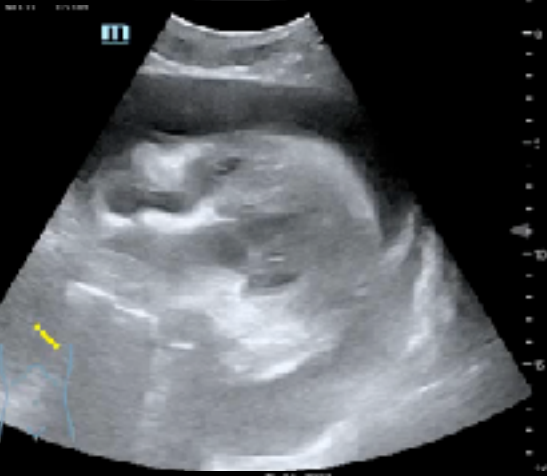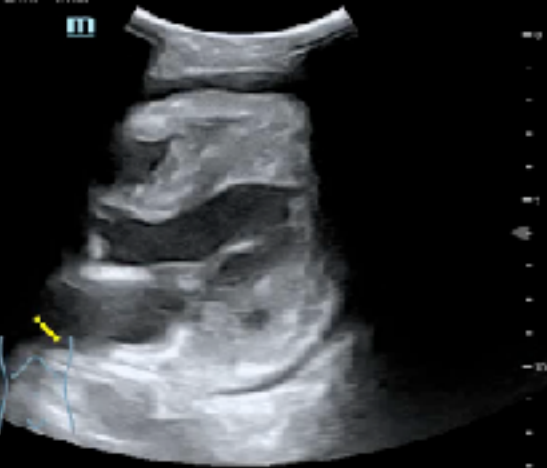5.0cm

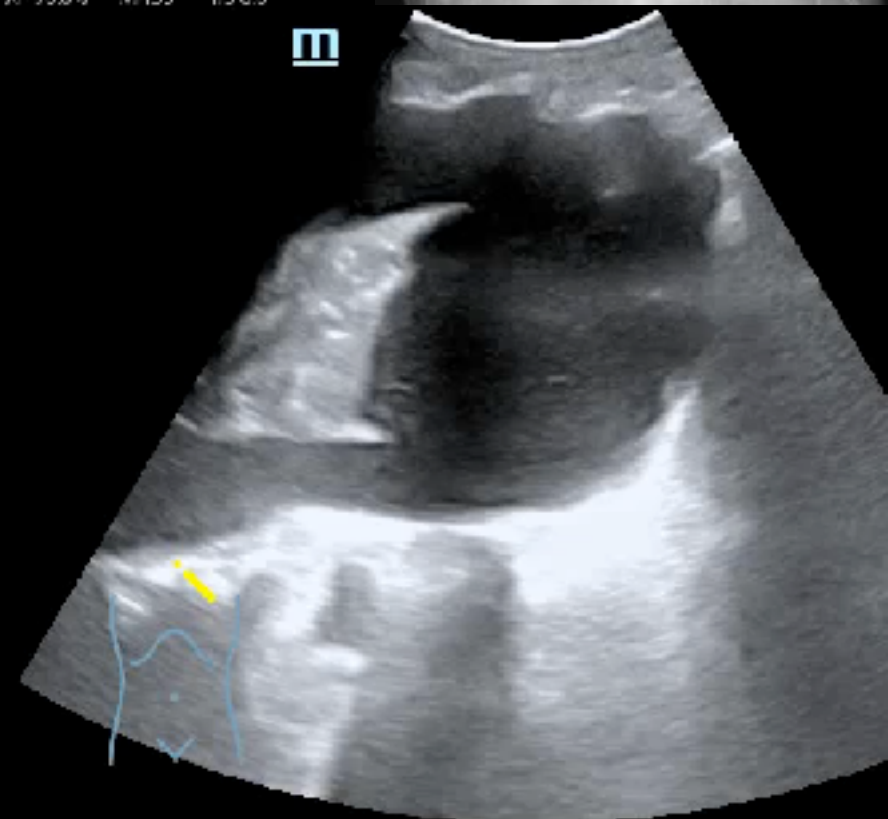
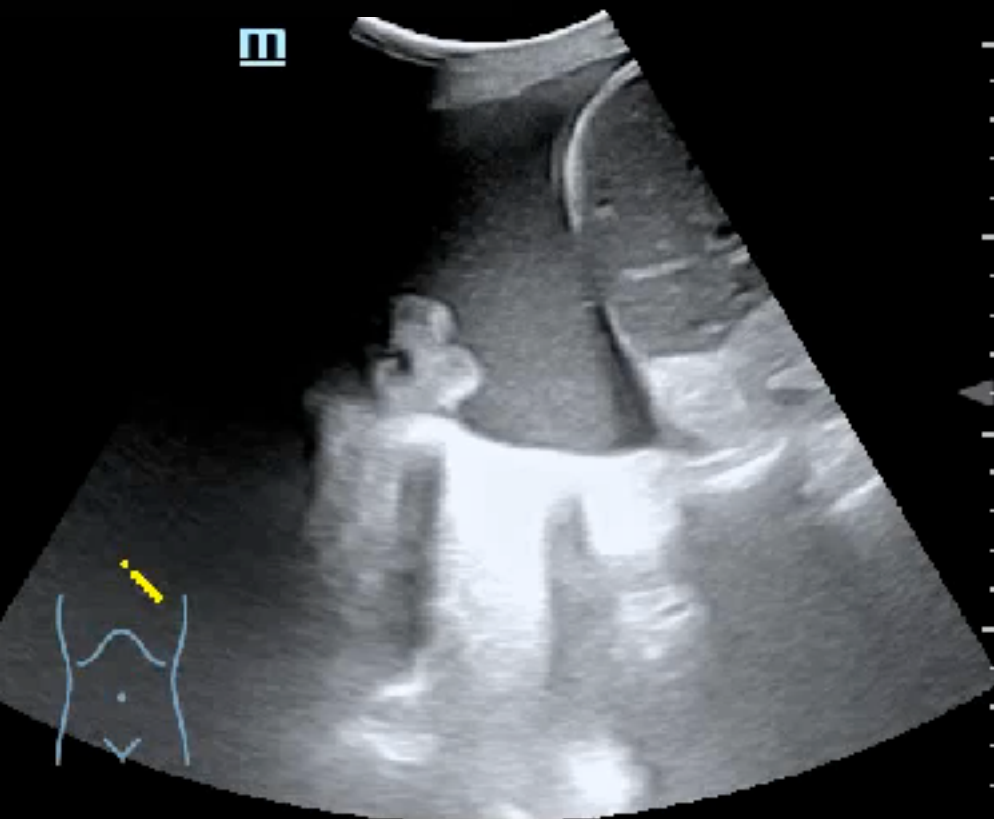
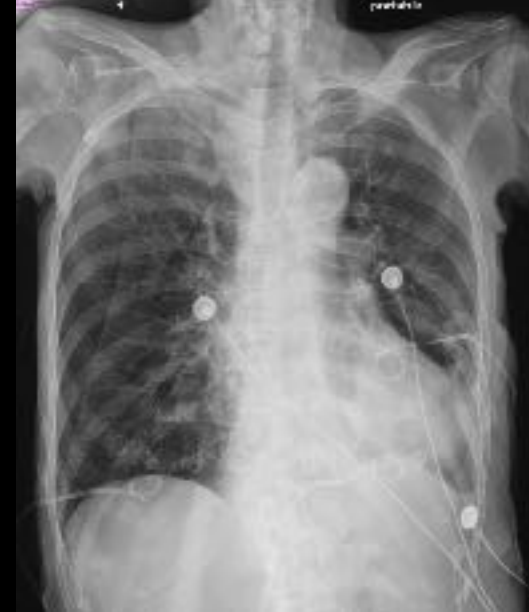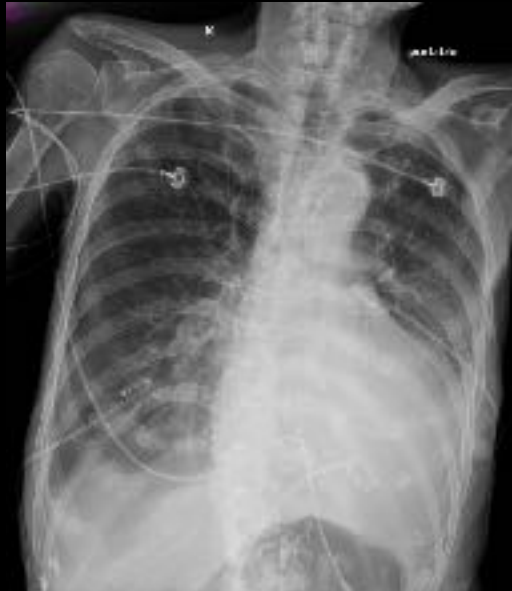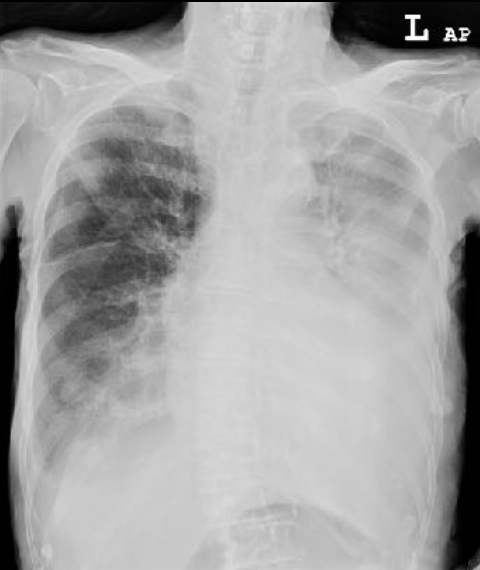Monitor after drainage



85M, AMS with shock, 外院轉入



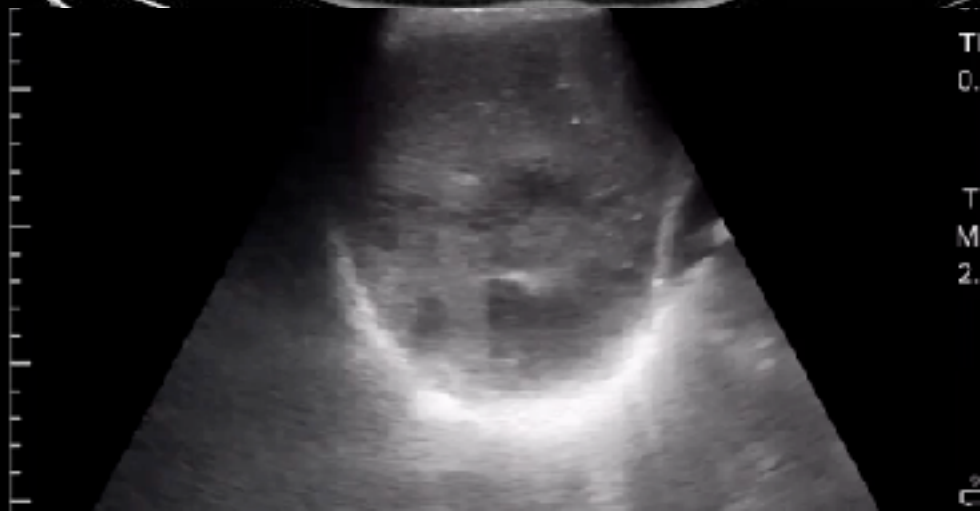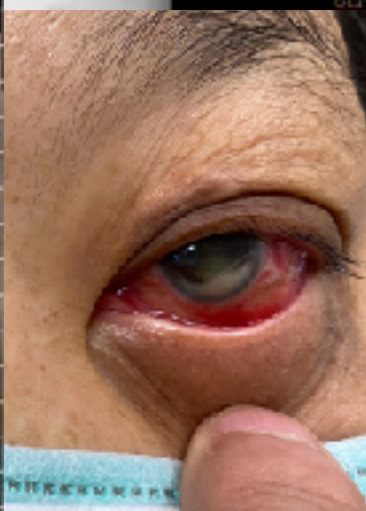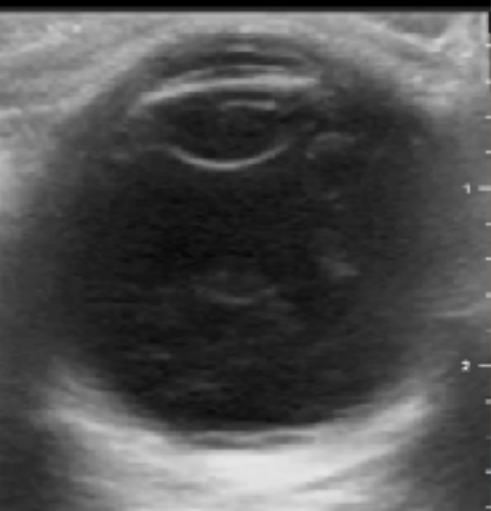
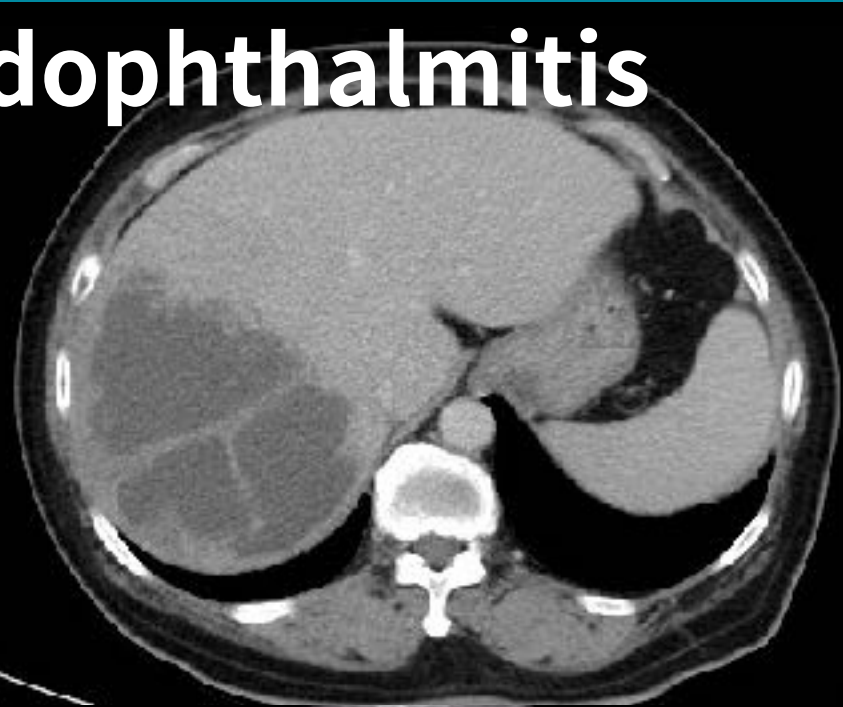


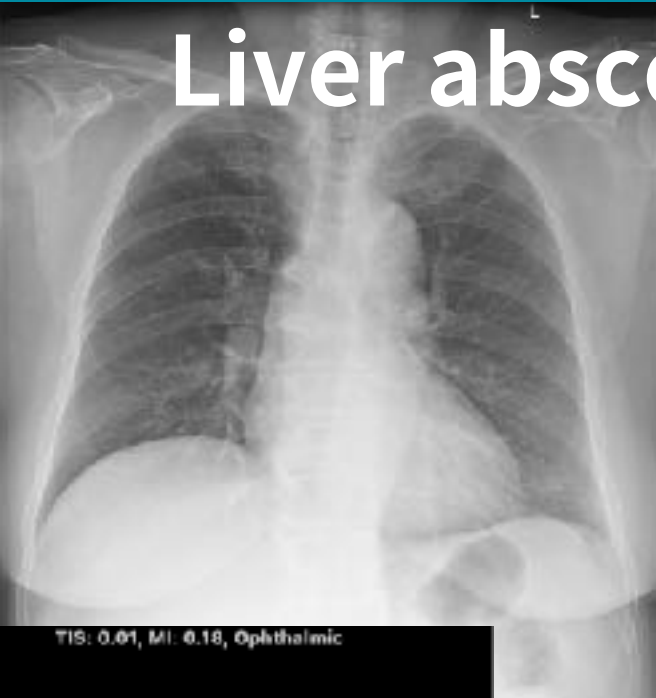


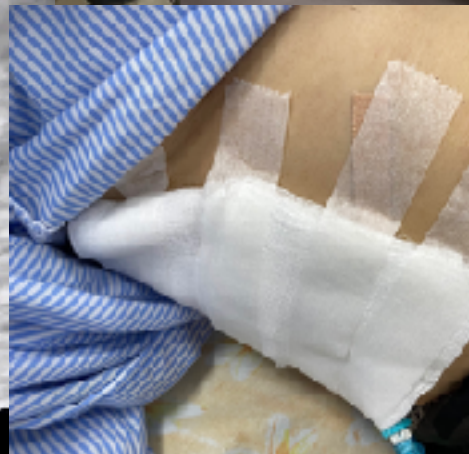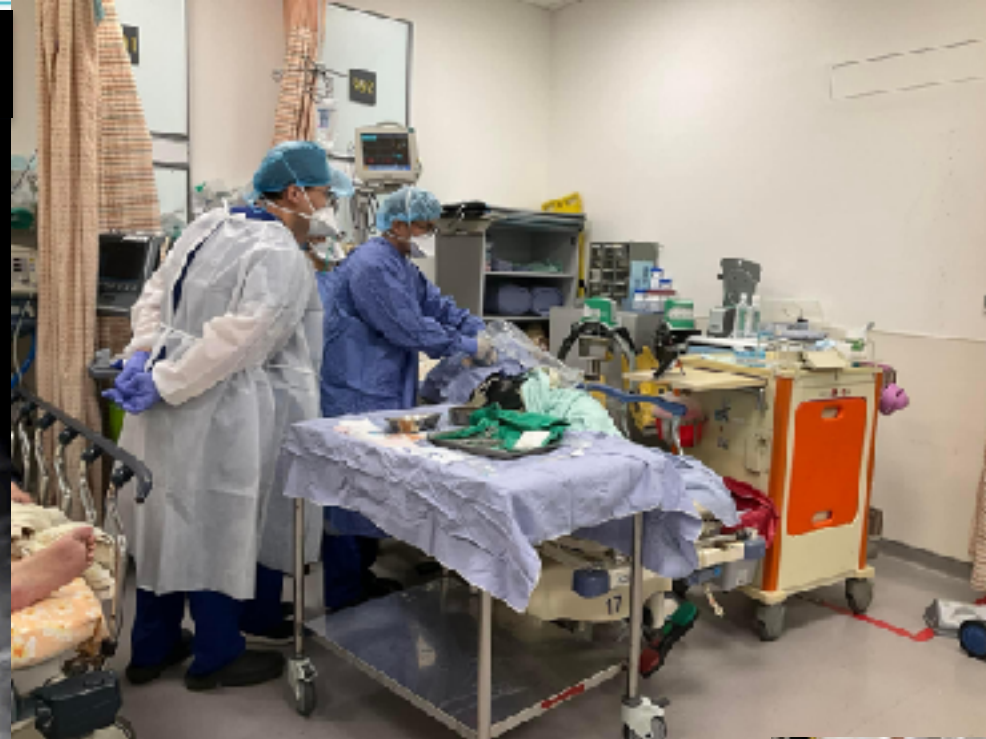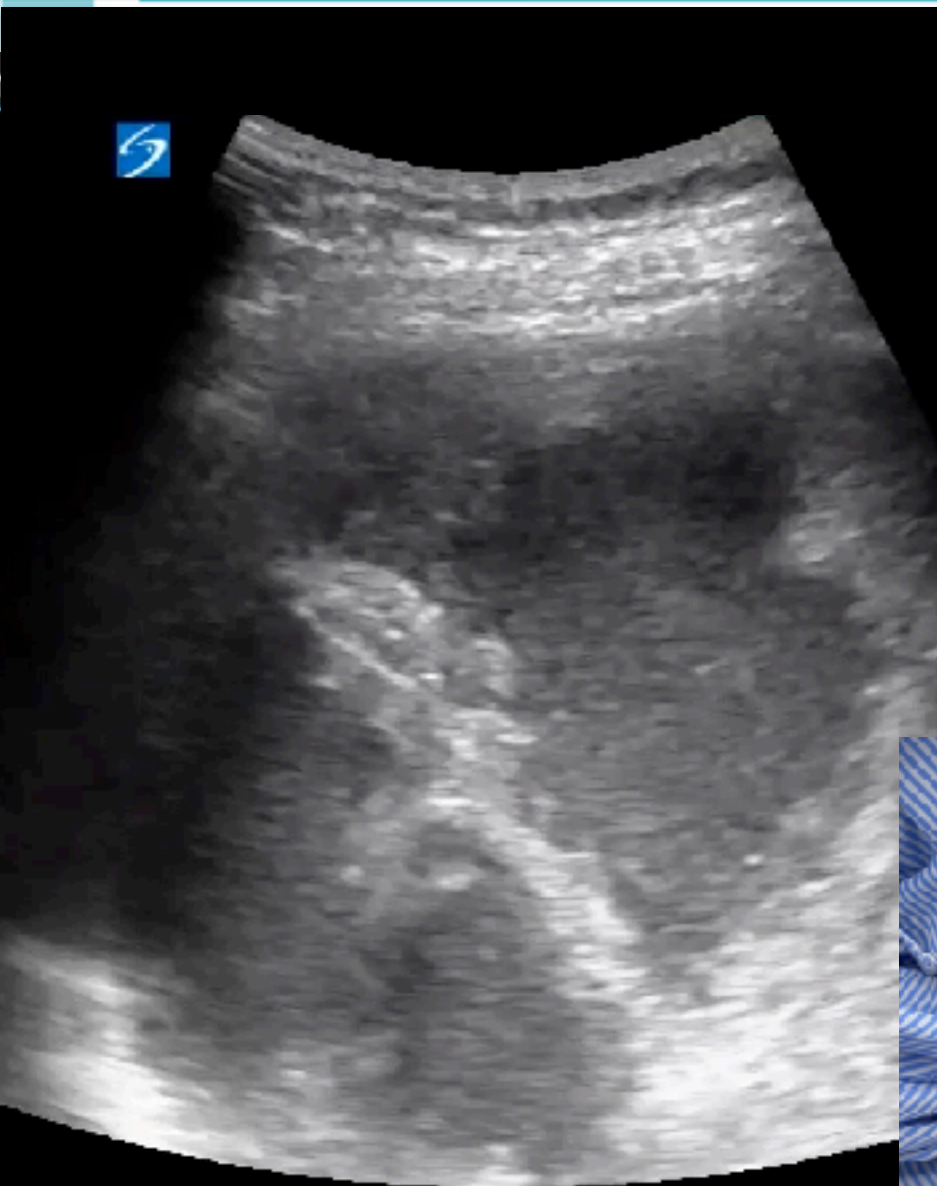
AP 95.6% M 133 T5 0.6

65F, left eye redness, pain; R chest pain

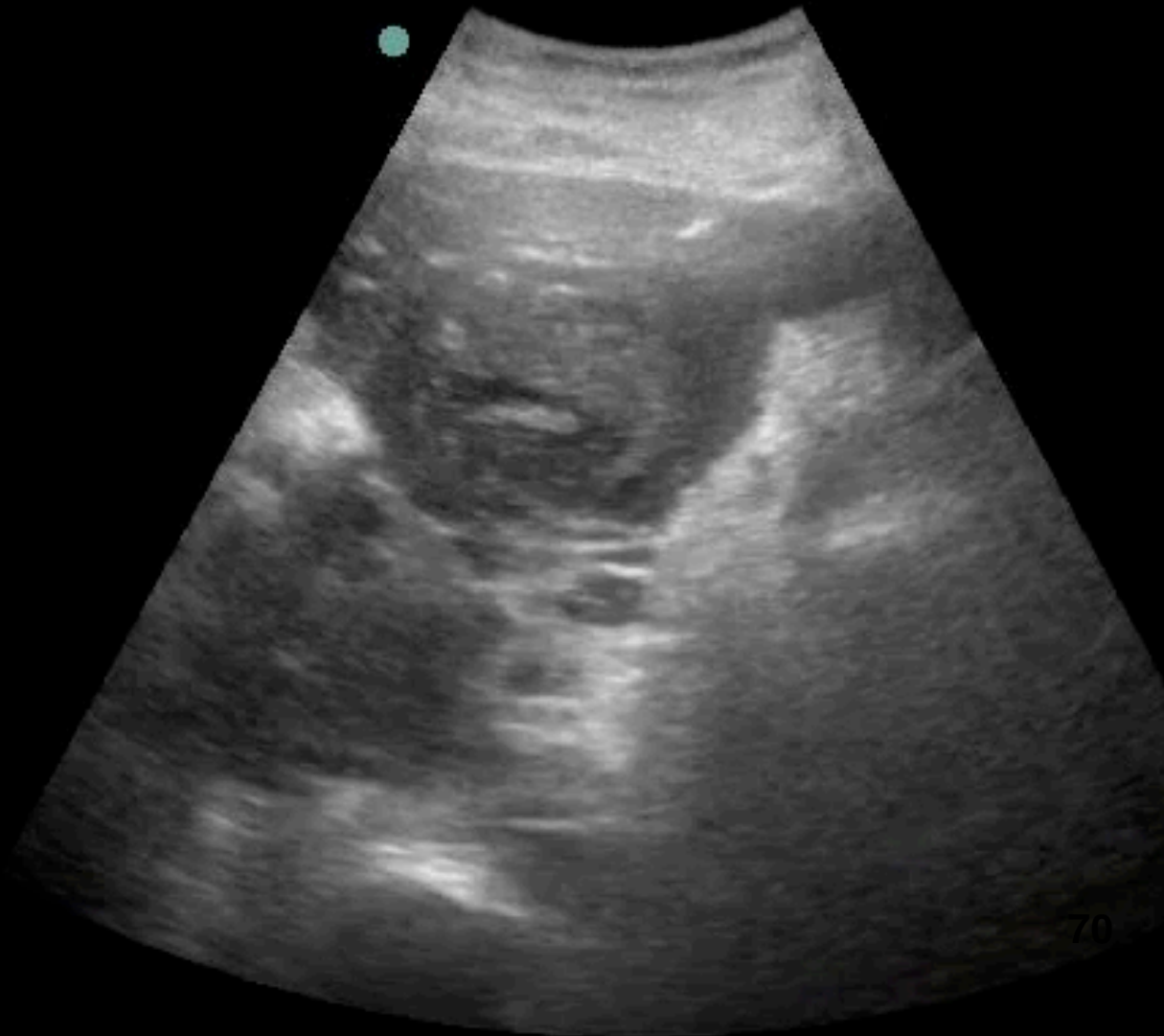
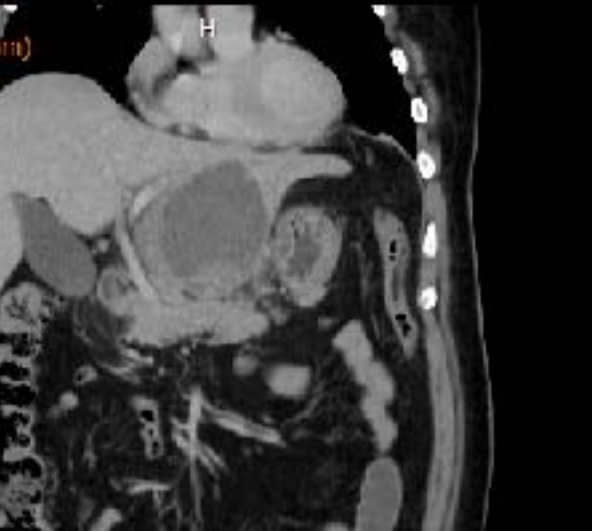
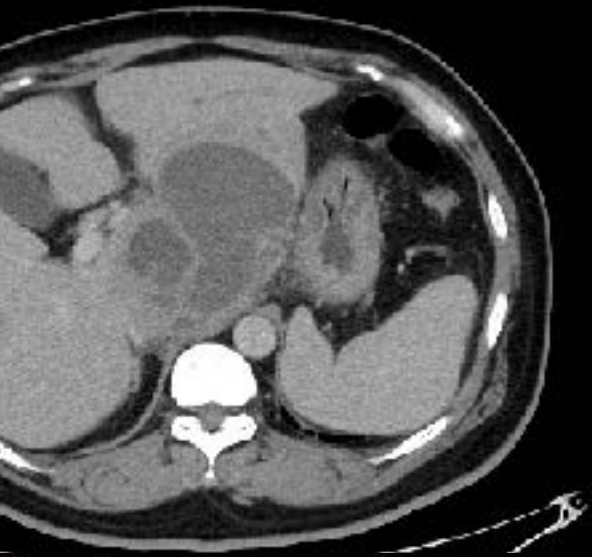
Liver abscess / Endophthalmitis



Pigtail for liver abscess drainage

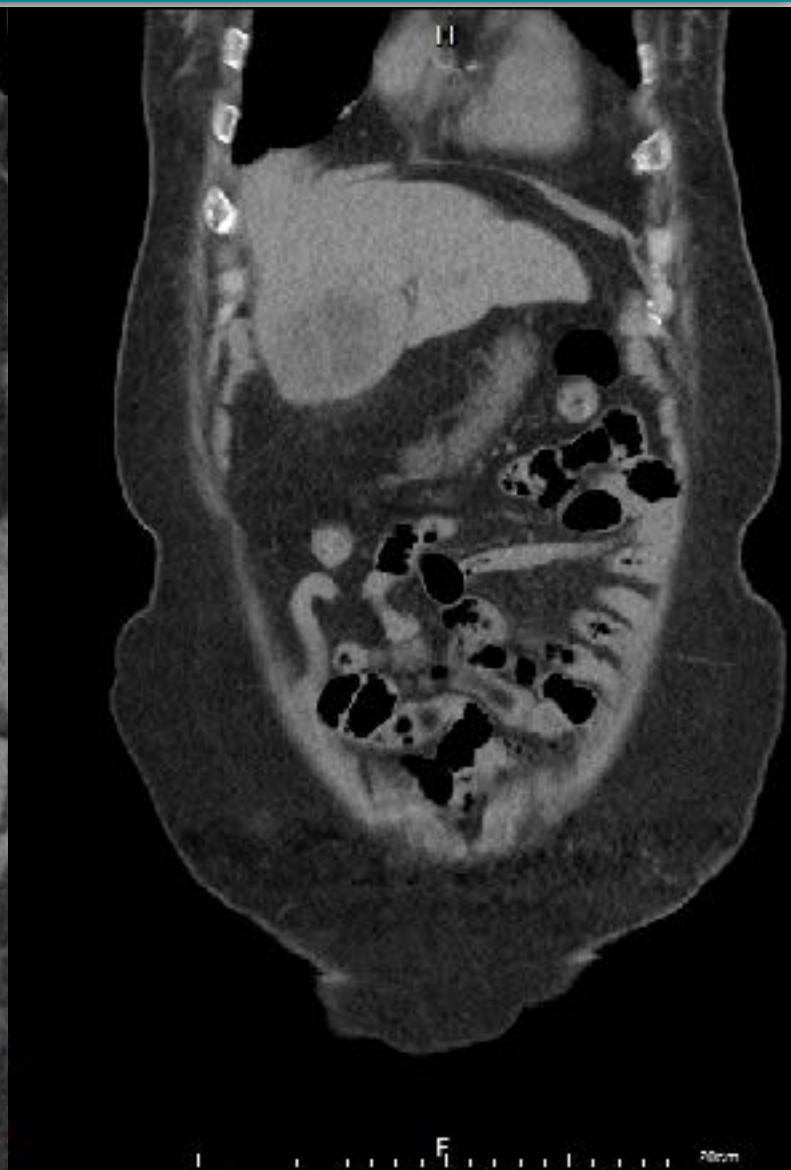
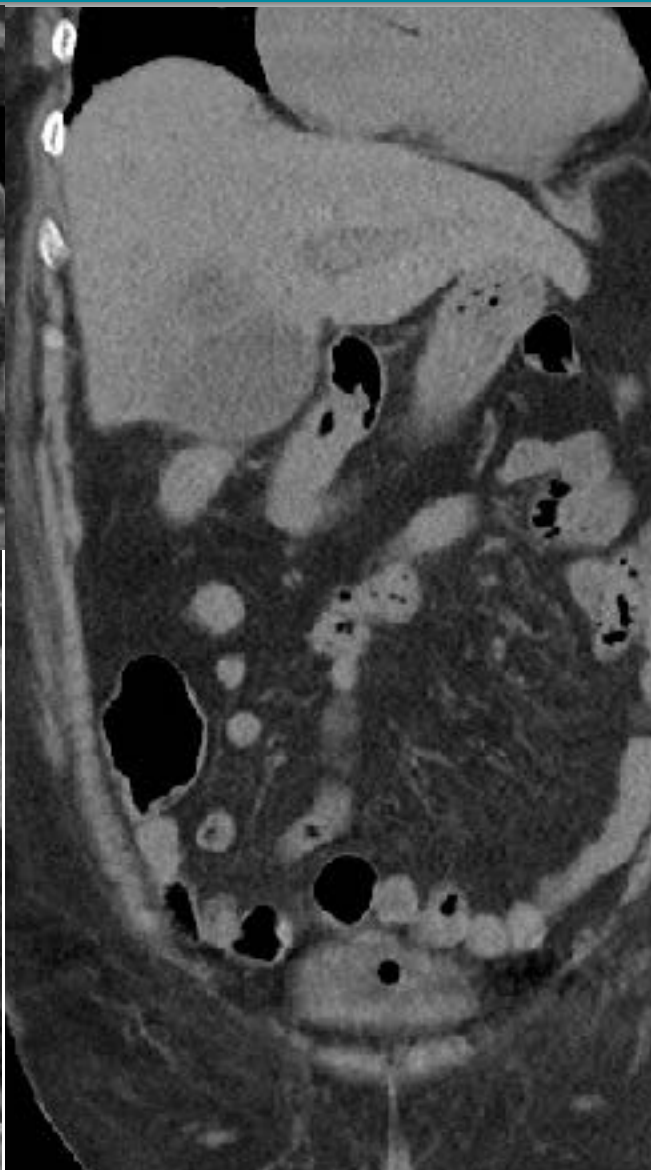
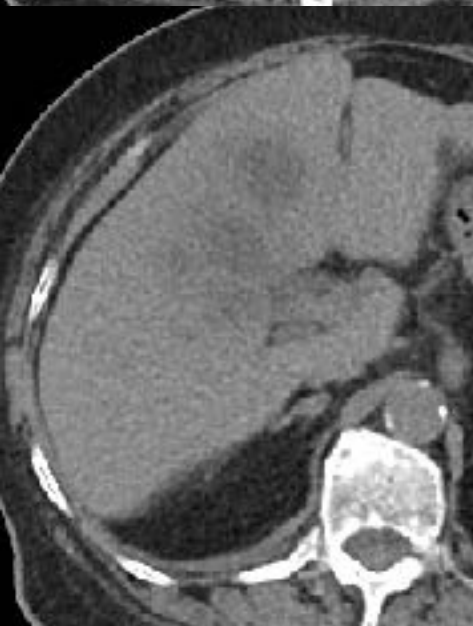
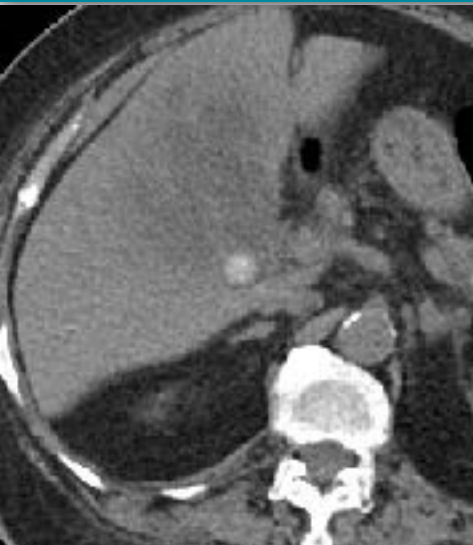
53M, liver abscess

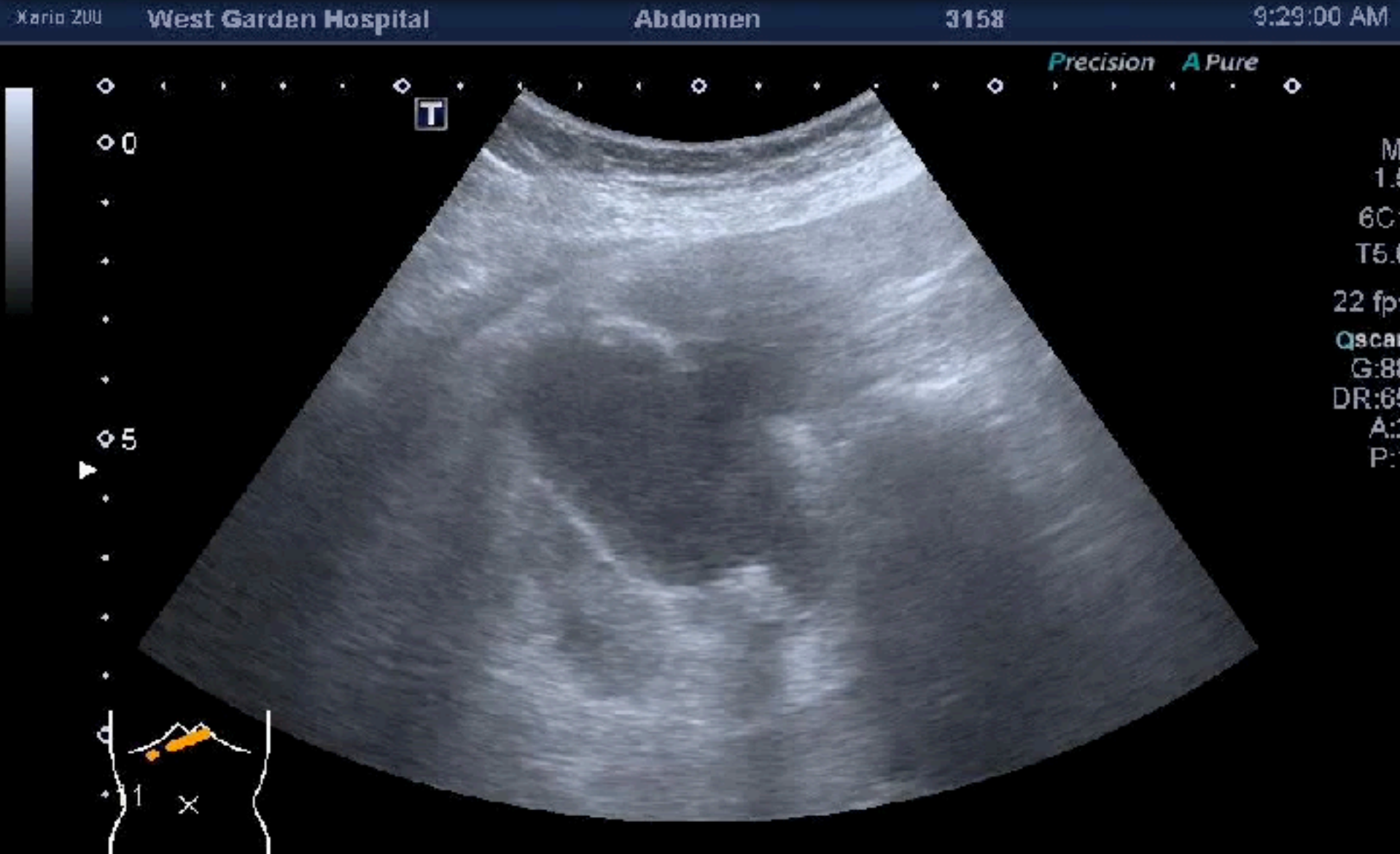

Total amount > 1000ml

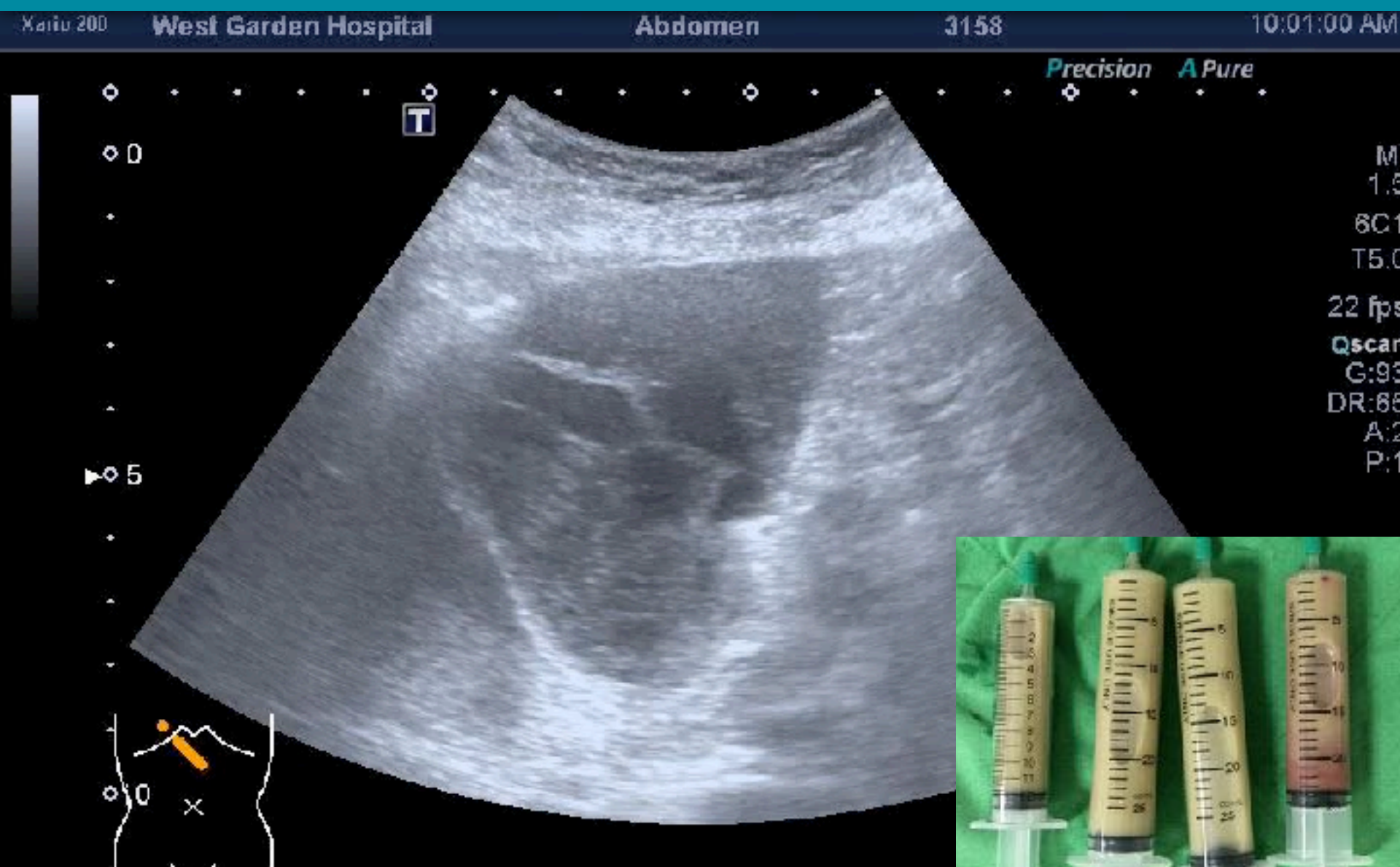
94F, right abdominal pain with fever



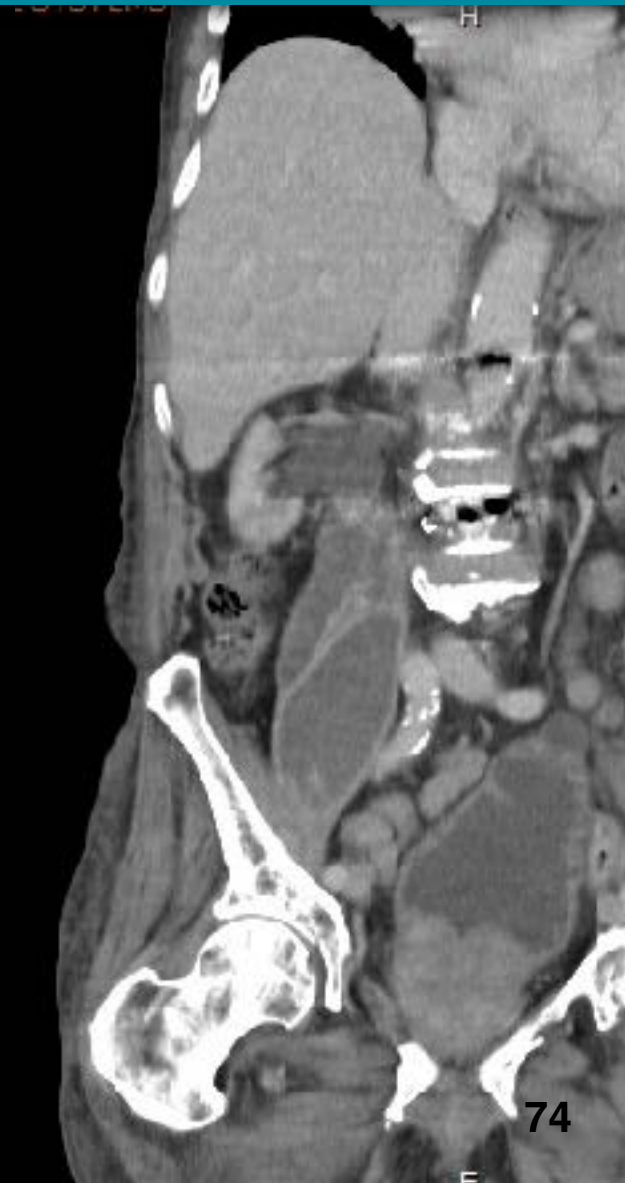
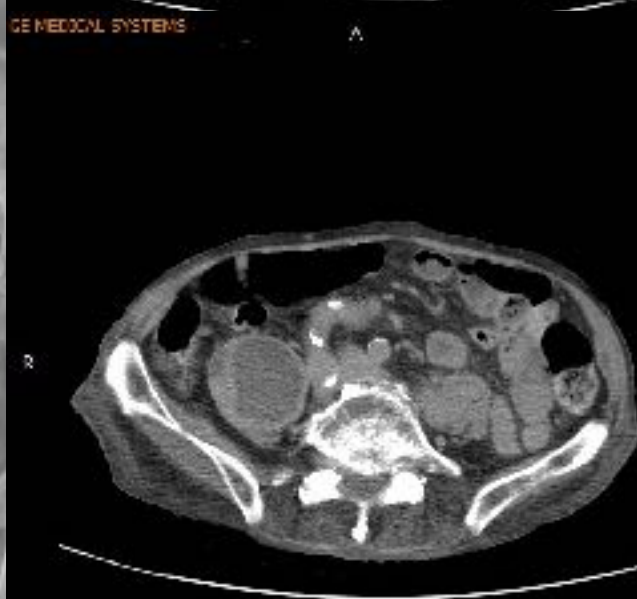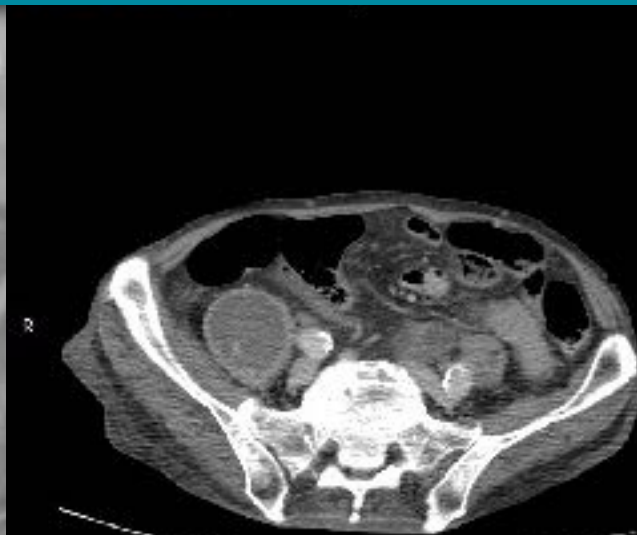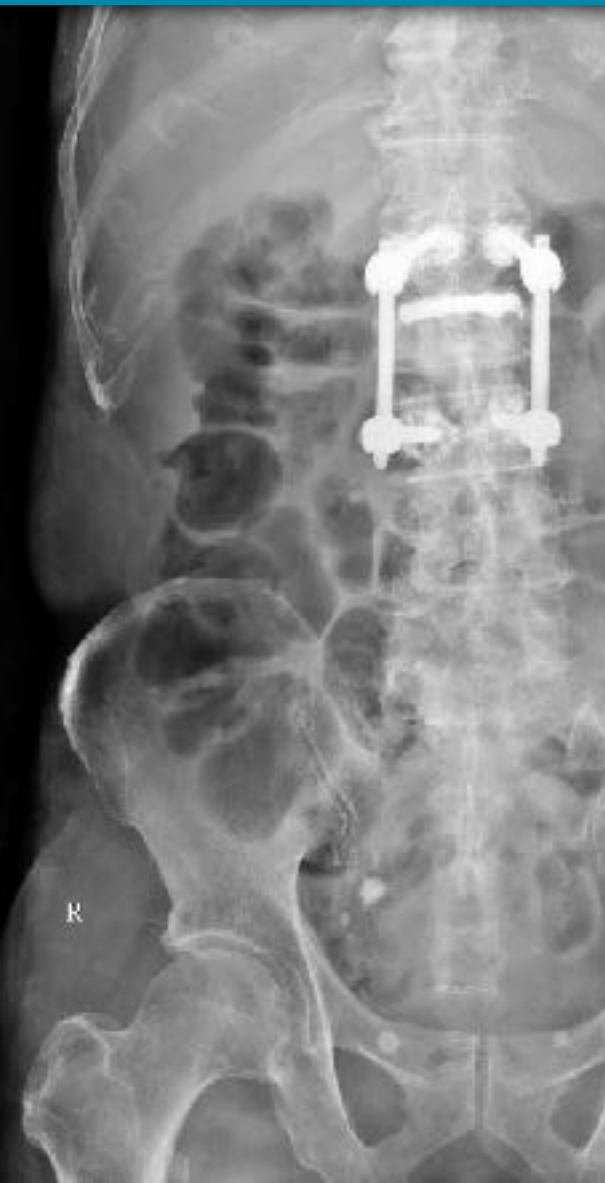GB empyema with rupture



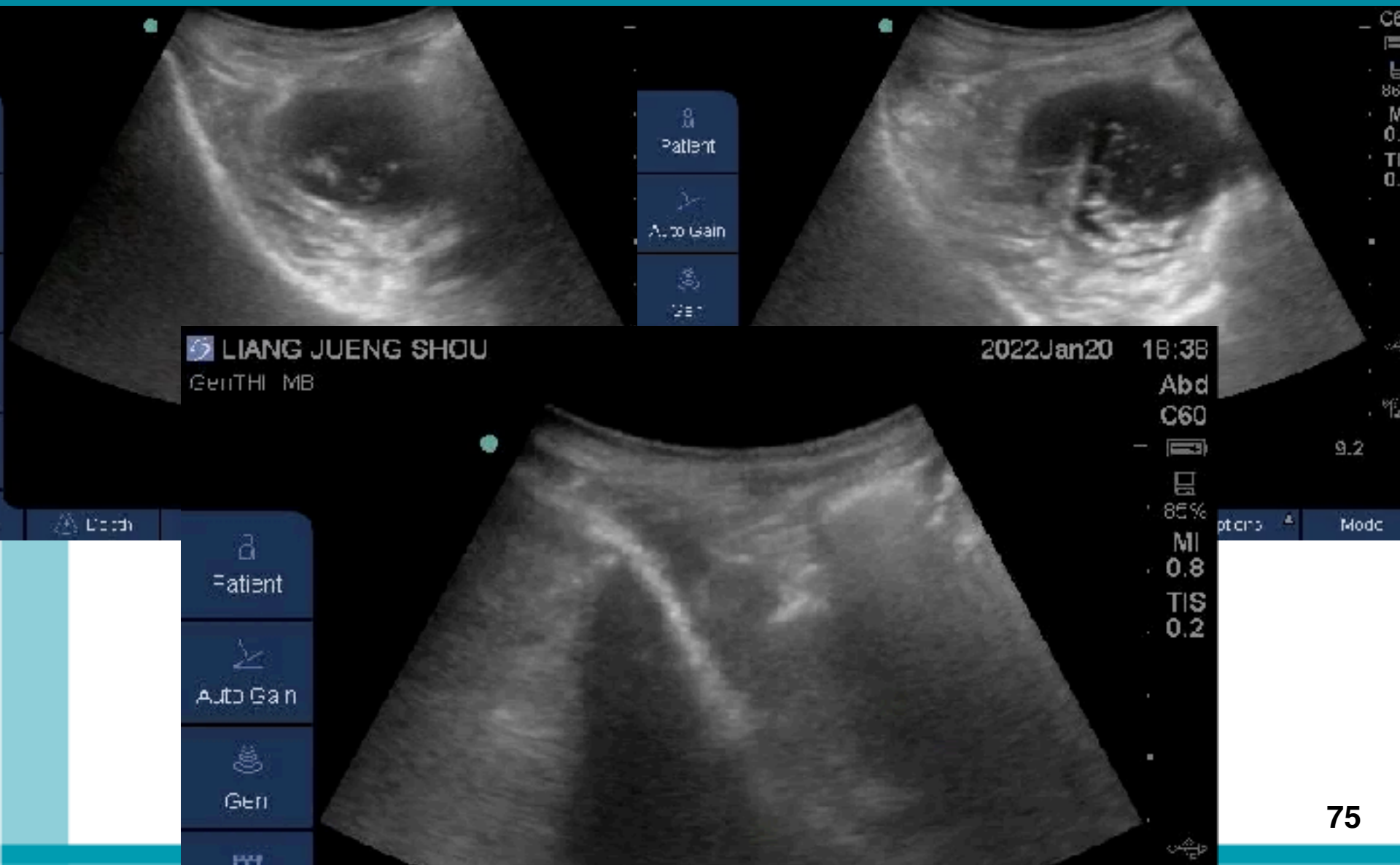
GB empyema with rupture



85, Psoas muscle abscess

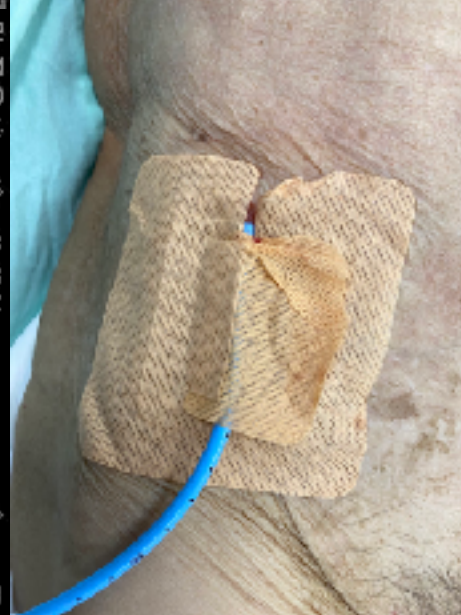
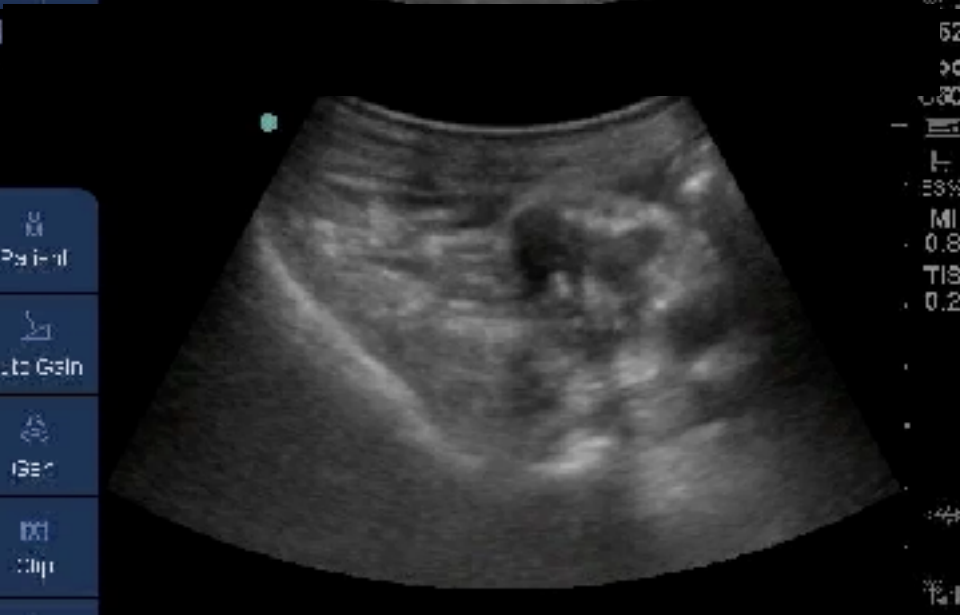
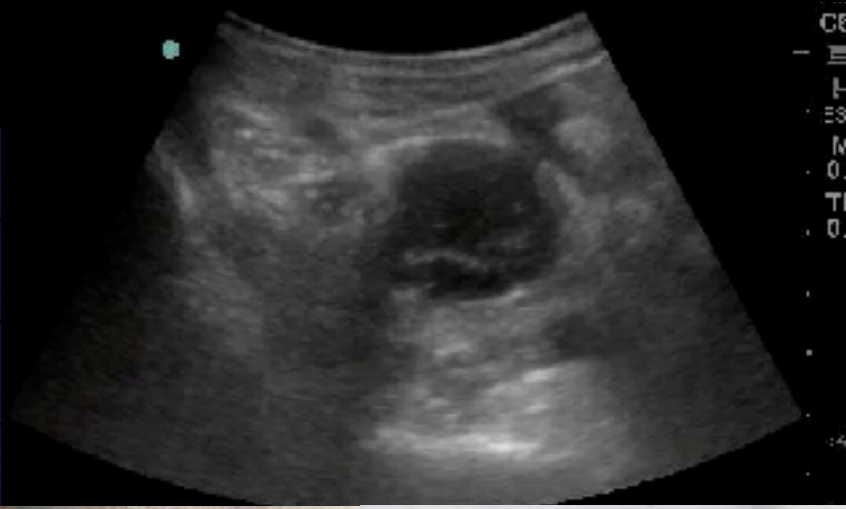
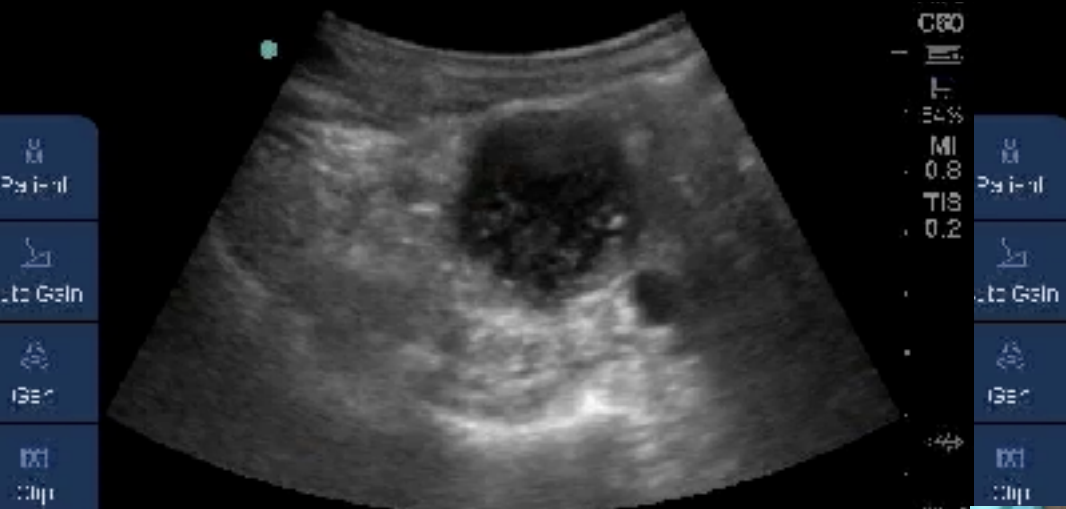85, Psoas muscle abscess

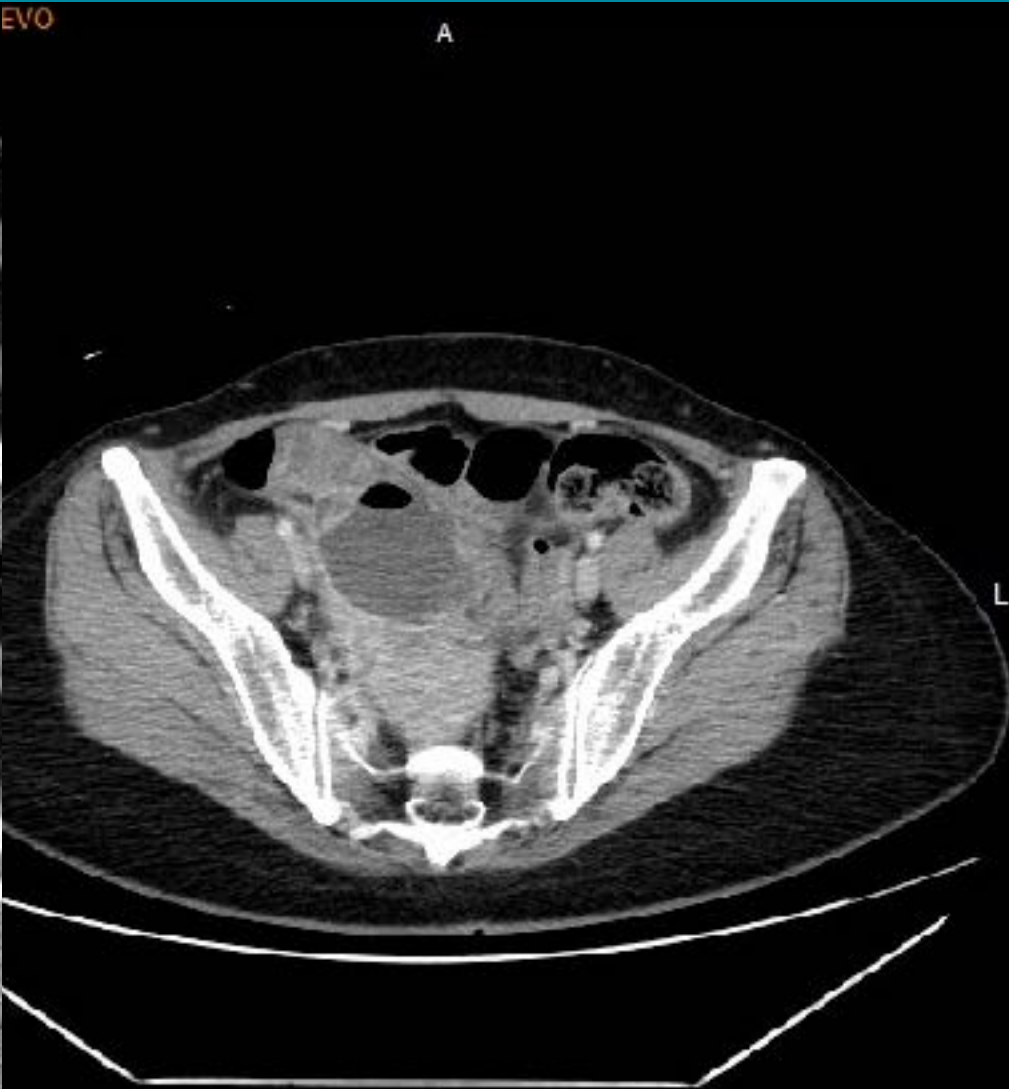
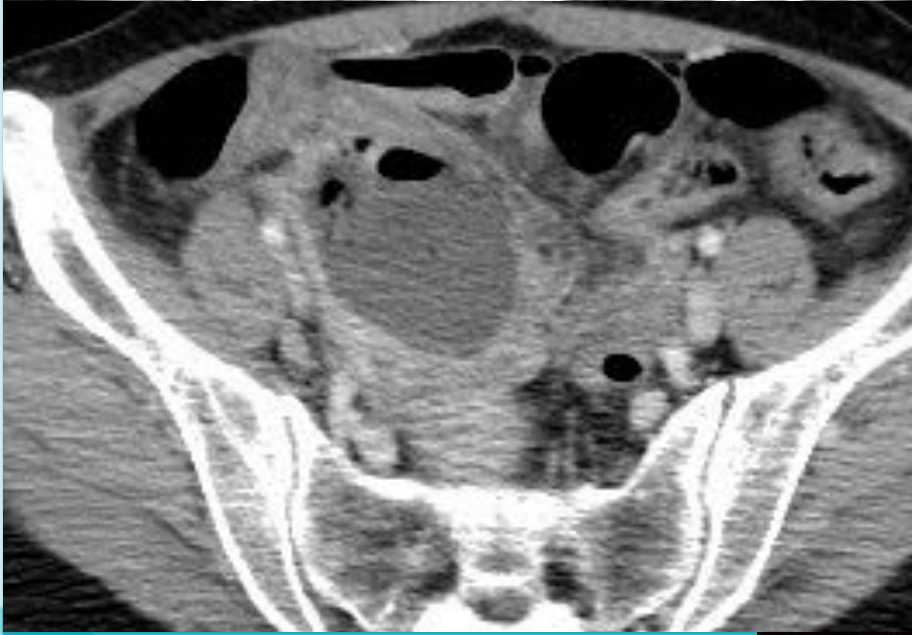
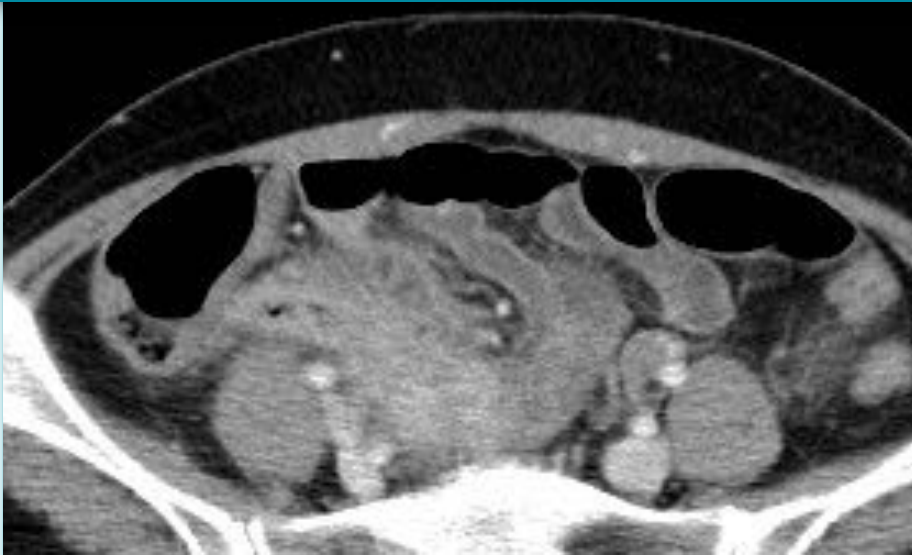

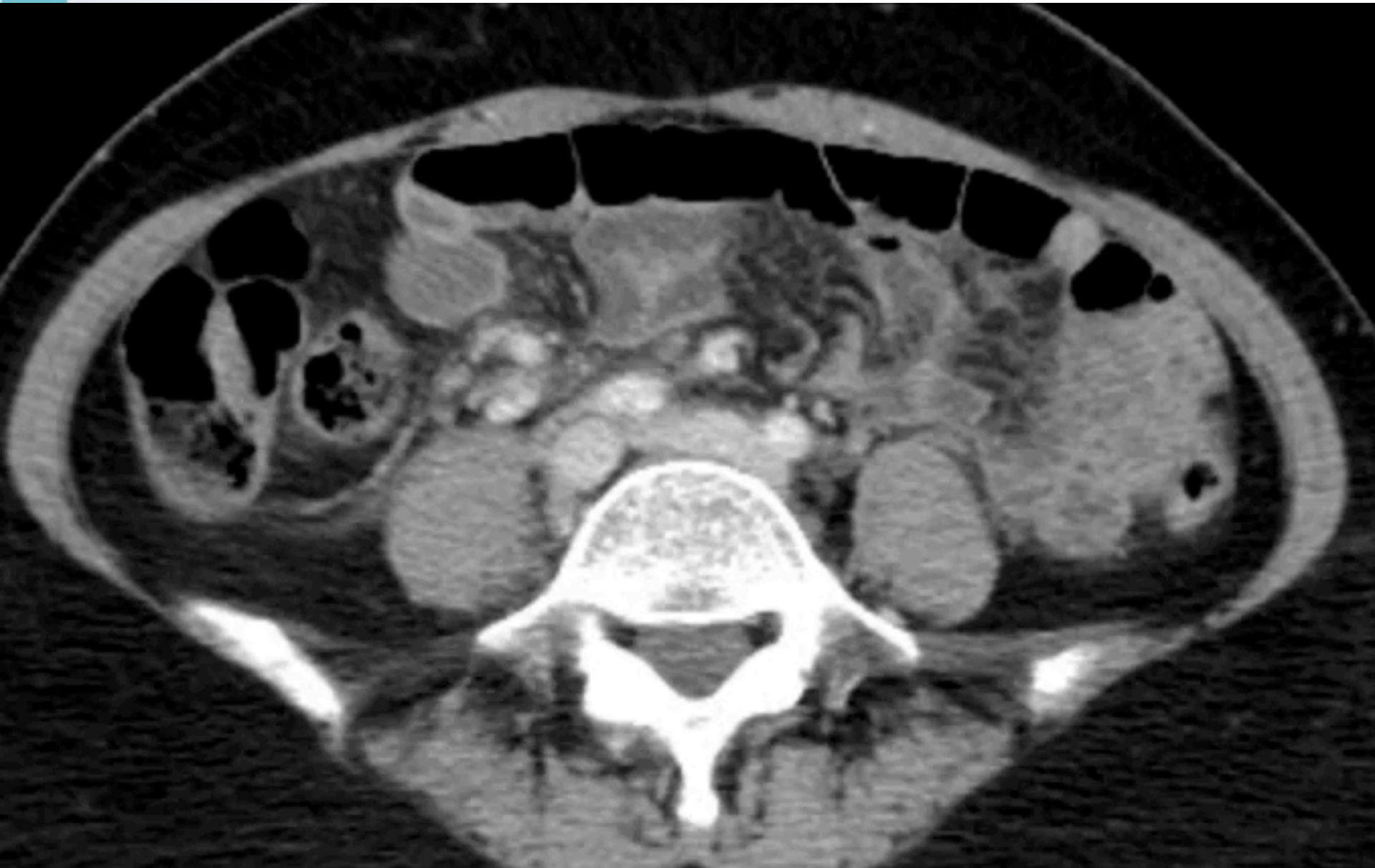14F pigtail with stylet



50F, RLQ pain for one week



Radiology refused this drainage



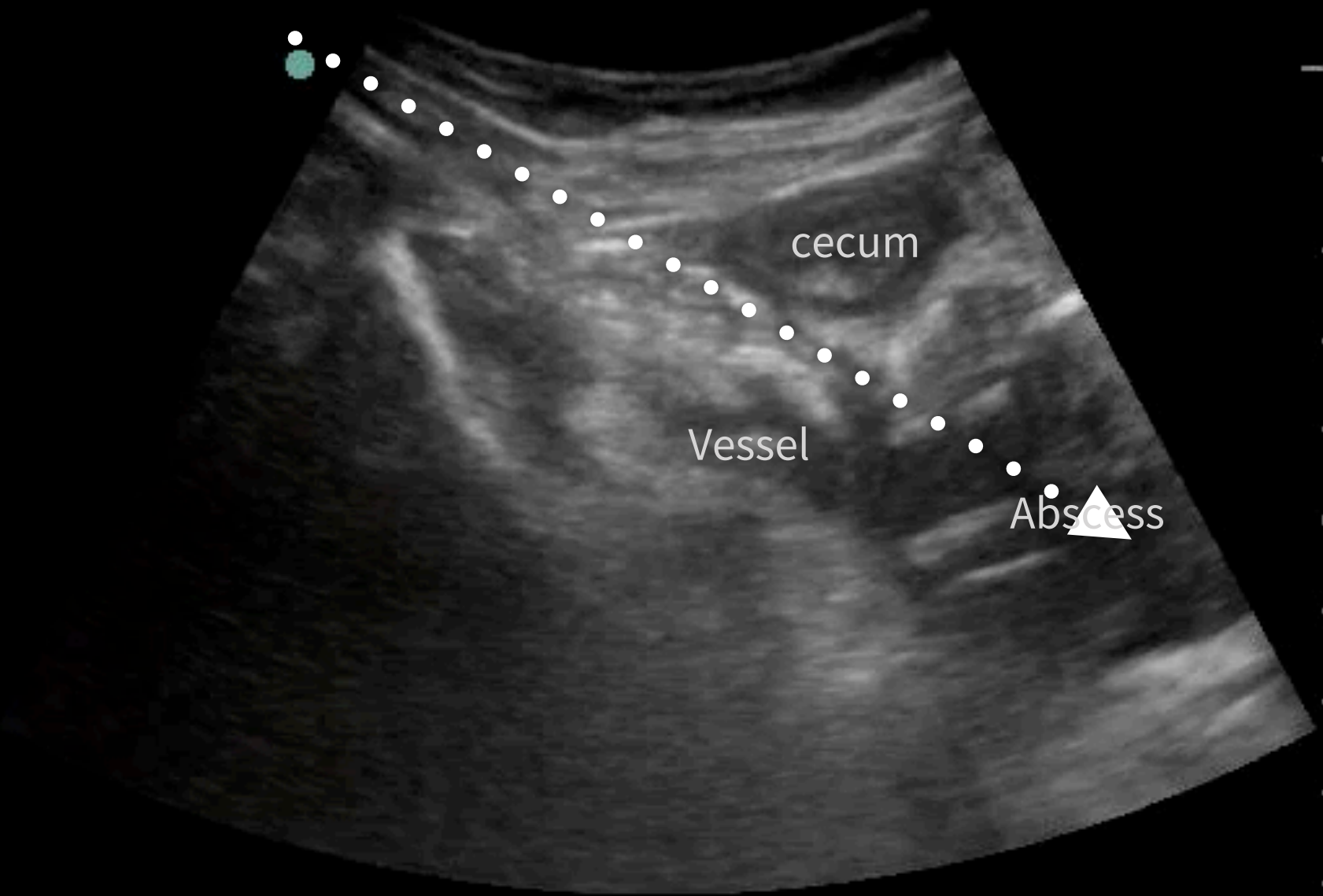
atient

to Gain

Gen

Clip

ge 1/3

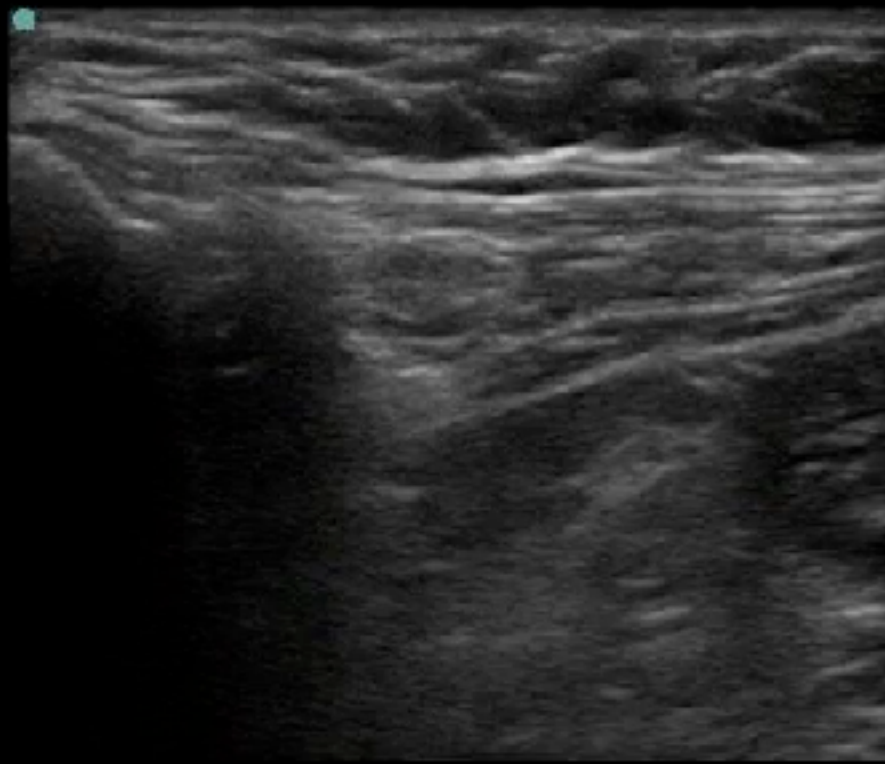


cecum

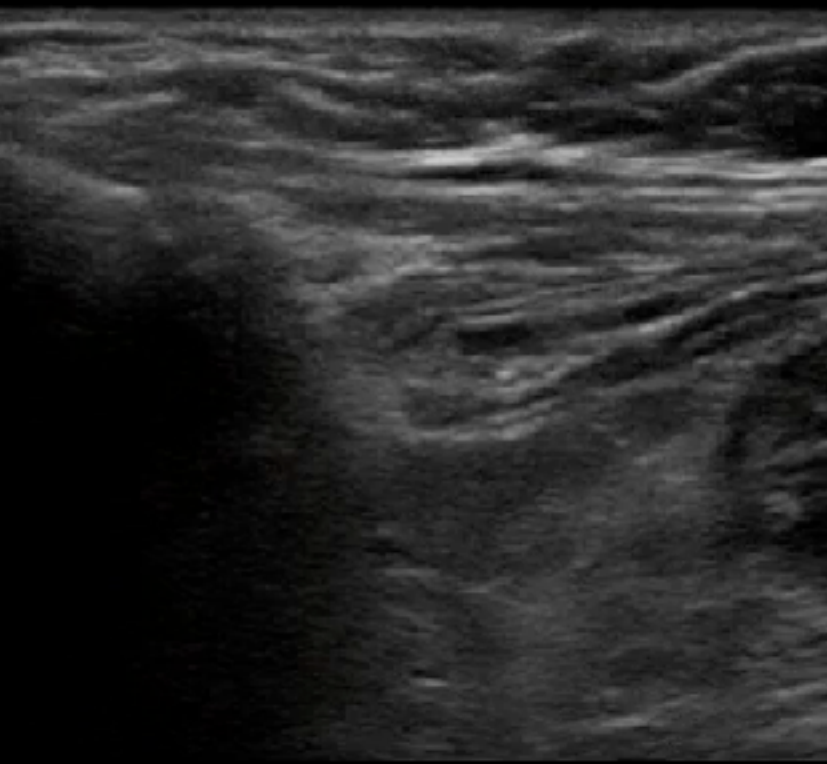
Vessel

Abscess

Ilioinguinal & iliohypogastric nerve block



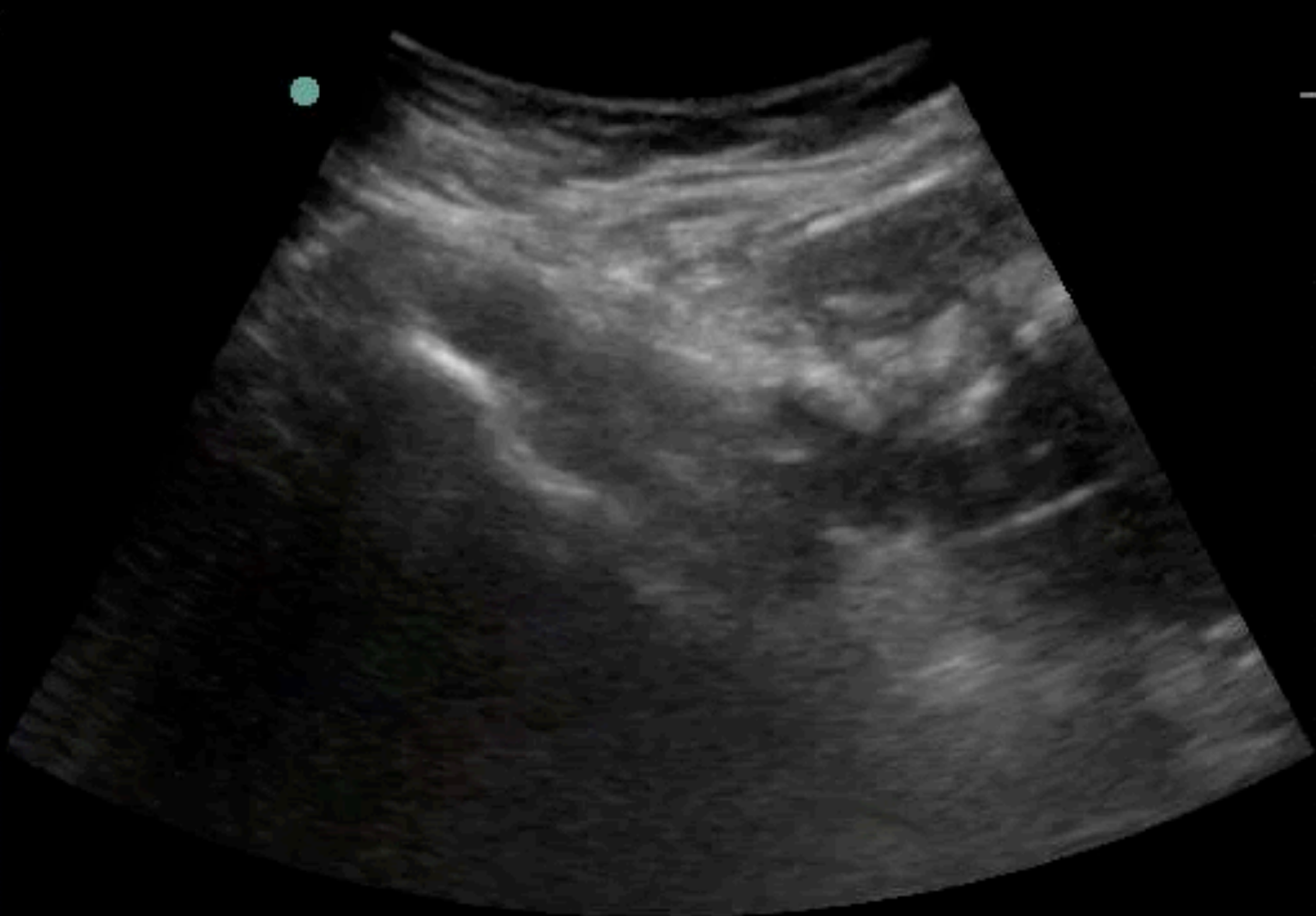
- Msk
HFL
E
73%
MI
0.8
TIS
0.1
3.3



Pigtail drainage - guiding needle



GenTHI MB



Abd

C60



71%

MI

0.8

TIS

0.2



Patient



Auto Gain



Gen



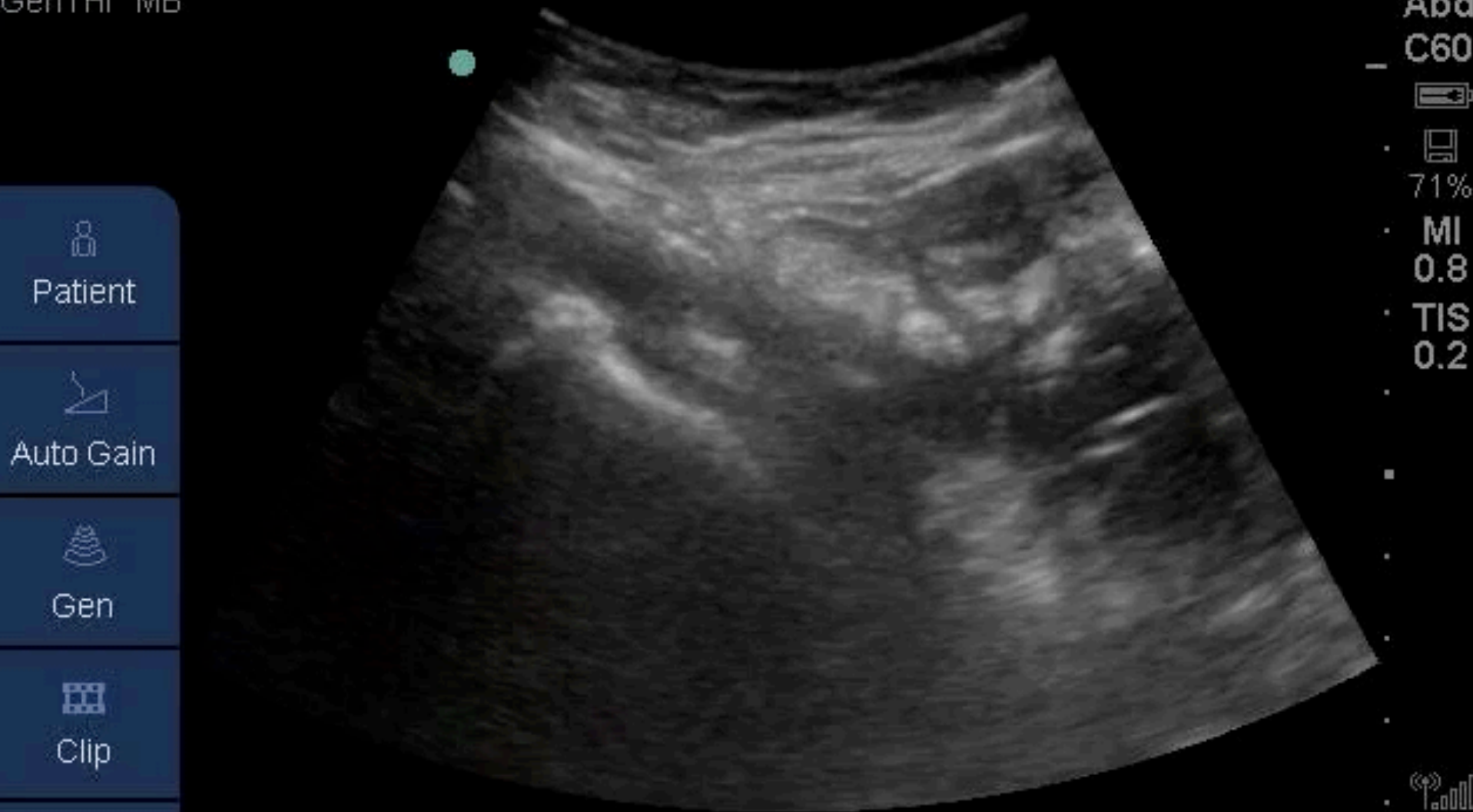
Clip



Pigtail drainage - guiding needle



GenTHI MB



Abd

C60



71%

MI

0.8

TIS

0.2



Patient



Auto Gain



Gen



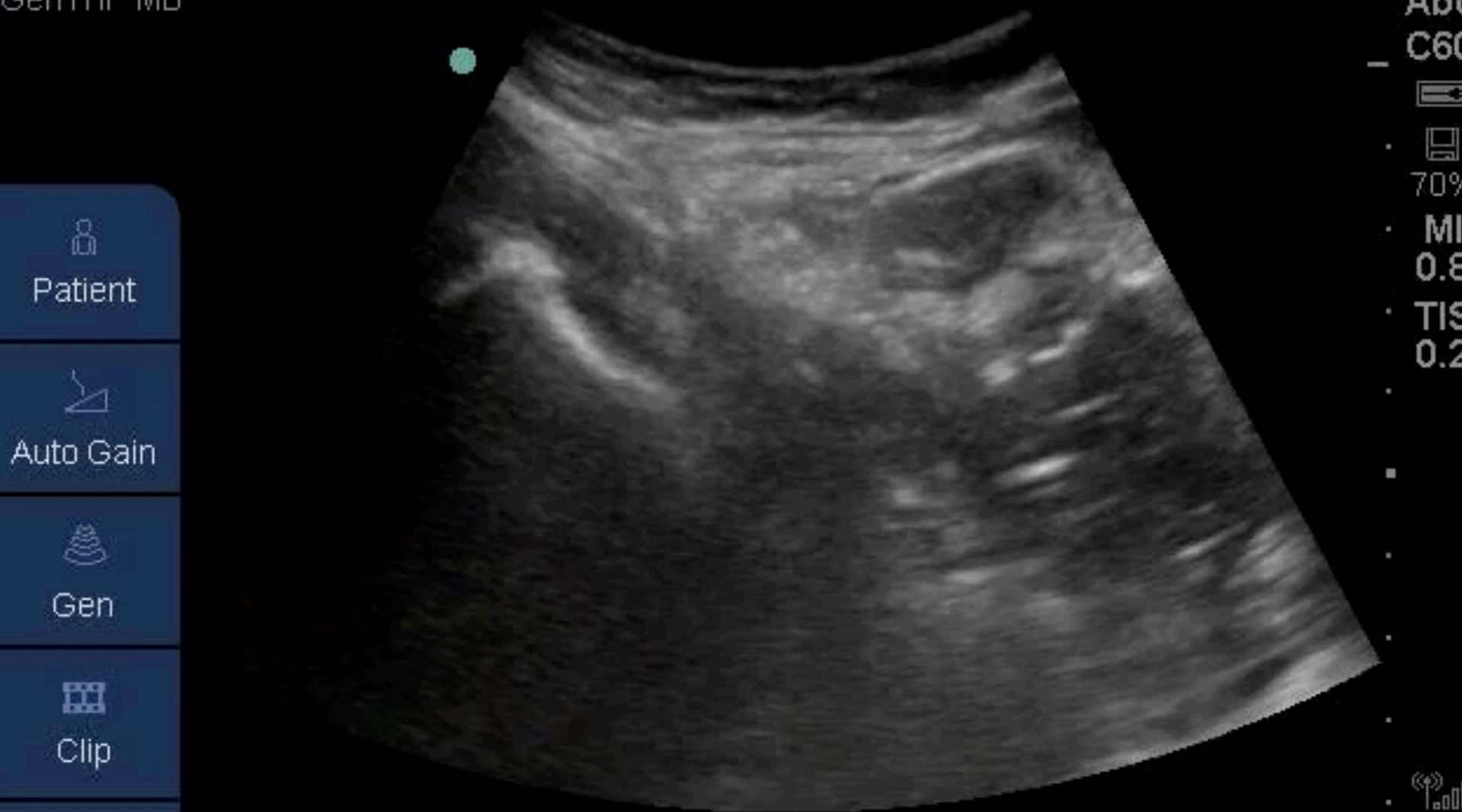
Clip



Pigtail drainage - guidewire



GenTHI MB



Patient



Auto Gain



Gen



Clip

Abc

C60



70%

MI

0.8

TIS






0.2

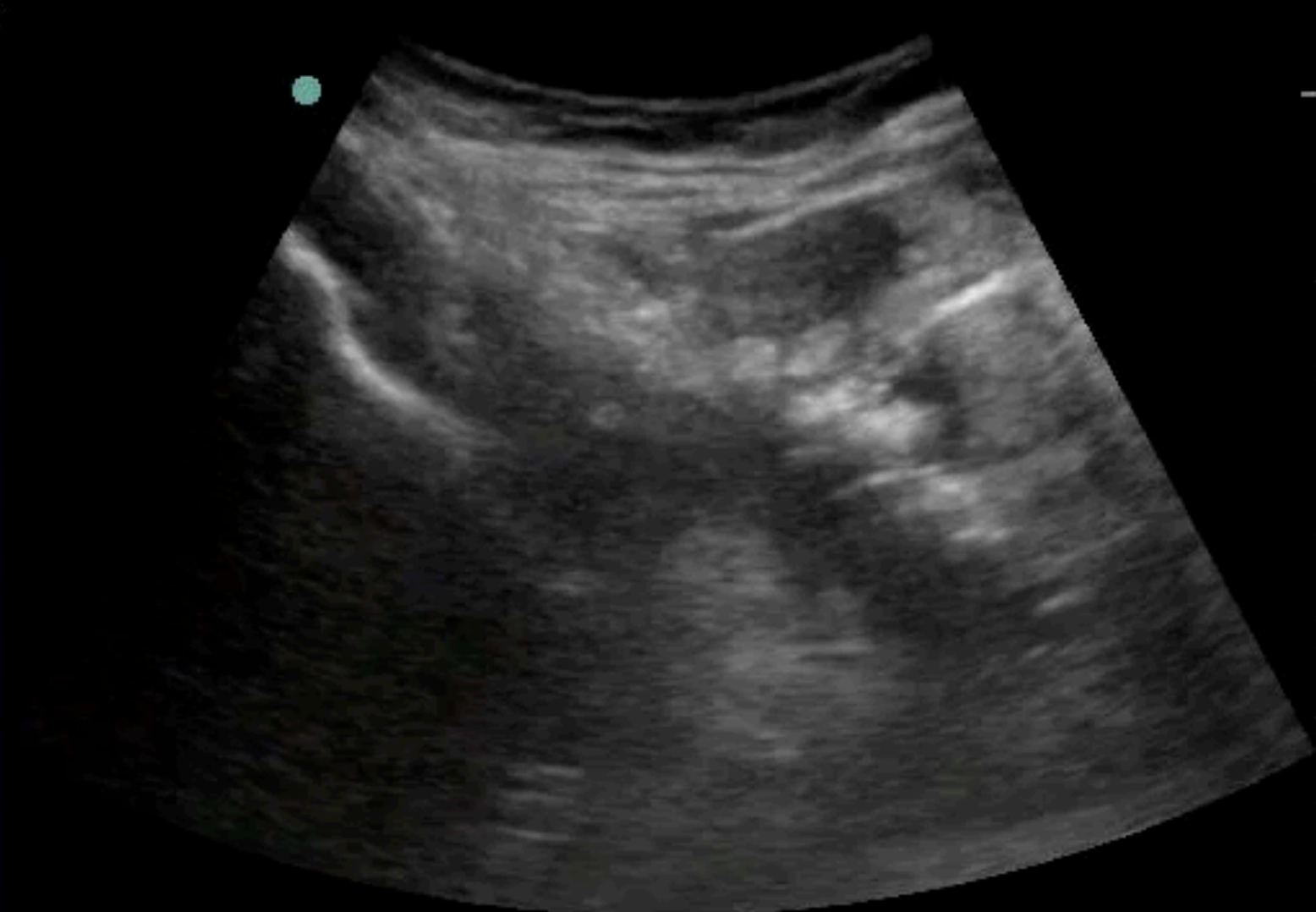

Pigtail drainage - pigtail through guidewire



GenTHI MB

-  Patient
-  Auto Gain
-  Gen
-  Clip
- 



Abd
C60

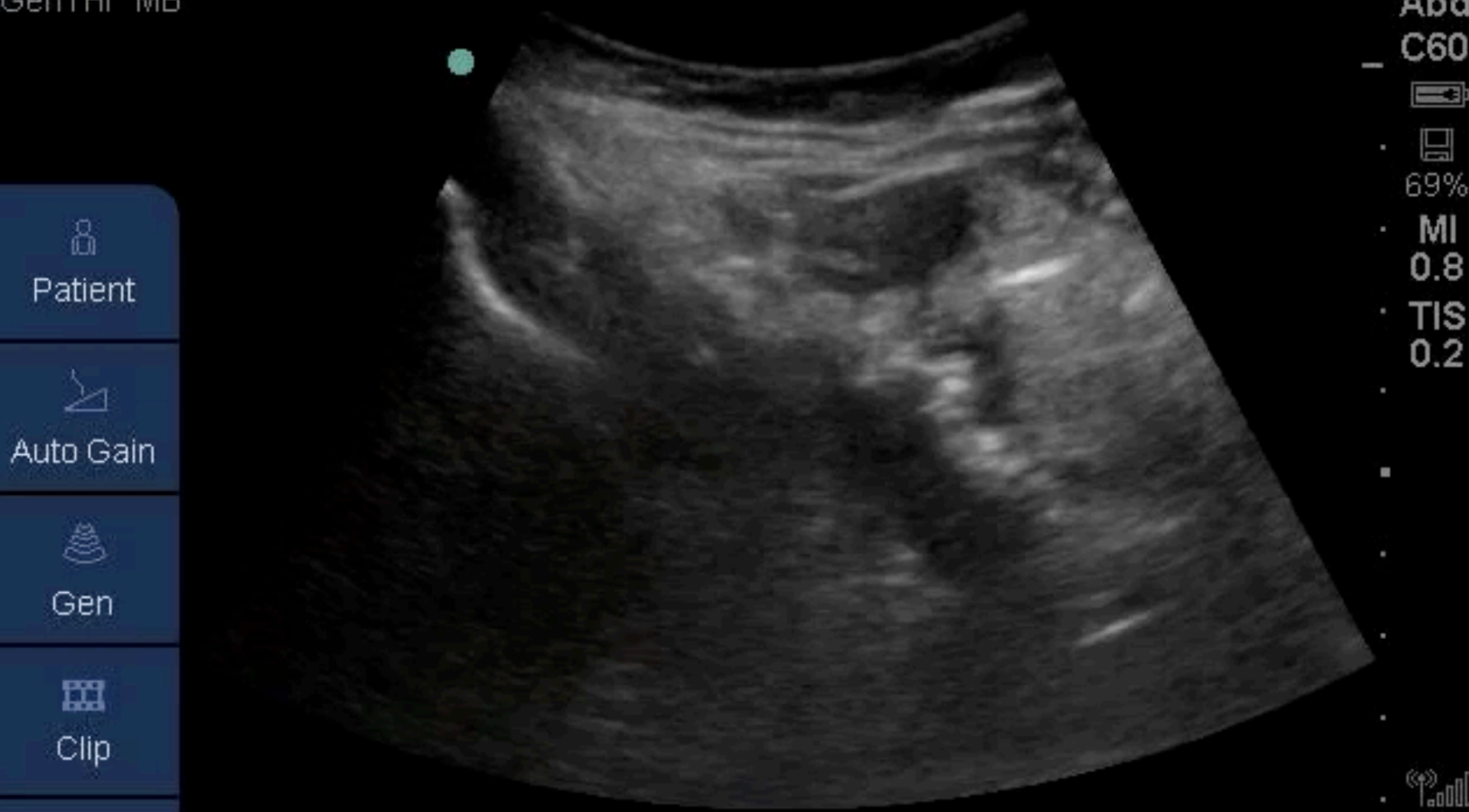

70%
MI
0.8
TIS
0.2



Pigtail drainage - pigtail through guidewire



GenTHI MB



Abd

C60



69%

MI

0.8

TIS

0.2



Patient



Auto Gain



Gen



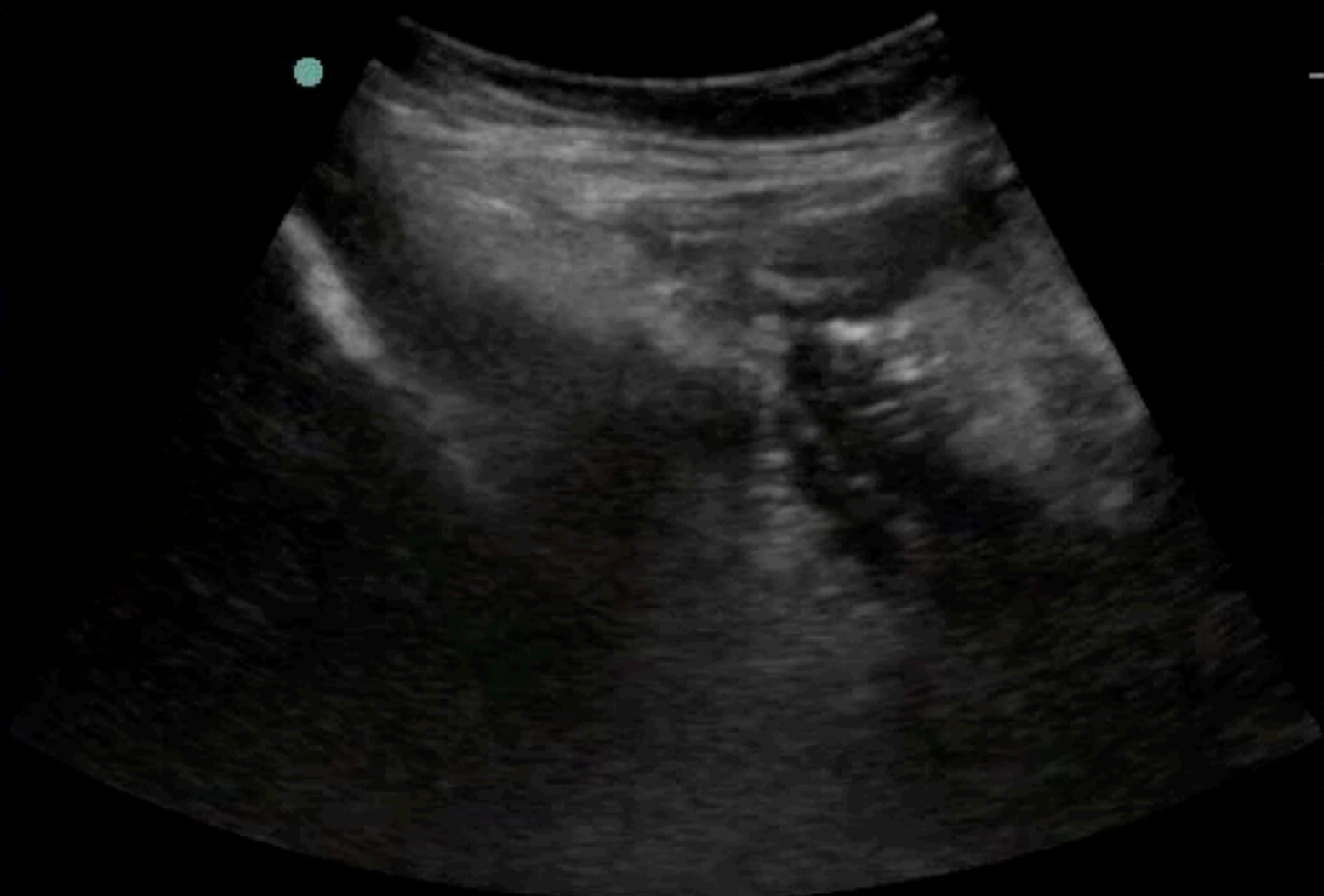
Clip



Pigtail drainage - pigtail



GenTHI MB



Abd

C60



69%

MI

0.8

TIS

0.2



Patient



Auto Gain



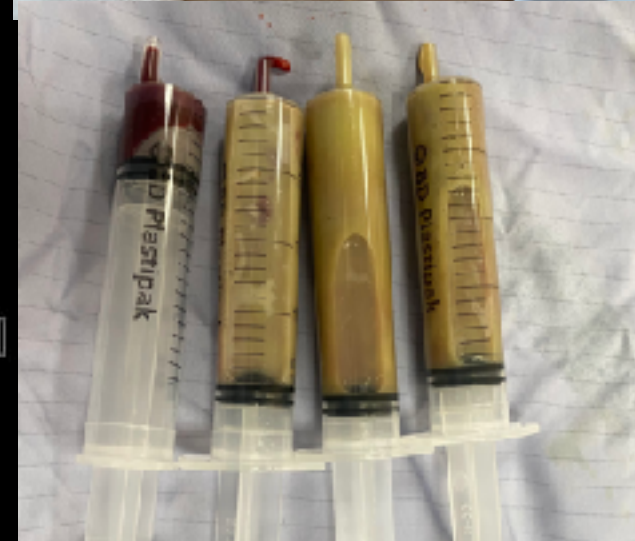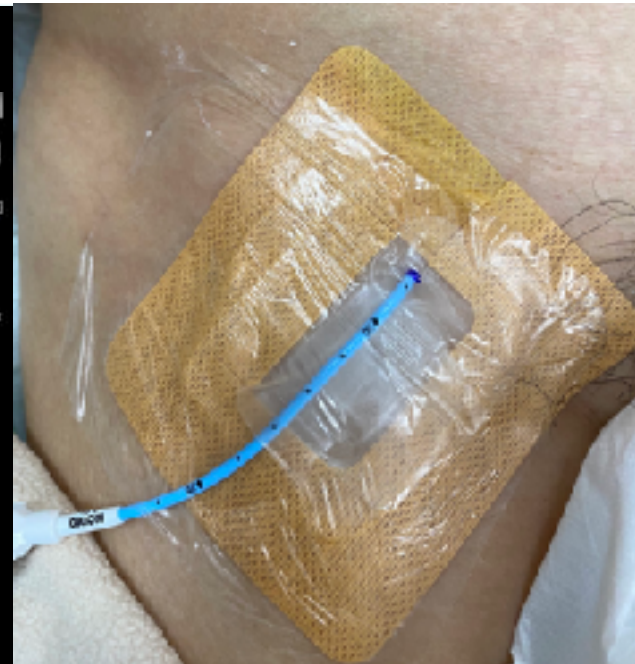
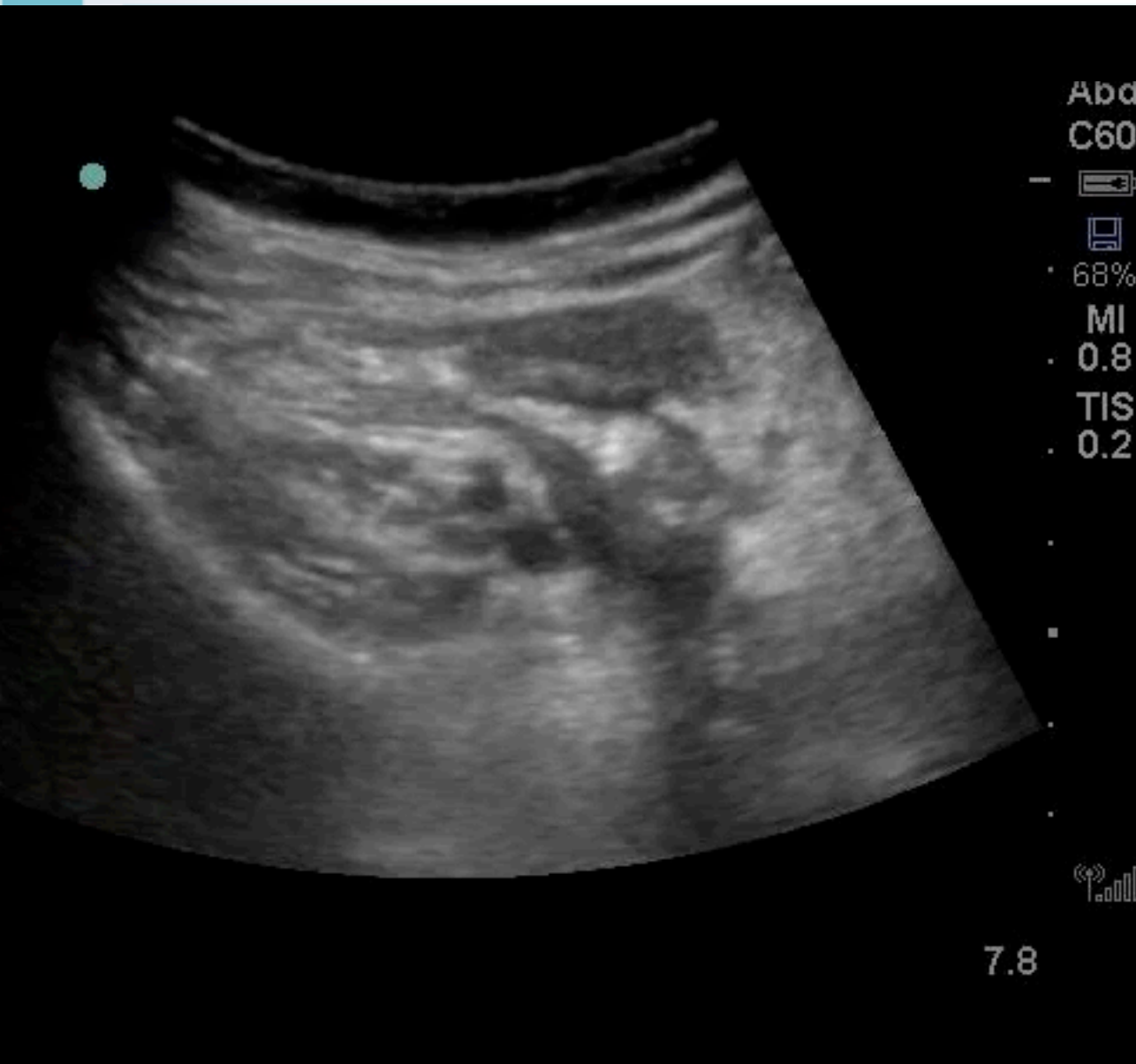
Gen



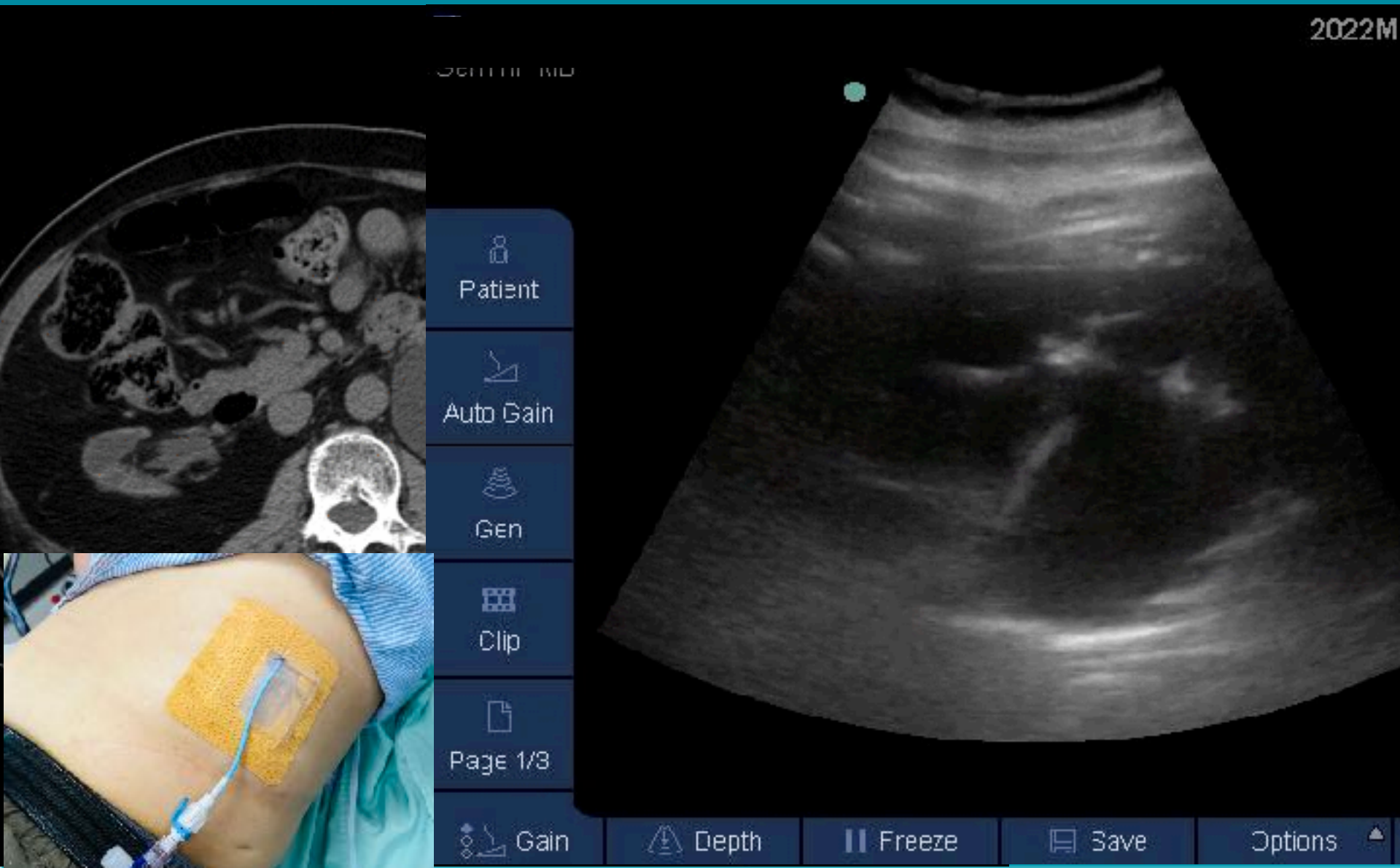
Clip



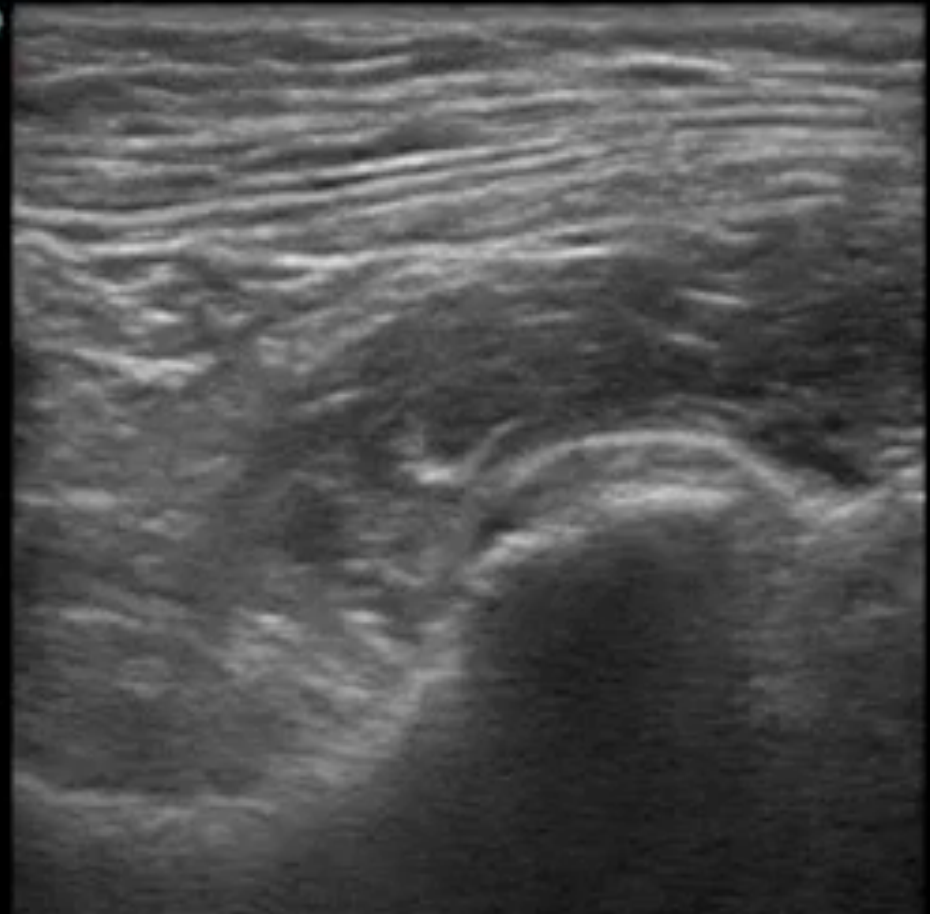
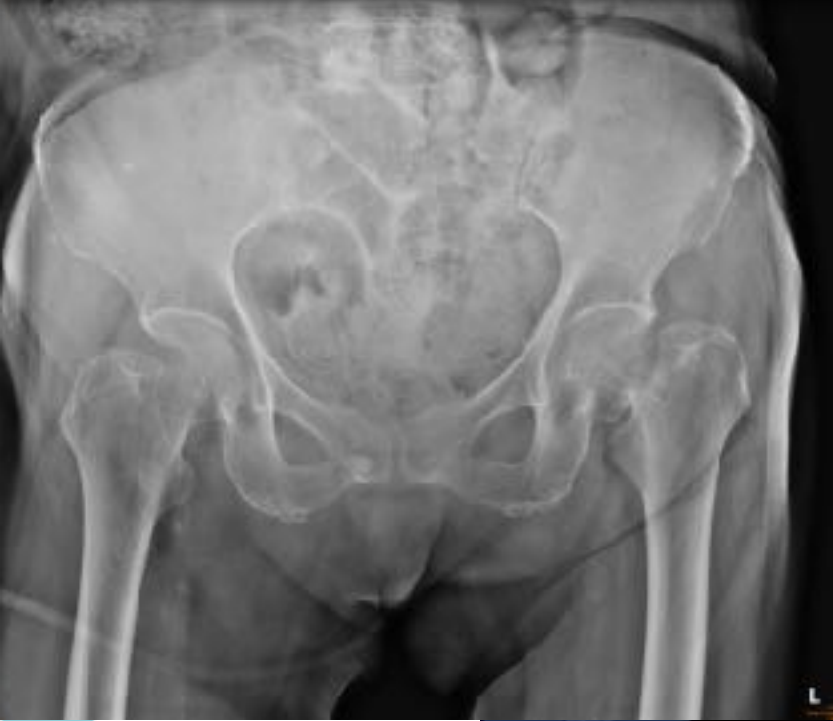FIRST: master needling



65M, left side flank pain



89F, PENG block for FNF Pericapsular Nerve Group block



Auto Gain



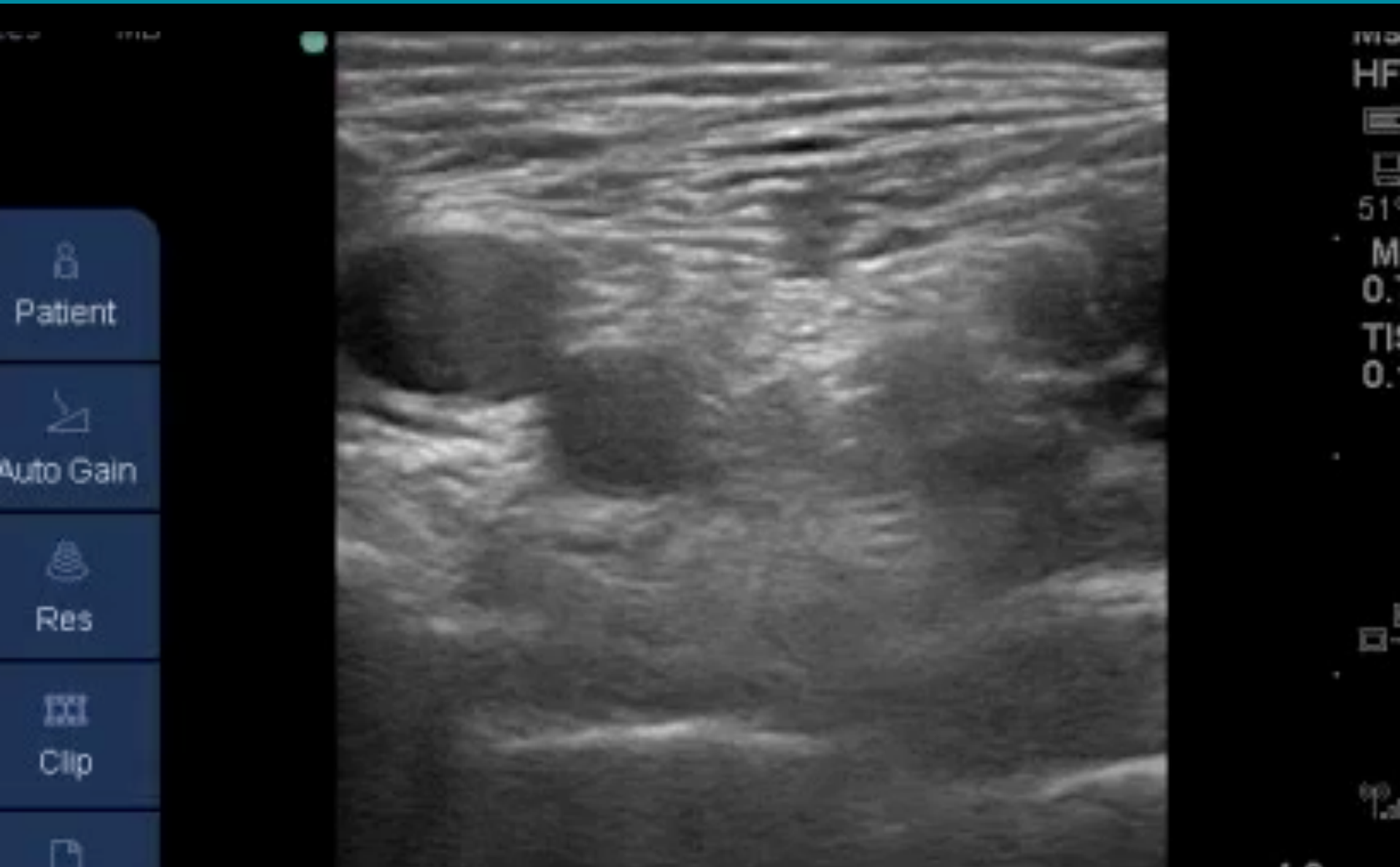
Res



Clip



FN & Lateral femoral cutaneous nerve



LFCN block



RES MID

MSK

HFL



94%

MI

0.8

TIS

0.1



Patient



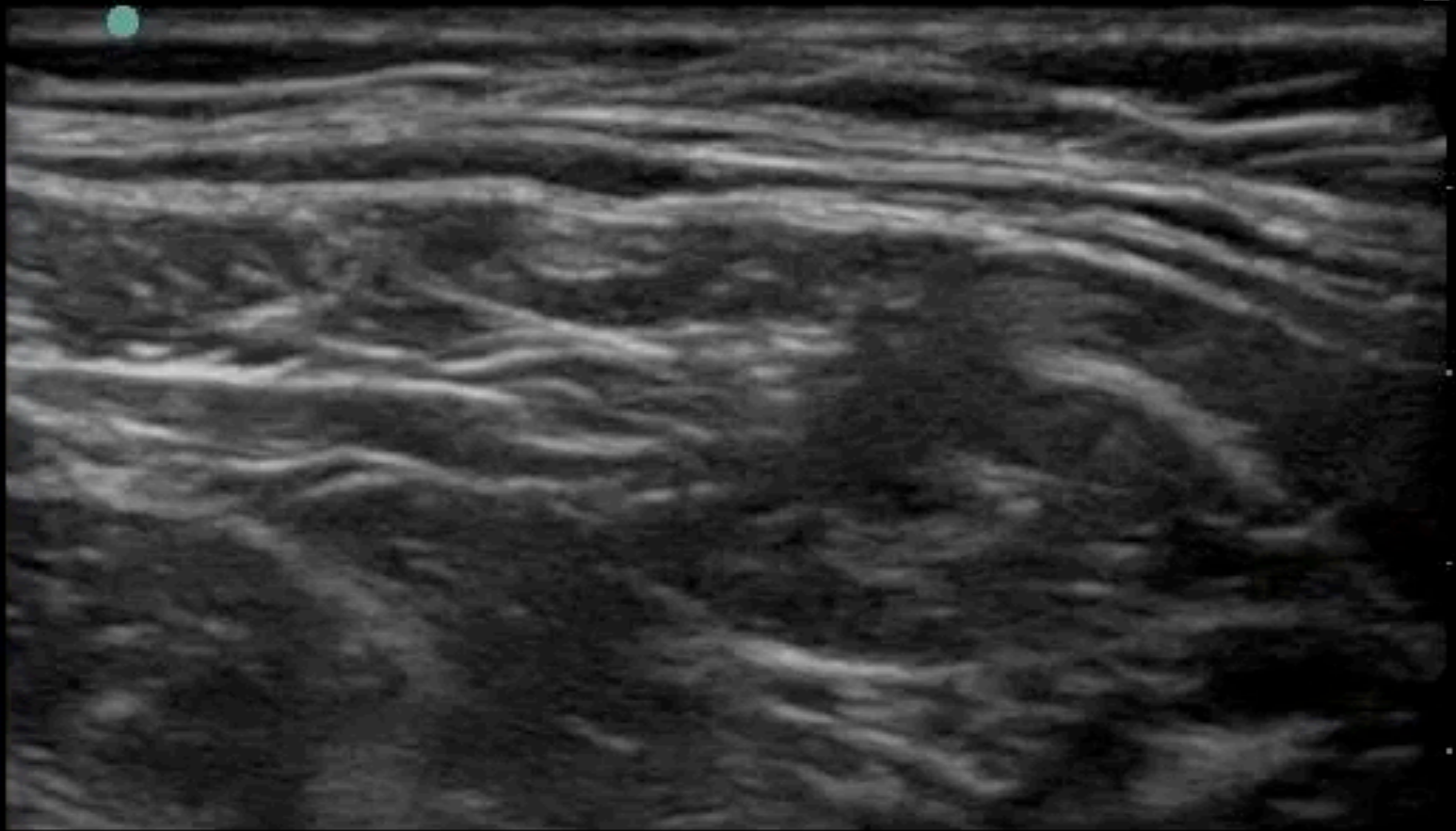
Auto Gain



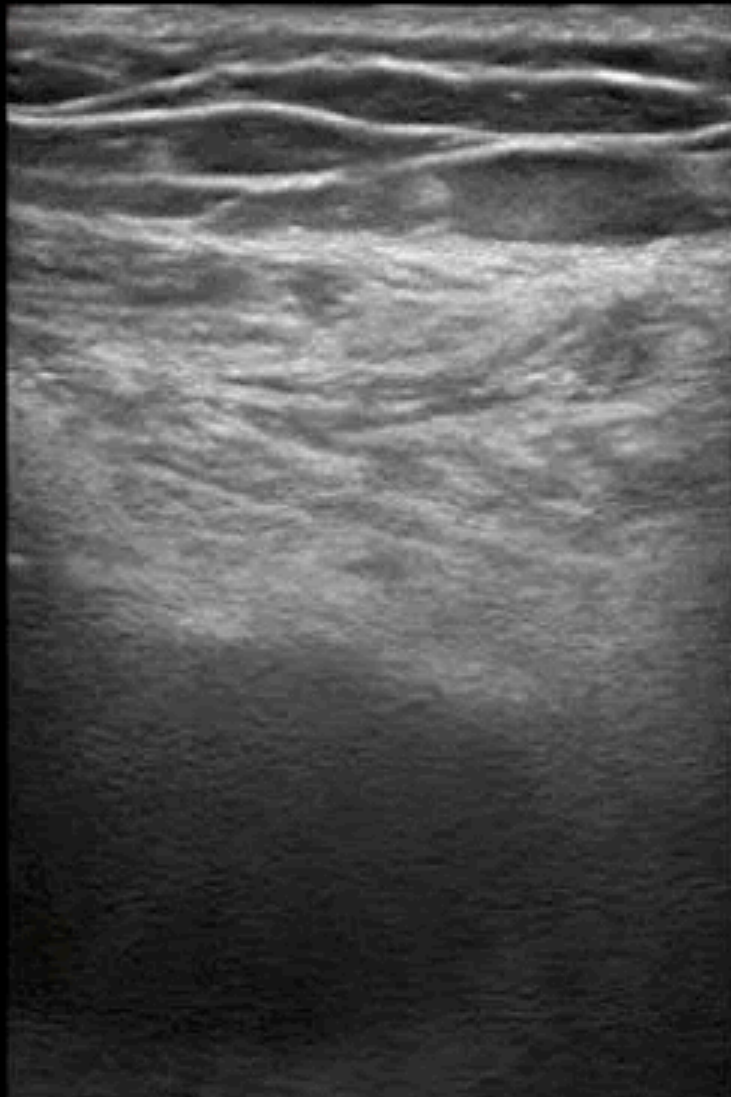
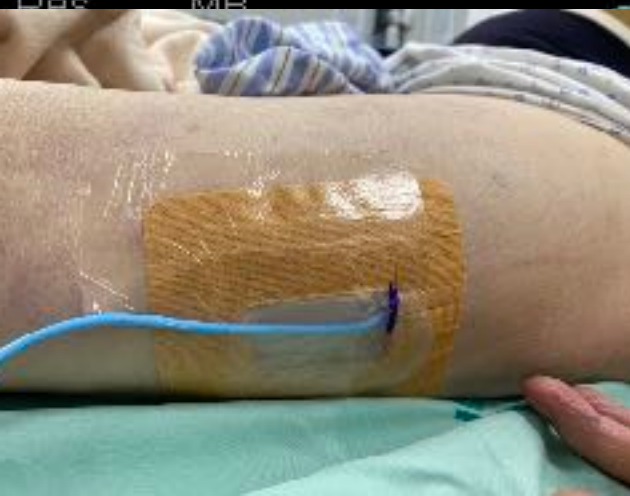Res



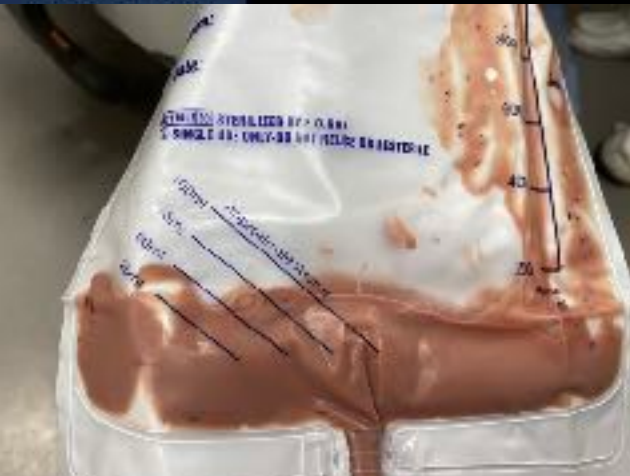Clip



Pigtail with stylet for thigh abscess



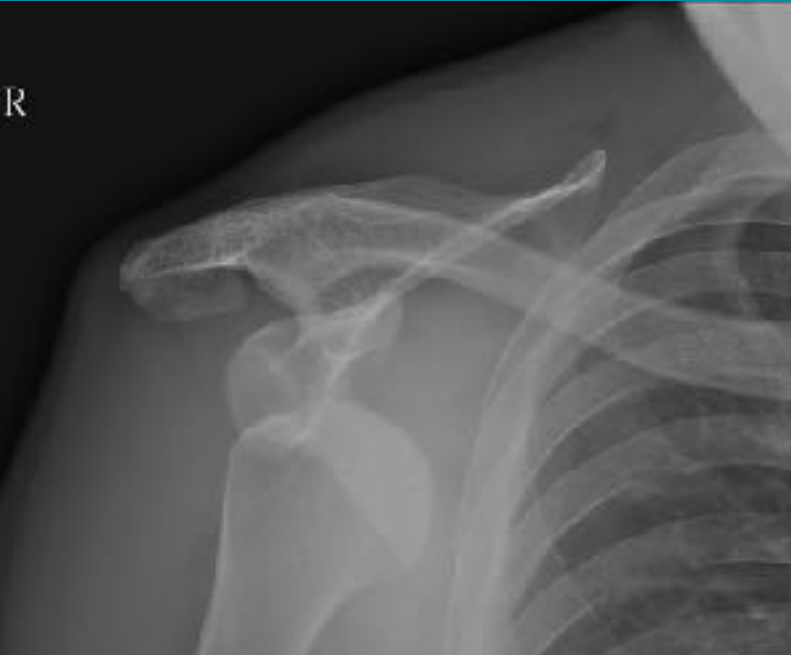Auto Gain



Msk
HFL
93%
MI
0.6
TIS
0.1



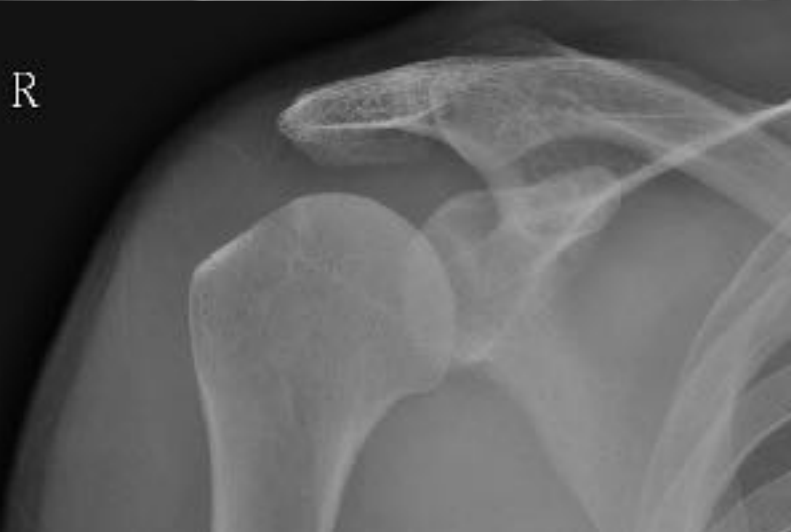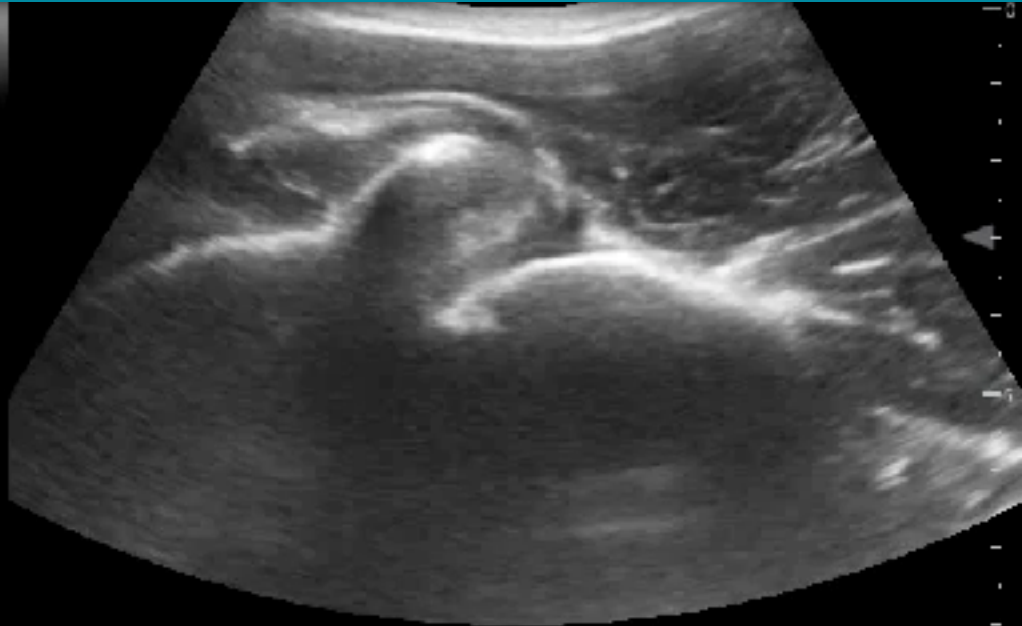26M, 打排球，右肩痛



R.O
92

Needle

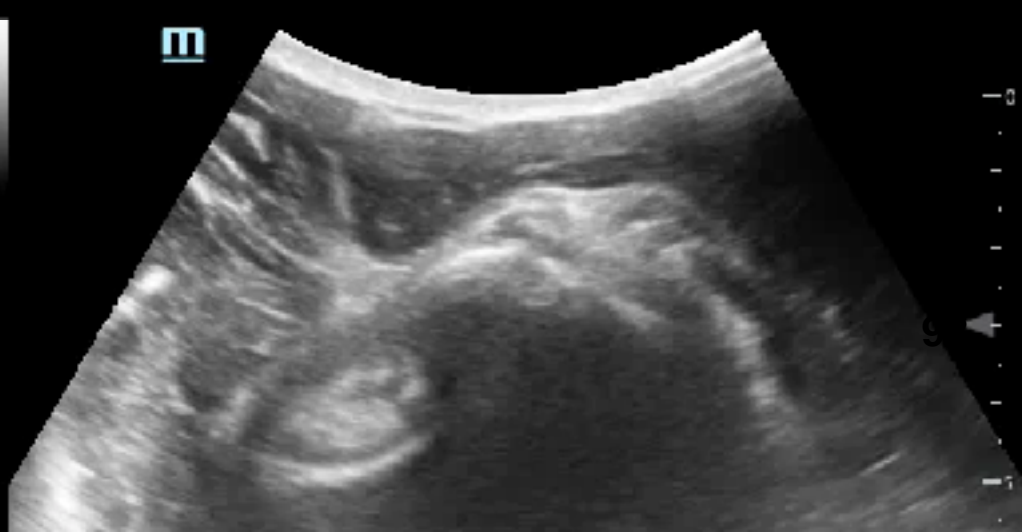Touch



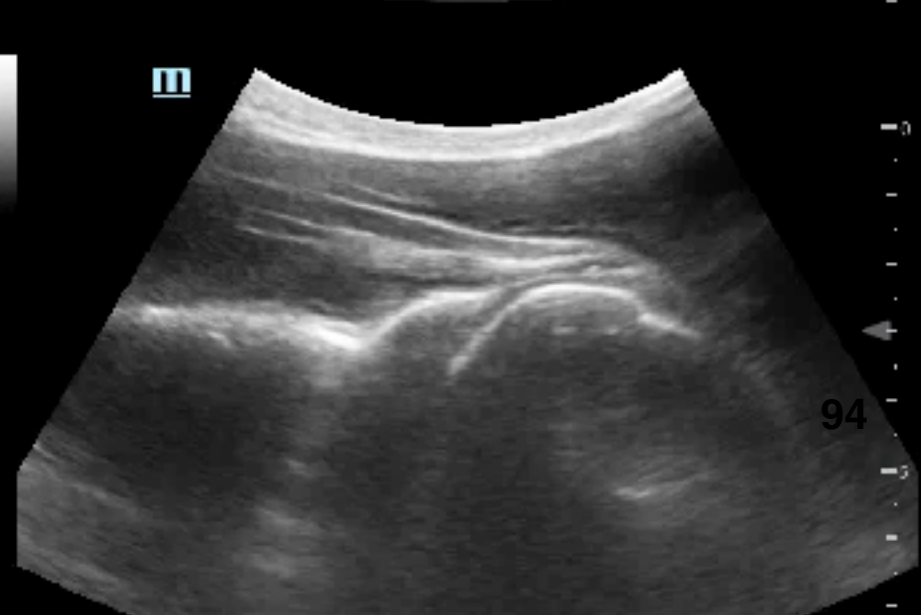
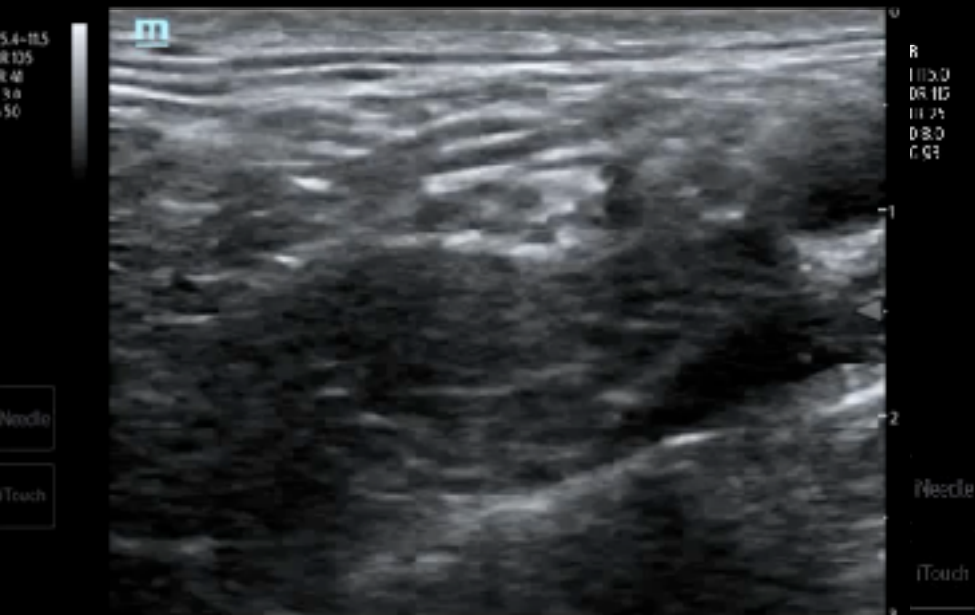
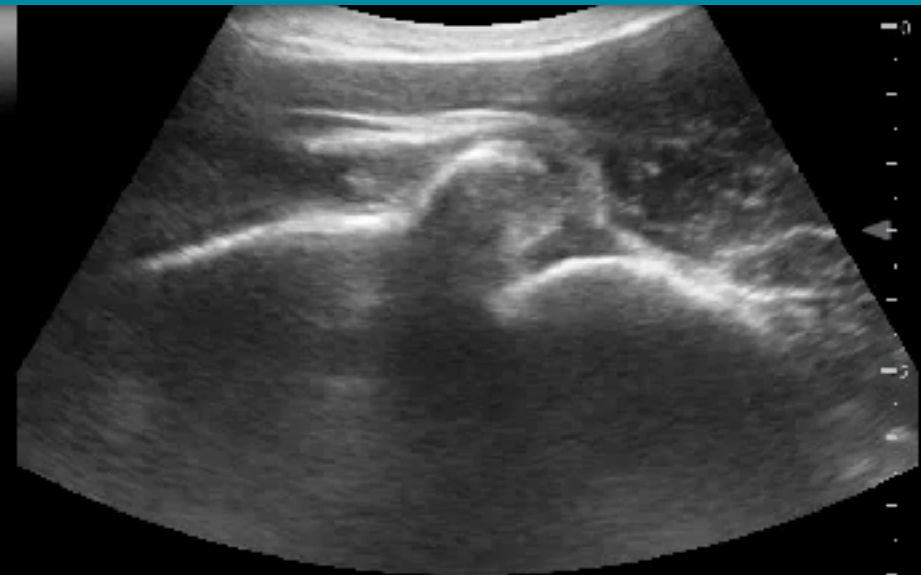
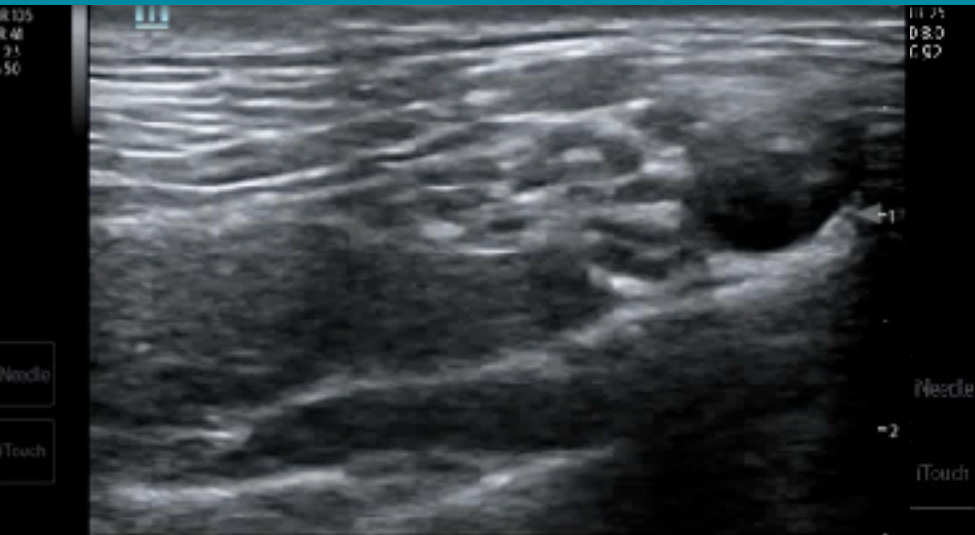
41.0
R15
4.2
R.O
92

m

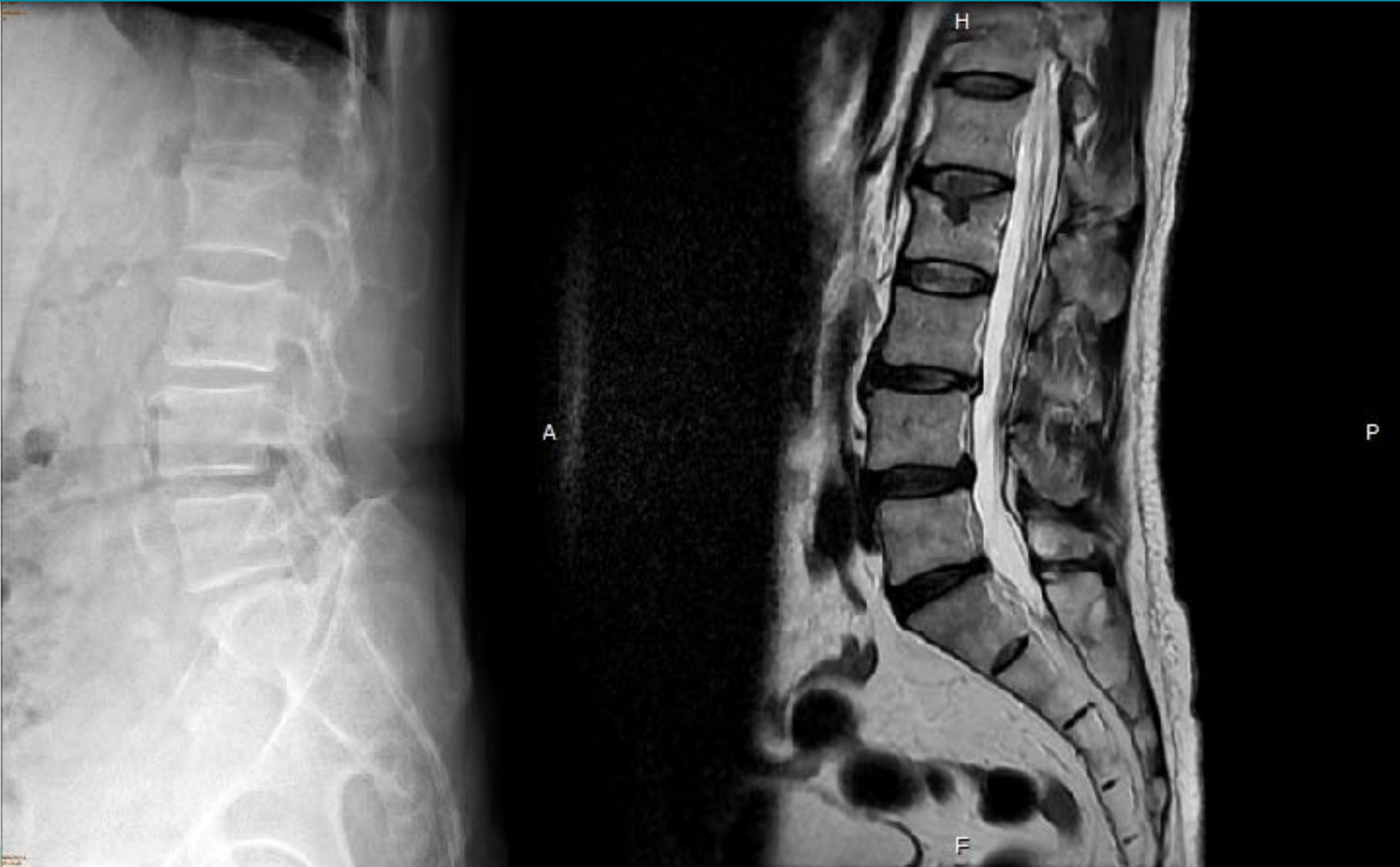Needle



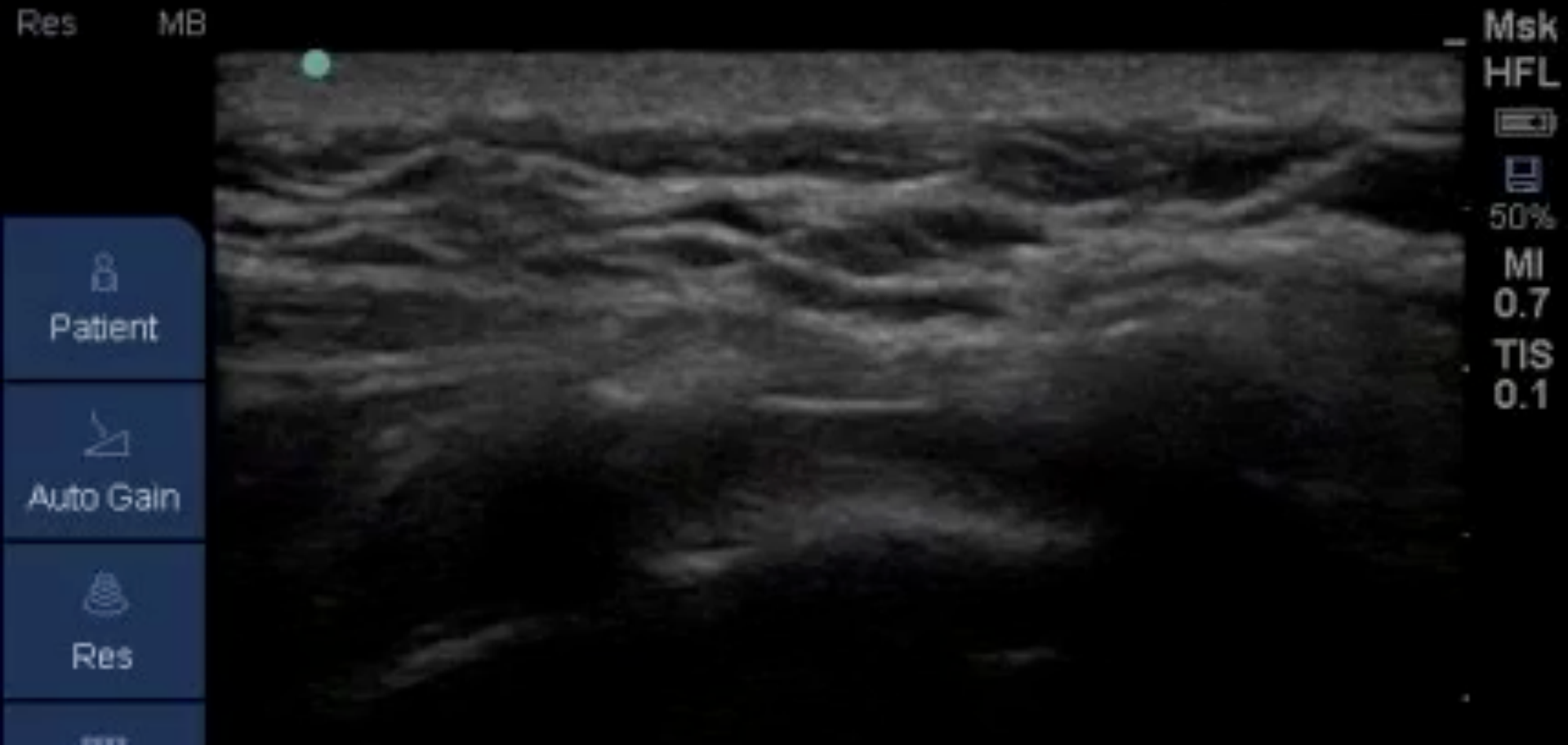
US-guided supraclavicular BP block



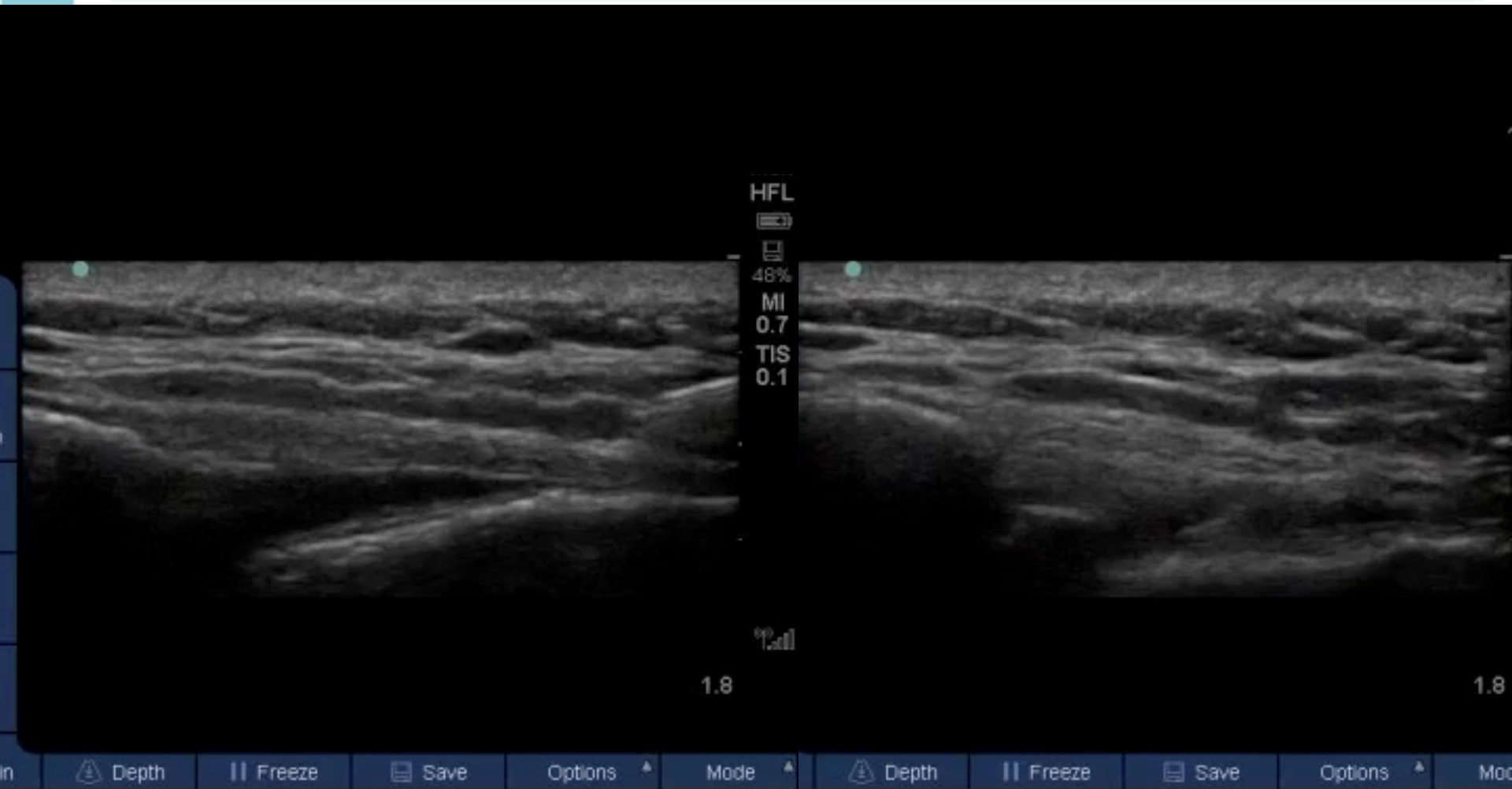63M, LBP with right sciatica



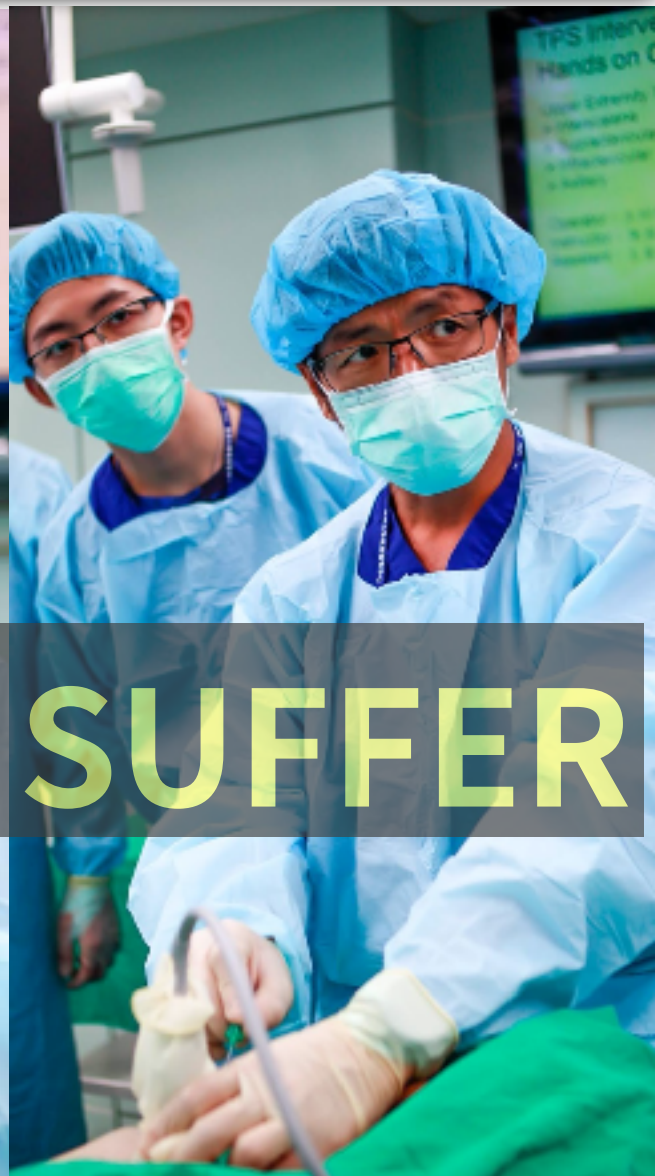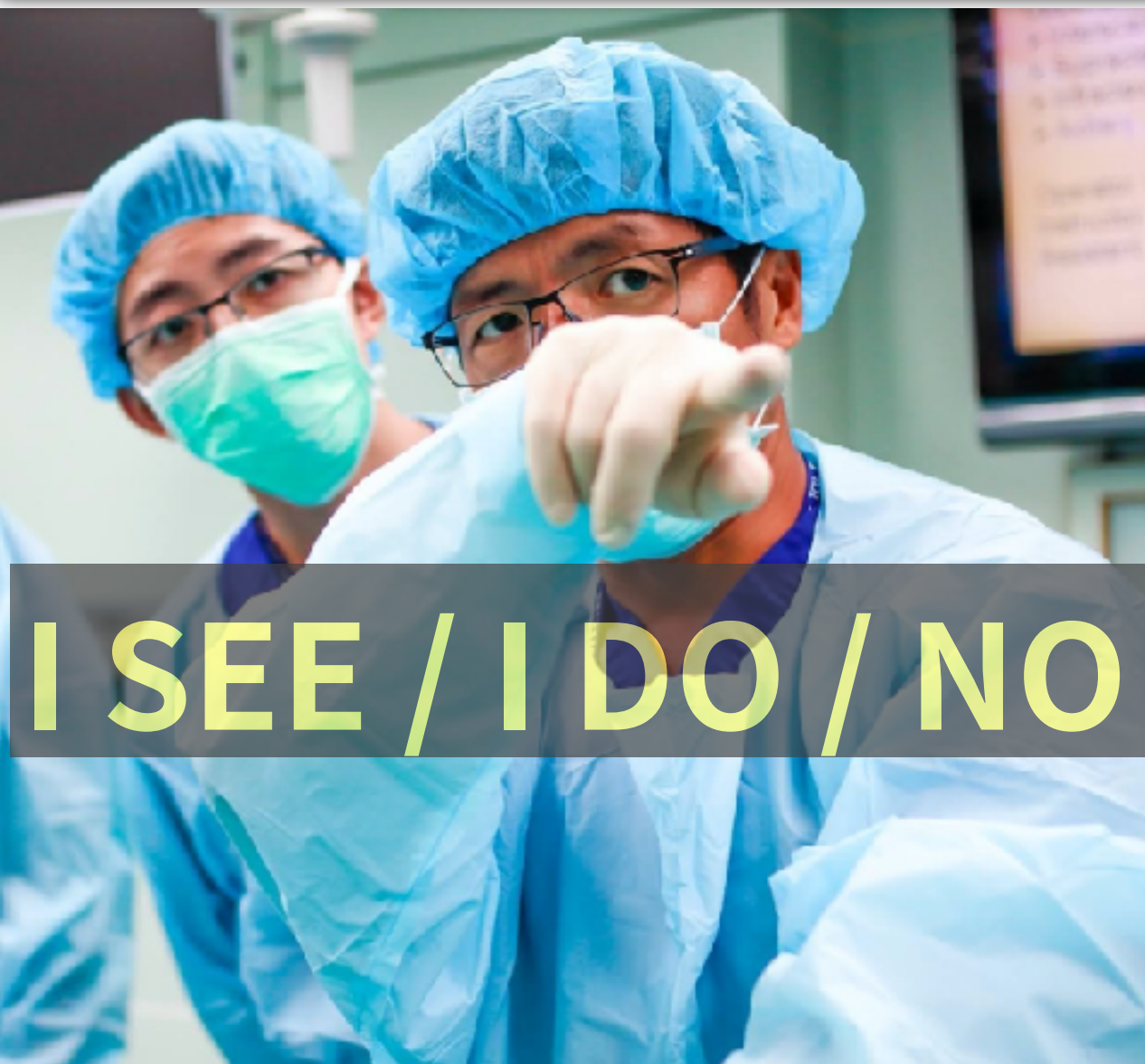Caudal block for acute low back pain



Marcaine 0.5% 20 ml



精準無痛個人化急診醫療就在你我手中



I SEE / I DO / NO SUFFER