



衛生福利部雙和醫院  
(委託臺北醫學大學興建經營)  
Taipei Medical University · Shuang Ho Hospital,  
Ministry of Health and Welfare



# Musculoskeletal US in ER 骨骼肌肉軟組織急症之應用

## 急診進階超音波

---

陳國智醫師 雙和醫院急診醫學科

[juice119@gmail.com](mailto:juice119@gmail.com)

[POCUSacademy.com](http://POCUSacademy.com)

# 陳國智 醫師



急診超音波臨床評核醫師  
醫用超音波學會指導醫師



WINFOCUS director / instructor  
Certified Interventional Pain Sonologist

**急診 / 重症 / 介入 / 急性疼痛**

經歷

新光急診超音波訓練中心主任

西園醫院急診醫學科主任

急診醫學會超音波委員會主委

台灣疼痛醫學會大體模擬手術講師

急救加護醫學會重症超音波負責人

REVIEW

Open Access



# An overview of point-of-care ultrasound for soft tissue and musculoskeletal applications in the emergency department

Kuo-Chih Chen<sup>1,2</sup>, Aning Chor-Ming Lin<sup>1,2\*</sup>, Chee-Fah Chong<sup>1,2</sup> and Tzong-Luen Wang<sup>1,2</sup>

## Musculoskeletal Ultrasound in the Emergency Department

Vito Chianca, MD<sup>1</sup> Francesco Di Pietto, MD, PhD<sup>2</sup> Marcello Zappia, MD, PhD<sup>3</sup>  
Domenico Albano, MD<sup>1,4</sup> Carmelo Messina, MD<sup>1,5</sup> Luca Maria Sconfienza, MD, PhD<sup>1,5</sup>

<sup>1</sup>IRCCS Istituto Ortopedico Galeazzi, Milano, Italy

<sup>2</sup>Dipartimento di Diagnostica per immagini, Pineta Grande Hospital, Castel Volturno (CE), Italy

<sup>3</sup>Department of Medicine and Health Sciences, Università del Molise, Campobasso, Italy

<sup>4</sup>Section of Radiological Sciences, Department of Biomedicine, Neurosciences and Advanced Diagnostics, University of Palermo, Palermo, Italy

<sup>5</sup>Dipartimento di Scienze Biomediche per la Salute, Università degli Studi di Milano, Milano, Italy

Semin Musculoskelet Radiol 2020;24:167–174.



Address for correspondence Vito Chianca, MD, IRCCS Istituto Ortopedico Galeazzi, via Riccardo Galeazzi 4, 20161 Milano, Italy (e-mail: vitochianca@gmail.com).

Soft tissue infection  
Joint effusion  
Foreign body  
Long bone fracture  
Muscle & Tendon injury  
Vascular occlusion  
Procedures

---

---

*Seminars in*

ROENTGENOLOGY

---

---

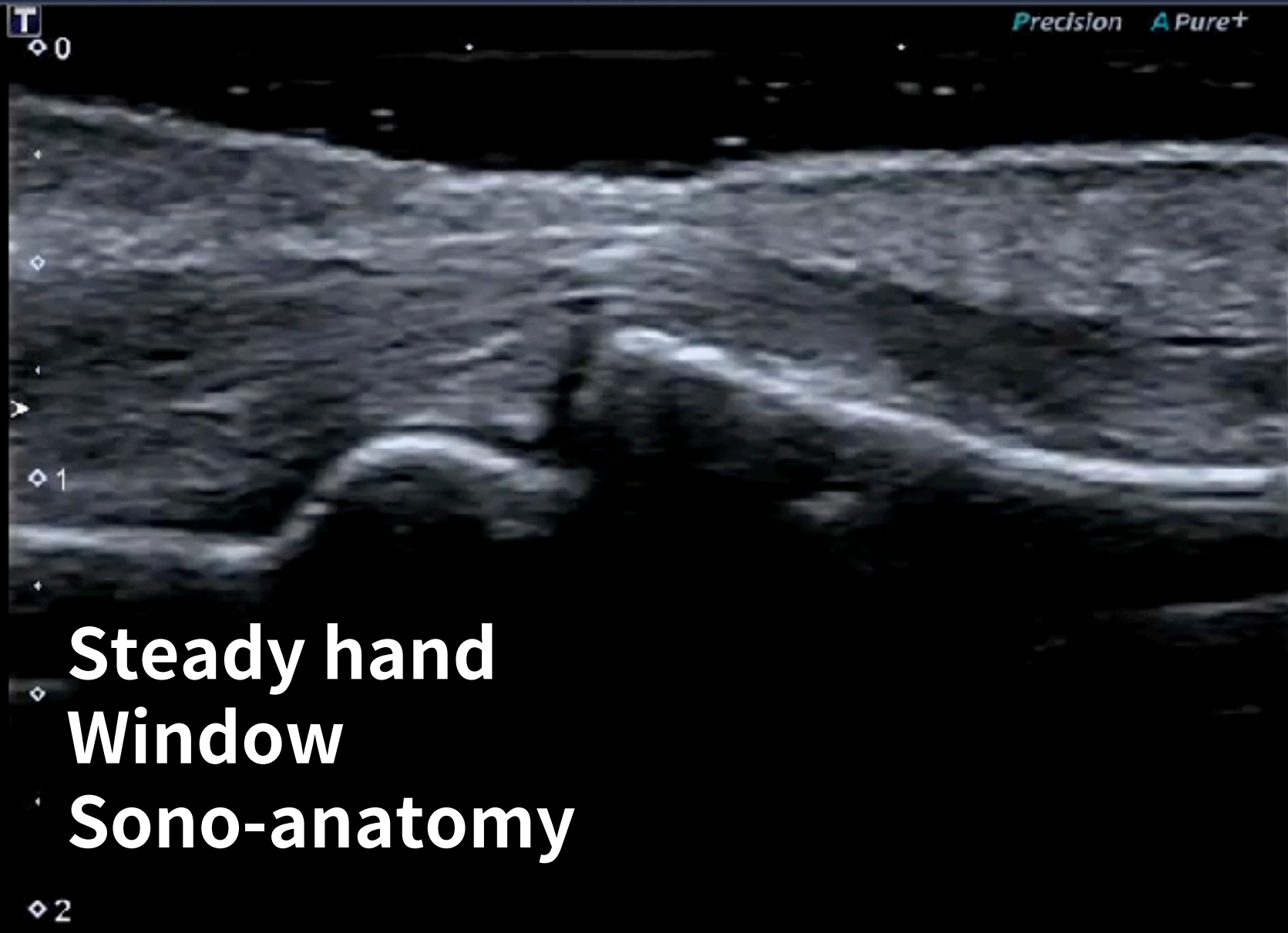# Musculoskeletal Ultrasound in the Emergency Department: Is There a Role?

Michael V. Perone, MD, and Corrie M. Yablon, MD <https://doi.org/10.1053/j.ro.2020.09.004>

# Limitations of US

In the hands of highly skilled practitioners, the performance of MSK US in the assessment of superficial soft tissue and tendon injury is equal to MRI. A barrier to the performance of MSK US in the ED is the high degree of training that is required of personnel, both to scan and to interpret the images. Sonographers must be able to recognize the artifacts inherent to MSK US and must be able to manipulate the various parameters in order to optimize image quality. It is vital to have a sophisticated understanding of MSK anatomy and the varied sonographic appearances of tissues such as skin, subcutaneous fat, muscle, tendon, ligament, and synovium, both when normal and abnormal. Without this high level of understanding, the resulting images can be confusing at best, and cause missed diagnoses at worst. <https://doi.org/10.1053/j.ro.2020.09.004>





Precision A Pure+

MI  
1.5  
14L5  
diff14M  
44 fps  
G:78  
DR:65  
A:7  
P:5

**Steady hand  
Window  
Sono-anatomy**

T  
0  
1  
2



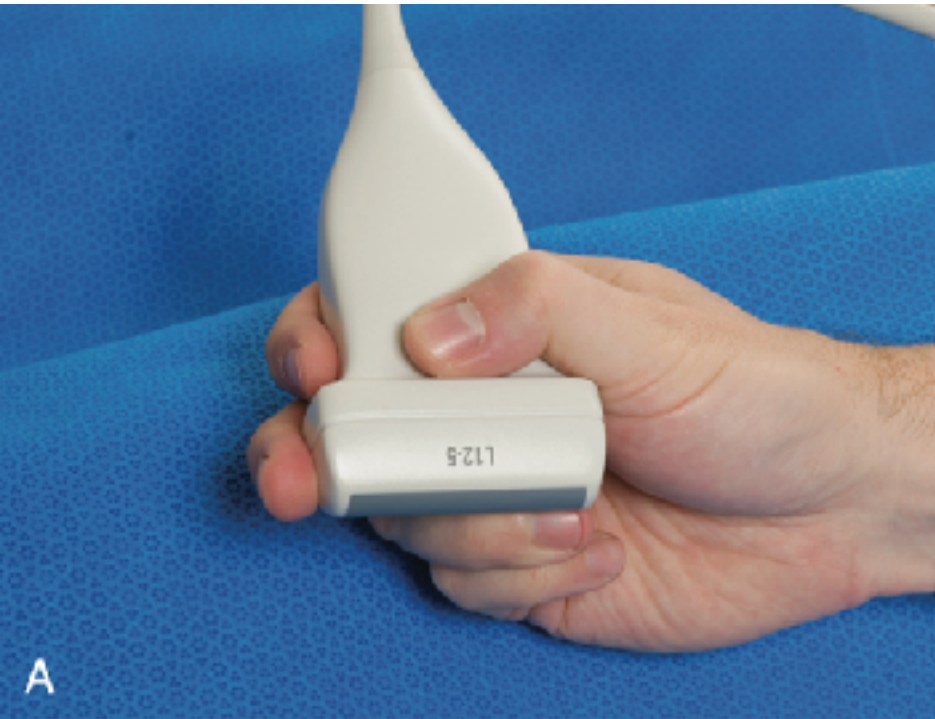# Steady Hand



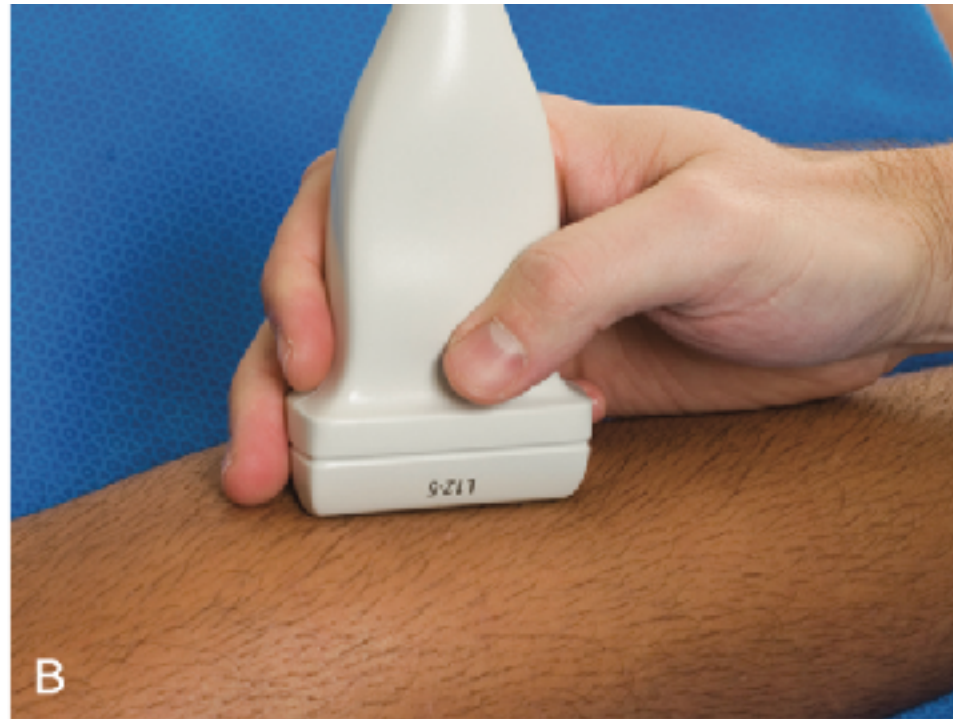探頭

操作者的手

皮膚

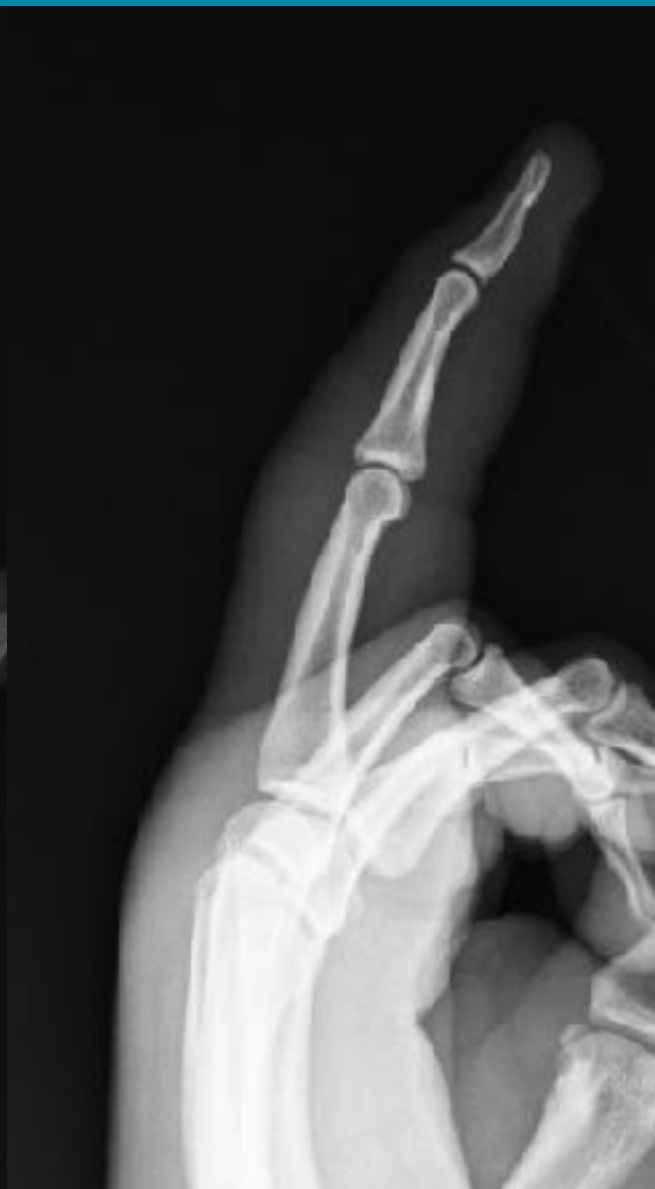
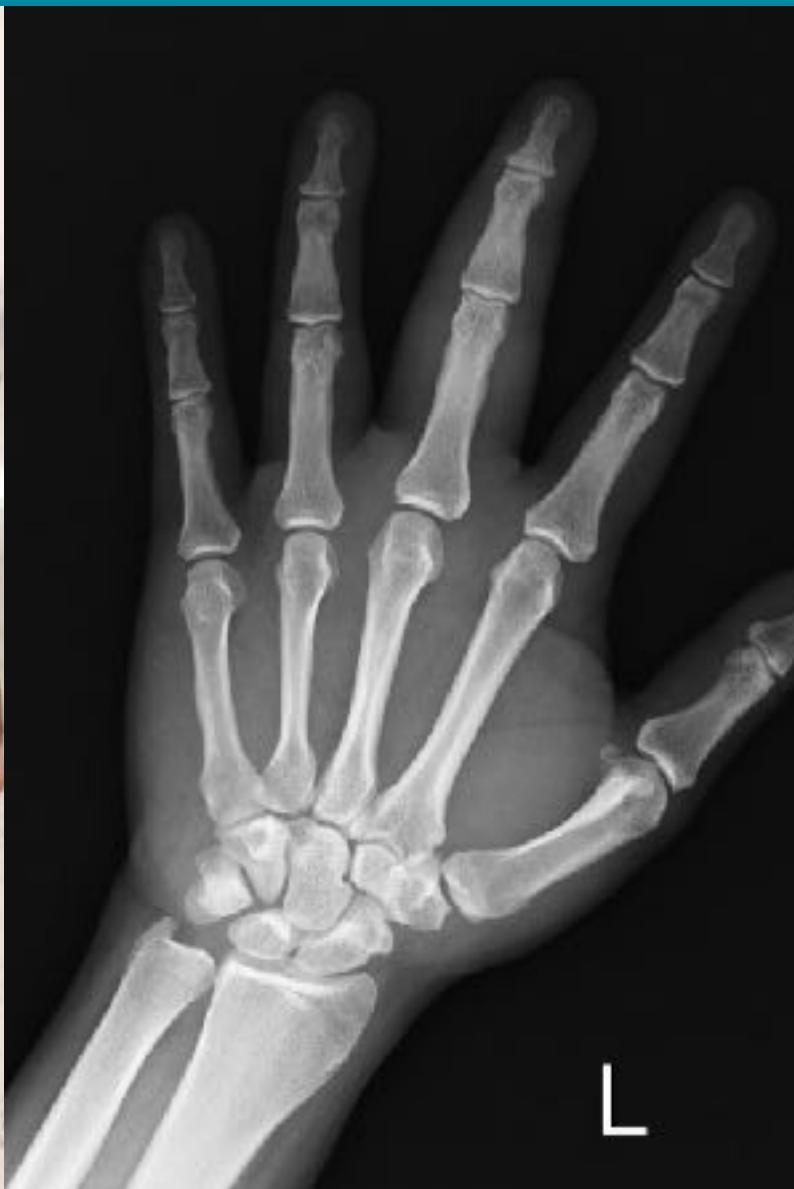
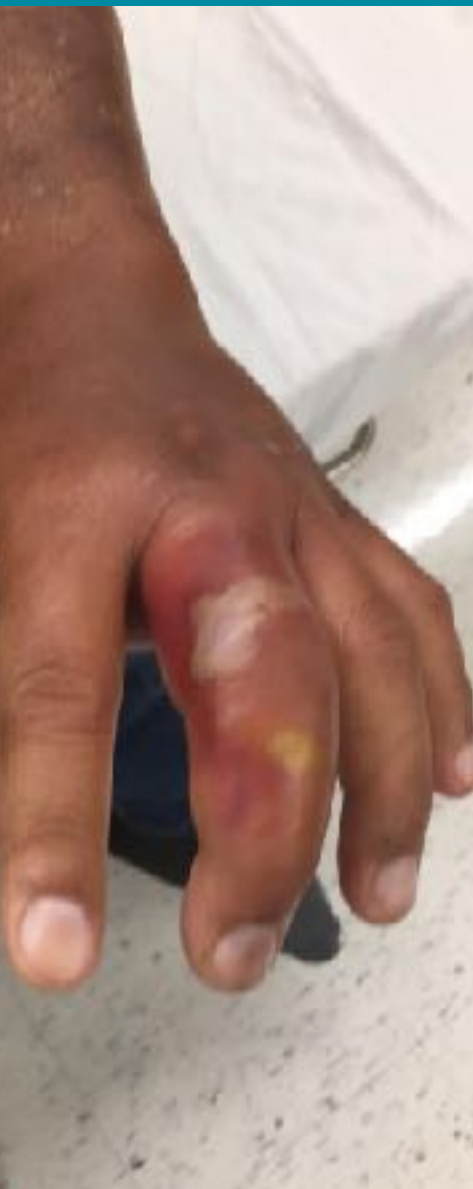A

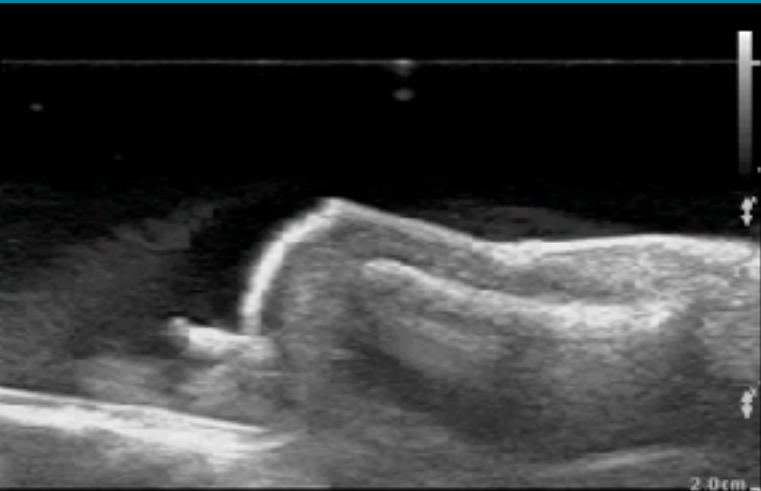

B

# 左手中指腫痛

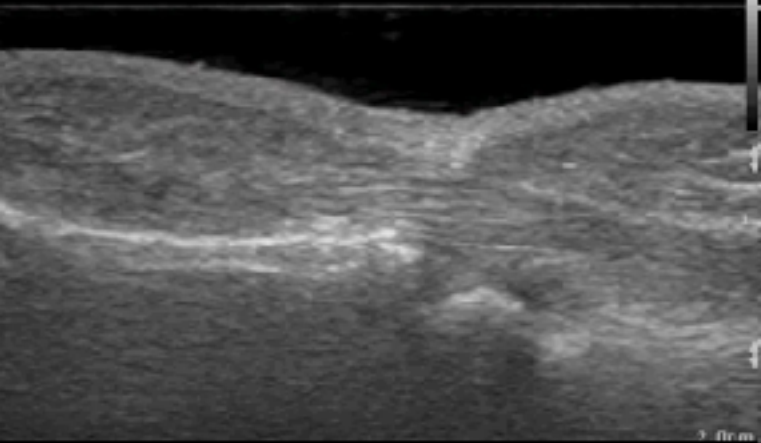


# Water bath method



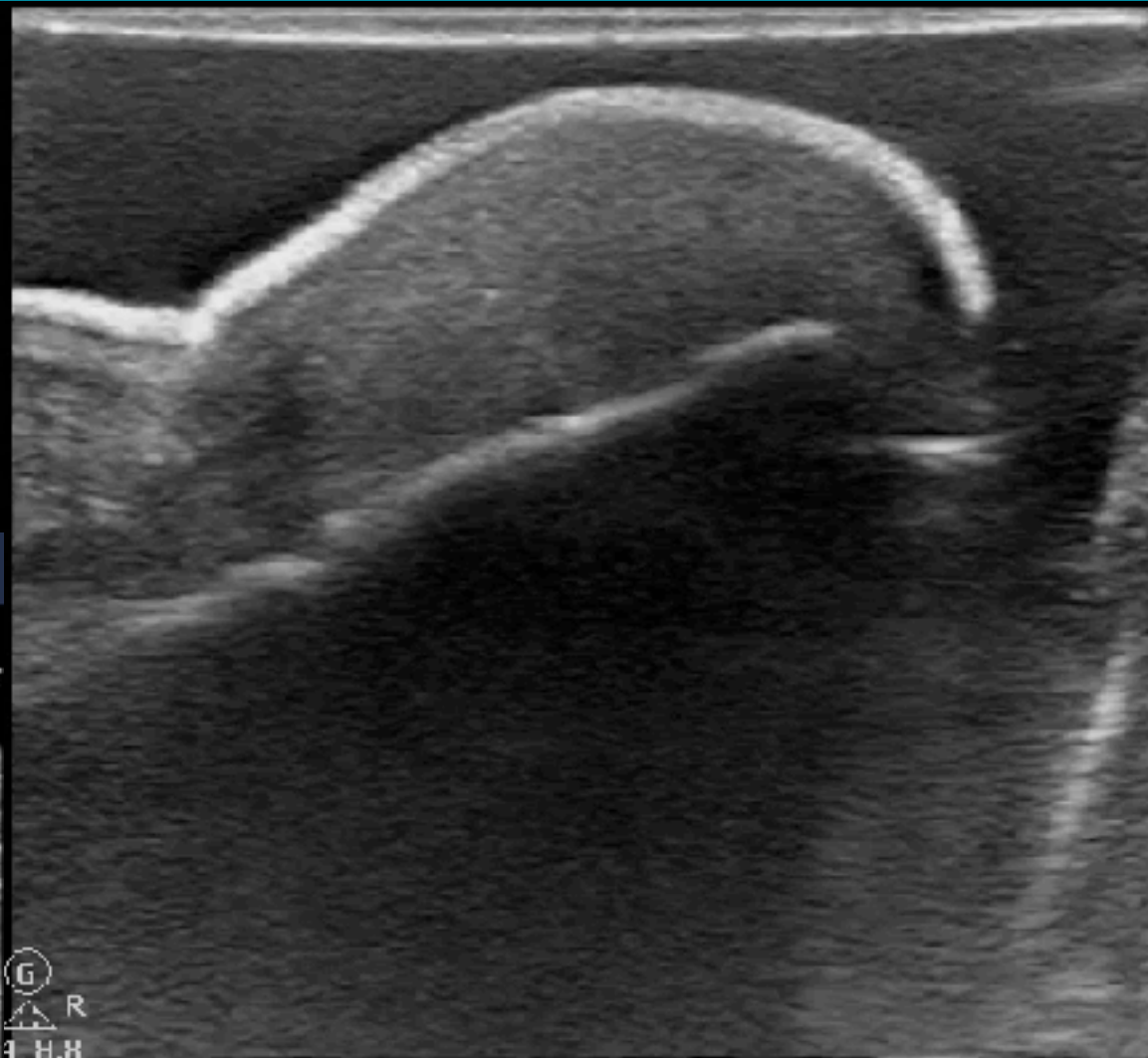G  
D R  
3.0 12.3

2.0cm



G  
P R  
2.0 12.0

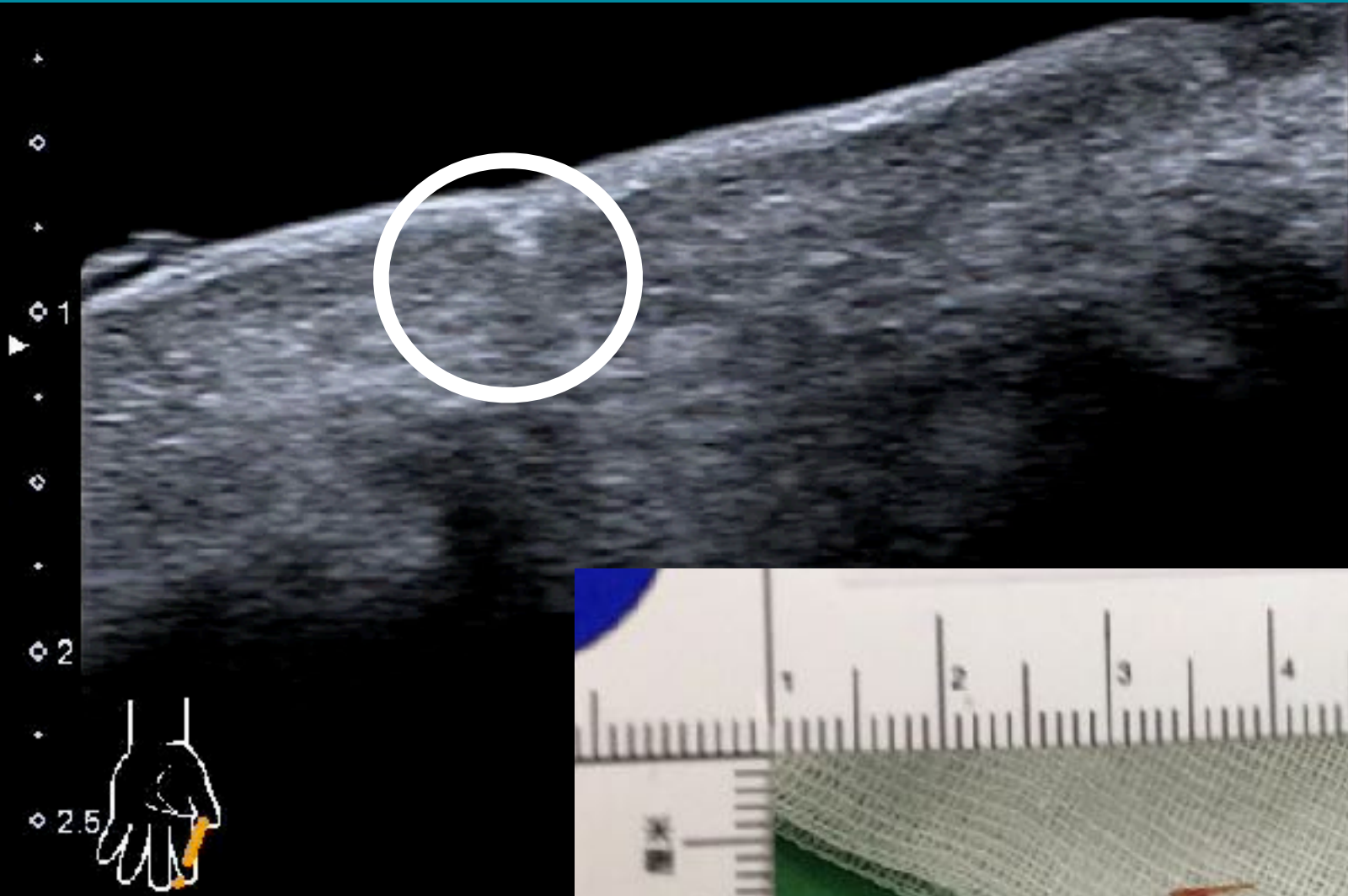
2.0cm




G  
R  
4 H.H



# Create window

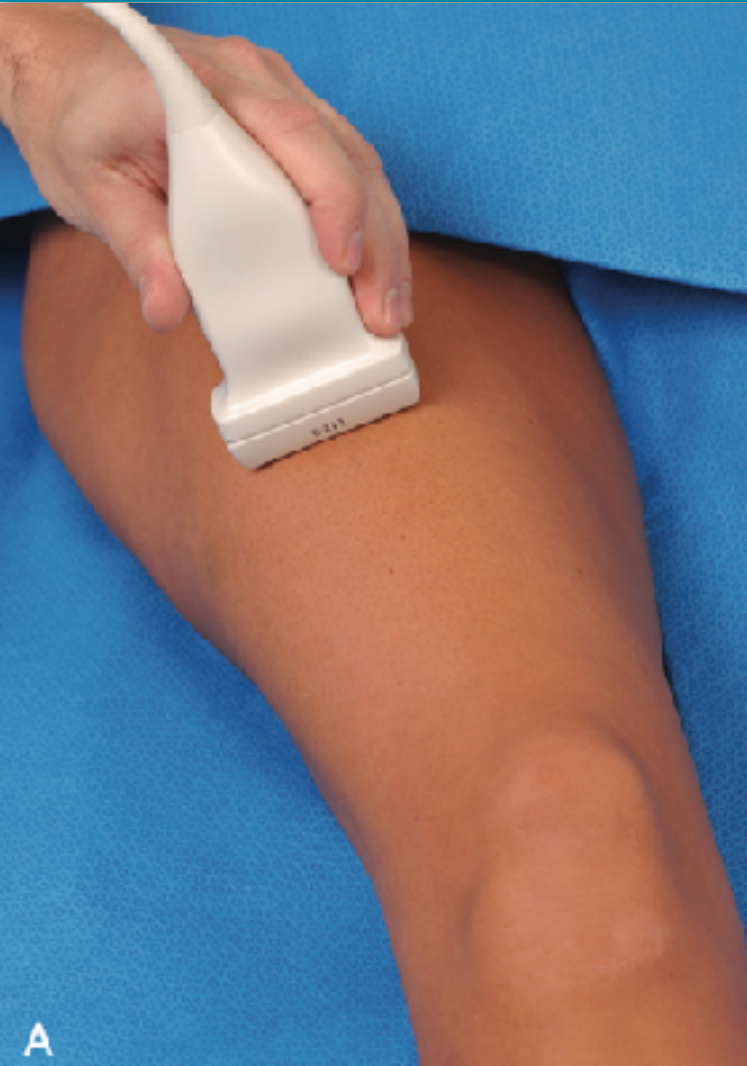

M  
1.5  
11L4  
diffT9.0  
30 fps  
G:86  
DR:60  
A:6  
P:3





# MSK掃描原則

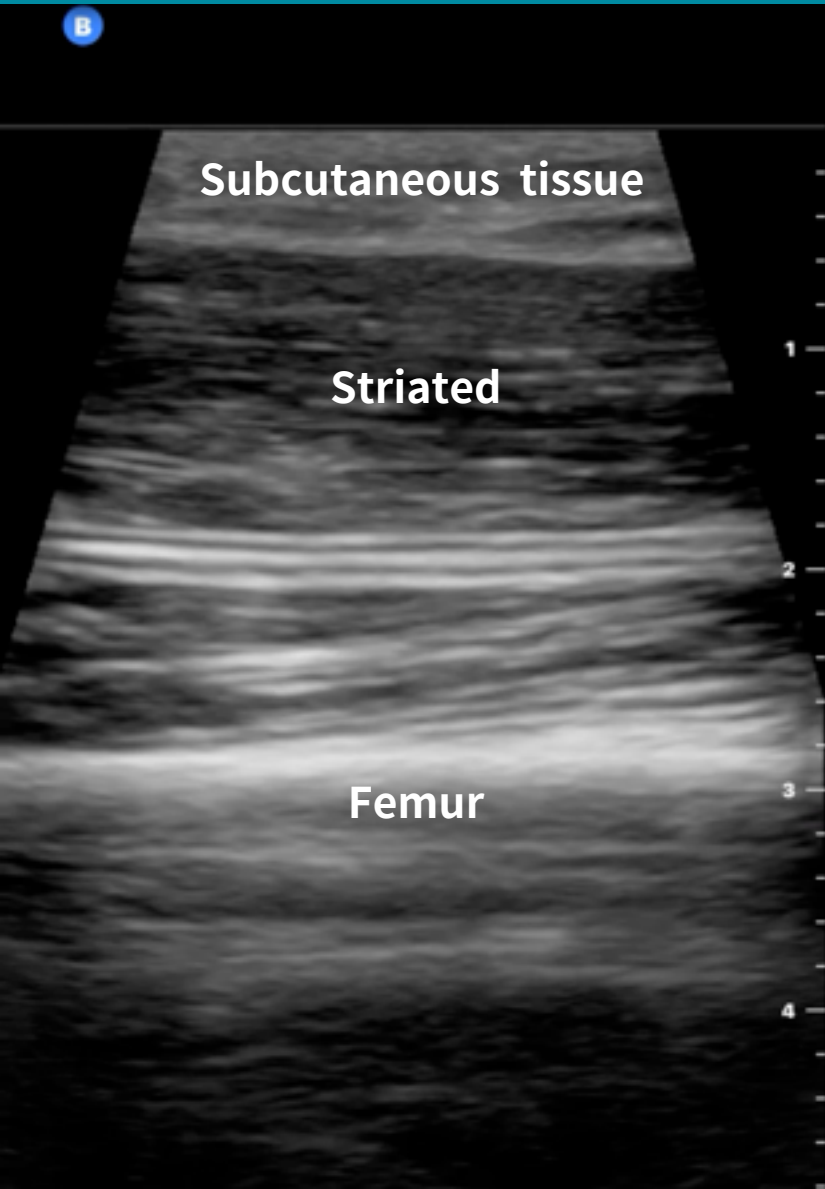


**管狀構造橫掃優先**

**先找外在明顯定位**

**確認內在明顯標的**

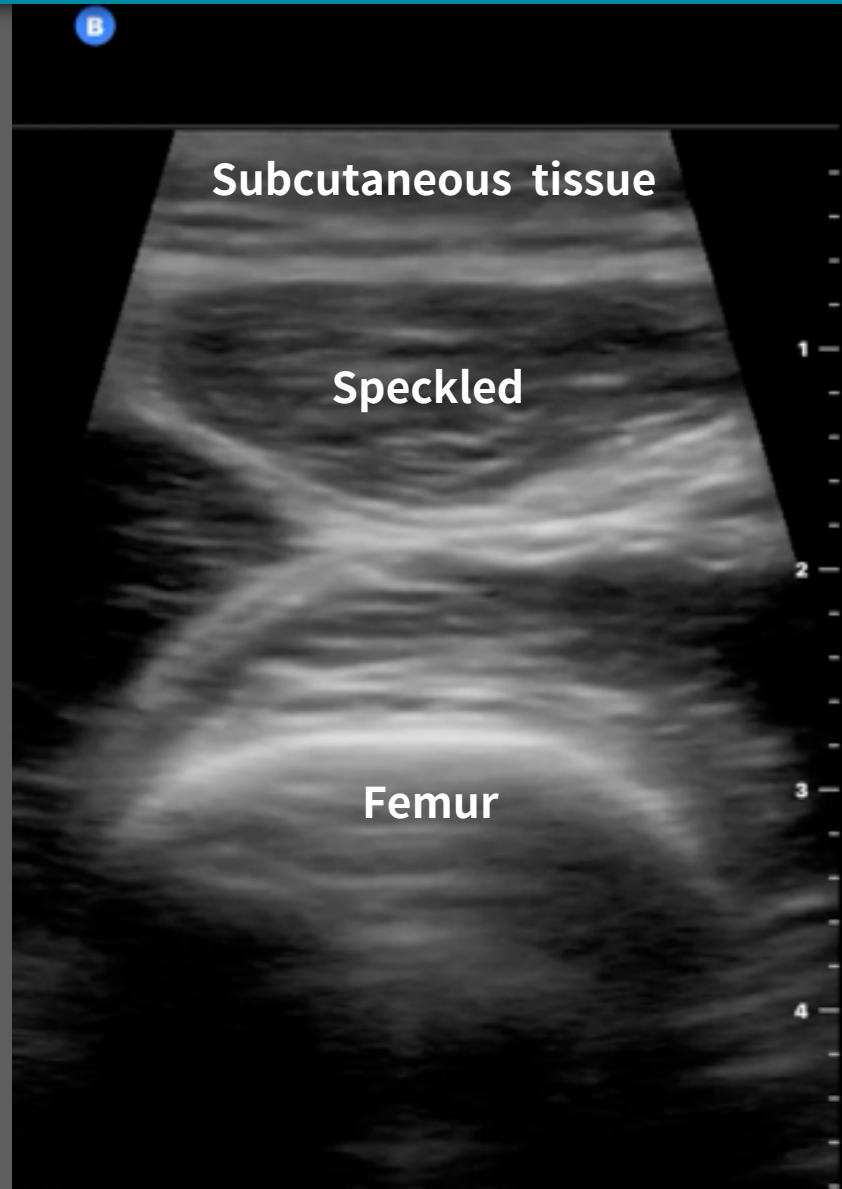
# MSK的重要三界線(白線)



皮膚

筋膜

骨頭

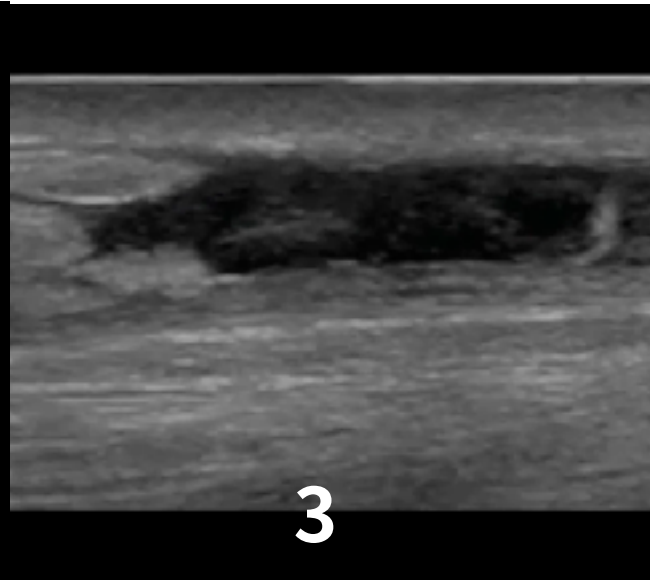
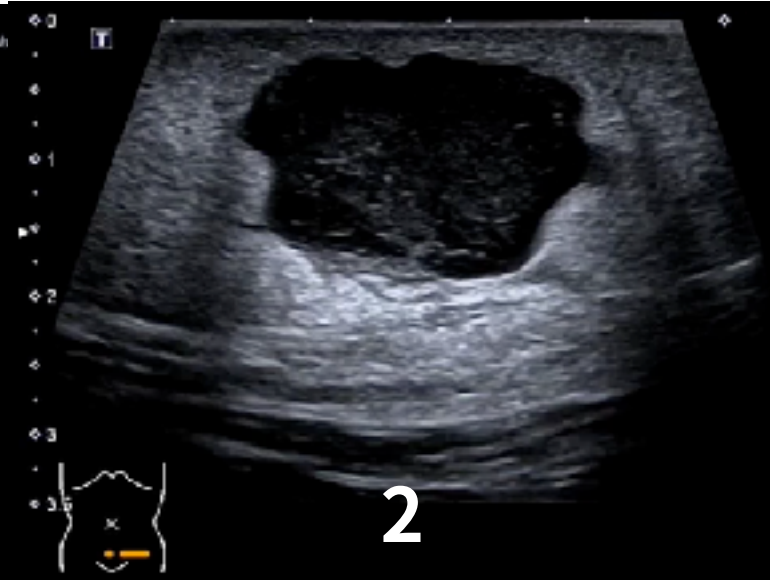
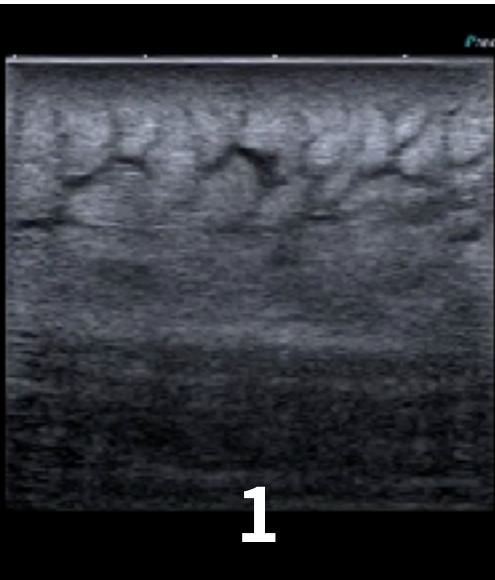


# 軟組織感染症

蜂窩性組織炎

膿瘍

壞死性筋膜炎



Cobblestone

Collection

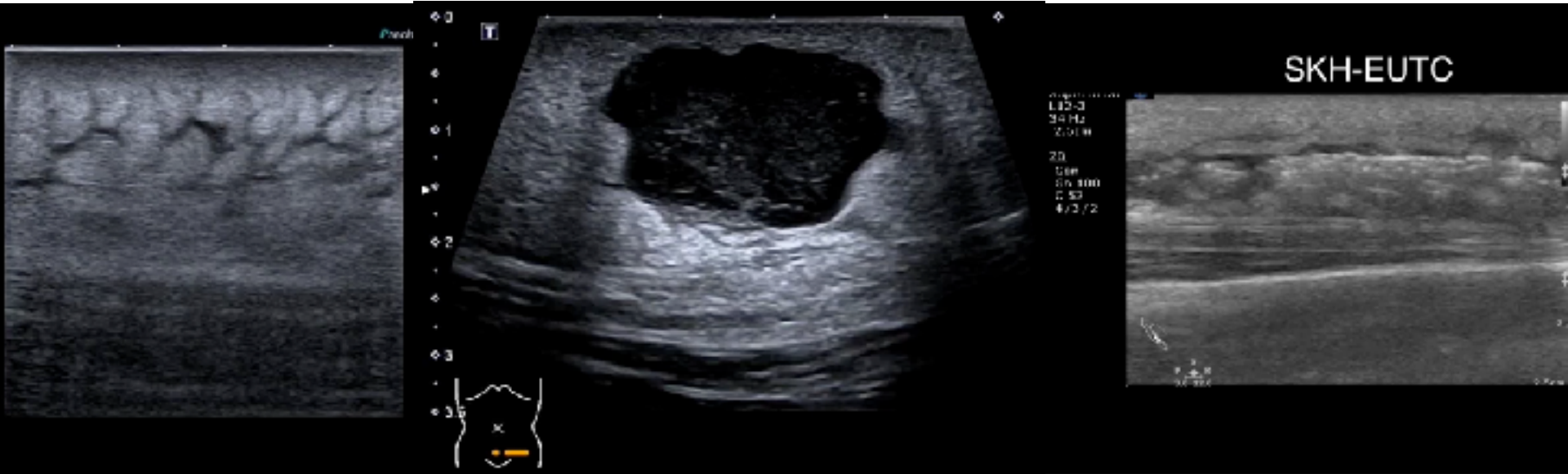Fascial fluid >4mm

# 軟組織感染症

蜂窩性組織炎

膿瘍

壞死性筋膜炎



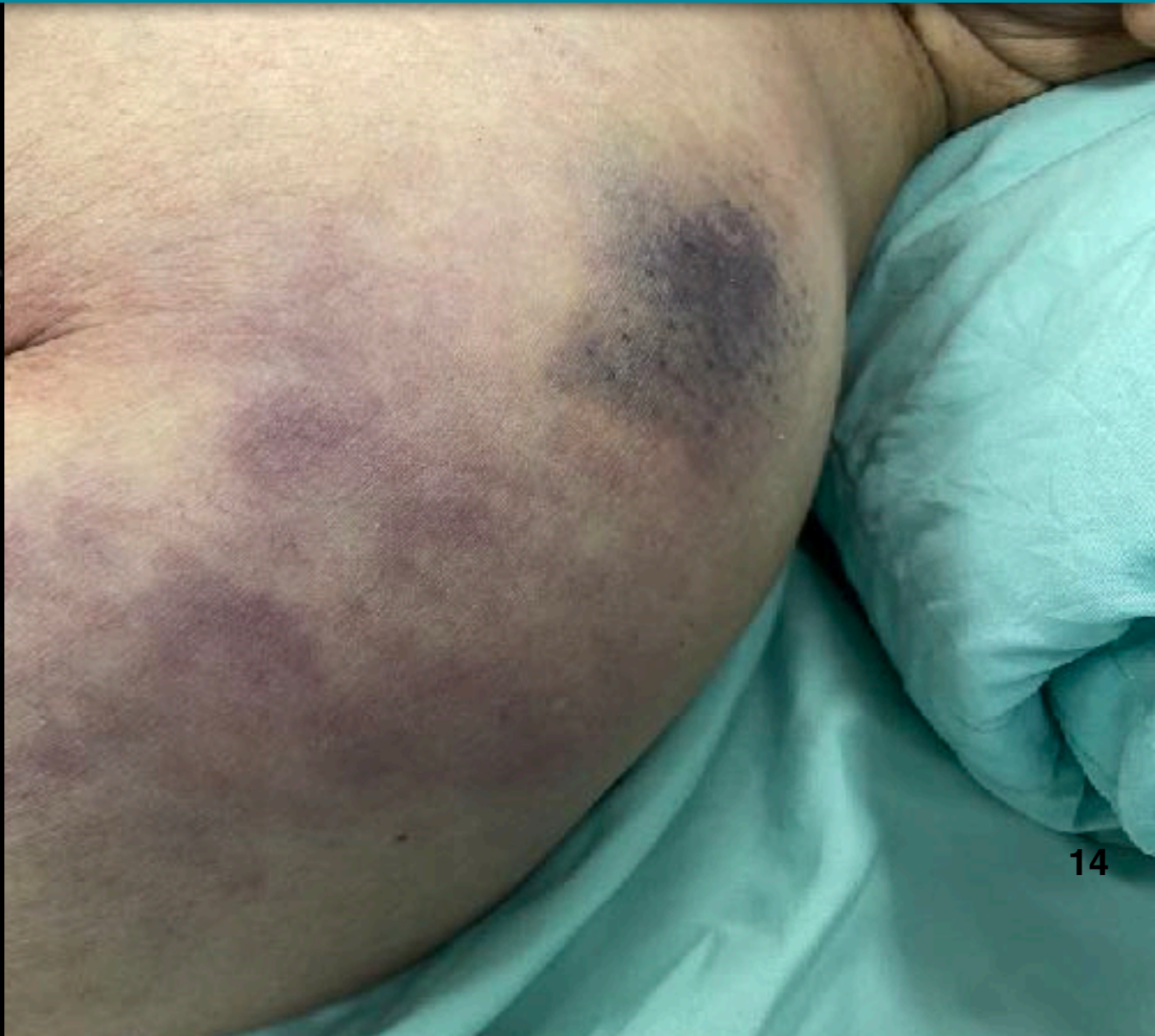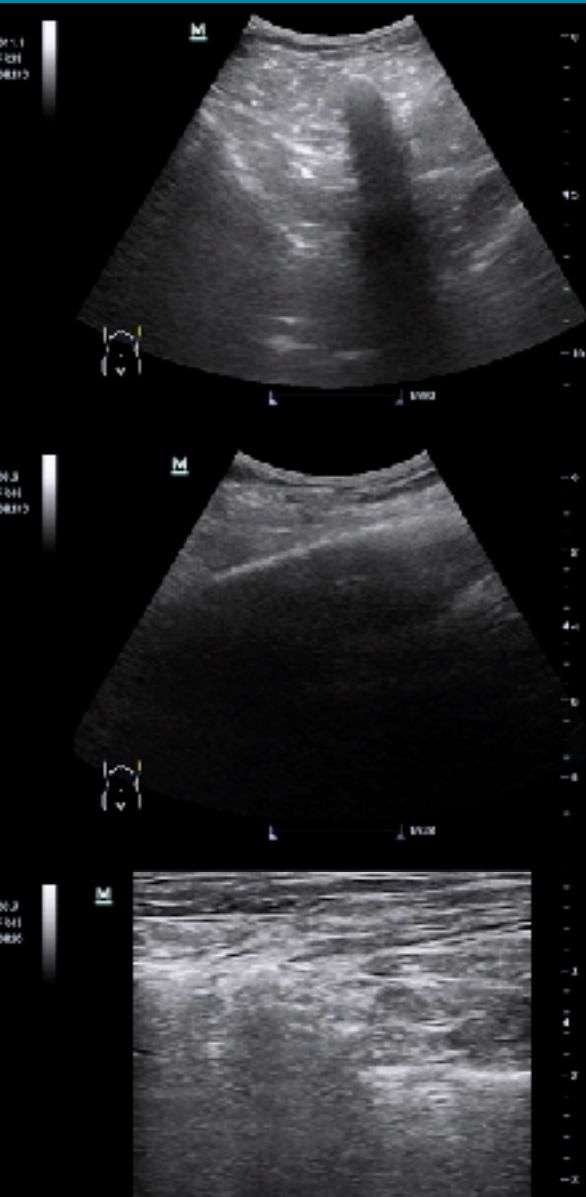
Cobblestone

Collection

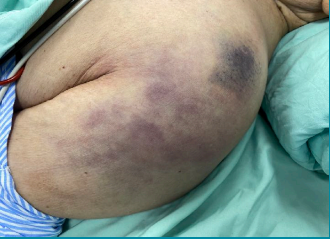Subcutaneous  
Thickening  
Air  
Fascial  
Fluid



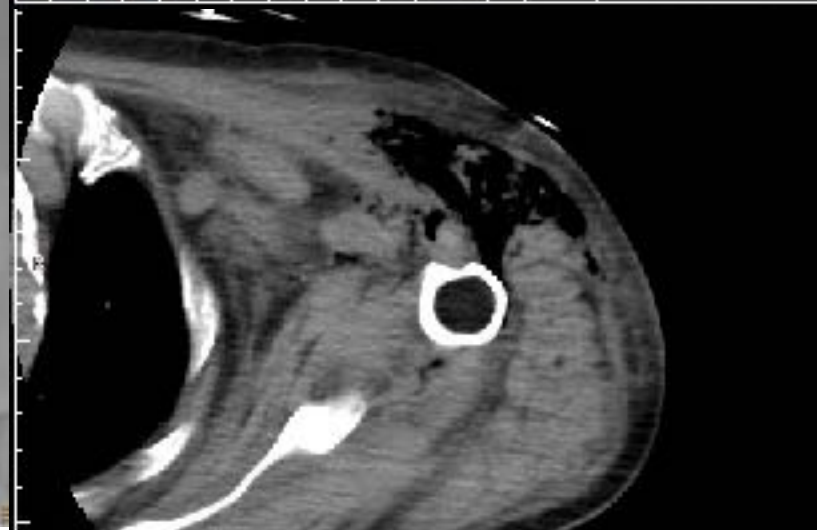
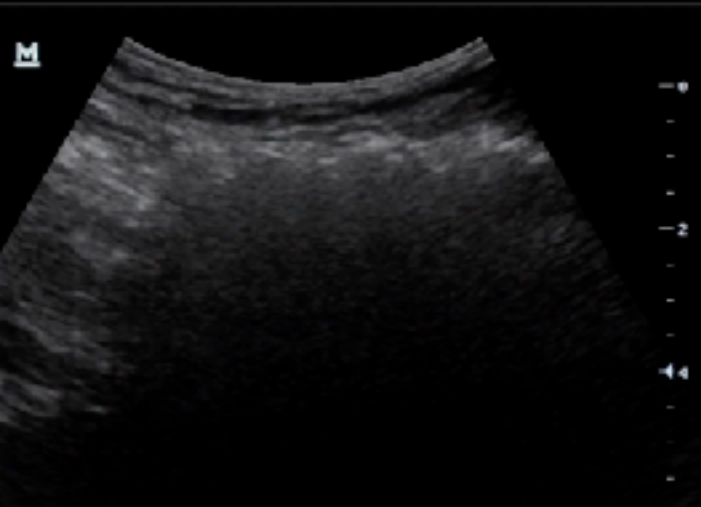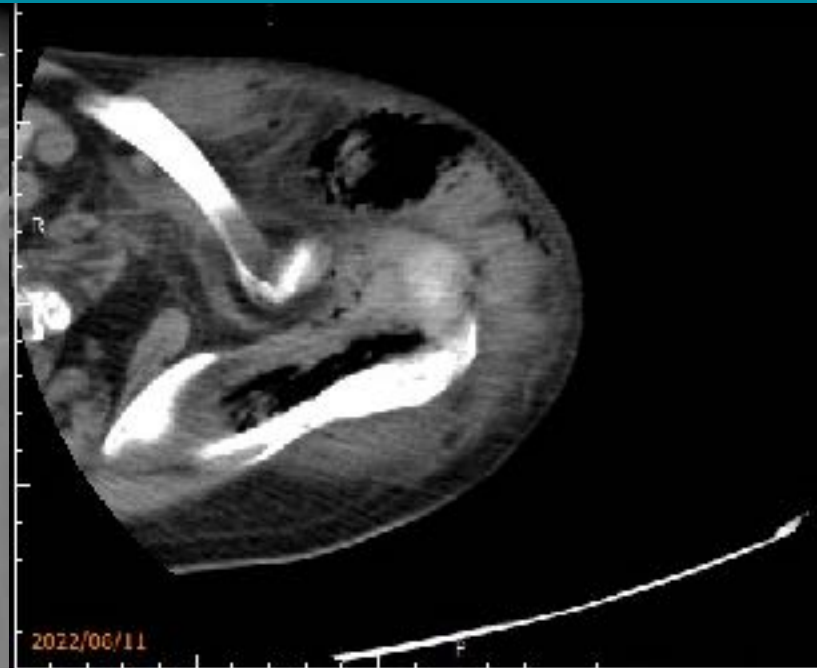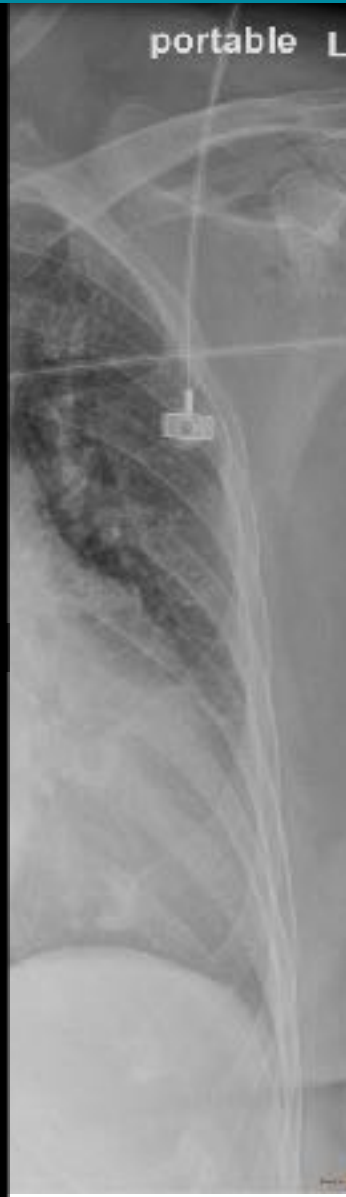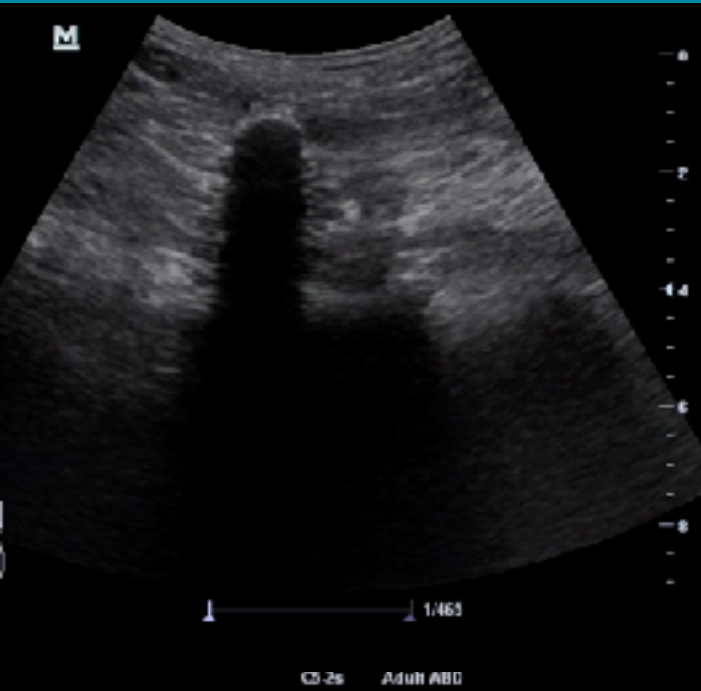
83F，前天跌倒，左手痛，BP 69/43



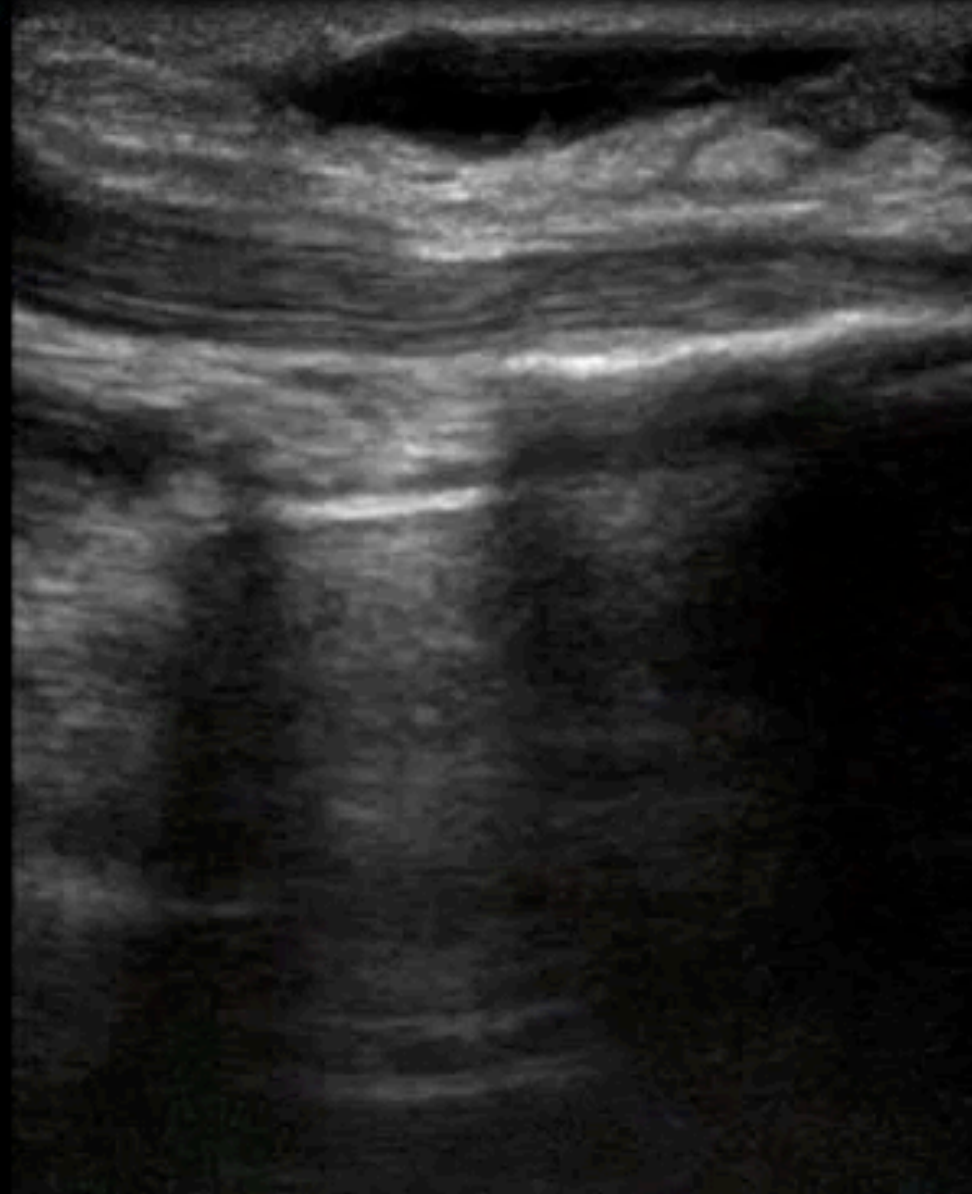
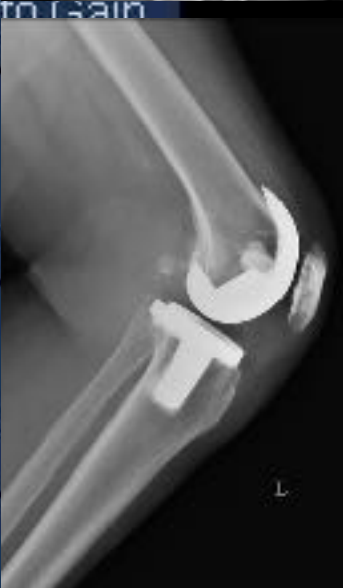
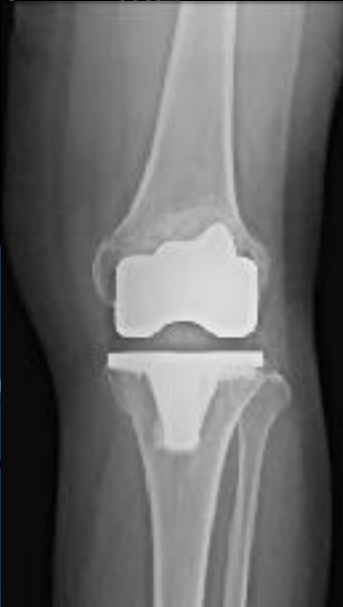


# NF with shock



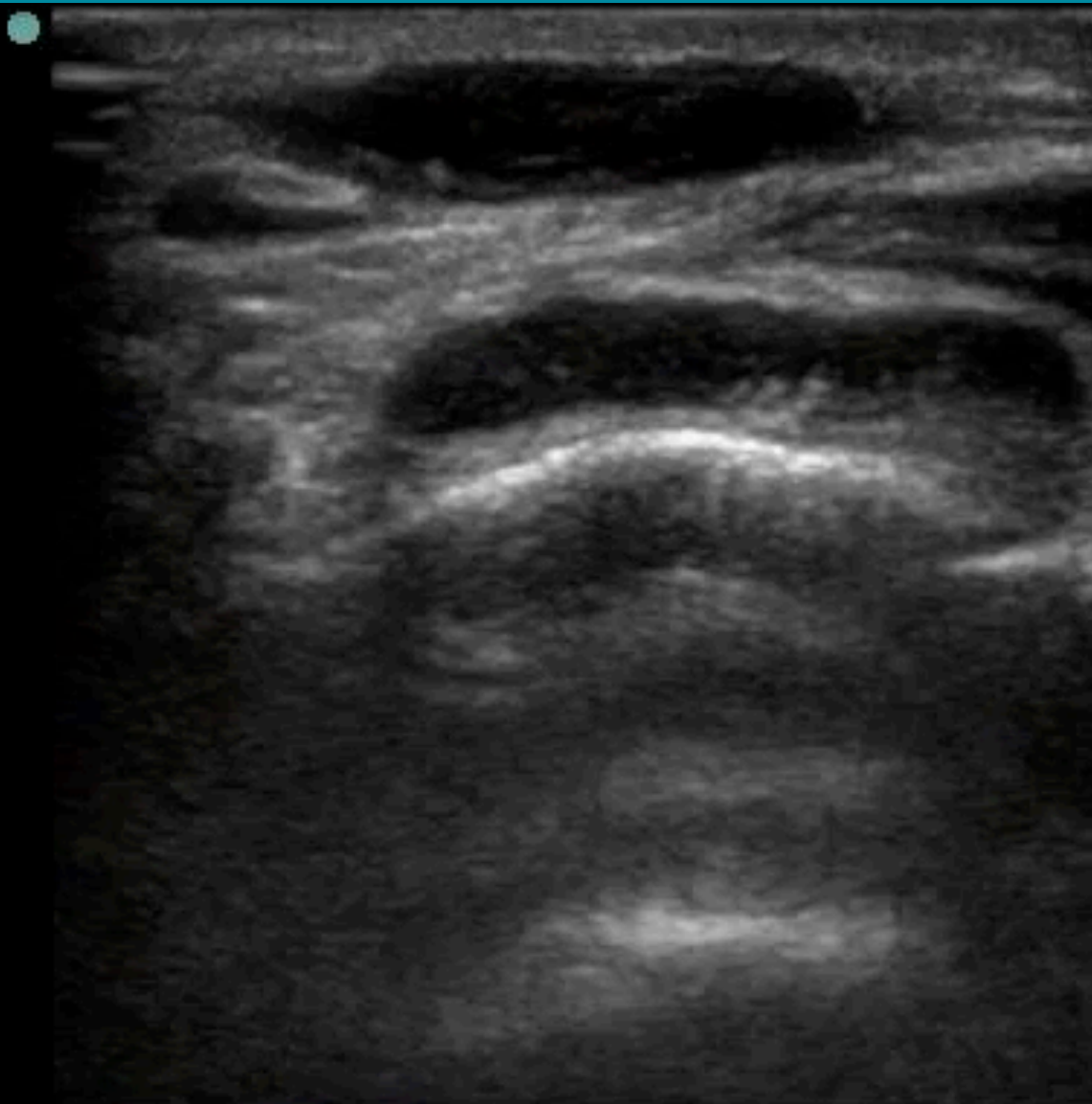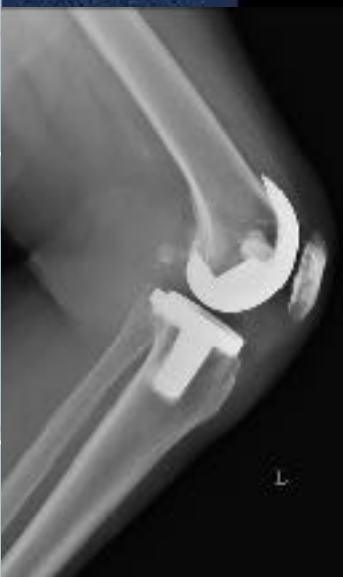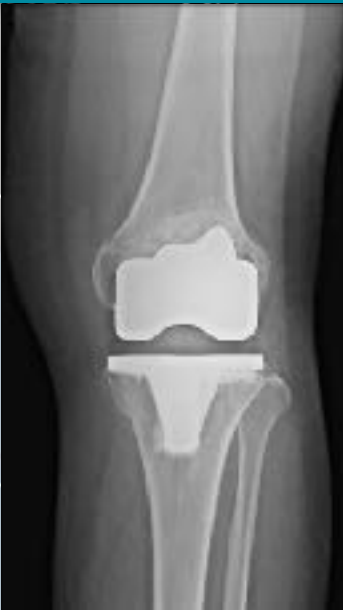# 72F, left knee cellulitis



H  
E  
2  
T  
0

1  
2  
3  
4  
5  
6  
7  
8  
9  
10  
11  
12

# 72F, left knee cellulitis

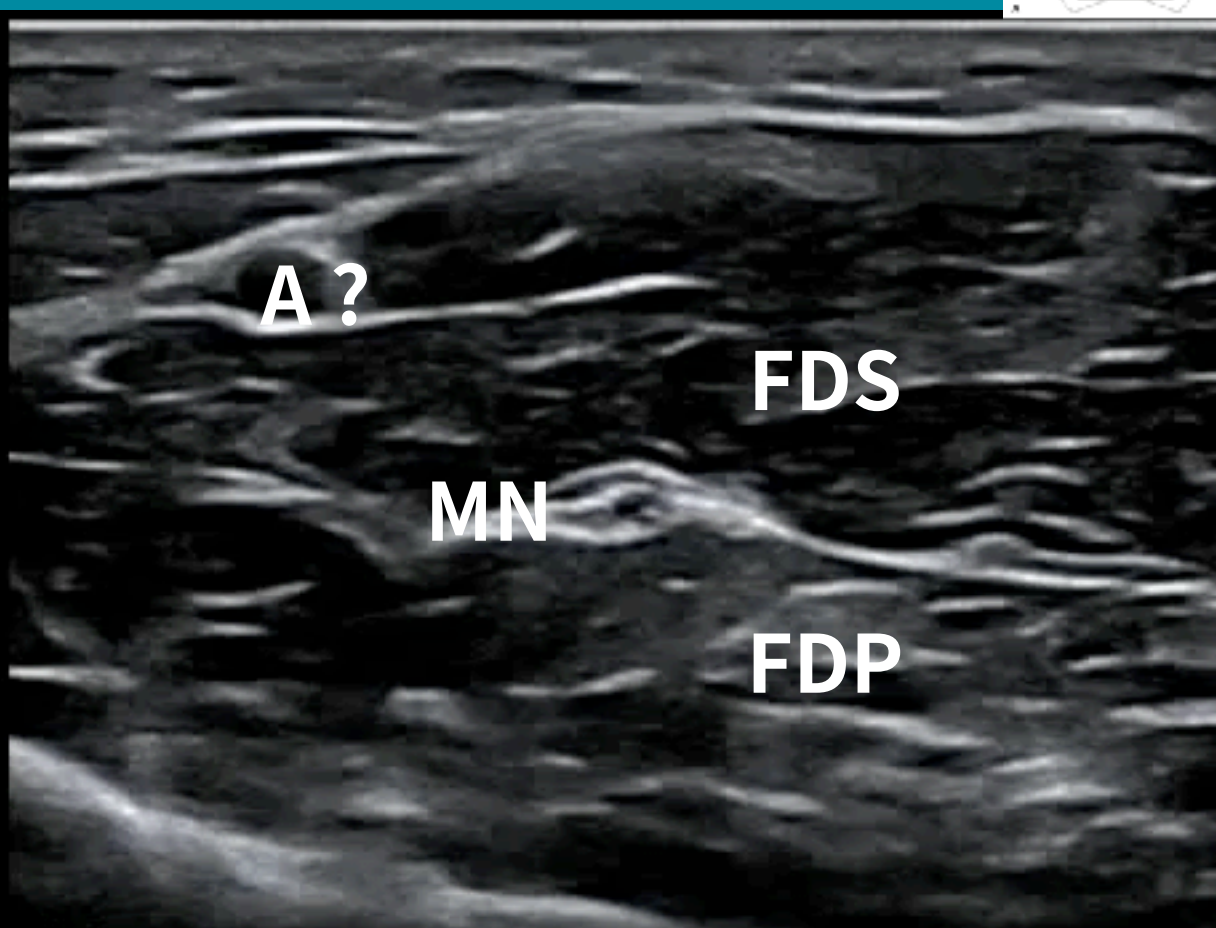
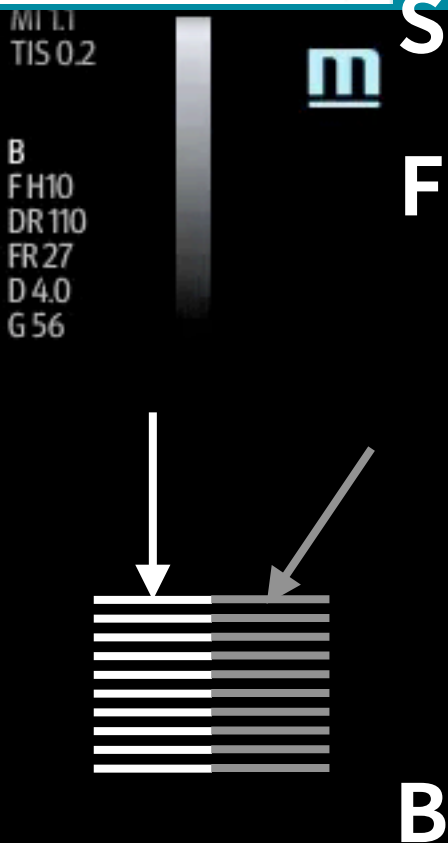
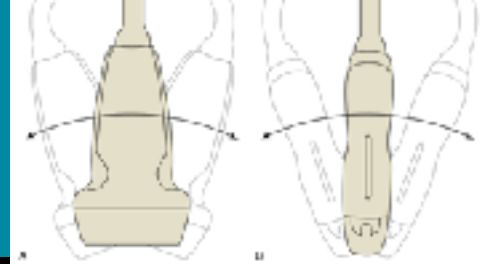
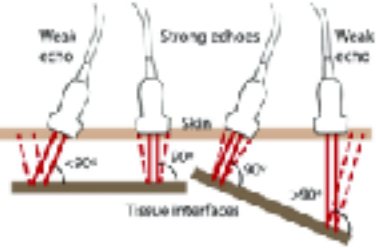


Vas  
HFL  
19%  
MI  
0.7  
TIS  
0.1



4.0

# Anisotropy



Tendon

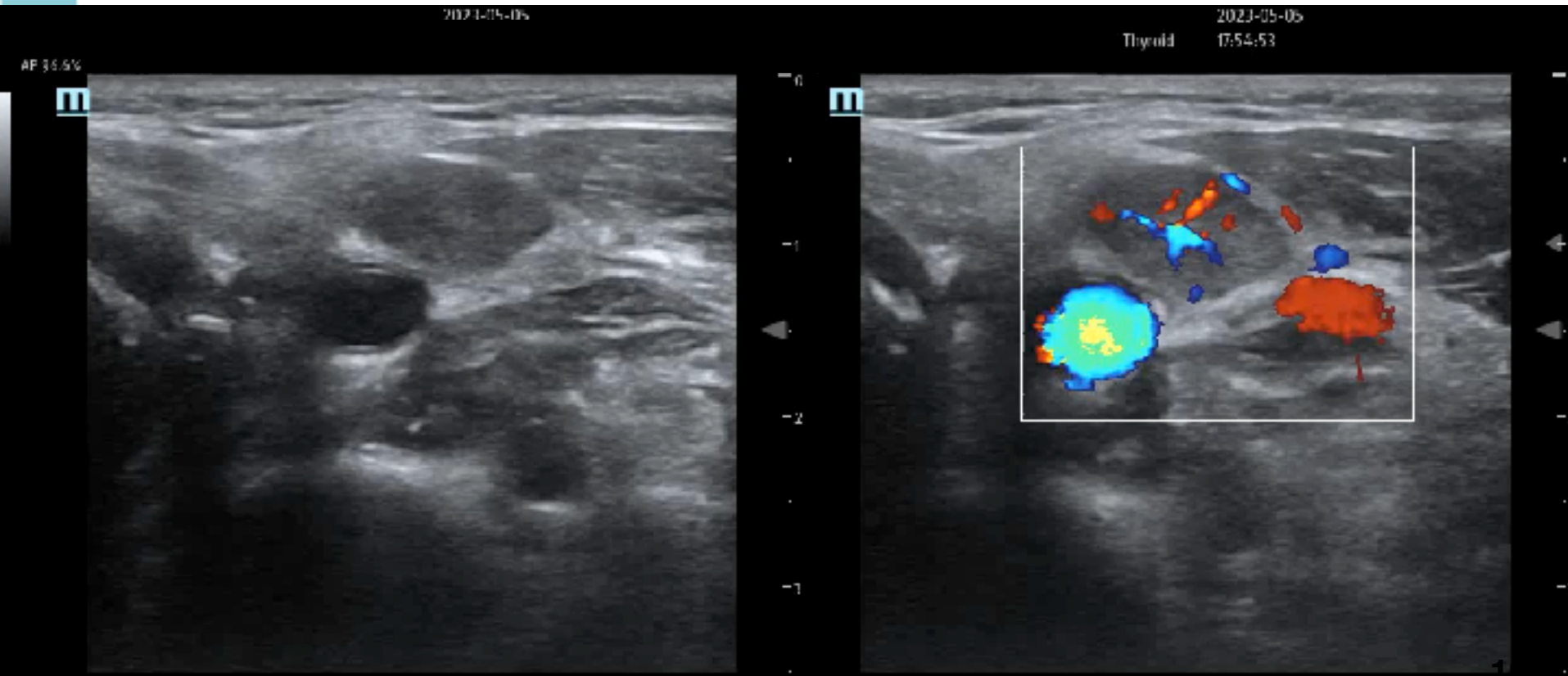
Nerve

Muscle



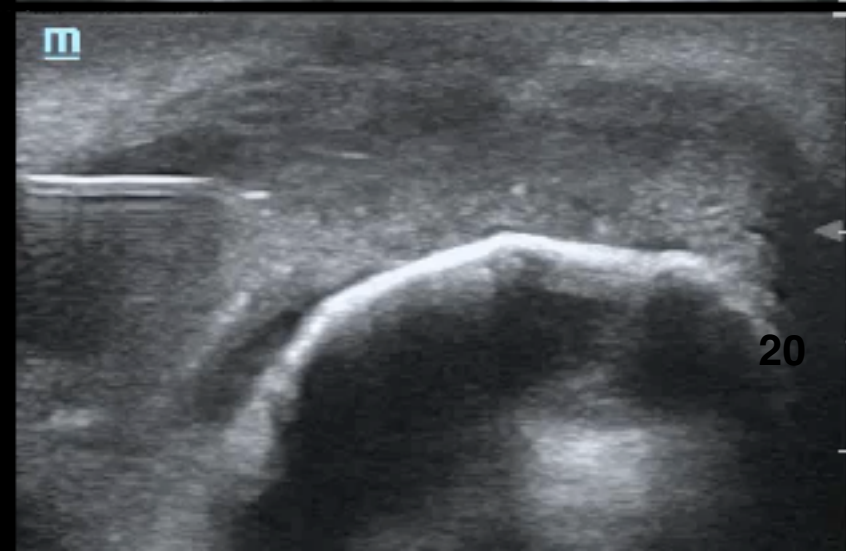
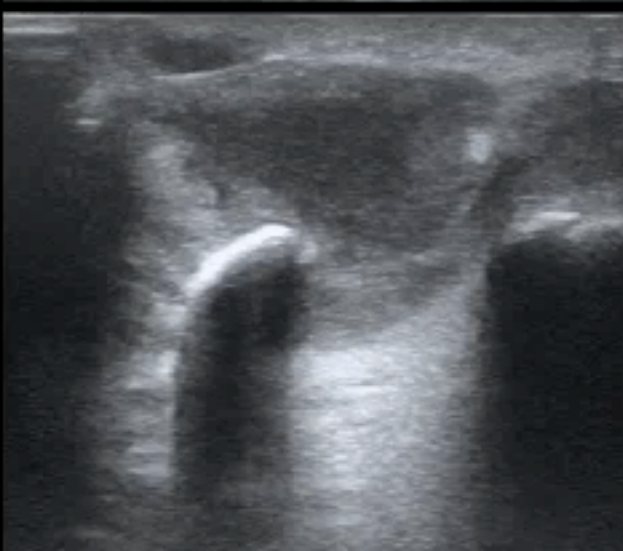
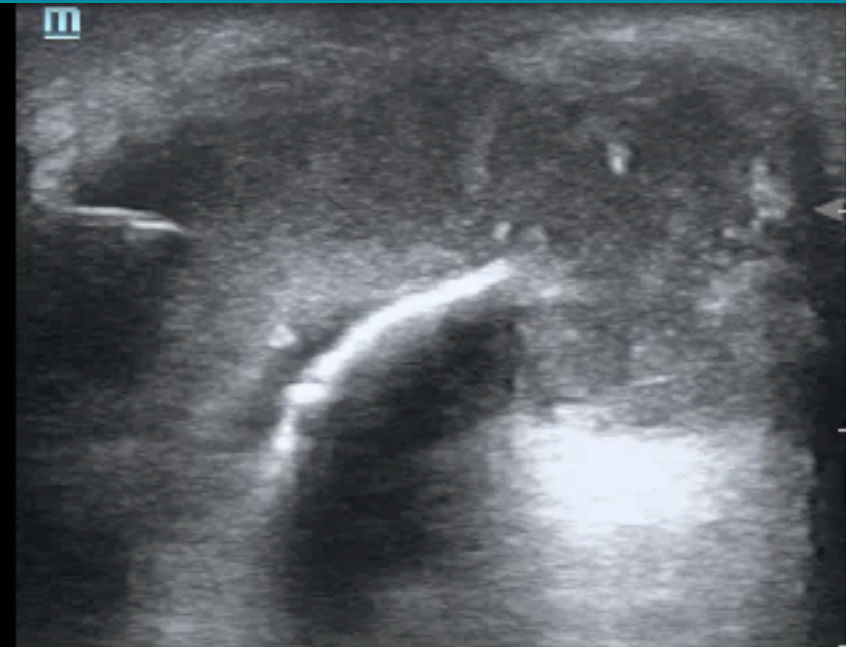
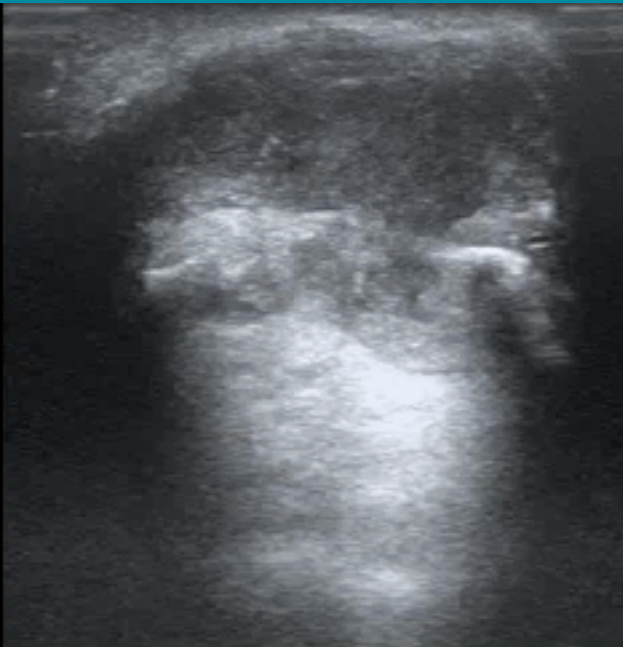
# 41F, fever & neck pain

## Cervical lymphadenitis

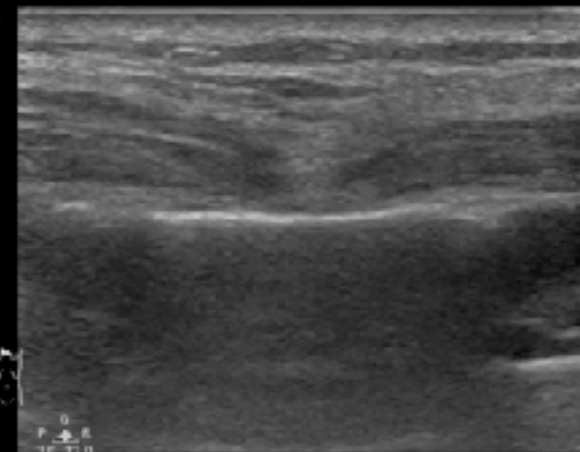
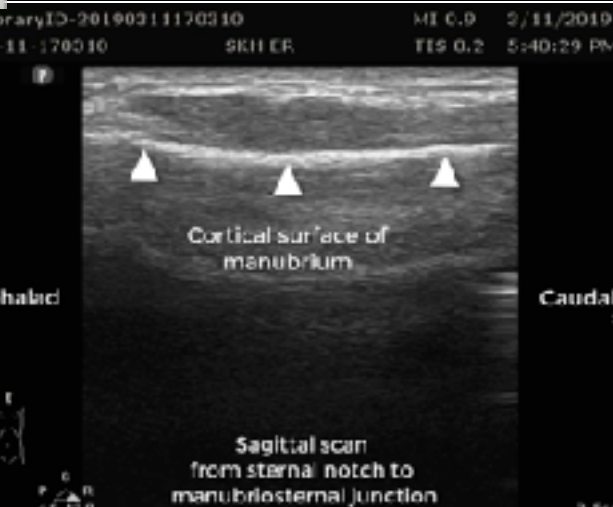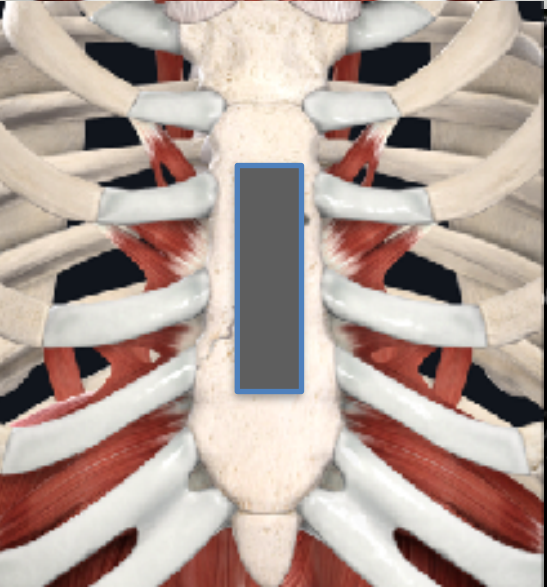
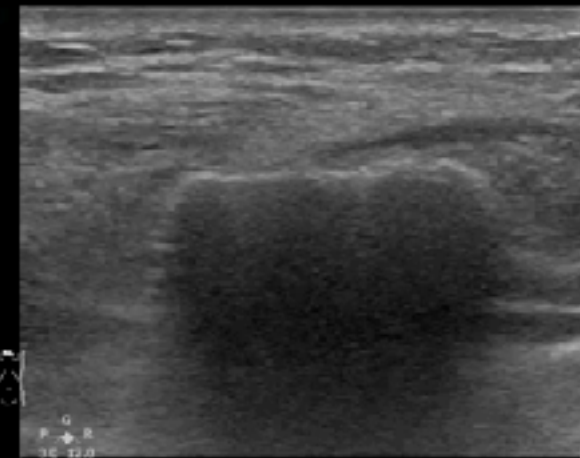
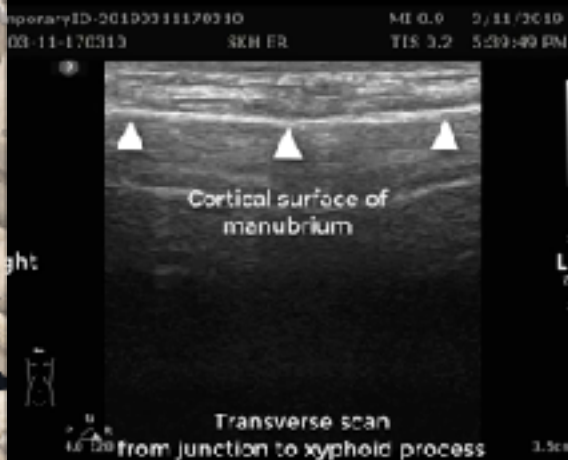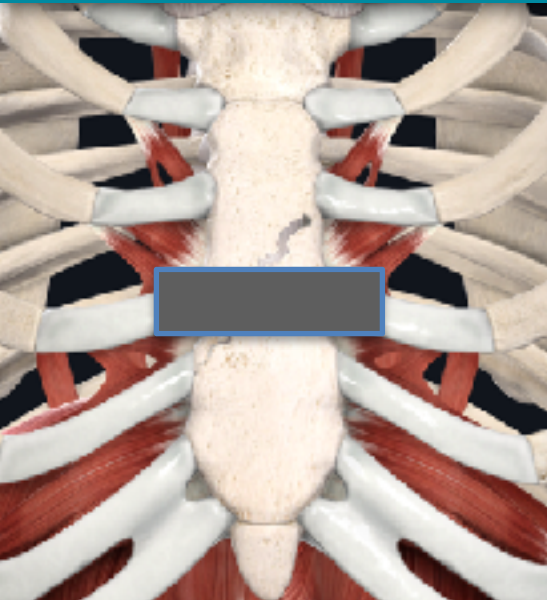




# 64M, submandibular abscess

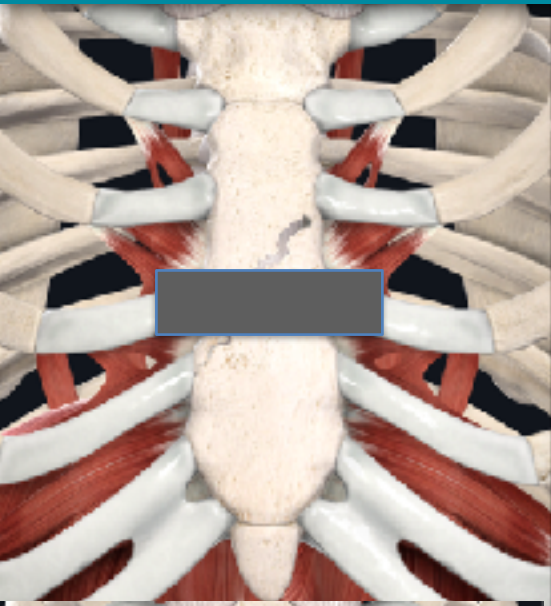

# Sternal fracture

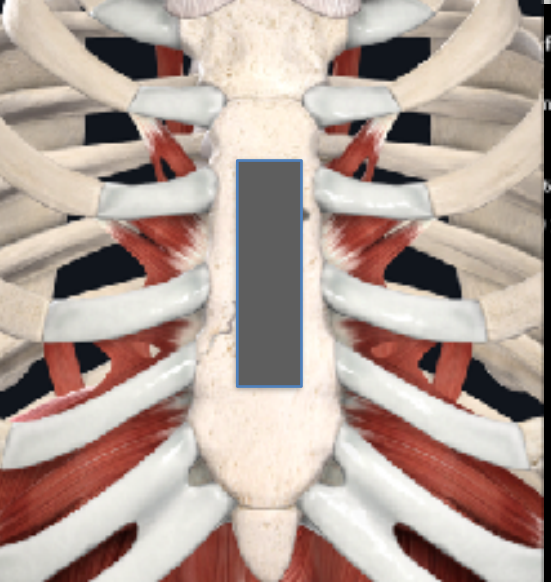
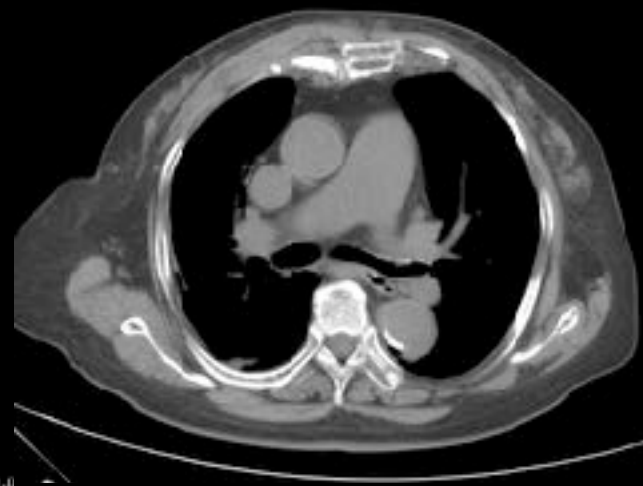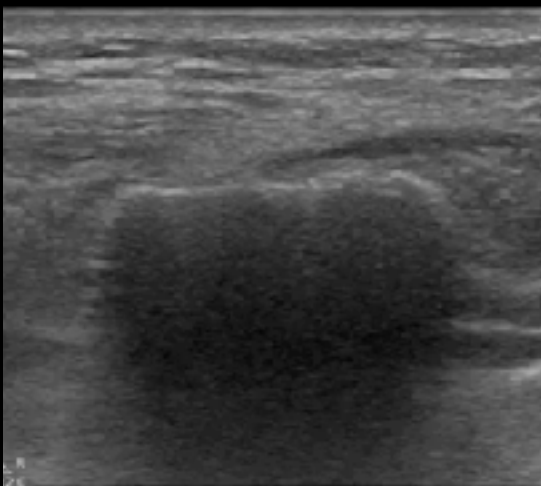




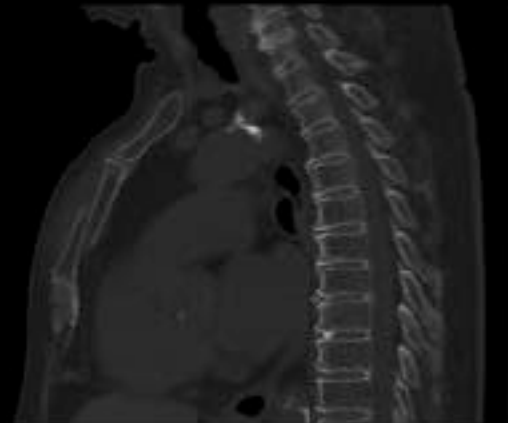
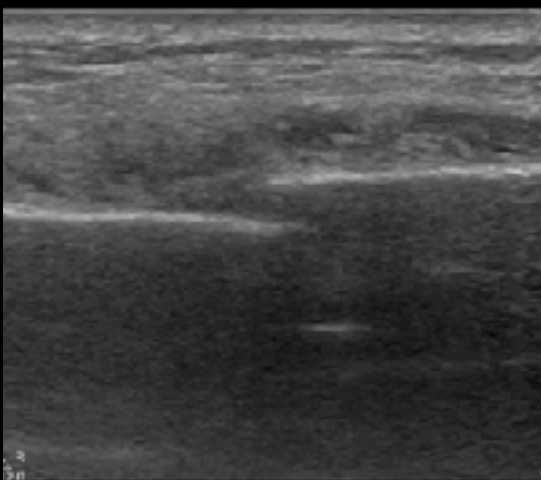
# 骨折判斷 - 適用長骨&平骨



高低落差

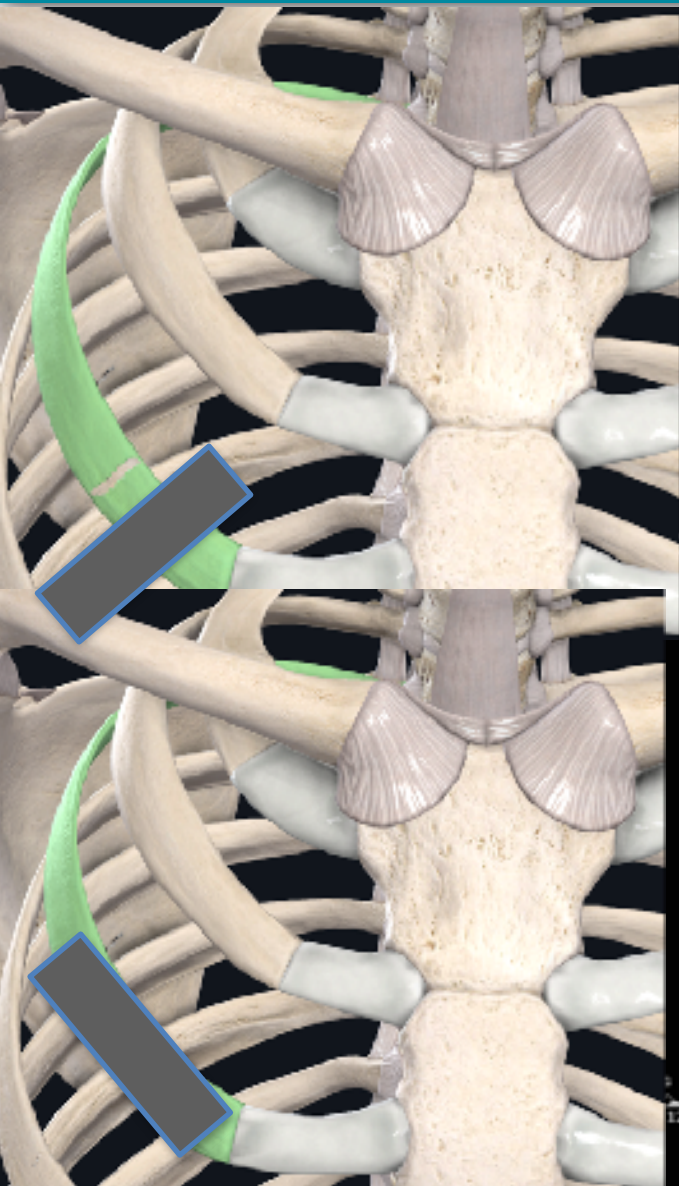


不連續

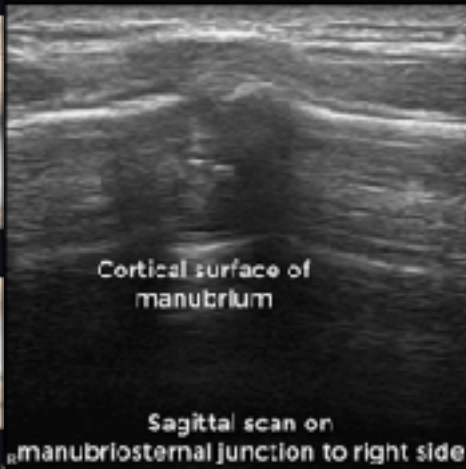

血腫

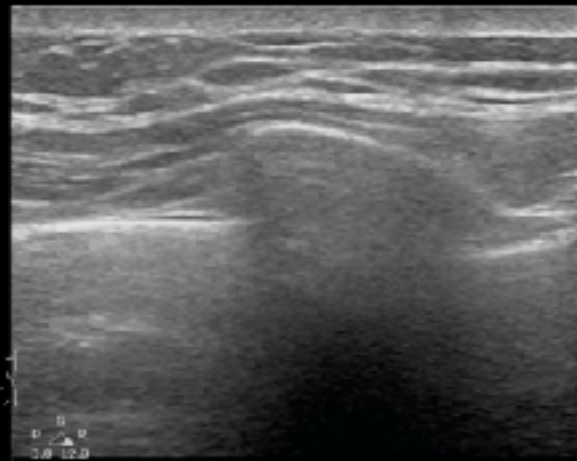
# Rib fracture



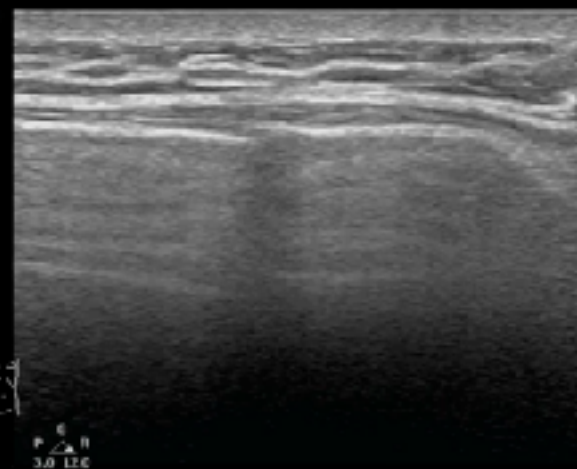
20190311170310 MI 0.9 3/11  
SID SKH-ER TIS 0.2 5:40



Superficial  
L12-3  
46 Hz  
3.0cm  
2D  
Res  
Gn 96  
C 56  
3/2 / 1

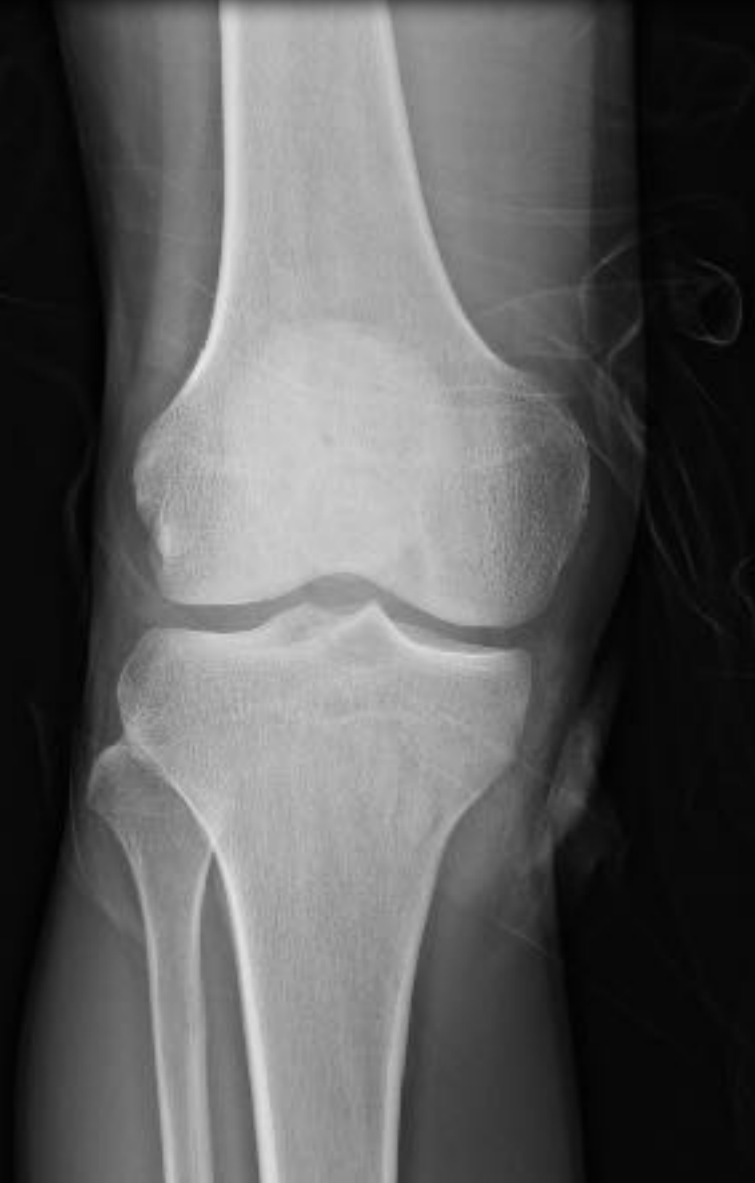

Superficial  
L12-3  
46 Hz  
3.0cm  
2D  
Res  
Gn 96  
C 56  
3/2 / 1

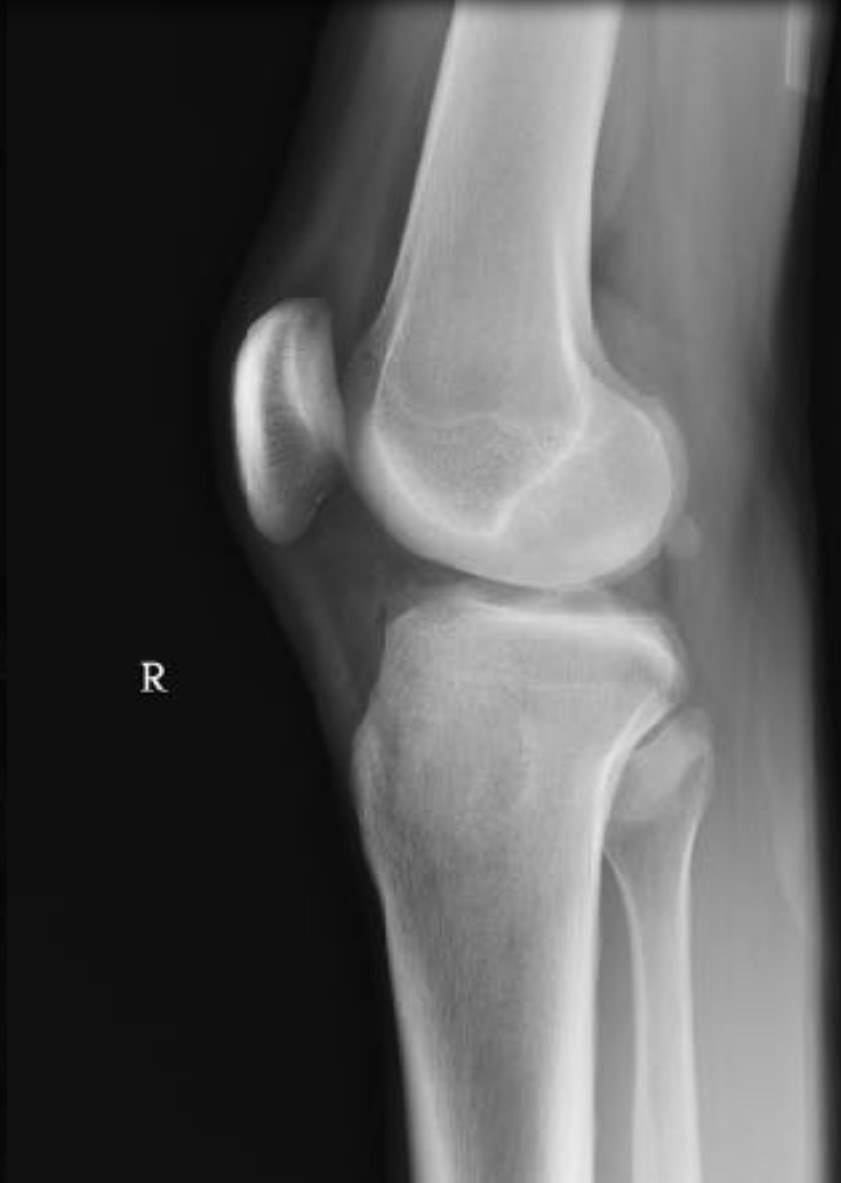

# 23M，車禍，右膝腫痛

R

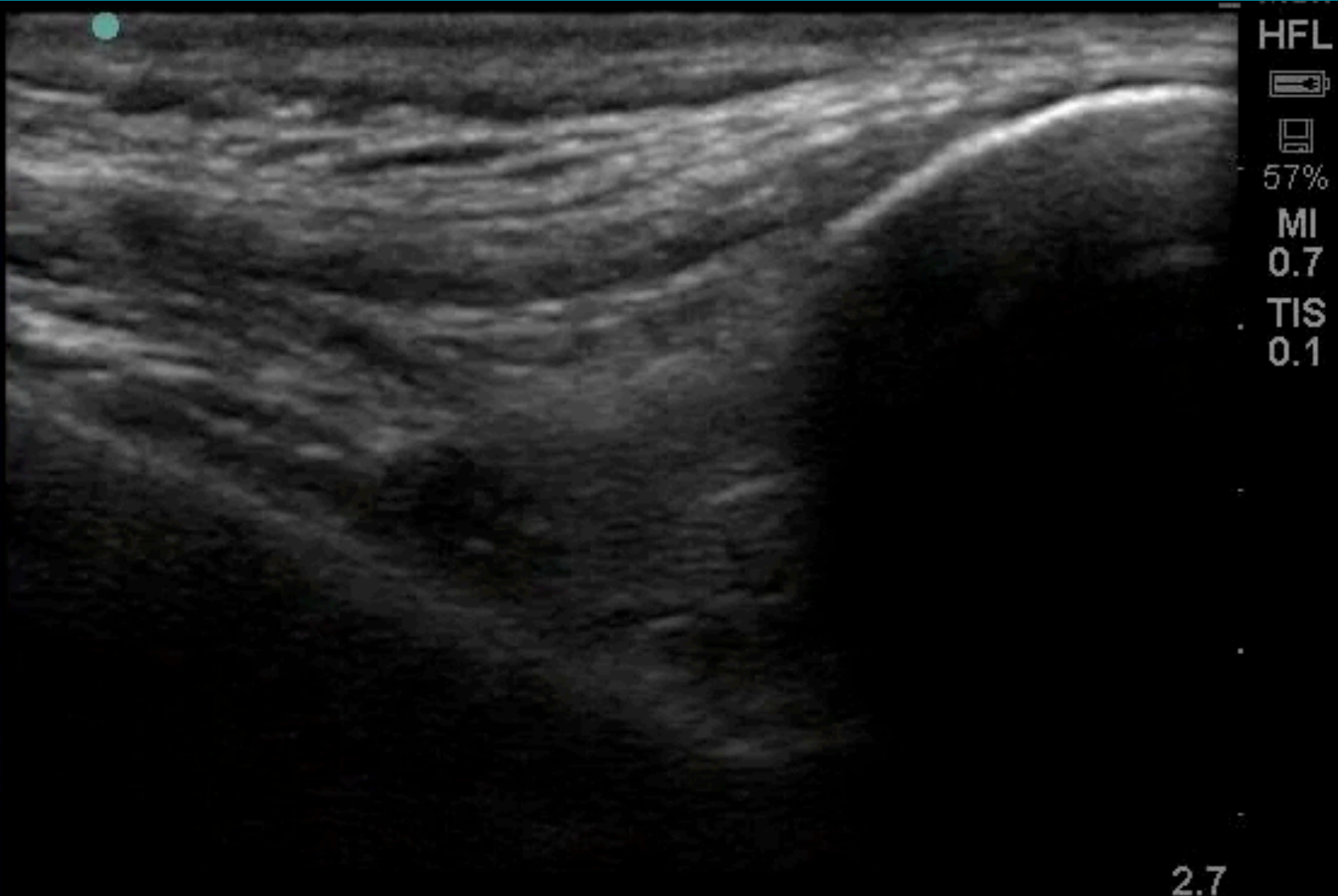

R





# 23M，車禍，右膝腫痛



HFL



57%

MI

0.7

TIS

0.1



Patient



Auto Gain



Res



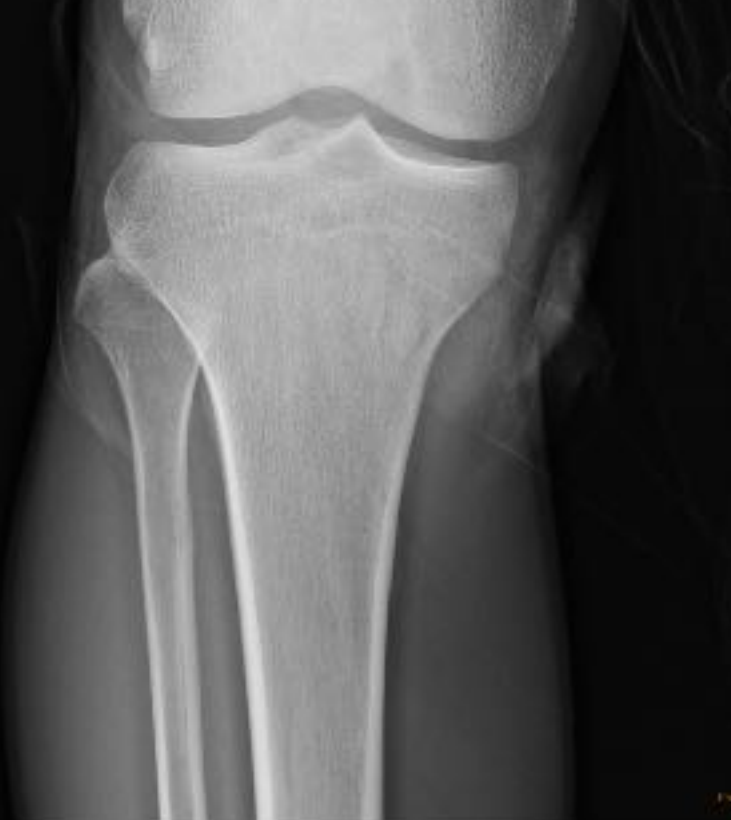Clip



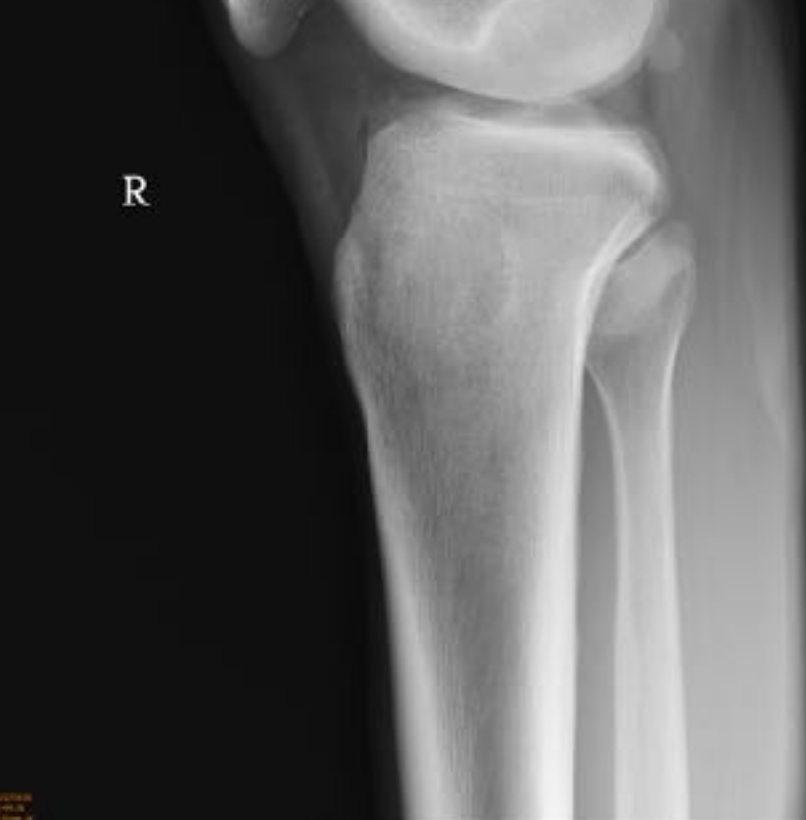Page 1/3

2.7

R



R



12/08/11  
14:43:34  
01/08/11

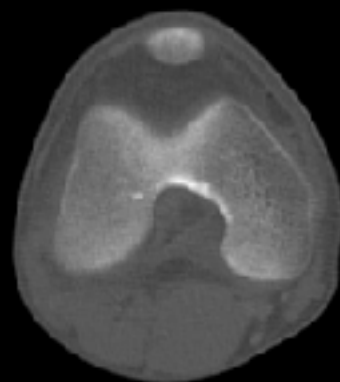
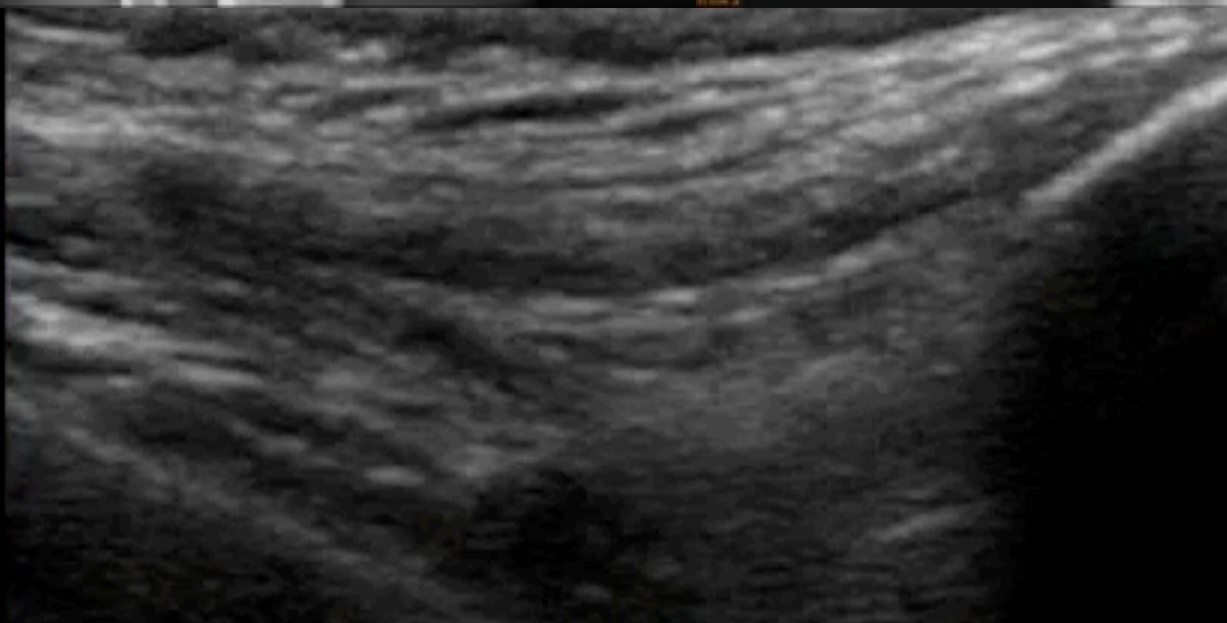12/08/11  
14:43:34  
01/08/11



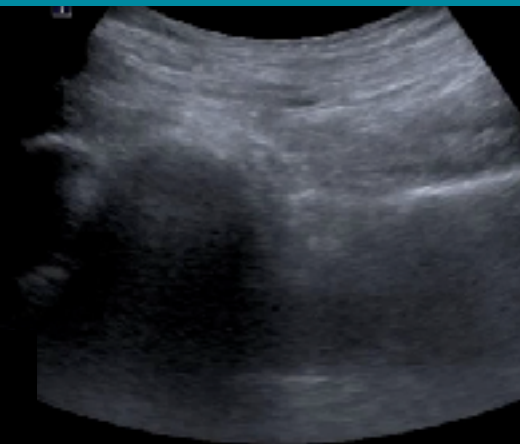Patient



Auto Gain

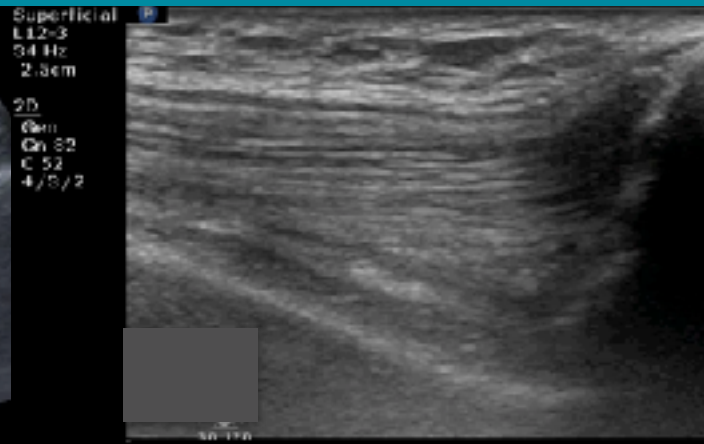


# Lower extremity joints



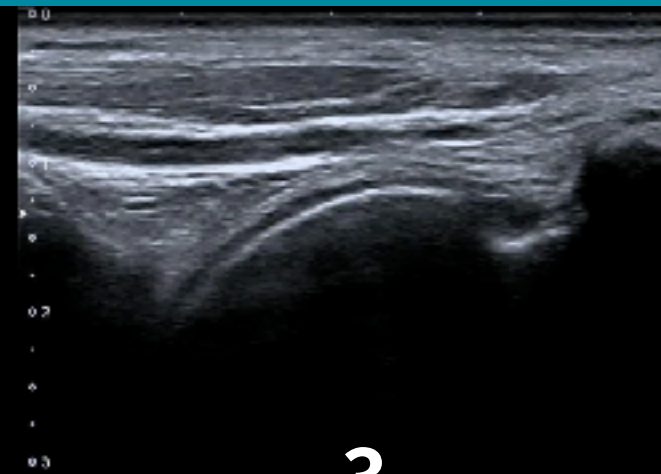1

Hip



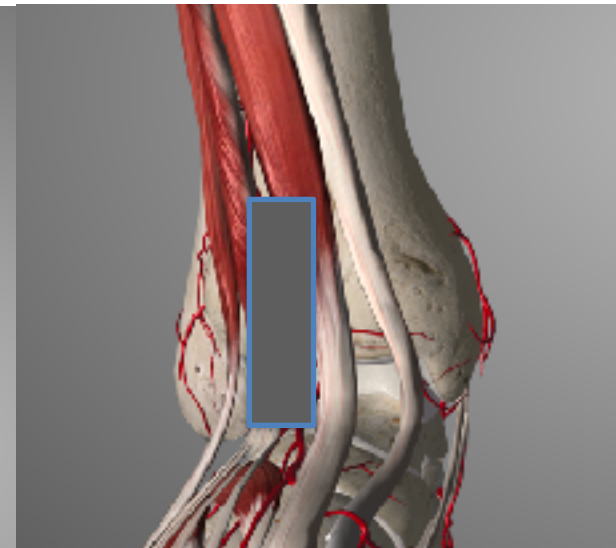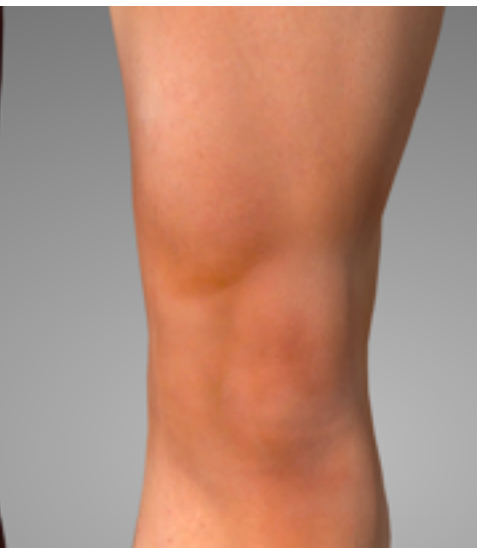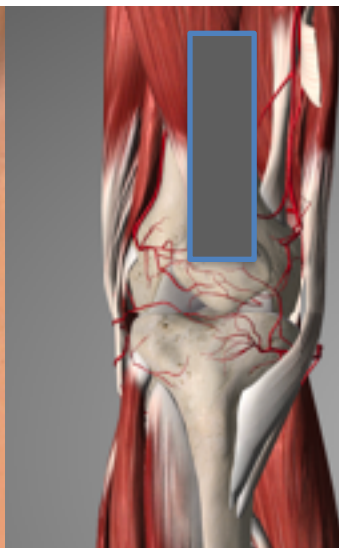
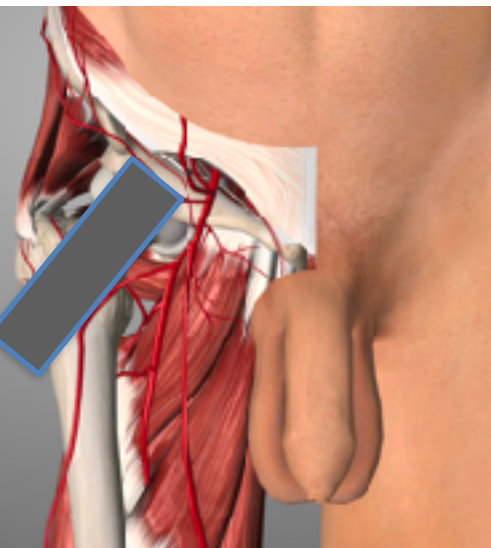
2

Knee



3

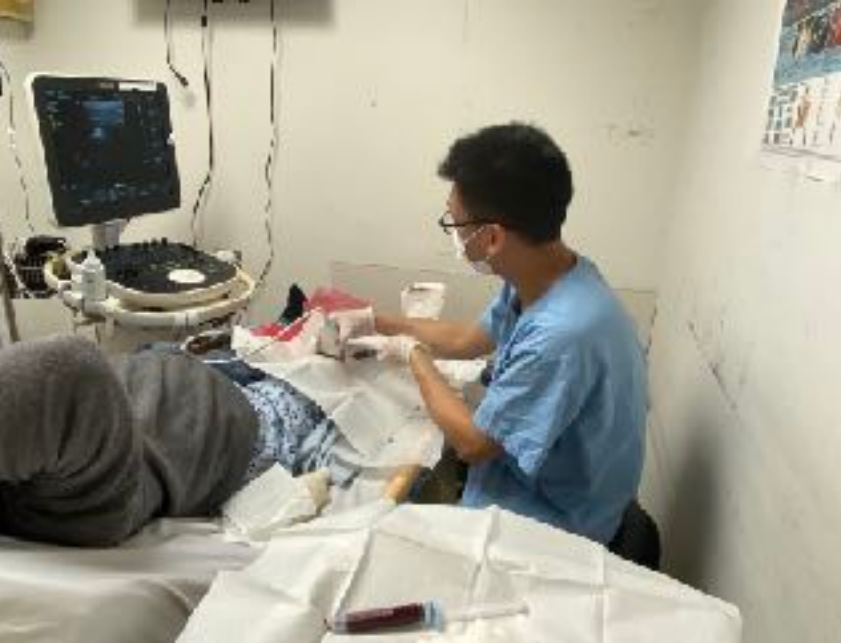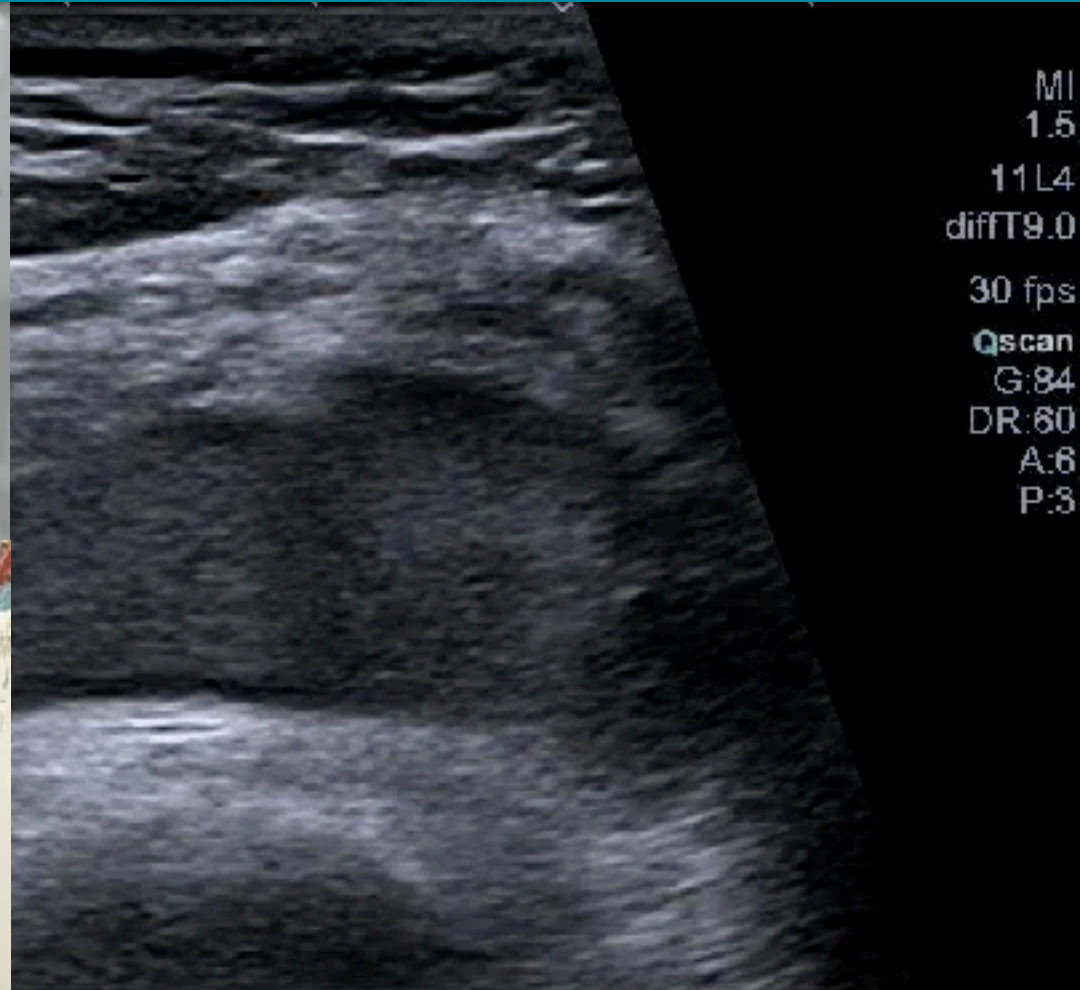
Ankle



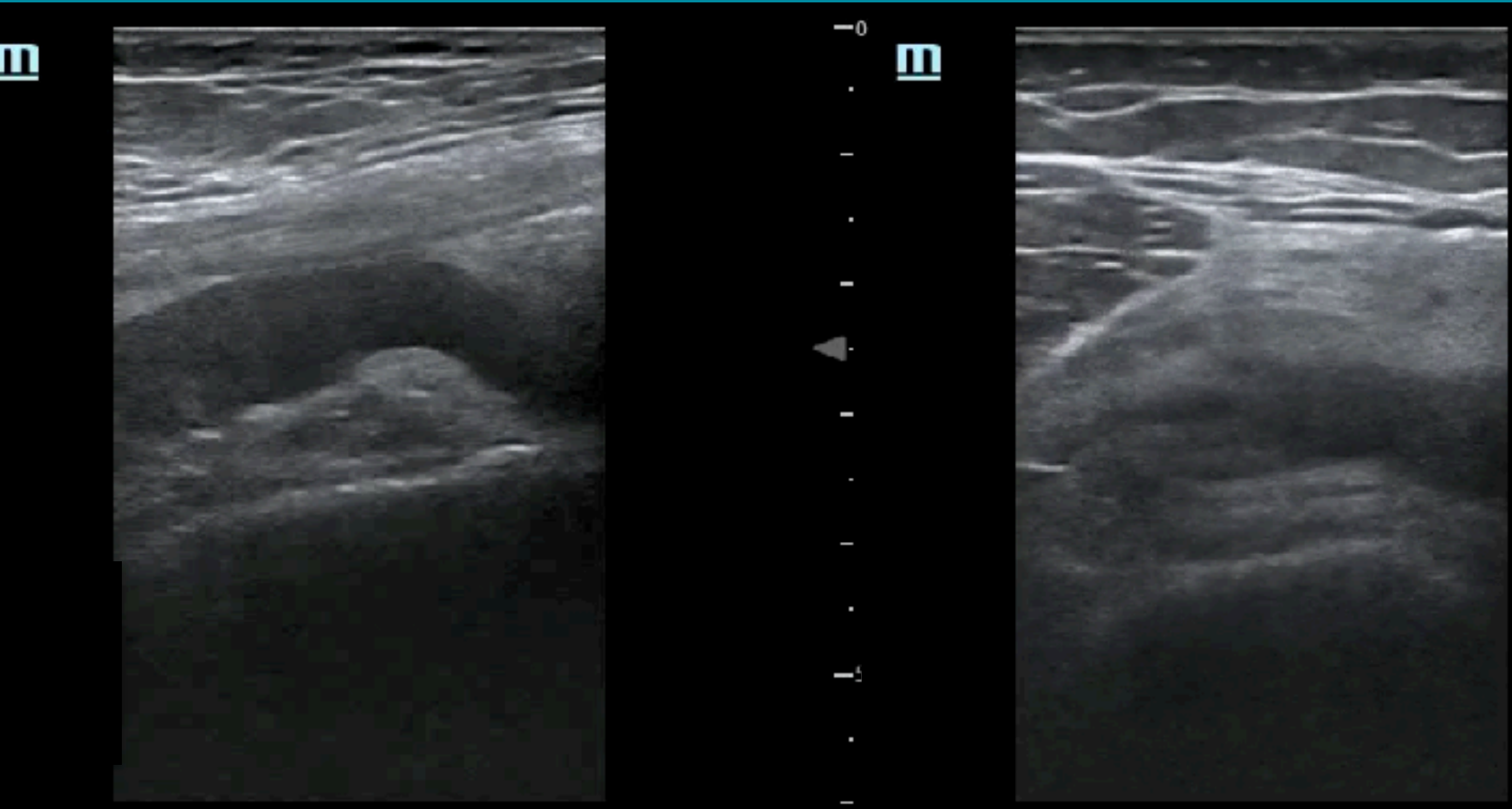




# Needling for hemarthrosis

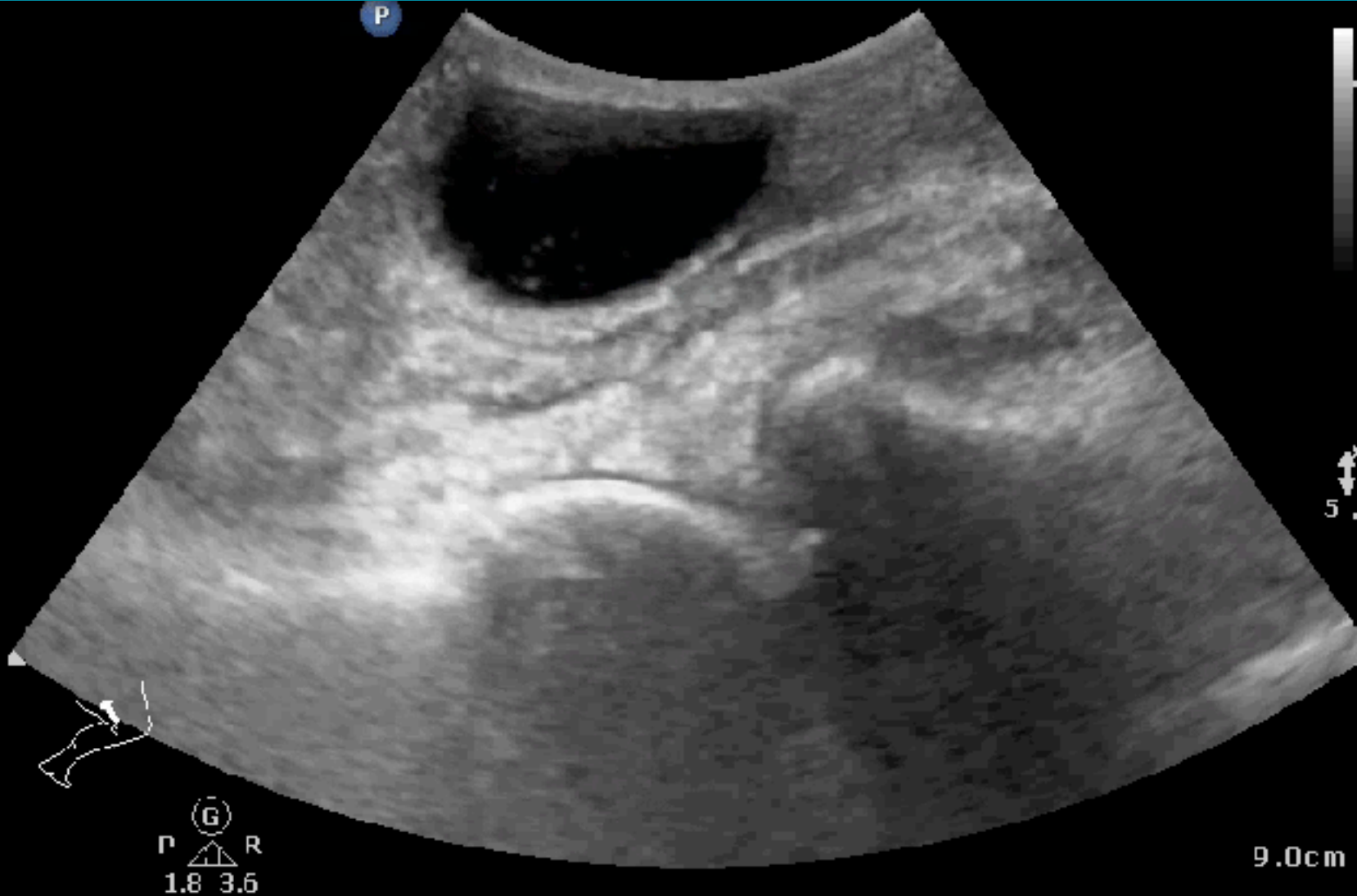

# Lipohemarthrosis



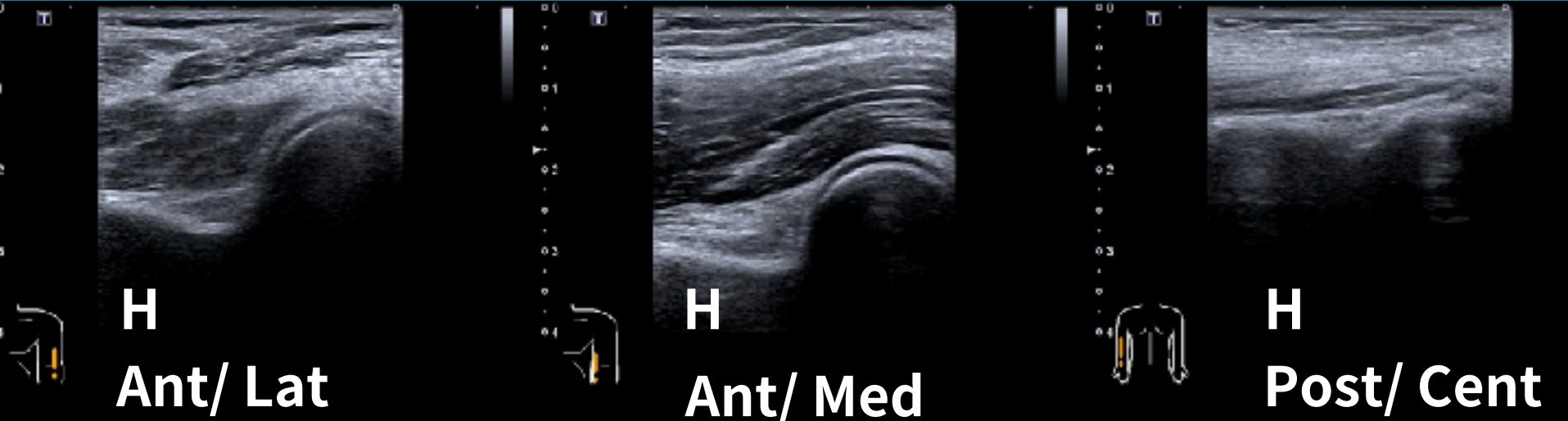
# Baker's cyst

ADU Gen7  
C5-1  
47 Hz  
9.0cm  
2D  
HGen  
Gn 85  
C 56  
3 / 3 / 3



9.0cm

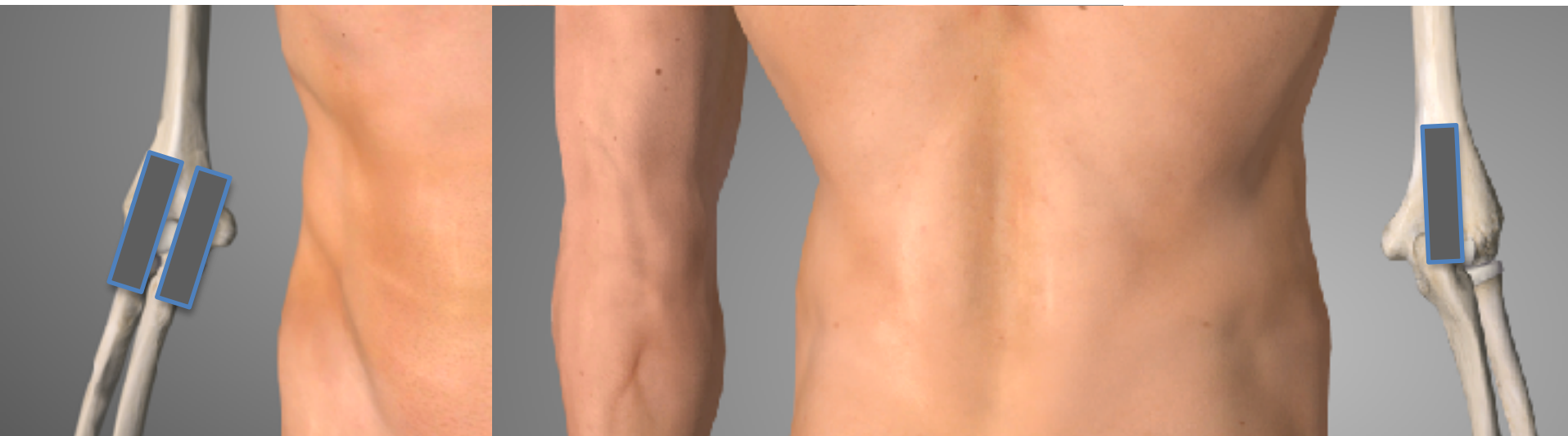# Elbow joint



Radial fossa

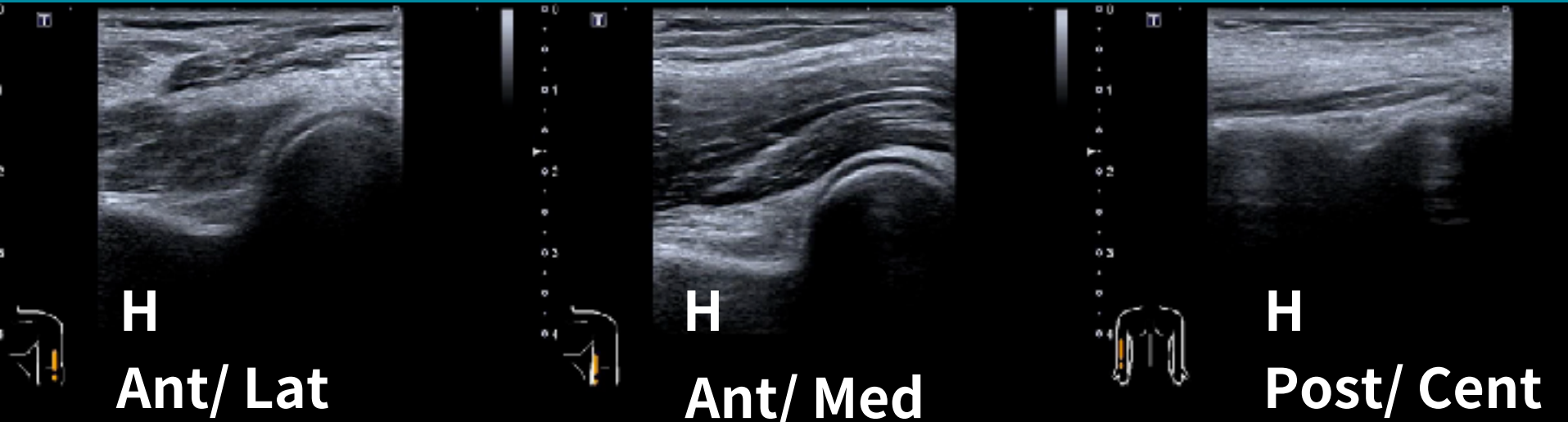
Coronoid fossa

Olecranon fossa





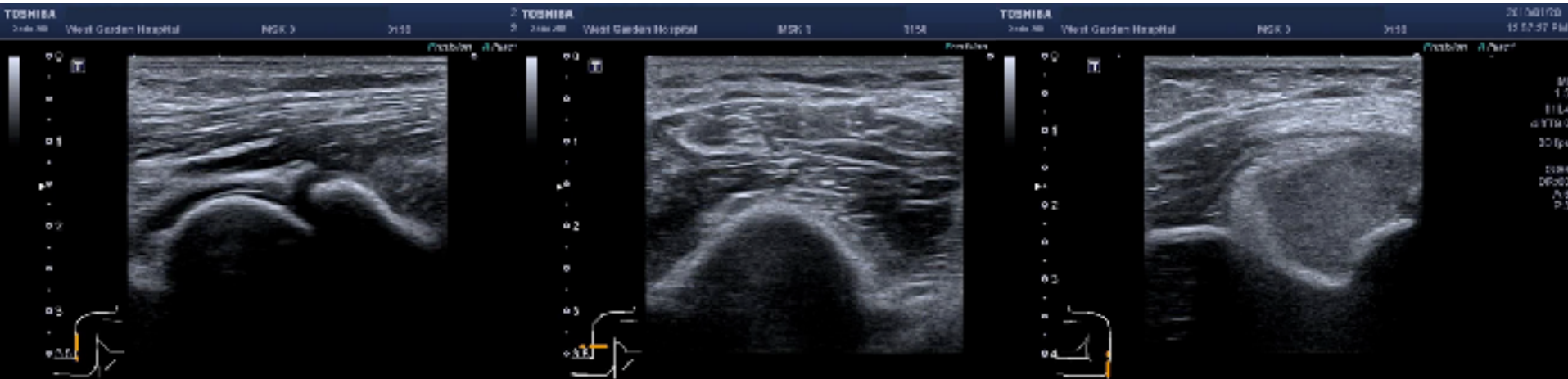
# Elbow effusion



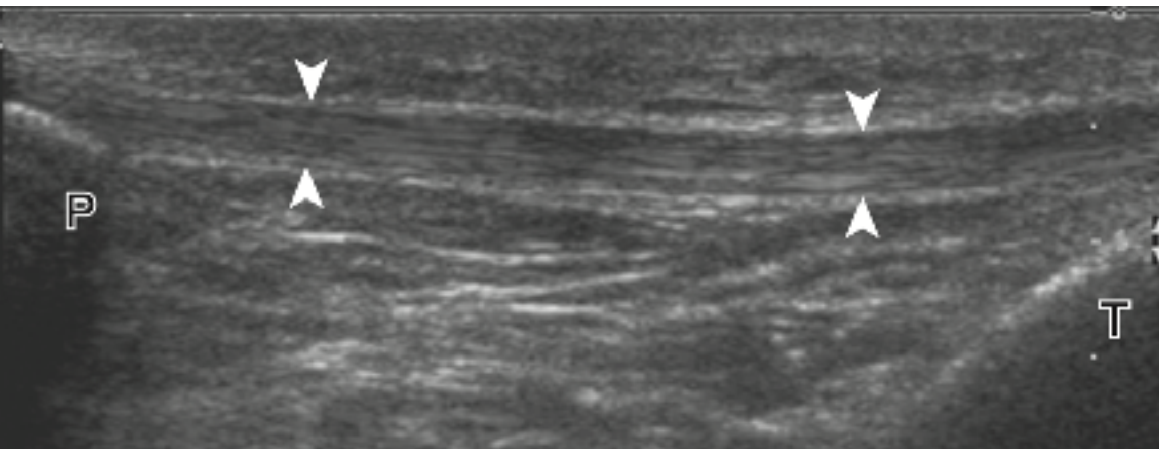
**Radial fossa**

**Coronoid fossa**

**Olecranon fossa**

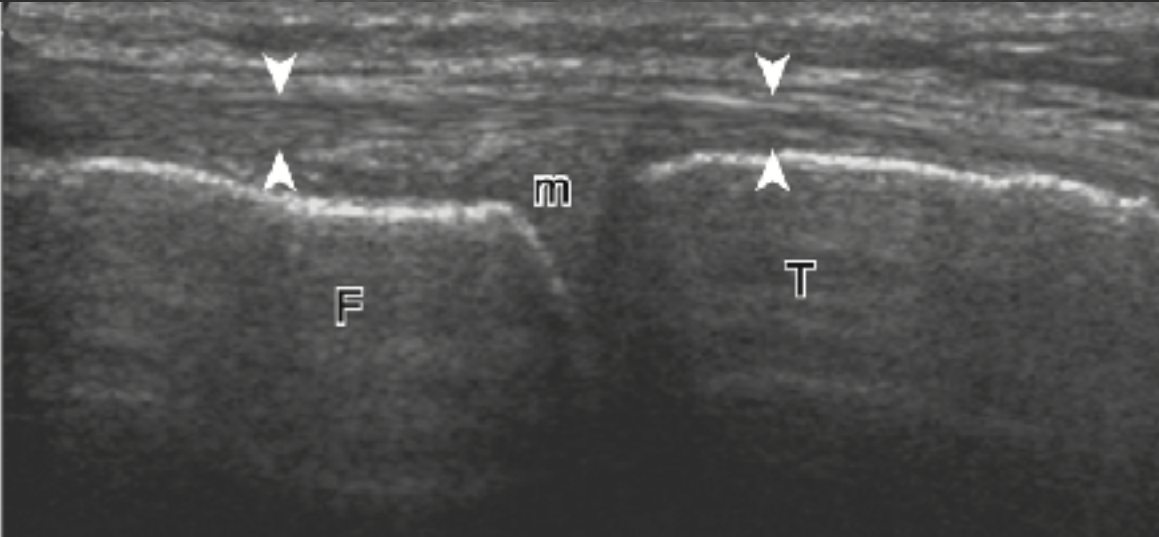


# Tendon 韌帶



高回音

Fibrillar



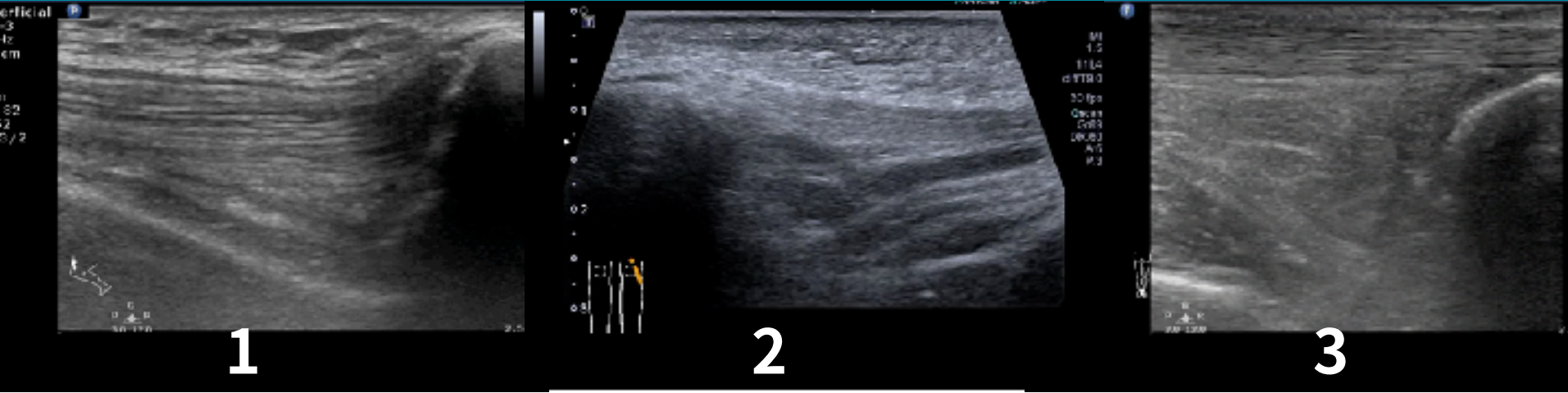
Grade of Injury

I : no fiber disruption

II : partial fiber disruption

III: complete fiber disruption

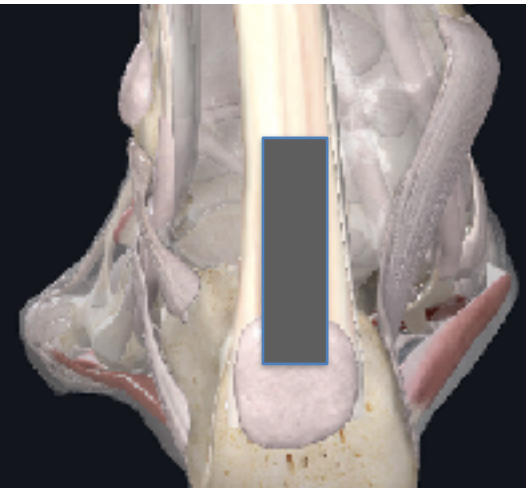
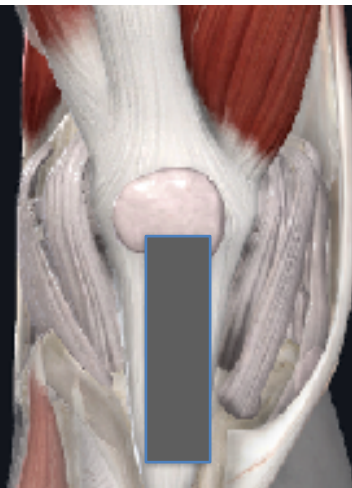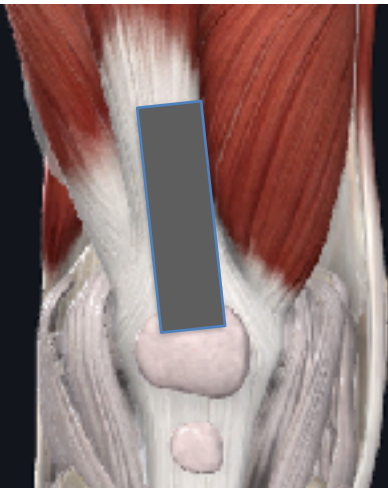# Tendon



**Quadriceps  
Tendon**

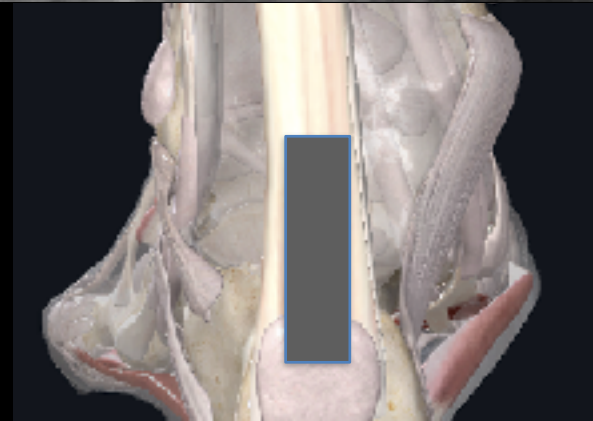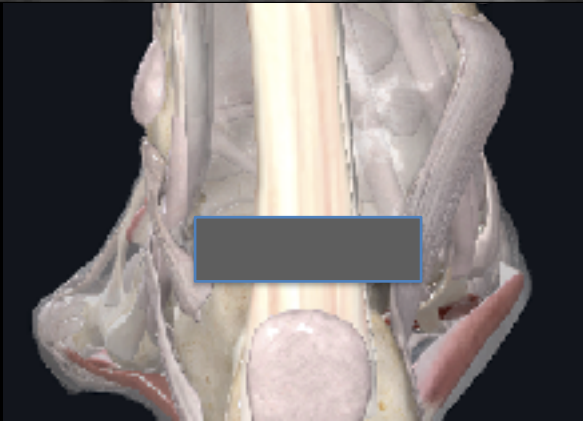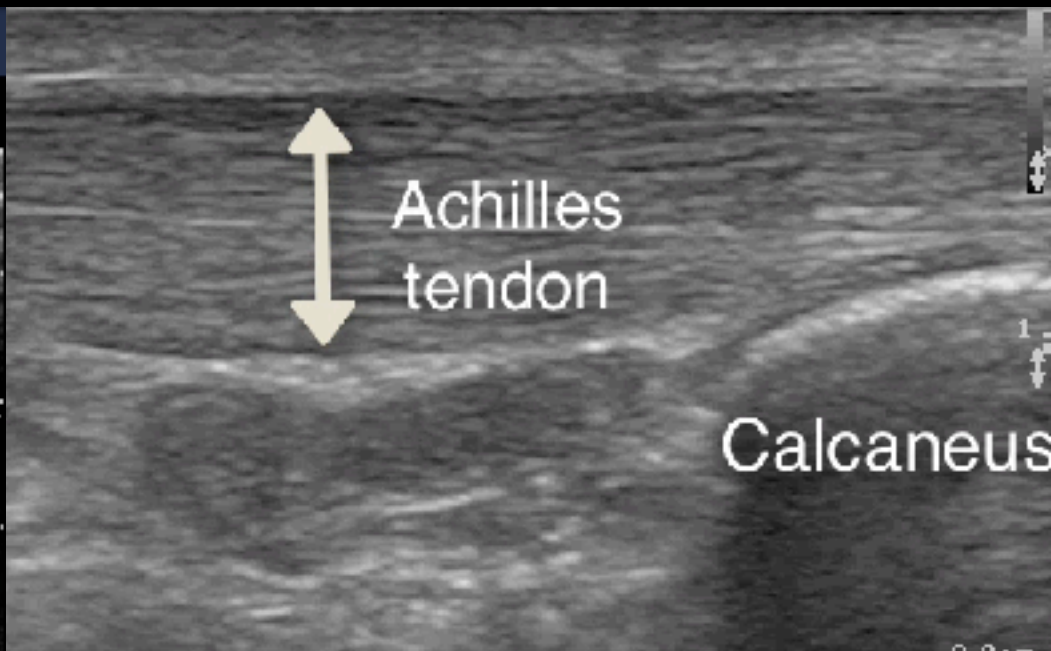
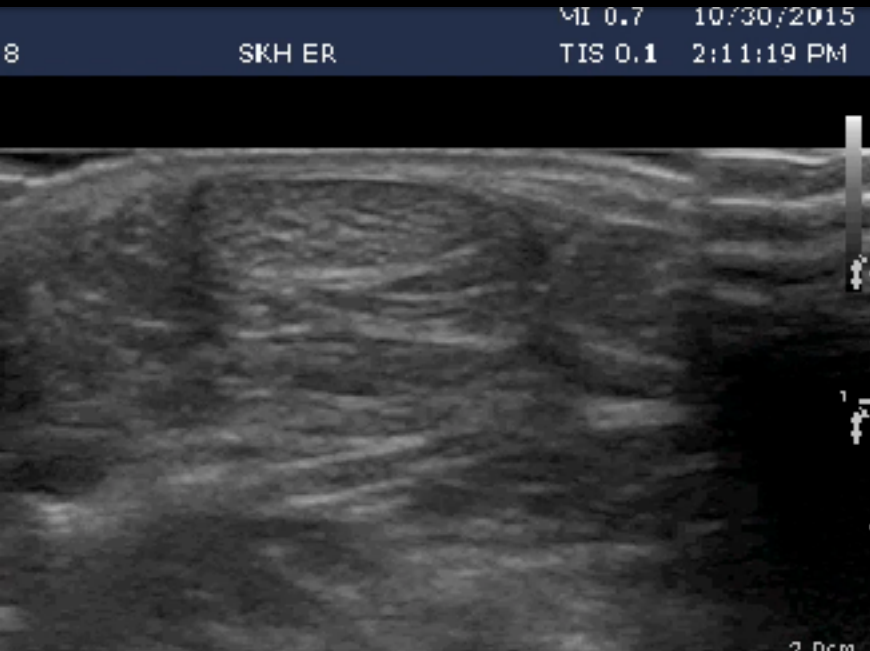
**Patellar  
Tendon**

**Achilles  
Tendon**



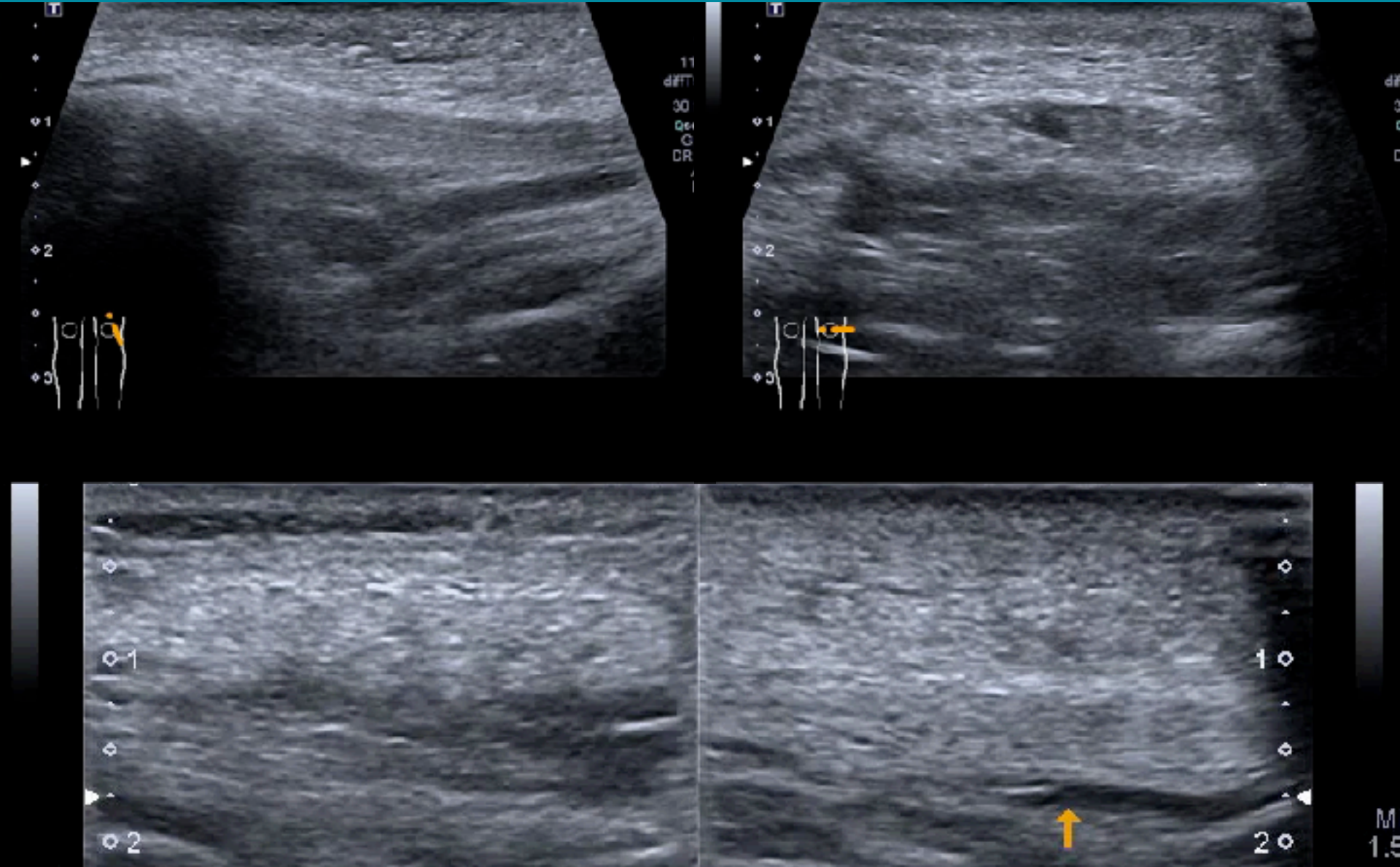


# Achilles tendon rupture





# Patellar tendon injury



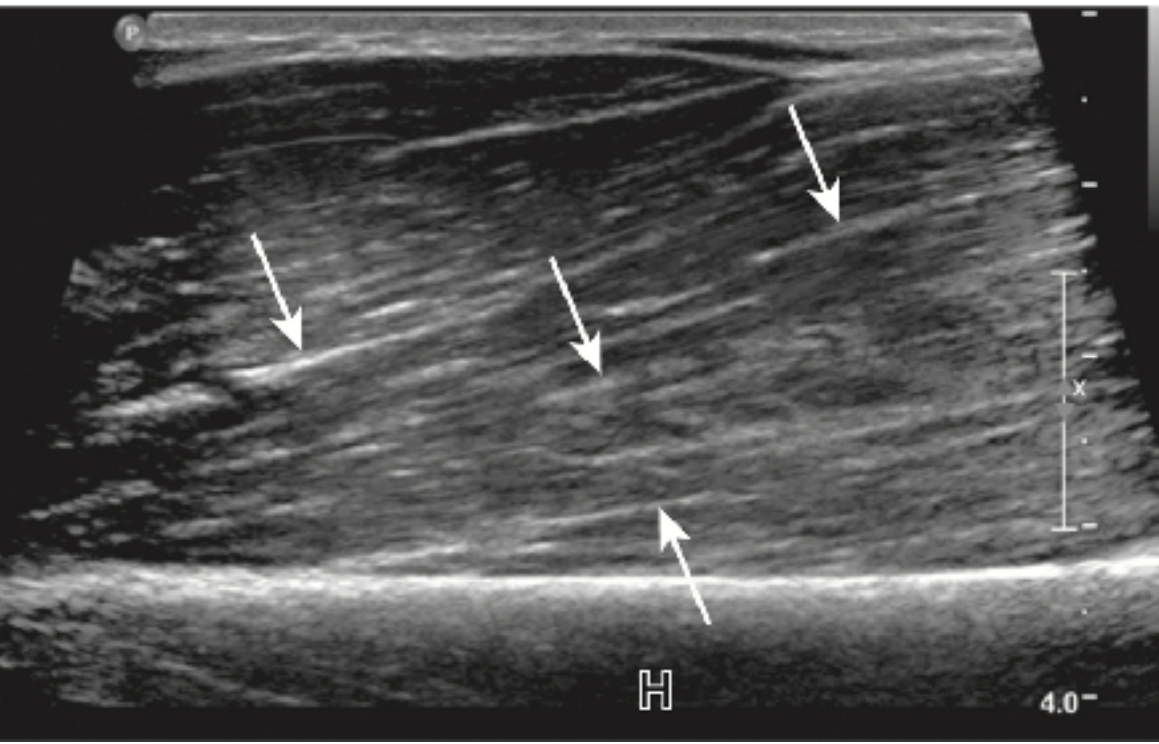
# Muscle 肌肉

## Grade of Injury

I : no fiber disruption

II : partial fiber disruption

III: complete fiber disruption

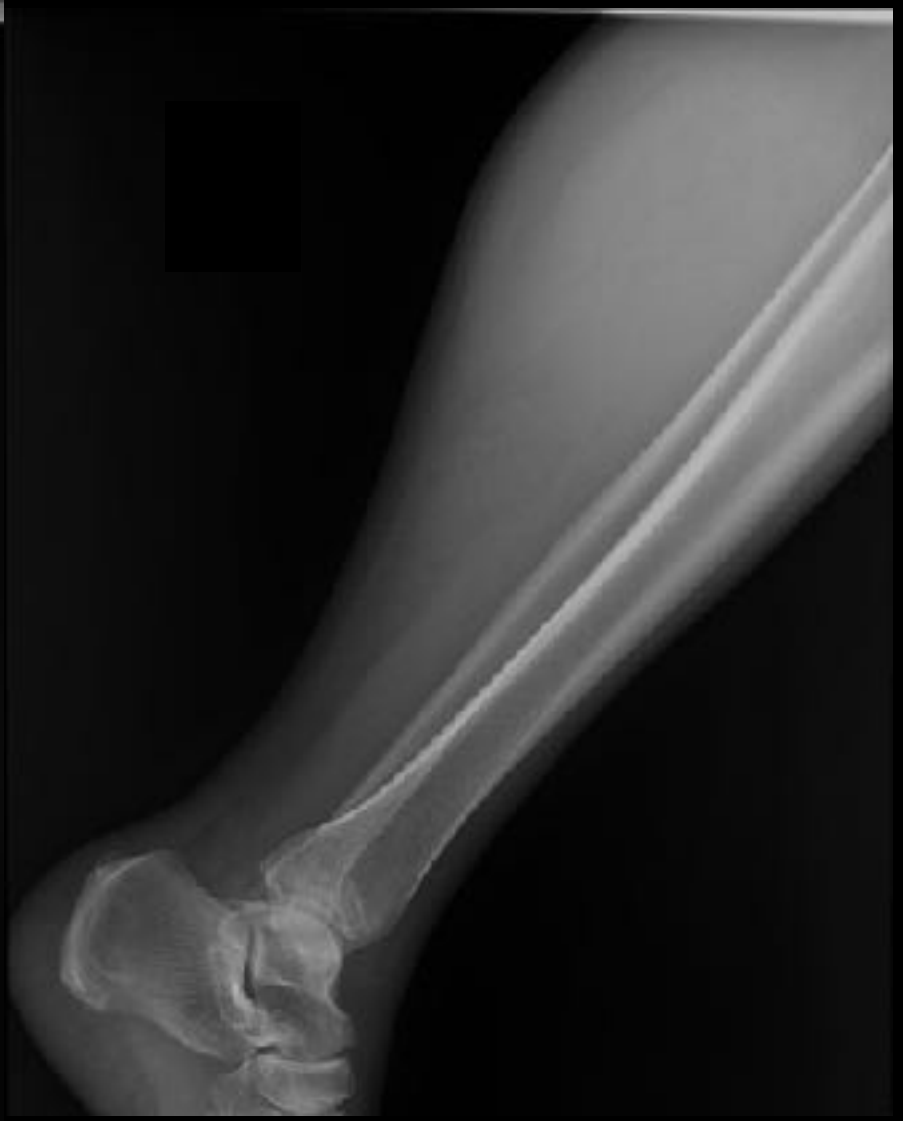
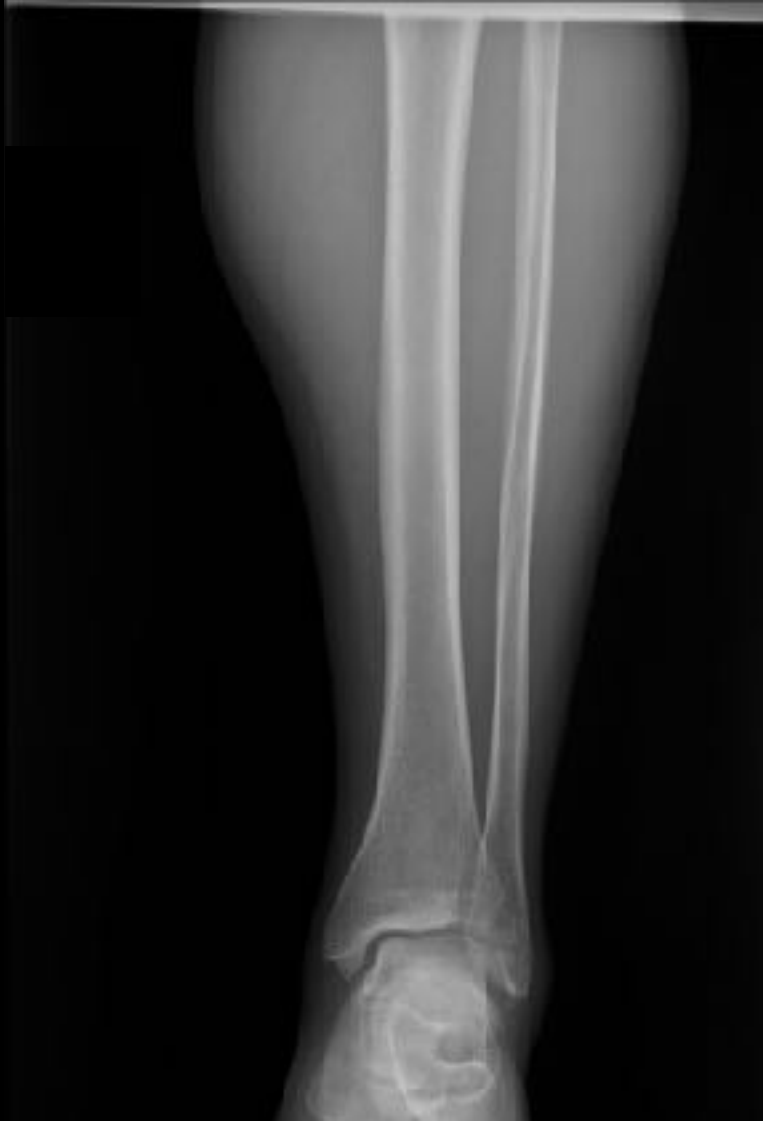
**Bristal brush**

**Hypoechoic  
mucle**

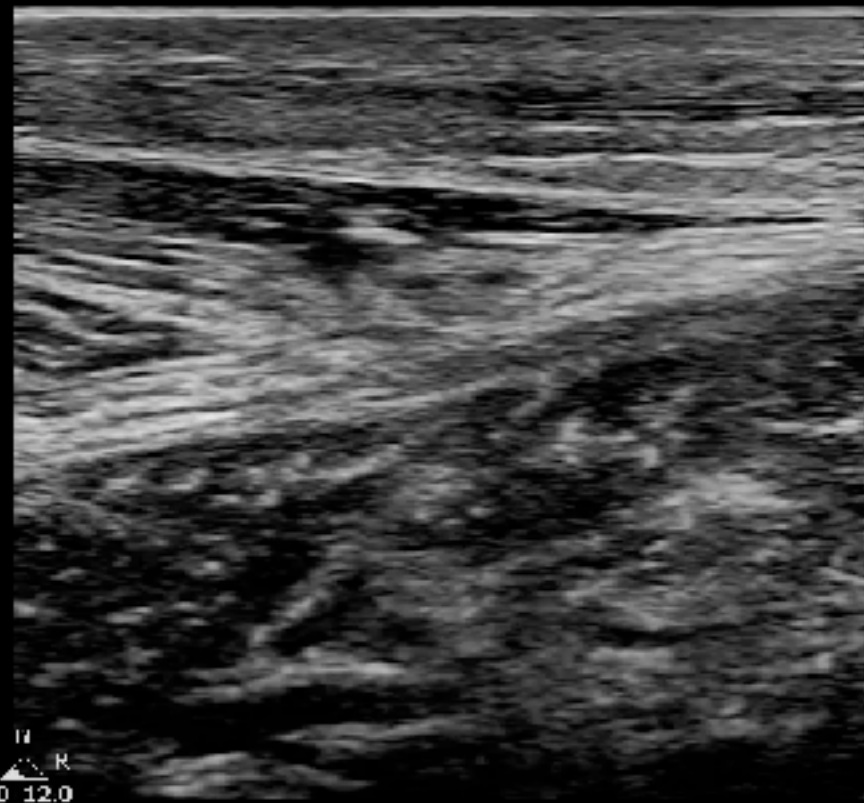**Hyperechoic  
fibroadipose tissue**

# 58M, right leg pain while running

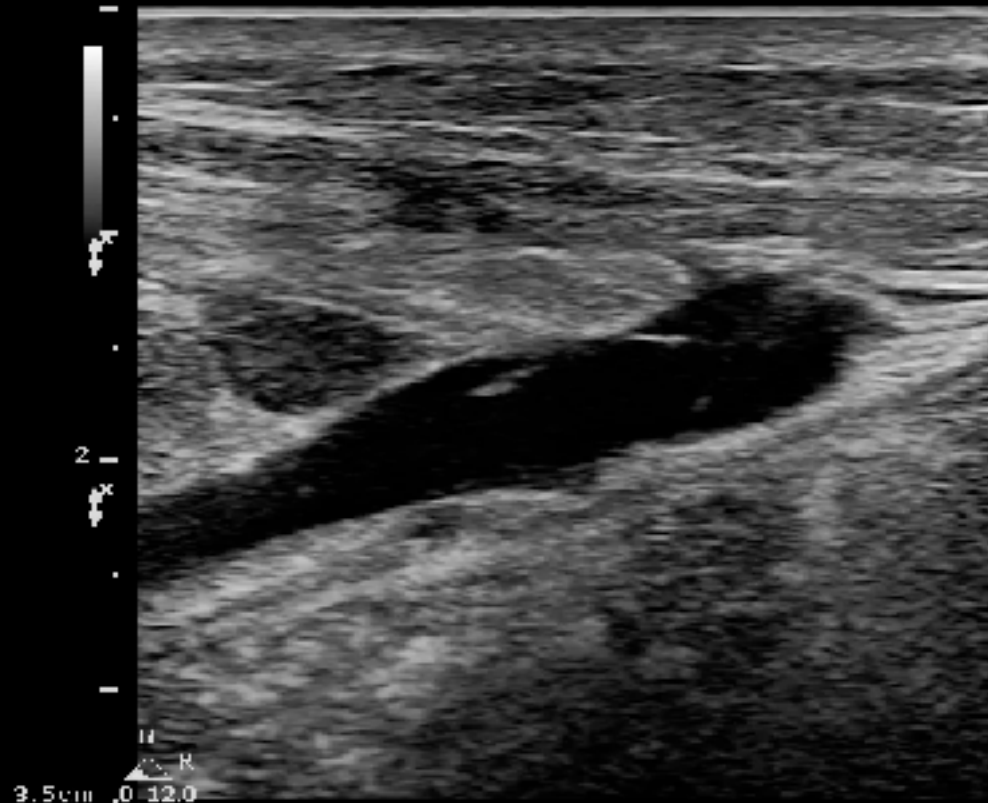


# Calf muscle tear

## Left calf

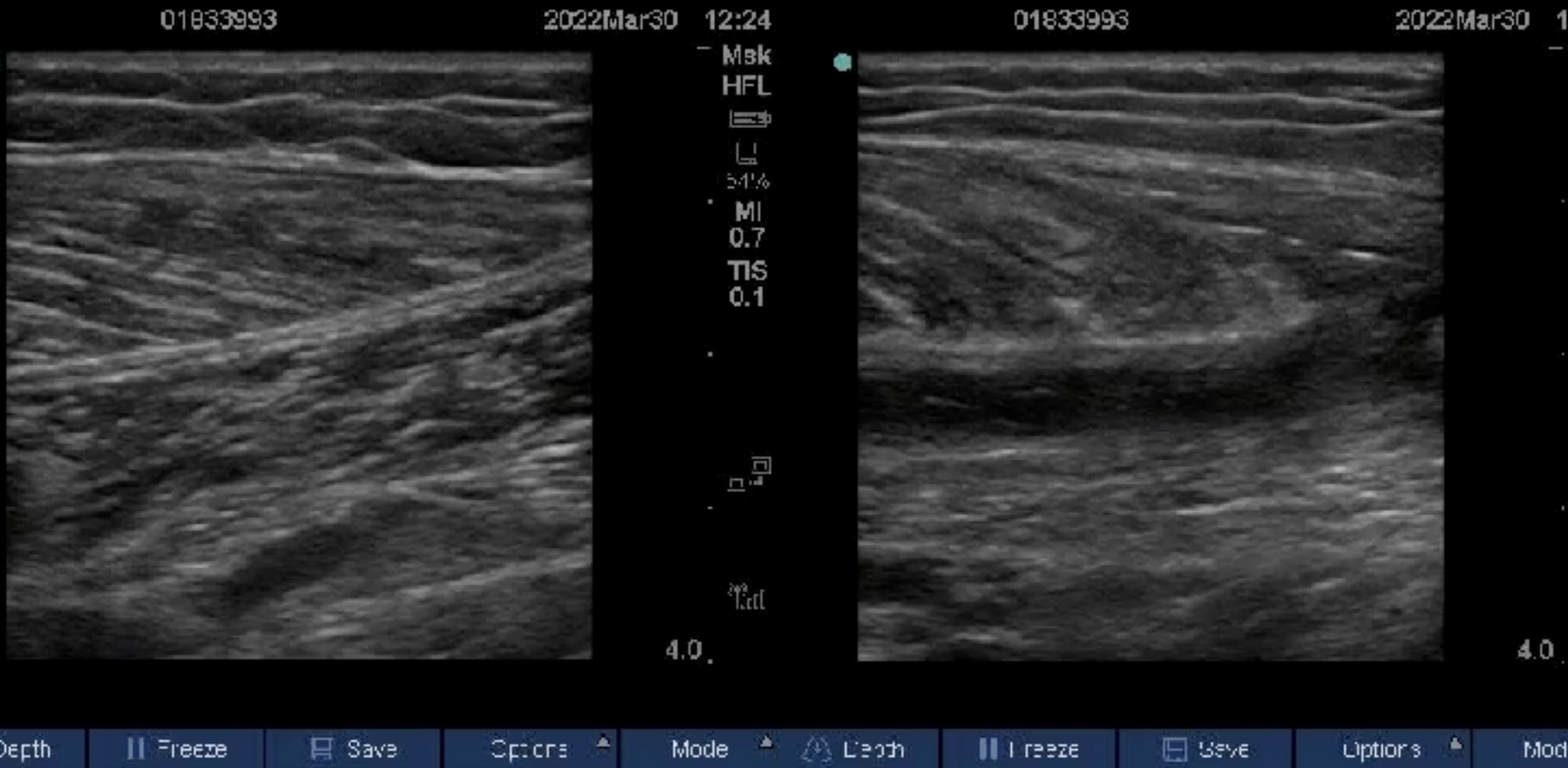


## Right calf

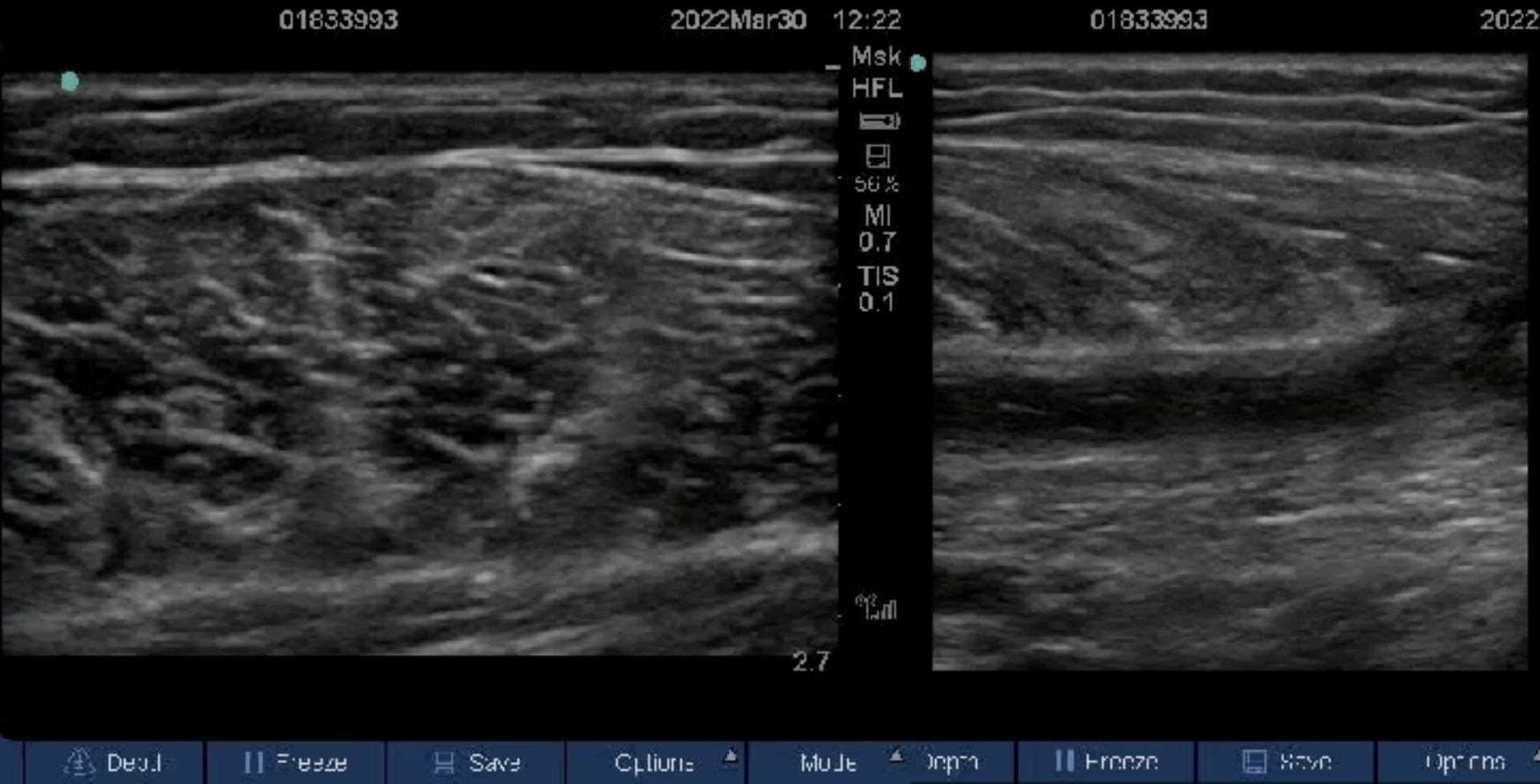




# Calf muscle tear



# Calf muscle tear





226 游: 3.8Km - 騎180Km - 跑42km

秀姑巒溪

新白陽

武嶺

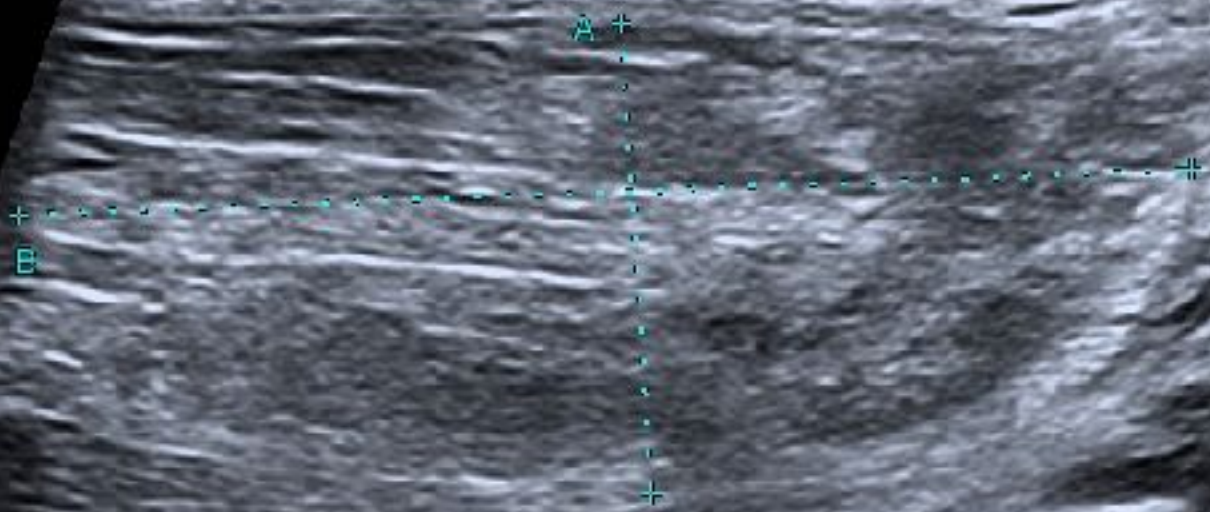
4天前  
左腳不小心  
撞到石頭。  
致血腫疼痛





T

0  
1  
2



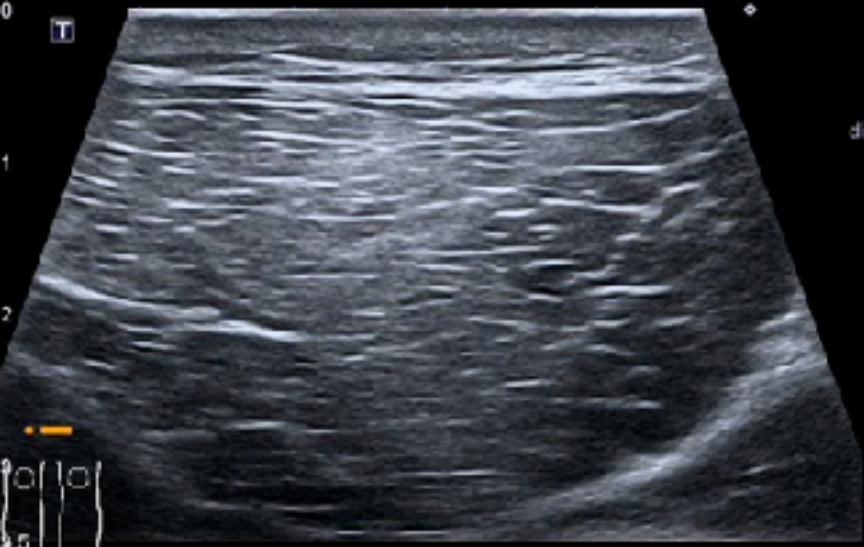
diffT  
30  
Q  
C  
D

2021/12/01 OSHIBA 2021/12/01  
 West Garden Hospital MSK 3 3155 11:20:25 AM 1100.738 West Garden Hospital MSK 3 3155 11:21:37 AM

Precision A Pure+

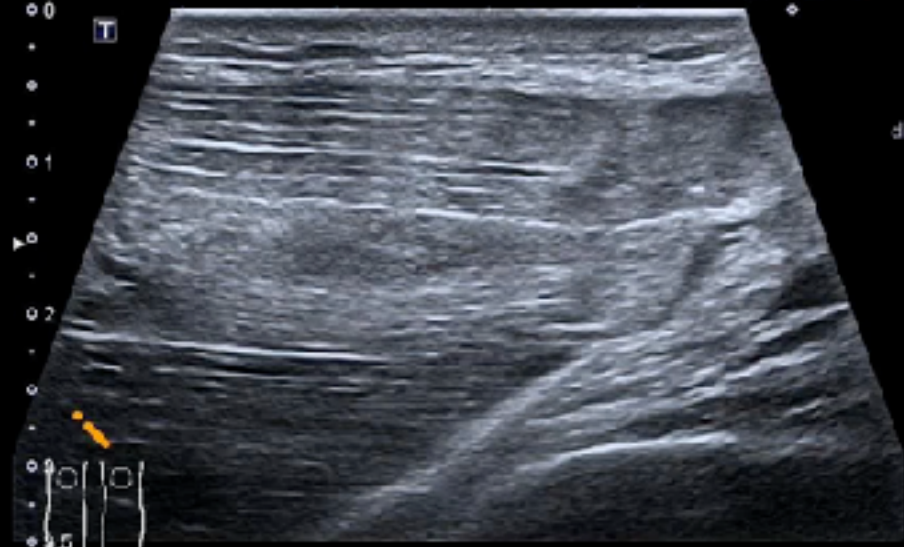
Precision A Pure+

T



M  
1.2  
18L7  
diffT14.0  
30 fps  
scan  
G 80  
DR 80  
A 6  
P 3

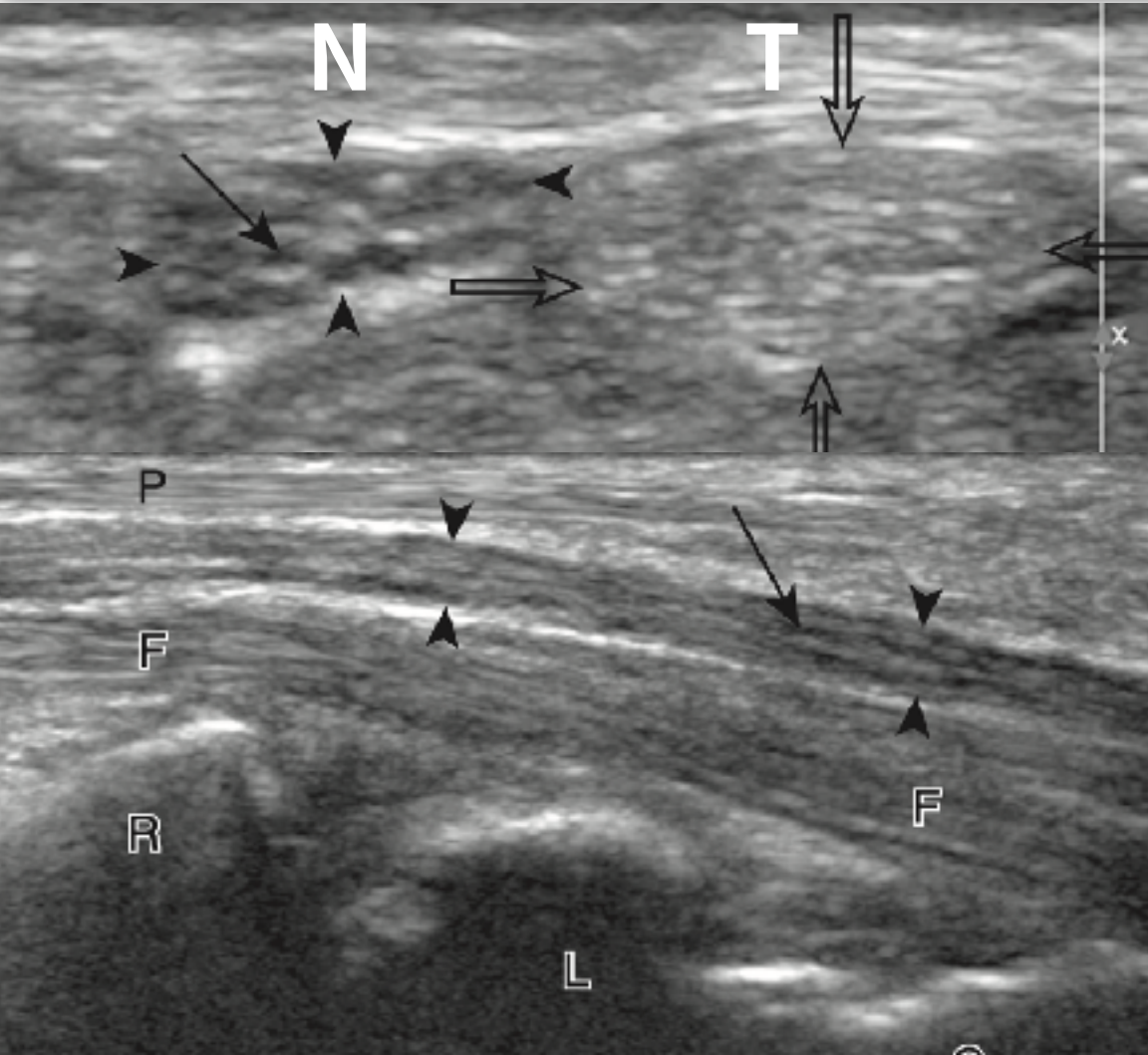
T



18  
diffT14  
30  
scan  
G 80  
DR 80  
A 6  
P 3



# Nerve



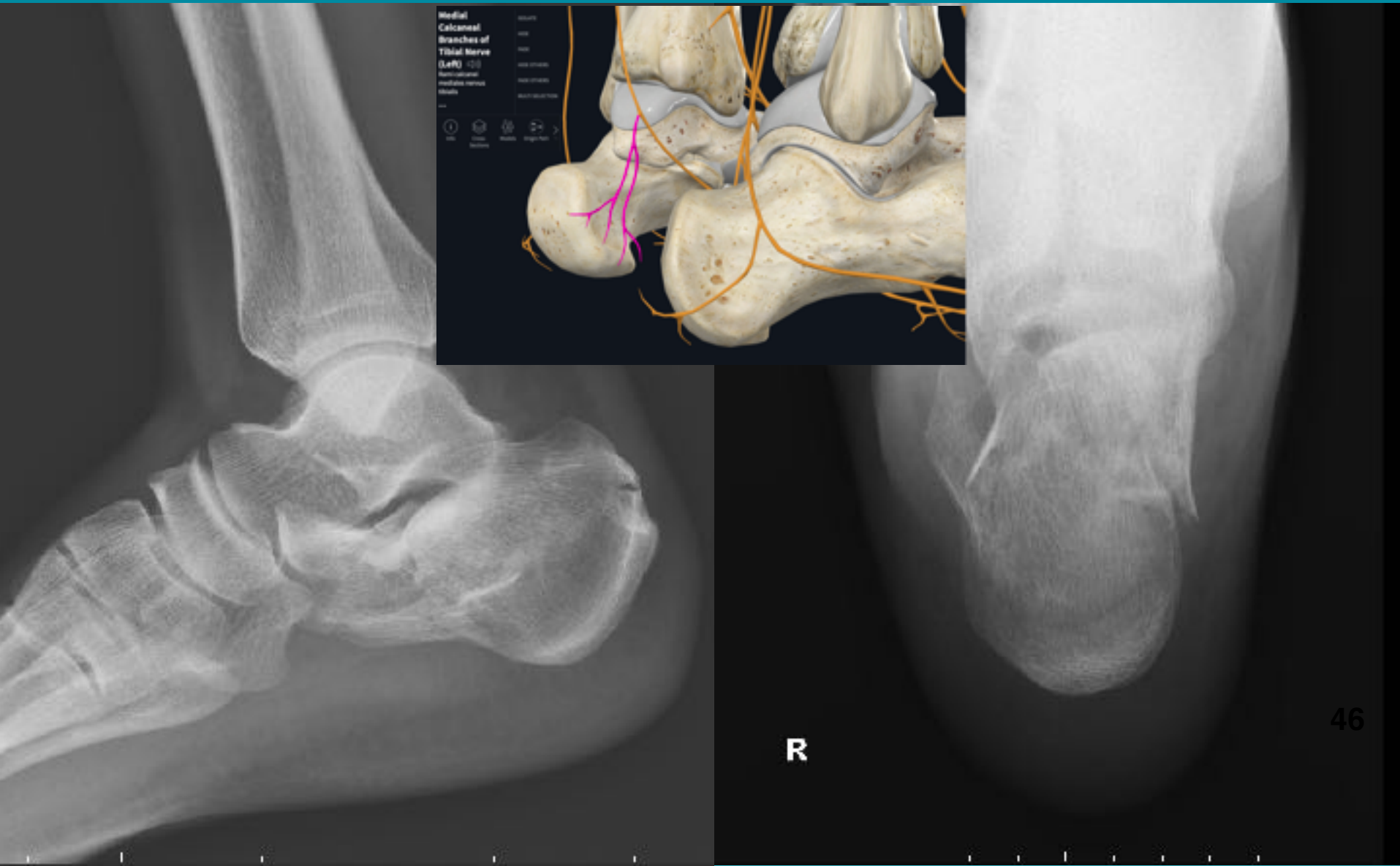
**Hypoechoic**

**Hyperechoic**

**Honeycomb**

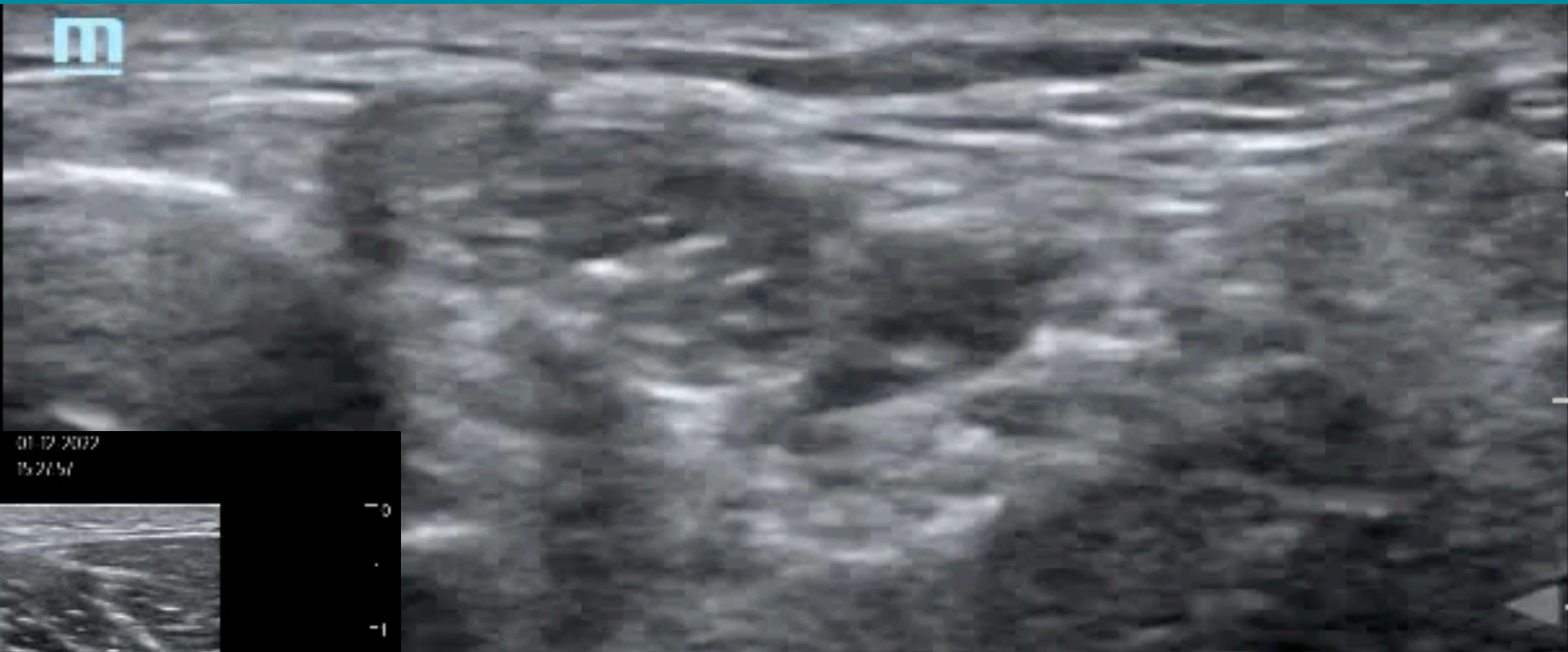
**Fibrillar**

# 34M，貨車車斗跌下，足踝腫痛

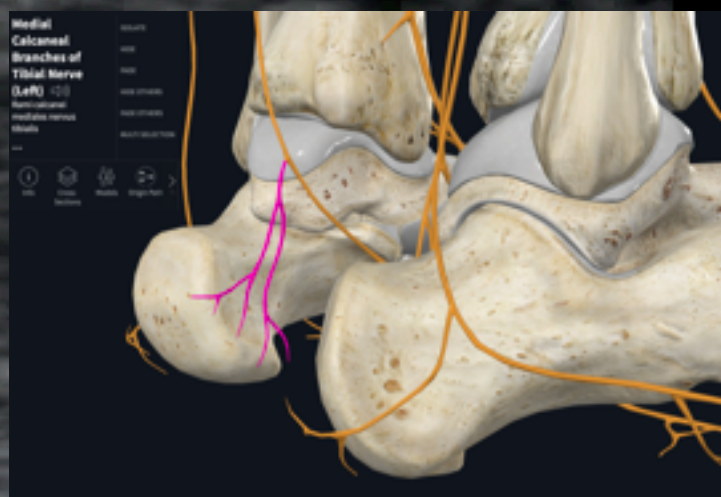
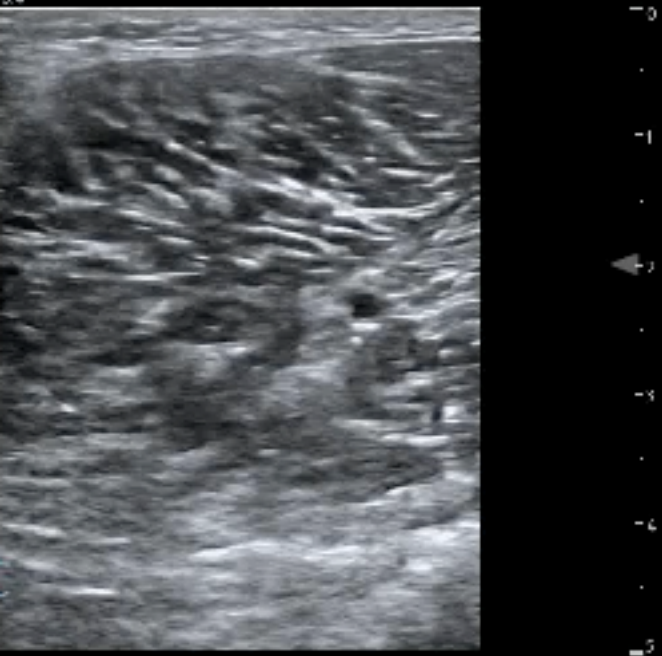


# Tibial nerve block

B  
F5.4~11.5  
DR 105  
FR 41  
D 3.0  
G 50



66H 24Years 01.12.2022  
0.4 Nerve 15.21.57

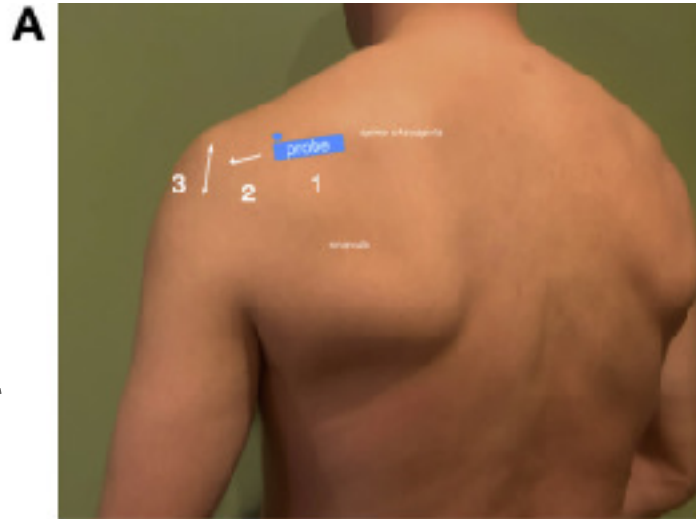




# Musculoskeletal Ultrasonography to Diagnose Dislocated Shoulders: A Prospective Cohort

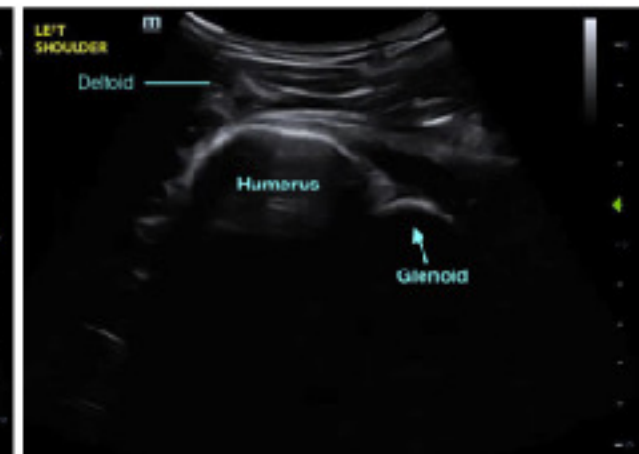
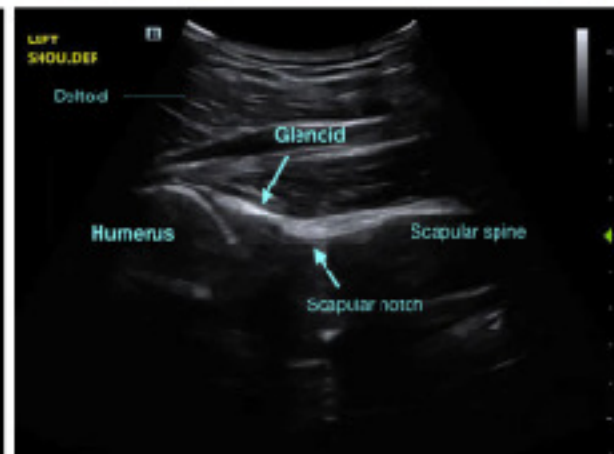
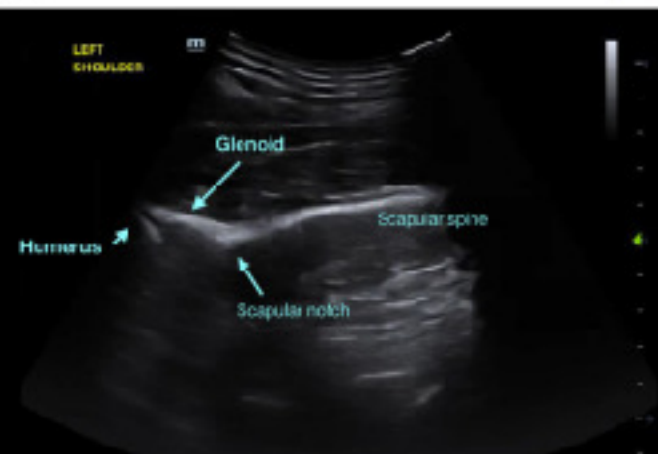Michael A. Secko, MD, RDMS\*; Lindsay Reardon, MD; Michael Gottlieb, MD; Eric J. Morley, MD; Mathew R. Lohse, MD; Henry C. Thode, Jr, PhD; Adam J. Singer, MD

Multicenter  
Prospective  
Observational

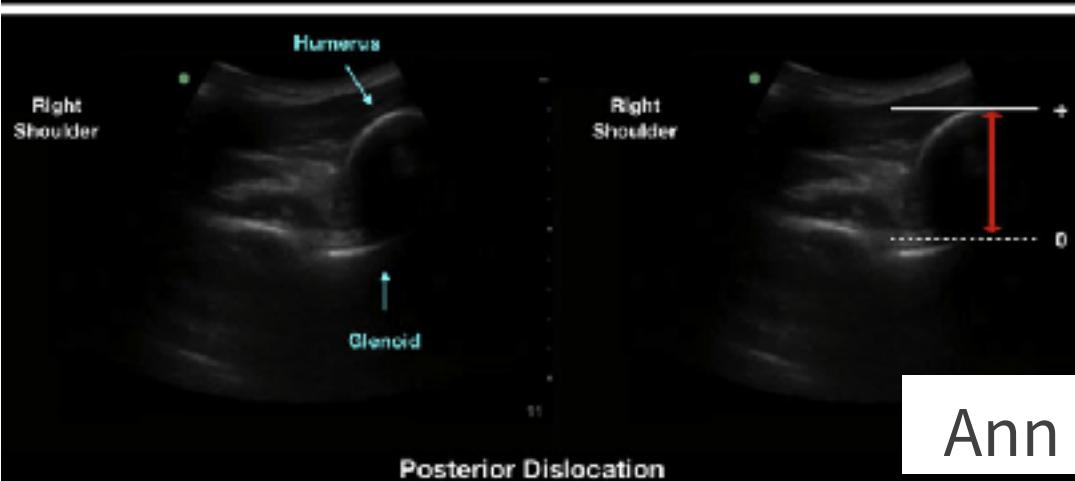
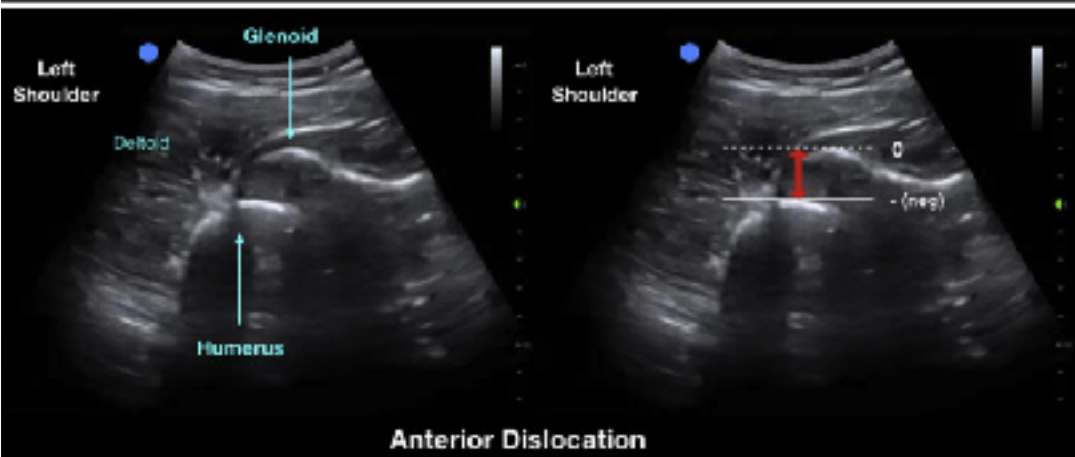
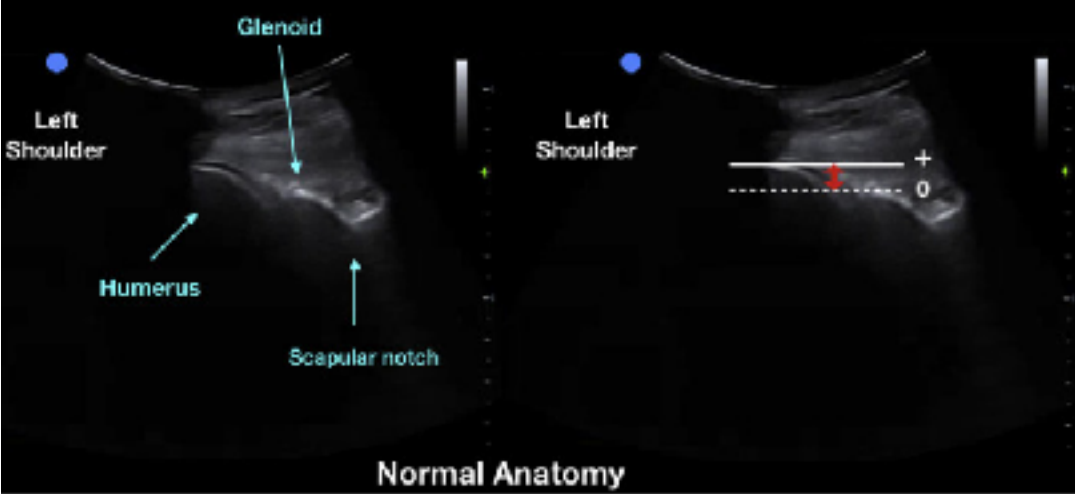


65 patients

**B**







Sensitivity 100%  
 Specificity 100%

Sens (Fx) 92%  
 Spes (Fx) 100%

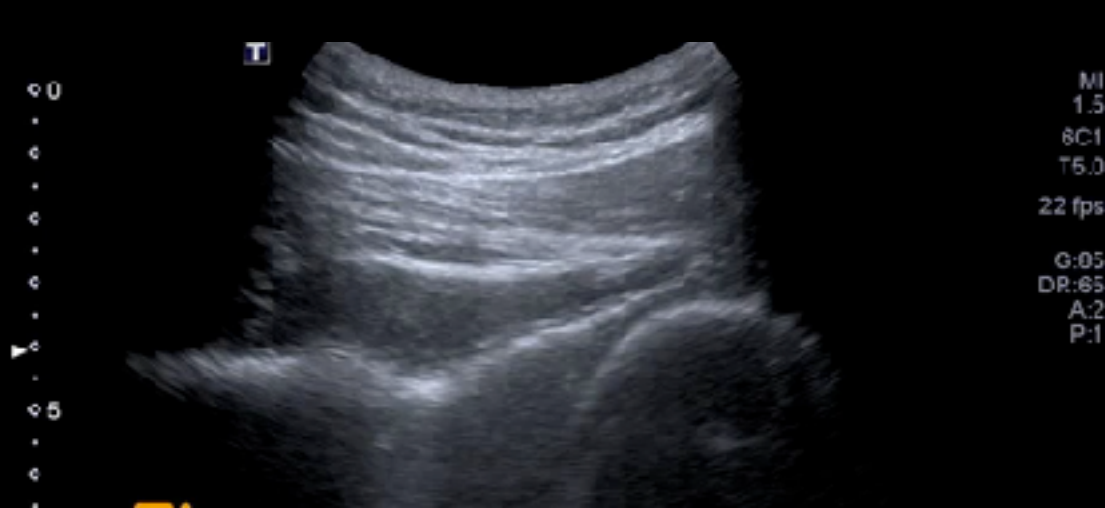
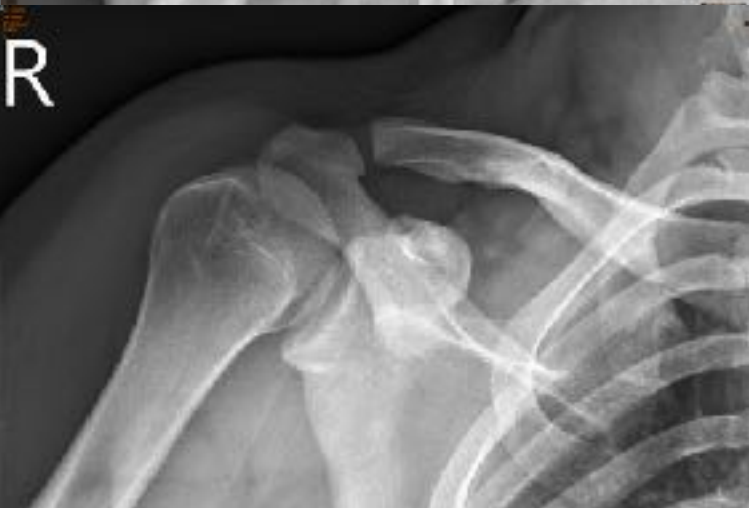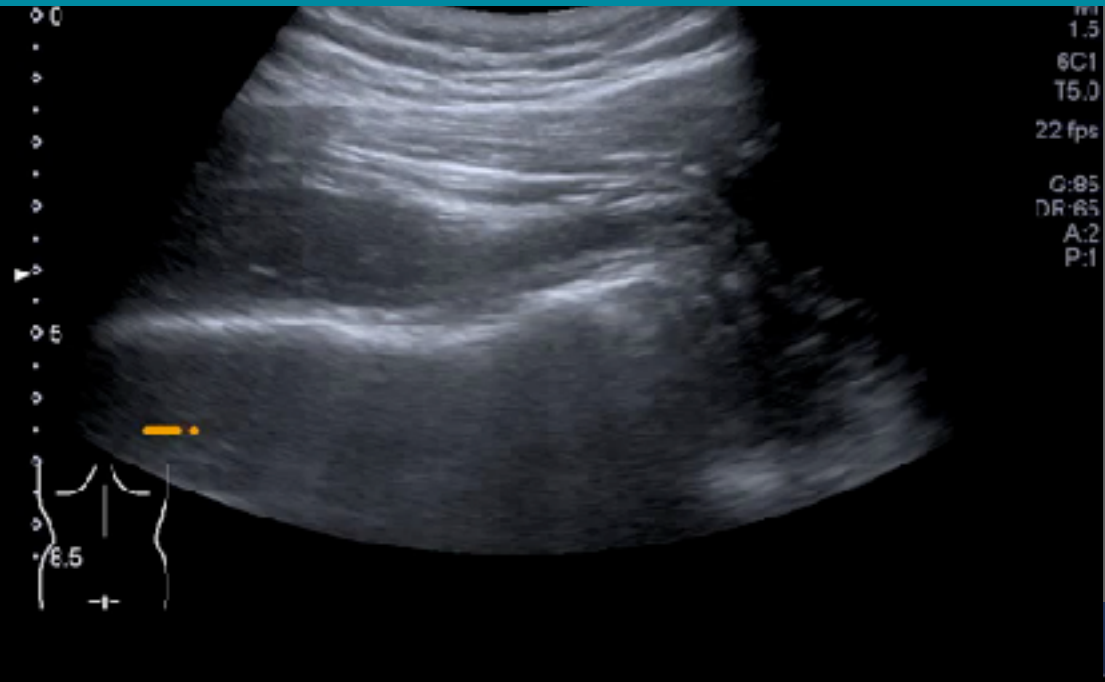
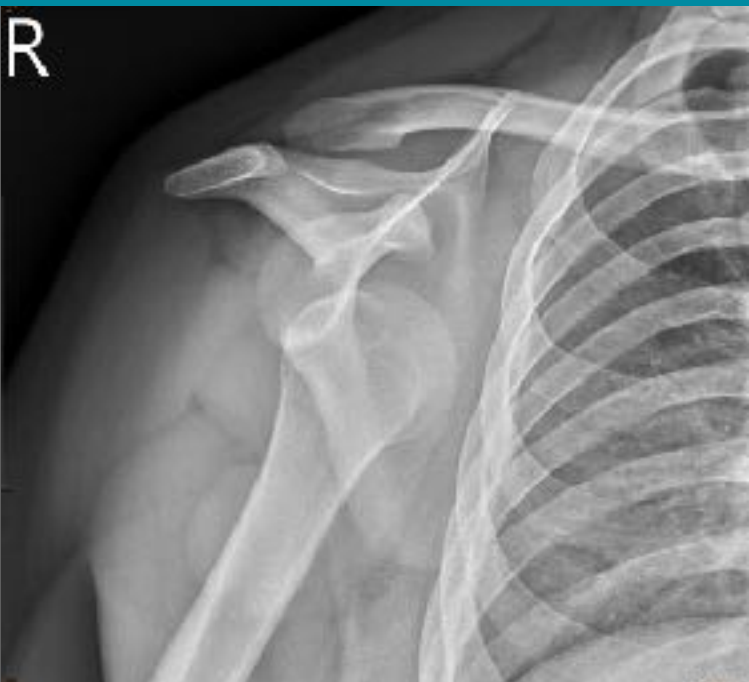Median 19s

GH(d-A) -1.83cm

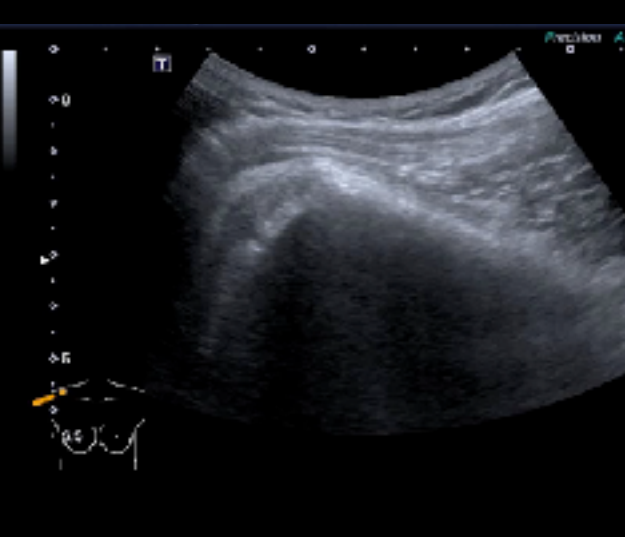
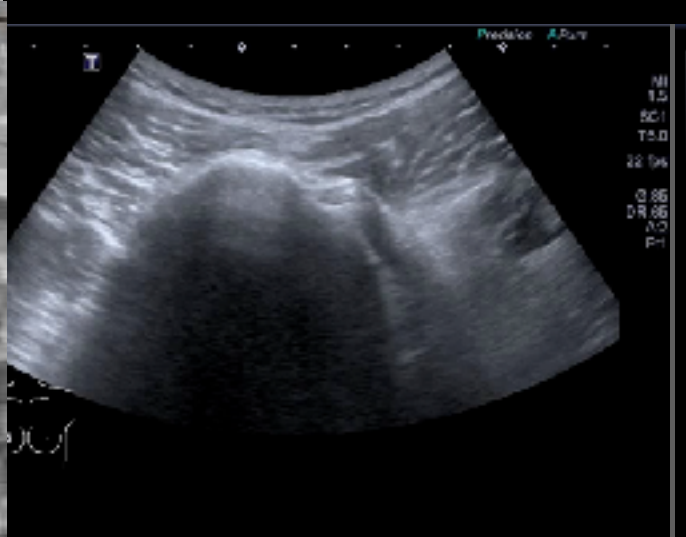
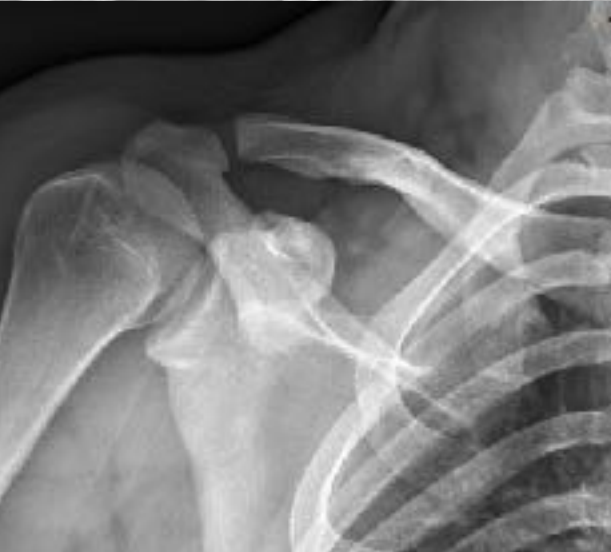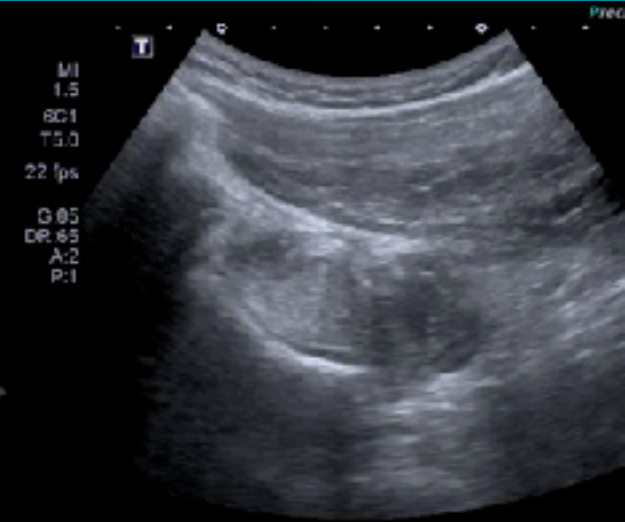
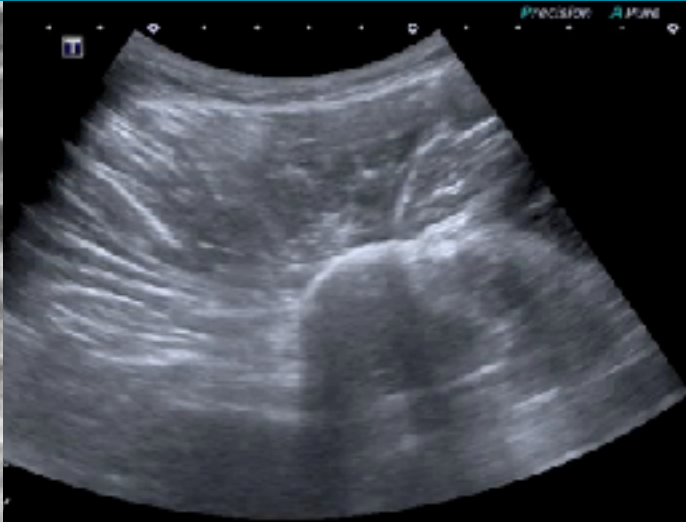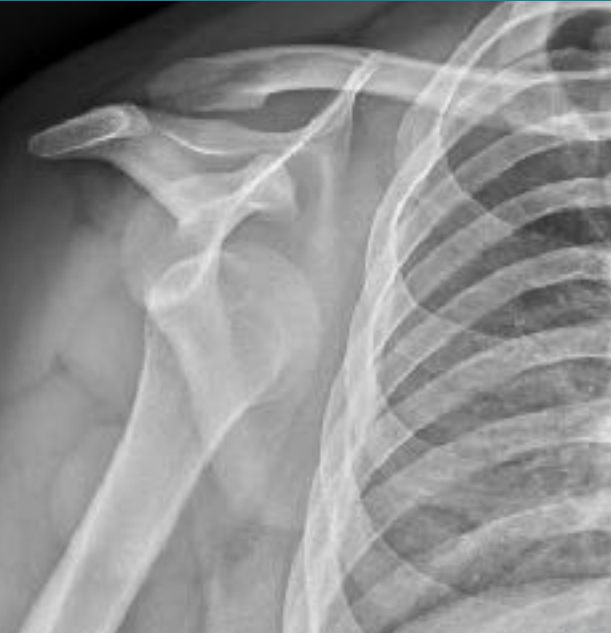GH(d-N) 0.22cm

GH(d-P) 3.3cm

# M/20, 工作時從階梯滑下用手去抓致右肩脫位

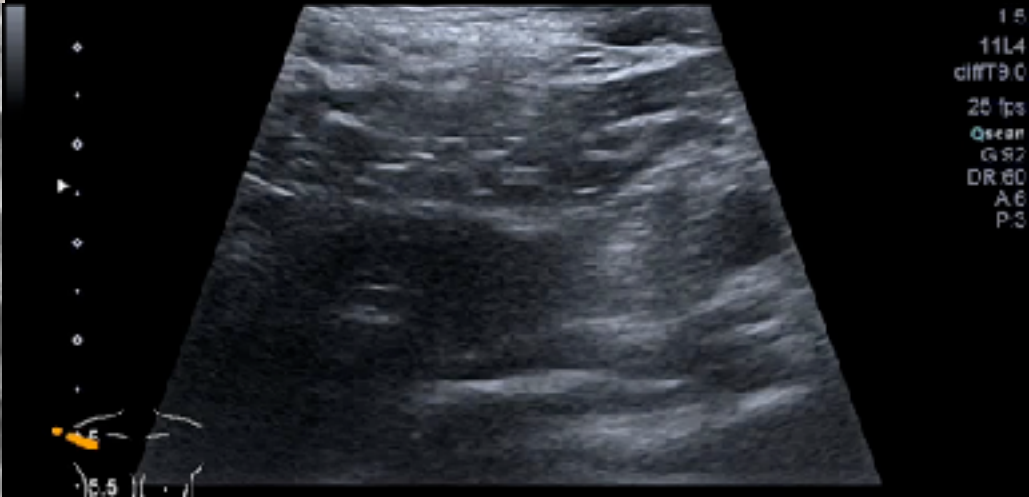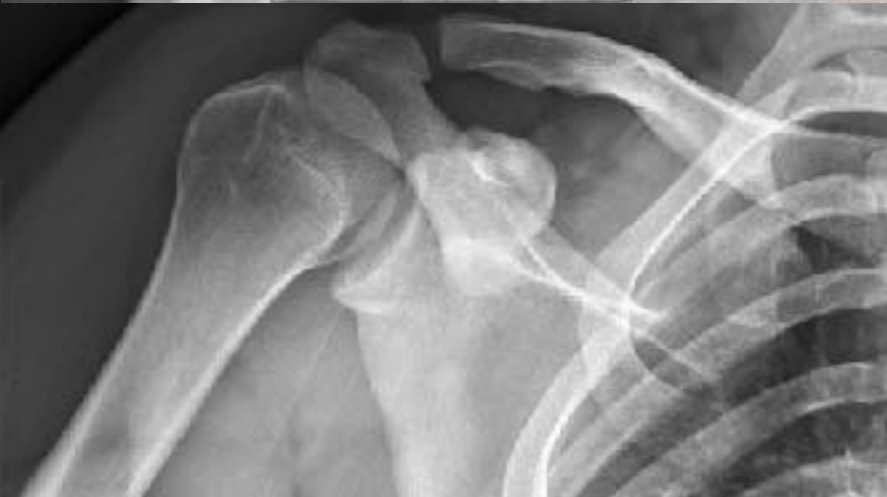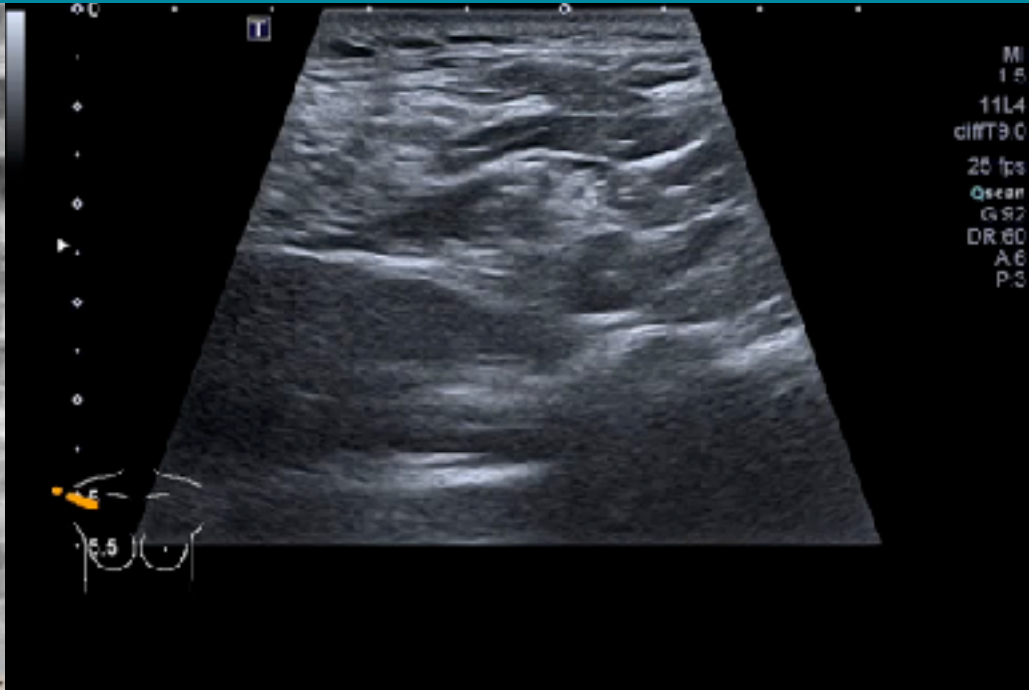


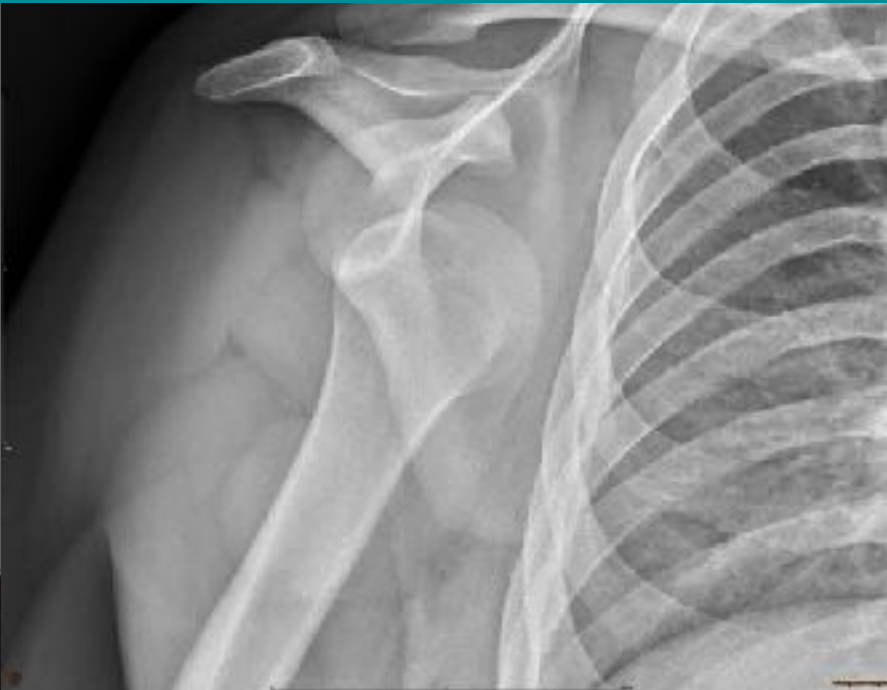# Anterior approach for diagnosis, block & reduction



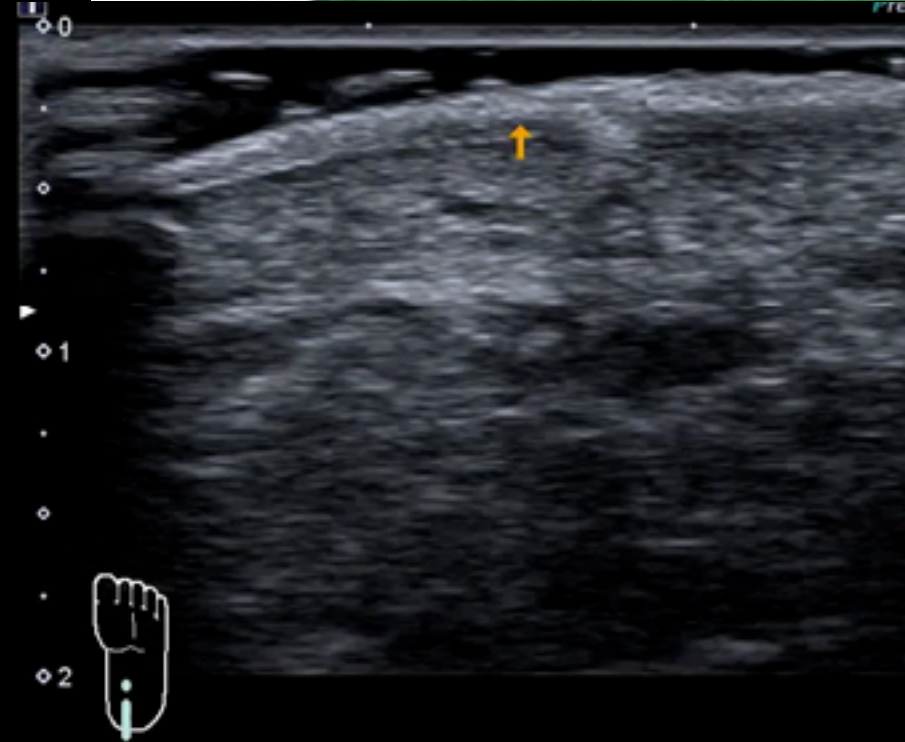
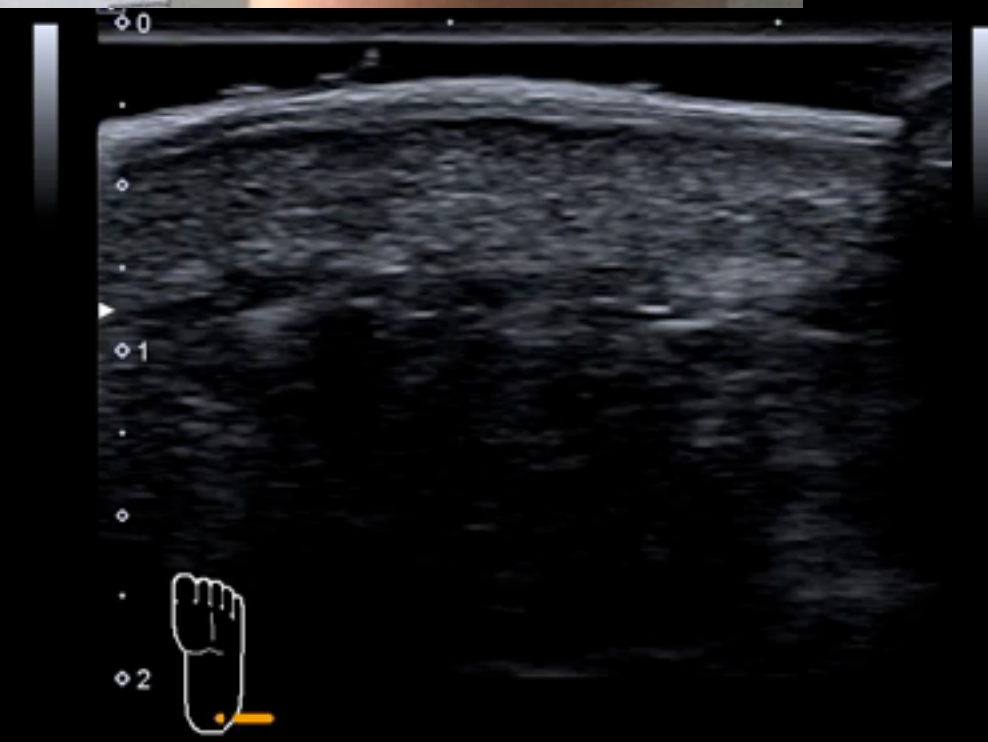
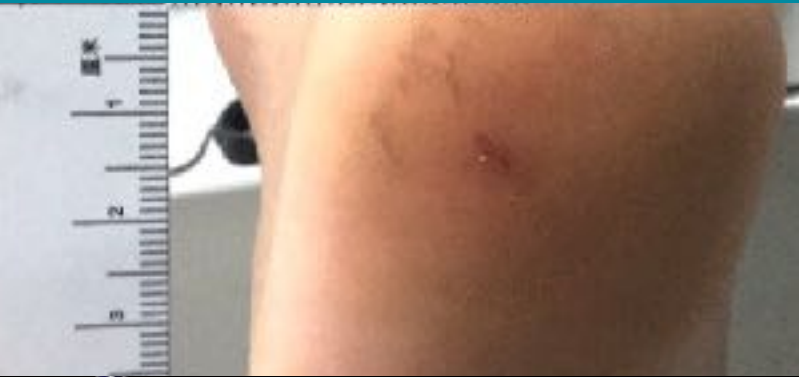

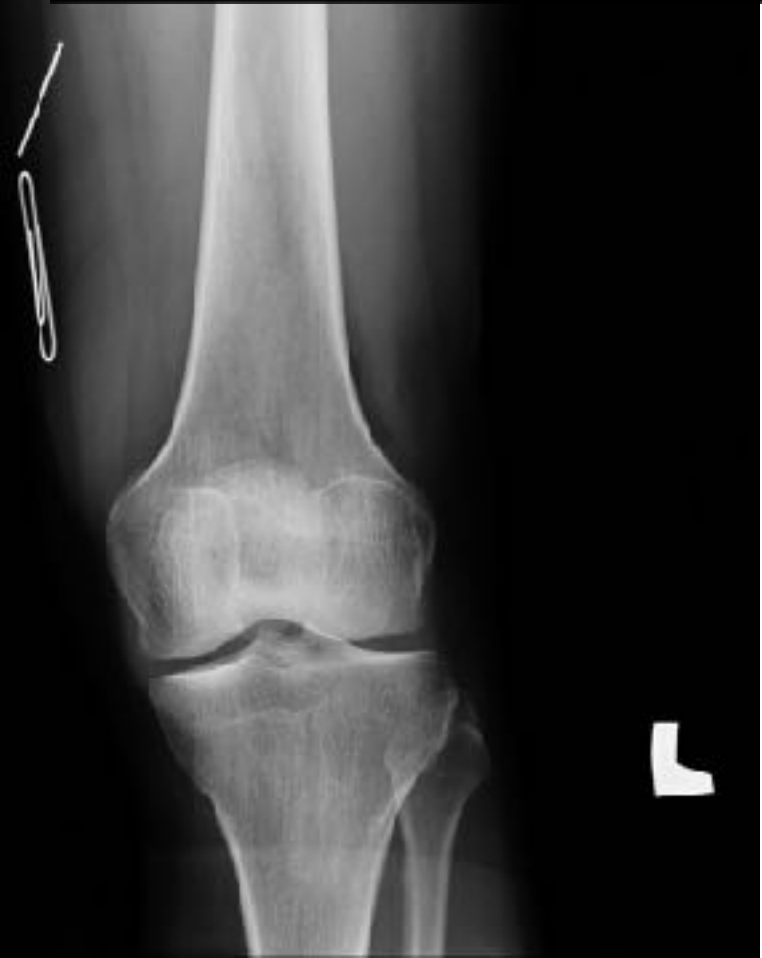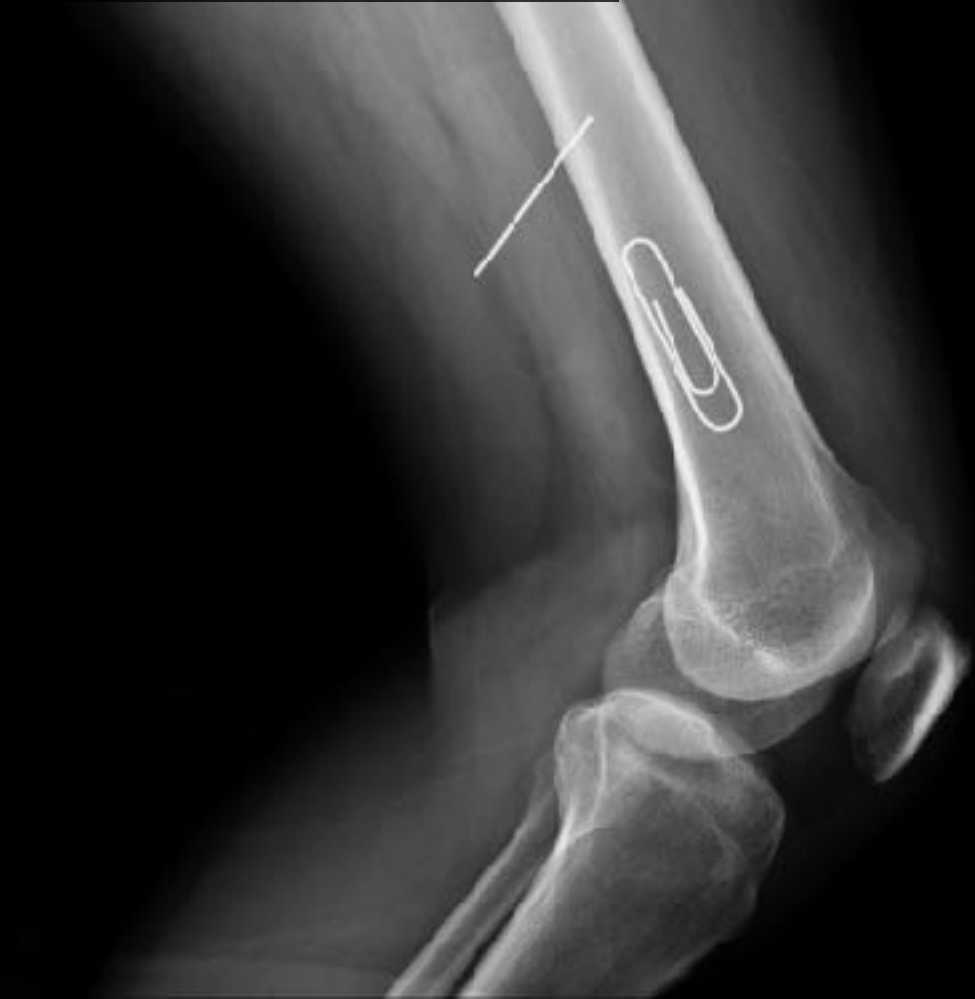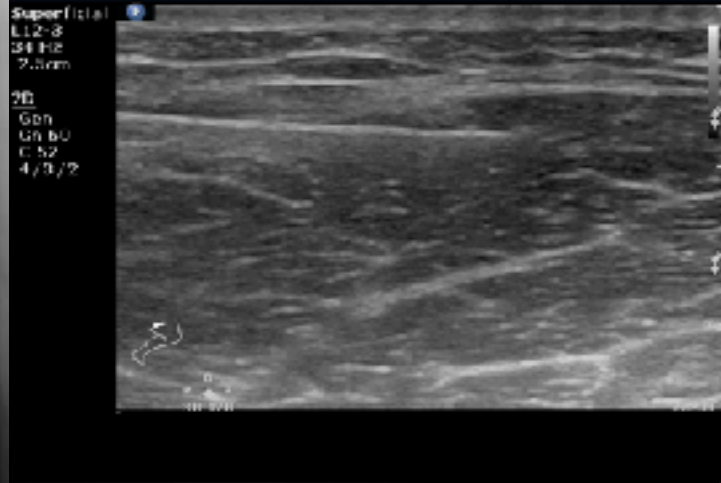
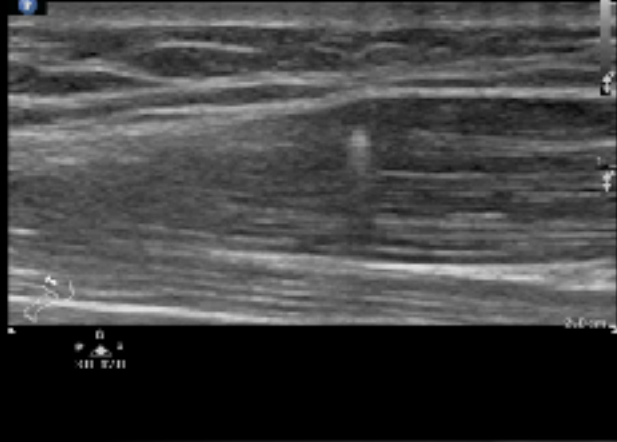
# Supraclavicular brachial plexus block





# 踩到碎玻璃，覺得有異物



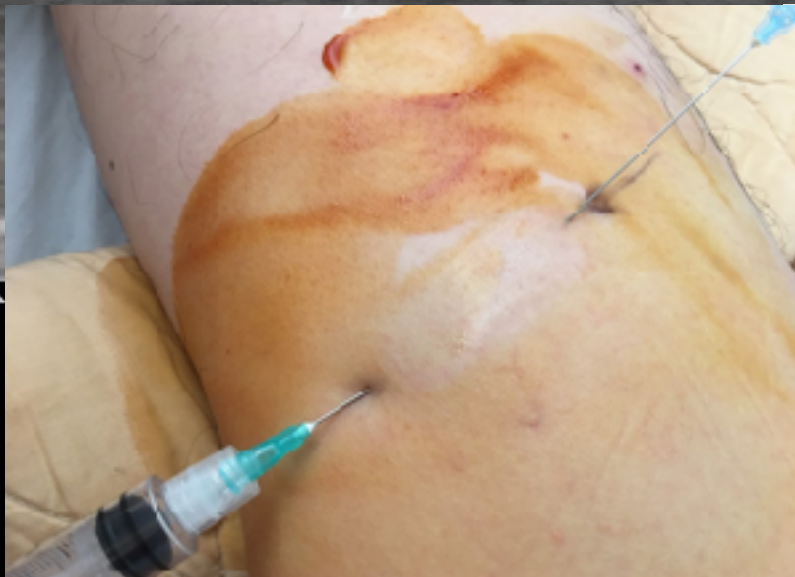
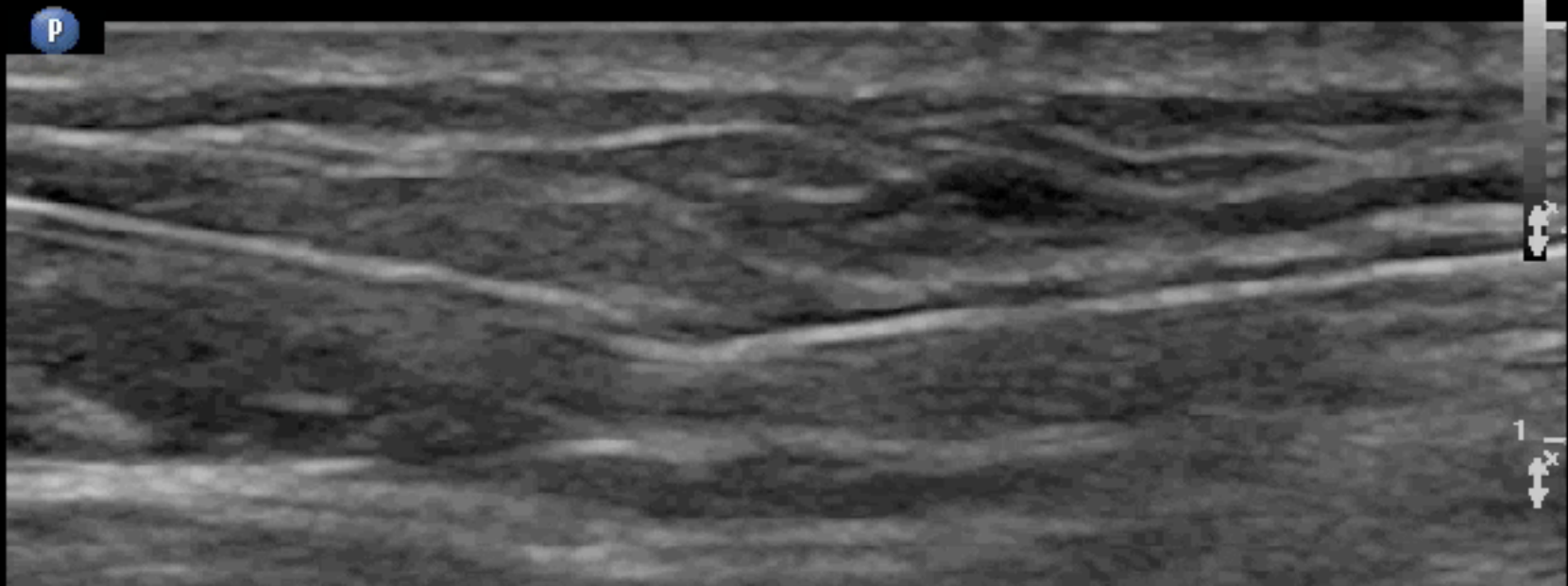


# Localization

# 2 needle

# Removal

12-5  
34 Hz  
2.0cm  
D  
Gen  
Gn 60  
C. 57  
4/3/2

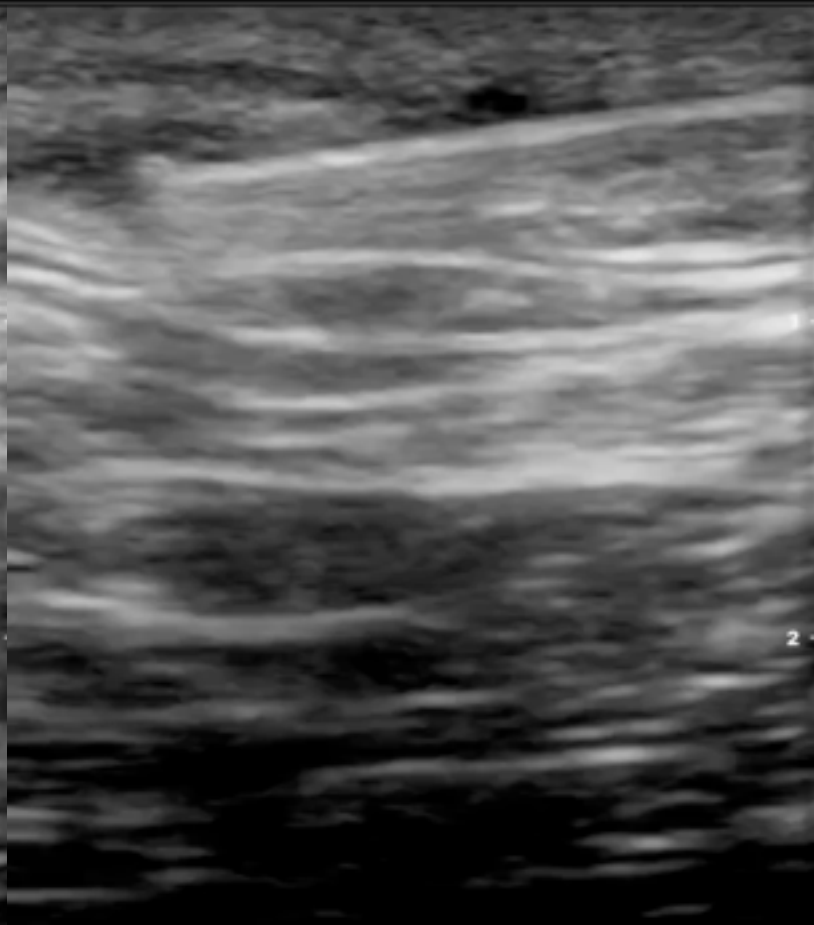
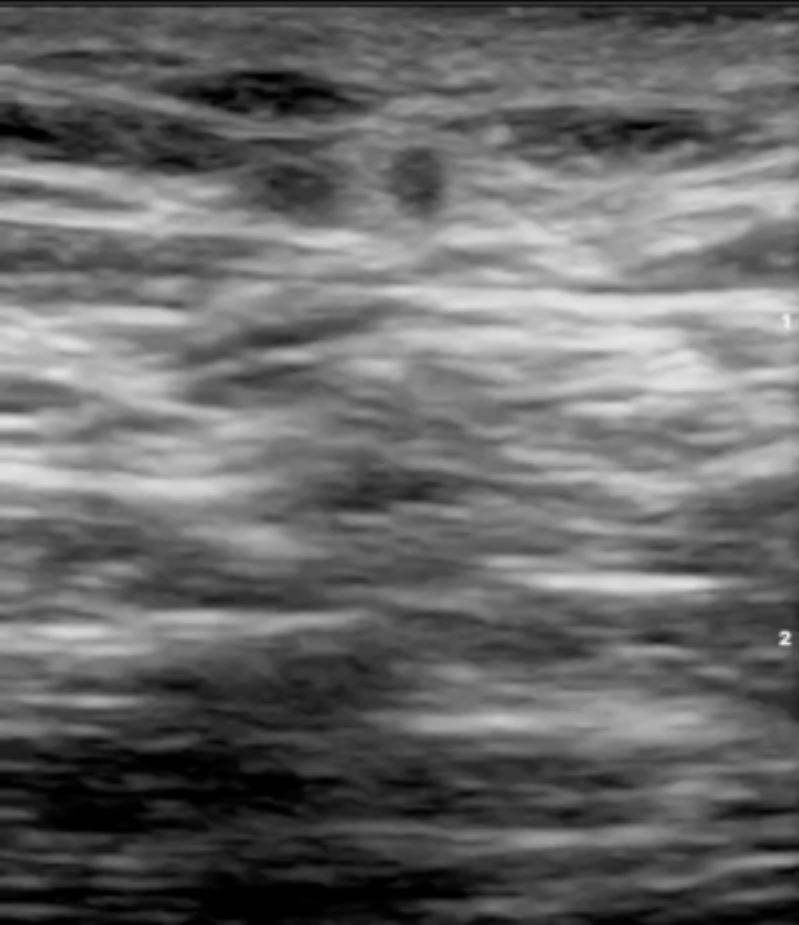


# 大腿痛和異物感

TIS: 0.01, MI: 0.26, Small Organ

TIS: 0.01, MI: 0.26, Small Organ

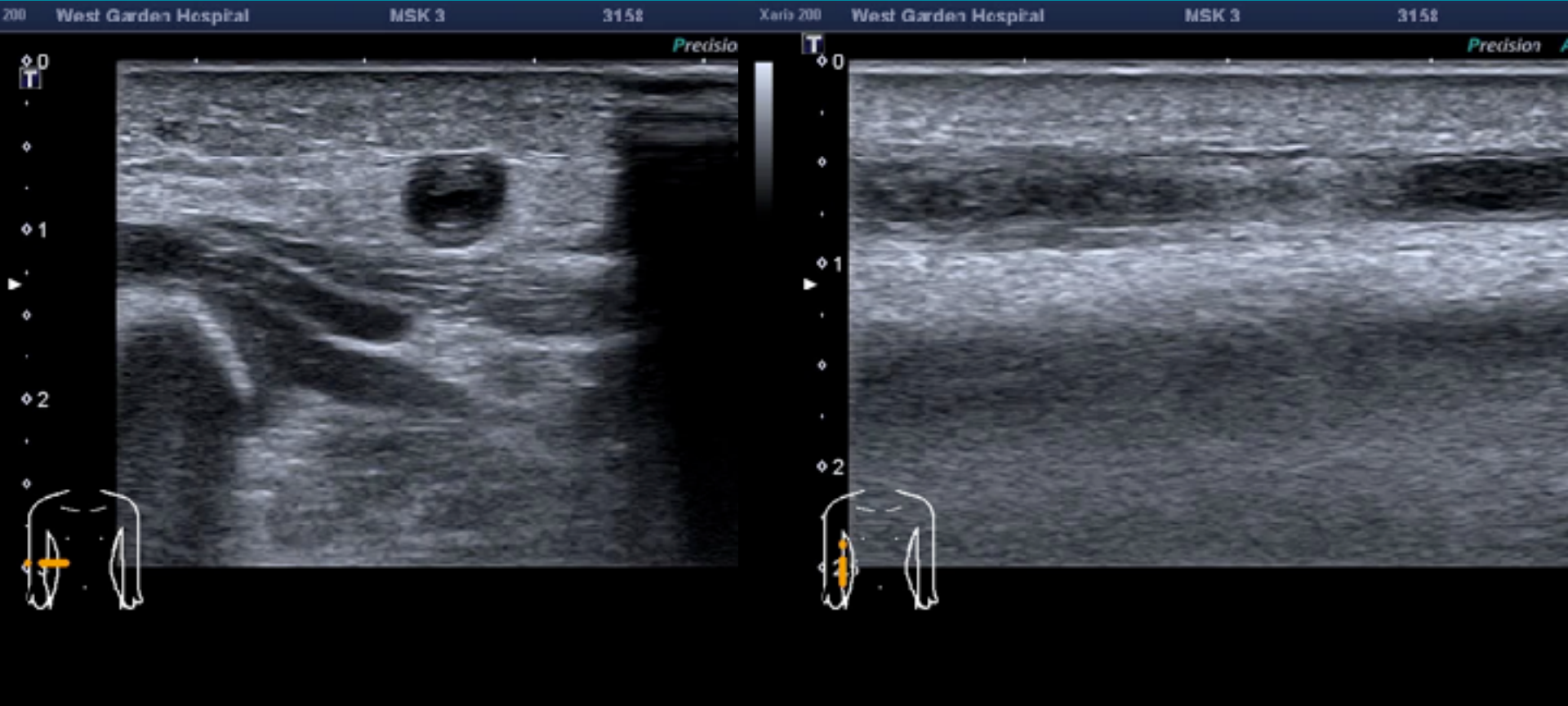
**Halo sign**





# 54歲男，注射處腫痛

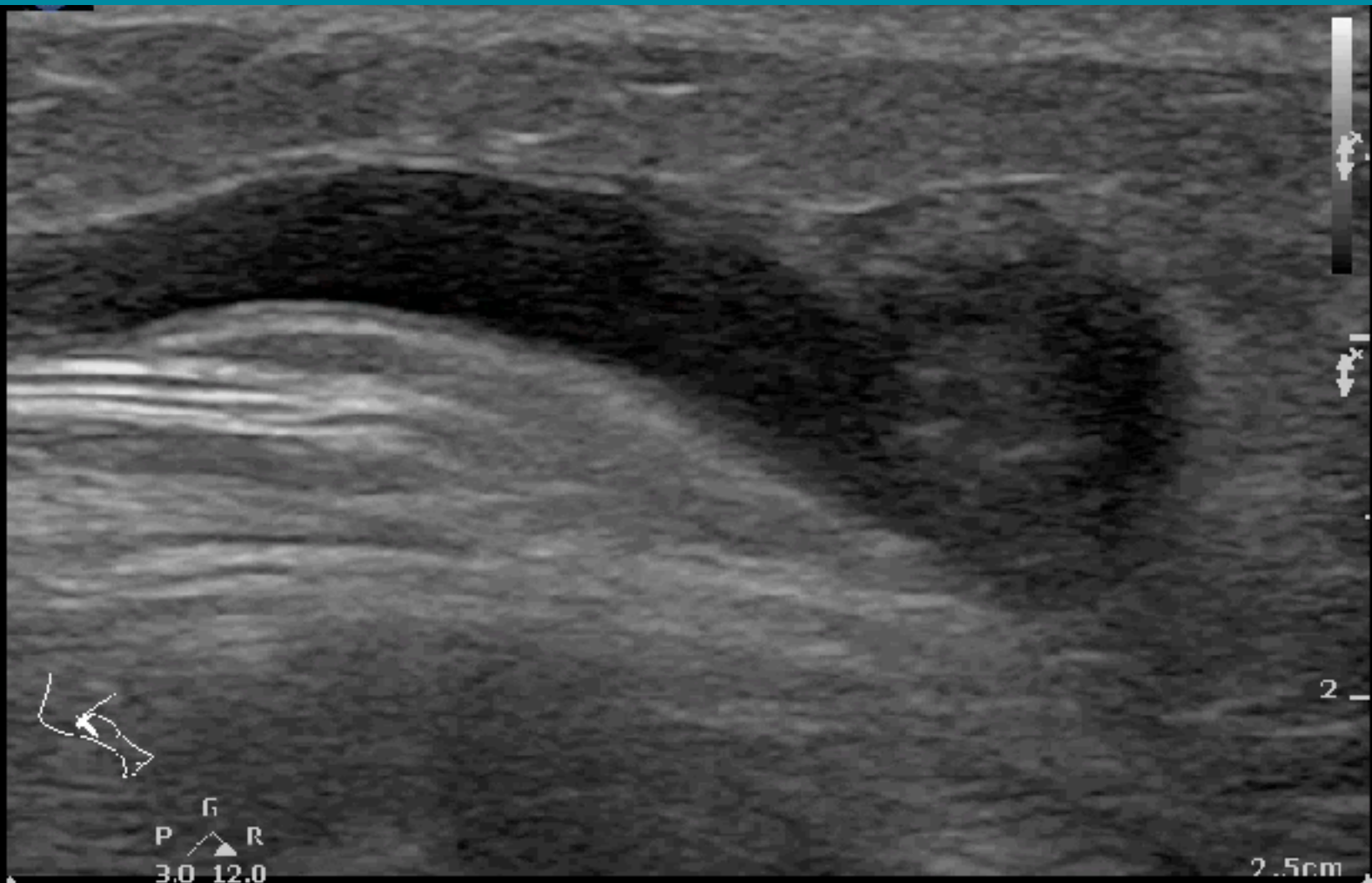
## Superficial thrombophlebitis



# 76F，小腿痛

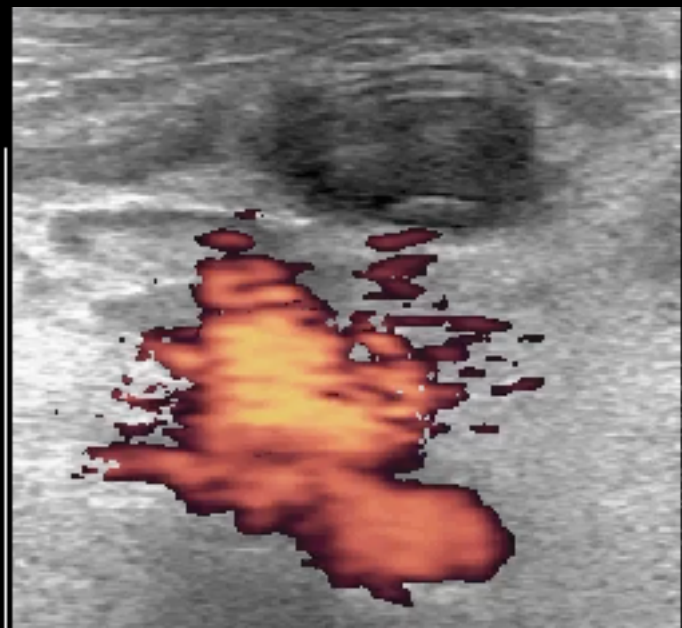
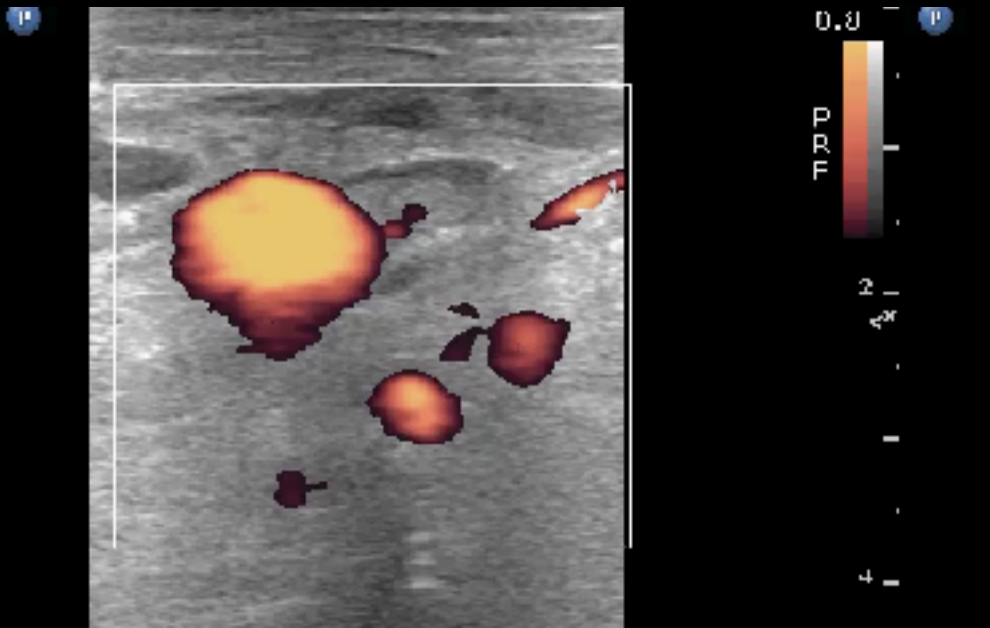
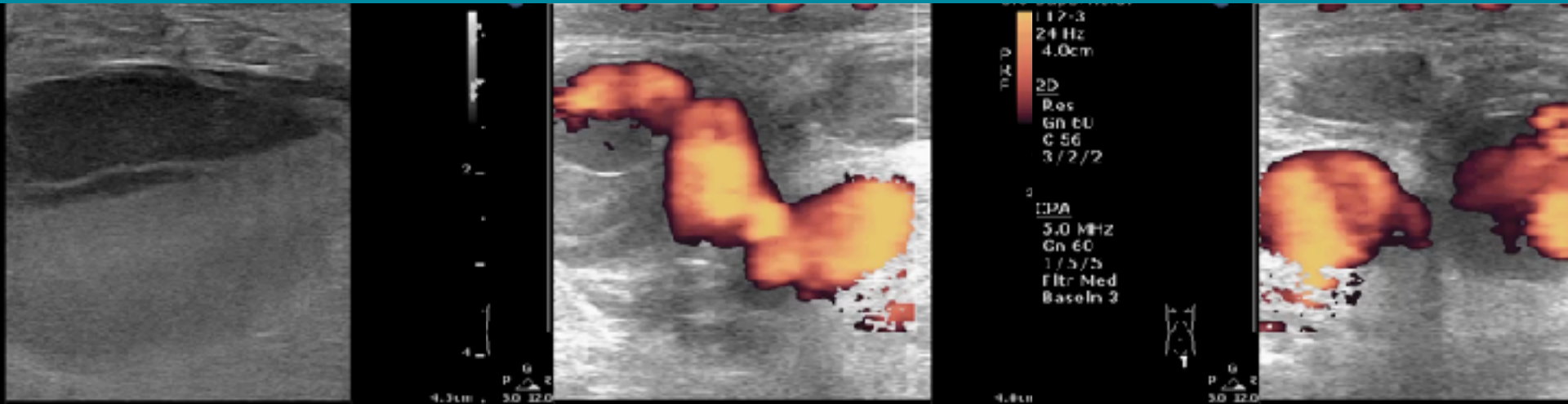
L12-3  
50 Hz  
2.5cm

2D  
Res  
Gn //  
C. 56  
3 / 2 / 1

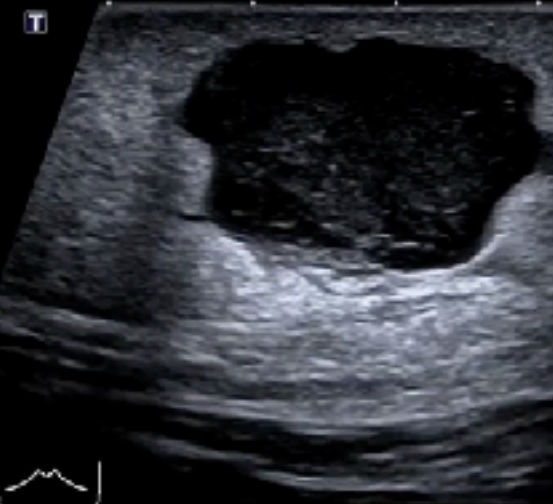


2.5cm

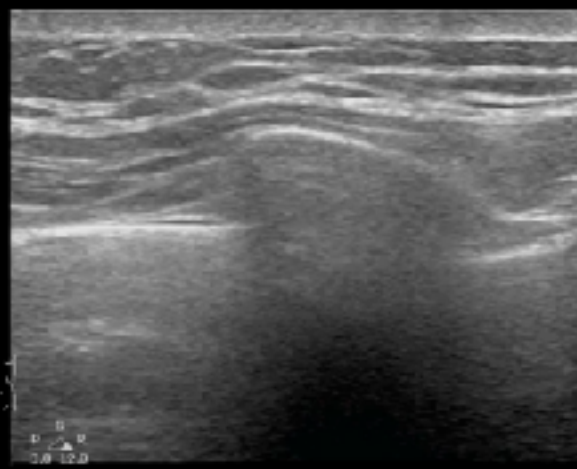
# Left femoral painful swelling



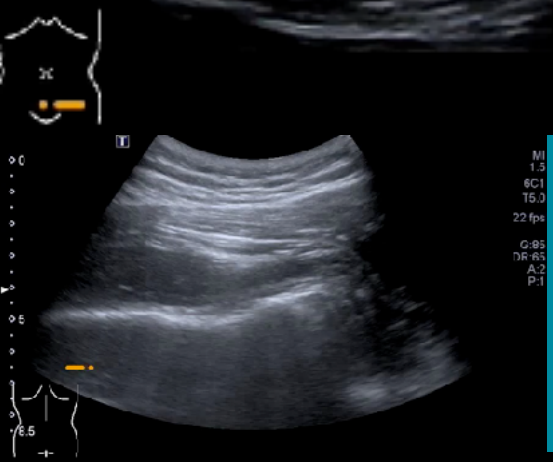
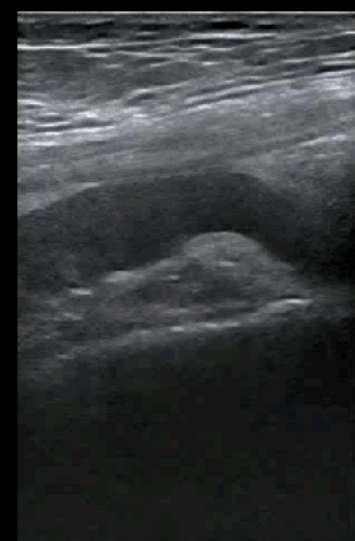



Superficial  
L12-3  
46 Hz  
3.0cm  
70  
Res  
Gn 96  
C 56  
3/2/1



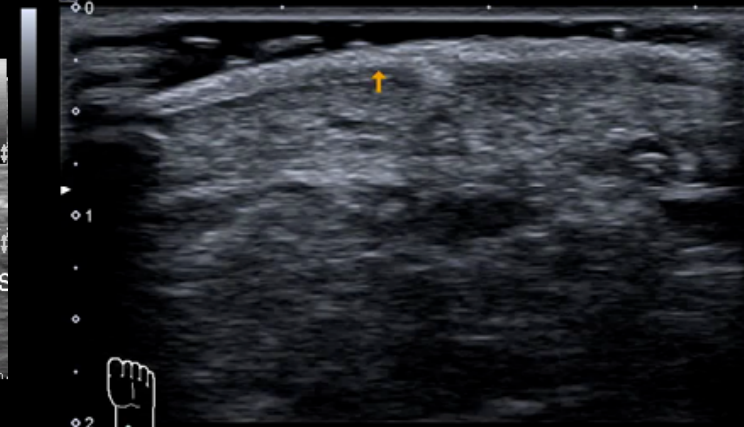
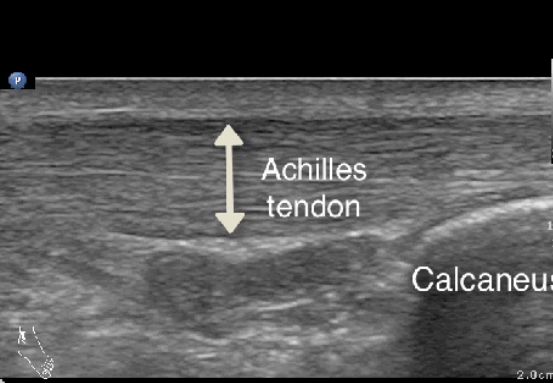
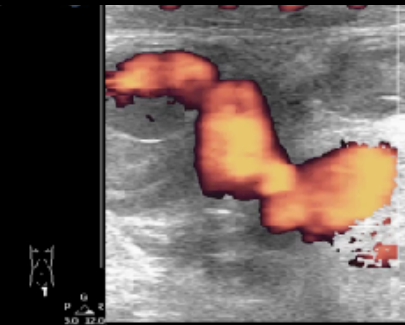
m  
3.0cm  
i



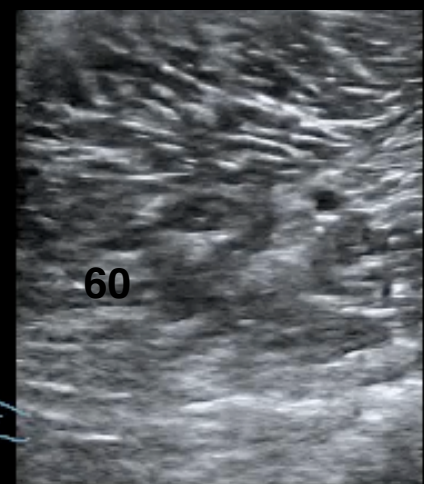
MI 1.5  
6C1  
T5.0  
22 fps  
G:89  
DR:65  
A:2  
P:1

# MSK US in ER

L12-3  
24 Hz  
4.0cm  
2D  
Res  
Gn 6U  
C 56  
3/2/2  
EPA  
5.0 MHz  
Gn 60  
1/5/5  
Filt: Med  
Baseline 2



MI 1.5  
11L4  
diffT9.0  
30 fps  
G:92  
DR:60  
A:6  
P:3



U  
P R  
3.0 12.0

