



雙和急診POCUS訓練

陳國智 醫師 / POCUSacademy.com



急診超音波臨床評核醫師
醫用超音波學會指導醫師



WINFOCUS director / instructor
Certified Interventional Pain Sonologist

急診 / 重症 / 介入 / 急性疼痛

經歷

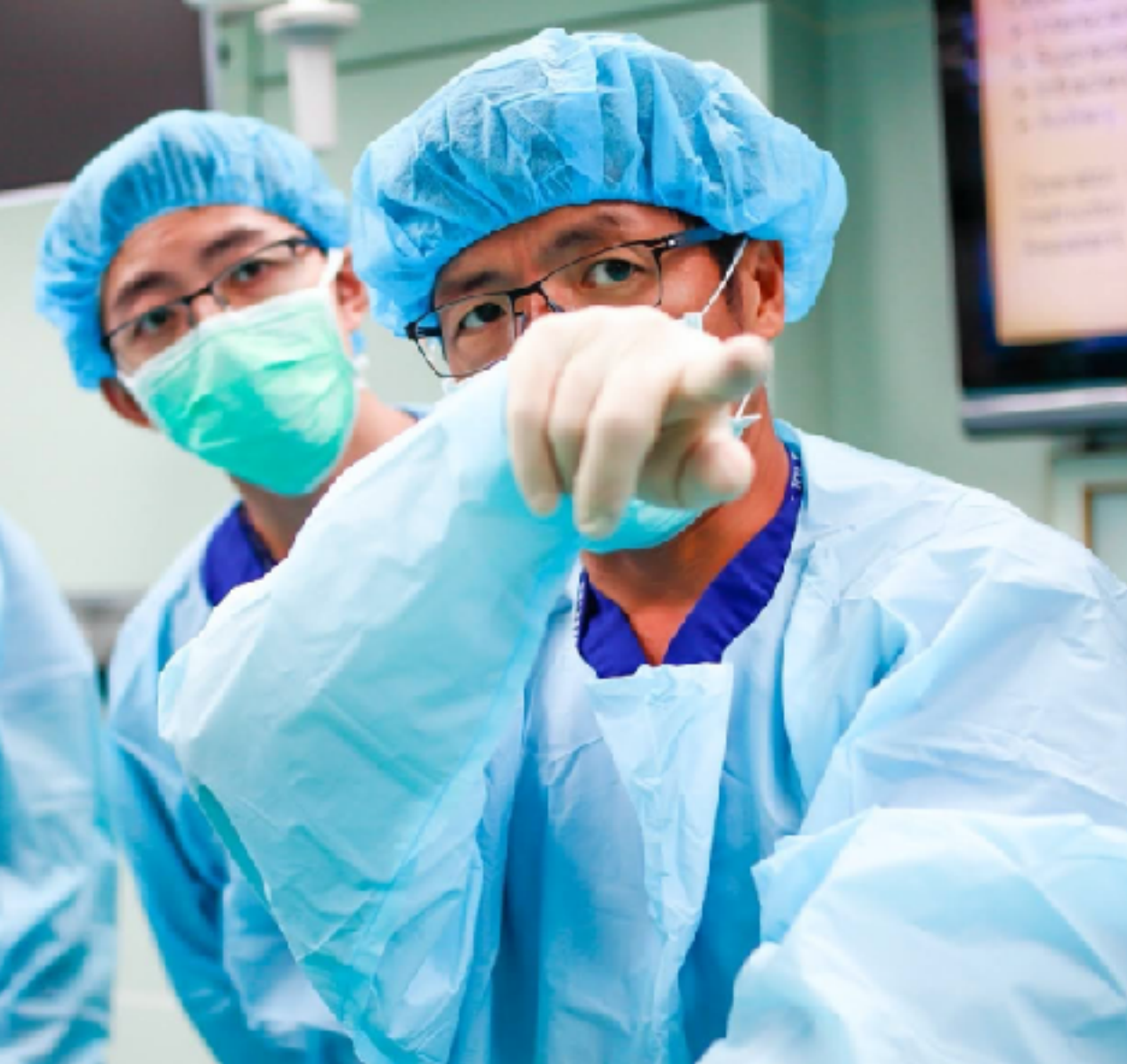新光急診超音波訓練中心主任

西園醫院急診醫學科主任

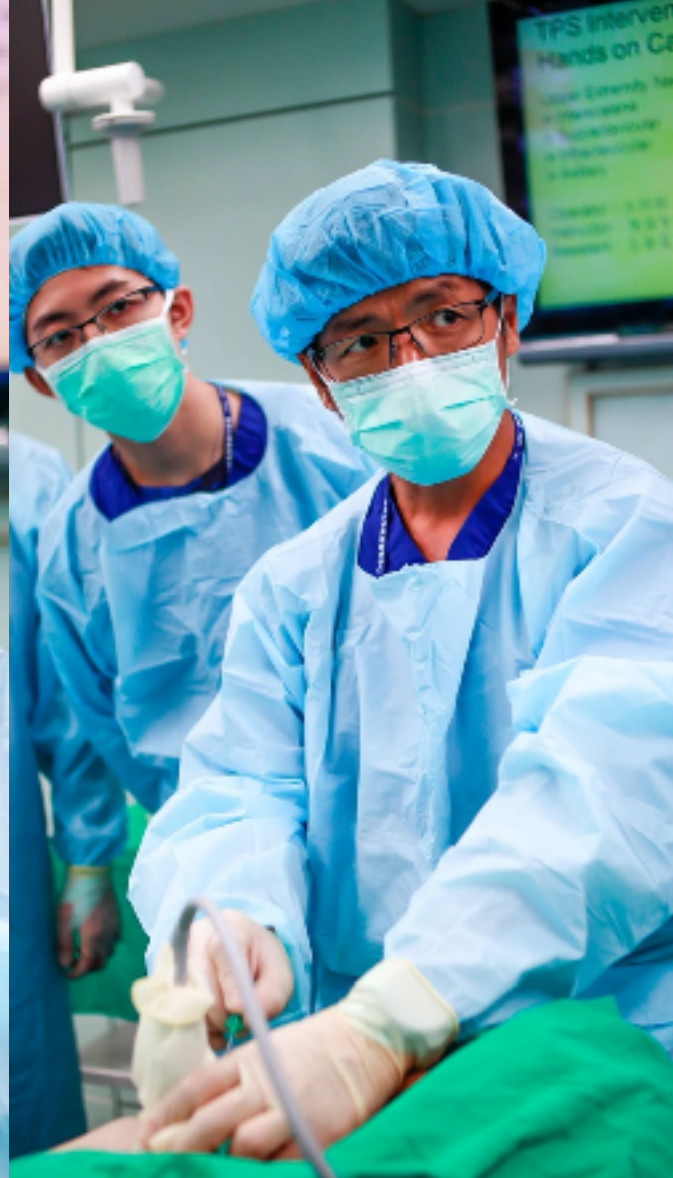急診醫學會超音波委員會主委

台灣疼痛醫學會大體模擬手術講師

急救加護醫學會重症超音波負責人

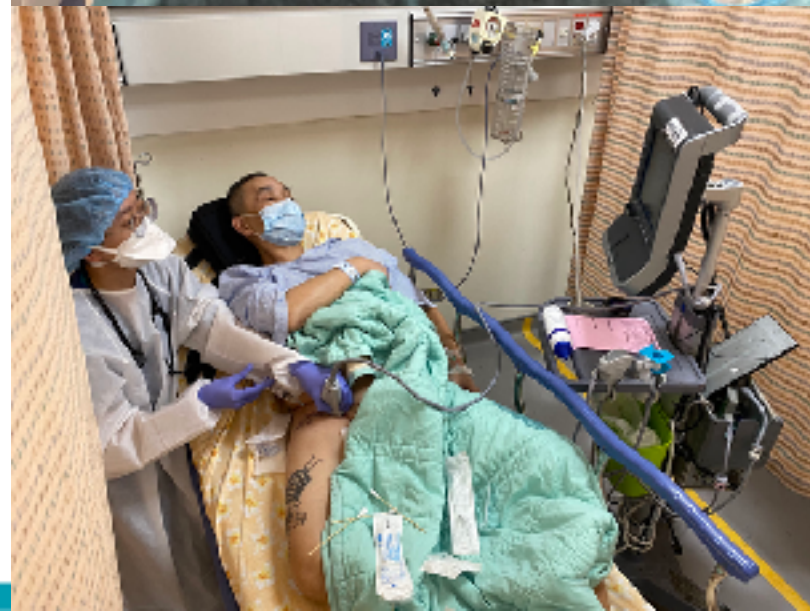
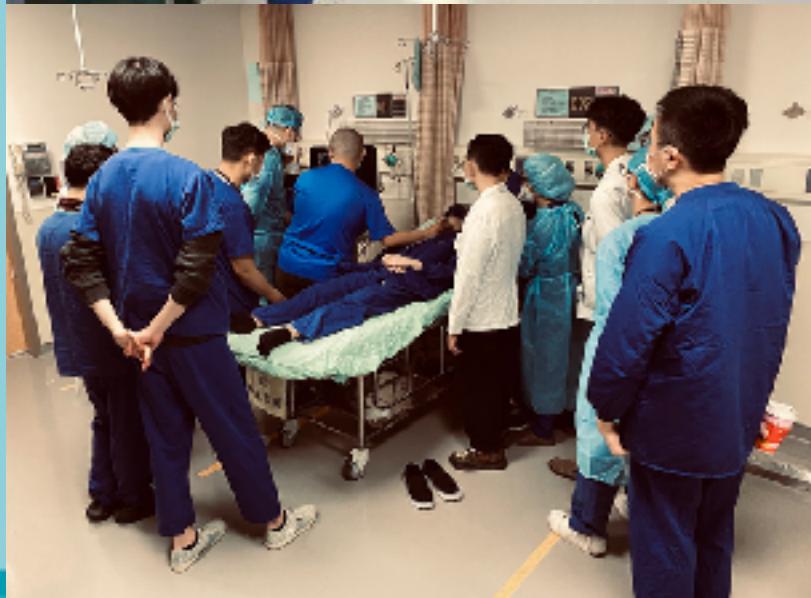
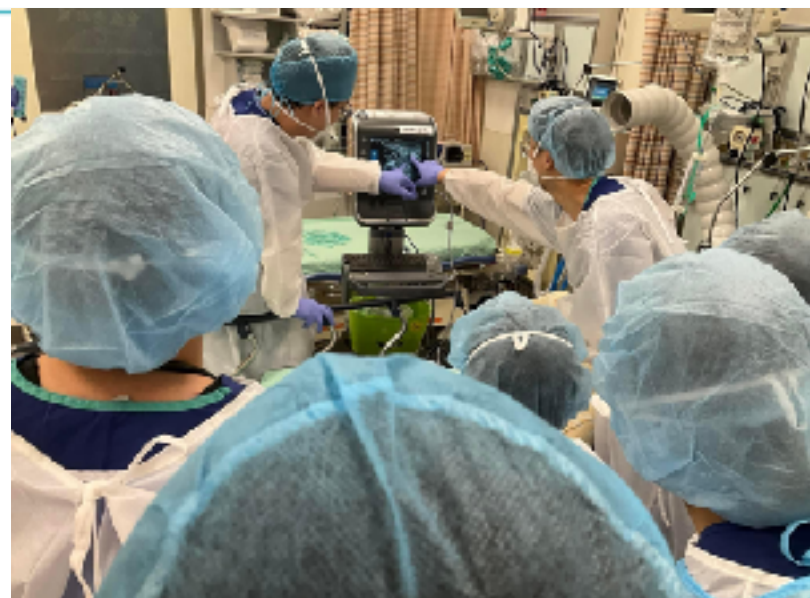Diagnostician

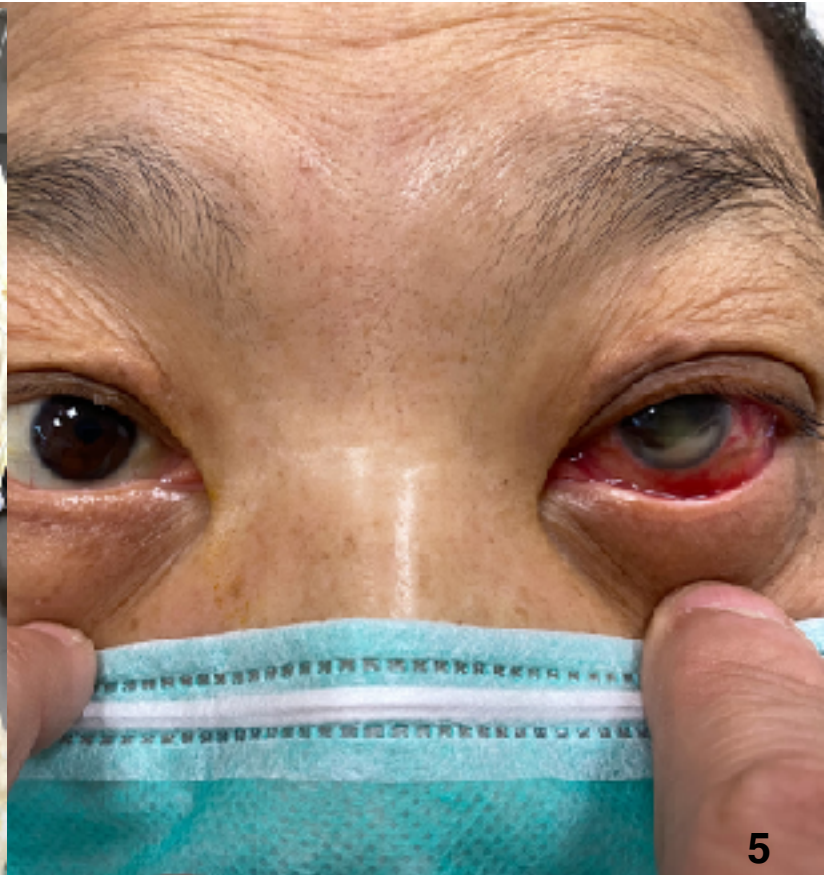
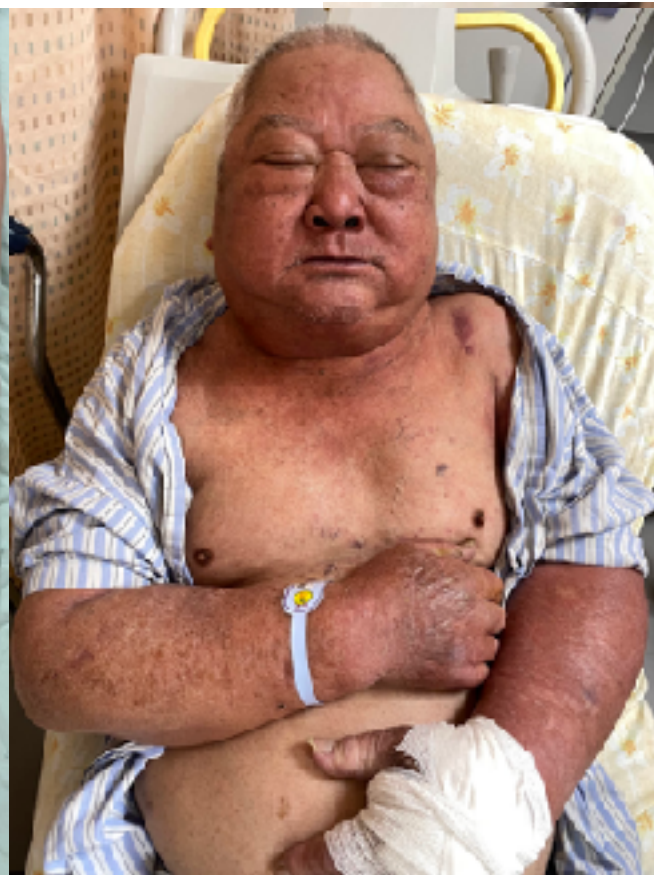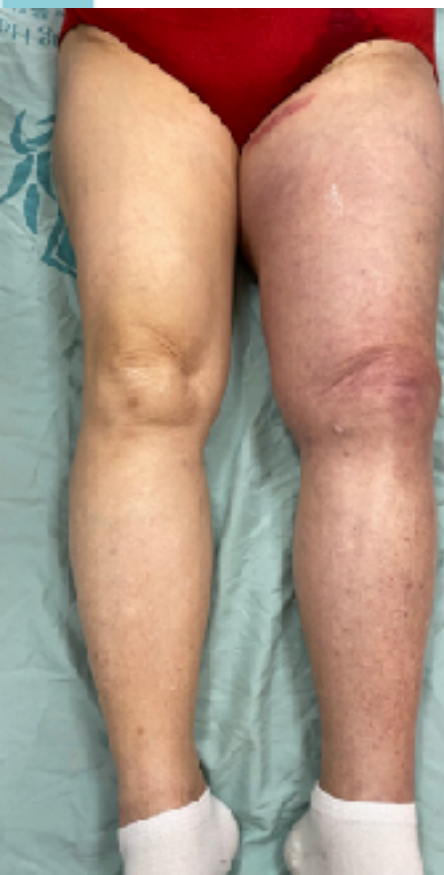


Interventionist

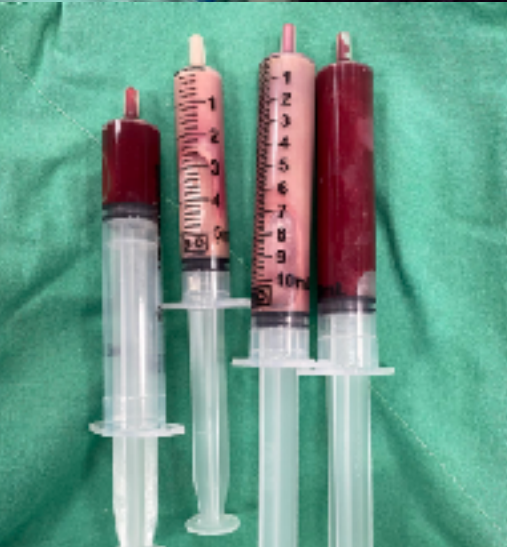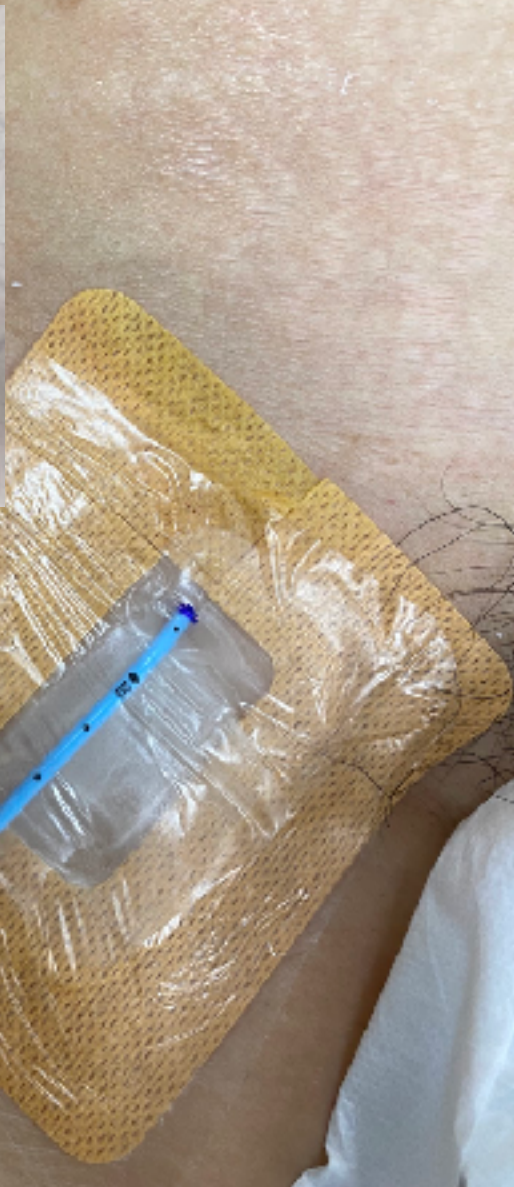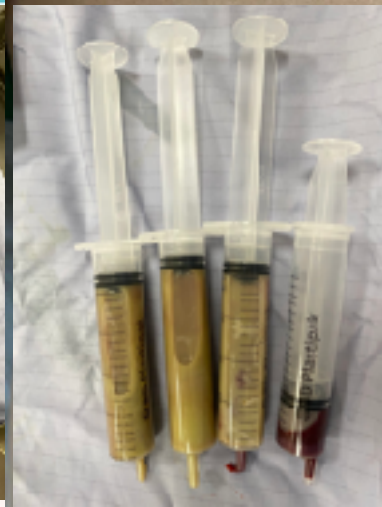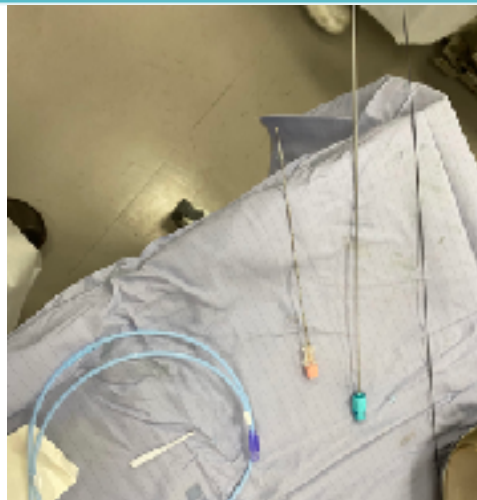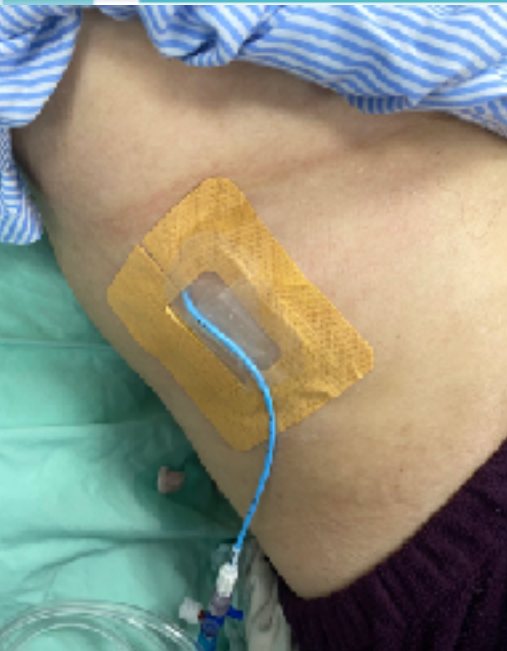POCUS主題訓練及臨床教學



雙和急診POCUS臨床訓練



超音波導引介入性治療



NEO-SOF
Hydrophilic Drainage Catheters

*和特®引流導管及穿刺導入系統

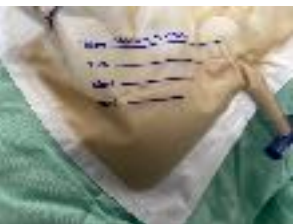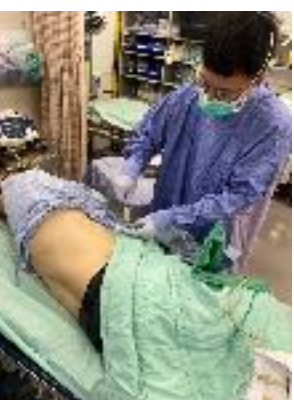引流導管組
Drainage Catheter Kit

規格：8FR - 帶線
表面親水性塗層設計
衛署醫器製字號00287D 號
藥商：邦特生物科技股份有限公司

8FR (2.5mm)
總長0.83M 帶線
A=30cm B=25cm

內容物：

(1) 導管	(1) 導管固定器
(1) 導管管	(1) 導管管
(1) 導管管	(1) 手袋袋
(1) 導管管 (1.5x20cm)	(1) 蓋帽
(1) 導管管 (1.5x10cm)	(1) 蓋帽
(1) 引流管 (0.037)	



優化臨床應用作業流程 導入超音波介入性治療 培訓臨床及教學師資群

雙和急診POCUS訓練目標

診
斷

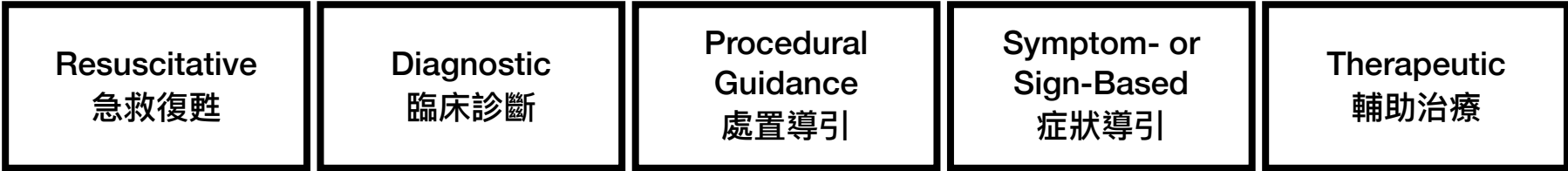監
測

介
入

POINT OF CARE ULTRASOUND

PROVIDER **PROBE** PATIENT

~ 存在於臨床需求之所在 ~



Core Applications (2023 ACEP Emergency Ultrasound Guidelines)
15項急診超音波核心應用

陳國智醫師

Aorta
 DVT
 Trauma
 Thoracic/Airway
 Cardia/HD assessment

Procedural Guidance
 US-guided NB
 Testicular
 Ocular
 Skin & Soft tissue

Hepatobiliary
 Urinary tract
 Pregnancy
 Bowel
 MSK

I-AIM

POINT



Acquire



Interpret



**Make
decision**

I-AIM (Trauma)

Free fluid ?



探頭/FAST介面



有無游離液體



臨床決策

Point-of-Care UltraSound

POCUS的核心在協助臨床決策

YES

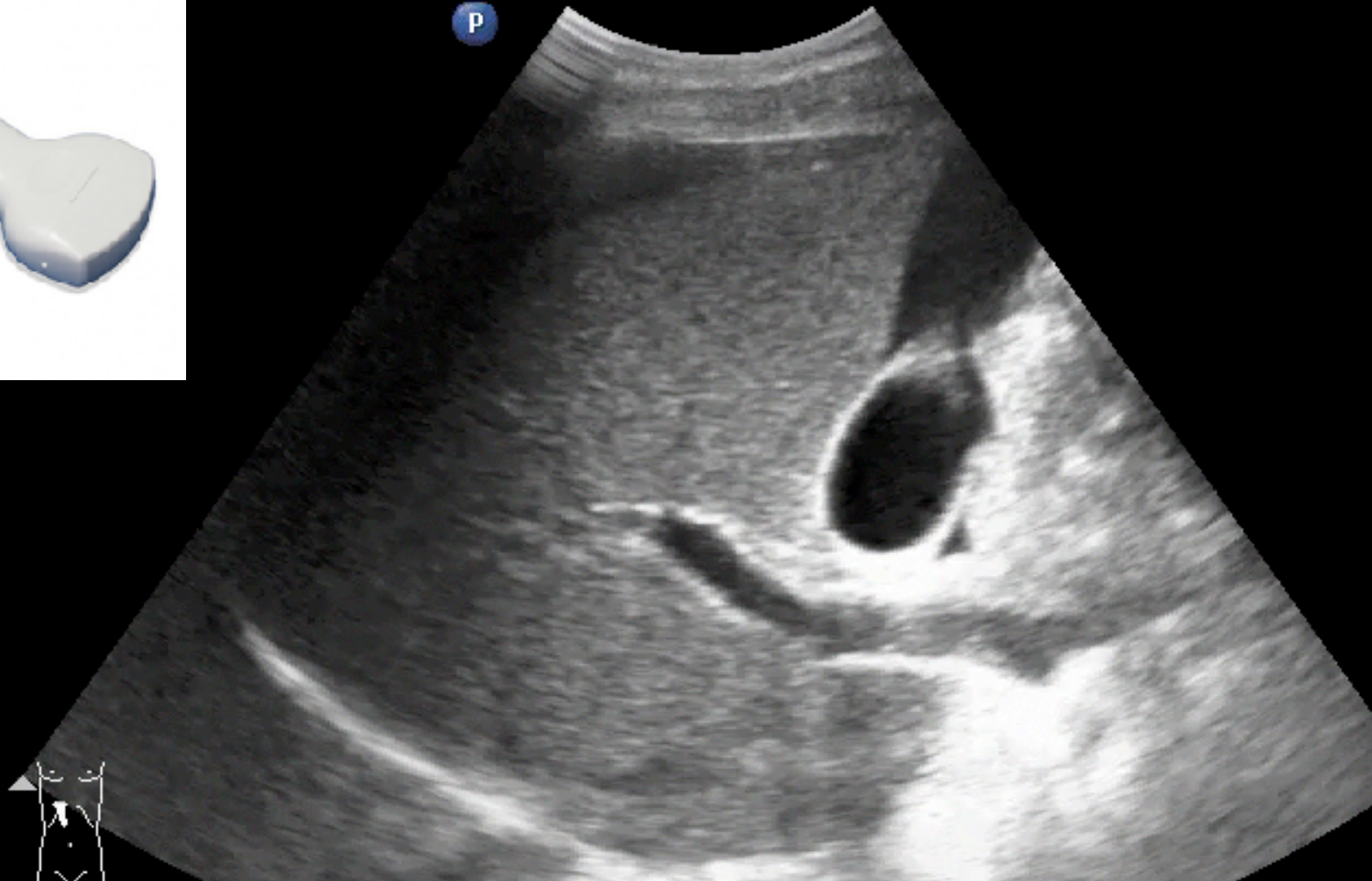


NO

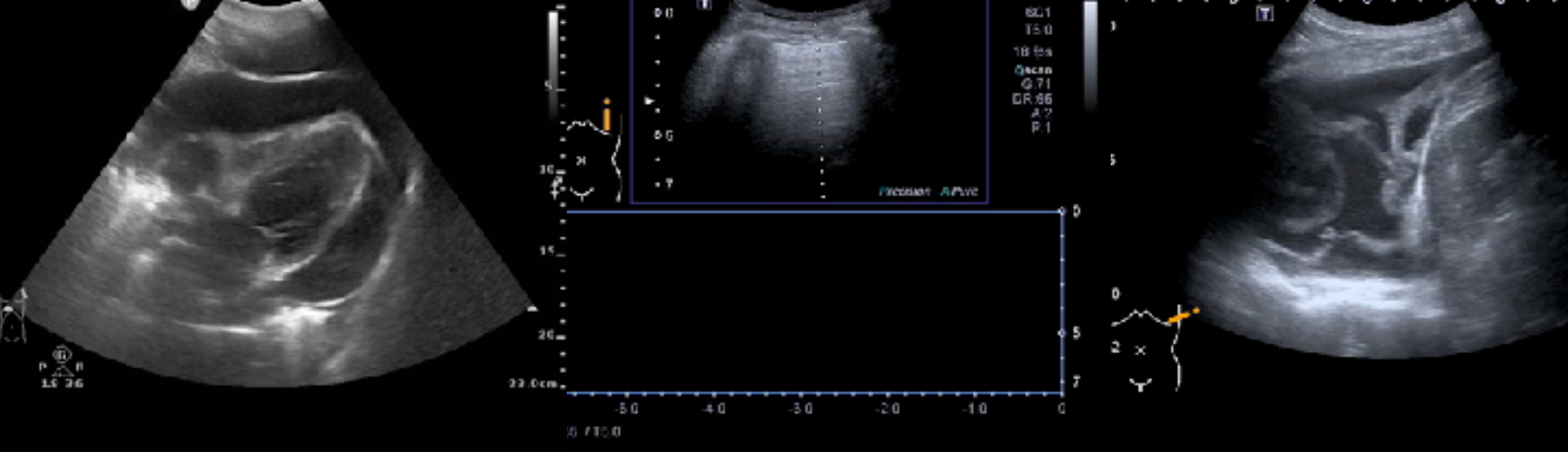
有無游離液體



3 / 3

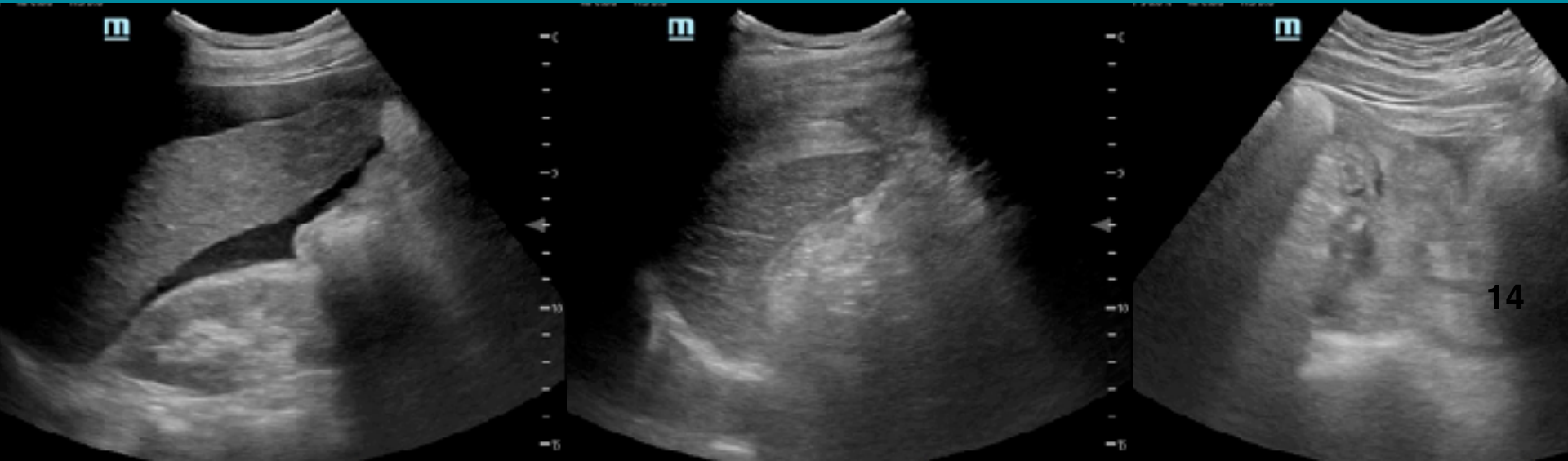

TRAUMA ULTRASOUND



EFAST

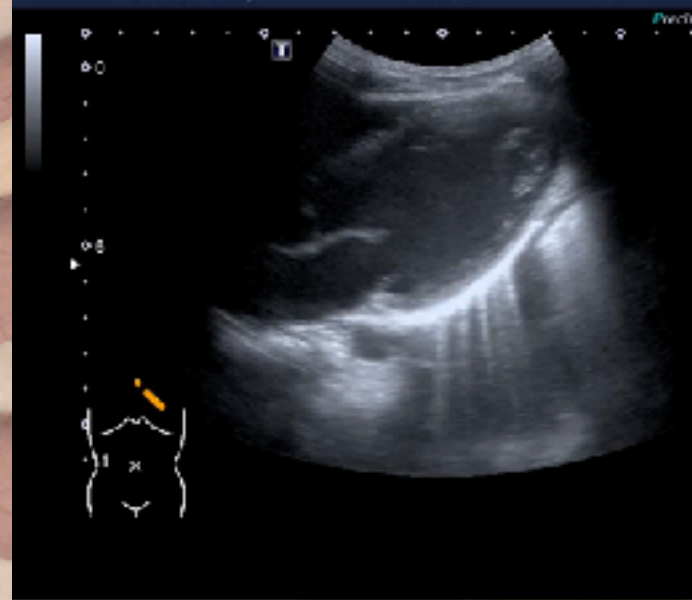
EXTENDED FOCUSED ASSESSMENT WITH SOGOGGRAPHY FOR TRAUMA



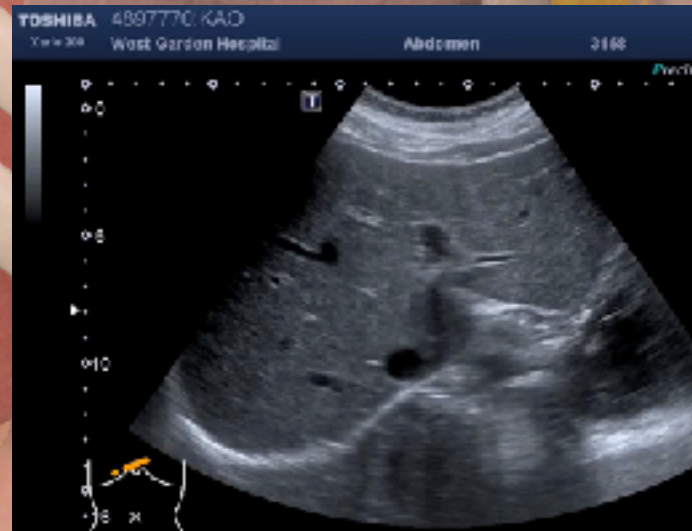掃描介面 (探頭)

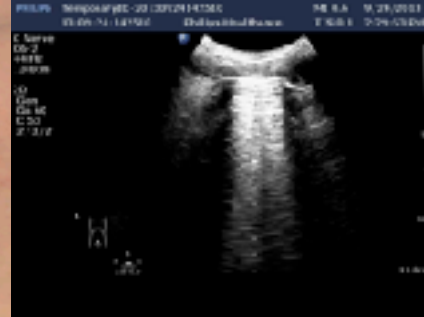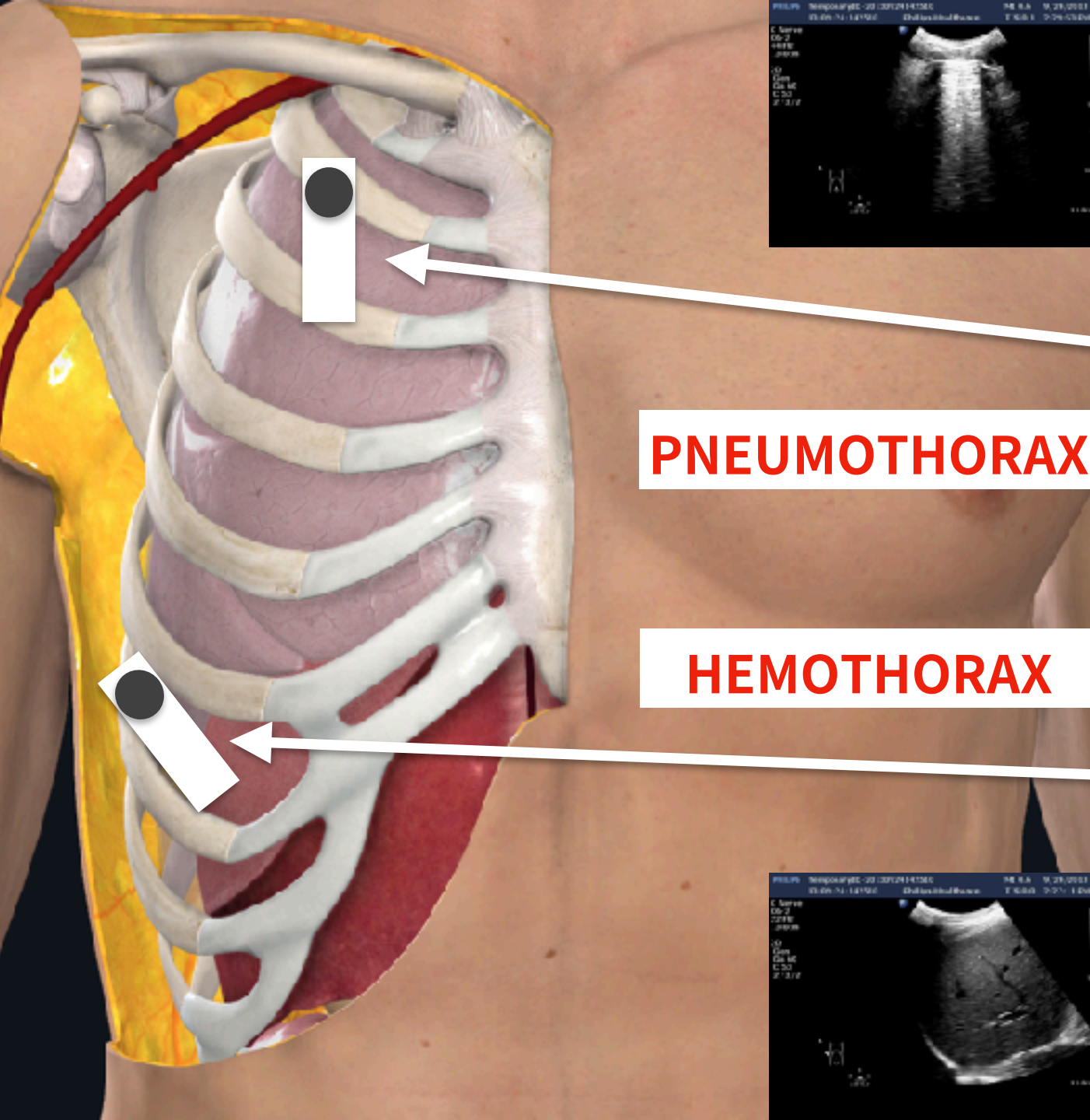
PSLA

S4C



HEMOPERICARDIUM



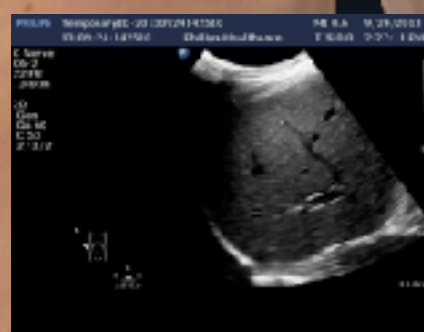


PNEUMOTHORAX

HEMOTHORAX

AIR

FLUID

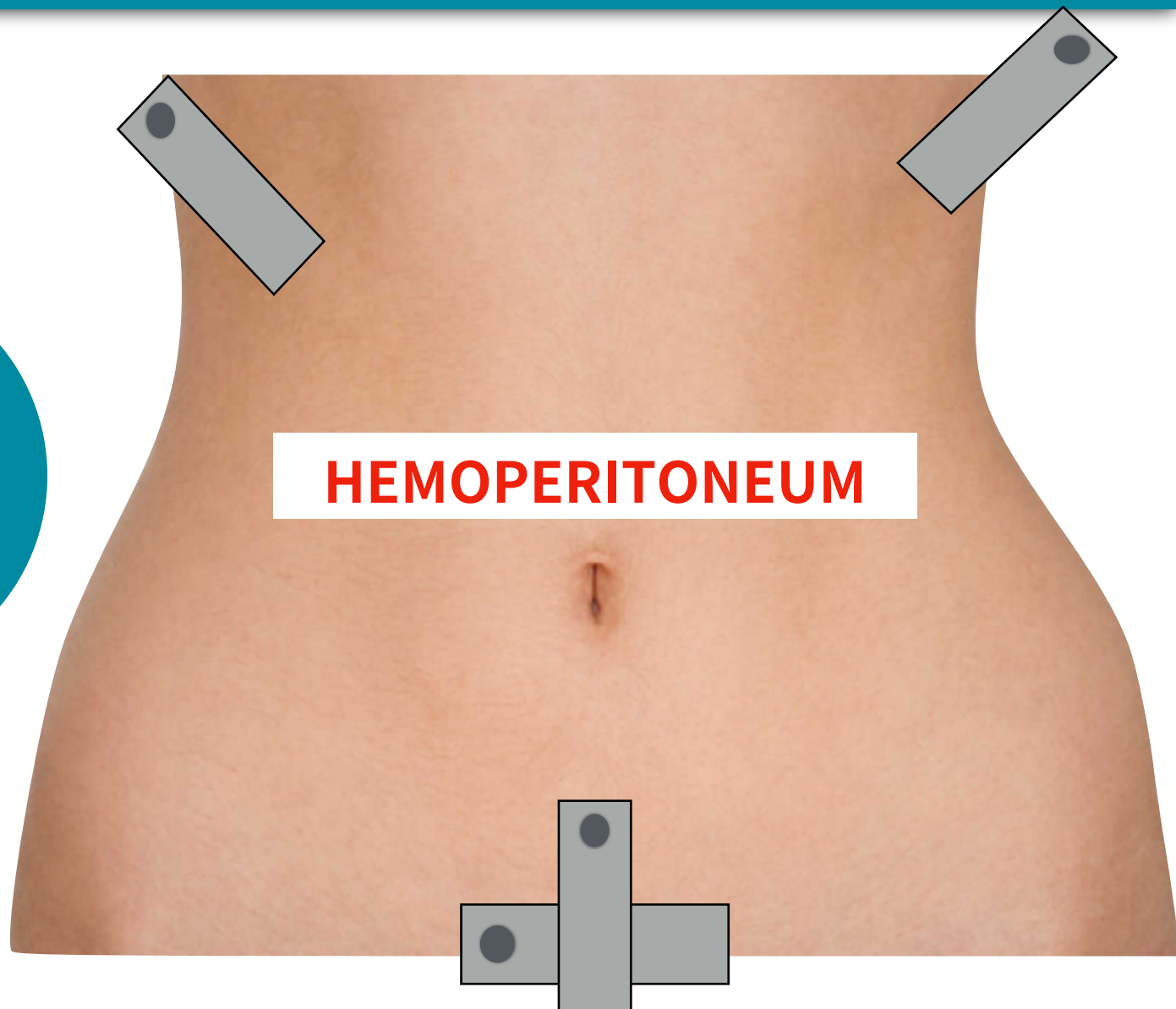




FAST: Free fluid

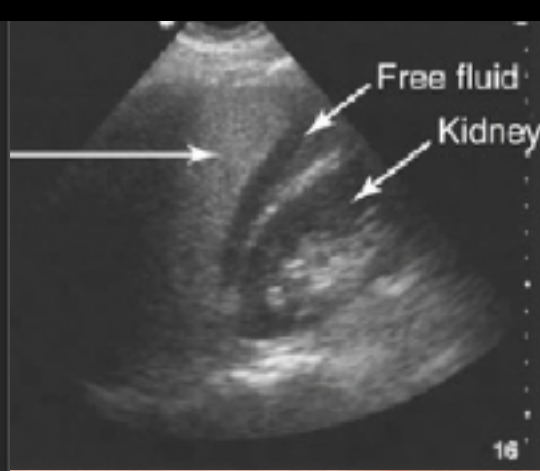
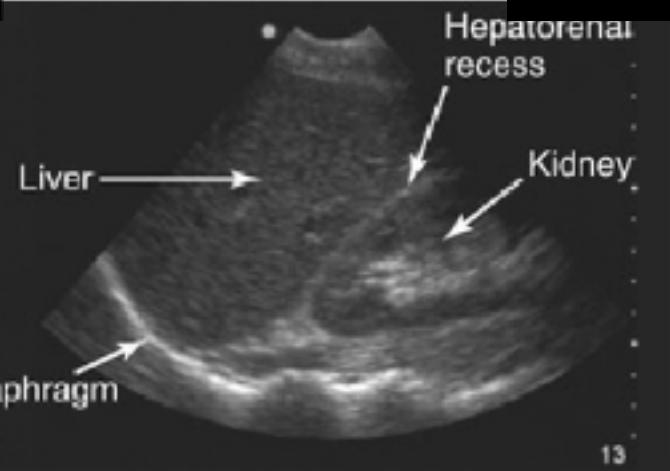
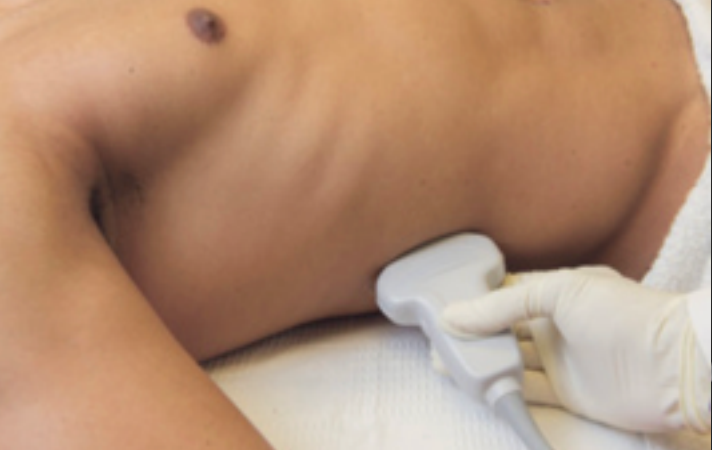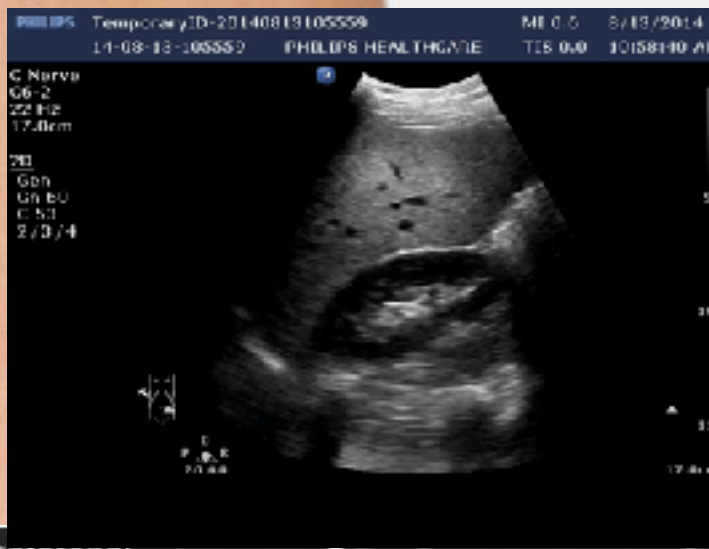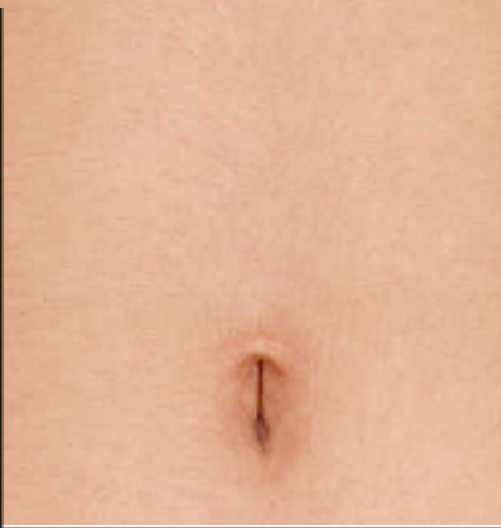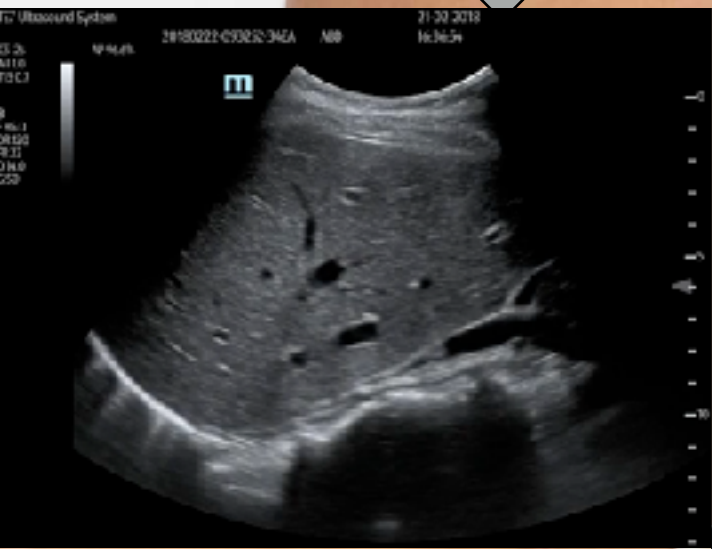倒三角
掃描介面

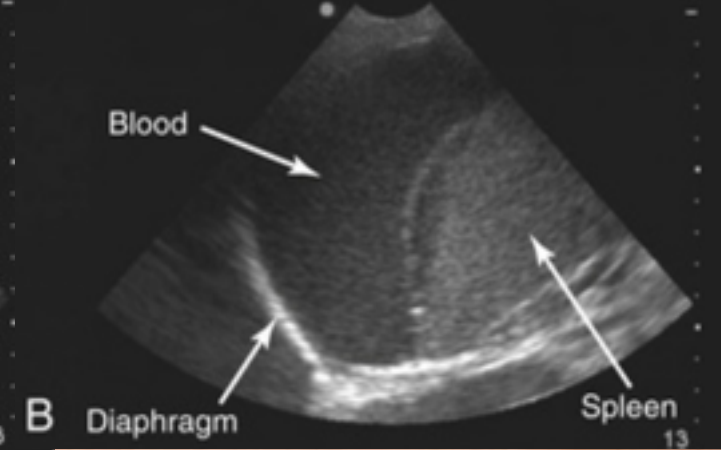
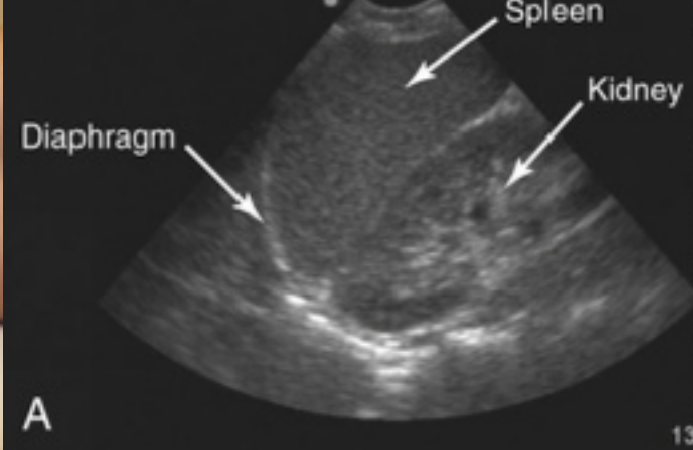
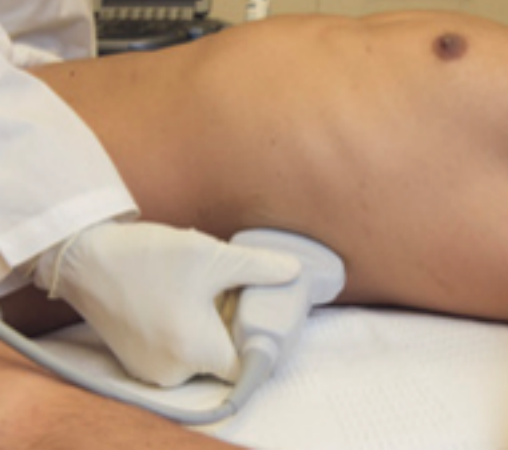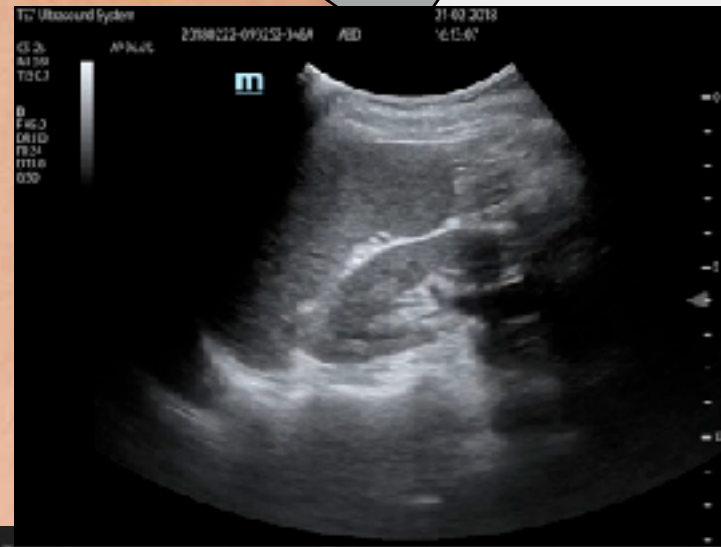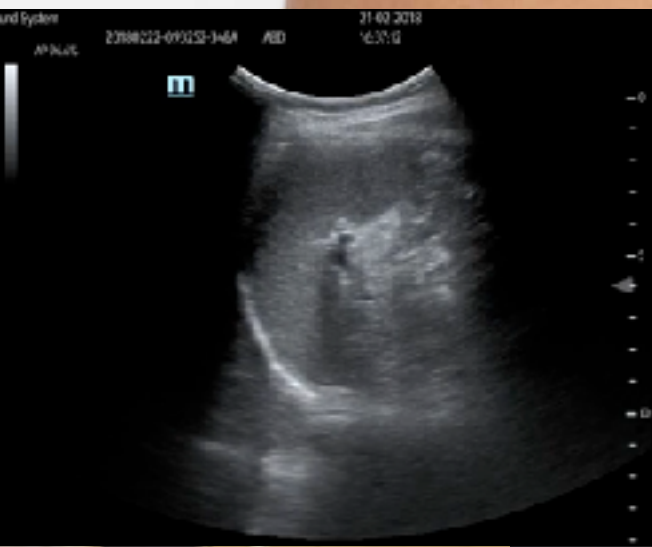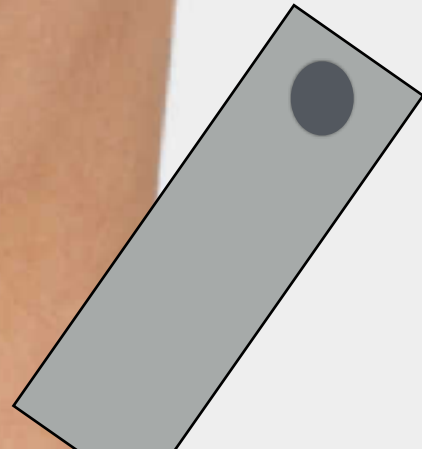


HEMOPERITONEUM

劍突-腋前線交界點
平行肋間掃描以避開肋骨
第一目標:肝腎介面(Morrison's pouch)
第二目標:橫膈膜



劍突-腋後線交界點
平行肋間掃描以避開肋骨
第一目標:橫膈膜下
第二目標:脾腎交界

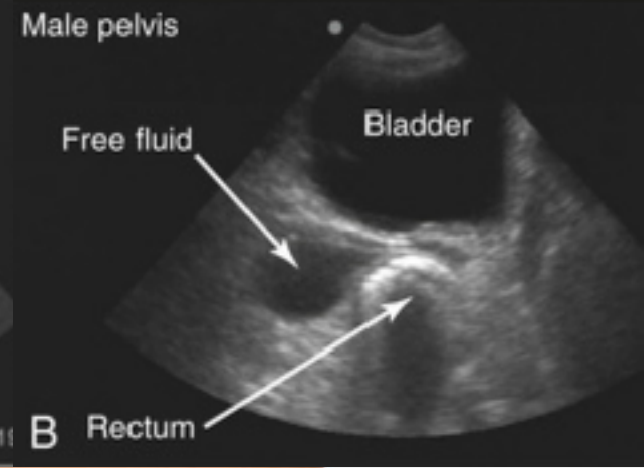
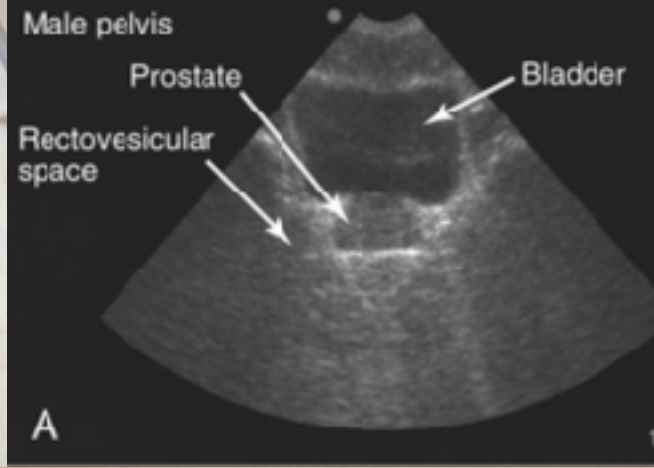
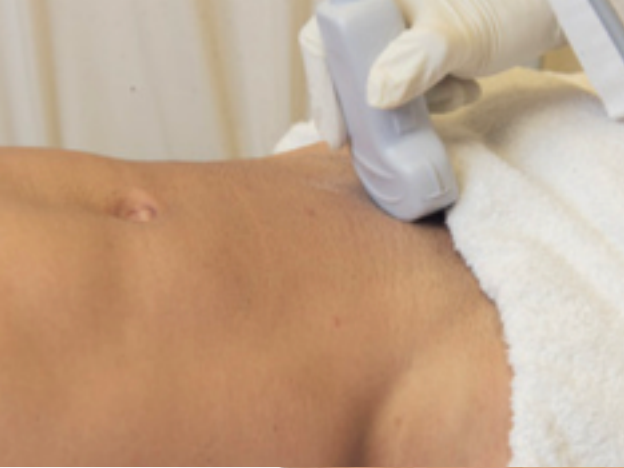

A

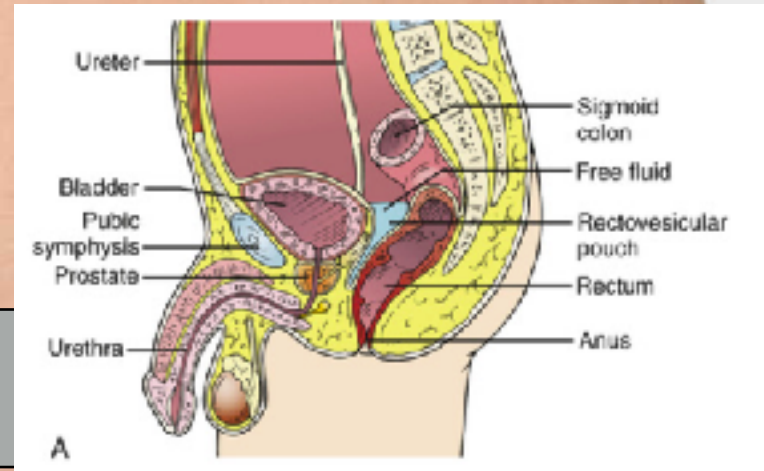
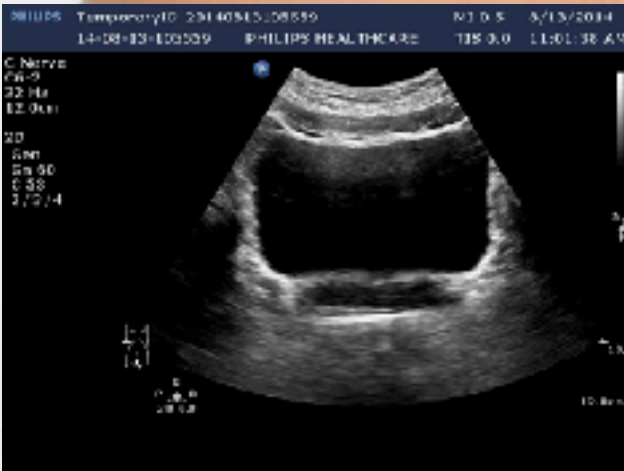B

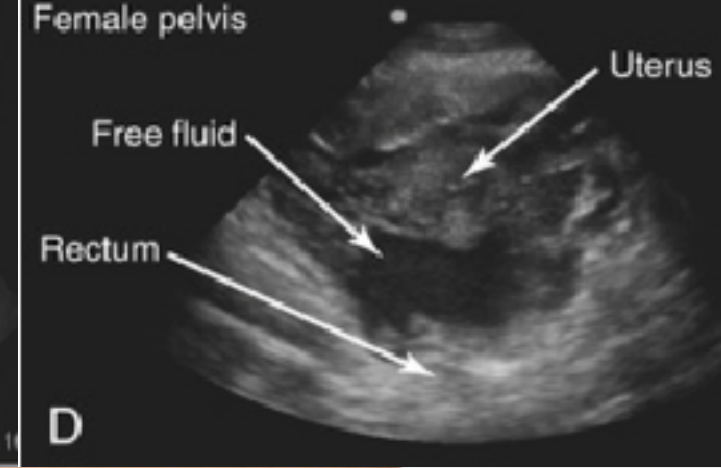
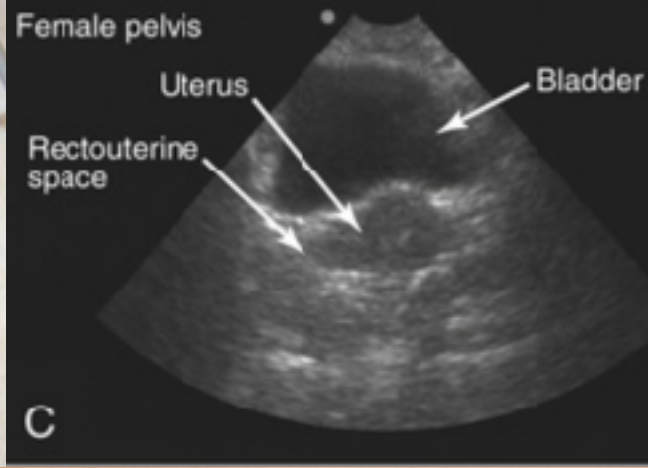
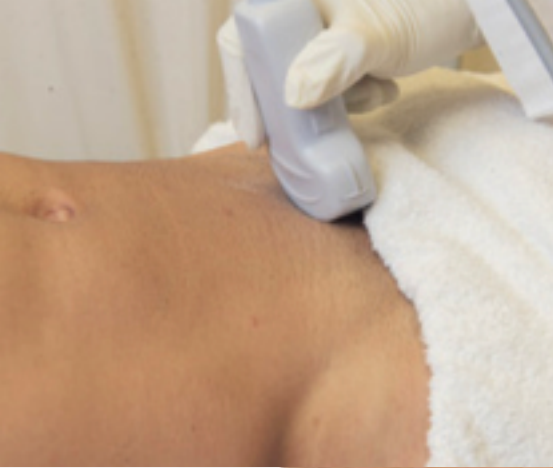13

13

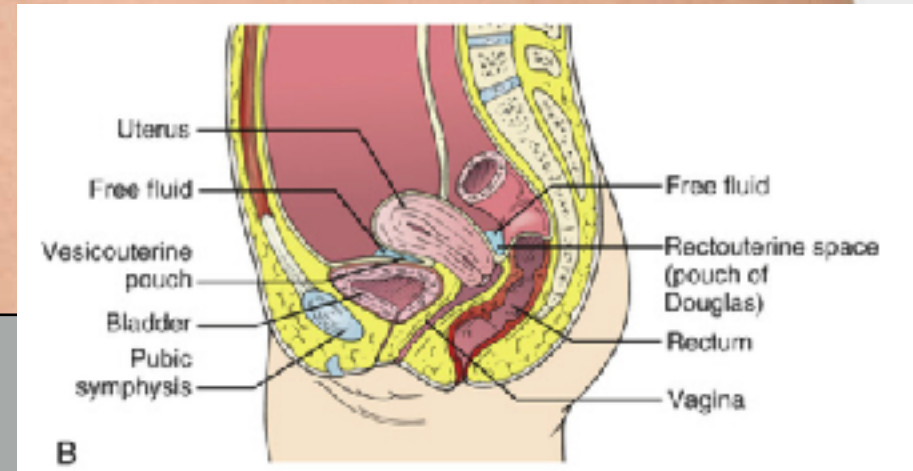
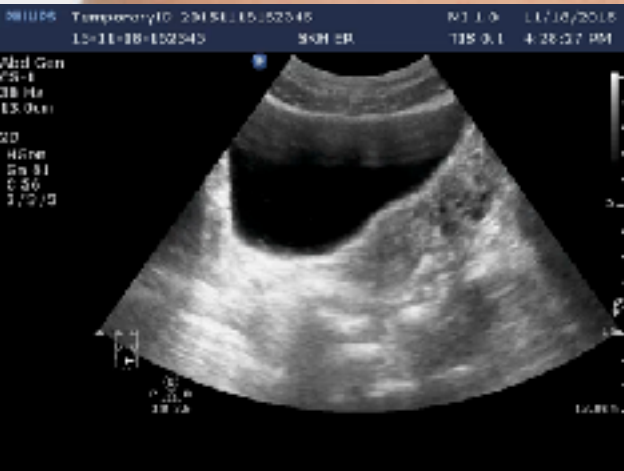

恥骨聯合上方
Tilt探頭進行掃描
要有好的視窗(尿液)
主要目標: 膀胱下方



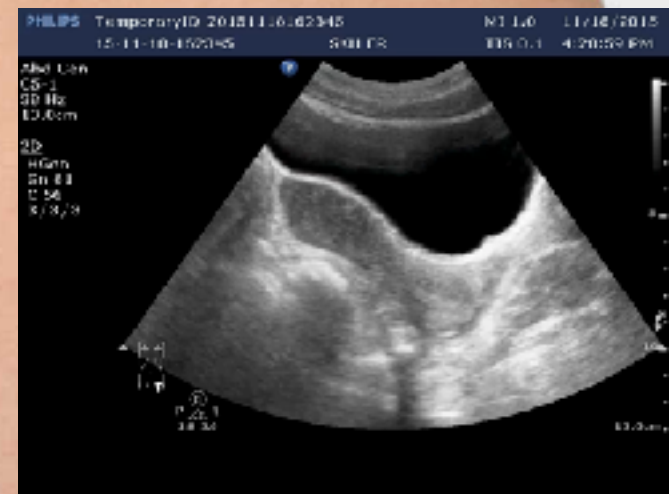
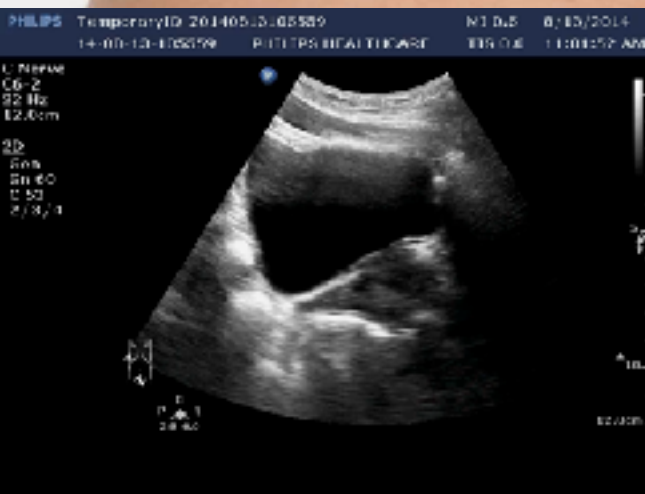


恥骨聯合上方
Tilt探頭進行掃描(頭腳)
要有好的視窗(尿液)
第一目標:子宮下方
第二目標:膀胱子宮間



為什麼一定要有這個介面呢？

恥骨聯合上方
Tilt探頭進行掃描(左右)
要有好的介面(尿液)
第一目標:子宮下方
第二目標:膀胱子宮間
男:膀胱下方

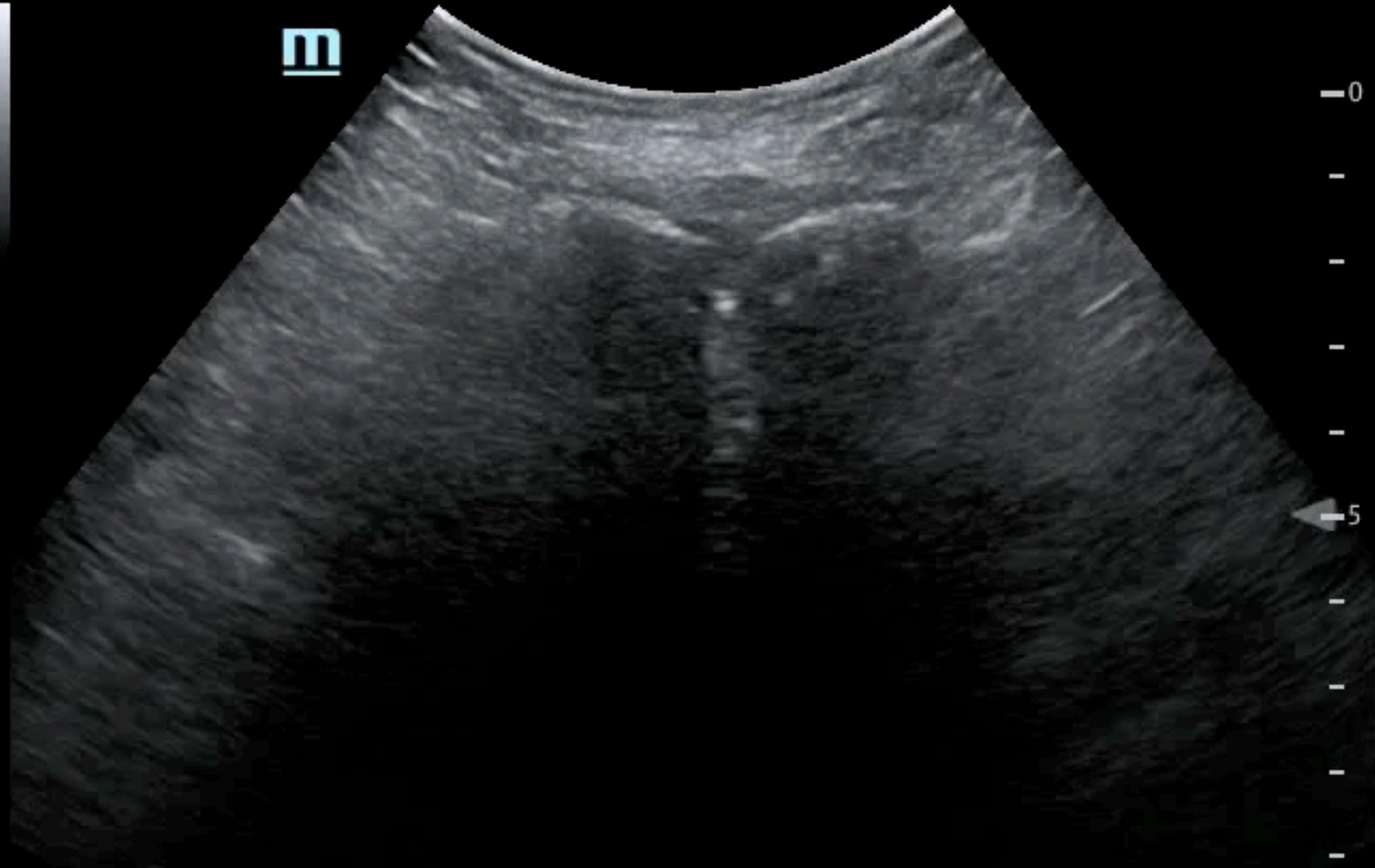


PUBIC SYMPHYSIS

MI 1.0
TIS 0.7



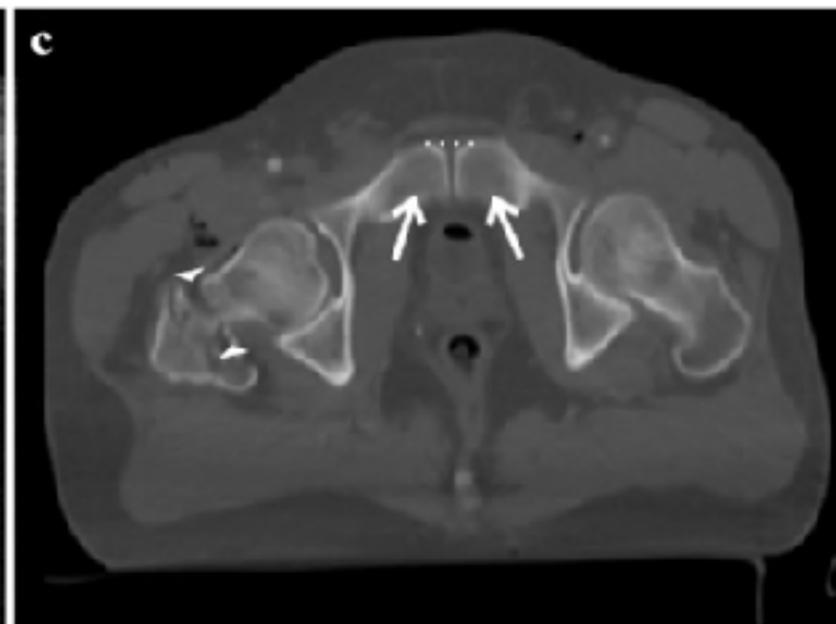
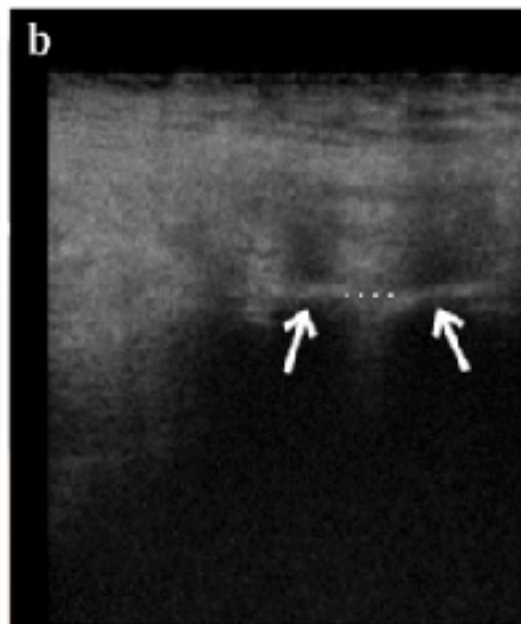
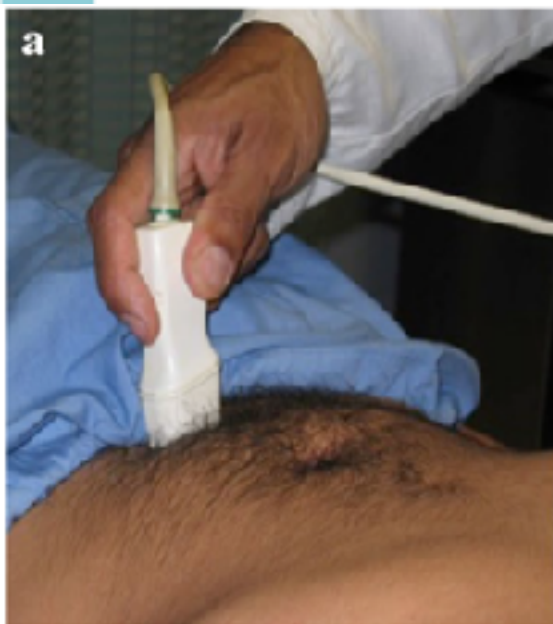B
FH5.0
DR120
FR28
D11.0
G47



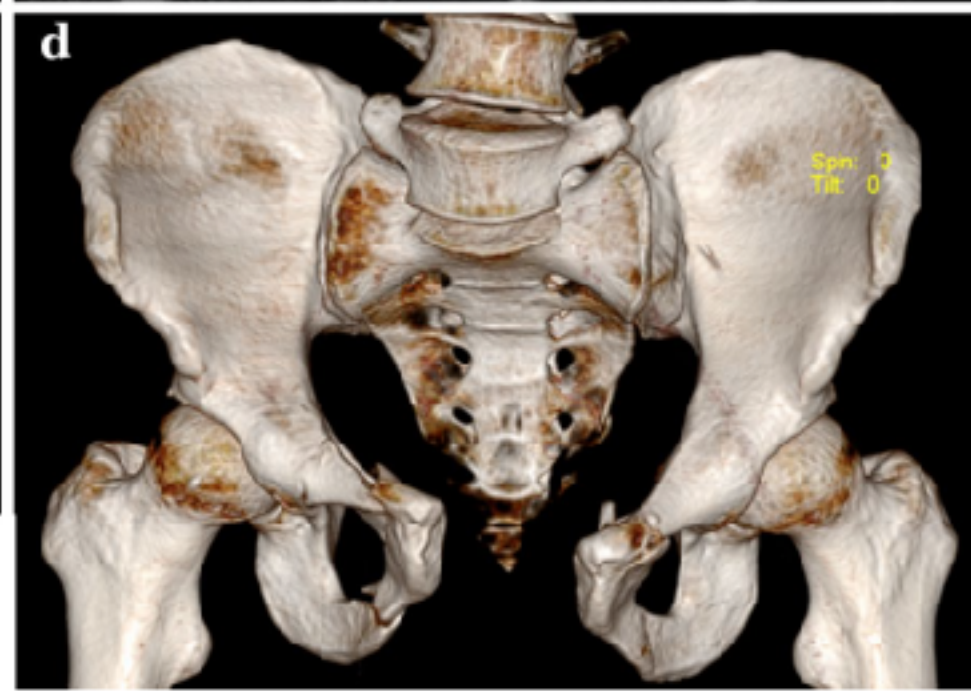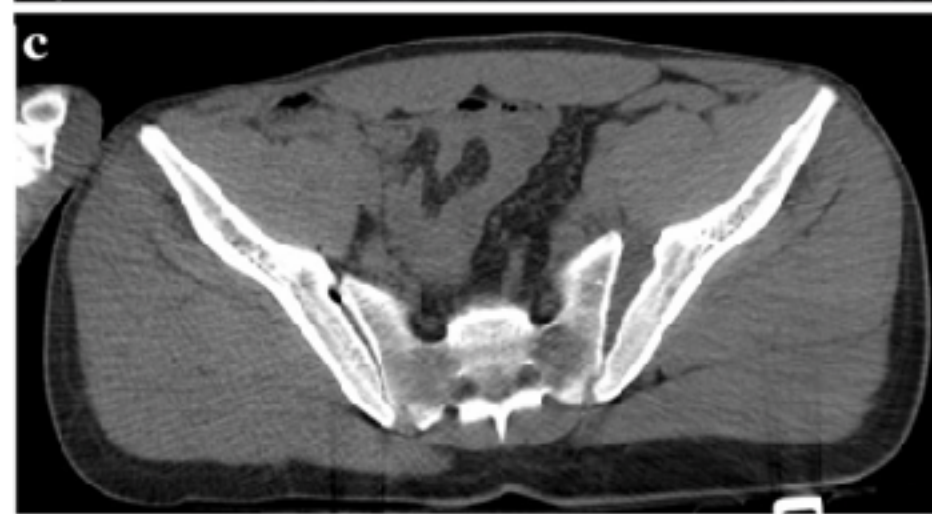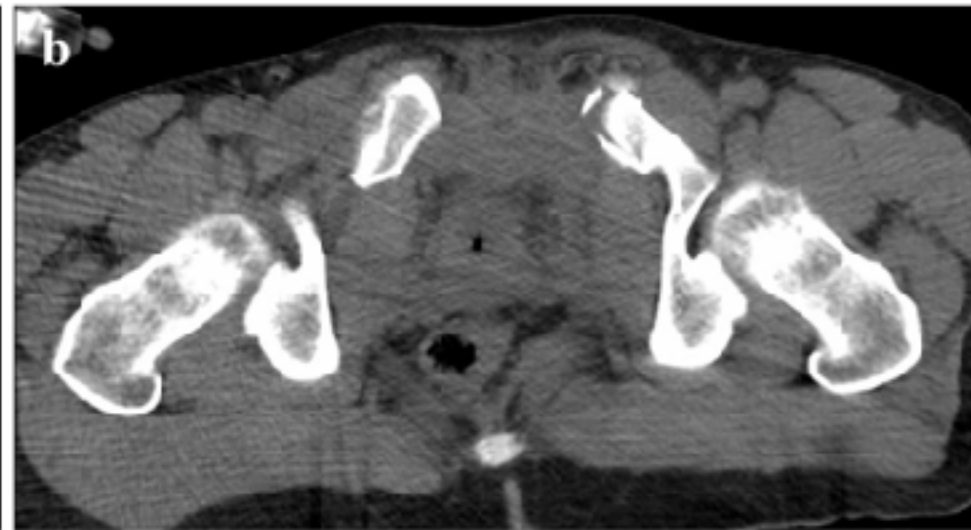
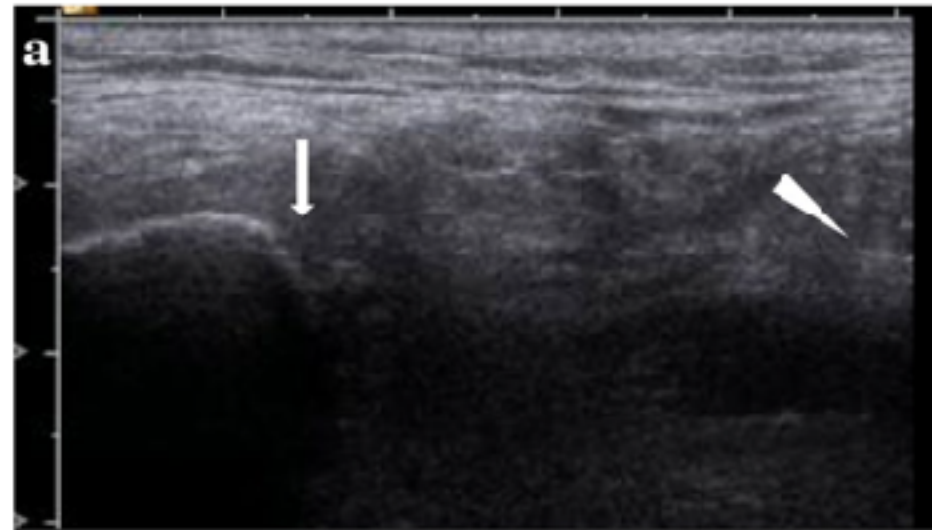
PS: 2.5CM

Diagnostic accuracy of pubic symphysis ultrasound in the detection of unstable pelvis in polytrauma patients during e-FAST: the value of FAST-PLUS protocol. A preliminary experience

Stefania Ianniello¹  · Paola Conte¹ · Marco Di Serafino²  · Vittorio Miele³  · Margherita Trinci¹  · Gianfranco Vallone⁴ · Michele Galluzzo¹ 



MAJOR TRAUMA + SHOCK



66M, TRAUMA

Triage: 2

E4V5M6

車禍，臉部擦傷

BT 37.3

左臉頰血腫，四肢擦傷

PR 87

不記得事發經過、背痛

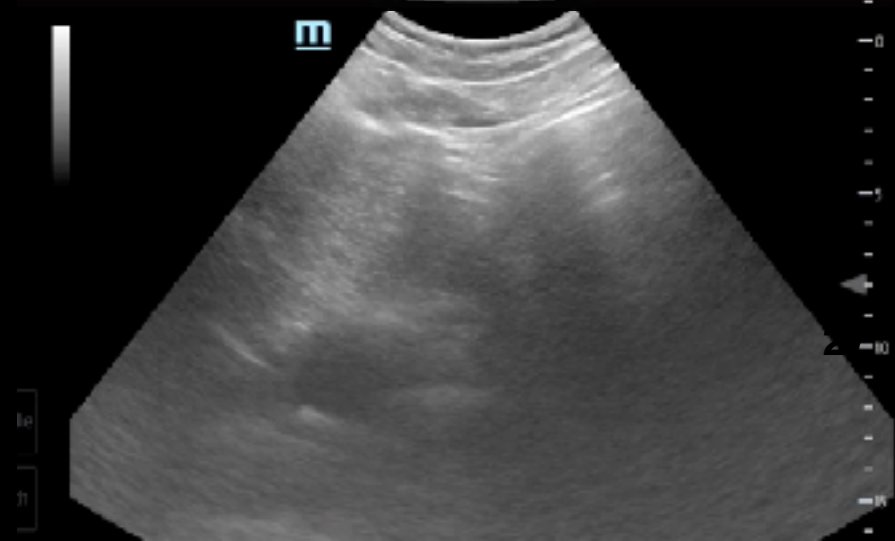
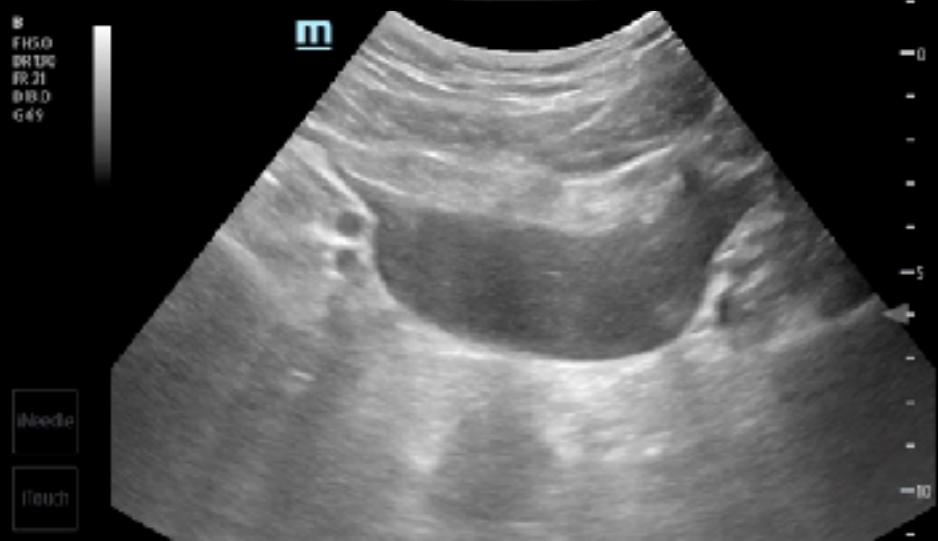
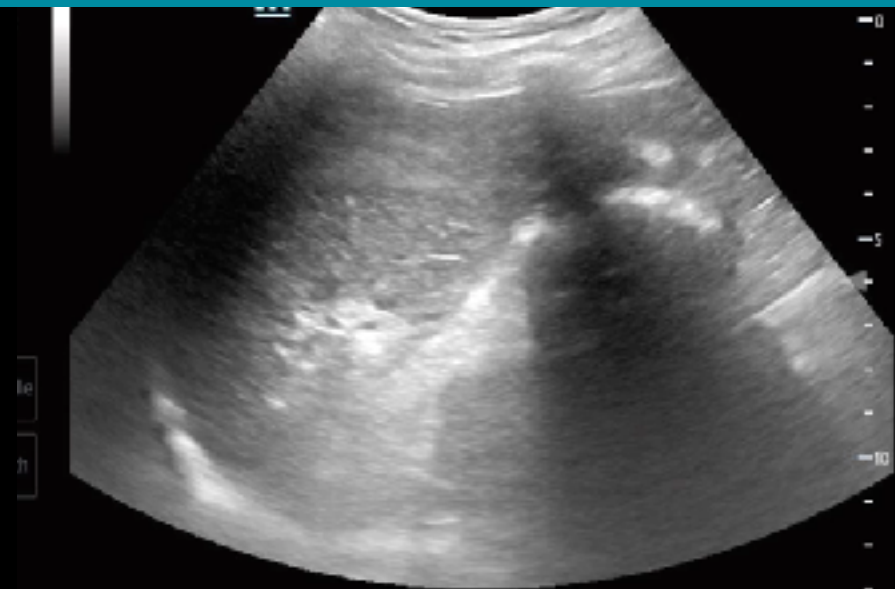
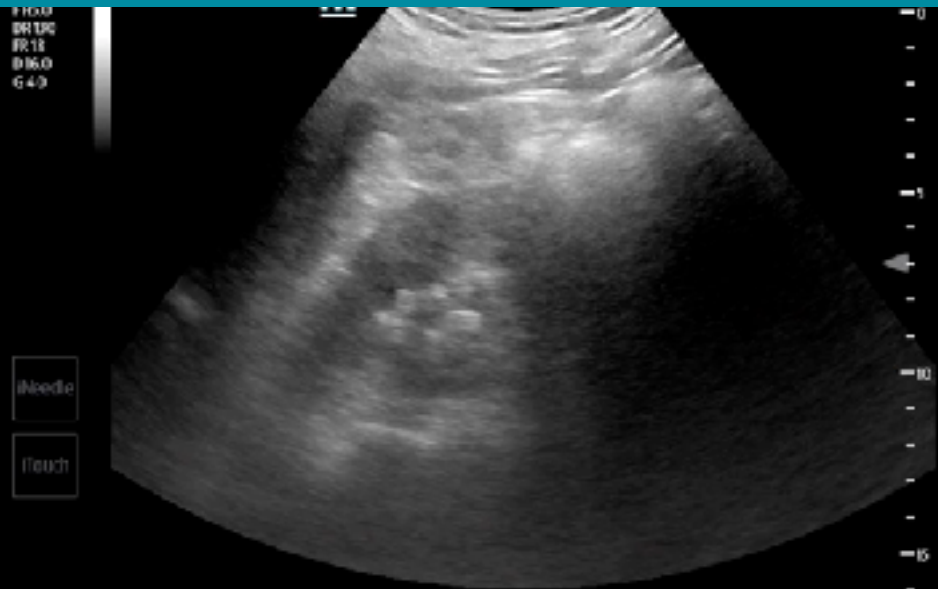
RR 20

EMT: 騎機車路倒無目擊者

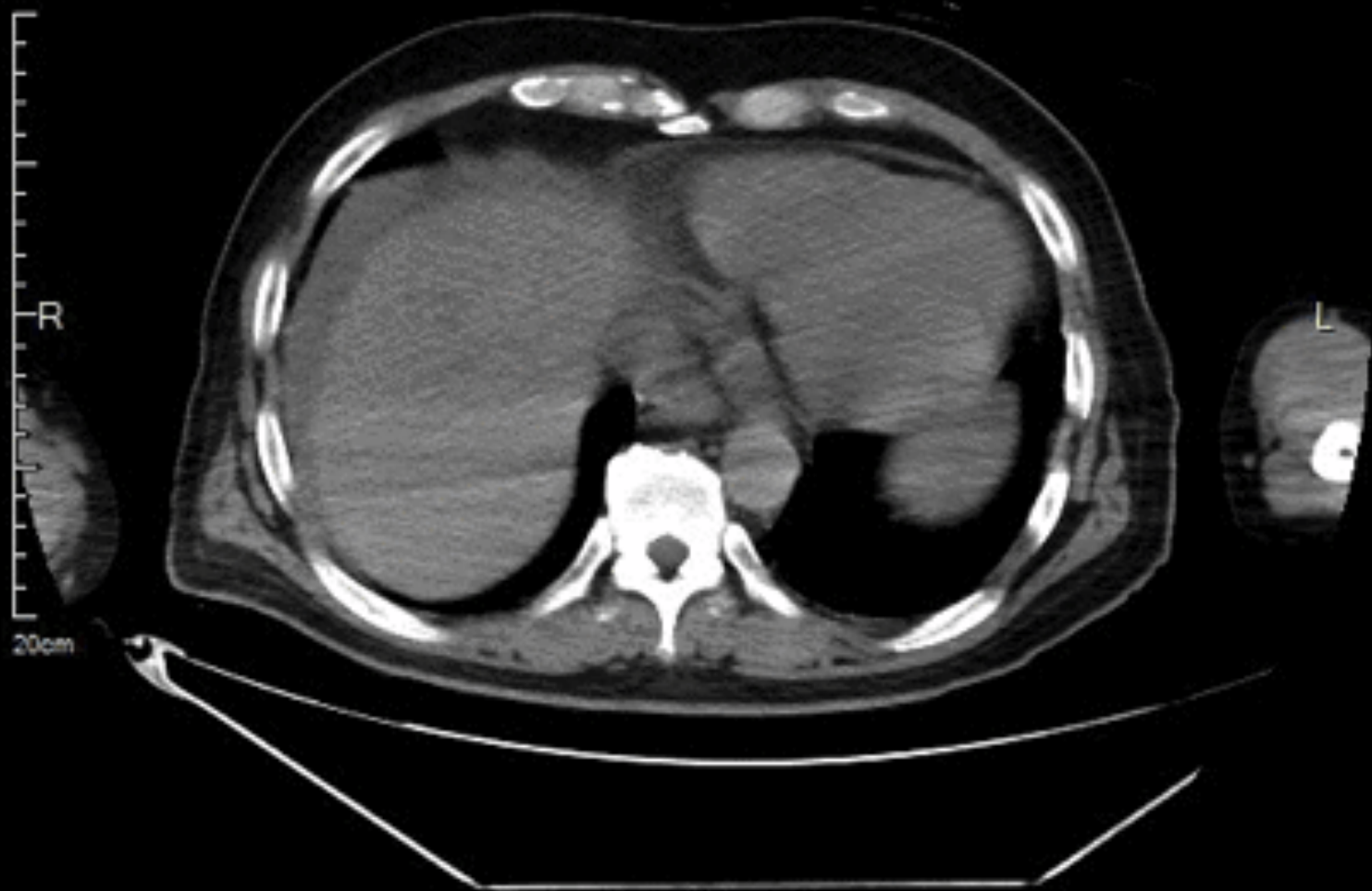
BP 118/65

SpO2 97%

66M, TRAUMA

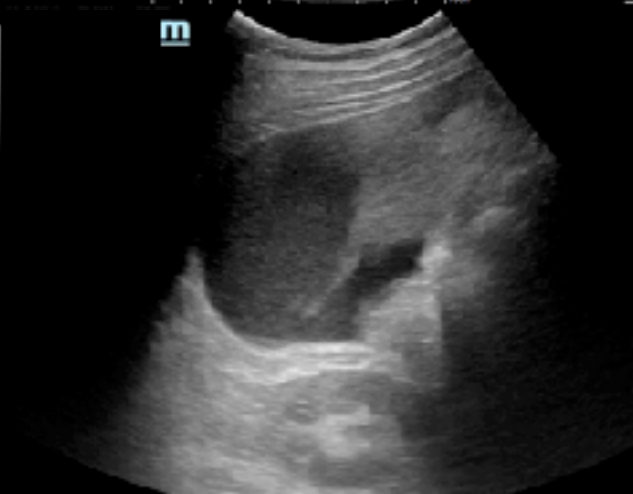
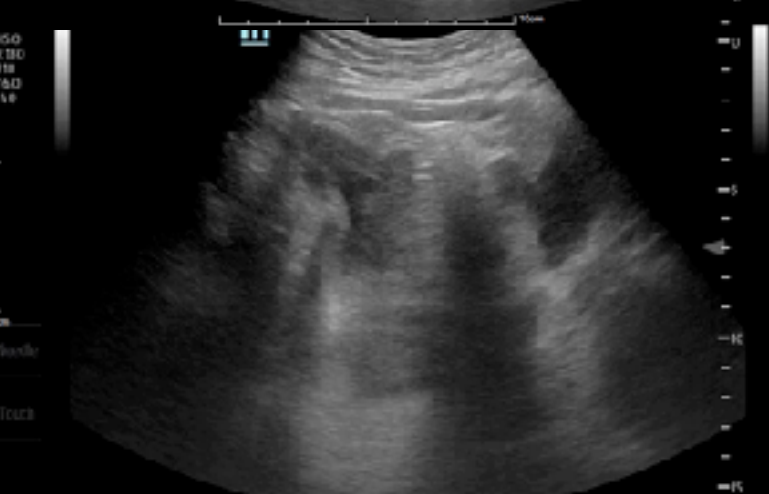
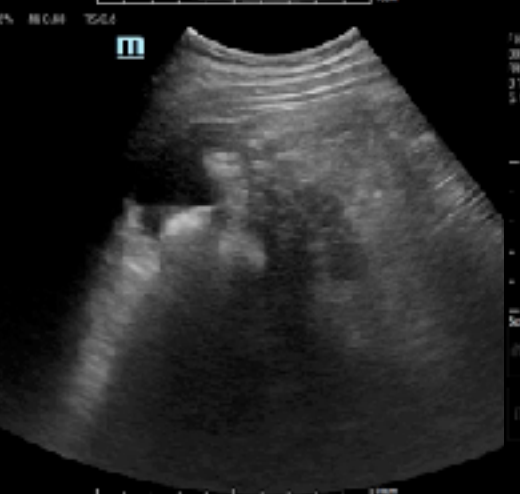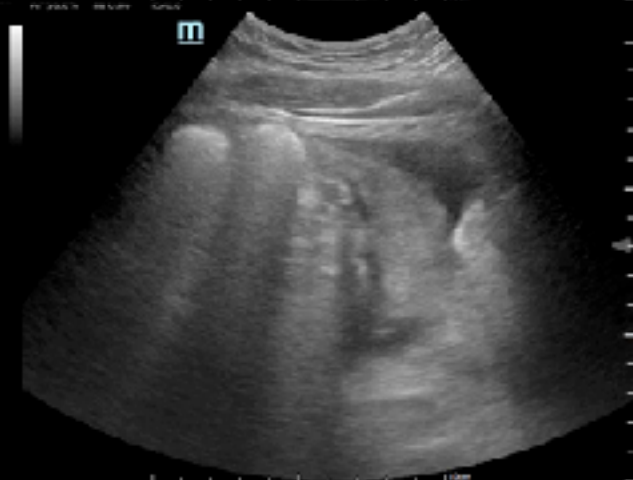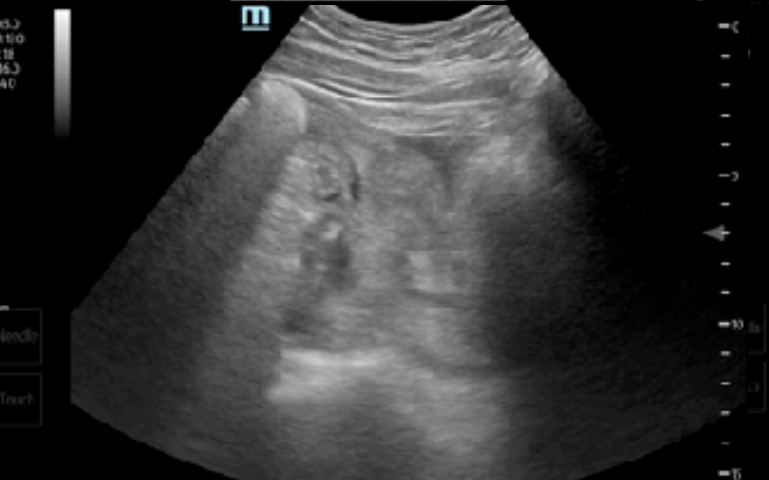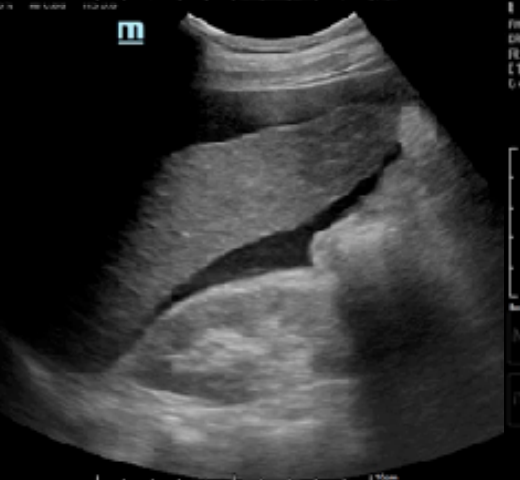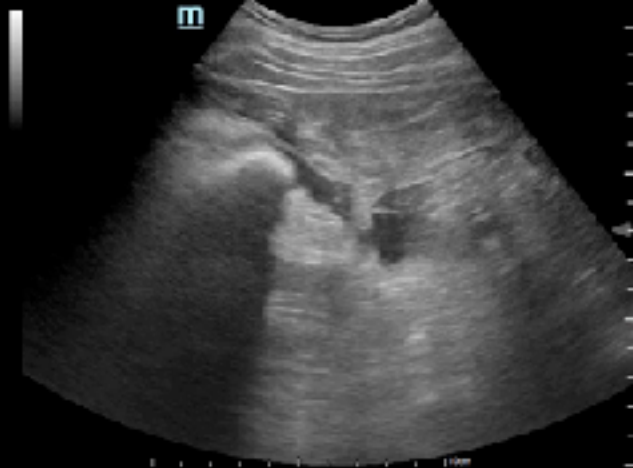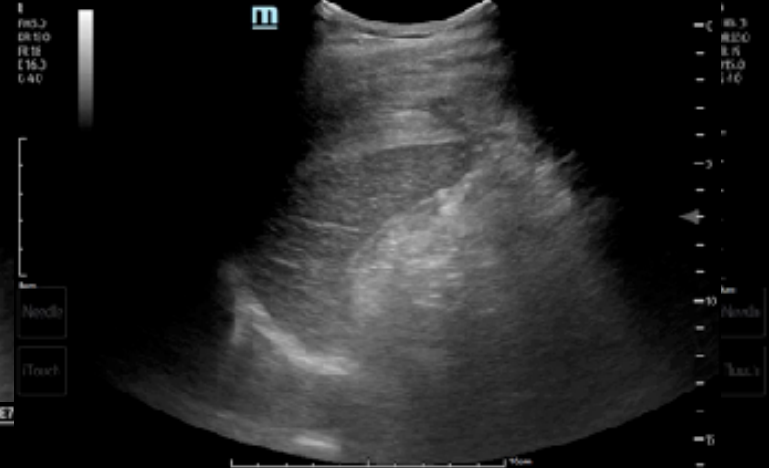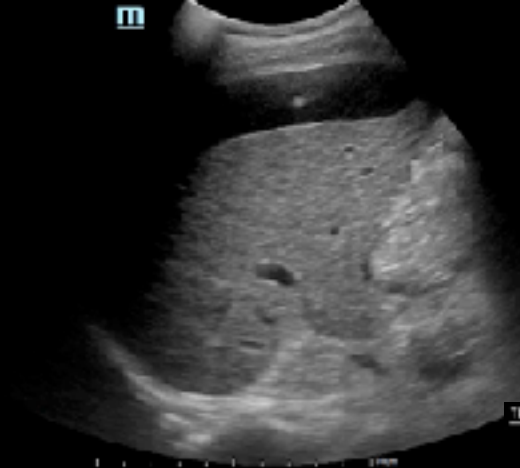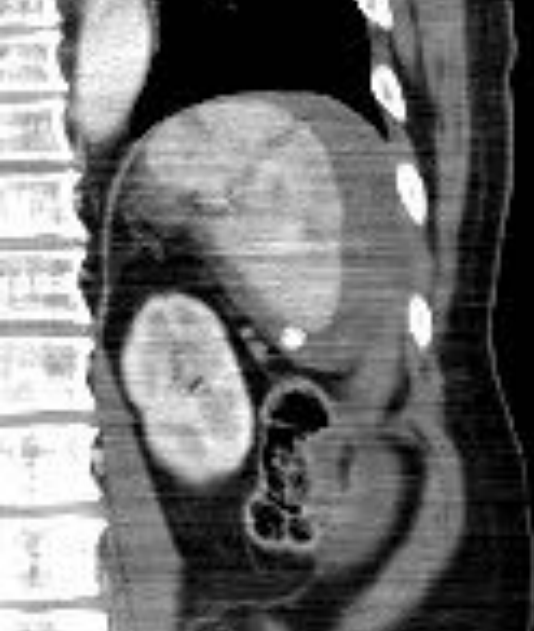A



P

20cm



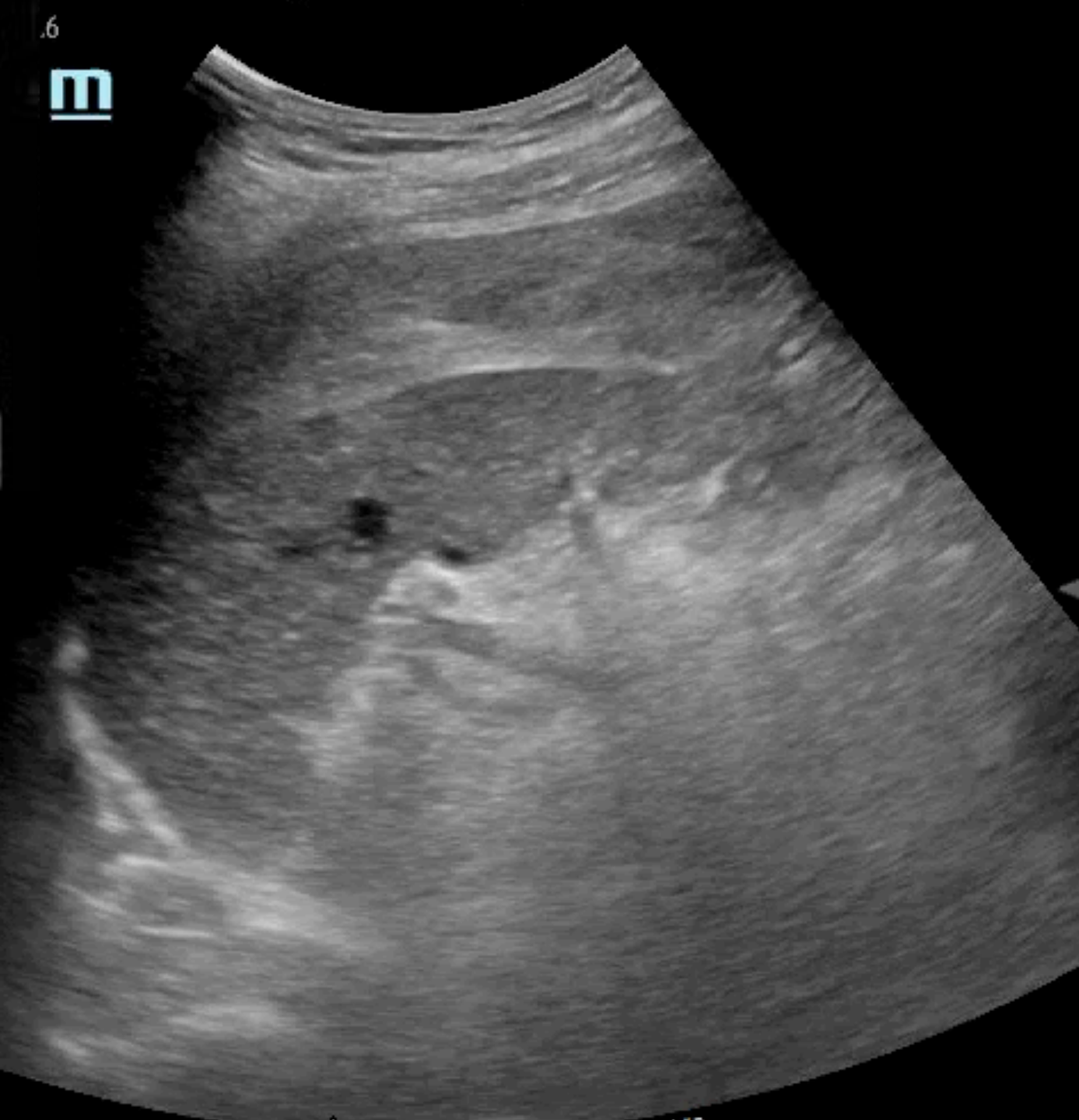

.6

m

dle

ch



30M, TRAUMA

Triage: 2

E4V5M6

騎機車為了閃車自摔

BT 36.5

上腹、胸口、右肩，頸部疼痛

PR 69

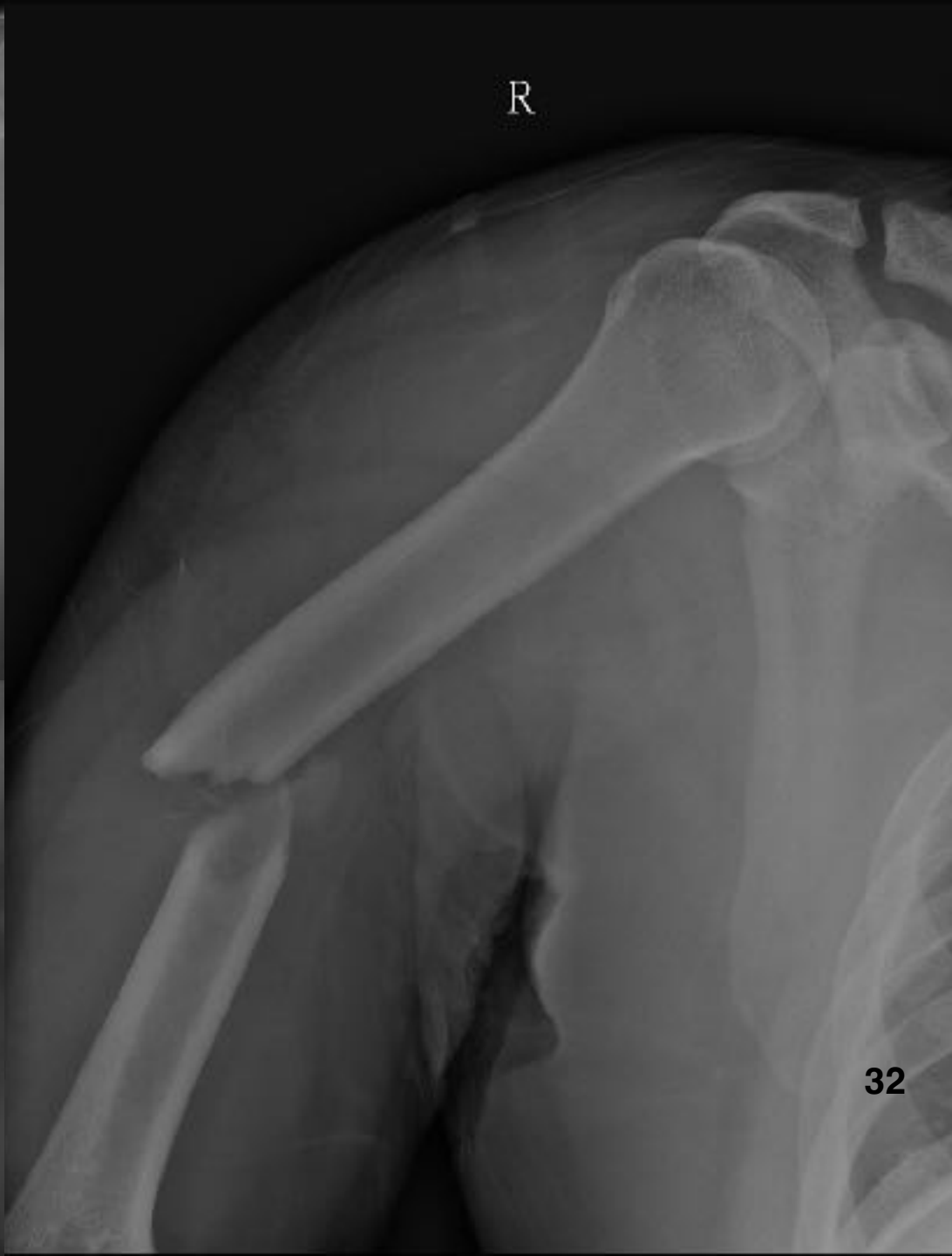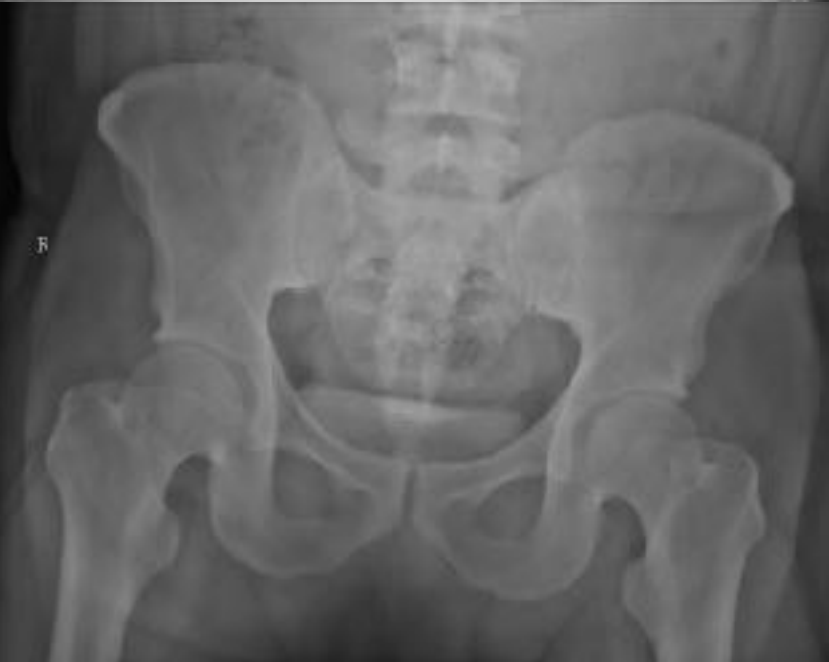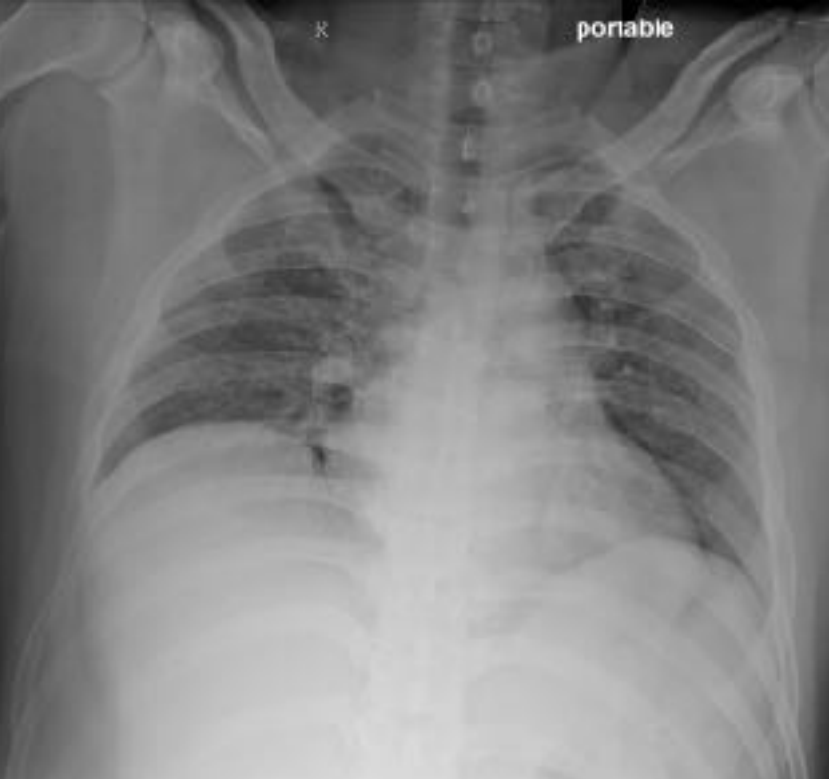冒冷汗

RR 20

VAS 7

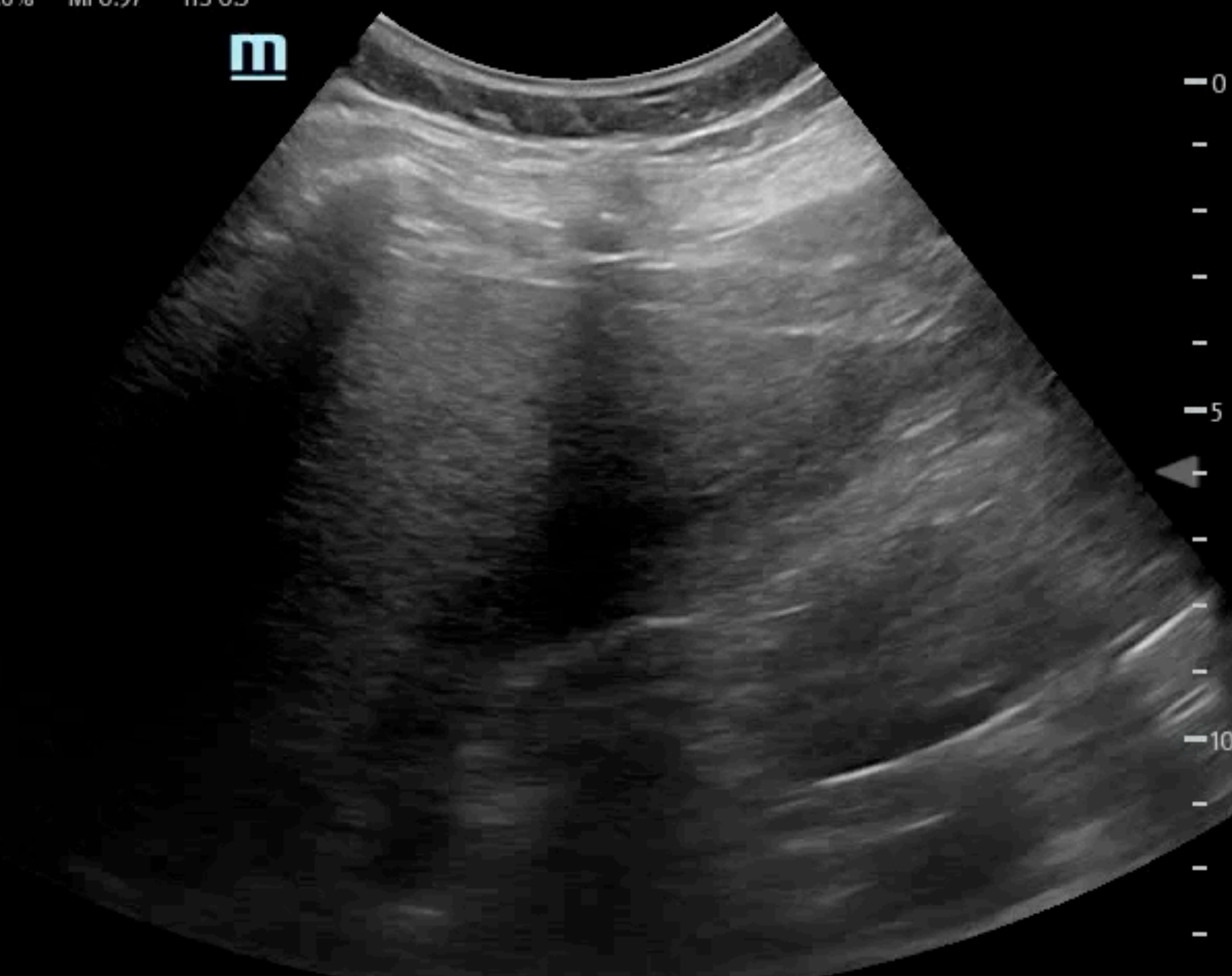
BP 103/69

SpO2 100%



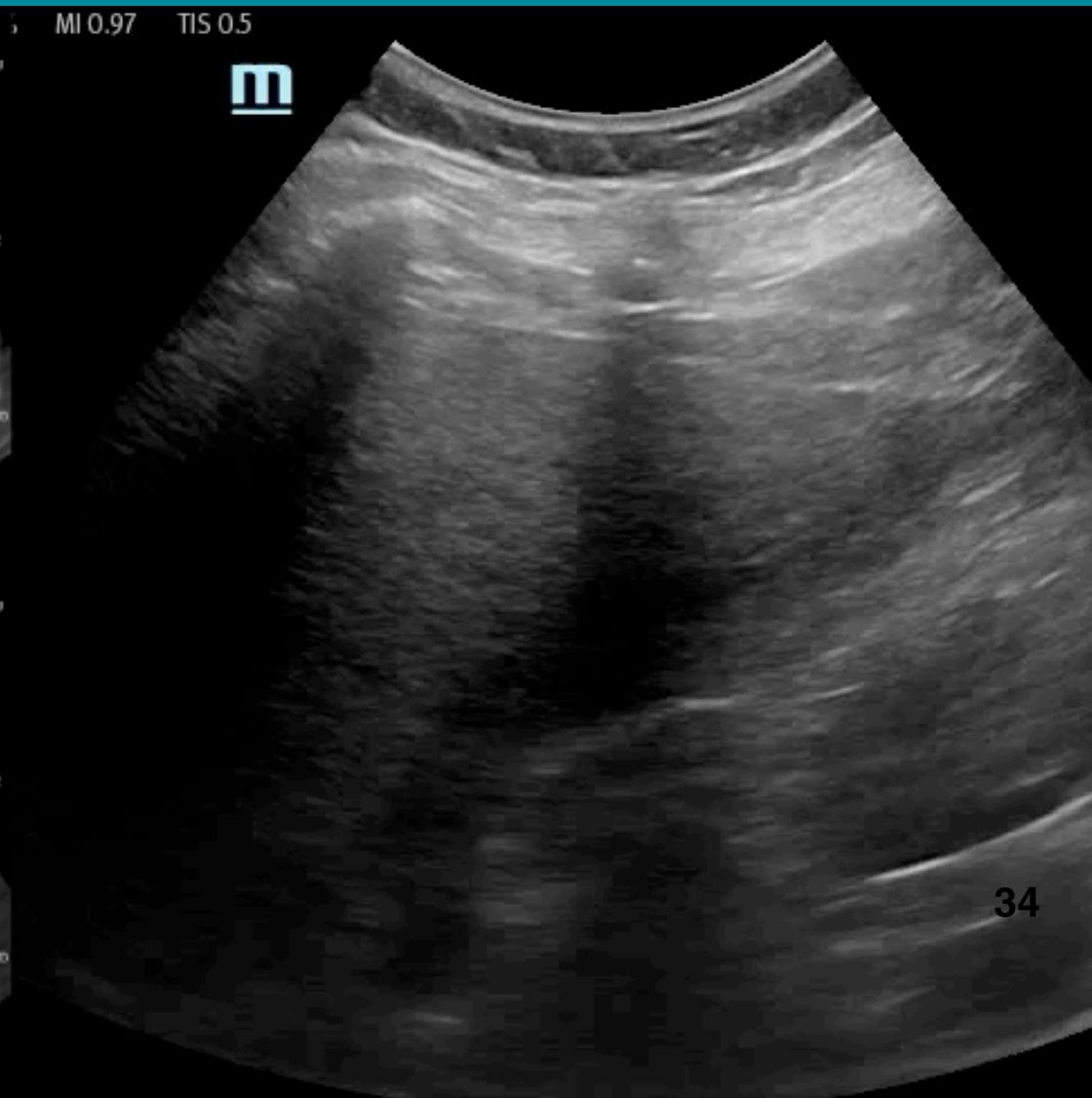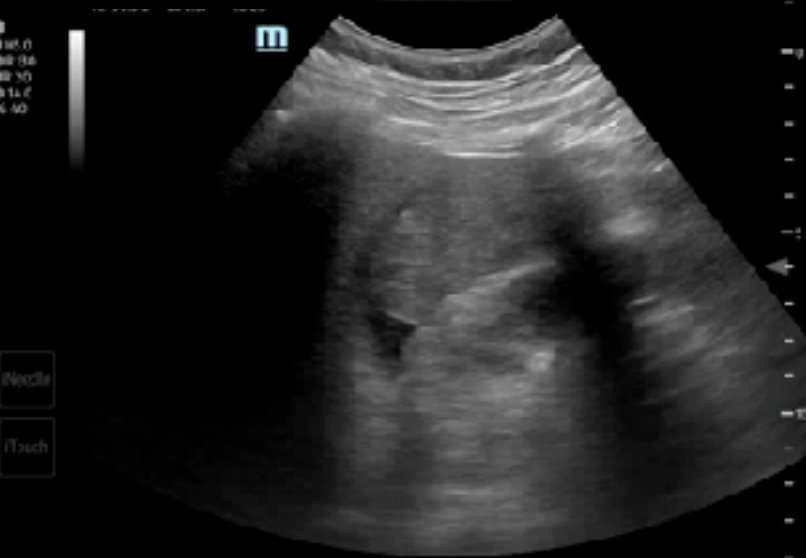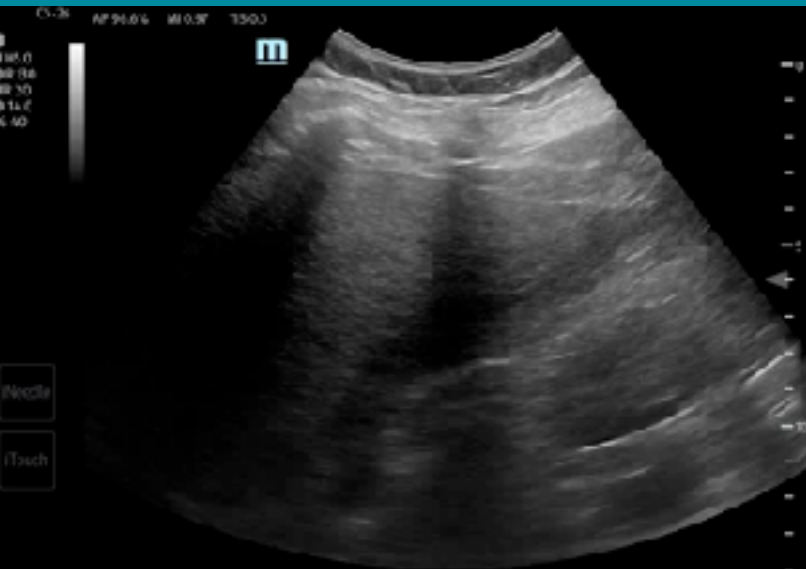-25 AP 96.6% MI 0.97 TIS 0.5

m

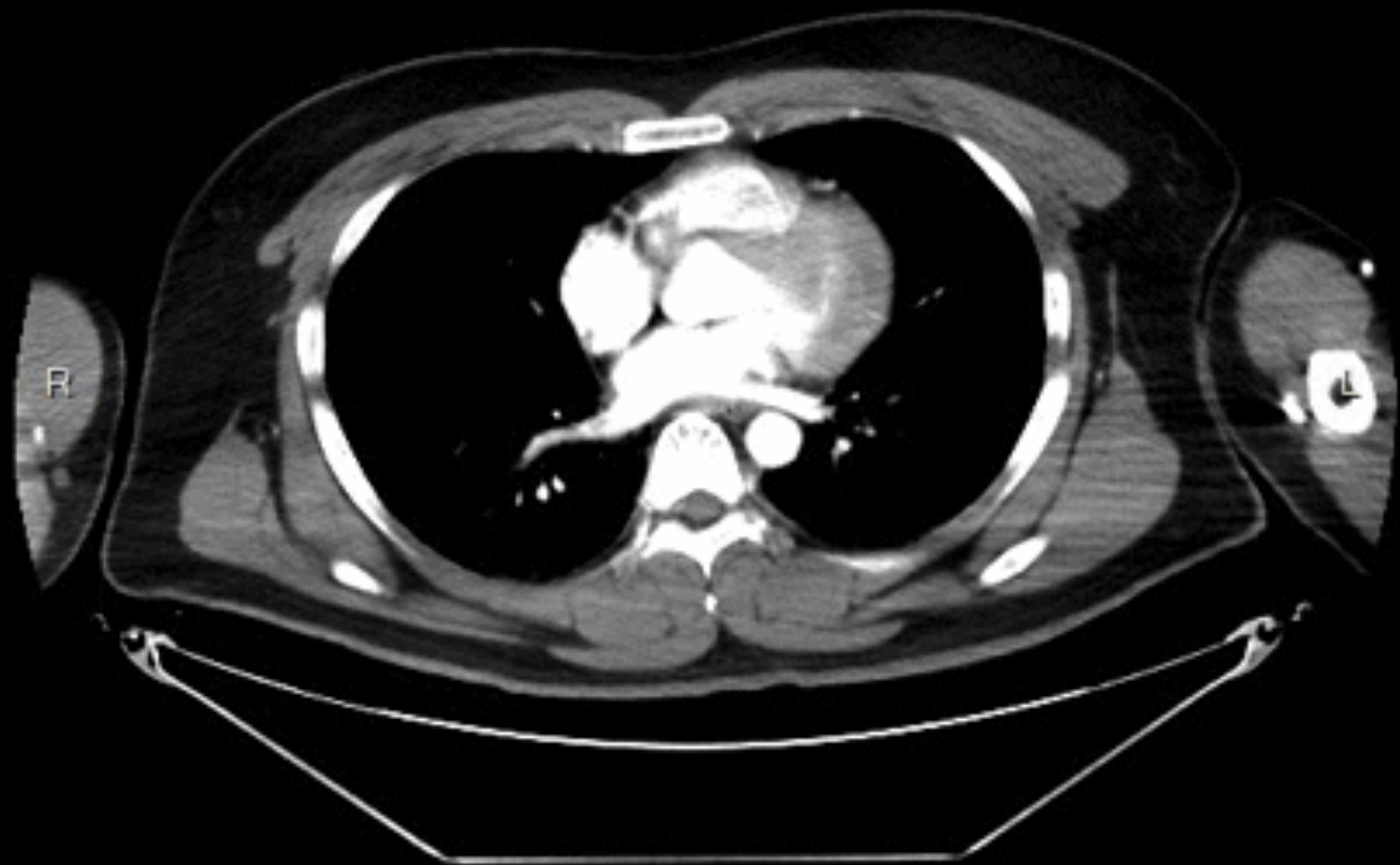

0
-
-
-
-
5
-
-
-
10
-
-
-
-

HEMOPERITONEUM



A

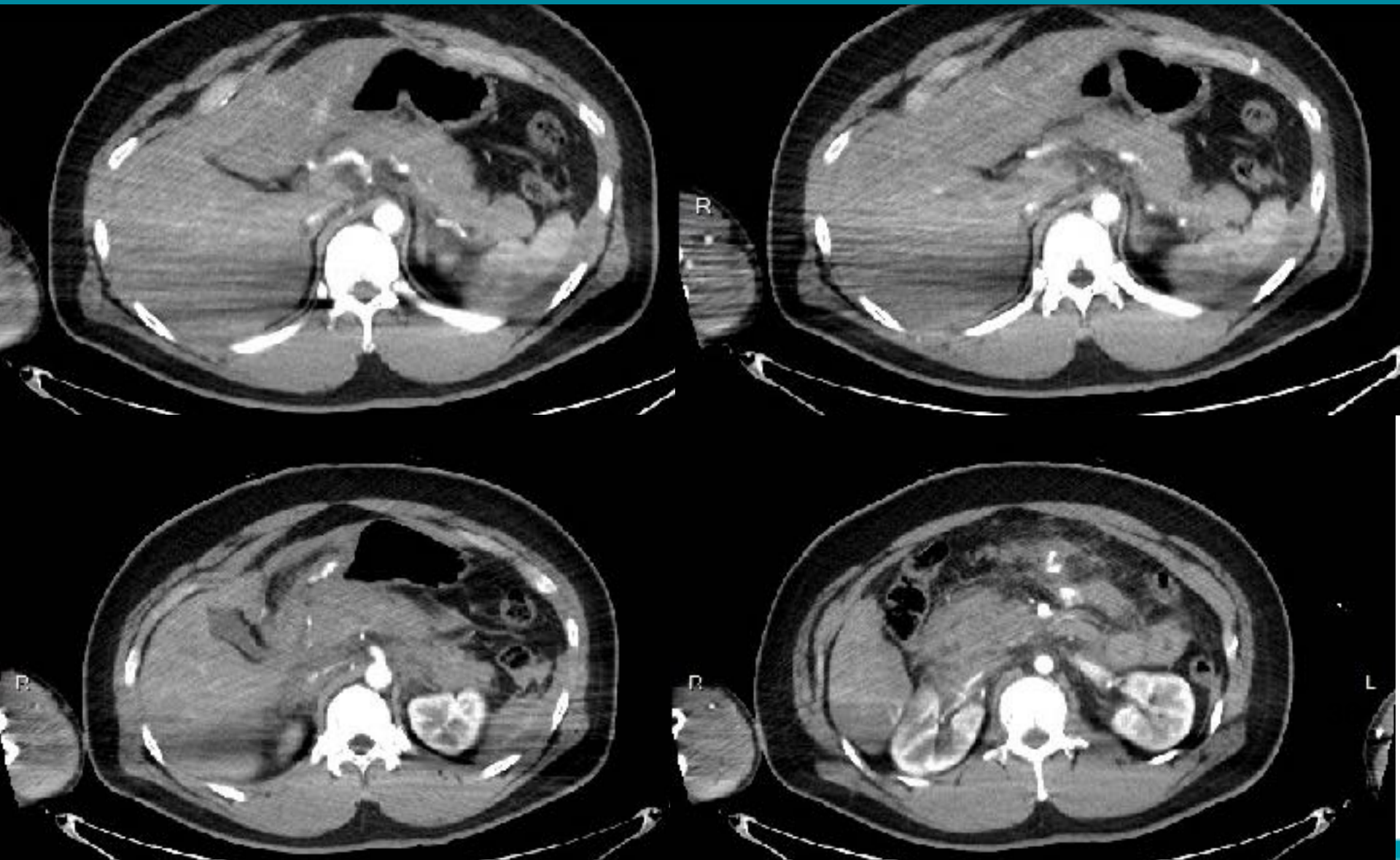


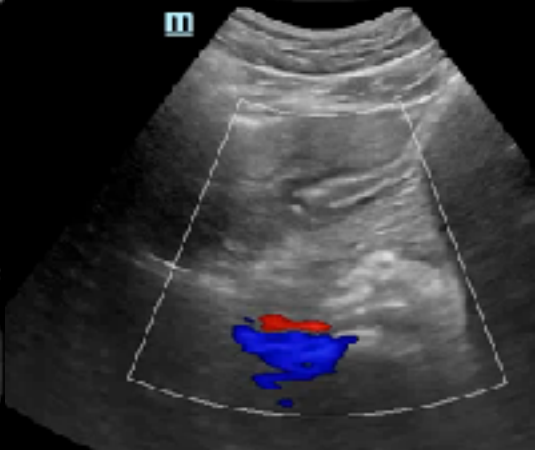
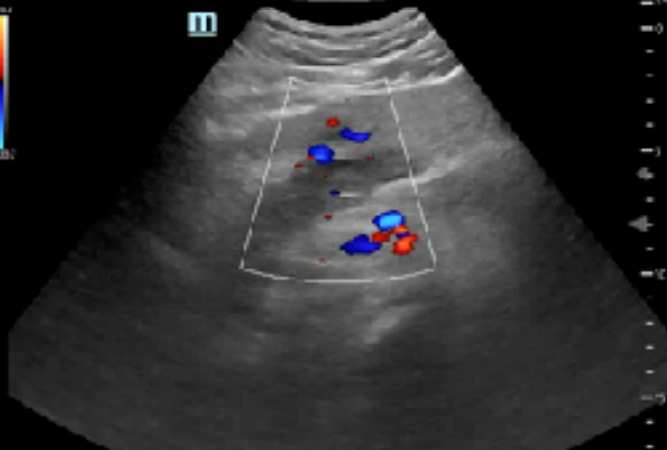
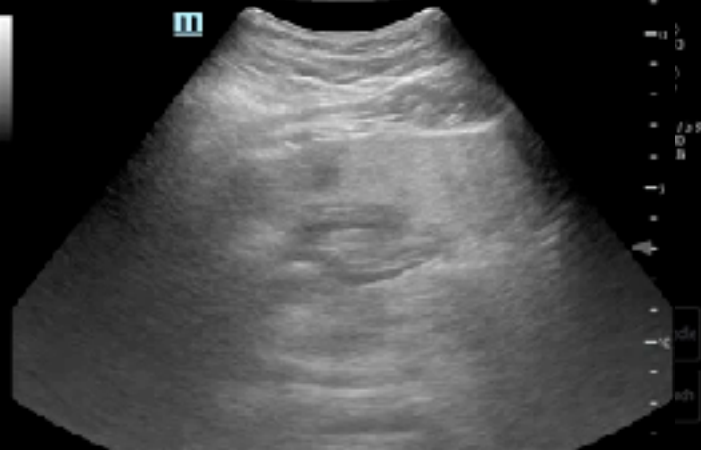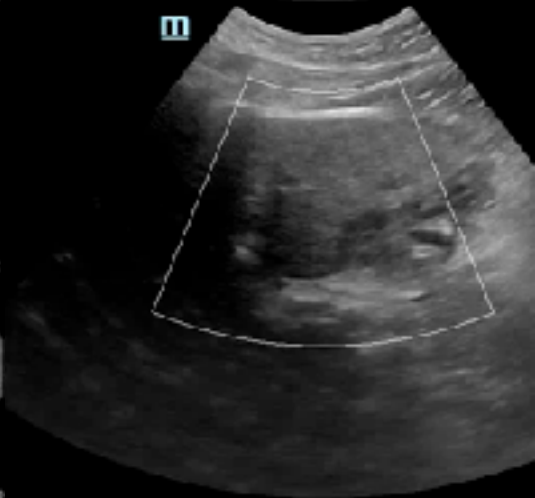
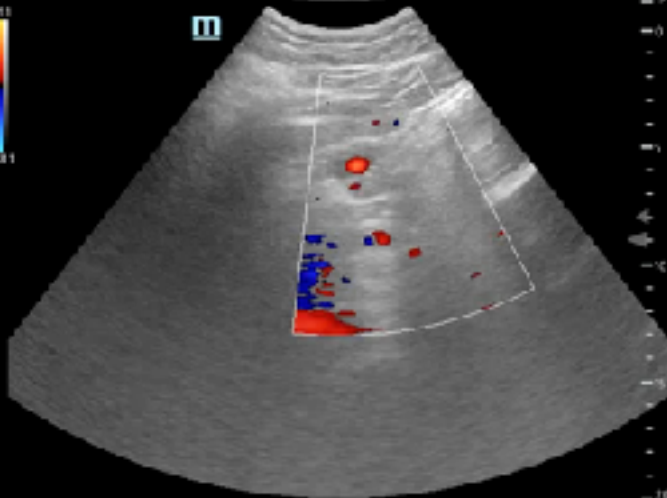
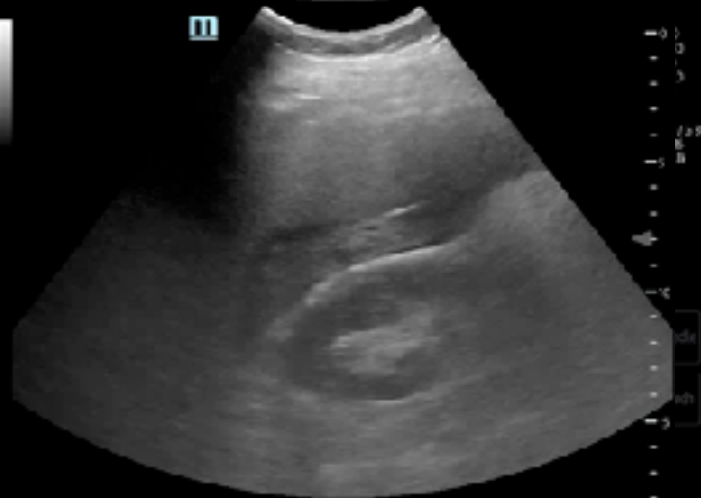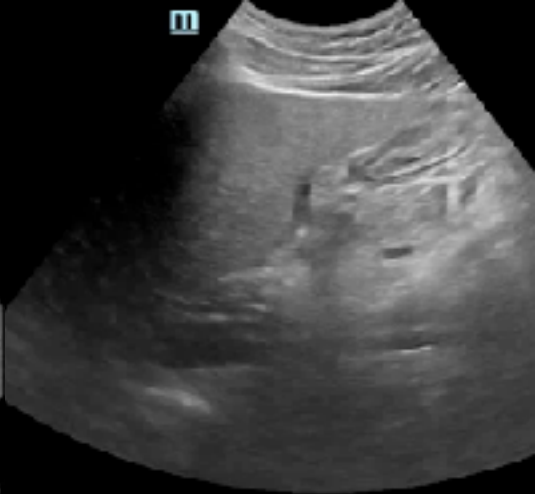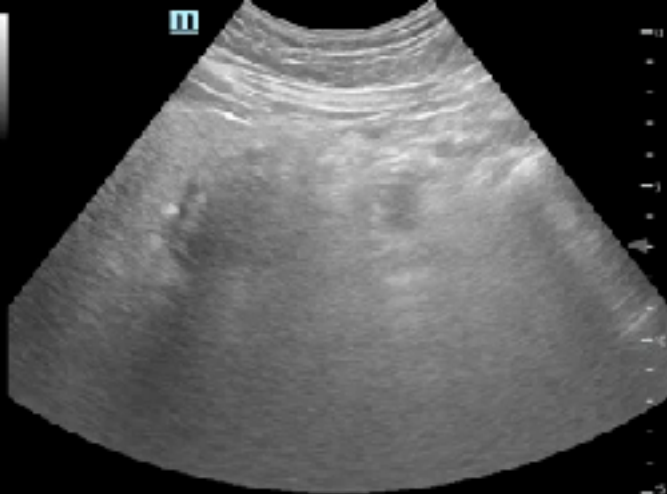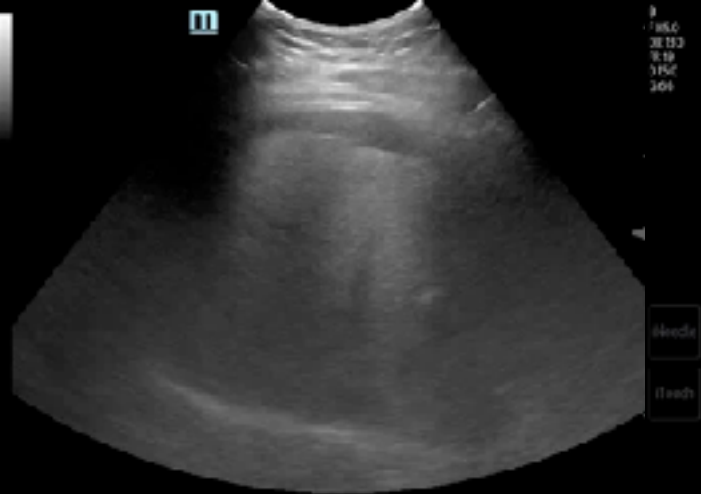R

L

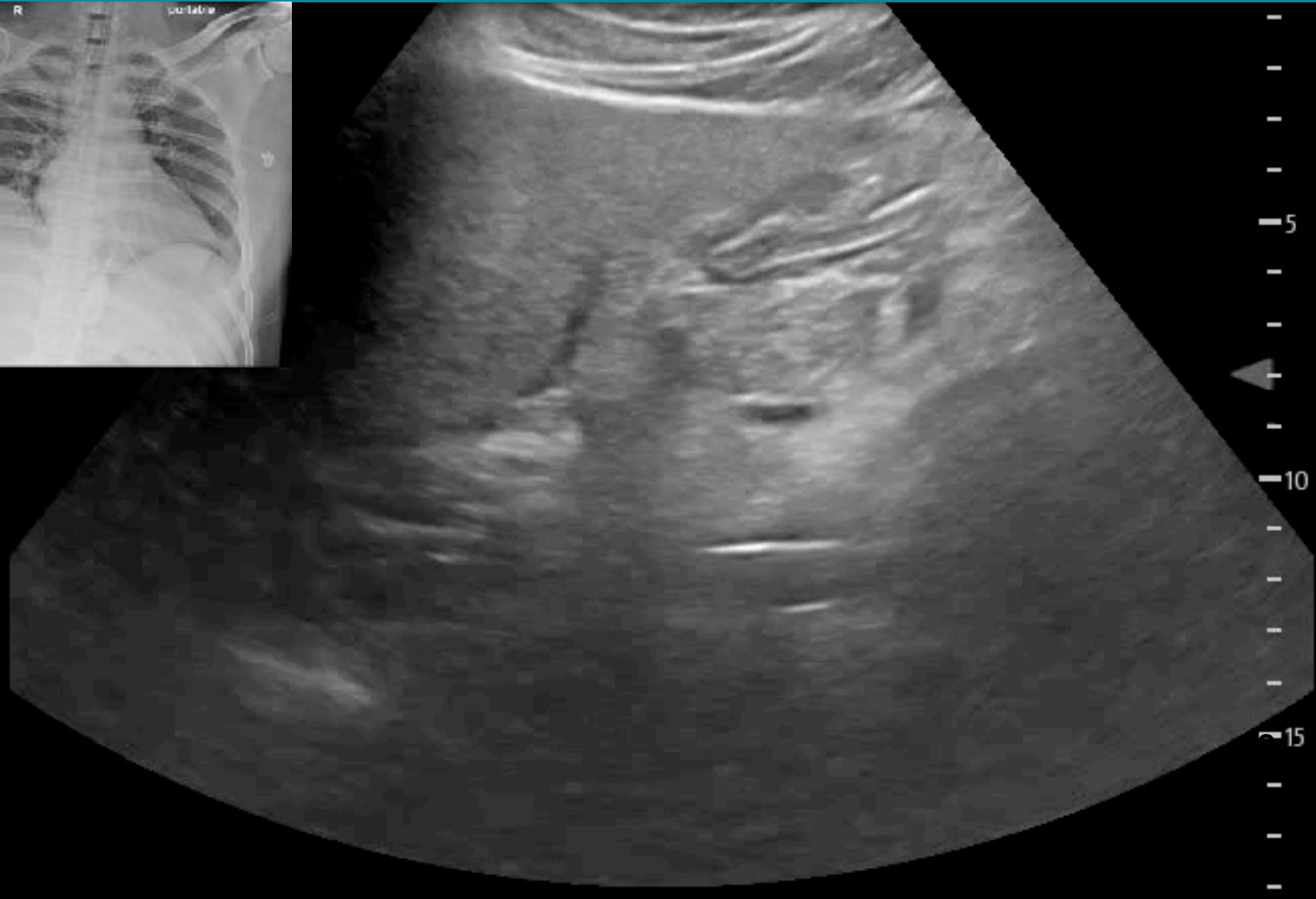
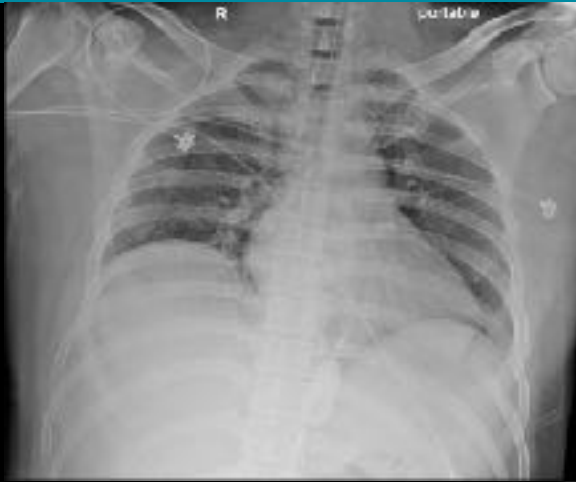P

Profound hypotension after CT



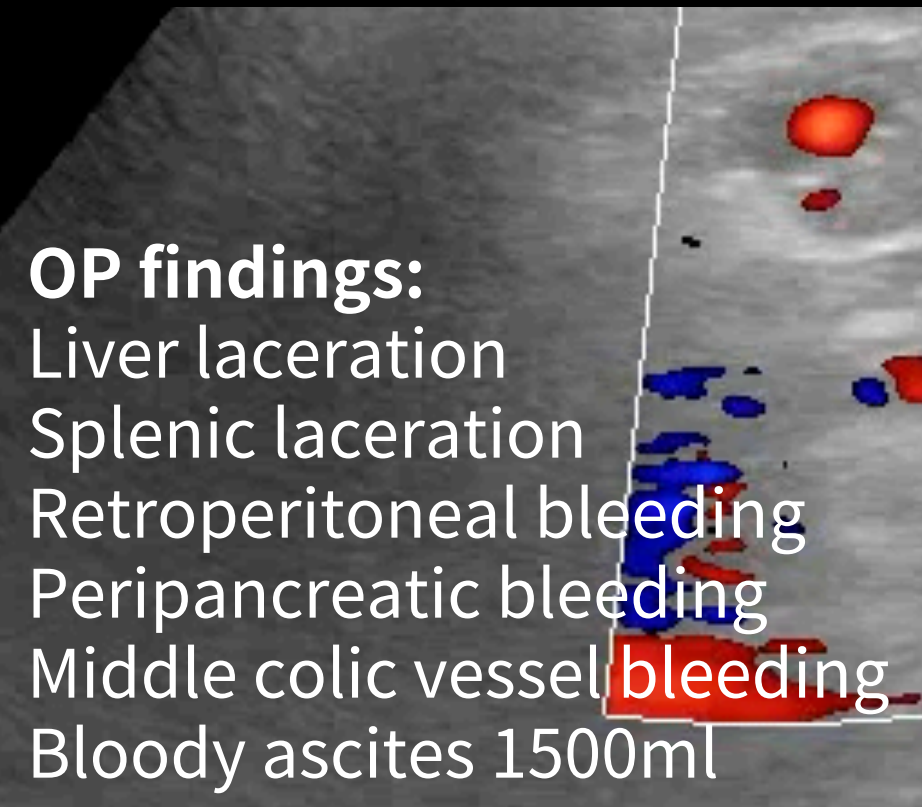
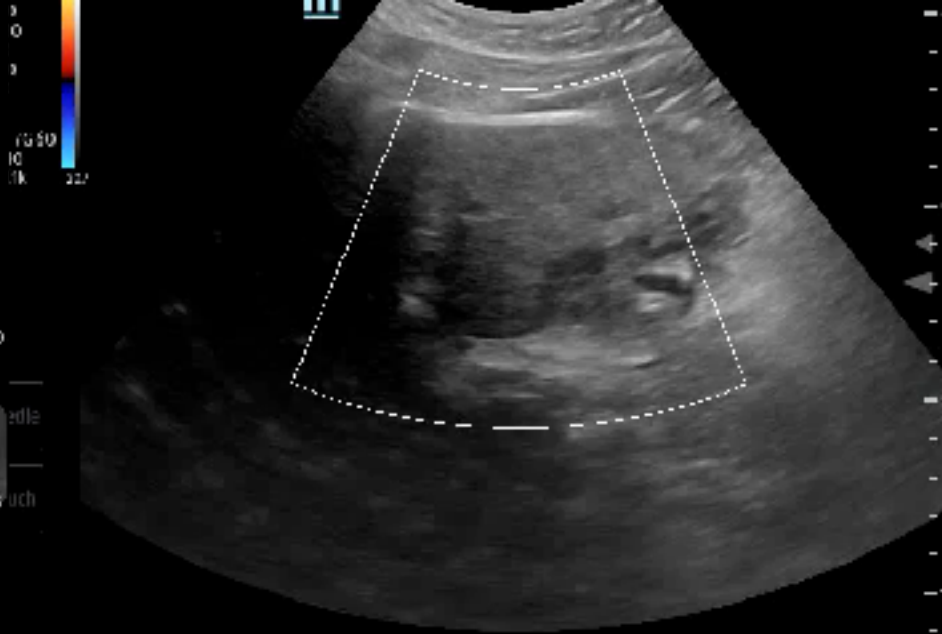
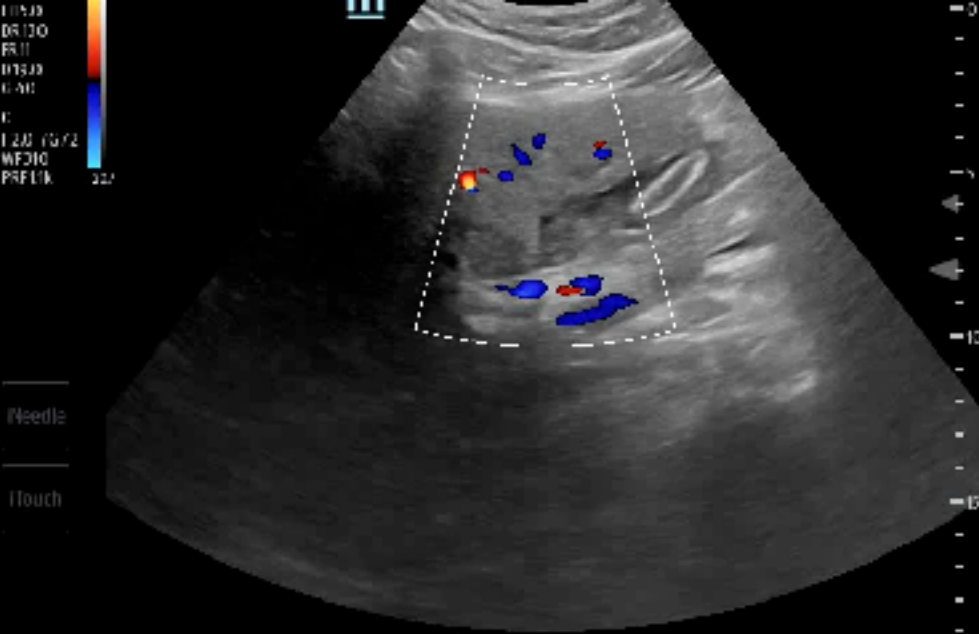


REBOA

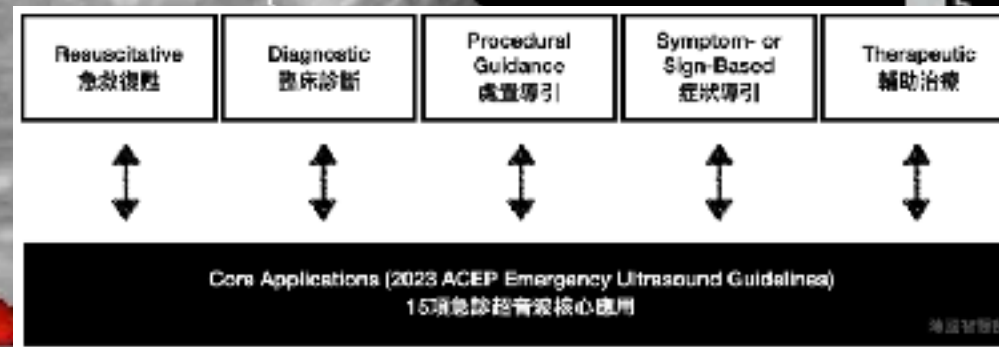

iNeedle

iTouch



OP findings:
 Liver laceration
 Splenic laceration
 Retroperitoneal bleeding
 Peripancreatic bleeding
 Middle colic vessel bleeding
 Bloody ascites 1500ml

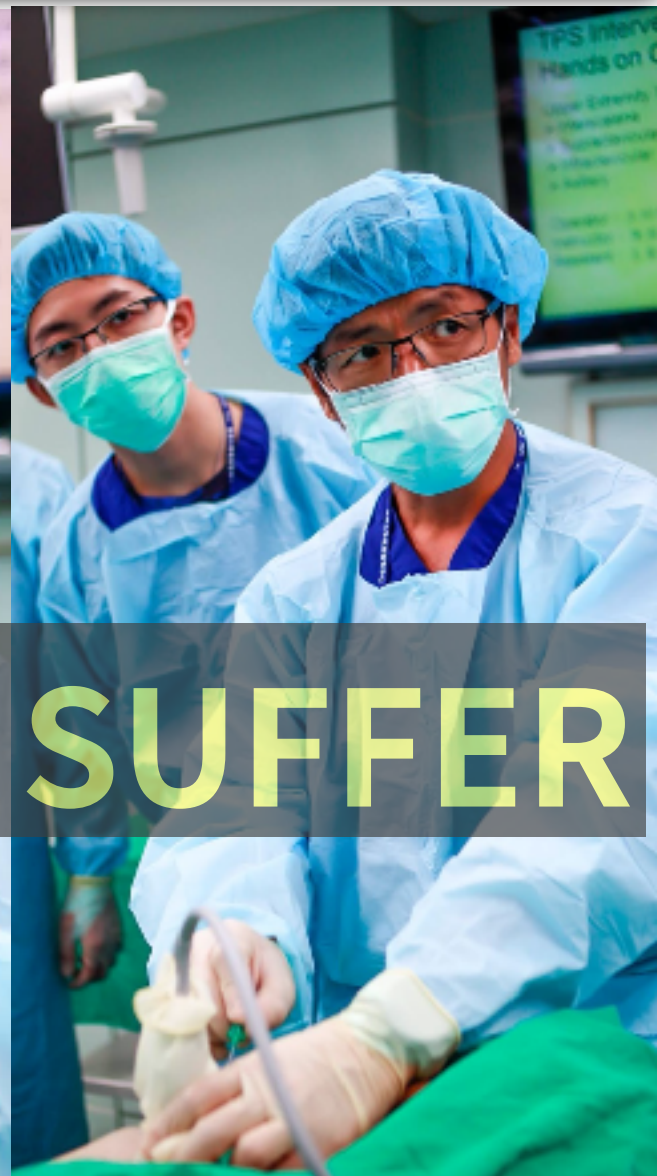
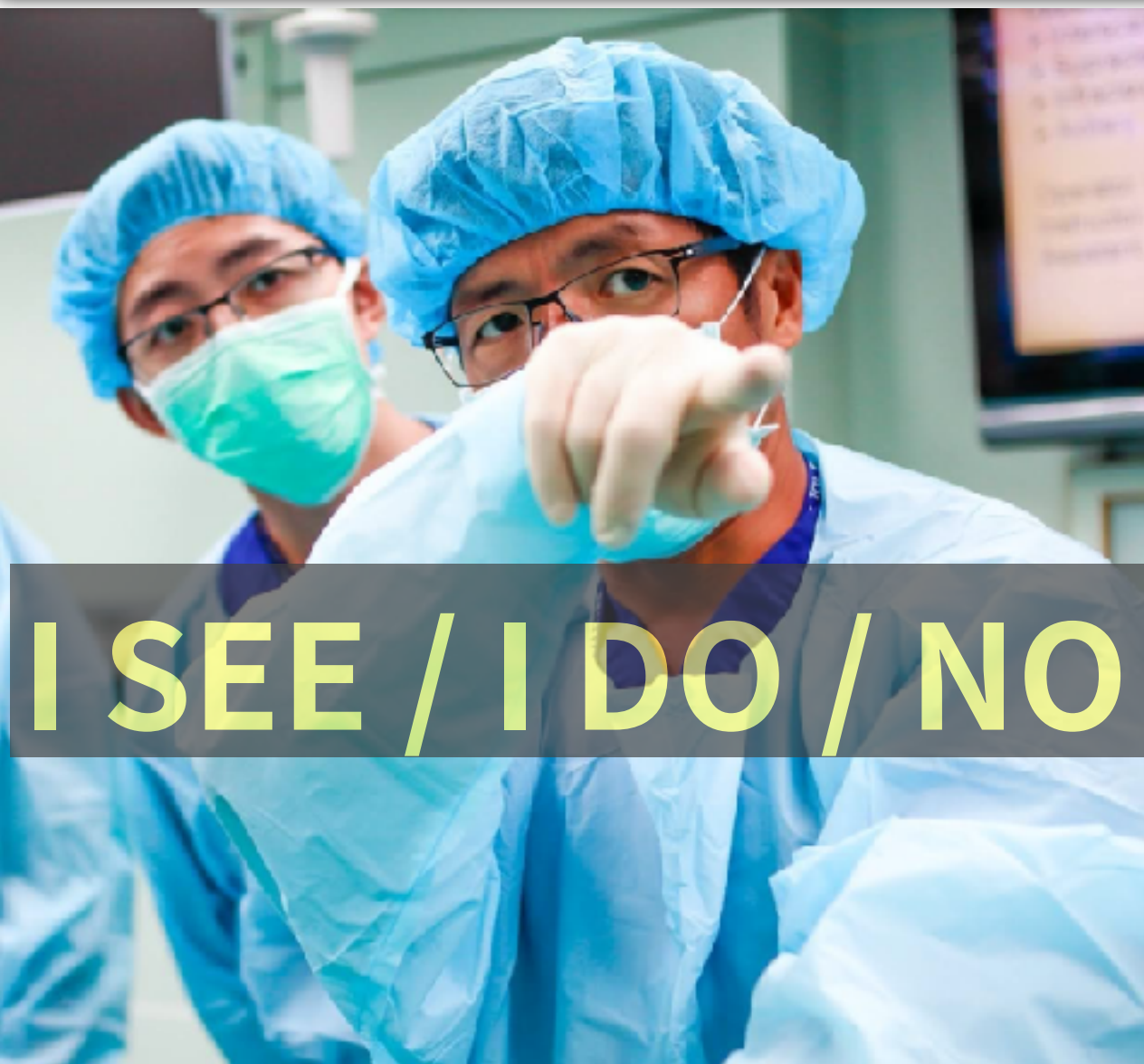
- Aorta
- DVT
- Trauma
- Thoracic/Airway
- Cardiac/HD assessment

- Procedural Guidance
- US-guided NB
- Testicular
- Ocular
- Skin & Soft tissue

- Hepatobiliary
- Urinary tract
- Pregnancy
- Bowel
- MSK

雙和急診提供精準無痛個人化急診醫療



I SEE / I DO / NO SUFFER