



雙和急診POCUS訓練



衛生福利部雙和醫院
(委託臺北醫學大學興建經營)
Taipei Medical University · Shuang Ho Hospital,
Ministry of Health and Welfare



基礎急診心臟超音波

Basic Cardiac Echo

陳國智醫師 雙和醫院急診醫學科

juice119@gmail.com

POCUSacademy.com

陳國智 醫師 / POCUSacademy.com



急診超音波臨床評核醫師
醫用超音波學會指導醫師
WINFOCUS director / instructor
Certified Interventional Pain Sonologist



急診 / 重症 / 介入 / 急性疼痛

經歷

新光急診超音波訓練中心主任

西園醫院急診醫學科主任

急診醫學會超音波委員會主委

台灣疼痛醫學會大體模擬手術講師

急救加護醫學會重症超音波負責人



診
斷

監
測

Diagnostician



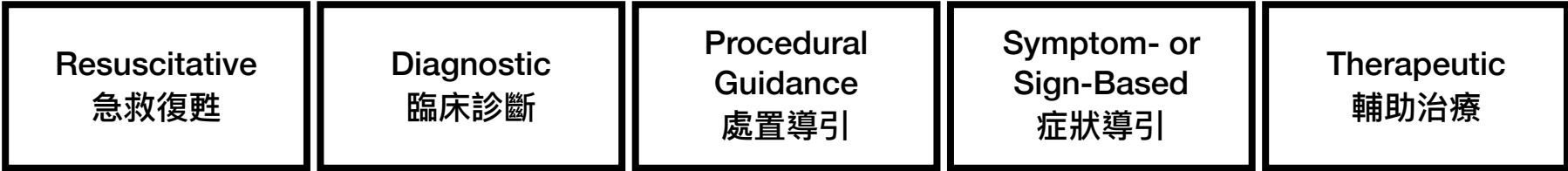介
入

Interventionist

POINT OF CARE ULTRASOUND

Provider - Probe - Patient

~ 存在於臨床需求之所在 ~



Core Applications (2023 ACEP Emergency Ultrasound Guidelines)
15項急診超音波核心應用

陳國智醫師

Aorta
 DVT
 Trauma
 Thoracic/Airway
 Cardia/HD assessment

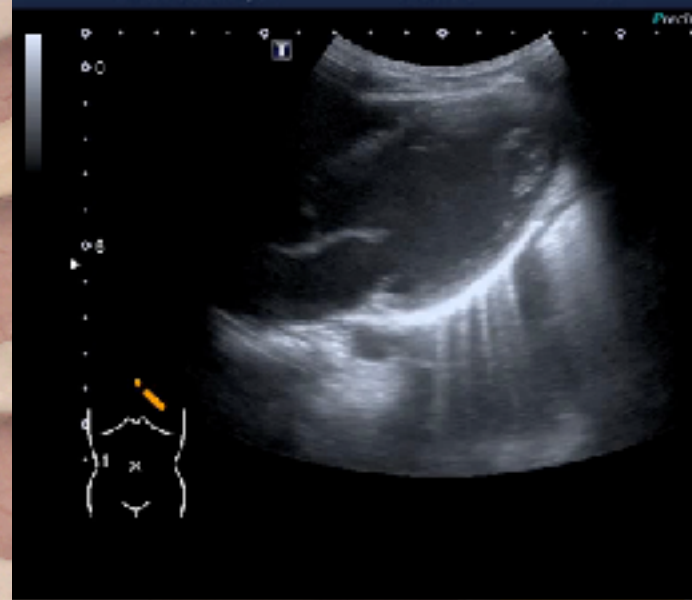
Procedural Guidance
 US-guided NB
 Testicular
 Ocular
 Skin & Soft tissue

Hepatobiliary
 Urinary tract
 Pregnancy
 Bowel
 MSK

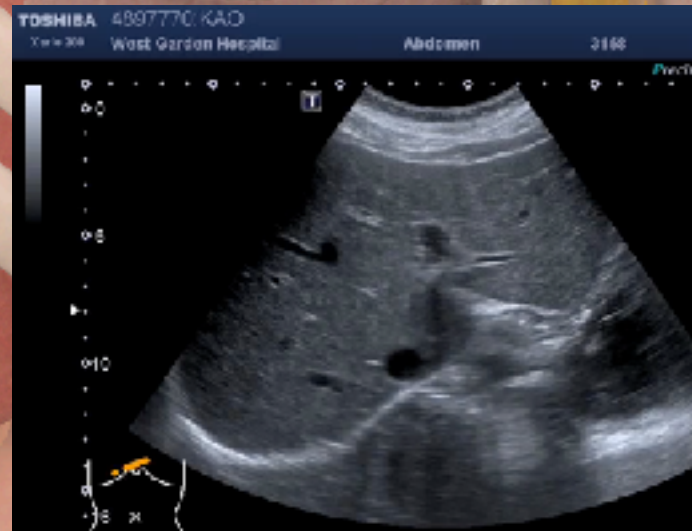掃描介面 (探頭)

PSLA

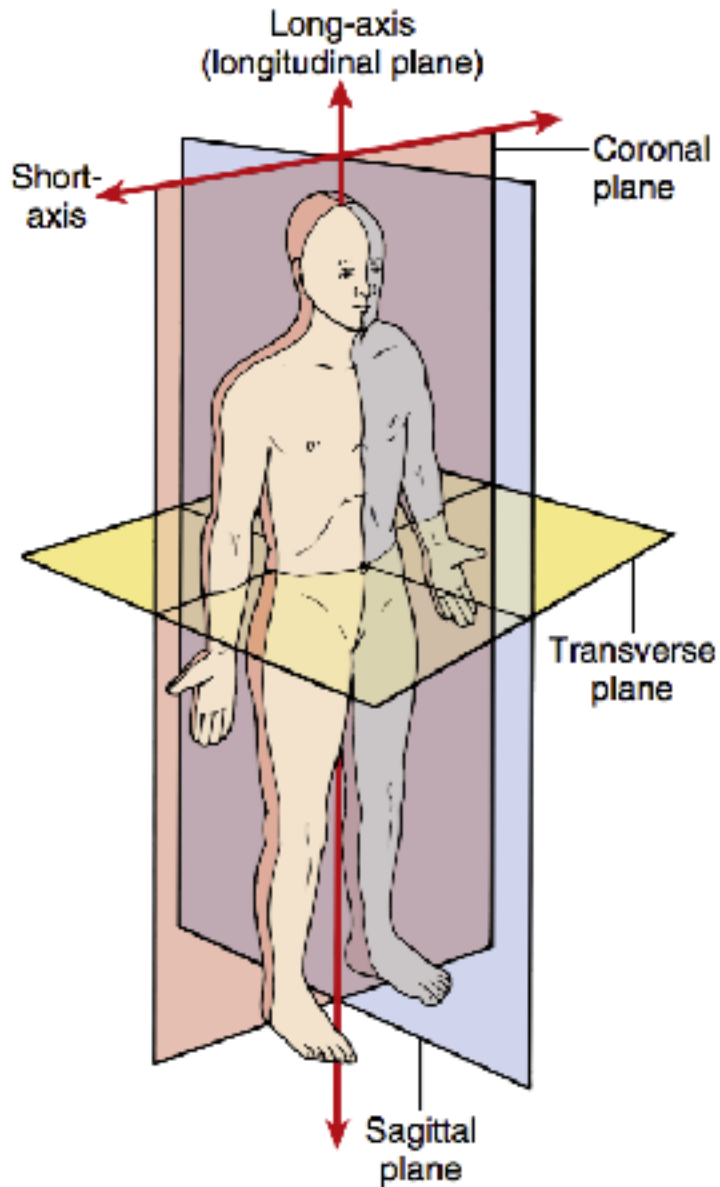
S4C



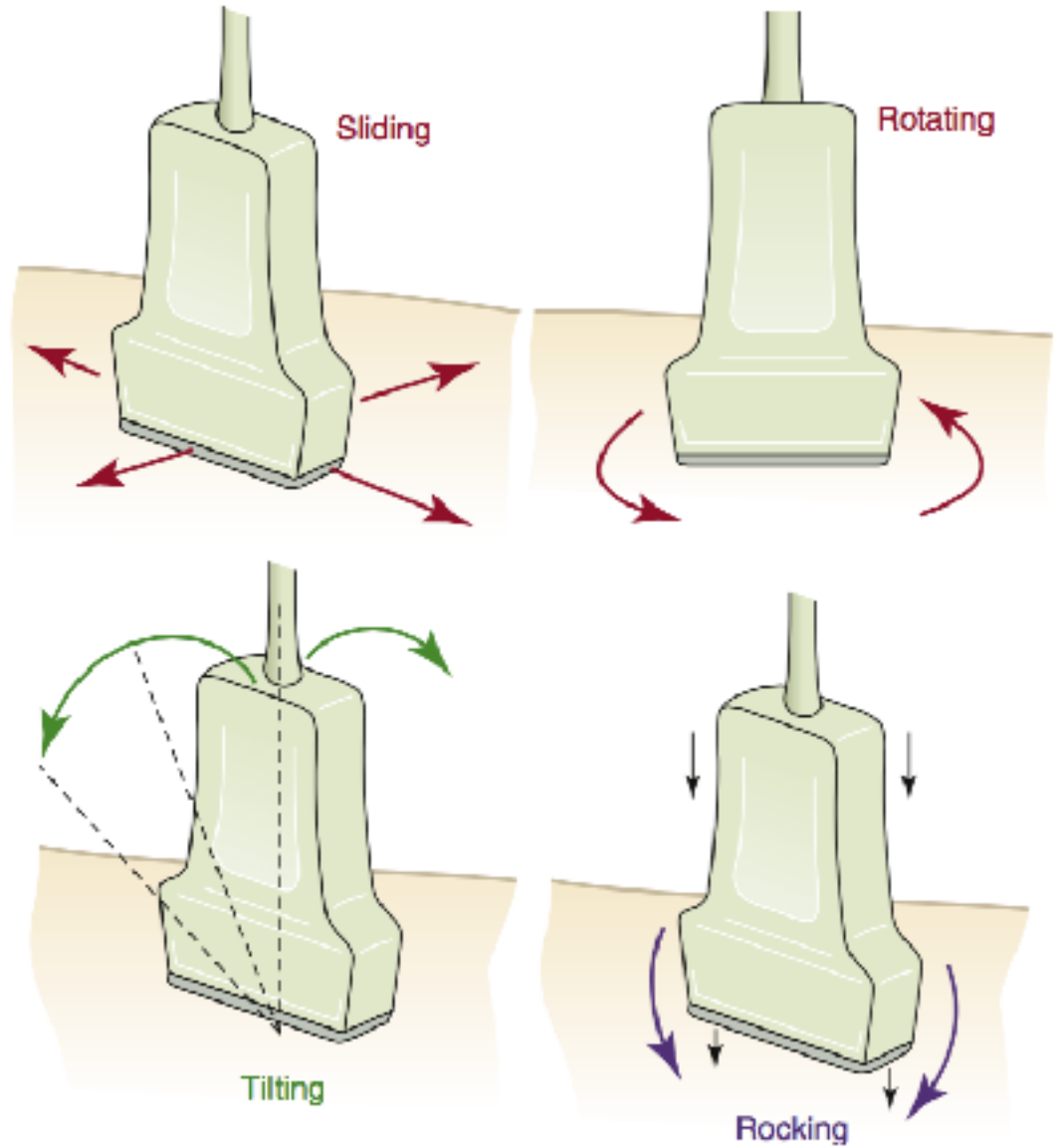
HEMOPERICARDIUM



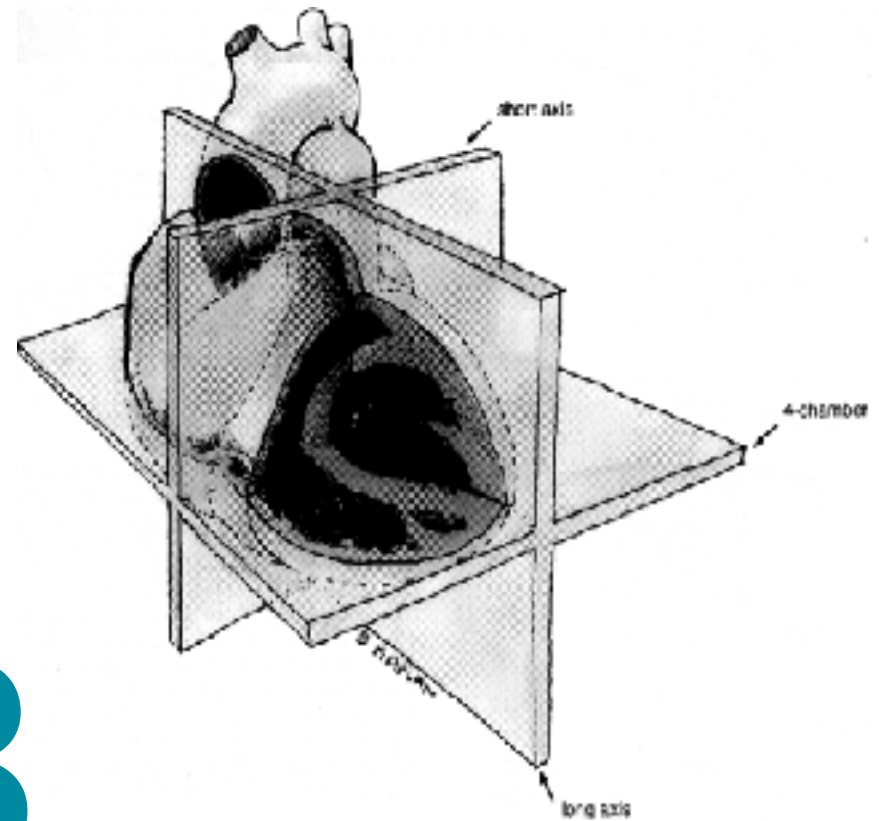
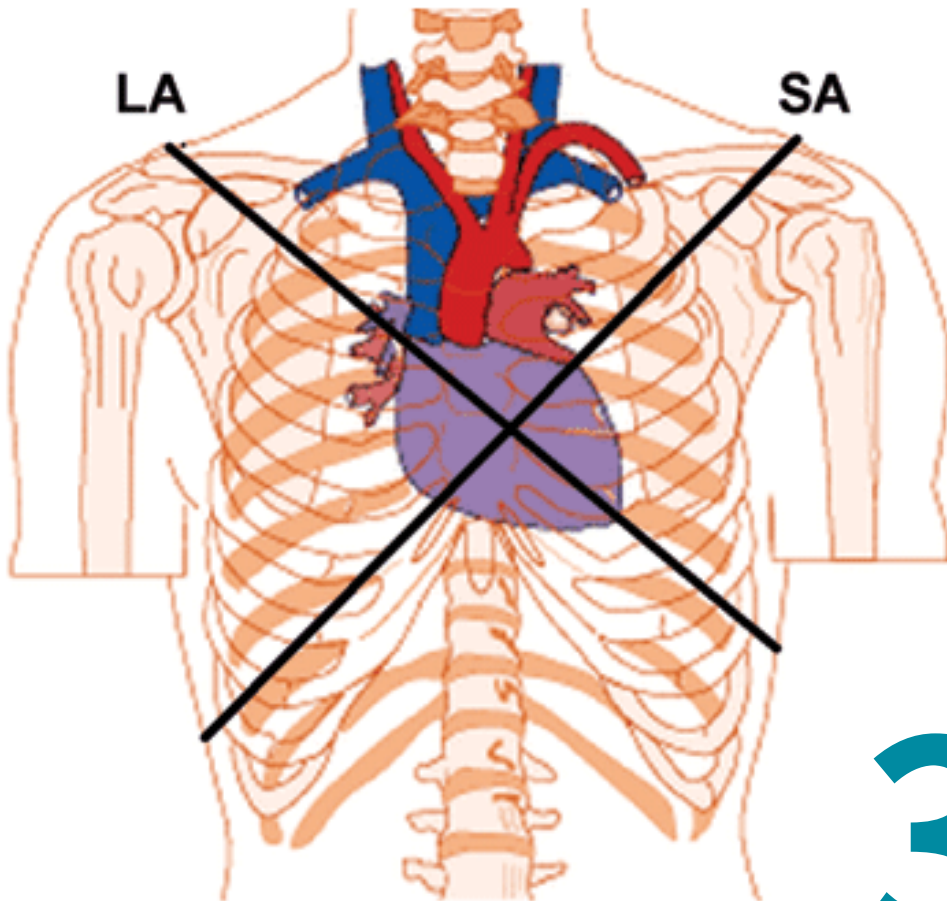
基本掃描軸線和探頭操作



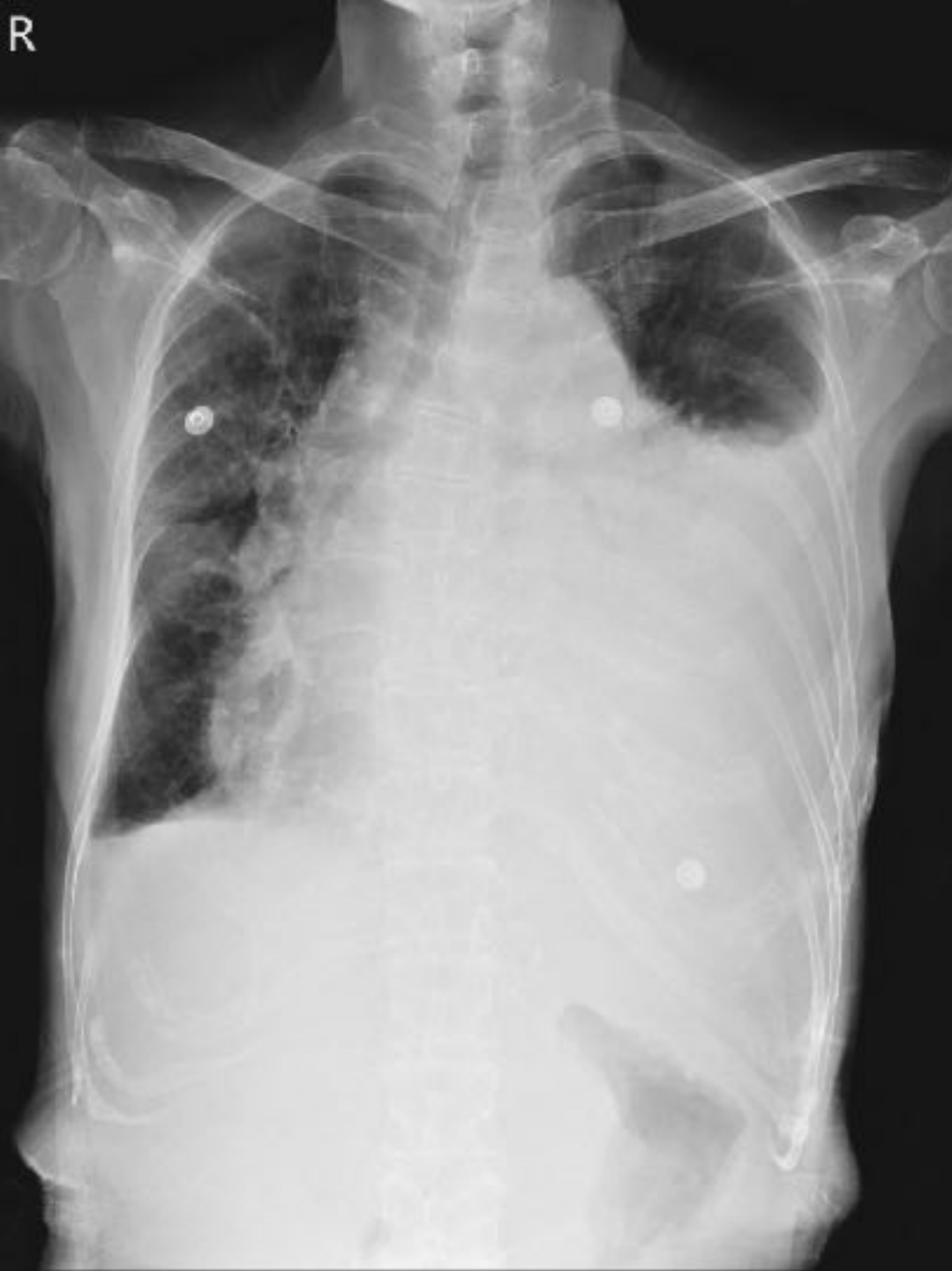Transducer Movements



基本心臟軸線介面



3



個案

62F

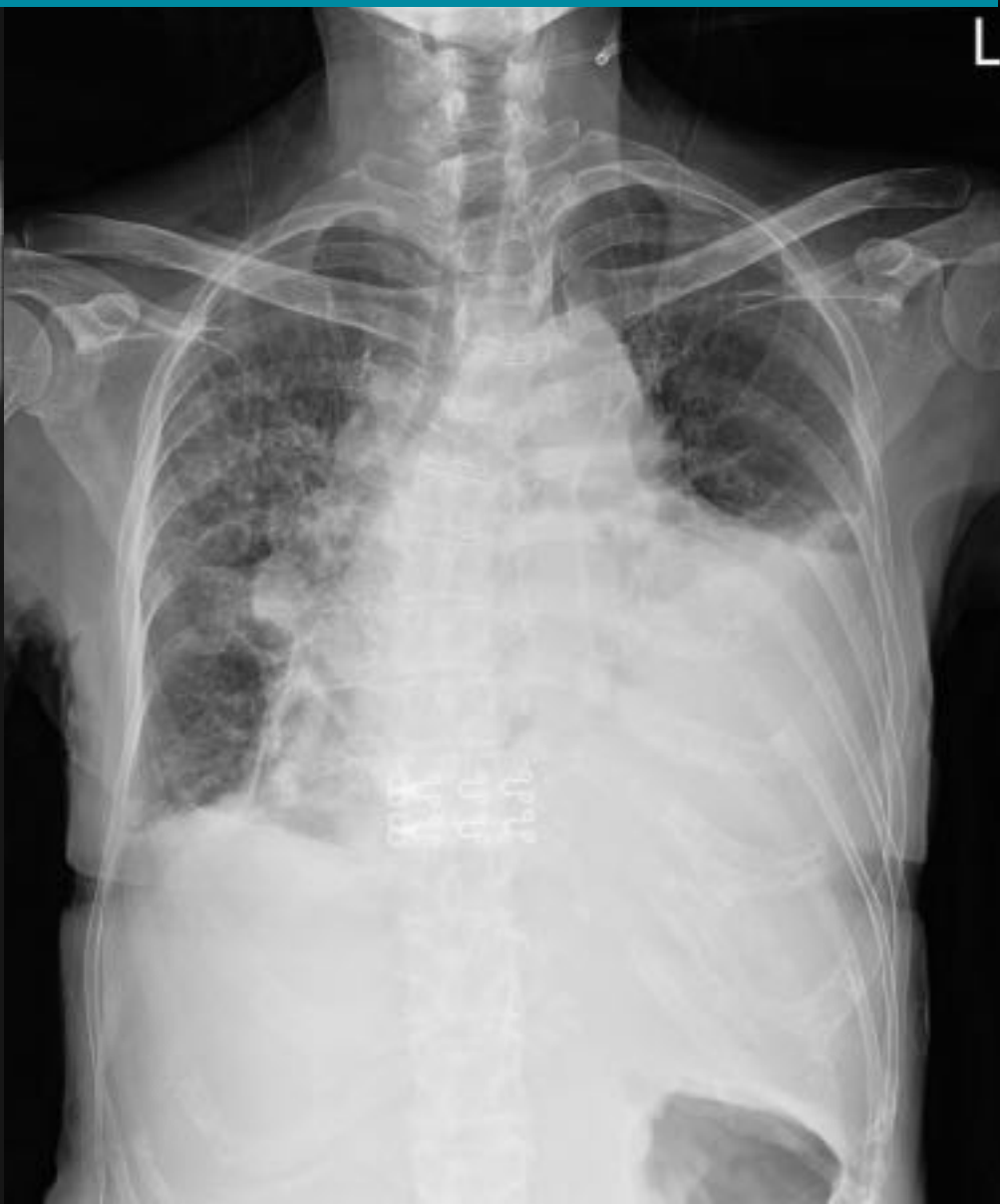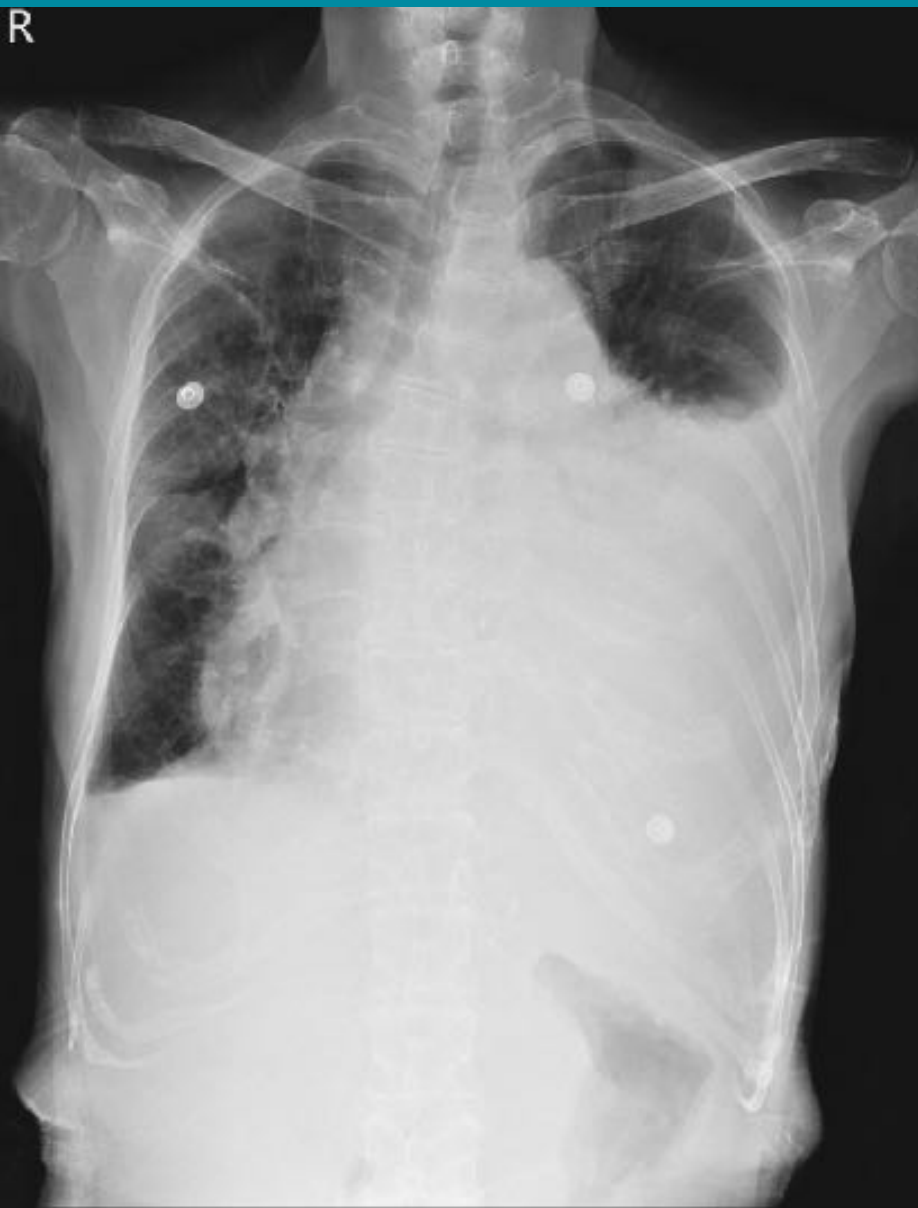Hx of breast cancer

4天前於急診進行
Pleural effusion
tapping 600 ml

主訴：
呼吸困難 &
心博過速

4天前

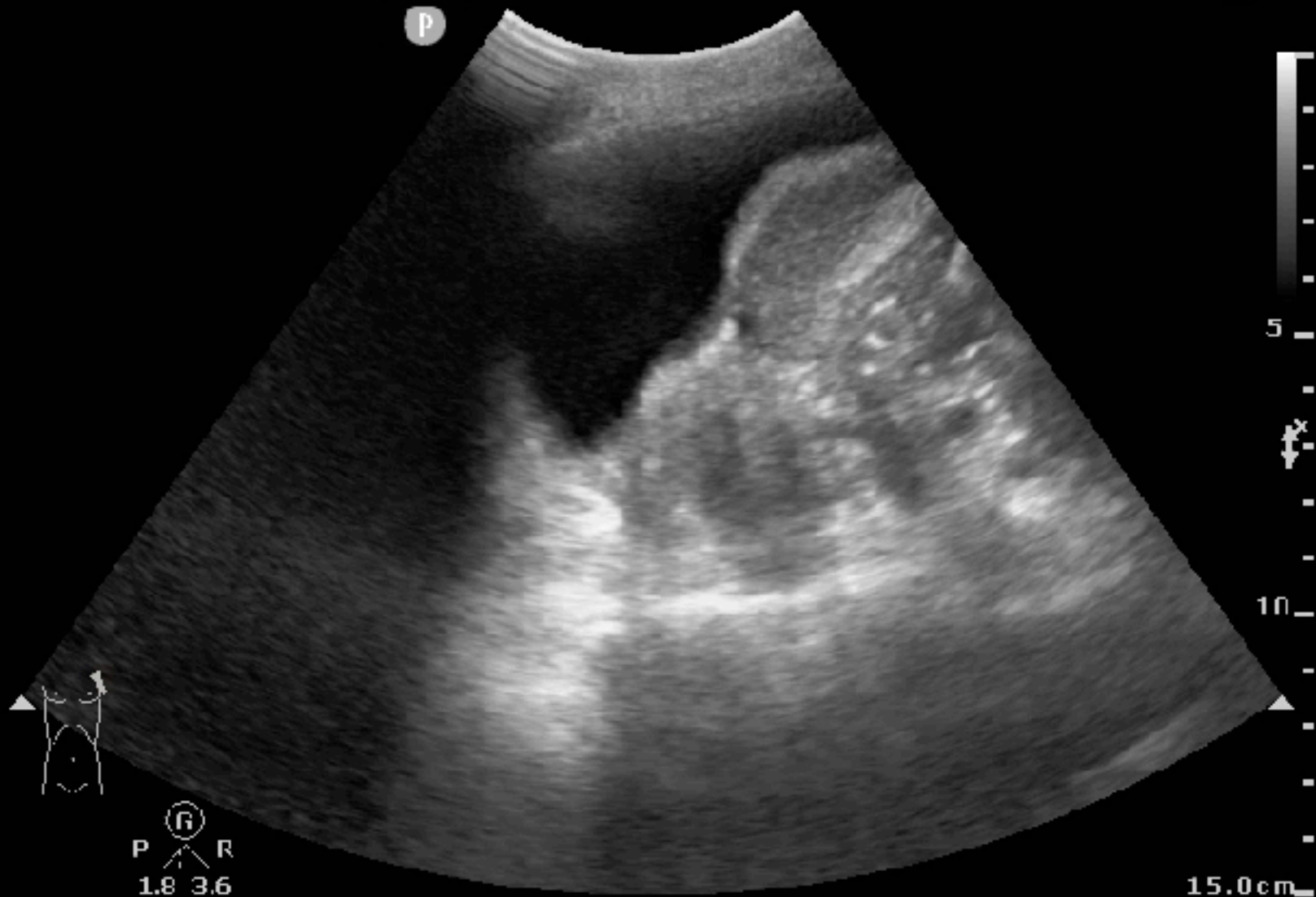
就診日



PLE相關？

Abd Gen
C5-1
34 Hz
15.0cm

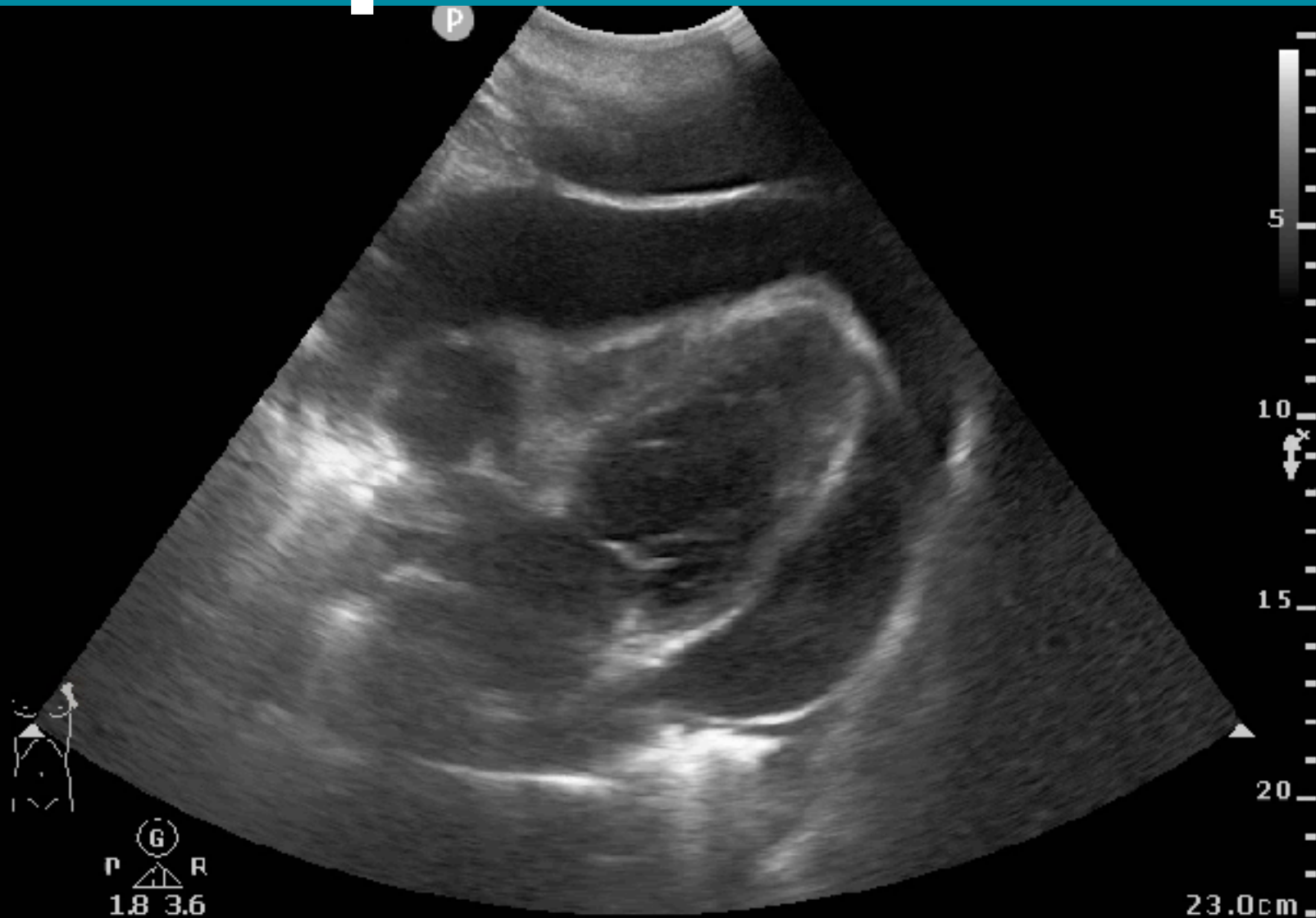
2D
HGen
Gn 100
C. 56
3/3/3



Tamponade ?

bd Gen
5-1
5 Hz
3.0cm

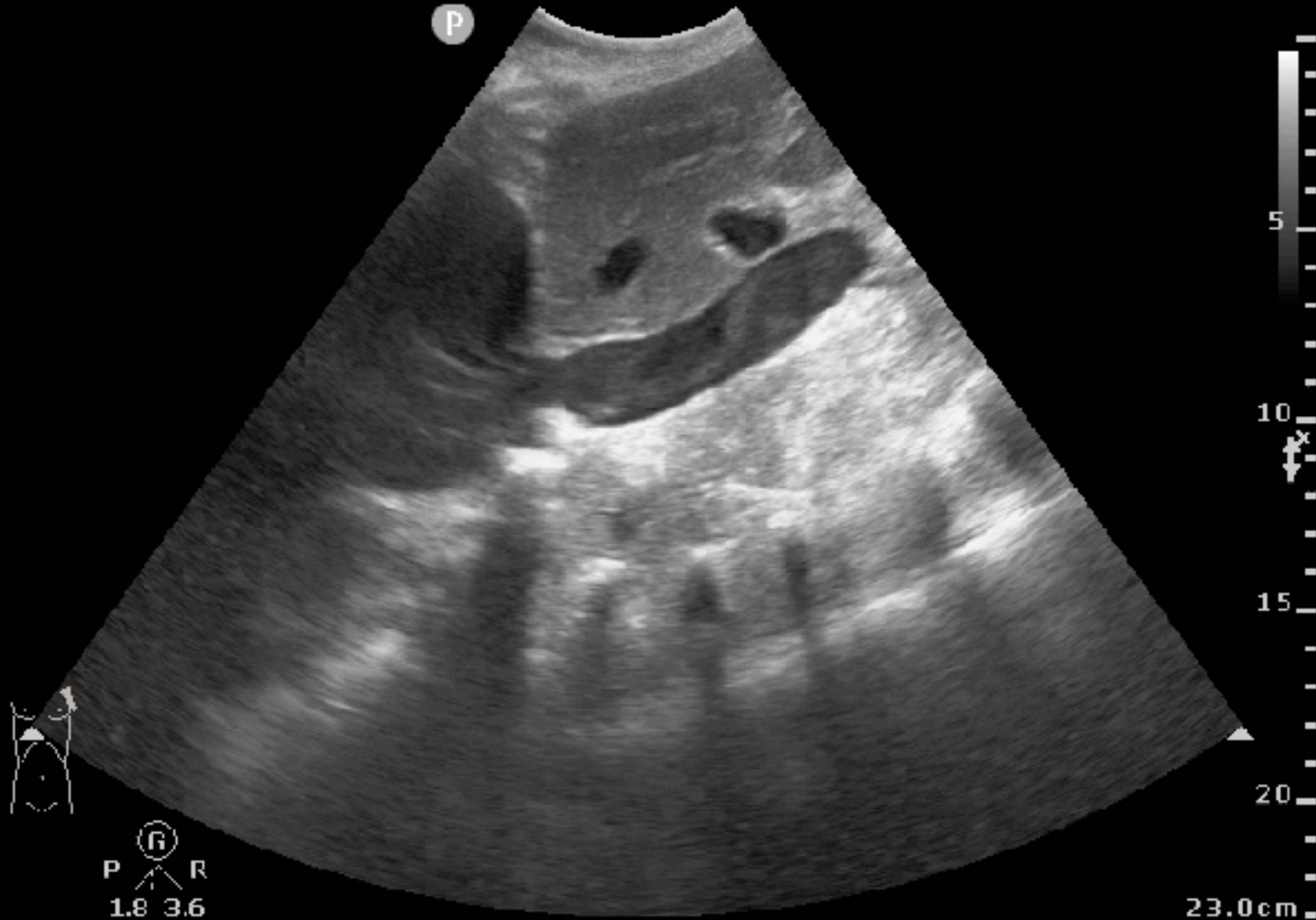D
HGen
Gn 100
C 56
3/3/3



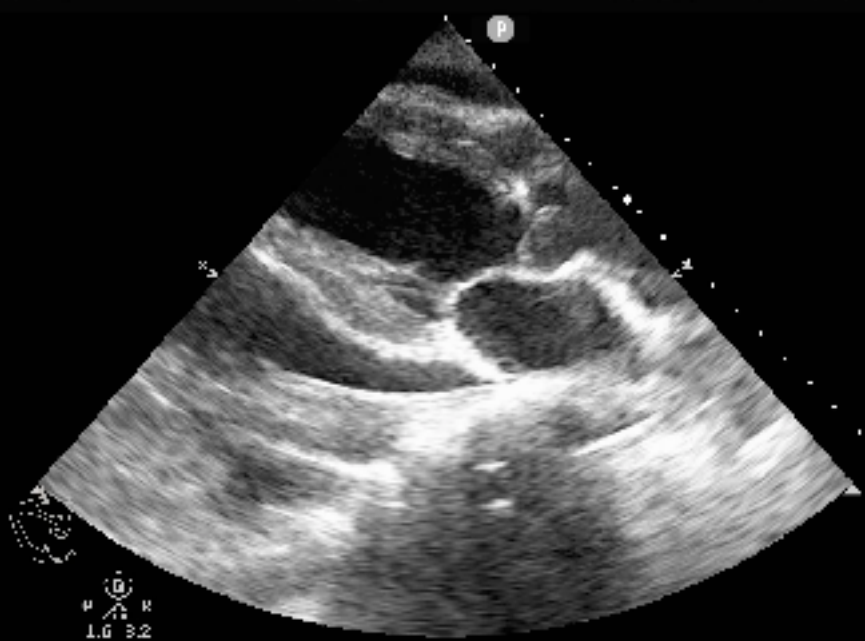
臨床/積液/鼓漲

Abd Gen
C5-1
25 Hz
23.0cm

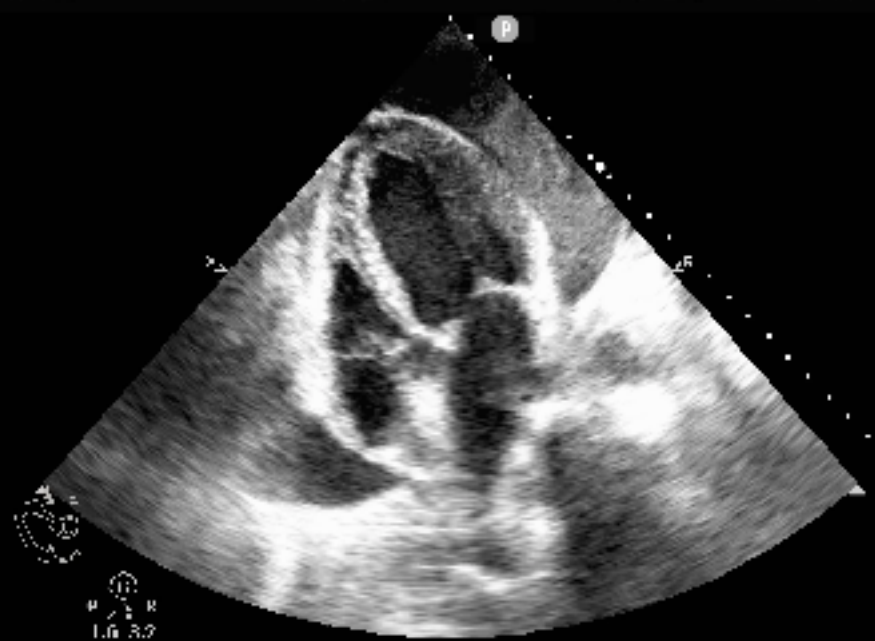2D
HGen
Gn 100
C. 56
3/3/3



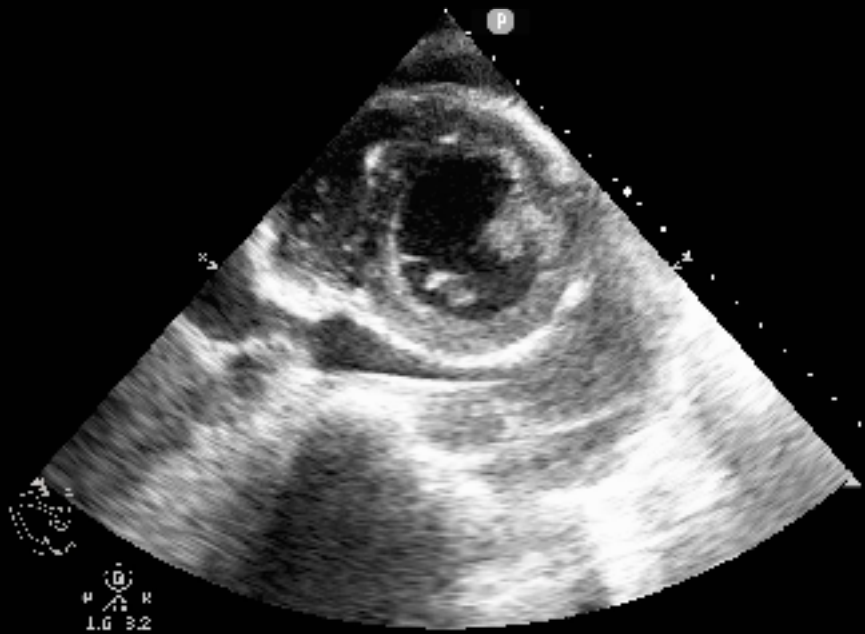cho



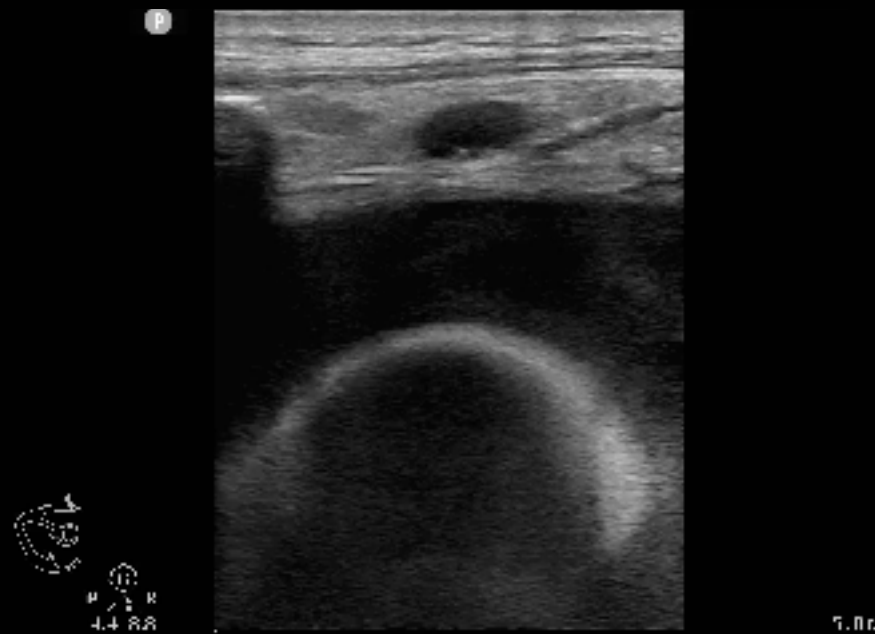
0



cho



0

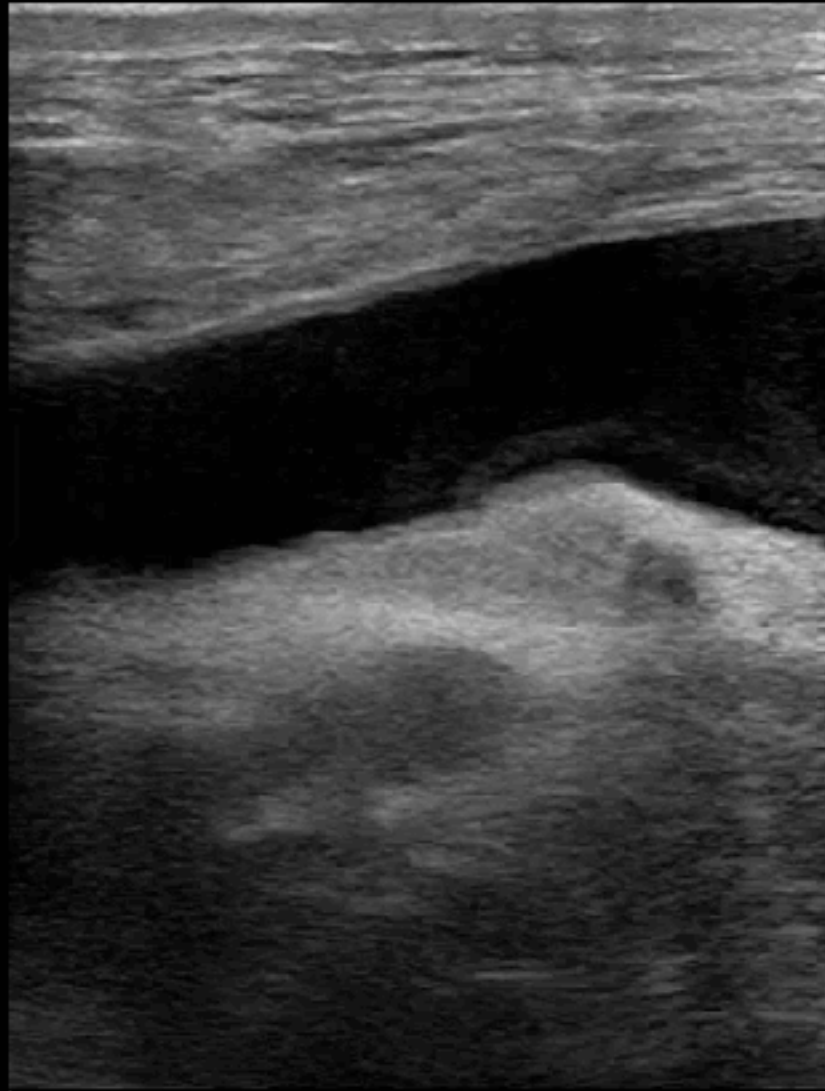


Step-by-step drainage

Arterial
L12-3
34 Hz
5.0cm

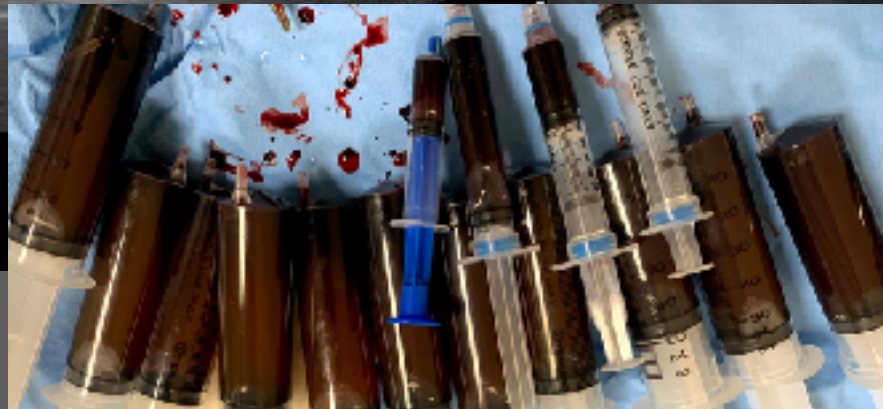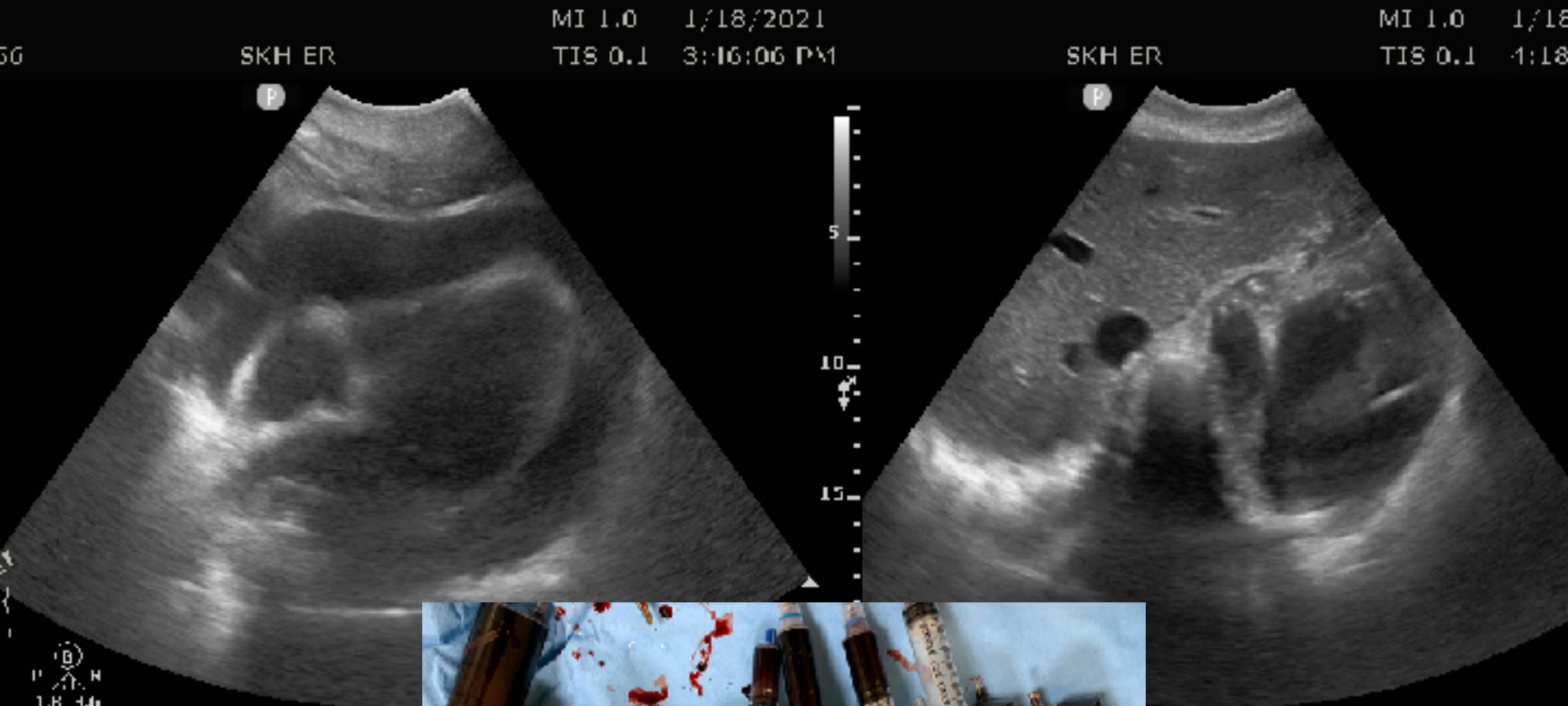
2D

HGen
Gn 66
C. 41
3/3/2



5.0cm

Monitor after drainage



Transducers



Linear



Curve

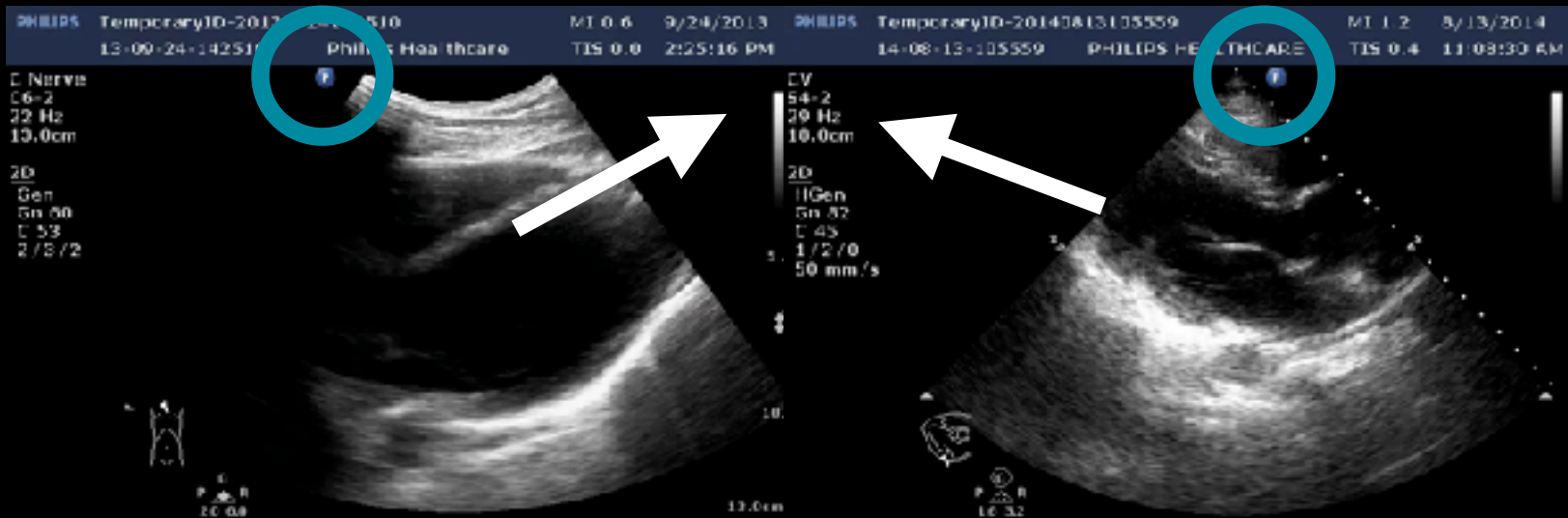


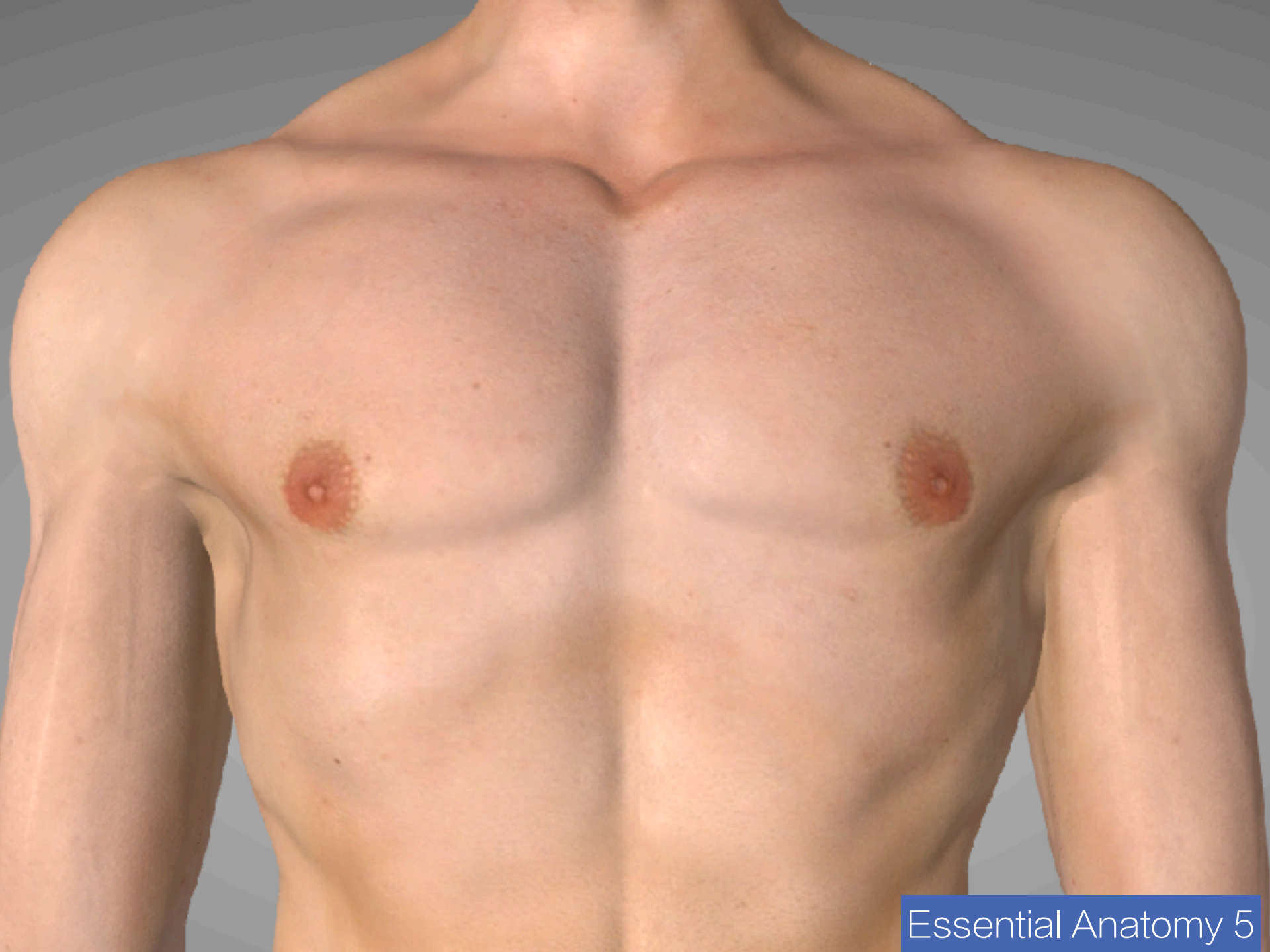
Sector

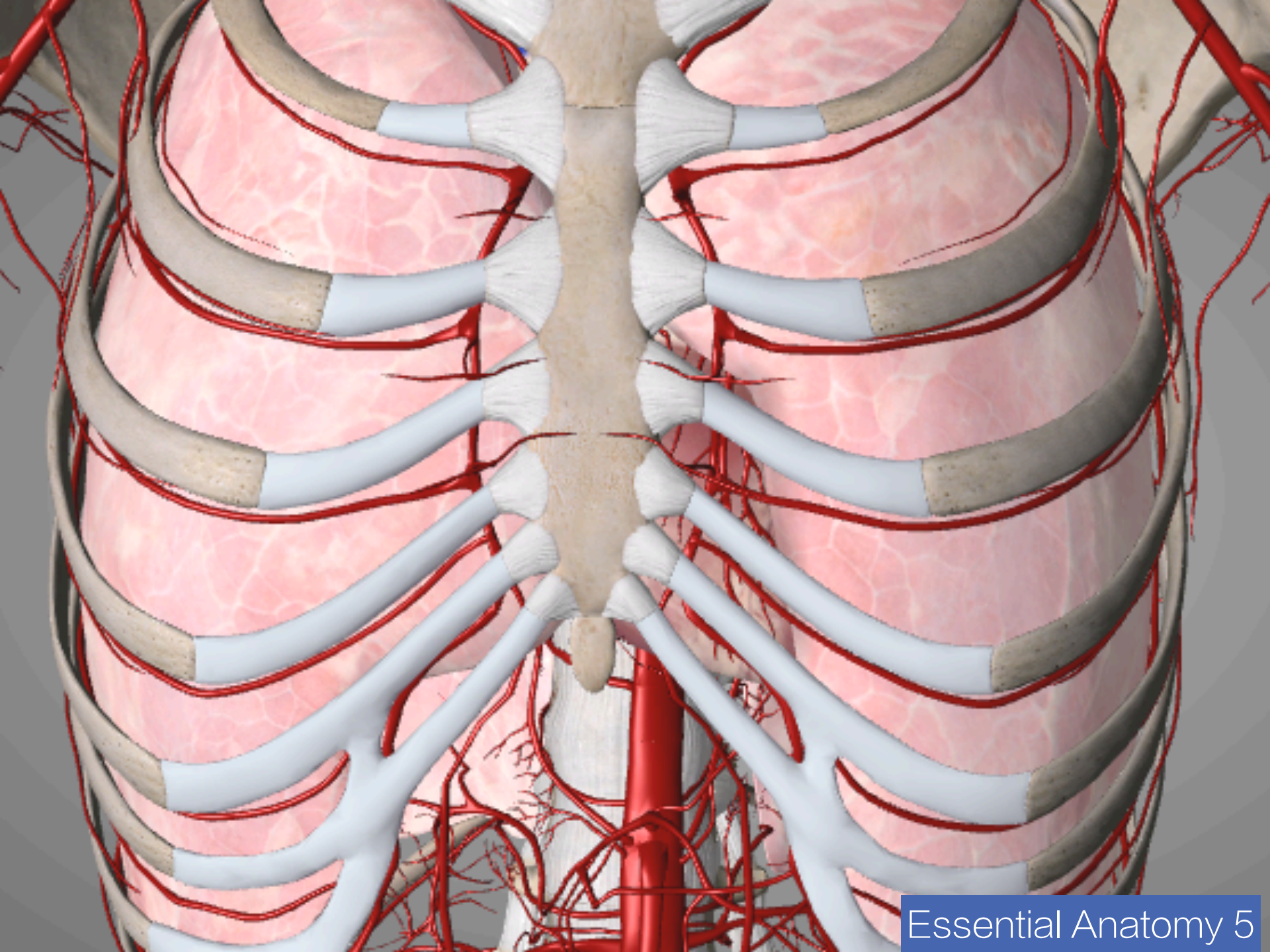
Orientation



Indicator
Apex



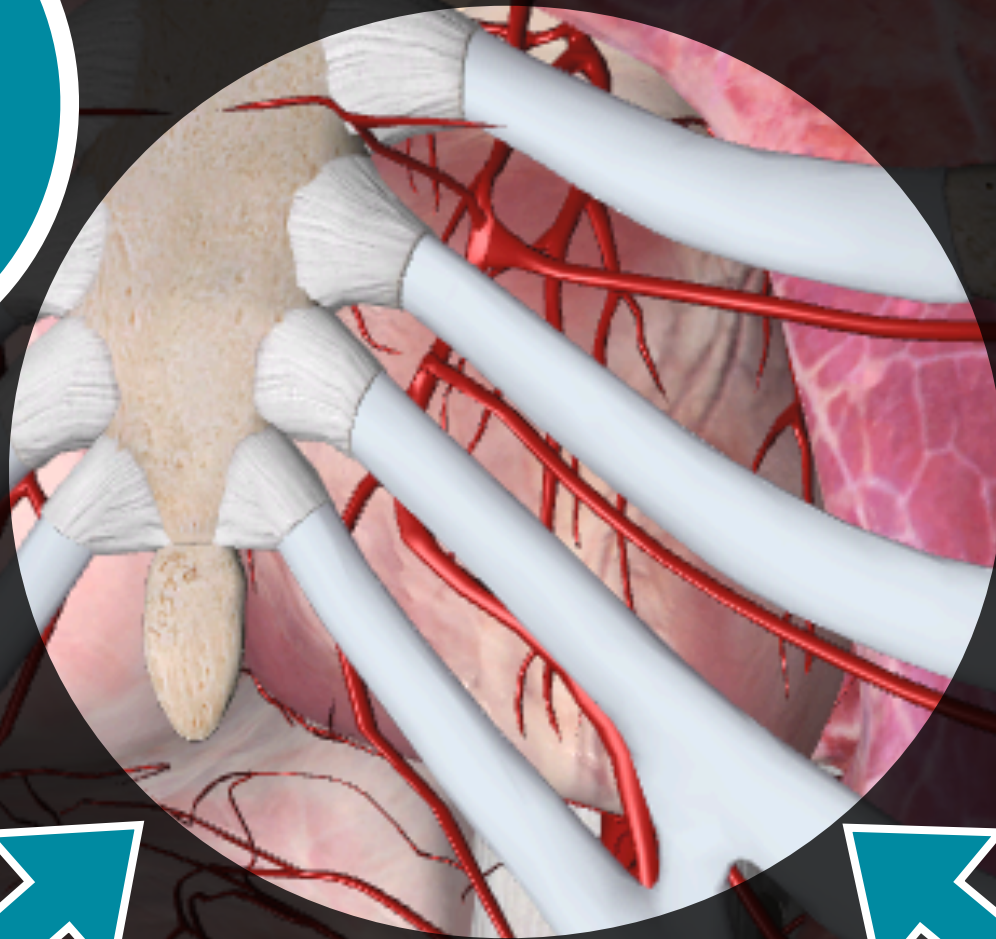



Parasternal



SPA



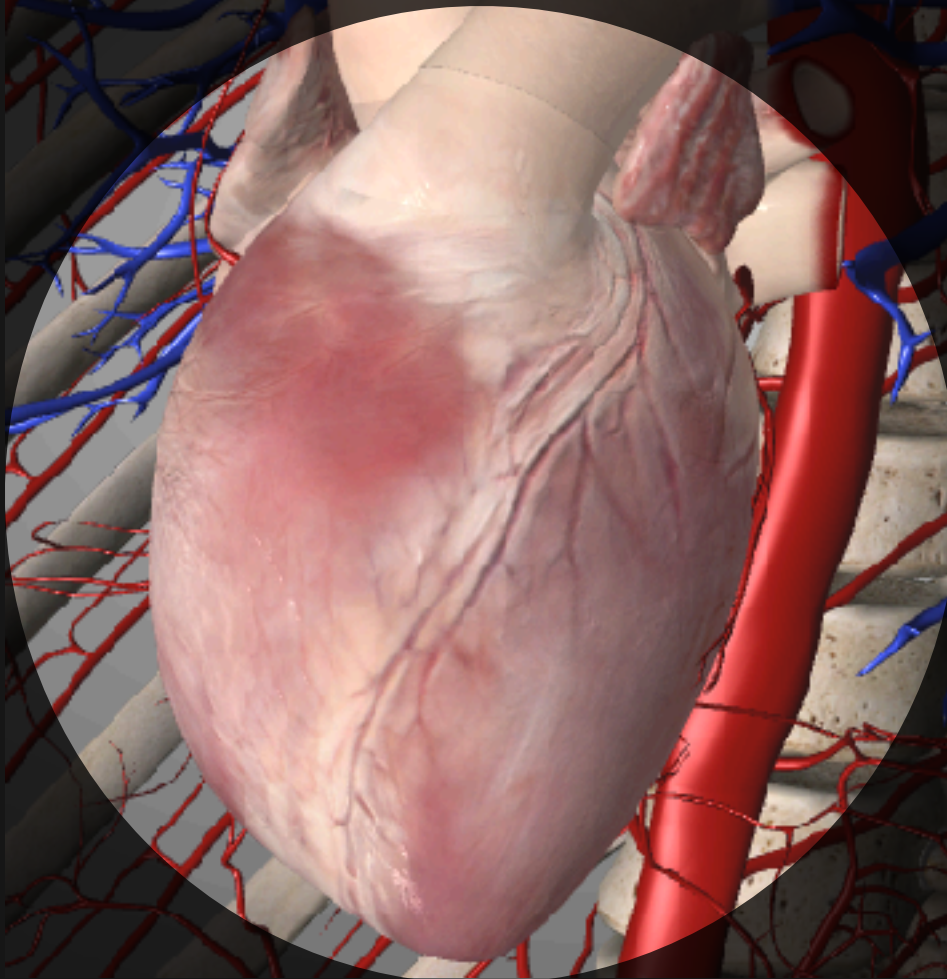
Subcostal



Apical



limited view

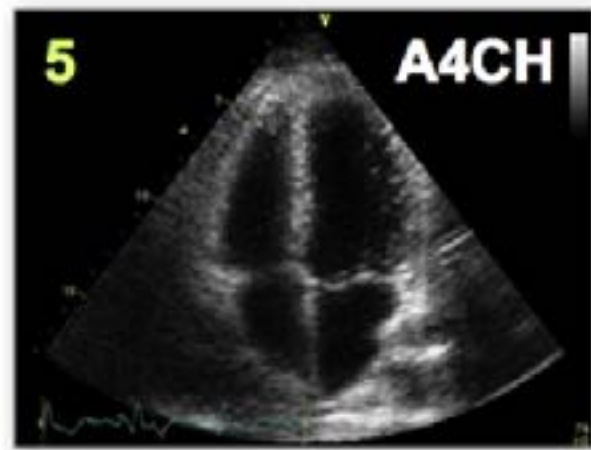
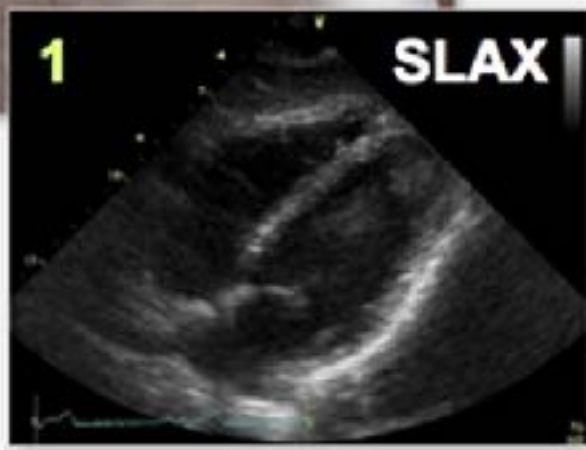
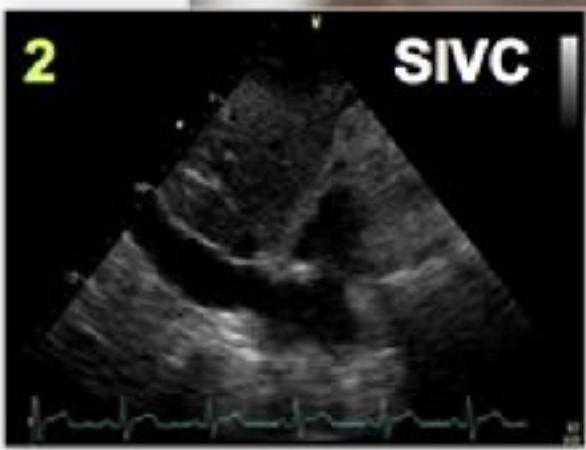
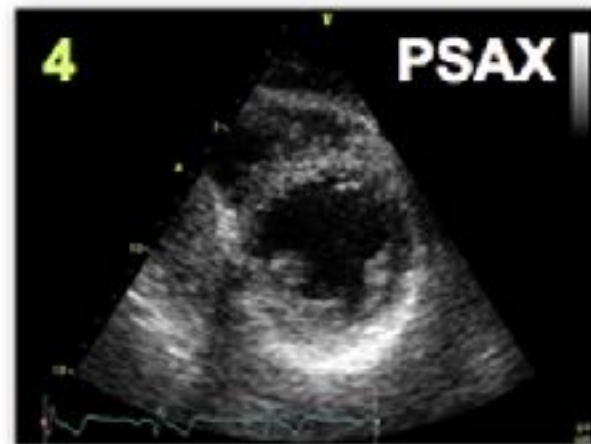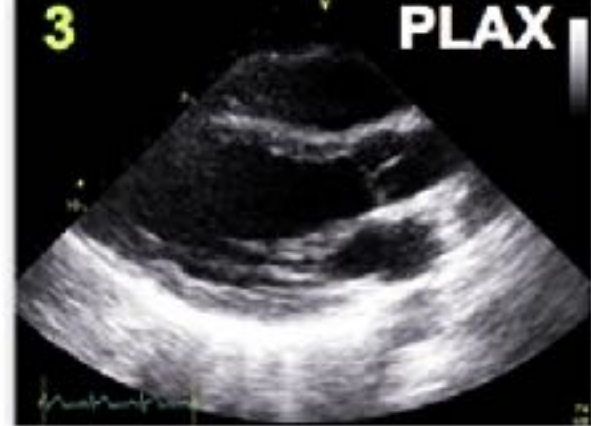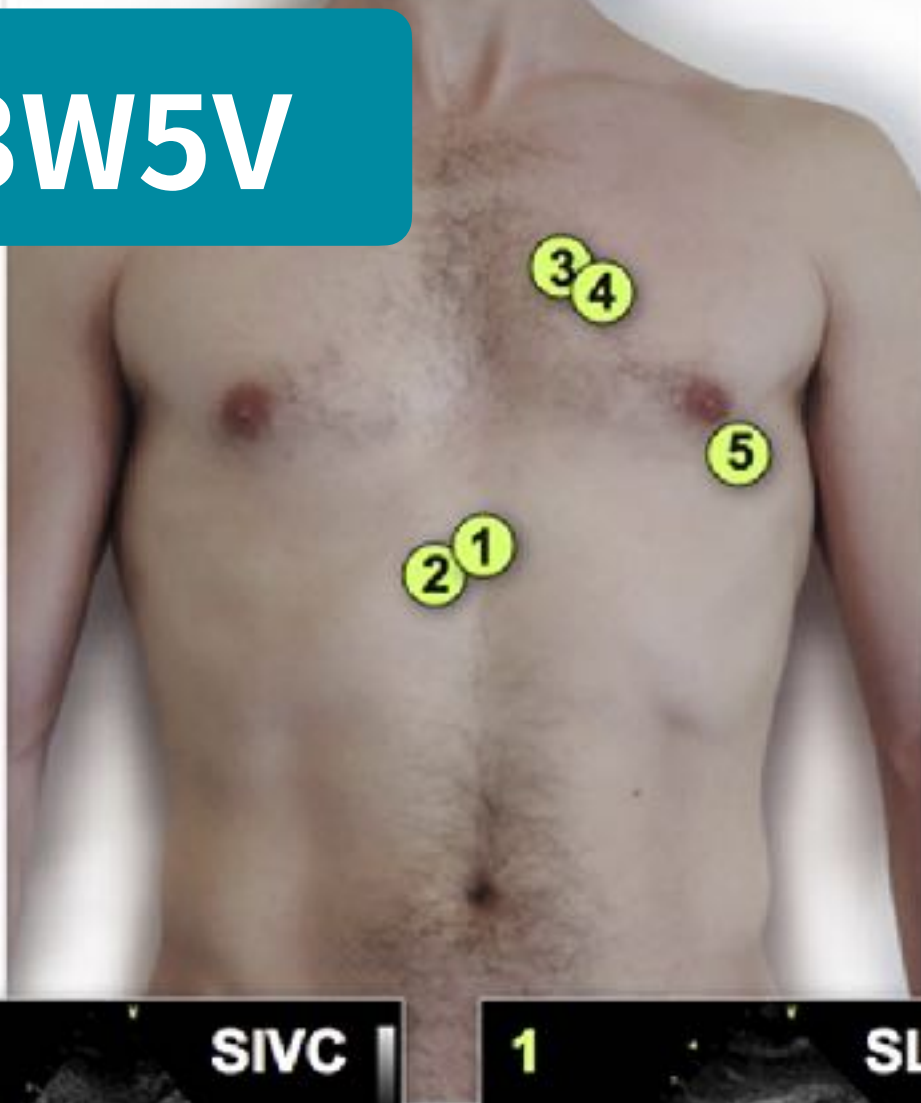Cardiac

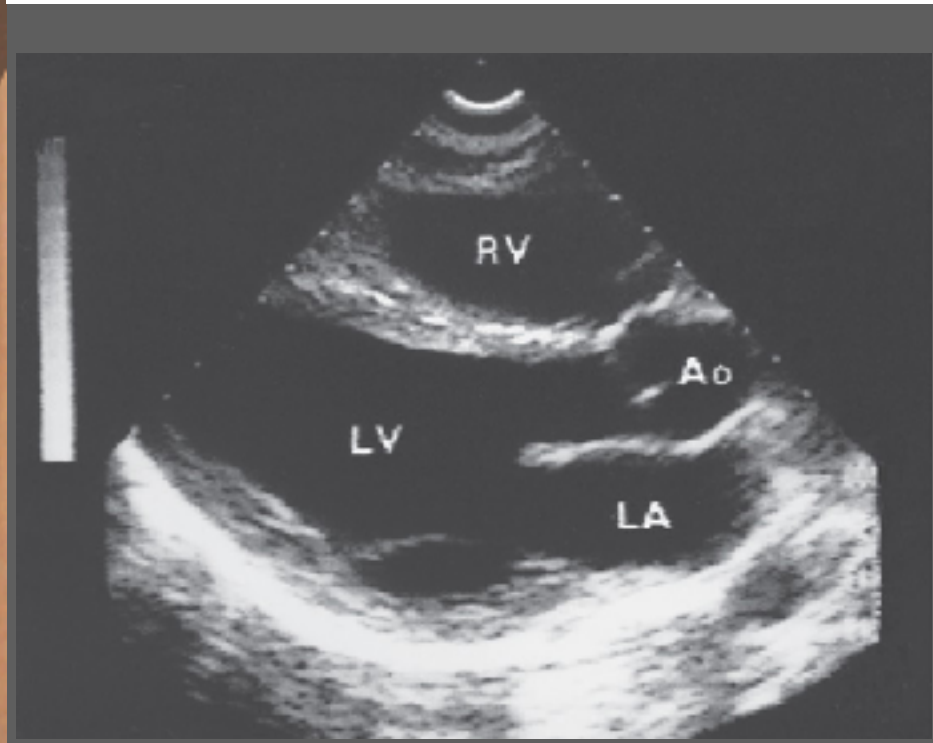
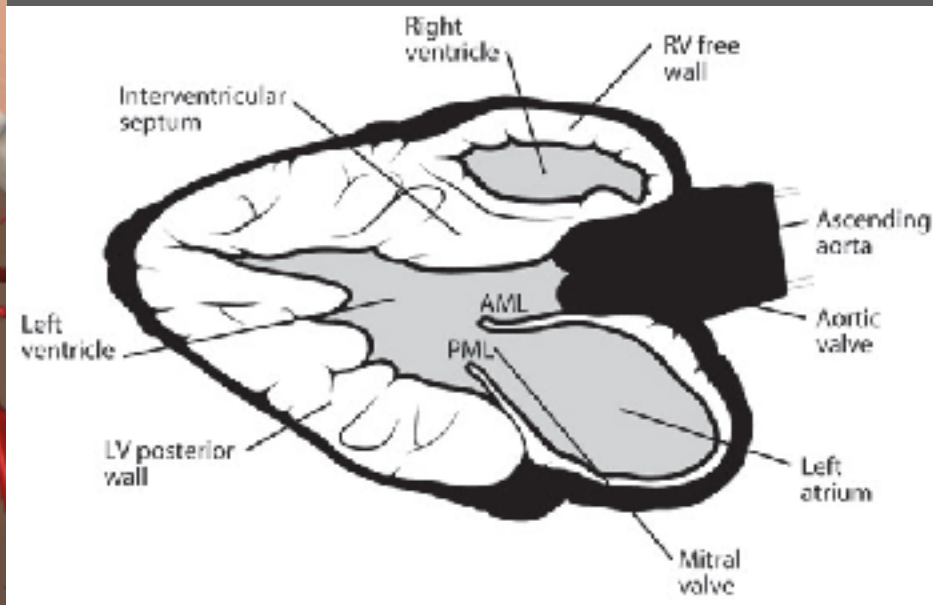
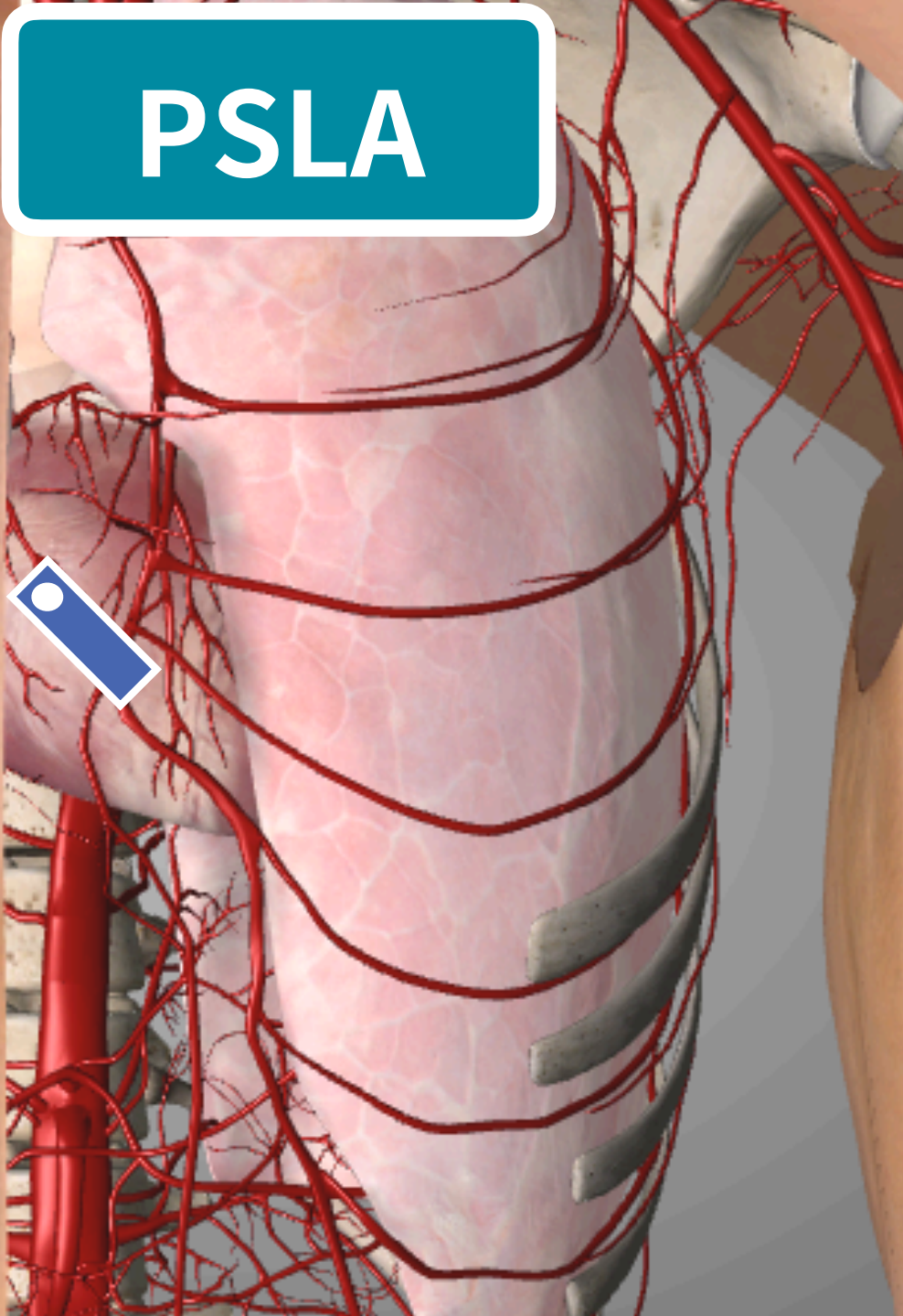
Ivc

Aorta

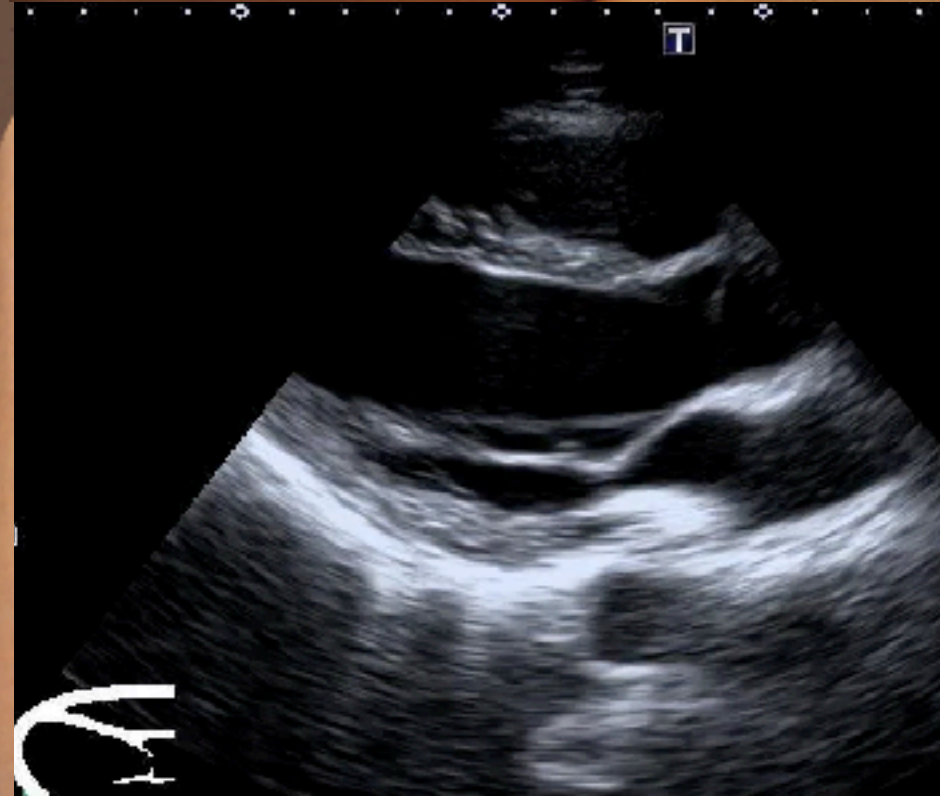
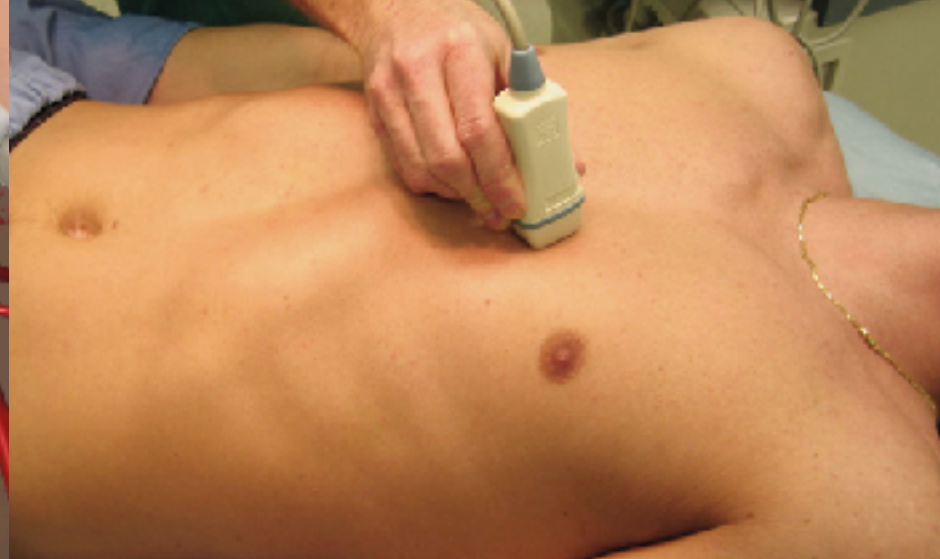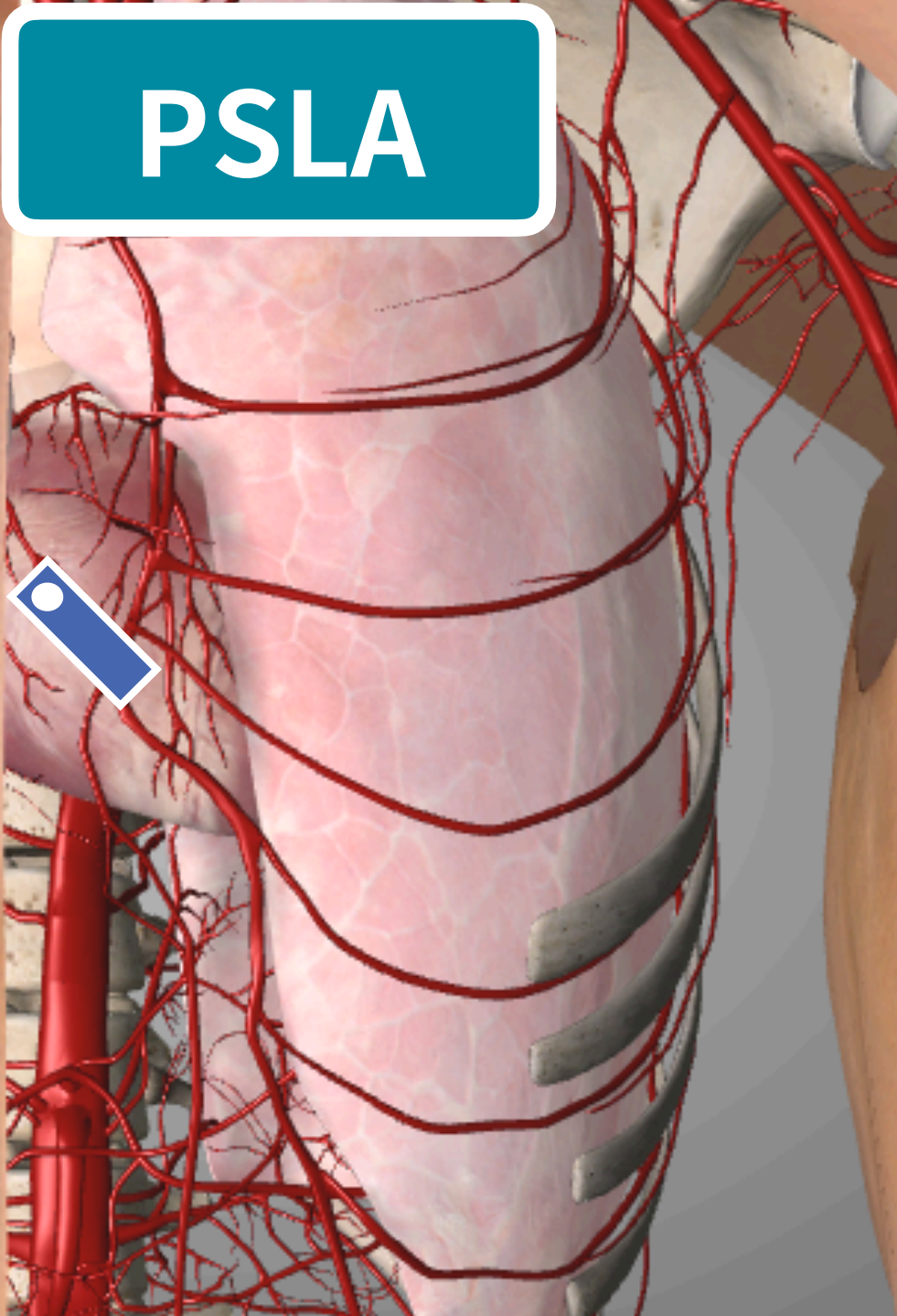
3W5V

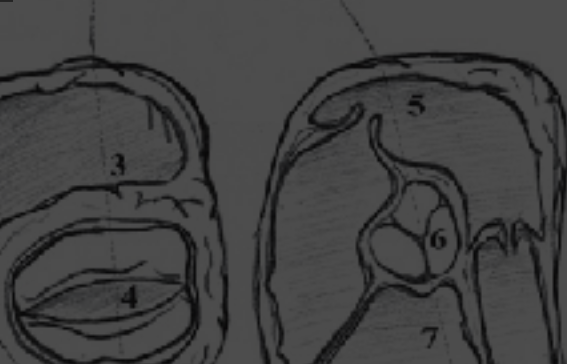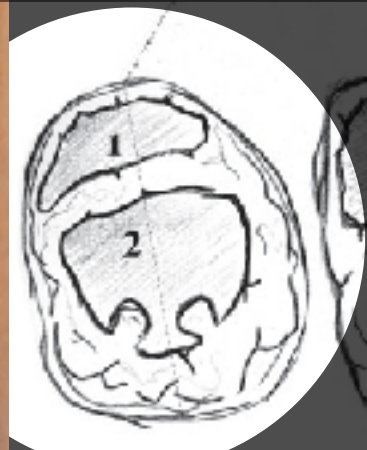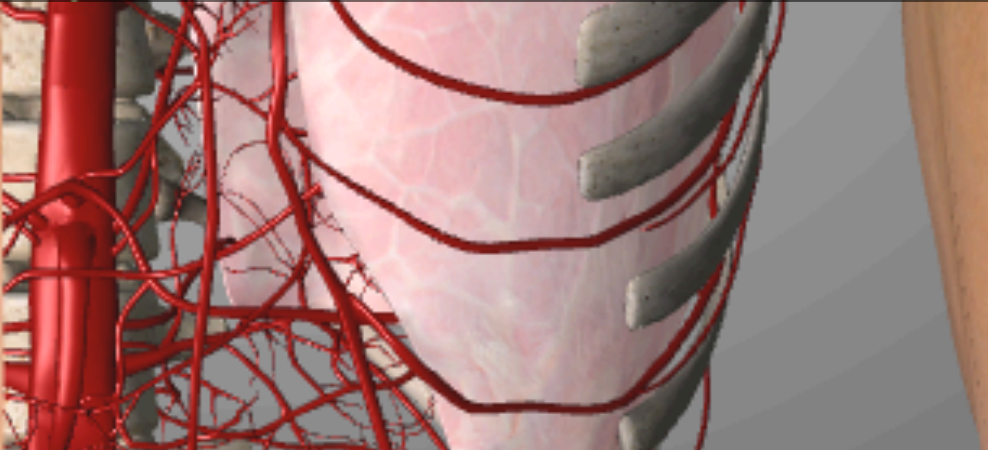
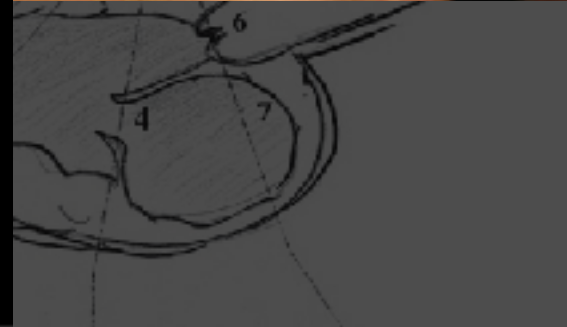
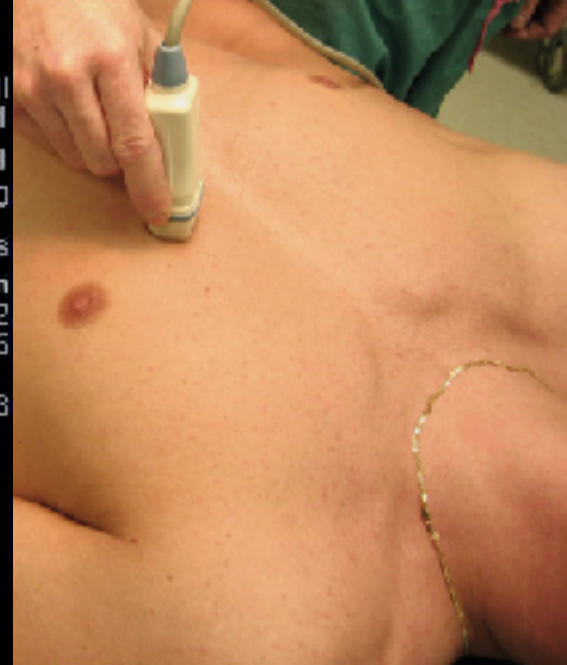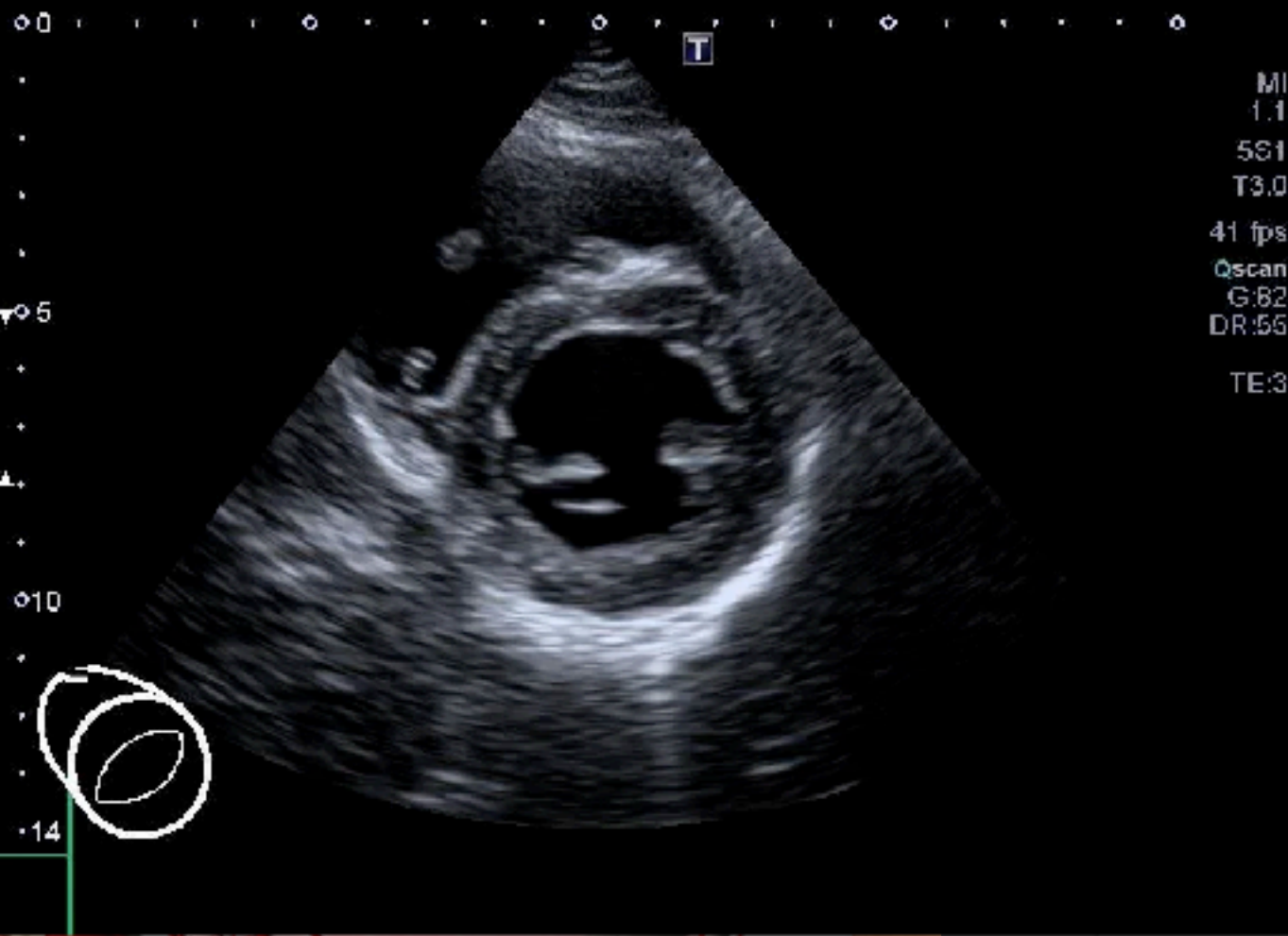


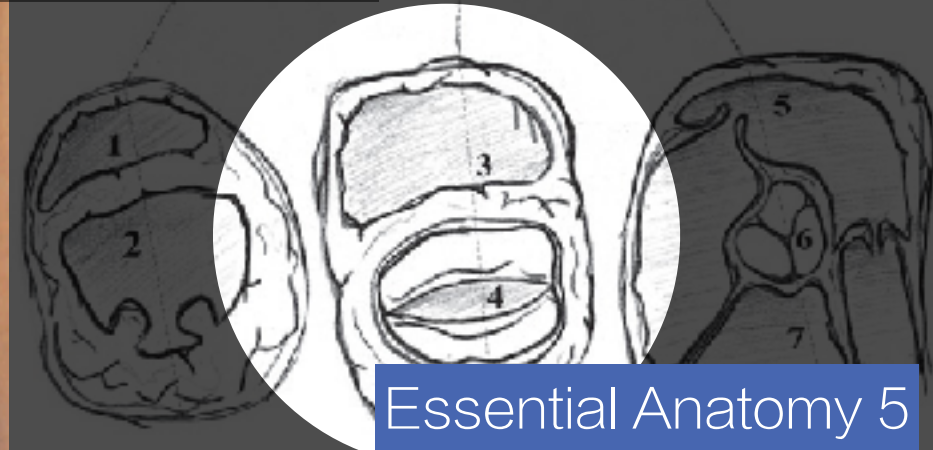
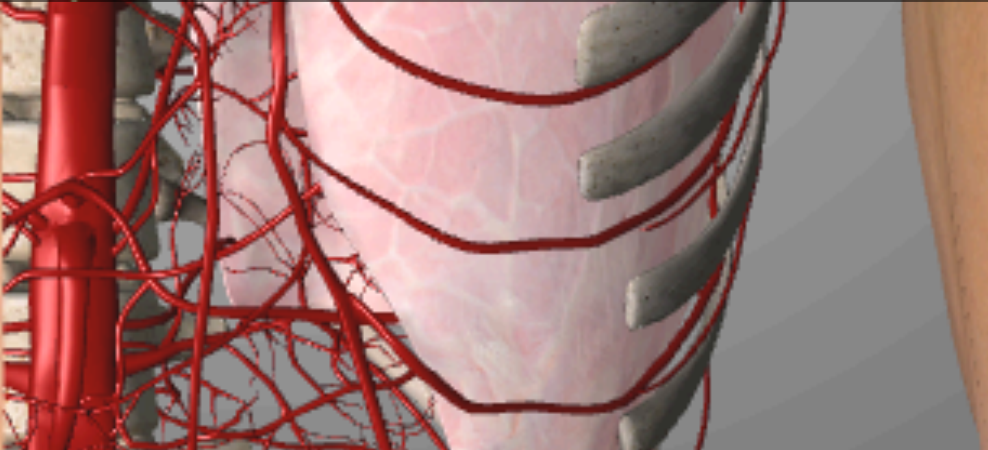
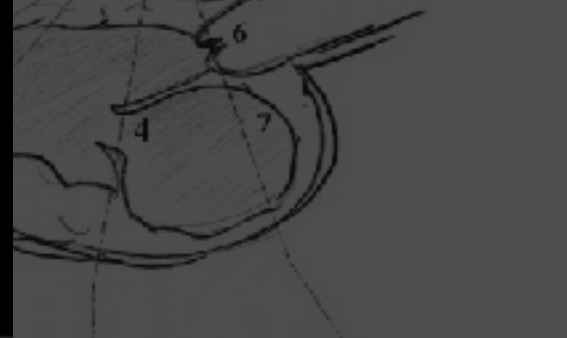
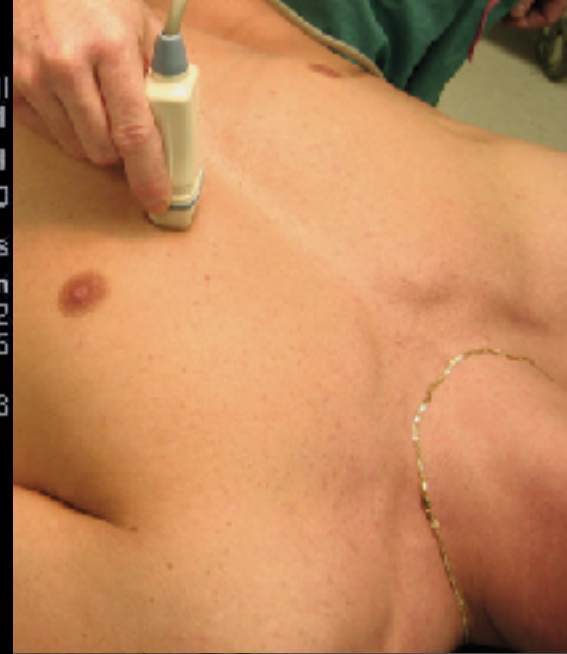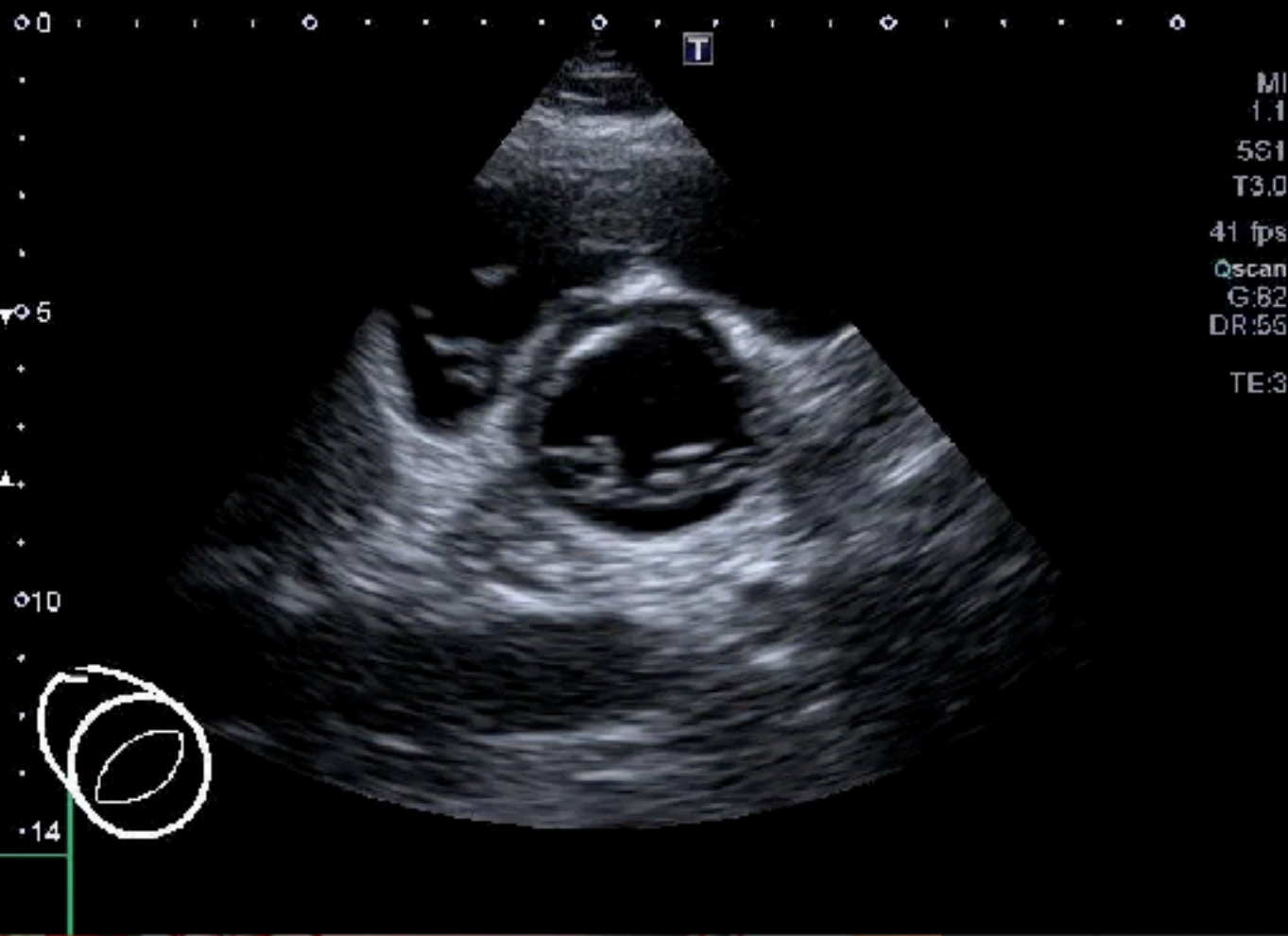
PSLA

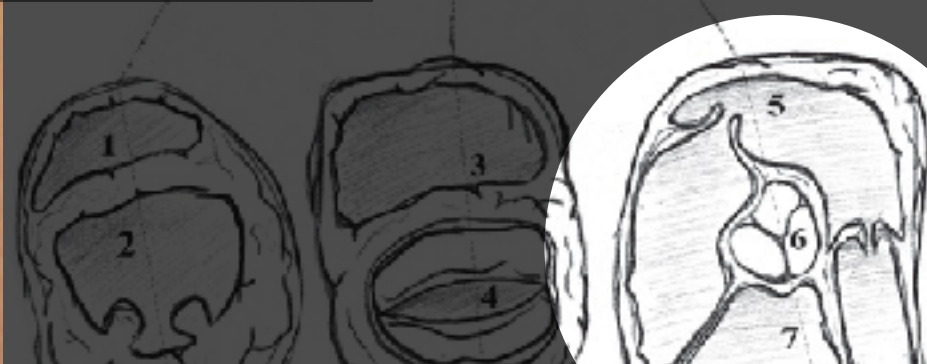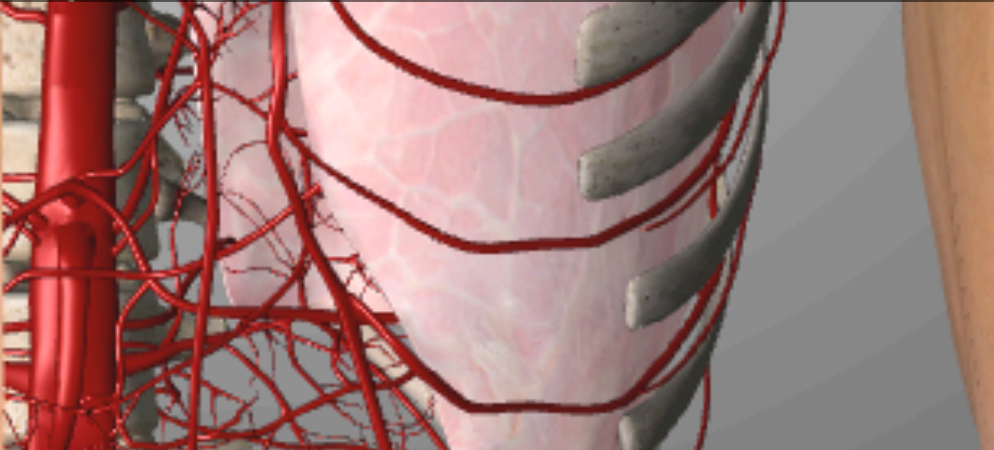
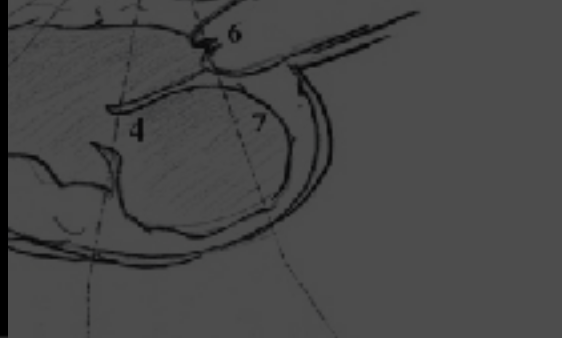
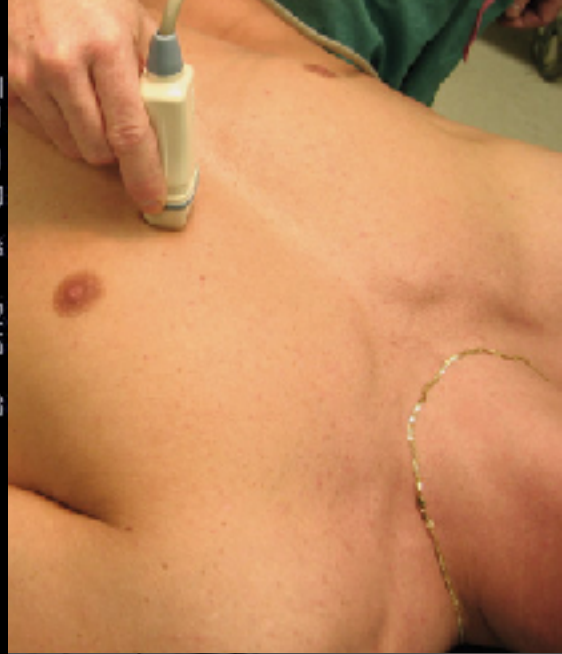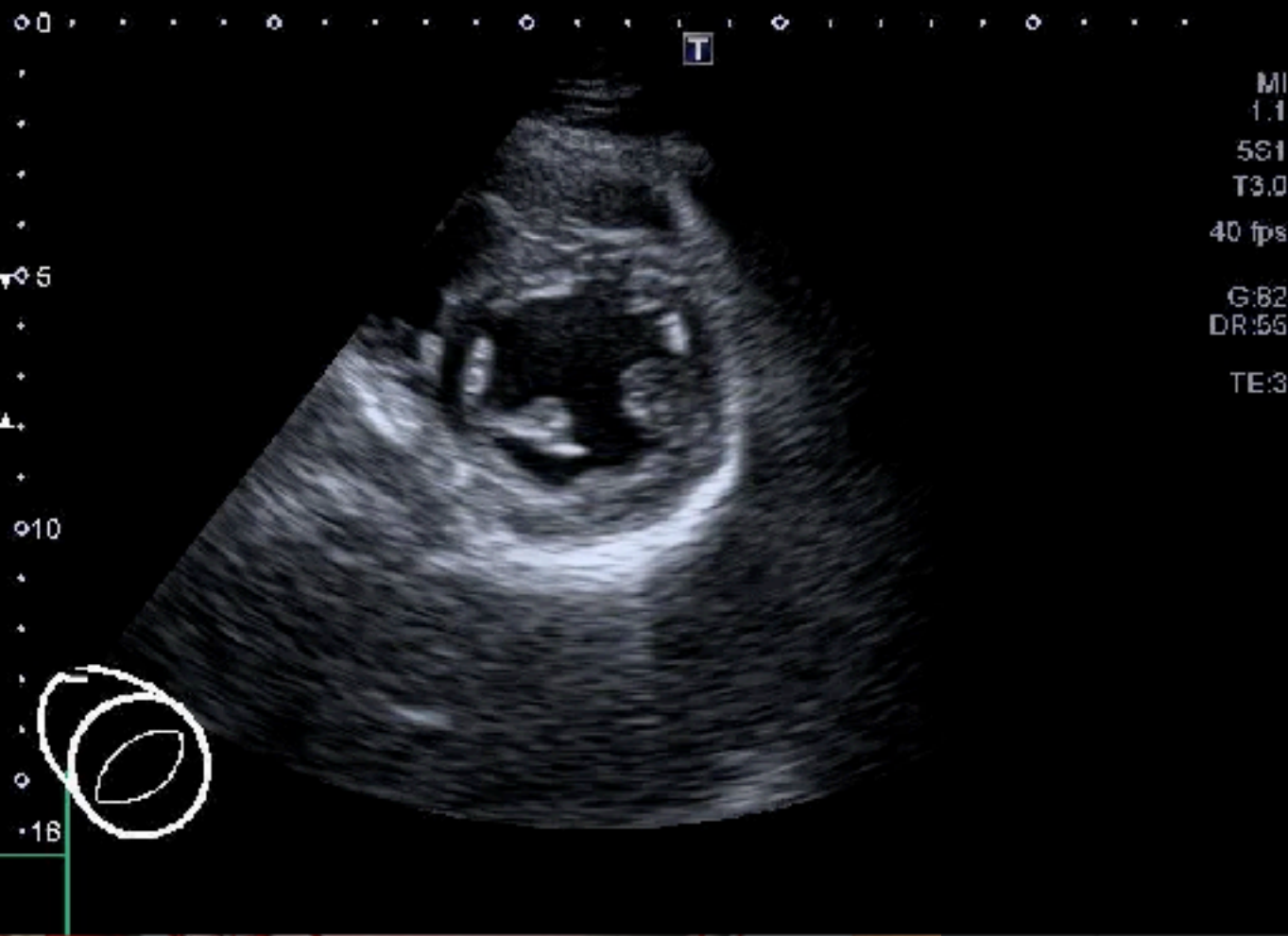


PSLA

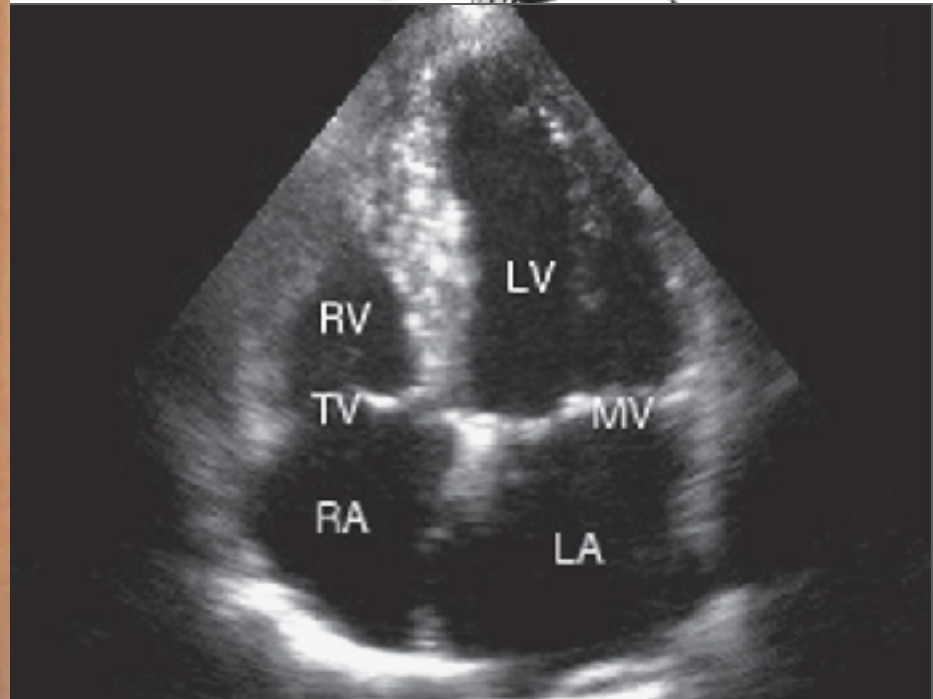
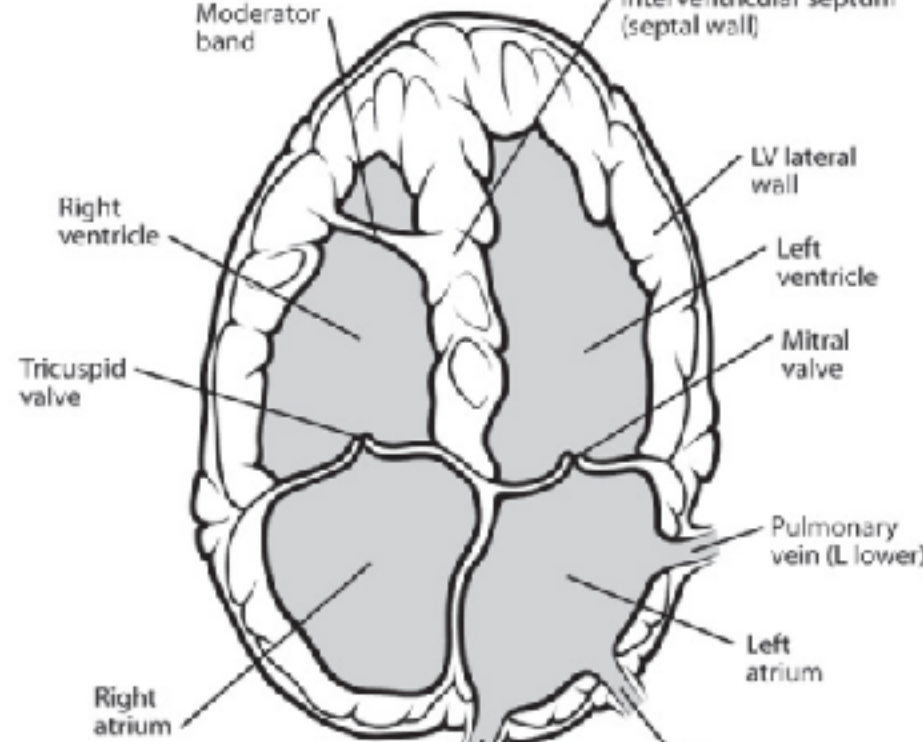
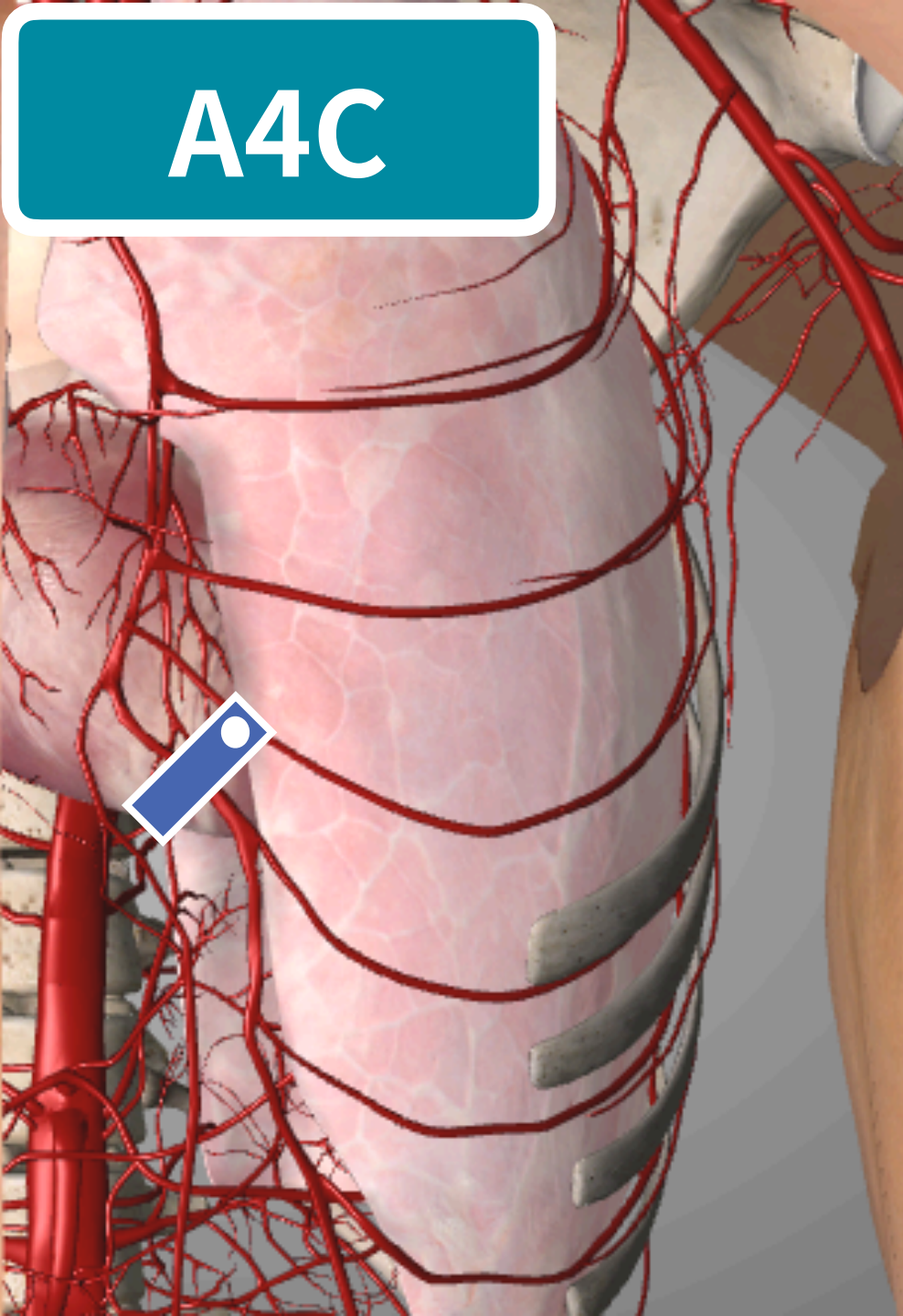




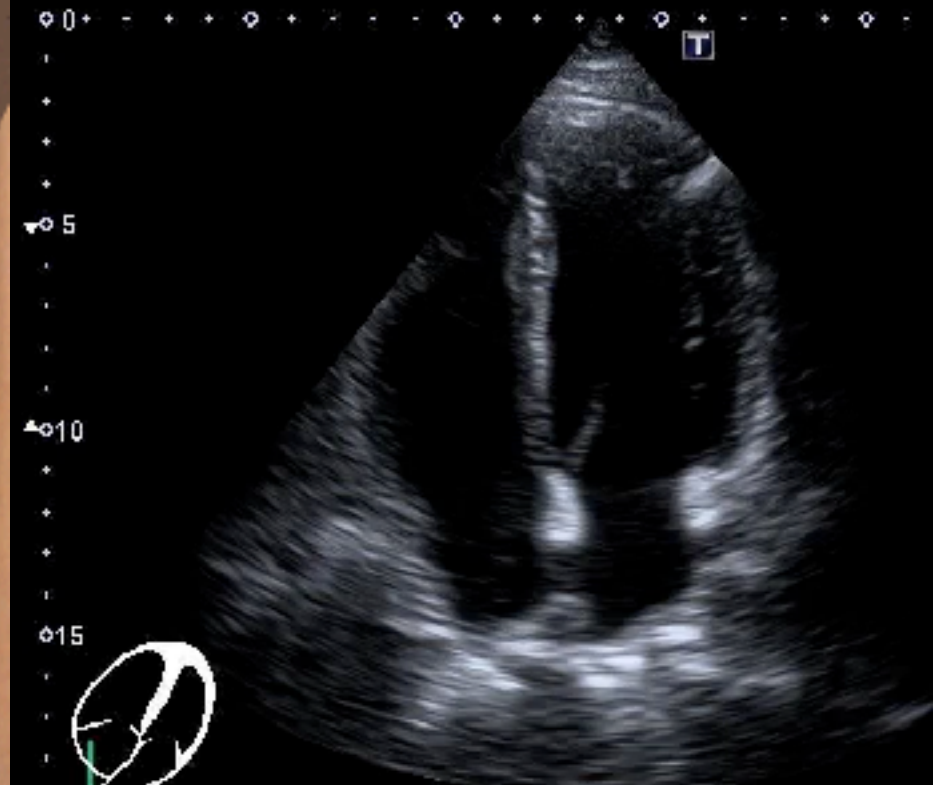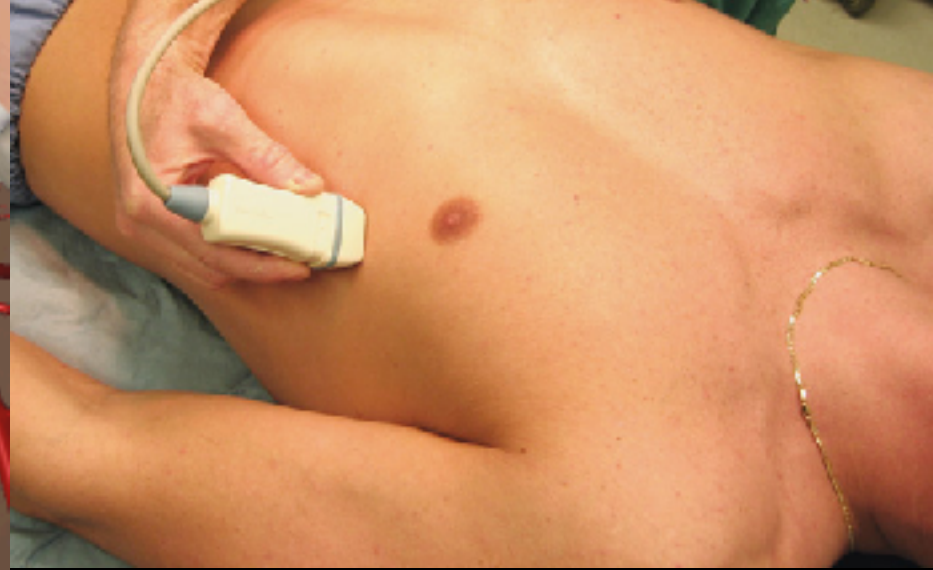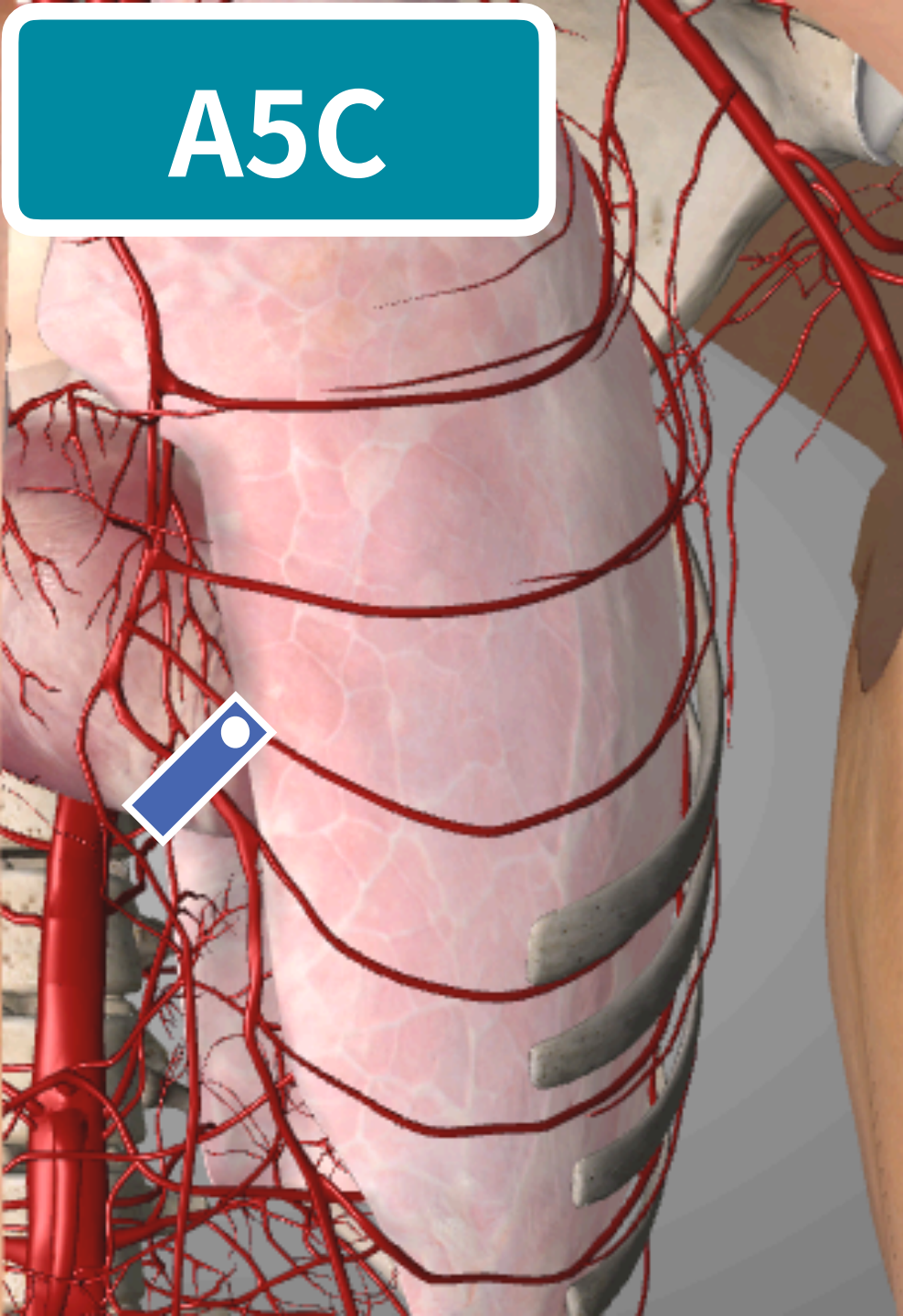




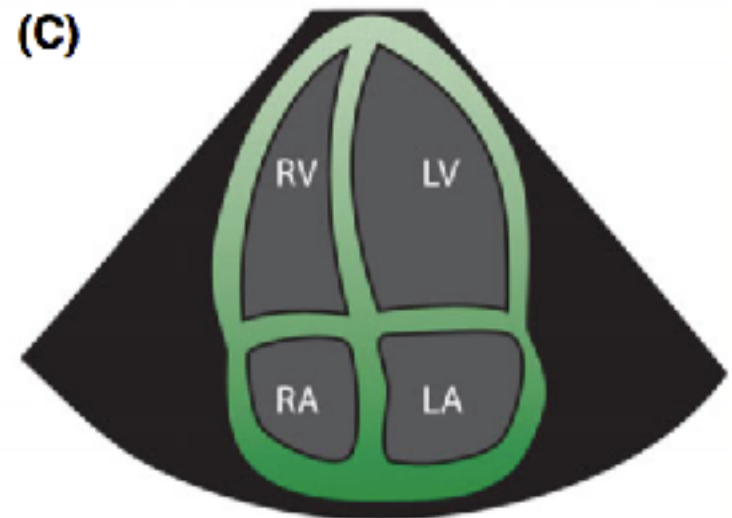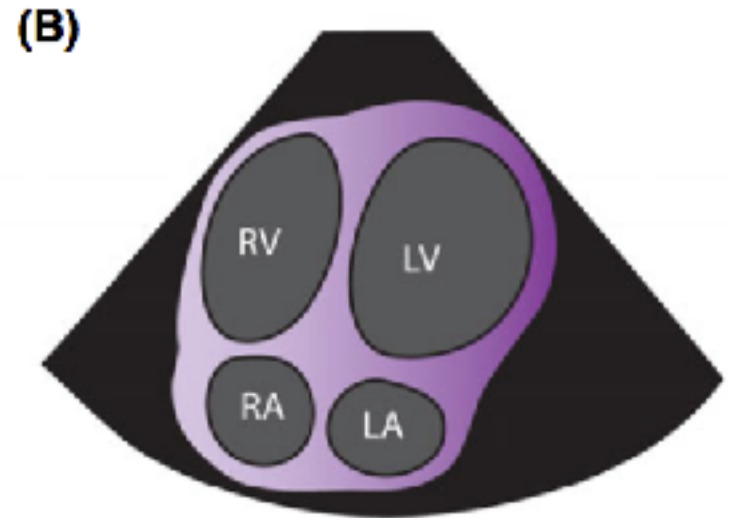
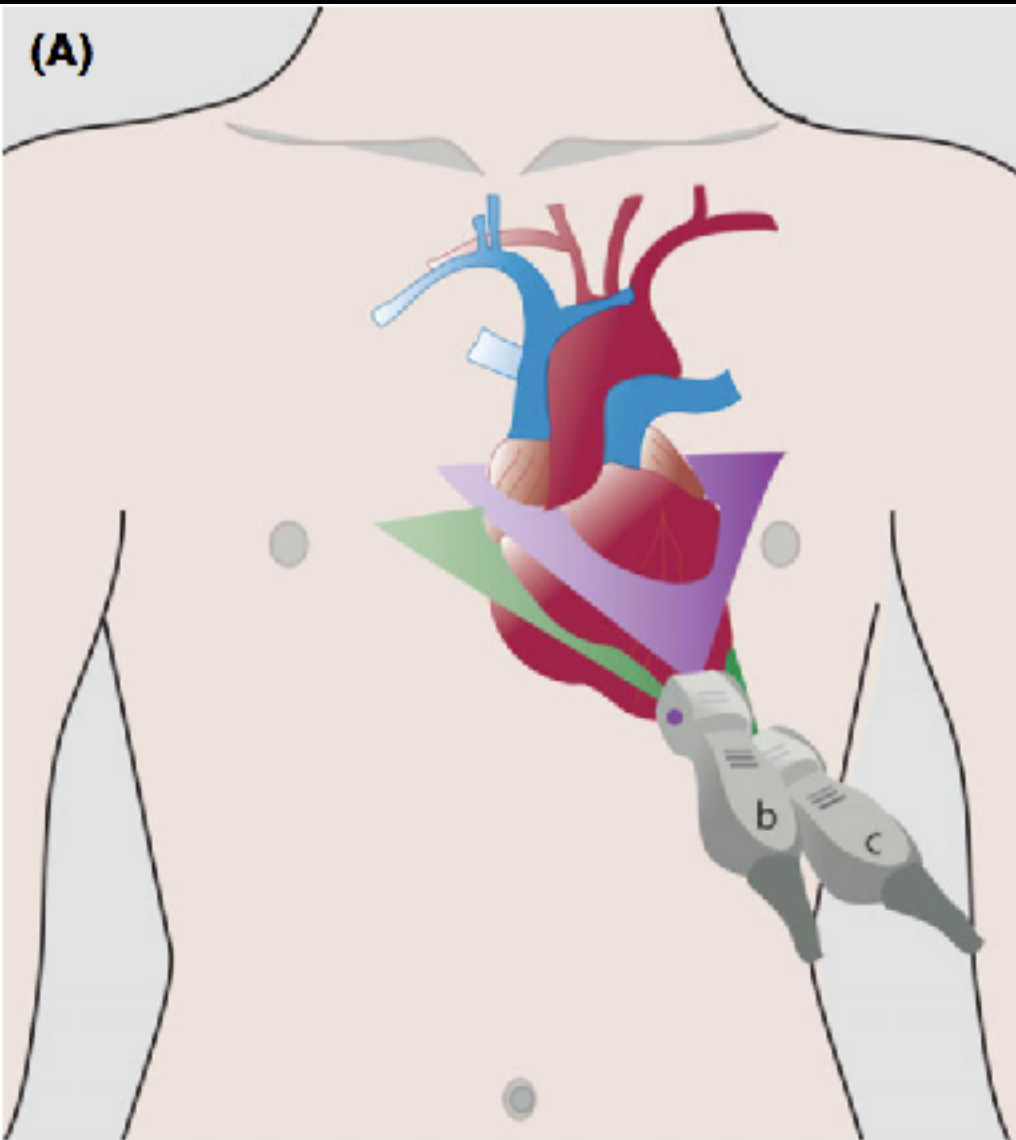
A4C



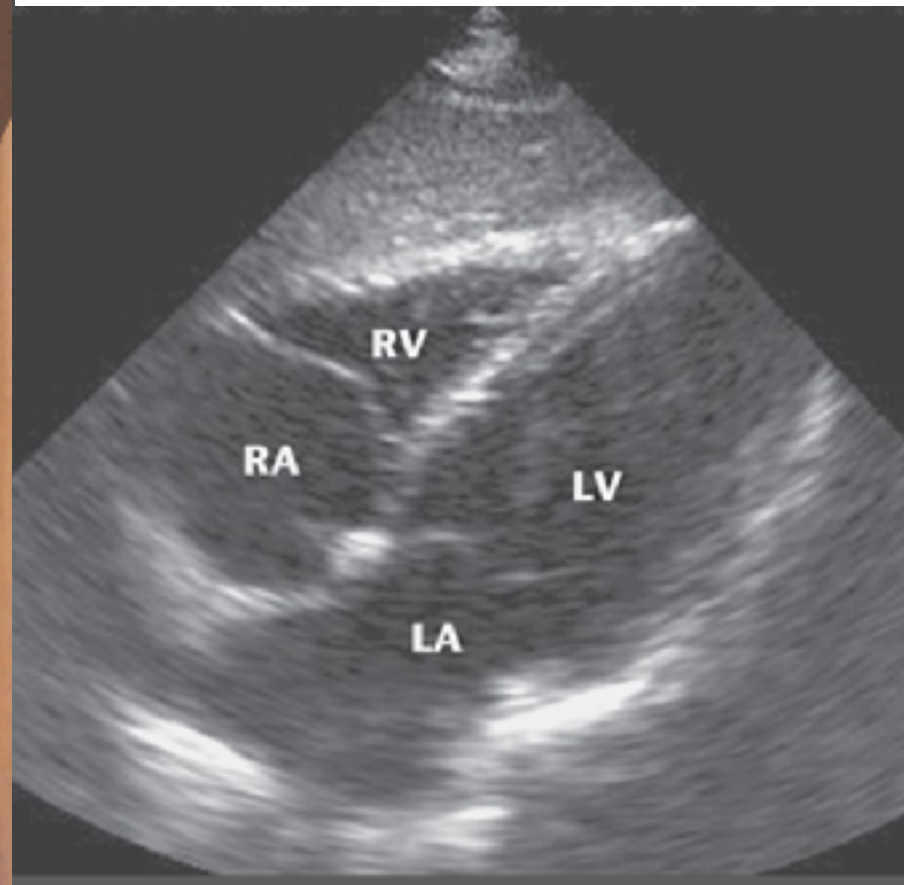
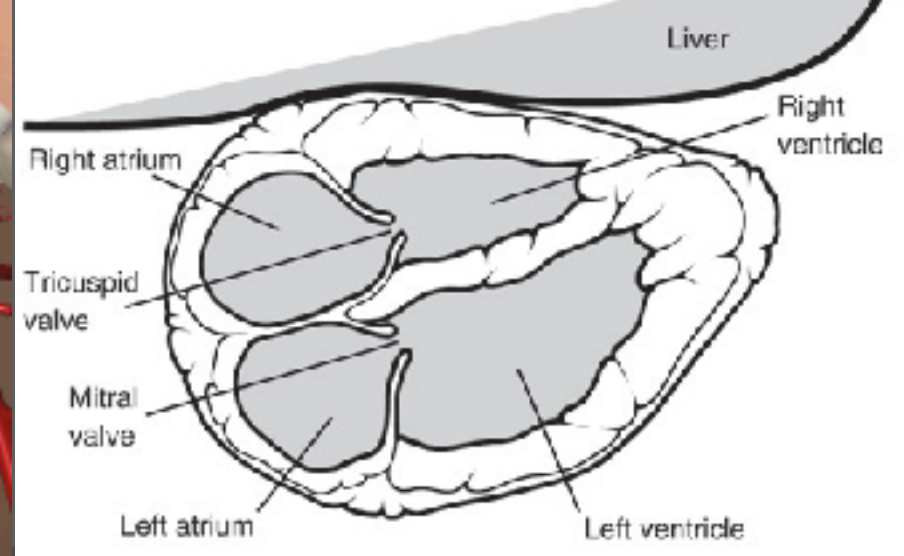
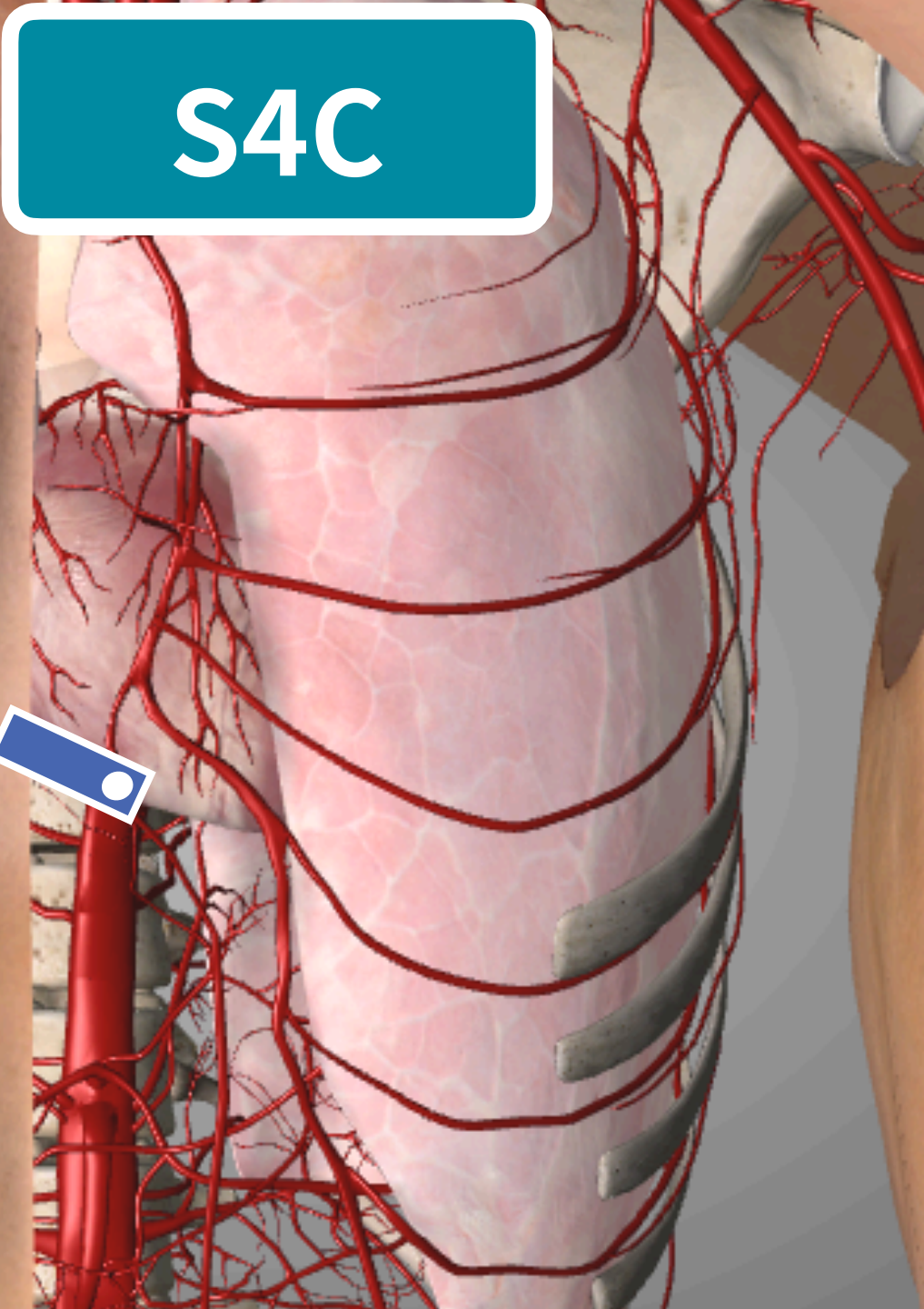
A5C



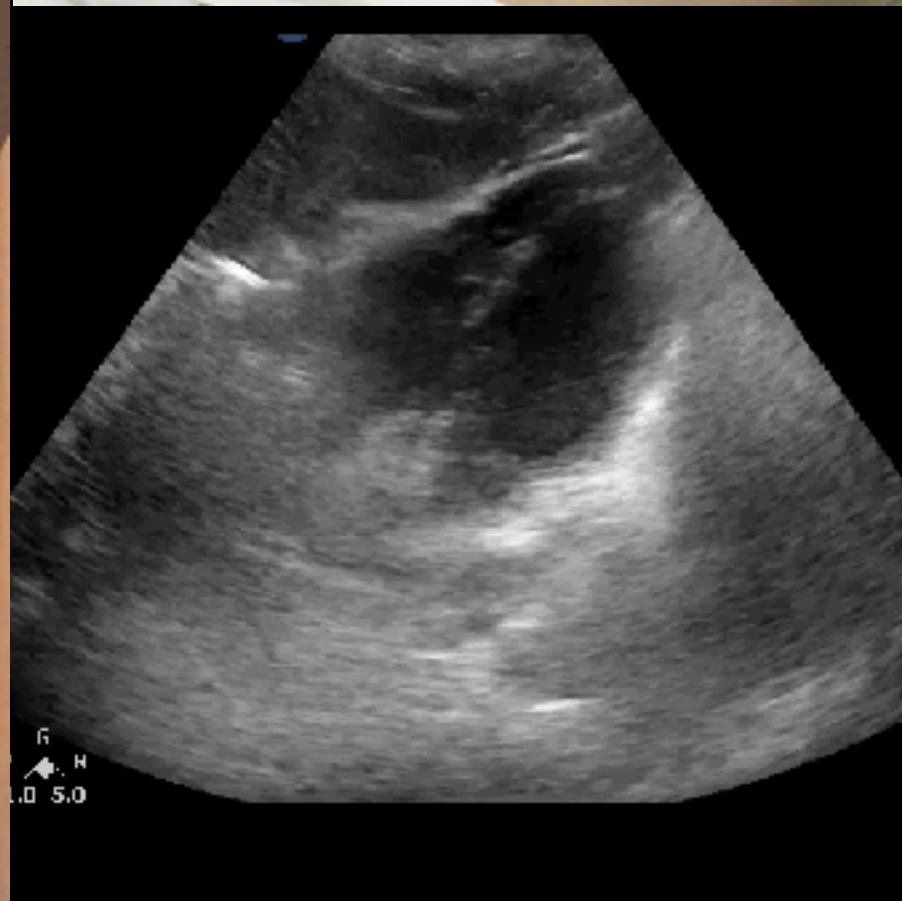
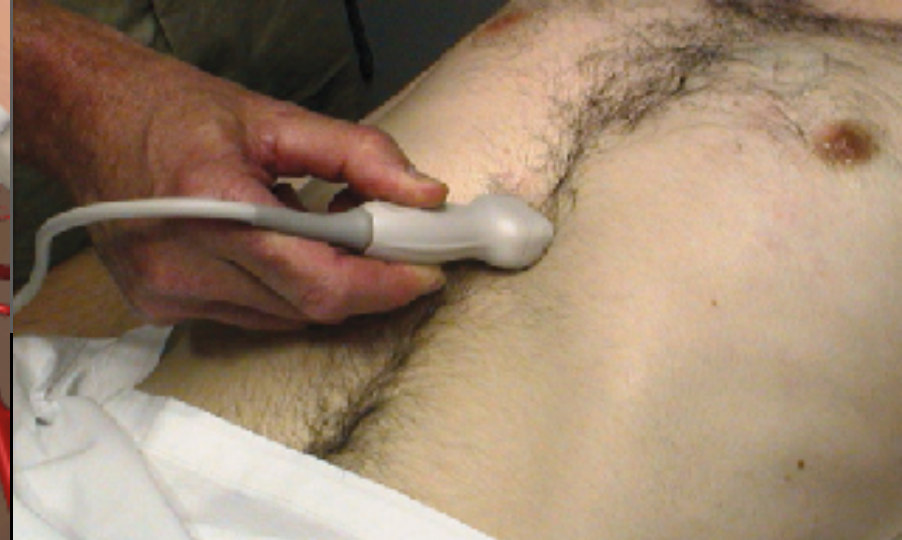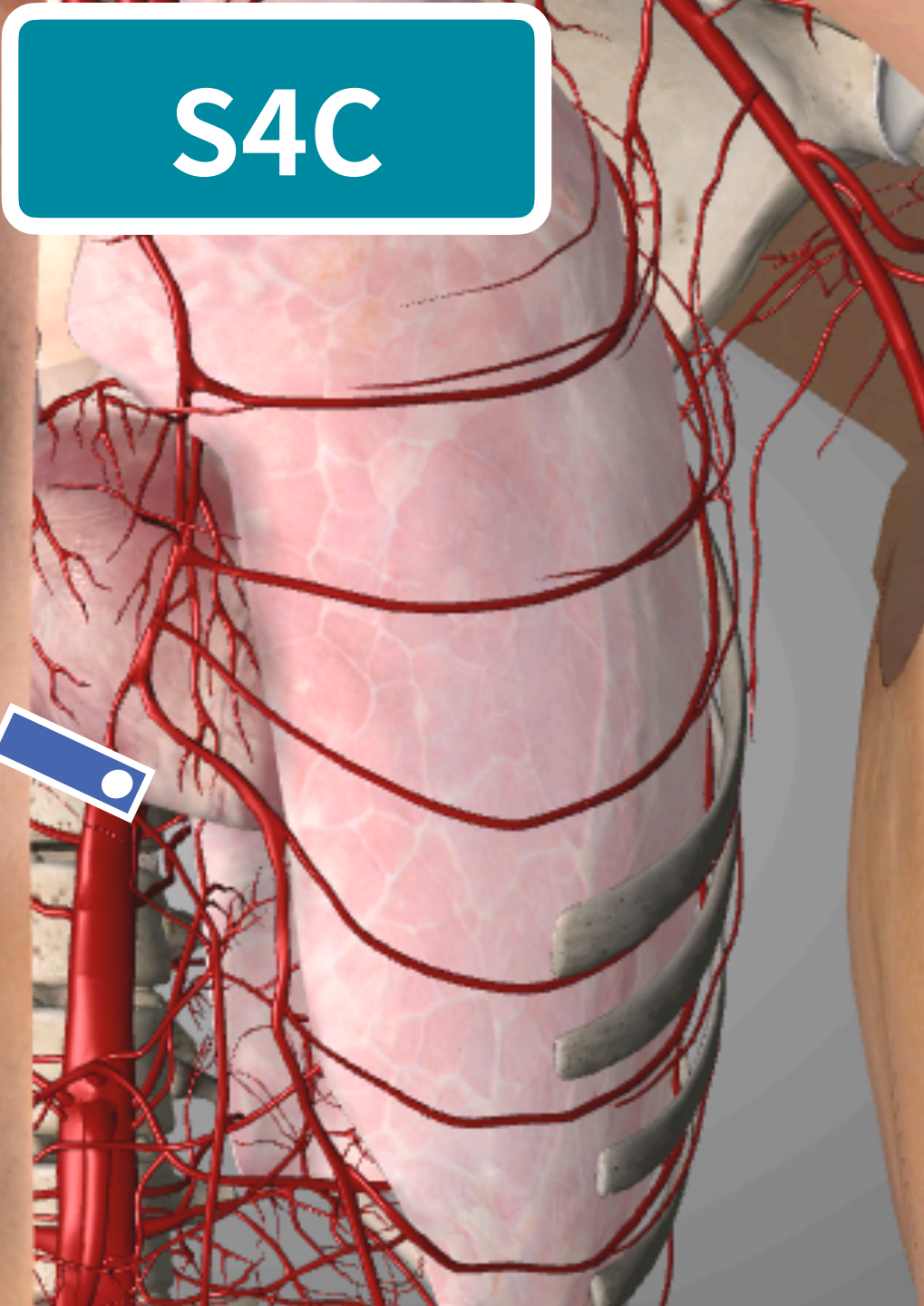
Underestimate



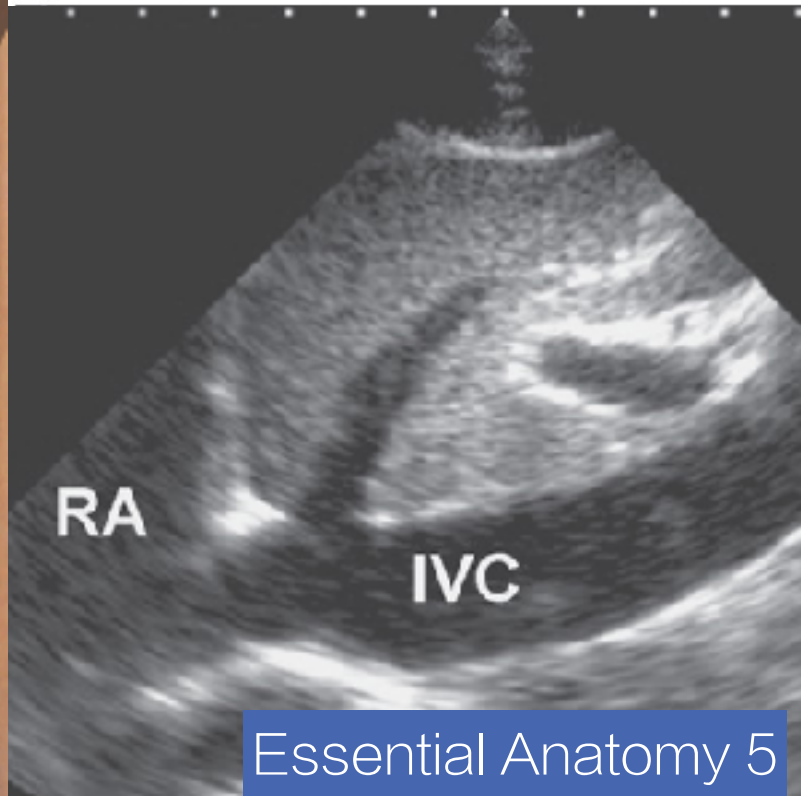
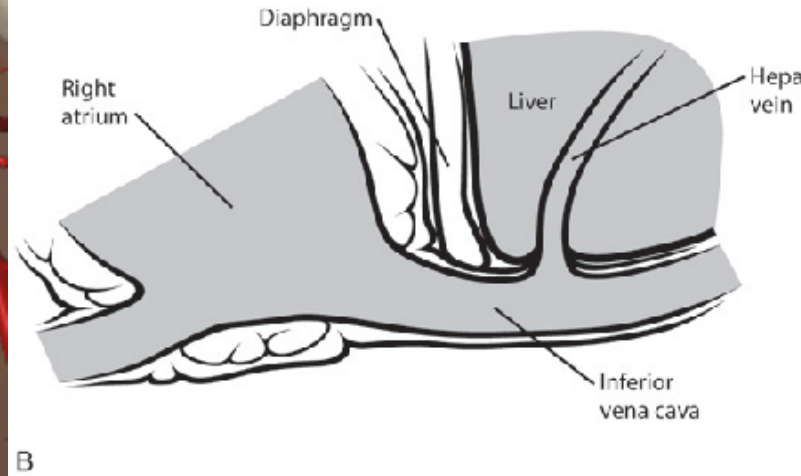
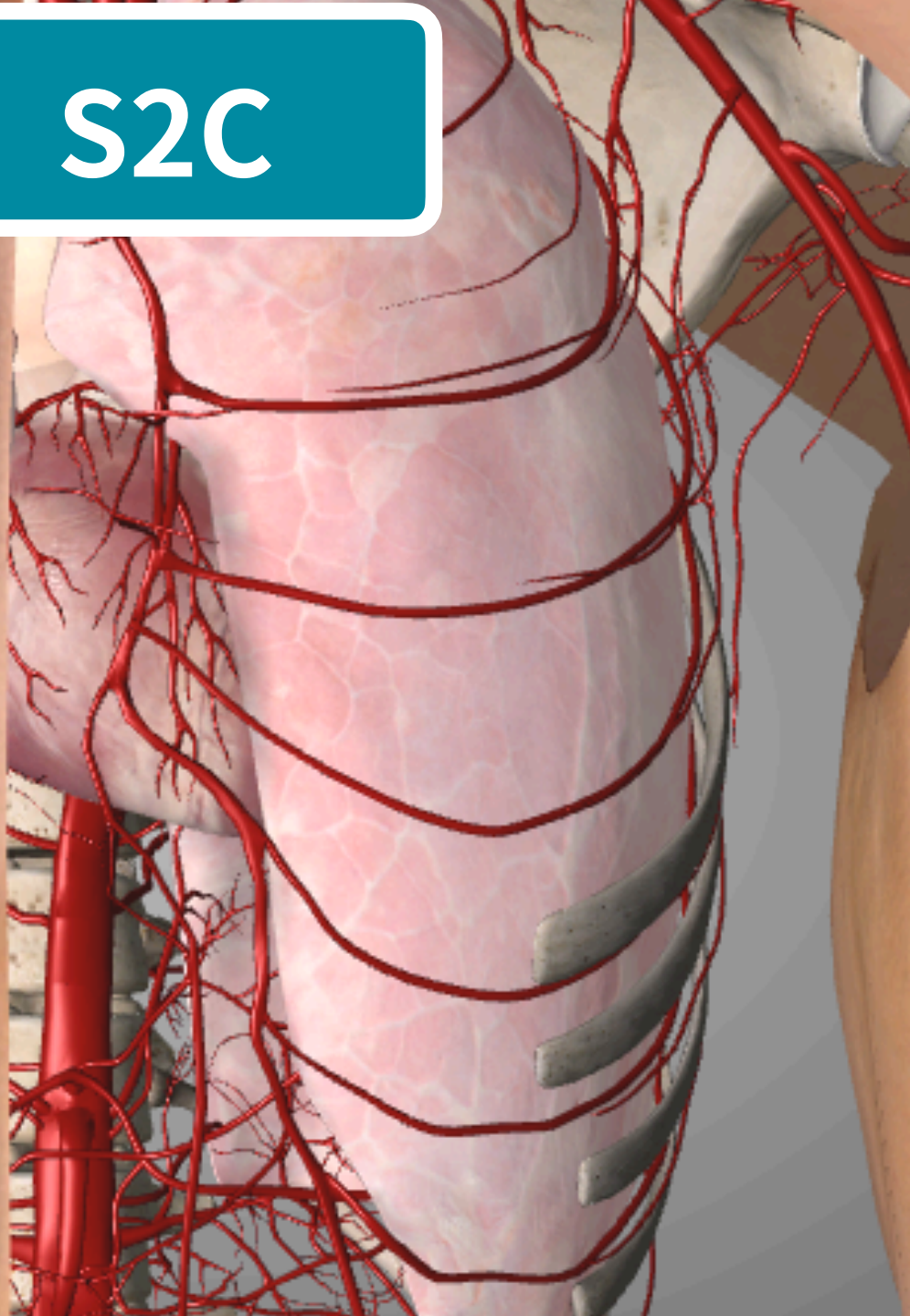
S4C



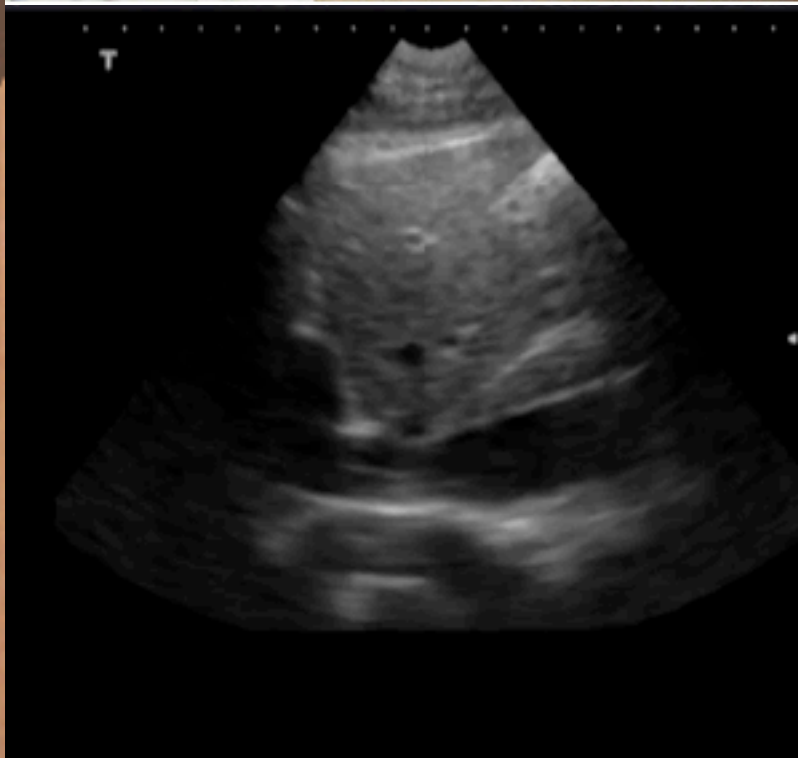
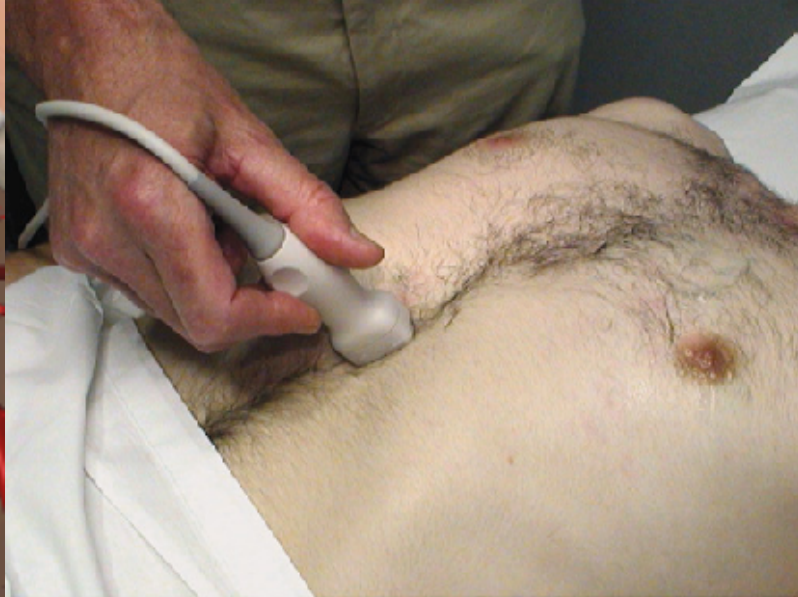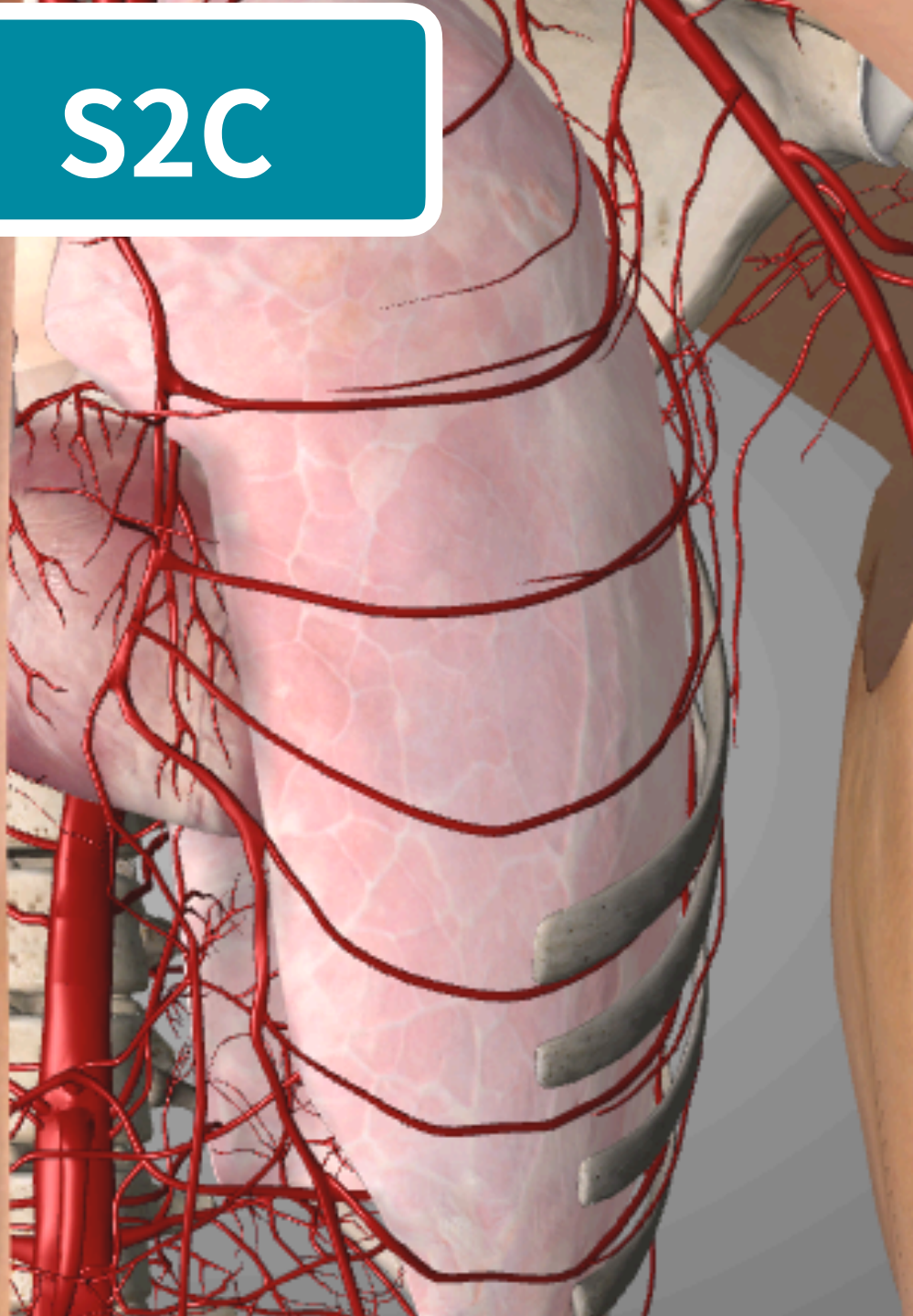
S4C

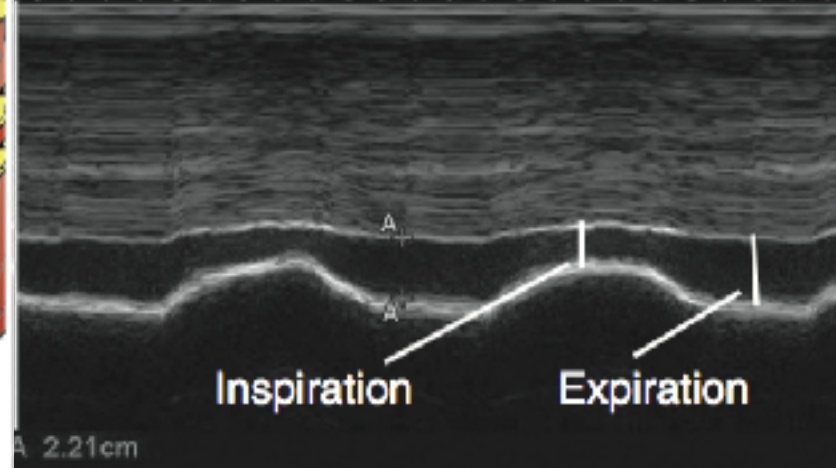
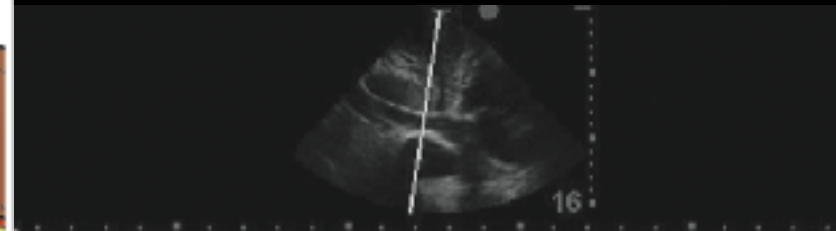
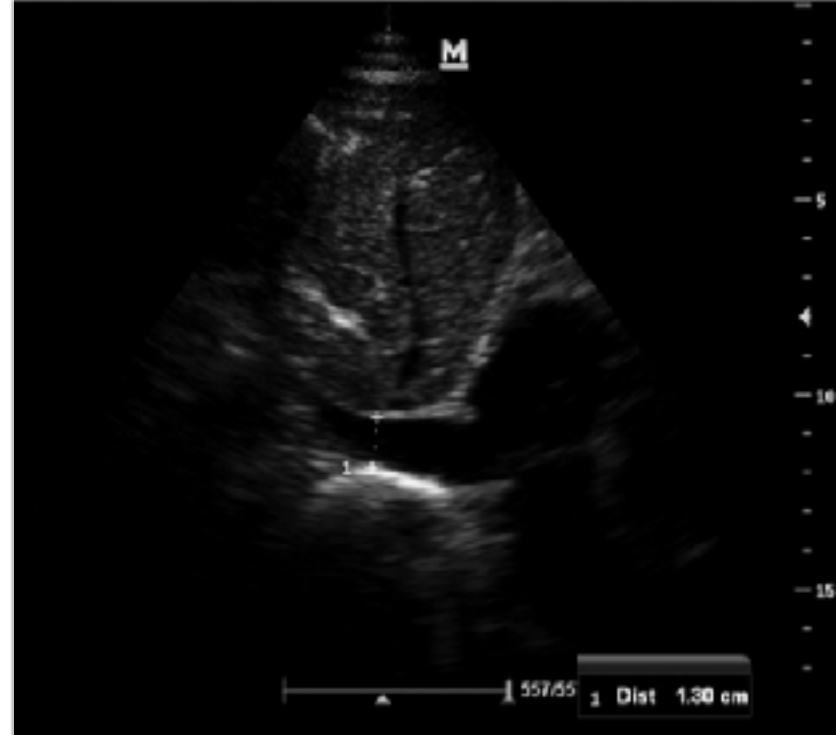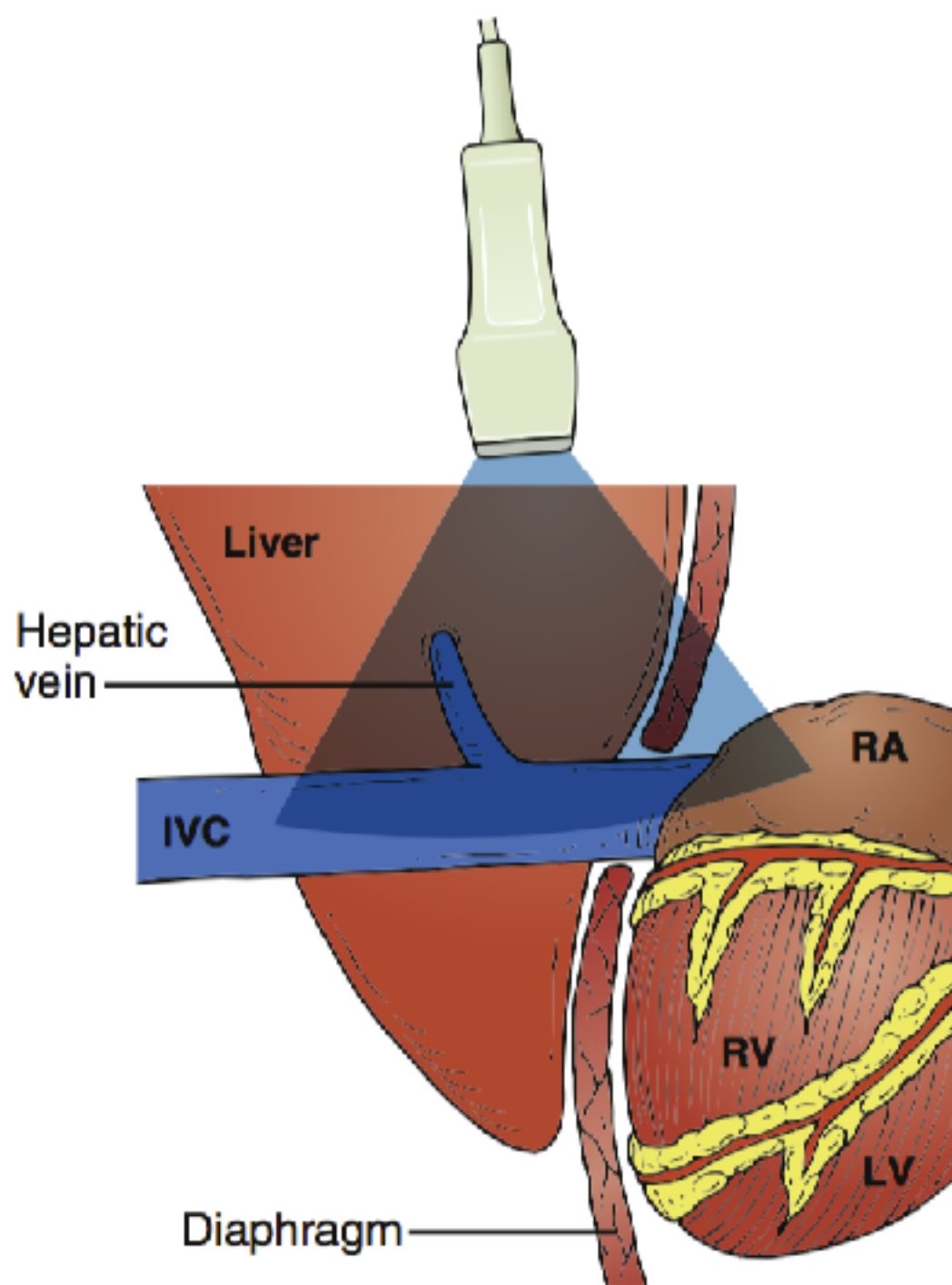


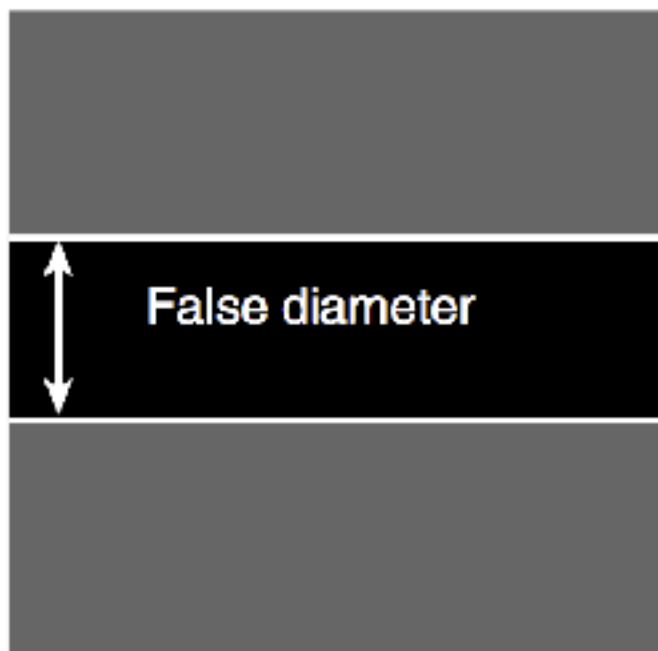
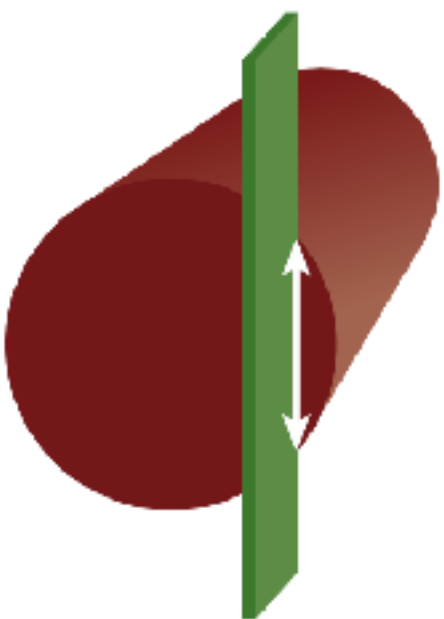
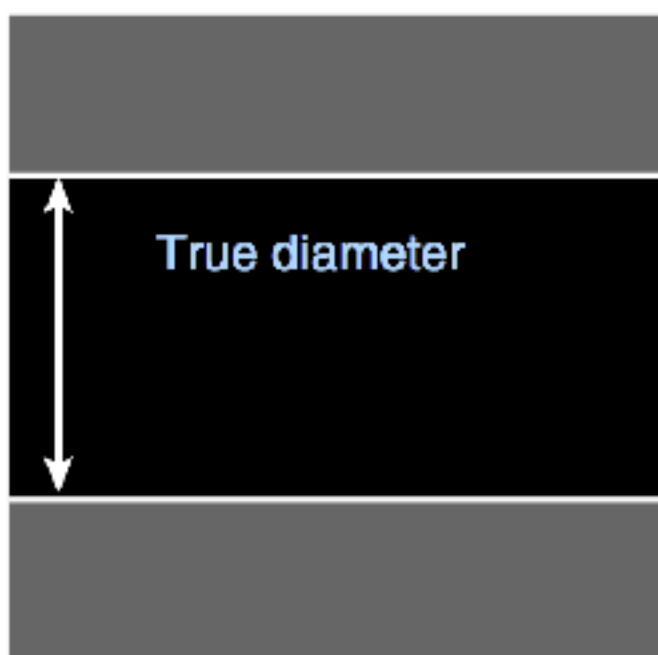

S2C



S2C

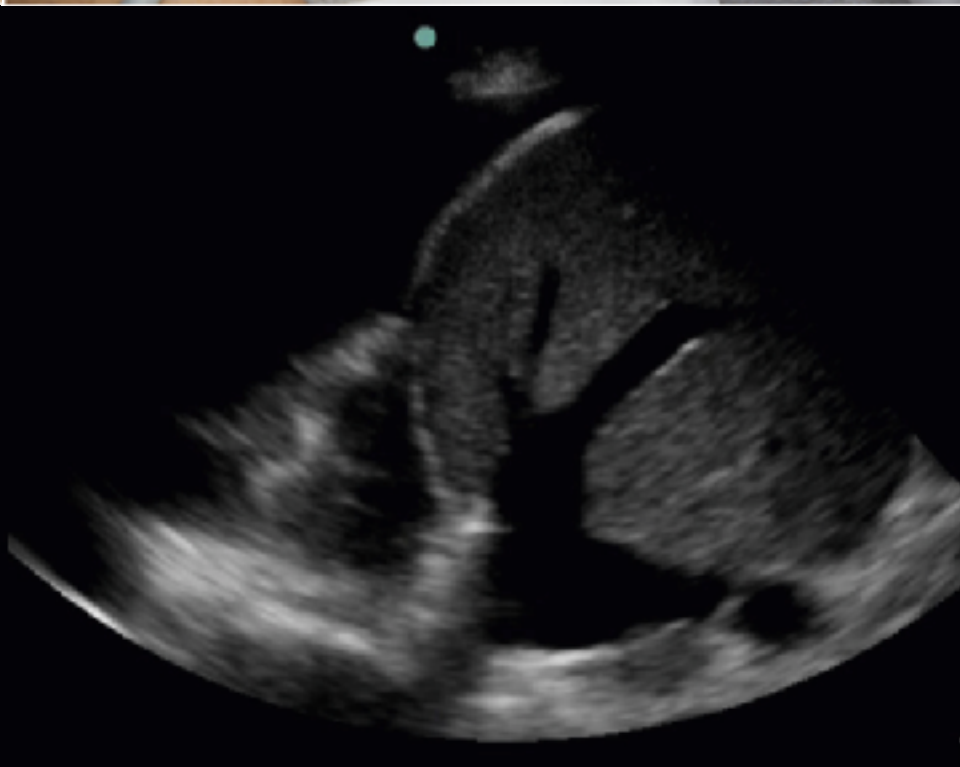
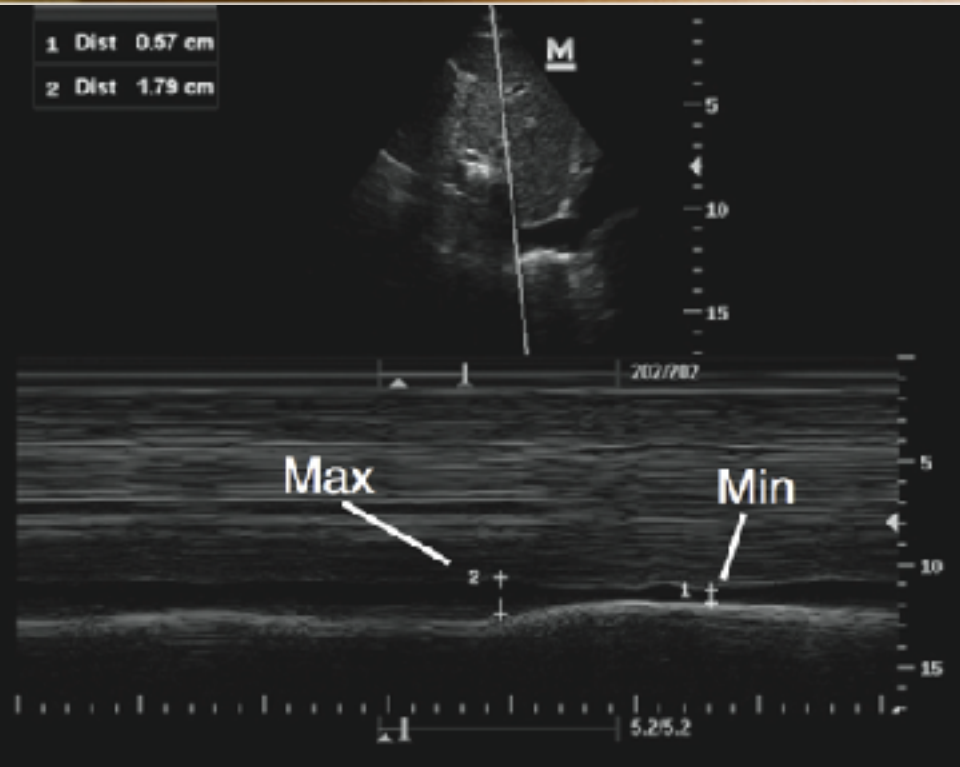
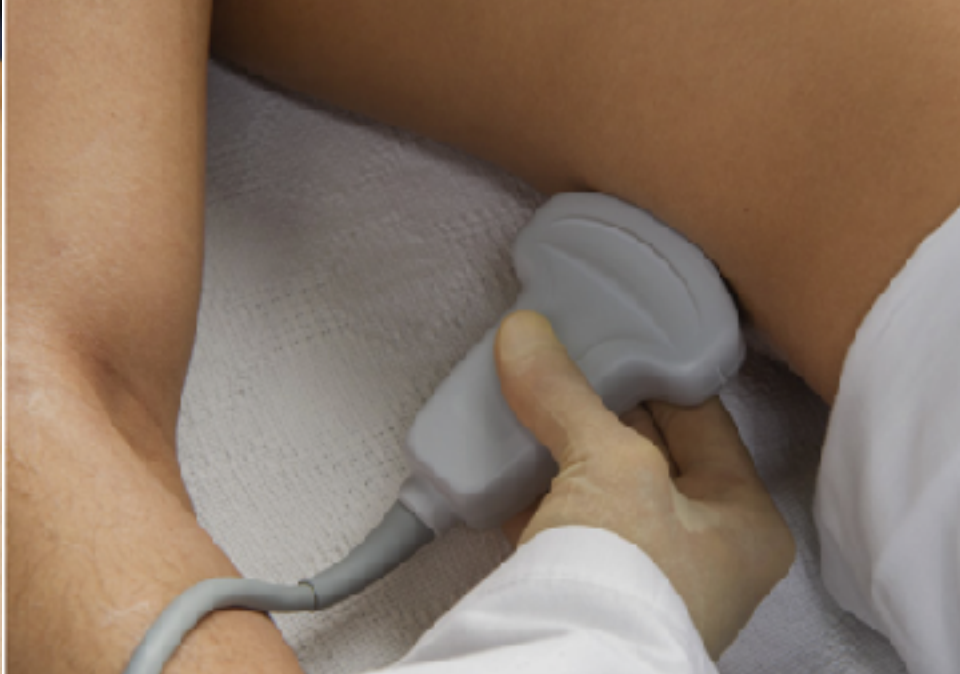
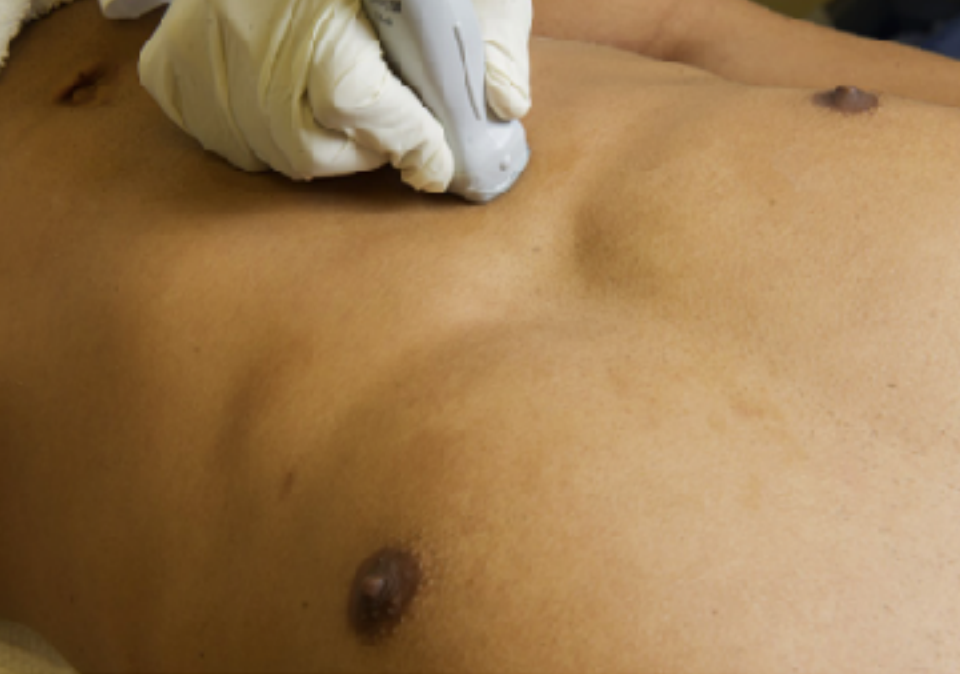




Beam placement

Screen image



ASE practice guideline 2020



J Am Soc Echocardiogr. 2020 Apr;33(4):409–422.e4.

Table 1 Definitions of cardiac ultrasound categories

	UAPE	Cardiac POCUS	CCE	Limited echo	Comprehensive echo
Diagnostic expectations	“Routine” performance of a single imaging protocol to augment bedside examination	Focused exams with specific imaging protocols based upon suspicion of a specific disease (e.g., rule out tamponade)	Focused on a collection of specific views/findings pertinent to the care of the critically ill (e.g., cardiac output, fluid responsive)	Focused on previously delineated findings as a follow-up exam; limited imaging protocol applied to answer a specific question	Comprehensive, all findings, quantification; increasingly use advanced techniques
Application frequency	Frequent, daily, multiple physicians	Usually once, per disease, but more frequently if change in clinical status	On admission or change in clinical status, potentially frequently	As follow up to comprehensive echo; potentially multiple times over weeks to months	Once (per admission, change in clinical status)
Interpretation of findings	Presence or absence of ultrasound “signs” indicative of cardiac abnormality	Findings related to the diagnosis sought in protocol	Primary and incidental findings recorded in views	All findings, primary and incidental, recorded in limited views	All findings, primary and incidental recorded in comprehensive imaging
Quantification	Usually Absent	Optional	Typically	Typically	Mandatory
Indication	Physical exam	Clinical suspicion	Medical necessity	Medical necessity	Medical necessity
Documentation	Images not recorded (except for QA), findings reported in physical exam	Image archiving and formal reporting controversial	Images archived, formal report	Images archived on PACS, formal report	Images archived on PACS, formal report
Teaching required	Introductory and modest (weeks)	Modest (weeks to months)	Advanced (months)	Advanced (years)	Advanced (years)
Notes	Used “in the manner and intent” of cardiac physical examination	Similar to UAPE, but disease specific	Imaging protocols specific to issues in the critically ill; comparison to available prior studies as indicated	Reading all findings increases training burden. Comparison to available prior studies is standard practice. Must be able to convert to comprehensive at bedside	Completely evaluates all findings, regardless of referral question or incidental nature. Comparison to available prior studies is standard practice.

CCE, critical care echocardiography; PACS, Picture Archival and Communication System; POCUS, point of care ultrasound; UAPE, ultrasound assisted physical examination.

Adapted from: Kimura BJ. Point-of-care cardiac ultrasound techniques in the physical examination: better at the bedside. *Heart* 2017;103:987–994. <https://doi.org/10.1136/heartnl-2016-309915>.

Diagnostic expectations	"Routine" performance of a single imaging protocol to augment bedside examination	Focused exams with specific imaging protocols based upon suspicion of a specific disease (e.g., rule out tamponade)	Focused on a collection of specific views/findings pertinent to the care of the critically ill (e.g., cardiac output, fluid responsive)
Application frequency	Frequent, daily, multiple physicians	Usually ones, per disease, but more frequently if change in clinical status	On admission or change in clinical status, potentially frequently
Interpretation of findings	Presence or absence of ultrasound "signs" indicative of cardiac abnormality	Findings related to the diagnosis sought in protocol	Primary and incidental findings recorded in views
Quantification	Usually Absent	Optional	Typically
Indication	Physical exam	Clinical suspicion	Medical necessity
Documentation	Images not recorded (except for QA), findings reported in physical exam	Image archiving and formal reporting controversial	Images archived, formal report
Teaching required	Introductory and modest (weeks)	Modest (weeks to months)	Advanced (months)
Notes	Used "in the manner and intent" of cardiac physical examination	Similar to UAPE, but disease specific	Imaging protocols specific to issues in the critically ill; comparison to available prior studies as indicated

急診心超三部曲

理學檢查

UAPE

快速判定

Cardiac POCUS

進階測量

CCE

UAPE-Quick check

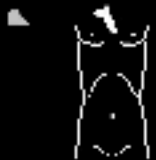C Nerve
C6-2
22 Hz
13.0cm

2D
Gen
Gn 60
C. 53
2/3/2

Base

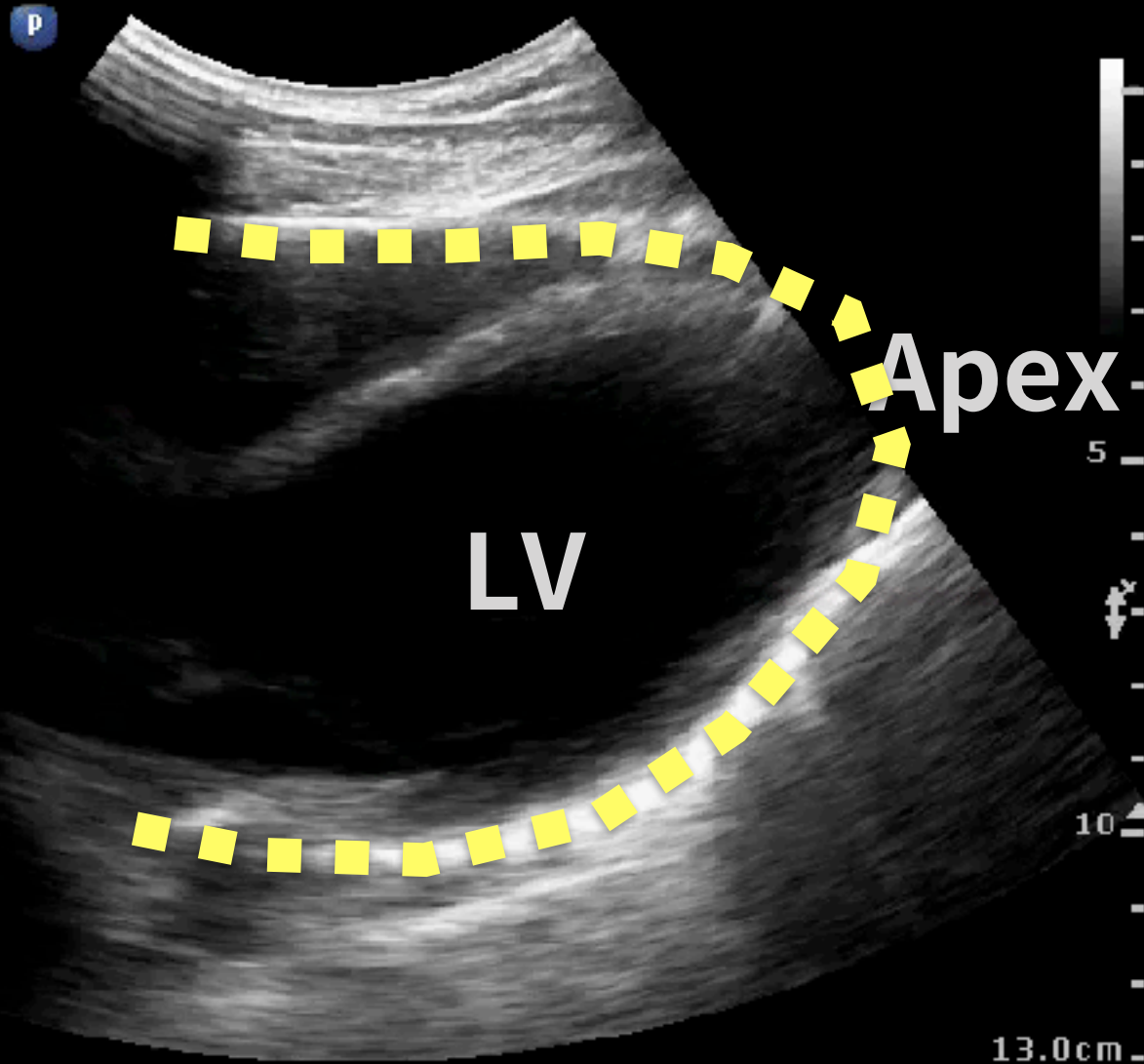
LV

Apex



R
P R
2.0 6.0

13.0cm



UAPE-Quick check

Adult Echo
S1-1
77 Hz
15.0cm

2D
HGen
Gn 100
55
3/2/0
50 mm/s

Leg

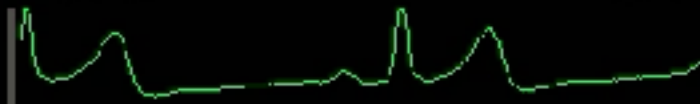Liver

Head

IVC

Diameter (1-2cm) / Variation (50%)

Ⓜ
P R
1.7 3.1



53
BPM

Adult Echo
S1-1
30 Hz
4.0cm
P1)
HGen
Gn 36
C 50
3/2/0

SKH-EUTC@ChenKC

PSLA

S4C

Cardiac POCUS

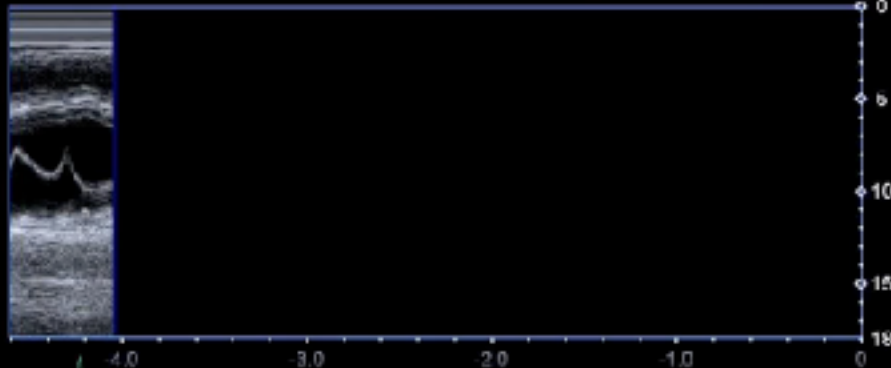
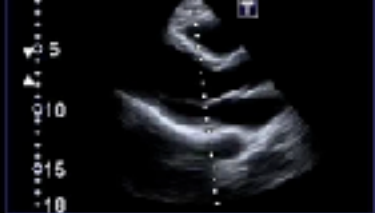PSSA

A4C

M
561
T3.0
40 fps 5
G:82
DR:55
TE:3

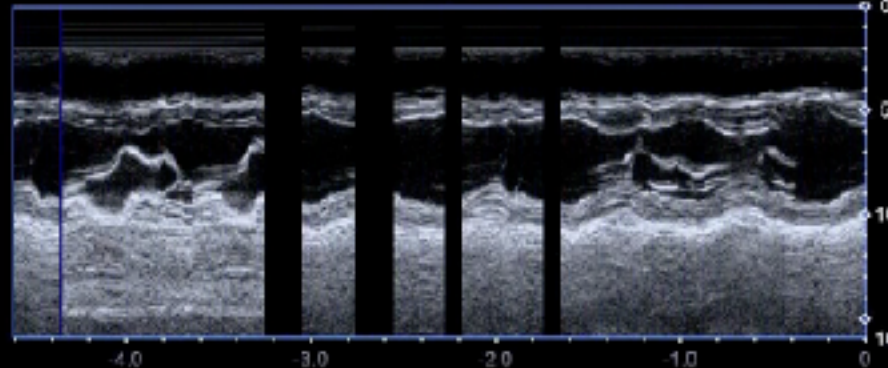
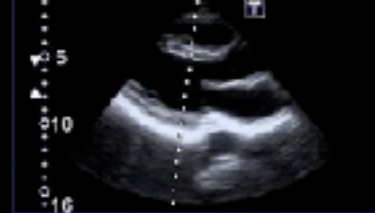EPSS

6S1
G:91
DR:55
TE:3



FS


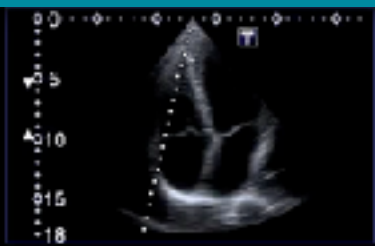
6S1
G:92
DR:55
TE:3



Cardiac POCUS - CCE

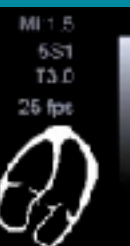
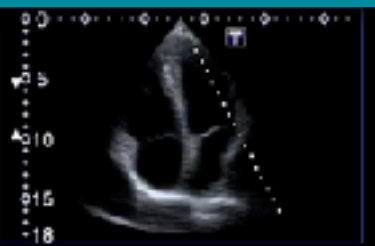TAPSE

6S1
G:94
DR:55
TE:3



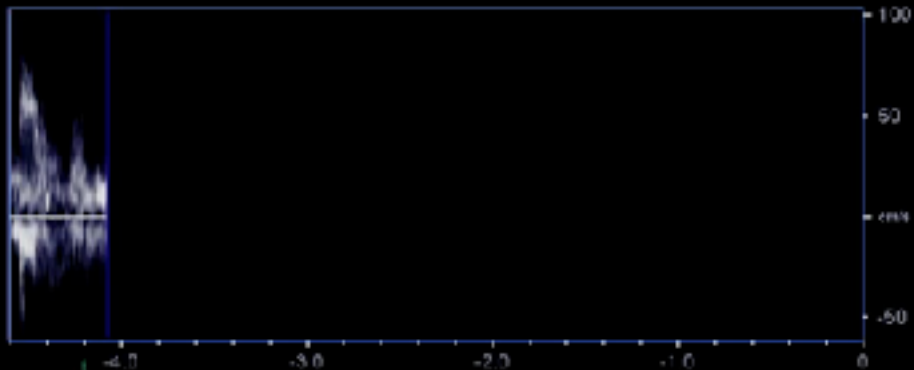
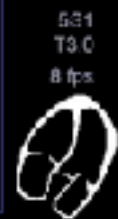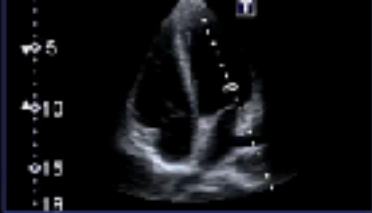MAPSE

6S1
G:95
DR:55
TE:3



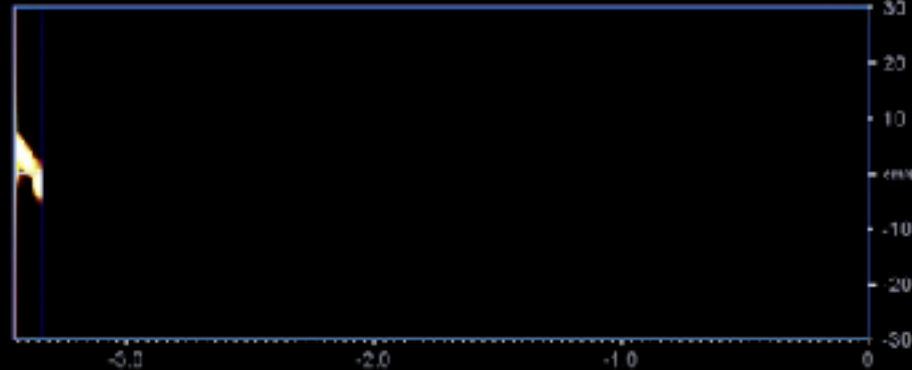
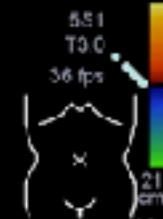
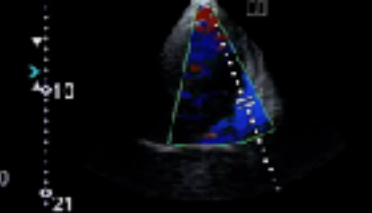
E/A

Qscan
G:92
DR:55
TE:3
0° 3.0
9.0cm



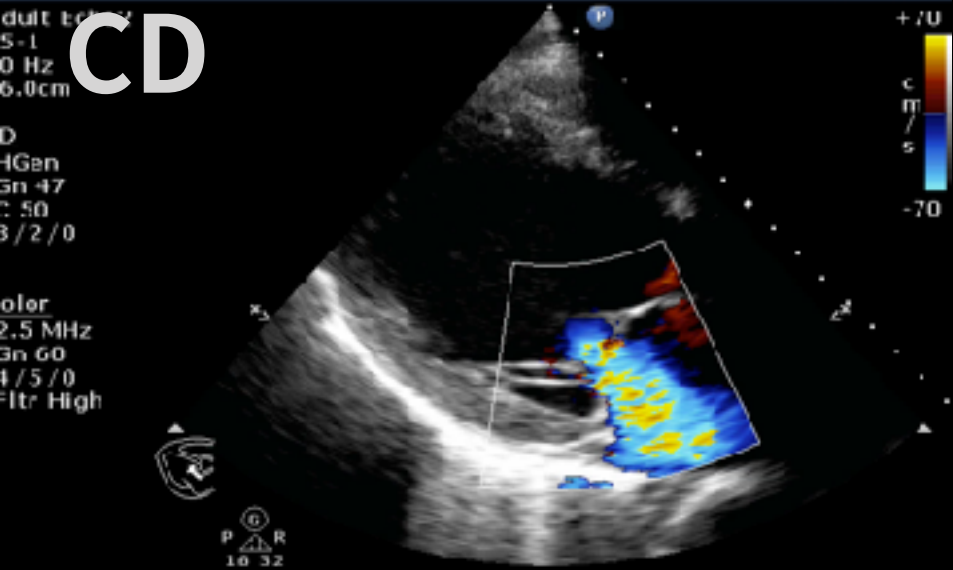
TDI

Qscan
G:96
DR:55
CF:2.5
CG:40
2.8h
F:0
0° 5.0
12.1cm

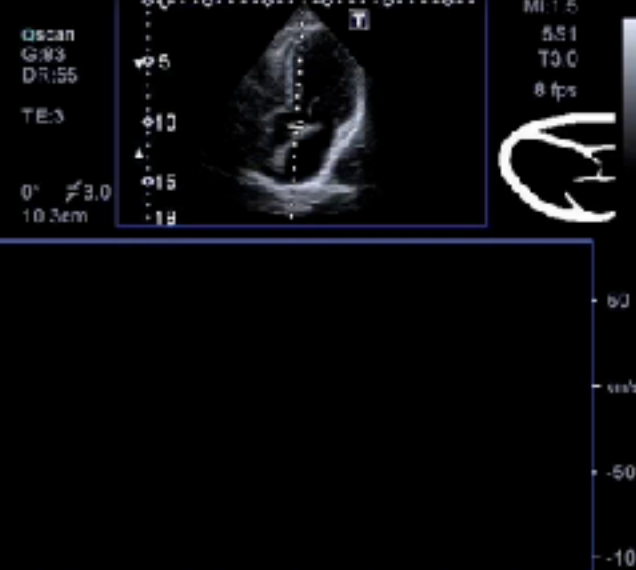


CCE

CD

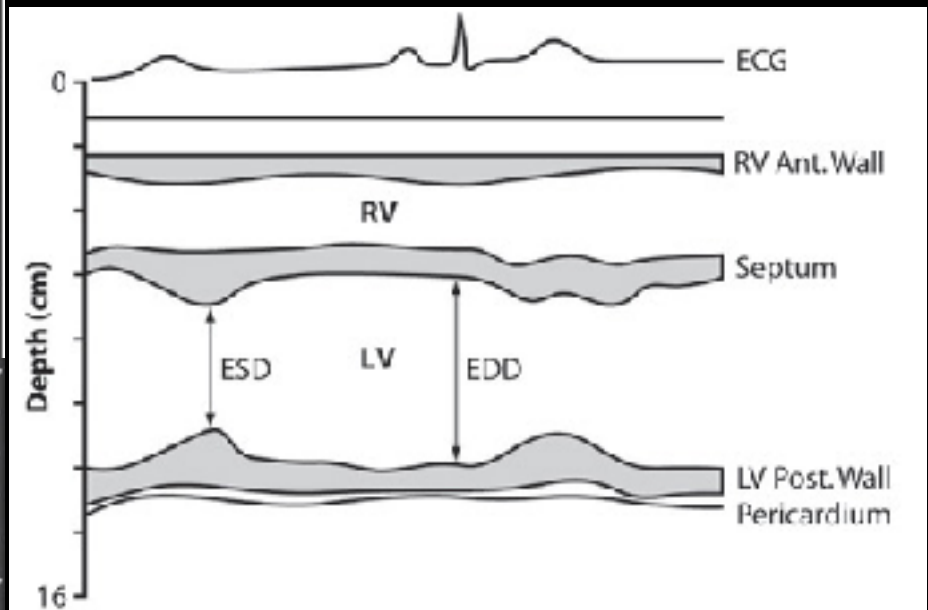


VTI



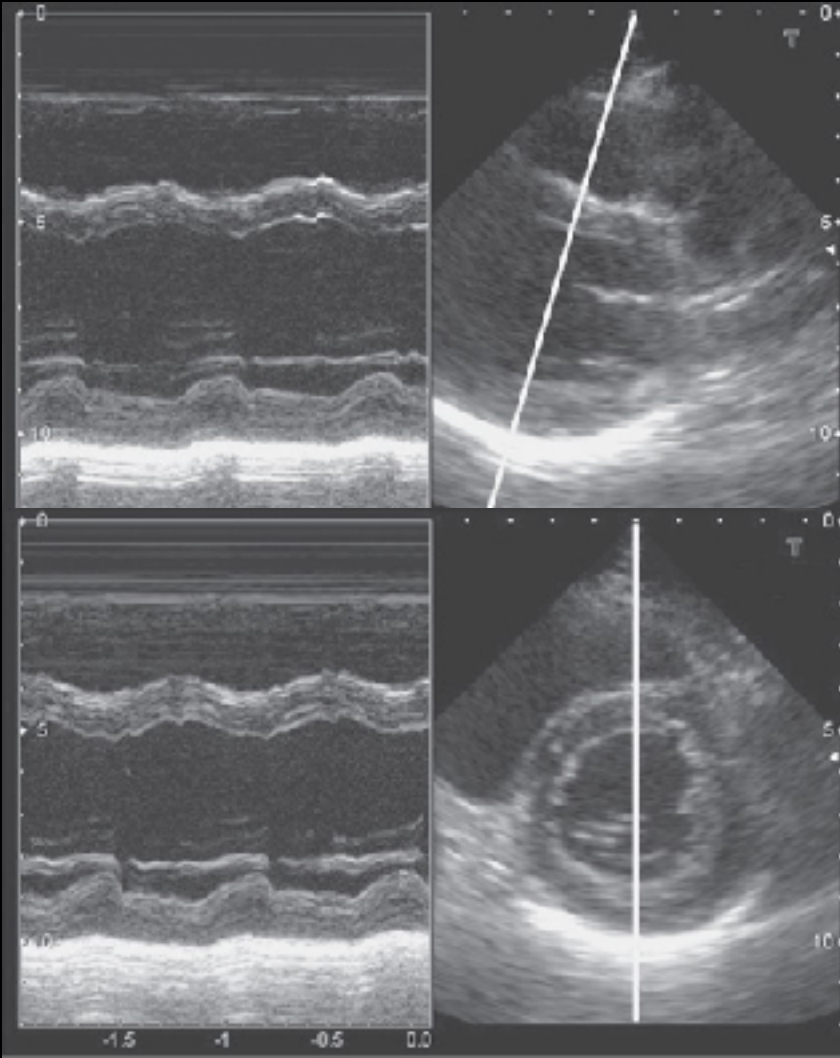
Fraction shortening

$$FS (\%) = 100 \times \frac{(LVEDD - LVESD)}{LVEDD}$$

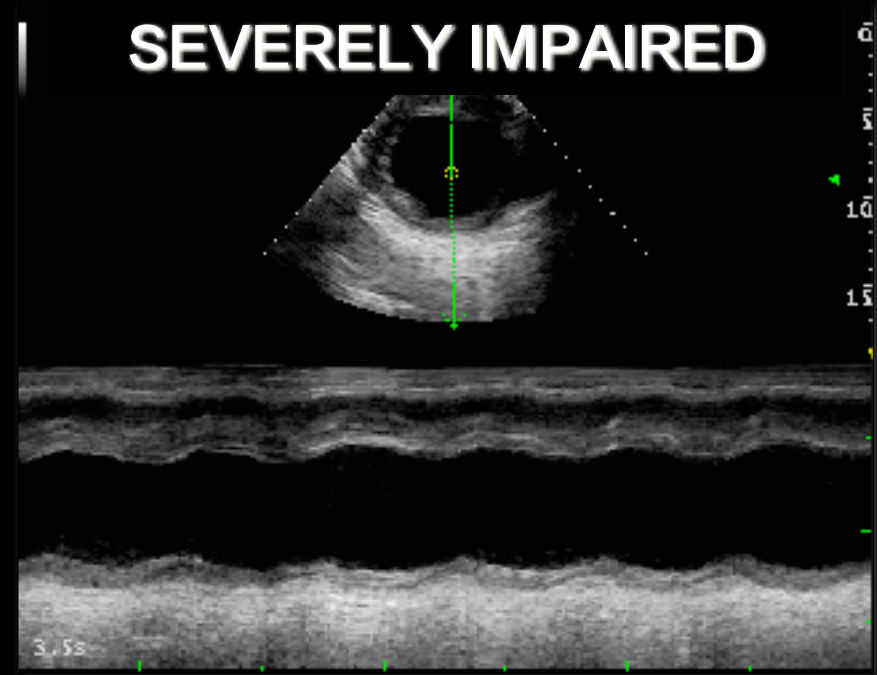
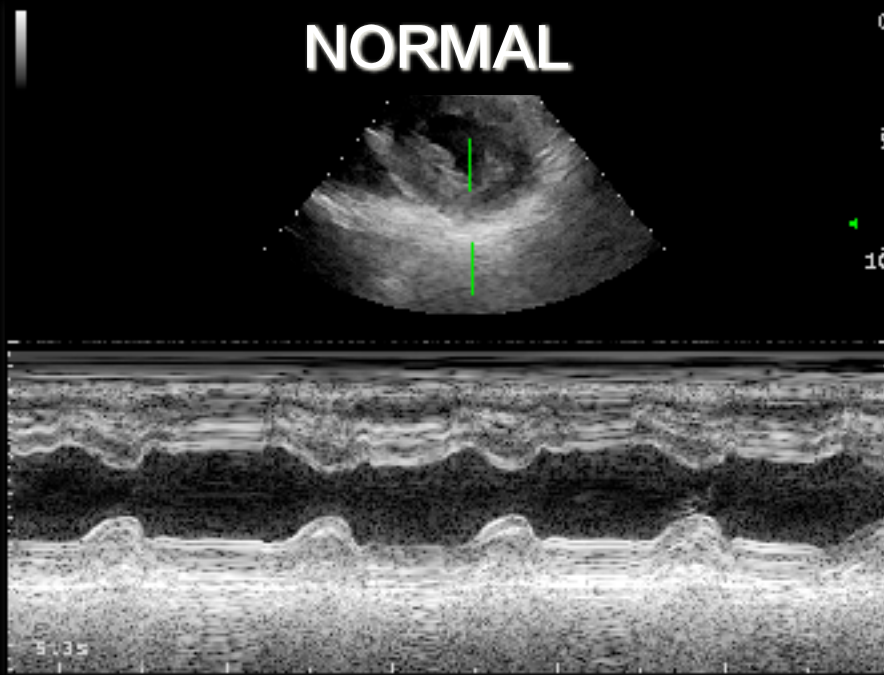


NORMAL $\geq 30\%$

SEVERELY IMPAIRED $< 20\%$



Fraction shortening

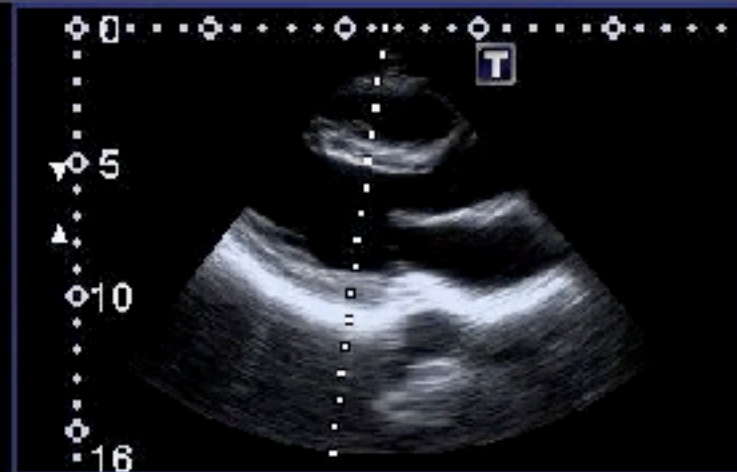


$$EF(\%) \approx FS(\%) \times 2 \quad (\text{ex. FS } 30\% \approx \text{EF } 60\%)$$

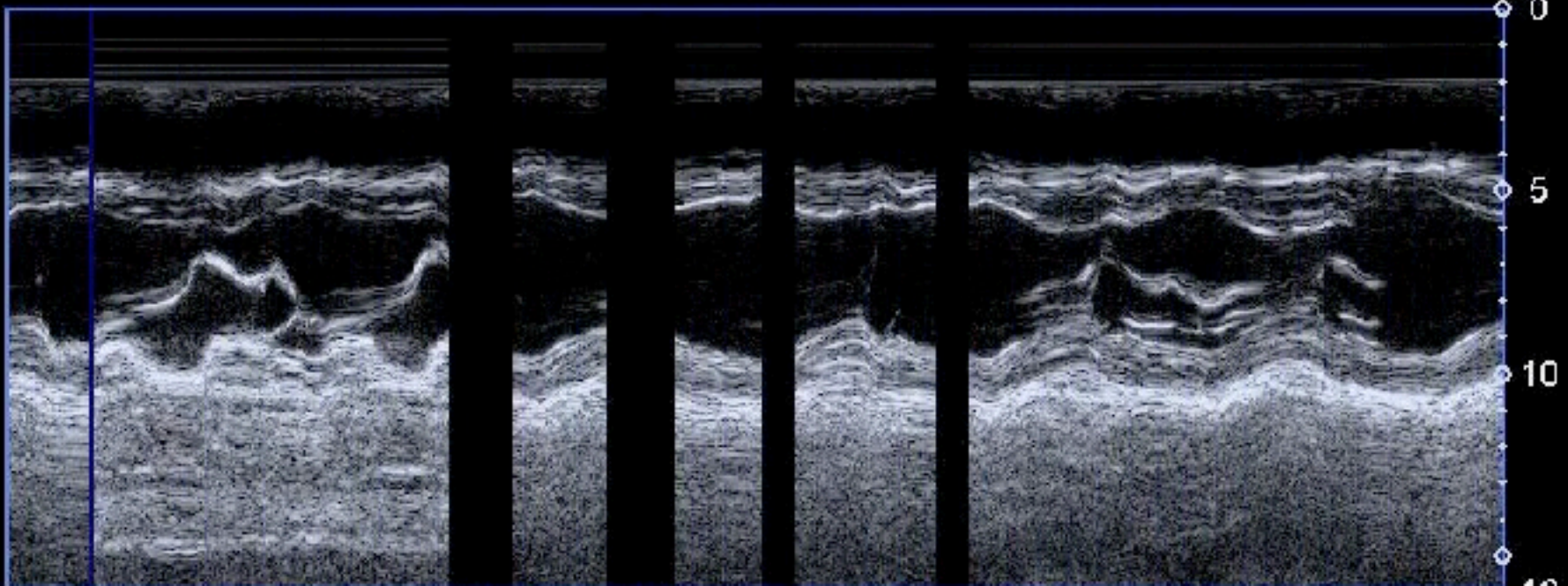
(Simplification of Teicholz method)

Fraction shortening

G:82
DR:55
TE:3

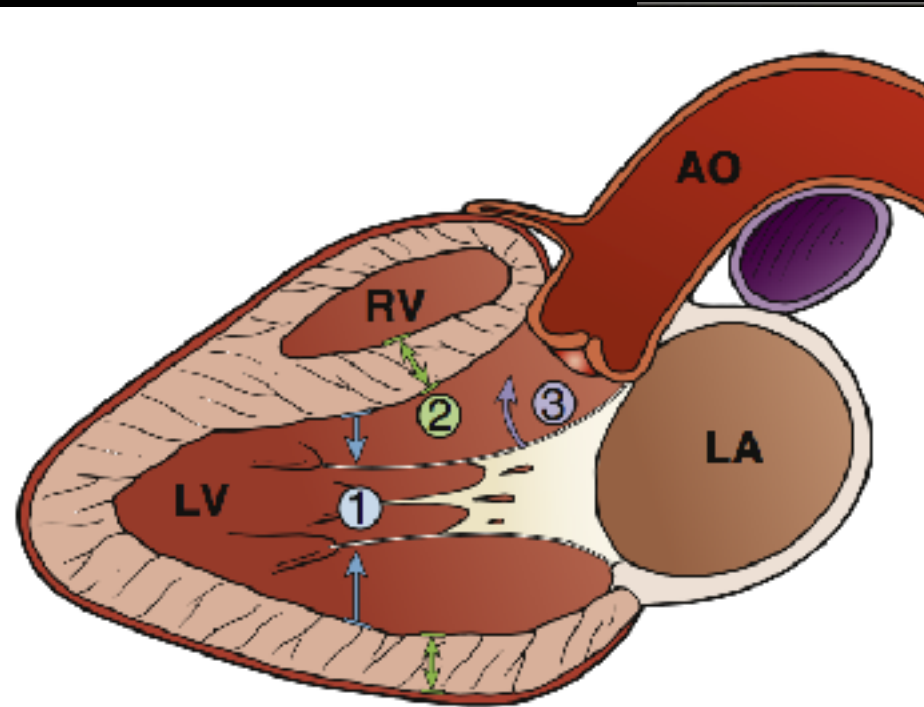


MI:1.5
581
T3.0
32 fps

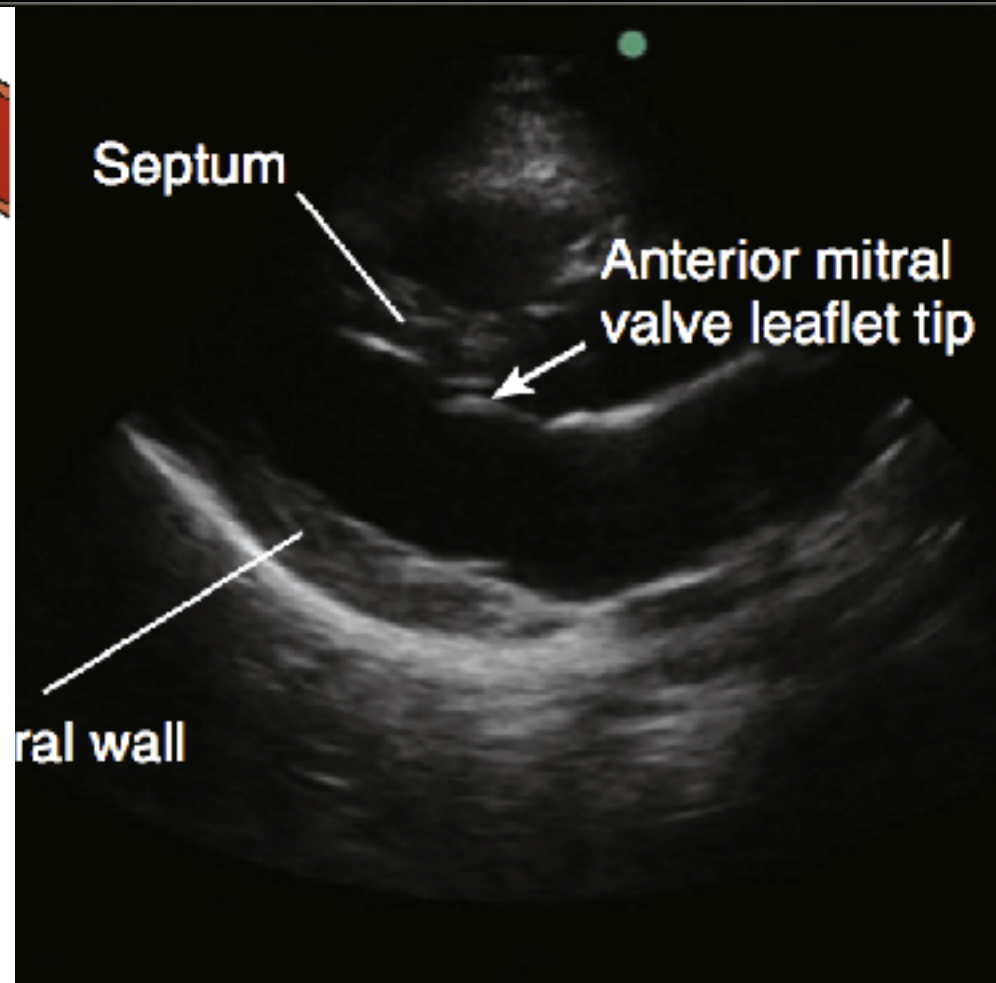


EPSS

E-point septal separation $>7\text{mm}$: LVEF $< 30\%$

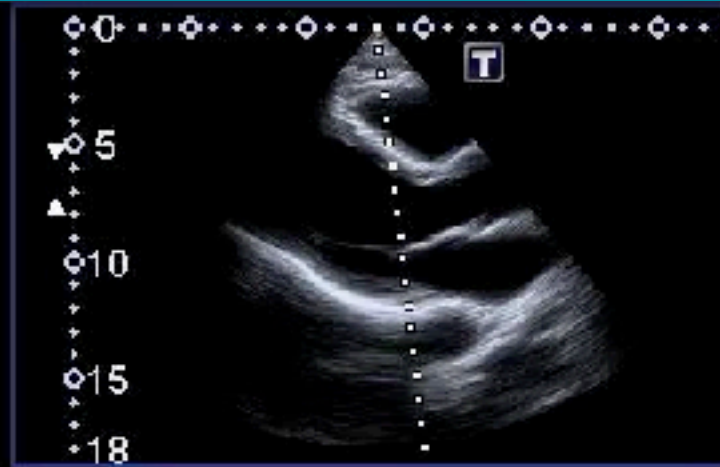

- 1 - Endocardial excursion
- 2 - Myocardial thickening
- 3 - Septal motion of anterior leaflet of mitral valve

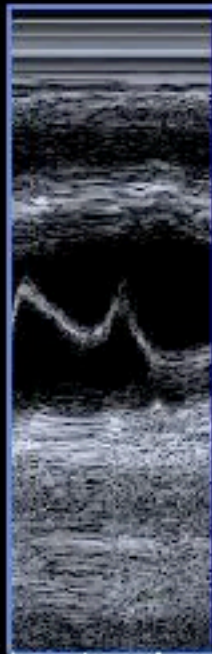


EPSS

Qscan
G:91
DR:55
TE:3



MI:1.5
5S1
T3.0
25 fps



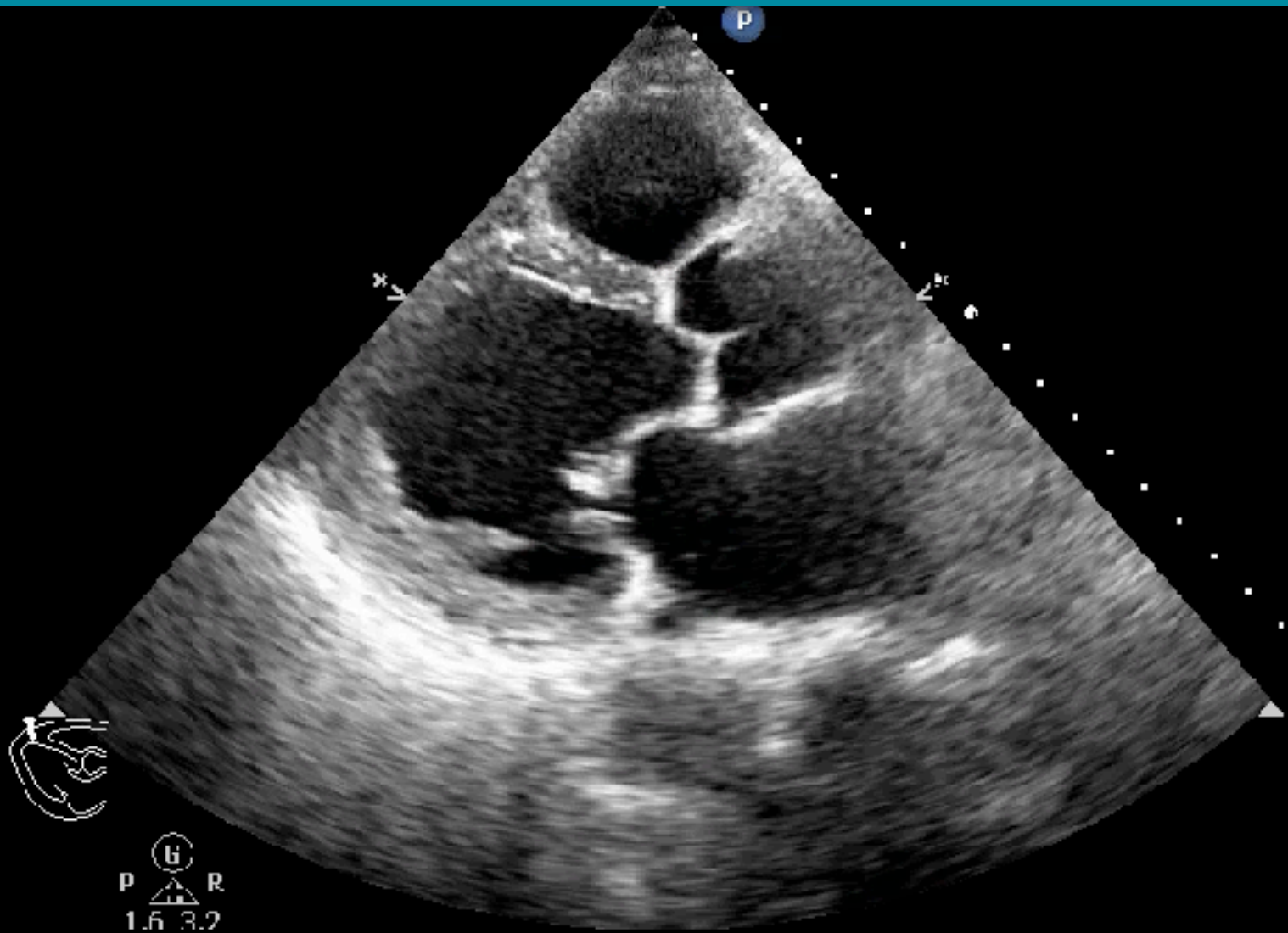
Qscan:86 / MDR:50 / T3.0

Heart failure ?

Adult Echo2
S5-1
78 H7
19.0cm

2D

HGen
Gn 34
C 50
3 / 2 / 0



HFrEF ?

Adult Echo2

55-1

34 Hz

15.0cm

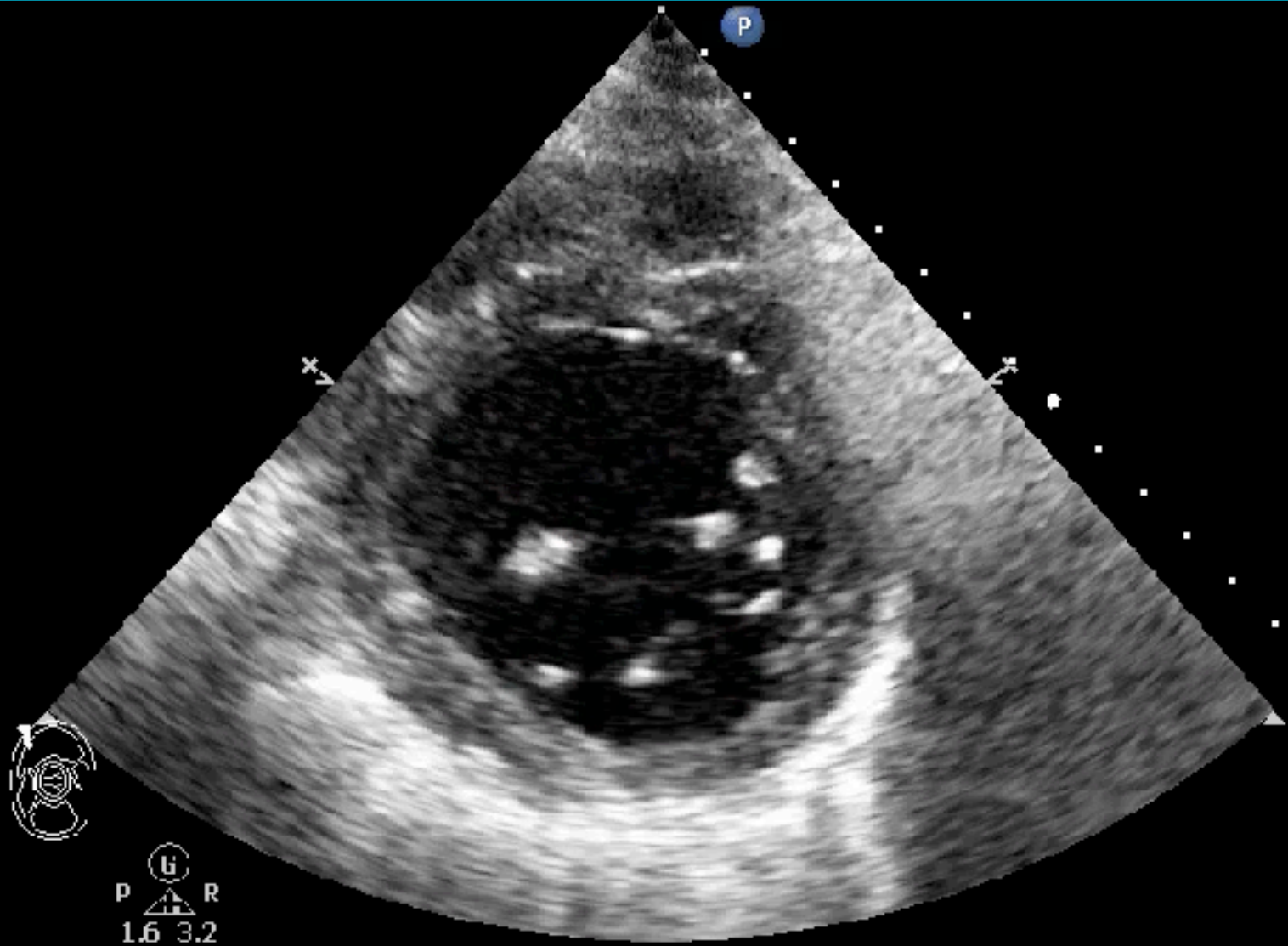
2D

HGen

Gn 34

C 50

3/2/0



熟練3W5V

