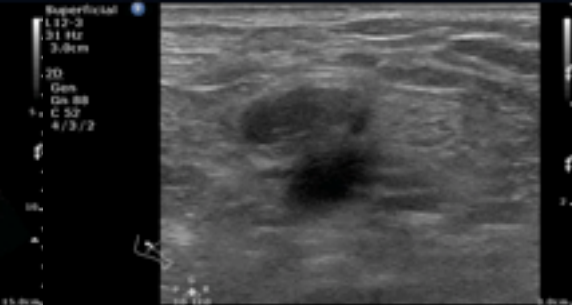
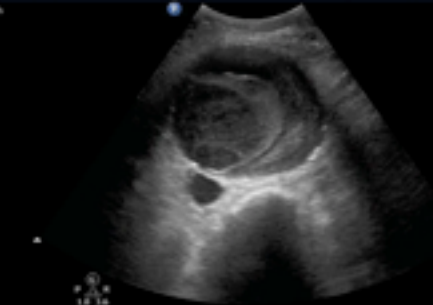
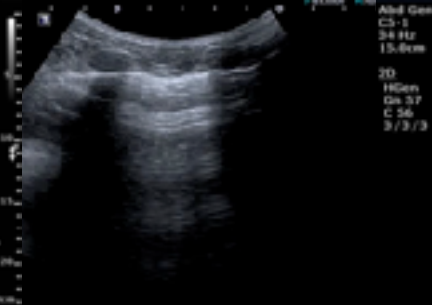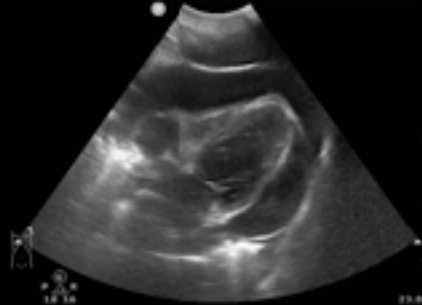HEART

LUNG

AORTA

DVT

KIDNEY

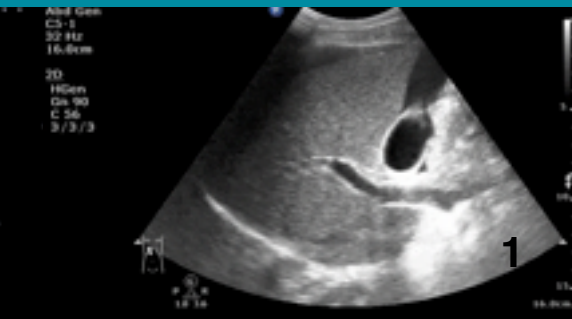
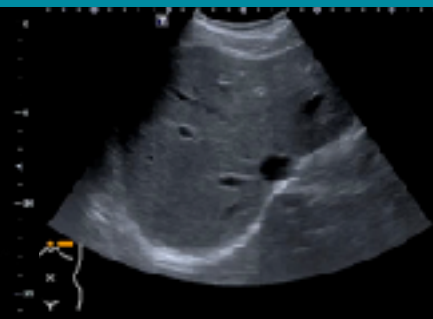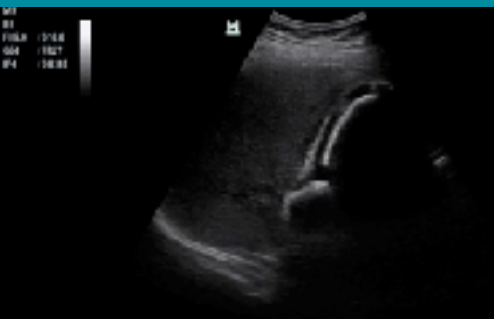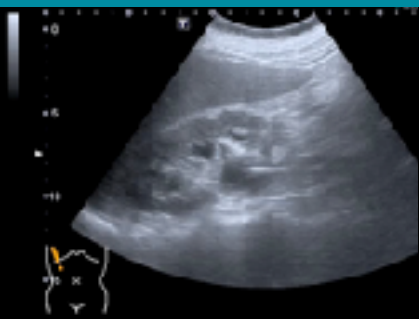GB

Liver

FAST

急診基礎超音波工作坊

陳國智醫師 雙和醫院急診醫學科



陳國智 醫師 / POCUSacademy.com



急診超音波臨床評核醫師
醫用超音波學會指導醫師
WINFOCUS director / instructor
Certified Interventional Pain Sonologist

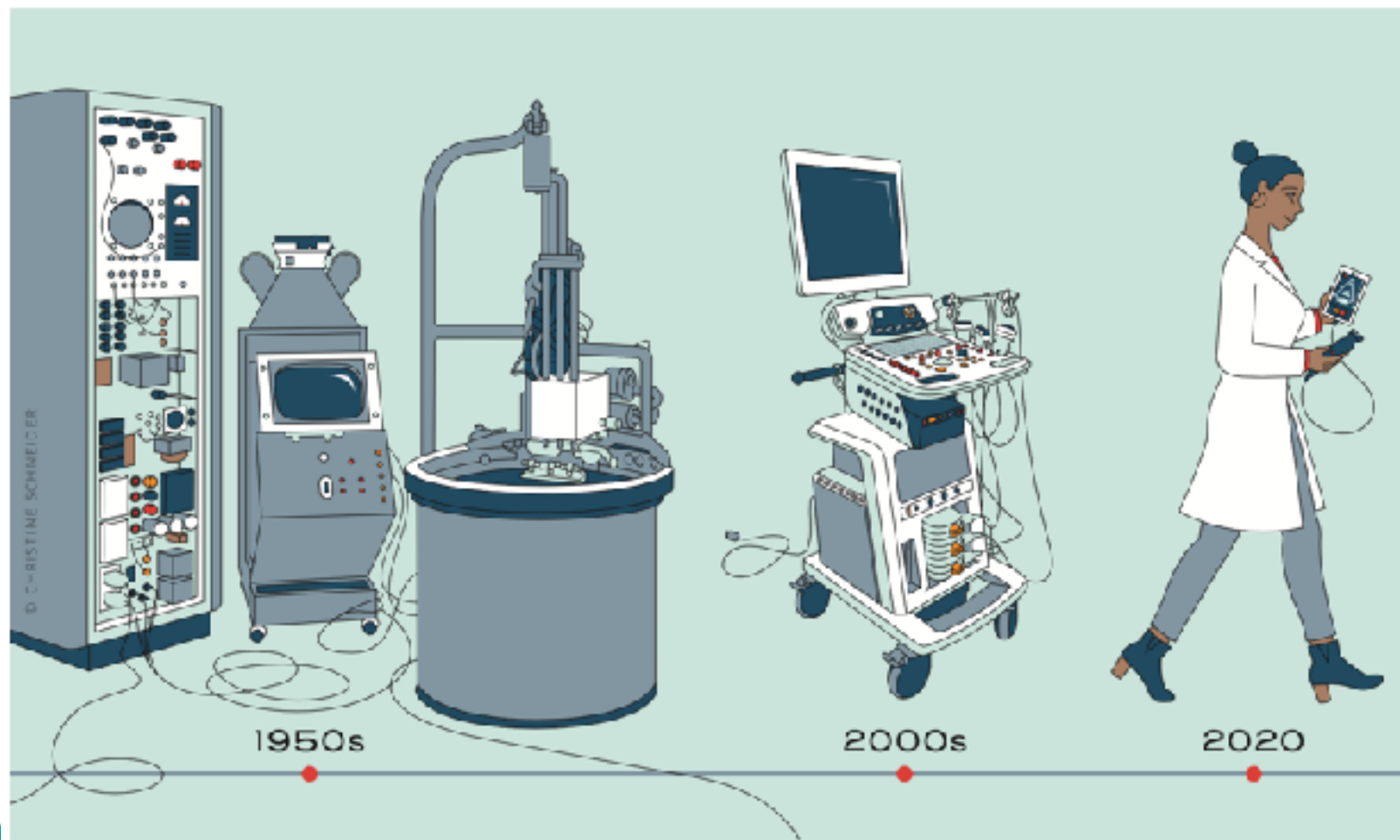
急診 / 重症 / 介入 / 急性疼痛

經歷

新光急診超音波訓練中心主任
西園醫院急診醫學科主任
急診醫學會超音波委員會主委
台灣疼痛醫學會大體模擬手術講師
急救加護醫學會重症超音波負責人

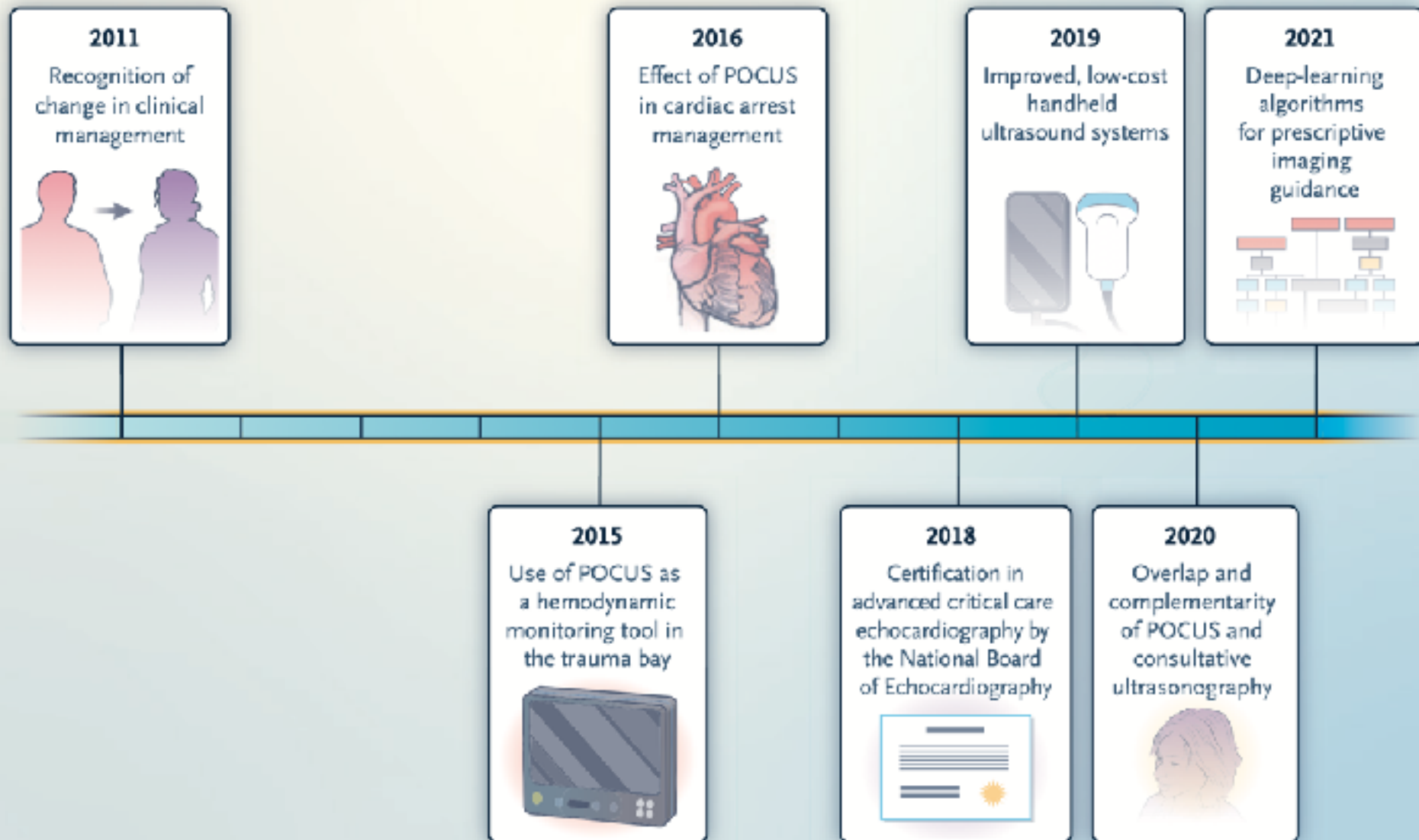


Point-of-Care Ultrasound: A Practical Guide for Primary Care



Point-of-Care Ultrasonography

José L. Díaz-Gómez, M.D., Paul H. Mayo, M.D., and Seth J. Koenig, M.D.



Point-of-Care Ultrasonography

Michael J. Arnold, MD, and Christopher E. Jonas, DO

Uniformed Services University of the Health Sciences, Bethesda, Maryland

Rachel E. Carter, MD, Naval Hospital Jacksonville, Jacksonville, Florida

The hands-on, “showing while telling” nature of POCUS advances physical diagnosis skills, fosters doctor-patient communication, and increases patient satisfaction.

Institute of Ultrasound in Medicine, the Society for Academic Emergency Medicine, the American College of Radiology, and others offer POCUS training. Training standards for POCUS have been defined for residency programs but are less established for credentialing. (*Am Fam Physician*. 2020;101(5):275-285. Copyright © 2020 American Academy of Family Physicians.)

POINT-OF-CARE ULTRASOUND USES



POCUS uses	Scope of use	Example questions
Physical exam extension	Focused	"Is this palpable mass a cystic or solid structure?" "Is the baby in the cephalic or breech presentation?"
Procedural	Focused	"Where is the best location to insert a needle?" "Where is the foreign body?"
Diagnostic	Focused	"Are there stones in the gallbladder?" "Is there a pregnancy in the uterus?"
Multi-organ scans	Extended	"Is the patient's hypotension due to sepsis, heart failure, or acute blood loss?" "What is causing the patient's dyspnea?"



POCUS FOR BEGINNERS

The best procedures for point-of-care ultrasound (POCUS) beginners are impactful for the patient, easy to perform (require a small number of quickly obtained views), simple to interpret (limited diagnostic endpoints), and low liability for patient and physician.

Tissue/system	Learn this first	Then proceed to	Transducer type
Skin and soft tissue	Cellulitis vs. abscess	Lumps and bumps	High frequency
Musculoskeletal	Knee effusions	Needle guidance	High frequency
Pelvis and obstetrics	Bladder obstruction	Intrauterine pregnancy labor and delivery	Low frequency
Abdomen	Abdominal ascites	Hydronephrosis	Low frequency
Chest	Pleural effusion	Pulmonary edema	Low frequency



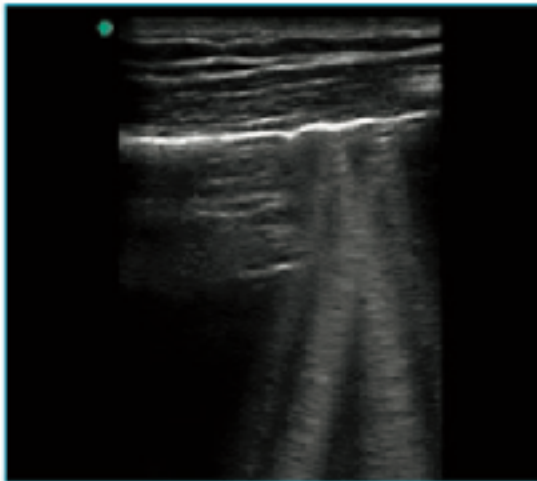POCUS MULTI-ORGAN SCANS

Name	Clinical use	Diagnostic targets
EFAST (Extended Focused Assessment with Sonography for Trauma) ¹	Blunt trauma of the abdomen and chest	Free fluid in the abdomen and pelvis, pericardial fluid, and pneumothorax and pleural fluid
Labor and delivery ²	Late third trimester exams and labor and delivery	“5 Ps” of pregnancy: <ul style="list-style-type: none">• Parity (number)• Pulse (fetal heartbeat)• Pocket (fluid)• Placenta (location)• Presentation (cephalic vs. breech)
RUSH (Rapid Ultrasound for Shock and Hypotension) ³	Undifferentiated hypotension or signs of shock	Multi-organ protocol to assess for etiology of shock and hypotension
CLUE (Cardiopulmonary Limited Ultrasound Exam) ⁴	Cardiopulmonary dysfunction	Heart, inferior vena cava, and lung views to determine heart failure physiology
PEARLS (Parasternal, Epigastric, Anterior lung, Right upper quadrant, Left upper quadrant, and Suprapubic) ⁵	Core physical exam for generalist (routine inpatient or outpatient use)	A layered, window-based approach to teaching and learning core ultrasound exam

Acute Pulmonary Edema

Sensitivity: 88%

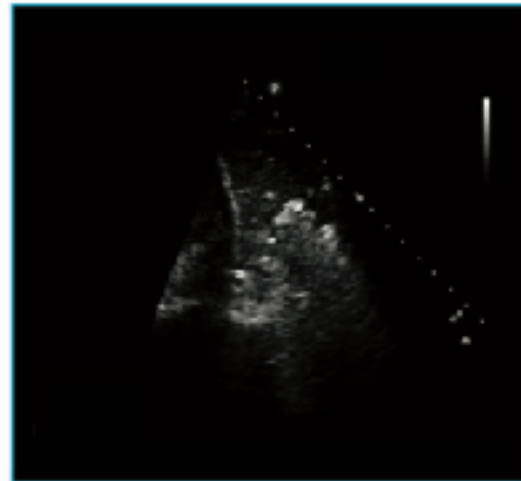
Specificity: 90%



Pneumonia

Sensitivity: 88%

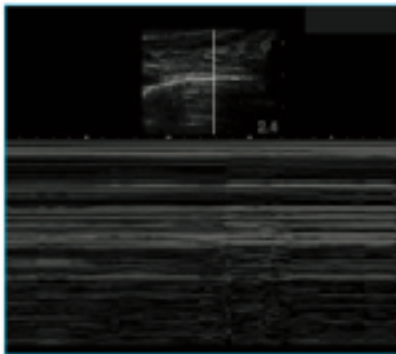
Specificity: 93%



Pneumothorax

Sensitivity: 81%

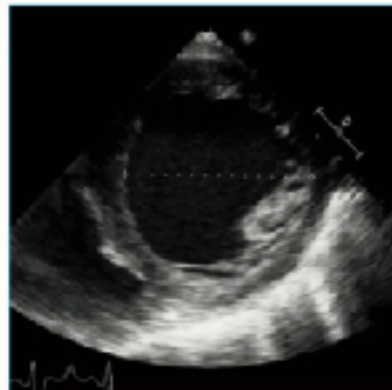Specificity: 100%



Left Ventricular Dysfunction

Sensitivity: 69–94%

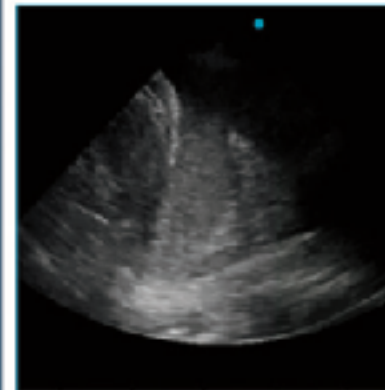
Specificity: 88–96%



Thoracoabdominal Trauma

Sensitivity: 74%

Specificity: 96%



Tools of the Trade: Point-of-Care Ultrasonography as a Stethoscope

Hiroshi Sekiguchi, MD¹

¹Division of Pulmonary and Critical Care Medicine, Mayo Clinic, Rochester, Minnesota

Address for correspondence Hiroshi Sekiguchi, MD, Division of Pulmonary and Critical Care Medicine, Mayo Clinic, 200 First St SW, Rochester, MN 55905 (e-mail: sekiguchi.hiroshi@mayo.edu).

Semin Respir Crit Care Med 2016;37:68–87.

Inspection

Palpation

Percussion

Auscultation

Insonation

I-AIM


POINT



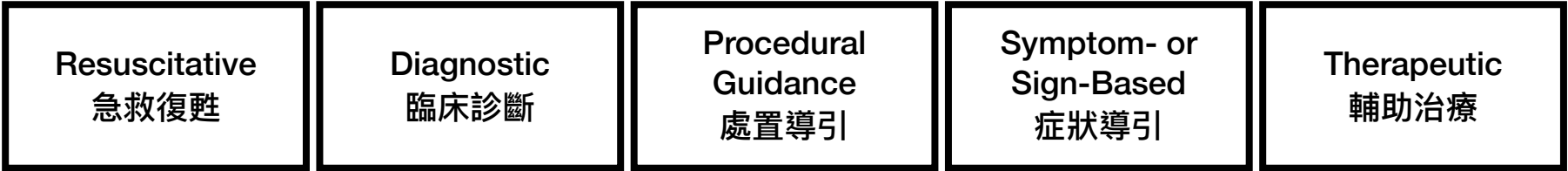Acquire



Interpret



**Make
decision**



Core Applications (2023 ACEP Emergency Ultrasound Guidelines)
15項急診超音波核心應用

陳國智醫師

Aorta

DVT

Trauma

Thoracic/Airway

Cardia/HD assessment

Procedural Guidance

US-guided NB

Testicular

Ocular

Skin & Soft tissue

Hepatobiliary

Urinary tract

Pregnancy

Bowel

MSK

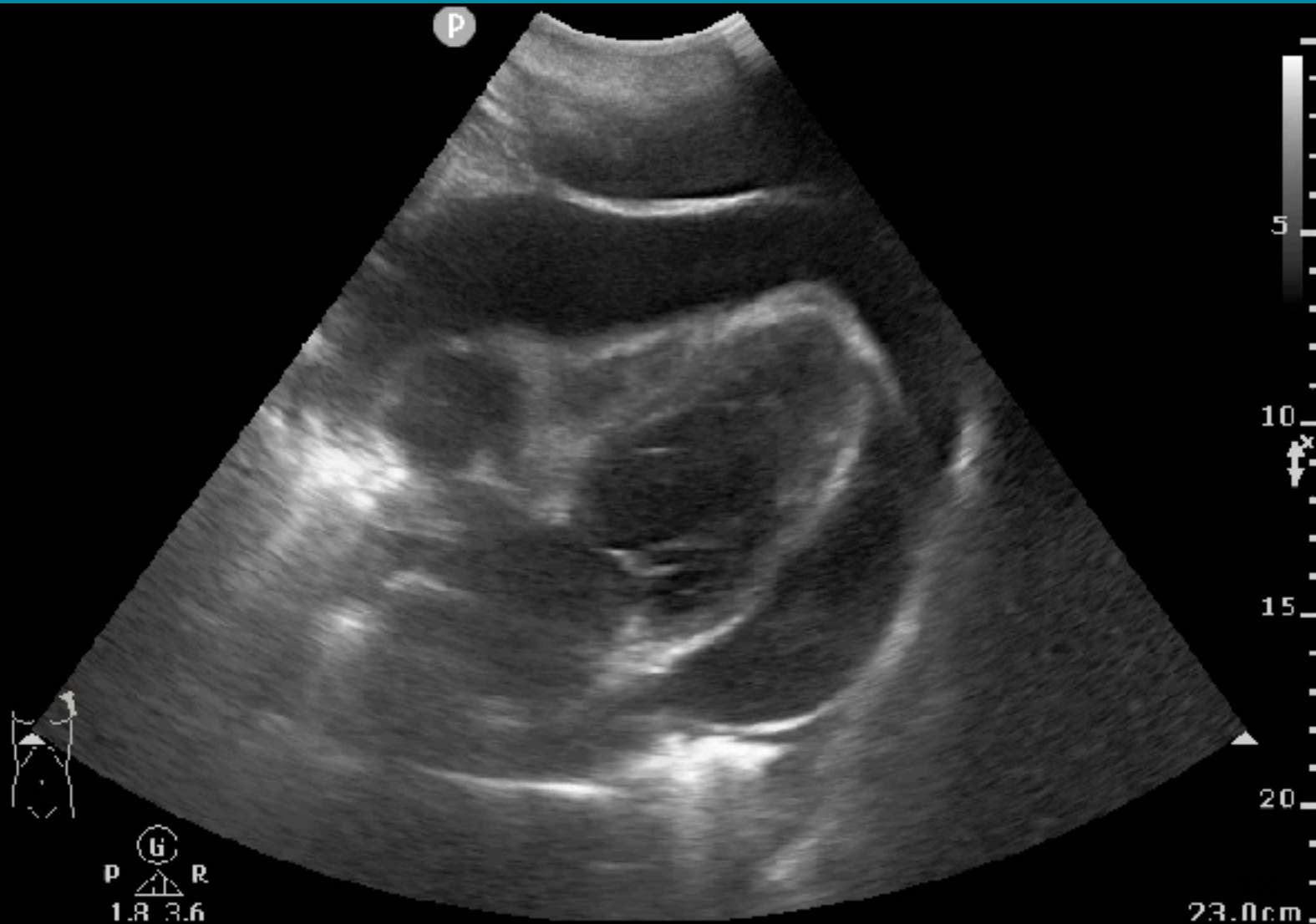


HEART

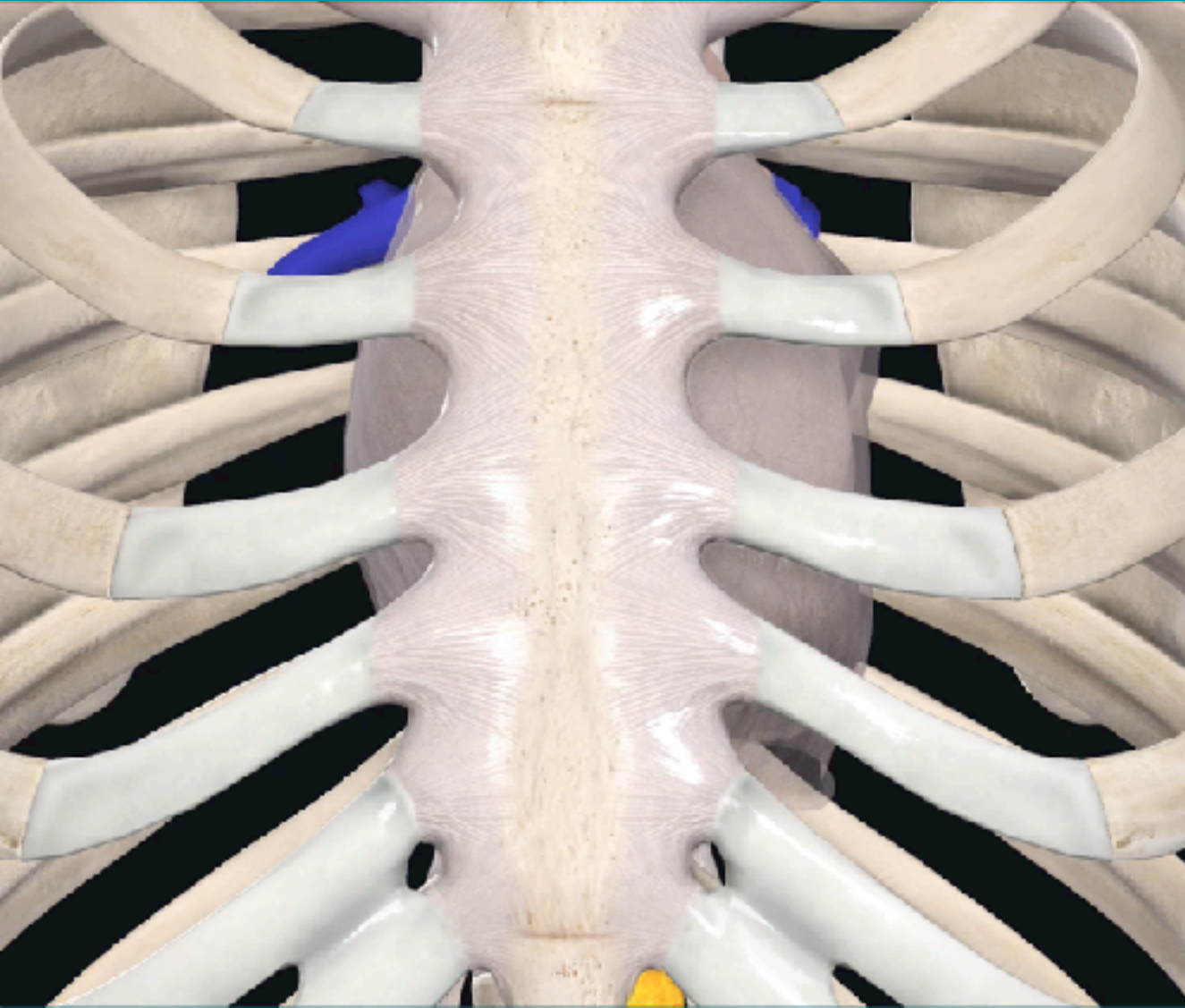
Abd Gen
C5-1
75 H7
23.0cm

2D

HGen
Gn 100
C 56
3 / 3 / 3



HEART



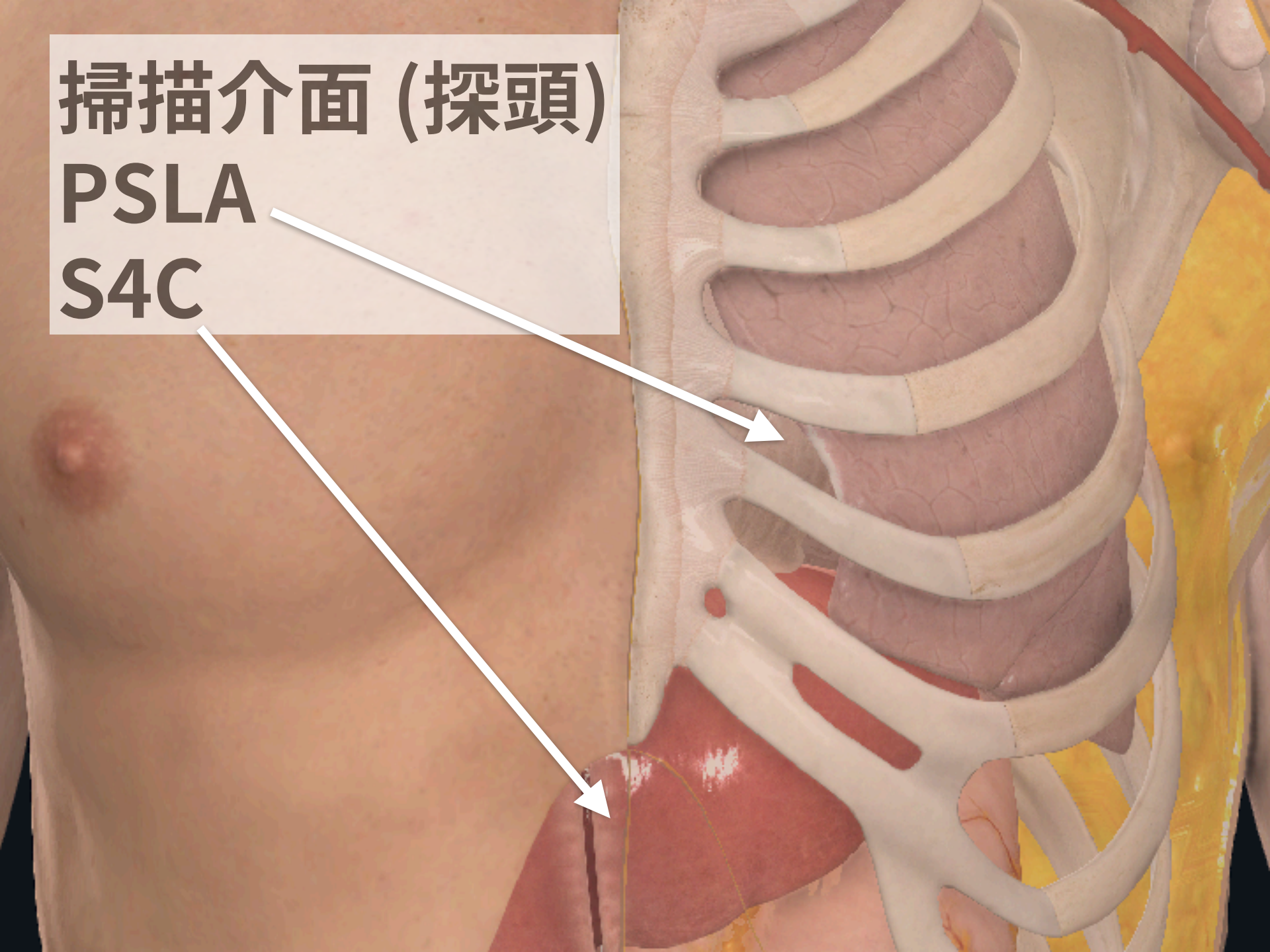
Arrest
Activity

Shock
Effusion

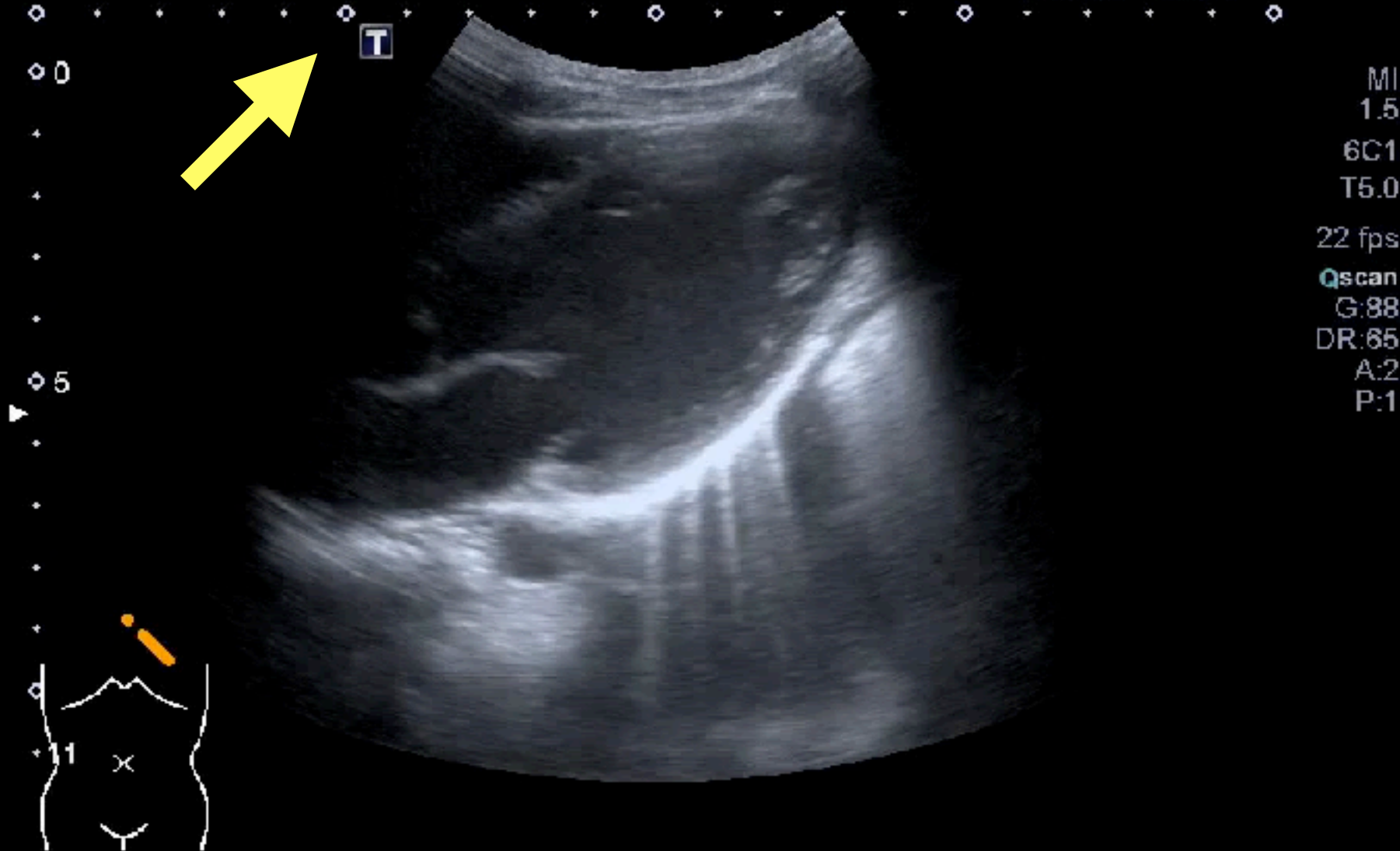
掃描介面 (探頭)

PSLA

S4C



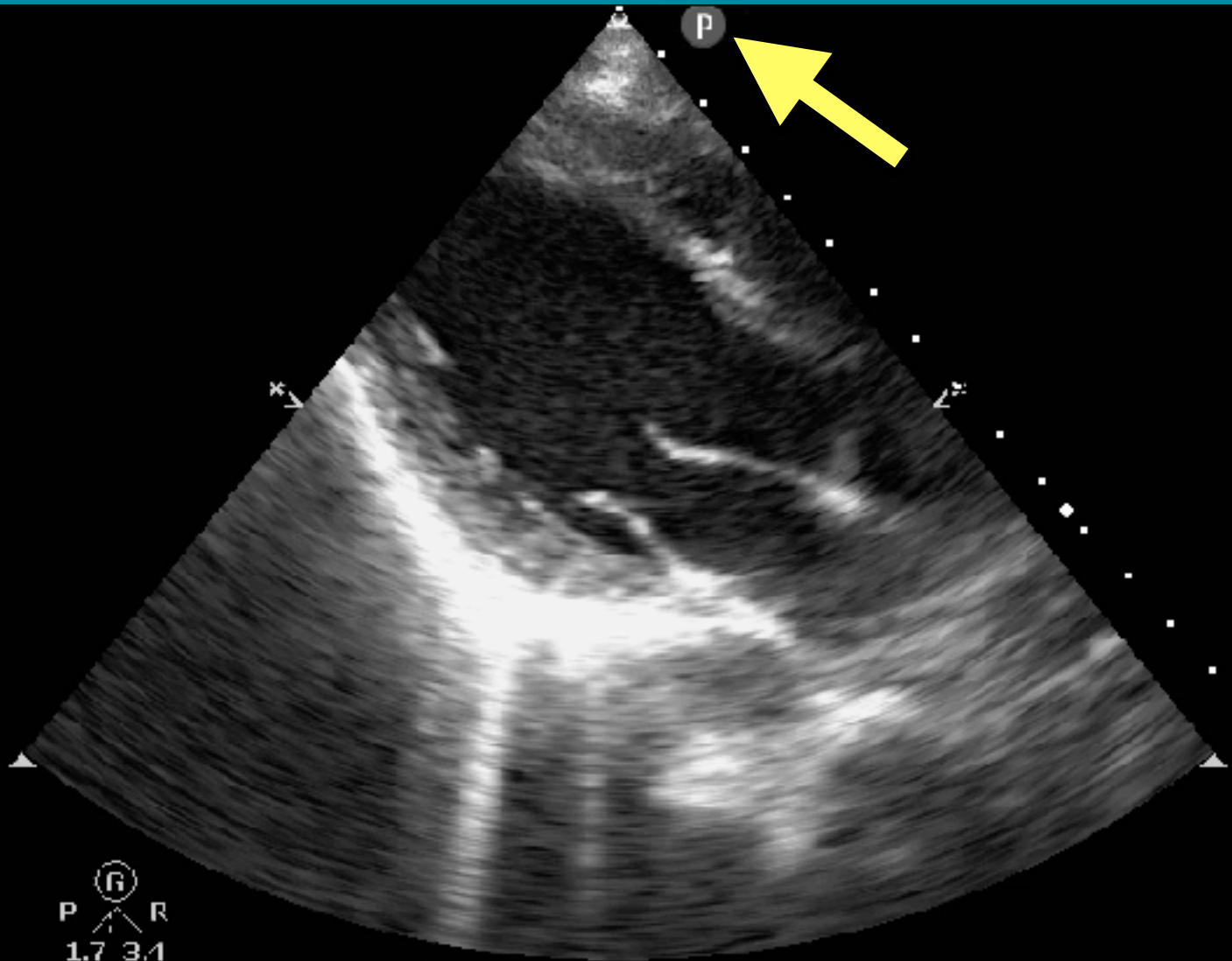
PARASTERNAL LONG AXIS



PARASTERNAL LONG AXIS

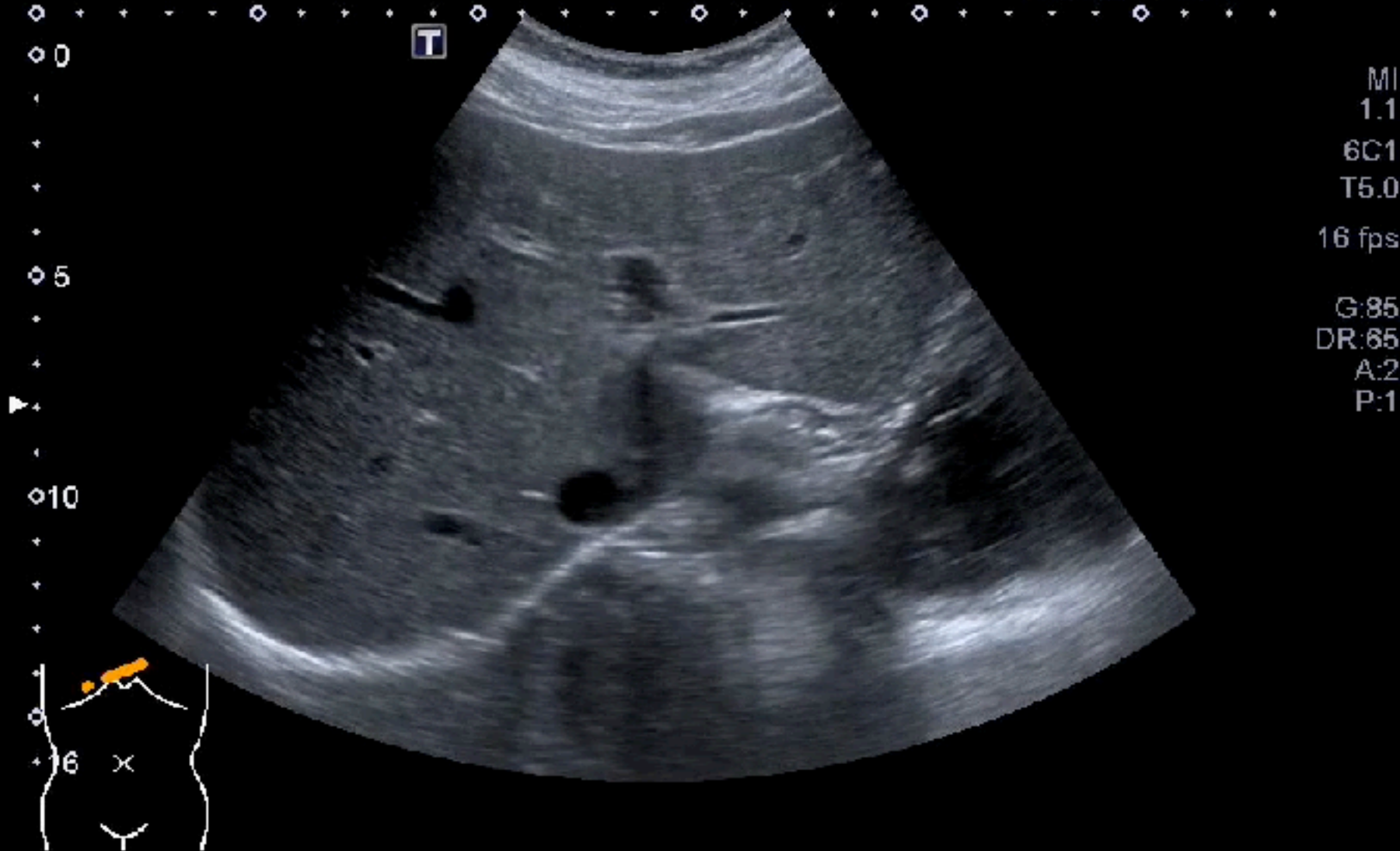
Adult Echo
S1-1
77 Hz
15.0cm

2D
HGen
Gn 100
55
3/2/0
50 mm/s

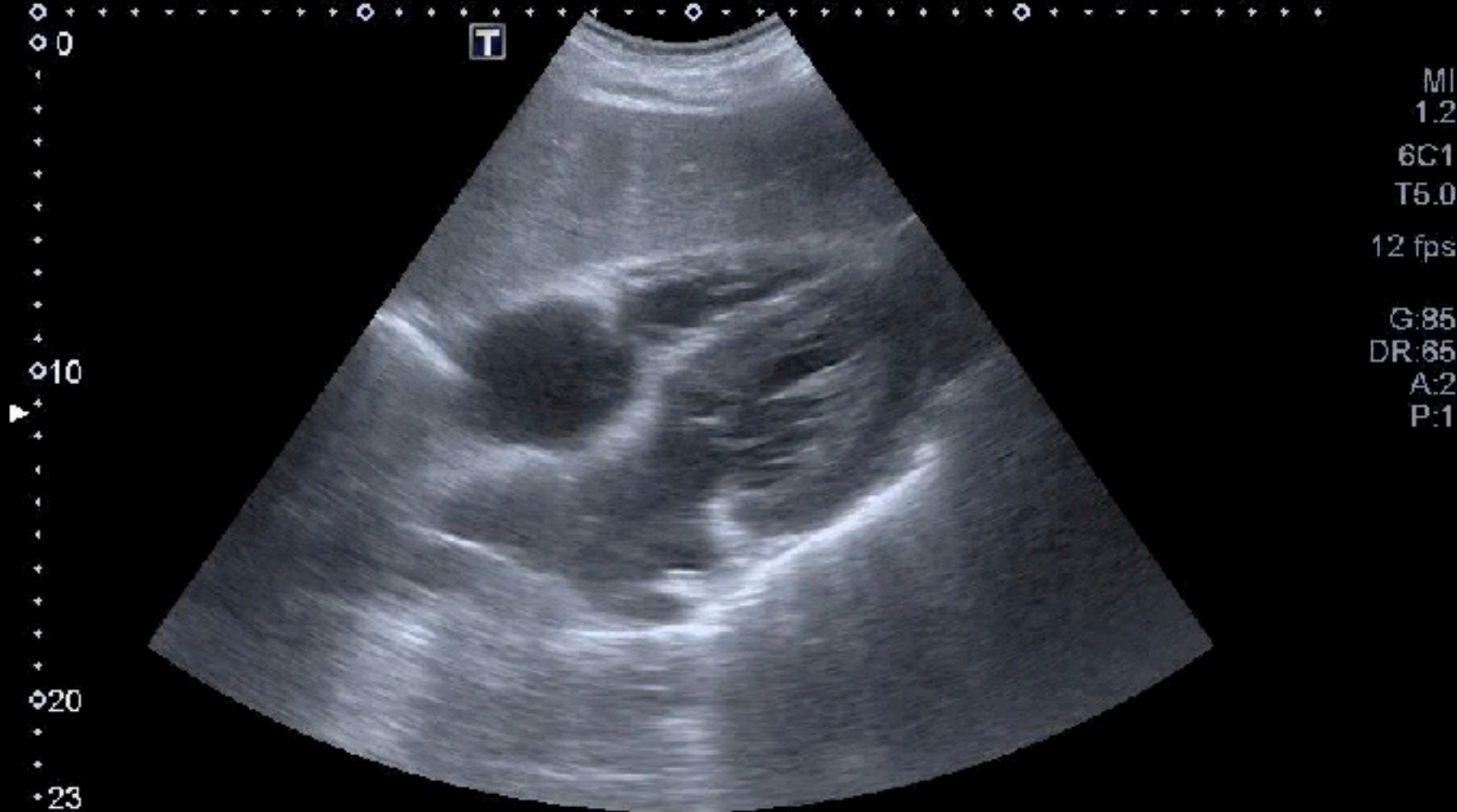

Ⓜ
P R
1.7 3.1

SUBCOSTAL 4 CHAMBER



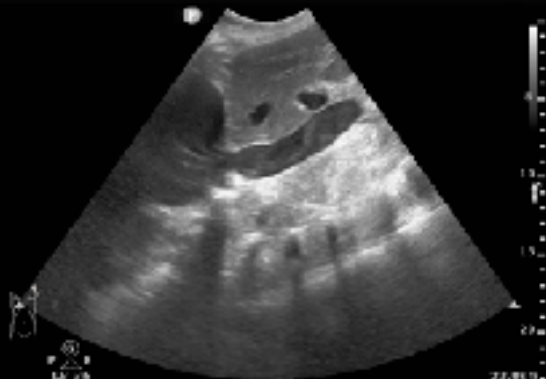CARDIAC ARREST



CARDIAC TAMPONADE

1.5d Con
3-1
3.8Hz
7.0cm

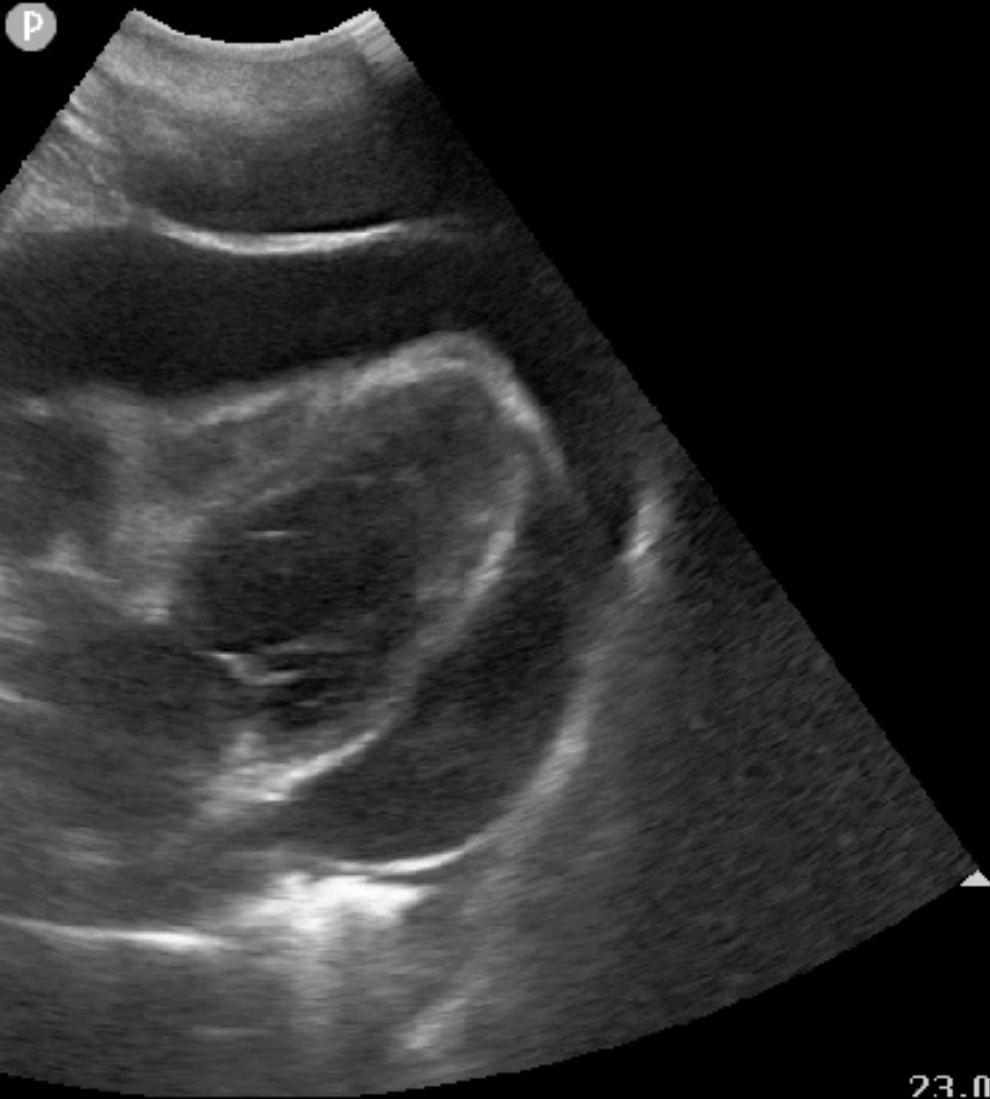
HD
H0cm
10.0cm
0.56
3/3/3



3/3/3



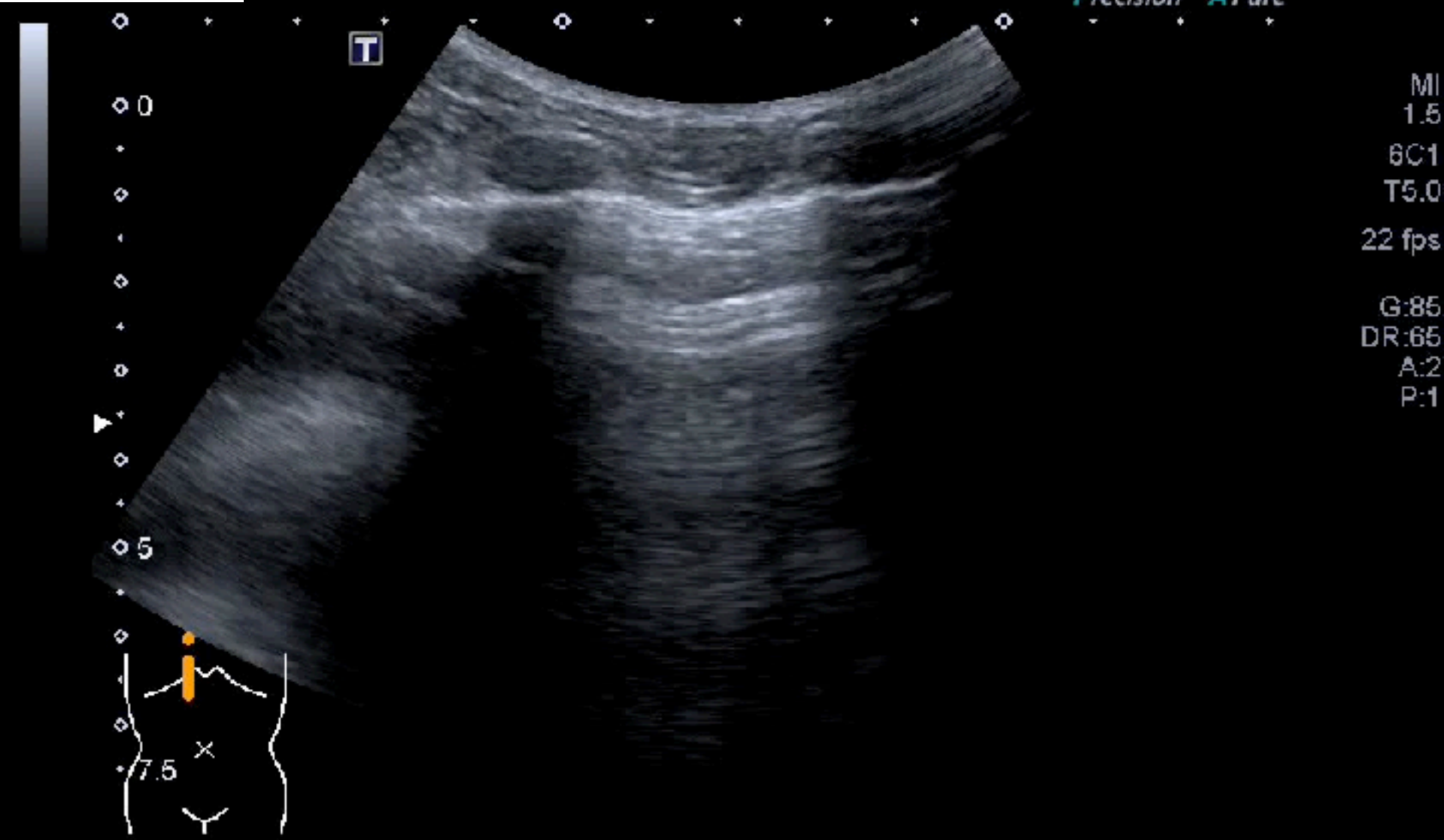
G
P R
1.8 3.6



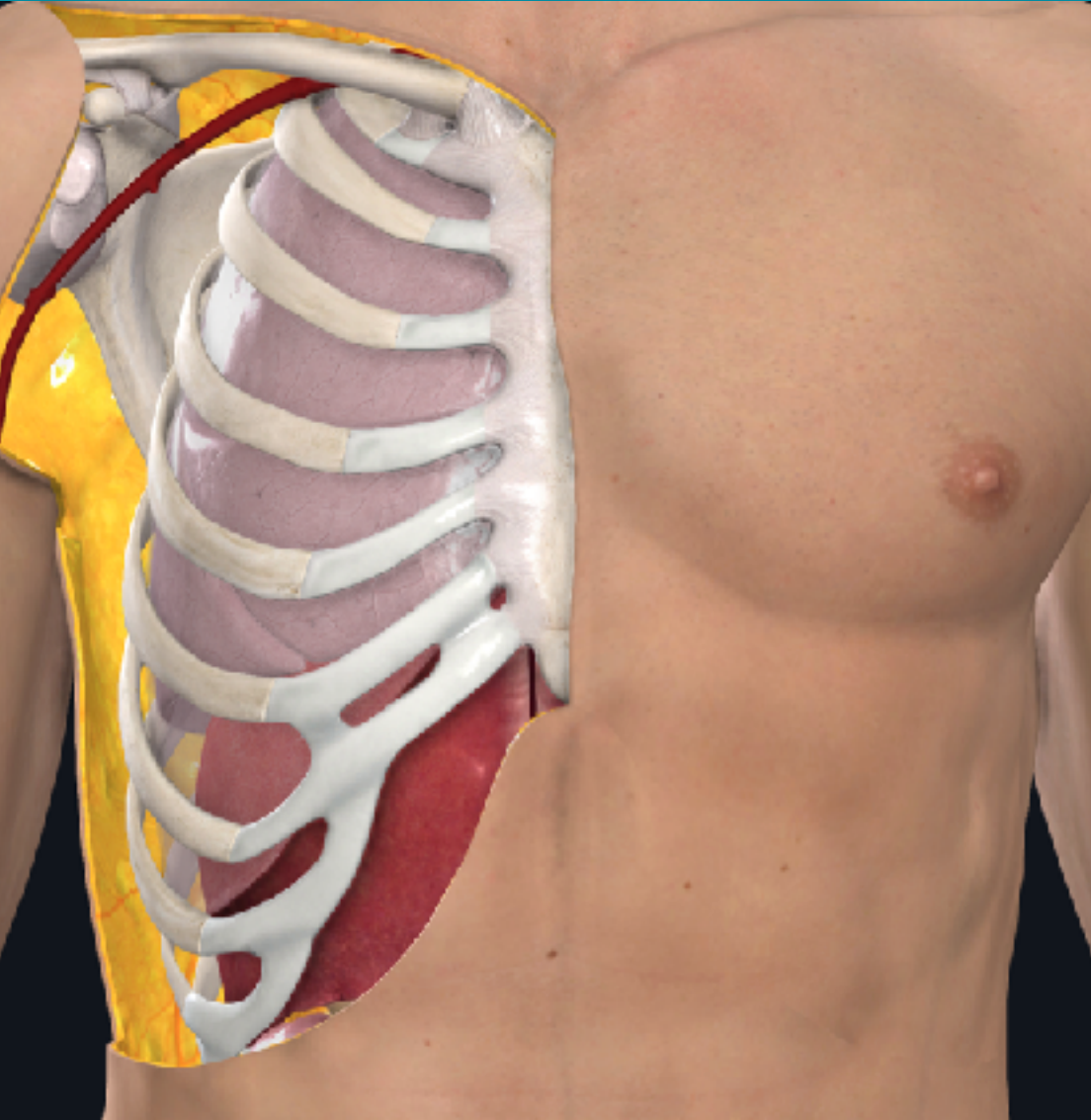
23.0cm



LUNG

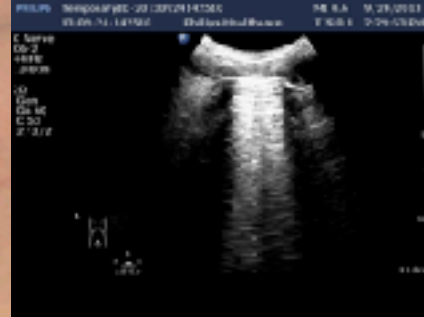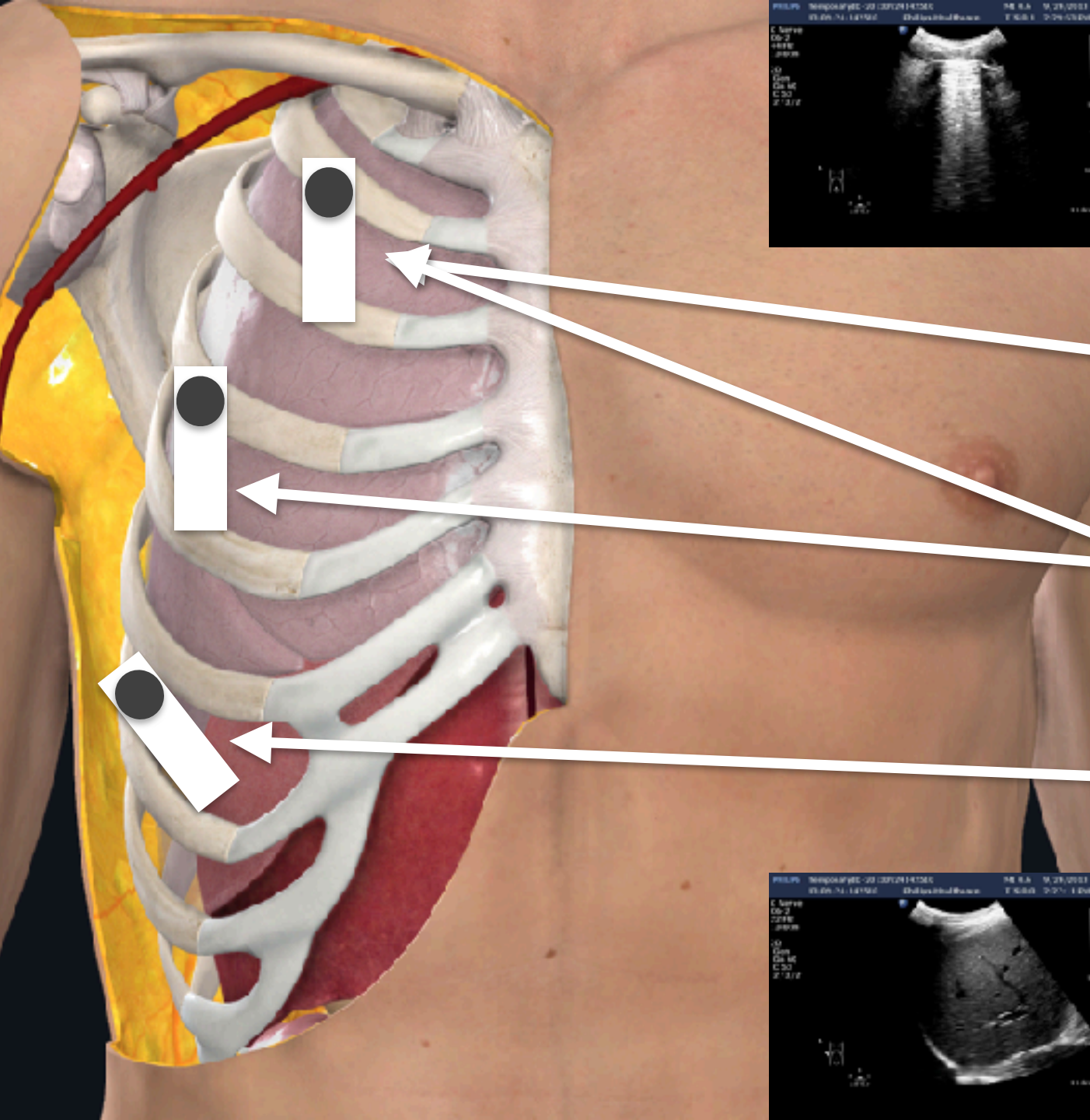


LUNG



Dyspnea
Chest pain

PTX
AIS
PLE

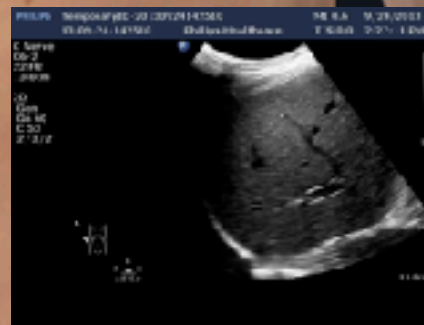


AIR

PTX

AIS

PLE



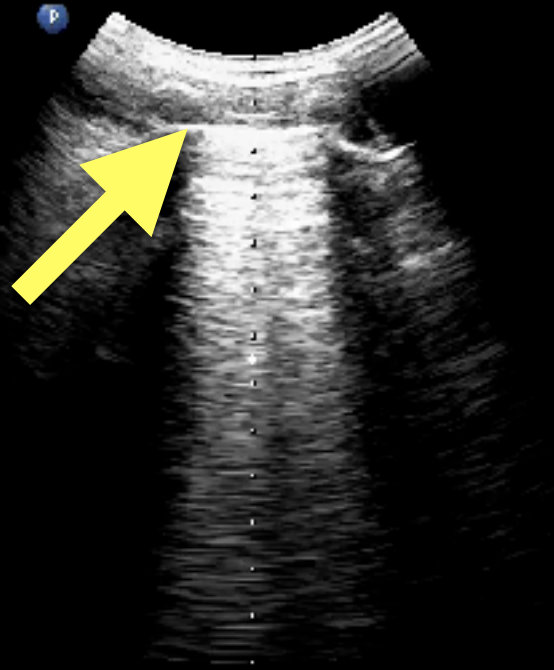FLUID

NORMAL LUNG

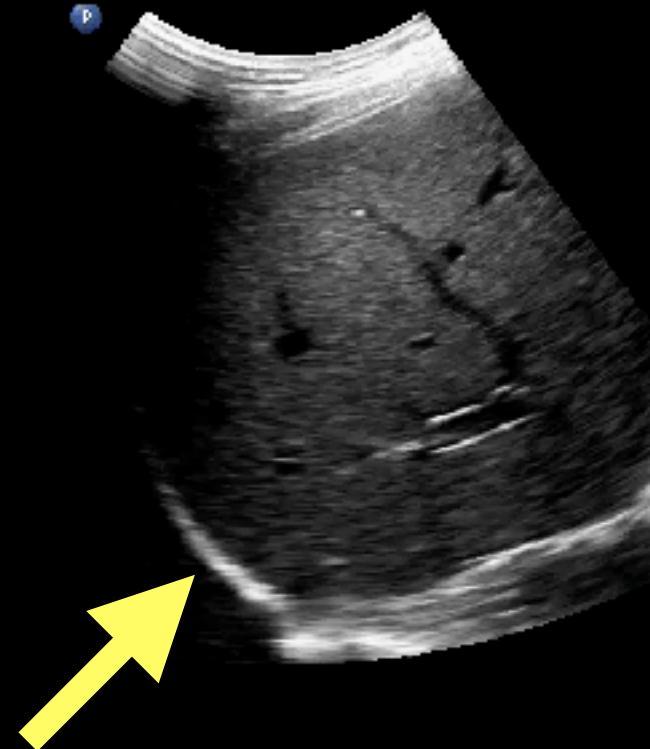
肋膜/滑動

橫膈膜/移動

TemporaryID 20130924142510 MT 0.6 9: PHILIPS 13 09 24 142510 Philips Healthcare TIS 0.1 2: TemporaryID 20130924142510 MT 0.6 9:24 13 09 24 142510 Philips Healthcare TIS 0.0 2:27



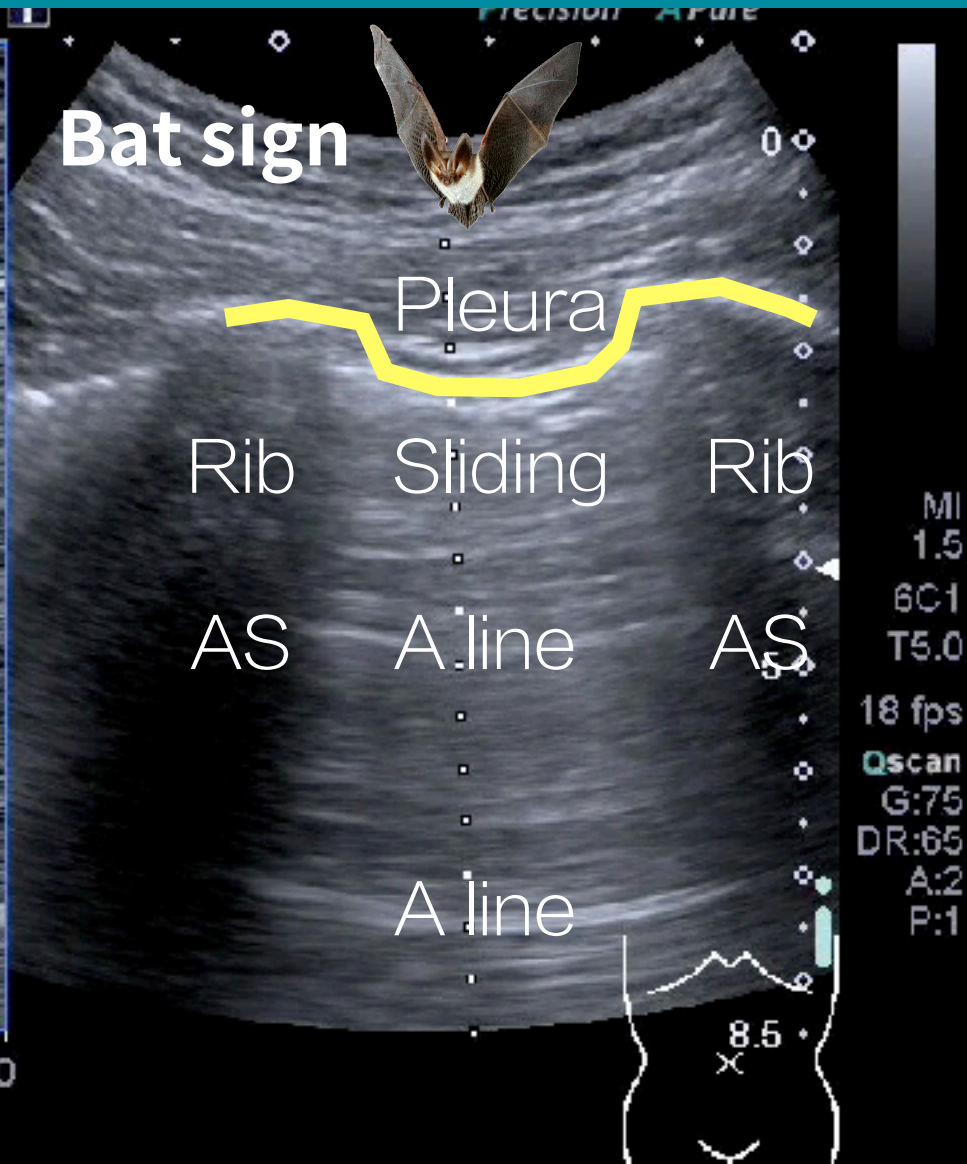
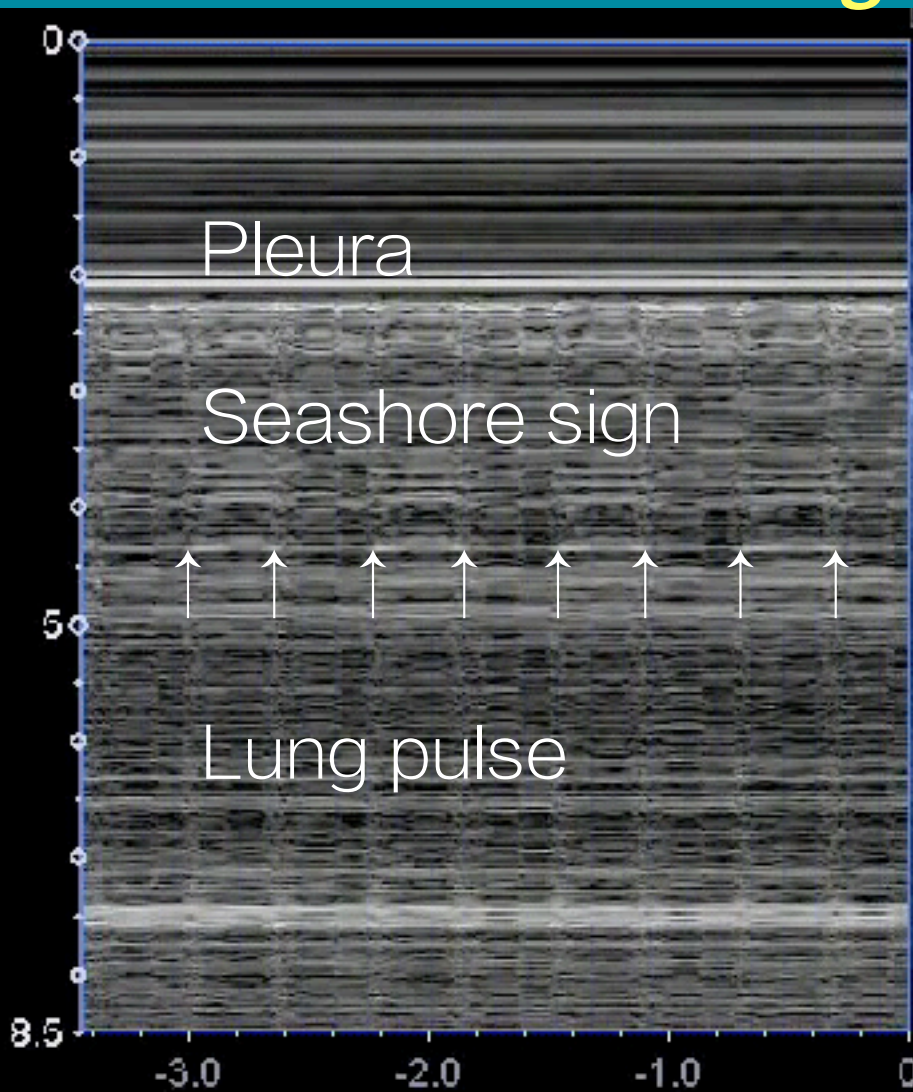
C Nerve
CG-2
22 Hz
13.0cm
2D
Gen
Gr 60
C 53
2/3/2



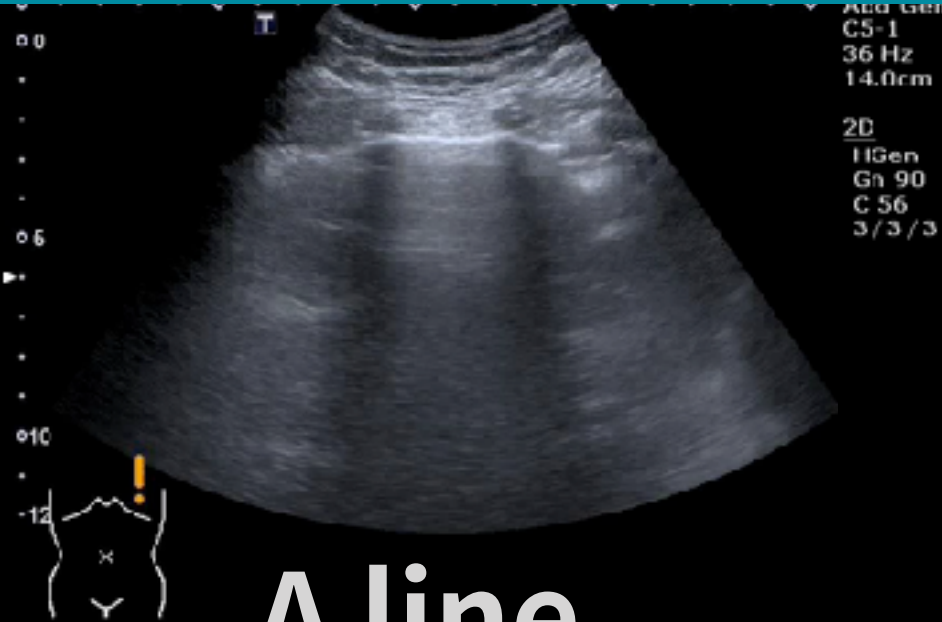G
P K
2.0 G.0

NORMAL LUNG

Sliding + A lines

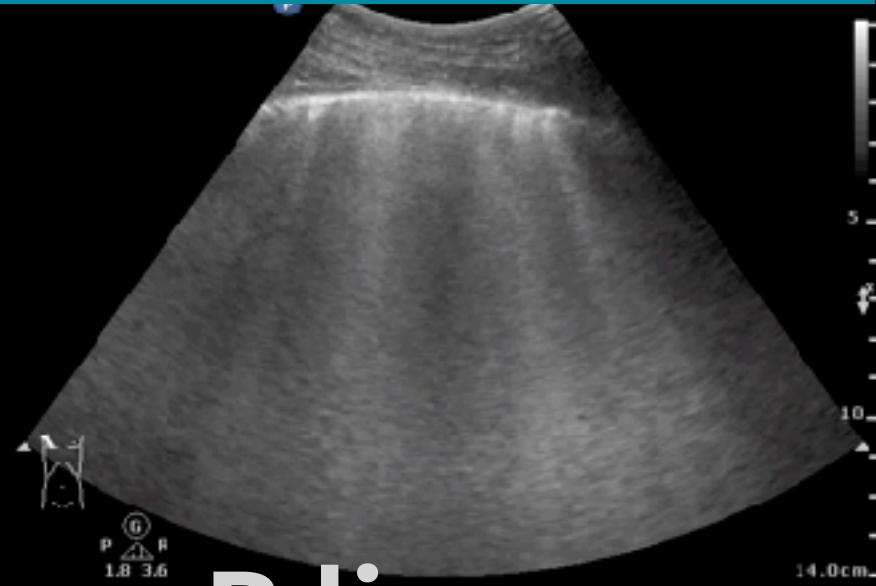

SLIDING FIRST



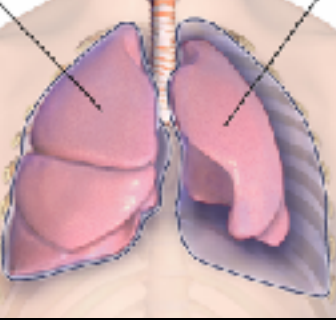
A line

肋膜下
水平線
等距離



B line

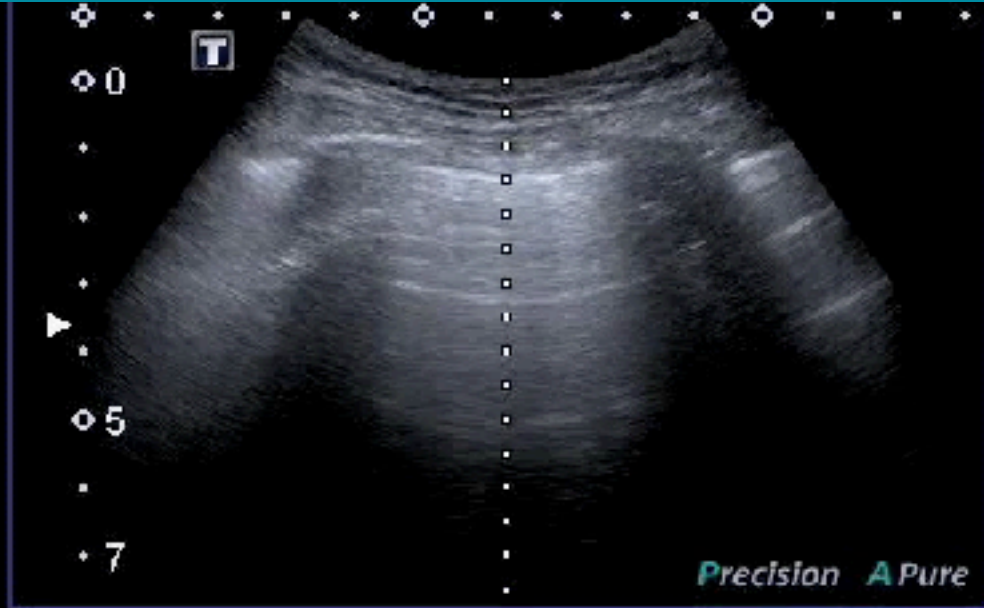
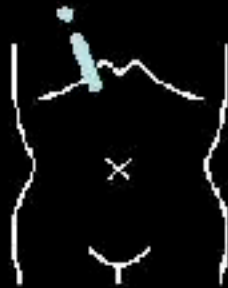肋膜下
垂直線
大於三



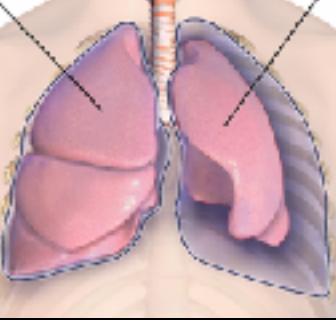
PNEUMOTHORAX ?

Sliding + A lines = Normal pleura

Seashore sign



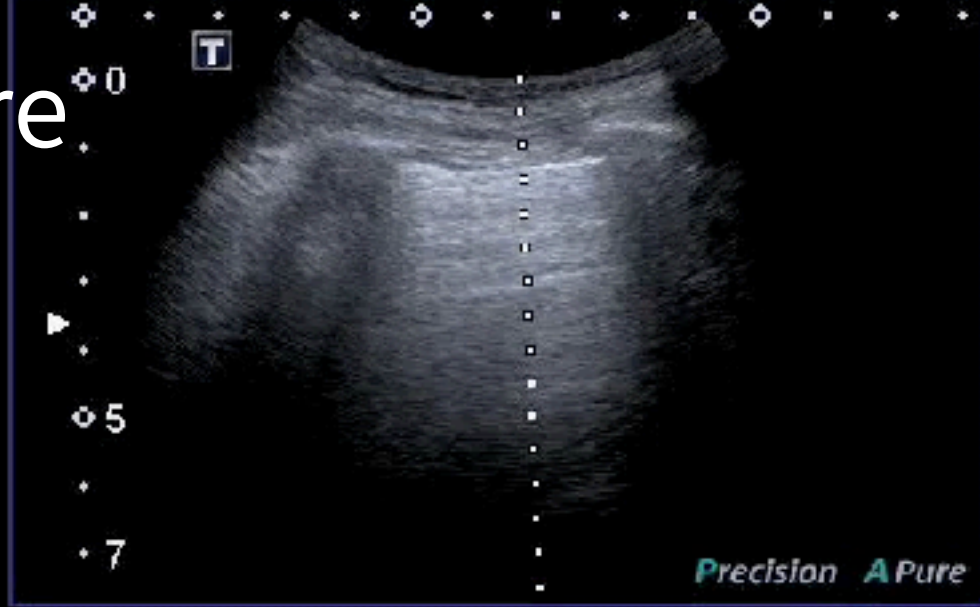
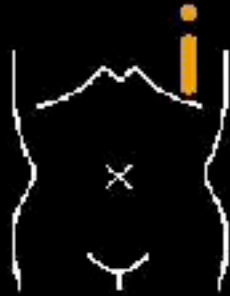0
5
7



PNEUMOTHORAX ?

No Sliding + A lines >> Consider PTX

Stratosphere
sign



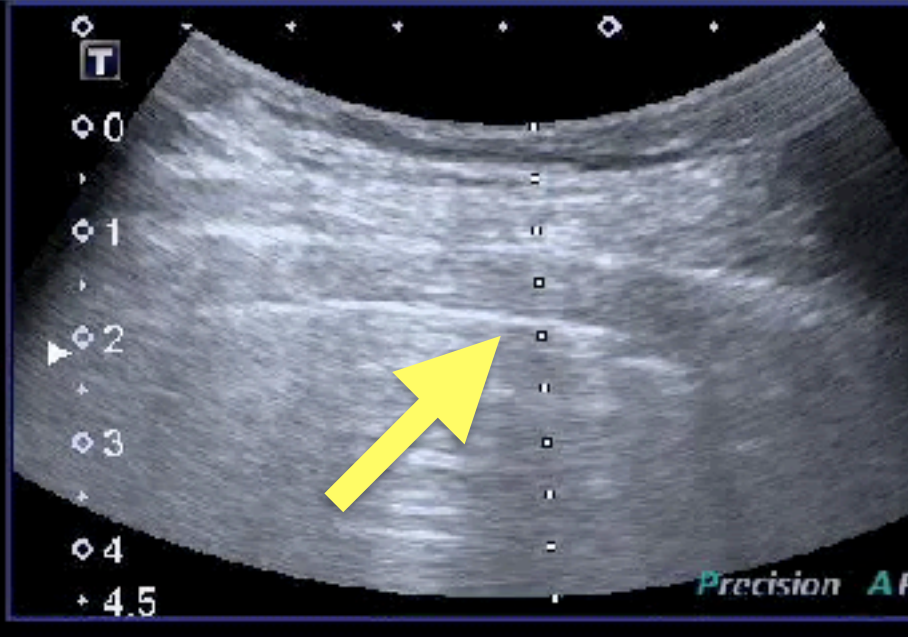
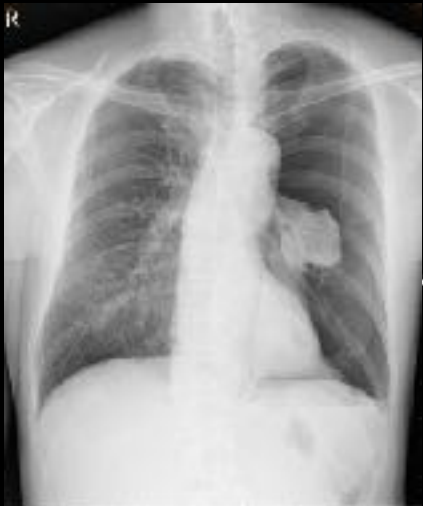MI:1.5
6C1
T5.0
18 fps
Qscan
G:71
DR:65
A:2
P:1



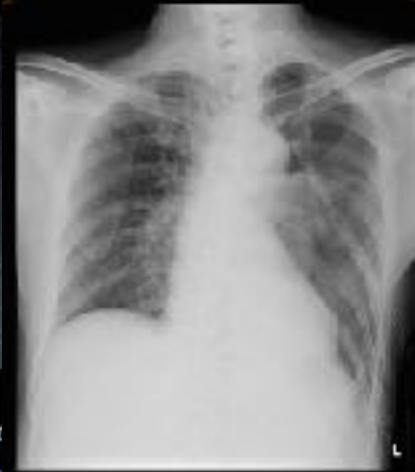
0
5
7

Lung Point

A

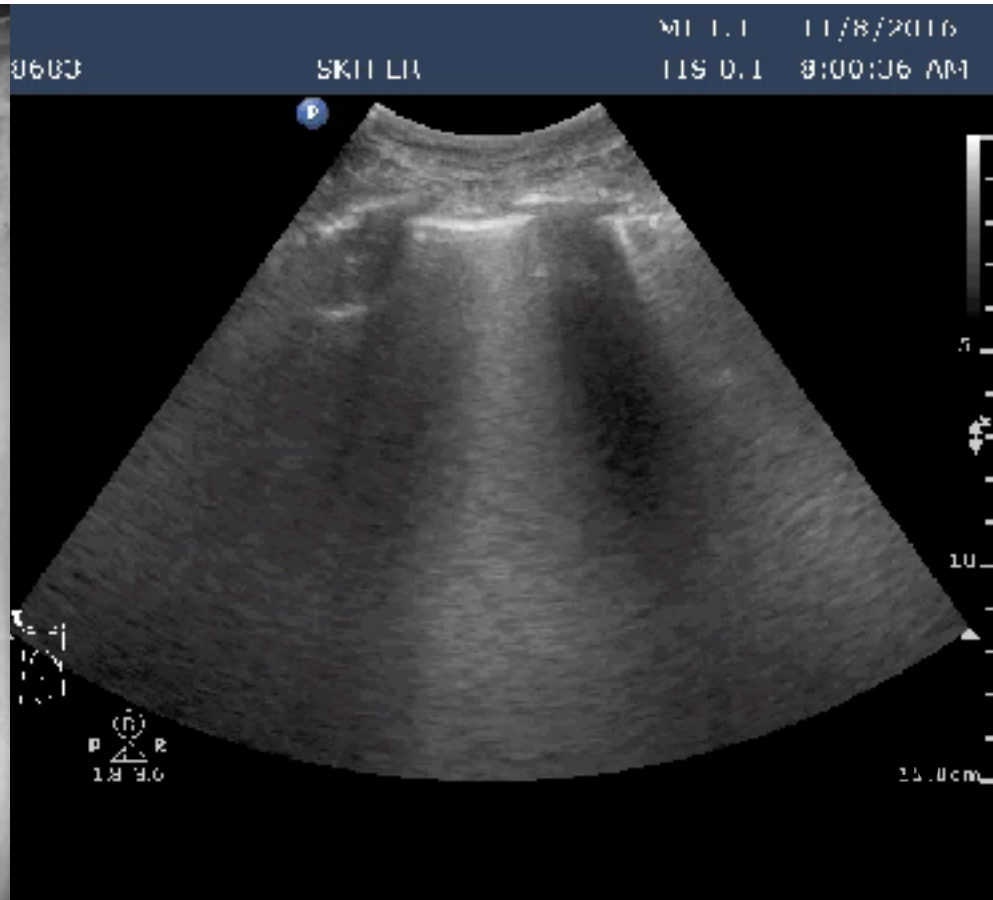
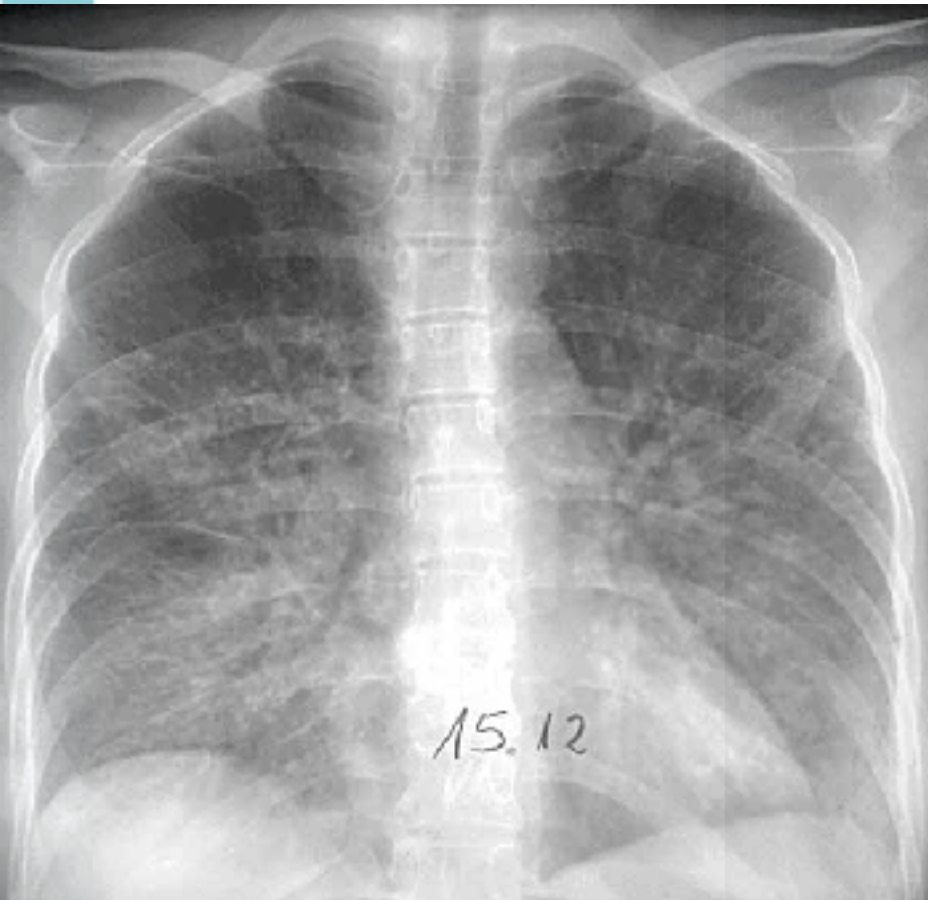


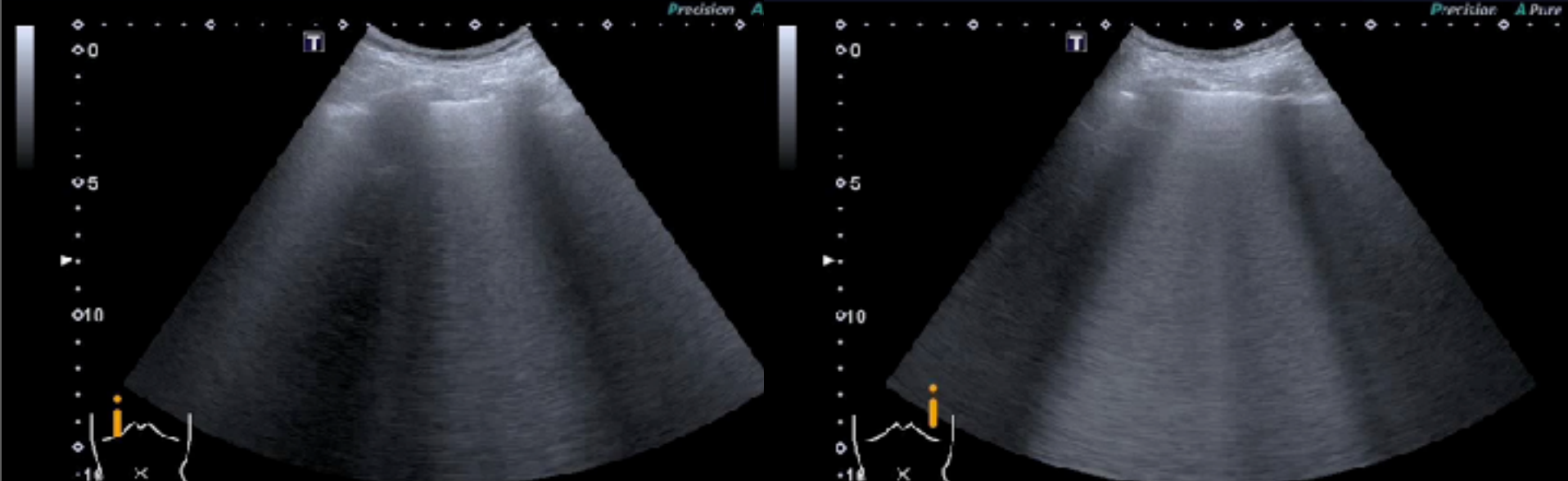
B



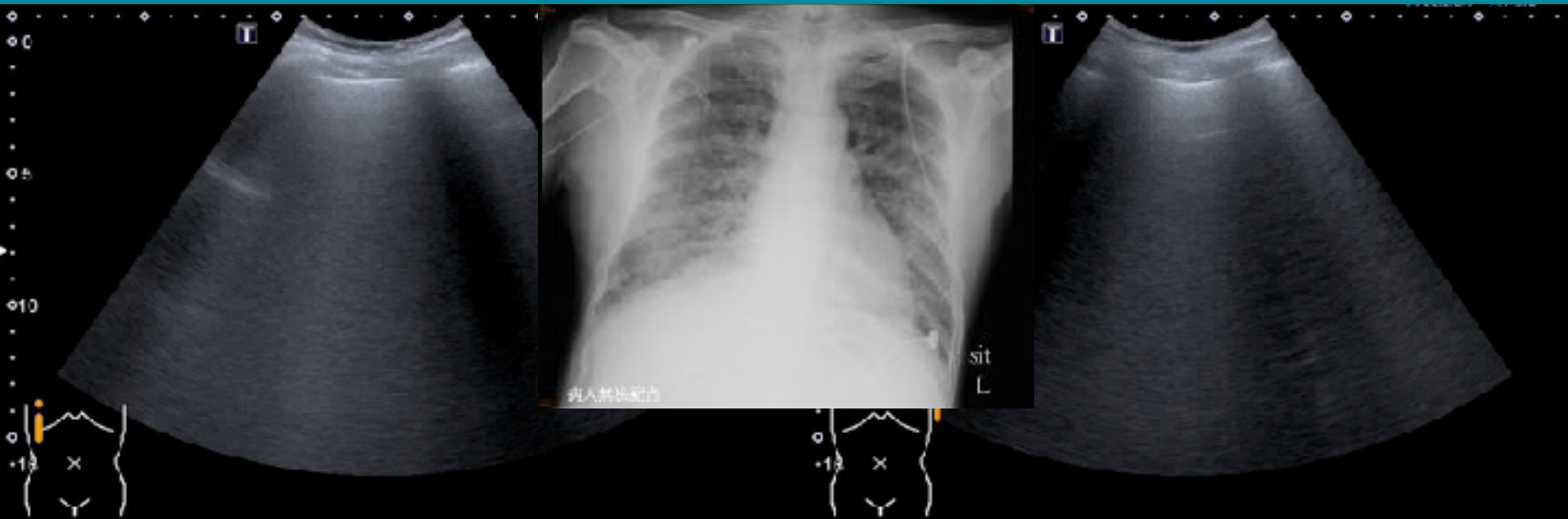
LUNG ROCKETS

ICS > 3 B lines

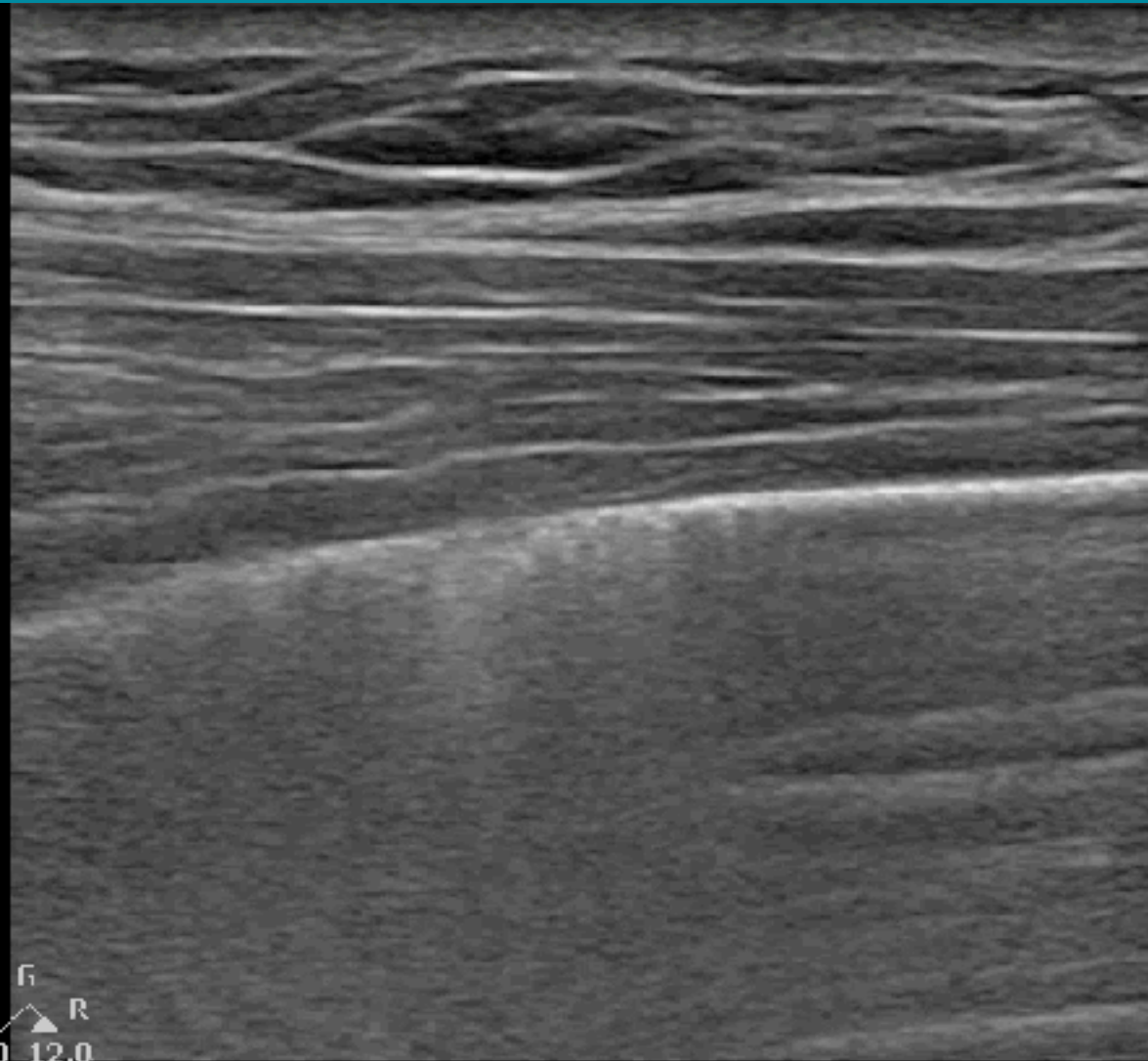




ALEVOLAR INTERSTITIAL SYNDROME



AIS: Localized



Pneumonia

Pneumonitis

Atelectasis

Contusion

Infarction

Pleural disease

Neoplasia

Normal lung

PLEURAL EFFUSION

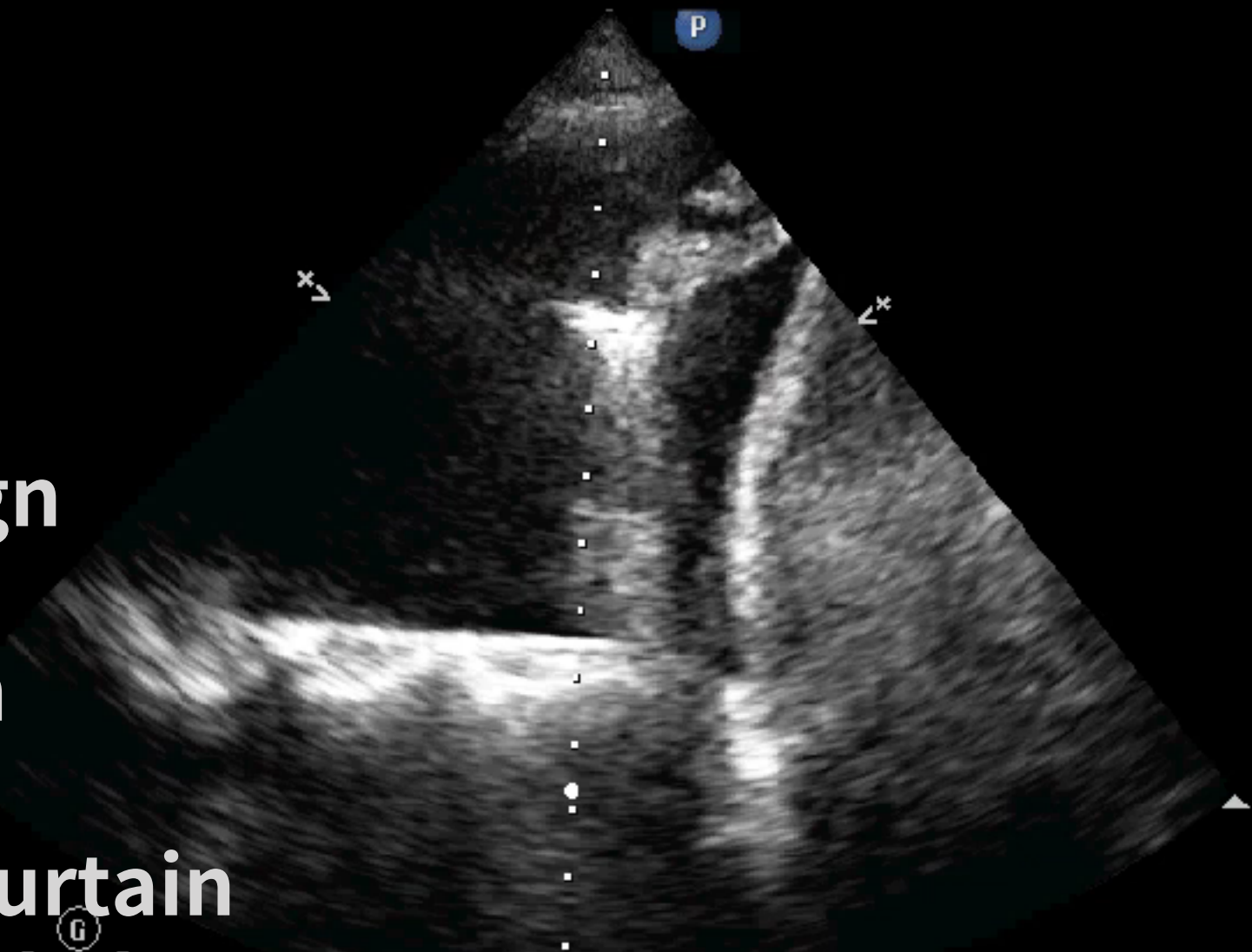
Adult Echo2
G-1
: Hz
5.0cm

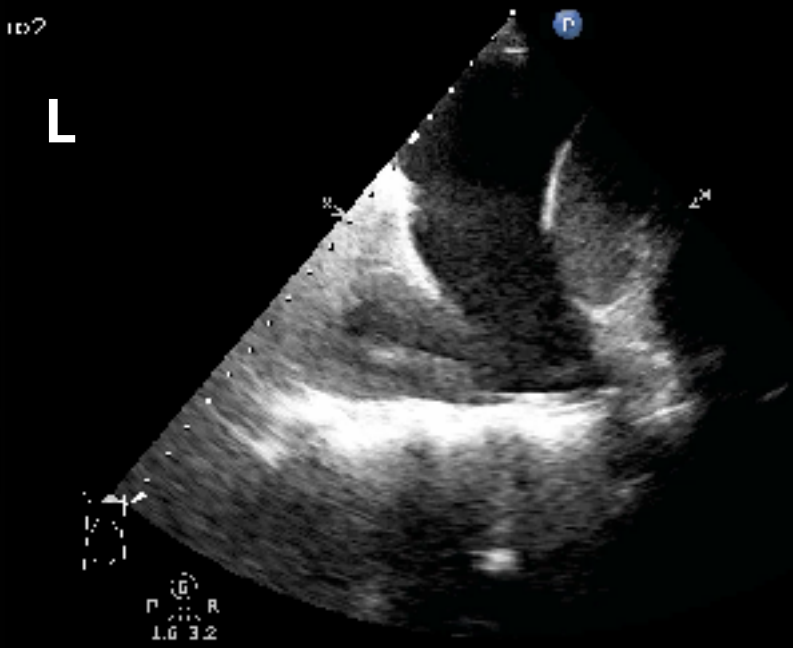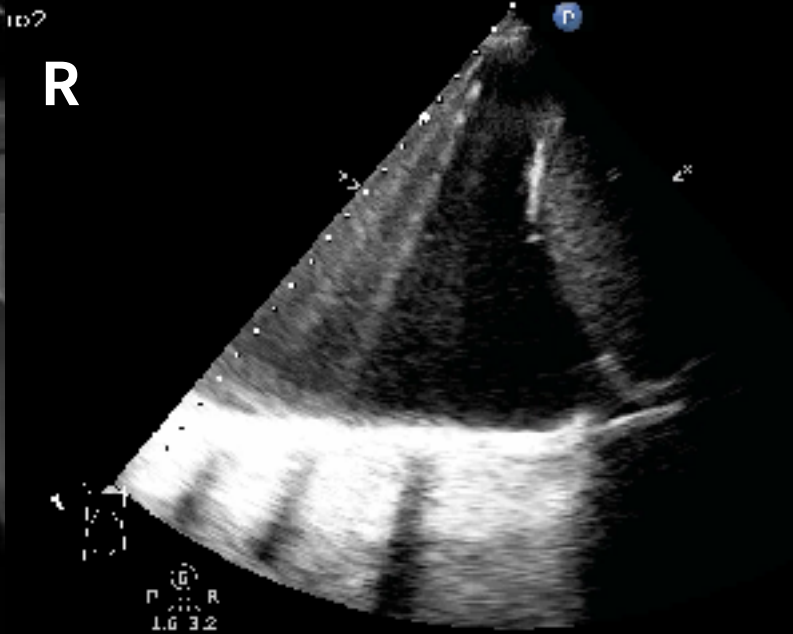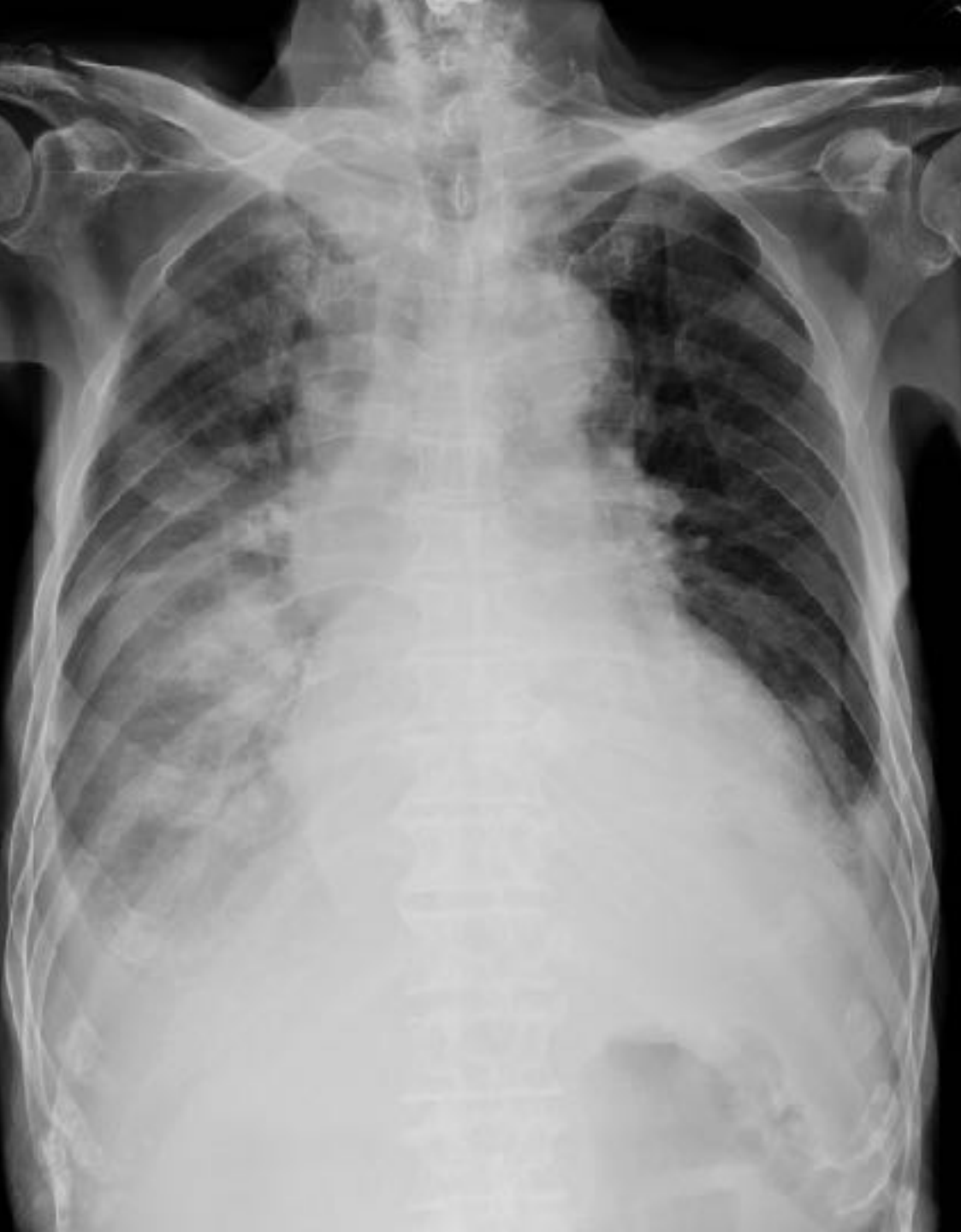Gen
n 30
50
/ 2 / 0

Spine sign

Jelly fish

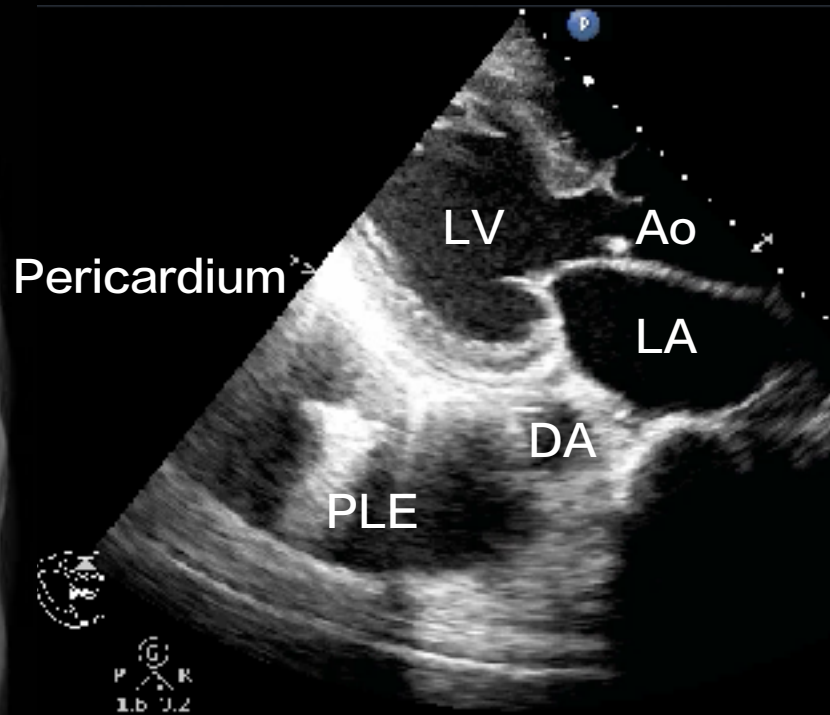
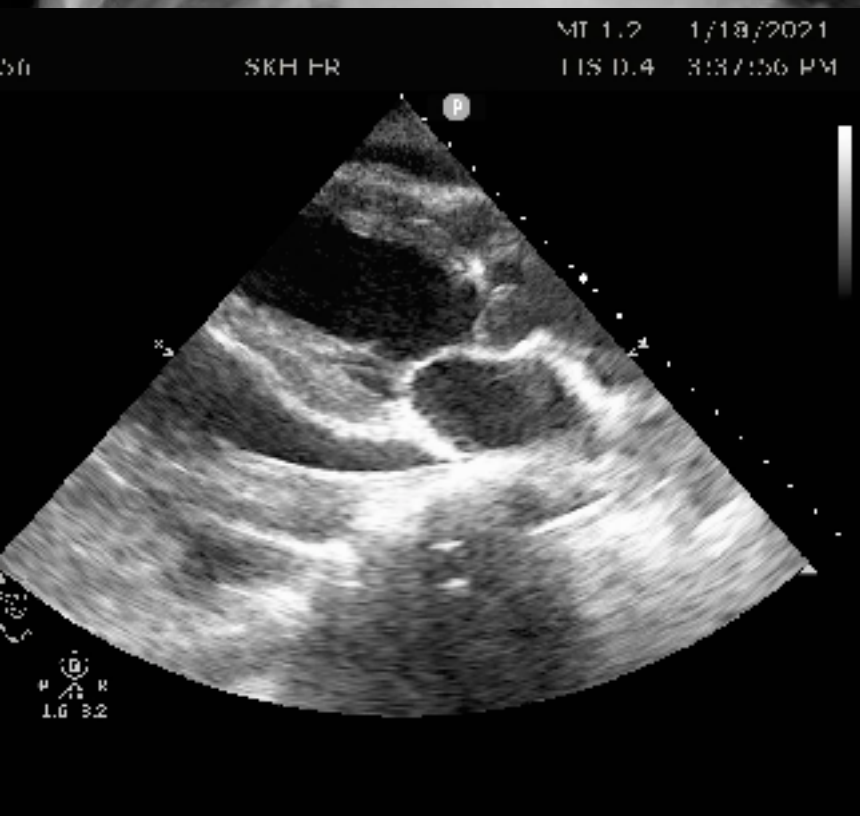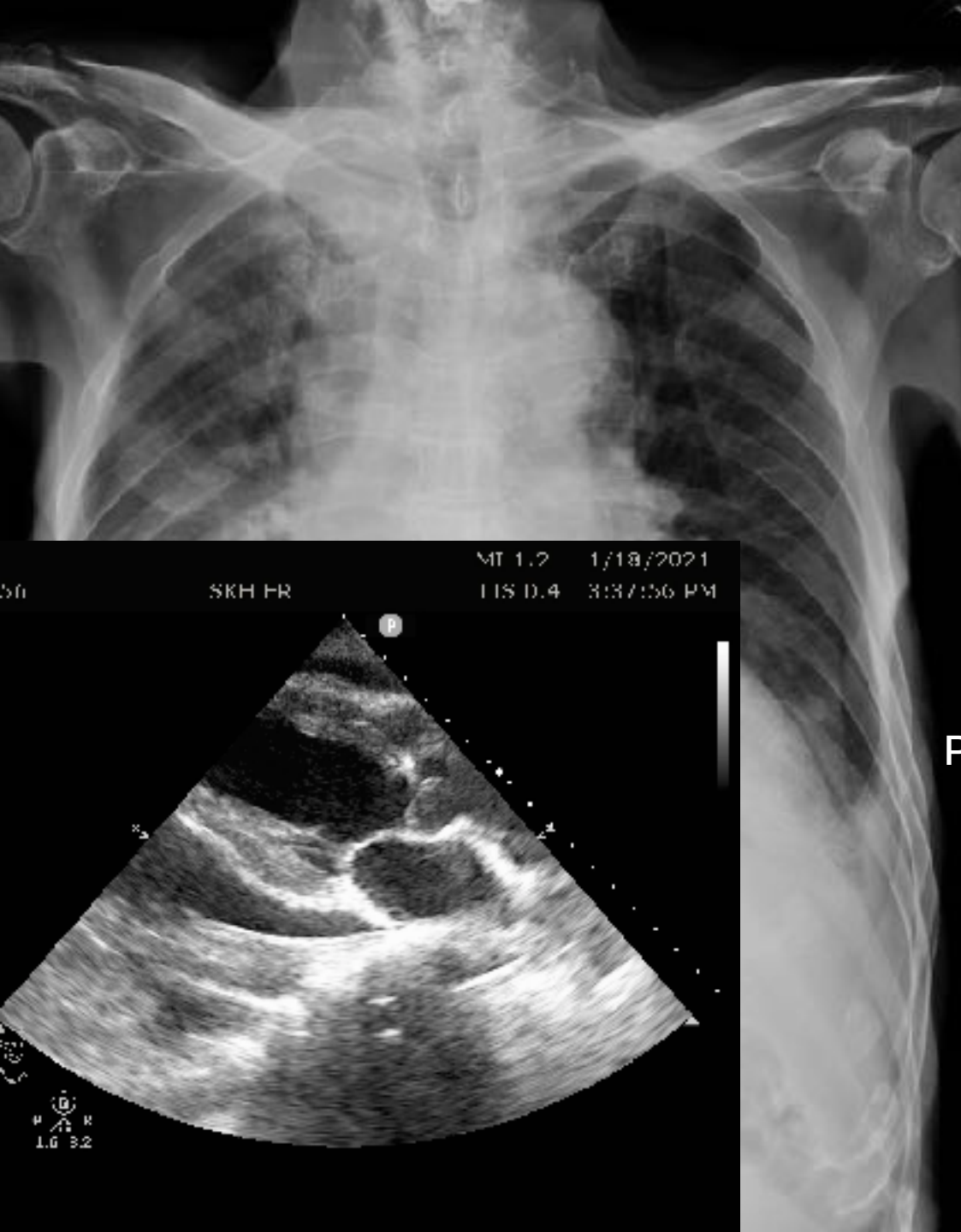
Loss of curtain





D aorta

Pericardial vs Pleural



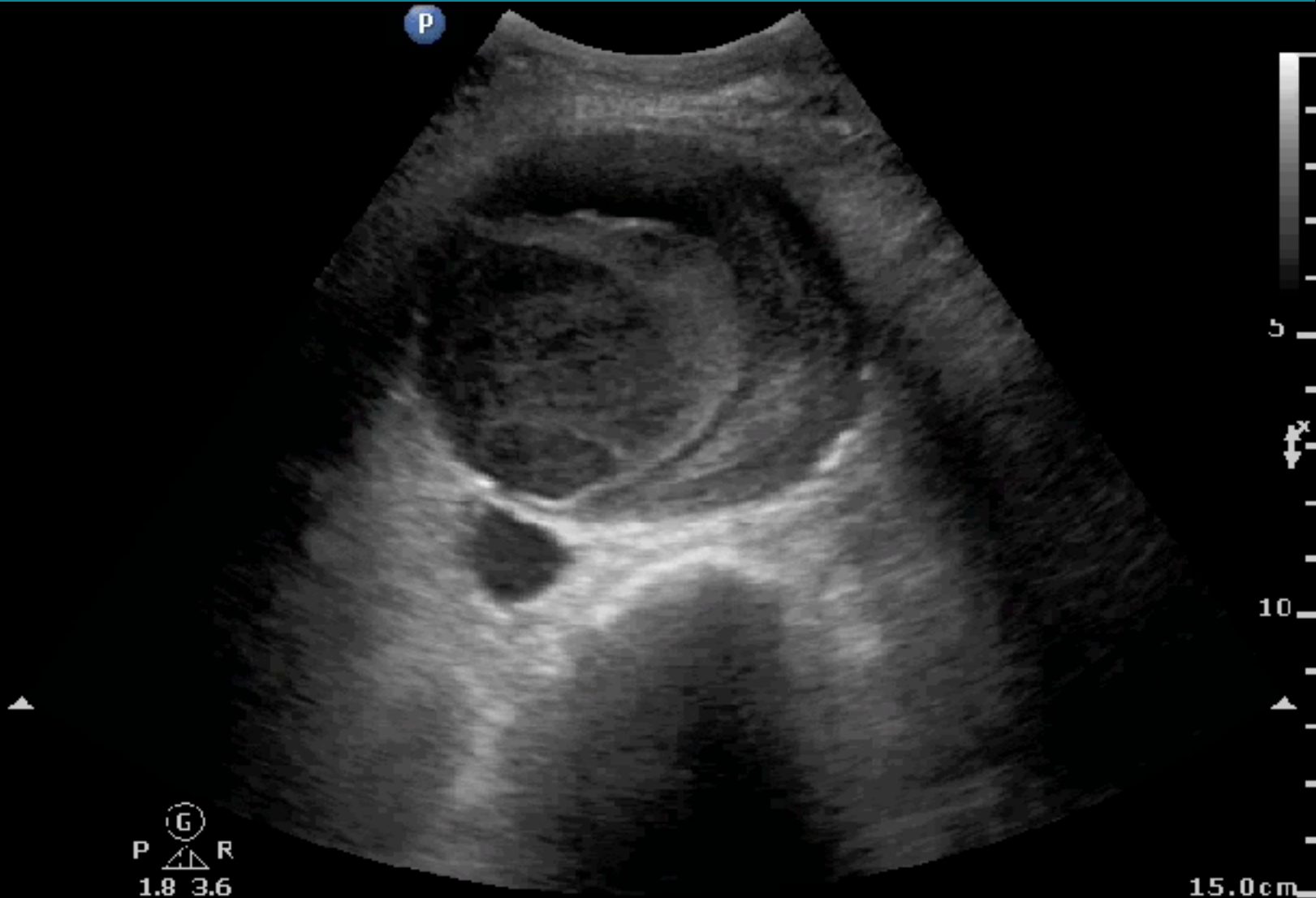


AORTA

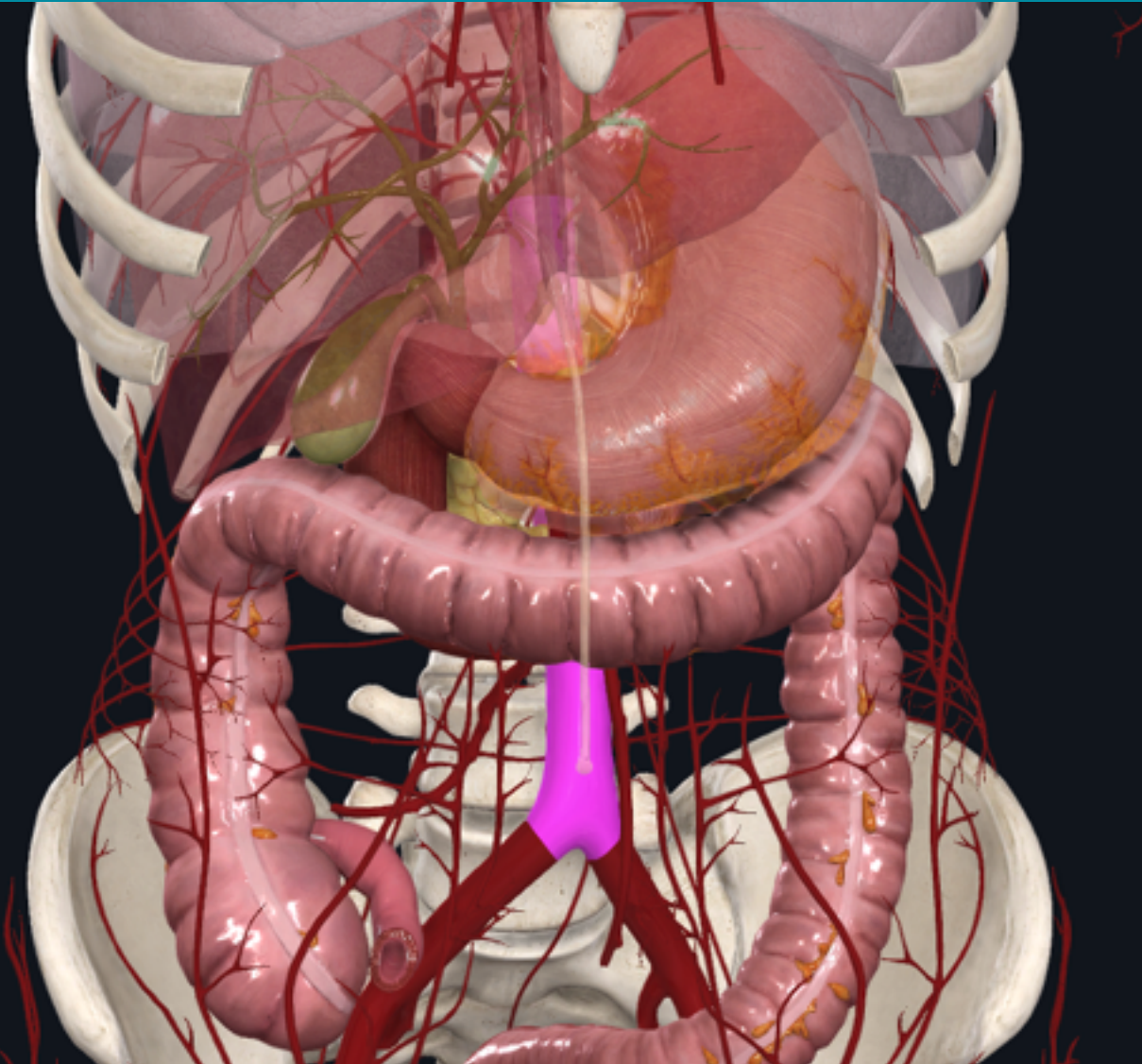
Abd Gen
C.5-1
34 Hz
15.0cm

2D

HGen
Gn 57
C 56
3 / 3 / 3



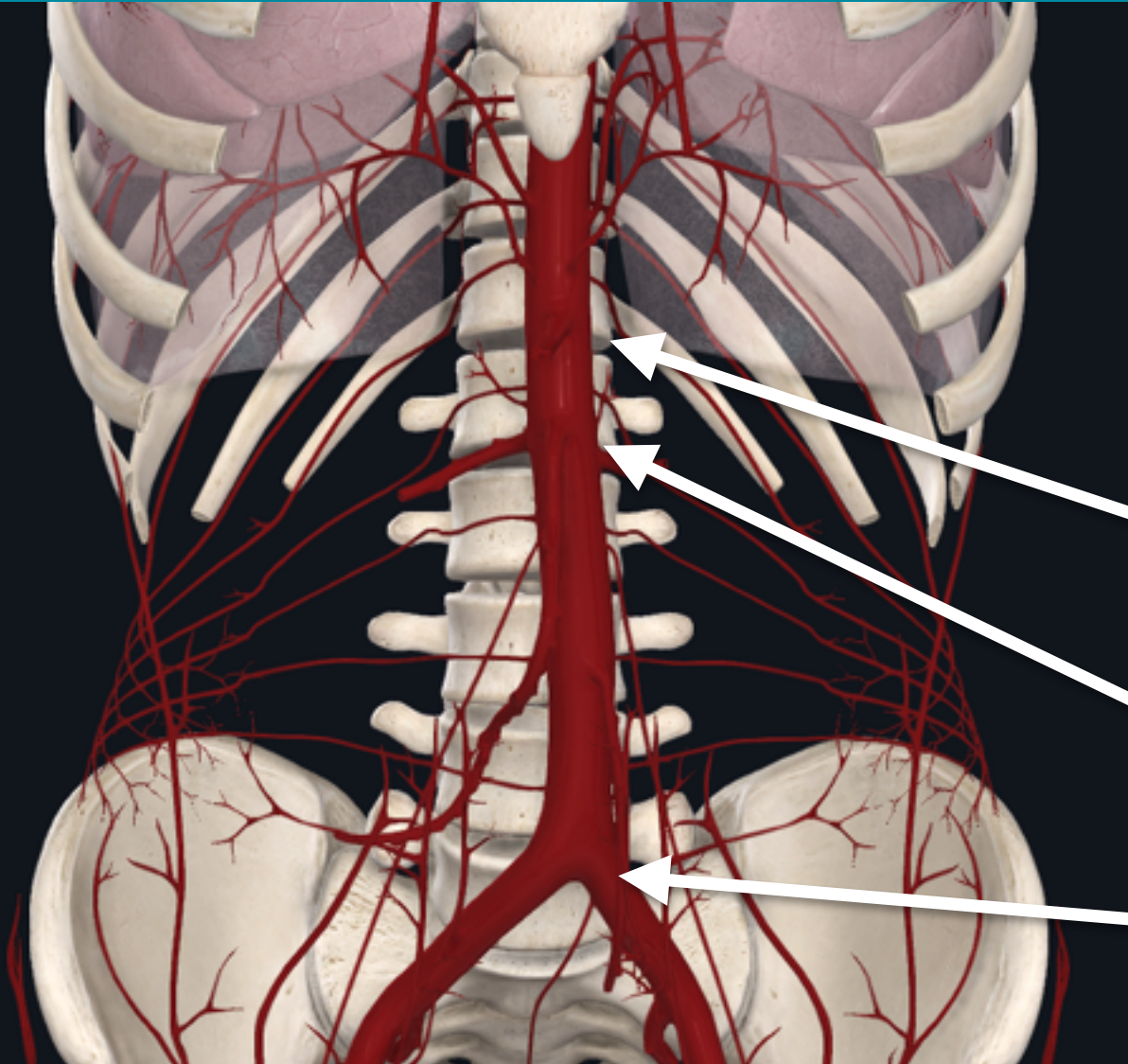
AORTA



Pain
Shock

AAA

AORTA



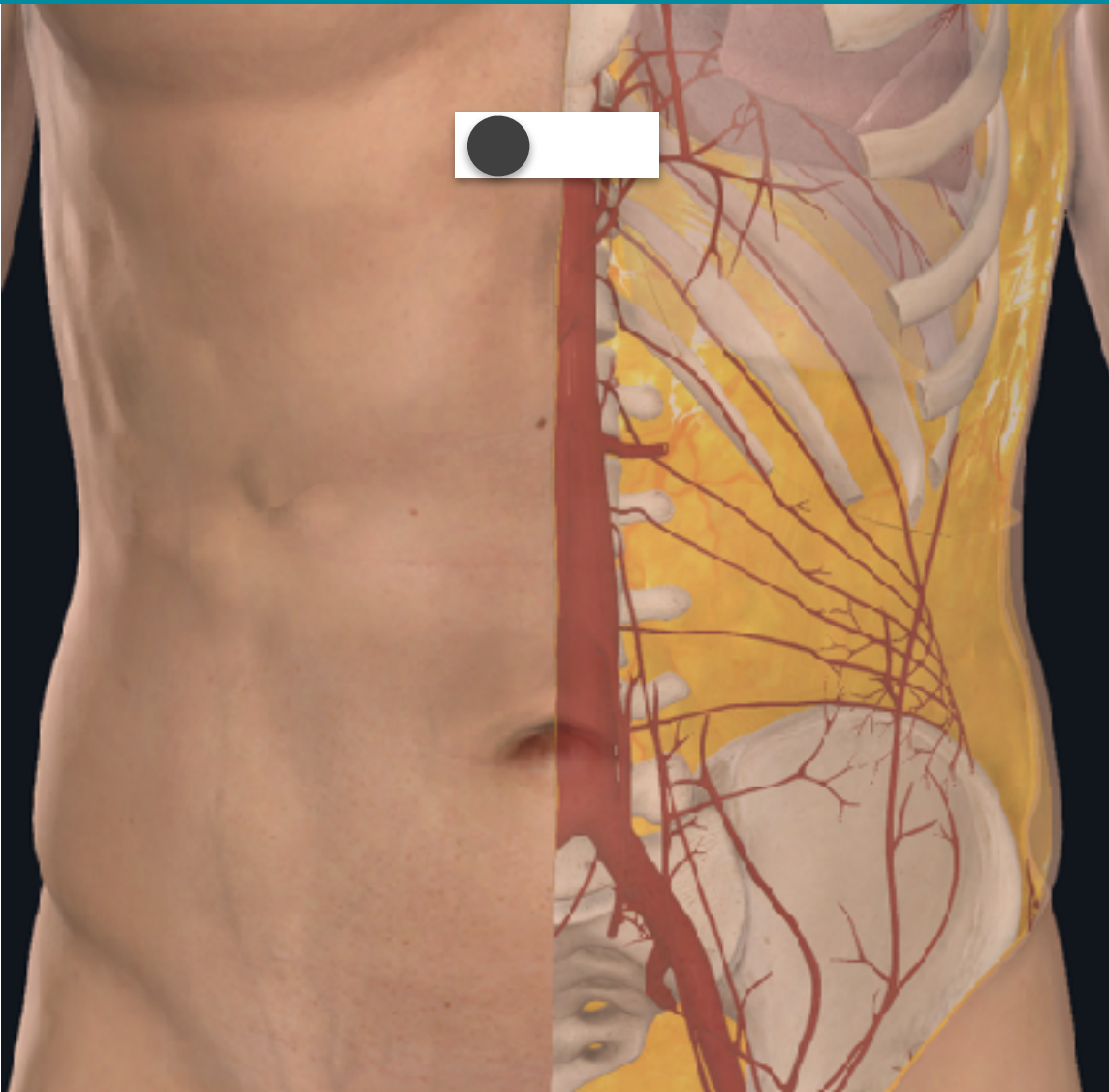
**Abdominal
Aorta (3cm)**

Celiac trunk

SMA

Bifurcation

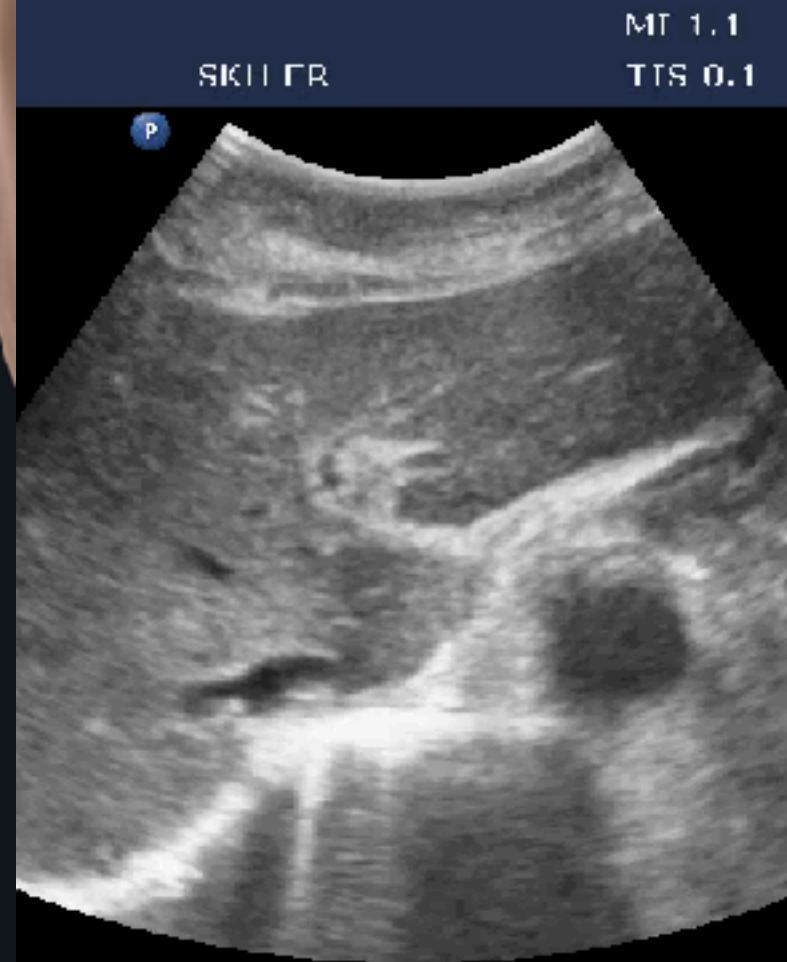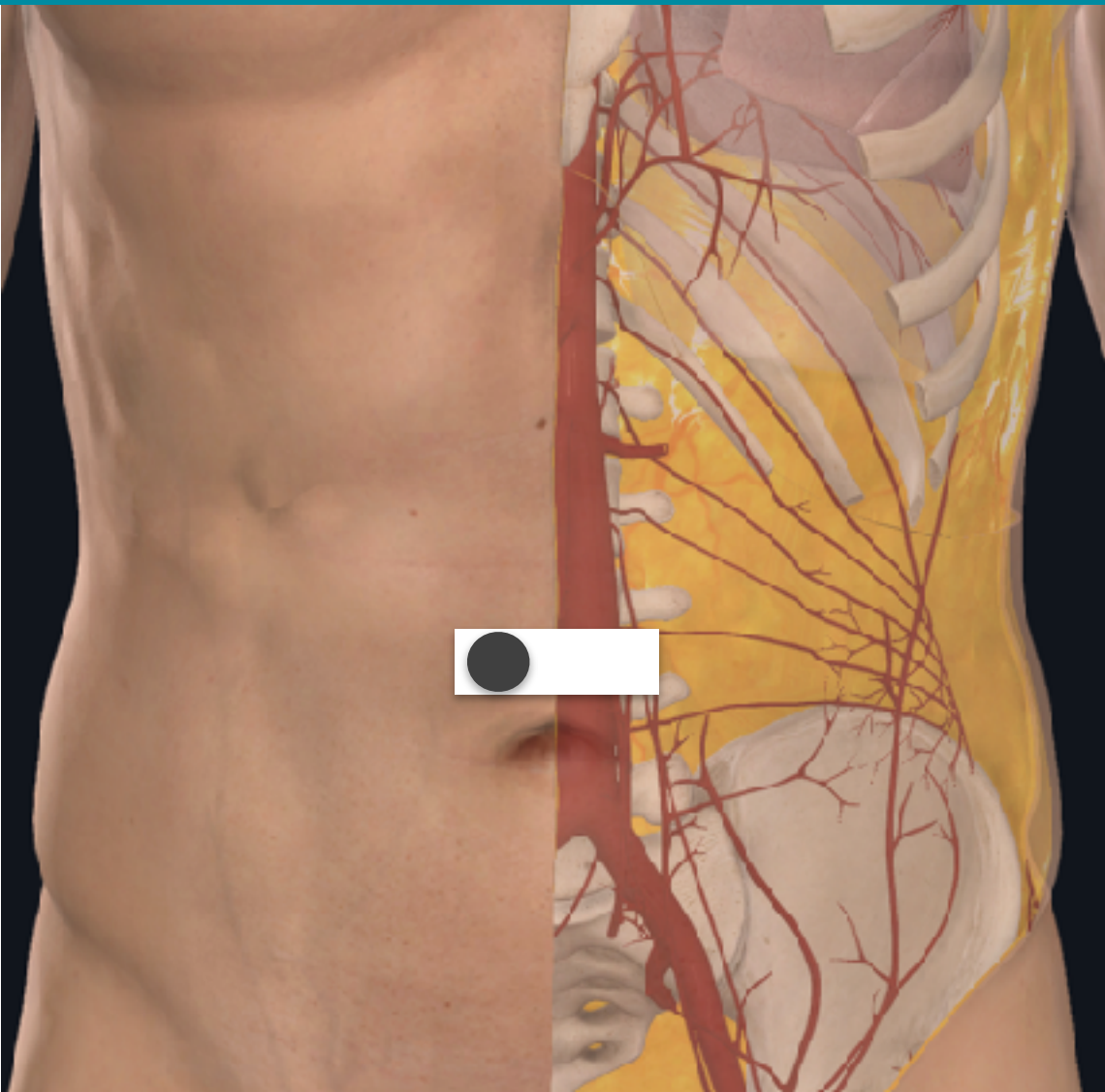
AORTA



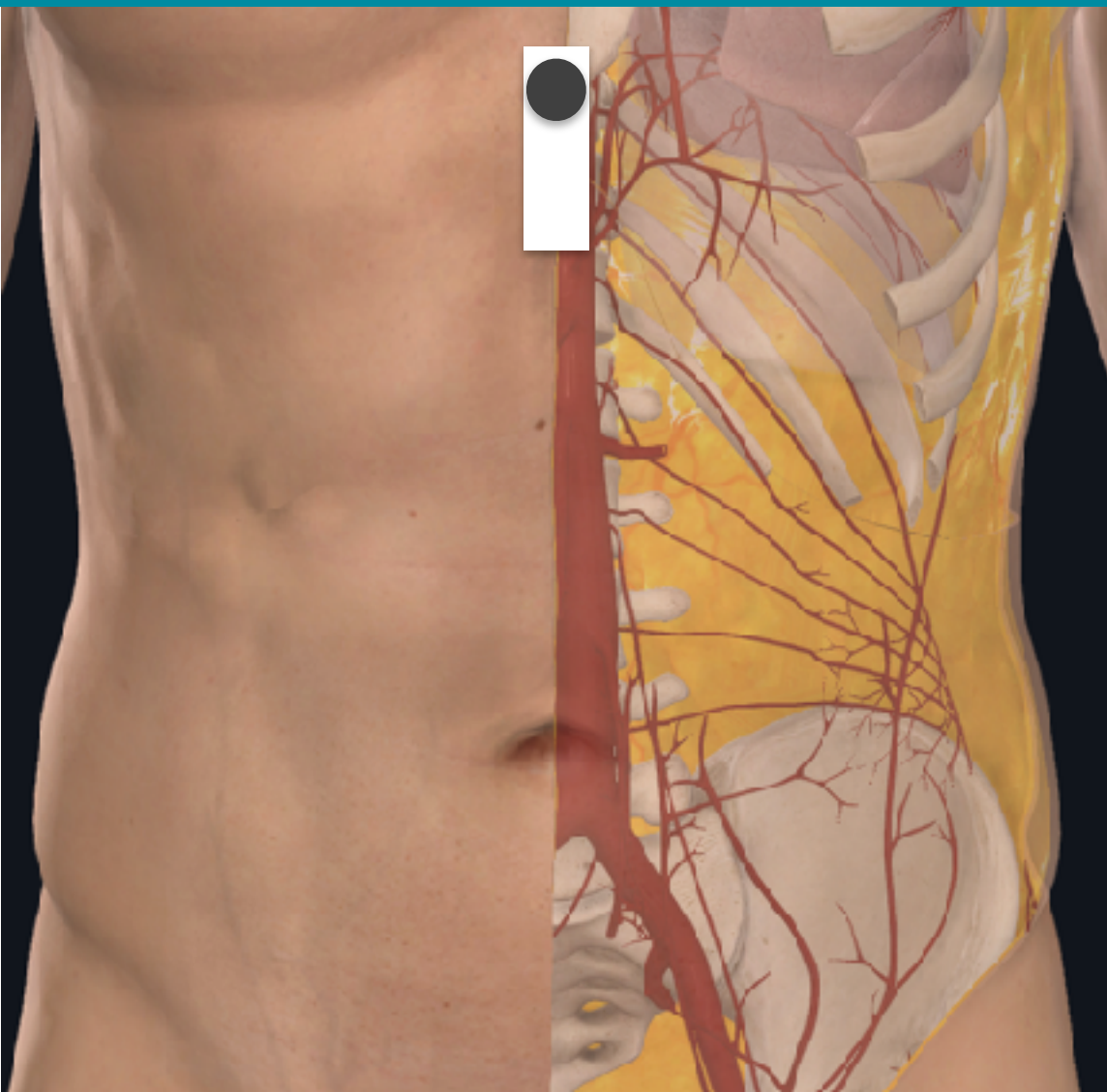
探頭: 弧形

位置: 劍突下

AORTA



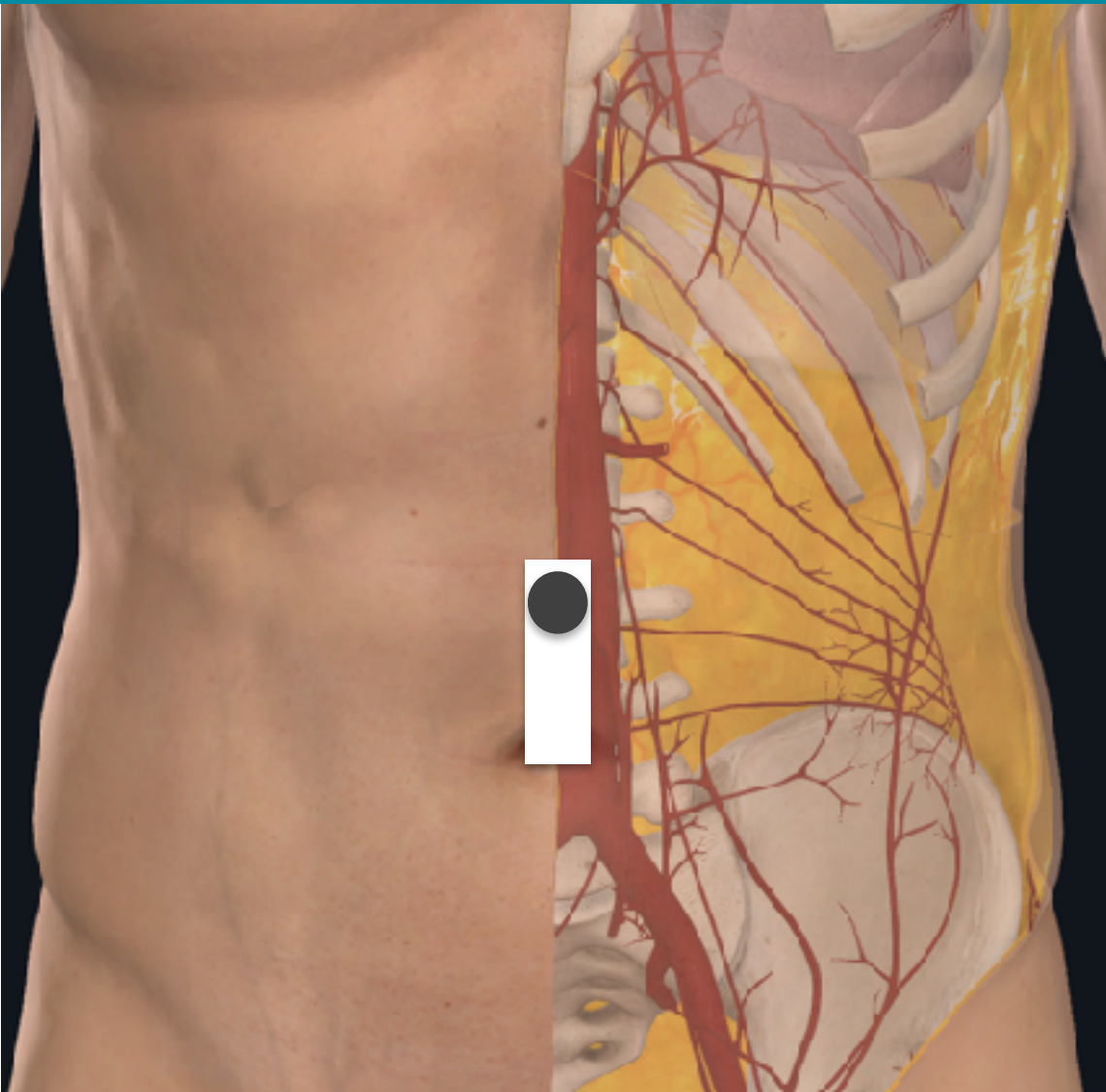
AORTA



探頭: 弧形

位置: 劍突下

AORTA

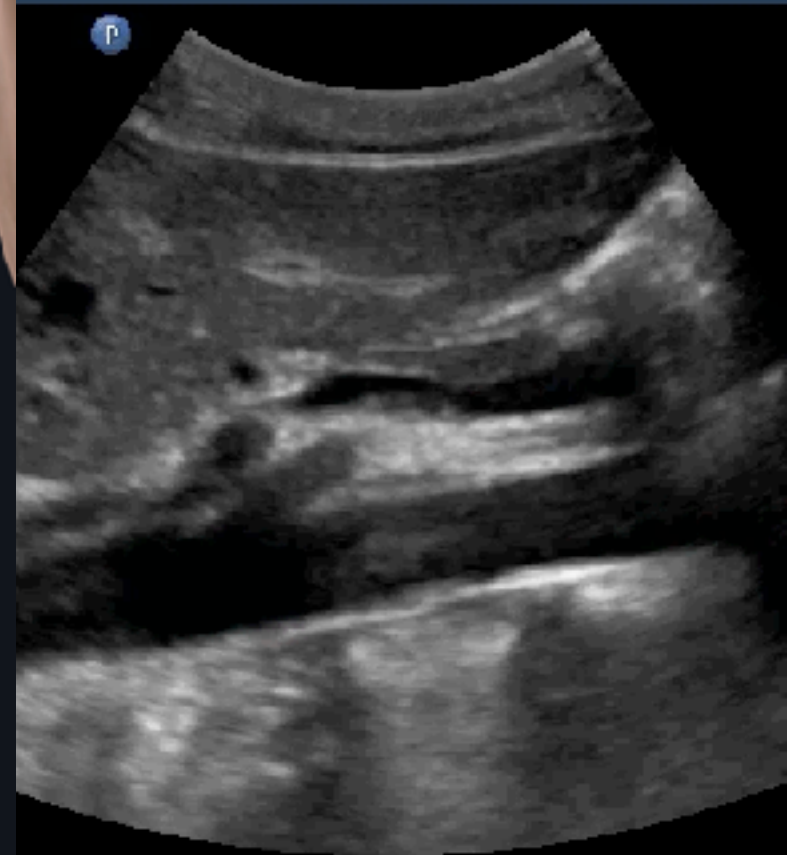

160331172347

SKII ER

MI 1.1

TIS 0.1

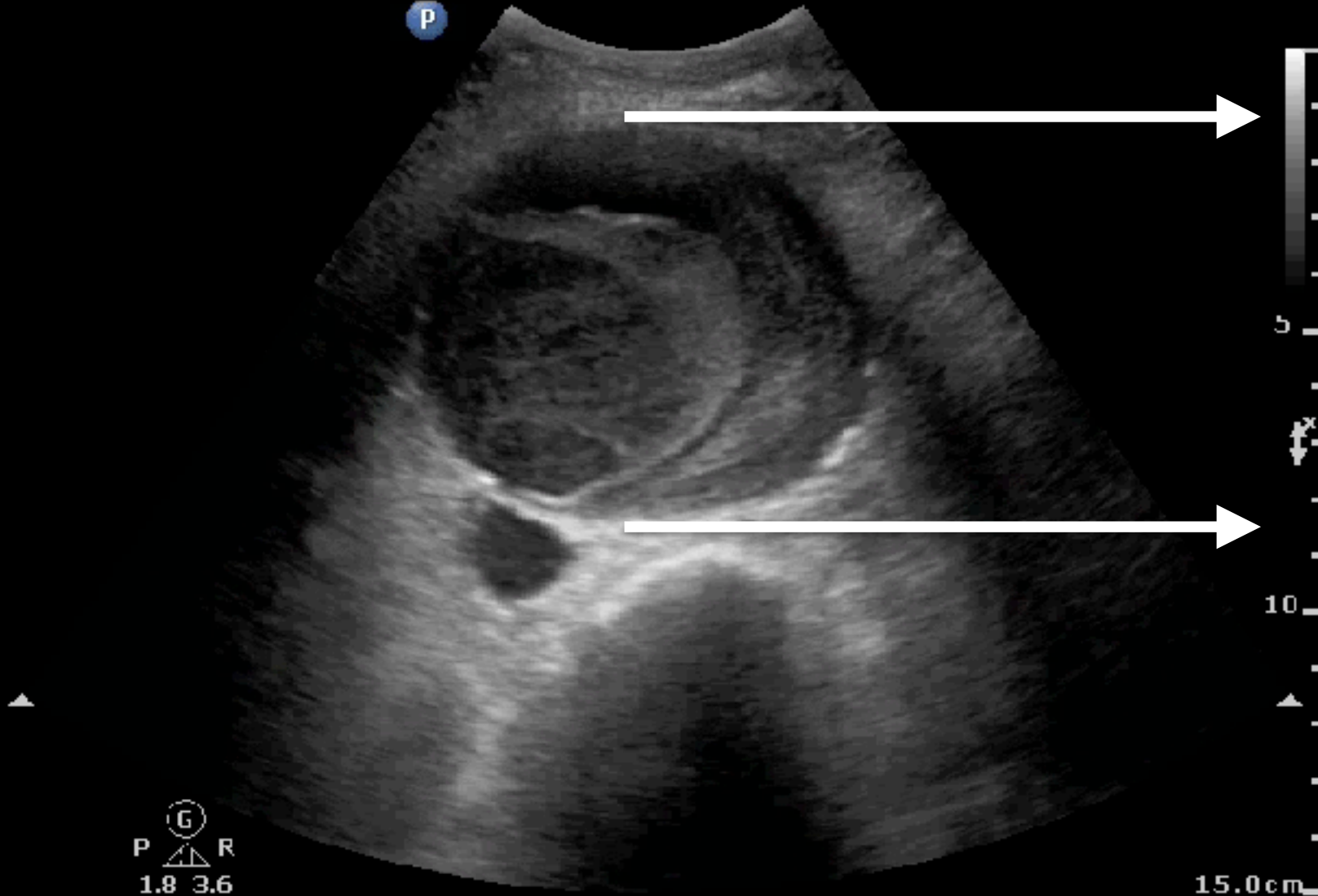


AAA: EYEBALLING

Abd Gen
C.5-1
34 Hz
15.0cm

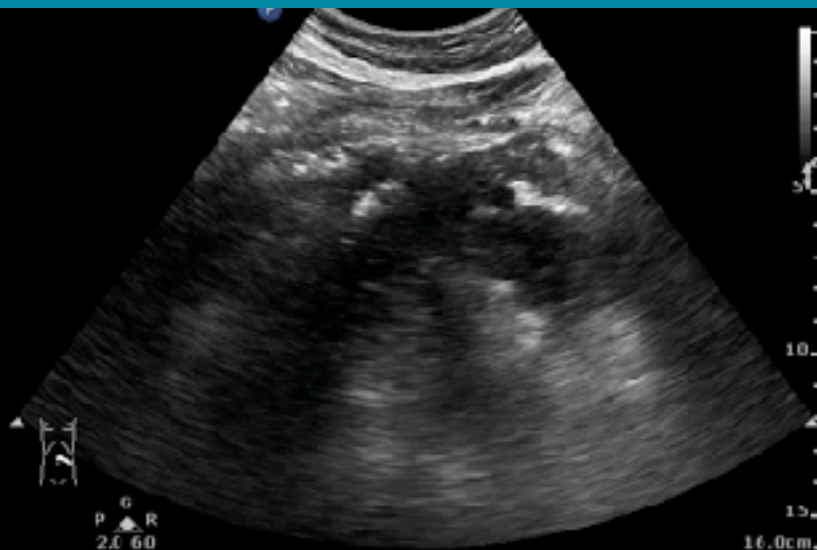
2D

HGen
Gn 57
C 56
3/3/3

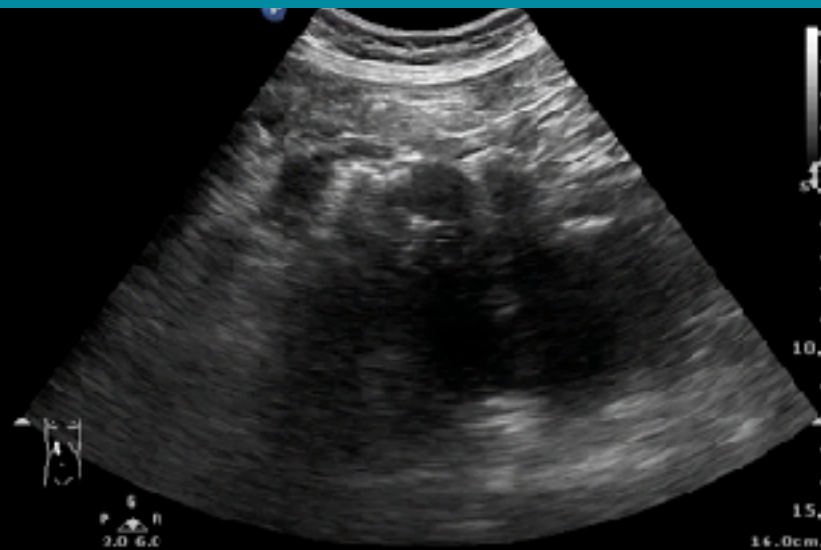


AAA ? RUPTURE ?

C Nerve
C6-2
22 Hz
16.0cm

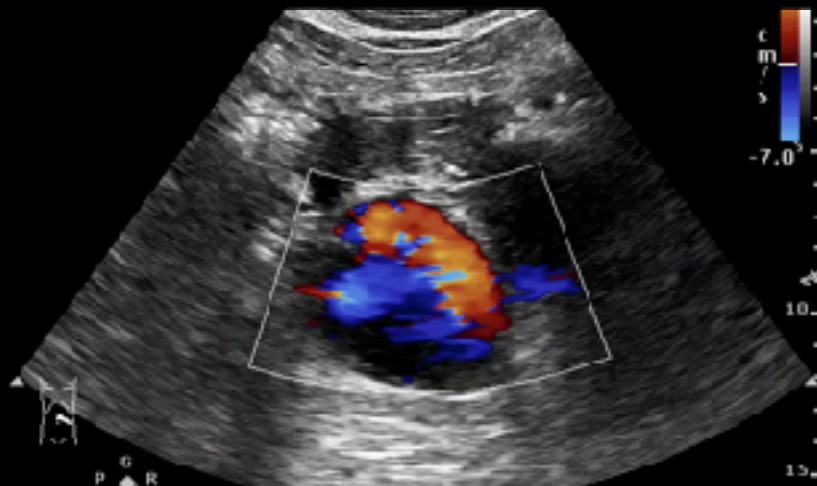


C Nerve
C6-2
22 Hz
16.0cm



11 Hz
16.0cm

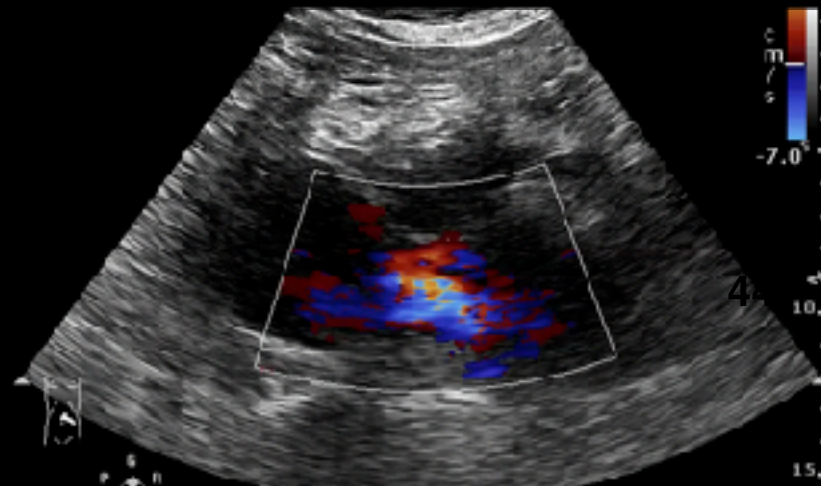
2D
Gen
Gh 60
C 53
2/3/3



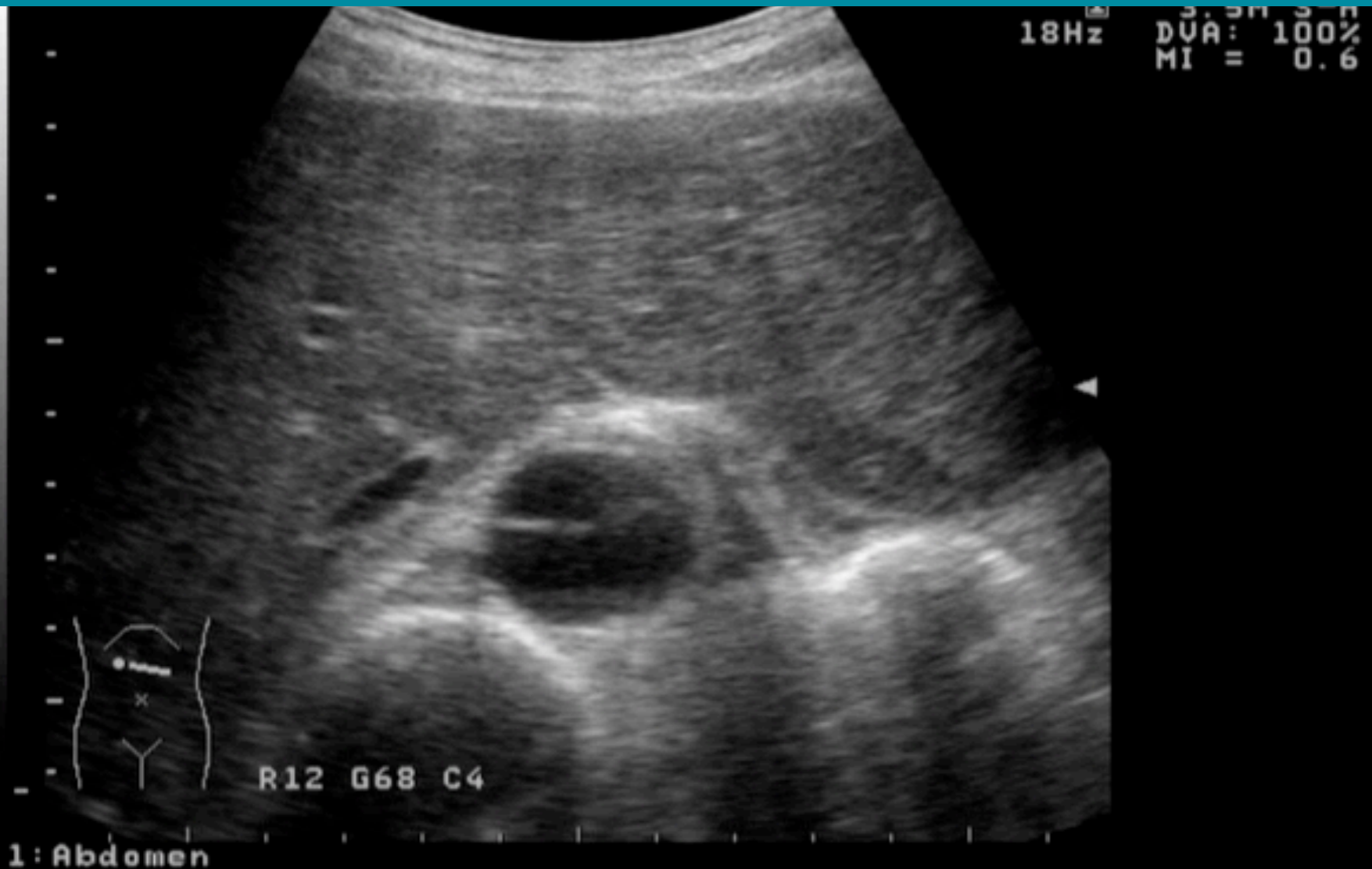11 Hz
16.0cm

2D
Gen
Gh 60
C 53
2/3/3

Color
2.5 MHz
Gh 66
3/5/4
Filtr Med



AAA ?



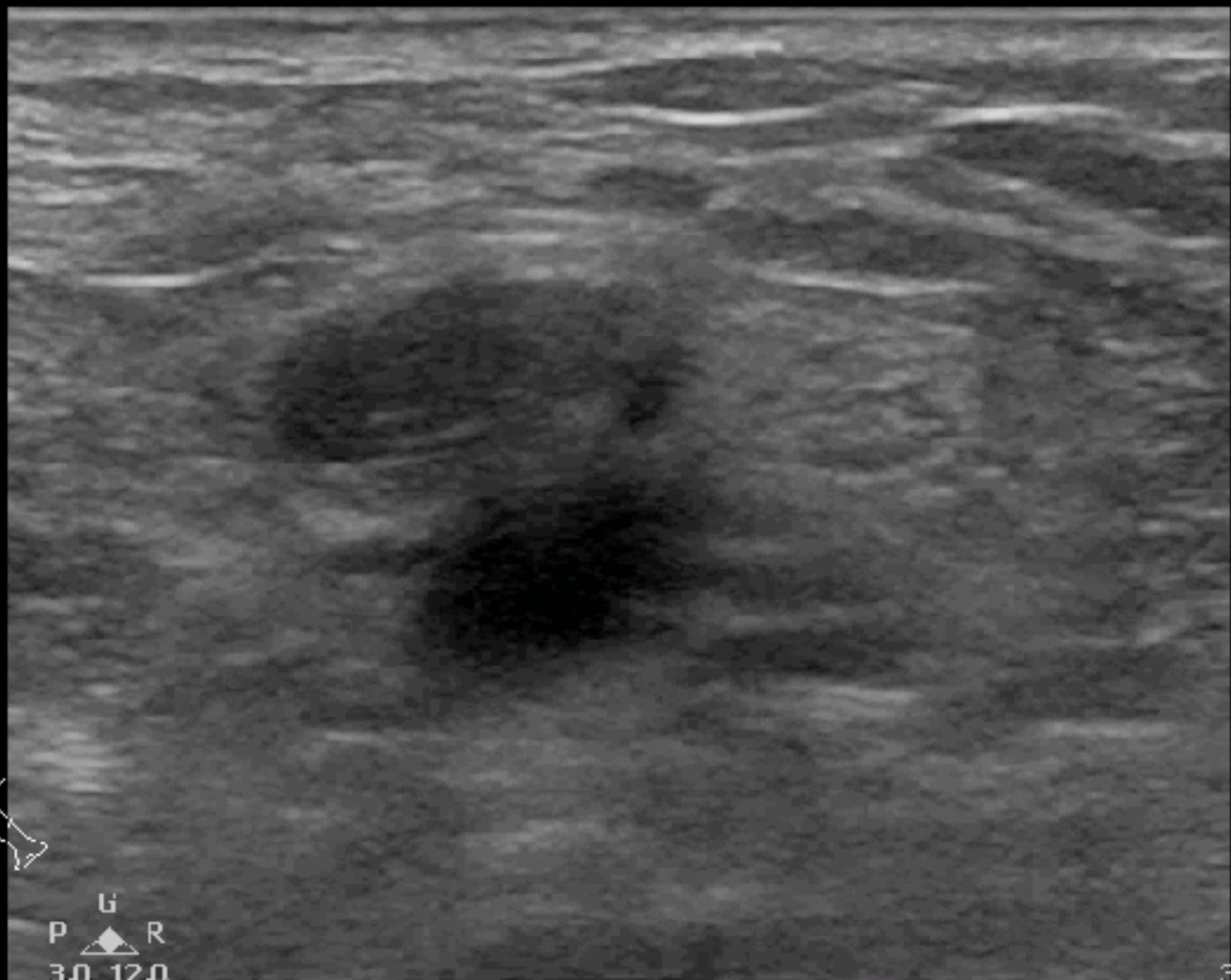
DVT



Superficial
_12-3
31 Hz
3.0cm

P

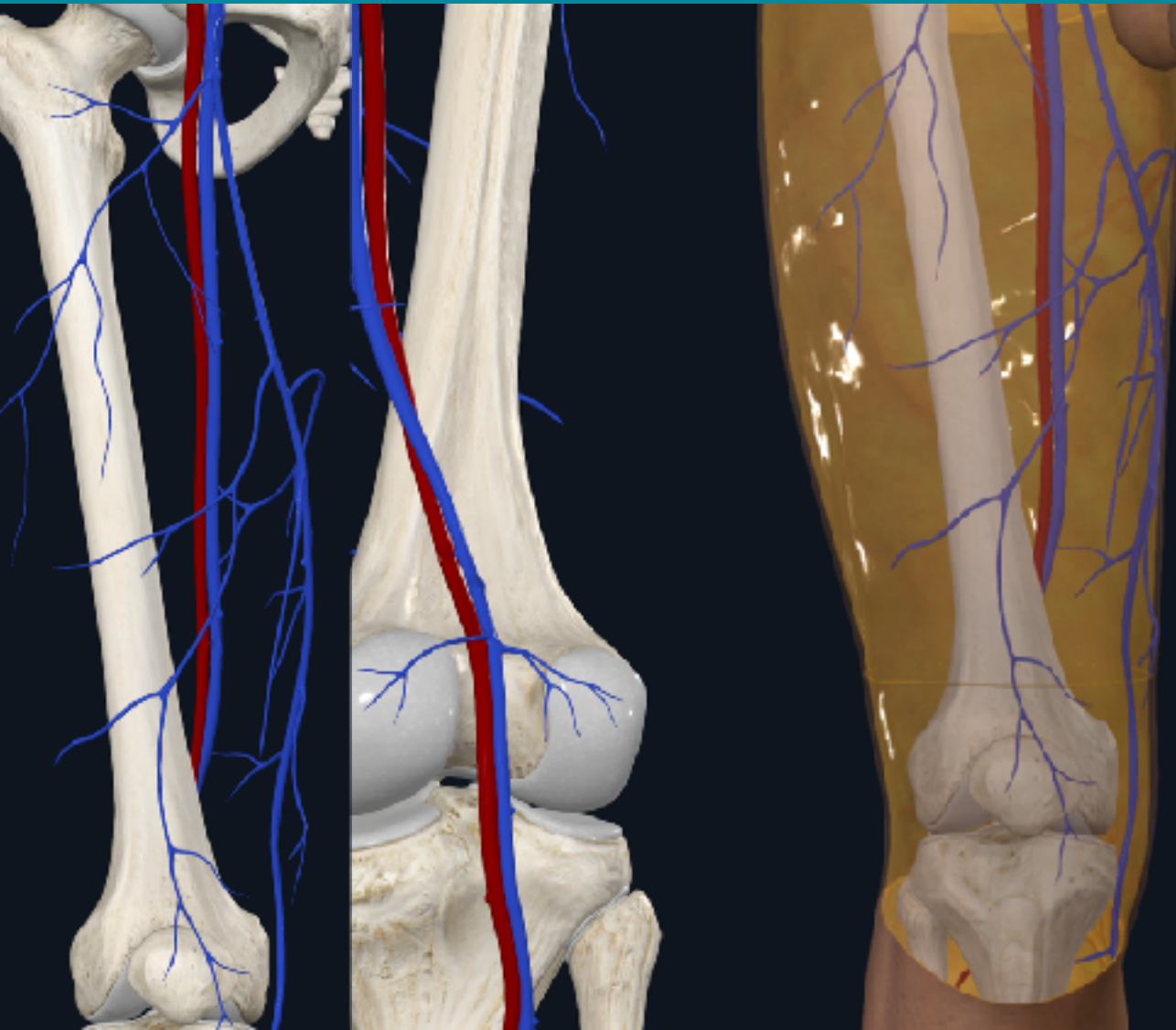
2D
Gen
Gn 88
C 52
4/3/2



G
P ▲ R
3.0 12.0

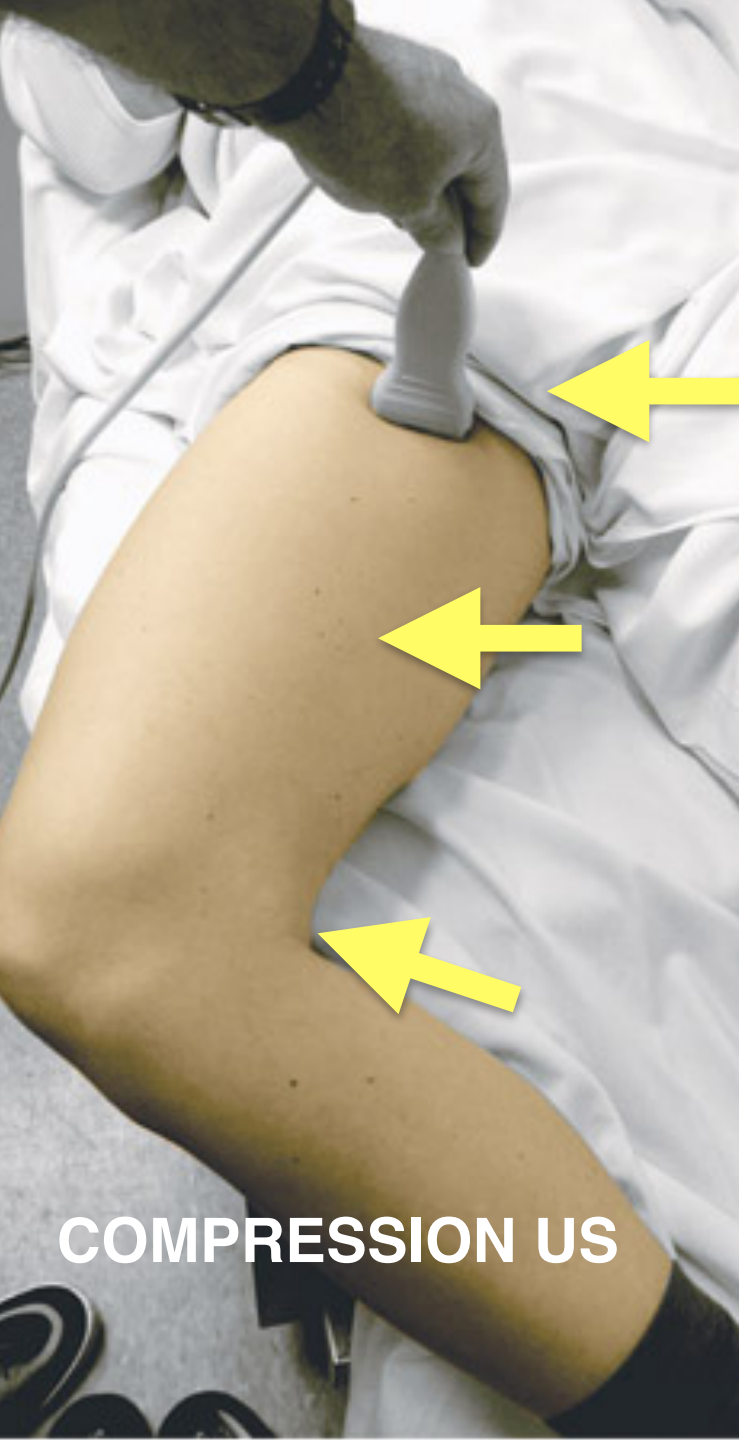
3.0cm

DVT

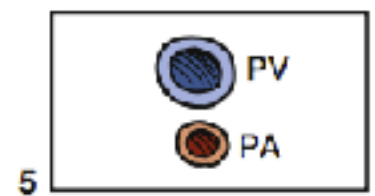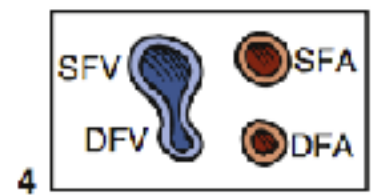
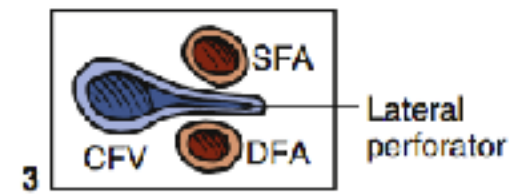
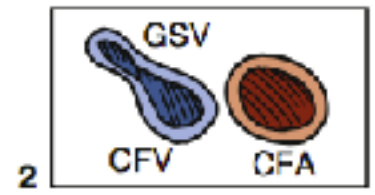
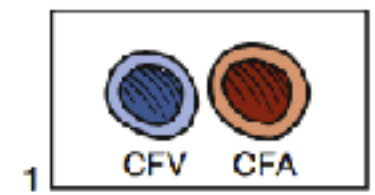
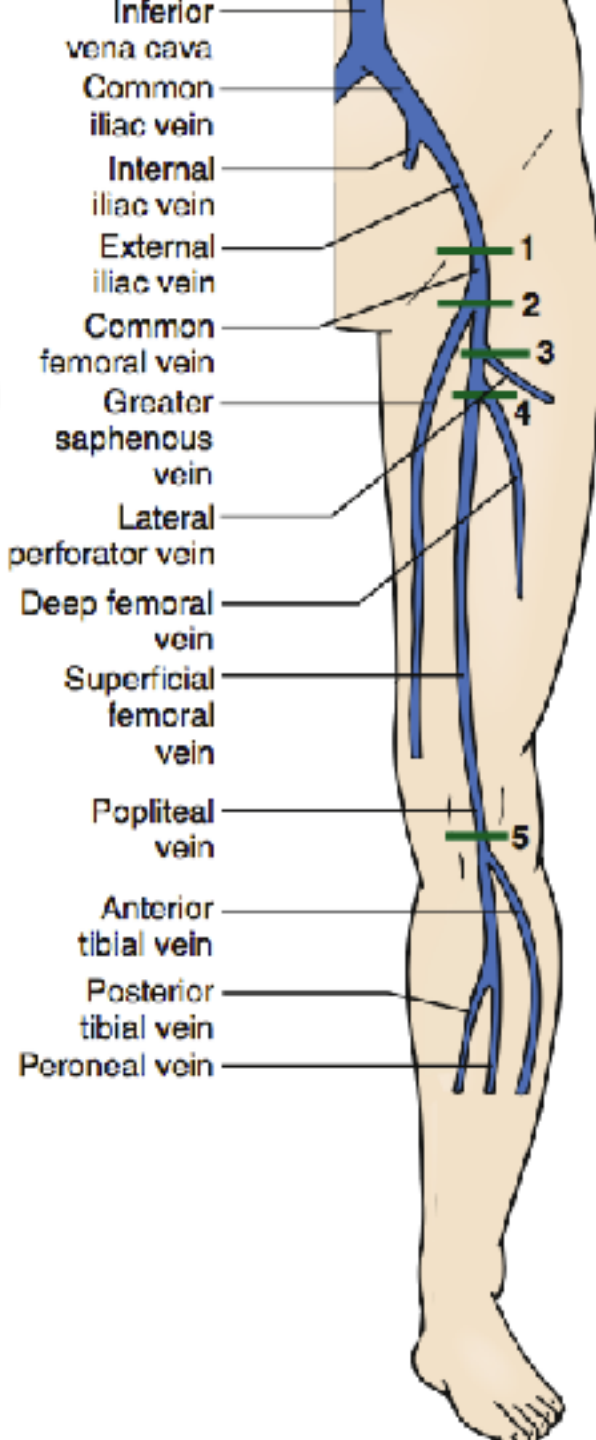


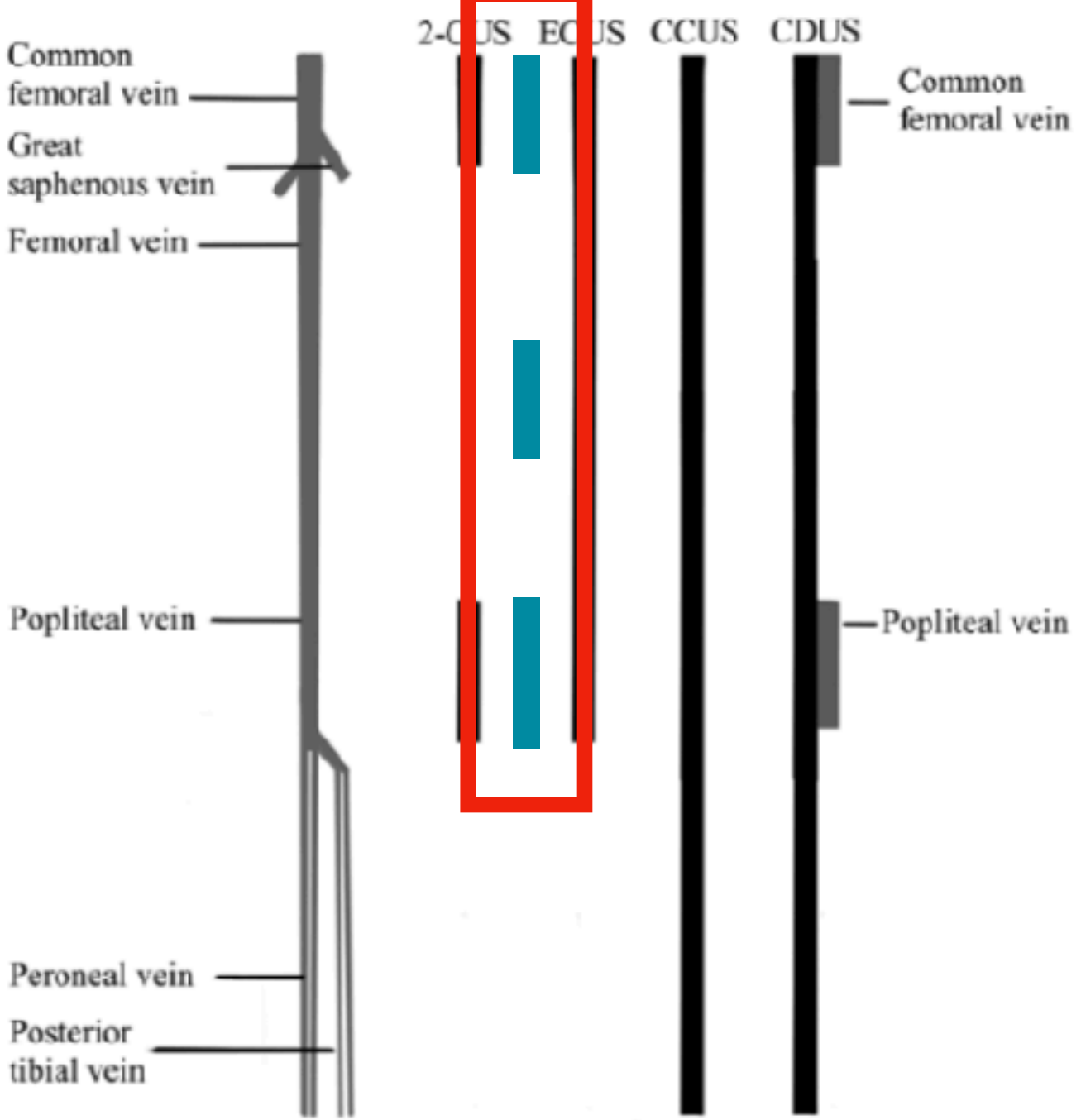
Swelling
Dyspnea
Shock

DVT



COMPRESSION US



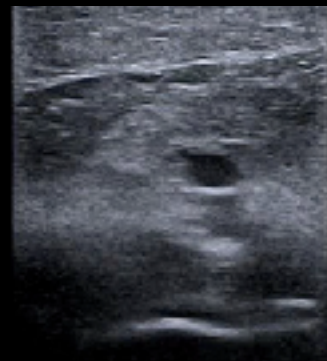
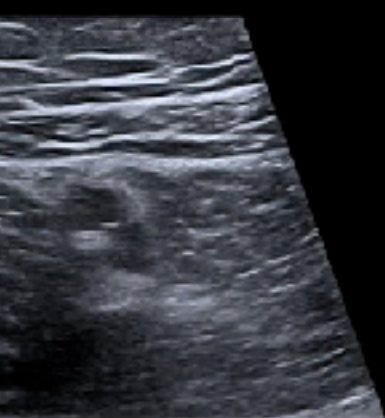
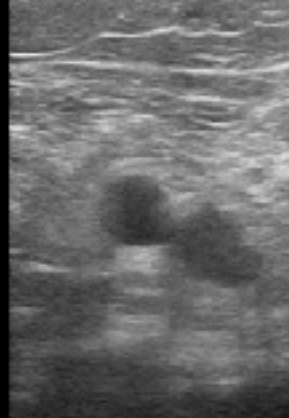


3 regions
Sen 90.57%
Spe 98.52%

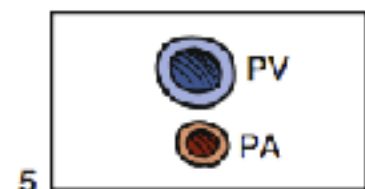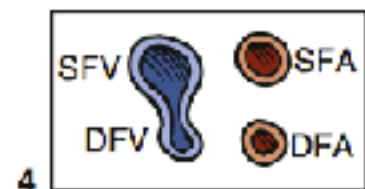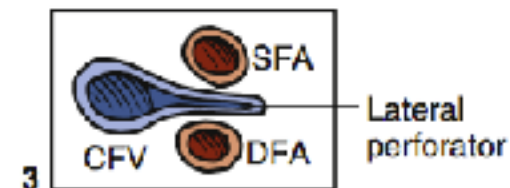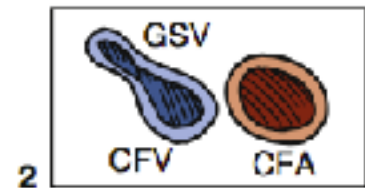
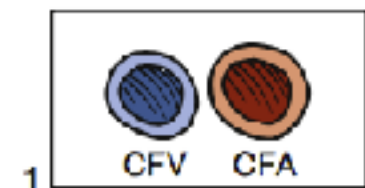
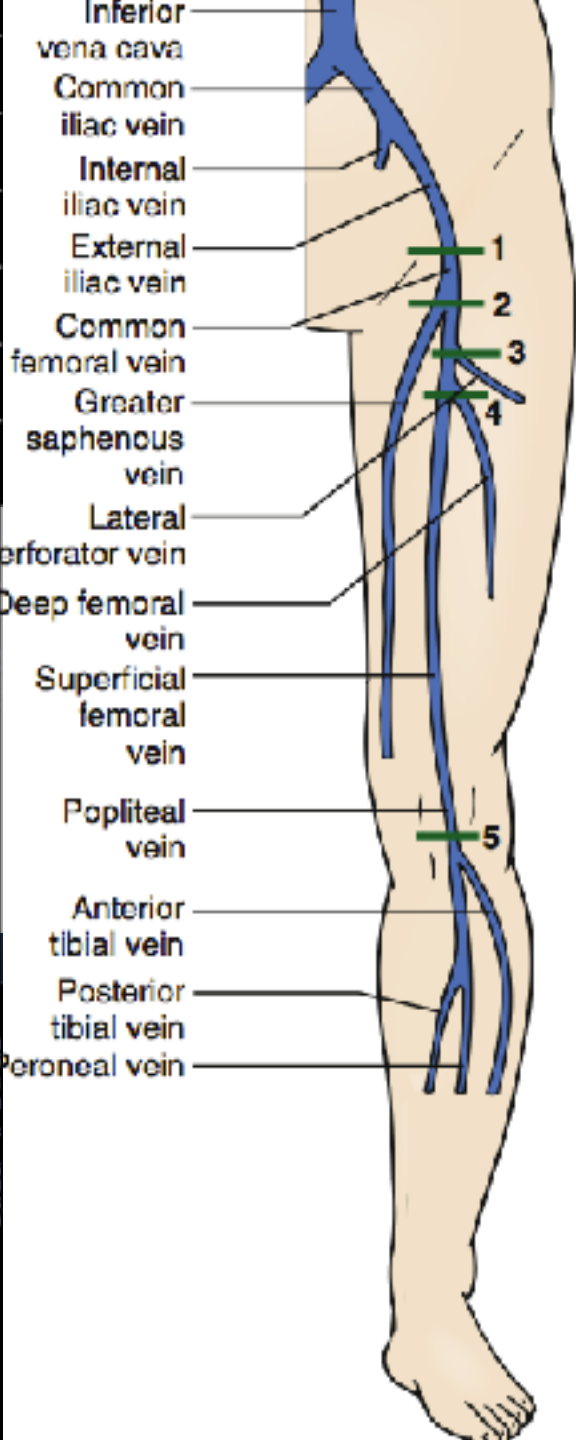
2 regions
Sen 82.76%
Spe 98.52%

Heather Hale, MD

0cm
Gen
n 32
41
7/3/12

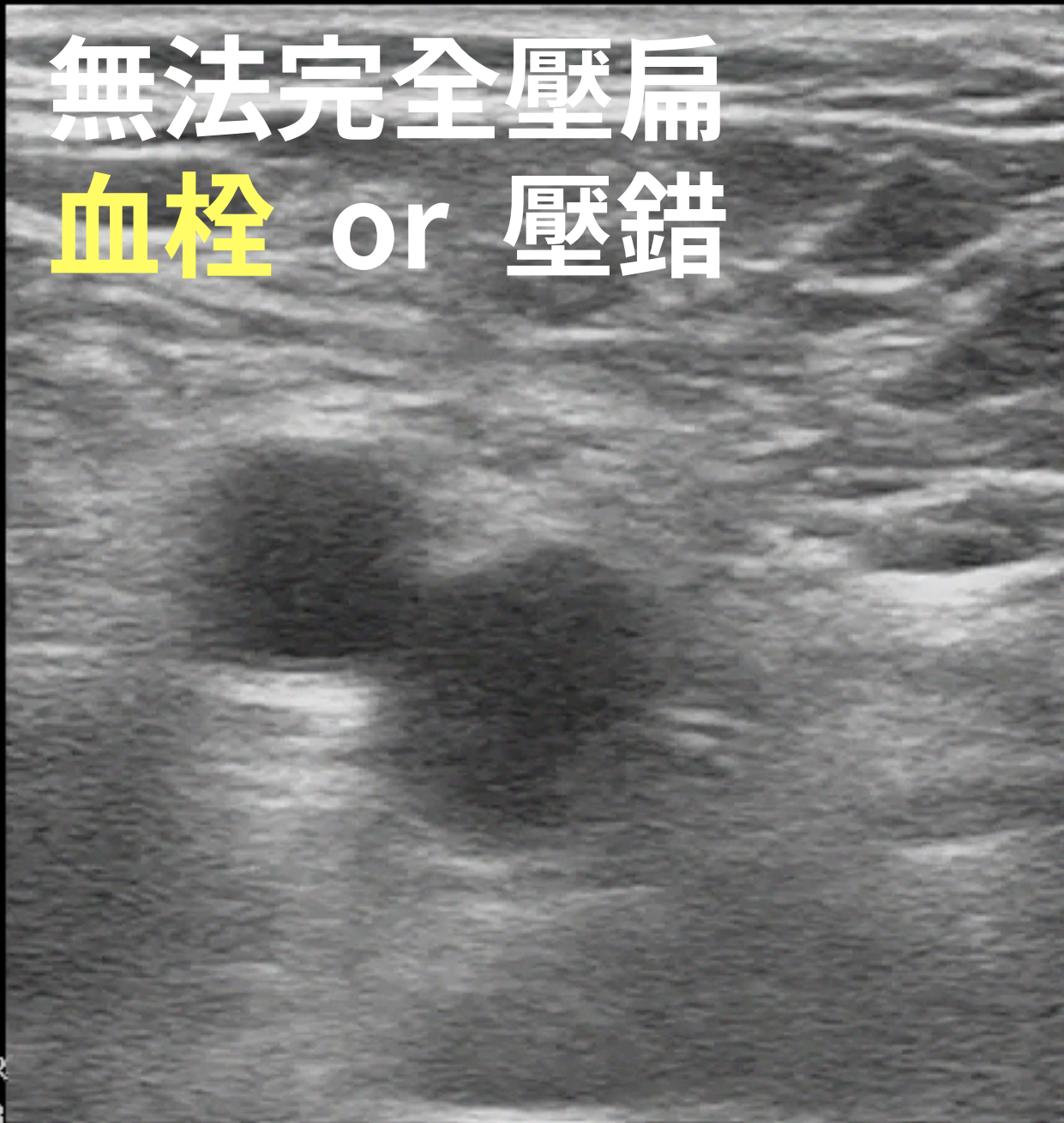


6.0cm
MI 1.5
11L4
dWT0.0
25 fps
G86
DR.80
A15
P3



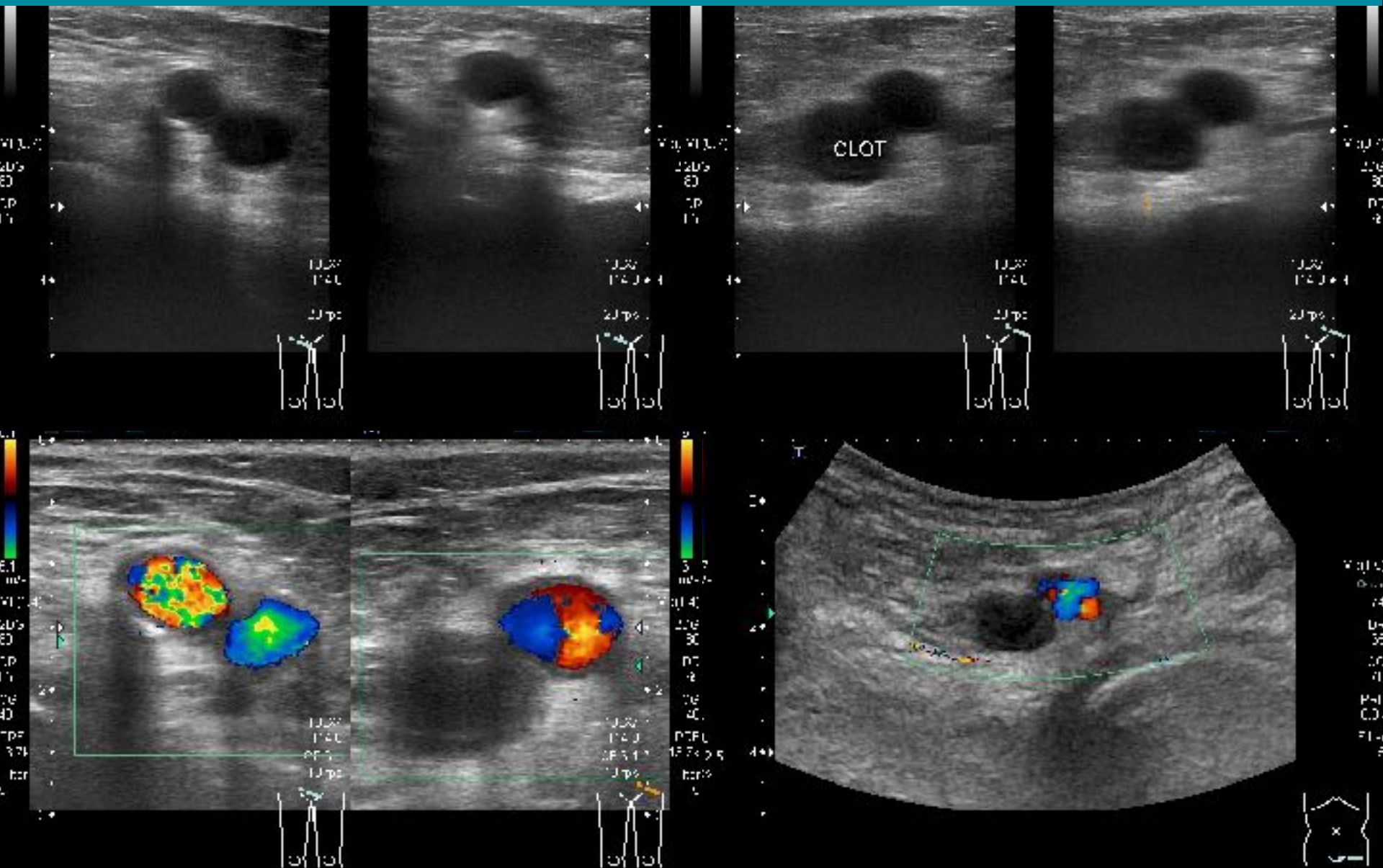
P

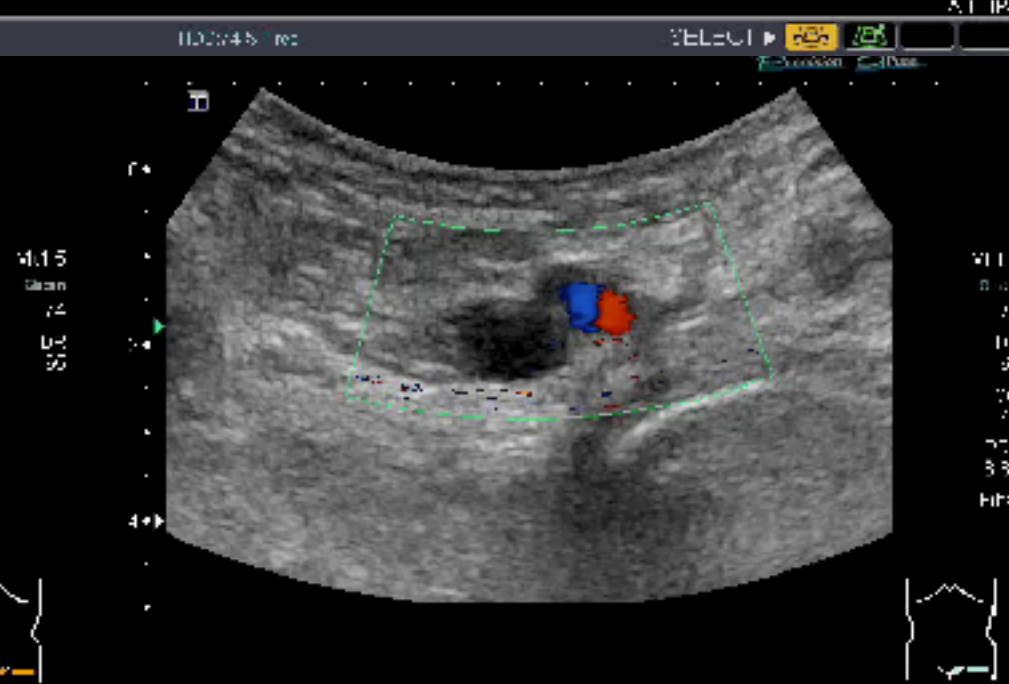
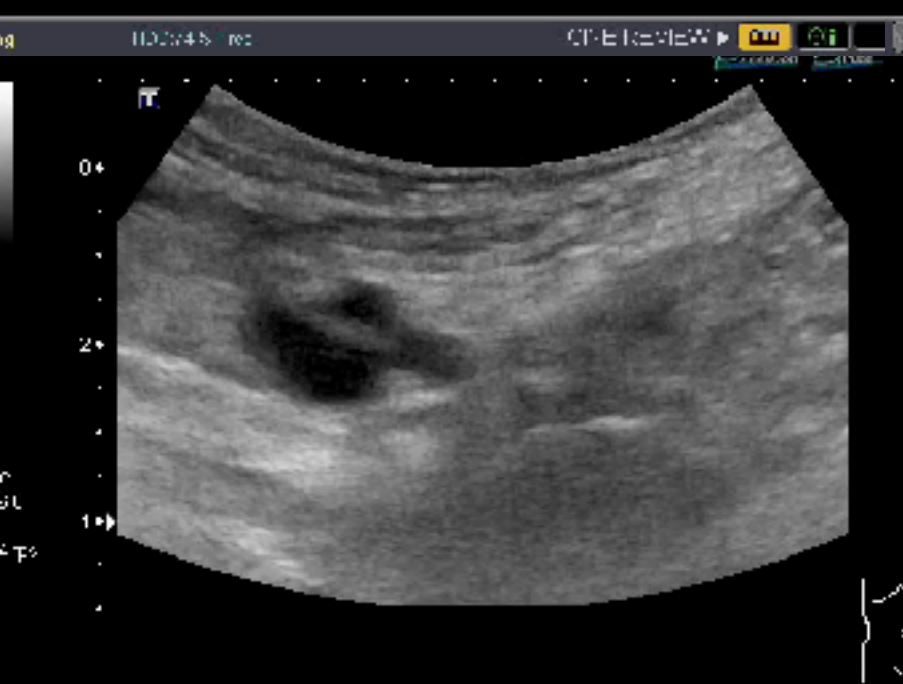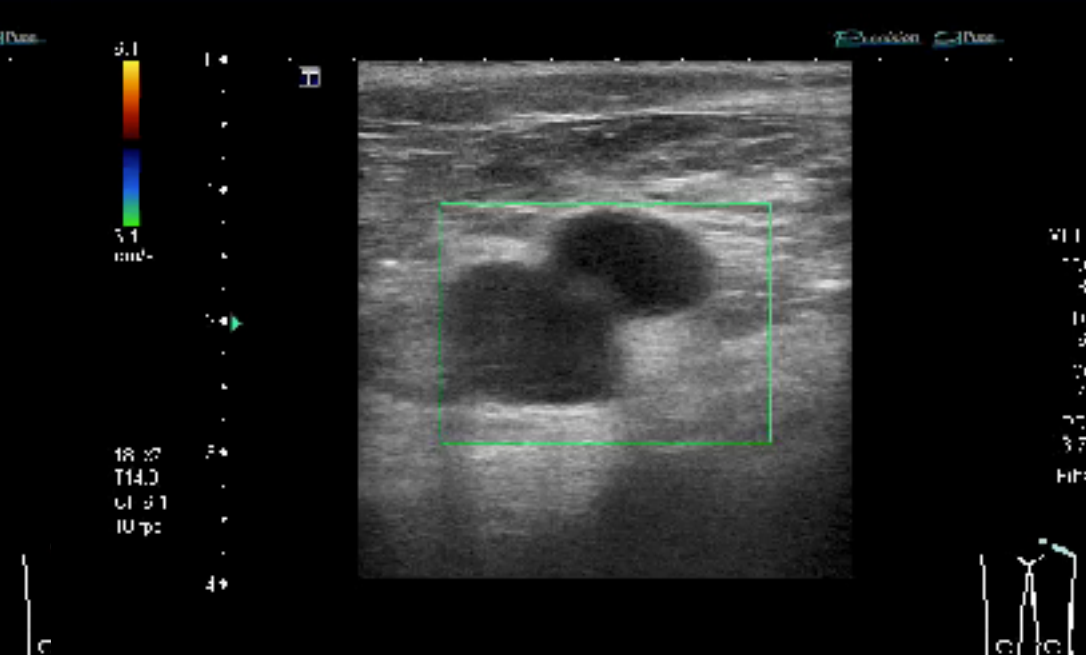
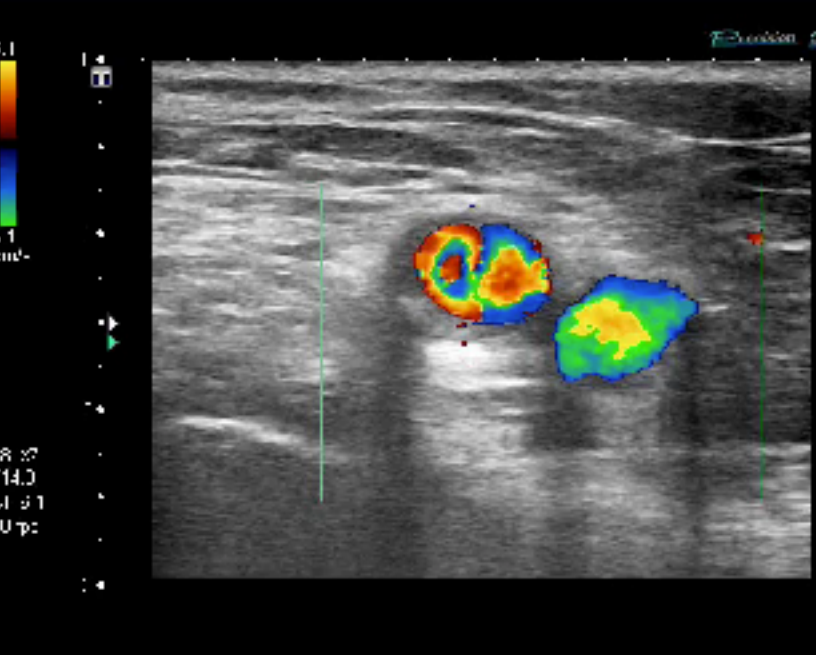
無法完全壓扁
血栓 or 壓錯



G
P R
4.4 8.8

DVT的記錄





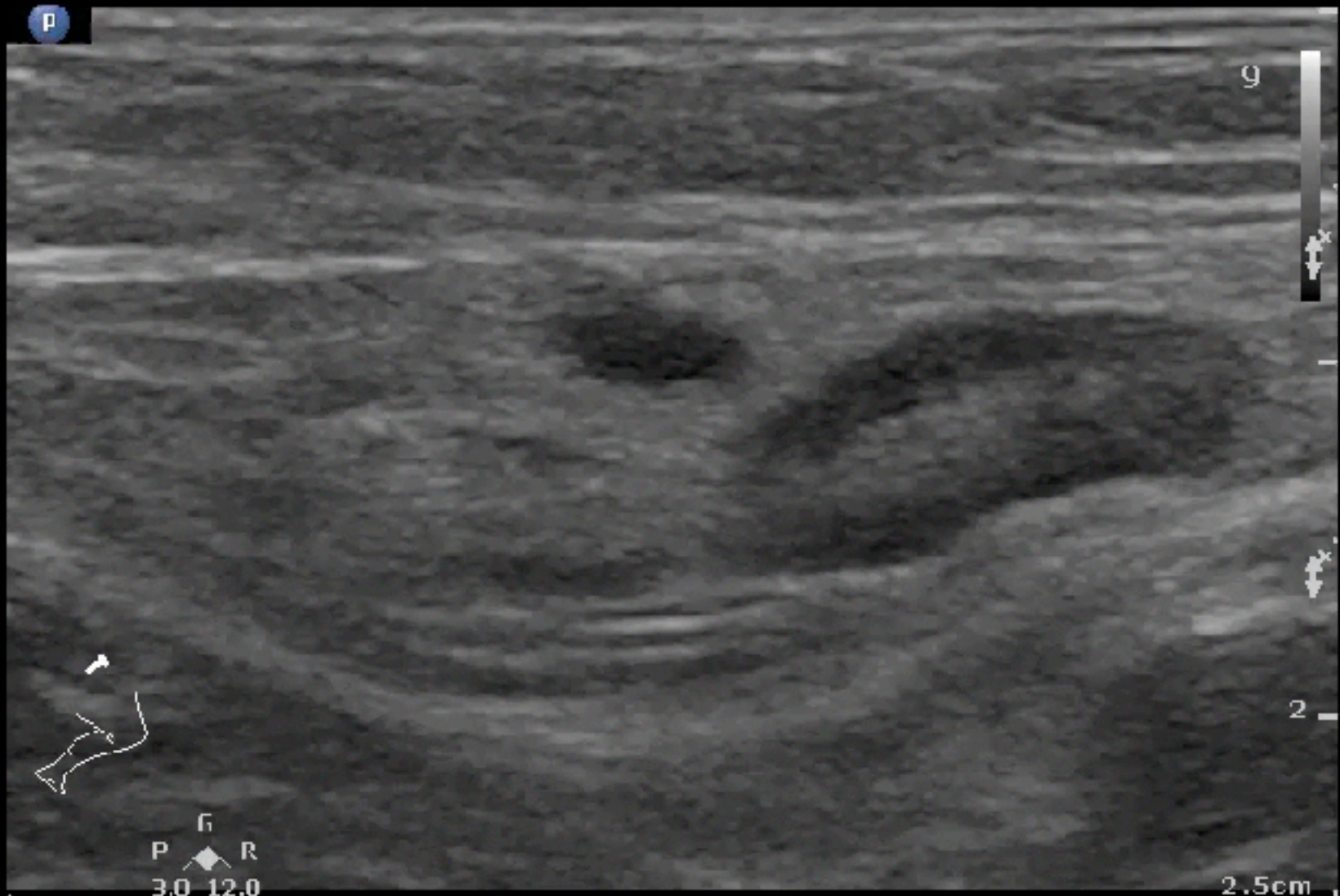DVT ?

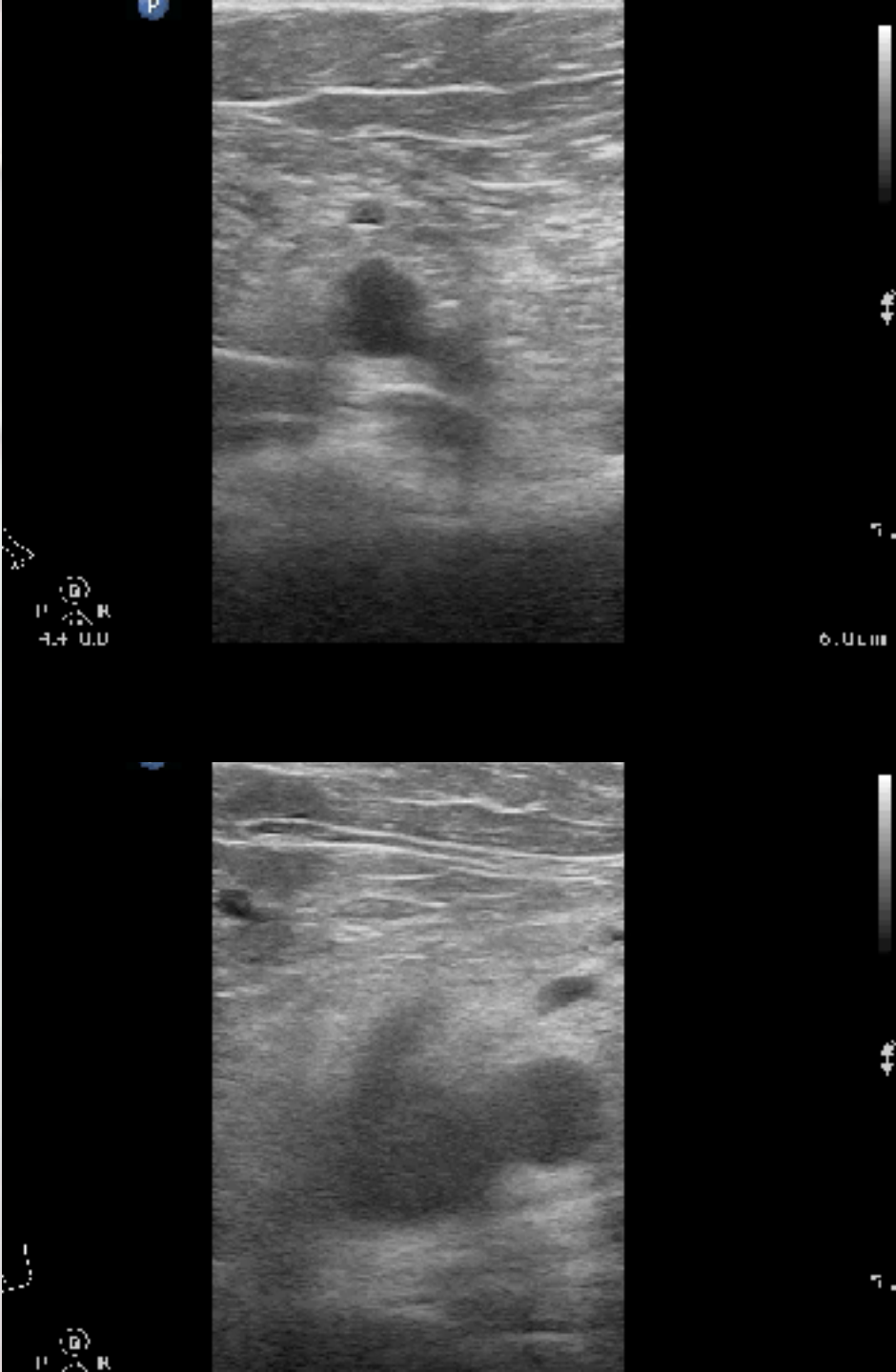
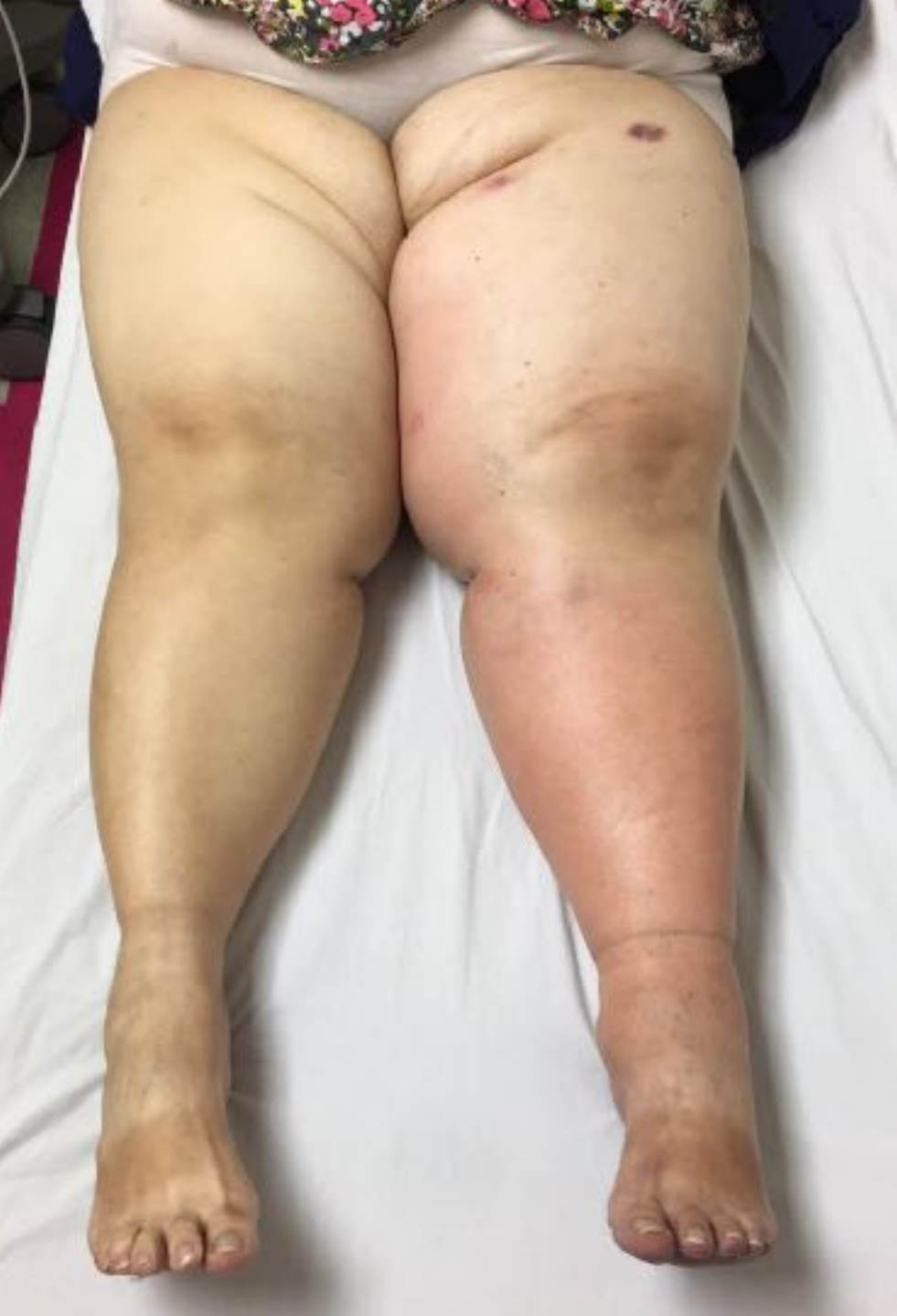Superficial

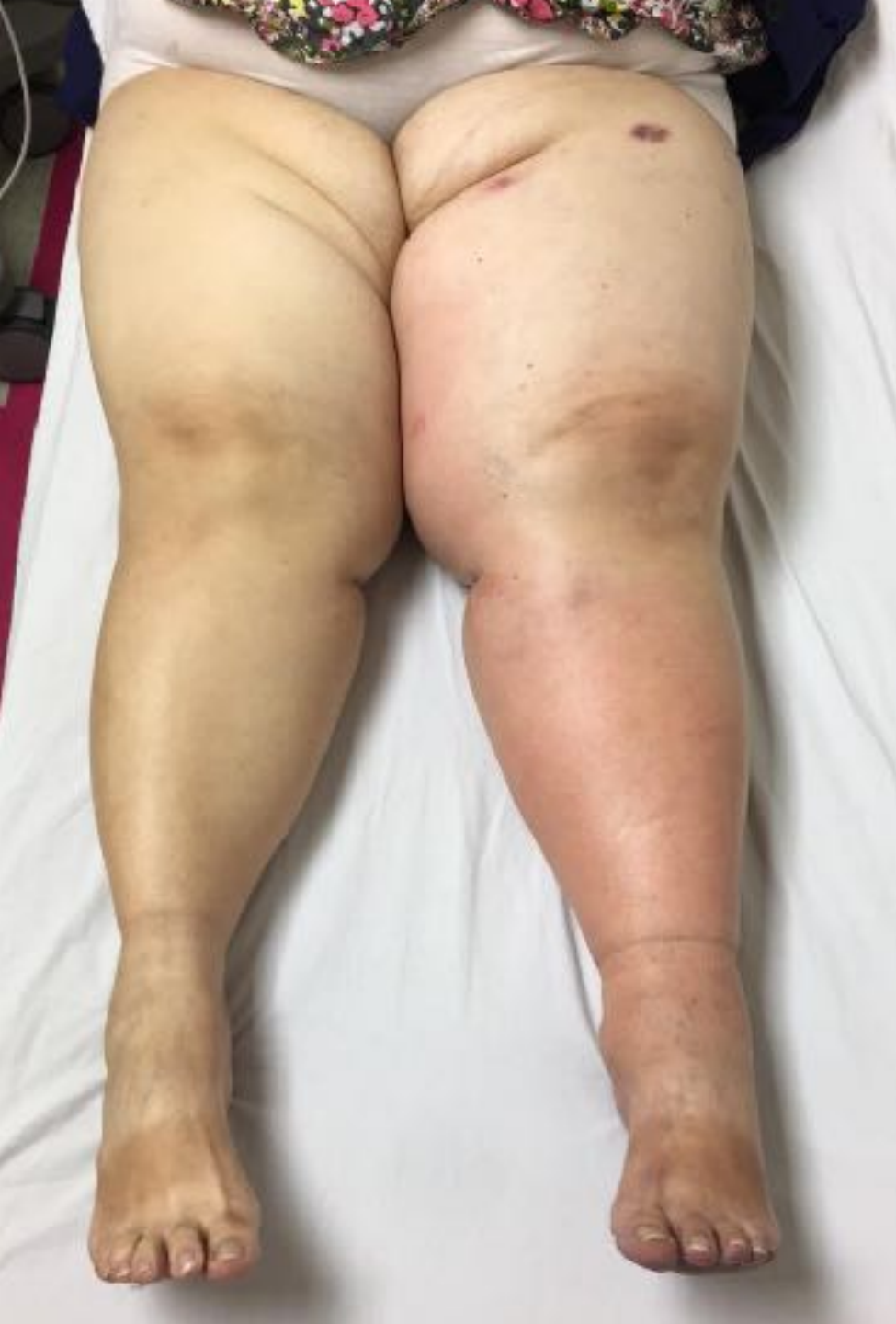L12-3
34 Hz
2.5cm

2D

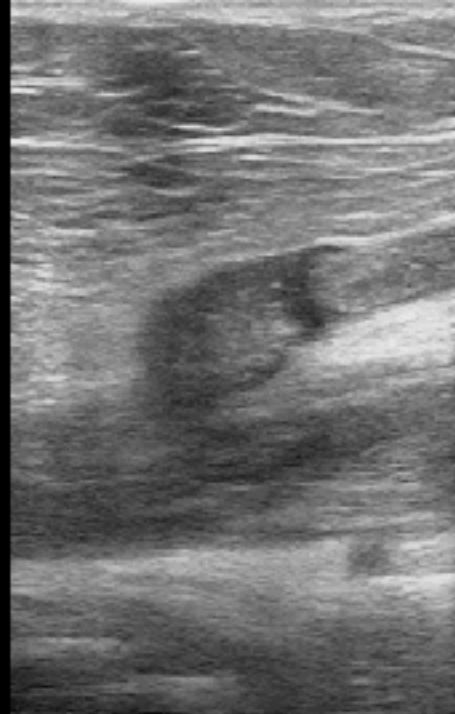
Gen
Gn 60
C. 57
4/3/2





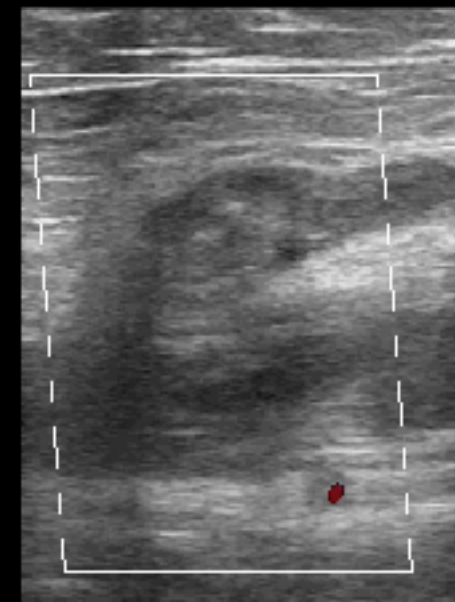


P
R
D.D



6.0cm

P
R
D.D

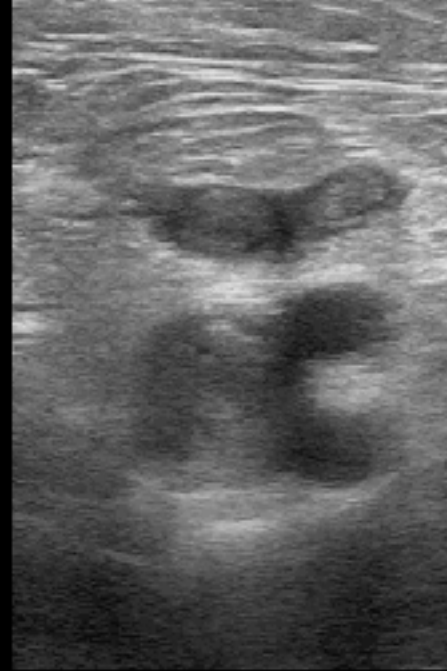

cm/s
-1.0

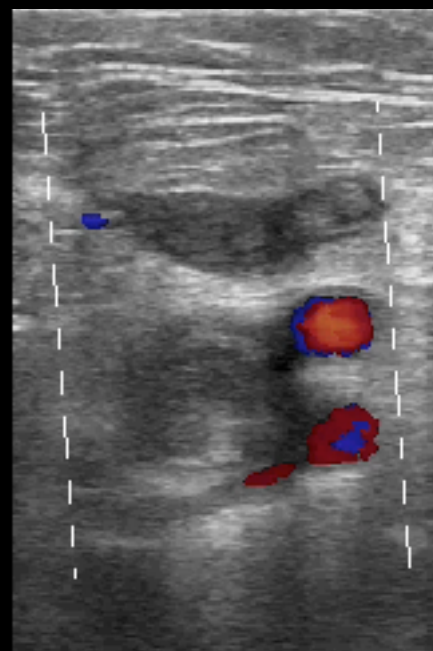


P
R
4.1 8.8

P
R
4.1 8.8



6.0cm



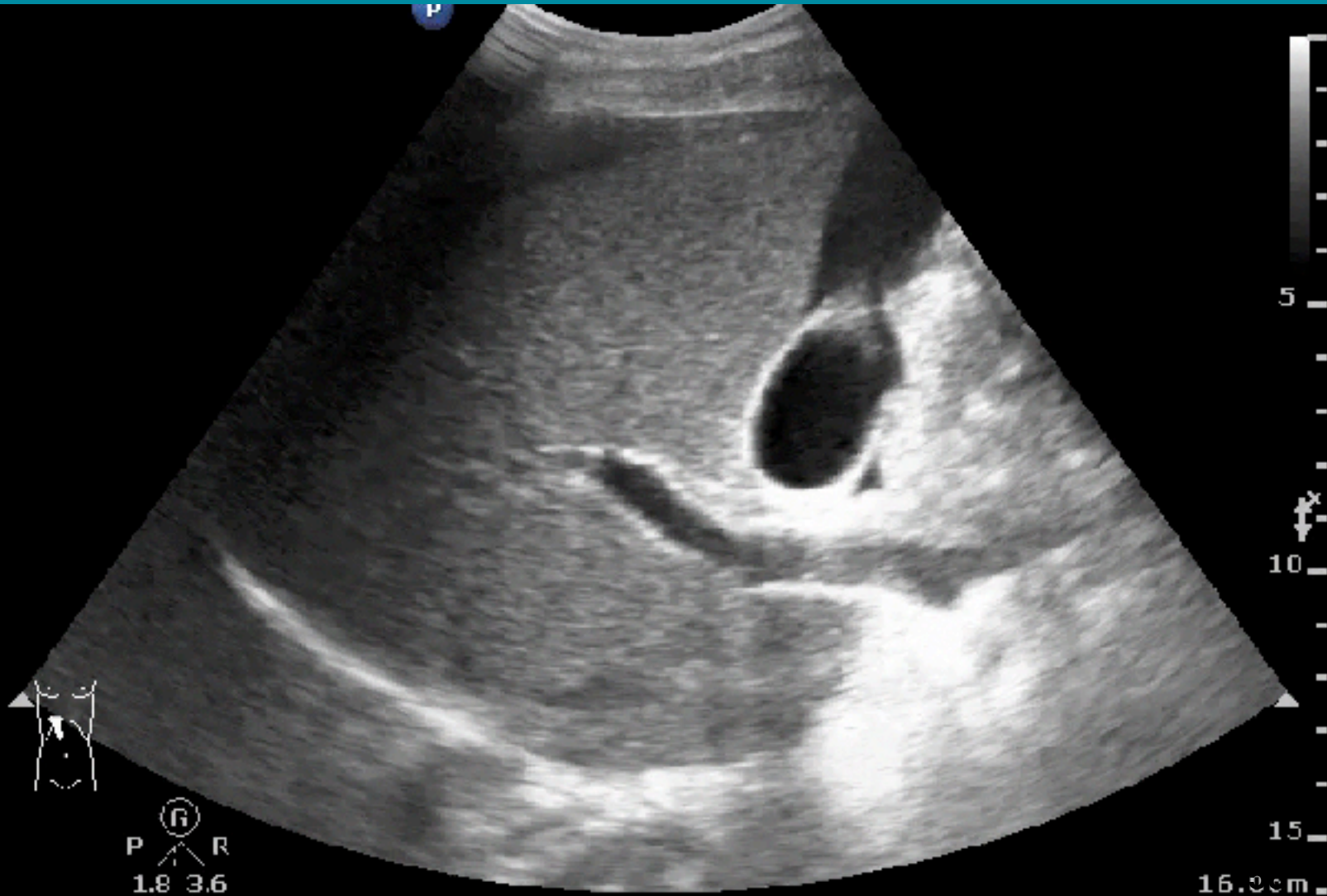
7.0
cm/s
-7.0

FAST

FOCUSED ASSESSMENT WITH SONOGRAPHY FOR TRAUMA

Abd Gen
C5-1
32 Hz
16.0cm

2D
HGen
Gn 90
C. 56
3 / 3 / 3

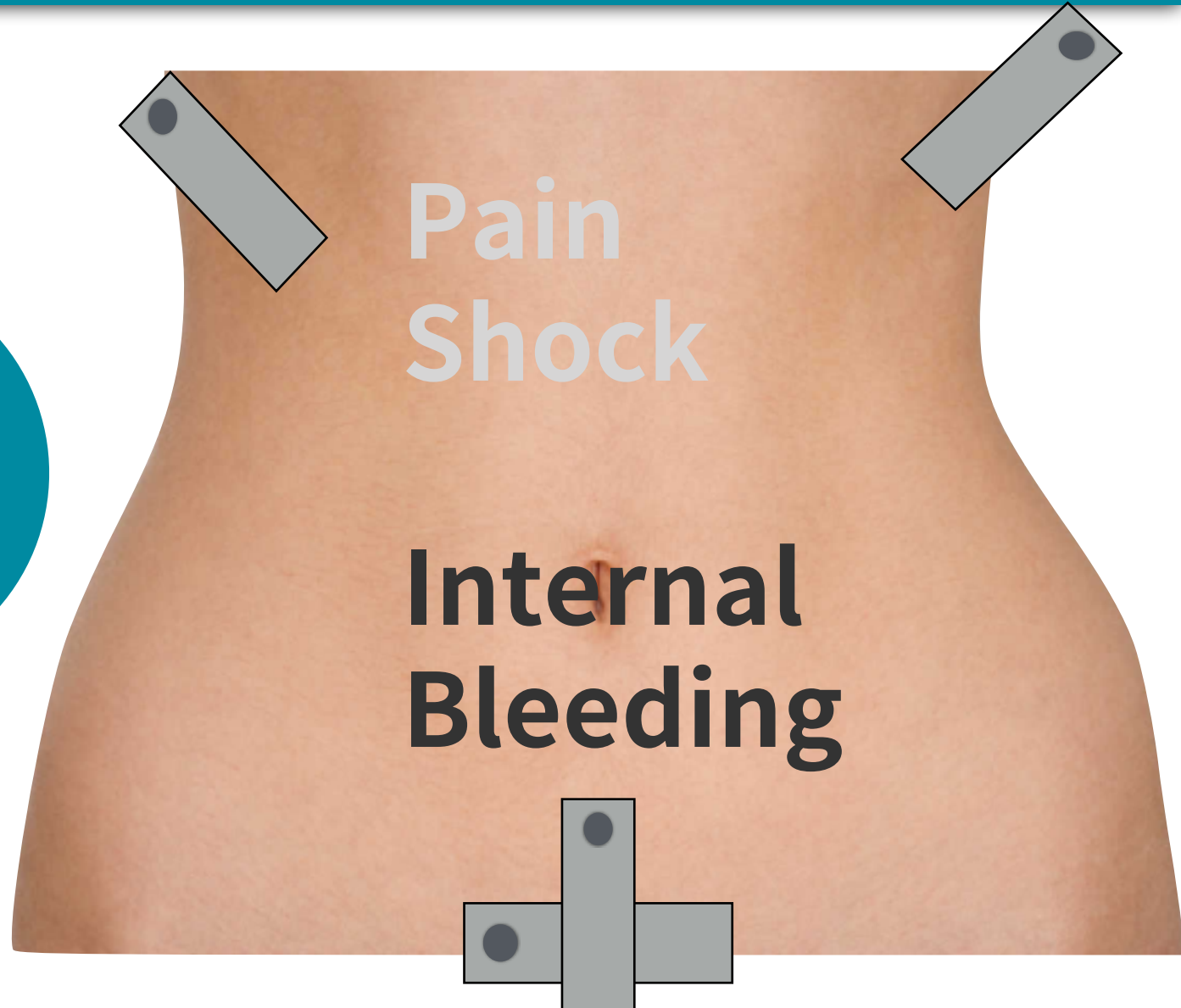




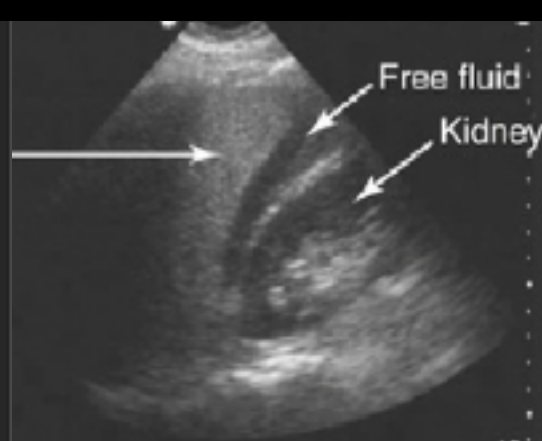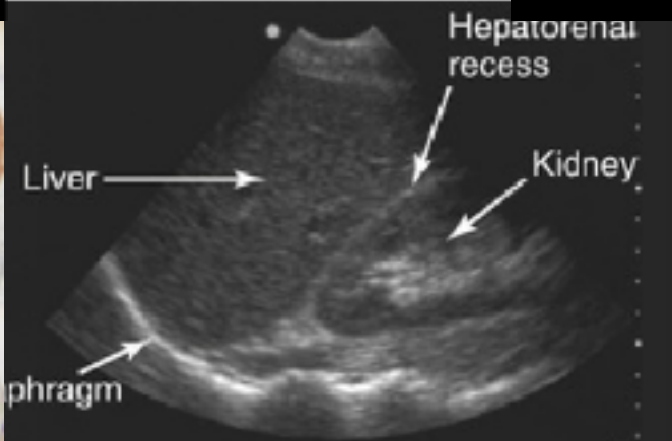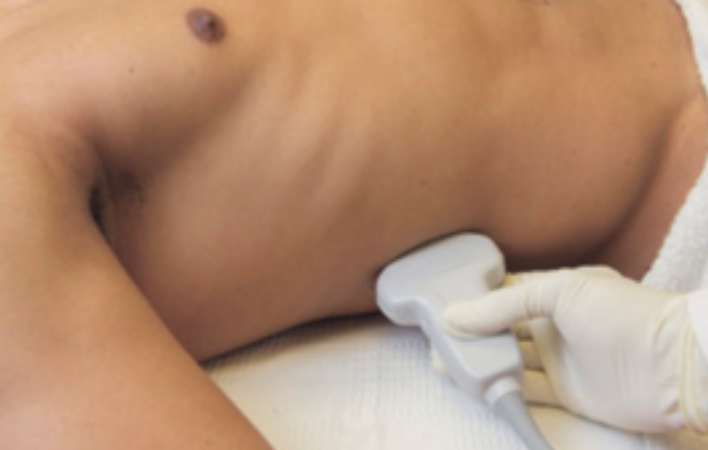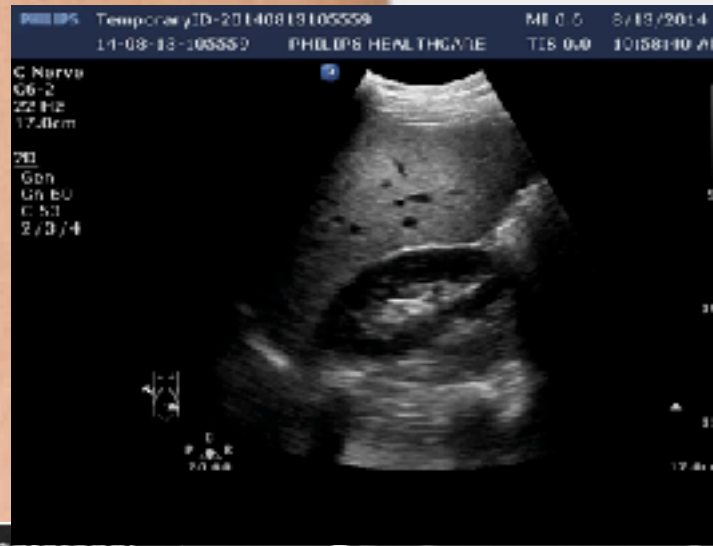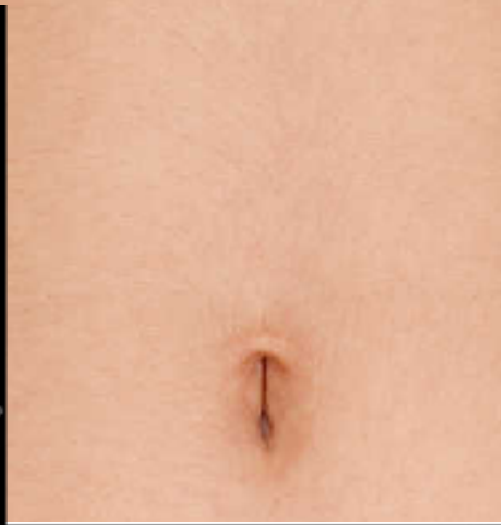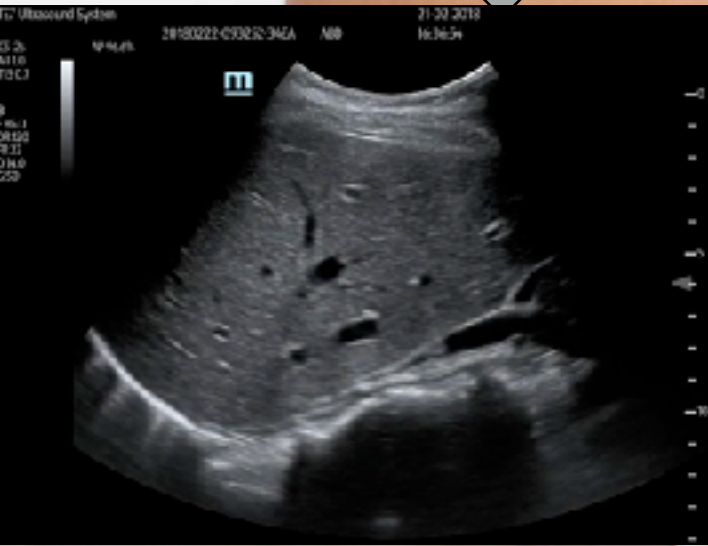Free fluid



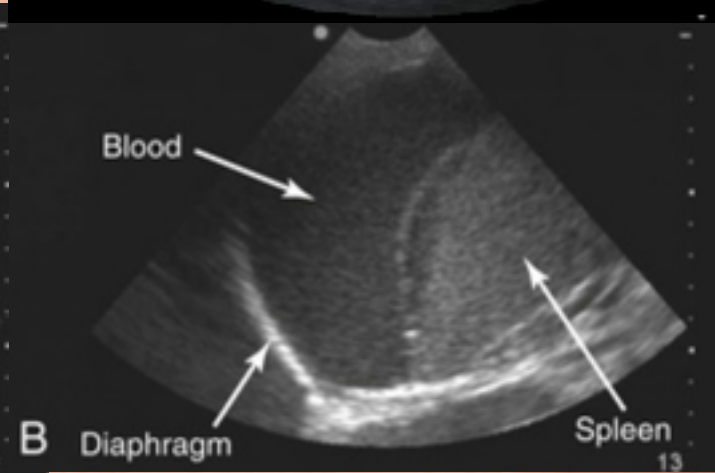
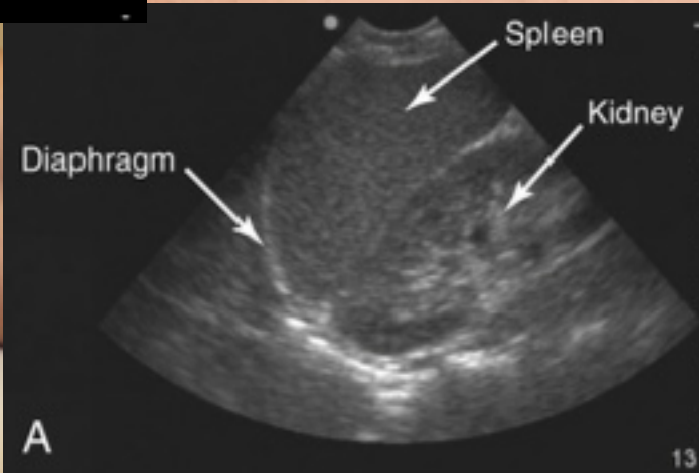
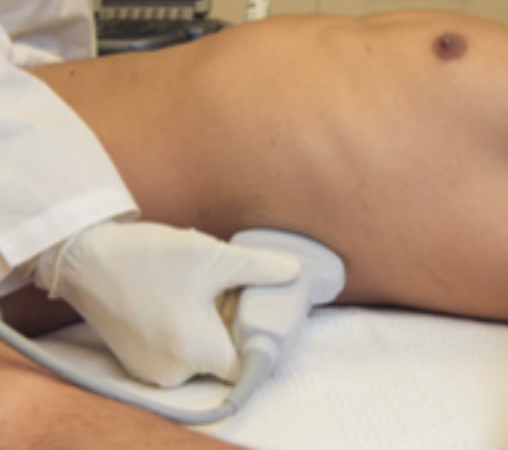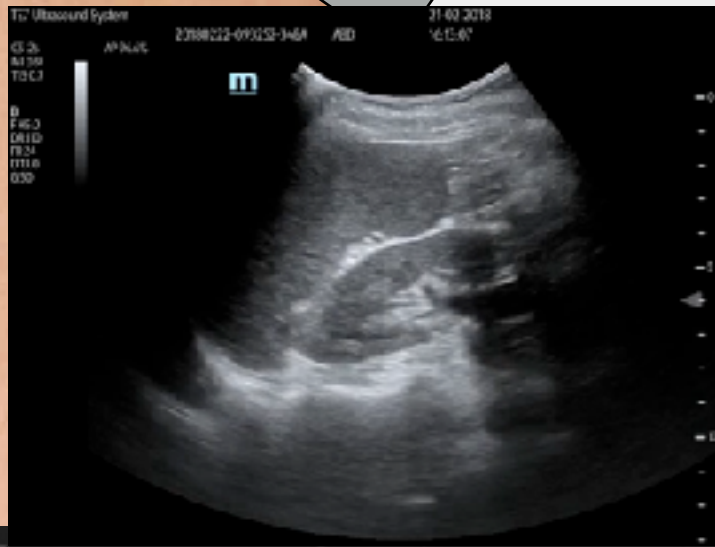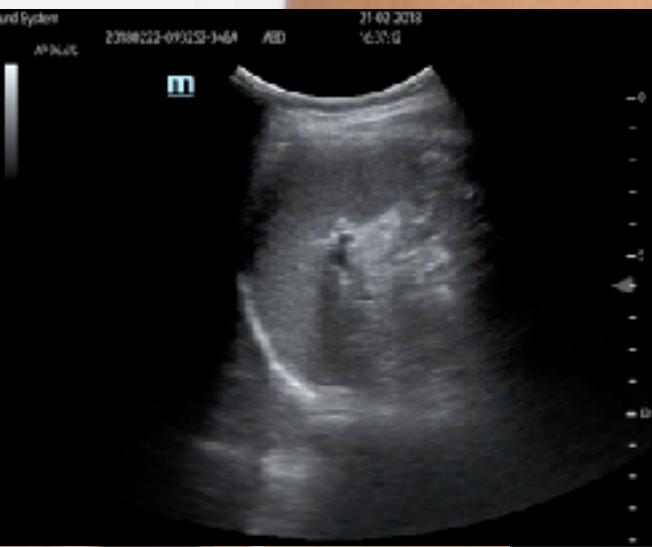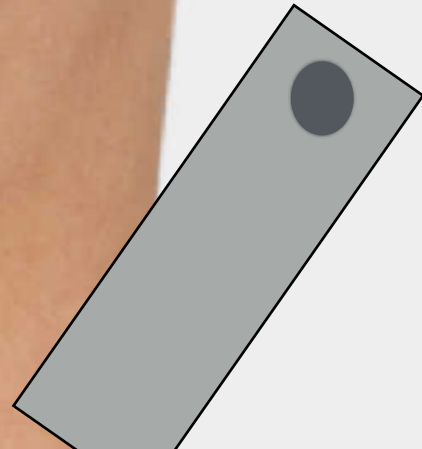
倒三角
掃描介面



劍突-腋前線交界點
平行肋間掃描以避開肋骨
第一目標:肝腎介面(Morrison's pouch)
第二目標:橫膈膜



劍突-腋後線交界點
平行肋間掃描以避開肋骨
第一目標:橫膈膜下
第二目標:脾腎交界

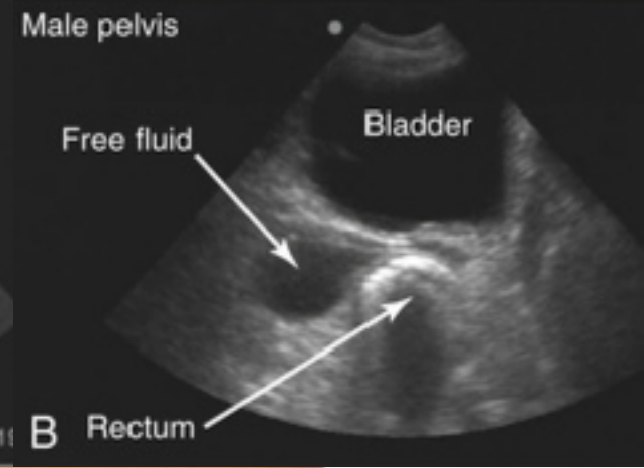
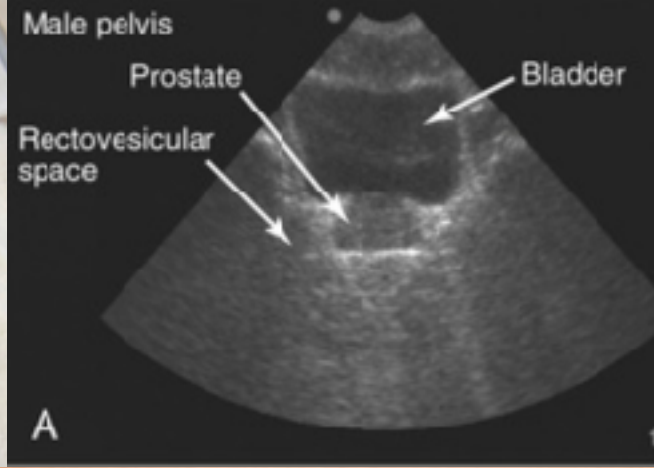
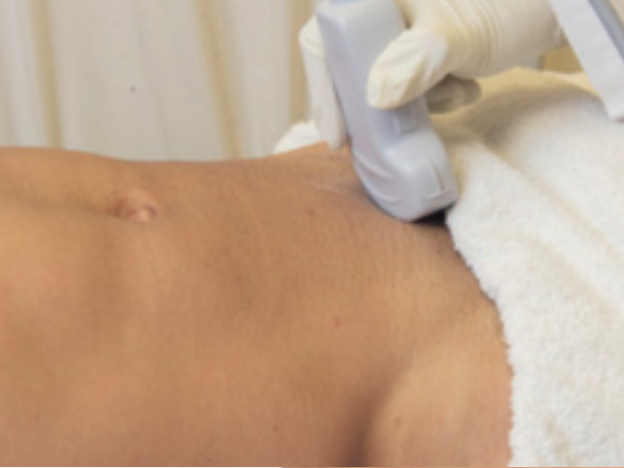

A

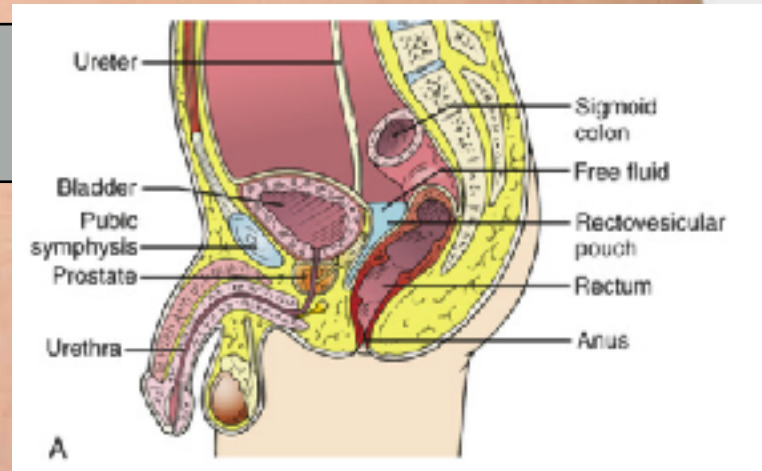
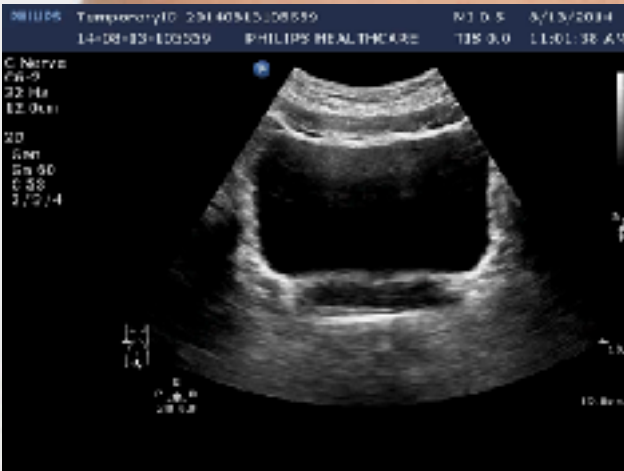B

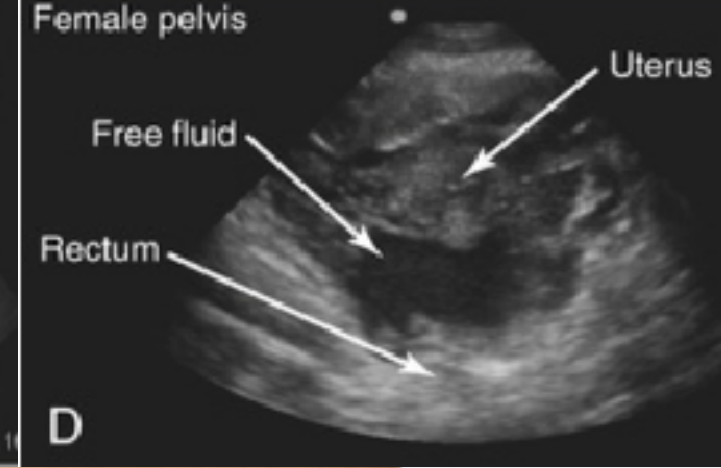
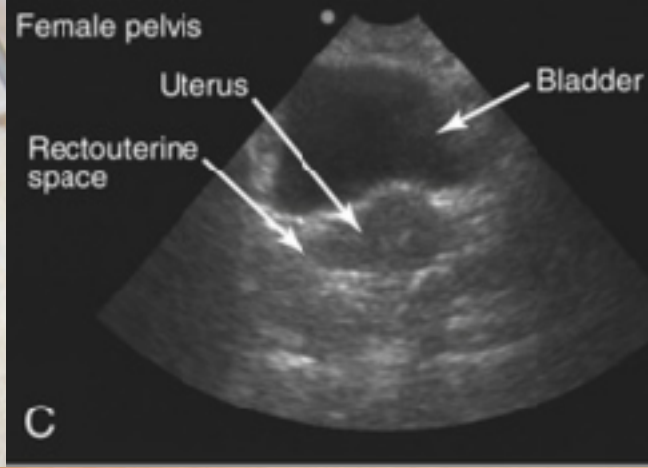
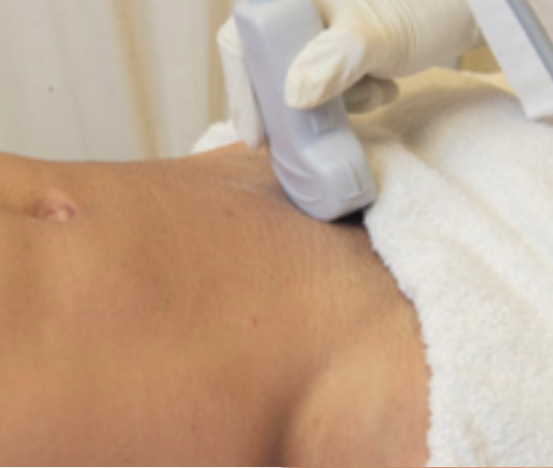13

13

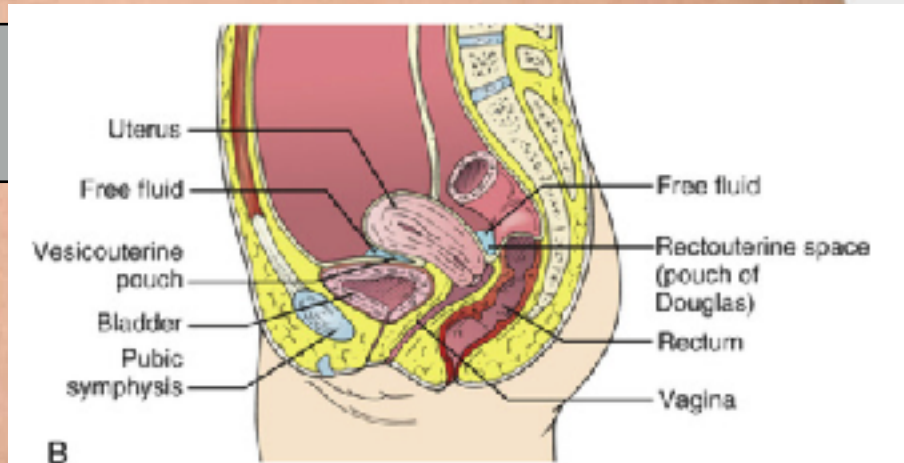
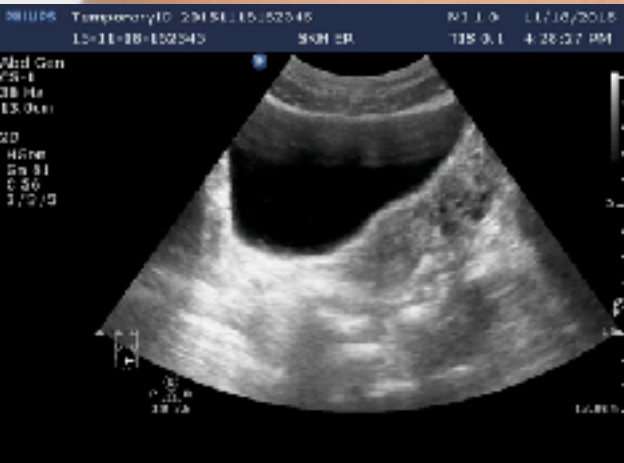


恥骨聯合上方
Tilt探頭進行掃描
要有好的視窗(尿液)
主要目標: 膀胱下方



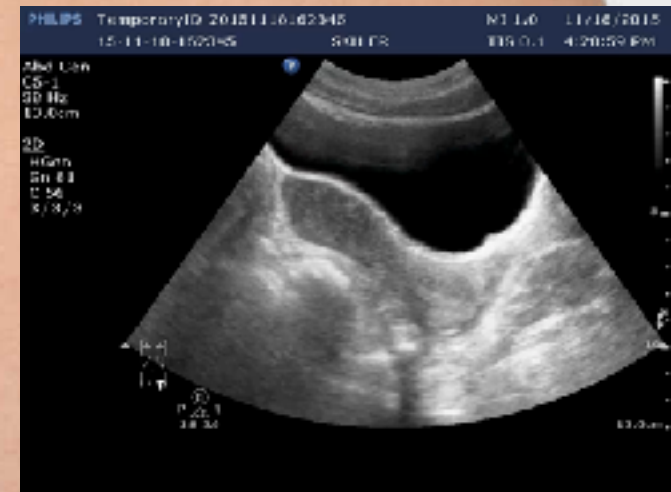
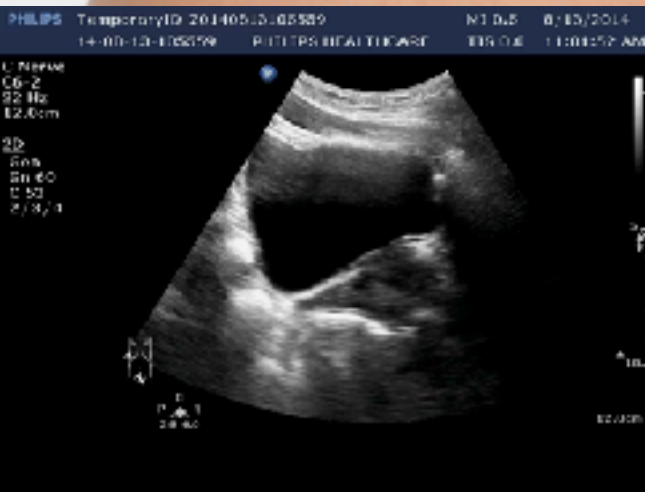


恥骨聯合上方
Tilt探頭進行掃描(頭腳)
要有好的視窗(尿液)
第一目標:子宮下方
第二目標:膀胱子宮間



為什麼一定要有這個介面呢？

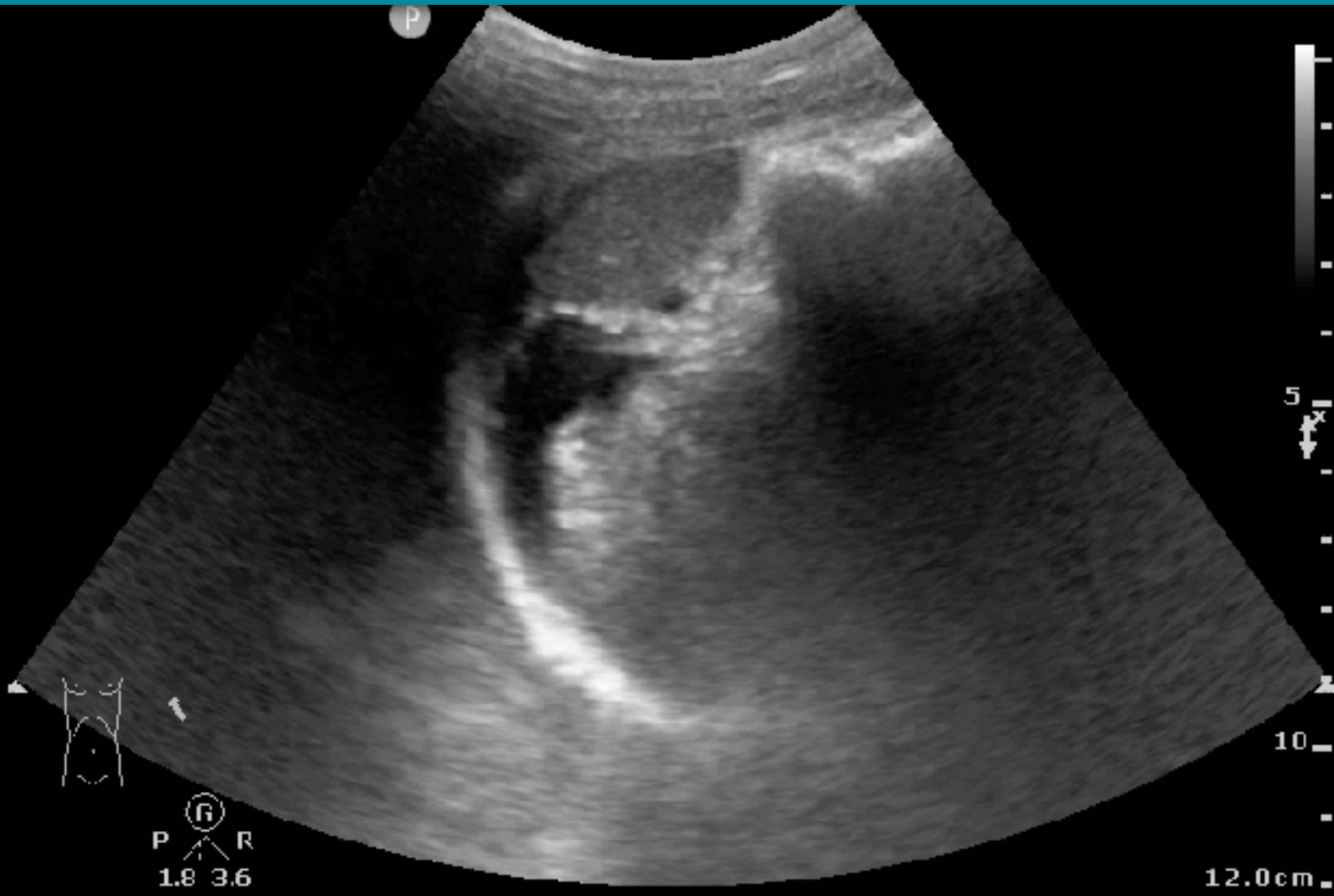
恥骨聯合上方
Tilt探頭進行掃描(左右)
要有好的介面(尿液)
第一目標:子宮下方
第二目標:膀胱子宮間
男:膀胱下方



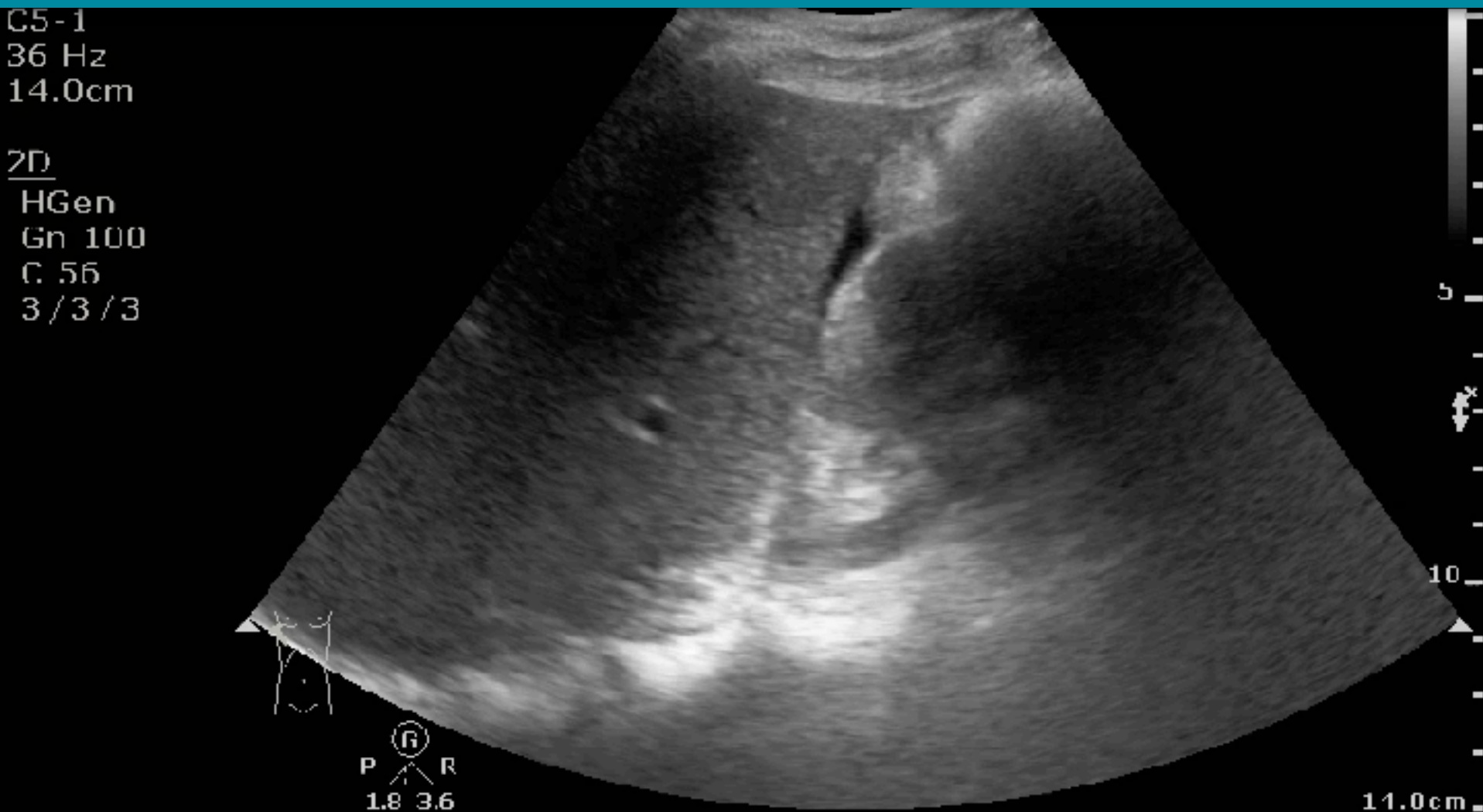Free fluid ?

Abd Gen
C5-1
39 Hz
12.0cm

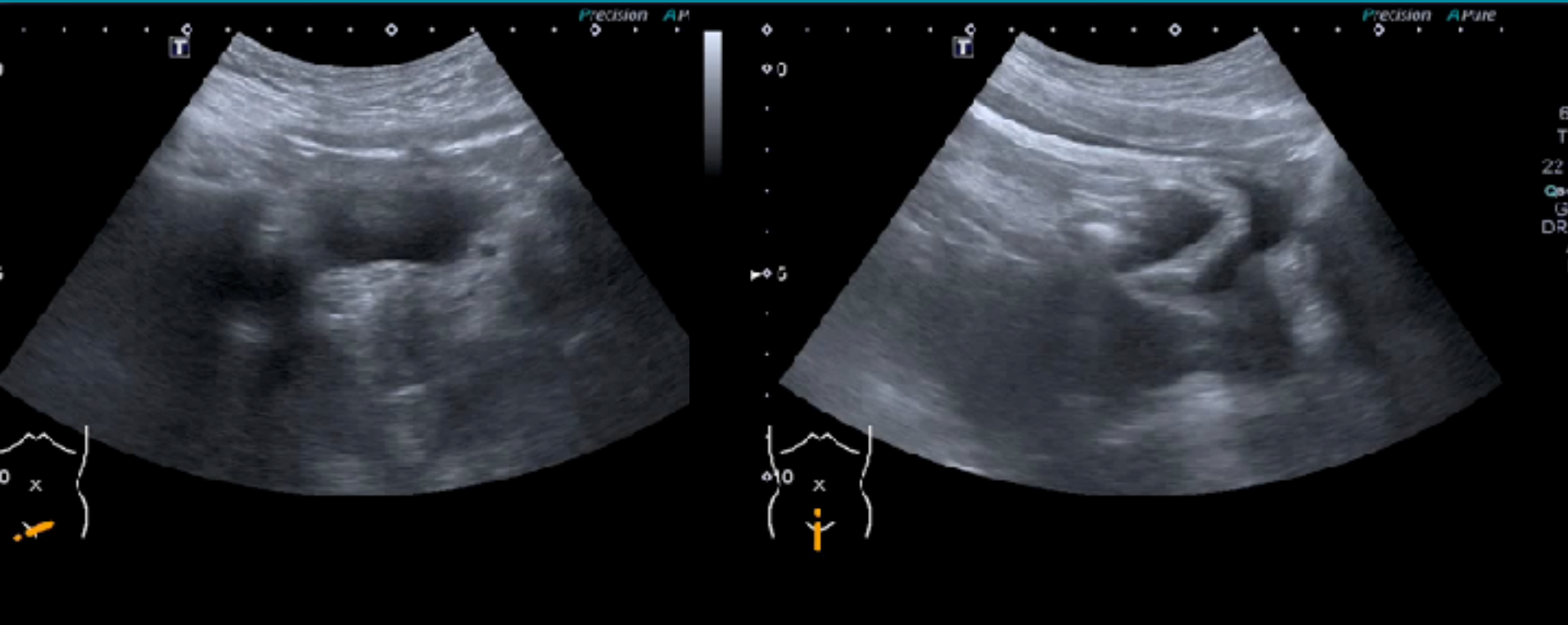
2D
HGen
Gn 100
C. 56
3/3/3



Free fluid ?



Free fluid ?



Transverse + Sagittal views = Standard

腹腔積液Free fluid



有無游離液體

患者姿勢
患者體形
積液來源
經過時間
影像品質
掃描技術

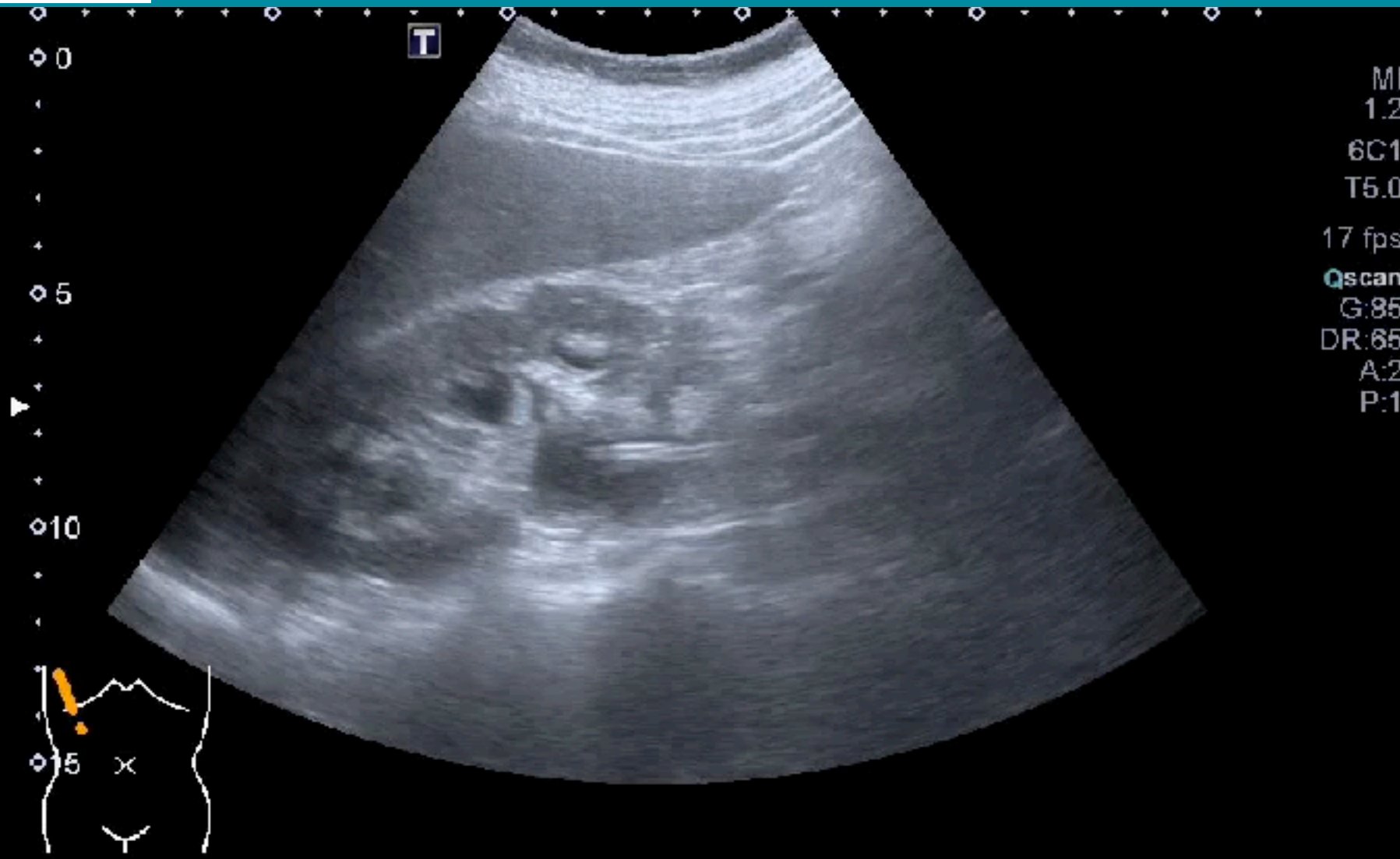增加介面

增加頻次

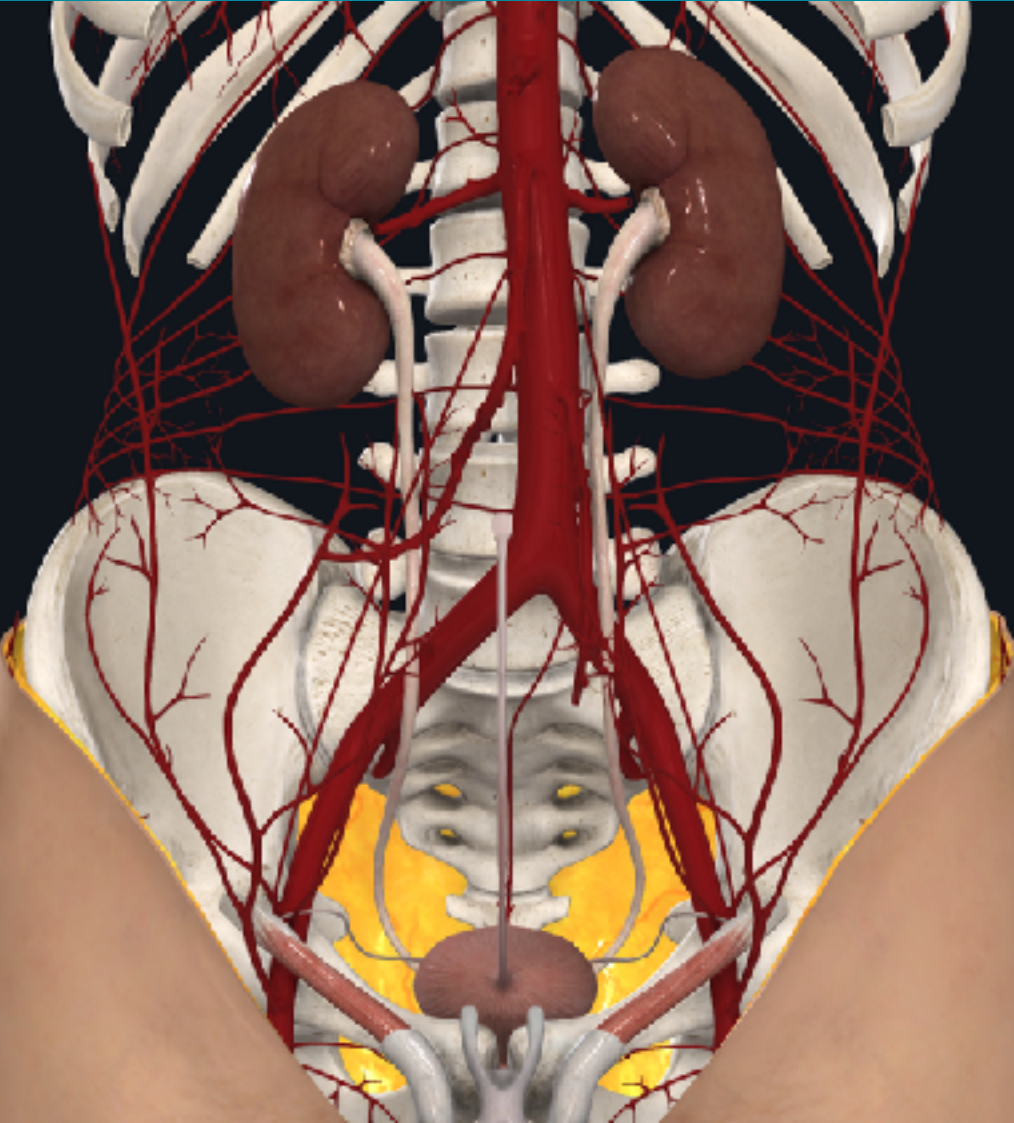替代影像



KIDNEY



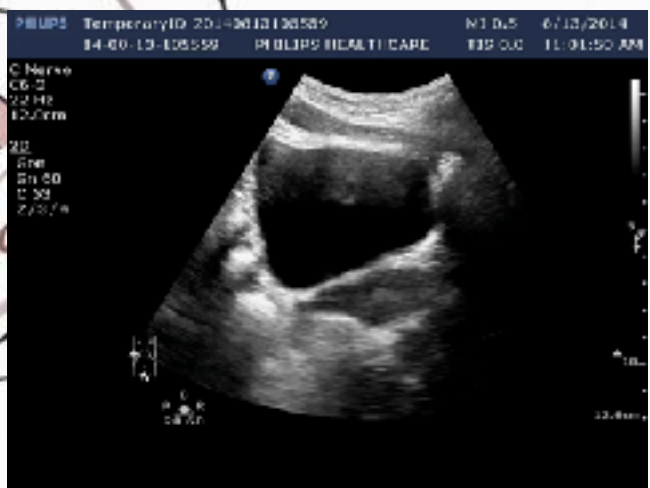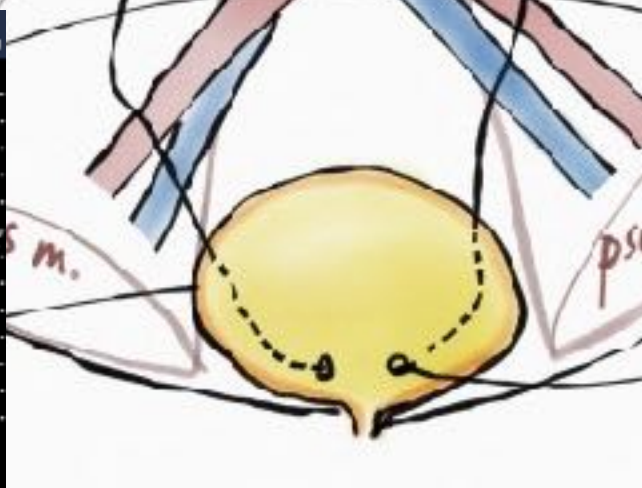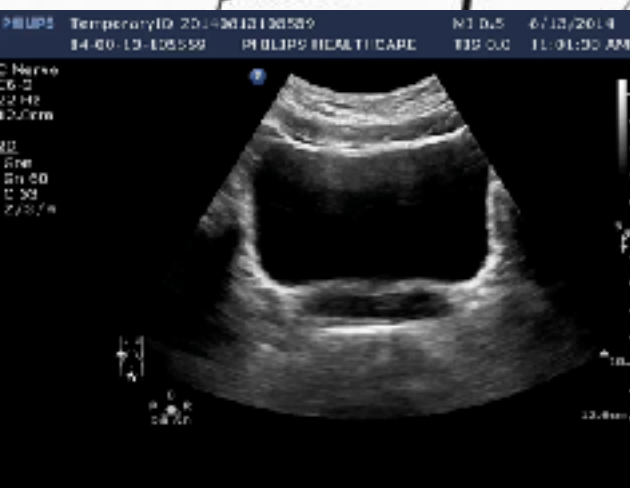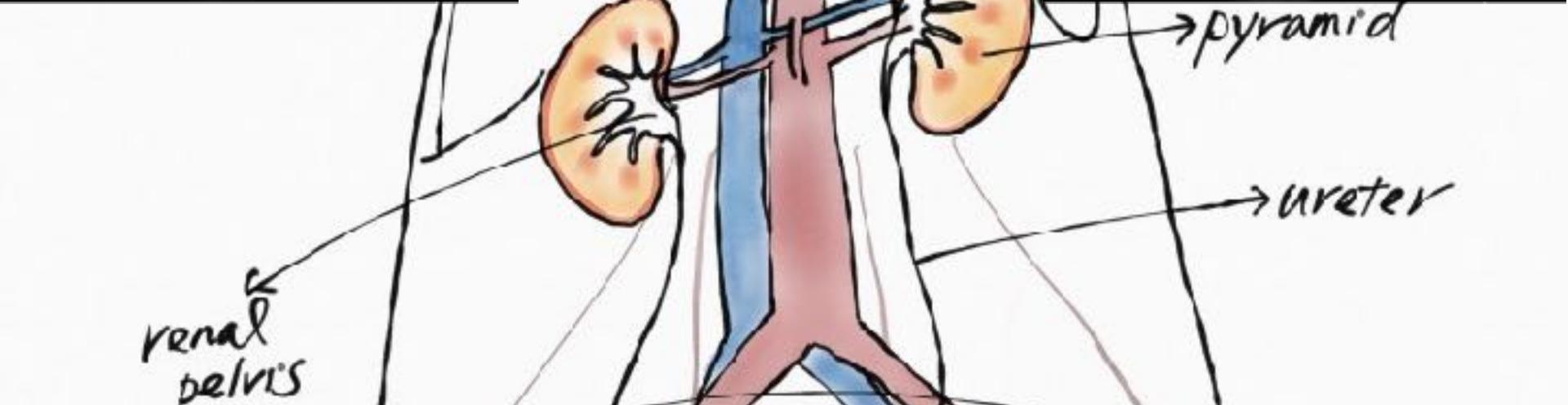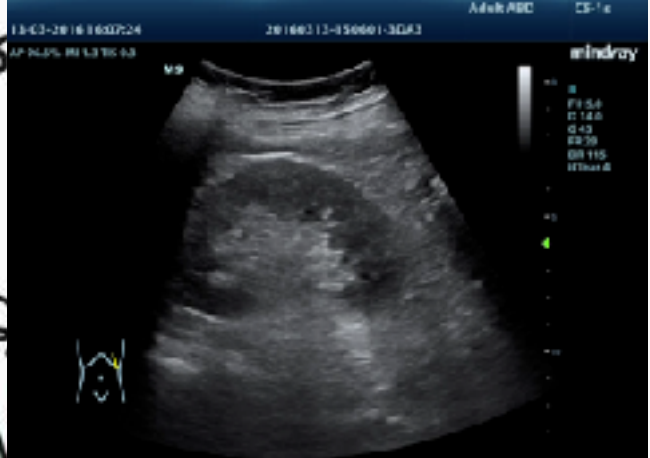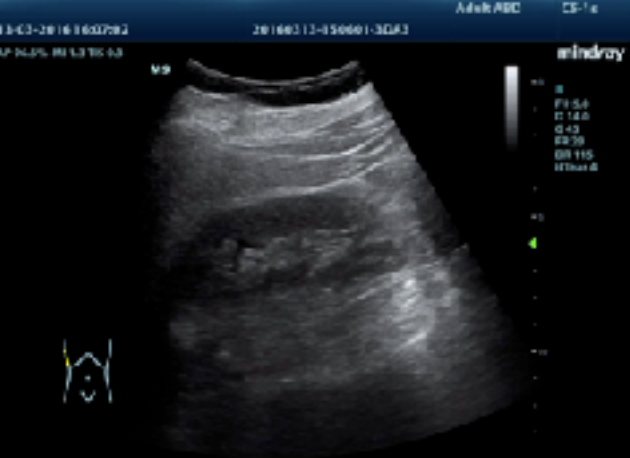KIDNEY & UB



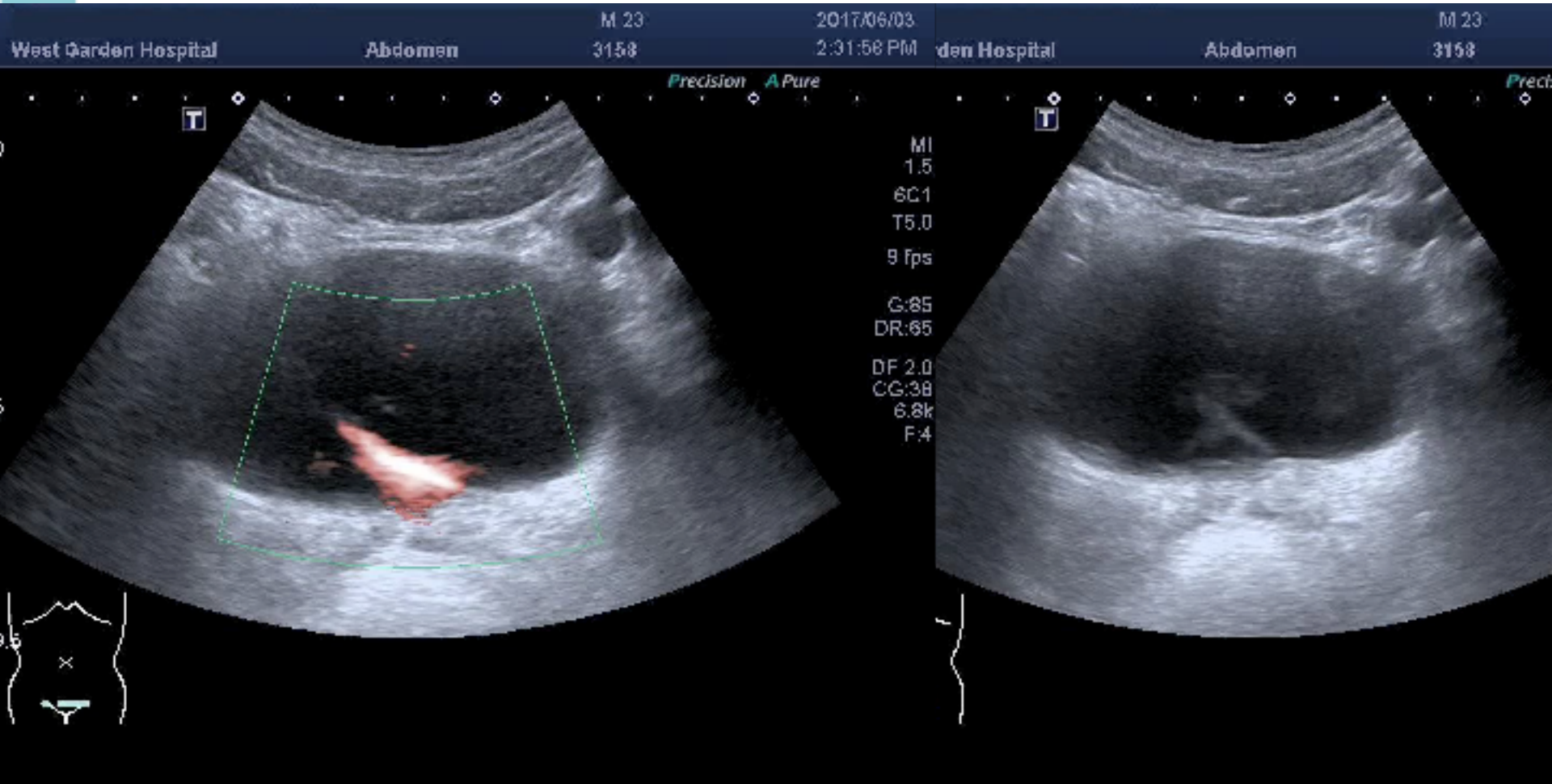
Pain
Infection
Renal failure

Obstruction

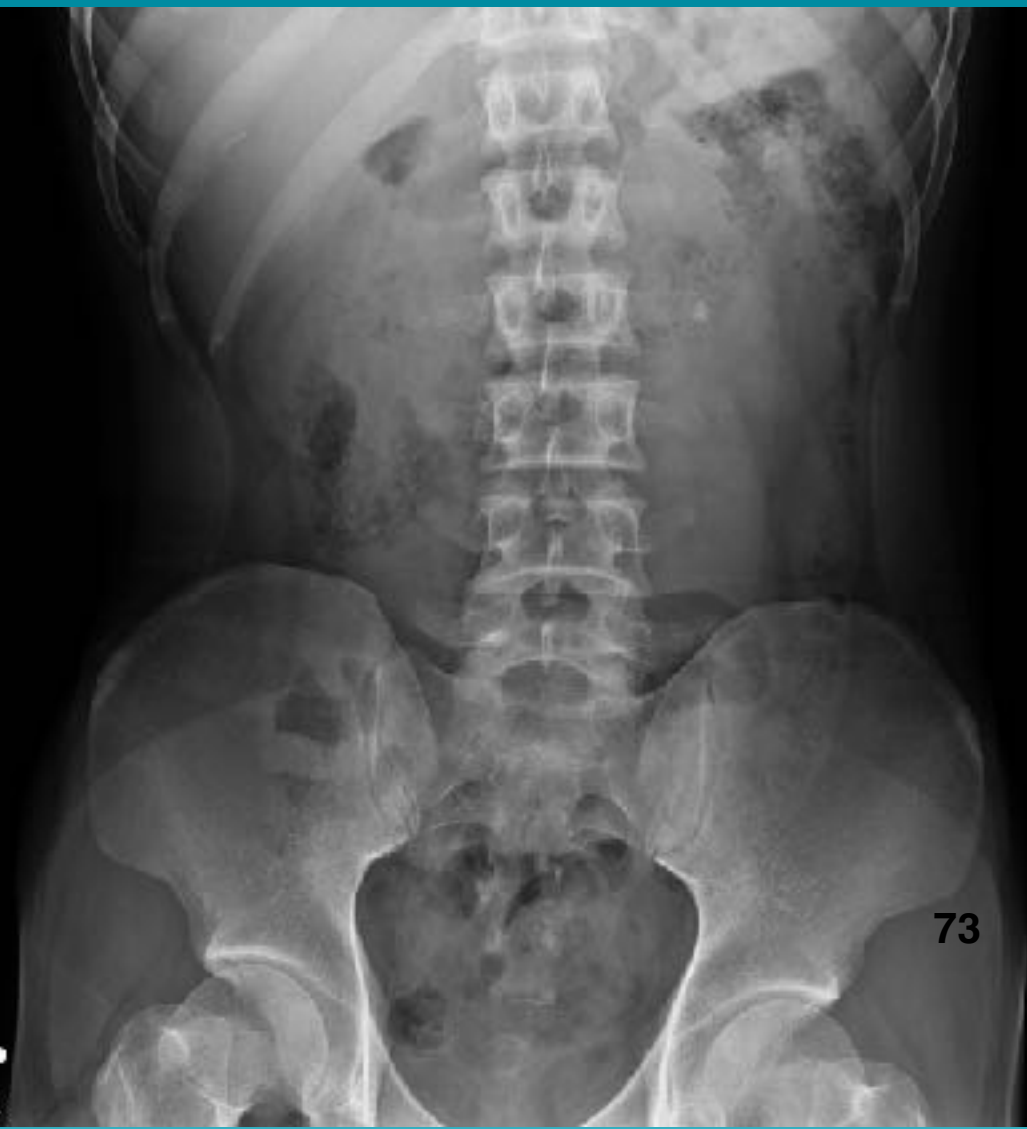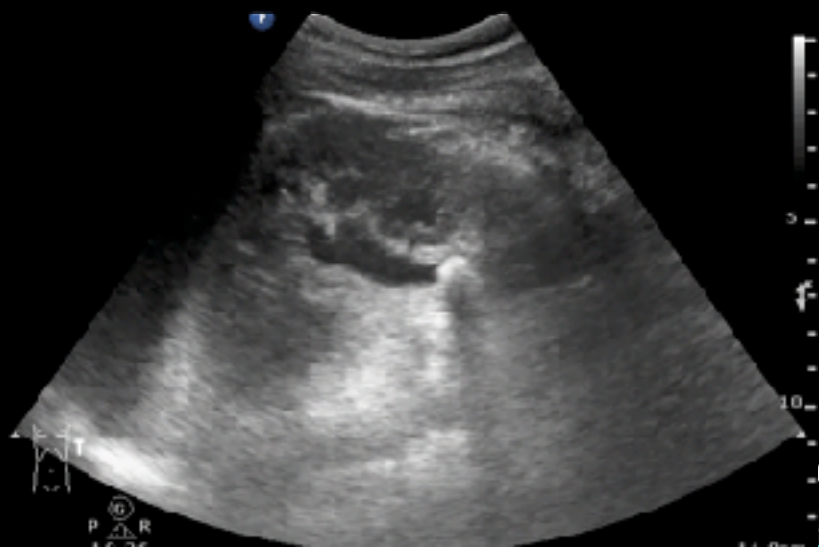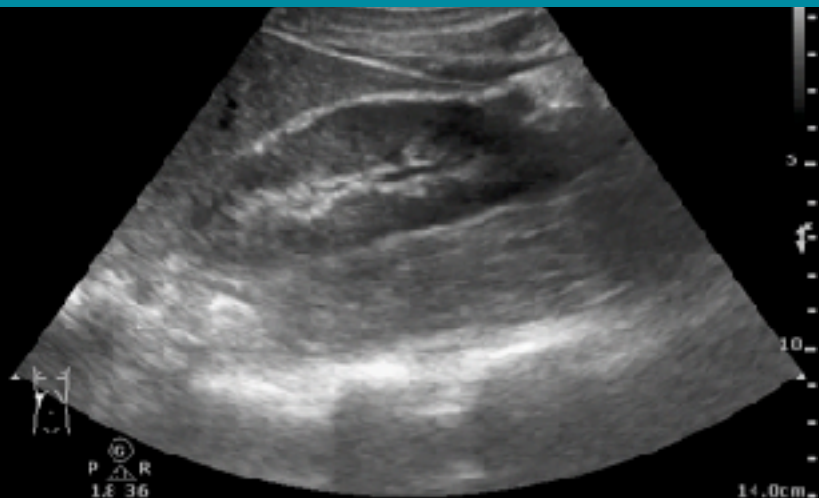
永遠要想到AAA



URINARY JET

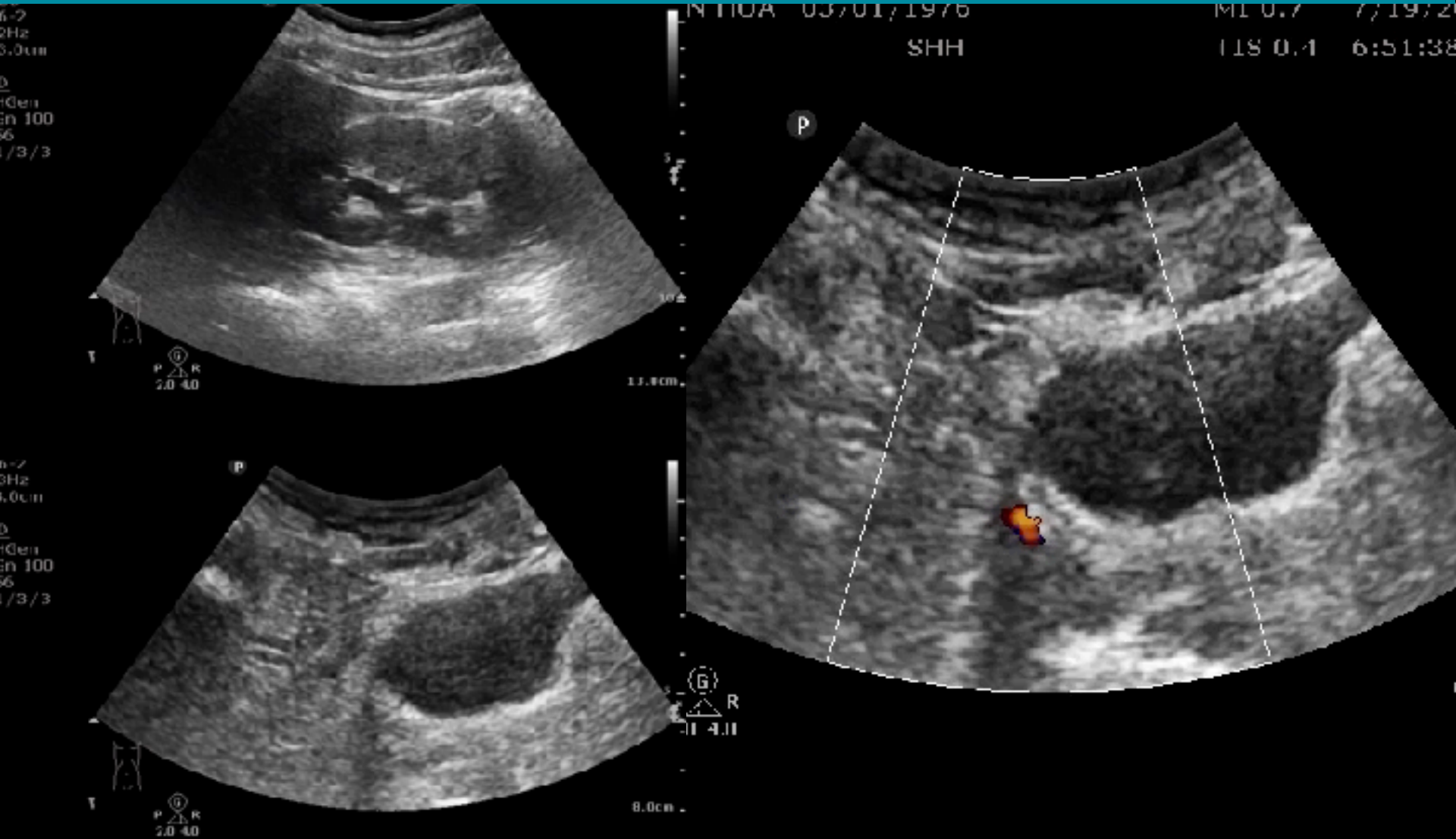


LEFT FLANK PAIN



R ABDOMINAL PAIN

TWINKLING ARTIFACT

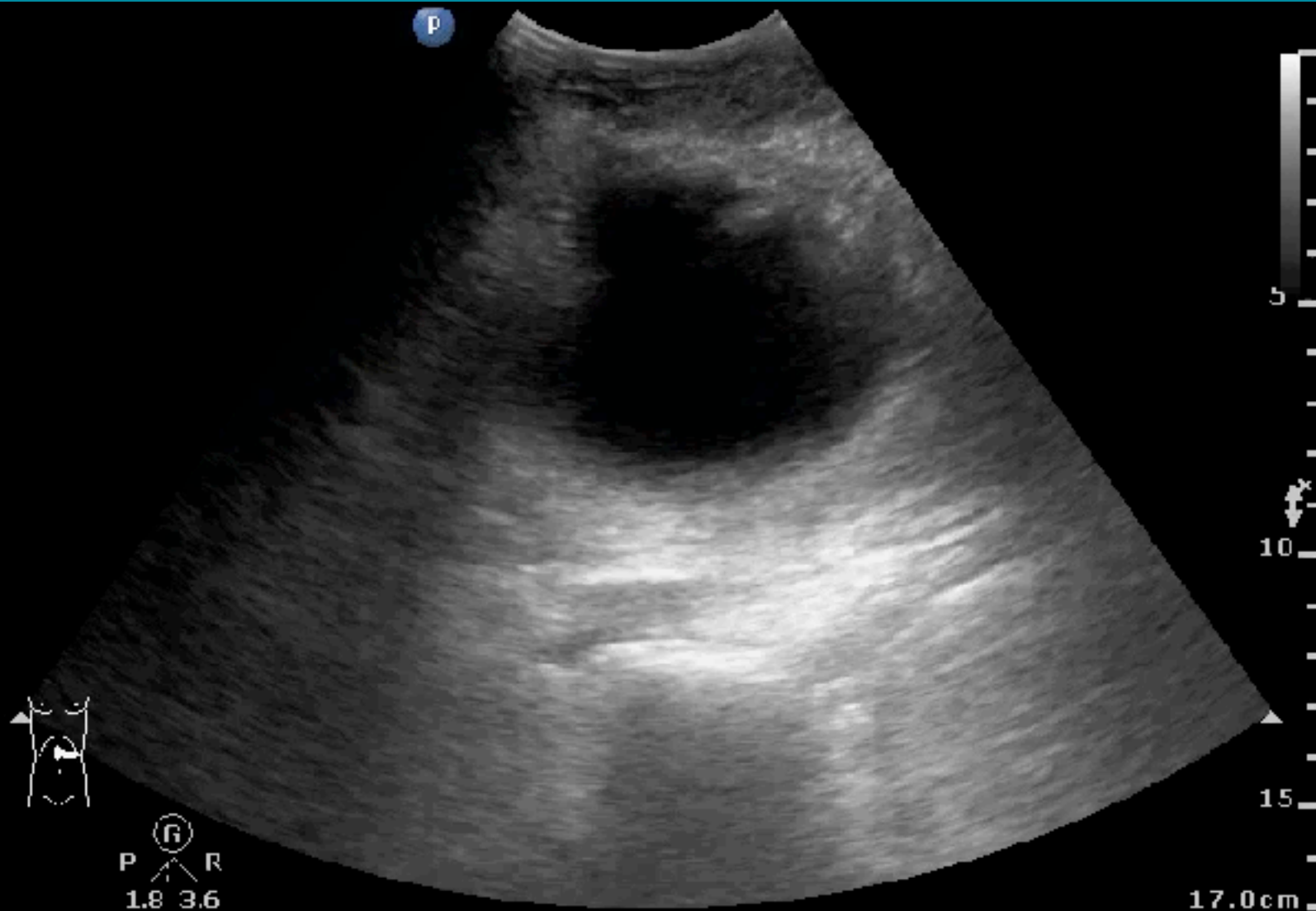


AUR

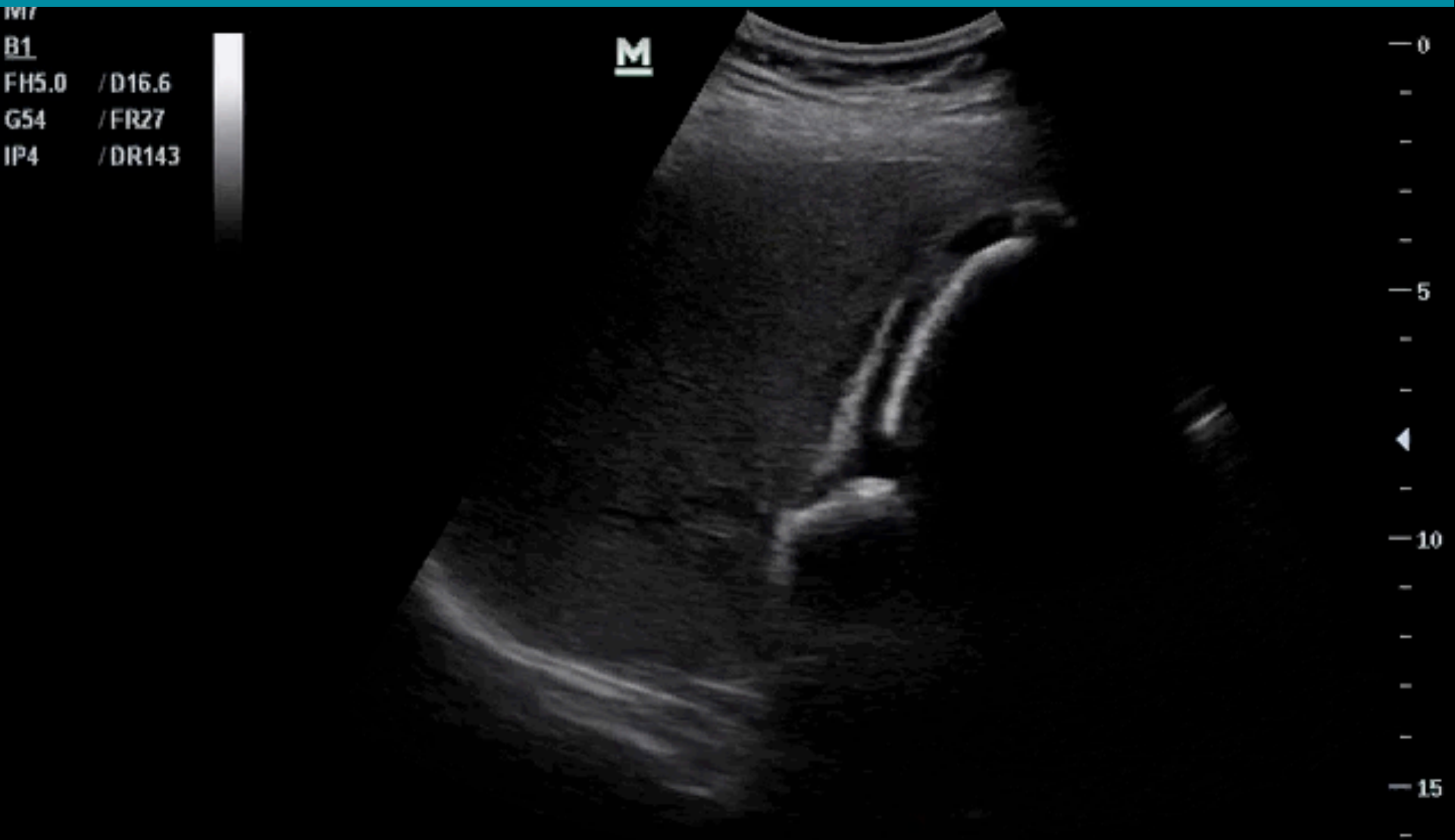
Abd Gen
C5-1
31 Hz
17.0cm

2D

HGen
Gn 60
C. 56
3 / 3 / 3

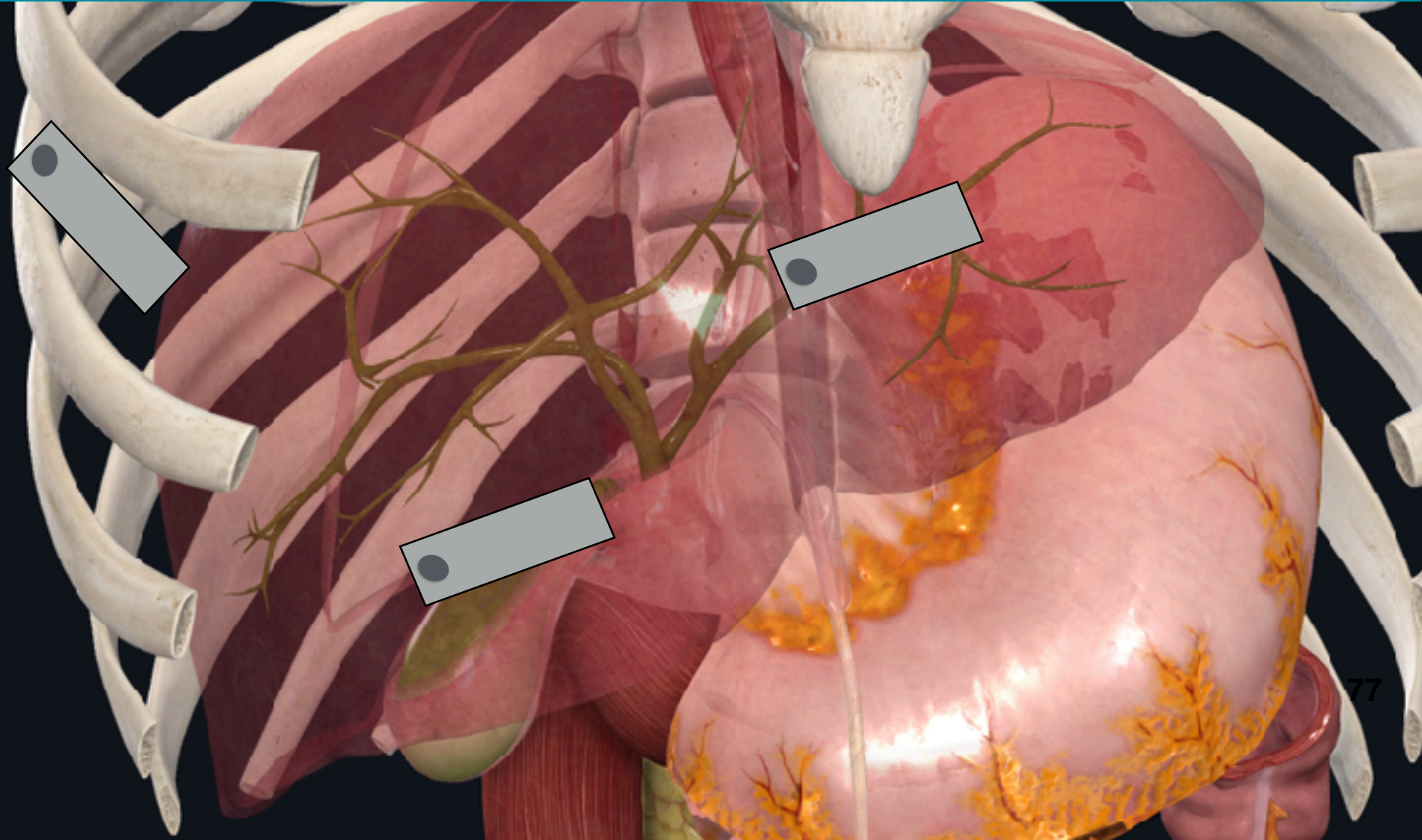


HEPATO-BILIARY



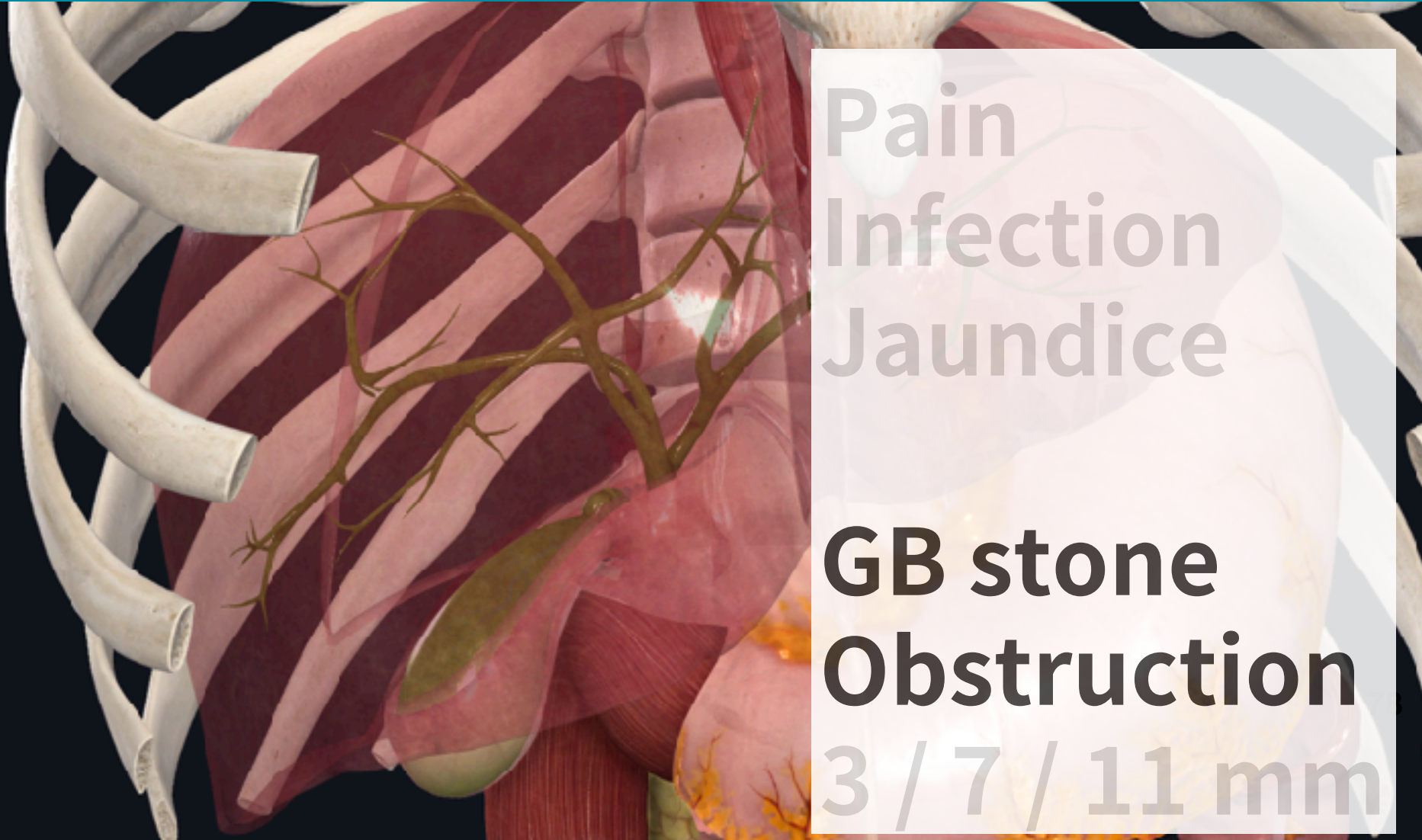


HEPATO-BILIARY





HEPATO-BILIARY



Pain
Infection
Jaundice

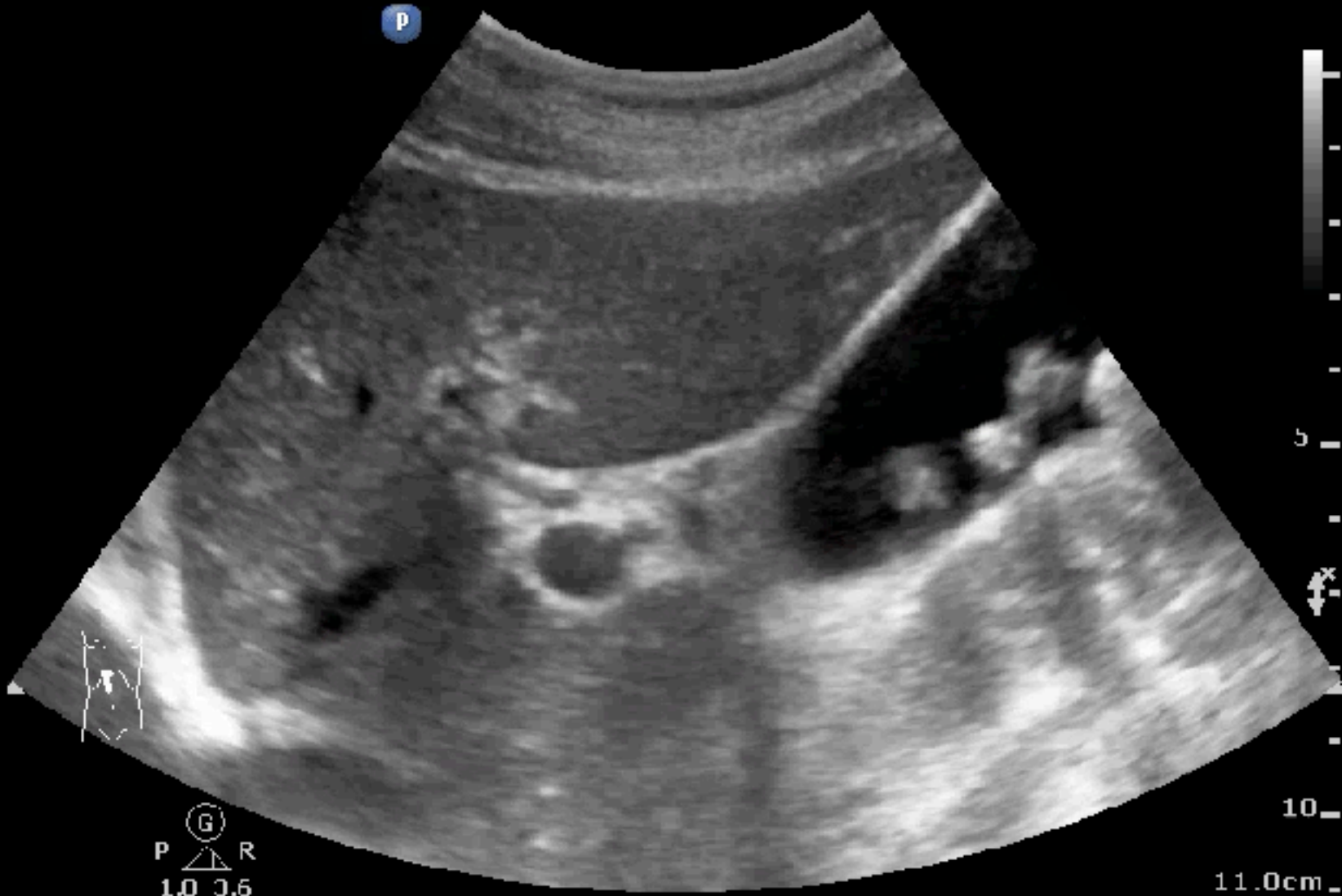
GB stone
Obstruction
3 / 7 / 11 mm

Mickey Mouse sign

Abd Gen
C5-1
42 Hz
11.0cm

2D

HGen
Gn 80
C 56
3 / 3 / 3

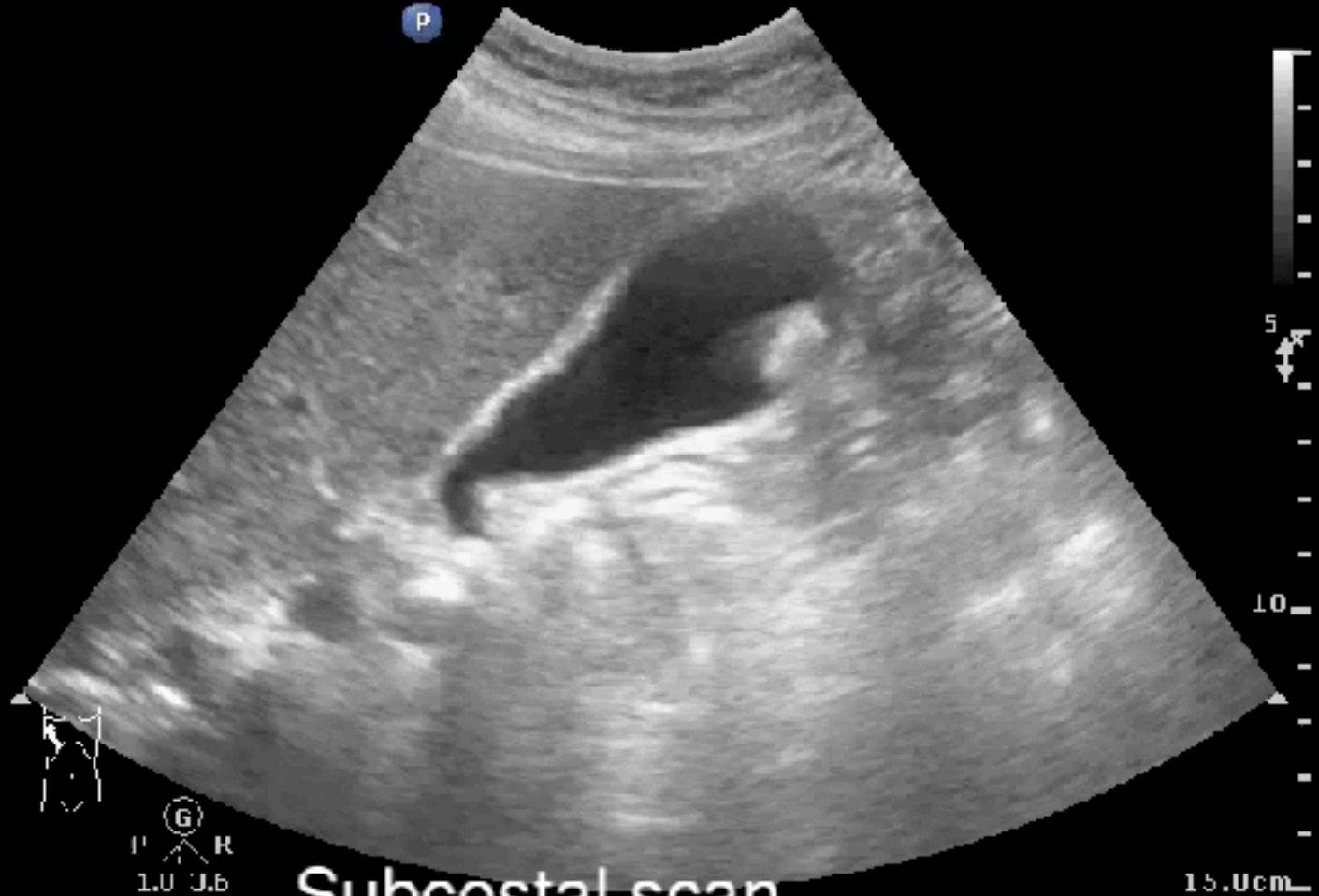

11.0cm

GB stone ?

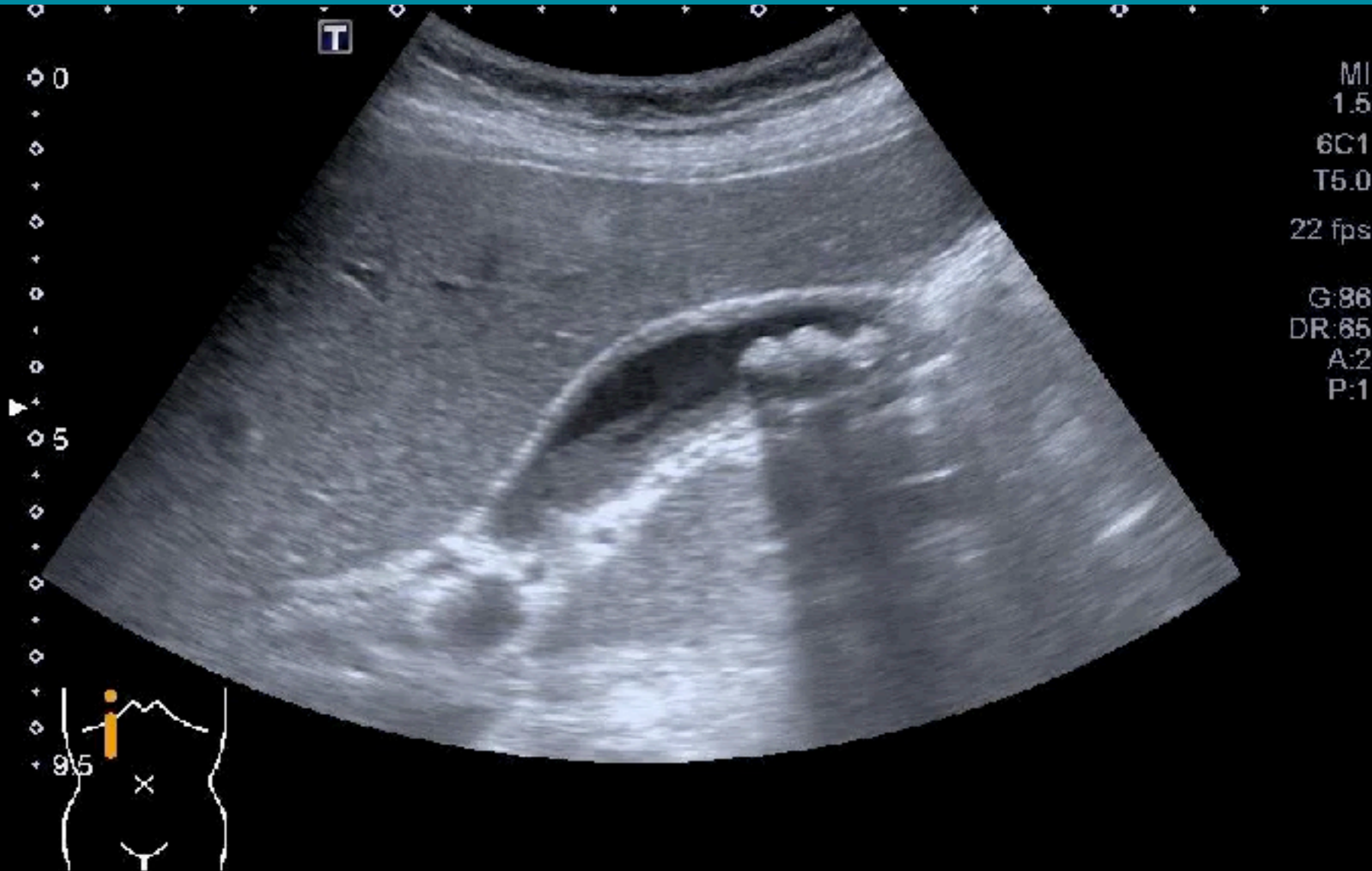Abd Gen
C5 1
34 Hz
15.0cm

2D
HGen
Gr 100
C 63
3 / 3 / 3

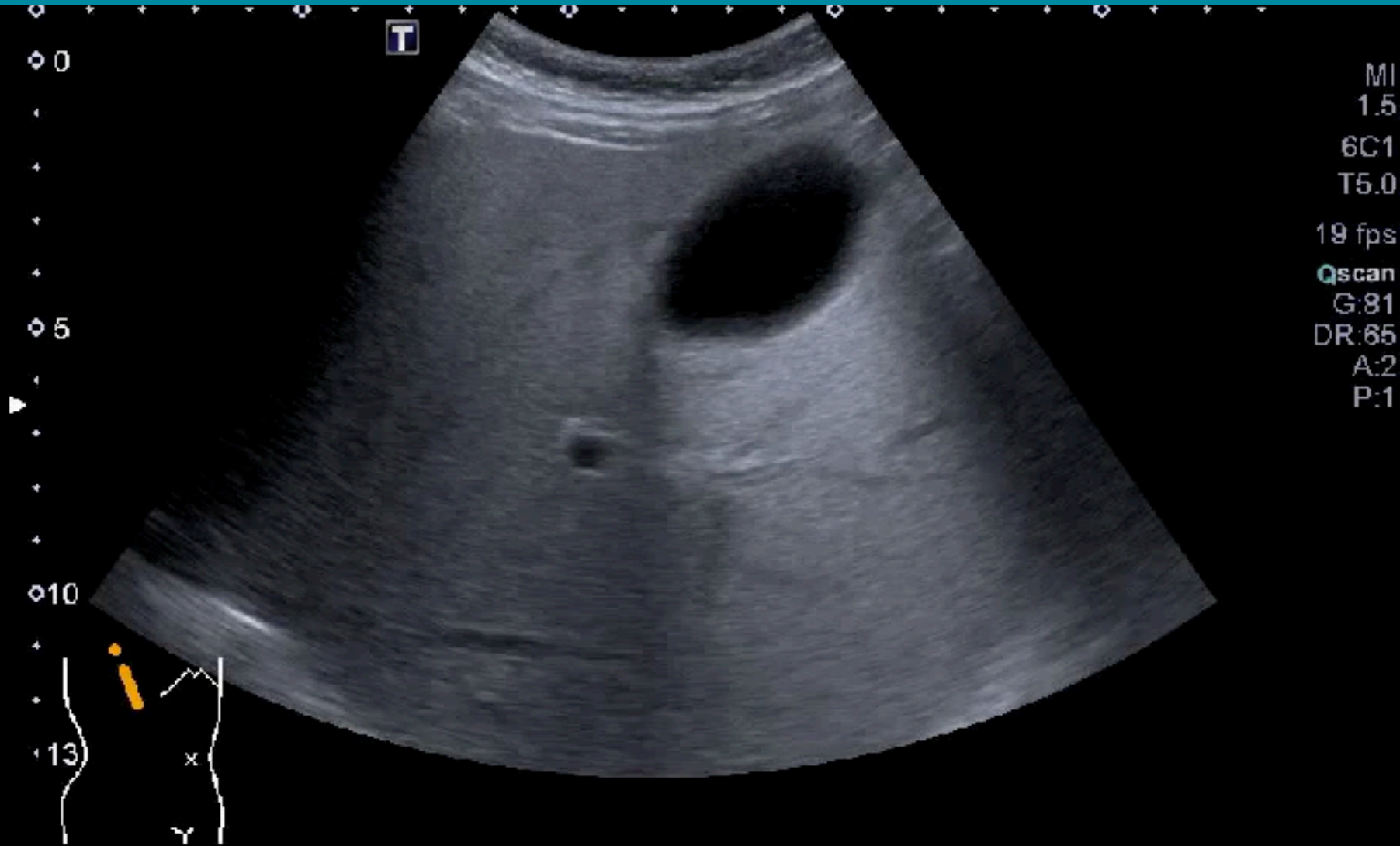


Subcostal scan
L decubitus position

GB stone / polyp / sludges



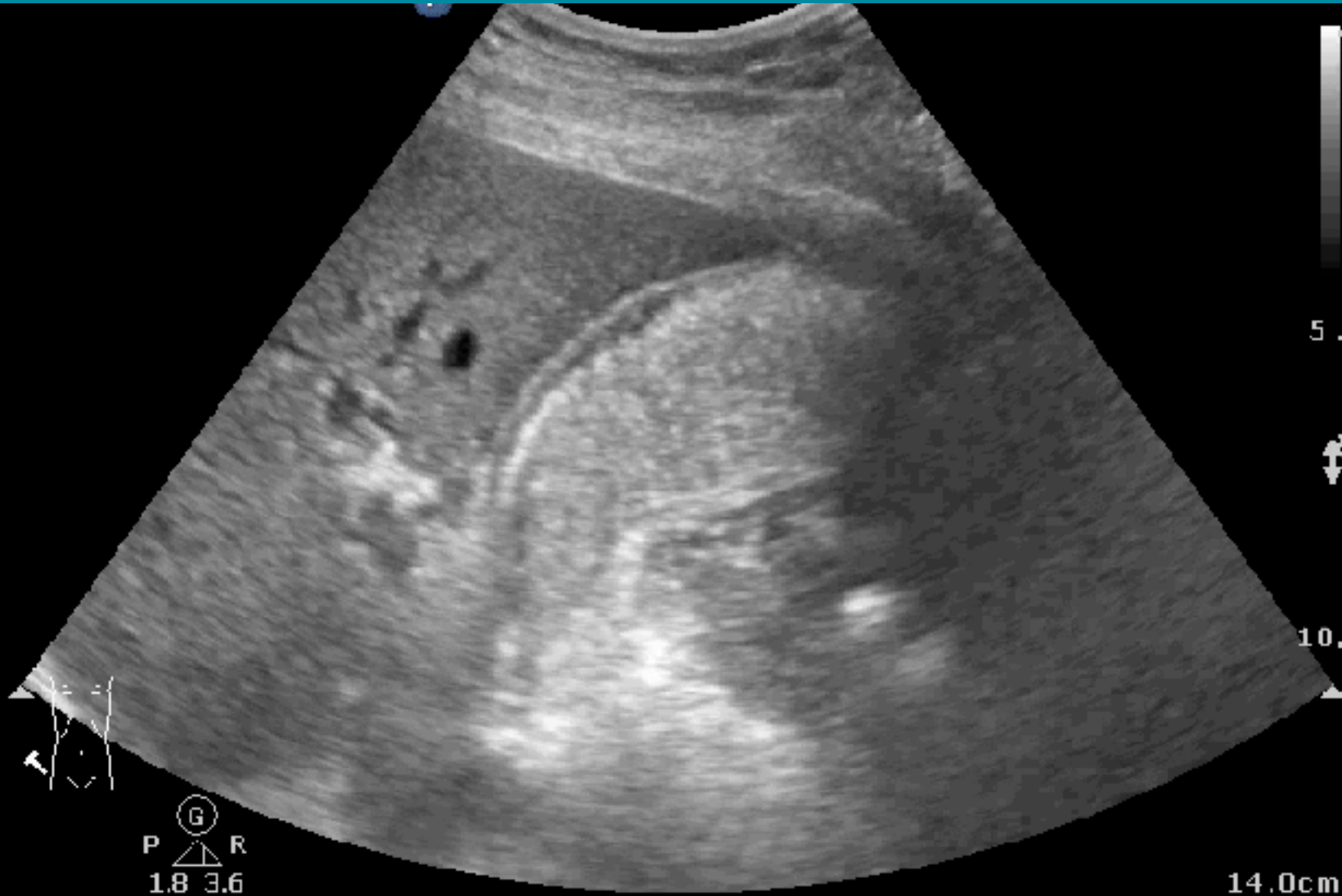
GB stone ?



GB stone ?

100.0cm
25 1
36 Hz
14.0cm

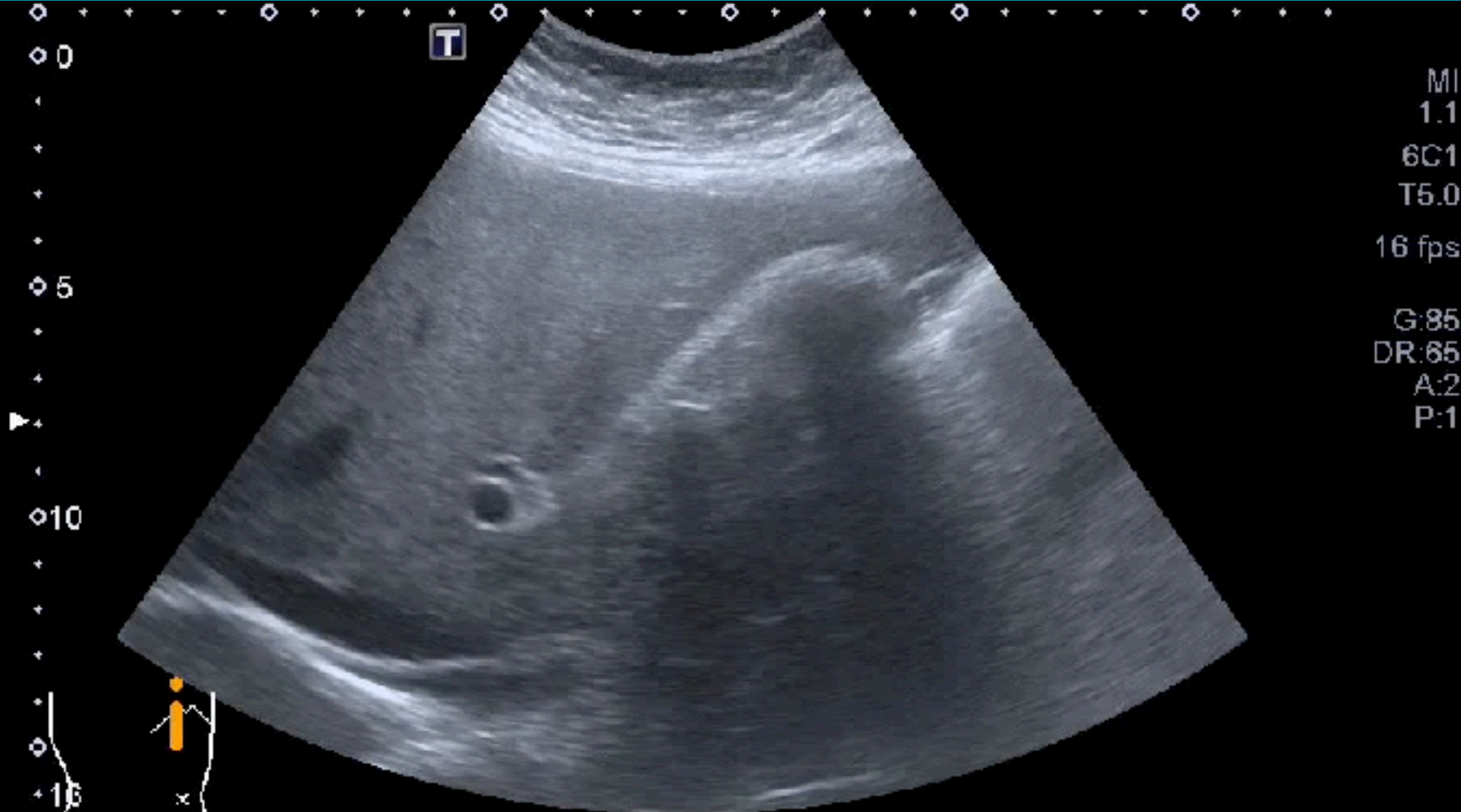
2D
HGen
Gn 100
C 56
3 / 3 / 3



G
P R
1.8 3.6

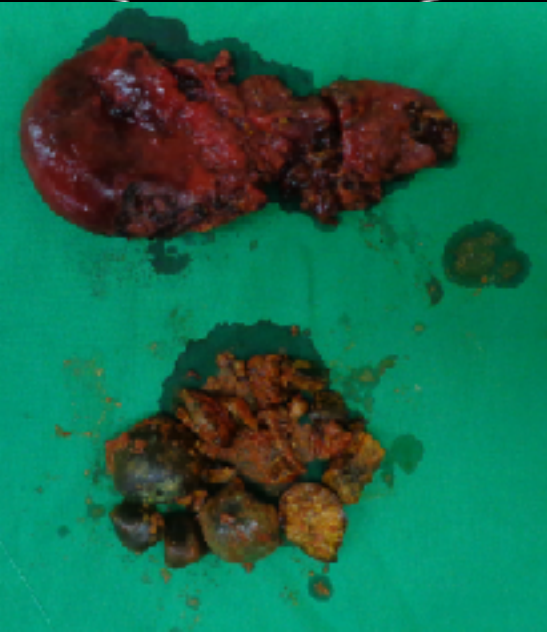
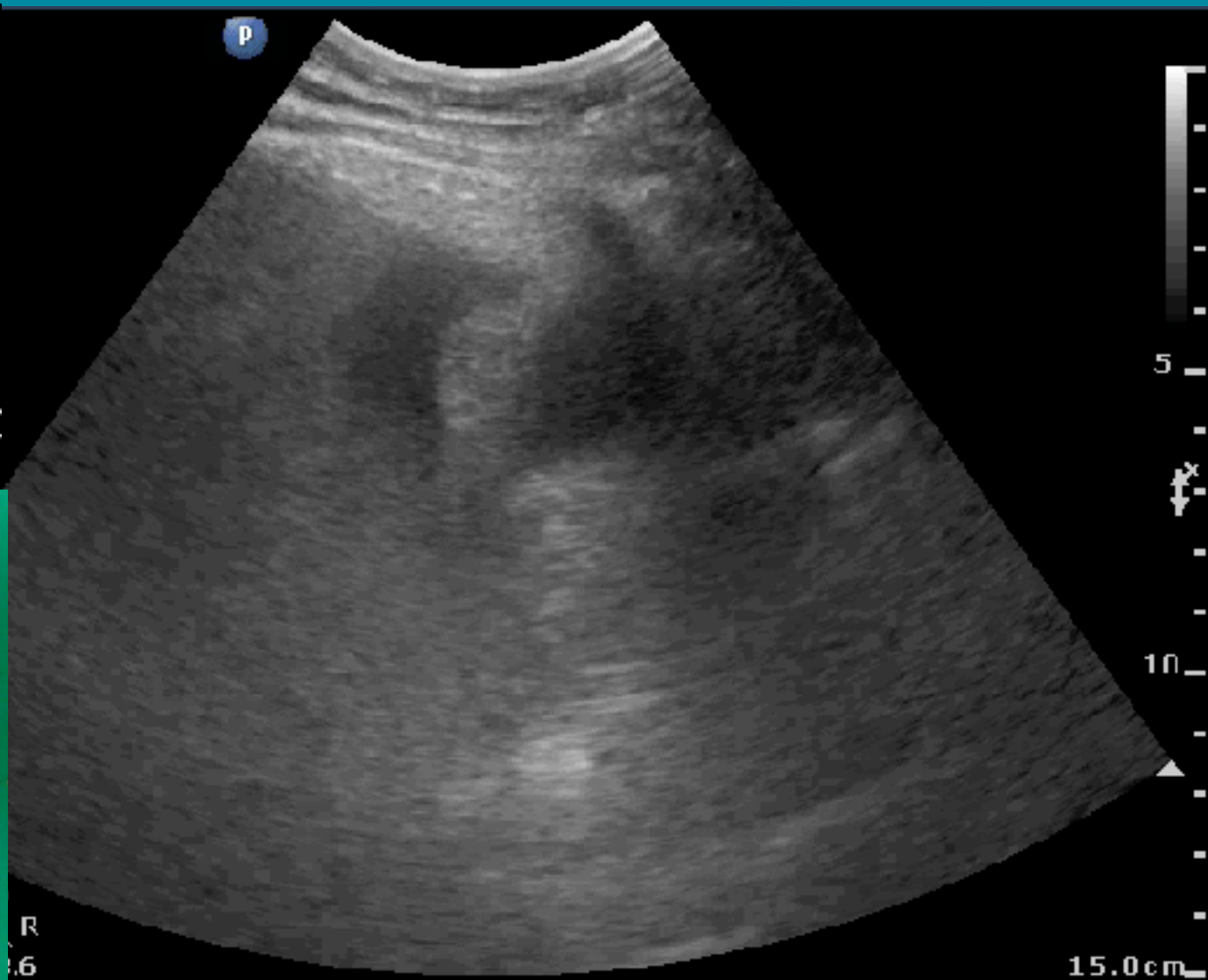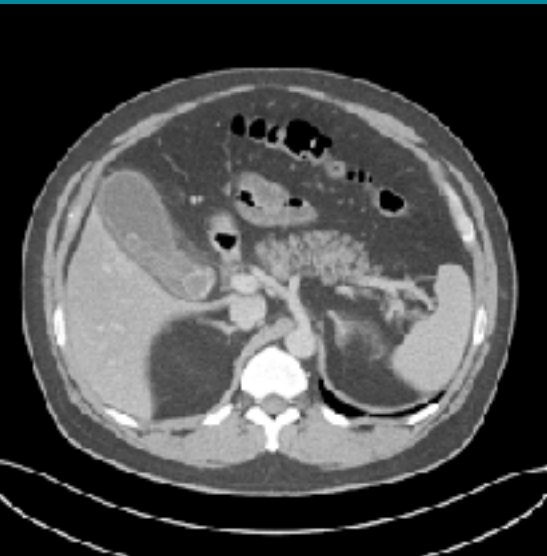
14.0cm

GB stone ?



Wall Echo Shadow (WES) sign

45M, RUQ pain & fever



R
6

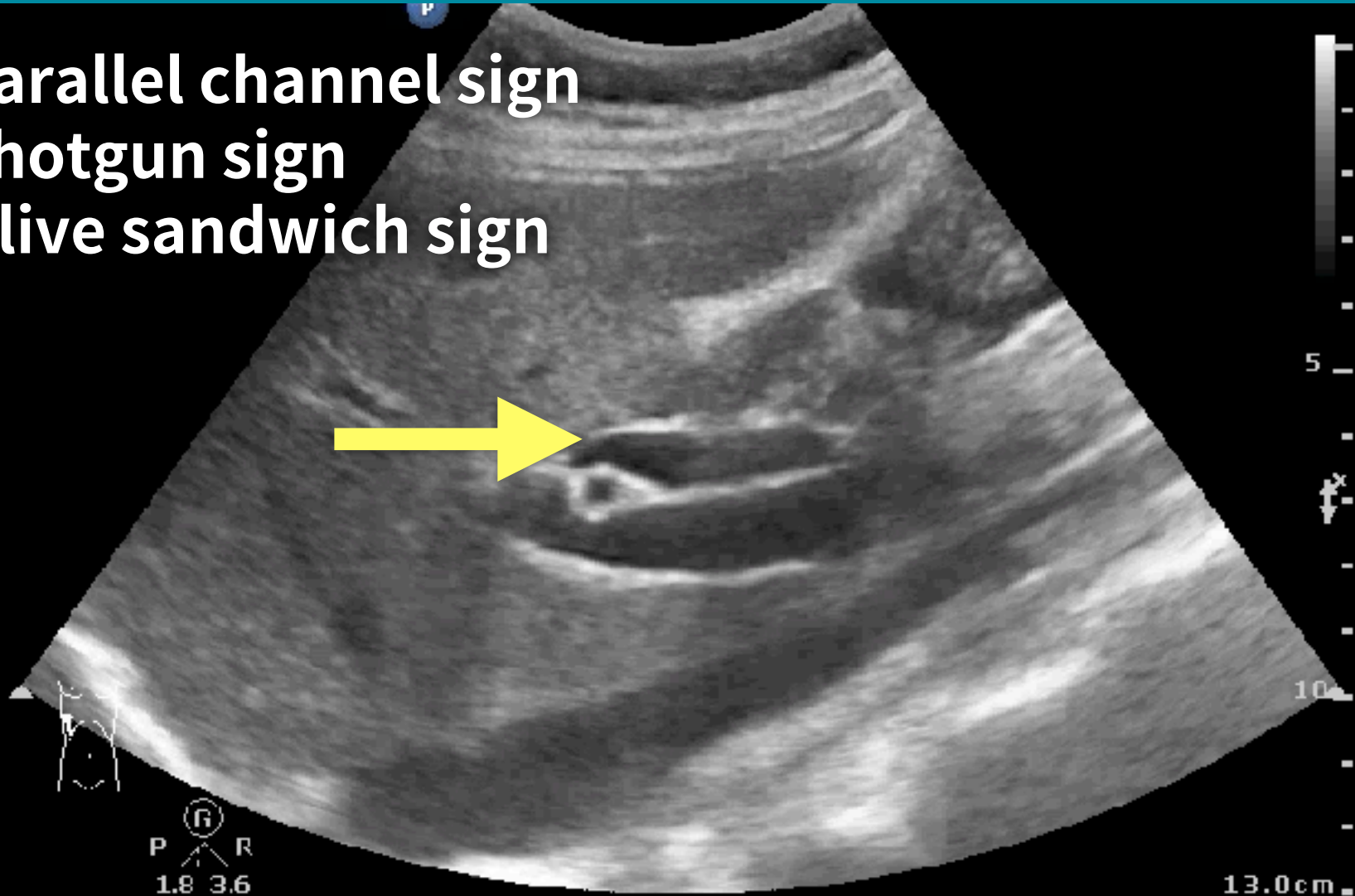
15.0 cm

Biliary dilatation ?

Abd Gen
C5-1
38 Hz
13.0cm

2D
HGen
Gn 82
C. 56
3/3/3

Parallel channel sign
Shotgun sign
Olive sandwich sign



P
R
1.8 3.6

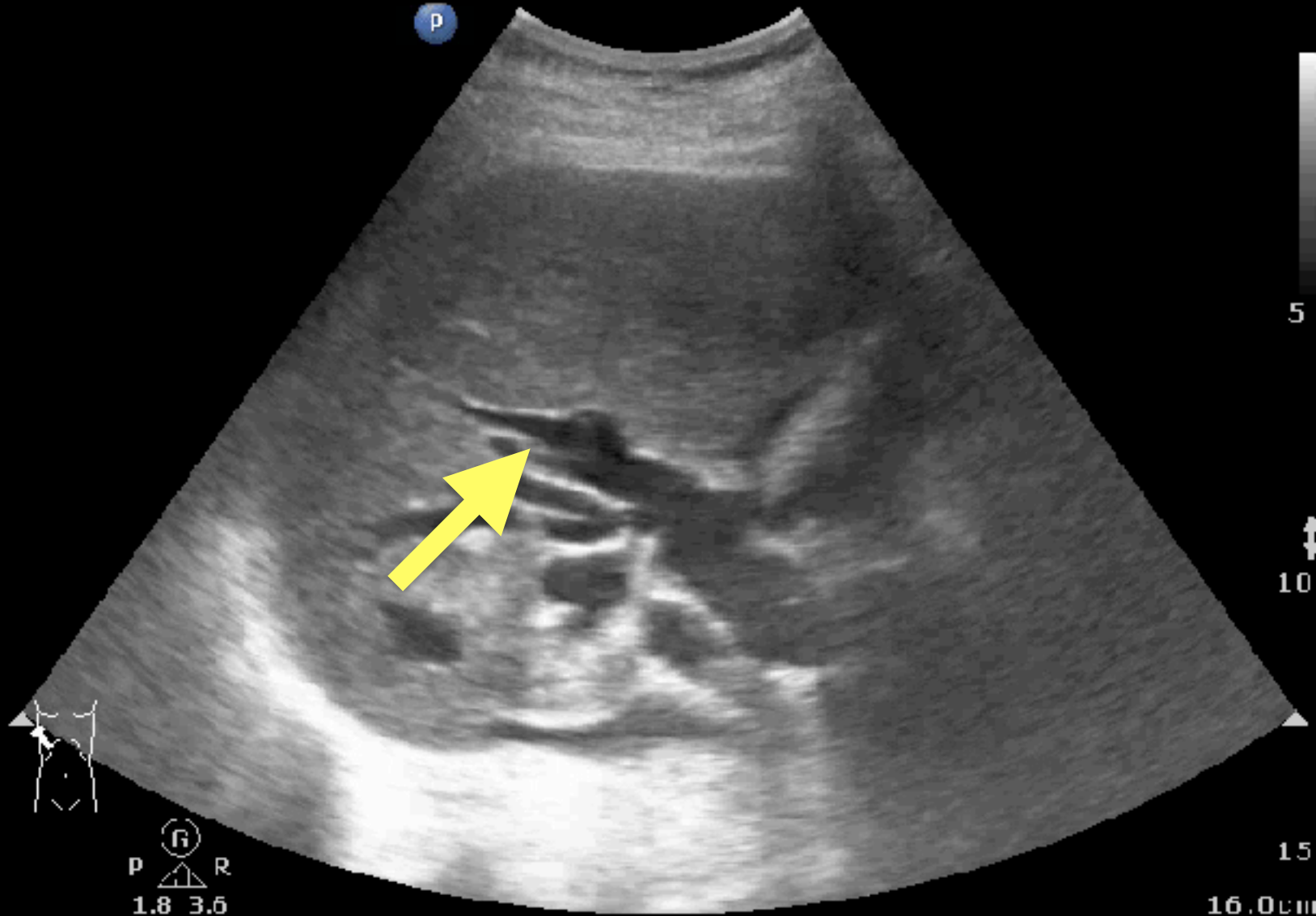
13.0cm

76F, Fever & Chills

Biliary dilatation ?

Abd Gen2
C5-1
2 Hz
6.0cm

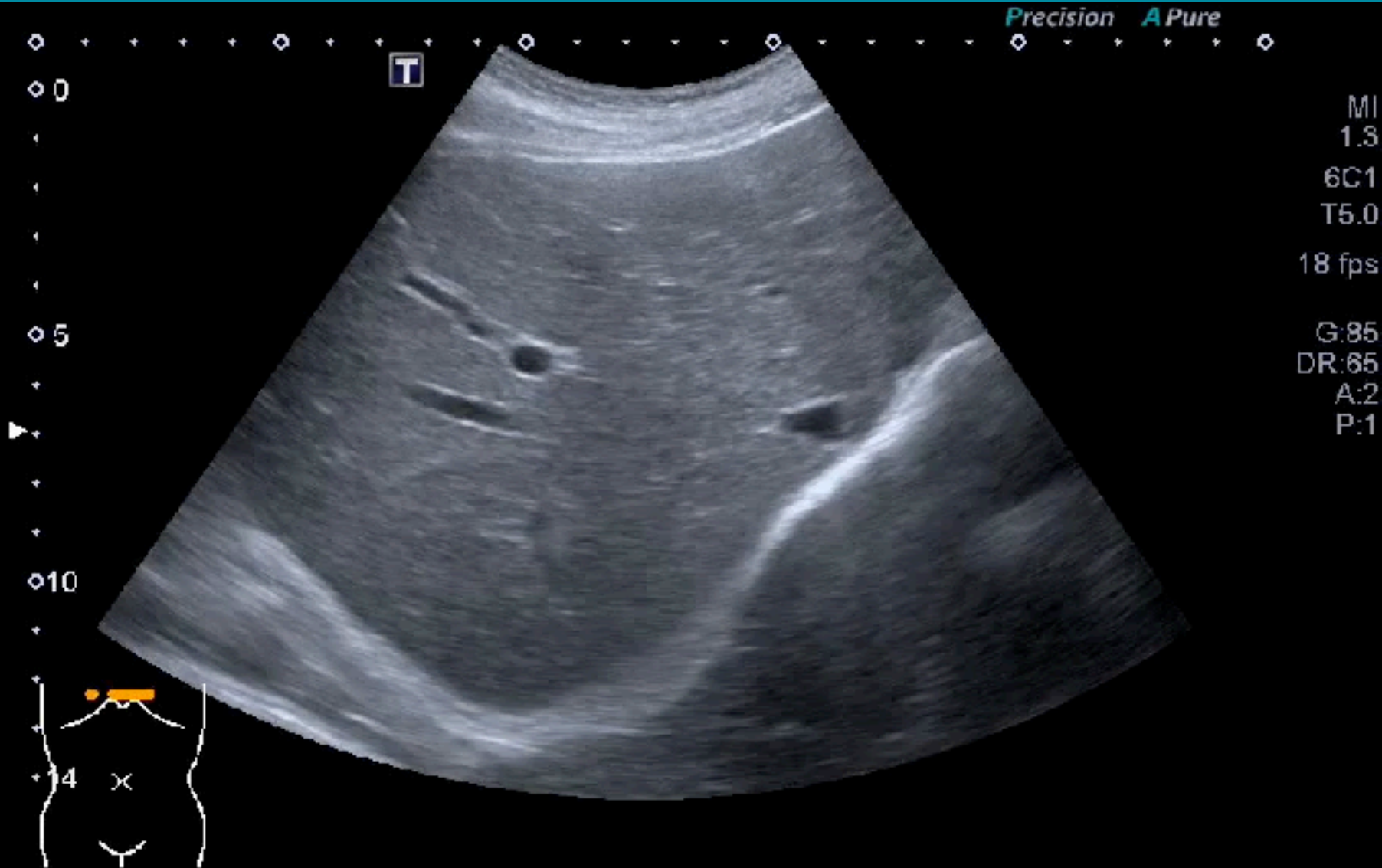
D
HGen
Gn 100
C 56
3/3/3



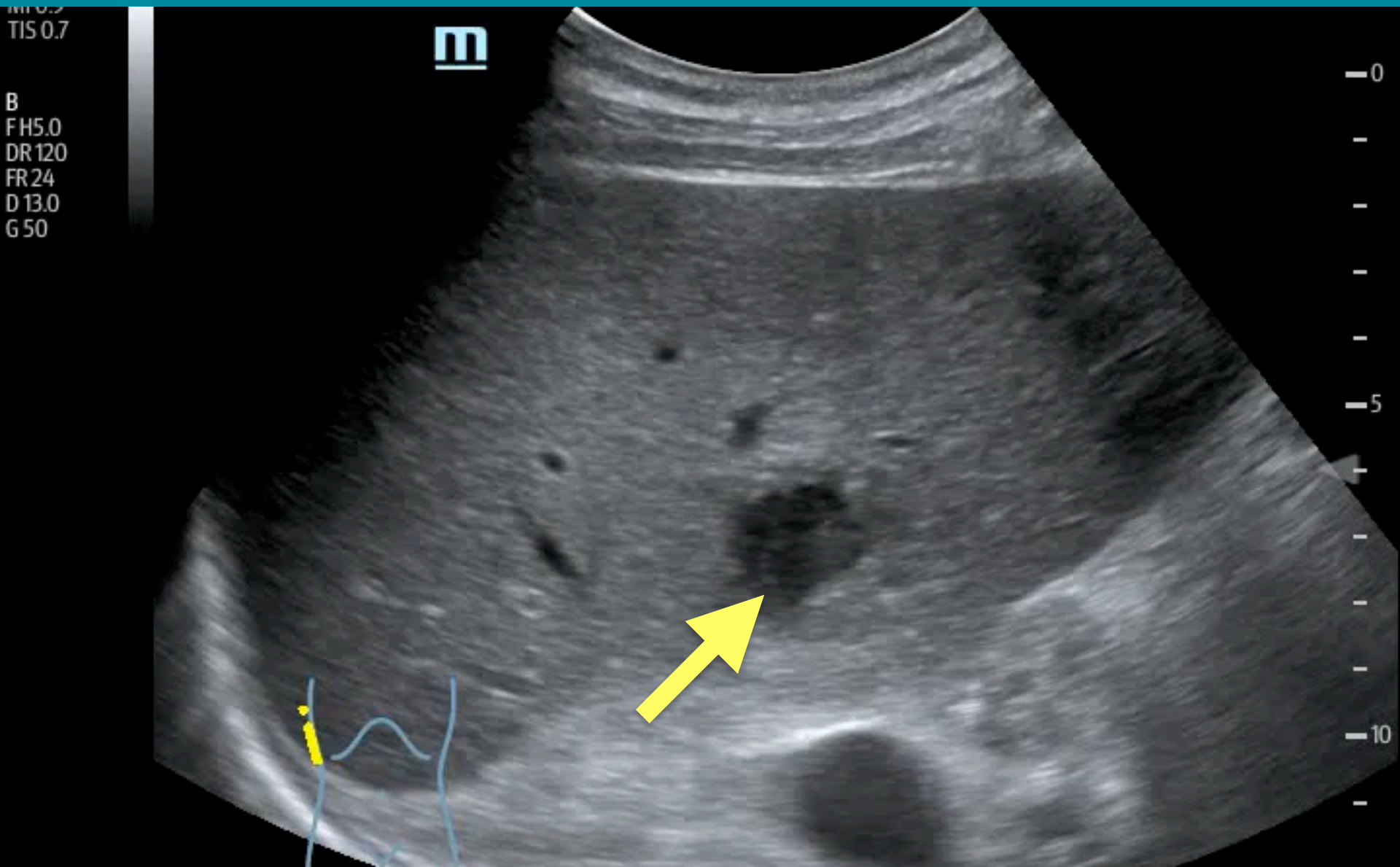
P R
1.8 3.6

15
16.0cm

Subcostal liver scan



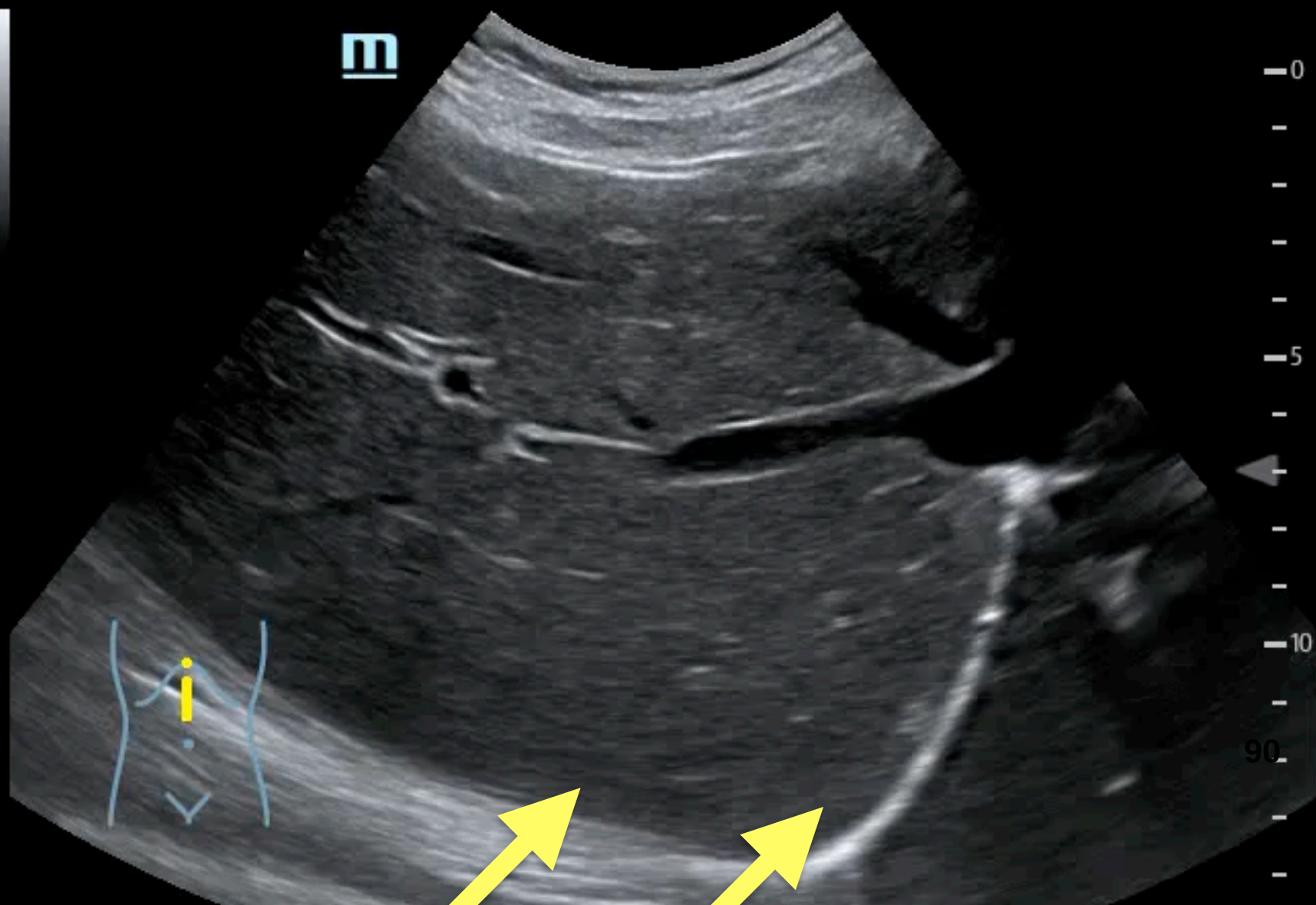
Liver abscess



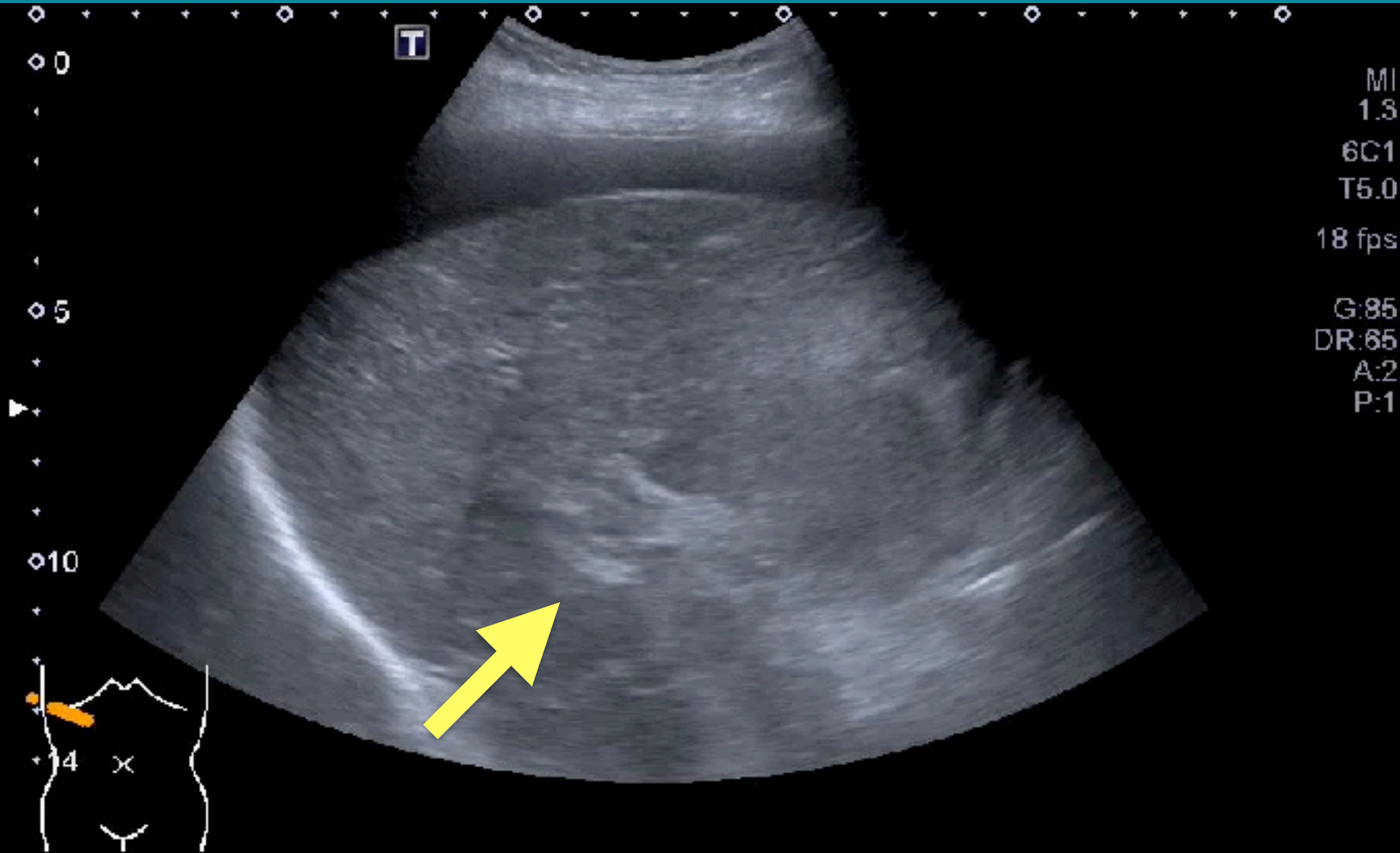
Hemangioma

MI 0.9
TIS 0.7

B
FH5.0
DR120
FR 21
D 16.0
G 47



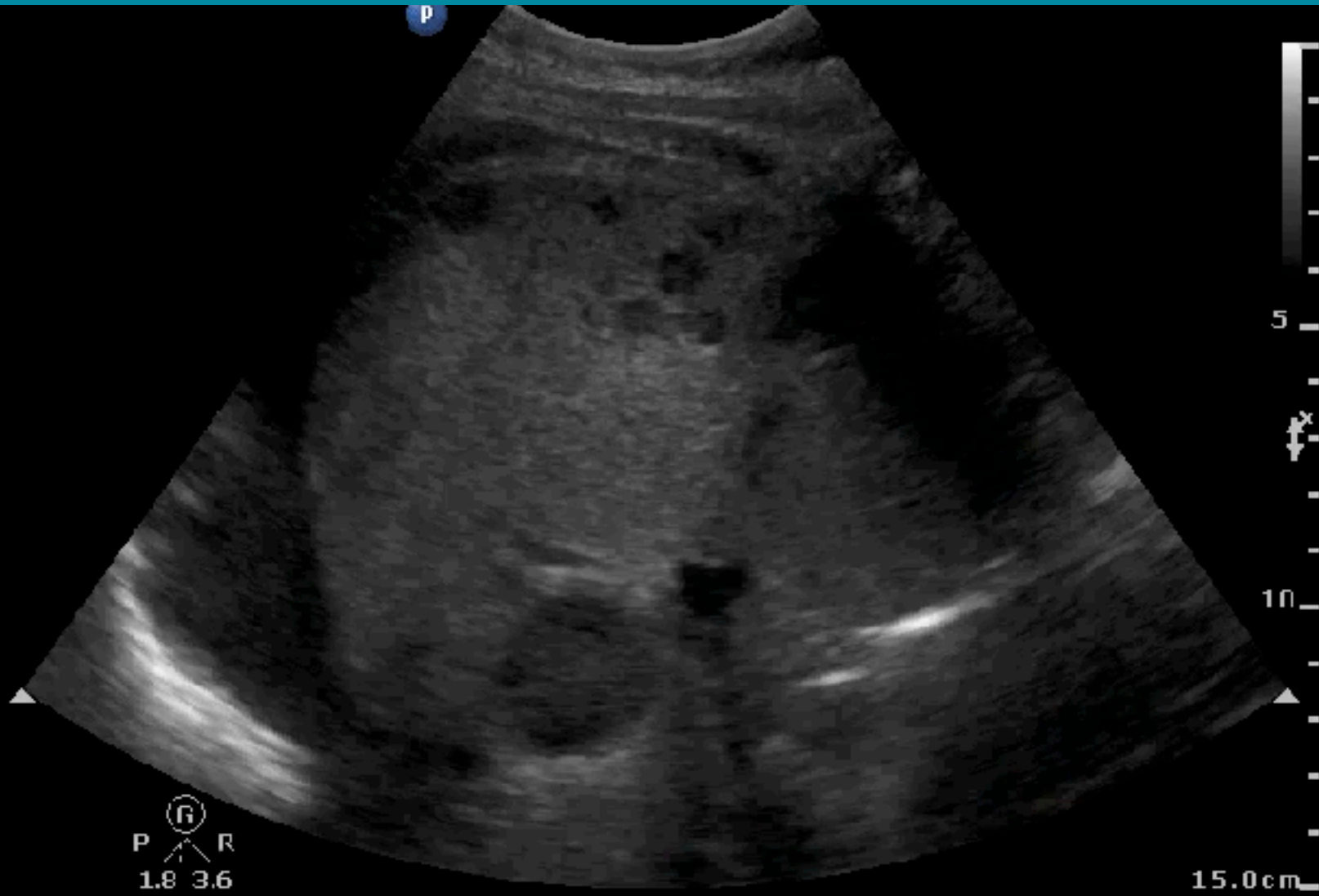
PVT



Metastatic liver tumor

Abd Gen
C5-1
34 Hz
15.0cm

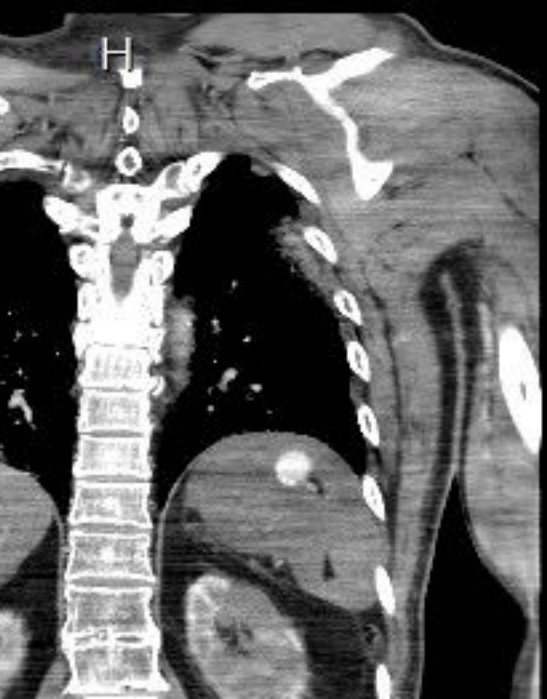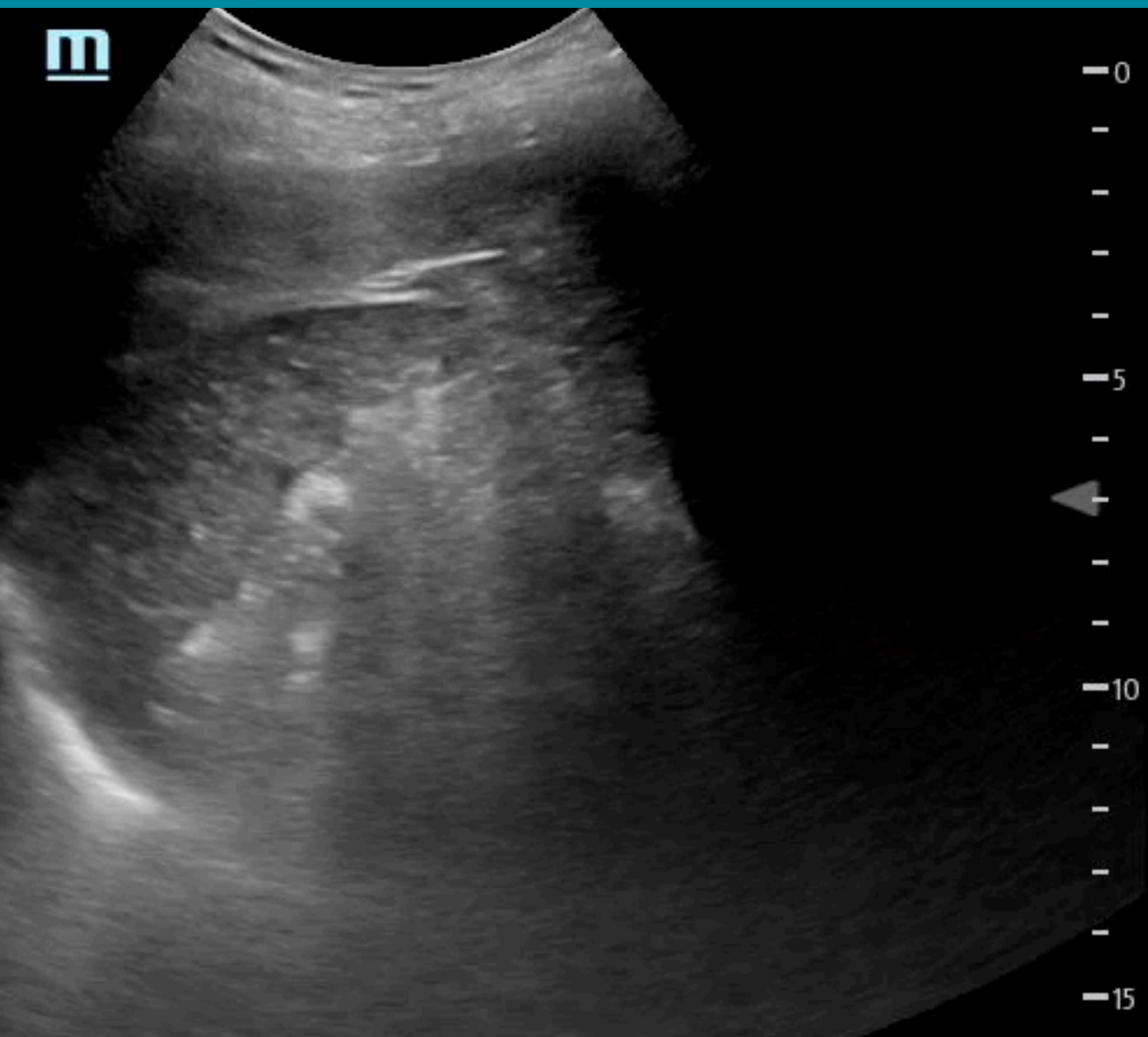
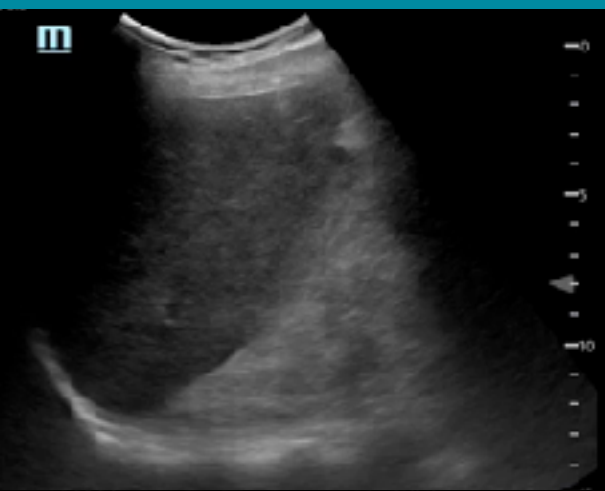2D
HGen
Gn 82
C. 56
3 / 3 / 3

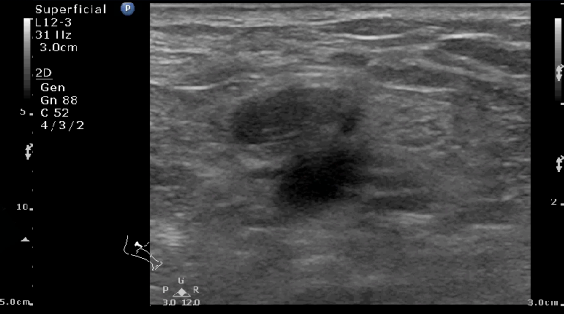
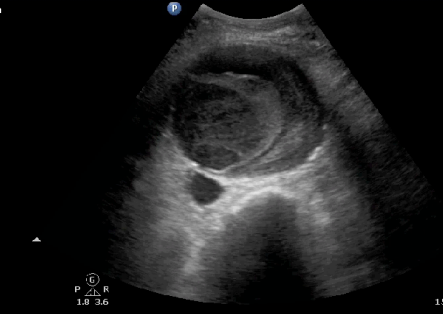
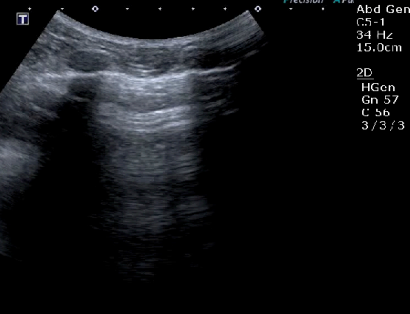
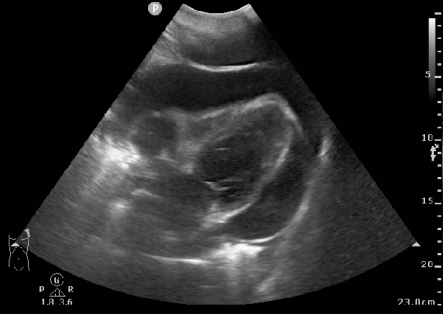


P R
1.8 3.6

15.0cm

Major trauma, internal bleeding ?





HEART

LUNG

AORTA

DVT

KIDNEY

GB

Liver

FAST

TAKE HOME IMAGES

