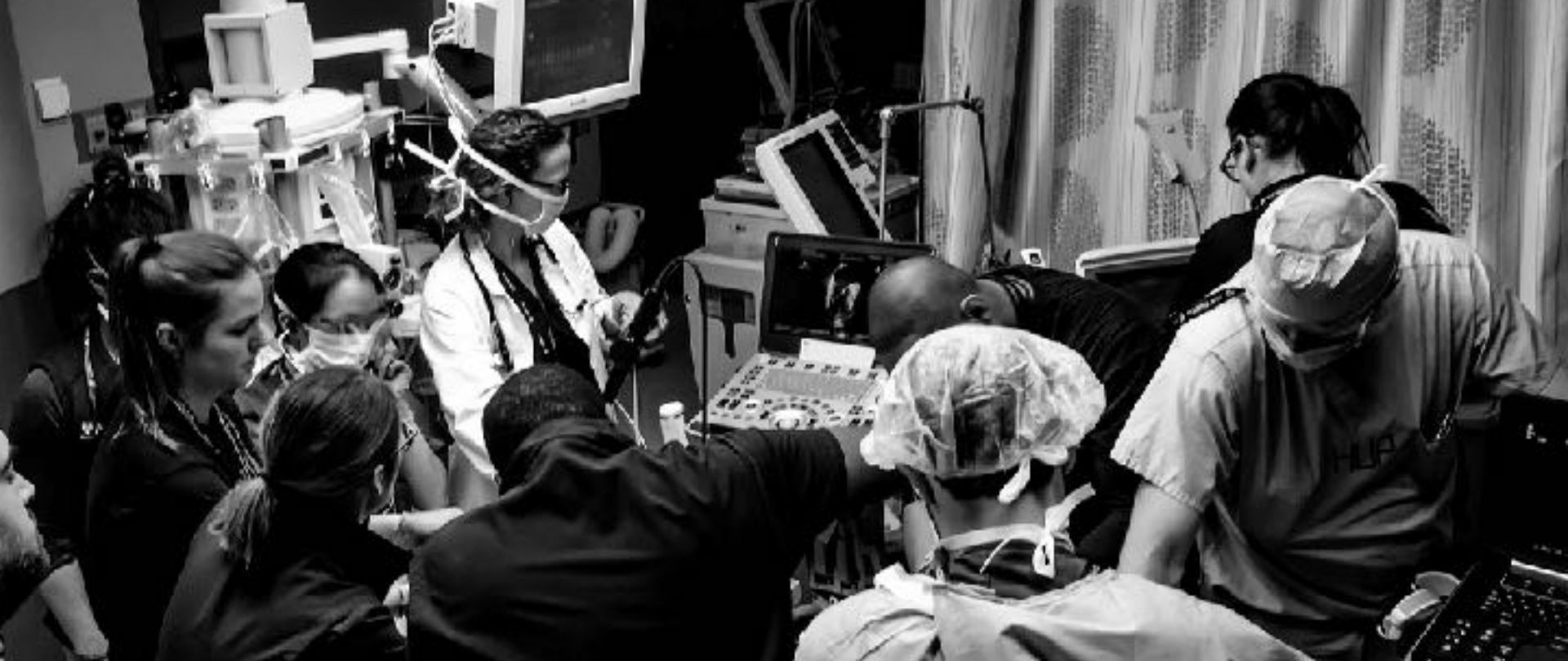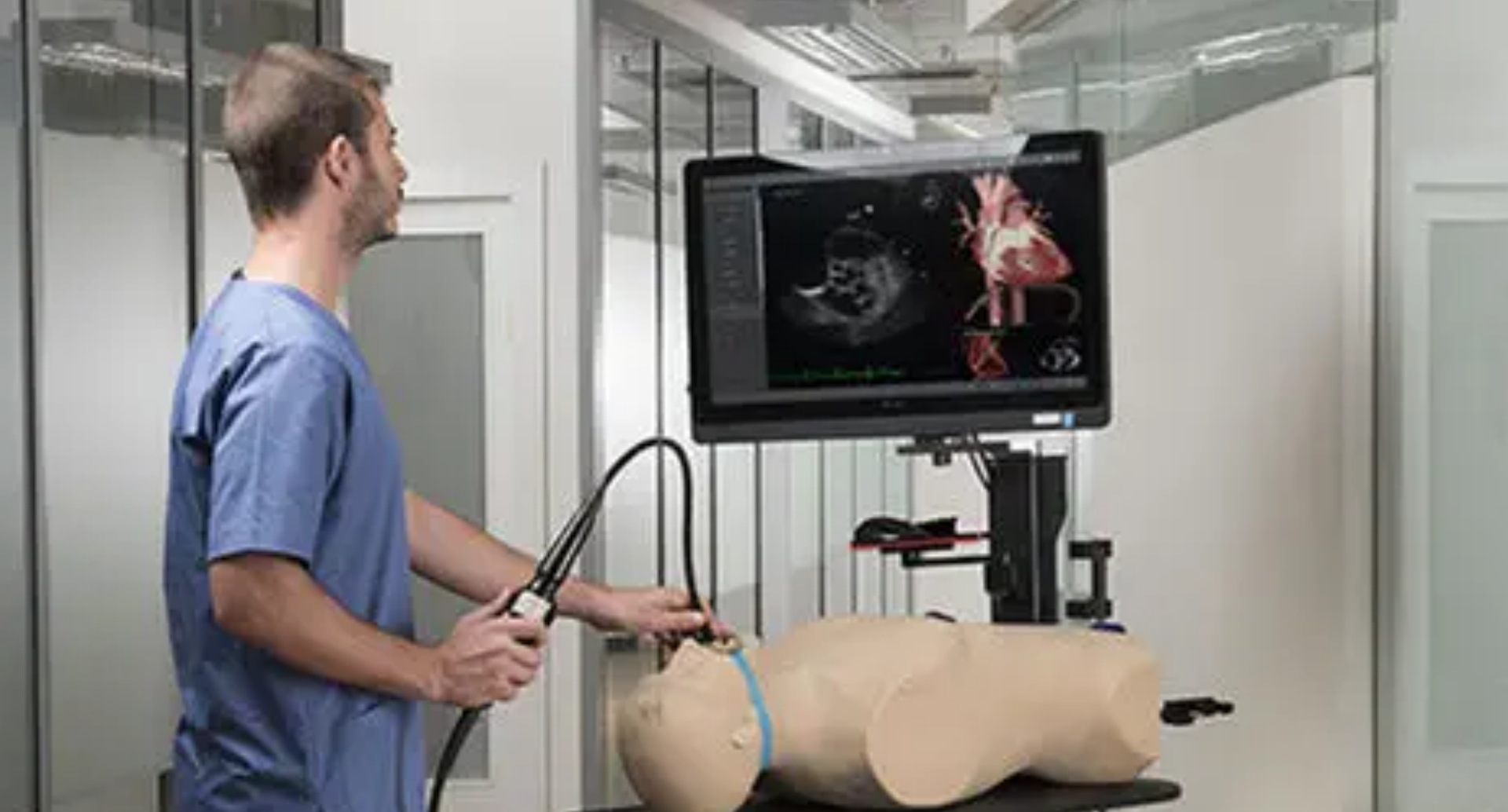




# BASIC TEE IN ER

Resuscitative TEE Project  
<https://www.resuscitativetee.com/>

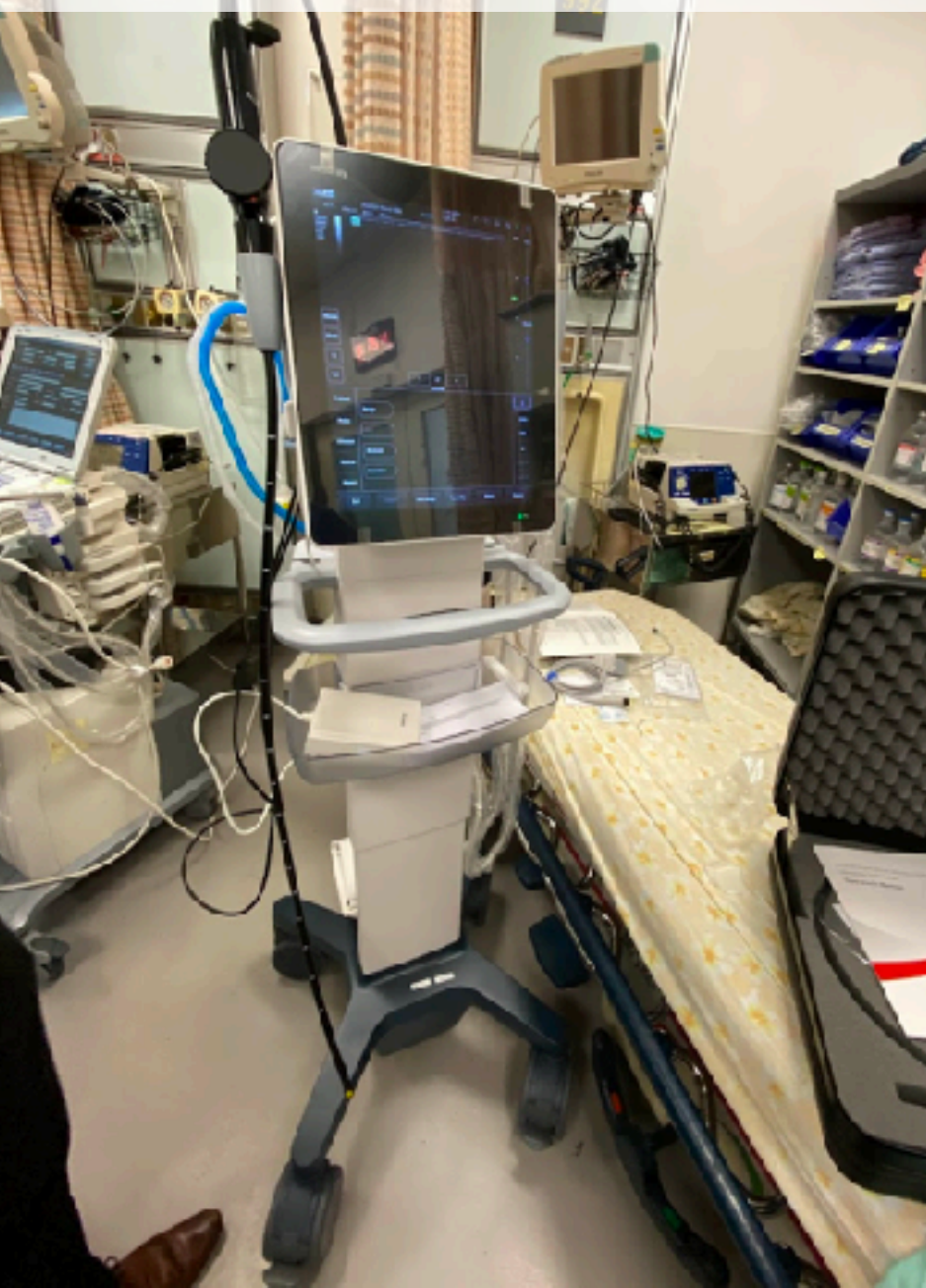

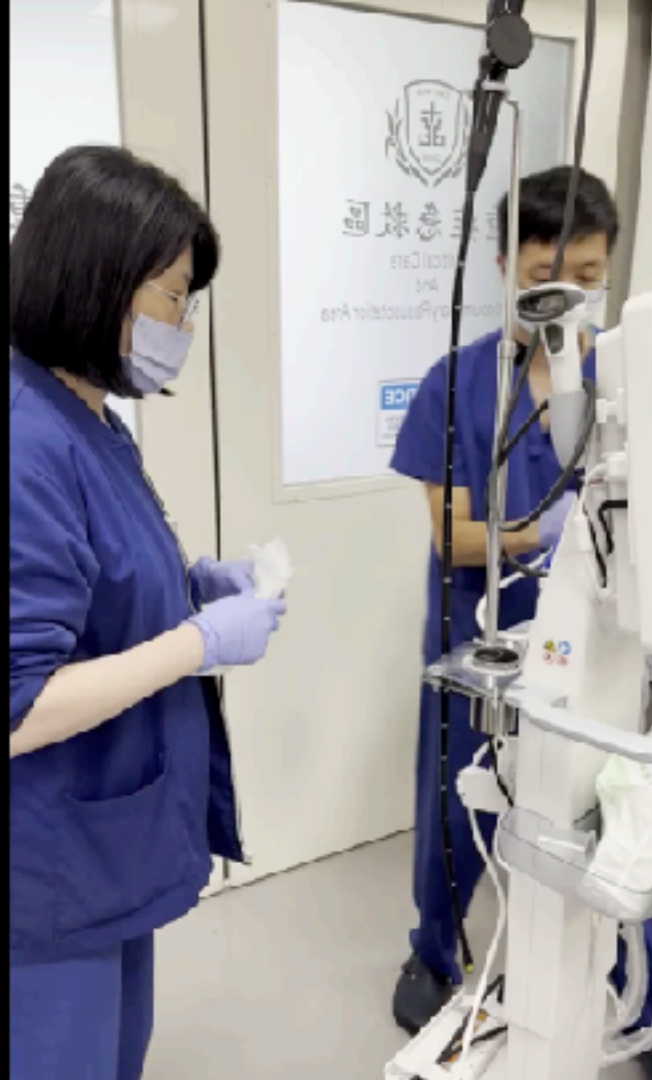# 永達儀器

# Surgical science



# 20221123 TE7 & TEE

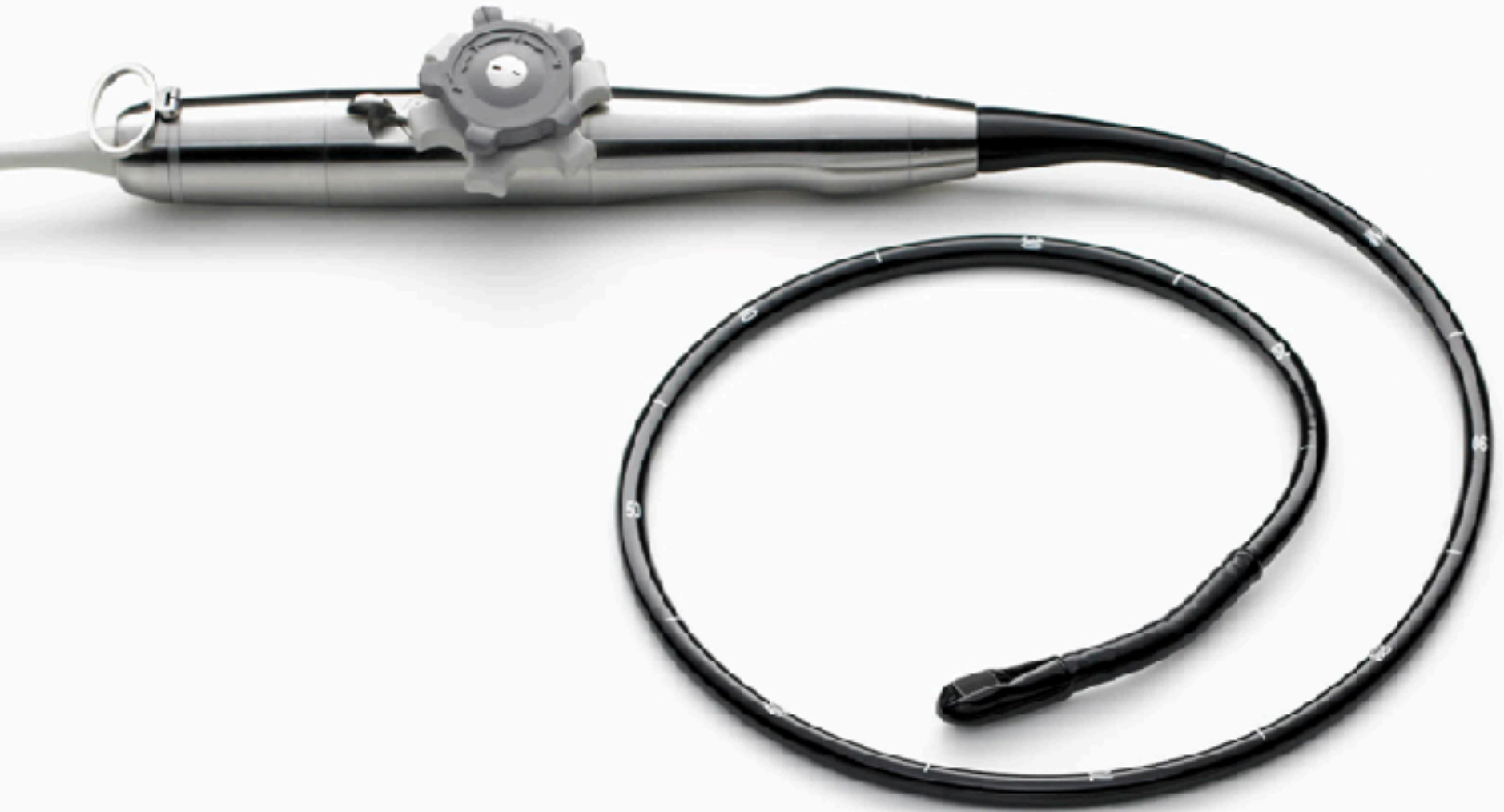



# TEE 清消作業教學

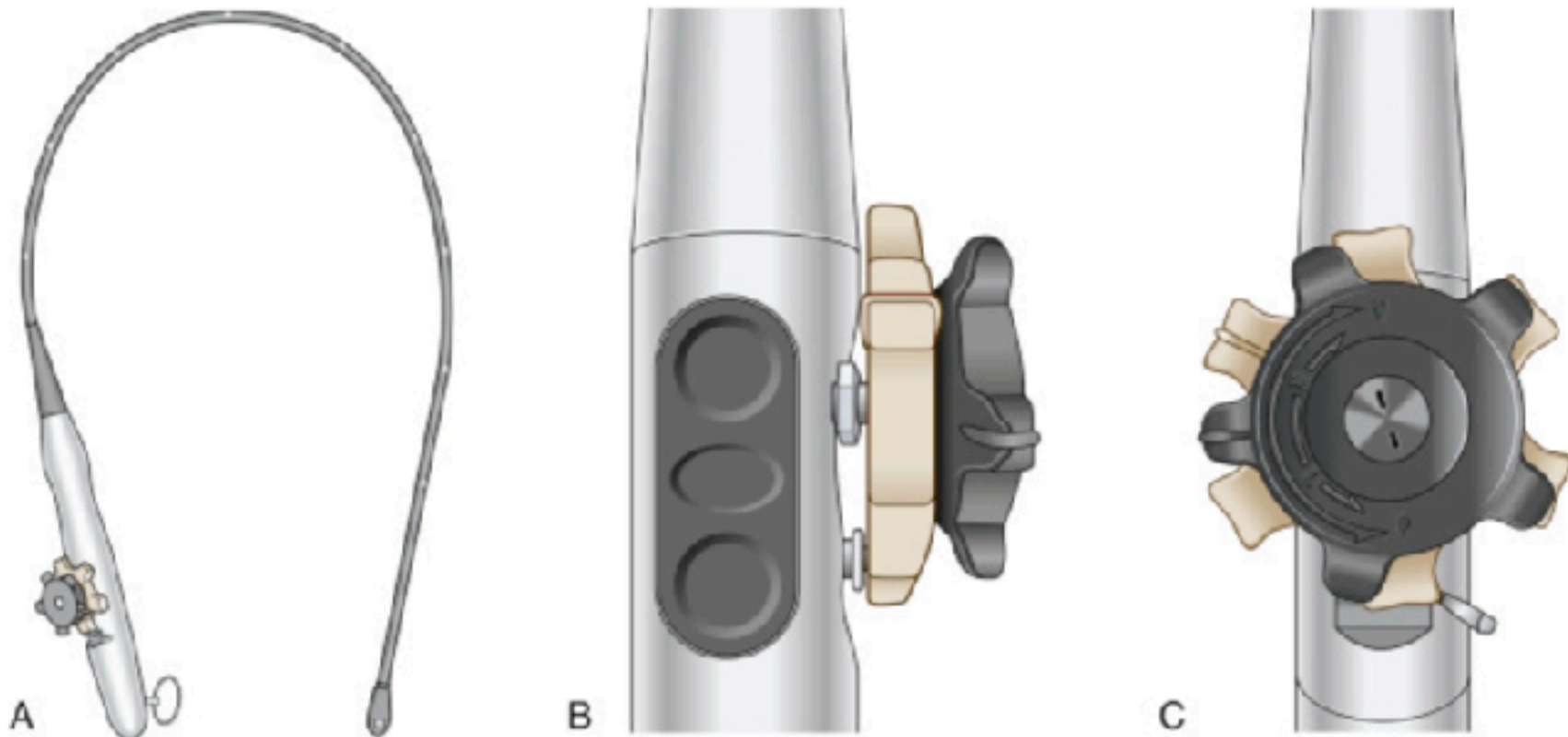


# TransEsophageal Echocardiography



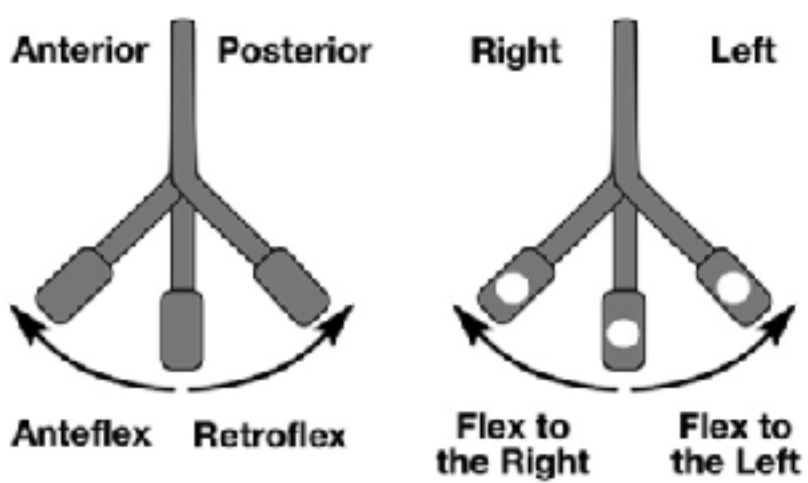
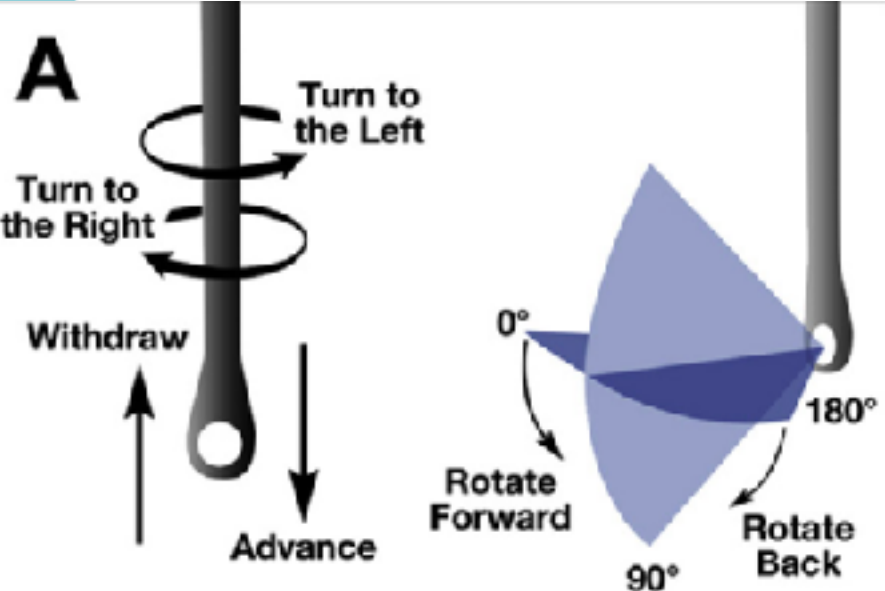
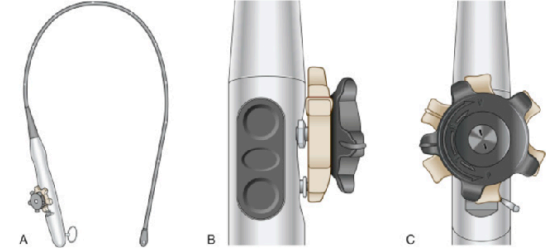


# TransEsophageal Echocardiography



- 1主線: 前進後退加順逆轉動
- 2轉輪: 控制前後左右彎曲
- 2按鈕: 調節晶體角度 (0~180)

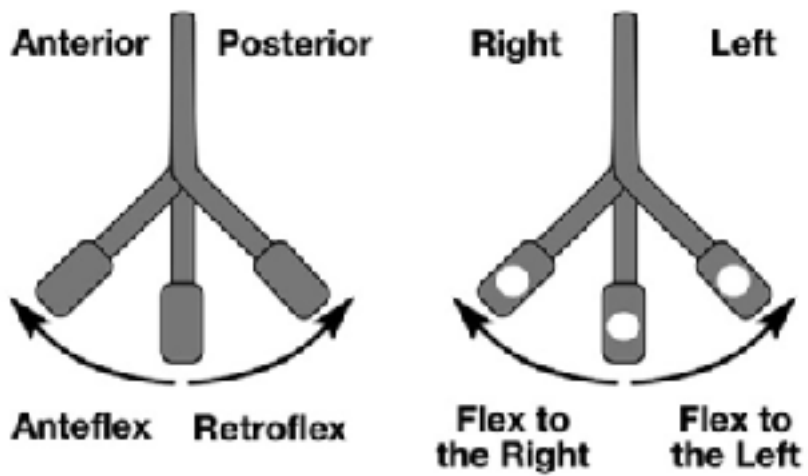
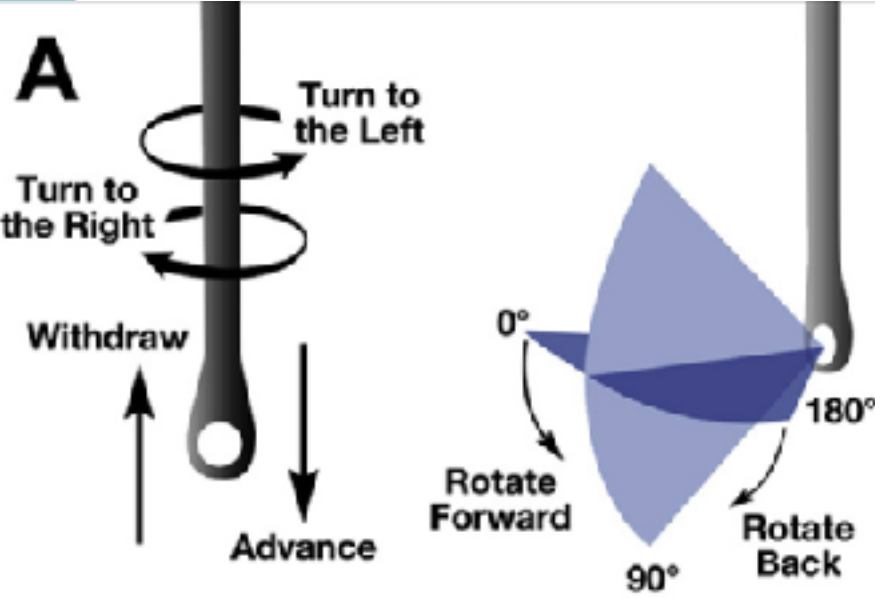
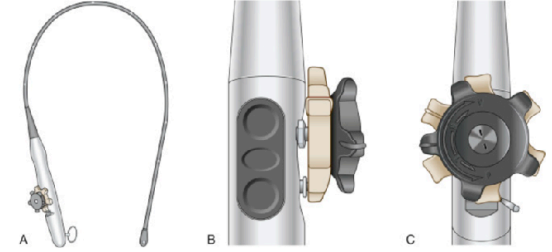
# How to perform TEE ?



**進和退**  
**順逆轉**  
**面朝前** 晶體旋  
 前後彎  
 左右彎



# How to perform TEE ?



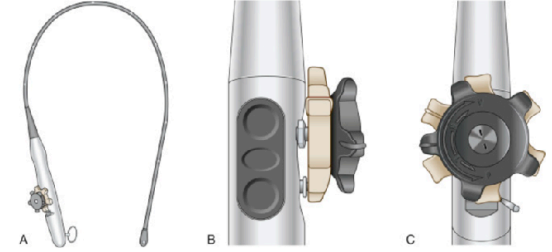
主幹線順時鐘：看腔靜脈

大轉輪順時鐘：向前彎曲

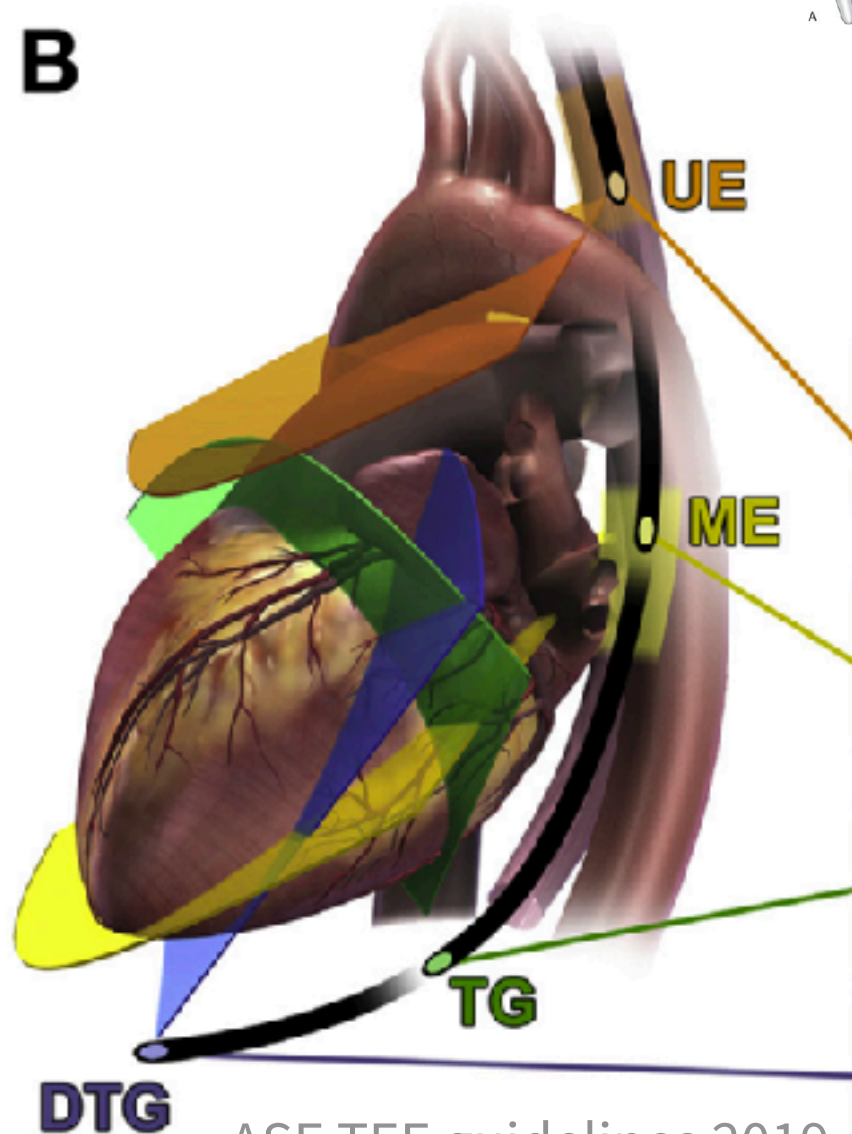
小轉輪順時鐘：向右彎曲

# How deep should we go ?

4



**B**

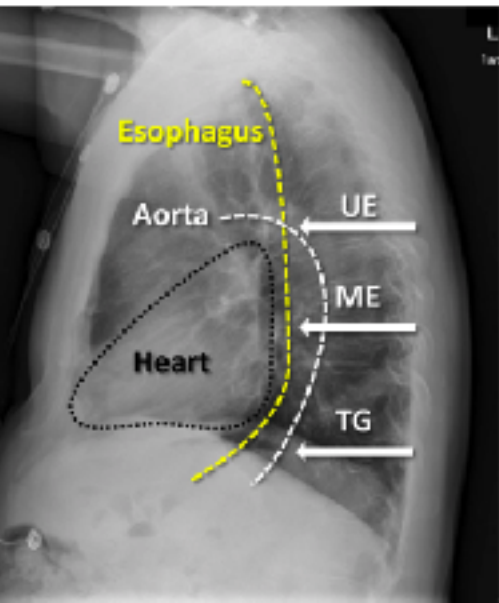


Upper Esophageal (UE)

Mid Esophageal (ME)

Transgastric (TG)

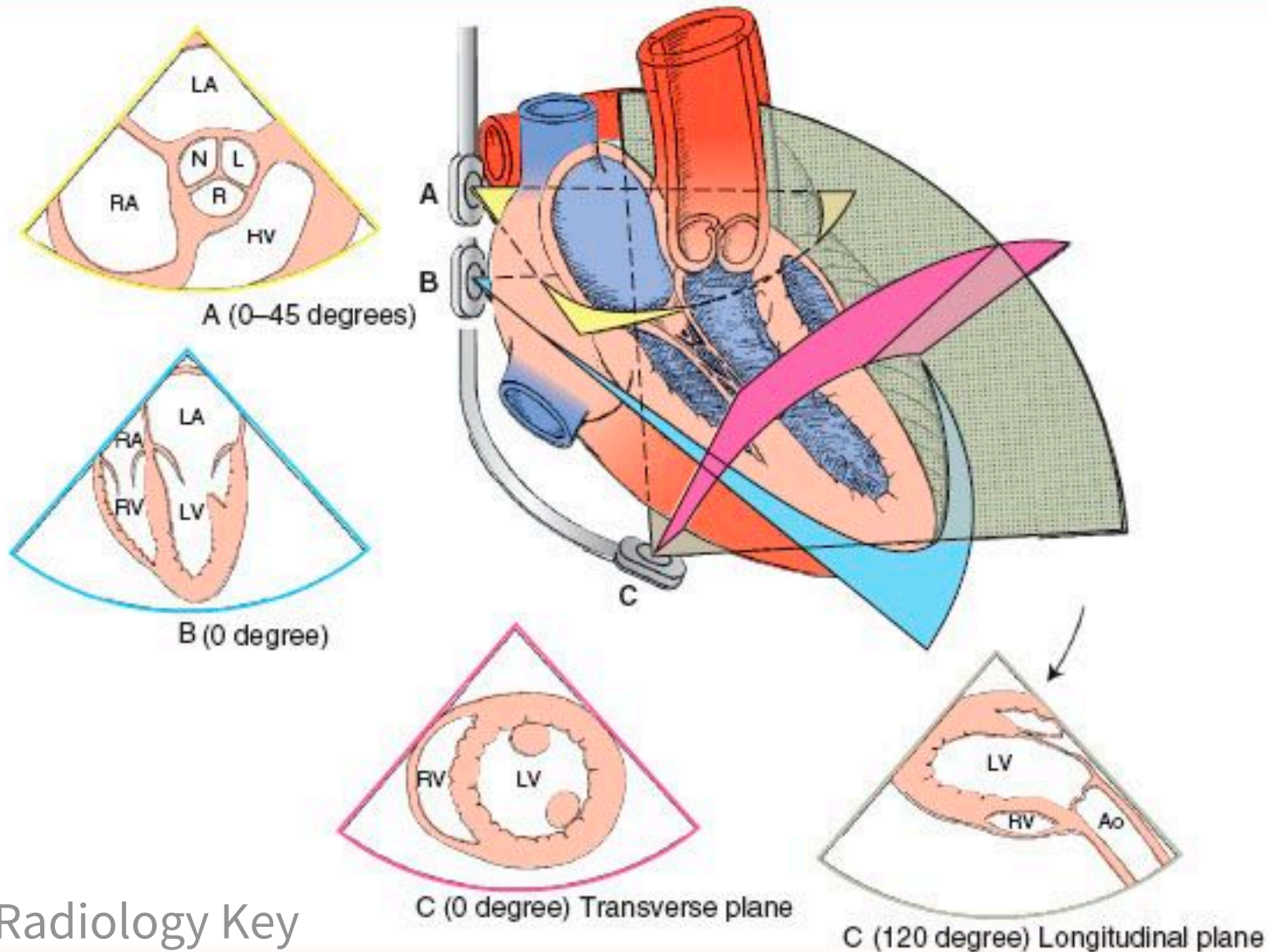
Deep Transgastric (DTG)



**DTG**

ASE TEE guidelines 2019

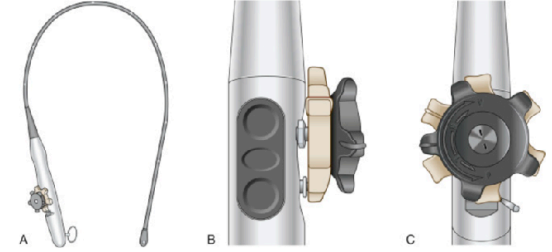
# TEE Basic Views at different levels



~ Radiology Key



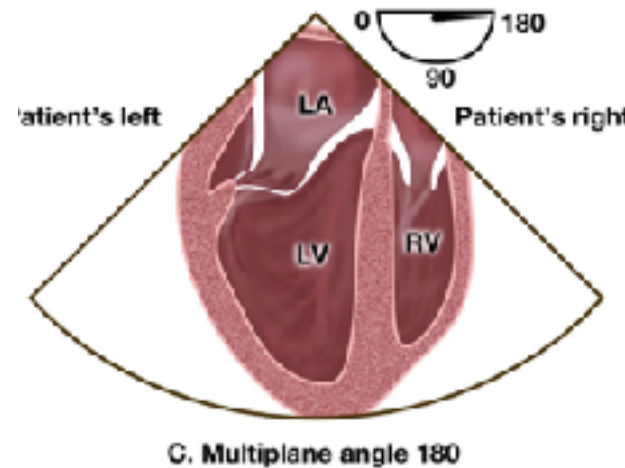
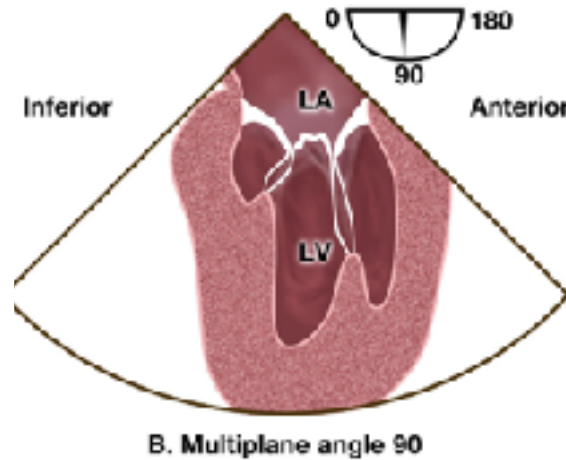
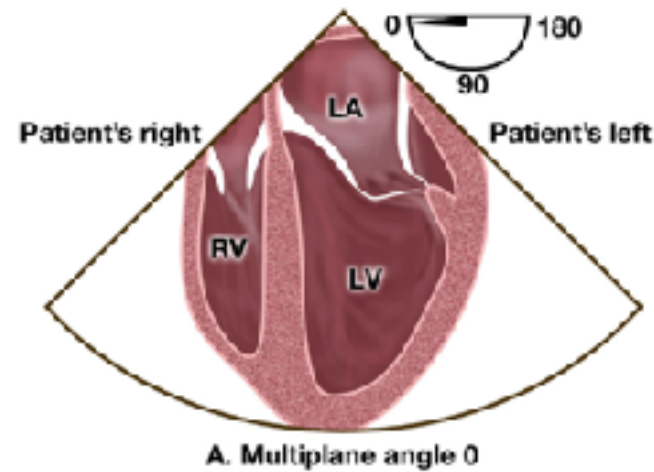
# How to define degree ?



0°

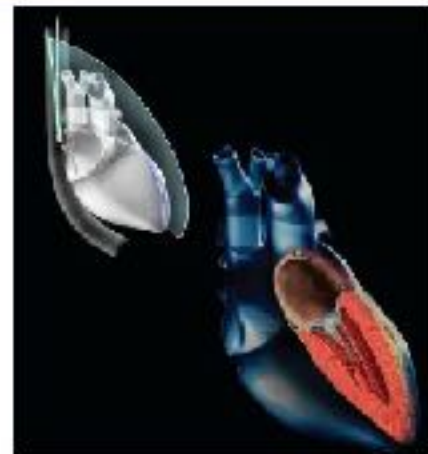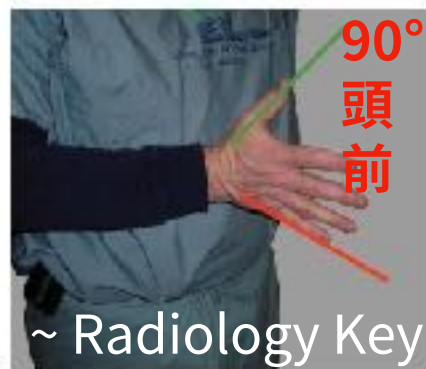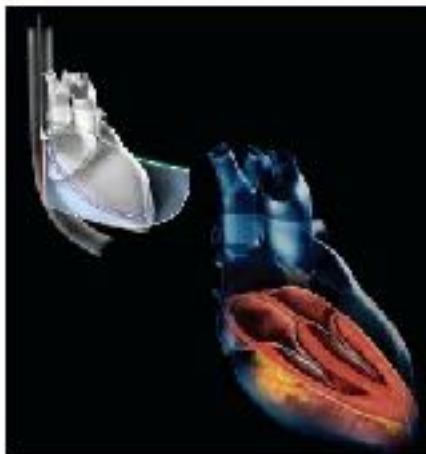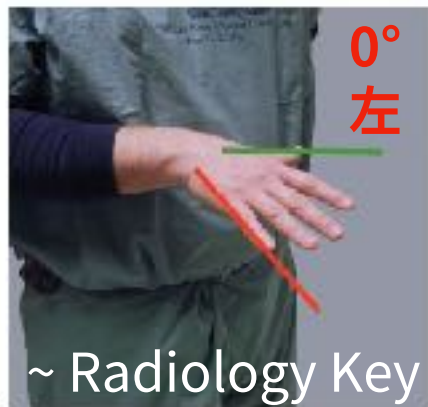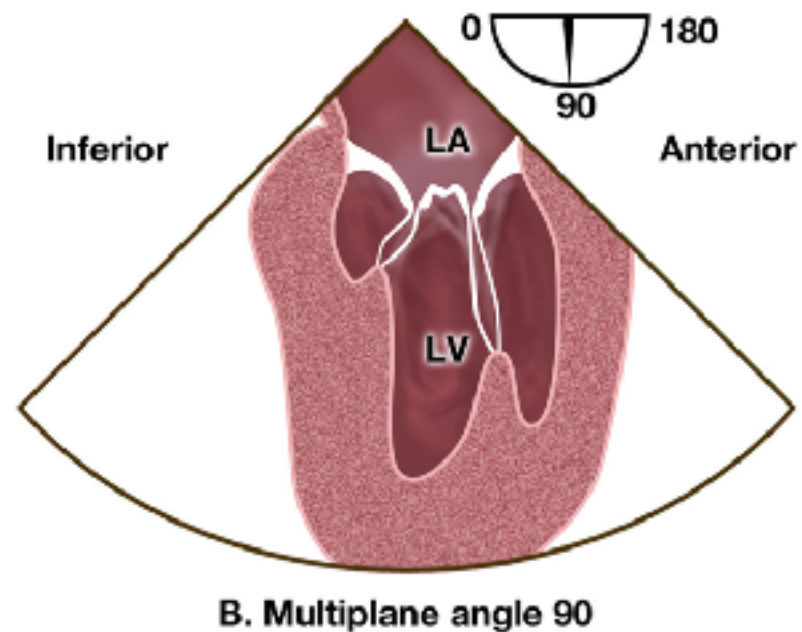
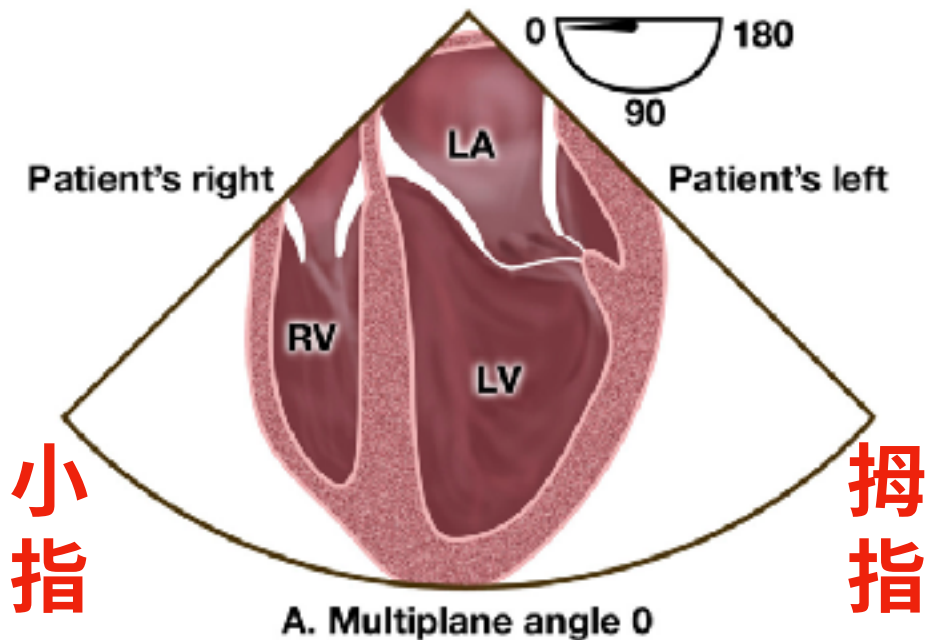
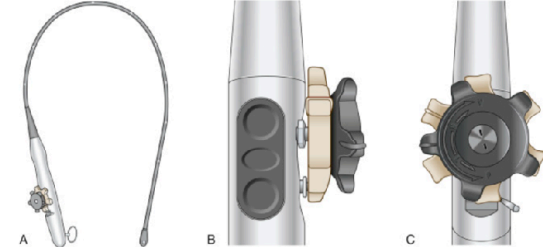
90°

180°



最接近TEE的腔室為 **LA**

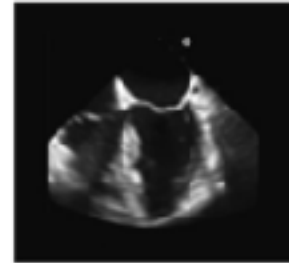
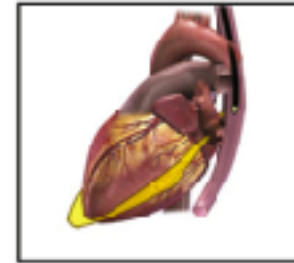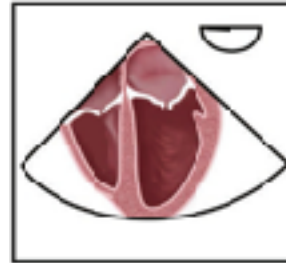# 確認0°和90°的定位



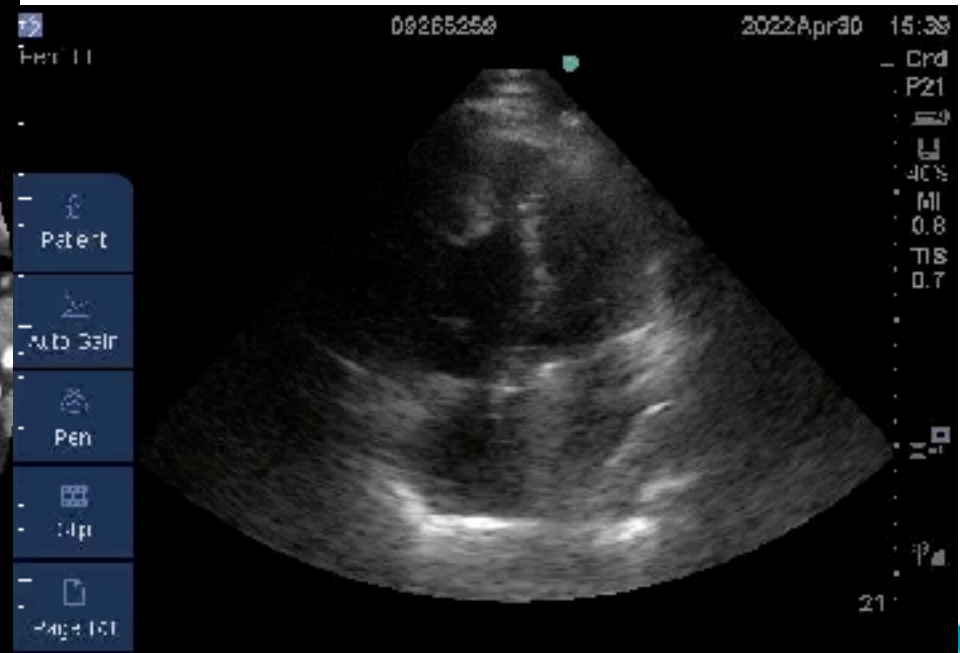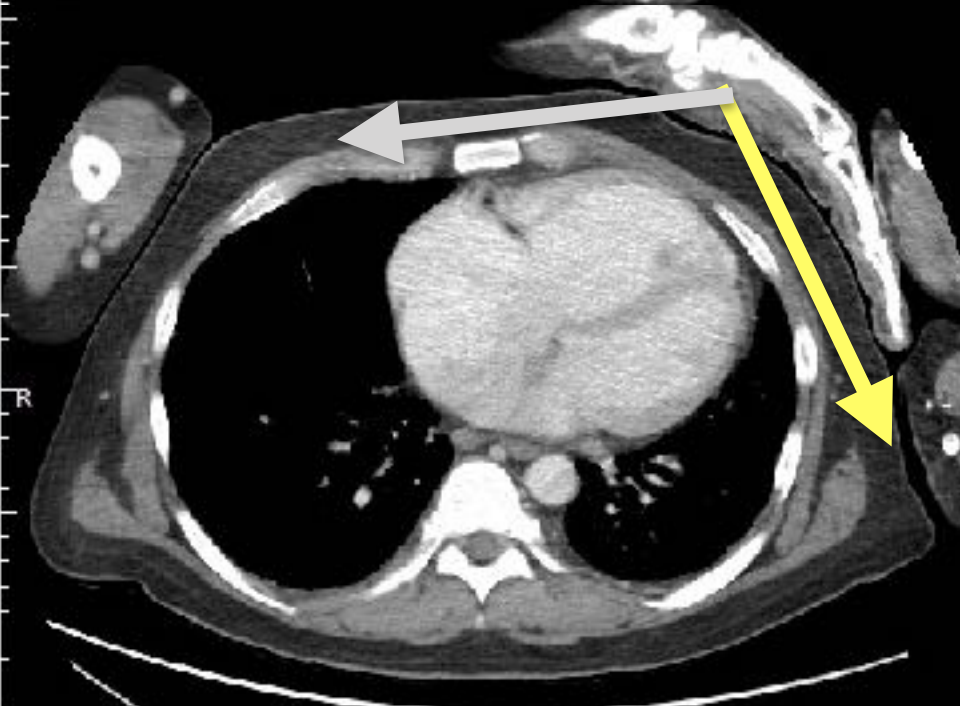
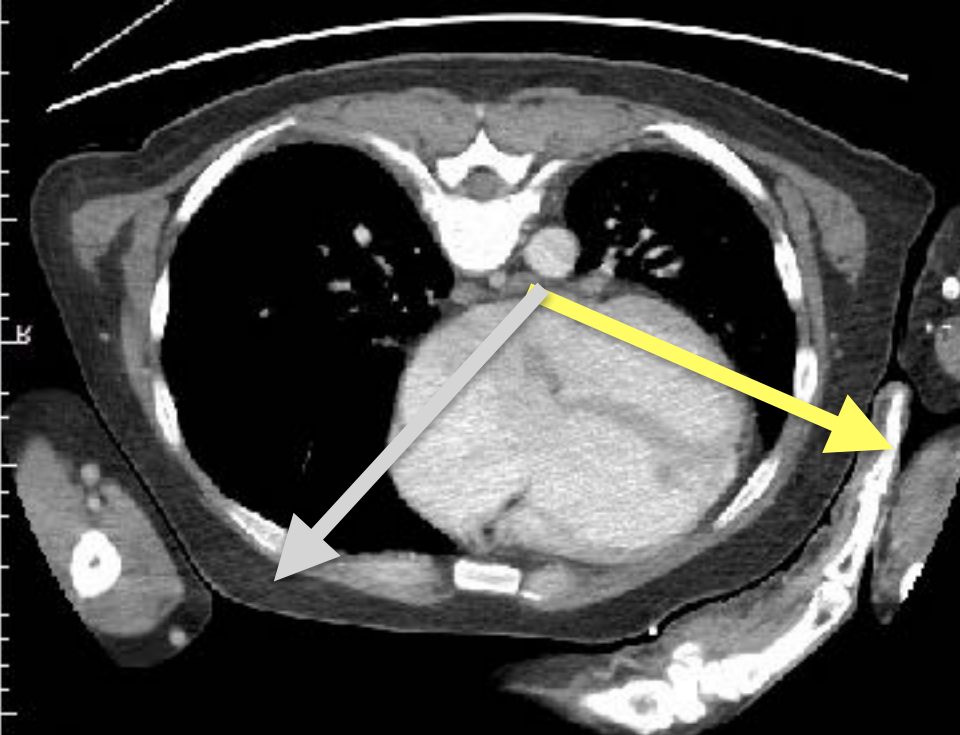


# TEE: ME-4C (0°)

ME 4-Ch



# TTE: A4C








# WHY TEE IN ER ?

Resuscitative TEE Project  
<https://www.resuscitativetee.com/>



American College of  
Emergency Physicians®

ADVANCING EMERGENCY CARE 


# POLICY STATEMENT

Approved April 2017

## *Guidelines for the Use of Transesophageal Echocardiography (TEE) in the ED for Cardiac Arrest*

補足TTE不完美之處

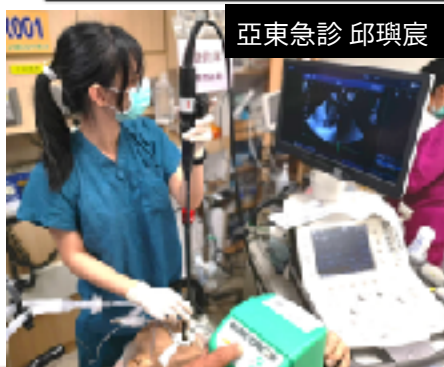中斷 壓胸 骨頭 肺臟 血管



American College of  
Emergency Physicians®

ADVANCING EMERGENCY CARE 

# POLICY STATEMENT




亞東急診 邱瑛宸

## *Guidelines for the Use of Transesophageal Echocardiography (TEE) in the ED for Cardiac Arrest*

**對象：急救 / 插管患者**

**禁忌：食道、氣管、頸部損傷**





American College of  
Emergency Physicians®

ADVANCING EMERGENCY CARE 

# POLICY STATEMENT

Approved April 2017

## *Guidelines for the Use of Transesophageal Echocardiography (TEE) in the ED for Cardiac Arrest*

**需具備資格**

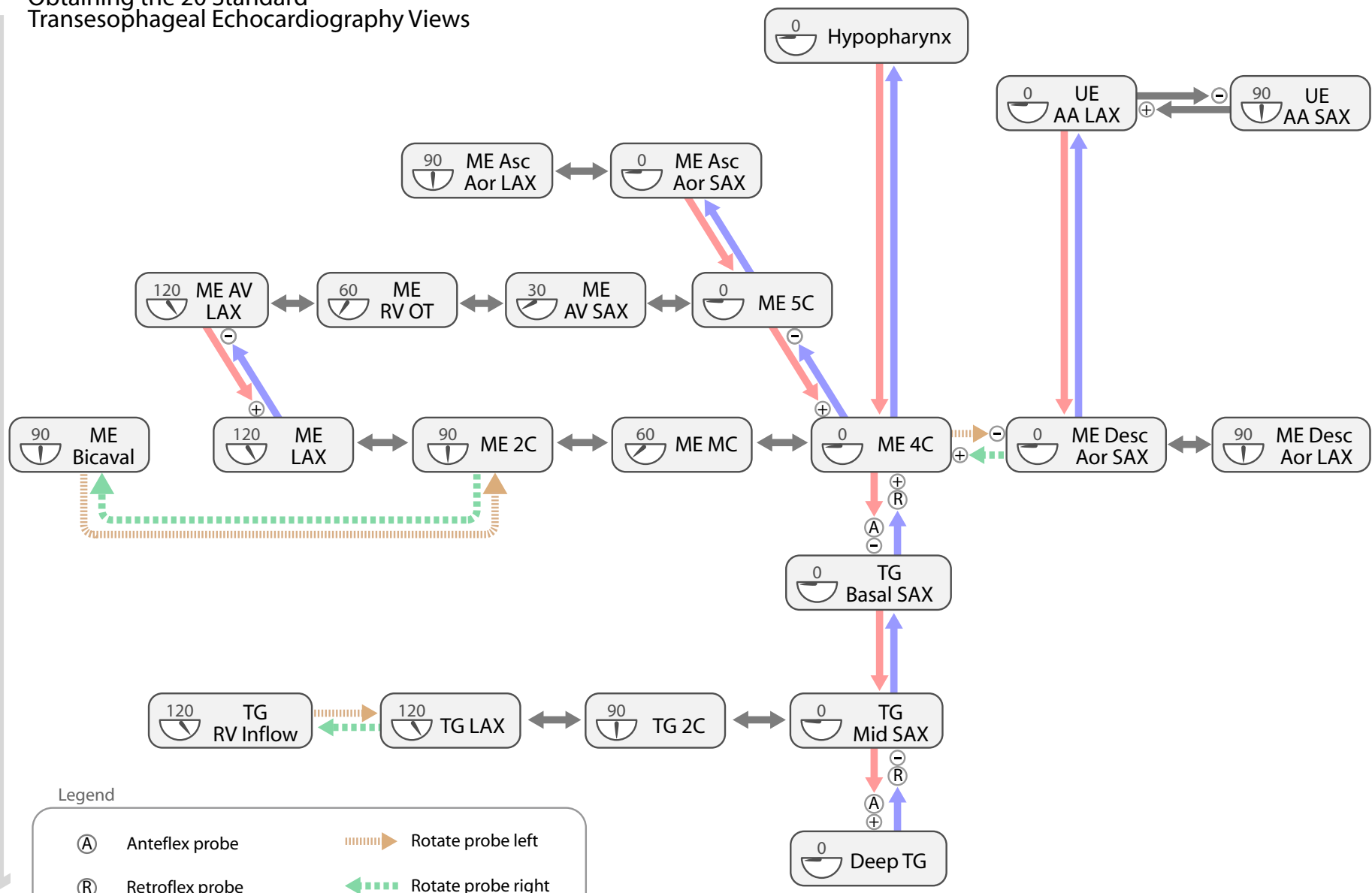
**初學者: 25例 / TTE經驗: 10例**





# Obtaining the 20 Standard Transesophageal Echocardiography Views

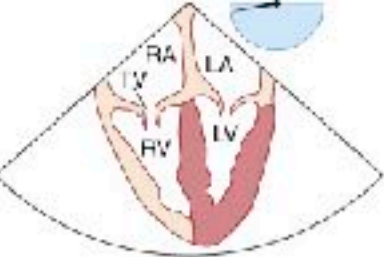
Probe Depth



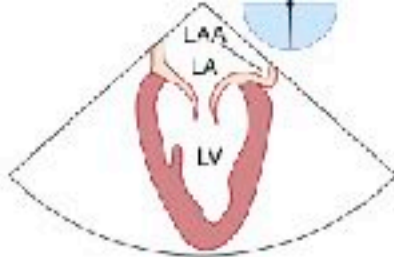
## Legend

Ⓐ	Anteflex probe	⤵	Rotate probe left
Ⓔ	Retroflex probe	⤵	Rotate probe right
⊖	Decrease omniplane depth (display depth)	↓	Increase probe depth
⊕	Increase omniplane depth (display depth)	↑	Decrease probe depth
↔	Change omniplane angle	90°	Omniplane angle

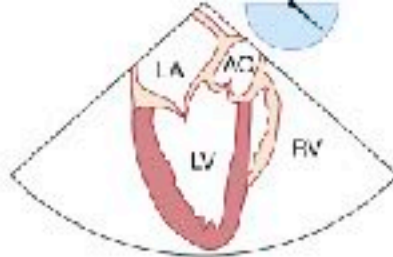
2C - Two Chamber	Asc Aor - Ascending Aortic	ME - Mid Esophageal
4C - Four Chamber	Desc Aor - Descending Aortic	RV - Right Ventricle
5C - Five Chamber	OT - Outflow Tract (Inflow-Outflow)	SAX - Short Axis
AA - Aortic Arch	LAX - Long Axis	TG - Transgastric
AV - Aortic Valve	MC - Mitral Commissural	UE - Upper Esophageal



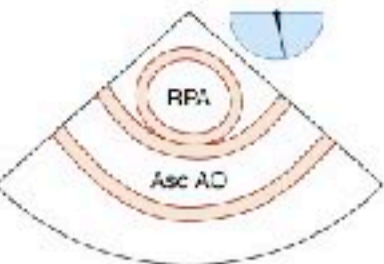
A. ME Four Chamber



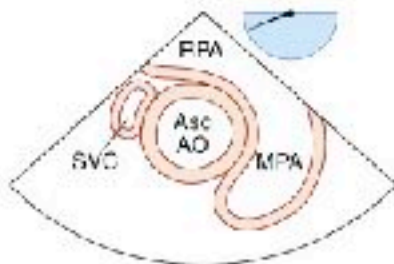
B. ME Two Chamber



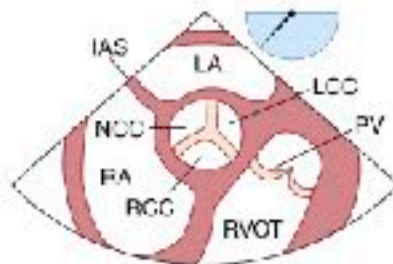
C. ME LAX



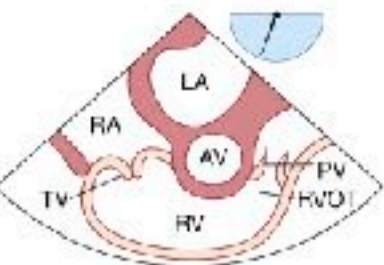
D. ME Asc Aortic LAX



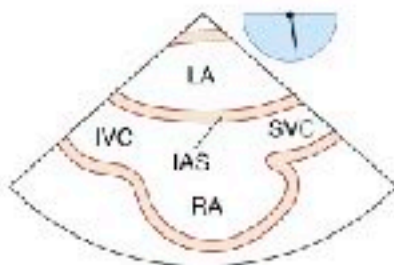
E. ME Asc Aortic SAX



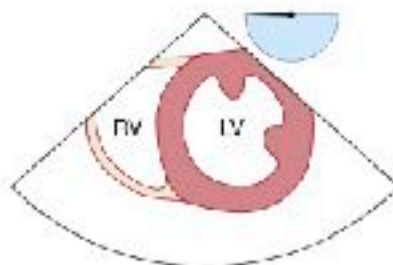
F. ME AV SAX



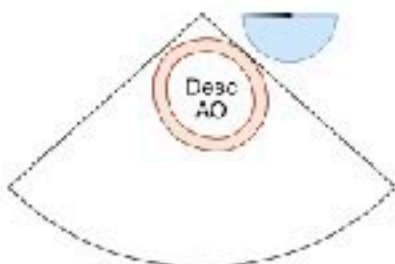
G. ME IV Inflow-Outflow



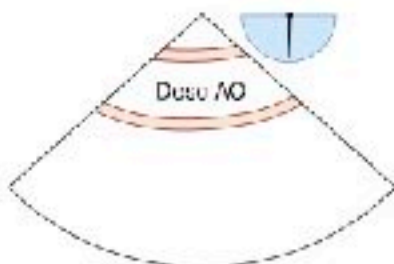
H. ME B-caval



I. TG Mid SAX



J. Desc Aortic SAX



K. Desc Aortic LAX

# ASE/SCA

# 11

# Basic

# Peri-OP

# Views

# RESUSCITATIVE TEE VIEW GUIDE

**ME 4C** RL, LA, RV LV  
180° TV anterior

• Pathology pericardium • BPPV  
• LADV size & function • Mitral pathology

**ME LAX** LRA, RZ, AZ

• Quality of CO (MPO) • LV function  
• Pathology MA • Pathology LV

**TG SAX PAP** LV, RV

• LV function • RVNA • Pathology pericardium

**ME Bicaval** VL, VA, SVC

• Diaphragm position • Venous position  
• BPPV • Volume measurement

**ME 2C** L, R, LV, RZ, LBB

• Pathology LV • LV size  
• Pathology MV • Thrombus in LA

**ME AV SAX** Cusp of A, LA, RA, Aortic valve

• Aortic cusp • BPPV  
• Pathology RVOT • RCA and LCA

**ME Asc Ao SAX** Distal PA, Heart PA

• Asc Aorta • Pathology of PA • Pathology pericardium

**ME Asc Ao LAX** Rgt. LA, Asc. Ao, Aorta

• Diaphragm position • Pathology PA  
• Collateral vessels • LVAD

**ME RV I-O** LA, RV, TR, RVOT

• Pathology RVOT • Tricuspid TV

**ME DTA SAX** RRA

• BPPV • Aortic • LA DDMO

**ME DTA LAX** RRA

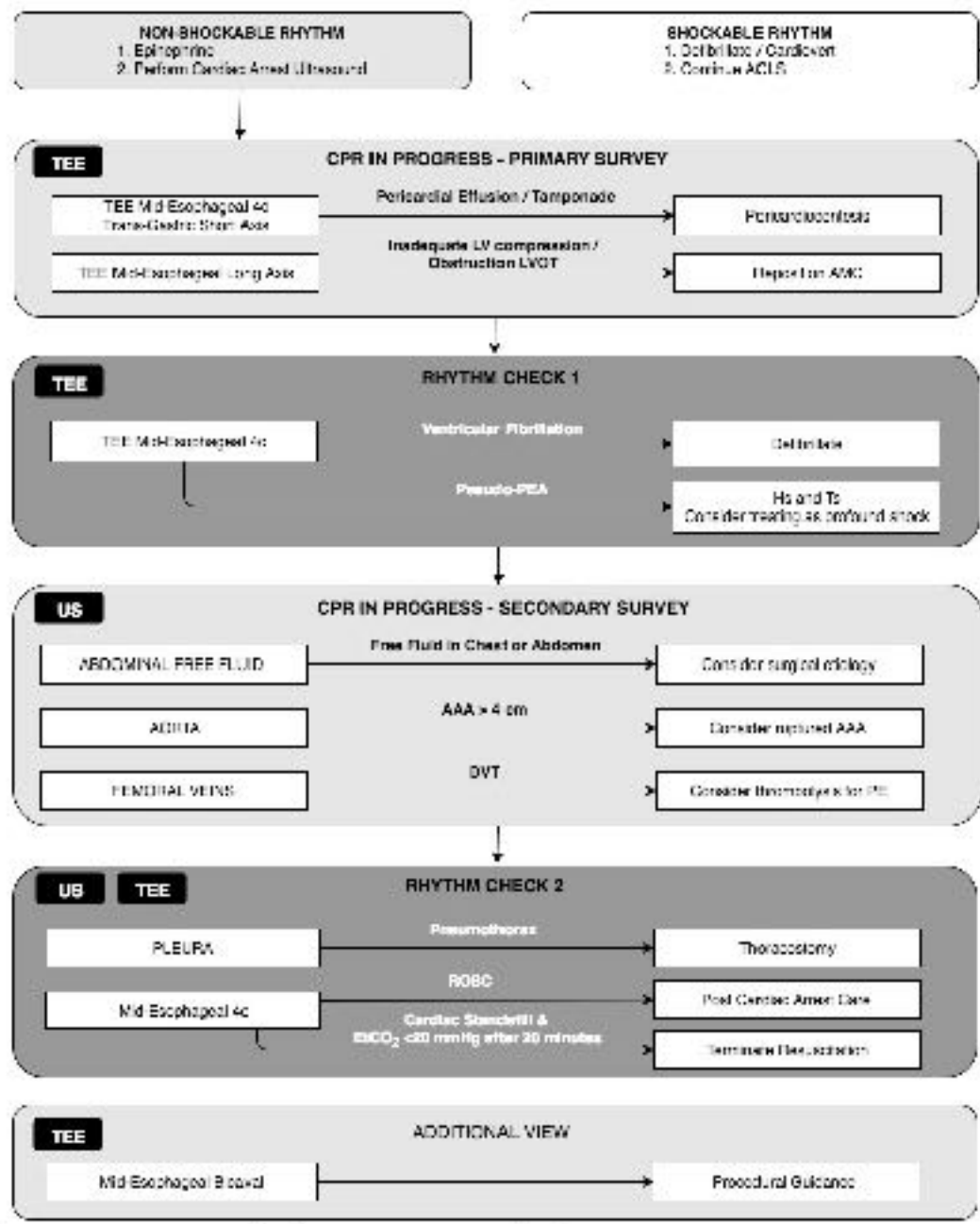
• Flow reversal LA • BPPV  
• Engage • LA DDMO

**Deep TG SC** LV, RV, AV, RV, LVOT

• Deep RV TV • LVOT

# TEE-GUIDED CARDIAC ARREST RESUSCITATION

R. Poonjara, R. F. Farnham



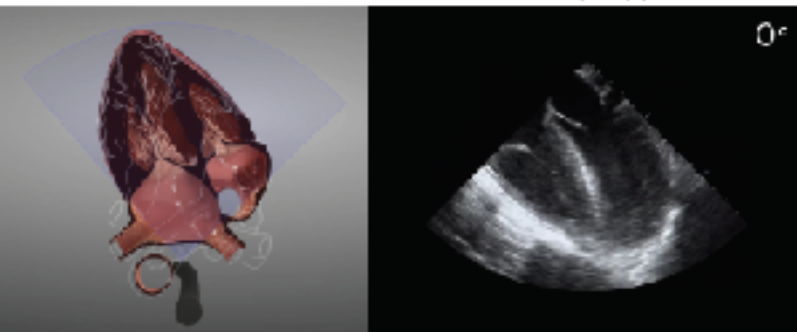




# RESUSCITATIVE TEE VIEW GUIDE

## ME 4C

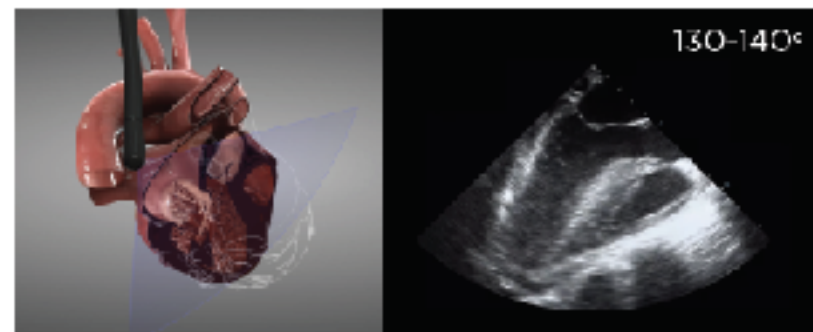
RA, LA, RV, LV  
MV, TV, pericardium



- Pathology pericardium
- RWMA
- LV/RV size & function
- Valvular pathology

## ME LAX

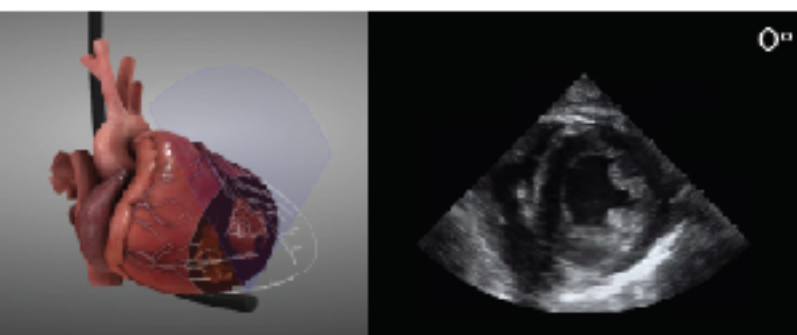
LV, LA, MV, AV



- Quality of CPR (AMC)
- Pathology MV
- LV function
- Pathology AV

## TG SAX PAP

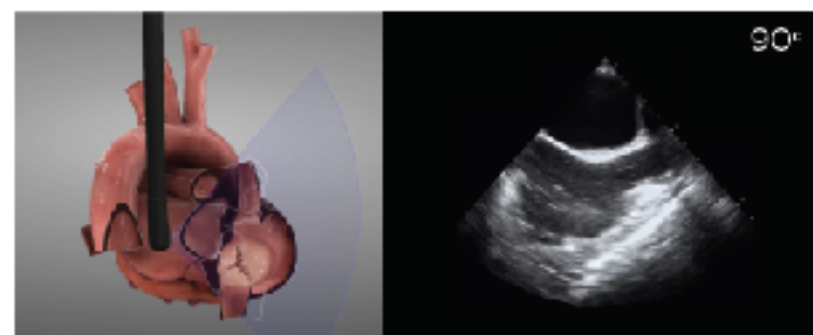
LV, RV



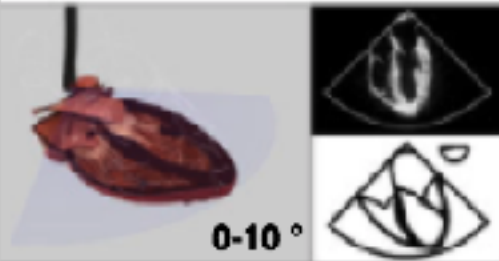



- LV function
- RWMA
- Pathology pericardium

## ME Bicaval

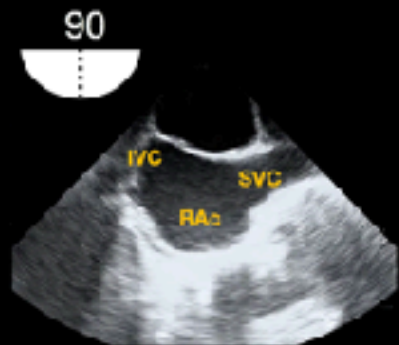
IVC, RA, SVC



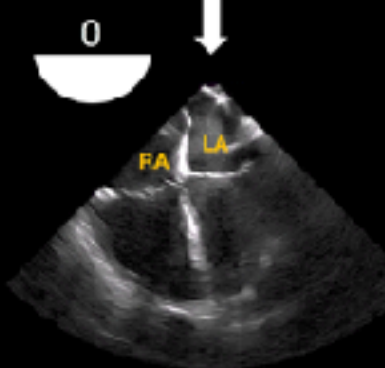
- Procedure guidance
- ECMO
- Venous guidewires
- Volume responsiveness

RESUSCITATIVE TEE views	Cardiac structures	TTE equivalent	Clinical Application
<b>Mid-esophageal 4 chamber (ME4C)</b>	 <p>0-10 °</p>	Four chambers, mitral and tricuspid valves and pericardium	Pericardial effusion Intra ventricular thrombus LV/RV function Valve lesions and dysfunction
<b>Mid-esophageal long axis (MELAX)</b>	 <p>120-140 °</p>	Left ventricle, left atrium, mitral and aortic valves	Quality of CPR LV function Pericardial effusion Mitral / aortic valve dysfunction
<b>Transgastric short (TG)</b>	 <p>0-20 °</p>	Left ventricle	Parasternal short axis Left ventricular function (RWMA) Pericardial effusion
<b>Mid-esophageal Bicaval (ME Bicaval)</b>	 <p>90-110 °</p>	Simultaneous view of IVC, RA and SVC	N/A Procedural guidance Volume responsiveness

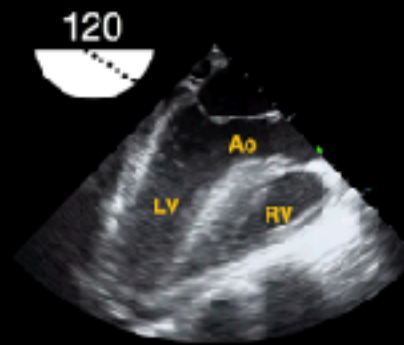
**HYPOPHARYNX**



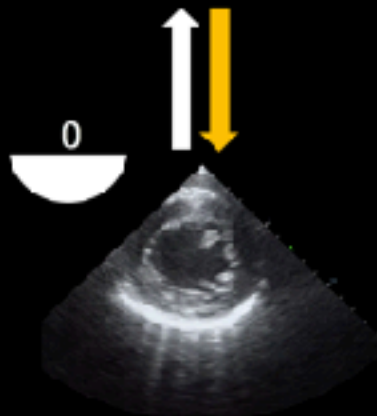
**ME Bicaval**



**ME 4C**

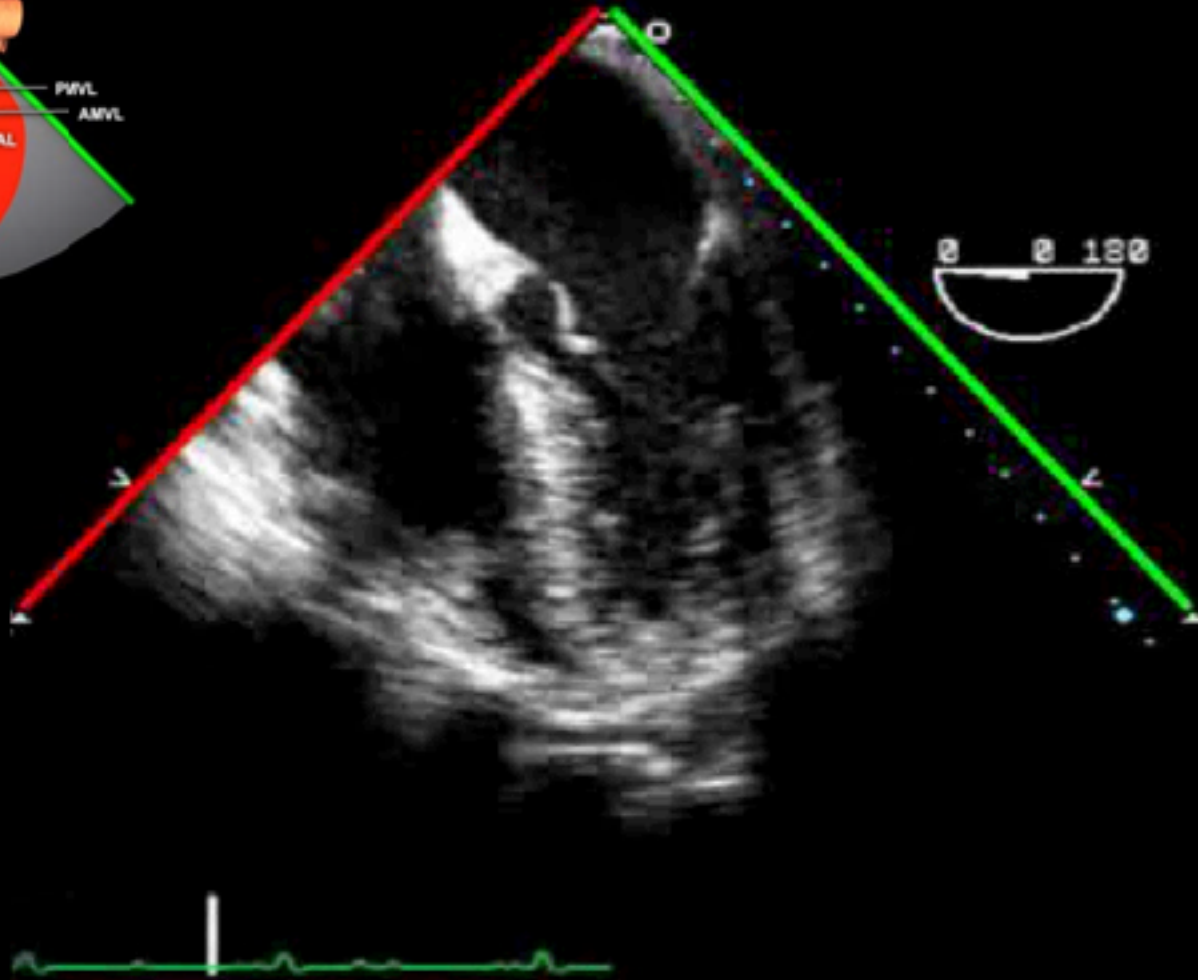
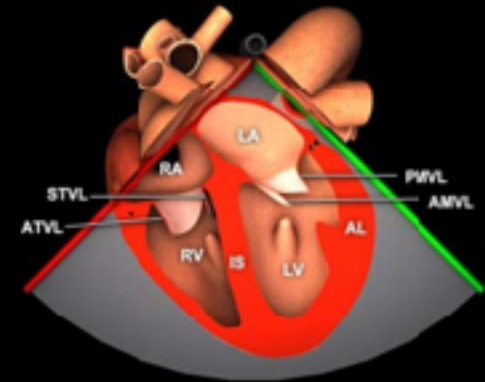


**ME LAX**



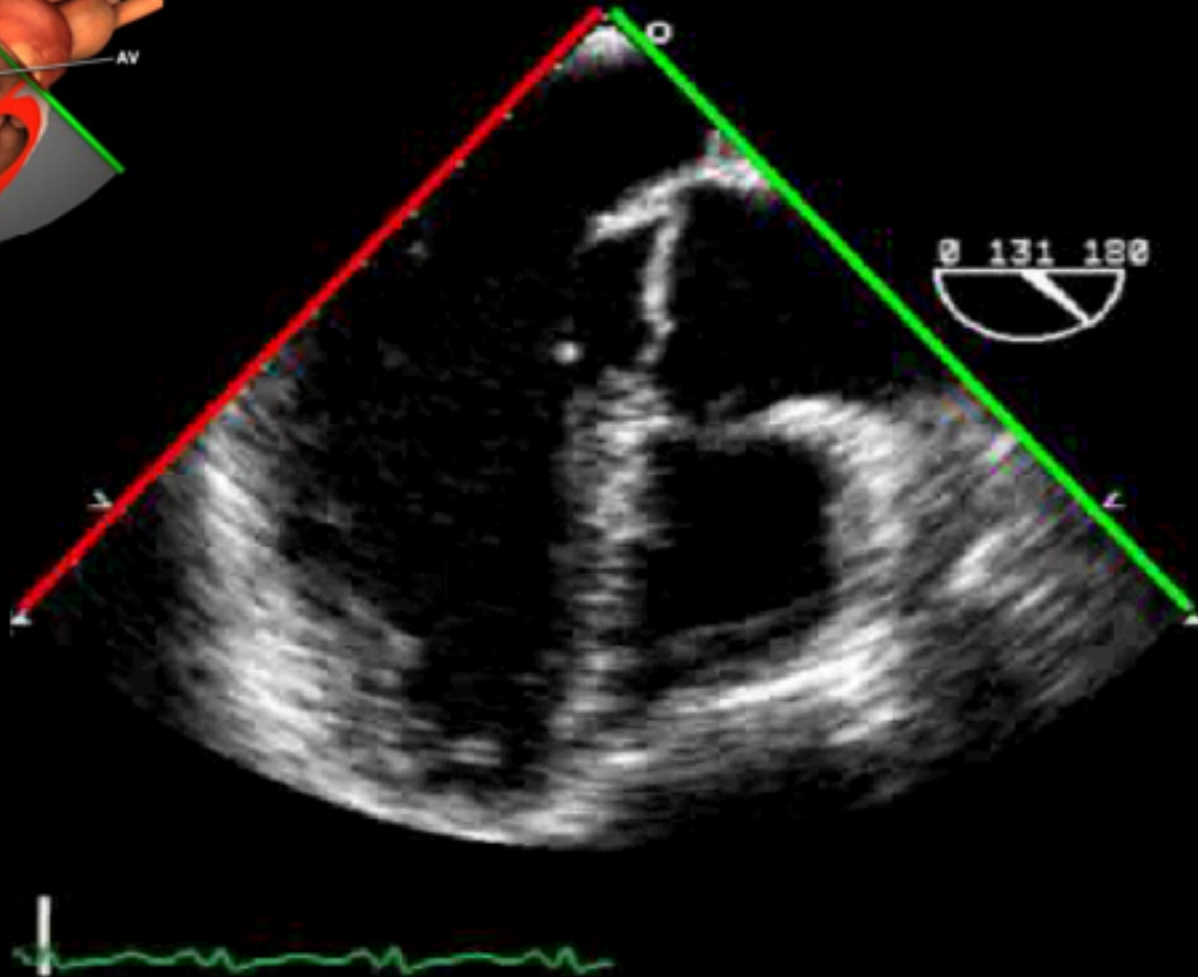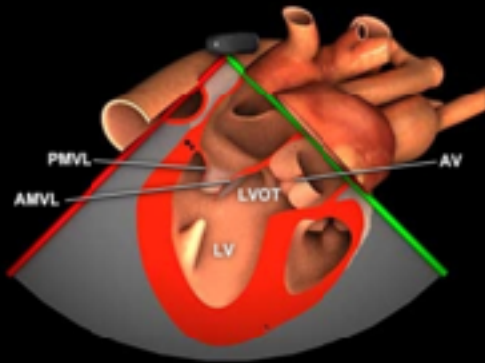
**TG SAX**

# ME 4C view (0°)



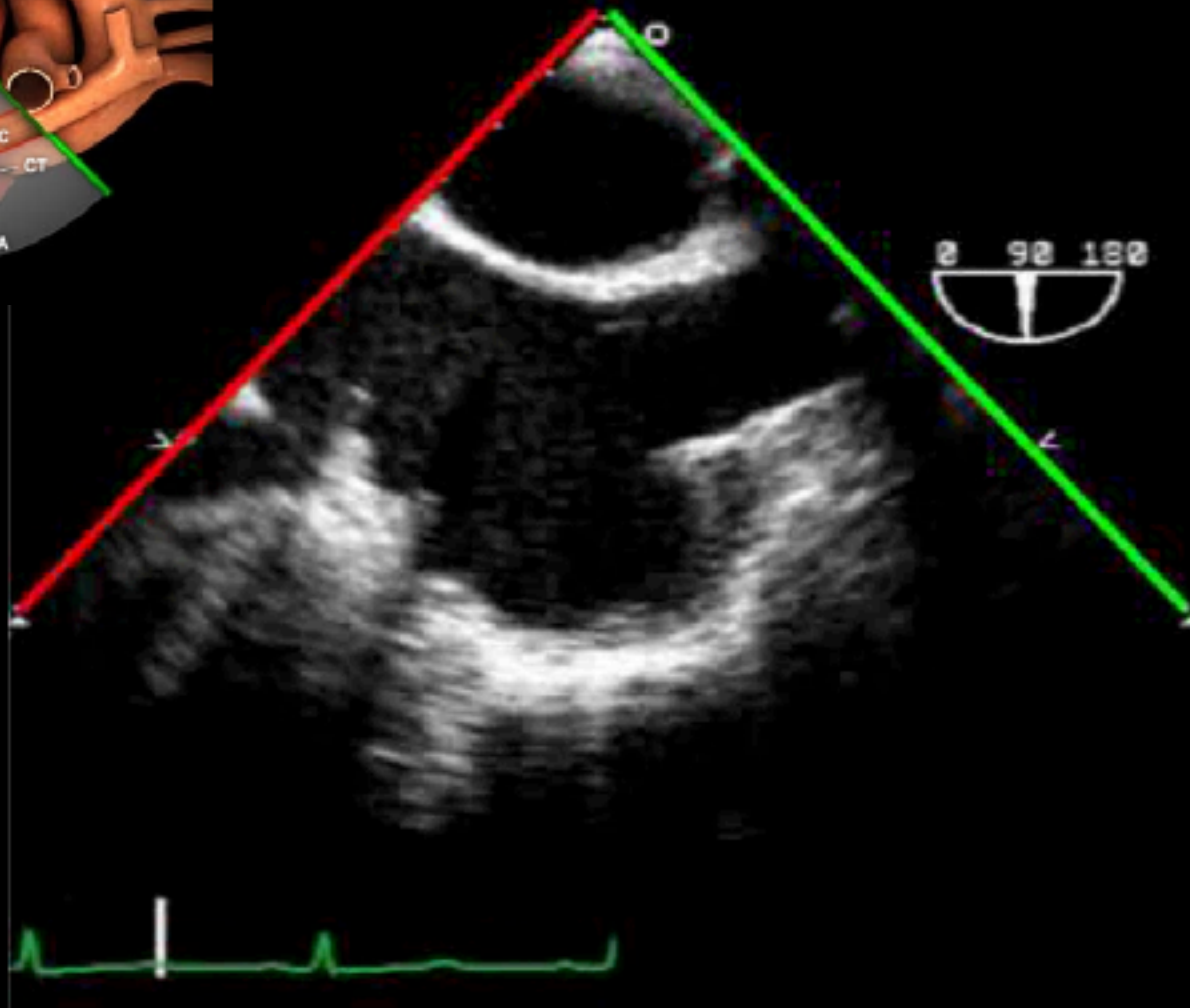
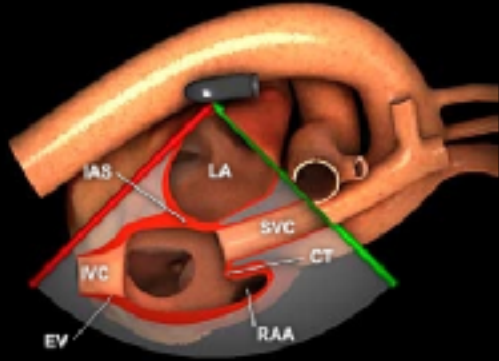


# ME LAX view (120°)



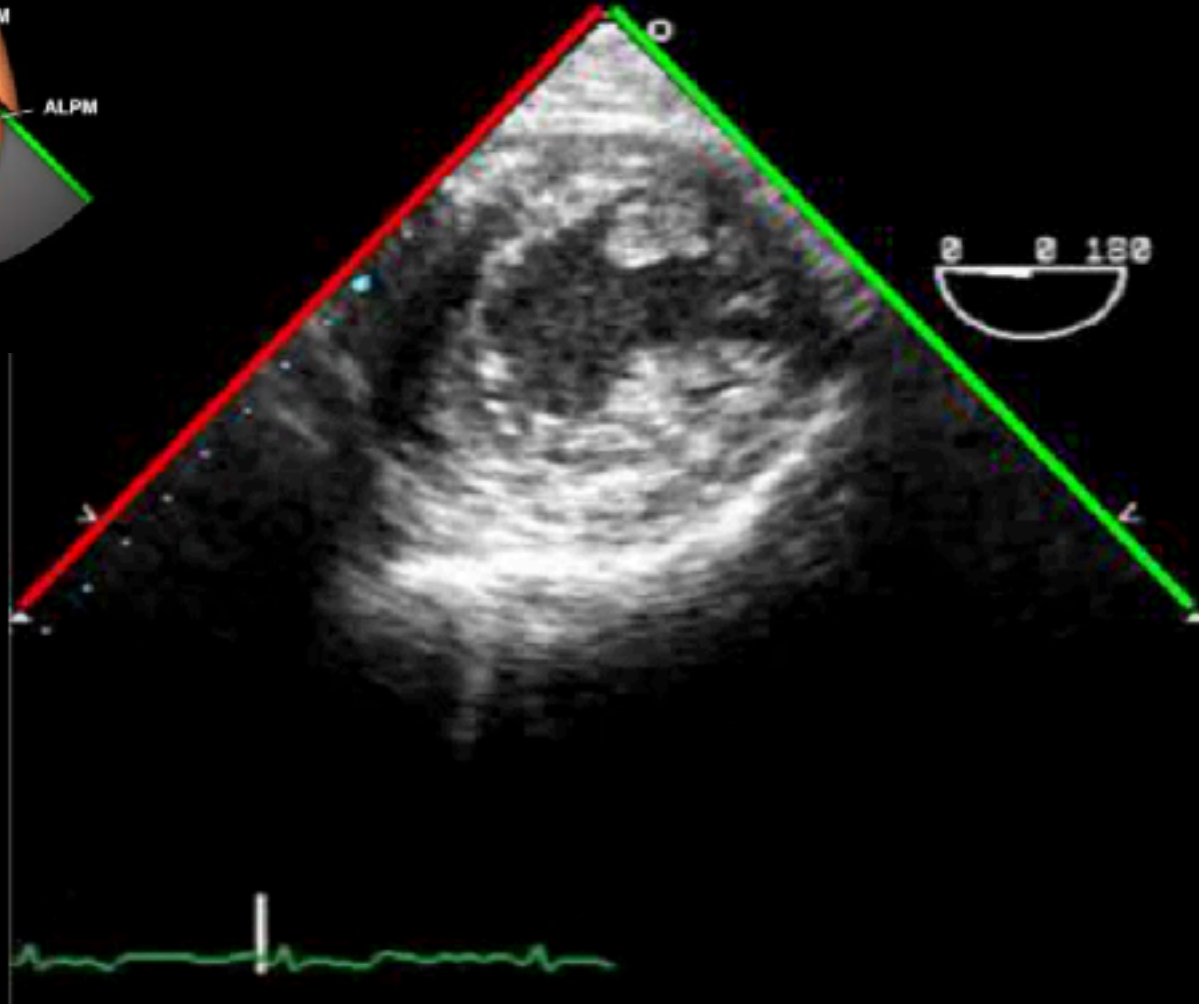
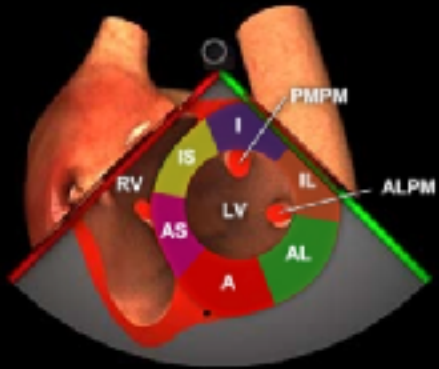


# ME Bicaval view (90°)



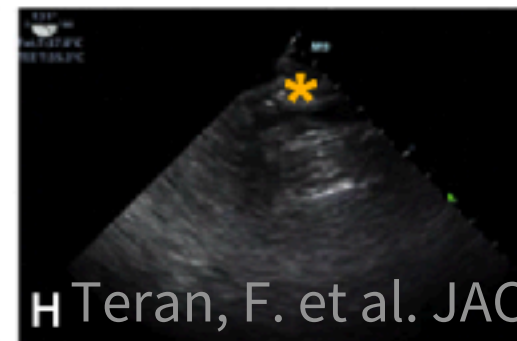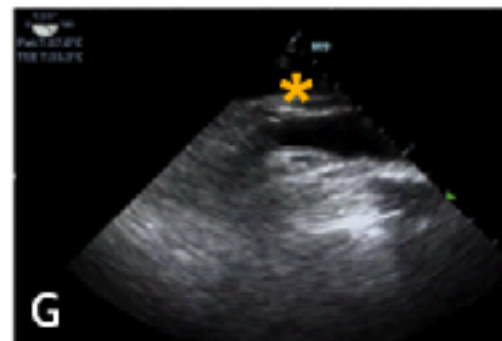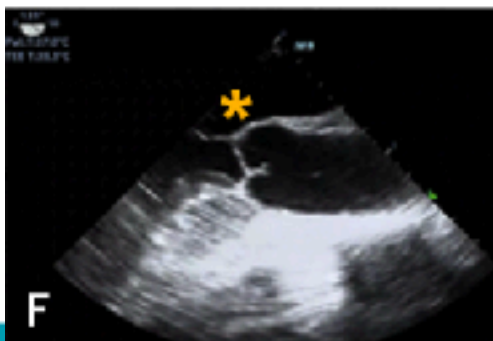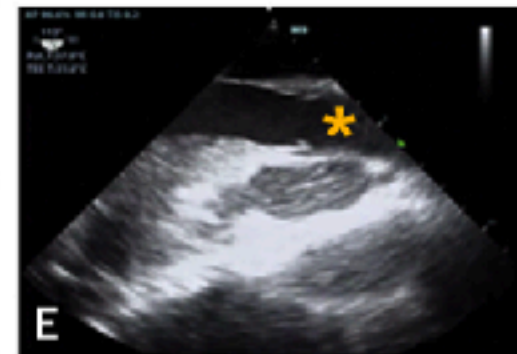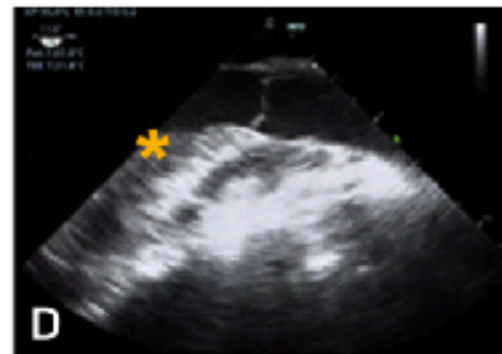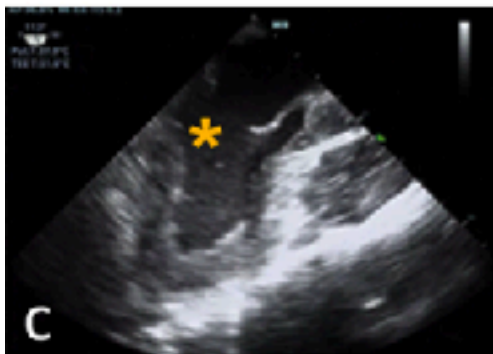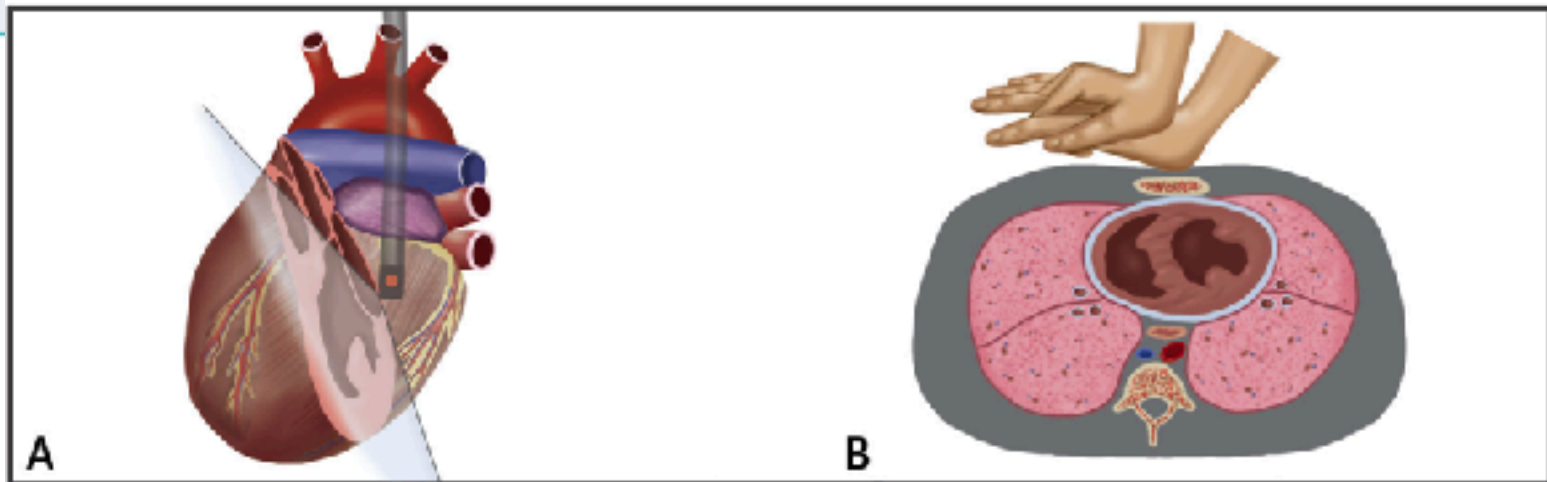


# TG Mid SAX view (0°)

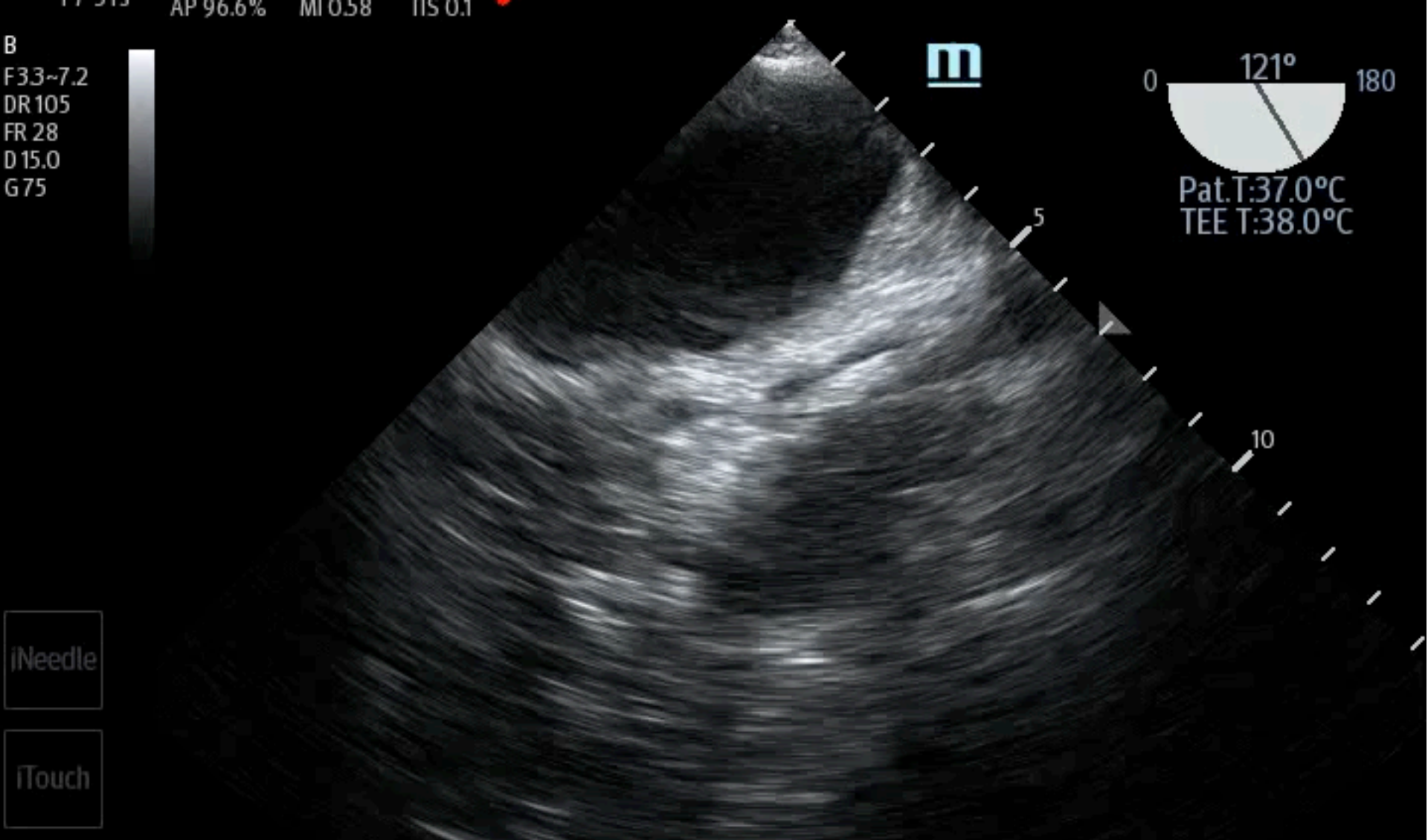


## Enhancing Quality of CPR

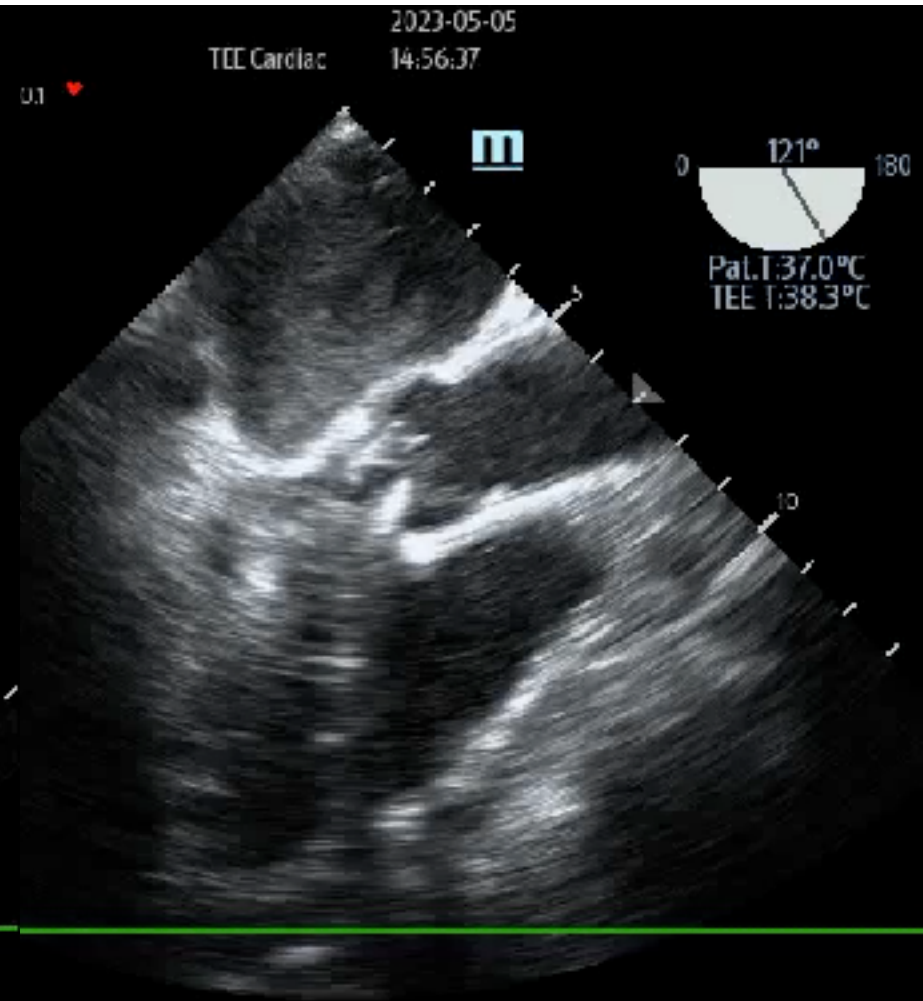
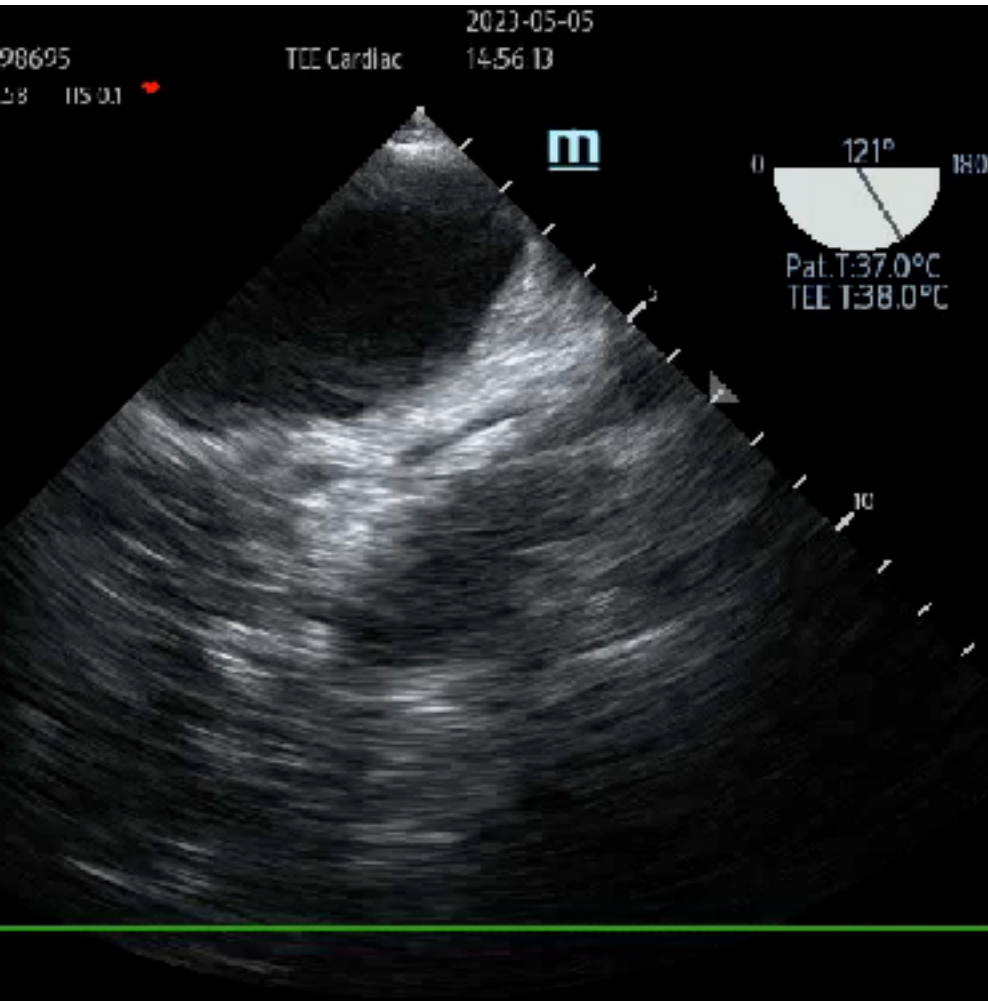
- Minimize interruptions of CPR
- Allow real-time feedback of quality of chest compressions (i.e., obstruction of LVOT/Ao)







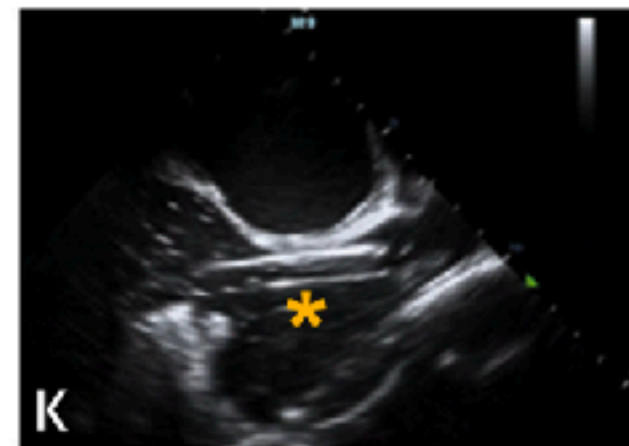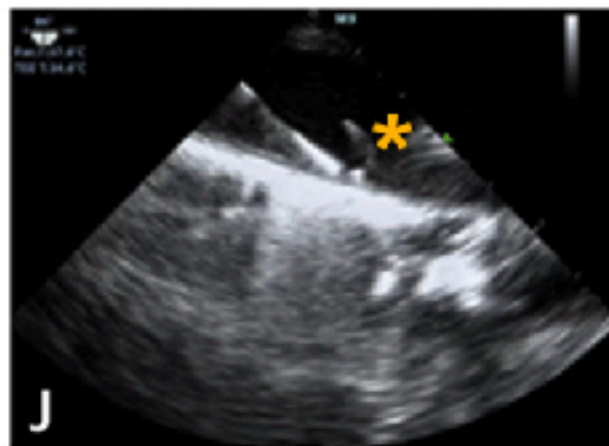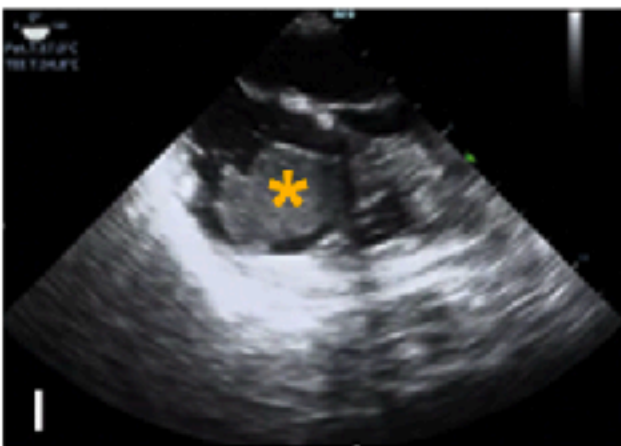# TEE GUIDED COMPRESSION



# TEE GUIDED COMPRESSION

## Diagnostic Role/Procedural Guidance

- Identification of potentially treatable pathologies (i.e., cardiac tamponade)
- Intra- or peri-arrest procedural guidance (i.e., ECMO)



## Prognostic Role

- Characterization of myocardial activity (i.e., cardiac standstill, organized vs. disorganized contractions)
- Continuous imaging of cardiac function



TE7 ACE

2023-05-05

00398695

TEE Cardiac

15:03:13

P7-3Ts

AP 96.6%

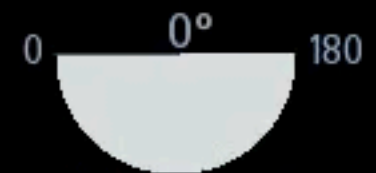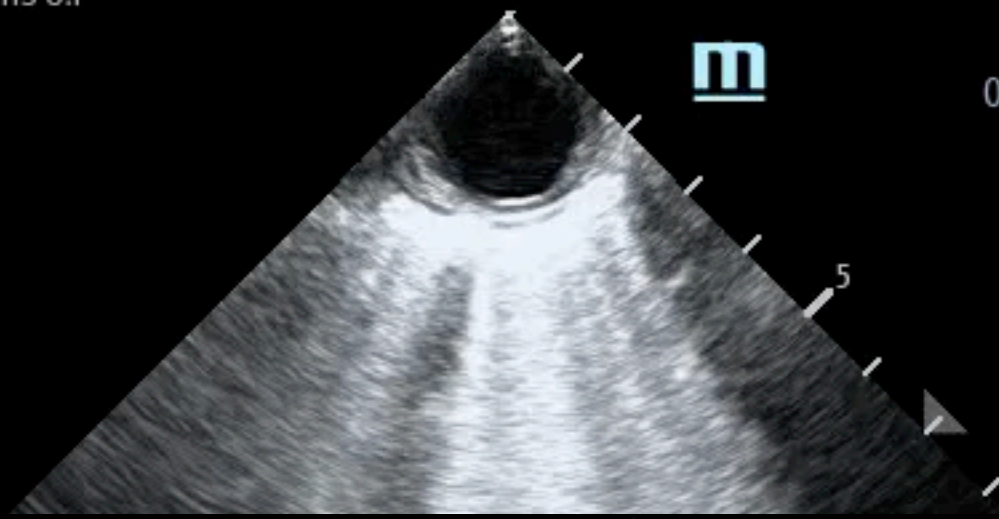
MI 0.58

TIS 0.1



B

F33~7.2  
DR 105  
FR 28  
D 15.0  
G 75



Pat.T:37.0°C  
TEE T:38.5°C

TE7 ACE

2023-05-05

00398695

TEE Cardiac

15:02:31

P7-3Ts

AP 96.6%

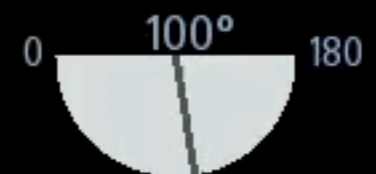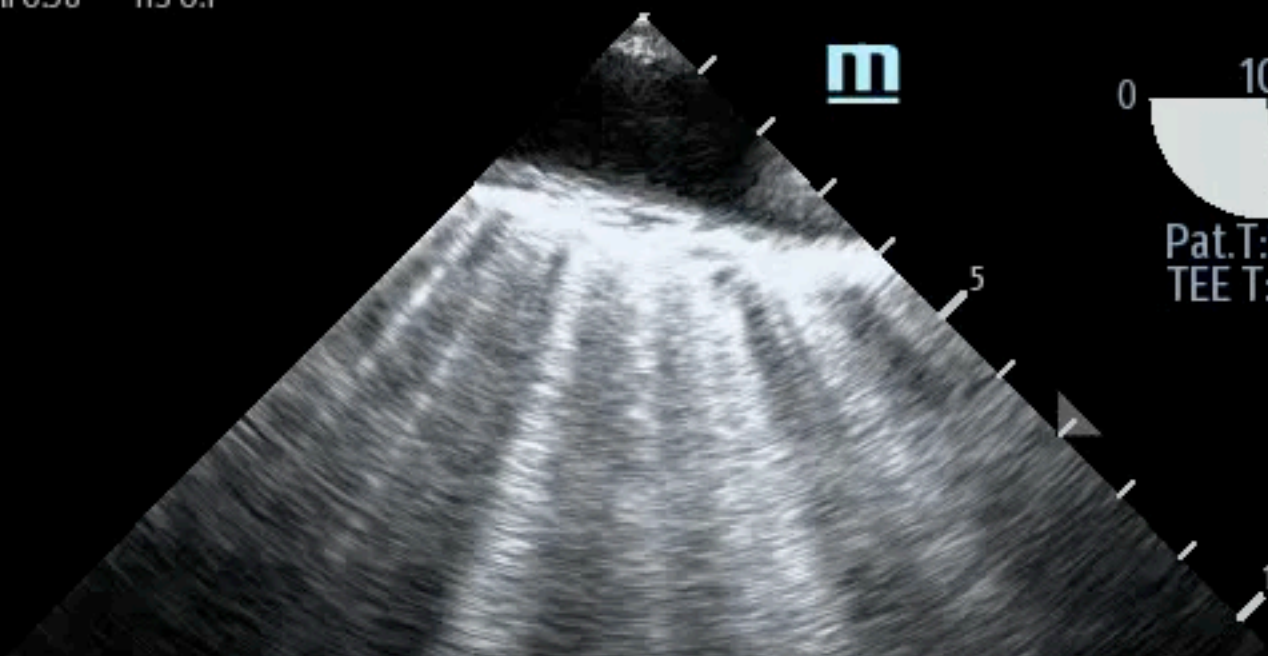
MI 0.58

TIS 0.1



B

F33~7.2  
DR 105  
FR 28  
D 15.0  
G 75



Pat.T:37.0°C  
TEE T:38.6°C



P7-3Ts

AP 96.6%

MI 0.58

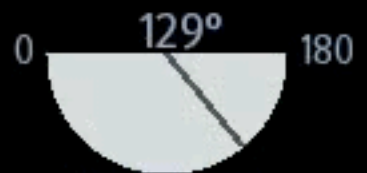TIS 0.1



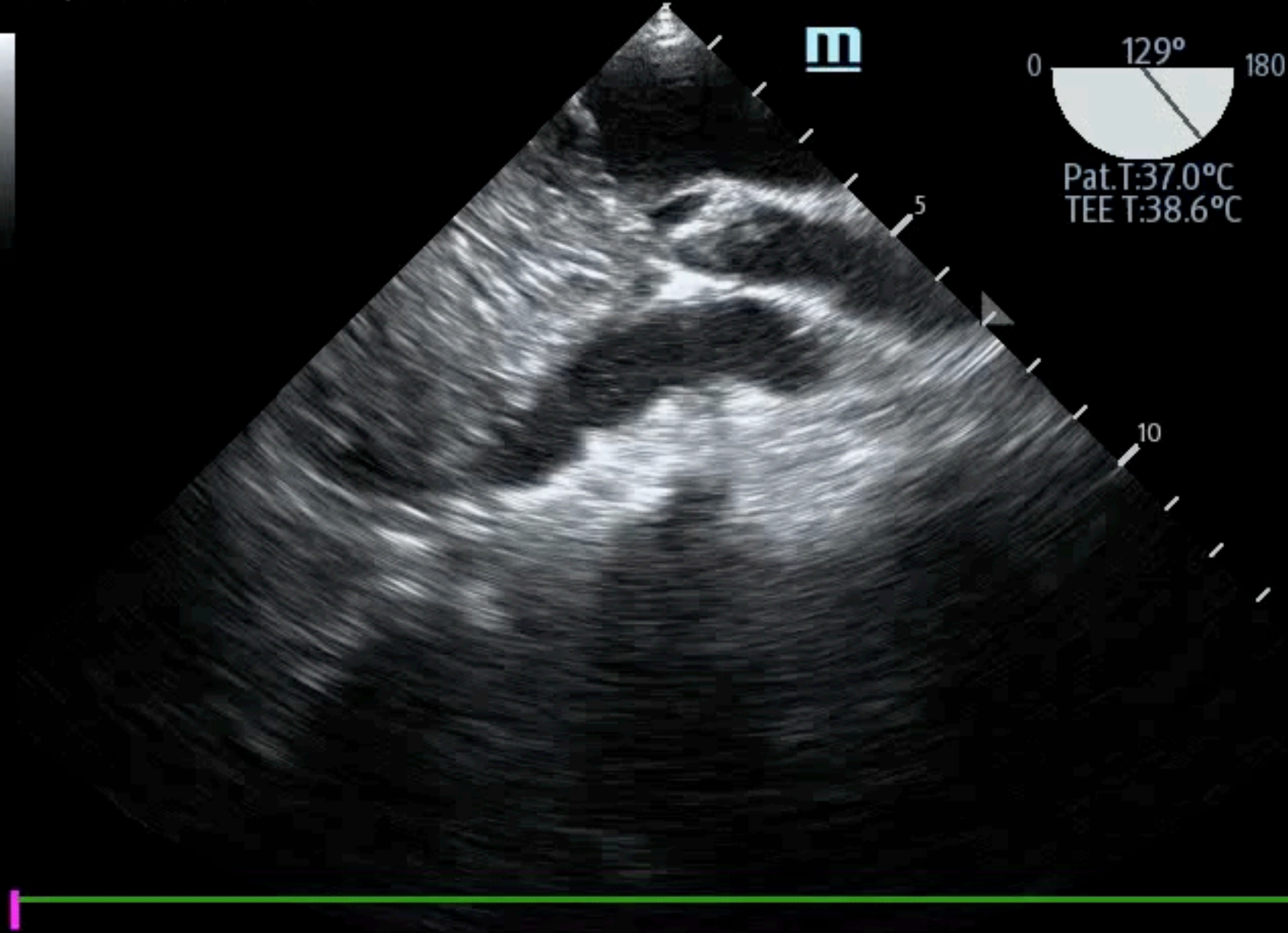
B  
F33~7.2  
DR 105  
FR 28  
D 15.0  
G 75



**m**



Pat.T:37.0°C  
TEE T:38.6°C



iNeedle

iTouch



P7-3Ts

AP 96.6%

MI 0.58

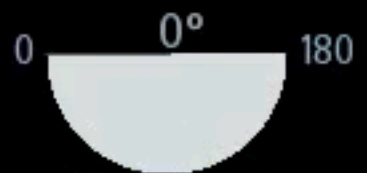TIS 0.1



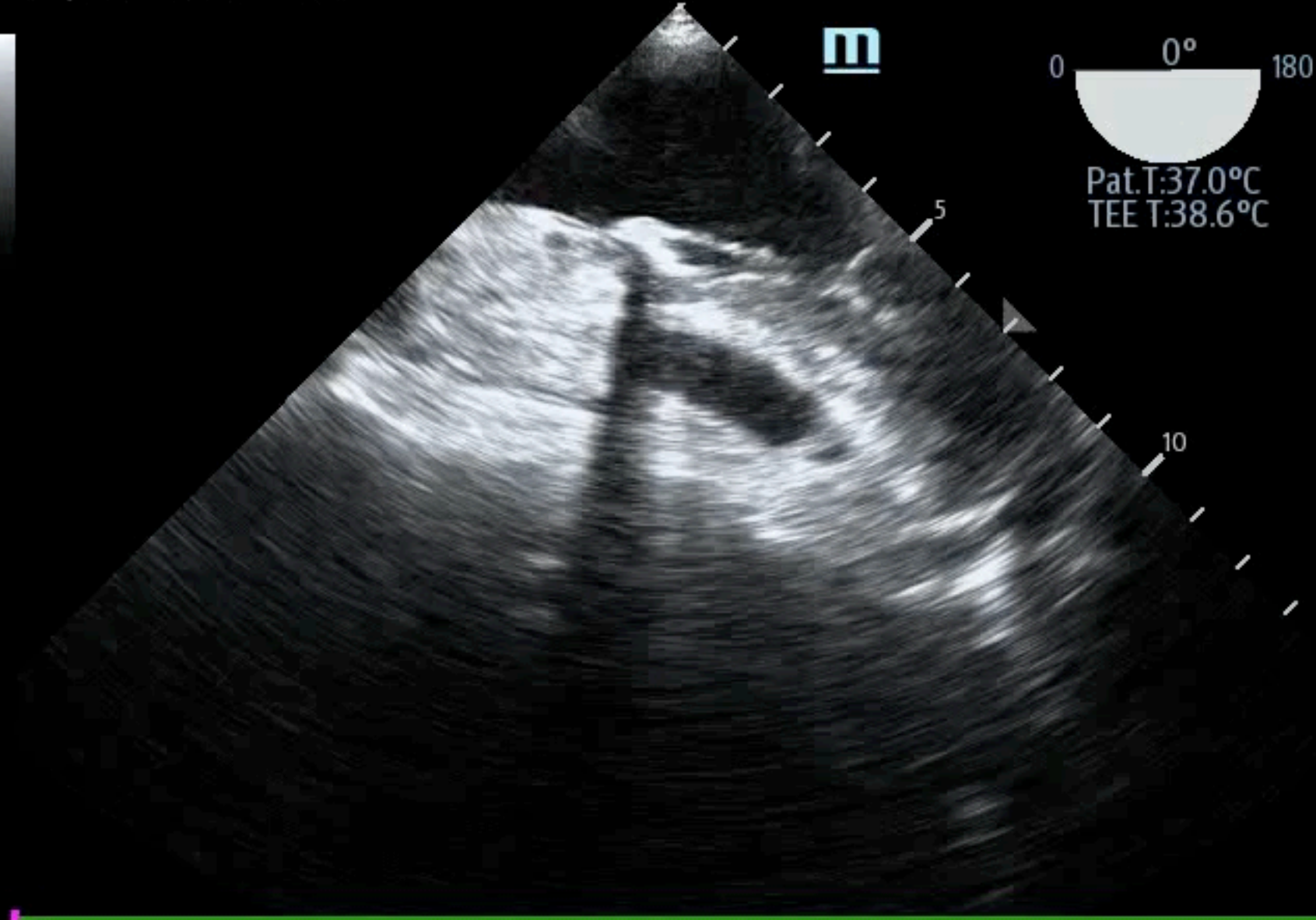
B  
F33~7.2  
DR 105  
FR 28  
D 15.0  
G 75



m



Pat.T:37.0°C  
TEE T:38.6°C



iNeedle

iTouch



P7-3Ts

AP 96.6%

MI 0.58

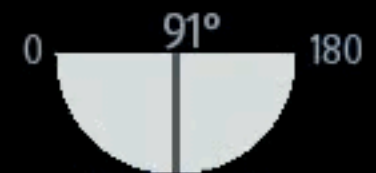TIS 0.1



B  
F33~7.2  
DR 105  
FR 28  
D 15.0  
G 75



m



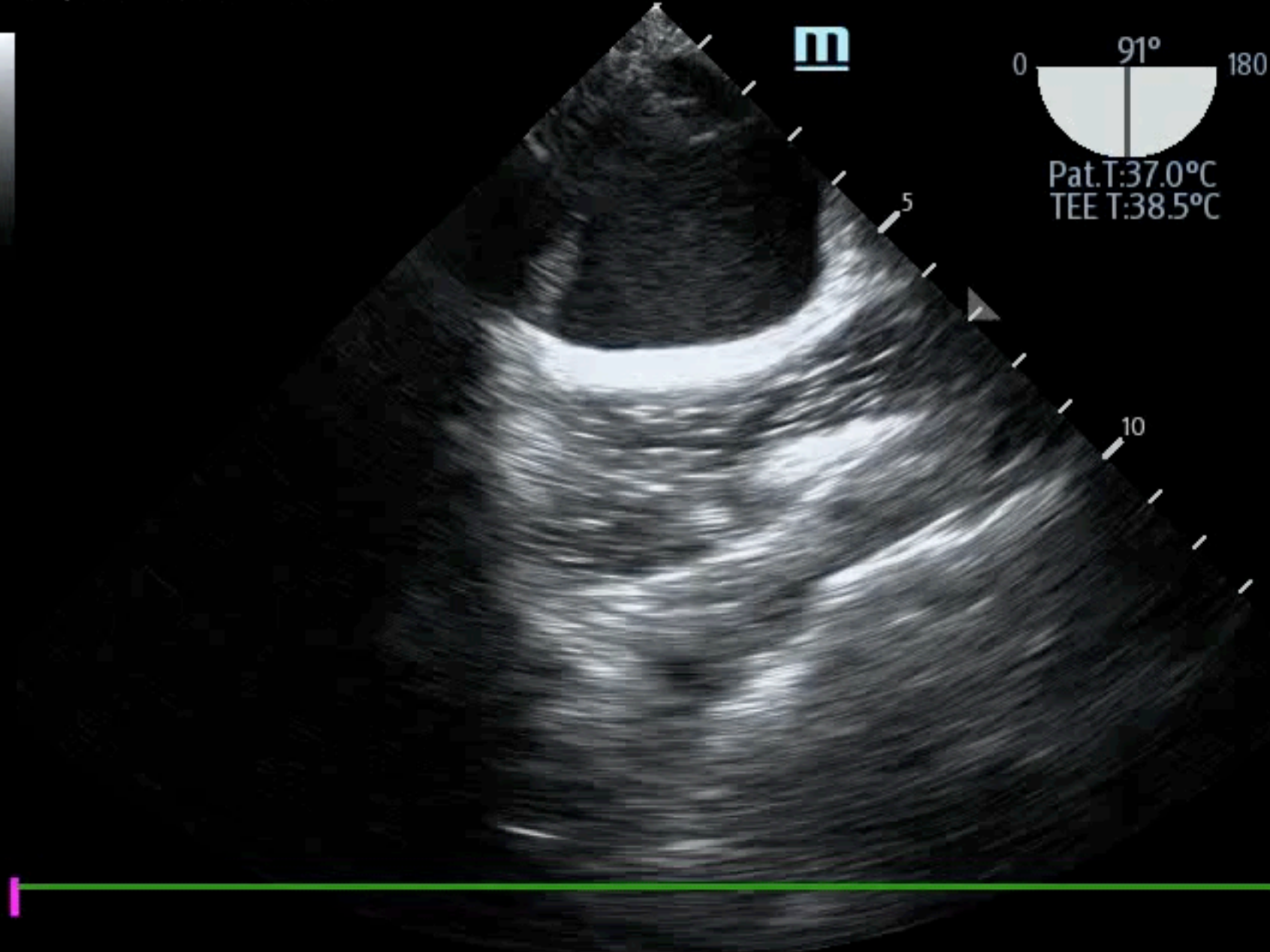
Pat.T:37.0°C  
TEE T:38.5°C

5

10

iNeedle

iTouch





P7-3Ts

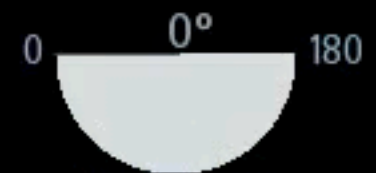AP 96.6%

MI 0.58

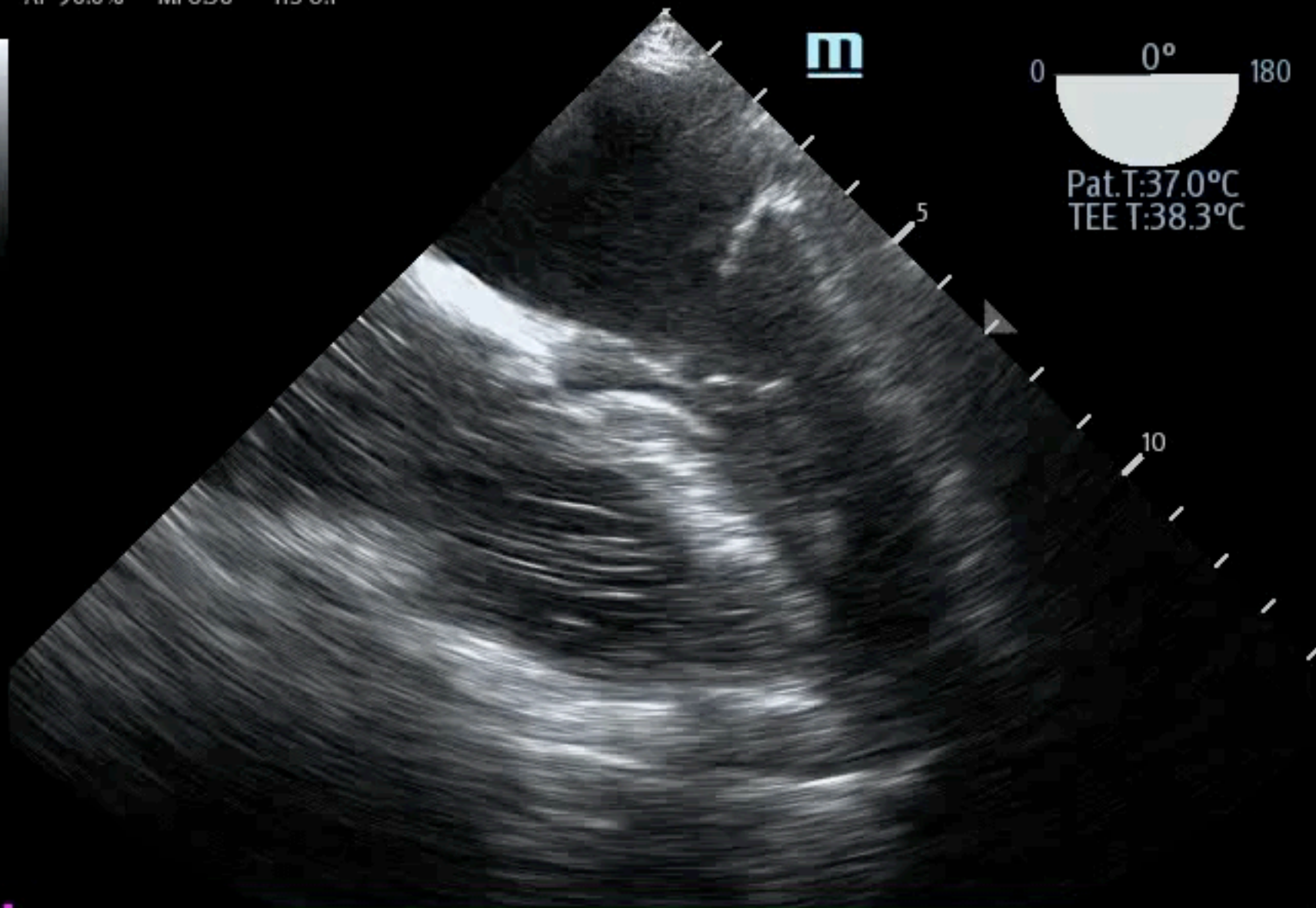
TIS 0.1



B  
F33~7.2  
DR 105  
FR 28  
D 15.0  
G 75




Pat.T:37.0°C  
TEE T:38.3°C



iNeedle

iTouch





P7-3Ts

AP 96.6%

MI 0.58

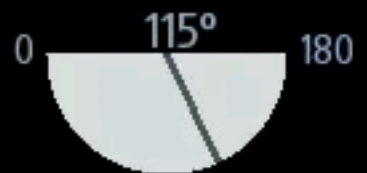TIS 0.1



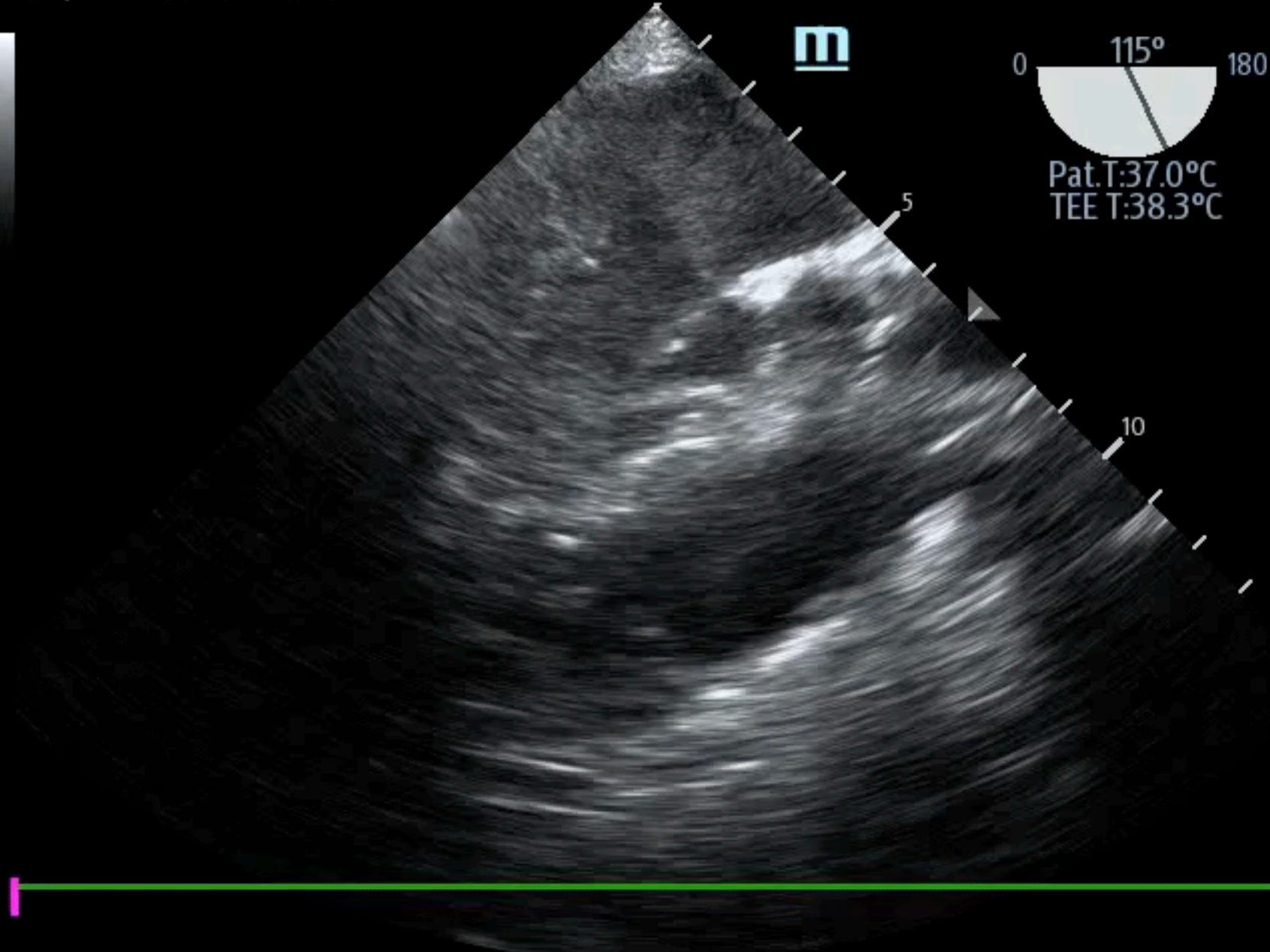
B  
F33~7.2  
DR 105  
FR 28  
D 15.0  
G 75



m



Pat.T:37.0°C  
TEE T:38.3°C



iNeedle

iTouch



P7-3Ts

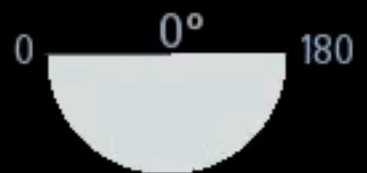AP 96.6%

MI 0.58

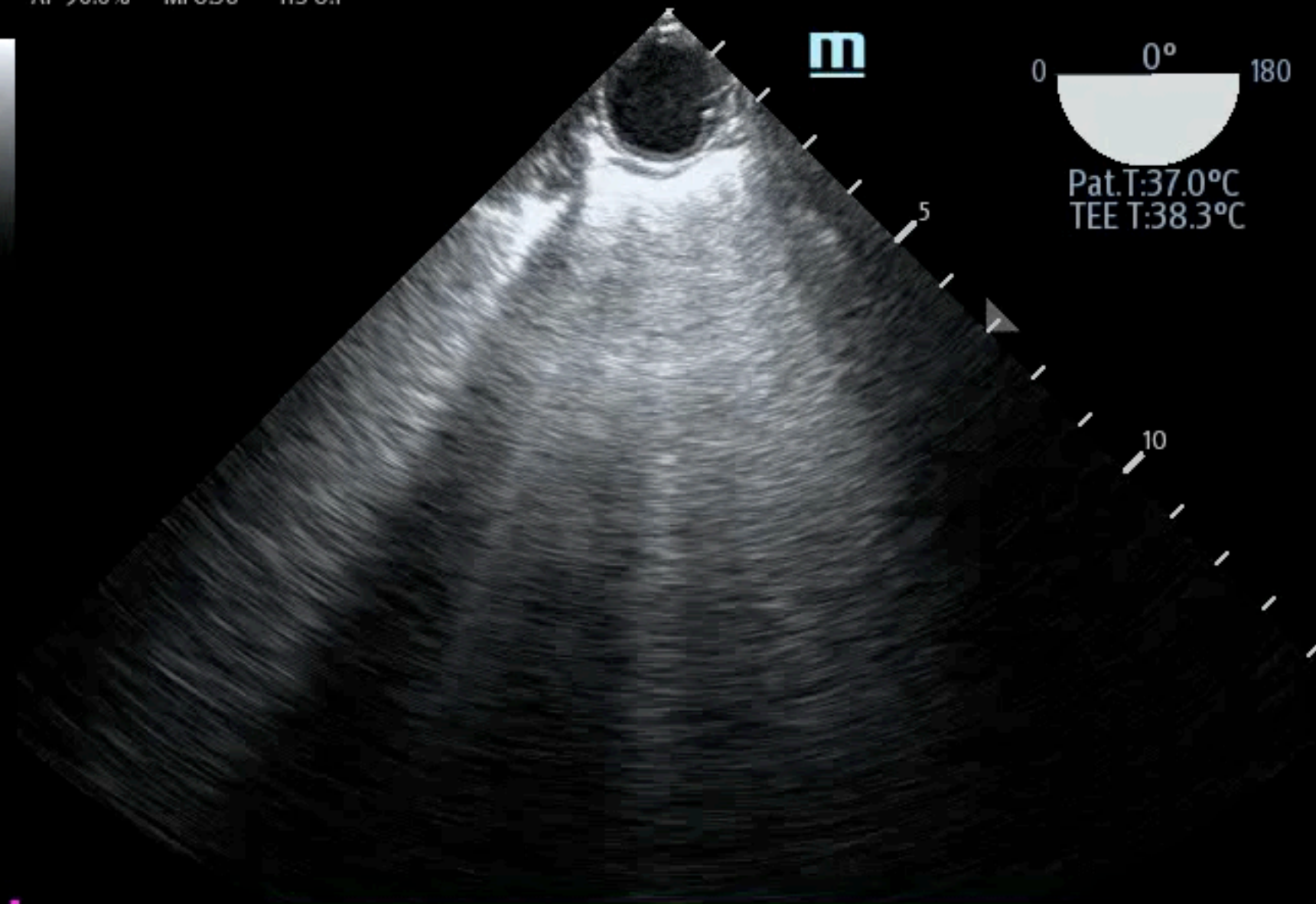
TIS 0.1



B  
F33~7.2  
DR 105  
FR 28  
D 15.0  
G 75



Pat.T:37.0°C  
TEE T:38.3°C



iNeedle

iTouch



P7-3Ts

AP 96.6%

MI 0.58

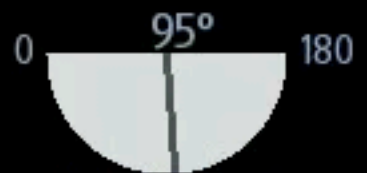TIS 0.1



B  
F33~7.2  
DR 105  
FR 28  
D 15.0  
G 75



m




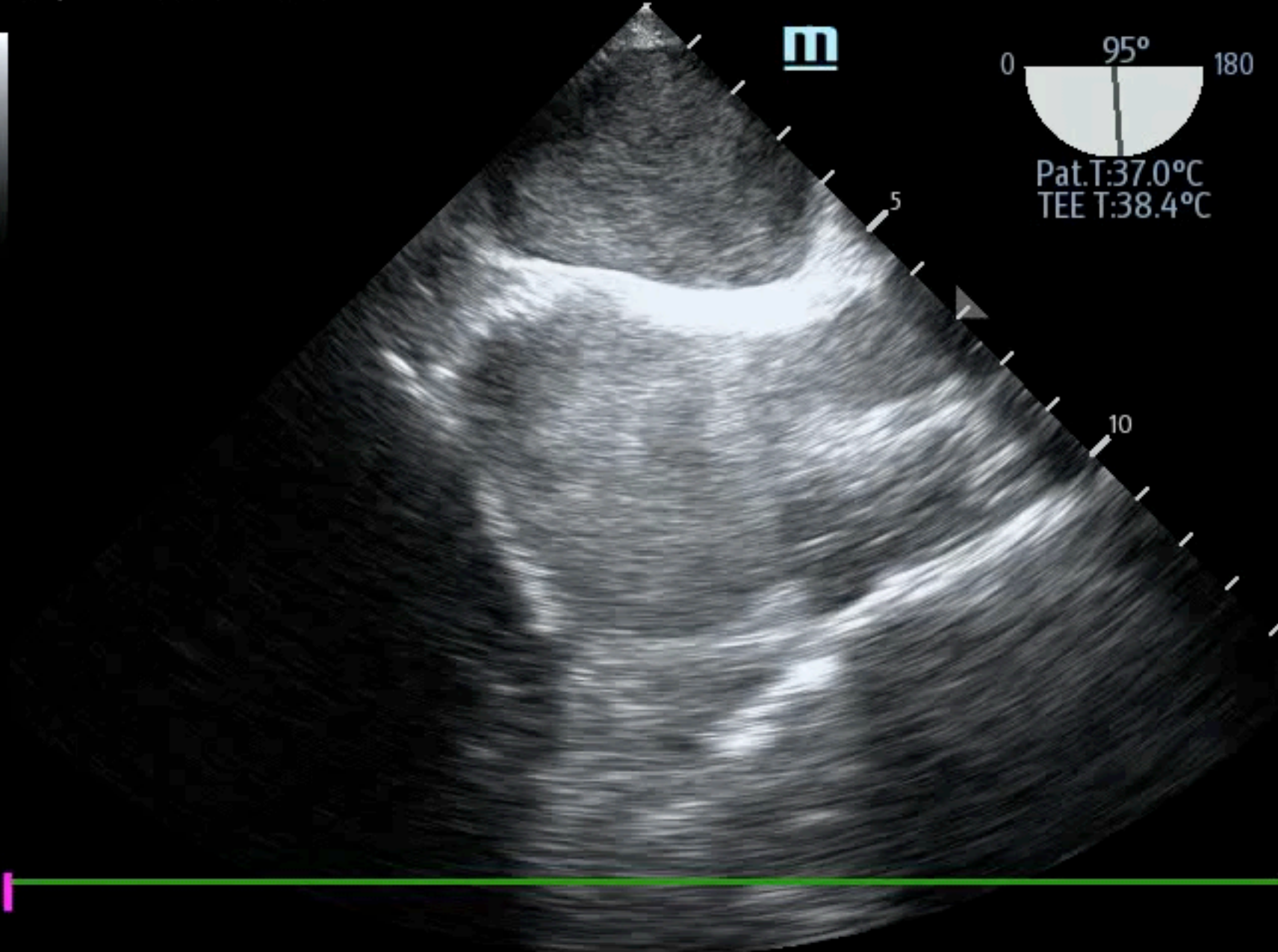
Pat.T:37.0°C  
TEE T:38.4°C

5

10

iNeedle

iTouch





P7-3Ts

AP 96.6%

MI 0.58

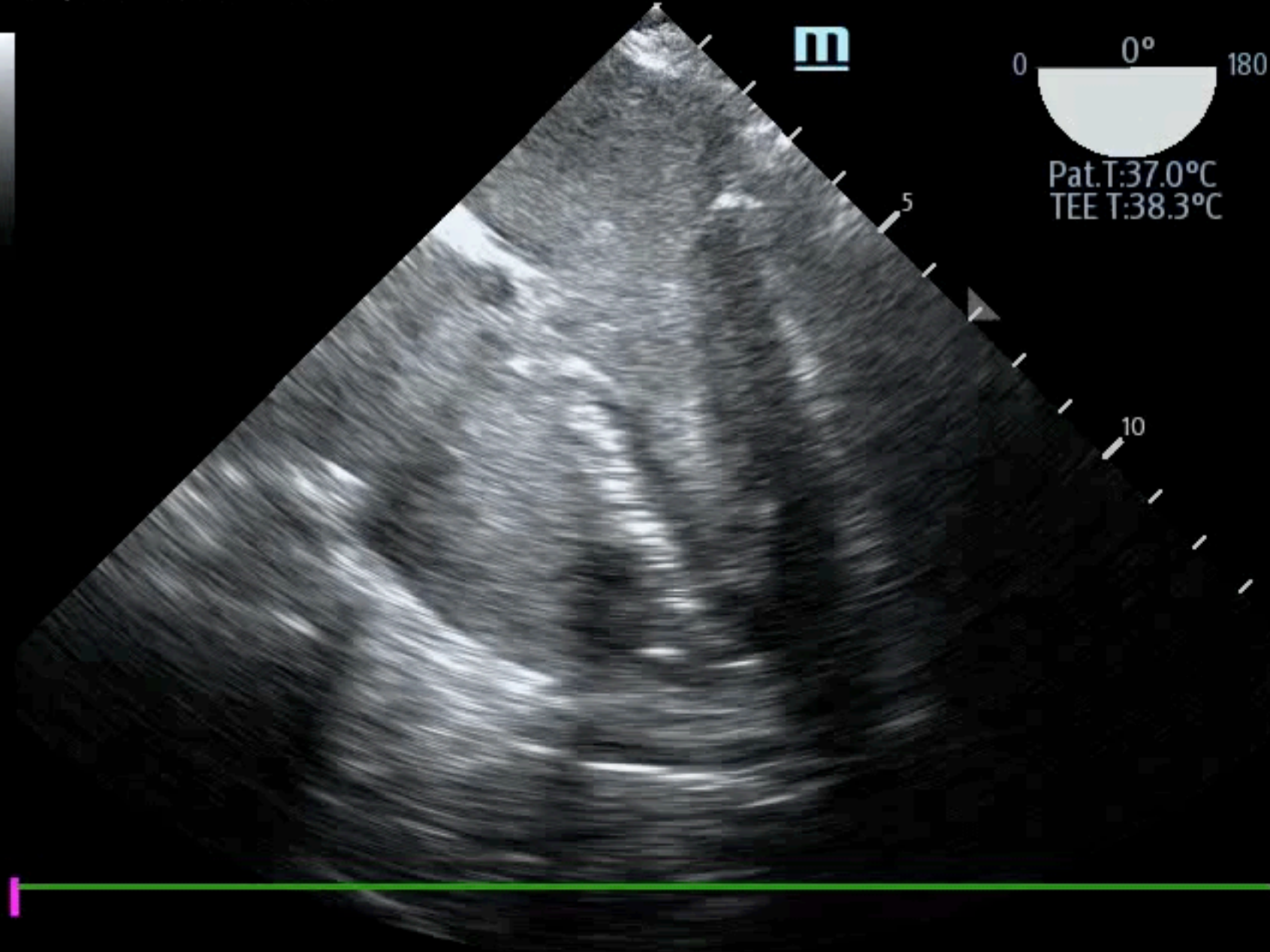
TIS 0.1



B  
F33~7.2  
DR 105  
FR 28  
D 15.0  
G 75



Pat.T:37.0°C  
TEE T:38.3°C



iNeedle

iTouch





P7-3Ts

AP 96.6%

MI 0.58

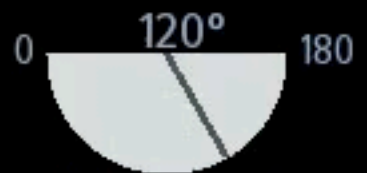TIS 0.1



B  
F33~7.2  
DR 105  
FR 28  
D 15.0  
G 75



**m**



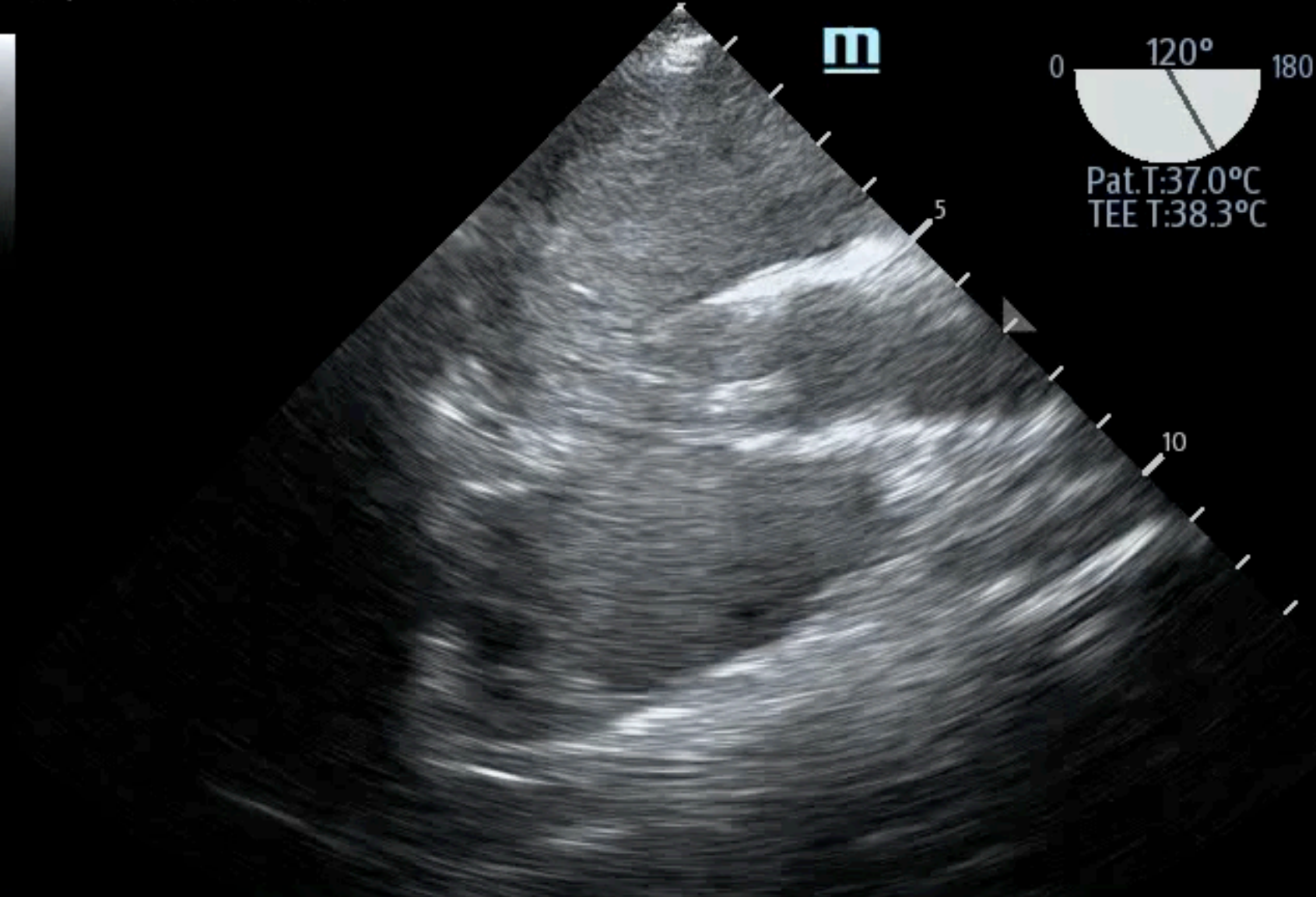

Pat.T:37.0°C  
TEE T:38.3°C

5

10

iNeedle

iTouch



P7-3Ts

AP 96.6%

MI 0.58

TIS 0.1



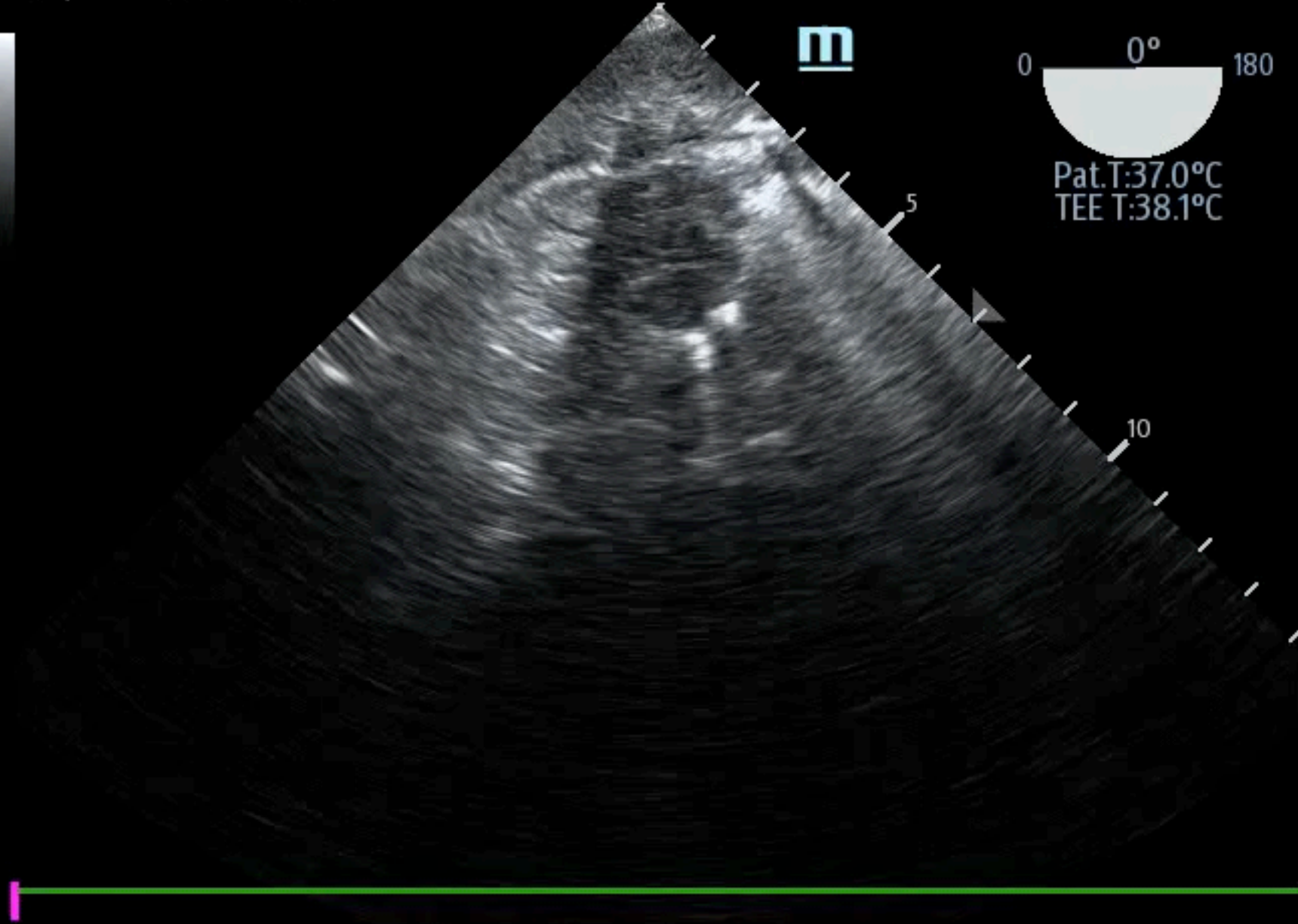
B  
F33~7.2  
DR 105  
FR 28  
D 15.0  
G 75



m




Pat.T:37.0°C  
TEE T:38.1°C



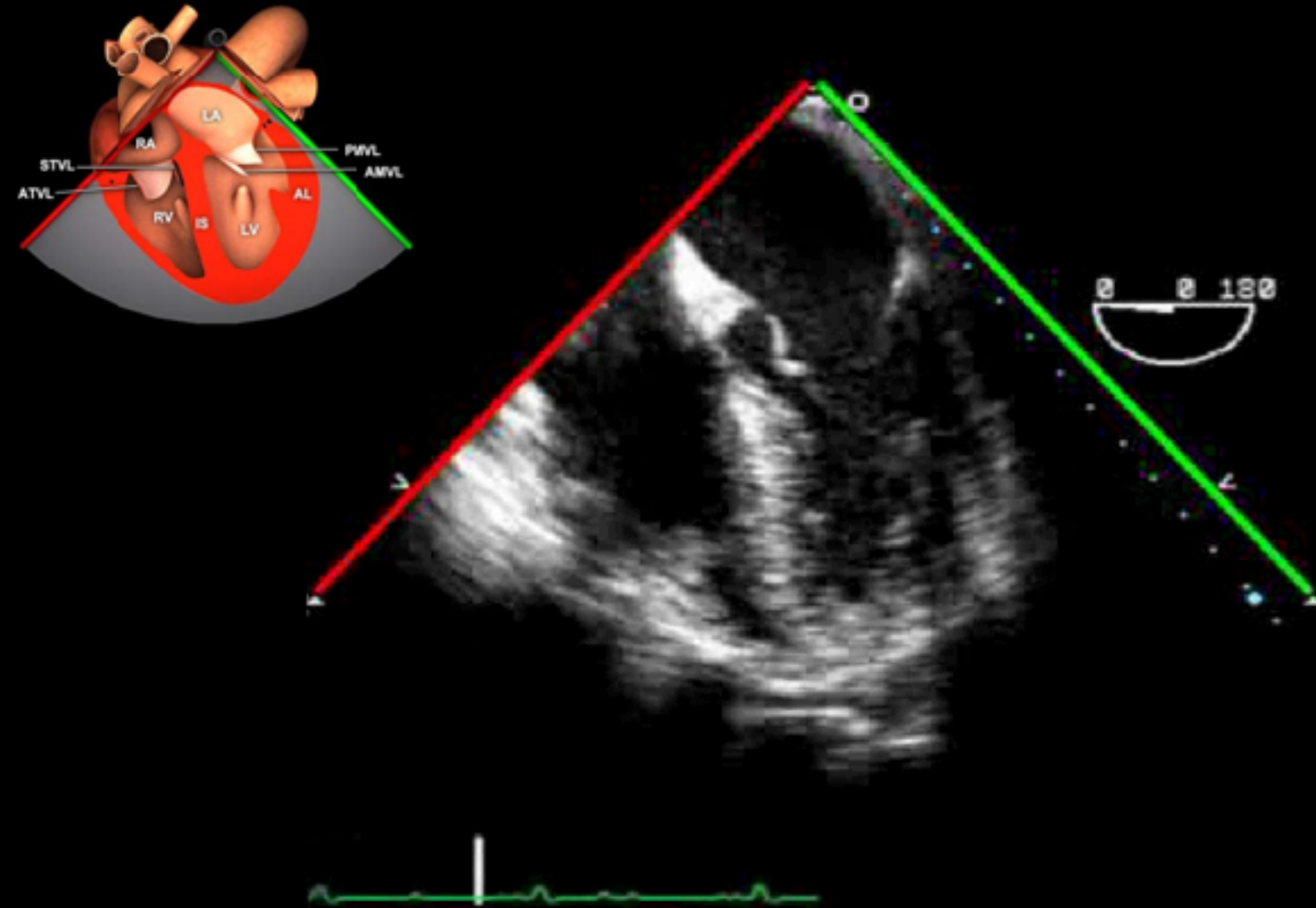
iNeedle

iTouch



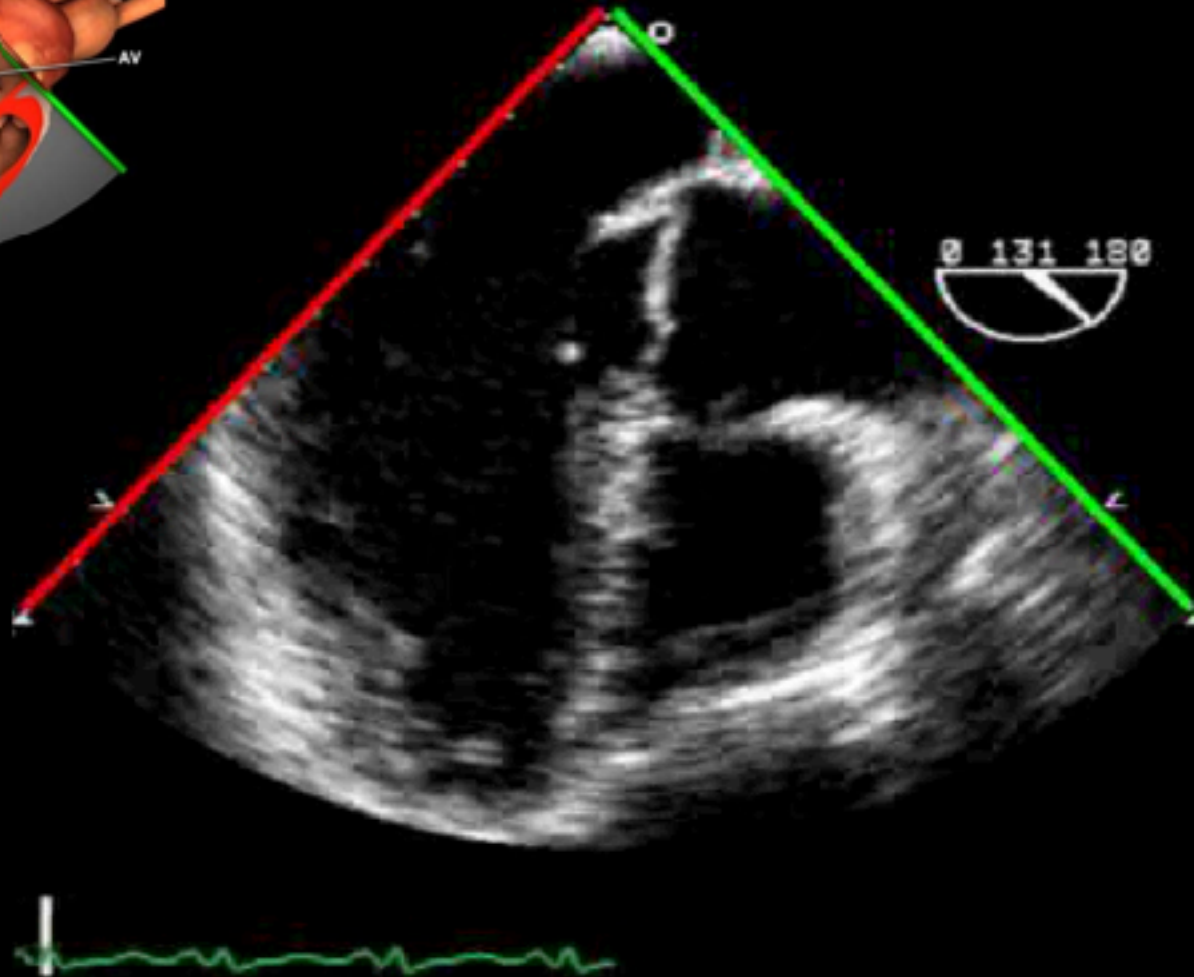
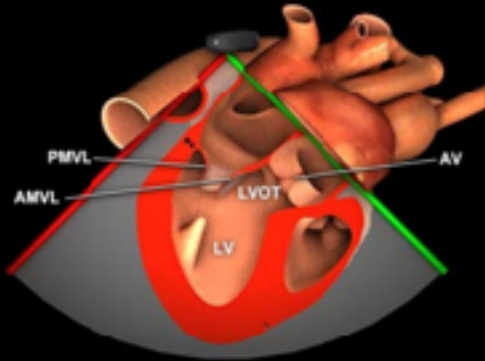


# ME 4C view (0°) (定位點)





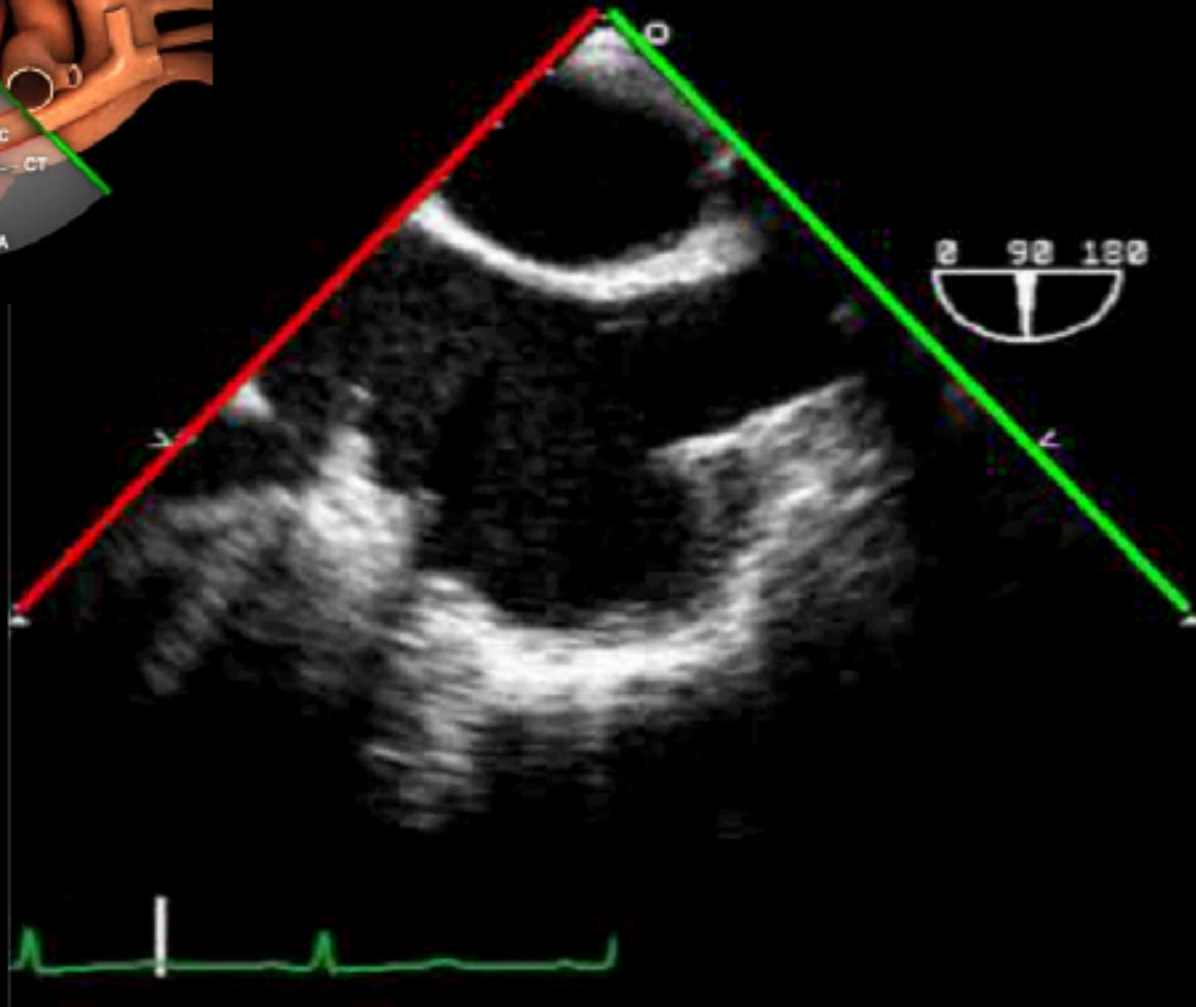
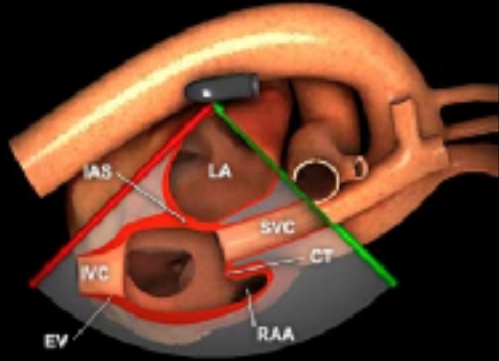
# ME LAX view (120°) (CPR 品質)





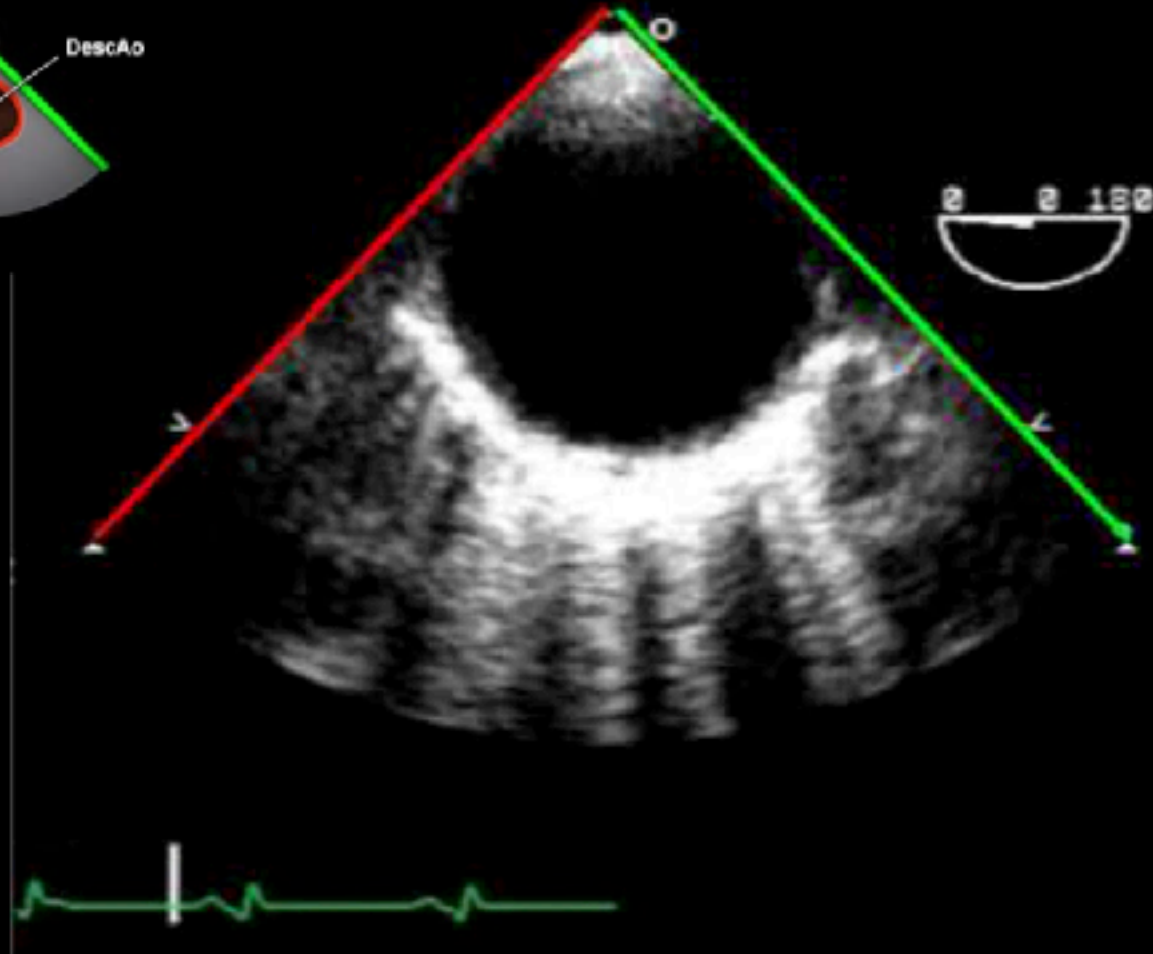
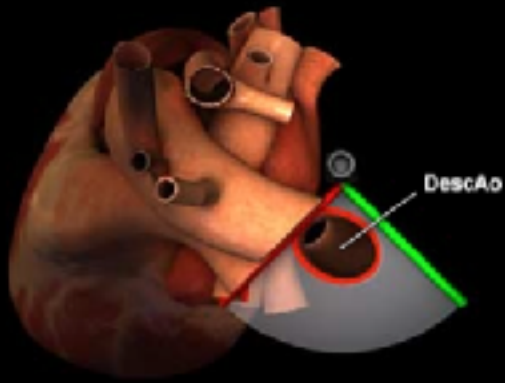


# ME Bicaval view (90°)(管路/容積)



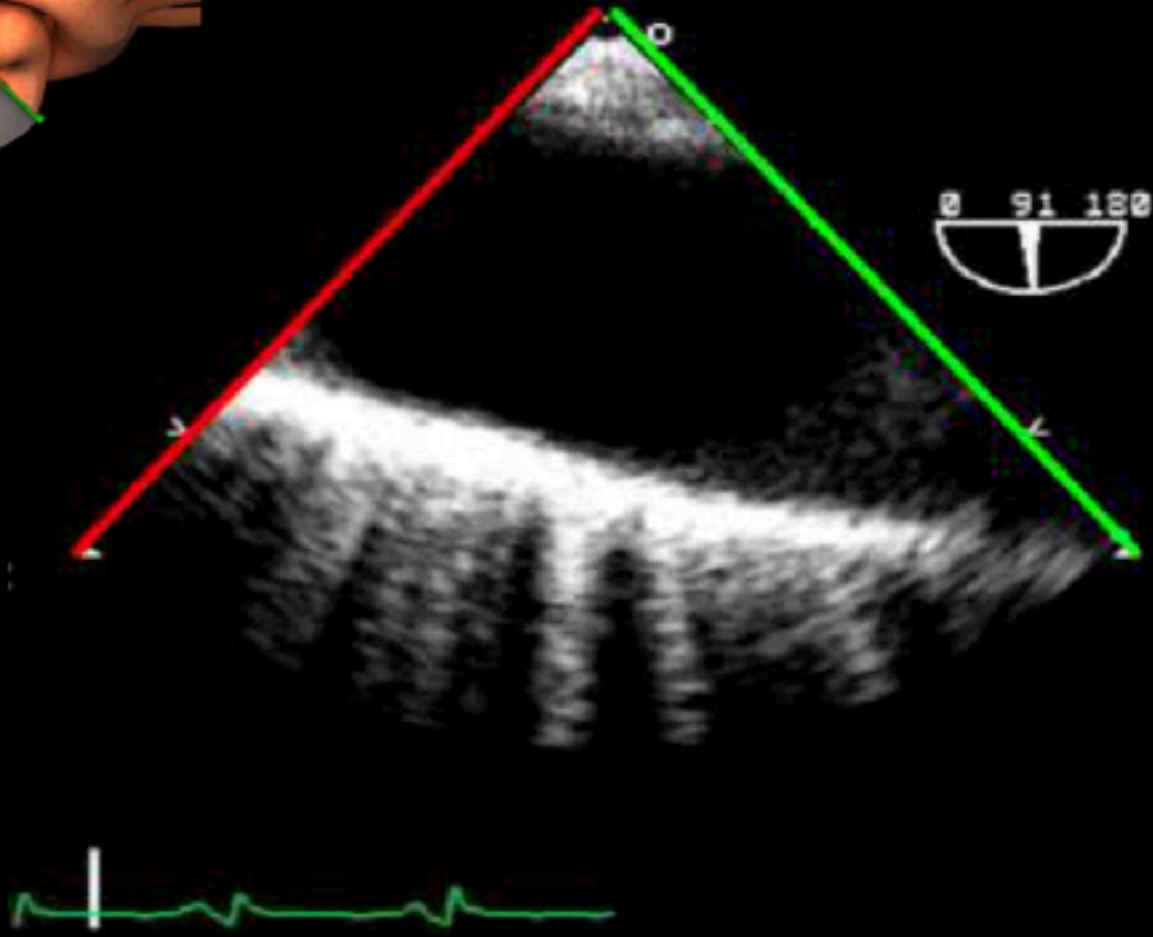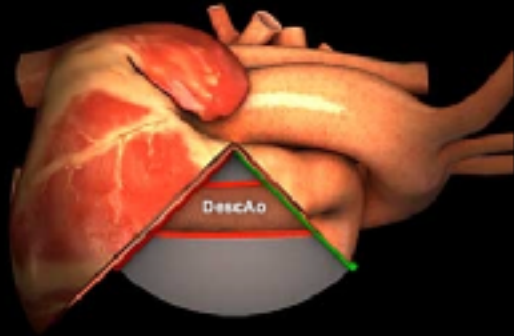


# ME Descending aorta SAX view (逆轉向身後)



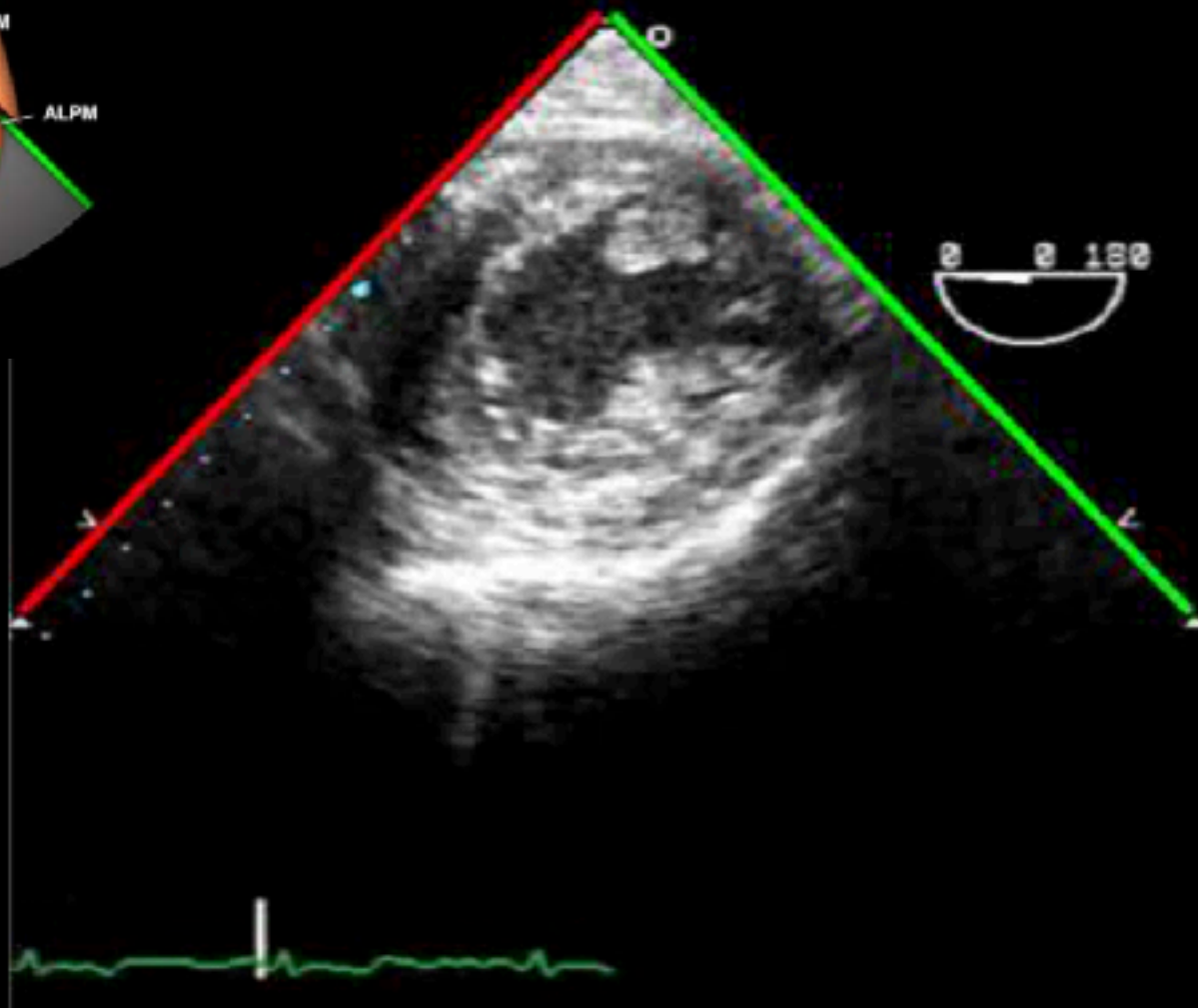
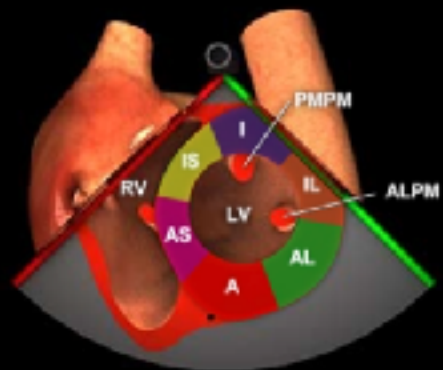


# ME Descending aorta LAX view(逆轉向身後)





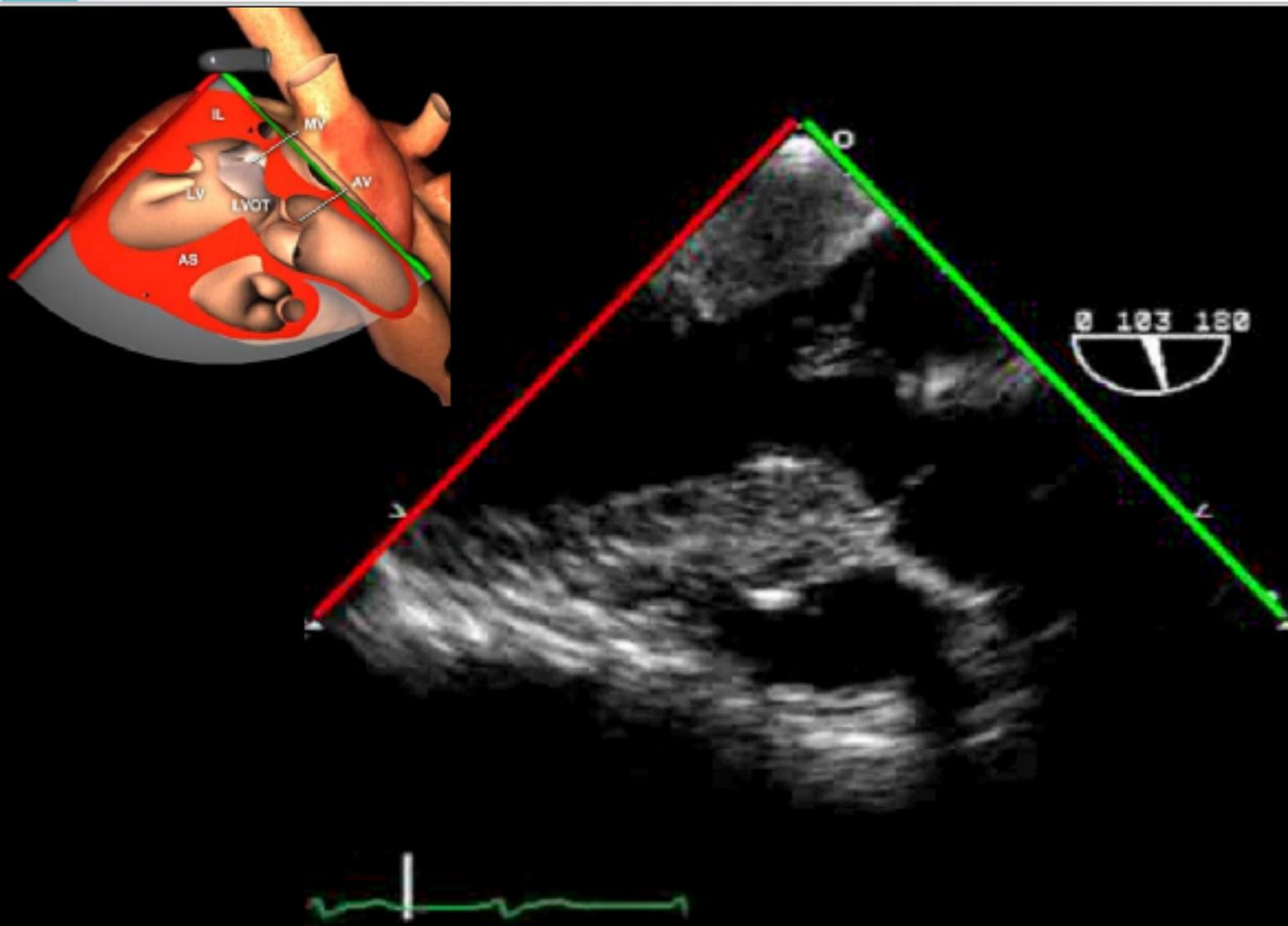
# TG Mid SAX view (0°) (大輪順轉前彎向心)





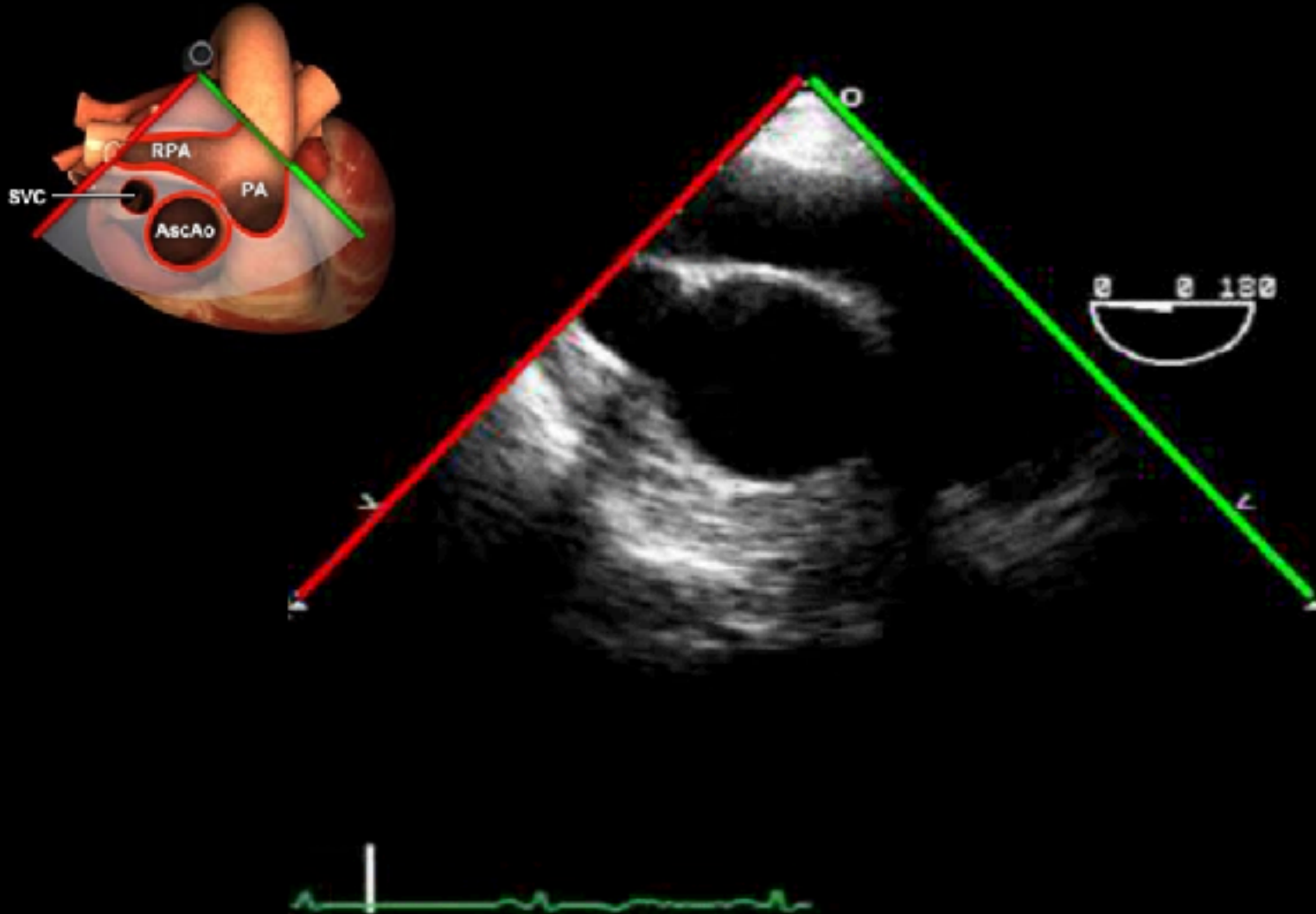


# TG LAX view (CPR 品質另一選擇)

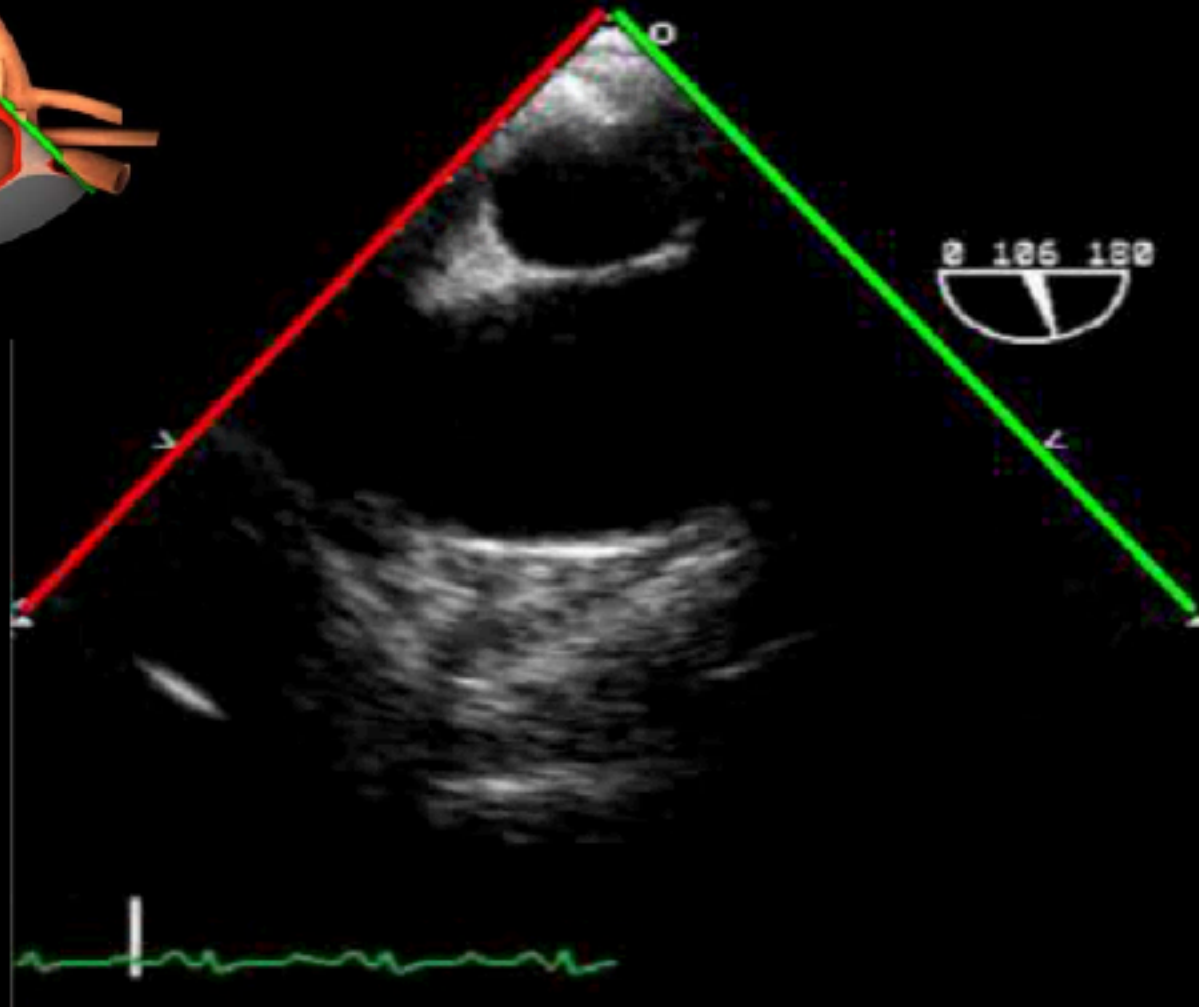
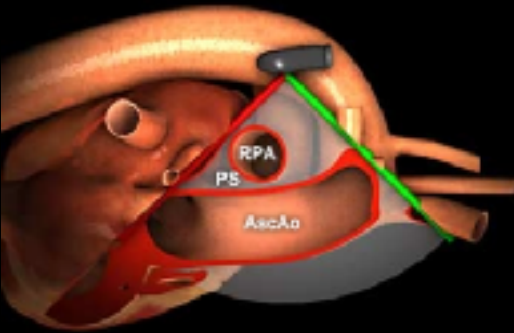




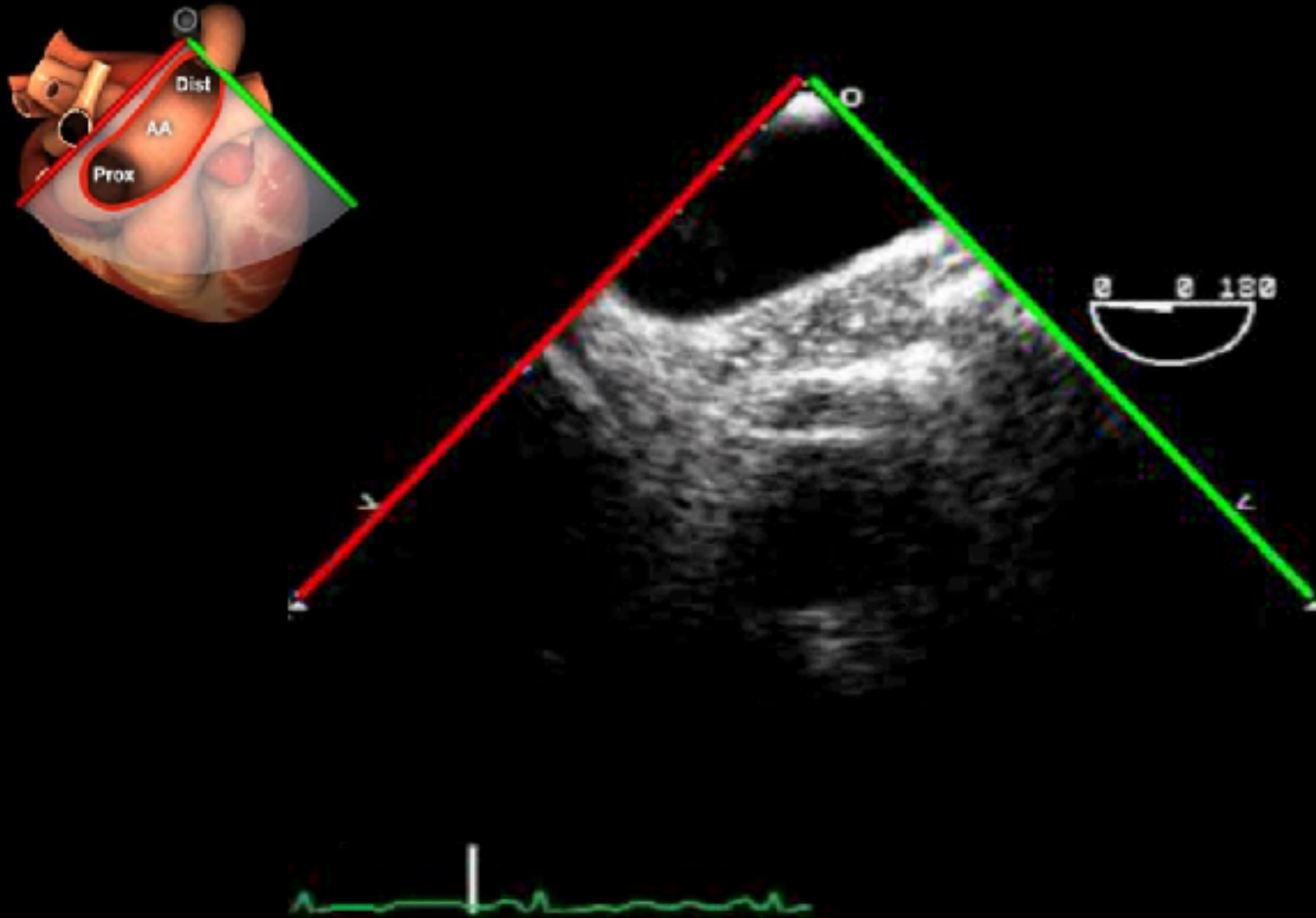
# ME Ascending aorta SAX view



# ME Ascending aorta LAX view

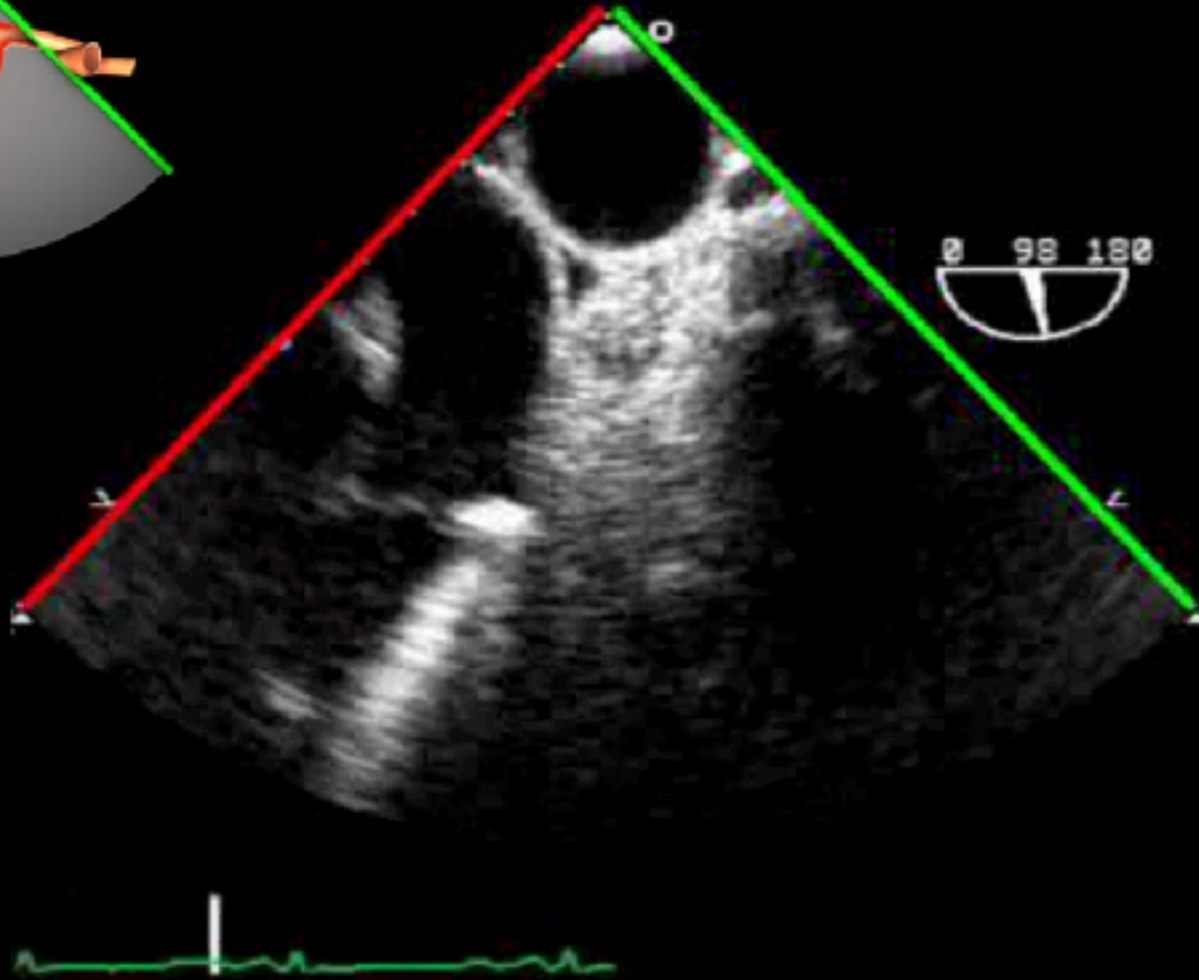
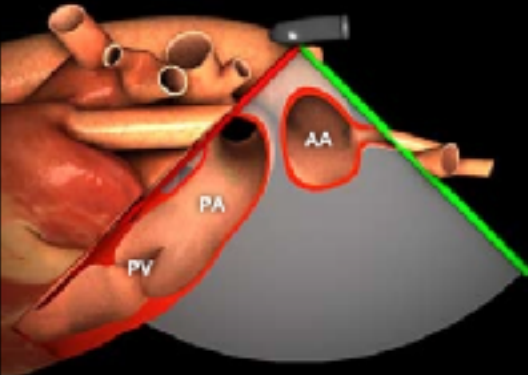


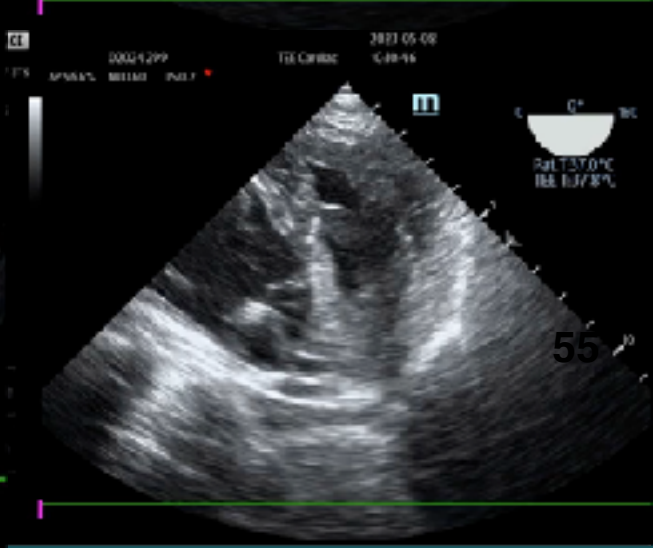
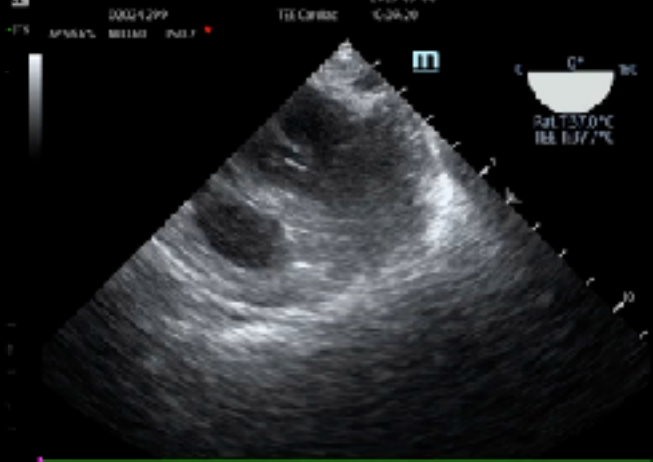
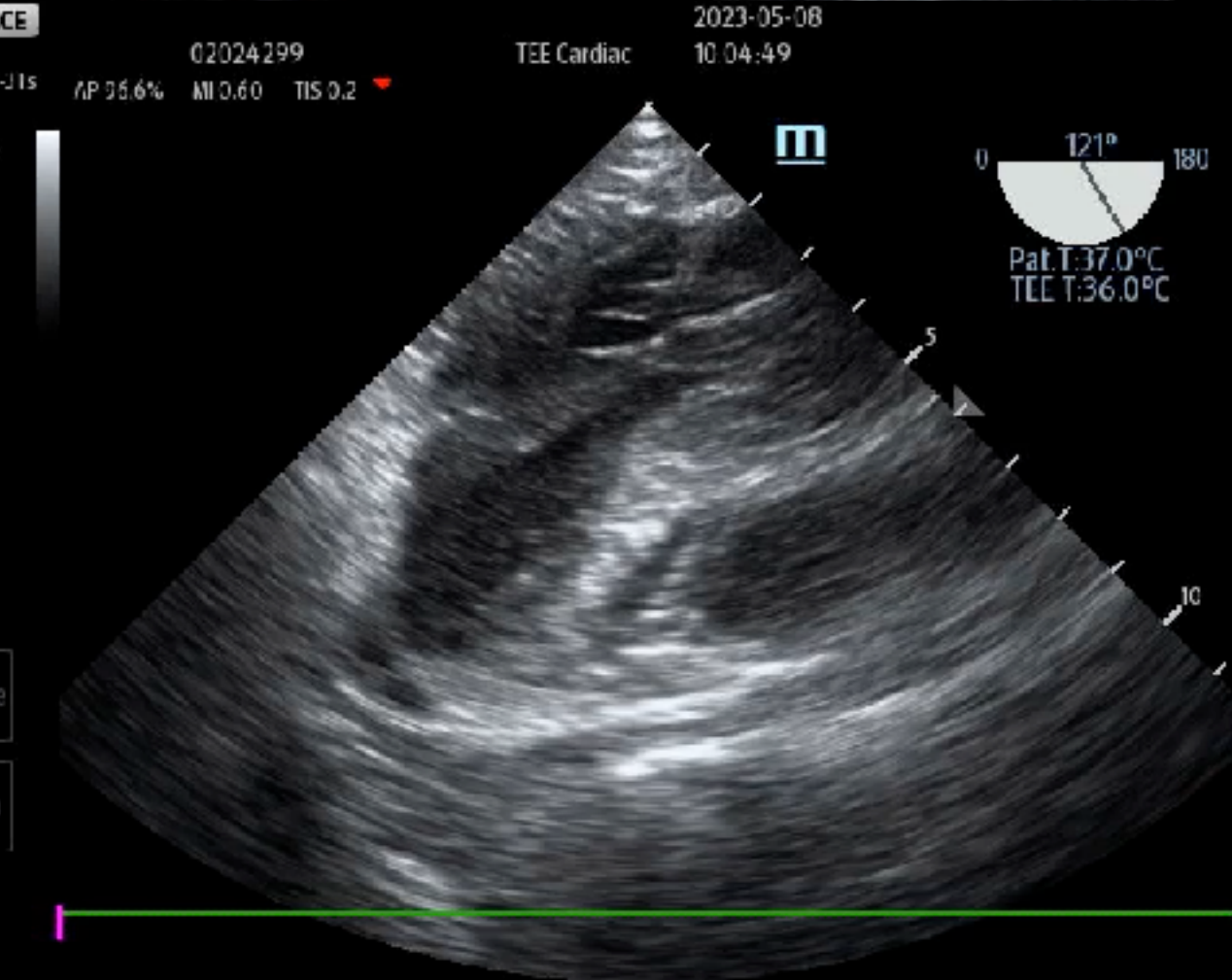
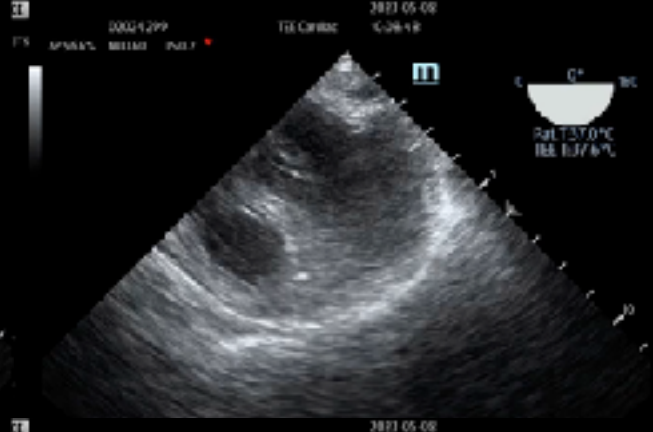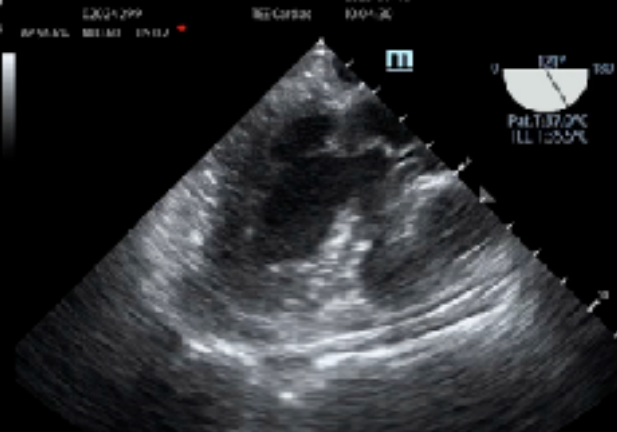
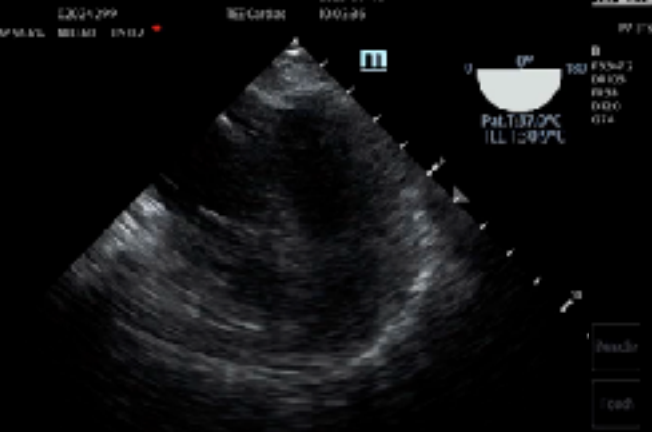
# UE Aortic arch LAX view





# UE Aortic arch SAX view

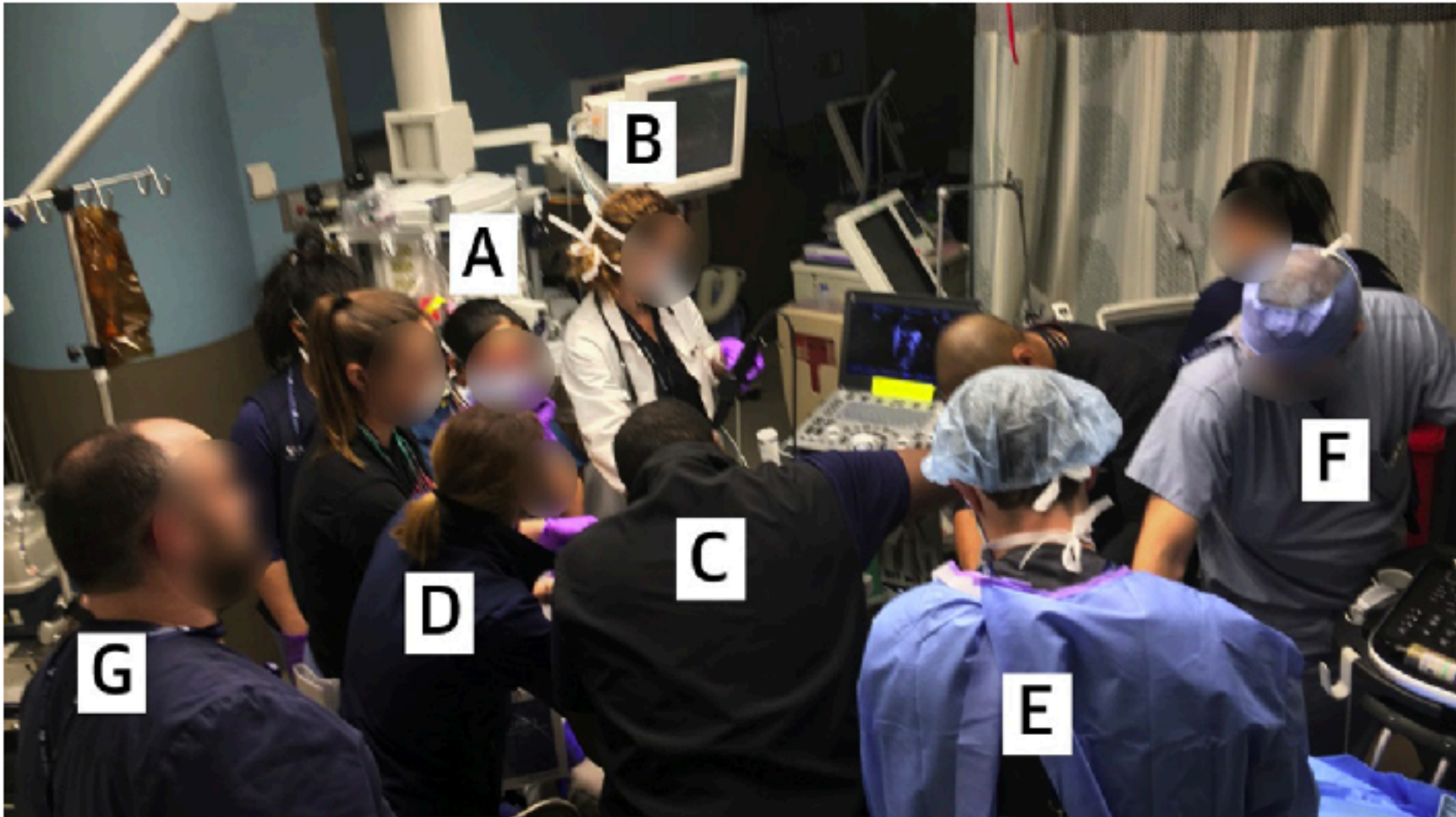




# TEAM

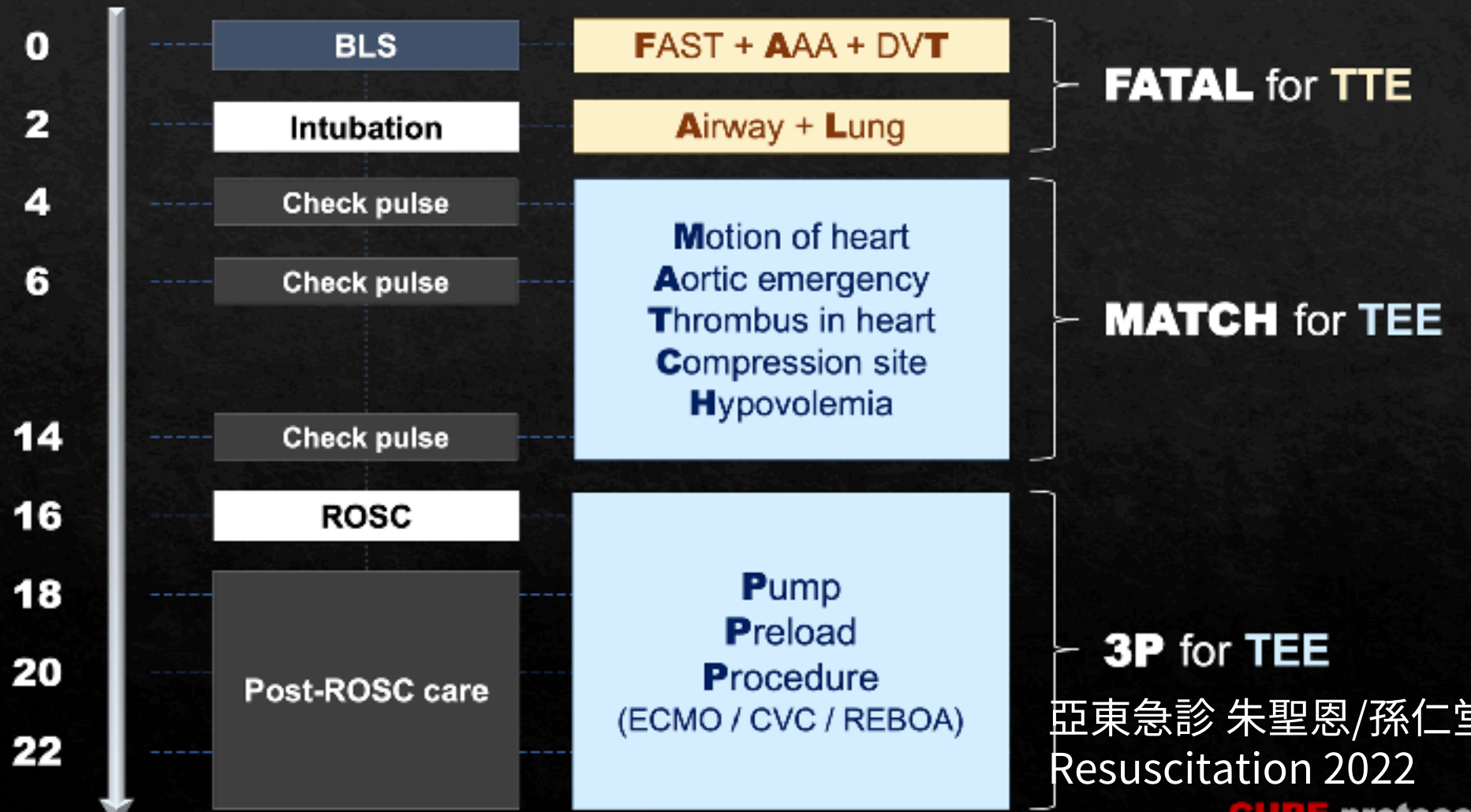


**FIGURE 2** Incorporation of Focused TEE During Cardiac Arrest Resuscitation Care





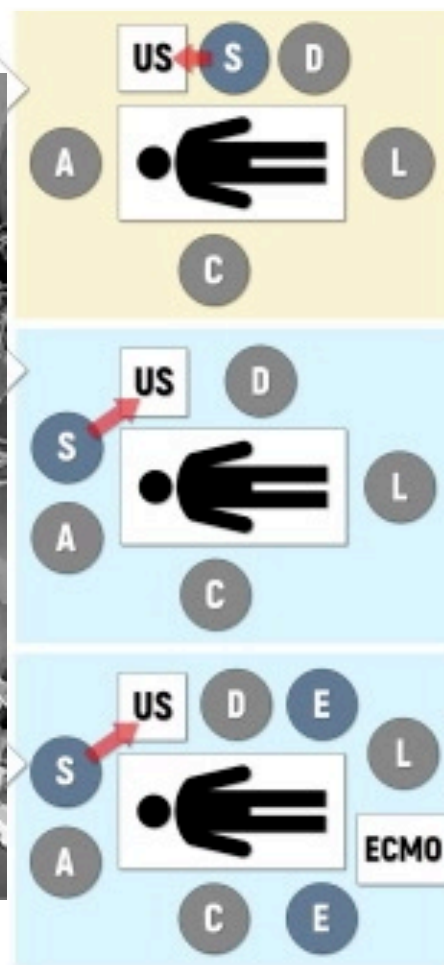
# Core Ultrasound in REsuscitation (CURE): A novel protocol for ultrasound-assistant life support via application of both transesophageal and transthoracic ultrasound



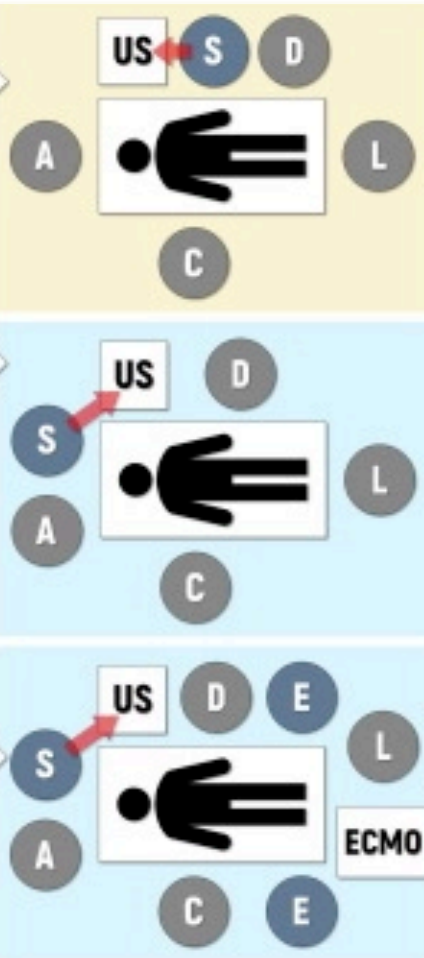
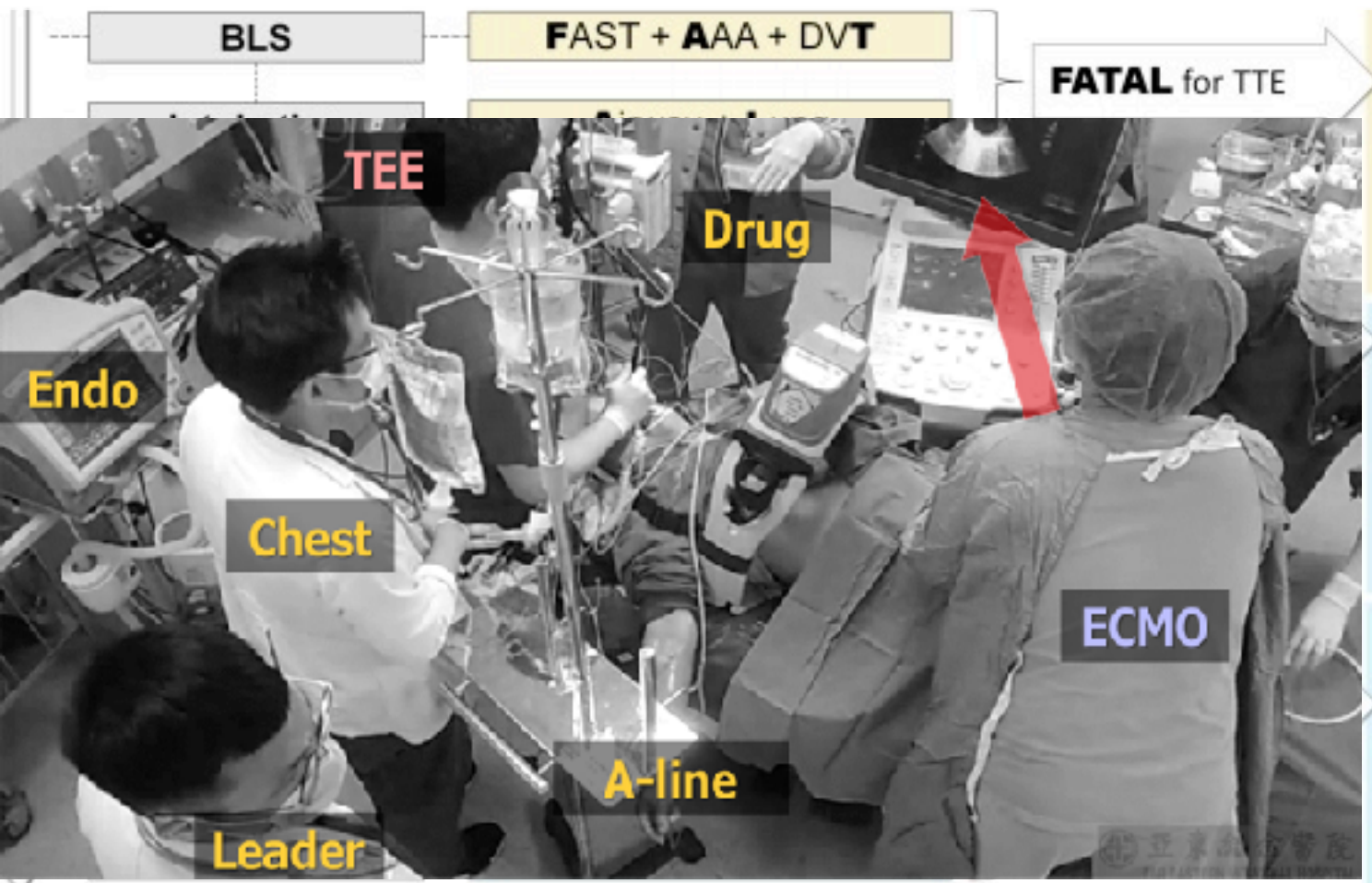
亞東急診 朱聖恩/孫仁堂  
Resuscitation 2022



# Core Ultrasound in REsuscitation (CURE): A novel protocol for ultrasound-assistant life support via application of both transesophageal and transthoracic ultrasound

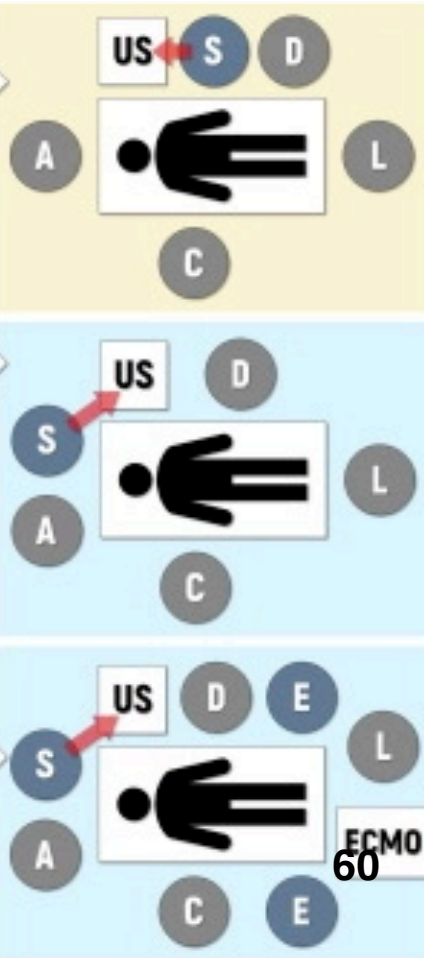
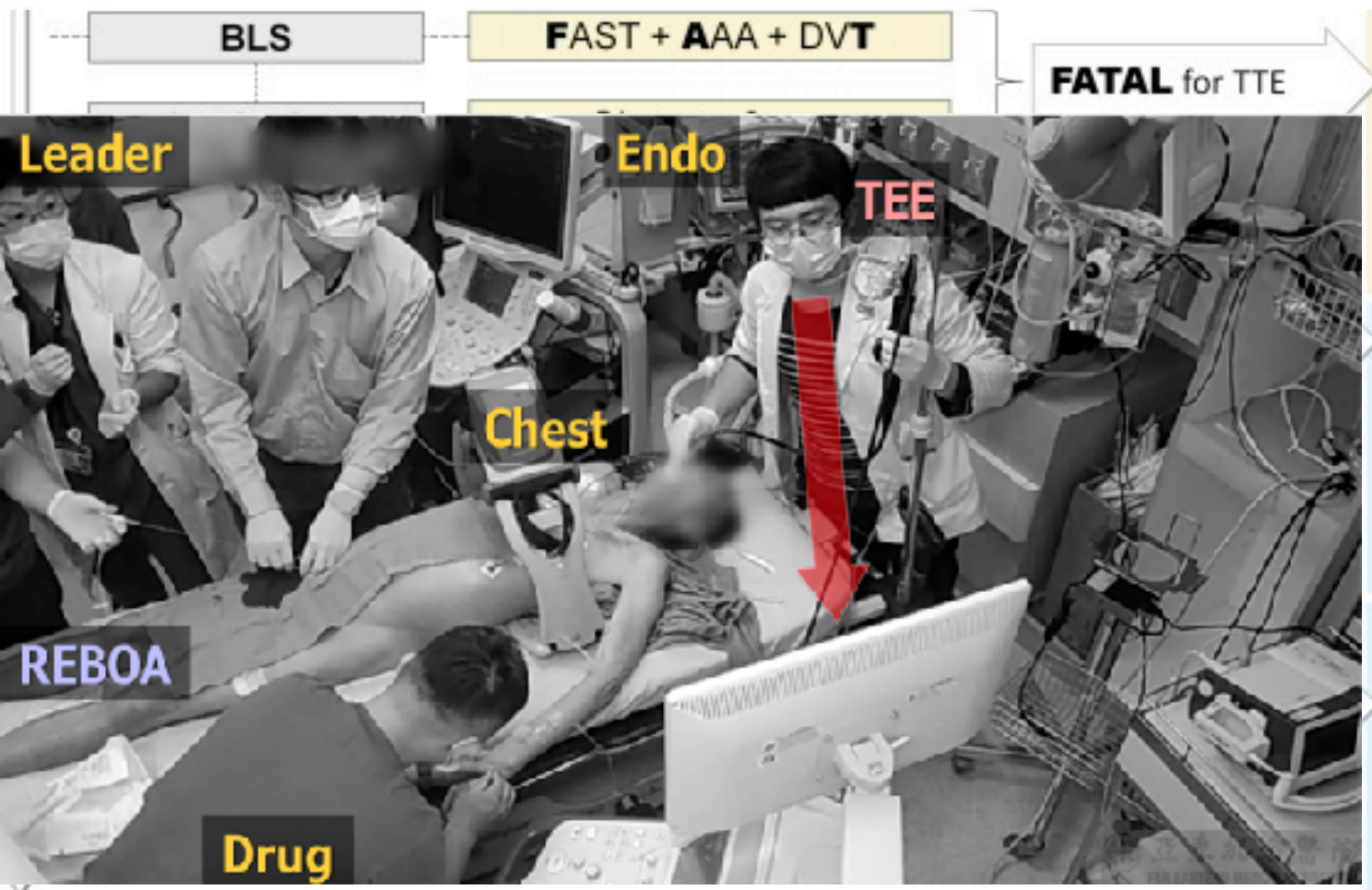


# Core Ultrasound in REsuscitation (CURE): A novel protocol for ultrasound-assistant life support via application of both transesophageal and transthoracic ultrasound



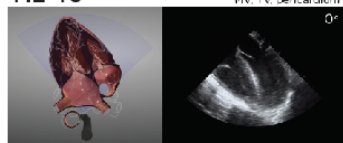


# Core Ultrasound in REsuscitation (CURE): A novel protocol for ultrasound-assistant life support via application of both transesophageal and transthoracic ultrasound



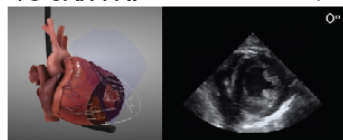
# RESUSCITATIVE TEE VIEW GUIDE

## ME 4C



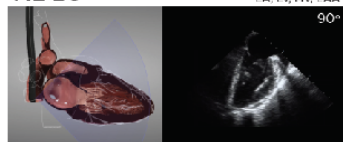
- Pathology pericardium
- RWMA
- LV/RV size & function
- Valvular pathology

## TG SAX PAP



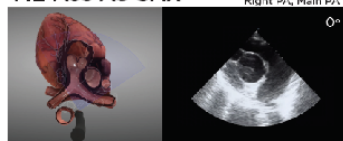
- LV function
- RWMA
- Pathology pericardium

## ME 2C



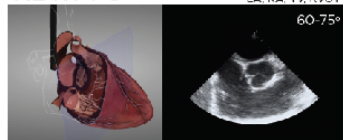
- Pathology LV
- LV axis
- Pathology MV
- Thrombus LAA

## ME Asc Ao SAX



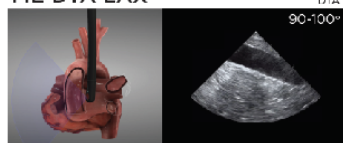
- Asc Aorta
- Pathology of PA
- Pulmonary embolism

## ME RV I-O



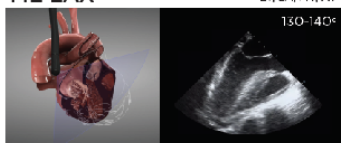
- Pathology RVOT
- Doppler TV

## ME DTA LAX



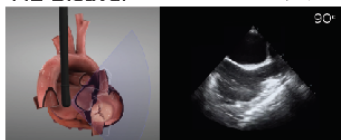
- Flow reversal (AI)
- IARP
- Impella
- VA ECMO

## ME LAX



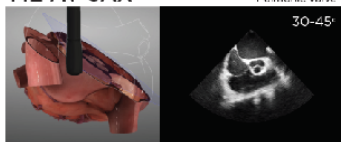
- Quality of CPR (AMC)
- Pathology MV
- LV function
- Pathology AV

## ME Bicaval



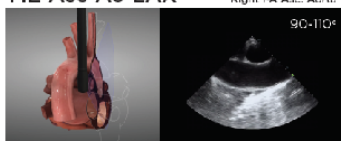- Procedure guidance
- ECMO
- Venous guidewire
- Volume responsiveness

## ME AV SAX



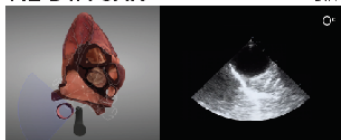- Aortic stenosis
- Pathology RVOT
- ASD
- RCA and LMCA

## ME Asc Ao LAX



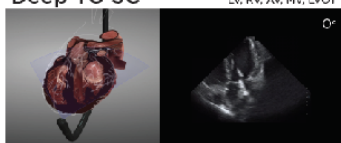
- Pulmonary embolism
- Outflow cannula
- Pathology PA
- LVAD

## ME DTA SAX



- IARP
- Impella
- VA ECMO

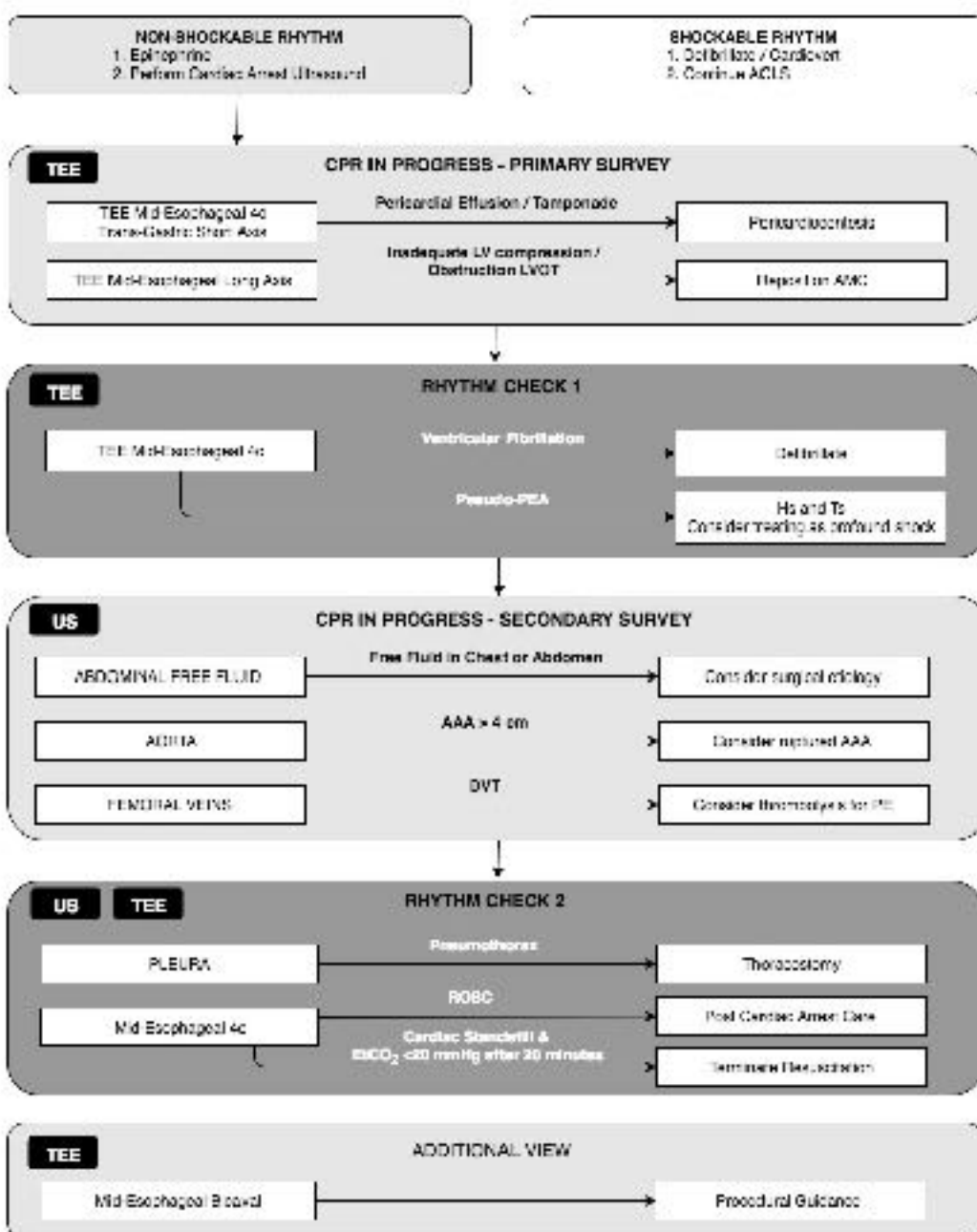
## Deep TG SC



- Doppler (VTI) LVOT

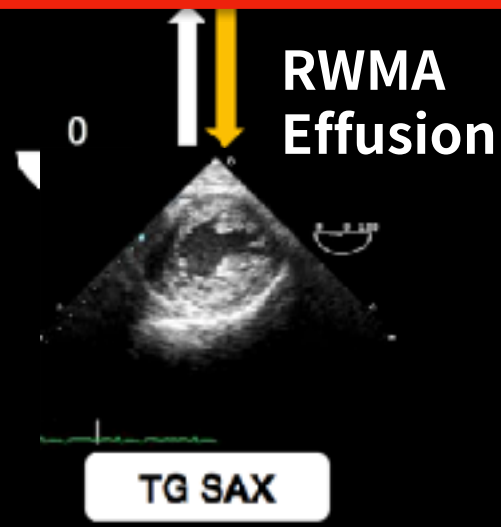
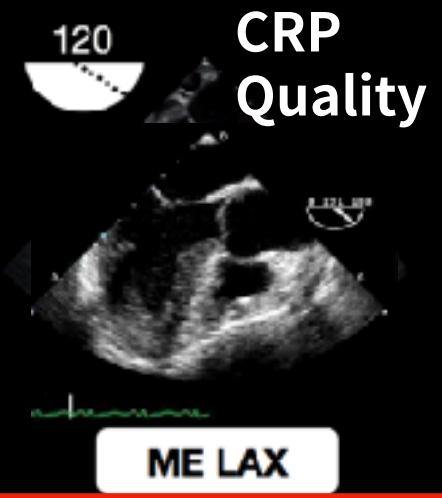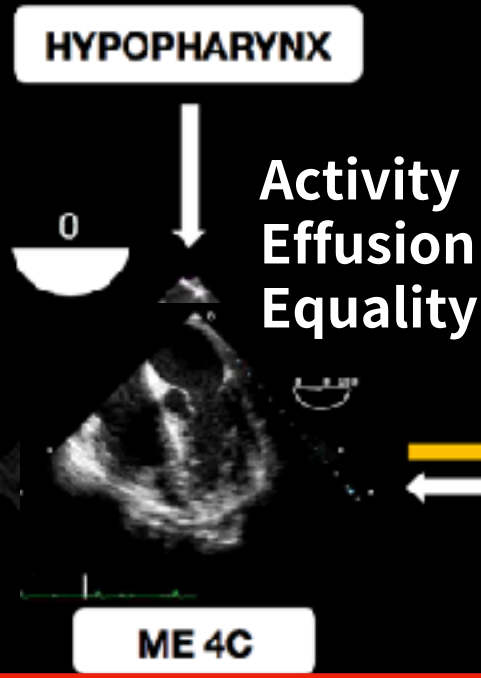
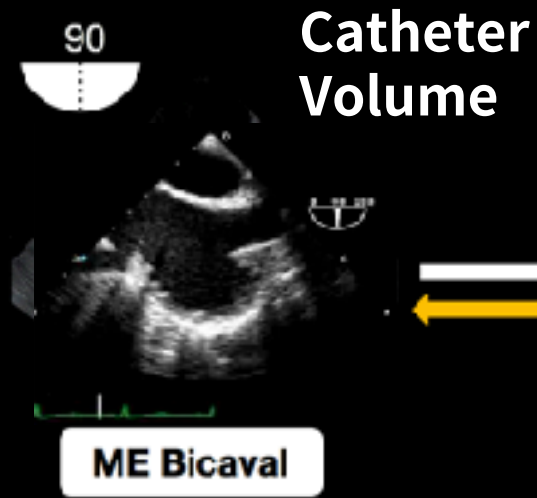
# TEE-GUIDED CARDIAC ARREST RESUSCITATION

R. Ponsius, B. F. Thoenes

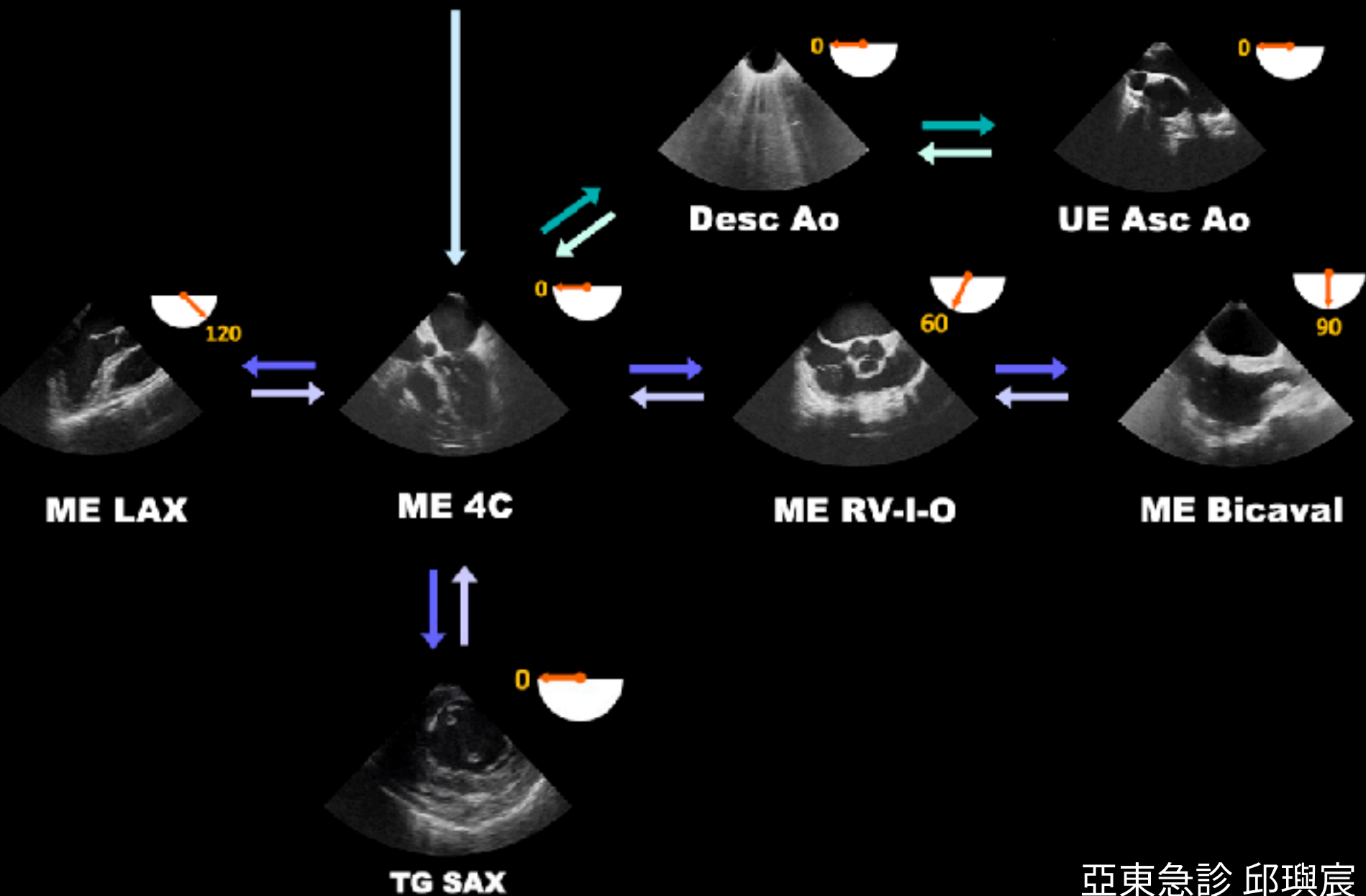


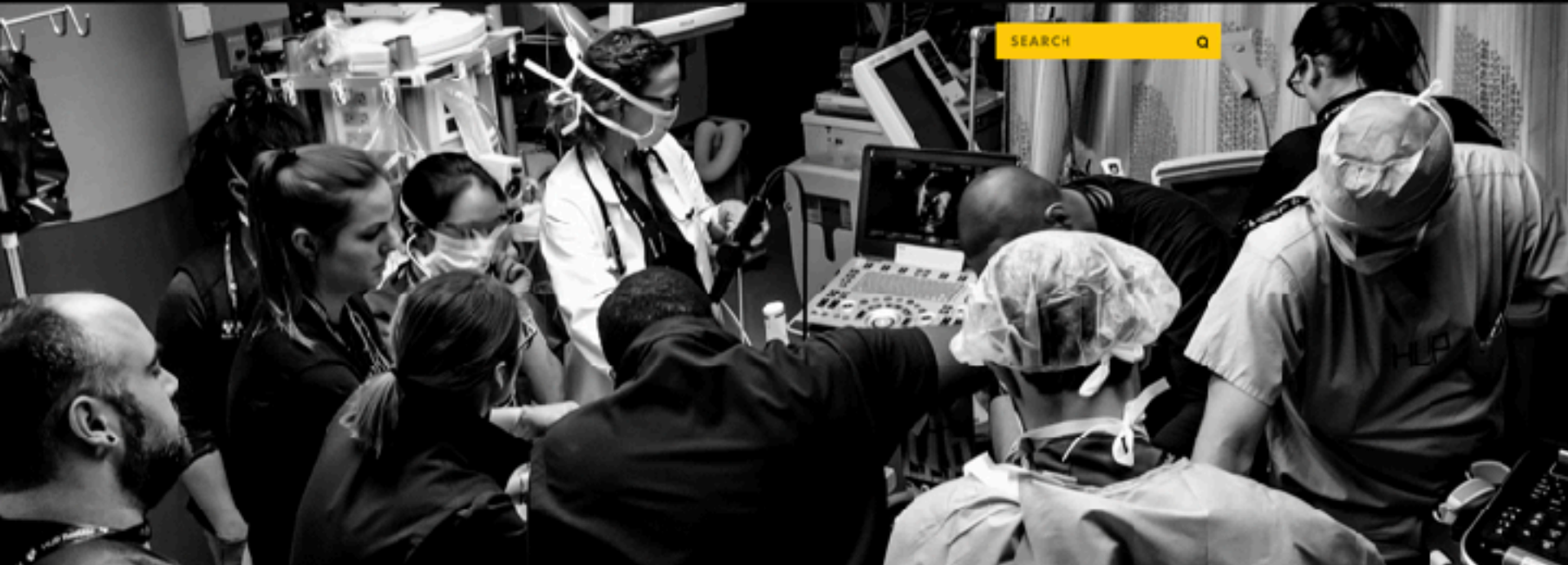

# SHH-1st Goal



# HYPOPHARYNX





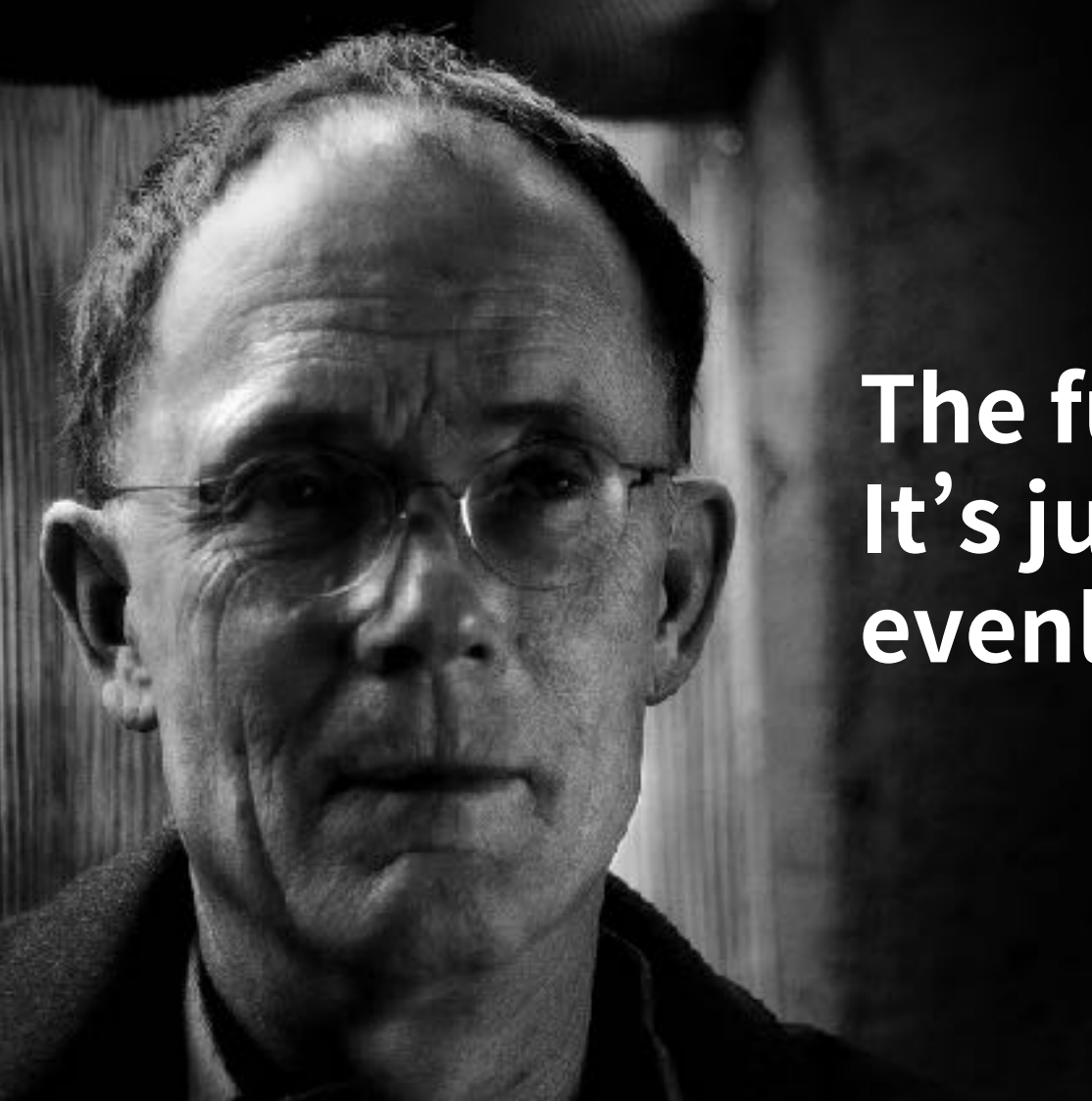
SEARCH

# TEE RESOURCES



**Virtual** Transesophageal Echocardiography

Toronto General Hospital Department of Anesthesia  
Perioperative Interactive Education



**The future is here.  
It's just not  
evenly distributed yet.**

**~Willian Gibson**

## How to Perform Resuscitative Transesophageal Echocardiography in the Emergency Department

By Michael O'Neil, MD; Arun Nagdev, MD; and Felipe Teran, MD | on July 21, 2020 | 0 Comment