衛生福利部雙和醫院
(委託臺北醫學大學興建經營)
Taipei Medical University · Shuang Ho Hospital,
Ministry of Health and Welfare

POCUS for Airway & Neck

陳國智醫師 雙和醫院急診醫學科
juice119@gmail.com
POCUSacademy.com

陳國智 醫師 / POCUSacademy.com

急診超音波臨床評核醫師
醫用超音波學會指導醫師
WINFOCUS director / instructor
Certified Interventional Pain Sonologist

急診 / 重症 / 介入 / 急性疼痛

經歷
新光急診超音波訓練中心主任
西園醫院急診醫學科主任
急診醫學會超音波委員會主委
台灣疼痛醫學會大體模擬手術講師
急救加護醫學會重症超音波負責人

Resuscitative 急救復甦	Diagnostic 臨床診斷	Procedural Guidance 處置導引	Symptom- or Sign-Based 症狀導引	Therapeutic 輔助治療

Core Applications (2023 ACEP Emergency Ultrasound Guidelines)
15項急診超音波核心應用

陳國智醫師

Aorta	Procedural Guidance	Hepatobiliary
DVT	US-guided NB	Urinary tract
Trauma	Testicular	Pregnancy
Thoracic/Airway	Ocular	Bowel
Cardia/HD assessment	Skin & Soft tissue	MSK

I-AIM

POINT

Acquire

Interpret

Make decision

Bahner DP, et al. J Ultrasound Med 2012

Match !!

1

2

3

4

5 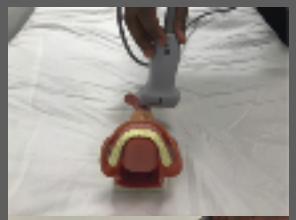

6

7

8

A 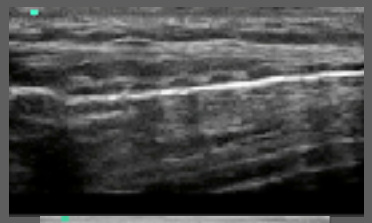

B

C 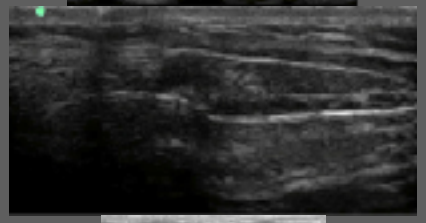

D

E 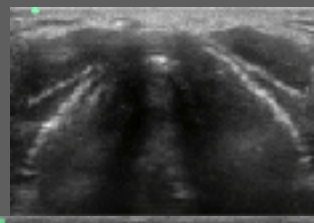

F 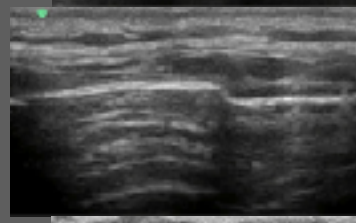

G

H

How good you are ?

1

2

3

4

5

6

7

8

B 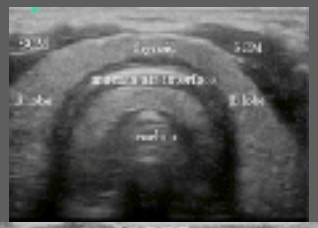

G

D

E 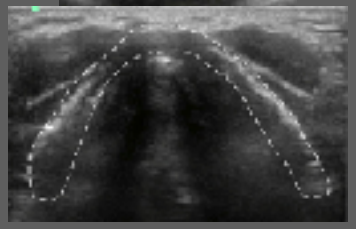

H

A

F

C

AIRWAY POCUS IN ER

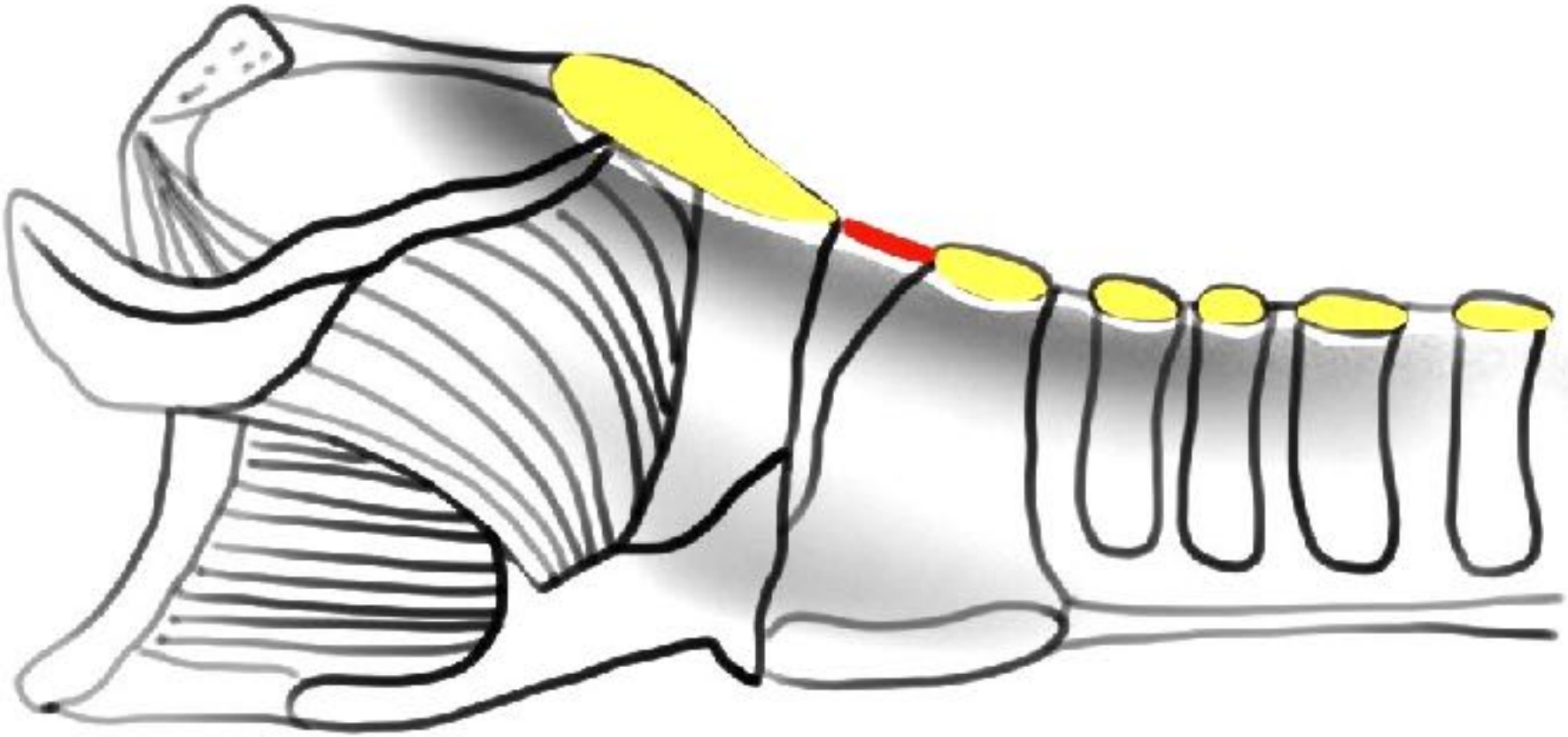

Airway management

Anatomical structure examined	Clinical indications	Type of study*
Cricothyroid membrane and trachea	Pre-anesthetic airway evaluation to be prepared for emergency front of neck airway access[6-8]	Randomized-controlled trial, prospective cohort, narrative review
	For elective tracheostomy[9] and other kinds of access to the airway via the anterior neck[1]	Randomized-controlled trial, prospective cohort
Tracheal placement of endotracheal tube	Evaluation of the placement of a breathing tube, in trachea, main-stem bronchus or esophagus[10,11]	Randomized-controlled trial, prospective cohort and observational, systematic review, meta-analysis
Trachea	Predicting the optimal size of endotracheal, double-lumen, and tracheostomy-tubes[12-14]	Randomized-controlled trial, prospective cohort and observational, case series
Vocal cords	Identification of vocal cord palsy and other pathology[15,16]	Prospective cohort and observational

You-Ten KE, et al. Can J Anesth 2018

Airway
Breathing
Circulation
Diaphragm
Esophagus
Fasting

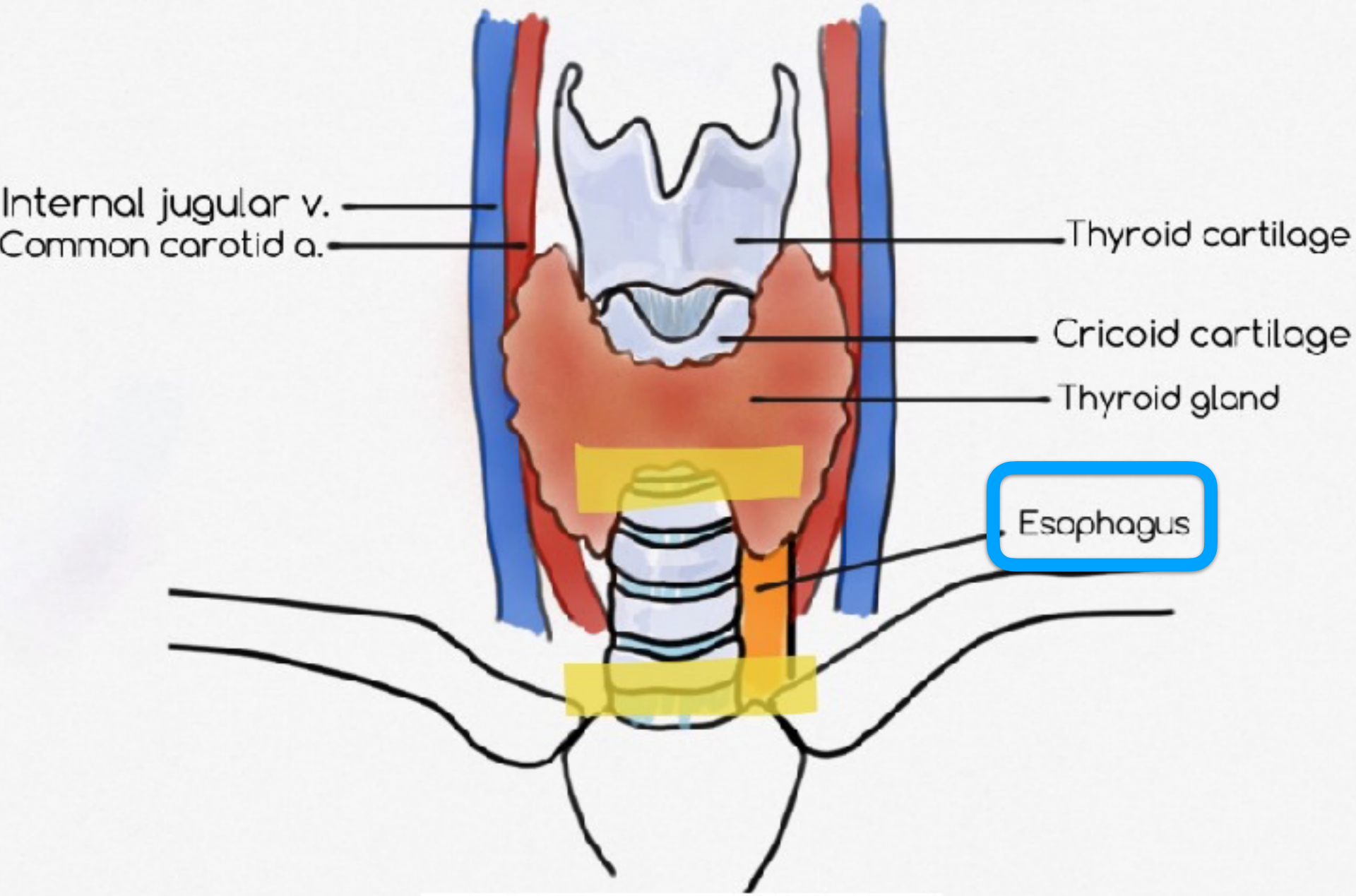

Copyright © 2016 HSU CHE CHANG. All rights reserved

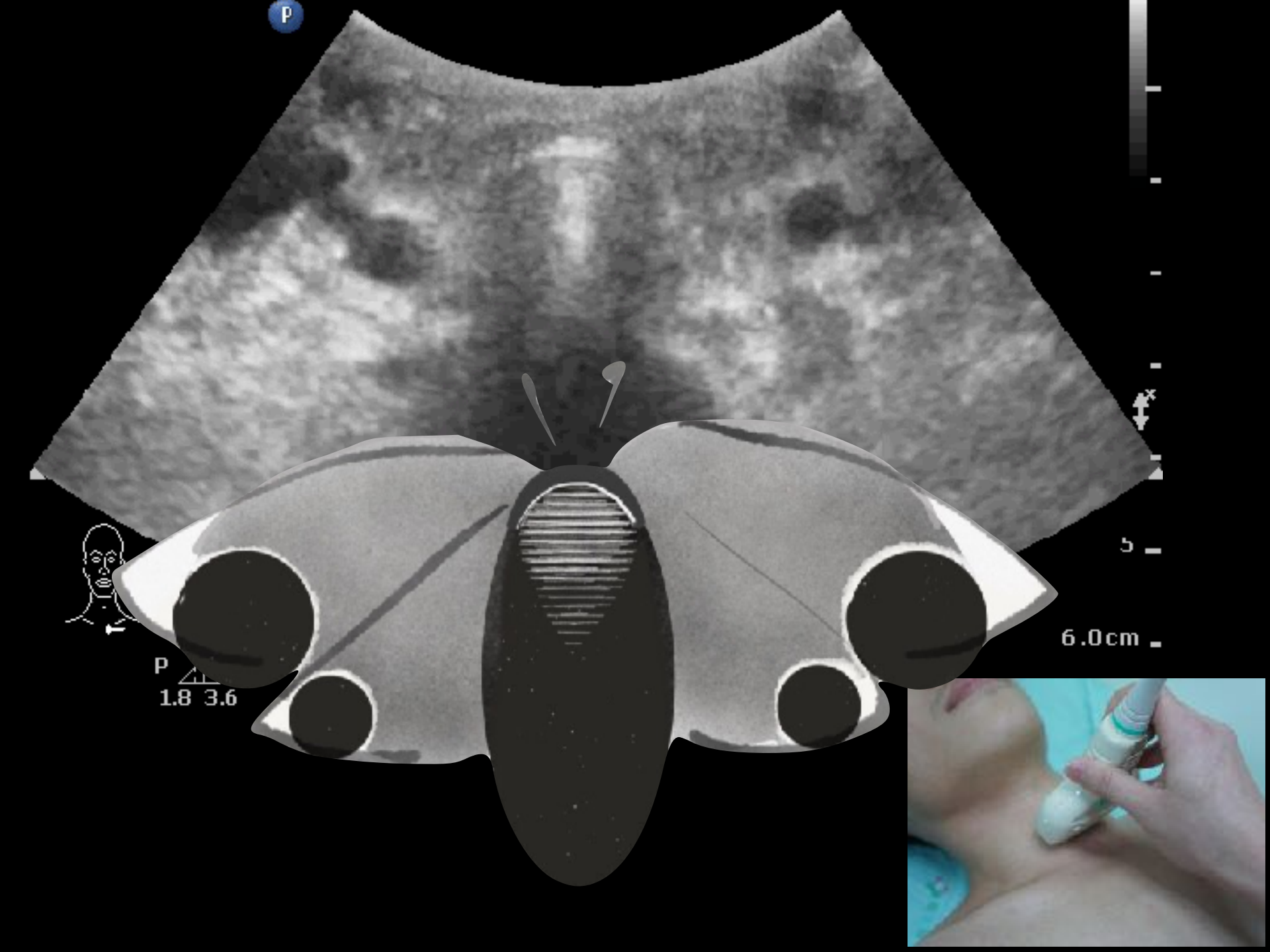
P
6.0cm
P
1.8 3.6

AIRWAY (ONE TRACT)

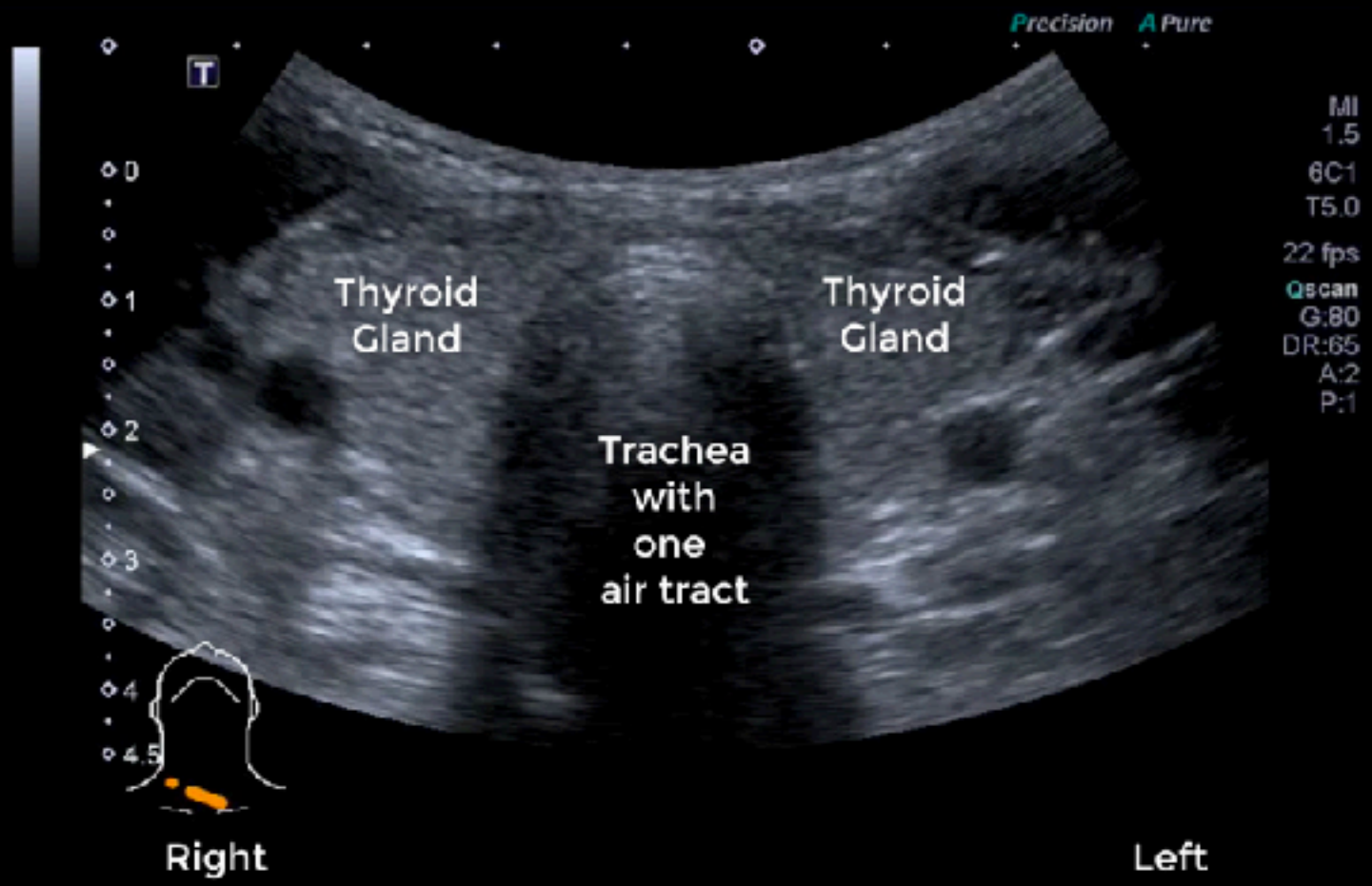

AIRWAY (ONE TRACT)

AIRWAY (COMPRESSION)

AIRWAY & ESOPHAGUS

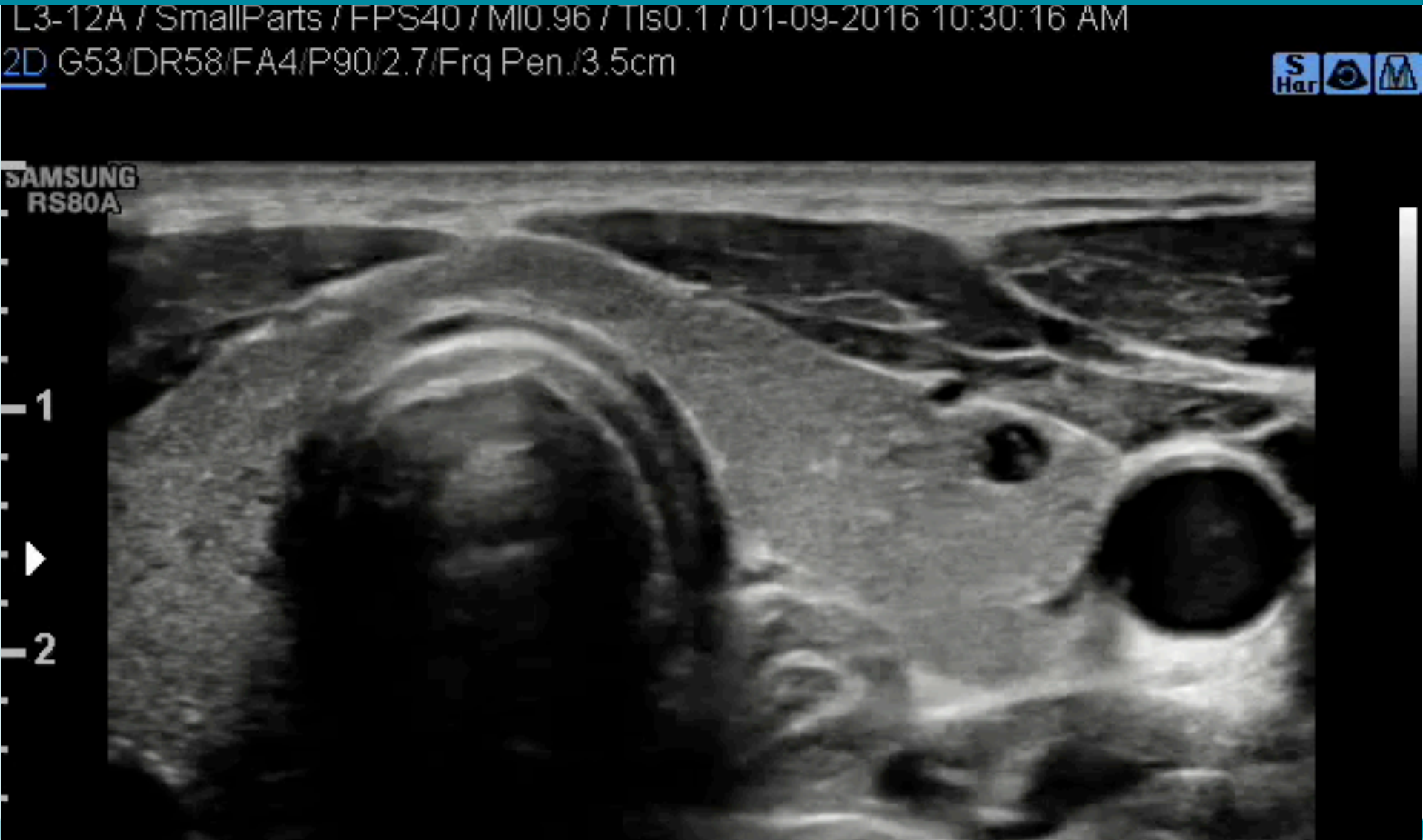

AIRWAY (ONE TRACT)

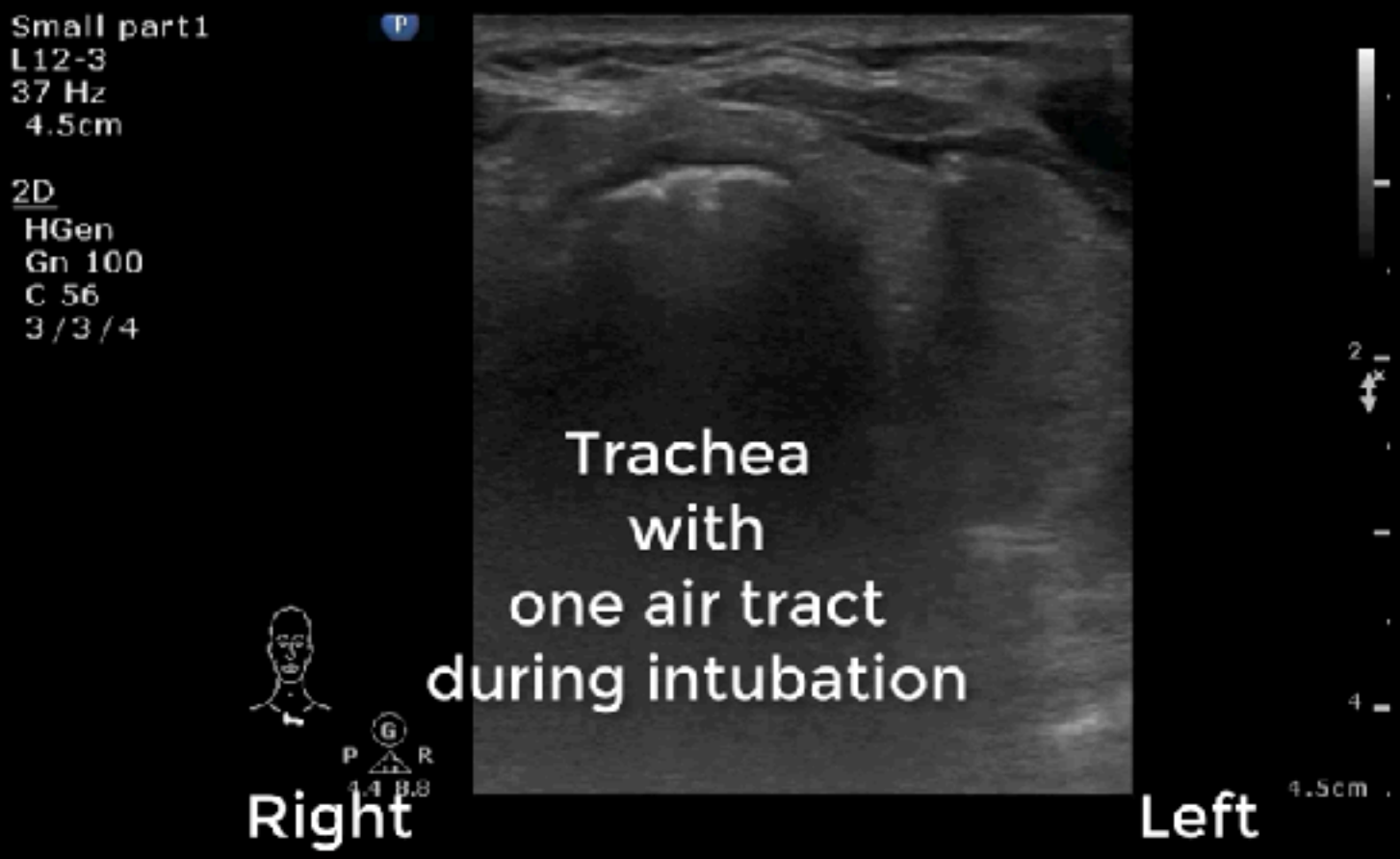

Cricothyrotomy

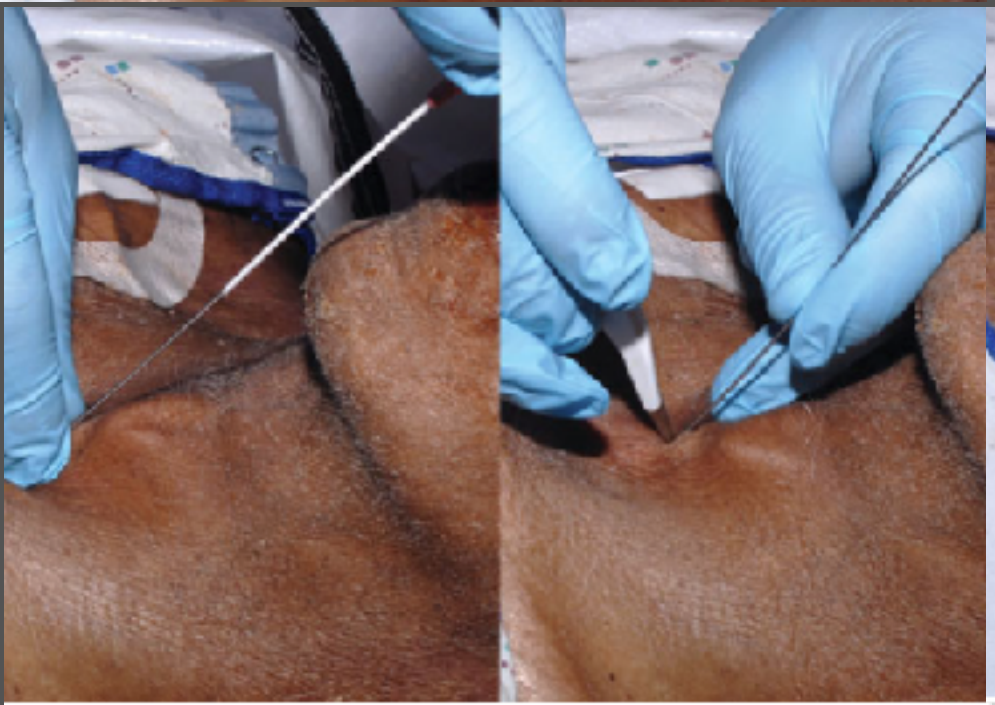

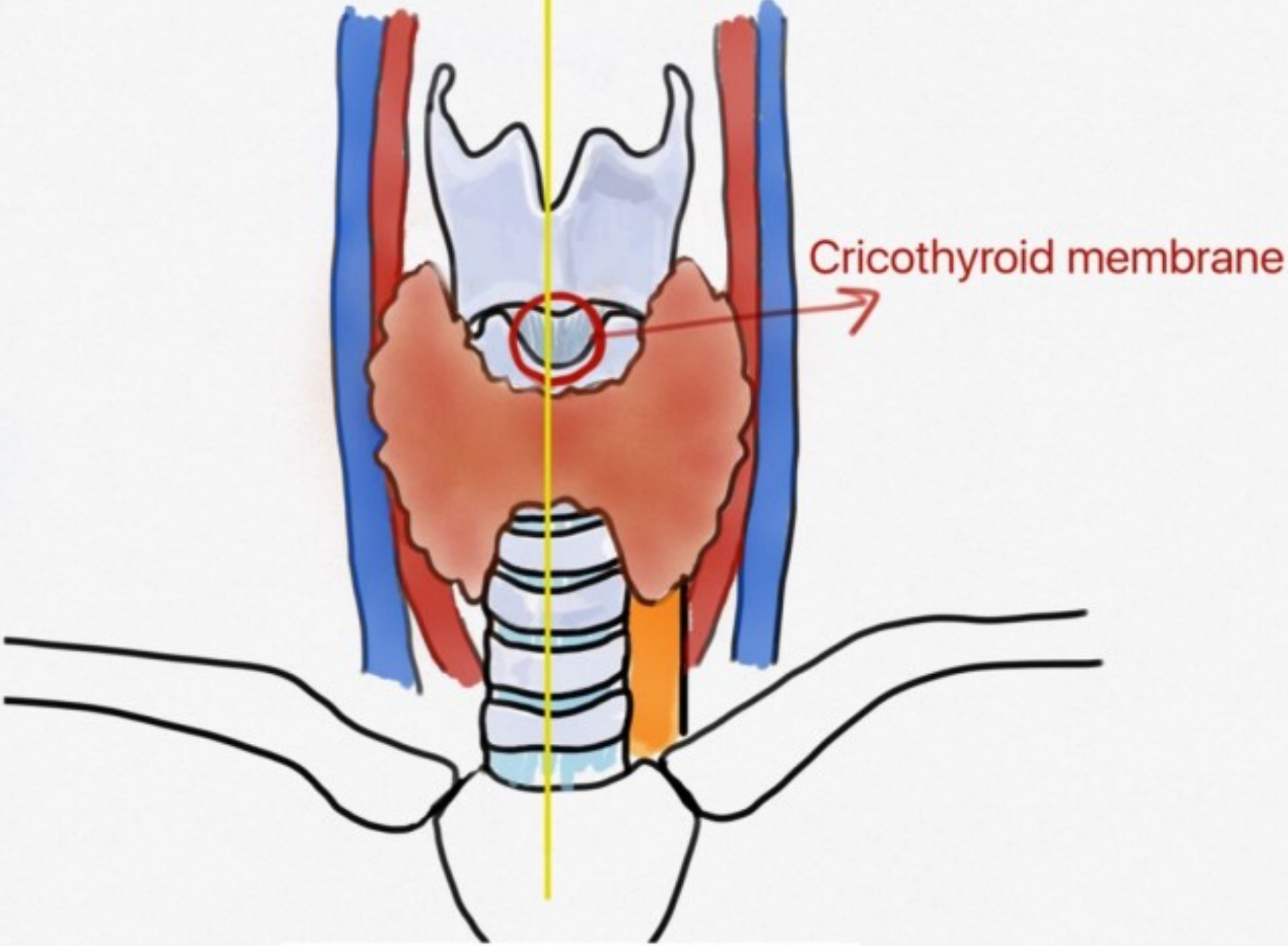

Copyright © 2016 HSU CHE CHANG. All rights reserved

CTM LOCALIZATION PRIOR TO INTUBATION

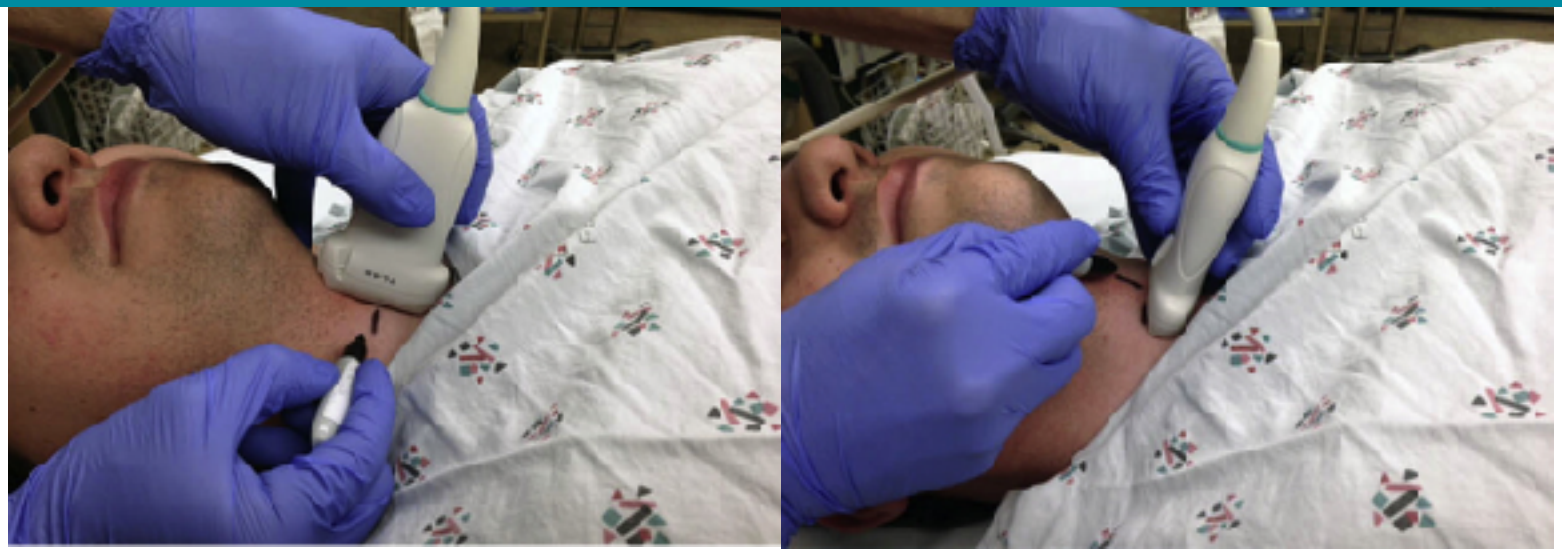

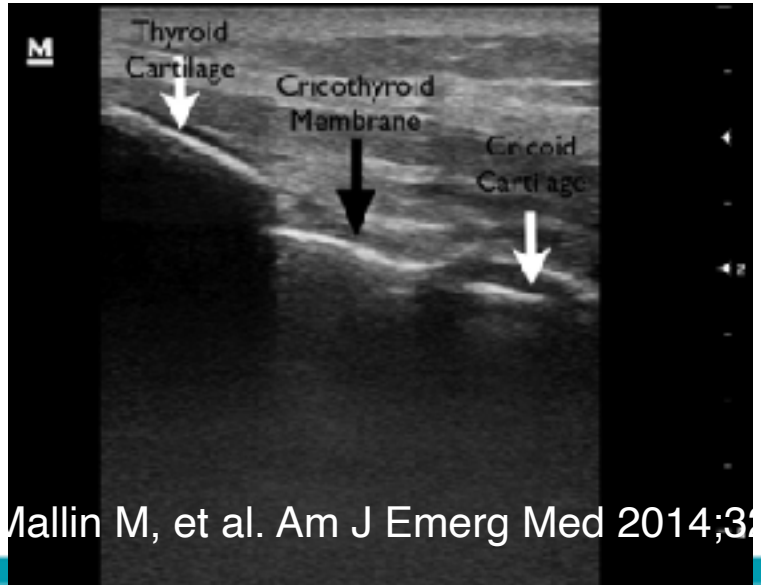

Mallin M, et al. Am J Emerg Med 2014;32

AIRWAY & CTM

L3-12A / SmallParts / FPS40 / MI0.96 / TIs0.1 / 01-09-2016 10:29:39 AM
2D G53/DR58/FA4/P90/2.7/Frq Pen./3.5cm
SAMSUNG
RS80A
1
2
3
Right
Left
Vocal cord
Transverse scan on trachea

ESO INTUBATION (2 TRACTS)

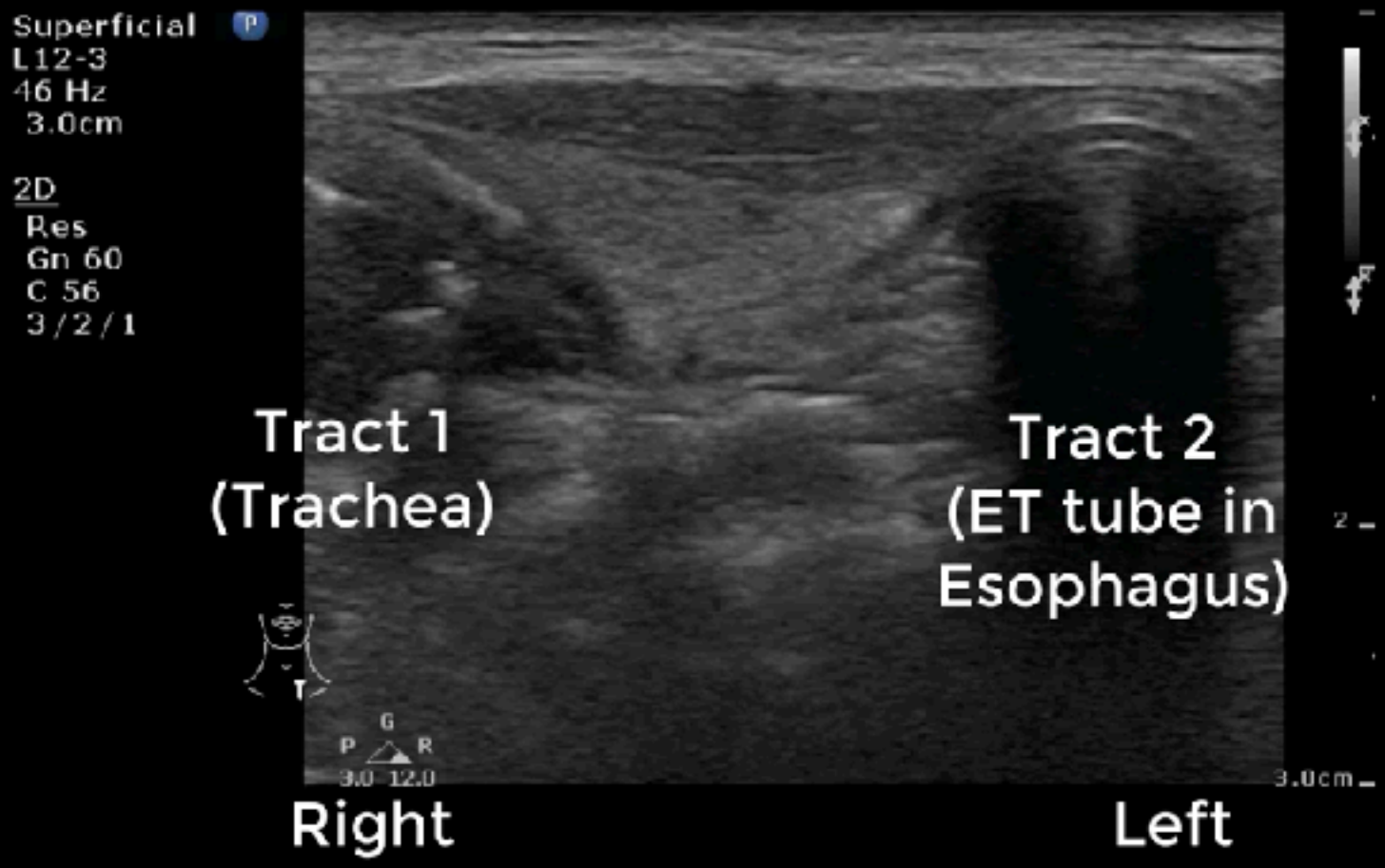

ESO INTUBATION (REMOVED)

4 MONTH GIRL, SPO2 70%

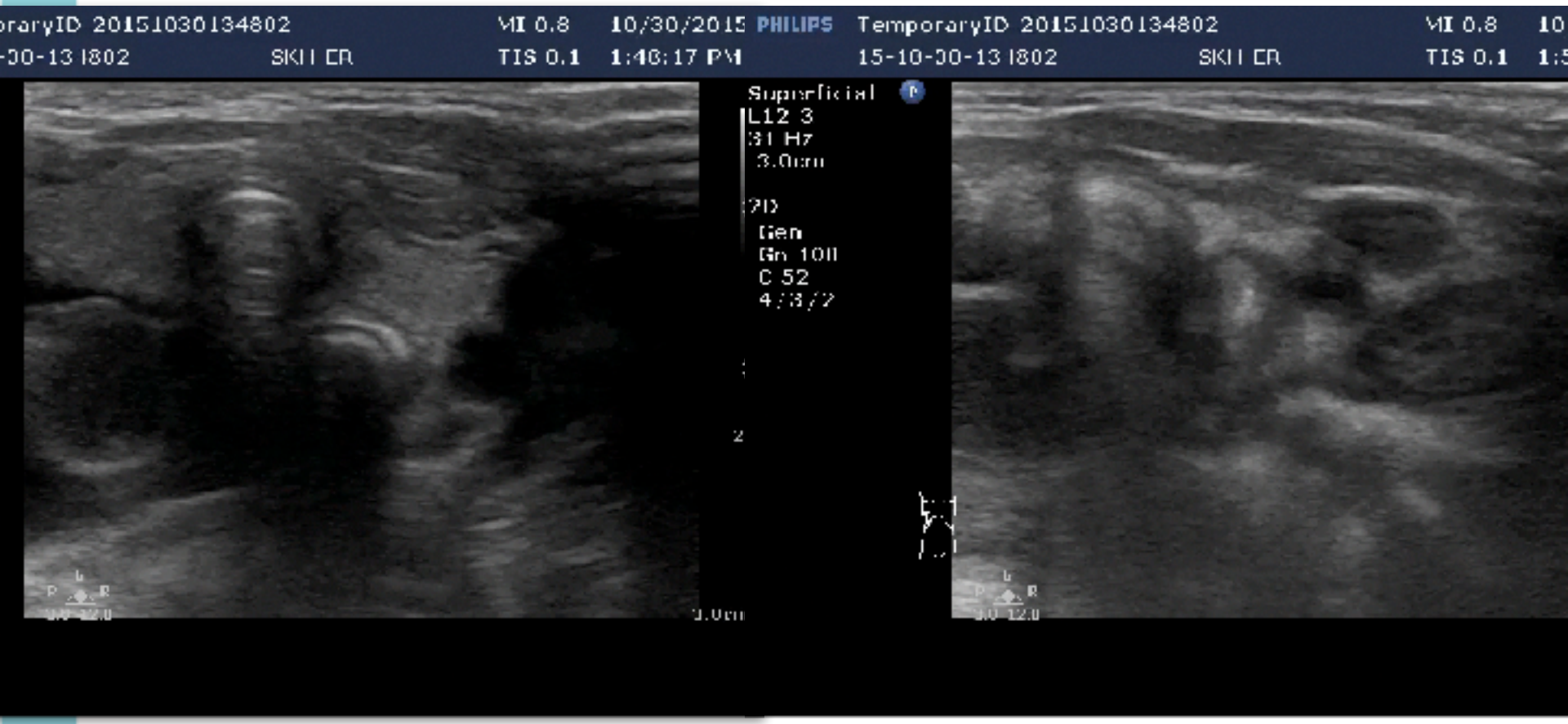

CURTAIN SIGN & DIAPHRAGM MOVEMENT

CURTAIN SIGN & DIAPHRAGM MOVEMENT

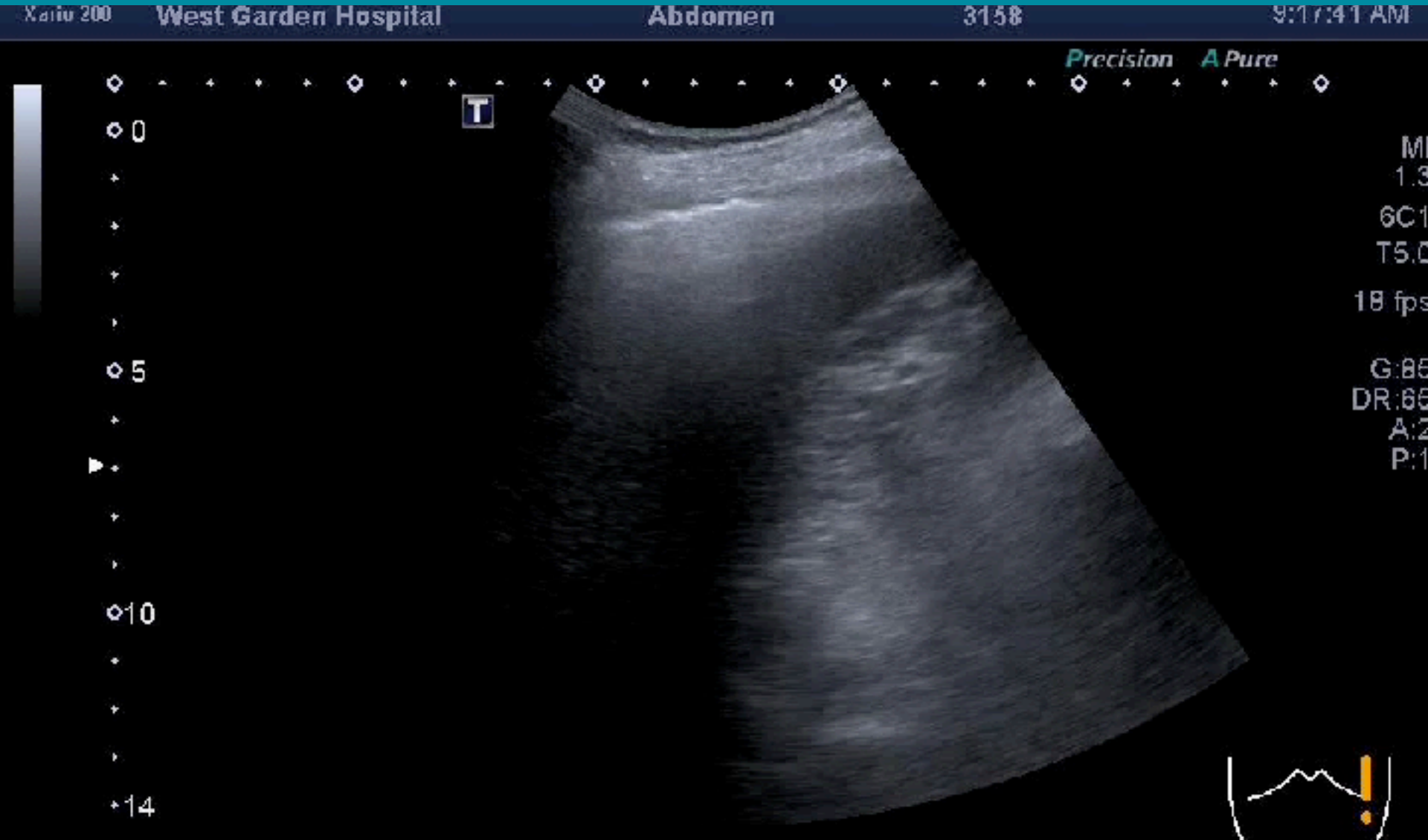

RESPIRATORY DRIVE BY DIAPHRAGM

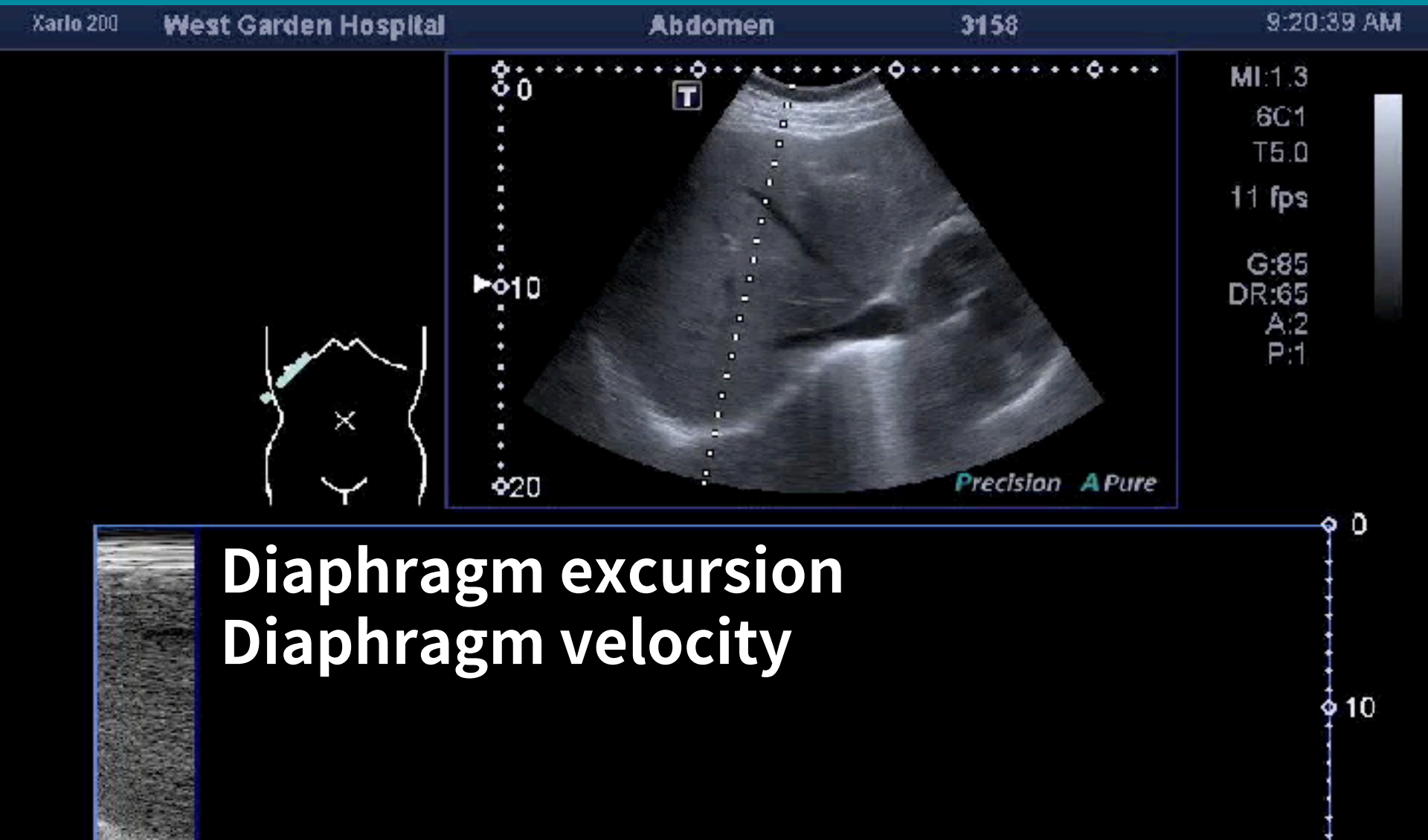

Diaphragm excursion
Diaphragm velocity

RESPIRATORY DRIVE BY DIAPHRAGM

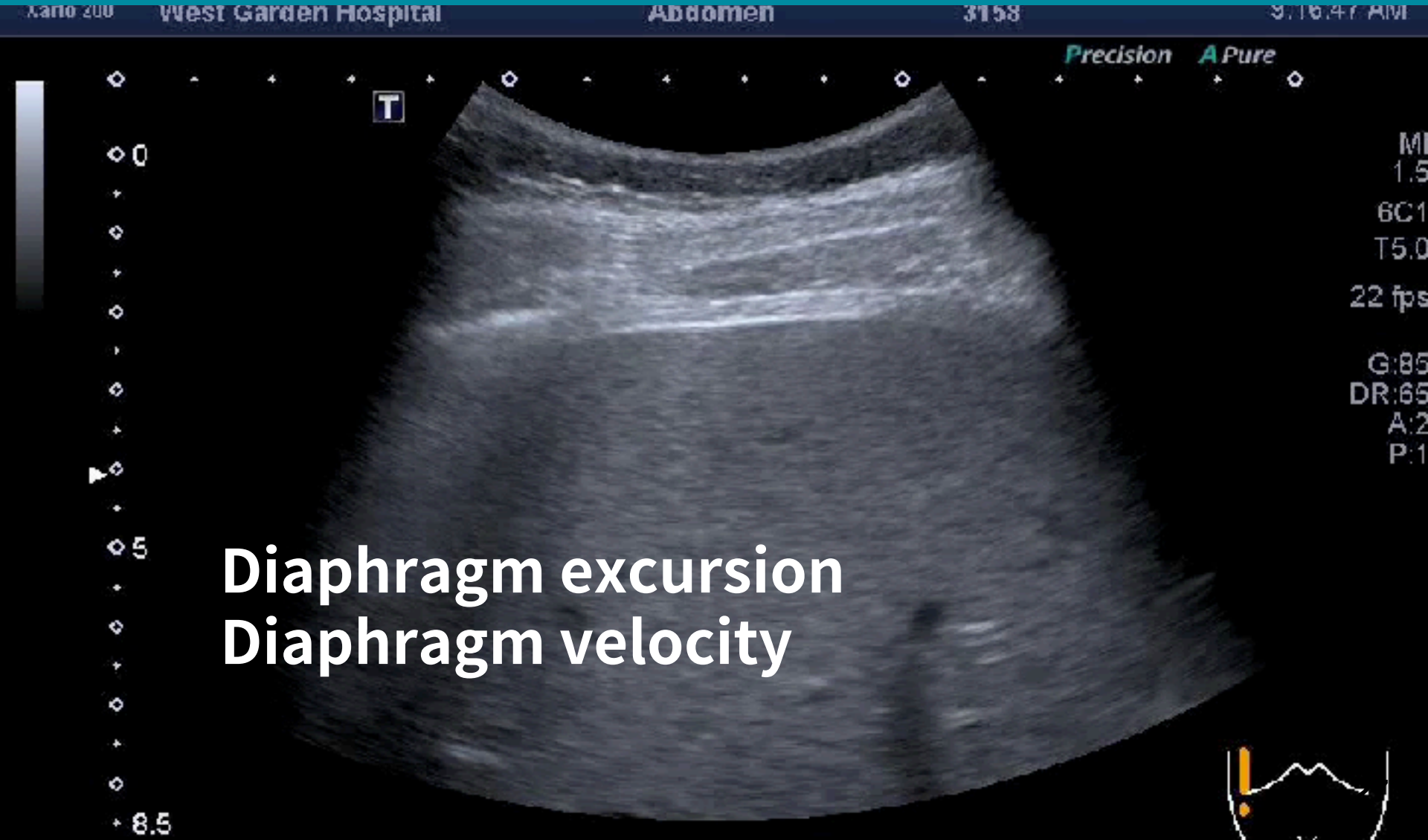

Diaphragm excursion
Diaphragm velocity

RESPIRATORY DRIVE BY DIAPHRAGM

ETT & BILATERAL VENTILATION



TRUST

Tracheal Rapid Ultrasound Saline Test confirming correct ET Depth in children

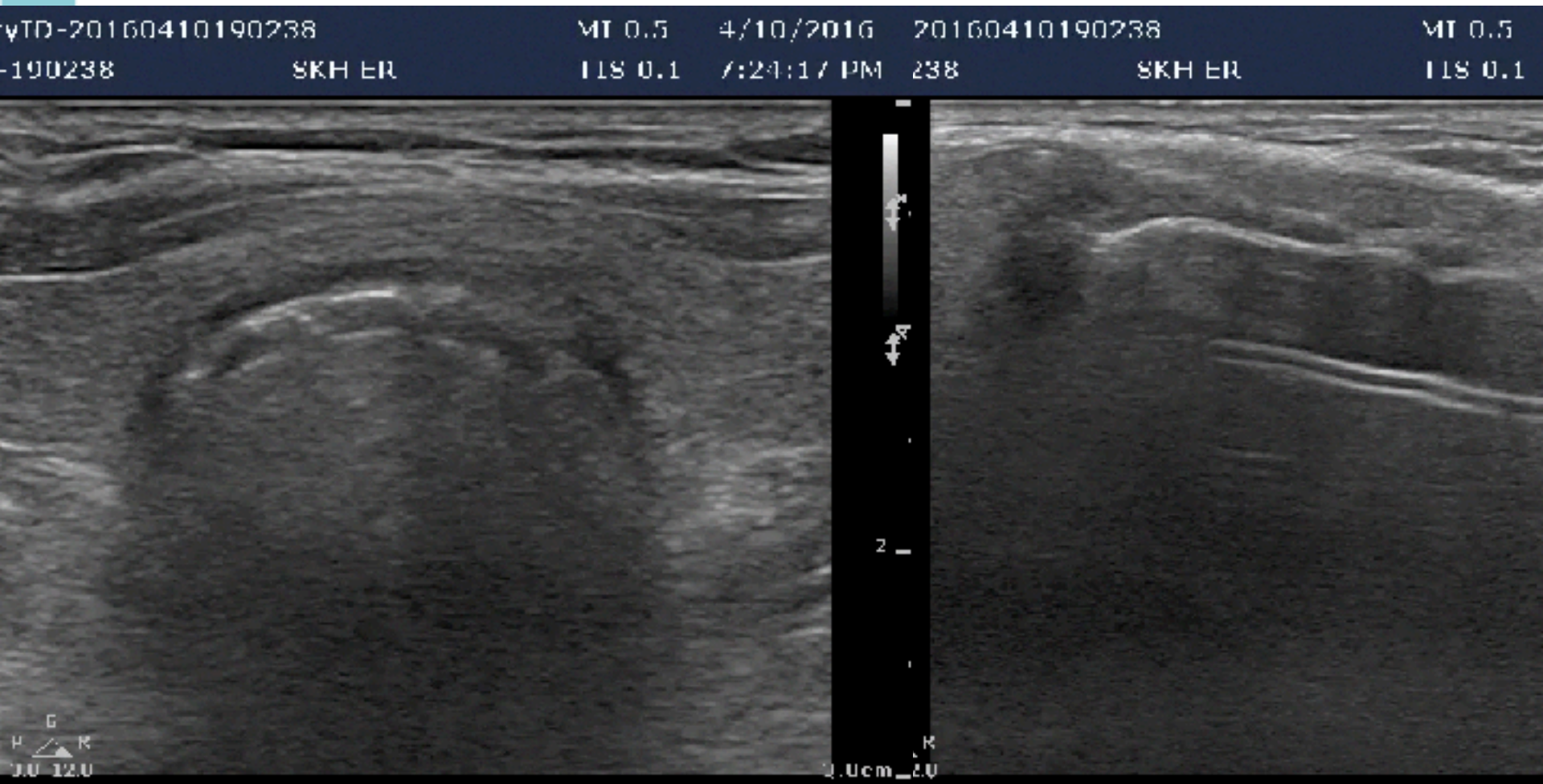

TRACHEAL COMPRESSION FOR ETT VISUALISATION

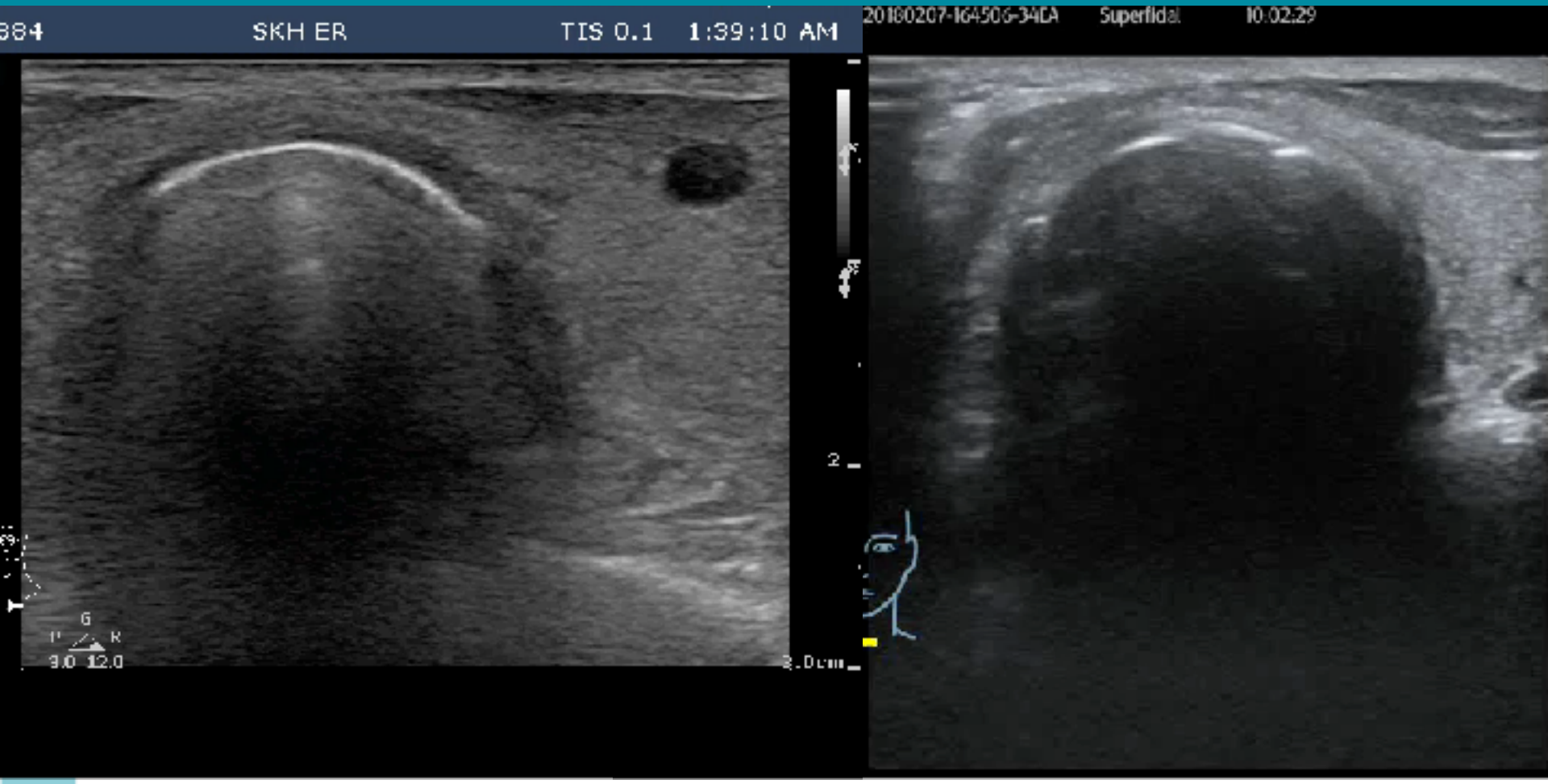

Kao JS, et al. Anaesth Crit Care Pain Med 2018

TRACHEAL COMPRESSION FOR ETT VISUALISATION

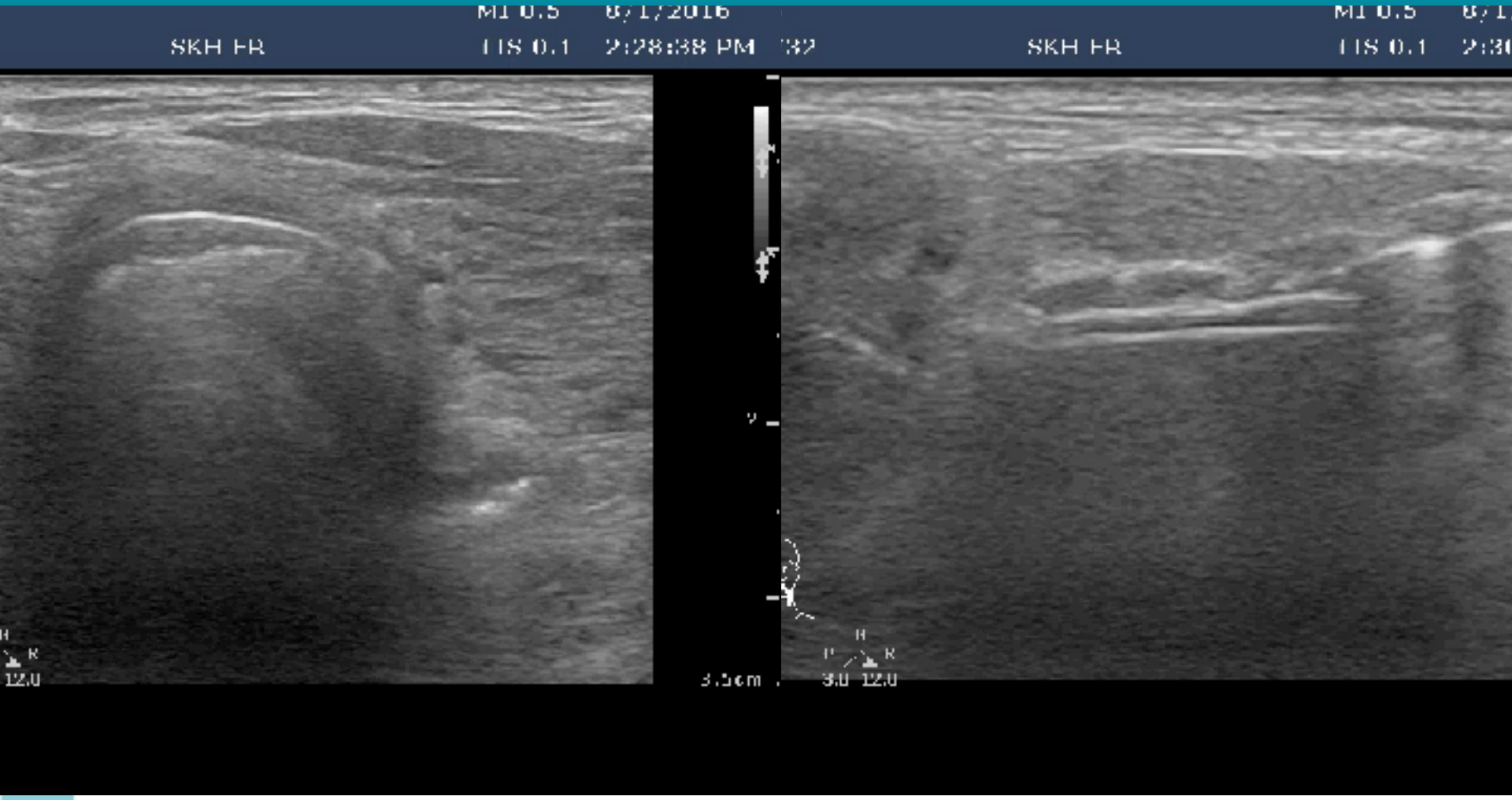

TRACHEAL COMPRESSION FOR ETT VISUALISATION

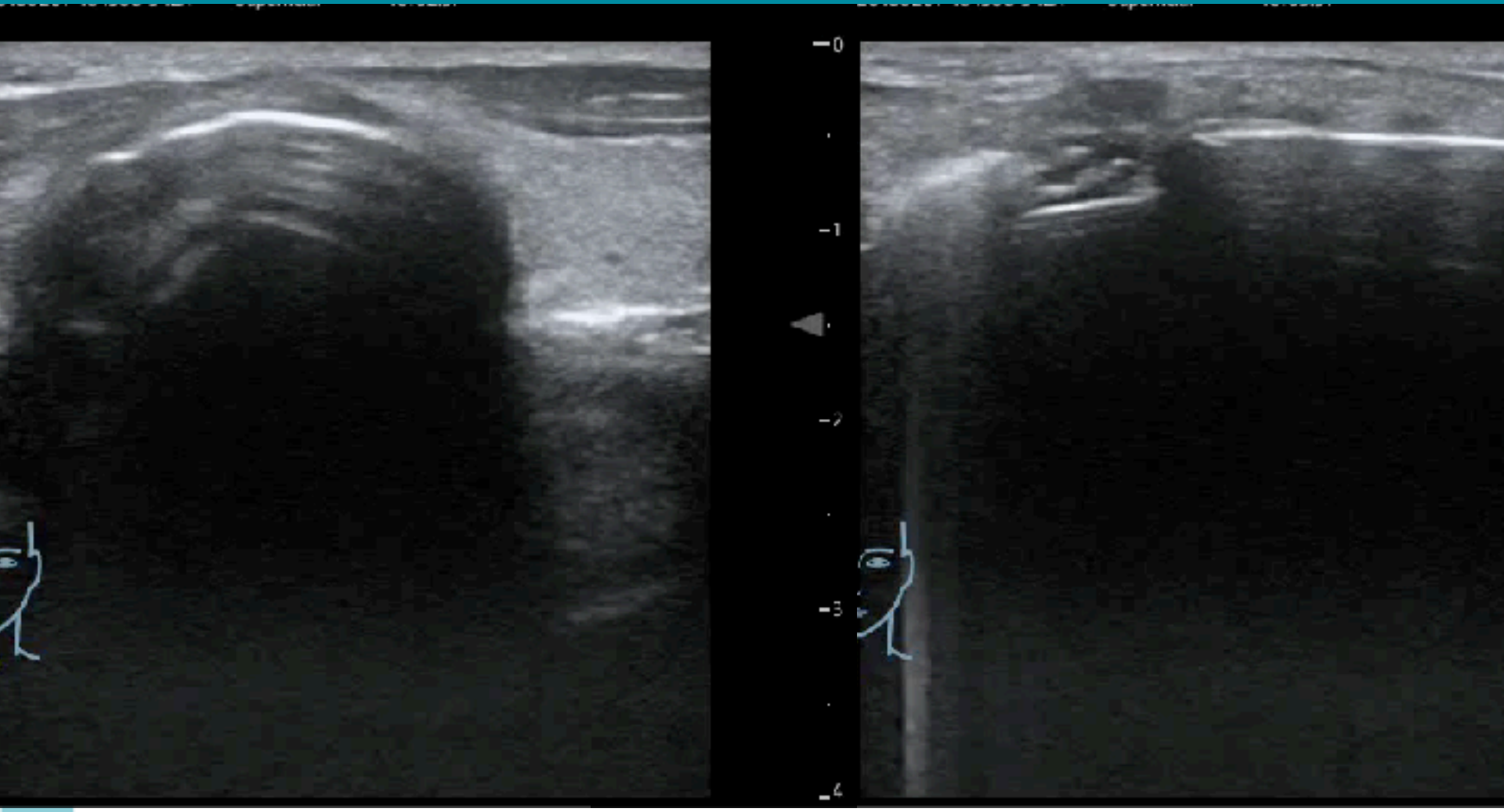

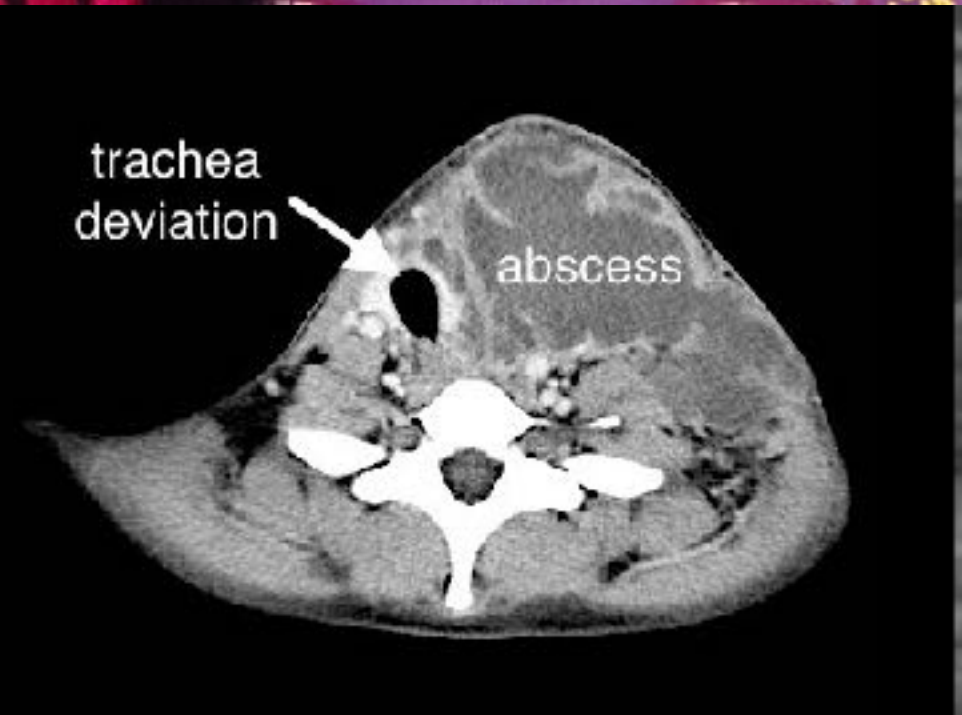
trachea
deviation
abscess

#: 359
14:23:59
0.8
TI: 0.2
25/Apr/2015
4cm

Neck hematoma

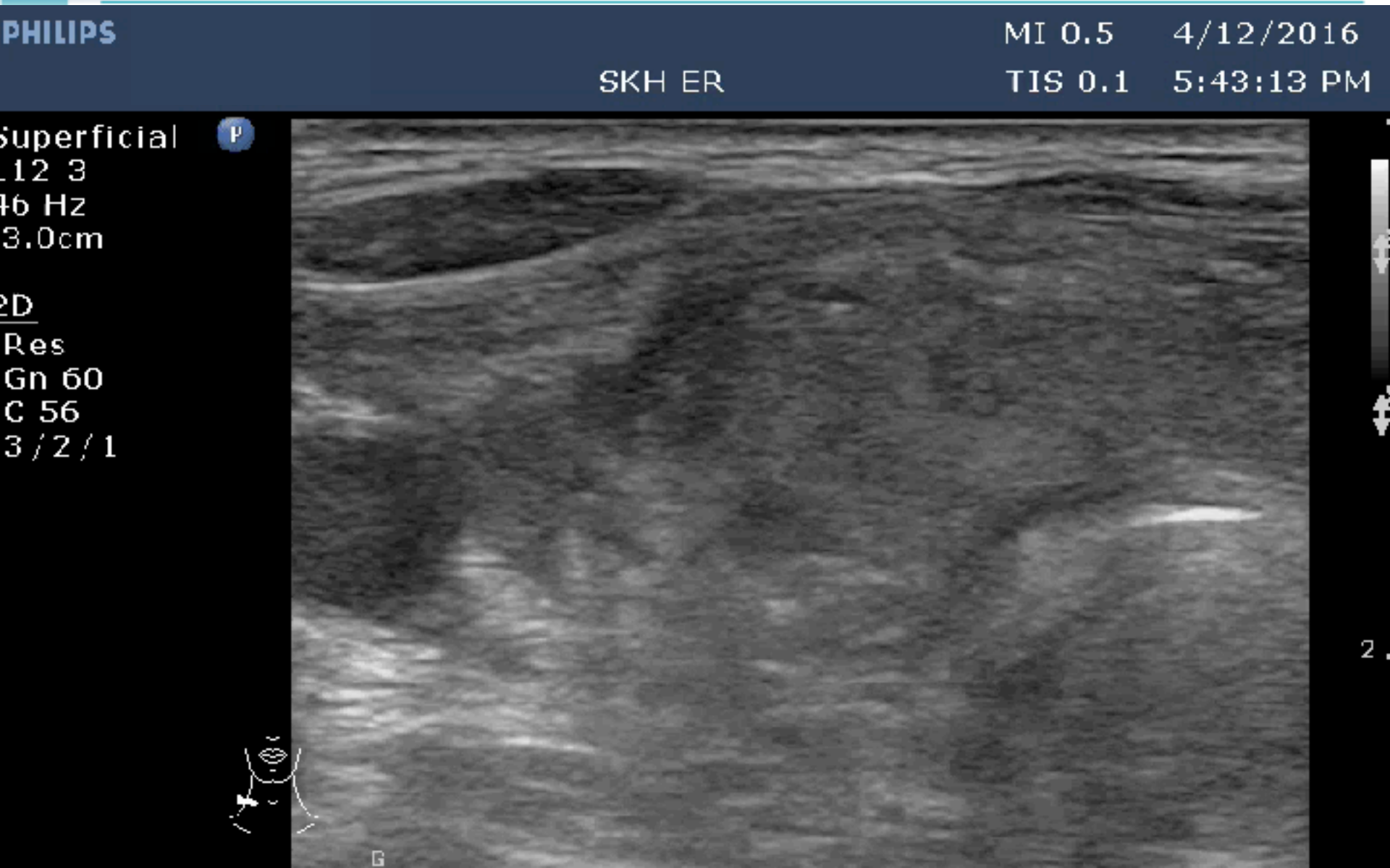

Abnormal gas

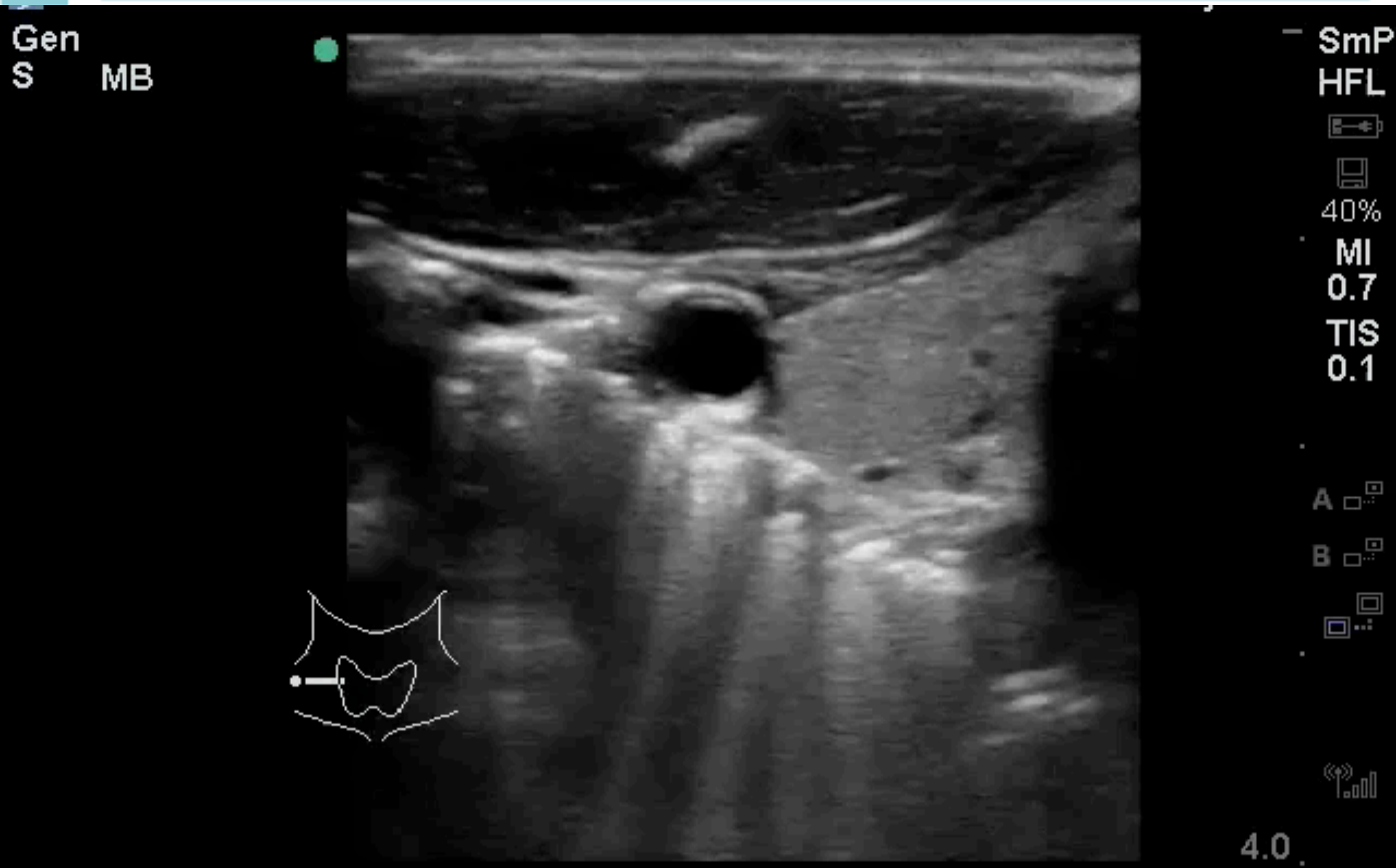

Stridor & Dyspnea

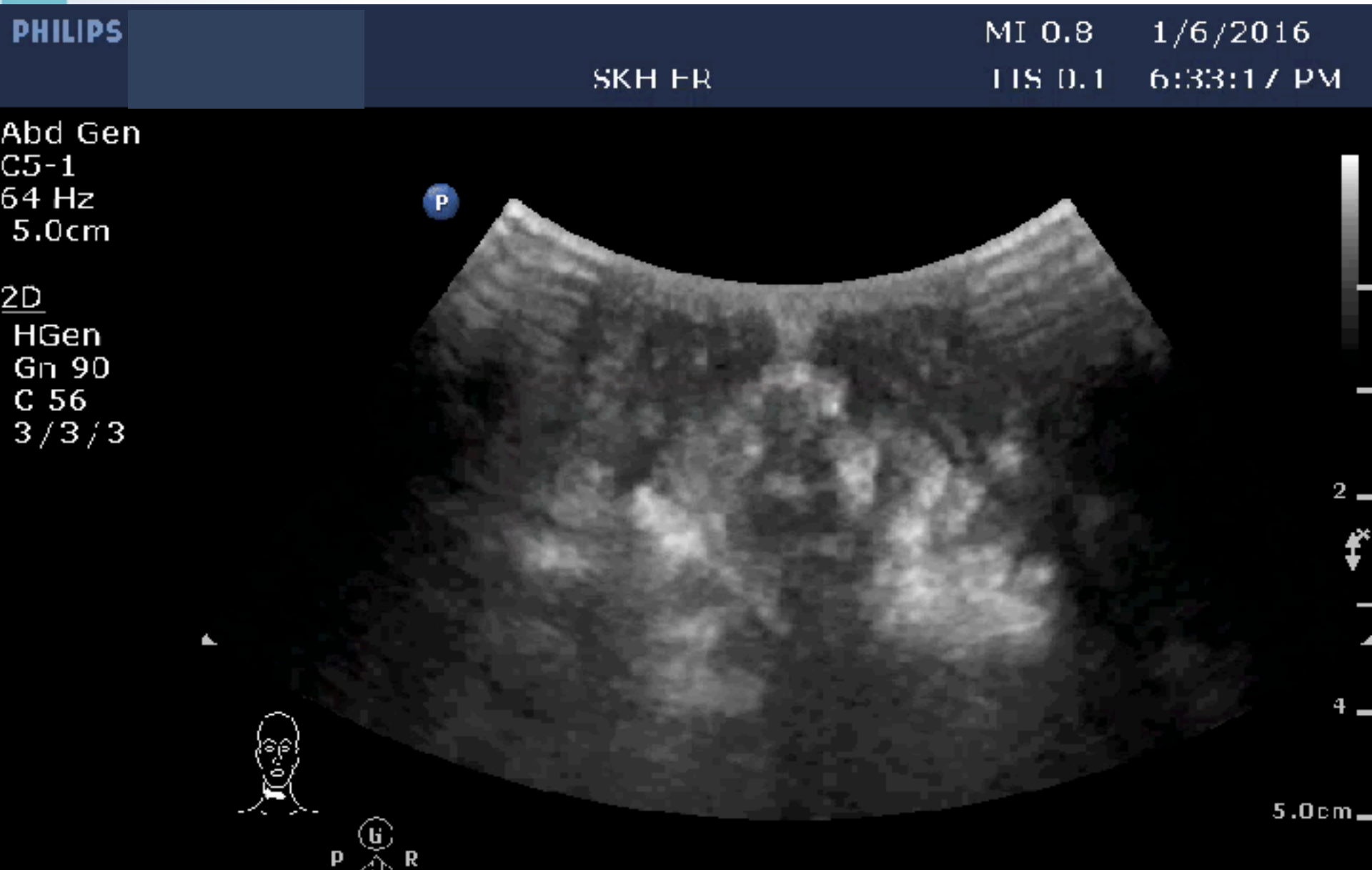

Stridor & Dyspnea

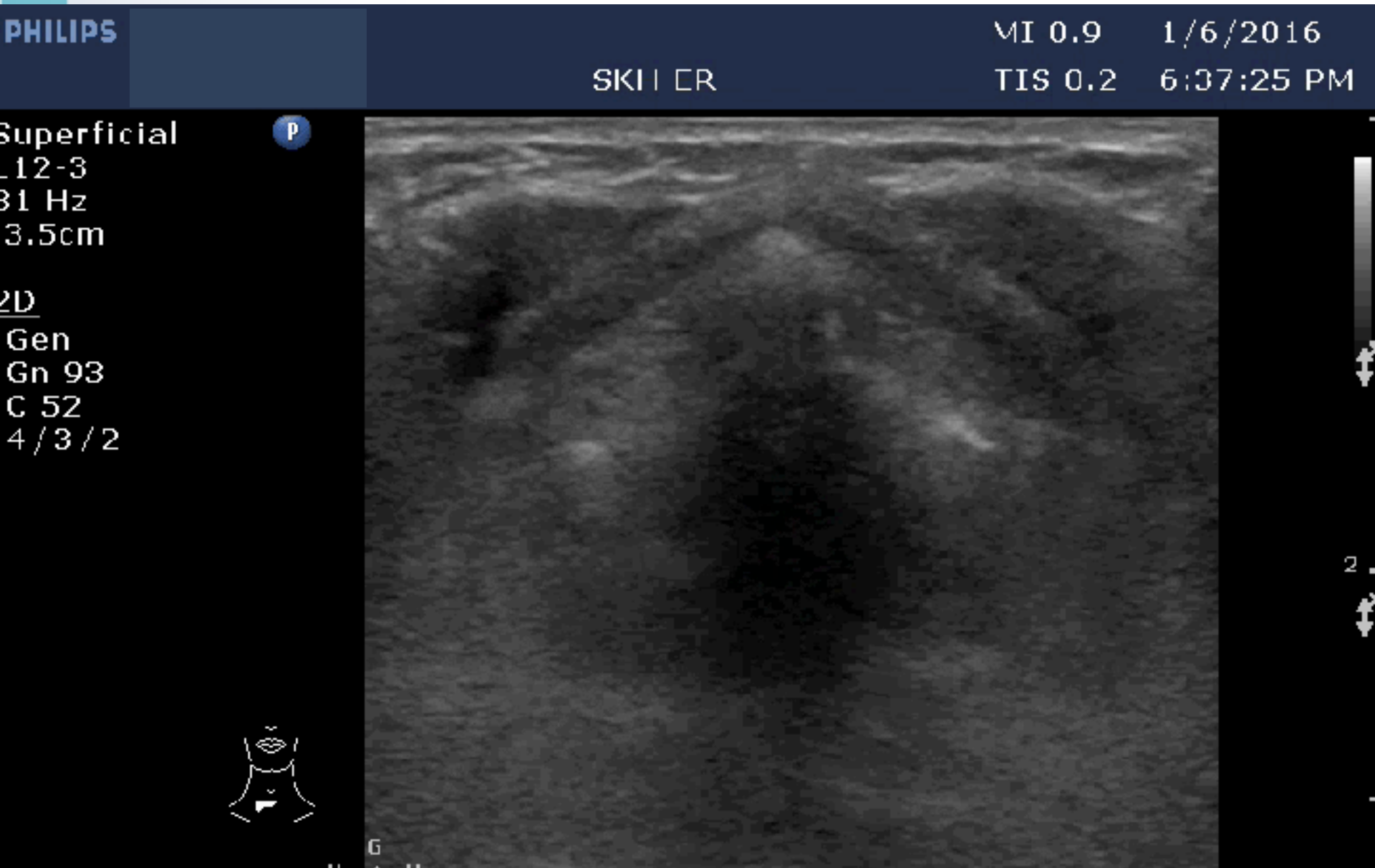

How to manage this airway ?

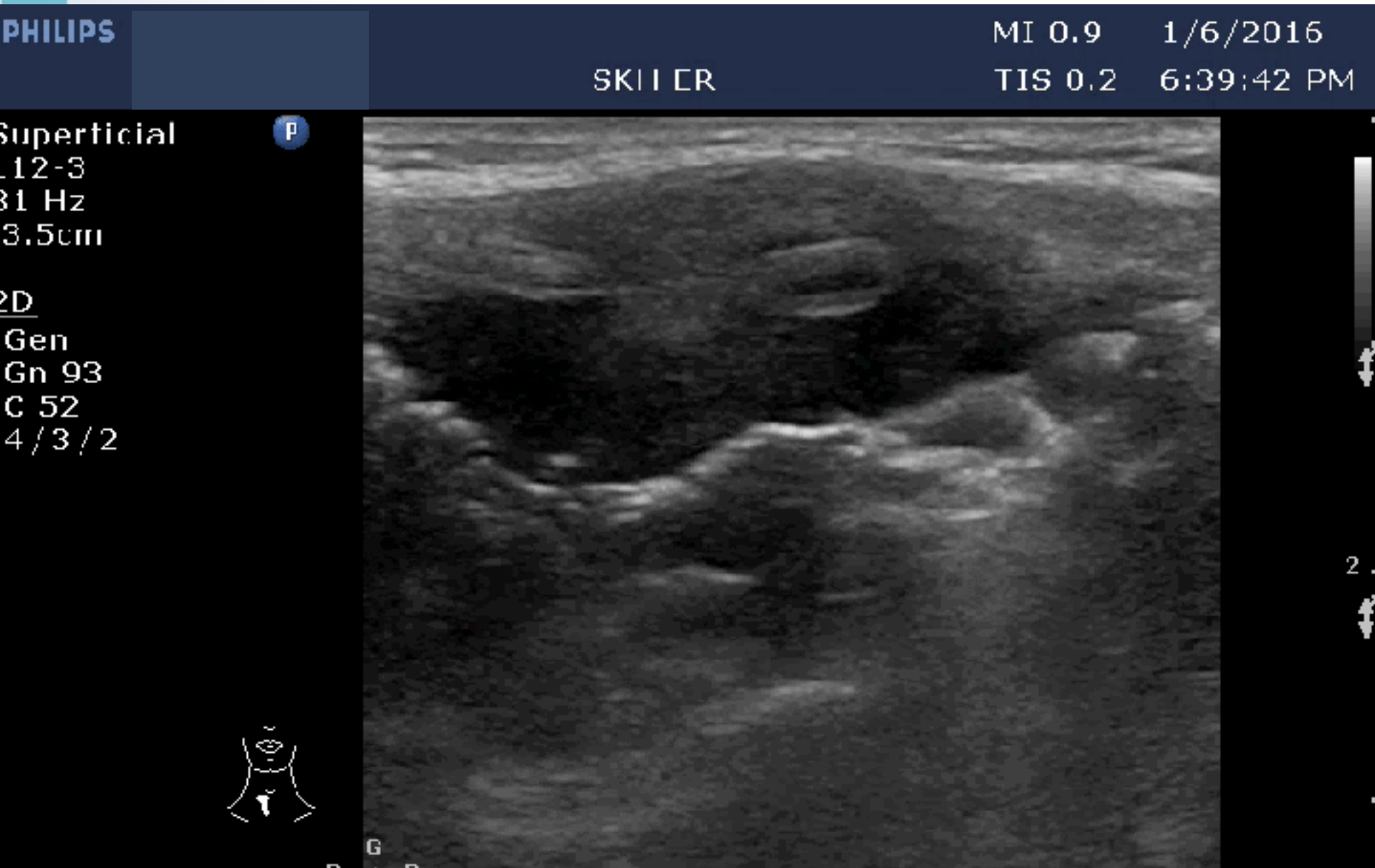

ENT POCUS IN ER

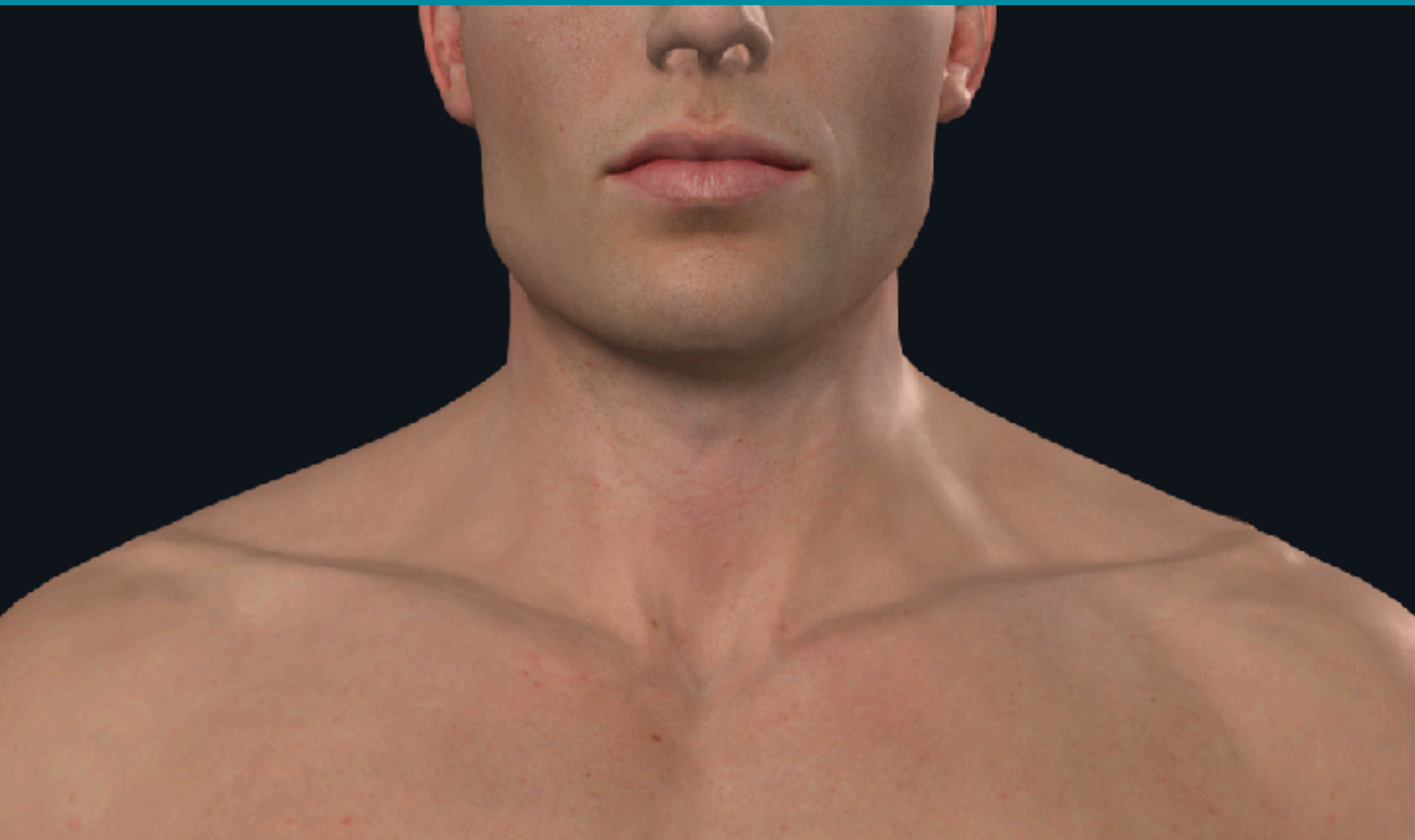

1 Epiglottis

2 Tonsils

3 Glands

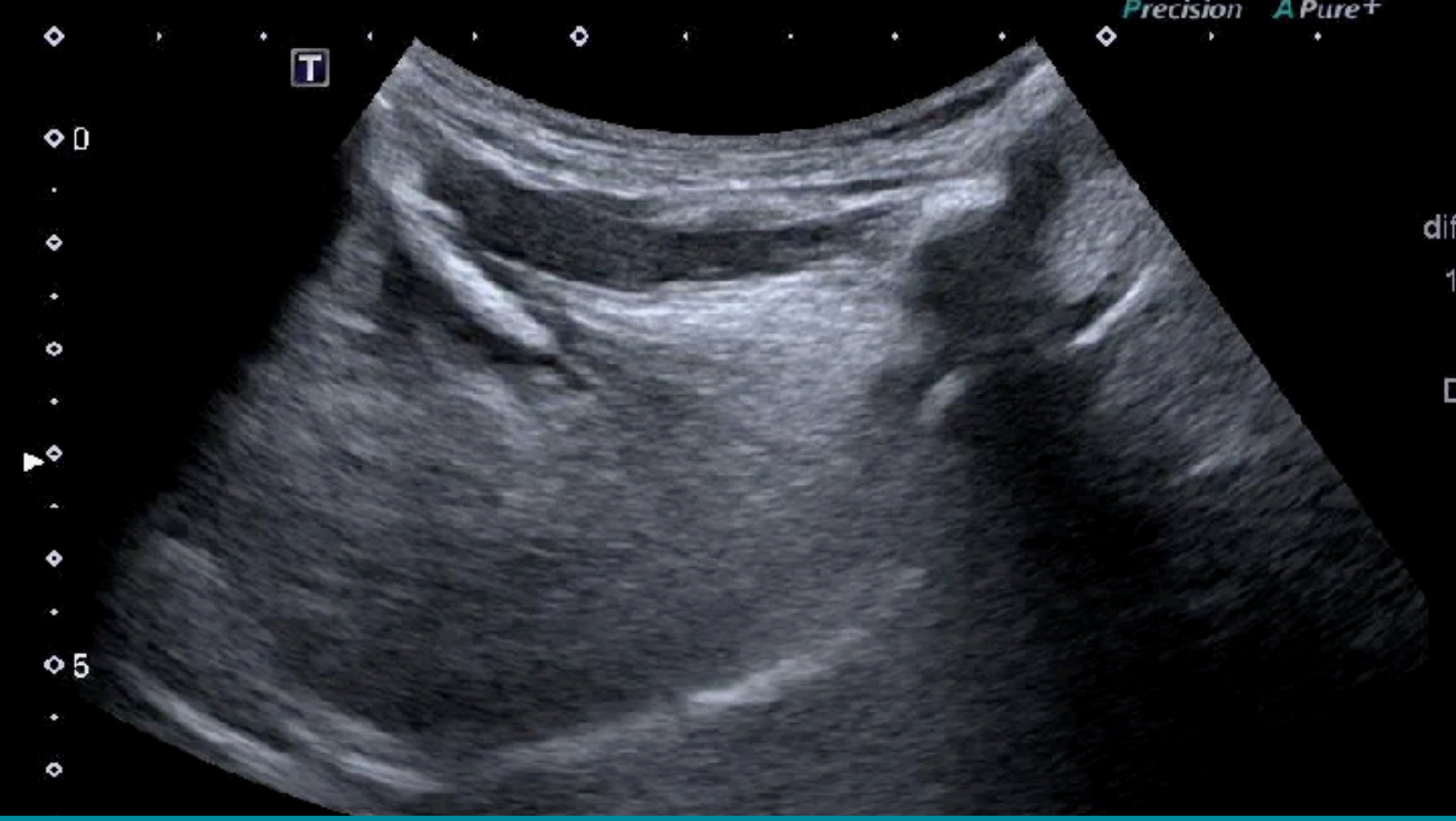

SONOANATOMY

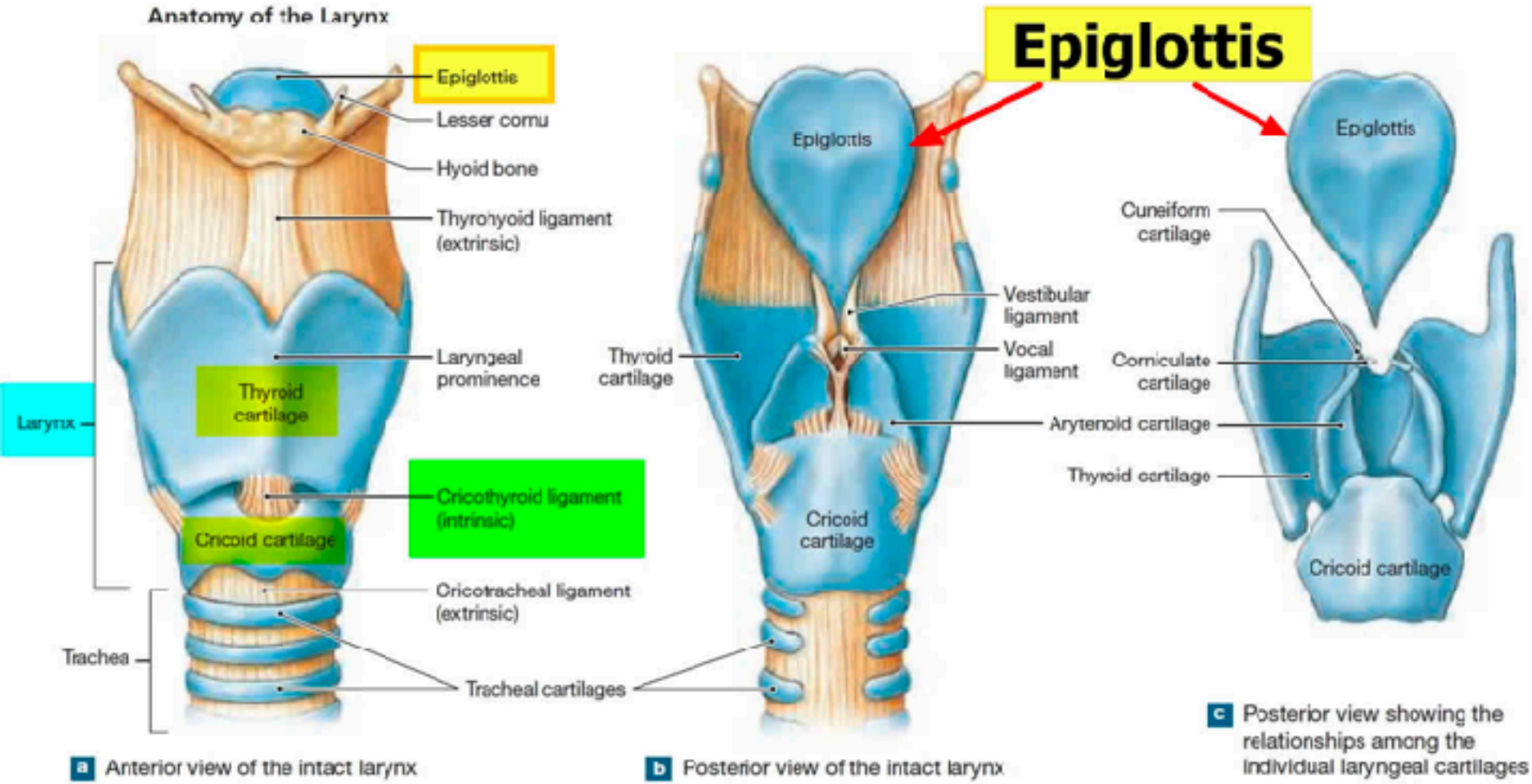

https://healthjade.net/epiglottis/

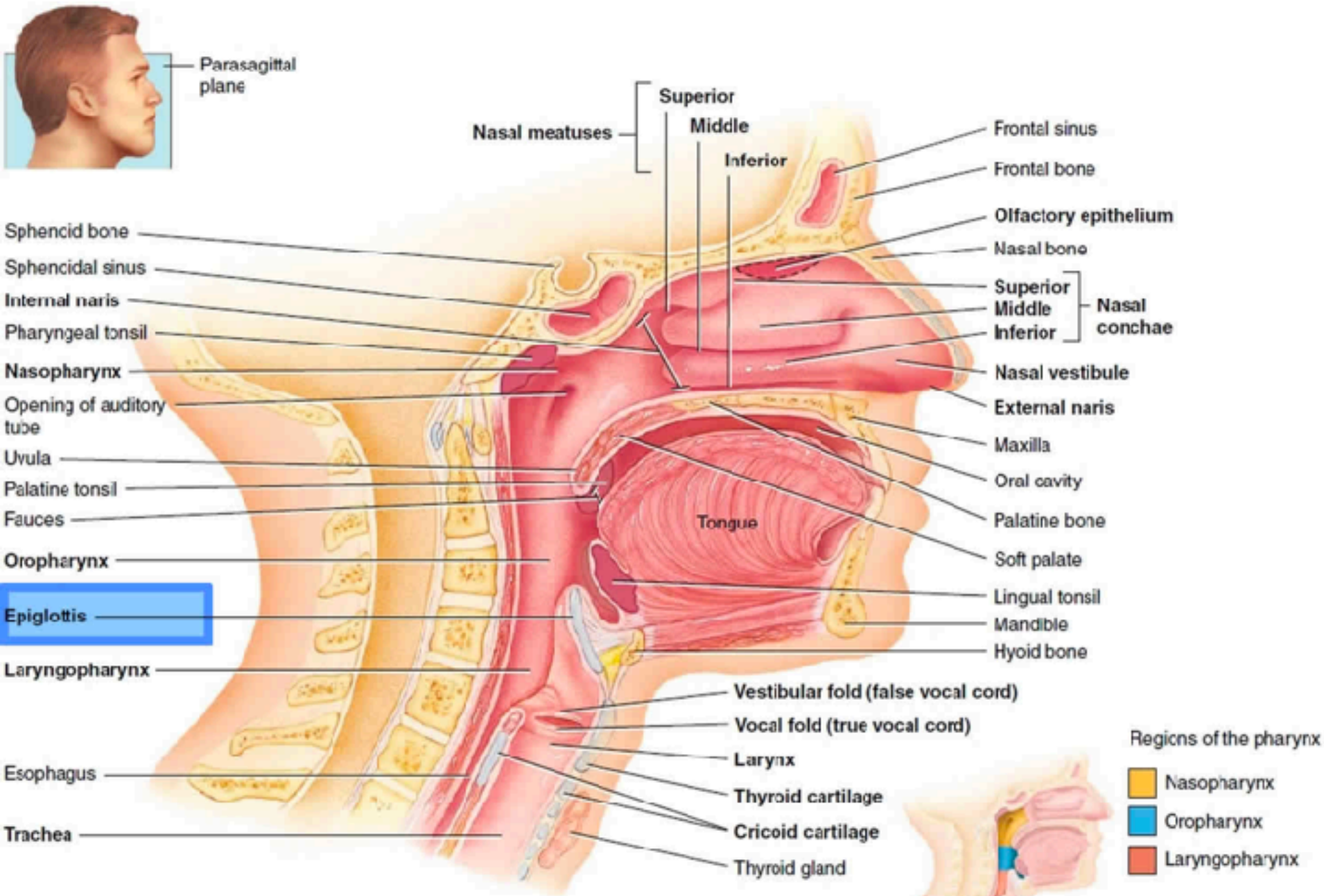

Parasagittal section of left side of head and neck showing location of respiratory structures

https://healthjade.net/epiglottis/

Hyoid bone: landmark for epiglottis

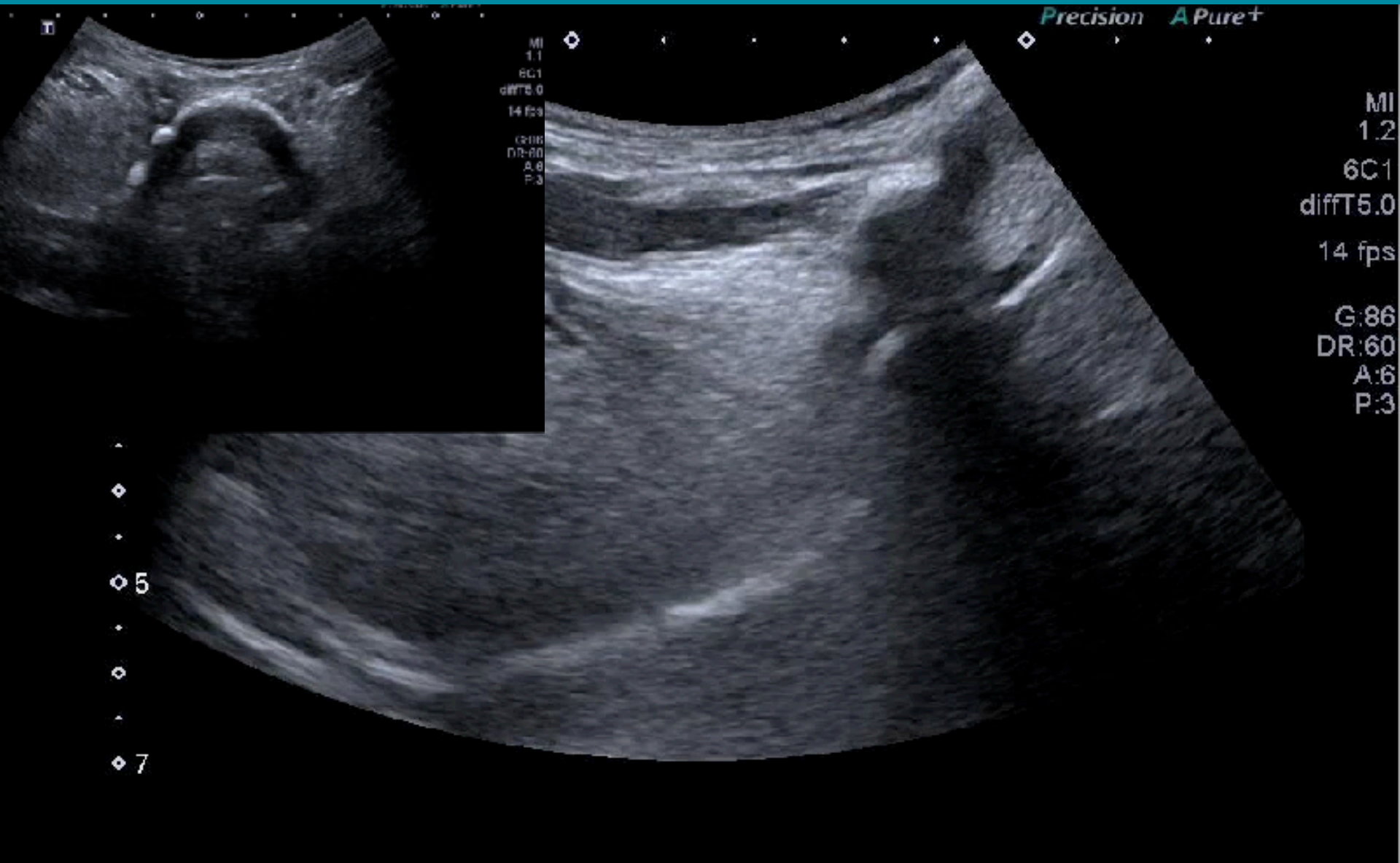

Epiglottis

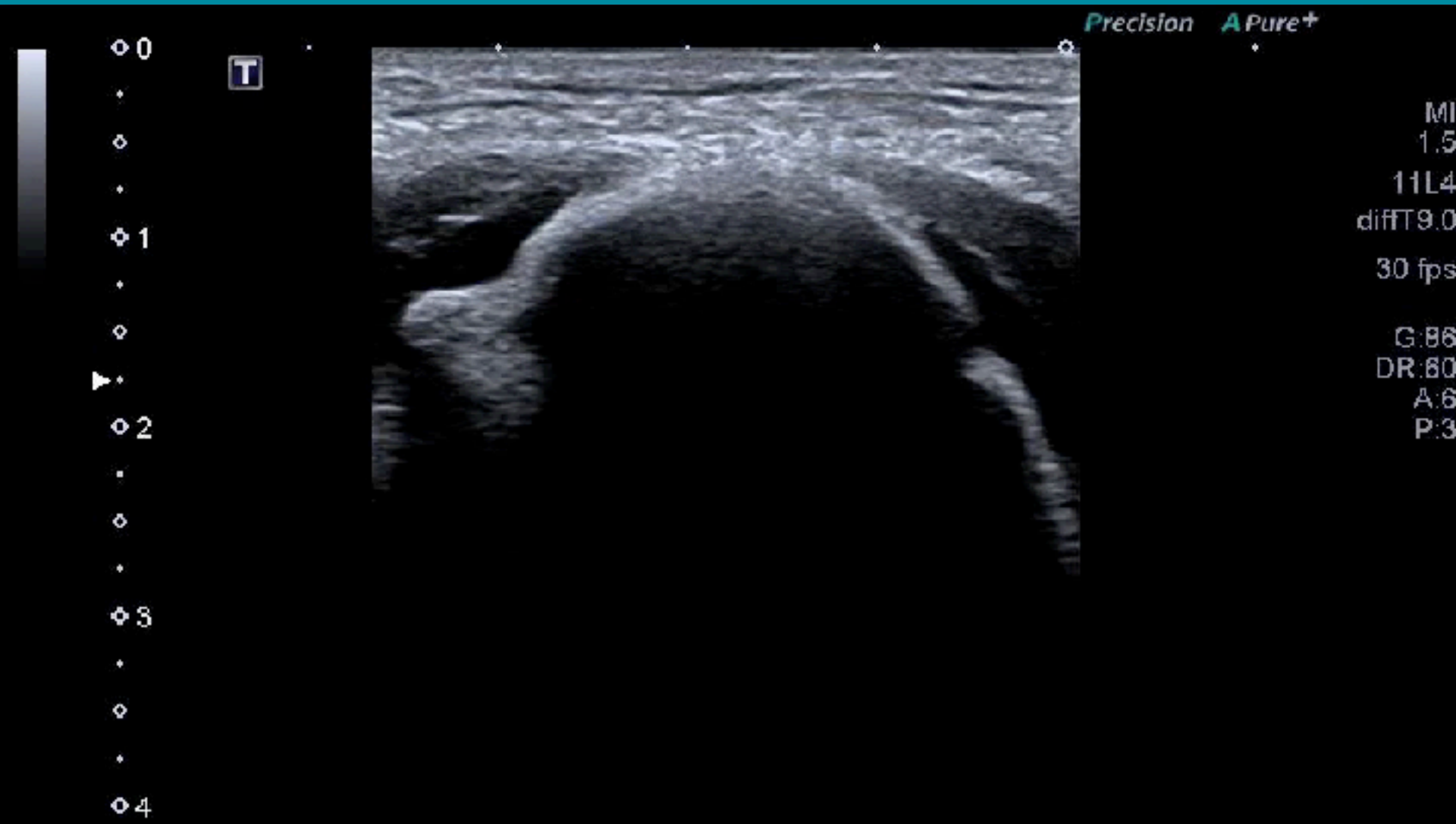

Landmark: hyoid bone

Epiglottis

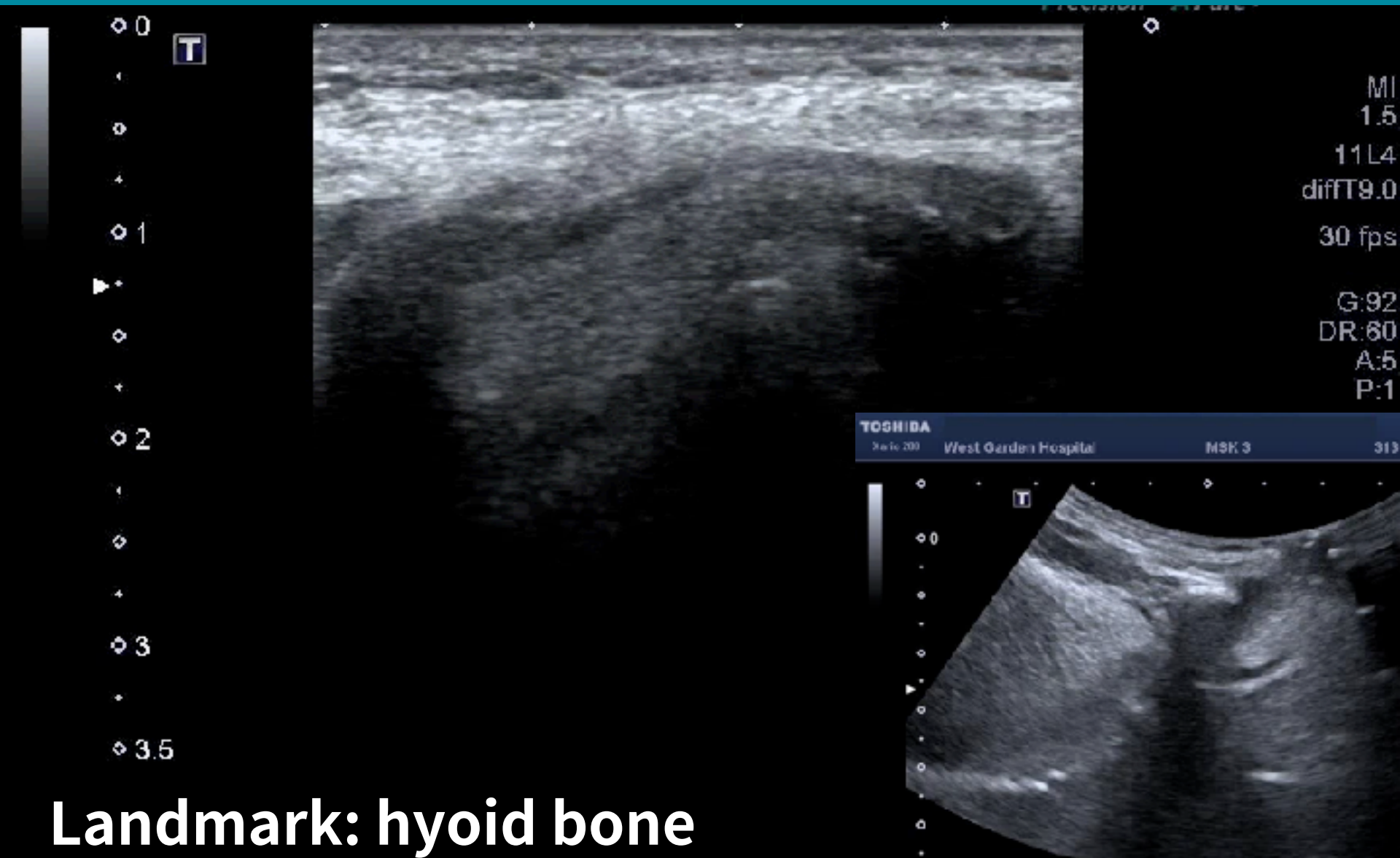

Landmark: hyoid bone

Epiglottitis

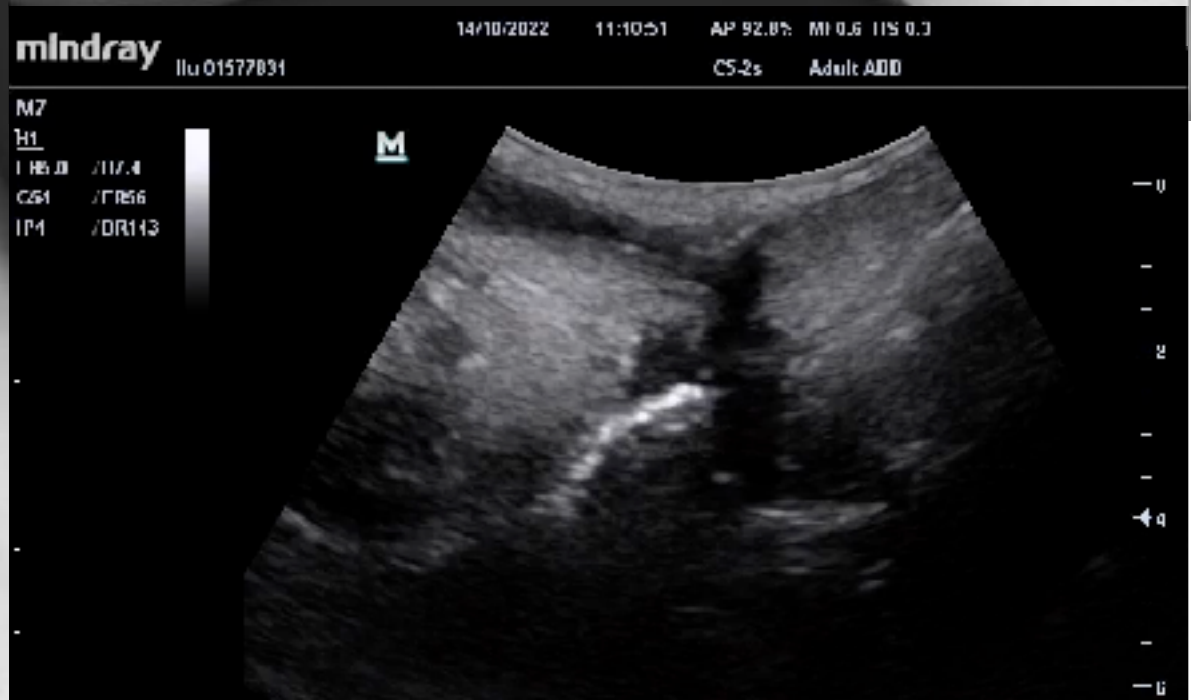

Acute epiglottitis

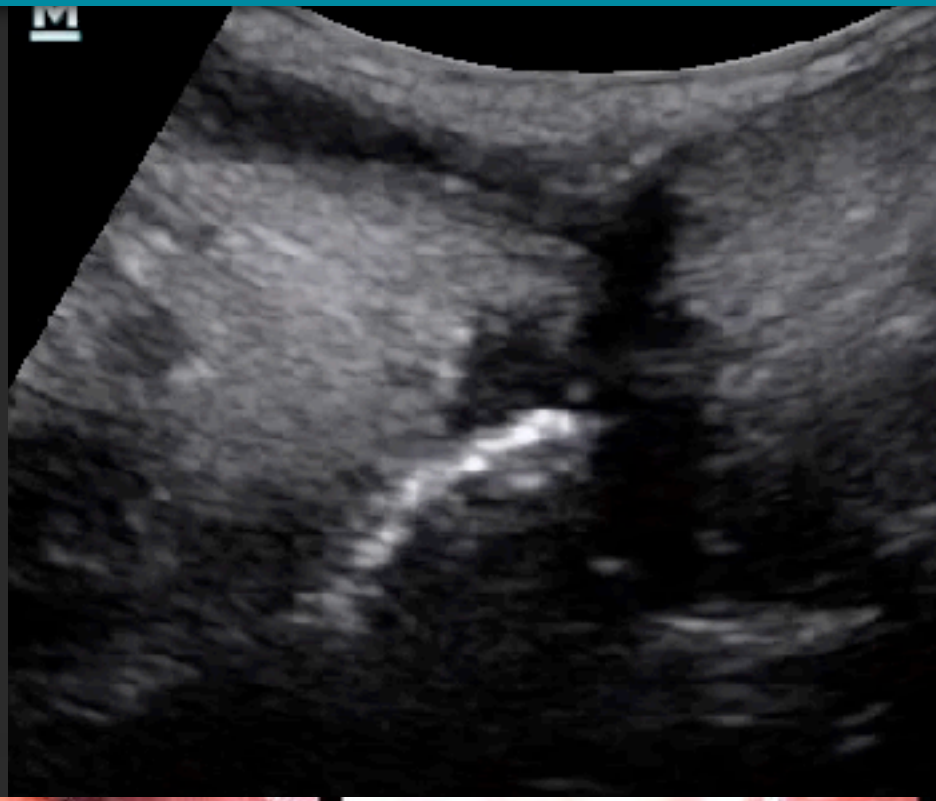

Vocal cords

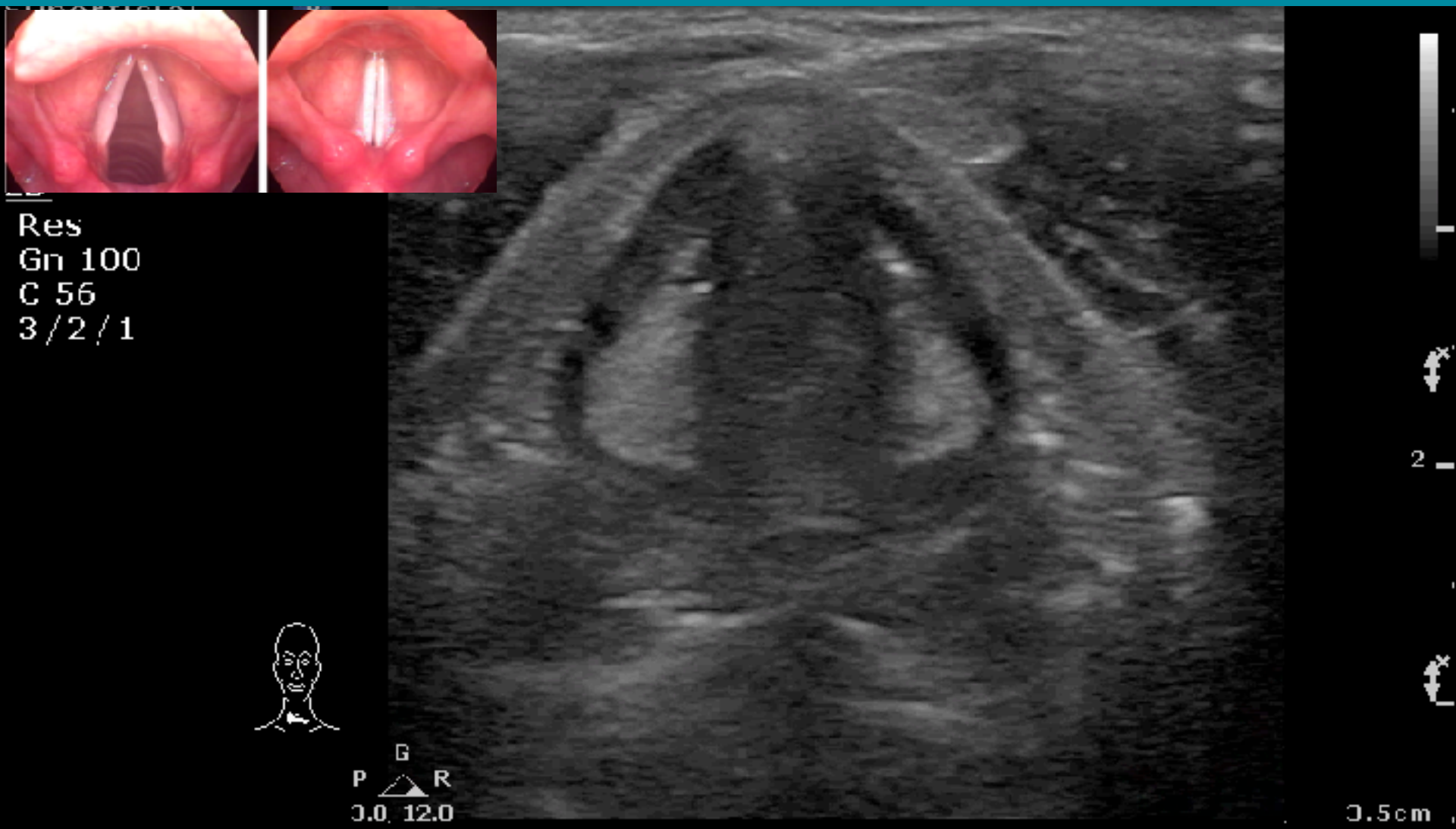

Landmark: thyroid cartilage

Phonation

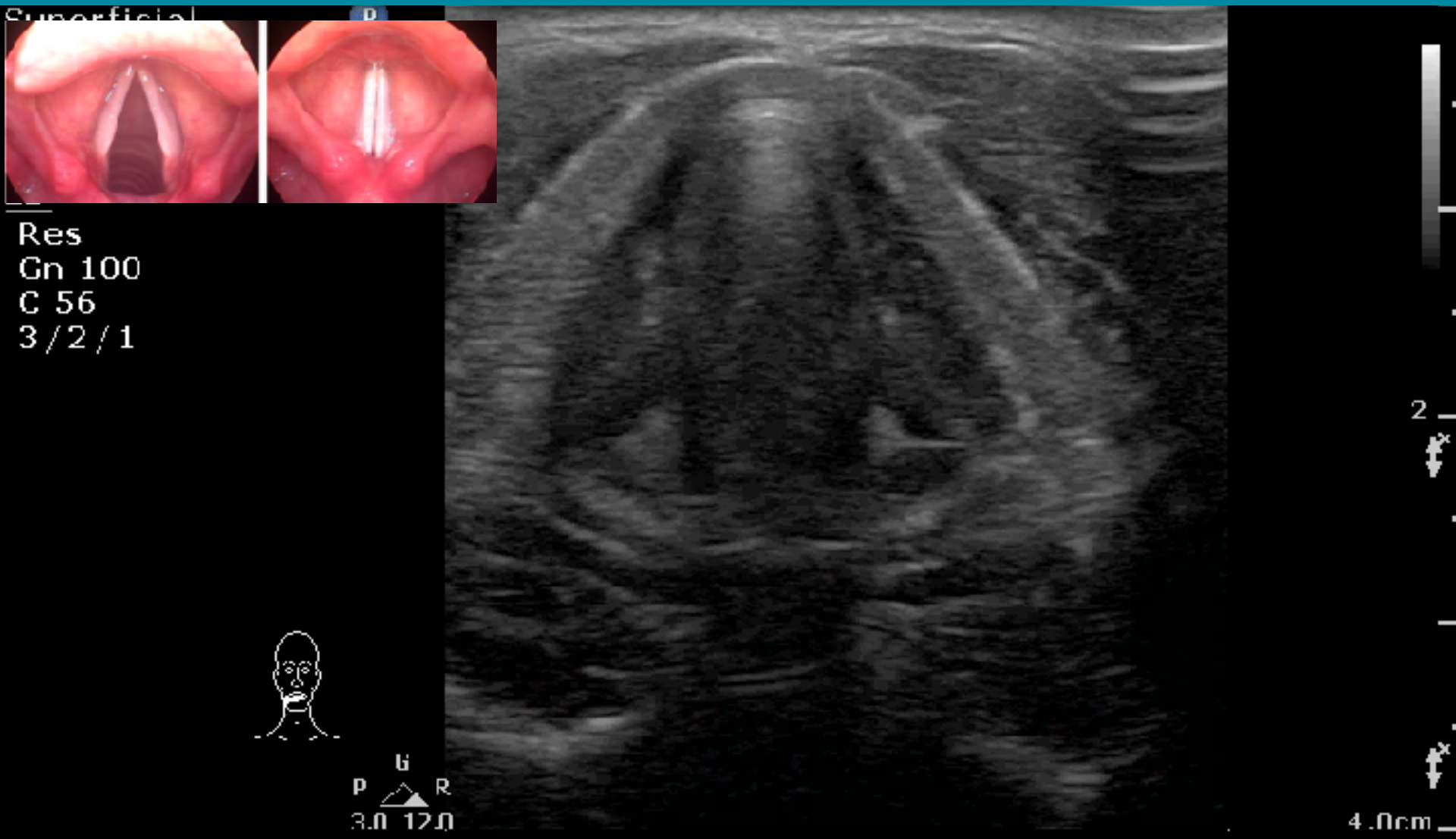

Landmark: thyroid cartilage

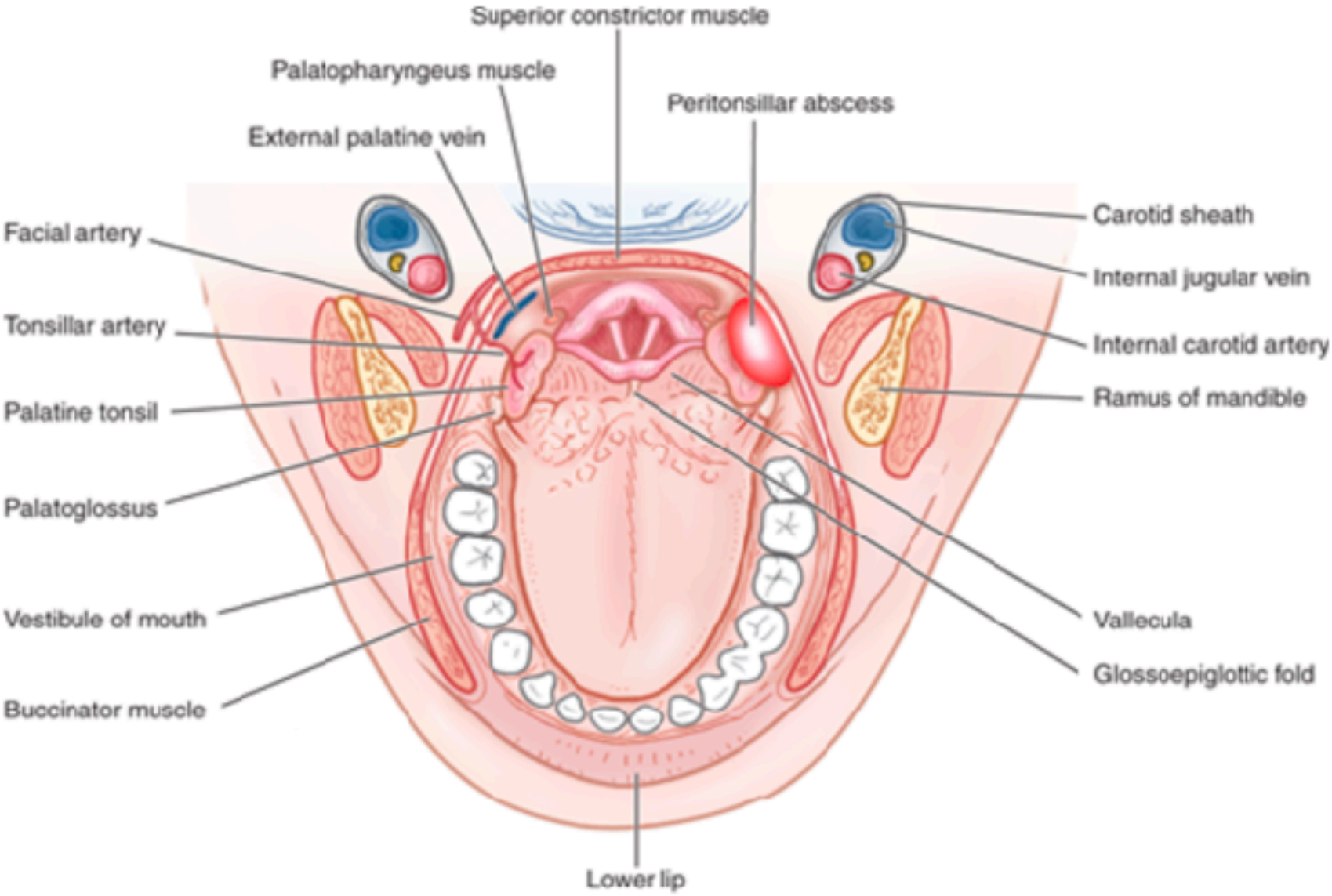

Source: Reichman EF: Emergency Medicine Procedures, Second Edition: www.accessemergencymedicine.com
Copyright © The McGraw-Hill Companies, Inc. All rights reserved.

2

http://www.emdocs.net/unlocking-common-ed-procedures-peritonsillar-abscess-drainage/

Tonsil

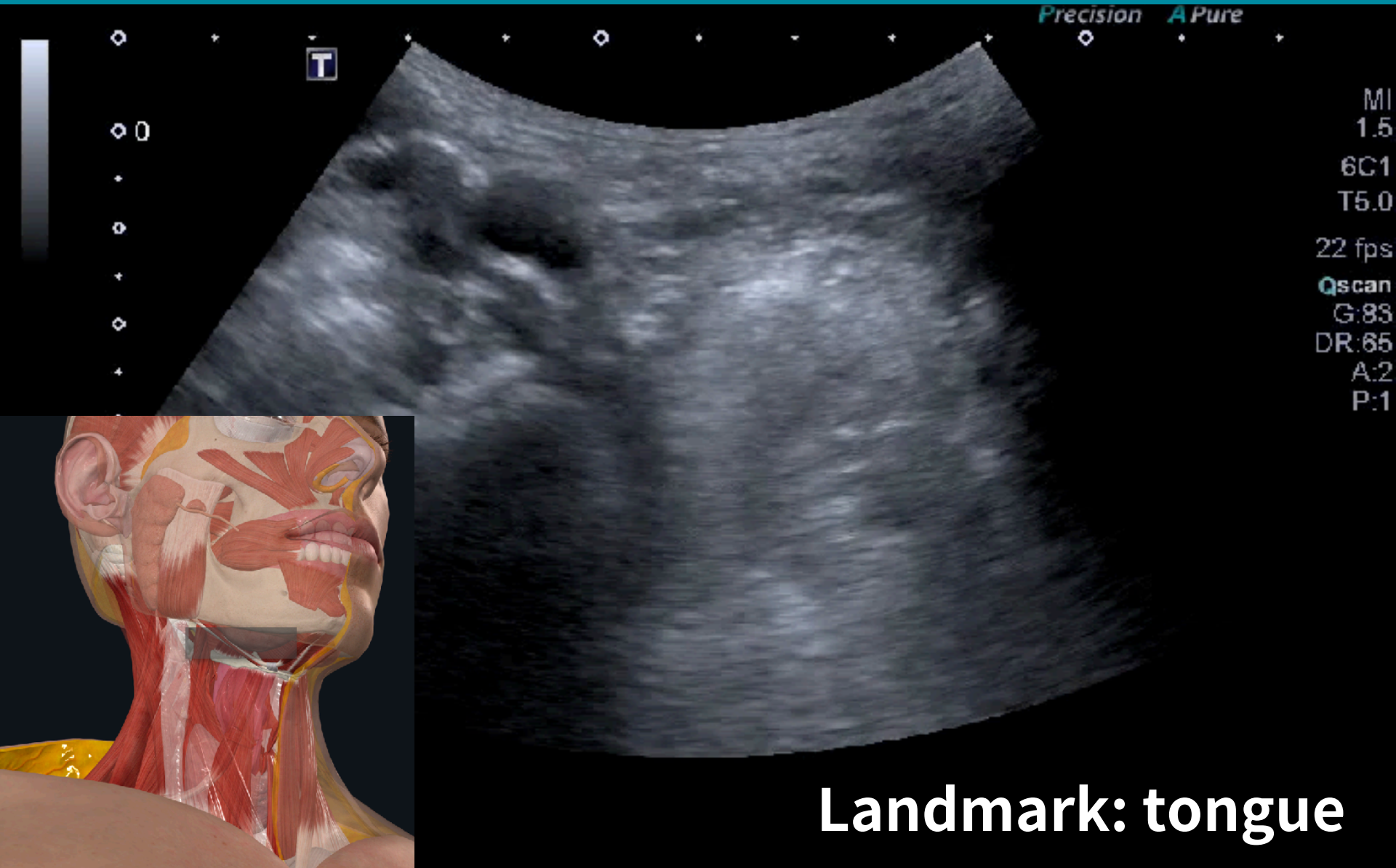
Precision
A Pure
T
0
MI
1.5
6C1
T5.0
22 fps
Qscan
G:83
DR:65
A:2
P:1
Landmark: tongue

26M, severe left throat pain

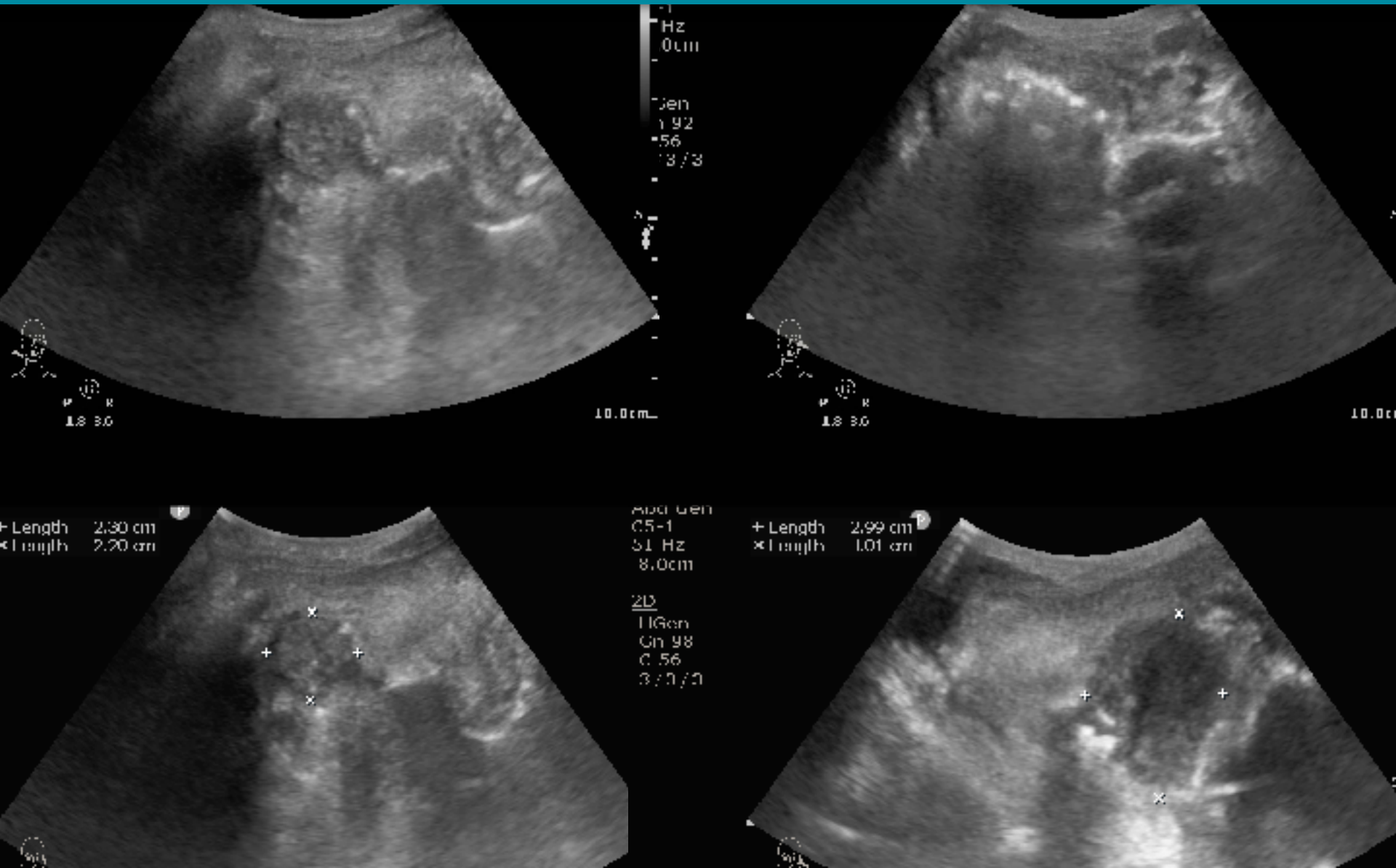

Peritonsillar abscess

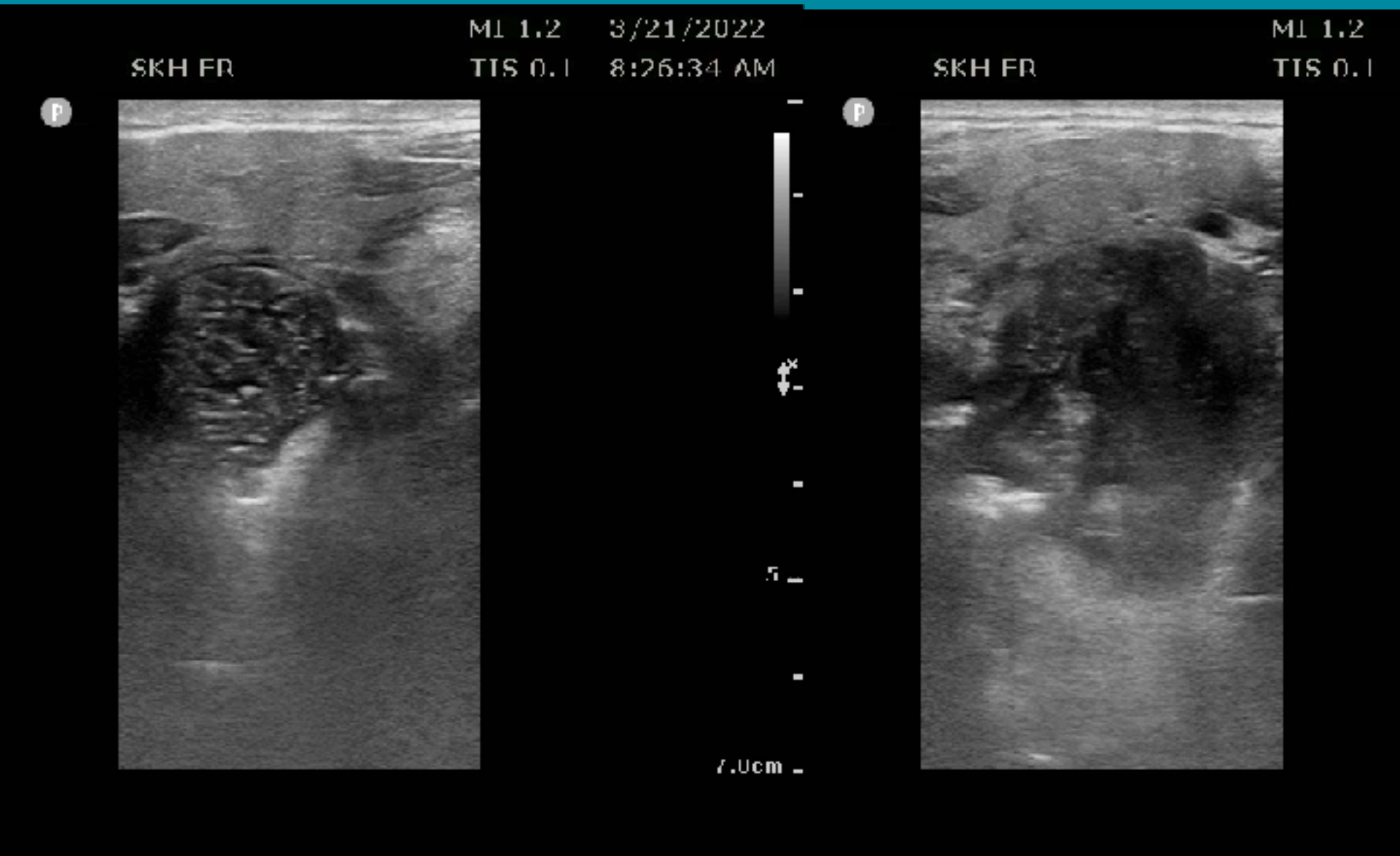

Parotid gland

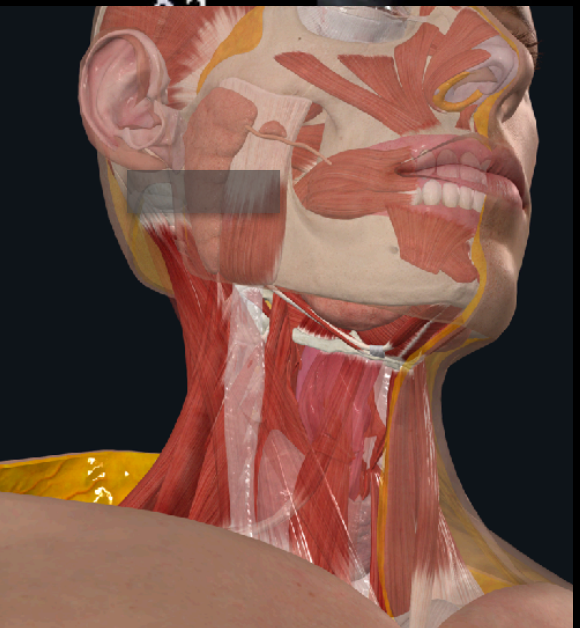

Landmark: mandible & mastoid

69M, 右臉腫，門診轉入腮腺炎

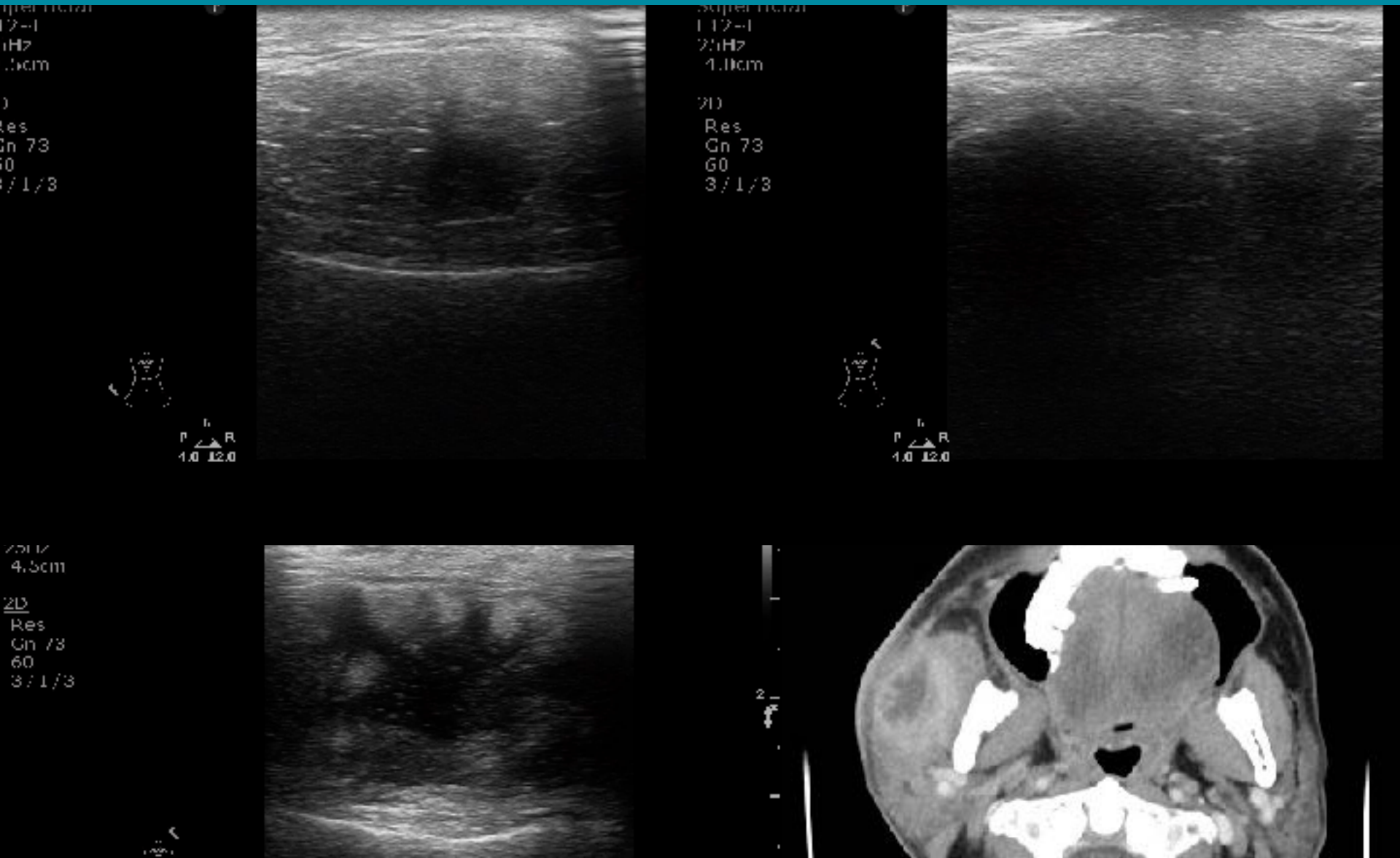

Submandibular gland

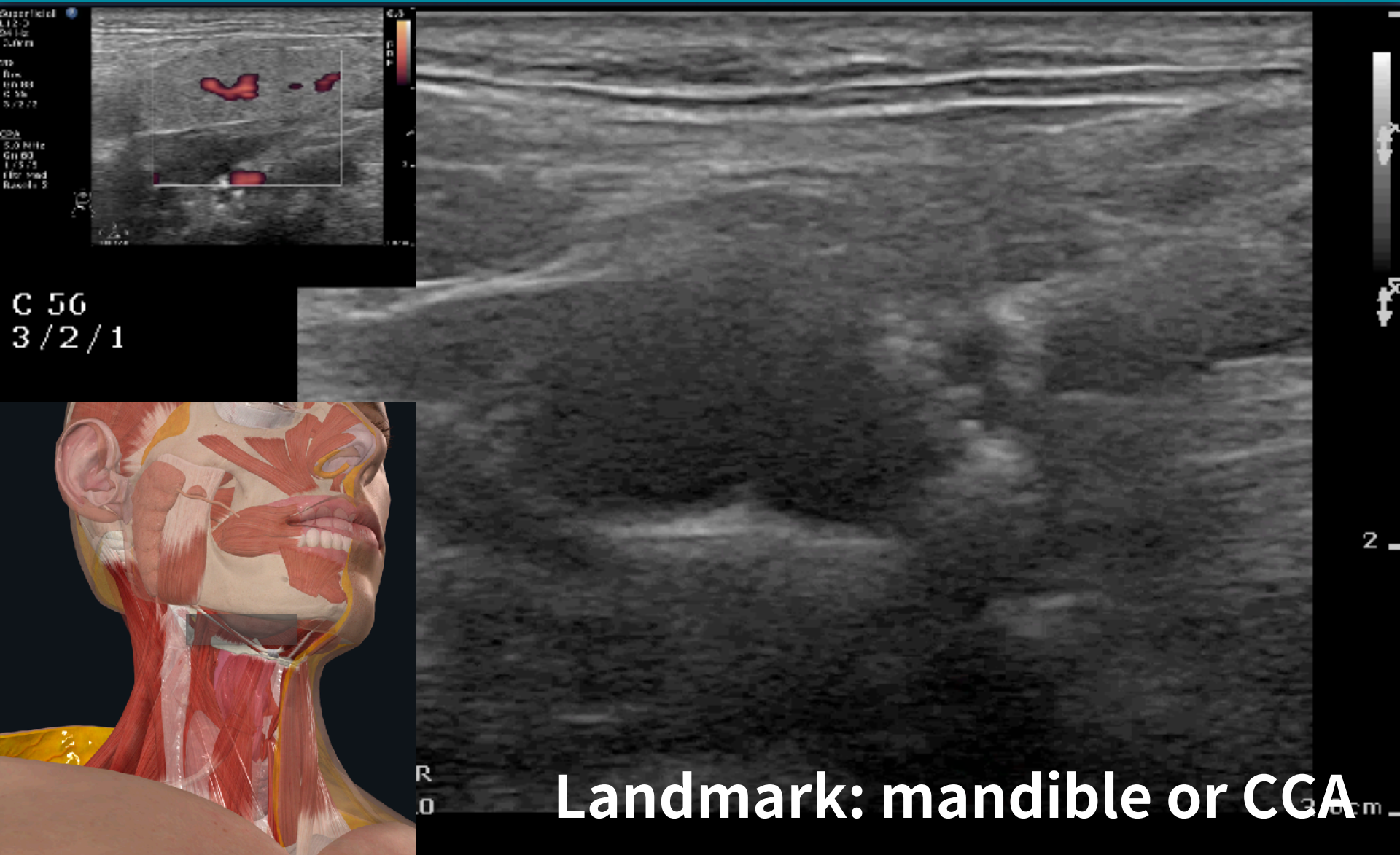

57F,左下巴痛好幾週

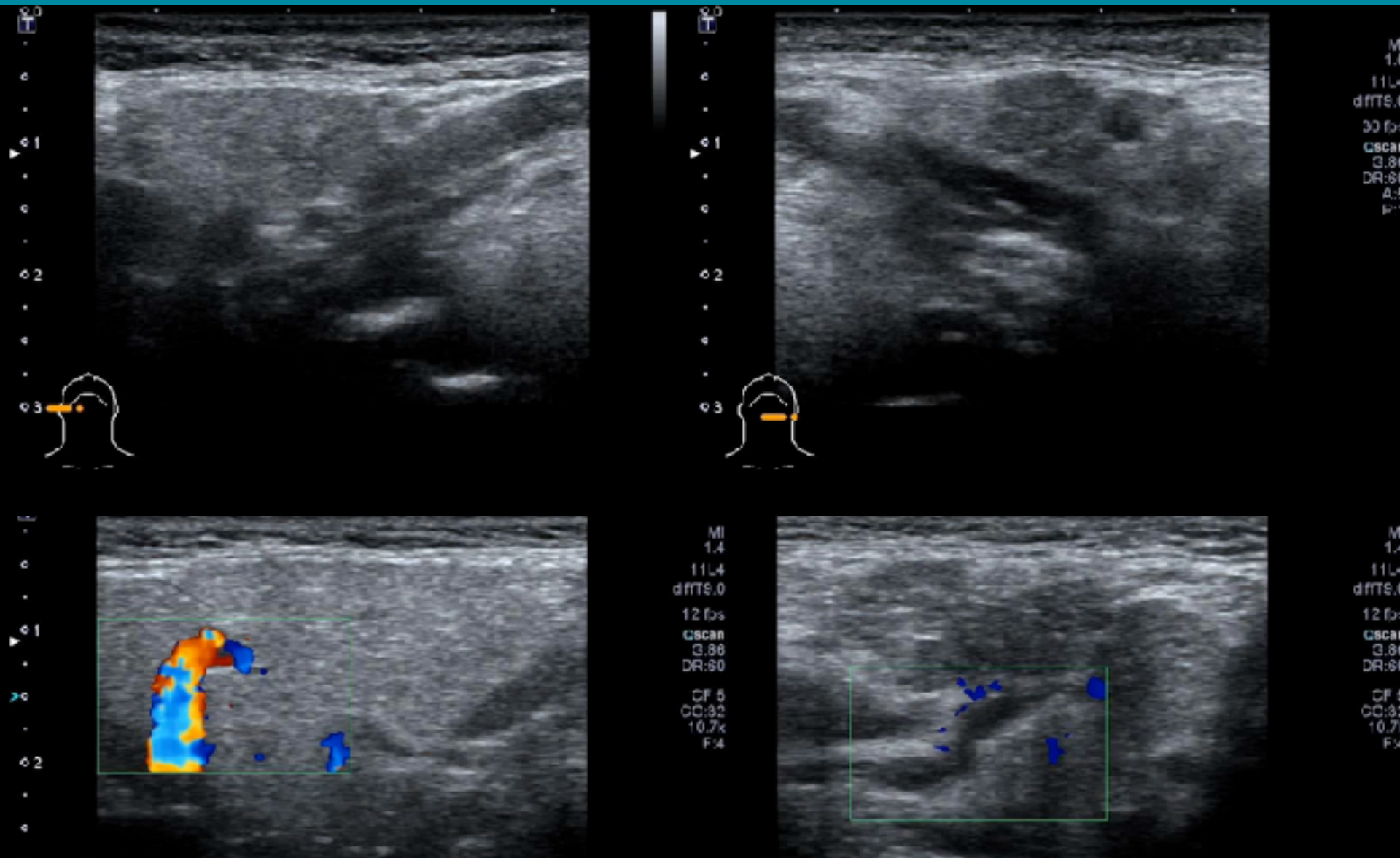

57F,左下巴痛好幾週

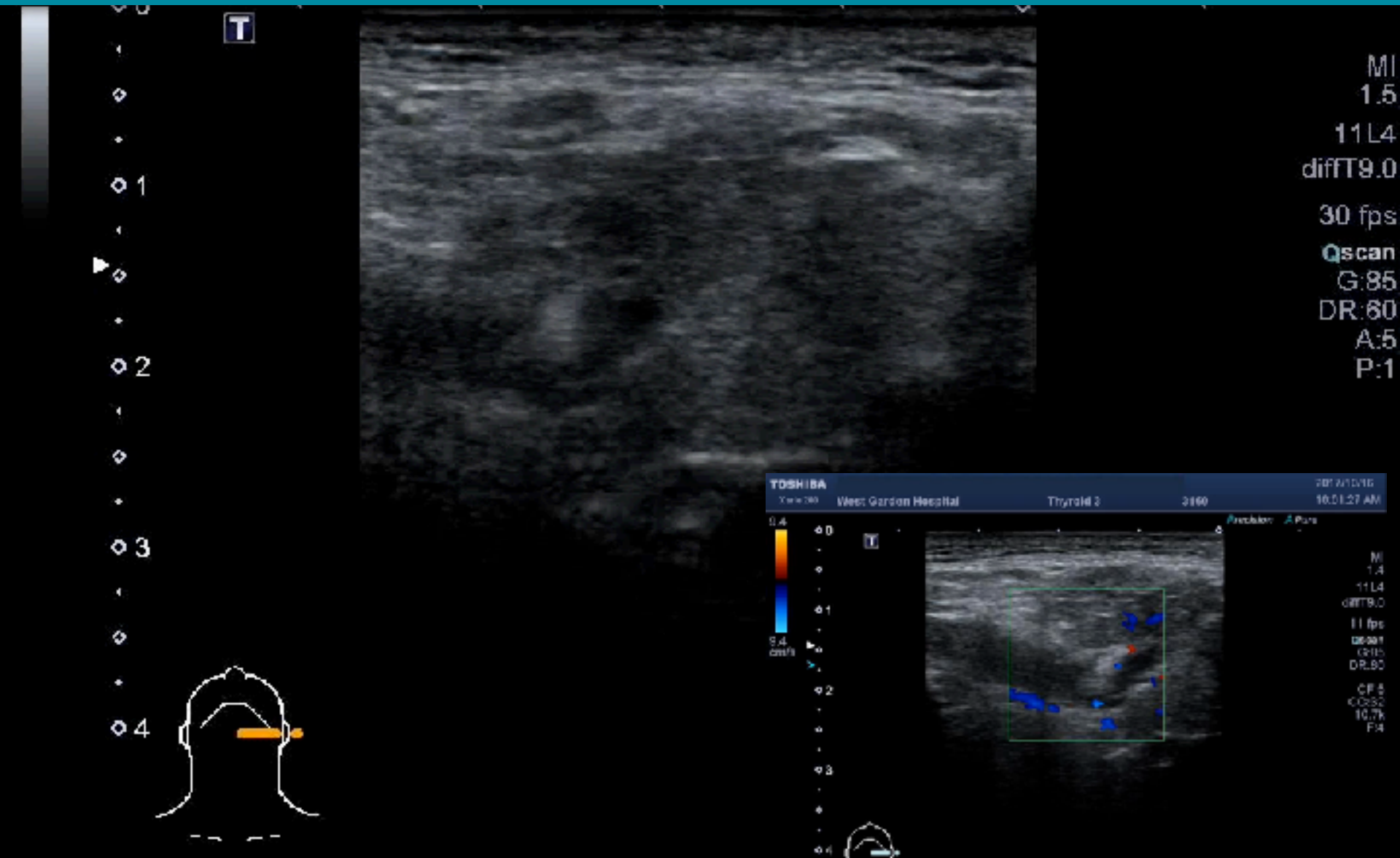
MI
1.5
11L4
diffT9.0
30 fps
Qscan
G:85
DR:60
A:5
P:1
TOSHIBA
West Garden Hospital
Thyroid 2

Sialolithiasis

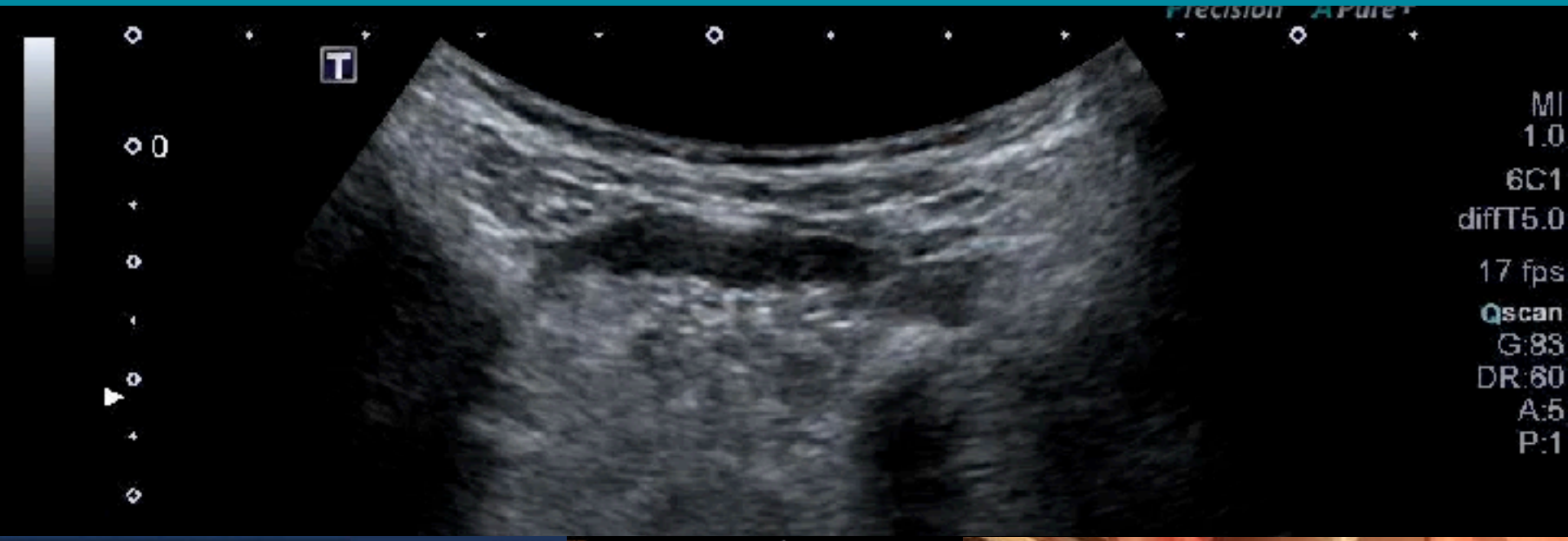

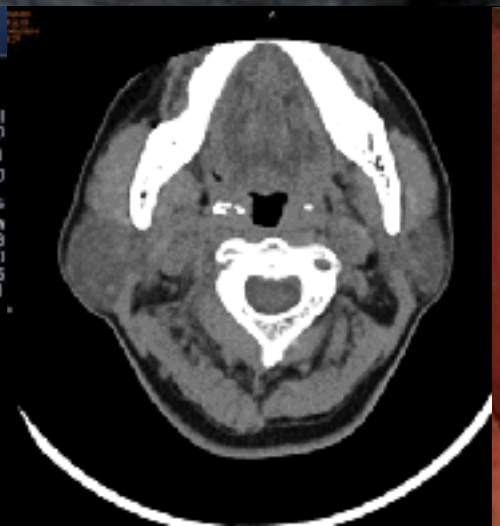

Thyroid gland

Landmark: suprasternal notch & trachea

36F, 雙腳無力低血鉀

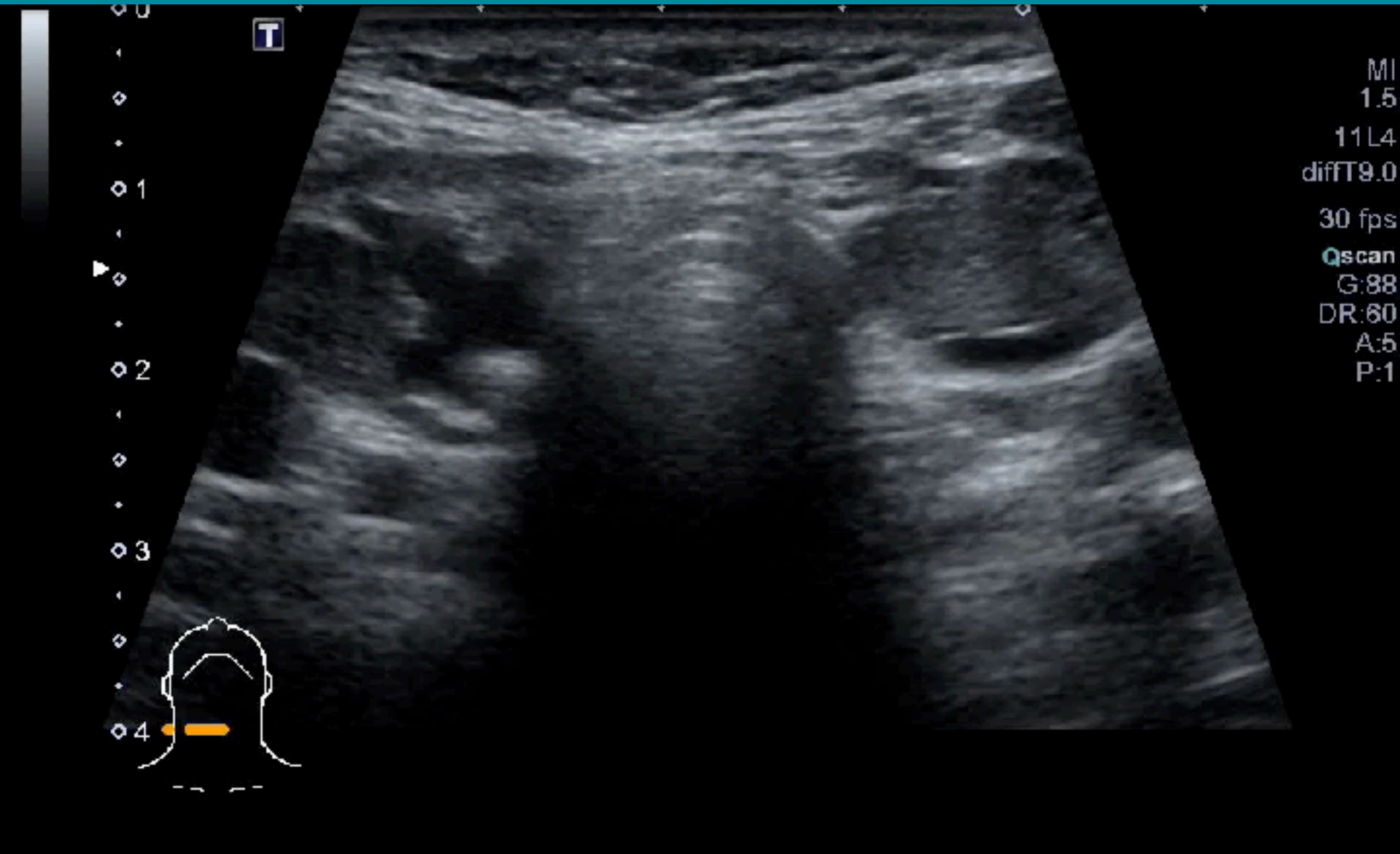

Hyperthyroidism

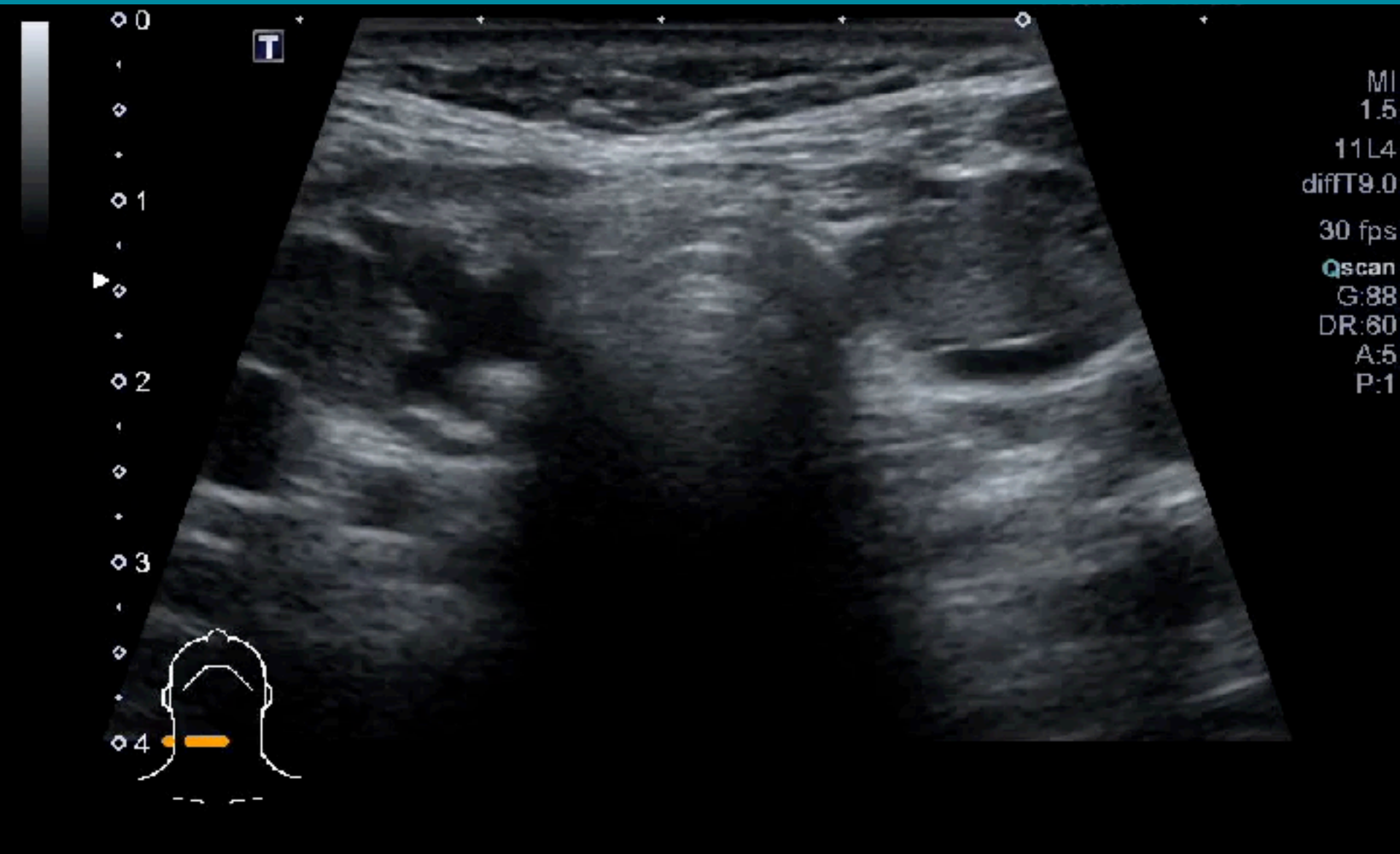

1 Epiglottis

2 Tonsils

3 Glands

CHECK LIST

Airway	Neck
Hyoid bone	Parotid gland
Epiglottis	Submandibular gland
Thyroid cartilage	Thyroid gland
Cricothyroid membrance	CCA
Cricoid cartilage	IJV
Thyroid cartilage	SCM
Cervical esophagus	Mandible / Mastoid / ASM / MSM