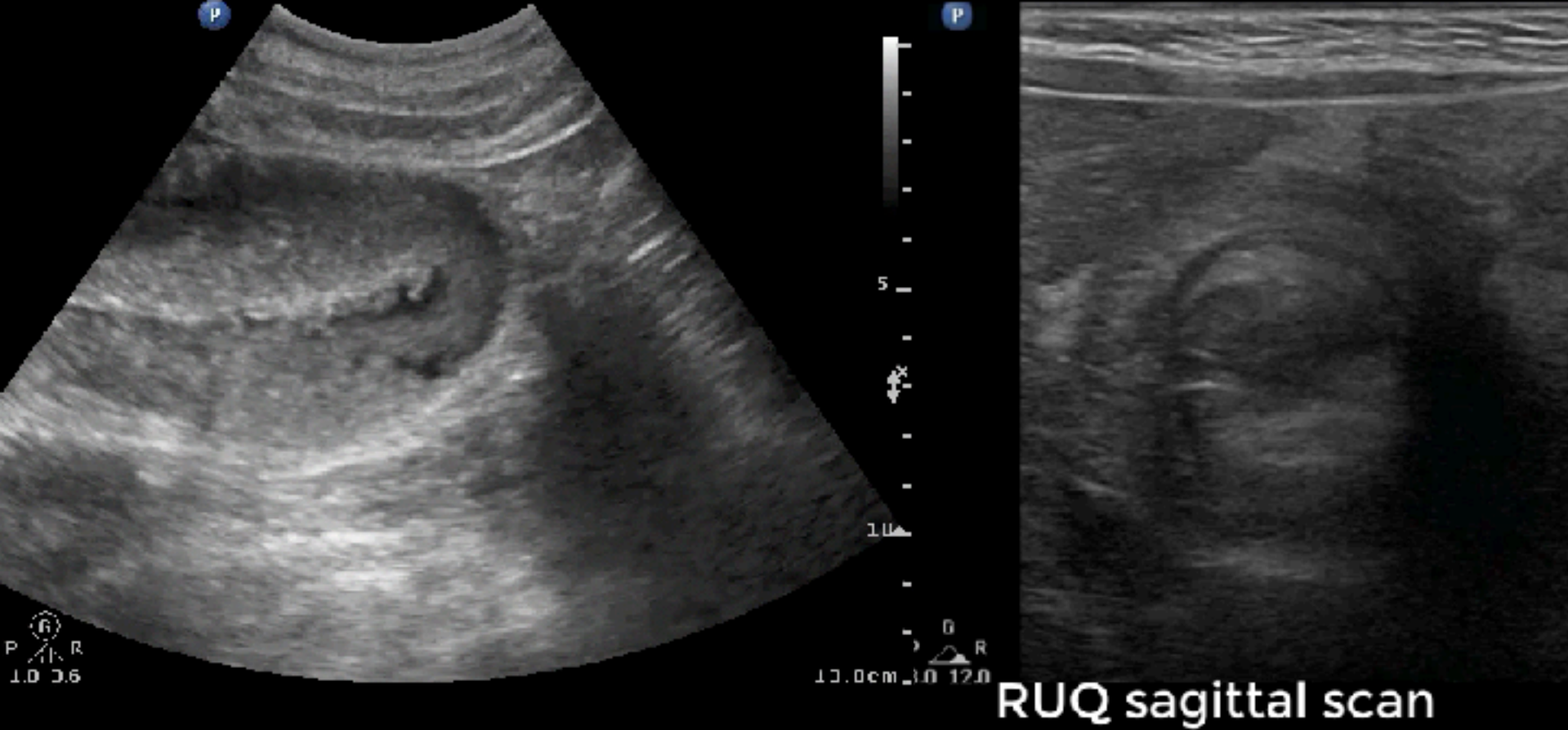

SEEING YOUR GUT FEELING

POINT-OF-CARE GASTROINTESTINAL ULTRASOUND

陳國智 醫師



台灣疼痛醫學會專科醫師
急診超音波臨床評核醫師
醫用超音波學會指導醫師
WINFOCUS director / instructor
Certified Interventional Pain Sonologist

急診 / 重症 / 介入 / 急性疼痛

經歷

新光急診超音波訓練中心主任
西園醫院急診醫學科主任
急診醫學會超音波委員會主委
台灣疼痛醫學會大體模擬手術講師
急救加護醫學會重症超音波負責人



診
斷

監
測

Diagnostician



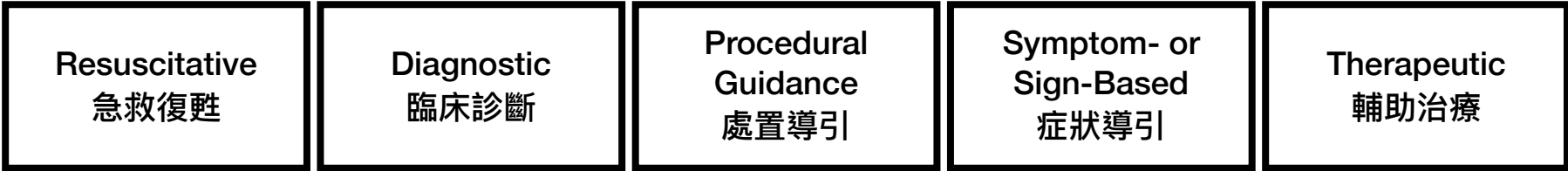介
入

Interventionist

POINT OF CARE ULTRASOUND

Provider - Probe - Patient

~ 存在於臨床需求之所在 ~



Core Applications (2023 ACEP Emergency Ultrasound Guidelines)
15項急診超音波核心應用

陳國智醫師

Aorta

DVT

Trauma

Thoracic/Airway

Cardia/HD assessment

Procedural Guidance

US-guided NB

Testicular

Ocular

Skin & Soft tissue

Hepatobiliary

Urinary tract

Pregnancy

Bowel

MSK

解剖

Anatomy

形態

Pattern

診斷

Diagnosis

HOLISTIC ULTRASOUND

Holistic medicine

Treatment that deal with the whole person,
not just the injury or disease



ELSEVIER

Available online at www.sciencedirect.com

ScienceDirect

journal homepage: www.jmu-online.com



EDUCATIONAL FORUM

Application of Gastrointestinal Tract Ultrasound in Emergency and Critical Medicine

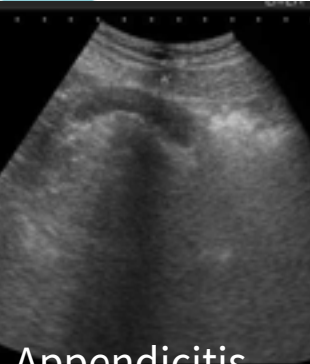
Layers: 5

Thickness: 5 mm

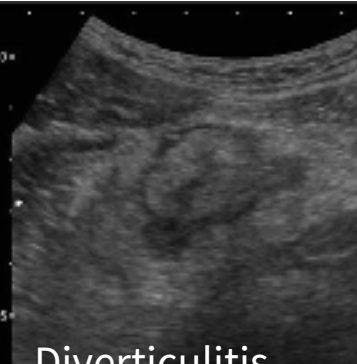Size: 2.5 cm & 5 cm

Peristalsis

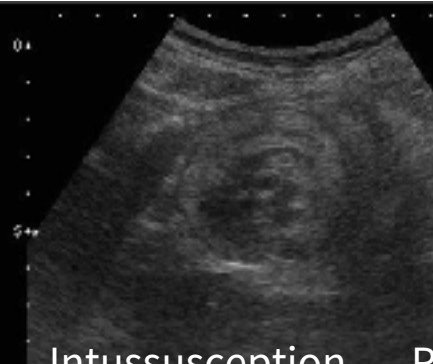Jen-Tang Sun ¹, Wan-Ching Lien ², Hsiu-Po Wang ^{3*}



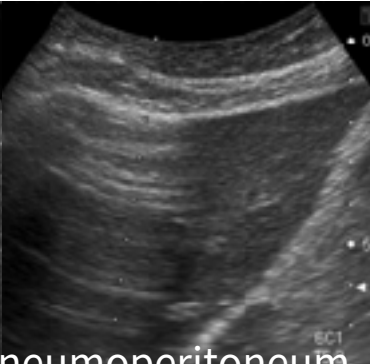
Appendicitis



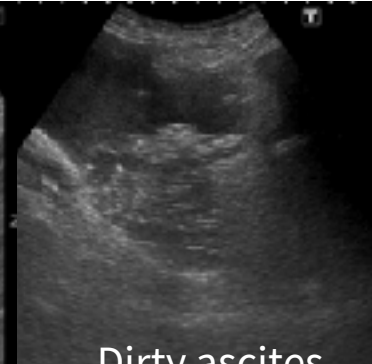Diverticulitis



Intussusception

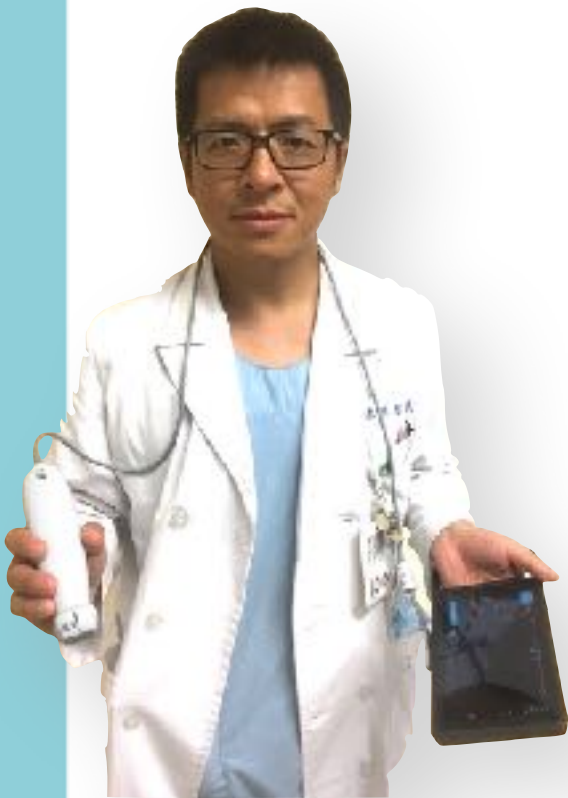

Pneumoperitoneum



Dirty ascites

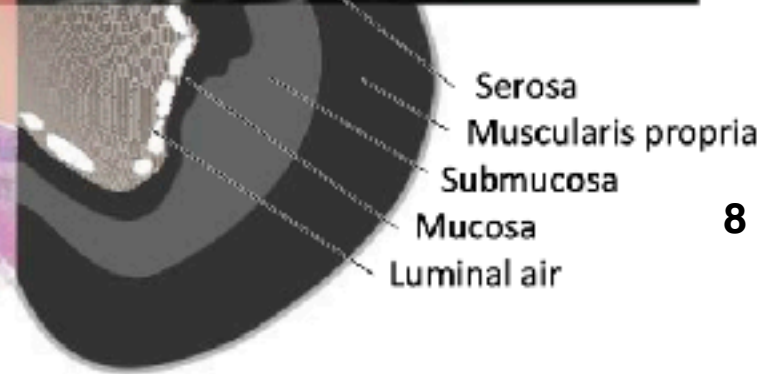
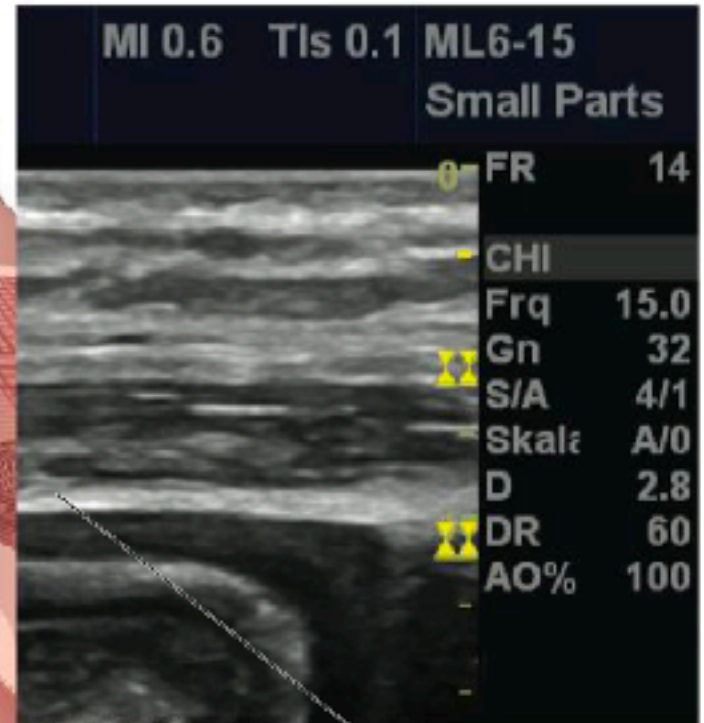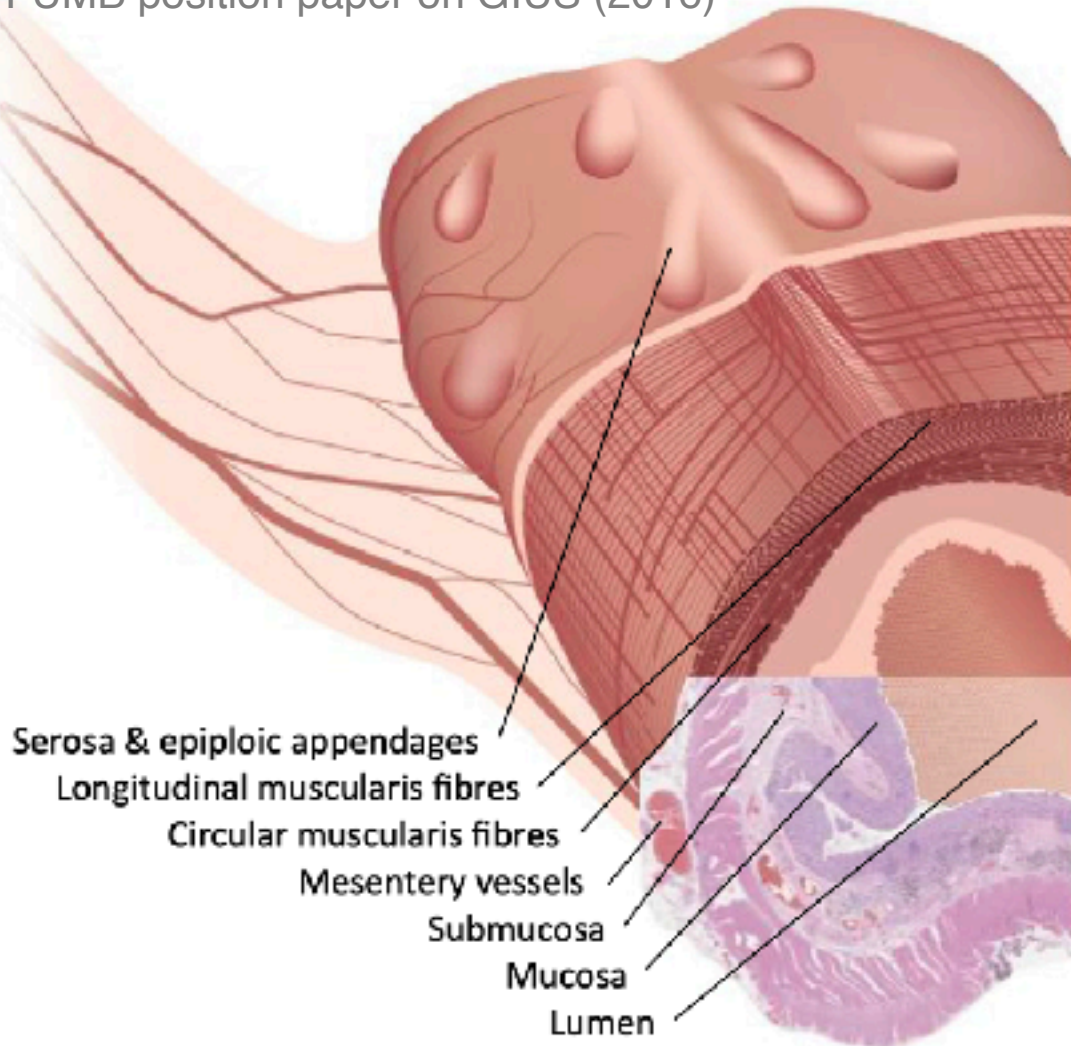
GI ULTRASOUND: PATHOLOGIC PATTERNS



1. **Diameter** distended (3cm & 5cm)
2. **Unable to compress** during examination
3. **Wall** thickening (>5mm/1cm for stomach)
4. **Wall** stratification disappeared
5. **Luminal content** decreased at lesion sites
6. **Peristalsis** decreased
7. **Associated findings** (LN, Fat, ascites, abscess)

SONOANATOMY OF BOWEL WALL LAYERS

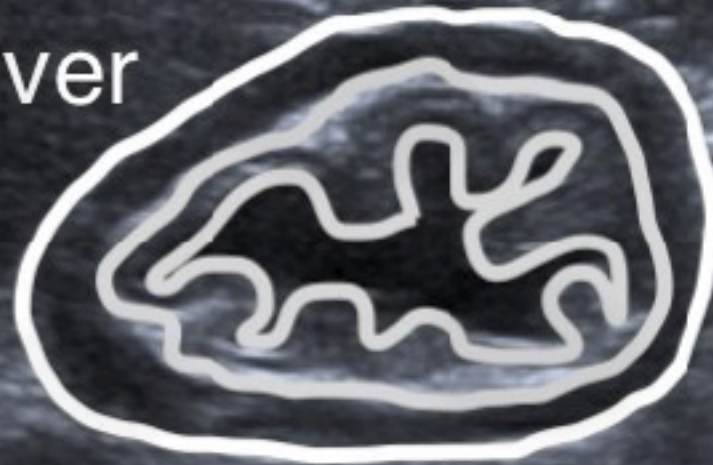
WFUMB position paper on GIUS (2016)



5 LAYERS >5 mm (wall thickening)

- White – Serosa
- Black – Muscularis propria
- White – Submucosa
- Black – Mucularis mucosa
- White – Mucosa/lumen interface

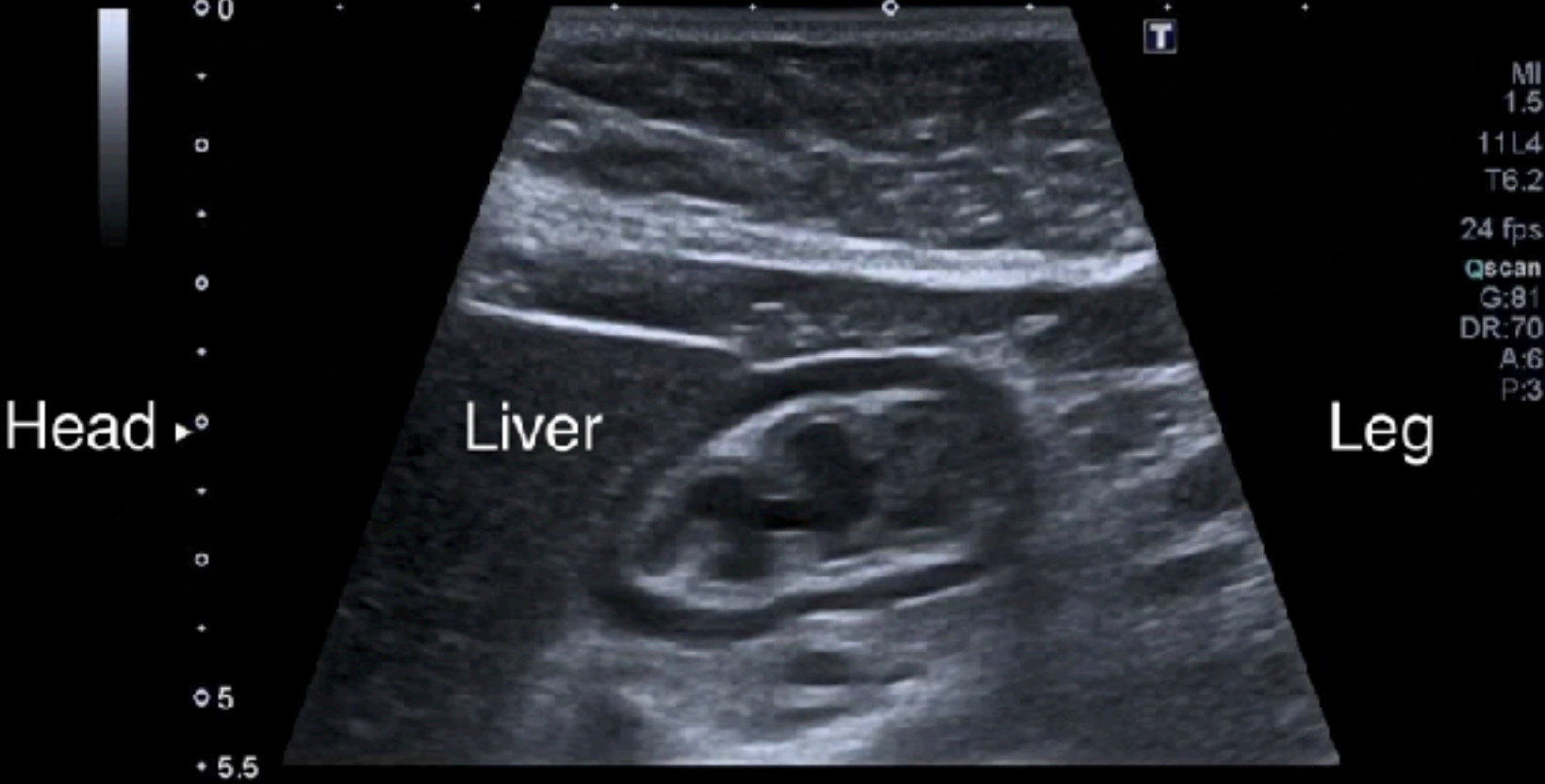Liver



Cranial - Longitudinal axis - Caudal

5 LAYERS >5 mm (wall thickening)

POCUSAcademy©ChenKC



longitudinal scan at subxyphoid area

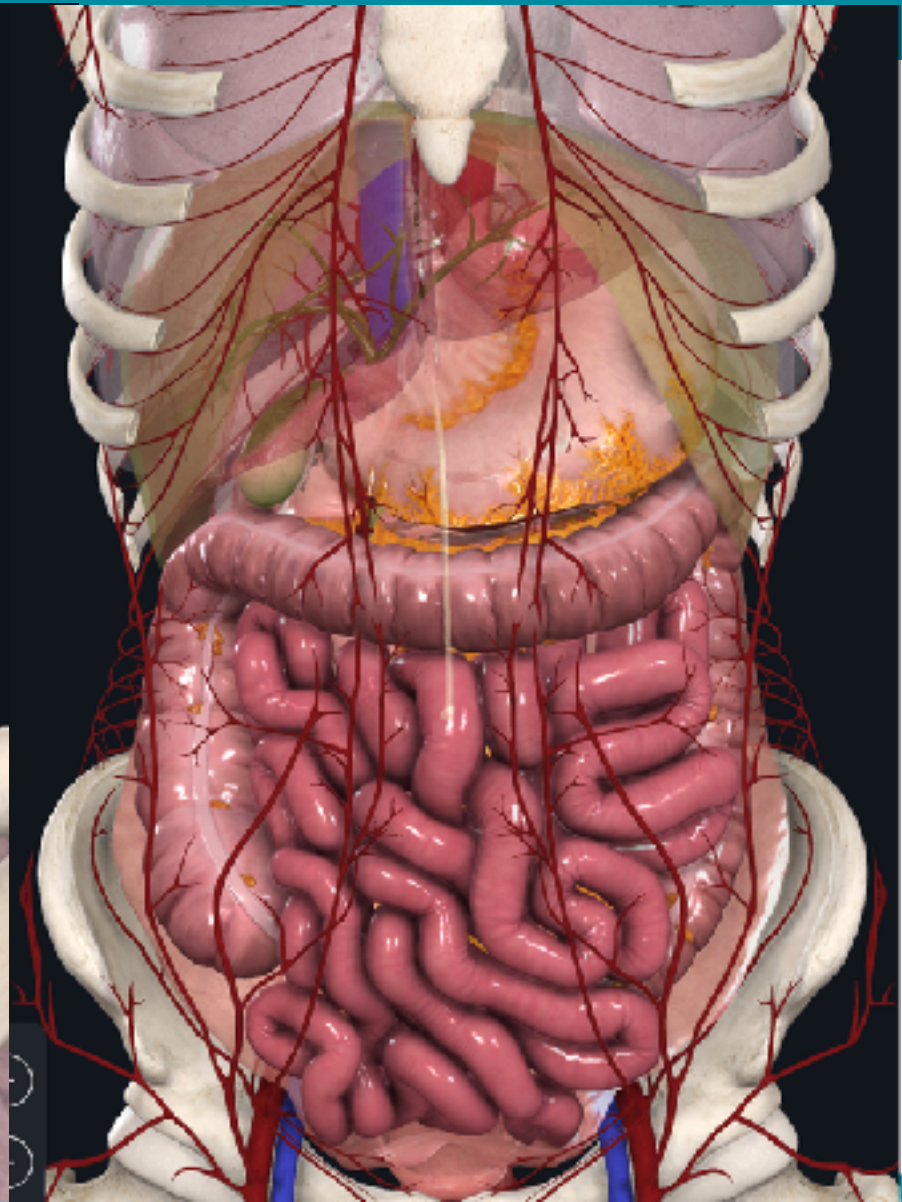
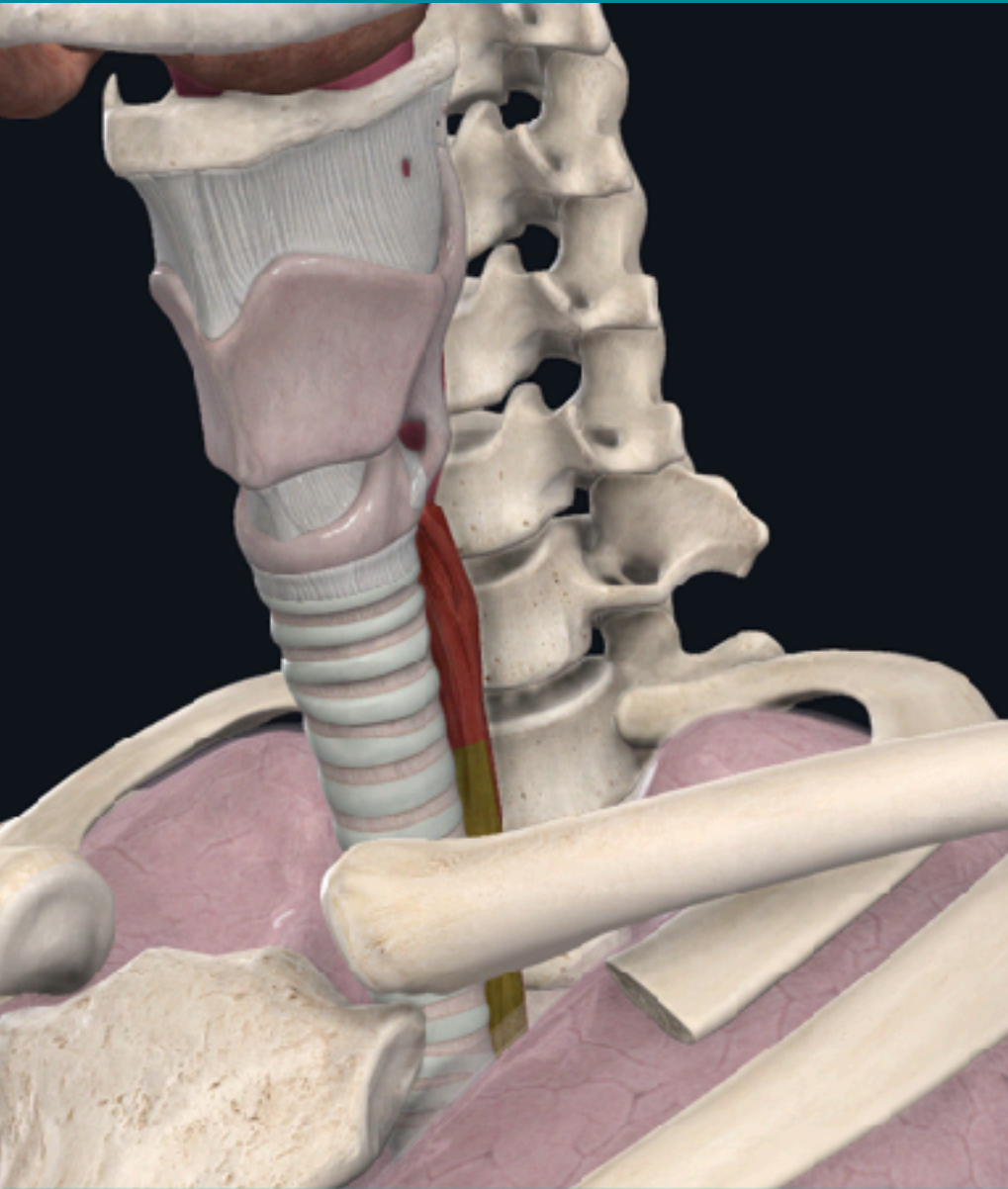


External landmarks

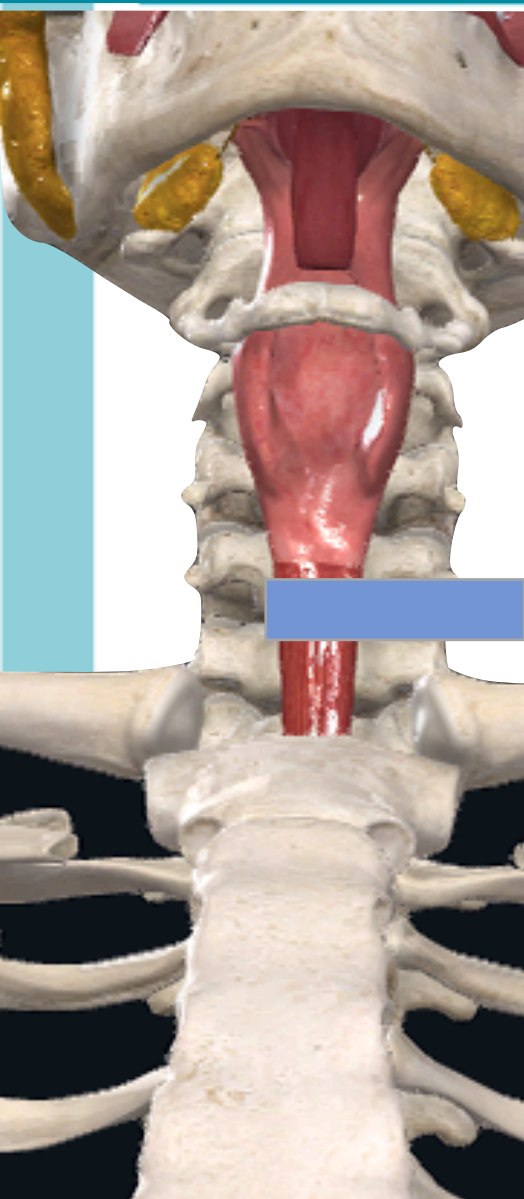
Find GI tracts
Recognize sonoanatomy

Fixed parts first

GI TRACTS



CERVICAL ESOPHAGUS



PHILIPS TemporaryID-20160728163242
16 07 28 163242

SKH ER

MI 0.7

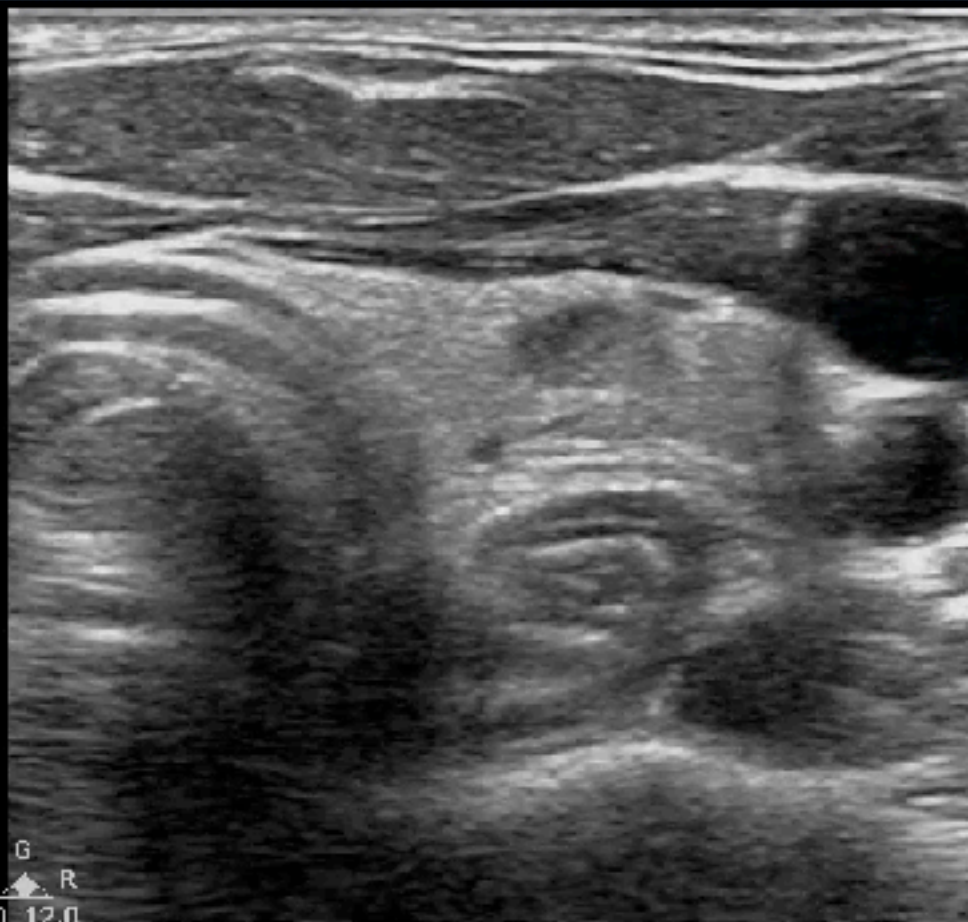TIS 0.1

Superficial
L12-3
16 Hz
3.5cm

P

2D

Gen
Gn 91
C 35
3/2/1



P G R
3.0 12.0

CERVICAL ESOPHAGUS

Precision

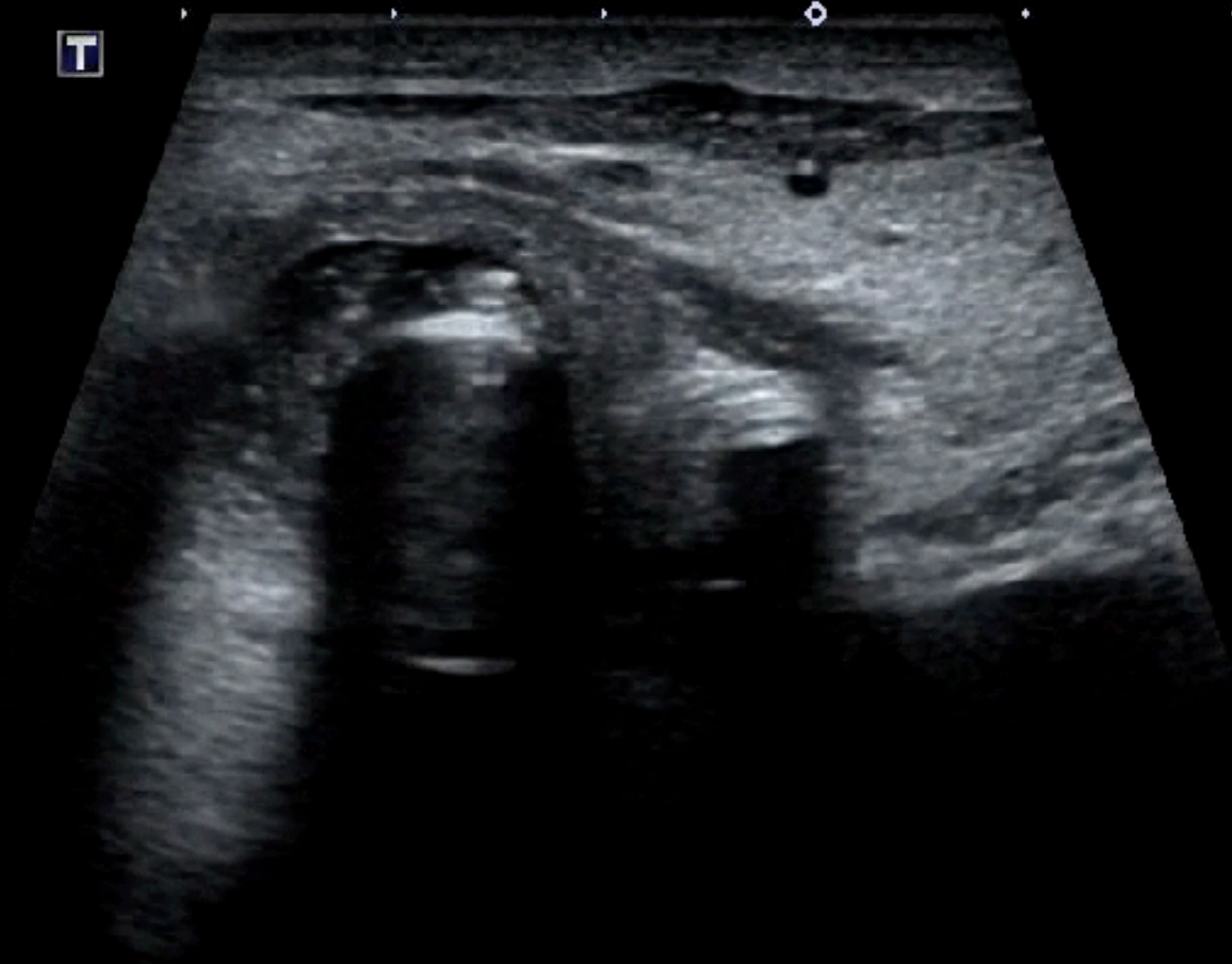M
1 E
11L4
ΔFT9.0
30 fps
G 22
DR 60
Λ 6
P.1



M
1 E
11L4
ΔFT9.0
30 fps
G 22
DR 60
Λ 6
P.1



T

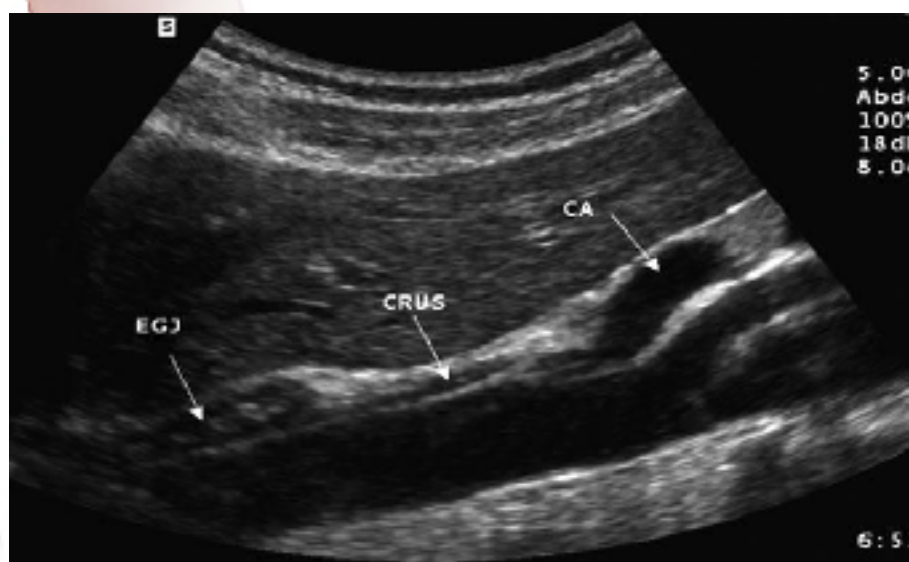
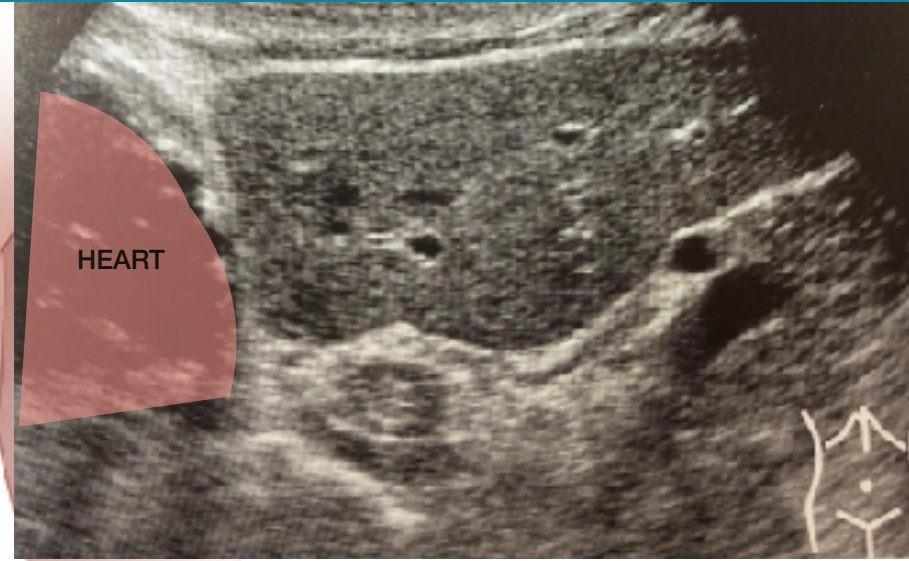
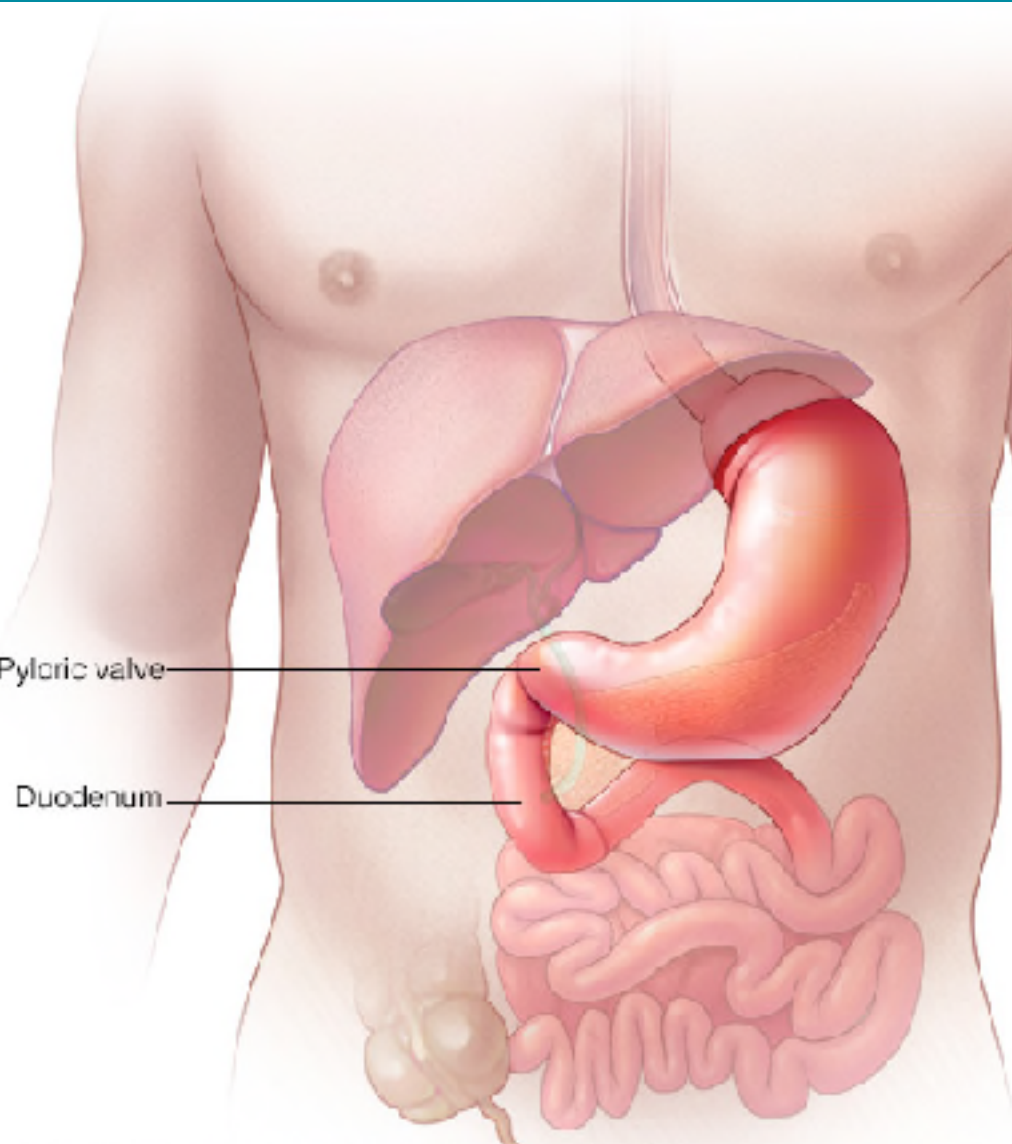


11
diffT9
30 f
Qsc
G:
DR:
A
P



ETT & NG confirmation

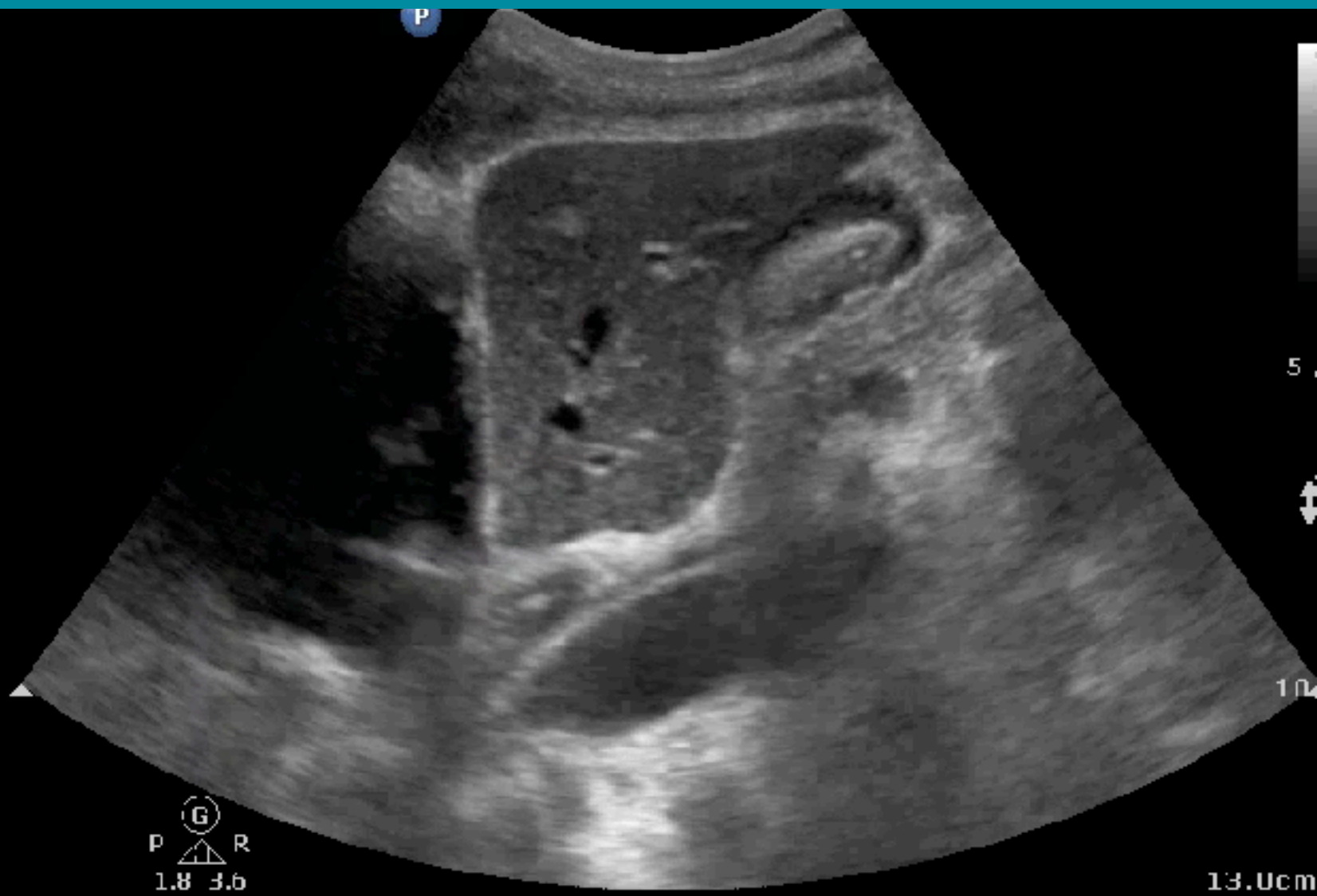
EC JUNCTION



EC JUNCTION

Abd Gen
C5-1
38 Hz
3.0cm

PD
HGen
Gn 76
C 56
3/3/3



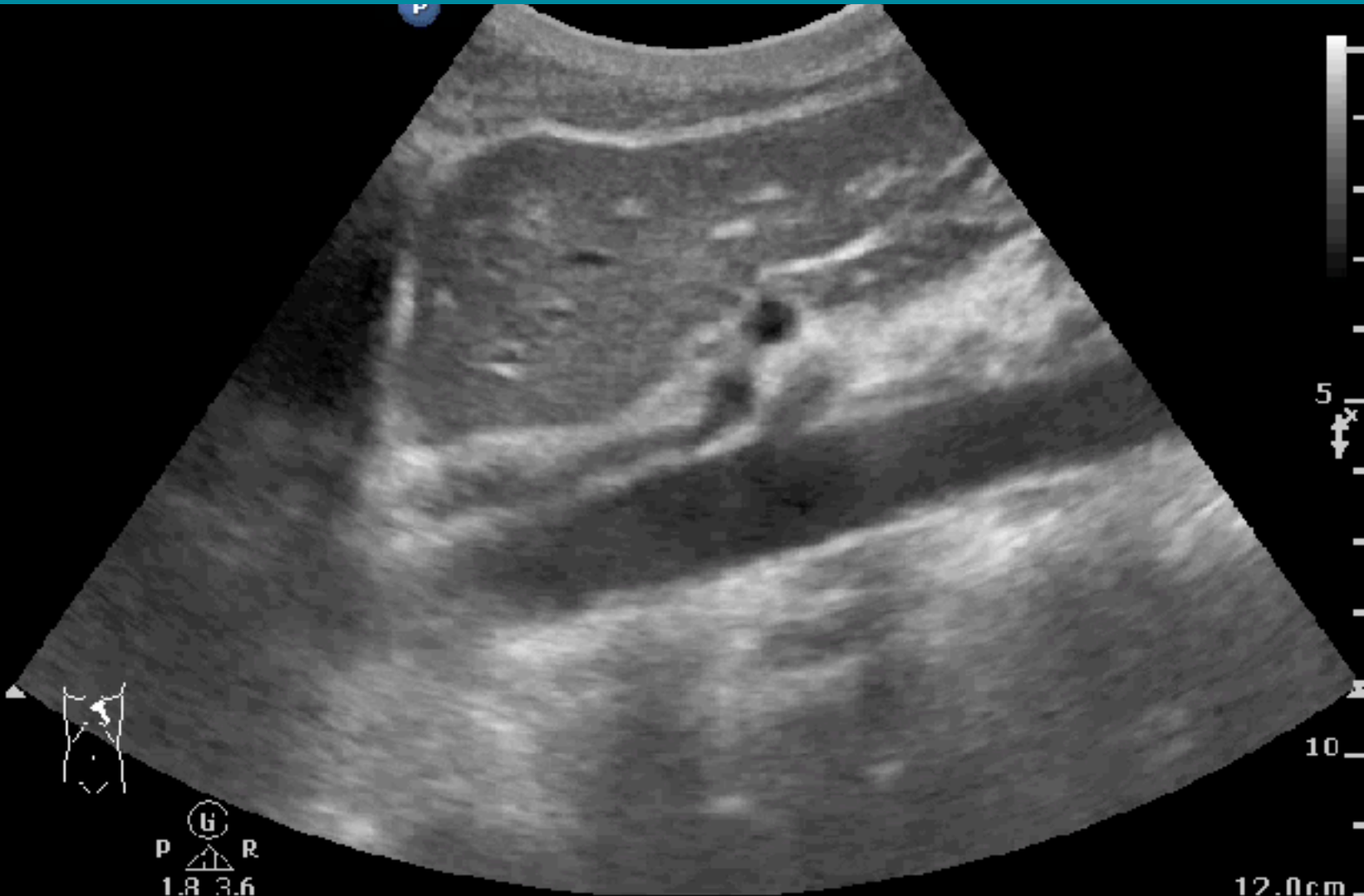
13.Ucm

PNEUMOPERITONEUM LANDMARK

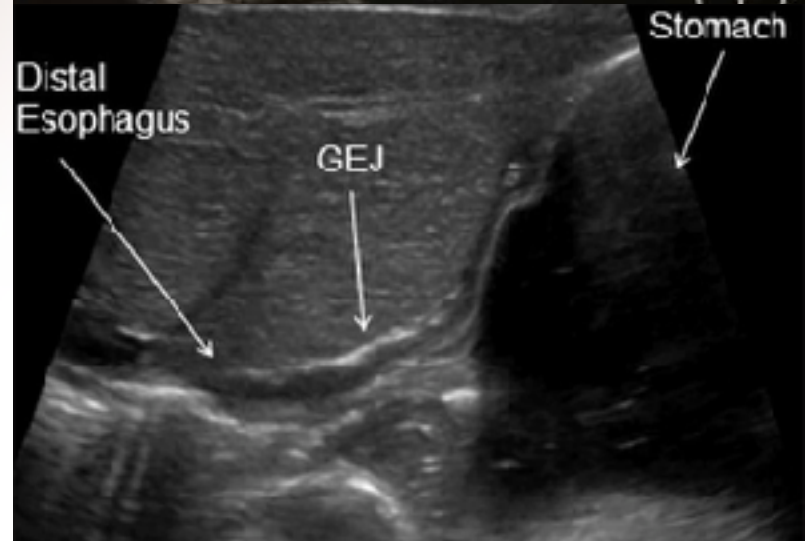
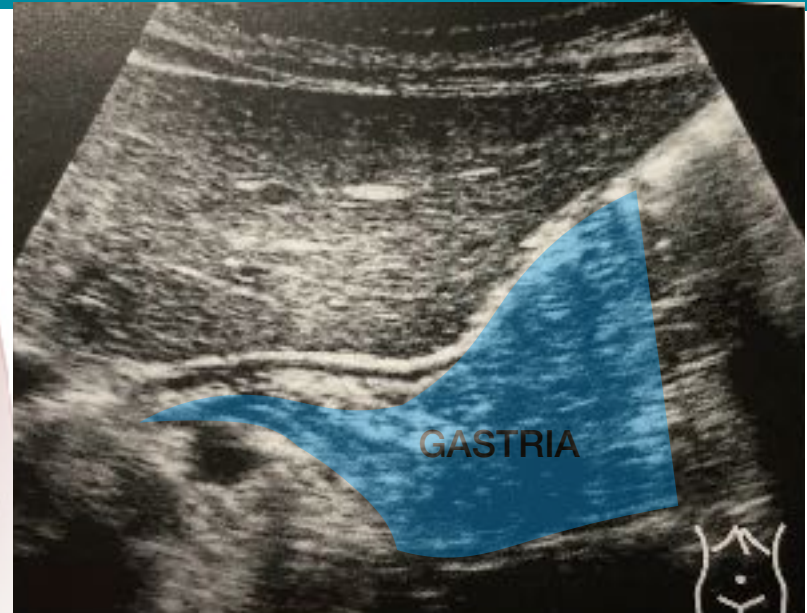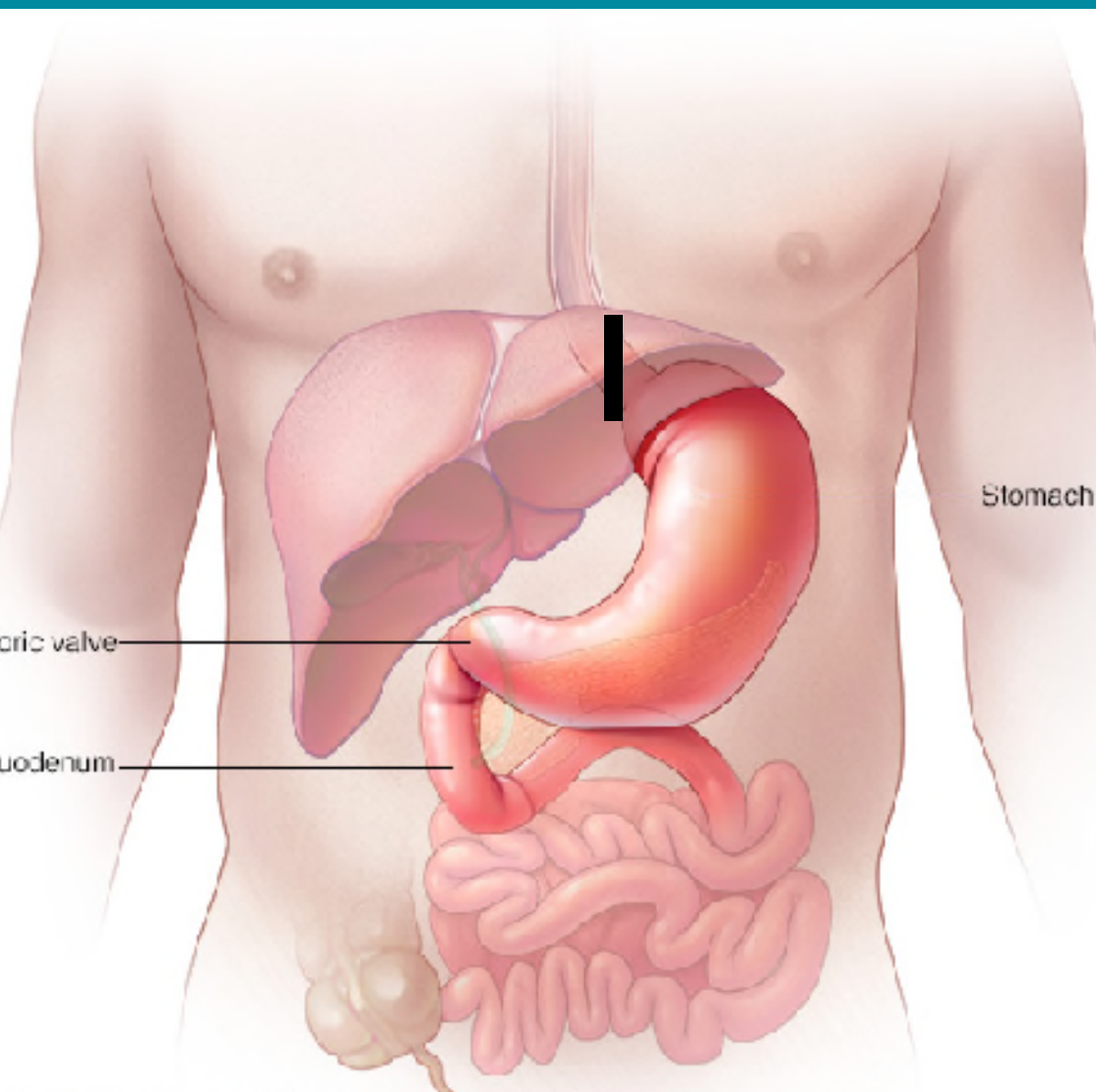
Abd Gen
C5-1
39 H7
12.0cm

2D

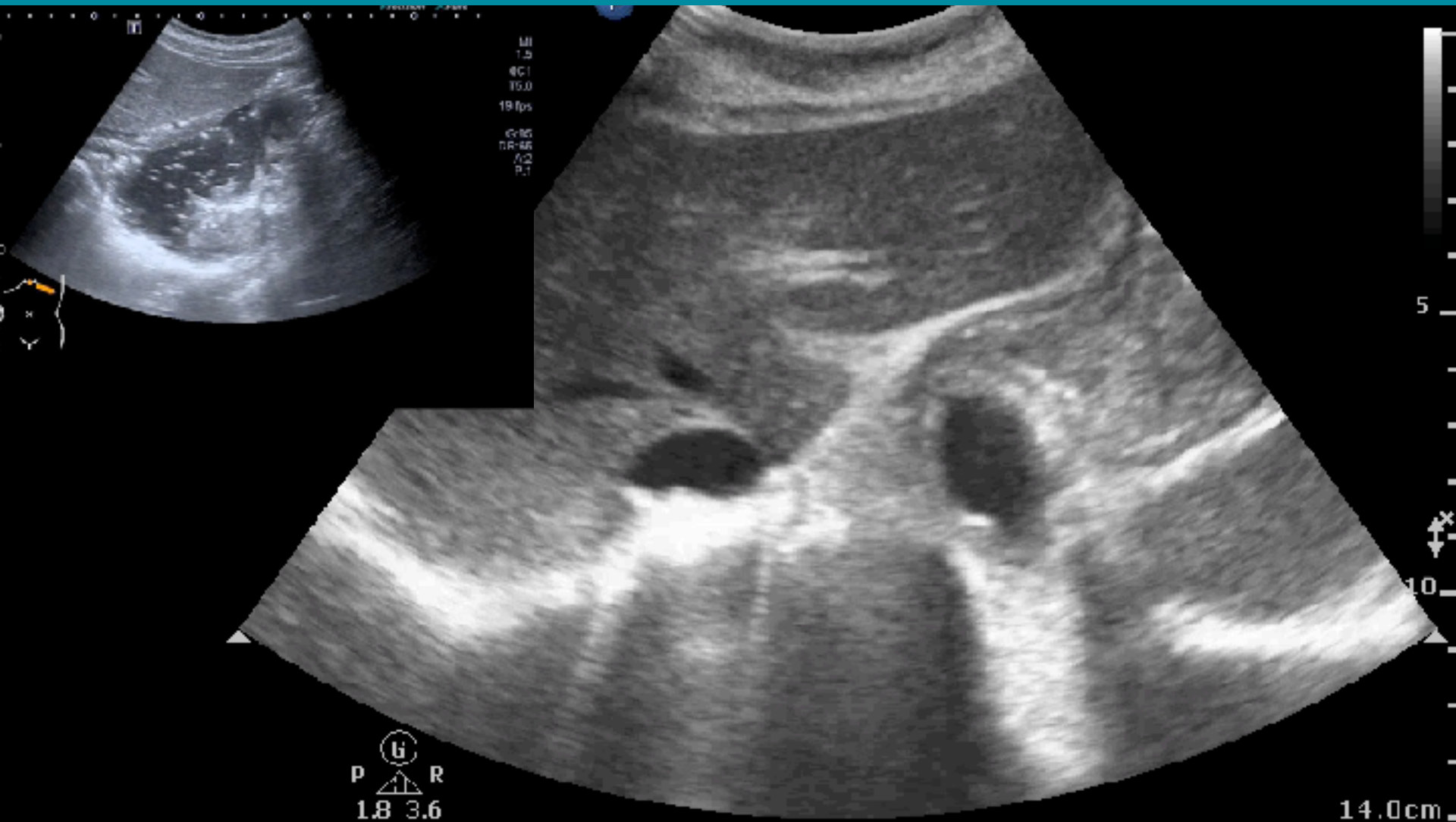
HGen
Gn 100
C 56
3 / 3 / 3



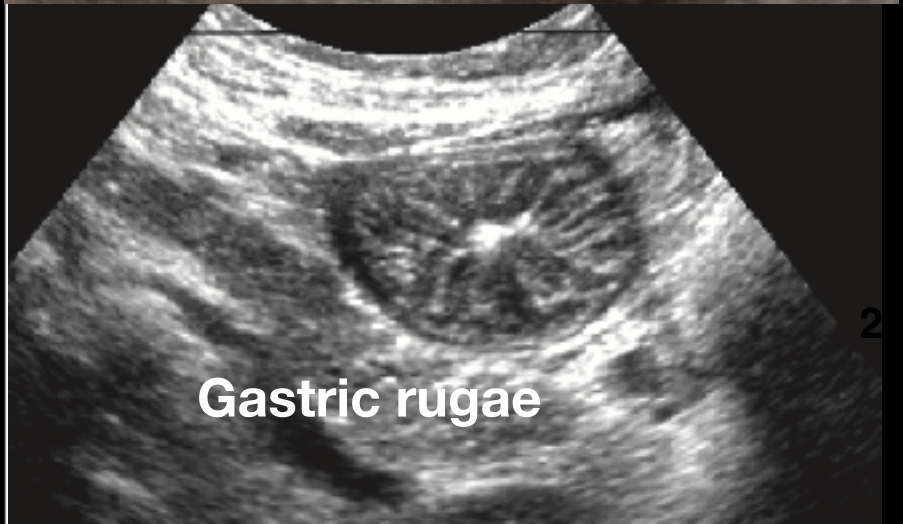
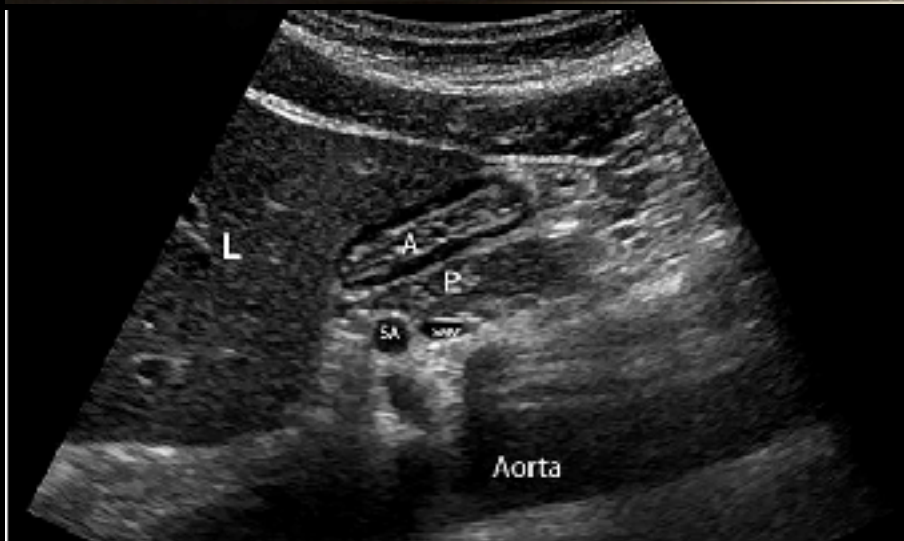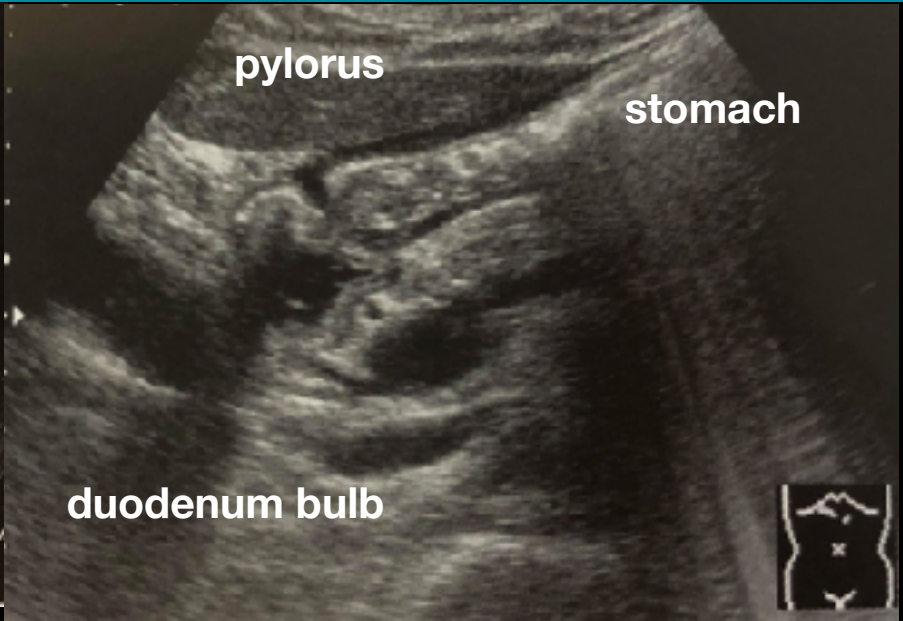
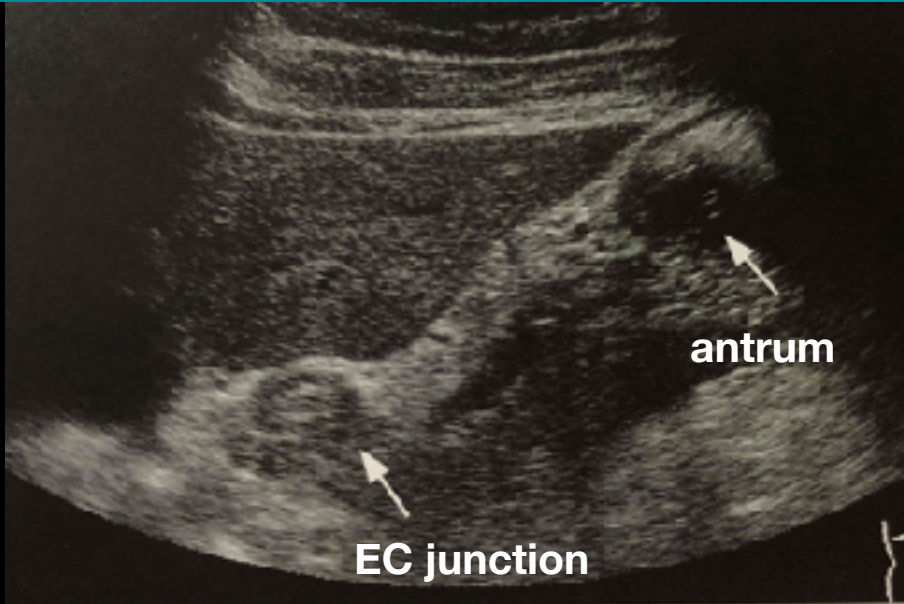
EC JUNCTION - STOMACH



EC JUNCTION - STOMACH



STOMACH



STOMACH

TE7 Ultrasound System

20180226-173114-34EA

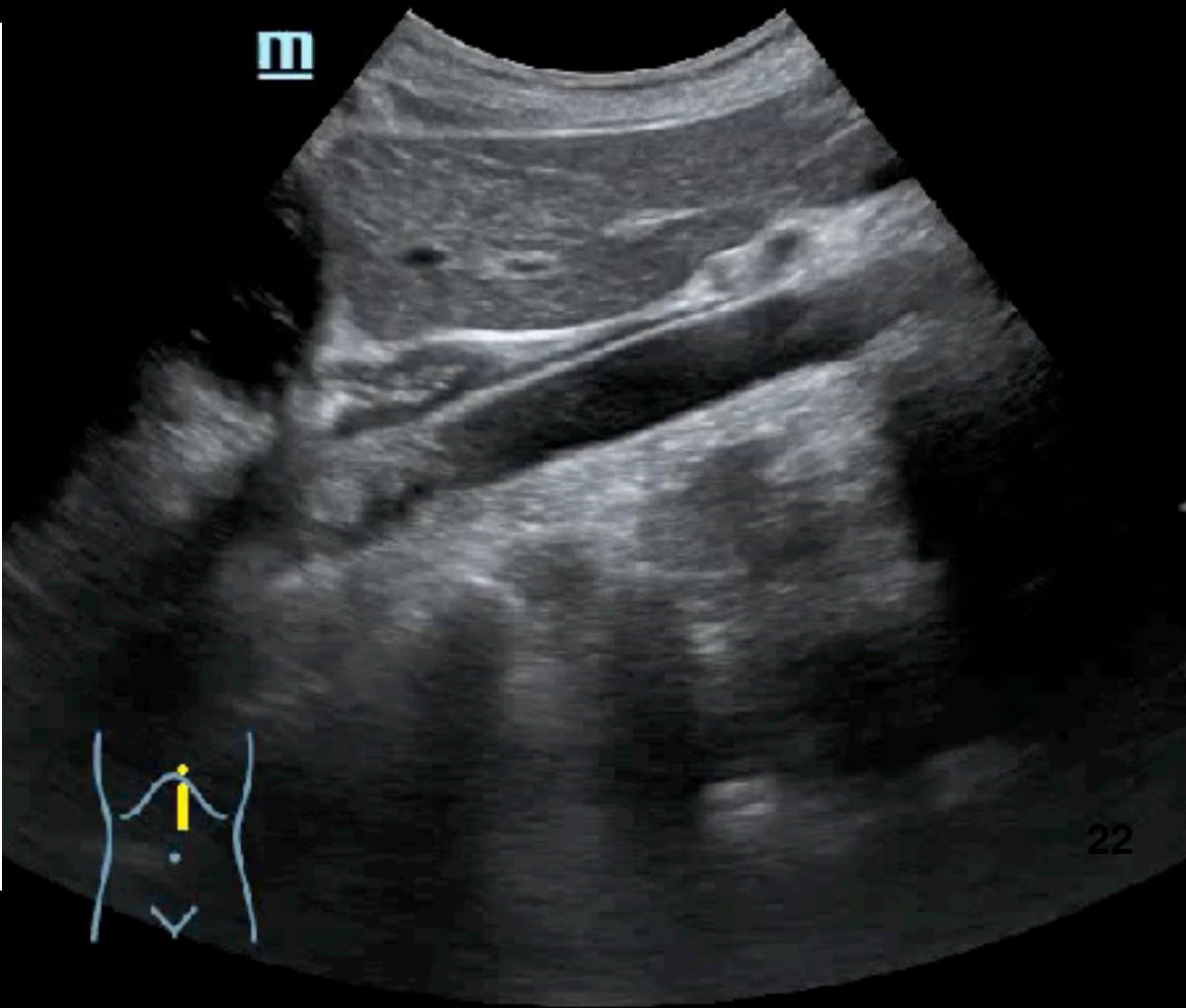
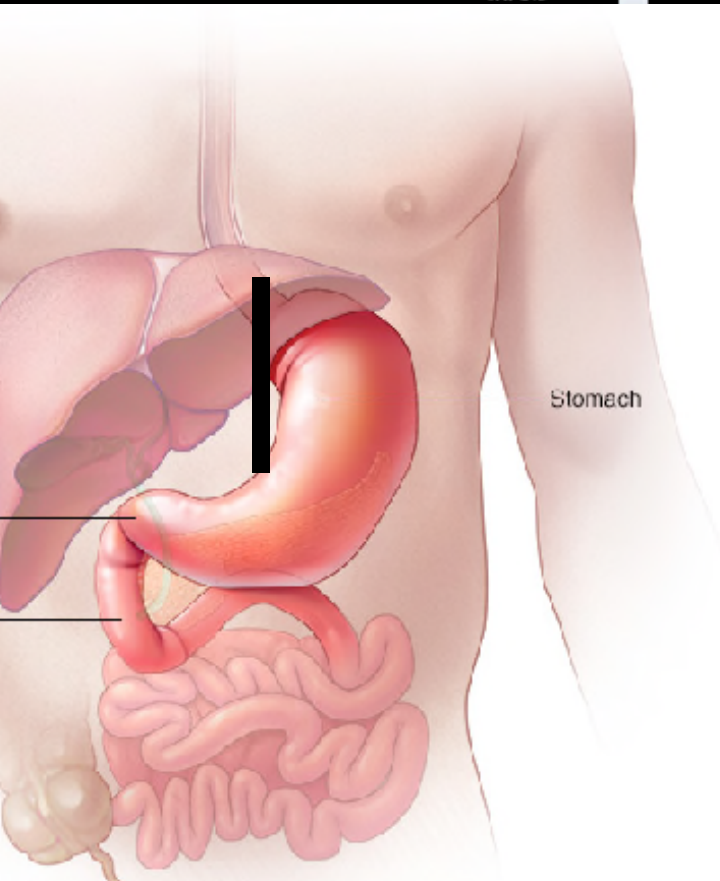
ASD

28-02-2018

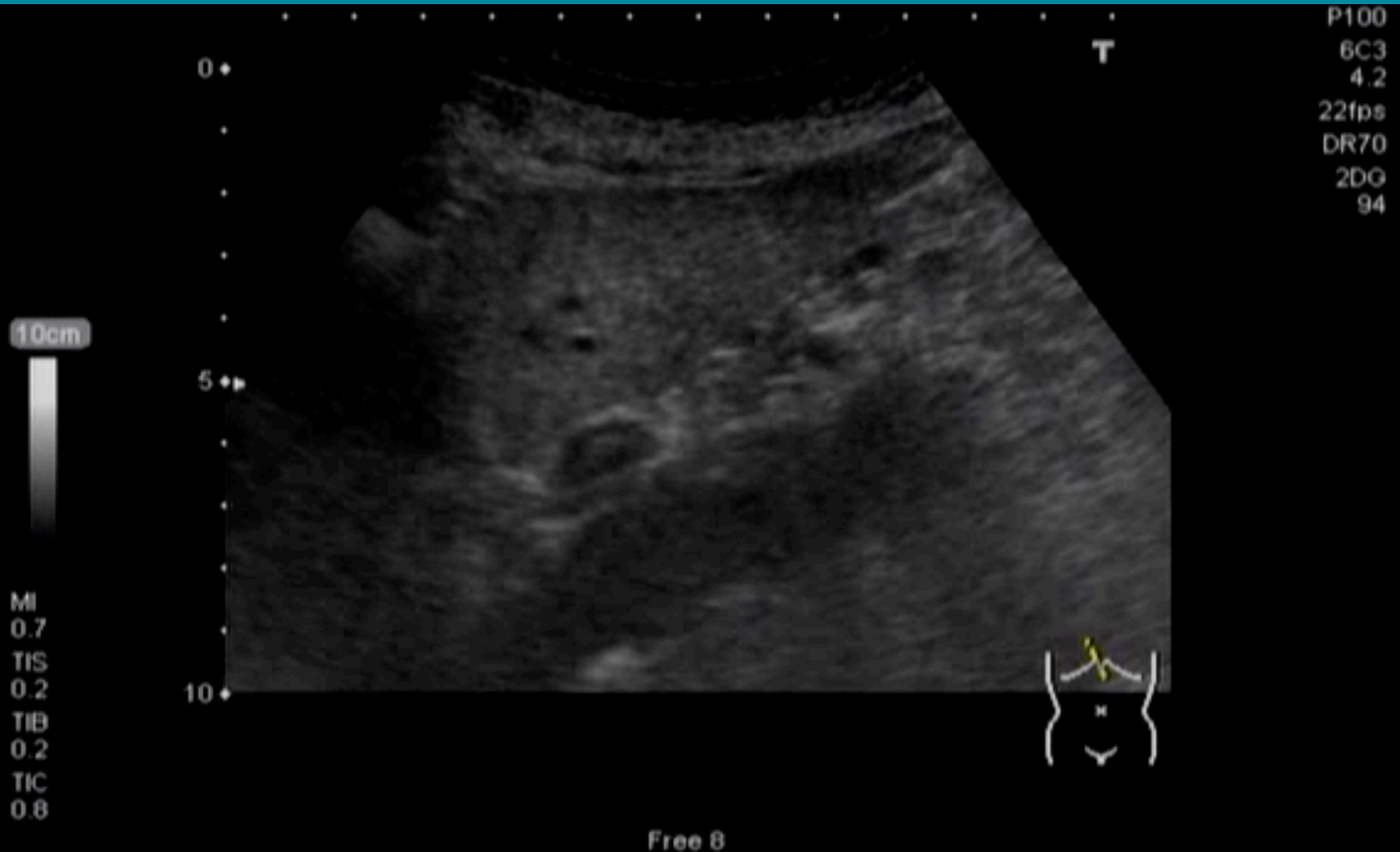07:06:21

C5-2s
MI 0.9

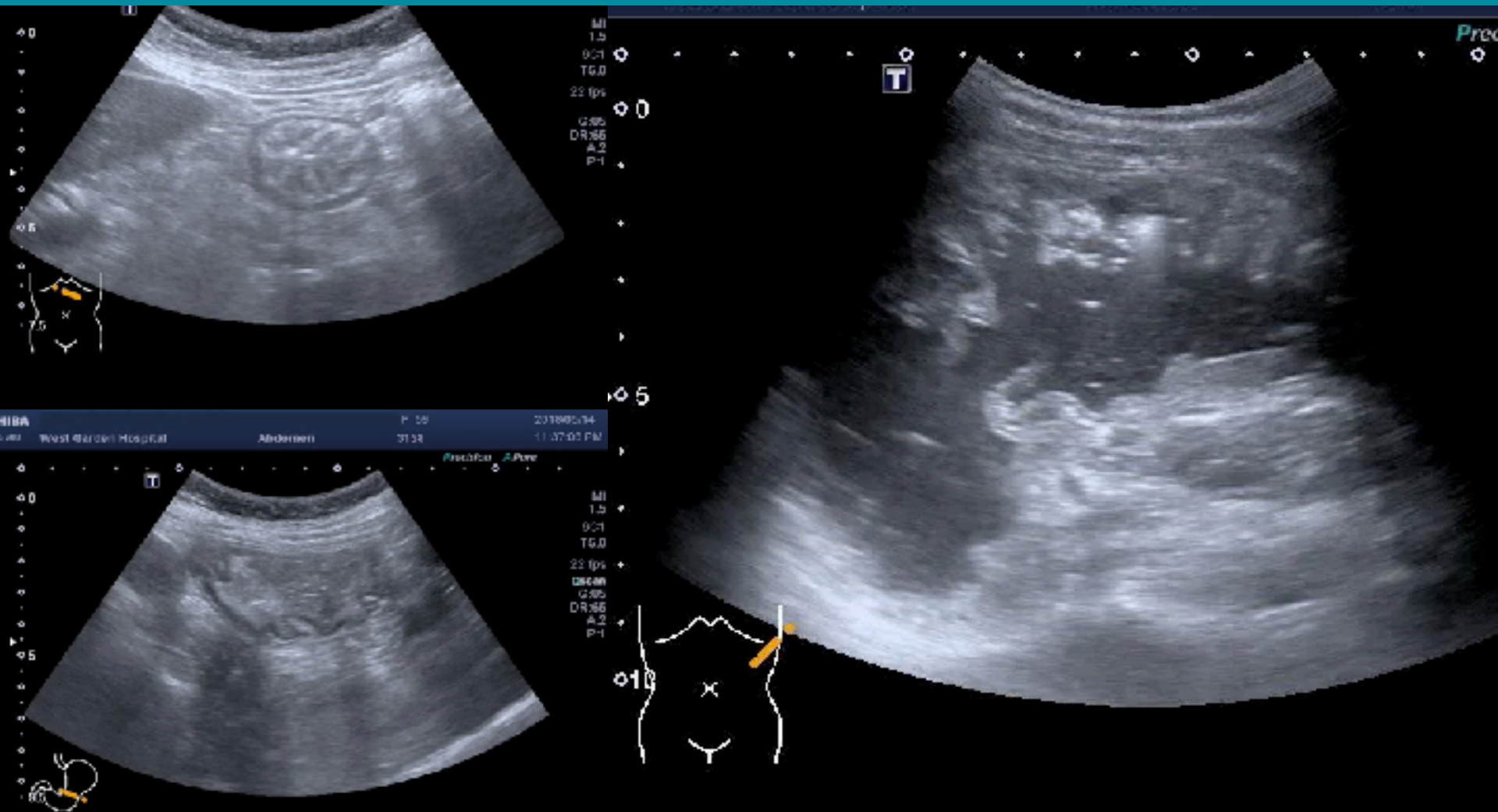
AP 96.6%



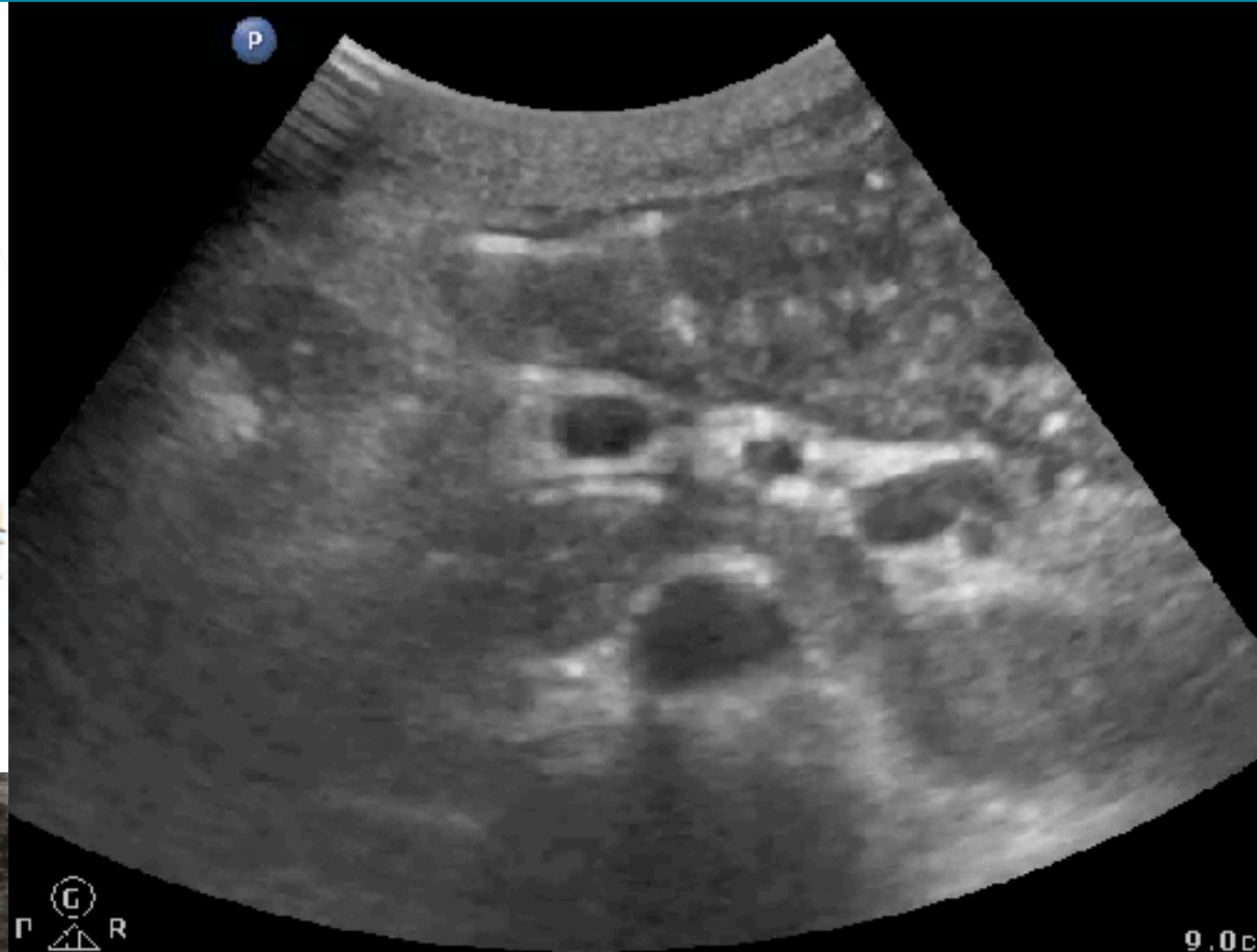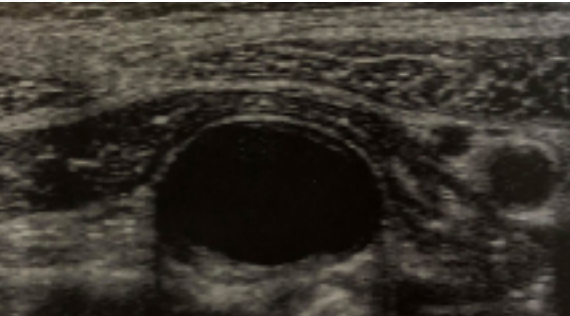
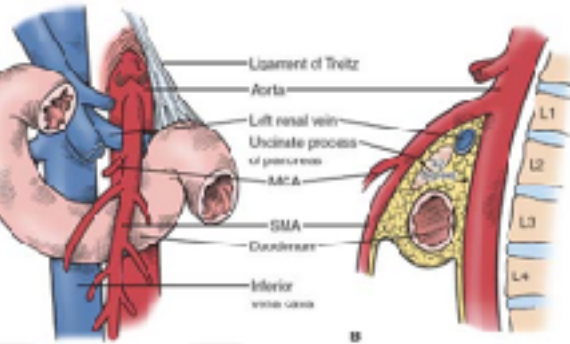
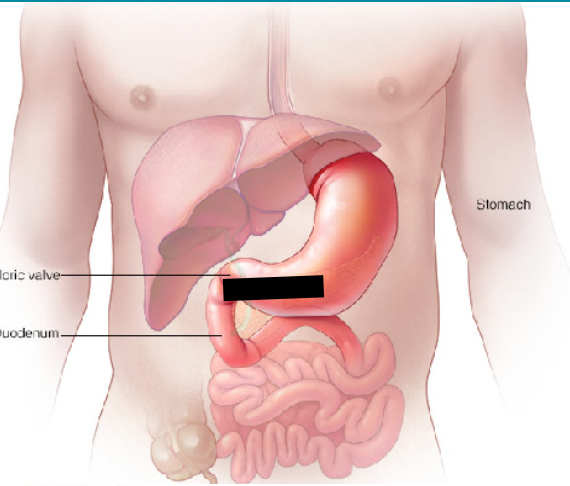
RUGAE



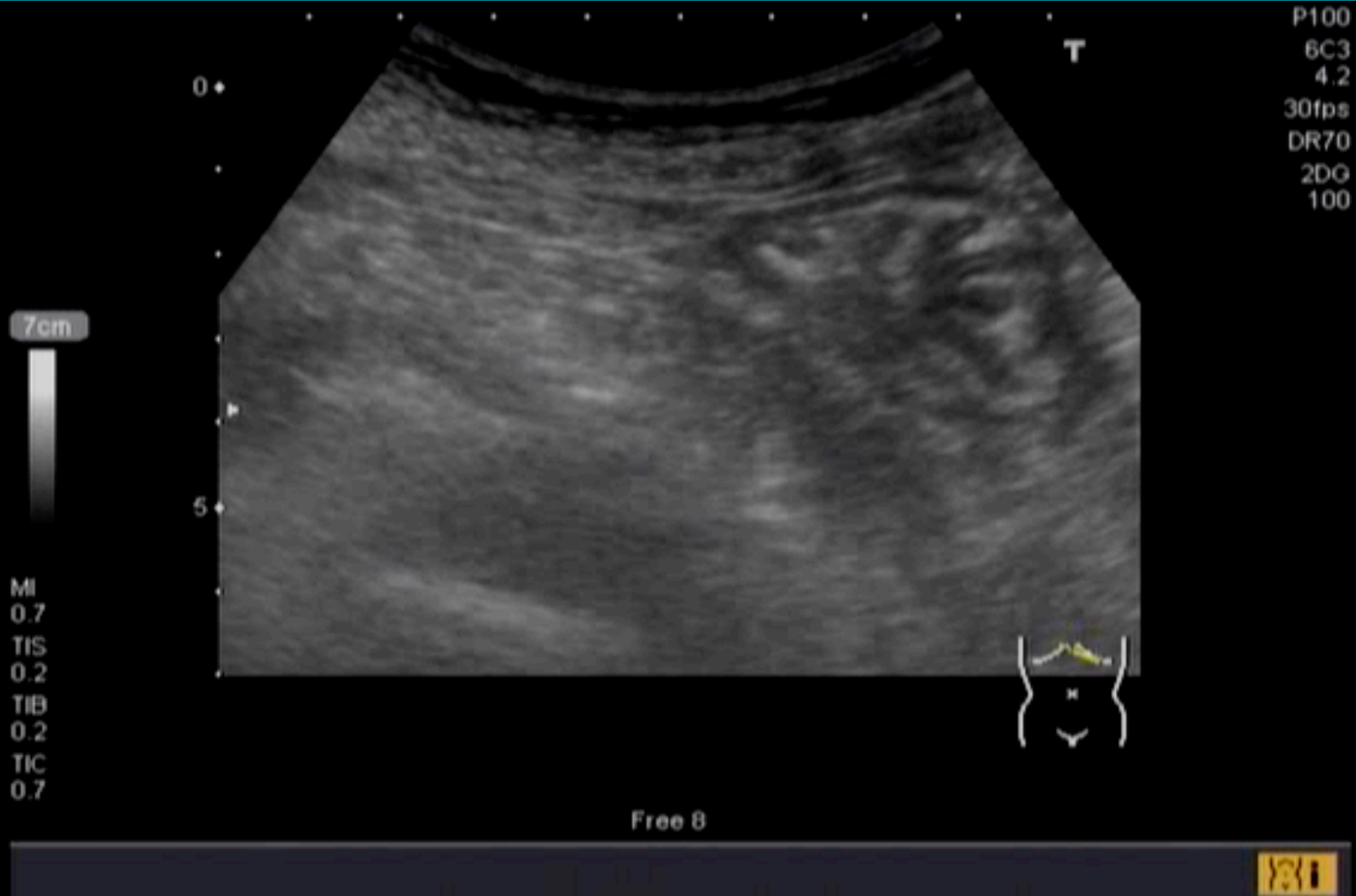RUGAE



STOMACH-ANTRUM-DUODENUM



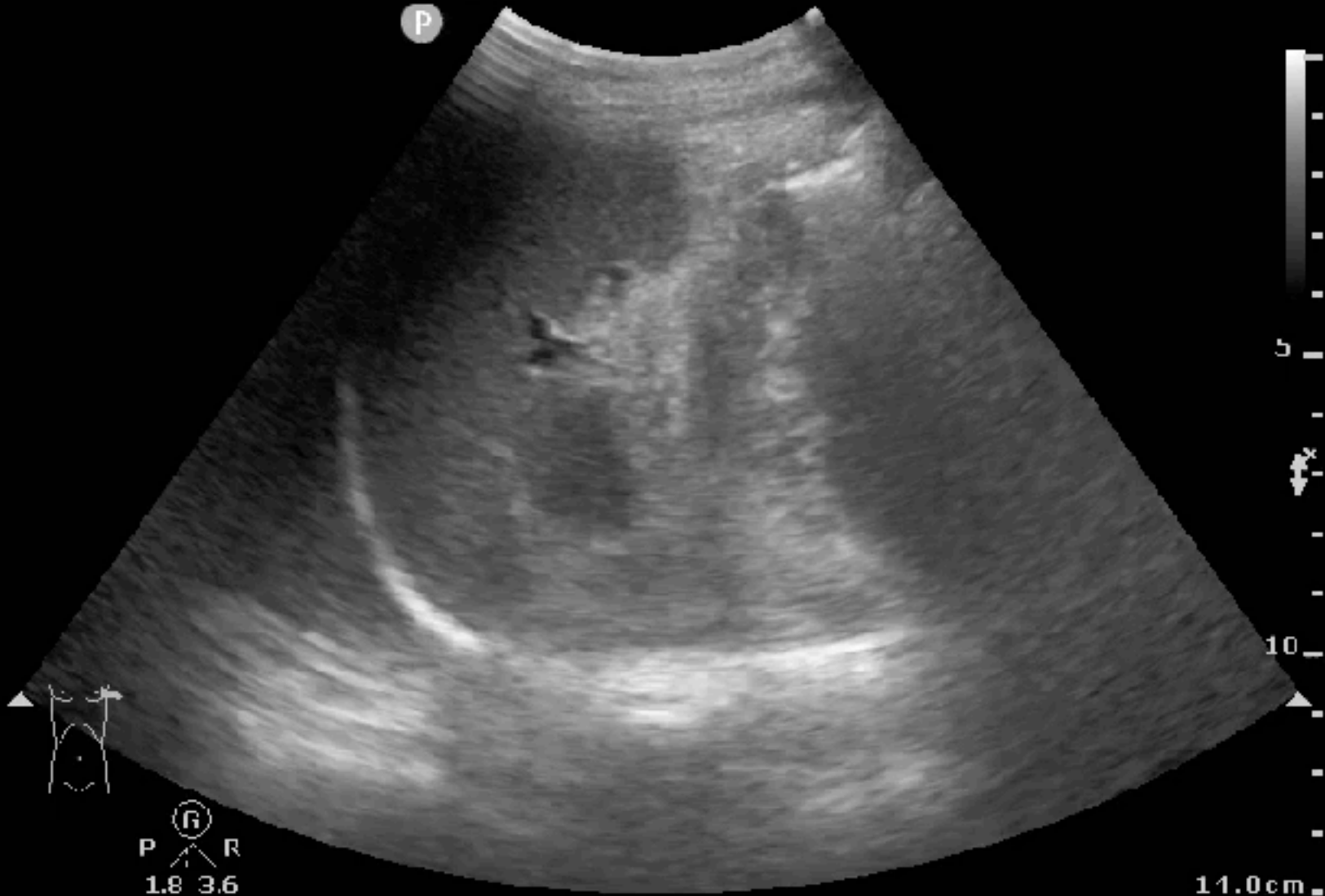STOMACH-ANTRUM-DUODENUM



STOMACH

Abd Gen
C5-1
36 Hz
14.0cm

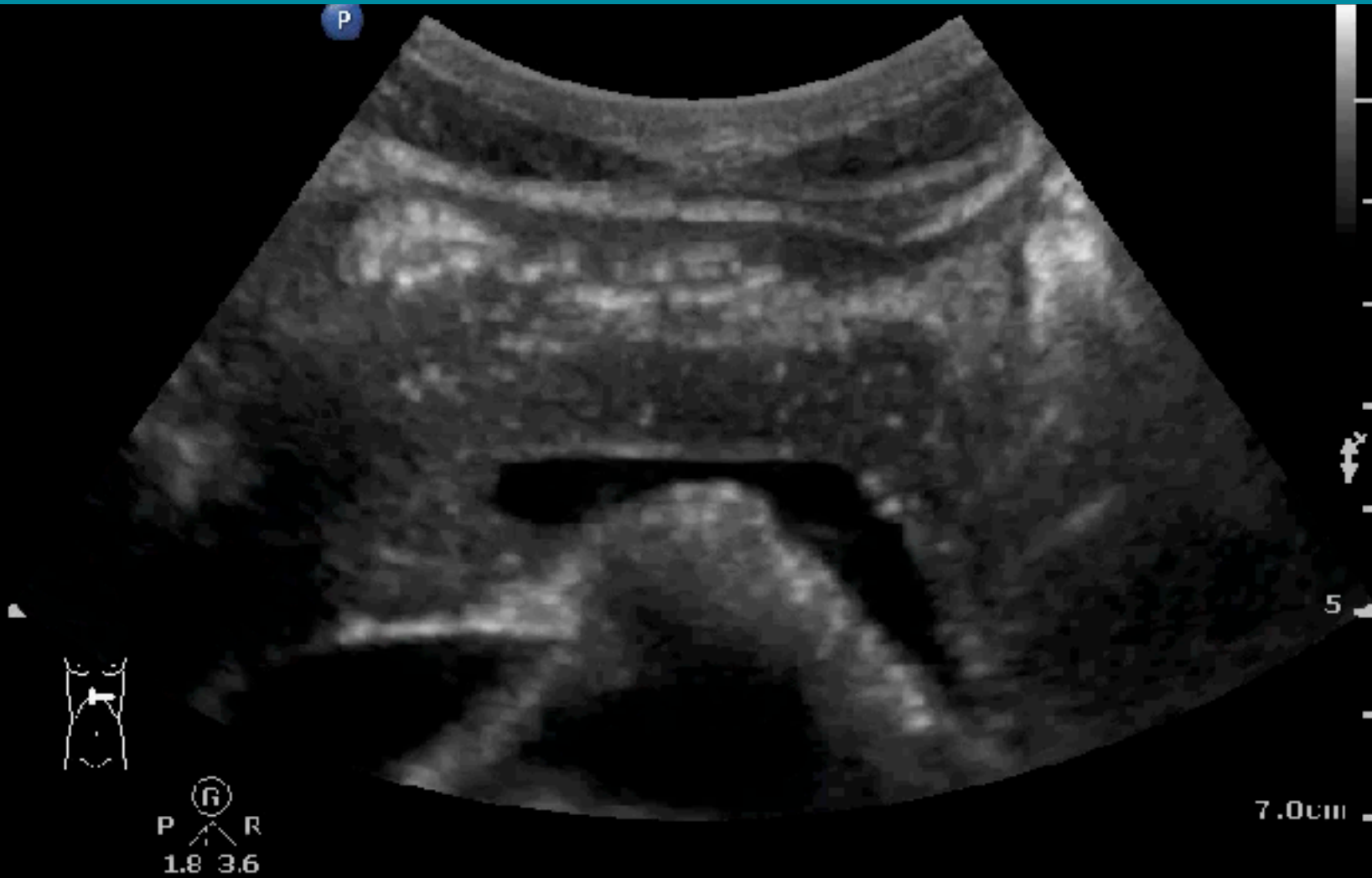2D
HGen
Gn 100
C. 56
3/3/3



ANTRUM

C5-1
55 Hz
7.0cm

2D
HGen
Gn 60
C. 56
3/3/3



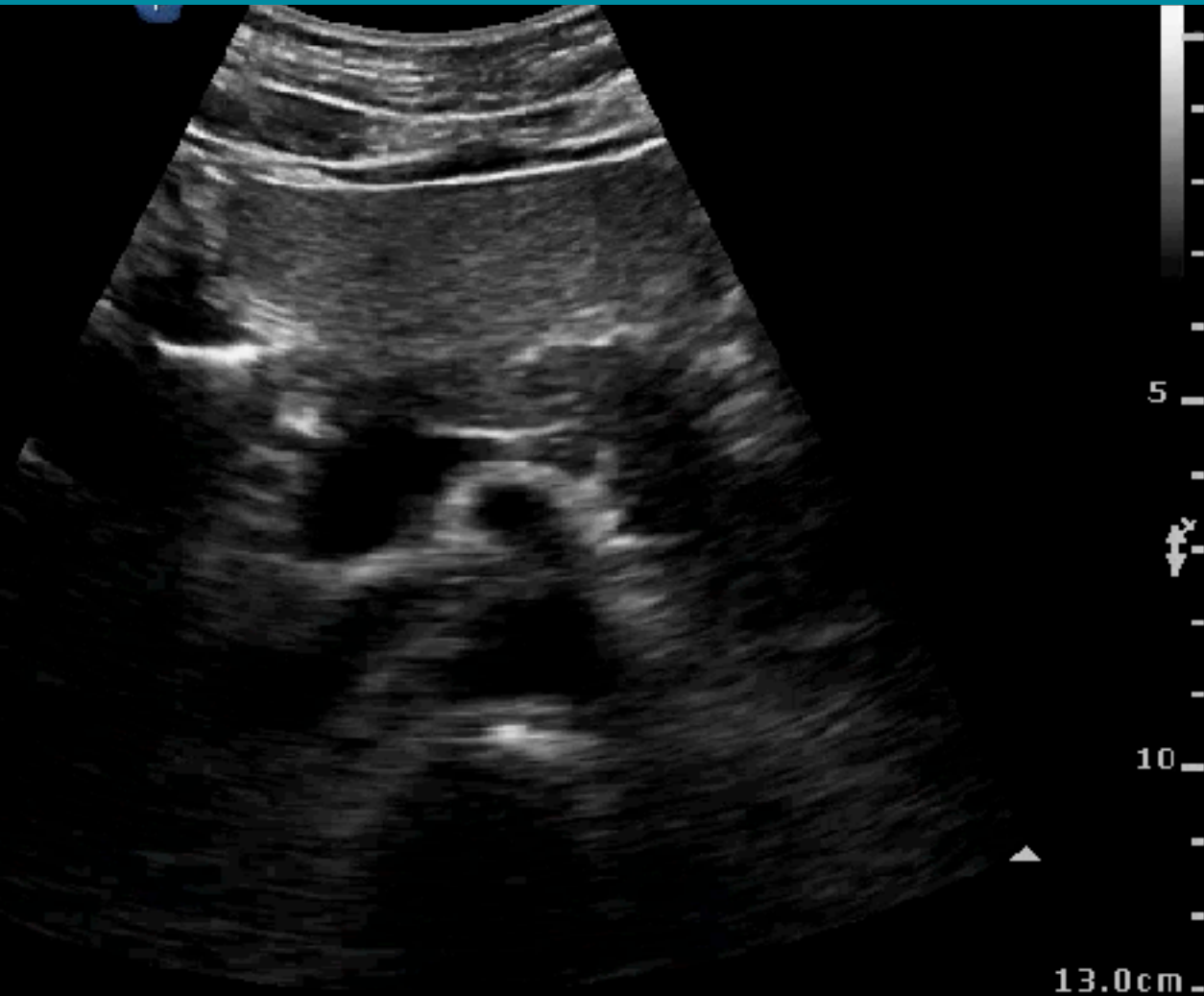
ANTRUM

C6-2
22 Hz
13.0cm

2D
Gen
Gn 52
C. 49
2/3/4

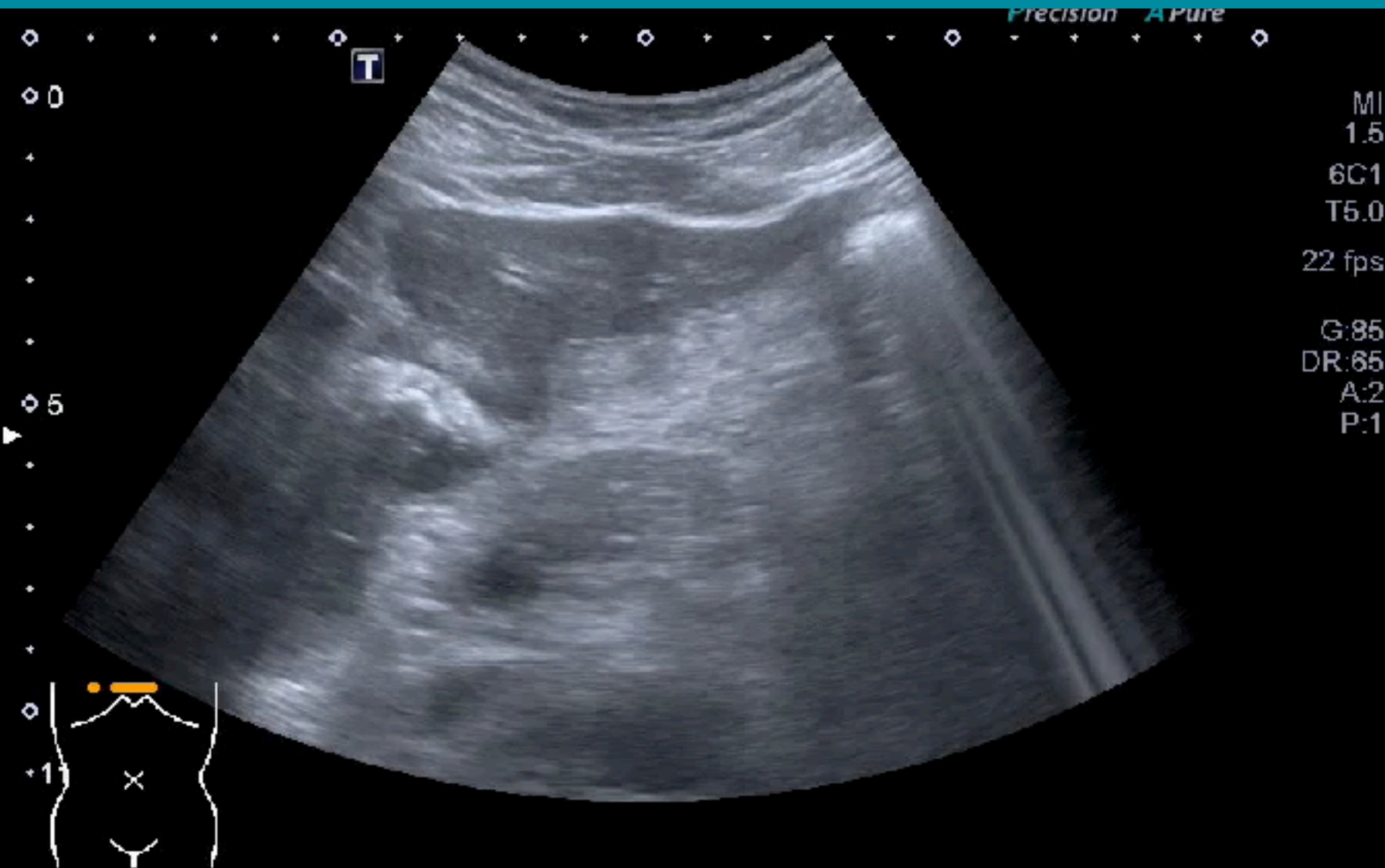


R
P R
2.0 6.0

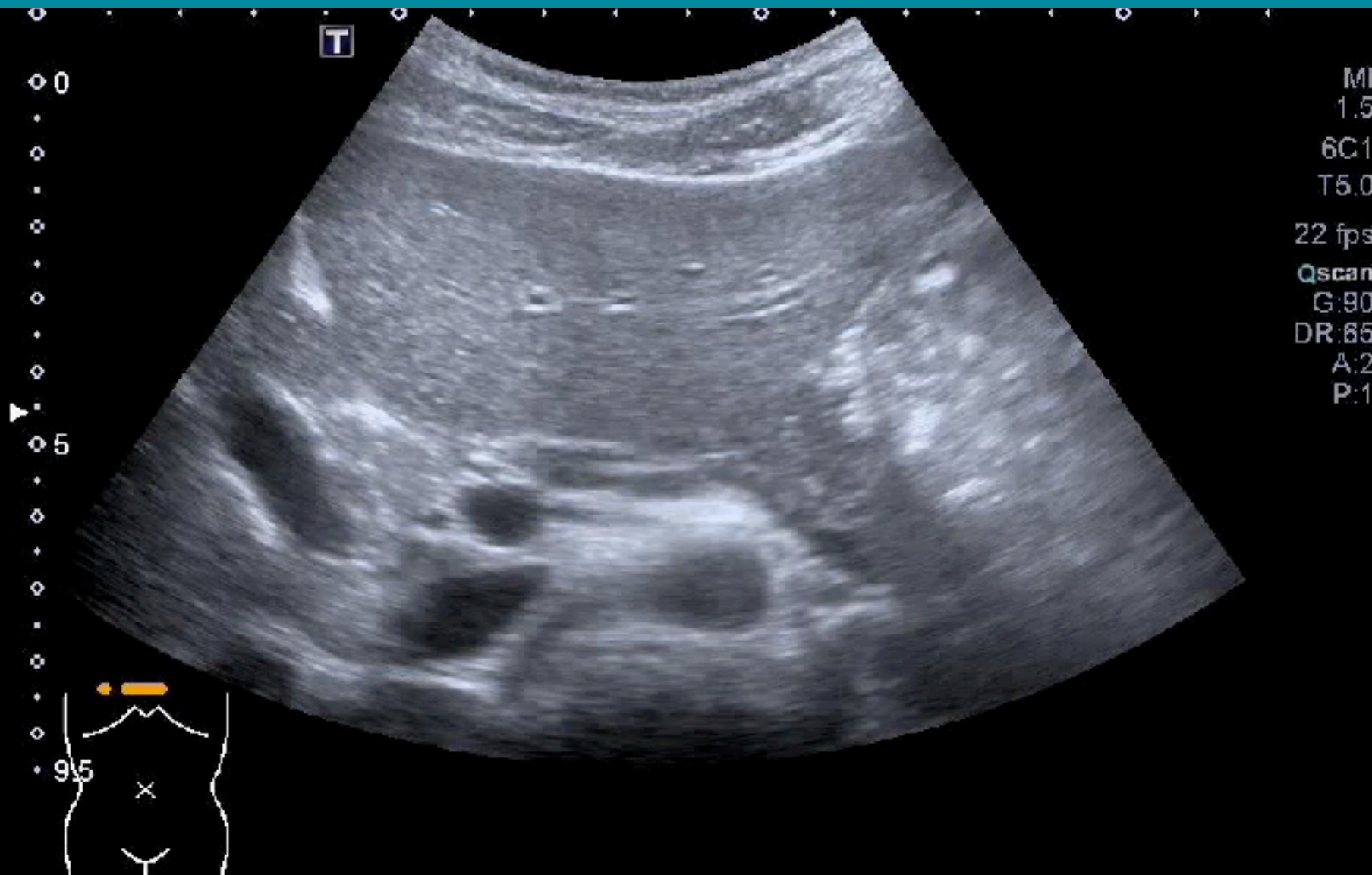


13.0cm

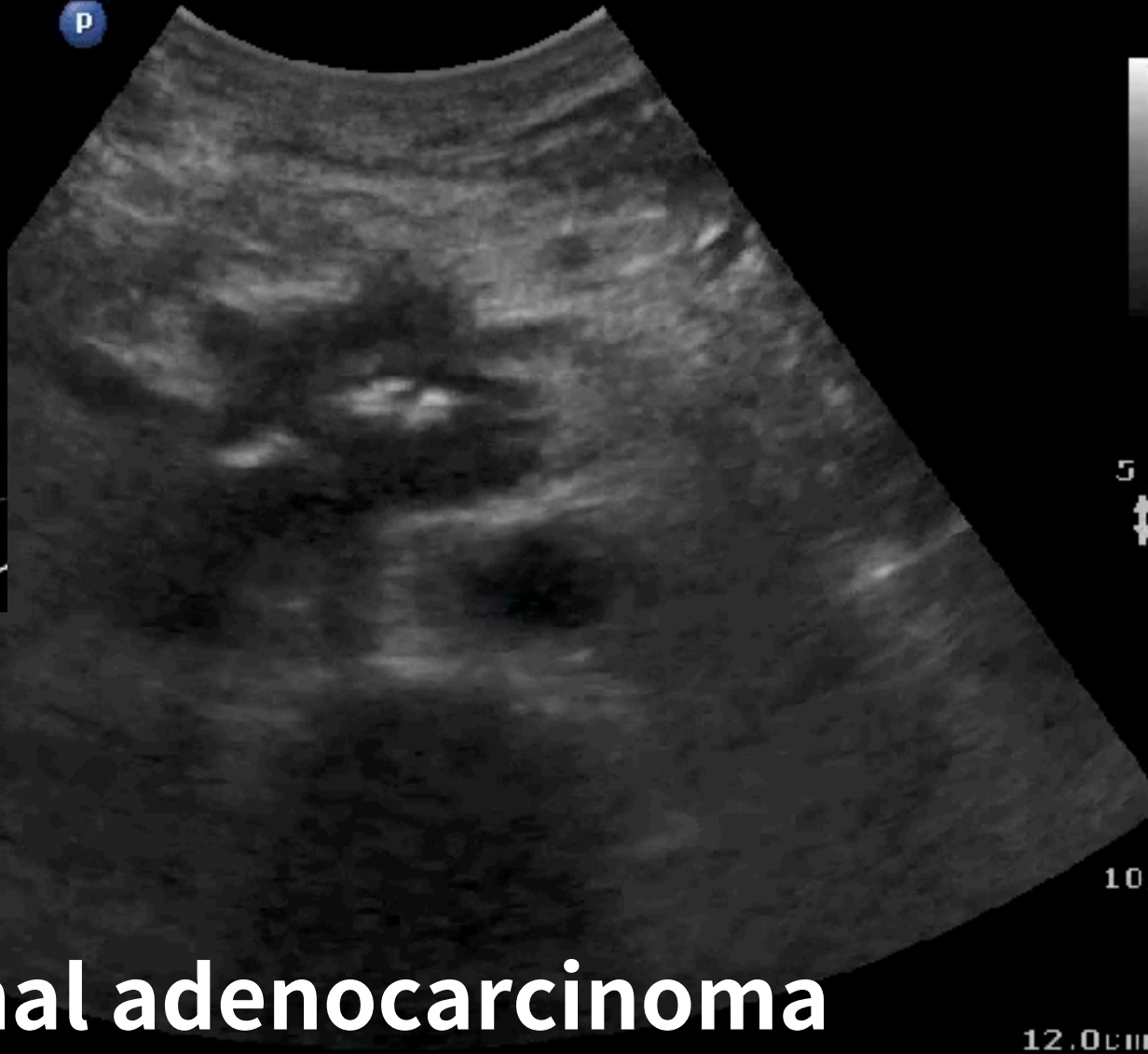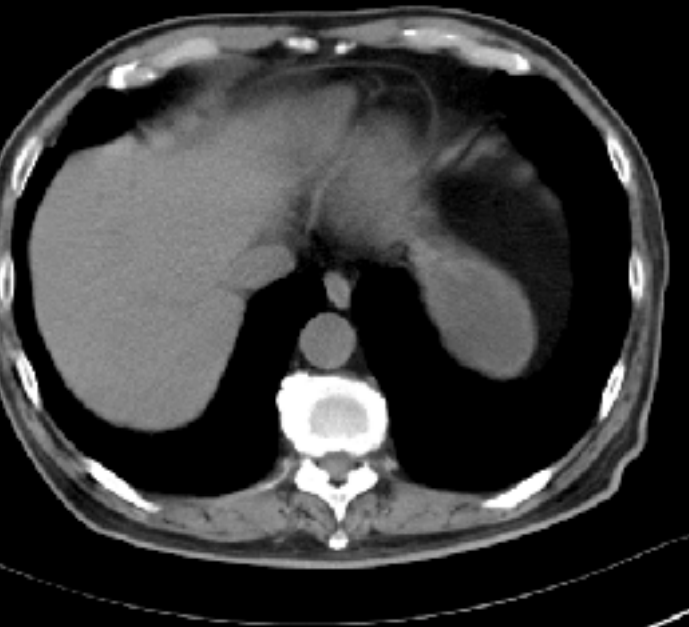
ANTRUM-DUODENUM



GASTRIC OUTLET OBSTRUCTION EVALUATION



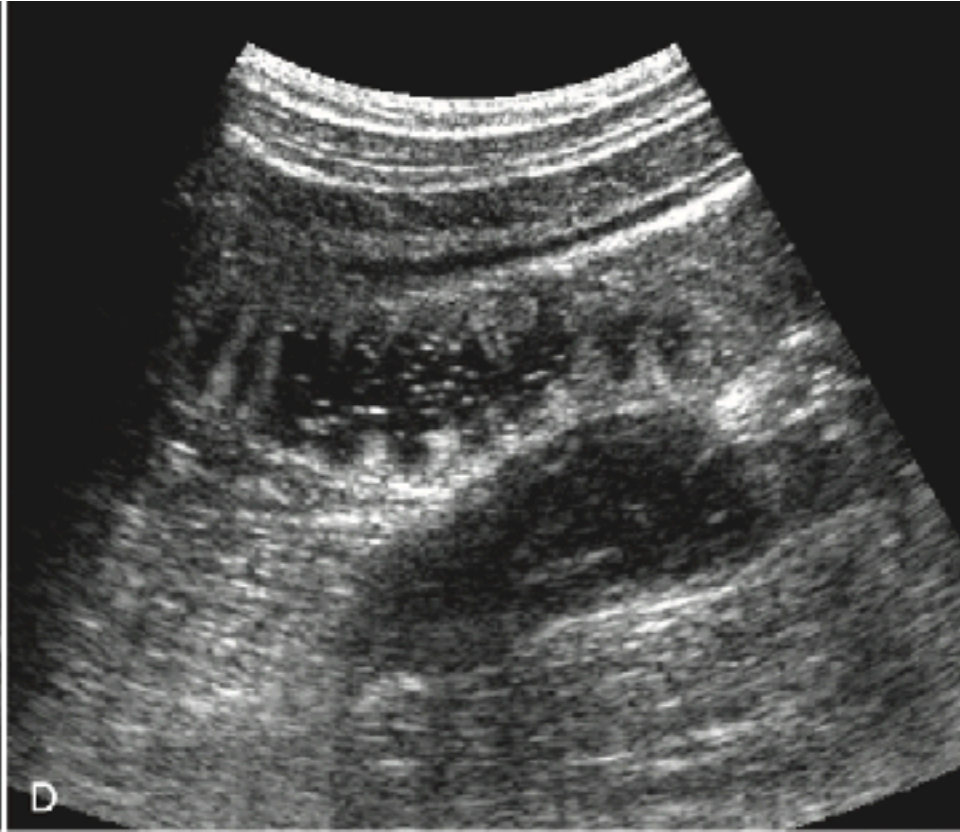
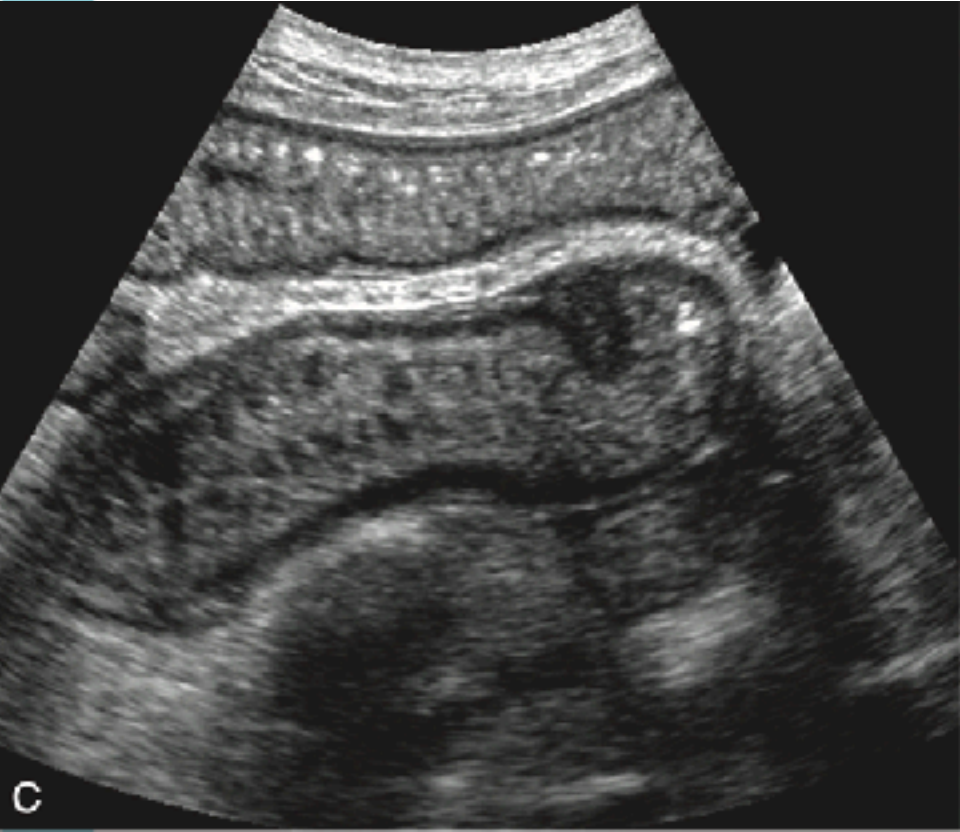
63M , EPIGASTALGIA



Duodenal adenocarcinoma

SMALL BOWEL

Fold of Kerckring (Valvulae conniventes)



SMALL BOWEL

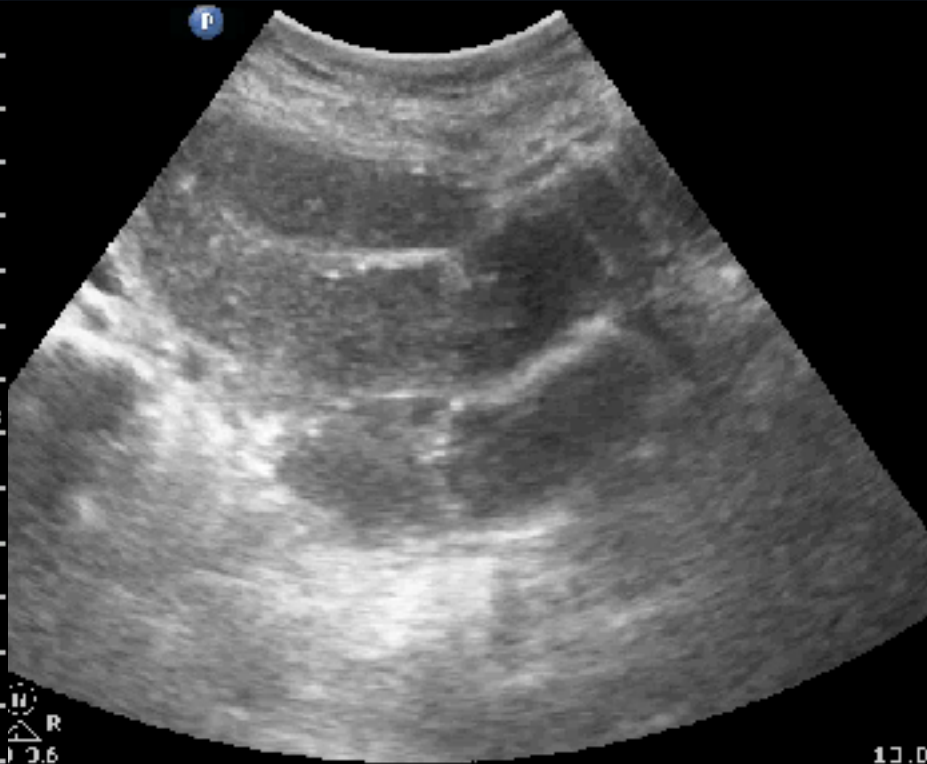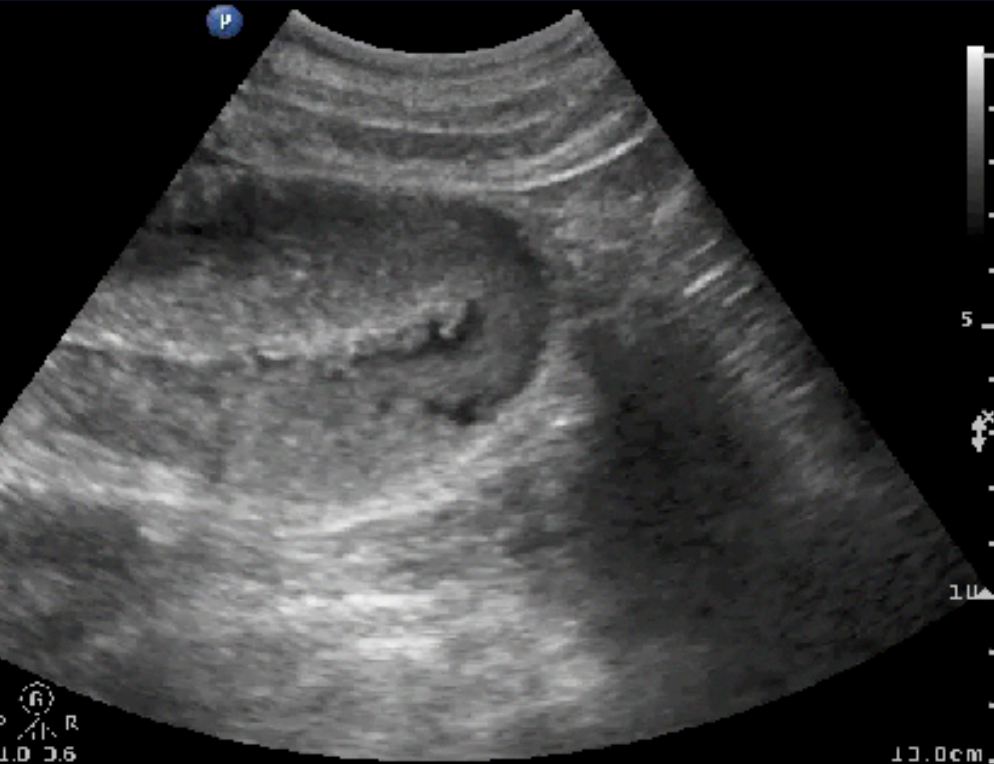
Fold of Kerckring (Valvulae conniventes)

Jejunum

Ileum

MI 1.1 1/5/2016
TIS 0.1 12:29:57 PM
SKH ER

MI 1.1 3/15/2017
TIS 0.1 11:21:44
SKH ER

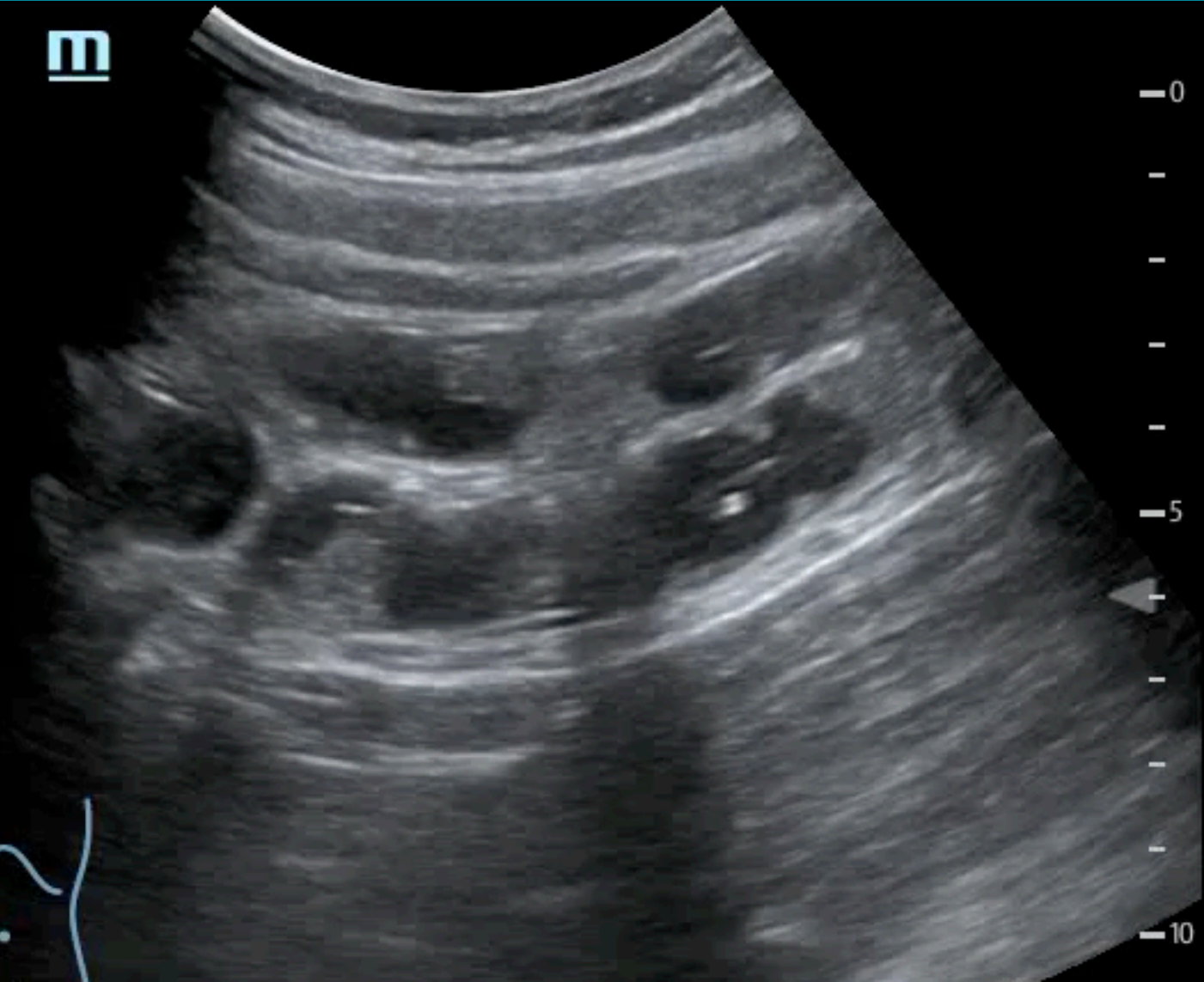
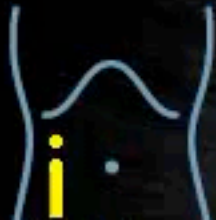
SMALL BOWEL

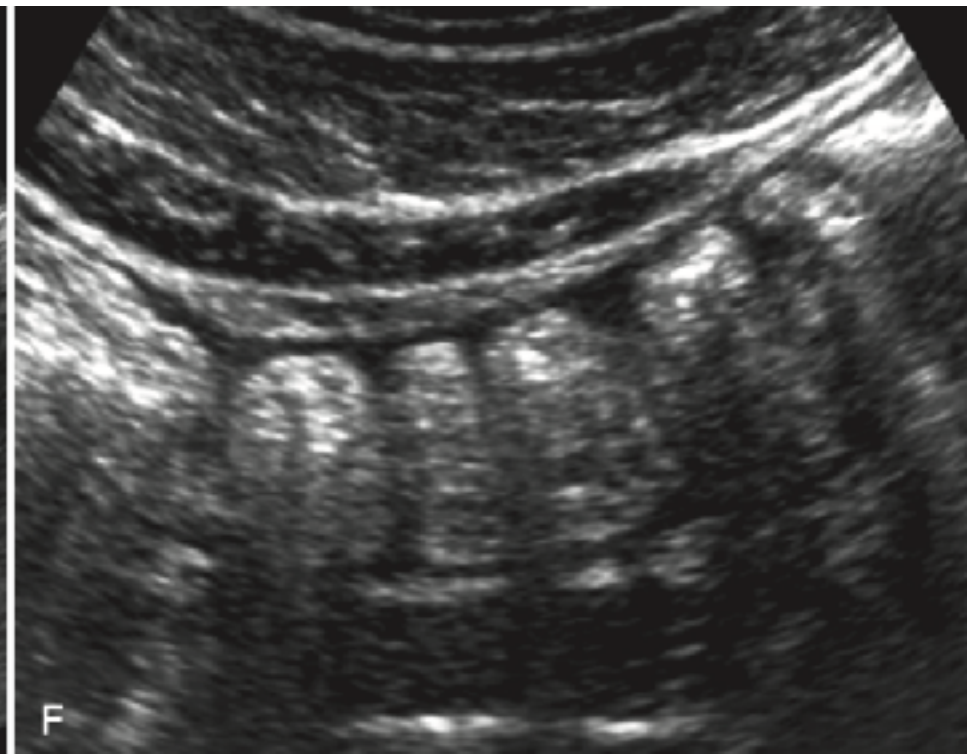
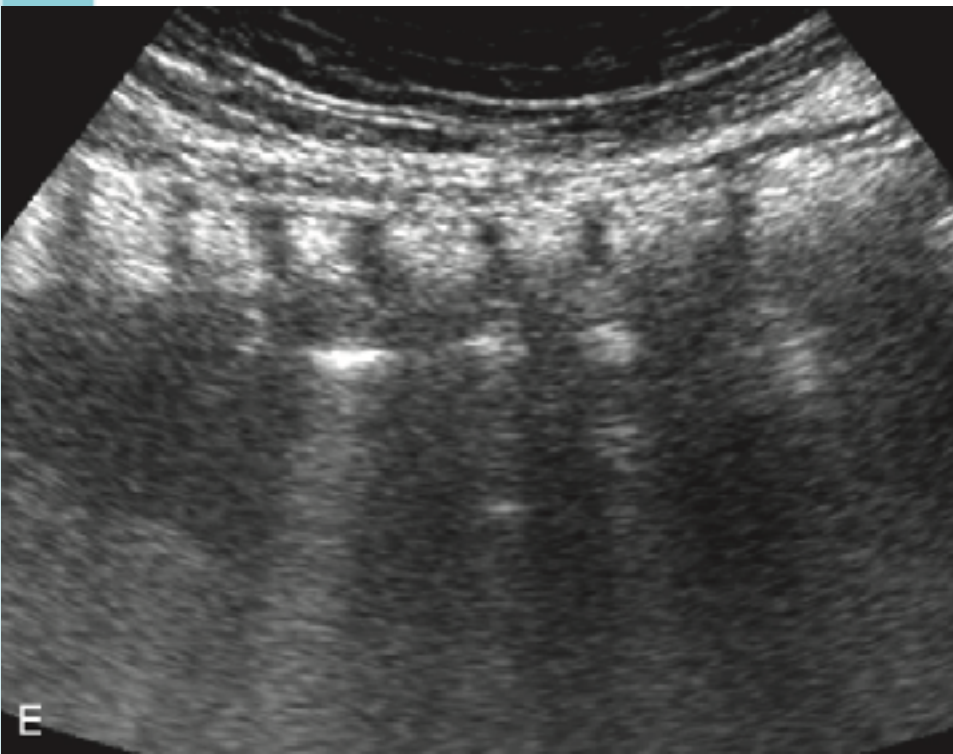
MI 0.9
TIS 0.7

B
FH5.0
DR120
FR26
D12.0
G50

m



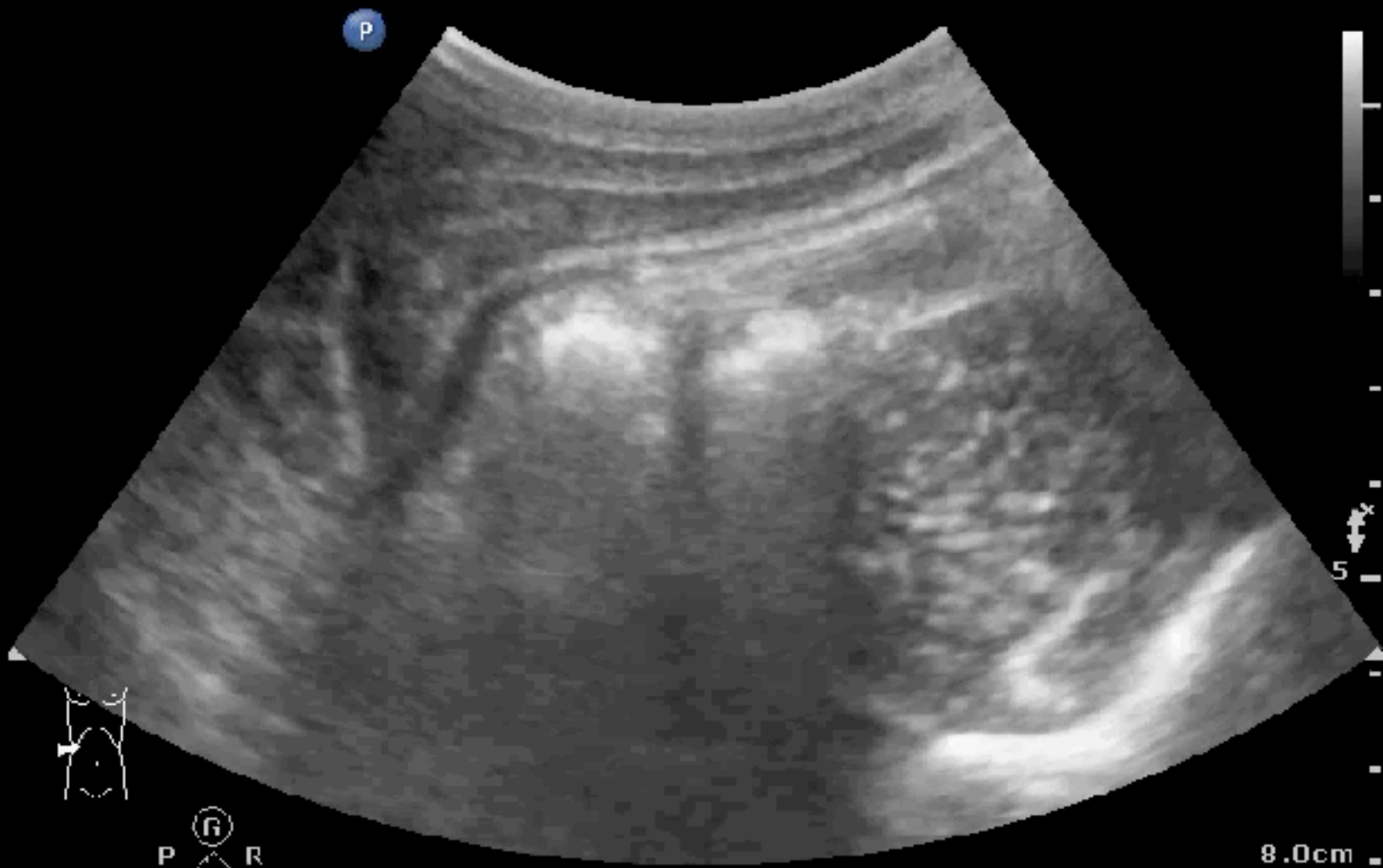COLON-HAUSTRATION



COLON: A COLON

Abd Gen
C5-1
51 Hz
8.0cm

2D
HGen
Gn 100
C. 56
3/3/3



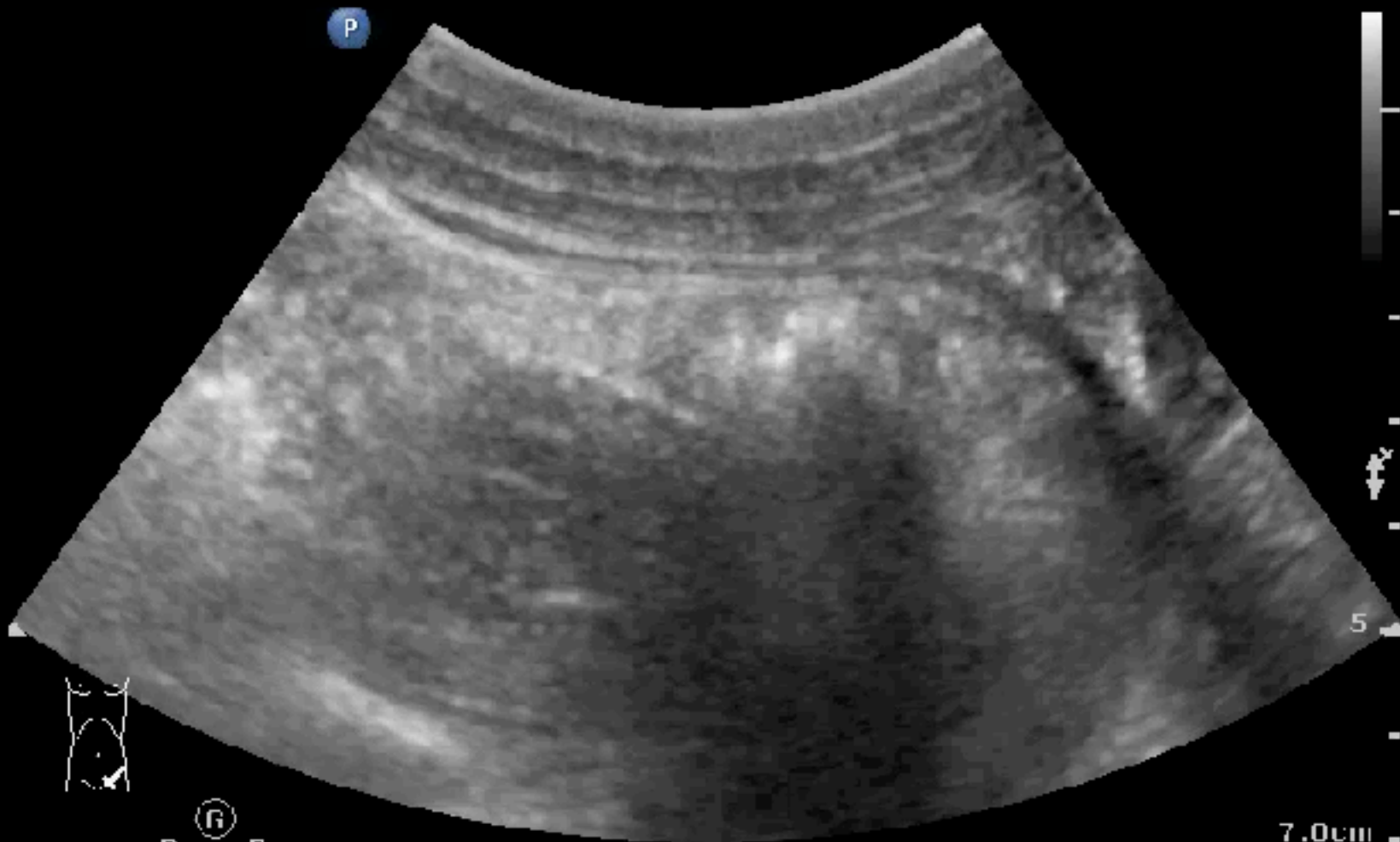P R
1.8 3.6

8.0cm

COLON: D COLON

Abd Gen
C5-1
55 Hz
7.0cm

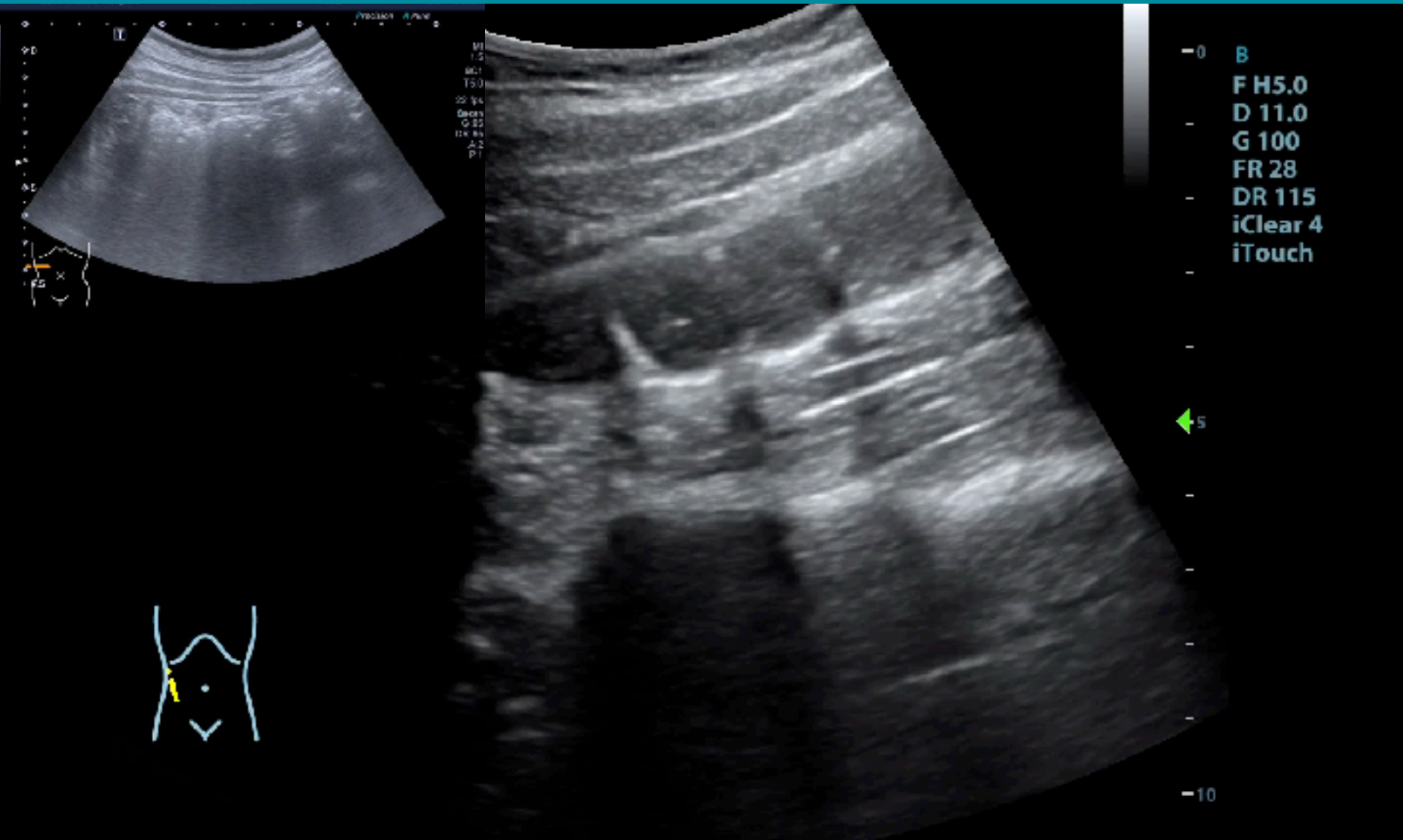
2D
HGen
Gn 86
C. 56
3/3/3



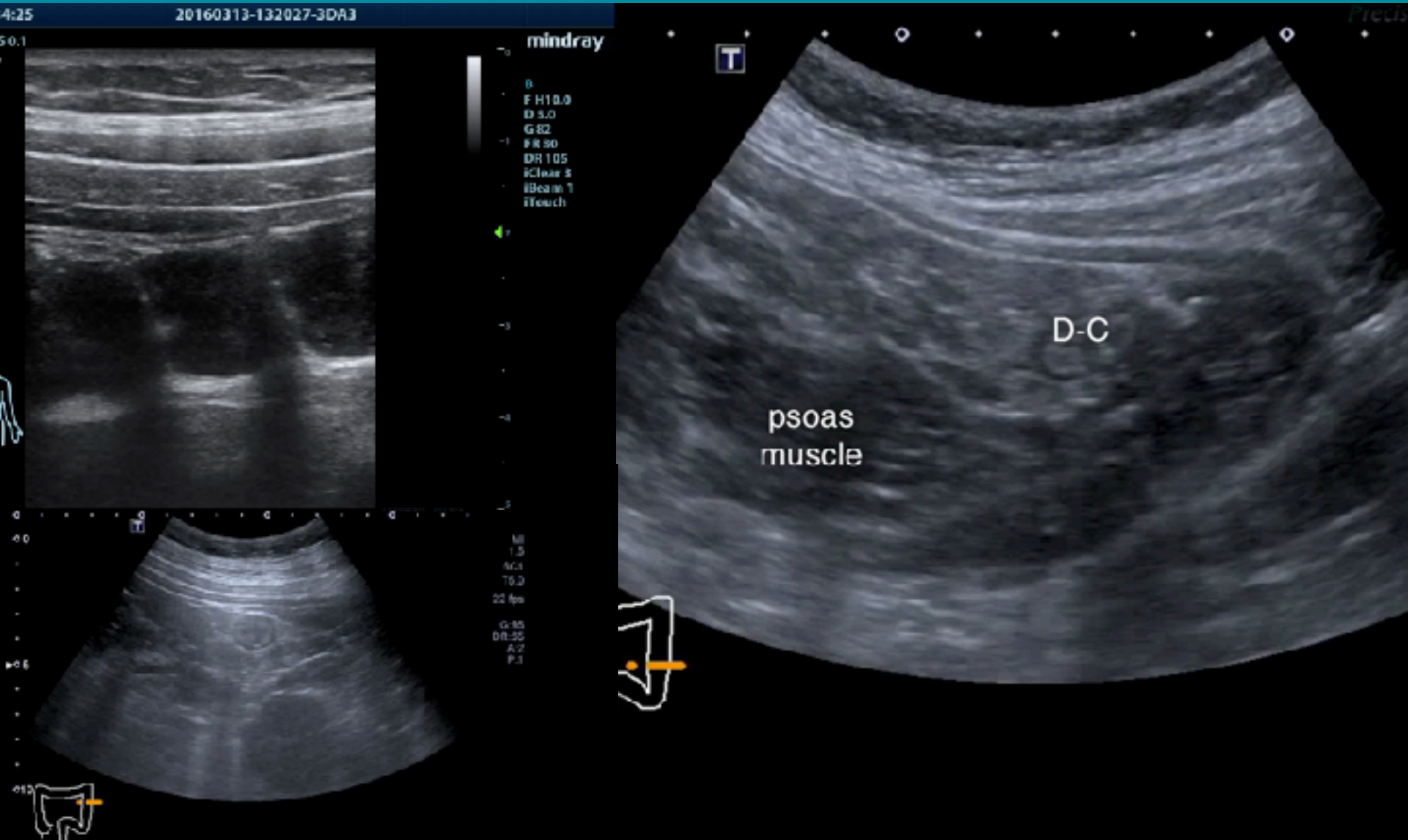
P R
1.8 3.6

7.0cm

COLON-HAUSTRATION



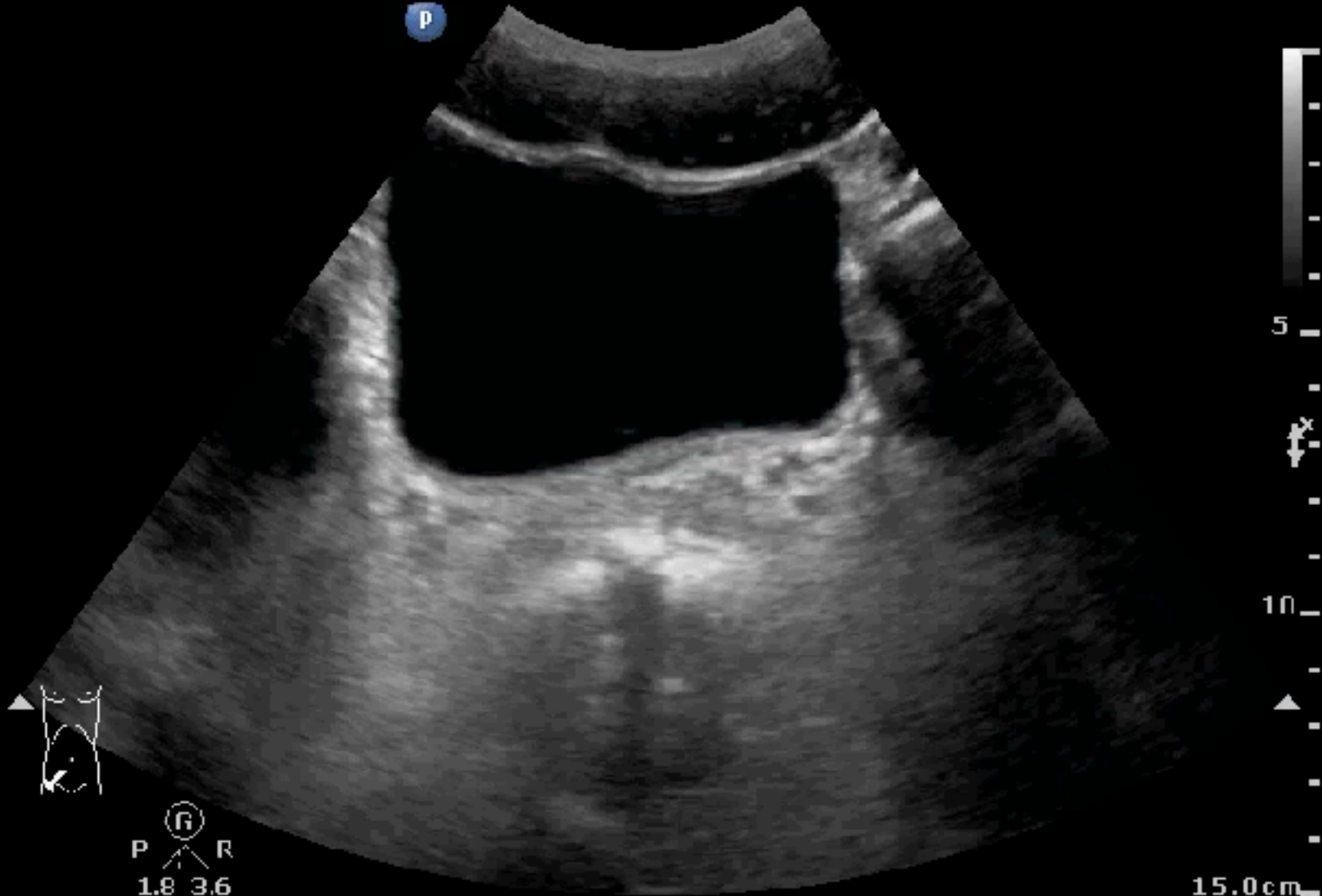
COLON-HAUSTRATION



RECTUM

Abd Gen
C5-1
34 Hz
15.0cm

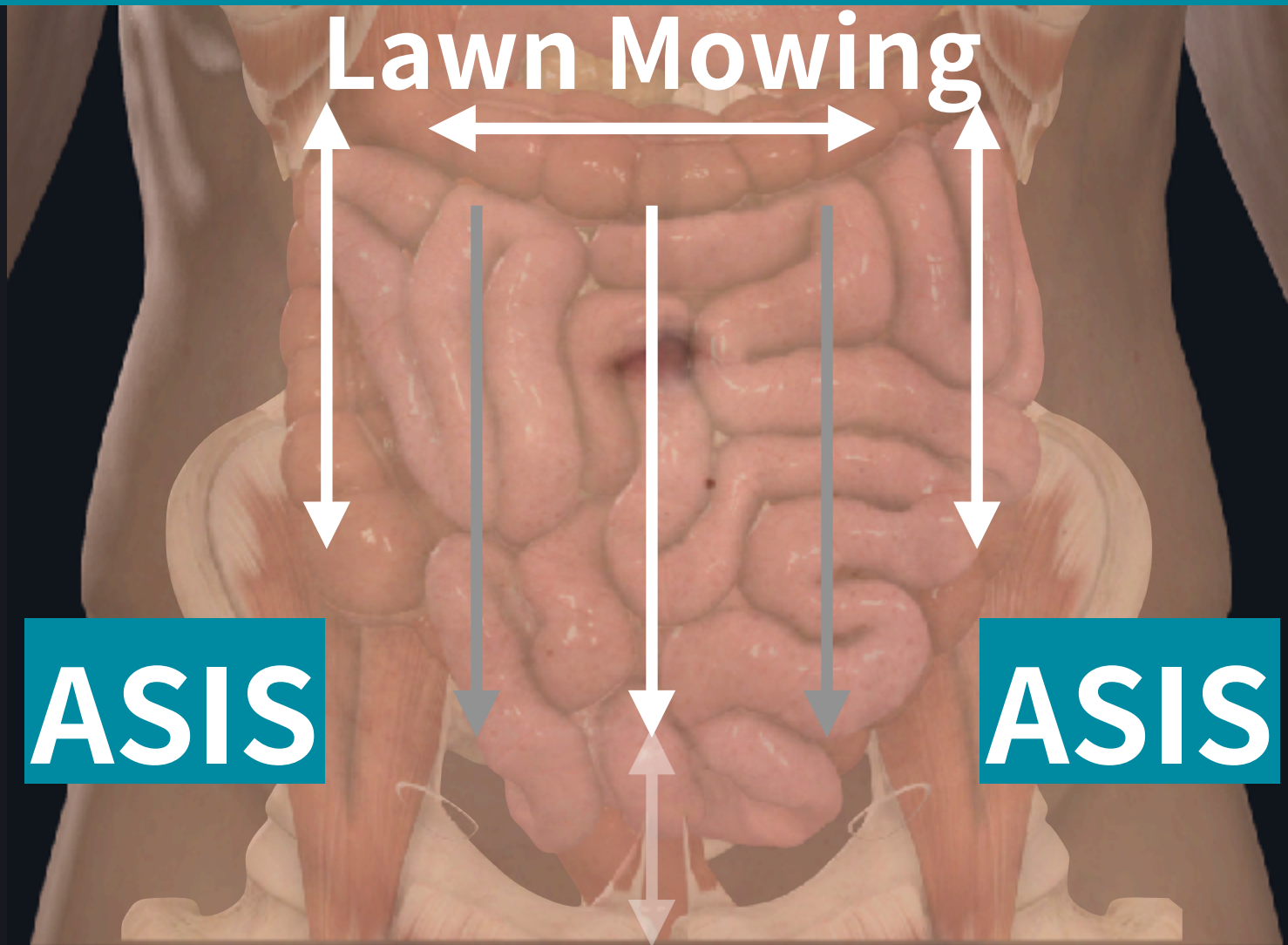
2D
HGen
Gn 55
C. 56
3/3/3

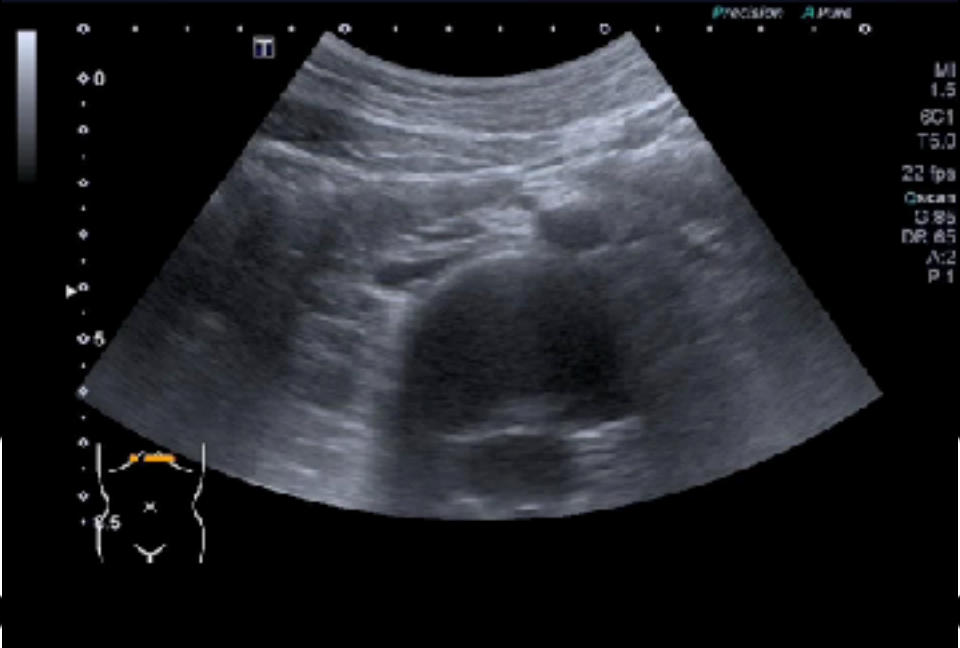


15.0cm

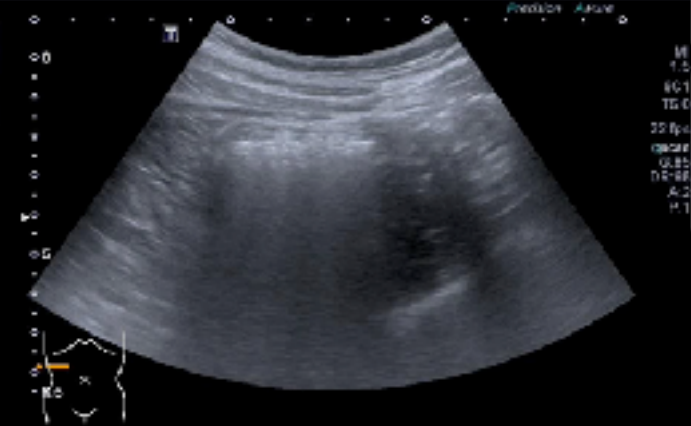FIXED PARTS FIRST

FOR SMALL & LARGE INTESTINE

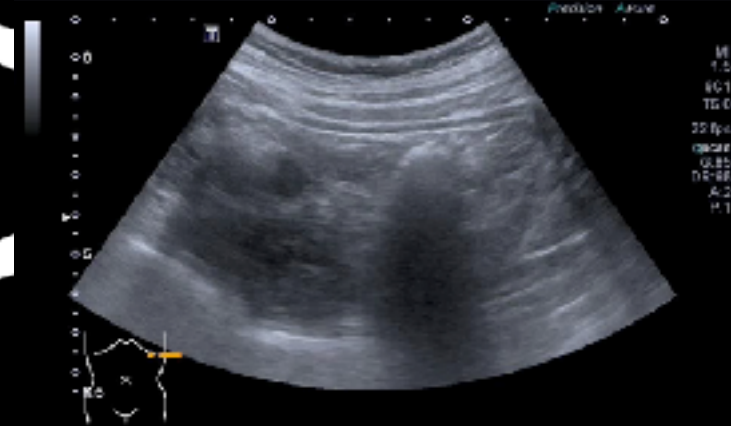




SHIMADA
Date: 01/20/2021
West Gardes Hospital
Abdomen
F: 23
1153
2021/06/27
2:25:42 AM



TOSHIBA
Date: 01/20/2021
West Gardes Hospital
Abdomen
F: 23
1153
2021/06/27
2:25:18 AM



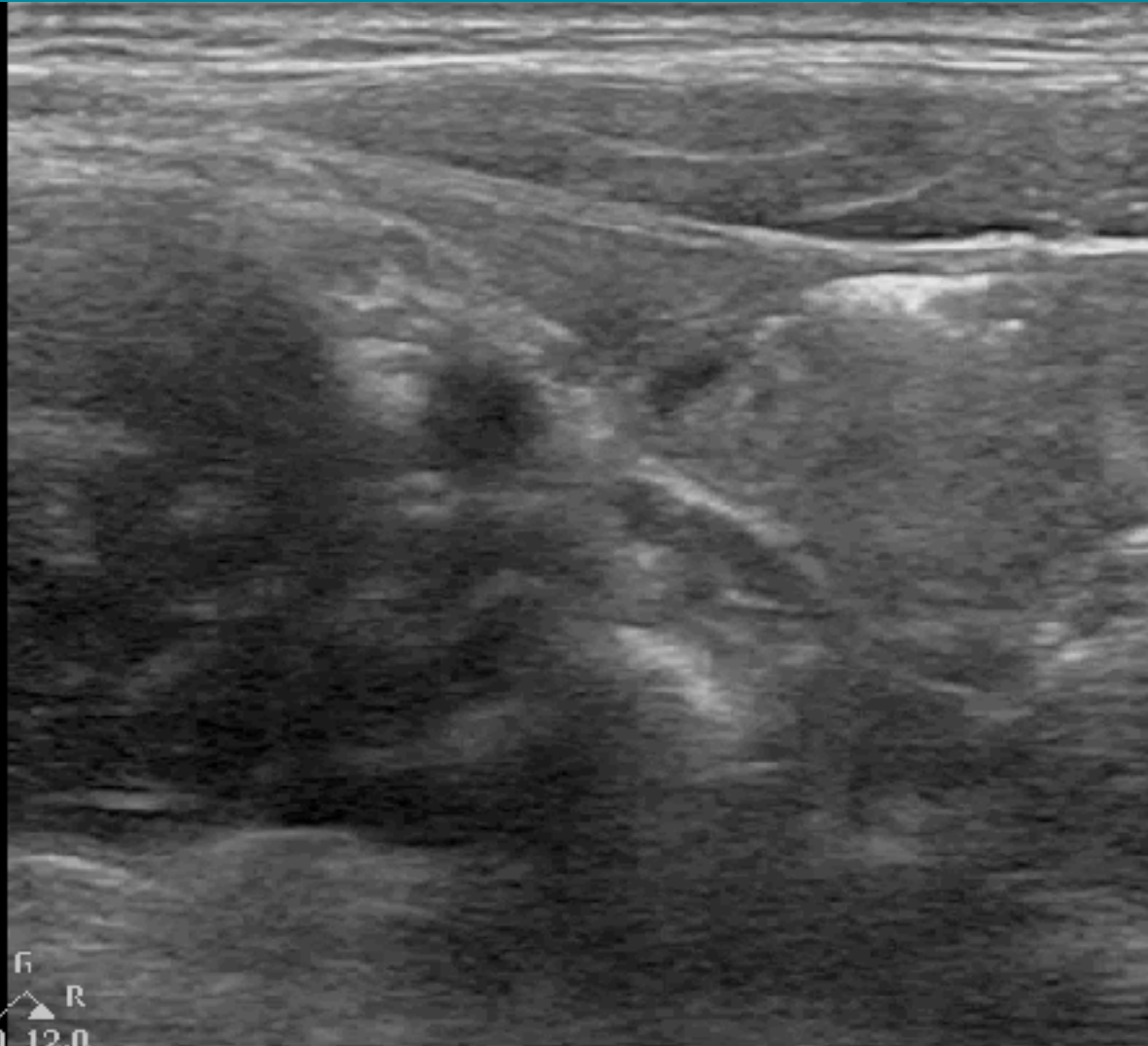
SMALL BOWEL / LYMPH NODES

Superficial
L12-3
46 Hz
3.5cm

2D
Res
Gn 100
C. 56
3 / 2 / 1

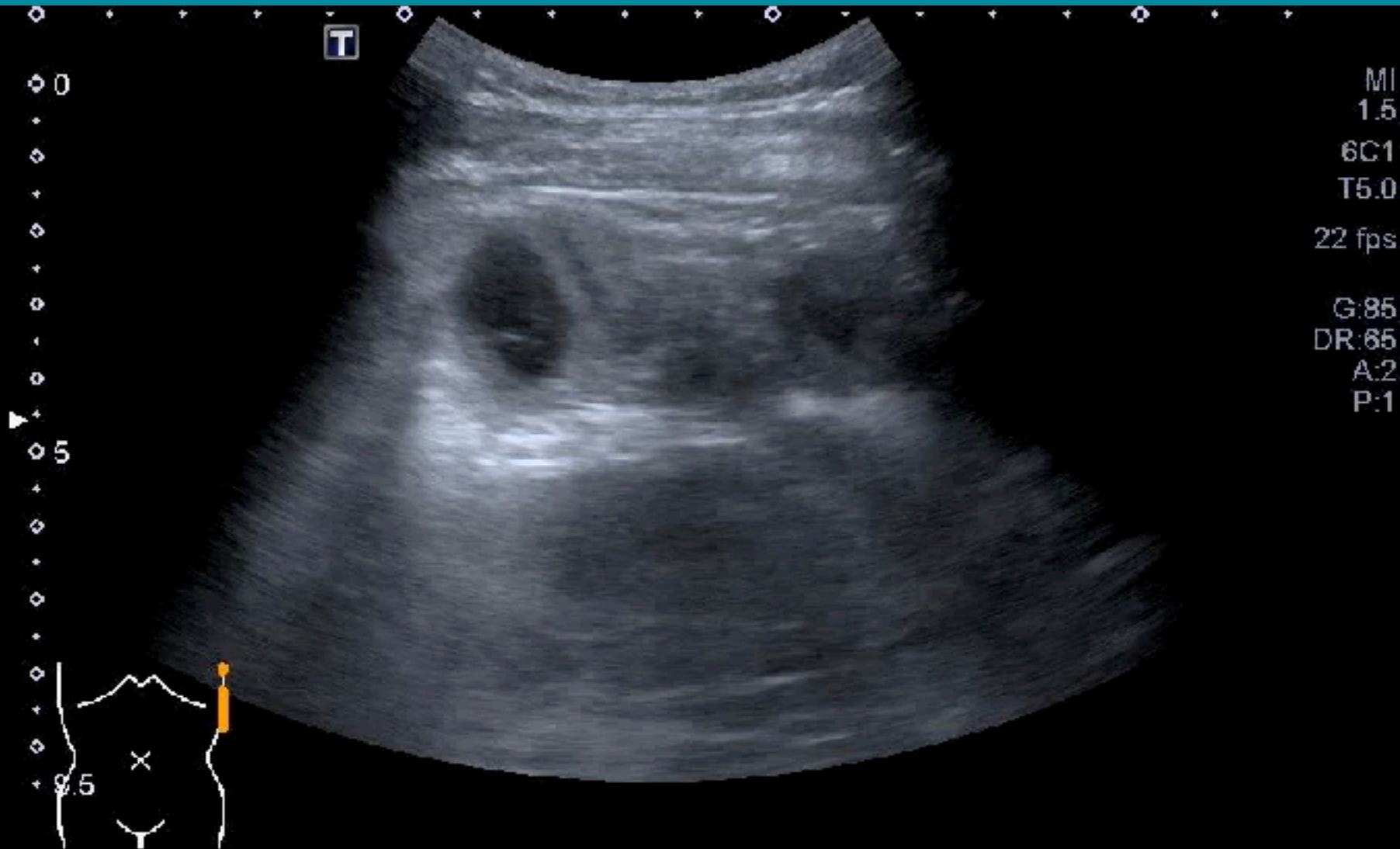


P R
3.0 12.0

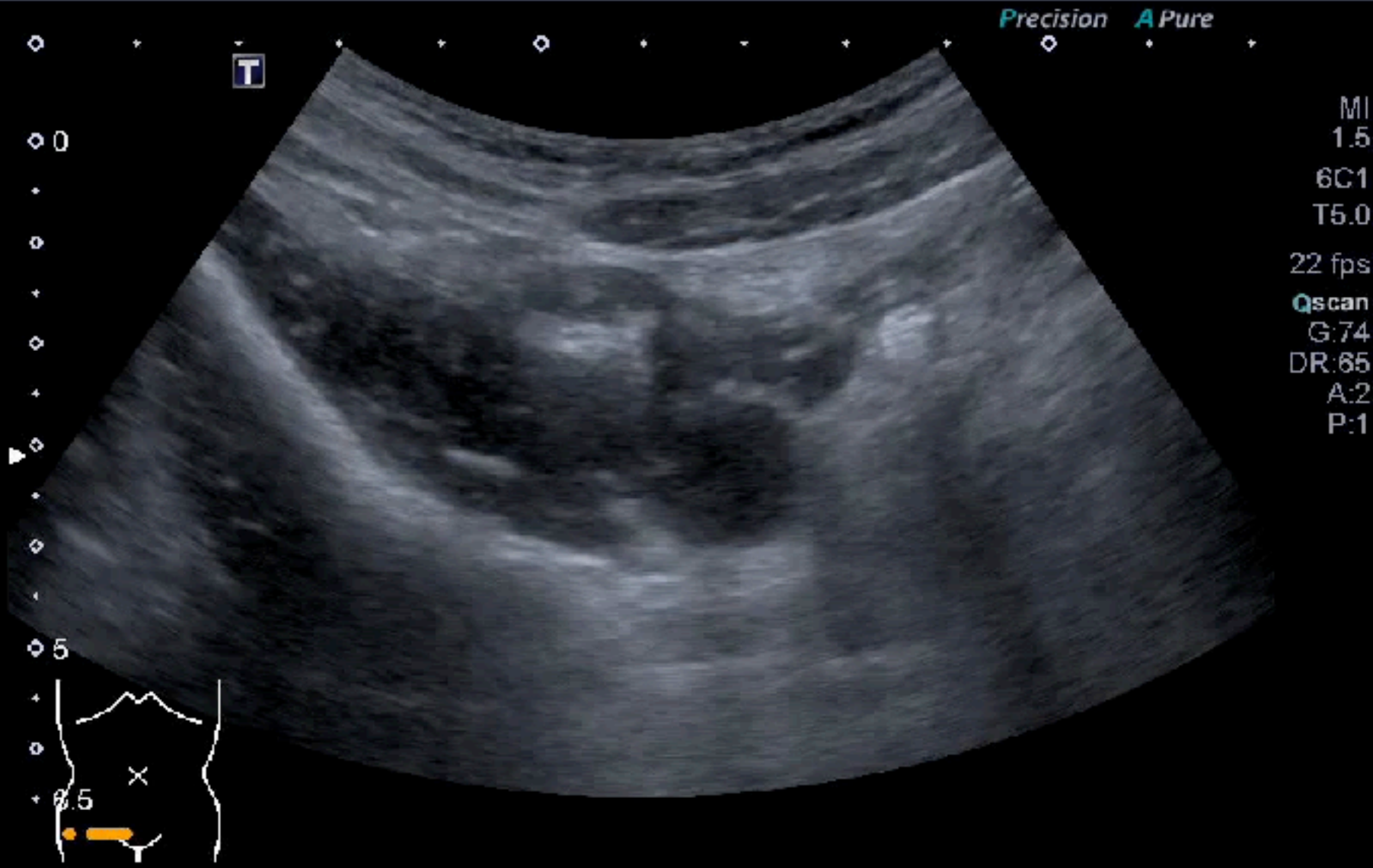


3.5cm

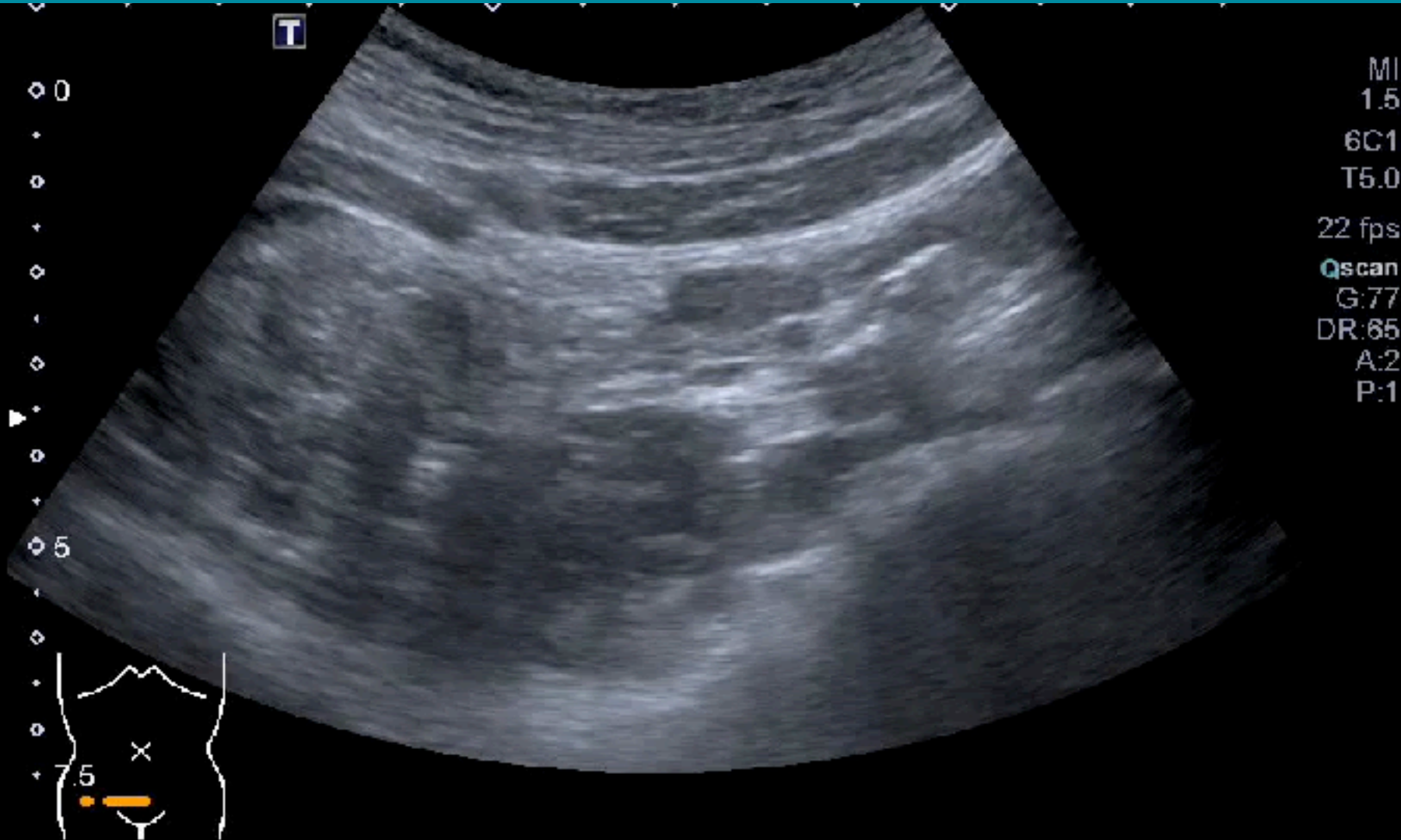
SMALL BOWEL



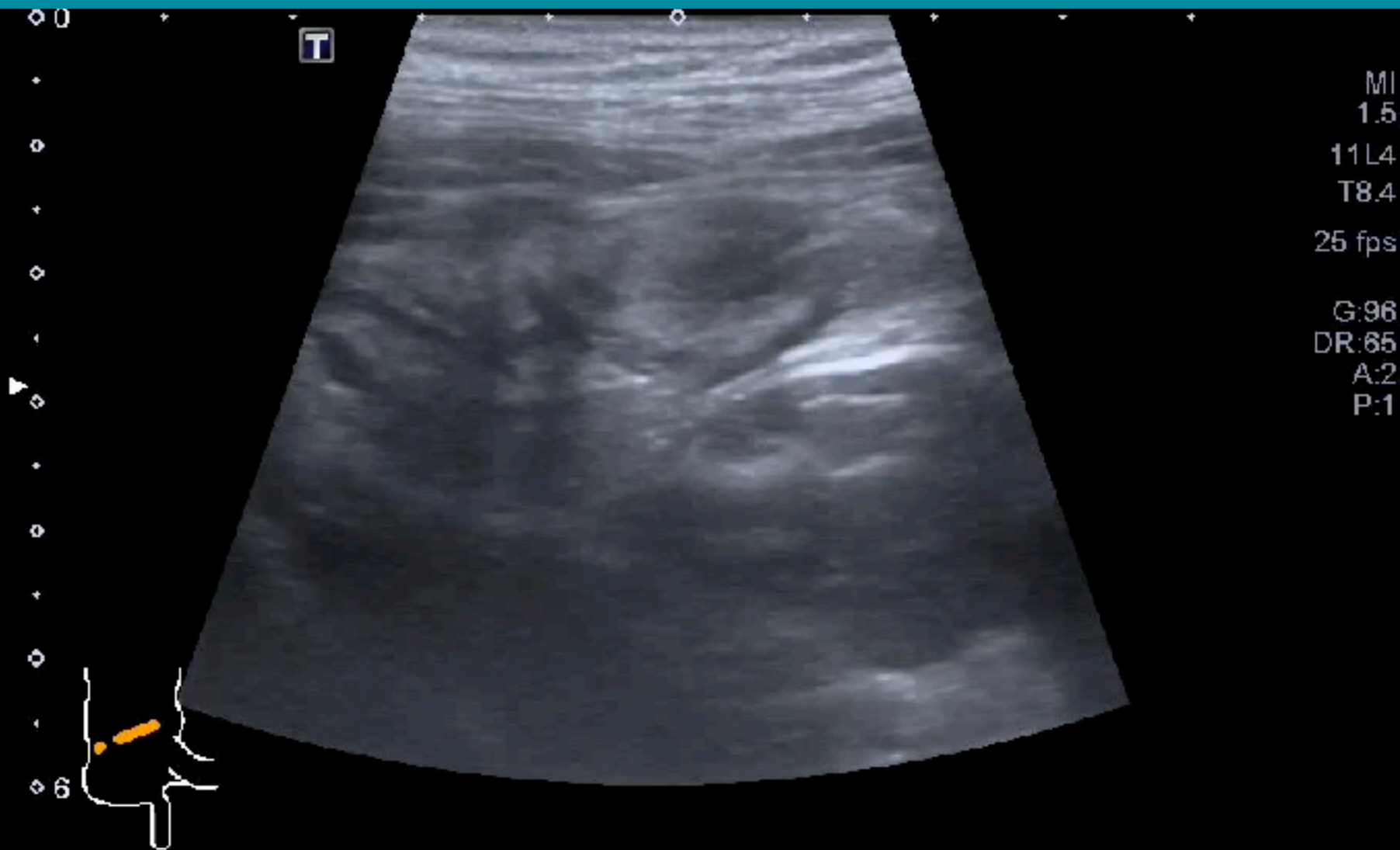
ILEOCECAL VALVE



APPENDIX



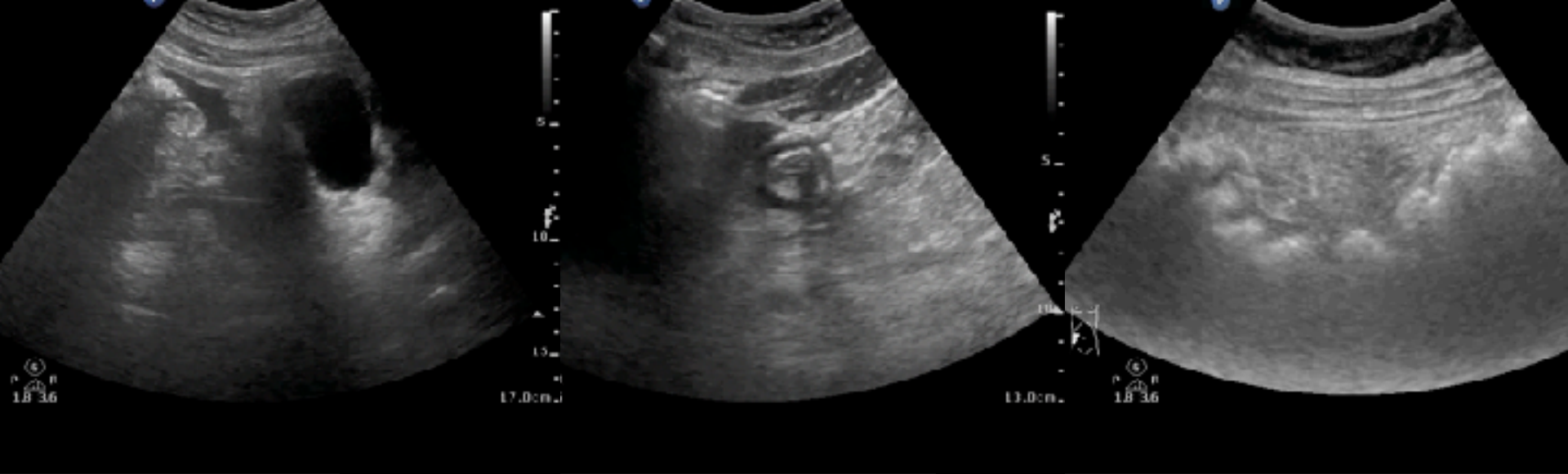
APPENDIX



GI ULTRASOUND: PATHOLOGIC PATTERNS



1. **Diameter** distended (3cm & 5cm)
2. **Unable to compress** during examination
3. **Wall** thickening (>5mm/1cm for stomach)
4. **Wall** stratification disappeared
5. **Luminal content** decreased at lesion sites
6. **Peristalsis** decreased
7. **Associated findings** (LN, Fat, ascites, abscess)



Ascites

Air

Fat

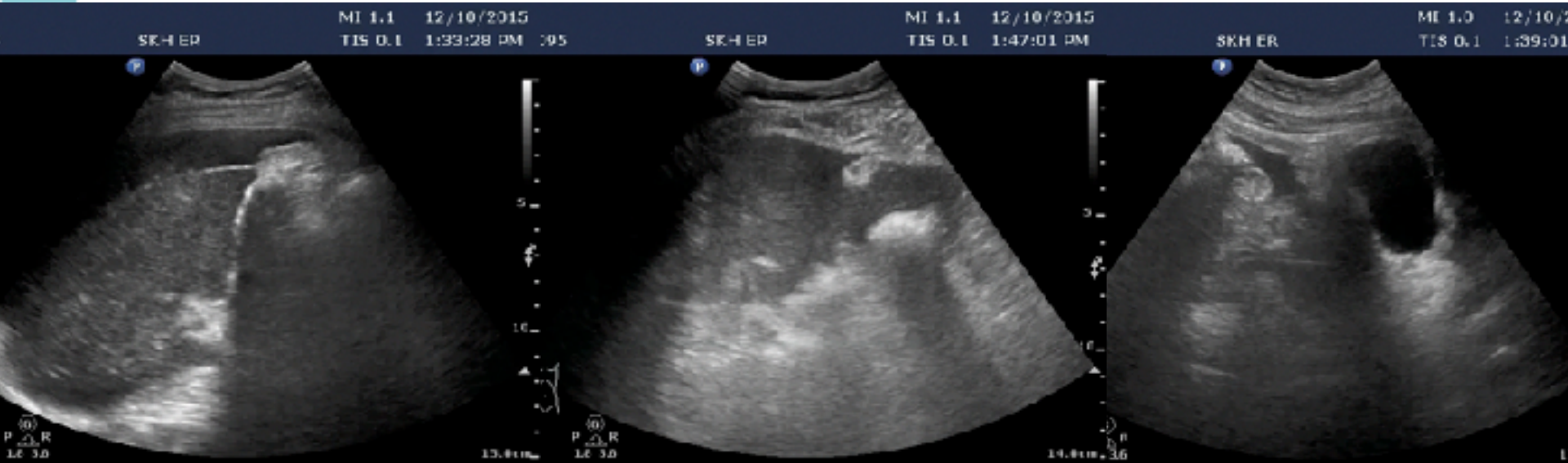RECOGNIZE PATTERNS

ASCITES (DIRTY/ECHOGENIC)

Around liver

Paracolic gutter

Pelvis

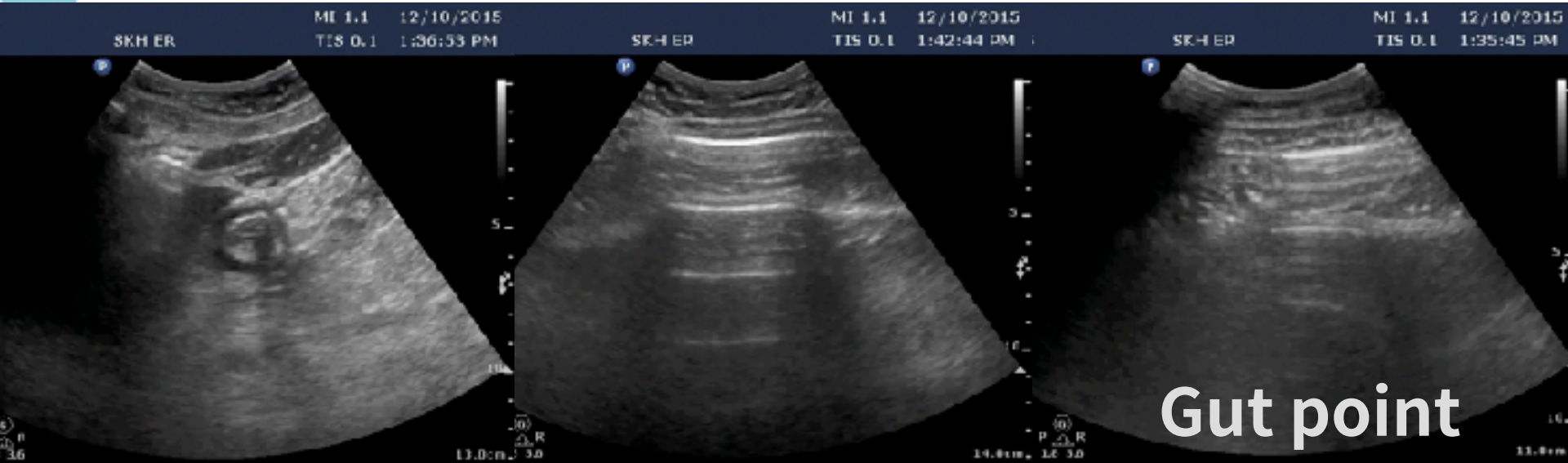


AIR (EXTRALUMINAL)

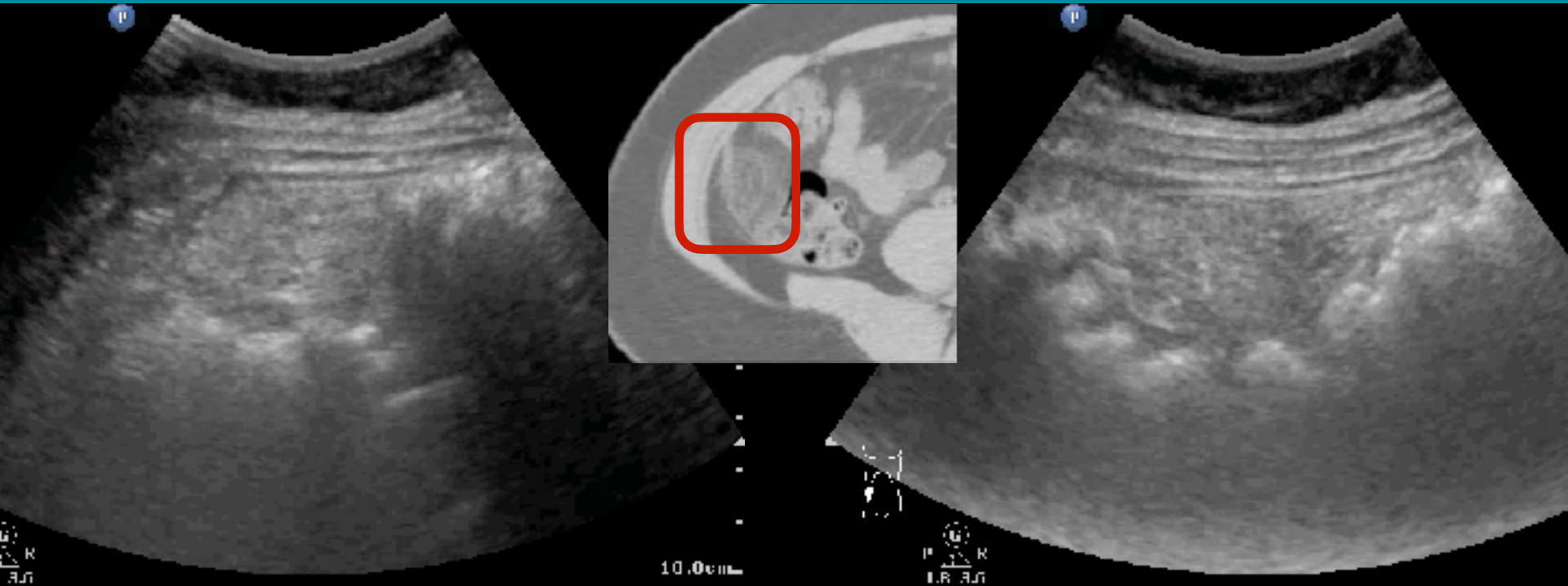
Liver surface

Curtain sign

EPSS

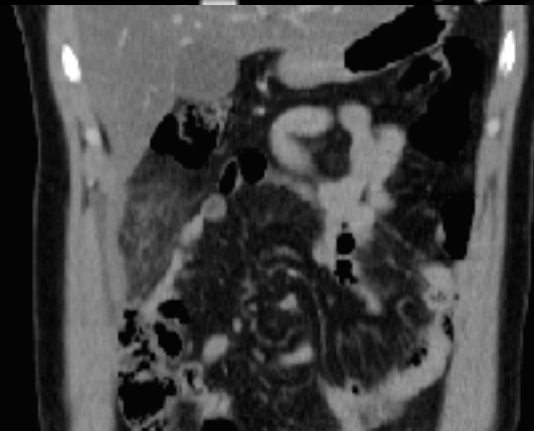
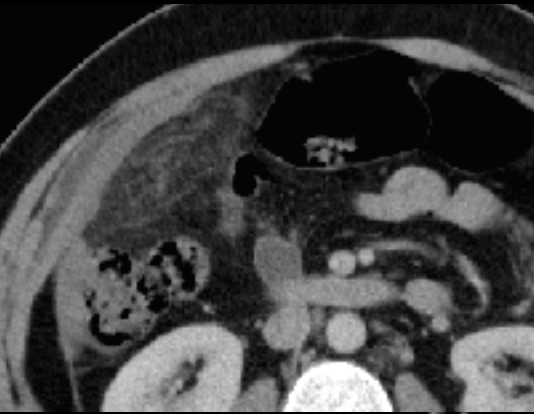

FAT (ECHOGENIC/INFLAMMATORY)

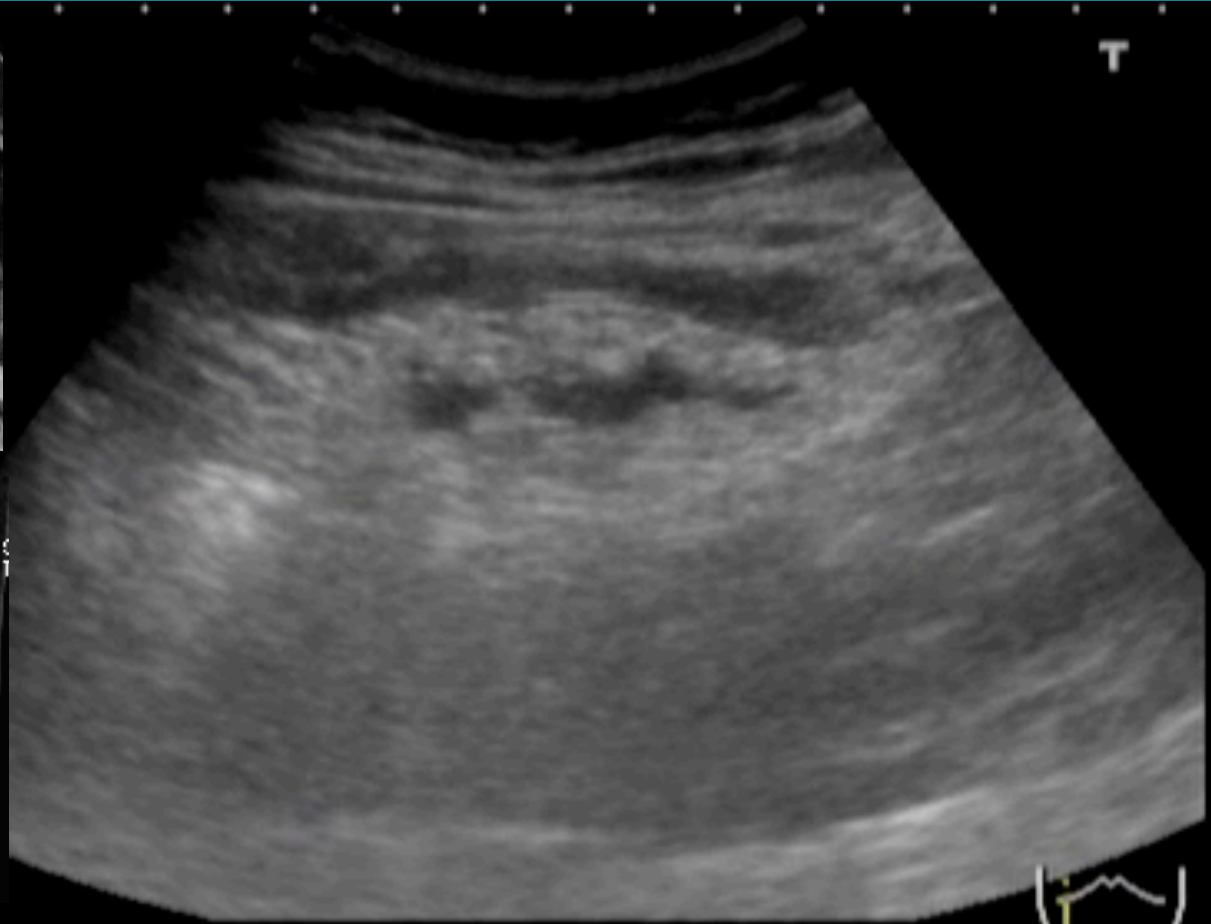

Epiploic appendagitis

FAT (ECHOGENIC/INFLAMMATORY)



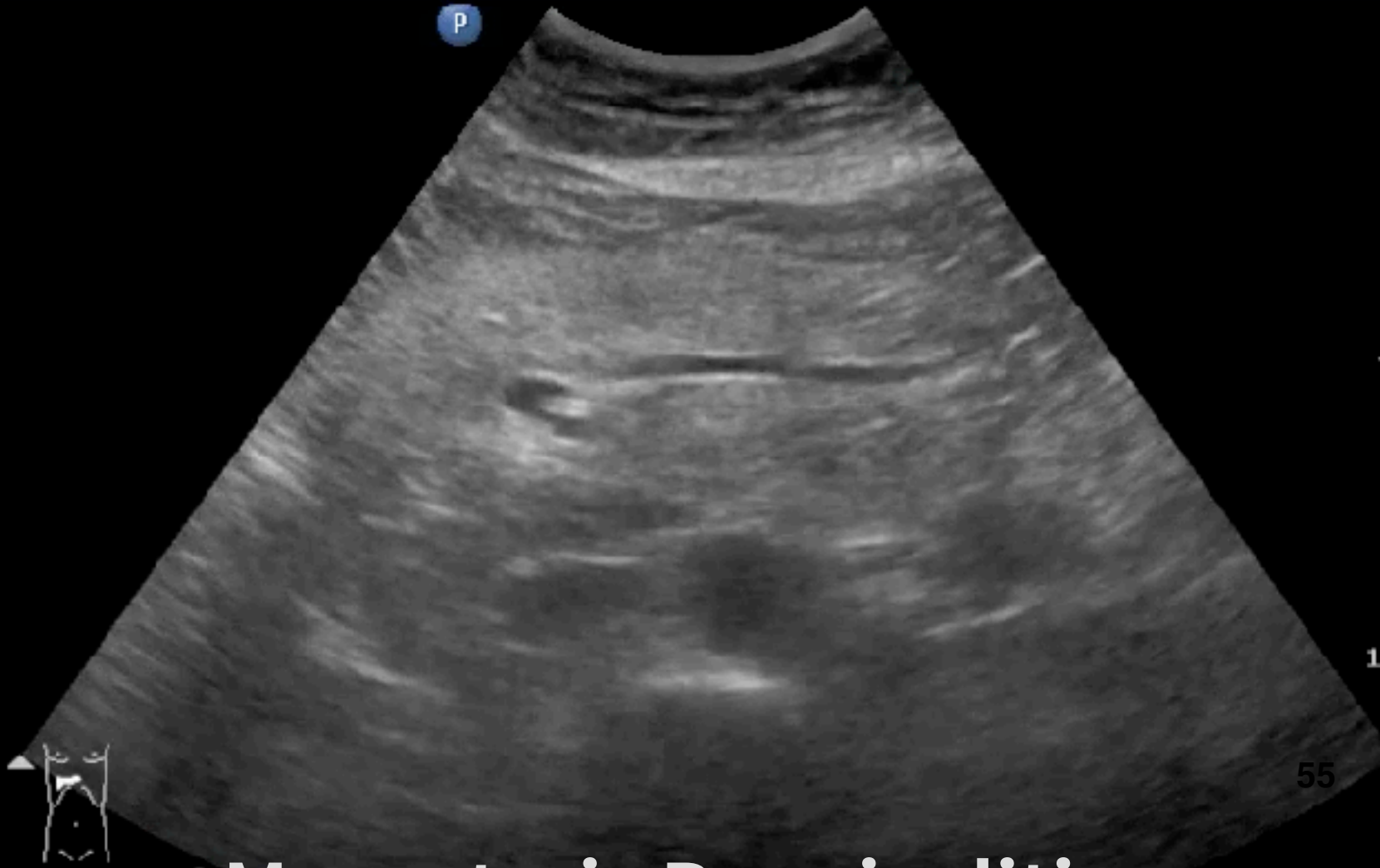0.2
TIB
0.2
TIC
0.8



Omentum infarction

FAT (ECHOGENIC/INFLAMMATORY)

d Gen2
-1
Hz
.0cm
Gen
n 62
56
/3/3



Mesenteric Panniculitis

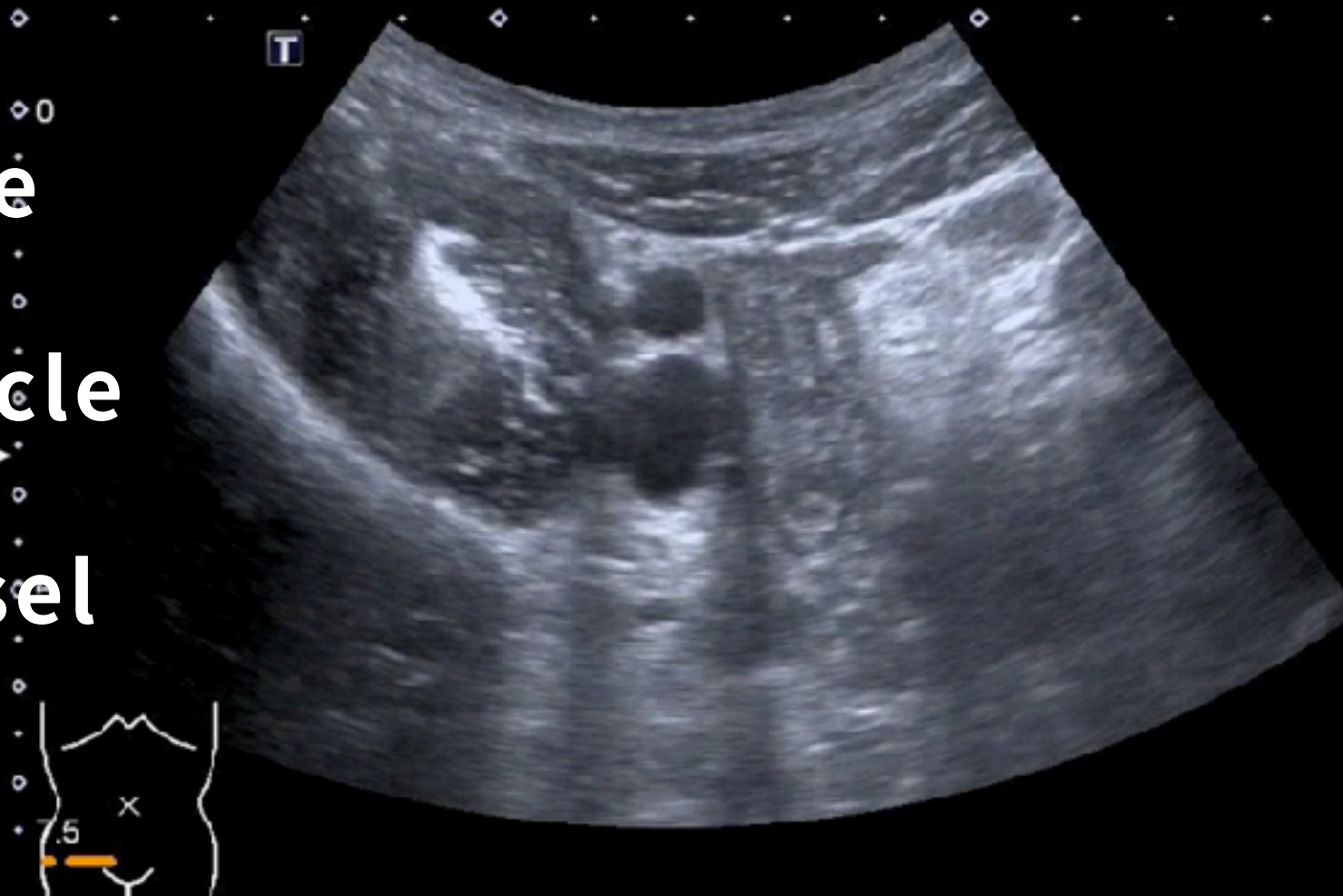
RLQ PAIN: ASIS (ANTERIOR SUPERIOR ILIAC SPINE)

POCUSAcademy©ChenKC

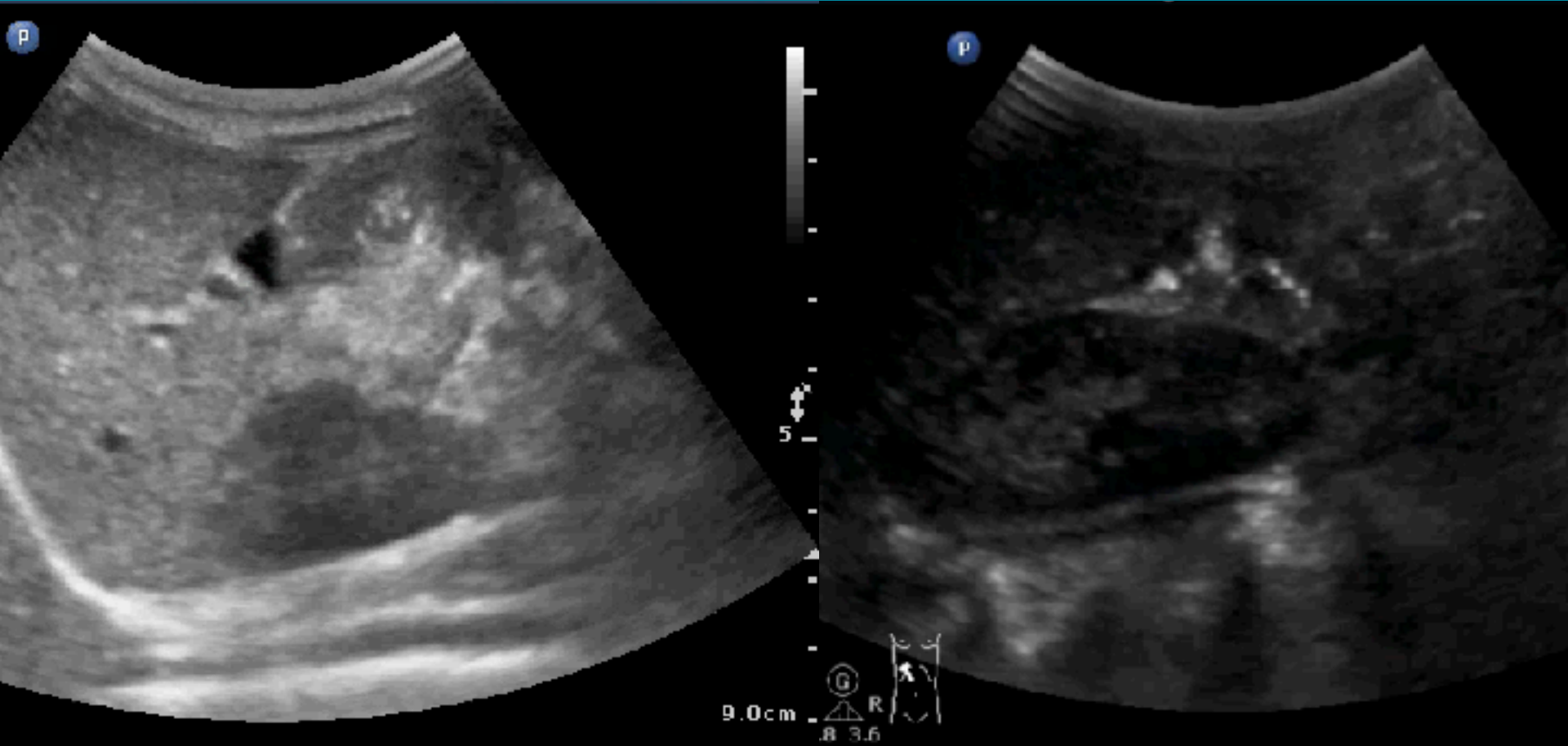
Bone

Muscle

Vessel



INTUSSUSUSCEPTION (PED)? RUQ SCAN FIRST



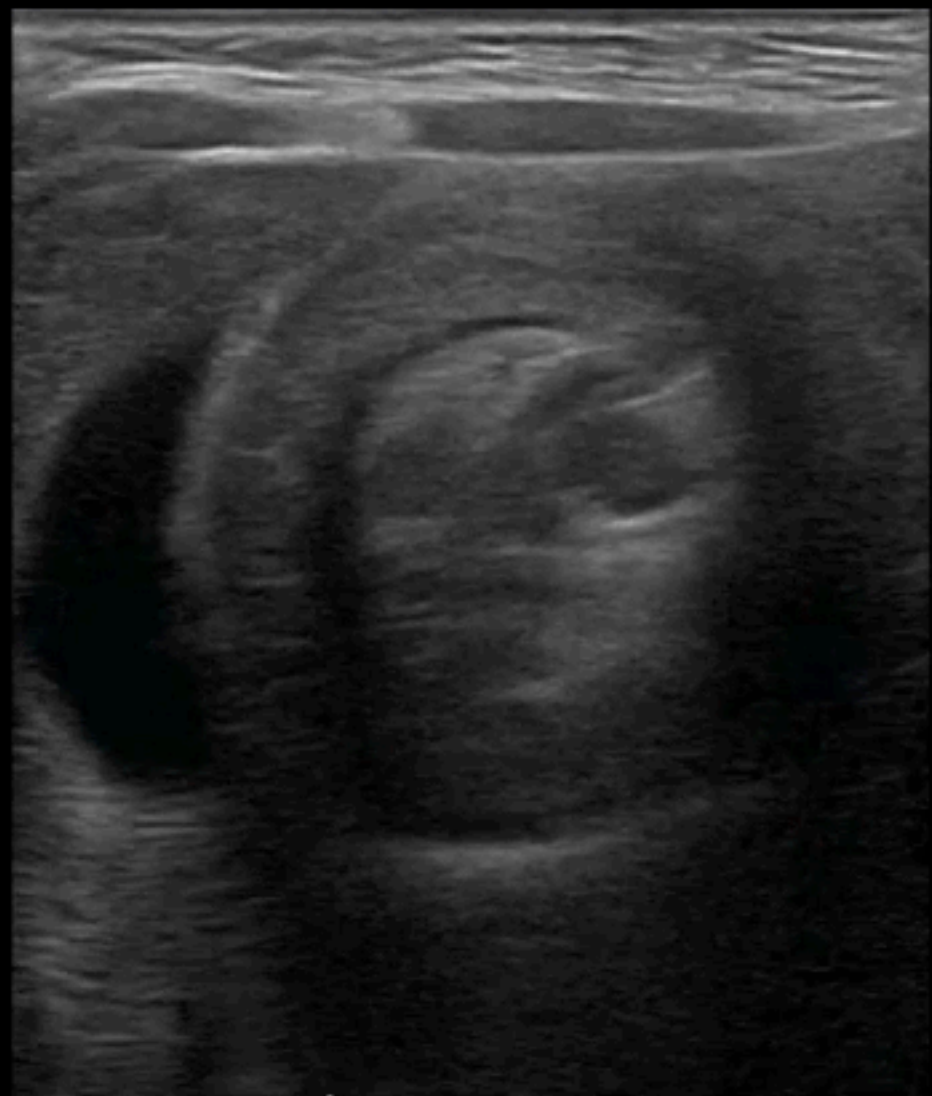Target sign

Pseudokidney sign

Superficial
L12-3
43 Hz
4.5cm

2D
Res
Gn 90
C 56
3/2/1

p



cranial

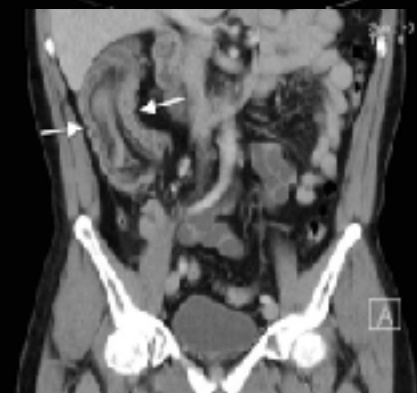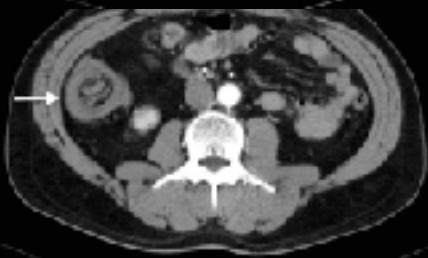
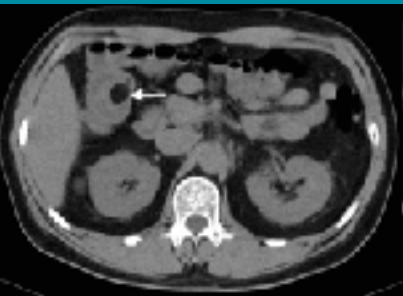
caudal



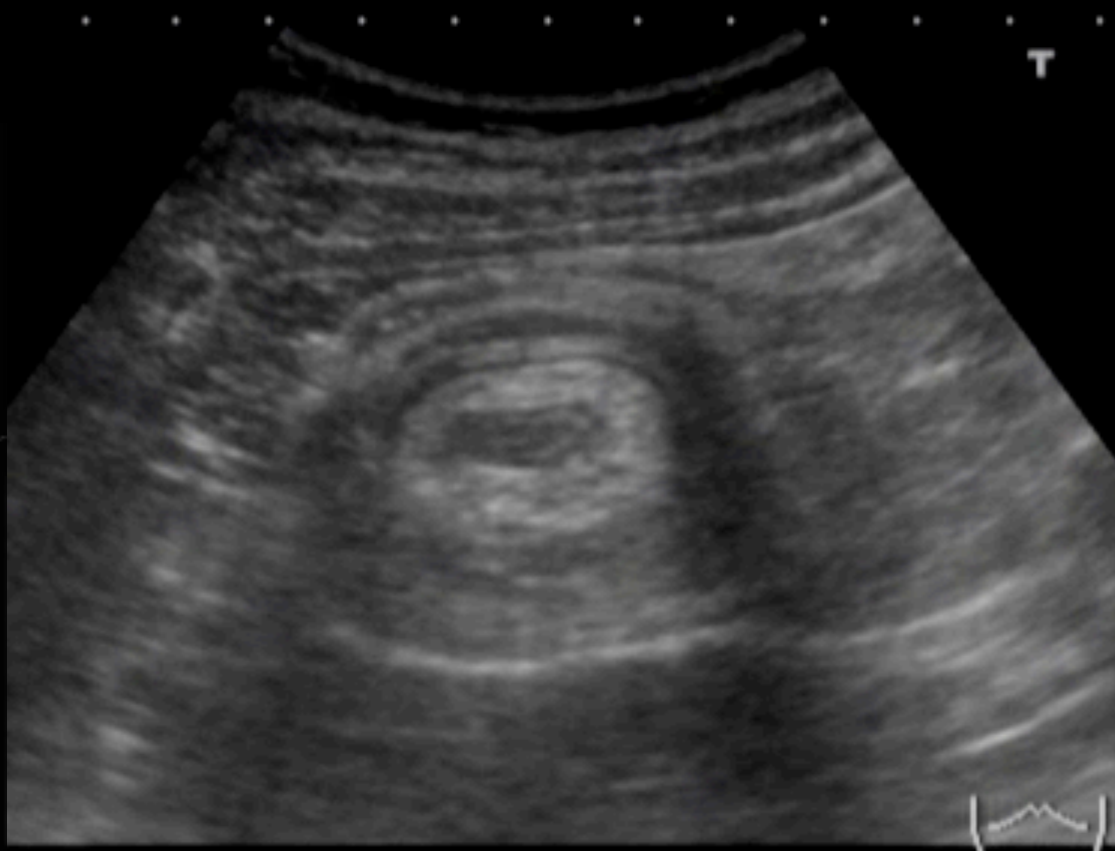
RUQ sagittal scan

4.5cm

51M, ABD PAIN AND TARRY STOOL



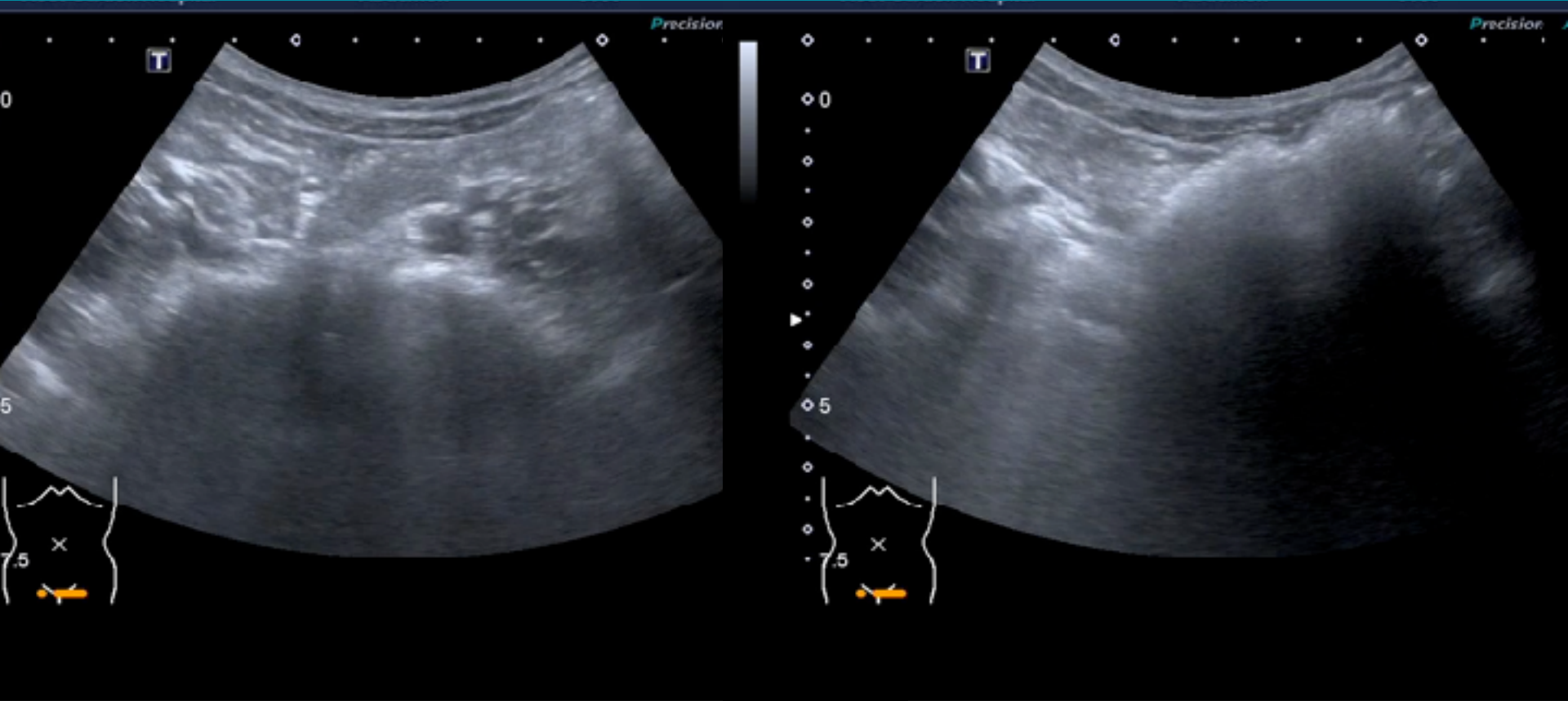
LI KONG MEMORIAL HOSPITAL LIVER 2014/05/09 08:47:12AM



P100
6C3
4.2
24fps
DR70
2DG
94

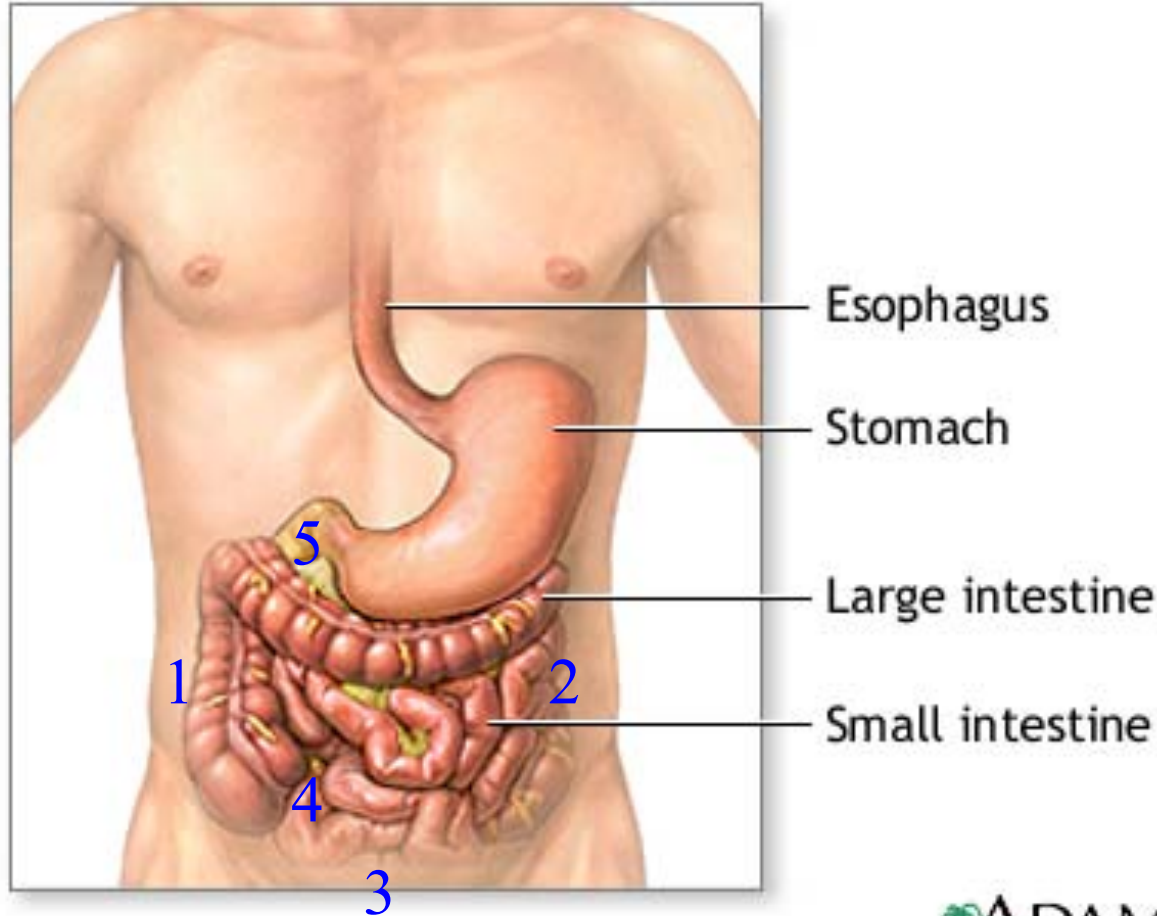
TIB
0.2
TIC
0.8

7F, INTERMITTENT ABDOMINAL PAIN



Transient intussusception

BISECTION APPROXIMATION METHOD FOR GI OBSTRUCTION



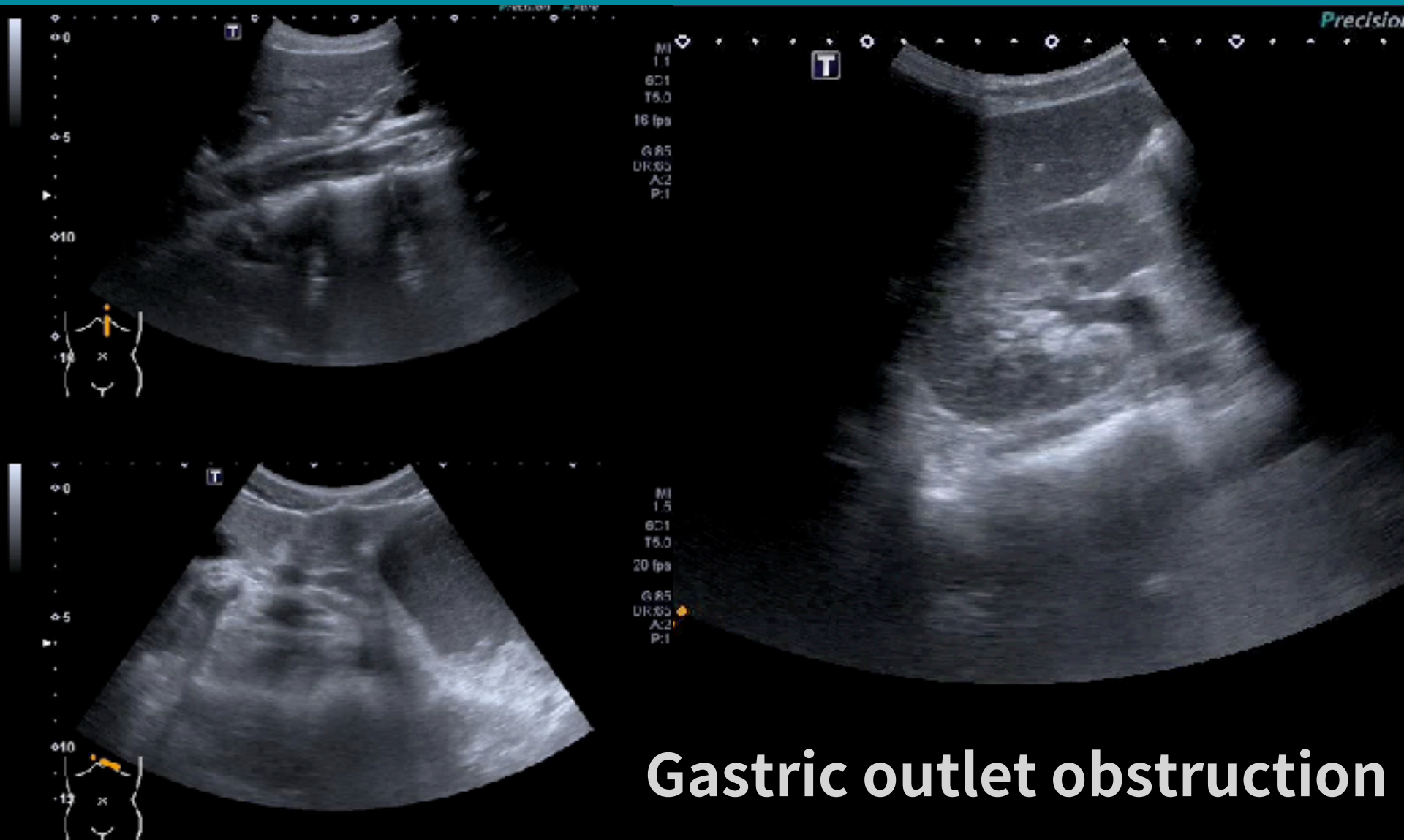
ADAM.

[Hepatogastroenterology. 2006;53:547-51.](#)

BISECTION APPROXIMATION METHOD FOR GI OBSTRUCTION

Location of US examination (From 1 – 5)					Possible lesion site
1. A-C	2. D-C	3. Rectum	4. IC region	5. Gastric outlet or duodenum	
Dilated	Collapsed				From 1-2
Dilated	Dilated	Collapsed			From 2-3
Collapsed	-	-	Dilated		From 1-4
Collapsed	-	-	Collapsed	Dilated	From 4-5
Collapsed	-	-	Collapsed	Collapsed	Above 5

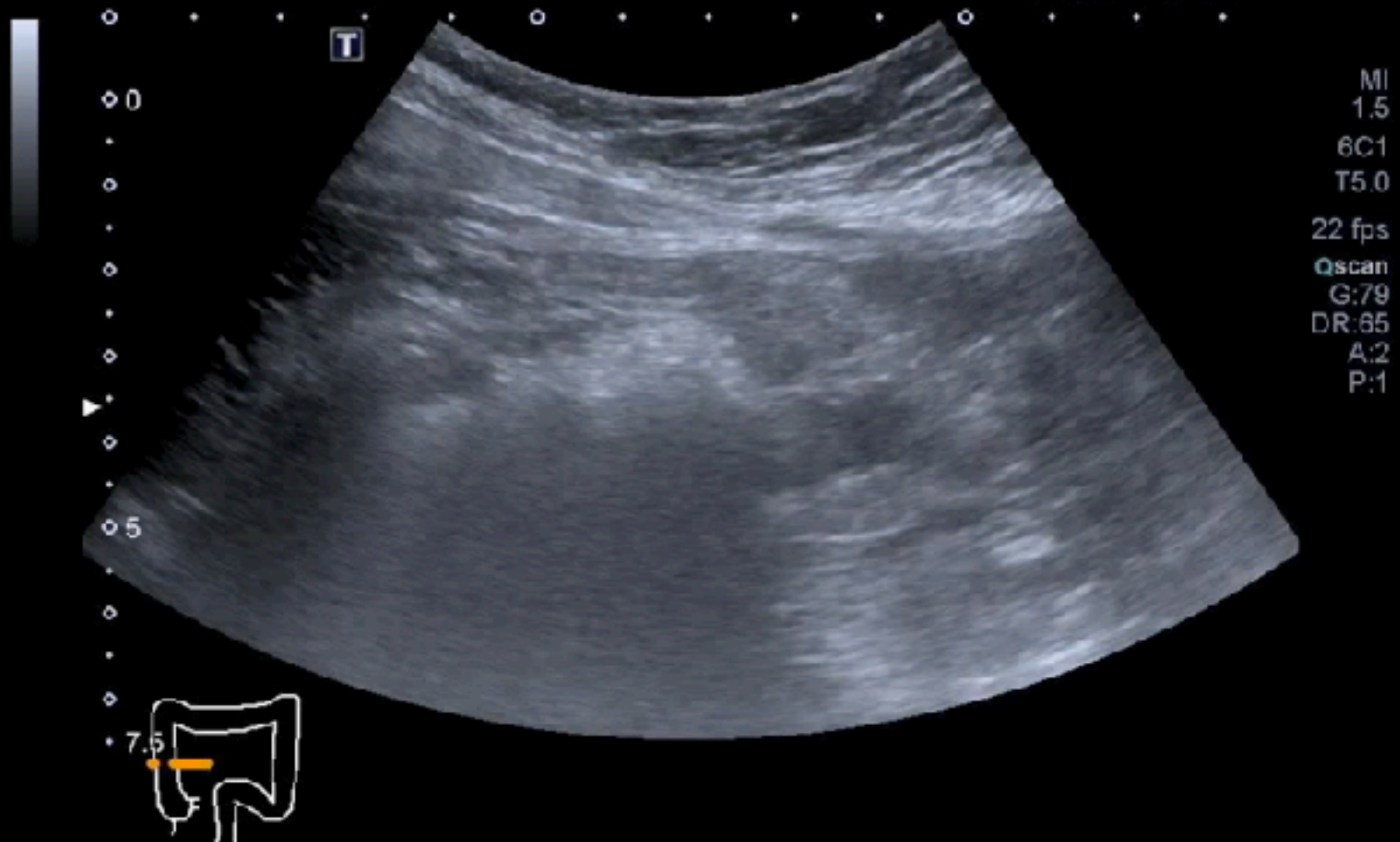
M/19, EPIGASTRIC PAIN & PERSISTENT VOMITING

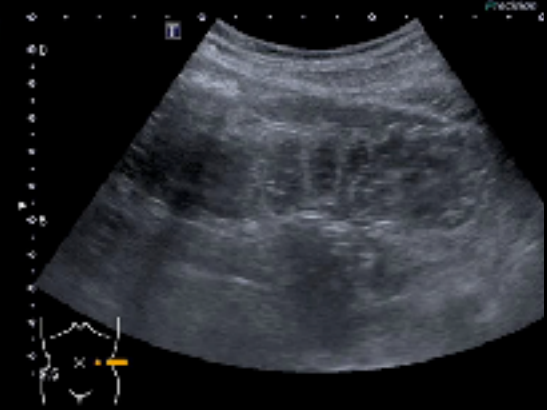


Gastric outlet obstruction

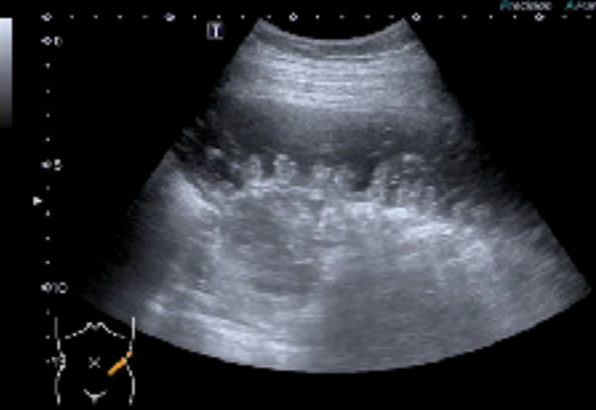
BOWEL OBSTRUCTION ? BAM METHOD FIRST

POCUSAcademy©ChenKC

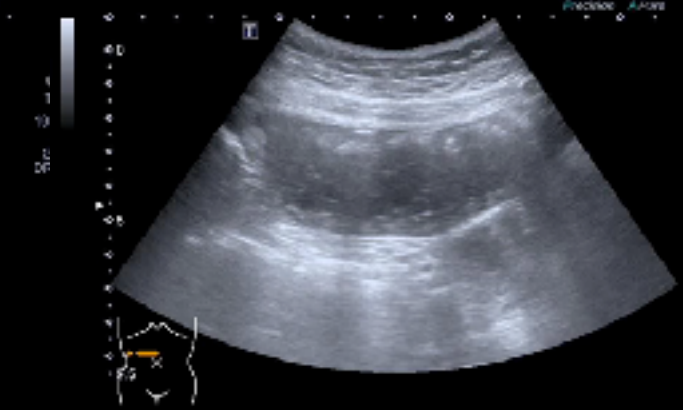




To & Fro

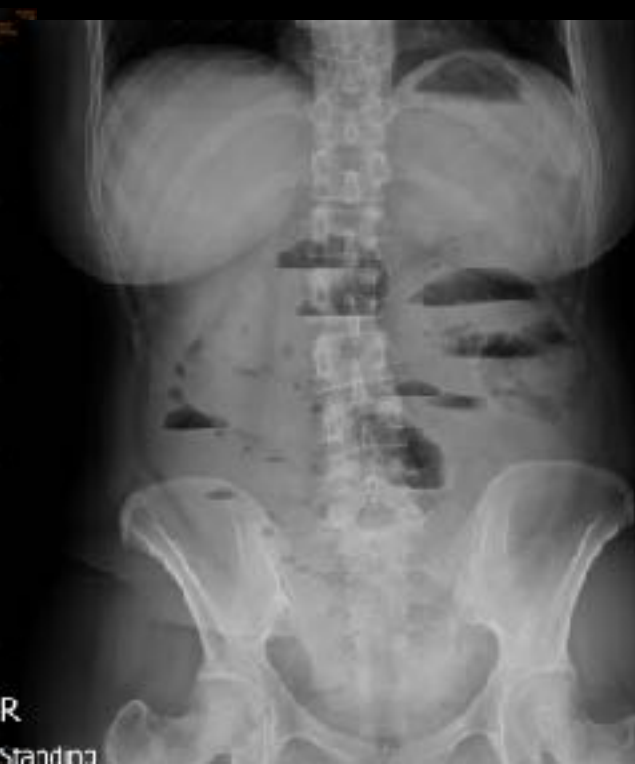
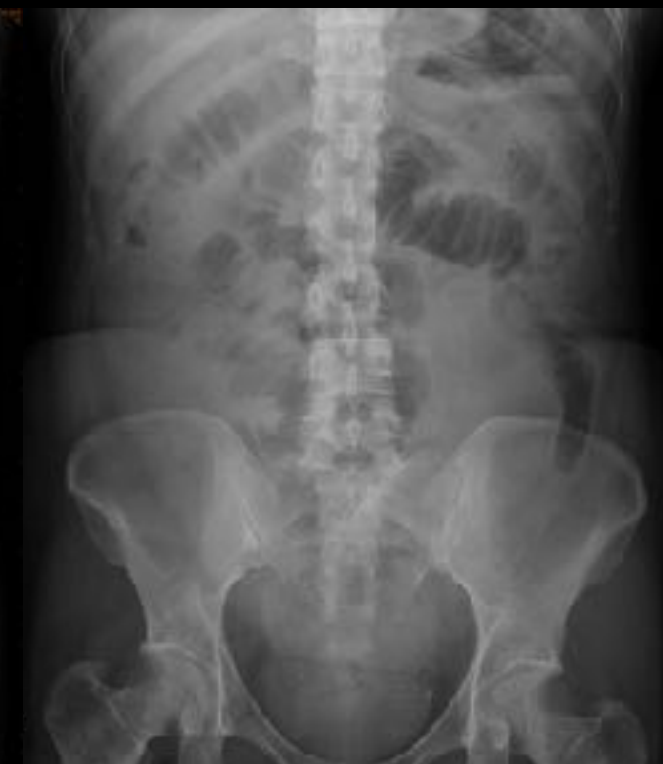
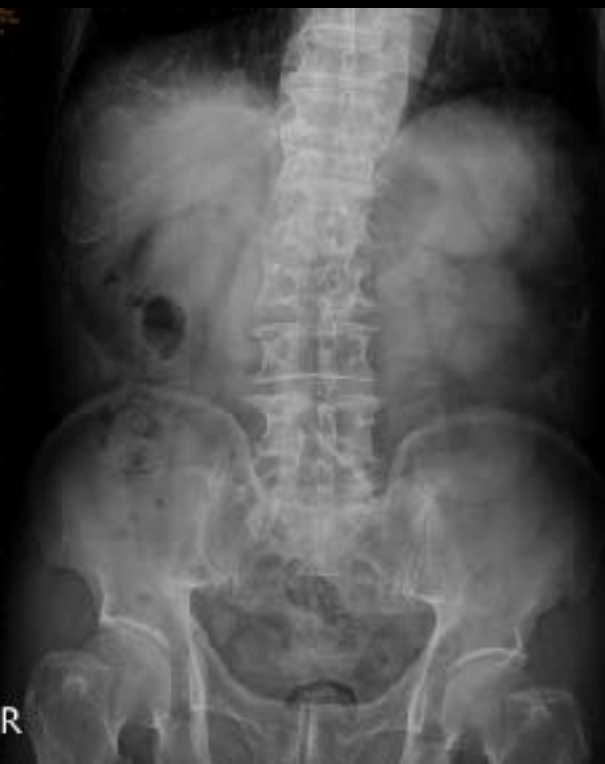Keyboard



String-of-beads

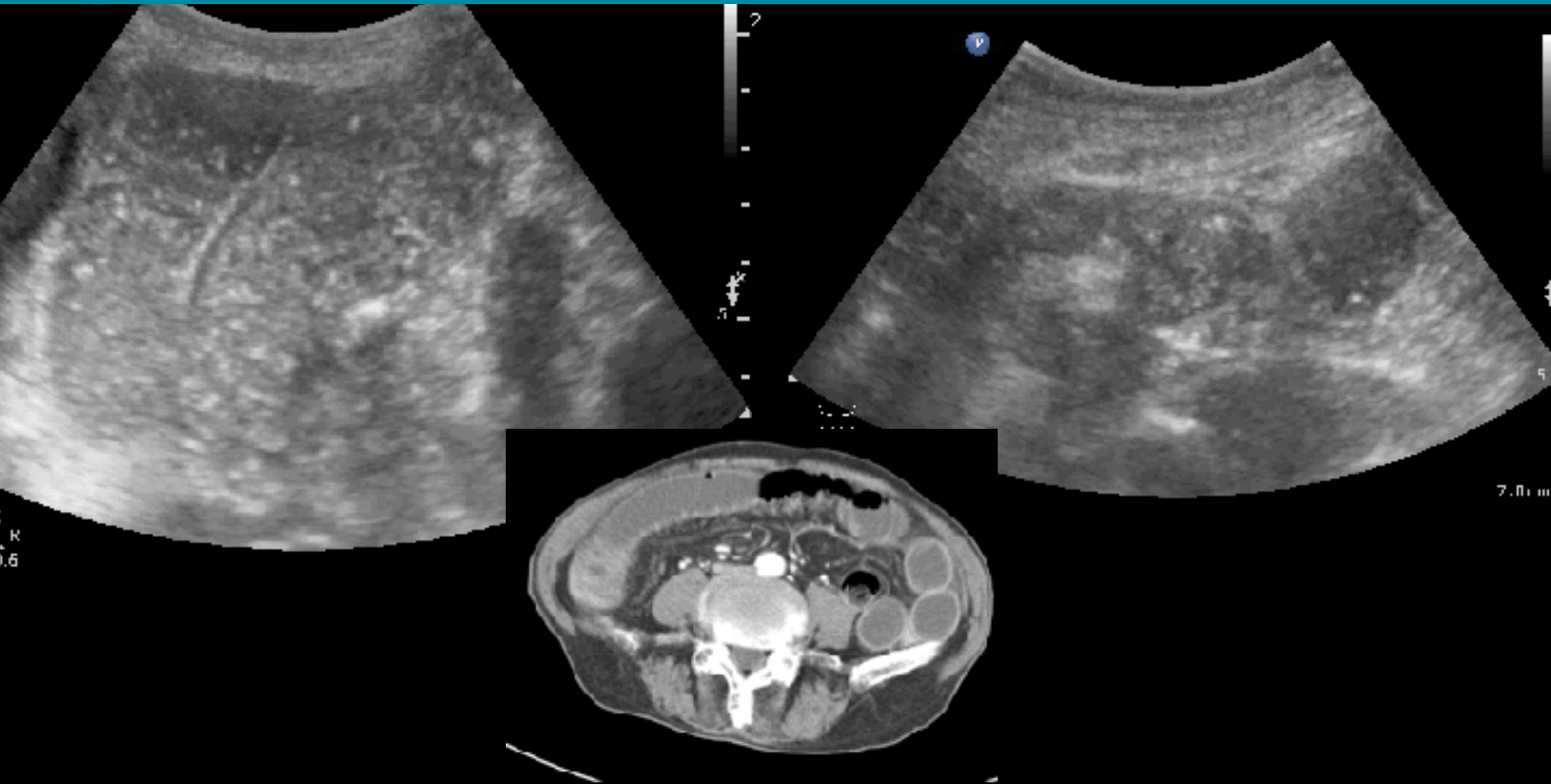
Extremely helpful for gasless bowel obstruction



R

R
Standing

90M, RLQ PAIN 2D >> BAM METHOD



Cecal tumor

US FOR SBO DIAGNOSIS: LR + > 20

Cottlieb M, et al. AJEM 2017

TAKE-HOME MESSAGE

For trained operators, ultrasonography possesses sensitivity and specificity comparable to that of abdominal computed tomography (CT) for the diagnosis of small bowel obstruction.

Ultrasonographic Diagnosis of SBO	Specificity (95% CI)	Sensitivity (95% CI)	+LR (95% CI)	-LR (95% CI)	SROC AUC (95% CI)
Overall	0.97 (0.88-0.99)	0.92 (0.89-0.95)	27.5 (7.7-98.4)	0.08 (0.06-0.11)	0.96 (0.94-0.97)
ED	0.96 (0.86-0.99)	0.93 (0.89-0.95)	21.1 (6.5-68.9)	0.08 (0.05-0.12)	0.96 (0.94-0.97)
Non-ED	0.99 (0.60-1.00)	0.92 (0.85-0.96)	70.8 (1.5-3279.7)	0.08 (0.05-0.15)	0.96 (0.94-0.98)

CI, Confidence interval; +LR, positive likelihood ratio; -LR, negative likelihood ratio; SBO, small bowel obstruction; SROC, summary receiver operating characteristic; AUC, area under the curve.

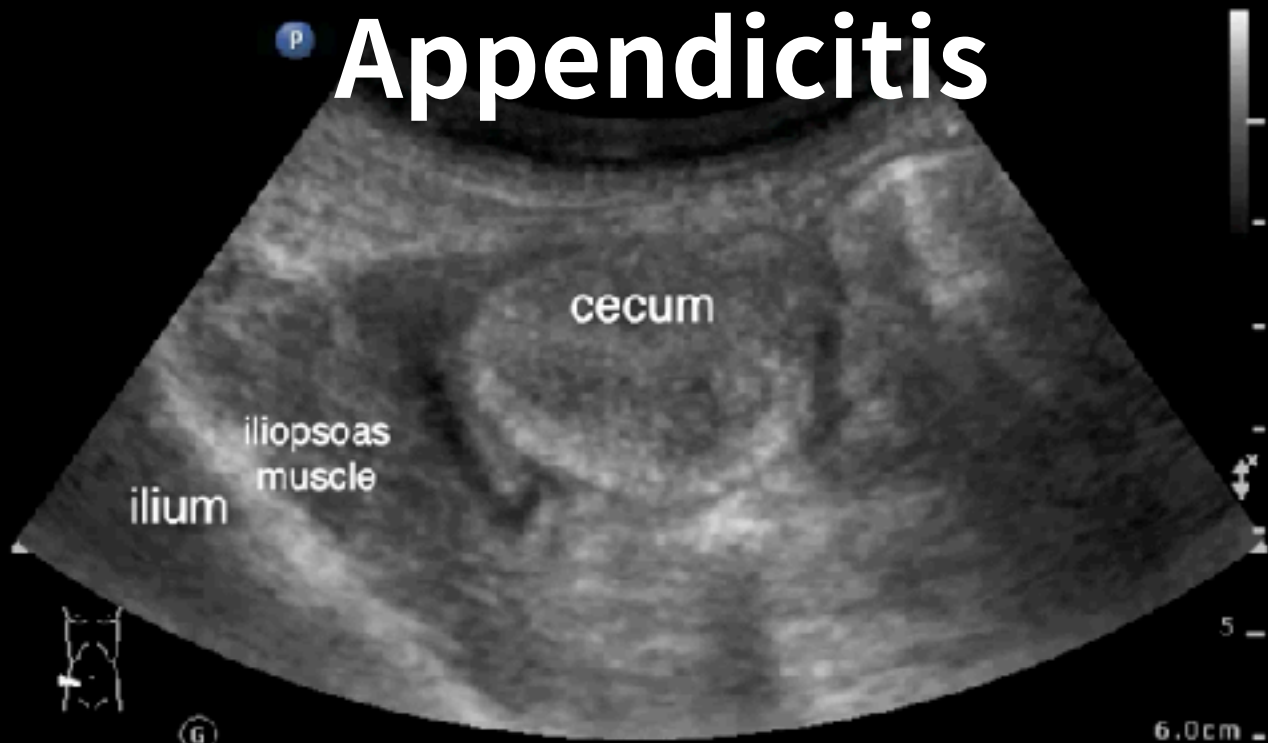
LANDMARK / TRANSVERSE / PAIN-ORIENTED

PHILIPS IFF 20628754 POCUSAcademy©ChenKC 11/7/2018 9:04:11 AM

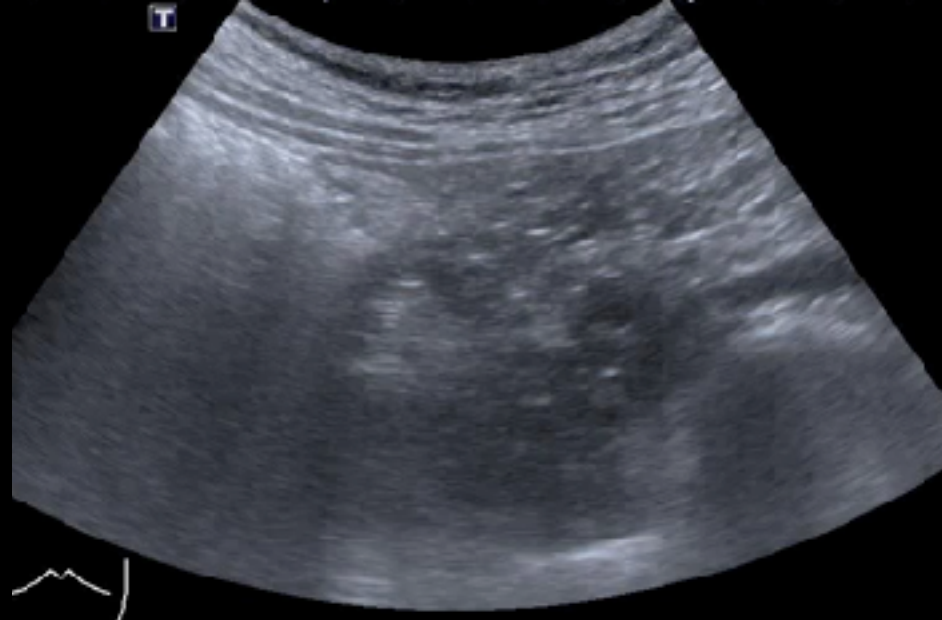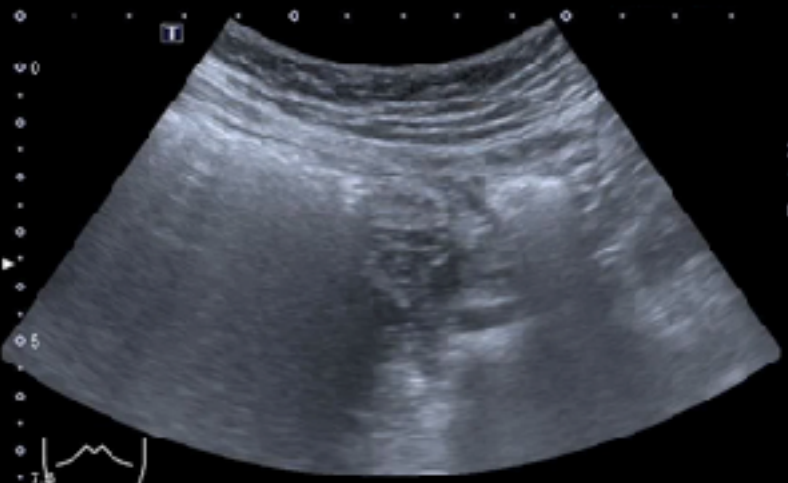Abd Gen2
C5-1
58 Hz
6.0cm

2D
HGen
Gn 60
C 56
3 / 3 / 3

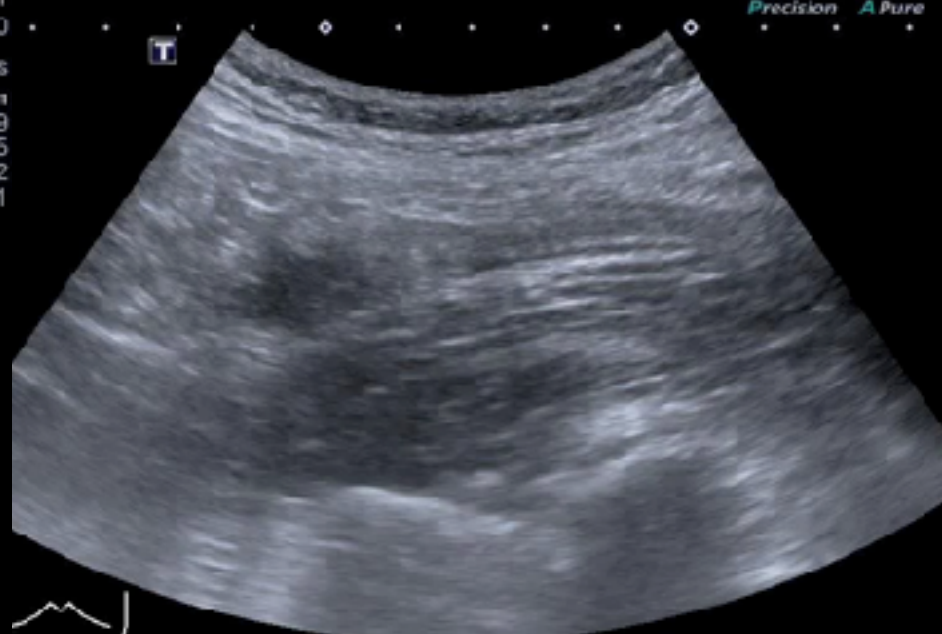
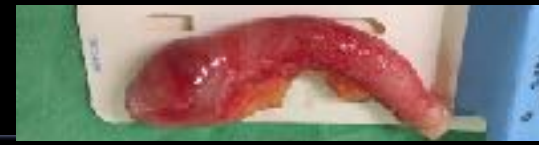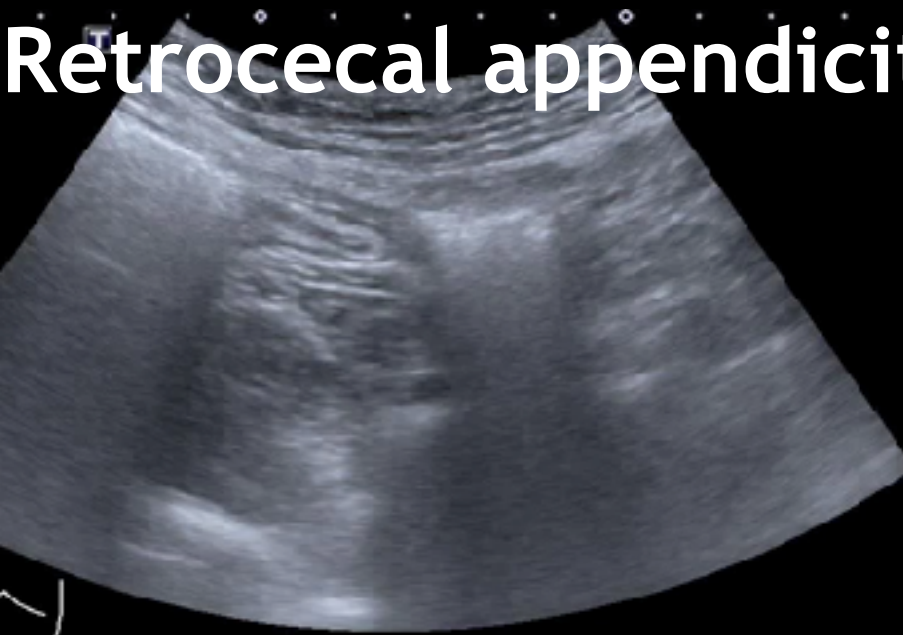
P Appendicitis



Transverse scan over RLQ area

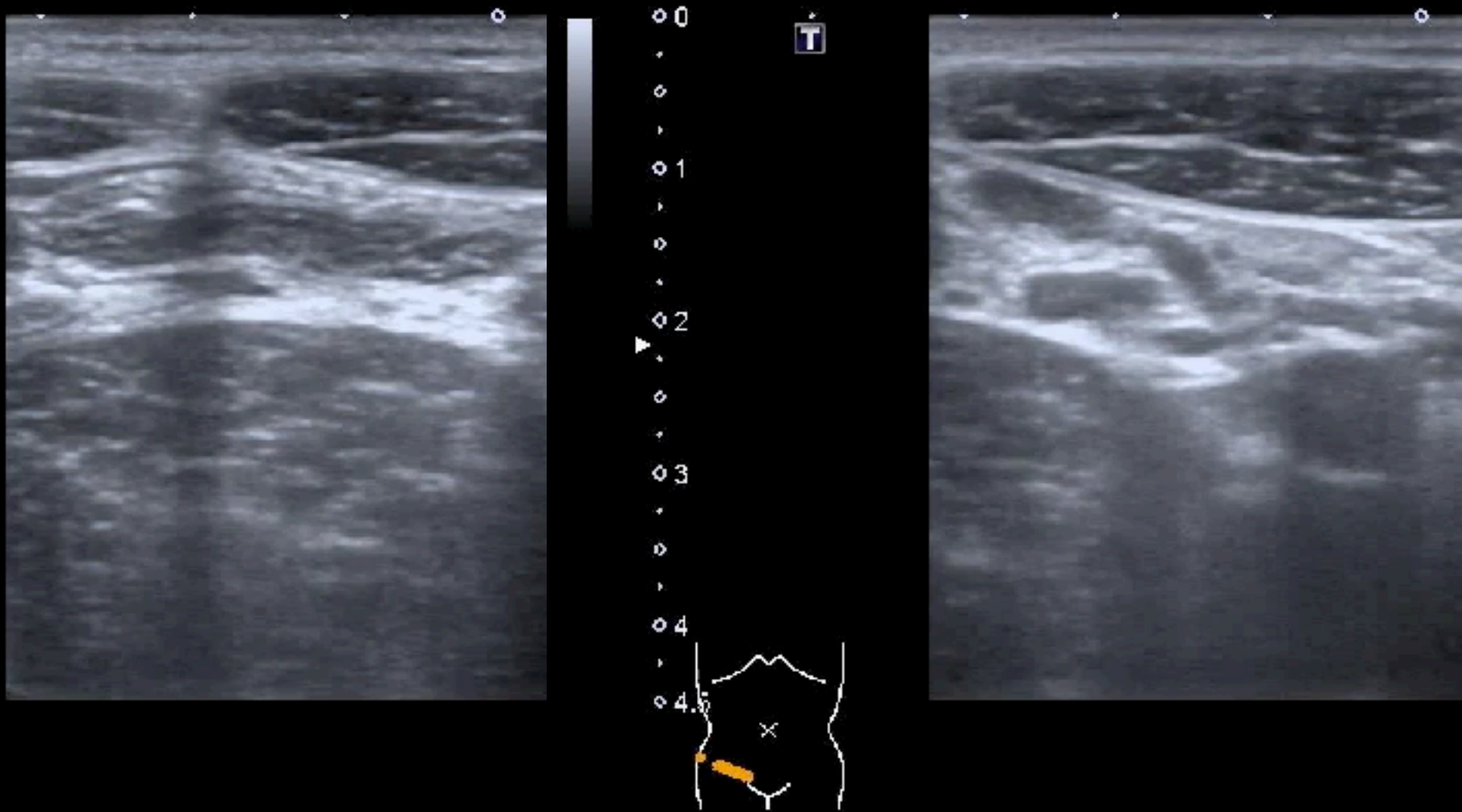


Retrocecal appendicitis

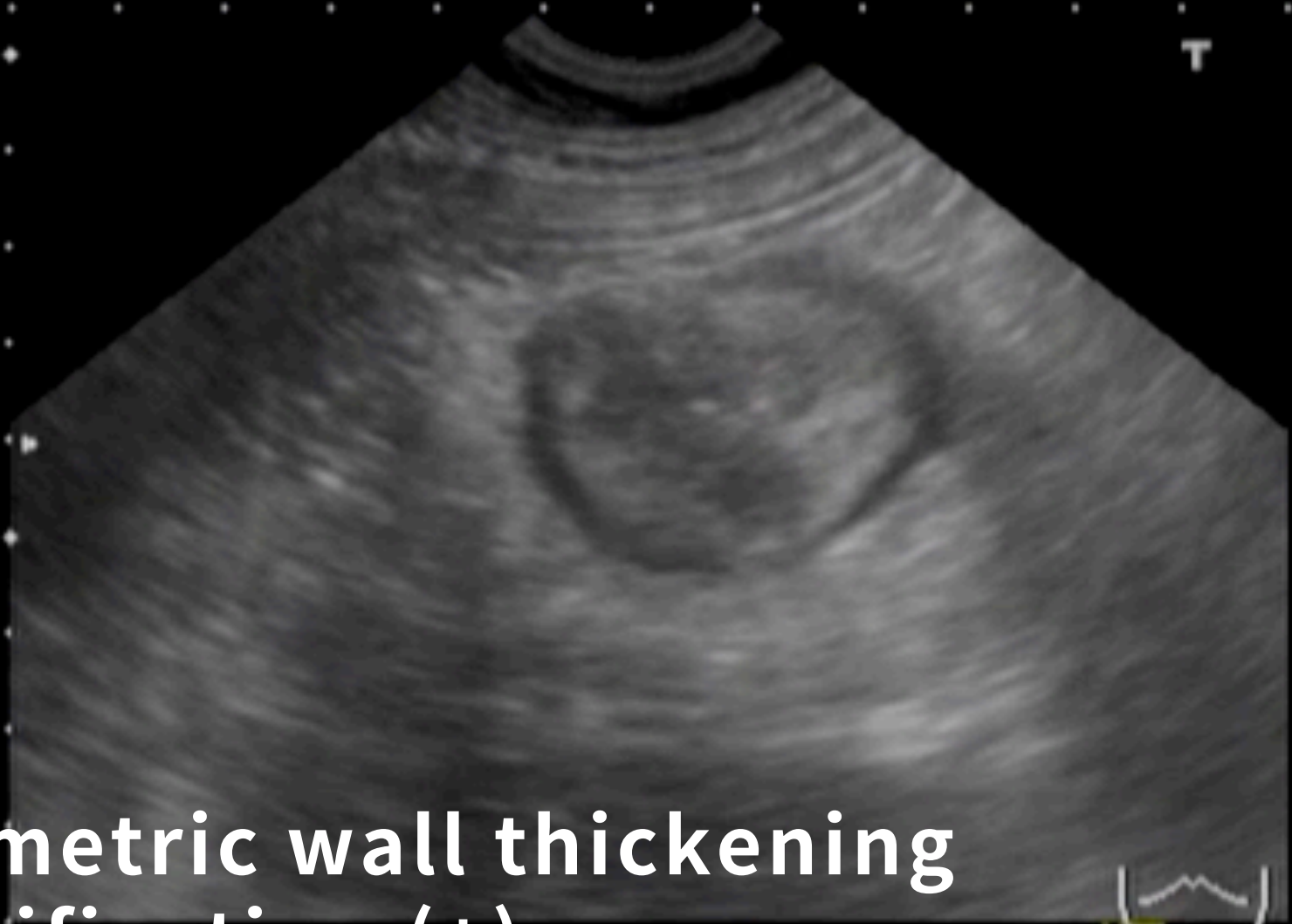

Steady compression

15M, RLQ PAIN & TENDERNESS

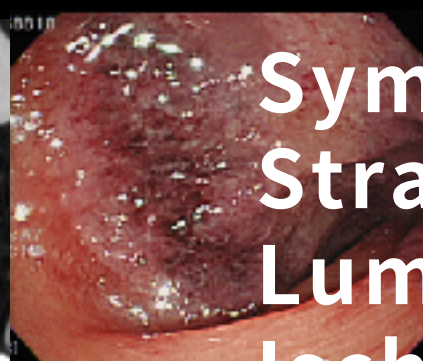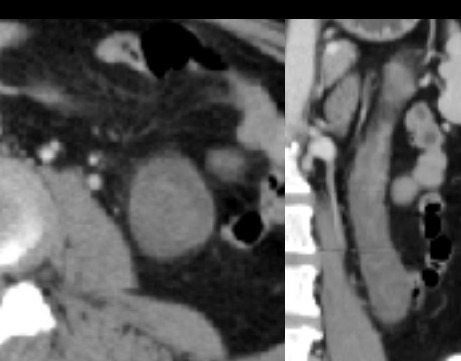
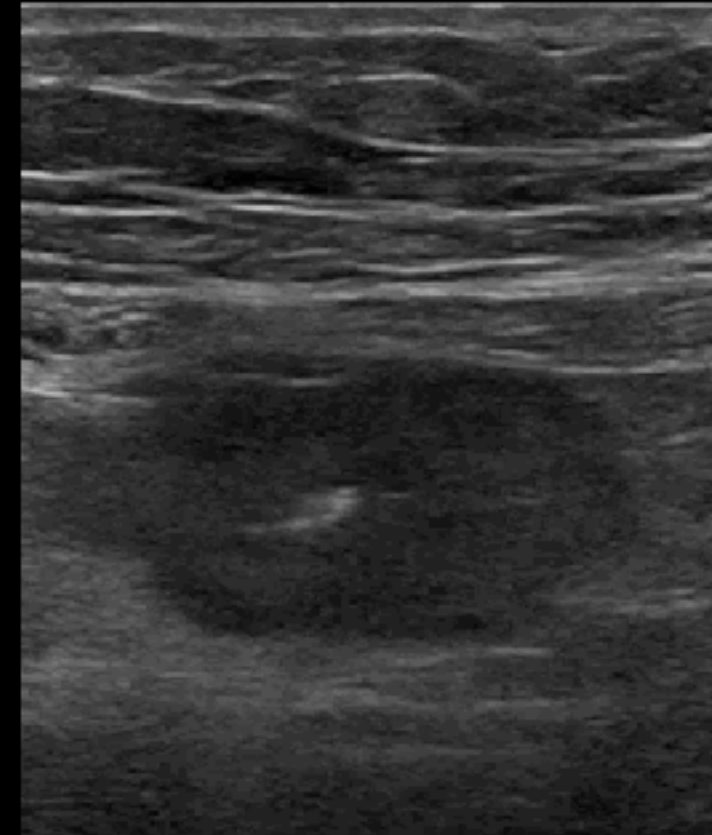

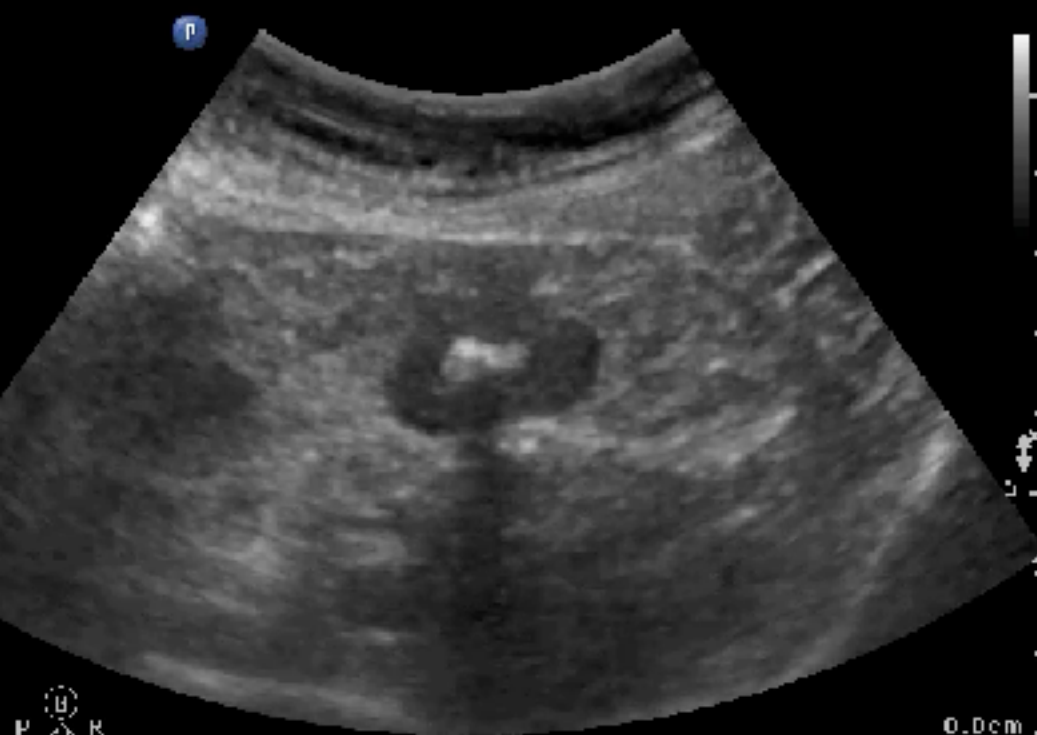
Mesenteric adenitis

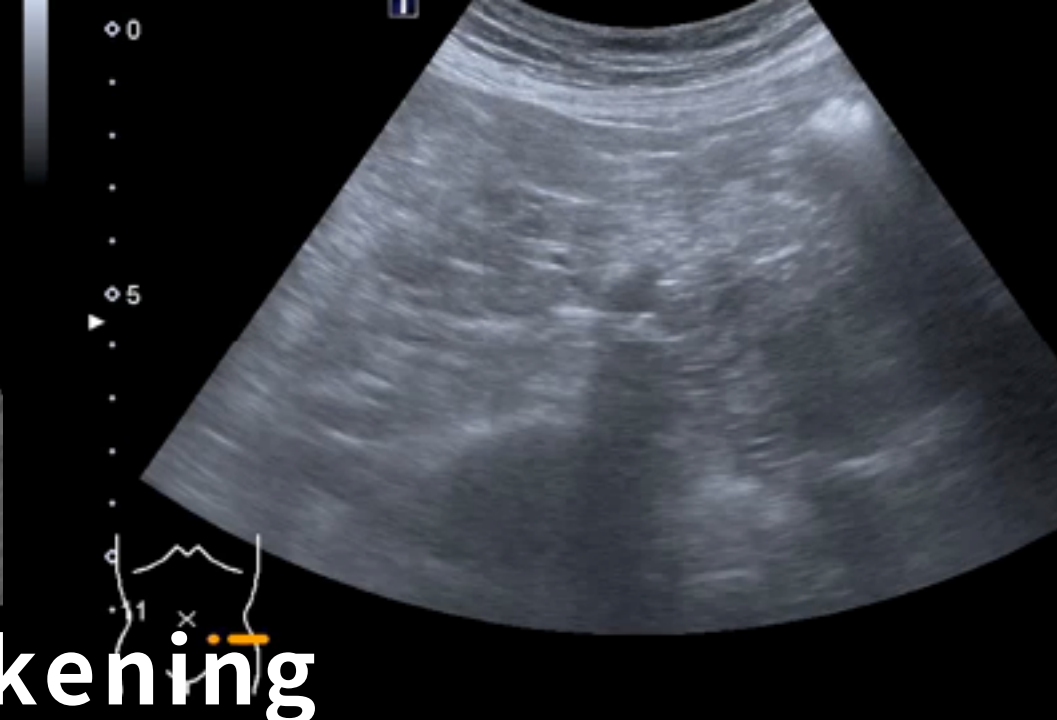
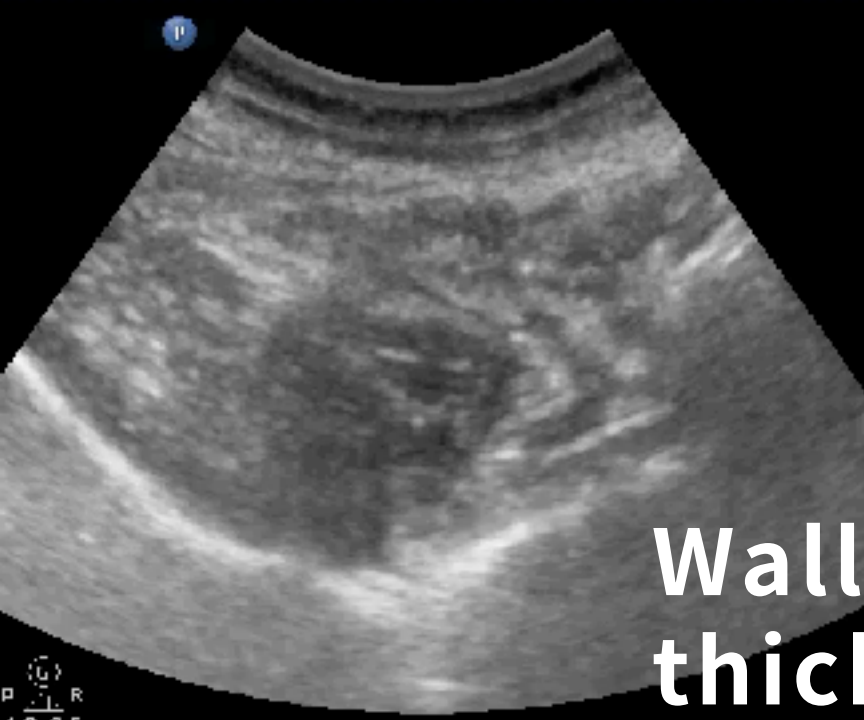

Symmetric wall thickening
Stratification (+)
Decreased luminal content
Infectious colitis

Free 8



**Symmetric wall thickening
Stratification (-)
Luminal content decreased
Ischemic colitis**

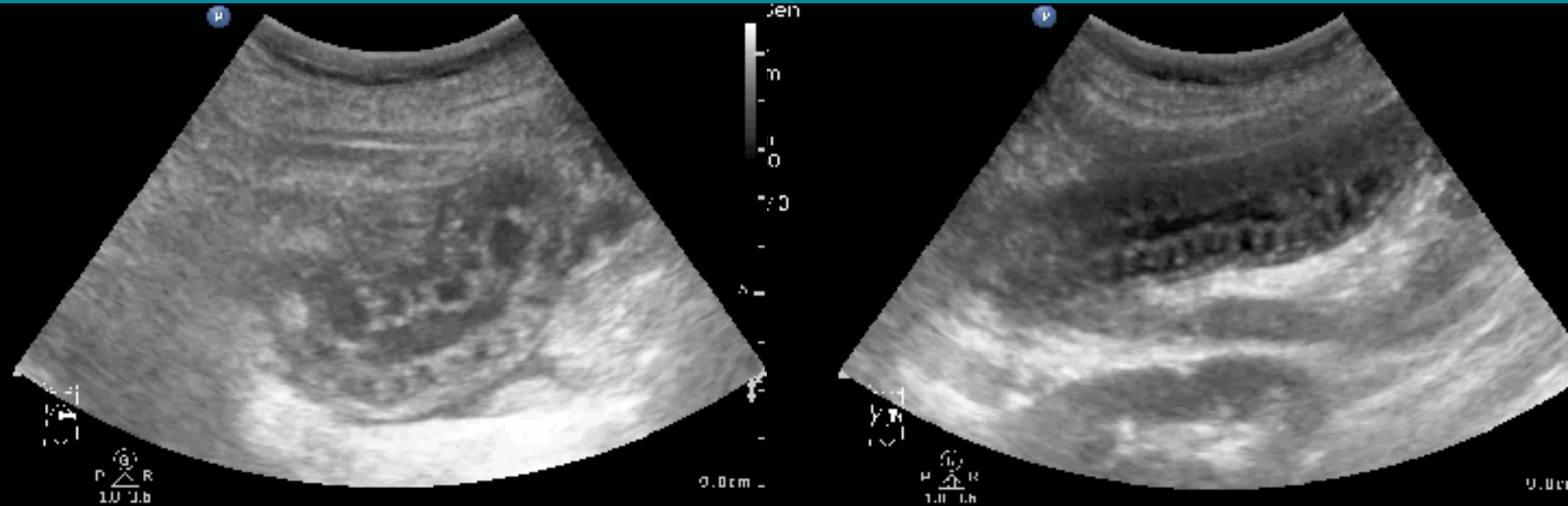


**Wall
thickening**

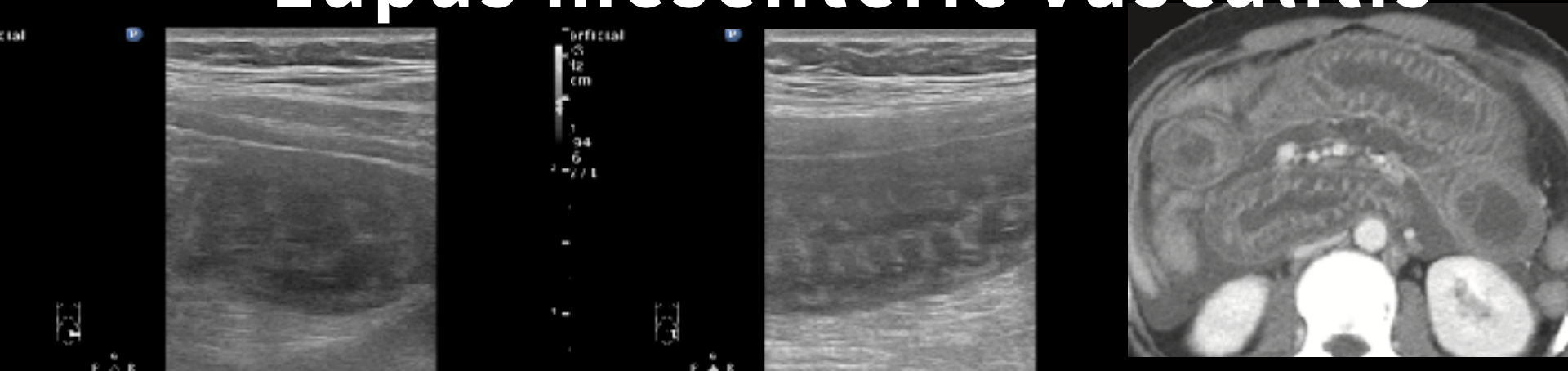
**Symmetric
Stratification (+)
Infectious colitis**

**Asymmetric
Stratification (-)
Sigmoid colon cancer**

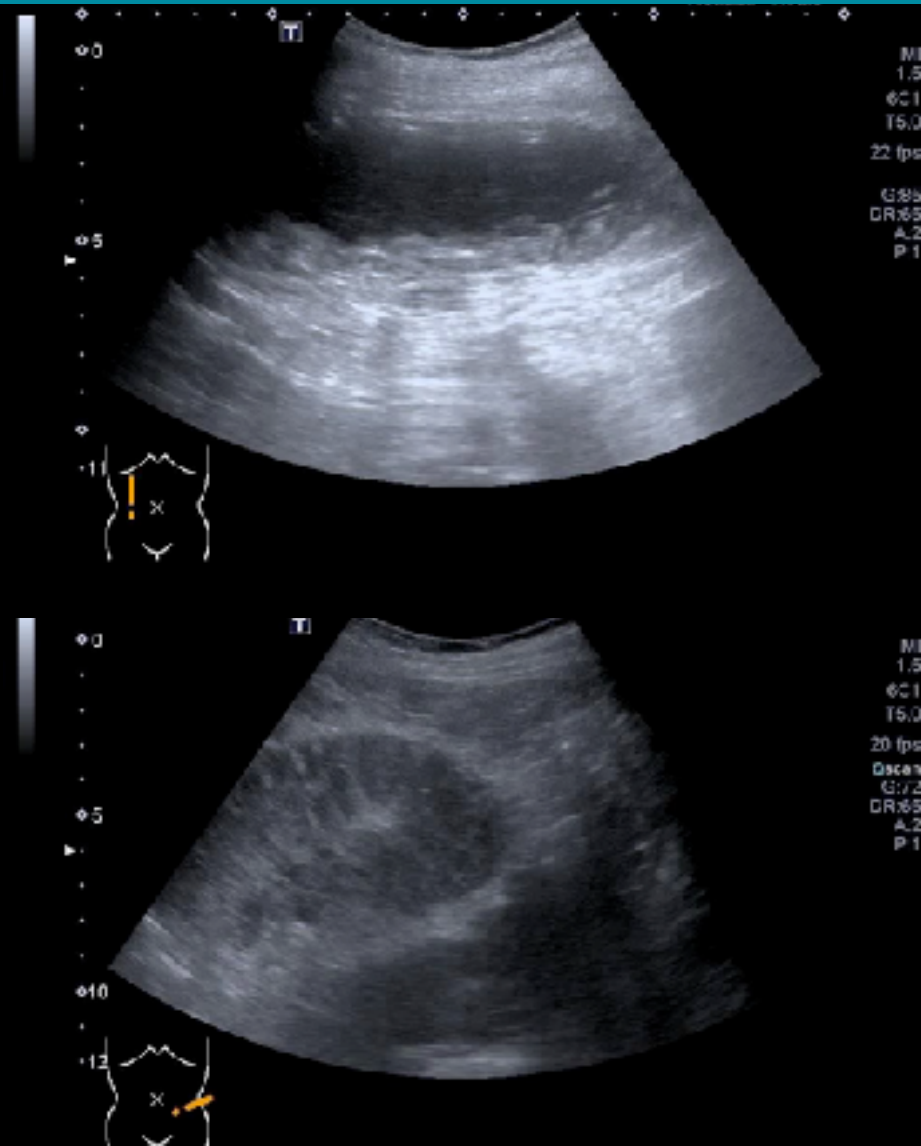
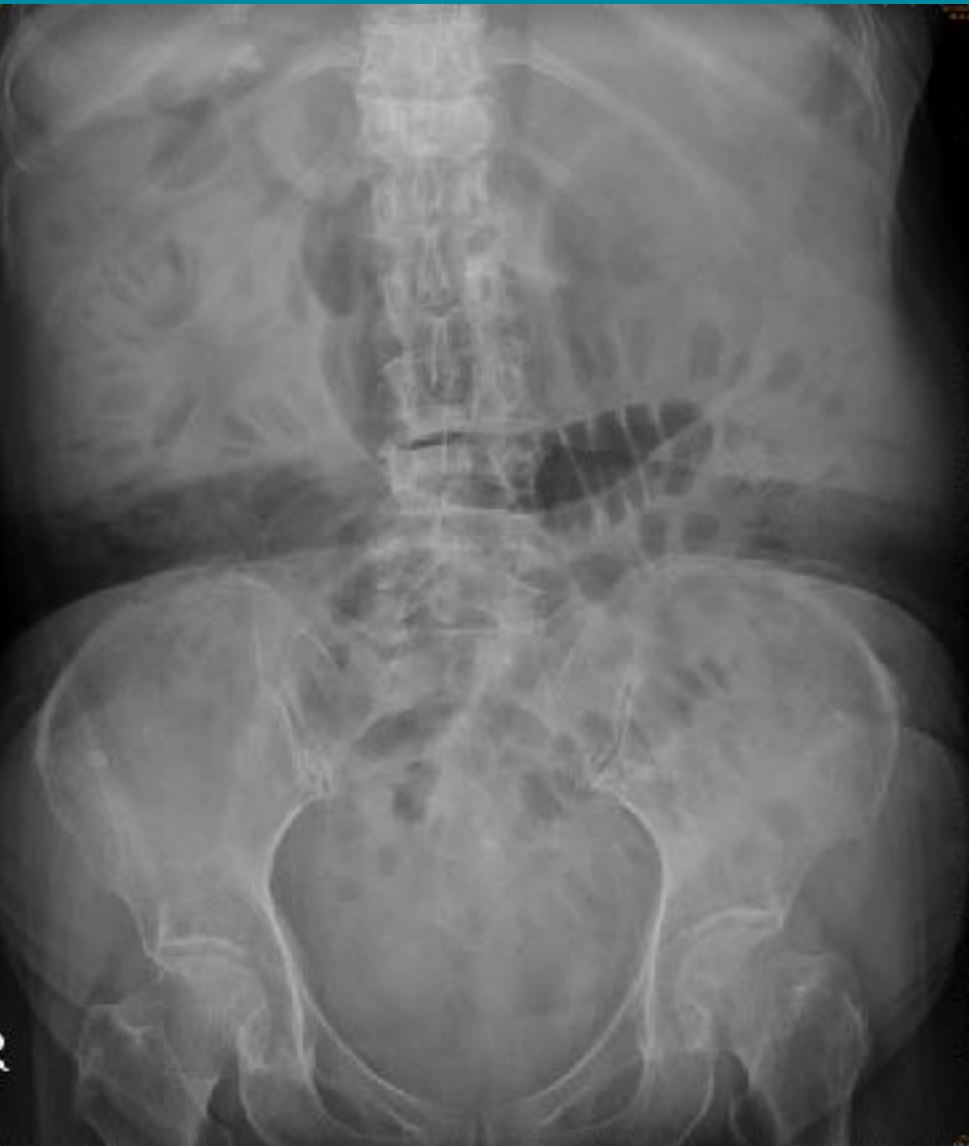WALL THICKENING



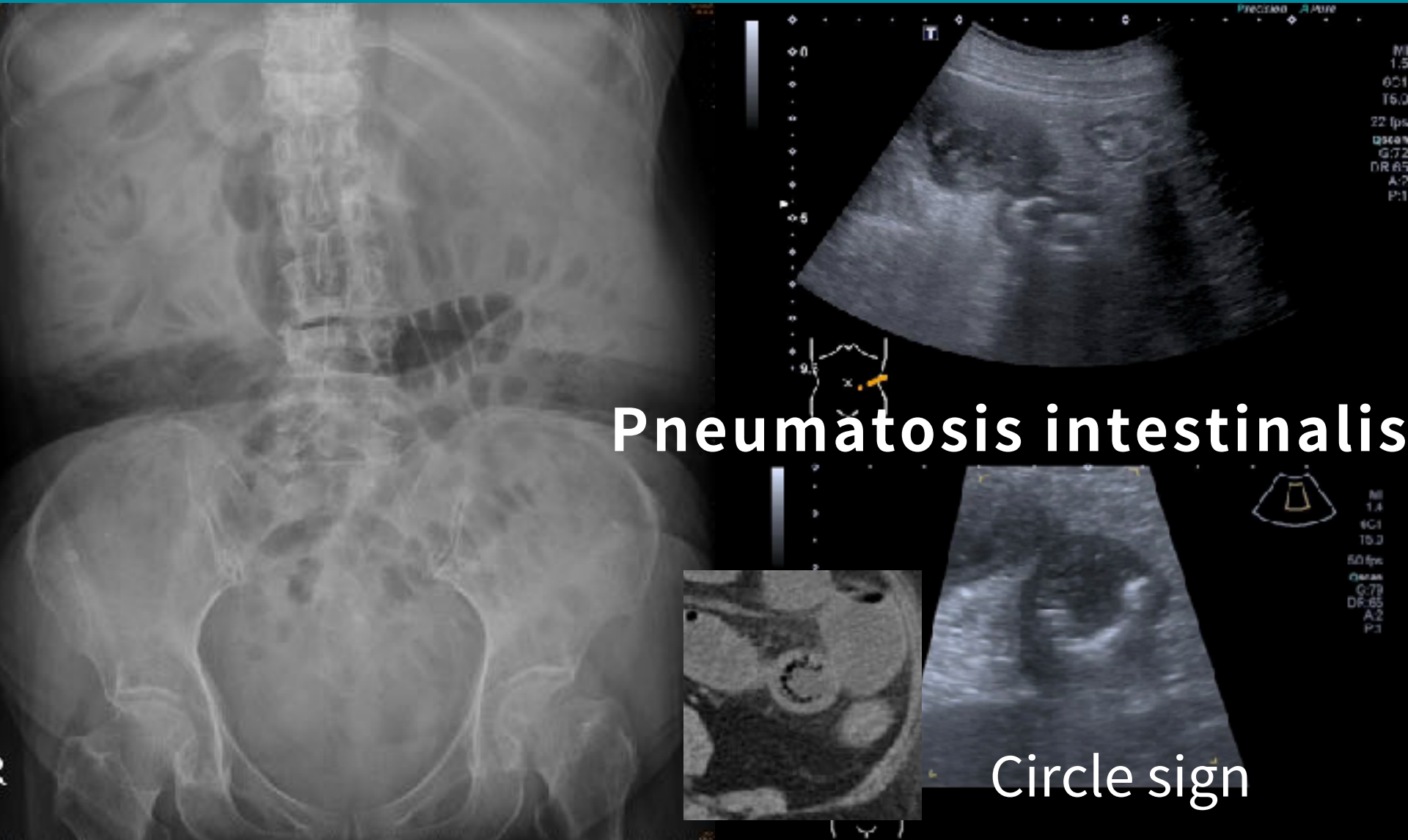
Lupus mesenteric vasculitis



WALL THICKENING ? ABNORMAL GAS ?



WALL THICKENING ? ABNORMAL GAS ?



Pneumatosis intestinalis

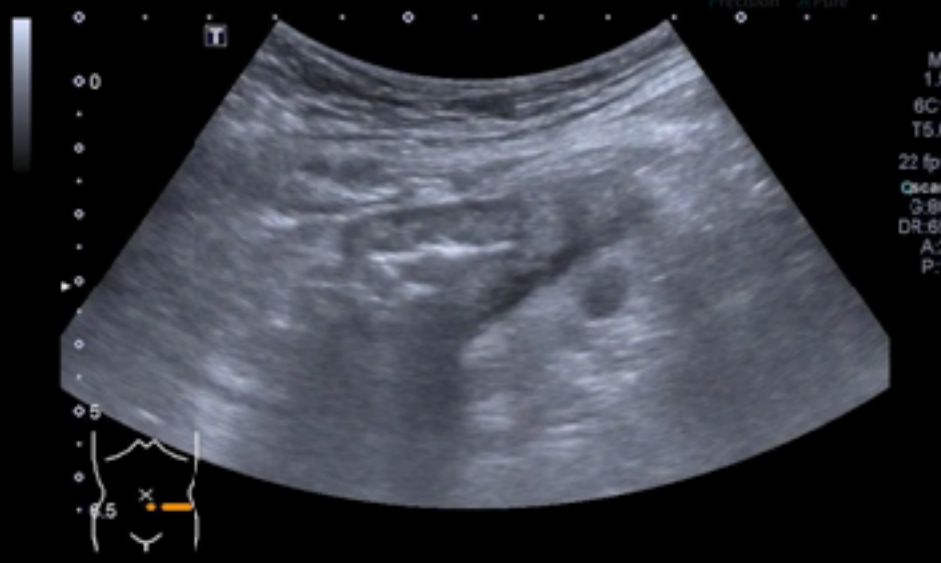Circle sign

LLQ PAIN. NOTICE WALL THICKENING & ASSOCIATED FINDINGS

Asymmetric wall thickening
Echogenic fat
Dome sign

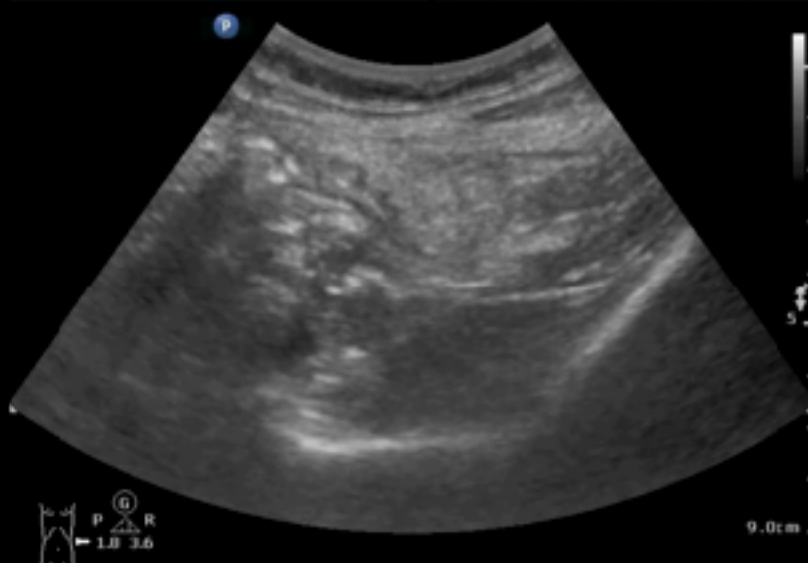Normal bowel wall
Echogenic fat

TOSHIBA
POCUSAcademy@ChenKC
01/04/13 12:47 PM



transverse scan on LLQ area

POCUSAcademy@ChenKC
01/04/13 12:47 AM

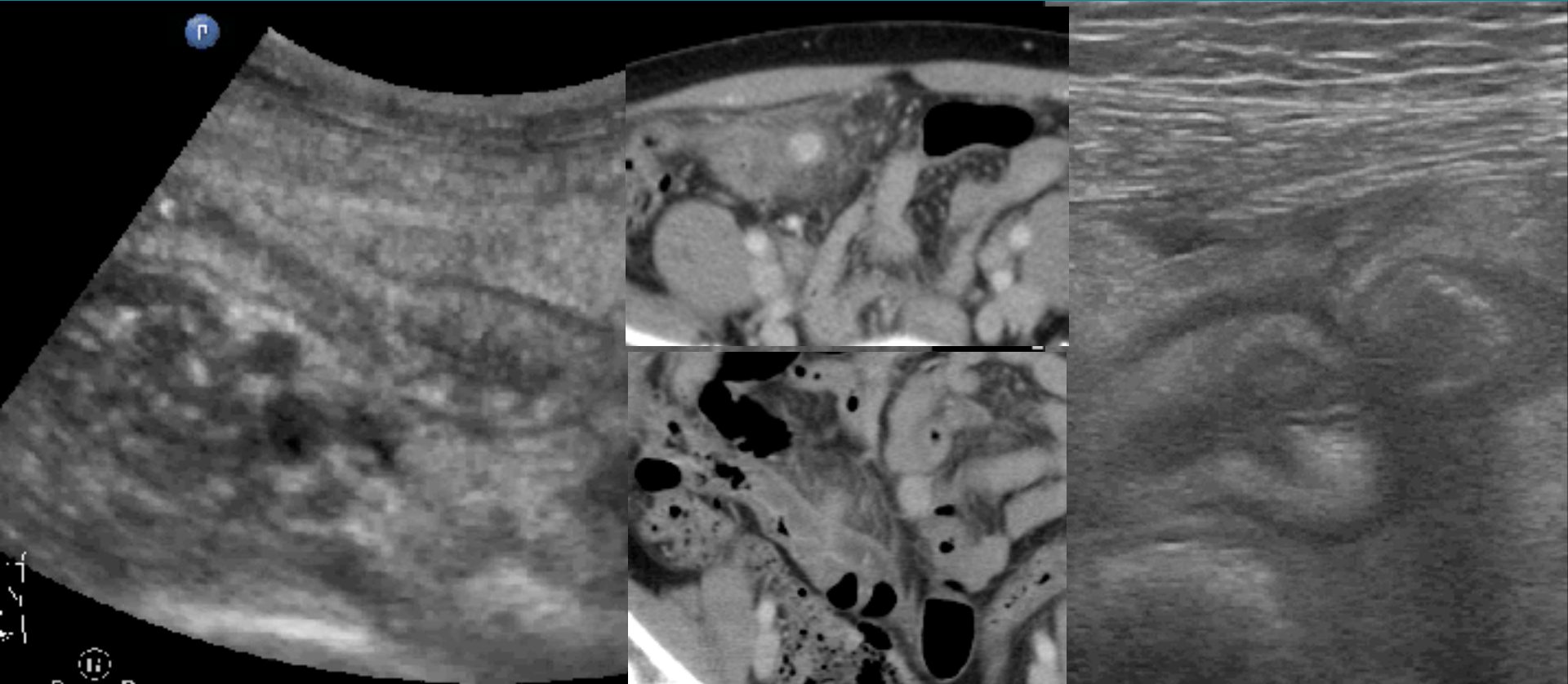


transverse scan on LLQ area

Diverticulitis

Epiploic appendagitis

DIVERTICULITIS

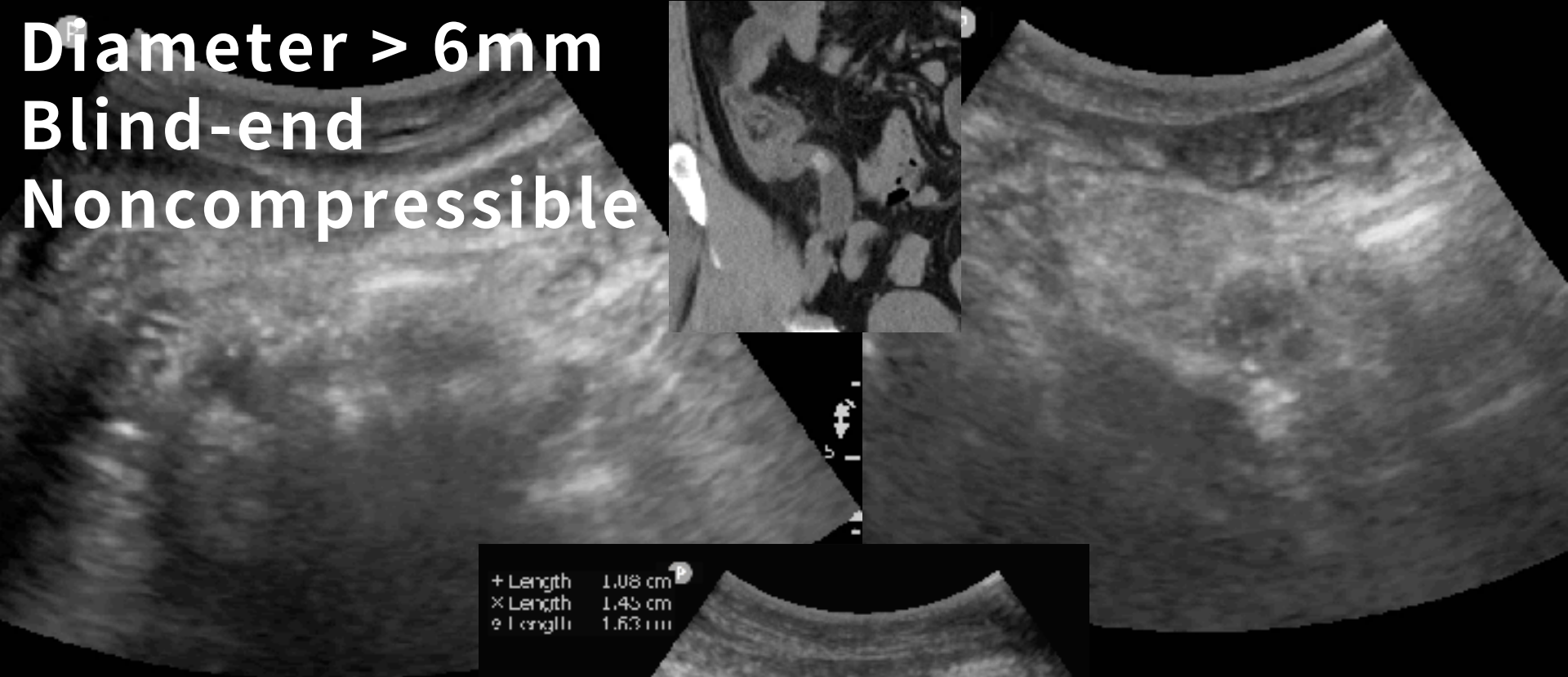
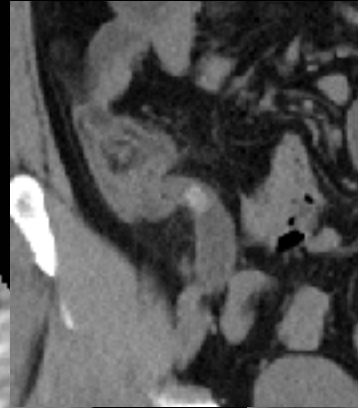


Asymmetric wall thickening
Echogenic fat
Dome sign

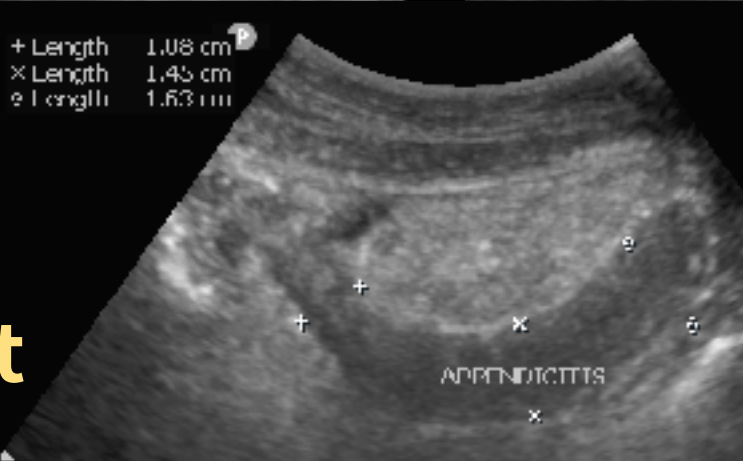
APPENDICITIS

(40M, EPIGASTRIC PAIN W/ RLQ TENDERNESS)

Diameter > 6mm
Blind-end
Noncompressible

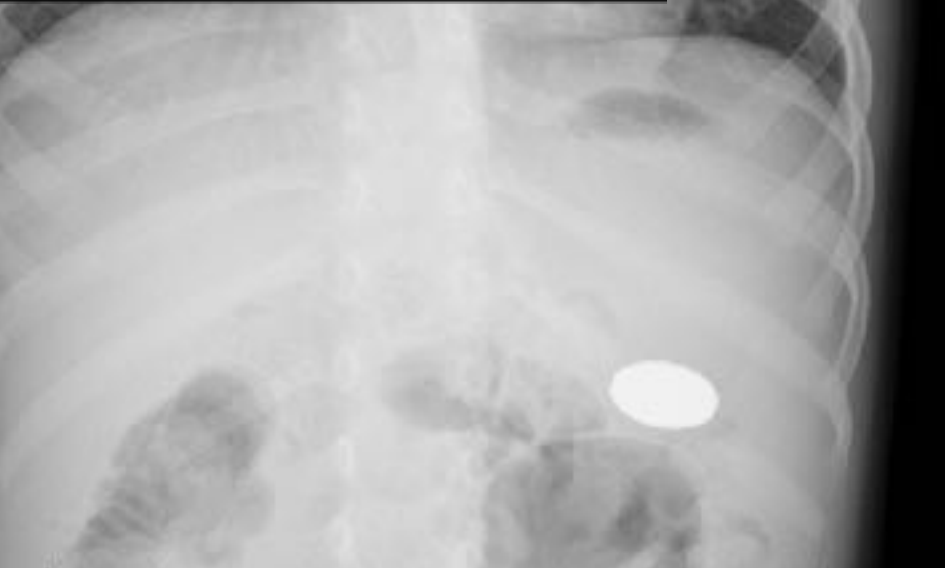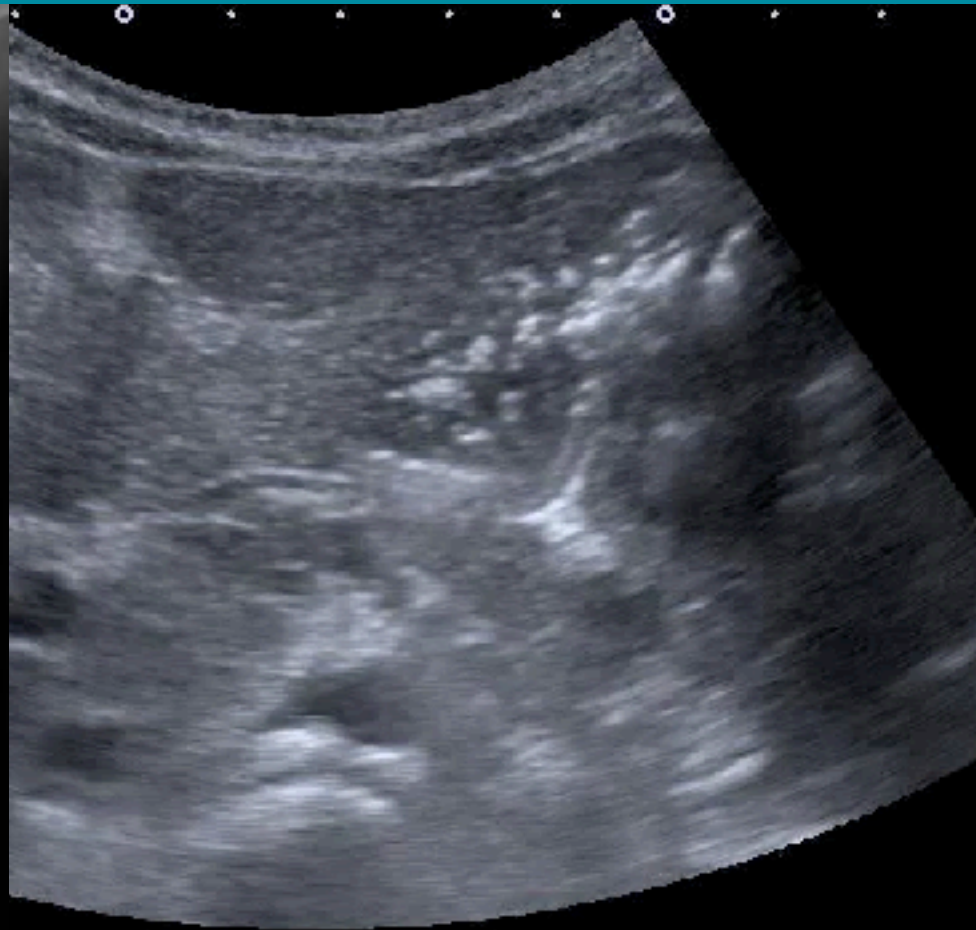
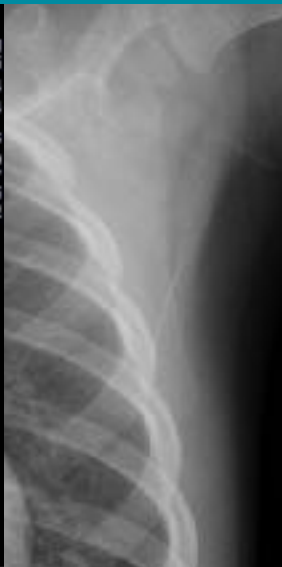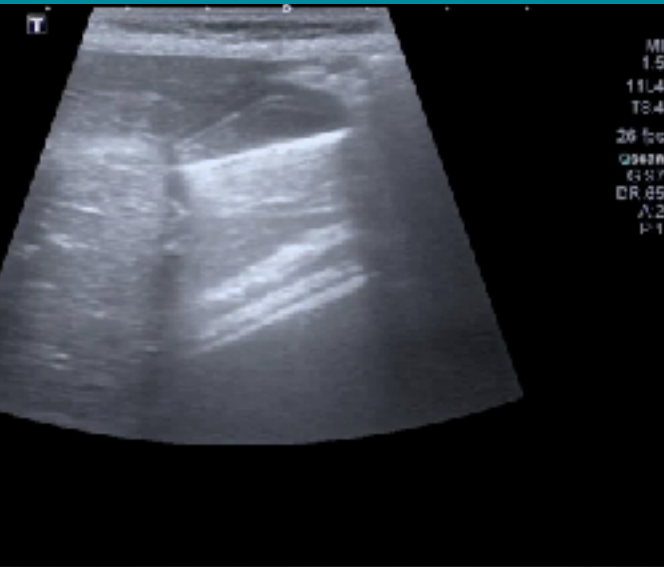


+ Length 1.08 cm
x Length 1.45 cm
e Length 1.63 cm



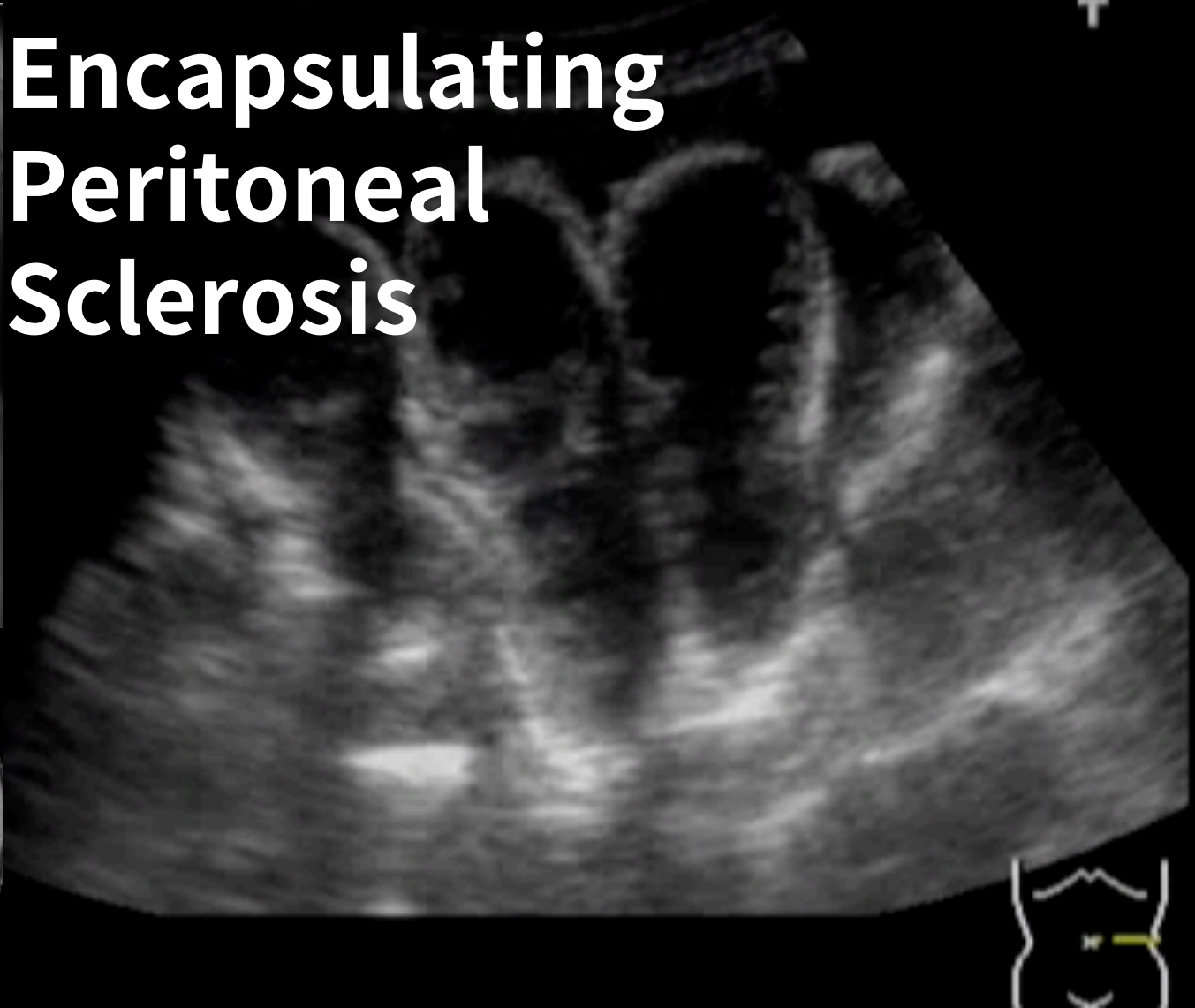
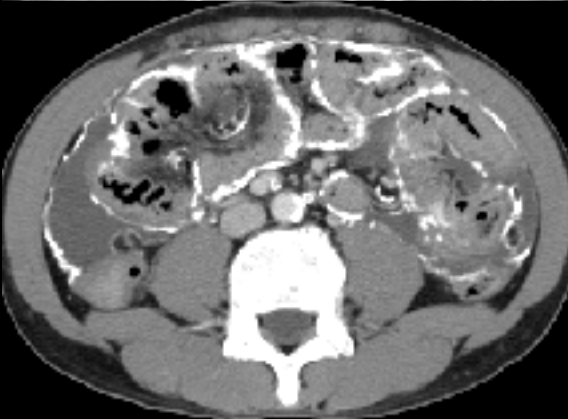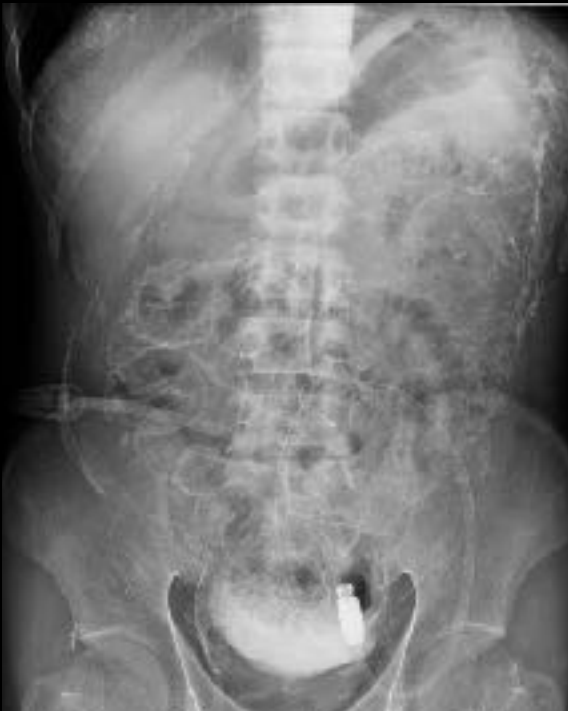Echogenic fat

2F, COIN MIS-SWALLOWING

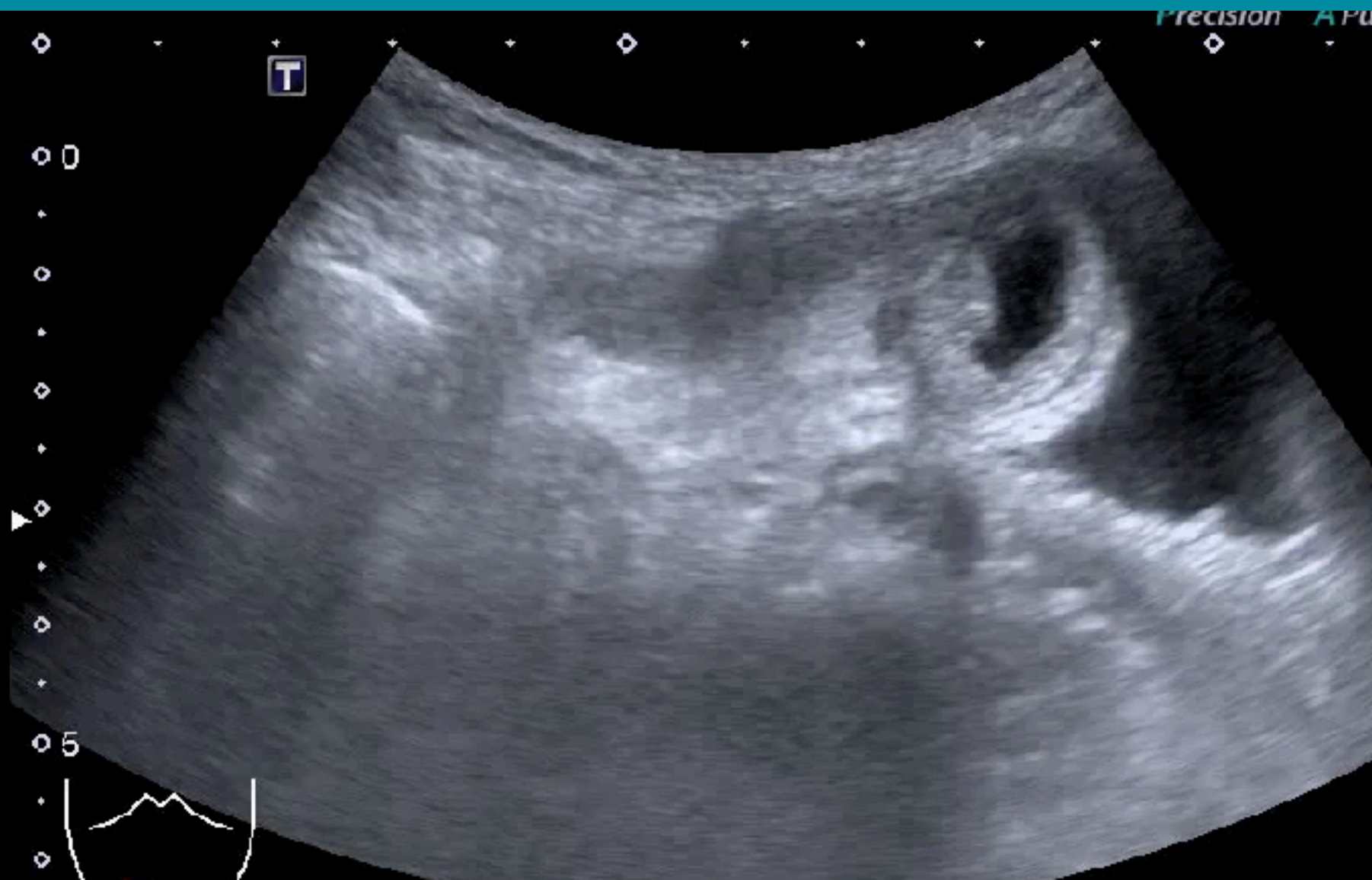


DIFFUSE ABDOMINAL PAIN

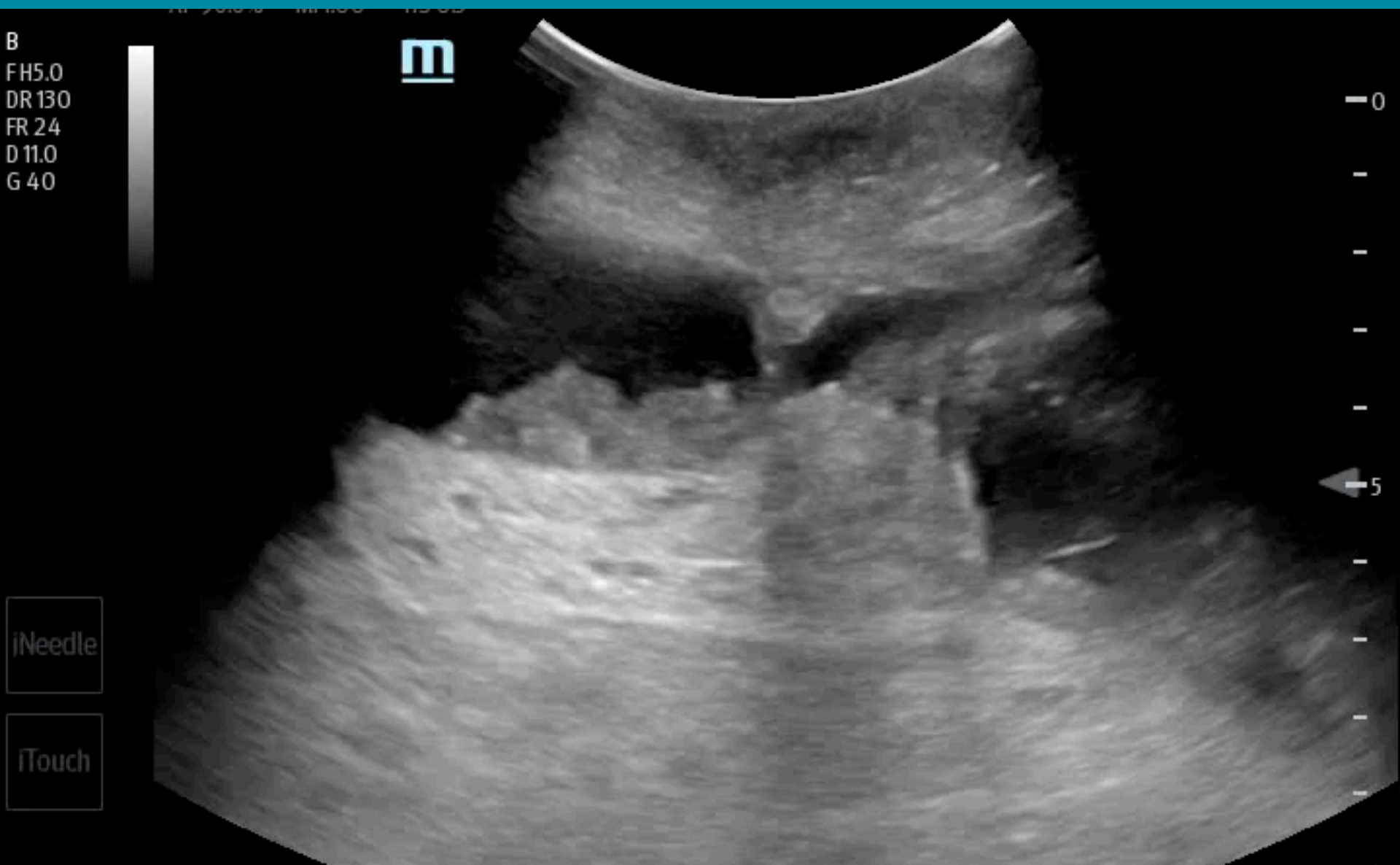
Encapsulating Peritoneal Sclerosis

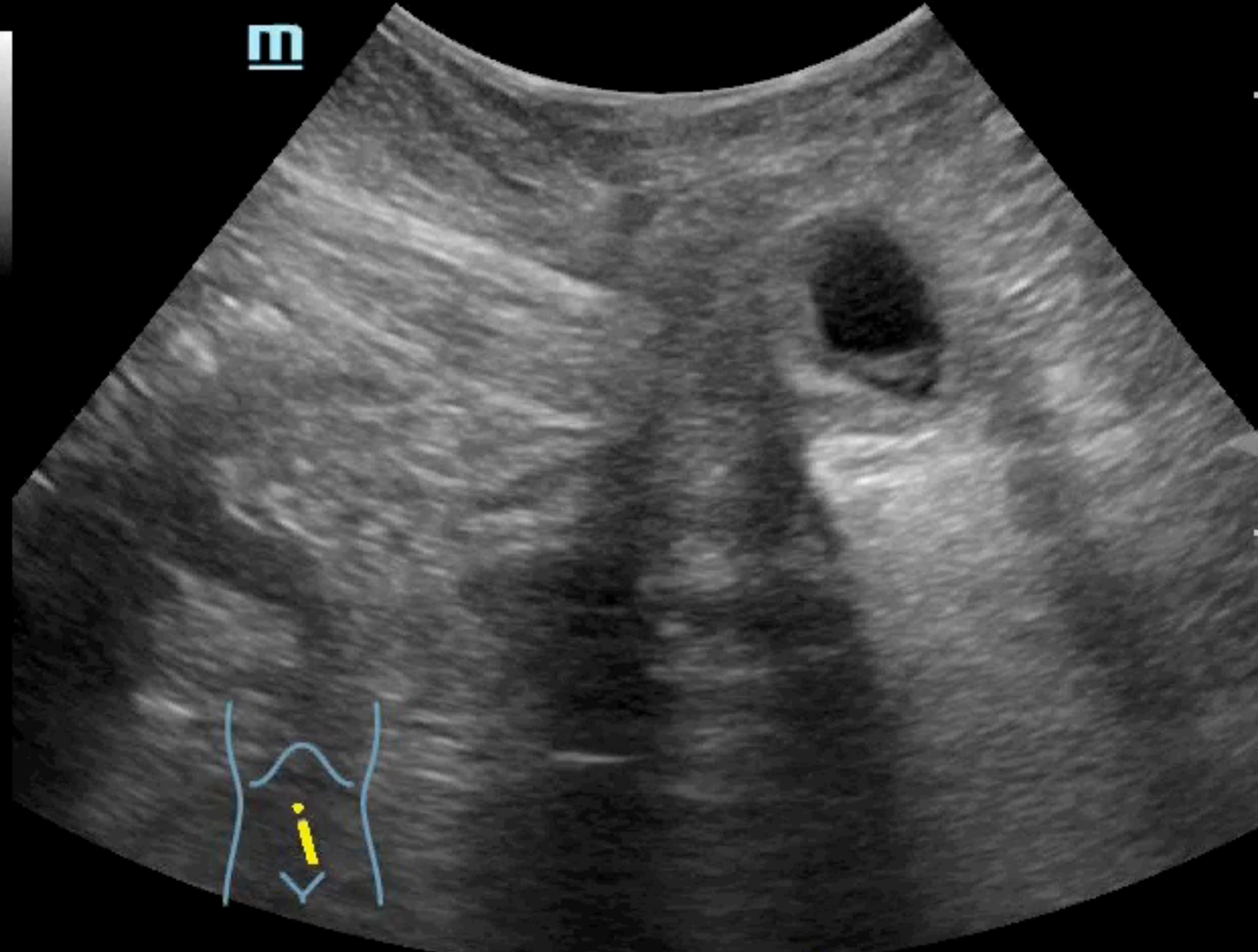


ULTRASOUND GUIDED HERNIA REDUCTION



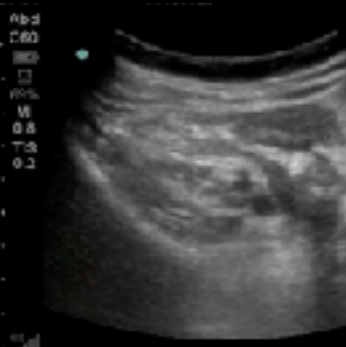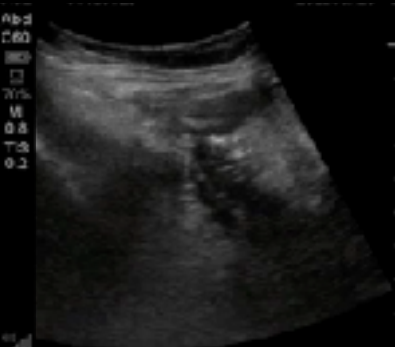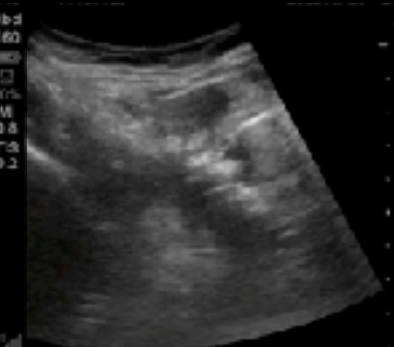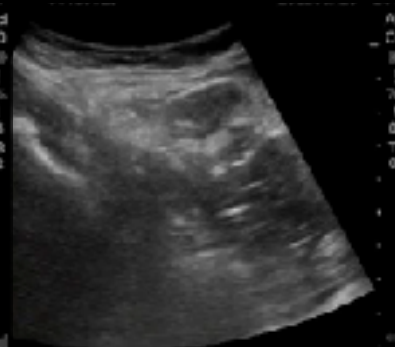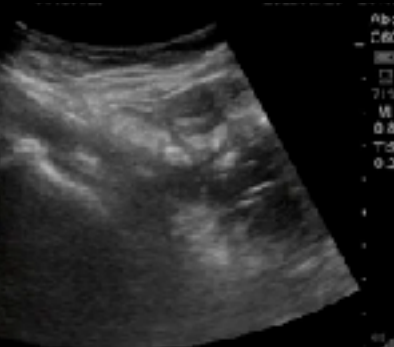
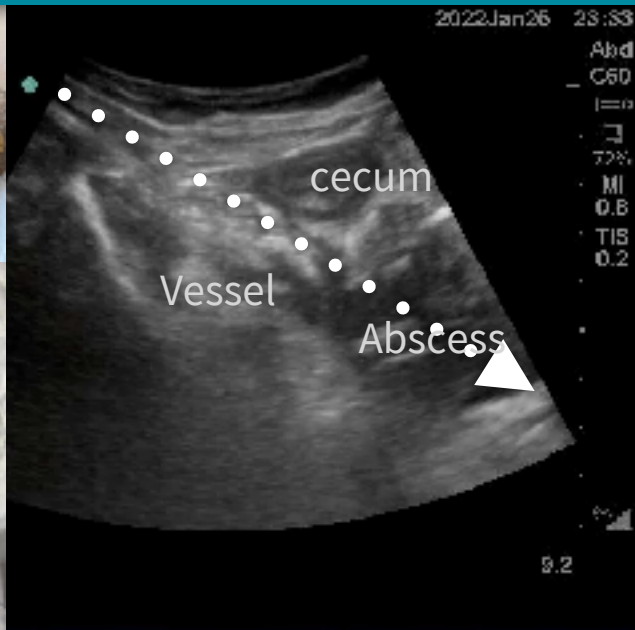
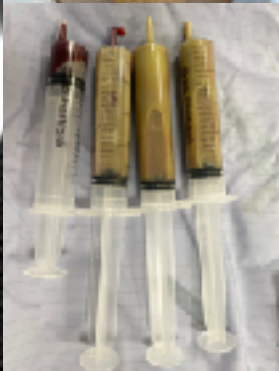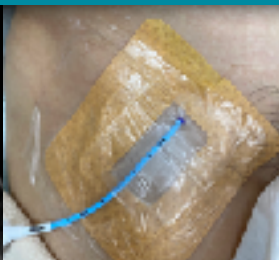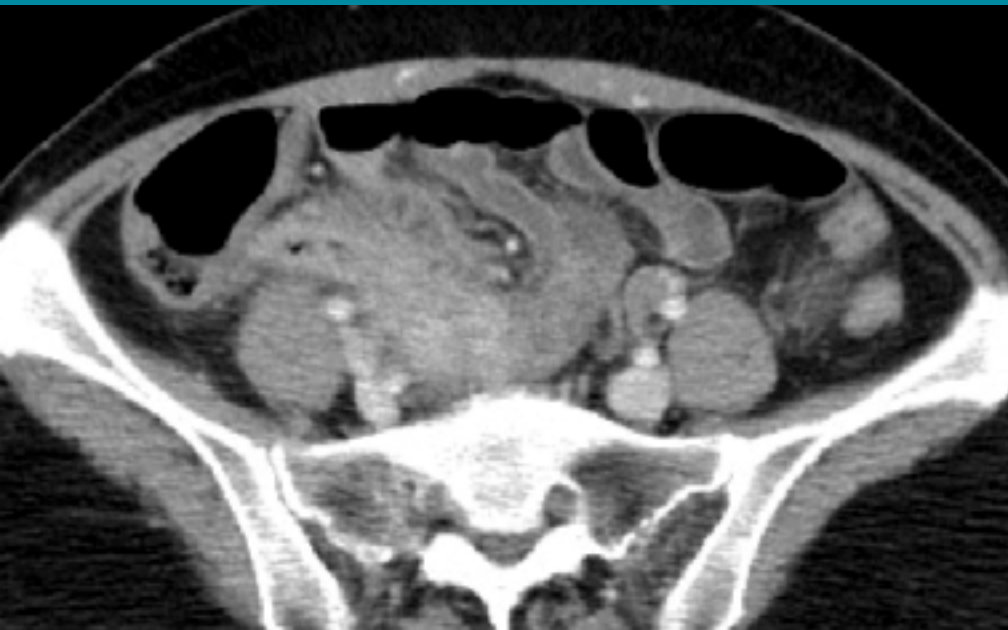Ultrasound guided hernia reduction





50F, RLQ pain for one week

Ultrasound guided pigtail for abscess drainage



Guiding needle

Guidewire

Pigtail

Pigtail in abscess

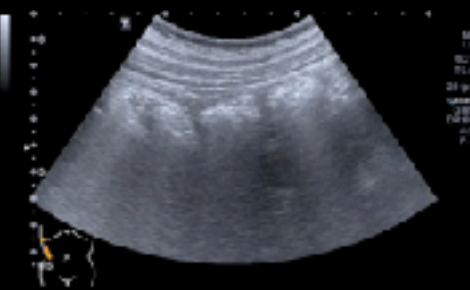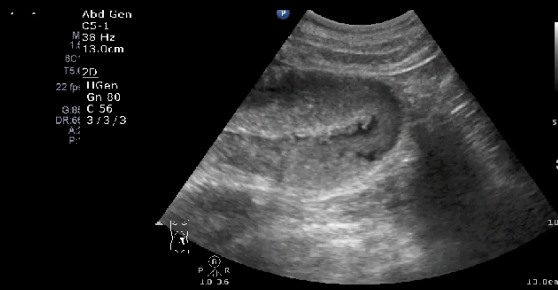
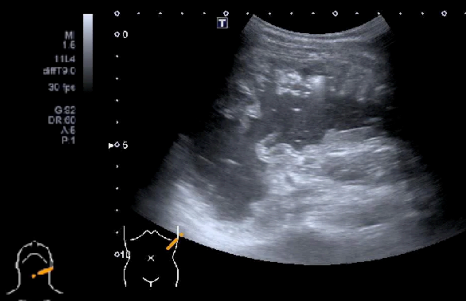
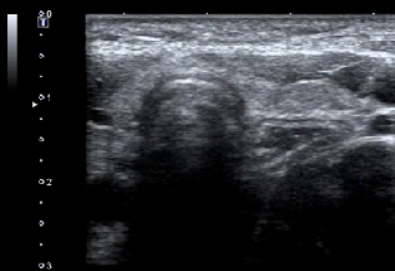
After drainage



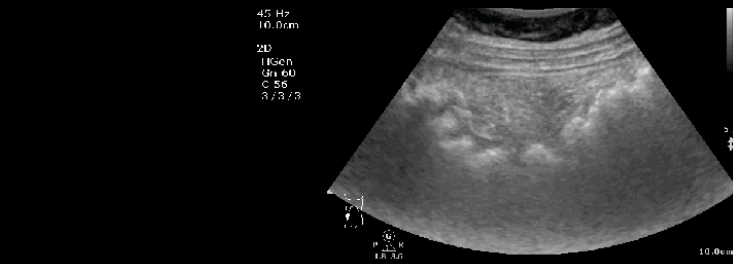
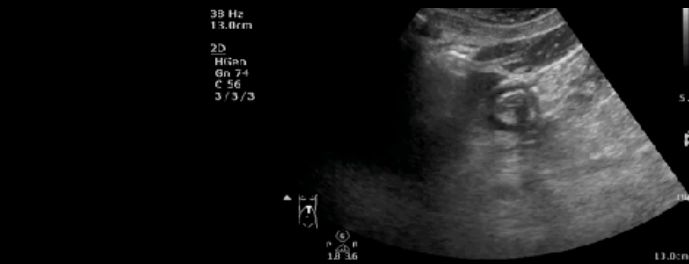
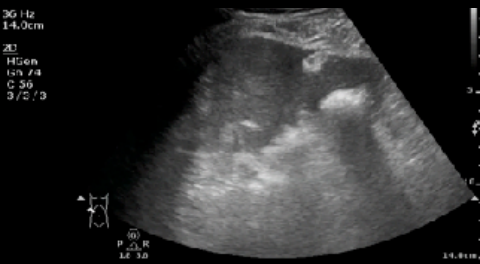External landmarks

Find GI tracts
Recognize sonoanatomy

Fixed parts first



Recognize GI tract Find patterns



Seeing your Gut feeling to facilitate diagnosis & management



1. Recognize GI sonoanatomy
2. Start your scanning on landmarks
3. Scan transversely on targets
4. **Compress steadily**
5. Identify pathologic patterns
6. **Size first then wall & layers**
7. Pay attention to **direct & indirect findings**