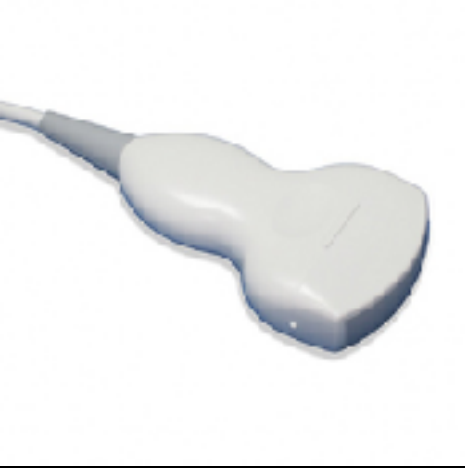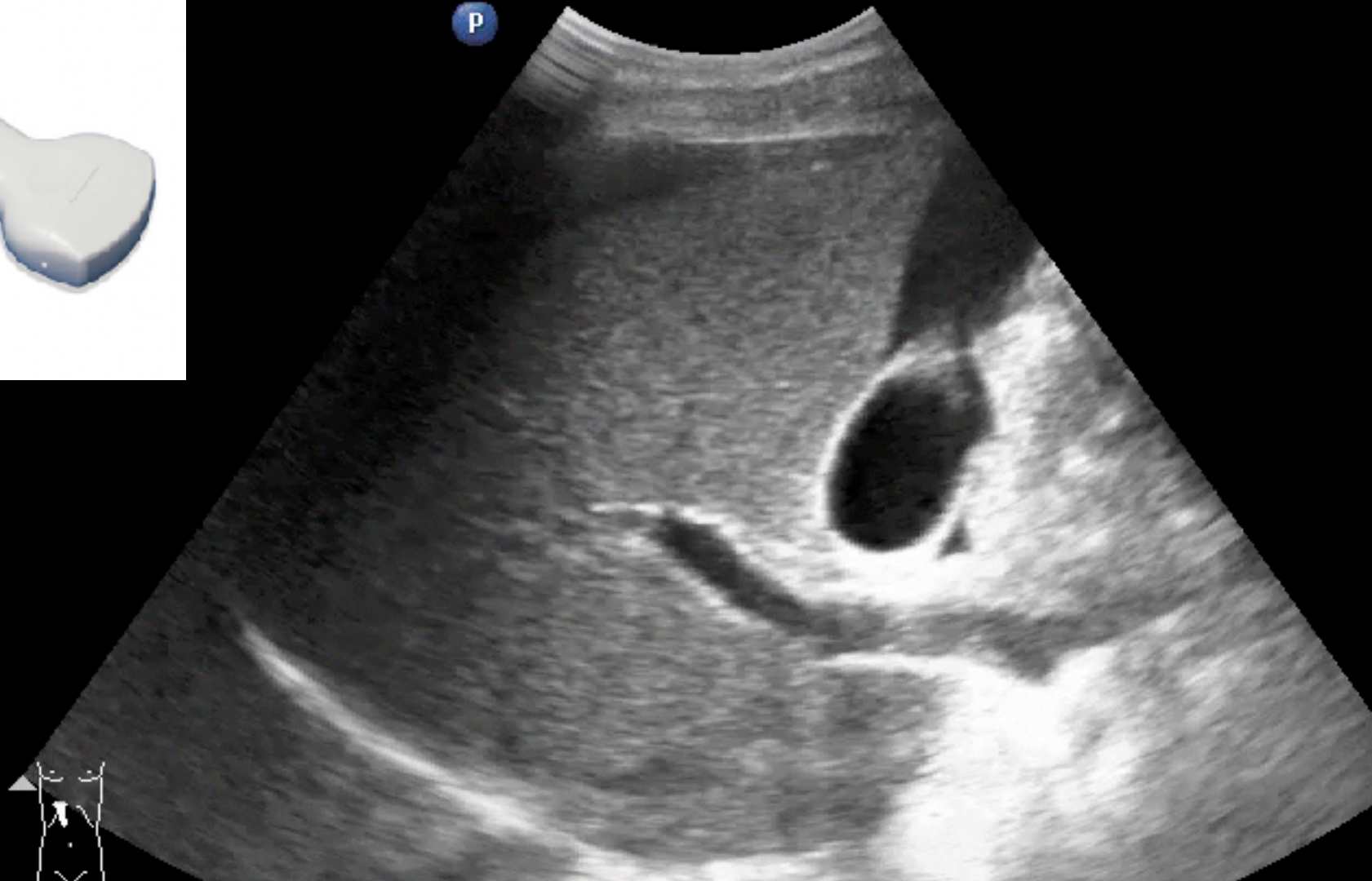




3 / 3



# TRAUMA ULTRASOUND

# 陳國智 醫師 / [POCUSacademy.com](http://POCUSacademy.com)



台灣疼痛醫學會專科醫師  
急診超音波臨床評核醫師  
醫用超音波學會指導醫師  
WINFOCUS director / instructor  
Certified Interventional Pain Sonologist

**急診 / 重症 / 介入 / 急性疼痛**

經歷

新光急診超音波訓練中心主任  
西園醫院急診醫學科主任  
急診醫學會超音波委員會主委  
台灣疼痛醫學會大體模擬手術講師  
急救加護醫學會重症超音波負責人



診  
斷

監  
測

Diagnostician



介  
入

Interventionist

# POINT OF CARE ULTRASOUND

Provider - Probe - Patient

~ 存在於臨床需求之所在 ~

Resuscitative  
急救復甦

Diagnostic  
臨床診斷

Procedural  
Guidance  
處置導引

Symptom- or  
Sign-Based  
症狀導引

Therapeutic  
輔助治療



Core Applications (2023 ACEP Emergency Ultrasound Guidelines)  
15項急診超音波核心應用

陳國智醫師

Aorta

DVT

Trauma

Thoracic/Airway

Cardia/HD assessment

Procedural Guidance

US-guided NB

Testicular

Ocular

Skin & Soft tissue

Hepatobiliary

Urinary tract

Pregnancy

Bowel

MSK

# I-AIM

## POINT



**Acquire**



**Interpret**



**Make  
decision**

# I-AIM (Trauma)

## Free fluid ?



探頭/FAST介面



有無游離液體



臨床決策

# Point-of-Care UltraSound

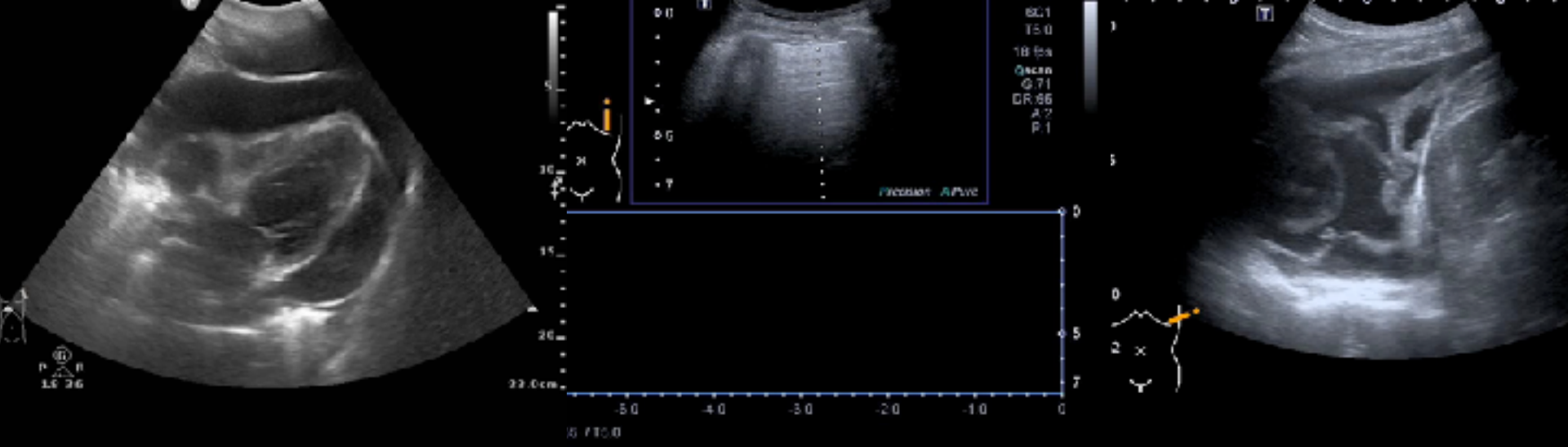
## POCUS的核心在協助臨床決策

**YES**



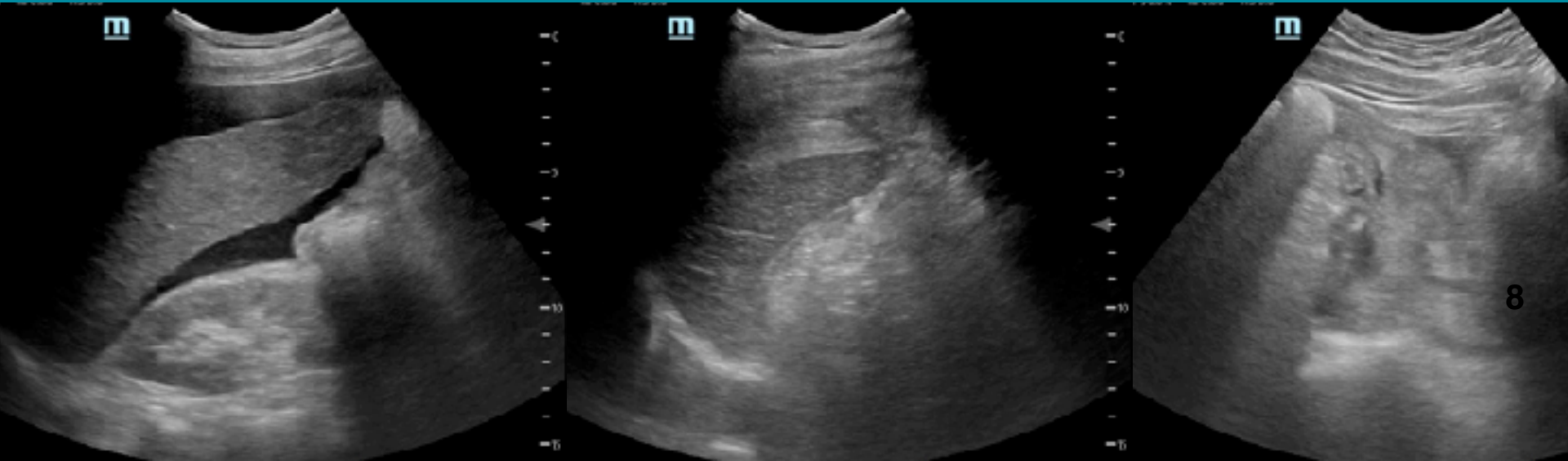
**NO**

有無游離液體



# EFAST

EXTENDED FOCUSED ASSESSMENT WITH SOGOGGRAPHY FOR TRAUMA

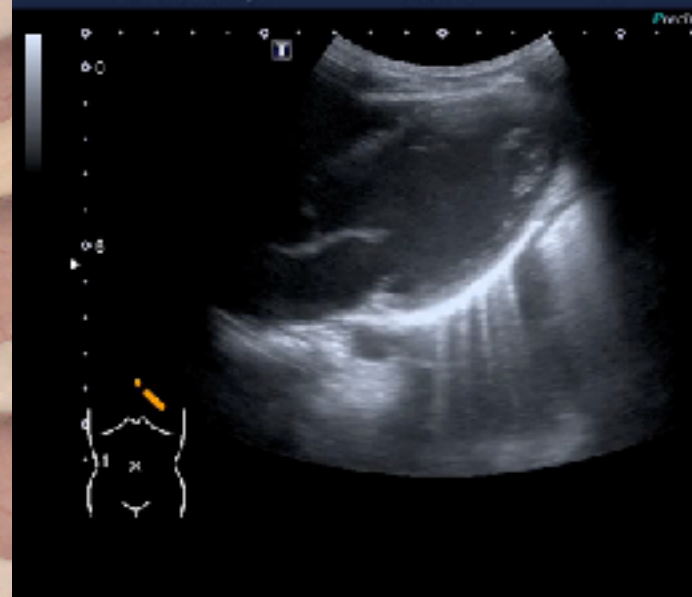




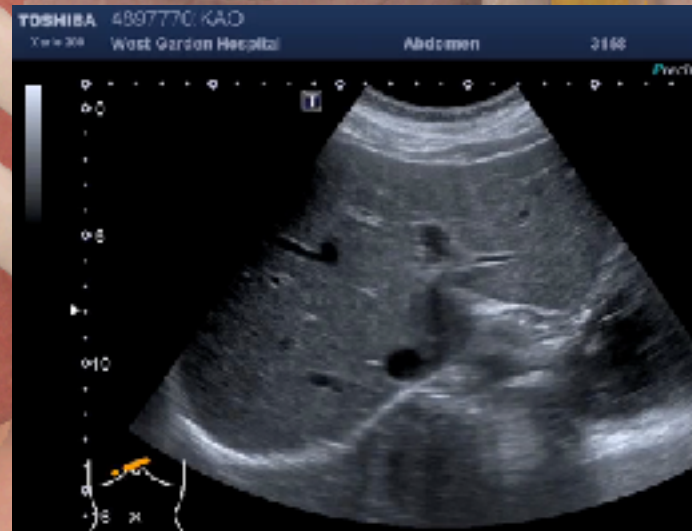掃描介面 (探頭)

PSLA

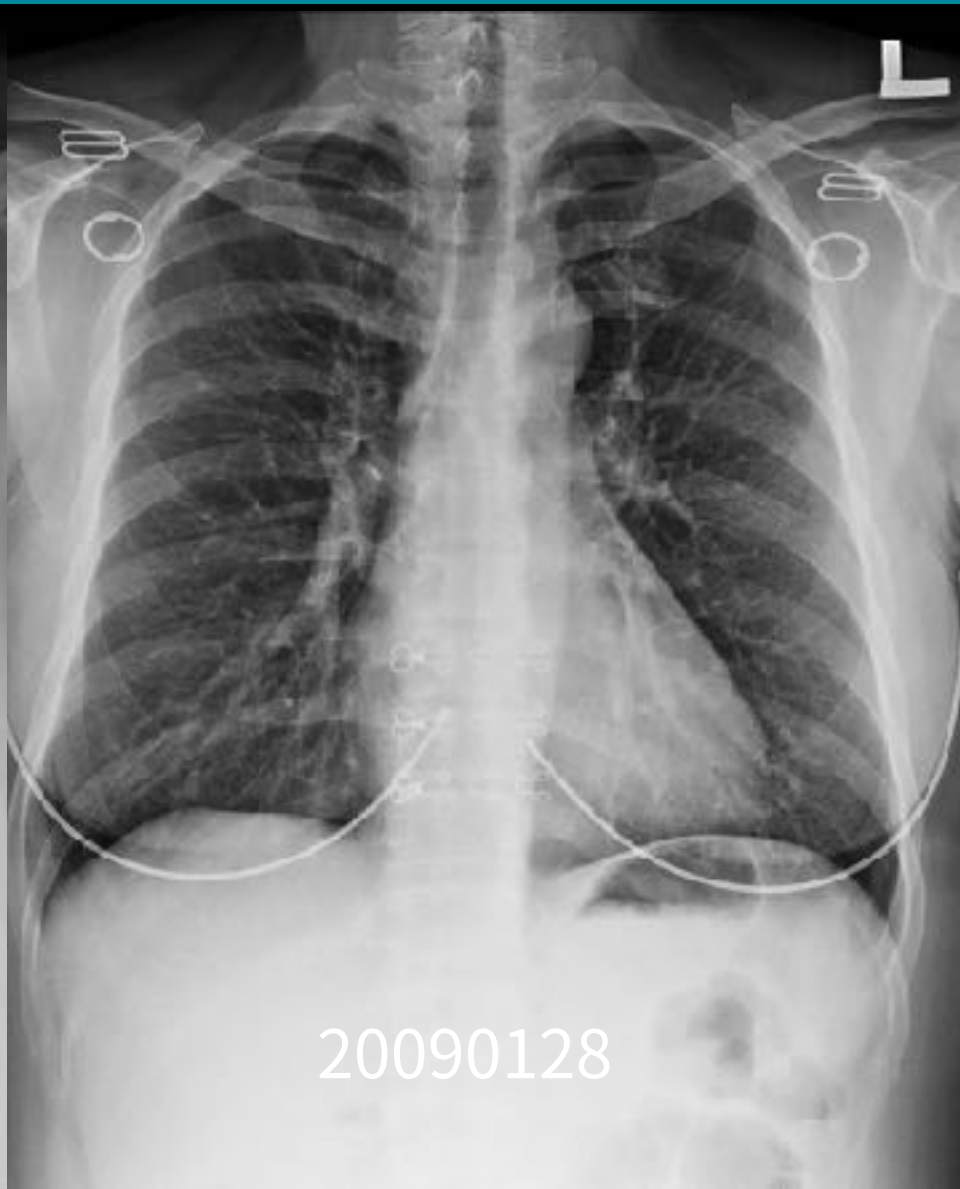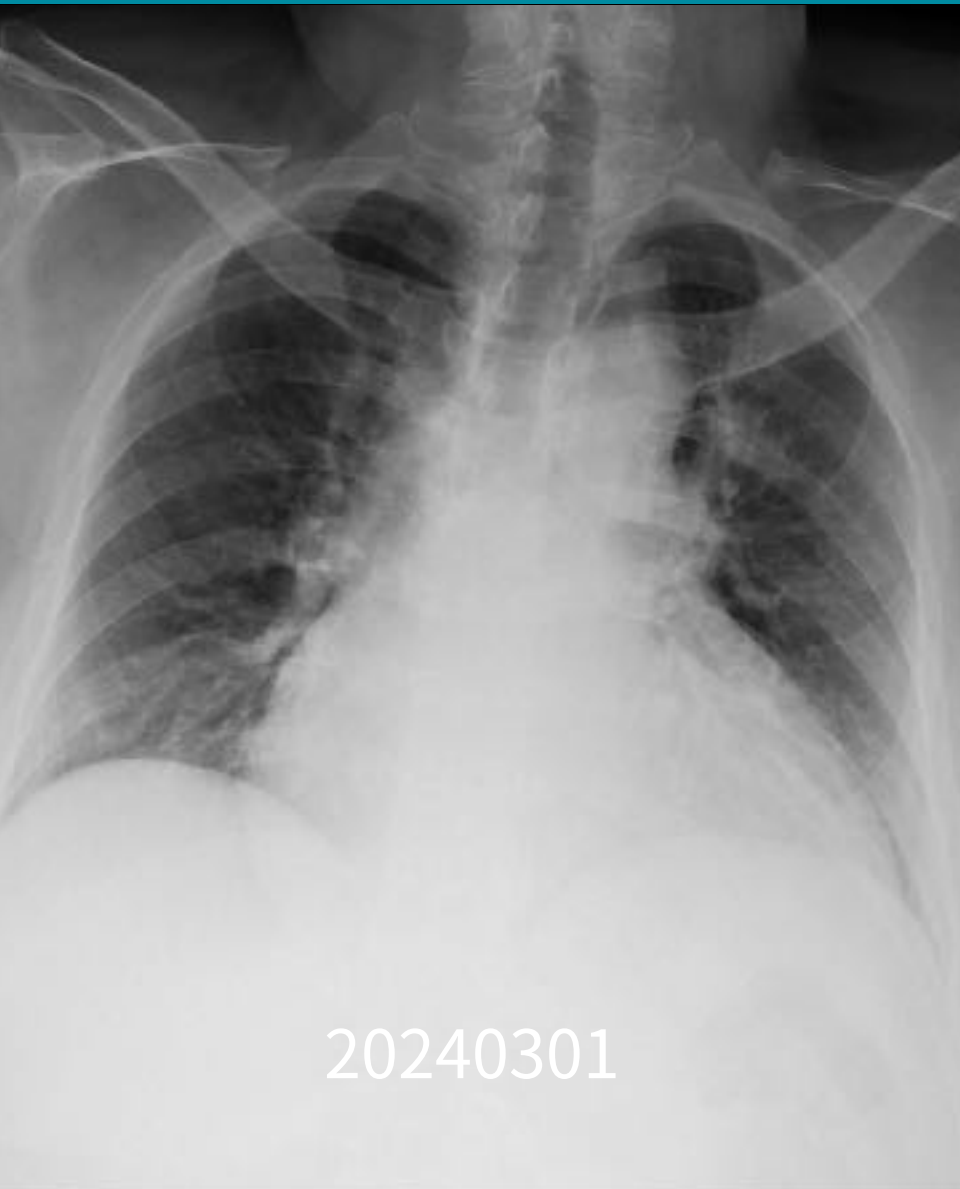S4C



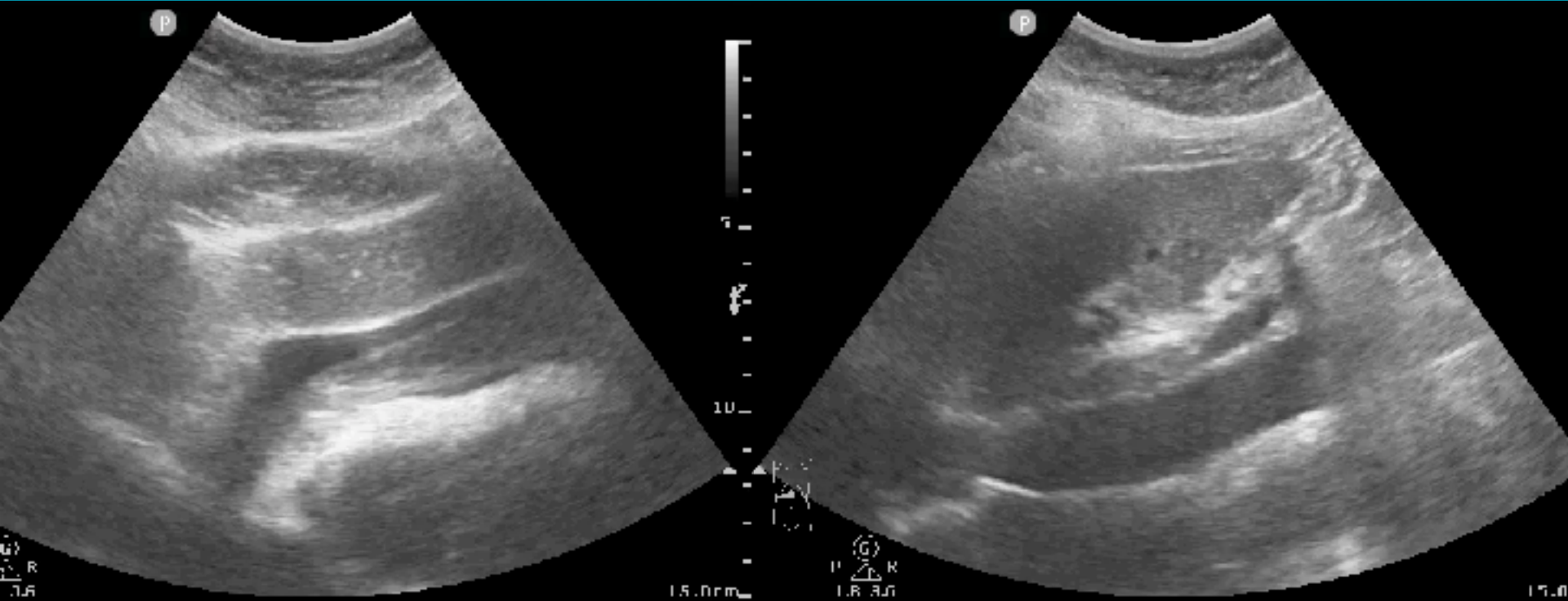
**HEMOPERICARDIUM**



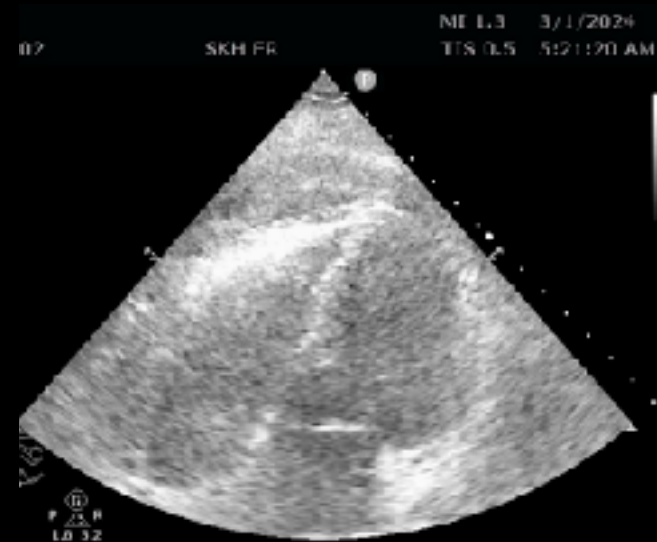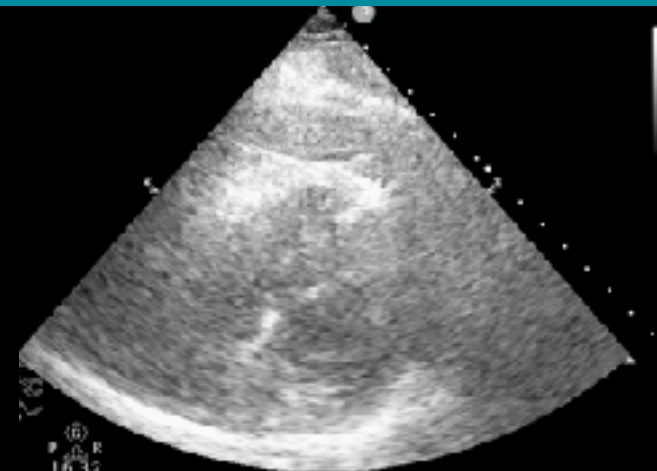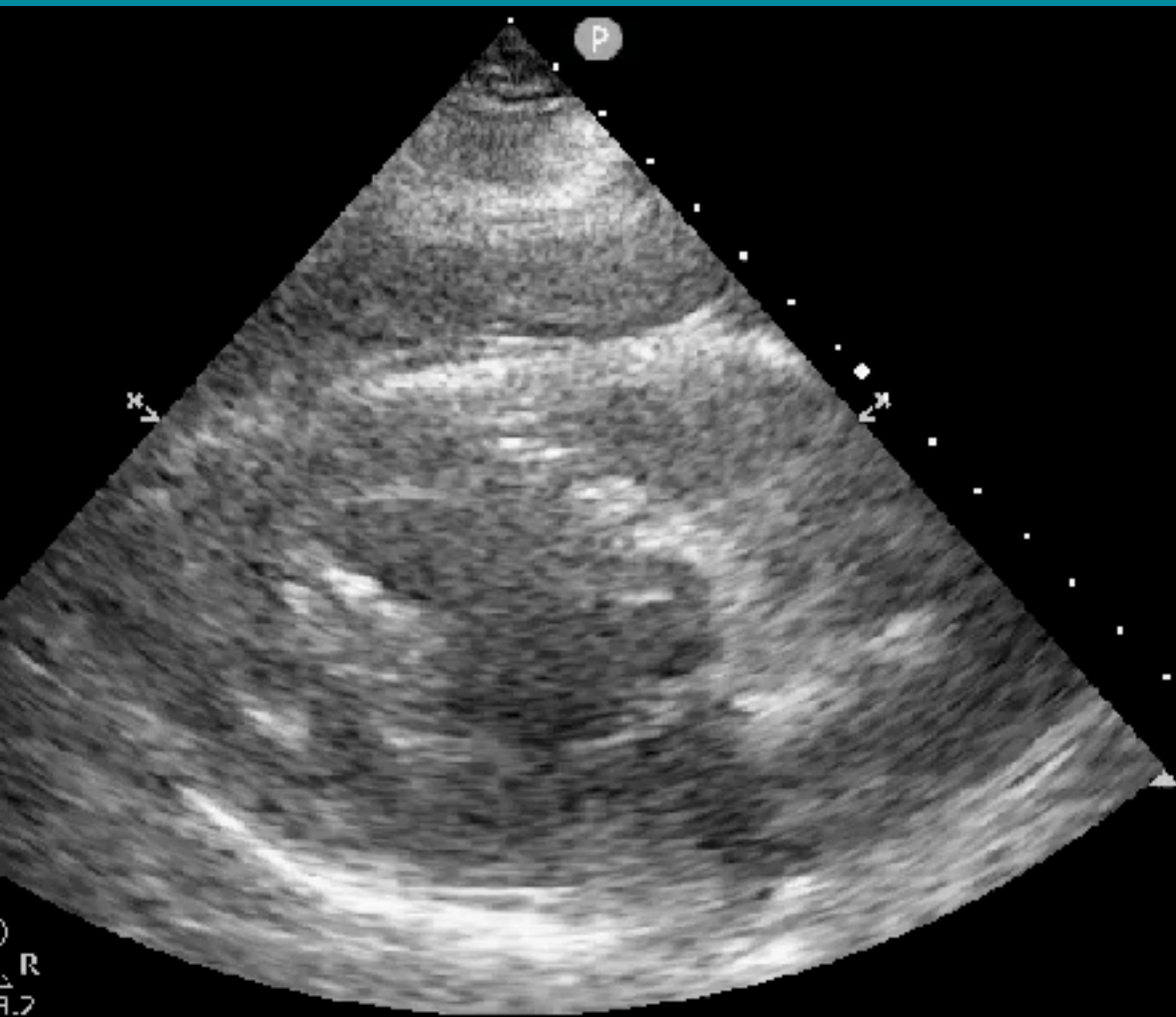
55F, 01點洗澡後開始全身不舒服，冒冷汗，持續數小時  
頭暈、噁心，胸悶痛，坐起來更不舒服，躺下好些



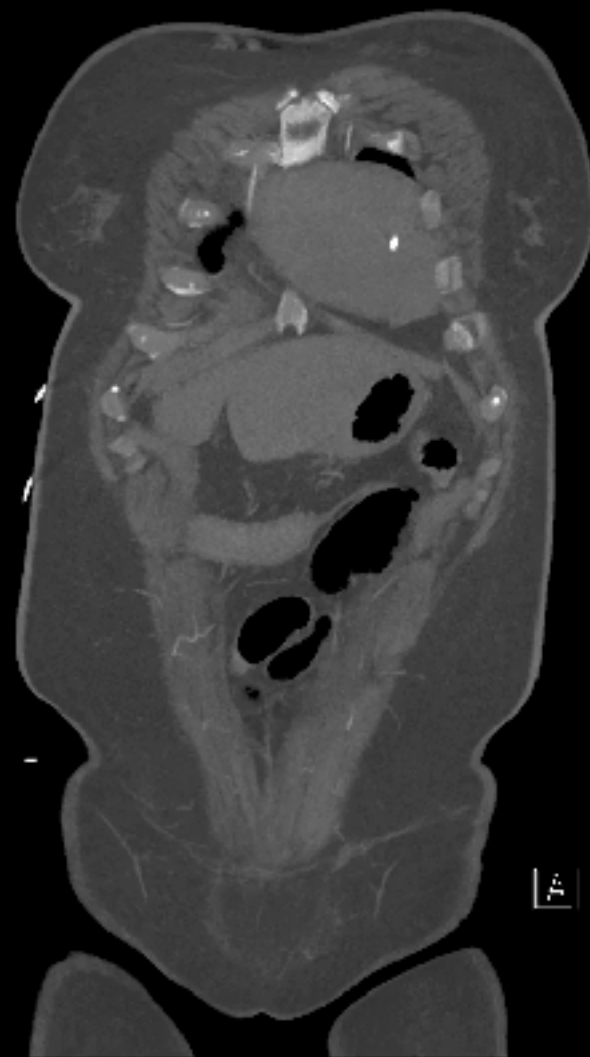
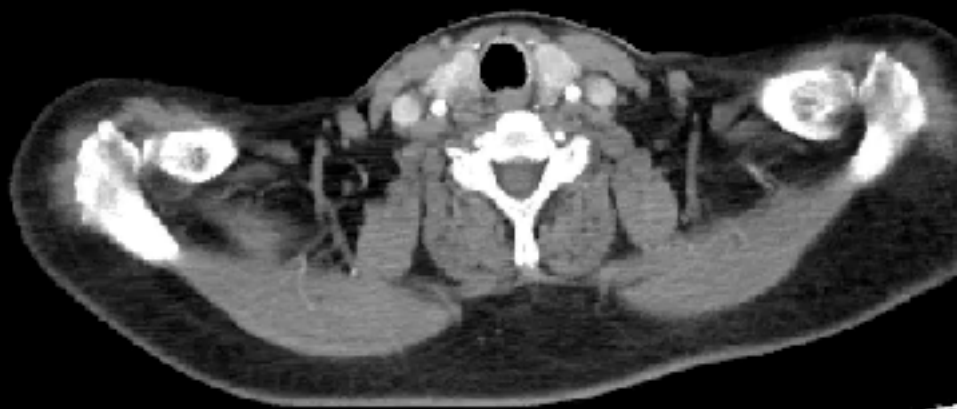55F, 01點洗澡後開始全身不舒服，冒冷汗，持續數小時  
頭暈、噁心，胸悶痛，坐起來更不舒服，躺下好些



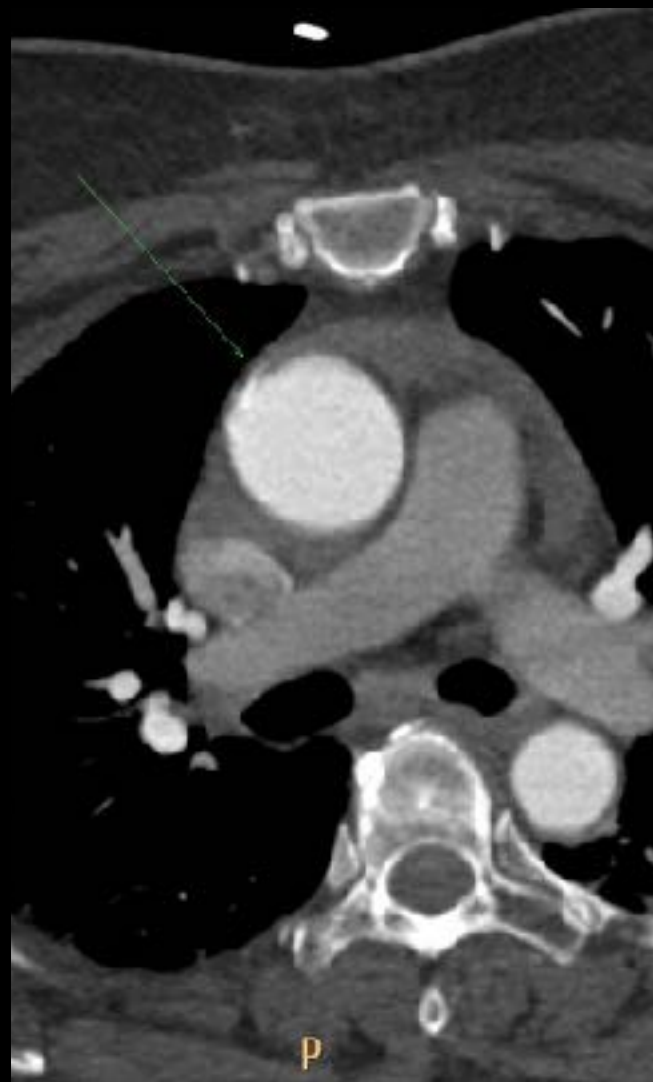
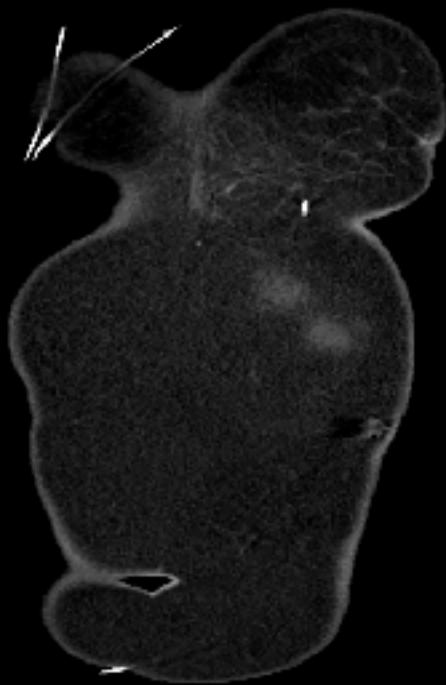
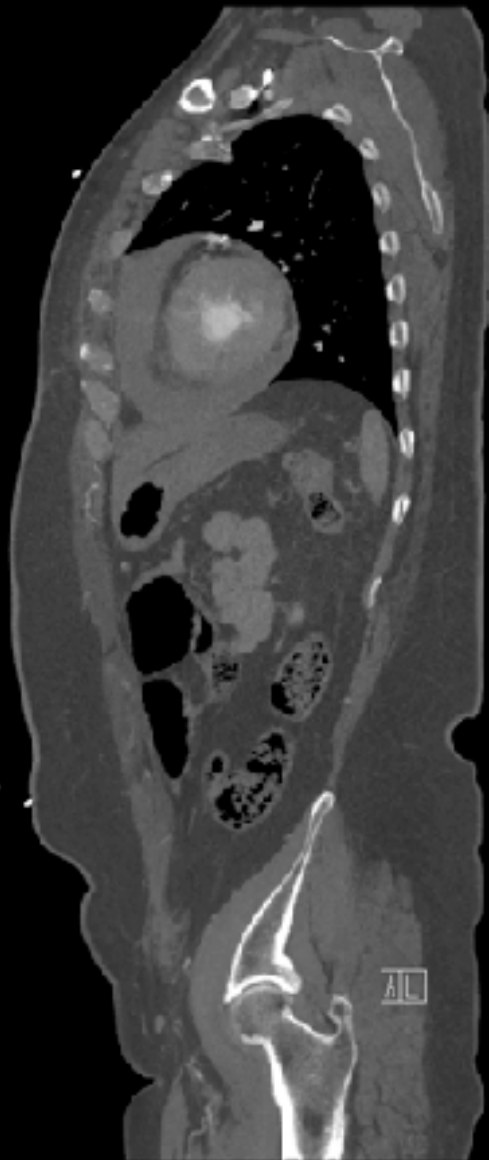
55F, 01點洗澡後開始全身不舒服，冒冷汗，持續數小時  
頭暈、噁心，胸悶痛，坐起來更不舒服，躺下好些



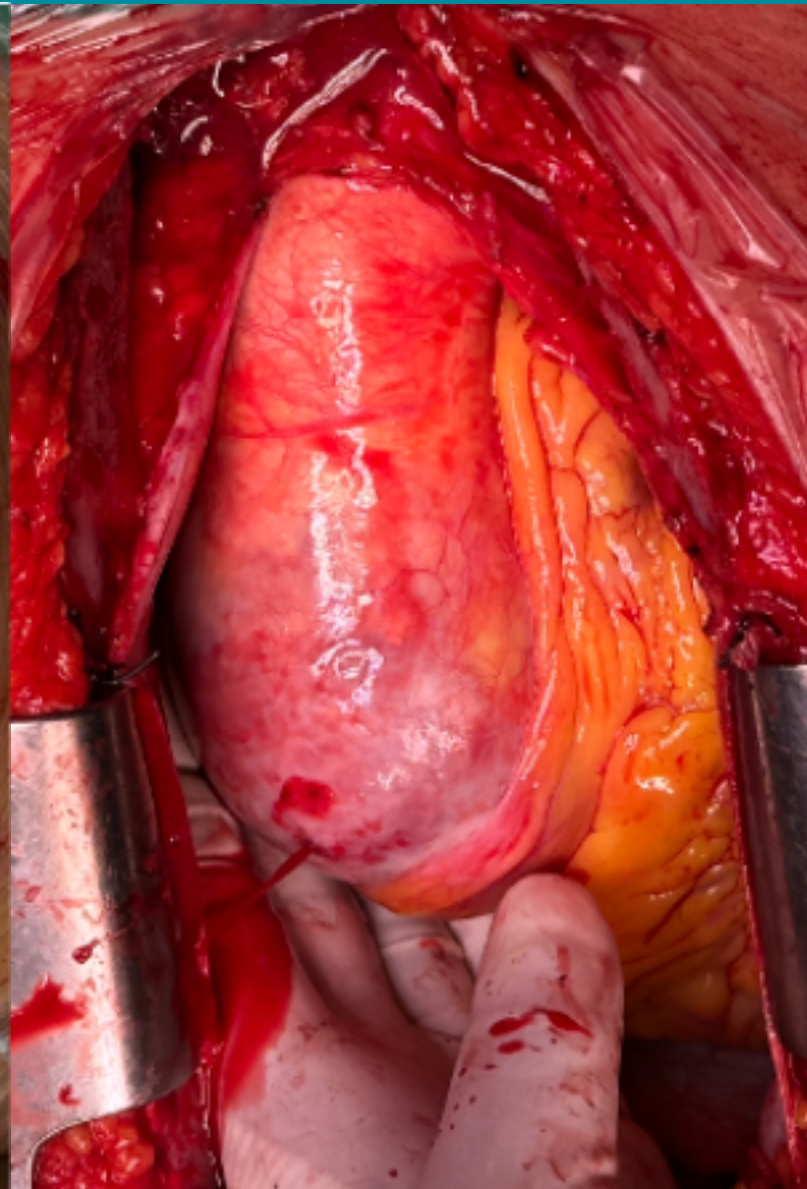
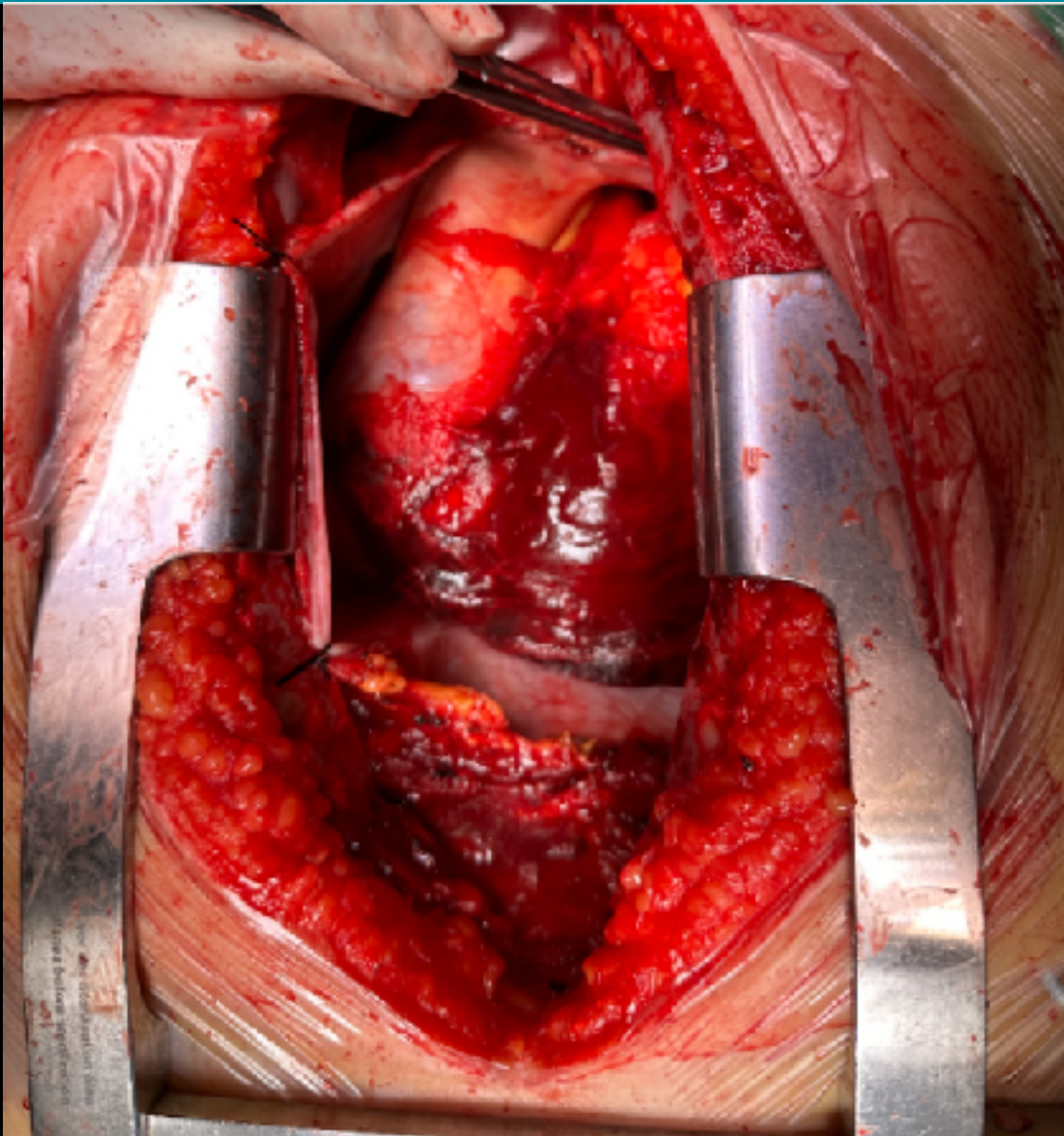
55F, 01點洗澡後開始全身不舒服，冒冷汗，持續數小時  
頭暈、噁心，胸悶痛，坐起來更不舒服，躺下好些

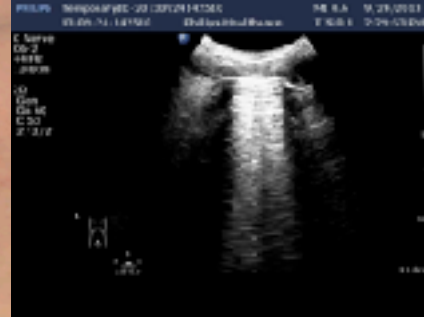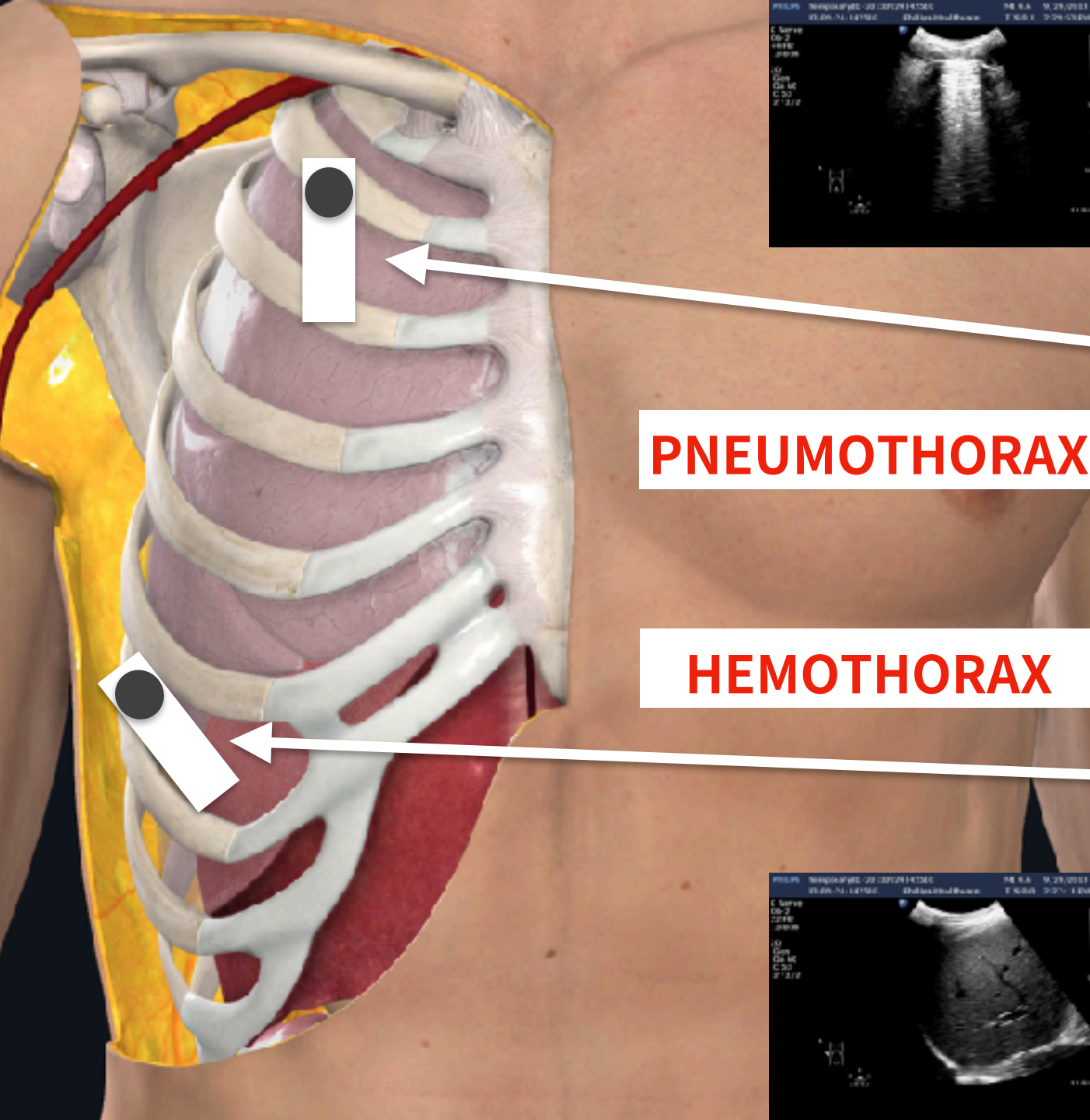


55F, 01點洗澡後開始全身不舒服，冒冷汗，持續數小時  
頭暈、噁心，胸悶痛，坐起來更不舒服，躺下好些



# ASCENDING AORTIC ANEURYSM CONTAINED RUPTURE



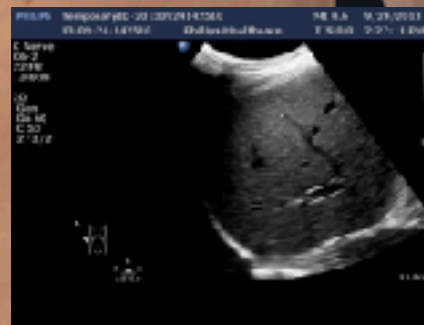


**PNEUMOTHORAX**

**AIR**

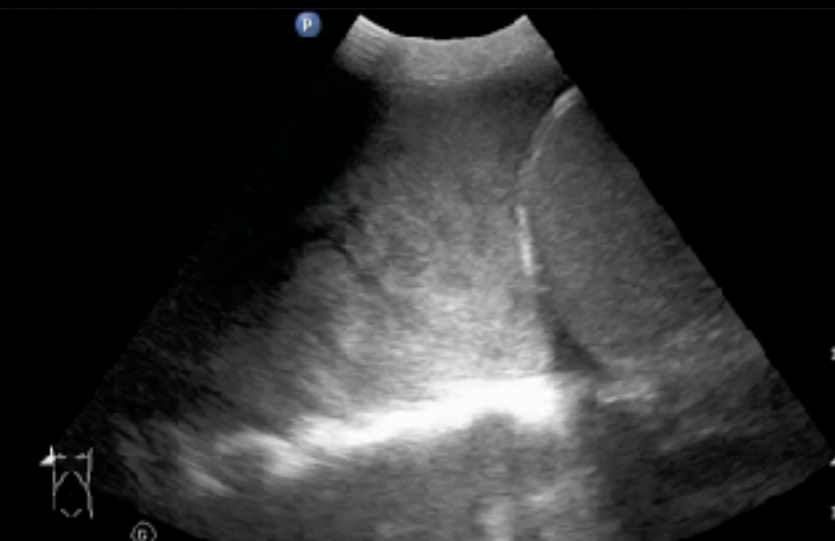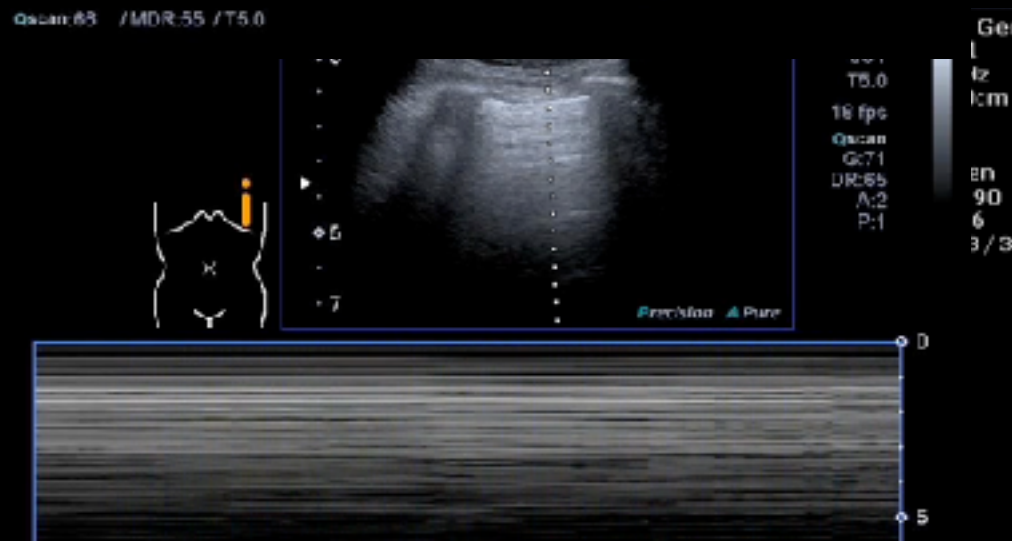
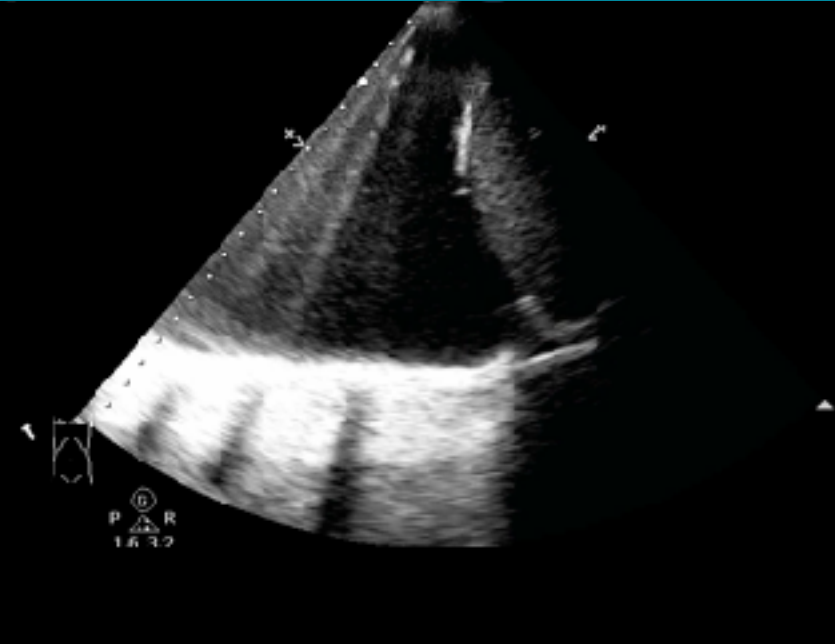
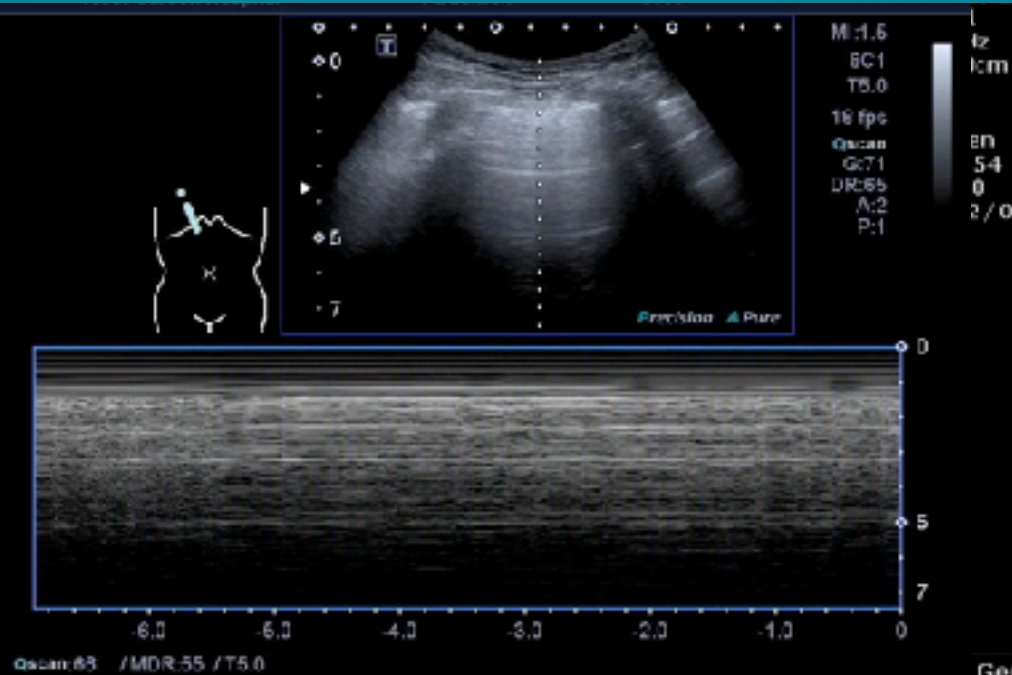
**HEMOTHORAX**

**FLUID**





# I-AIM (Lung US)

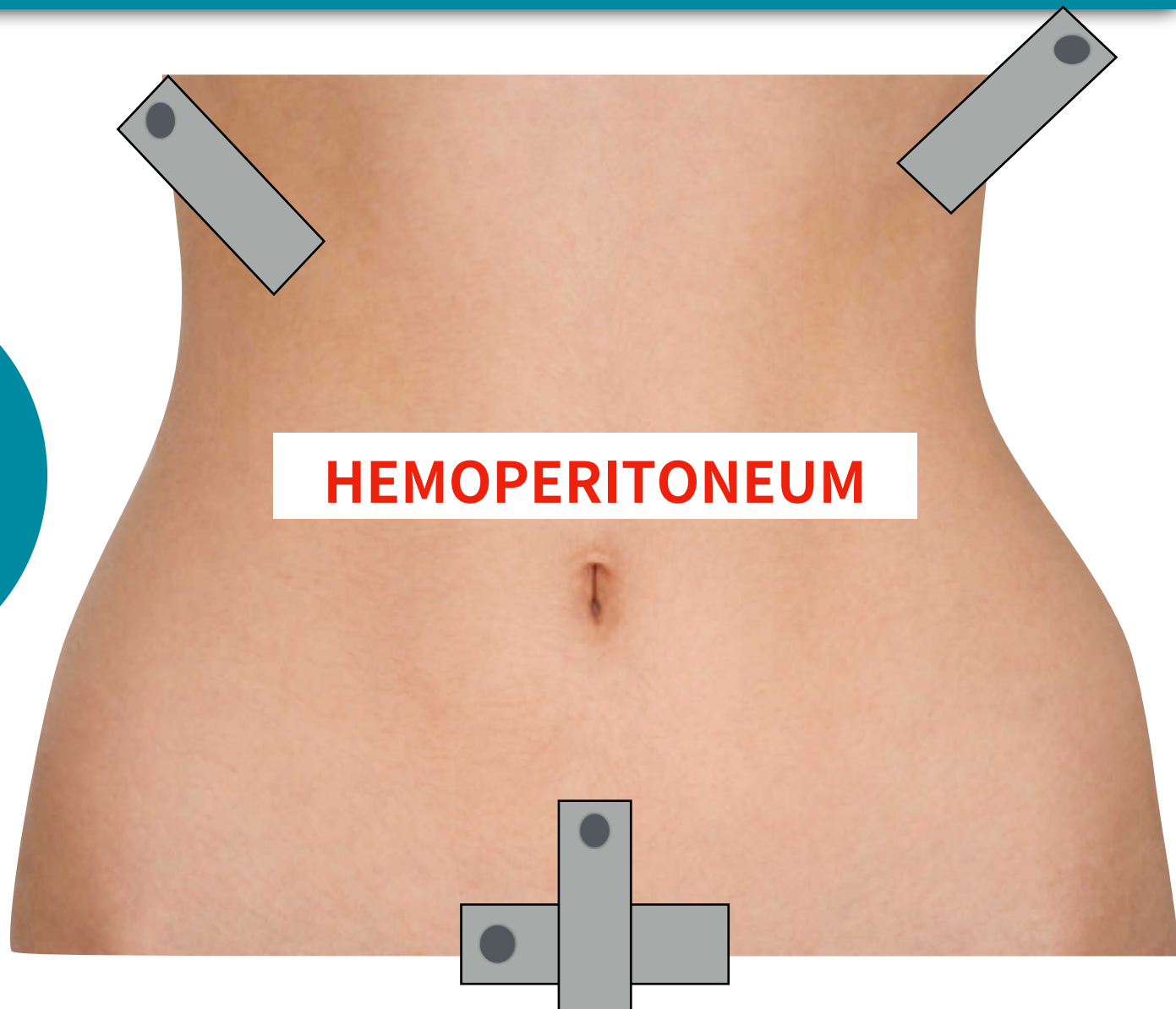




# FAST: Free fluid

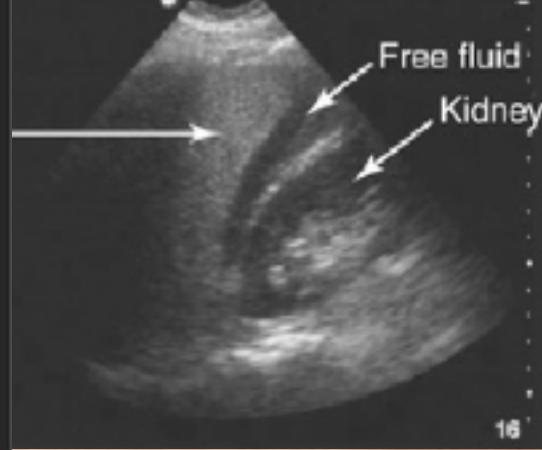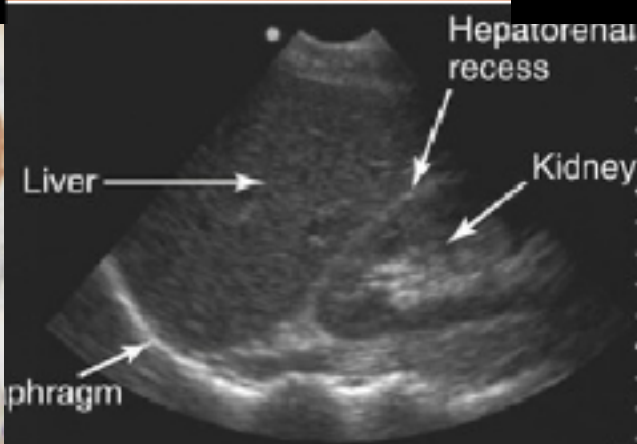
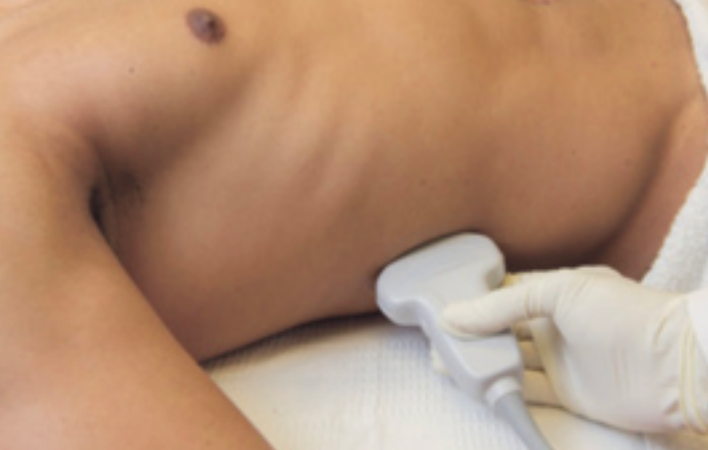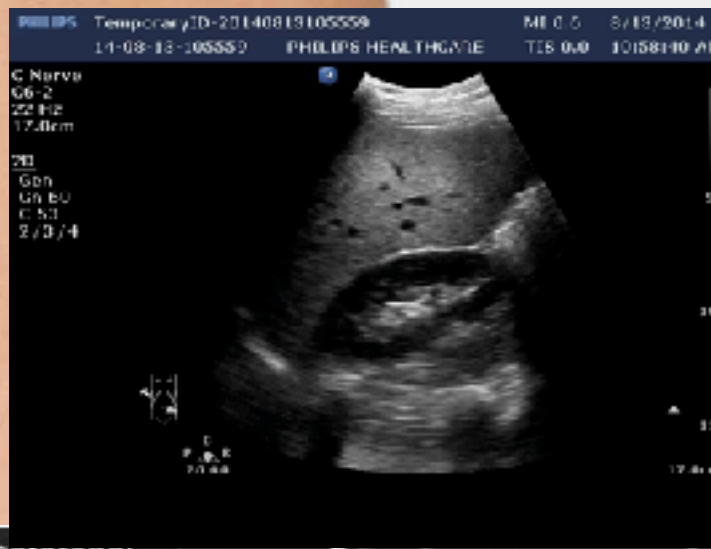


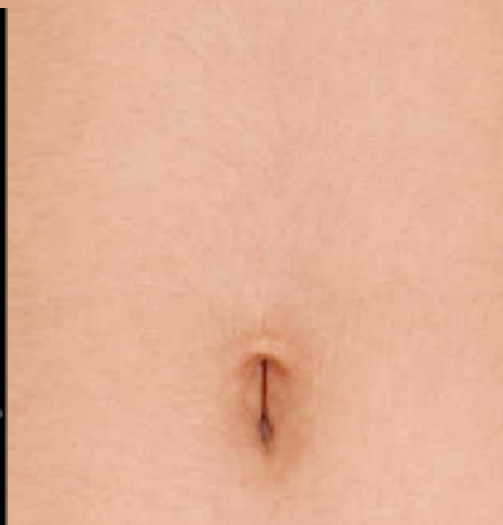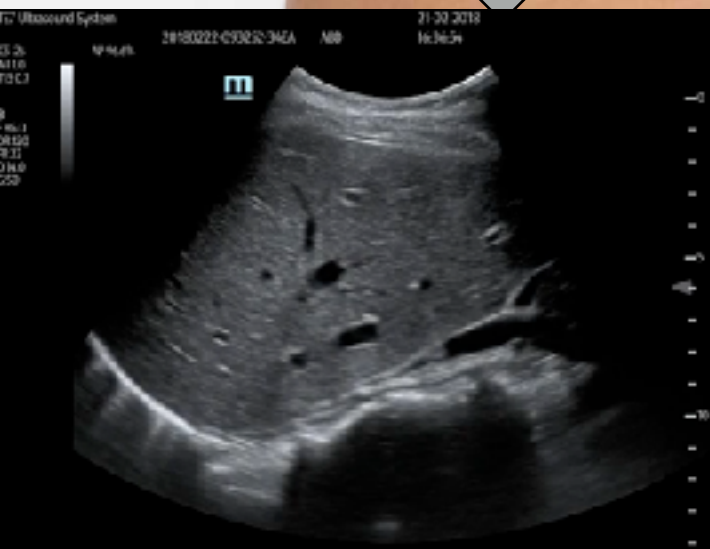倒三角  
掃描介面

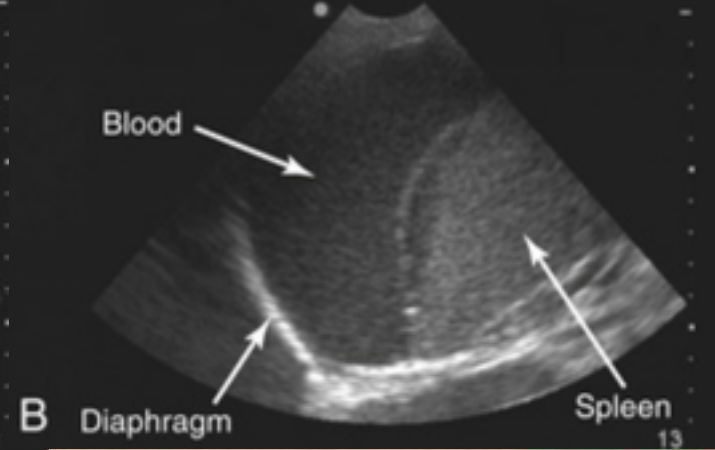
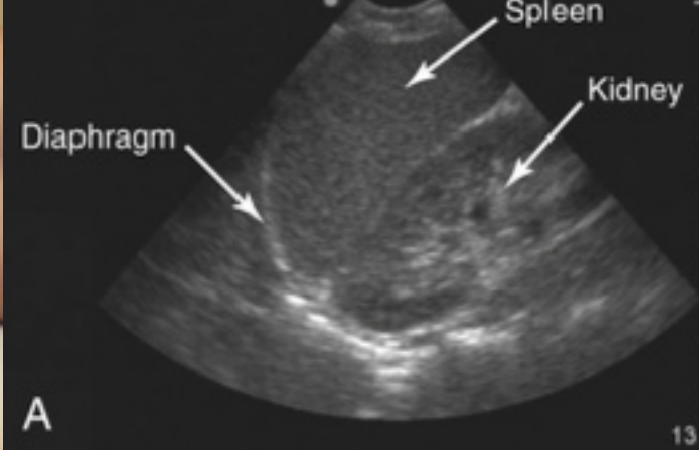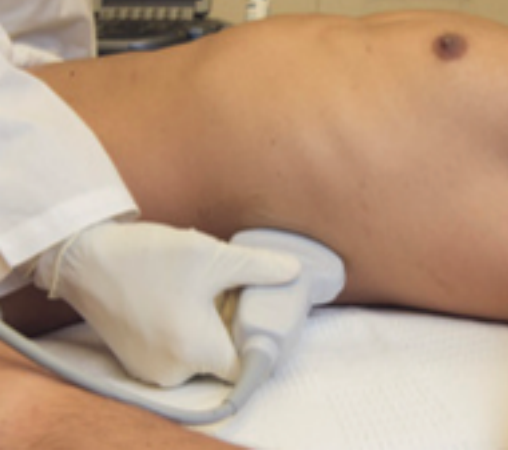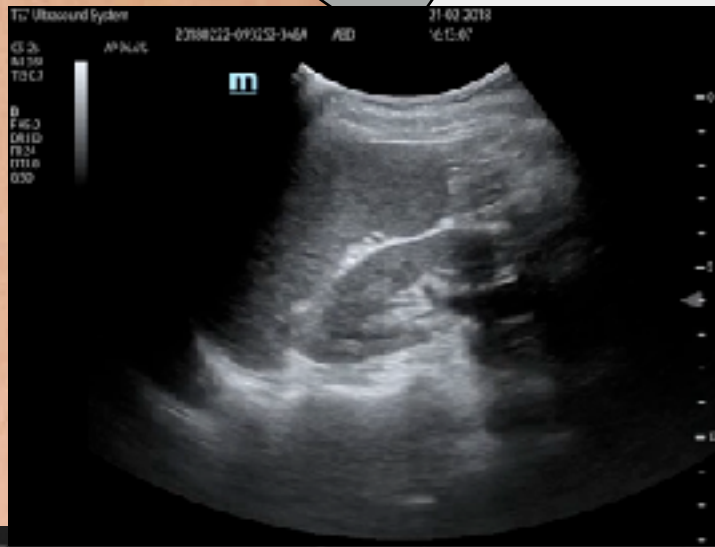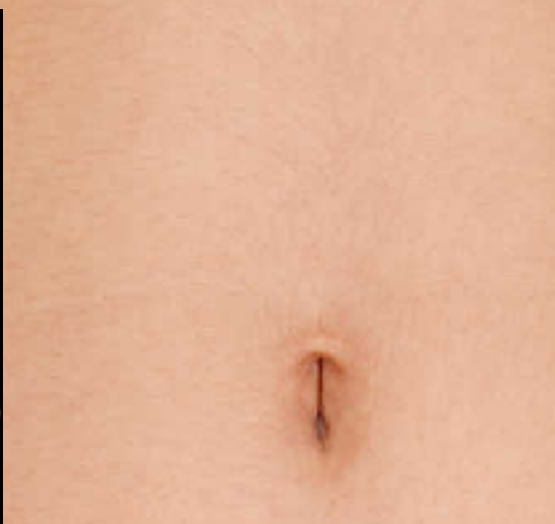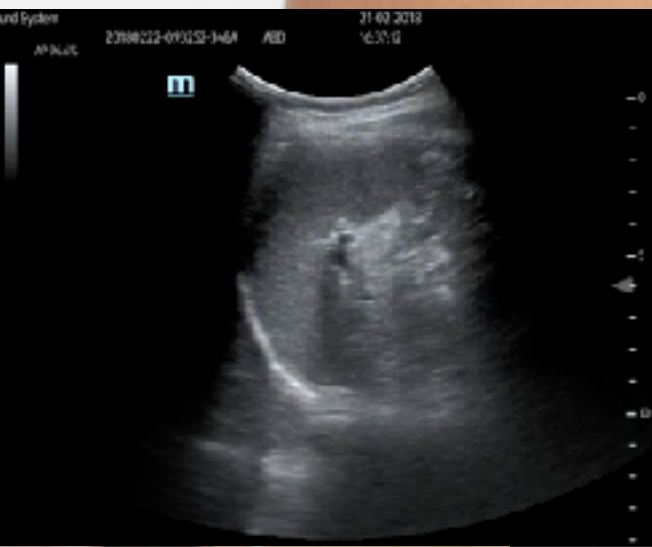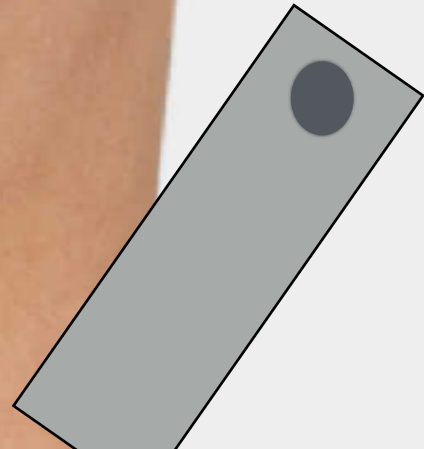


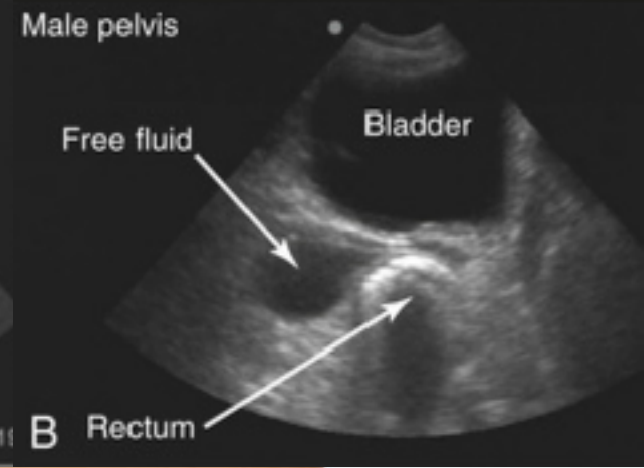
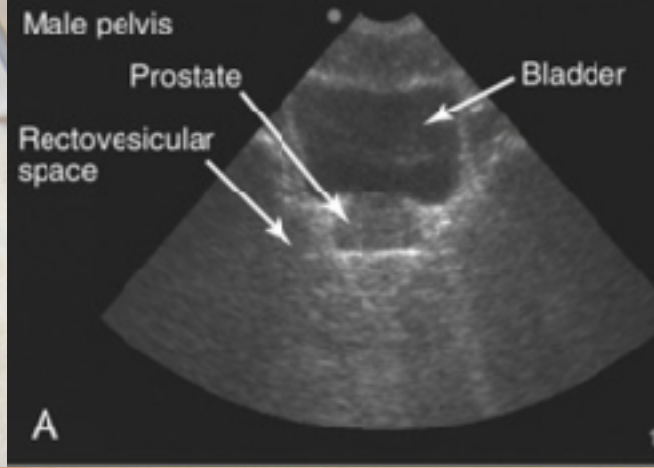
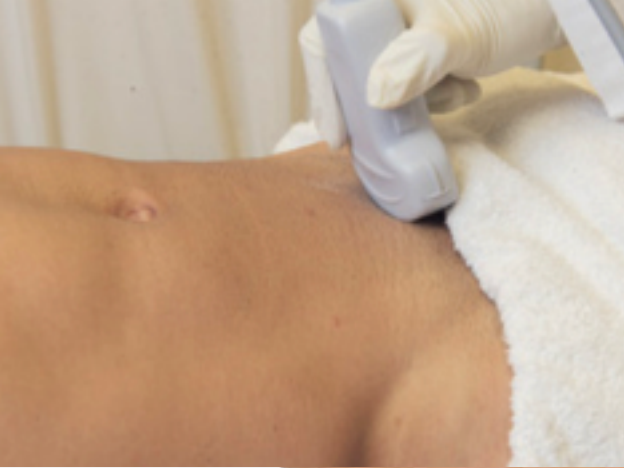HEMOPERITONEUM

劍突-腋前線交界點  
平行肋間掃描以避開肋骨  
第一目標:肝腎介面(Morrison's pouch)  
第二目標:橫膈膜

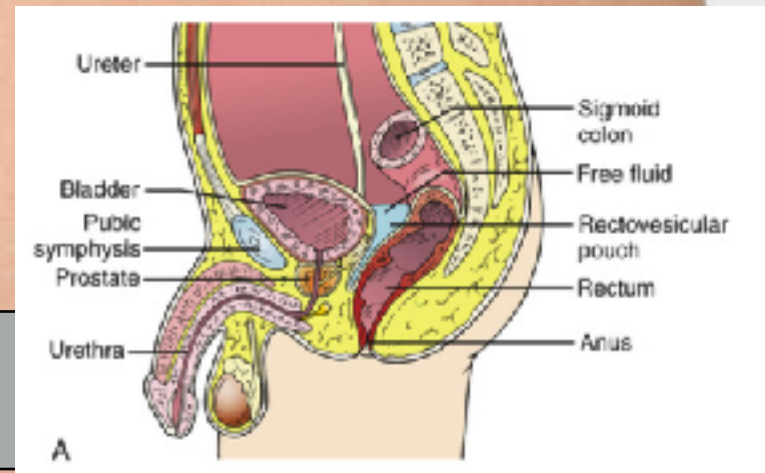
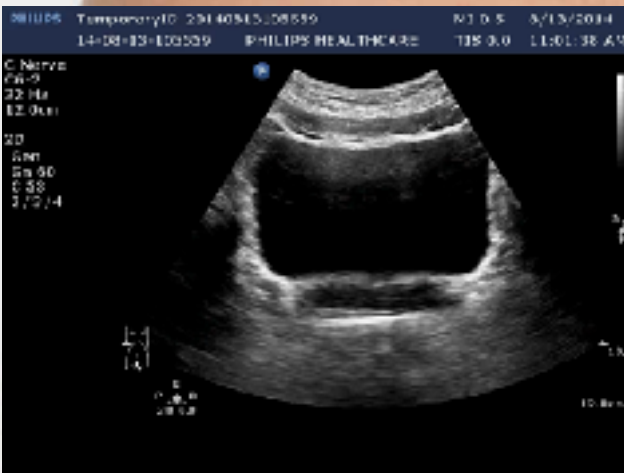

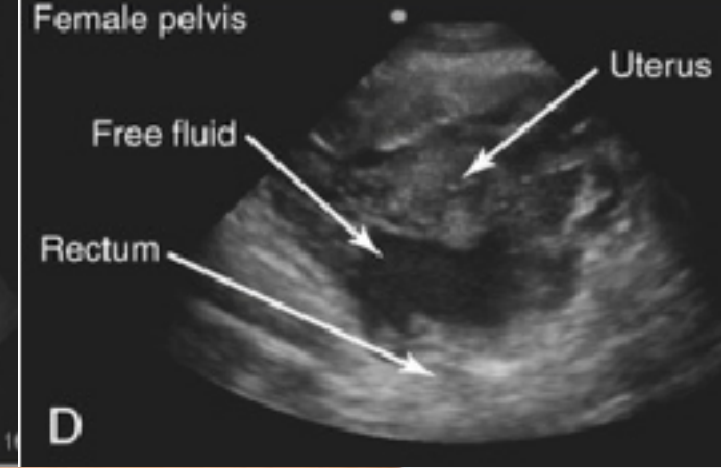
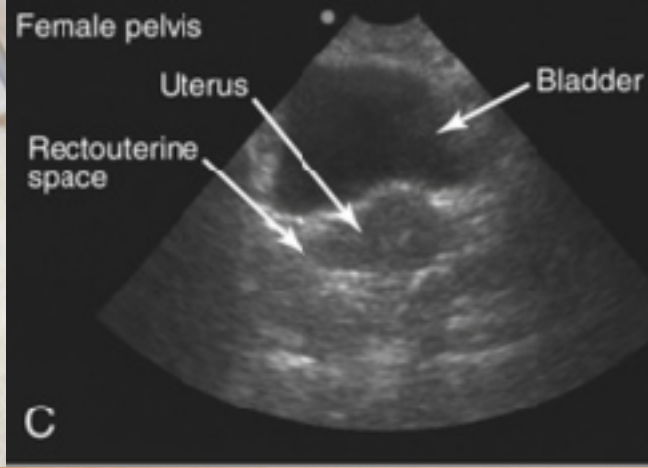
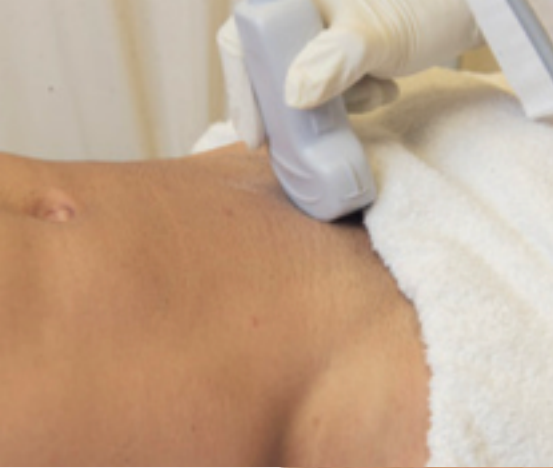劍突-腋後線交界點  
平行肋間掃描以避開肋骨  
第一目標:橫膈膜下  
第二目標:脾腎交界



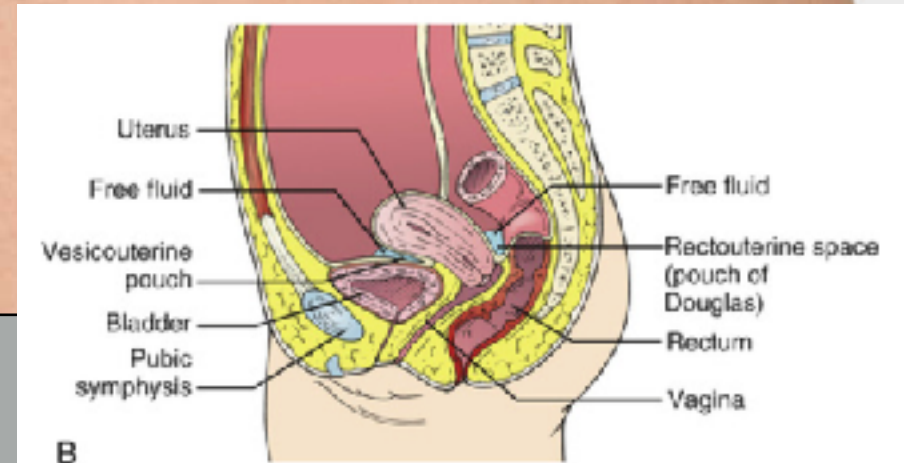
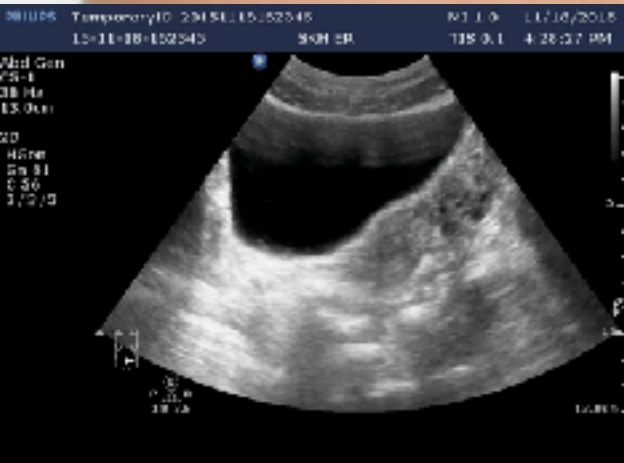


恥骨聯合上方  
Tilt探頭進行掃描  
要有好的視窗(尿液)  
主要目標: 膀胱下方



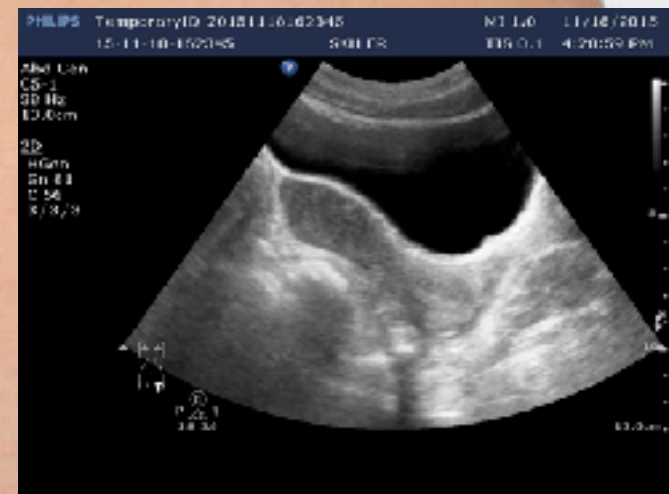
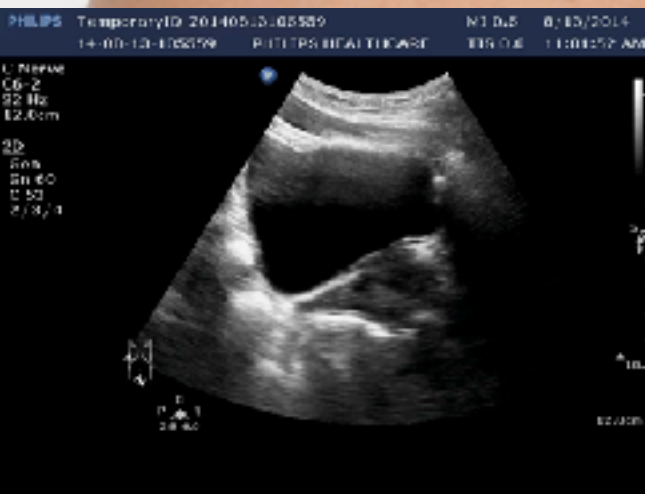

恥骨聯合上方  
Tilt探頭進行掃描(頭腳)  
要有好的視窗(尿液)  
第一目標:子宮下方  
第二目標:膀胱子宮間



# 為什麼一定要有這個介面呢？

恥骨聯合上方  
Tilt探頭進行掃描(左右)  
要有好的介面(尿液)  
第一目標:子宮下方  
第二目標:膀胱子宮間  
男:膀胱下方

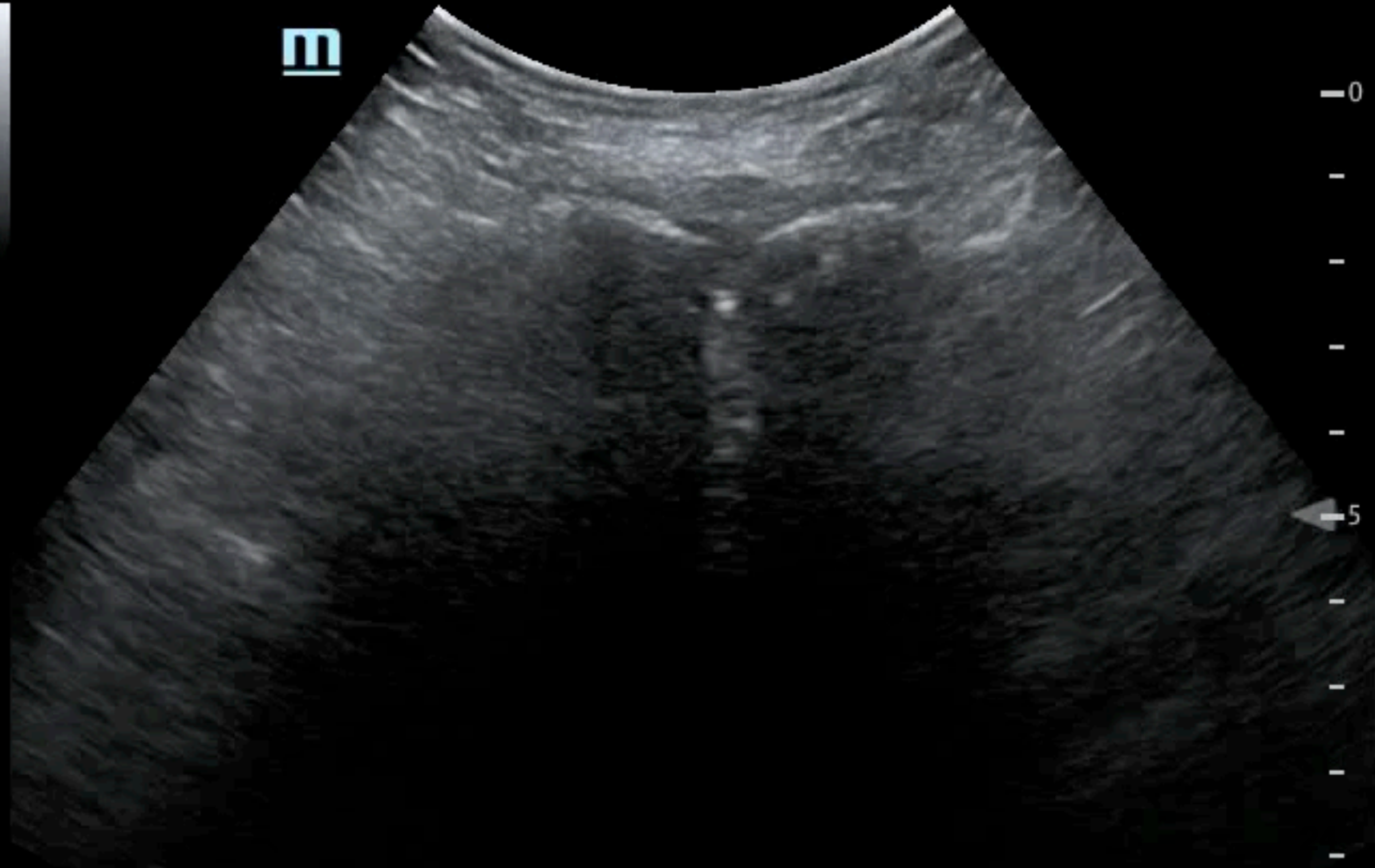


# PUBIC SYMPHYSIS

MI 1.0  
TIS 0.7



B  
FH5.0  
DR120  
FR28  
D 11.0  
G 47

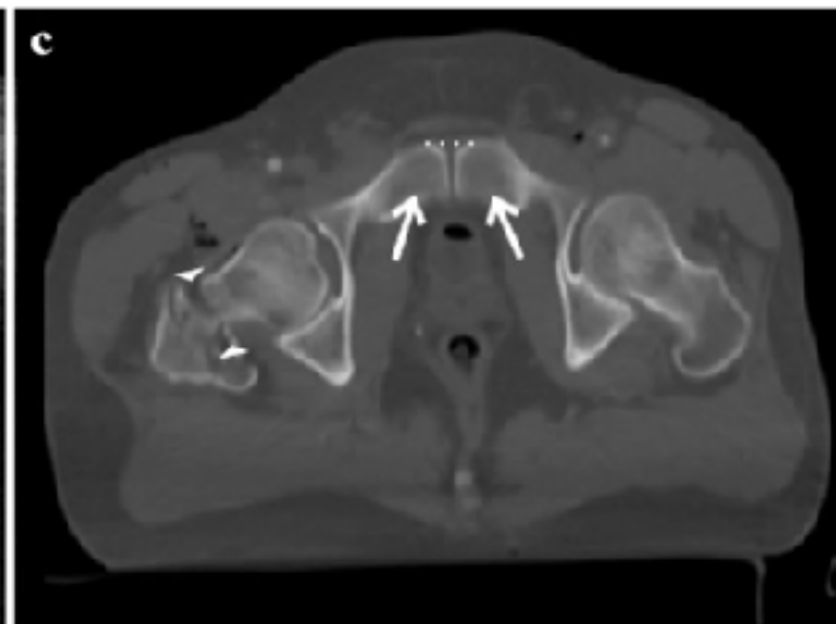
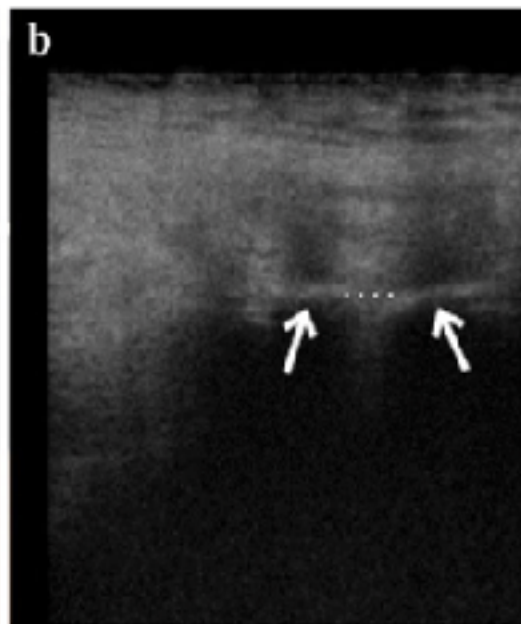
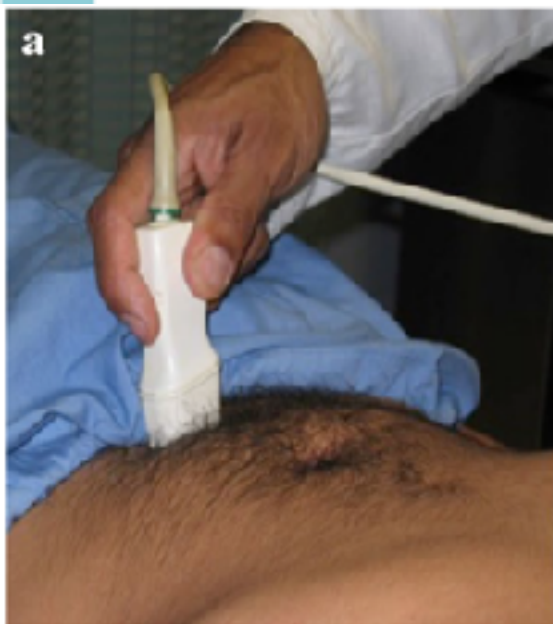



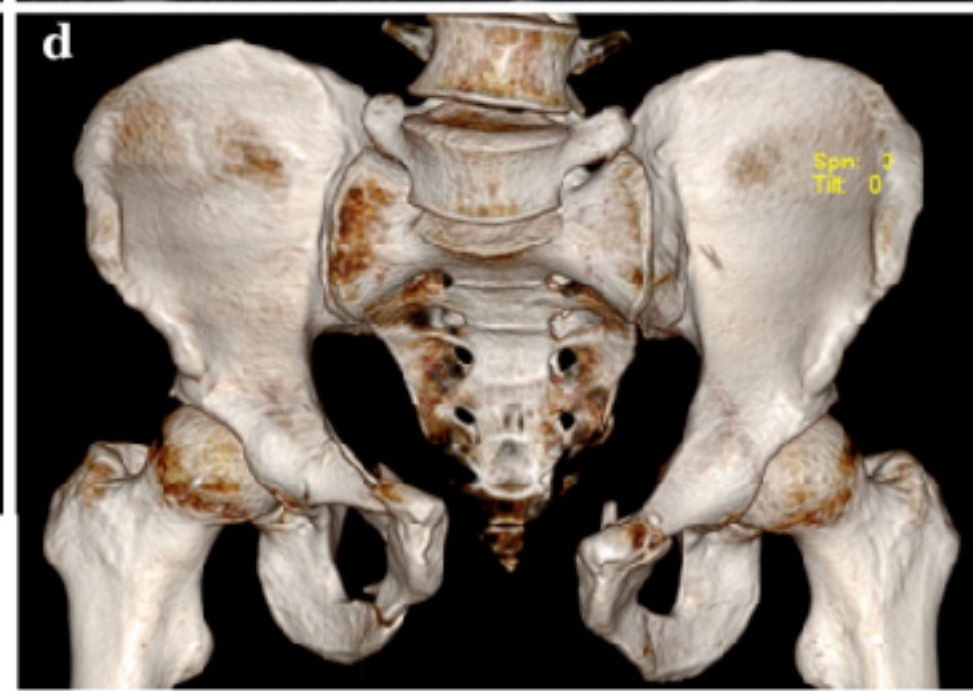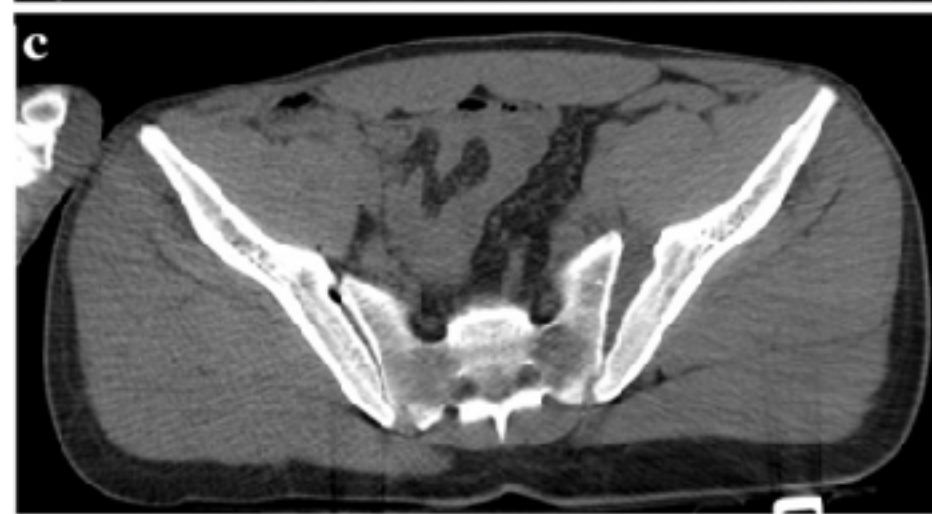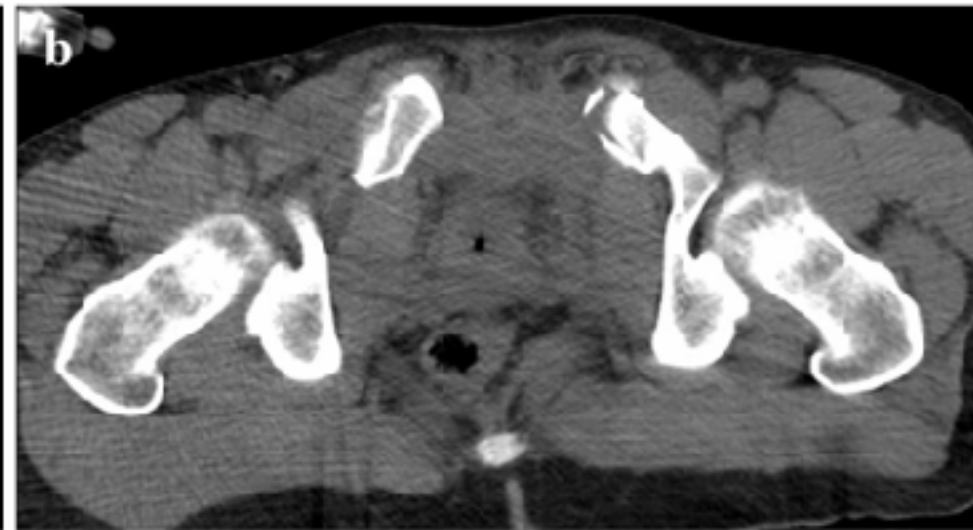
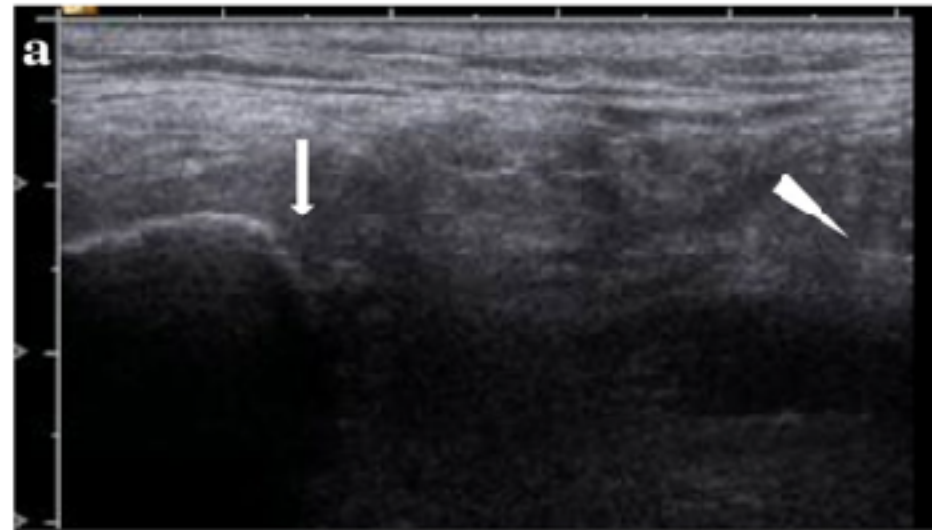
# PS: 2.5CM

## Diagnostic accuracy of pubic symphysis ultrasound in the detection of unstable pelvis in polytrauma patients during e-FAST: the value of FAST-PLUS protocol. A preliminary experience

Stefania Ianniello<sup>1</sup>  · Paola Conte<sup>1</sup> · Marco Di Serafino<sup>2</sup>  · Vittorio Miele<sup>3</sup>  · Margherita Trinci<sup>1</sup>  · Gianfranco Vallone<sup>4</sup> · Michele Galluzzo<sup>1</sup> 



# MAJOR TRAUMA + SHOCK



# 66M, TRAUMA

**Triage: 2**

**E4V5M6**

**車禍，臉部擦傷**

**BT 37.3**

**左臉頰血腫，四肢擦傷**

**PR 87**

**不記得事發經過、背痛**

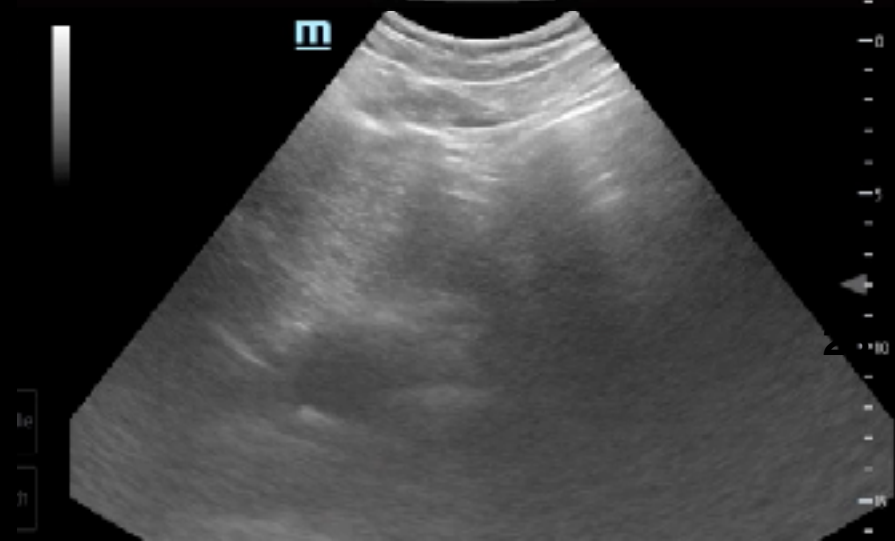
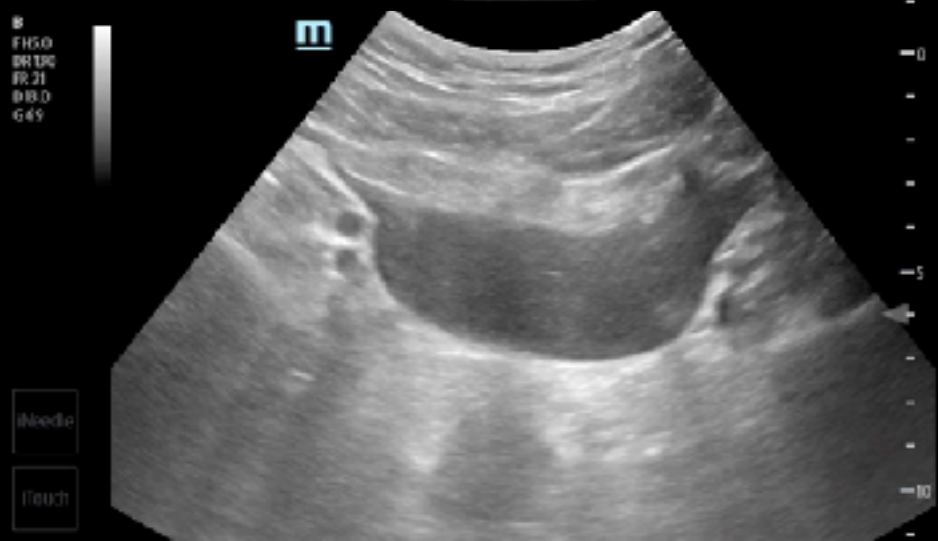
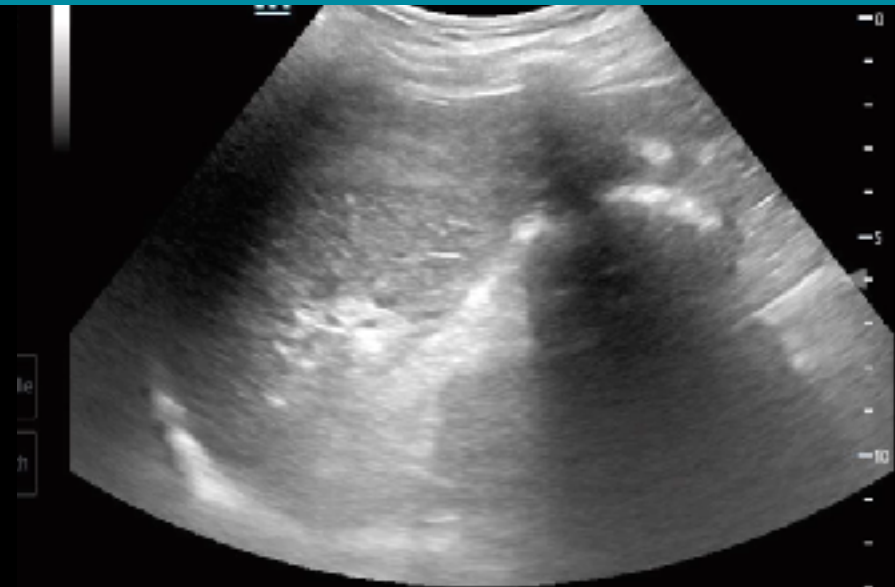
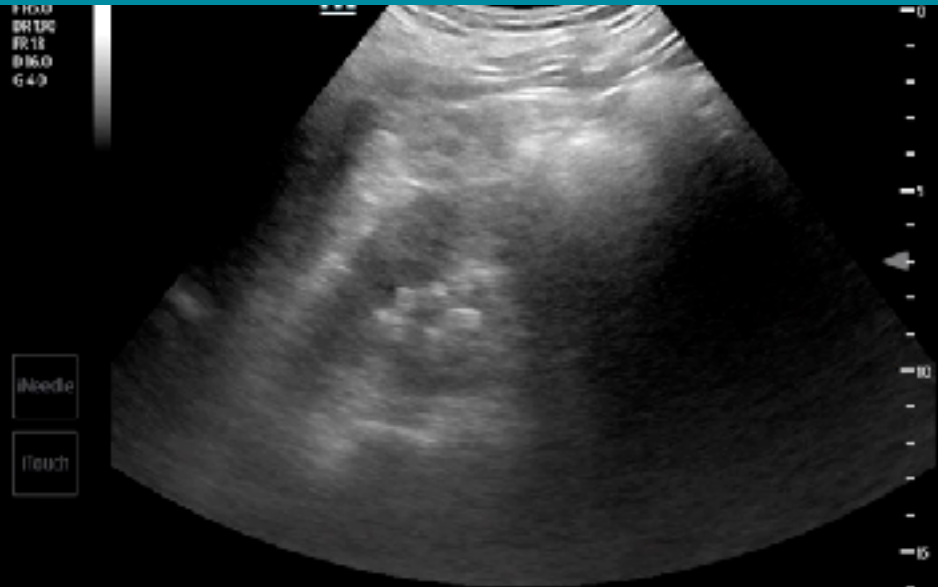
**RR 20**

**EMT: 騎機車路倒無目擊者**

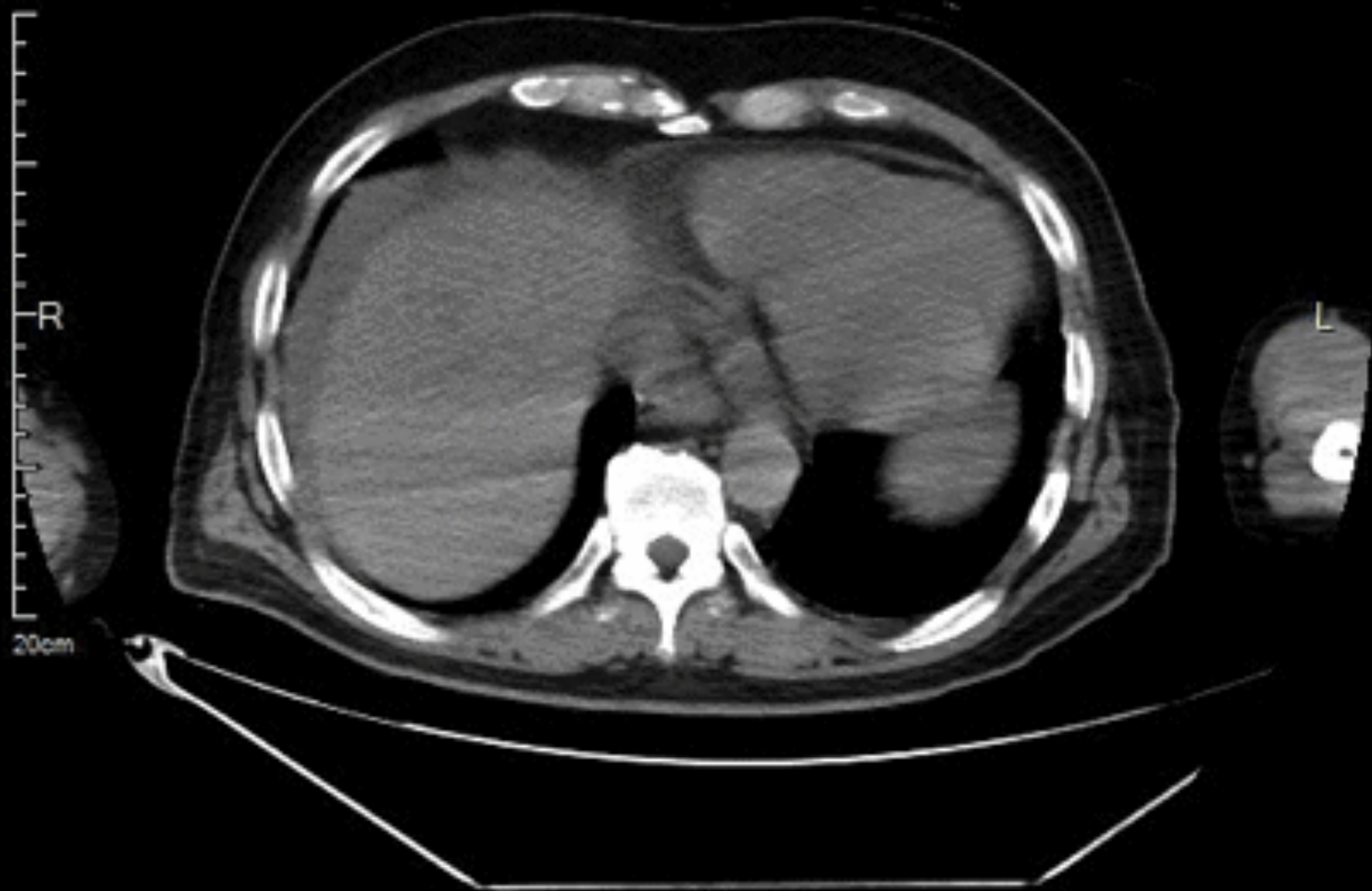
**BP 118/65**

**SpO2 97%**

# 66M, TRAUMA

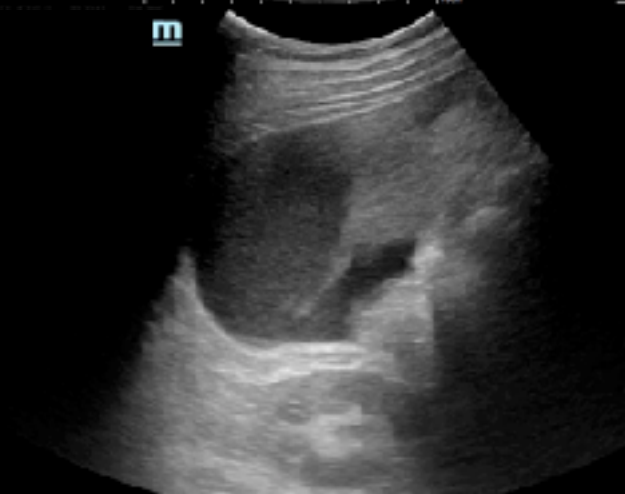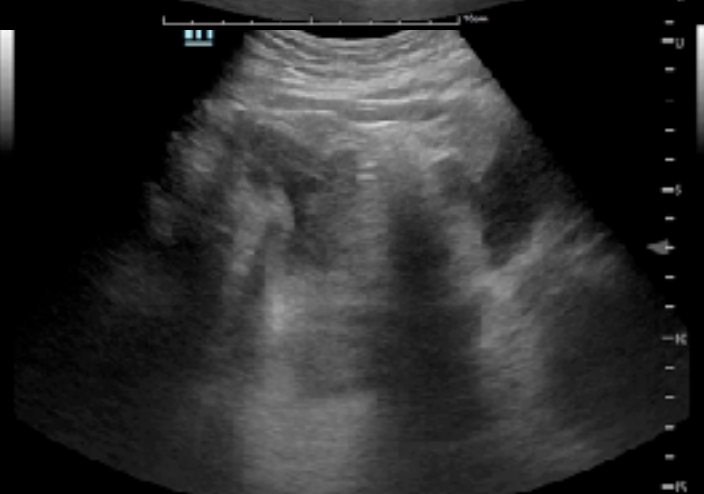

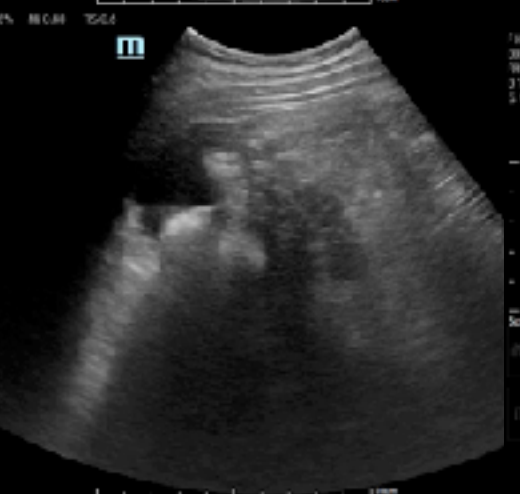
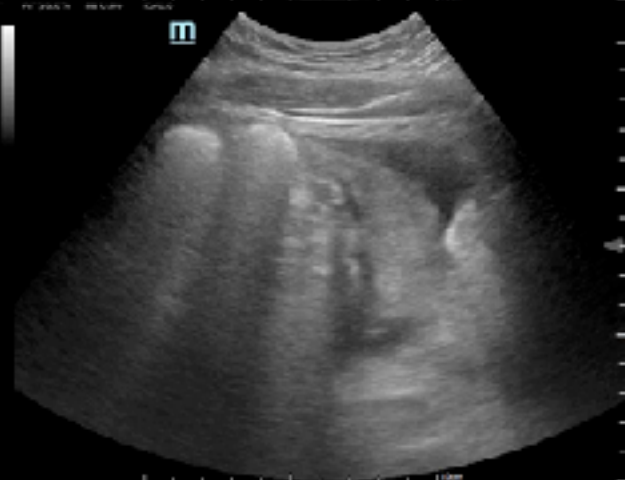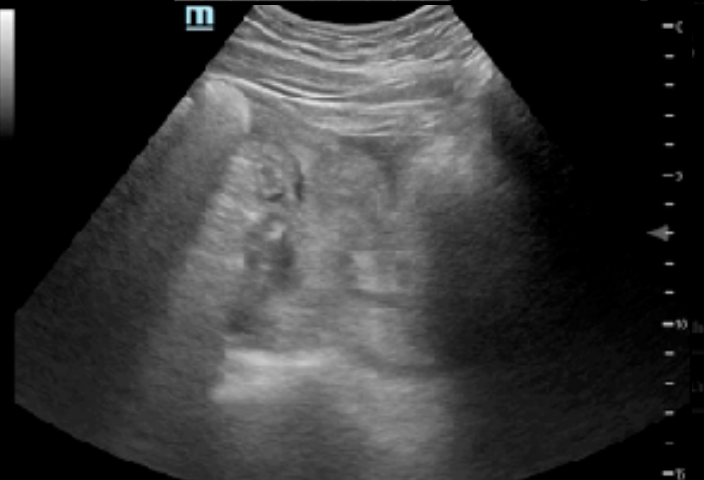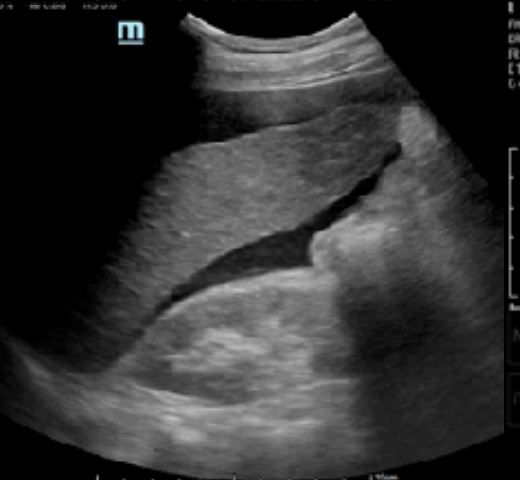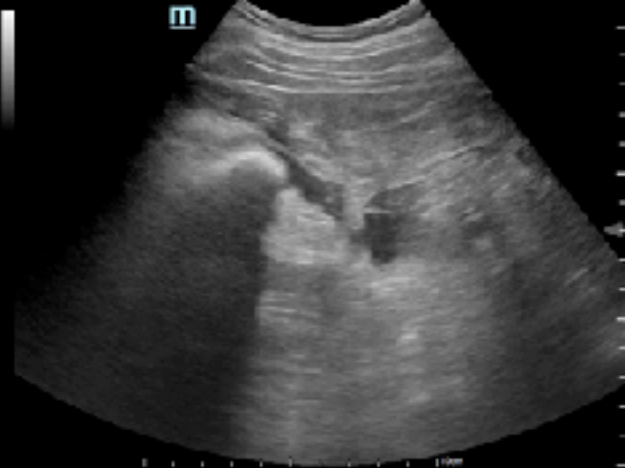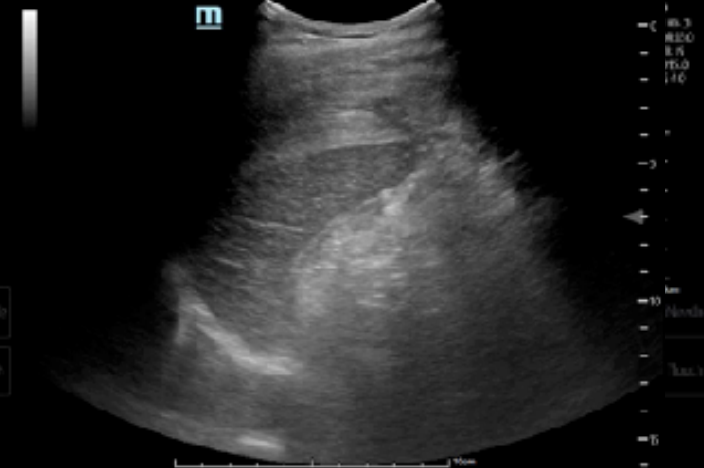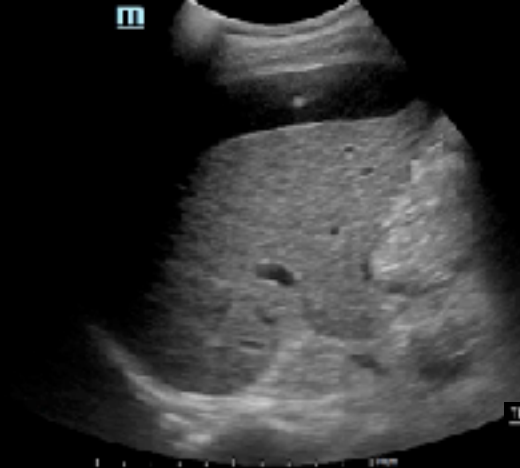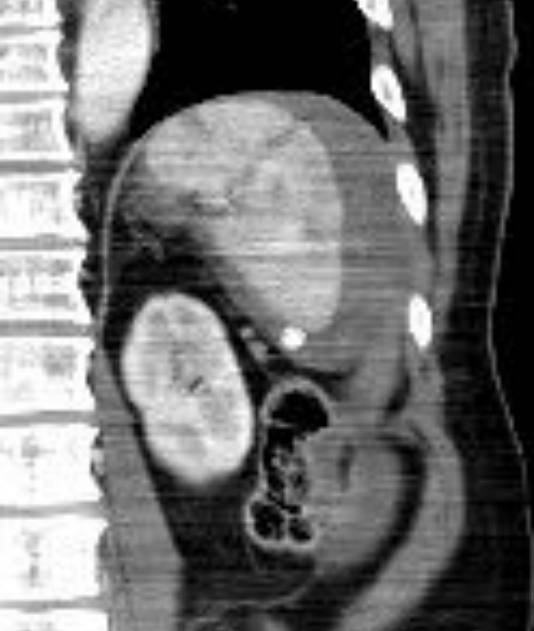A



P

20cm



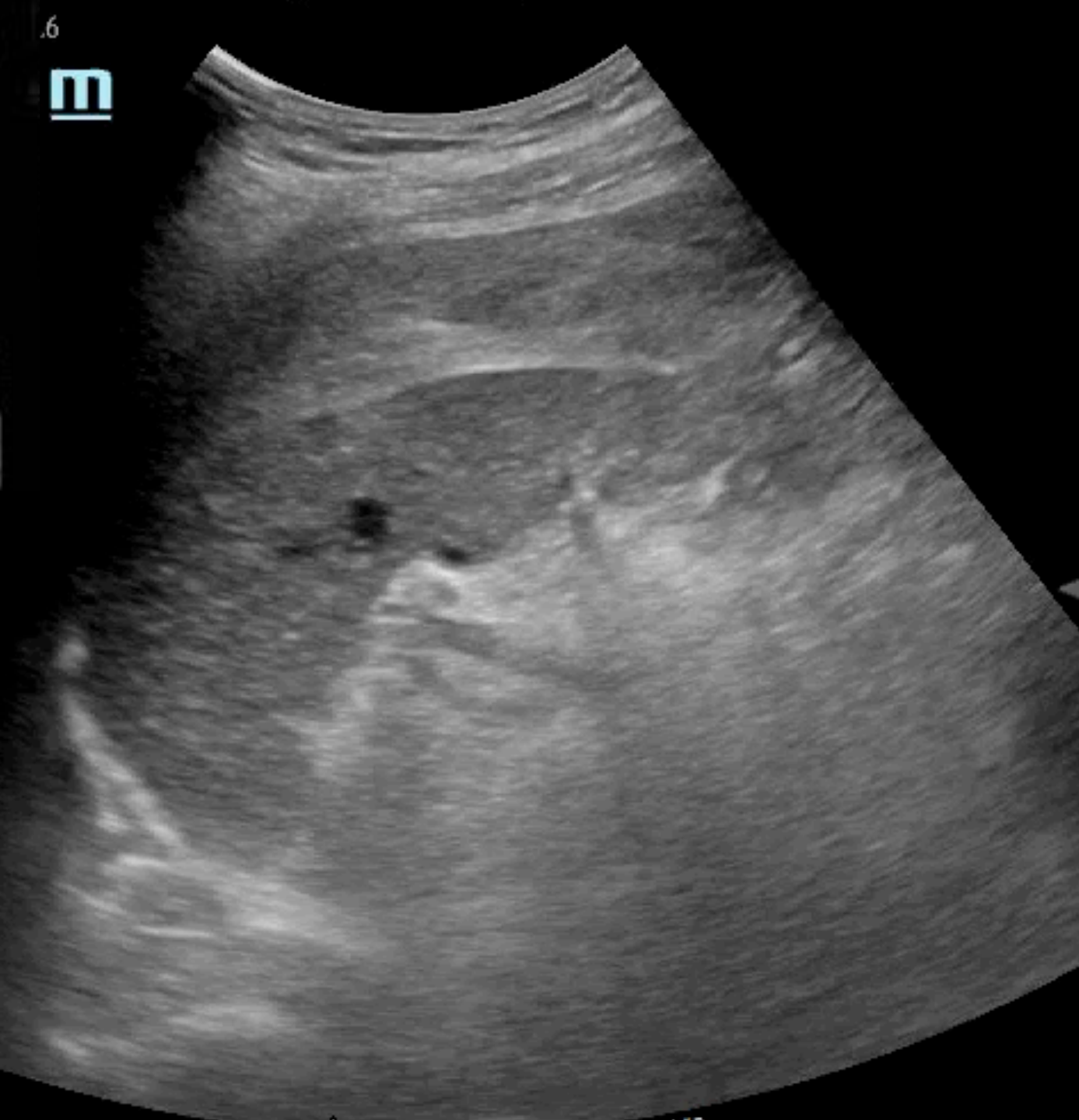

.6

m

dle

ch



# 30M, TRAUMA

**Triage: 2**

**E4V5M6**

**騎機車為了閃車自摔**

**BT 36.5**

**上腹、胸口、右肩，頸部疼痛**

**PR 69**

**冒冷汗**

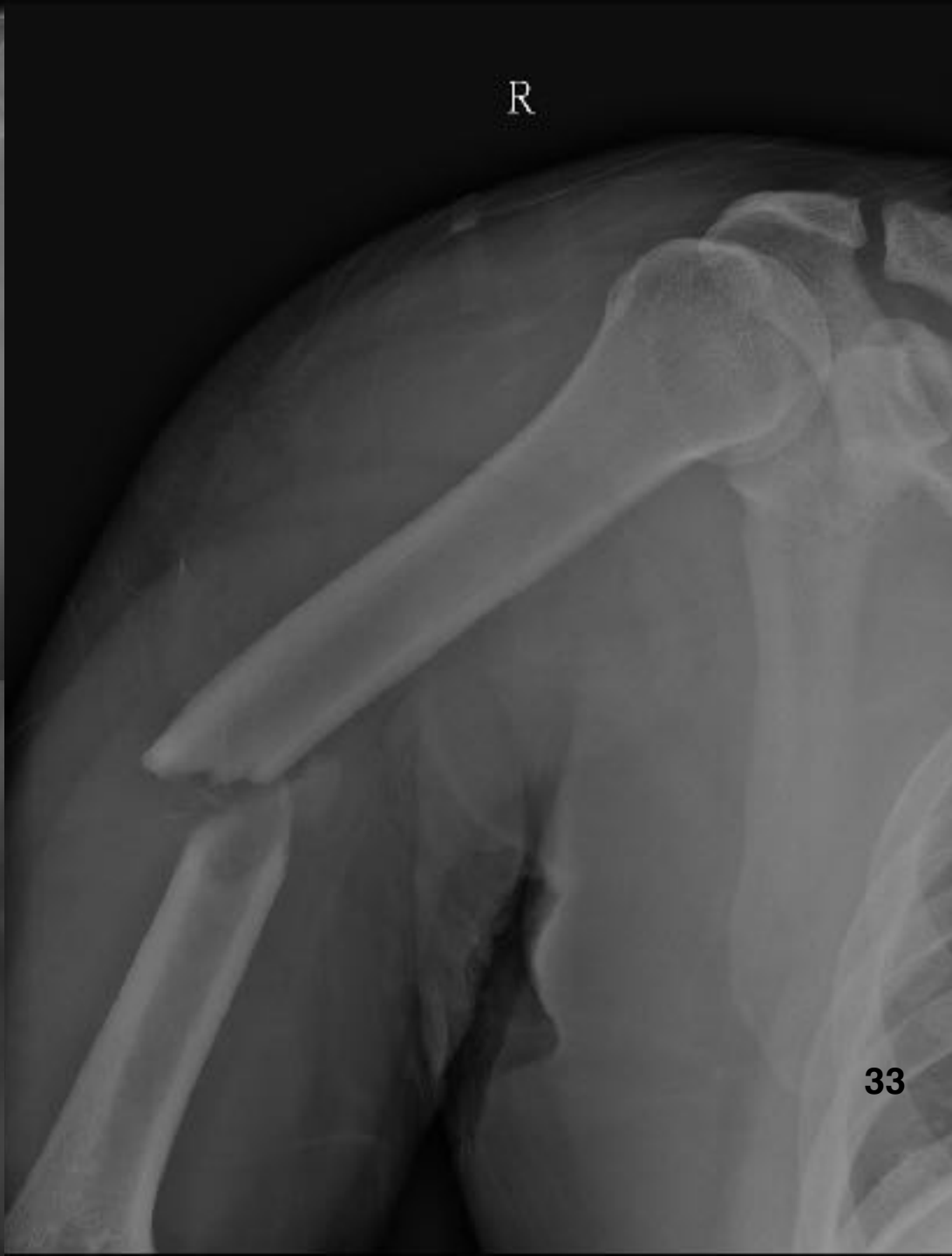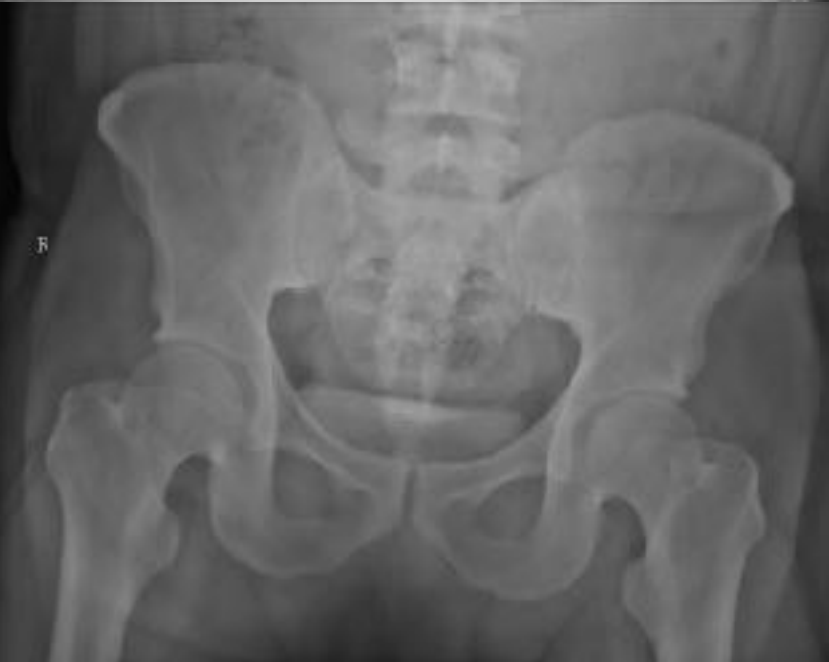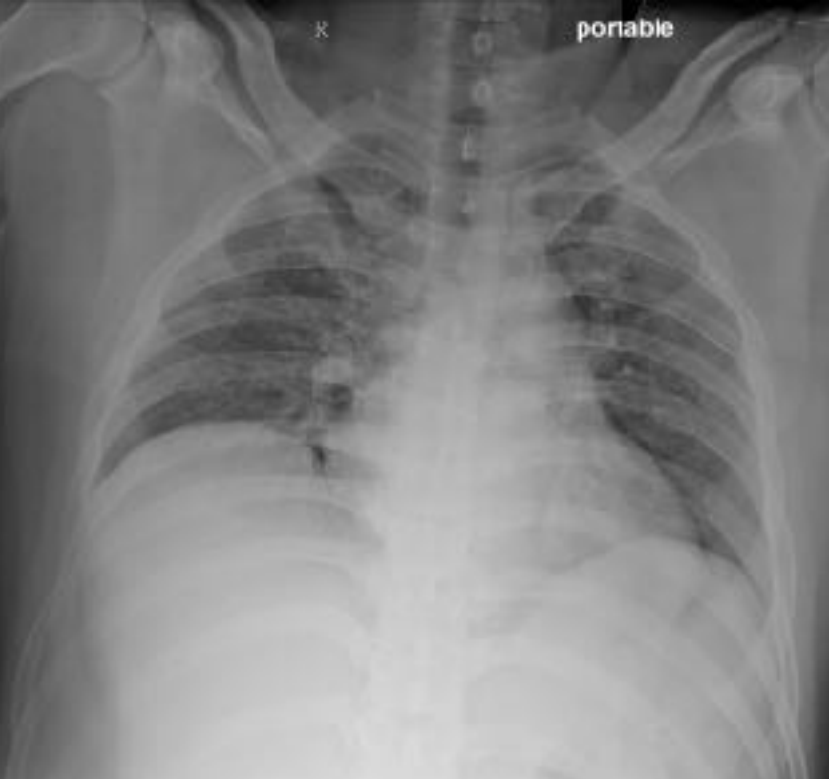**RR 20**

**VAS 7**

**BP 103/69**

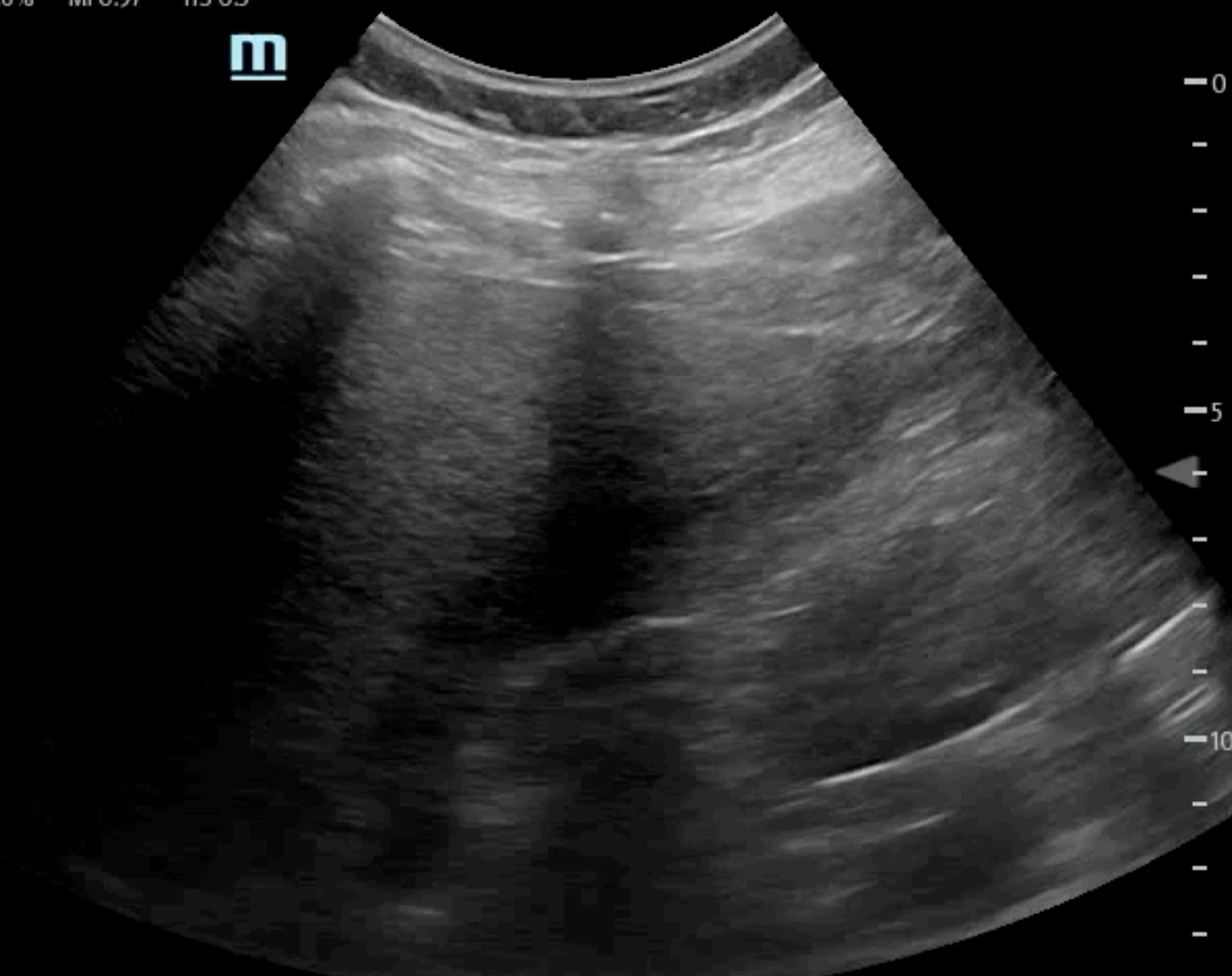
**SpO2 100%**





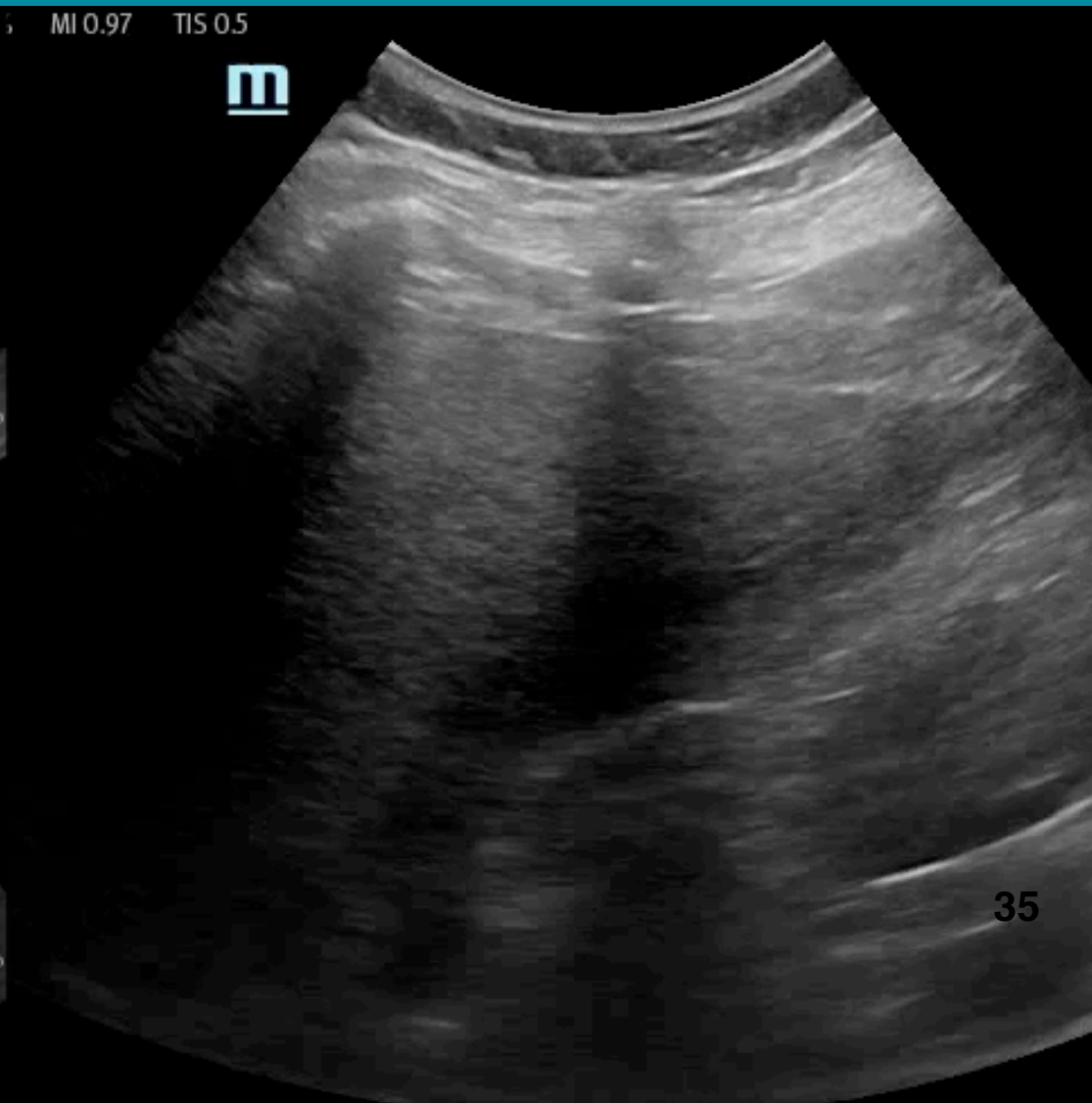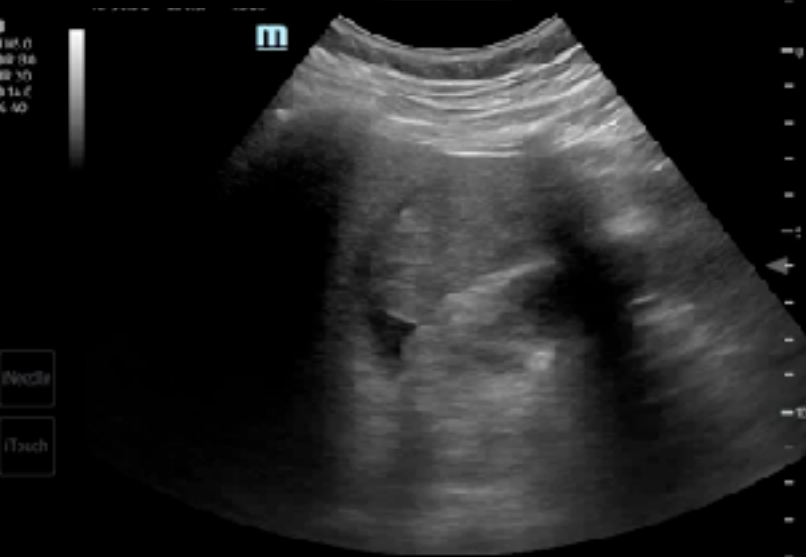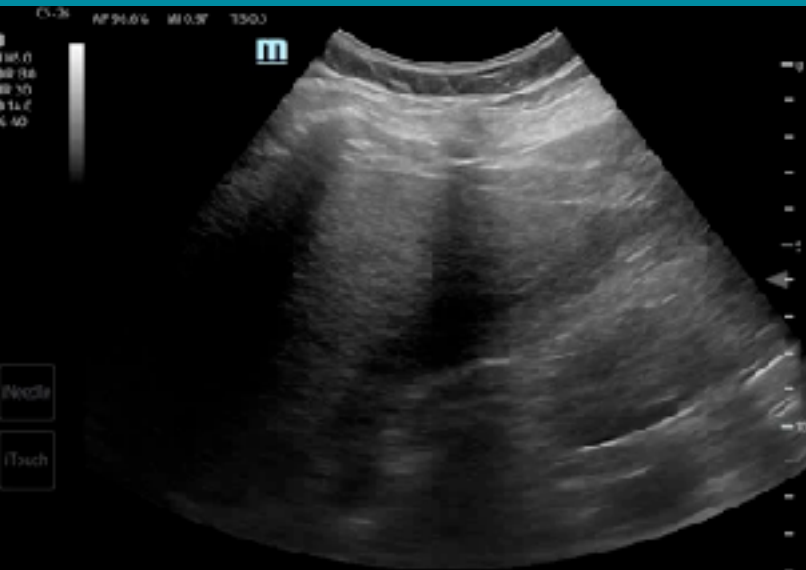-25 AP 96.6% MI 0.97 TIS 0.5

**m**

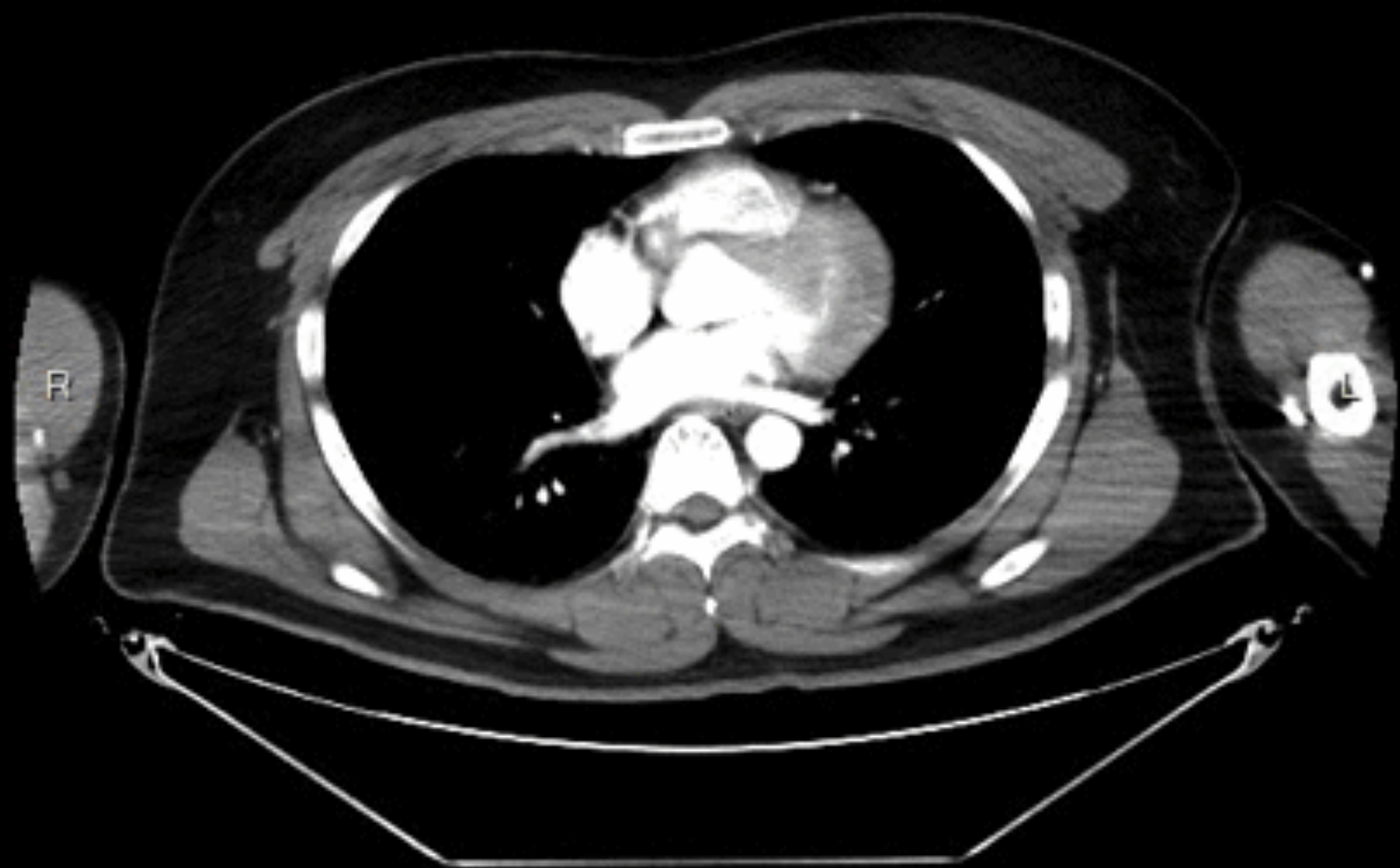


0  
-  
-  
-  
-  
5  
-  
-  
-  
10  
-  
-  
-  
-

# HEMOPERITONEUM



A

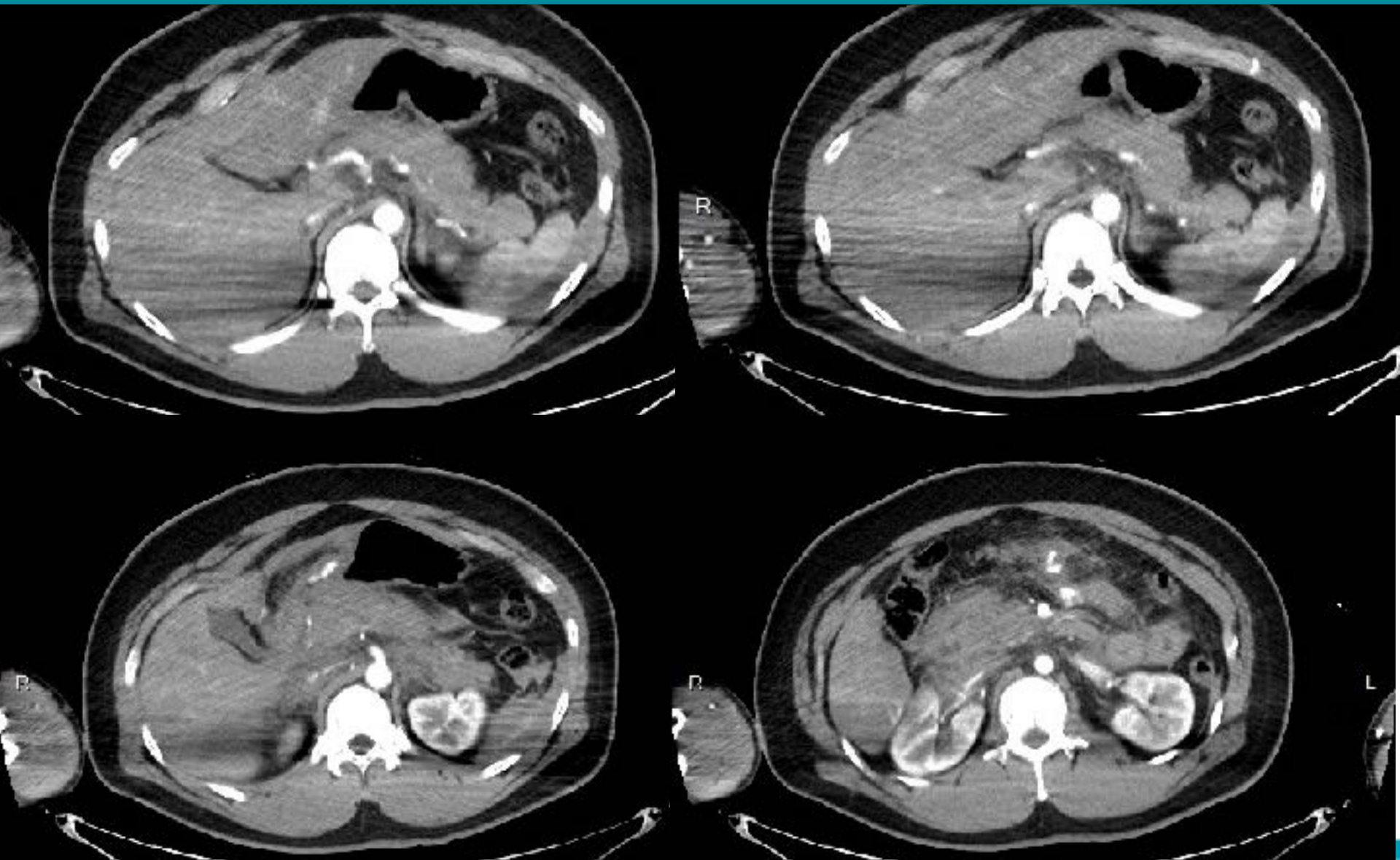


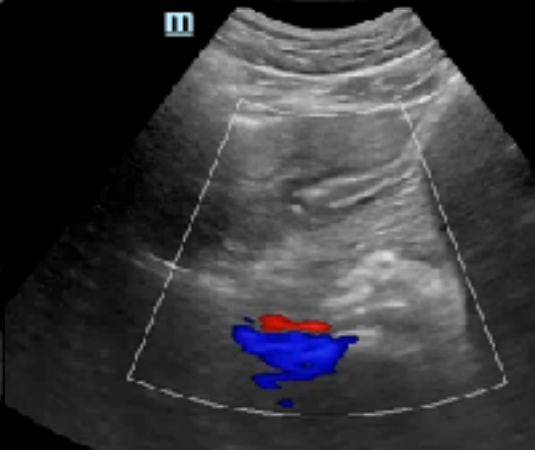
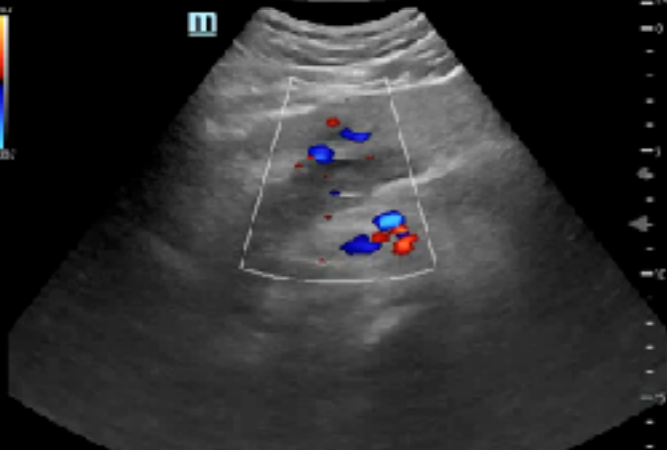
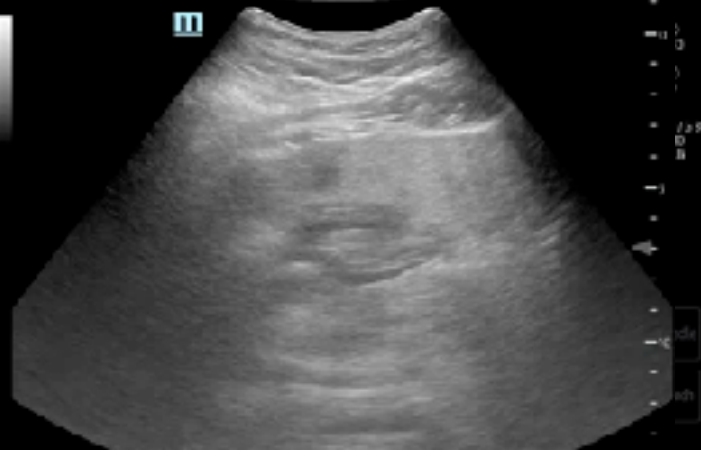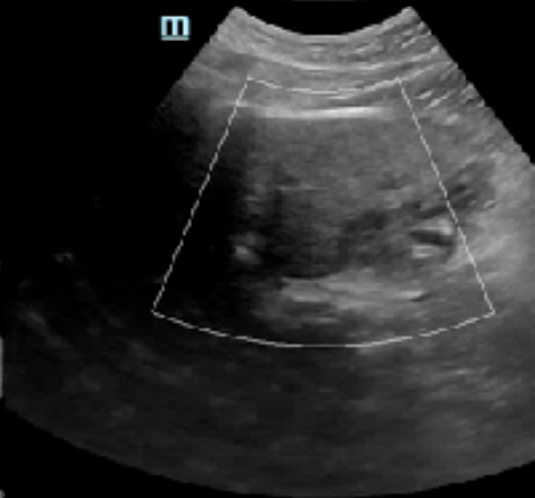
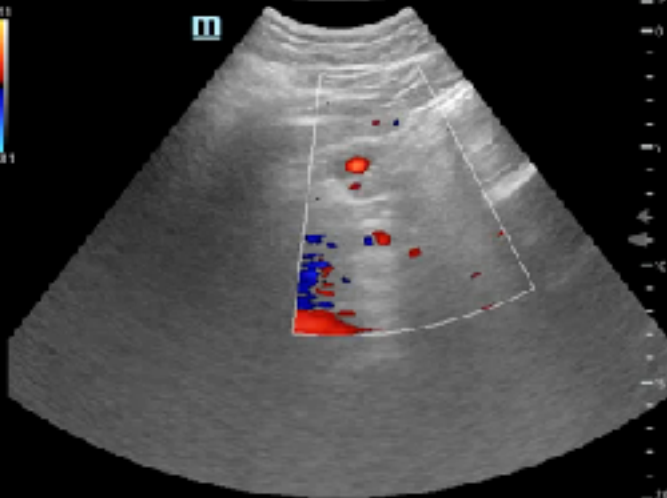
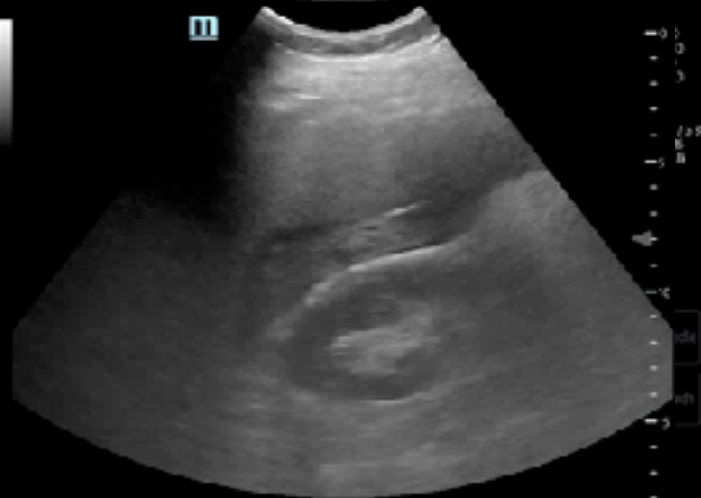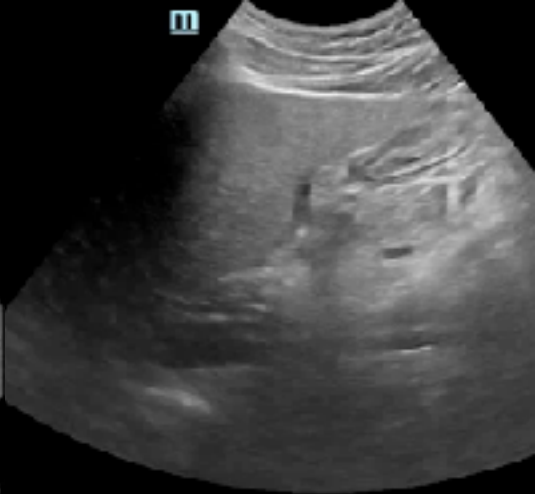
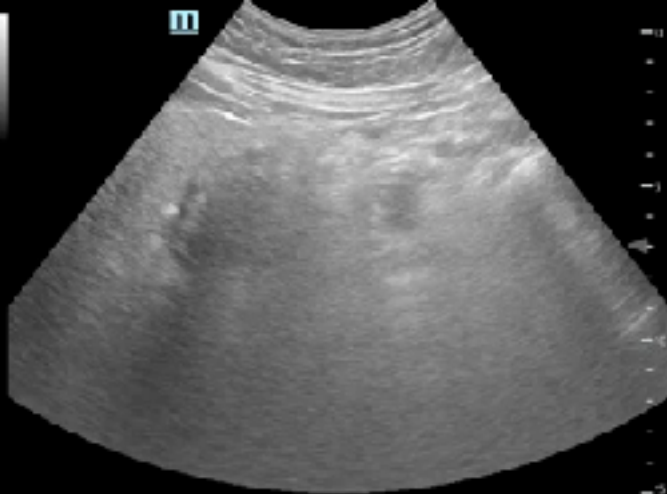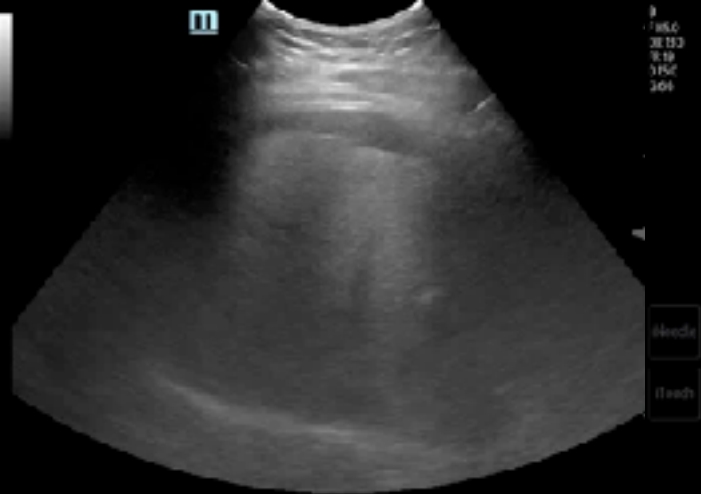R

L

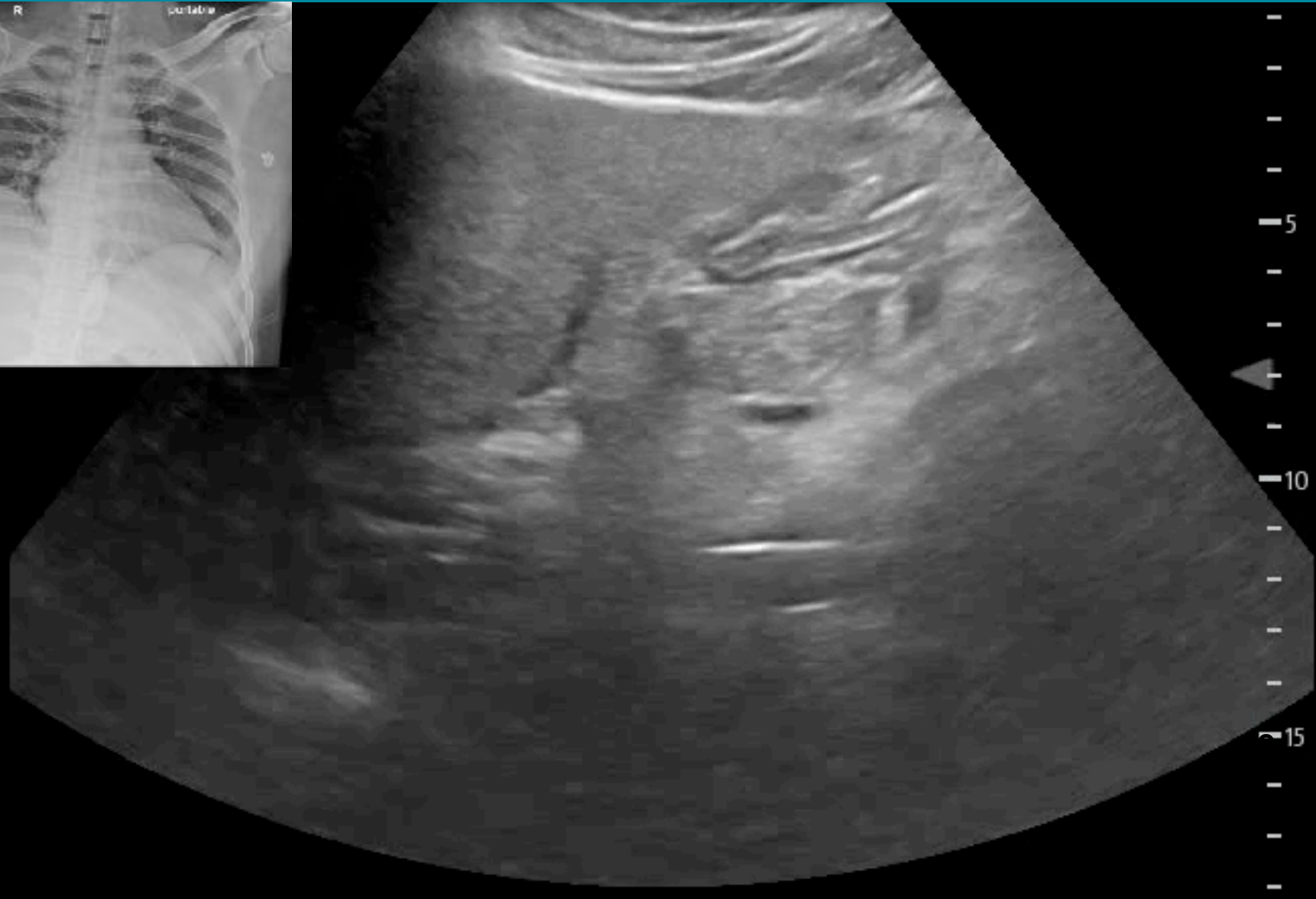
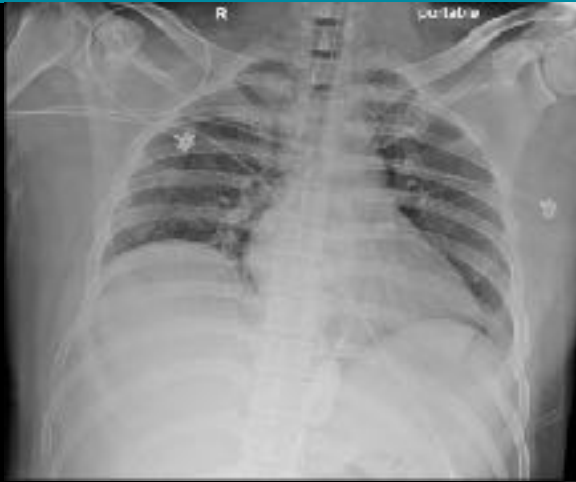P

# Profound hypotension after CT



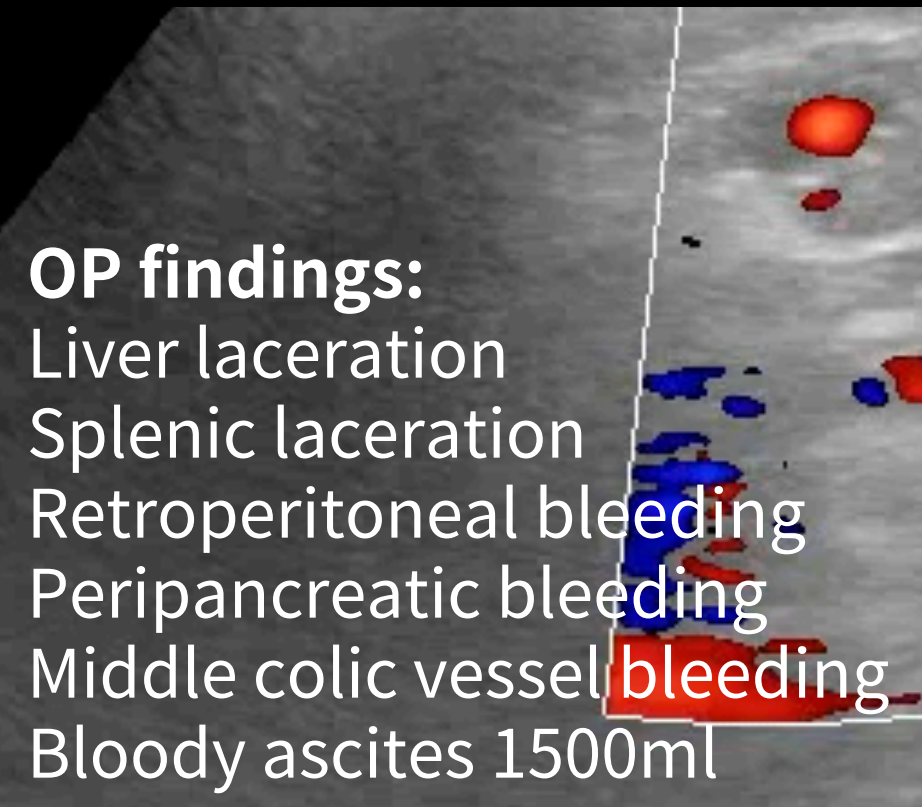
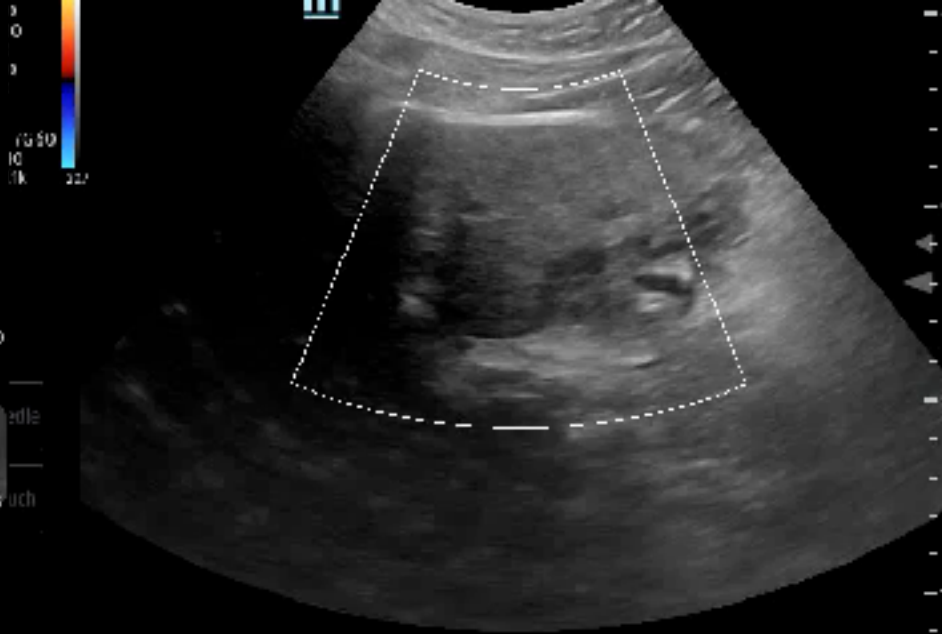
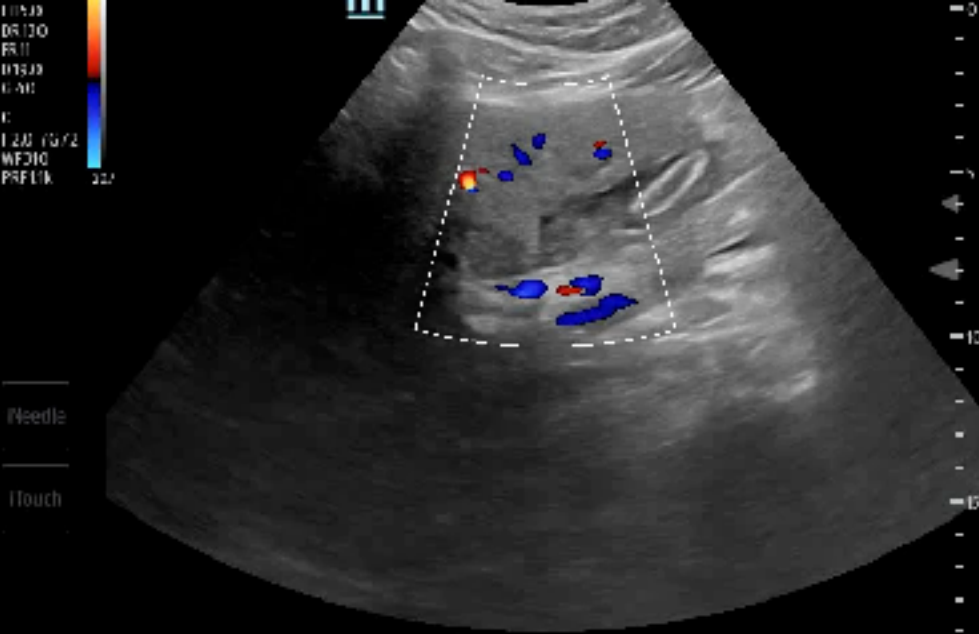


# REBOA

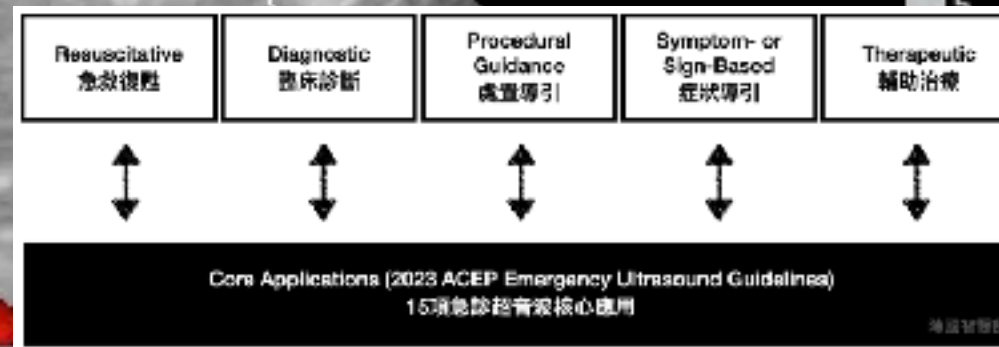

iNeedle

iTouch



**OP findings:**  
 Liver laceration  
 Splenic laceration  
 Retroperitoneal bleeding  
 Peripancreatic bleeding  
 Middle colic vessel bleeding  
 Bloody ascites 1500ml

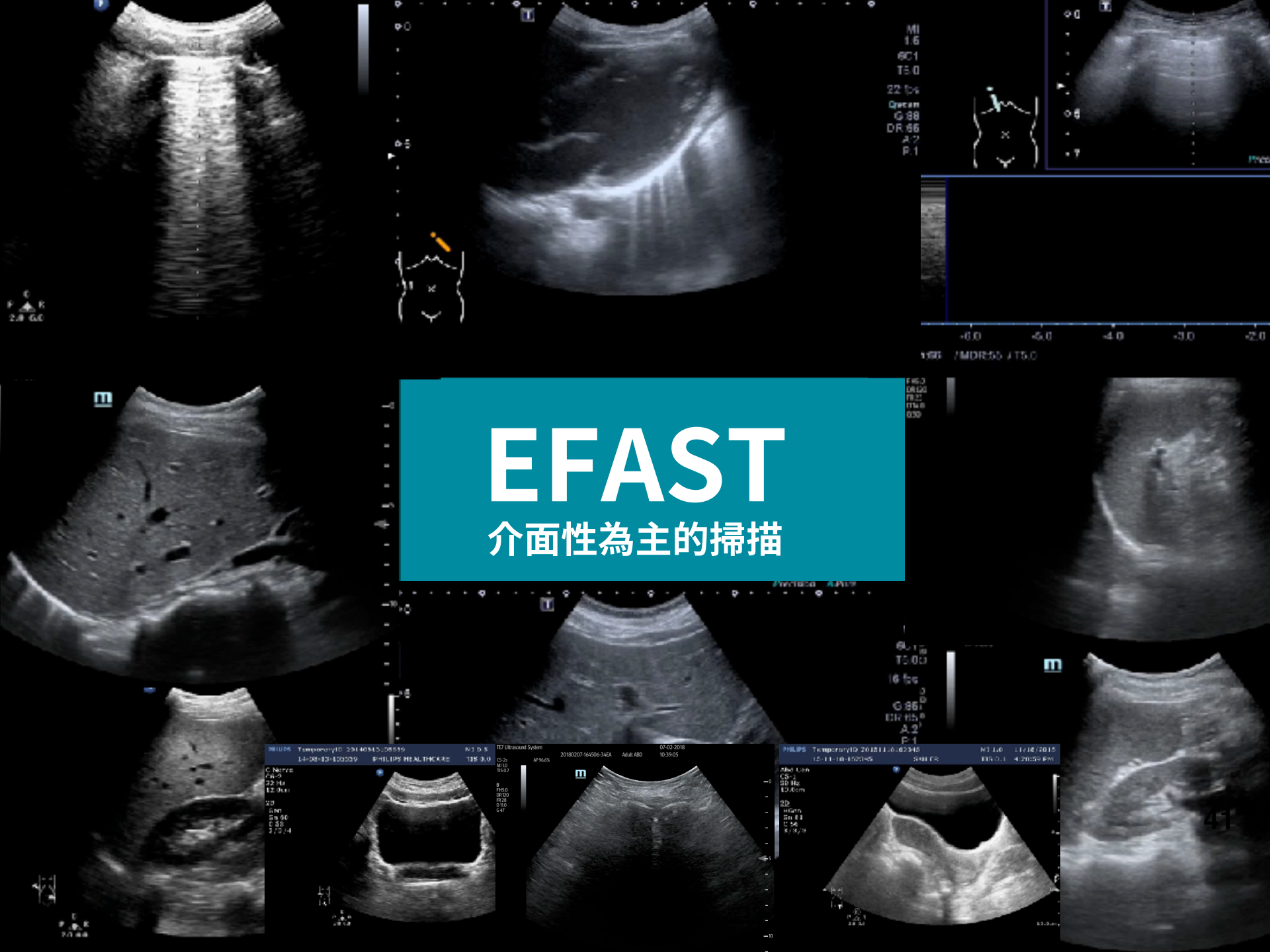


- Aorta
- DVT
- Trauma
- Thoracic/Airway
- Cardiac/HD assessment

- Procedural Guidance
- US-guided NB
- Testicular
- Ocular
- Skin & Soft tissue

- Hepatobiliary
- Urinary tract
- Pregnancy
- Bowel
- MSK





# EFAST

介面性為主的掃描

PHILIPS Temporarily 20181116.02345 N1 L6 11/16/2018  
14:08:23-120529 PHILIPS HEAL THC X 3 17S 3.0 IT7 Ultrasound System 20180207-164506-34E Adult ABD 07/02/2018 10:39:05

C Nerve  
Fw 9  
22 Hz  
12.9kV  
2D  
ANT  
25.90  
2.55  
3.72,14

PHILIPS Temporarily 20181116.02345 N1 L6 11/16/2018  
15:11:18-152145 SMI PR

Abd Lax  
GS-1  
20 Hz  
13.40m  
2D  
HGain  
25.83  
2.56  
6.78,9