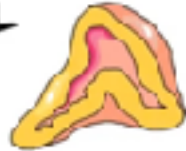
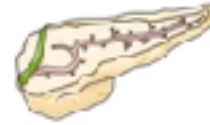
Medical Mnemonic: RETROPERITONEAL ORGANS

S SUPRARENAL
(ADRENAL)
GLANDS



P PANCREAS



E ESOPHAGUS



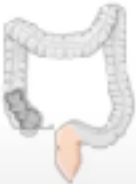A AORTA
+ INFERIOR
VENA CAVA



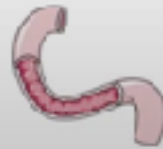U URETERS



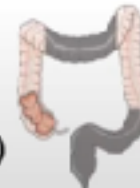R RECTUM




D DUODENUM
(2nd + 3rd
SEGMENTS)



C COLON
(ASCENDING
+ DESCENDING)



K KIDNEYS



RETROPERITONEUM

1

Rhesus Medicine



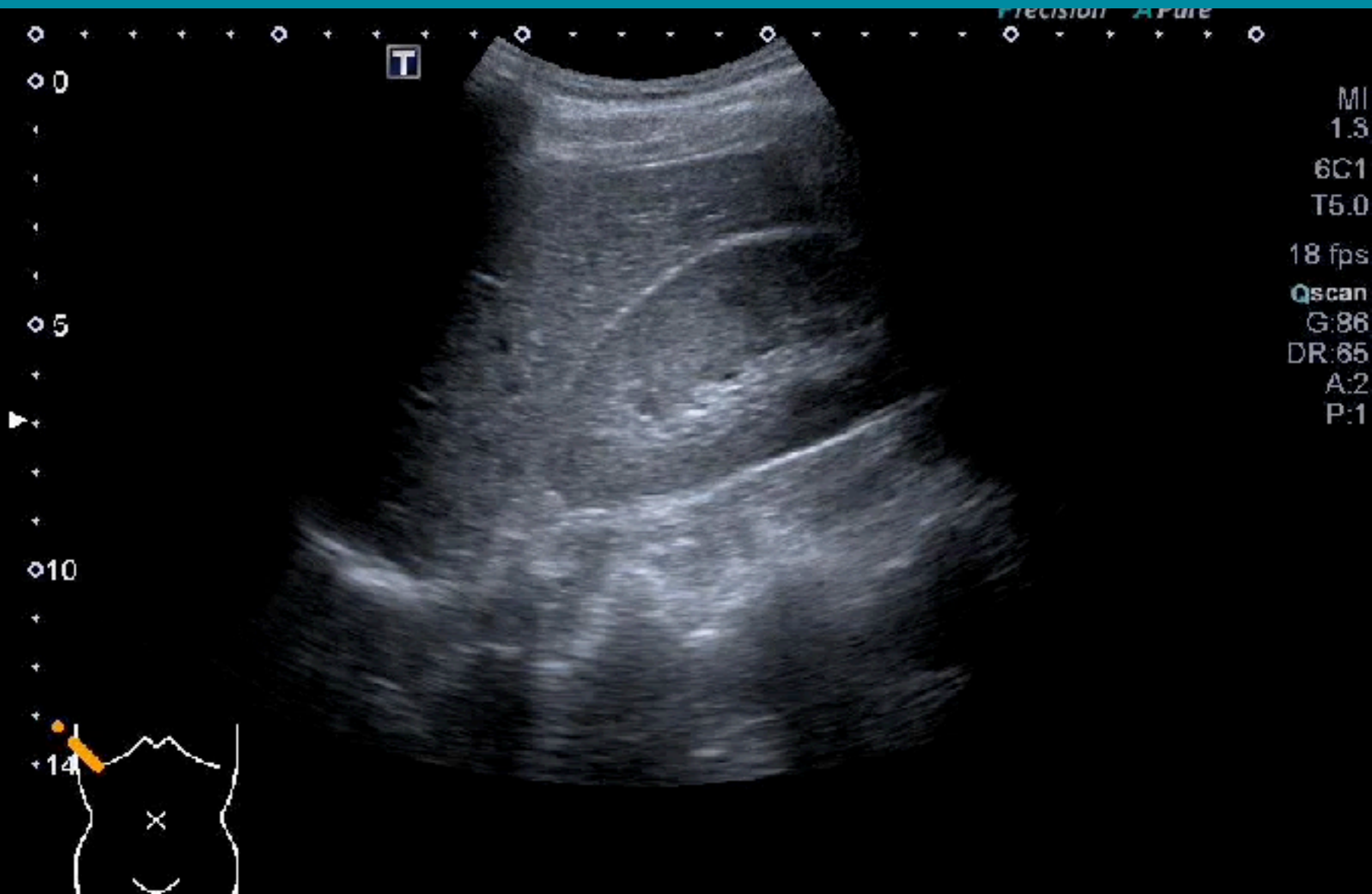
台灣疼痛醫學會專科醫師
急診超音波臨床評核醫師
醫用超音波學會指導醫師
WINFOCUS director / instructor
Certified Interventional Pain Sonologist

急診 / 重症 / 介入 / 急性疼痛

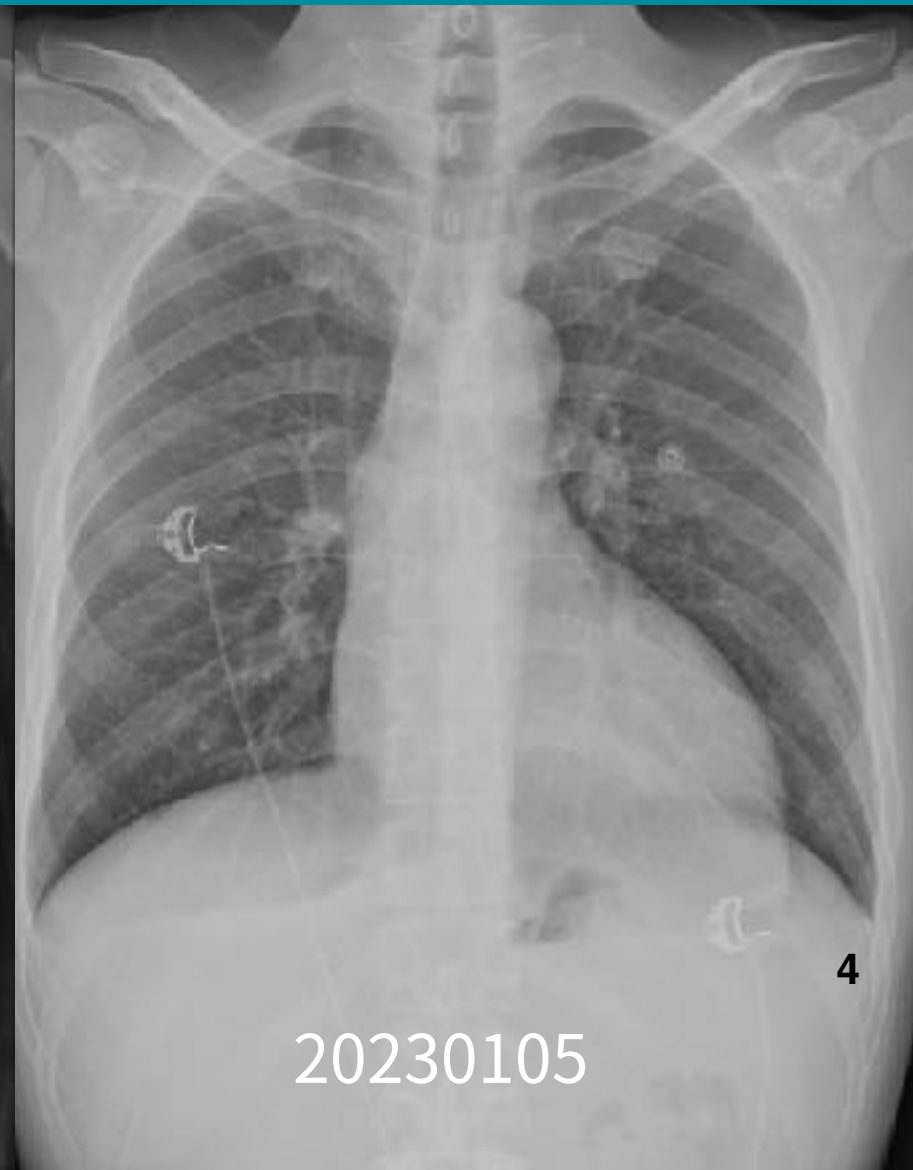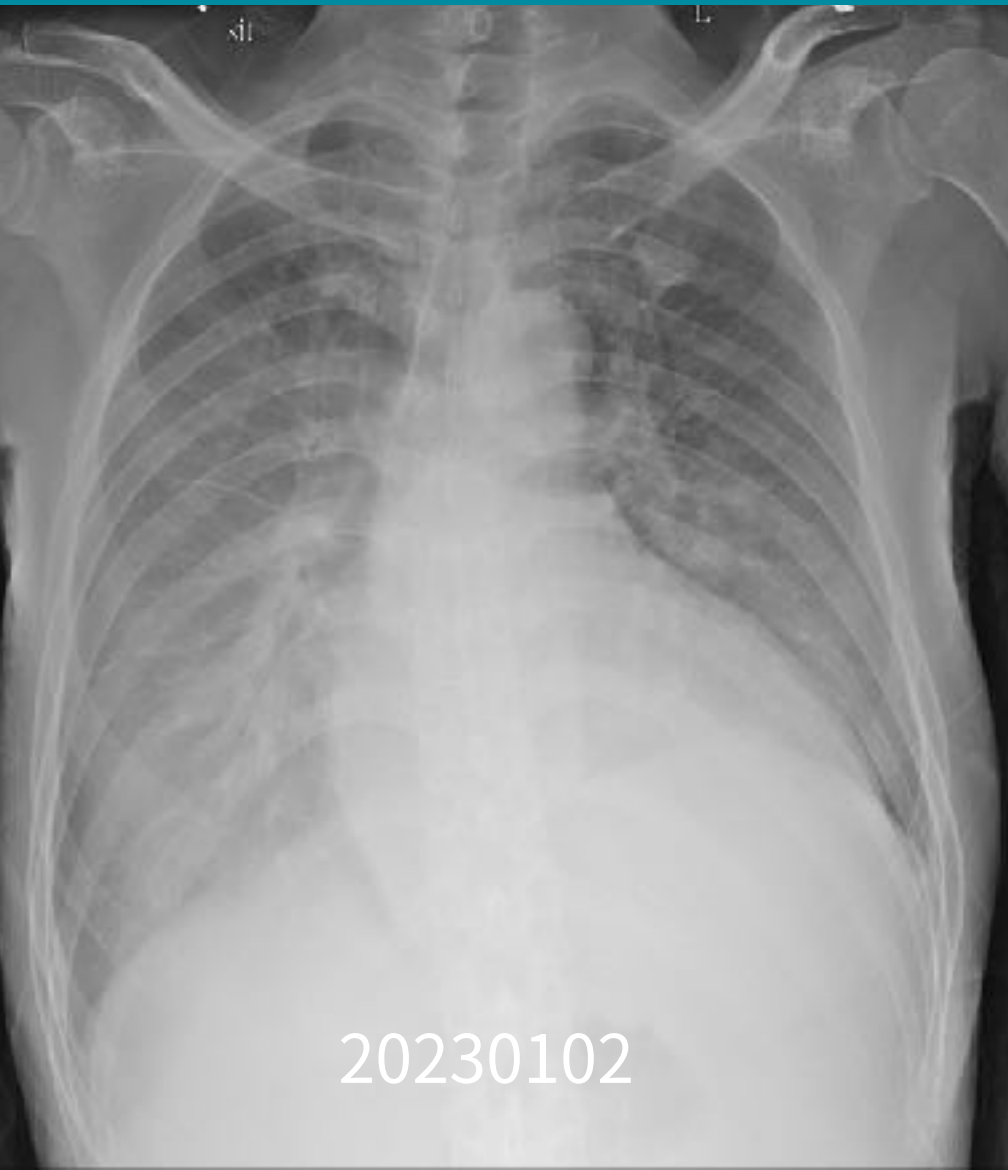經歷

新光急診超音波訓練中心主任
西園醫院急診醫學科主任
急診醫學會超音波委員會主委
台灣疼痛醫學會大體模擬手術講師
急救加護醫學會重症超音波負責人

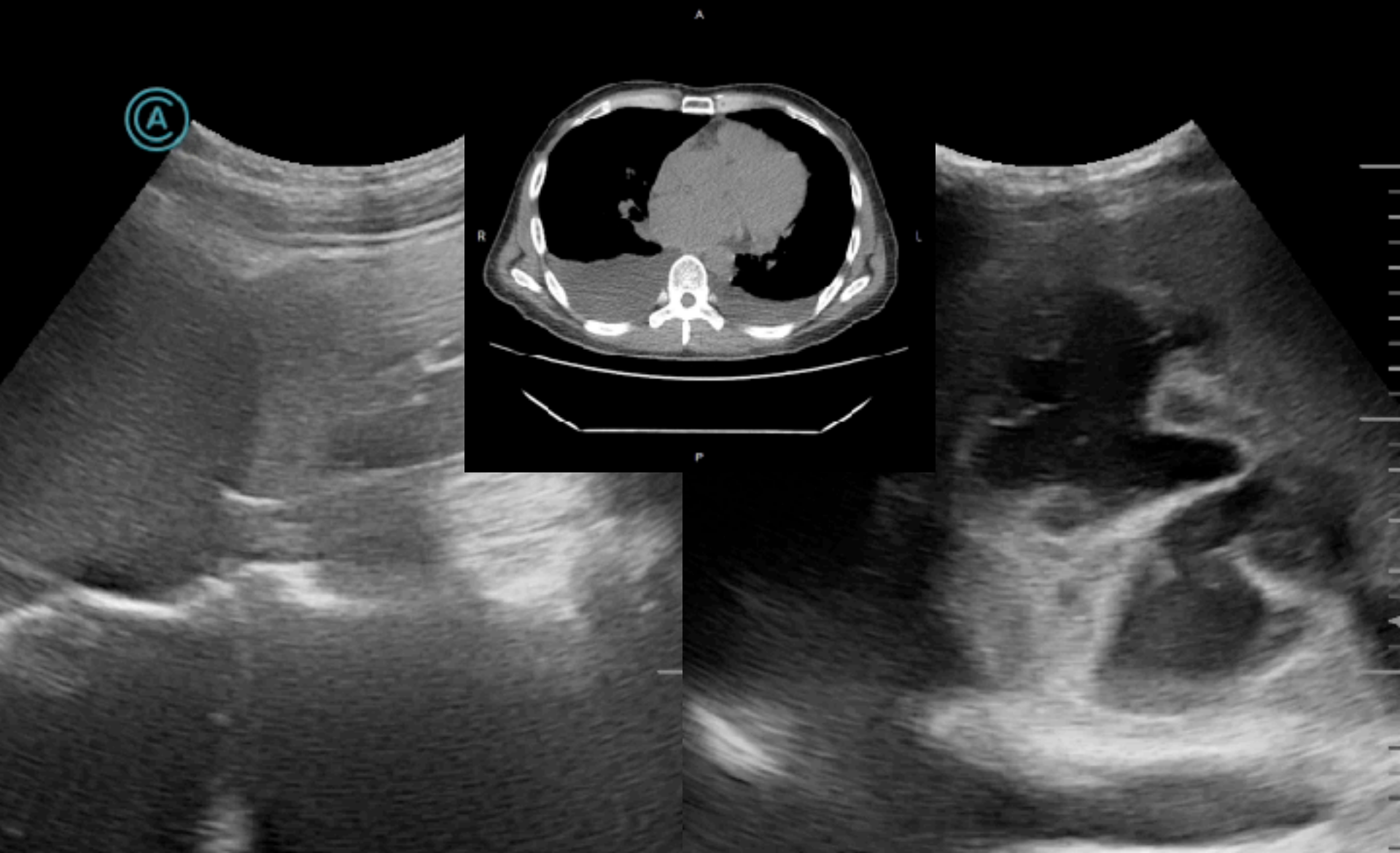SUPRARENAL (ADRENAL GLAND)



SUPRARENAL (ADRENAL GLAND)



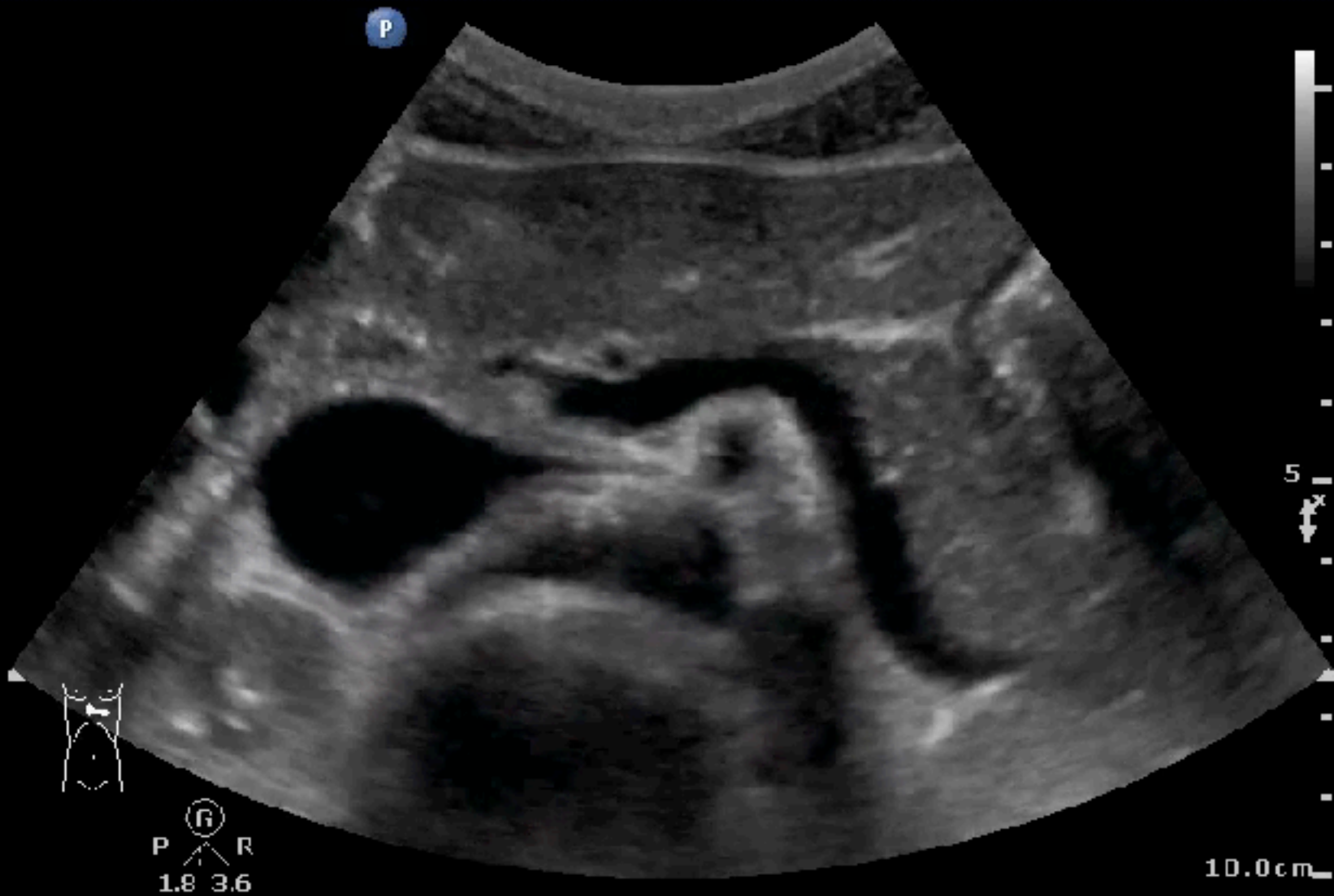
SUPRARENAL (ADRENAL GLAND)



AORTA + IVC

Abd Gen
C5-1
45 Hz
10.0cm

2D
HGen
Gn 60
C. 56
3/3/3

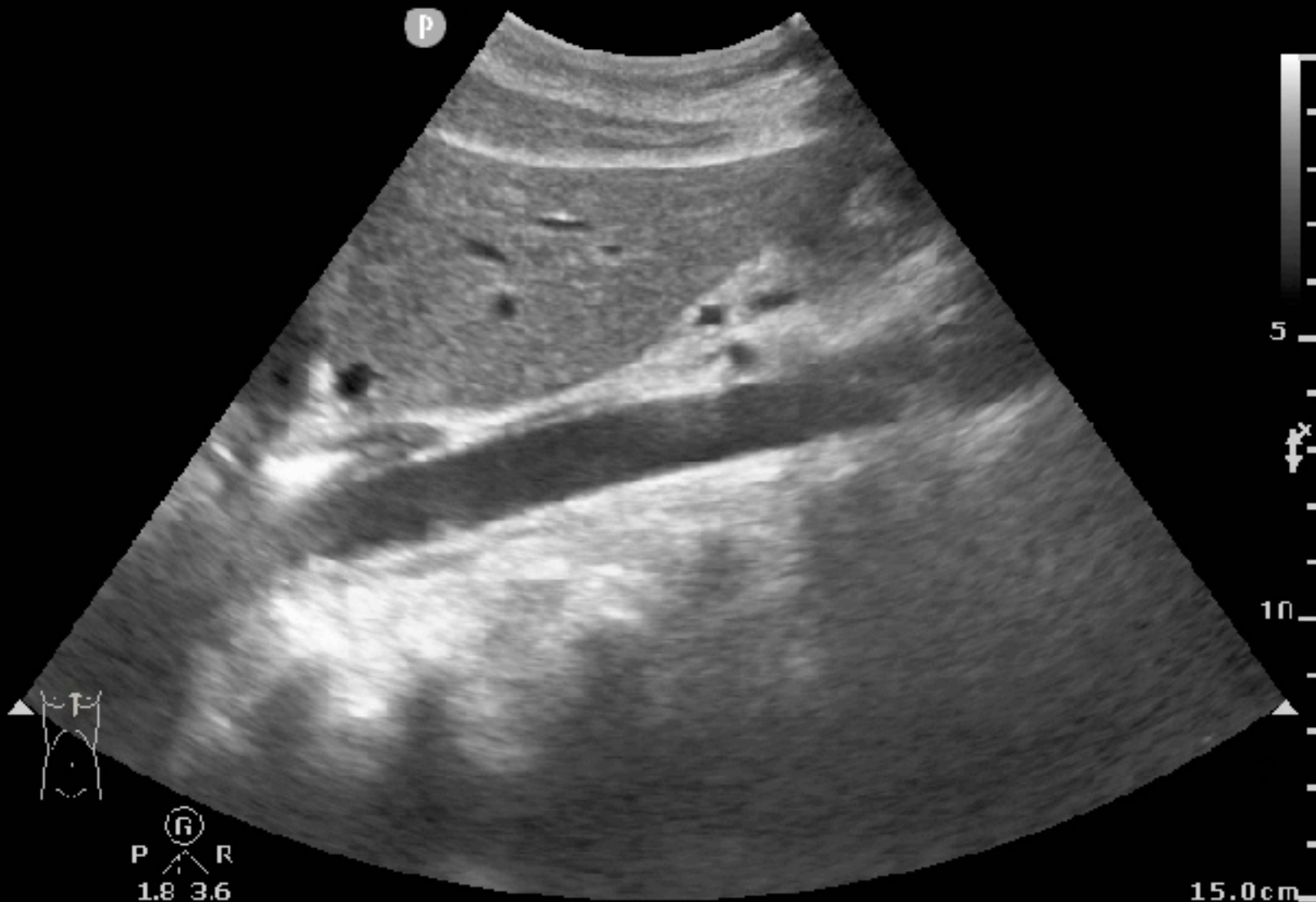

10.0cm

AORTA + IVC

Abd Gen
C5-1
34 Hz
15.0cm

2D
HGen
Gn 100
C. 56
3/3/3



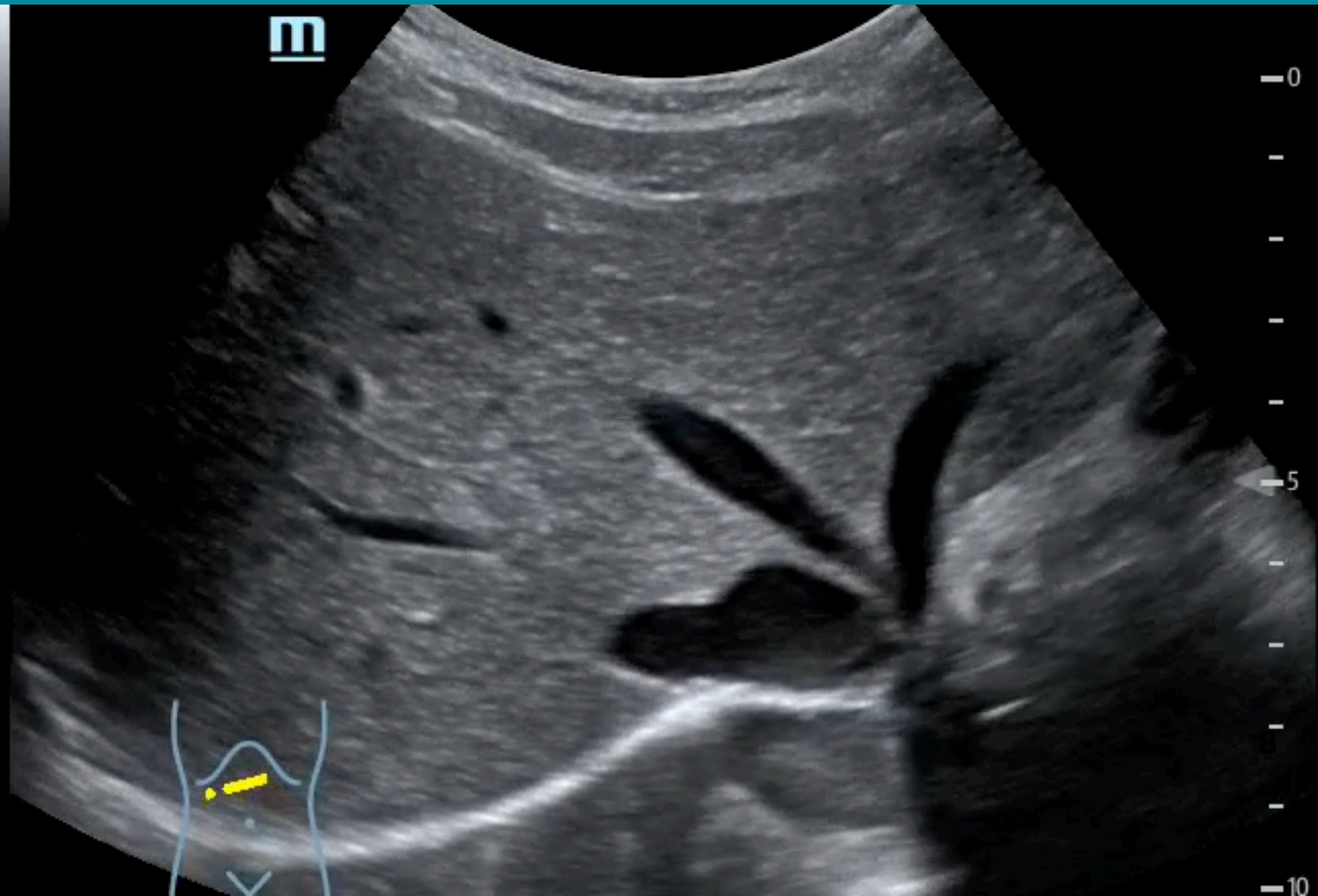
15.0cm

AORTA + IVC

TIS 0.7



B
FH5.0
DR120
FR28
D11.0
G50



0

-

-

-

-

5

-

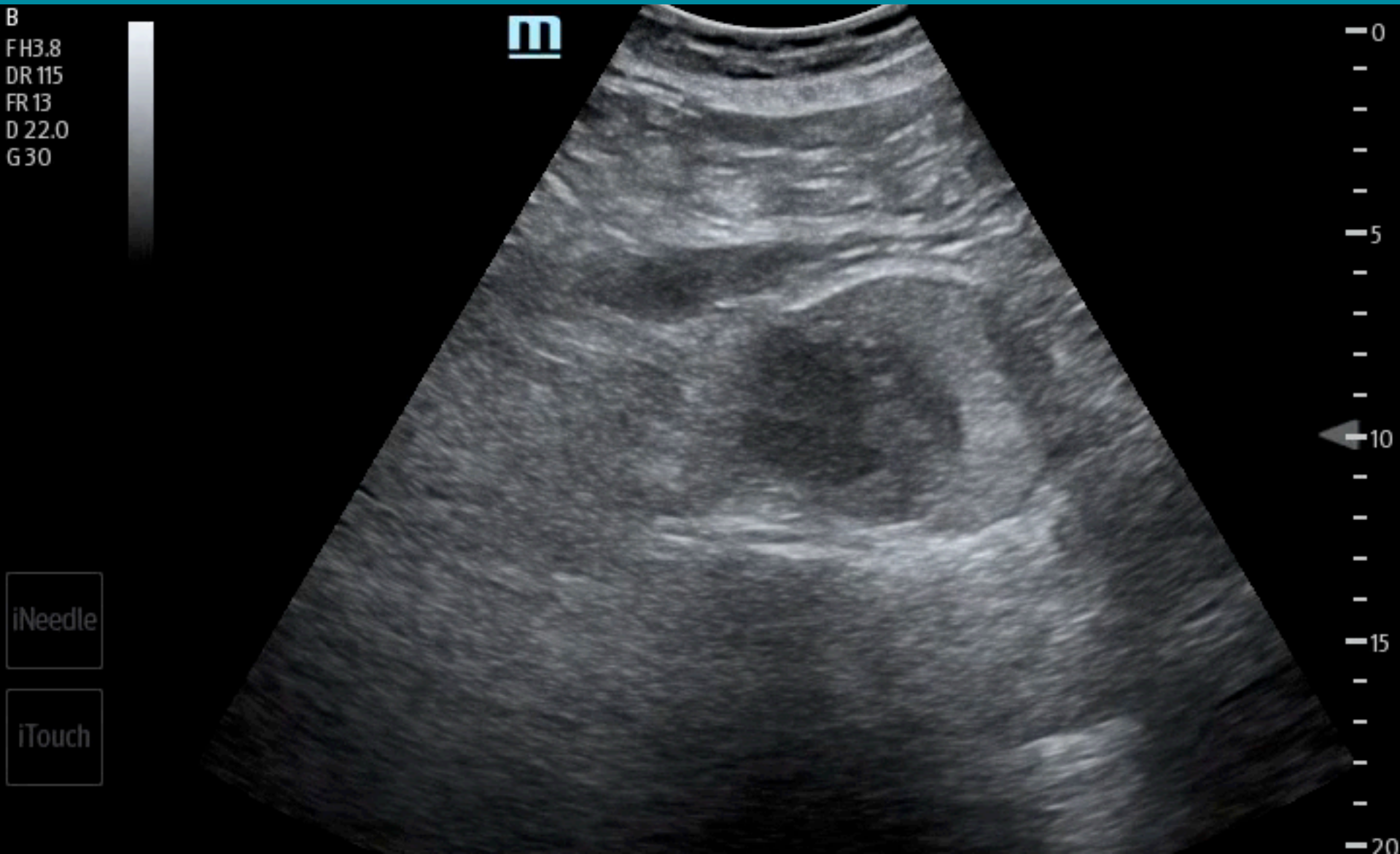
-

-

-

10

AORTA + IVC

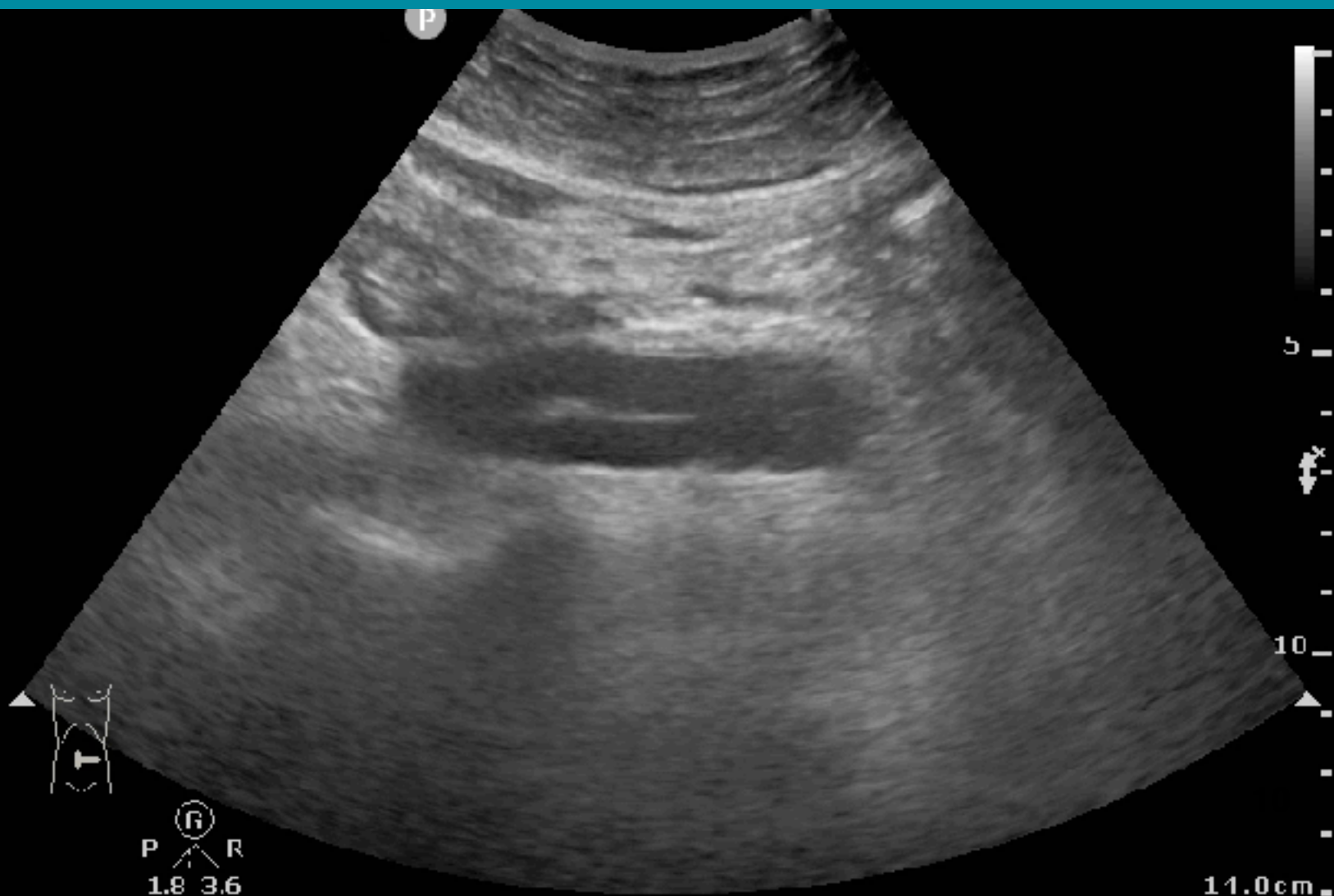

AORTA + IVC

Abd Gen
C5-1
36 Hz
14.0cm

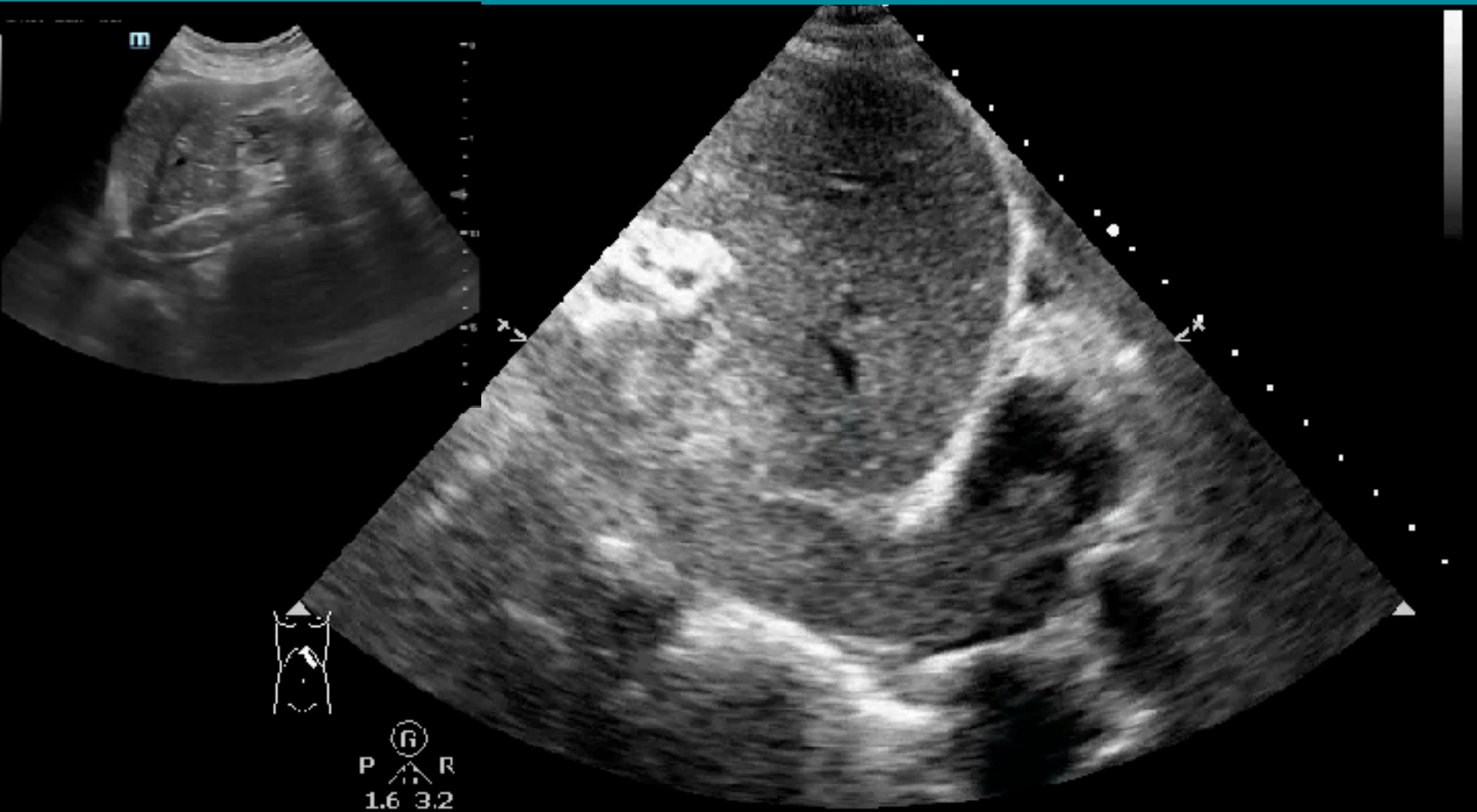
2D

HGen
Gn /1
C. 56
3/3/3

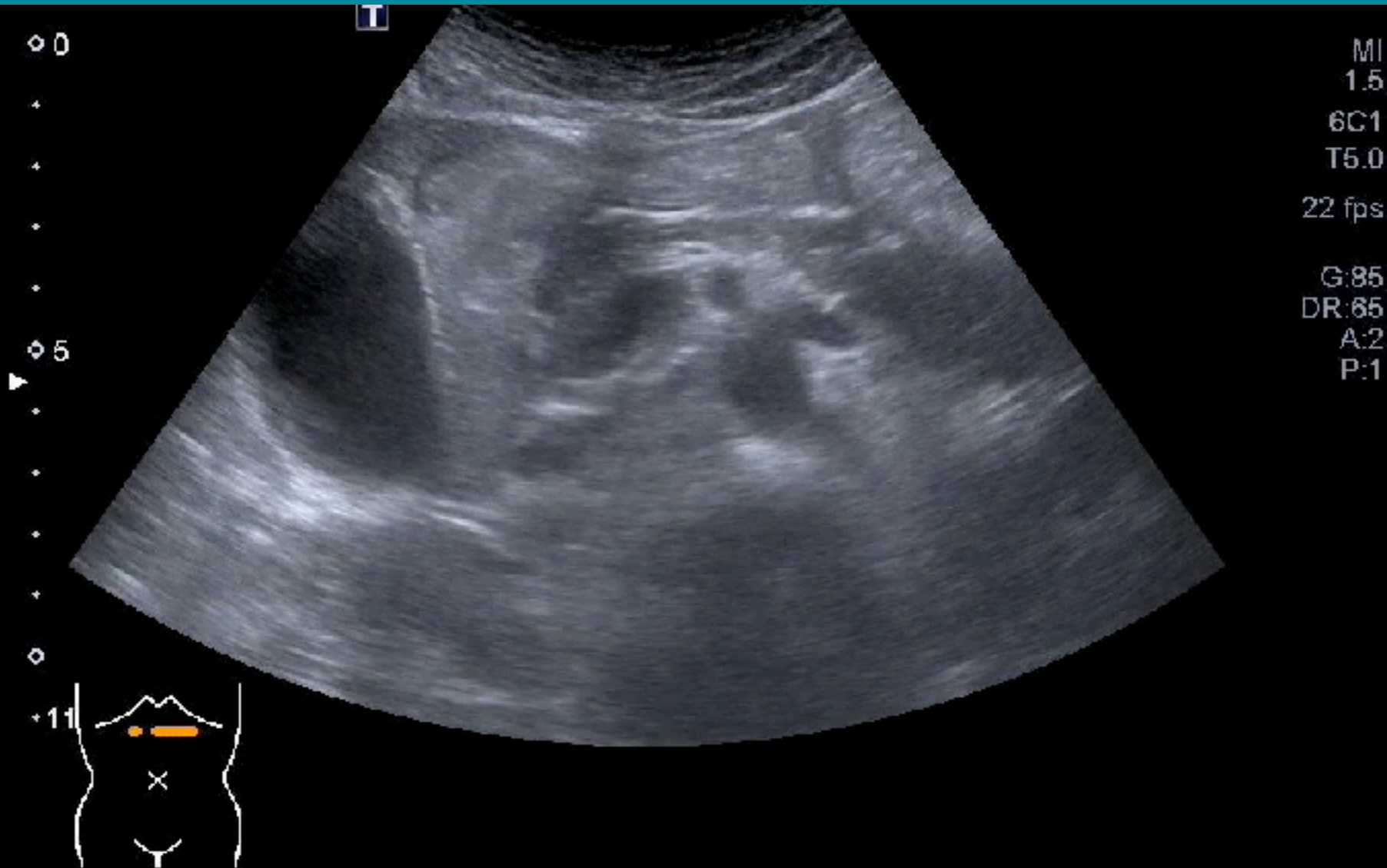

11.0cm

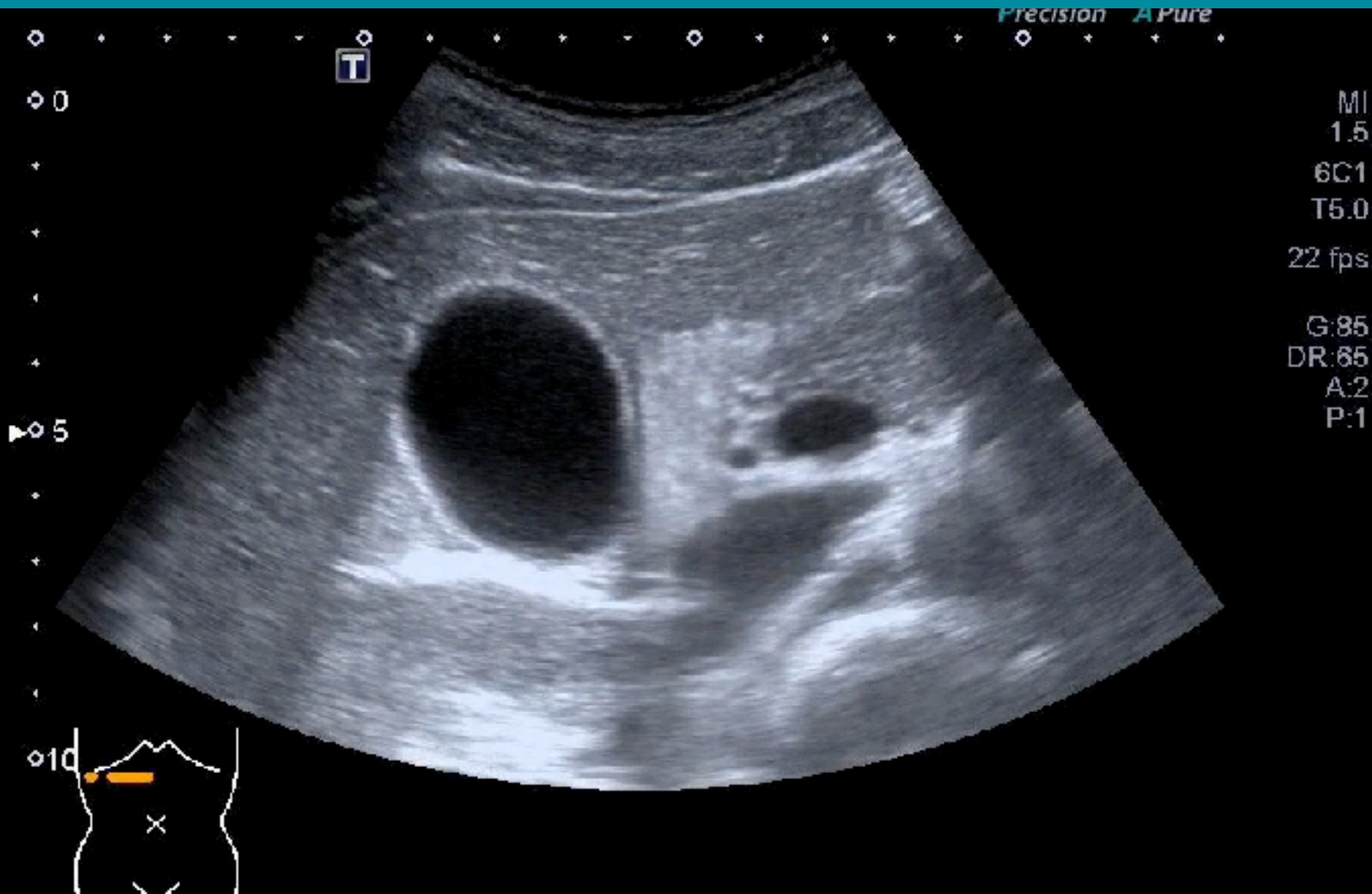
AORTA + IVC



DUODENUM (2ND/ 3RD SEGMENTS)



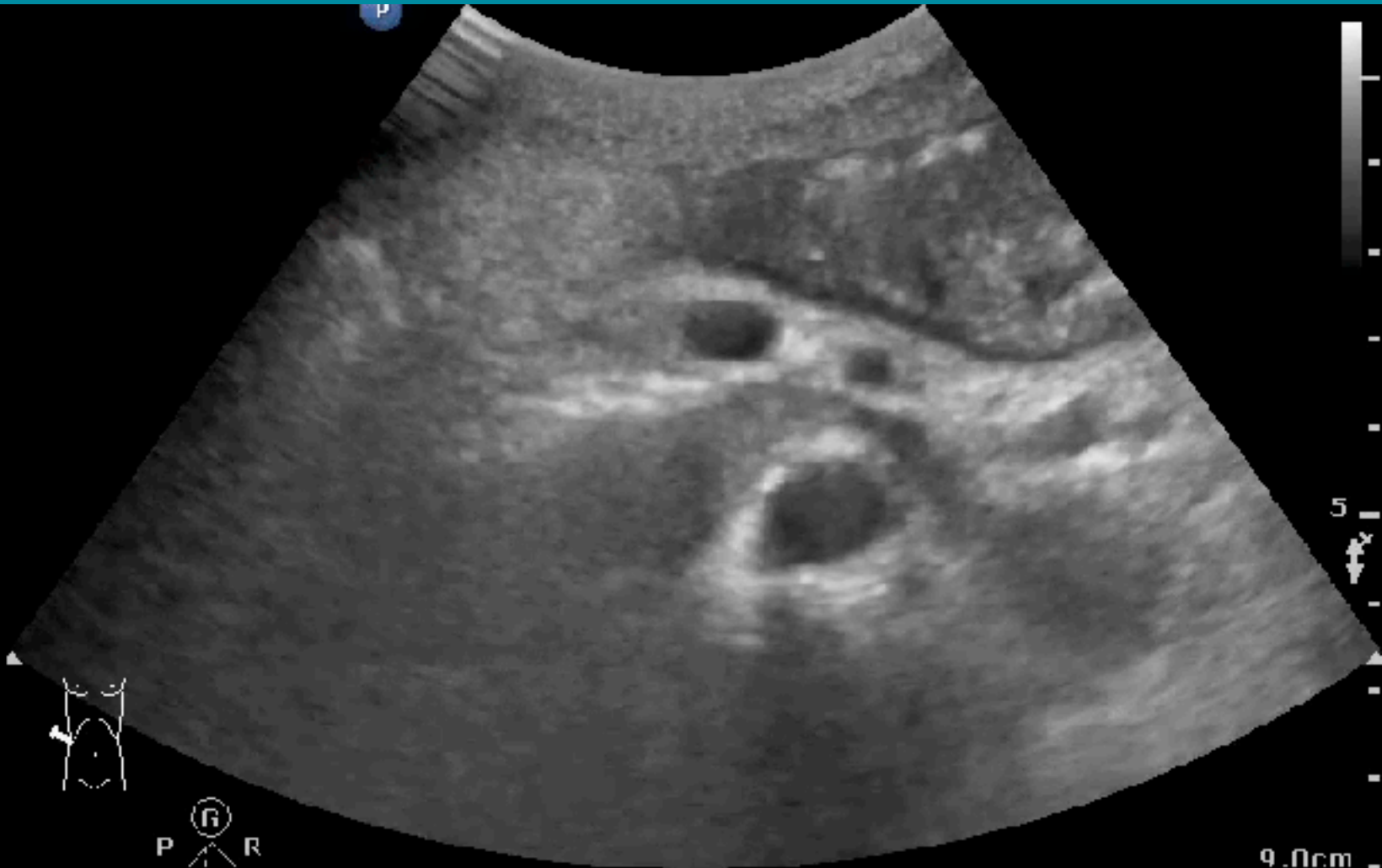DUODENUM (2ND/ 3RD SEGMENTS)



DUODENUM (2ND/ 3RD SEGMENTS)

C5-1
47 Hz
9.0cm

2D
HGen
Gn /6
C. 56
3/3/3



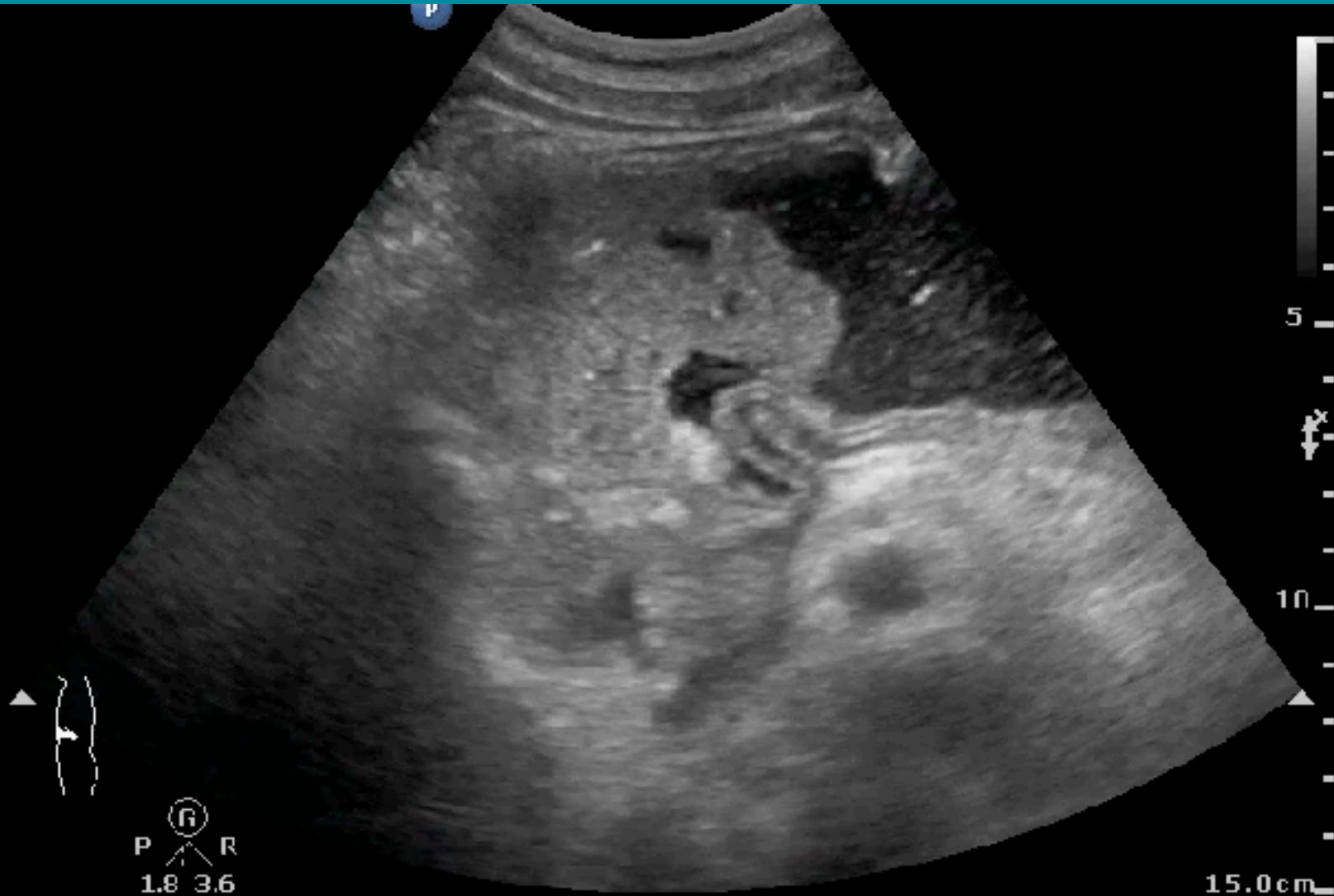P R
1.8 3.6

9.0cm

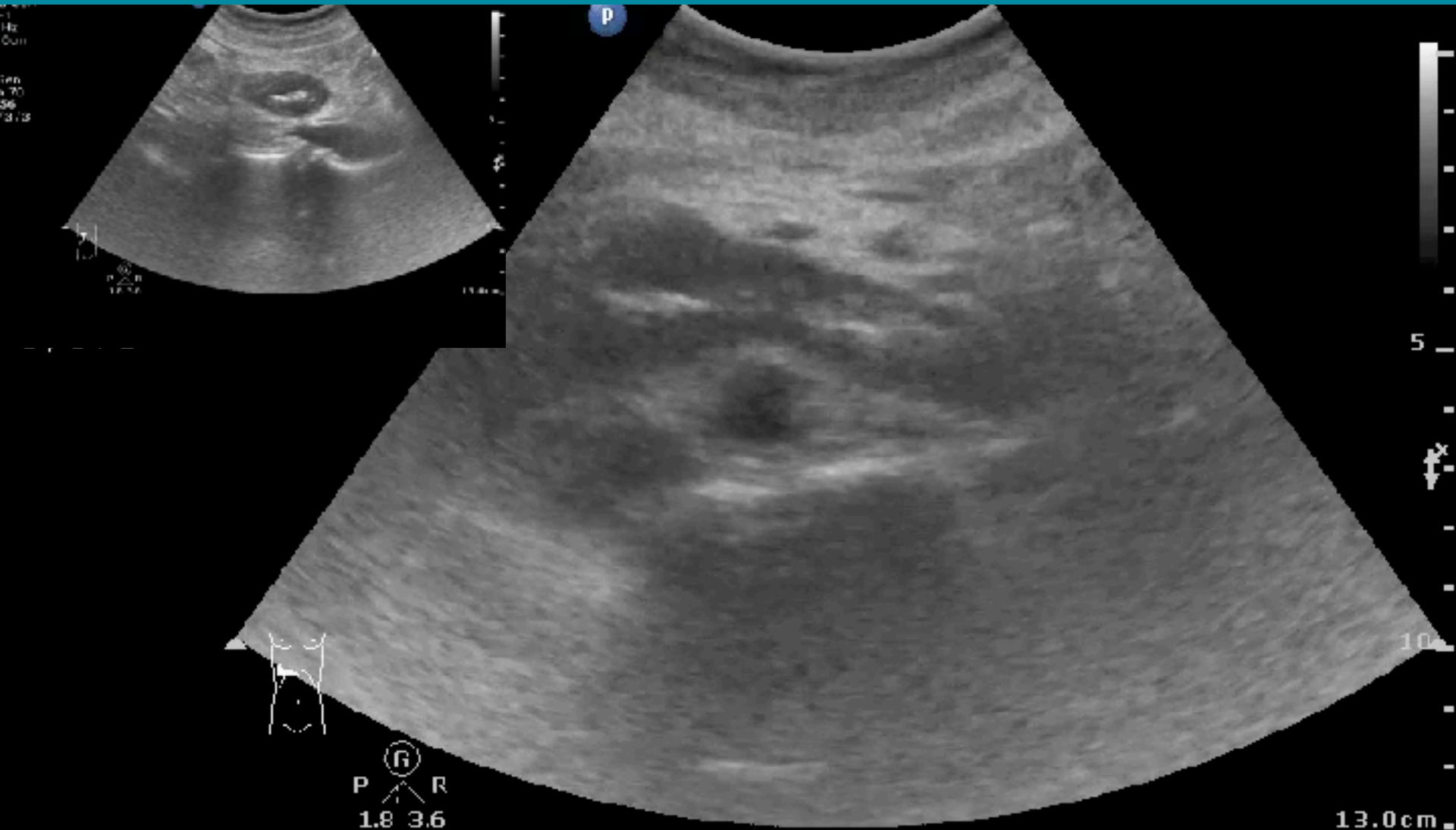
DUODENUM (2ND/ 3RD SEGMENTS)

Abd Gen2
C5-1
34 Hz
15.0cm

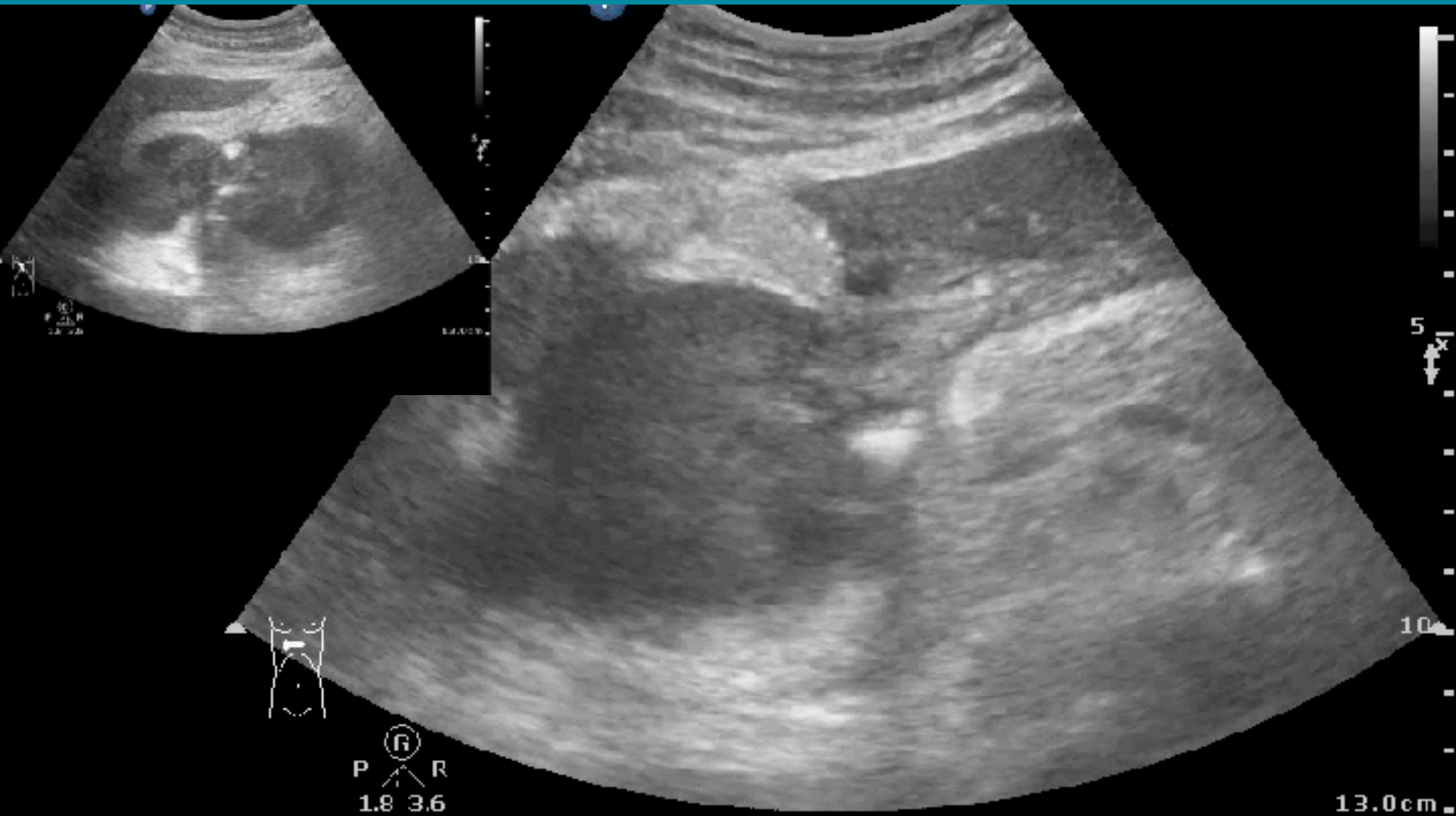2D
HGen
Gn 63
C. 56
3 / 3 / 3



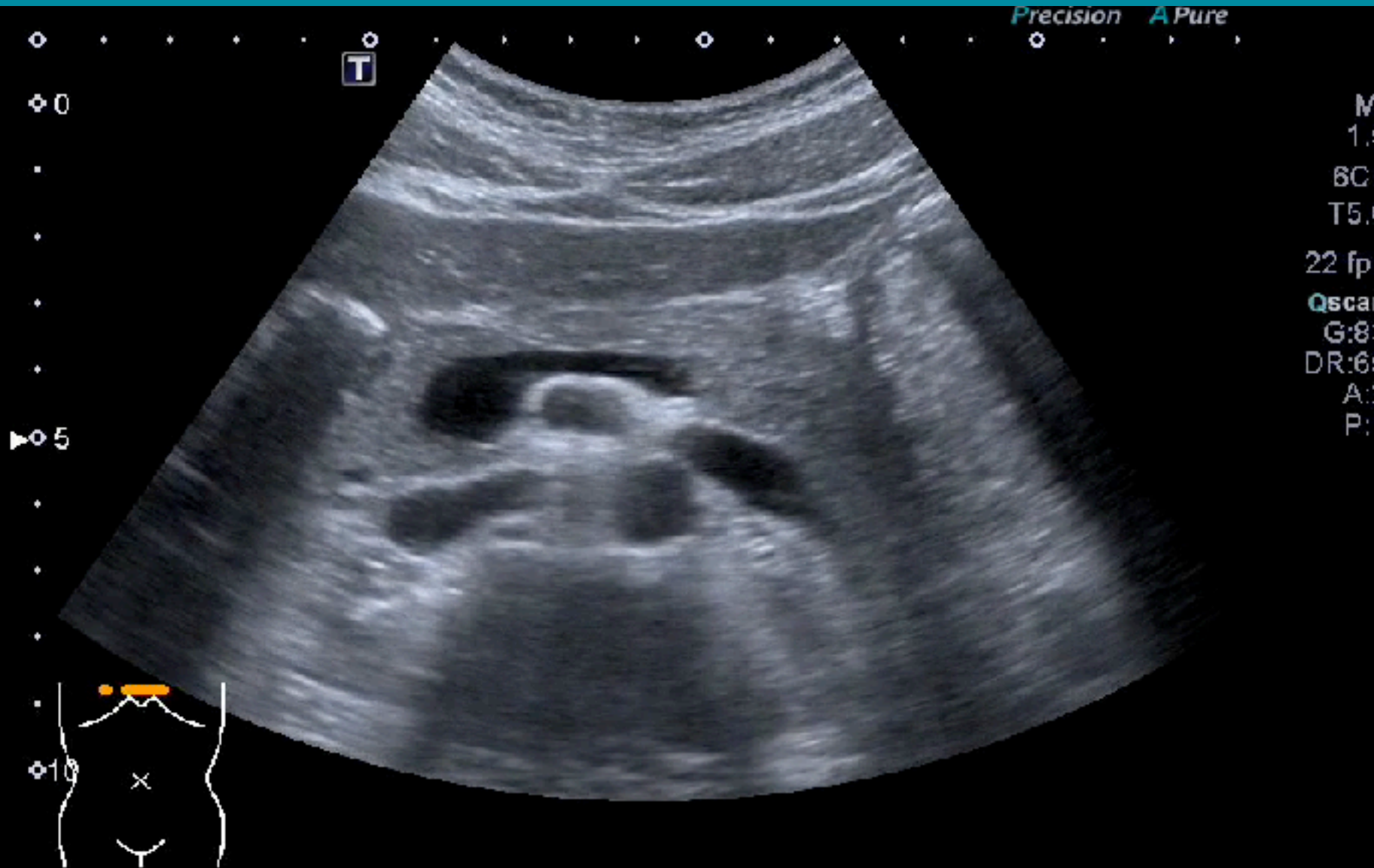DUODENUM (2ND/ 3RD SEGMENTS)



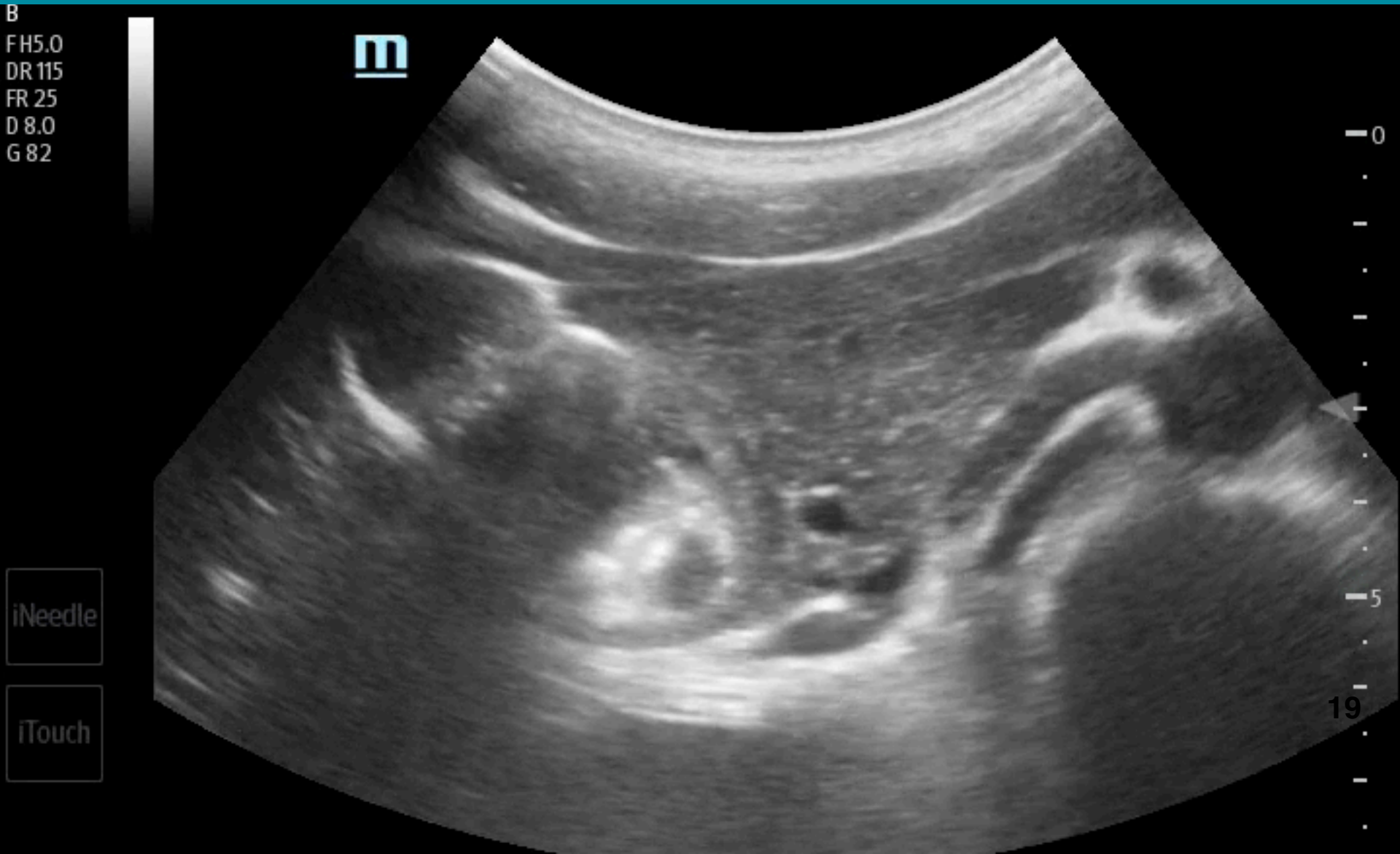
DUODENUM (2ND/ 3RD SEGMENTS)



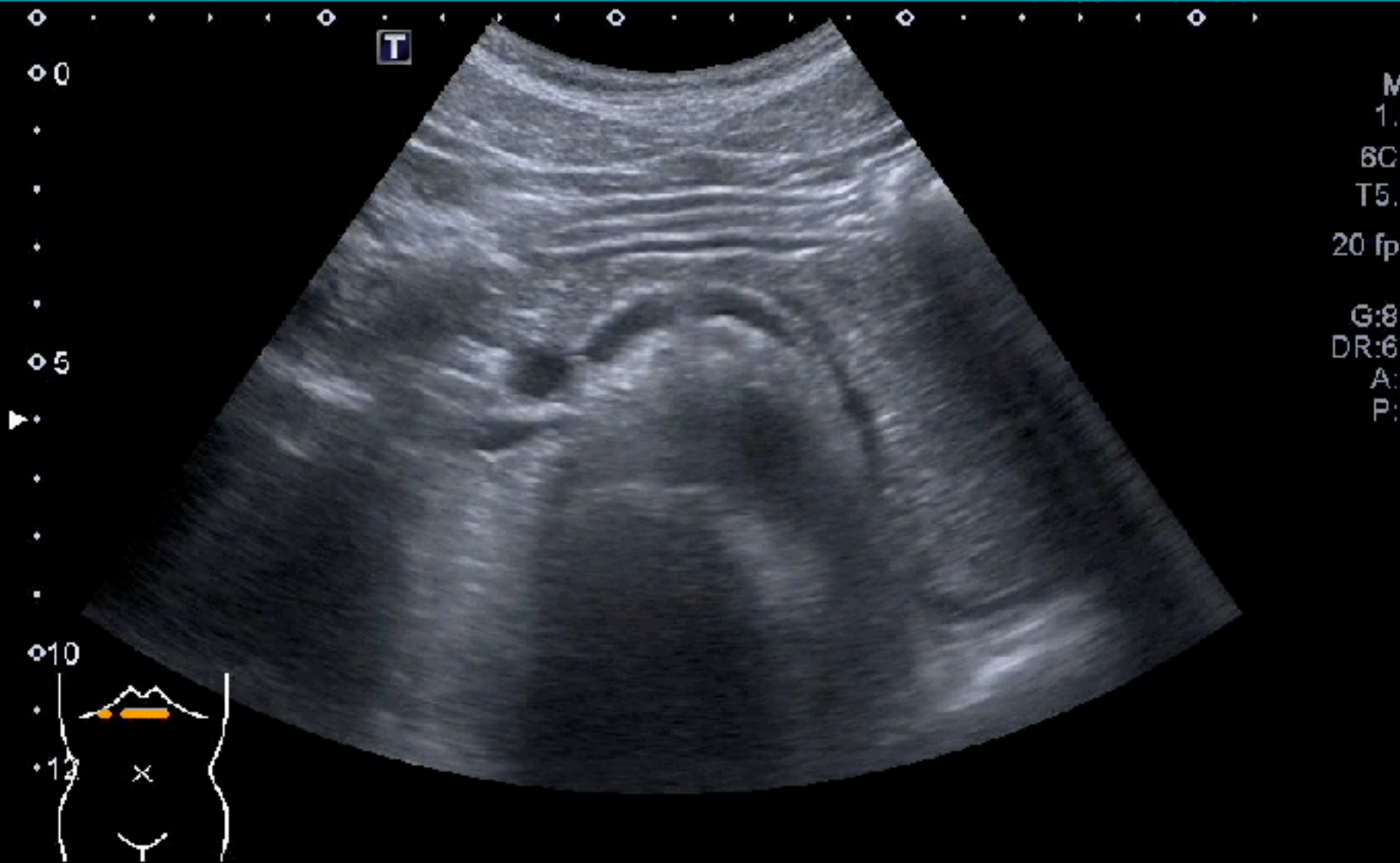
PANCREAS



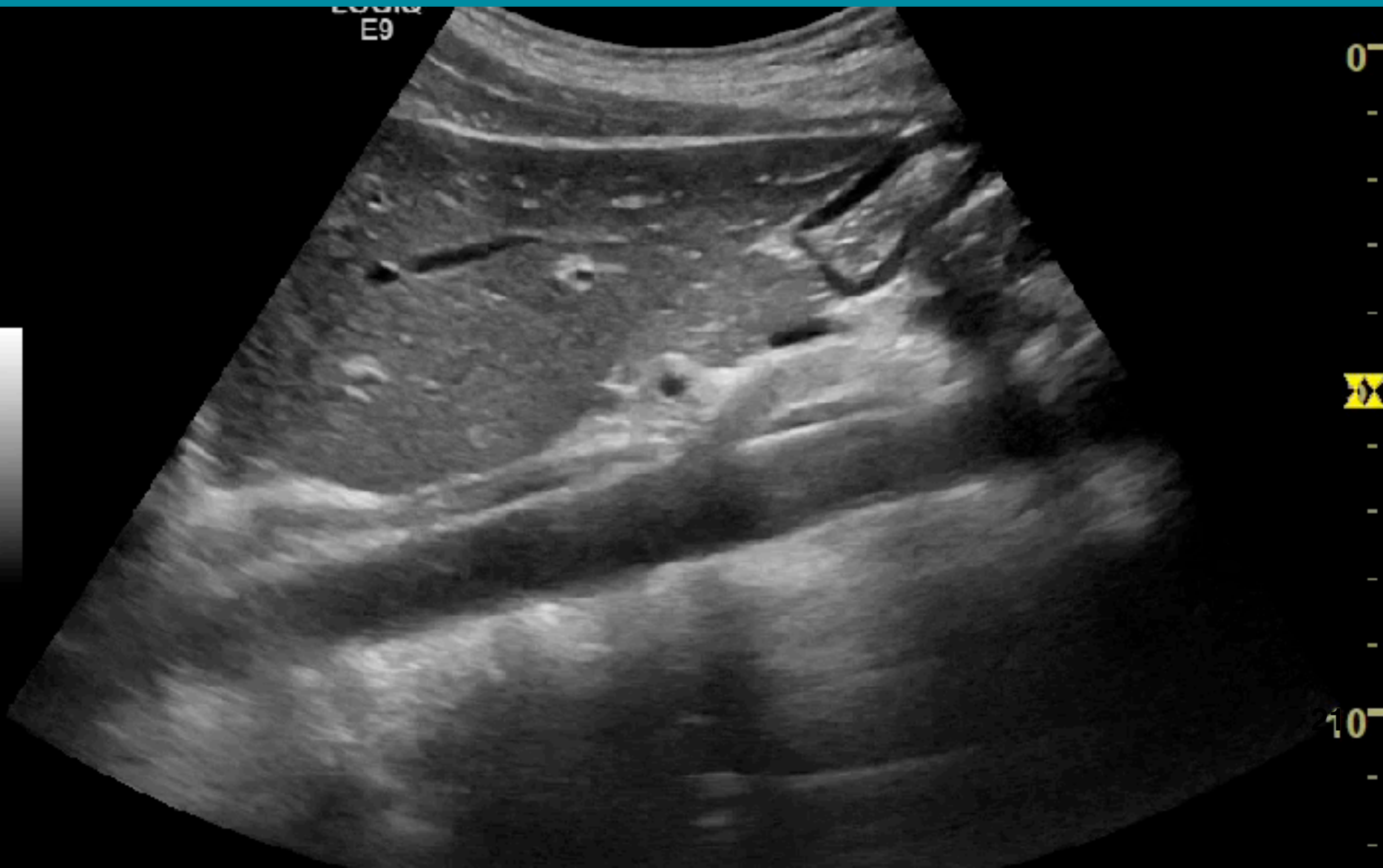PANCREAS



PANCREAS



PANCREAS

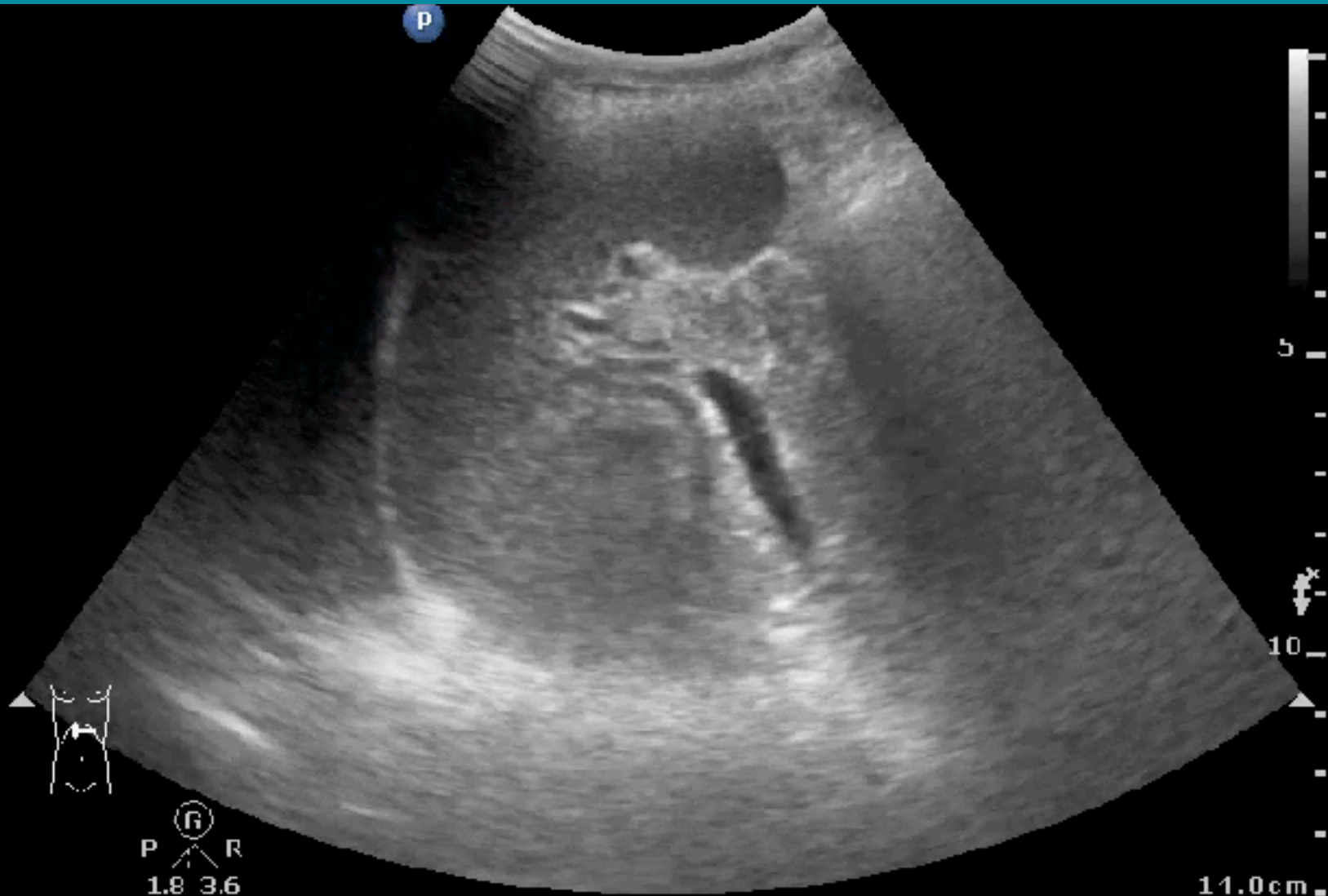


PANCREAS

Abd Gen
C5-1
36 Hz
14.0cm

2D

HGen
Gn 9/
C. 56
3/3/3



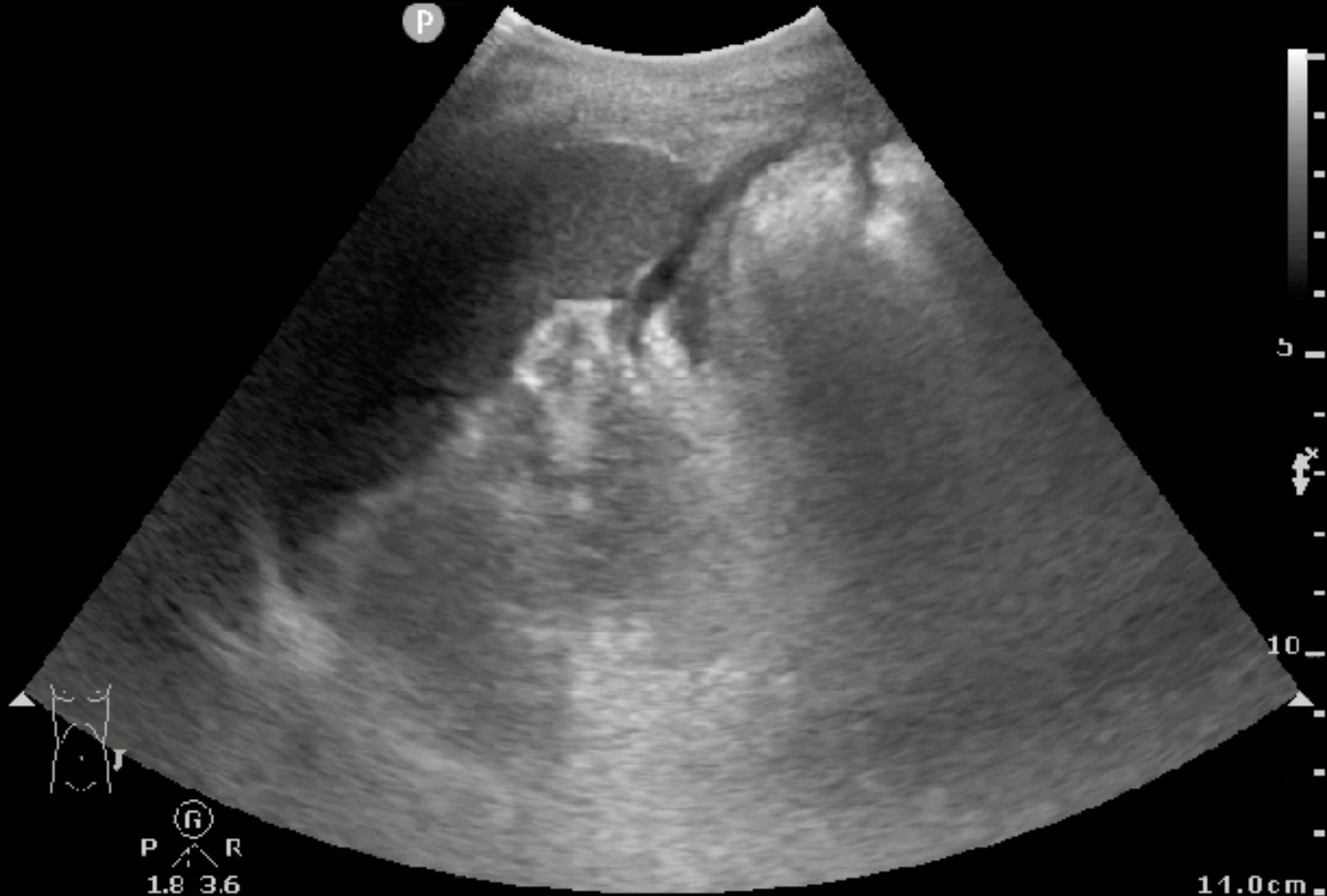11.0cm

6
P R
1.8 3.6

PANCREAS

Abd Gen
C5-1
36 Hz
14.0cm

2D
HGen
Gn 100
C. 56
3/3/3

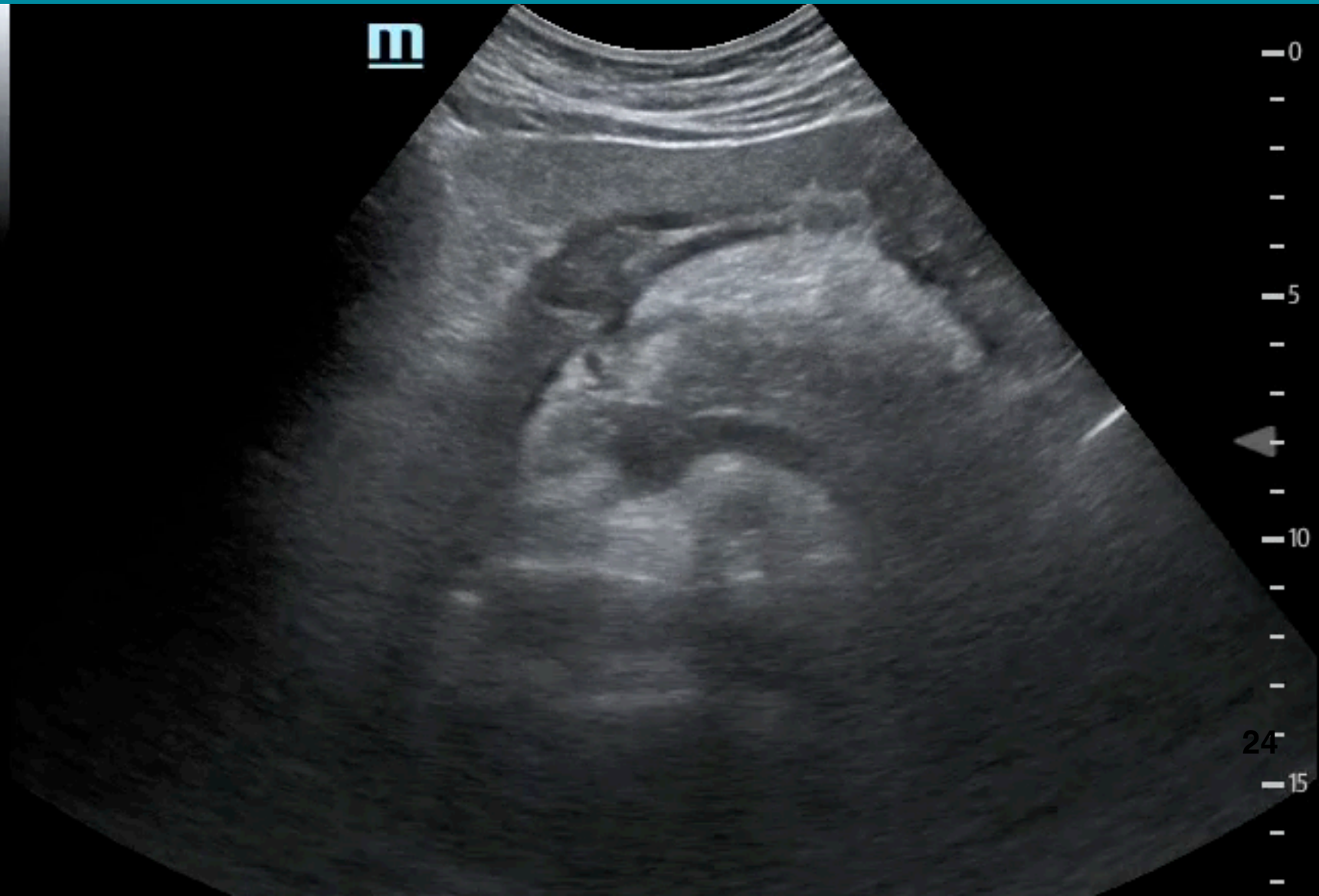


11.0cm

PANCREAS

TI 0.7
TIS 0.7

B
FH5.0
DR120
FR18
D 19.0
G 39



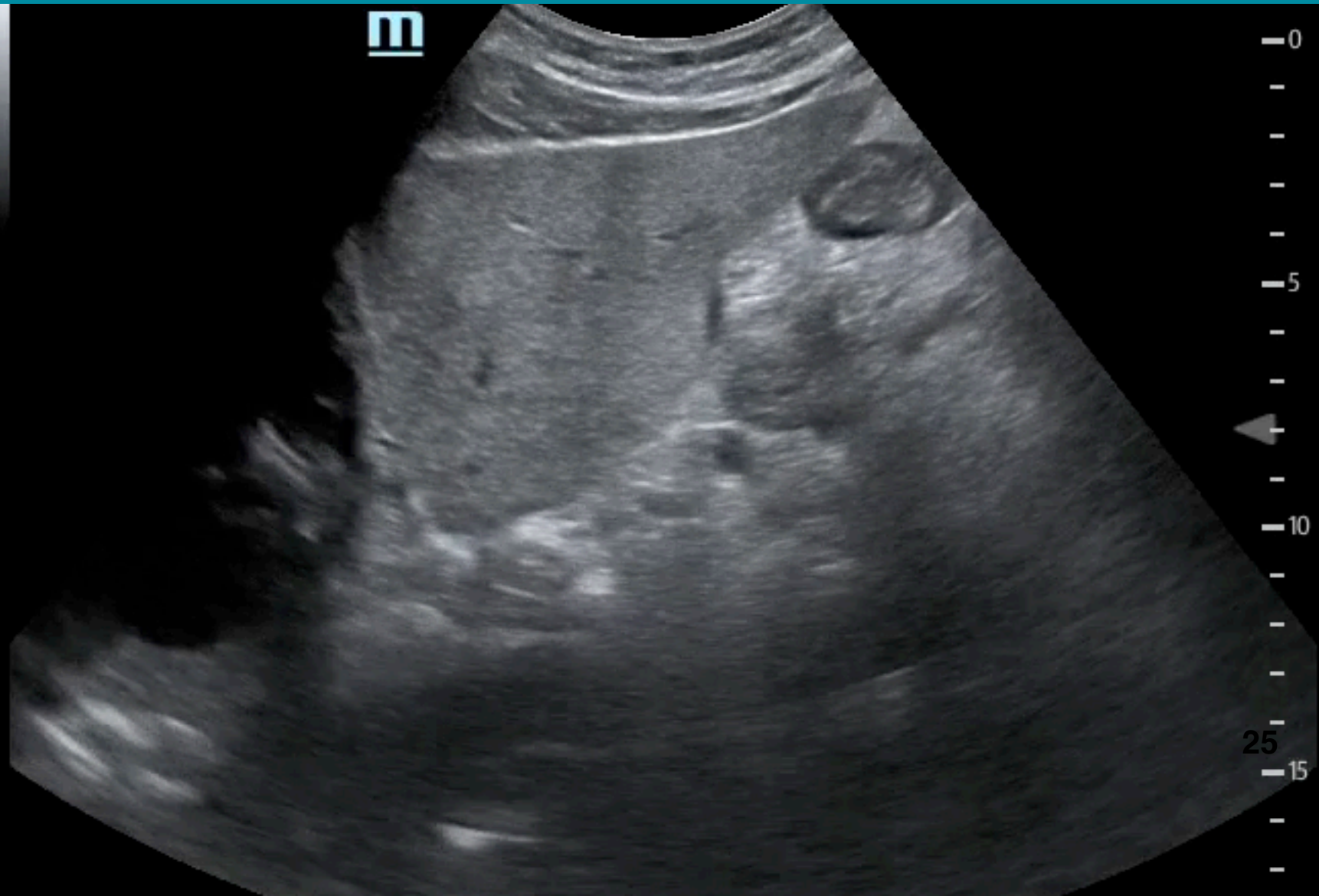
0
-
-
-
-
5
-
-
-
-
10
-
-
-
24
15
-

PANCREAS

TIS 0.7



B
FH5.0
DR120
FR18
D19.0
G39



0
5
10
15
25

PANCREAS

TIS 0.7



B
FH5.0
DR120
FR22
D15.0
G50

0

-

-

-

-

5

-

-

-

-

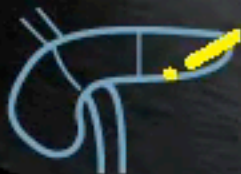10



26

-

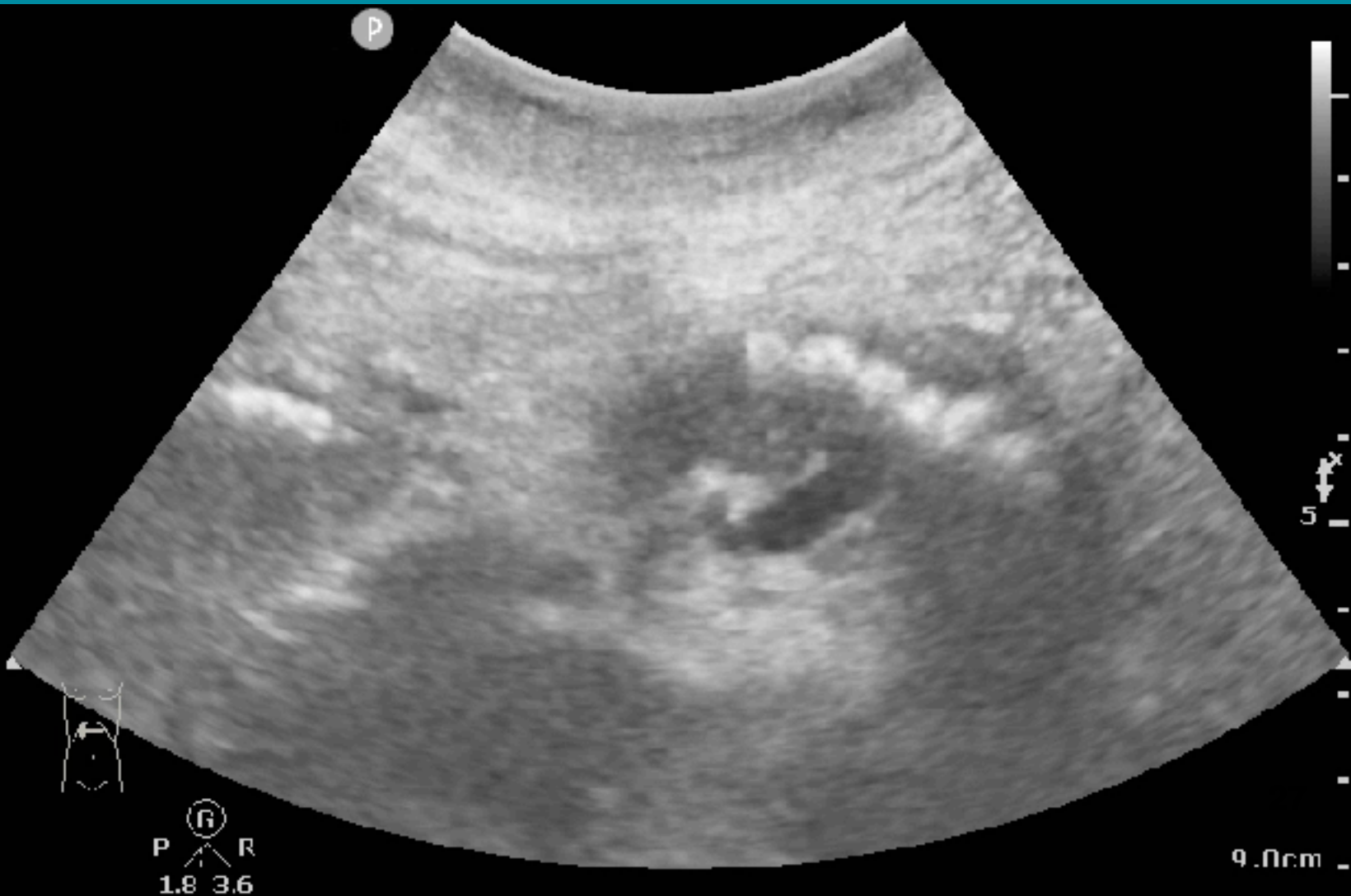
-



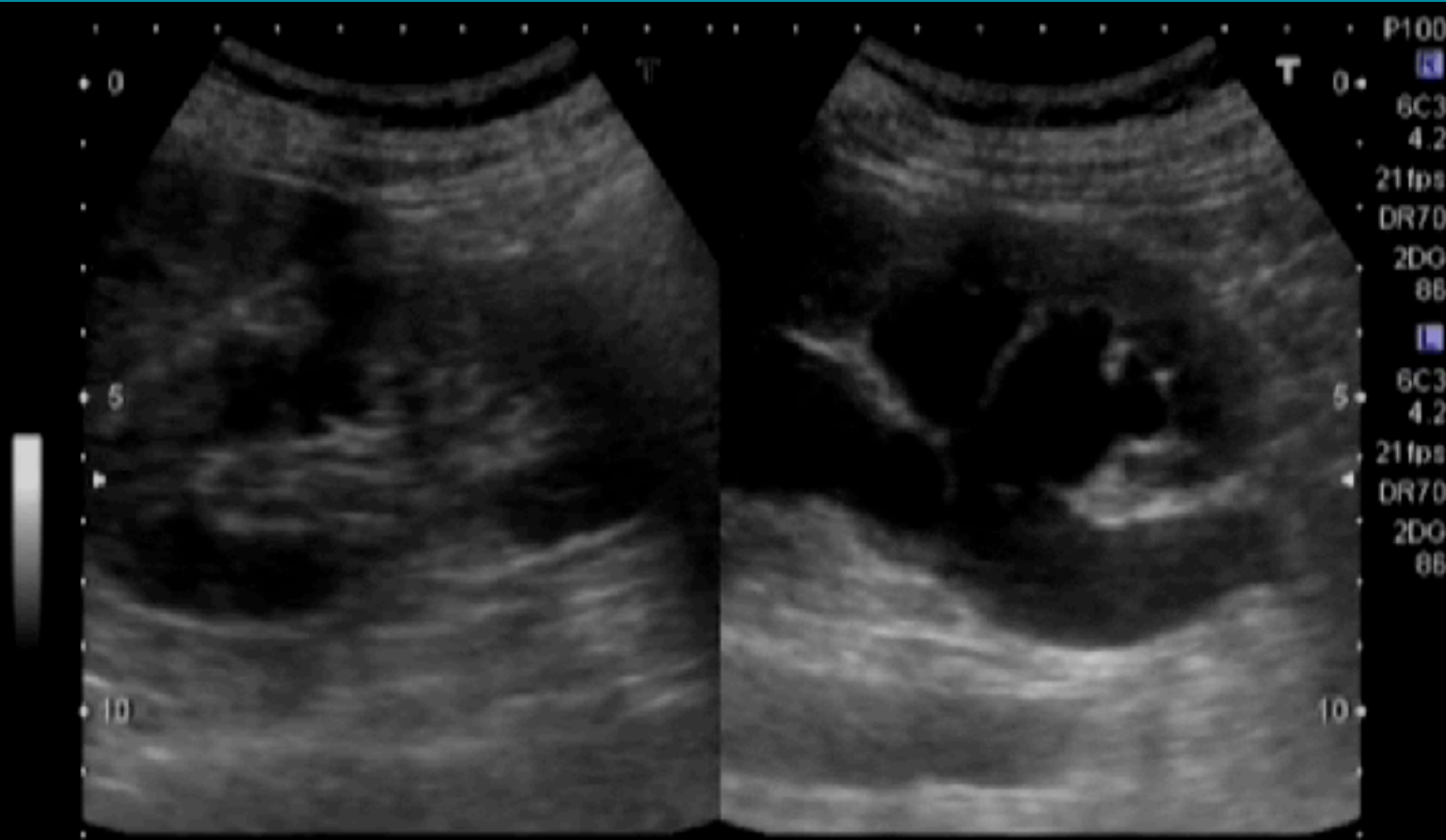
PANCREAS

Abd Gen
C5-1
47 Hz
9.0cm

2D
HGen
Gn 100
C. 56
3/3/3



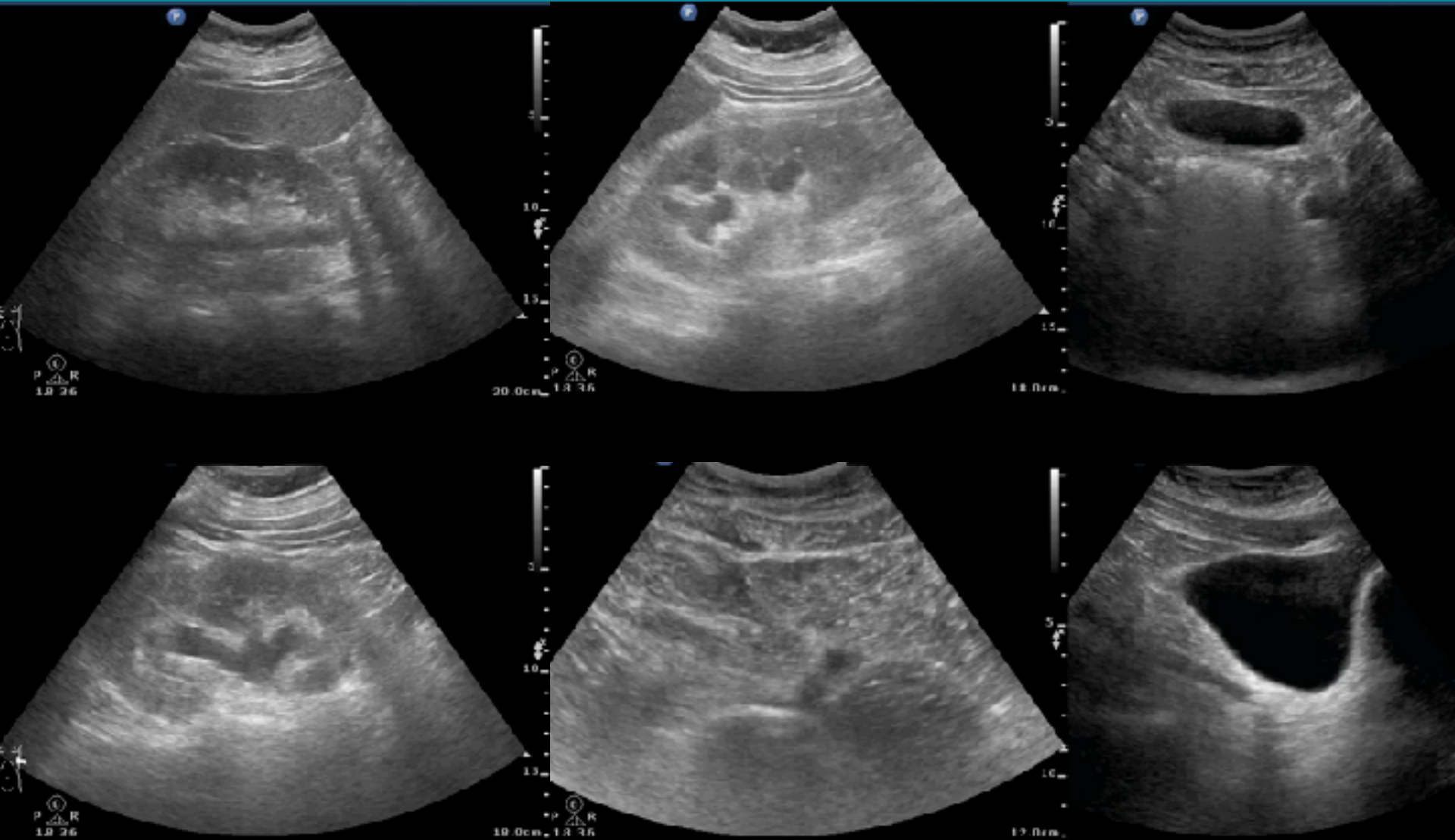
URETERS



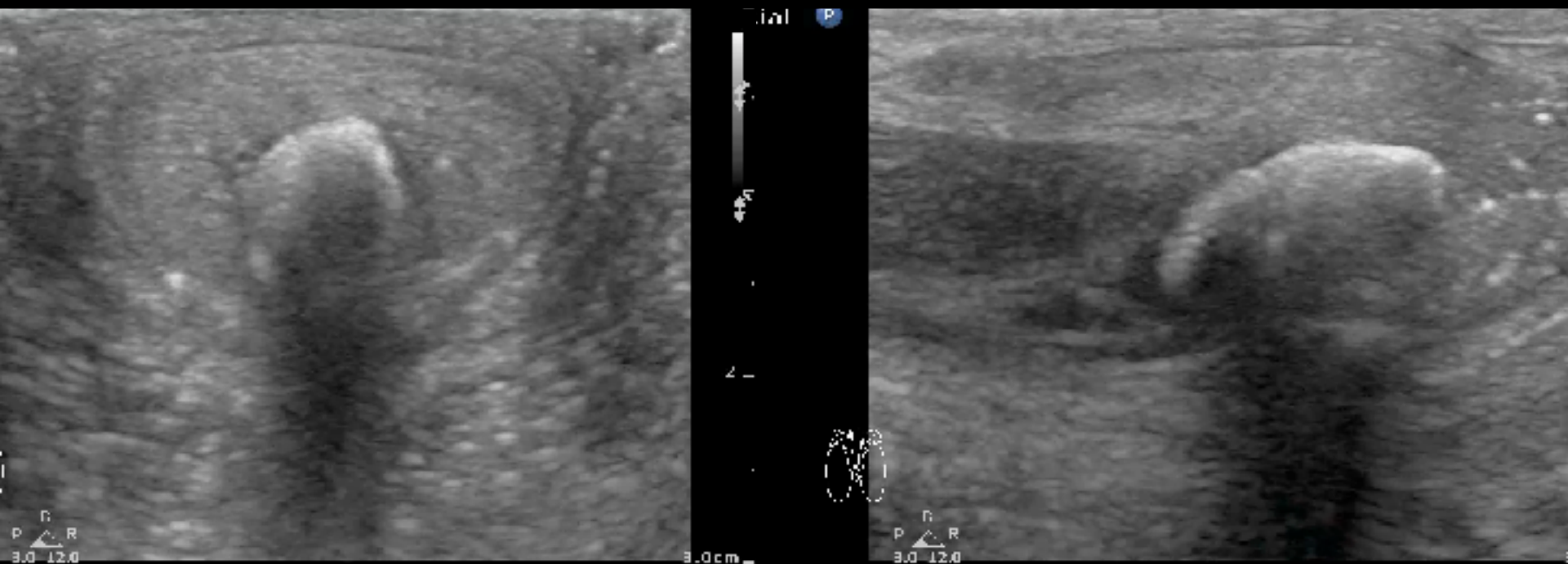
Free B



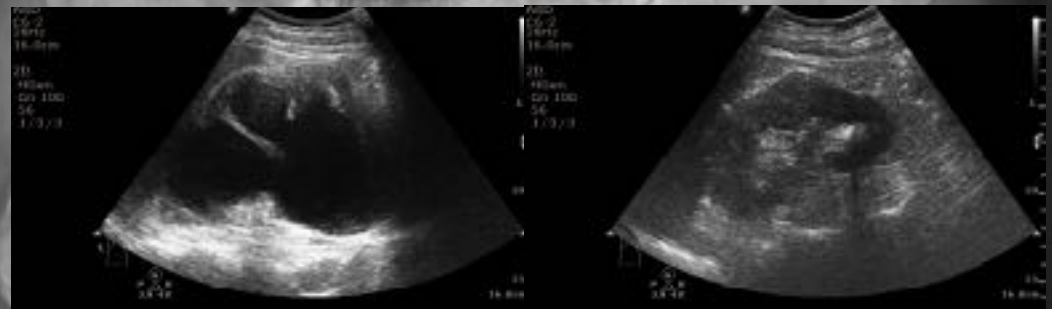
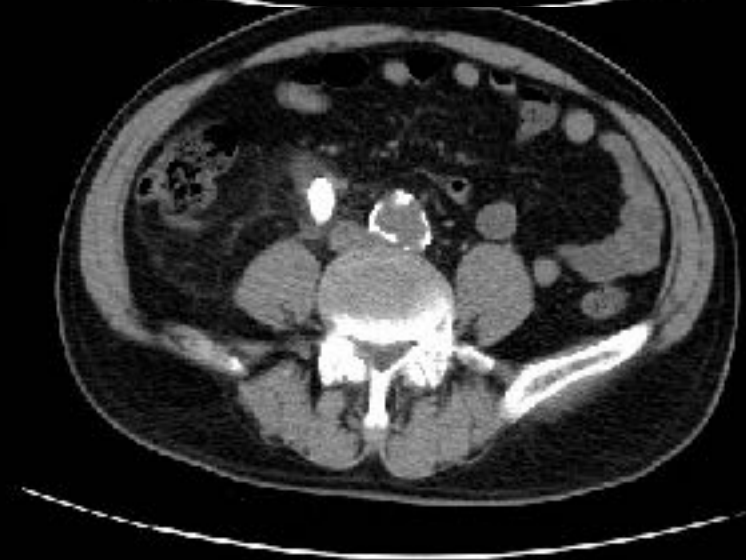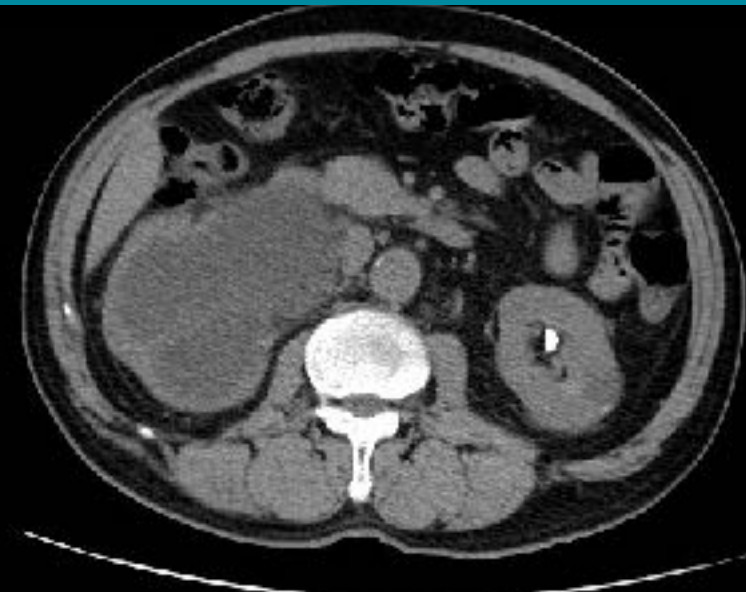
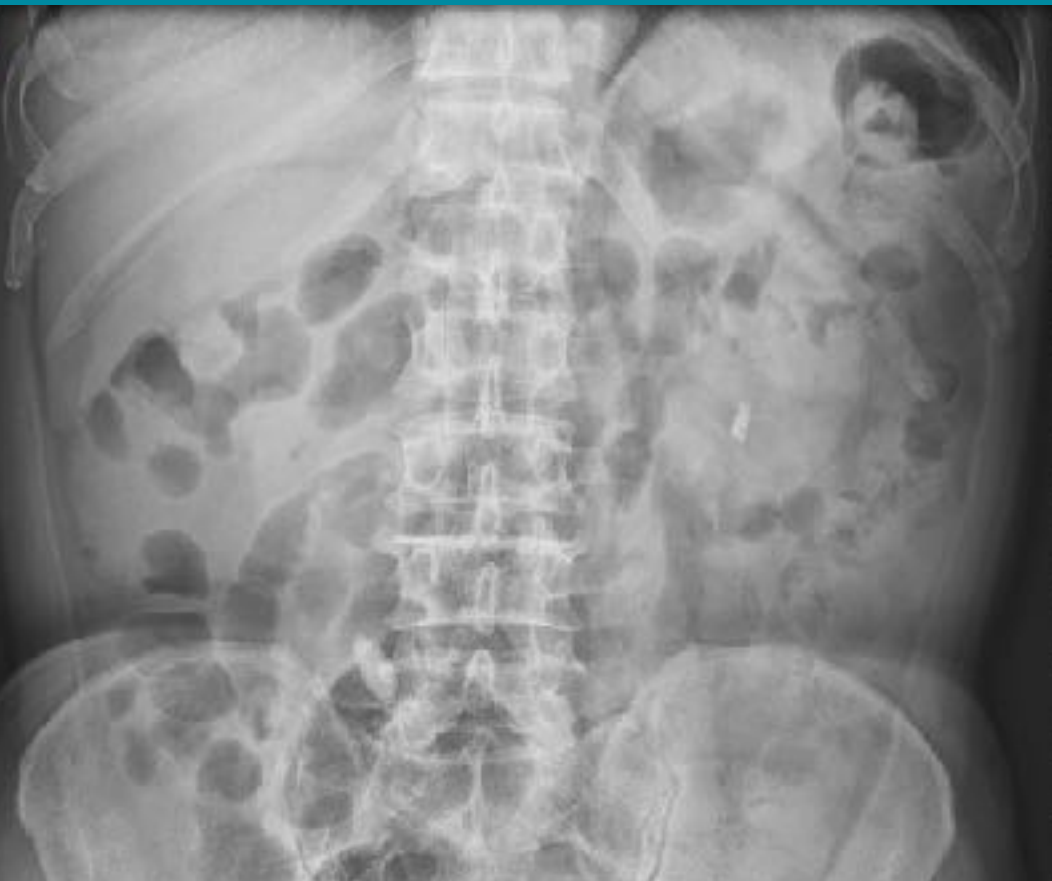URETERS



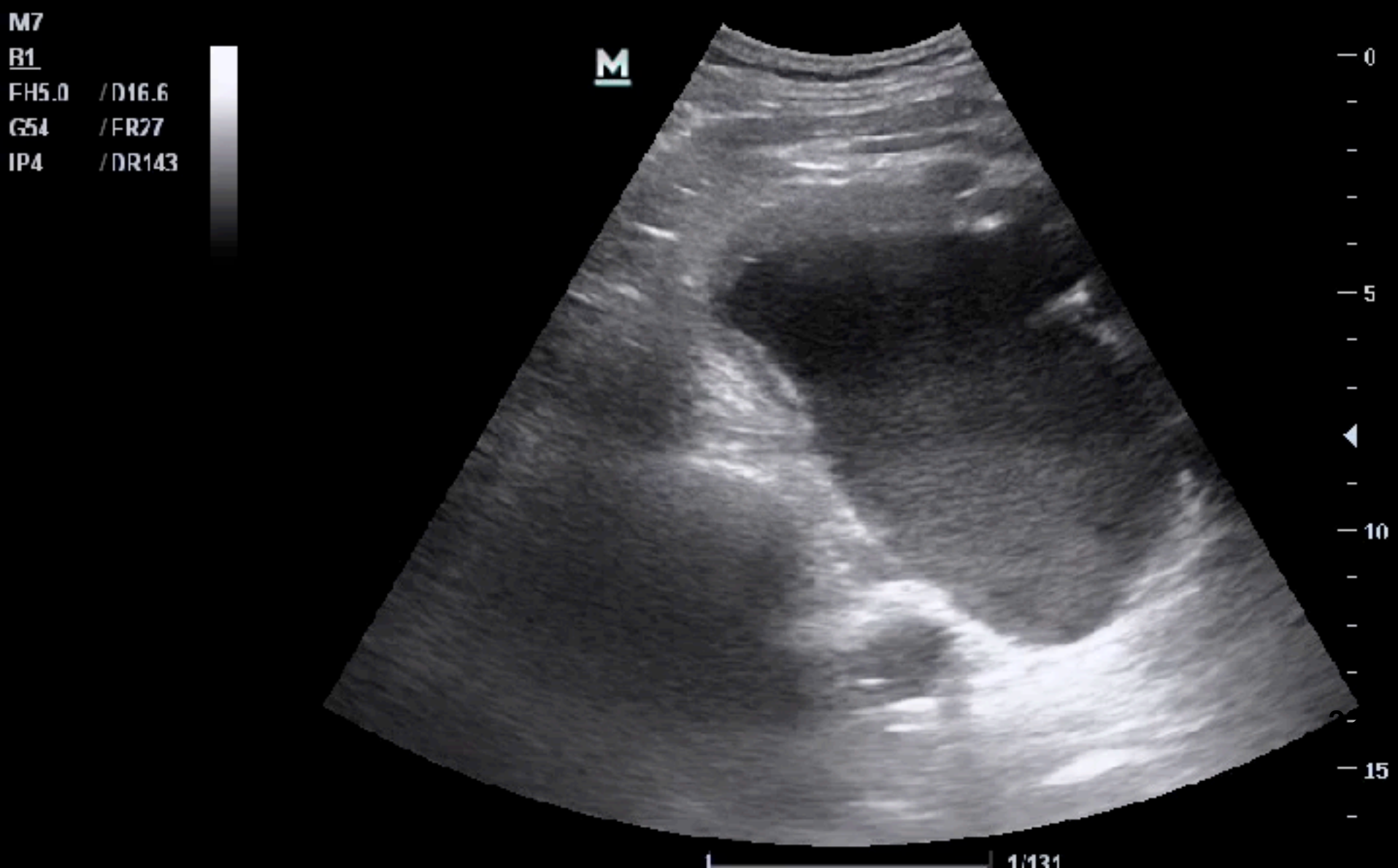
URETERS

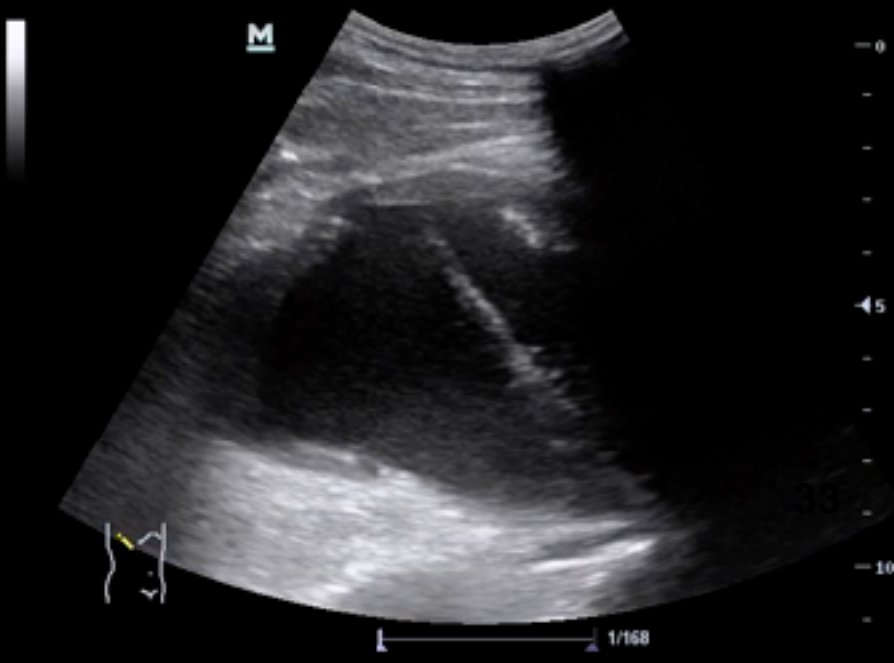
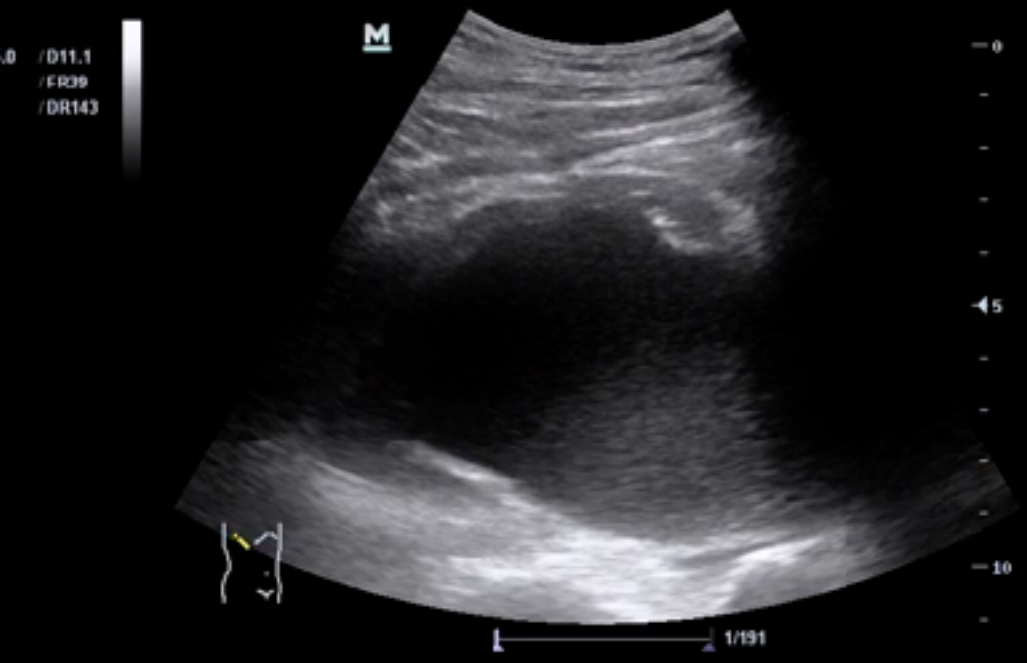
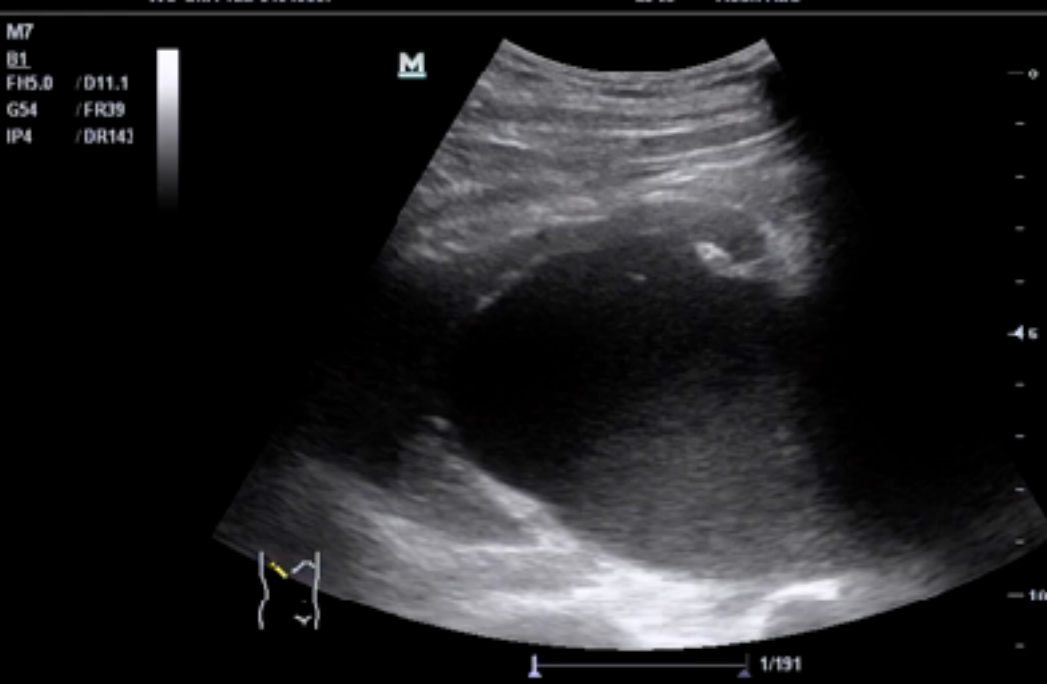
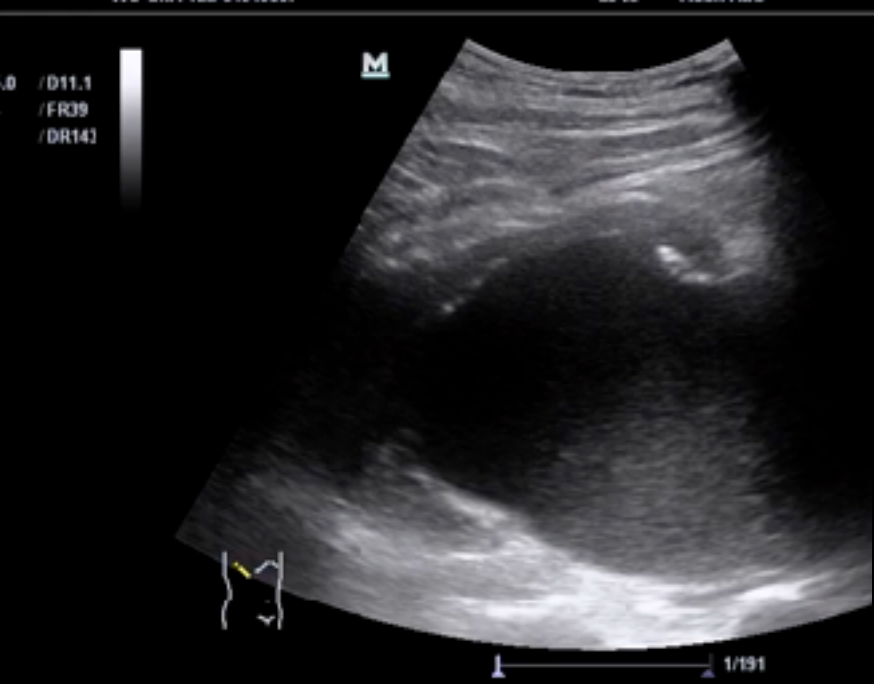


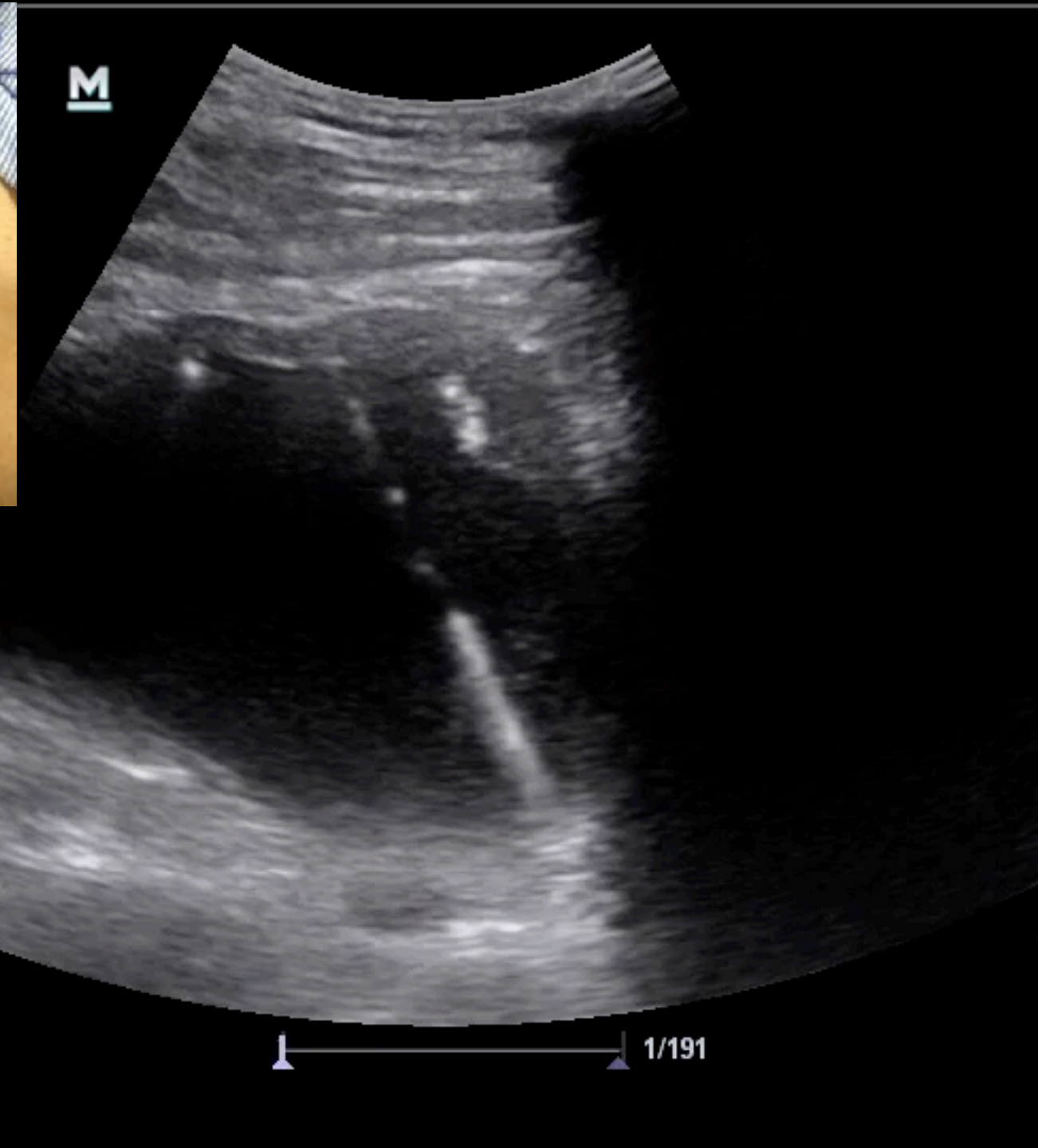
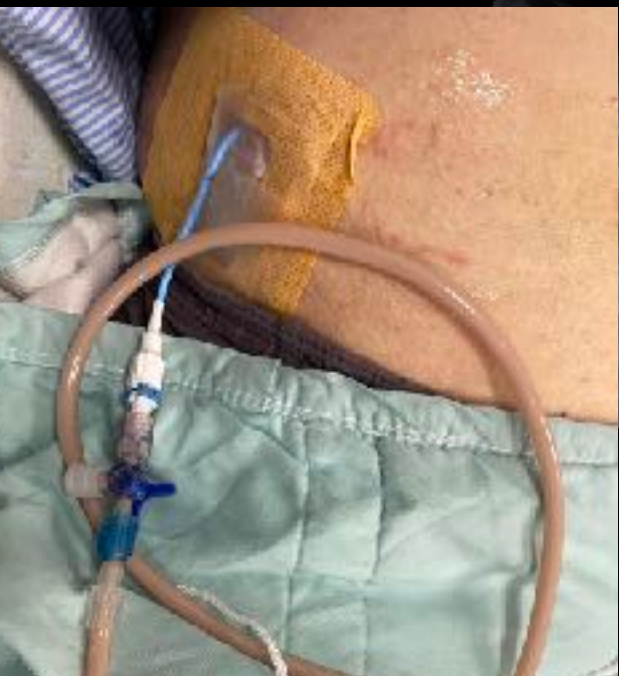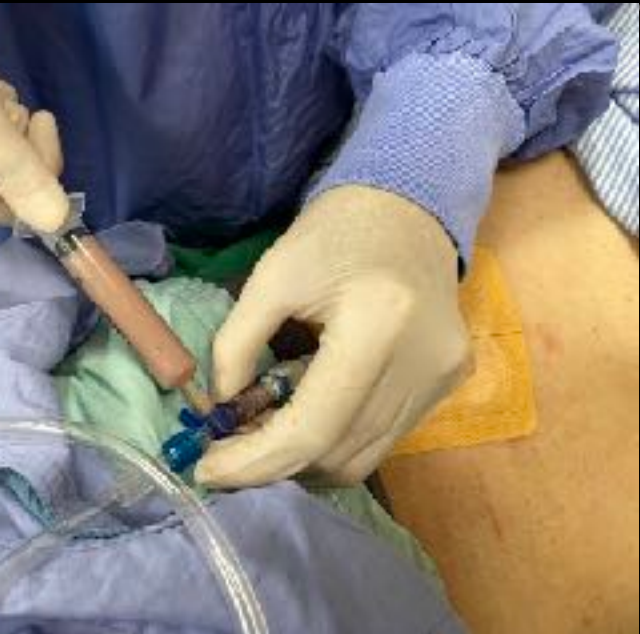62M, 腹痛



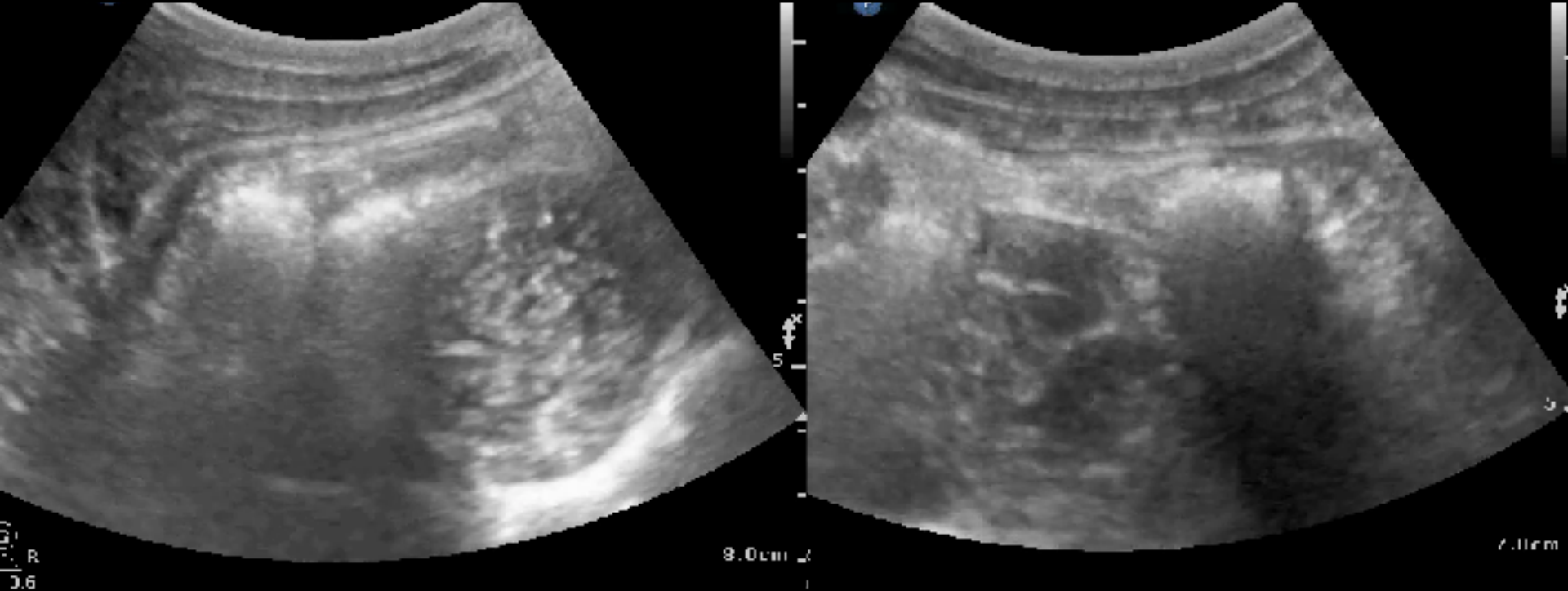
PCN for severe pyonephrosis



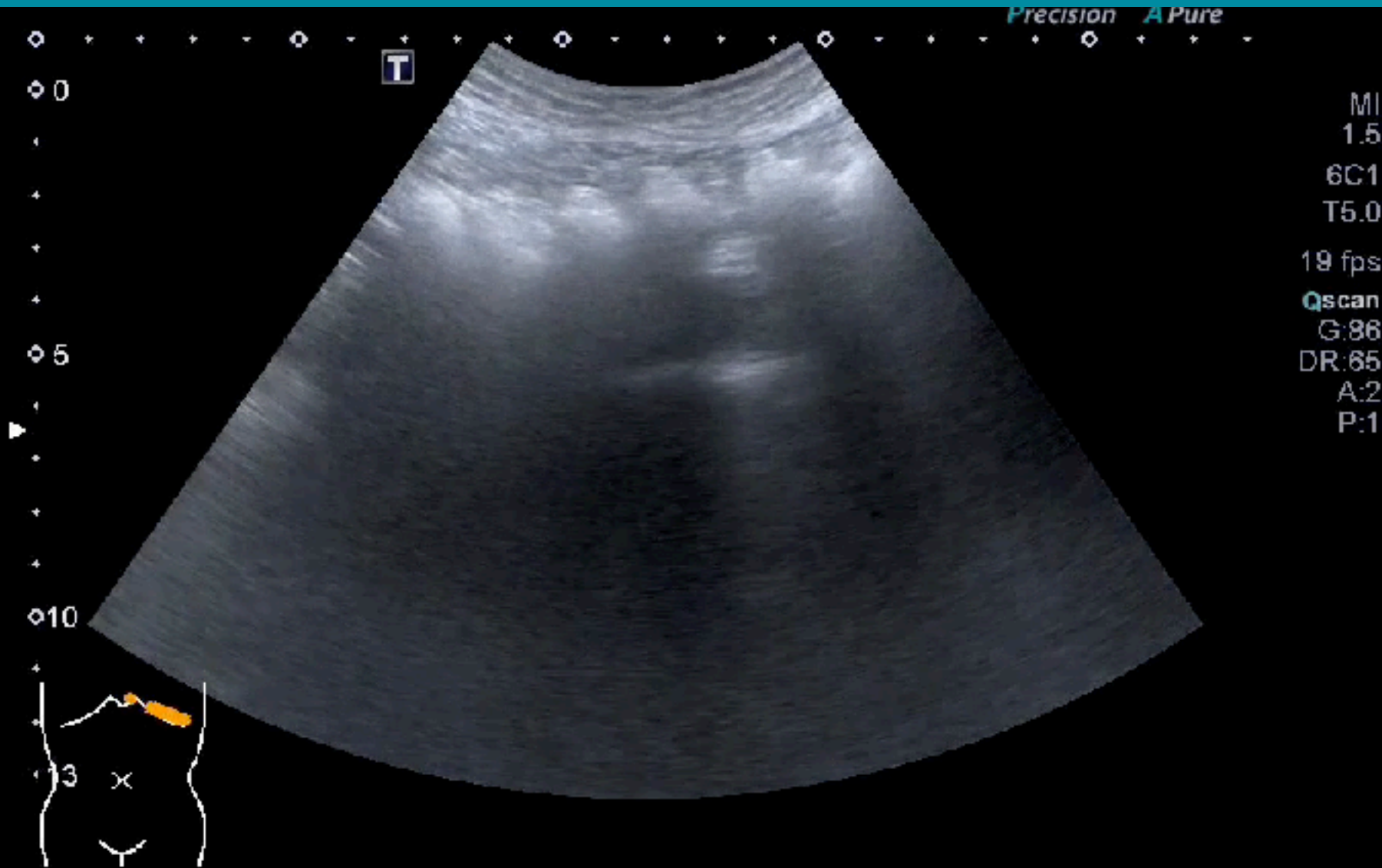




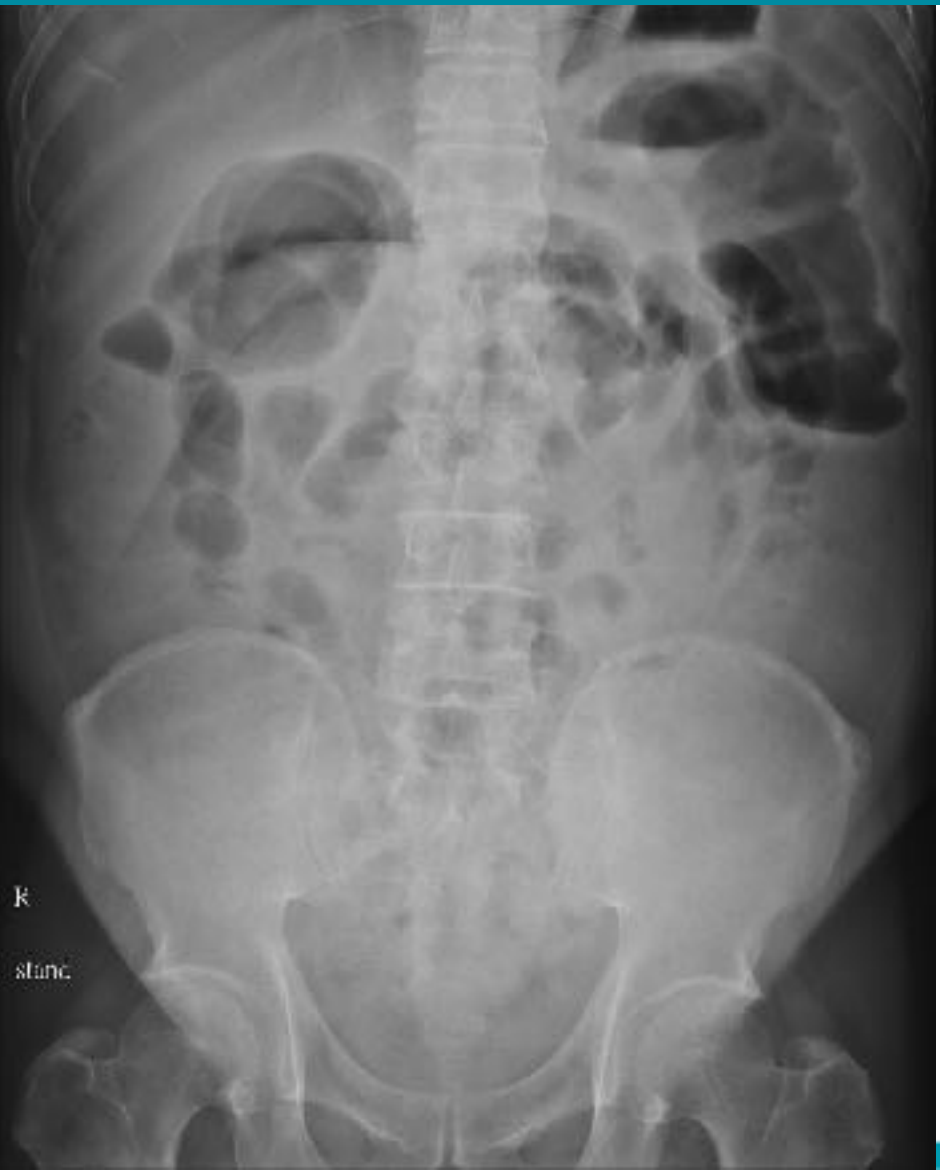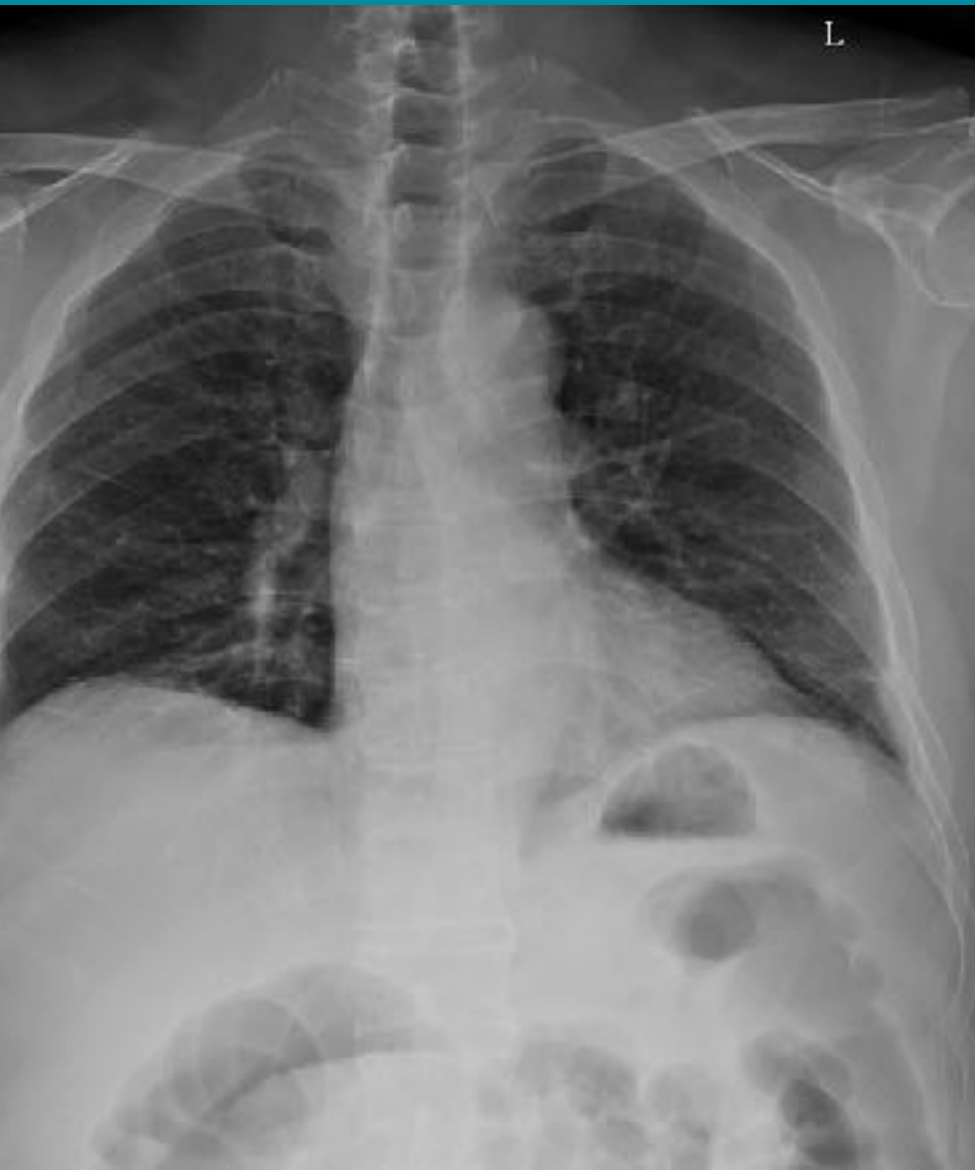COLON (ASCENDING + DESCENDING)



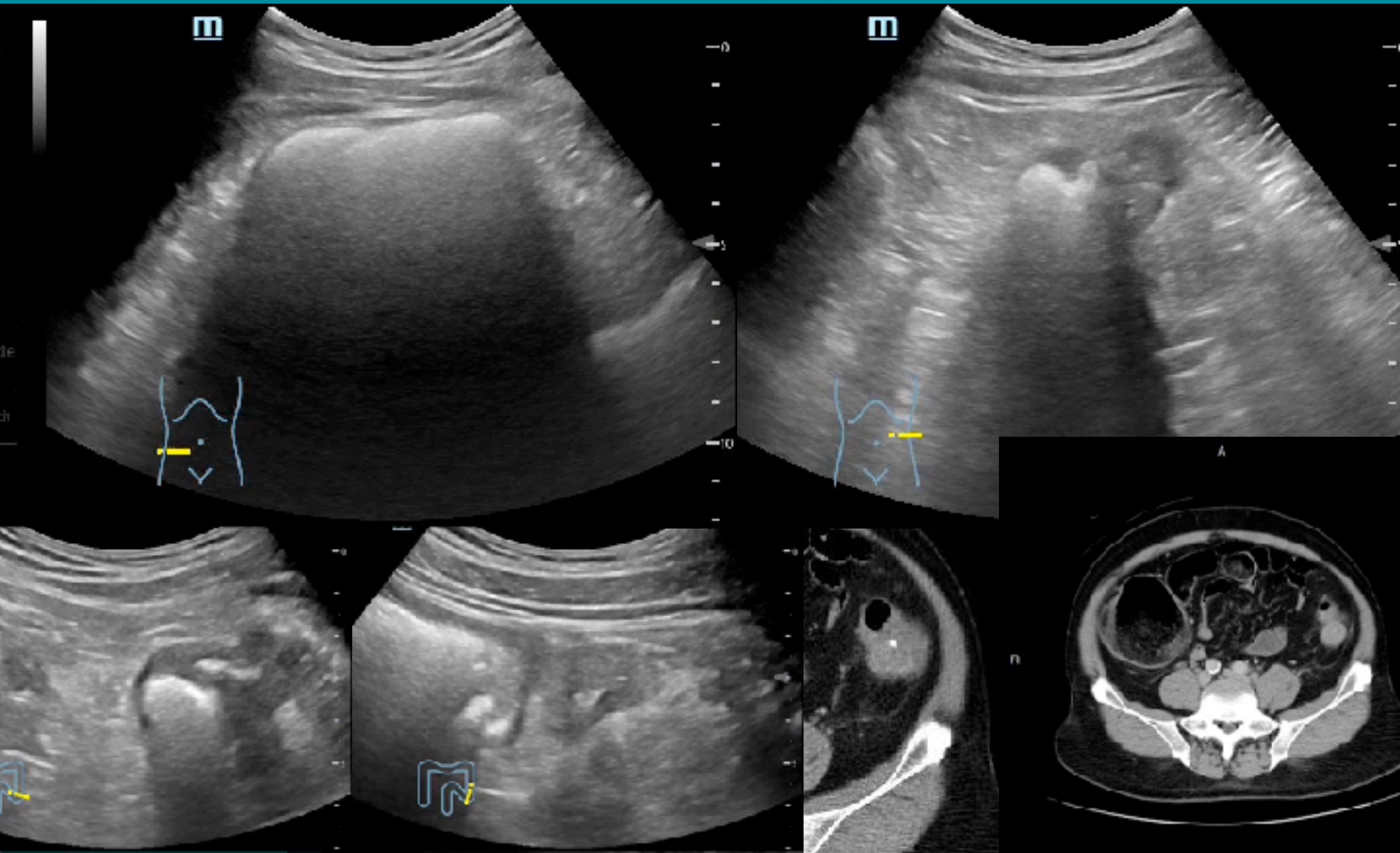
COLON (ASCENDING + DESCENDING)



COLON (ASCENDING + DESCENDING)



COLON (ASCENDING + DESCENDING)



KIDNEYS

StudyID-20140813105559

MI 0.6

8/19/06/11 03:37:11PM ADM

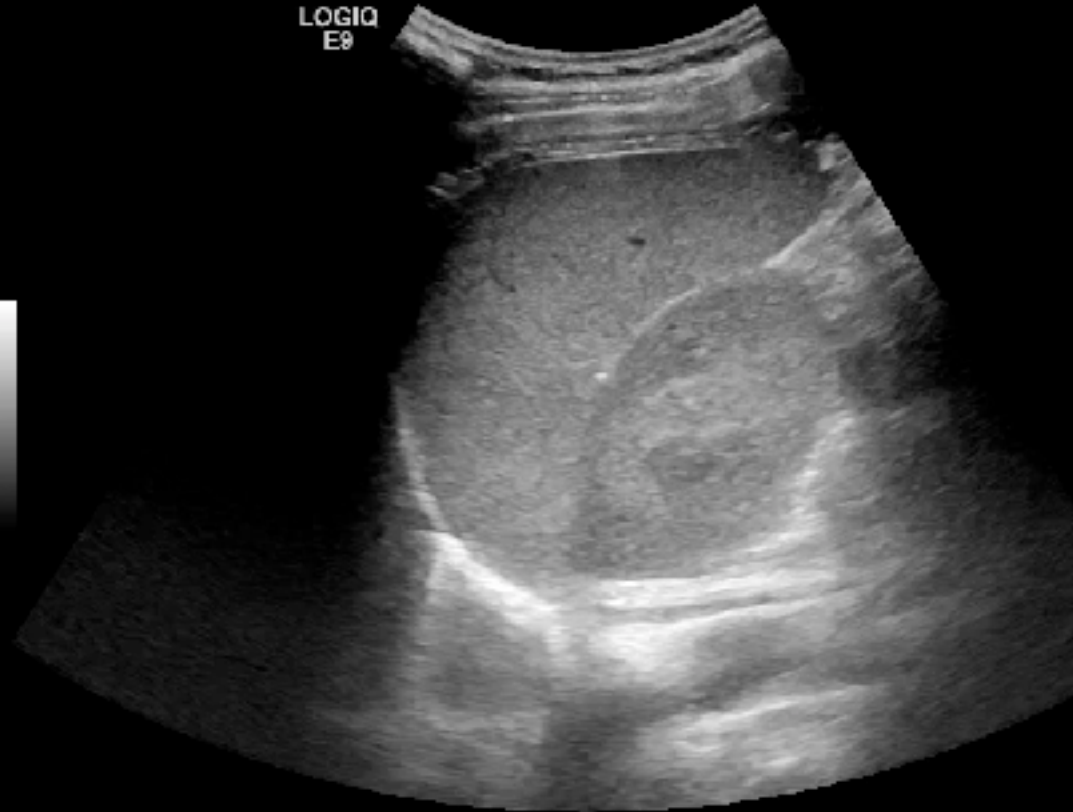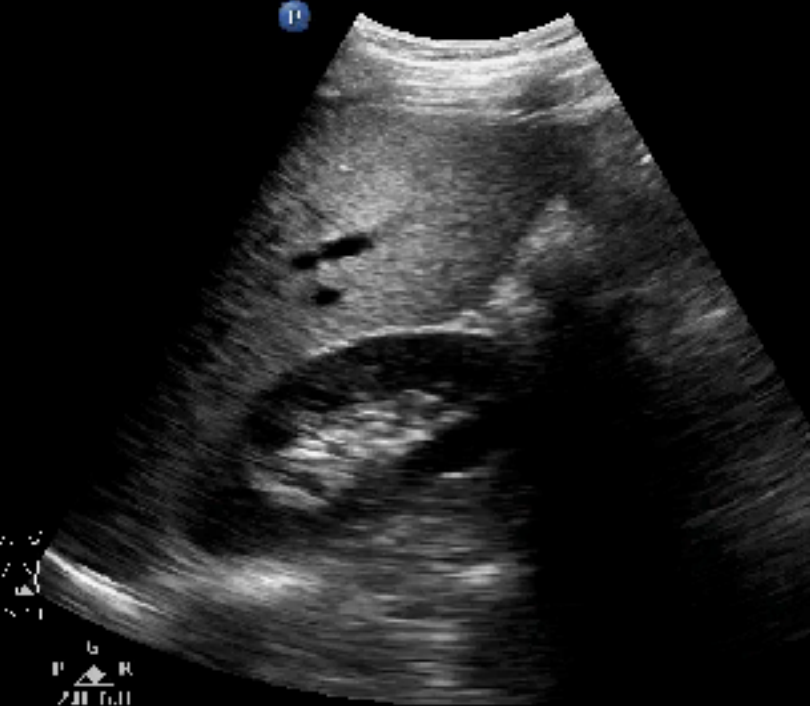C1-6 ABD1 MI 1.2 T

13-105559

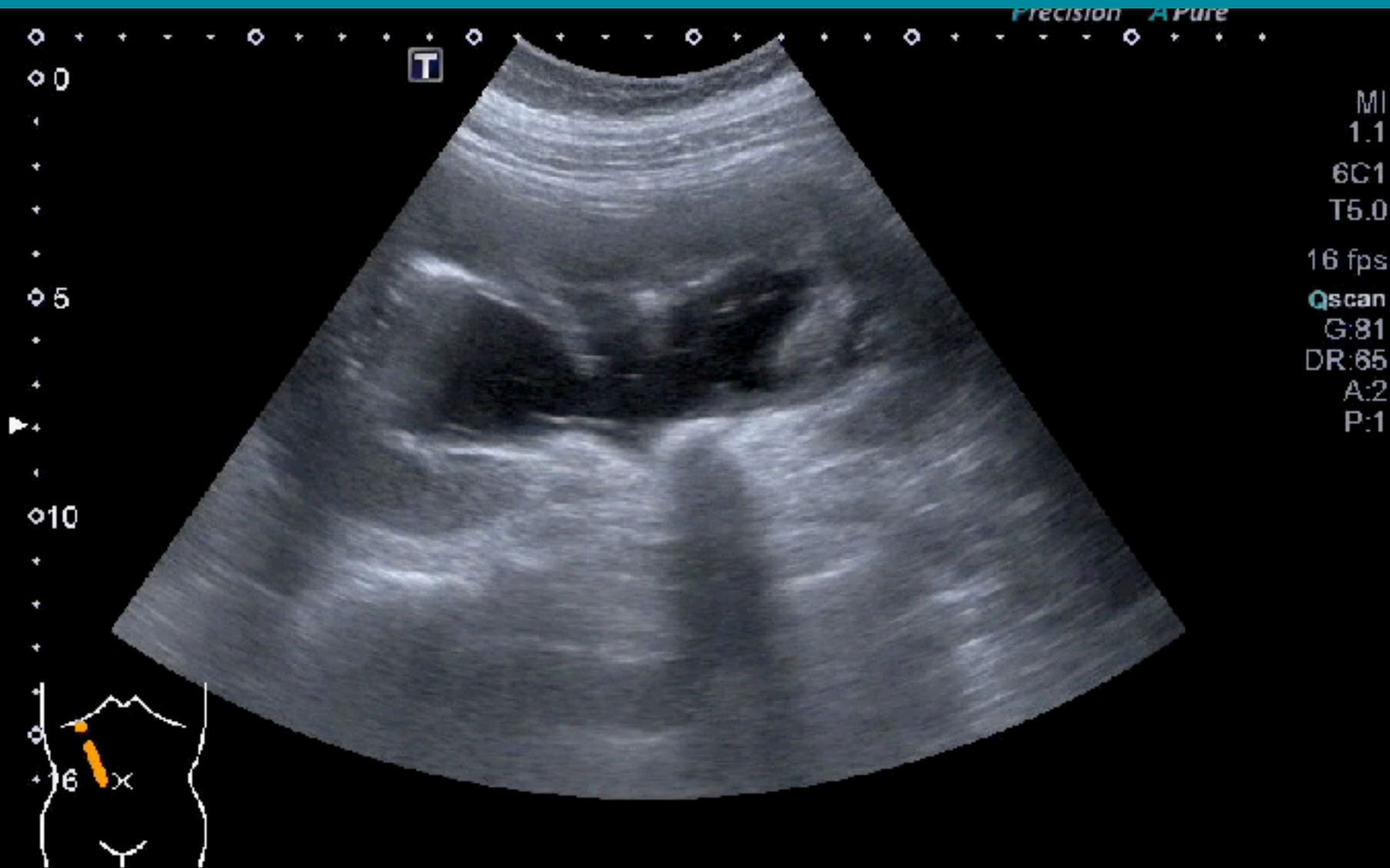
PHILIPS HEALTHCARE

TTS 0.0

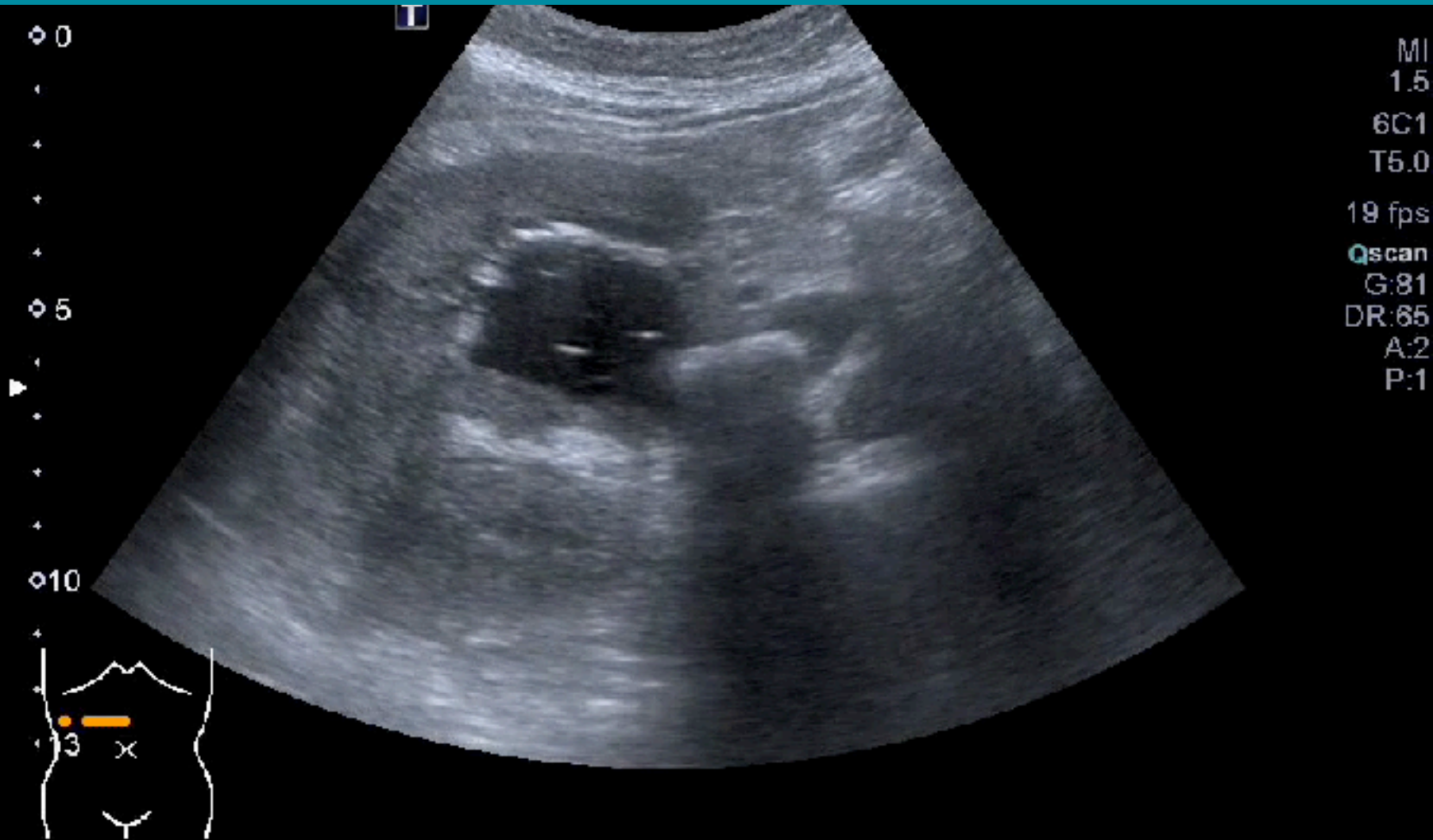
LOGIQ
E9



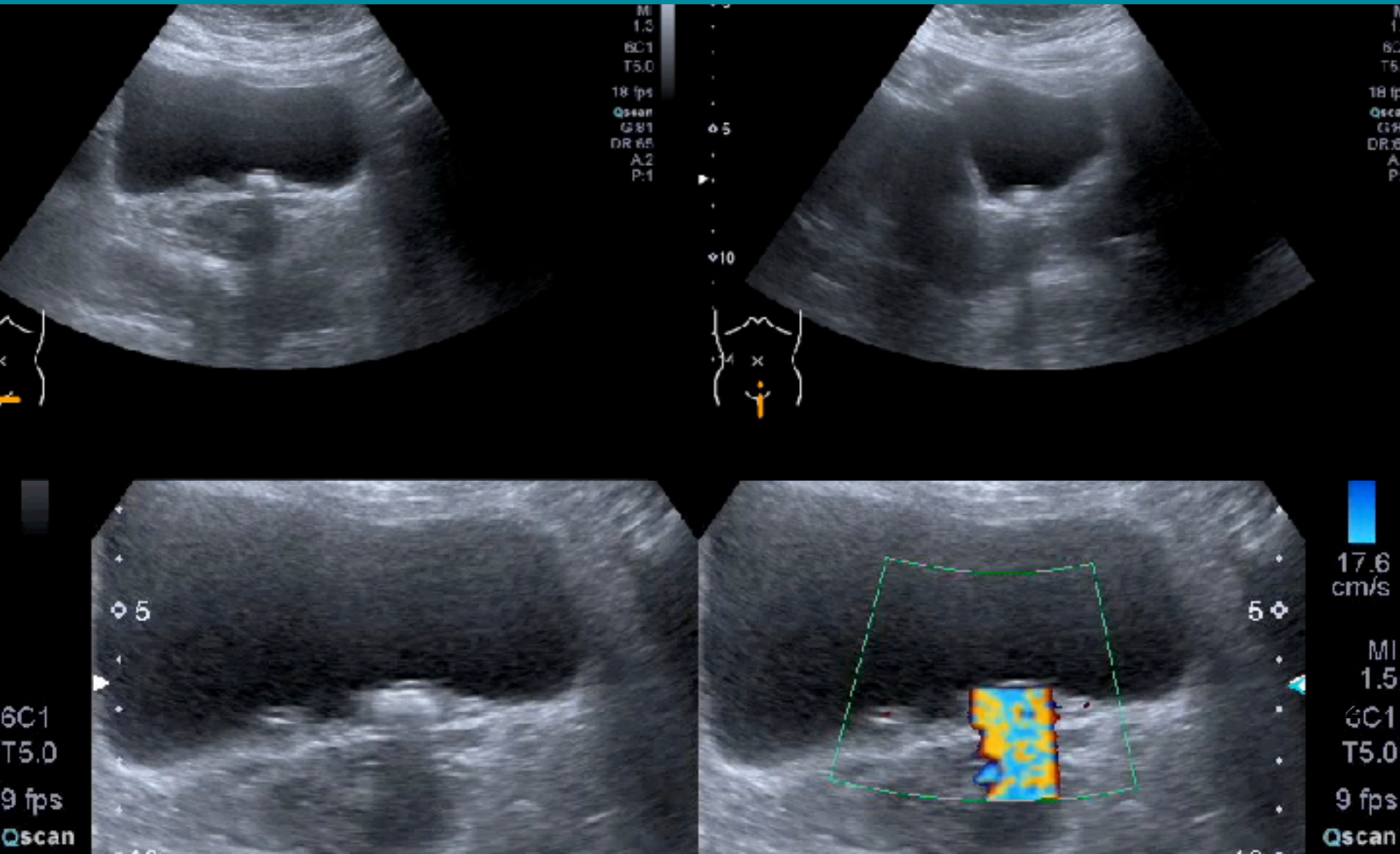
KIDNEYS



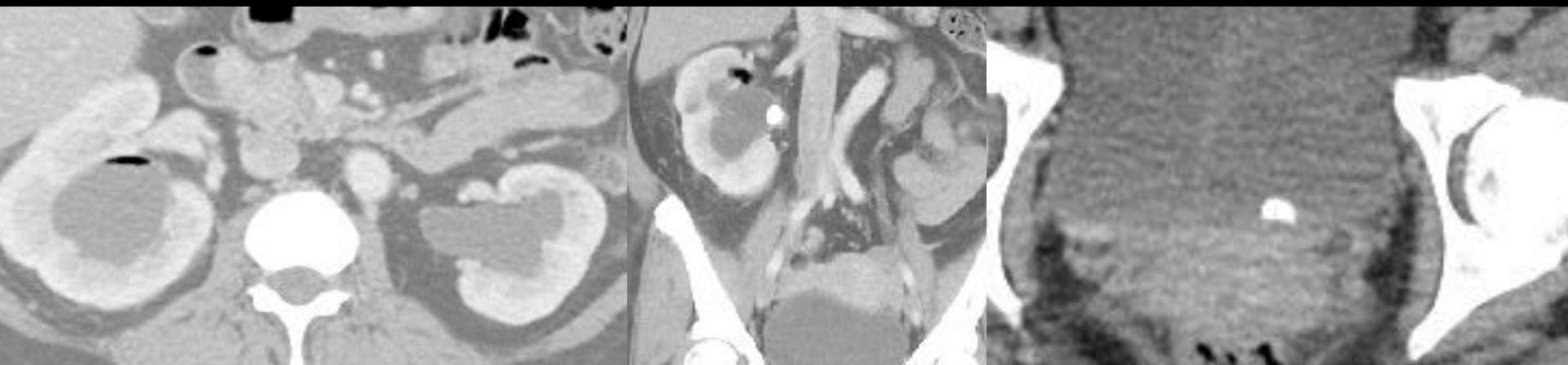
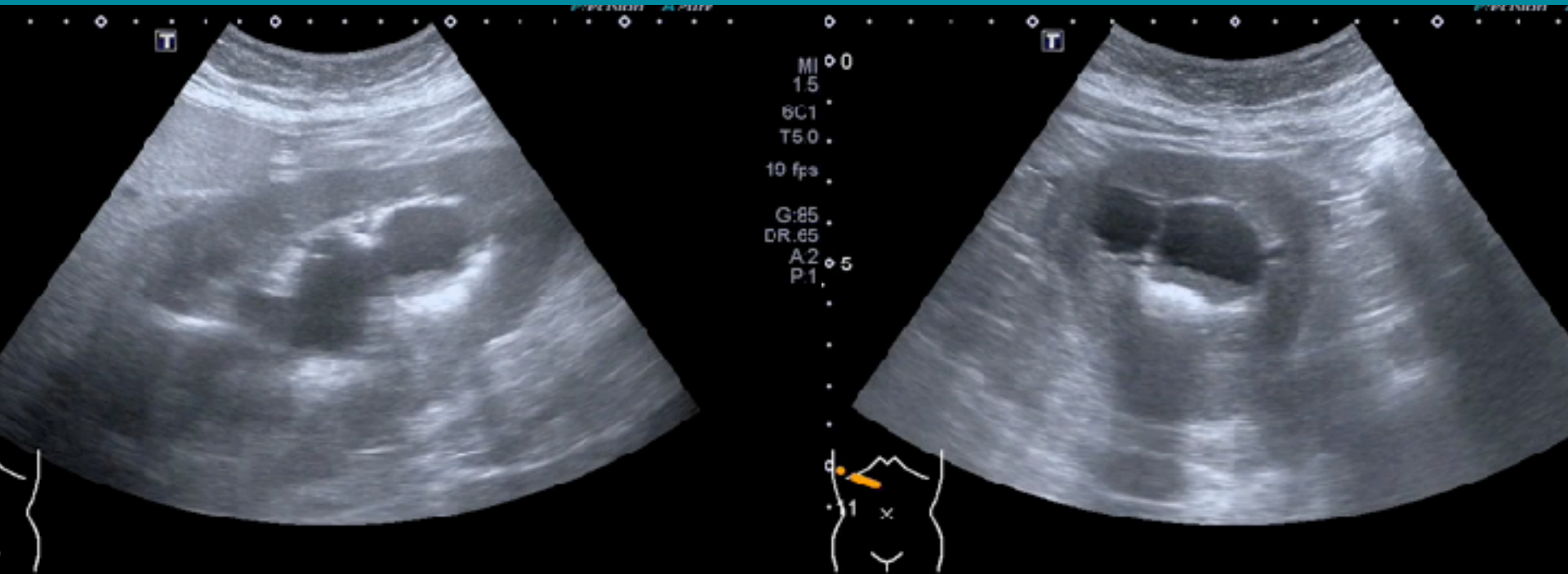
KIDNEYS



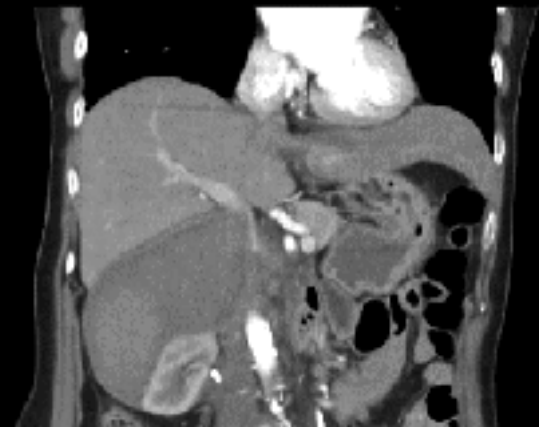
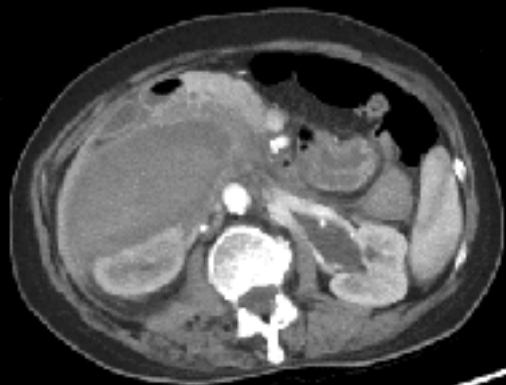
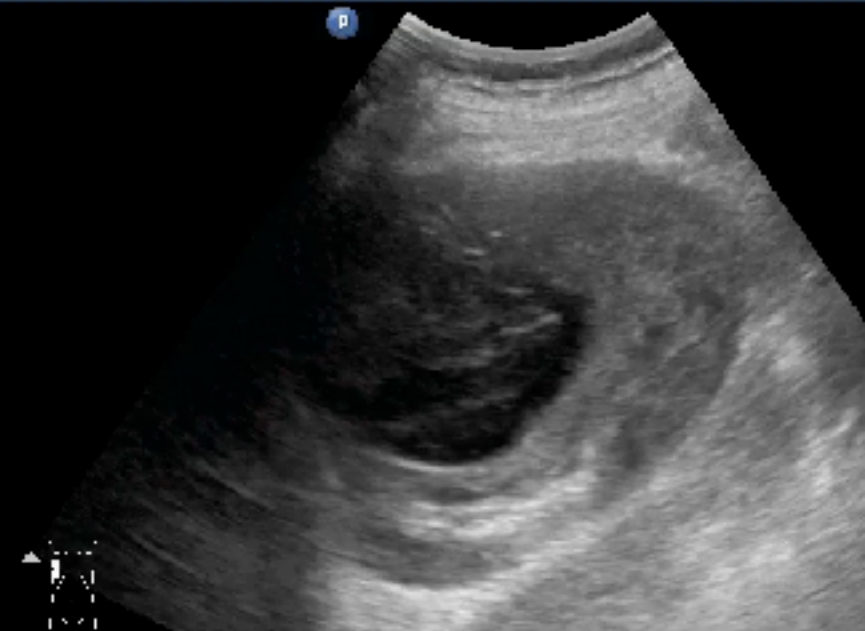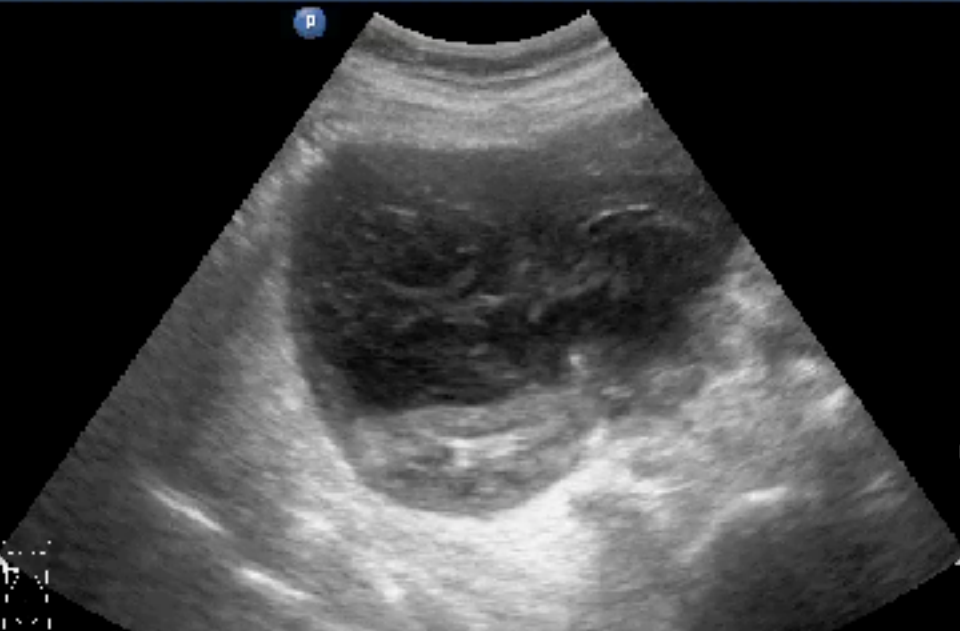KIDNEYS



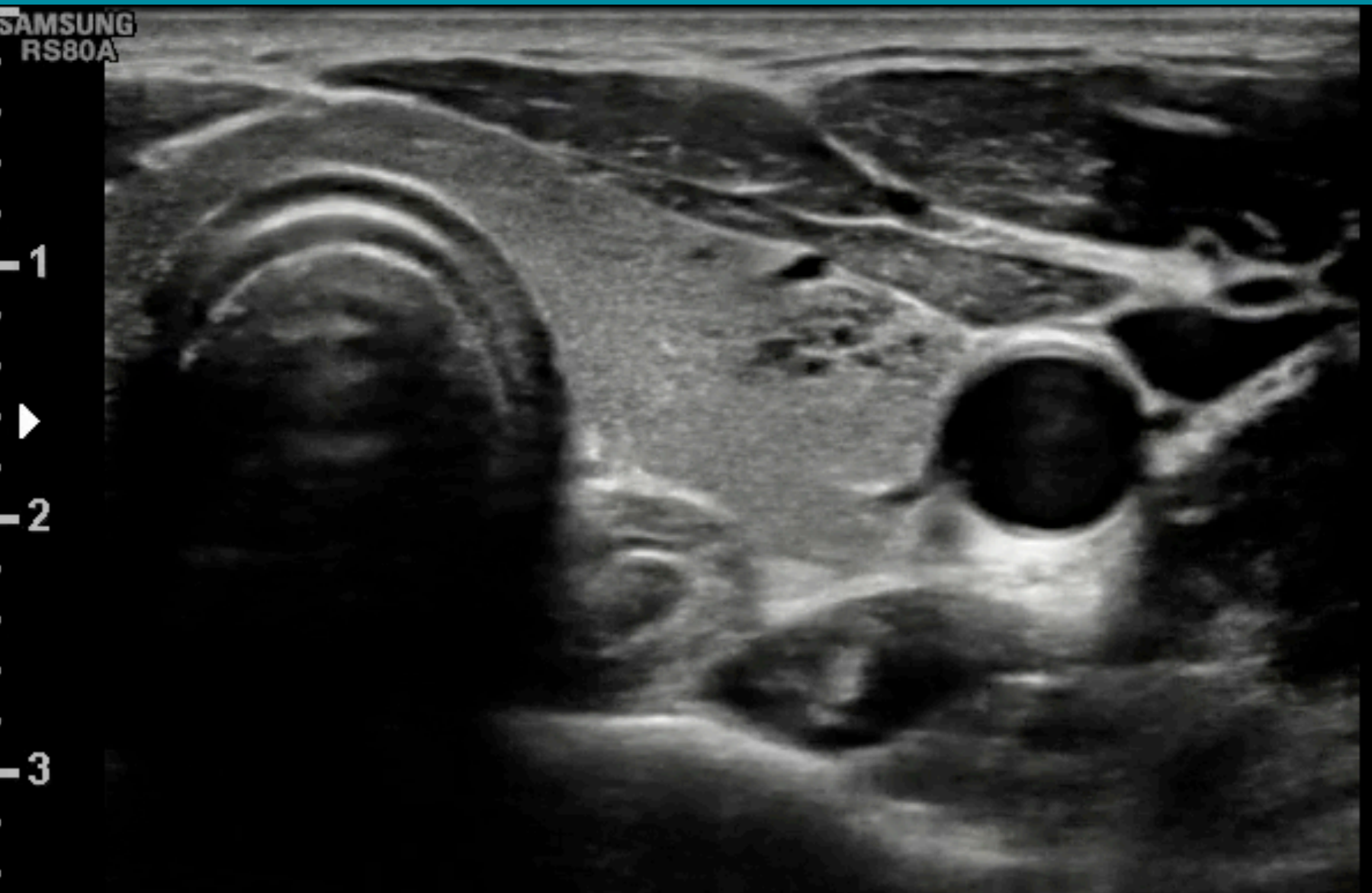KIDNEYS



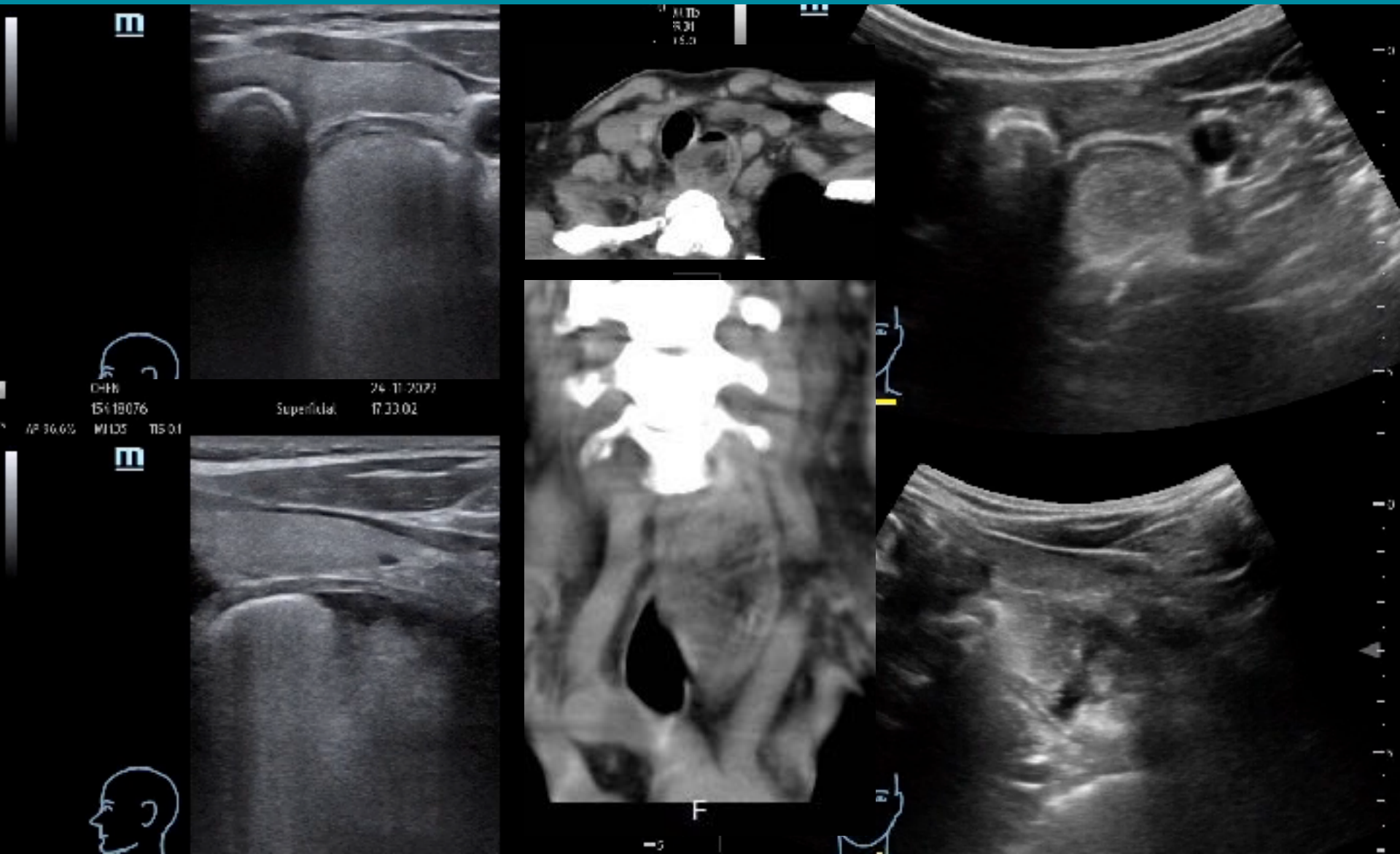
KIDNEYS



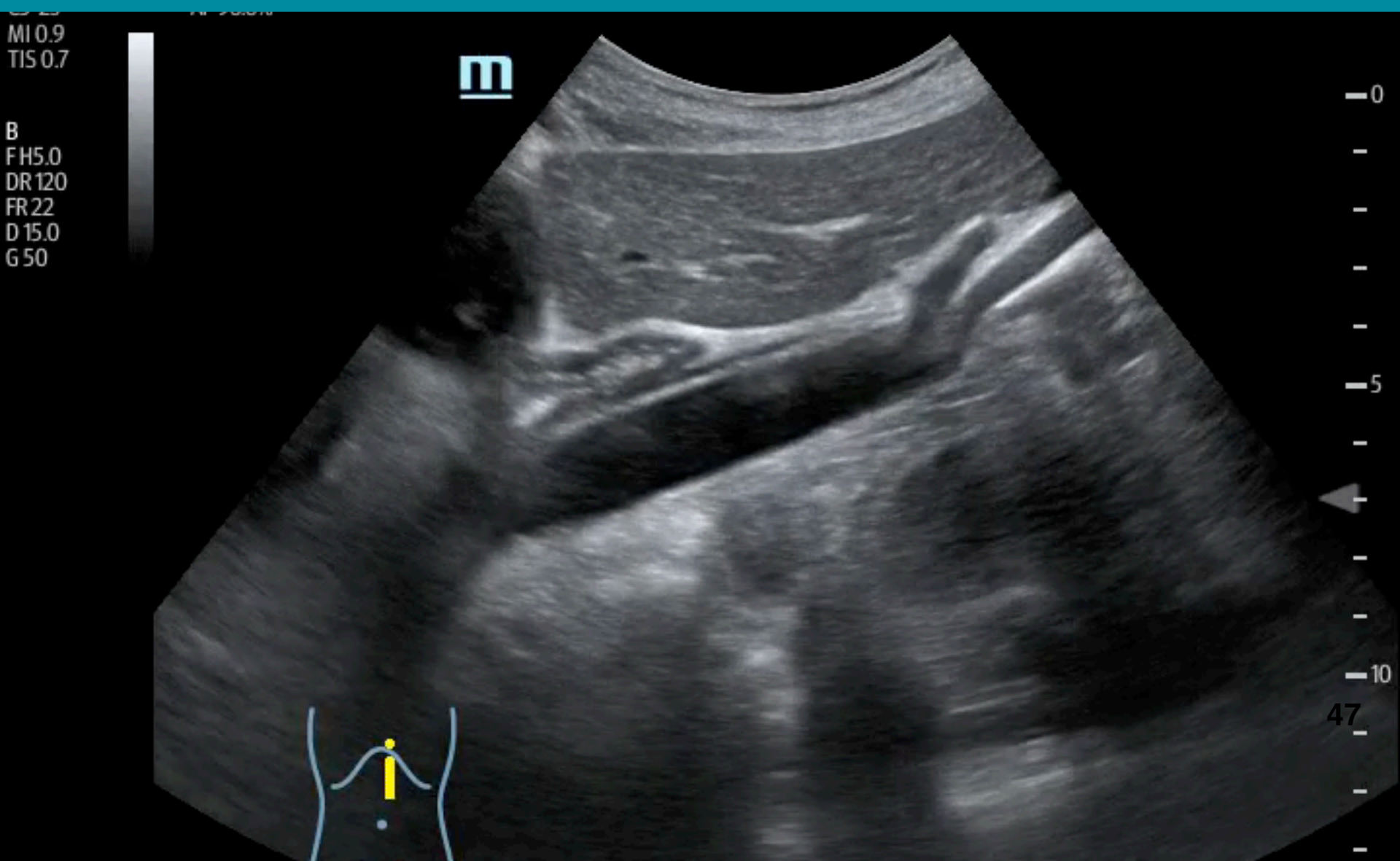
ESOPHAGUS



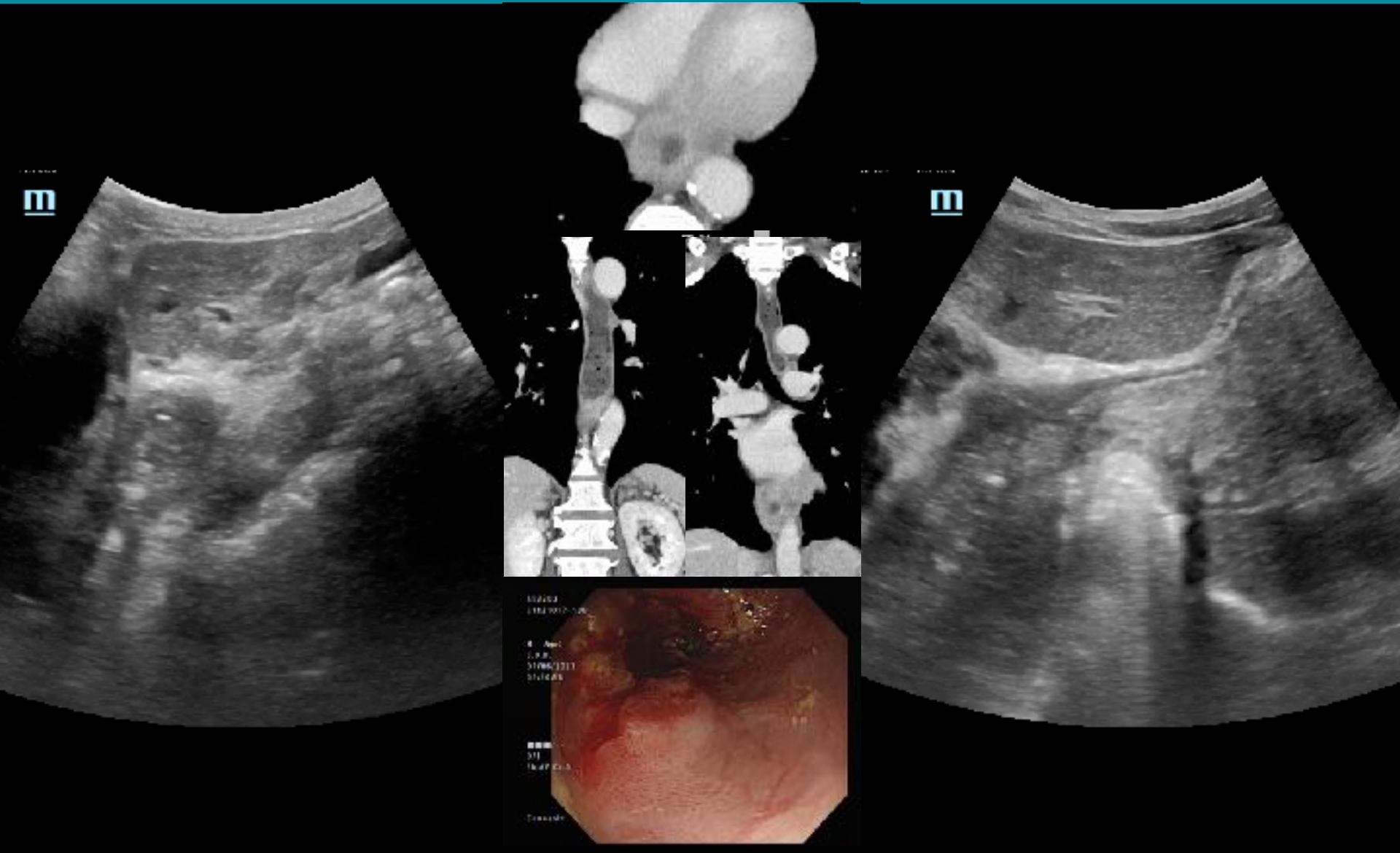
ESOPHAGUS



ESOPHAGUS



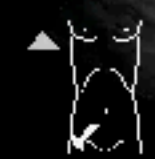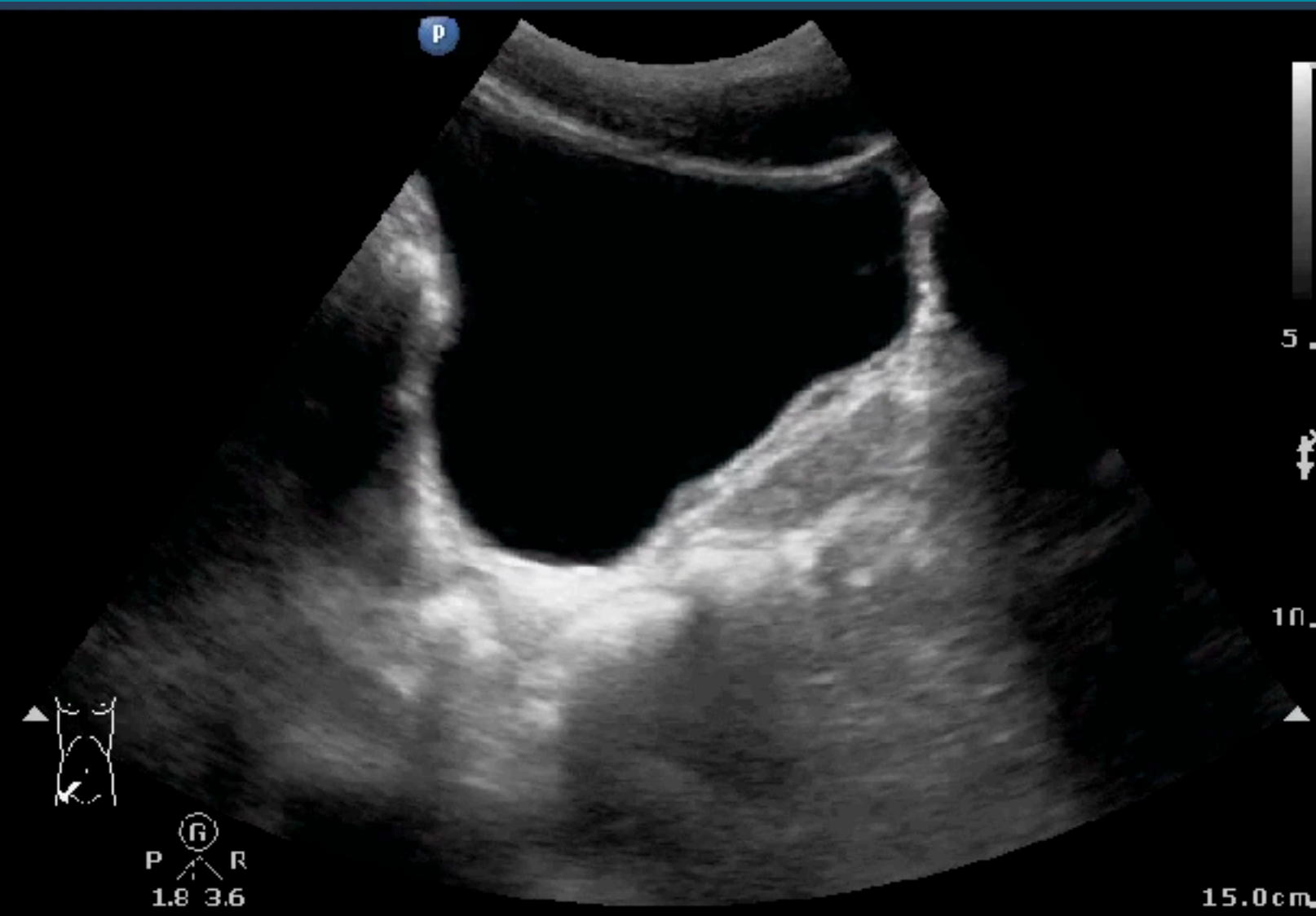ESOPHAGUS



RECTUM

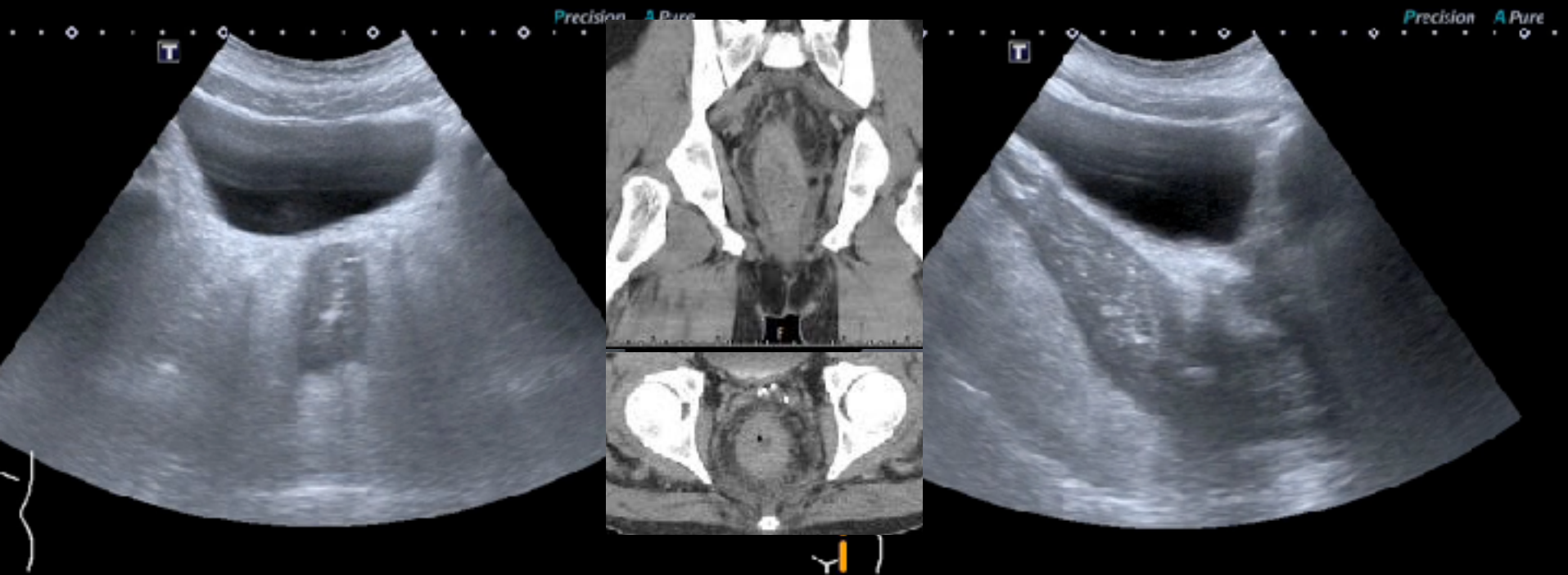
Abd Gen
C5-1
34 Hz
15.0cm

2D
HGen
Gn 55
C. 56
3 / 3 / 3

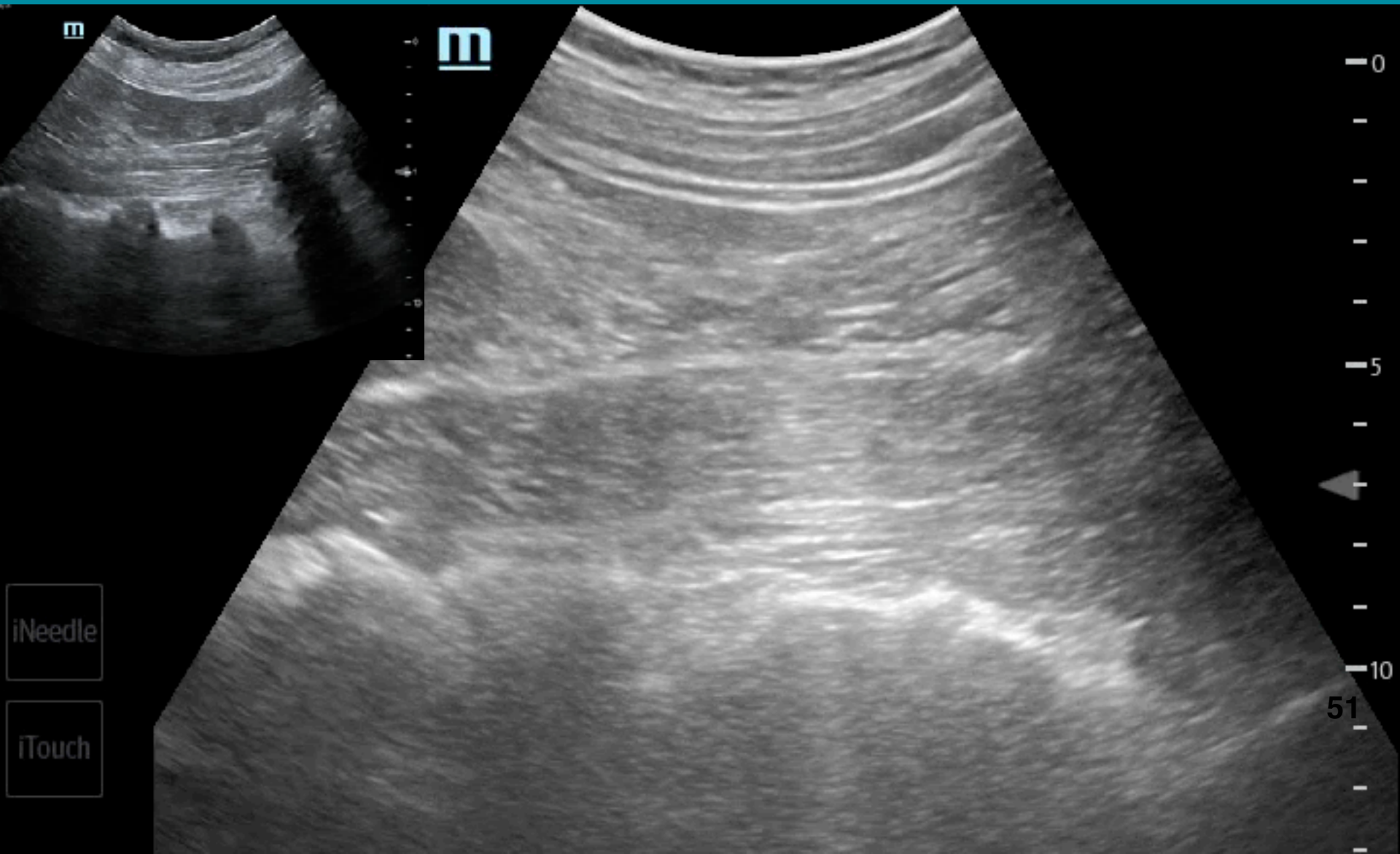


15.0cm

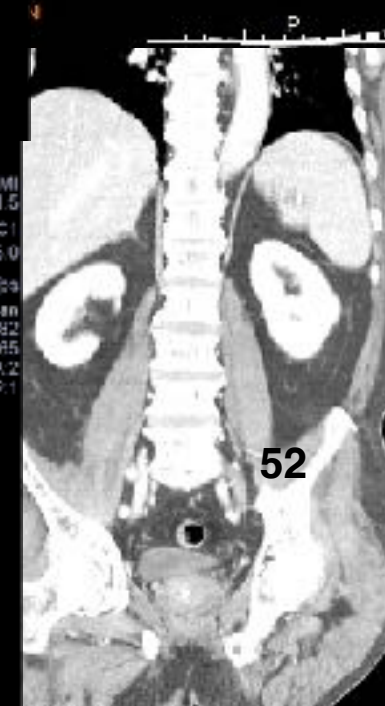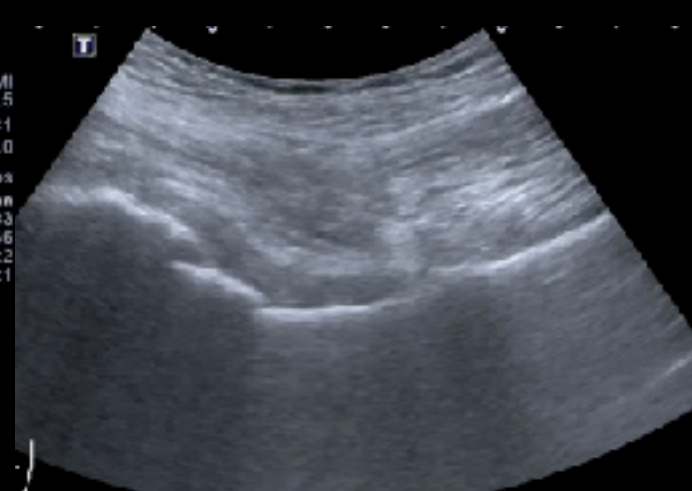
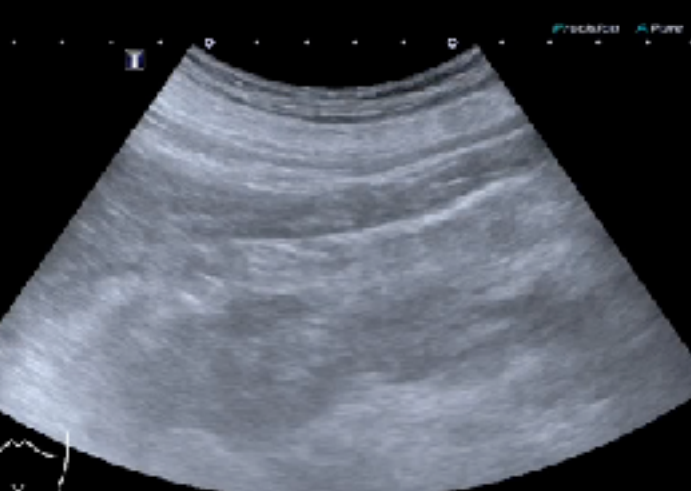
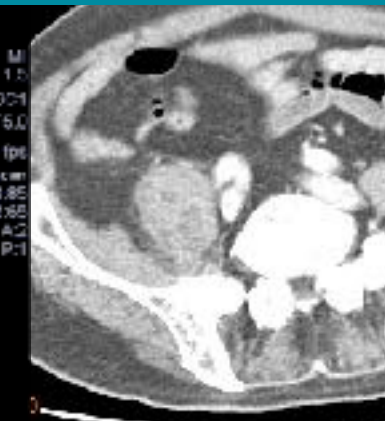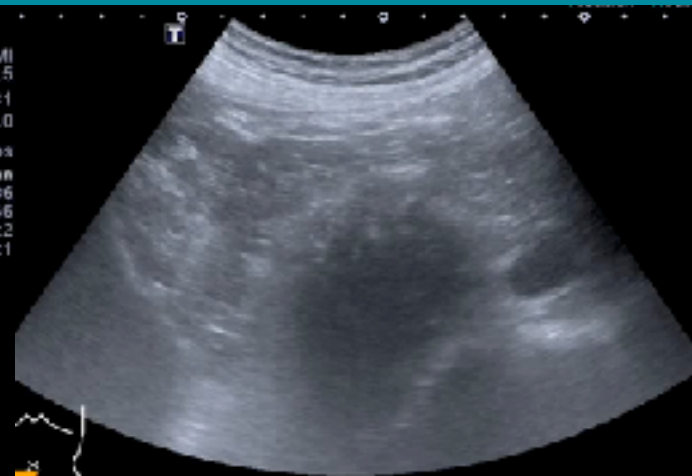
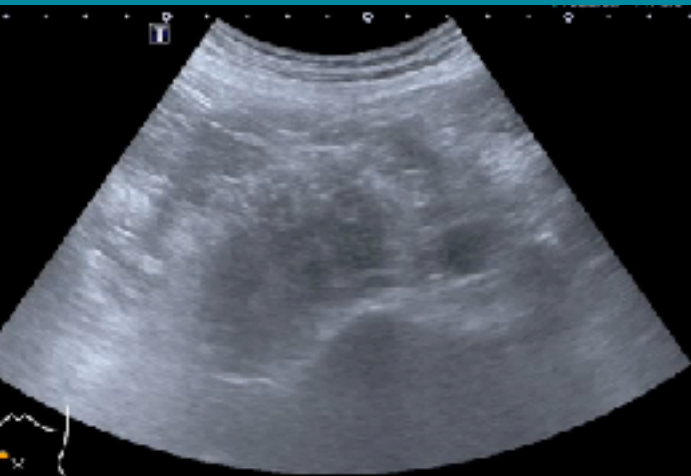RECTUM



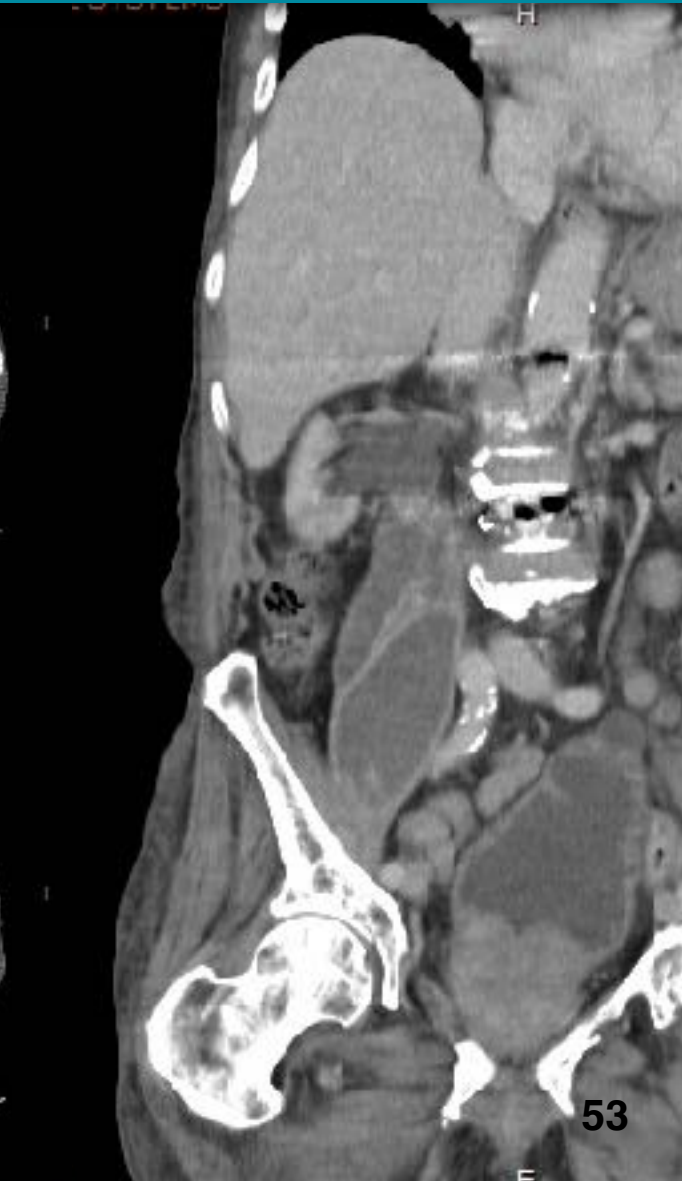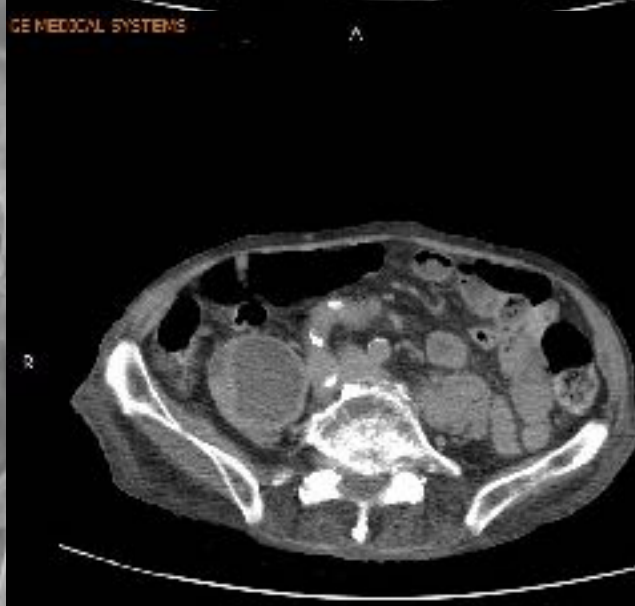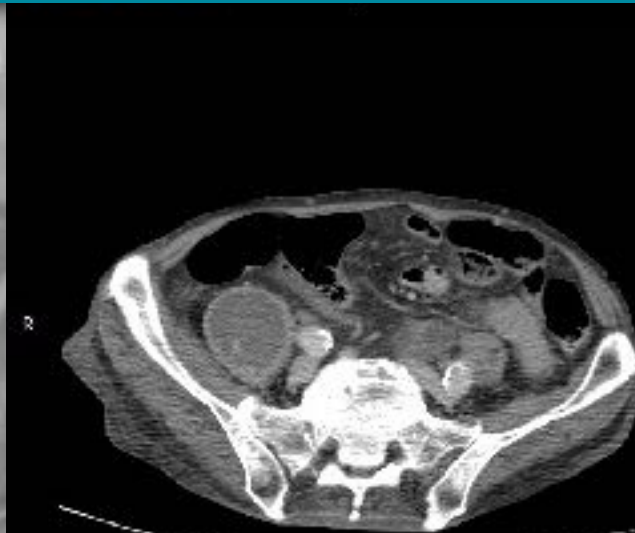
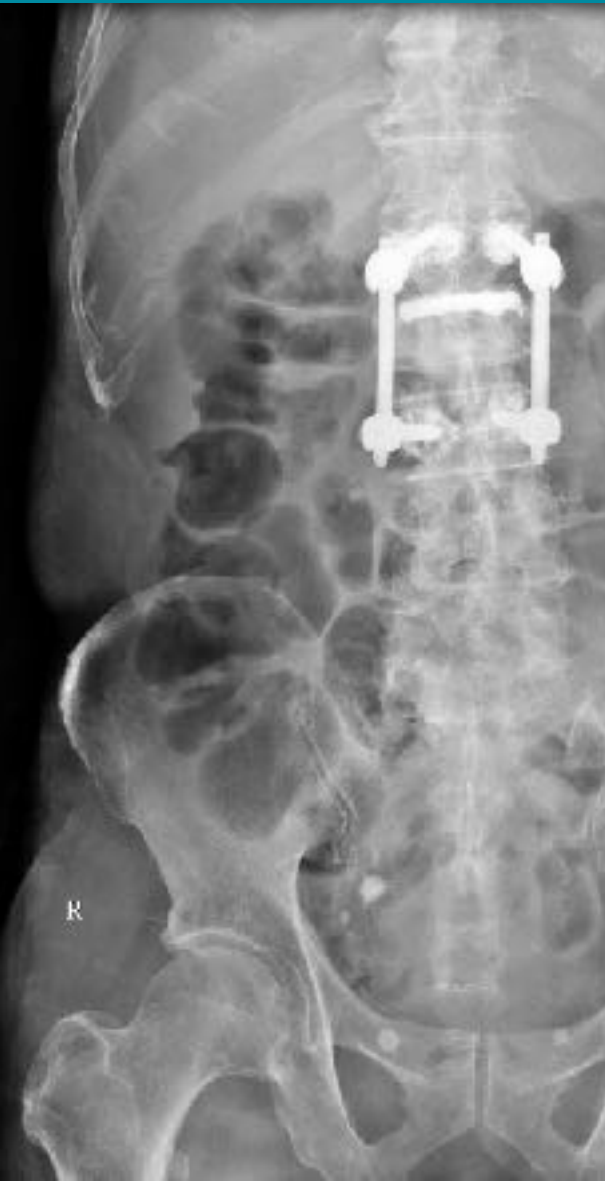PSOAS MUSCLE



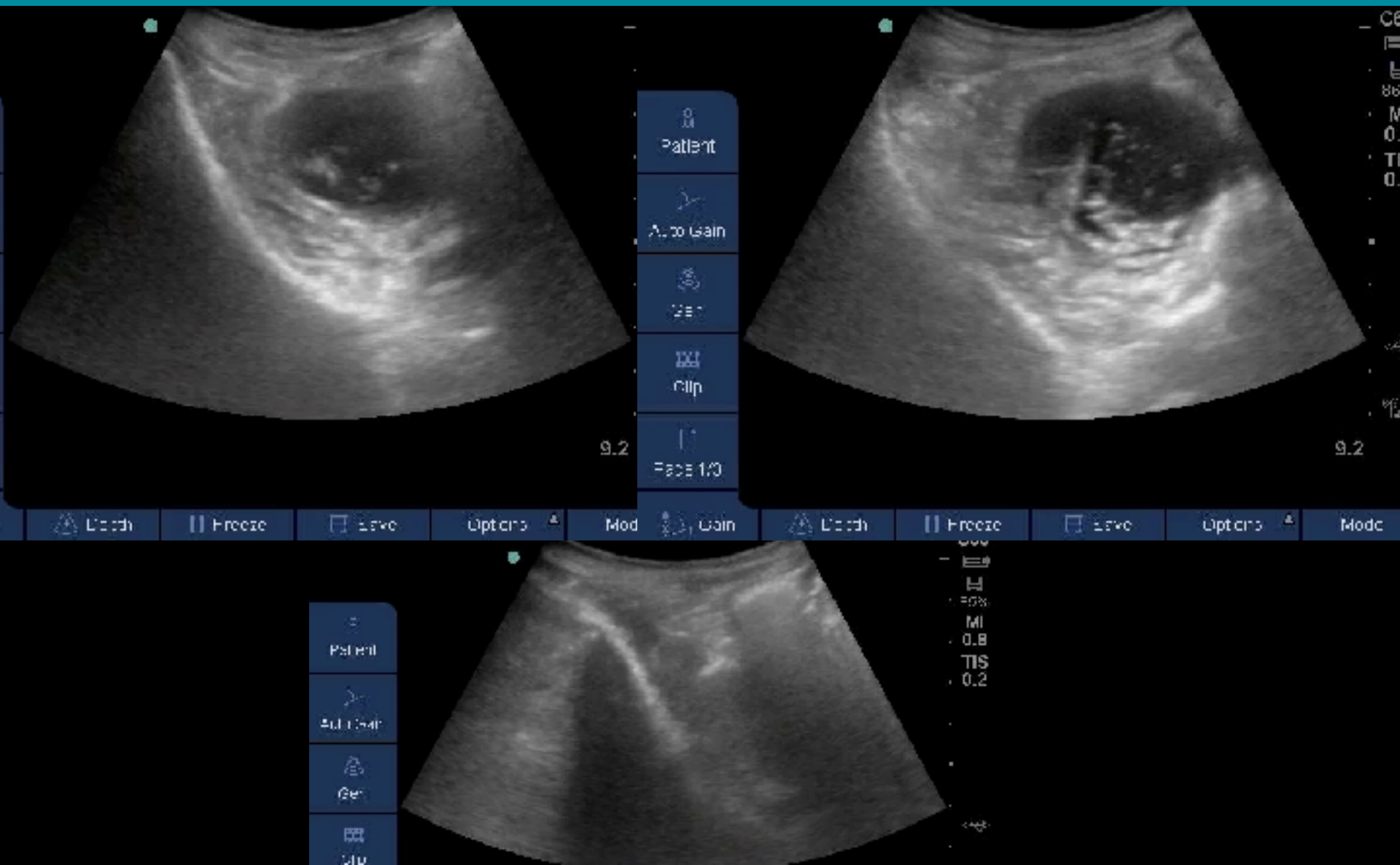
PSOAS MUSCLE



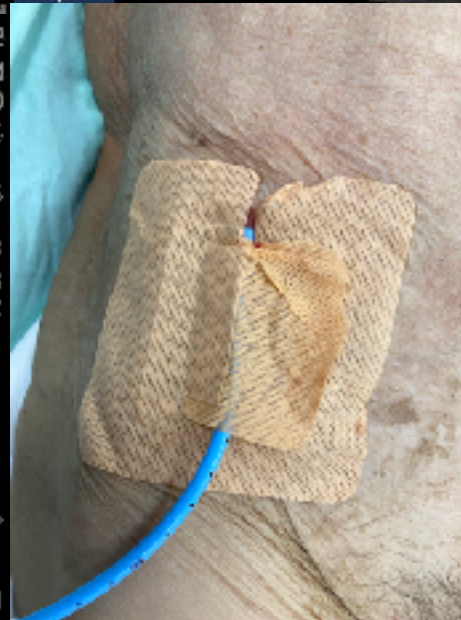
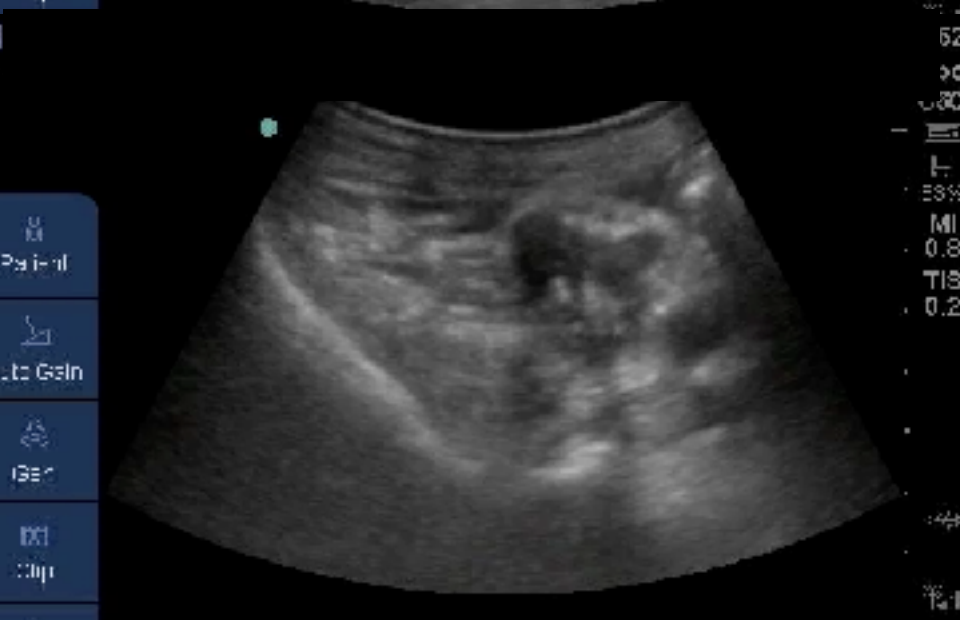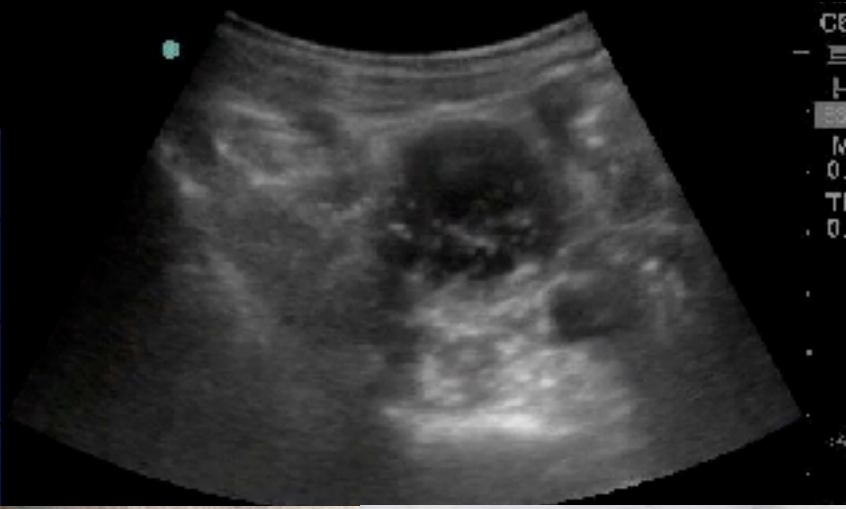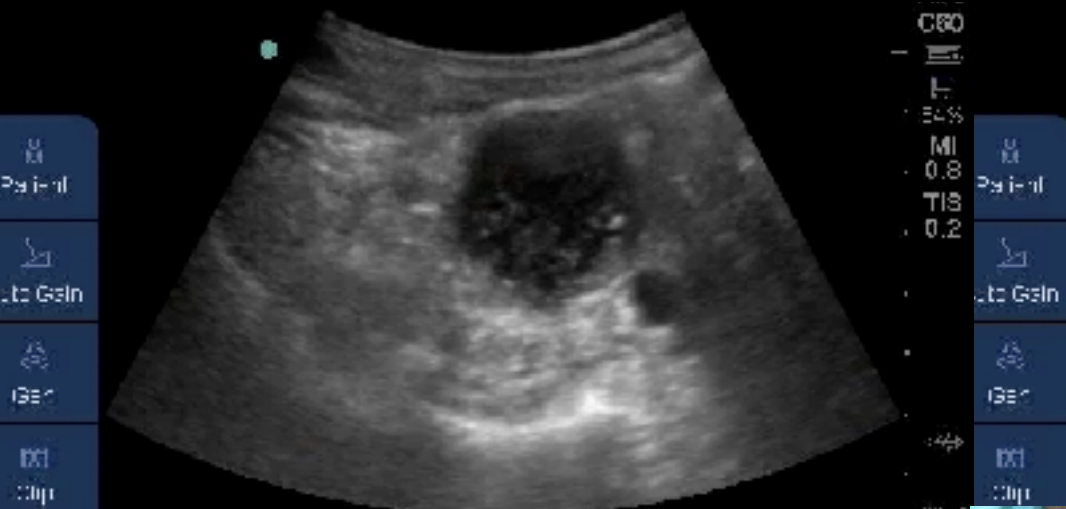85, Psoas muscle abscess



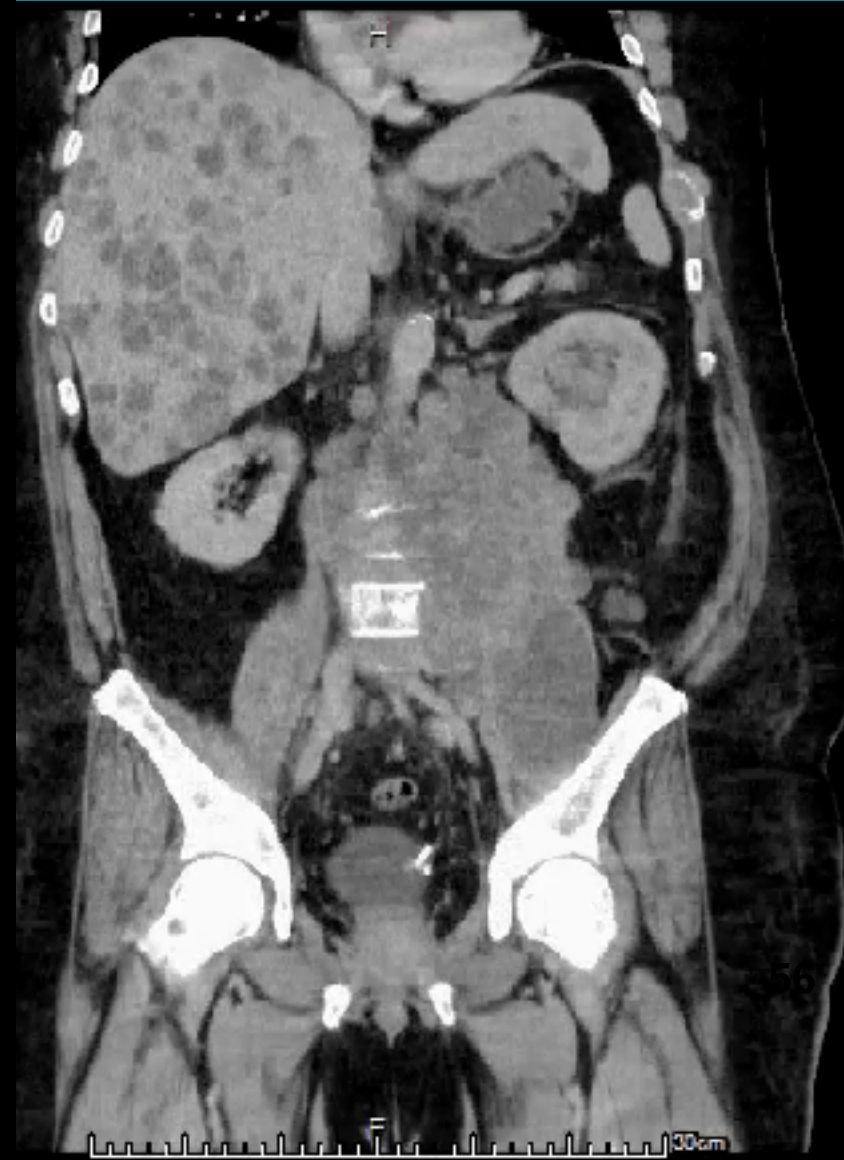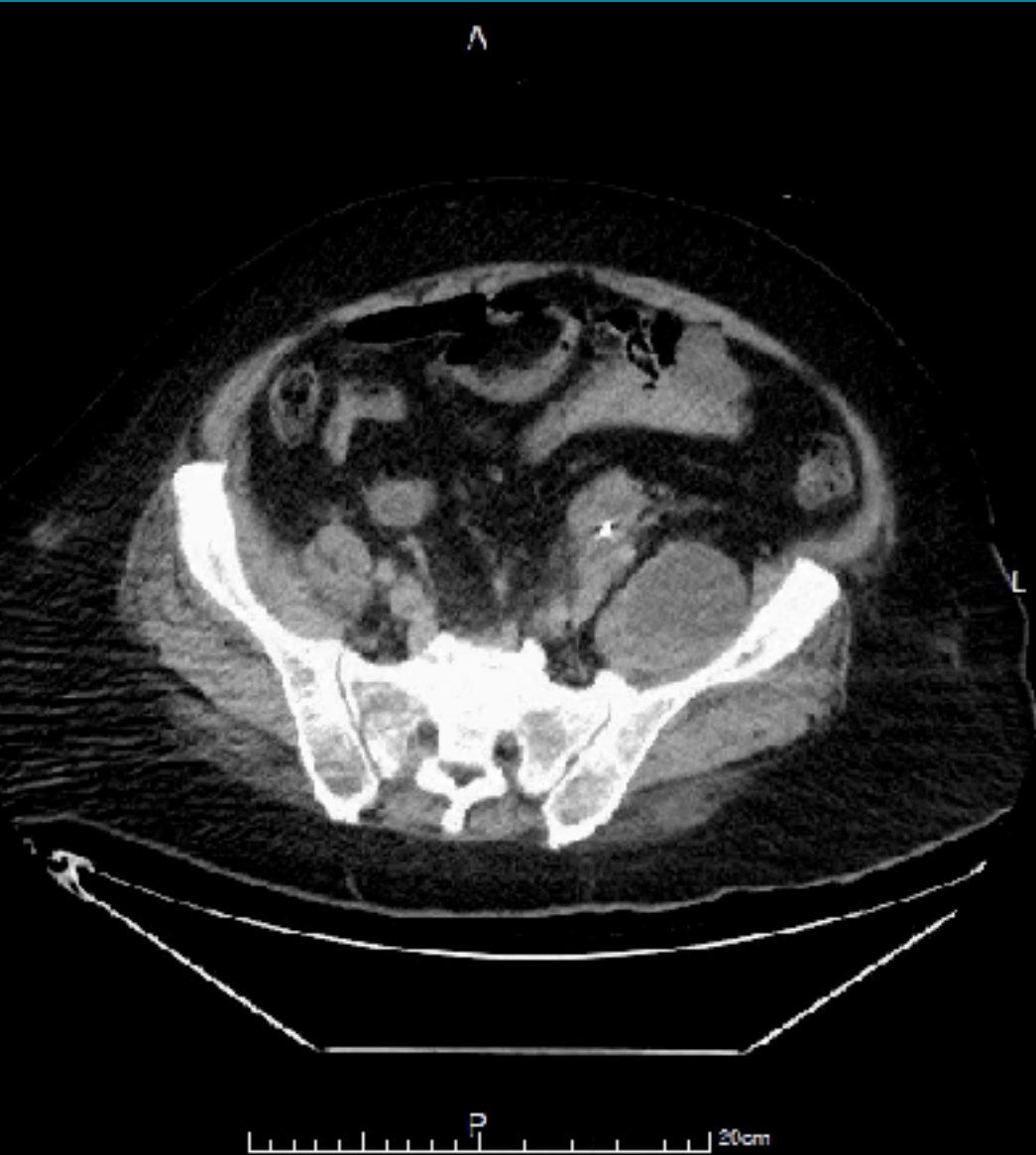85, Psoas muscle abscess

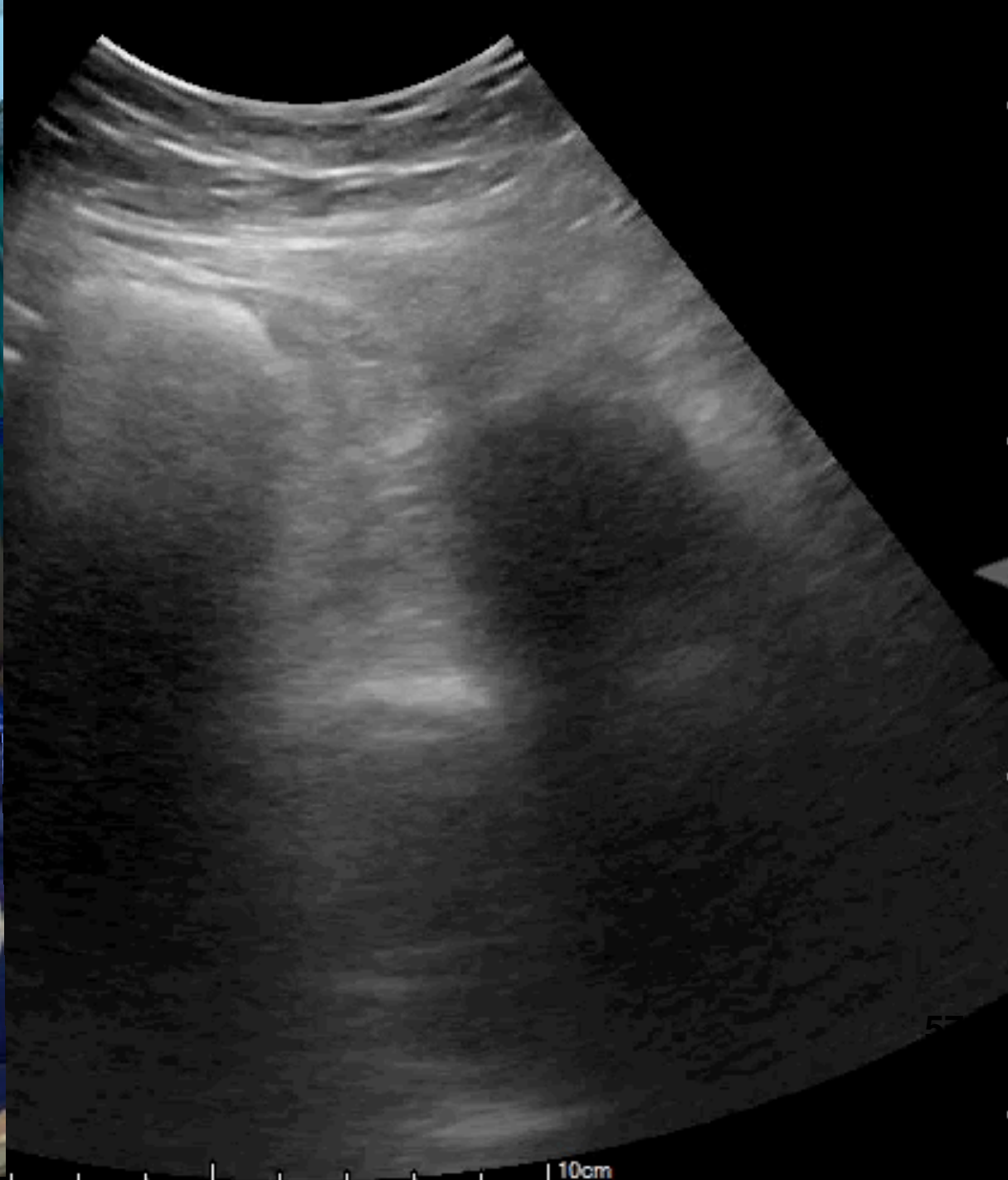
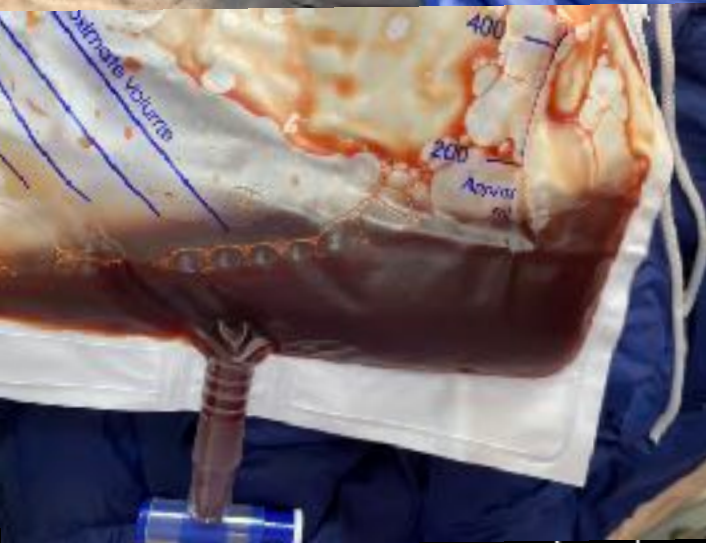
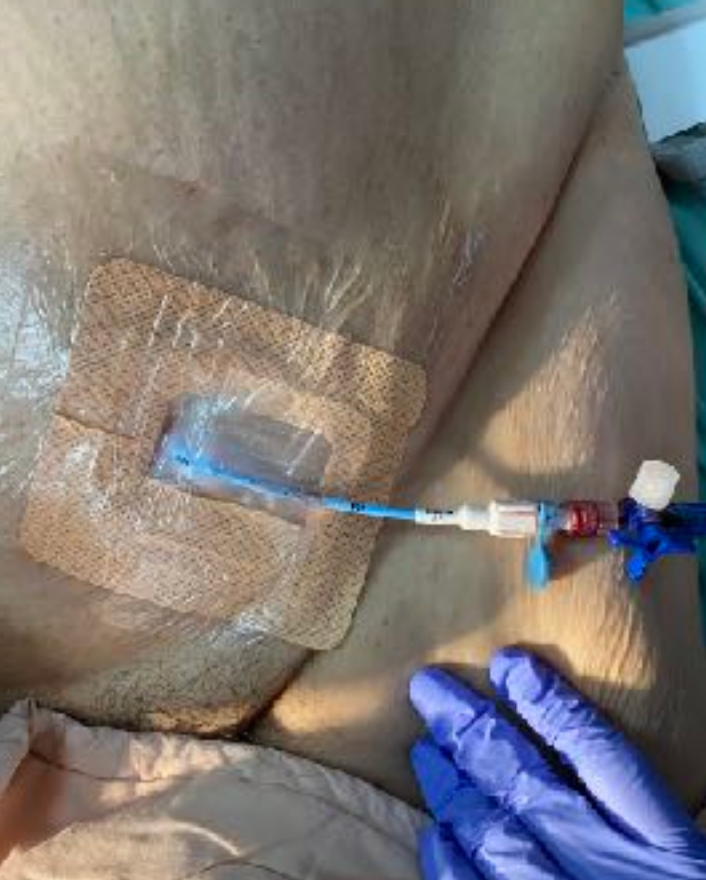
14F pigtail with stylet



50M, left retroperitoneal lesion





RETROPERITONEUM POCUS

SAD	PUCKER
Suprarenal glands	Pancreas
Aorta + IVC	Ureter
Duodenum (2nd / 3rd portion)	Colon (Ascending + Descending)
Humeral head	Kindeg
	Esophagus
Psoas muslce	Rectum