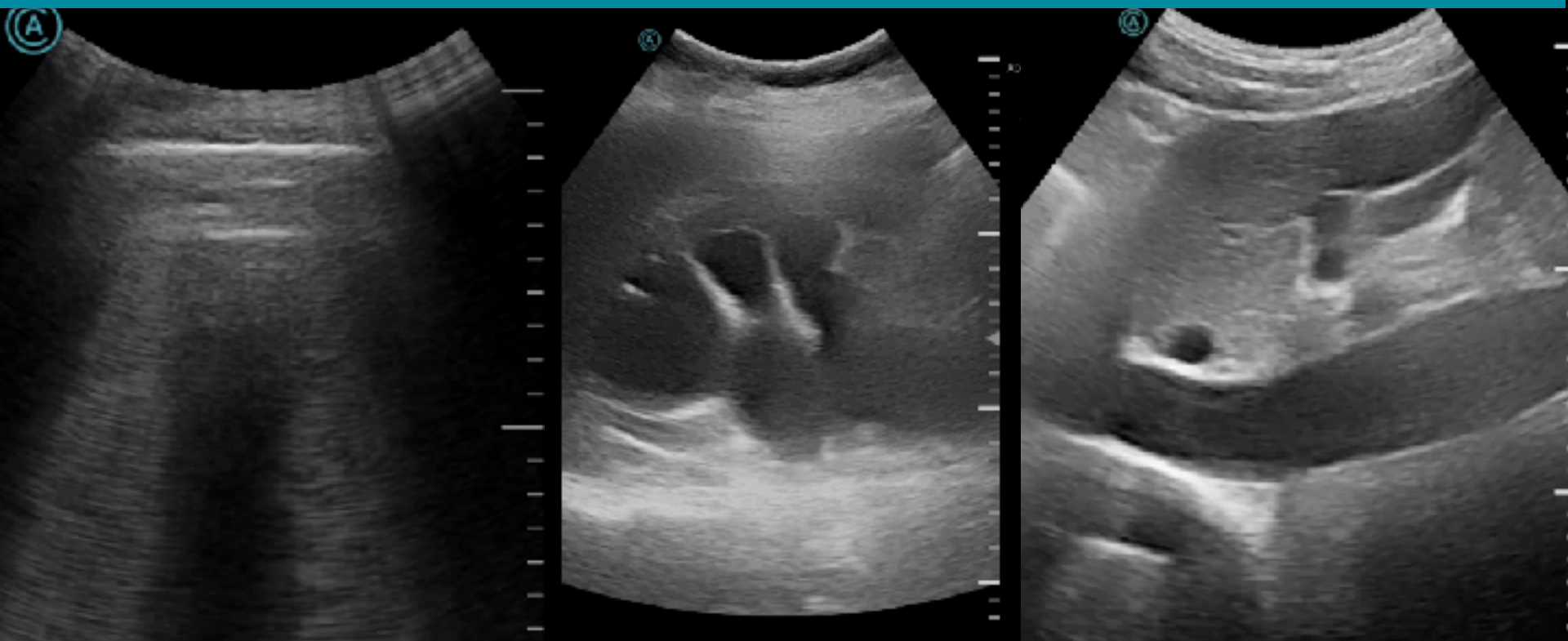

# 居家POCUS應用

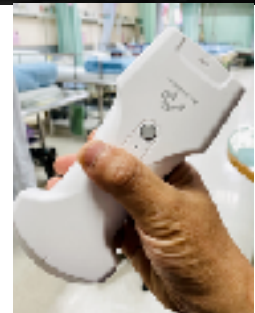胸腔

泌尿

IVC



台灣在宅醫療學會  
Taiwan Society of Home Health Care



# 陳國智 醫師 / [POCUSacademy.com](http://POCUSacademy.com)



台灣疼痛醫學會專科醫師  
急診超音波臨床評核醫師  
醫用超音波學會指導醫師  
WINFOCUS director / instructor  
Certified Interventional Pain Sonologist

**急診 / 重症 / 介入 / 急性疼痛**

經歷

新光急診超音波訓練中心主任  
西園醫院急診醫學科主任  
急診醫學會超音波委員會主委  
台灣疼痛醫學會大體模擬手術講師  
急救加護醫學會重症超音波負責人

[juice119@gmail.com](mailto:juice119@gmail.com)

# I-AIM 模板

## Indication

Point / 掃描目的



**Acquire**  
取得影像

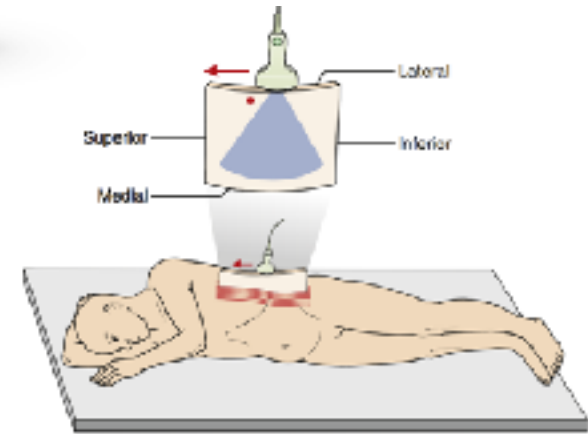
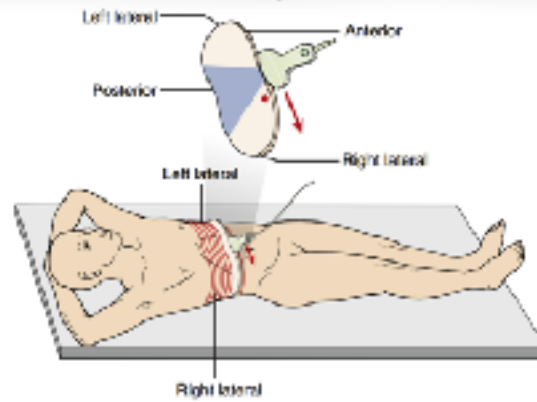
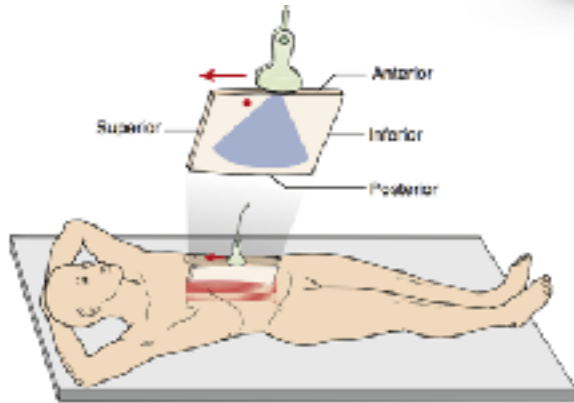


**Interpret**  
判讀影像



**Make decision**  
臨床決策

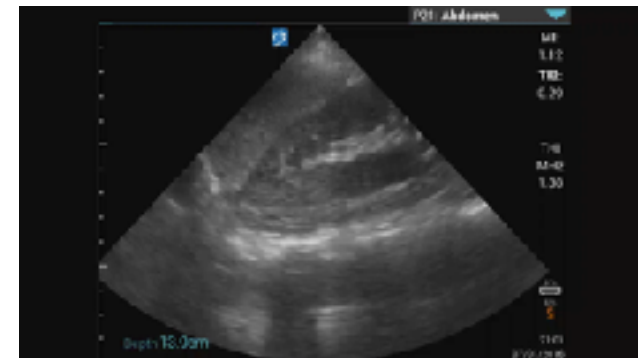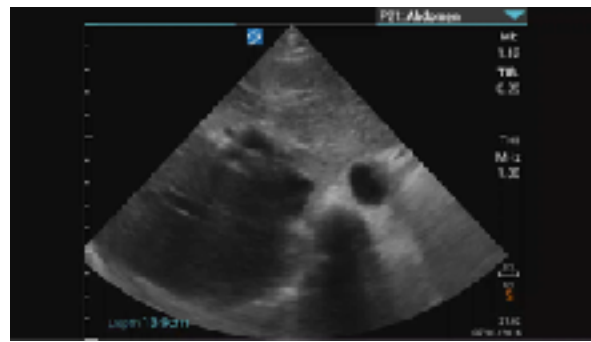
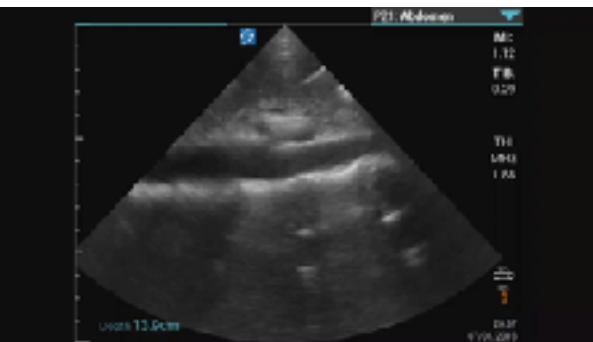# 3D立體介面



Sagittal 縱

Transverse 橫

Coronal 側

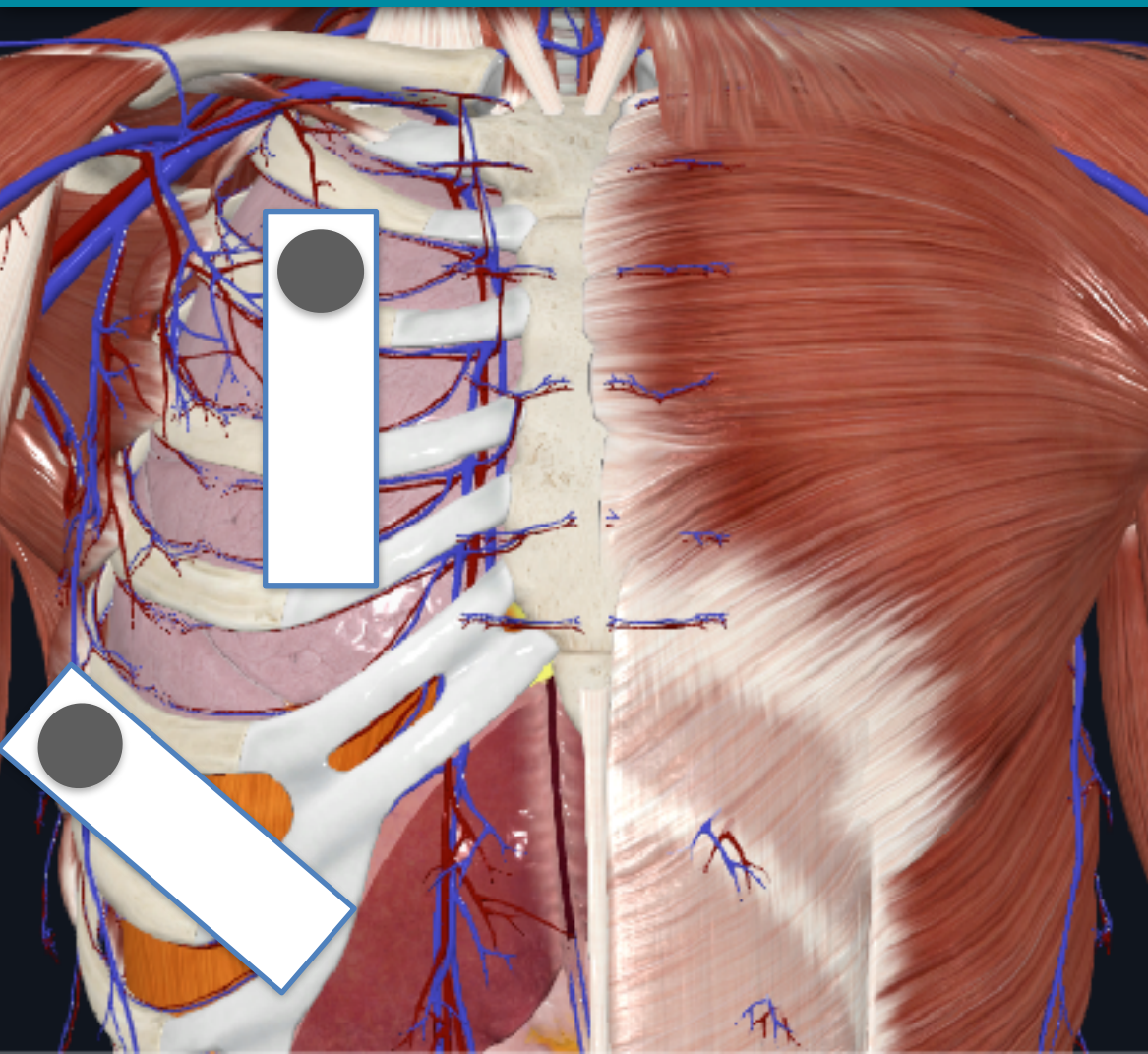


# 掃描前先想探頭該怎麼擺效果最好

最佳視野  
最大視窗  
最好路線  
最小調整

隨身設備用來  
看最重要發現

# Lung

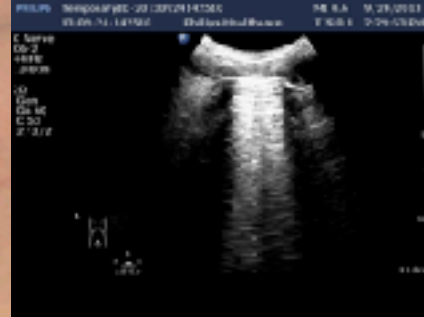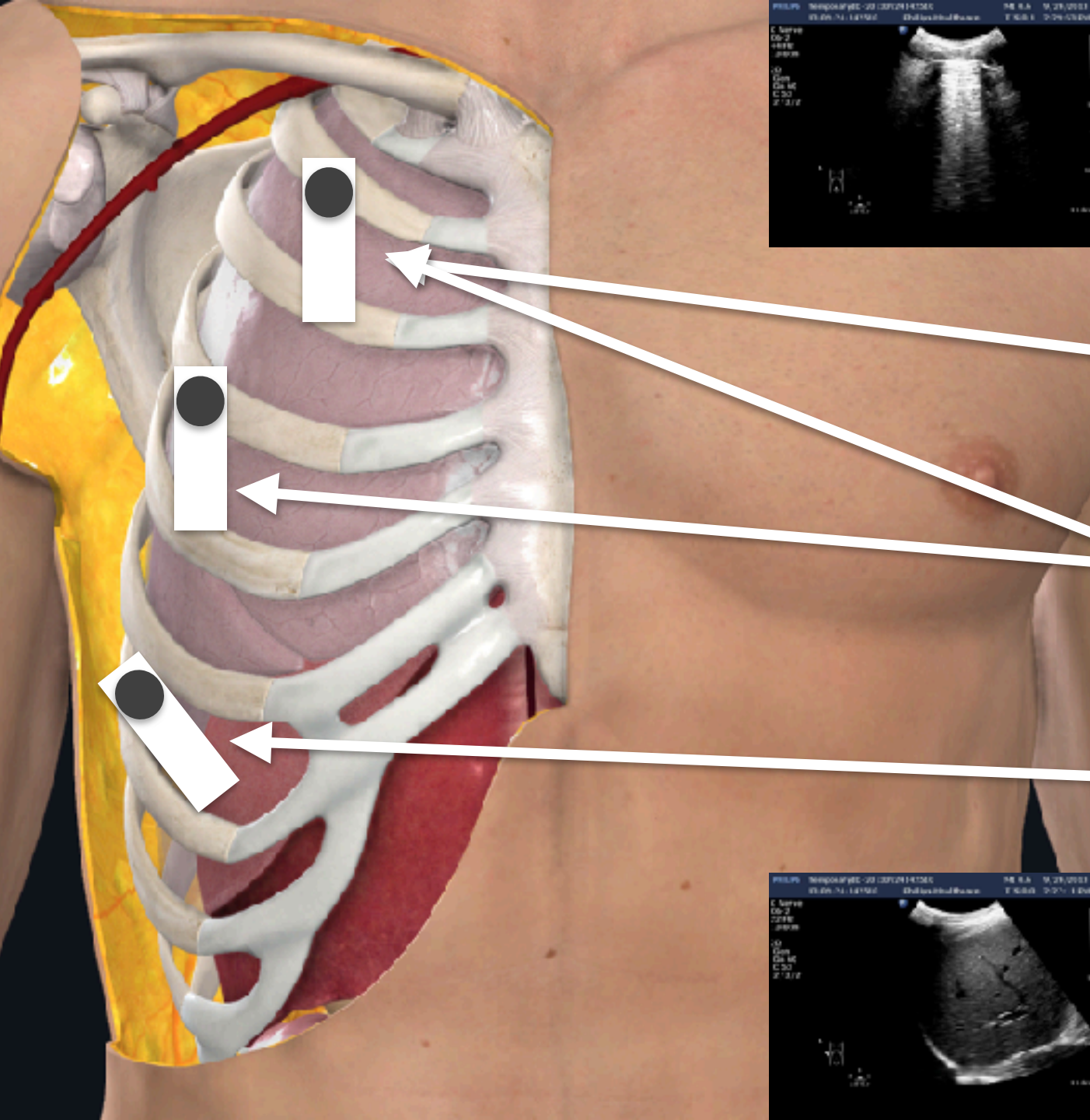


## 肋膜

高回音  
有滑動  
縱向掃描  
鎖骨中線之最高點

## 橫膈膜

高回音  
有移動  
肋間掃描  
劍突腋前/後線交界

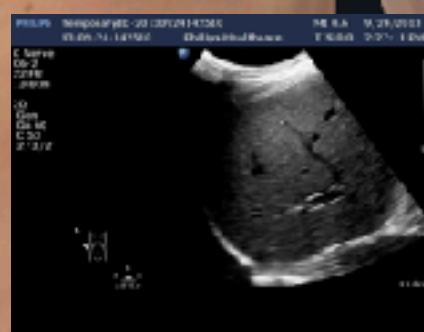


**AIR**

**PTX**

**AIS**

**PLE**



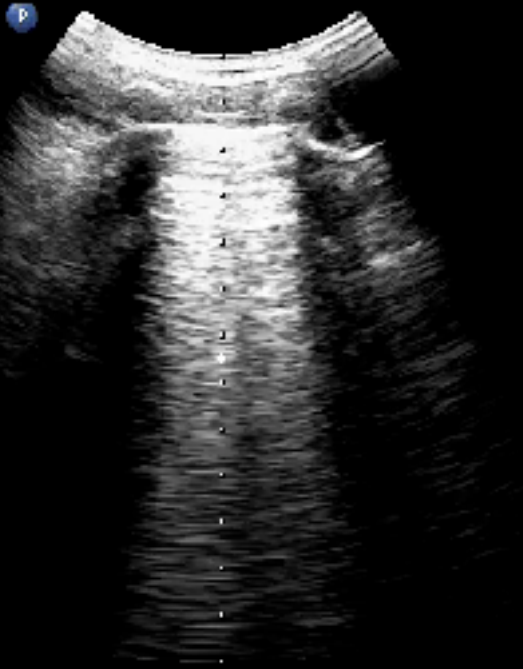**FLUID**

# NORMAL LUNG

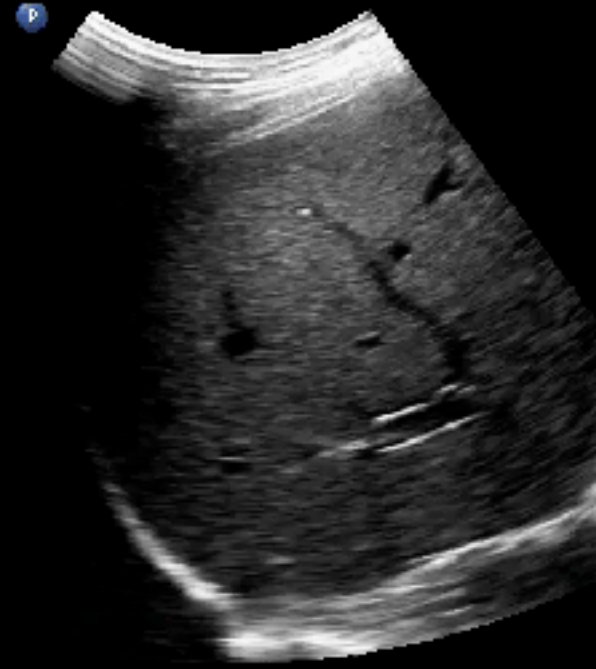
肋膜/滑動

橫膈膜/移動

TemporaryID 20130924142510 MT 0.6 9: PHILIPS 13 09 24 142510 Philips Healthcare TIS 0.1 2: TemporaryID 20130924142510 MT 0.6 9:24 13 09 24 142510 Philips Healthcare TIS 0.0 2:27



C Nerve  
CG-2  
22 Hz  
13.0cm  
2D  
Gen  
Gr 60  
C 53  
2/3/2



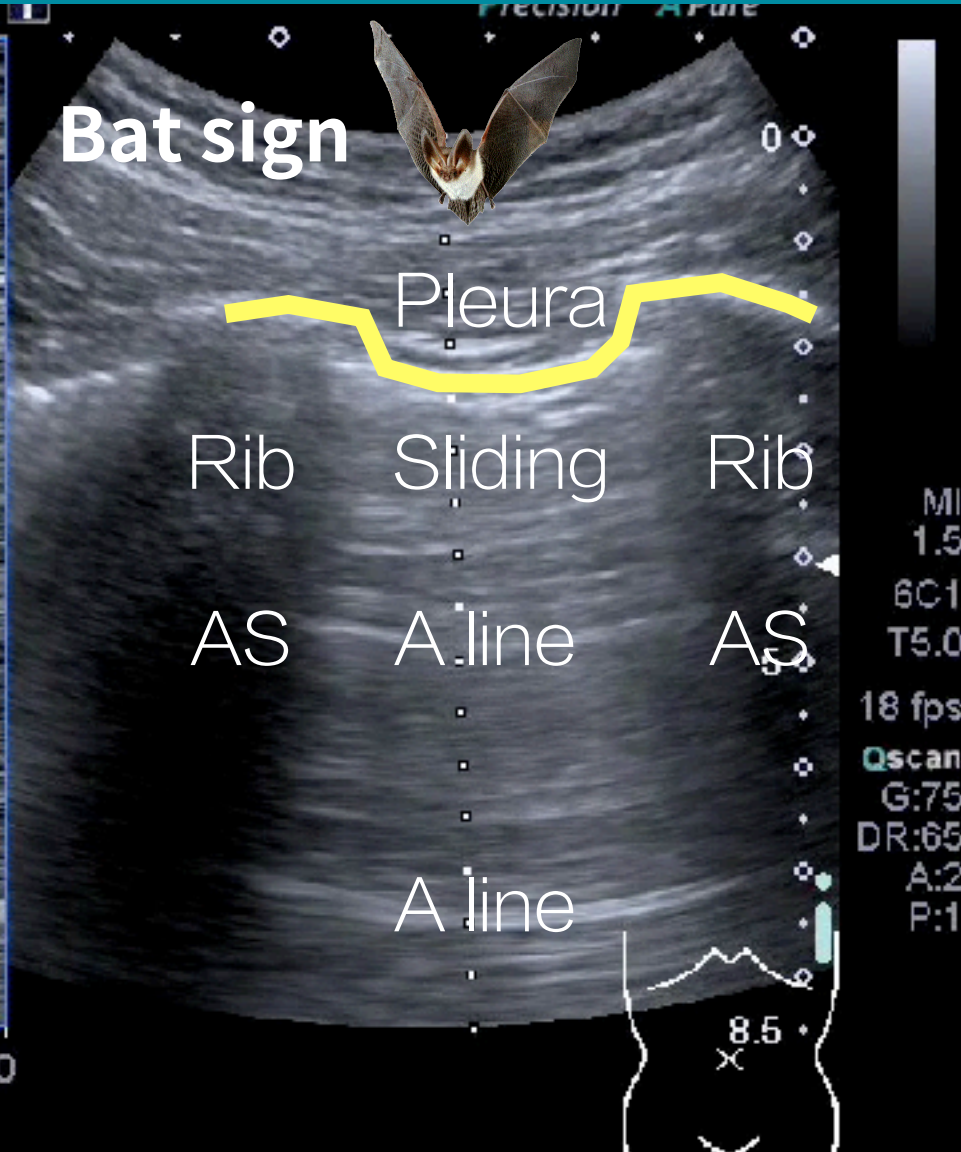
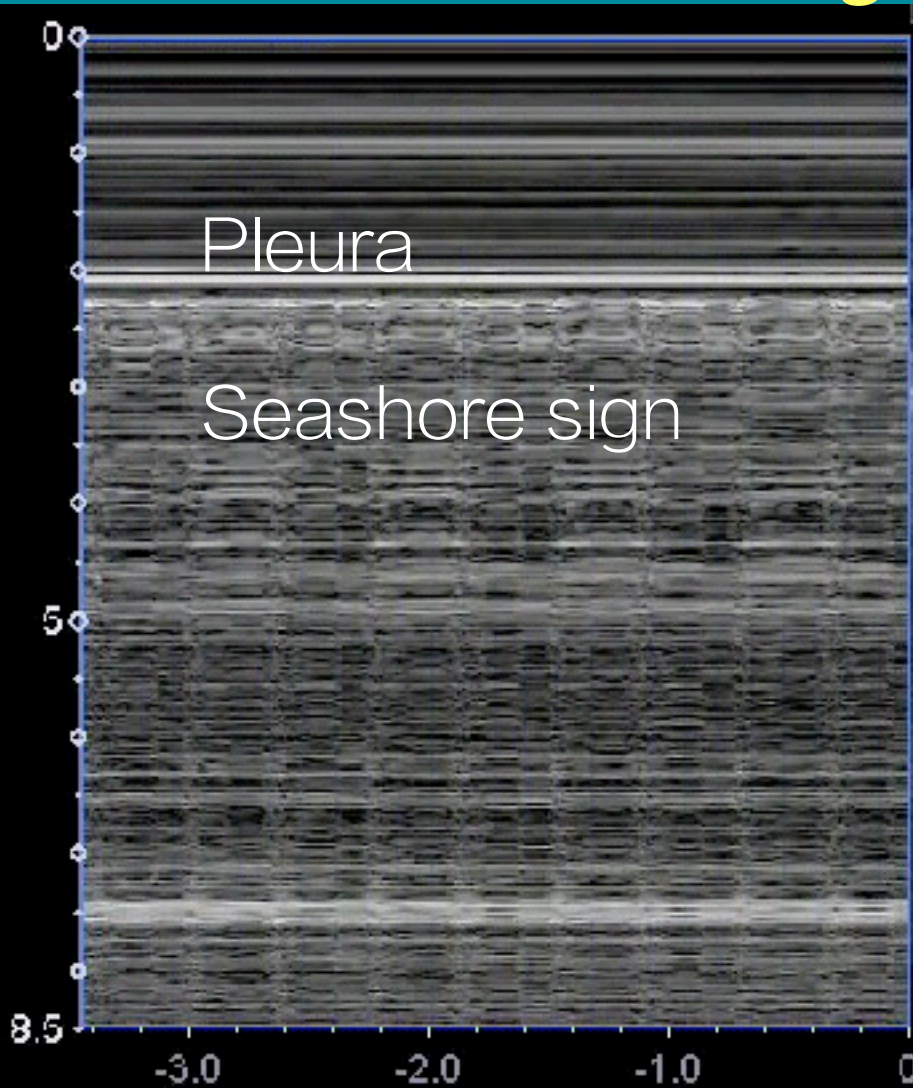
G  
P K  
2.0 6.0

G  
P K  
2.0 6.0

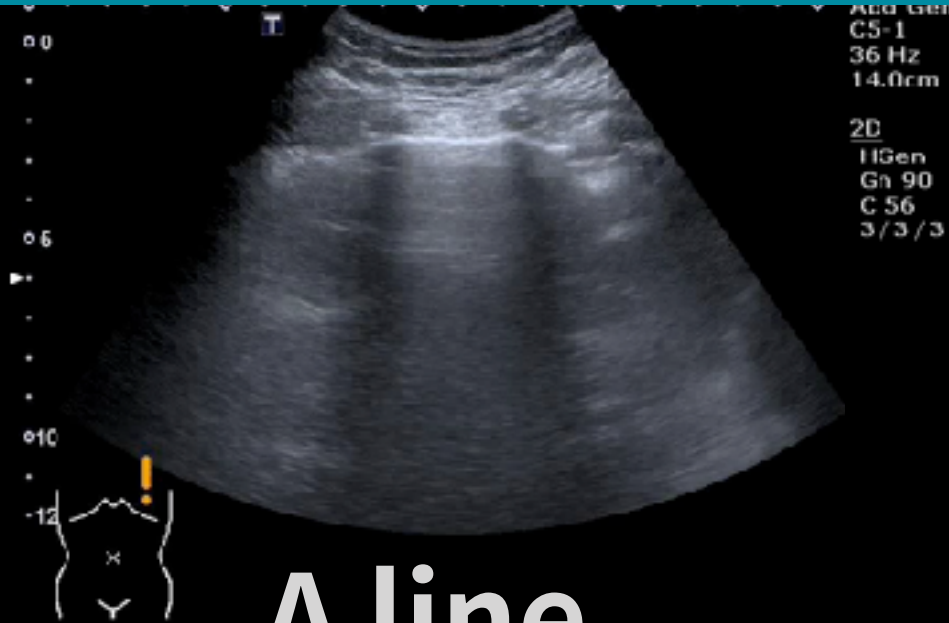

# NORMAL LUNG

## Sliding + A lines

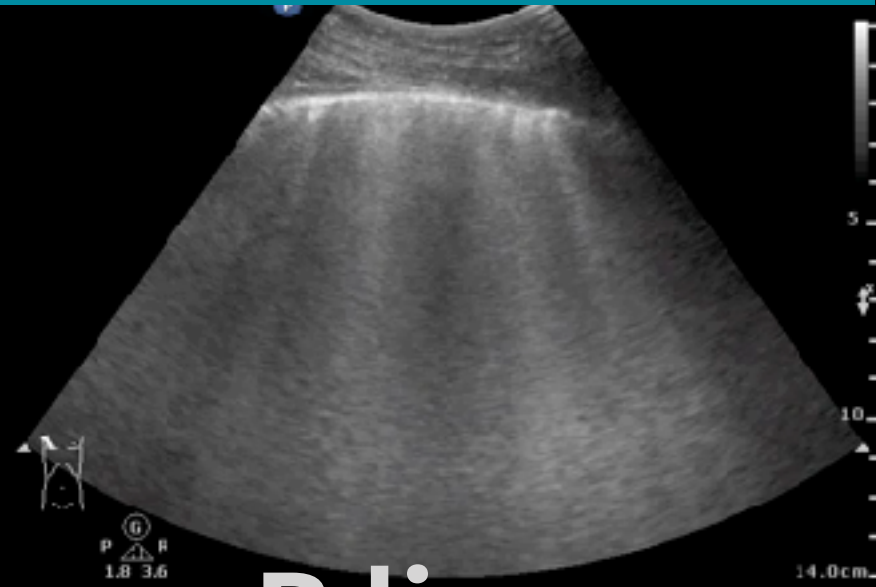

# SLIDING FIRST



A line

肋膜下  
水平線  
等距離



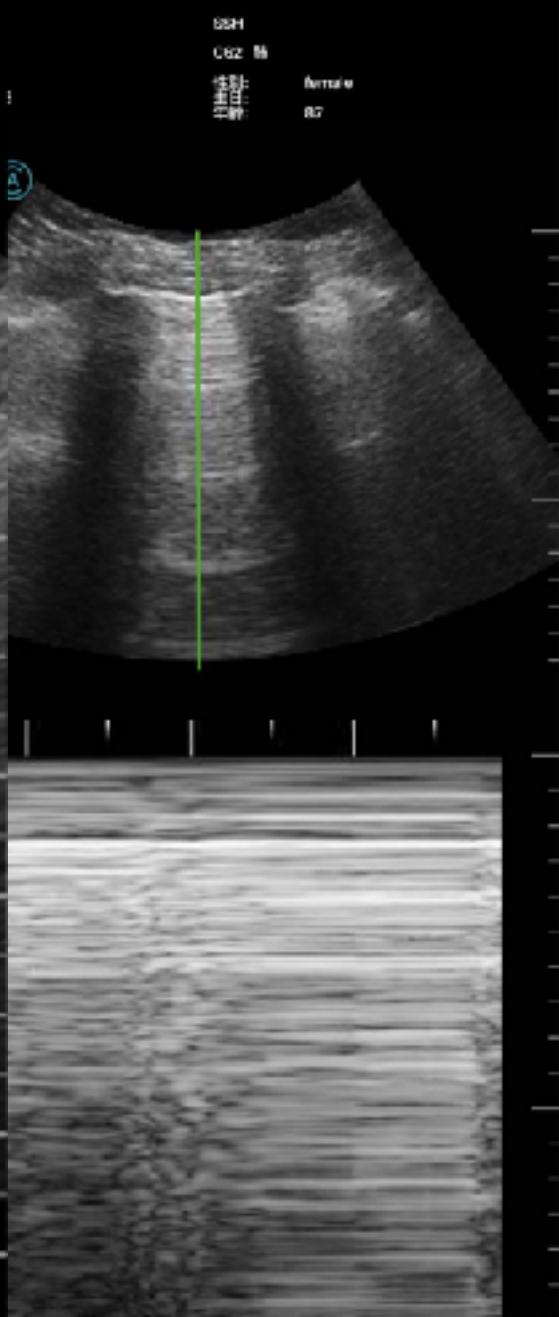
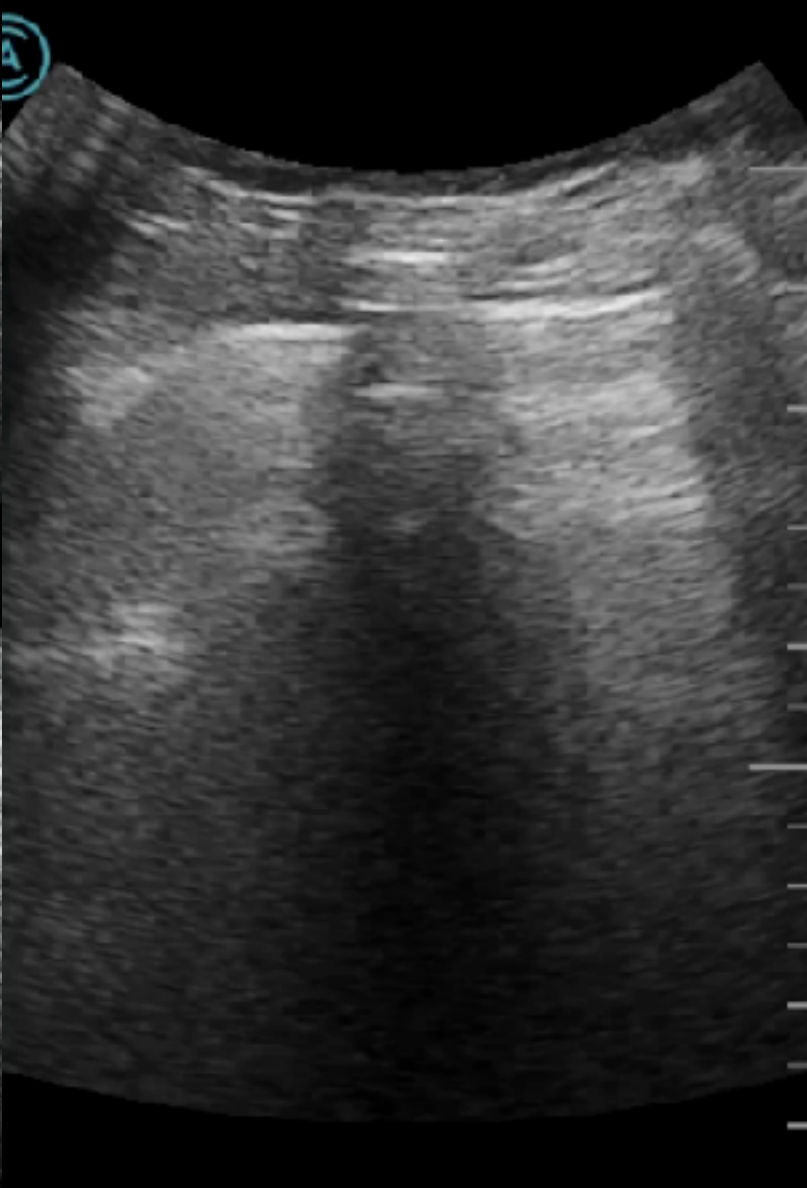
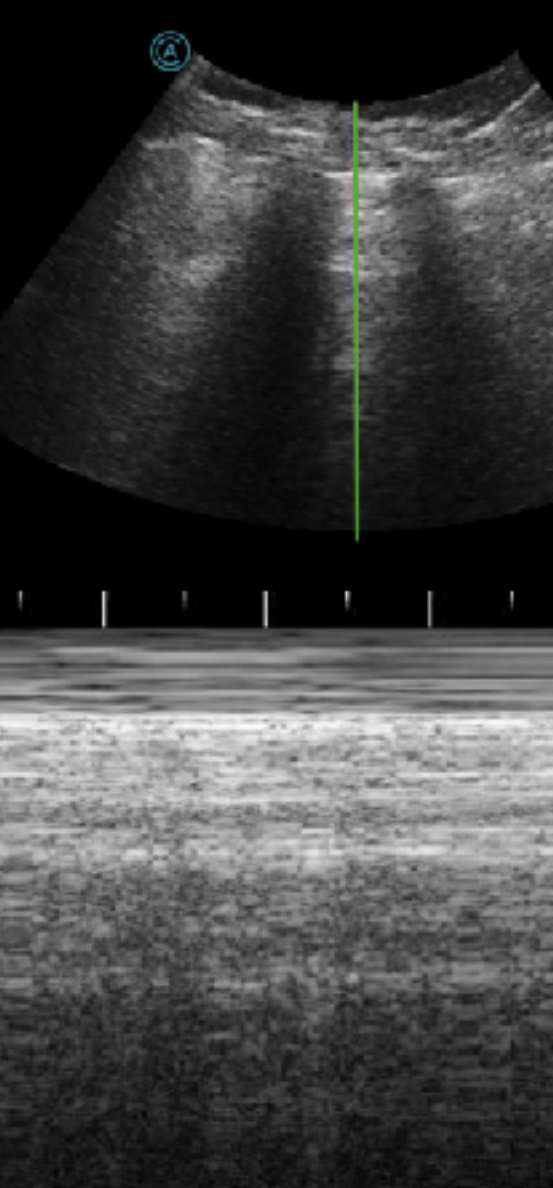
B line

肋膜下  
垂直線  
大於三

乾 --- 溼

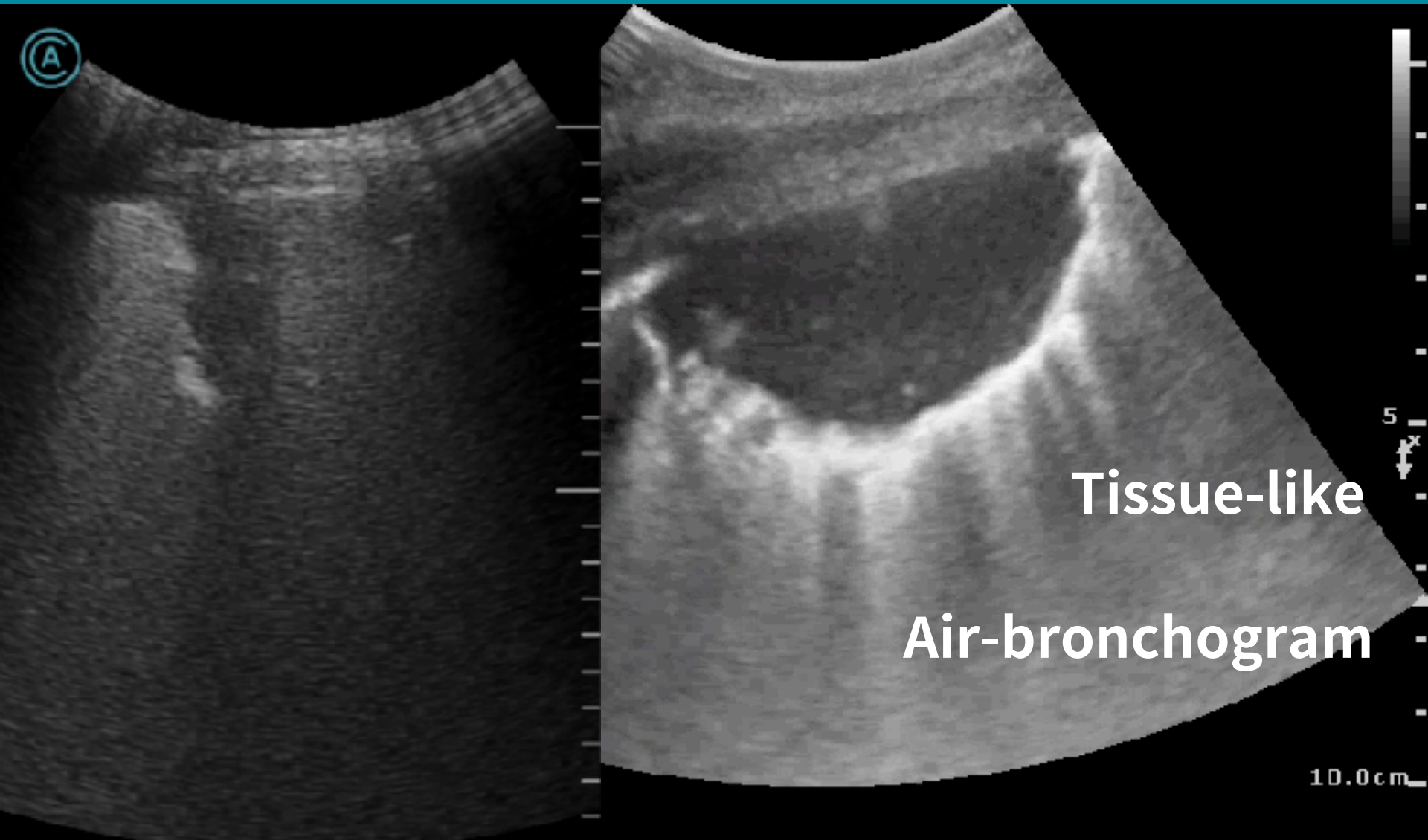
DATE: 2022-04-21 10:55:42  
Accession: 14386001  
ID: 14386001  
姓名: 梁日

DSH  
C62 精  
性别: 男性  
年龄: 67



DSH  
C62 精  
性别: 男性  
年龄: 67

# C profile (實質/肝質化)

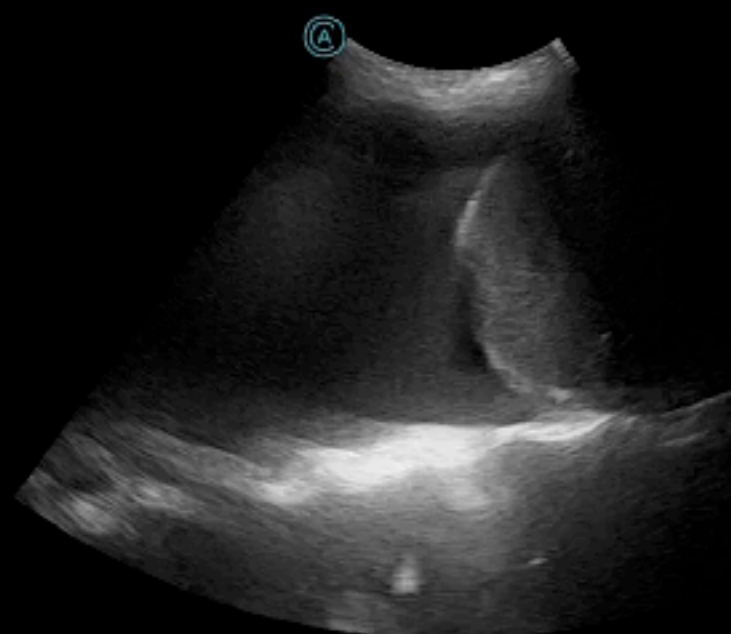
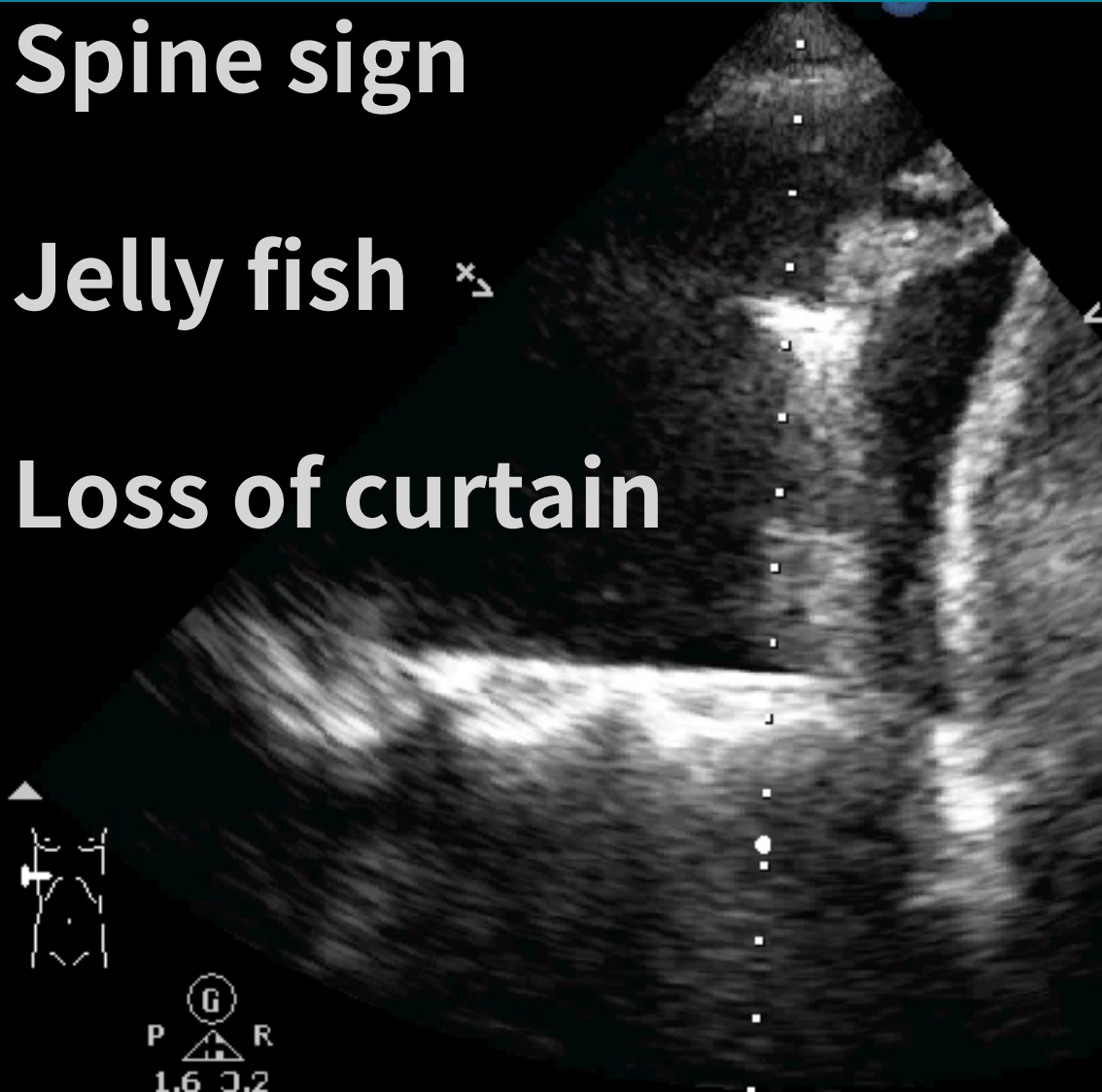


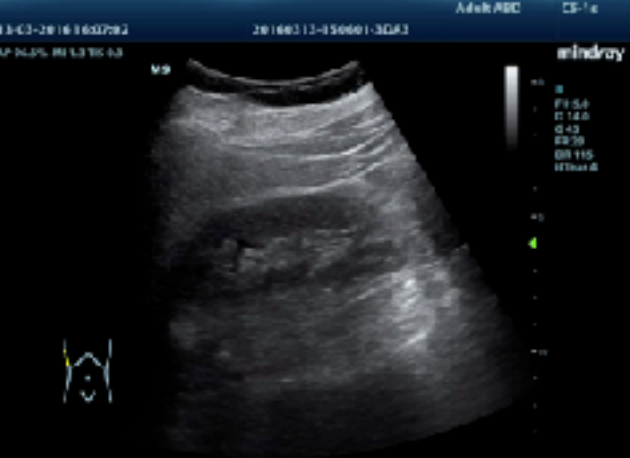# PLEURAL EFFUSION (肋膜積液)

Spine sign

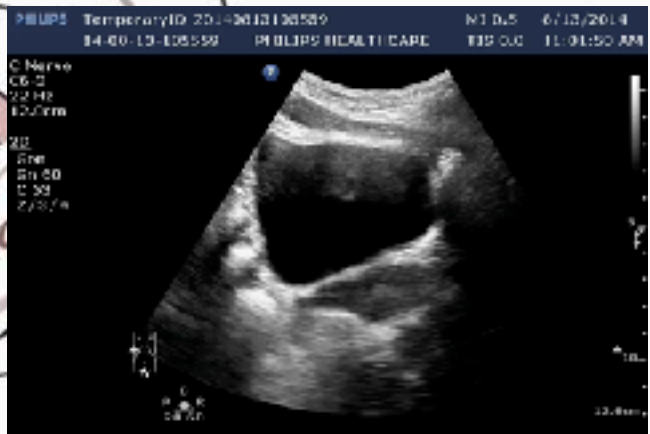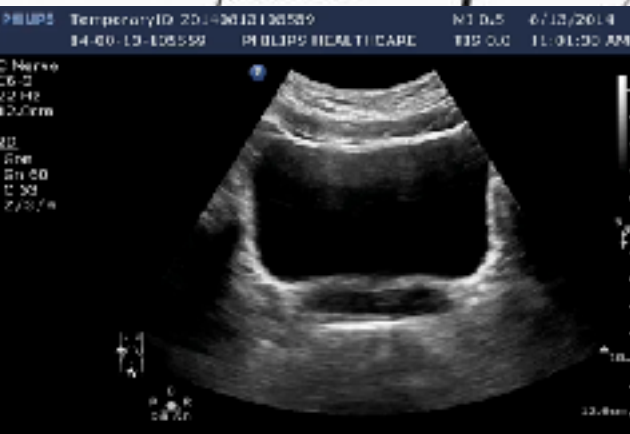
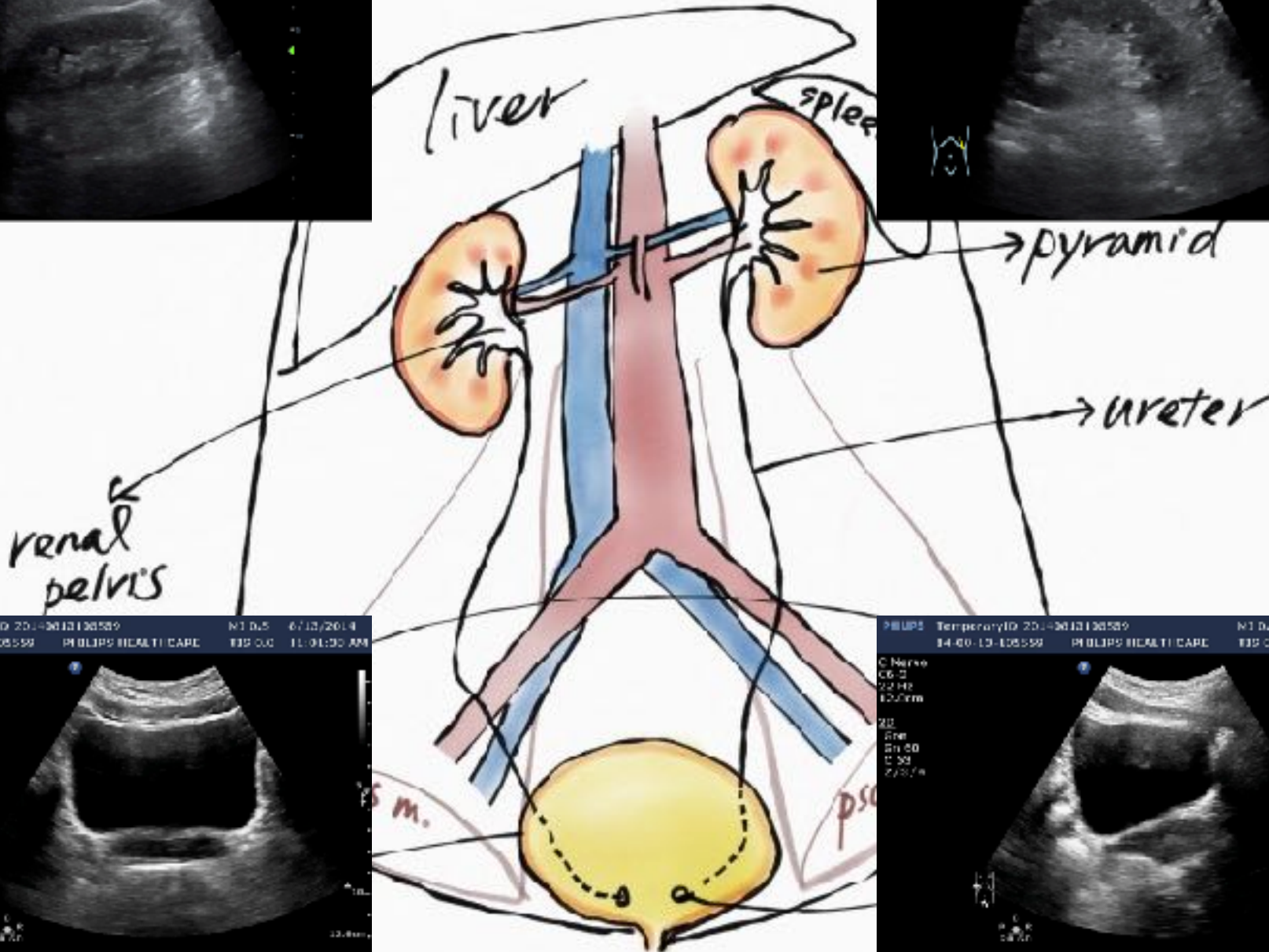
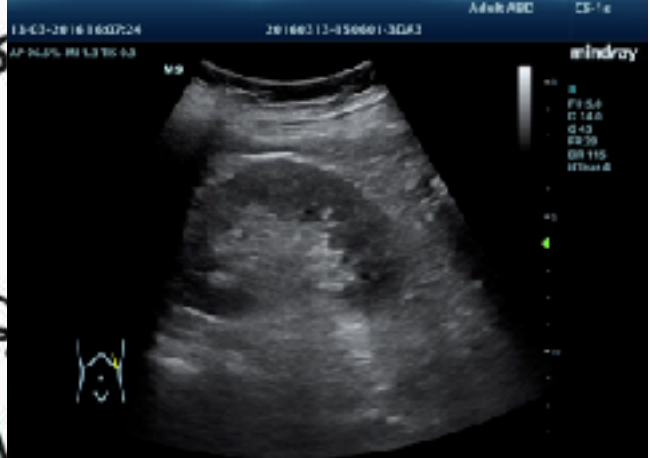Jelly fish <sup>\*</sup>

Loss of curtain

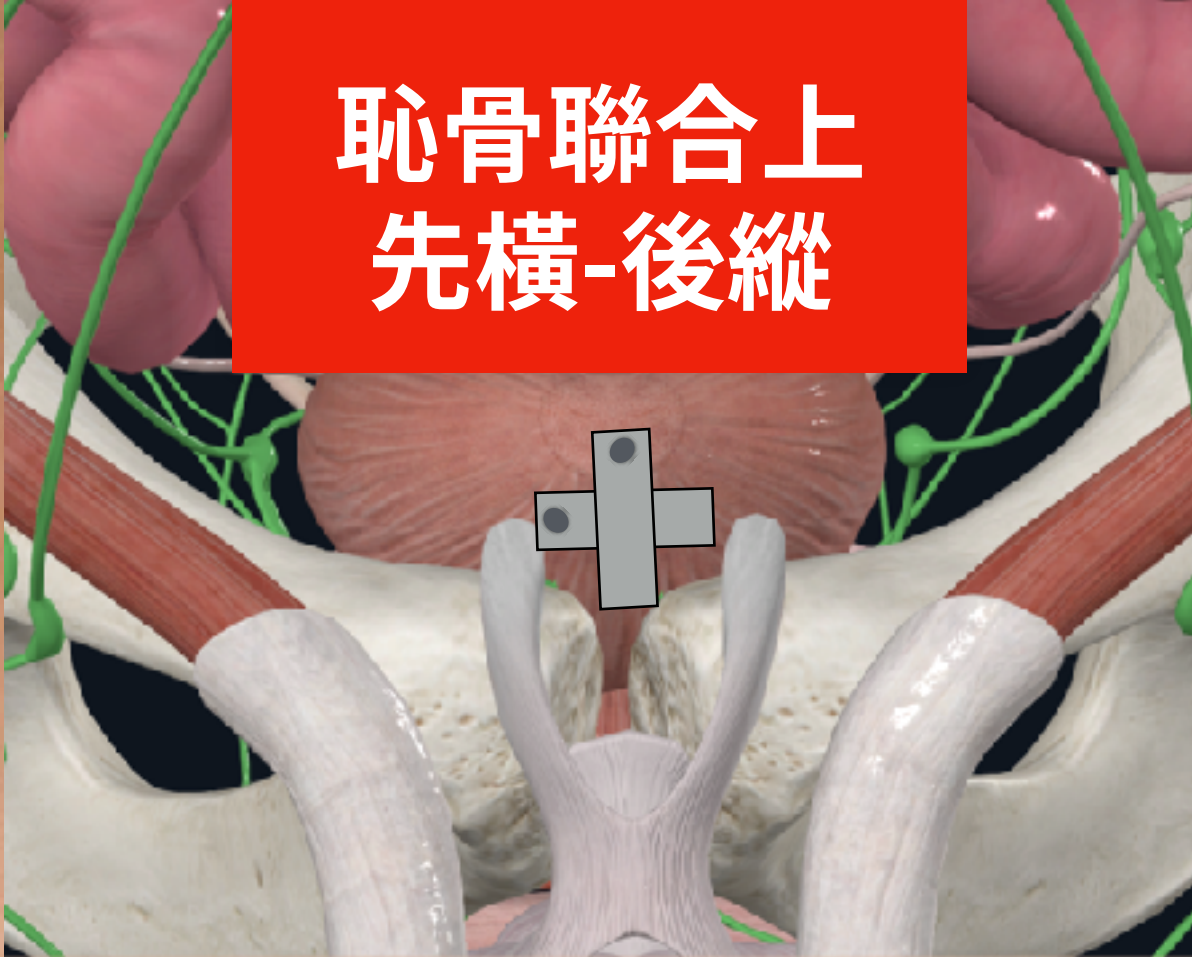



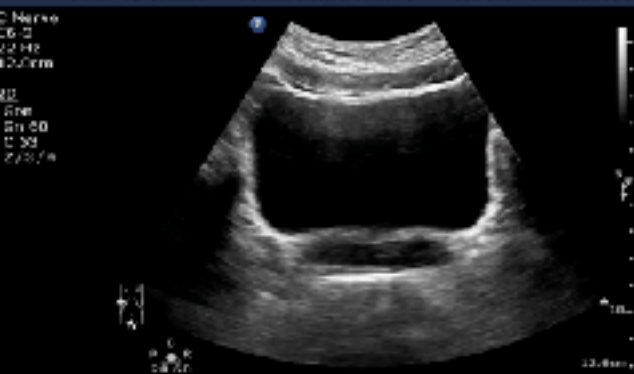
SIZE CHANGE. All rights reserved



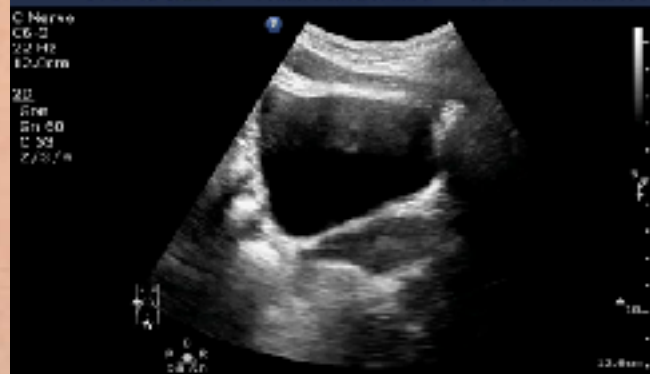
# 恥骨聯合上 先橫-後縱

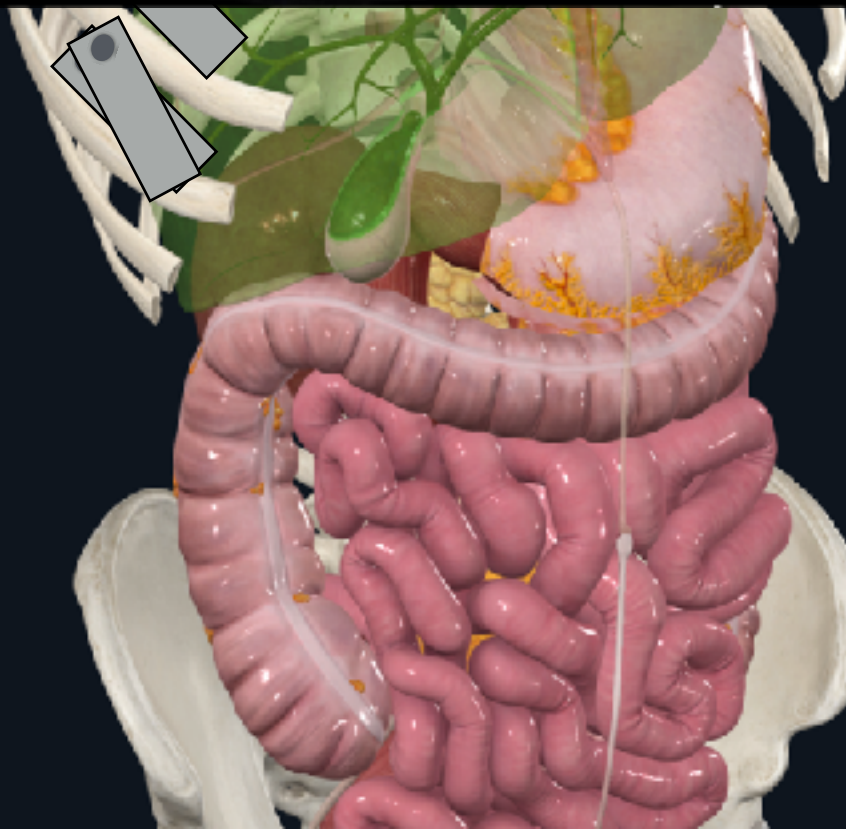
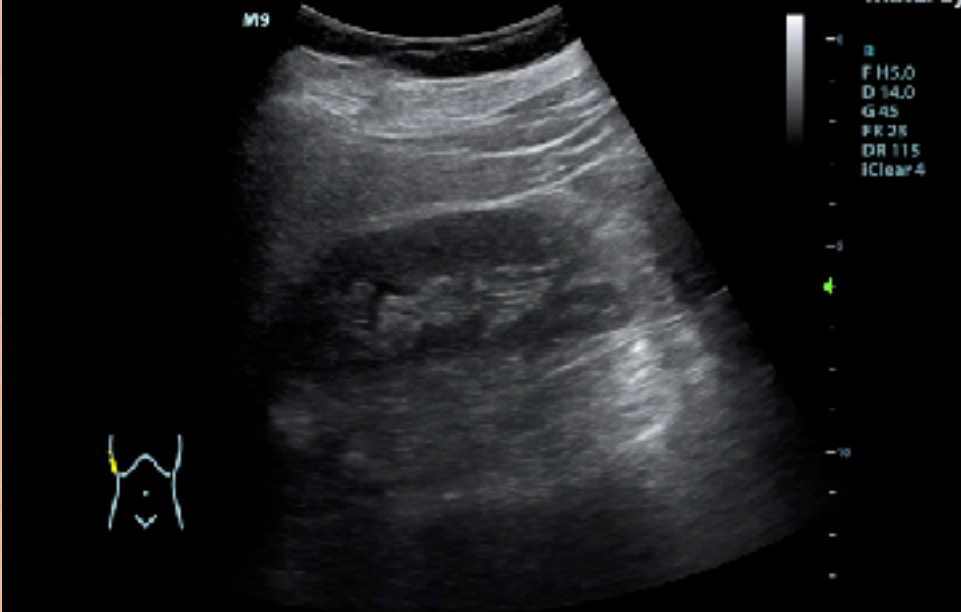


PHIPS TemporaryID: 2014010108589 N1 D.5 6/12/2014  
14-00-13-108559 PHILIPS HEALTH CARE F19 0.0 11:01:50 AM



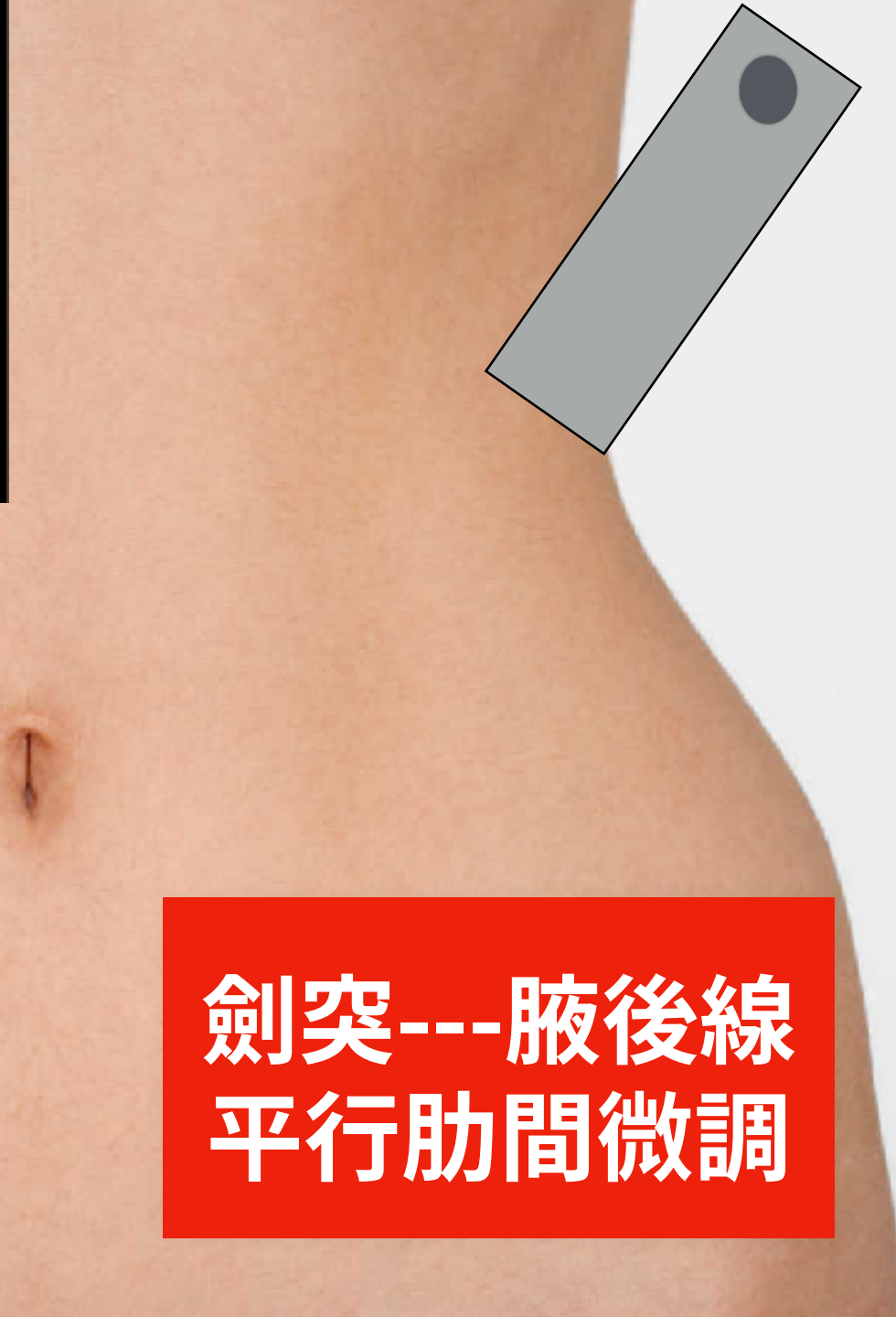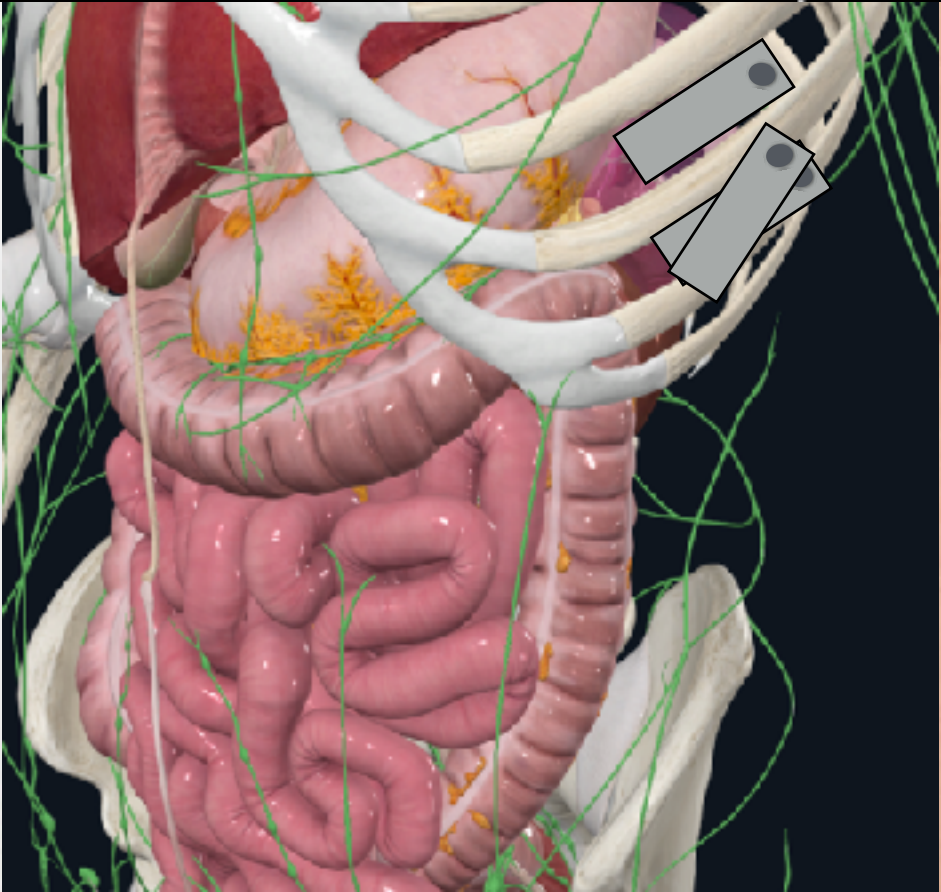
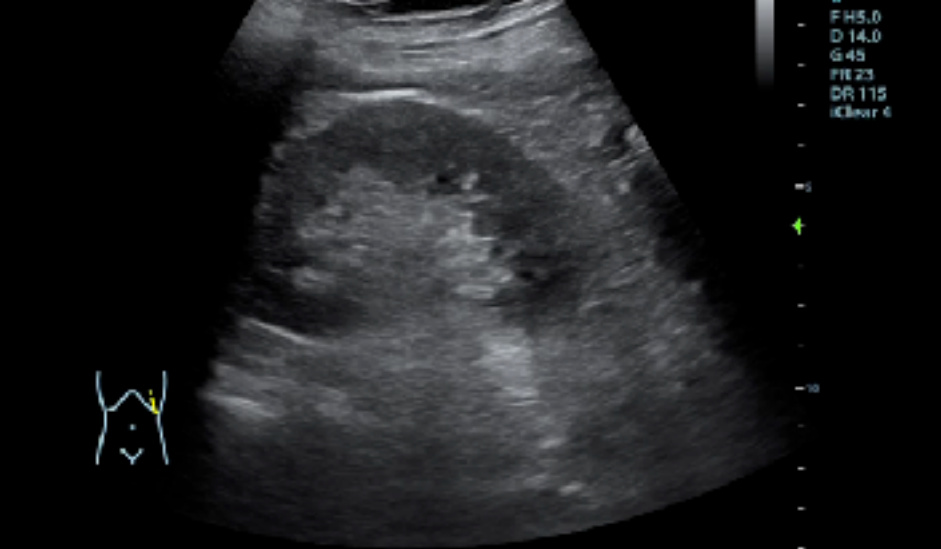PHIPS TemporaryID: 2014010108589 N1 D.5 6/12/2014  
14-00-13-108559 PHILIPS HEALTH CARE F19 0.0 11:01:50 AM



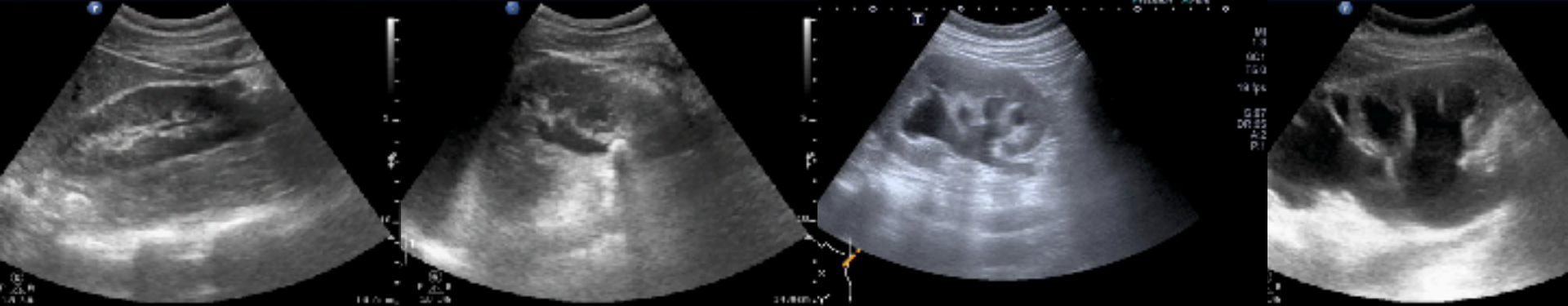


**劍突---腋前線  
肋間擺位微調**

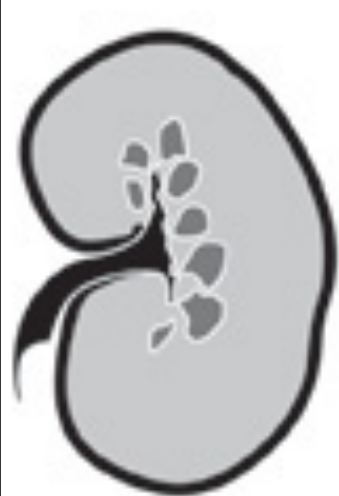



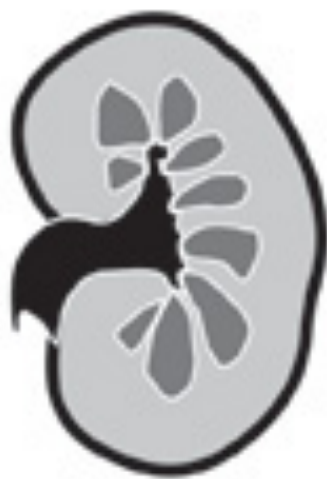劍突---腋後線  
平行肋間微調



# HYDRONEPHROSIS嚴重度



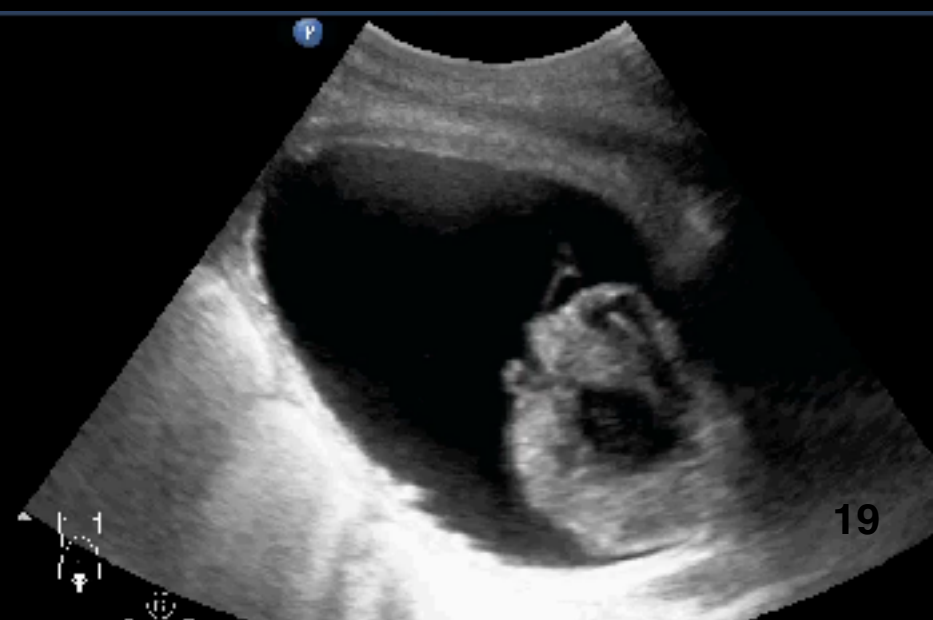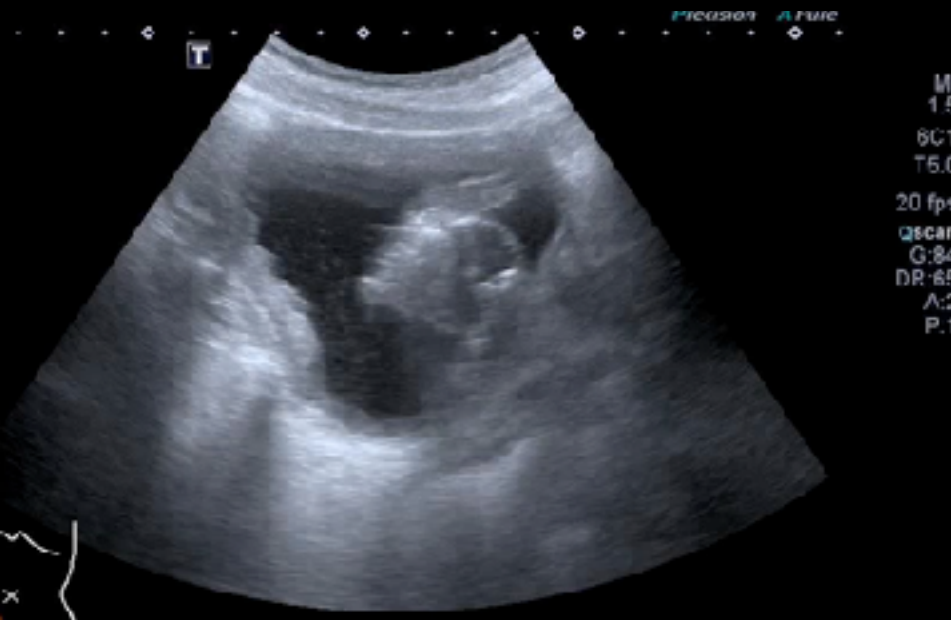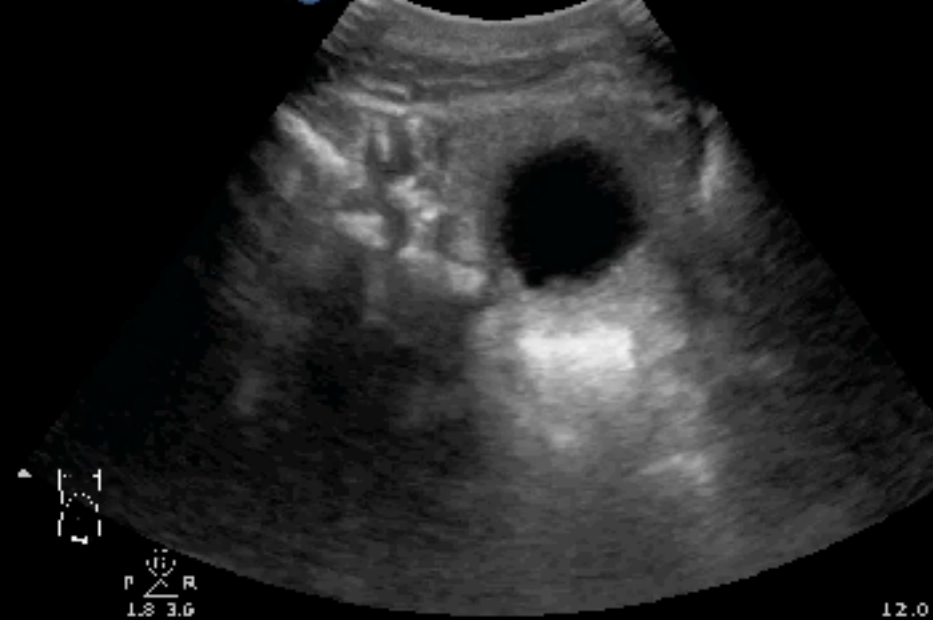
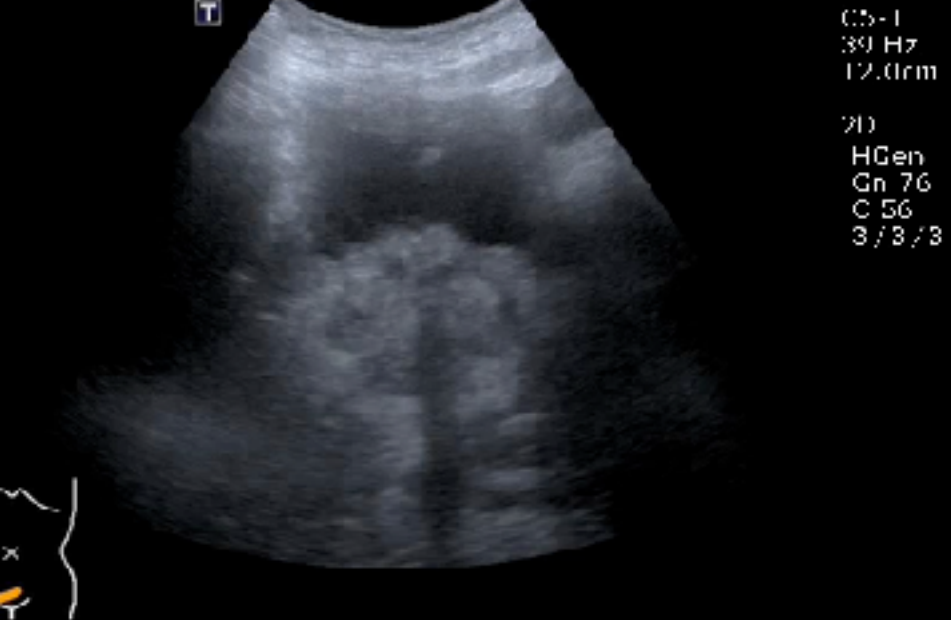
MILD



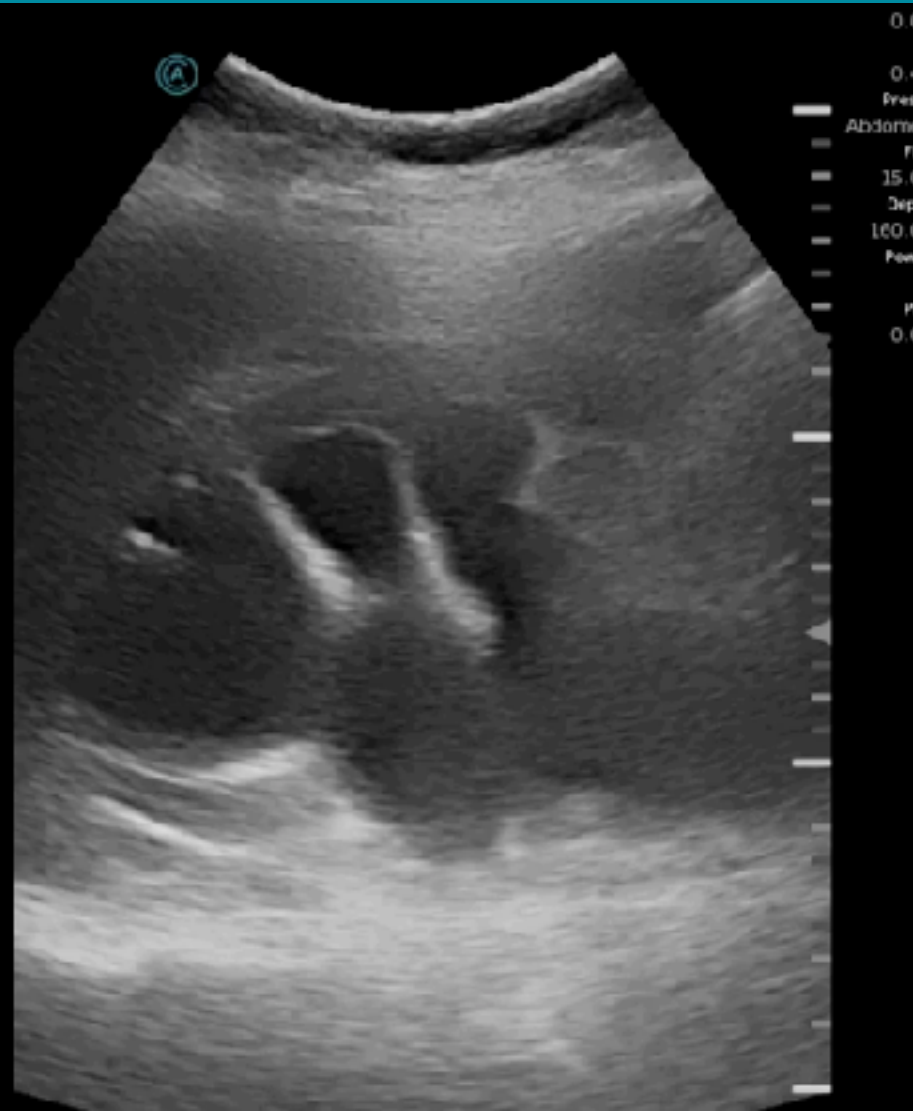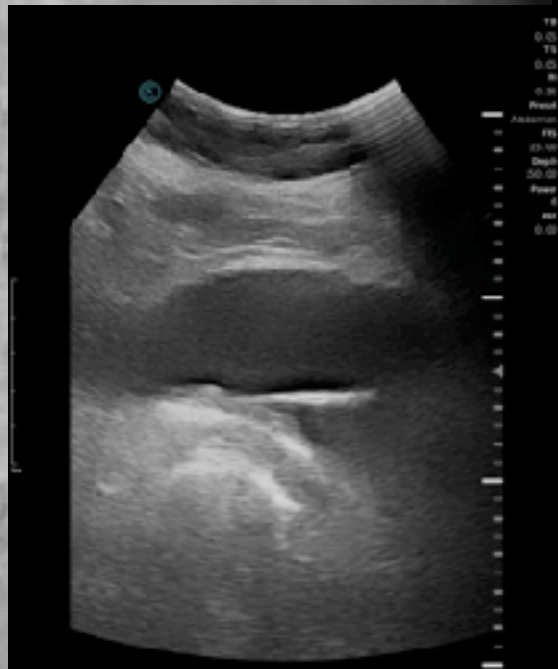
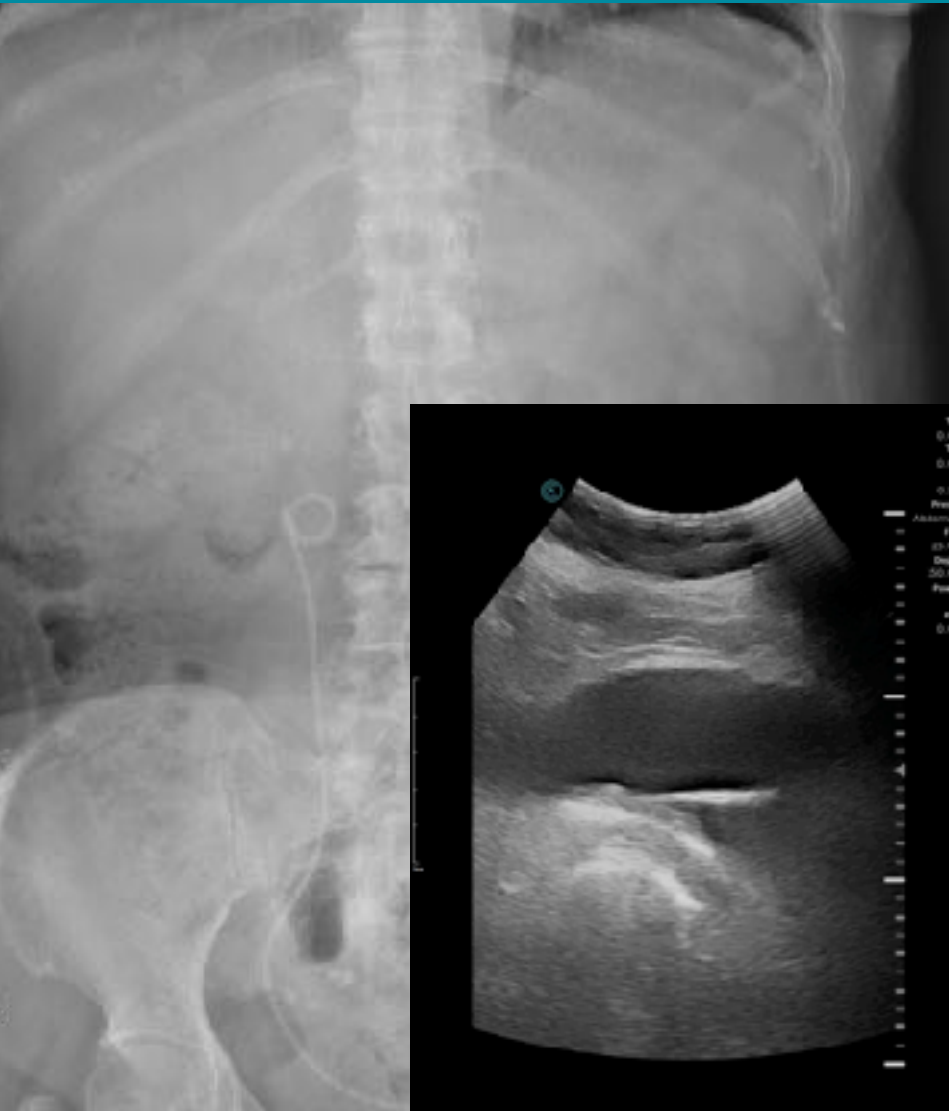MODERATE



SEVERE

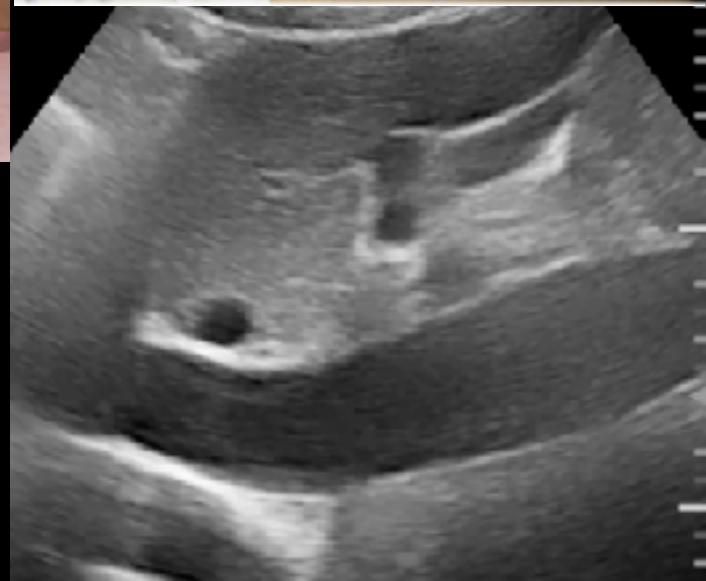
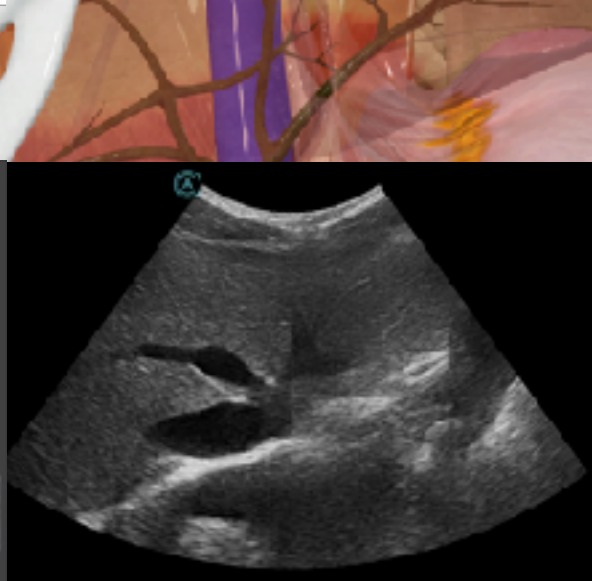
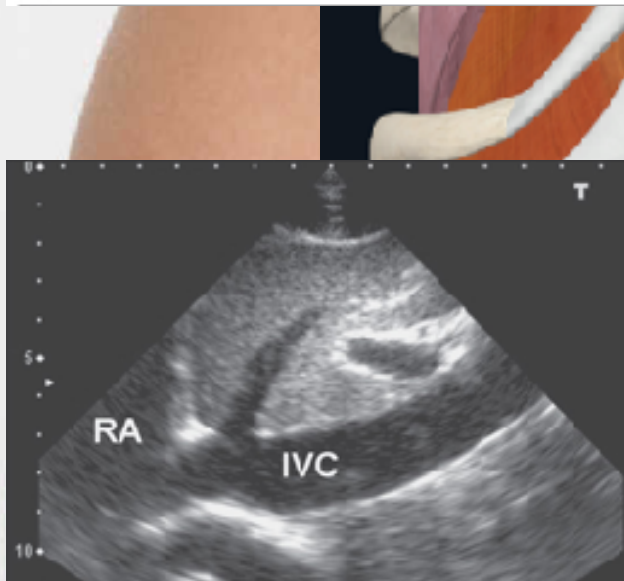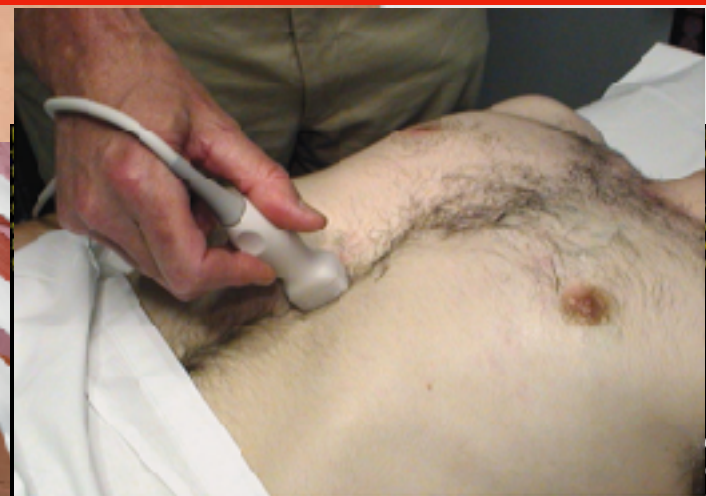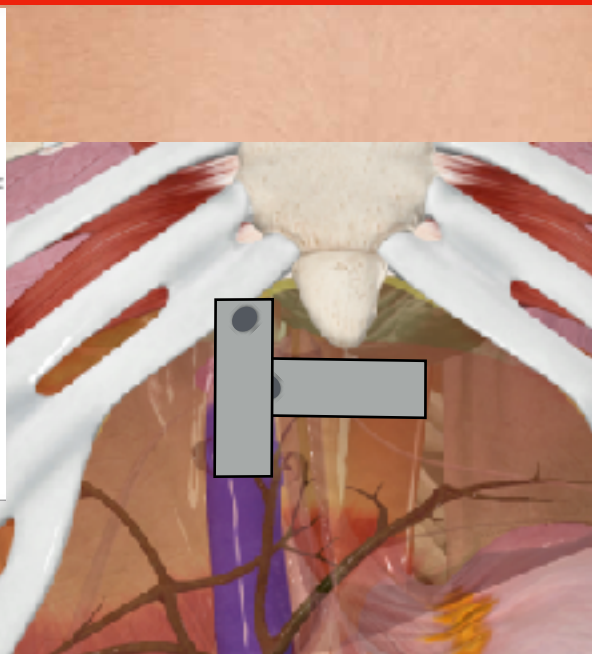
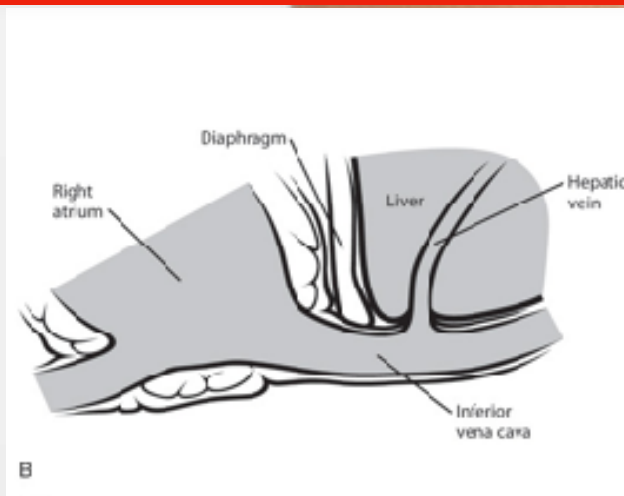


# 71F，居家個案，高燒畏寒

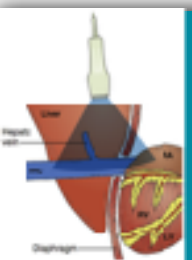


# IVC

## 劍突下 / 利用肝的視窗



# UAPE-Quick check



Adult Echo  
S1-1  
77 Hz  
15.0cm

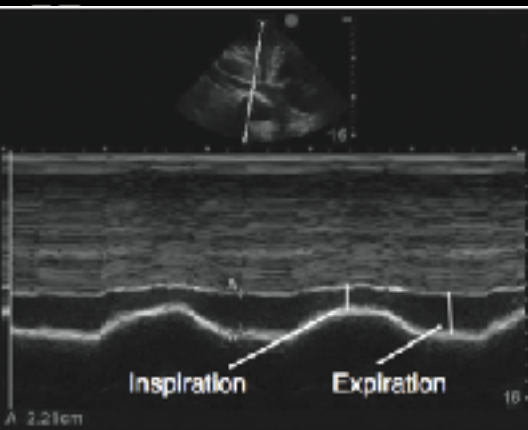
2D  
HGen  
Gn 100

Leg

Liver

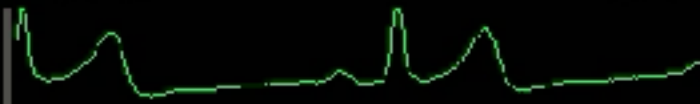Head

IVC



**Diameter (1-2cm) / Variation (50%)**

P  
1.7  
R  
3.1



53  
BPM

# 居家POCUS查核表

胸腔	泌尿	IVC
Rib / Pleura / Bat sign	Kidney, R	Liver
A line	Kidney, L	IVC, longitudinal
Sliding sign	Cortex	IVC, transverse
Seashore sign	Pelvis	Hepatic veins
Diaphragm, R	UB, transverse	RA / IVC junction
Diaphragm, L	UB, longitudinal	M mode for variation