



衛生福利部雙和醫院
(委託臺北醫學大學興建經營)
Taipei Medical University · Shuang Ho Hospital,
Ministry of Health and Welfare



Musculoskeletal US in ER 骨骼肌肉軟組織急症之應用

急診進階超音波

陳國智醫師 雙和醫院急診醫學科

juice119@gmail.com

POCUSacademy.com

陳國智 醫師 / POCUSacademy.com



台灣疼痛醫學會專科醫師
急診超音波臨床評核醫師
醫用超音波學會指導醫師
WINFOCUS director / instructor
Certified Interventional Pain Sonologist

急診 / 重症 / 介入 / 急性疼痛

經歷

新光急診超音波訓練中心主任
西園醫院急診醫學科主任
急診醫學會超音波委員會主委
台灣疼痛醫學會大體模擬手術講師
急救加護醫學會重症超音波負責人

juice119@gmail.com

REVIEW

Open Access



An overview of point-of-care ultrasound for soft tissue and musculoskeletal applications in the emergency department

Kuo-Chih Chen^{1,2}, Aning Chor-Ming Lin^{3,2*}, Chee-Fah Chong^{1,2} and Tzong-Luen Wang^{1,2}

Musculoskeletal Ultrasound in the Emergency Department

Vito Chianca, MD¹ Francesco Di Pietto, MD, PhD² Marcello Zappia, MD, PhD³
Domenico Albano, MD^{1,4} Carmelo Messina, MD^{1,5} Luca Maria Sconfienza, MD, PhD^{1,5}

¹IRCCS Istituto Ortopedico Galeazzi, Milano, Italy

²Dipartimento di Diagnostica per immagini, Pineta Grande Hospital, Castel Volturno (CE), Italy

³Department of Medicine and Health Sciences, Università del Molise, Campobasso, Italy

⁴Section of Radiological Sciences, Department of Biomedicine, Neurosciences and Advanced Diagnostics, University of Palermo, Palermo, Italy

⁵Dipartimento di Scienze Biomediche per la Salute, Università degli Studi di Milano, Milano, Italy

Semin Musculoskelet Radiol 2020;24:167–174.



Address for correspondence: Vito Chianca, MD, IRCCS Istituto Ortopedico Galeazzi, via Riccardo Galeazzi 4, 20161 Milano, Italy (e-mail: vitochianca@gmail.com).

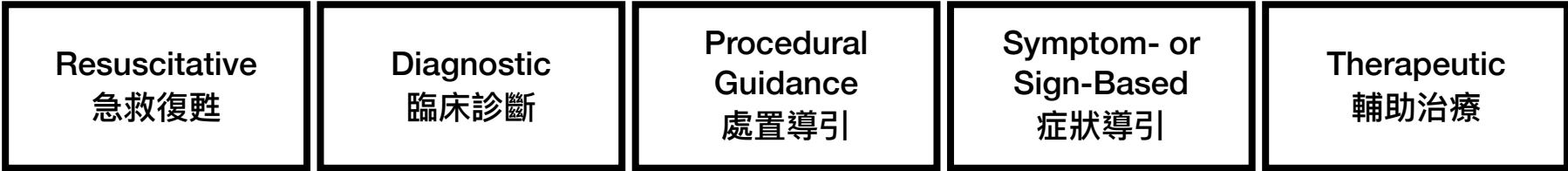

Seminars in
ROENTGENOLOGY

Soft tissue infection
Joint effusion
Foreign body
Long bone fracture
Muscle & Tendon injury
Vascular occlusion
Procedures

Musculoskeletal Ultrasound in the Emergency Department: Is There a Role?

Michael V. Perone, MD, and Corrie M. Yablon, MD <https://doi.org/10.1053/j.ro.2020.09.004>



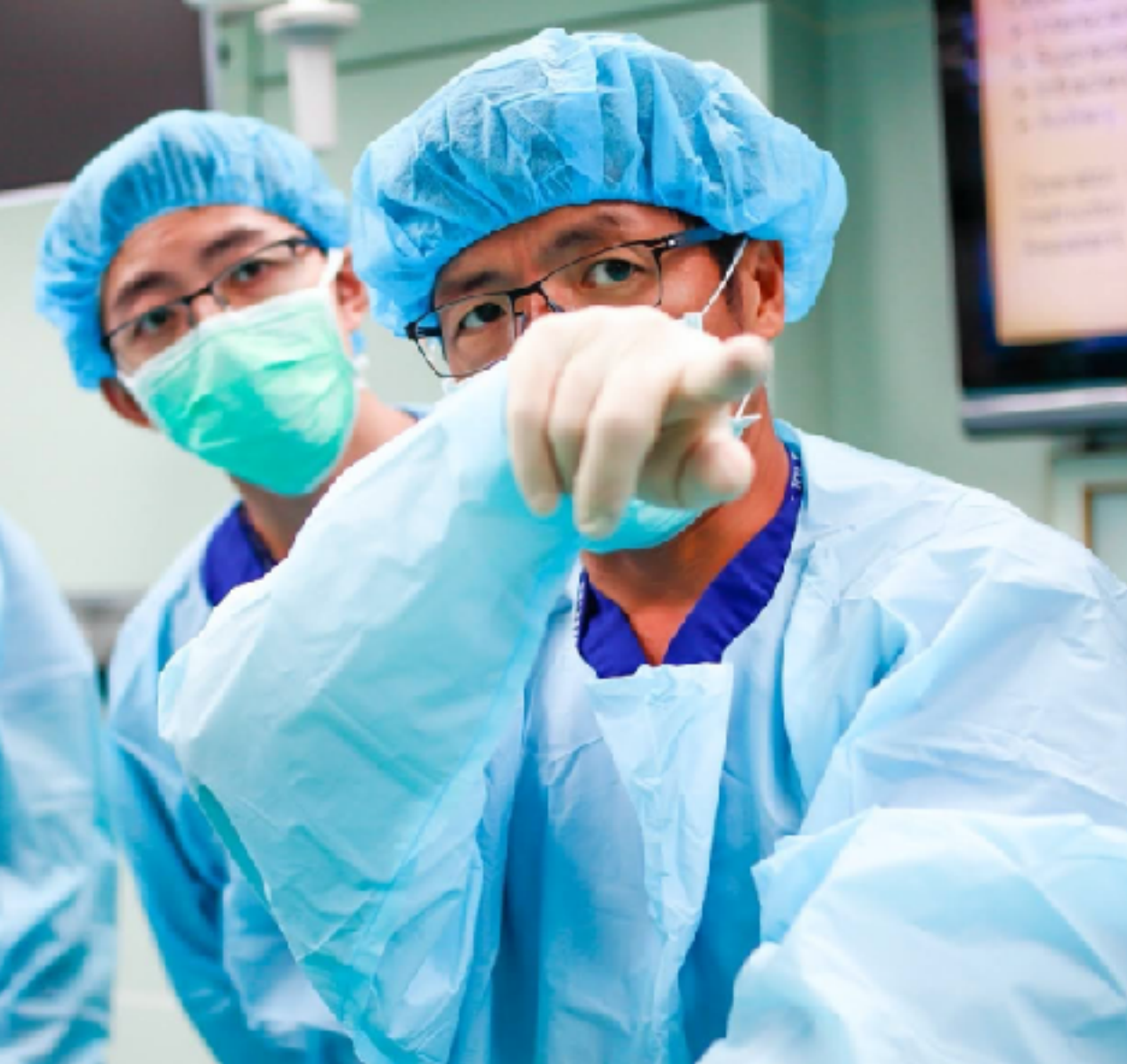Core Applications (2023 ACEP Emergency Ultrasound Guidelines)
15項急診超音波核心應用

陳國智醫師

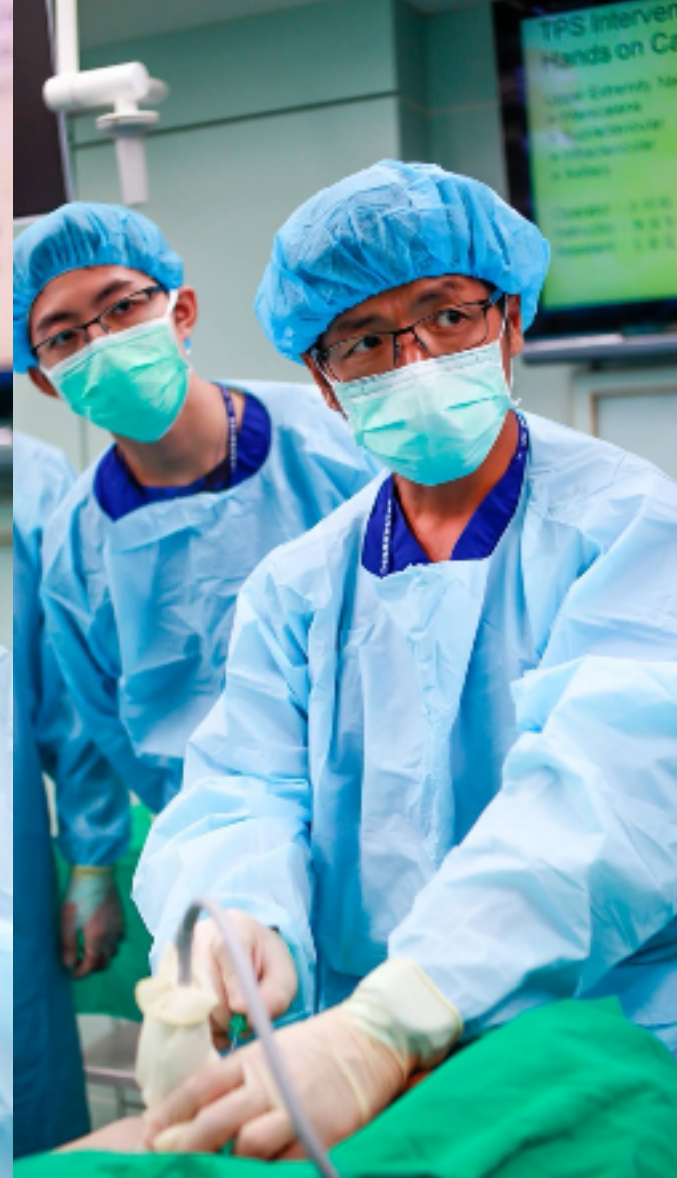Aorta
 DVT
 Trauma
 Thoracic/Airway
 Cardia/HD assessment

Procedural Guidance
 US-guided NB
 Testicular
 Ocular
 Skin & Soft tissue

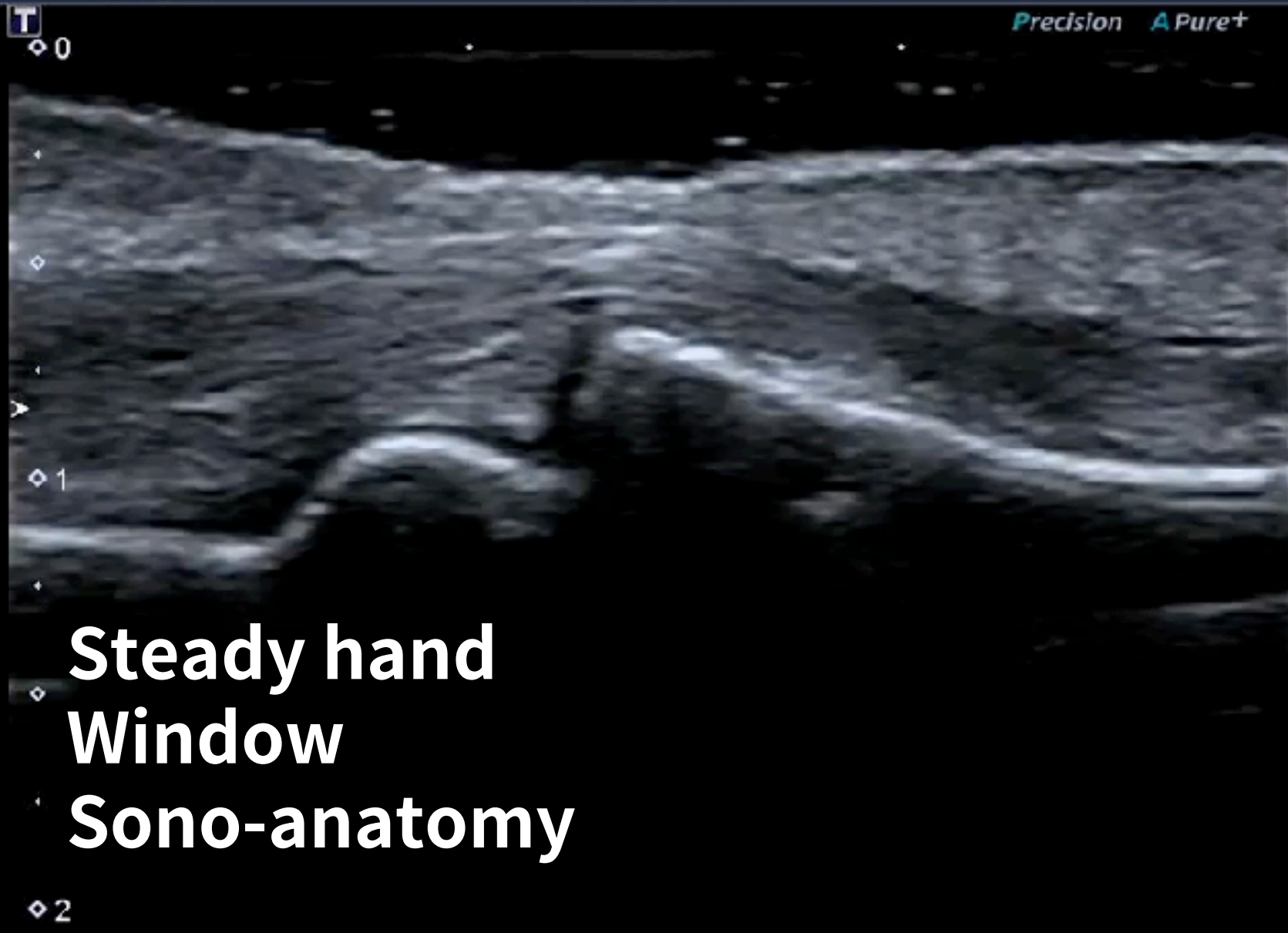Hepatobiliary
 Urinary tract
 Pregnancy
 Bowel
 MSK



Diagnostician



Interventionist



MI
1.5
14L5
diff14M
44 fps
G:78
DR:65
A:7
P:5

**Steady hand
Window
Sono-anatomy**

T
0
1
2



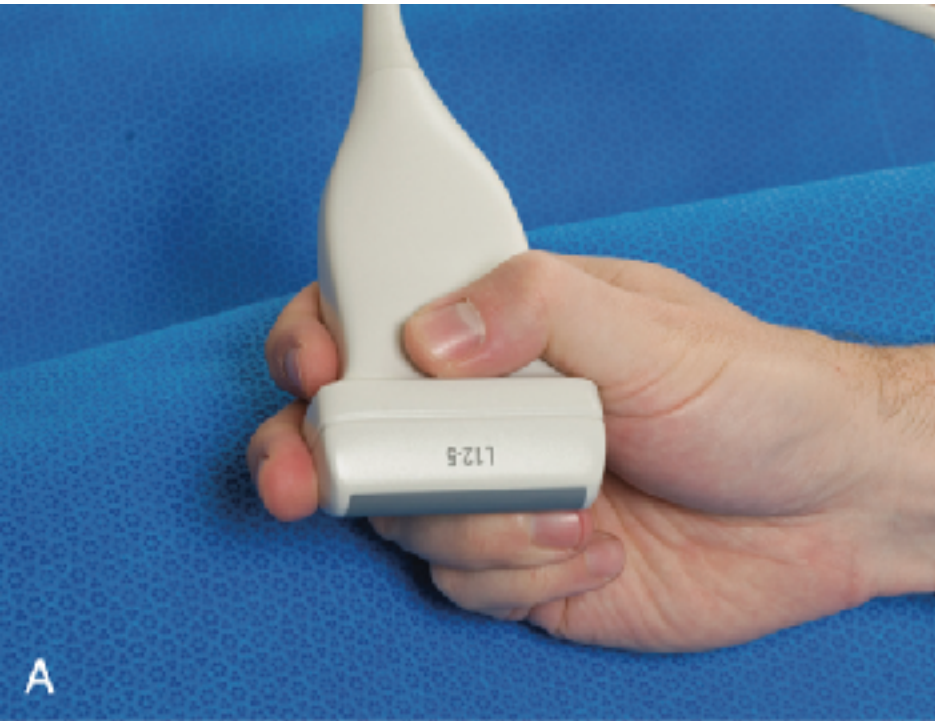Steady Hand



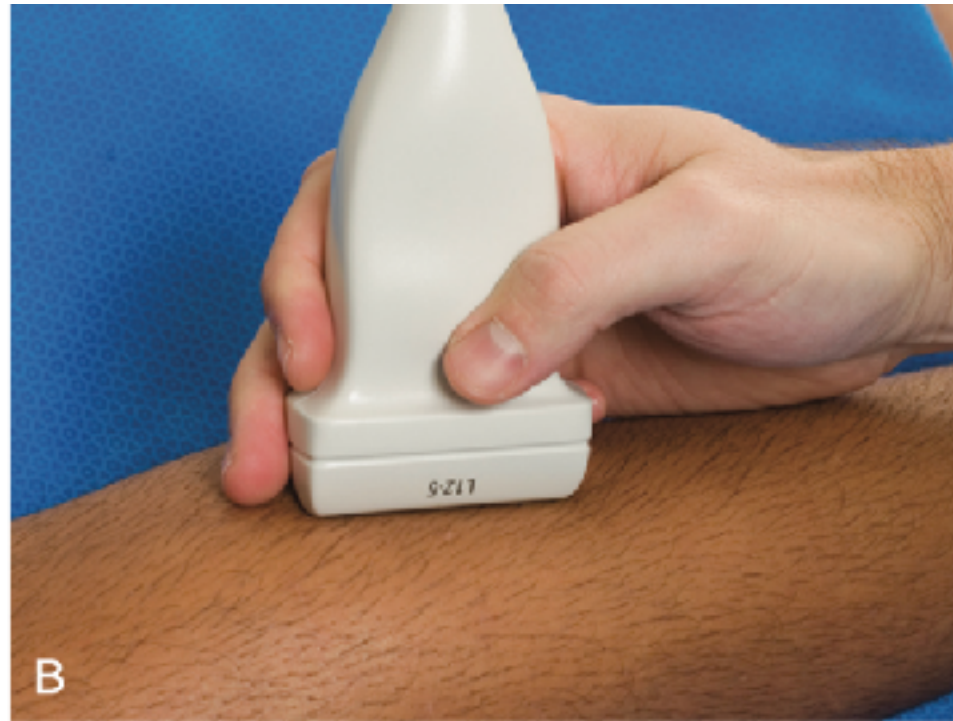探頭

操作者的手

皮膚

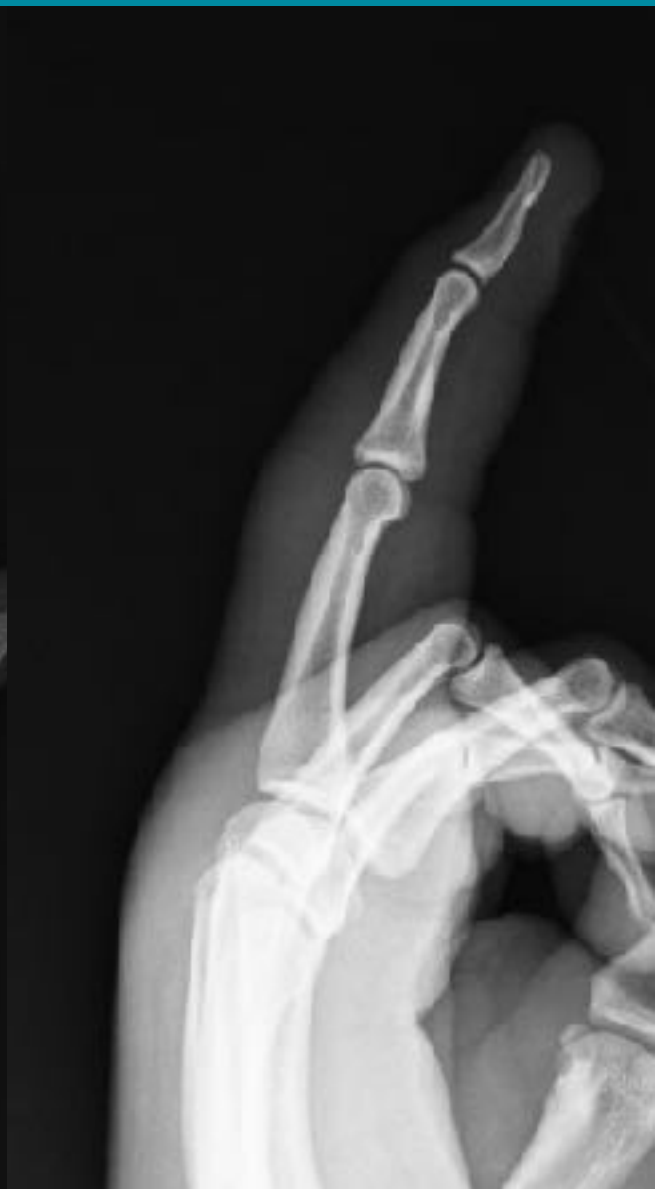
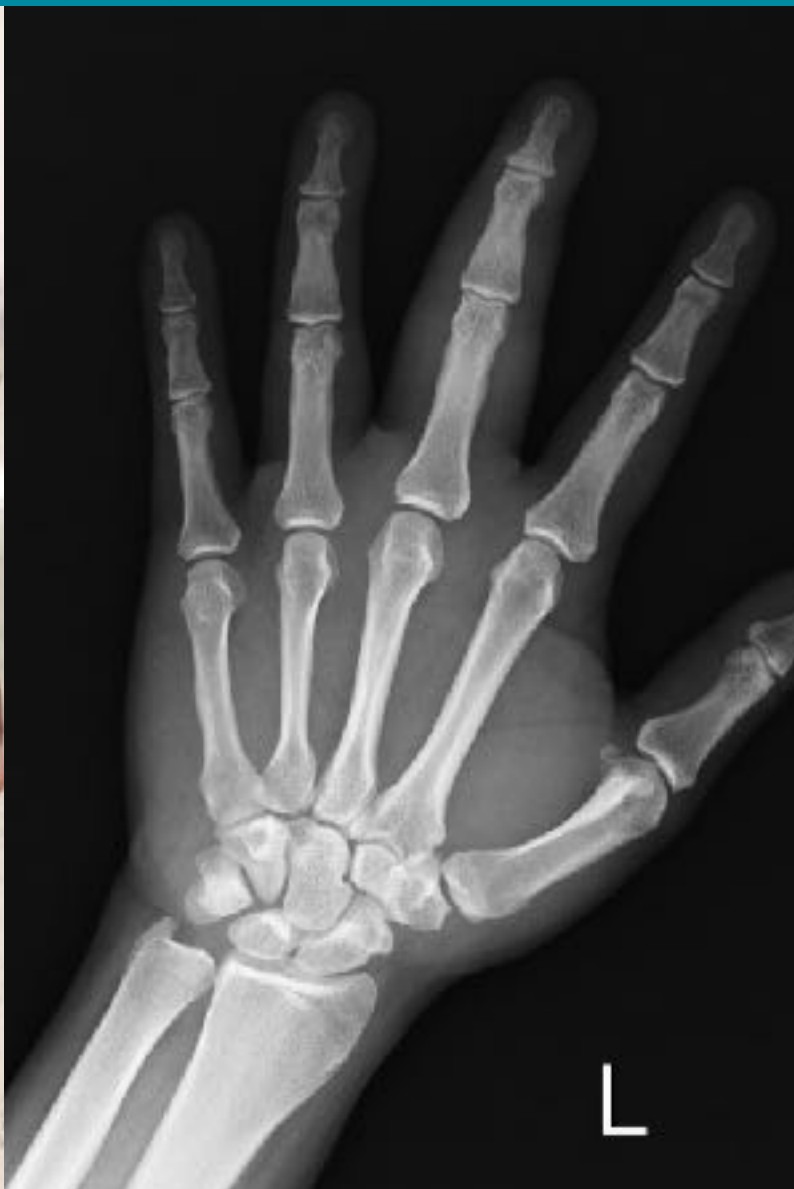
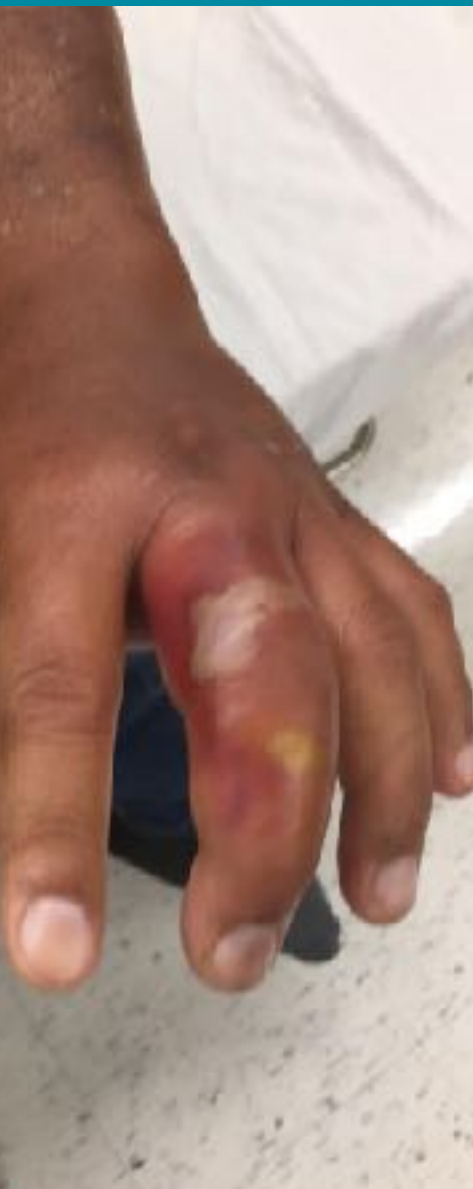A

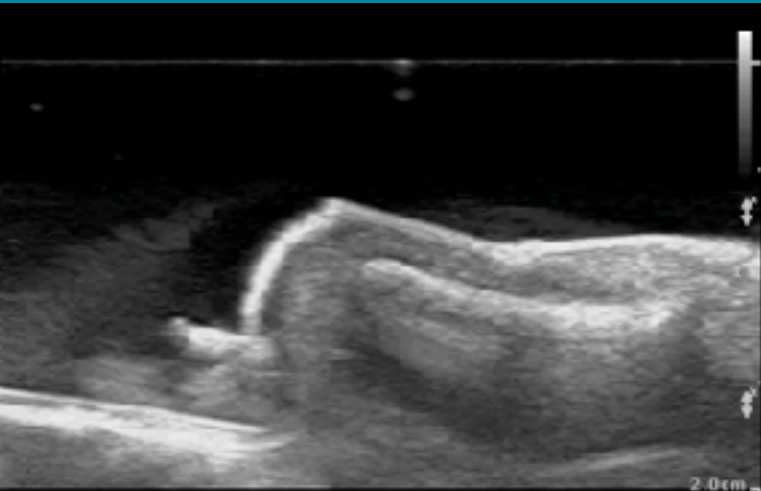

B

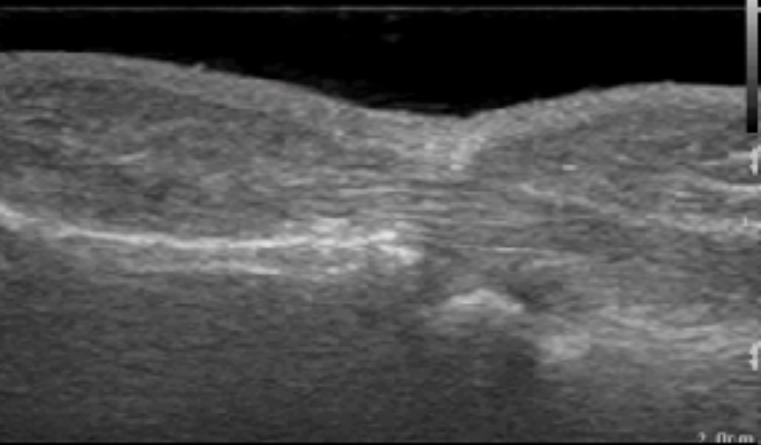
左手中指腫痛



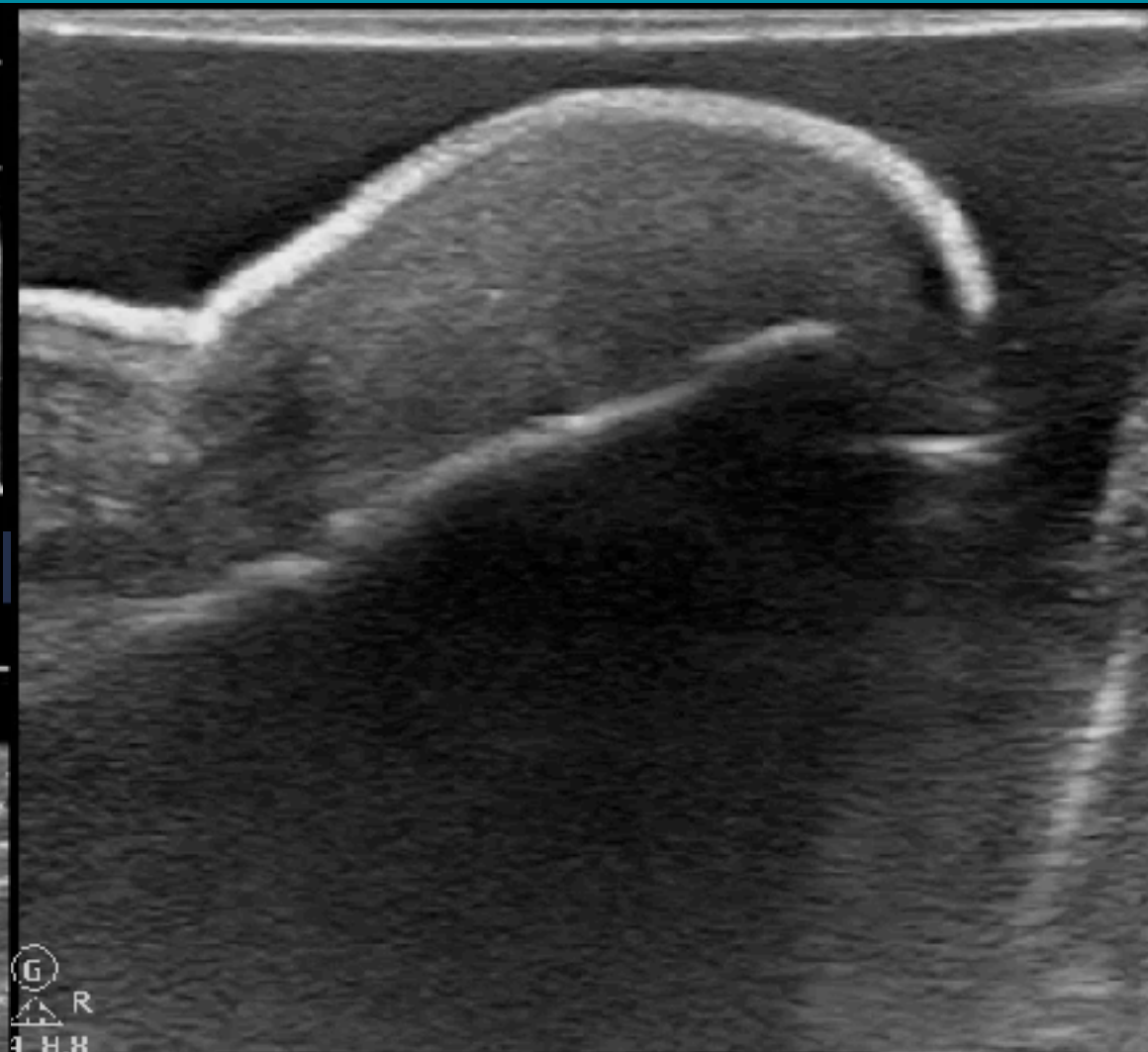Water bath method



G
D R
3.0 12.3


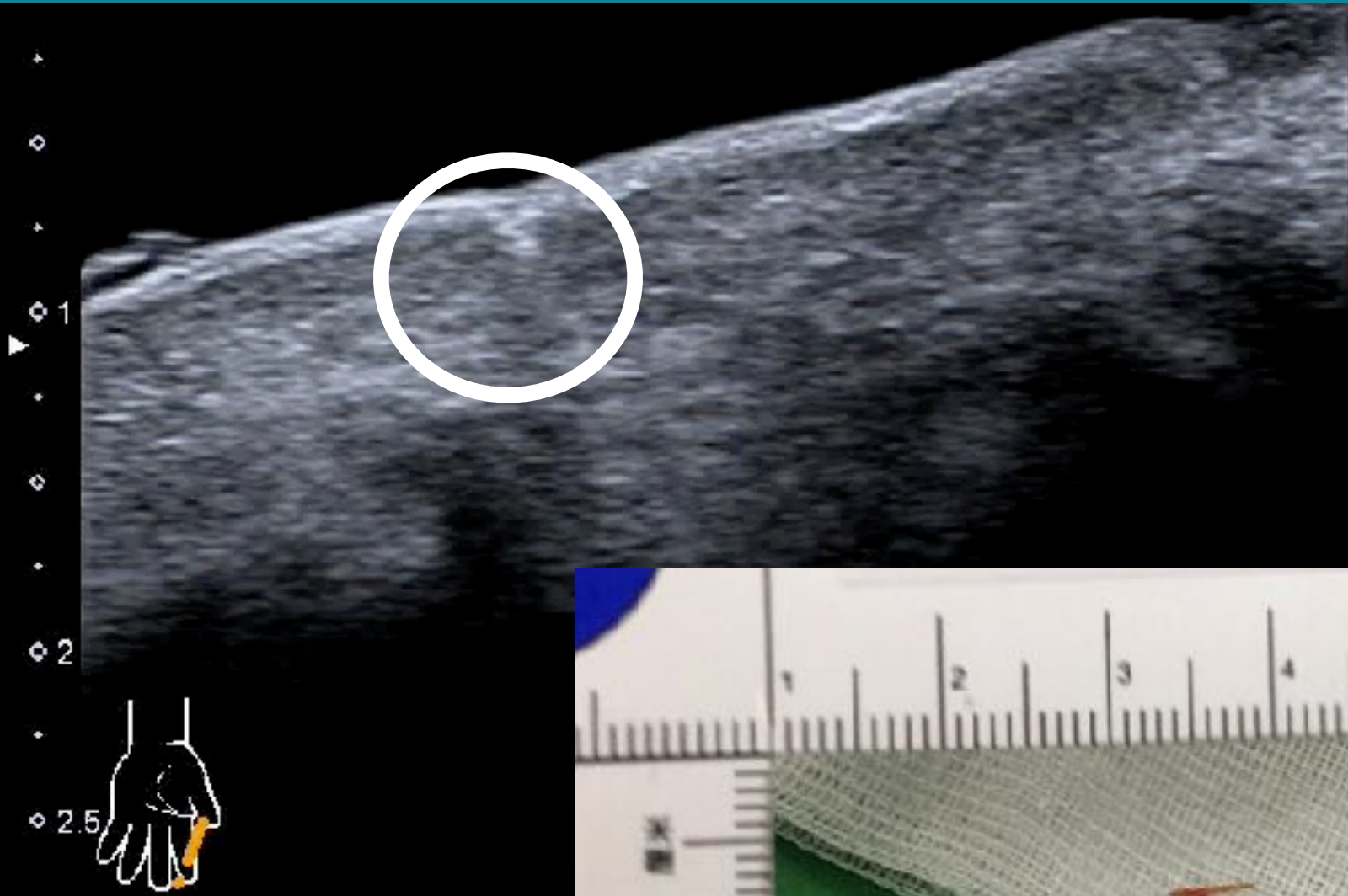


G
P R
2.0 12.0

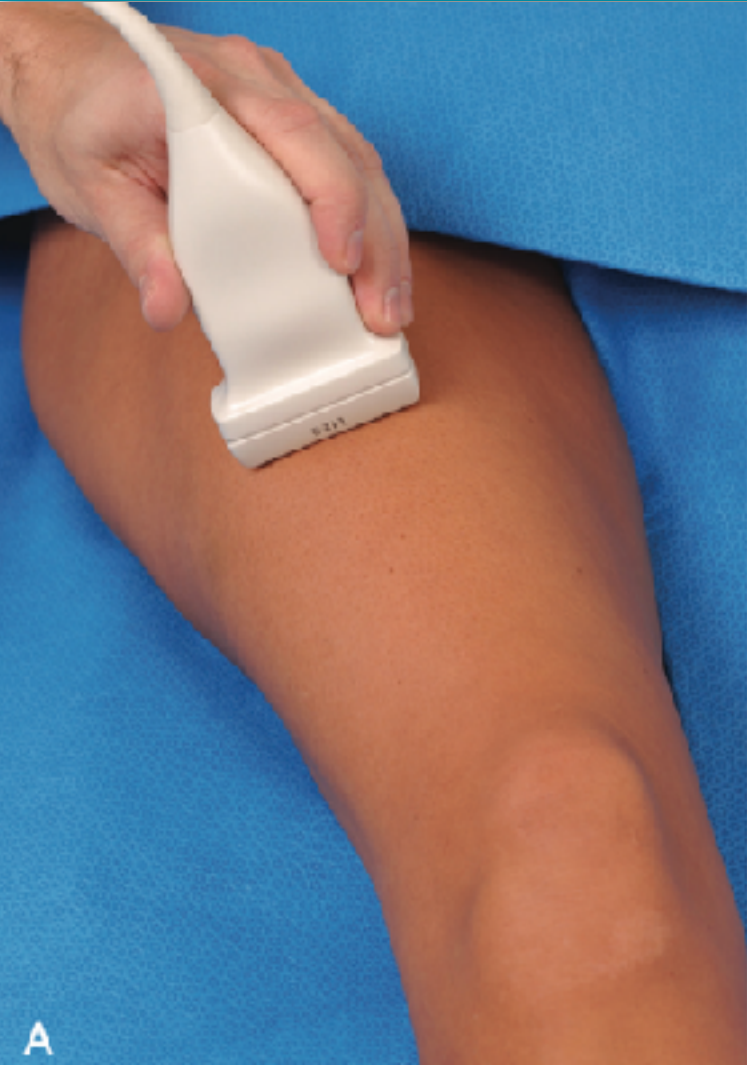

G
R
4 H.H

Create window



MSK掃描原則

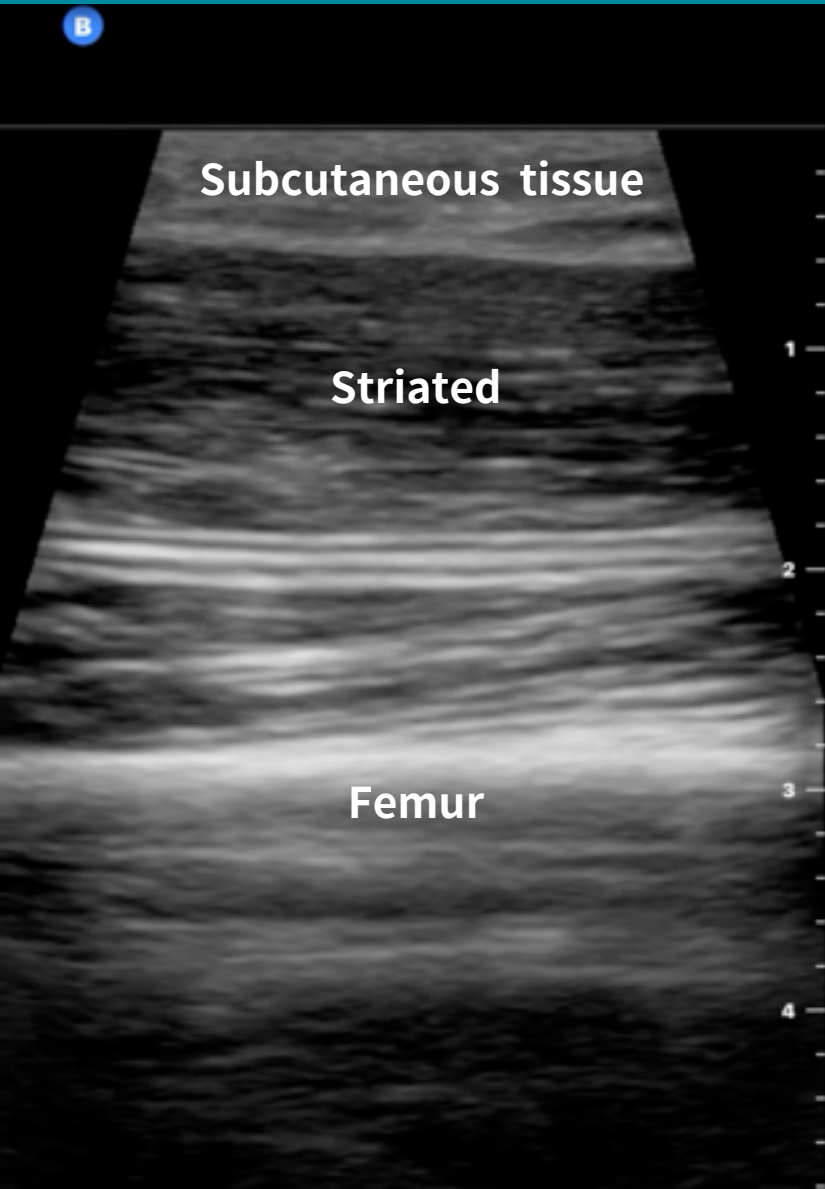


管狀構造橫掃優先

先找外在明顯定位

確認內在明顯標的

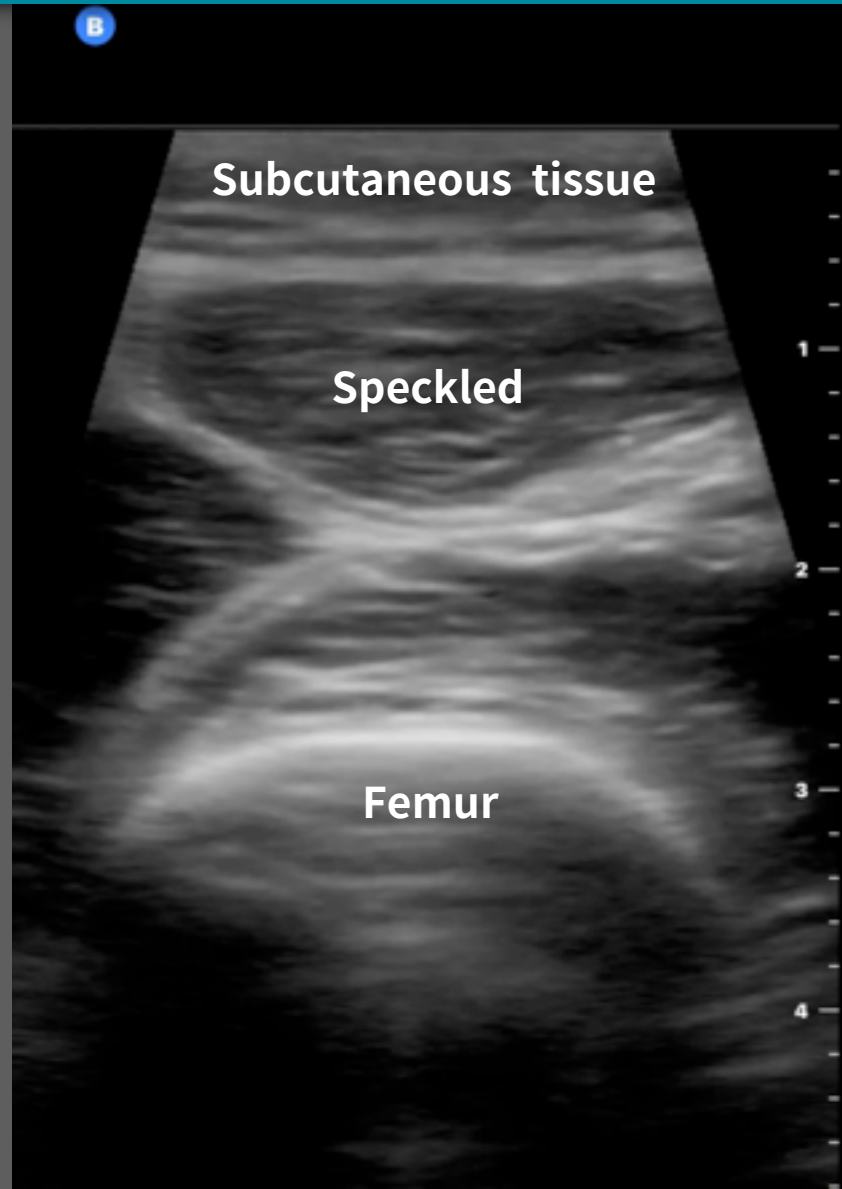
MSK的重要三界線(白線)



皮膚

筋膜

骨頭

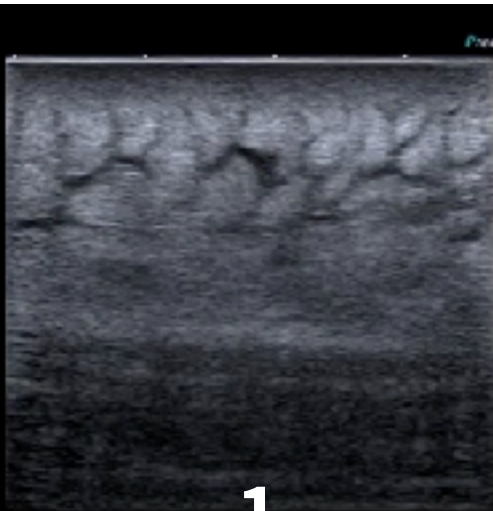

軟組織感染症

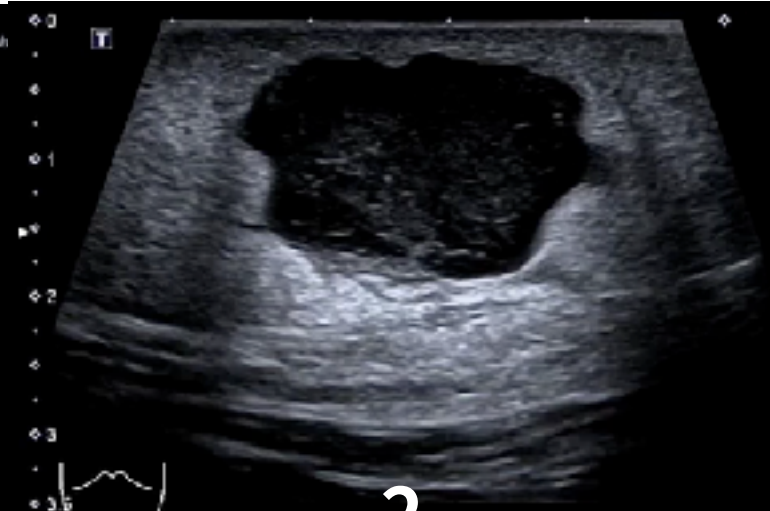蜂窩性組織炎

膿瘍

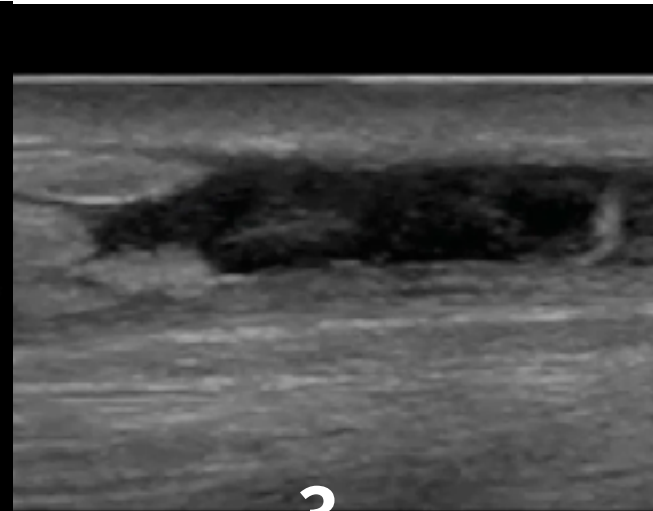
壞死性筋膜炎



1



2



3

Cobblestone

Collection

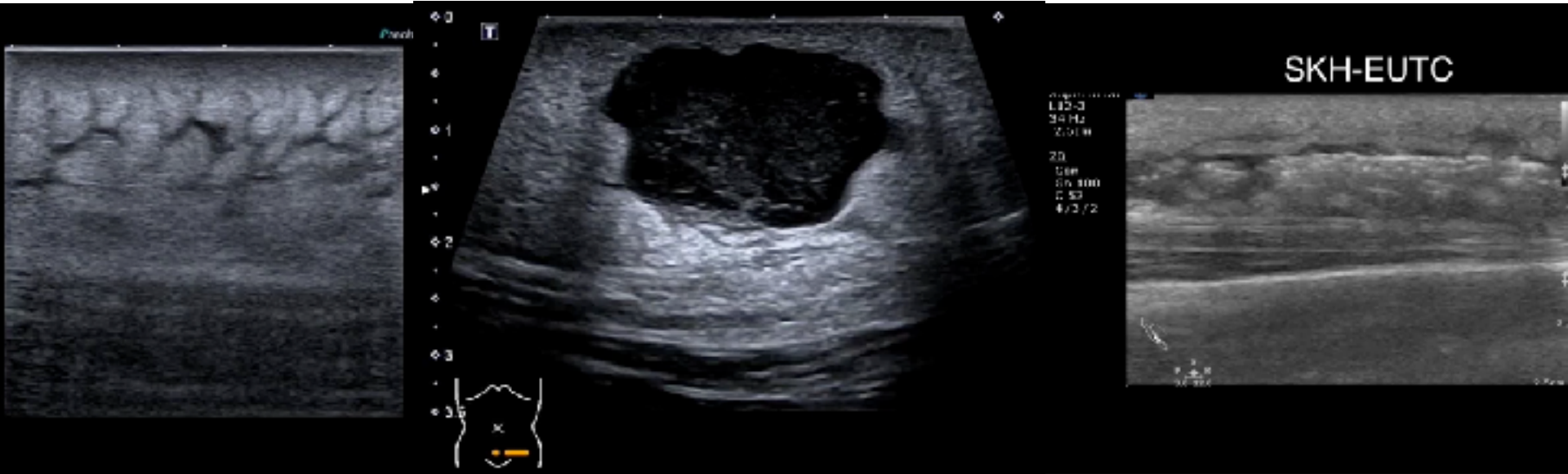Fascial fluid >4mm

軟組織感染症

蜂窩性組織炎

膿瘍

壞死性筋膜炎

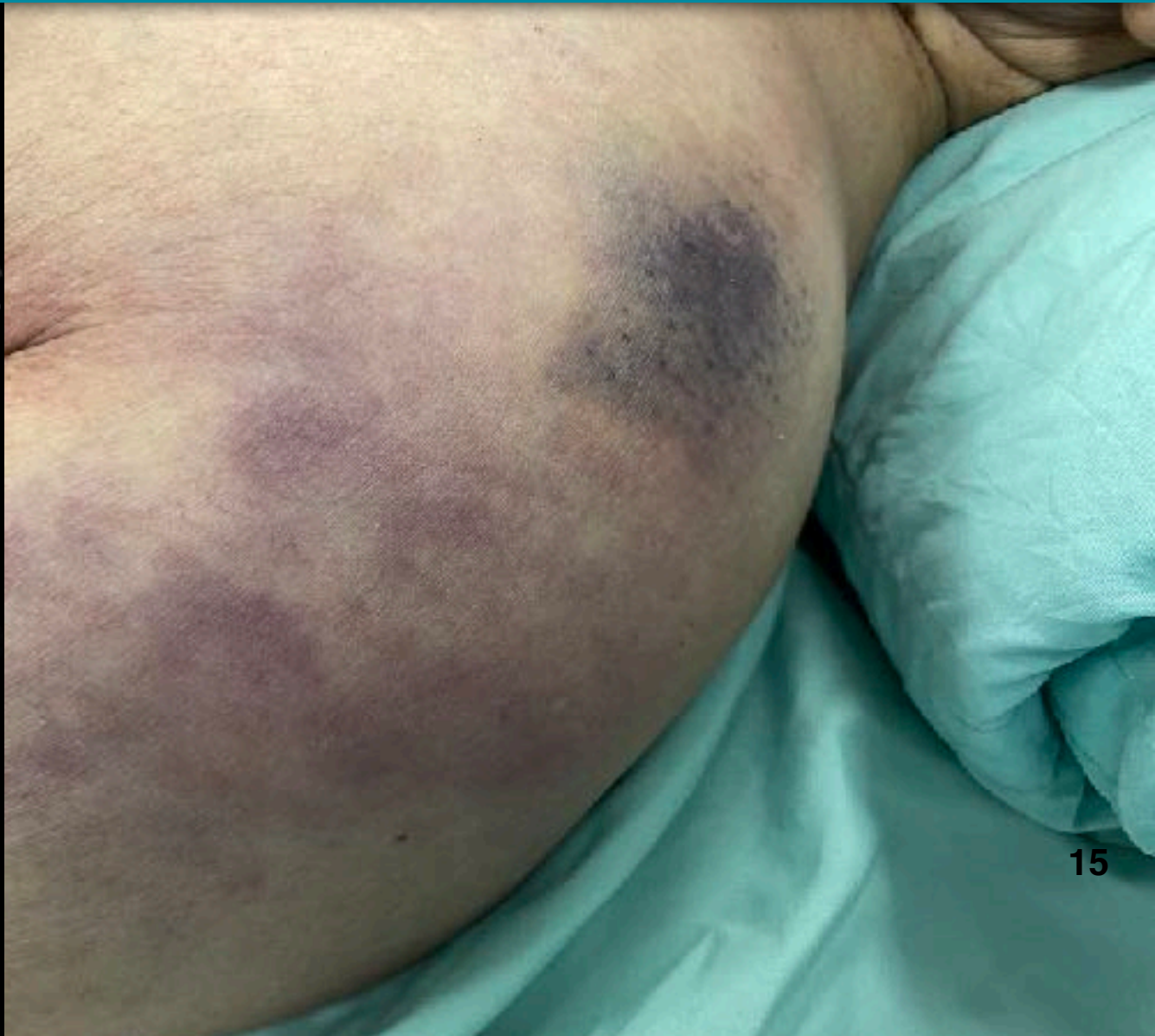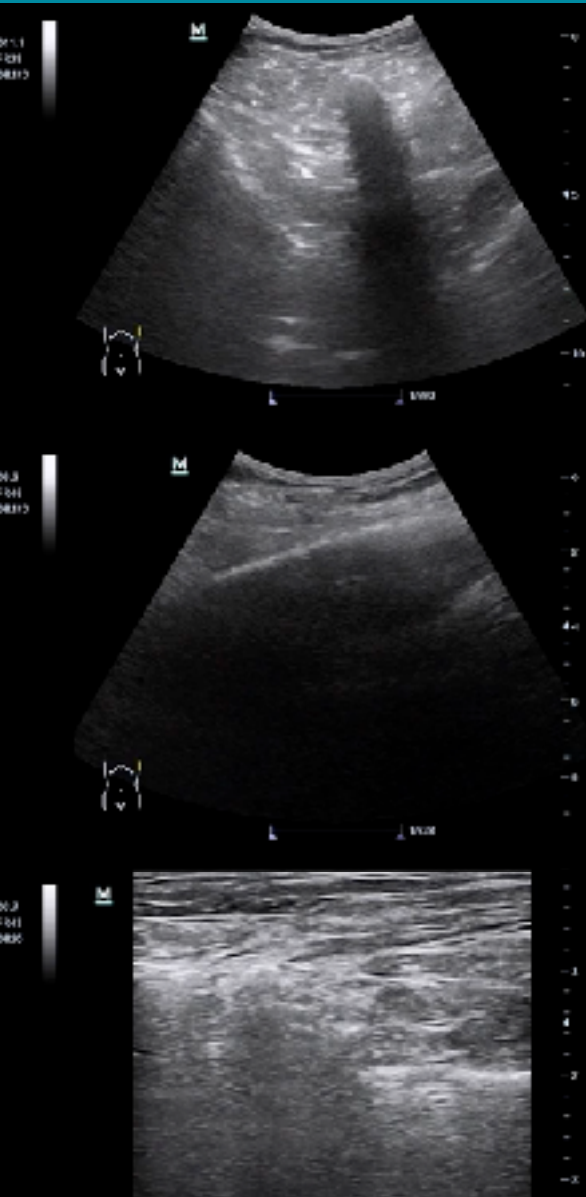


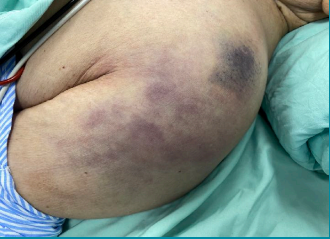Cobblestone

Collection

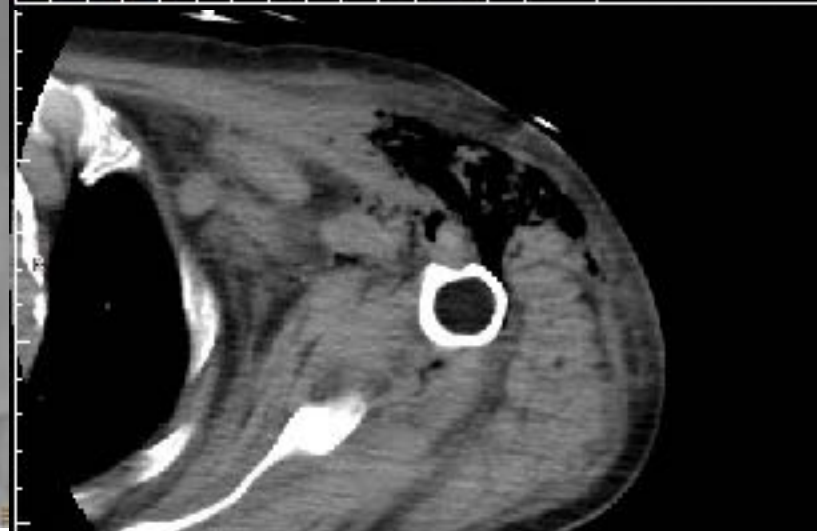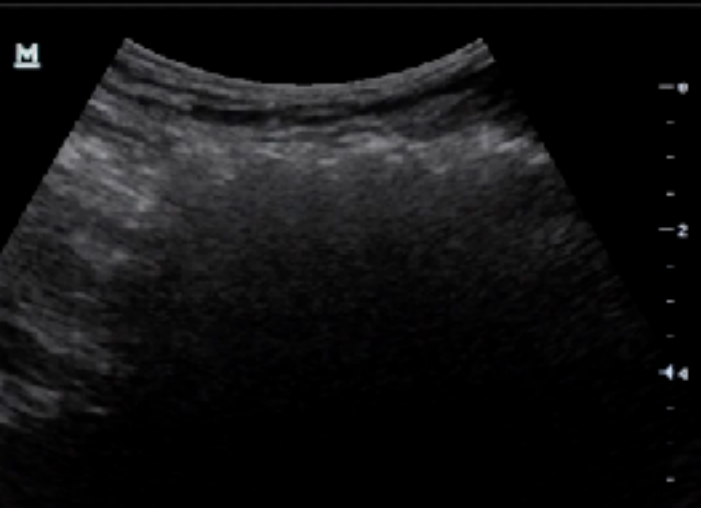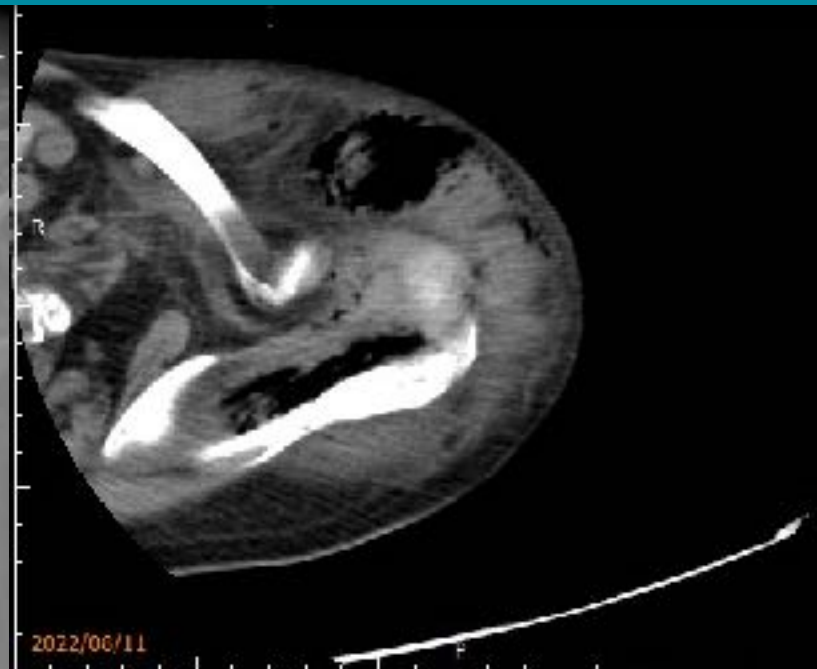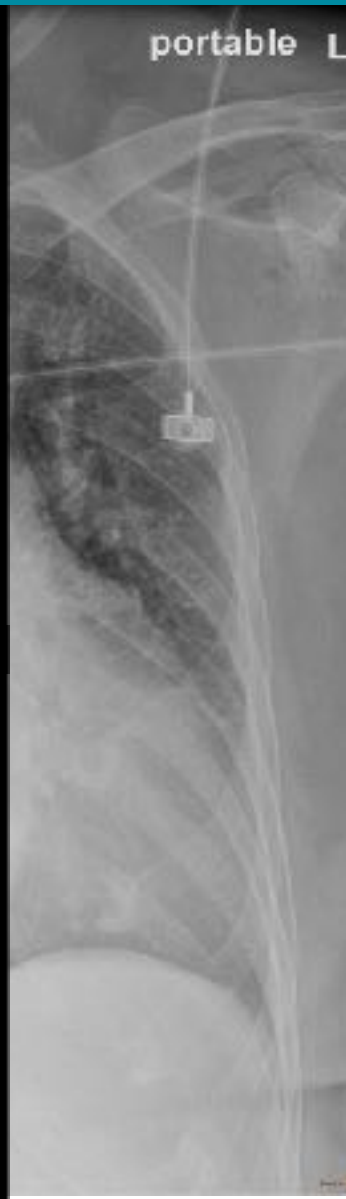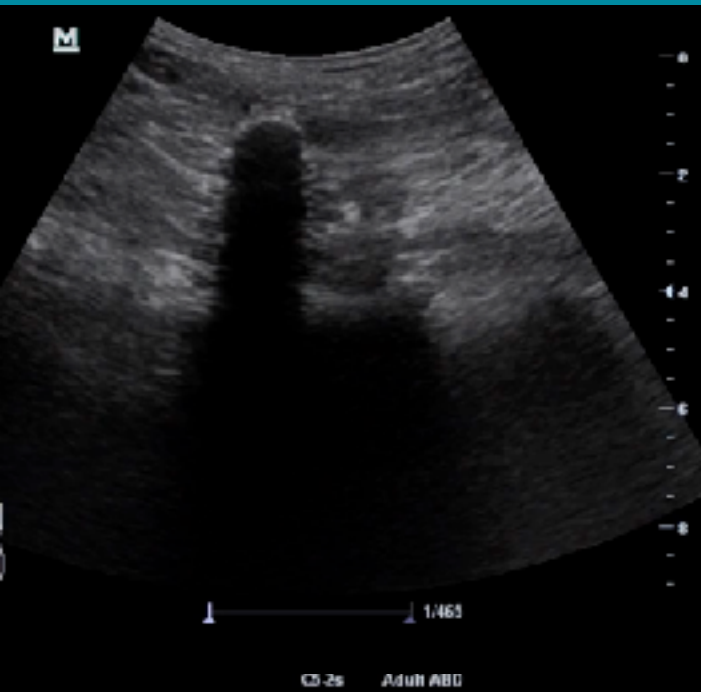
Subcutaneous
Thickening
Air
Fascial
Fluid

83F，前天跌倒，左手痛，BP 69/43

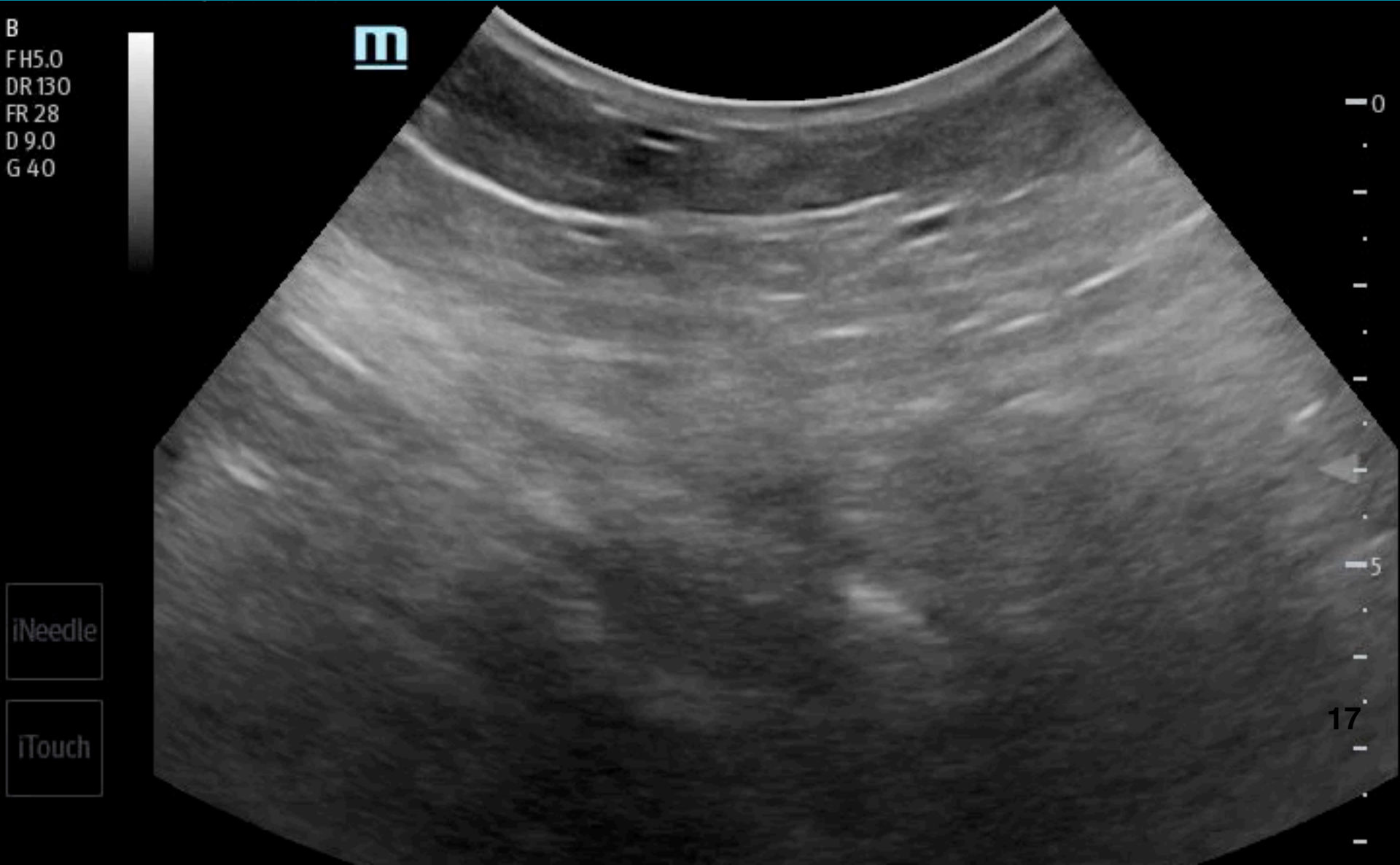




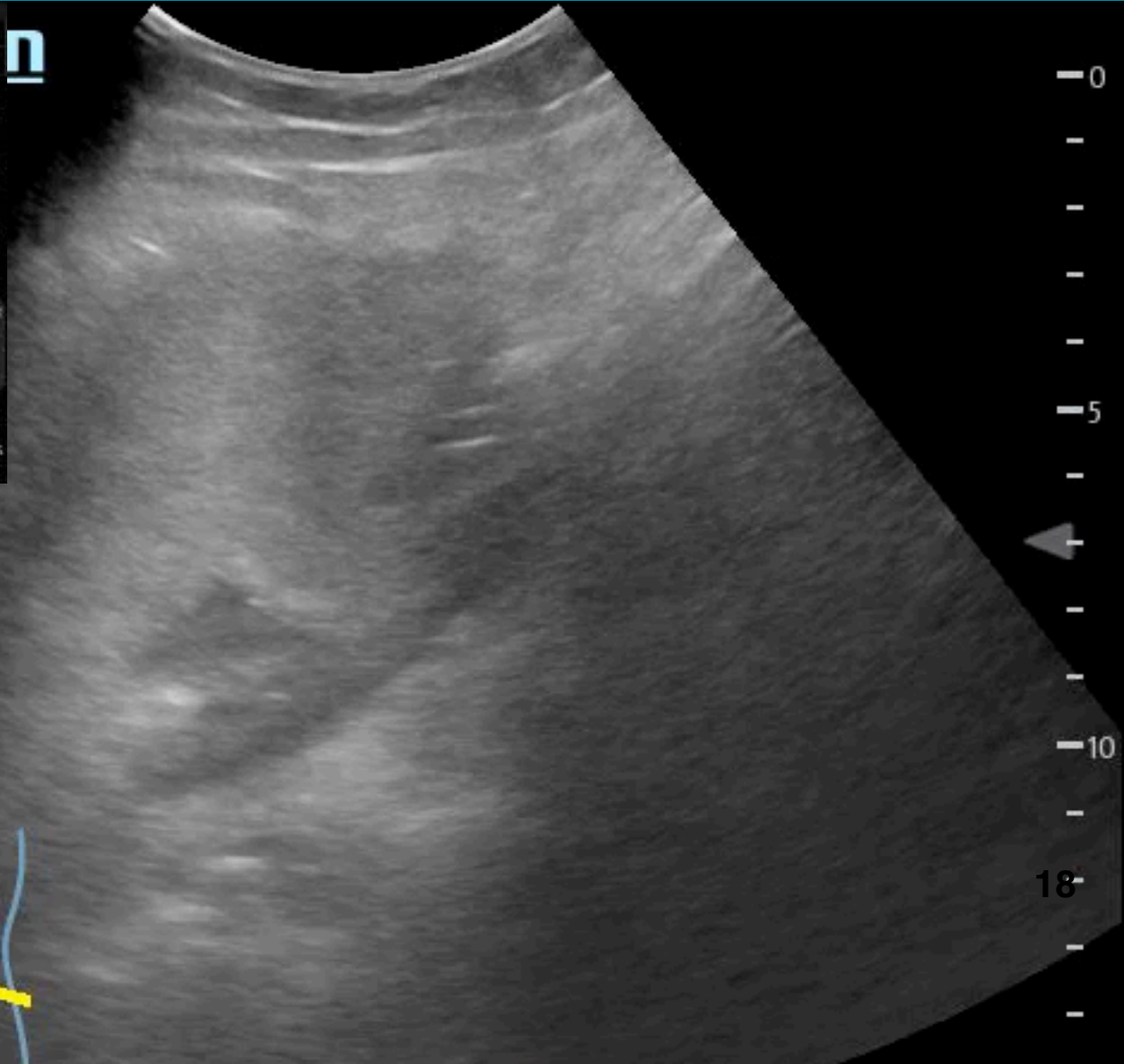
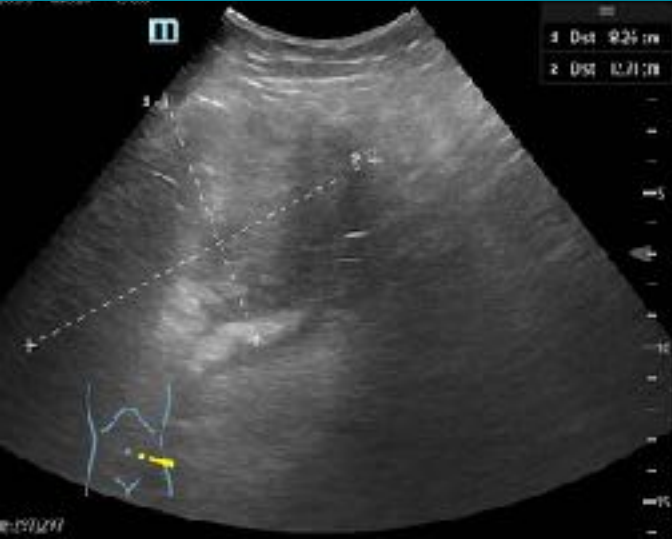NF with shock



72F, 左腹腫痛、食慾下降及腹瀉約1個月， 這兩天開始紅腫



72F, 左腹腫痛、食慾下降及腹瀉約1個月， 這兩天開始紅腫

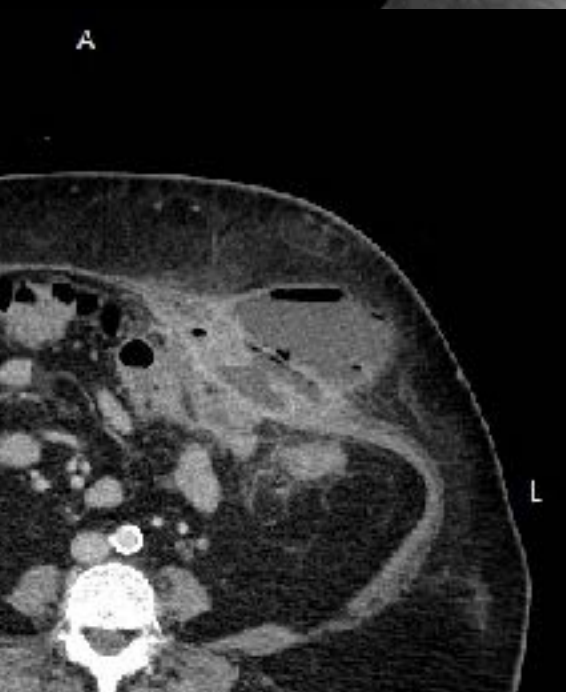
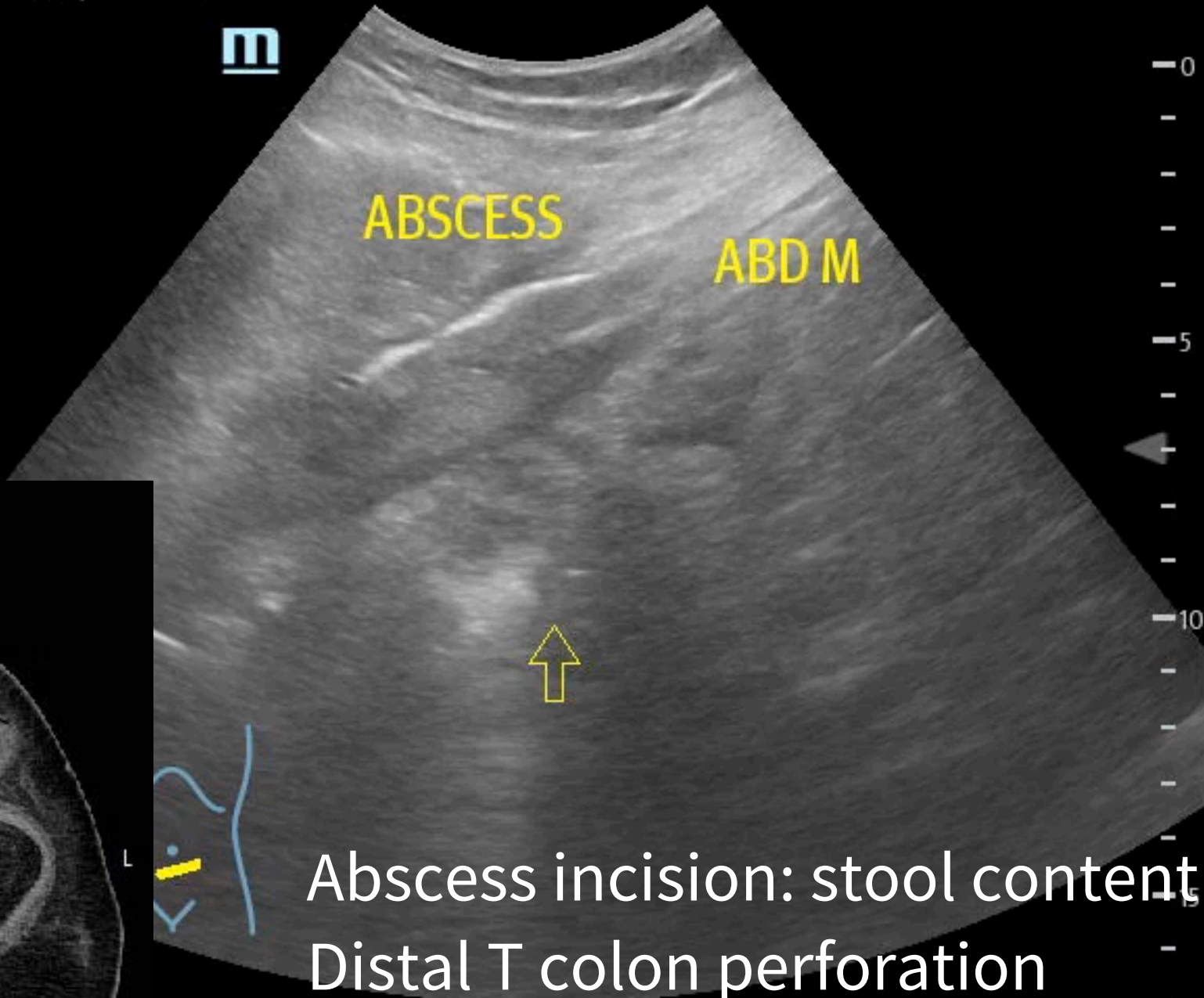


iNeedle

iTouch

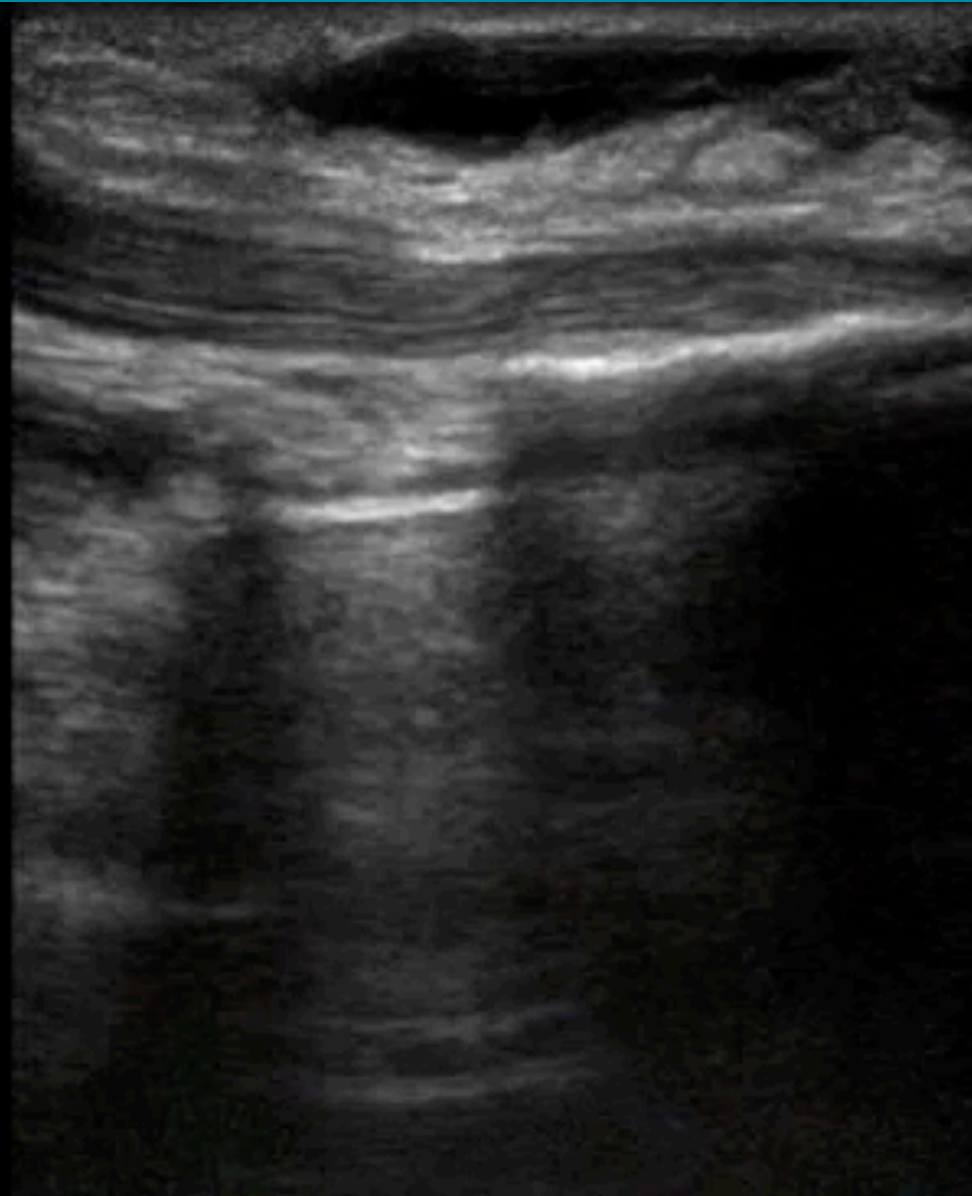
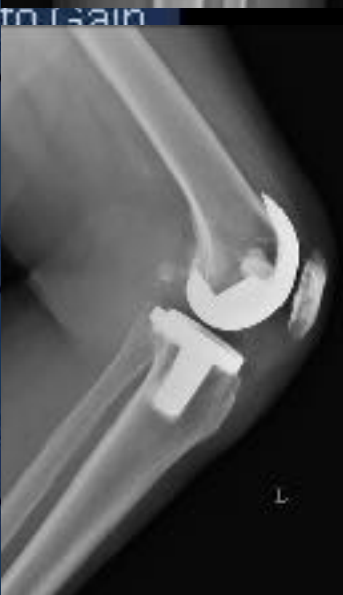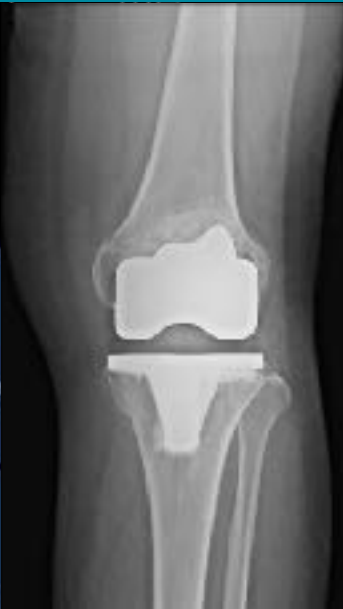C5-2s AP 96.6% MI 0.91 TIS 0.6

B
FH5.0
DR 130
FR 17
D 17.0
G 50



Abscess incision: stool content
Distal T colon perforation

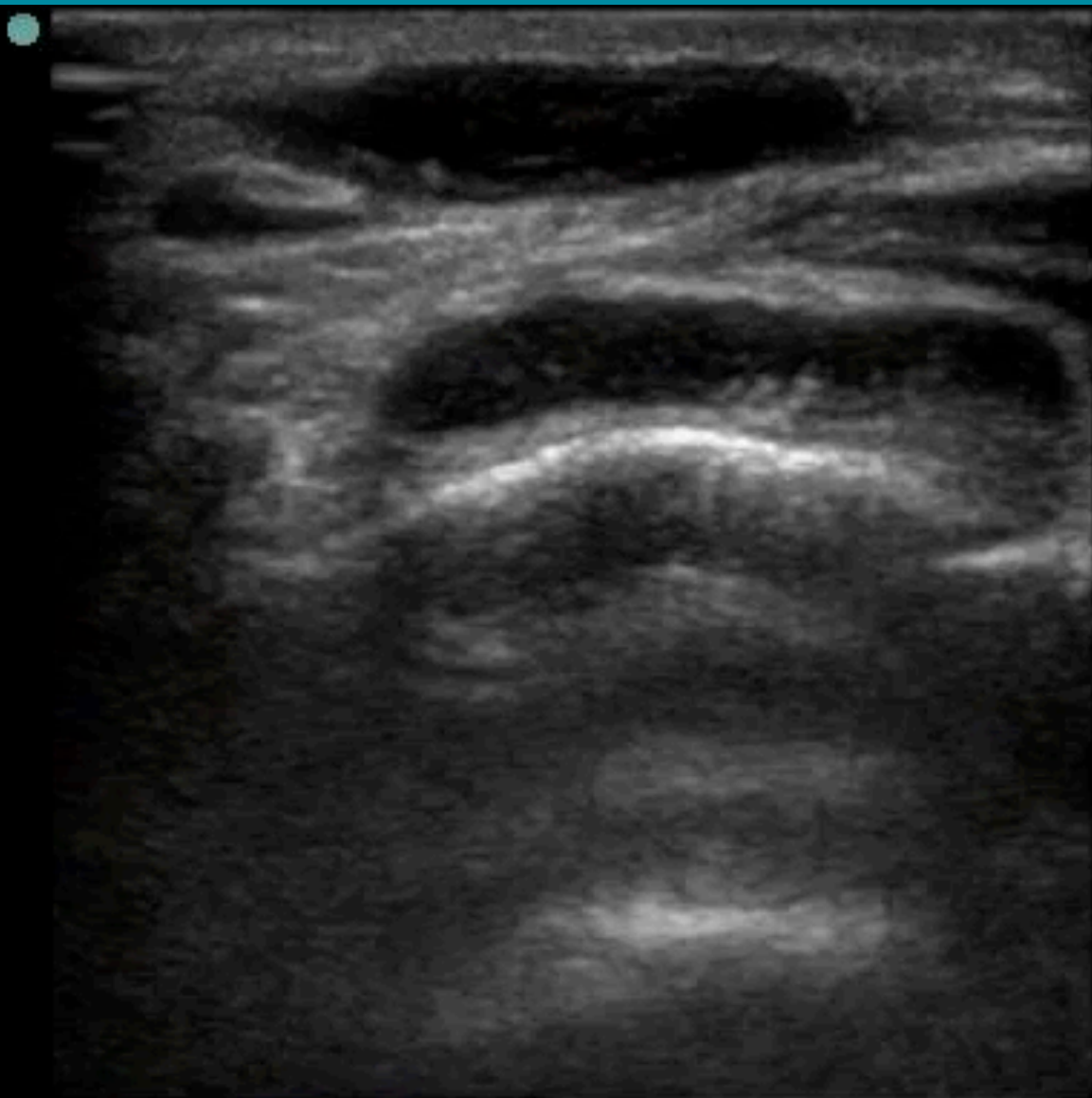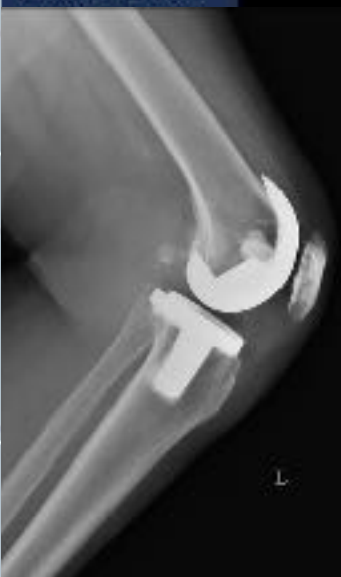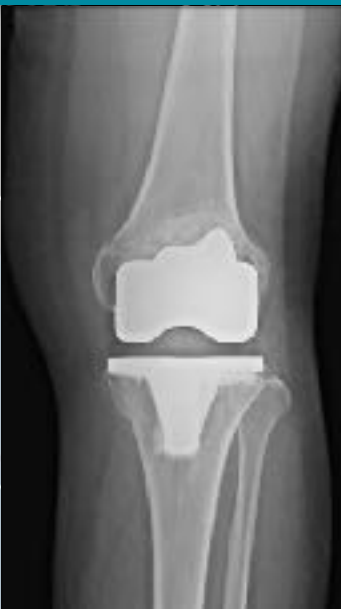72F, left knee cellulitis



H
E
2
T
0

18

72F, left knee cellulitis

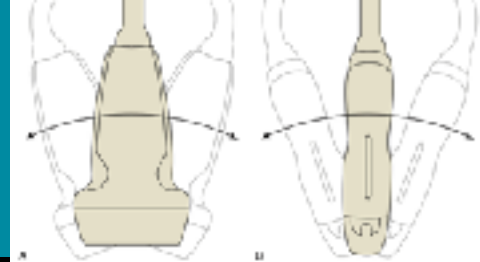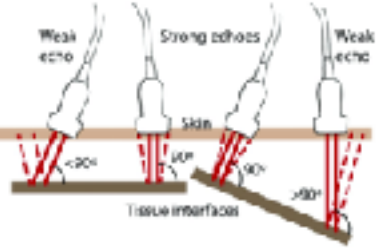


Vas
HFL
19%
MI
0.7
TIS
0.1



4.0

Anisotropy

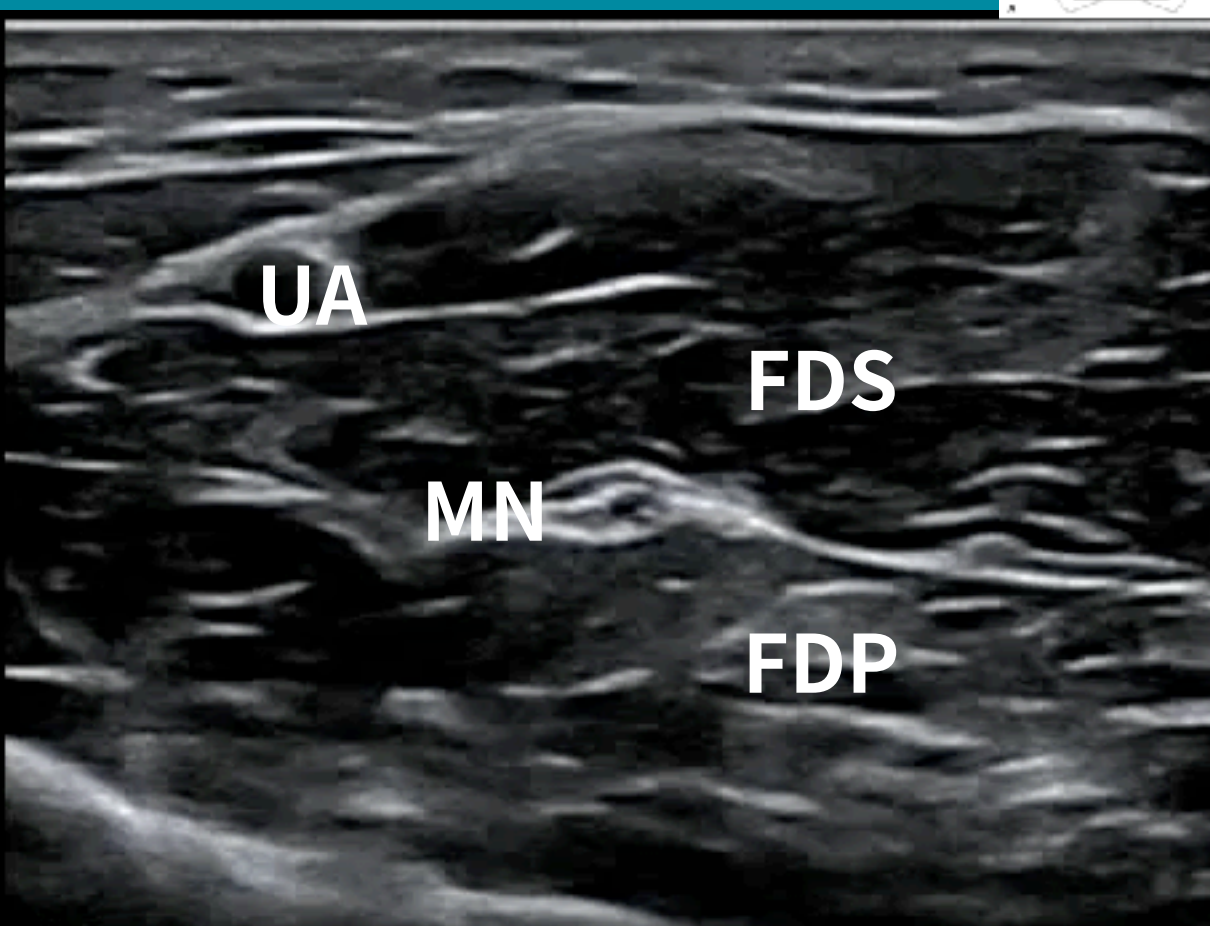


MI L1
TIS 0.2

B
FH10
DR 110
FR 27
D 4.0
G 56

S
F

B



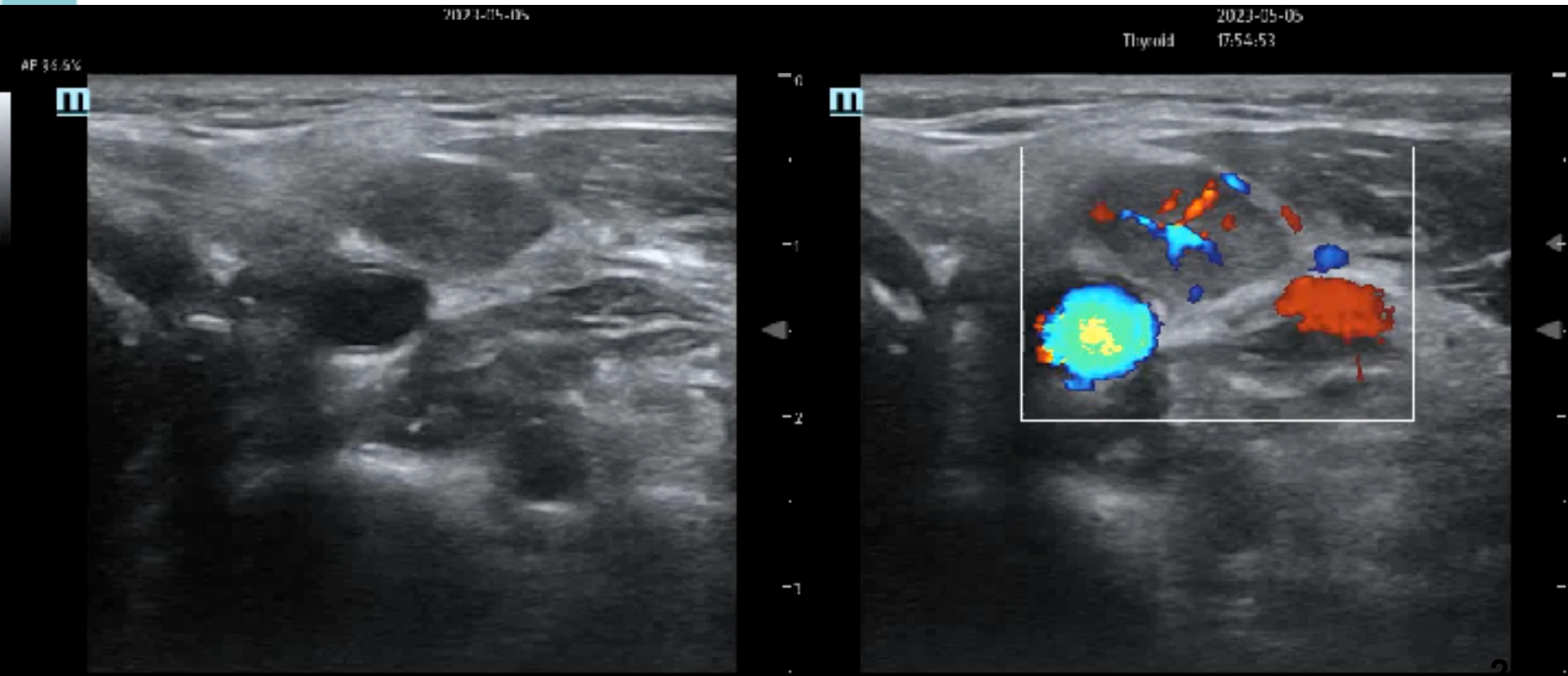
Tendon

Nerve

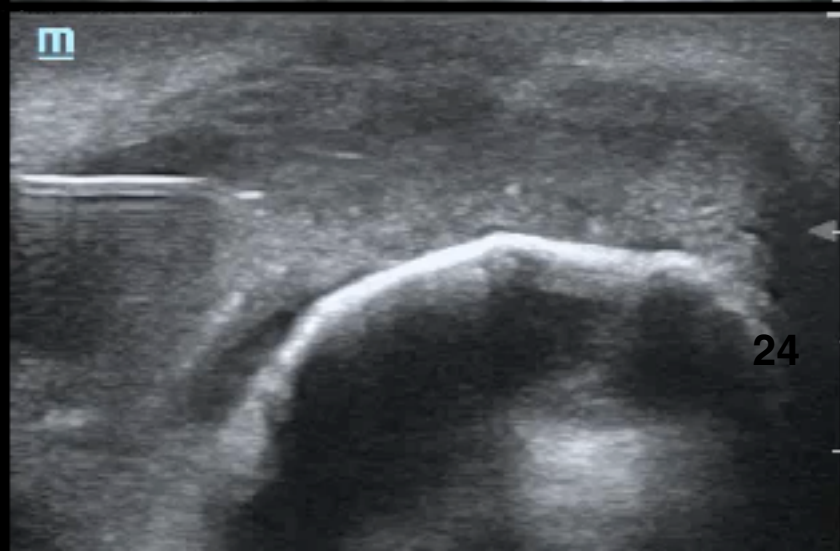
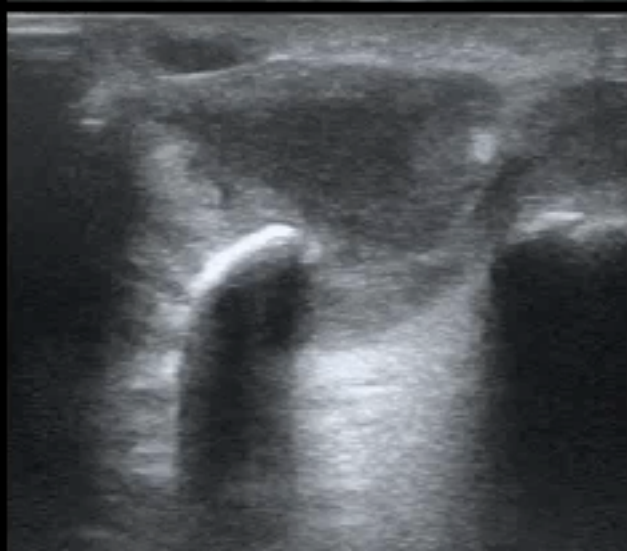
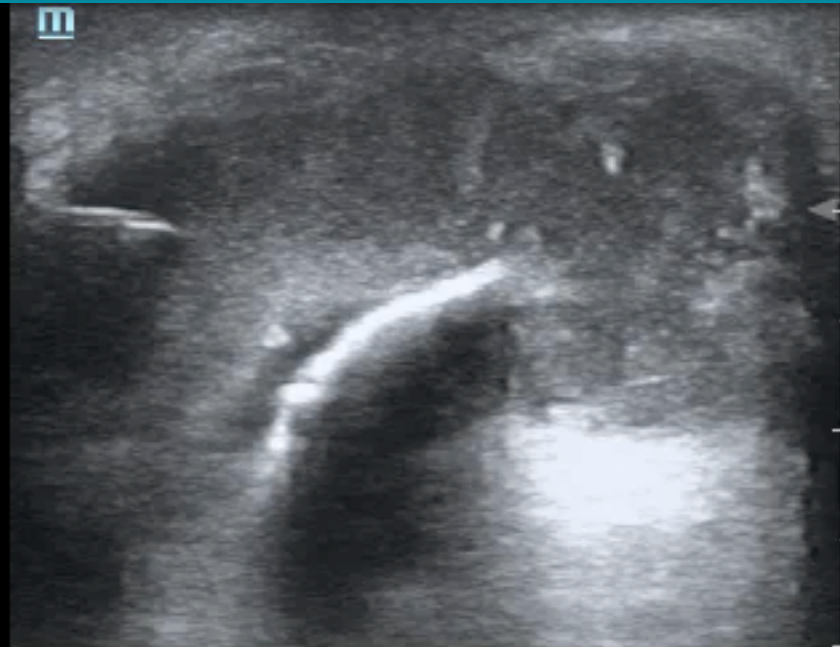
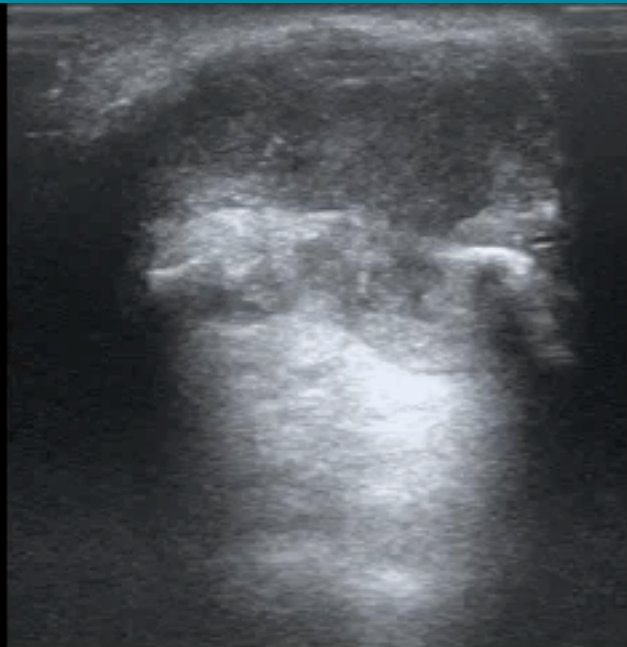
Muscle

41F, fever & neck pain

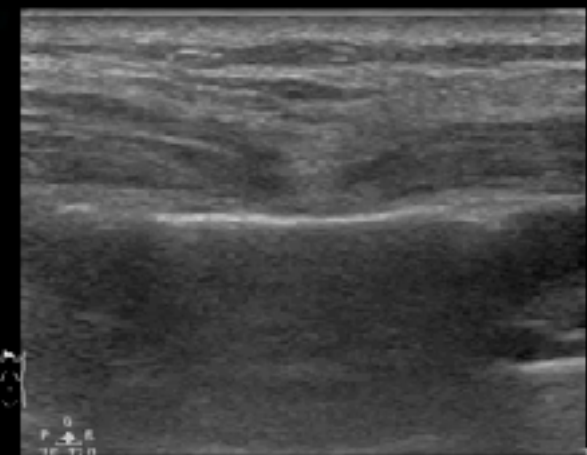
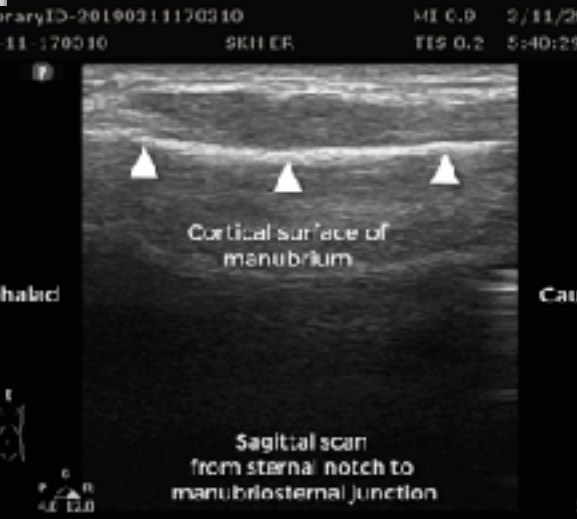
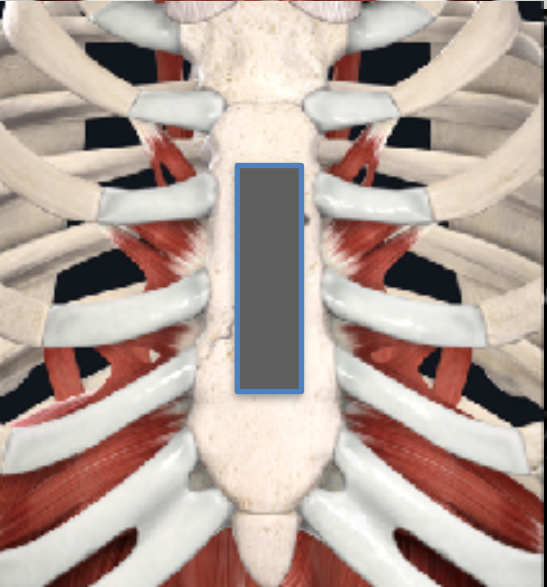
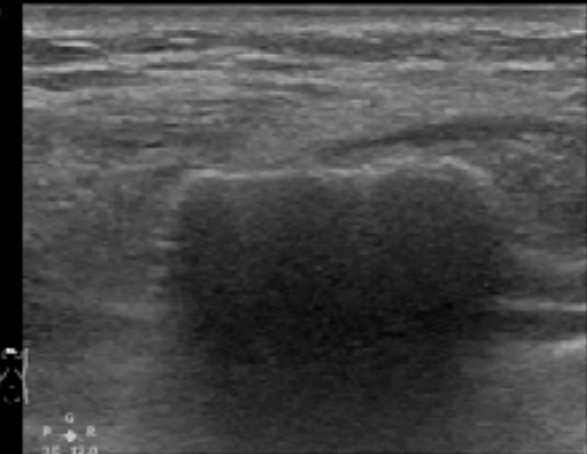
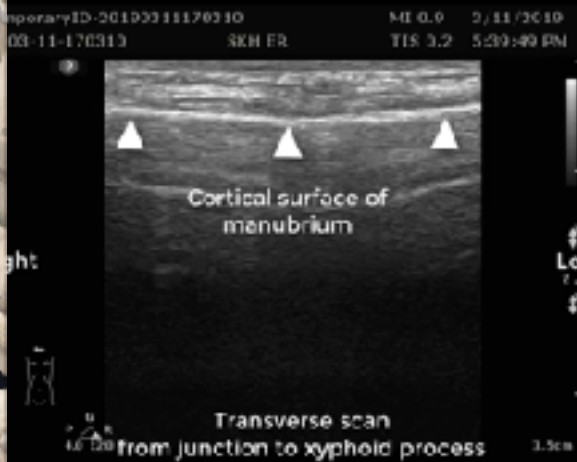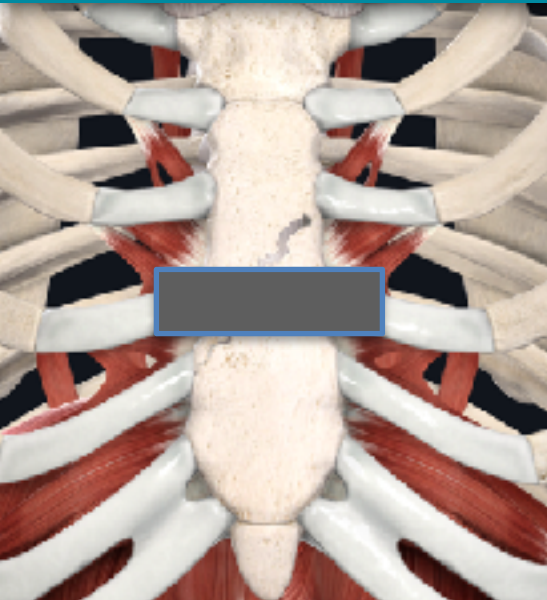
Cervical lymphadenitis



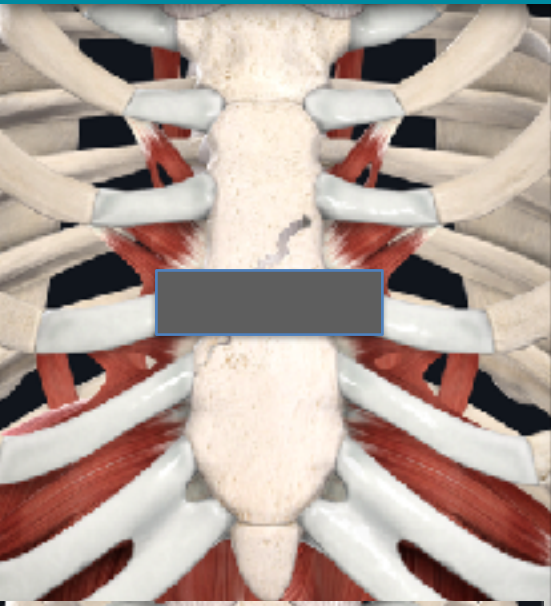
64M, submandibular abscess



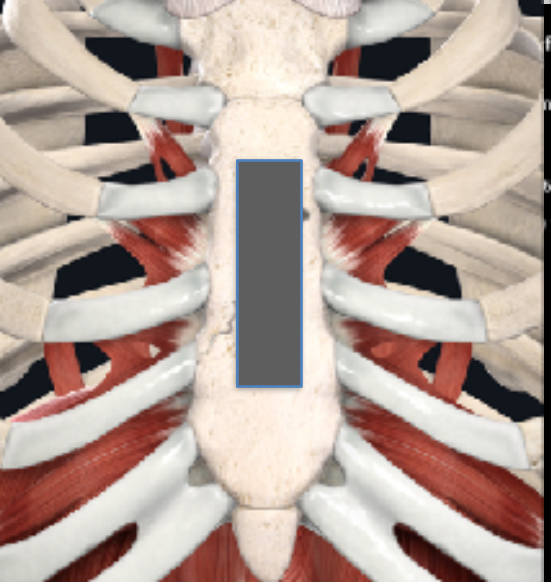
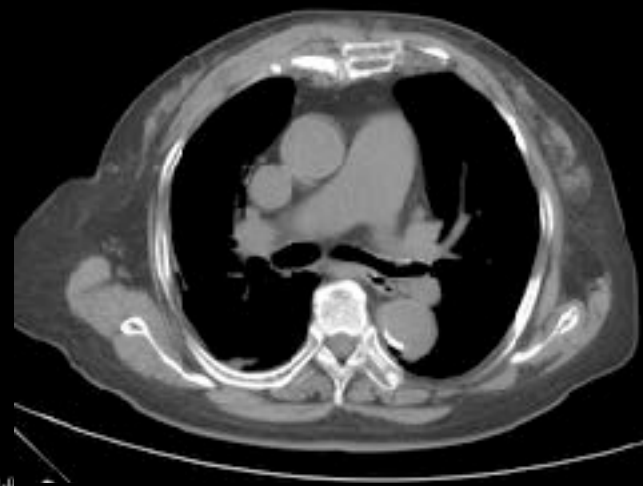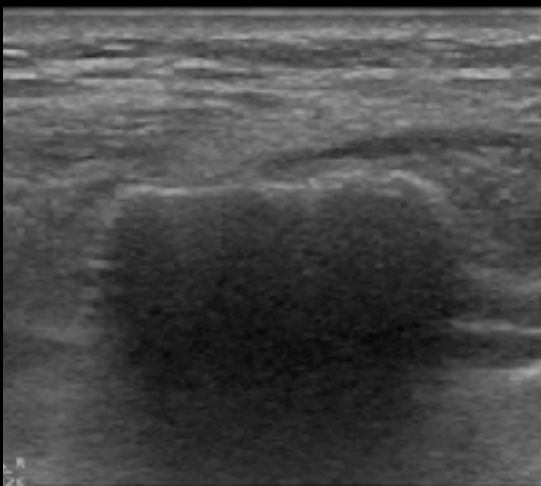
Sternal fracture



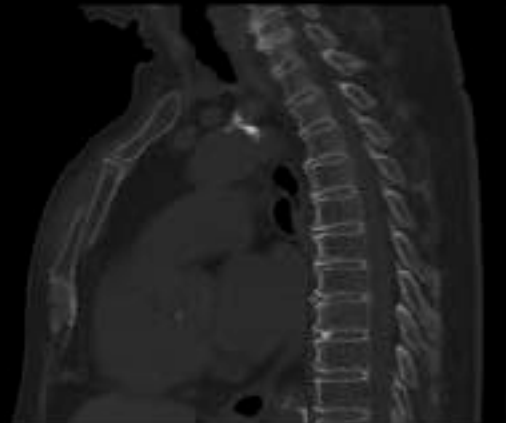
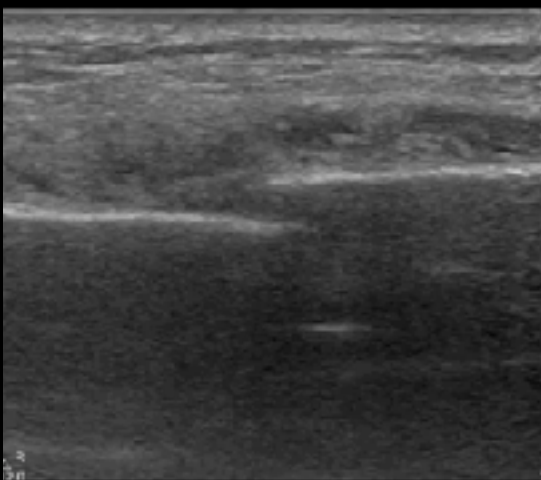
骨折判斷 - 適用長骨&平骨



高低落差

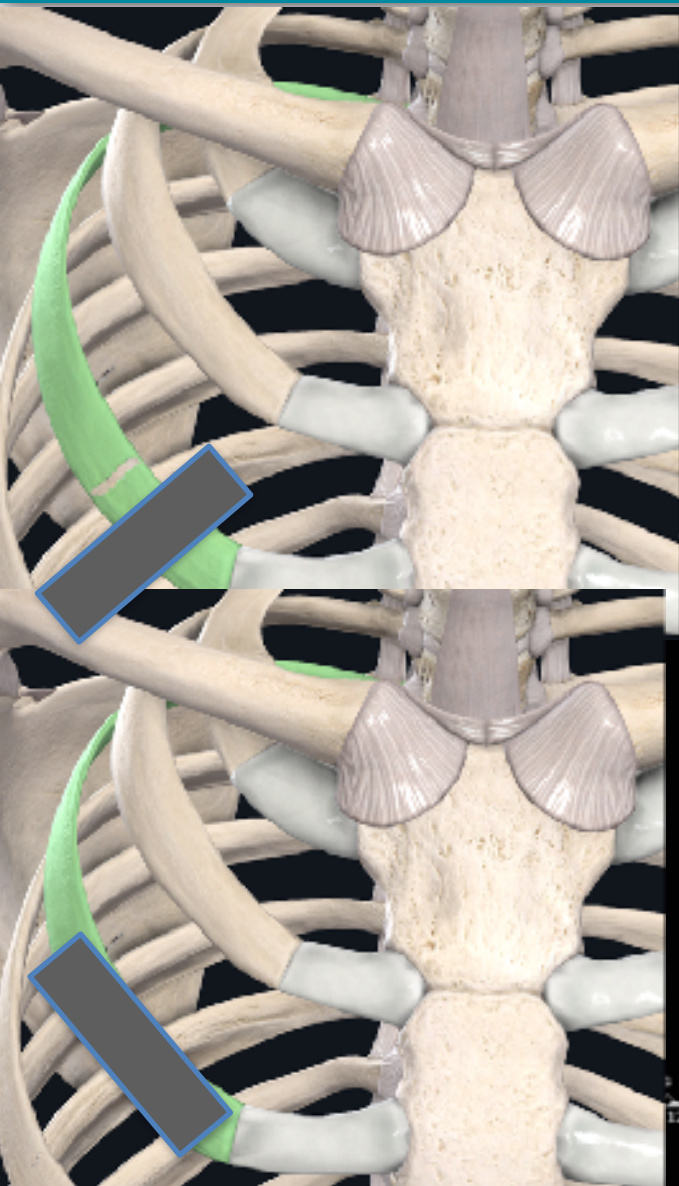


不連續

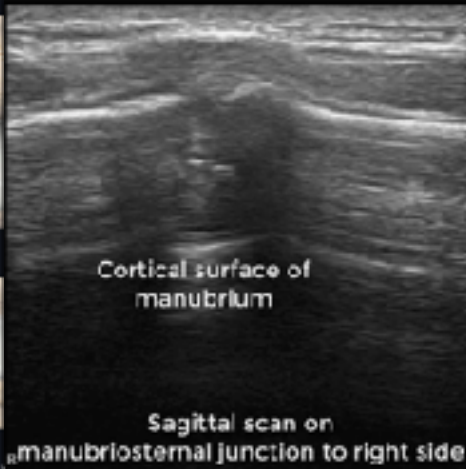

血腫

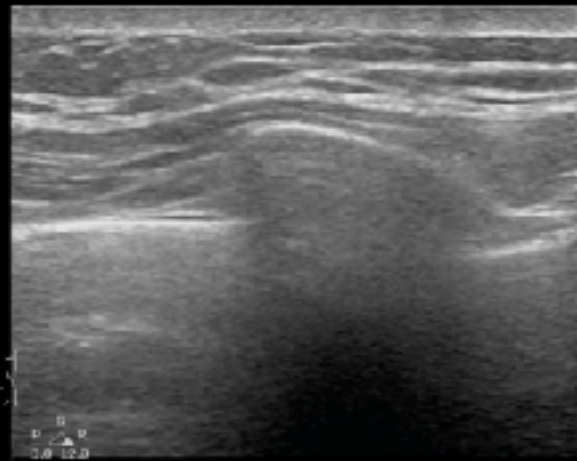
Rib fracture



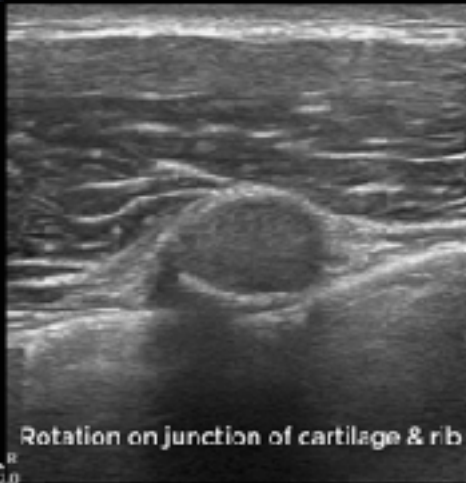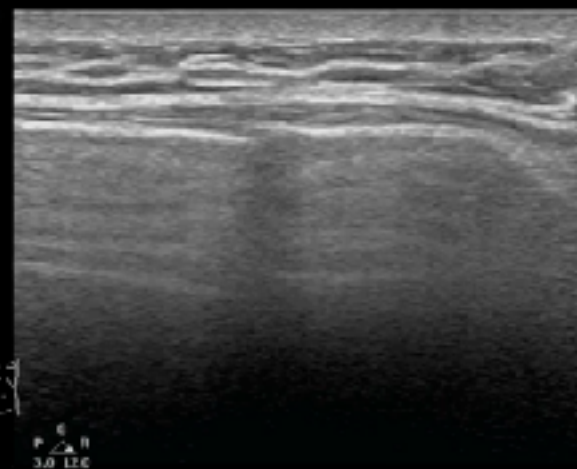
20190311170310 MI 0.9 3/11
SID SKH-ER TIS 0.2 5:40



Superficial
L12-3
46 Hz
3.0cm
2D
Res
Gn 96
C 56
3/2 / 1

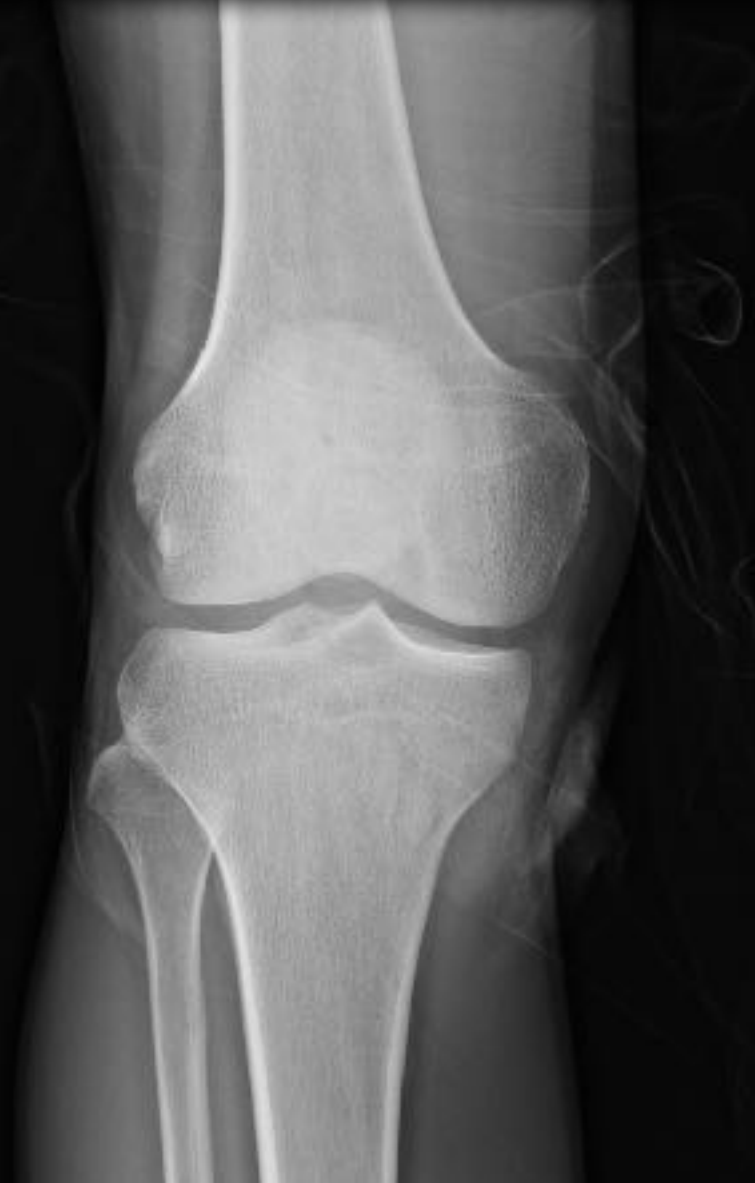

Superficial
L12-3
46 Hz
3.0cm
2D
Res
Gn 96
C 56
3/2 / 1

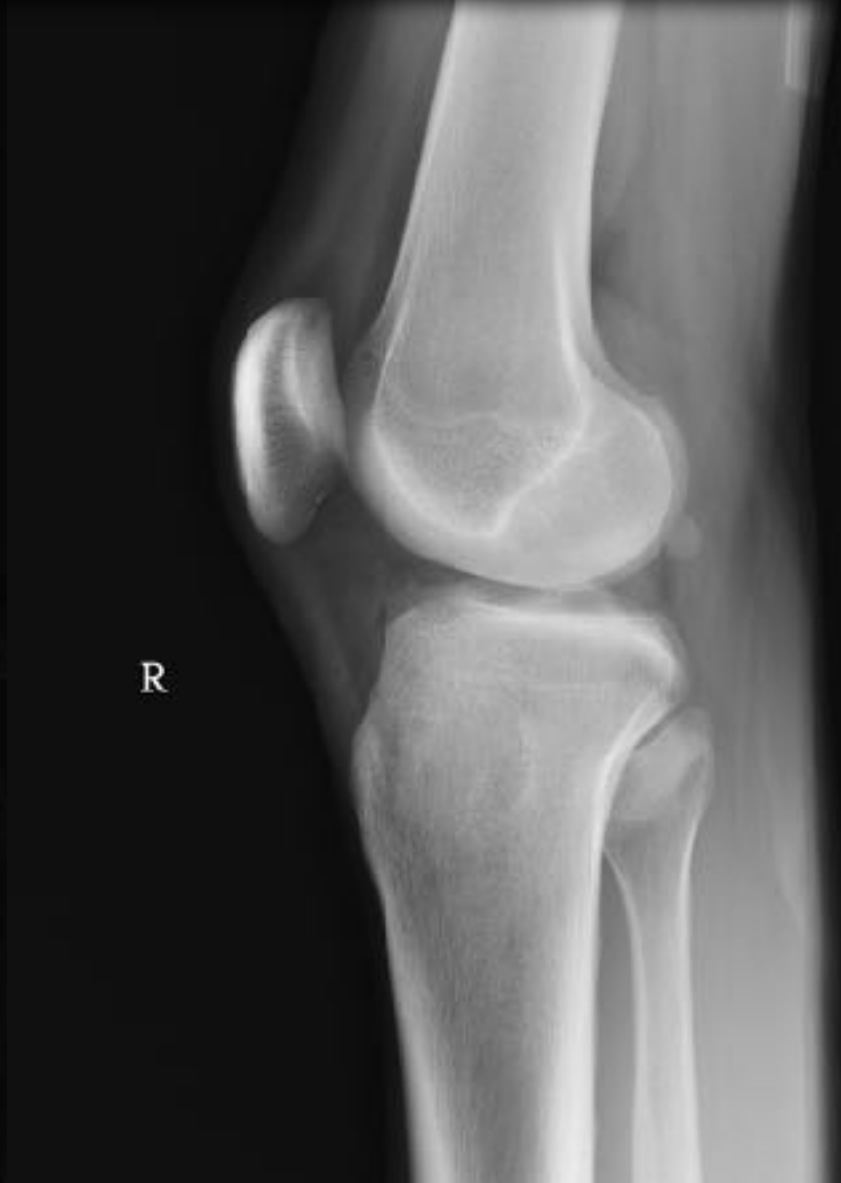

23M，車禍，右膝腫痛

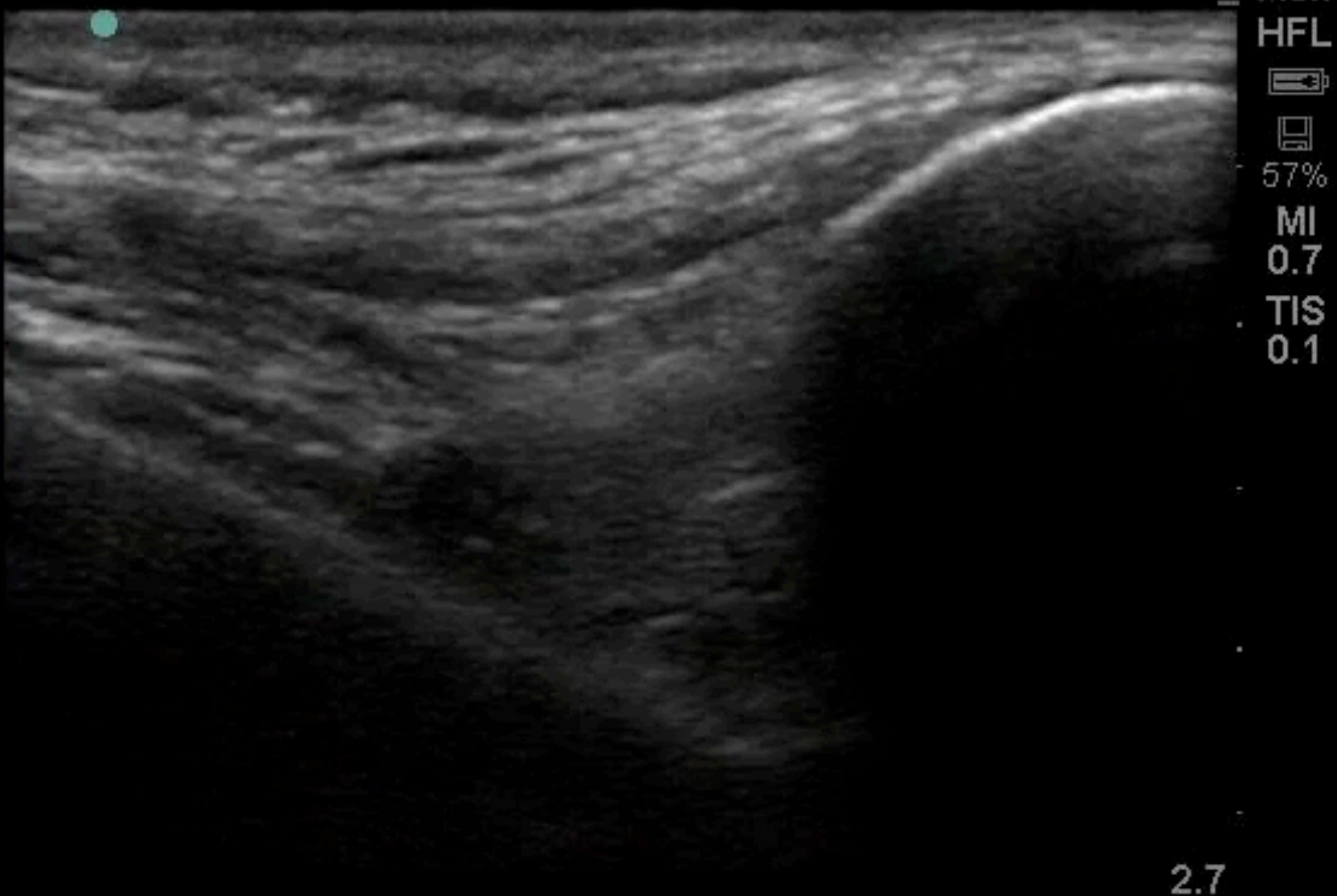
R



R



23M，車禍，右膝腫痛



HFL



57%

MI

0.7

TIS

0.1



Patient



Auto Gain



Res



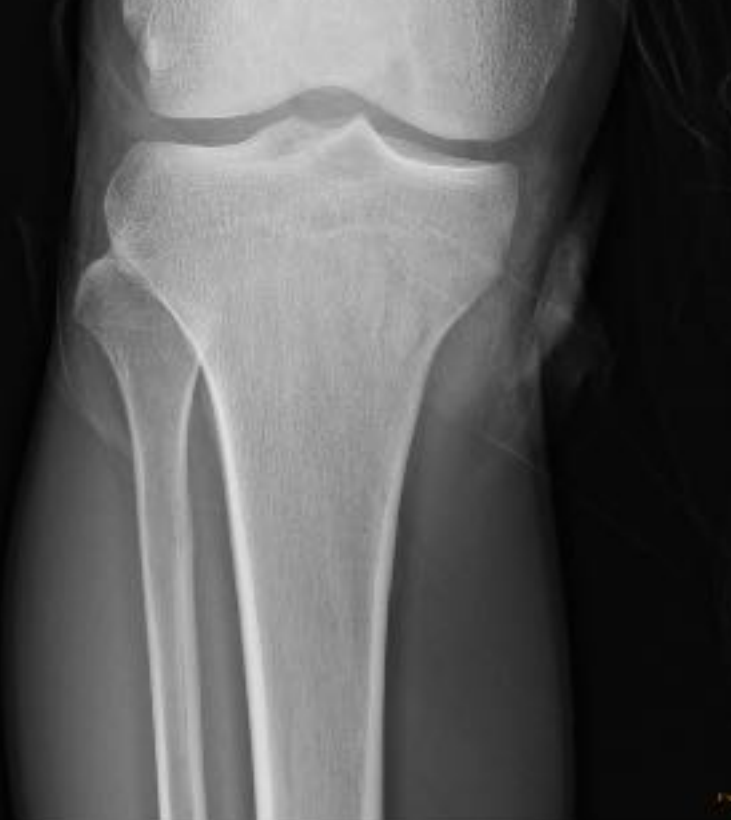Clip



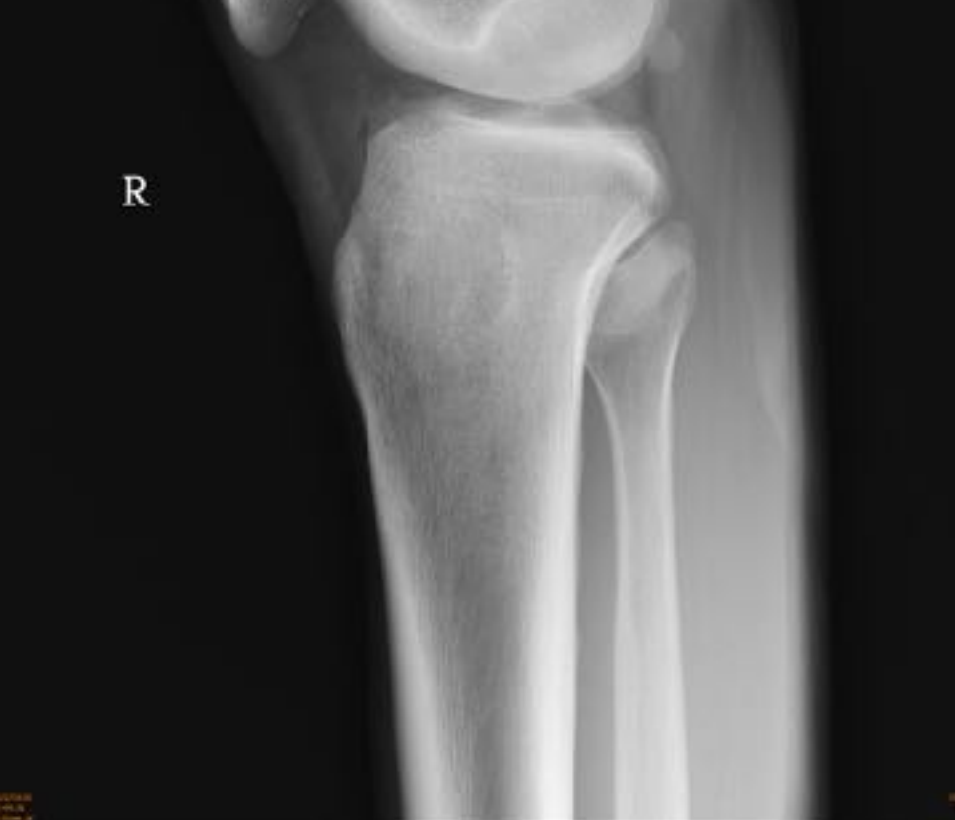Page 1/3

2.7

R



R



12/08/15
14:43:34
01/08/15

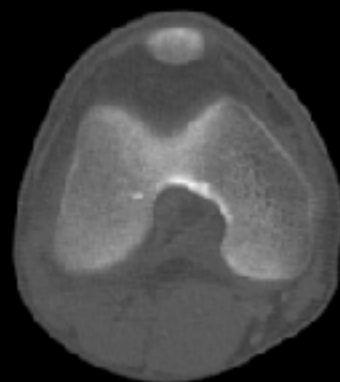
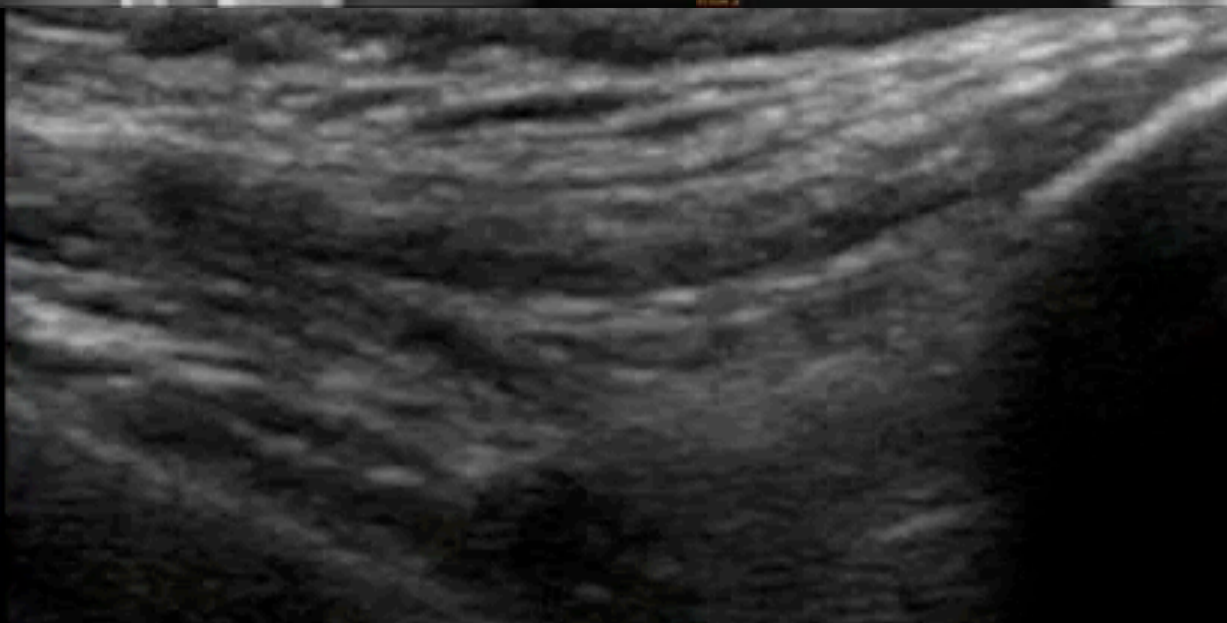12/08/15
14:43:34
01/08/15



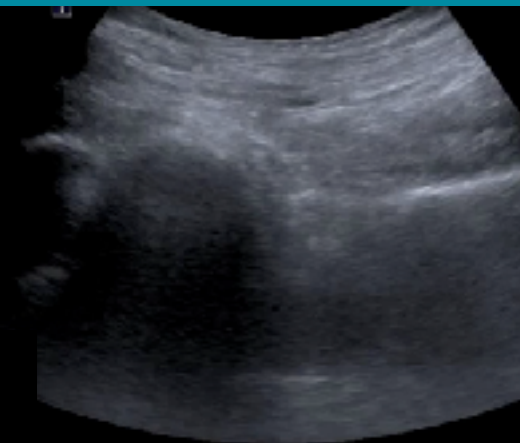Patient



Auto Gain

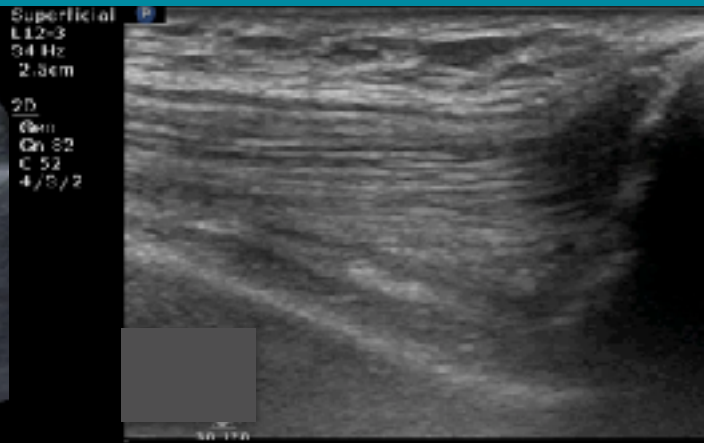


Lower extremity joints



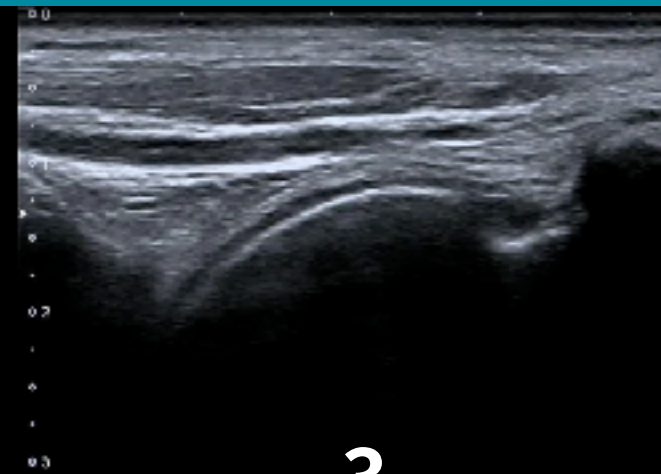1

Hip



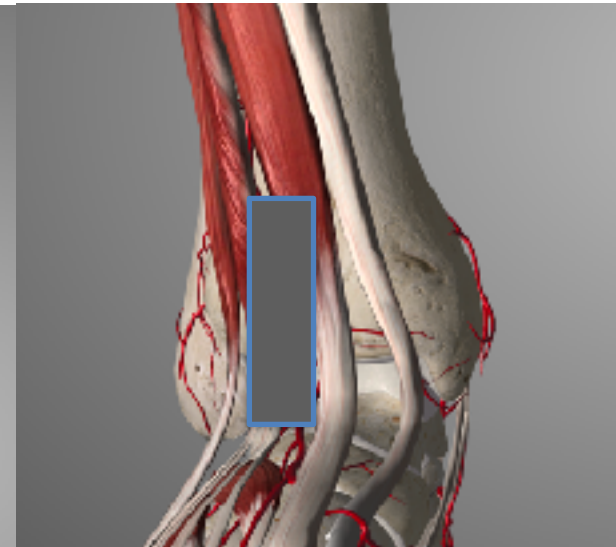
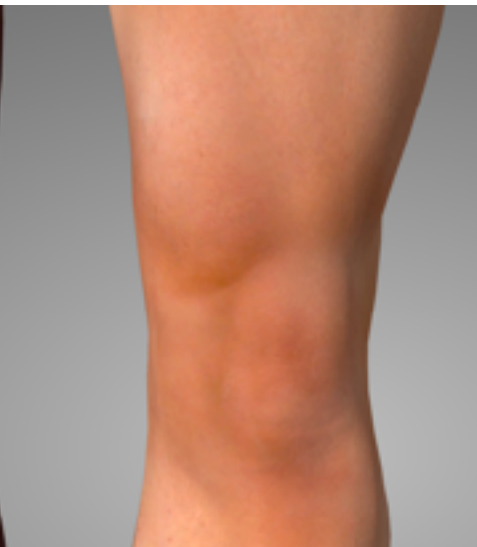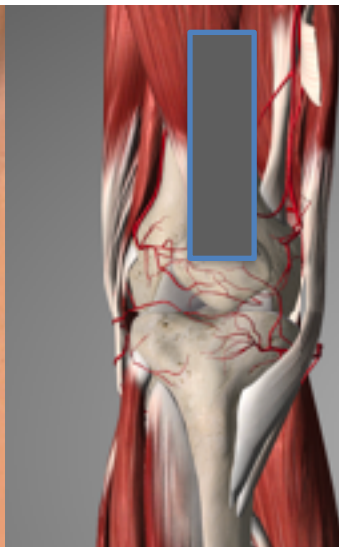
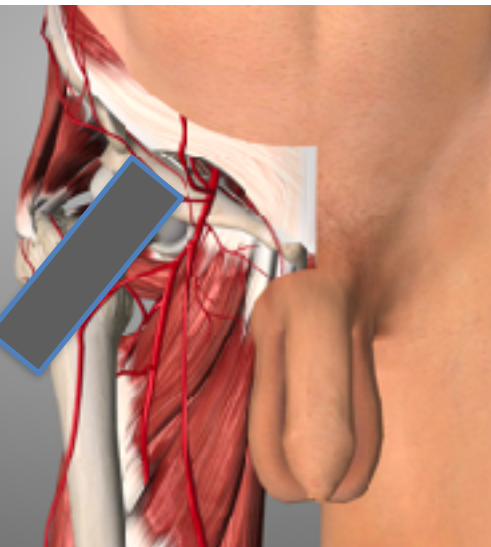
2

Knee

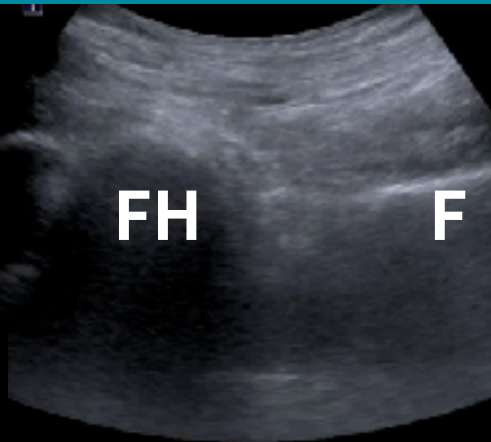


3

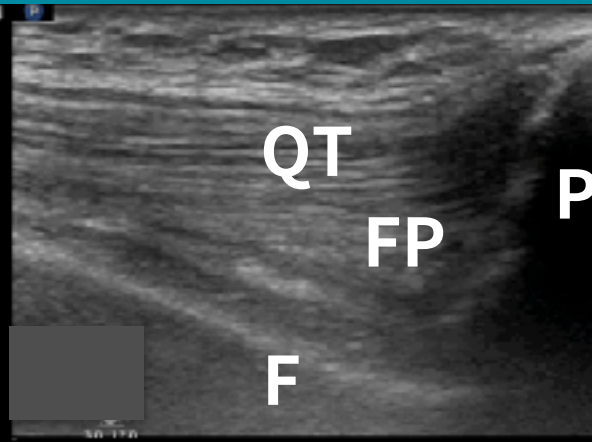
Ankle



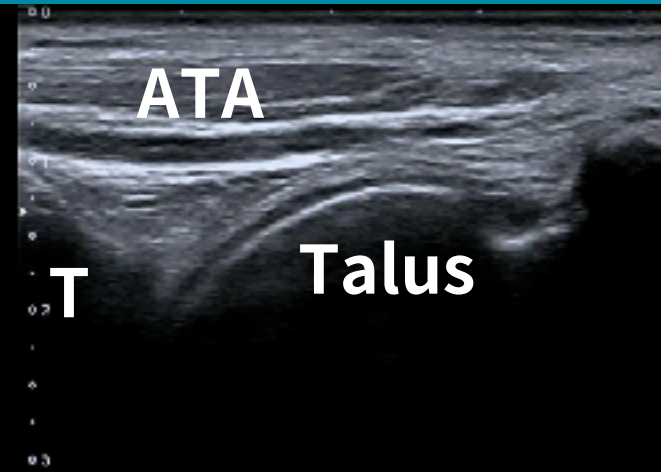
LE Joint effusion



Hip

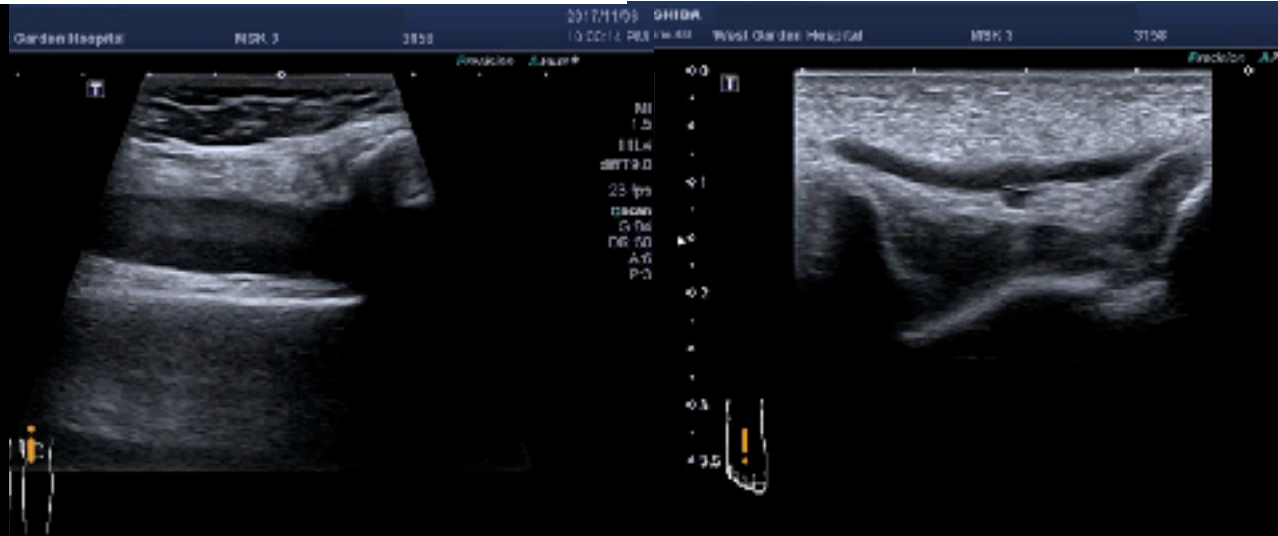
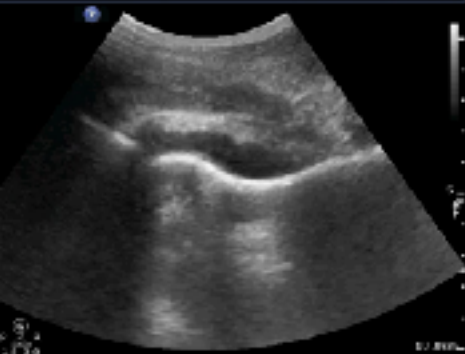

Knee

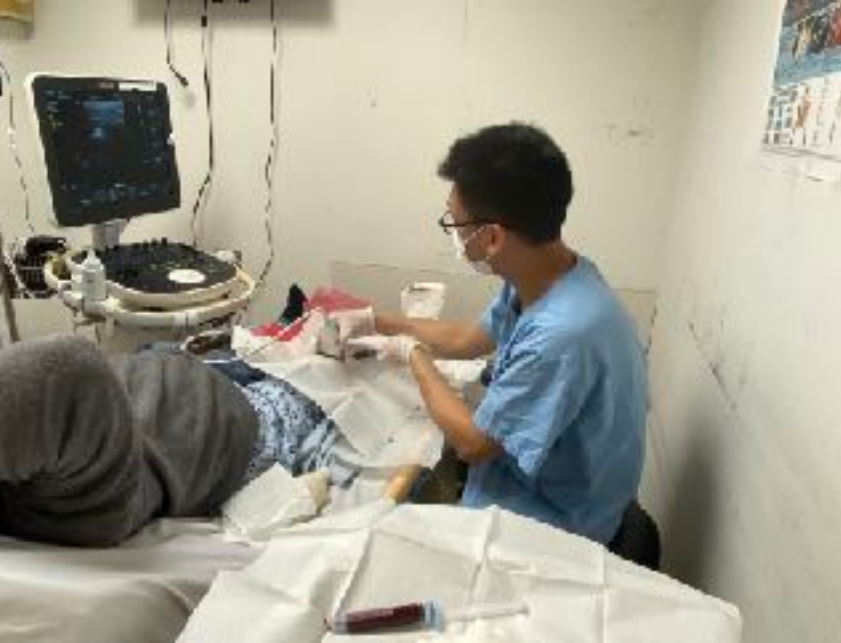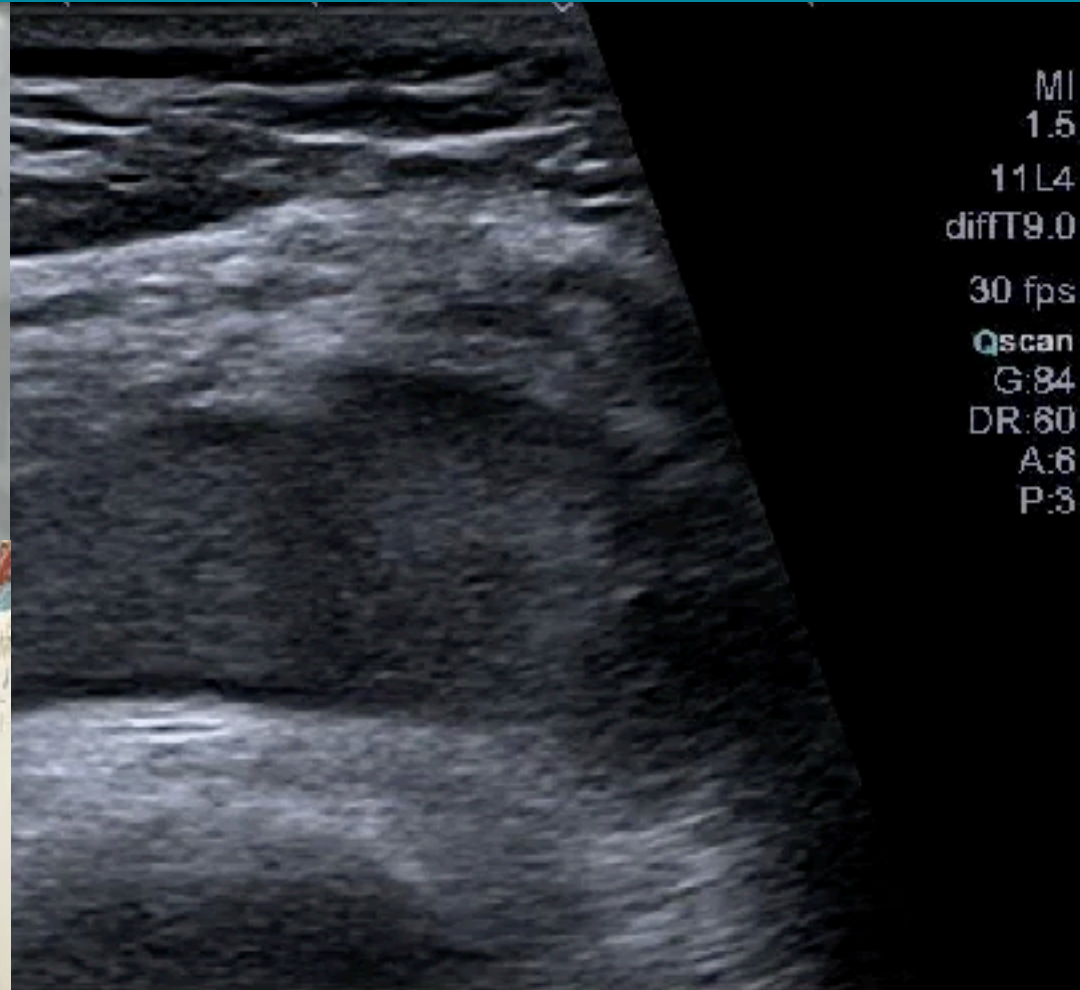


Ankle

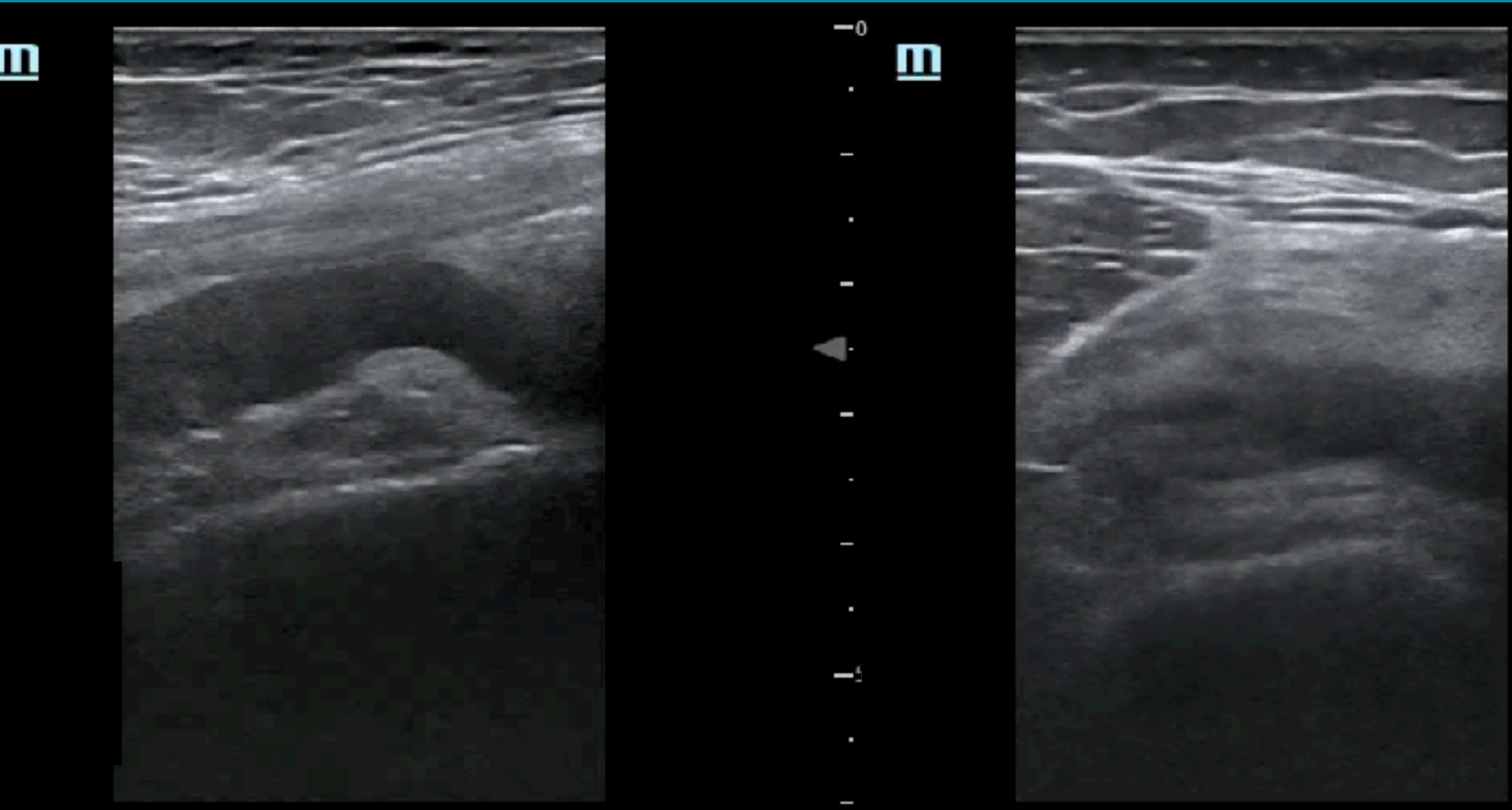
SKH-EUTC©ChenKC



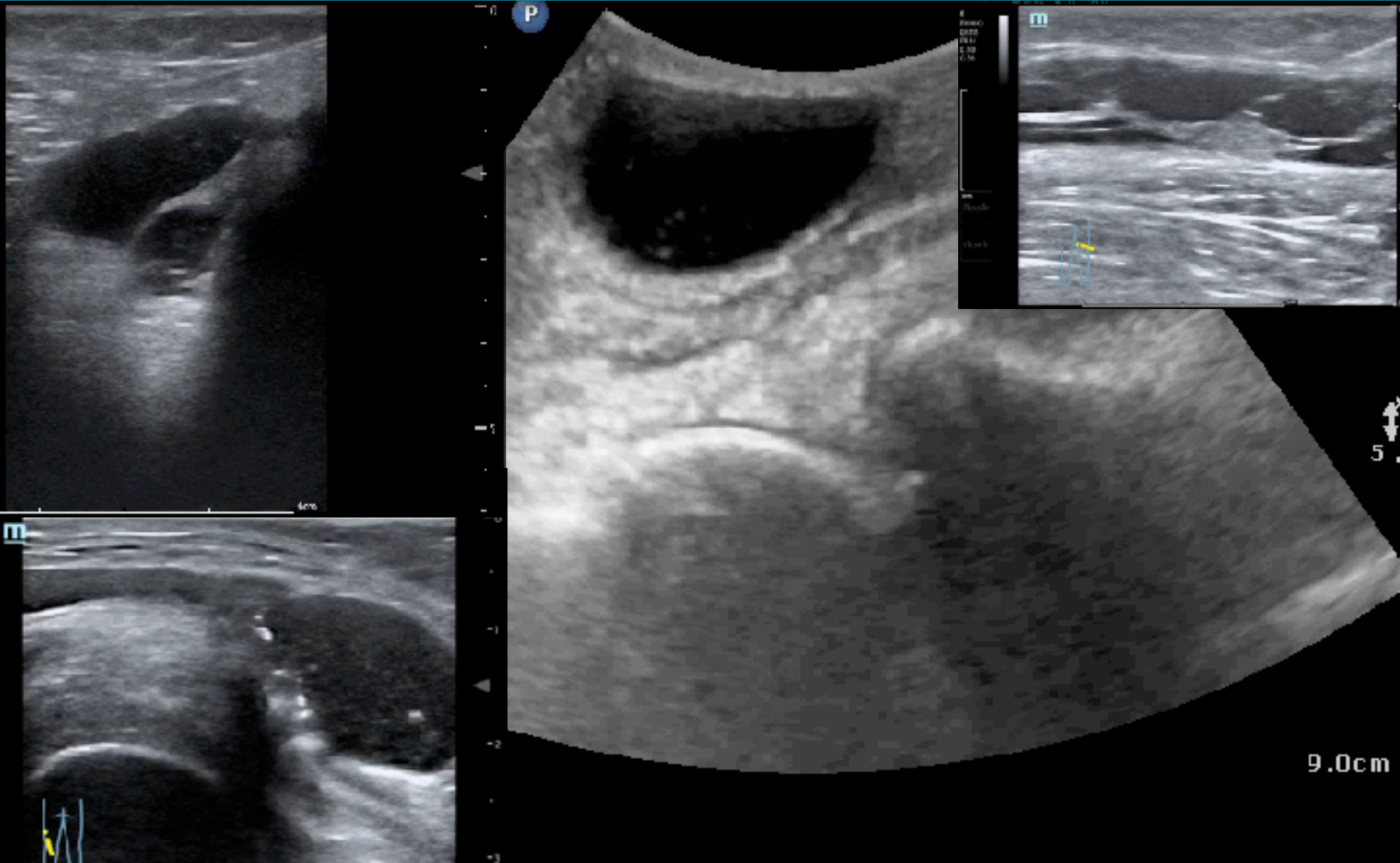
Needling for hemarthrosis



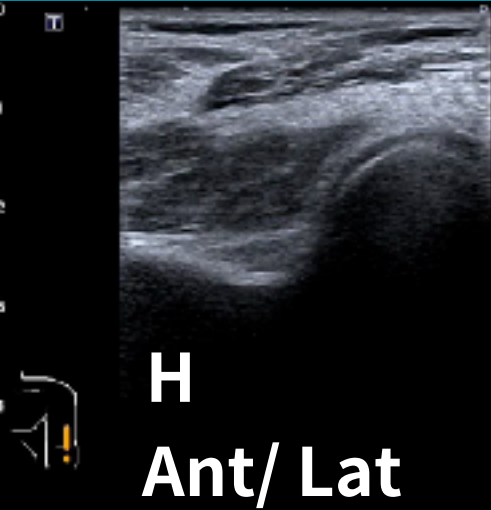
Lipohemarthrosis



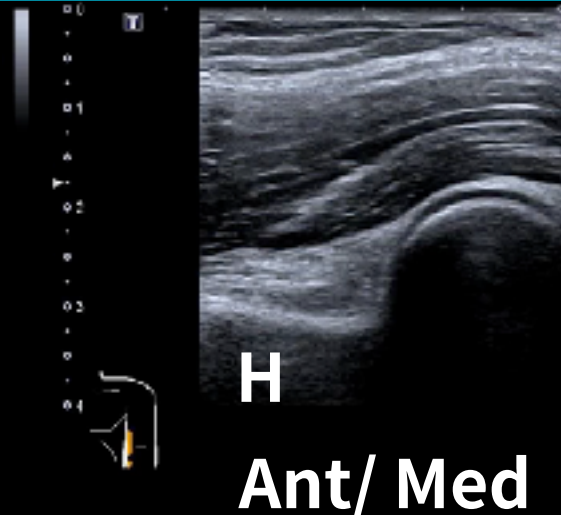
Baker's cyst



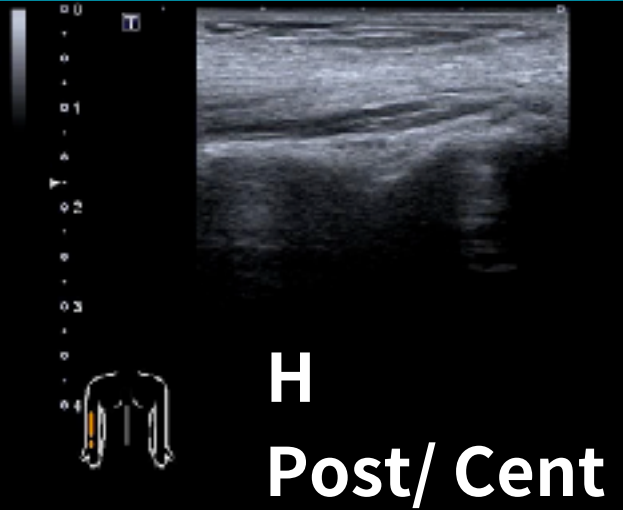
Elbow joint



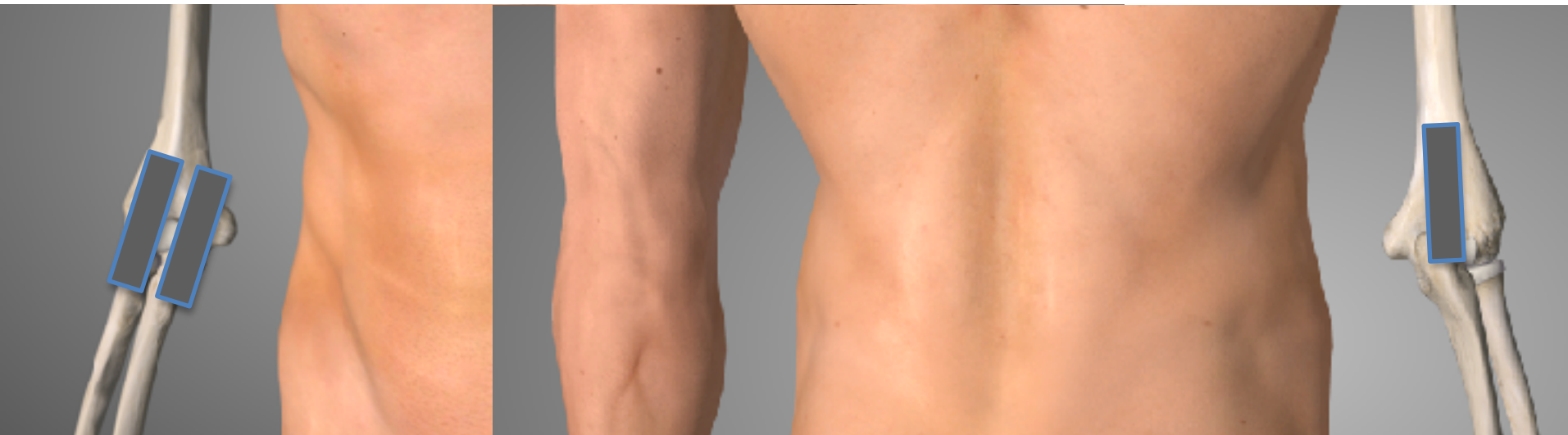Radial fossa



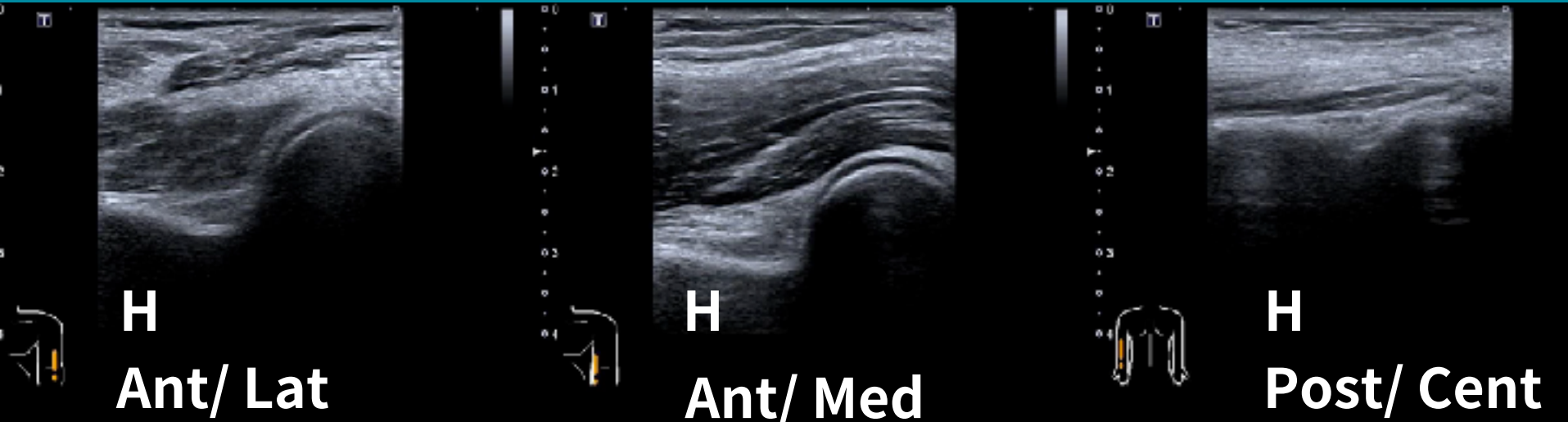
Coronoid fossa



Olecranon fossa



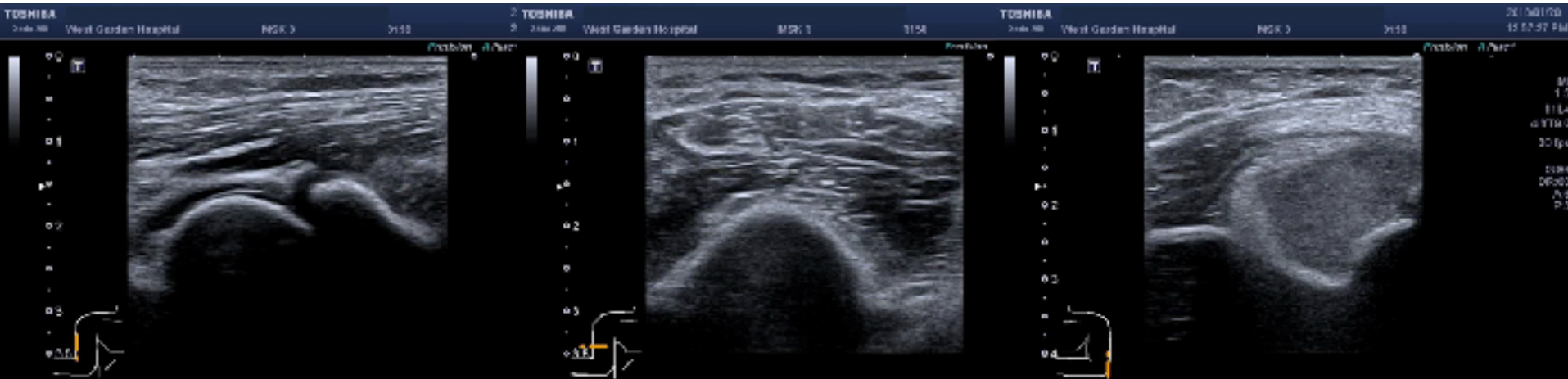Elbow effusion



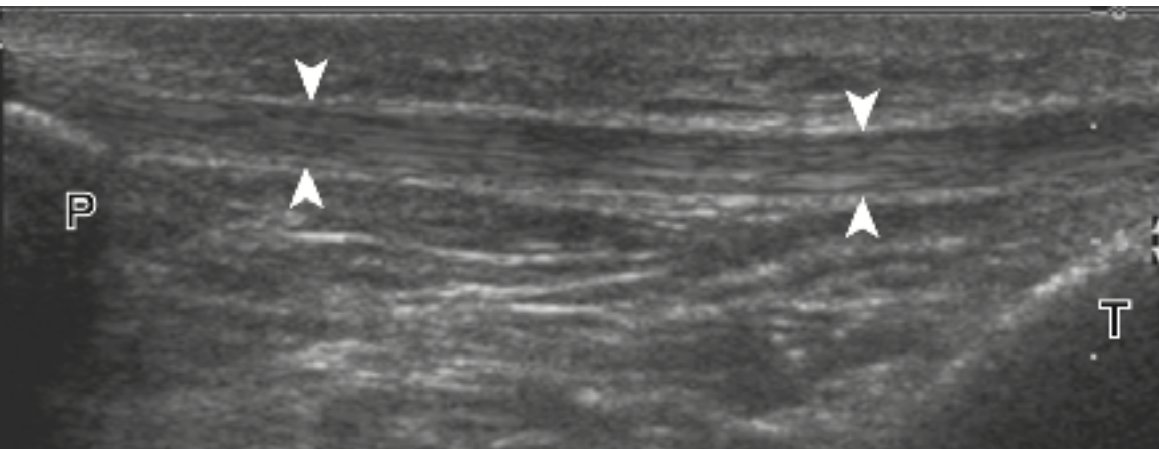
Radial fossa

Coronoid fossa

Olecranon fossa

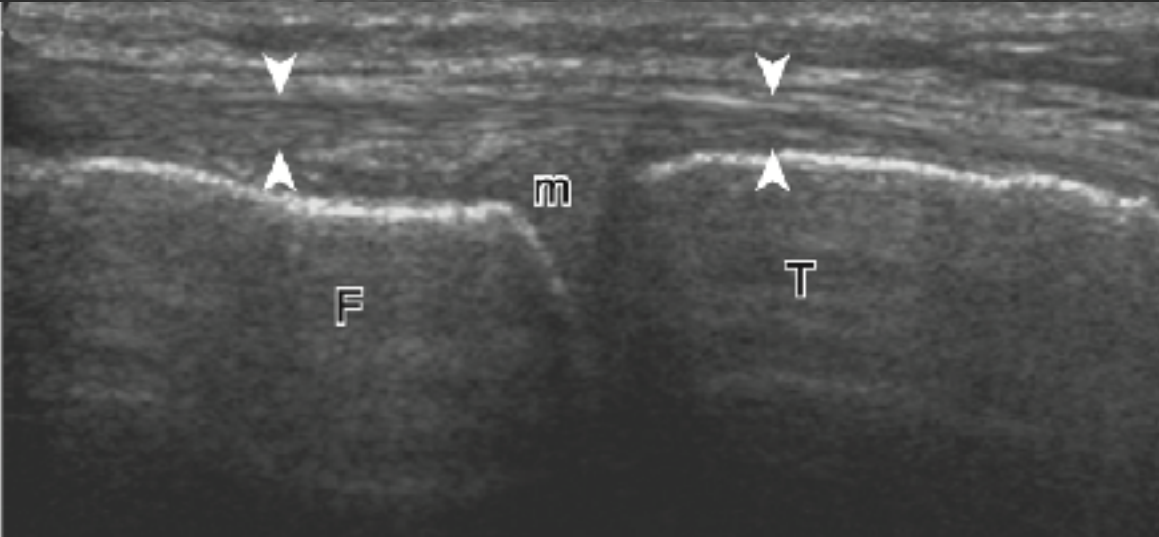


Tendon 韌帶



高回音

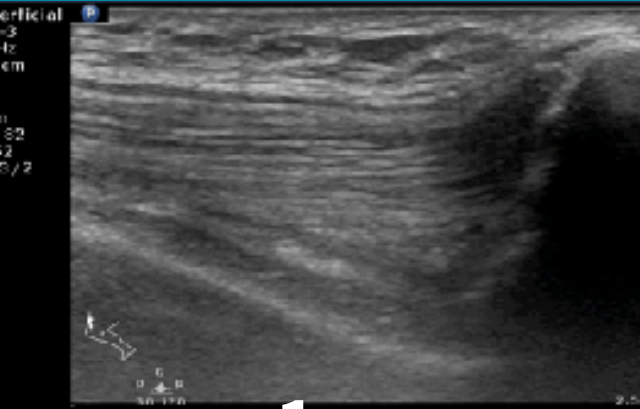Fibrillar



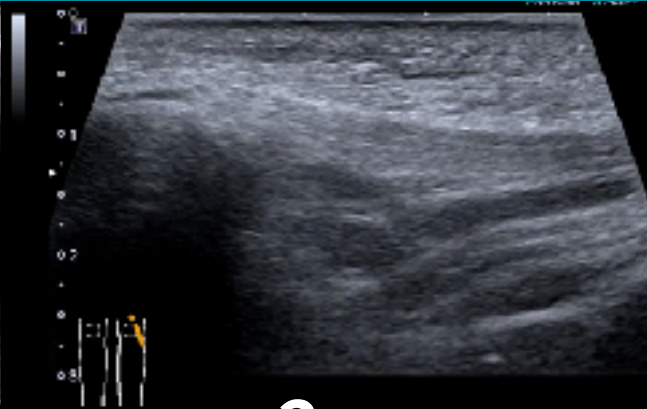
Grade of Injury

- I : no fiber disruption
- II : partial fiber disruption
- III: complete fiber disruption

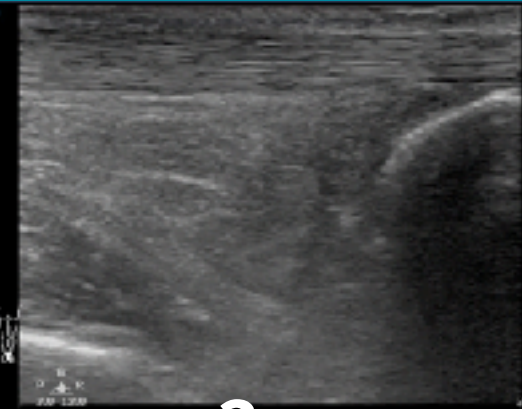Tendon



1



2

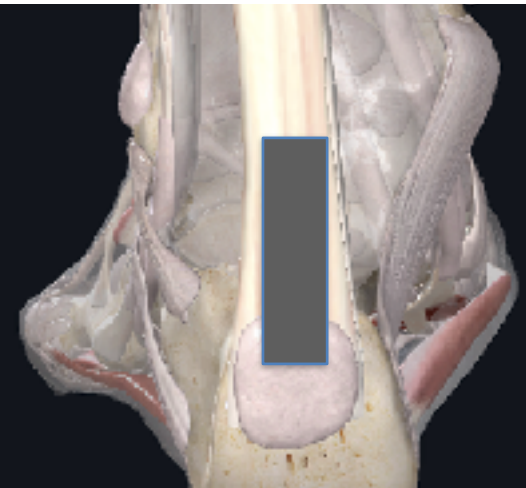
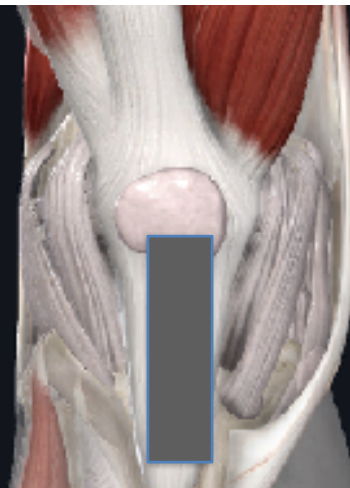
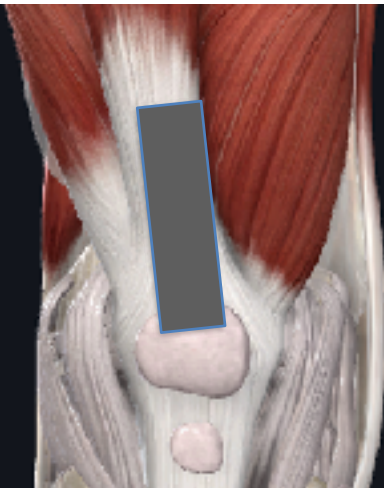
3

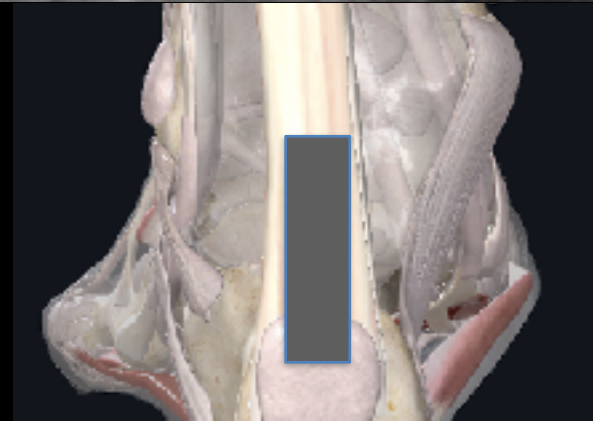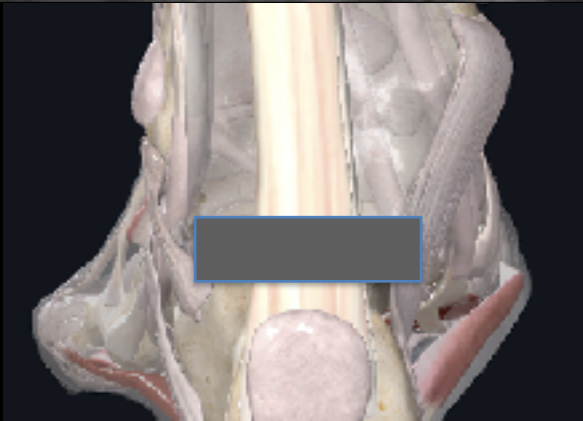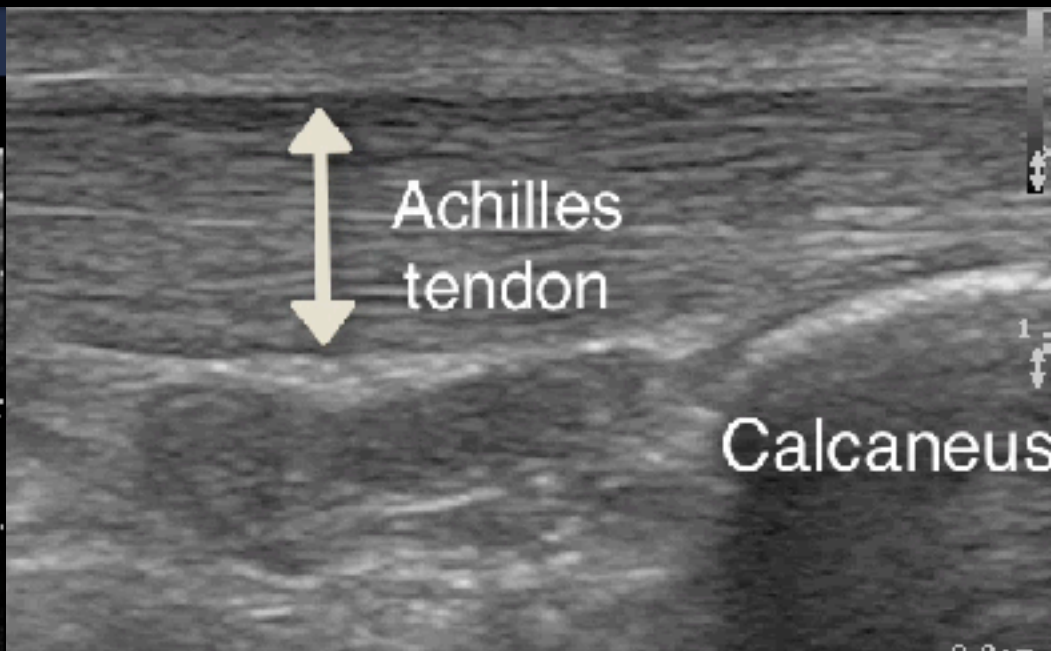
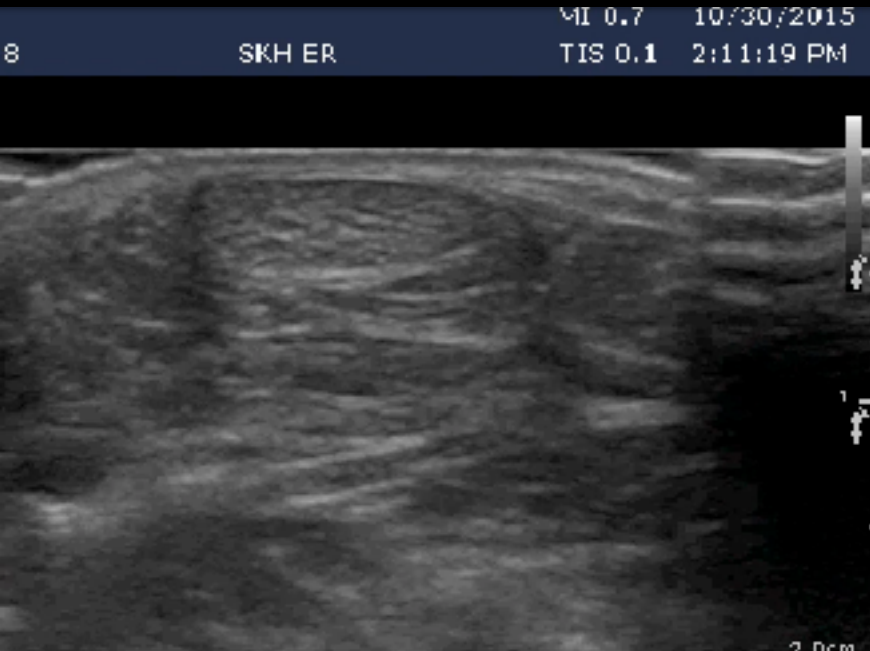
**Quadriceps
Tendon**

**Patellar
Tendon**

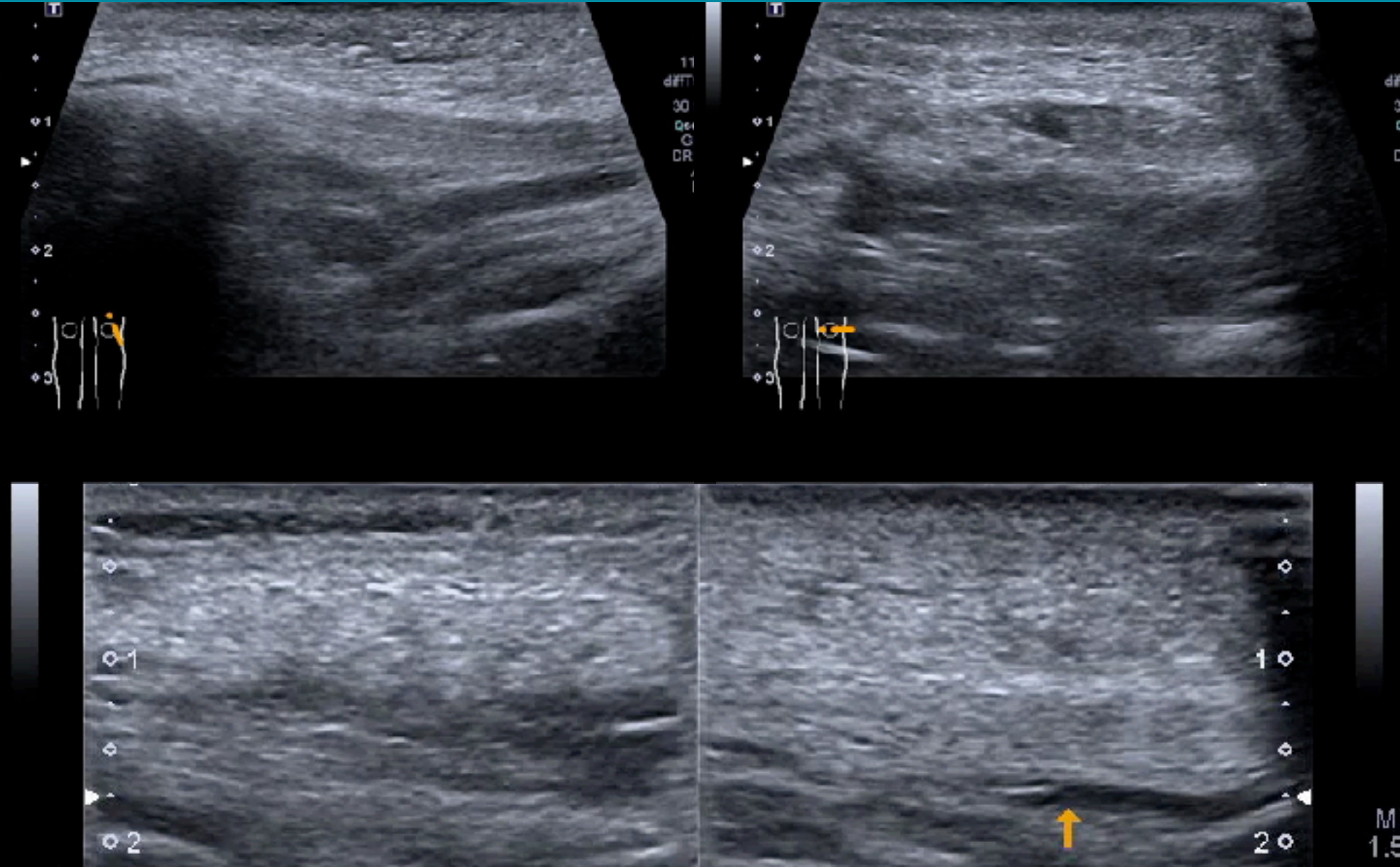
**Achilles
Tendon**



Achilles tendon rupture



Patellar tendon injury



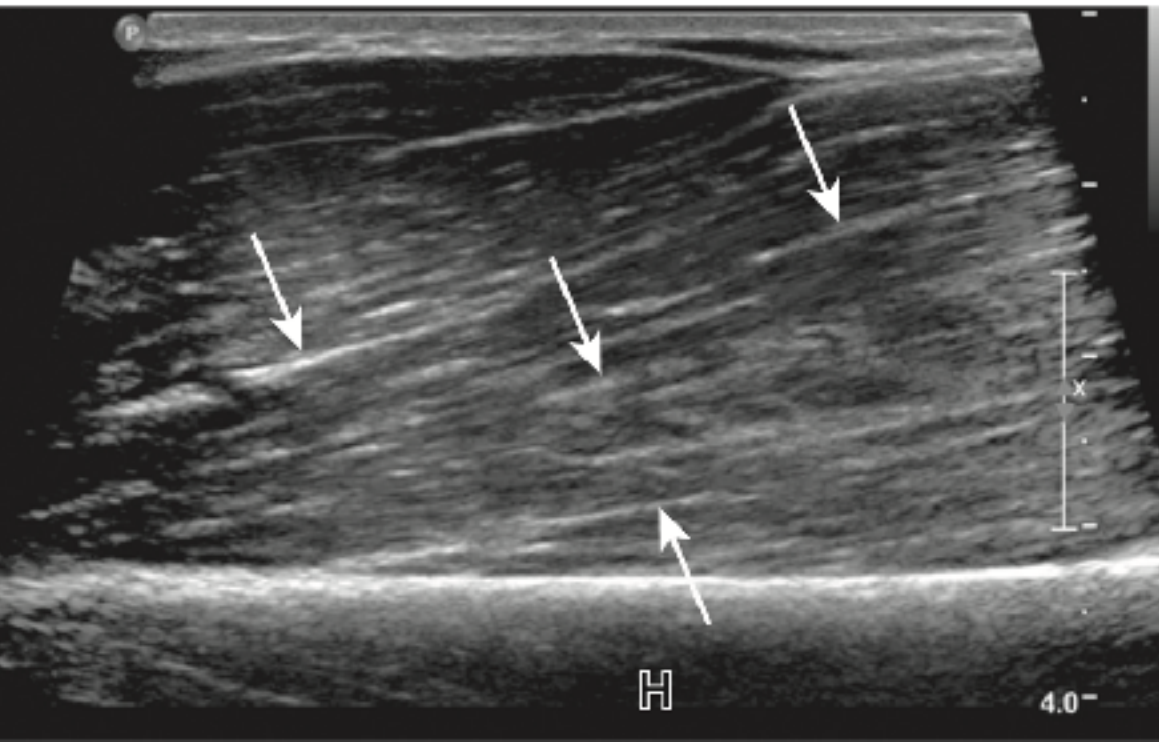
Muscle 肌肉

Grade of Injury

I : no fiber disruption

II : partial fiber disruption

III: complete fiber disruption

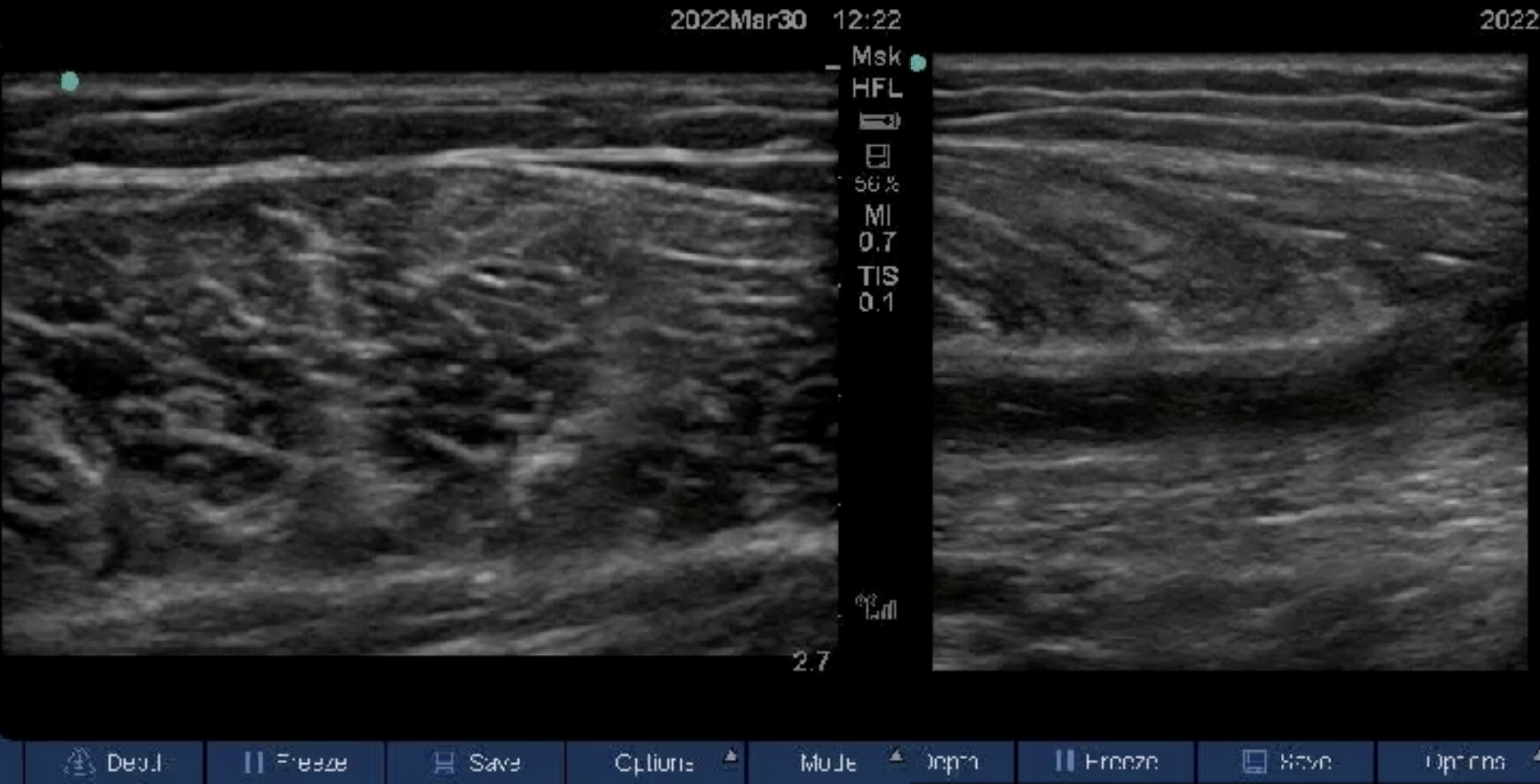


Bristal brush

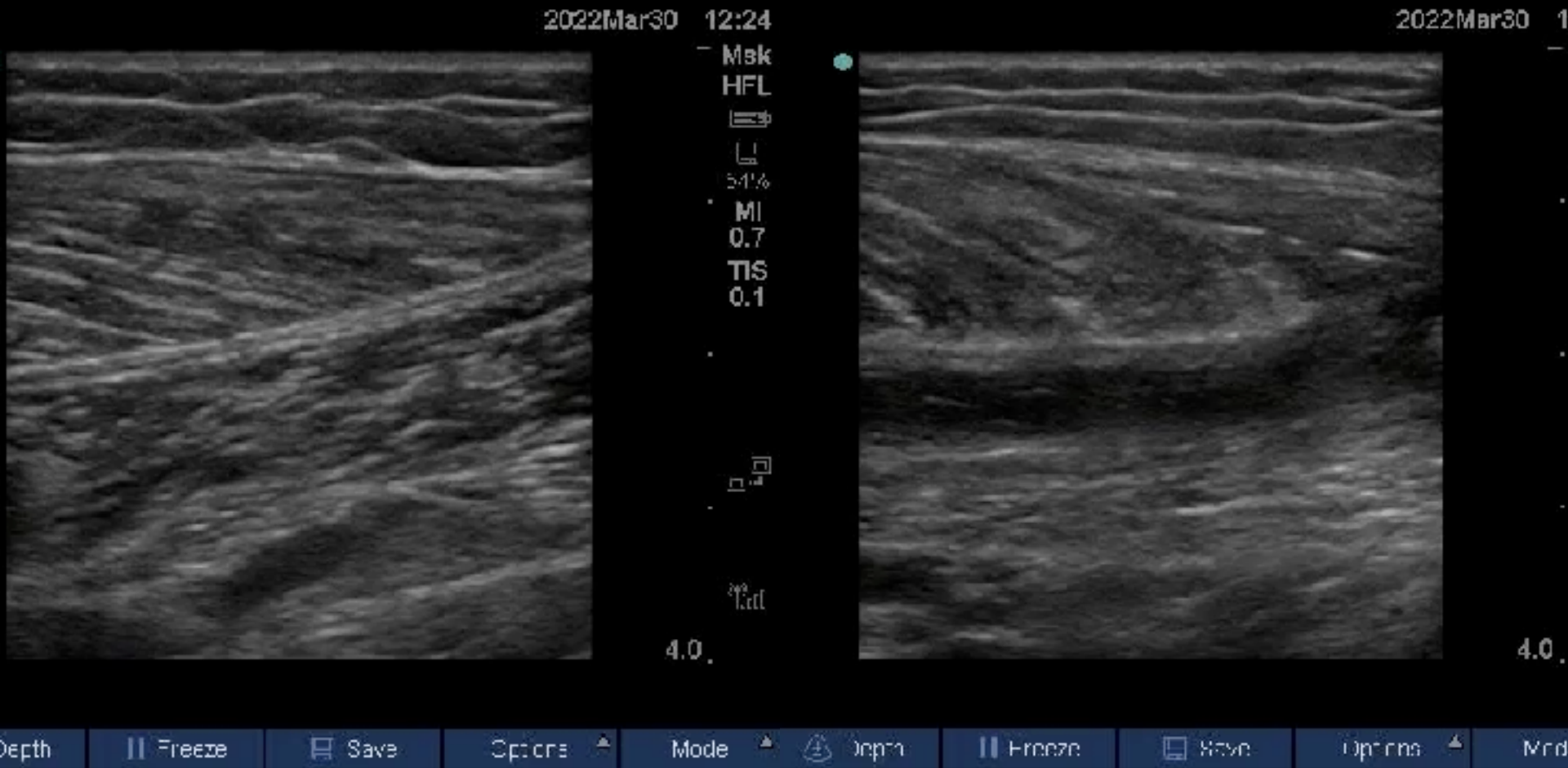**Hypoechoic
mucle**

**Hyperechoic
fibroadipose tissue**

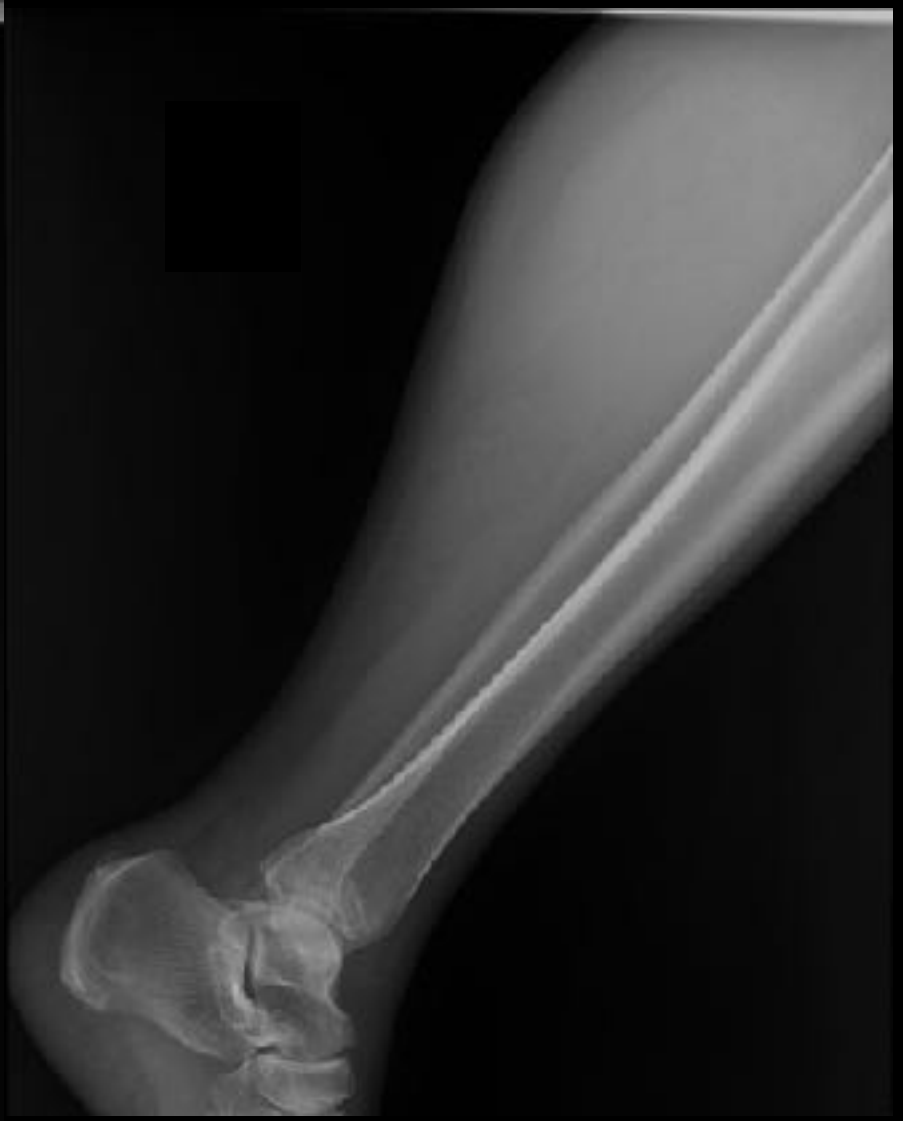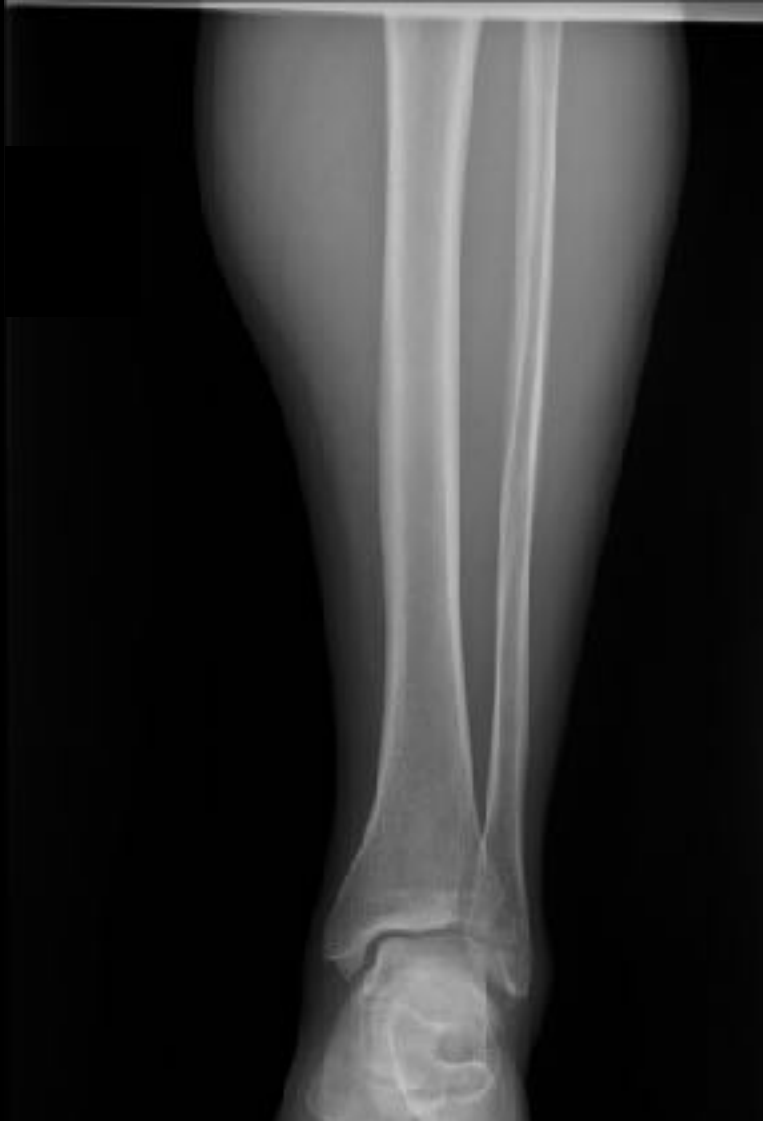Calf muscle tear



Calf muscle tear

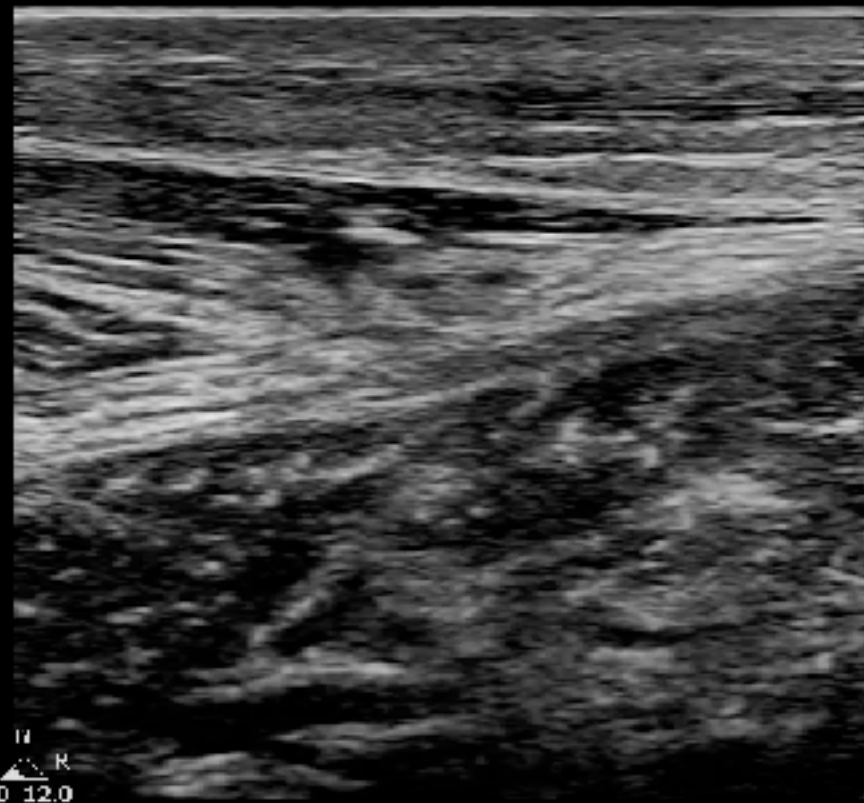

58M, right leg pain while running

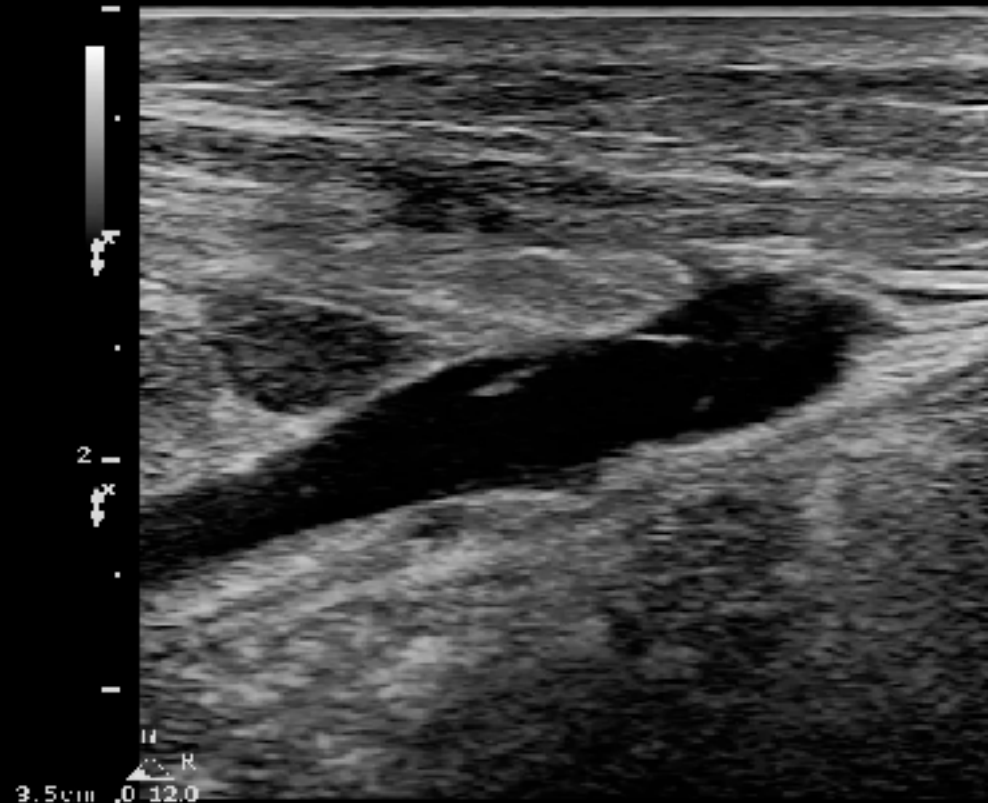


Calf muscle tear

Left calf



Right calf





226 游: 3.8Km - 騎180Km - 跑42km

秀姑巒溪

新白陽

武嶺

4天前
左腳不小心
撞到石頭。
致血腫疼痛



T

0

1

2

3

4

5

6

7

8

9

A +

B

+

diffT

30

Q

C

D

2021/12/01 OSHIBA

11:20:25 AM 1.00.7.00

2021/12/01

11:21:37 A

West Garden Hospital

MSK_3

3155

West Garden Hospital

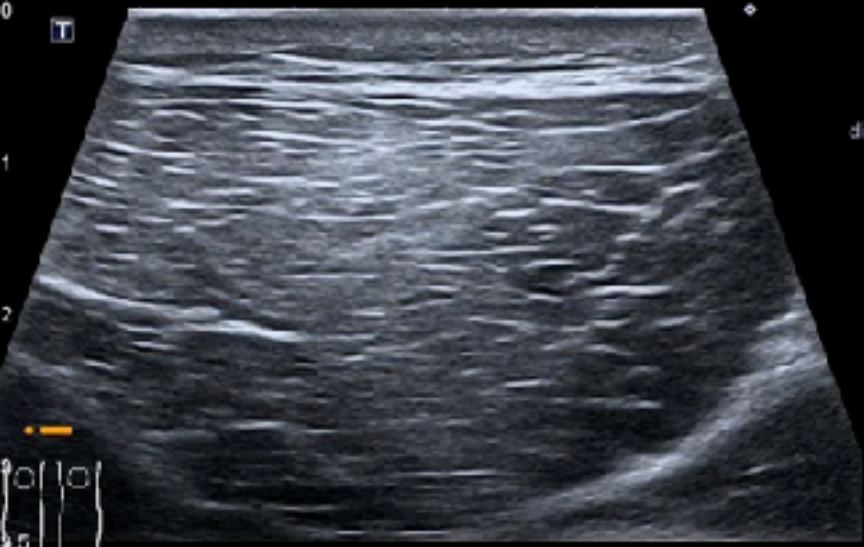
MSK_3

3155

Precision A Pure+

Precision A Pure+

T



M

1.2

18L7

diffT14.0

30 fps

scan

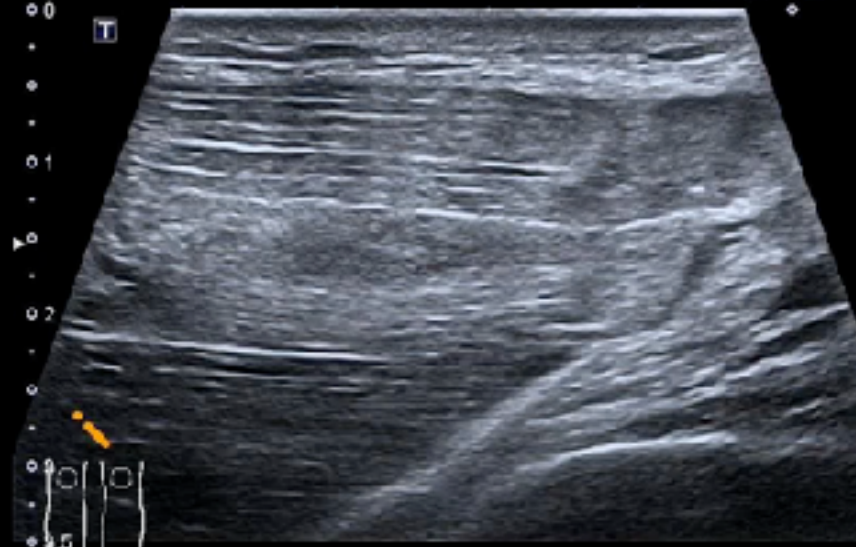
G.80

DR.80

A.6

P.3

T



18

diffT14

30

scan

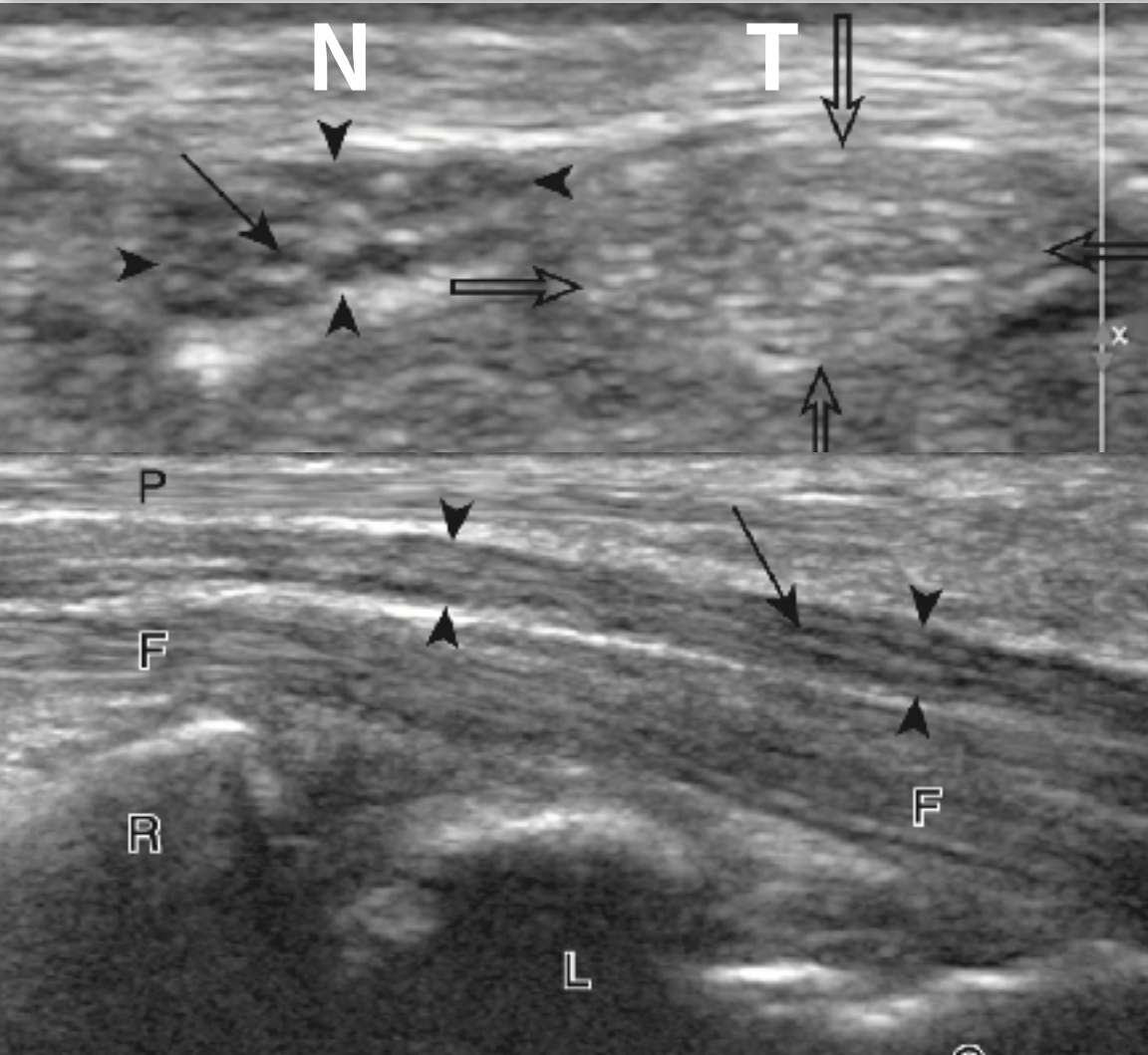
G.80

DR.80

A.6

P.3

Nerve



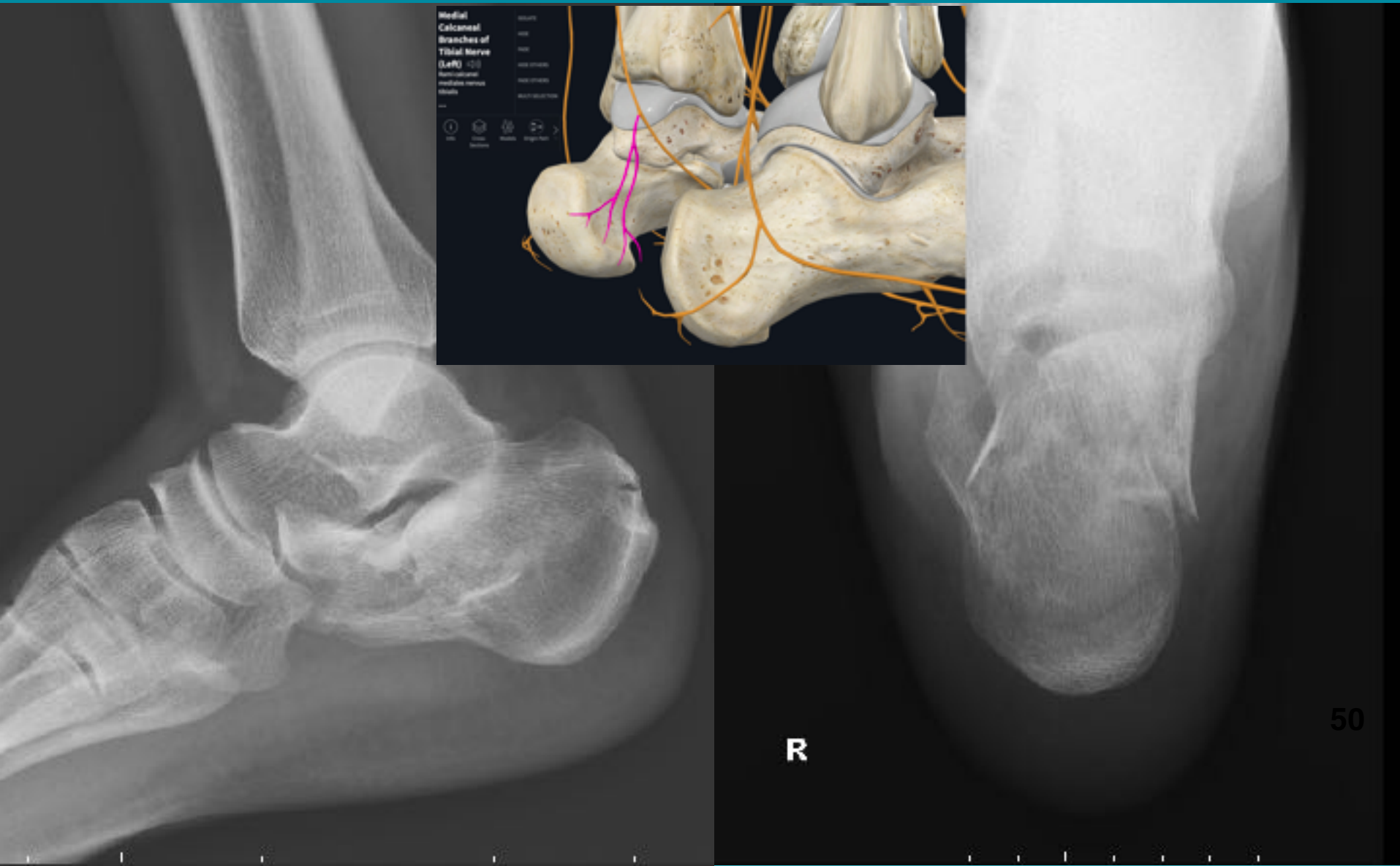
Hypoechoic

Hyperechoic

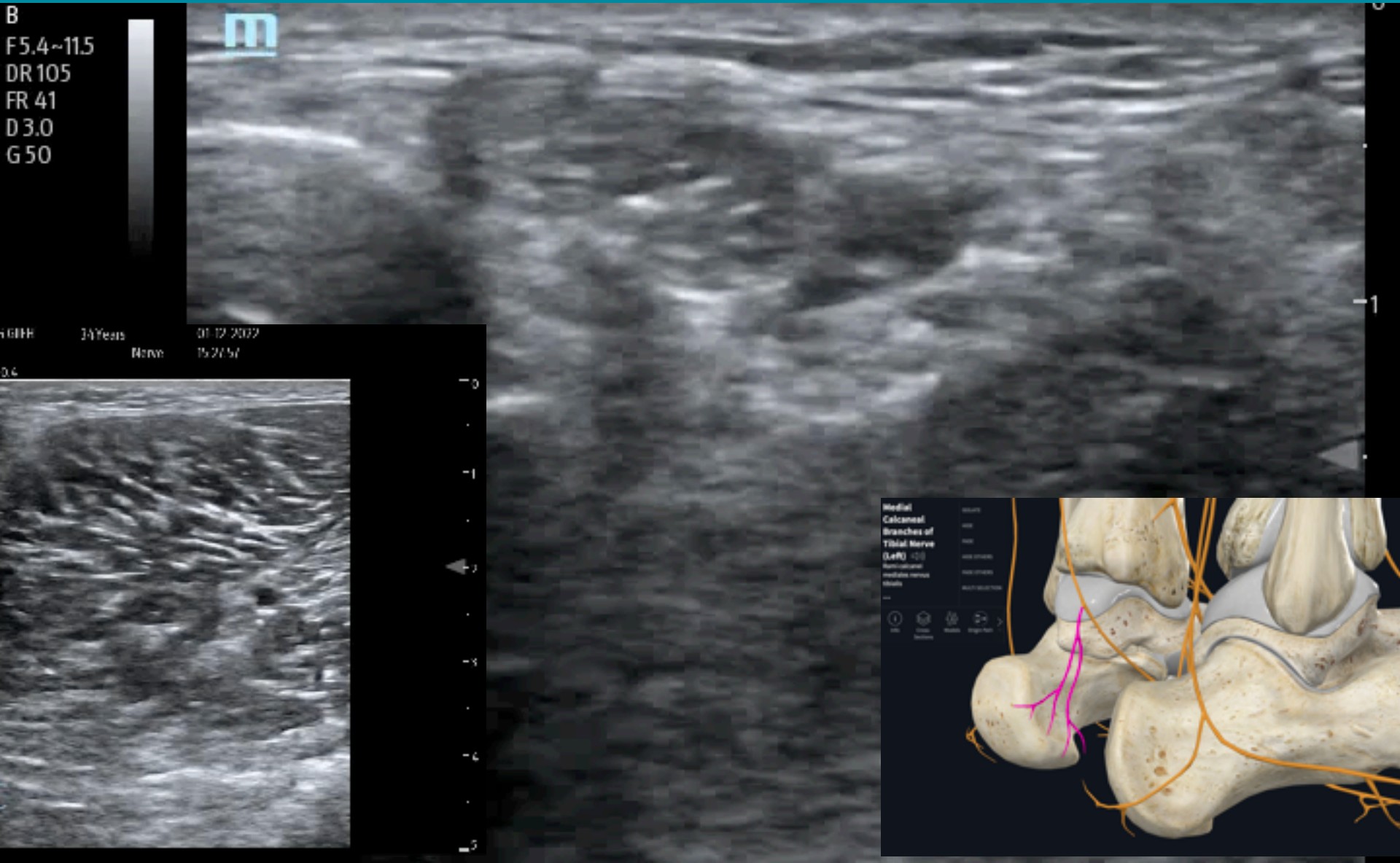
Honeycomb

Fibrillar

34M，貨車車斗跌下，足踝腫痛



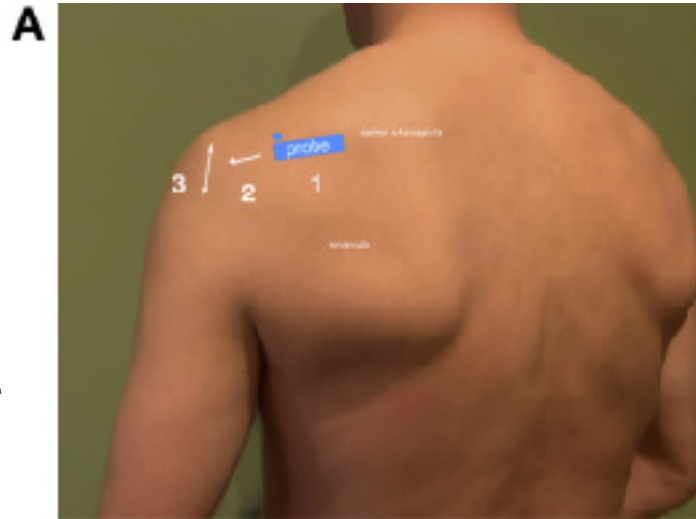
Tibial nerve block



Musculoskeletal Ultrasonography to Diagnose Dislocated Shoulders: A Prospective Cohort

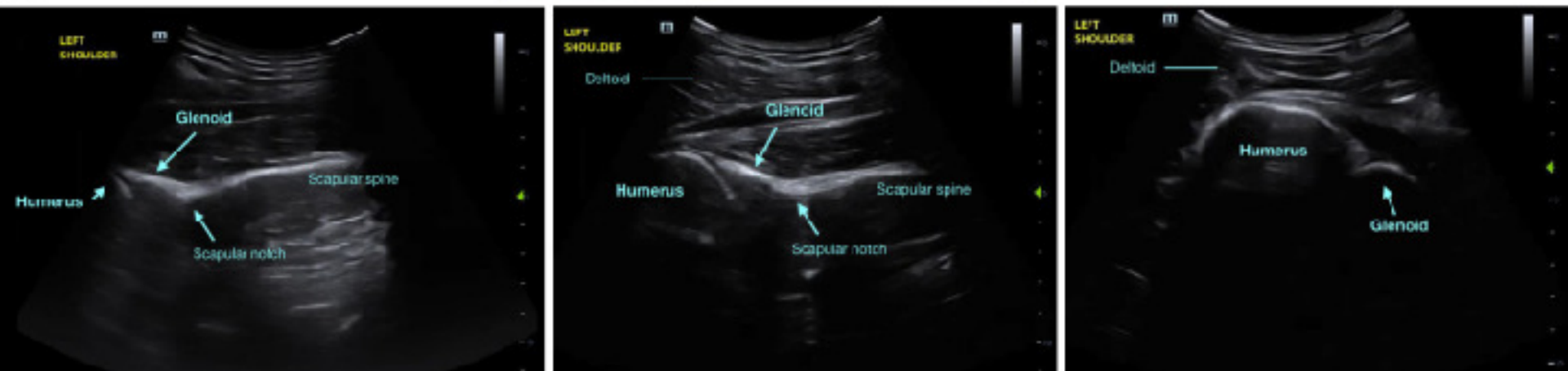Michael A. Secko, MD, RDMS*; Lindsay Reardon, MD; Michael Gottlieb, MD; Eric J. Morley, MD; Mathew R. Lohse, MD; Henry C. Thode, Jr, PhD; Adam J. Singer, MD

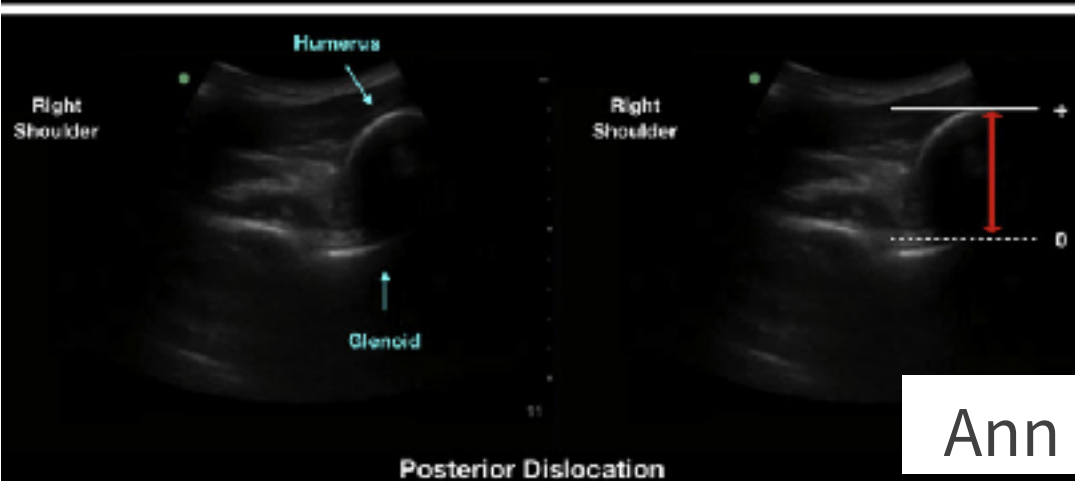
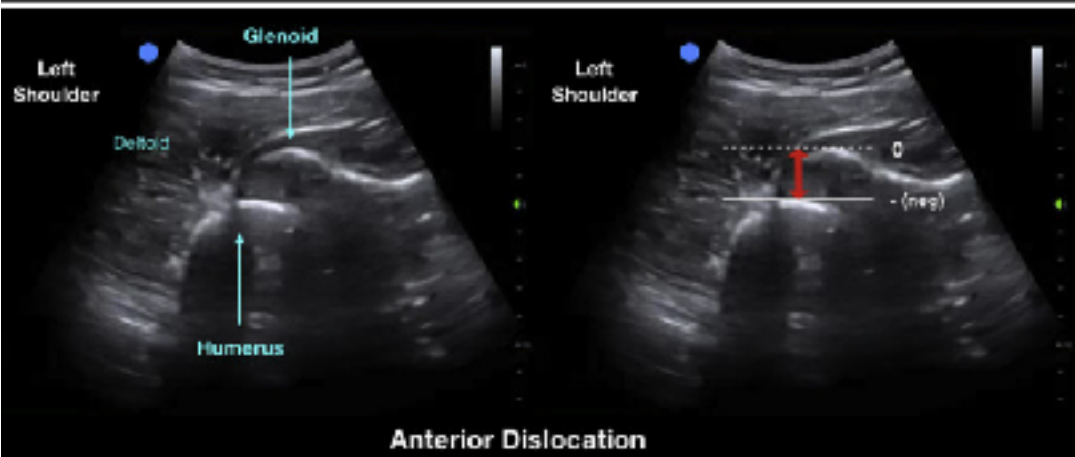
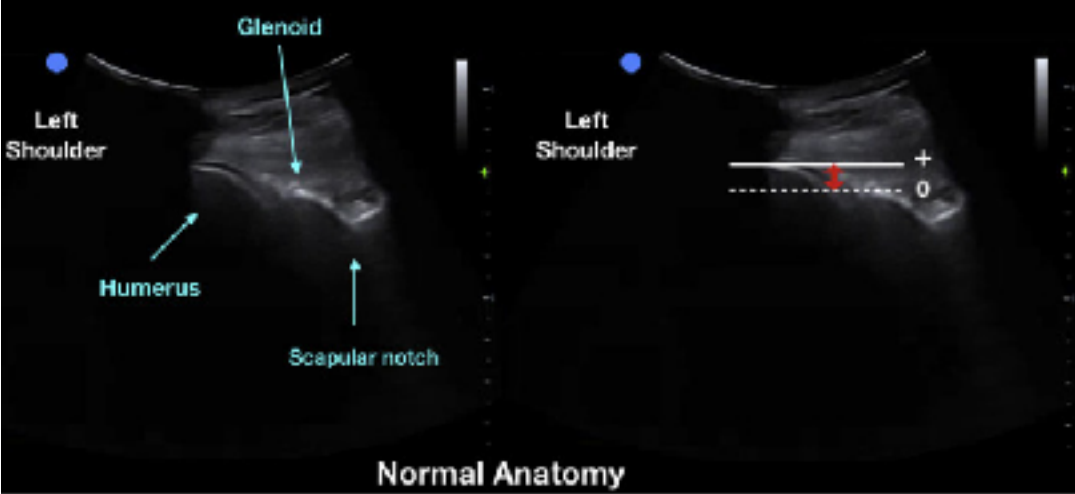
Multicenter
Prospective
Observational



65 patients

B





Sensitivity 100%
 Specificity 100%

Sens (Fx) 92%
 Spes (Fx) 100%

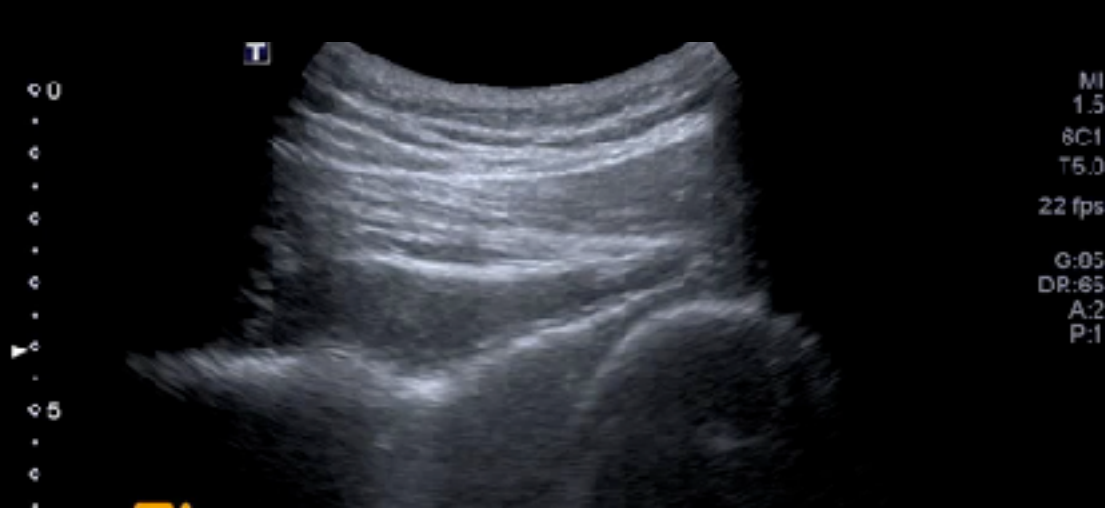
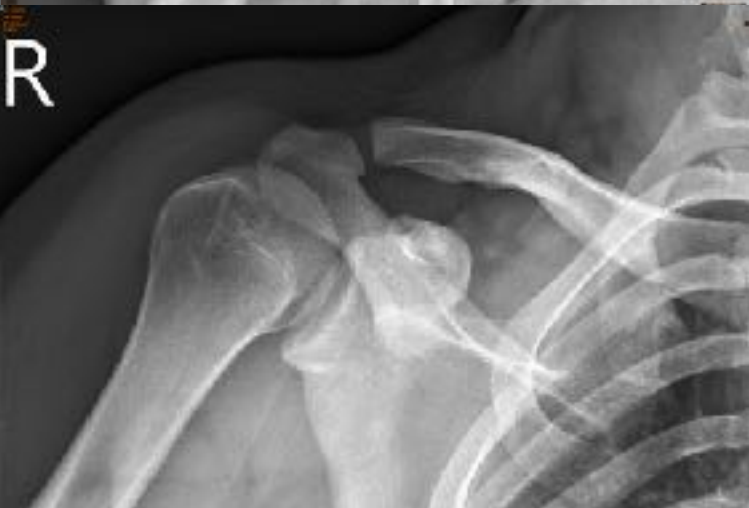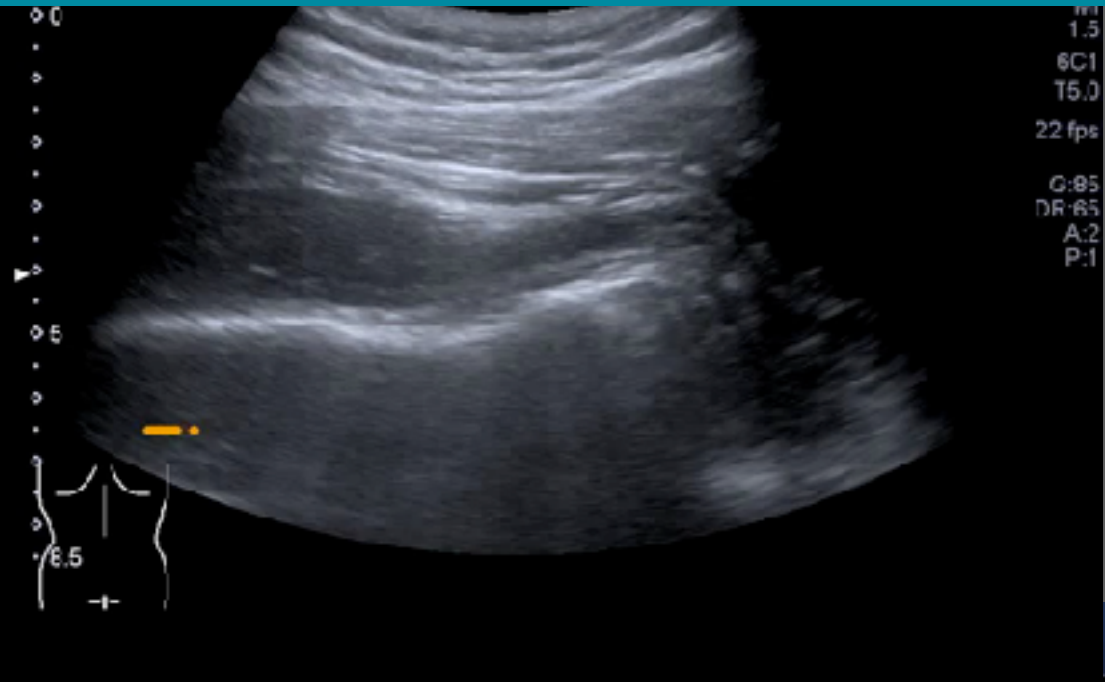
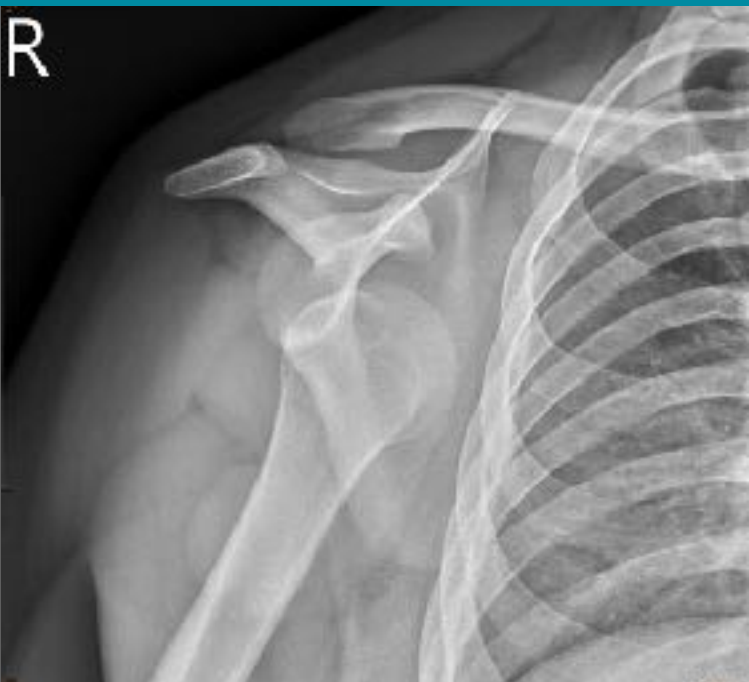Median 19s

GH(d-A) -1.83cm

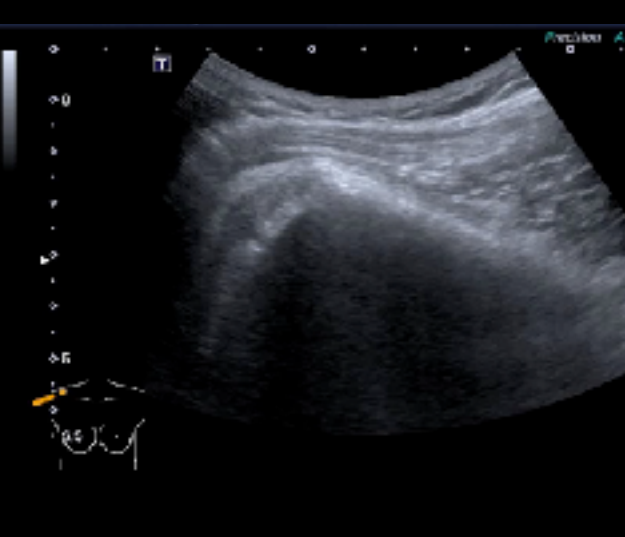
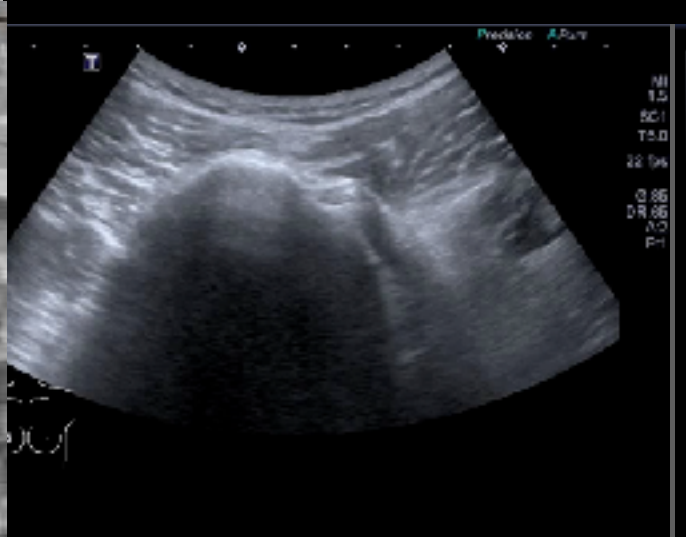
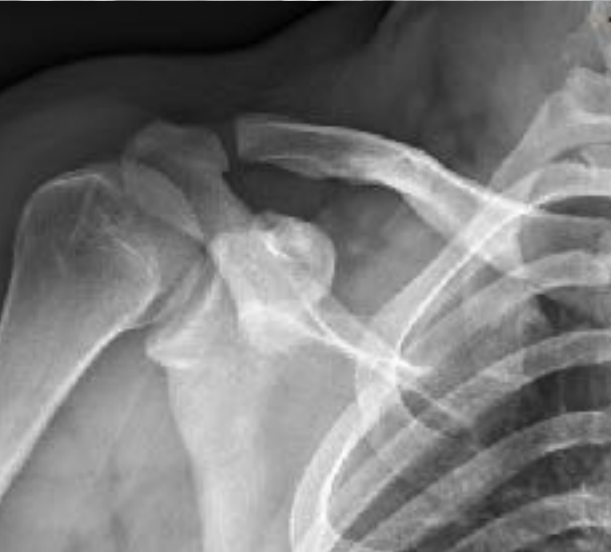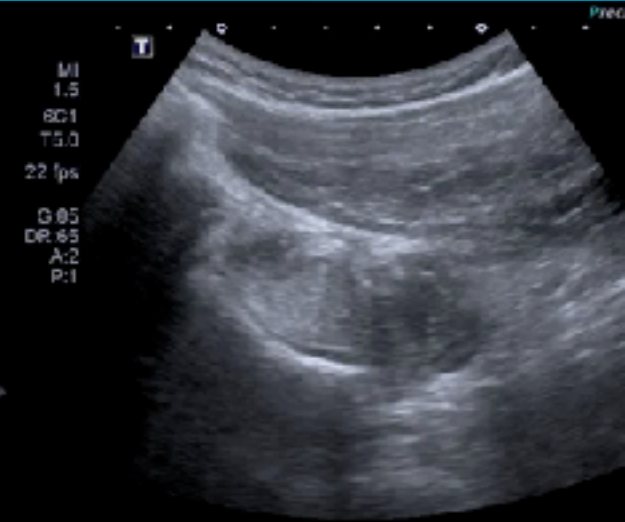
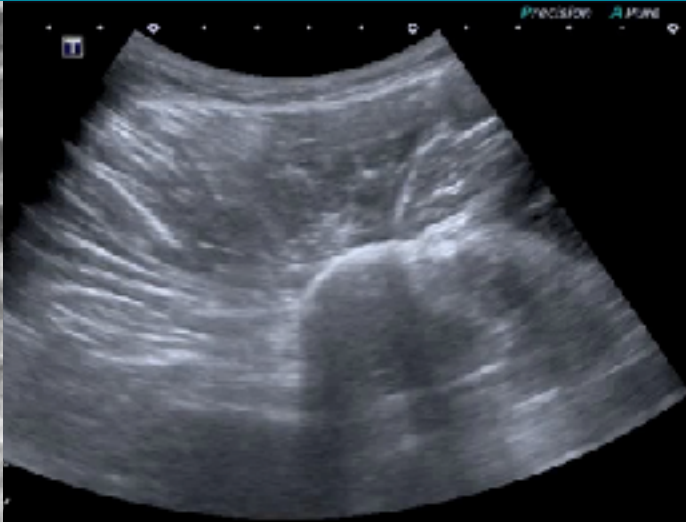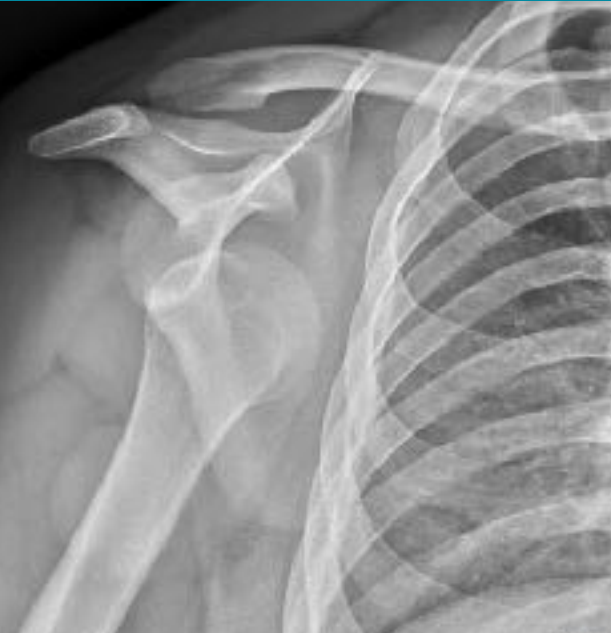GH(d-N) 0.22cm

GH(d-P) 3.3cm

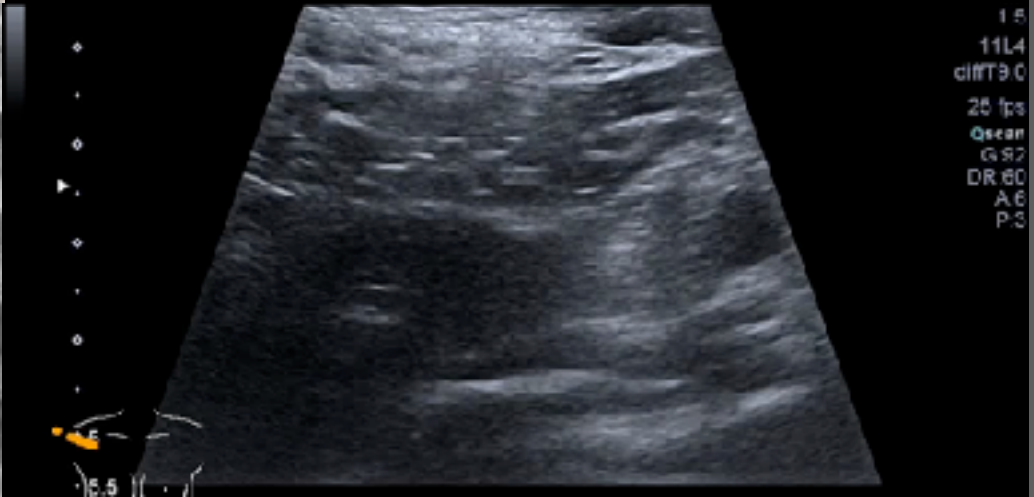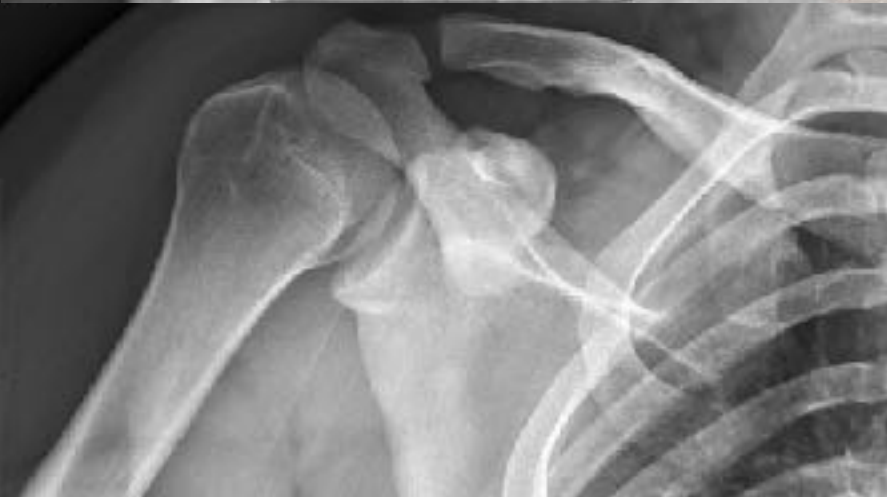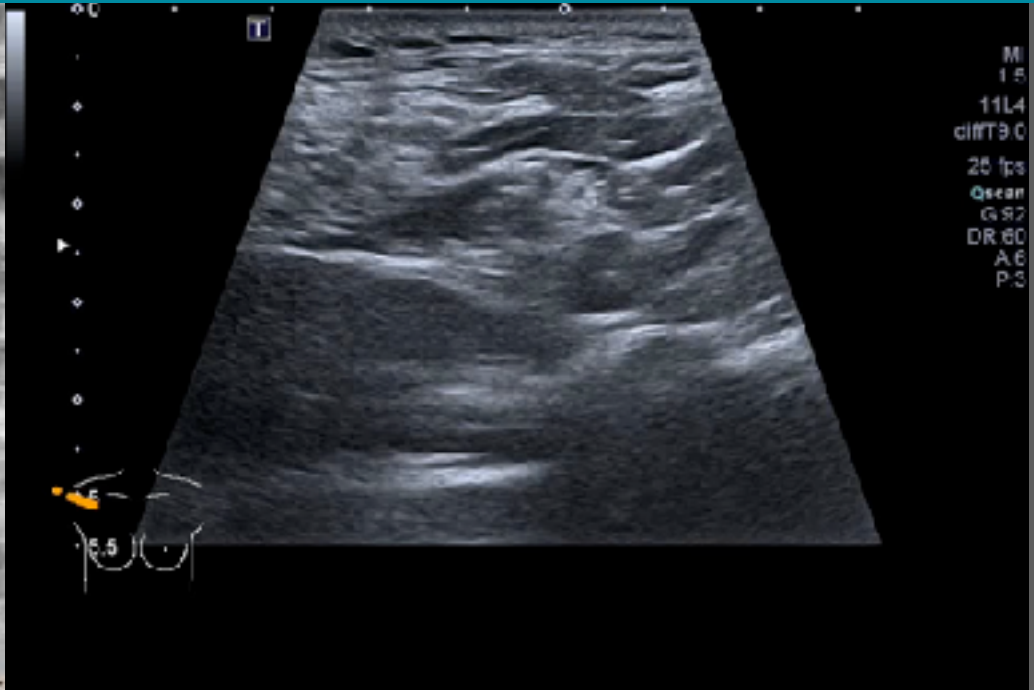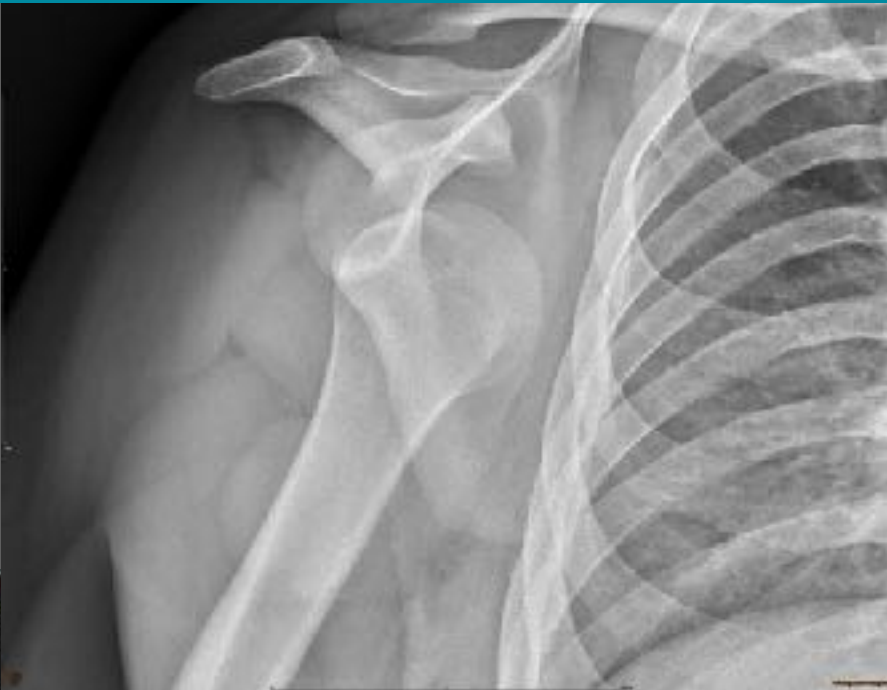M/20, 工作時從階梯滑下用手去抓致右肩脫位



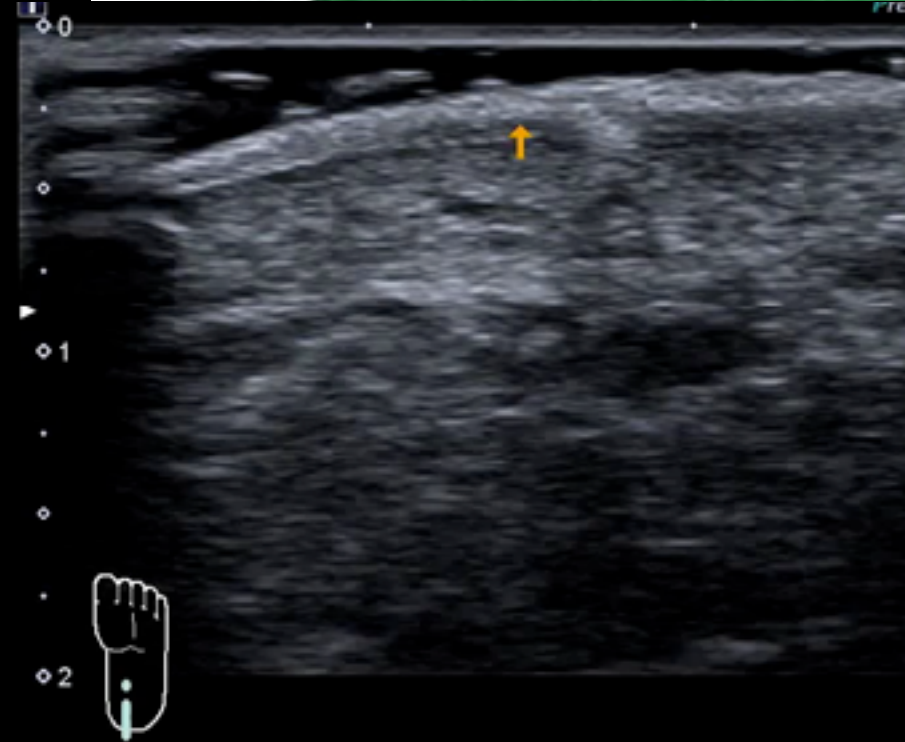
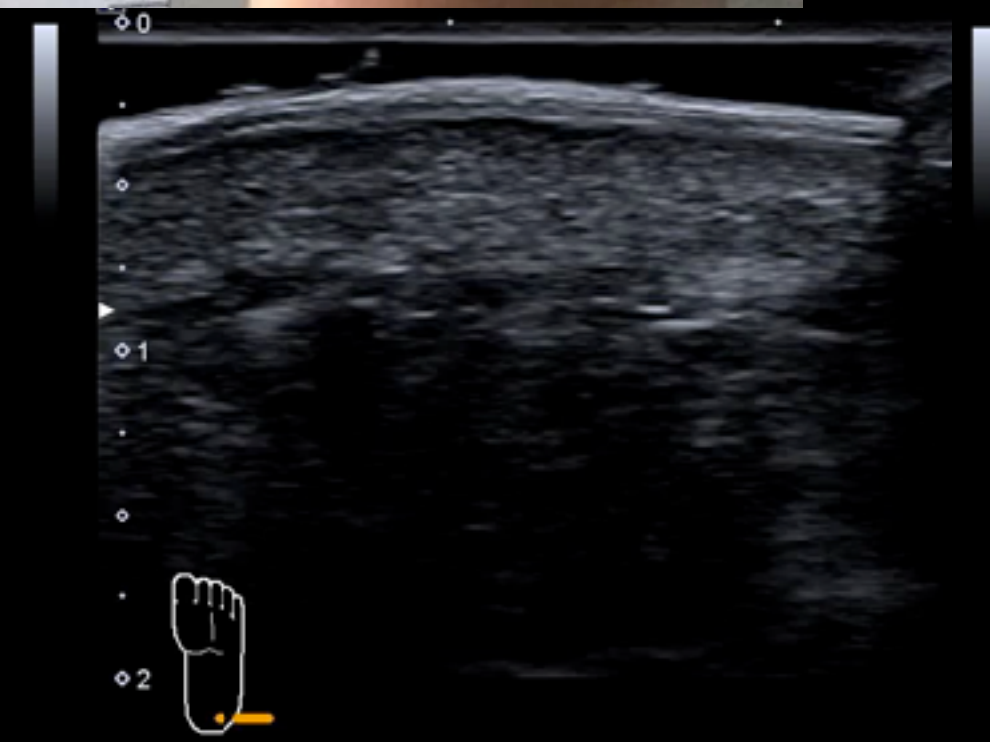
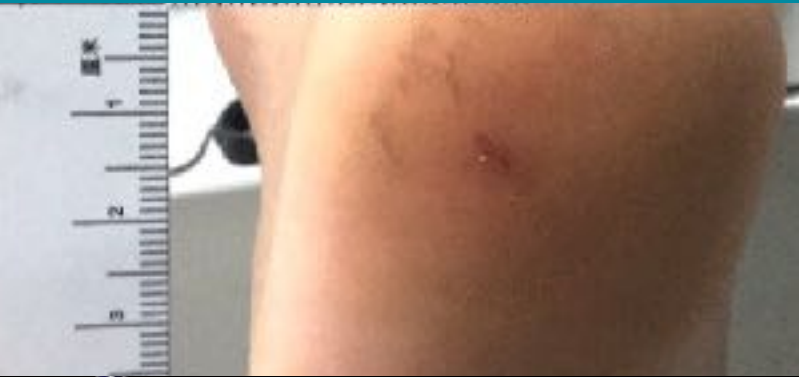Anterior approach for diagnosis, block & reduction

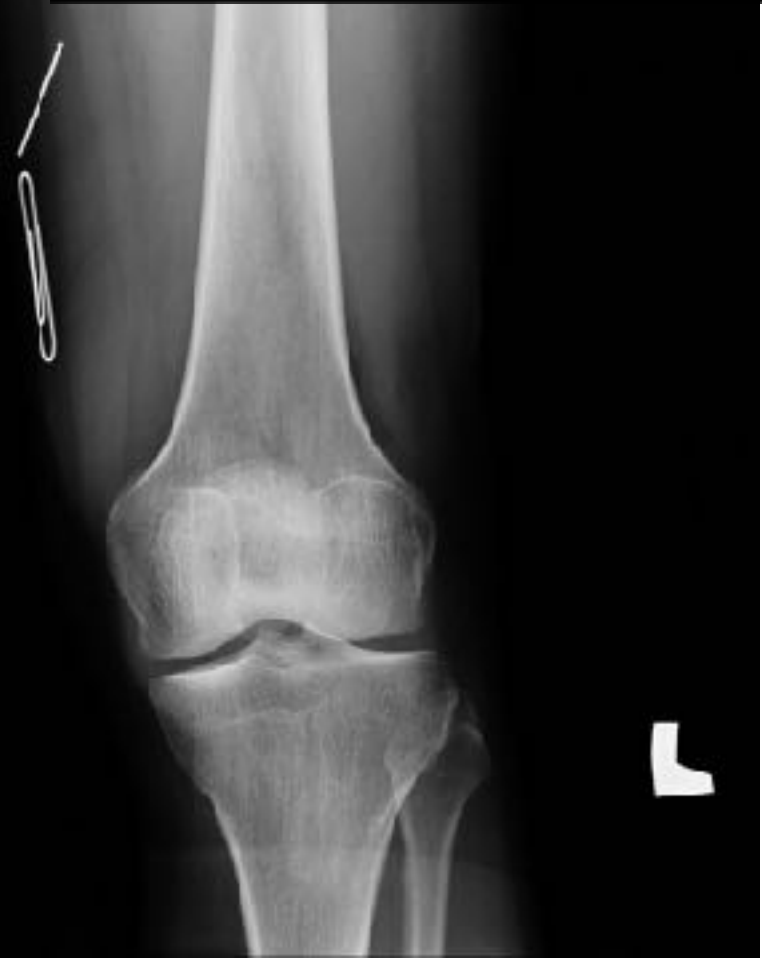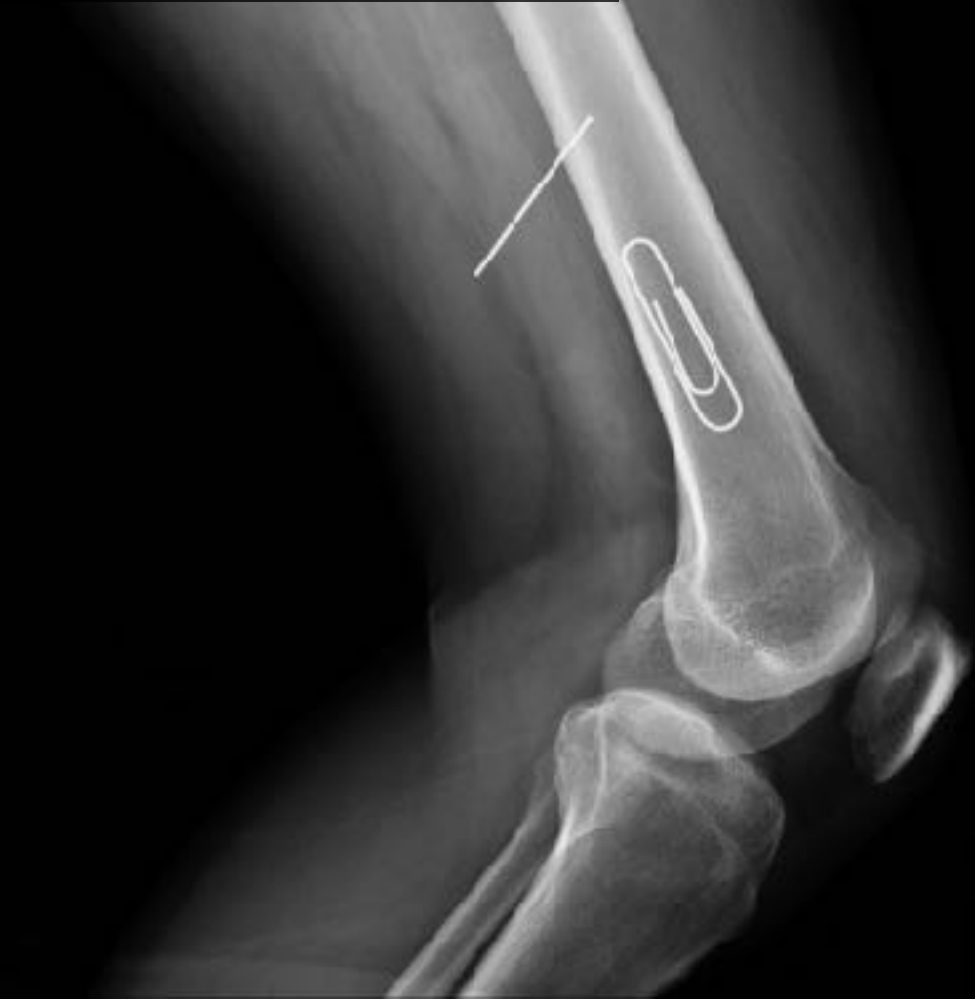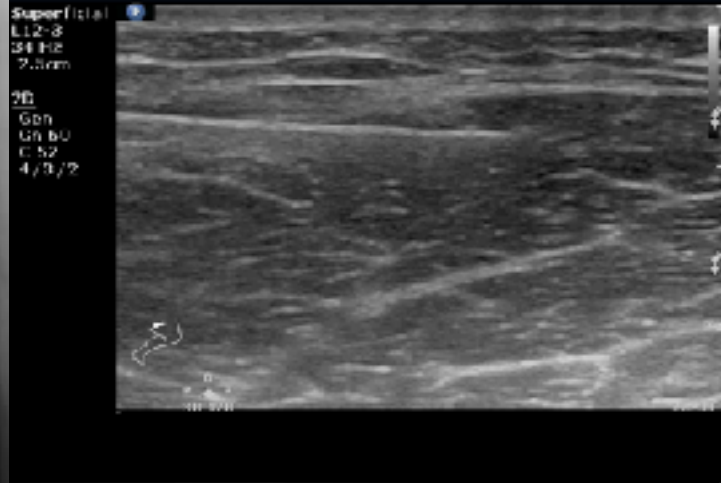
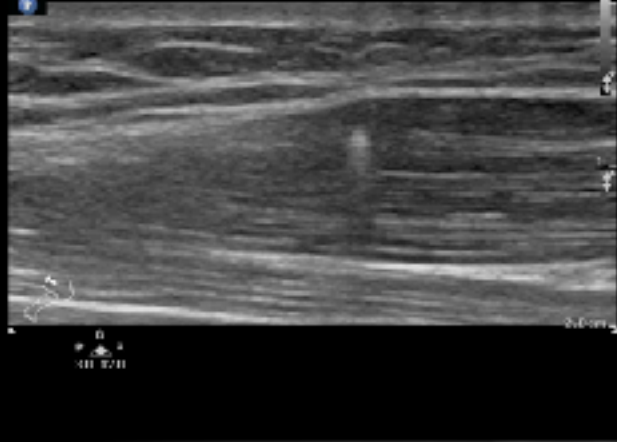


Supraclavicular brachial plexus block



踩到碎玻璃，覺得有異物



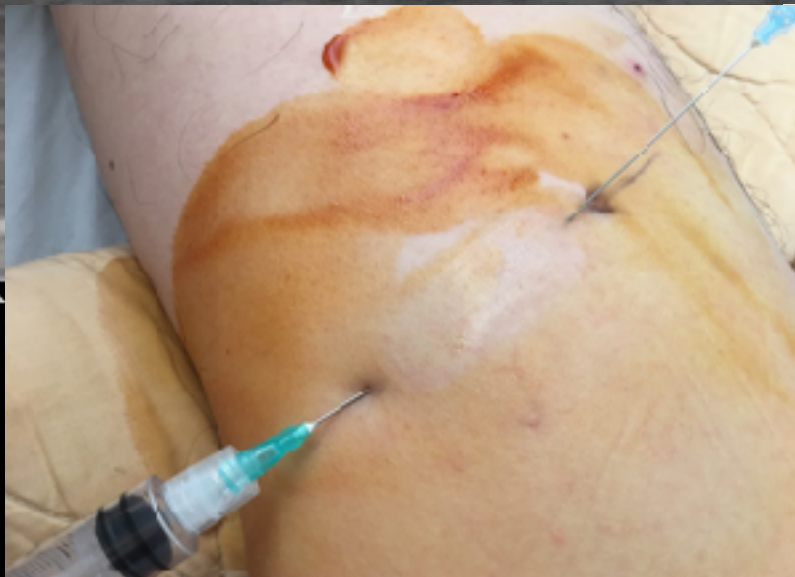
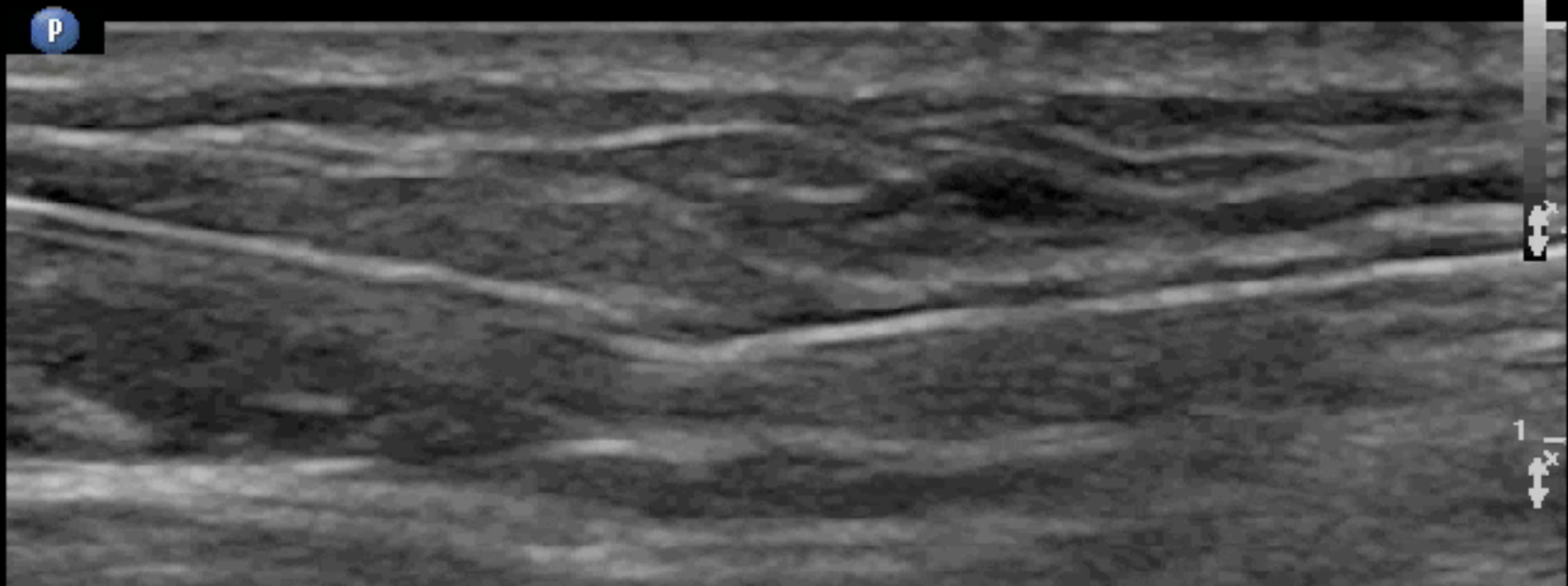


Localization

2 needle

Removal

12-5
34 Hz
2.0cm
D
Gen
Gn 60
C. 57
4/3/2

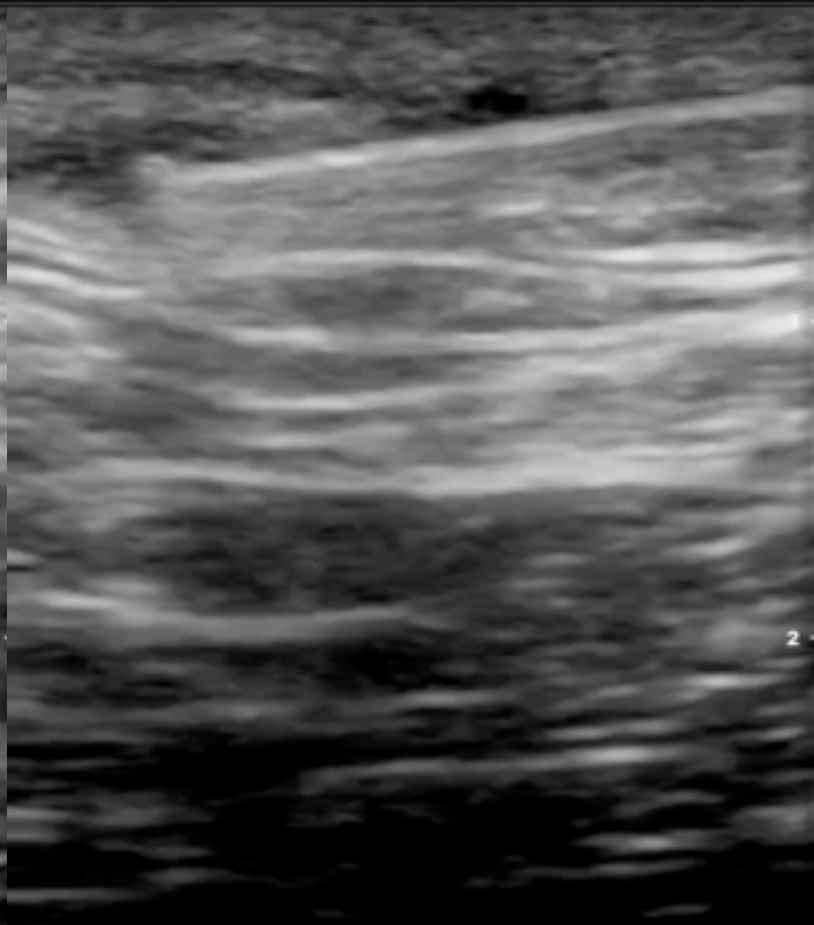
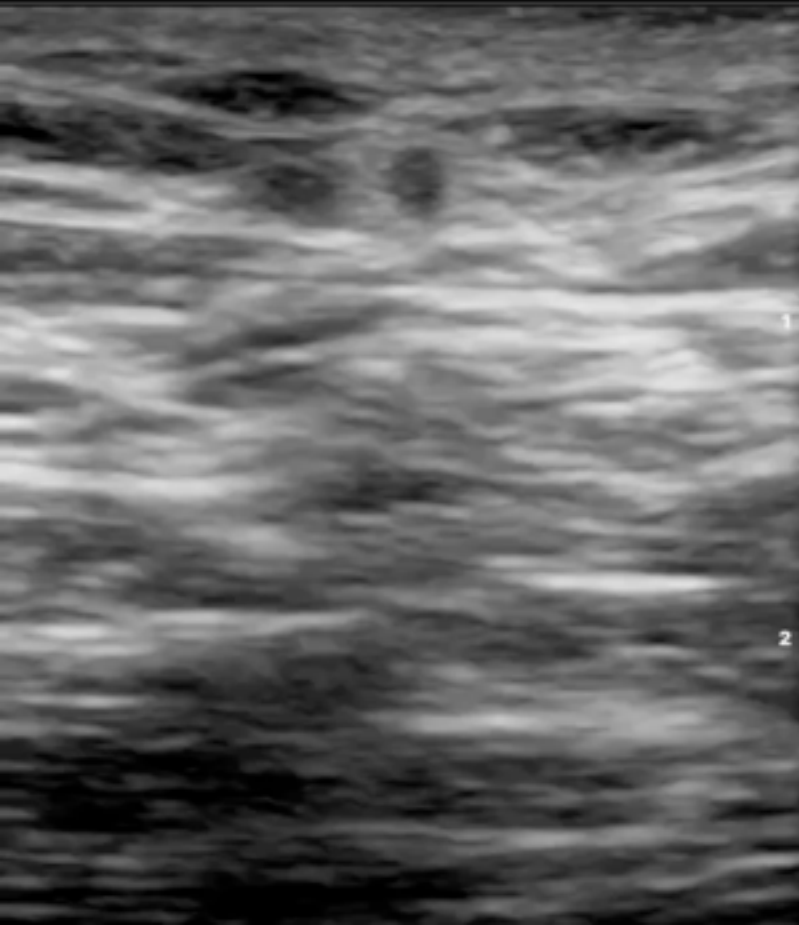


大腿痛和異物感

TIS: 0.01, MI: 0.26, Small Organ

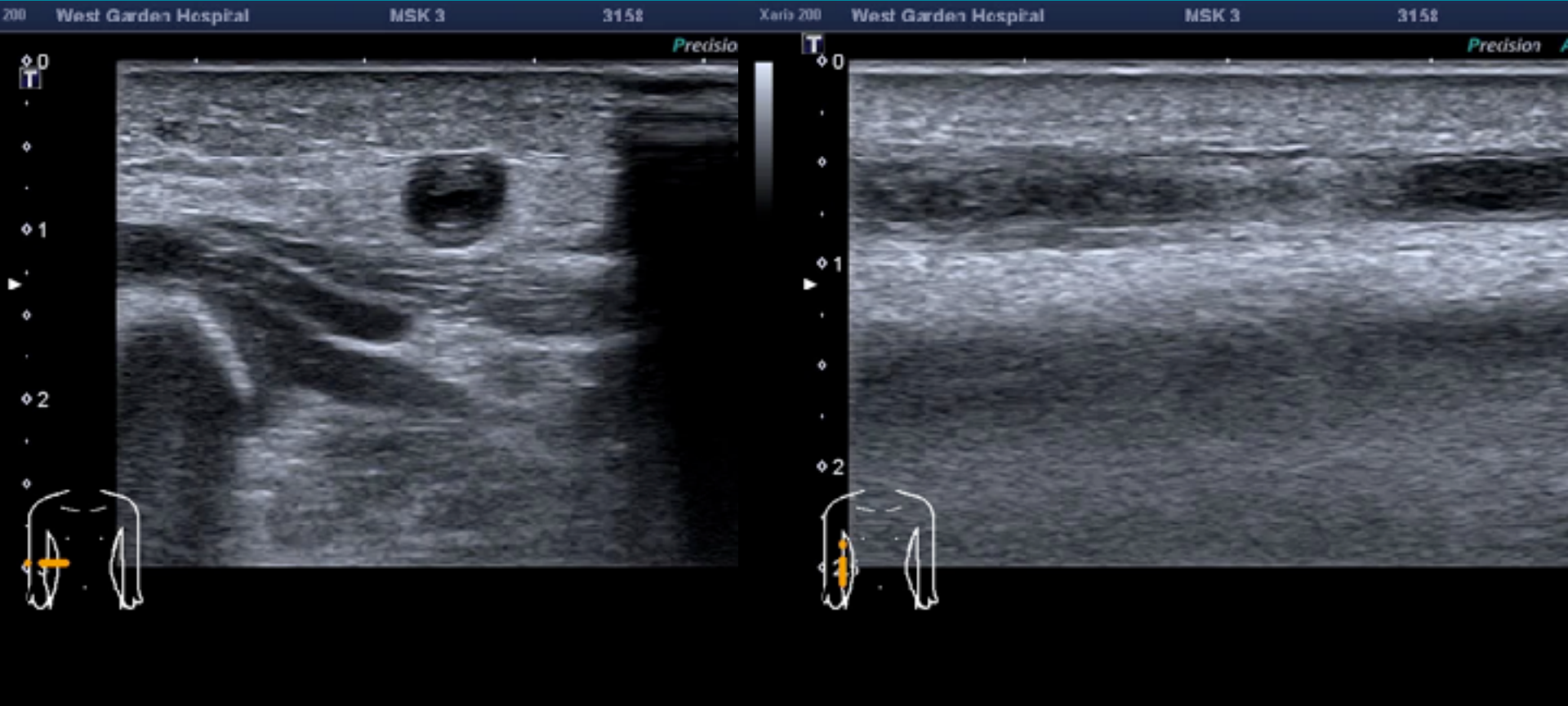
TIS: 0.01, MI: 0.26, Small Organ

Halo sign



54歲男，注射處腫痛

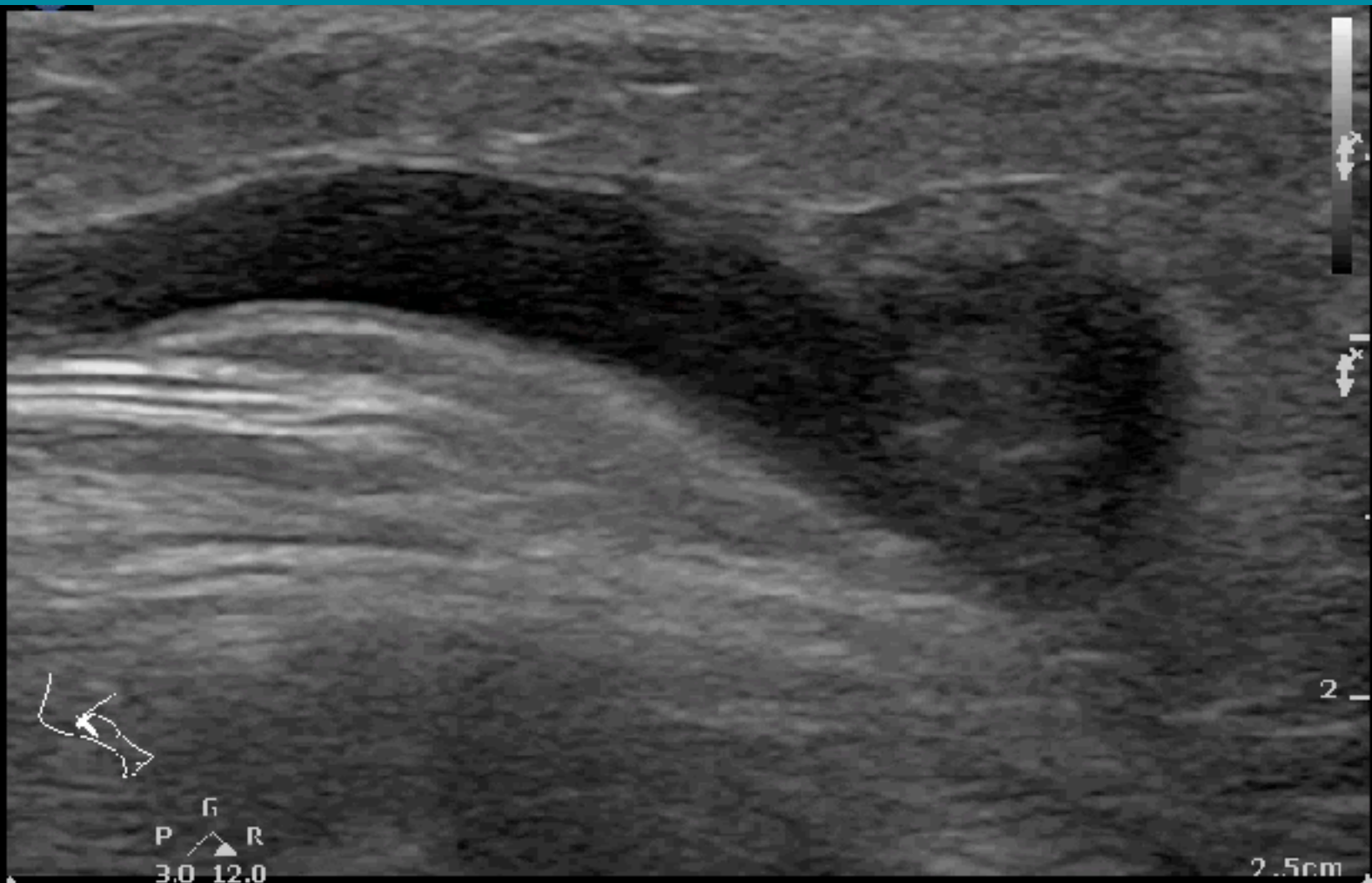
Superficial thrombophlebitis



76F，小腿痛

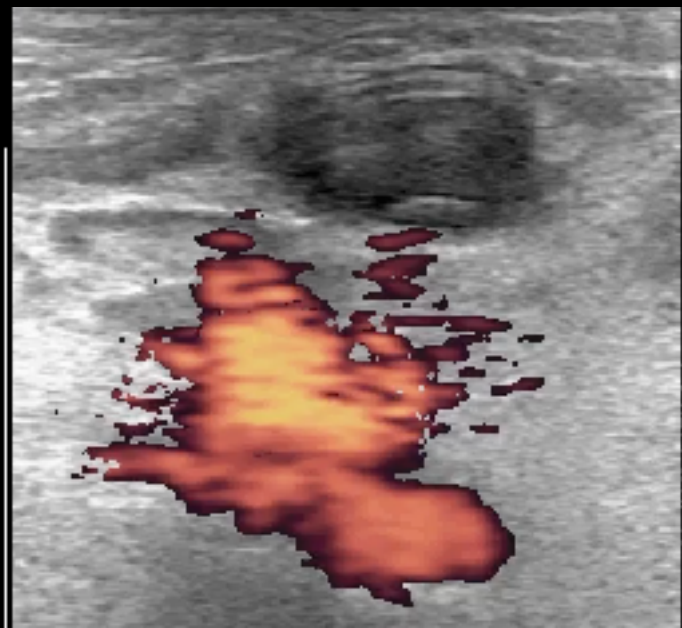
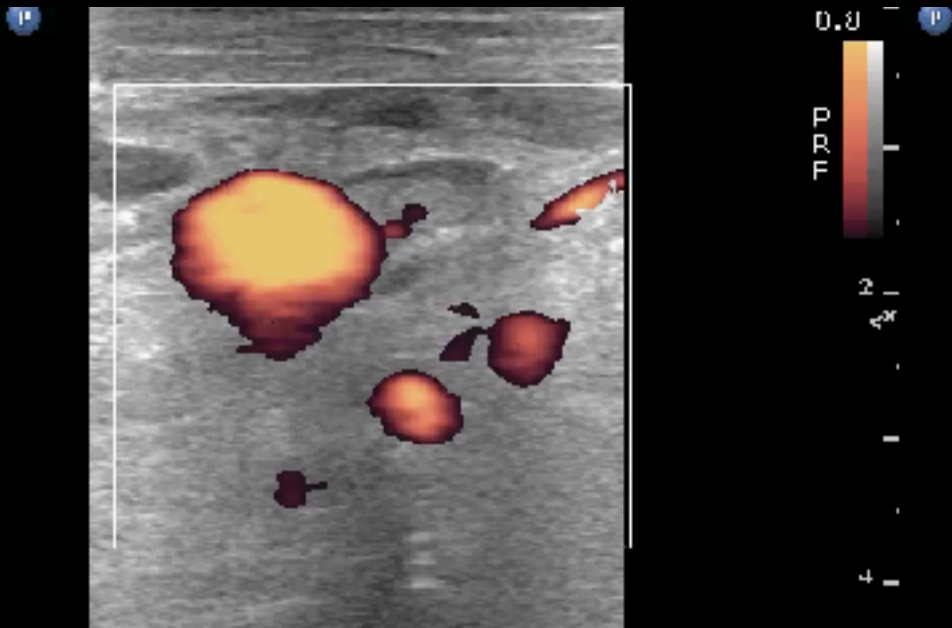
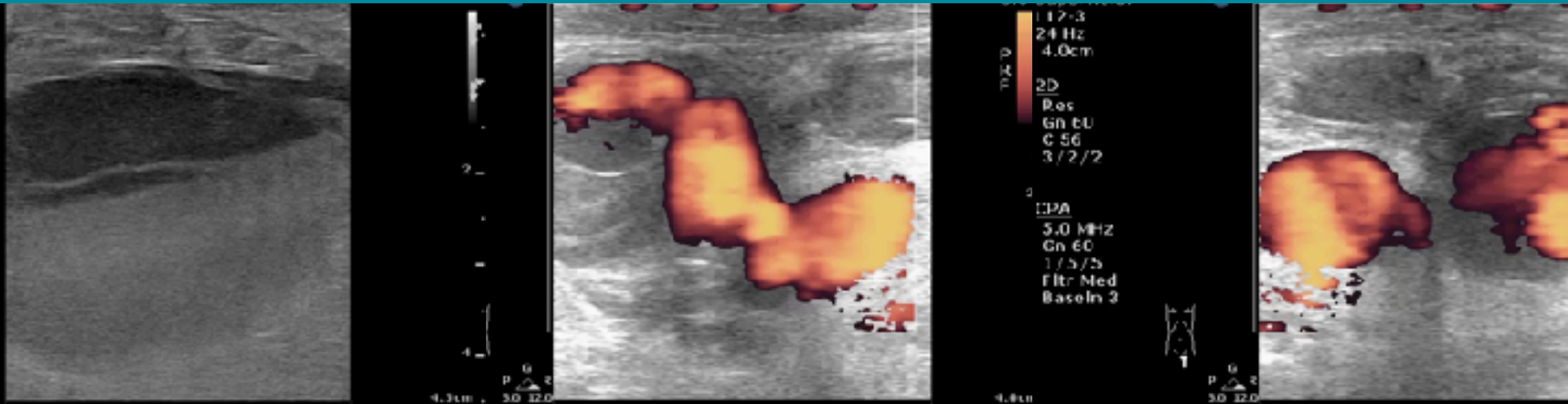
L12-3
50 Hz
2.5cm

2D
Res
Gn //
C. 56
3 / 2 / 1

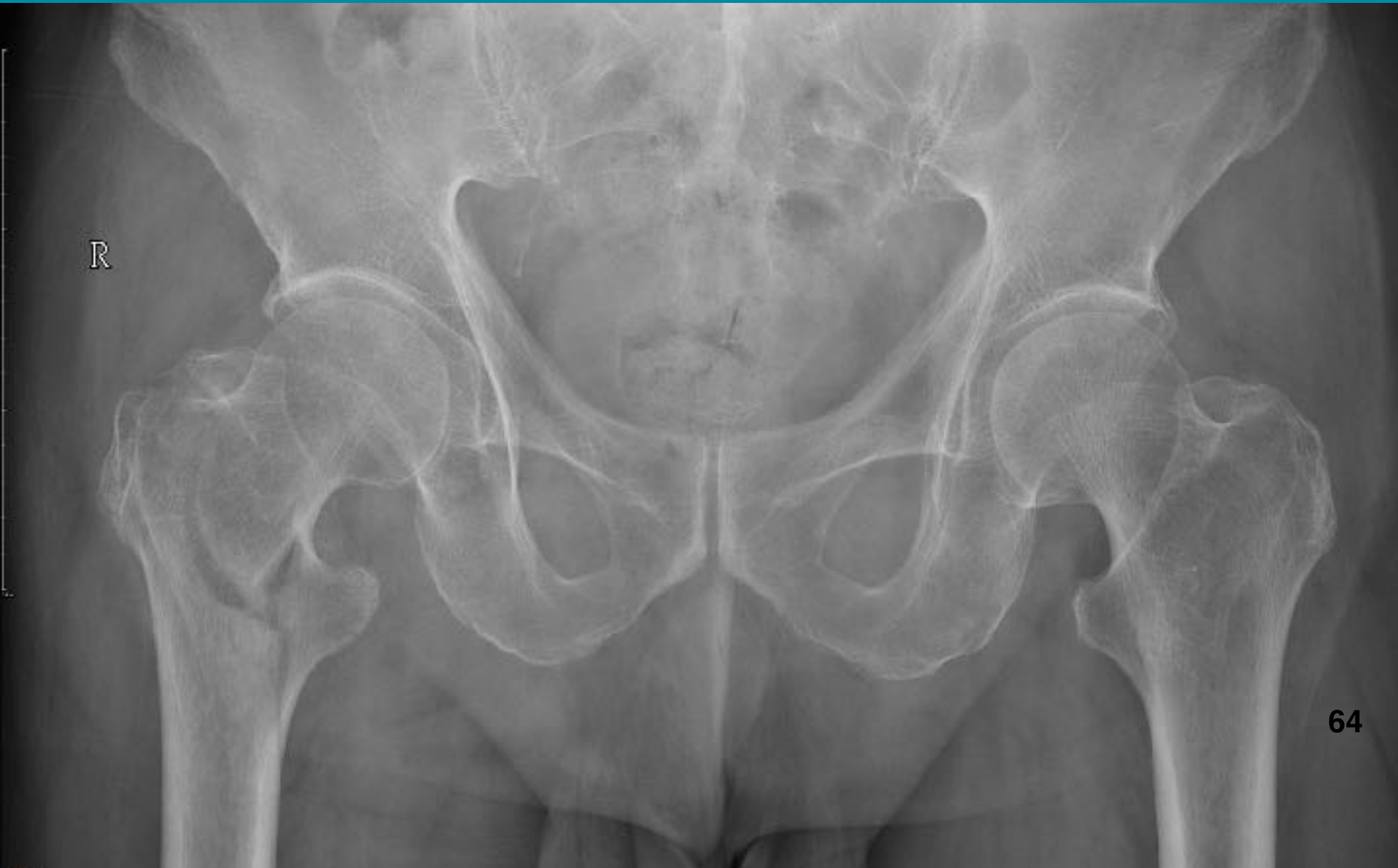

2.5cm

Left femoral painful swelling

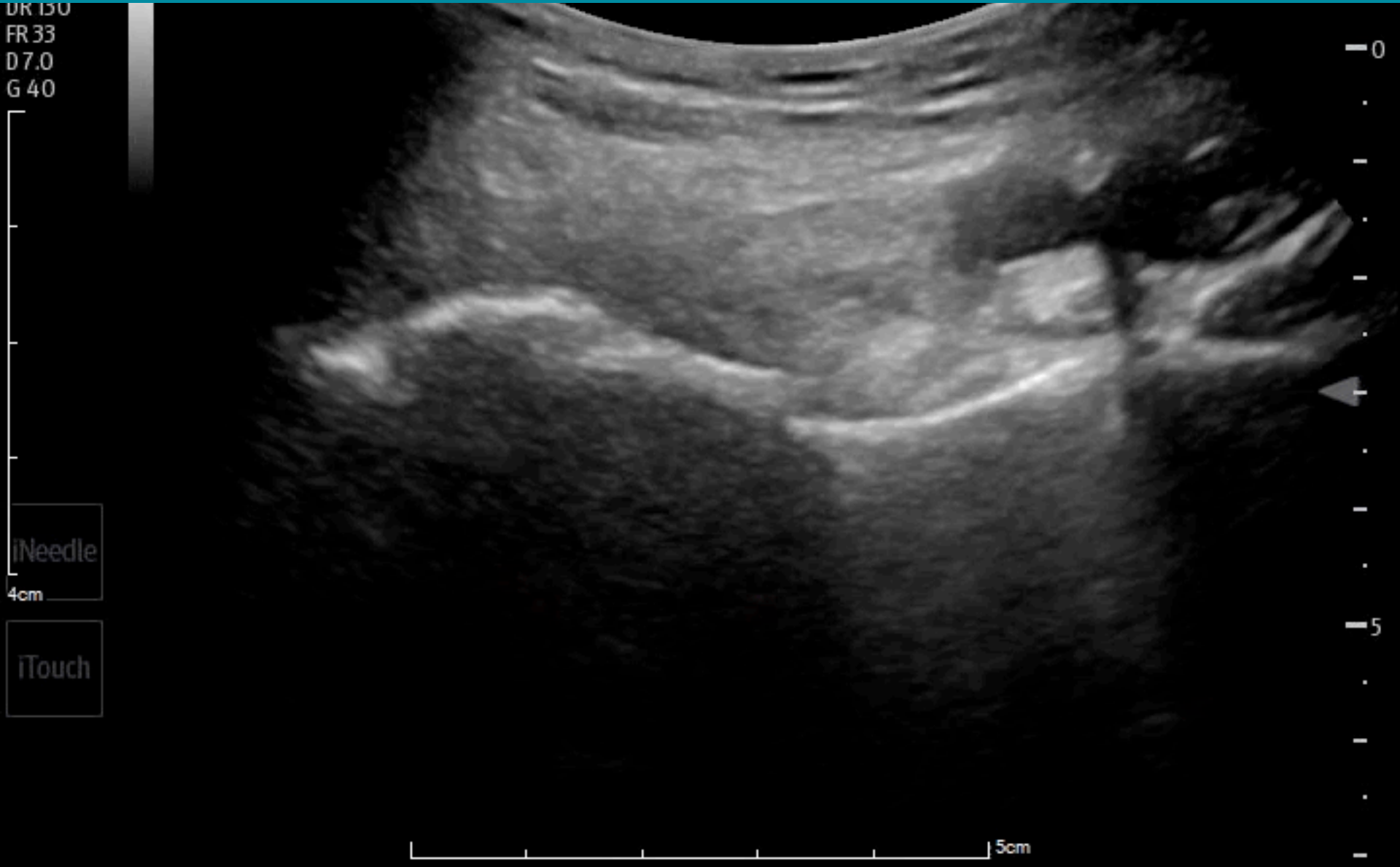

81F, NERVE BLOCK FOR ITC FRACTURE



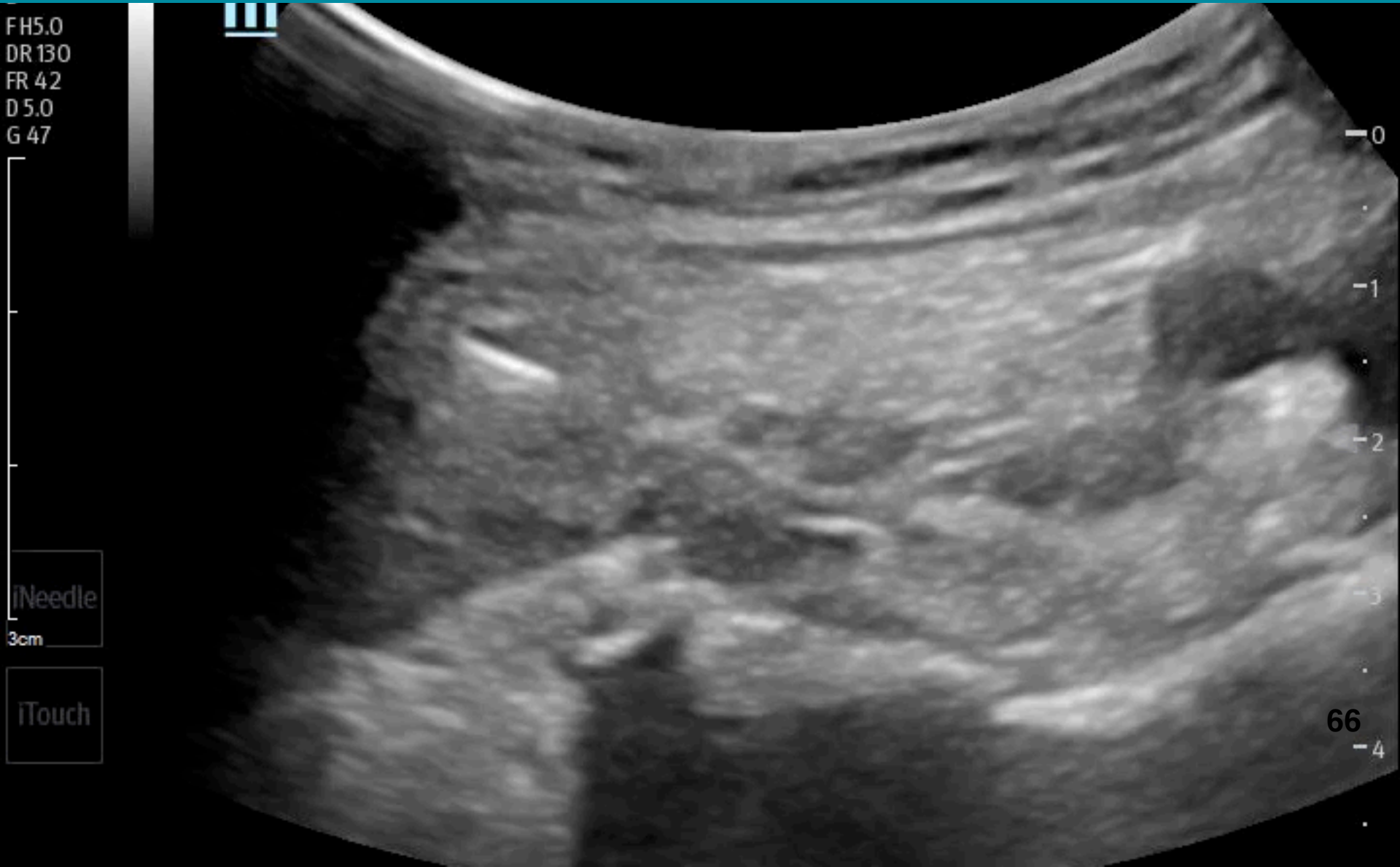
PENG BLOCK

PEricapsular Nerve Group block



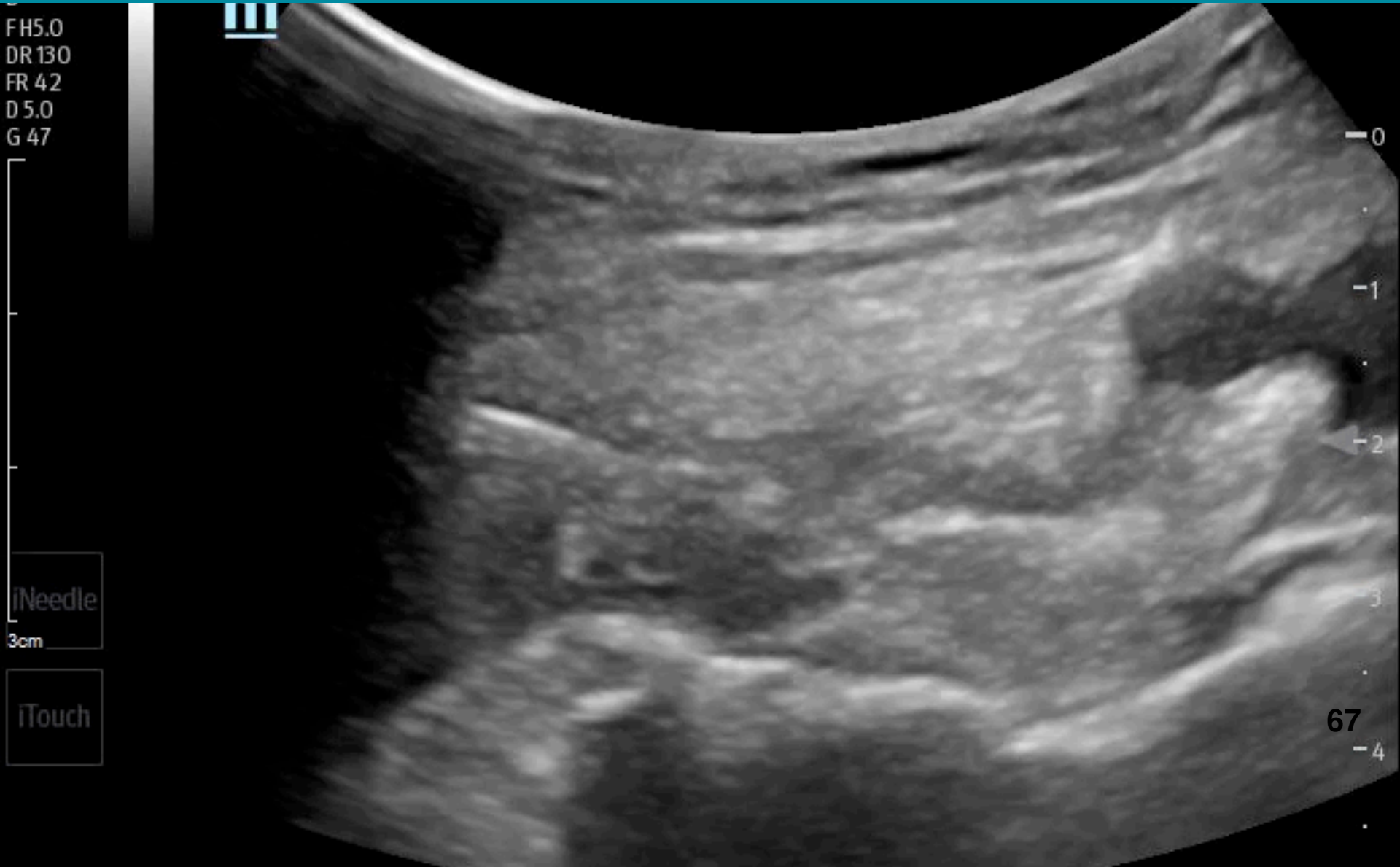
PENG BLOCK

PEricapsular Nerve Group block



PENG BLOCK

PEricapsular Nerve Group block



ANISOTROPY

Femoral nerve

B

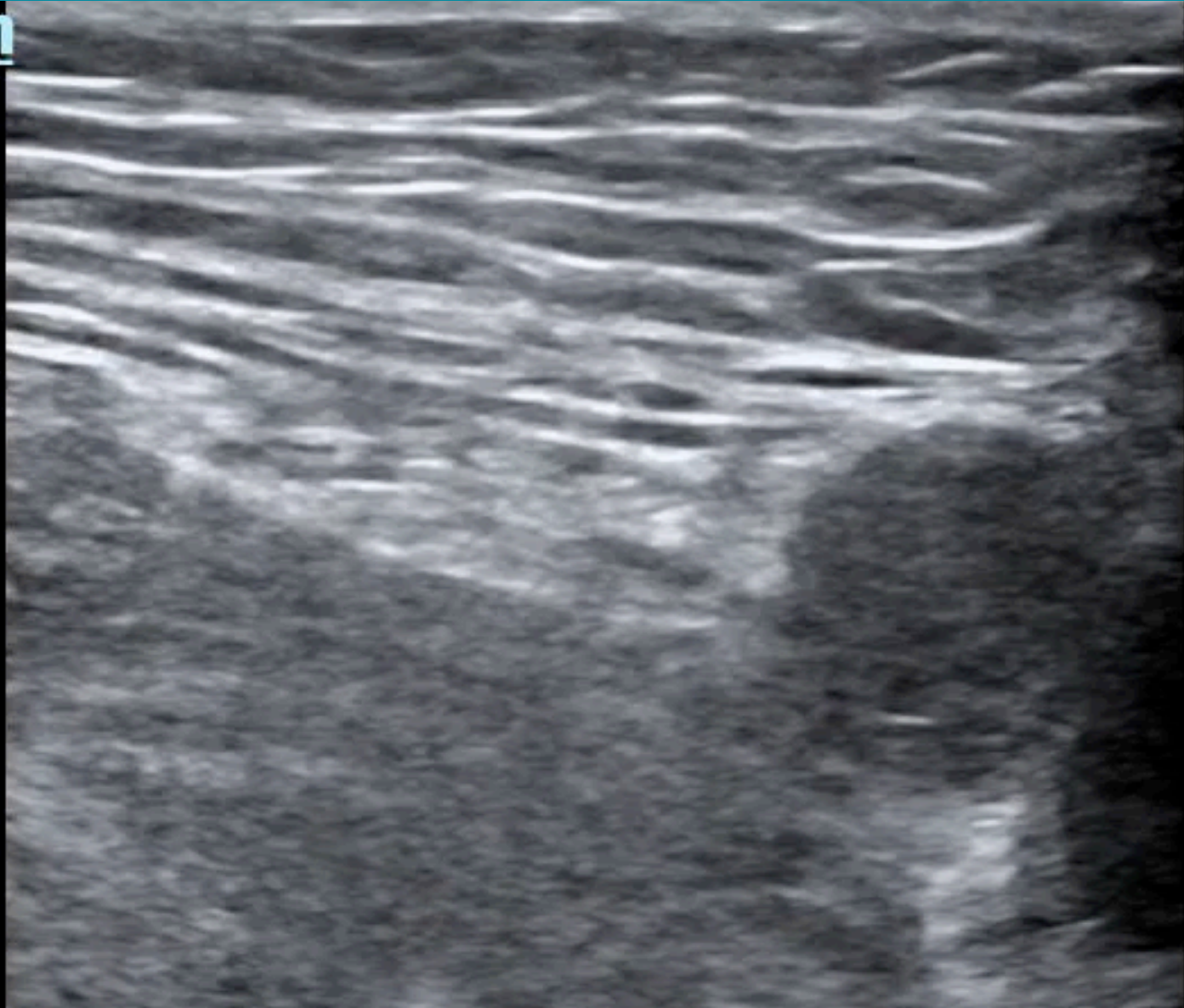
F5.4~11.5

DR 105

FR 41

D 3.5

G 50



0

-1

-2

-3



1cm

iNeedle

iTouch

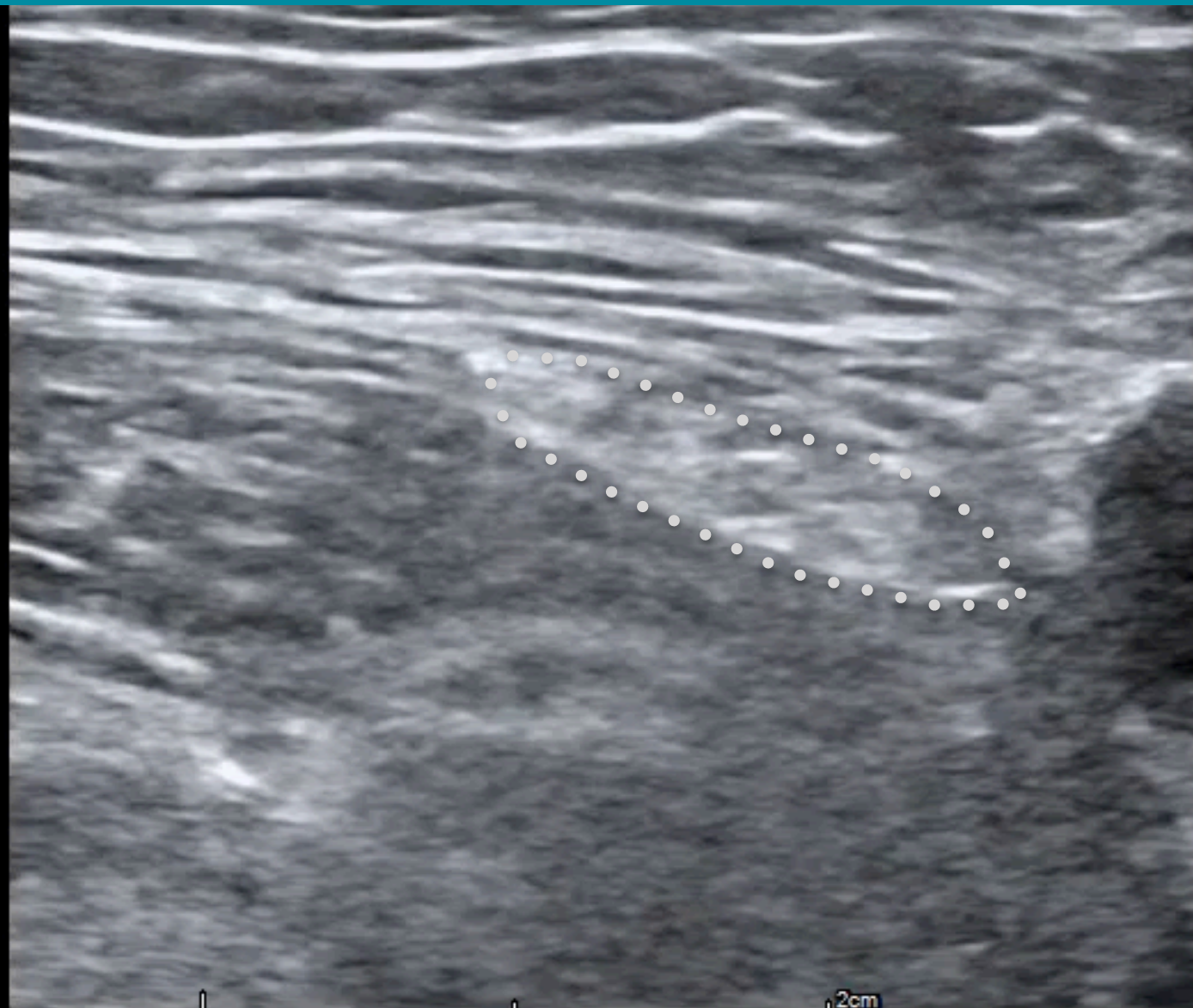
FEMORAL NERVE

DR 105
FR 41
D3.5
G50



iNeedle

iTouch



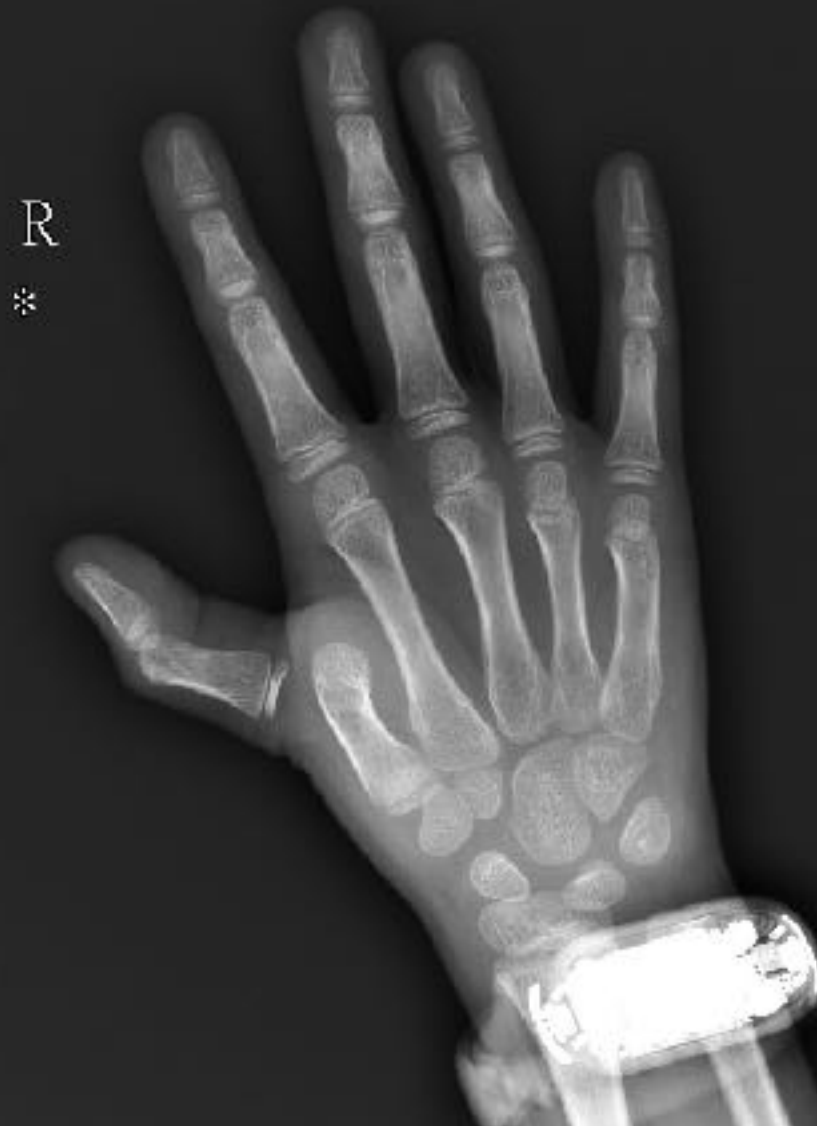-1

-2

-3

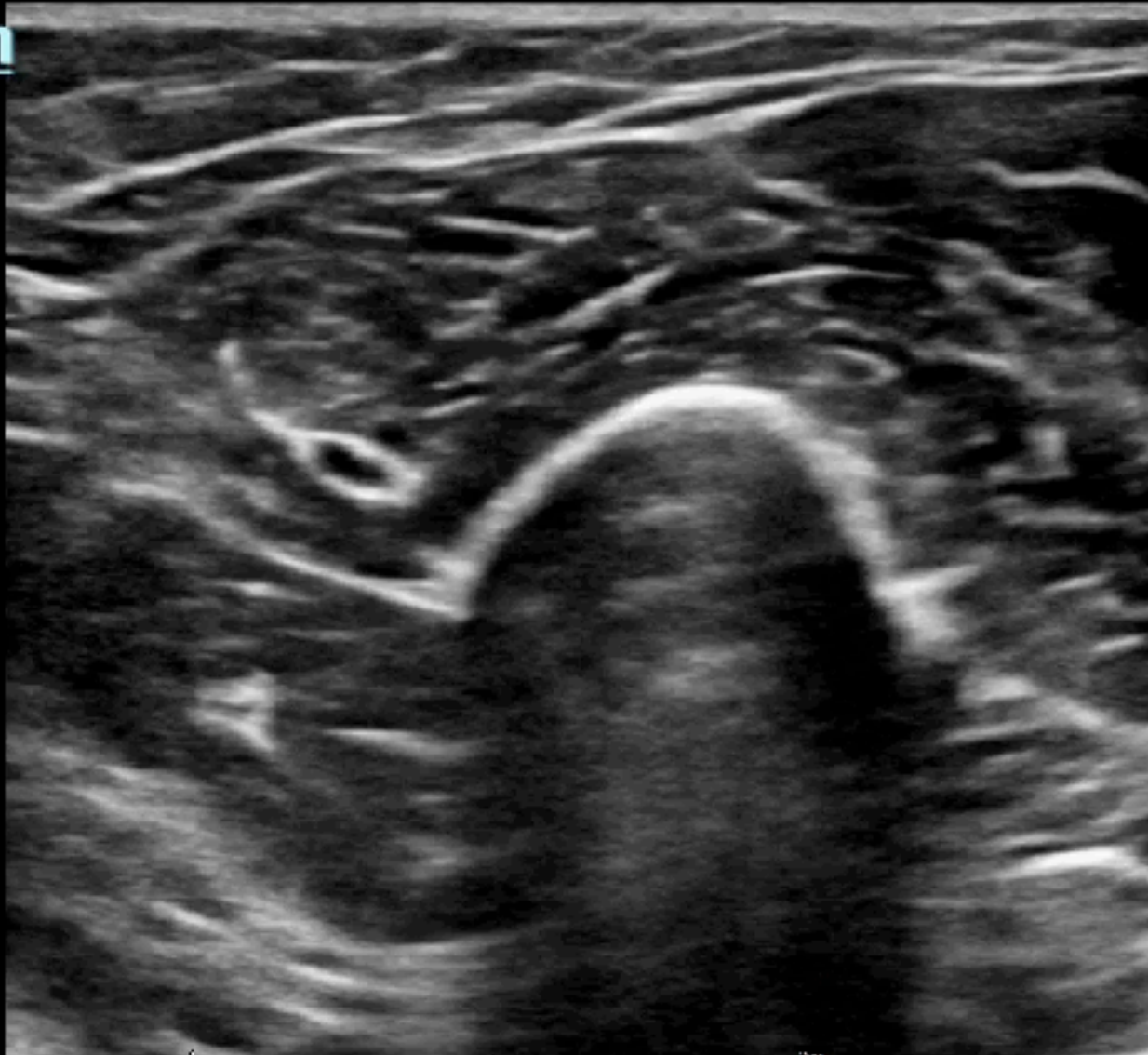2cm

10M，右大拇指被足球踢到後變形



RADIAL NERVE ABOVE ELBOW

B
F 6.6-13.0
DR 115
FR 45
D 3.5
G 60



0

-1

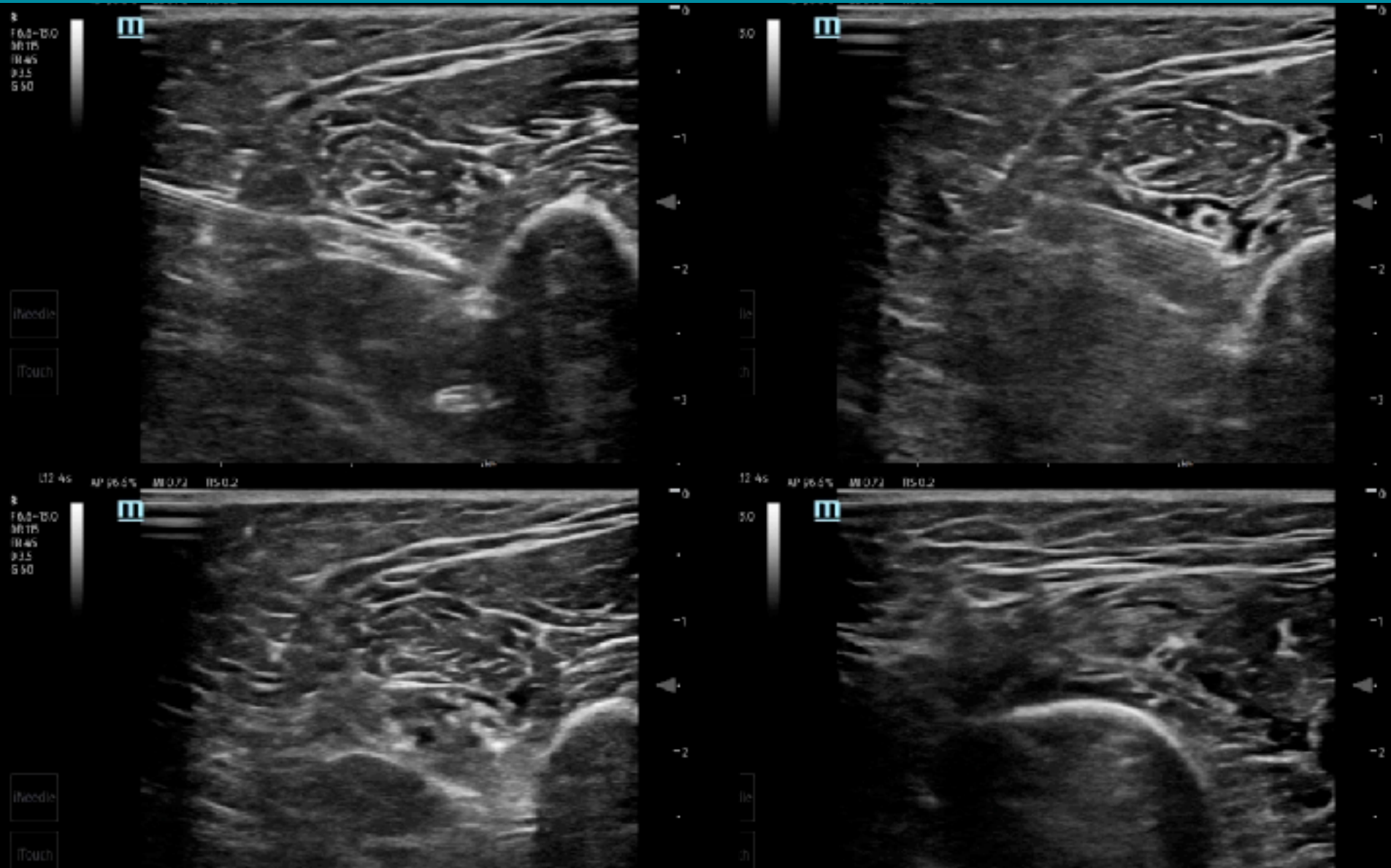
-2

-3

iNeedle

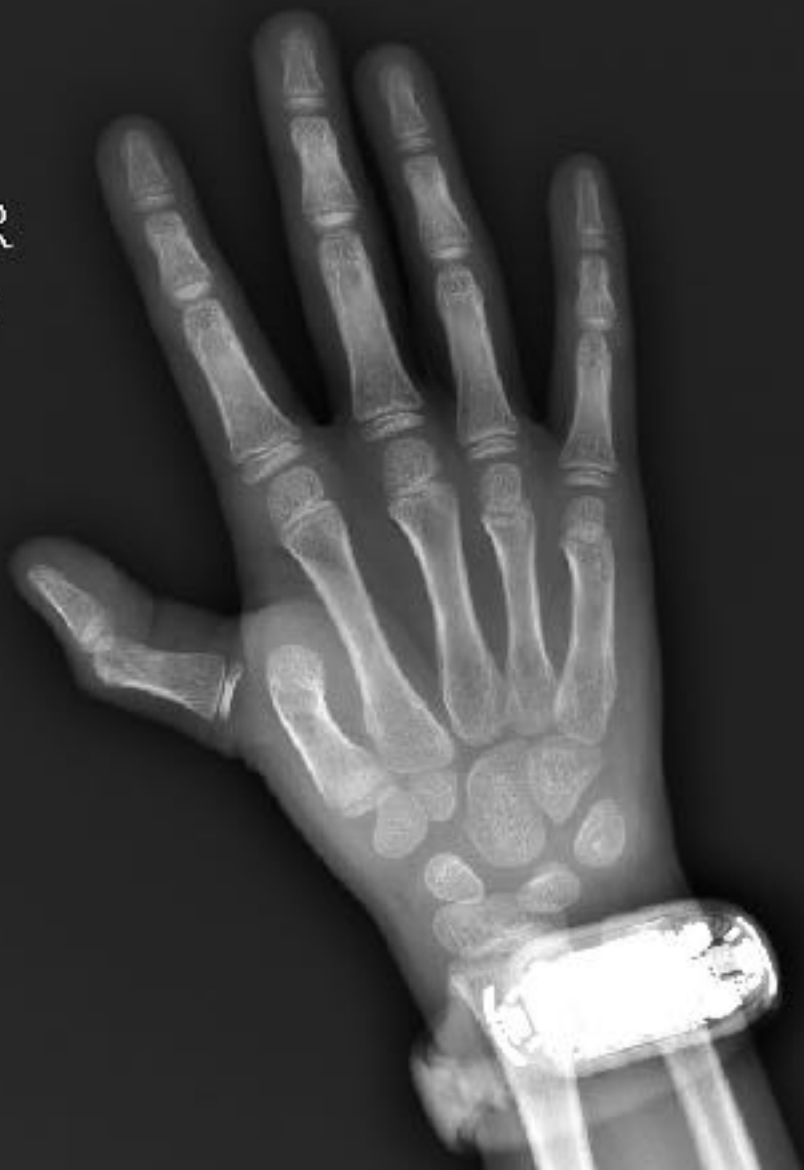iTouch

RADIAL NERVE BLOCK

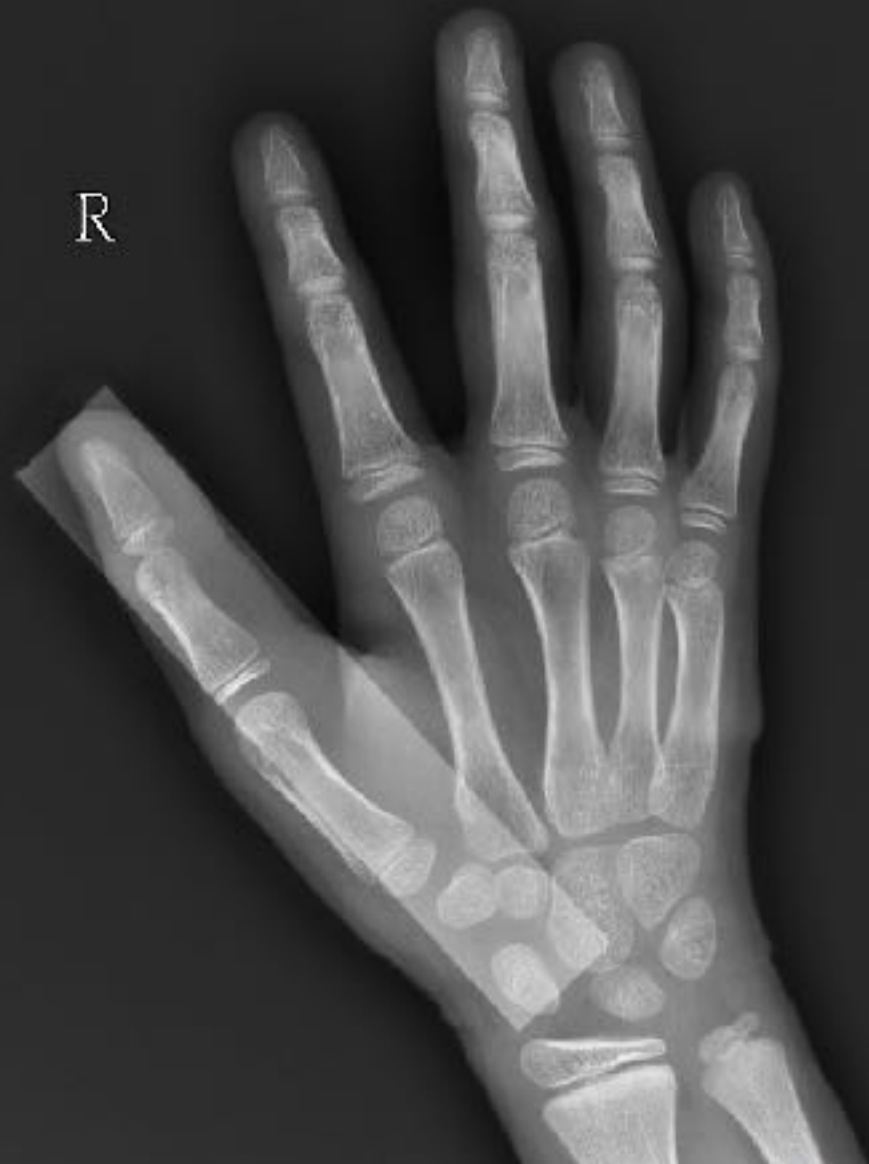

SUCCESSFUL REDUCTION AFTER RN BLOCK

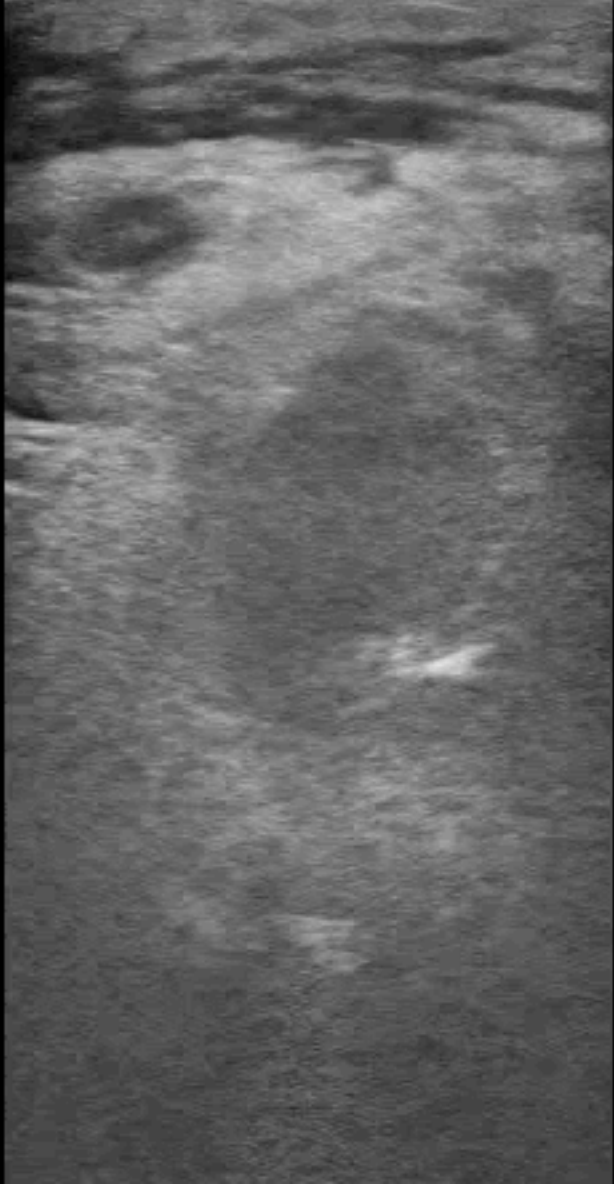
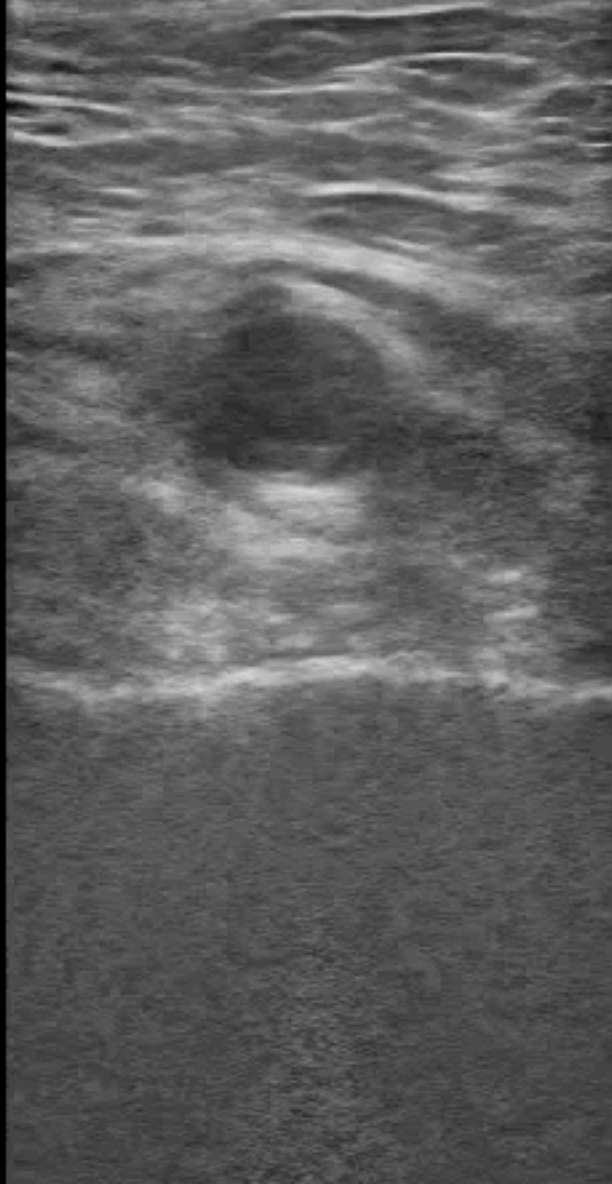
R
*



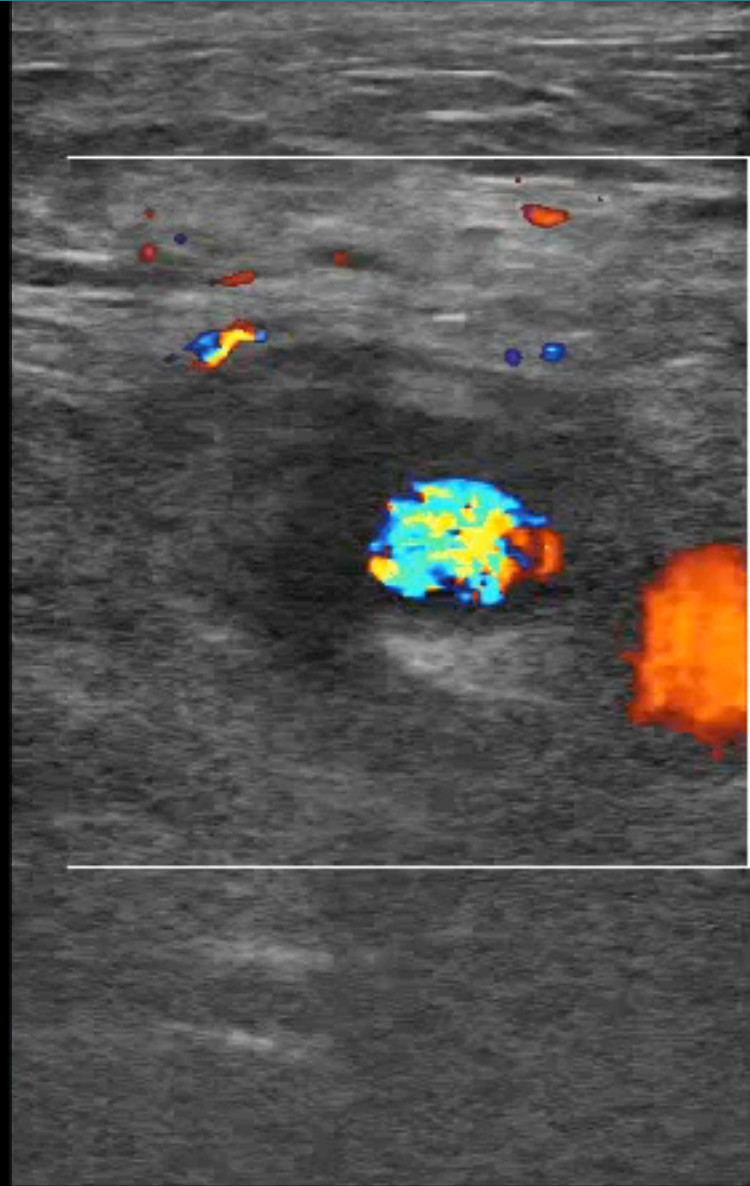

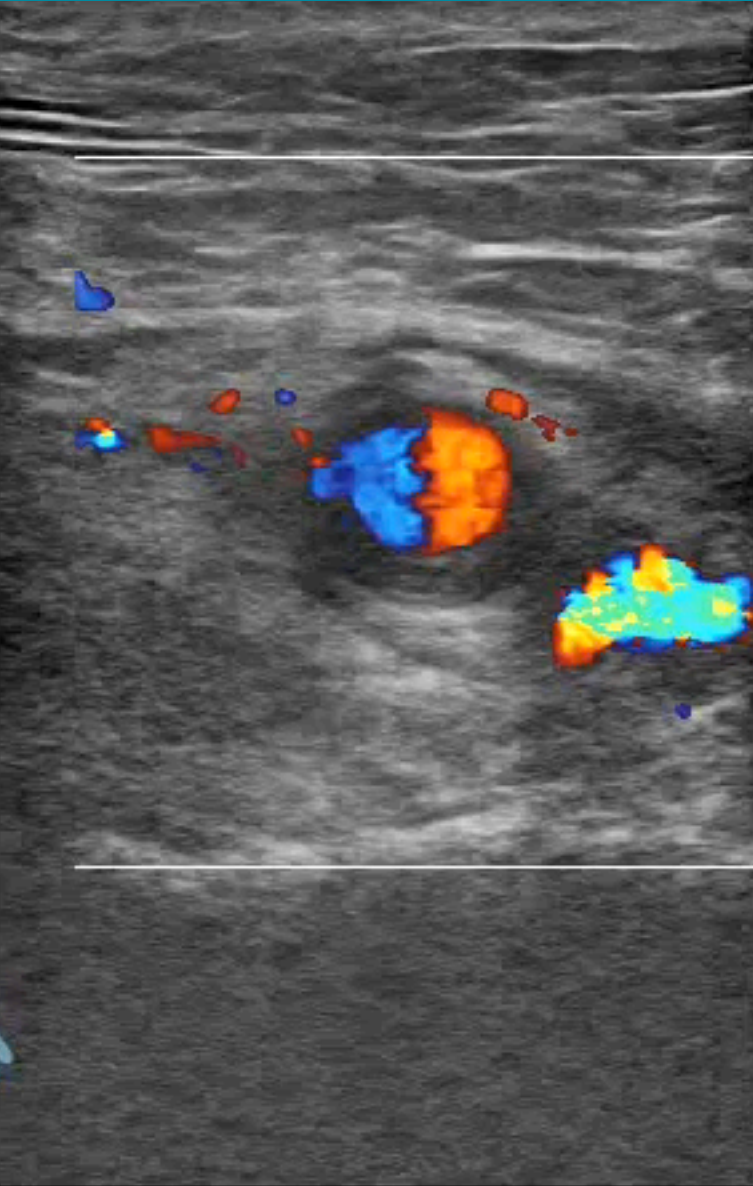
R



**65M, CVA WITH LEFT SIDE WEAKNESS
RIGHT INGUINAL CARBUNCLE & PUS DISCHARGE**

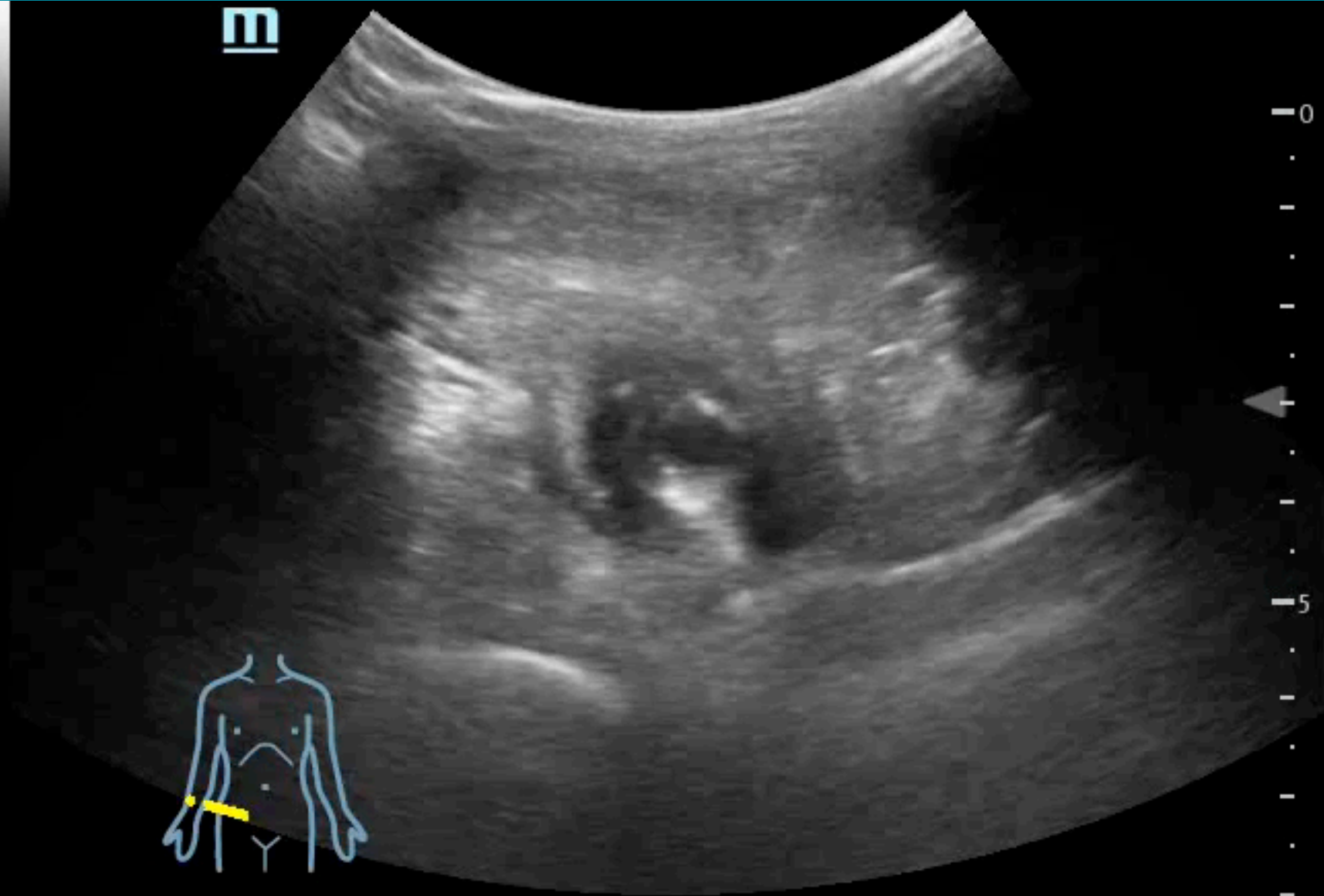


WBC 10050; CRP 12.55; GLU 237; PUS: KP



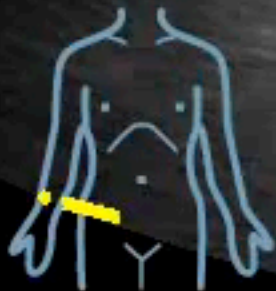WBC 10050; CRP 12.55; GLU 237; PUS: KP

FH5.0
DR 115
FR 25
D 8.0
G 63



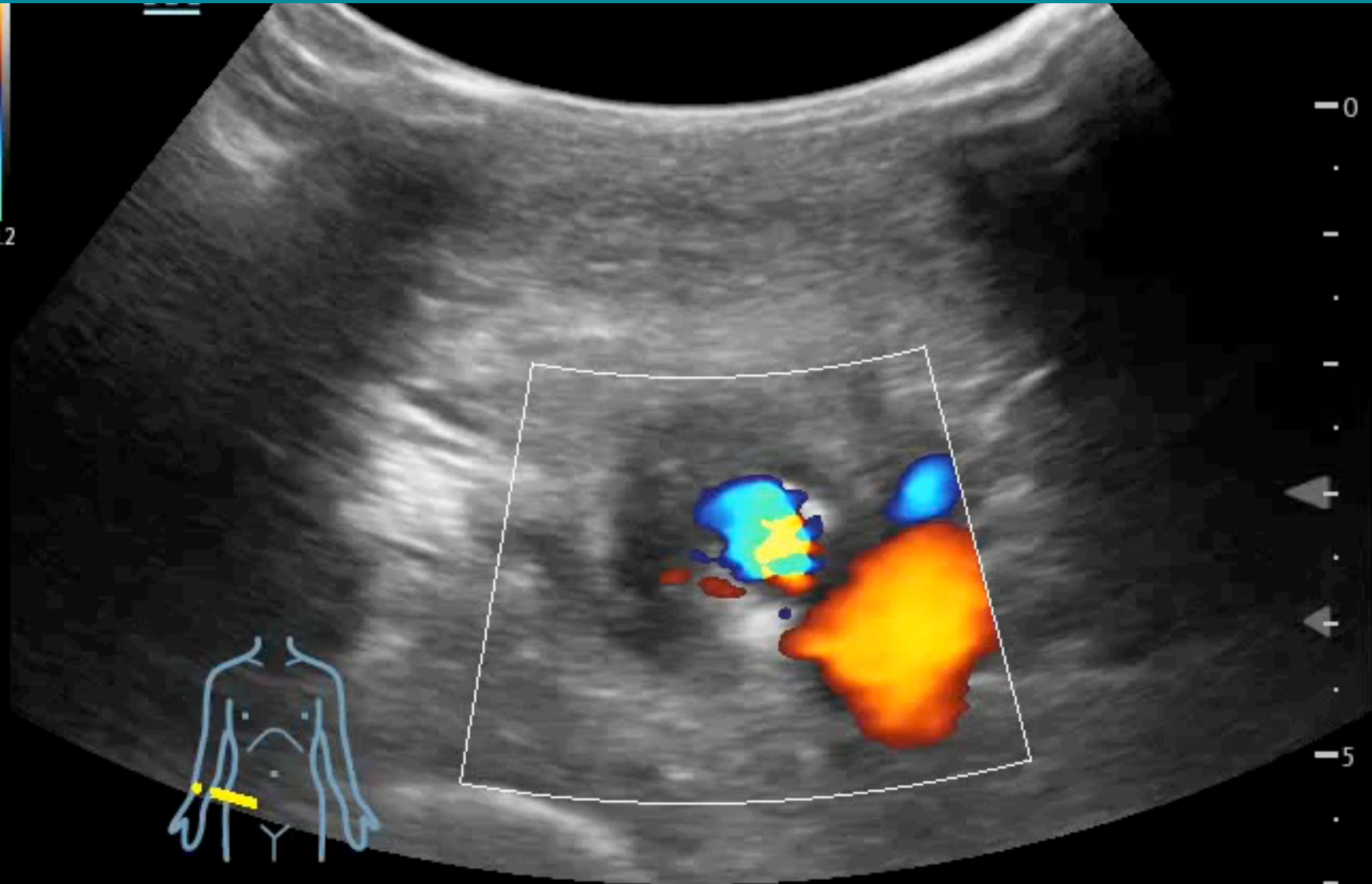
iNeedle

iTouch



WBC 10050; CRP 12.55; GLU 237; PUS: KP

DR 115
FR 20
D 6.0
G 63
C
F2.5 /G30
WF171
PRF0.6k -9.2

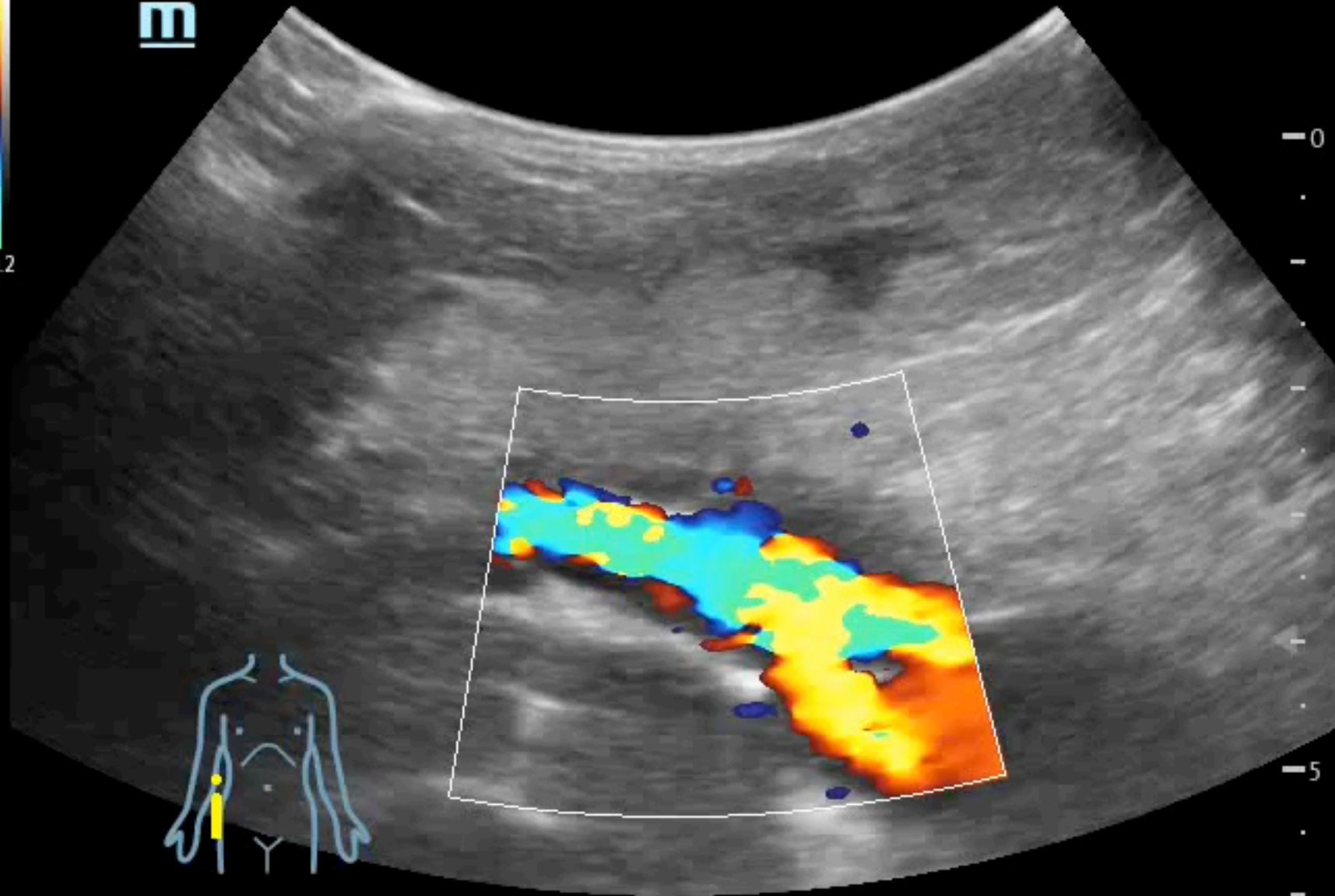


iNeedle

iTouch

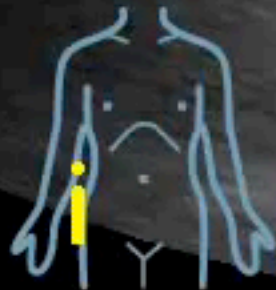WBC 10050; CRP 12.55; GLU 237; PUS: KP

FH5.0
DR 115
FR 20
D 6.0
G 63
C
F 2.5 /G 26
WF171
PRF0.6k -9.2

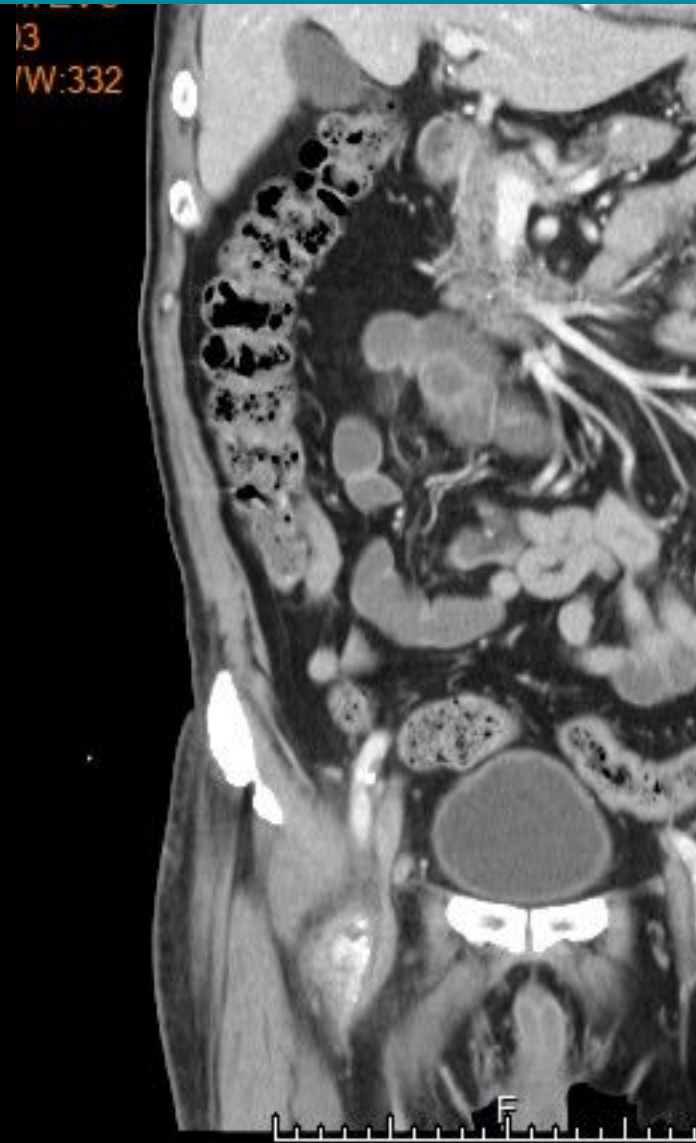
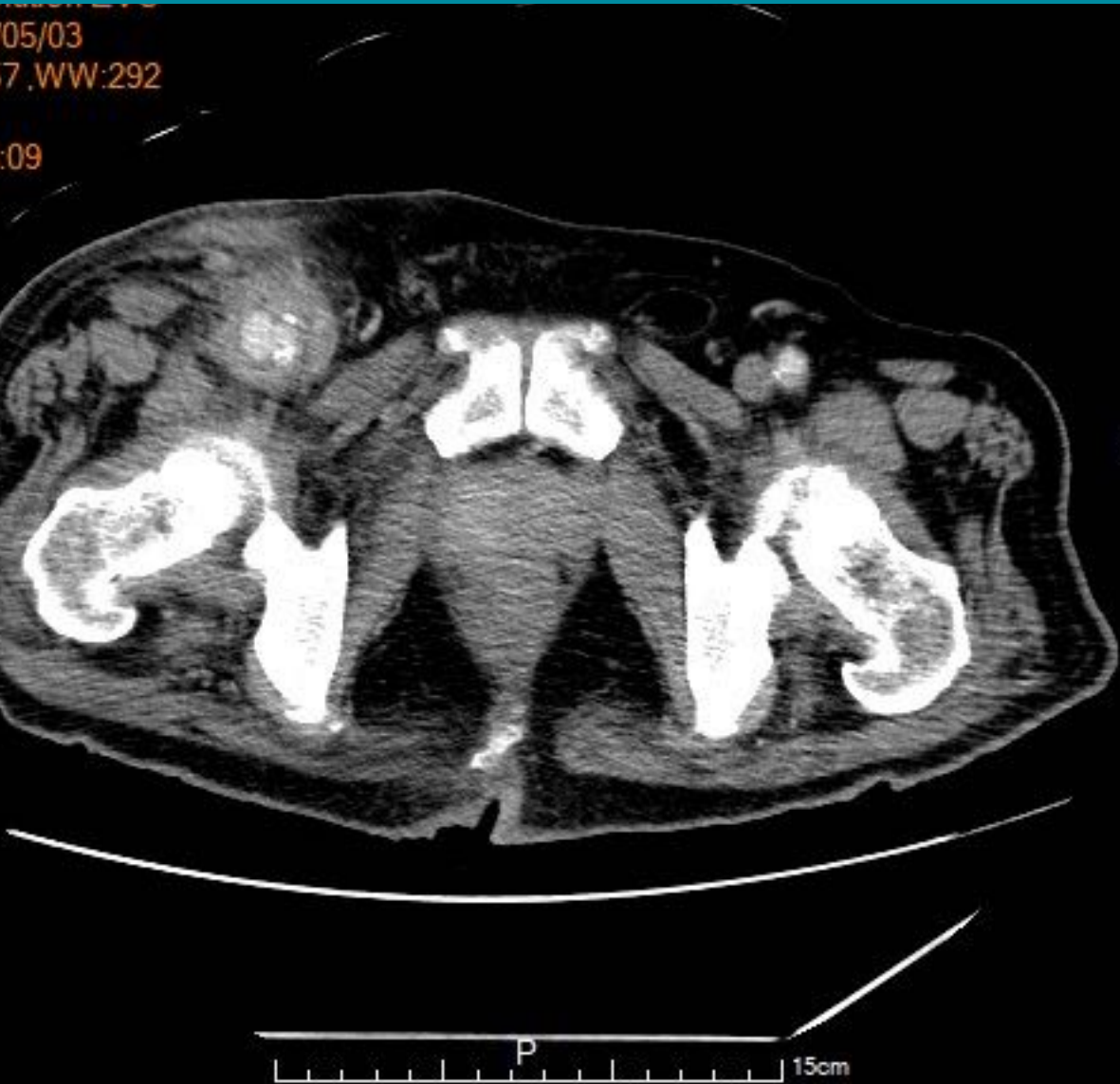

iNeedle

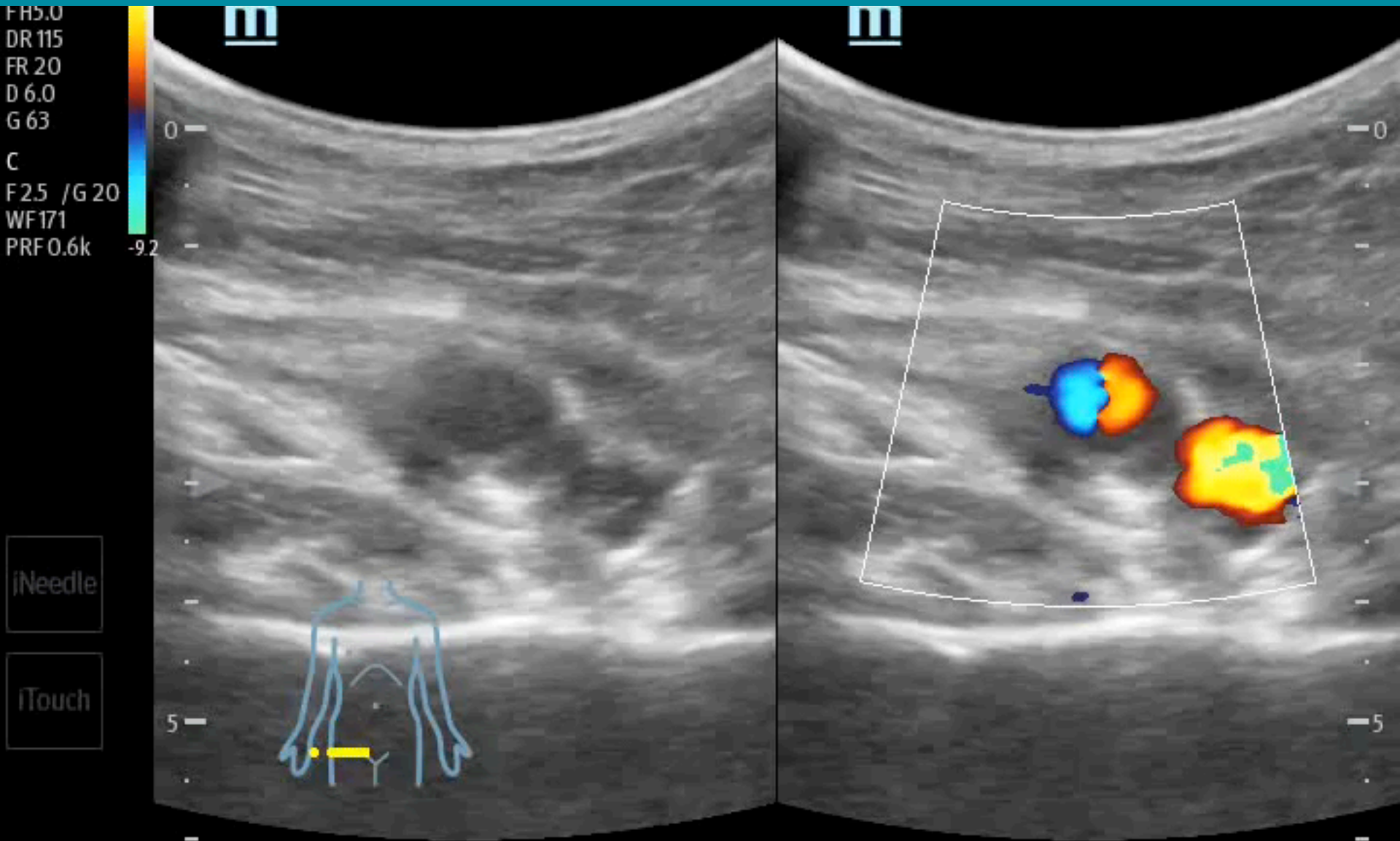
iTouch

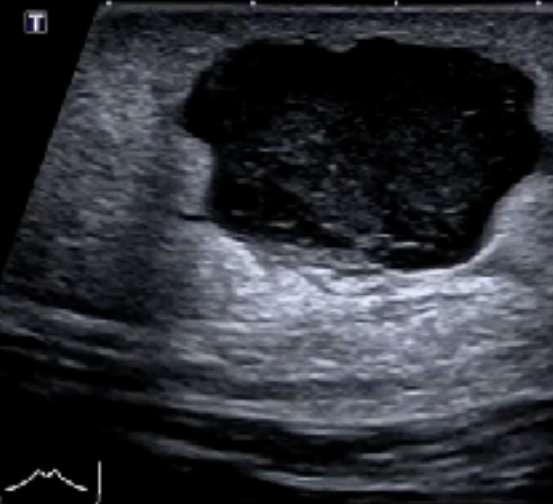


MYCOTIC ANEURYSM

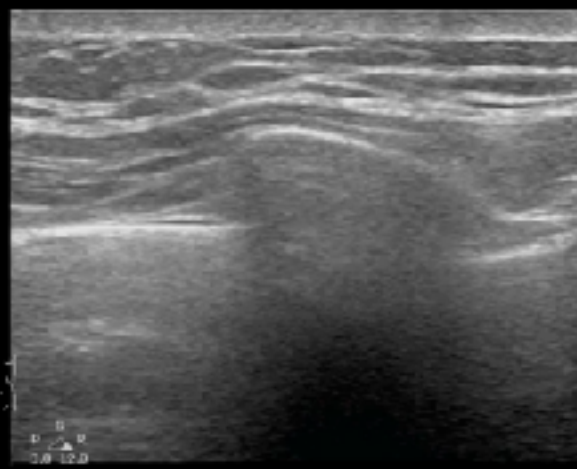


MYCOTIC ANEURYSM

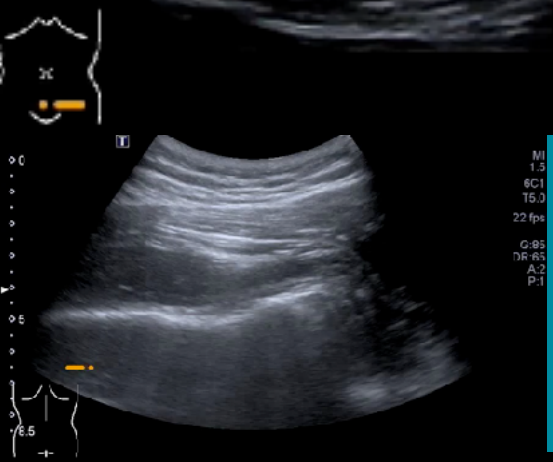
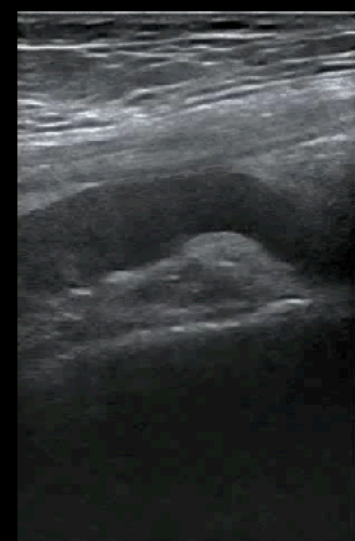



Superficial
L12-3
46 Hz
3.0cm
70
Res
Gn 96
C 56
3/2/1



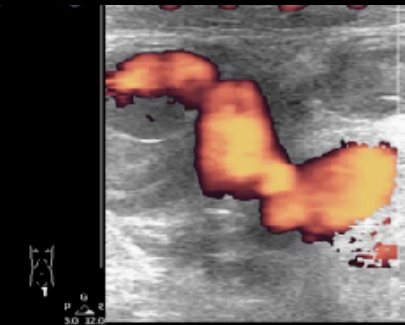
m
3.0cm
i



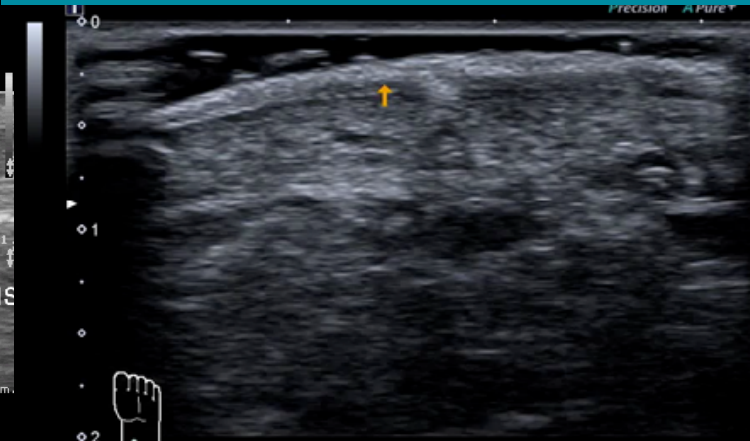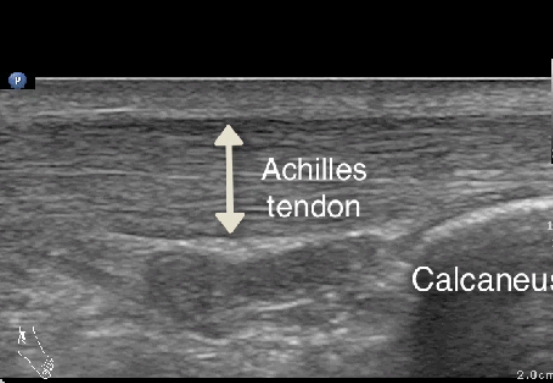
MI 1.5
6C1
T5.0
22 fps
G:89
DR:65
A:2
P:1

MSK US in ER

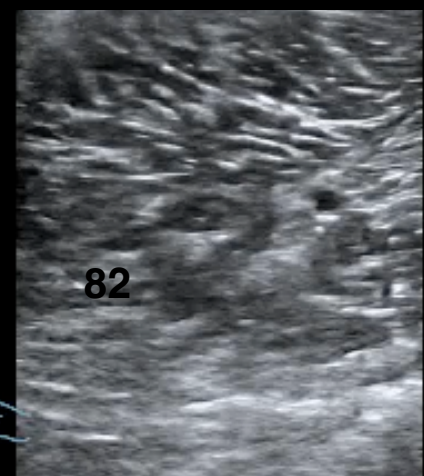
L12-3
24 Hz
4.0cm
2D
Res
Gn 6U
C 56
3/2/2



EPA
5.0 MHz
Gn 60
1/5/5
Filt: Med
Baseline 2



Precision A Pure
MI 1.5
11L4
diffT9.0
30 fps
G:92
DR:60
A:6
P:3



U
P R
3.0 12.0

