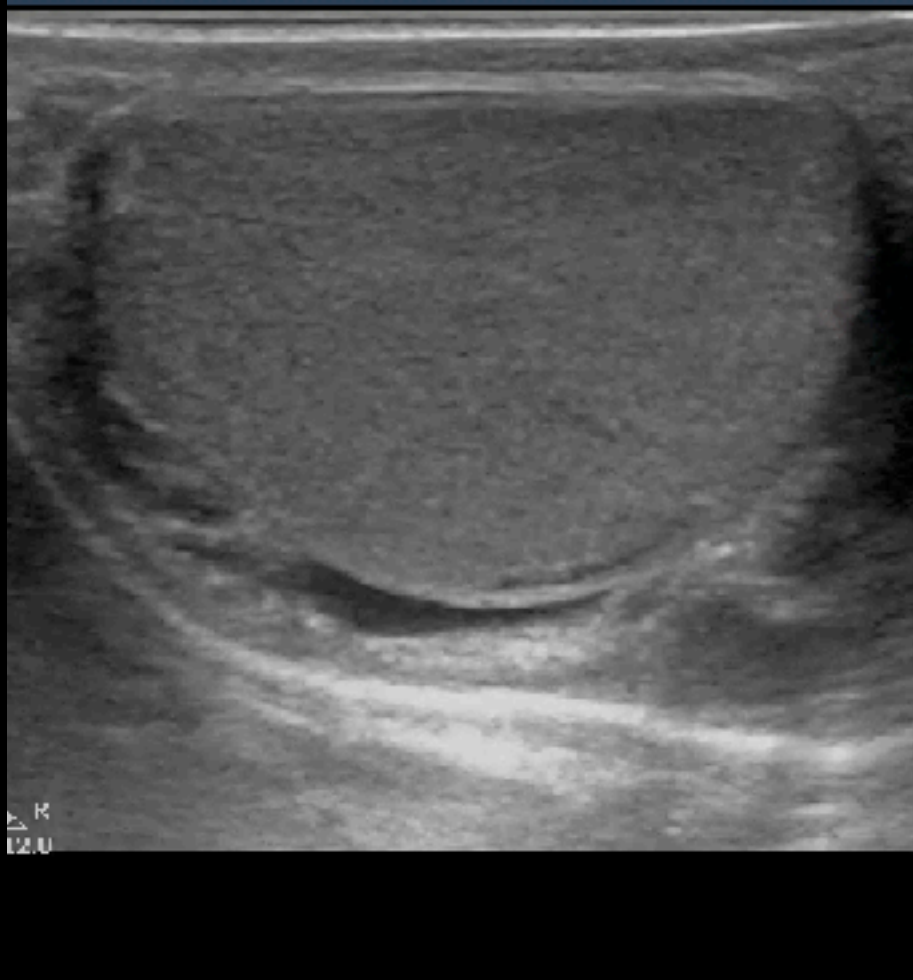
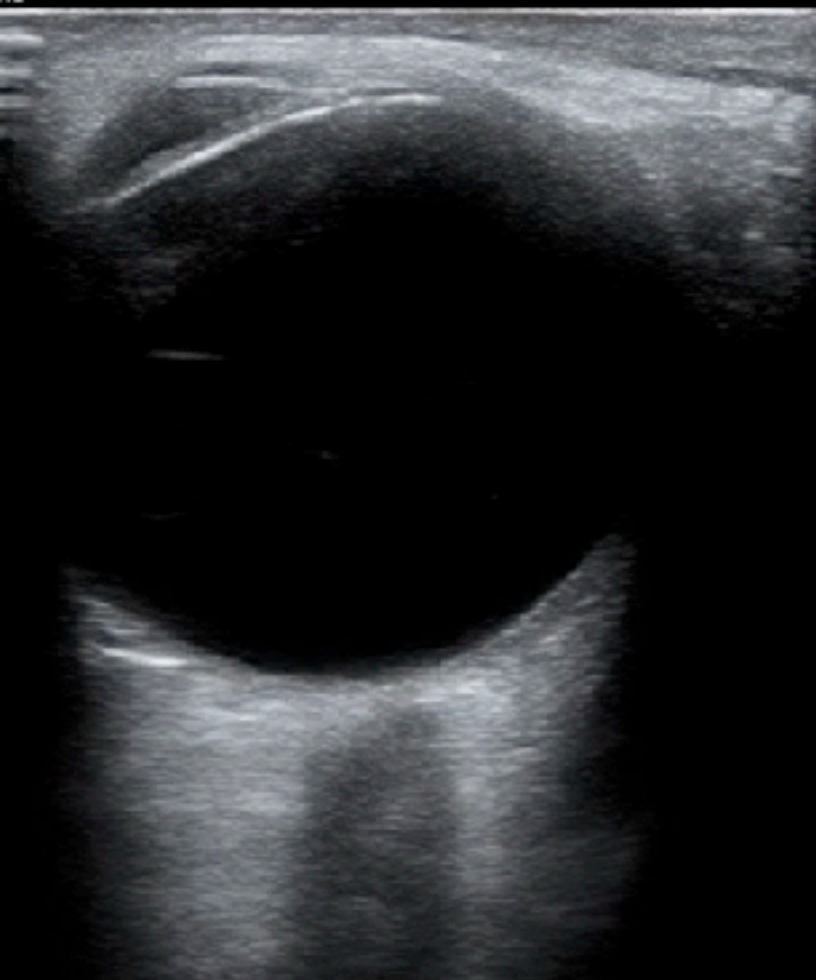
KEEP YOUR EYE ON THE BALL
POINT-OF-CARE ULTRASOUND FOR EYEBALL & TESTIS

陳國智 醫師 / POCUSacademy.com



台灣疼痛醫學會專科醫師
急診超音波臨床評核醫師
醫用超音波學會指導醫師
WINFOCUS director / instructor
Certified Interventional Pain Sonologist

急診 / 重症 / 介入 / 急性疼痛

經歷

新光急診超音波訓練中心主任
西園醫院急診醫學科主任
急診醫學會超音波委員會主委
台灣疼痛醫學會大體模擬手術講師
急救加護醫學會重症超音波負責人

juice119@gmail.com



診
斷

監
測

Diagnostician



介
入

Interventionist

POINT OF CARE ULTRASOUND

Provider - Probe - Patient

~ 存在於臨床需求之所在 ~

POCUS應用/學習模板: I-AIM

Indication

Point / 掃描目的



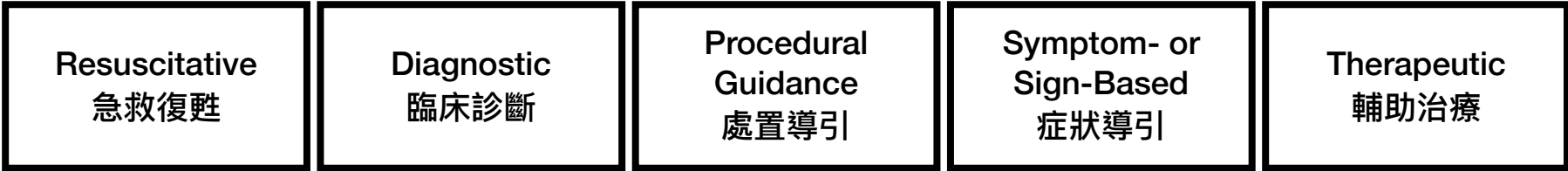Acquire
取得影像



Interpret
判讀影像



Make decision
臨床決策



Core Applications (2023 ACEP Emergency Ultrasound Guidelines)
15項急診超音波核心應用

陳國智醫師

Aorta
 DVT
 Trauma
 Thoracic/Airway
 Cardia/HD assessment

Procedural Guidance
 US-guided NB
 Testicular
 Ocular
 Skin & Soft tissue

Hepatobiliary
 Urinary tract
 Pregnancy
 Bowel
 MSK

解剖

Anatomy



形態

Pattern

診斷

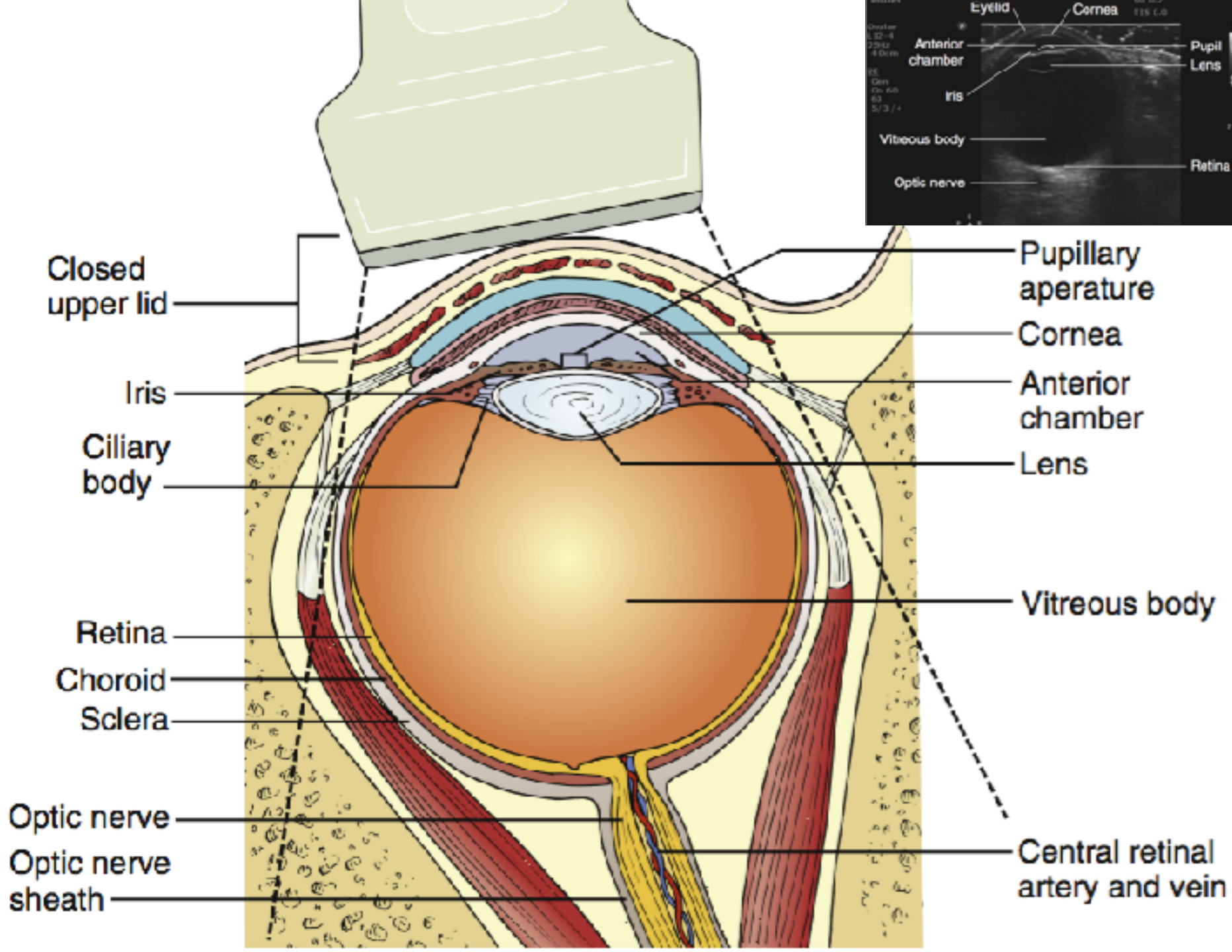
Diagnosis

HOLISTIC ULTRASOUND

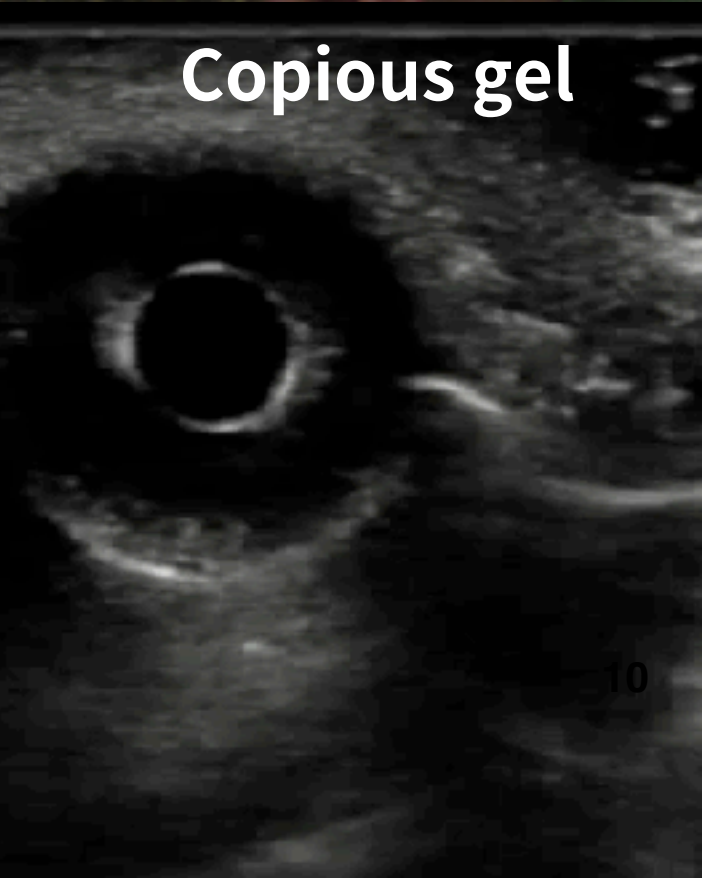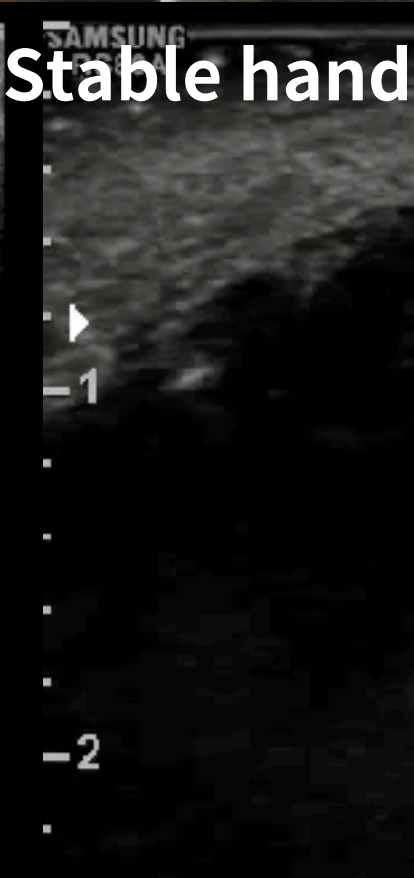
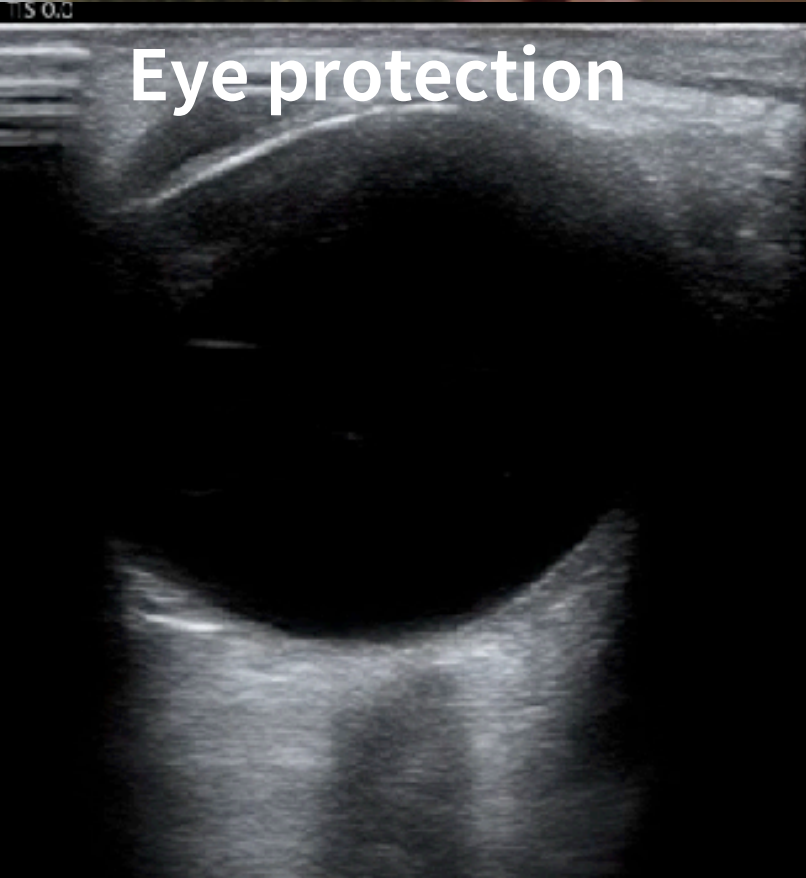
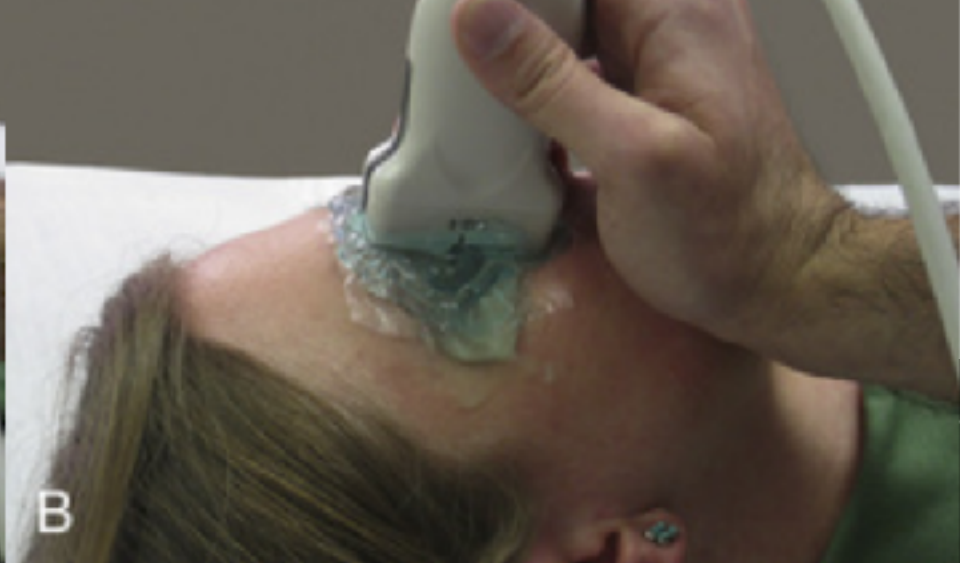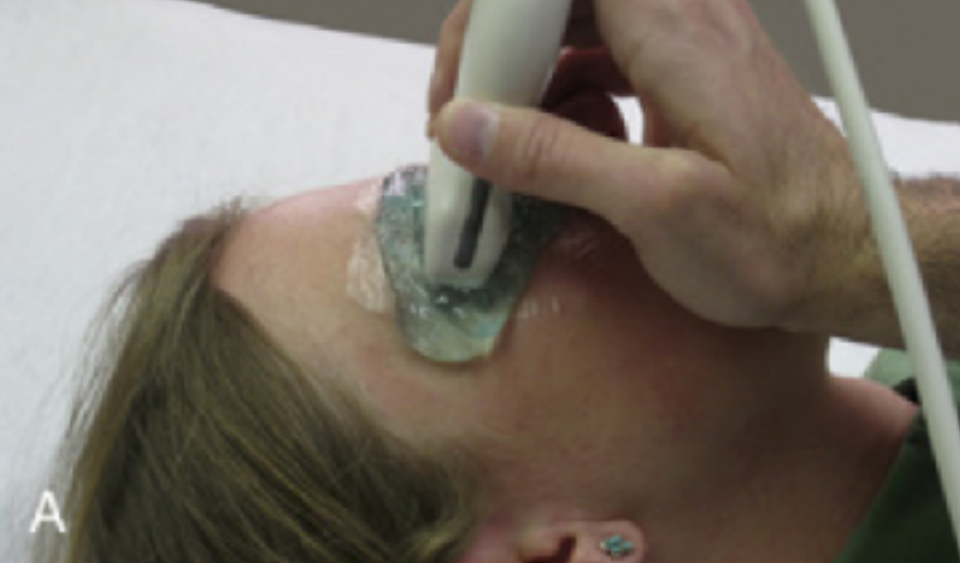Holistic medicine

Treatment that deal with the whole person,
not just the injury or disease

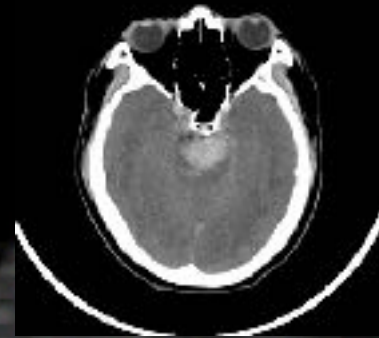
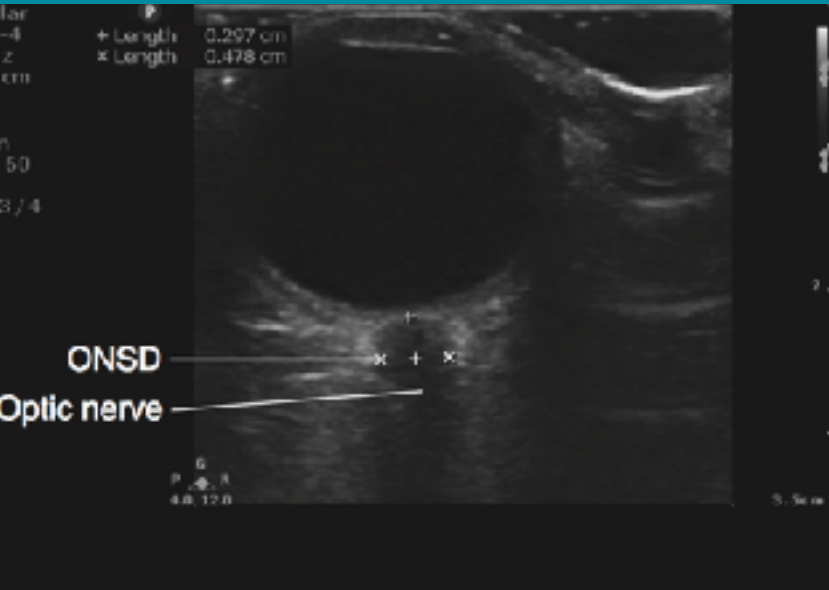








Optic Nerve Sheath Diameter (ONSD)



3mm處測橫軸

5mm >> ICP 20 cmH2O

Sen 87-90%

Spe 79-85%



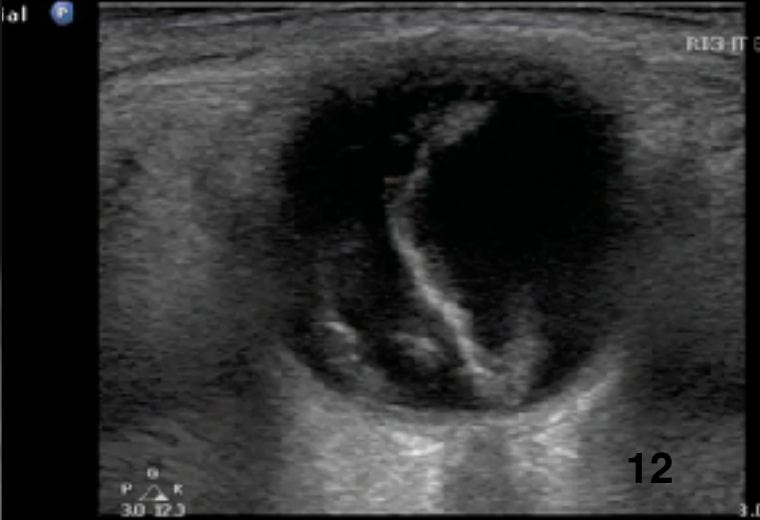
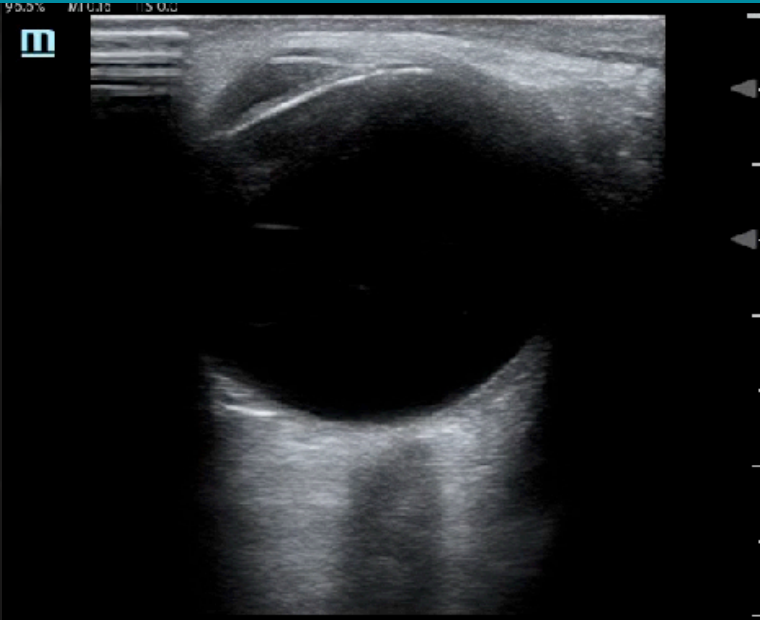Retinal detachment (RD)

Hyperechoic membrane

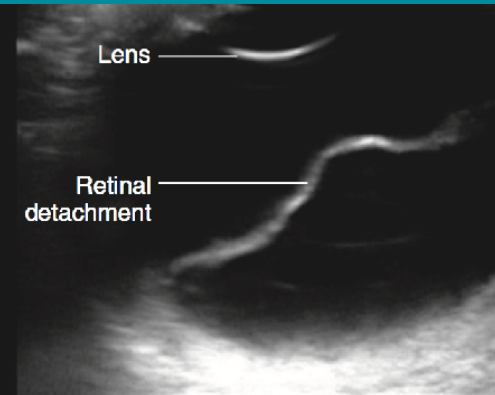
Optic nerve

Lens

Retinal detachment

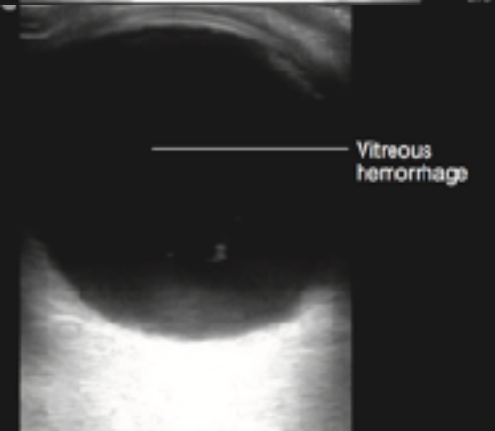
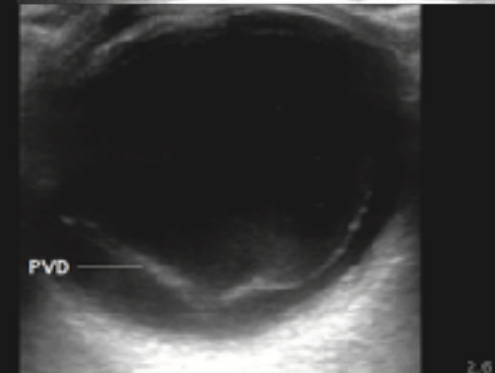
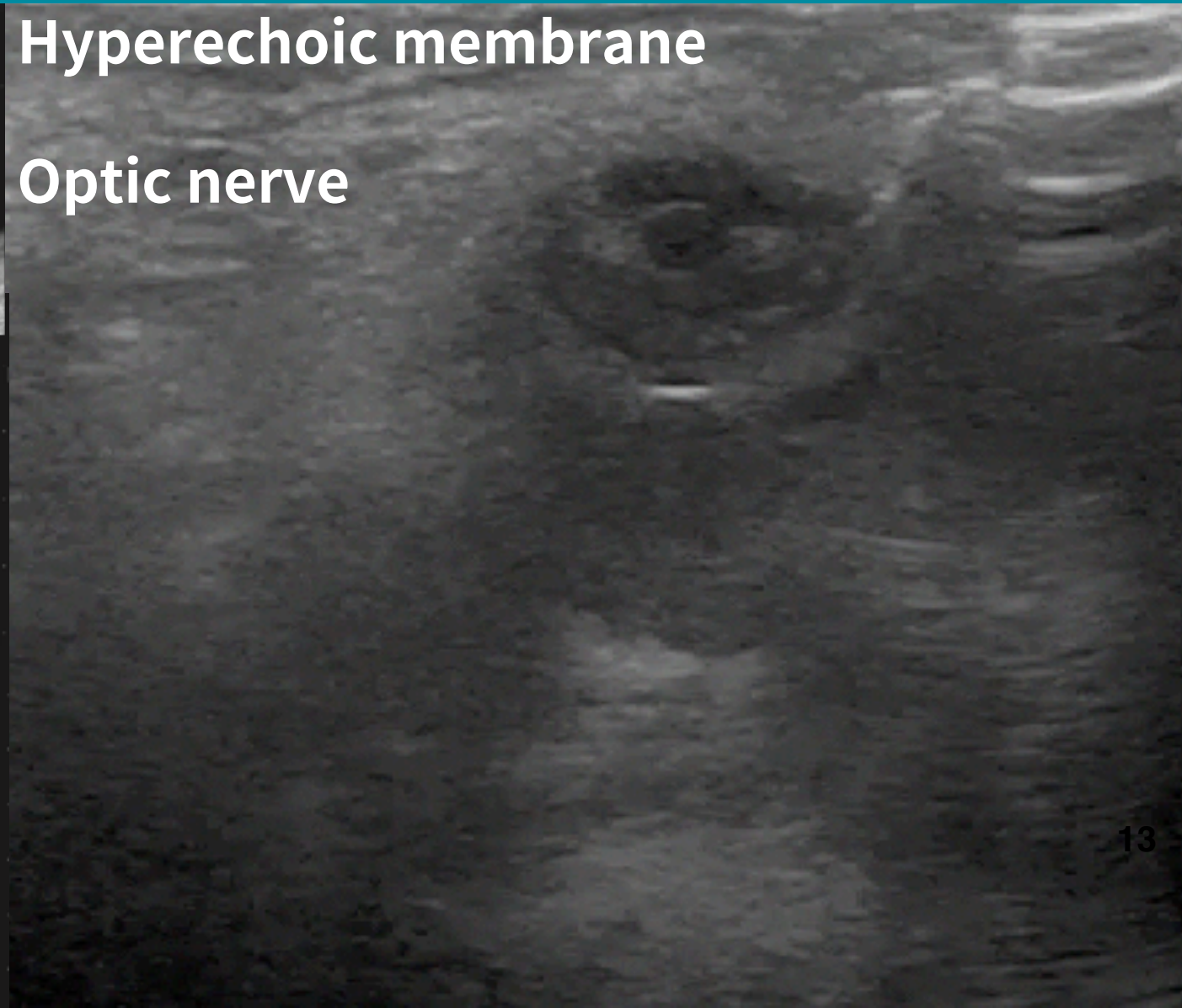


Vitreous detachment (VD) vs hemorrhage

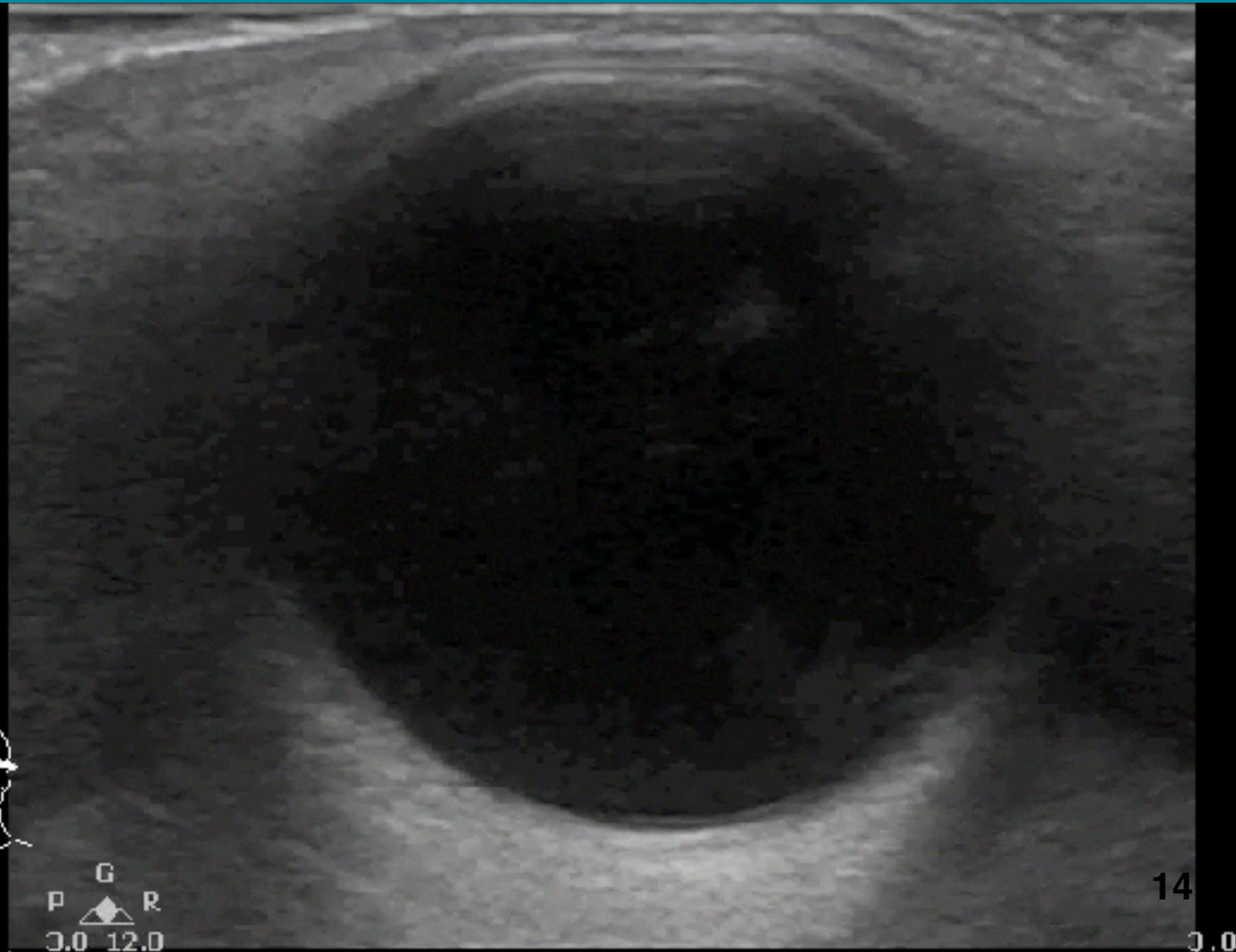
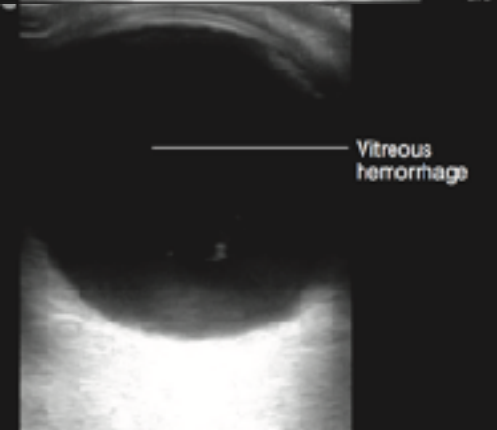
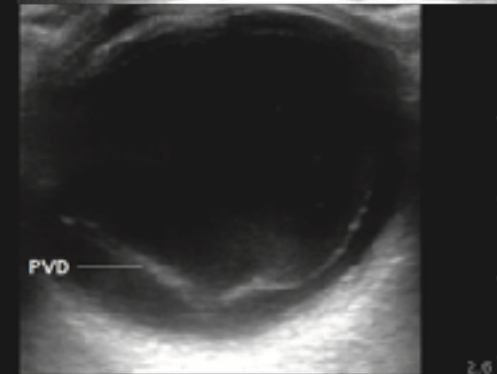
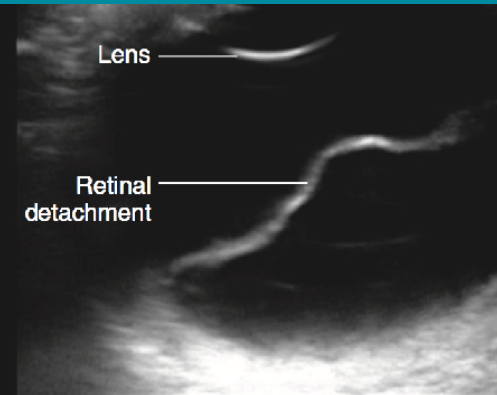


Hyperechoic membrane

Optic nerve

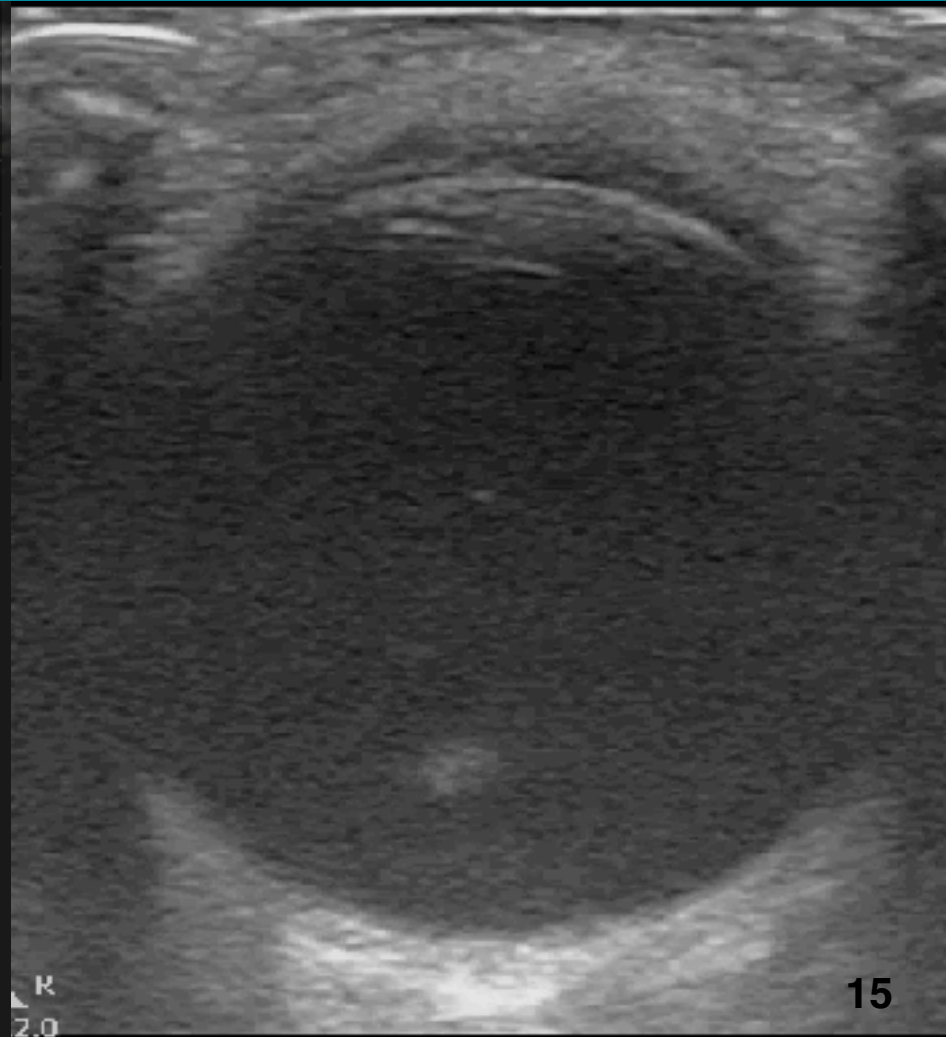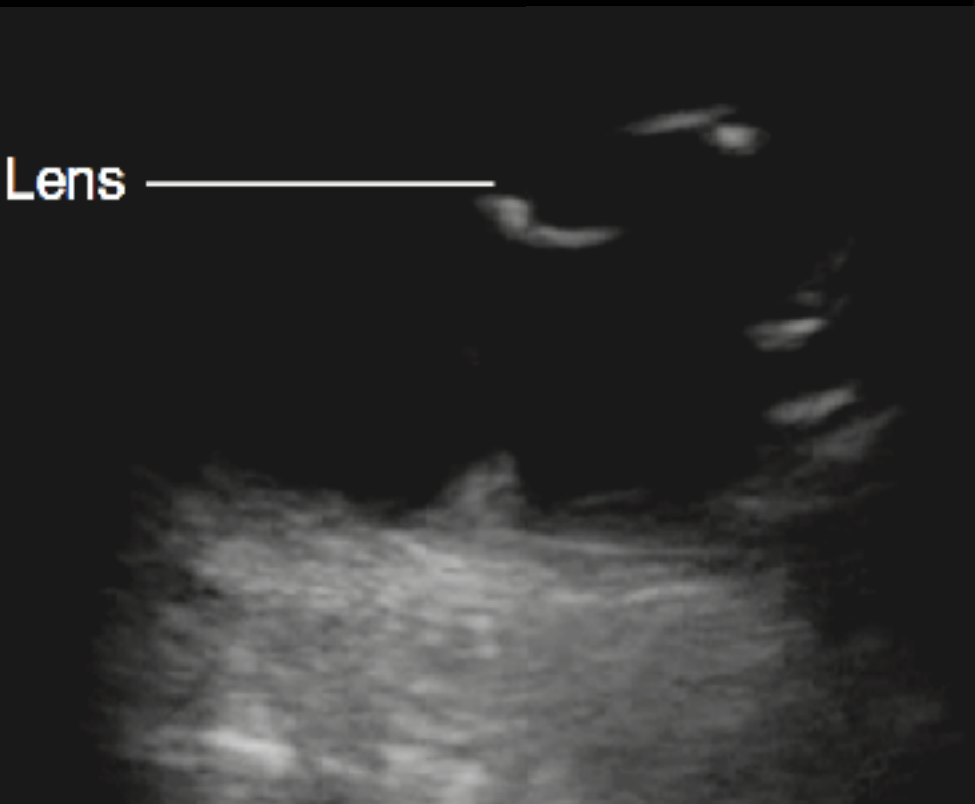
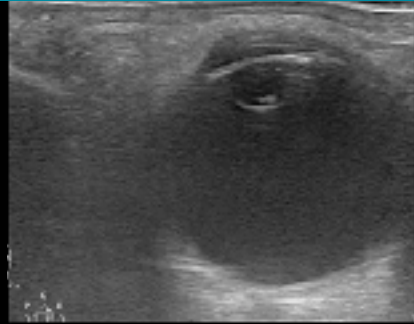

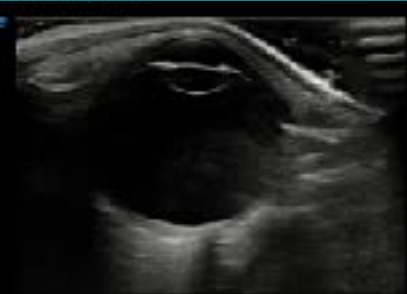
Vitreous detachment (VD) vs hemorrhage



VH: Clothes in a washing machine

Lens dislocation

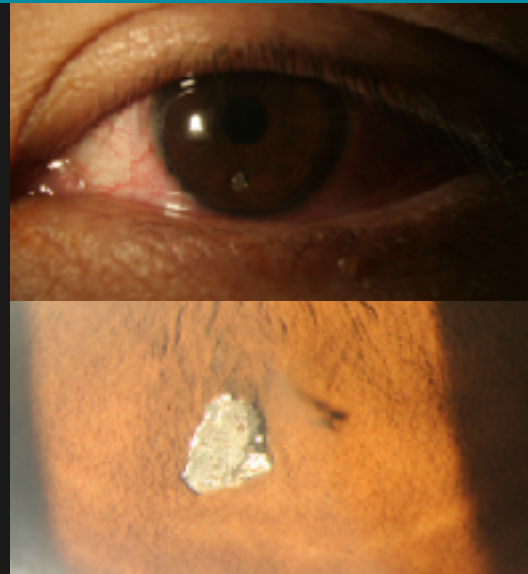

Intraocular foreign body

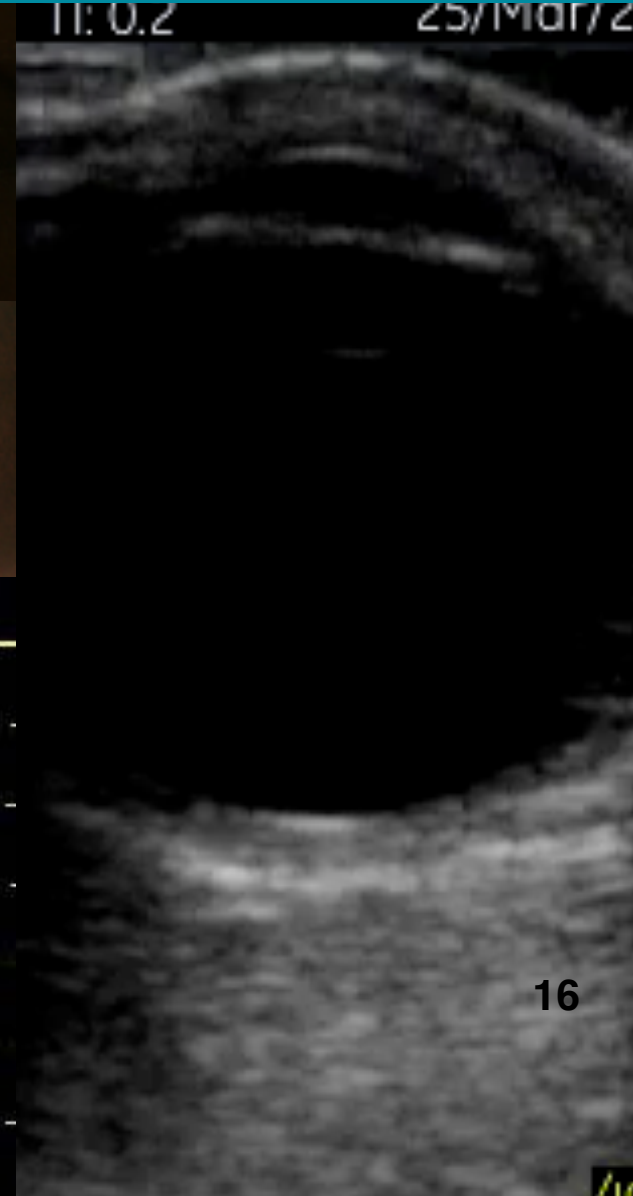
CT: gold standard

IOFB

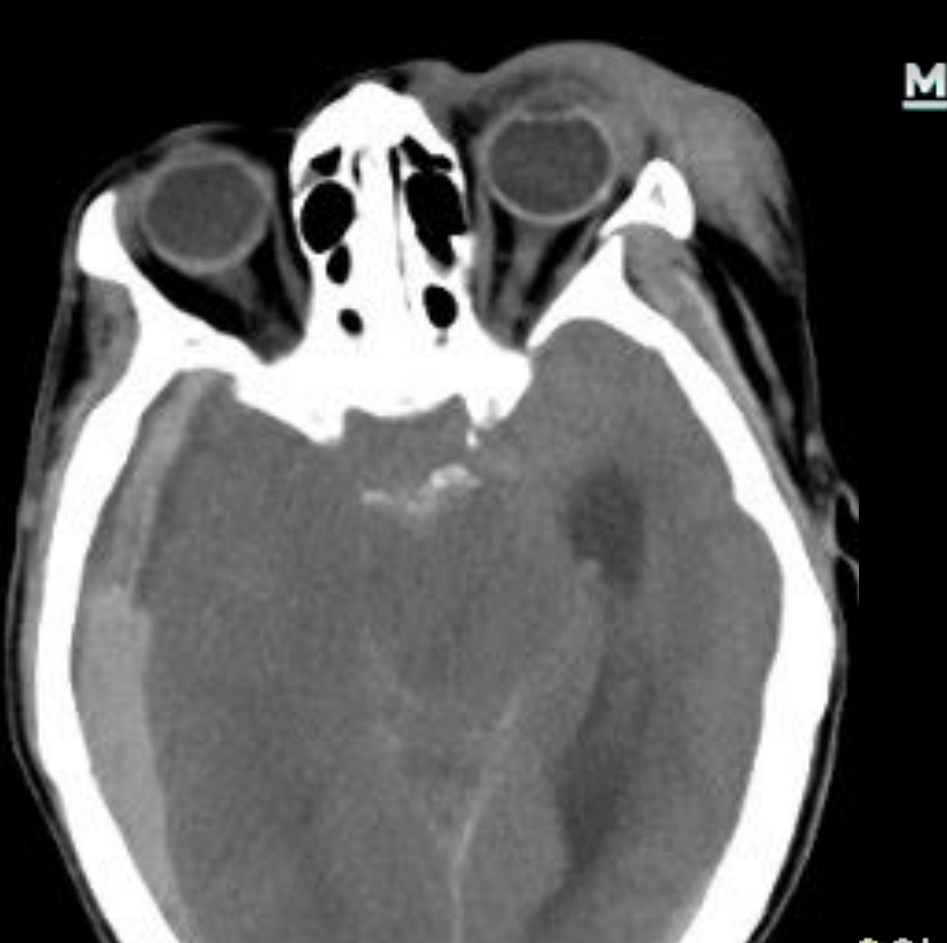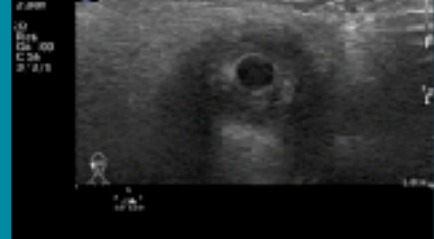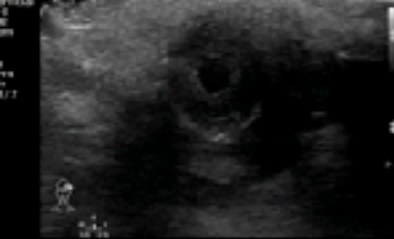Reverberation artifact



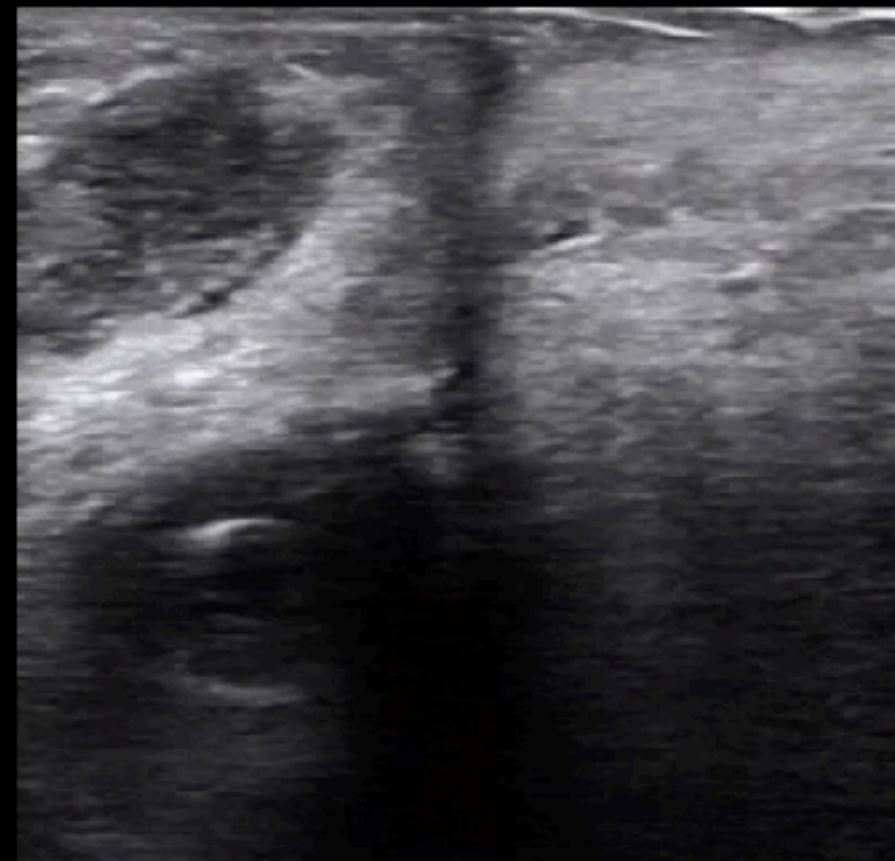
#: 228 16:51:27
MI: 0.8 TI: 0.2 25/Mar/2015



Pupillary reflex



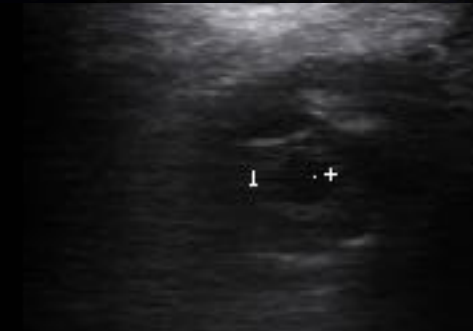M



1 Dist 0.30 cm

1 Dist 0.30 cm

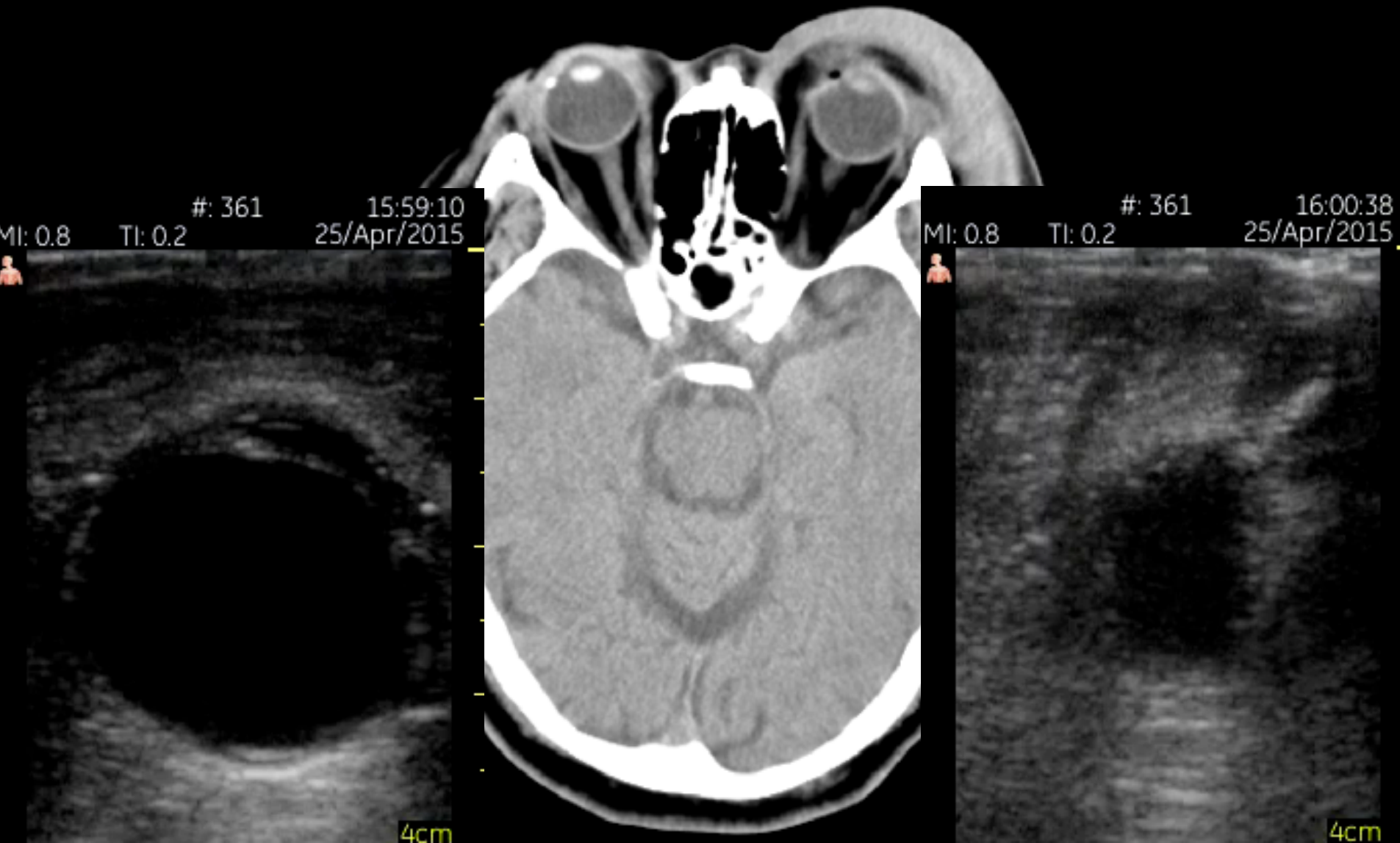
2 Dist 0.62 cm



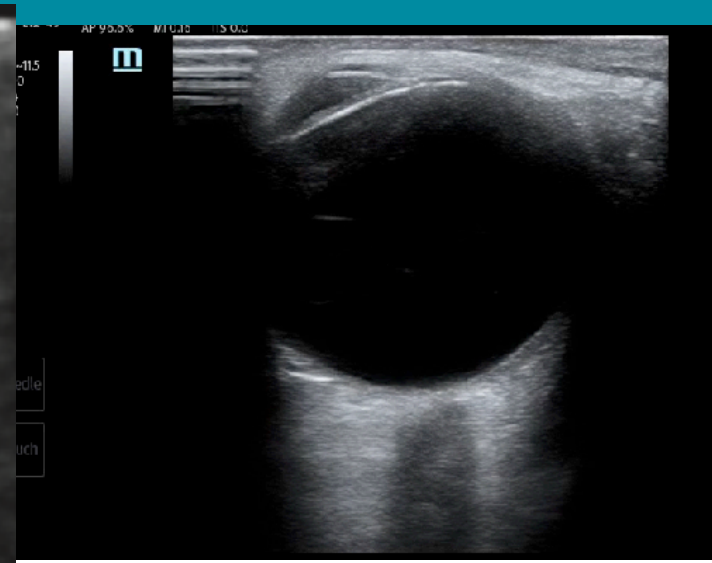
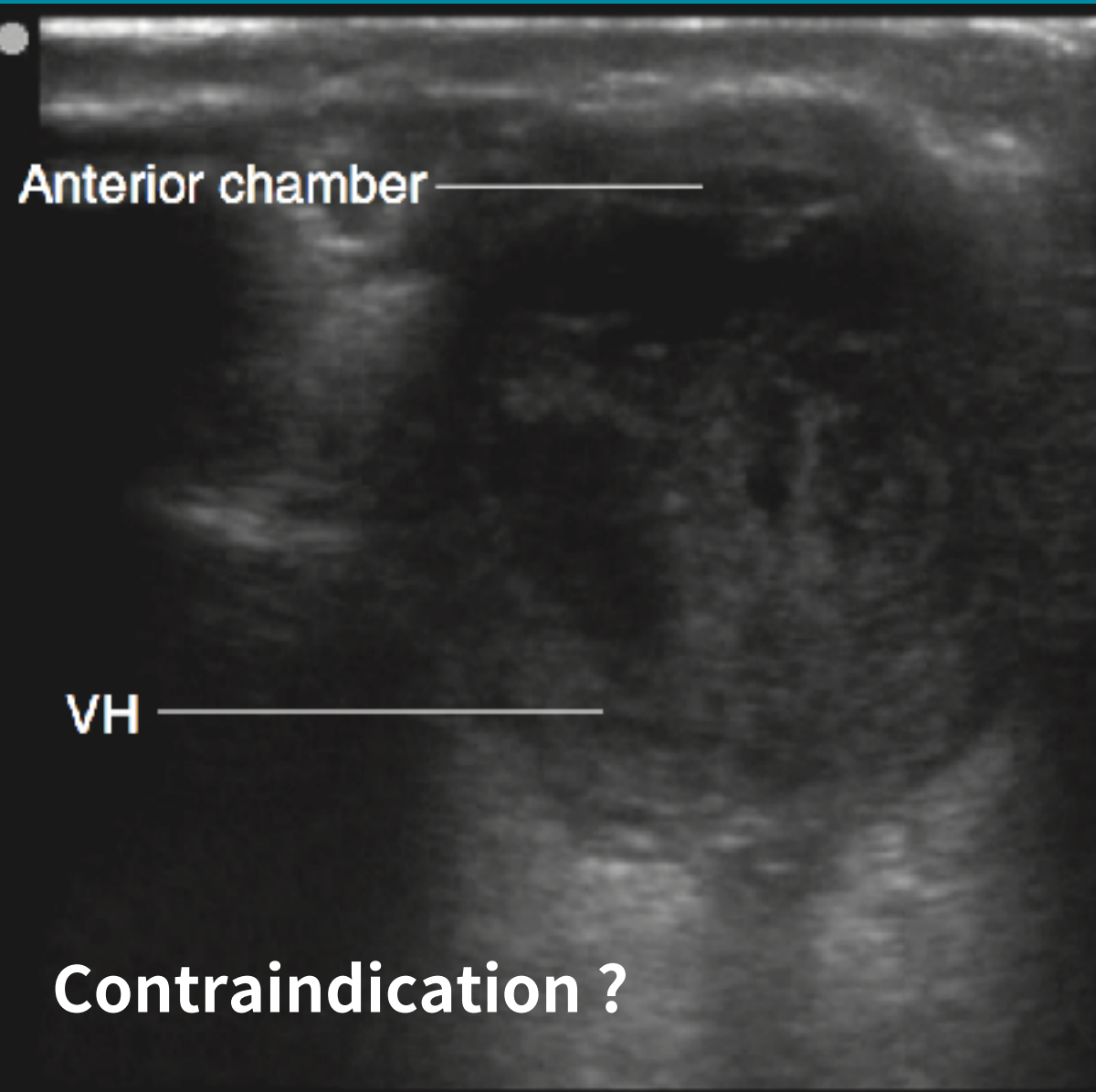
1 +



Blunt eye injury



Eyeball rupture



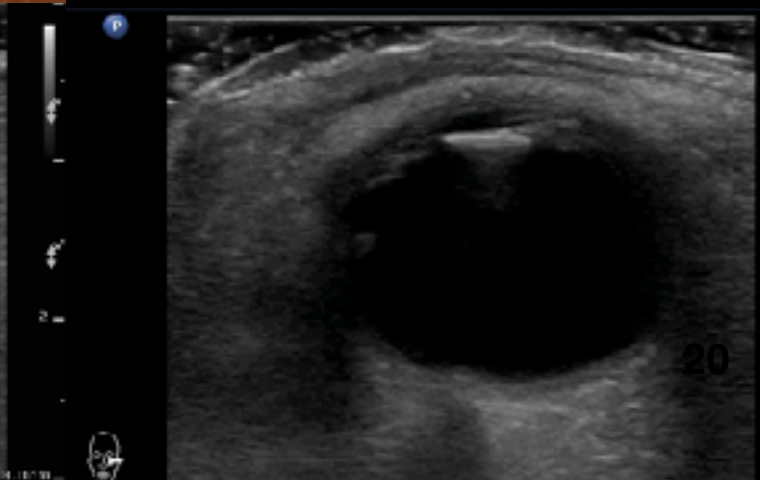
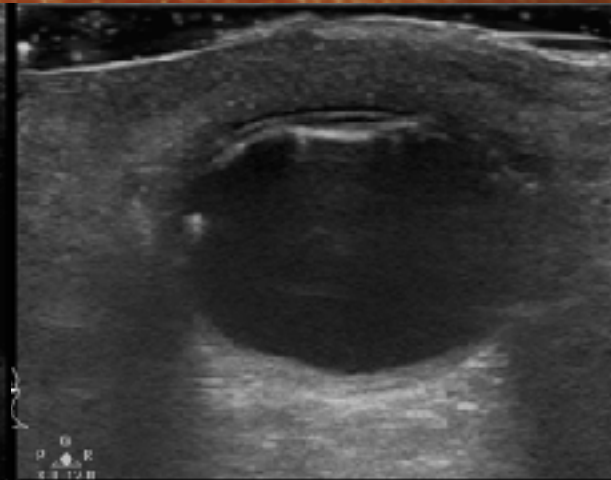
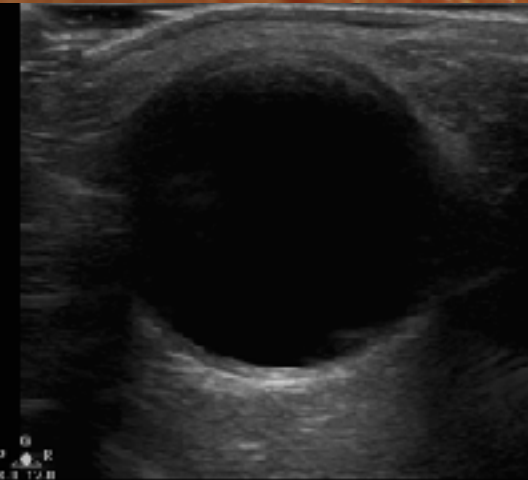
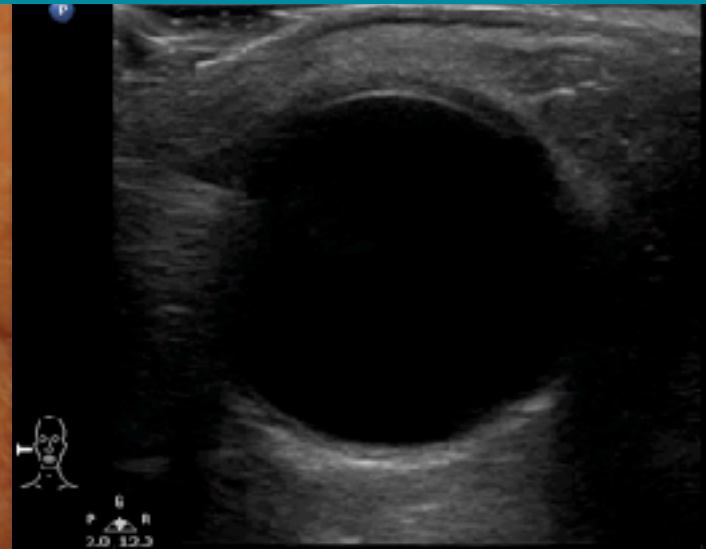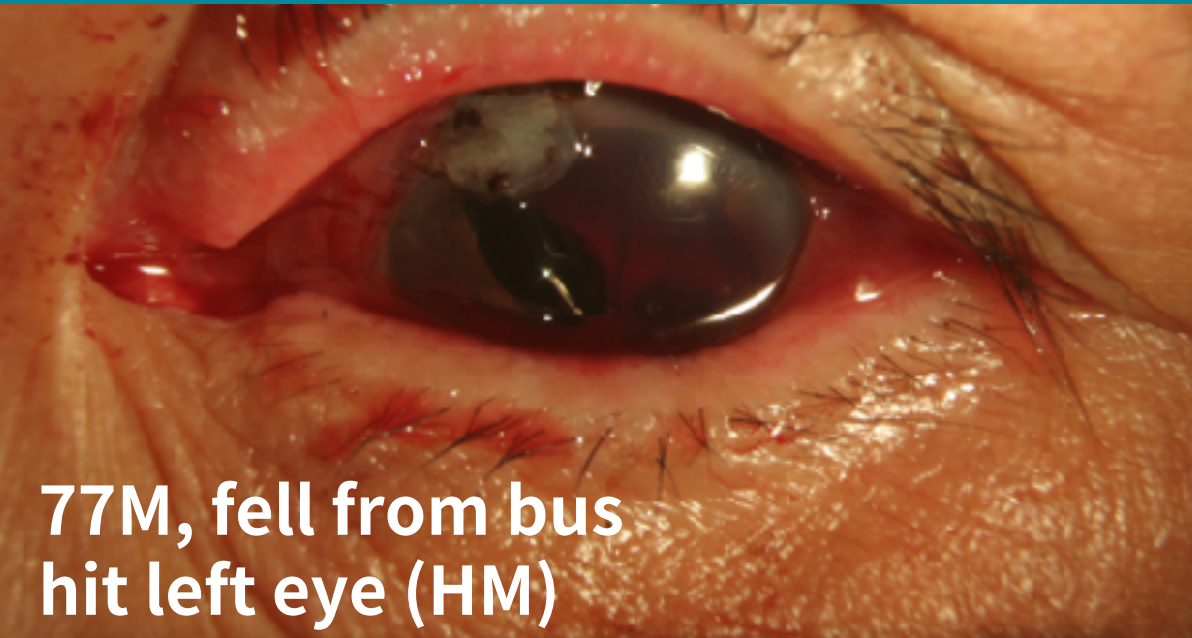
Surface

Shape

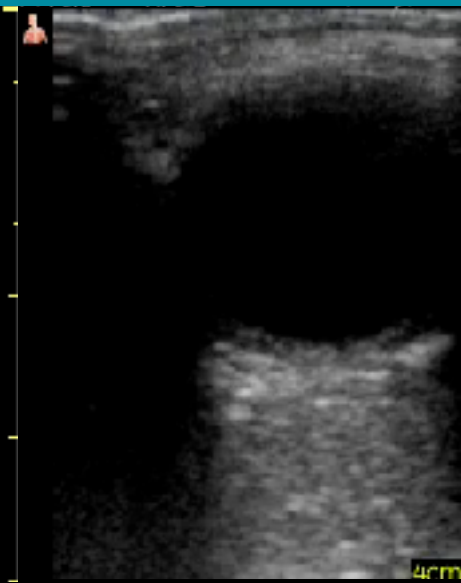
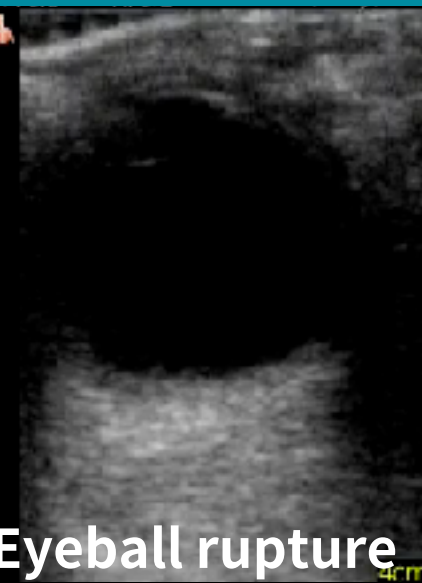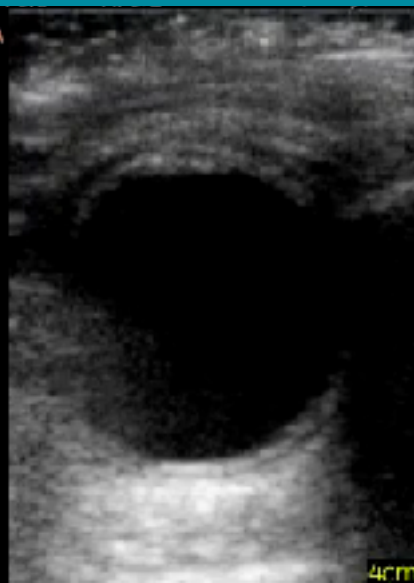
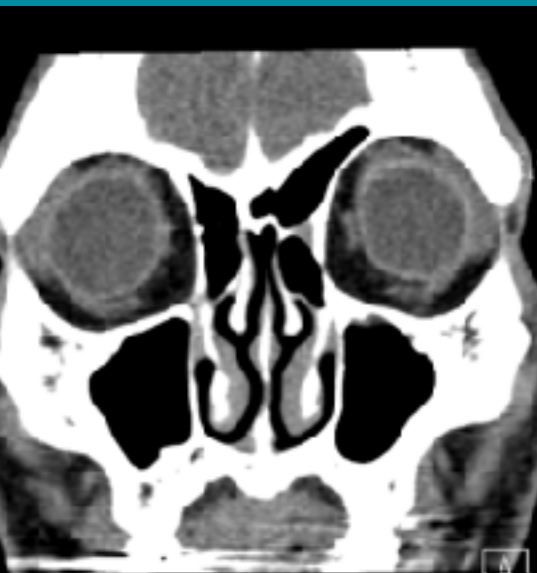Internal content¹⁹

Anterior chamber

Eyeball rupture



36M, 左眼鐵釘穿刺 (HM only)

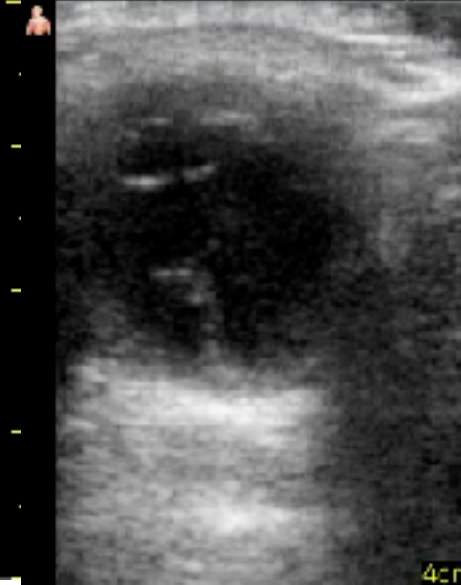
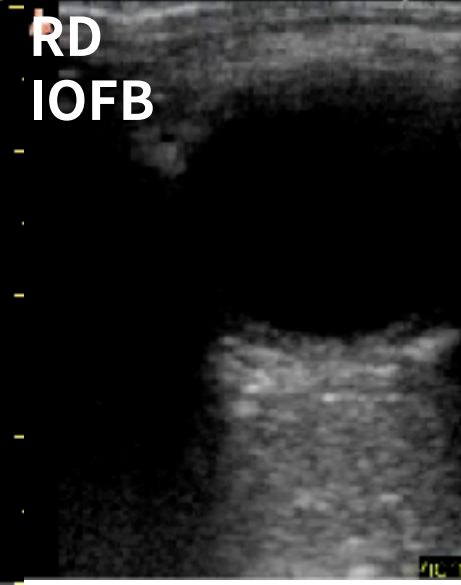
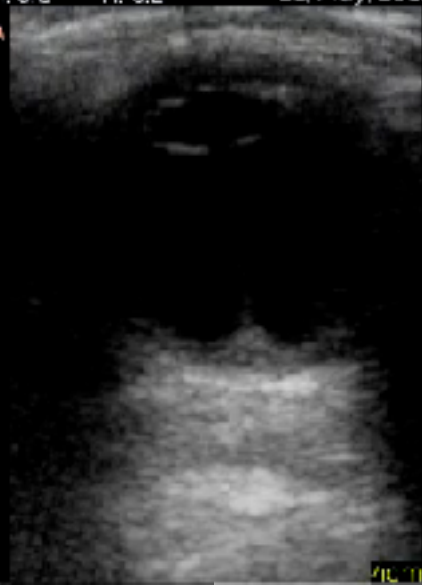
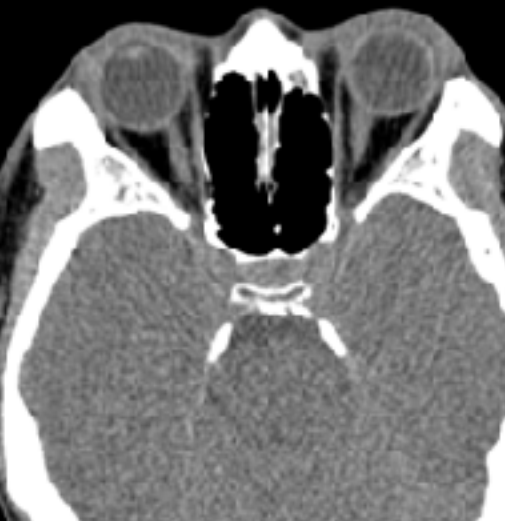
481 19:06:43
M: 0.8 TI: C.2 21/May/2015

481 19:07:30
M: 0.8 TI: C.2 21/May/2015

481 19:07:30
M: 0.8 TI: C.2 21/May/2015

**eyeball rupture
Traumatic cataract
RD
IOFB**

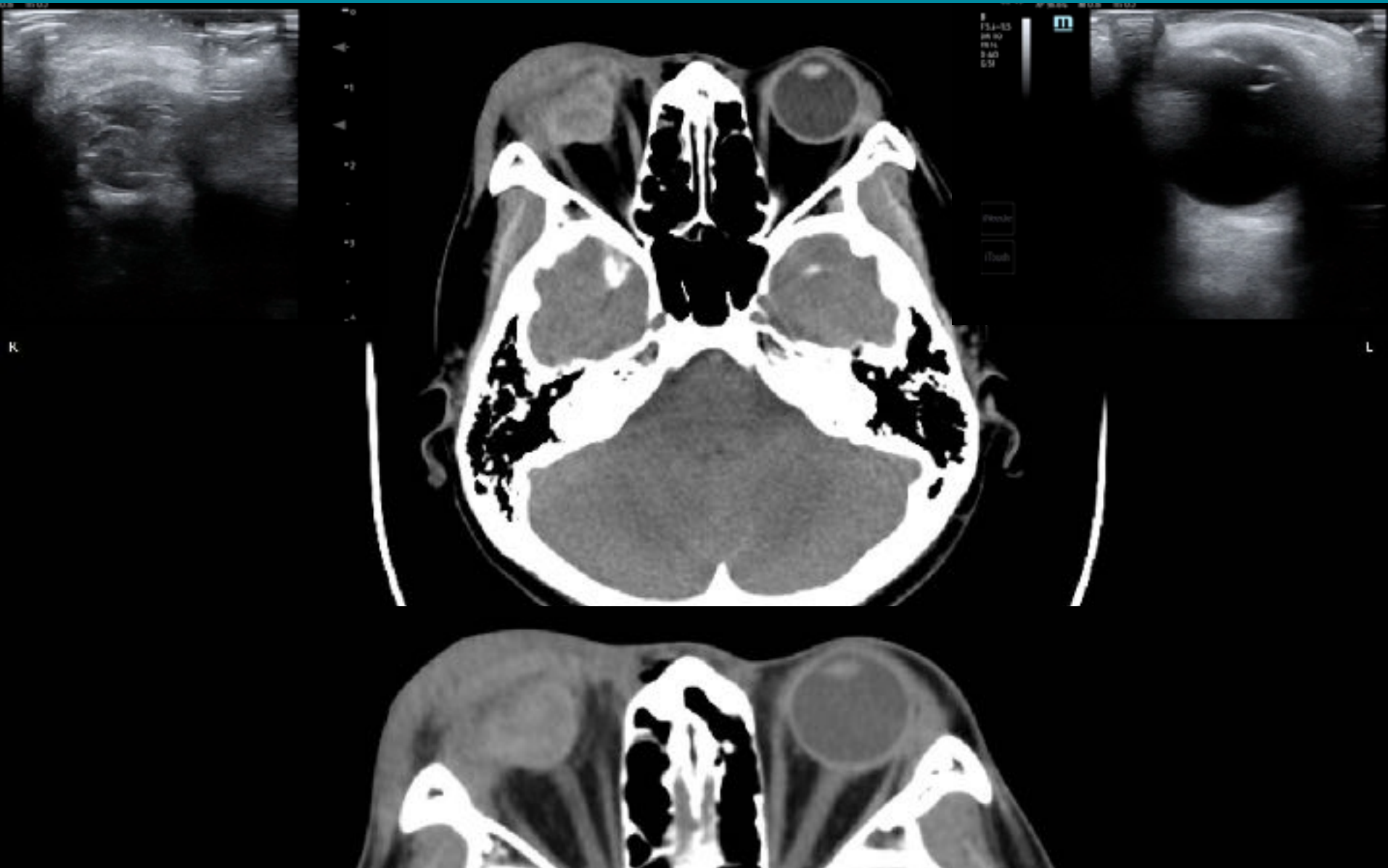


4cm

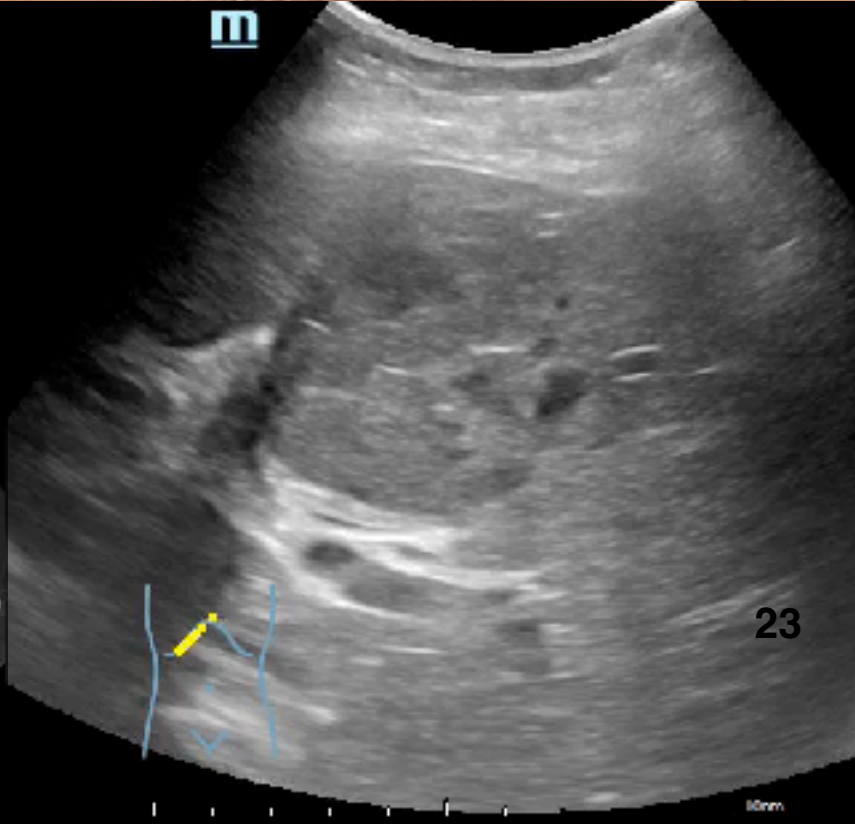
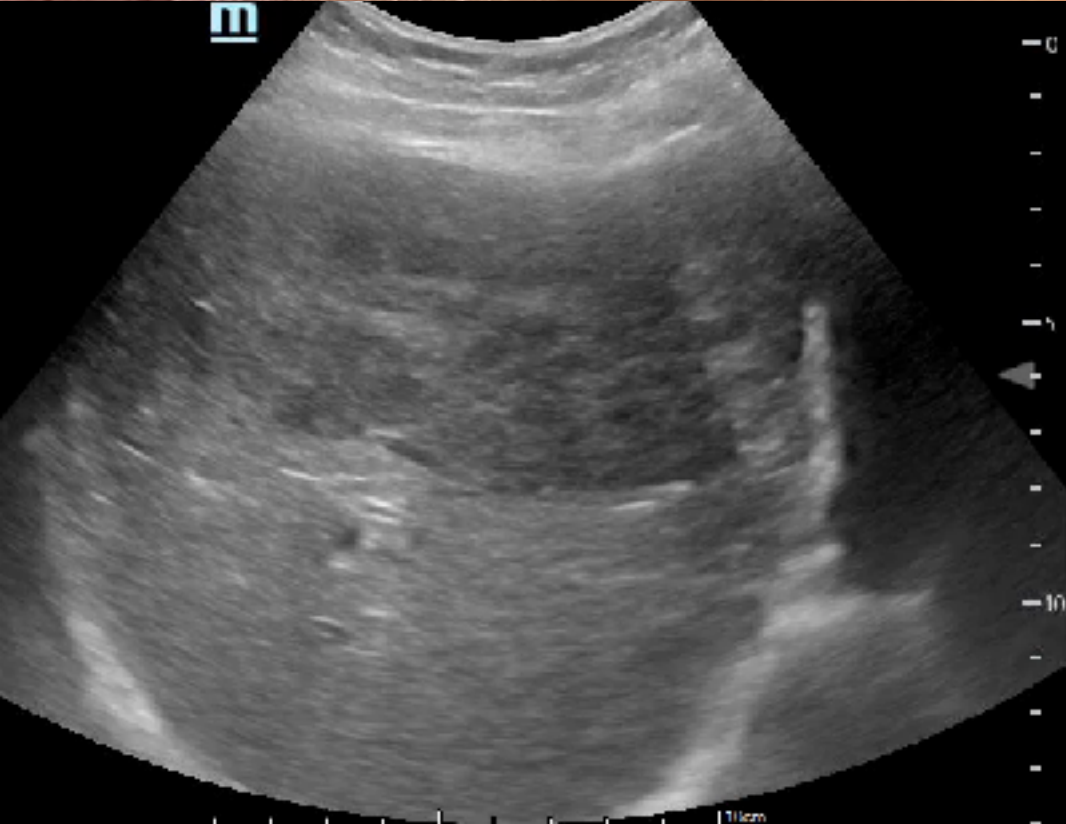
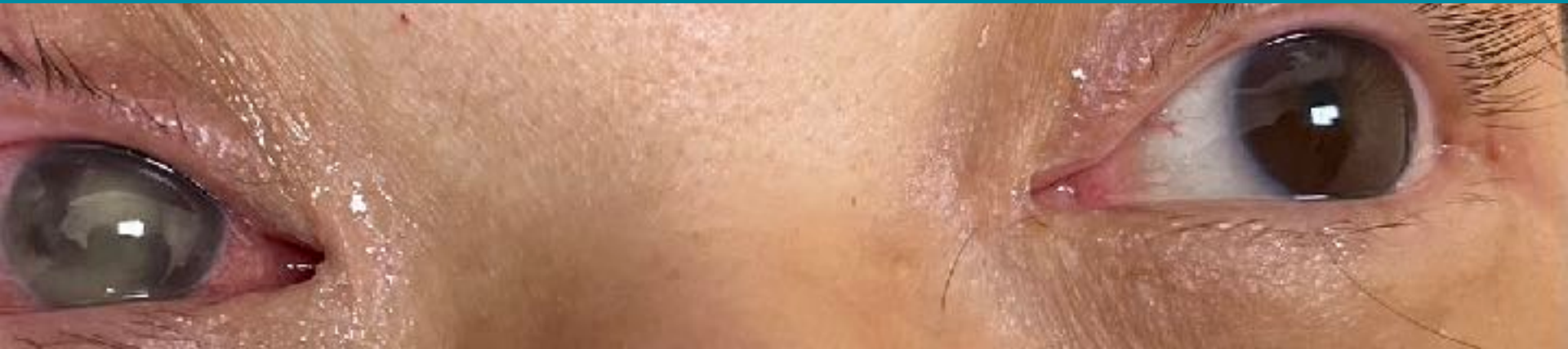4cm

4cm

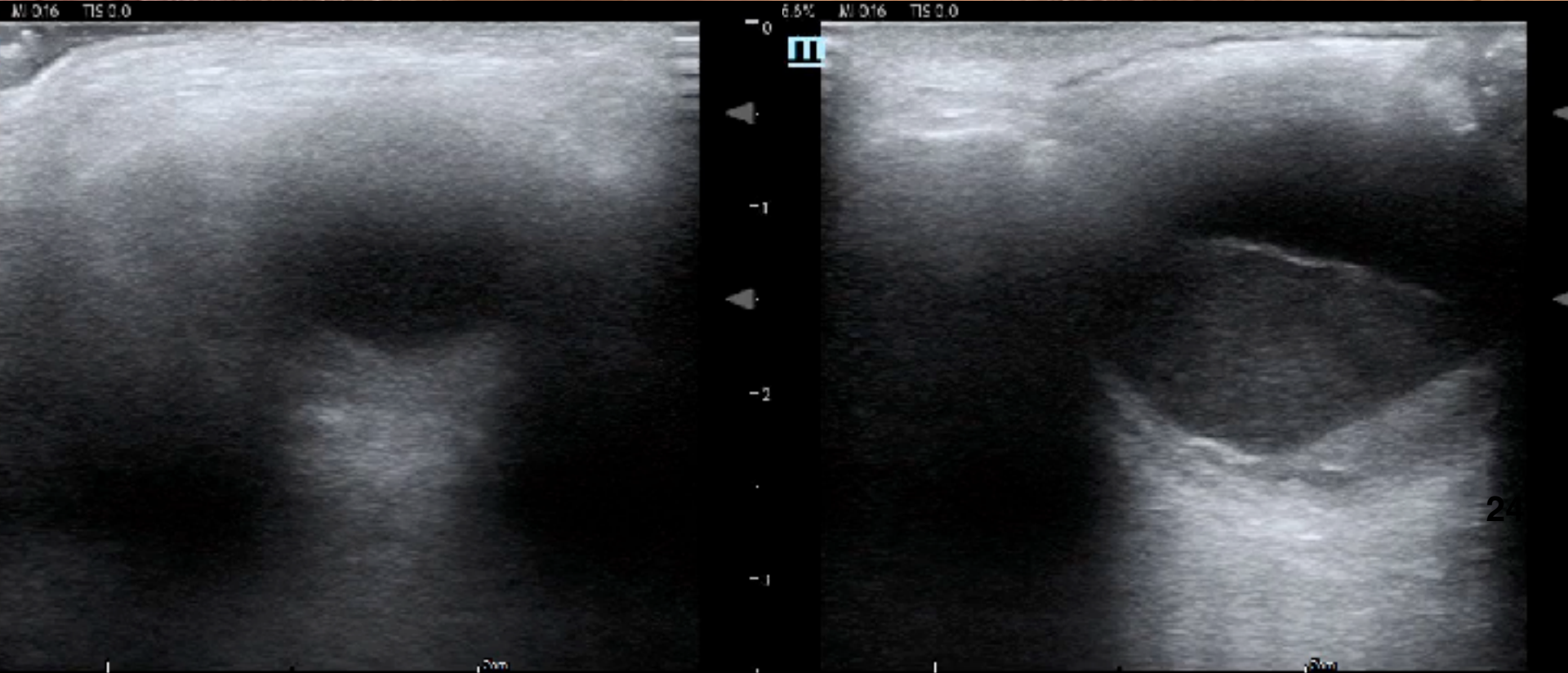
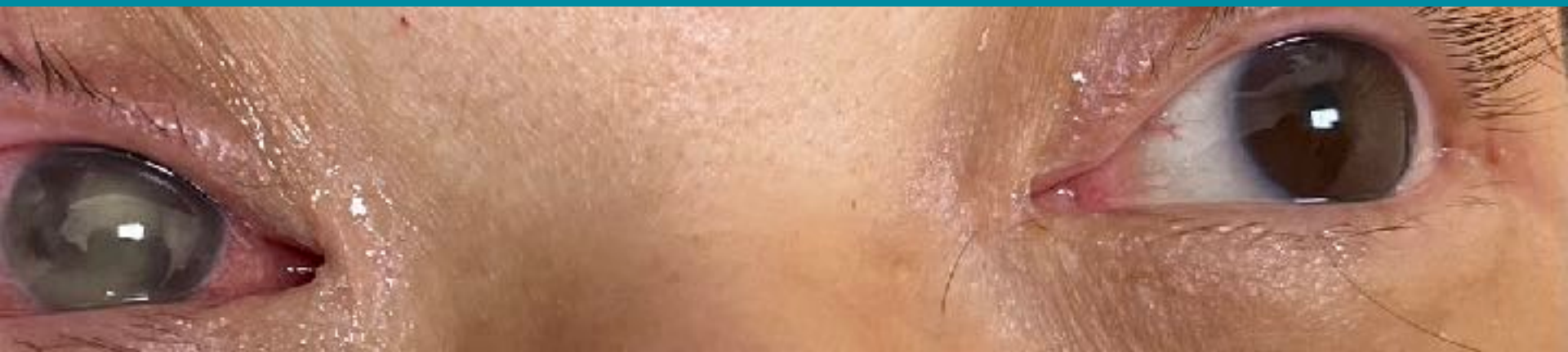19F, TA, right eye swelling



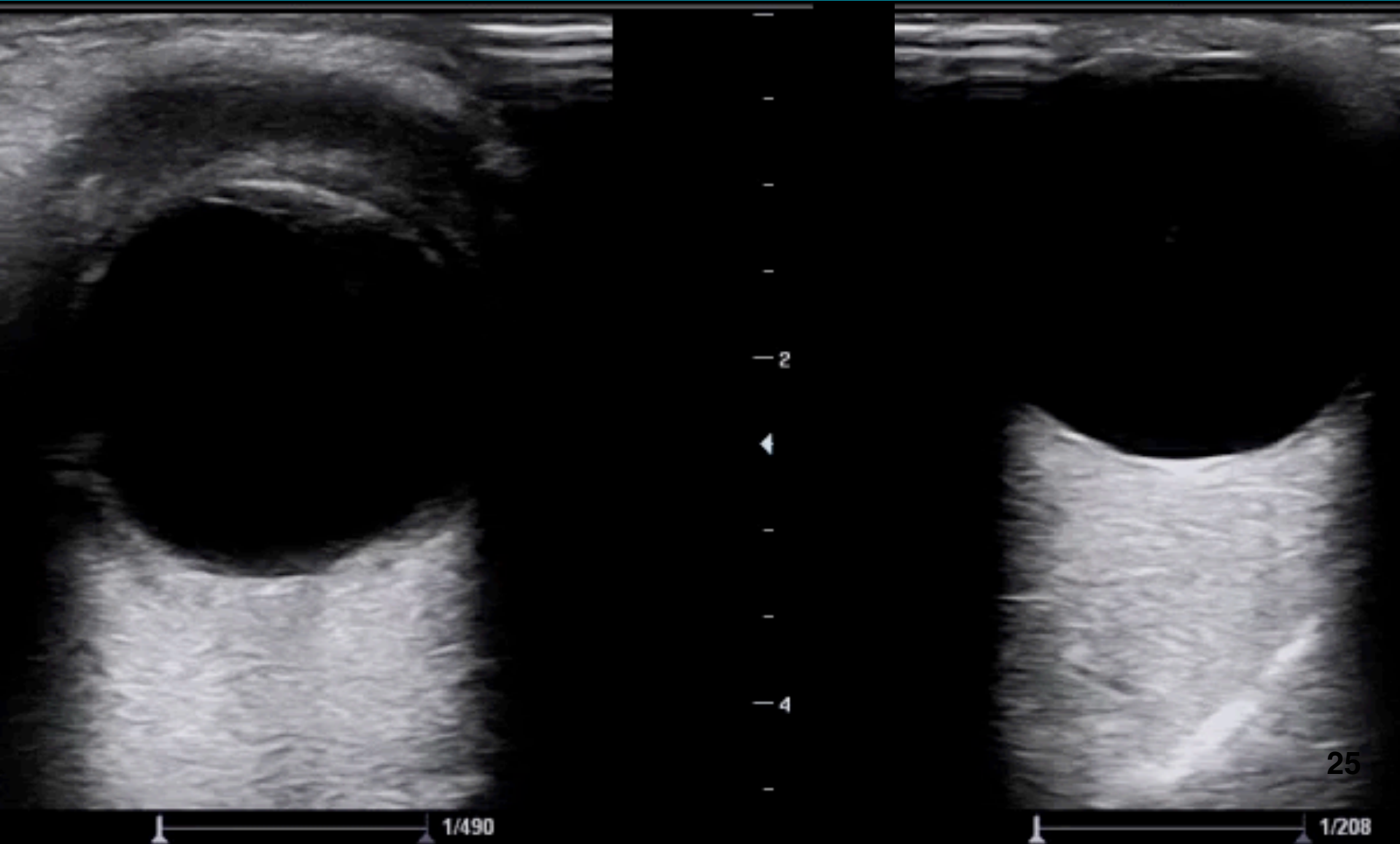
Endophthalmitis



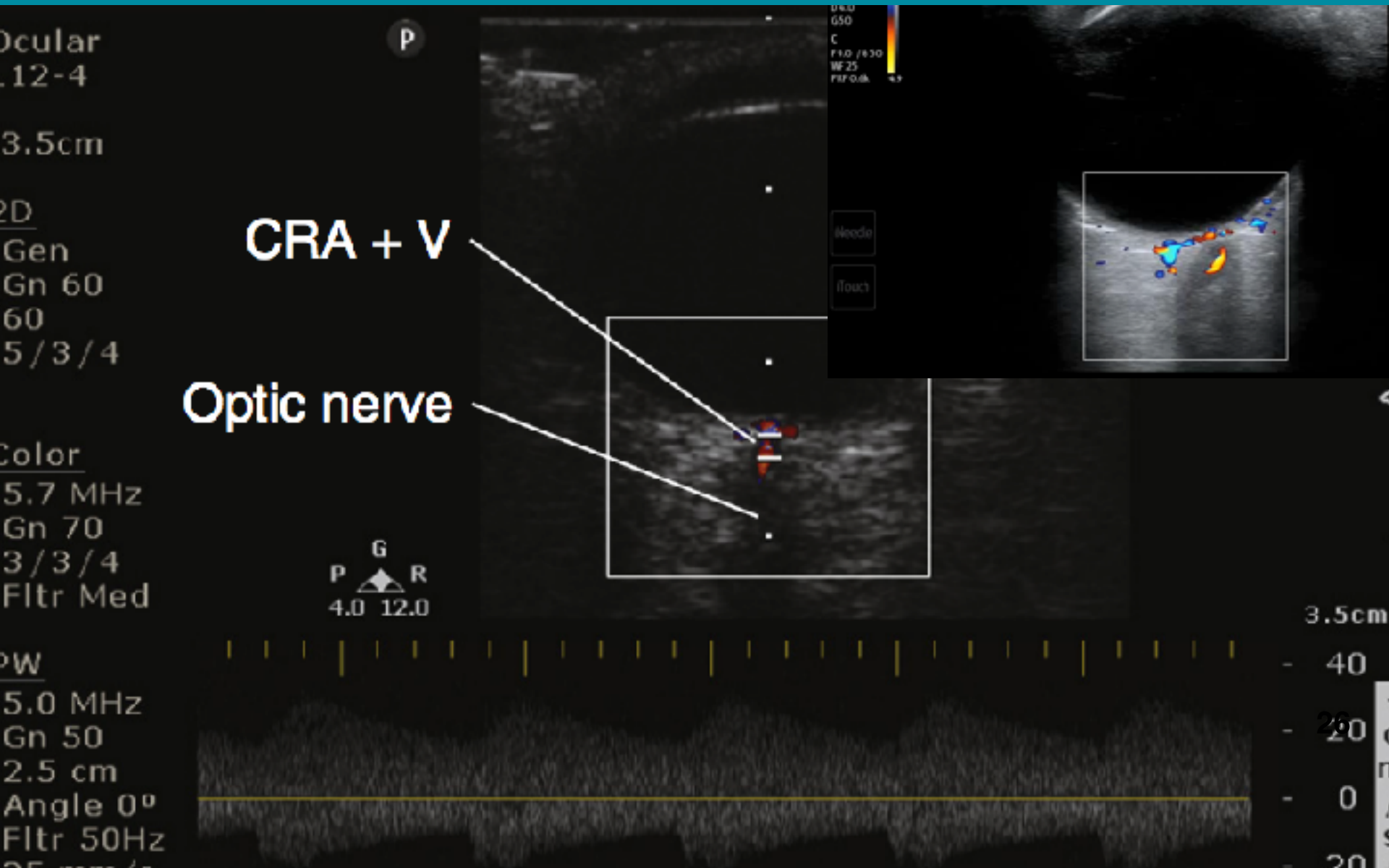
Endophthalmitis



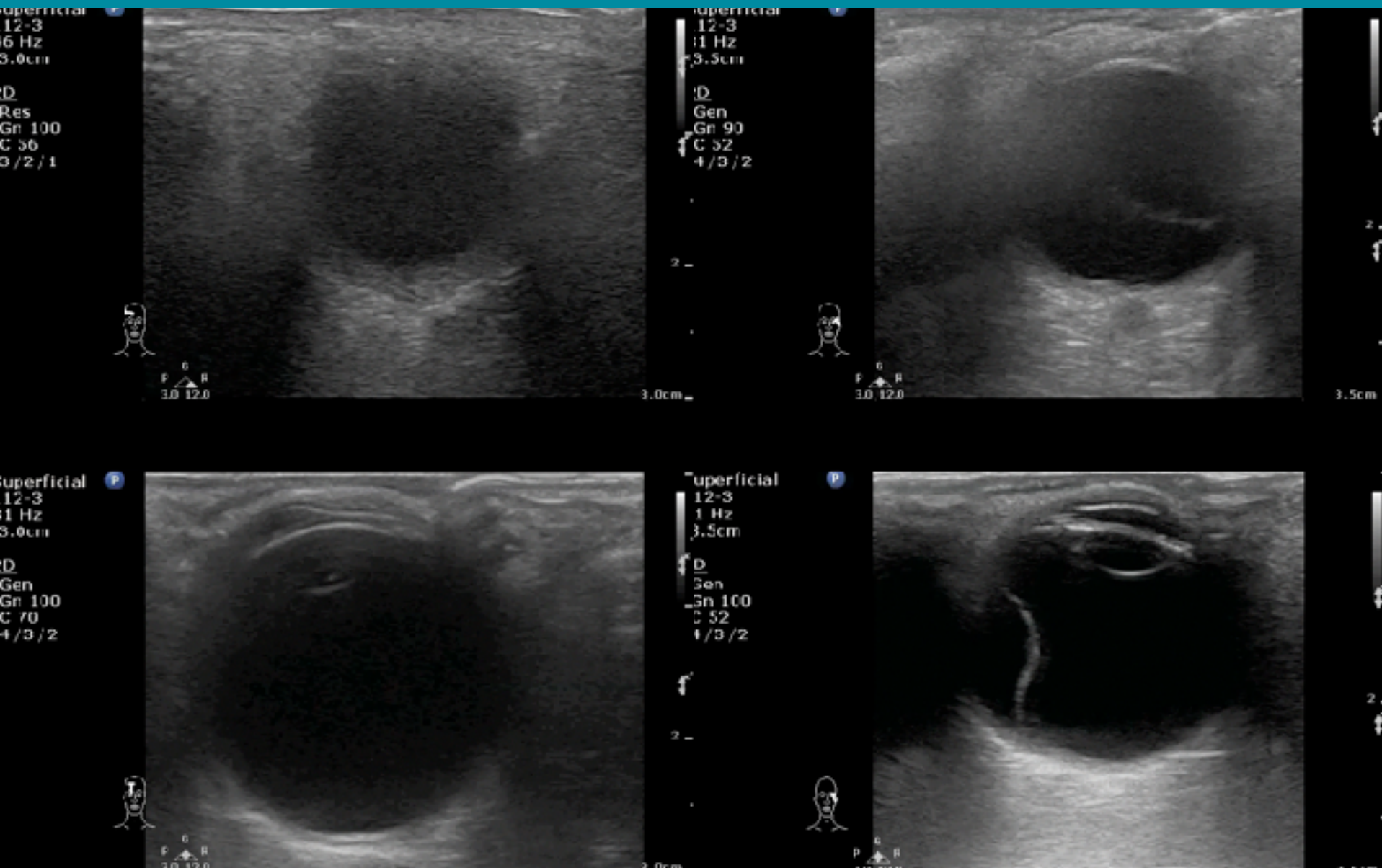
Preseptal cellulitis

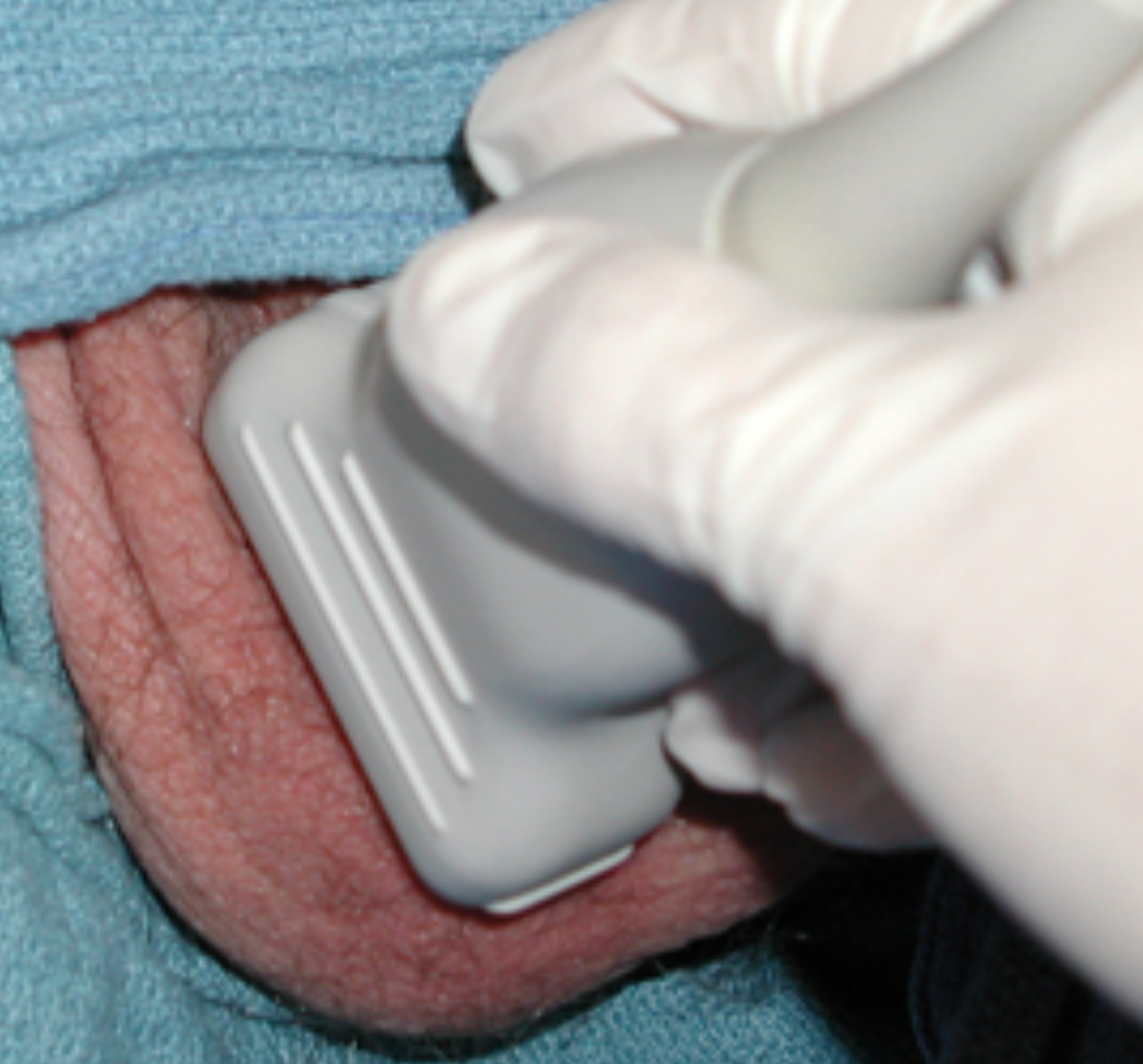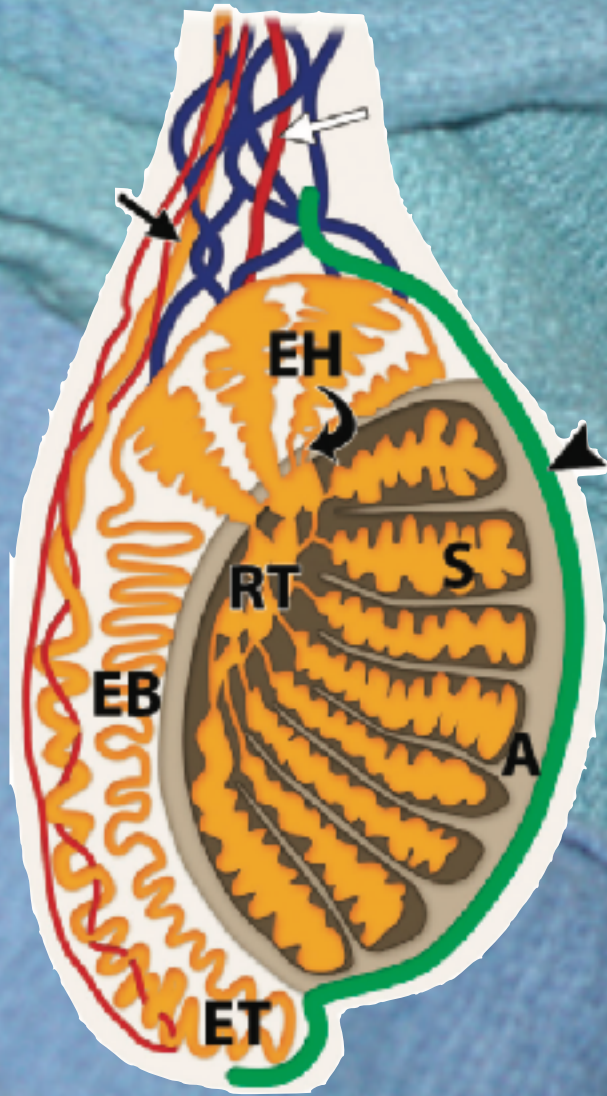


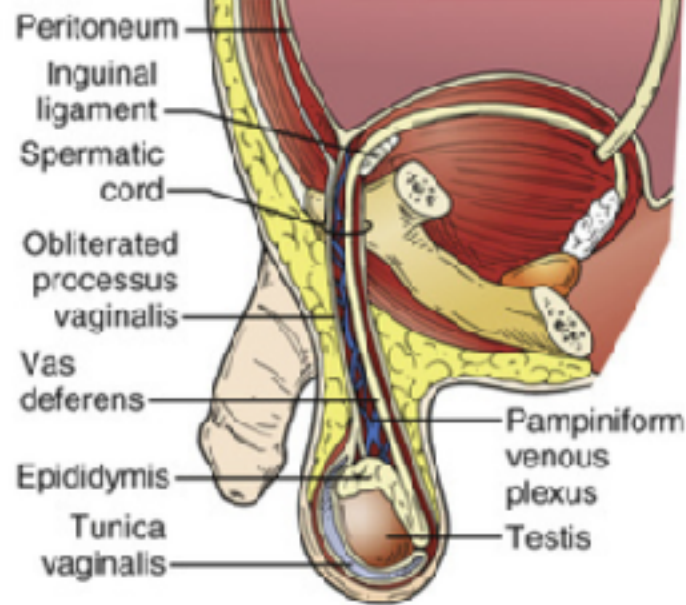
Central retinal artery & vein occlusion



Keep your eye on the ball



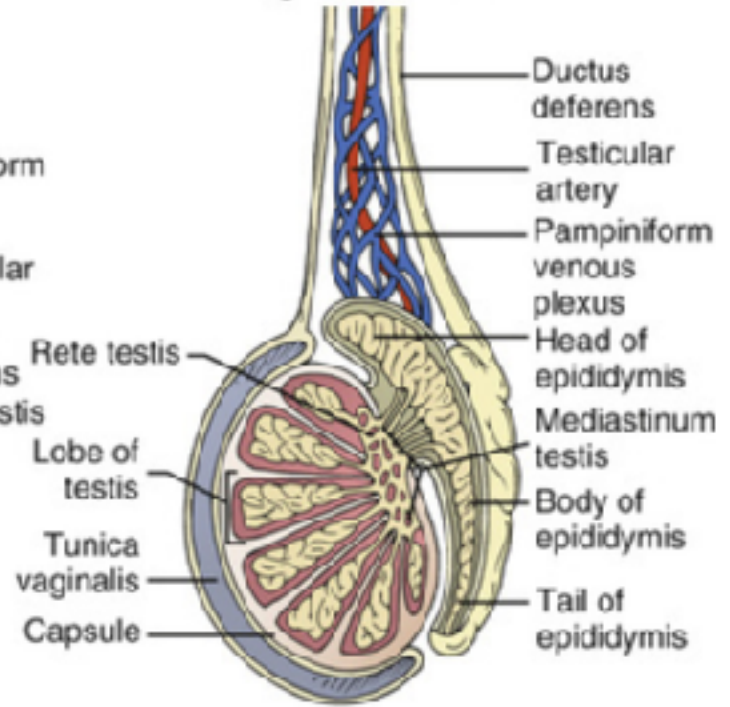
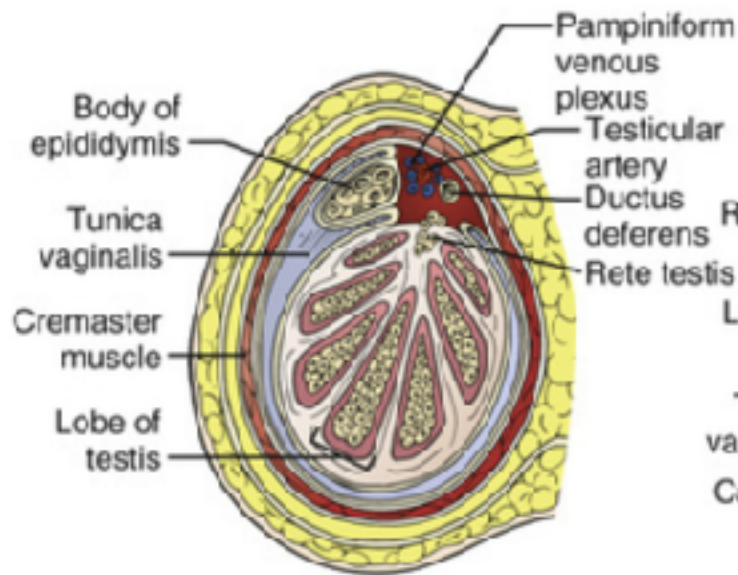




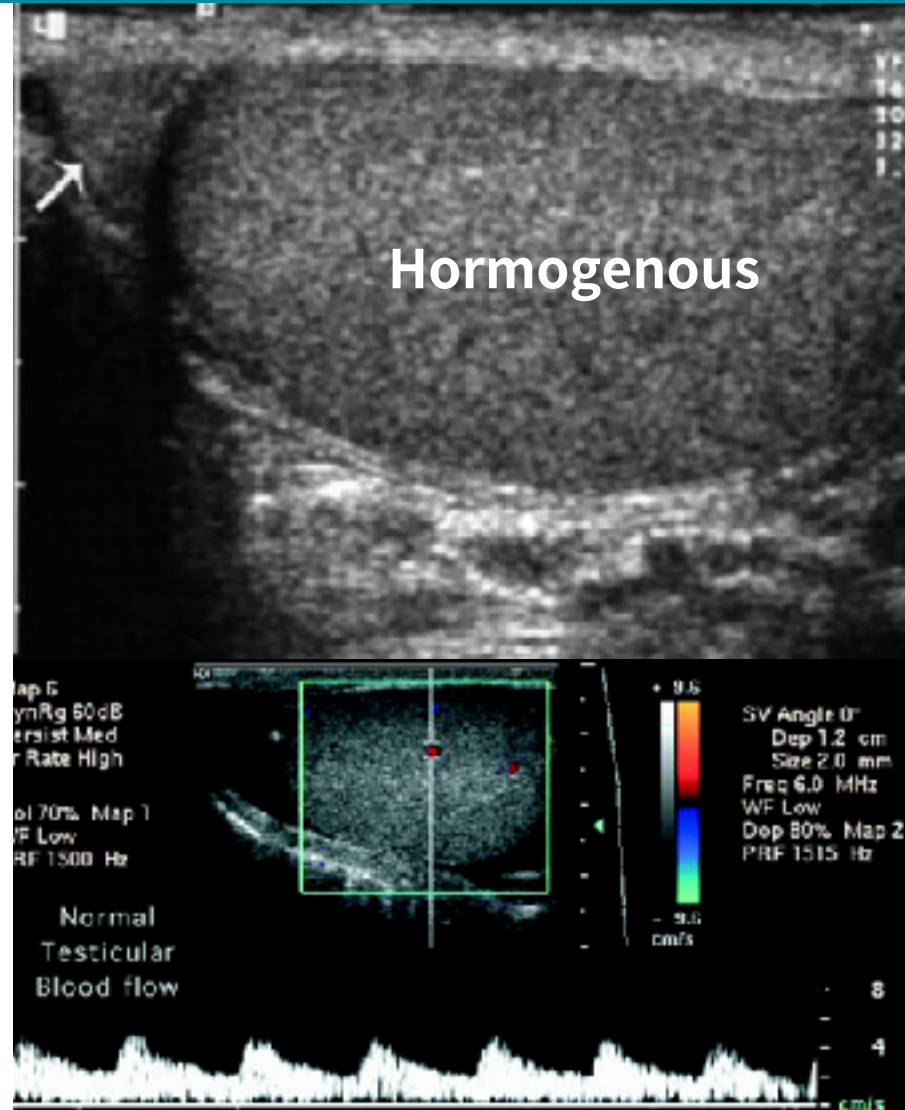
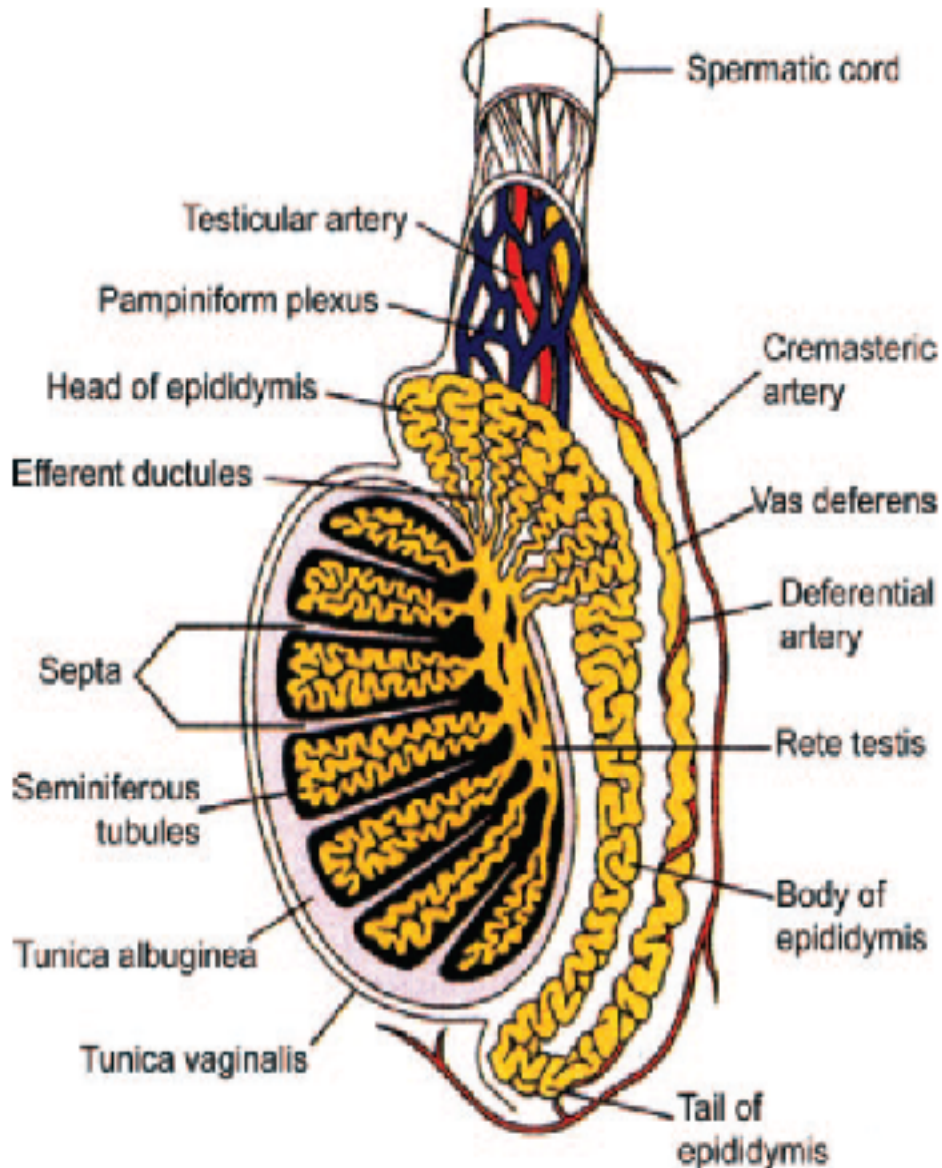
B.

Transverse Plane

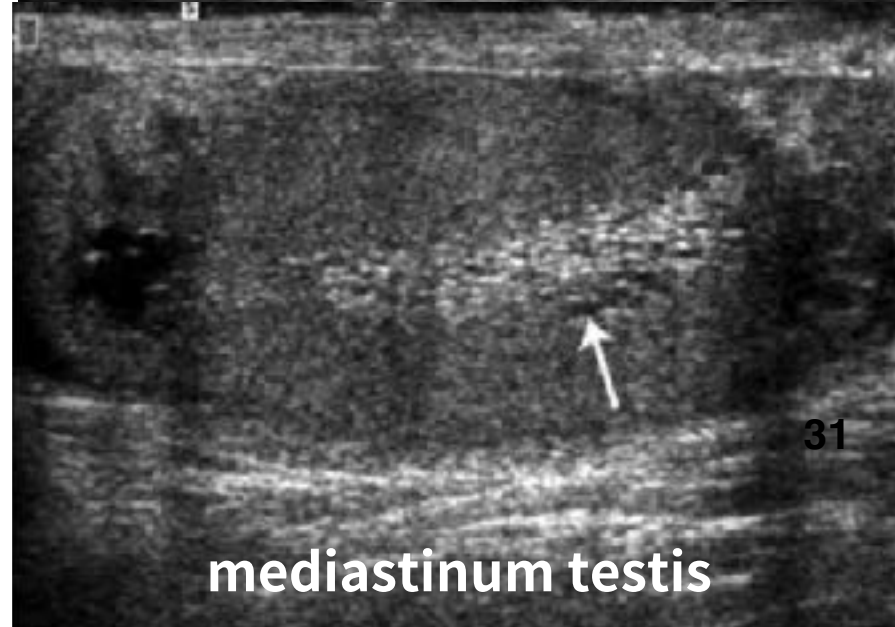
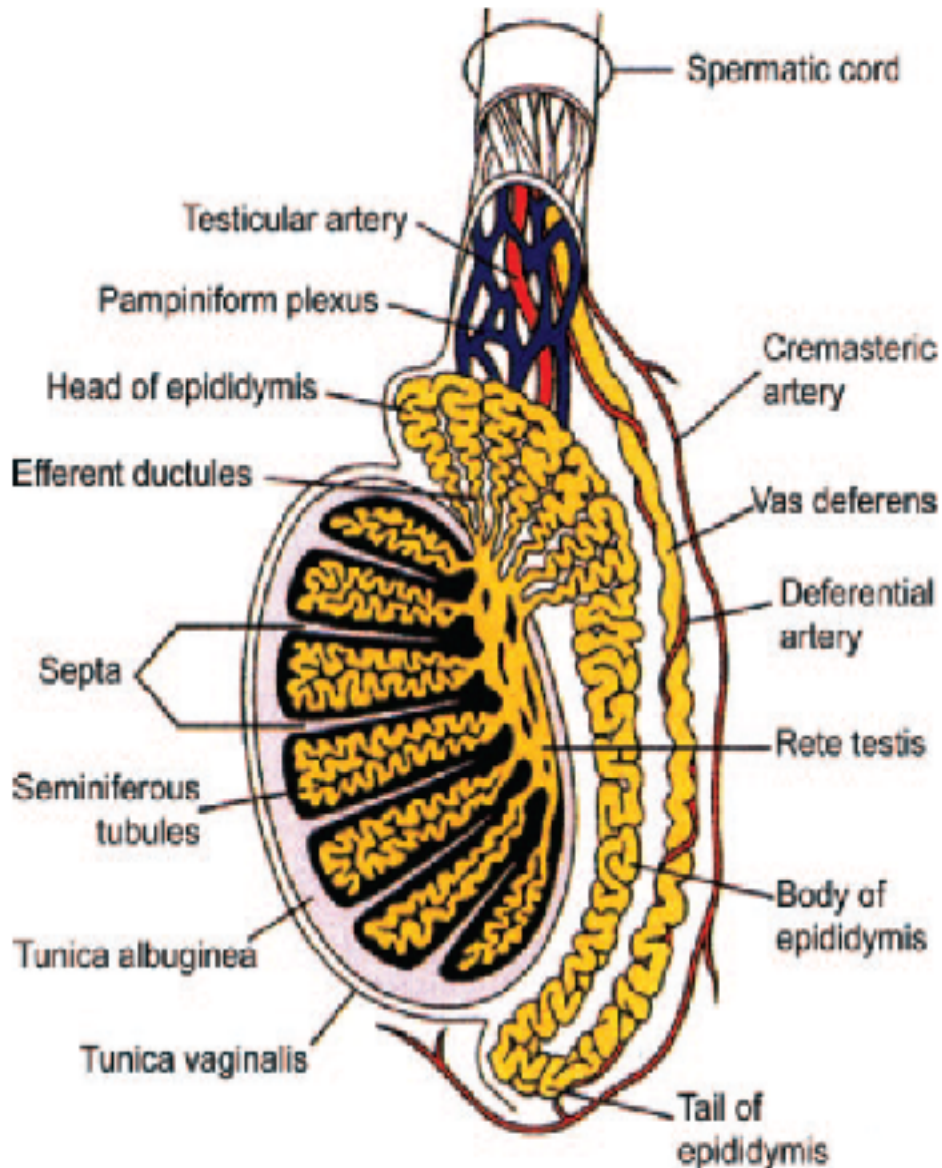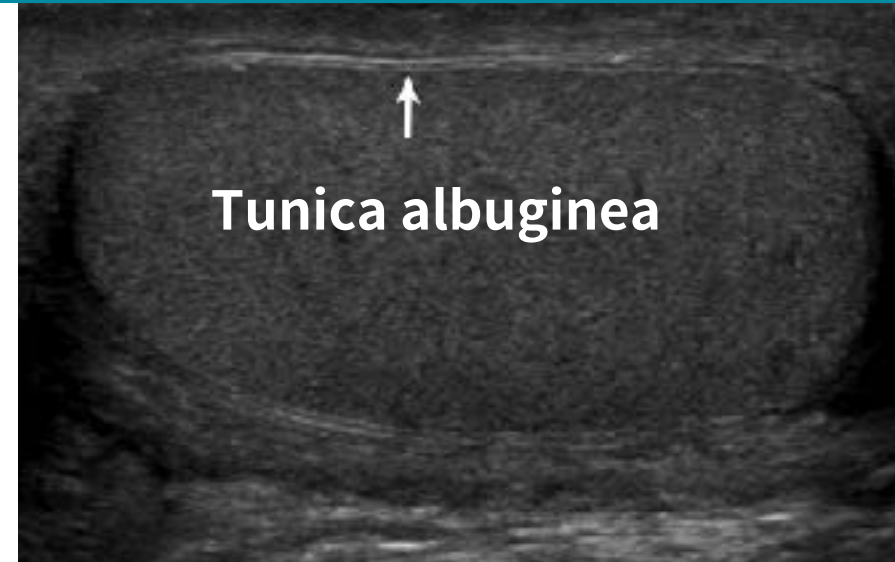
Longitudinal Plane

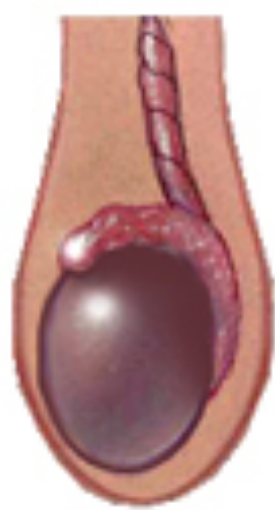

Keep your eye on the ball

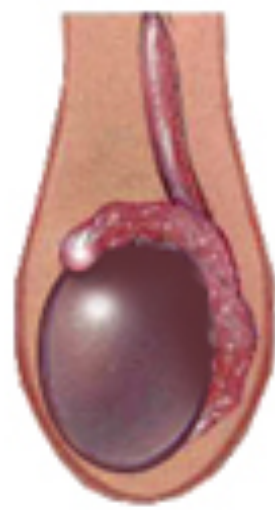

Keep your eye on the ball

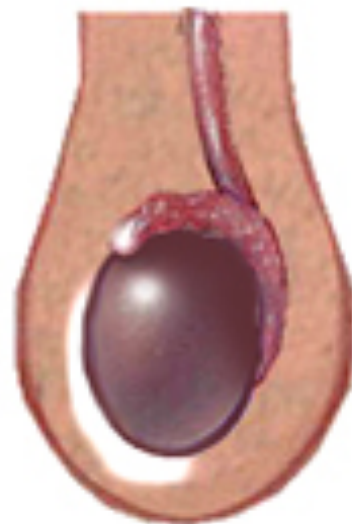



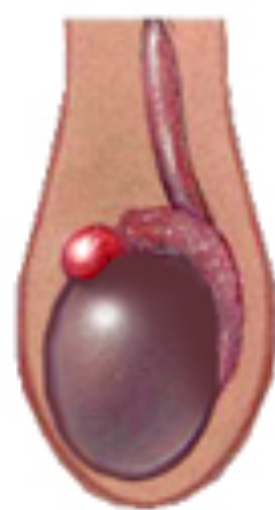testis torsion



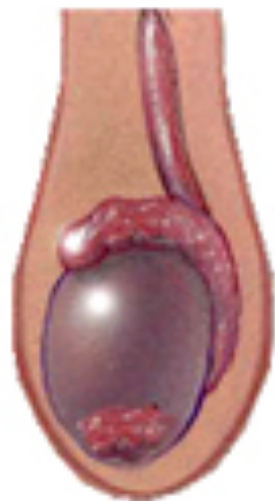epididymitis



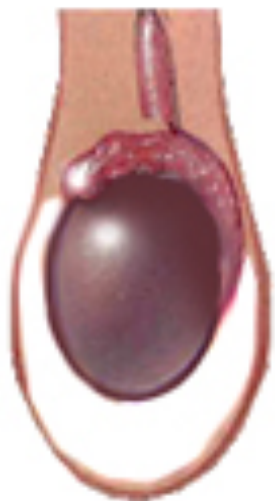orchitis



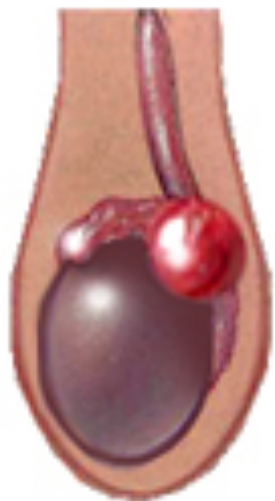appendix testis torsion



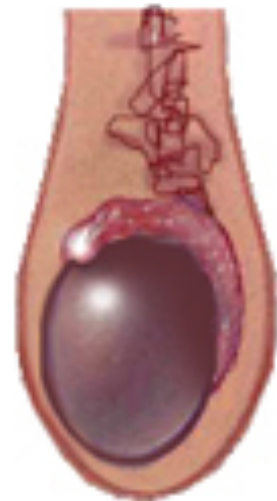testicular mass



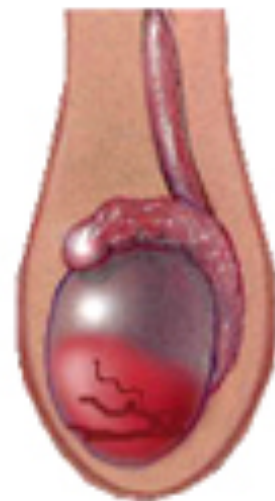
hydrocele



spermatocele



varicocele



testicular rupture

testicular abnormalities

A. Testicular Ultrasound

2D ultrasound

(Long & short-axis views)

- Scan through testicle in both axes
- Assess size and echotexture
- Spectacle view



Color Doppler

(Long-axis view)

- Assess for blood flow with color flow or power Doppler ultrasound



Pulsed-wave Doppler

(Long-axis view)

- Assess for arterial and venous flow

B. Epididymal Ultrasound

2D ultrasound

(Long-axis views)

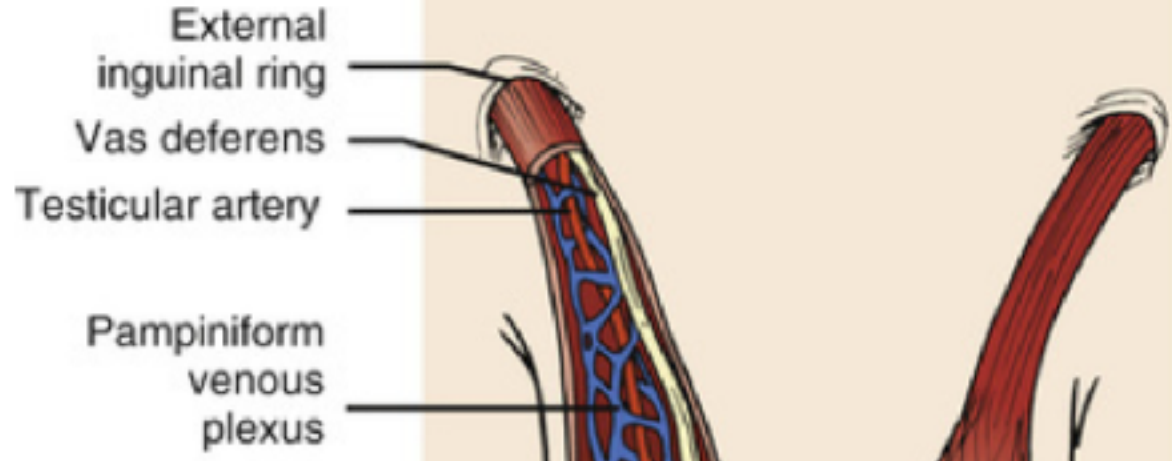
- Scan through testicle
- Assess size and echotexture



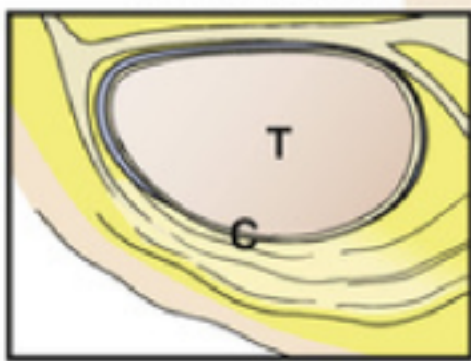
Color Doppler

(Long-axis view)

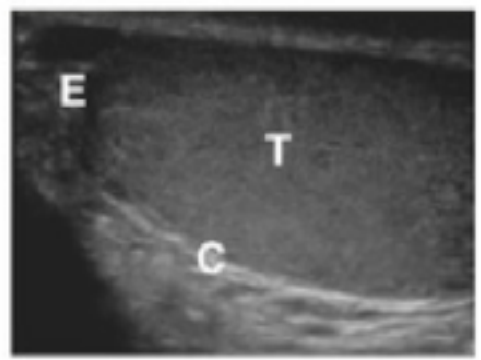
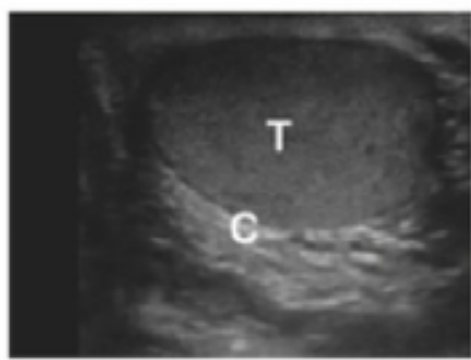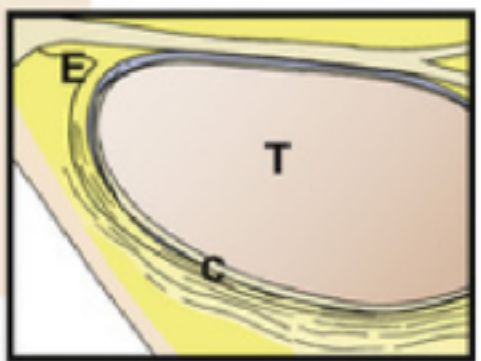
- Assess for blood flow with color flow or power Doppler ultrasound



Transverse view



Longitudinal view



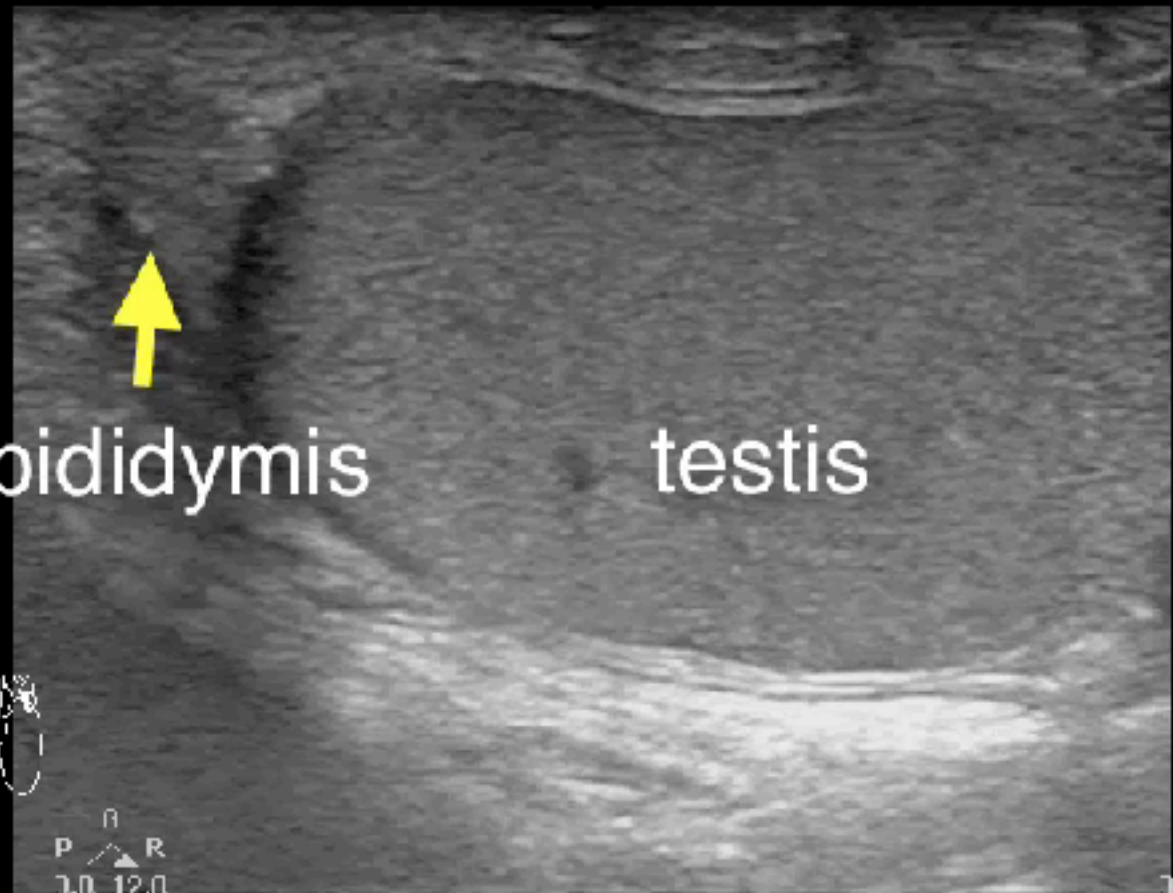
T- Testis
 C- Capsule
 E- Epididymis

PHILIPS

SKH-EUTC©ChenKC

Superficial
L12-3
46 Hz
3.0cm

2D
Res
Gn 100
C 56
3 / 2 / 1

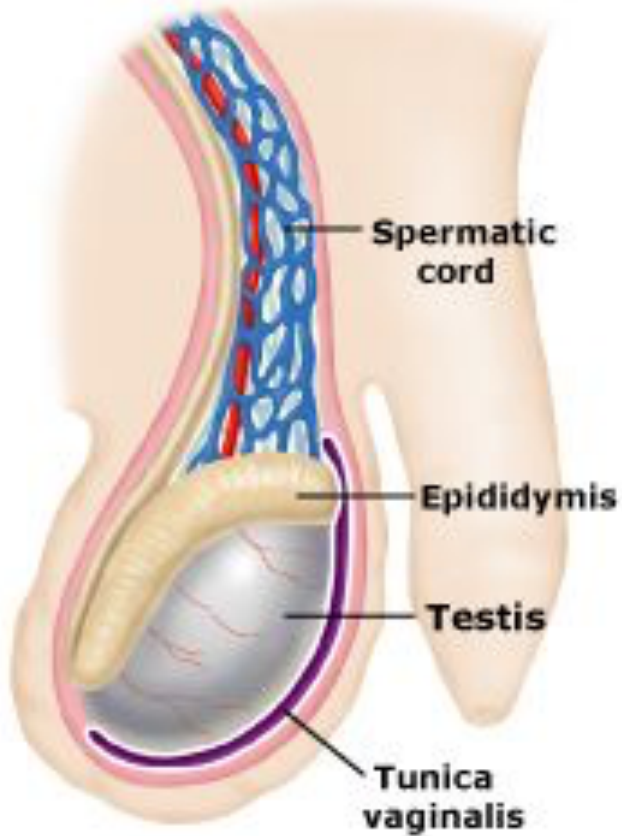


epididymis

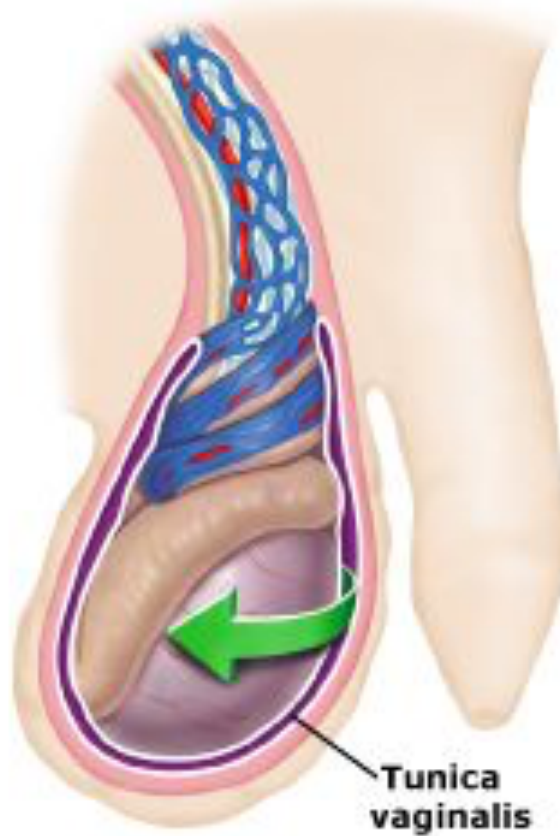
testis

longitudinal scan of testis

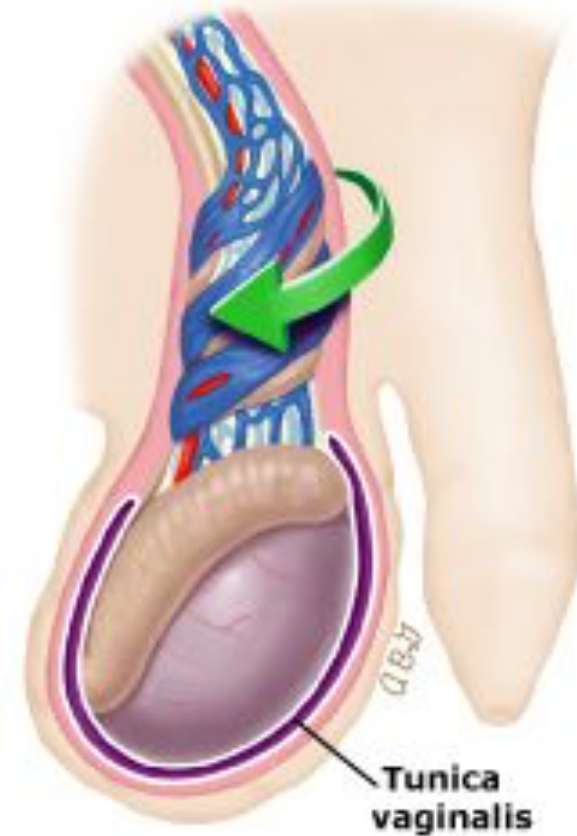
Testicular torsion



Normal



Intravaginal torsion



Extravaginal torsion

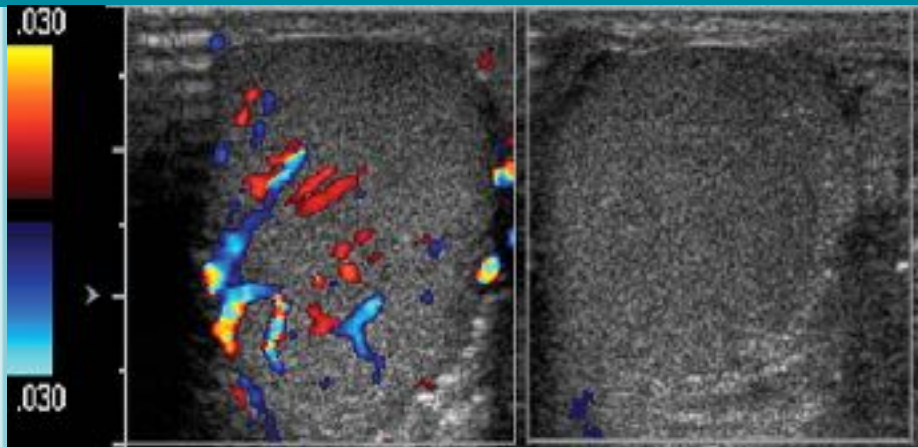
Role of Doppler Ultrasonography in the Triage of Acute Scrotum in the Emergency Department

Yael Yagil, MHA, MD, Inna Naroditsky, MD, Jumana Milhem, BSc, Ronit Leiba, MSc, Maxim Leiderman, MD, Shadie Badaan, MD, Diana Gaitini, MD

Table 4. Performance of DUS in the Diagnosis of Testicular Torsion, Malignancy, and Hematoma

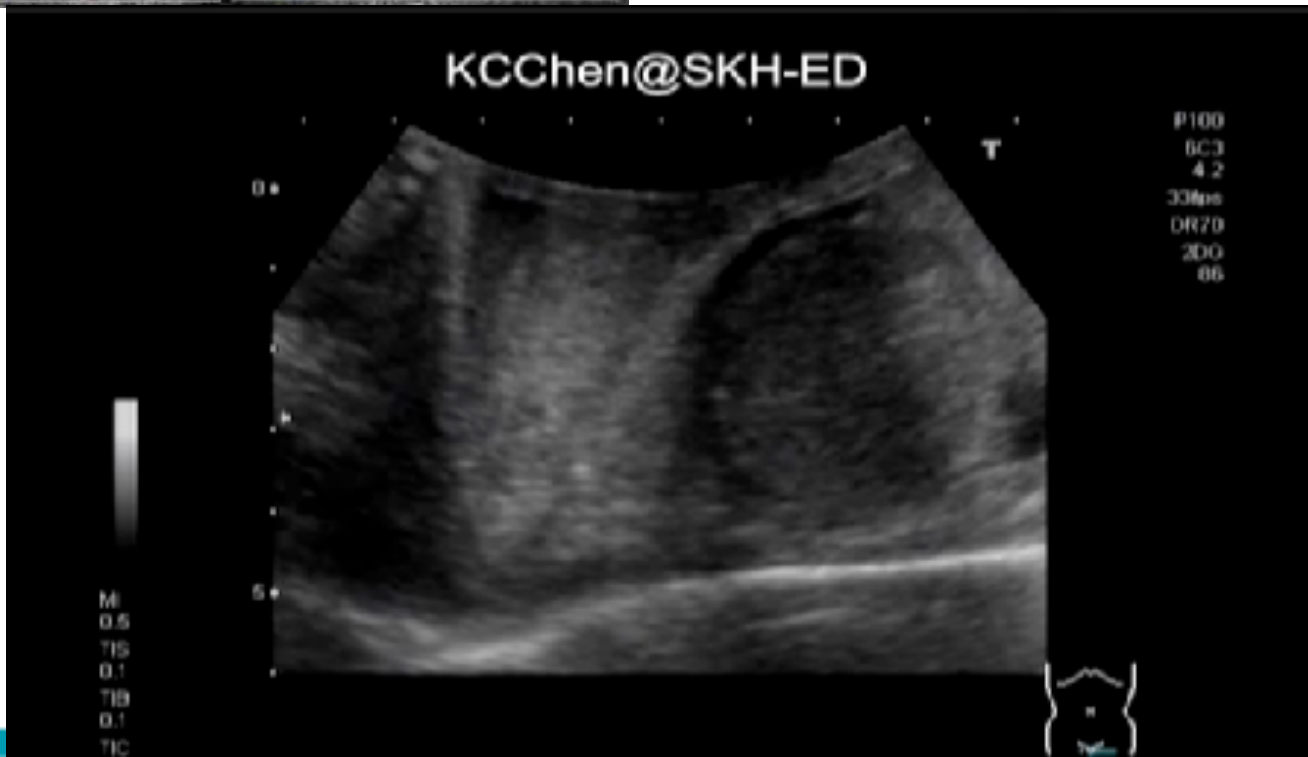| DUS Finding | True +, n | True -, n | False +, n | False -, n | Sensitivity, % | Specificity, % | Accuracy, % | PPV, % | NPV, % |
|-----------------------|-----------|-----------|------------|------------|----------------|----------------|-------------|--------|--------|
| Testicular torsion | 17 | 48 | 2 | 1 | 94 | 96 | 95.5 | 89 | 98 |
| Testicular malignancy | 11 | 53 | 3 | 1 | 92 | 95 | 94 | 78.5 | 98 |
| Testicular hematoma | 7 | 60 | 1 | 0 | 100 | 98 | 98.5 | 87.5 | 100 |

Testicular torsion

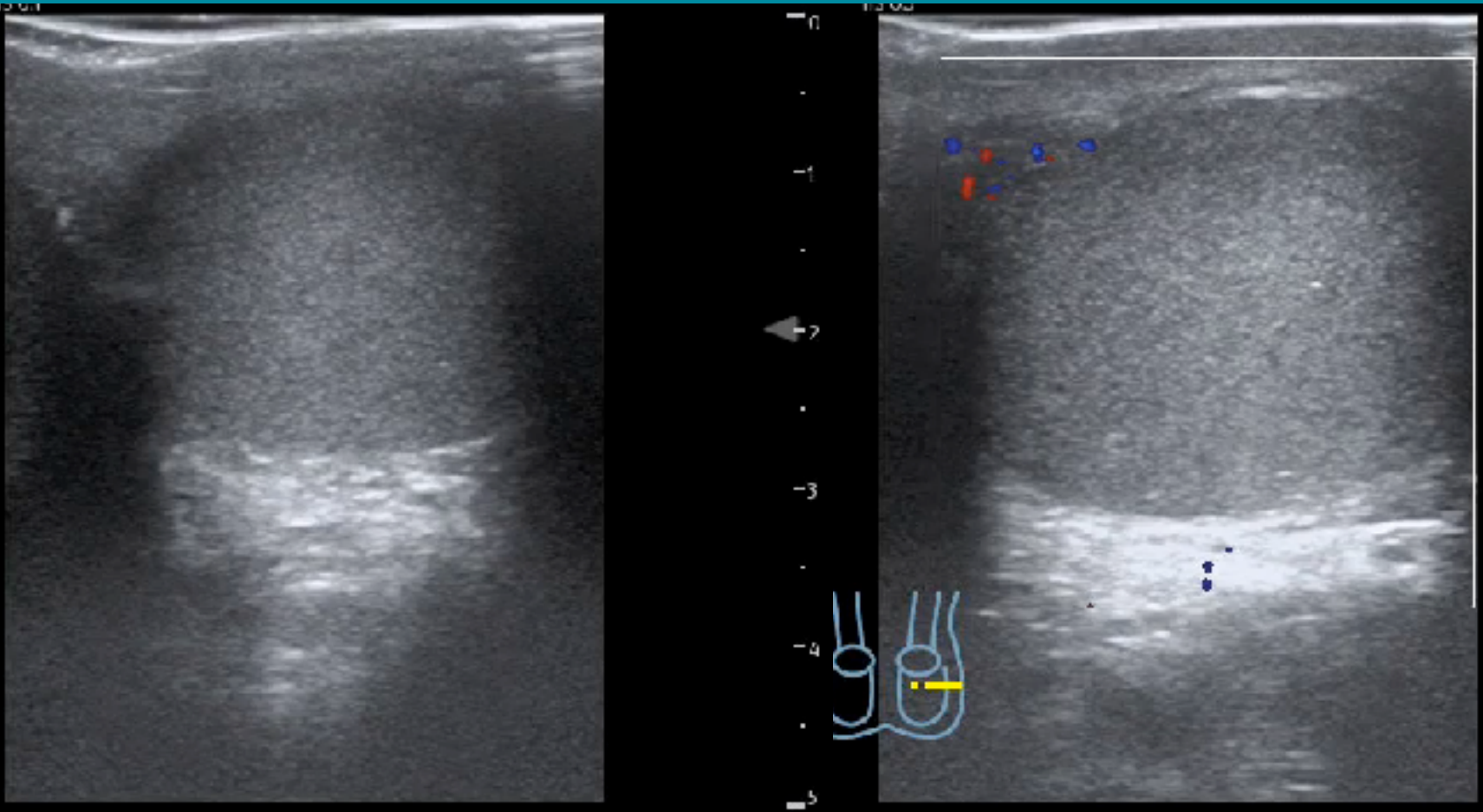


Most common: 12-18 years
Golden hours: 6 hours

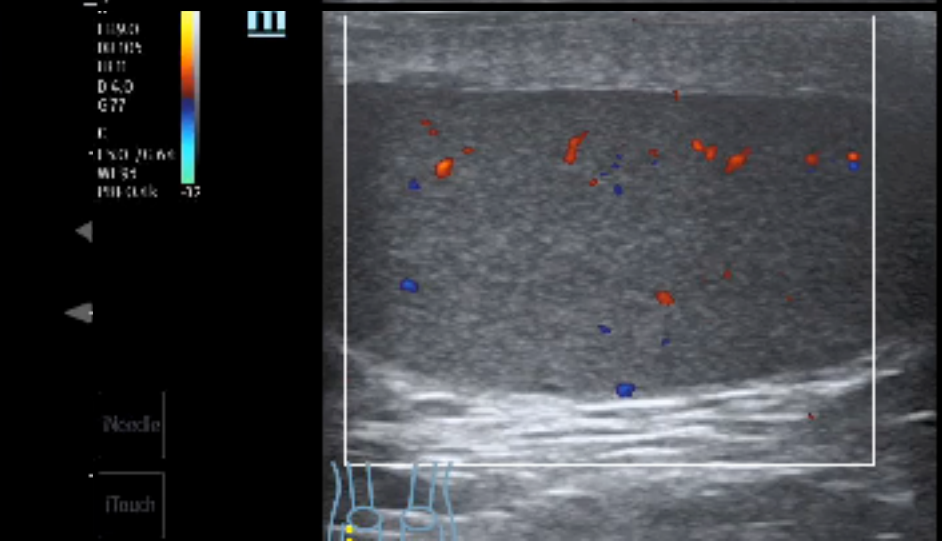
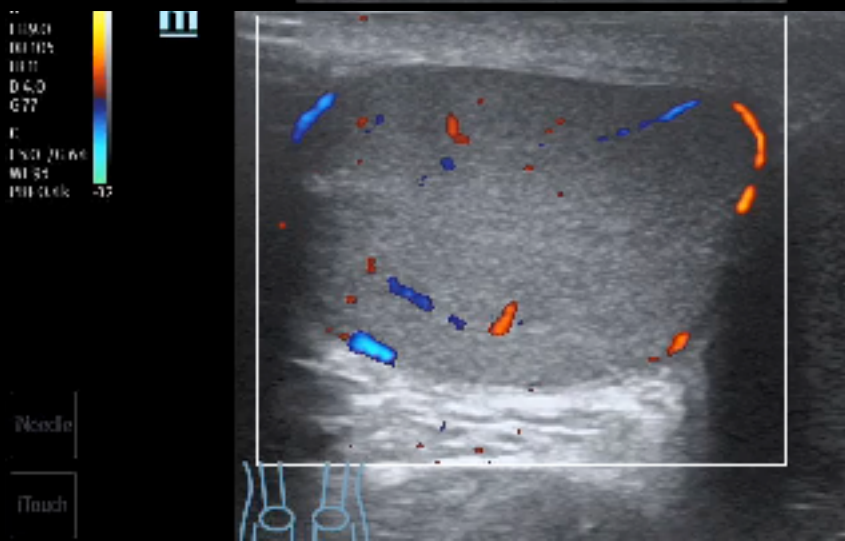
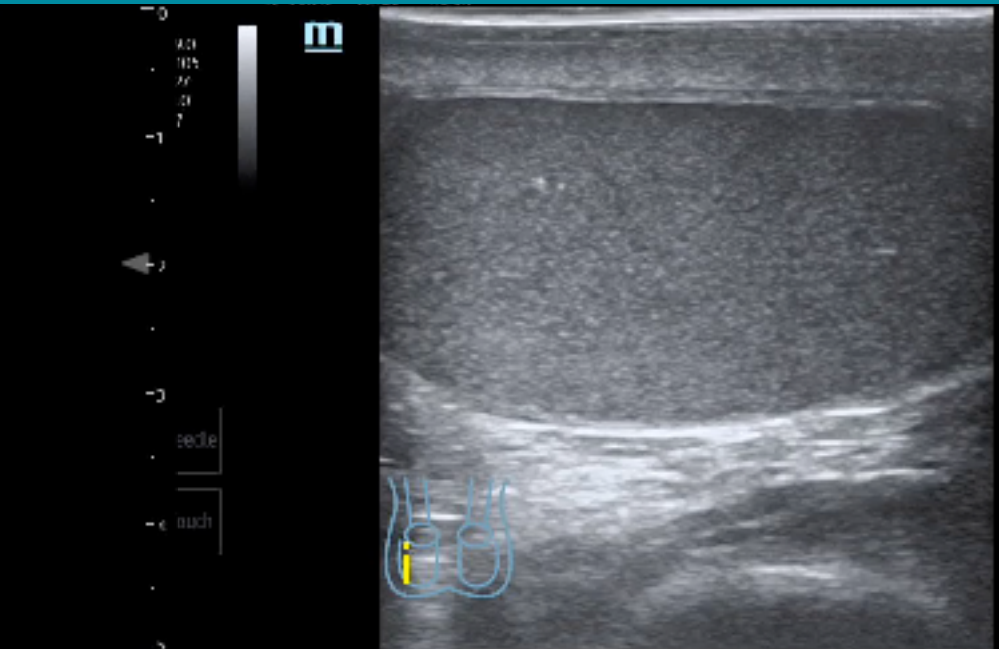
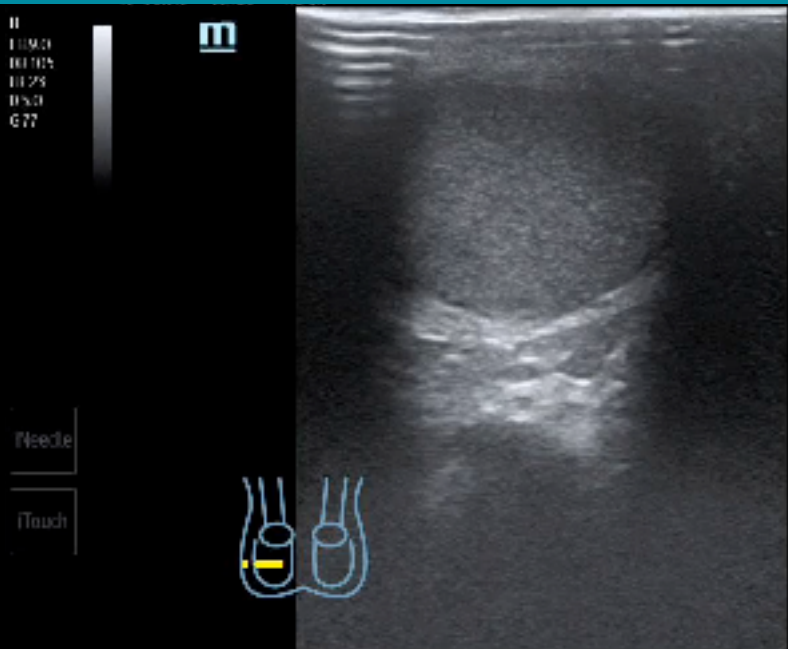
Bhatt S , Dogra V S Radiographics 2008;28:1617-1629



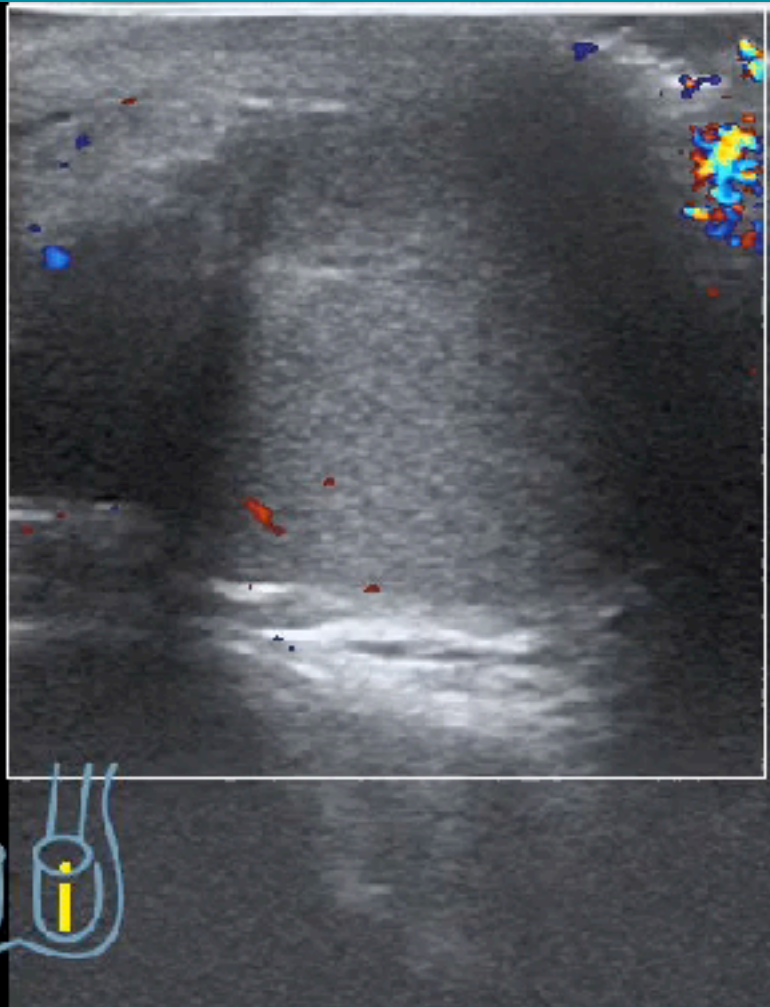
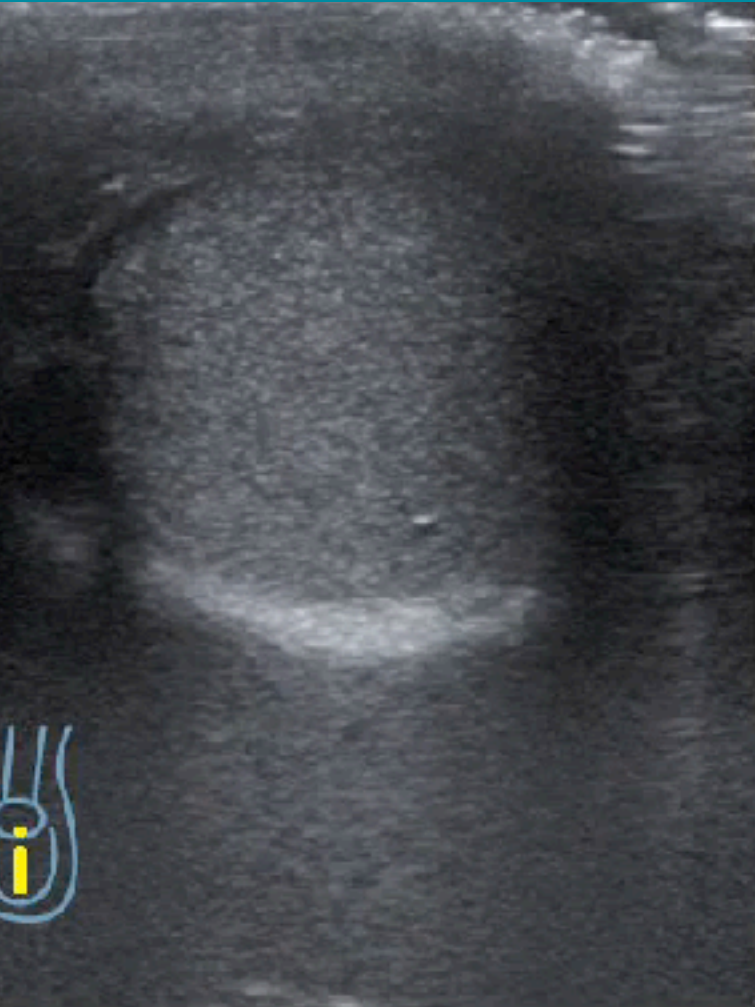
18M, SUDDEN ONSET LEFT SCROTAL PAIN; VAS 7



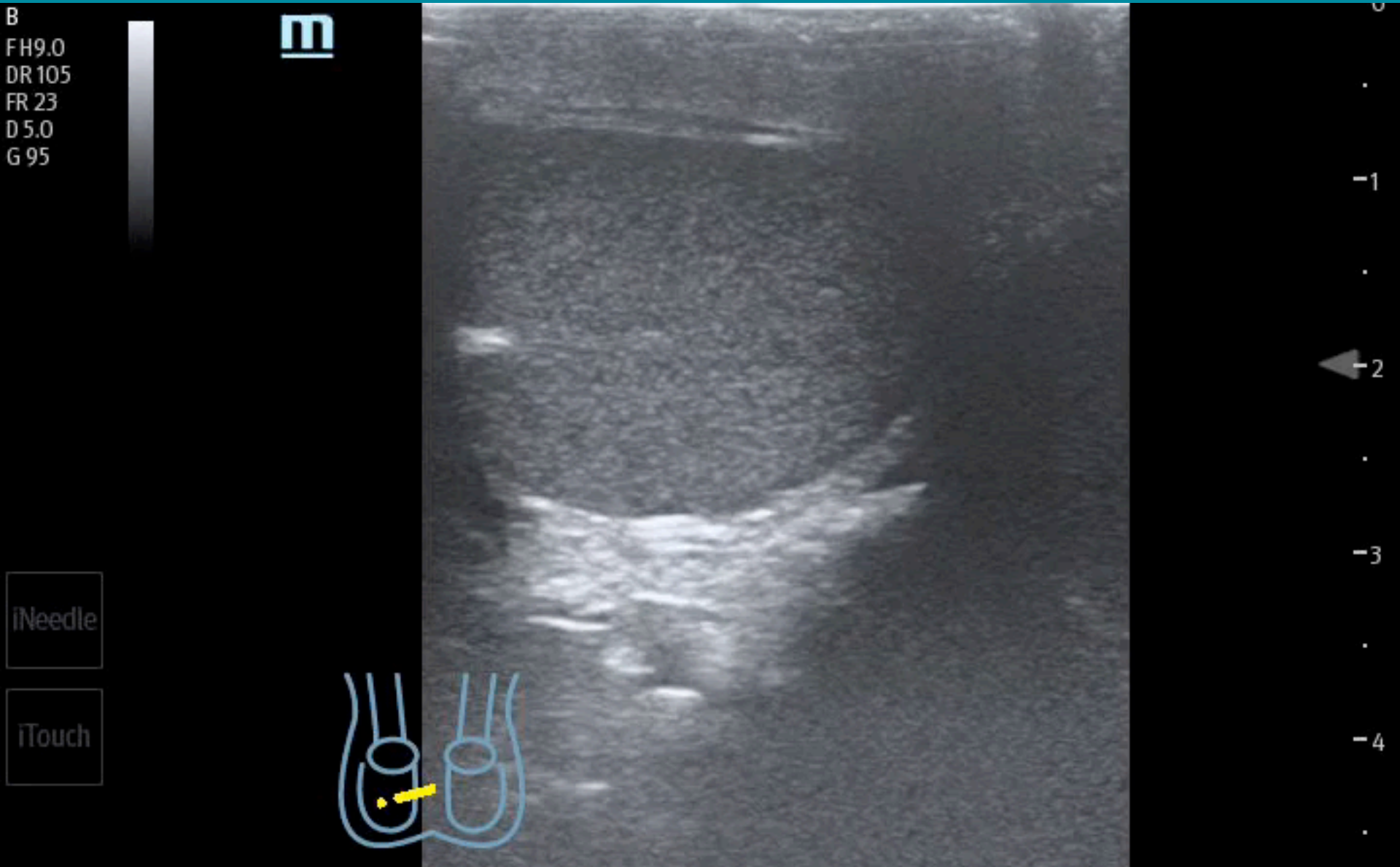
18M, SUDDEN ONSET LEFT SCROTAL PAIN; VAS 7



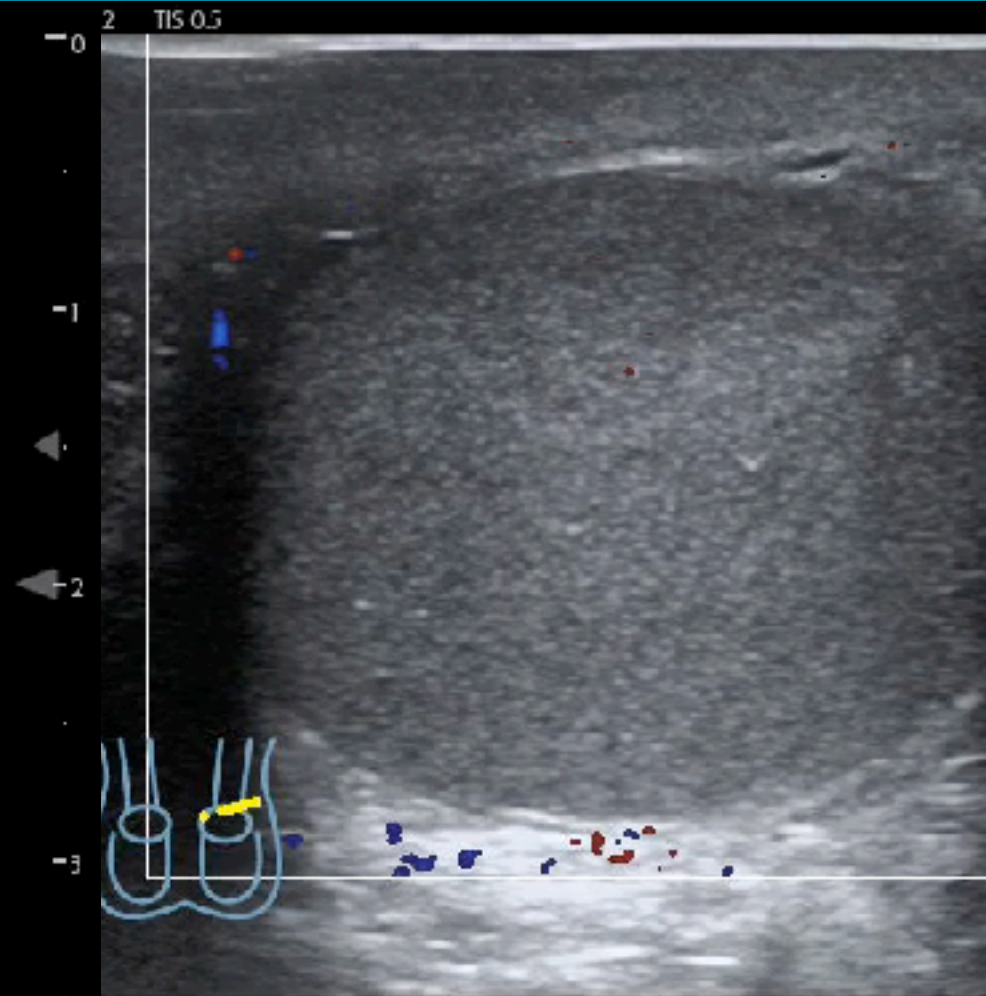
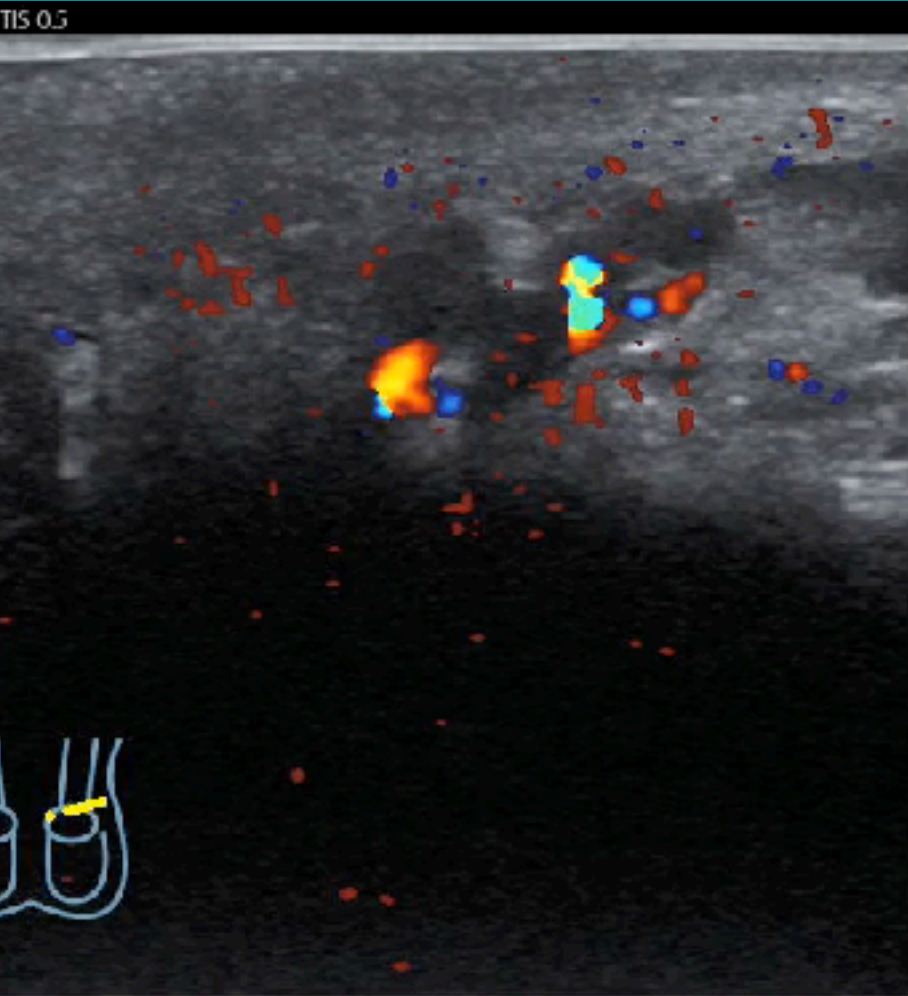
18M, SUDDEN ONSET LEFT SCROTAL PAIN; VAS 7



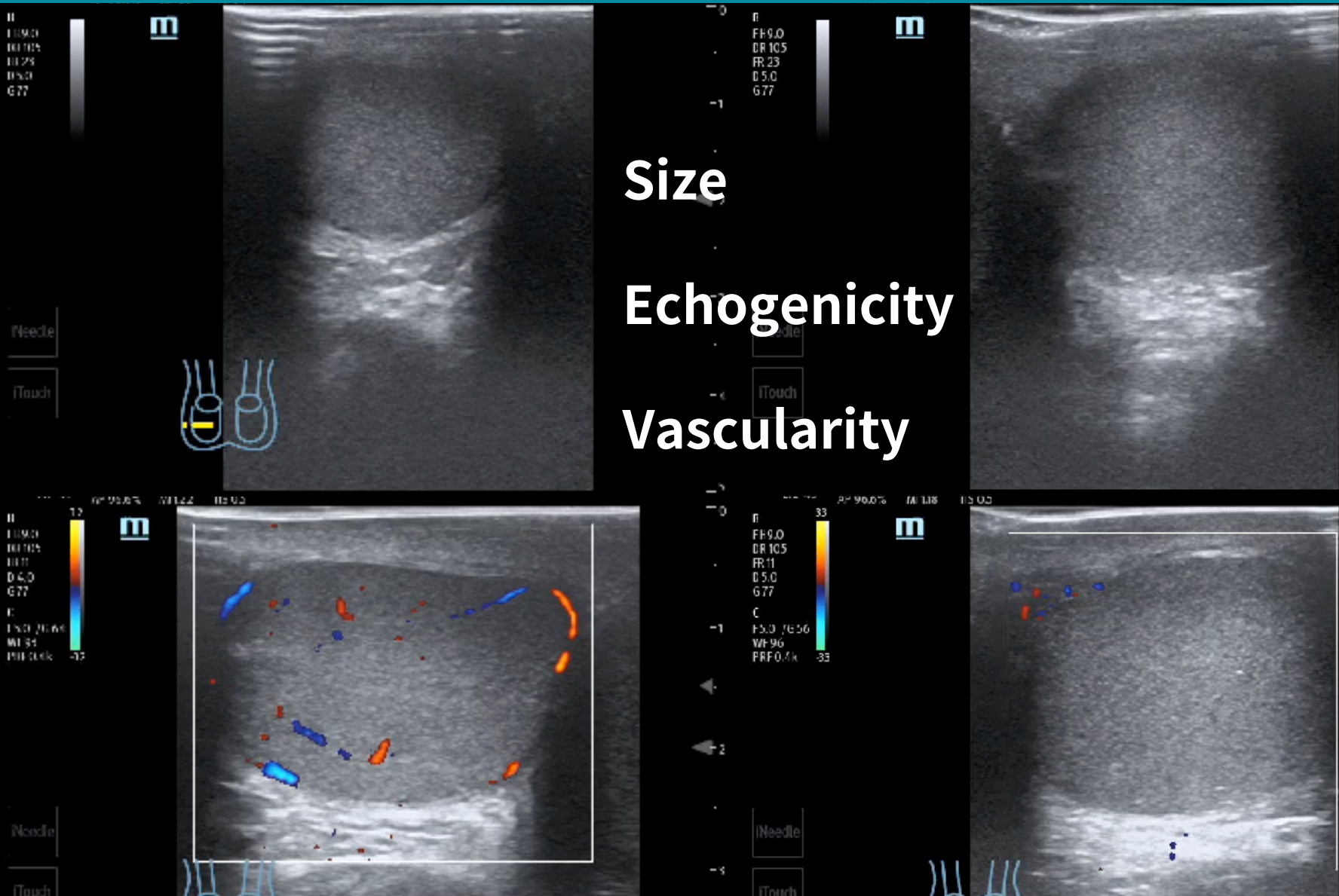
18M, SUDDEN ONSET LEFT SCROTAL PAIN; VAS 7



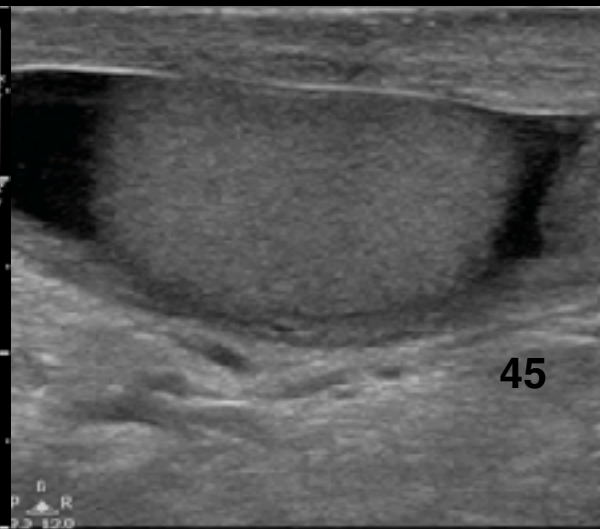
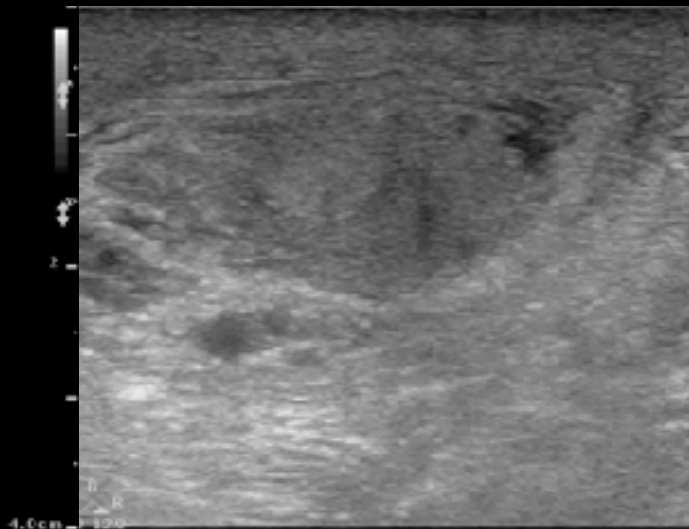
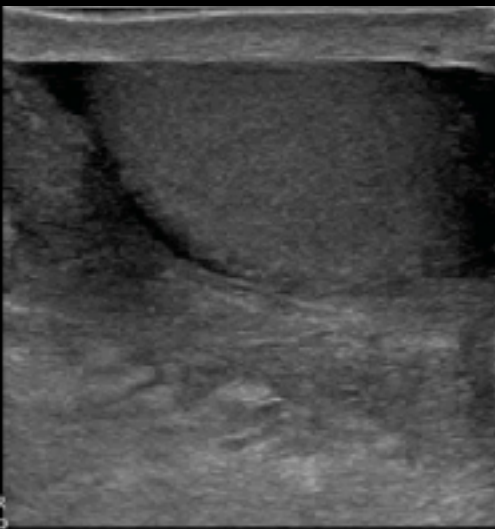
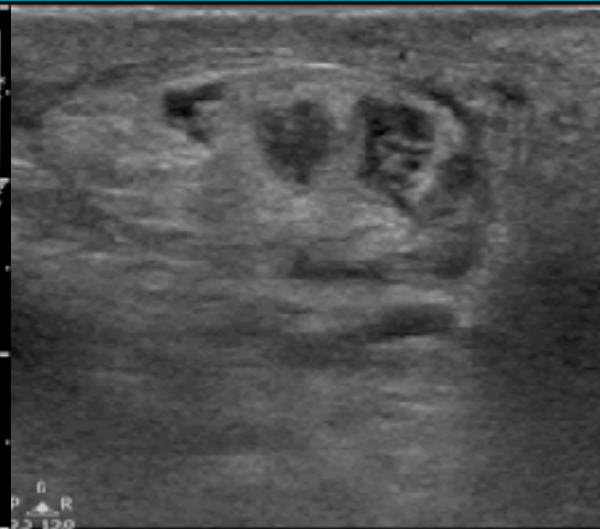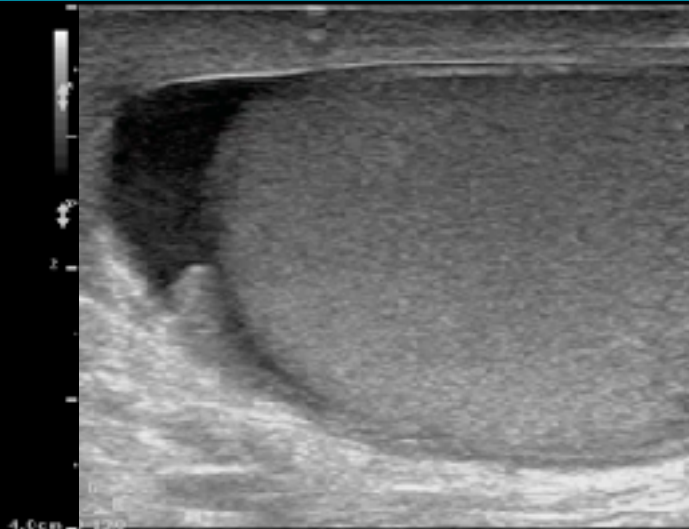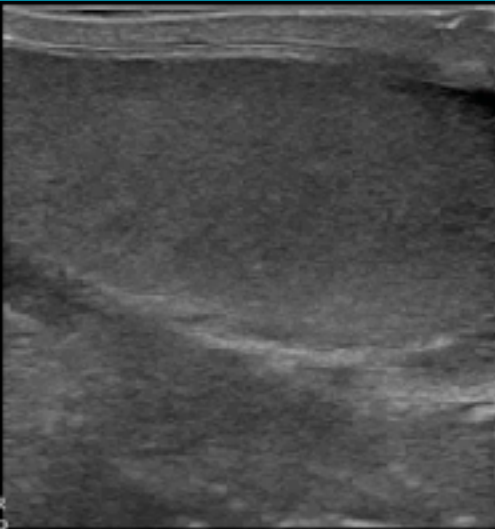
18M, SUDDEN ONSET LEFT SCROTAL PAIN; VAS 7



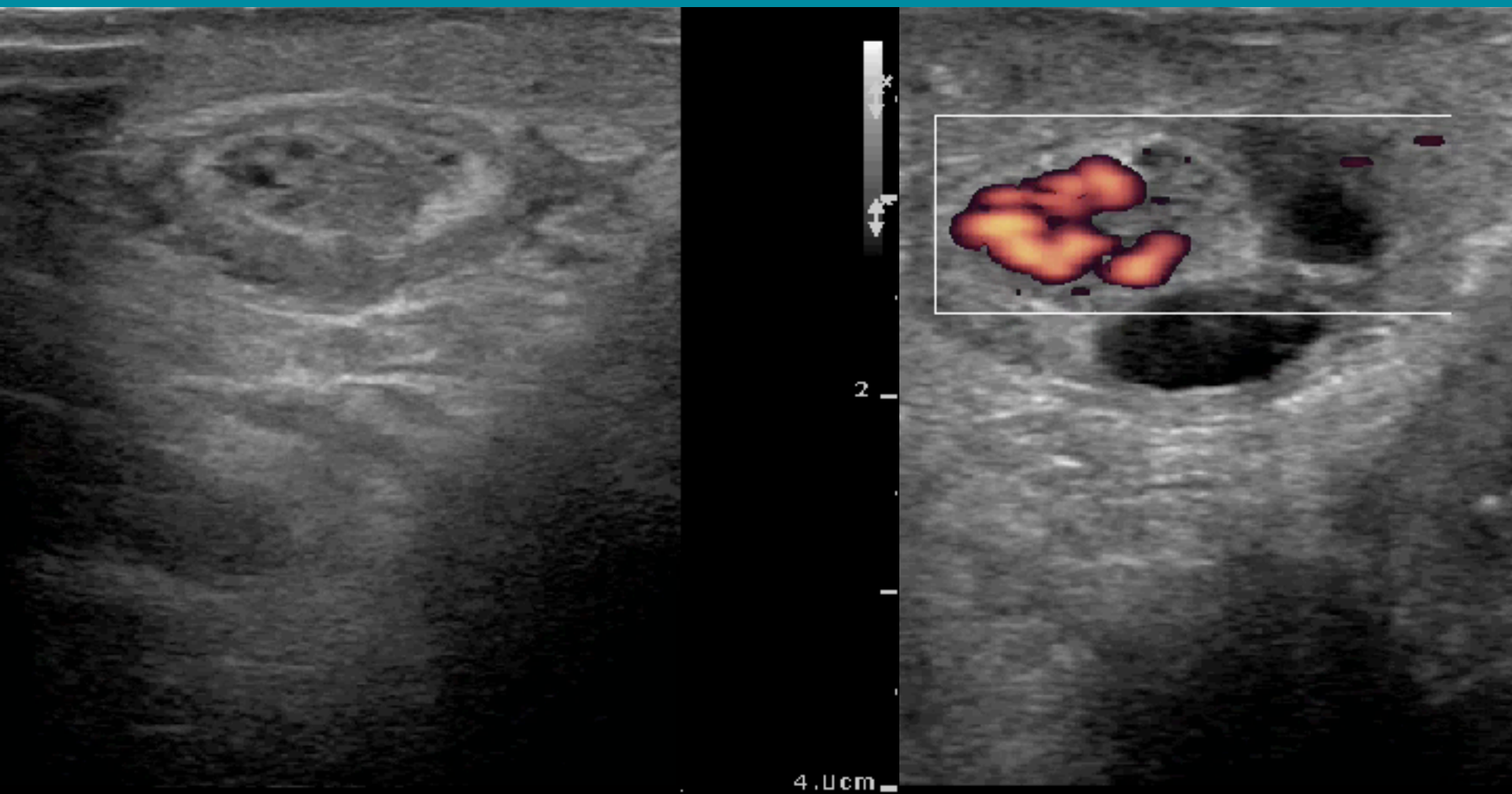
TESTICULAR TORSION



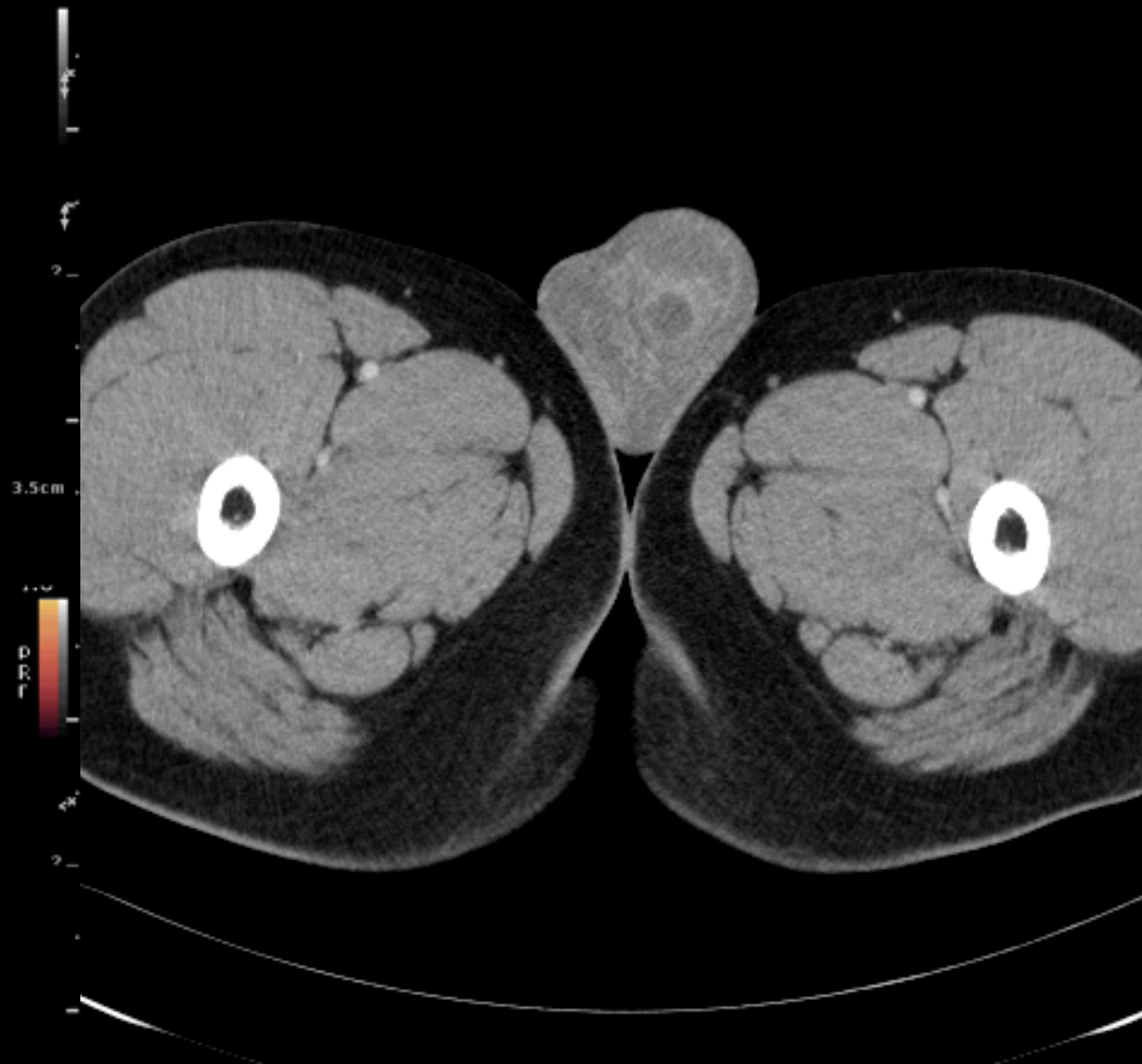
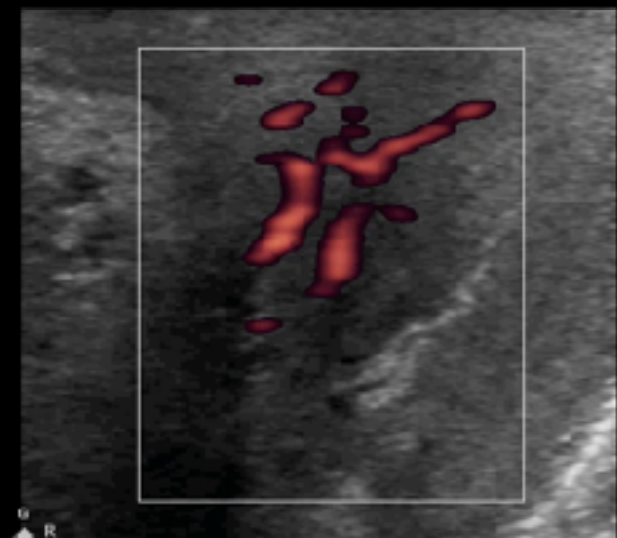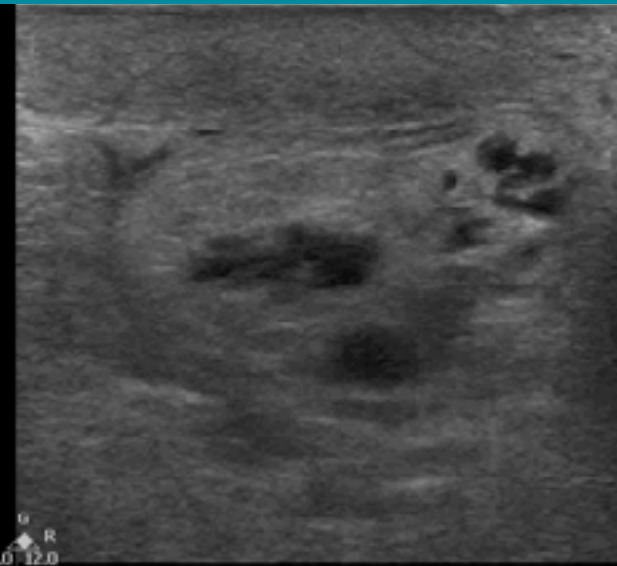Epididymitis



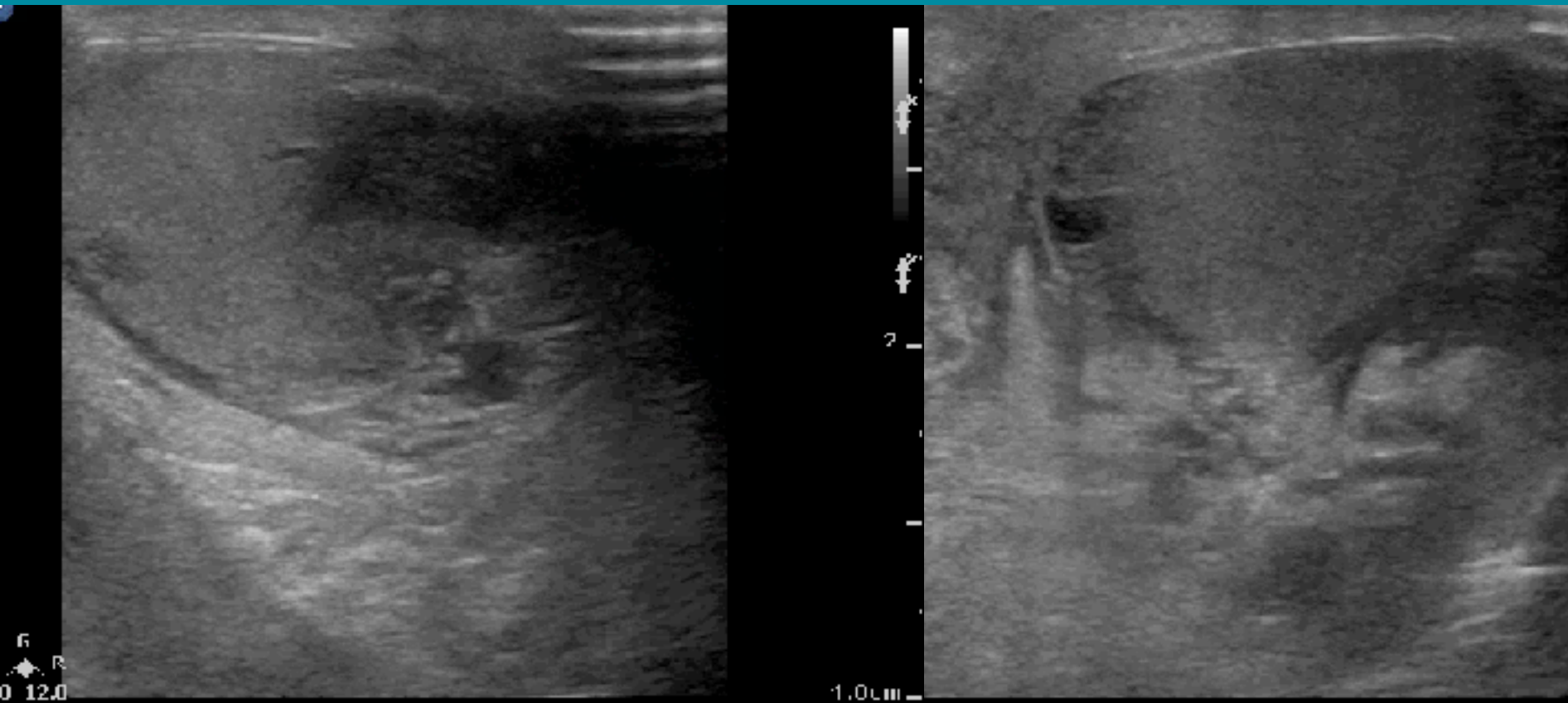
Orchitis



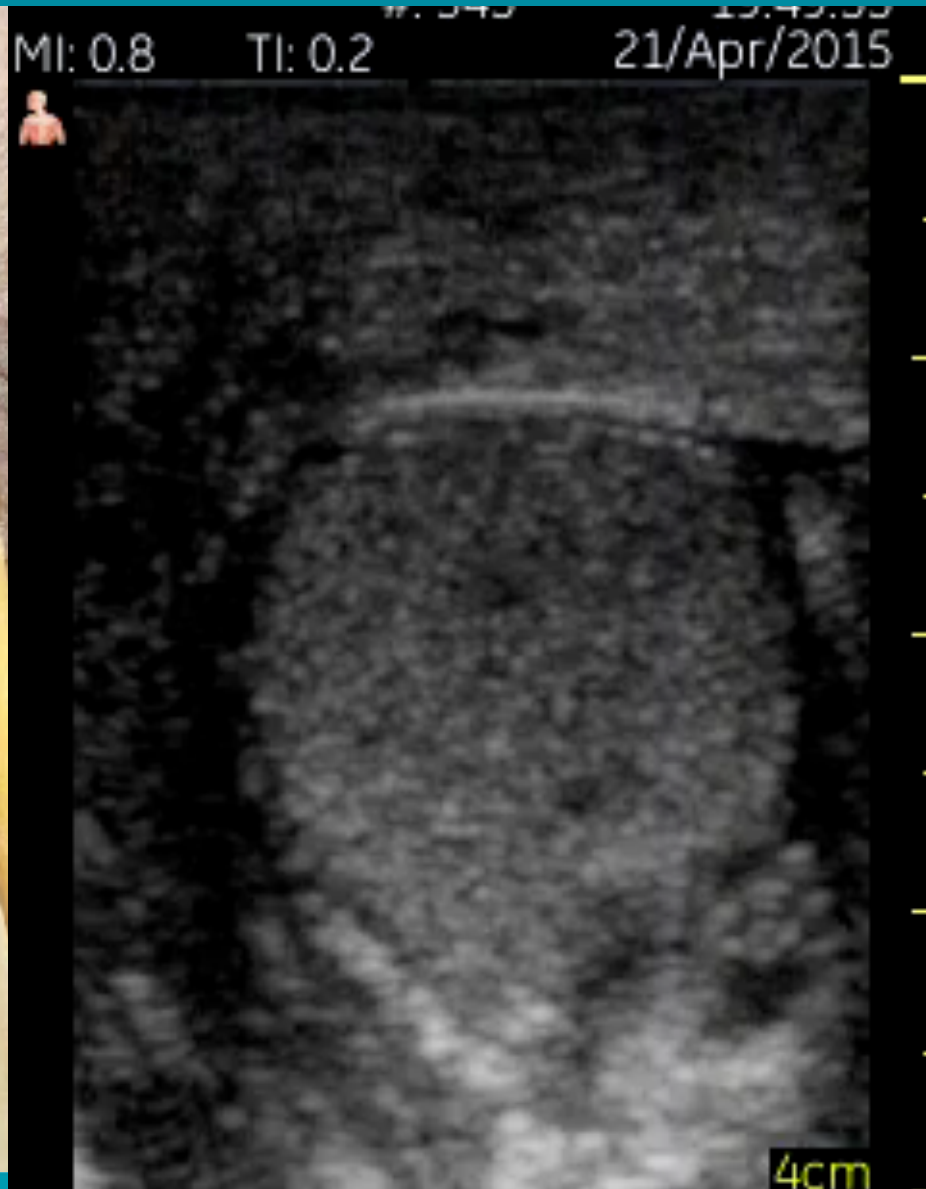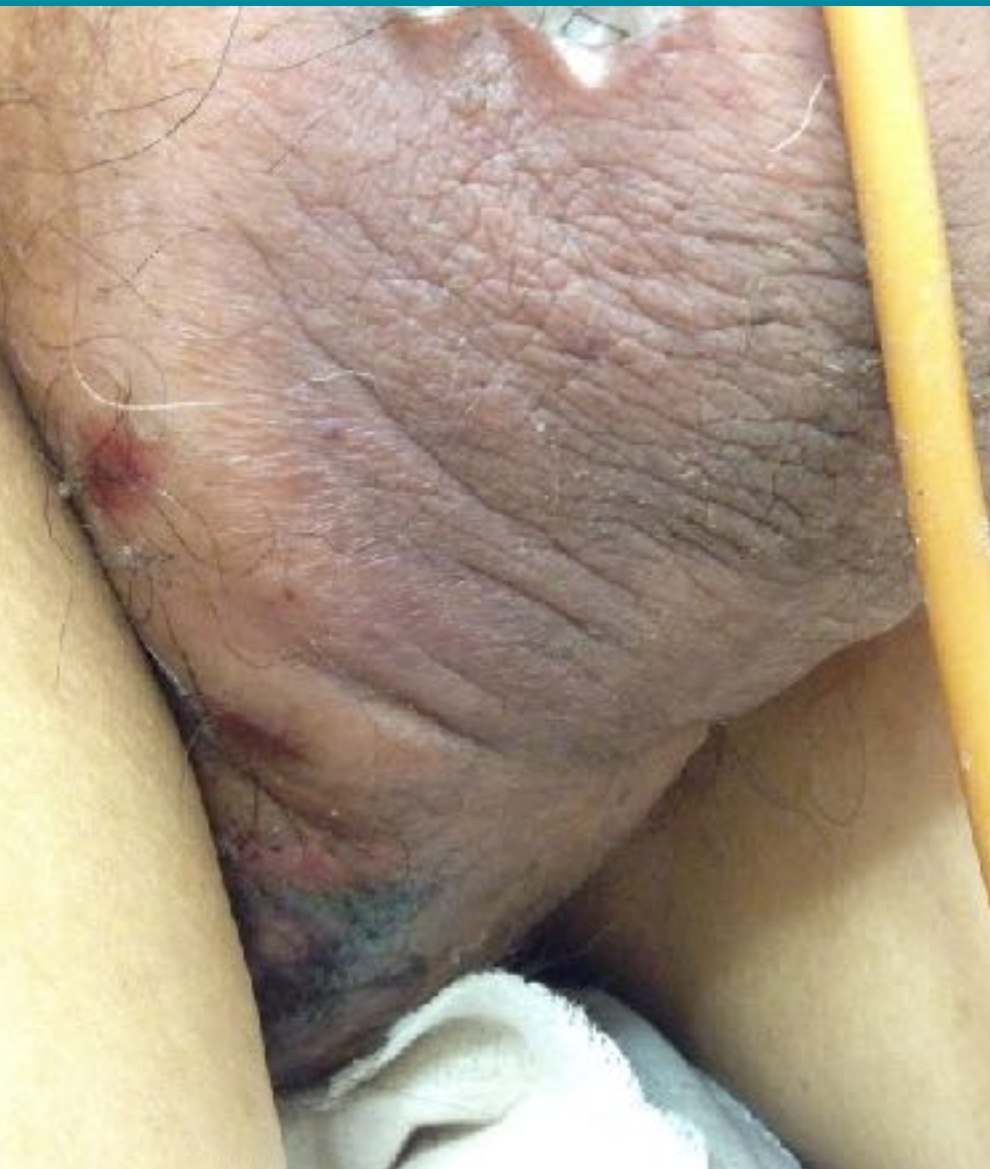Epididymal abscess



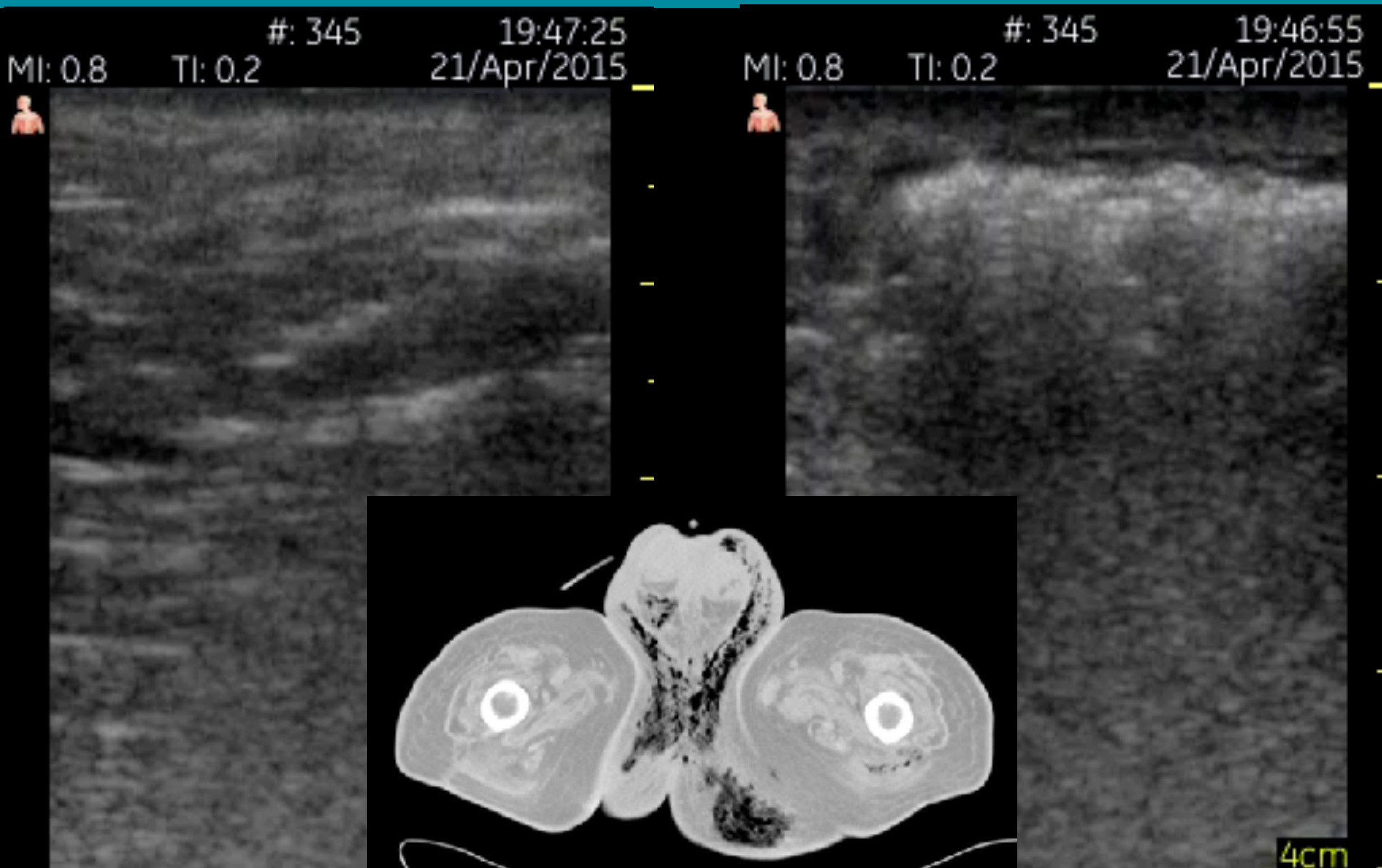
Epididymal abscess



Fournier's gangrene

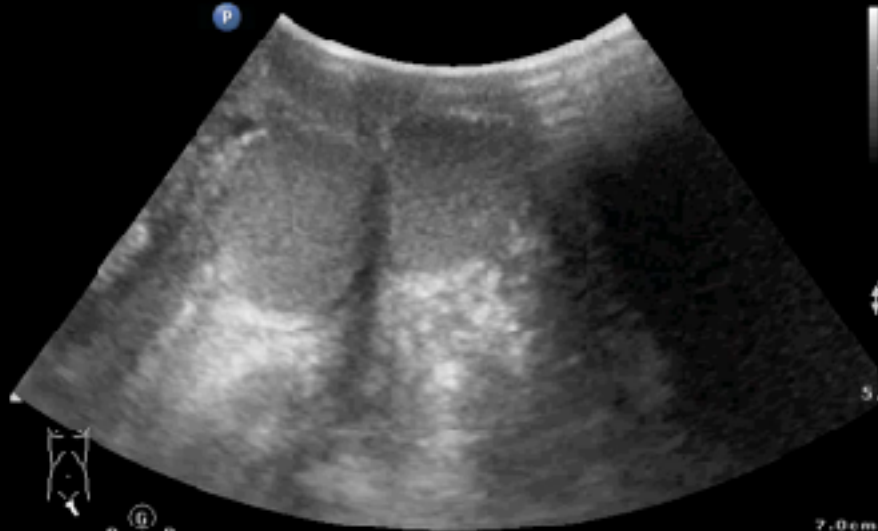

Fournier's gangrene



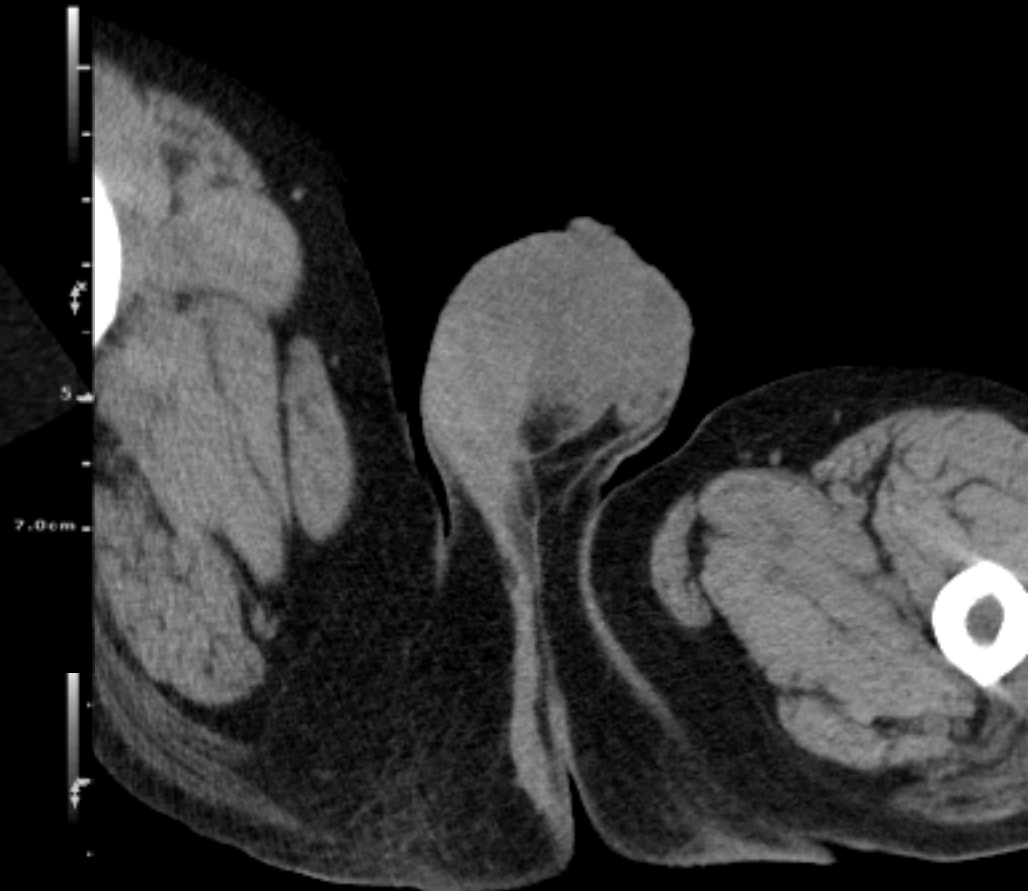
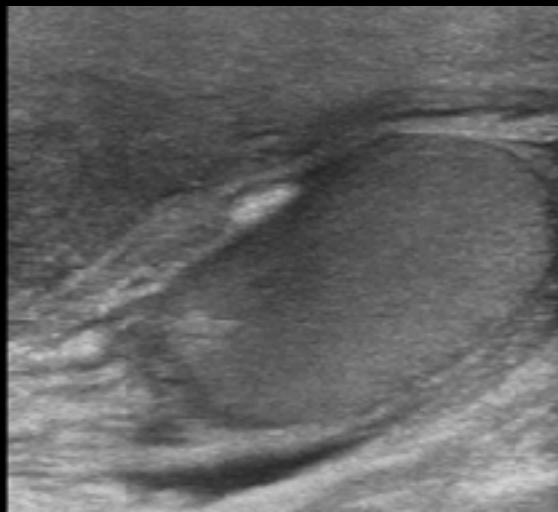
Perineal abscess

Gen
1
Hz
cm
en
100
6
3/3



P
R
1.8 3.6

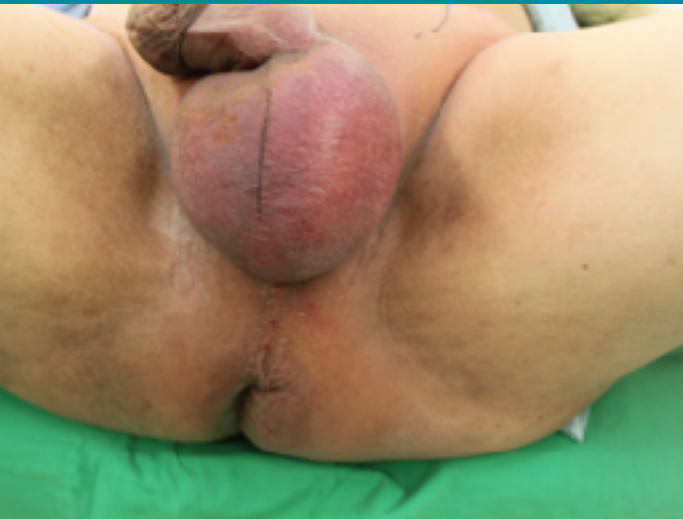Hz
cm
en
100
2
3/2



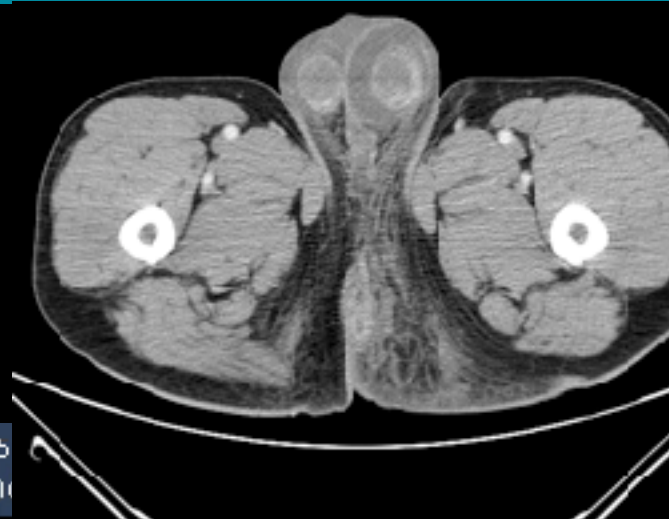7.0 cm

2

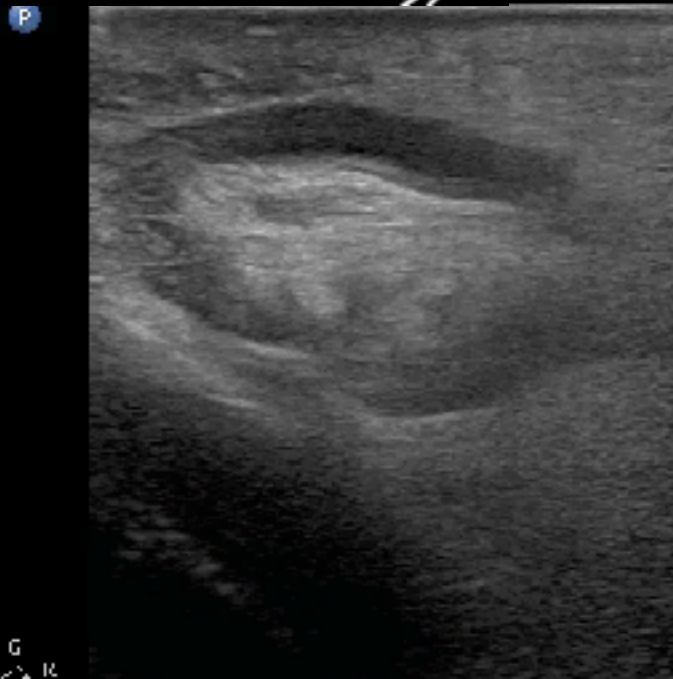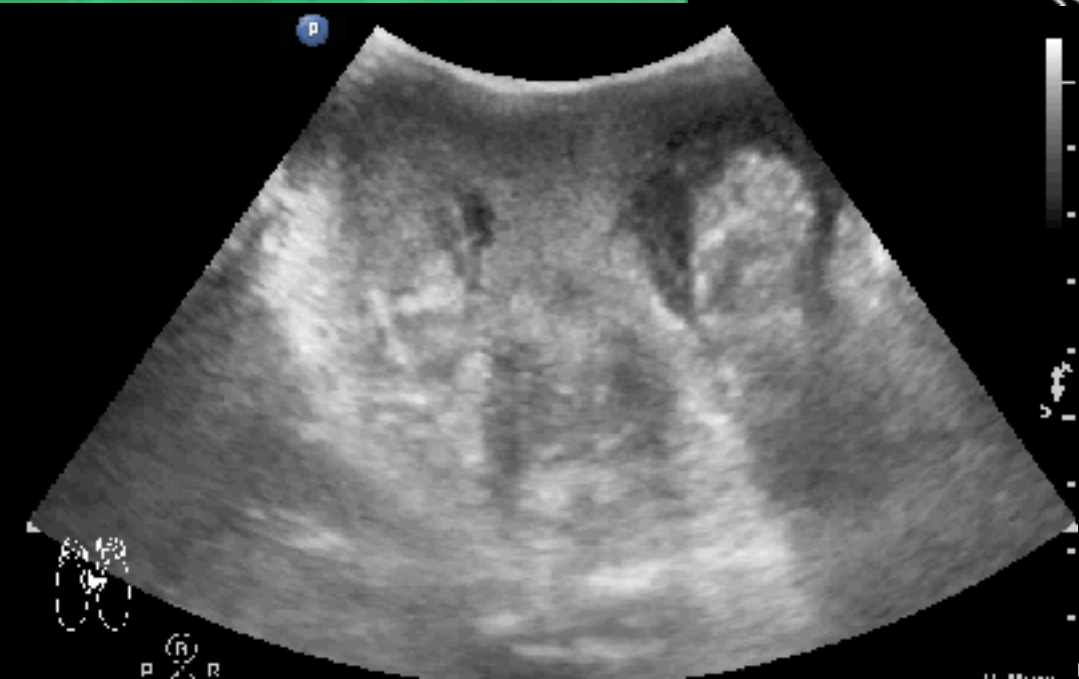Perineal abscess



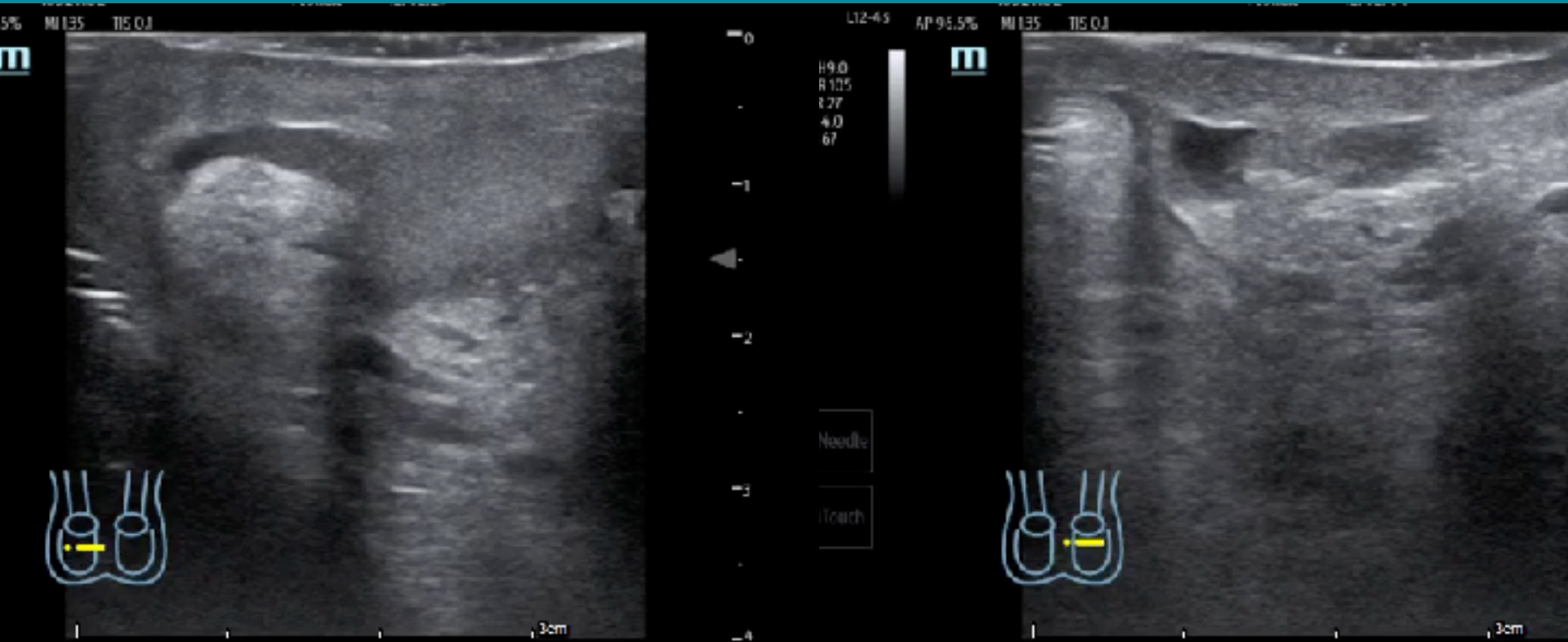
MI 1.1 12/5
TTS 0.1 11:00



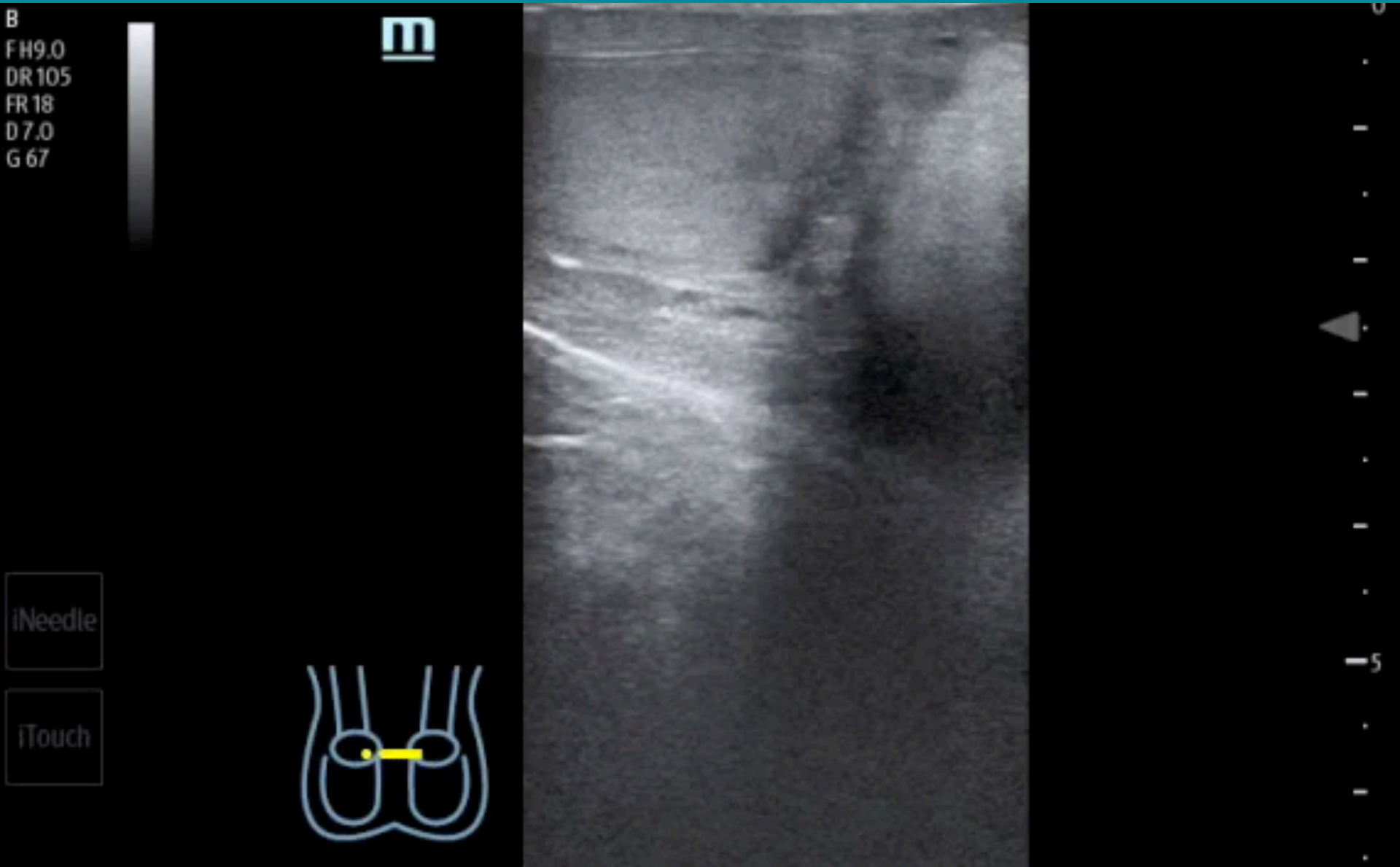
MI 0.6 12/5/2
TTS 0.2 11:02:0



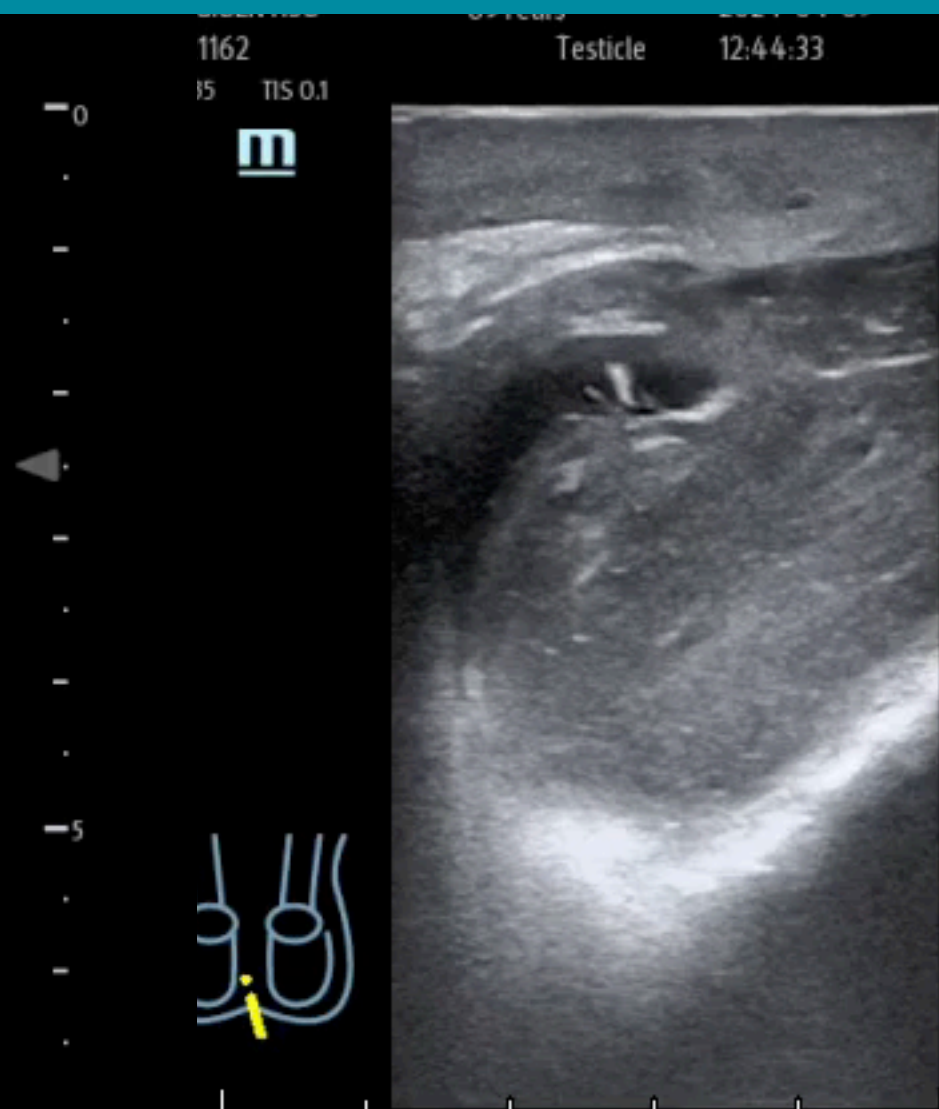
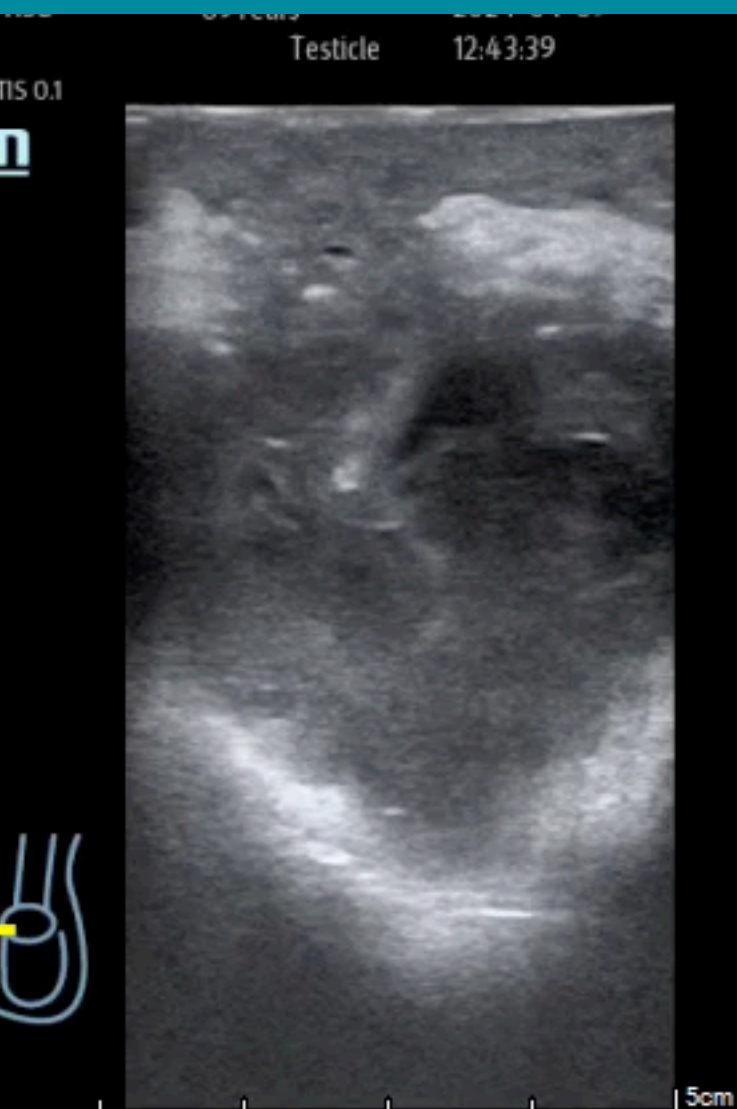69M, ICH HX; BEDRIDDEN; SCROTAL SWELLING 3 DAYS



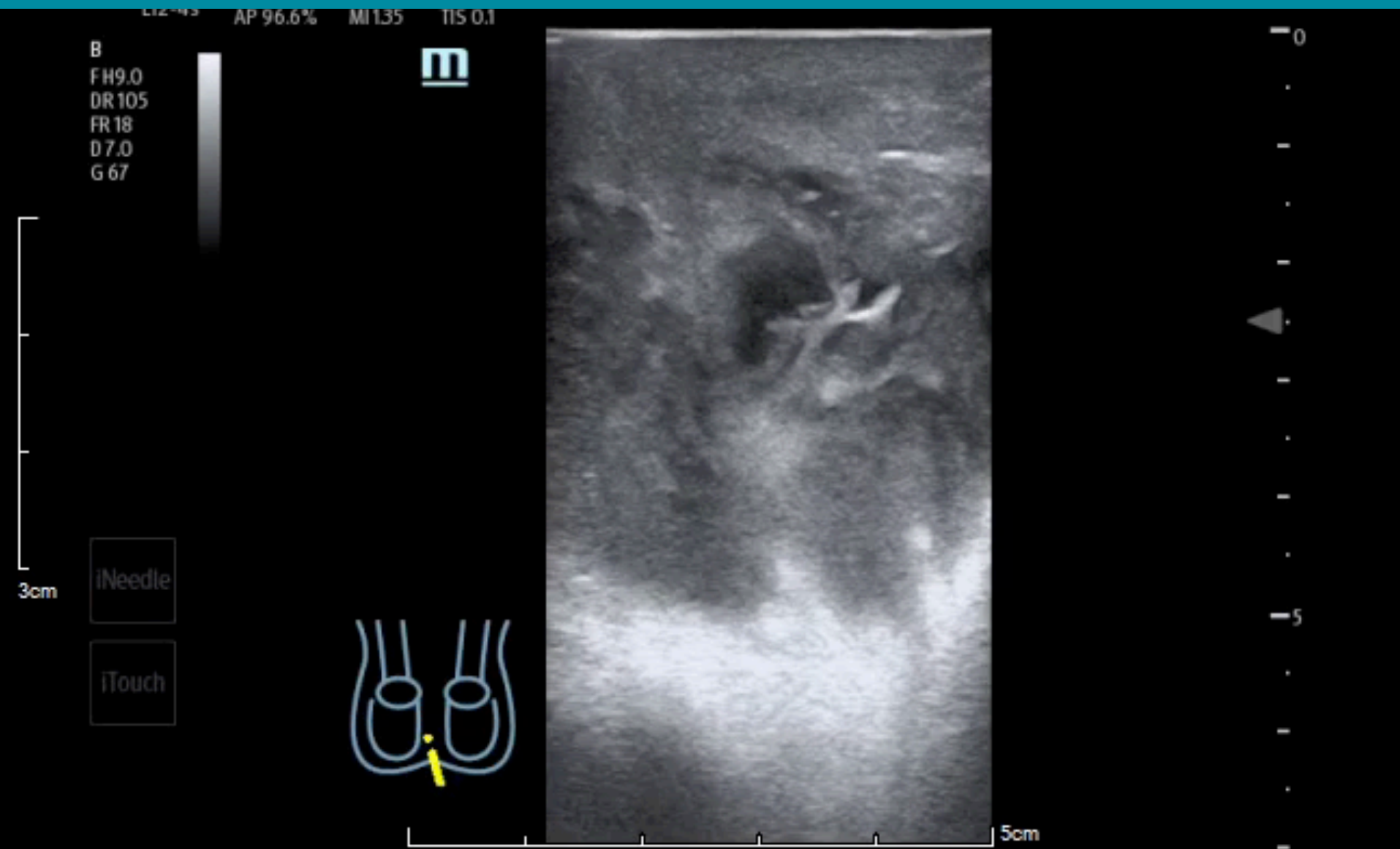
69M, ICH HX; BEDRIDDEN; SCROTAL SWELLING 3 DAYS



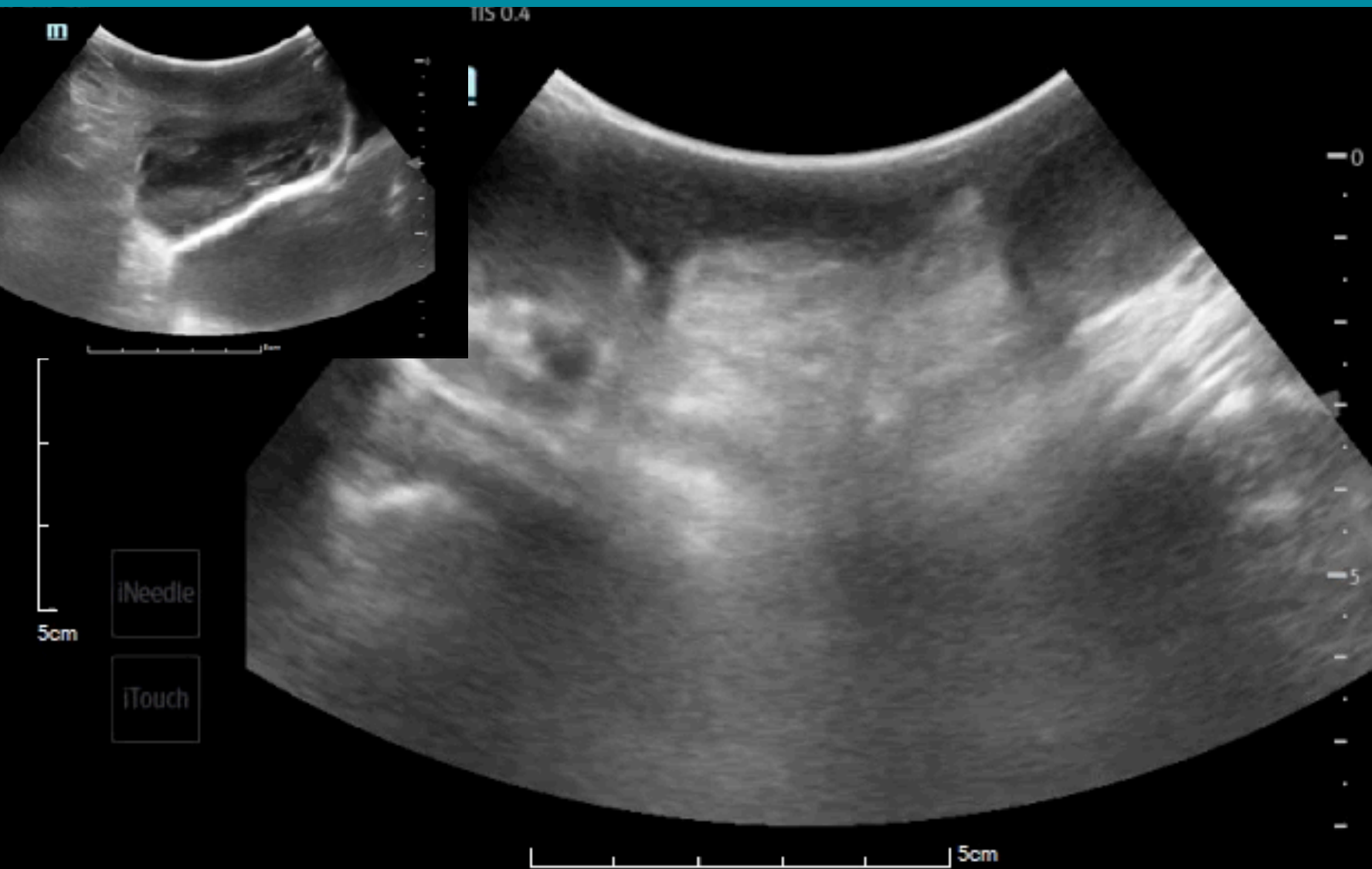
69M, ICH HX; BEDRIDDEN; SCROTAL SWELLING 3 DAYS



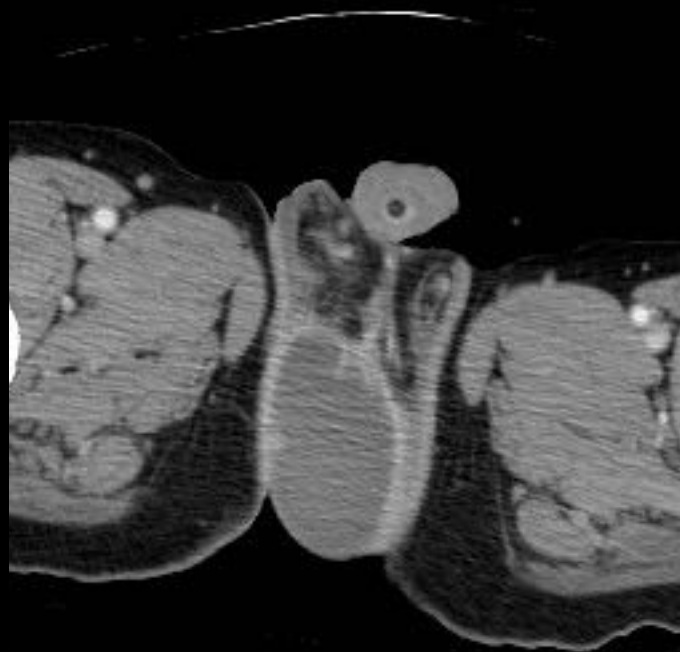
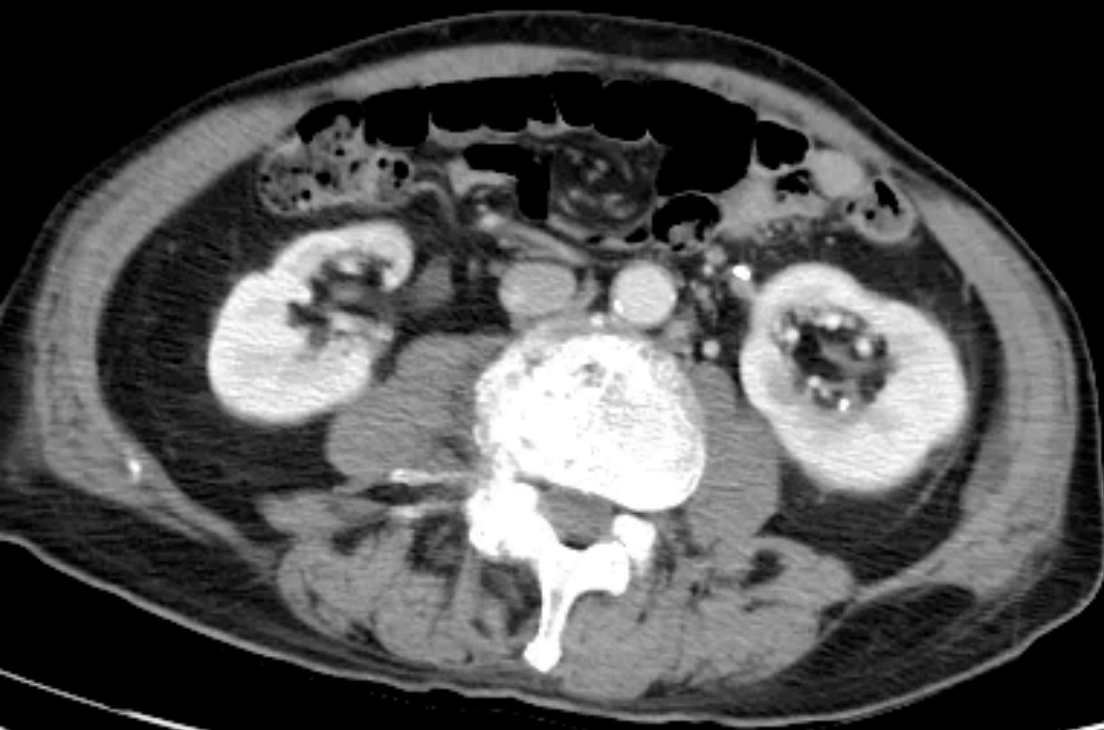69M, ICH HX; BEDRIDDEN; SCROTAL SWELLING 3 DAYS



69M, ICH HX; BEDRIDDEN; SCROTAL SWELLING 3 DAYS



69M, ICH HX; BEDRIDDEN; SCROTAL SWELLING 3 DAYS

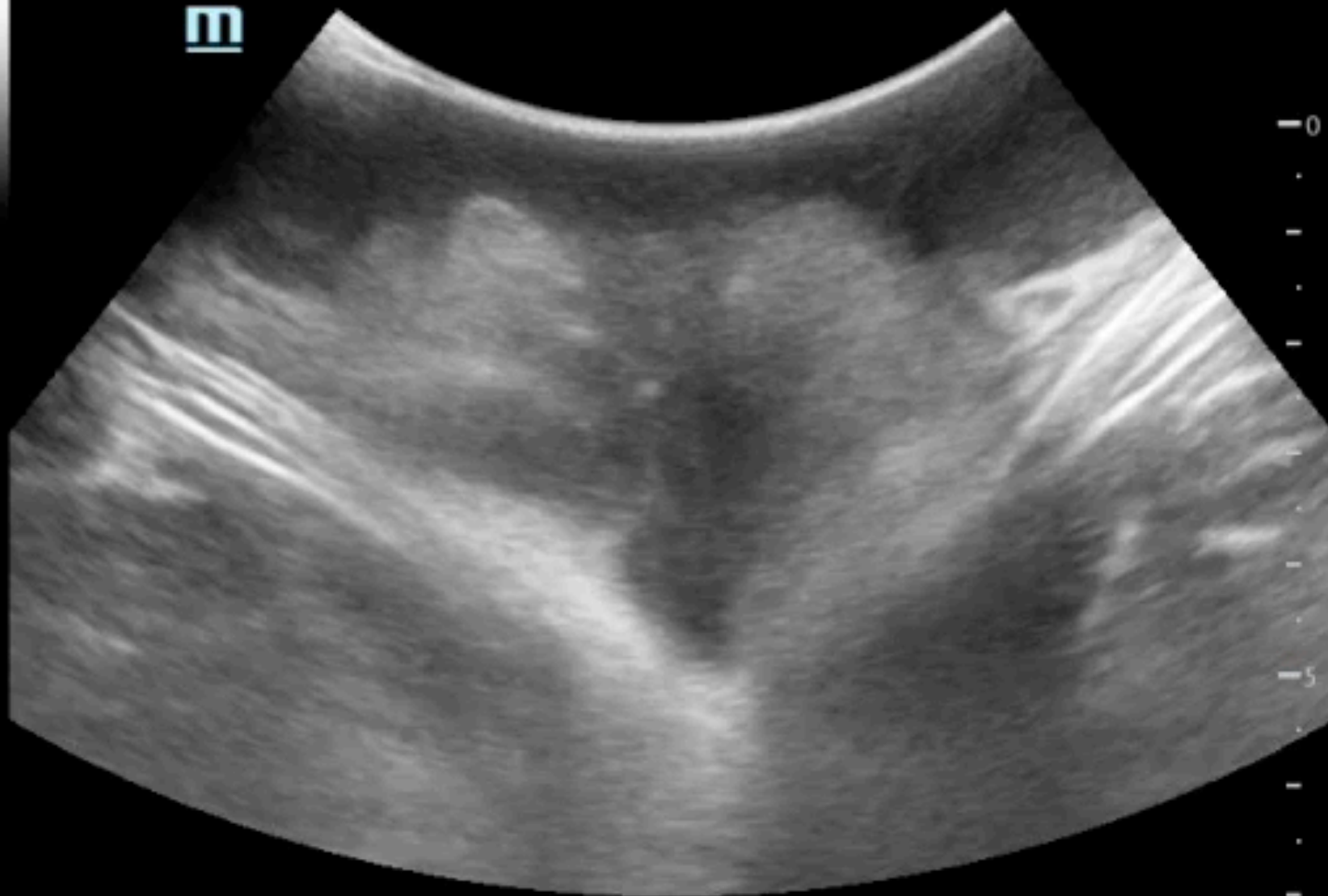

69M, ICH HX; BEDRIDDEN; SCROTAL SWELLING 3 DAYS

B

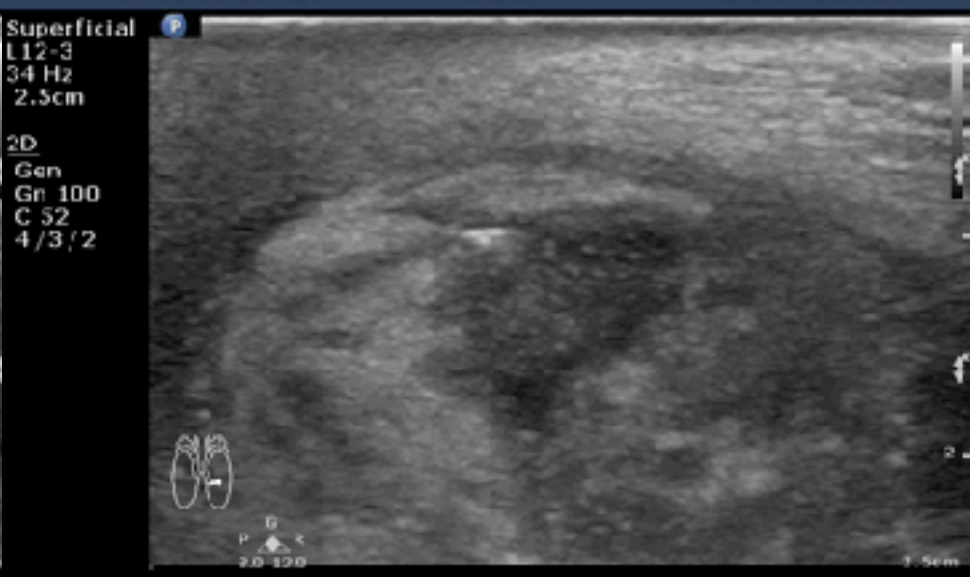
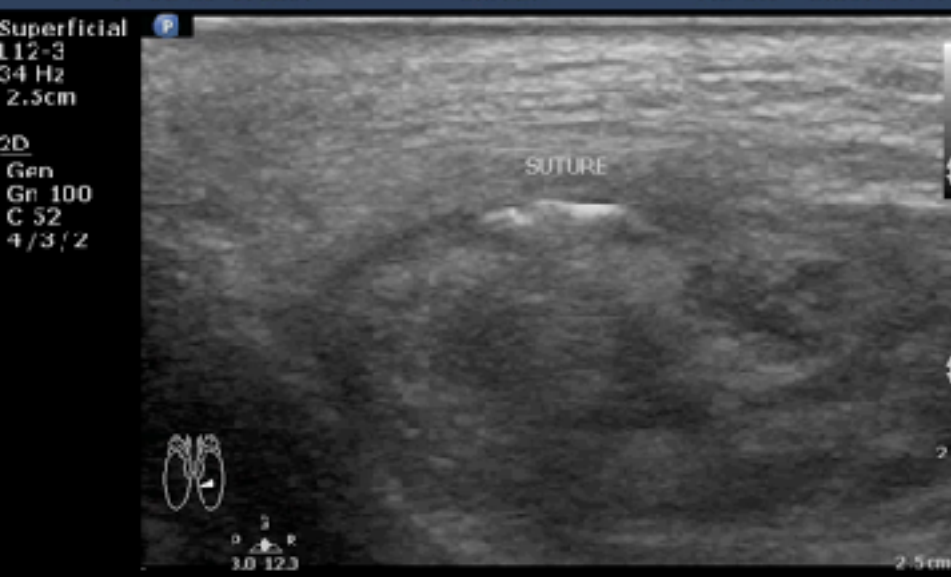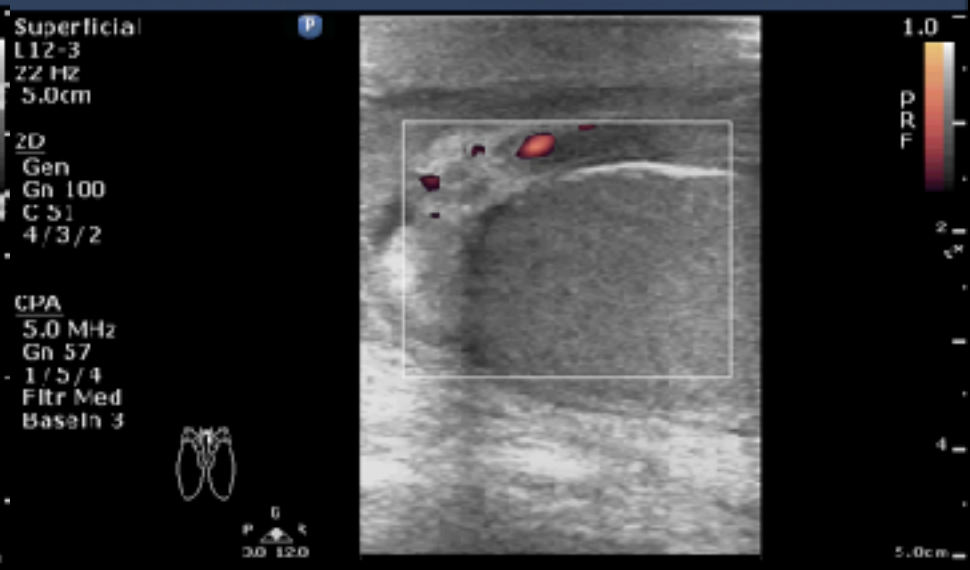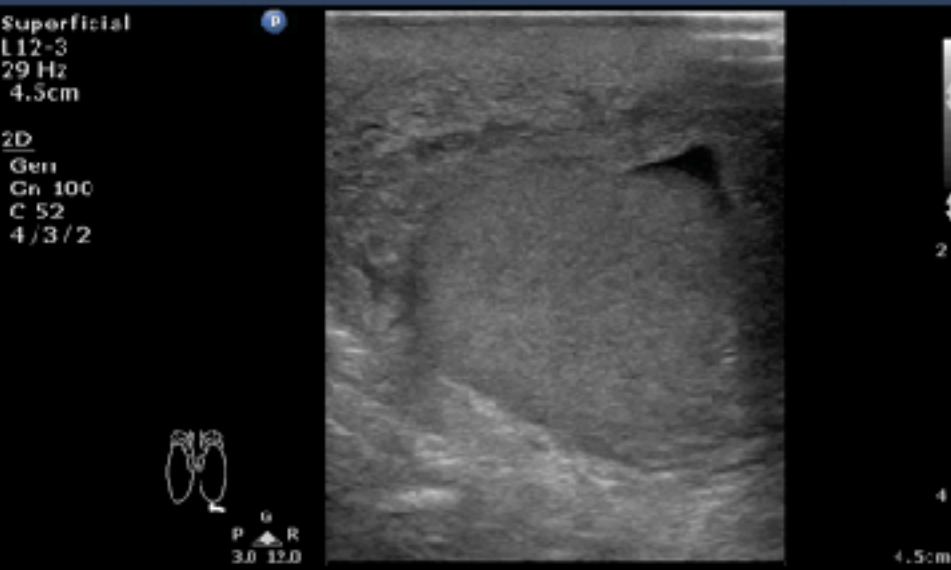FH5.0
DR 115
FR 28
D7.0
G71

m

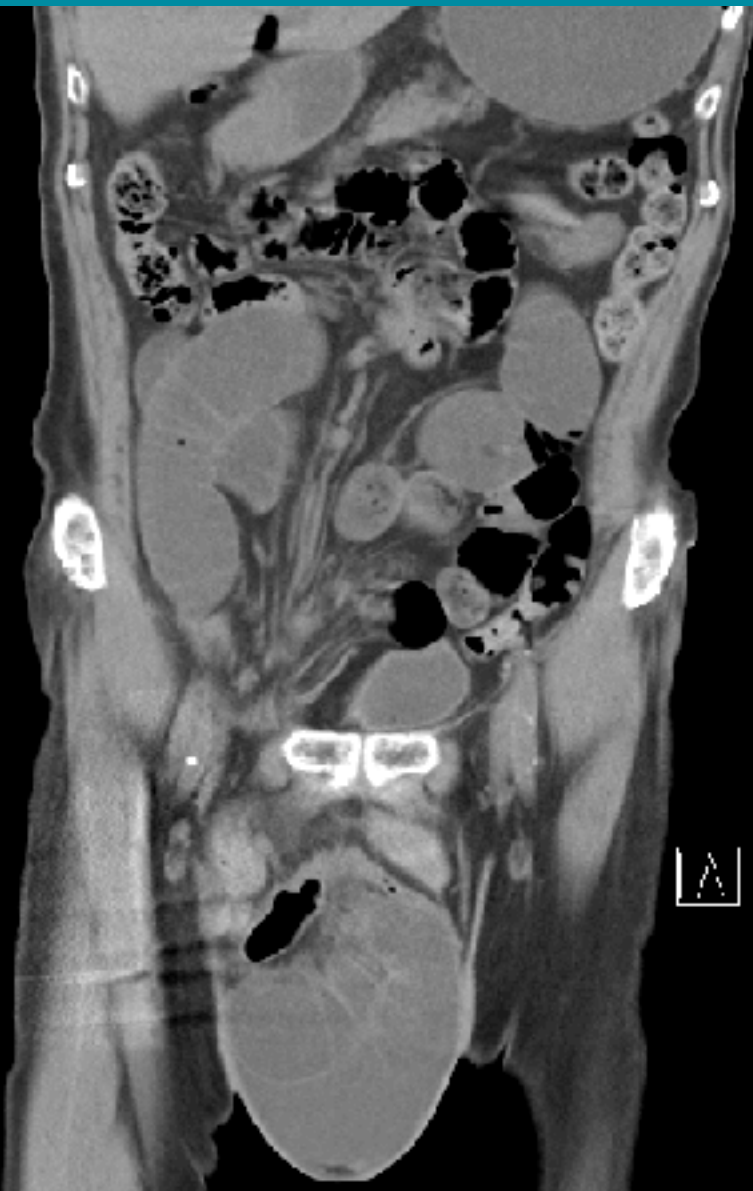

iNeedle

iTouch

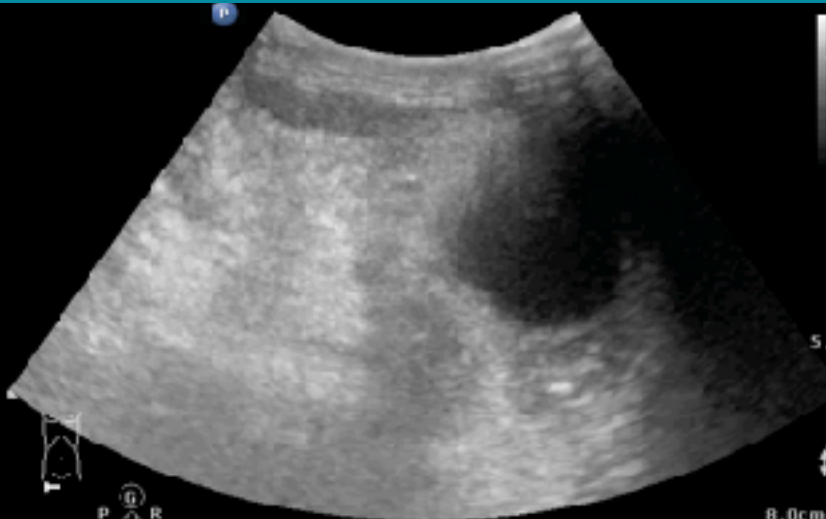

Hernia



5-1
3 Hz
1.0cm

D
1Gen
2n 97
: 56
3/3/3

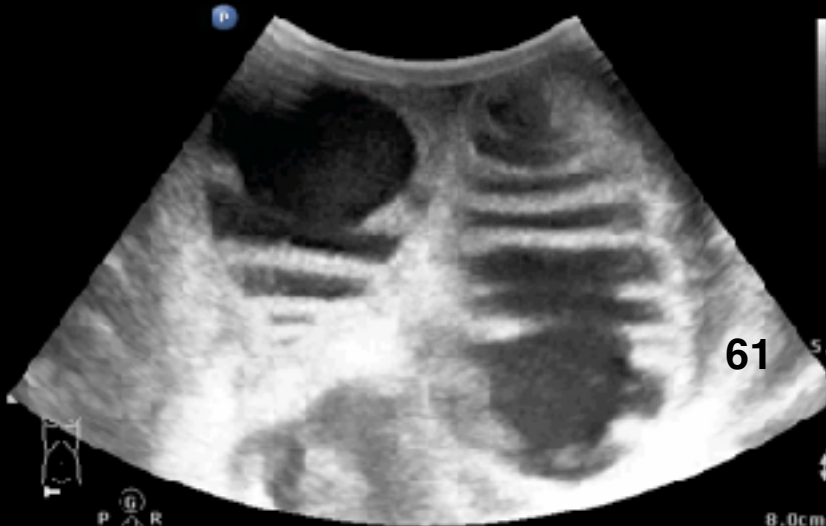

P R
1.8 3.6

8.0cm

5-1
3 Hz
1.0cm

D
1Gen
2n 97
: 56
3/3/3

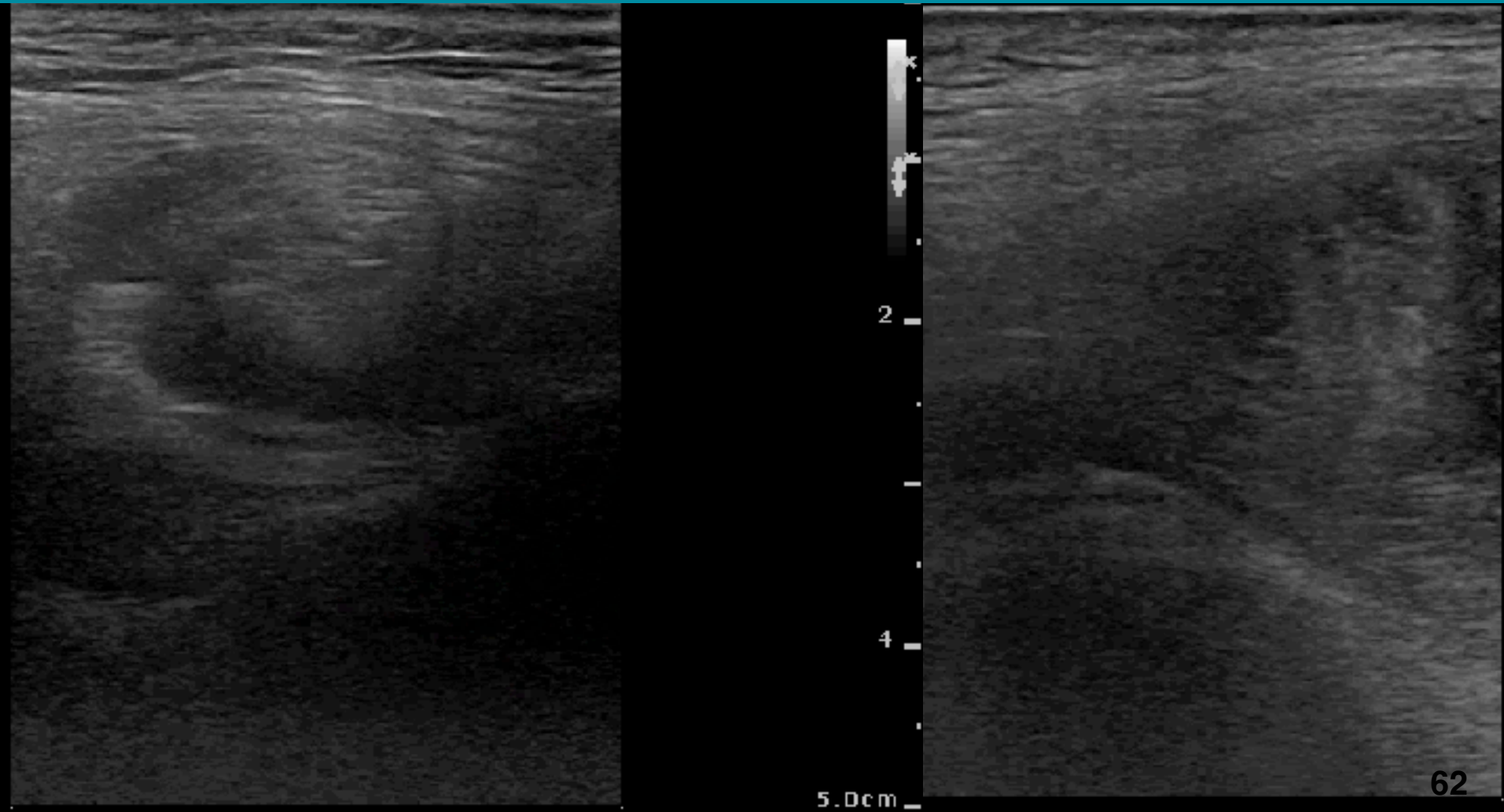


P R
1.8 3.6

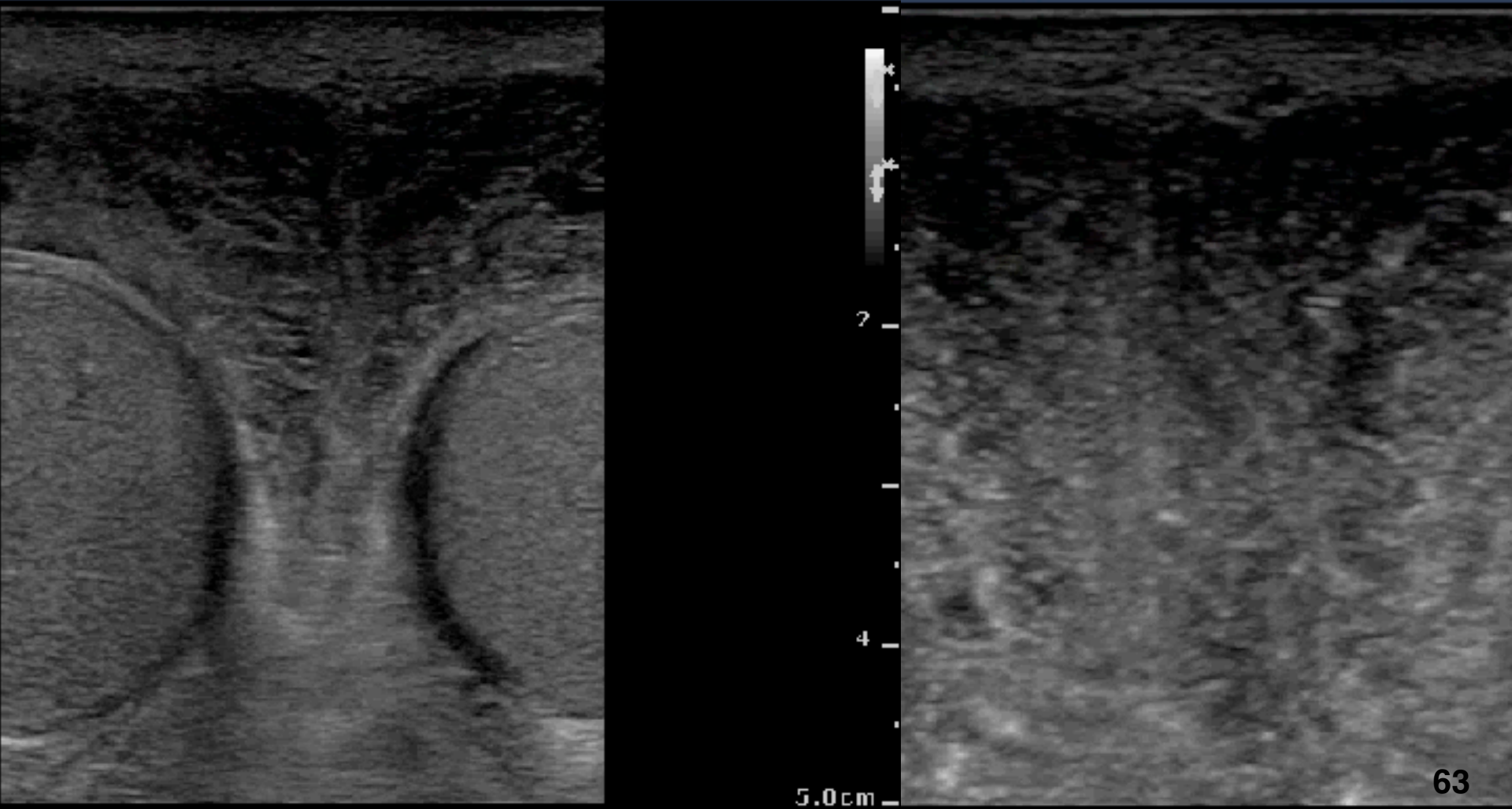
8.0cm

61

Hernia

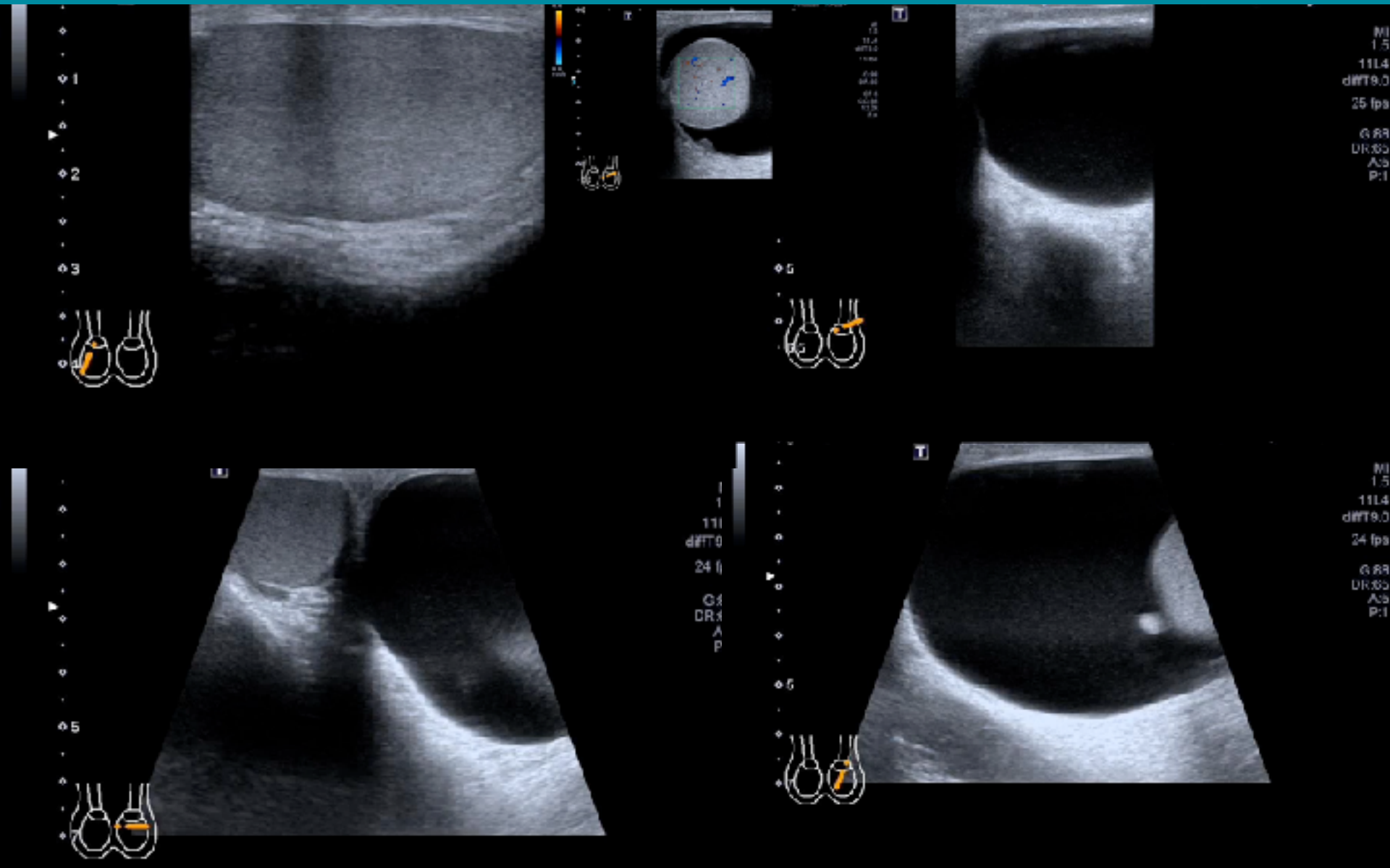


Scrotal edema



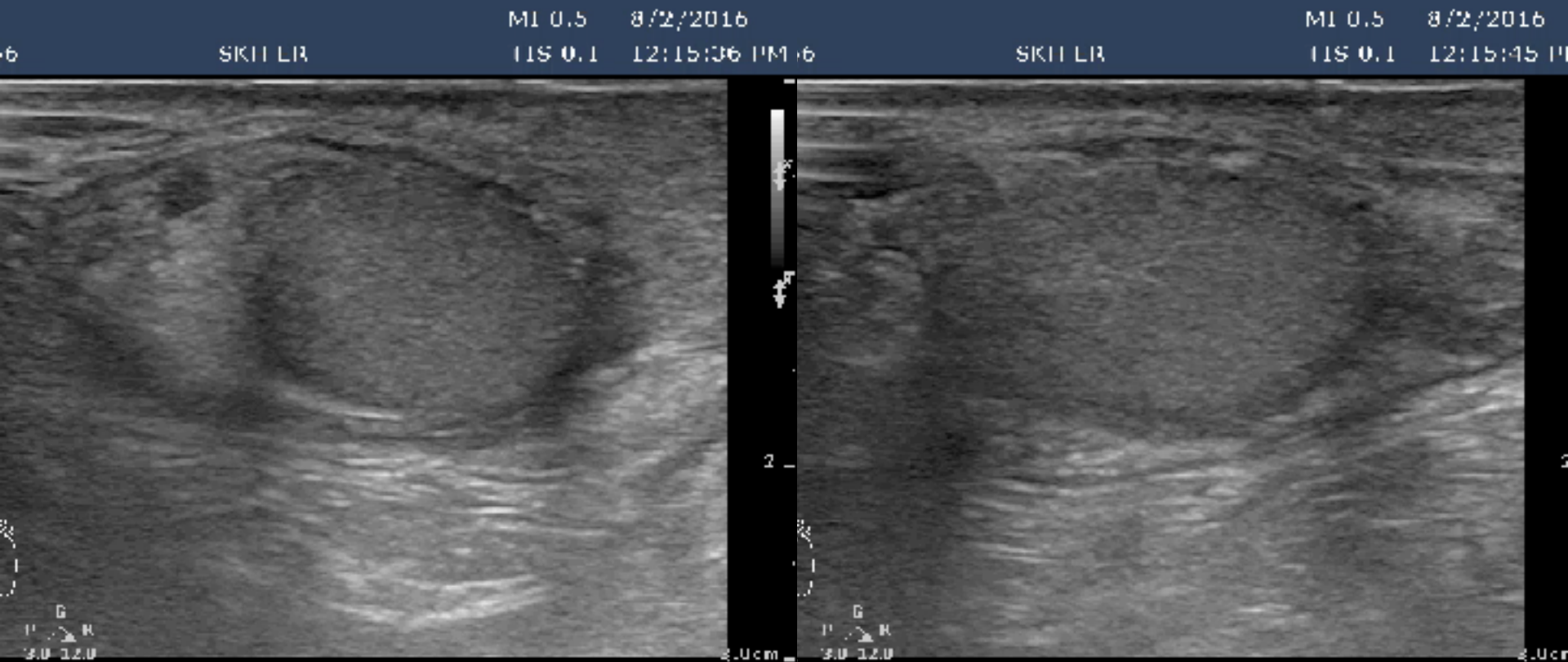
5.0 cm

Hydrocele



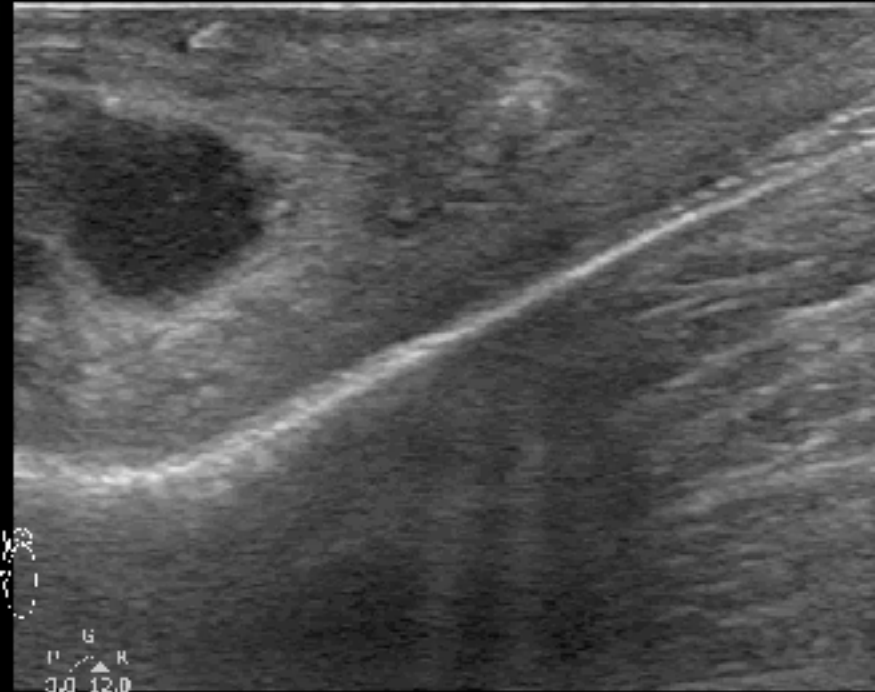
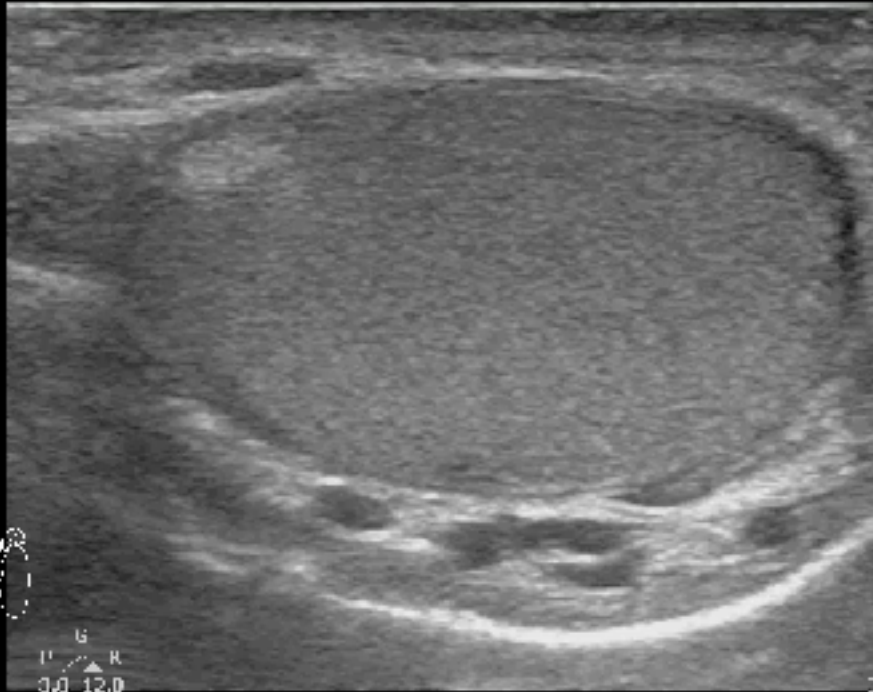| Injury Type | US Findings | Management |
|--------------------------------|--|--|
| Blunt trauma | | |
| Testicular | | |
| Rupture | Tunica albuginea rupture, contour irregularity, heterogeneous echotexture of testis | Surgery |
| Fracture | Linear, hypoechoic, avascular area within testis, with or without tunica albuginea rupture | Surgery |
| Hematoma | Variable appearance, depending on hematoma age: echogenic to anechoic or complex | Conservative if the hematoma is small; surgical exploration if it is very large |
| Dislocation | Testis absent from scrotum | Open surgical reduction |
| Torsion | Blood flow absent from testis | Surgical detorsion or orchiectomy, depending on the salvageability of the testis |
| Pseudoaneurysm | Yin-yang sign and to-and-fro flow pattern at color and spectral Doppler imaging | Conservative or surgical management, depending on pseudoaneurysm size and symptom severity |
| Estratesticular | | |
| Hematocele | Variable appearance, depending on hematocele age: echogenic (acute) to complex anechoic (chronic) | Conservative if the hematocele is small; surgical exploration if it is large |
| Scrotal wall hematoma | Thickened scrotal wall with echogenic or hypoechoic areas | Usually conservative; surgical drainage if the hematoma is large |
| Traumatic epididymitis | Enlarged heterogeneous epididymis with hyperemia | Conservative management |
| Epididymal fracture or rupture | Fragmented or absent epididymis (diagnosis is usually postoperative) | Conservative or surgical, depending on the severity of symptoms |
| Spermatic cord hematoma | Mass with variable echogenicity (echogenic to complex anechoic) located superior to the testis | Conservative if the hematoma is small; surgical exploration if it is large |
| Penetrating trauma | Missile track, air inside or outside testicular parenchyma, presence of foreign bodies (eg, bullets) | Conservative or surgical, depending on the severity of injury to the scrotal contents |

Scrotal injury with laceration

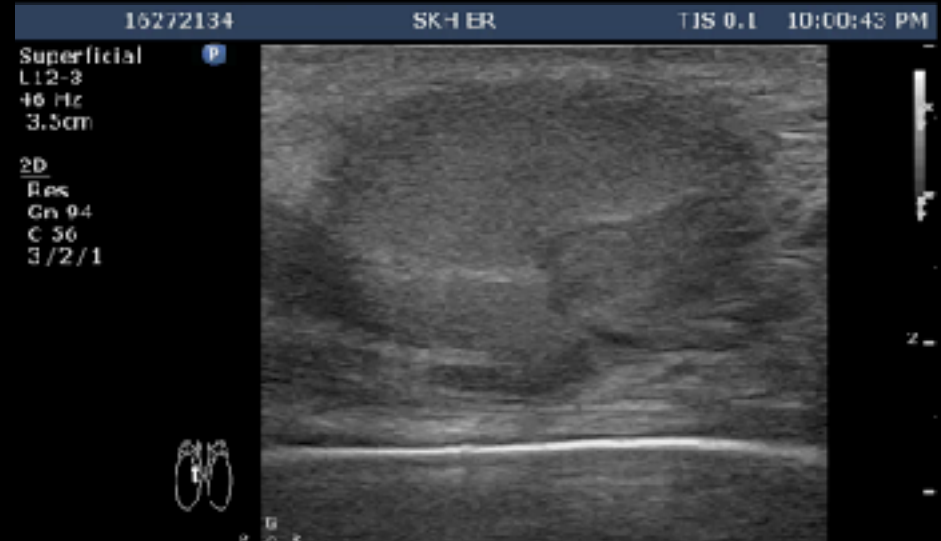
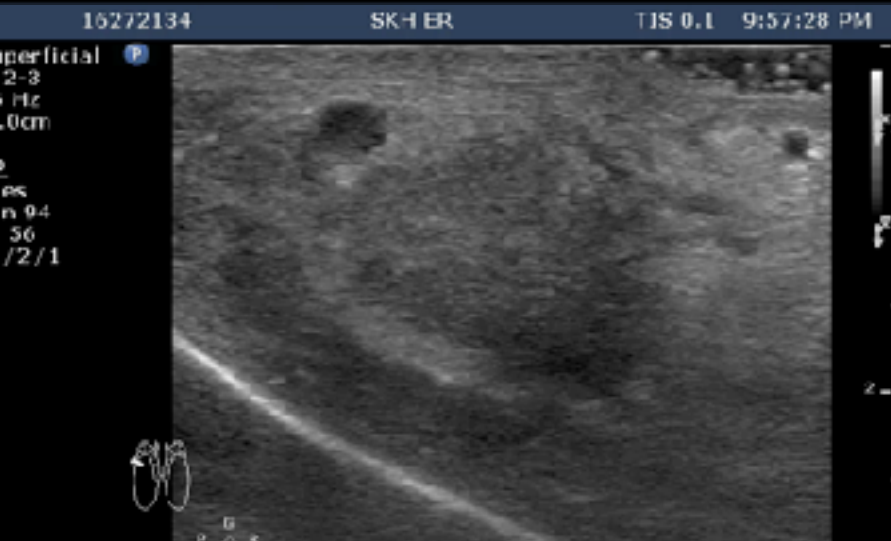
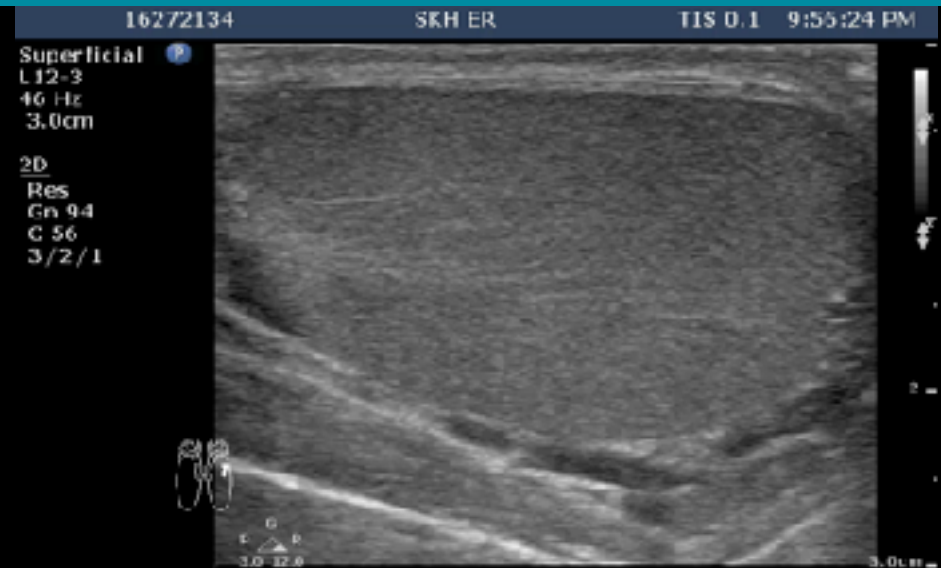
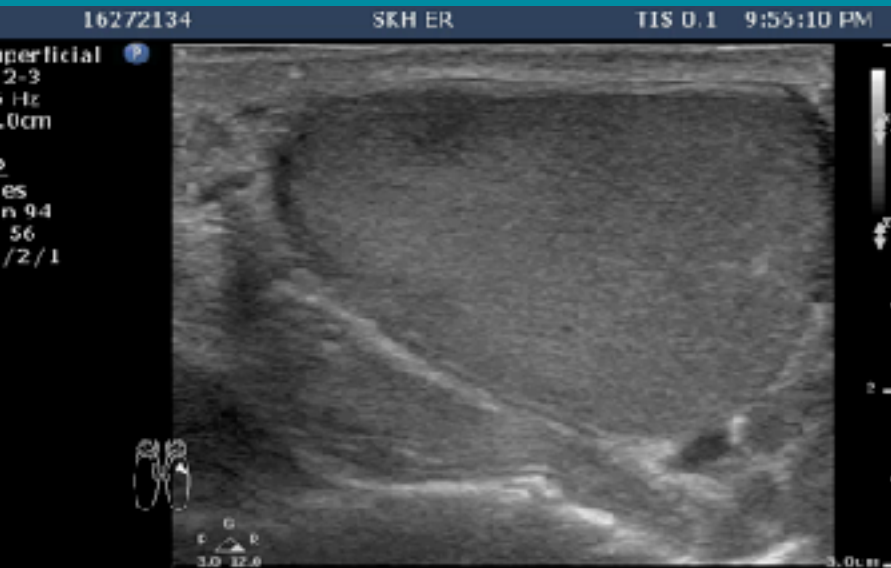
Penetrating injury

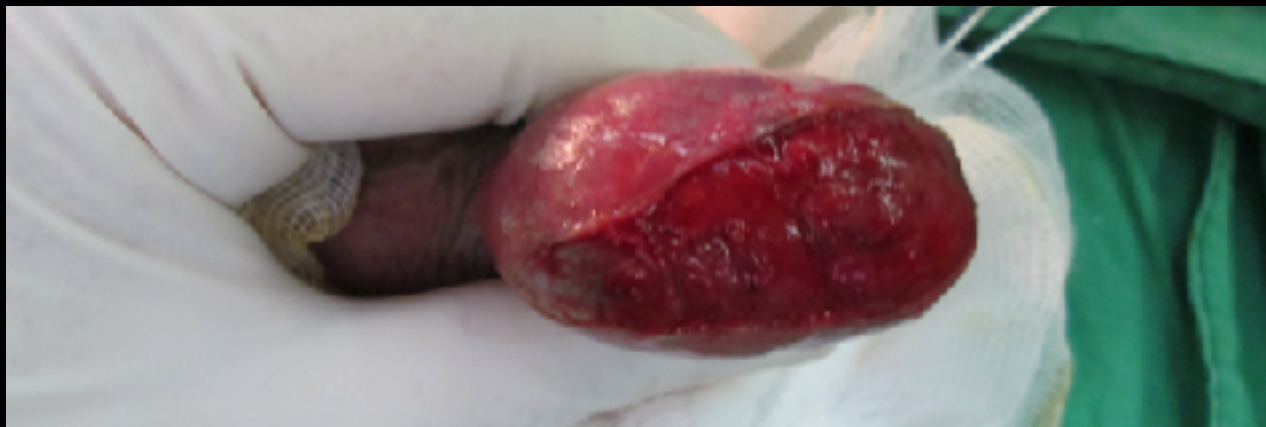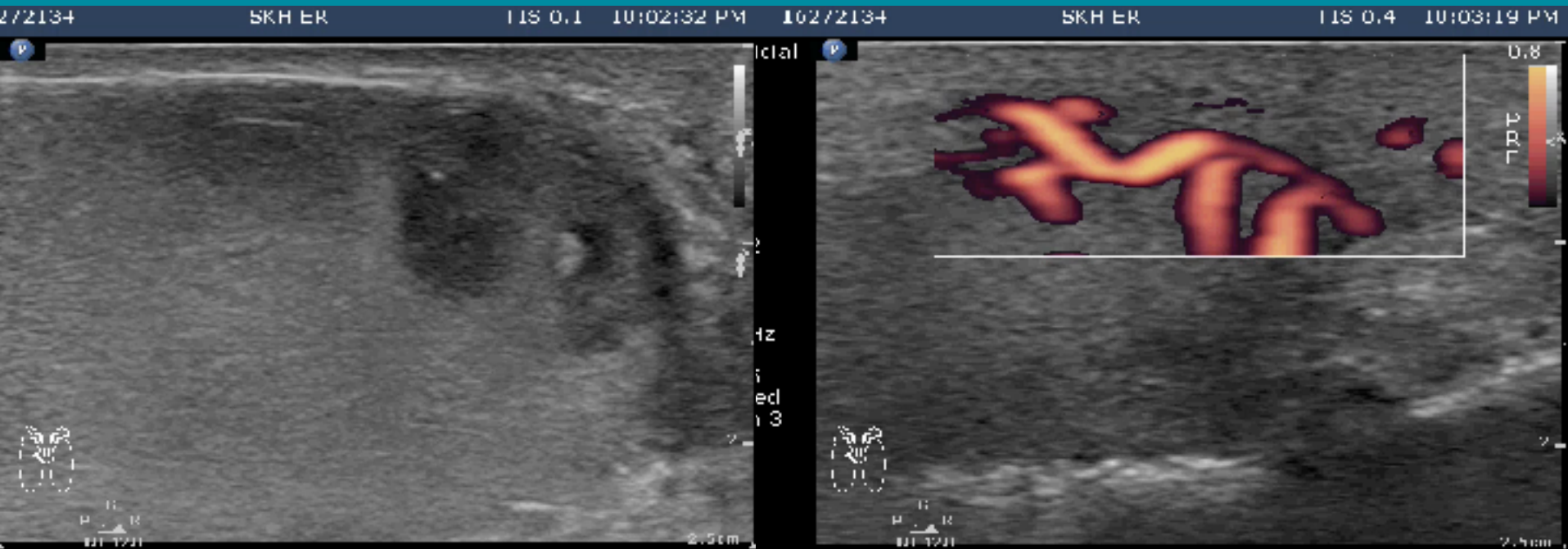
temporaryID-20160801110843 MI 0.5 8/1/2016 temporaryID-20160801110843 MI 0.5 8/1/2016
8-01-143843 SKII CR TIS 0.1 2:42:00 PM 08-01-143843 SKII CR TIS 0.1 2:42:41



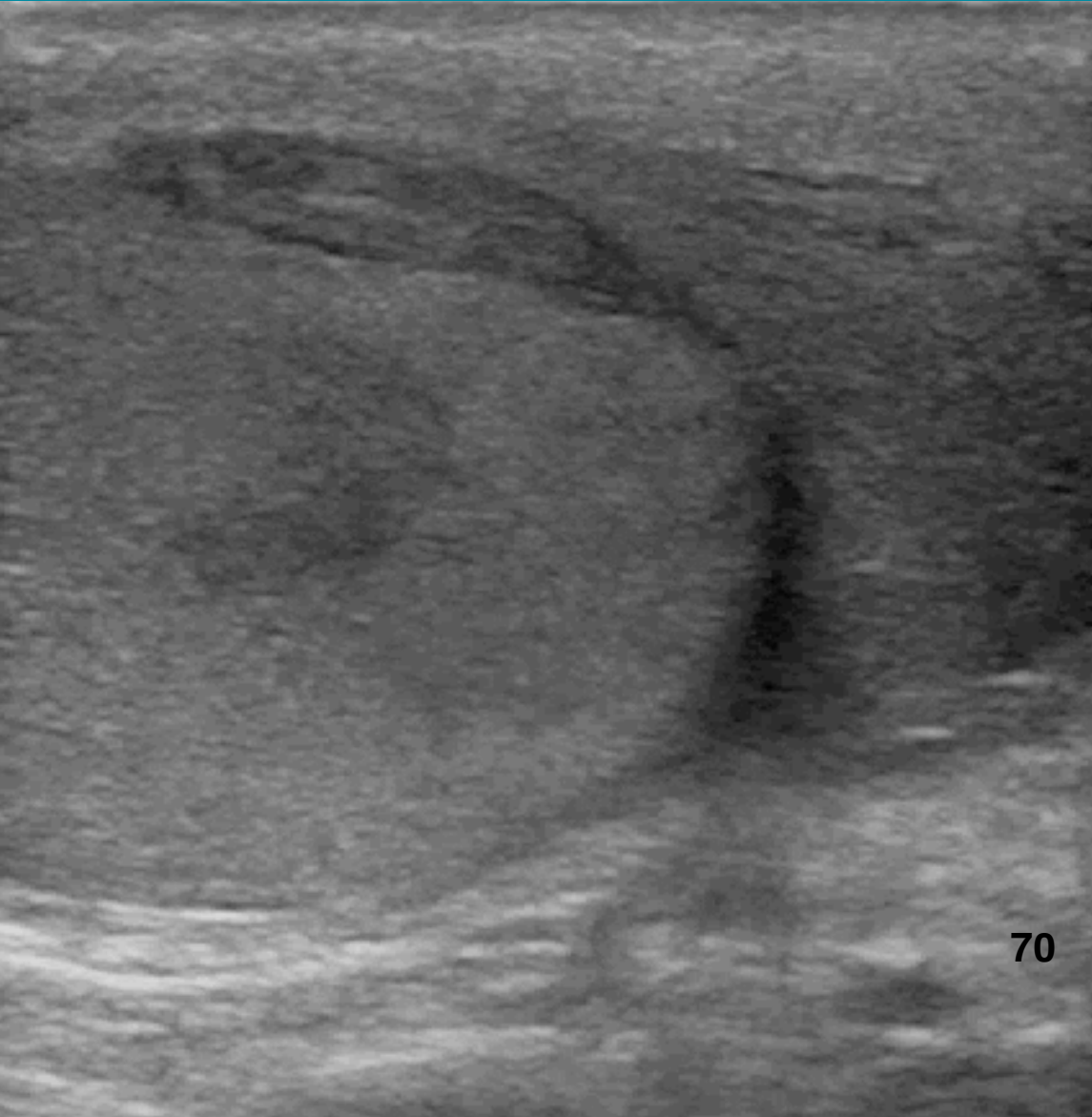

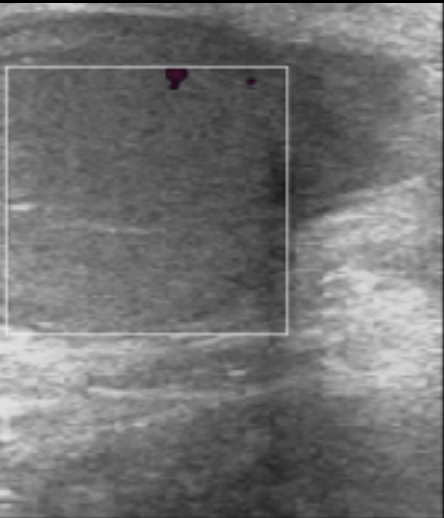
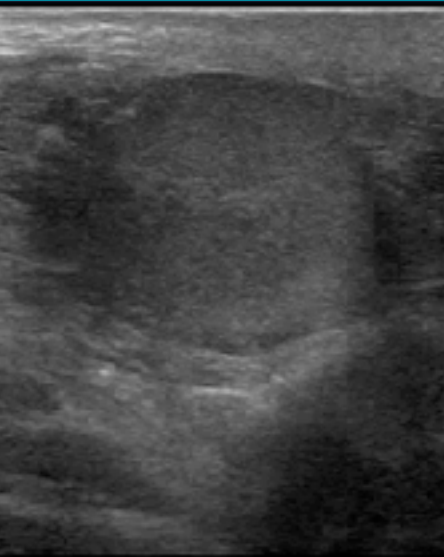
Testicular injury



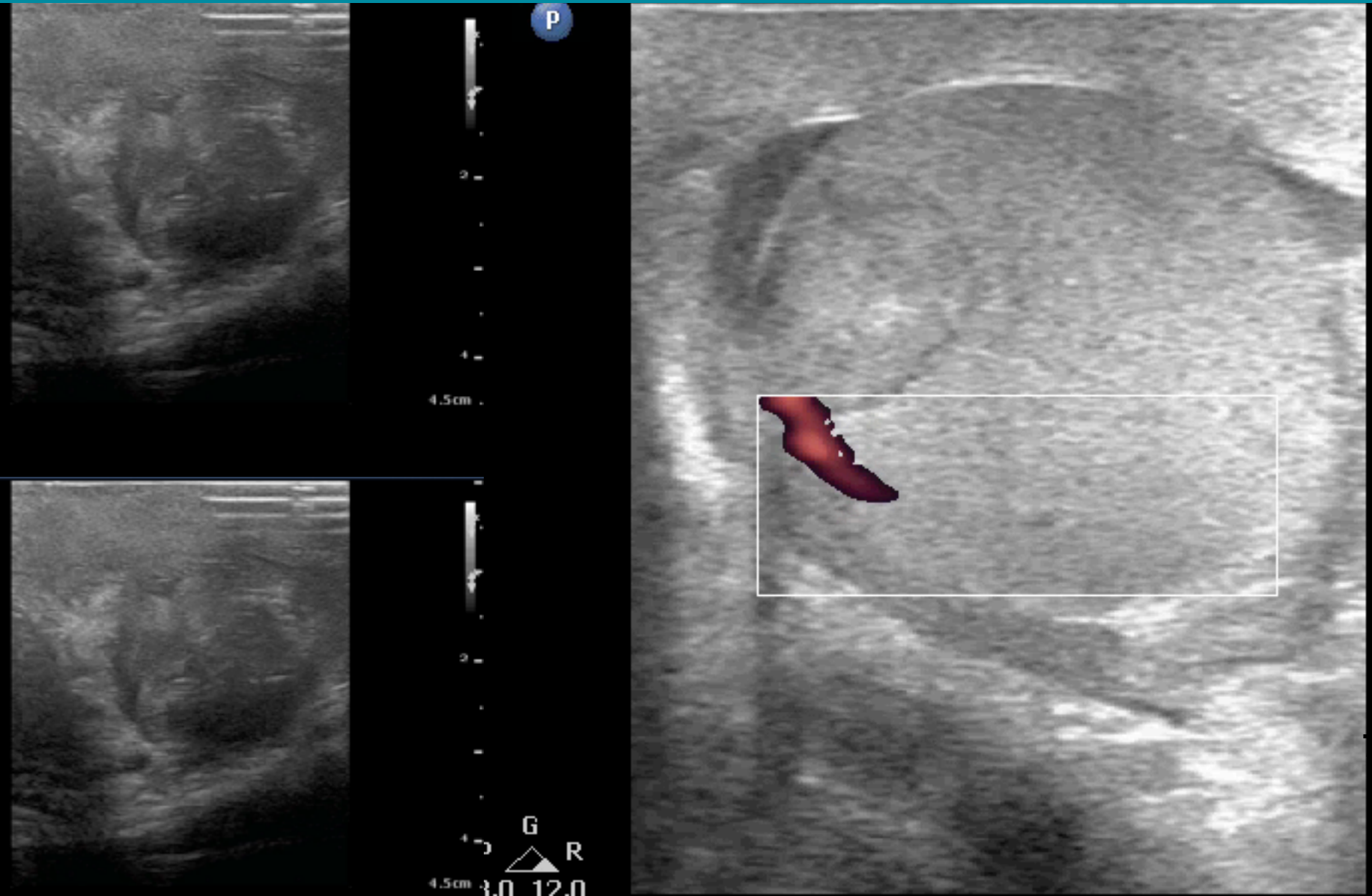Testicular injury



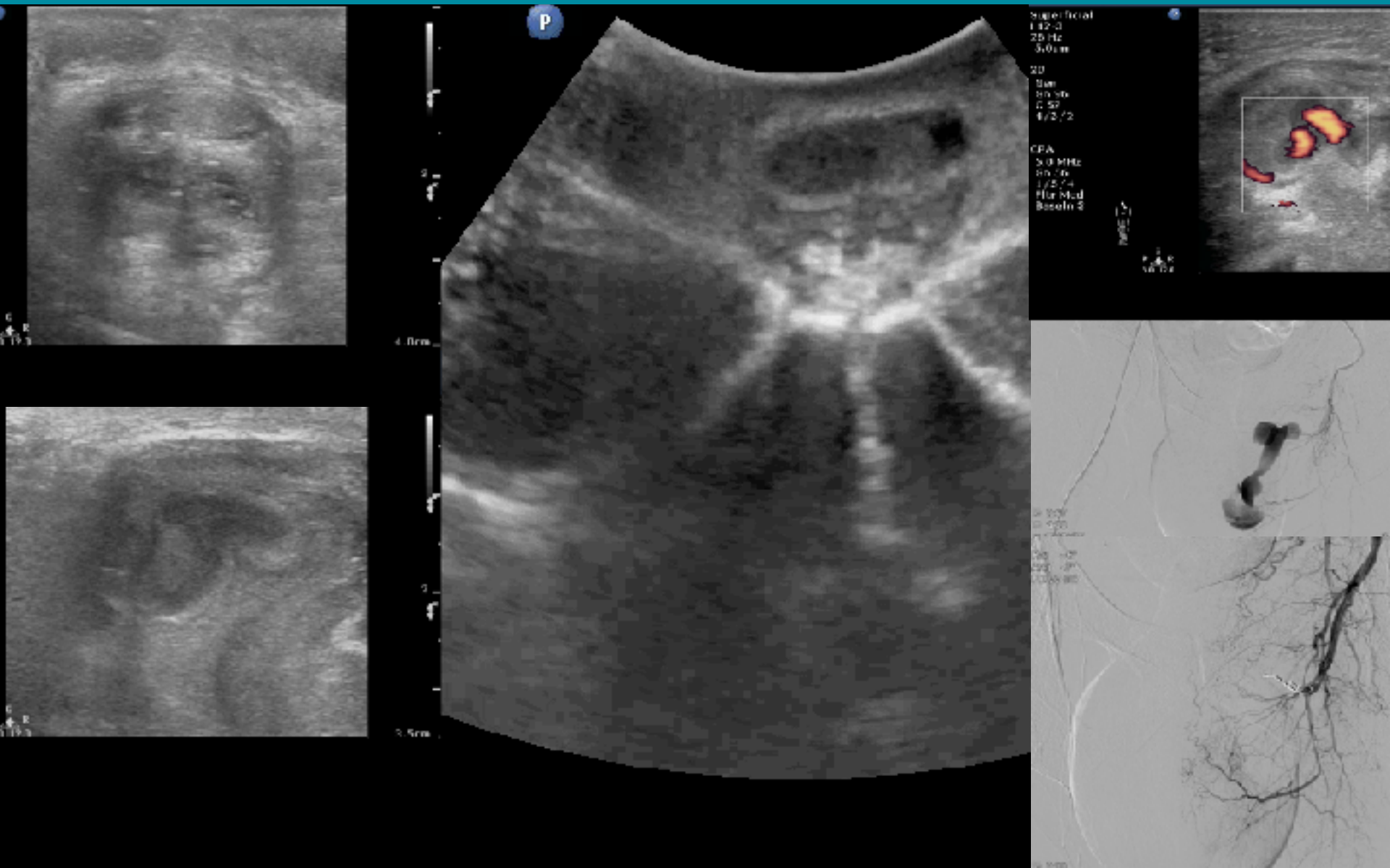
Testicular injury



Testicular injury



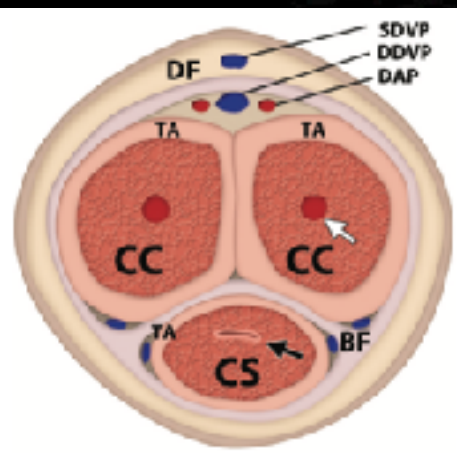
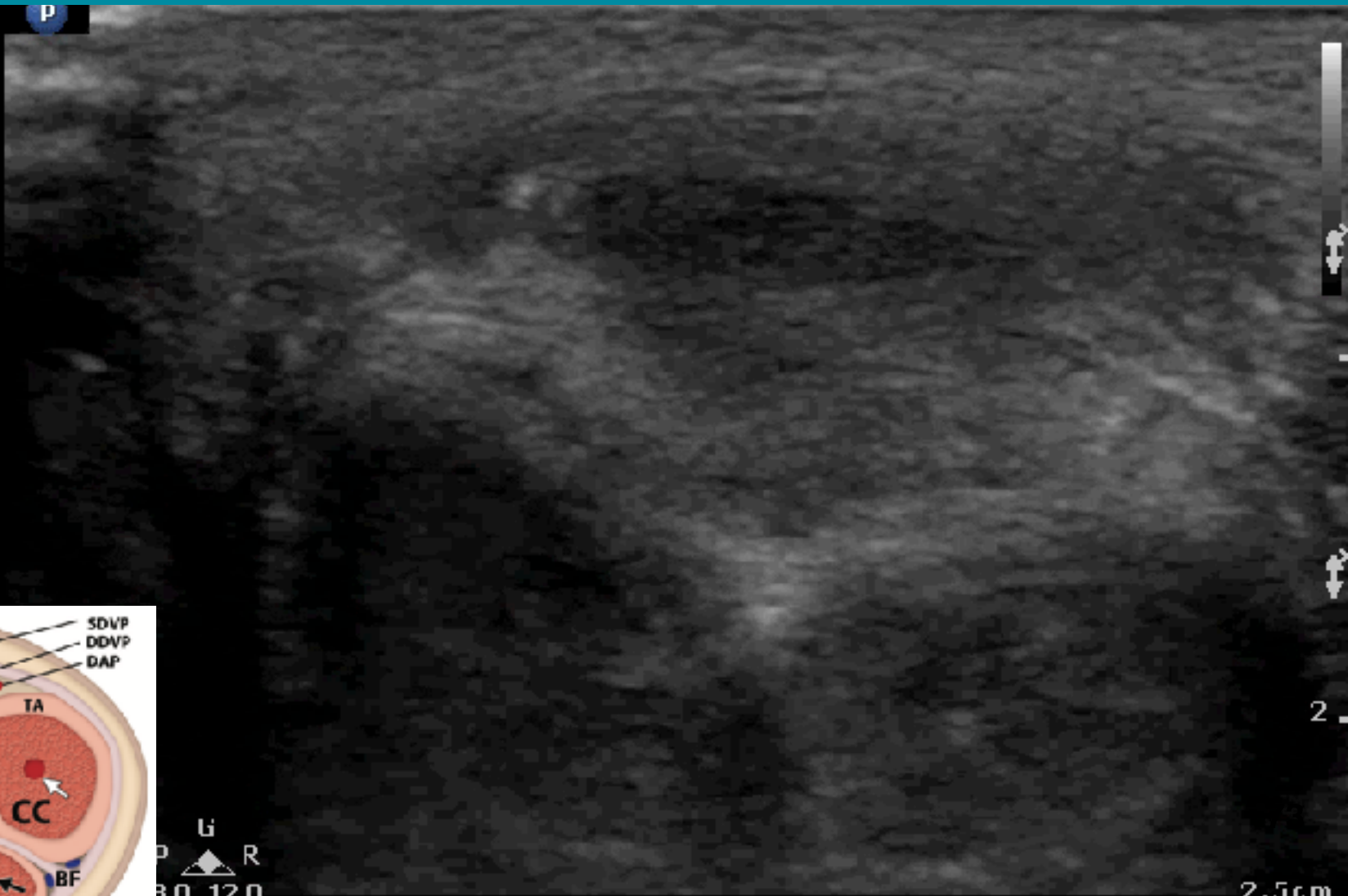Genital contusion



Penile abscess

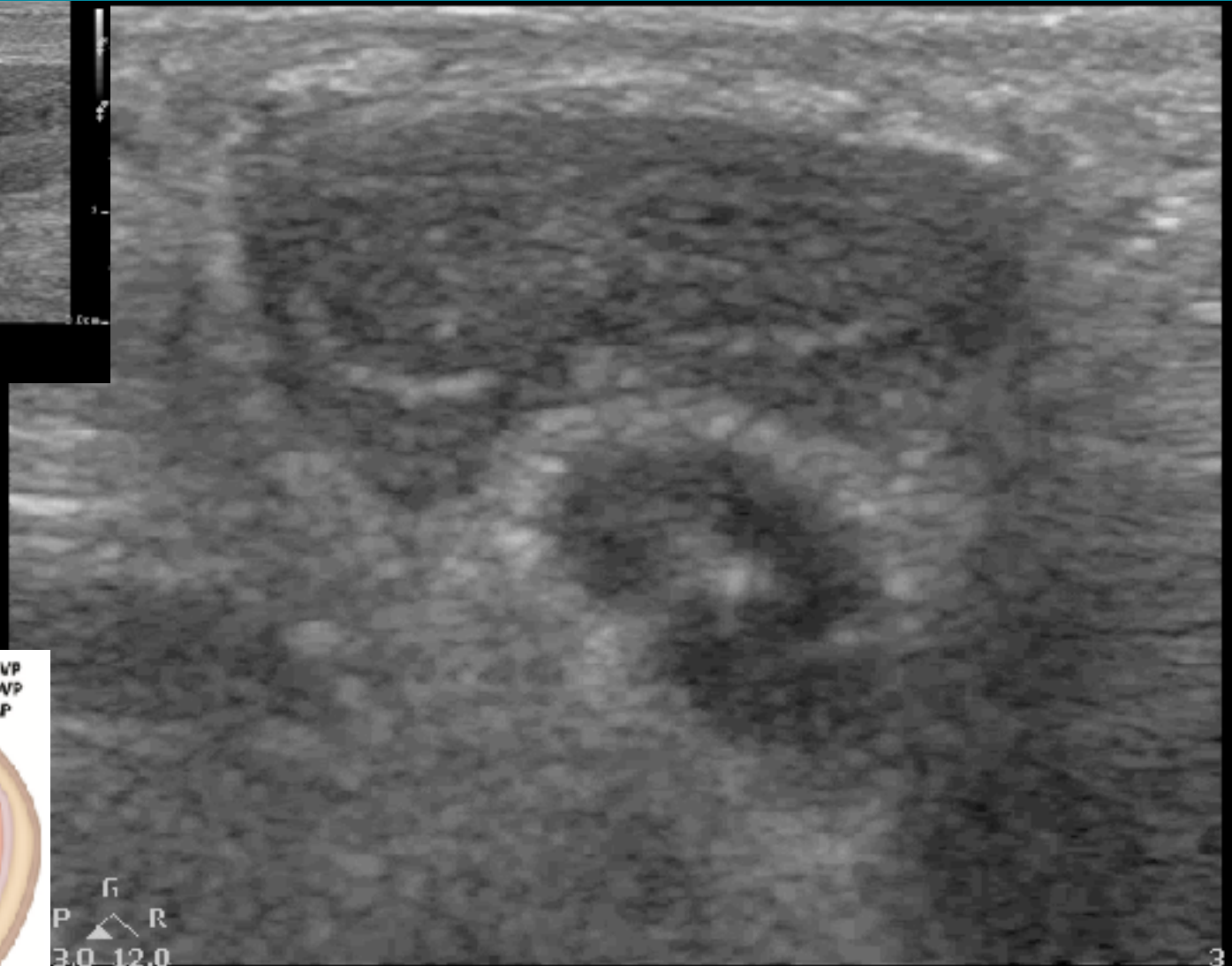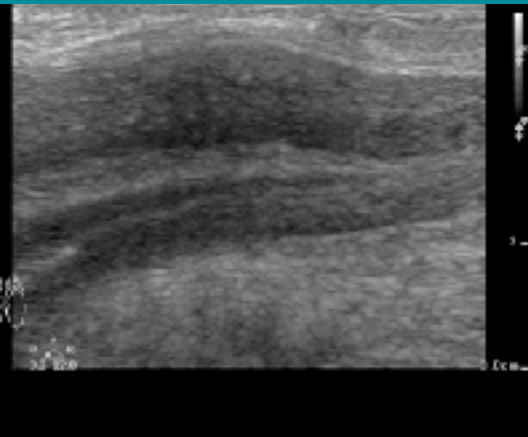
Superficial
_12-3
34 Hz
2.5cm

2D
Gen
Gn 93
C 52
4/3/2

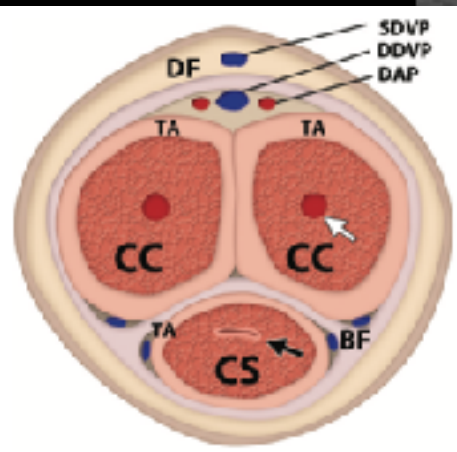


2.5 cm

Urethral stone



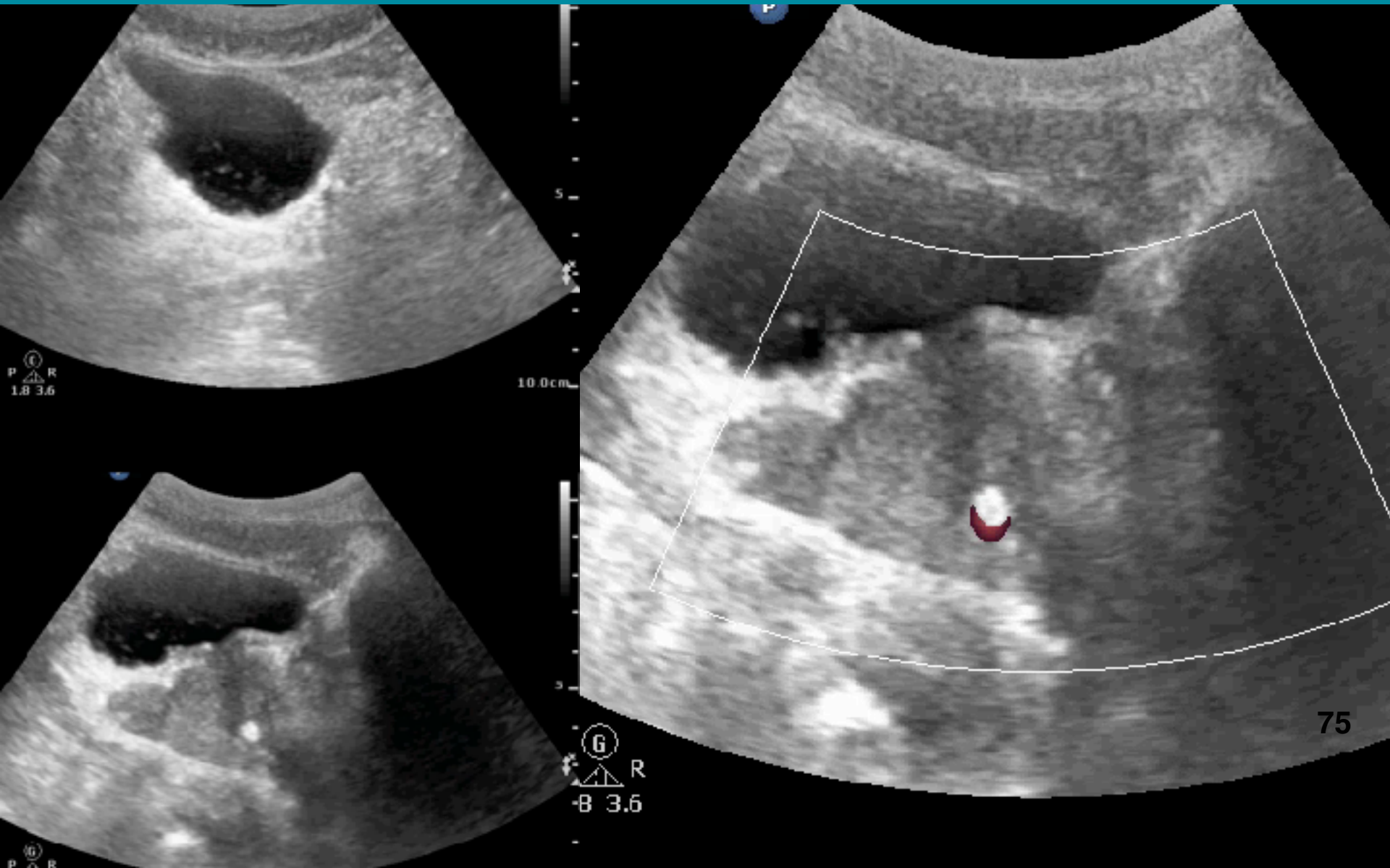
3 / 2 / 1



P R
3.0 12.0

3.0cm

Urethral stone



Urethral stone

temporaryID-20151015195112

MI 0.7

10/15/2015

temporaryID-20151015195112

MI 0.7

10/15/2015

10 15 195112

SKH ER

11S 0.1

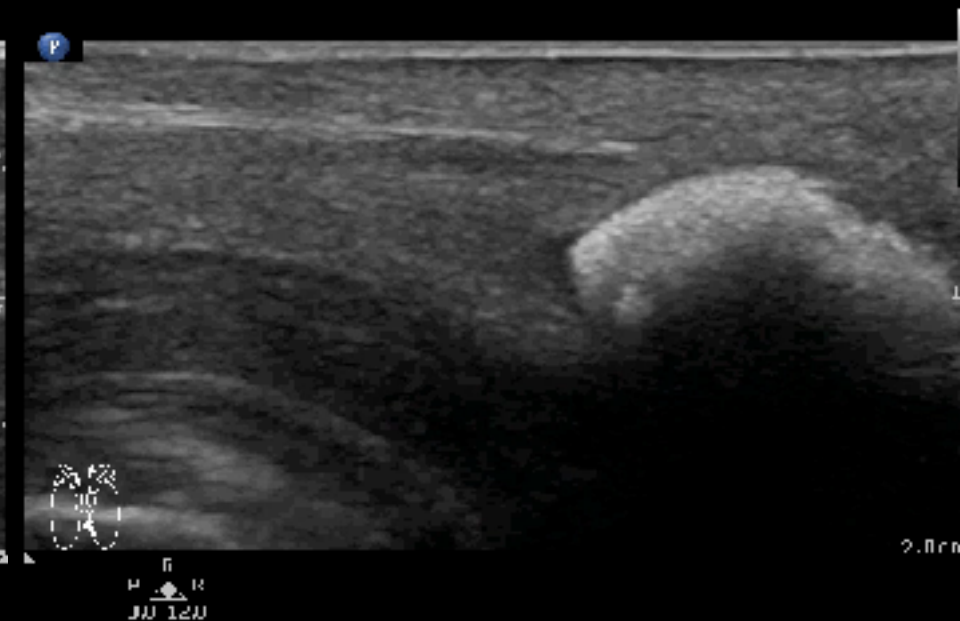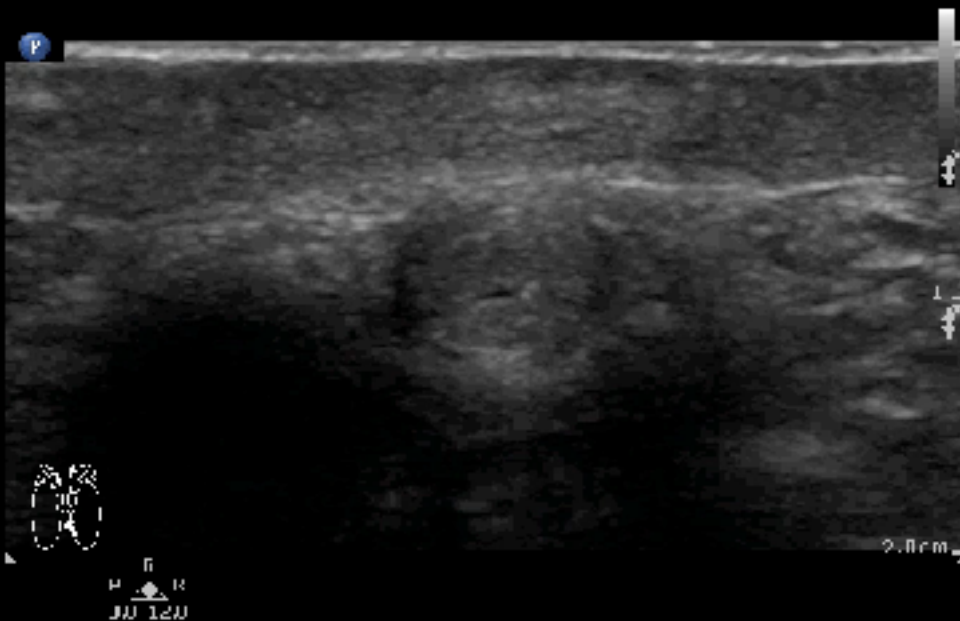
7:58:19 PM

10 15 195112

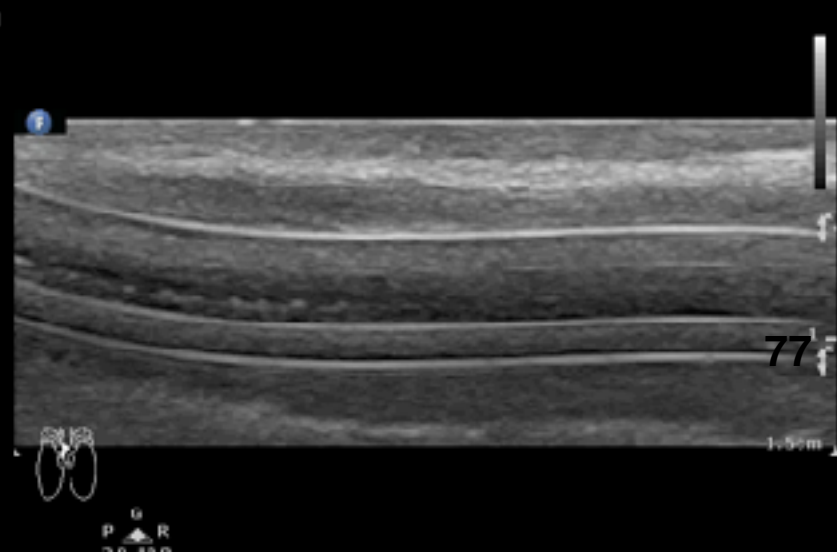
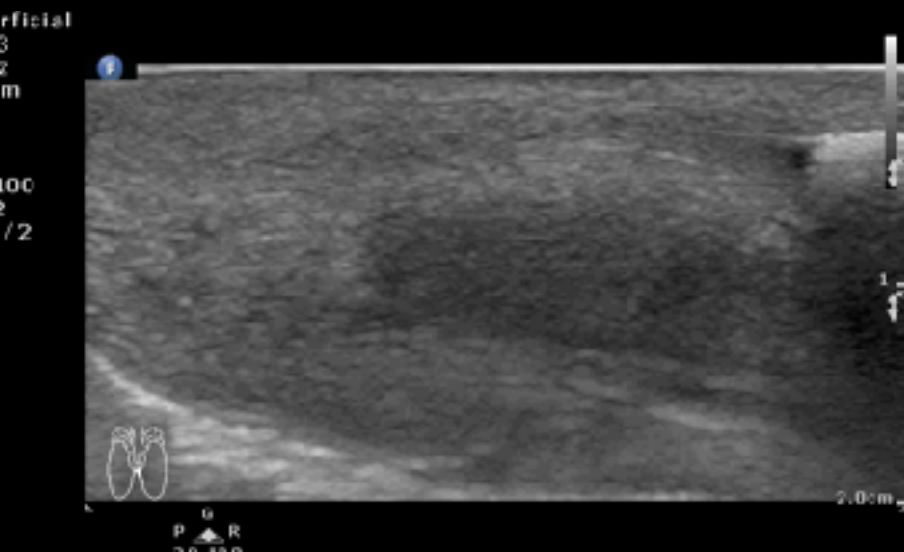
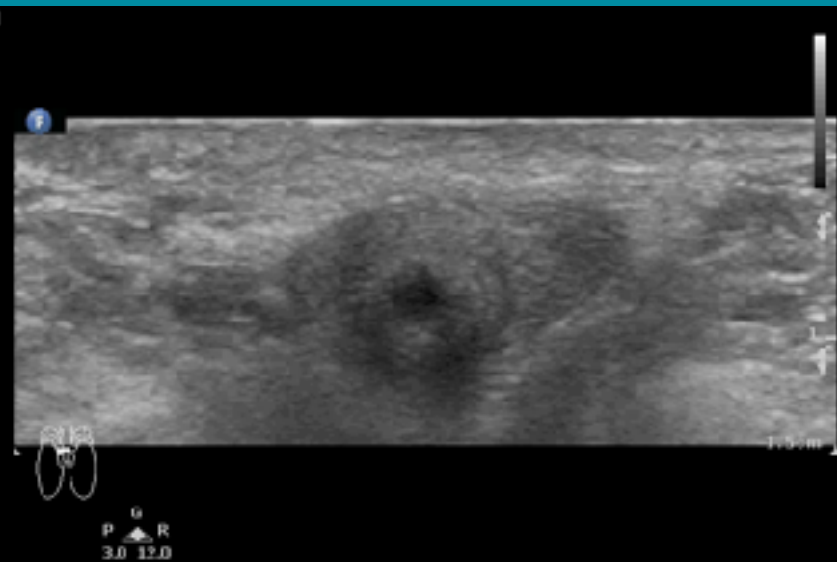
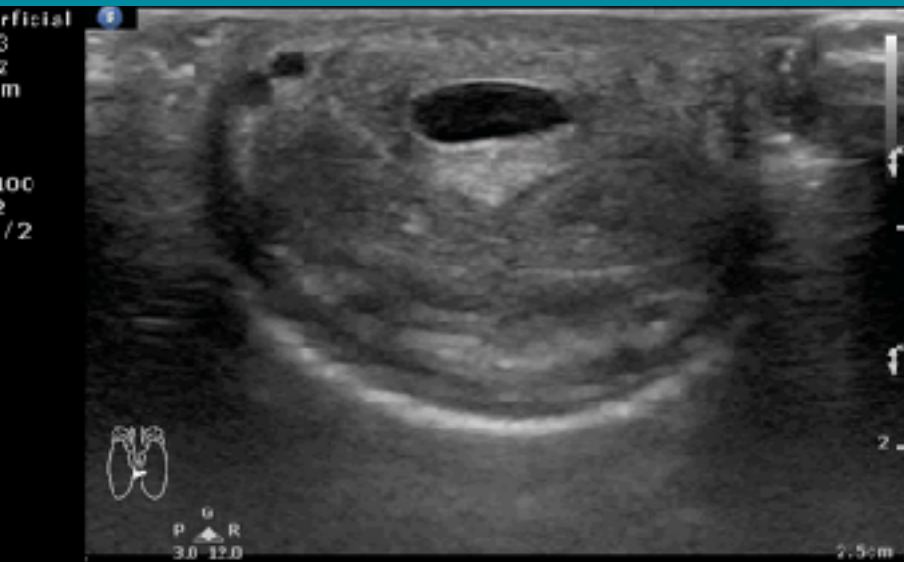SKH ER

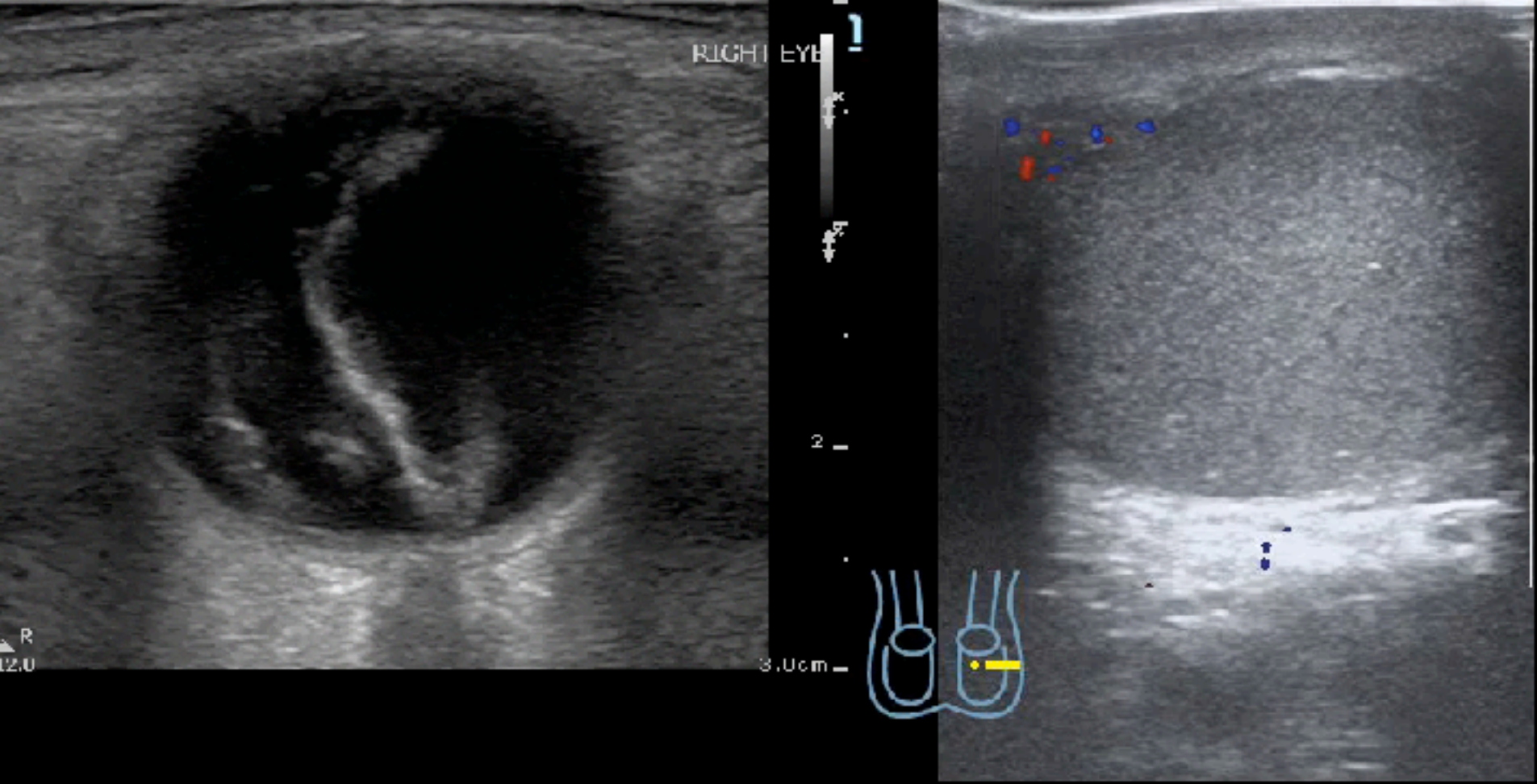
11S 0.1

7:57:27 PM



Urethral stone





KEEP YOUR EYE ON THE BALL