



衛生福利部雙和醫院  
(委託臺北醫學大學興建經營)  
Taipei Medical University · Shuang Ho Hospital,  
Ministry of Health and Welfare



# US-guided procedures

## Basic procedures

---

陳國智醫師 雙和醫院急診醫學科

[juice119@gmail.com](mailto:juice119@gmail.com)

[POCUSacademy.com](http://POCUSacademy.com)

# 陳國智 醫師

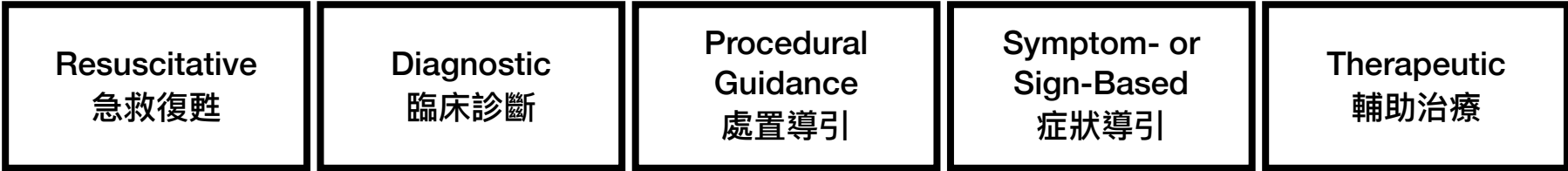

台灣疼痛醫學會專科醫師  
急診超音波臨床評核醫師  
醫用超音波學會指導醫師  
WINFOCUS director / instructor  
Certified Interventional Pain Sonologist

**急診 / 重症 / 介入 / 急性疼痛**

經歷

新光急診超音波訓練中心主任  
西園醫院急診醫學科主任  
急診醫學會超音波委員會主委  
台灣疼痛醫學會大體模擬手術講師  
急救加護醫學會重症超音波負責人



**Core Applications (2023 ACEP Emergency Ultrasound Guidelines)**  
**15項急診超音波核心應用**

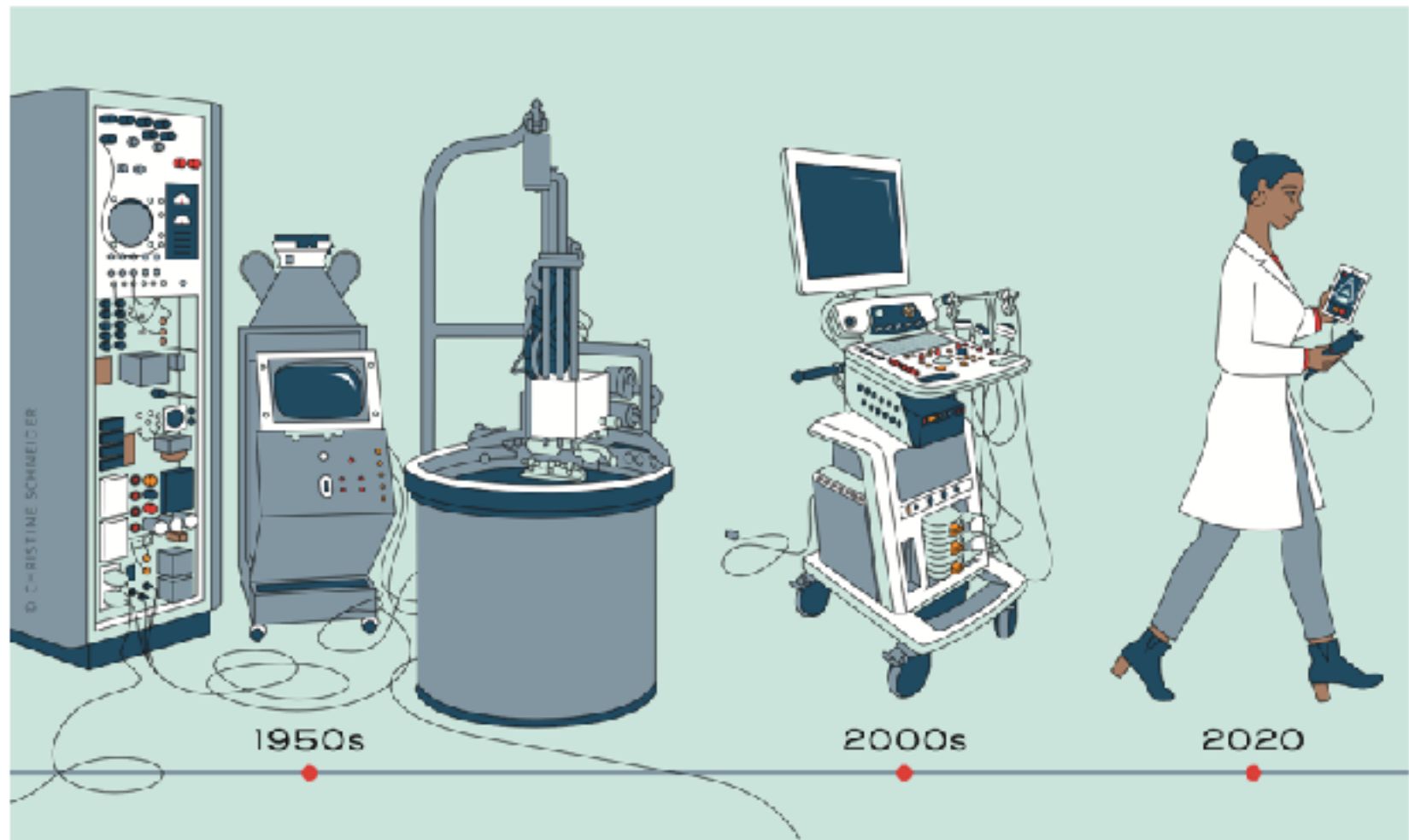
陳國智醫師

Aorta  
 DVT  
 Trauma  
 Thoracic/Airway  
 Cardia/HD assessment

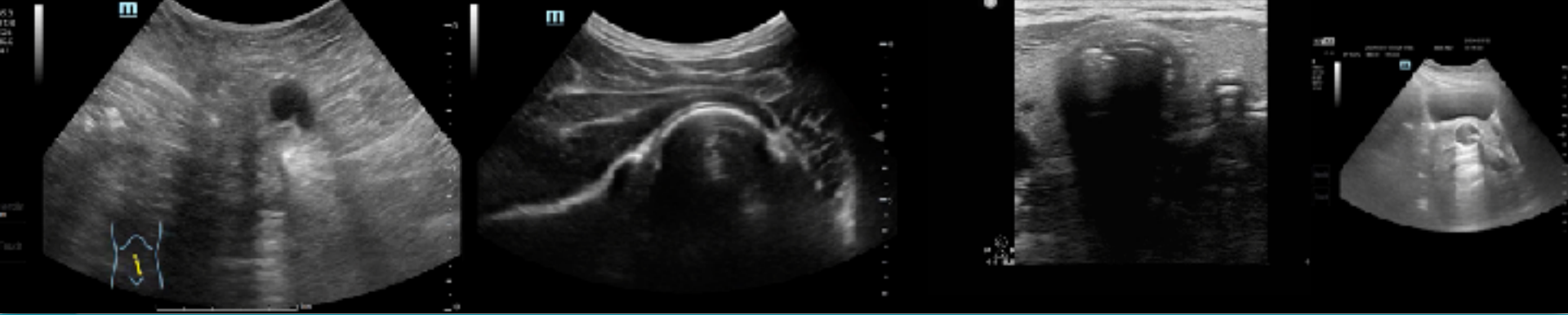
Procedural Guidance  
 US-guided NB  
 Testicular  
 Ocular  
 Skin & Soft tissue

Hepatobiliary  
 Urinary tract  
 Pregnancy  
 Bowel  
 MSK

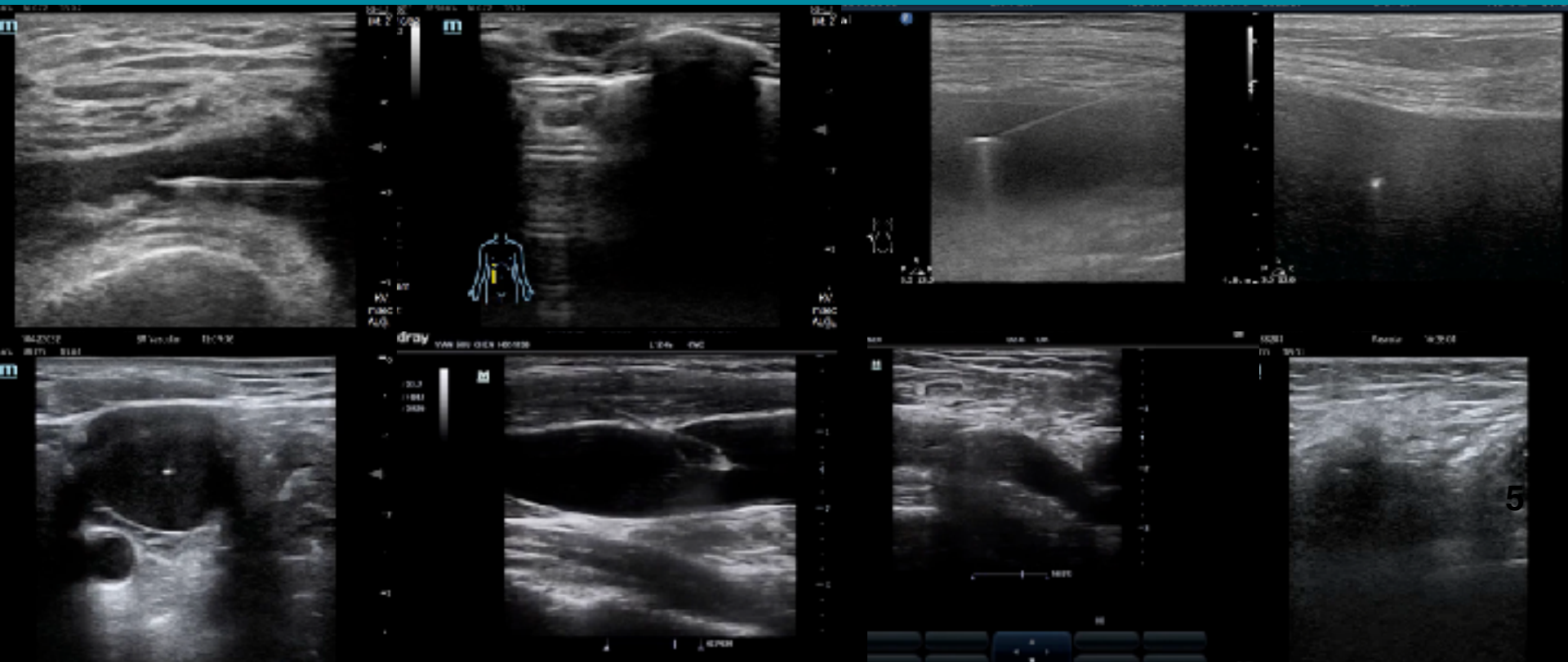
# Point-of-Care Ultrasound: A Practical Guide for Primary Care



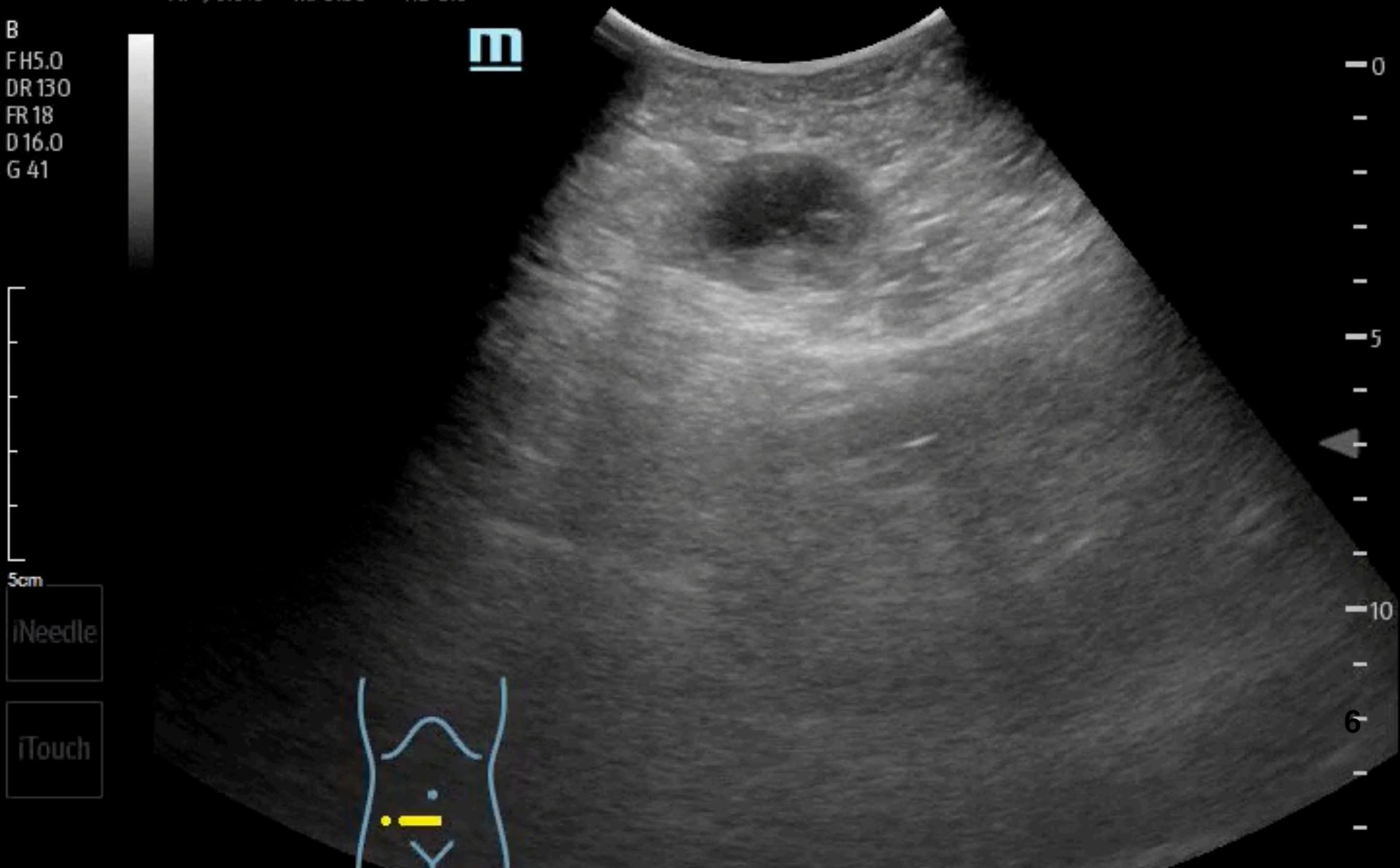




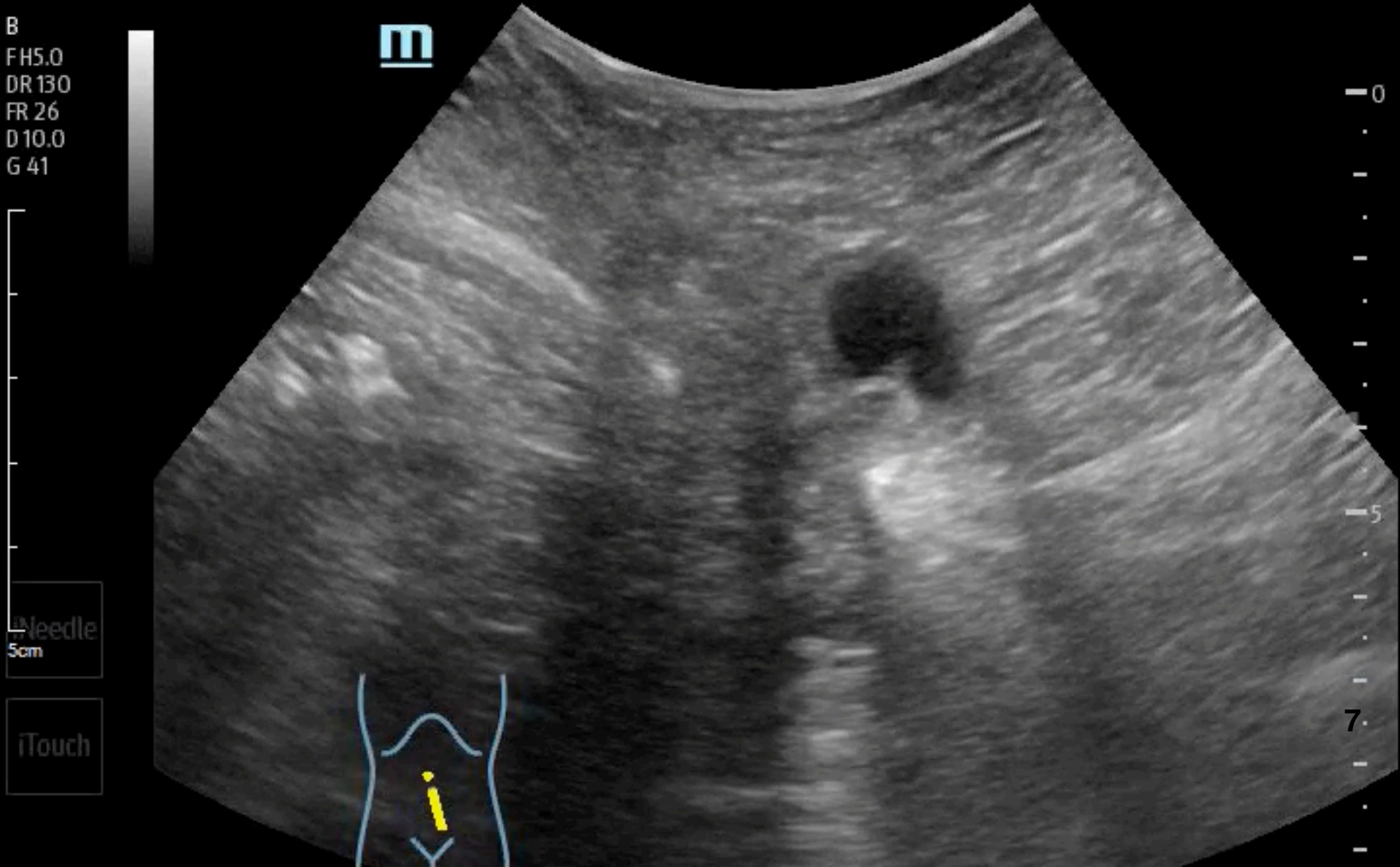
# POCUS - Basic Procedures



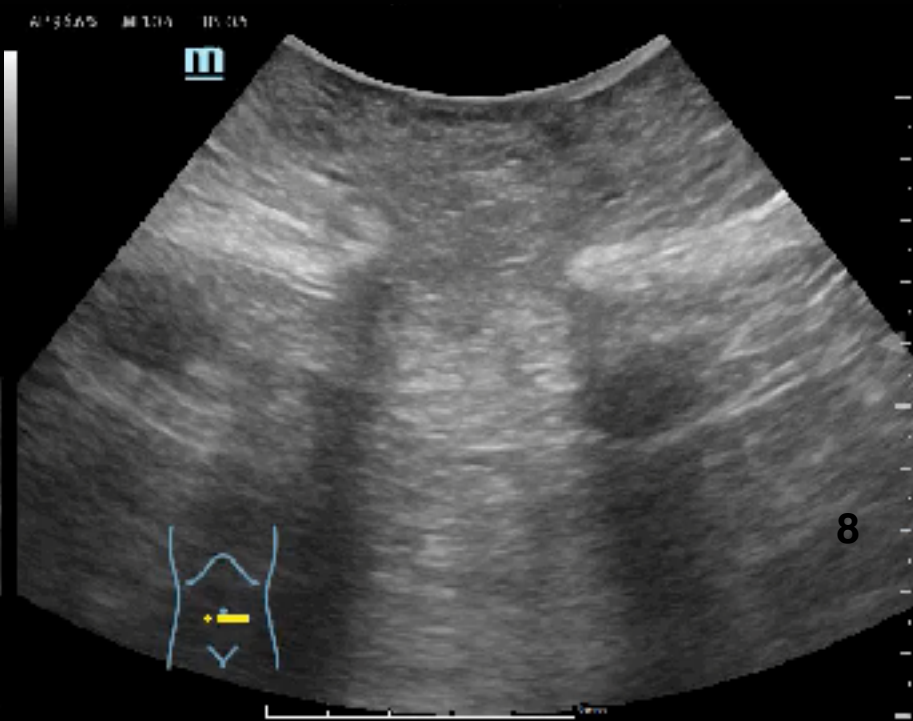
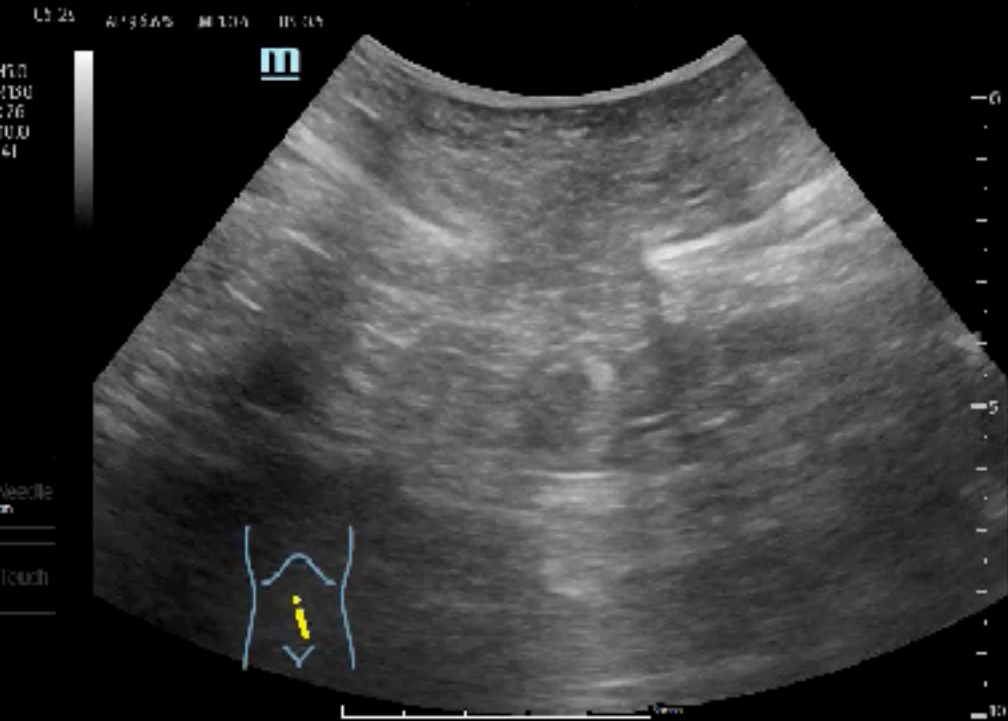
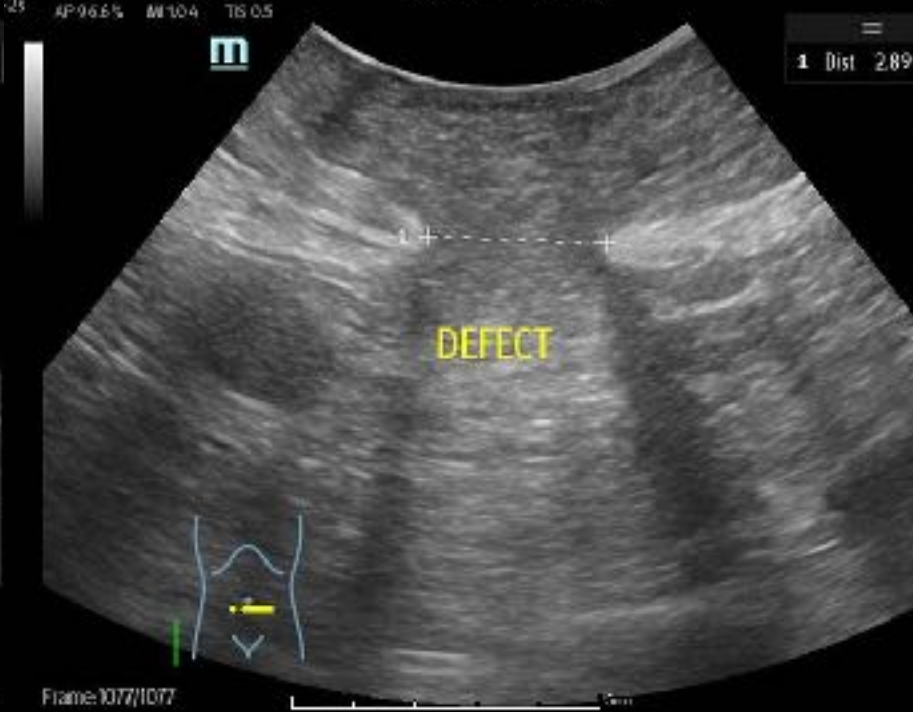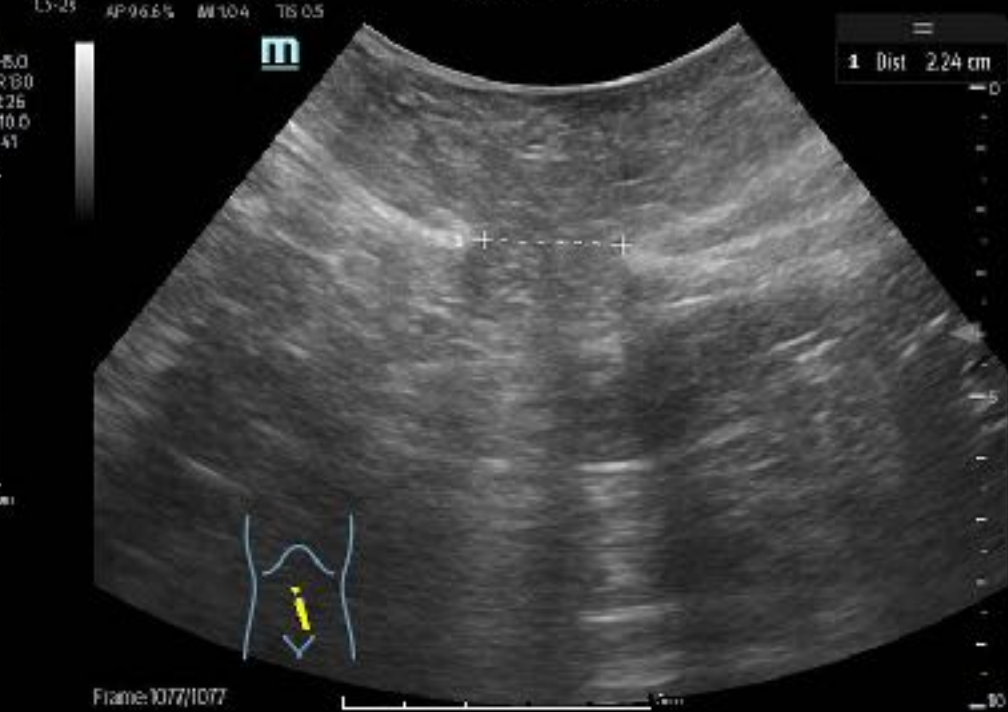# 82M , umbilical hernia for long time unable to push back

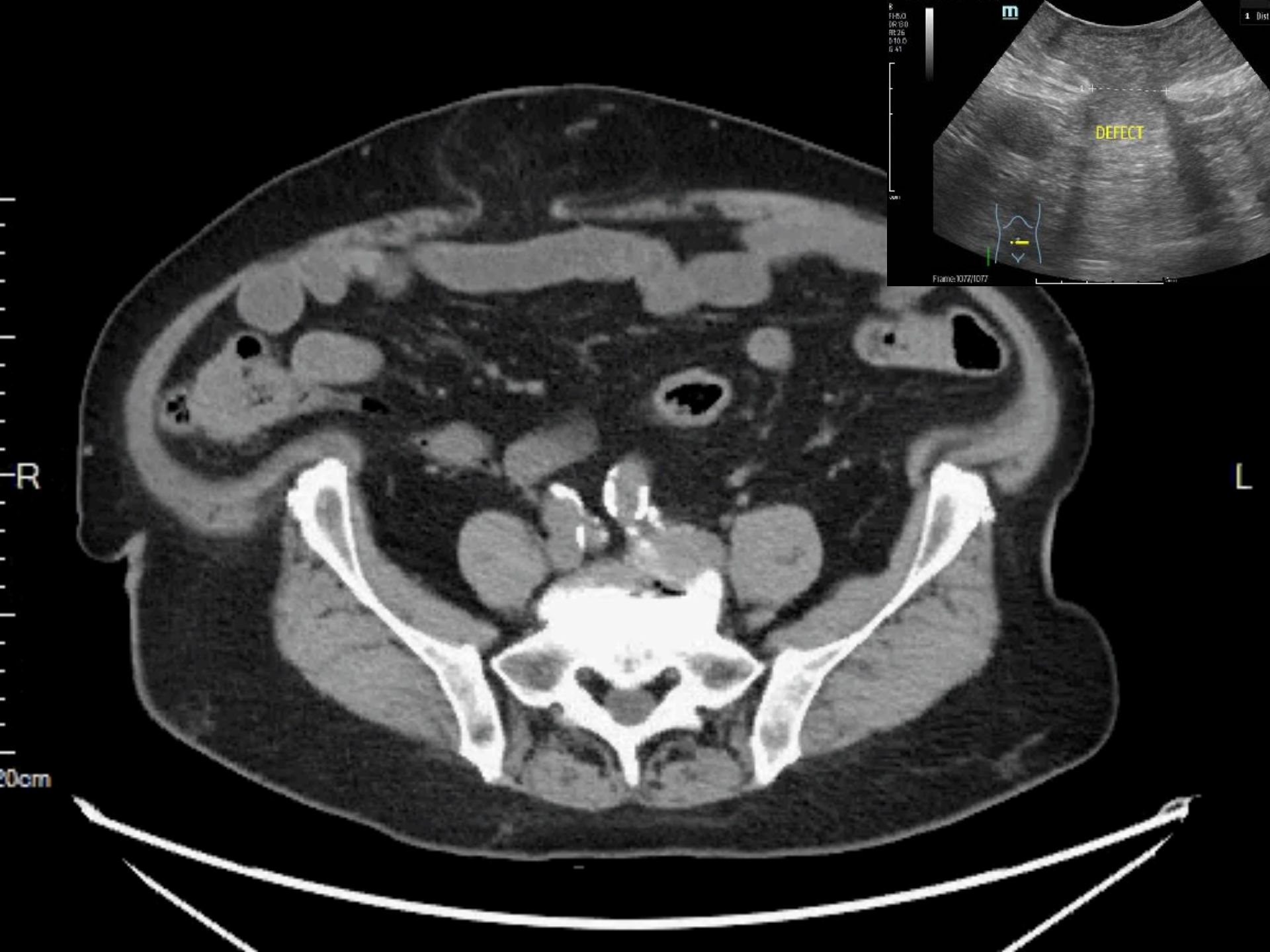

# 82M , umbilical hernia for long time unable to push back

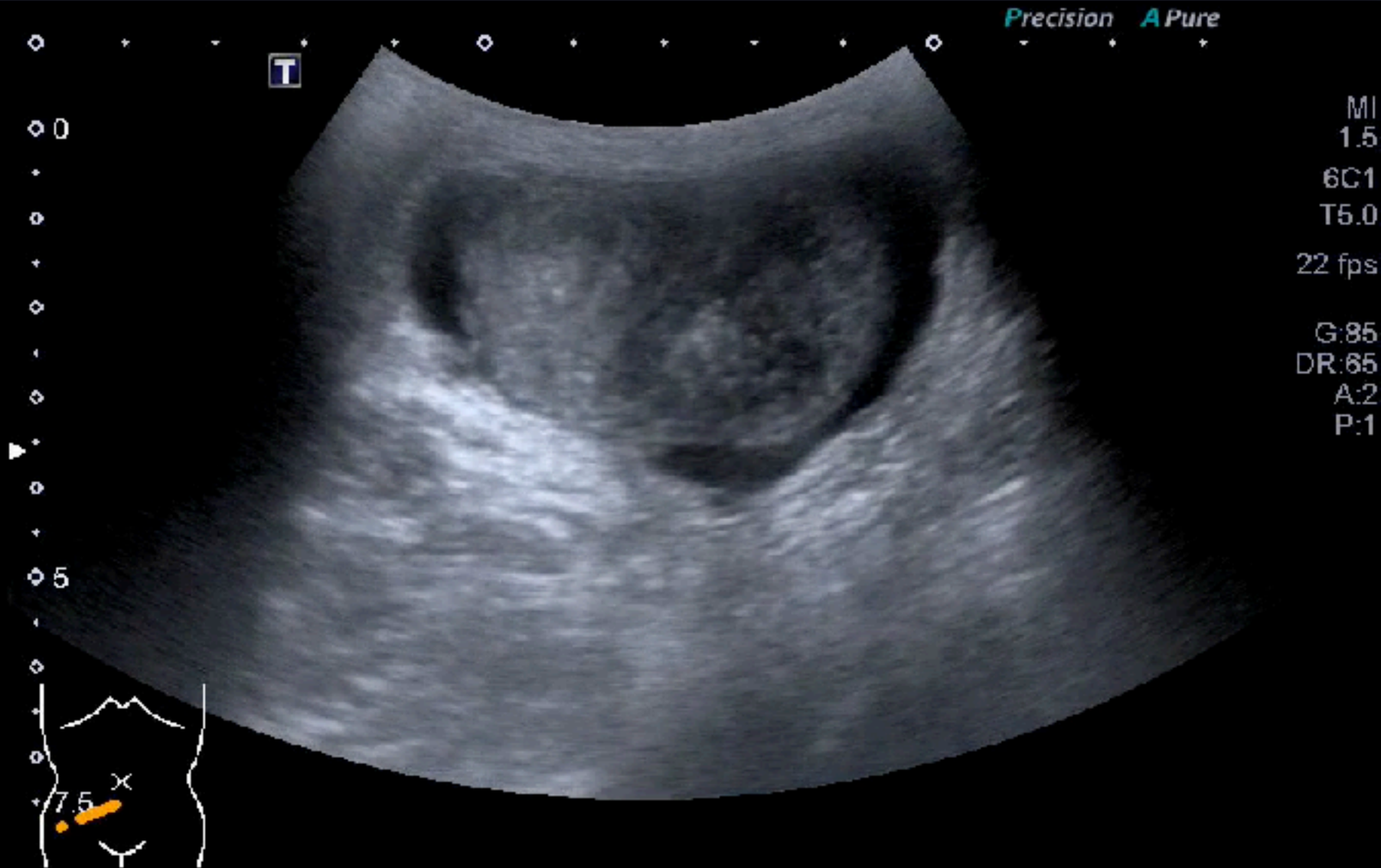






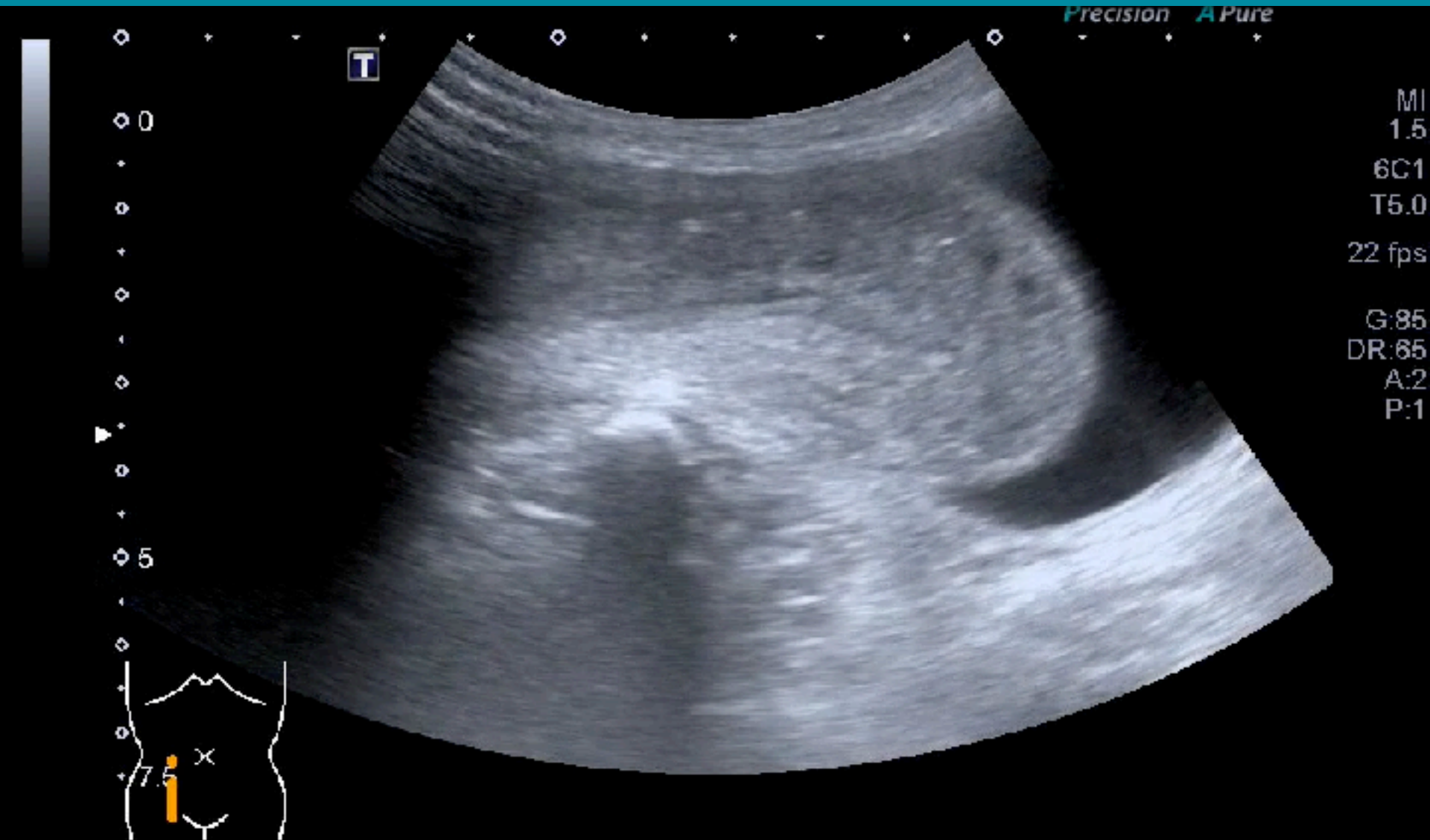


# 79M, right inguinal painful swelling for 3 hrs



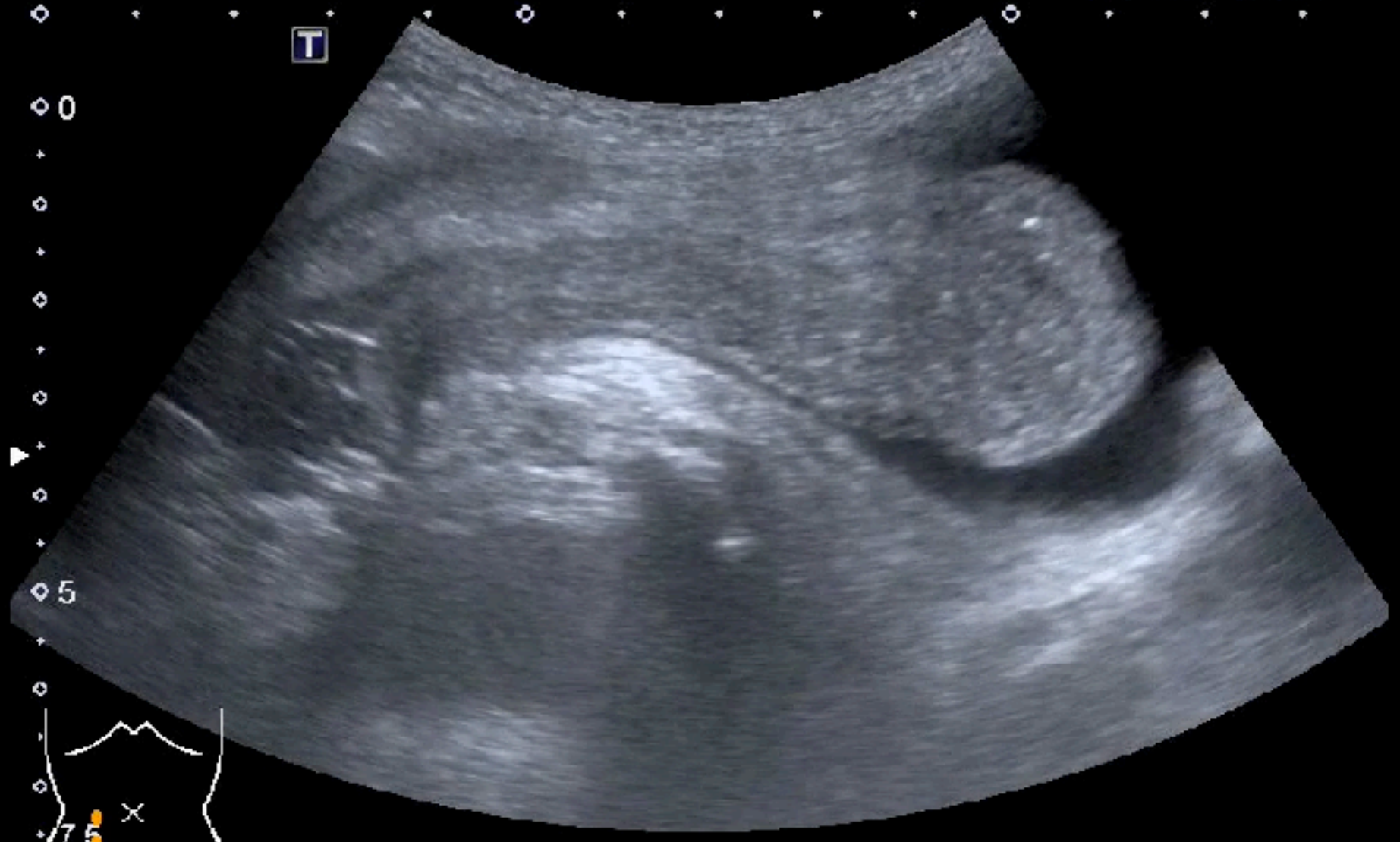


# 79M, right inguinal painful swelling for 3 hrs



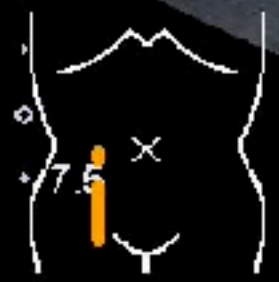

T



0

5

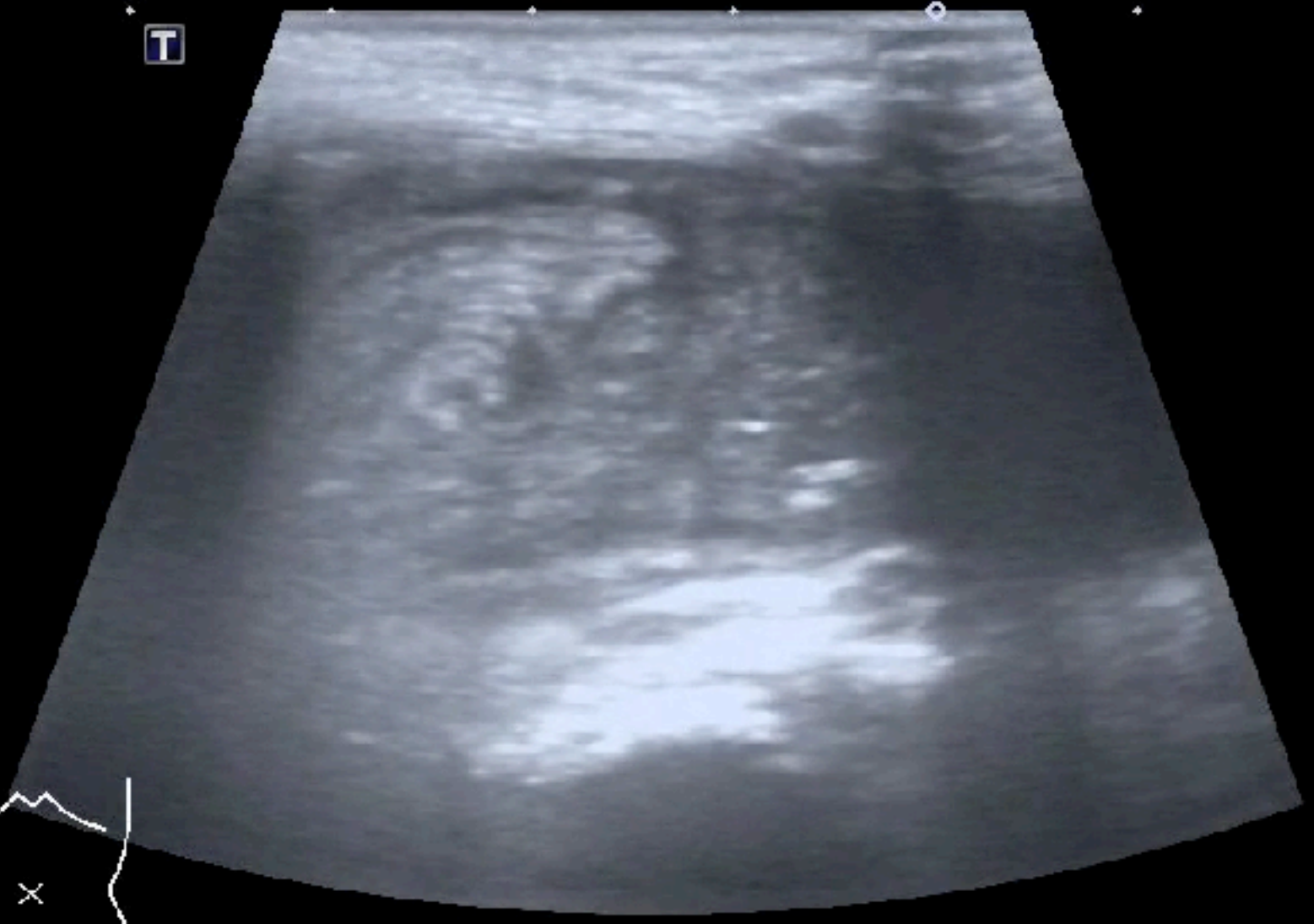


22

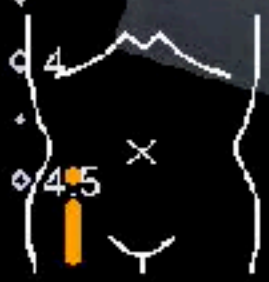D

T

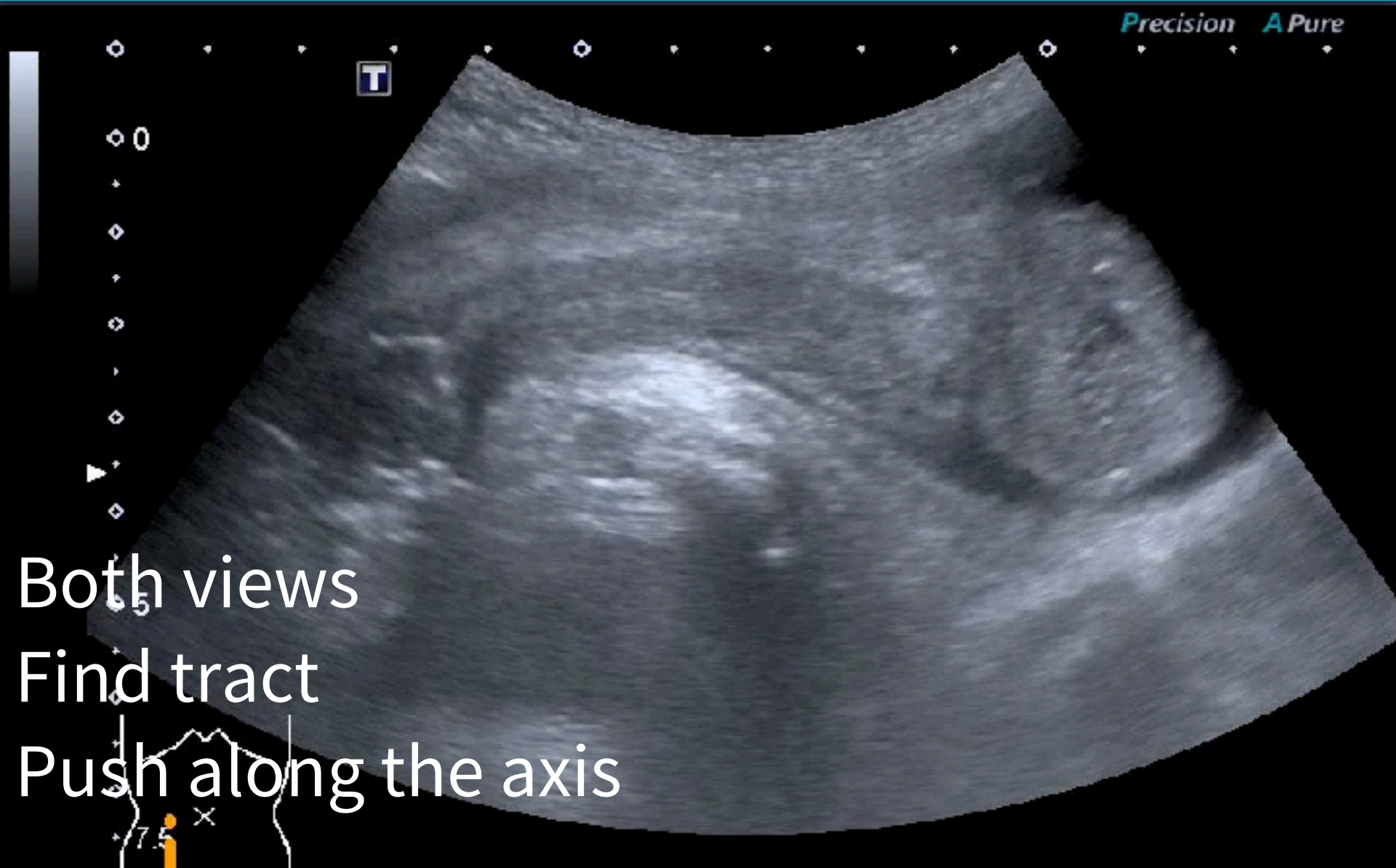0  
+  
+  
1  
+  
2  
+  
3  
+  
4  
+  
4.5  
+



1  
30  
C  
DF

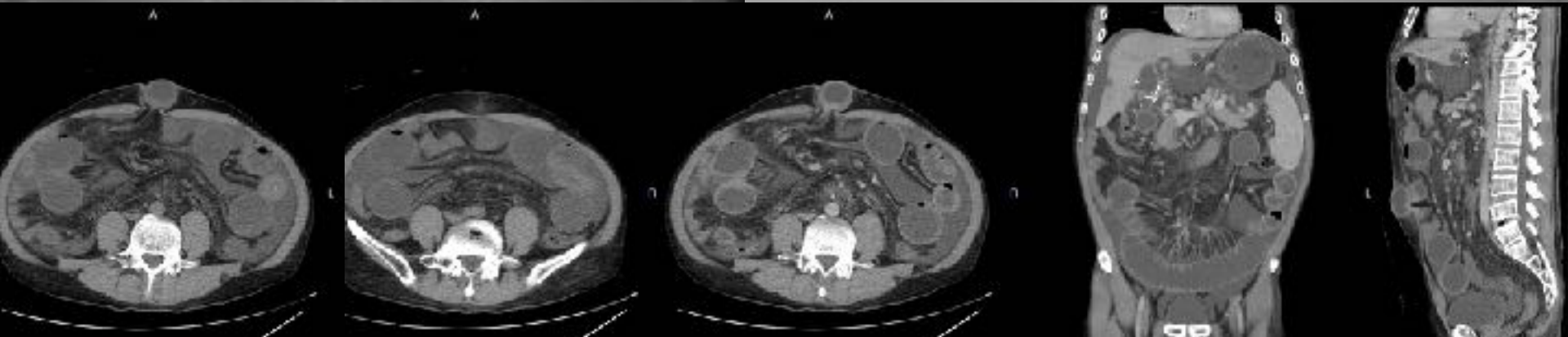
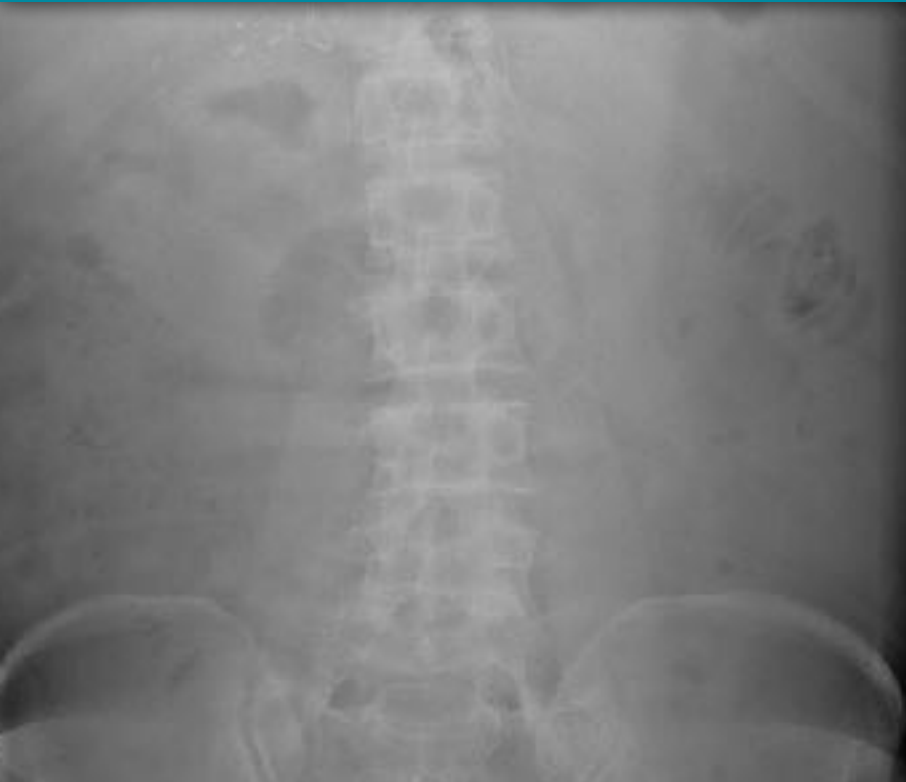
# US-guided hernia reduction

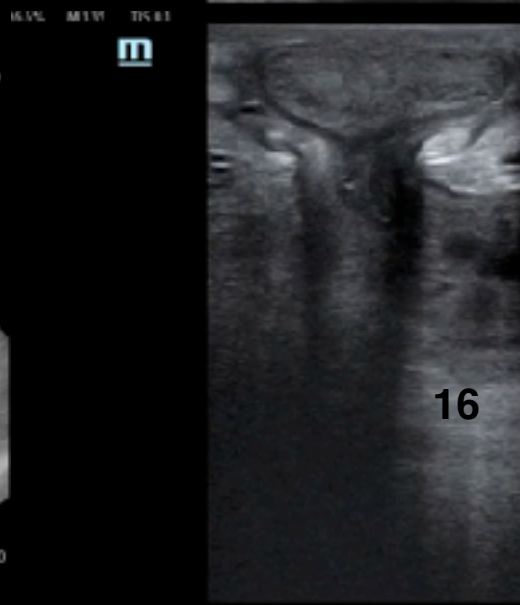
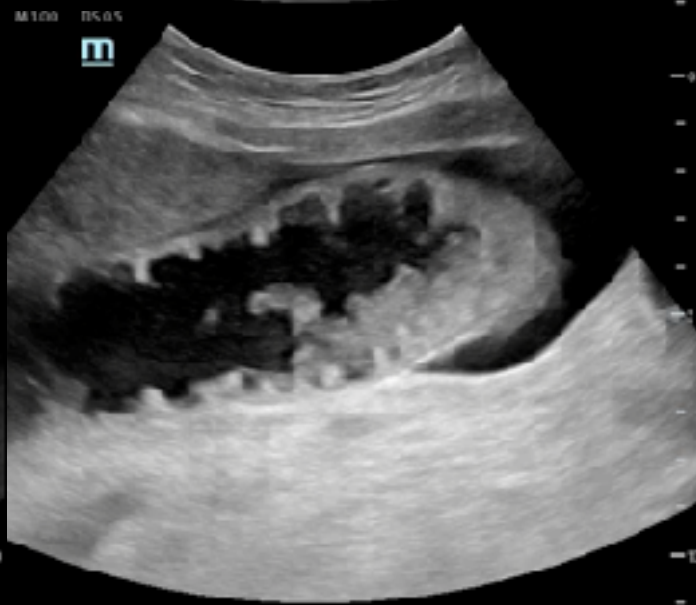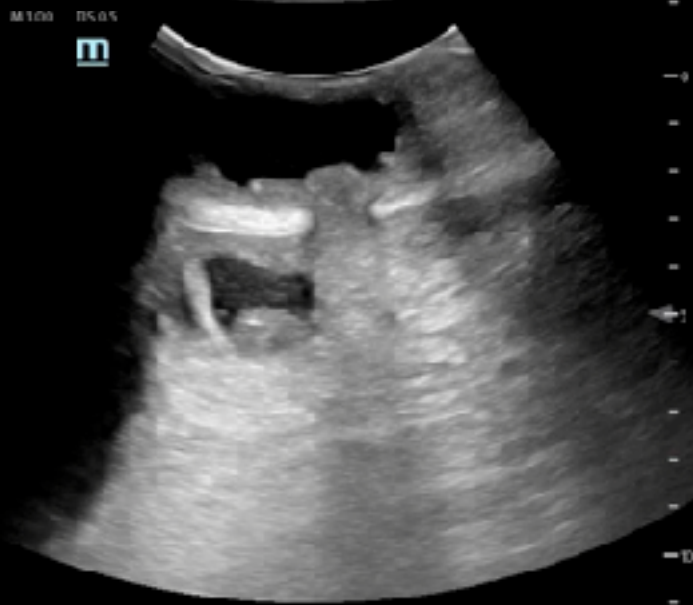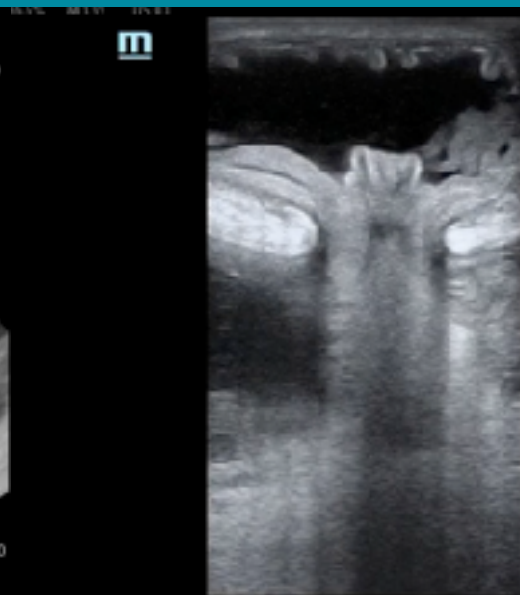
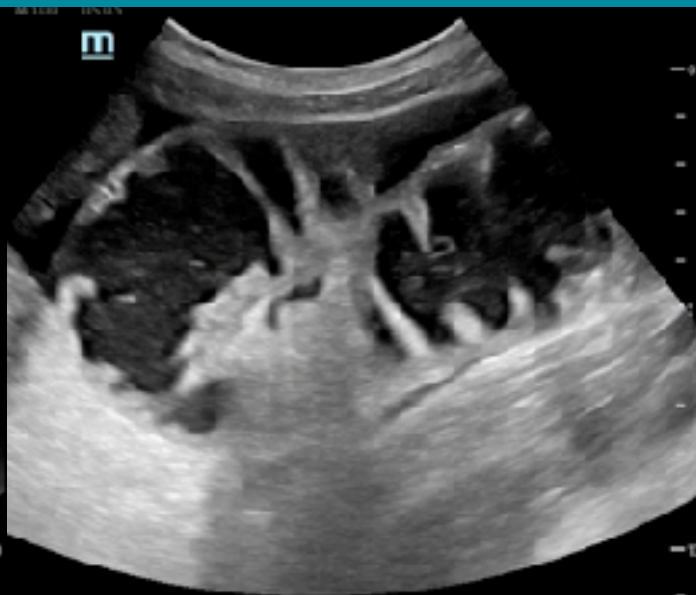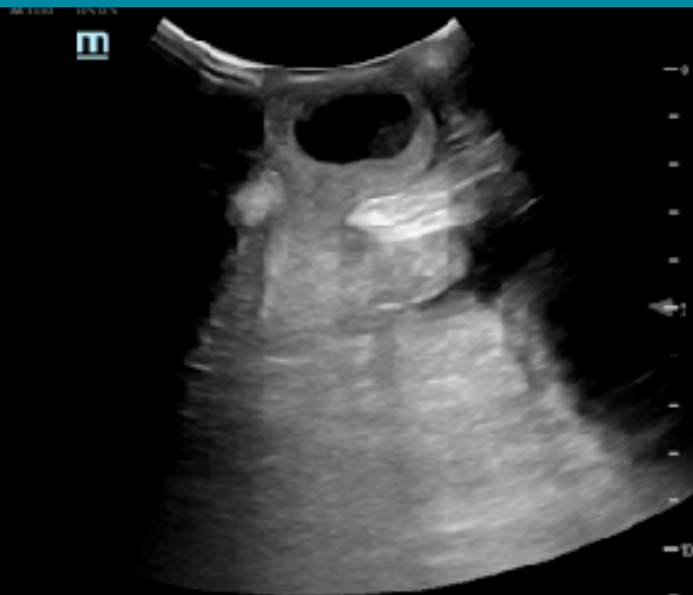




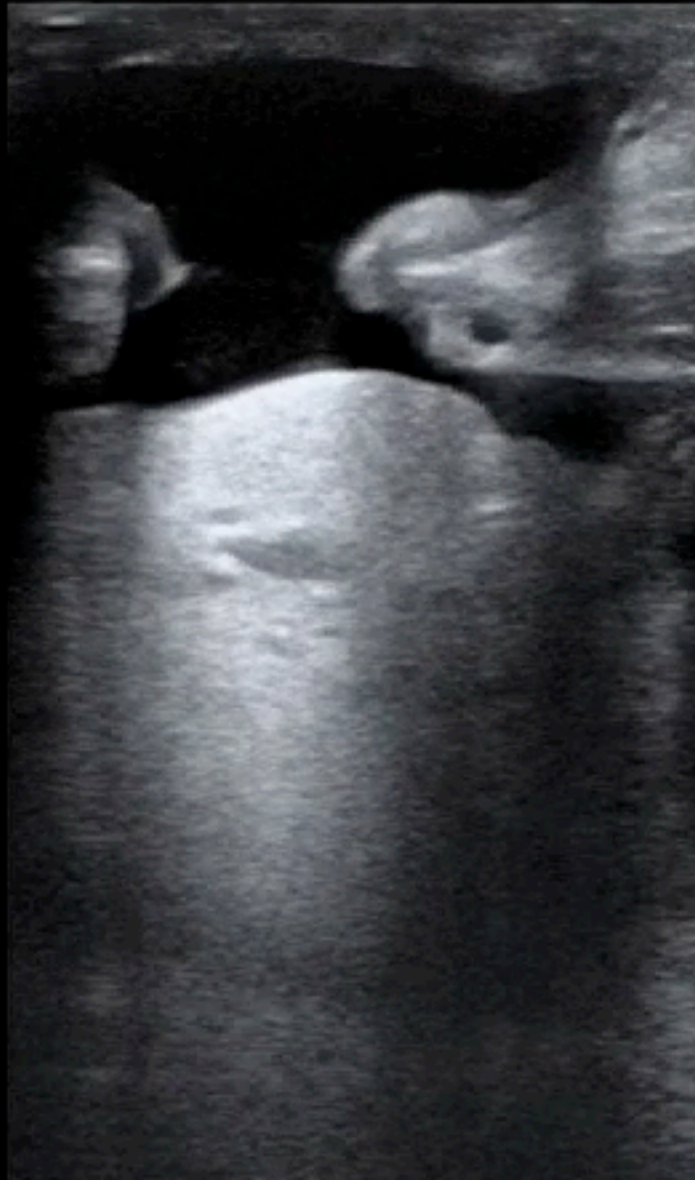
# 43M, Cirrhosis, diffuse ABD pain for hours



# POCUS - assisted reduction



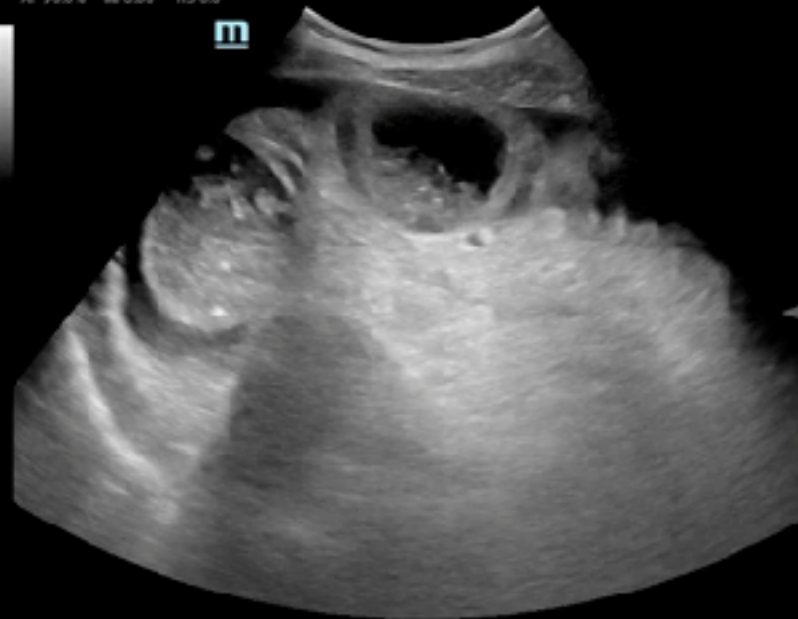
# Post reduction evaluation



AP 95.6% MI 0.85 TIS 0.6

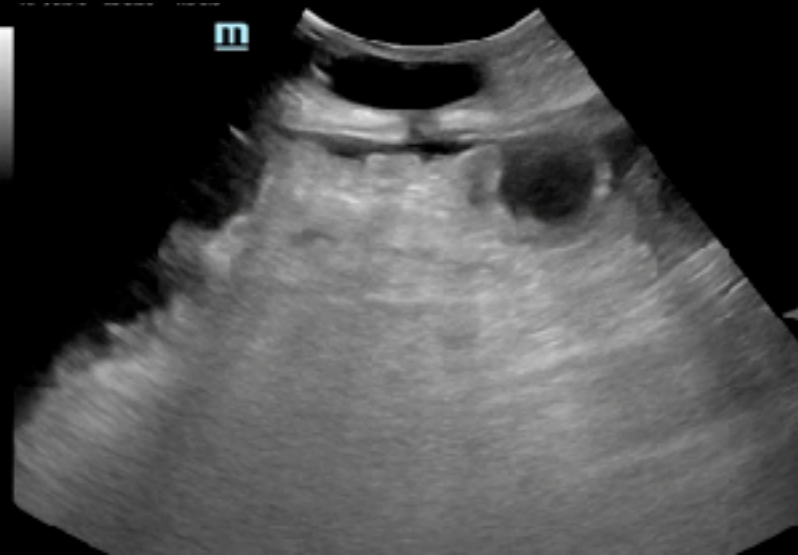
B  
FMS  
DR 1.0  
FR 15  
D 15.0  
G 40

Needle  
Touch

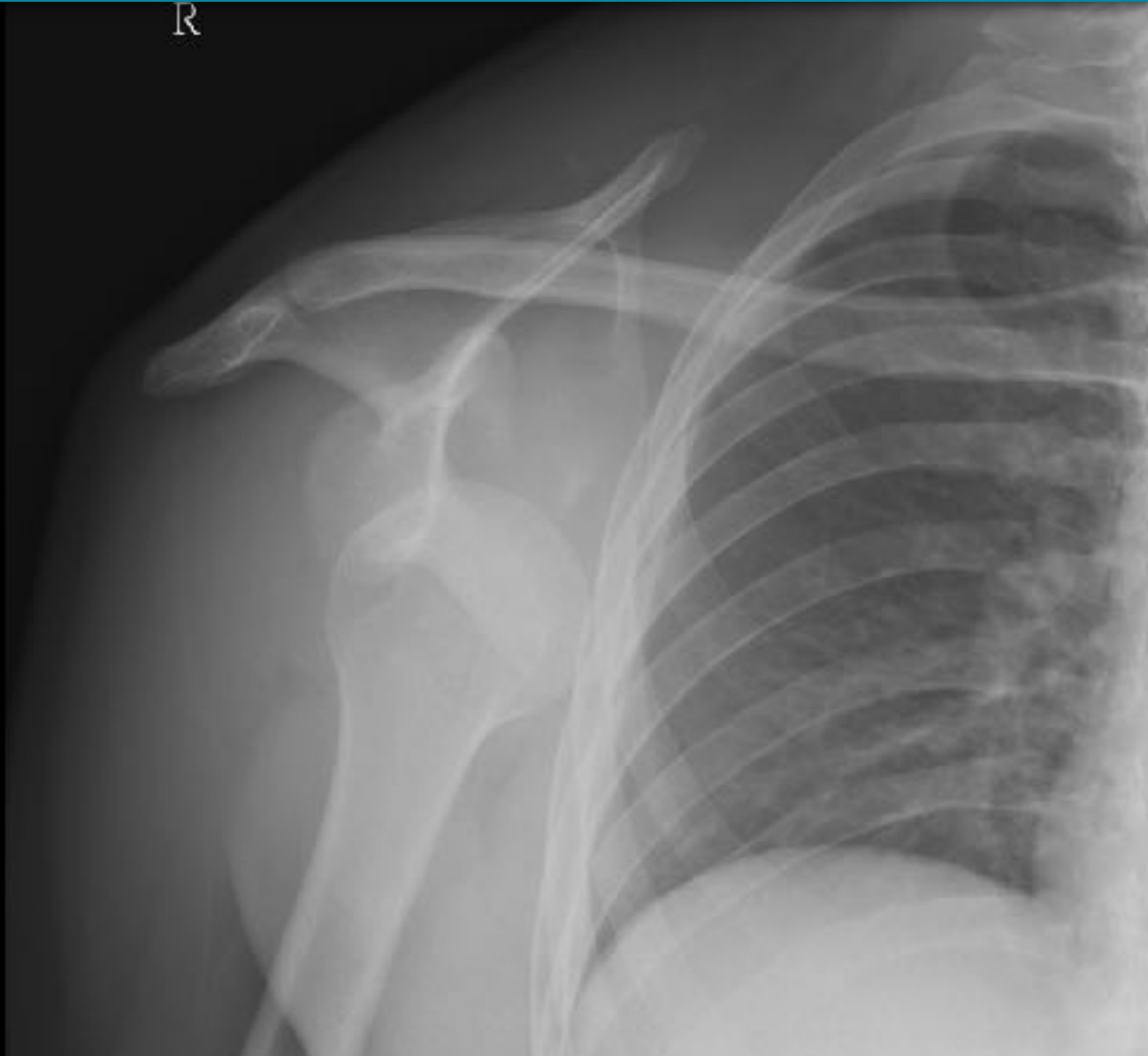

B  
FMS  
DR 1.0  
FR 15  
D 15.0  
G 40

Needle  
Touch

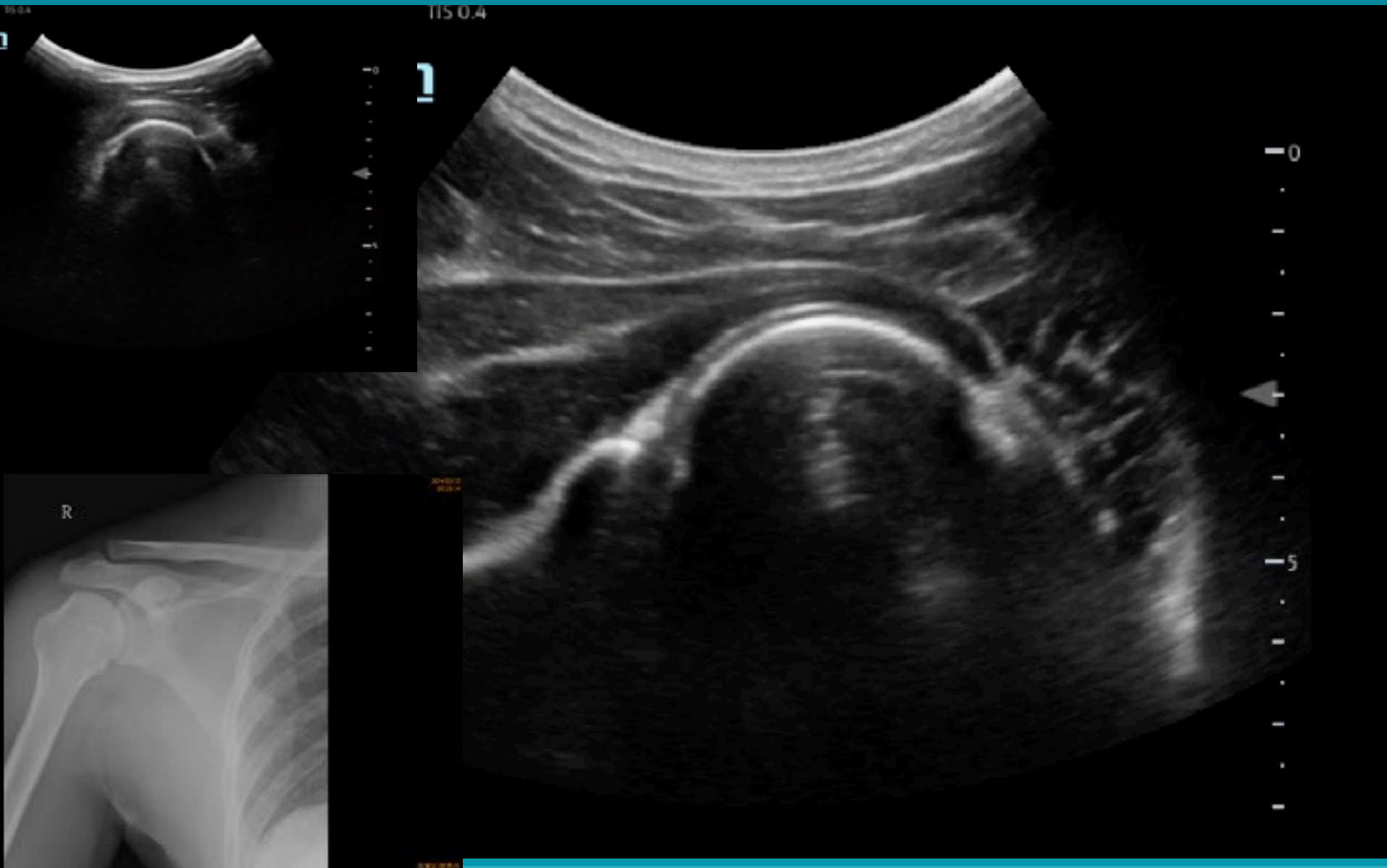


# 27F, falling injury with R shoulder pain

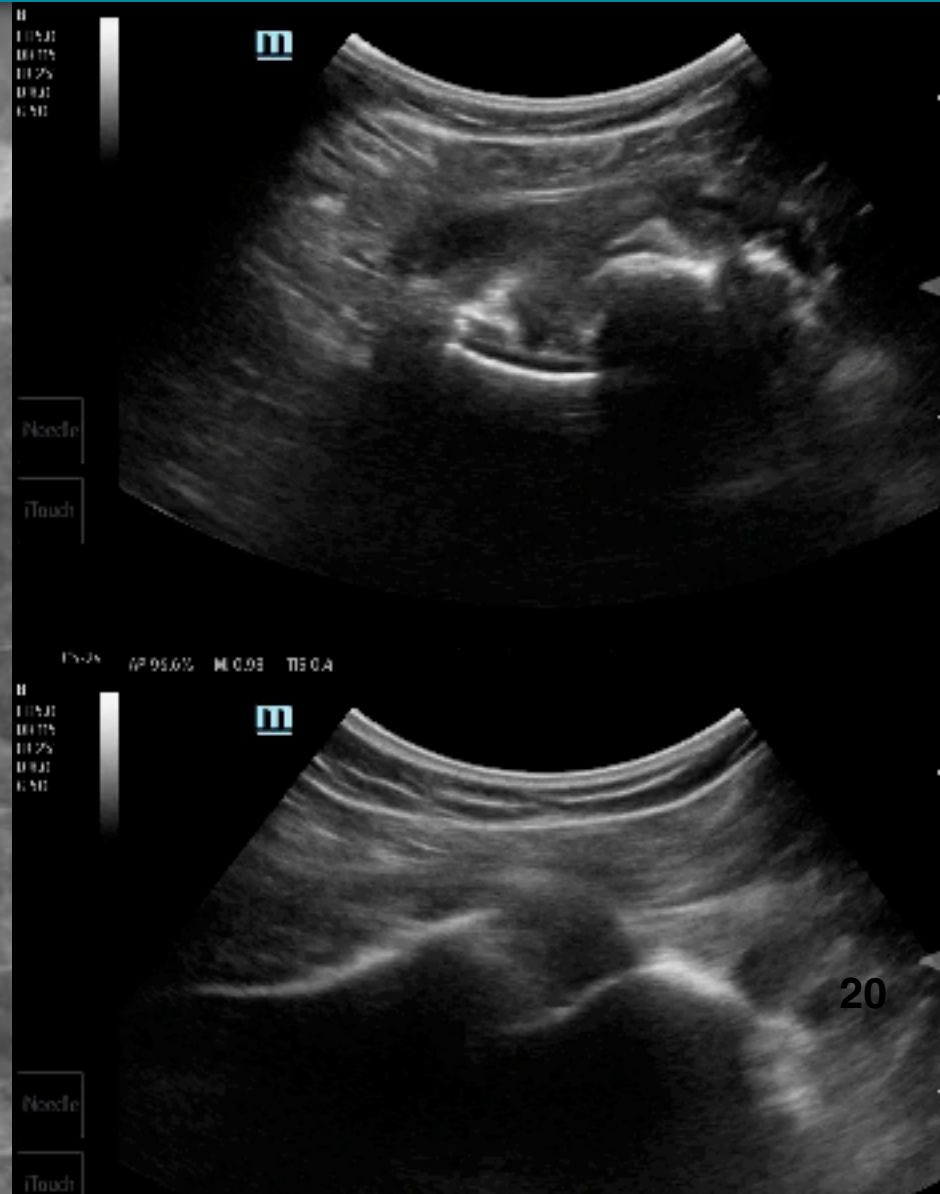
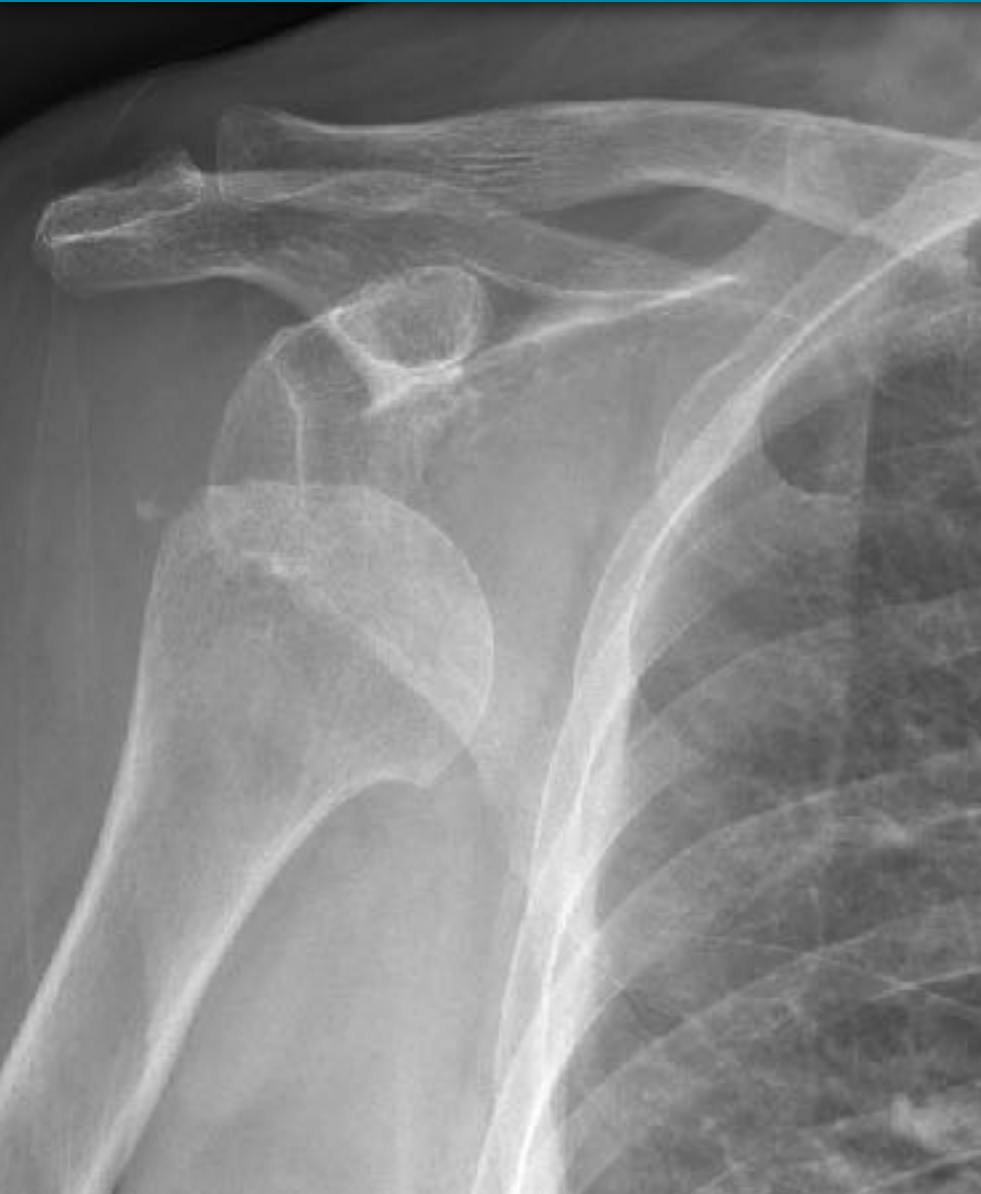



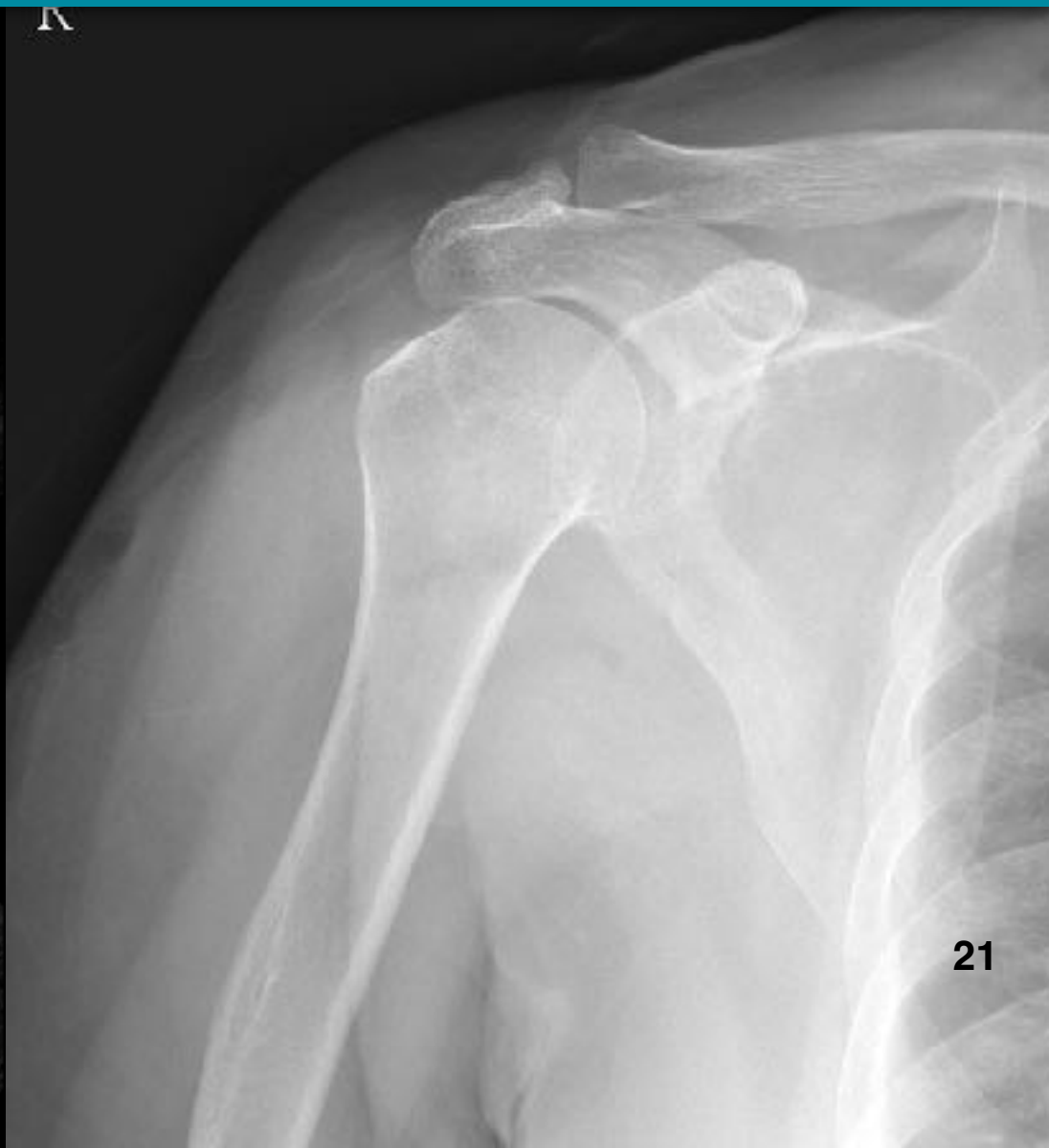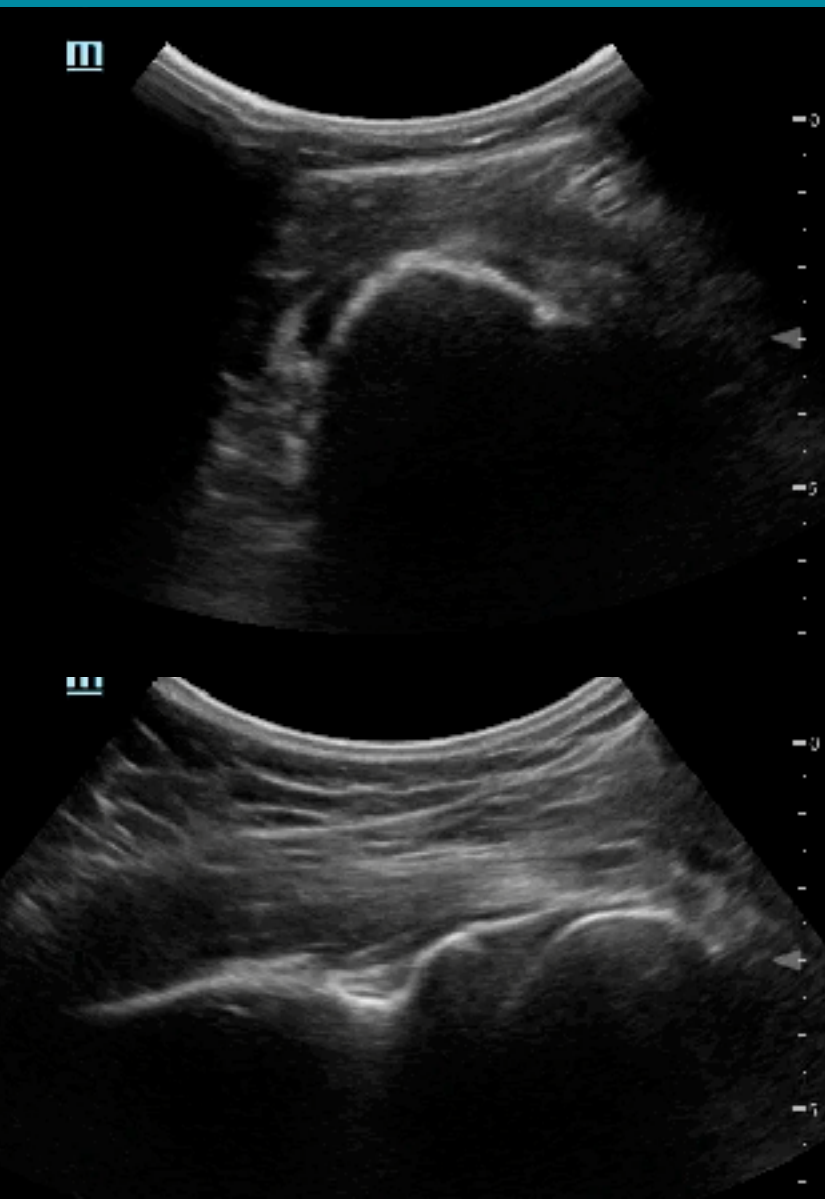
# Reduction: propofol / ketamine / morphine



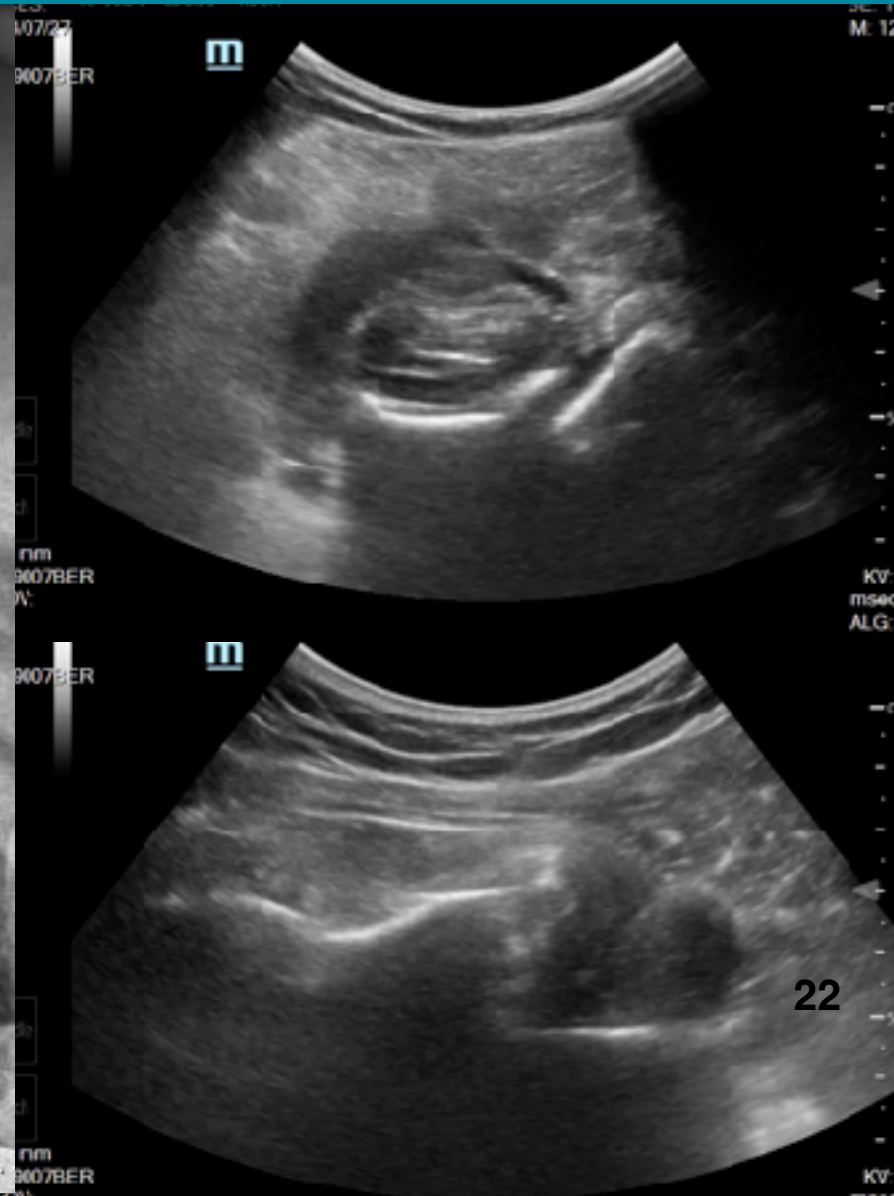
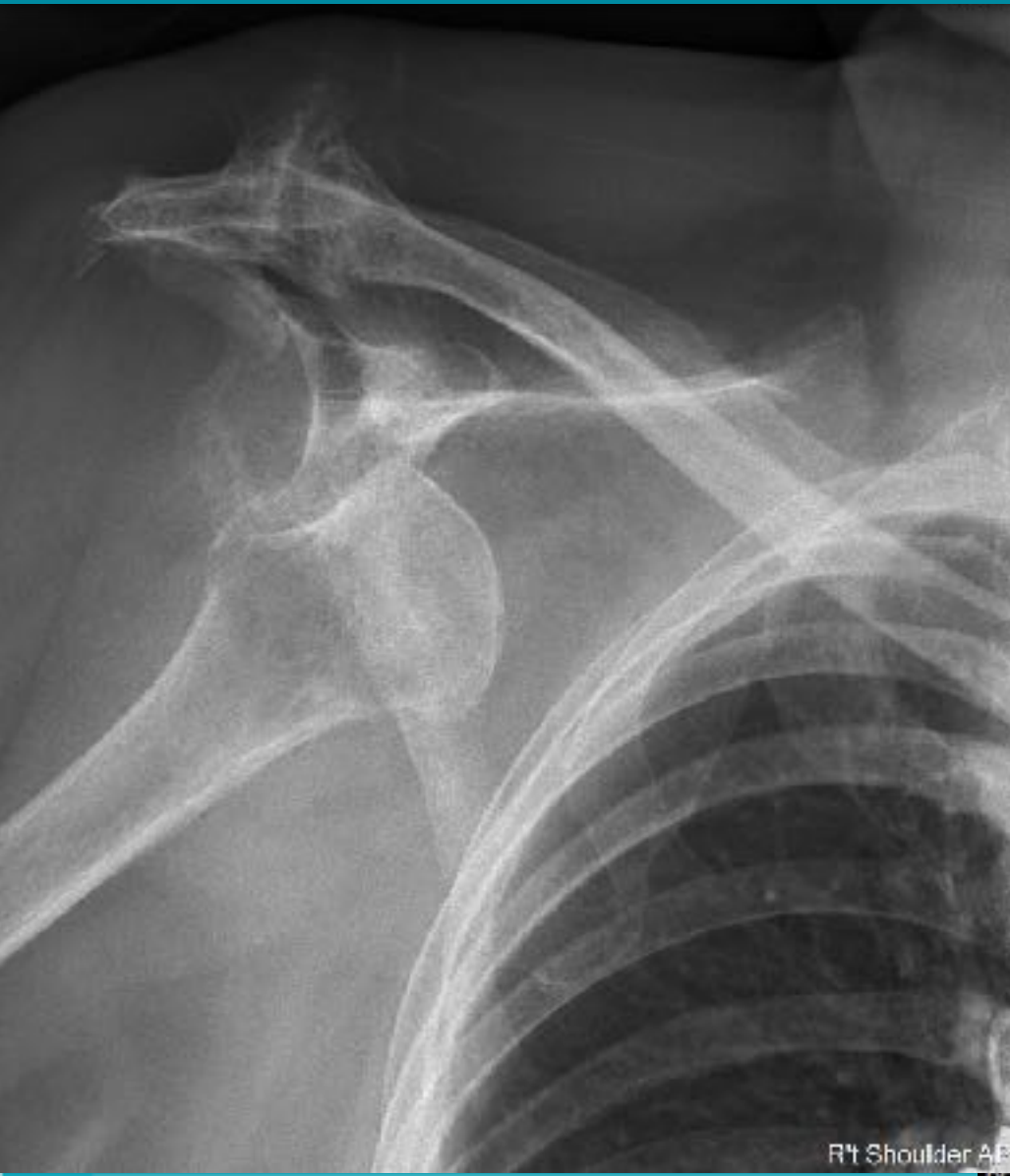# 74F, 半夜上廁所跌倒撞到右肩，舉不起來



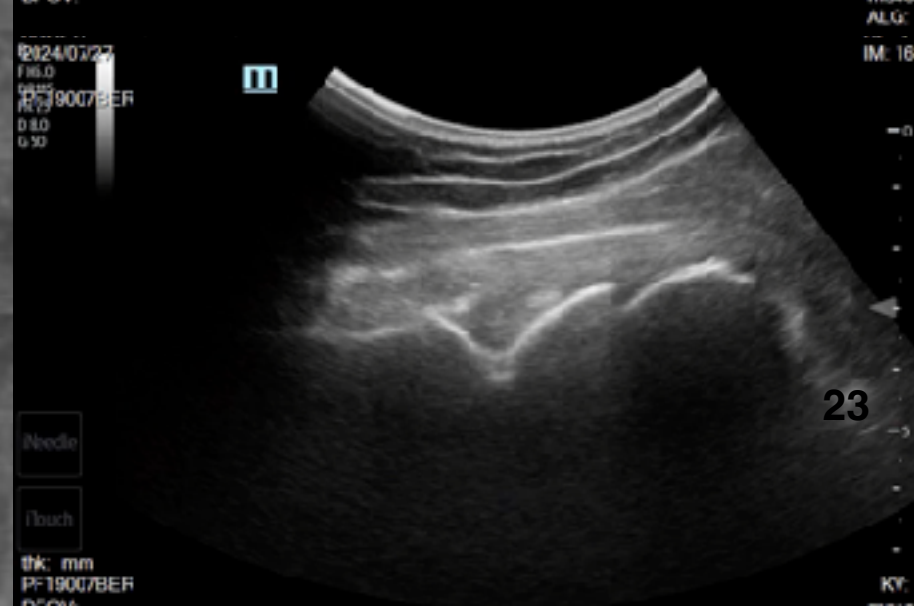
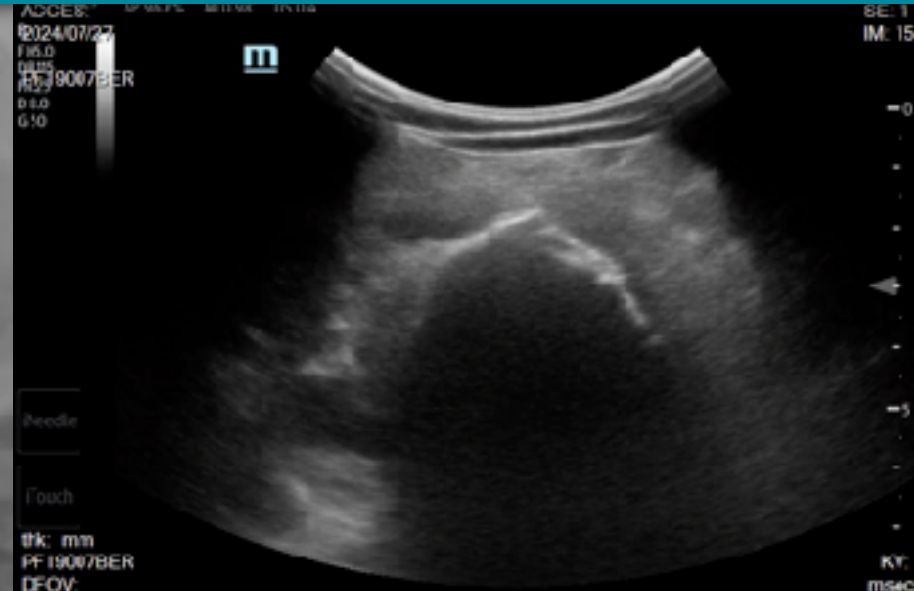
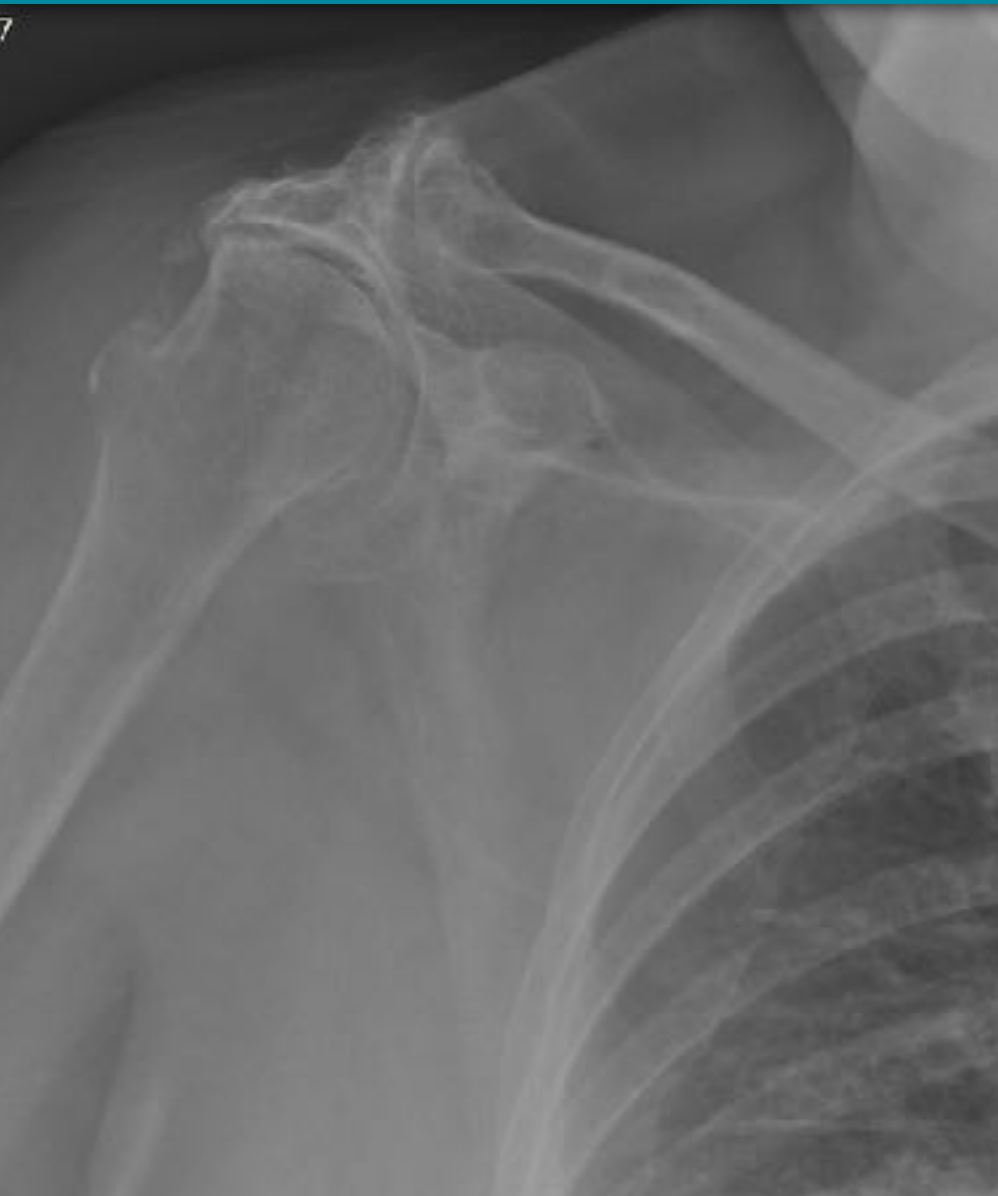# Reduction after NB



# 80F, 習慣性脫臼，5天前開始肩痛

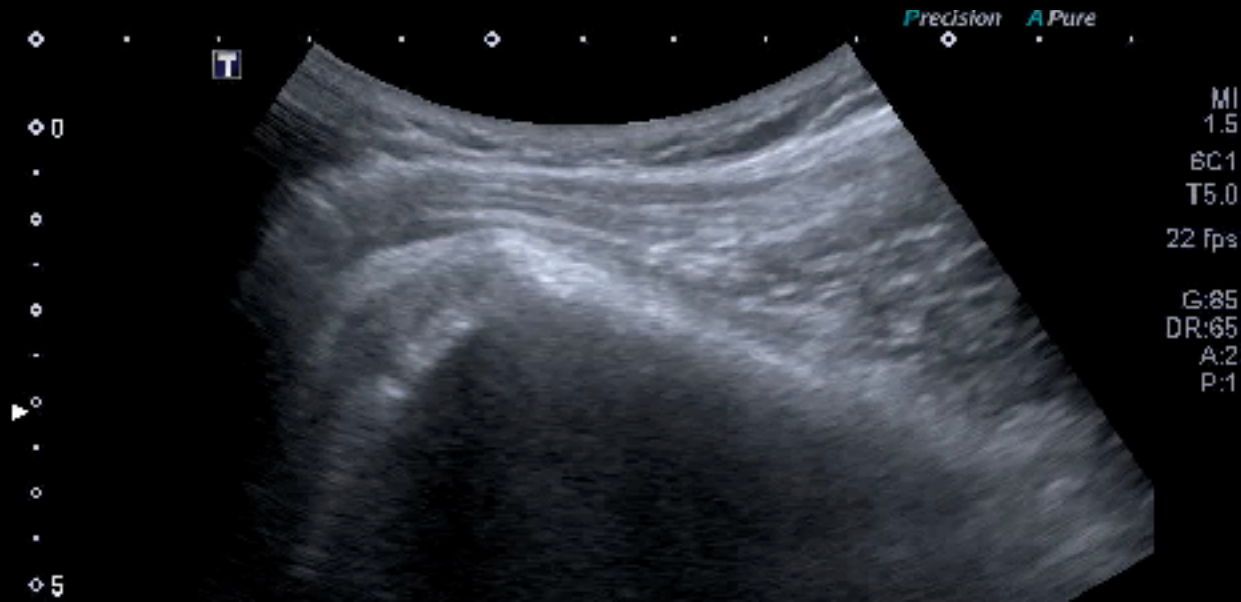
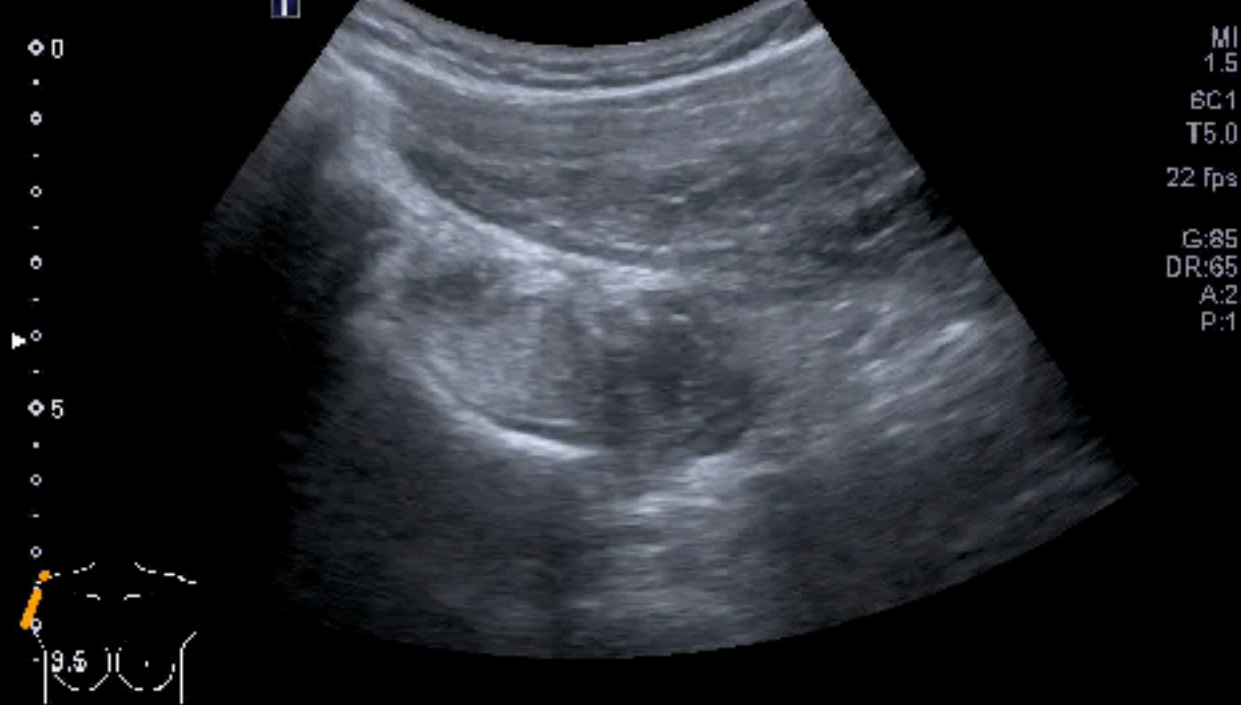
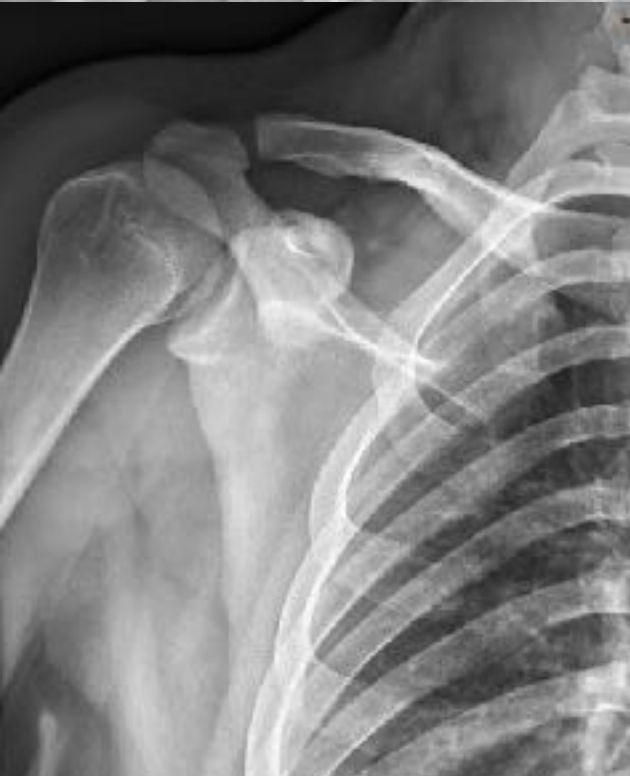
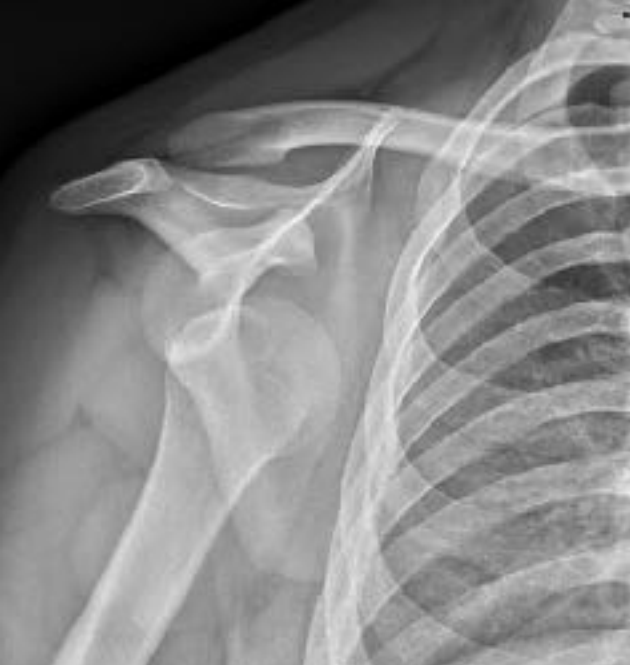
# Reduction after NB

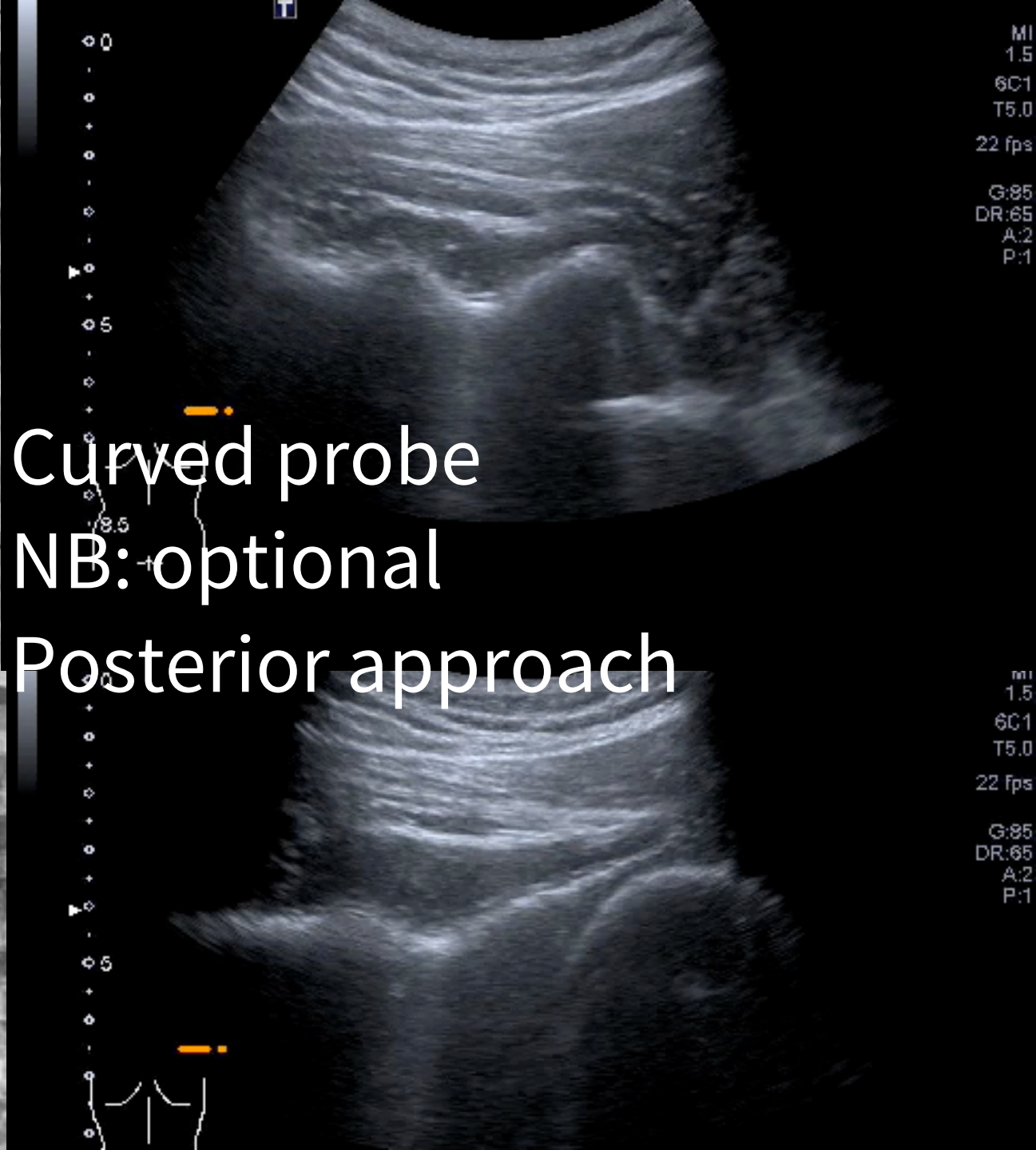
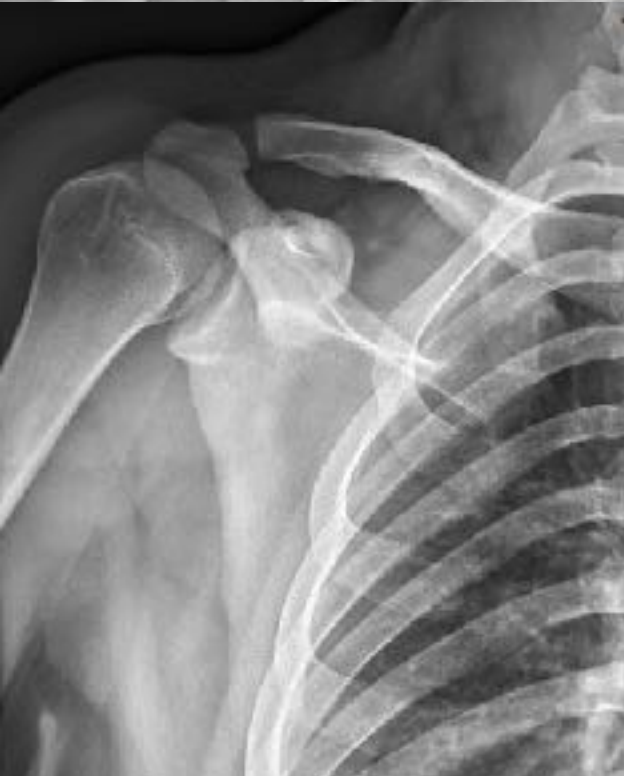
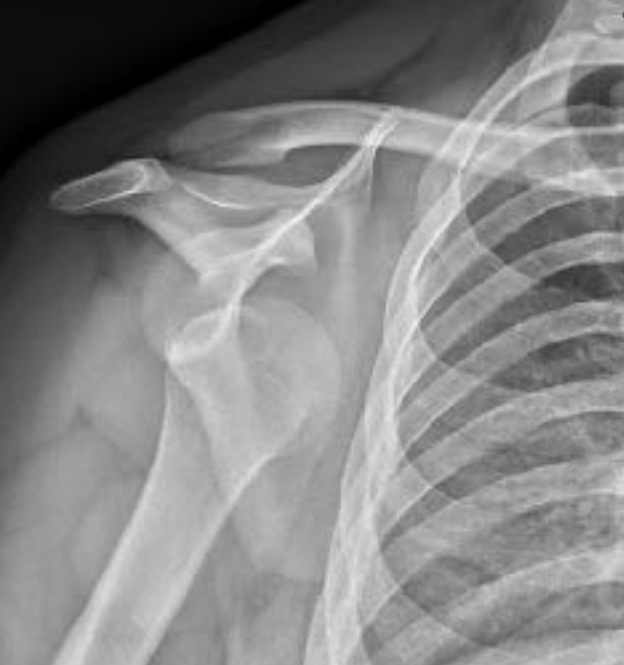










Curved probe

NB: optional

Posterior approach



# TRACHEAL INTUBATION

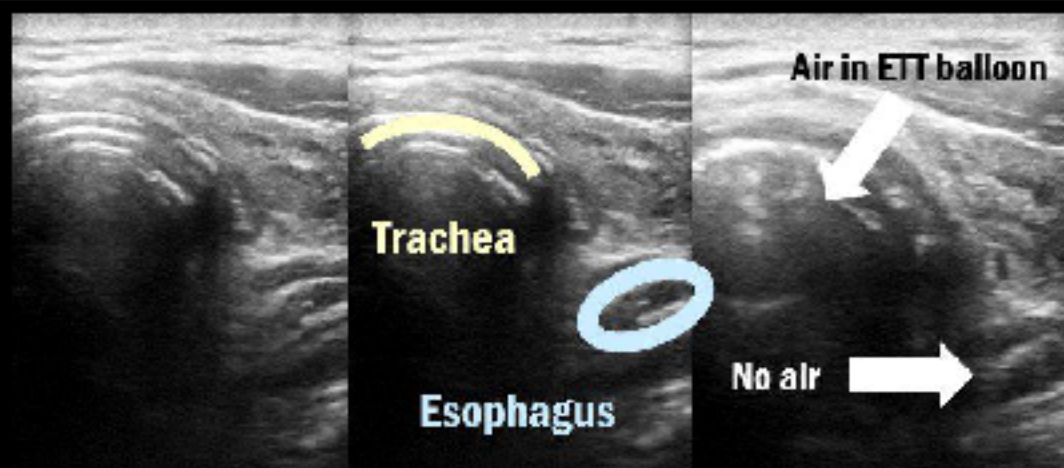
## Question:

Is POCUS accurate for confirming endotracheal intubation in the emergency department?

## Study:

Prospective observational convenience sample. Patients undergoing intubation received tracheal rapid US exam (TRUE) directly after tube placement to determine tracheal vs esophageal. Compared to quantitative waveform capnography.

**n = 100**



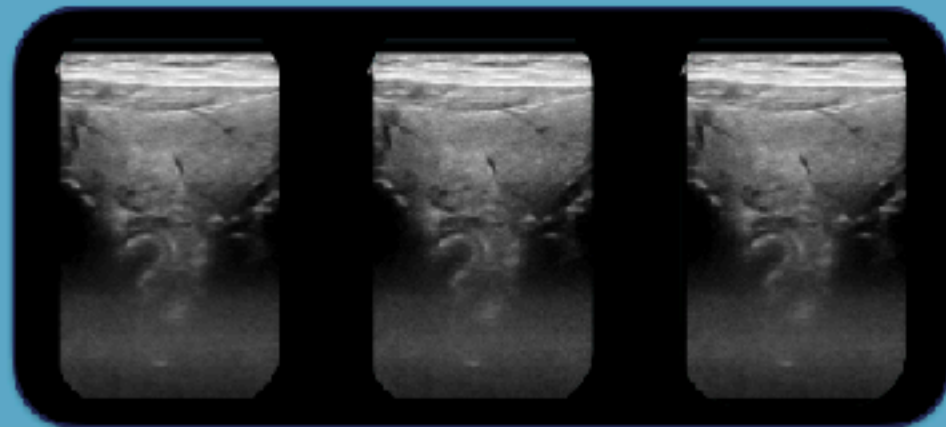
## Results

	Sens (%)	Spec (%)
TRUE	98.9	100



1  
3  
4

# NASOGASTRIC TUBE PLACEMENT



## **Question:**

Does POCUS guidance during NG tube insertion improve accuracy or reduce complications compared to conventional methods?

## **Methods:**

Prospective, open-label, randomized controlled trial. Primary outcome compared accuracy of POCUS of esophagus at cricoid to CXR for NG tube confirmation.

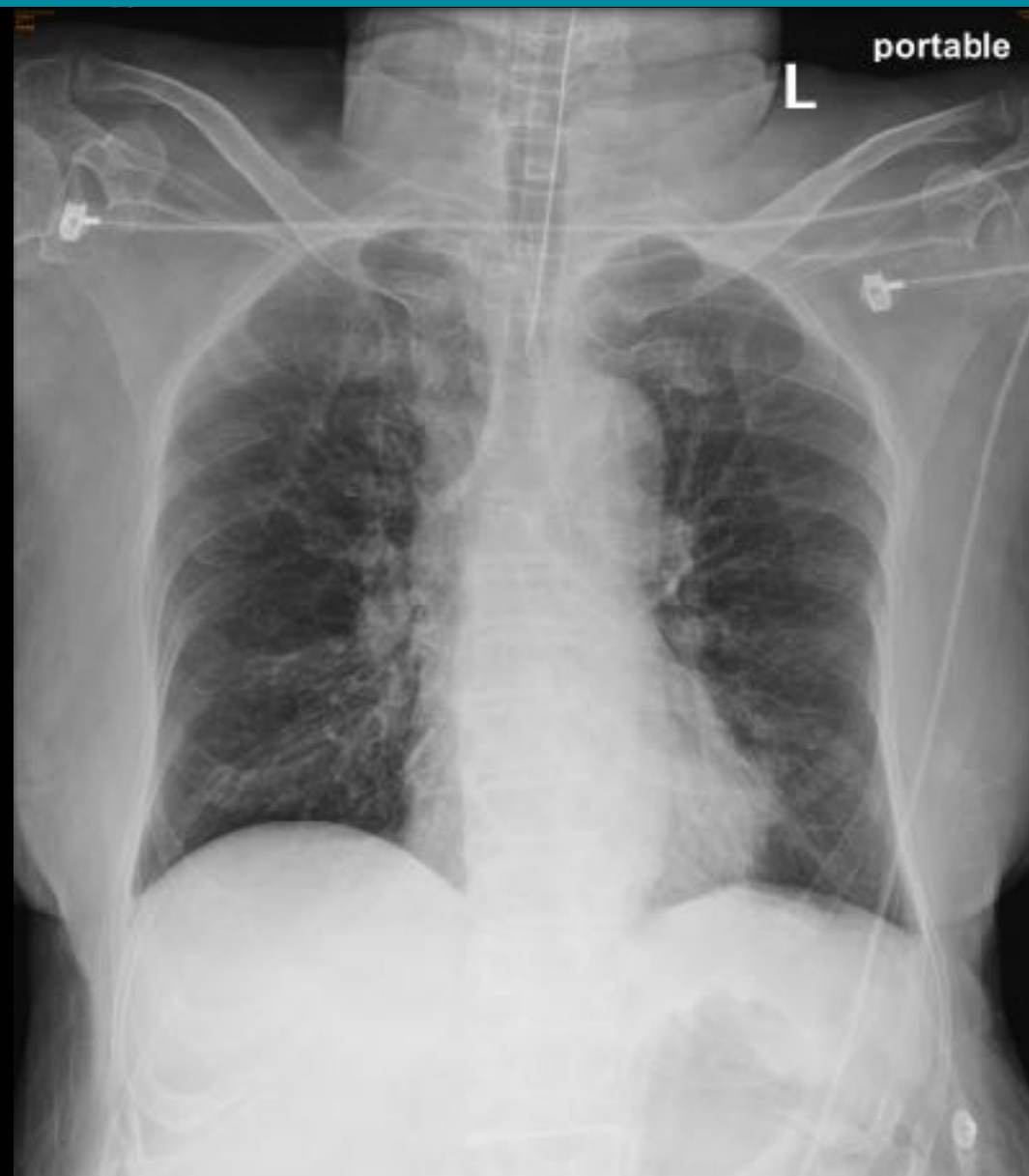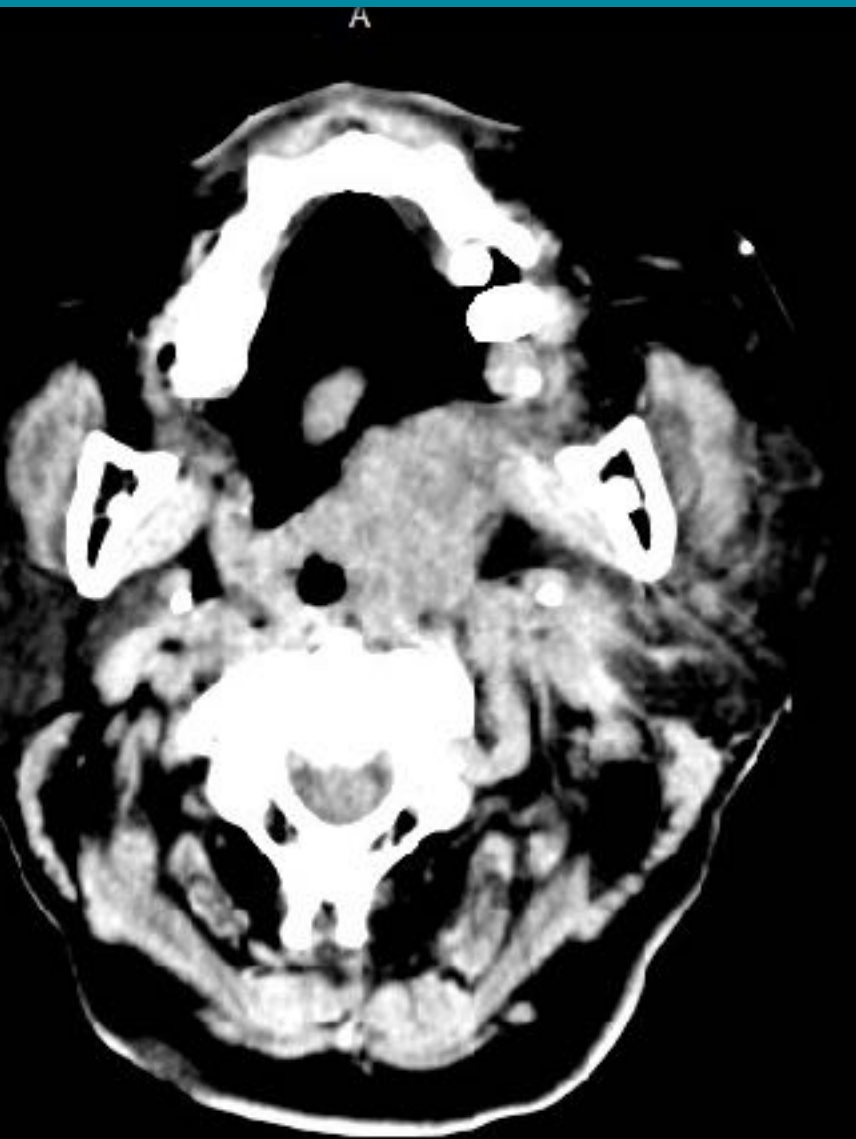
***n = 118***

## **Results**

	<b>POCUS</b>	<b>Control</b>
Accuracy	94.3%	86%
Attempts	1.19	1.8
Insertion time	4.3 min	228 min

Esophagus was seen in 96.8% of the POCUS group and 87% were on the left.

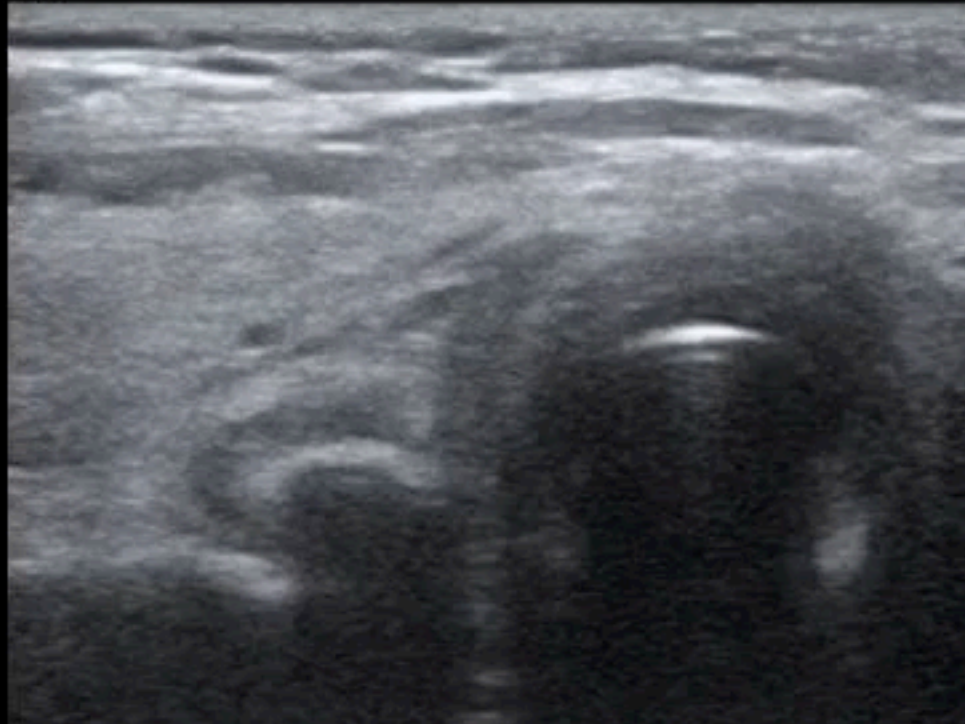
# 74F, peritonsillar abscess





# ETT & NG confirmation

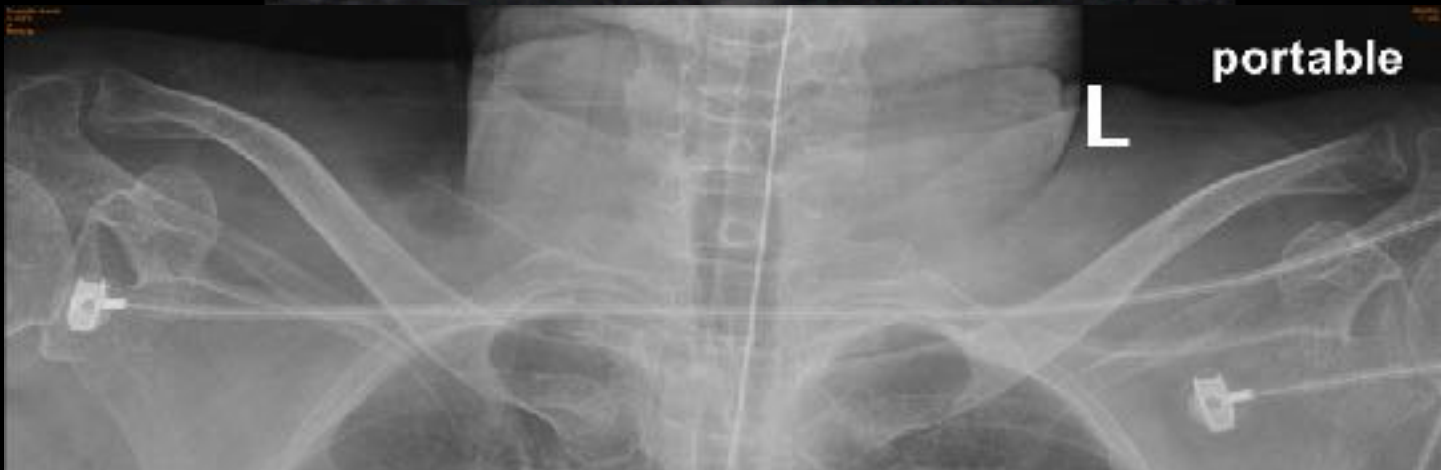B  
FH10.0  
DR105  
FR 26  
D5.0  
G70



0  
.  
-1  
.  
-2  
.  
-3  
.  
-4  
.

iNeedle

iTouch

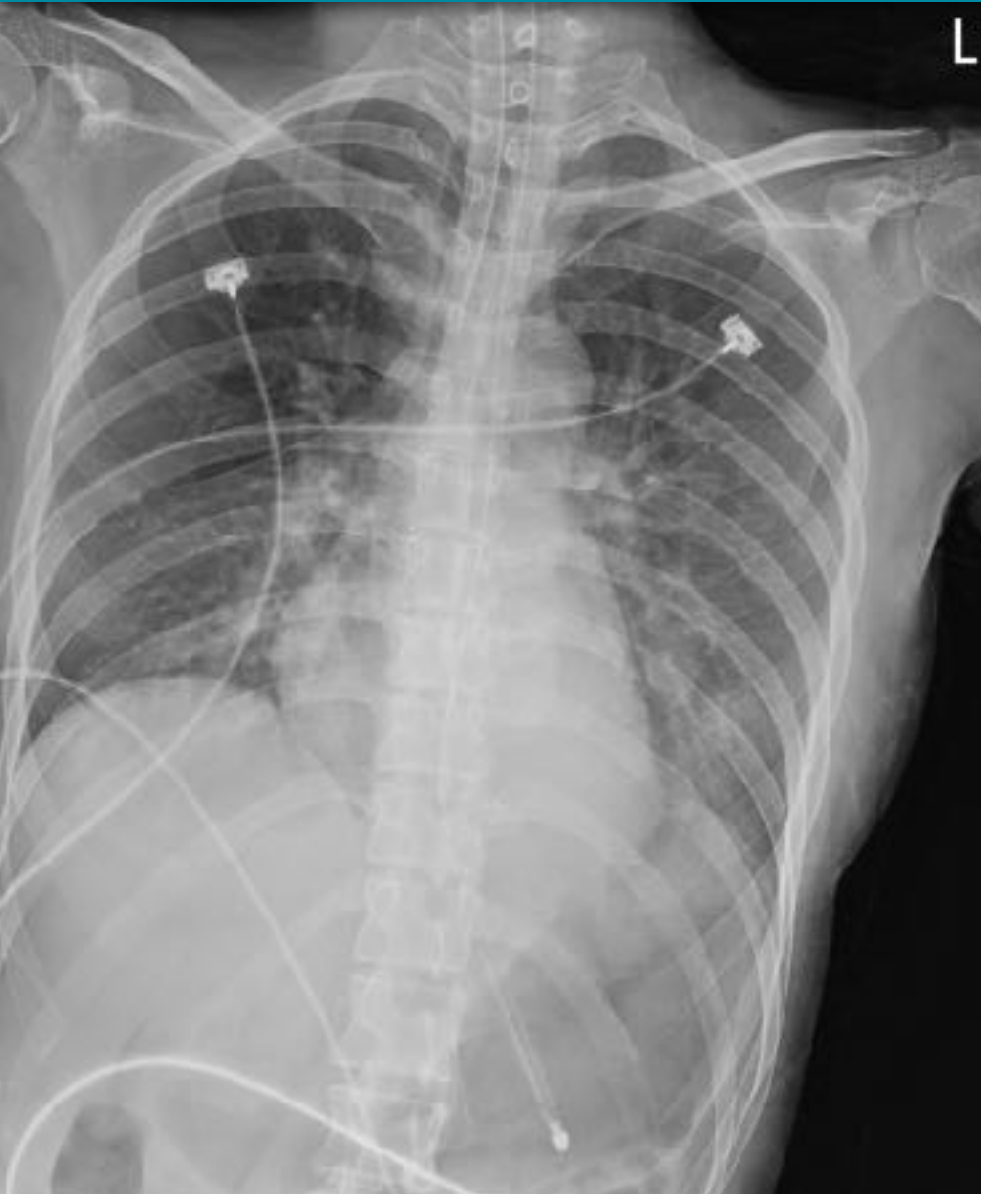

portable

L



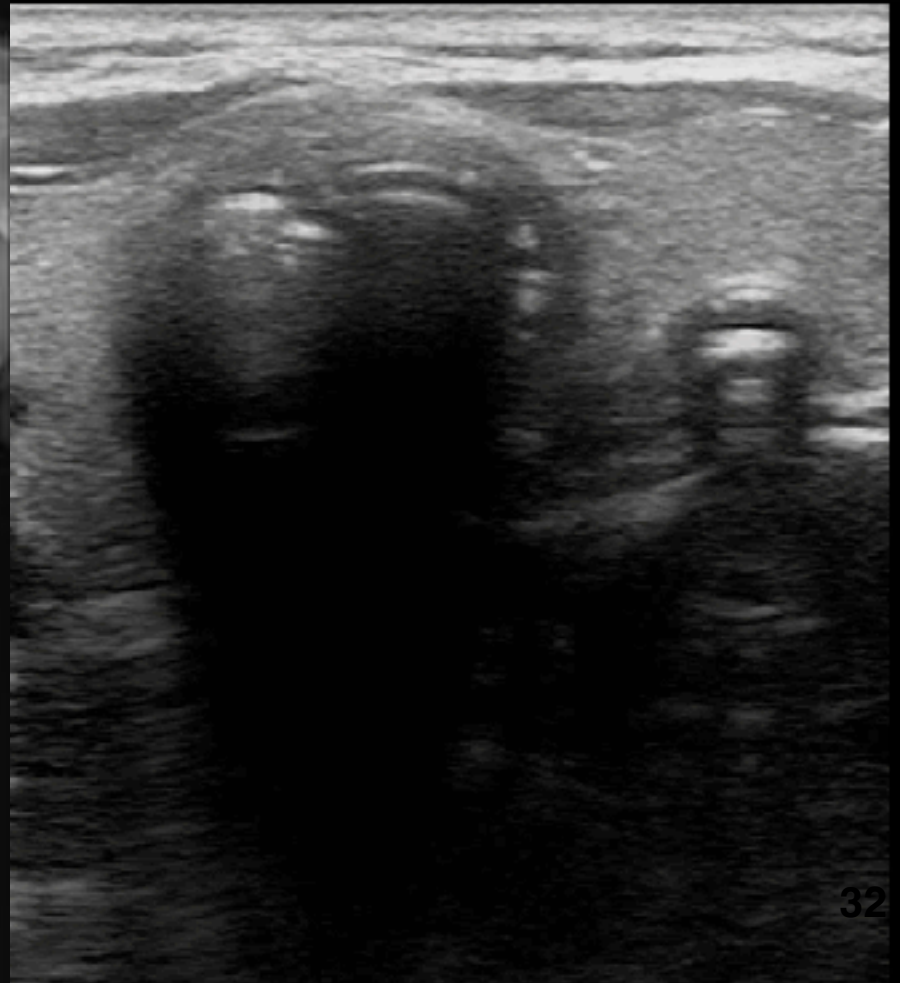# 30F, MG crisis



L

SKH ER

TIS 0.1 9:5



32



# ET tube / Cuff

Arterial

L12-3

49 Hz

2.5cm

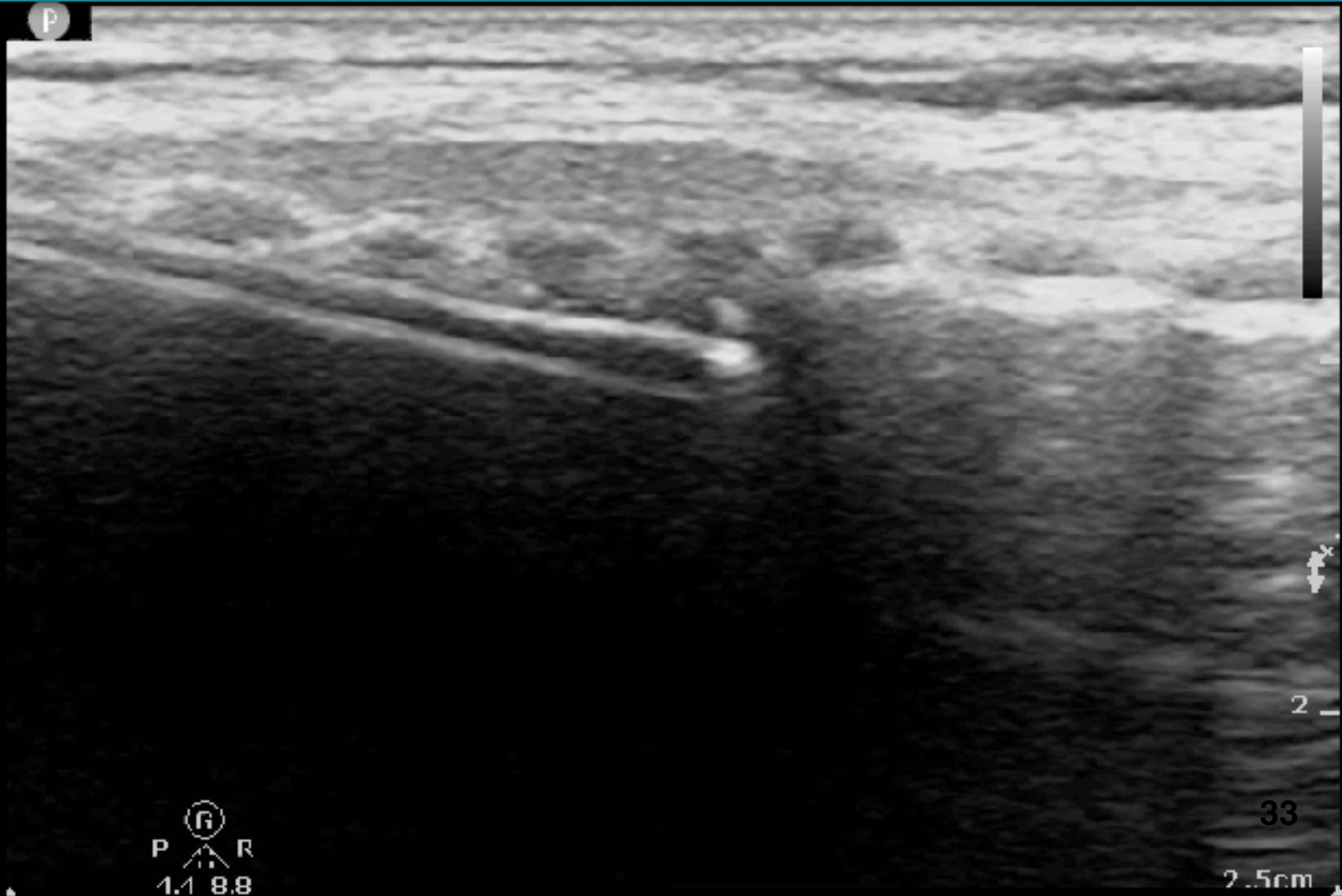
2D

HGen

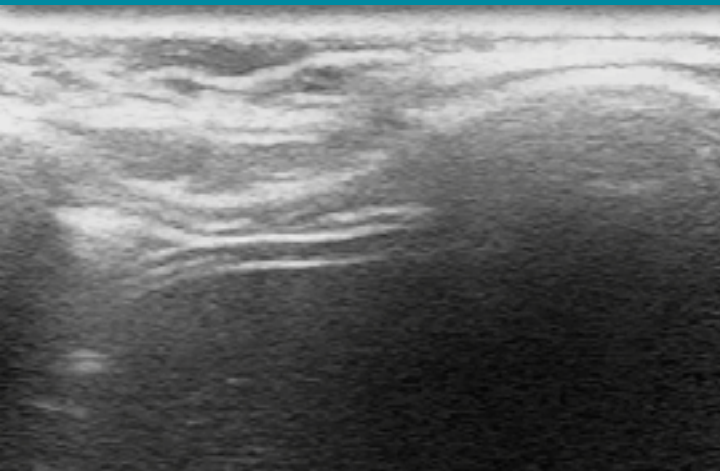
Gn 70

C. 41

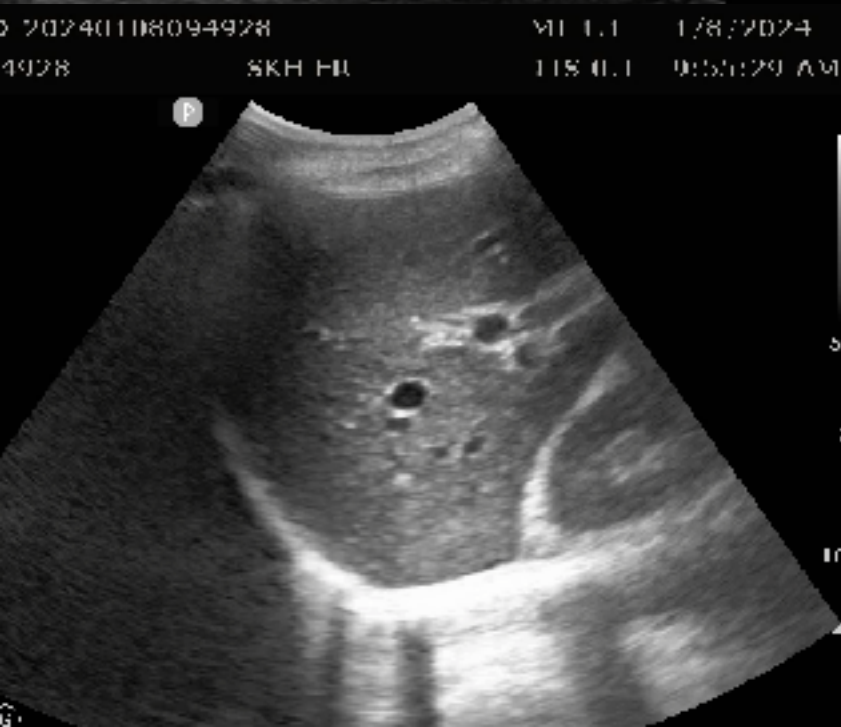3/3/2



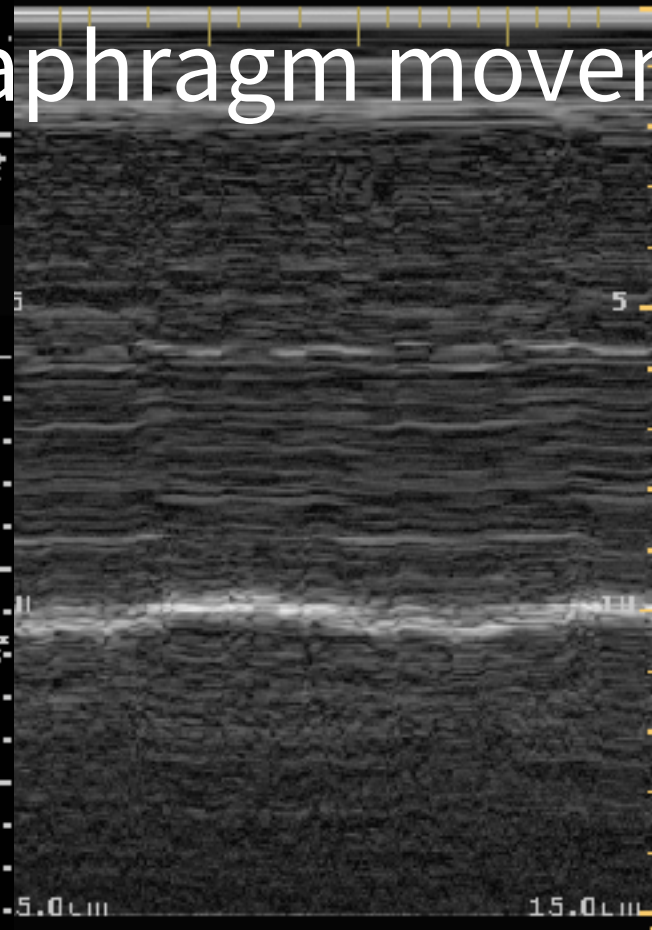
# Diaphragm POCUS



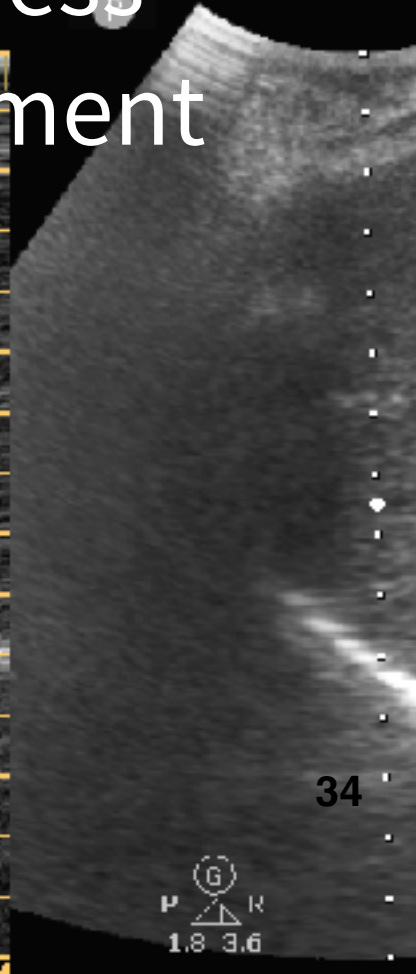
Diaphragm thickness  
Diaphragm movement



20240108094928  
MI 1.1  
TIS 0.1  
SKH ER



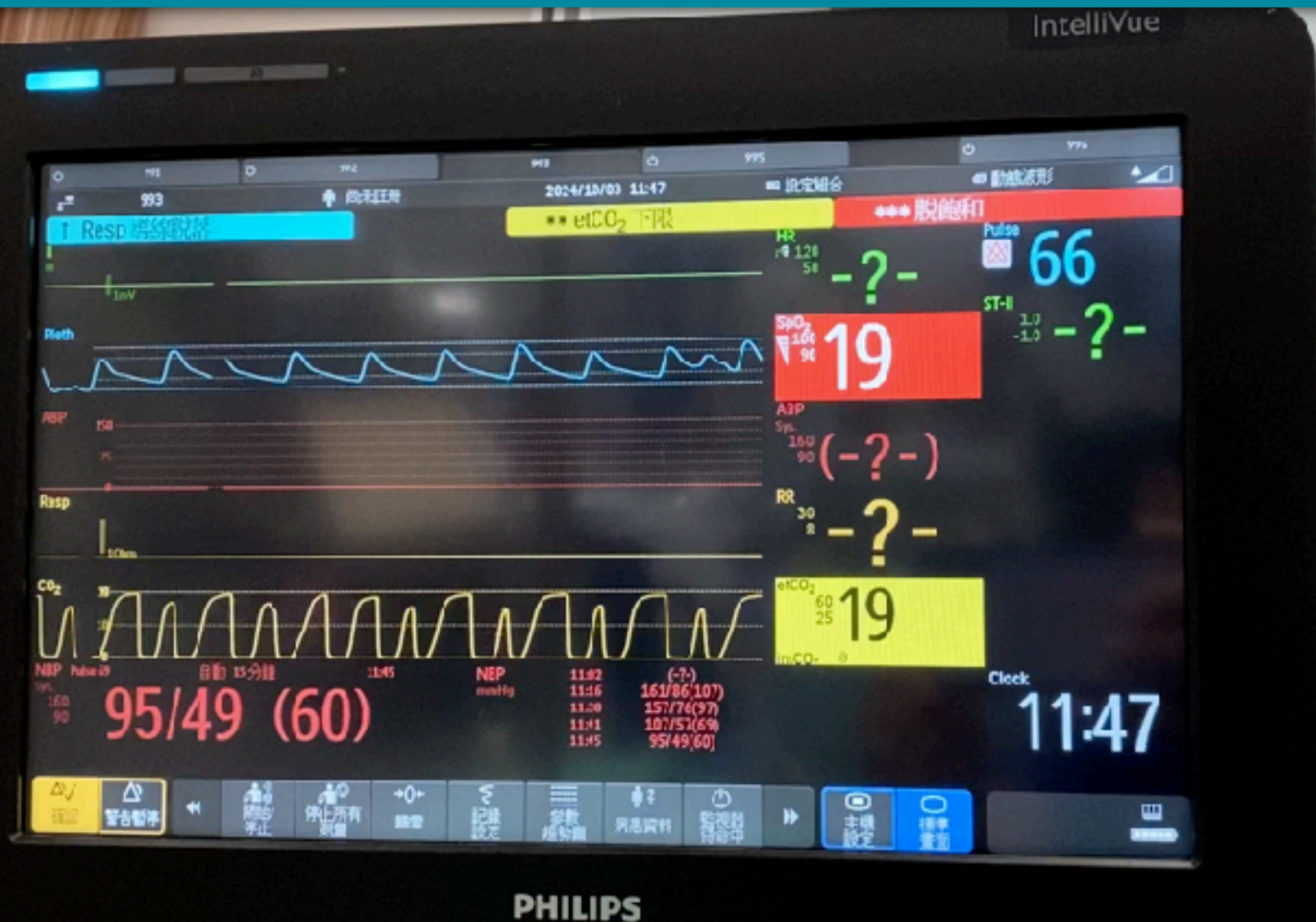
MI 1.1  
TIS 0.1



34

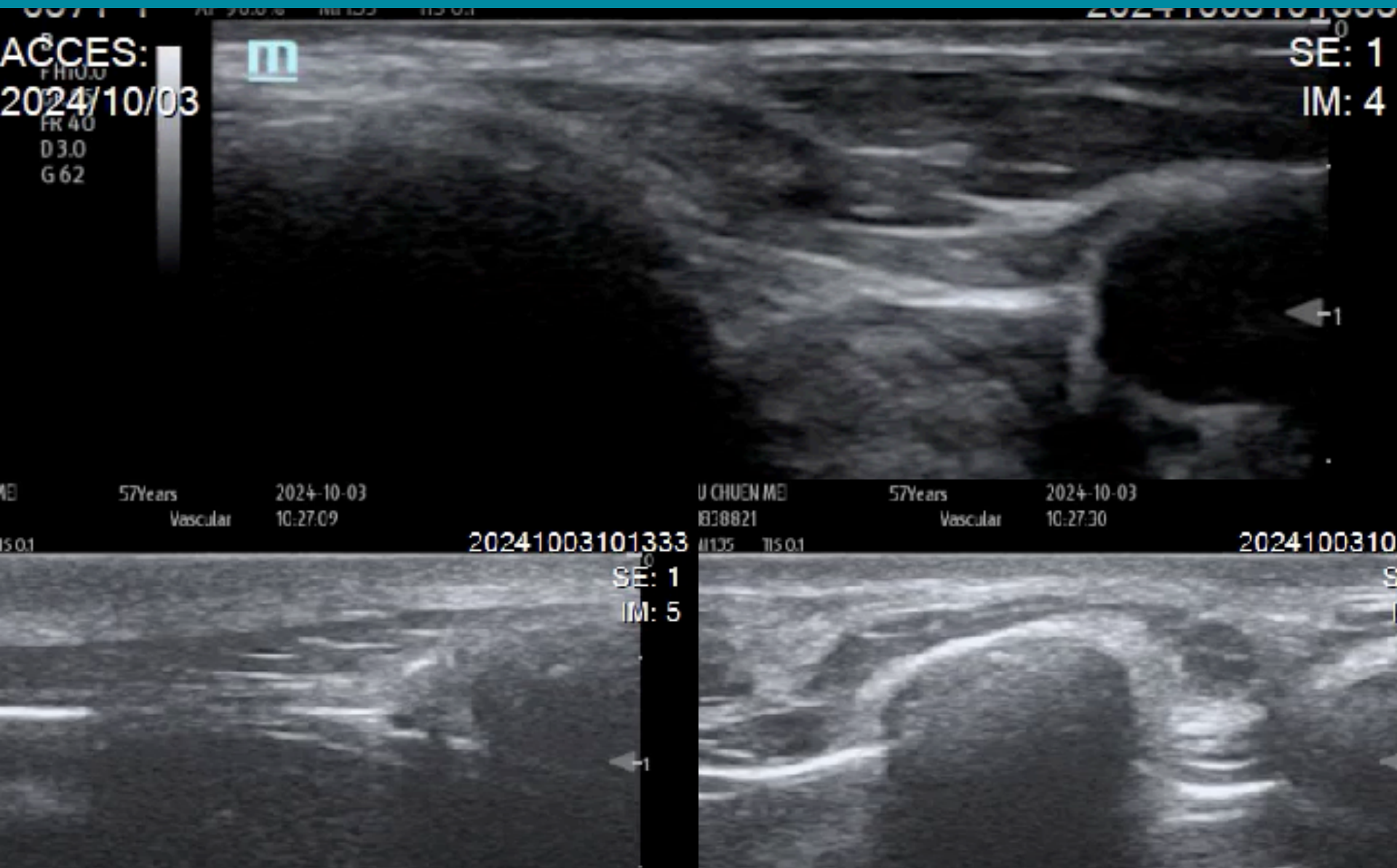
P  
G  
K  
1.8 3.6

# 57F, witnessed collapse while eating



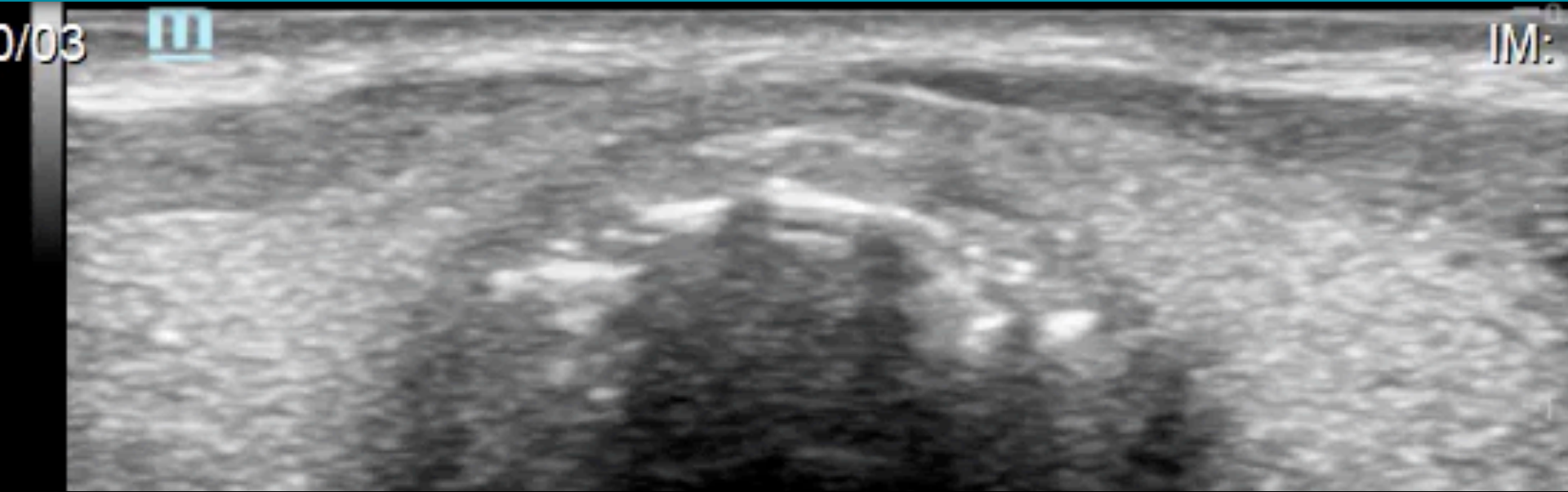


# One lung intubation ?

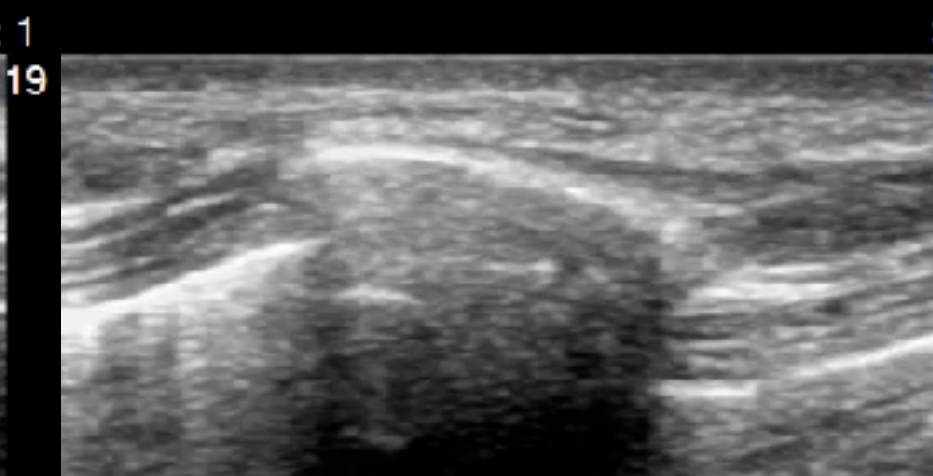
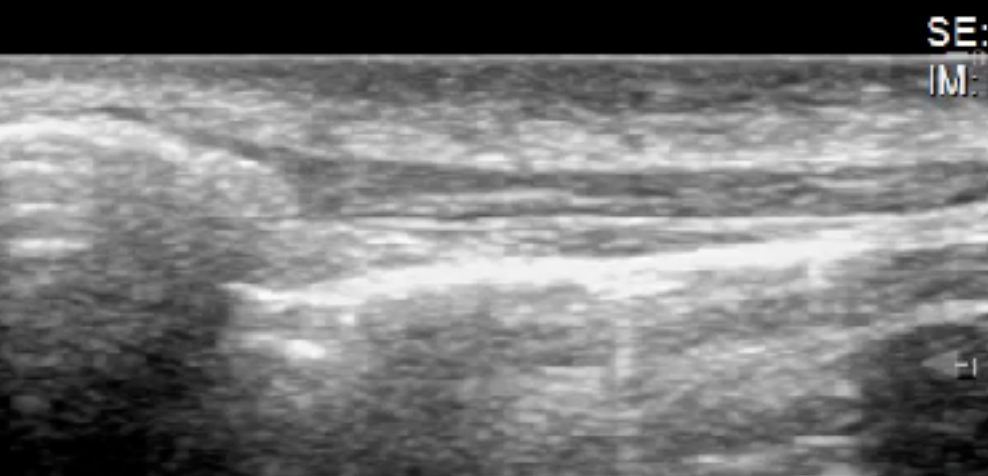




# Exchange larger ETT



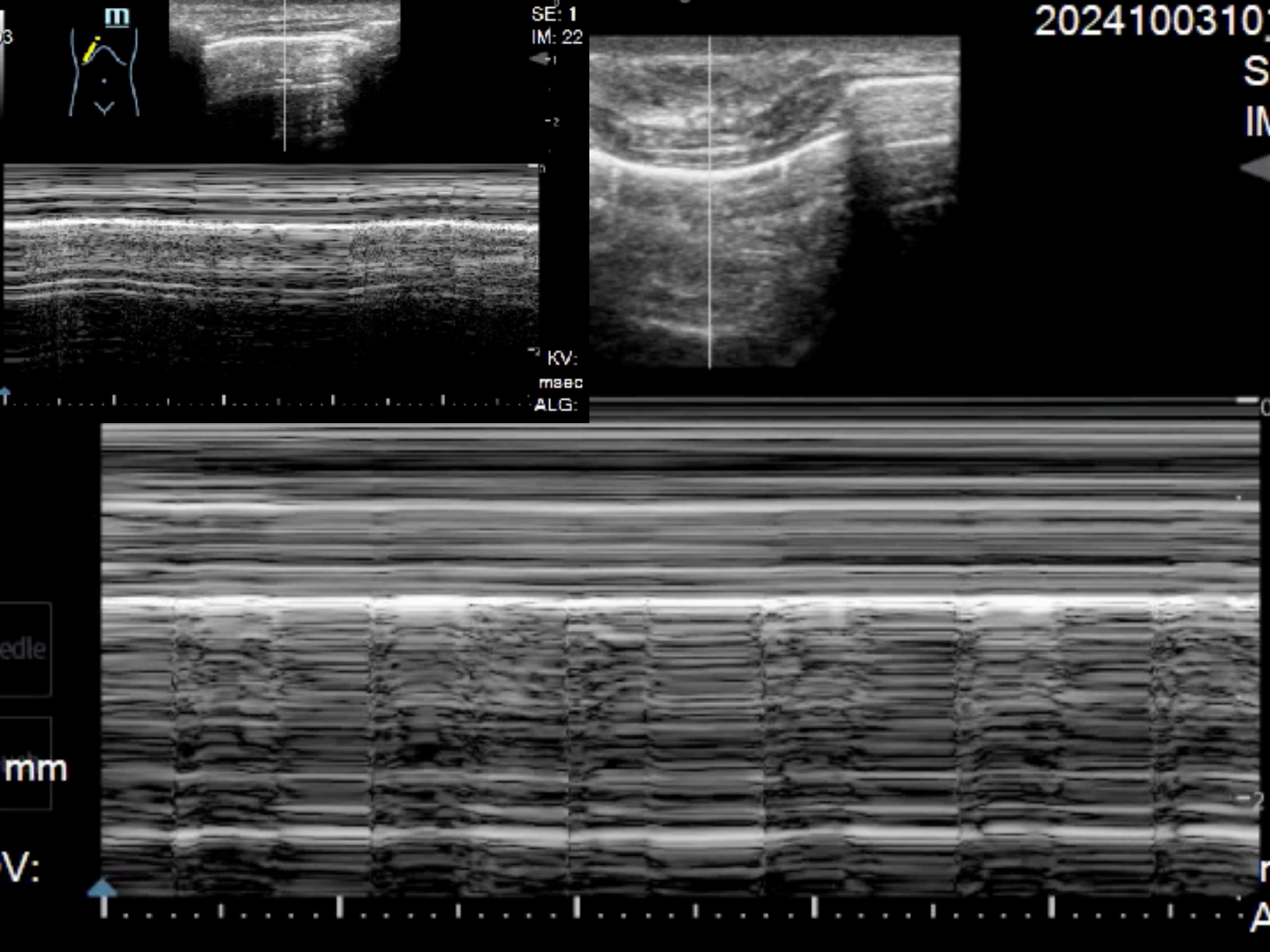
MEI 57years 2024-10-03 MEI 57years 2024-10-03  
821 Lung 10:42:21 Lung 10:42:48  
5 TSC3 20241003101333 1503 20241003101333



SE: 1  
IM: 22

← 1  
-2

KV:  
masc  
ALG:

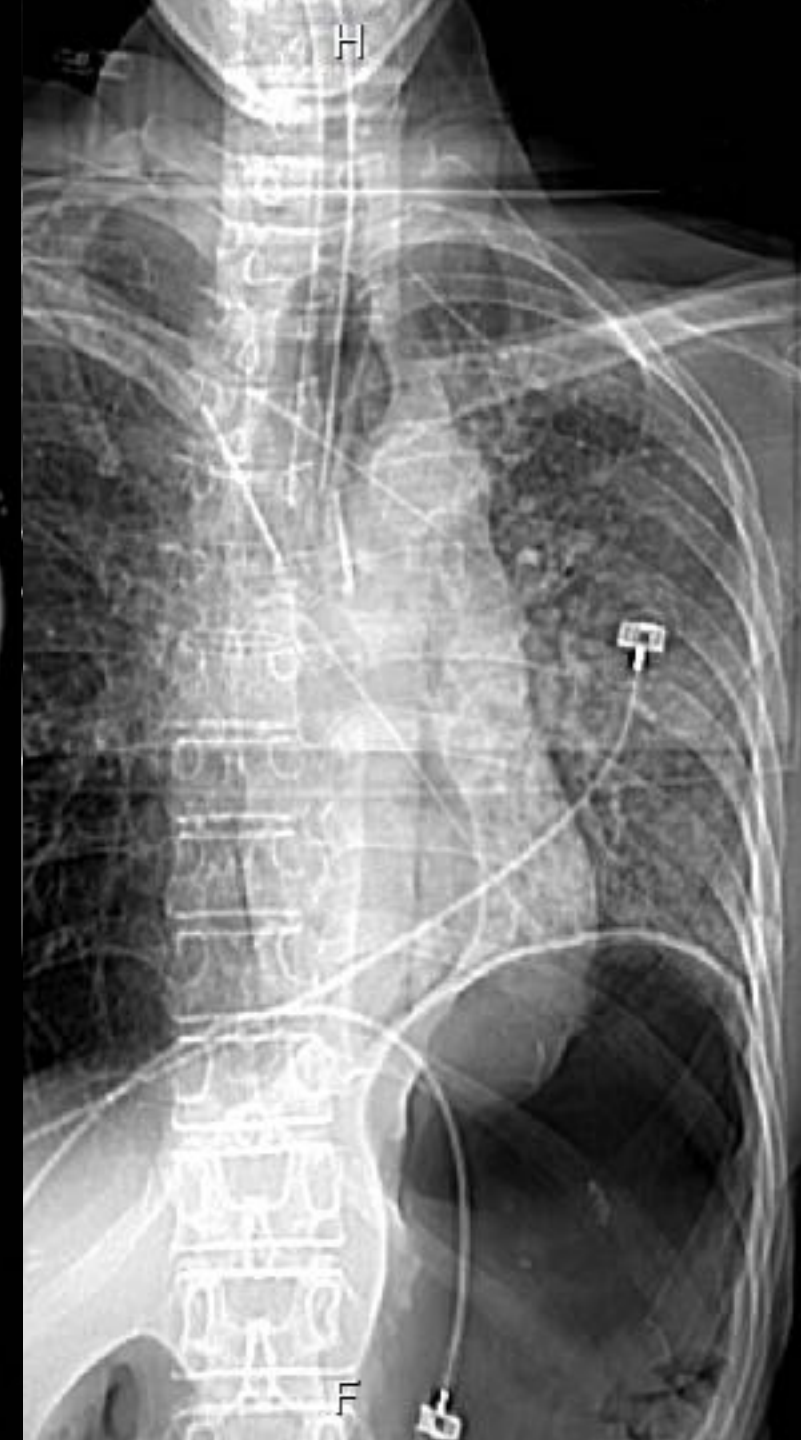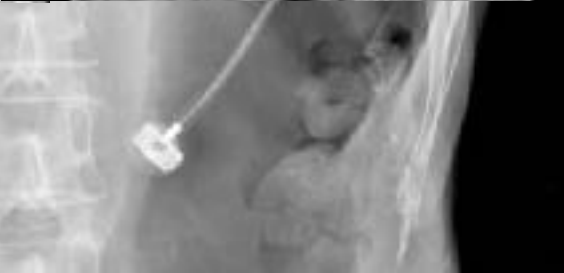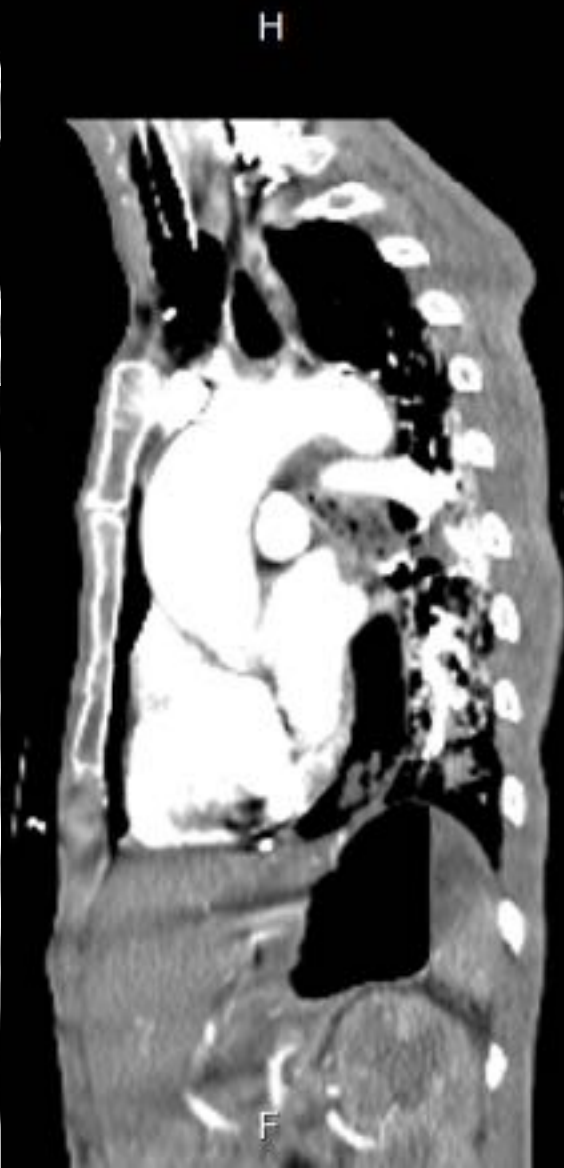
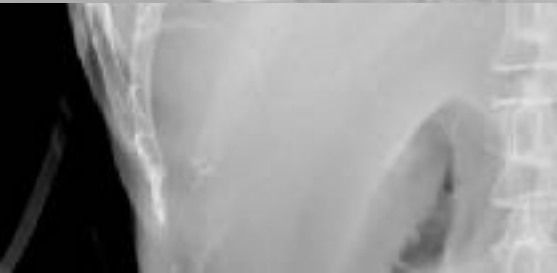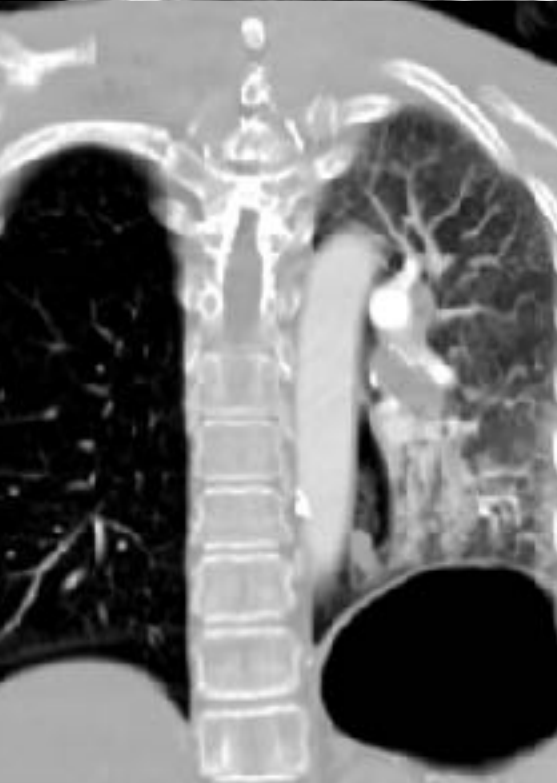


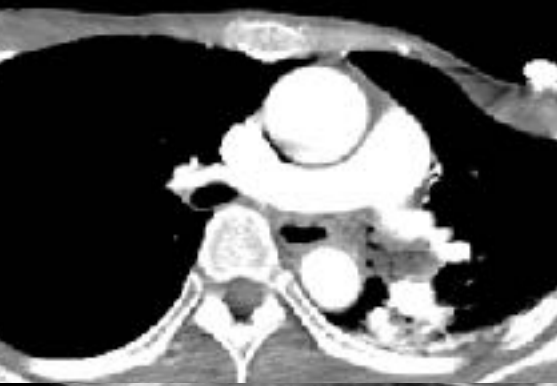edle


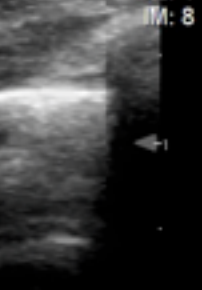
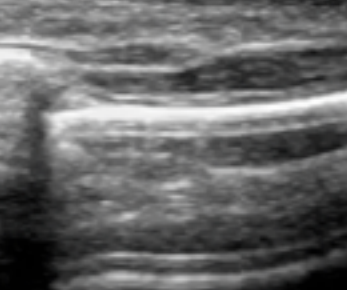
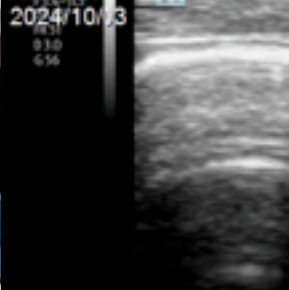


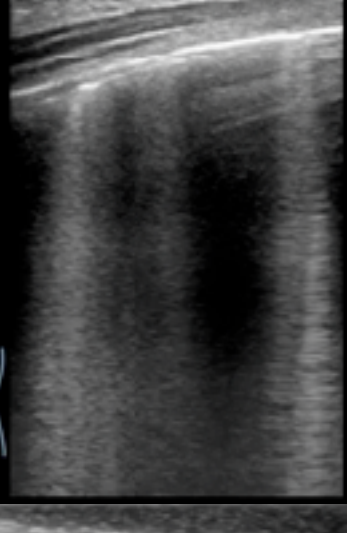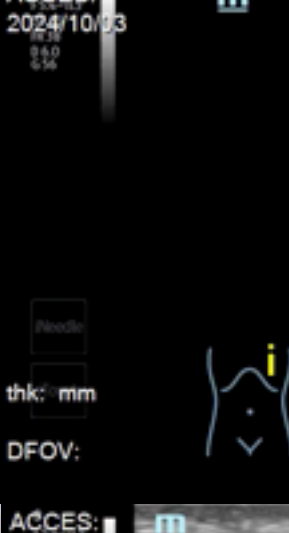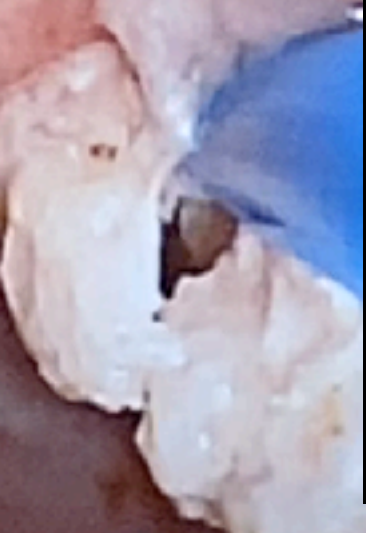
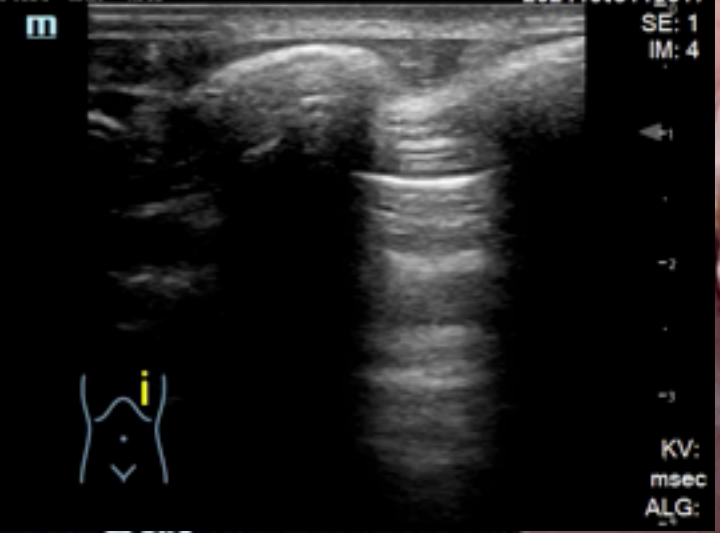

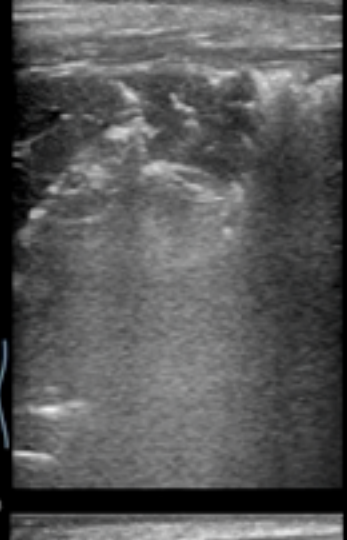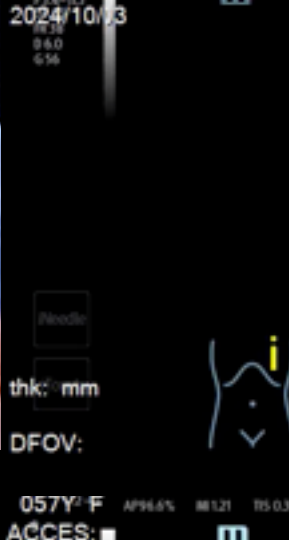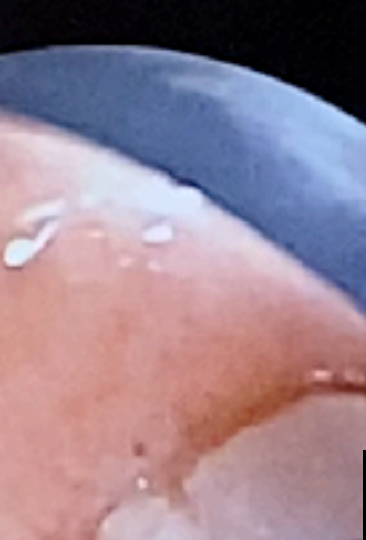
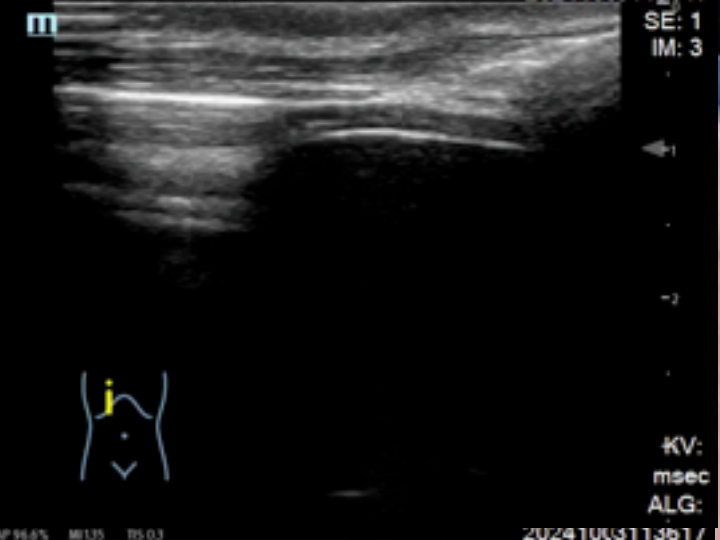
mm

V:

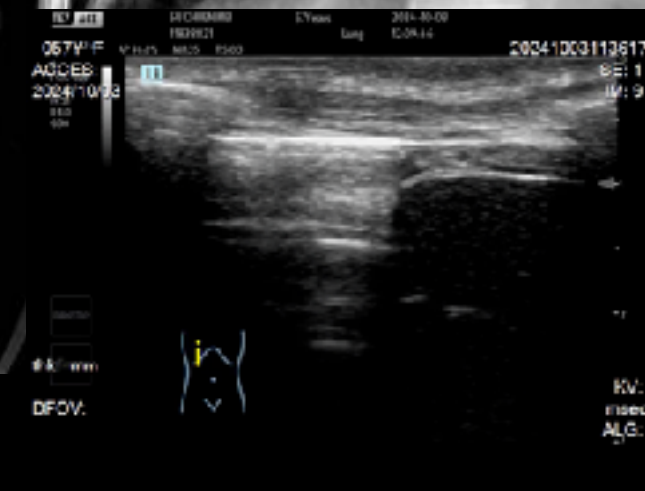
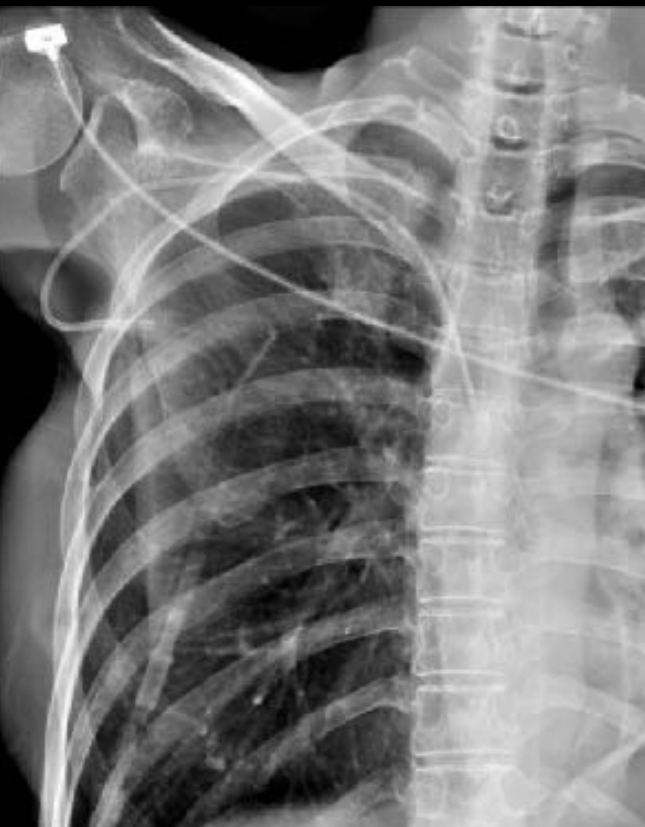r  
A





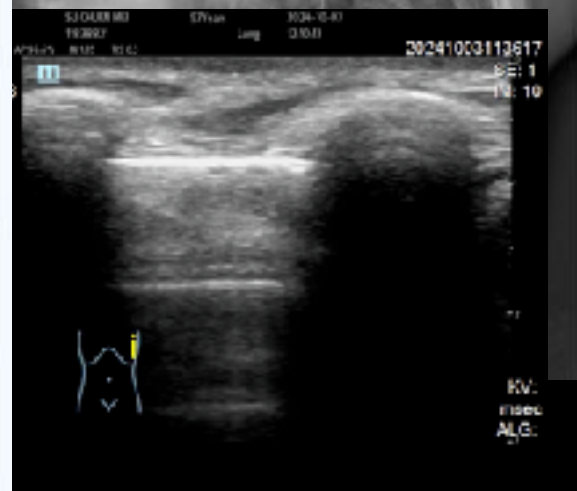
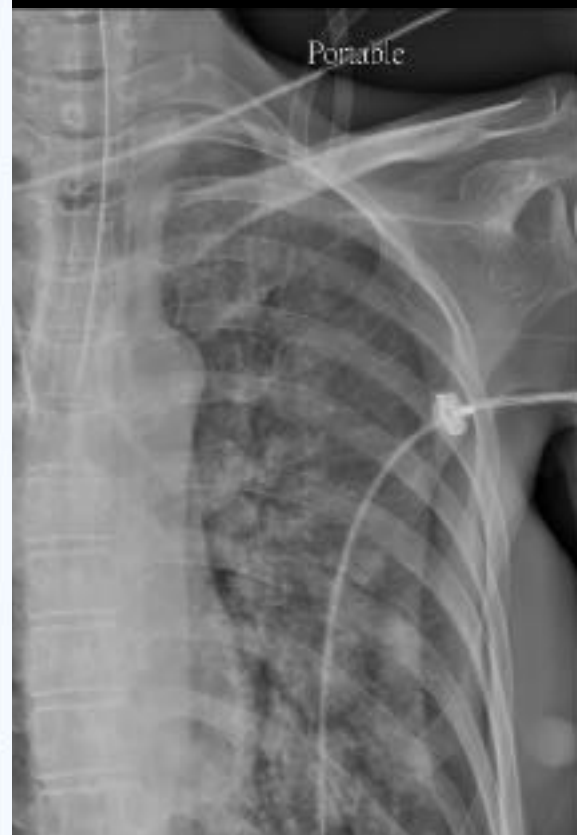


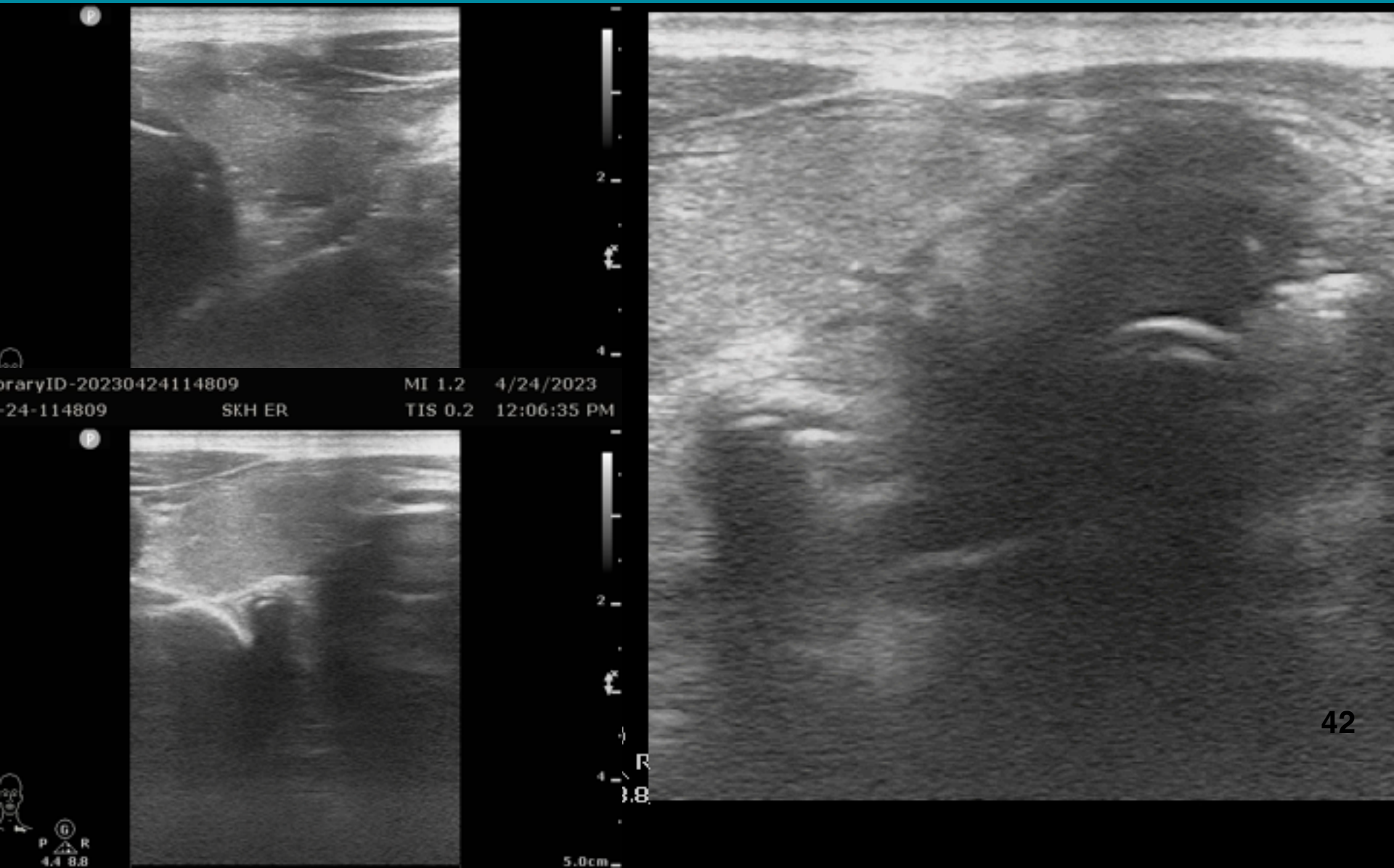


Profile Lab Image

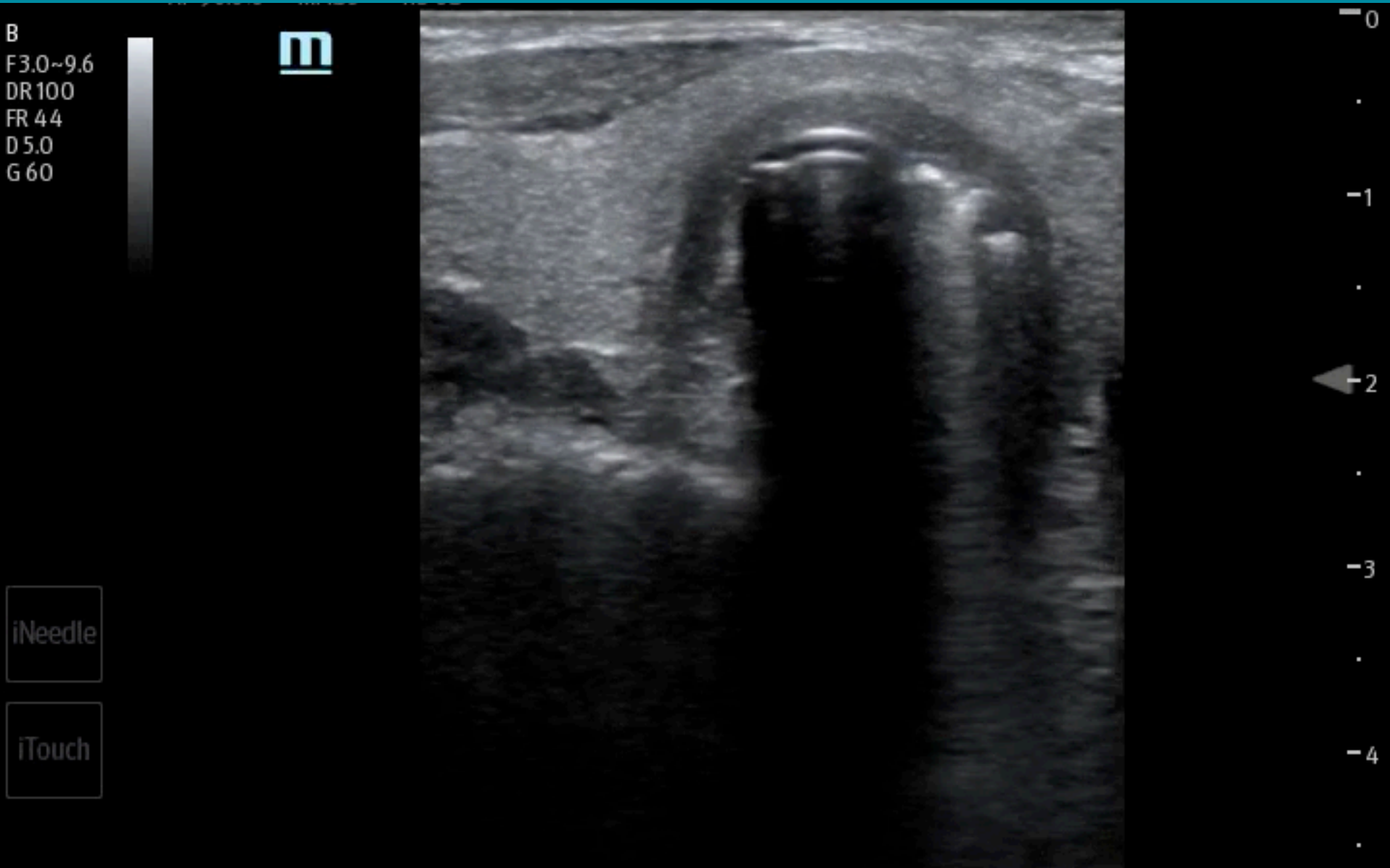
0.0-26.2	10/03	07/16
<b>Blood gas pH</b> 7.340-7.450	6.747	
	7.159	
	7.520	
<b>pCO2 (mmhg)</b> 32.0-45.0	136.2	
	47.5	
	19.8	
<b>pO2 (mmhg)</b> 75.0-100.0	104.7	
	22.1	
	407.5	
<b>tHb (g/dl)</b> 12.0-16.0	13.7	
	13.2	
	14.9	
<b>O2Iib (%)</b>	90.6	
	30.6	
	99.7	
<b>sO2 (%)</b>	88.1	
	26.0	
	99.9	
<b>COHB (%)</b> <2.0	0.2	
	0.7	
	0.2	
<b>MetHb (%)</b>	0.3	
	0.6	
	0.1	
<b>HCO3 (mmol/l)</b> 20.0-26.0	18.3	
	16.5	
	15.8	



# Secretion enhanced ETT visulization



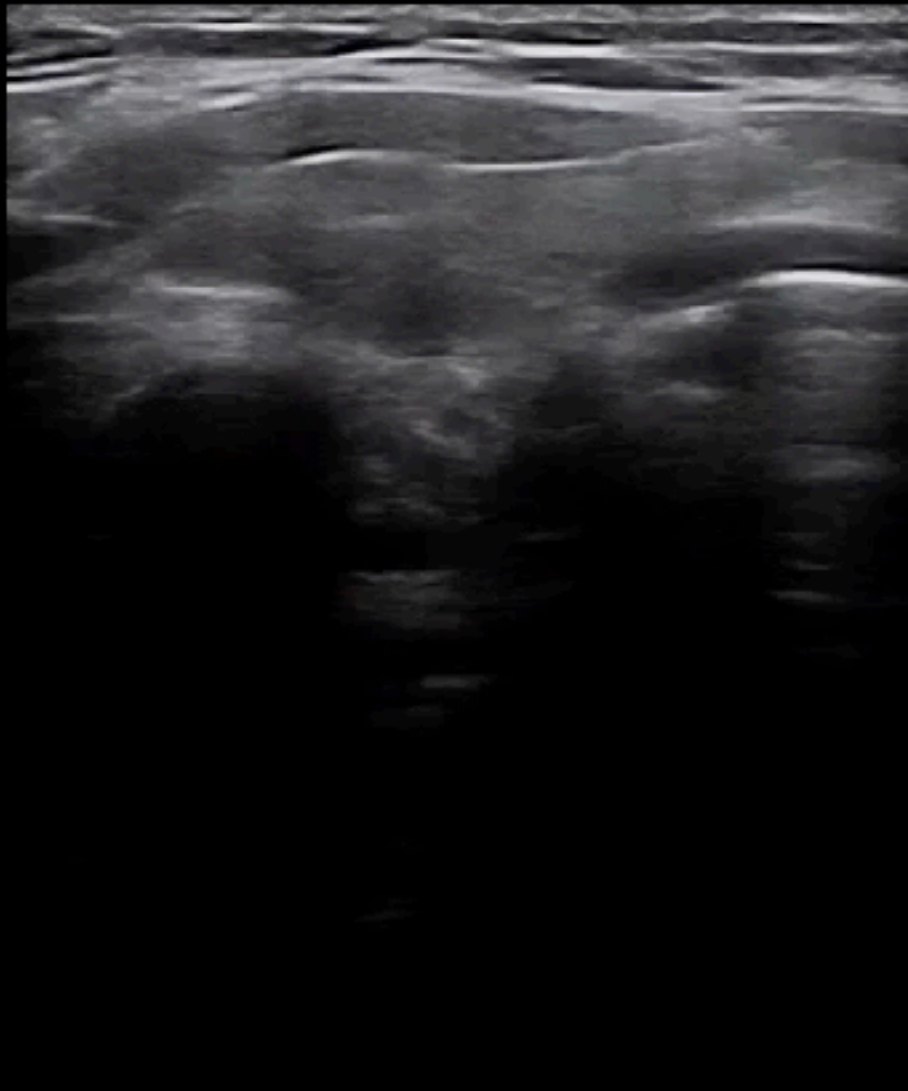# Compression enhanced ETT visualization



# Trauma OHCA

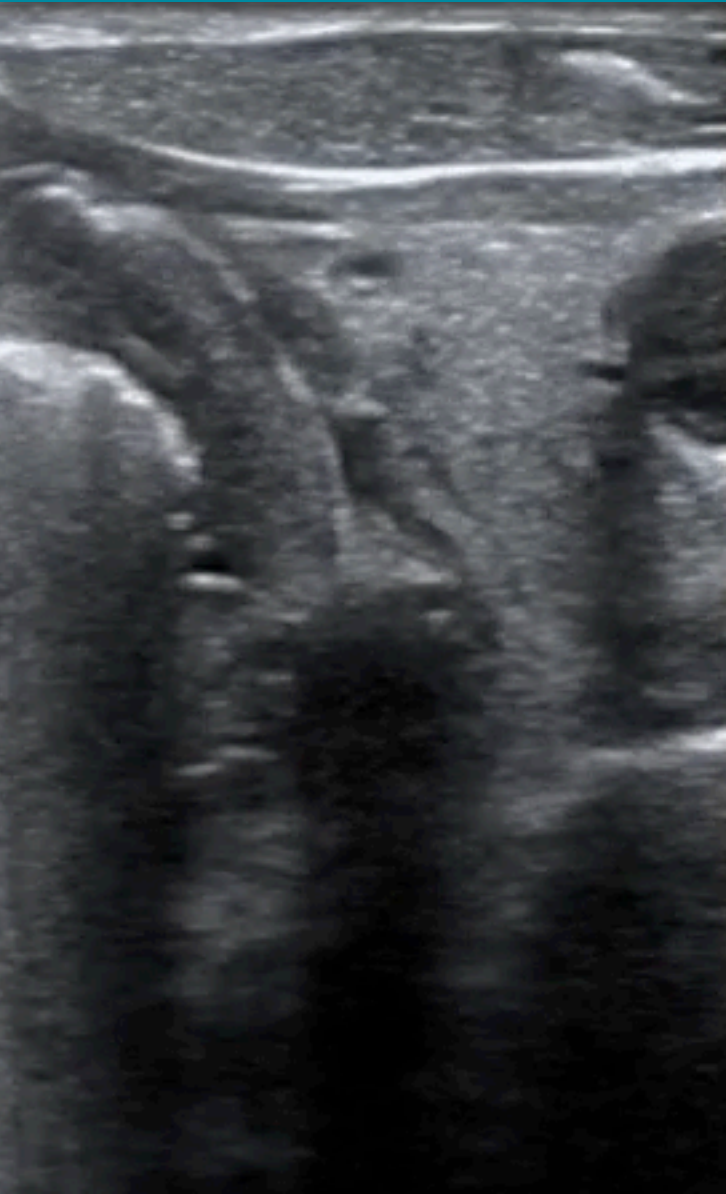

M

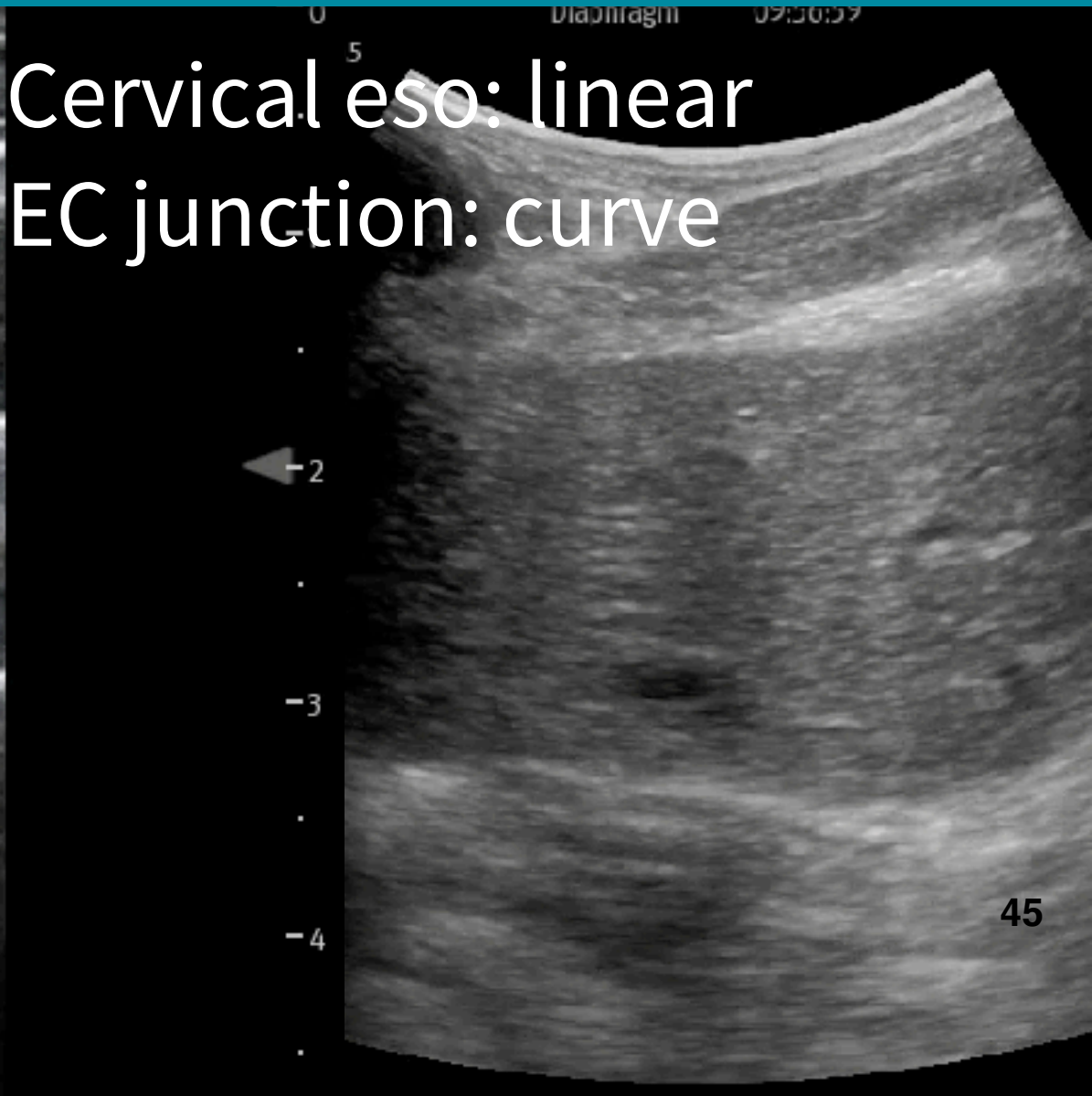




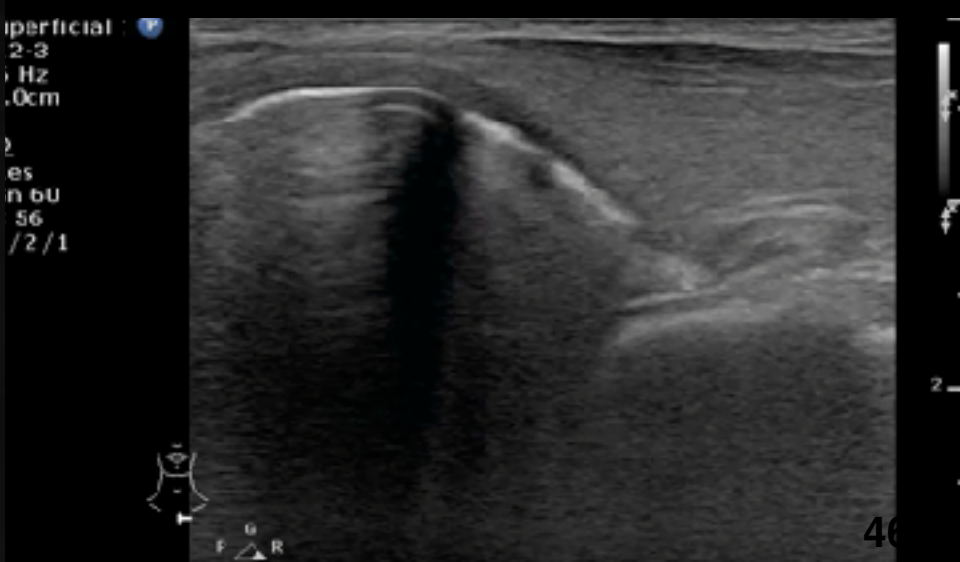
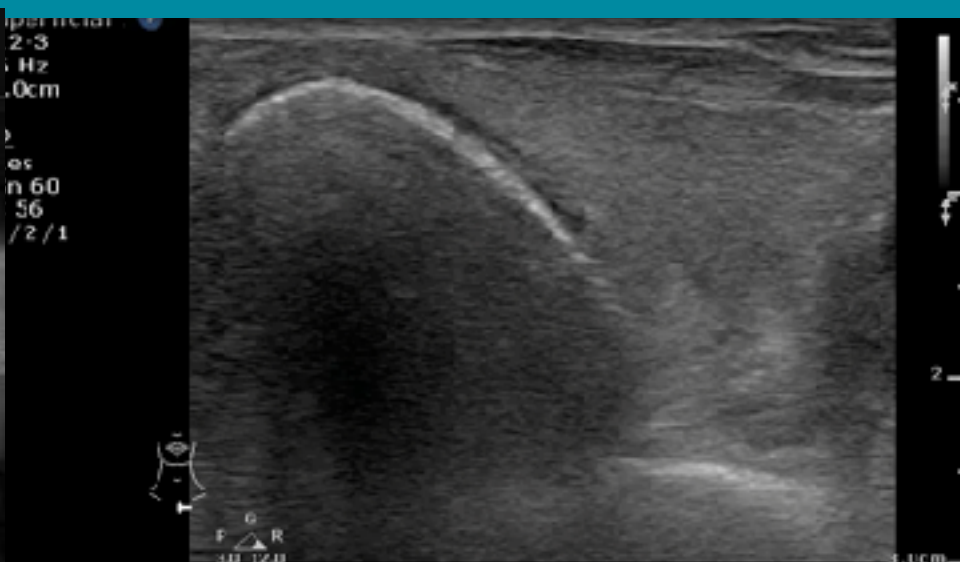
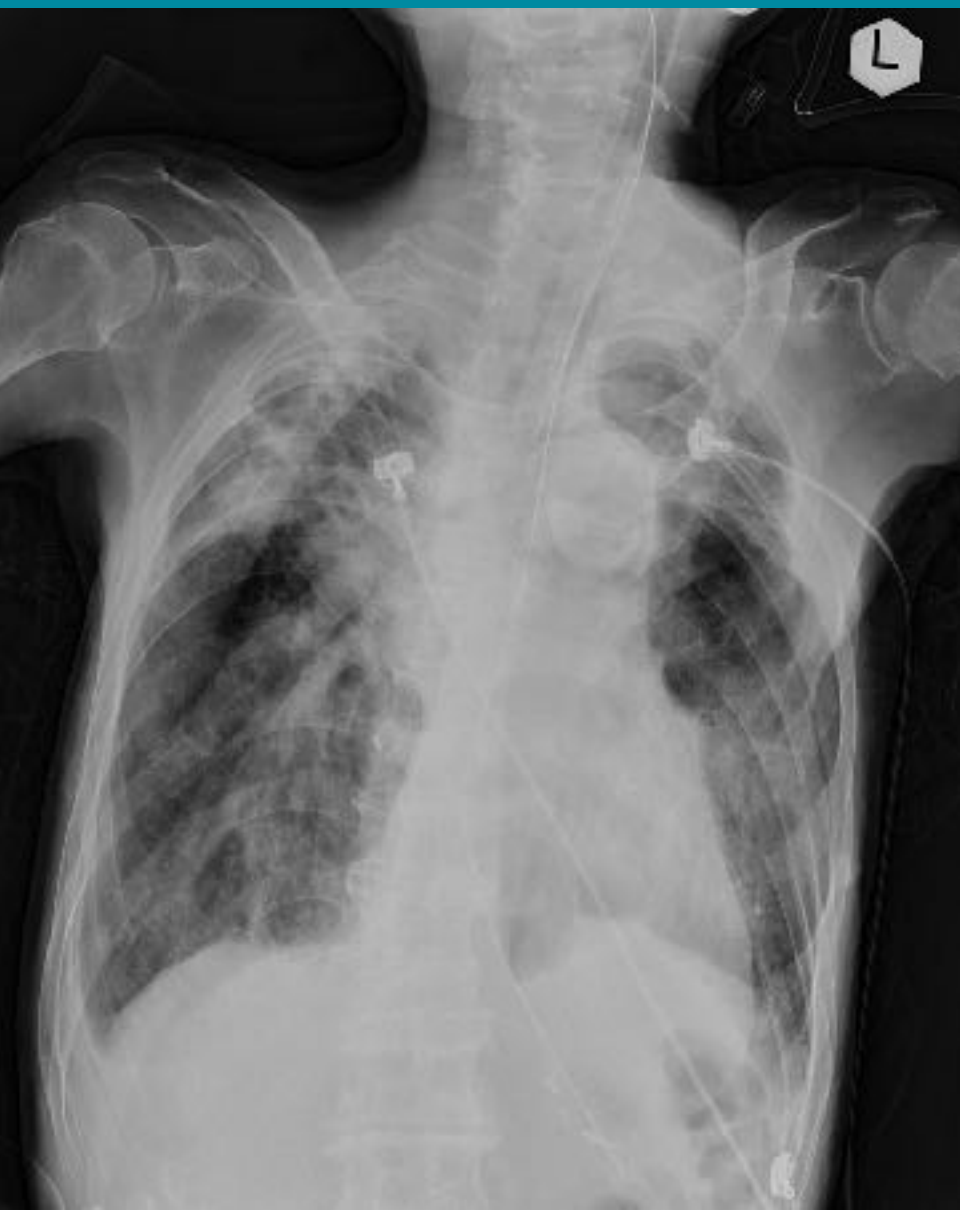# NG confirmation



Cervical eso: linear  
EC junction: curve



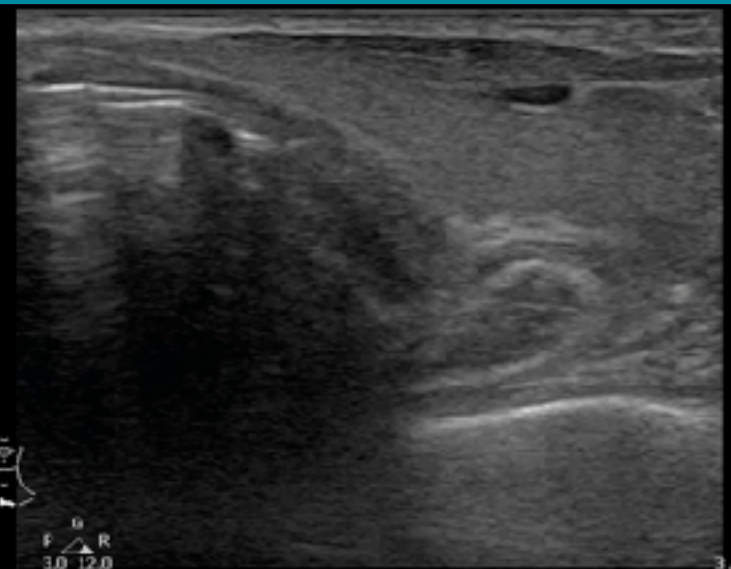
# Real time ETT confirmation



# NG confirmation

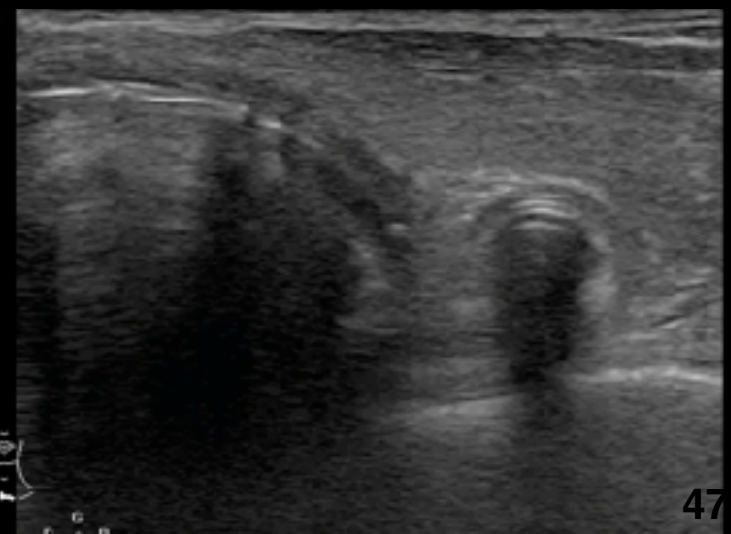


superficial :  
12-3  
5 Hz  
1.0cm  
D  
Res  
an bu  
: 56  
3/2/1



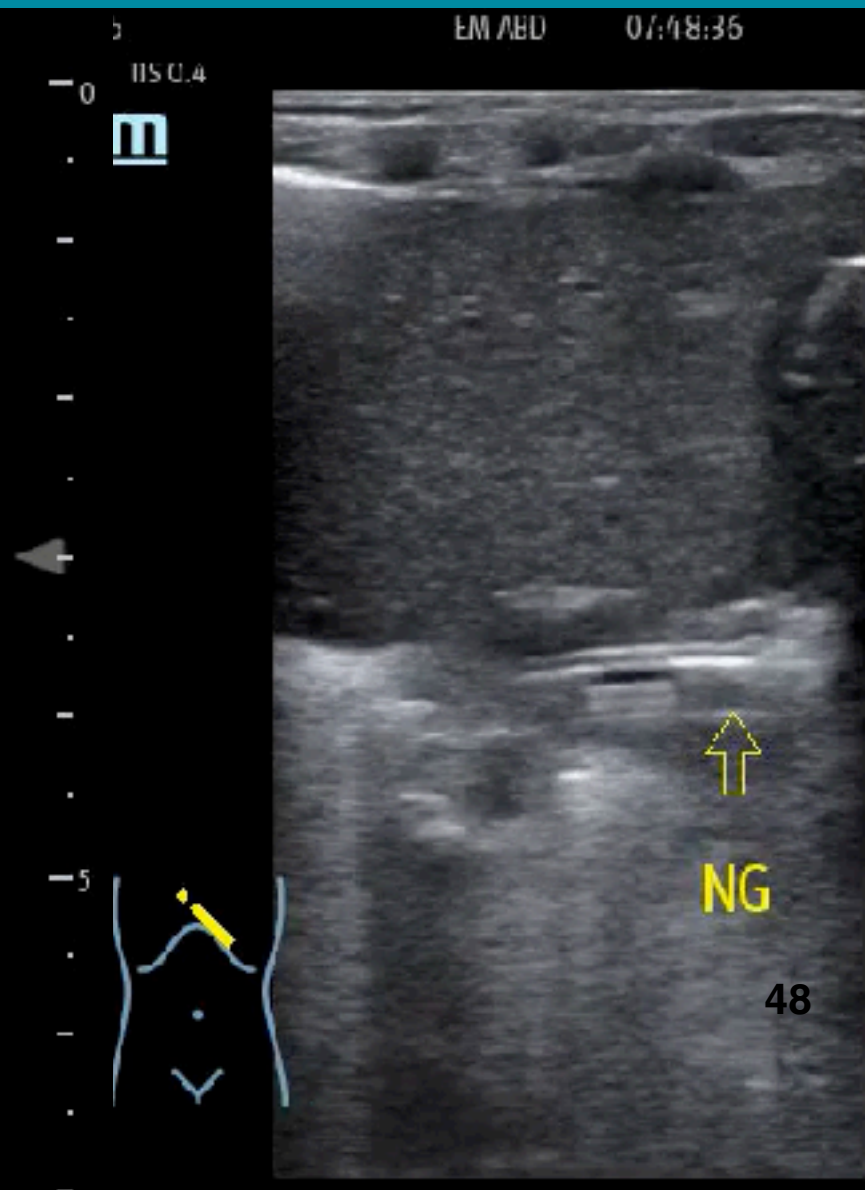
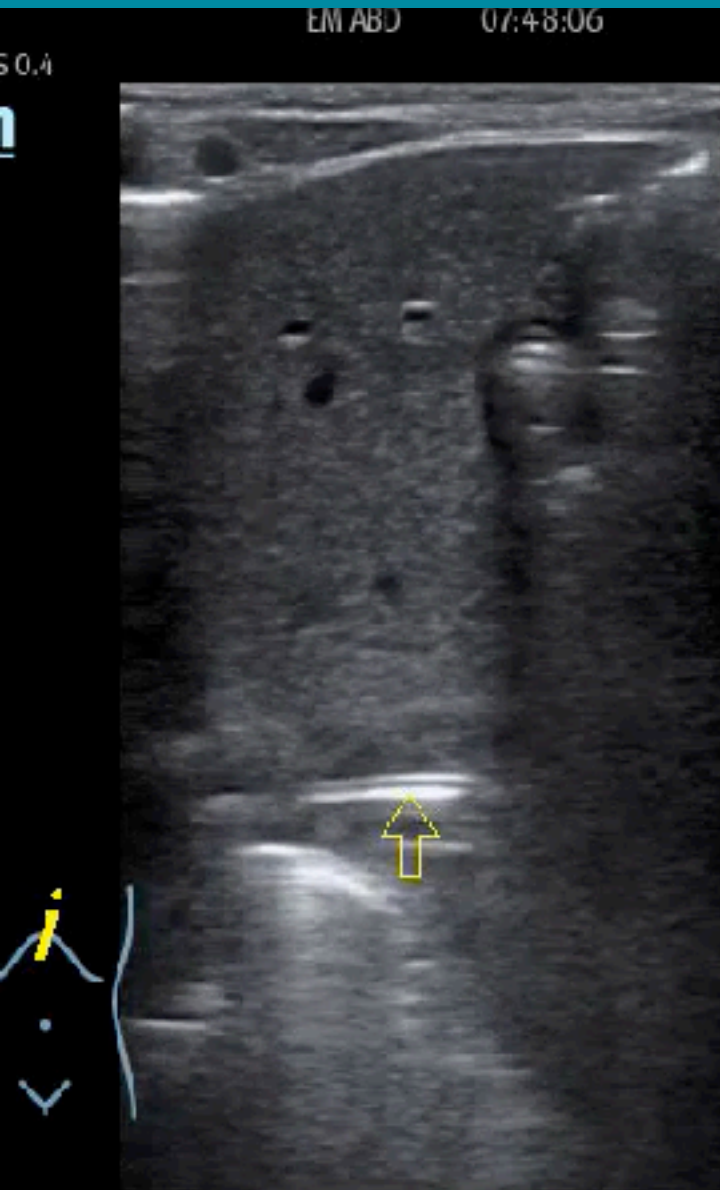F R  
3.0 12.0

superficial :  
12-3  
5 Hz  
1.0cm  
D  
Res  
an 60  
: 56  
3/2/1



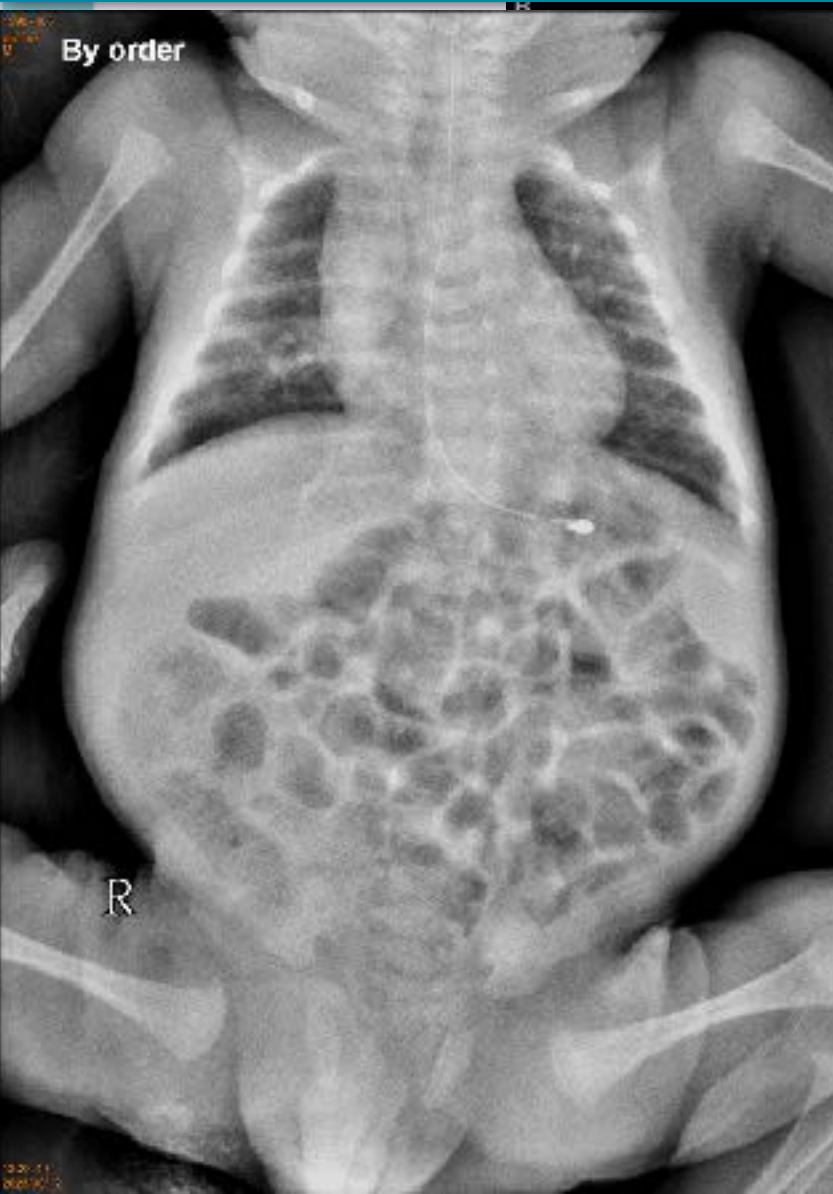

# 2 month boy , NG dislodgement

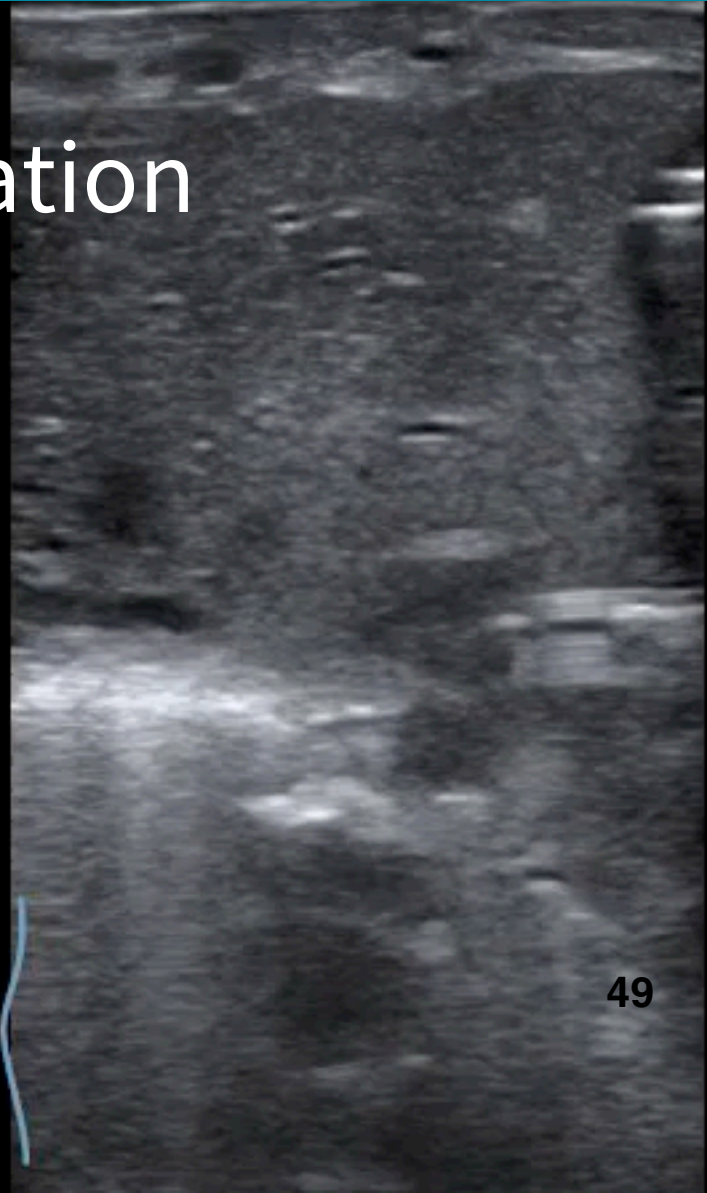



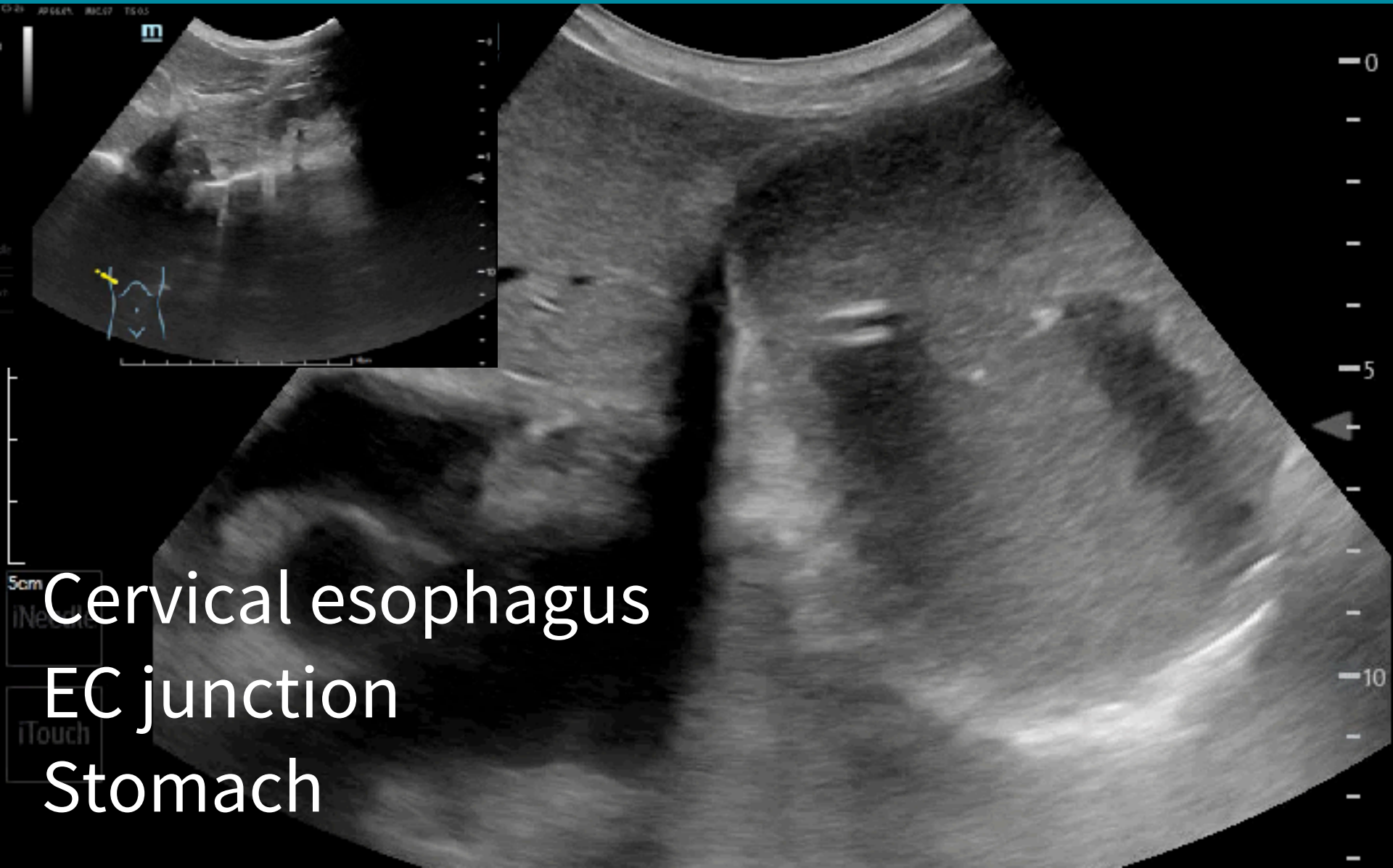
# 2 month boy , NG dislodgement 2 days later



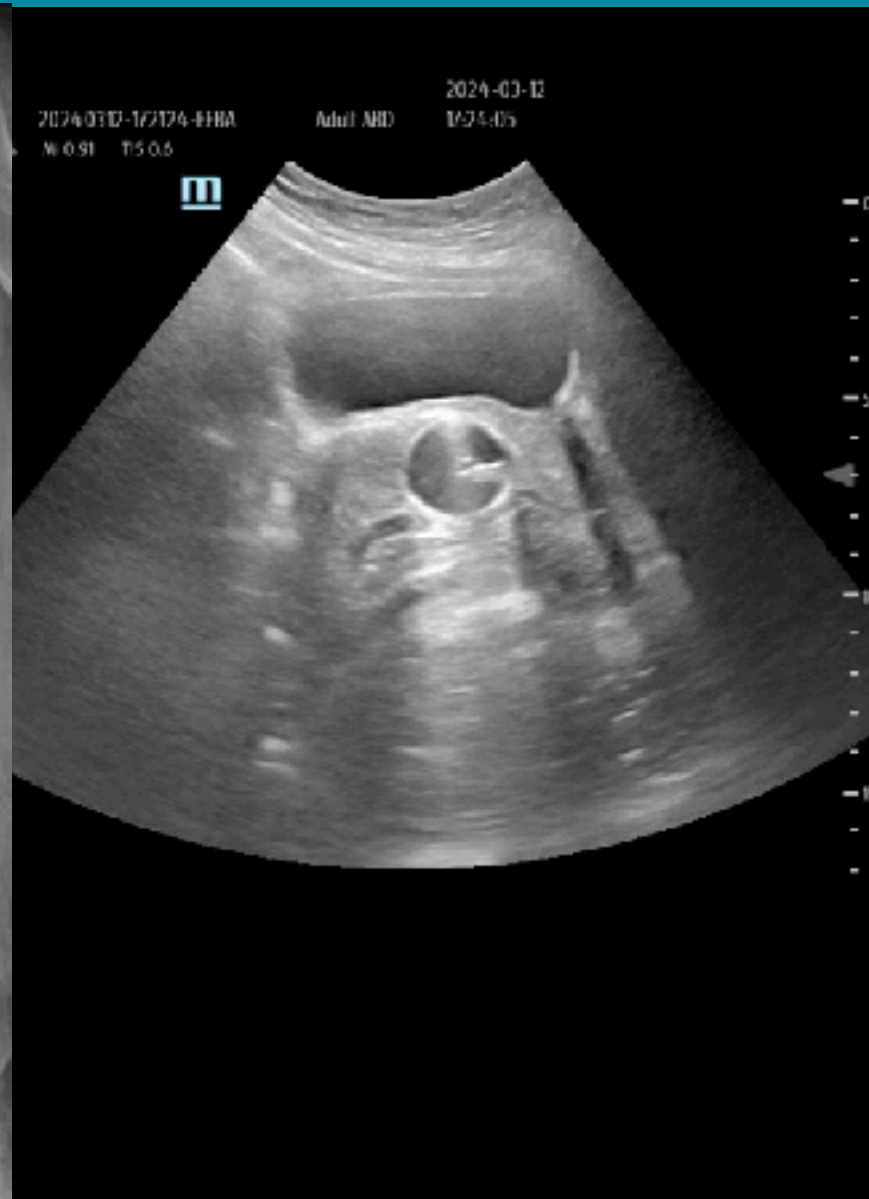
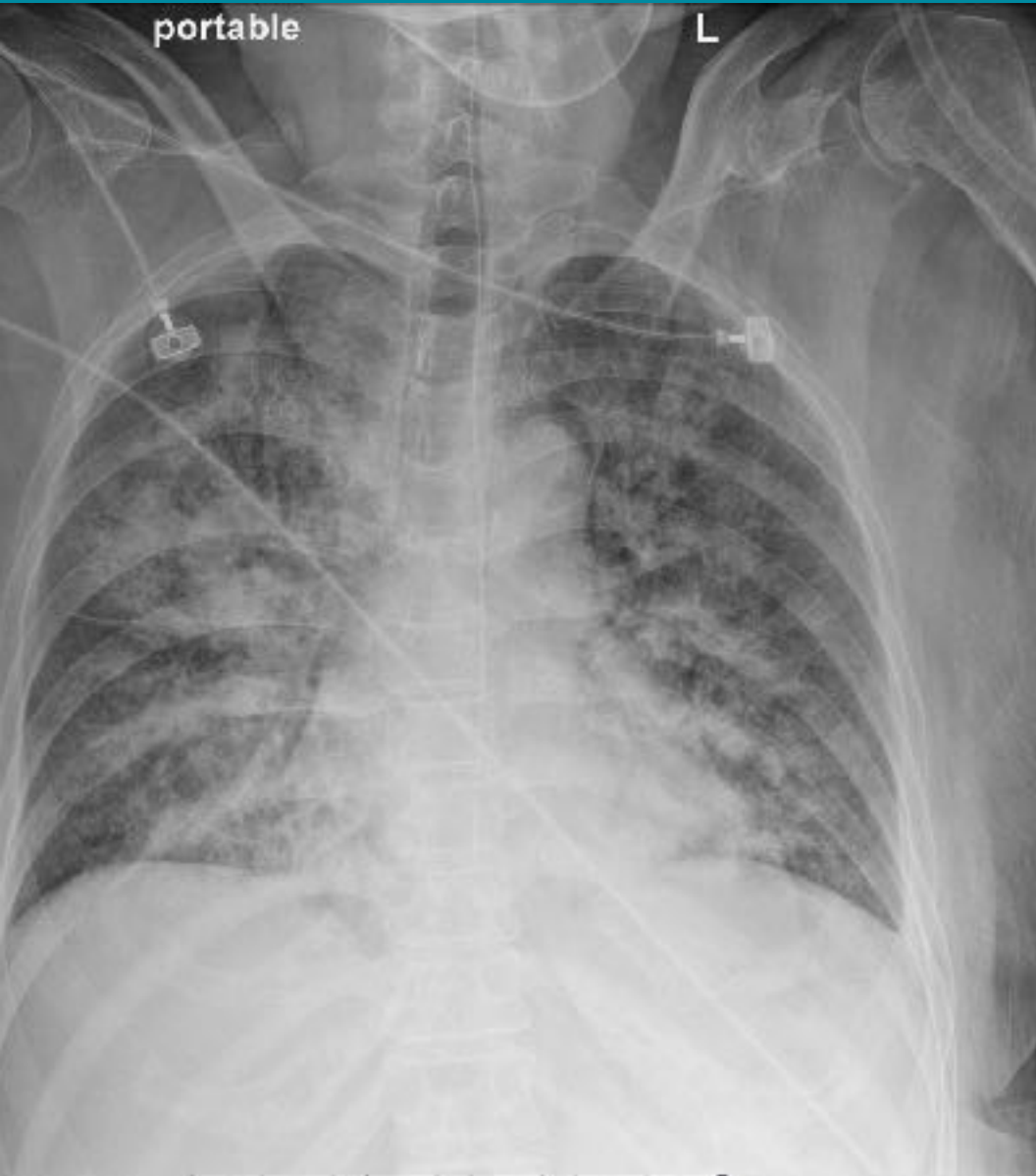Auscultation  
X-ray  
POCUS



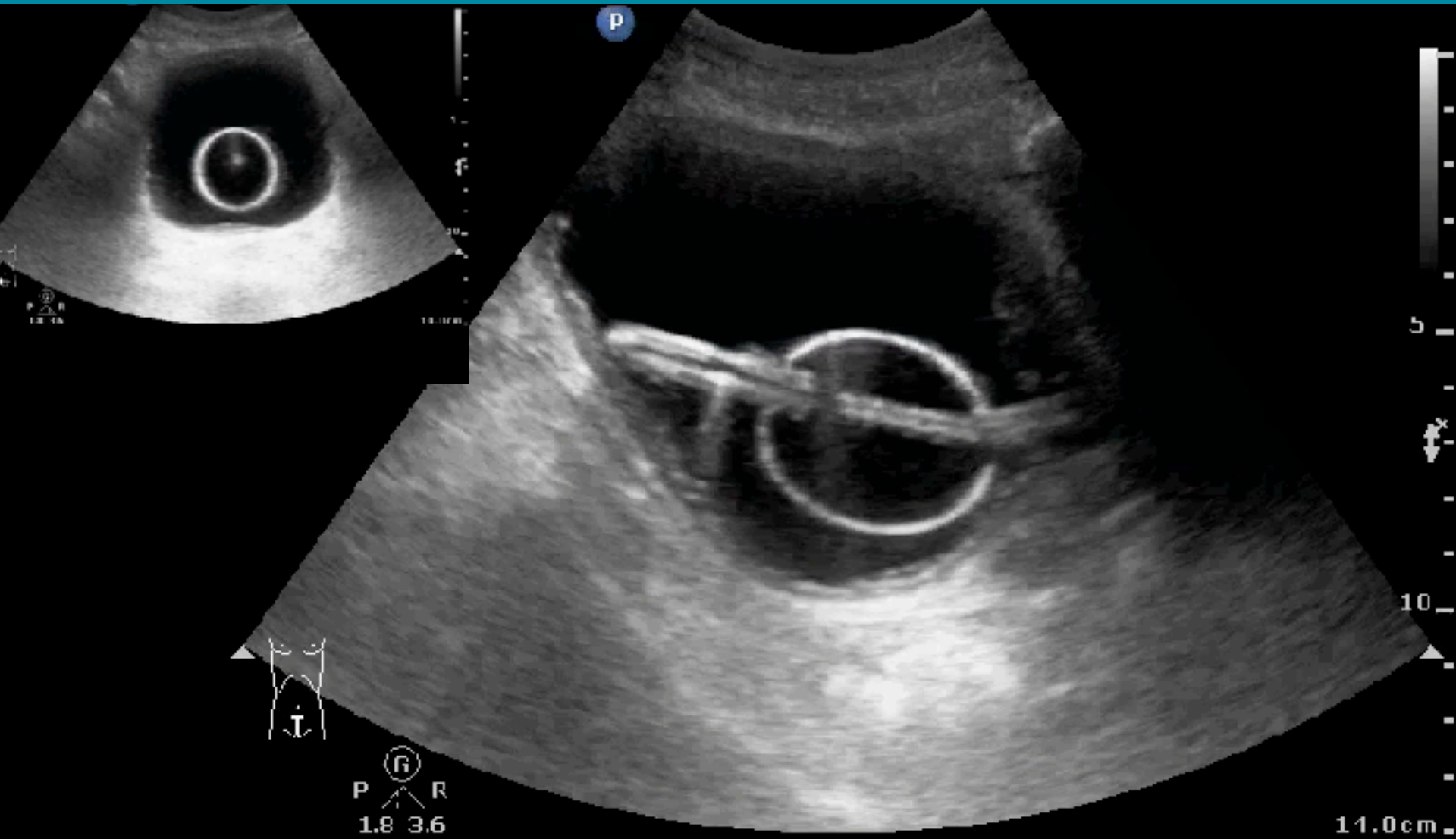
# NG tube



# 62F, PN with septic shock. Foley position ?

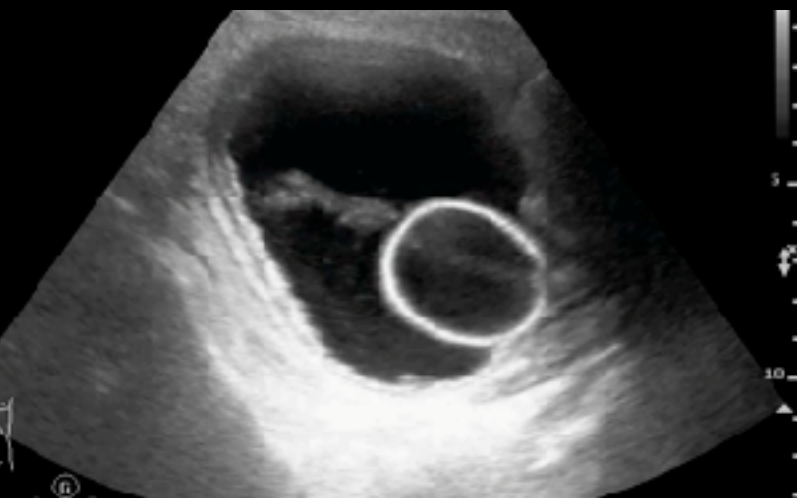
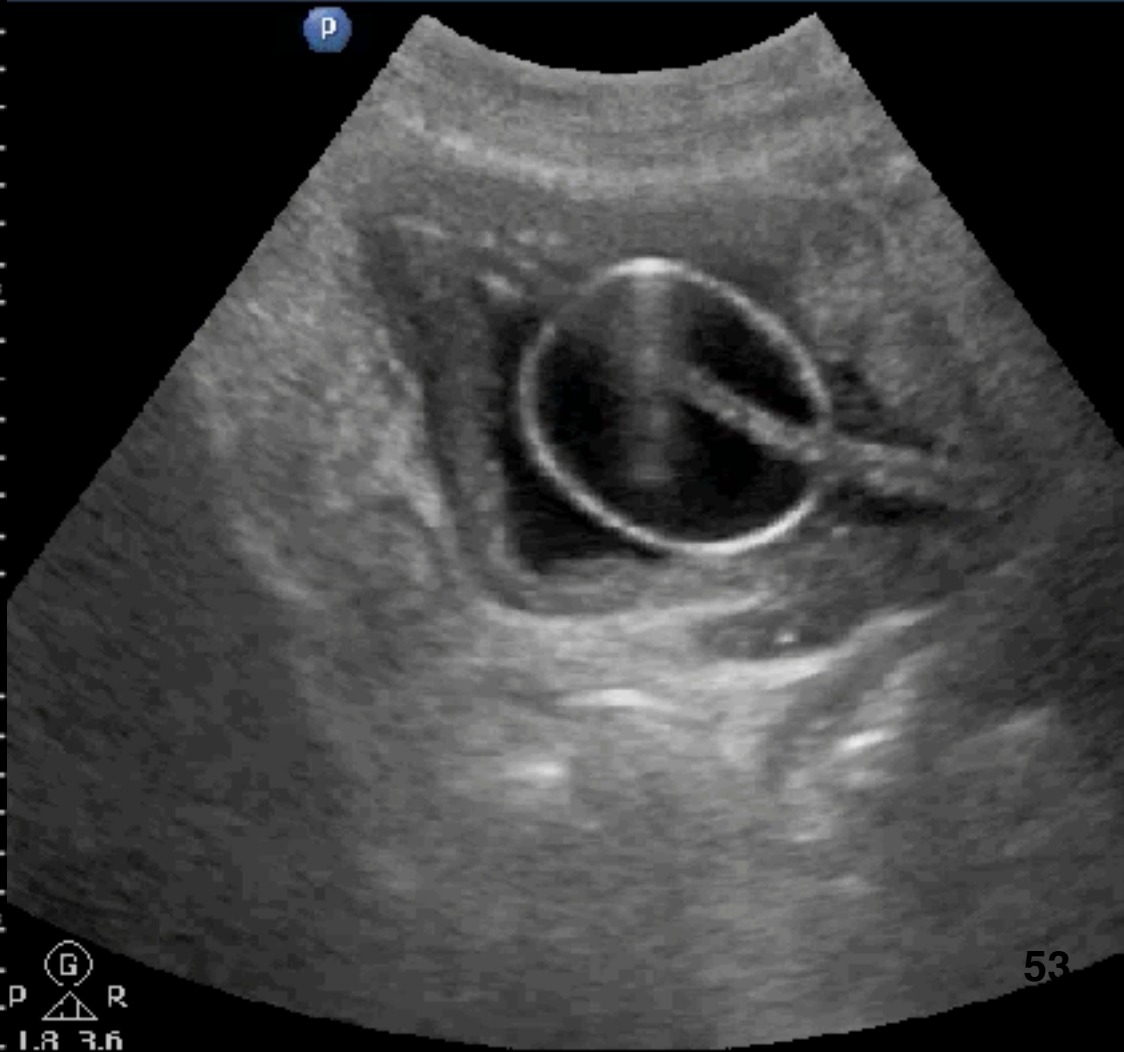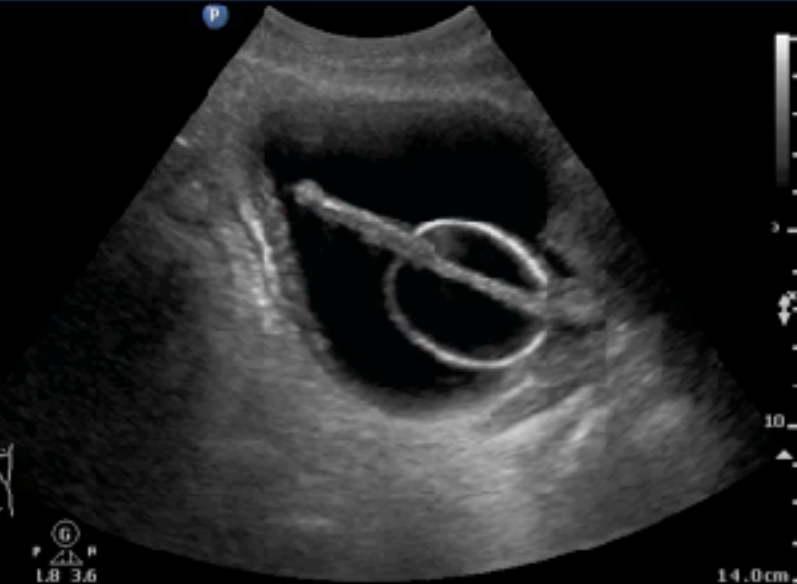


# No urine output

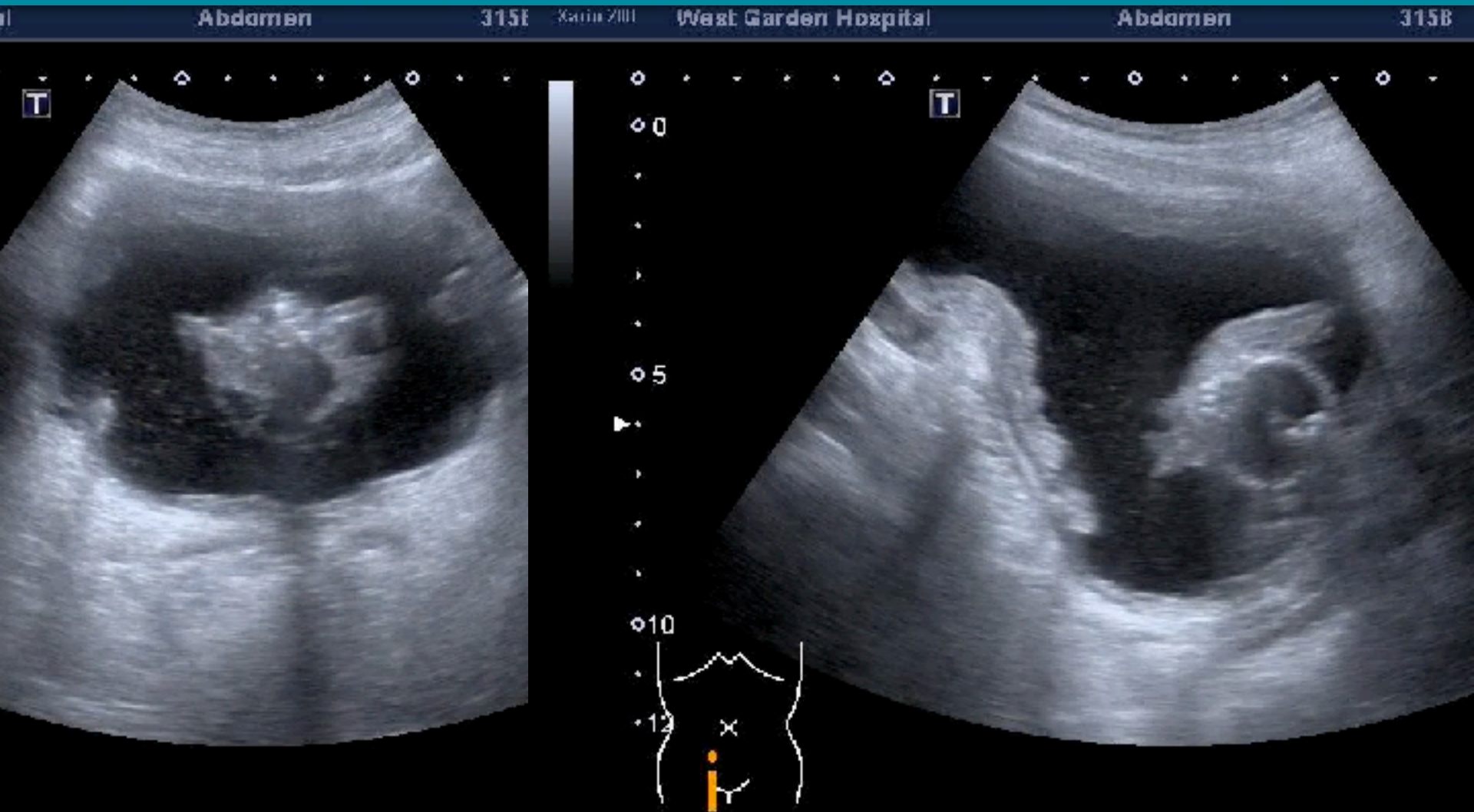




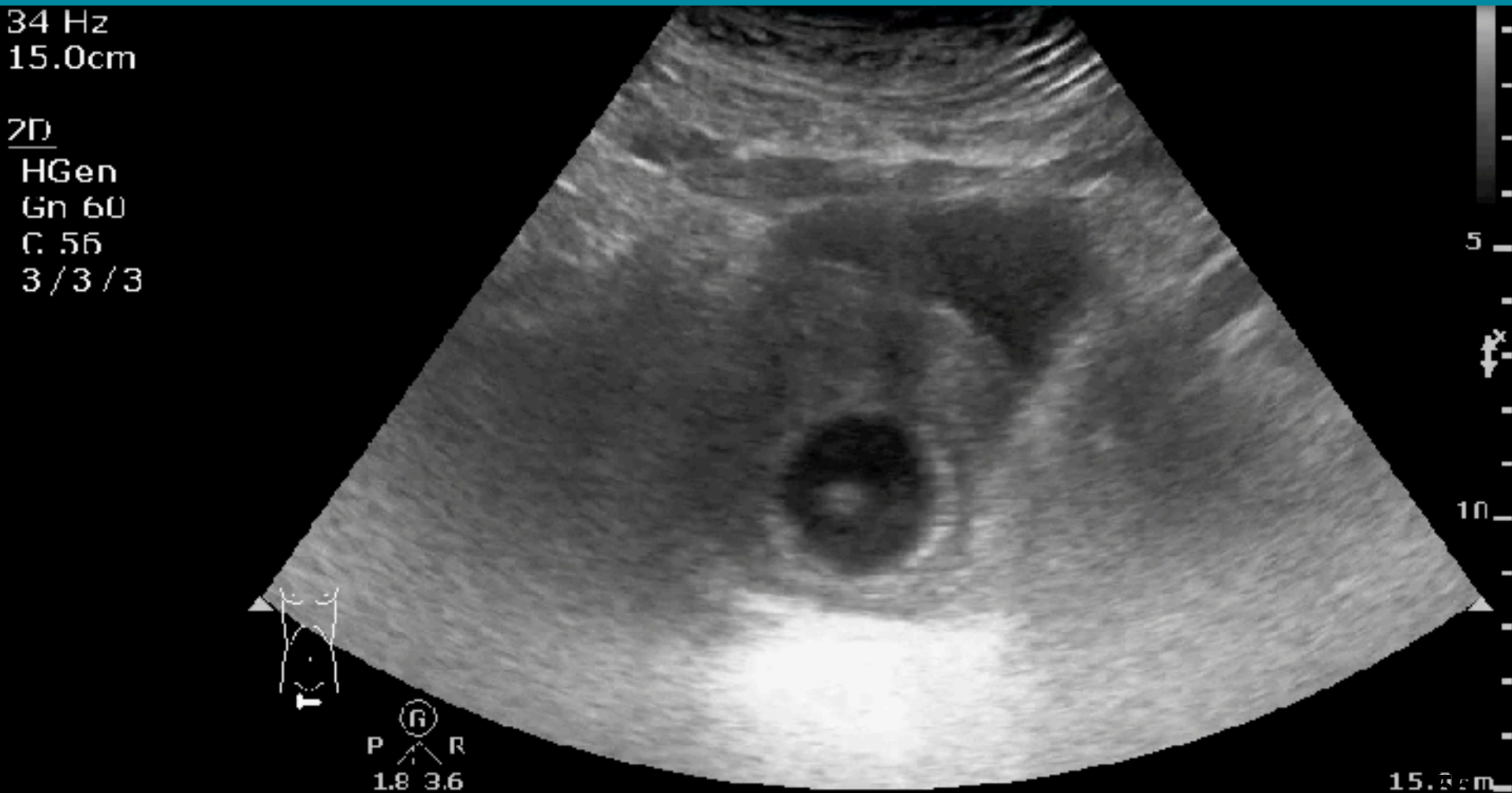
# Irrigation



# AUR due to Foley obstruction



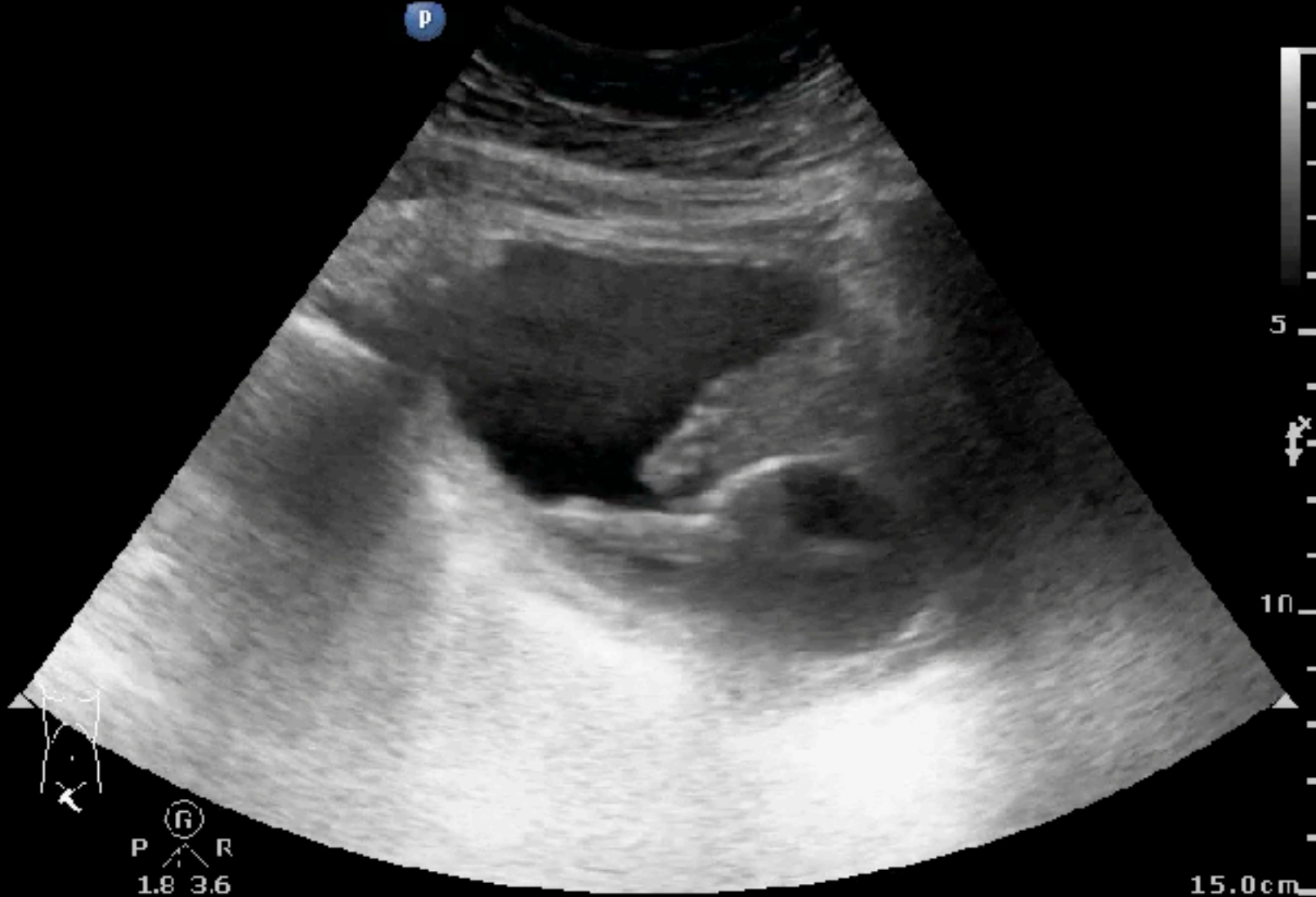# 41M, No urine output



# 41M, No urine output

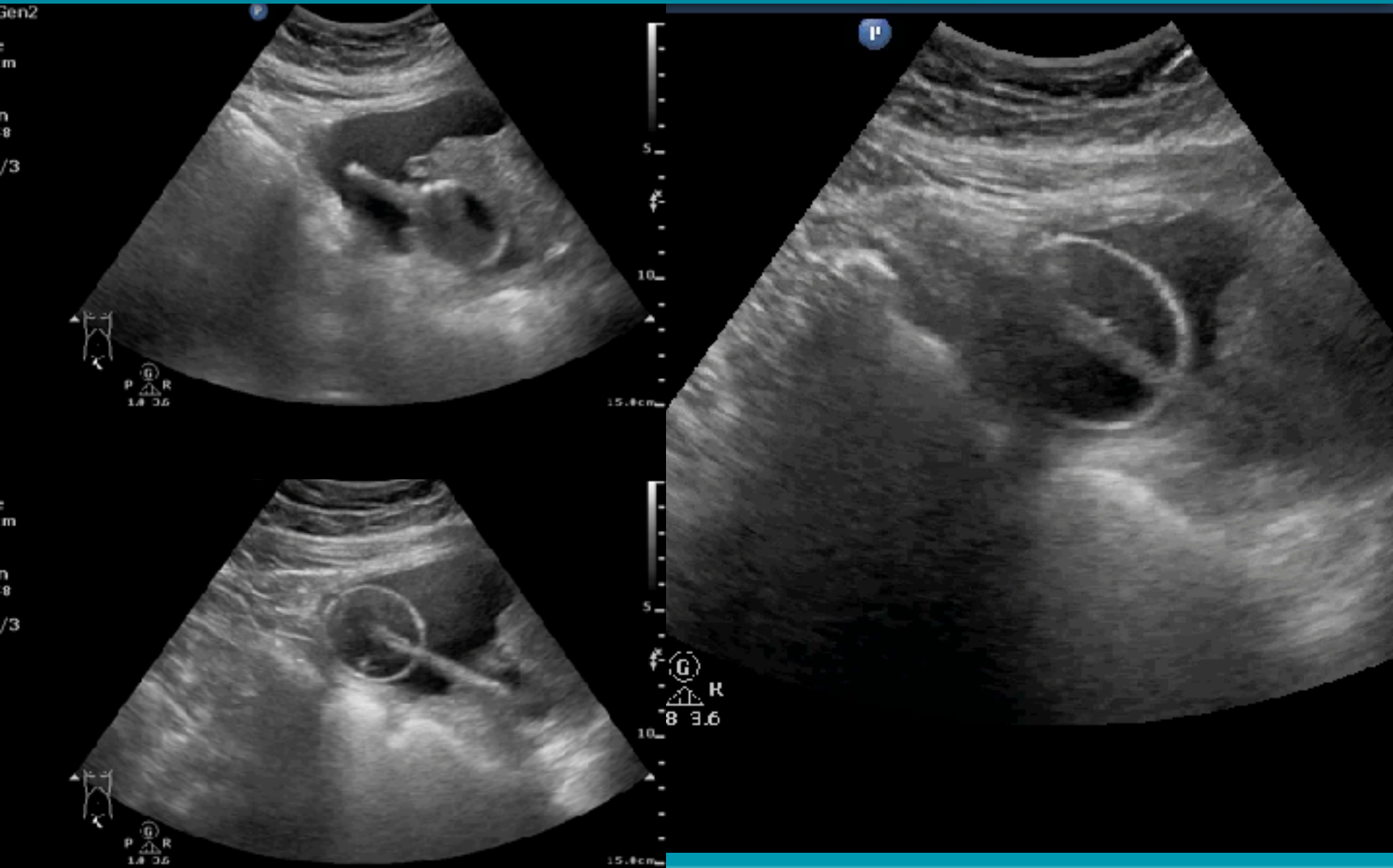
Abd Gen2  
C5-1  
34 Hz  
15.0cm

2D  
HGen  
Gn 60  
C. 56  
3/3/3

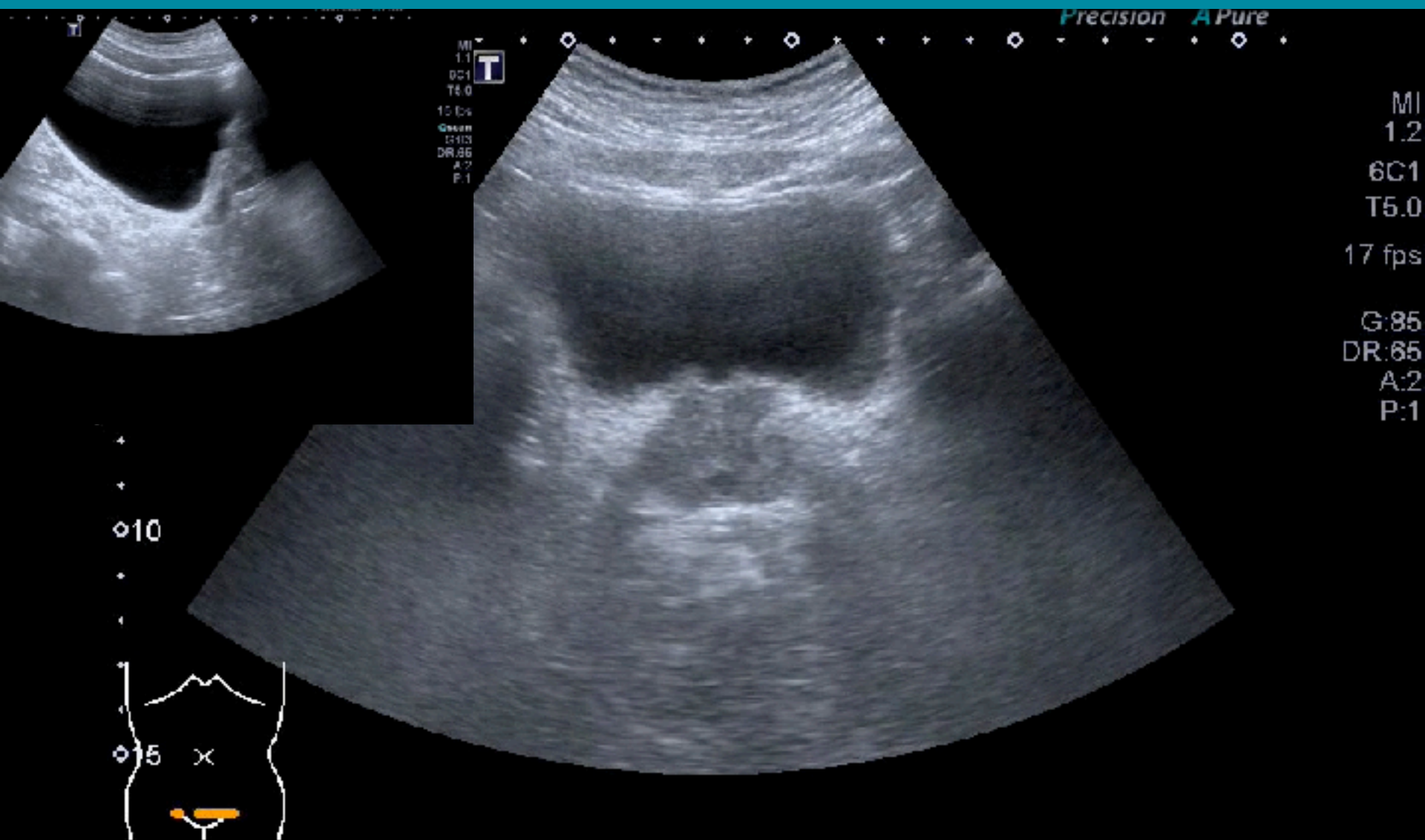




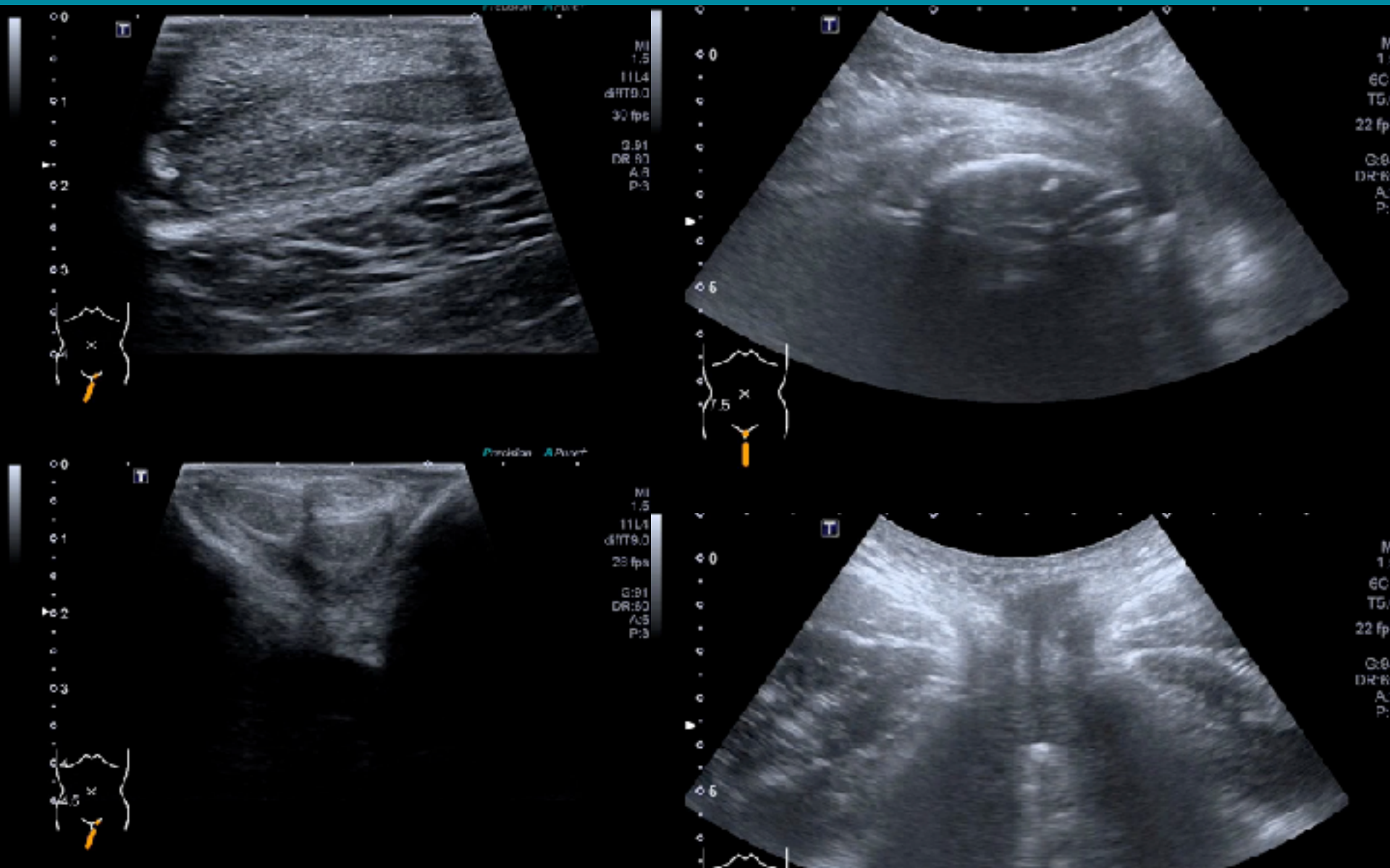
# Management



# 38M, sudden onset dysuria & AUR

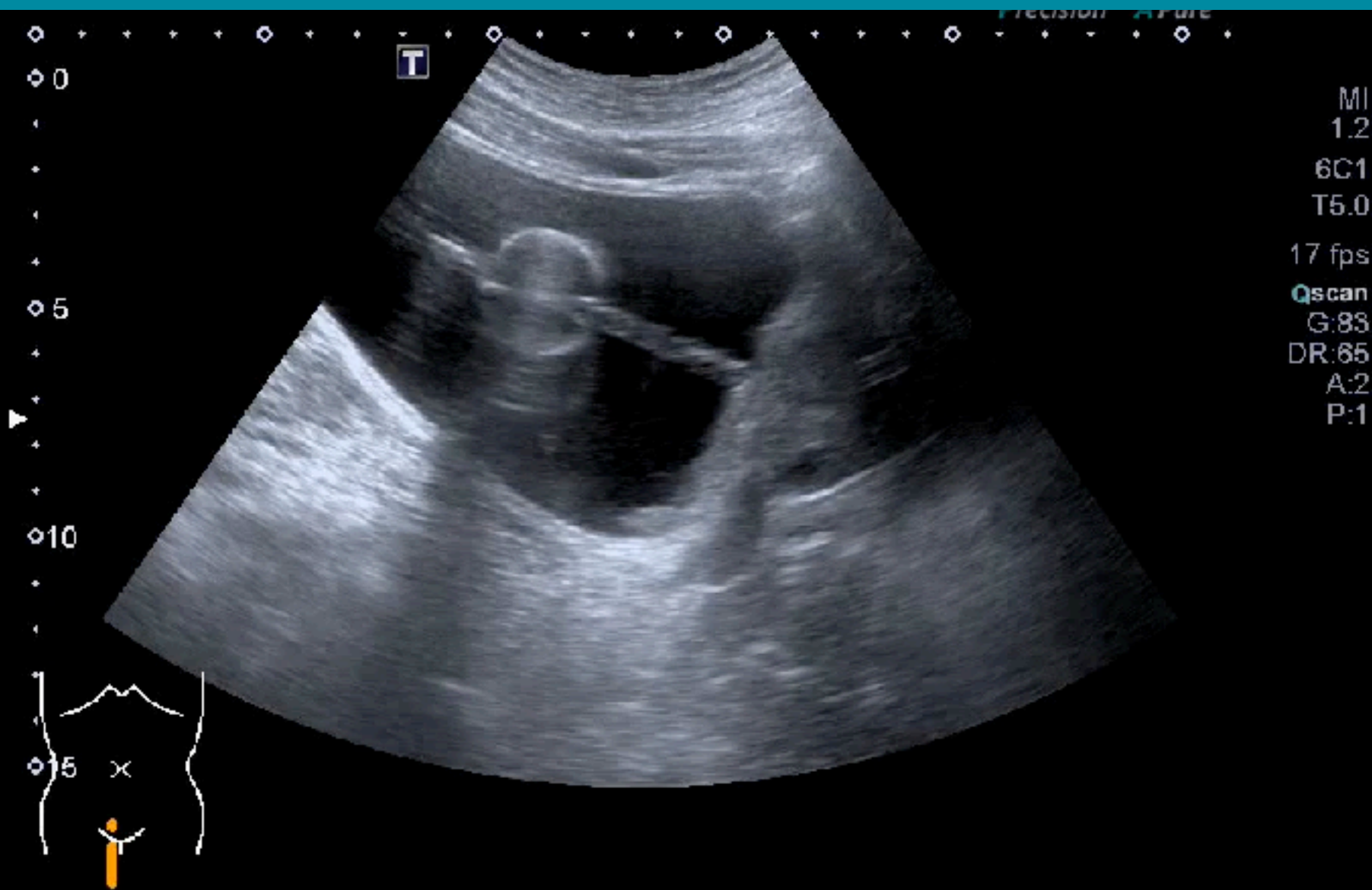


# 38M, sudden onset dysuria & AUR



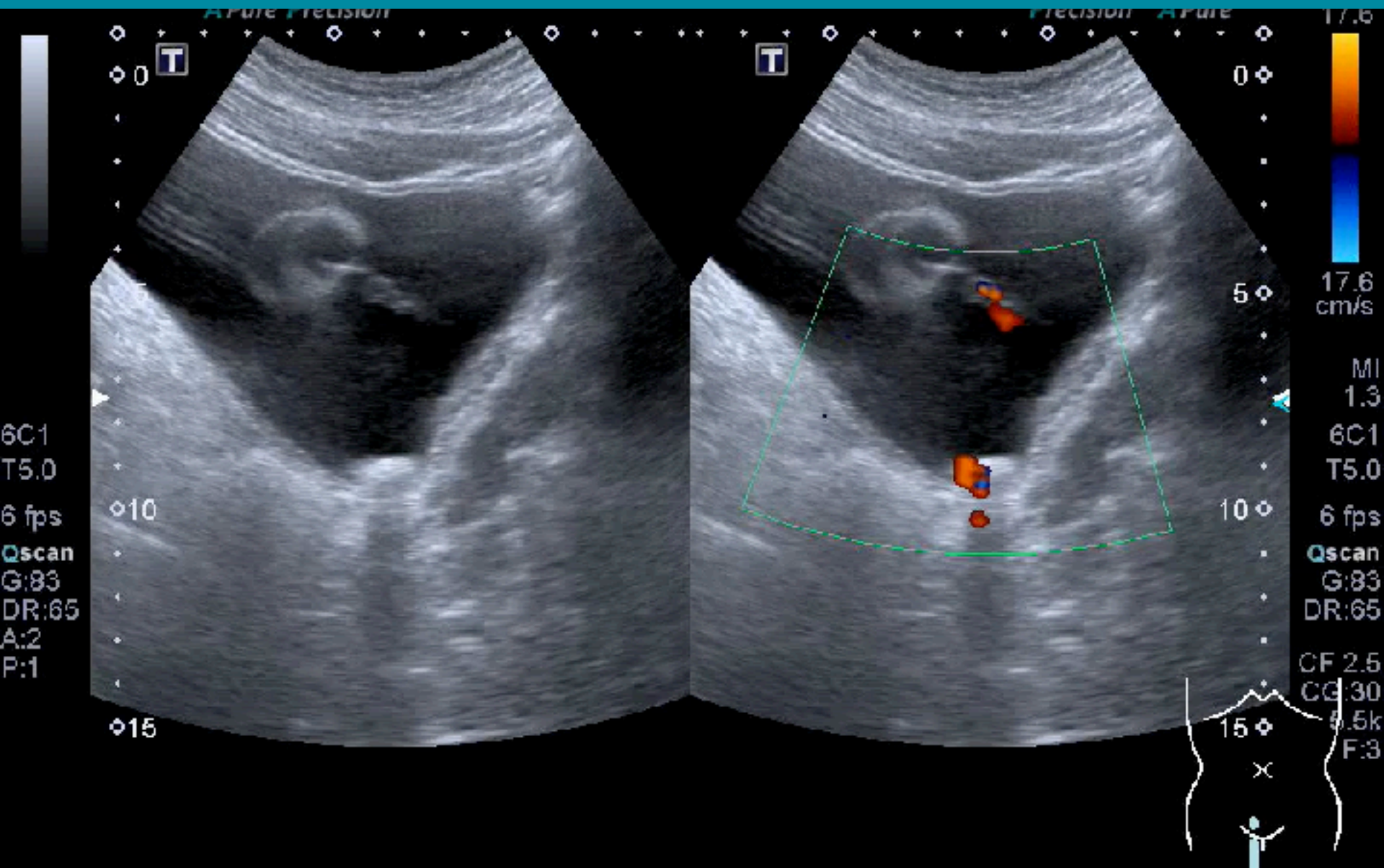


# Foley drainage





# Twinkling artifact



探頭先走  
要往回看  
緊盯針尖

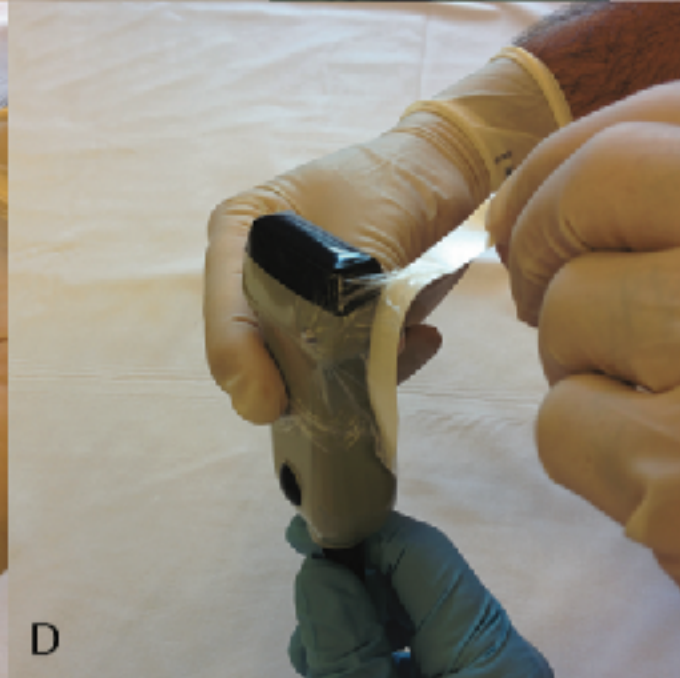
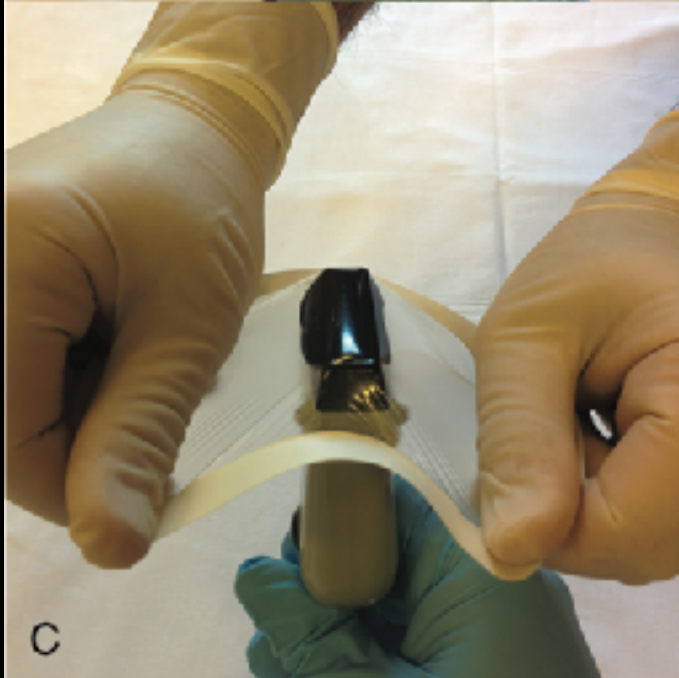
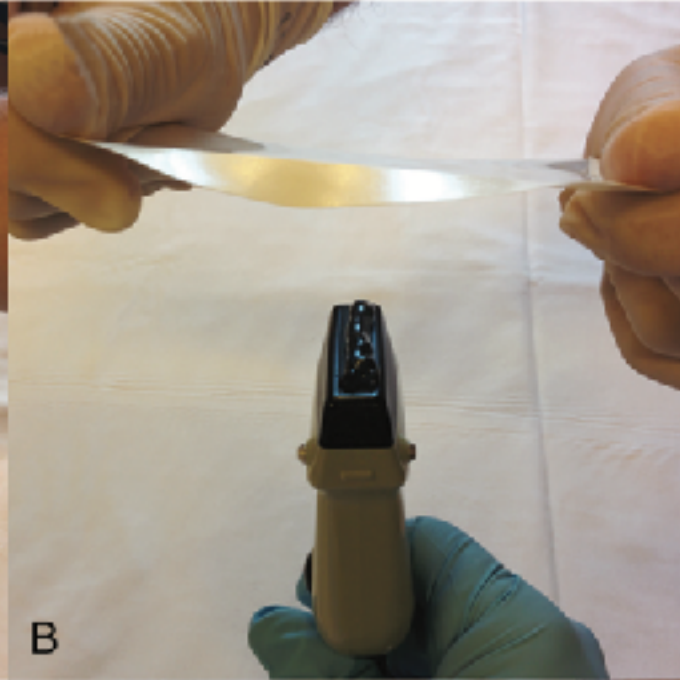
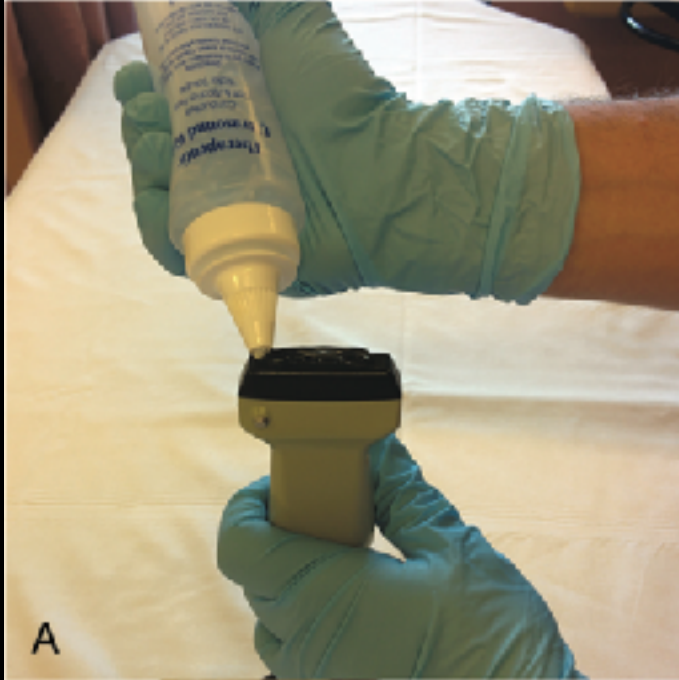


探頭要正  
目標不動  
淺淺入針

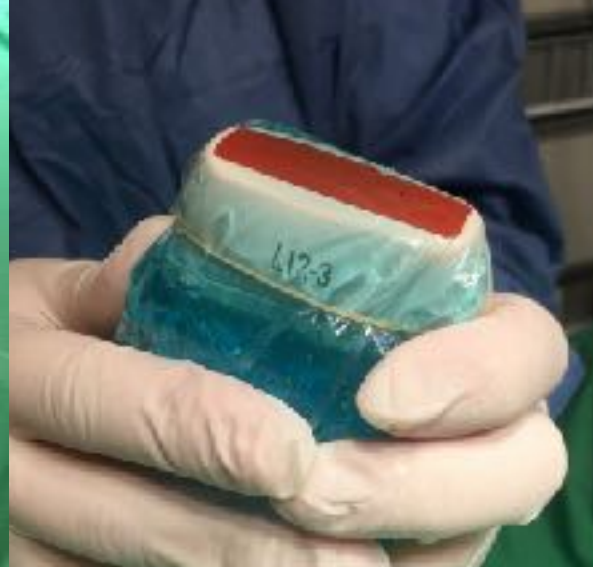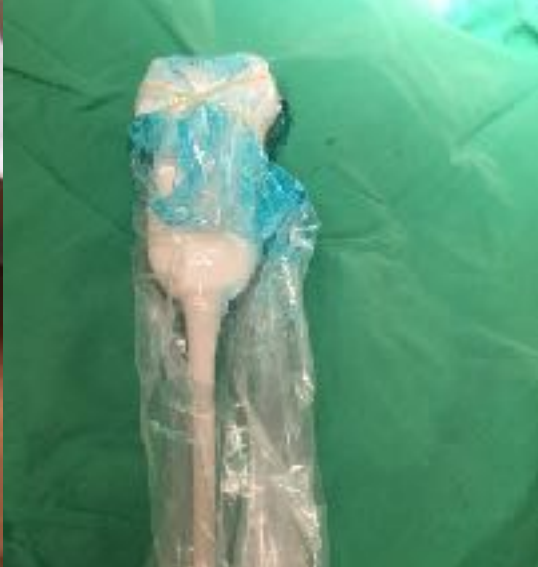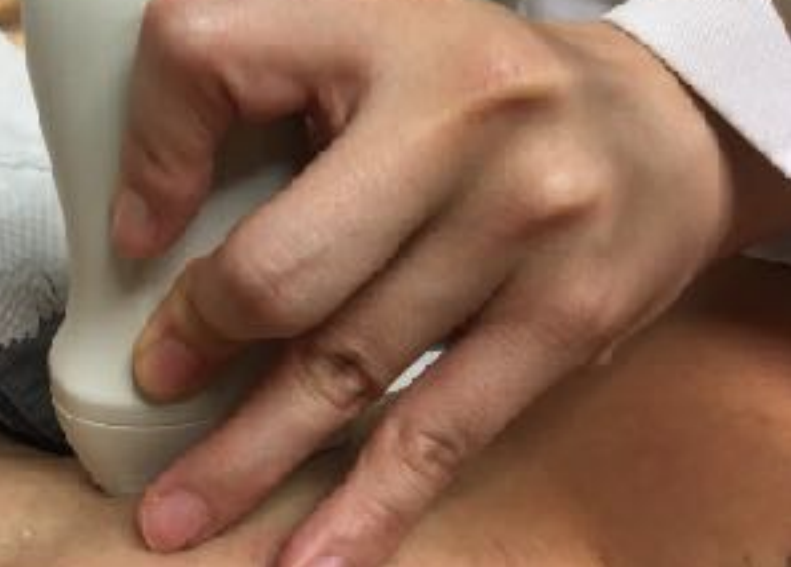## MASTER NEEDLING

Off-plane

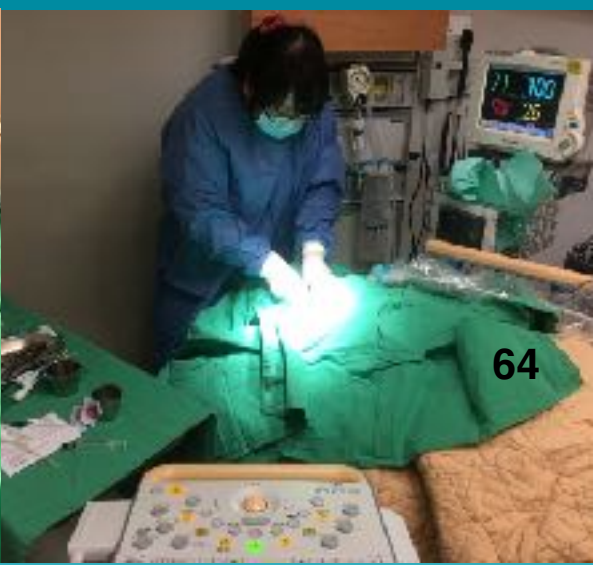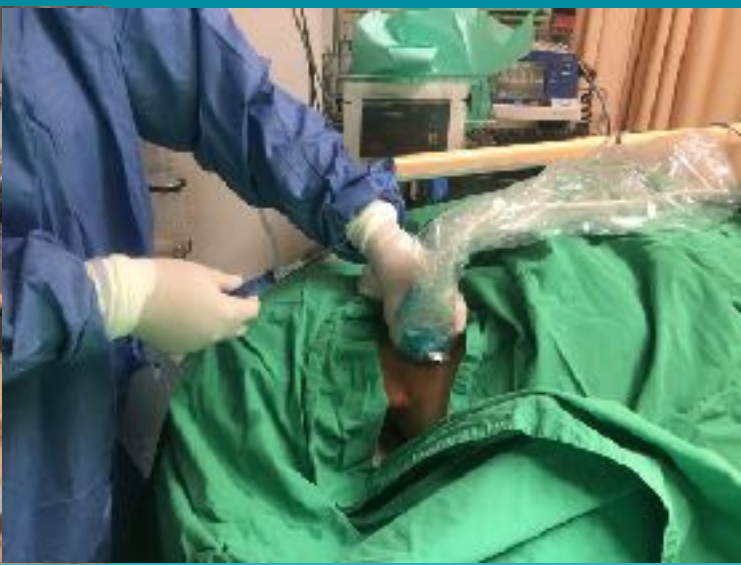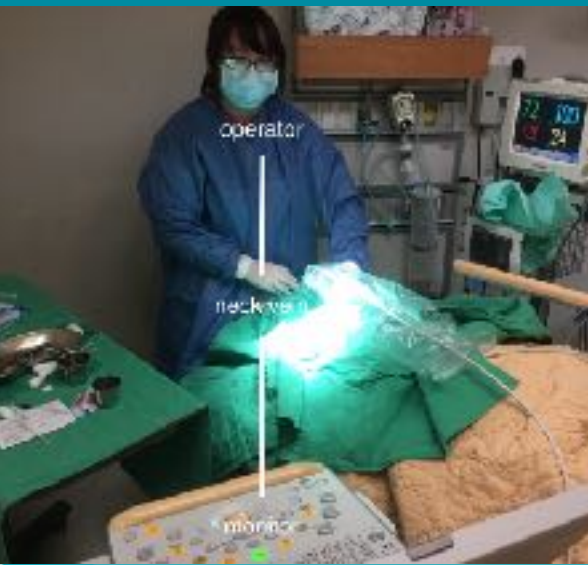In-plane





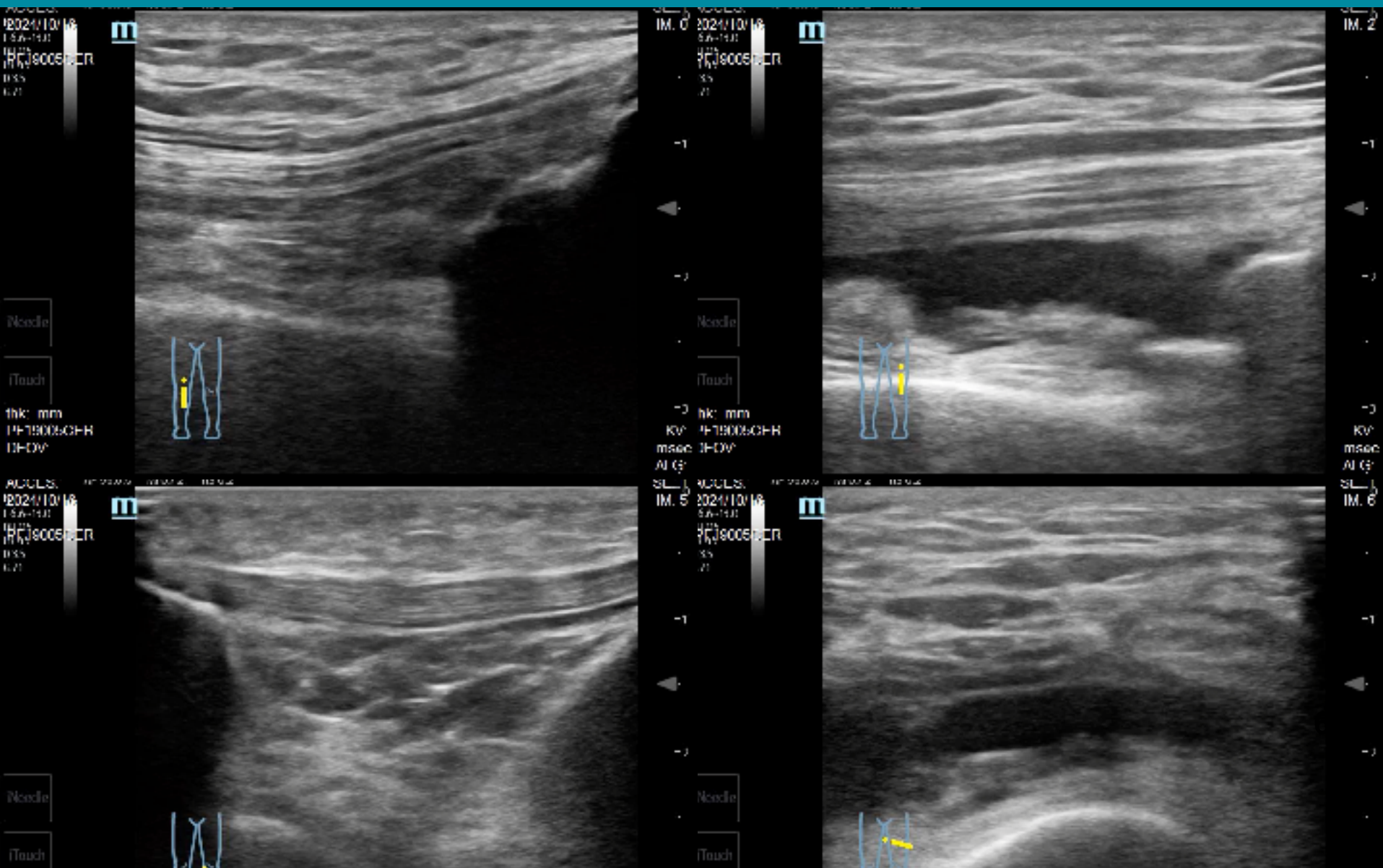


# US-GUIDED CVC



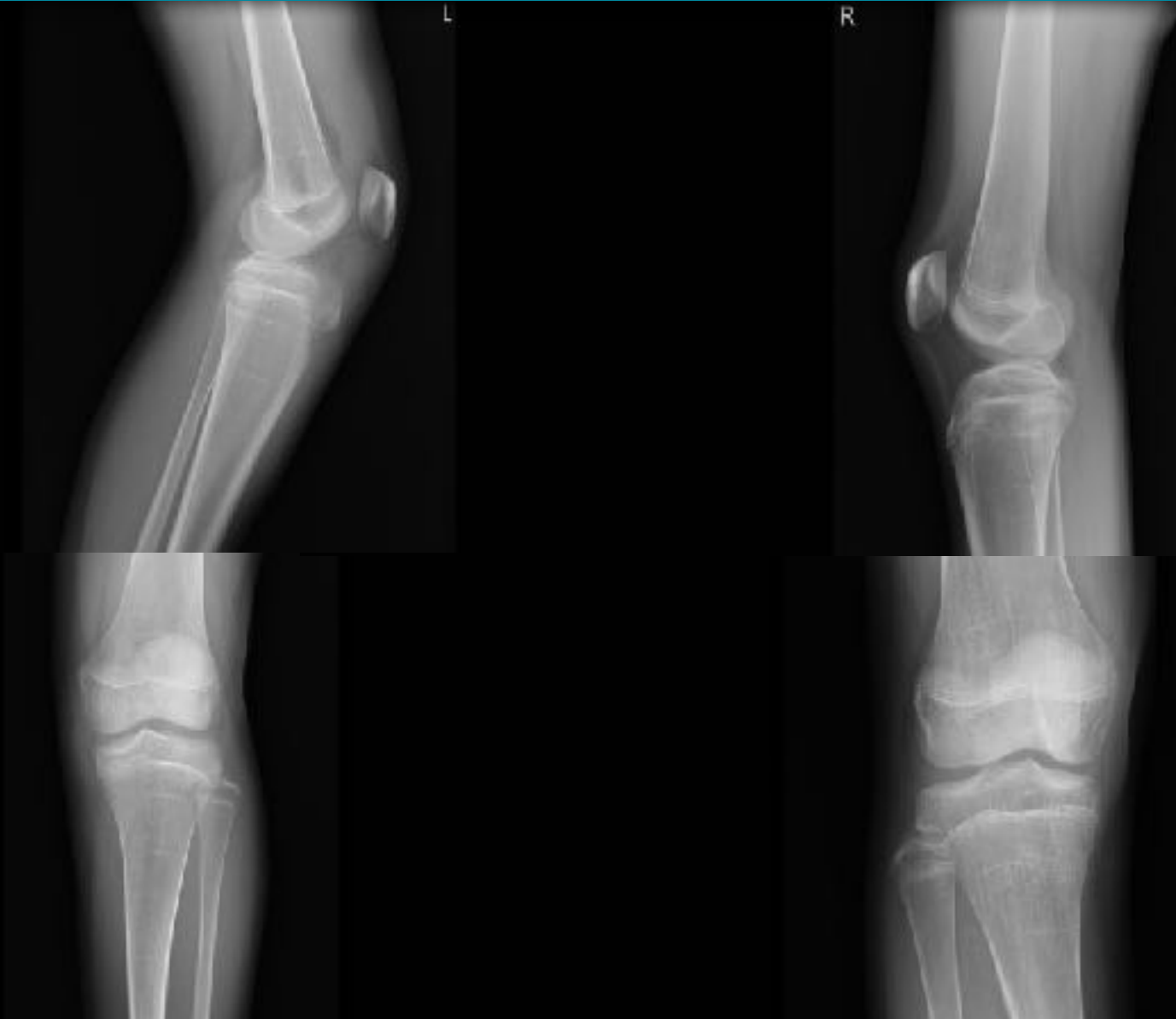


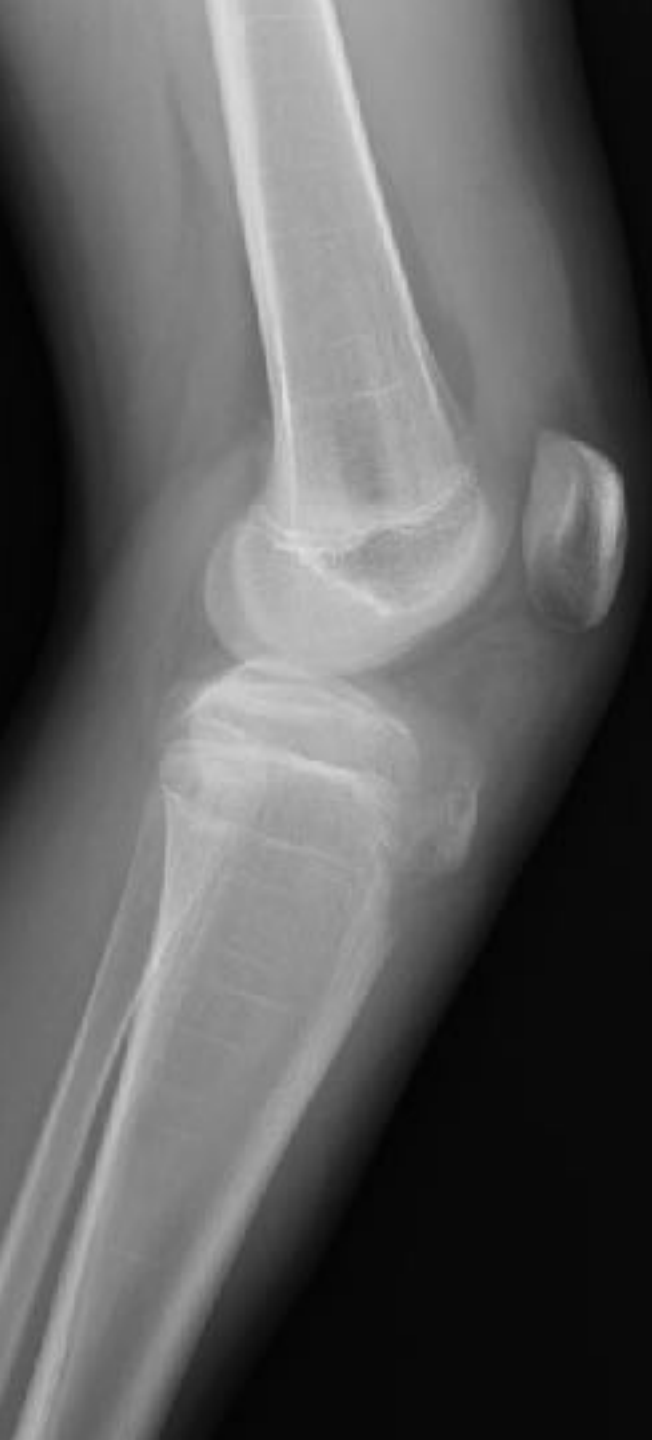# 75F, 左膝疼痛多日，昨推拿完更腫痛





# 14M, left knee injury with joint swelling





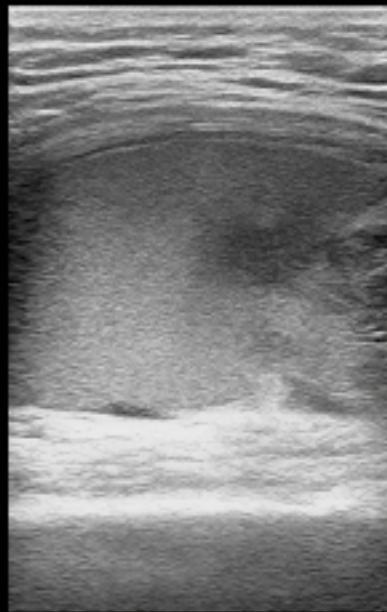
SKH ER

11S 0.2

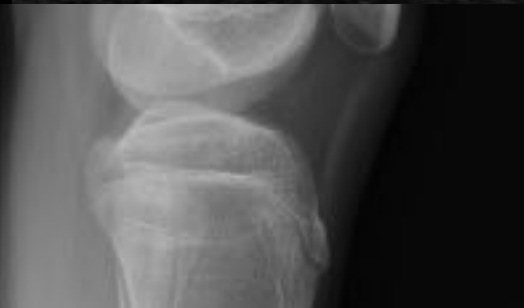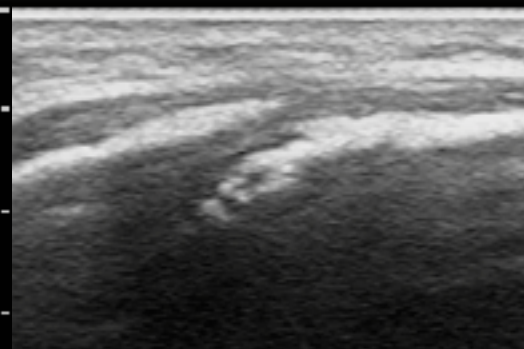
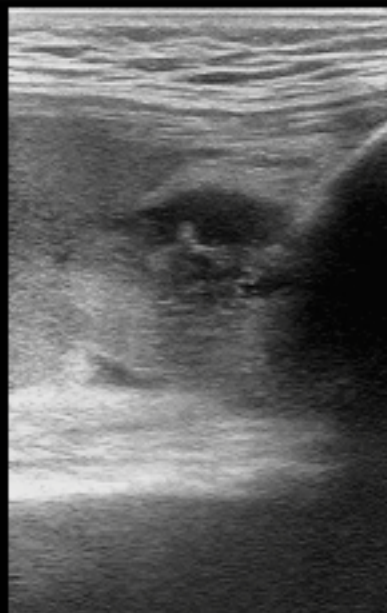
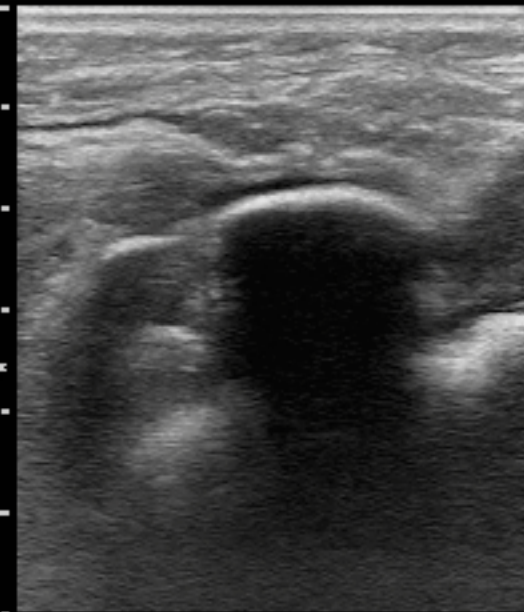
2:11:07 PM

SKH ER

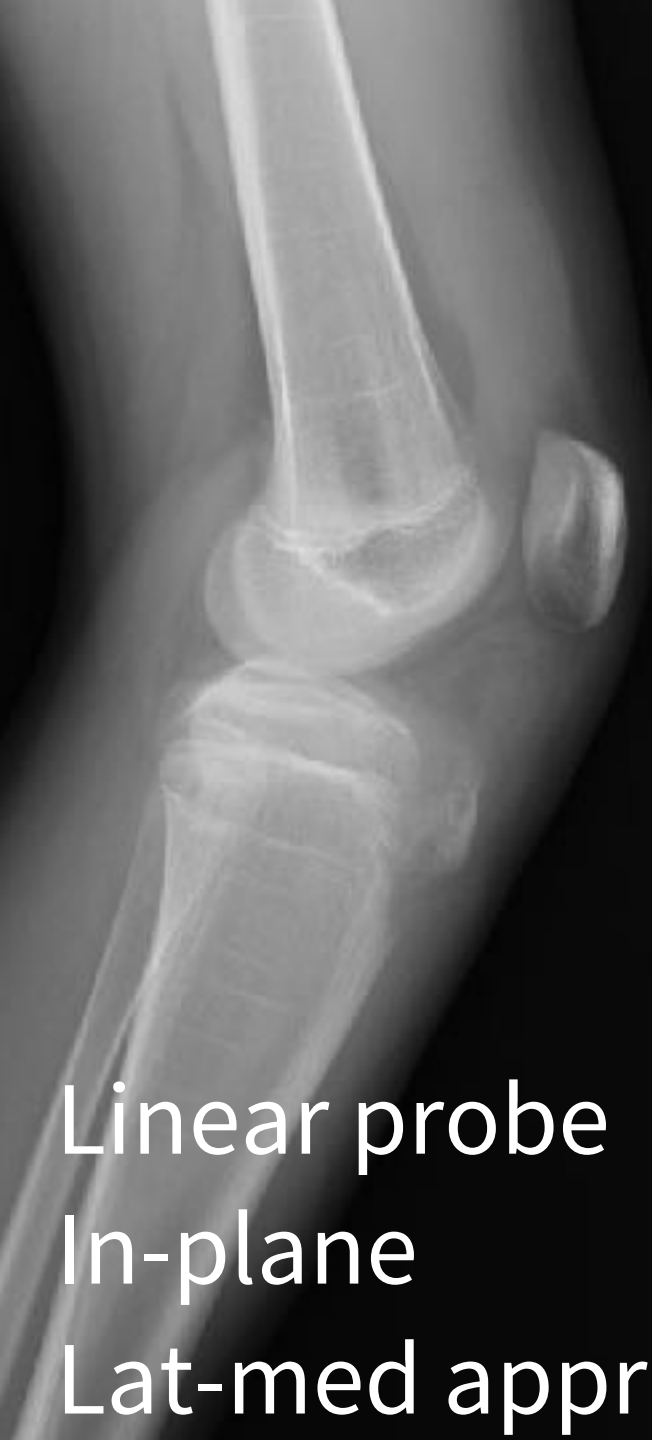11S 0.2



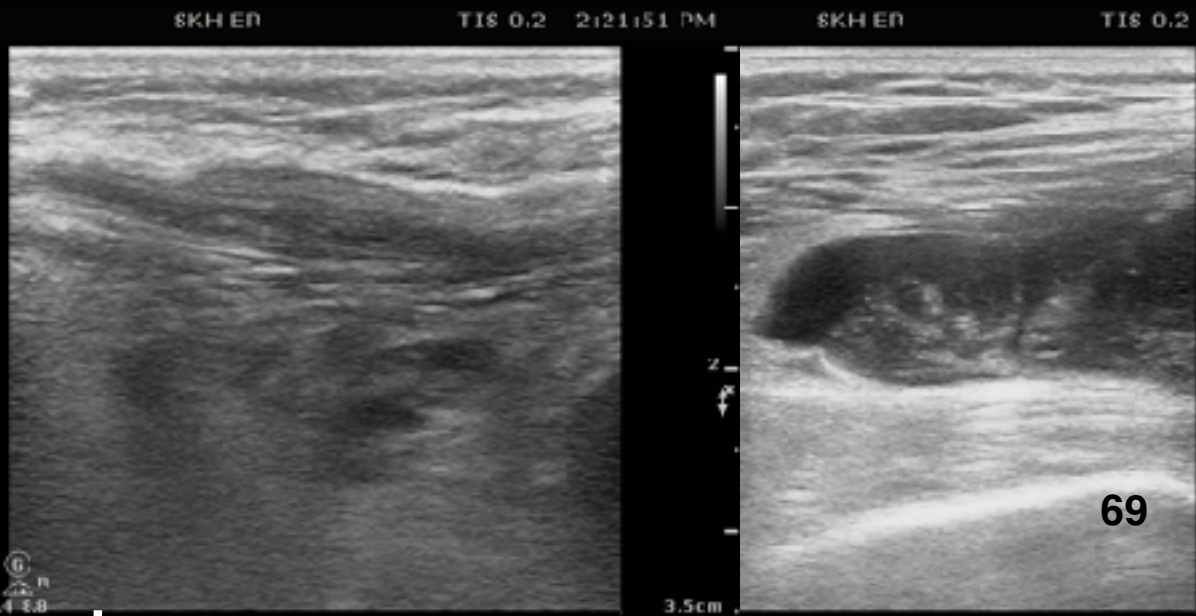
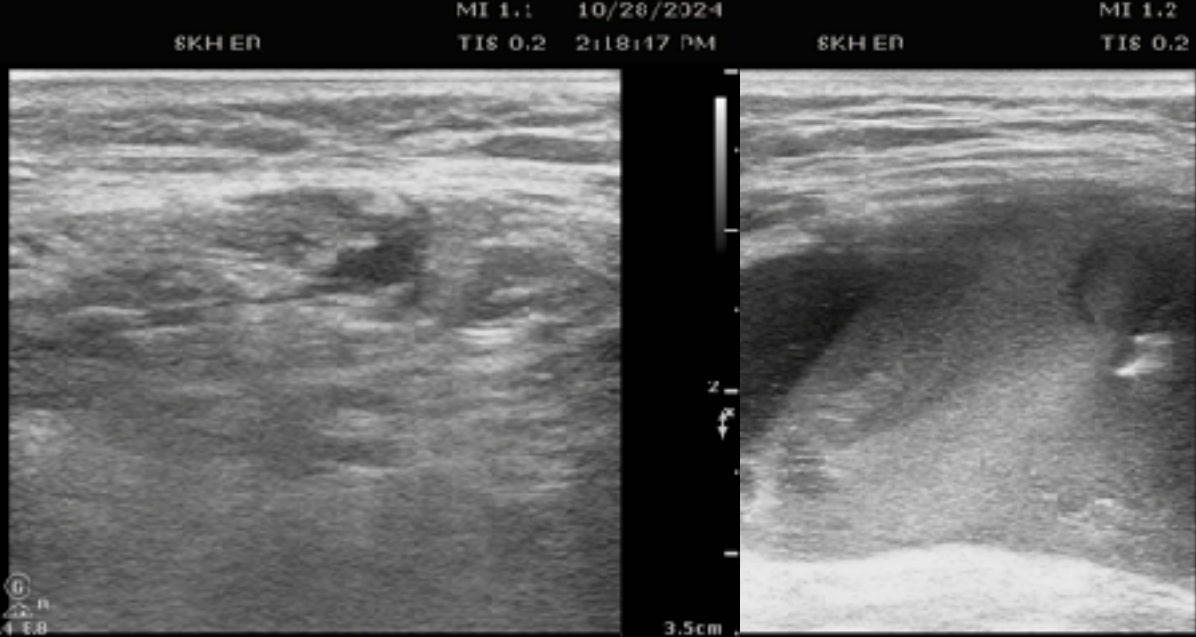
0.0cm



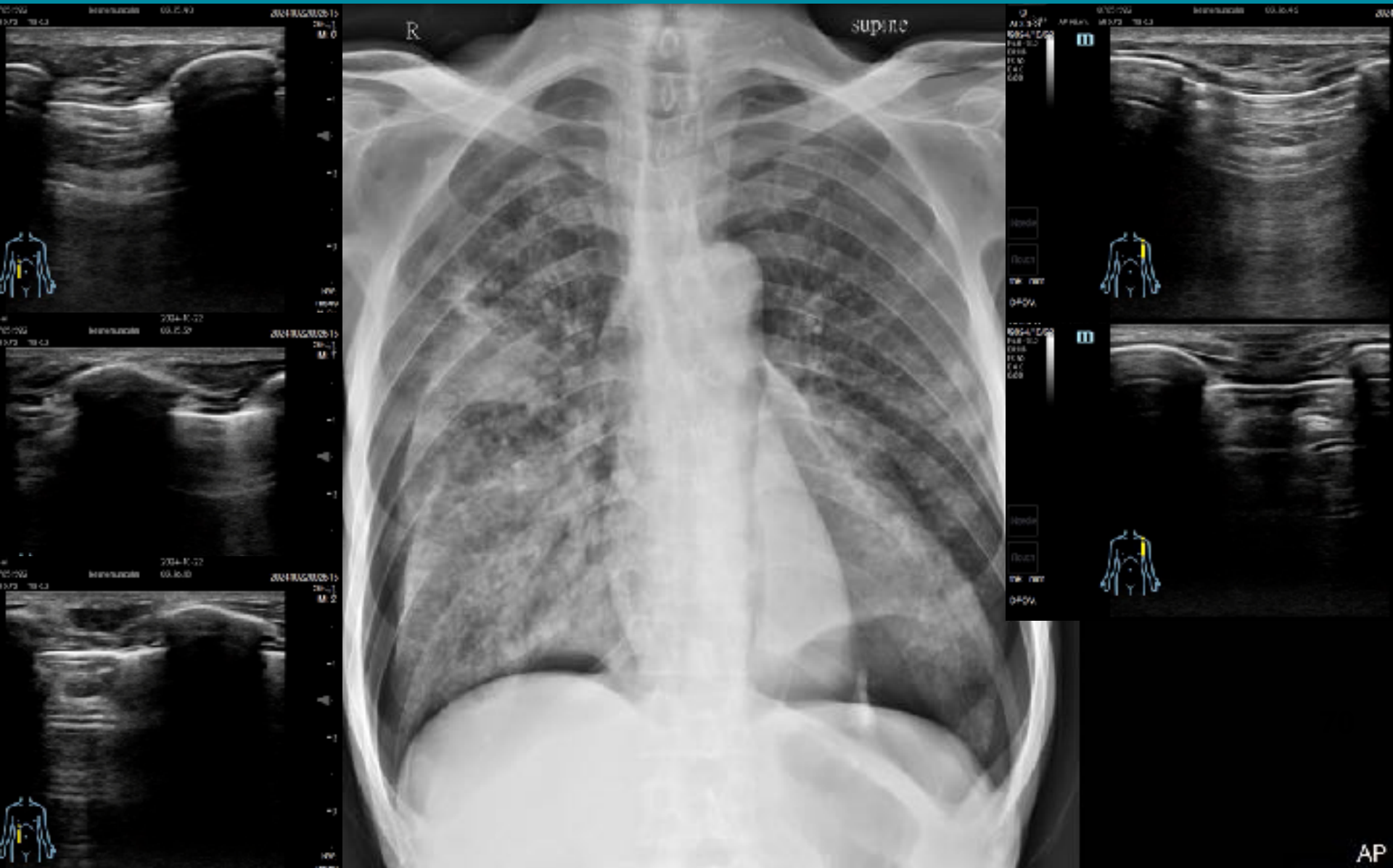



Linear probe  
In-plane  
Lat-med approach



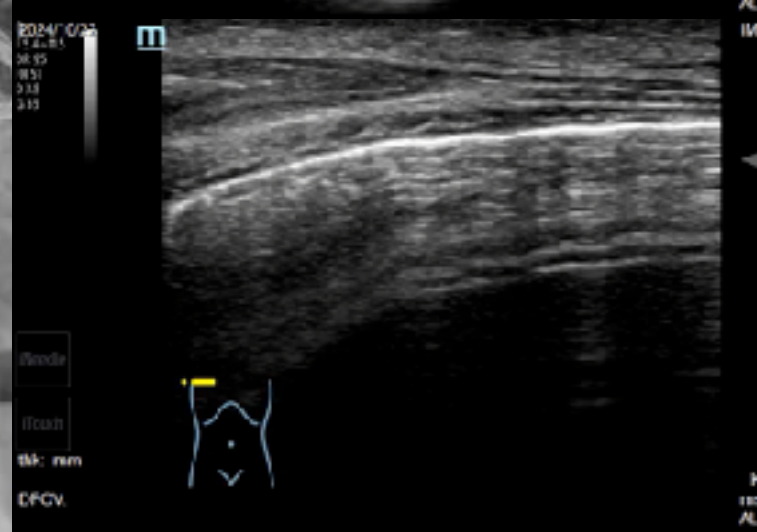
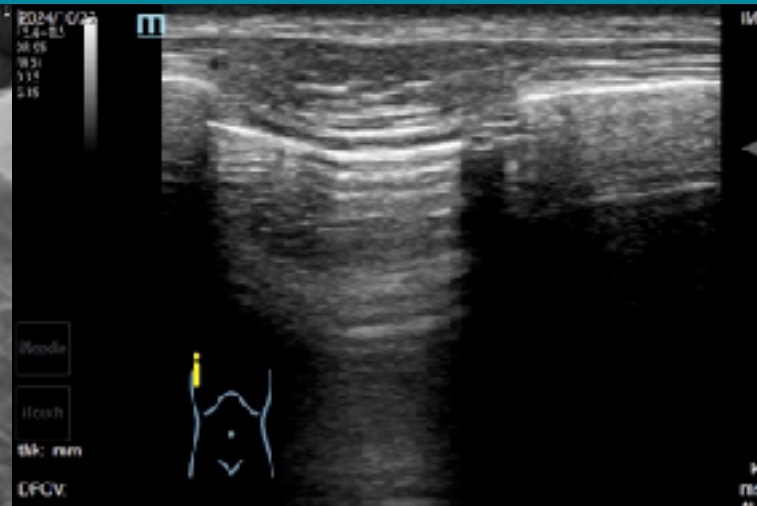
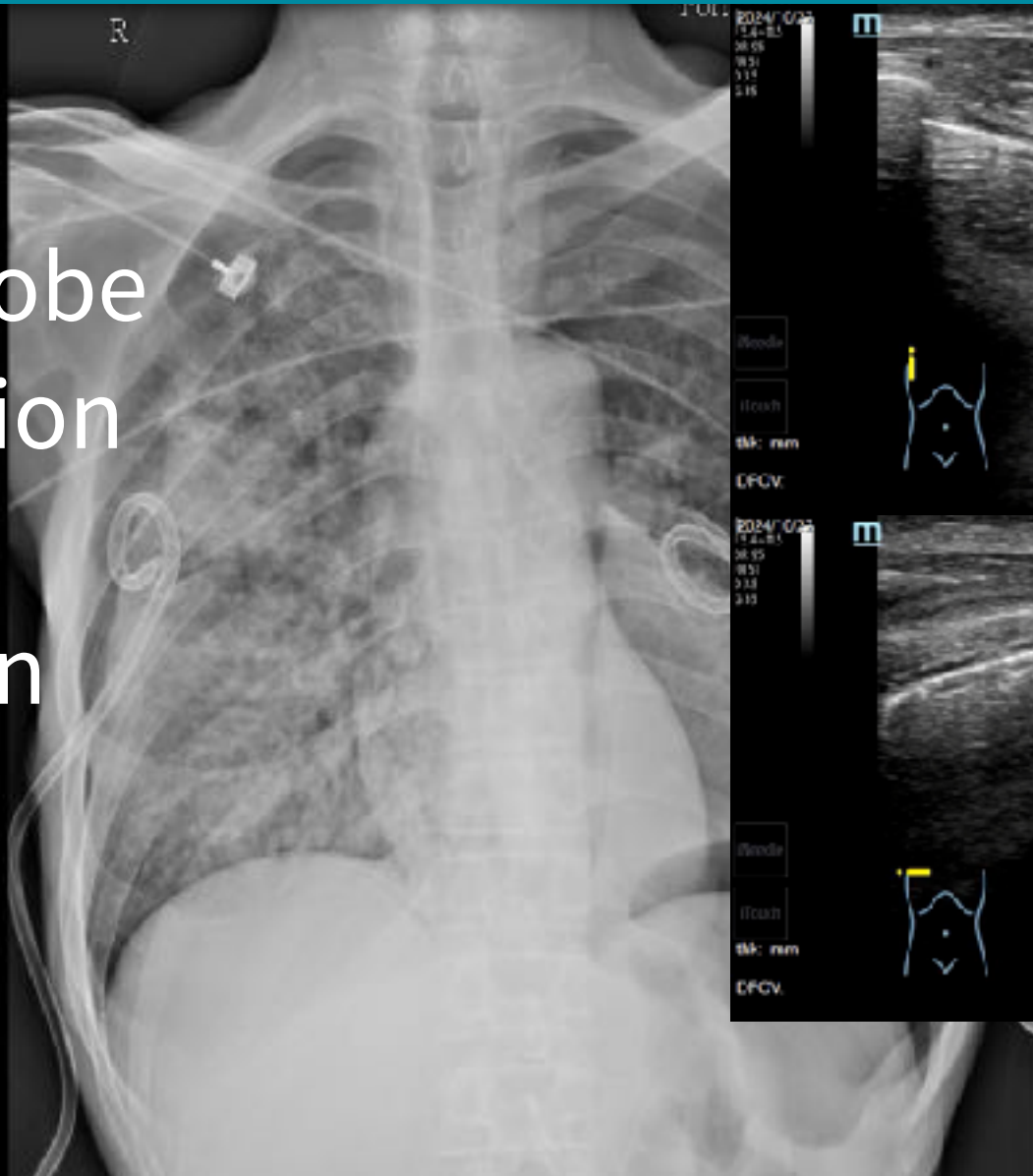
# 59M, productive cough & SOB for 1wk



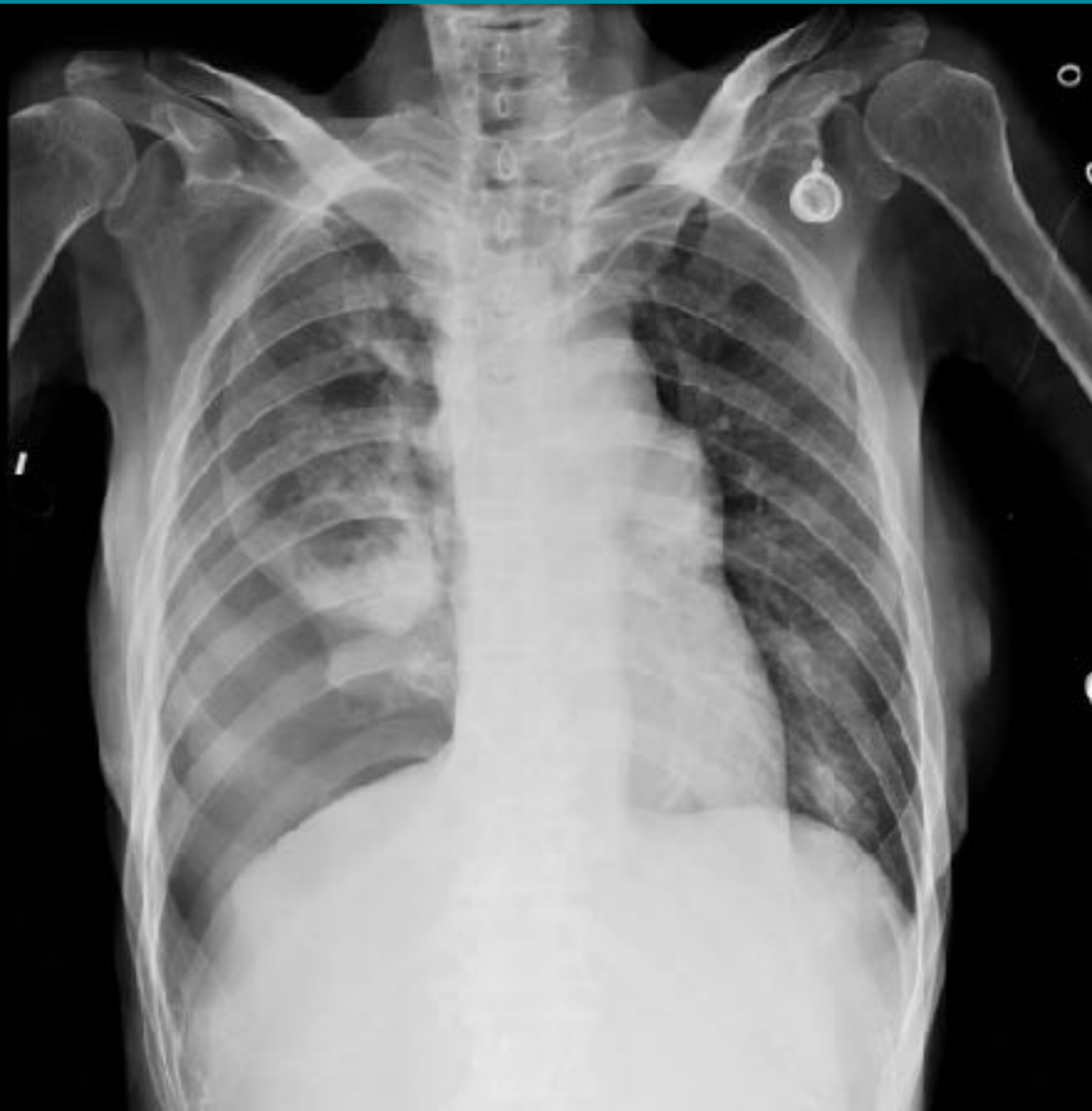# Post pigtail drainage

0581 MI  
PID:  
ACC:  
2024/10/22  
10:24:25

Linear probe  
Localization  
Depth  
Expansion



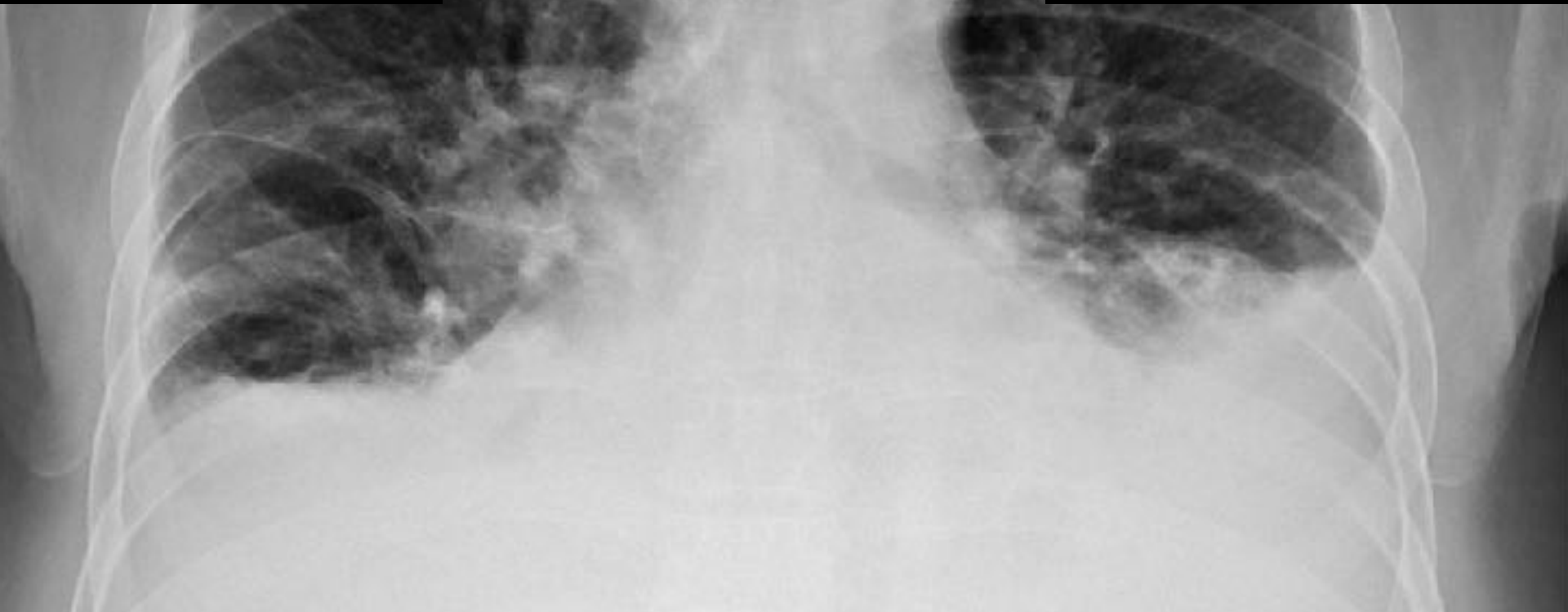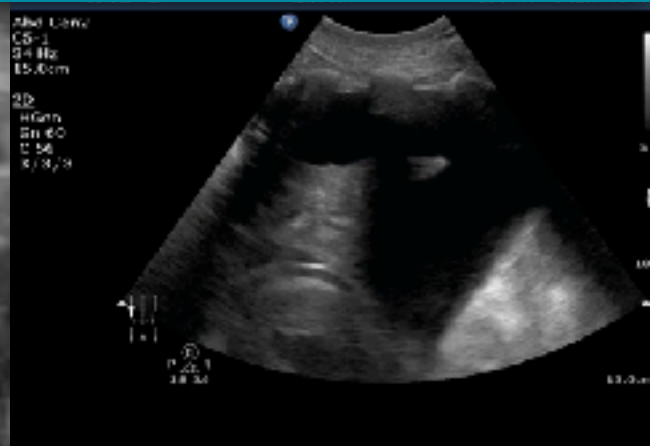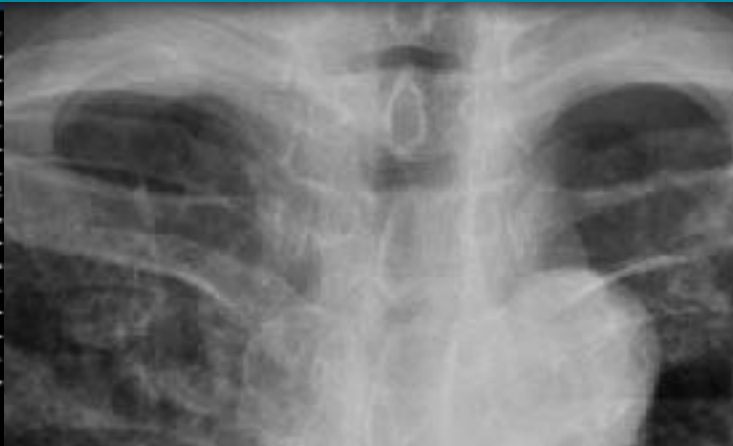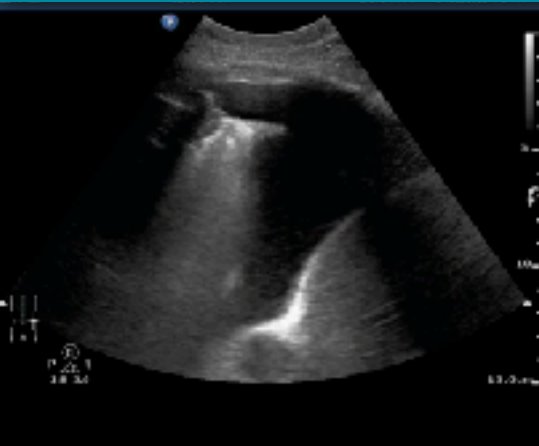# Ovarian ca with carcinomatosis



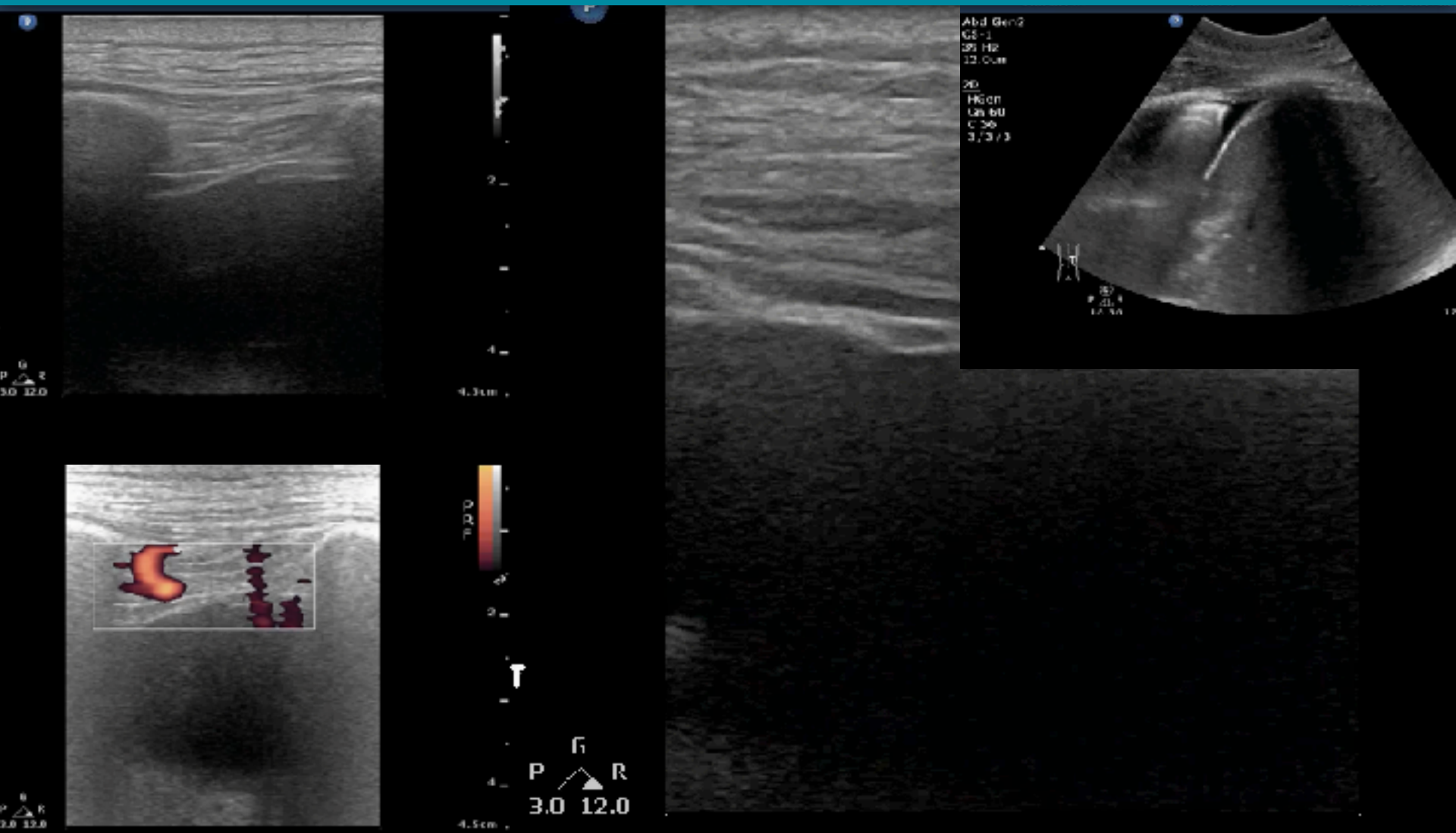




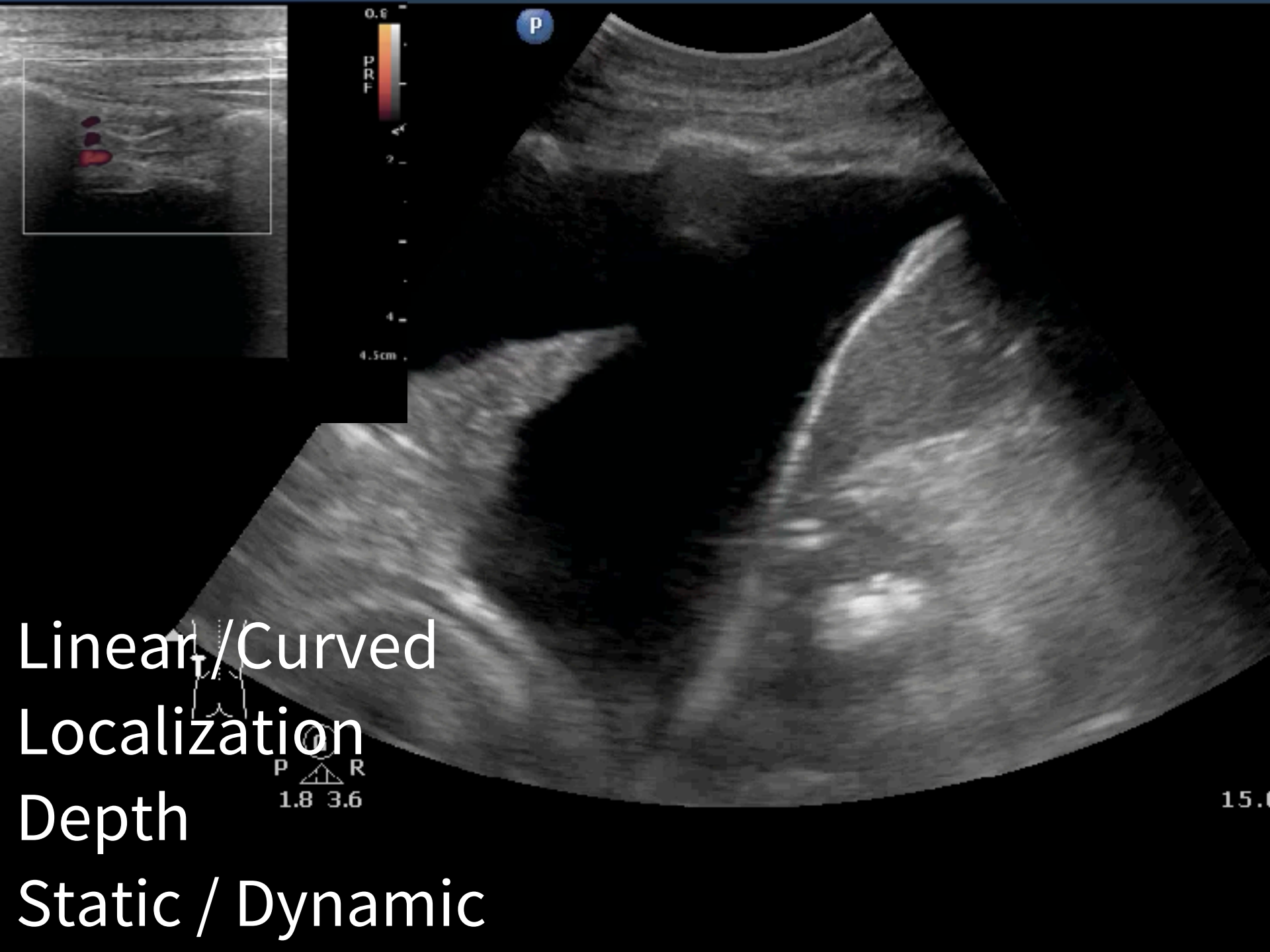
# Bilateral PLE



# Real time thoracentesis 1000ml



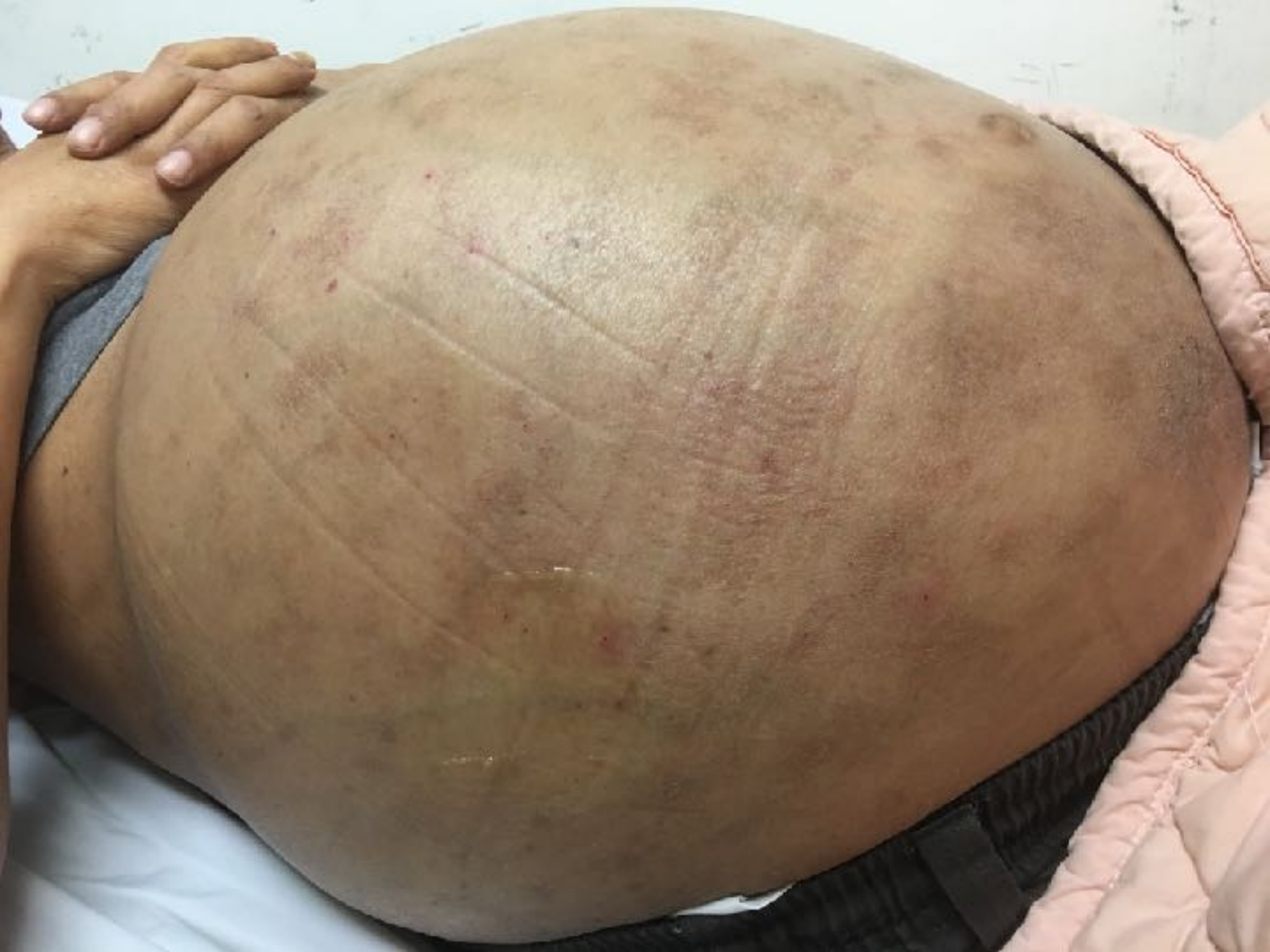



Linear / Curved  
Localization  
Depth  
Static / Dynamic



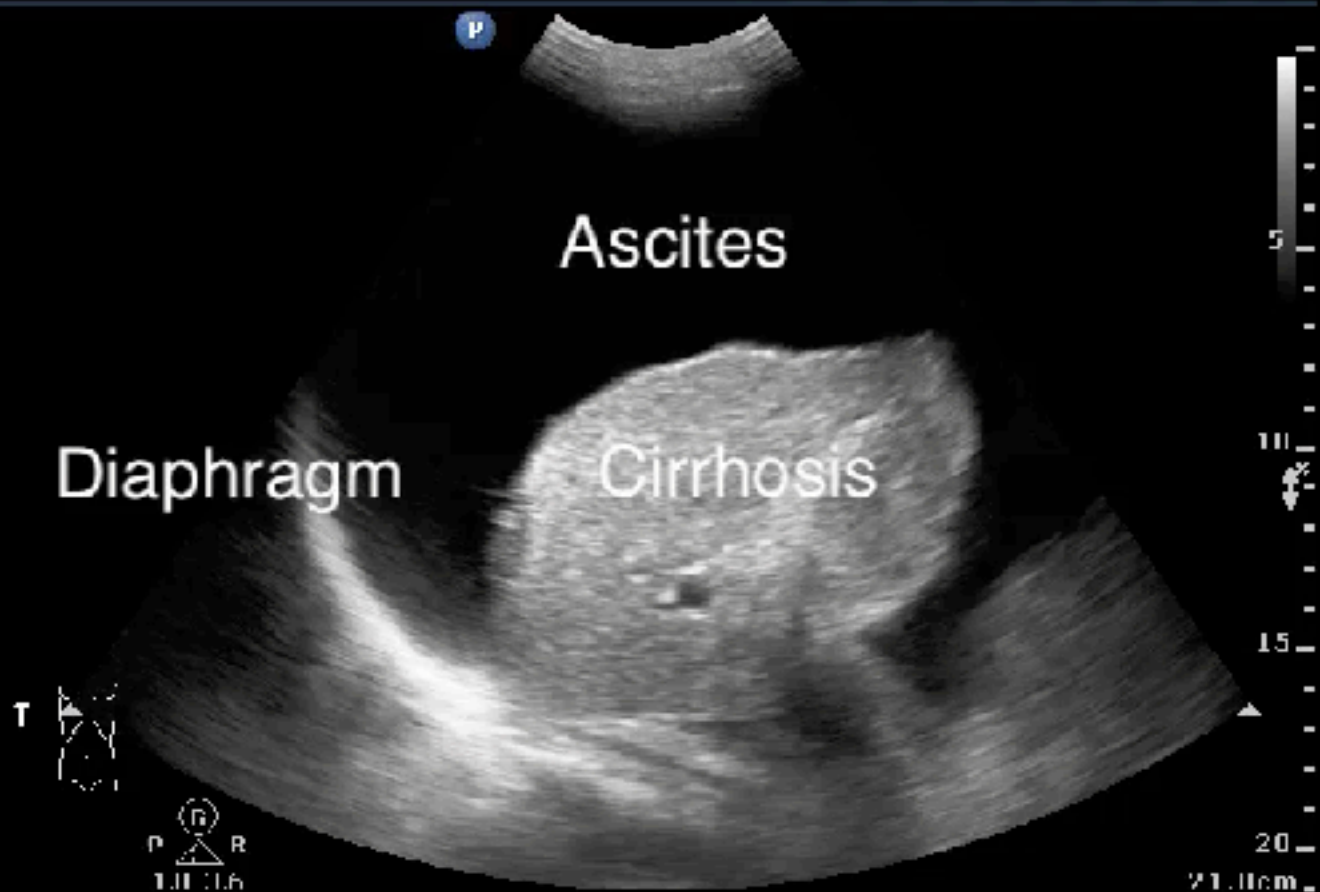15.0



# Real time paracentesis

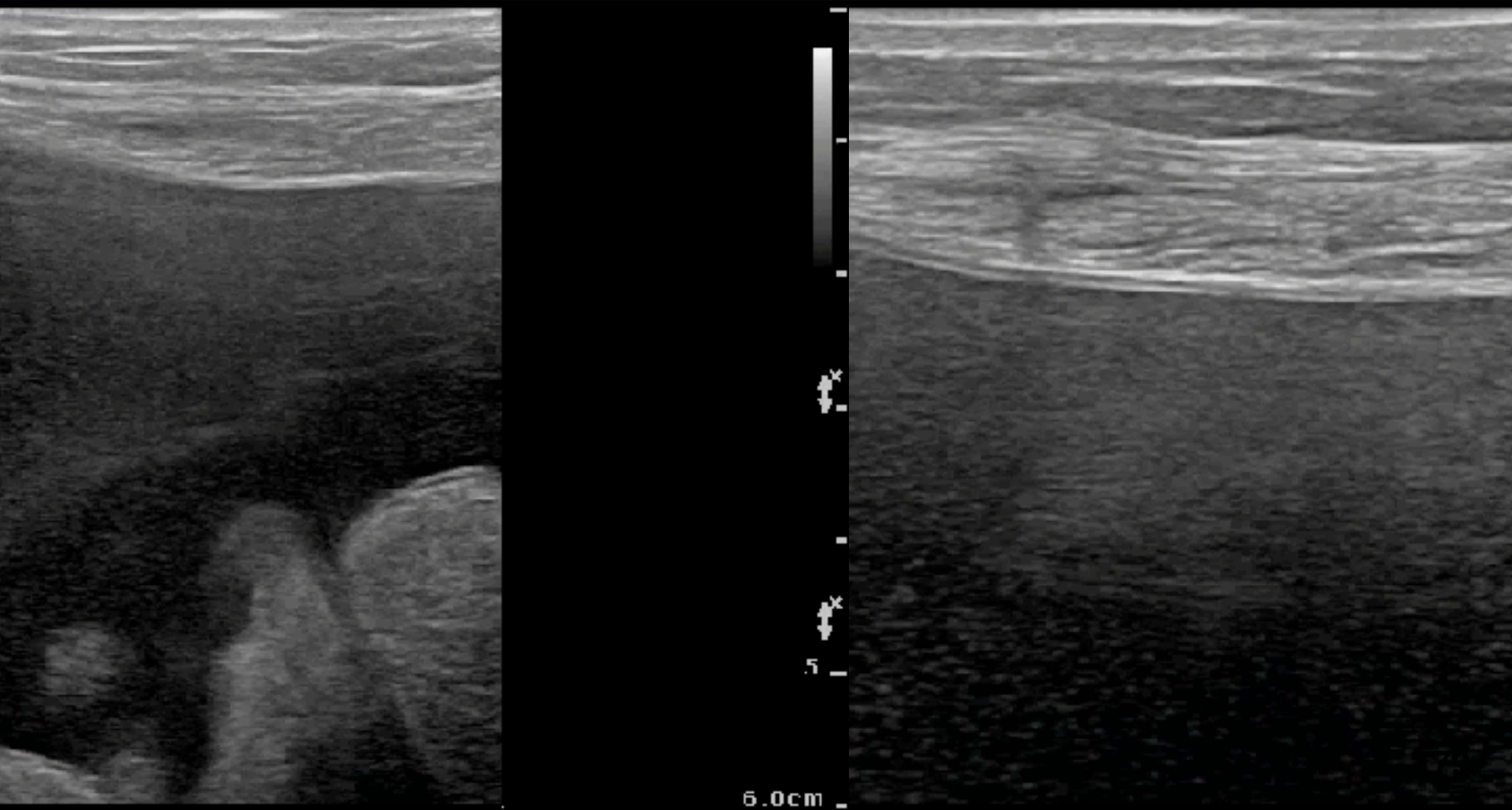
Abd Gen  
C5 1  
27 Hz  
21.0cm

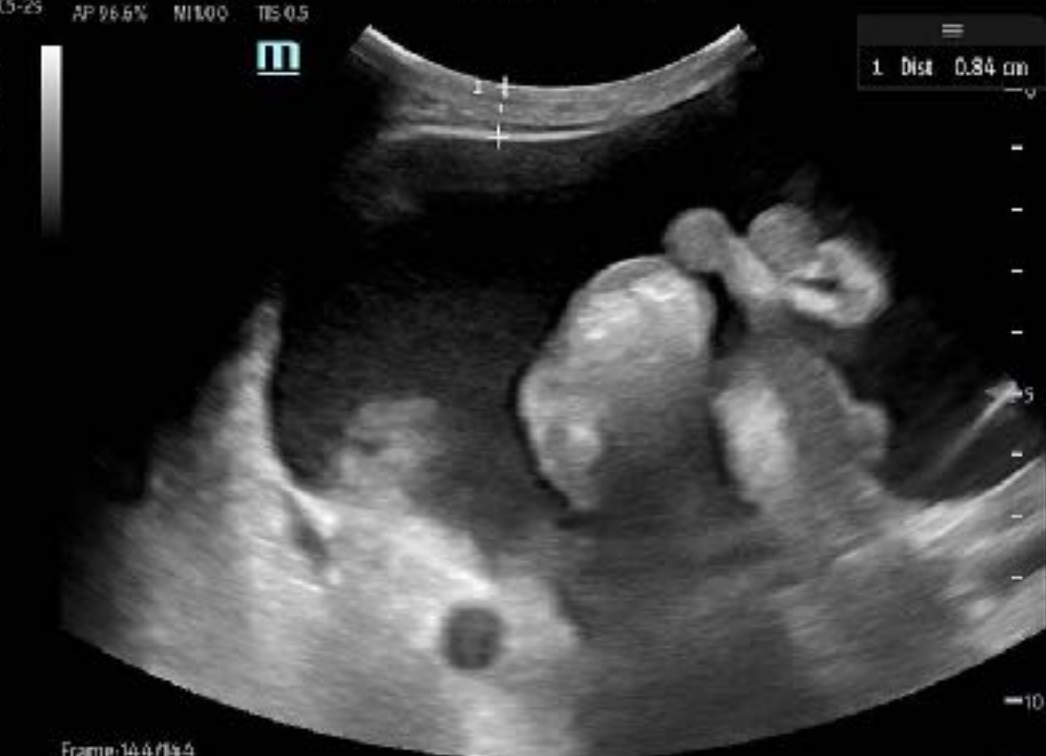2D  
HGen  
Gn 84  
C 56  
3 / 3 / 3



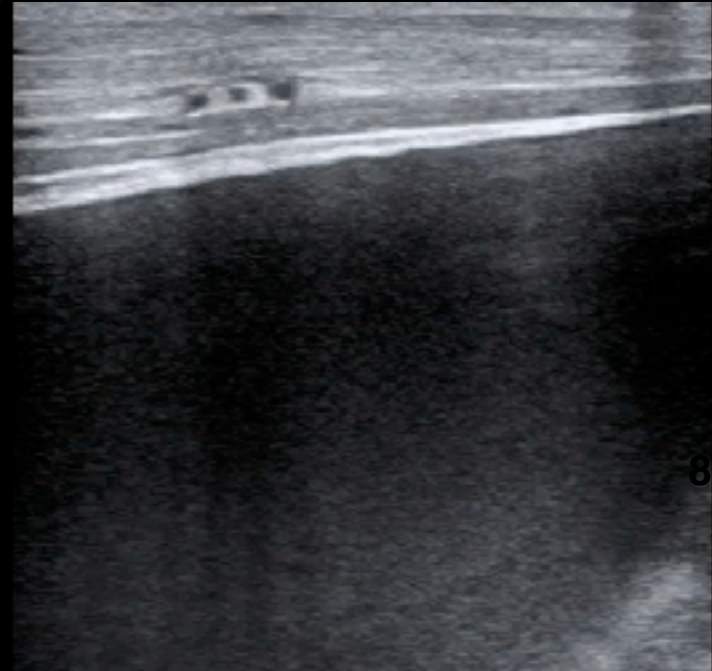
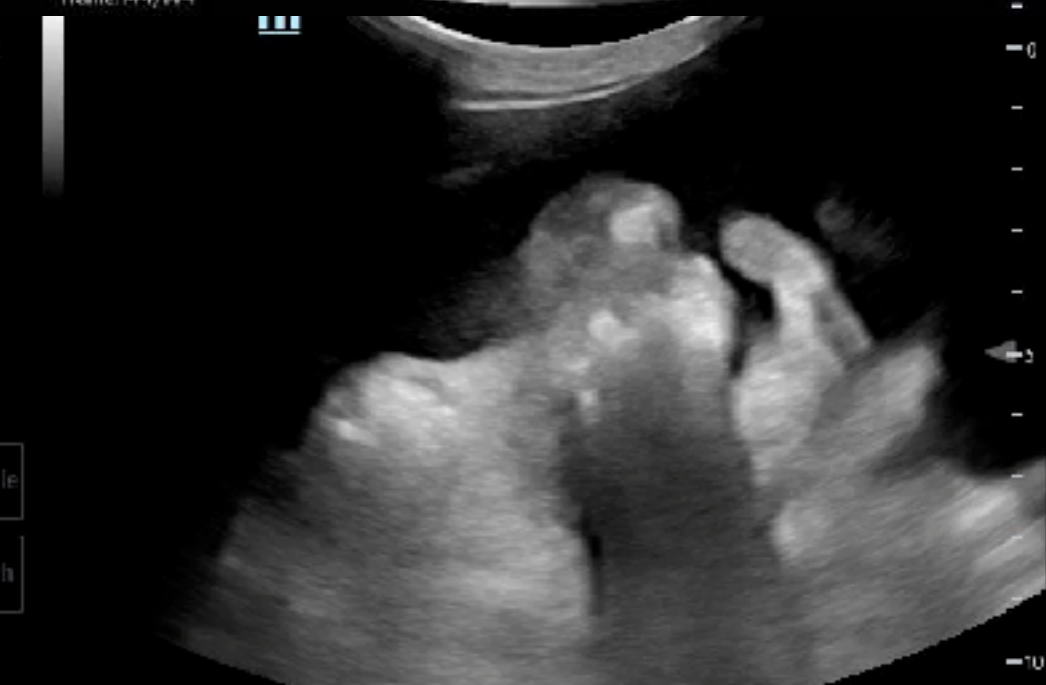
# Real time paracentesis

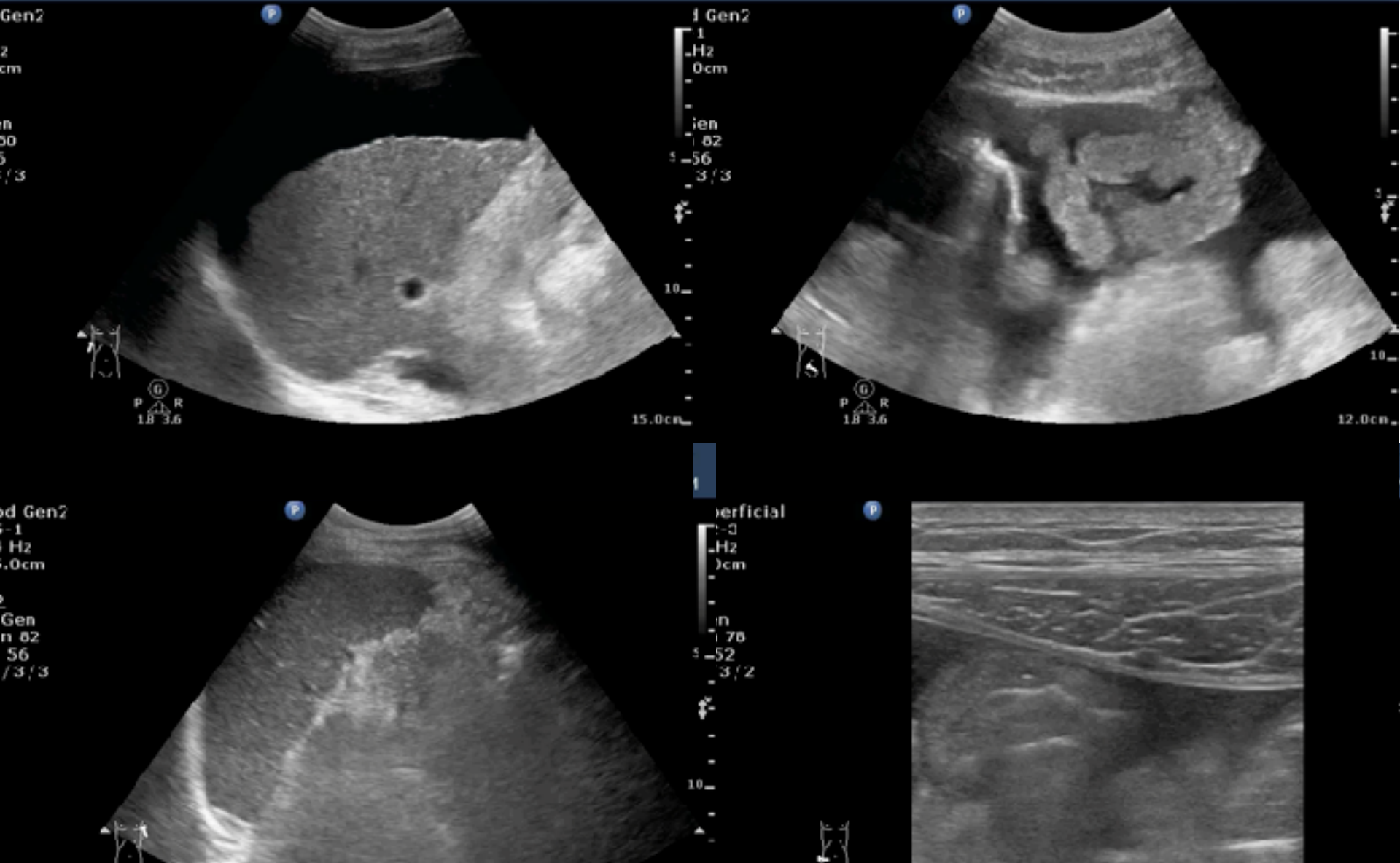




Location  
Depth  
Bowel  
Vessels (IEA)



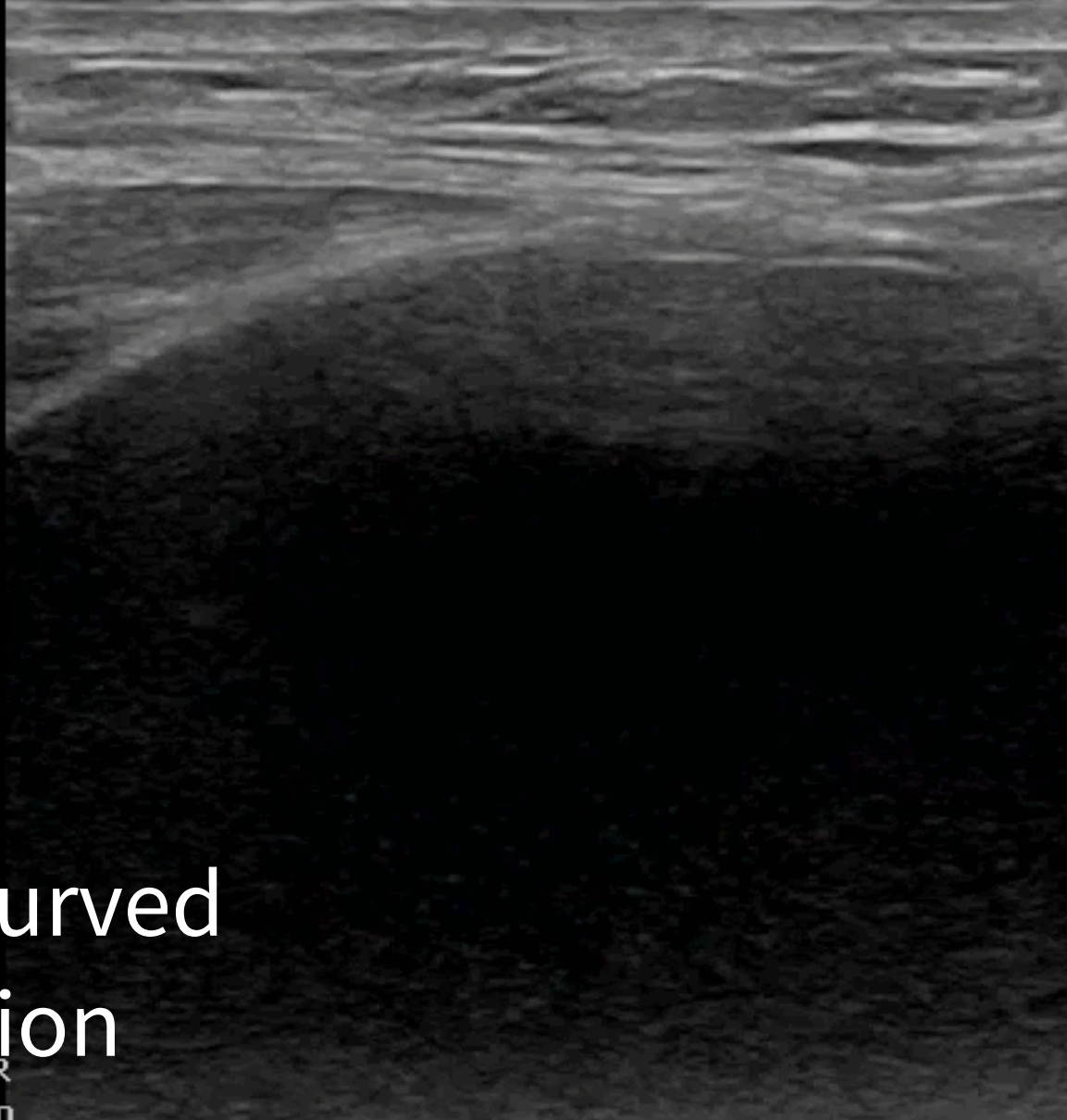
# Real time paracentesis





ial

P



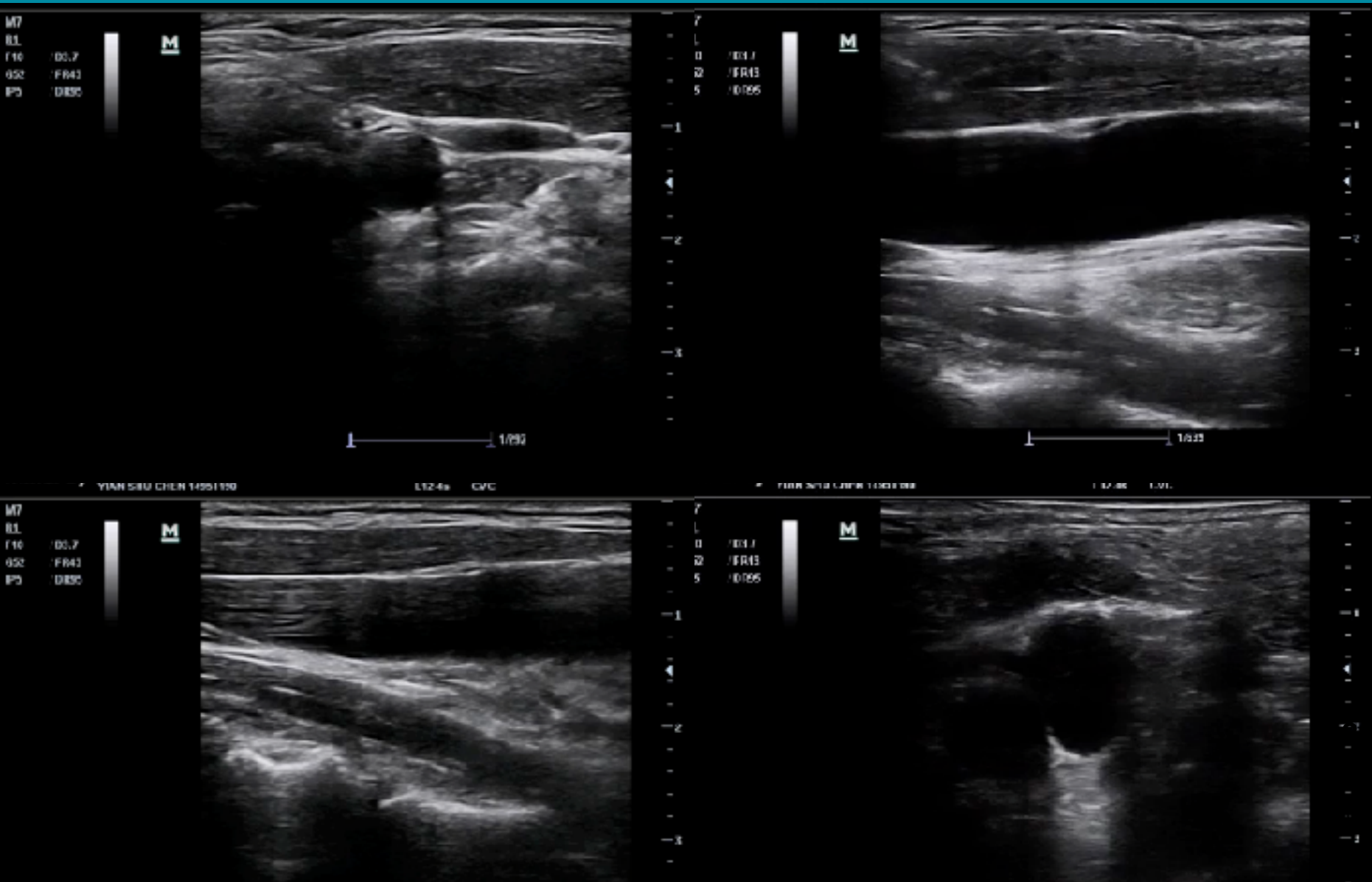
2

4.0cm

Linear / Curved  
Localization  
Depth  
Static / Dynamic



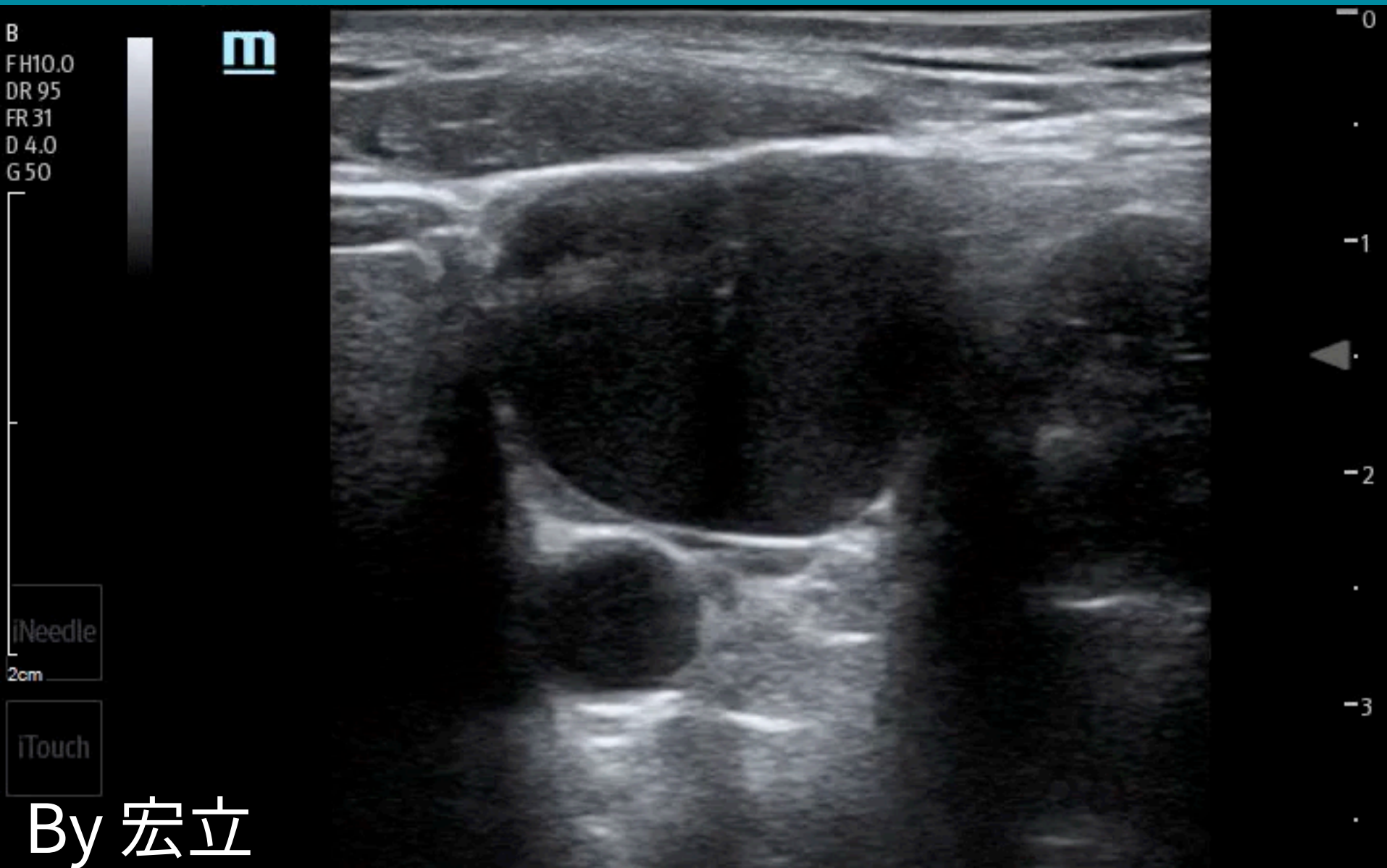
# 43F, Septic shock for CVC



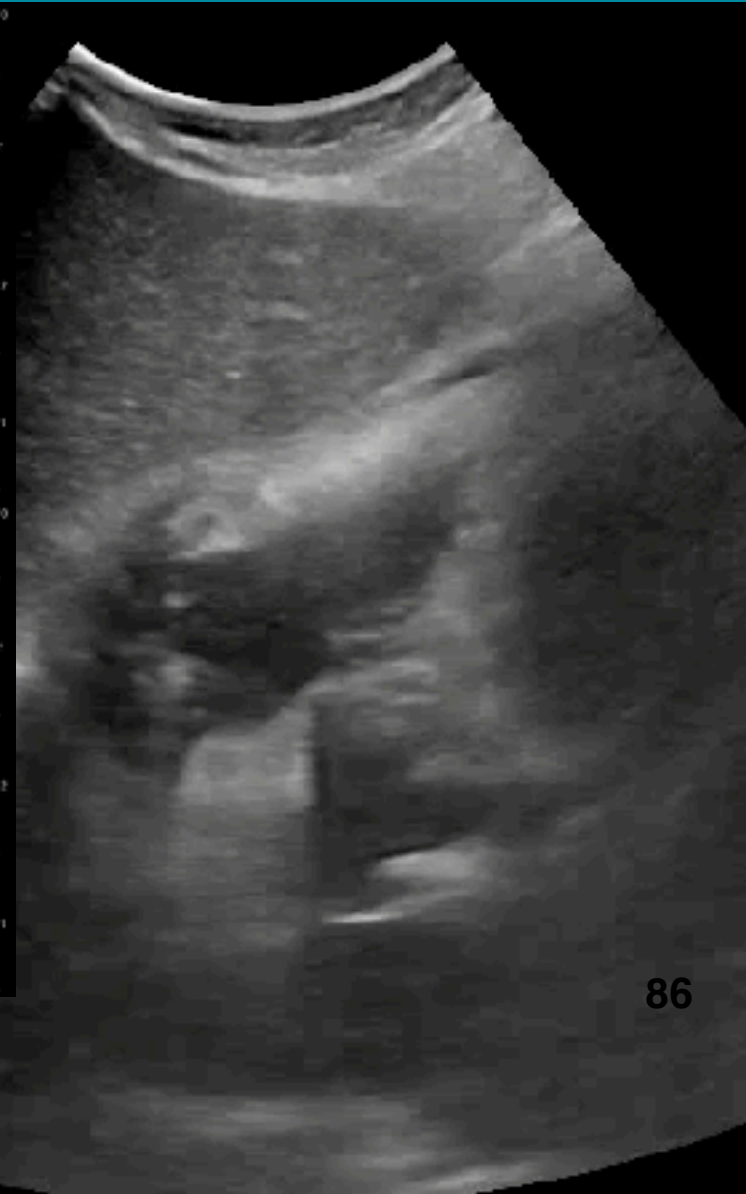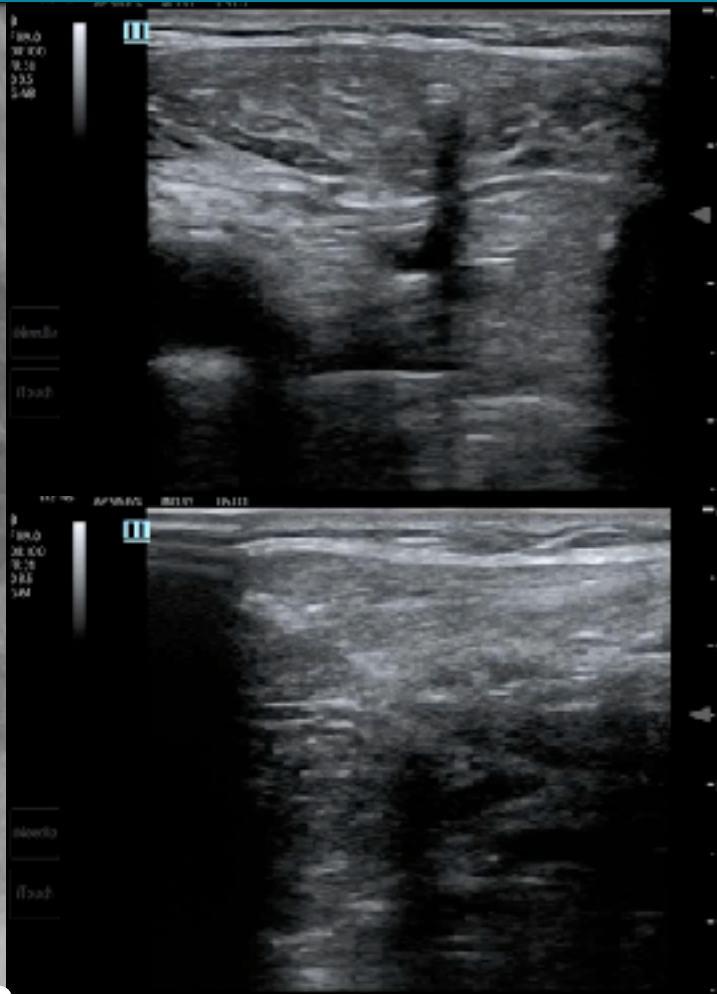

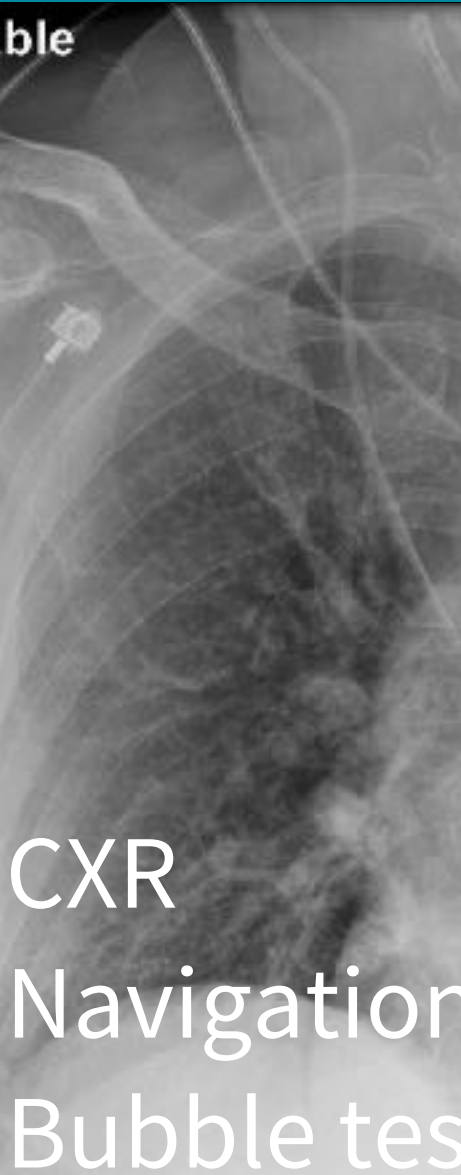


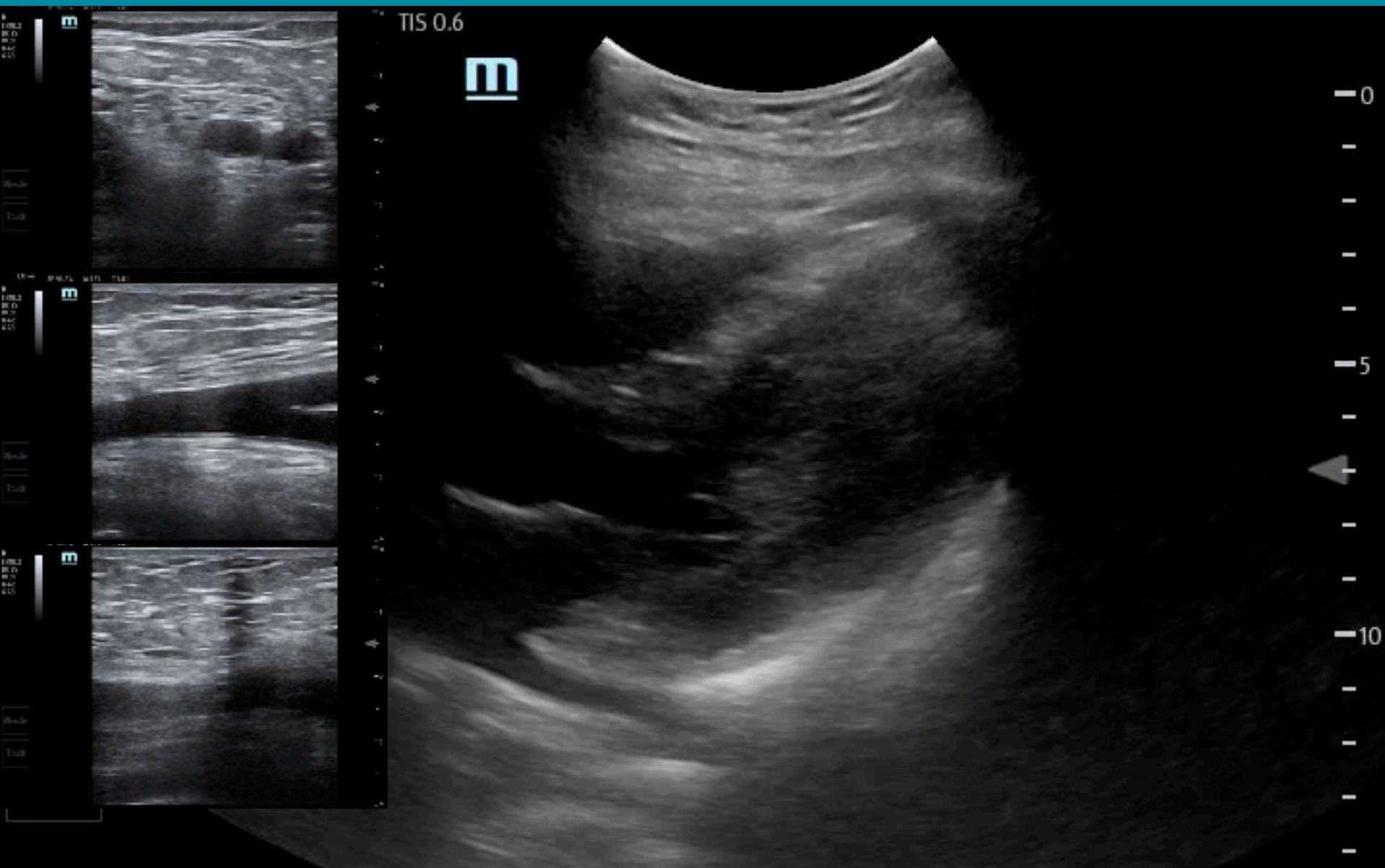
# 52M, CBD stone with BTI & septic shock



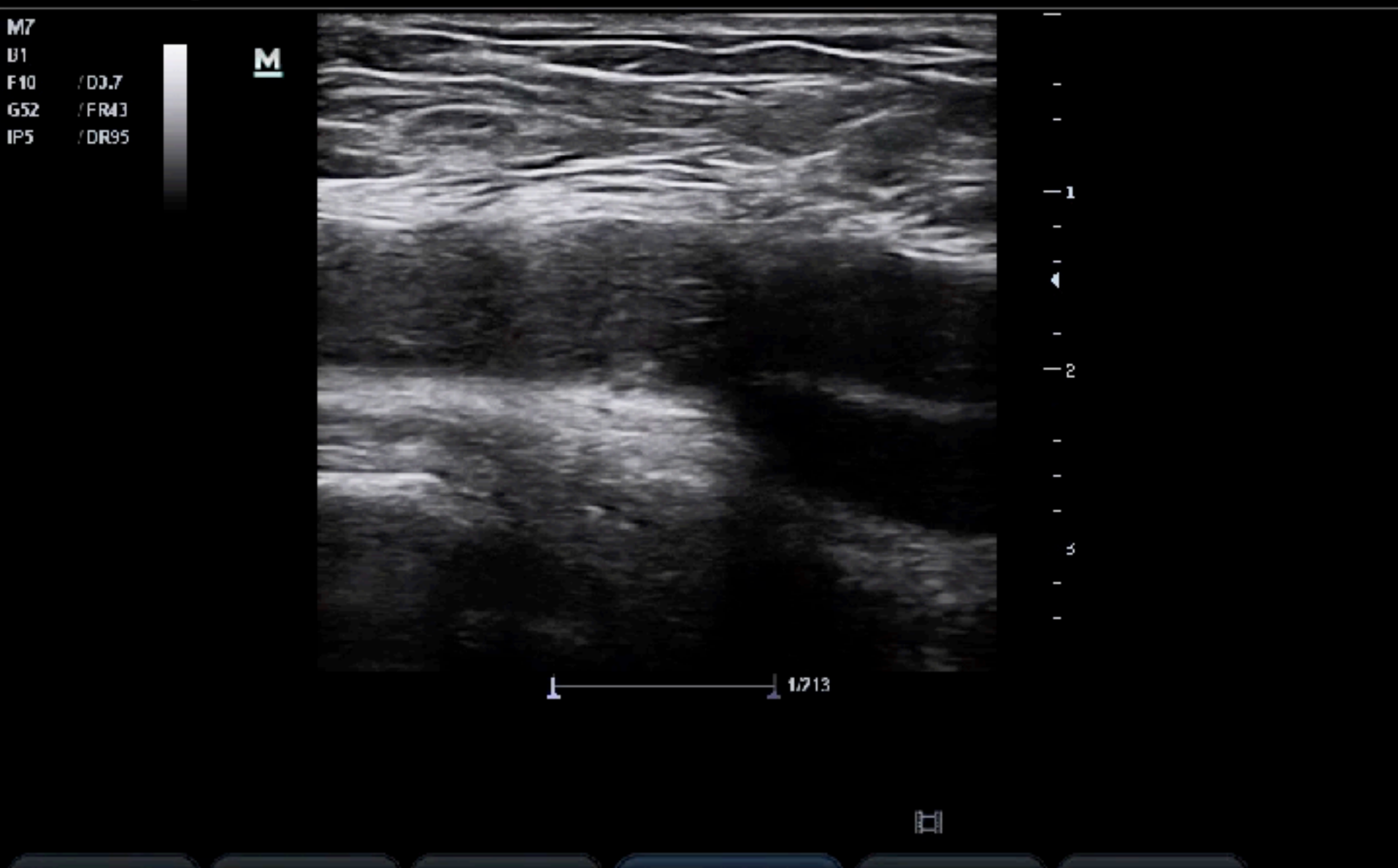
# 91F, Septic shock



# 51M, OHCA

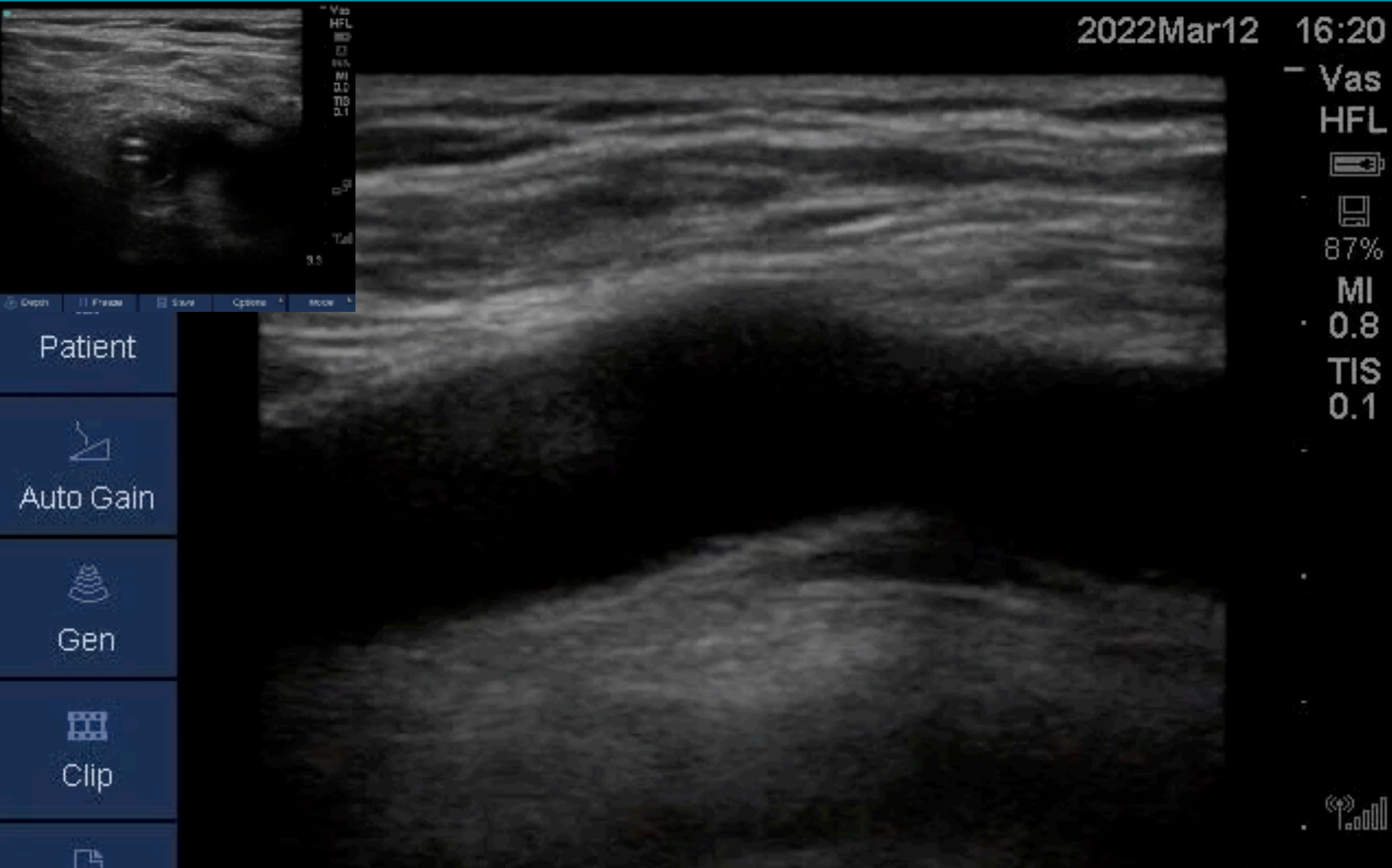


# Trauma OHCA with ROSC / Femoral A line

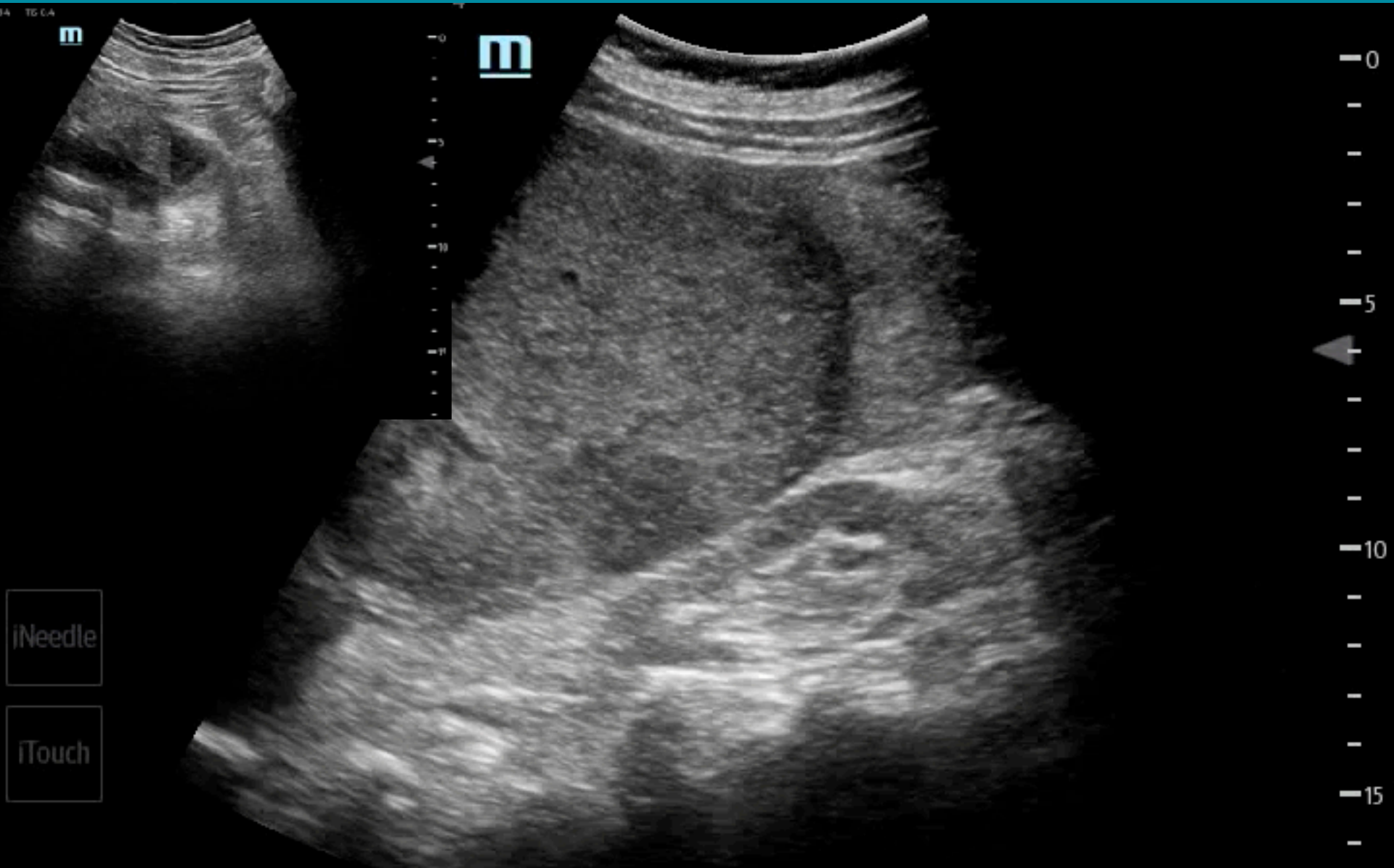




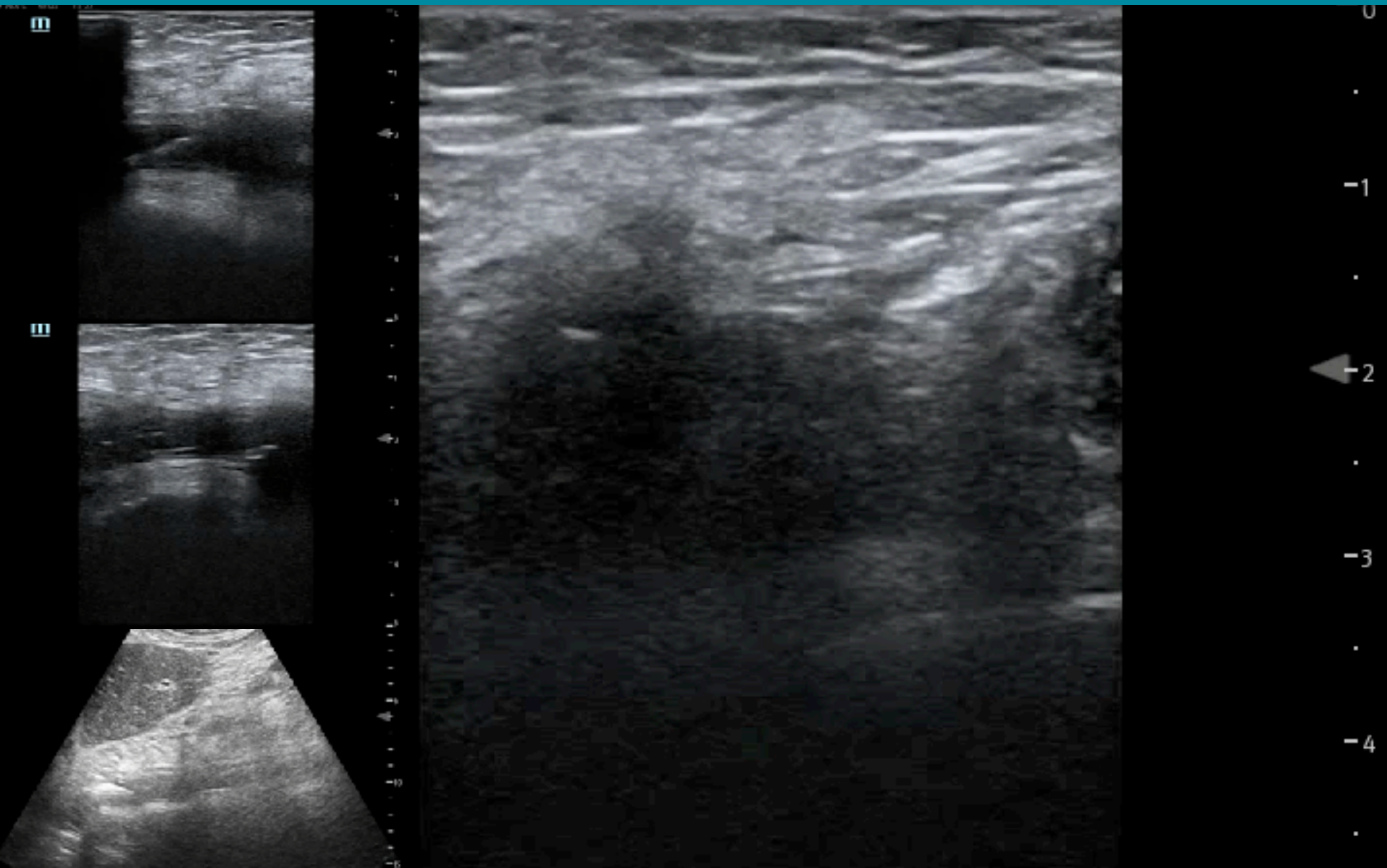
# 87M, OHCA (drowning in swimming pool)



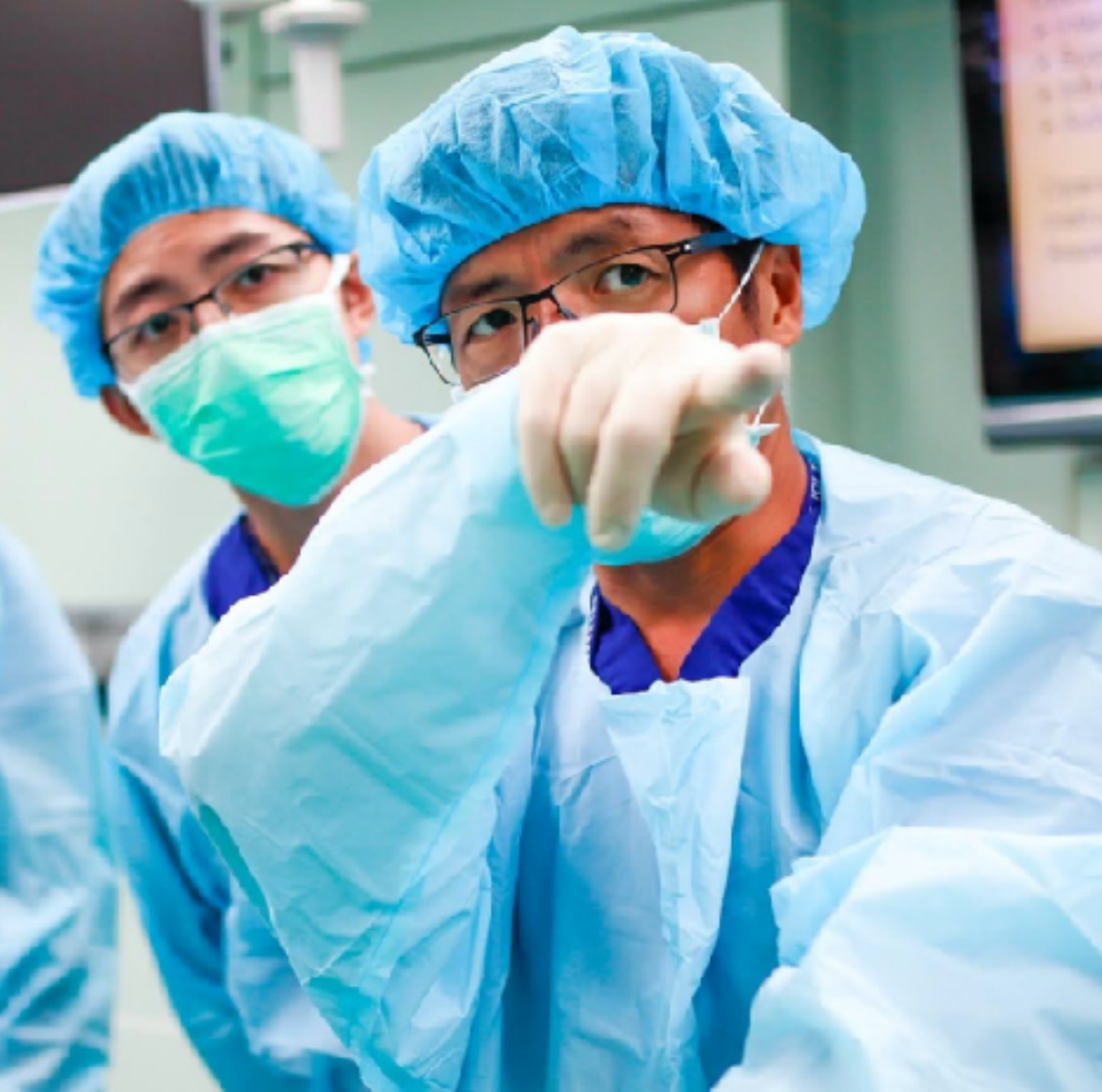# 71M, Altered consciousness at home



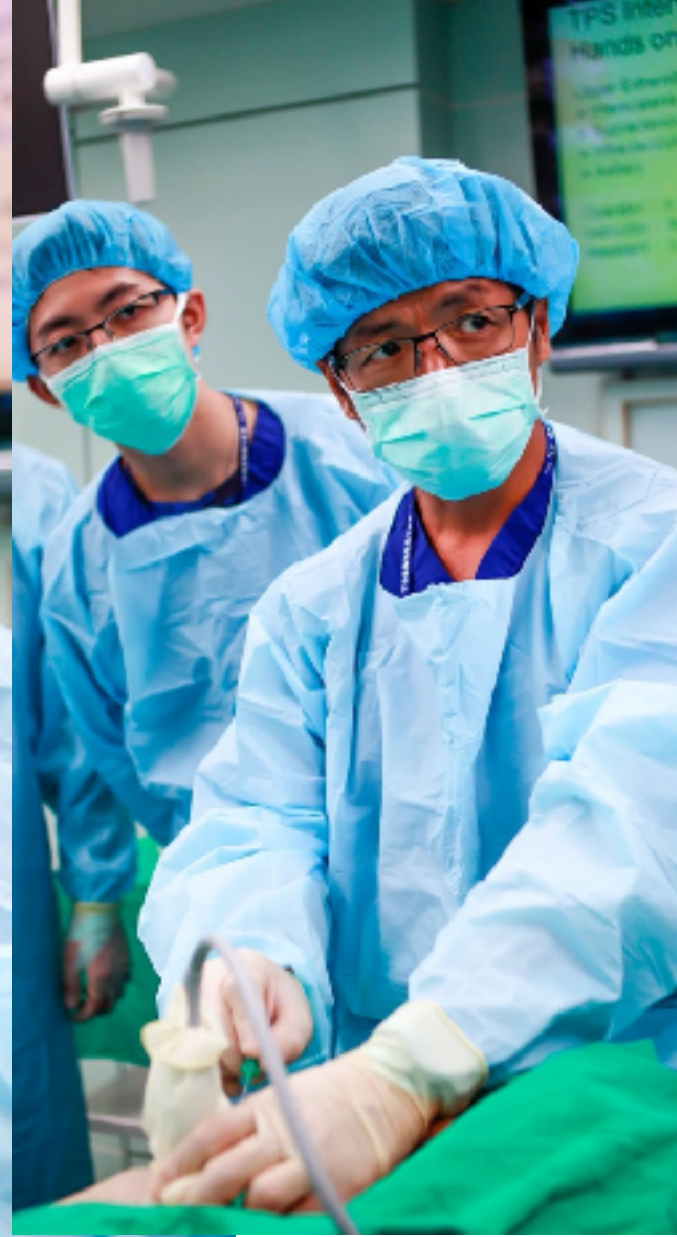# REBOA







**Diagnostician**



**Interventionist**